Seventh Edition
Volumes 1 & 2

Fitzpatrick's DERMATOLOGY IN GENERAL MEDICINE

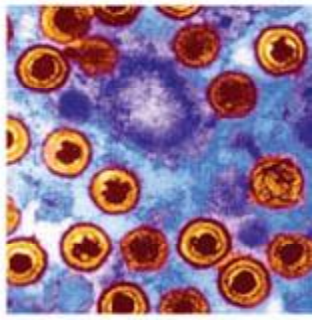

KLAUS WOLFF • LOWELL A. GOLDSMITH
STEPHEN I. KATZ • BARBARA A. GILCHREST
AMY S. PALLER • DAVID J. LEFFELL

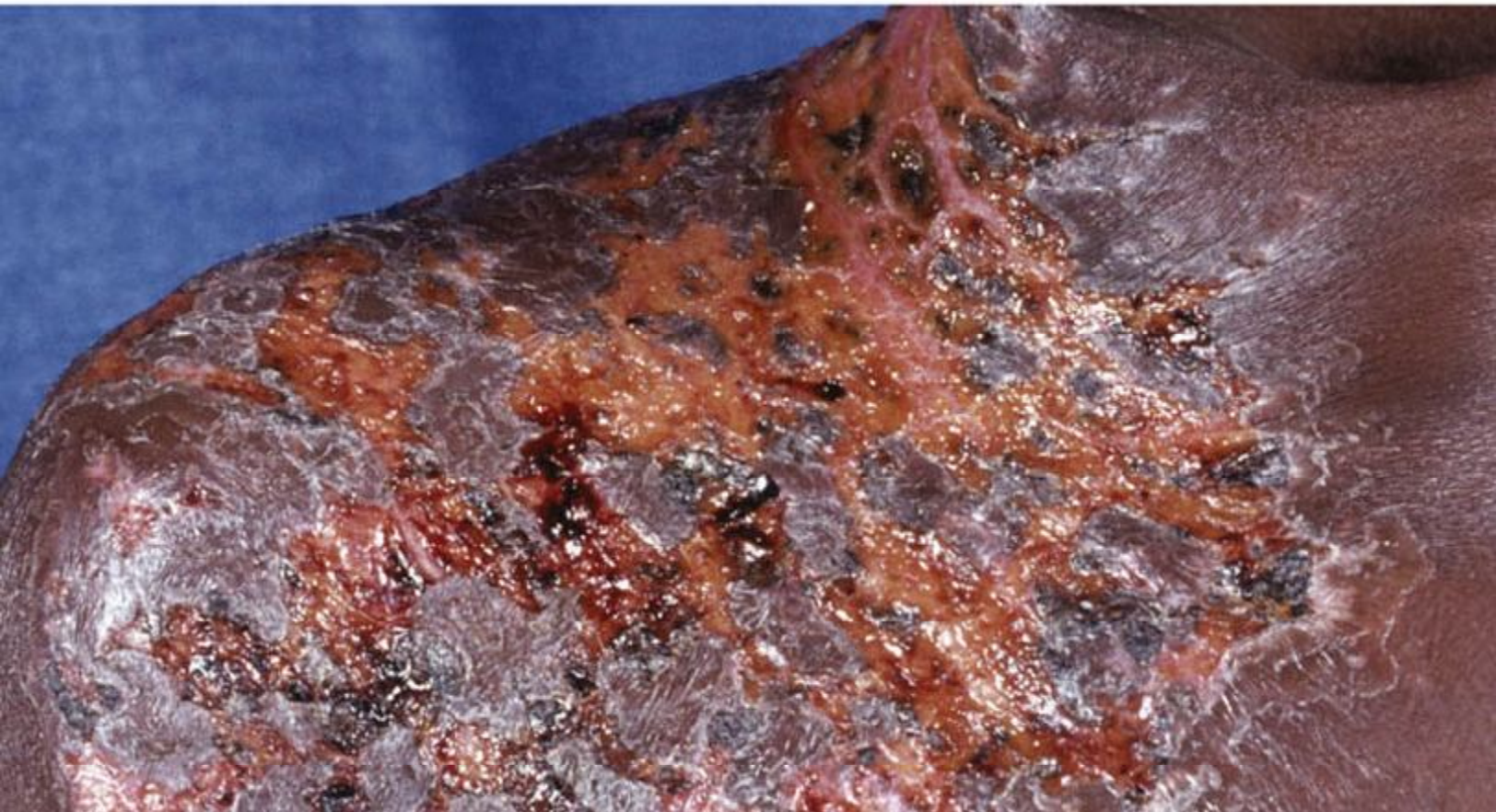

Fitzpatrick's Dermatology in General Medicine

SEVENTH EDITION

KLAUS WOLFF, MD, FRCP
Professor of Dermatology
Chairman Emeritus
Department of Dermatology
Medical University of Vienna
Vienna, Austria

LOWELL A. GOLDSMITH, MD
Professor of Dermatology
University of North Carolina School of Medicine
Chapel Hill, North Carolina
Dean Emeritus
University of Rochester School of Medicine and Dentistry
Rochester, New York

STEPHEN I. KATZ, MD, PHD
Director, National Institute of Arthritis and Musculoskeletal and Skin Diseases
National Institutes of Health
Bethesda, Maryland

BARBARA A. GILCHREST, MD
Professor and Chair of Dermatology
Department of Dermatology
Boston University School of Medicine
Boston, Massachusetts

AMY S. PALLER, MD
Walter J. Hamlin Professor and Chair of Dermatology
Professor of Pediatrics
Feinberg School of Medicine
Northwestern University
Chicago, Illinois

DAVID J. LEFFELL, MD
Professor of Dermatology and Surgery
Chief, Section of Dermatologic Surgery and Cutaneous Oncology
Department of Dermatology
Yale University School of Medicine
New Haven, Connecticut

Fitzpatrick's Dermatology in General Medicine

SEVENTH EDITION

EDITORS

KLAUS WOLFF, MD, FRCP

LOWELL A. GOLDSMITH, MD

STEPHEN I. KATZ, MD, PHD

BARBARA A. GILCHREST, MD

AMY S. PALLER, MD

DAVID J. LEFFELL, MD



New York Chicago San Francisco Lisbon London Madrid Mexico City
Milan New Delhi San Juan Seoul Singapore Sydney Toronto

The McGraw-Hill Companies

Copyright © 2008 by The McGraw-Hill Companies, Inc. All rights reserved. Manufactured in the United States of America. Except as permitted under the United States Copyright Act of 1976, no part of this publication may be reproduced or distributed in any form or by any means, or stored in a database or retrieval system, without the prior written permission of the publisher.

0-07-154448-8

The material in this eBook also appears in the print version of this title: 0-07-146690-8.

All trademarks are trademarks of their respective owners. Rather than put a trademark symbol after every occurrence of a trademarked name, we use names in an editorial fashion only, and to the benefit of the trademark owner, with no intention of infringement of the trademark. Where such designations appear in this book, they have been printed with initial caps.

McGraw-Hill eBooks are available at special quantity discounts to use as premiums and sales promotions, or for use in corporate training programs. For more information, please contact George Hoare, Special Sales, at george_hoare@mcgraw-hill.com or (212) 904-4069.

TERMS OF USE

This is a copyrighted work and The McGraw-Hill Companies, Inc. ("McGraw-Hill") and its licensors reserve all rights in and to the work. Use of this work is subject to these terms. Except as permitted under the Copyright Act of 1976 and the right to store and retrieve one copy of the work, you may not decompile, disassemble, reverse engineer, reproduce, modify, create derivative works based upon, transmit, distribute, disseminate, sell, publish or sublicense the work or any part of it without McGraw-Hill's prior consent. You may use the work for your own noncommercial and personal use; any other use of the work is strictly prohibited. Your right to use the work may be terminated if you fail to comply with these terms.

THE WORK IS PROVIDED "AS IS." McGRAW-HILL AND ITS LICENSORS MAKE NO GUARANTEES OR WARRANTIES AS TO THE ACCURACY, ADEQUACY OR COMPLETENESS OF OR RESULTS TO BE OBTAINED FROM USING THE WORK, INCLUDING ANY INFORMATION THAT CAN BE ACCESSED THROUGH THE WORK VIA HYPERLINK OR OTHERWISE, AND EXPRESSLY DISCLAIM ANY WARRANTY, EXPRESS OR IMPLIED, INCLUDING BUT NOT LIMITED TO IMPLIED WARRANTIES OF MERCHANTABILITY OR FITNESS FOR A PARTICULAR PURPOSE. McGraw-Hill and its licensors do not warrant or guarantee that the functions contained in the work will meet your requirements or that its operation will be uninterrupted or error free. Neither McGraw-Hill nor its licensors shall be liable to you or anyone else for any inaccuracy, error or omission, regardless of cause, in the work or for any damages resulting therefrom. McGraw-Hill has no responsibility for the content of any information accessed through the work. Under no circumstances shall McGraw-Hill and/or its licensors be liable for any indirect, incidental, special, punitive, consequential or similar damages that result from the use of or inability to use the work, even if any of them has been advised of the possibility of such damages. This limitation of liability shall apply to any claim or cause whatsoever whether such claim or cause arises in contract, tort or otherwise.

DOI: 10.1036/0071466908

Professional



Want to learn more?

We hope you enjoy this McGraw-Hill eBook! If you'd like more information about this book, its author, or related books and websites, please click here.

DEDICATION

This Seventh Edition of *Fitzpatrick's Dermatology in General Medicine* is dedicated to the memory of two innovators in the field, whose visionary approach to dermatology is reflected throughout:

Thomas B. Fitzpatrick, MD, PhD
and
Irwin M. Freedberg, MD

Dr. Fitzpatrick (d. 2003) was Wigglesworth Professor of Dermatology Emeritus at Harvard Medical School, and the Founder of DIGM as well as its Editor-in-Chief for the first four editions.

Dr. Freedberg (d. 2006) was the George Miller MacKee Professor of Dermatology, New York University Medical Center, and the Editor-in-Chief for the fifth and sixth editions and led the book to new heights.

Copyright © 2008 by The McGraw-Hill Companies, Inc. Click here for terms of use.

This page intentionally left blank

For more information about this title, click here

CONTENTS

Contributors xvii
Preface xxxiii
Acknowledgments xxxv

Volume One

PART 1 1

INTRODUCTION

SECTION 1. General Considerations 3

1 The Epidemiology and Burden of Skin Disease 3
Martin A. Weinstock, MD, PhD, and Mary-Margaret Chren, MD

2 Evidence-Based Dermatology 8
Michael Bigby, MD, Rosamaria Corona, DSc, MD, and Moyses Szklo, MD, MPH, DrPH

3 Public Health in Dermatology 18
Hywel C. Williams, MSc, PhD, FRCP, Sinéad Langan, MRCP, and Carsten Flohr, MRCPCH

SECTION 2: Approach to Dermatologic Diagnosis 23

4 Structure of Skin Lesions and Fundamentals of Clinical Diagnosis 23
Amit Garg, MD, Nikki A. Levin, MD, PhD, and Jeffrey D. Bernhard, MD

5 Diagnostic Procedures and Devices 40
Alon Scope, MD, and Allan C. Halpern, MD

6 Basic Pathologic Reactions of the Skin 43
Martin C. Mihm, Jr., MD, Abdul-Ghani Kibbi, MD, FACP, and Klaus Wolff, MD, FRCP

SECTION 3: Overview of Biology, Development, and Structure of Skin 57

7 Development and Structure of Skin 57
David H. Chu, MD, PhD

8 Genetics in Relation to the Skin 73
John A. McGrath, MD, and W. H. Irwin McLean, MD

9 Basic Science Approaches to the Pathophysiology of Skin Disease 87
Paul R. Bergstresser, MD

PART 2 93

DISORDERS PRESENTING IN SKIN AND MUCOUS MEMBRANES

SECTION 4. Inflammatory Disorders Based on T-Cell Reactivity and Dysregulation 95

10 Innate and Adaptive Immunity in the Skin 95
Robert L. Modlin, MD, Jenny Kim, MD, PhD, Dieter Maurer, MD, Christine Bangert, MD, and Georg Stingl, MD

11 Cytokines 115
Ifor R. Williams, MD, PhD, Benjamin E. Rich, PhD, and Thomas S. Kupper, MD

12 Chemokines 127
Sam T. Hwang, MD, PhD

13 Allergic Contact Dermatitis 135
David E. Cohen, MD, MPH, and Sharon E. Jacob, MD

14 Atopic Dermatitis (Atopic Eczema) 146
Donald Y. M. Leung, MD, PhD, Lawrence F. Eichenfield, MD, and Mark Boguniewicz, MD

15 Nummular Eczema and Lichen Simplex Chronicus/Prurigo Nodularis 158
Susan Burgin, MD

16 Vesicular Palmoplantar Eczema 162
Daven N. Doshi, MD, and Alexa B. Kimball, MD, MPH

17 Autosensitization Dermatitis 167
Donald V. Belsito, MD

18 Psoriasis 169
Johann E. Gudjonsson, MD, PhD, and James T. Elder, MD

19 Psoriatic Arthritis 194
Robert Winchester, MD

20 Reactive Arthritis 207
Andrew Keat, MD

21 Pustular Eruptions of Palms and Soles 215
Ulrich Mrowietz, MD

22 Seborrheic Dermatitis 219
Gerd Plewig, MD, and Thomas Jansen, MD

23 Exfoliative Dermatitis 225
Jane Margaret Grant-Kels, MD, Megan L. Bernstein, MD, and Marti J. Rothe, MD

24 Pityriasis Rubra Pilaris 232
Daniela Bruch-Gerharz, MD, and Thomas Ruzicka, MD

25 Parapsoriasis and Pityriasis Lichenoides 236
Gary S. Wood, MD, Chung-Hong Hu, MD, and Andrea L. Garrett, MD

26 Lichen Planus 244
Mark R. Pittelkow, MD, and Mazen S. Daoud, MD

27 Lichen Nitidus 255
Mark R. Pittelkow, MD, and Mazen S. Daoud, MD

28 Graft-Versus-Host Disease 258
Misty T. Sharp, MD, and Thomas D. Horn, MD

29 Skin Disease in Acute and Chronic Immunosuppression 267
Lynda Kauls, MD, and Andrew Blauvelt, MD

SECTION 5. Inflammatory Diseases Based on Neutrophils and Eosinophils 279

30 Regulation of the Production and Activation of Neutrophils and Eosinophils 279
Steven M. Holland, MD, James Loveless, MD, and Lisa A. Beck, MD

31 Acute Febrile Neutrophilic Dermatosis (Sweet Syndrome) 289
Philip R. Cohen, MD, Herbert Hönigsmann, MD, and Razelle Kurzrock, MD, FACP

32 Pyoderma Gangrenosum 296
Frank C. Powell, MD, and Bridget C. Hackett, MRCPI

33 Granuloma Faciale 302
Darius R. Mehregan, MD, and David A. Mehregan, MD

34 Sub-Corneal Pustular Dermatosis (Sneddon-Wilkinson Disease) 305
Franz Trautinger, MD, and Herbert Hönigsmann, MD

35 Eosinophils in Cutaneous Diseases 307
Kristin M. Leiferman, MD, and Margot S. Peters, MD

SECTION 6. Inflammatory Diseases Based on Abnormal Humoral Reactivity and Other Inflammatory Diseases 319

36 Humoral Immunity and Complement 319
Lela A. Lee, MD

37 Urticaria and Angioedema 330
Allen P. Kaplan, MD

38 Erythema Multiforme 343
Jean-Claude Roujeau, MD

39 Epidermal Necrolysis (Stevens-Johnson Syndrome and Toxic Epidermal Necrolysis) 349
L. Valeyrie-Allanore, MD, and Jean-Claude Roujeau, MD

40 Cutaneous Reactions to Drugs 355
Neil H. Shear, MD, Sandra R. Knowles, BScPhm, and Lori Shapiro, MD

41 Pityriasis Rosea 362
Andrew Blauvelt, MD

42 Erythema Annulare Centrifugum and Other Figurate Erythemas 366
Walter H. C. Burgdorf, MD

43 Granuloma Annulare 369
Julie S. Prendiville, MD, MRCPI, FRCPC

SECTION 7. Disorders of Epidermal Differentiation and Keratinization 375

44 Epidermal Growth and Differentiation 375
Stanley J. Miller, MD, Tung-Tien Sun, MD, and Pierre A. Coulombe, PhD

45 Skin as an Organ of Protection 383
Ehrhardt Proksch, MD, PhD, and Jens-Michael Jensen, MD

46 Irritant Contact Dermatitis 395
Antoine Amado, MD, James S. Taylor, MD, and Apra Sood, MD

47 The Ichthyoses 401
Philip Fleckman, MD, and John J. DiGiovanna, MD

48 Inherited Keratodermas of Palms and Soles 424
David P. Kelsell, MD, and Irene M. Leigh, MD

49 Acantholytic Disorders of the Skin: Darier-White Disease, Acrokeratosis Verruciformis, Grover Disease, and Hailey-Hailey Disease 432
Alain Hovnanian, MD, PhD

50 Porokeratosis 442
Grainne M. O'Regan, MRCPI, and Alan D. Irvine, MD, FRCPI, MRCP

SECTION 8. Disorders of Epidermal and Dermal-Epidermal Cohesion and Vesicular and Bullous Disorders 447

51 Epidermal and Epidermal-Dermal Cohesion 447
Leena Bruckner-Tuderman, MD, and John R. Stanley, MD

52 Pemphigus 459
John R. Stanley, MD

53 Paraneoplastic Pemphigus 468
Grant J. Anhalt, MD, and Carlos H. Nousari, MD

54 Bullous Pemphigoid 475
John R. Stanley, MD

55 Cicatricial Pemphigoid 481
Kim B. Yancey, MD

56 Linear Immunoglobulin A Dermatosis and Chronic Bullous Disease of Childhood 485
Caroline L. Rao, MD, and Russell P. Hall III, MD

57 Pemphigoid Gestationis (Herpes Gestationis) 490
Jeff K. Shornick, MD, MHA

58 Epidermolysis Bullosa Acquisita 494
David T. Woodley, MD, and Mei Chen, PhD

59 Dermatitis Herpetiformis 500
Russell P. Hall III, MD, and Stephen I. Katz, MD, PhD

60 Inherited Epidermolysis Bullosa 505
M. Peter Marinkovich, MD, and Eugene A. Bauer, MD

SECTION 9. Disorders of the Dermal Connective Tissue 517

61 Collagen, Elastic Fibers, and Extracellular Matrix of the Dermis 517
Jouni Uitto, MD, PhD, Mon-Li Chu, PhD, Richard Gallo, MD, PhD, and Arthur Z. Eisen, MD

62 Morphea 543
Vincent Falanga, MD, FACP, and Christina E. Killoran, MD

63 Lichen Sclerosus 546
Ulrich R. Hengge, MD

64 Dermal Hypertrophies 550
Mandy Harting, MD, M. John Hicks, MD, DDS, PhD, and Moise L. Levy, MD

65 Anetoderma and Other Atrophic Disorders of the Skin 557
Catherine Maari, MD, and Julie Powell, MD

66 Constricting Bands (Ainhum and Pseudoainhum) 562
Robert T. Brodell, MD, and Stephen E. Helms, MD

67 Acquired Perforating Disorders 564
Mark Lebwohl, MD

SECTION 10. Disorders of Subcutaneous Tissue 569

68 Panniculitis 569
Luis Requena, MD, Evaristo Sánchez Yus, MD, and Heinz Kutzner, MD

69 Lipodystrophy 585
Meredith P. Sheedy, MD, and Sarah A. Myers, MD

SECTION 11. Disorders of Melanocytes 591

70 Biology of Melanocytes 591
Hee-Young Park, PhD, Marinya Pongpudpunth, MD, Jin Lee, MD, MBA, and Mina Yaar, MD

71 Albinism and Other Genetic Disorders of Pigmentation 608
Thomas J. Hornyak, MD, PhD

72 Vitiligo 616
Rebat M. Halder, MD, and Sumayah J. Taliaferro, MD

73 Hypomelanoses and Hypermelanoses 622
Hilde Lapeere, MD, Barbara Boone, MD, Sofie De Schepper, MD, Evelien Verhaeghe, MD, Katia Ongenae, MD, PhD, Nanja Van Geel, MD, PhD, Jo Lambert, MD, PhD, Lieve Brochez, MD, PhD, and Jean-Marie Naeyaert, MD, PhD

SECTION 12. Disorders of the Oral and Genital Integument 641

74 Biology and Pathology of the Oral Cavity 641
Ginat Wintermeyer Mirowski, DMD, MD, and Eva Rawlings Parker, MD

75 Diseases and Disorders of the Male Genitalia 654
Christopher Barry Bunker, MA, MD, FRCP

76 Diseases and Disorders of the Female Genitalia 675
Rochelle R. Torgerson, MD, PhD, and Libby Edwards, MD

PART 3 685

DISORDERS OF THE SKIN APPENDAGES

SECTION 13. Disorders of the Sebaceous Glands 687

77 Biology of Sebaceous Glands 687
Amanda M. Nelson, PhD, and Diane M. Thiboutot, MD

78 Acne Vulgaris and Acneiform Eruptions 690
Andrea L. Zaenglein, MD, Emmy M. Graber, MD, Diane M. Thiboutot, MD, and John S. Strauss, MD

79 Rosacea 703
Michelle T. Pelle, MD

80 Perioral Dermatitis 709
Sarah L. Chamlin, MD, and Leslie P. Lawley, MD

SECTION 14. Disorders of the Eccrine and Apocrine Glands 713

81 Biology of Eccrine, Apocrine, and Apoeccrine Sweat Glands 713
Theodora M. Mauro, MD, and Lowell A. Goldsmith, MD

82 Disorders of the Eccrine Sweat Glands and Sweating 720
Robert D. Fealey, MD, and Kenzo Sato, MD, PhD

83 Disorders of the Apocrine Sweat Glands 731
Marni C. Wiseman, MD, FRCPC

SECTION 15. Disorders of the Hair and Nails 739

84 Biology of Hair Follicles 739
George Cotsarelis, MD, and Vladimir Botchkarev, MD, PhD

85 Keratosis Pilaris and Other Inflammatory Follicular Keratotic Syndromes 749
Maureen Rogers, MD

86 Hair Growth Disorders 753
Ralf Paus, MD, Elise A. Olsen, MD, and Andrew G. Messenger, MD

87 Biology of Nails and Nail Disorders 778
Antonella Tosti, MD, and Bianca Maria Piraccini, MD

PART 4 795

DISORDERS DUE TO THE ENVIRONMENT

SECTION 16: Disorders Due to Ultraviolet Radiation 797

88 Fundamentals of Cutaneous Photobiology and Photoimmunology 797
Irene E. Kochevar, PhD, Charles R. Taylor, MD, and Jean Krutmann, MD

89 Acute and Chronic Effects of Ultraviolet Radiation on the Skin 809
Antony R. Young, PhD, and Susan L. Walker, PhD

90 Abnormal Responses to Ultraviolet Radiation: Idiopathic, Probably Immunologic, and Photo-Exacerbated 816
John L. M. Hawk, MD, and James Ferguson, MD

91 Abnormal Responses to Ultraviolet Radiation: Photosensitivity Induced by Exogenous Agents 828
Henry W. Lim, MD

SECTION 17. Skin Changes Due to Other Physical and Chemical Factors 835

92 Thermoregulation 835
Dean L. Kellogg, Jr., MD, PhD

93 Cold Injuries 844
Gérald E. Piérard, MD, PhD, Frédérique Henry, MD, and Claudine Piérard-Franchimont, MD, PhD

94 Thermal Injuries 852
Robert L. Sheridan, MD

95 Radiobiology and Radiation Effects 858
Frederick D. Malkinson, MD, and Renato G. Panizzon, MD

96 Skin Problems in Amputees and Ostomates . . . 862
Calum C. Lyon, FRCP, MB BChir, and Michael H. Beck, FCRP, MB ChB

97 Corns and Calluses 871
Thomas M. DeLauro, DPM, and Nicole M. DeLauro, DPM

98 Sports Dermatology 873
Dirk M. Elston, MD

99 Decubitus (Pressure) Ulcers 878
Tania J. Phillips, MD, and Lilian M. Odo, MD

100 Body Art 886
Anne Laumann, MB ChB, MRCP

PART 5 893

NEUROCUTANEOUS AND PSYCHOCUTANEOUS ASPECTS OF SKIN DISEASE

SECTION 18. Neurocutaneous and Psychocutaneous Skin Disease 895

101 Neurobiology of the Skin 895
Martin Steinhoff, MD, PhD, and Thomas A. Luger, MD

102 Pathophysiology and Clinical Aspects of Pruritus 902
Gil Yosipovitch, MD, Aerlyn G. Dawn, MD, MBA, and Malcolm W. Greaves, MD, PhD, FRCP

103 Psychocutaneous Diseases 912
Andrea Sandoz, MD, Thomas Koenig, MD, Daniel Kusnir, MD, and Francisco A. Tausk, MD

104 Cutaneous Manifestations of Drug Abuse 921
Miguel R. Sanchez, MD

105 Skin Signs of Physical Abuse 927
Howard Pride, MD

PART 6 933

SKIN CHANGES ACROSS THE SPAN OF LIFE

SECTION 19. From Birth to Old Age 935

106 Neonatal, Pediatric, and Adolescent Dermatology 935
Mary Wu Chang, MD, and Seth J. Orlow, MD, PhD

107 Skin Changes and Diseases in Pregnancy 955
Julie K. Karen, MD, and Miriam Keltz Pomeranz, MD

108 Aging of Skin 963
Mina Yaar, MD, and Barbara A. Gilchrest, MD

PART 7 975

NEOPLASIA

SECTION 20. Carcinogenesis 977

109 Genome Instability, DNA Repair, and Cancer 977
Kenneth H. Kraemer, MD, and Thomas M. Rünger, MD

110 Carcinogenesis: Chemical 986
Andrzej A. Dlugosz, MD, and Stuart H. Yuspa, MD

111 Oncogenes, Tumor Suppressor Genes, and Viral Carcinogenesis 995
Nicole Basset-Séguin, MD, Celeste Lebbé, MD, Charlotte Proby, MD, and Alan Storey, MD

112 Carcinogenesis: Ultraviolet Radiation 999
Douglas E. Brash, PhD, Timothy Heffernan, PhD, and Paul Nghiem, MD, PhD

SECTION 21. Epidermal and Appendageal Tumors 1007

113 Epithelial Precancerous Lesions 1007
Karynne O. Duncan, MD, John K. Geisse, MD, and David J. Leffell, MD

114 Squamous Cell Carcinoma 1028
Douglas Grossman, MD, PhD, and David J. Leffell, MD

115 Basal Cell Carcinoma 1036
John A. Carucci, MD, and David J. Leffell, MD

116 Basal Cell Nevus Syndrome 1042
Anthony E. Oro, MD, PhD

117 Keratoacanthoma 1049
Lorenzo Cerroni, MD, and Helmut Kerl, MD

118 Benign Epithelial Tumors, Hamartomas, and Hyperplasias 1054
Valencia D. Thomas, MD, Neil A. Swanson, MD, and Ken K. Lee, MD

119 Appendage Tumors and Hamartomas of the Skin 1068
R. Stan Taylor, MD, Jennifer B. Perone, MD, Steven Kaddu, MD, and Helmut Kerl, MD

120 Merkel Cell Carcinoma 1087
Paul Nghiem, MD, PhD, and Natalia Jaimes, MD

121 Mammary and Extramammary Paget Disease 1094
Isaac M. Neuhaus, MD, and Roy C. Grekin, MD

SECTION 22. Melanocytic Tumors 1099

122 Benign Neoplasias and Hyperplasias of Melanocytes 1099
James M. Grichnik, MD, PhD, Arthur R. Rhodes, MD, MPH, and Arthur J. Sober, MD

123 Atypical Melanocytic Nevi 1122
Margaret A. Tucker, MD

124 Cutaneous Melanoma 1134
Sandra C. Paek, MD, Arthur J. Sober, MD, Hensin Tsao, MD, PhD, Martin C. Mihm, Jr., MD, and Timothy M. Johnson, MD

SECTION 23. Tumors and Hyperplasias of the Dermis and Subcutaneous Fat 1159

125 Malignant Fibrous Tumors of the Dermis 1159
Jennifer Z. Cooper, MD, and Marc D. Brown, MD

126 Vascular Tumors 1164
Tara Miller, MD, and Ilona J. Frieden, MD

127 Neoplasias and Hyperplasias of Muscular and Neural Origin 1172
Lucile E. White, MD, Ross M. Levy, MD, and Murad Alam, MD

128 Kaposi Sarcoma 1183
Erwin Tschachler, MD

129 Neoplasms of Subcutaneous Fat 1190
Thomas Brenn, MD, PhD

Volume Two

PART 8 1199

THE SKIN IN SYSTEMIC DISEASE

SECTION 24. Skin in Nutritional, Metabolic, and Heritable Disease 1201

130 Cutaneous Changes in Nutritional Disease 1201
Melinda Jen, MD, Kara N. Shah, MD, PhD, FAAP, and Albert C. Yan, MD

131 Cutaneous Changes in Errors of Amino Acid Metabolism 1219
Peter H. Itin, MD, and Lowell A. Goldsmith, MD

132 The Porphyrias 1228
David R. Bickers, MD, and Jorge Frank, MD

133 Amyloidosis and the Skin 1257
Helen J. Lachmann, MD, and Philip N. Hawkins, MD

134 Systemic Autoinflammatory Diseases 1265
John G. Ryan, MB, MRCPI, and Daniel L. Kastner, MD

135 Xanthomatoses and Lipoprotein Disorders 1272
Lucile E. White, MD

136 Fabry Disease 1281
Margarita M. Larralde, MD, and Paula C. Luna, MD

137 Lipoid Proteinosis 1288
Jonathan A. Dyer, MD

138 Cutaneous Mineralization and Ossification 1293
John S. Walsh, MD, and Janet A. Fairley, MD

139 Heritable Disorders of Connective Tissue with Skin Changes 1297
Mario E. Lacouture, MD, and Amy S. Paller, MD

140 Hereditary Disorders of Genome Instability and DNA Repair 1311
Thomas M. Rünger, MD, John J. DiGiovanna, MD, and Kenneth H. Kraemer, MD

141 Tuberous Sclerosis Complex 1325
Thomas N. Darling, MD, PhD

142 The Neurofibromatoses 1331
Robert Listernick, MD, and Joel Charrow, MD

143 Ectodermal Dysplasias 1339
Virginia P. Sybert, MD

144 Genetic Immunodeficiency Diseases 1348
Amy S. Paller, MD, and Melissa Abrams, MD

SECTION 25. Skin Manifestations of Bone Marrow and Blood Disorders 1373

145 Hematologic Diseases 1373
Bina A. Rashid, MD, Elizabeth Bahar Houshmand, MD, and Michael P. Heffernan, MD

146 Cutaneous Lymphoma 1386
Chalid Assaf, MD, and Wolfram Sterry, MD

147 Inflammatory Diseases That Simulate Lymphomas: Cutaneous Pseudolymphomas 1402
Gary S. Wood, MD

148 Langerhans Cell Histiocytosis 1414
Ruggero Caputo, MD, and Carlo Gelmetti, MD

149 Non–Langerhans Cell Histiocytosis 1424
Carlo Gelmetti, MD, and Ruggero Caputo, MD

150 Biology of Mast Cells and the Mastocytosis Syndromes 1434
Melody C. Carter, MD, and Dean D. Metcalfe, MD

SECTION 26. Skin Manifestations of Internal Organ Disorders 1445

151 The Skin and Disorders of the Alimentary Tract, the Hepatobiliary System, Kidney, and Cardiopulmonary System 1445
Graham A. Johnston, MB ChB, FRCP, and Robin A. C. Graham-Brown, MD

152 Diabetes Mellitus and Other Endocrine Diseases 1461
Andrea A. Kalus, MD, Andy J. Chien, MD, PhD, and John E. Olerud, MD

153 Sarcoidosis 1484
Richard M. Marchell, MD, Bruce Thiers, MD, and Marc A. Judson, MD

154 Cutaneous Manifestations of Internal Malignant Disease: Cutaneous Paraneoplastic Syndromes 1493
Christine A. DeWitt, MD, Lucinda S. Buescher, MD, and Stephen P. Stone, MD

SECTION 27. The Skin in Vascular and Connective Tissue and Other Autoimmune Disorders 1509

155 Mechanisms of Autoimmune Disease 1509
Insoo Kang, MD, and Joe Craft, MD

156 Lupus Erythematosus 1515
Melissa I. Costner, MD, and Richard D. Sontheimer, MD

157 Dermatomyositis 1536
Richard D. Sontheimer, MD, and Melissa I. Costner, MD

158 Scleroderma (Systemic Sclerosis) 1553
Christopher P. Denton, MD, and Carol M. Black, MD

159 Scleredema and Scleromyxedema 1562
Roger H. Weenig, MD, MPH, and Mark R. Pittelkow, MD

160 Relapsing Polychondritis 1567
Camille Frances, MD

161 Rheumatoid Arthritis, Rheumatic Fever, and Gout 1569
Christina L. Haverstock, MD, MS, and Joseph L. Jorizzo, MD

162 Sjögren Syndrome 1577
Stamatina Danielides, MD, and Gabor Illei, MD

SECTION 28. The Skin in Inflammatory and Other Vascular Disorders 1585

163 Endothelium in Inflammation and Angiogenesis 1585
Peter Petzelbauer, MD, Lisan S. Peng, MD, and Jordan S. Pober, MD

164 Cutaneous Necrotizing Venulitis 1599
Nicholas A. Soter, MD, and Jose L. Diaz-Perez, MD

165 Systemic Necrotizing Vasculitis 1606
Carmen E. Gota, MD, and Brian F. Mandell, MD, PhD, FACR

166 Erythema Elevatum Diutinum 1616
Nneka I. Comfere, MD, and Lawrence E. Gibson, MD

167 Adamantiades-Behçet Disease 1620
Christos C. Zouboulis, MD, PhD

168 Kawasaki Syndrome 1626
Donald Y. M. Leung, MD, PhD, H. Cody Meissner, MD, and Anne W. Lucky, MD

169 Pigmented Purpuric Dermatoses 1633
Theresa Schroeder-Devere, MD

170 Cryoglobulinemia and Cryofibrinogenemia 1637
Milan J. Anadkat, MD, Lynn A. Cornelius, MD, and Thomas J. Lawley, MD

171 Raynaud Phenomenon 1643
John H. Klippel, MD

172 Malignant Atrophic Papulosis (Degos Disease) 1648
Dan Lipsker, MD, PhD, and Jean-Hilaire Saurat, MD

173 Vascular Malformations 1651
Laurence M. Boon, MD, PhD, and Miikka Vikkula, MD, PhD

174 Cutaneous Changes in Peripheral Vascular Arterial Disease 1667
Mandeep Dhadly, MD, FACC, Steven M. Dean, DO, FACP, and Robert T. Eberhardt, MD

175 Cutaneous Changes in Venous and Lymphatic Insufficiency 1679
Claude S. Burton, MD, Craig N. Burkhart, MD, and Lowell A. Goldsmith, MD

PART 9 1687

DISEASE DUE TO MICROBIAL AGENTS, INFESTATIONS, BITES, AND STINGS

SECTION 29: Bacterial Disease 1689

176 General Considerations of Bacterial Diseases 1689
Timothy G. Berger, MD

177 Superficial Cutaneous Infections and Pyodermas 1694
Noah Craft, MD, PhD, Peter K. Lee, MD, PhD, Matthew T. Zipoli, MD, Arnold N. Weinberg, MD, Morton N. Swartz, MD, and Richard Allen Johnson, MD

178 Gram-Positive Infections Associated with Toxin Production 1710
Jeffrey B. Travers, MD, PhD, and Nico Mousdicas, MD

179 Soft-Tissue Infections: Erysipelas, Cellulitis, Gangrenous Cellulitis, and Myonecrosis 1720
Arturo Saavedra, MD, PhD, Arnold N. Weinberg, MD, Morton N. Swartz, MD, and Richard Allen Johnson, MD

180 Gram-Negative Coccal and Bacillary Infections 1731
Morton N. Swartz, MD

181 The Skin in Infective Endocarditis, Sepsis, Septic Shock, and Disseminated Intravascular Coagulation 1744
Laura Korb Ferris, MD, PhD, and Joseph C. English III, MD

182 Bartonellosis 1749
Timothy G. Berger, MD, and Francisco G. Bravo, MD

183 Miscellaneous Bacterial Infections with Cutaneous Manifestations 1755
Scott A. Norton, MD, MPH

184 Tuberculosis and Infections with Atypical Mycobacteria 1768
Gerhard Tappeiner, MD

185 Actinomycosis, Nocardiosis, and Actinomycetoma 1778
Francisco G. Bravo, MD, Roberto Arenas, MD, and Daniel Asz Sigall, MD

186 Leprosy 1786
Thomas H. Rea, MD, and Robert L. Modlin, MD

187 Lyme Borreliosis 1797
Meera Mahalingam, MD, PhD, FRCPath, Jag Bhawan, MD, Anne-Marie Chomat, MD, and Linden Hu, MD

SECTION 30. Fungal Diseases 1807

188 Superficial Fungal Infection: Dermatophytosis, Onychomycosis, Tinea Nigra, Piedra 1807
Shannon Verma, MD, and Michael P. Heffernan, MD

189 Yeast Infections: Candidiasis and Tinea (Pityriasis) Versicolor 1822
Matthew P. Janik, MD, and Michael P. Heffernan, MD

190 Deep Fungal Infections 1831
Roderick J. Hay, MD

SECTION 31. Viral and Rickettsial Diseases 1845

191 Viral Diseases: General Considerations 1845
Ammar M. Ahmed, MD, Vandana K. Madkan, MD, Natalie Mendoza, MD, Stephen K. Tyring, MD, PhD, MBA and Douglas R. Lowy, MD

192 Exanthematous Viral Diseases 1851
Leah Belazarian, MD, Mayra E. Lorenzo, MD, Nicole C. Pace, MD, Susan M. Sweeney, MD, and Karen M. Wiss, MD

193 Herpes Simplex 1873
Adriana R. Marques, MD, and Stephen E. Straus, MD

194 Varicella and Herpes Zoster 1885
Stephen E. Straus, MD, Michael N. Oxman, MD, and Kenneth E. Schmader, MD

195 Poxvirus Infections 1899
Wynnis Tom, MD, and Sheila Fallon Friedlander, MD

196 Warts 1914
Elliot J. Androphy, MD, and Douglas R. Lowy, MD

197 Human Retroviral Disease: Human T-Lymphotropic Viruses 1923
Erwin Tschachler, MD

198 Cutaneous Manifestations of Human Immunodeficiency Virus Disease 1927
Arturo Saavedra, MD, PhD, and Richard Allen Johnson, MD

199 The Rickettsioses, Ehrlichioses, and Anaplasmoses 1940
Analisa V. Halpern, MD, Justin J. Green, MD, and Warren R. Heymann, MD

SECTION 32. Sexually Transmitted Diseases 1955

200 Syphilis 1955
Miguel R. Sanchez, MD

201 Endemic (Non-Venereal) Treponematoses 1977
Miguel R. Sanchez, MD

202 Chancroid 1983
Stephan Lautenschlager, MD

203 Lymphogranuloma Venereum 1987
Samer H. Ghosn, MD, and Amal K. Kurban, MD

204 Granuloma Inguinale 1990
Abdul-Ghani Kibbi, MD, FACP, and Myrna El-Shareef, MD

205 Gonorrhea and Other Venereal Diseases 1993
Annabelle L. Garcia, BS, Vandana K. Madkan, MD, and Stephen K. Tyring, MD, PhD, MBA

SECTION 33. Infestations, Bites, and Stings 2001

206 Leishmaniasis and Other Protozoan Infections 2001
Samer H. Ghosn, MD, and Amal K. Kurban, MD

207 Helminthic Infections 2011
Mary Elizabeth Wilson, MD, and Eric Caumes, MD

208 Scabies, Other Mites, and Pediculosis 2029
Stephen P. Stone, MD, Jonathan N. Goldfarb, MD, and Rocky E. Bacelieri, MD

209 Bites and Stings of Terrestrial and Aquatic Life 2037
Jennifer S. Daly, MD, and Mark Jordan Scharf, MD

210 Arthropod Bites and Stings 2054
Christopher J. Steen, MD, and Robert A. Schwartz, MD, MPH

PART 10 2065

OCCUPATIONAL SKIN DISEASES AND SKIN DISEASES DUE TO BIOLOGIC WARFARE

SECTION 34. Occupational Skin Diseases 2067

211 Occupational Skin Diseases Due to Irritants and Allergens 2067
James S. Taylor, MD, Apra Sood, MD, and Antoine Amado, MD

212 Occupational Noneczematous Skin Diseases Due to Biologic, Physical, and Chemical Agents 2074
Apra Sood, MD, and James S. Taylor, MD

SECTION 35. The Skin in Bioterrorism and Biologic Warfare 2081

213 Cutaneous Manifestations of Biologic, Chemical, and Radiologic Terrorism Attacks 2081
Scott A. Norton, MD, MPH

PART 11 2089

THERAPEUTICS

SECTION 36. Topical Therapy 2091

214 Principles of Topical Therapy 2091
Kendra G. Bergstrom, MD, and Bruce E. Strober, MD

215 Pharmacokinetics and Topical Applications of Drugs 2097
Hans Schaefer, MD, Thomas E. Redelmeier, MD, Gerhard J. Nohynek, MD, and Jürgen Lademann, MD

216 Topical Corticosteroids 2102
Isabel C. Valencia, MD, and Francisco A. Kerdel, MD

217 Topical Retinoids 2106
Sewon Kang, MD, and John J. Voorhees, MD

218 Topical Antibiotics 2113
Mark W. Bonner, MD, Paul M. Benson, MD, and William D. James, MD, PhD

219 Topical Antifungal Agents 2116
Whitney A. High, MD, and James E. Fitzpatrick, MD

220 Topical and Intralesional Cytotoxic Agents 2122
Megan M. Moore, MD, and Bruce E. Strober, MD

221 Topical Immunomodulators 2125
Robert Sidbury, MD, and Jon M. Hanifin, MD

222 Other Topical Medications 2130
Craig N. Burkhart, MD, and Kenneth A. Katz, MD

223 Photoprotection and Sun Protective Agents 2137
Henry W. Lim, MD

224 Special Considerations for Topical Therapy of Ethnic Skin 2142
Roopal V. Kundu, MD

SECTION 37. Systemic Therapy 2147

225 Systemic Glucocorticoids 2147
Victoria P. Werth, MD

226 Dapsone 2154
Joni G. Sago, MD, and Russell P. Hall III, MD

227 Aminoquinolines 2157
Jeffrey R. LaDuca, MD, PhD, and Anthony A. Gaspari, MD

228 Cytotoxic and Antimetabolic Agents 2163
Whitney A. High, MD, and James E. Fitzpatrick, MD

229 Retinoids 2181
Anders Vahlquist, MD, PhD, Stéphane Kuenzli, MD, and Jean-Hilaire Saurat, MD

230 Antihistamines 2186
Susan L. Limb, MD, and Robert A. Wood, MD

231 Antibiotics 2194
Christopher C. Gasbarre, DO, Steven K. Schmitt, MD, and Kenneth J. Tomecki, MD

232 Antiviral Drugs 2203
Christine M. Hay, MD, and Richard C. Reichman, MD

233 Oral Antifungal Agents 2211
Margaret S. Lee-Bellantoni, MD, PhD, and Nellie Konnikov, MD

234 Immunosuppressive and Immunomodulatory Drugs 2217
Carlos H. Nousari, MD, and Grant J. Anhalt, MD

235 Immunobiologicals, Cytokines, and Growth Factors in Dermatology 2223
Stephen Richardson, MD, and Joel Gelfand, MD

236 Anti-Angiogenic Agents 2231
Kalpana Reddy, BS, and Jack Arbiser, MD

237 Drug Interactions 2236
Stephen E. Wolverton, MD

SECTION 38. Physical Treatments 2243

238 Therapeutic Photomedicine: Phototherapy 2243
Jean Krutmann, MD, and Akimichi Morita, MD, PhD

239 Photochemotherapy and Photodynamic Therapy 2249
Herbert Hönigsmann, MD, Rolf-Markus Szeimies, MD, and Robert Knobler, MD

240 Lasers and Flashlamps in Dermatology 2263
Fernanda H. Sakamoto, MD, Tomi Wall, MD, Mathew M. Avram, MD, and R. Rox Anderson, MD

241 Radiotherapy 2279
Renato Panizzon, MD

SECTION 39. Complementary and Alternative Dermatology 2285

242 Complementary and Alternative Medicine in Dermatology 2285
Alan Dattner, MD

SECTION 40. Surgery in Dermatology 2289

243 Dermatologic Surgery: Introduction to Anatomy and Approach 2289
Sumaira Z. Aasi, MD, and Brent Pennington, MD

244 Excisional Surgery and Repair, Including Flaps and Grafts 2302
June K. Robinson, MD

245 Mohs Micrographic Surgery 2315
Ken K. Lee, MD, Valencia D. Thomas, MD, and Neil A. Swanson, MD

246 Nail Surgery 2320
Robert Baran, MD

247 Cryosurgery and Electrosurgery 2330
Justin J. Vujevich, MD, and Leonard H. Goldberg, MD

248 Surgical Complications 2336
Richard Bennett, MD

249 Wound Repair: Mechanisms and Practical Considerations 2342
Vincent Falanga, MD, FACP, and Satori Iwamoto, MD, PhD

250 Treatment for Varicose and Telangiectatic Leg Veins 2349
Robert A. Weiss, MD, and Margaret A. Weiss, MD

SECTION 41. Cosmetic Dermatology 2357

251 Cosmetics and Skin Care in Dermatology 2357
Leslie Baumann, MD

252 Skin Resurfacing: Ablative Lasers, Chemical Peels, and Dermabrasion 2364
Elizabeth L. Tanzi, MD, and Tina S. Alster, MD

253 Cosmetic Applications of Non-Ablative Lasers and Other Light Devices 2372
Anne M. Chapas, MD, and Roy G. Geronemus, MD

254 Liposuction 2378
Aimee L. Leonard, MD, and C. William Hanke, MD, MPH, FACP

255 Soft-Tissue Augmentation 2380
Lisa M. Donofrio, MD

256 Botulinum Toxin 2388
Richard G. Glogau, MD

257 Hair Transplantation and Alopecia Reduction 2394
Walter P. Unger, MD, FRCP(C), FACP, Robin H. Unger, MD, and Mark Unger, MD

Index I-1

CONTRIBUTORS

Sumaira Z. Aasi, MD
Assistant Professor, Department of Dermatology
Yale University School of Medicine
New Haven, Connecticut

Melissa Abrams, MD
Departments of Dermatology and Pediatrics
Northwestern University
Chicago, Illinois

Ammar M. Ahmed, MD
Department of Dermatology
Baylor College of Medicine
Houston, Texas

Murad Alam, MD
Chief, Section of Cutaneous and Aesthetic Surgery
Associate Professor, Departments of Dermatology and Otolaryngology–Head & Neck Surgery
Feinberg School of Medicine
Northwestern University
Chicago, Illinois

L. Valeyrie-Allanore, MD
Department of Dermatology
Henri Mondor Hospital
University of Paris
Paris, France

Tina S. Alster, MD
Clinical Professor, Department of Dermatology
Johns Hopkins Medical Center
Baltimore, Maryland
Georgetown University Medical Center
Washington Institute of Dermatological Laser Surgery
Washington, D.C.

Antoine Amado, MD
Contact Dermatitis Fellow
Department of Dermatology
The Cleveland Clinic Foundation
Cleveland, Ohio

Milan J. Anadkat, MD
Division of Dermatology
Department of Medicine
Washington University School of Medicine
St. Louis, Missouri

R. Rox Anderson, MD
Professor of Dermatology
Harvard Medical School
Wellman Center for Photomedicine
Massachusetts General Hospital
Boston, Massachusetts

Elliot J. Androphy, MD
Barbara and Nathan Greenberg Chair in Biomedical Research
University of Massachusetts Medical School
Worcester, Massachusetts

Grant J. Anhalt, MD
Consultant, Department of Dermatology
Johns Hopkins Institutes of Medicine
Baltimore, Maryland

Jack Arbiser, MD
Department of Dermatology
Emory University
Atlanta, Georgia

Roberto Arenas, MD
Department of Dermatology
Mycology Section
Dr. Manuel Gea Gonzalez General Hospital
Mexico City, Mexico

Chalid Assaf, MD
Associate Professor, Department of Dermatology and Allergy
Charite-Universitatsmediczin, Berlin
Skin Cancer Center, Charite University of Medicine
Berlin, Germany

Mathew M. Avram, MD
Director, MGH Dermatology Laser and Cosmetics Center
Massachusetts General Hospital
Professor, Department of Dermatology
Harvard Medical School
Boston, Massachusetts

Rocky E. Bacelieri, MD
Division of Dermatology
Department of Internal Medicine
Southern Illinois University School of Medicine
Springfield, Illinois

Christine Bangert, MD
Department of Dermatology
Medical University of Vienna
Vienna, Austria

Robert Baran, MD
Nail Disease Centre
Cannes, France

Nicole Basset-Séguin, MD
Service de Dermatologie
Hôpital Saint-Louis
Paris, France

Eugene A. Bauer, MD
Lucy Becker Professor in Medicine Emeritus
Stanford University School of Medicine
Stanford, California

Leslie Baumann, MD
Professor, Department of Dermatology
Director, University of Miami Cosmetic Center
University of Miami Miller School of Medicine
Miami, Florida

*This contributor's work as author was performed outside the scope of his employment as a U.S. government employee. This work represents his personal and professional views and not necessarily those of the U.S. government.

Copyright © 2008 by The McGraw-Hill Companies, Inc. Click here for terms of use.

Lisa A. Beck, MD
Associate Professor, Department of Dermatology
University of Rochester School of Medicine
Rochester, New York

Michael H. Beck, FRCP, MB ChB
Consultant Dermatologist and Honorary Clinical Lecturer
University of Manchester School of Medicine
Hope Hospital
Manchester, England

Leah Belazarian, MD
Resident, Department of Dermatology
University of Massachusetts Medical School
Worcester, Massachusetts

Donald V. Belsito, MD
Clinical Professor of Medicine (Dermatology)
University of Missouri, Kansas City
Kansas City, Missouri

Richard Bennett, MD
Clinical Professor, Department of Dermatology
University of Southern California
Clinical Professor, Department of Medicine
University of California at Los Angeles
Los Angeles, California

Paul M. Benson, MD
TriCities Skin & Cancer
Johnson City, Tennessee

Timothy G. Berger, MD
Professor of Clinical Dermatology
Department of Dermatology
University of California, San Francisco
San Francisco, California

Paul R. Bergstresser, MD
James N. Gilliam Chair, Department of Dermatology
University of Texas Southwestern Medical Center
Dallas, Texas

Kendra G. Bergstrom, MD
Resident Physician, The Ronald O. Perelman Department of Dermatology
New York University Medical Center
New York, New York

Jeffrey D. Bernhard, MD
Professor of Medicine
Division of Dermatology
University of Massachusetts Medical School
University of Massachusetts Memorial Health Care
Worcester, Massachusetts

Megan L. Bernstein, MD
Intern, Mt. Sinai Hospital
New York, New York

Jag Bhawan, MD
Professor of Dermatology and Pathology
Head, Dermatopathology Section
Department of Dermatology
Boston University School of Medicine
Boston, Massachusetts

David R. Bickers, MD
Carl Truman Nelson Professor and Chair
Department of Dermatology
Columbia University
New York, New York

Michael Bigby, MD
Associate Professor, Dermatology
Harvard Medical School
Department of Dermatology
Beth Israel Deaconess Medical Center
Boston, Massachusetts

Carol M. Black, MD
Professor of Rheumatology
Centre for Rheumatology
Royal Free and University College Medical School
Hampstead Campus
London, England

Andrew Blauvelt, MD
Professor, Department of Dermatology and Department of Molecular Microbiology and Immunology
Oregon Health & Science University
Portland, Oregon

Mark Boguniewicz, MD
Department of Pediatrics
National Jewish Medical and Research Center
University of Colorado School of Medicine
Denver, Colorado

Mark W. Bonner, MD
Georgia Dermatology
Warner Robins, Georgia

Laurence M. Boon, MD, PhD
Center for Vascular Anomalies, Division of Plastic Surgery
Cliniques Universitaries St. Luc
Brussels, Belgium

Barbara Boone, MD
Department of Dermatology
University Hospital Ghent
Ghent, Belgium

Vladimir Botchkarev, MD, PhD
Associate Research Professor
Departments of Dermatology, Pathology and Laboratory Medicine
Boston University School of Medicine
Boston, Massachusetts

Douglas E. Brash, PhD
Professor, Department of Therapeutic Radiology
Yale University School of Medicine
New Haven, Connecticut

Francisco G. Bravo, MD
Associate Professor of Dermatology and Pathology
Universidad Peruana Cayetano Heredia
Lima, Peru

Thomas Brenn, MD, PhD
Consultant Dermatopathologist, Department of Pathology
Western General Hospital
The University of Edinburgh
Edinburgh, Scotland
University of Manchester
Salford, United Kingdom

Lieve Brochez, MD, PhD
Professor, Department of Dermatology
University Hospital Ghent
Ghent, Belgium

Robert T. Brodell, MD
Professor of Internal Medicine
Dermatology Section
Clinical Professor, Dermatopathology in Pathology
Northeastern Ohio Universities College of Medicine
Associate Clinical Professor of Dermatology
Case Western Reserve School of Medicine
Warren, Ohio

Marc D. Brown, MD
Professor, Department of Dermatology
Director, Division of Dermatologic Surgery, Oncology, and Mohs Surgery
University of Rochester School of Medicine
Strong Memorial Hospital
Rochester, New York

Daniela Bruch-Gerharz, MD
Professor, Department of Dermatology
Heinrich-Heine University
University Hospital of Duesseldorf
Duesseldorf, Germany

Leena Bruckner-Tuderman, MD
Professor and Chair, Department of Dermatology
University of Freiburg
Freiburg, Germany

Lucinda S. Buescher, MD
Associate Professor, Division of Dermatology
Department of Internal Medicine
Southern Illinois University School of Medicine
Springfield, Illinois

Christopher Barry Bunker, MA, MD, FRCP
Professor of Dermatology and Consultant Dermatologist
Imperial College School of Medicine
Chelsea & Westminster and Royal Marsden Hospitals
London, United Kingdom

Walter H. C. Burgdorf, MD
Clinical Lecturer
Department of Dermatology
Ludwig Maximilian University
Munich, Germany

Susan Burgin, MD
Instructor, Department of Dermatology
Beth Israel Deaconess Medical Center
Harvard Medical School
Boston, Massachusetts

Craig N. Burkhart, MD
Department of Dermatology
University of North Carolina
Chapel Hill, North Carolina

Claude S. Burton, MD
Department of Dermatology
Duke University Medical Center
Durham, North Carolina

Ruggero Caputo, MD
Professor of Dermatology
Institute of Dermatological Sciences
Milan, Italy (d. 2007)

Melody C. Carter, MD
Adjunct Faculty
National Institute of Allergy and Infectious Diseases
National Institutes of Health
Bethesda, Maryland

John A. Carucci, MD
Chief, Mohs Micrographic and Dermatologic Surgery
Weill Medical College of Cornell University
New York Presbyterian Hospital
New York, New York

Eric Caumes, MD
Professor of Infectious and Tropical Diseases
University Pierre et Marie Curie
Department of Infectious and Tropical Diseases
Hôpital Pitié-Salpêtrière
Paris, France

Lorenzo Cerroni, MD
Professor, Department of Dermatology
Medical University of Graz
Graz, Austria

Sarah L. Chamlin, MD
Associate Professor, Division of Dermatology
Children's Memorial Hospital
Northwestern University
Chicago, Illinois

Mary Wu Chang, MD
Chief, Pediatric Dermatology
Connecticut Children's Medical Center
Associate Professor of Dermatology & Pediatrics
University of Connecticut School of Medicine
Hartford, Connecticut

Anne M. Chapas, MD
Clinical Assistant Professor, The Ronald O. Perelman Department of Dermatology
Laser and Skin Surgery Center of New York
New York University Medical Center
New York, New York

Joel Charrow, MD
Associate Professor, Department of Pediatrics
Feinberg School of Medicine
Northwestern University
Head, Division of Genetics
Children's Memorial Hospital
Chicago, Illinois

Mei Chen, PhD
Department of Dermatology
Keck School of Medicine
University of Southern California
Los Angeles, California

Andy J. Chien, MD, PhD
Acting Assistant Professor, Division of Dermatology
University of Washington
Seattle, Washington

Anne-Marie Chomat, MD
Fellow in Infectious Diseases
Tufts-New England Medical Center
Boston, Massachusetts

Mary-Margaret Chren, MD
Professor in Residence
Department of Dermatology
University of California, San Francisco
Staff Dermatologist
Veterans Affairs Medical Center
San Francisco, California

David H. Chu, MD, PhD
Instructor, The Ronald O. Perelman Department of Dermatology
New York University School of Medicine
New York, New York

Mon-Li Chu, PhD
Professor and Vice Chair of Research
Department of Dermatology and Cutaneous Biology
Jefferson Medical College
Jefferson Institute of Molecular Medicine
Thomas Jefferson University
Philadelphia, Pennsylvania

David E. Cohen, MD, MPH
Associate Professor, The Ronald O. Perelman Department of Dermatology
The New York University School of Medicine
New York, New York

Philip R. Cohen, MD
Clinical Associate Professor, Department of Dermatology
University of Texas-Houston Medical School
Houston, Texas

Nneka I. Comfere, MD
Assistant Professor
Mayo Clinic College of Medicine
Consultant in Dermatology
Mayo Clinic
Rochester, Minnesota

Jennifer Z. Cooper, MD
Assistant Professor, Department of Dermatology
University of Maryland School of Medicine
Baltimore, Maryland

Lynn A. Cornelius, MD
Associate Professor and Chief, Division of Dermatology
Washington University
St. Louis, Missouri

Rosamaria Corona, DSc, MD
Istituto Dermopatico dell'Immacolata
Divisione di Immunodermatologia
Rome, Italy

Melissa I. Costner, MD
Assistant Professor, Department of Dermatology
University of Texas Southwestern Medical School at Dallas
Dallas, Texas

George Cotsarelis, MD
Associate Professor, Department of Dermatology
University of Pennsylvania Medical Center
Philadelphia, Pennsylvania

Pierre A. Coulombe, PhD
Professor, Departments of Biological Chemistry and Dermatology
Director, Graduate Program in Cellular and Molecular Medicine
Johns Hopkins University School of Medicine
Baltimore, Maryland

Joe Craft, MD
Section of Immunobiology
Department of Internal Medicine
Yale University
New Haven, Connecticut

Noah Craft, MD, PhD
Associate Program Director, Division of Dermatology
Harbor UCLA Medical Center
Los Angeles, California

Jennifer S. Daly, MD
Department of Medicine
Division of Infectious Diseases and Immunology
University of Massachusetts Medical School
Worcester, Massachusetts

Stamatina Danielides, MD
Sjögren's Syndrome Clinic
Gene Therapy and Therapeutics Branch
National Institute of Dental and Craniofacial Research
National Institutes of Health
Bethesda, Maryland

Mazen S. Daoud, MD
Fort Myers Dermatology
Fort Myers, Florida

Thomas N. Darling, MD, PhD
Associate Professor, Department of Dermatology
Uniformed Services University of the Health Sciences
Bethesda, Maryland

Alan Dattner, MD
New Rochelle, New York

Aerlyn G. Dawn, MD, MBA
Department of Dermatology
Wake Forest University School of Medicine
Winston-Salem, North Carolina

Steven M. Dean, DO, FACP
Division of Cardiovascular Medicine
Ohio State University
Columbus, Ohio

Nicole M. DeLauro, DPM
New York College of Podiatric Medicine
New York, New York

Thomas M. DeLauro, DPM
Professor
New York College of Podiatric Medicine
New York, New York

Christopher P. Denton, MD
Professor of Experimental Rheumatology
Centre for Rheumatology
Royal Free and University College Medical School
Hampstead Campus
London, England

Sofie De Schepper, MD
Department of Dermatology
University Hospital Ghent
Ghent, Belgium

Christine A. DeWitt, MD
Division of Dermatology
Department of Internal Medicine
Southern Illinois University School of Medicine
Springfield, Illinois

Mandeep Dhadly, MD, FACC
Section of Cardiovascular Medicine
Boston University School of Medicine
Boston, Massachusetts

Jose L. Diaz-Perez, MD
Cruces University Hospital
Plaza Cruces
Bilbao, Spain

John J. DiGiovanna, MD
Professor, Division of Dermatology
Director, Division of Dermatopharmacology
Brown University Medical School
Rhode Island Hospital
Providence, Rhode Island

Andrzej A. Dlugosz, MD
Professor, Department of Dermatology
Comprehensive Cancer Center
University of Michigan
Ann Arbor, Michigan

Lisa M. Donofrio, MD
Assistant Clinical Professor
Department of Dermatology
Yale University School of Medicine
New Haven, Connecticut

Daven N. Doshi, MD
Department of Dermatology
Harvard Medical School
Boston, Massachusetts

Karynne O. Duncan, MD
St. Helena, California

Jonathan A. Dyer, MD
Assistant Professor, Department of Dermatology
University of Missouri-Columbia
Columbia, Missouri

Robert T. Eberhardt, MD
Division of Cardiovascular Medicine
Boston University Medical Center
Boston, Massachusetts

Libby Edwards, MD
Chief, Division of Dermatology
Carolinas Medical Center
Charlotte, North Carolina
Clinical Associate Professor
Department of Dermatology
University of North Carolina
Chapel Hill, North Carolina

Lawrence F. Eichenfield, MD
Chief, Division of Pediatric and Adolescent Dermatology
Children's Hospital and Departments of Pediatrics and Medicine (Dermatology)
University of California San Diego
San Diego, California

Arthur Z. Eisen, MD
Winfred and Emma Showman
Professor, Division of Dermatology
Department of Medicine
Washington University Medical Center
St. Louis, Missouri

James T. Elder, MD
Professor, Department of Dermatology
University of Michigan
Ann Arbor Veterans Affairs Hospital
Ann Arbor, Michigan

Myrna El-Shareef, MD
Department of Dermatology
American University of Beirut Medical Center
Beirut, Lebanon

Dirk M. Elston, MD
Department of Dermatology
Geisinger Medical Center
Danville, Pennsylvania

Joseph C. English III, MD
Associate Professor, Department of Dermatology
University of Pittsburgh
Pittsburgh, Pennsylvania

Janet A. Fairley, MD
Professor, Department of Dermatology
Medical College of Wisconsin
Milwaukee, Wisconsin

Vincent Falanga, MD, FACP
Department of Dermatology and Skin Surgery
Roger Williams Medical Center
Providence, Rhode Island
Department of Dermatology and Biochemistry
Boston University
Boston, Massachusetts

Robert D. Fealey, MD
Assistant Professor, Department of Neurology
Mayo Clinic Medical School
Rochester, Minnesota

James Ferguson, MD
Photobiology Unit
Ninewells Hospital
Dundee, Scotland

Laura Korb Ferris, MD, PhD
Assistant Professor, Department of Dermatology
University of Pittsburgh
Pittsburgh, Pennsylvania

James E. Fitzpatrick, MD
Professor, Dermatology & Dermatopathology
University of Colorado Health Sciences Center
Denver, Colorado;
Dermatopathology Consultants, Anschutz Cancer Center
Department of Dermatology
Aurora, Colorado

Philip Fleckman, MD
Professor, Division of Dermatology
University of Washington
Seattle, Washington

Carsten Flohr, MRCPCH
Center of Evidence-Based Dermatology
Nottingham University Hospitals NHS Trust
Nottingham, United Kingdom

Camille Frances, MD
Université Paris VI
Service de Dermatologie-Allergologie
Hôpital Tenon
Paris, France

Jorge Franks, MD
Department of Dermatology
Maastricht University Center for Molecular Dermatology (MUCMD)
Maastricht, The Netherlands

Ilona J. Frieden, MD
Professor, Department of Dermatology
University of California, San Francisco
San Francisco, California

Sheila Fallon Friedlander, MD
Clinical Professor of Pediatrics and Medicine
University of California San Diego School of Medicine
Children's Hospital, San Diego
San Diego, California

Richard Gallo, MD, PhD
Chief, Adult Dermatology
Associate Clinical Professor, Pediatrics and Medicine
Department of Medicine
University of California, San Diego
La Jolla, California

Annabelle L. Garcia, BS
University of Texas Health Science Center
Houston, Texas

Amit Garg, MD
Assistant Professor of Medicine
Division of Dermatology
University of Massachusetts Medical School
University of Massachusetts Memorial Health Care
Worcester, Massachusetts

Andrea L. Garrett, MD
Department of Dermatology
University of Wisconsin
Madison, Wisconsin

Christopher C. Gasbarre, DO
Senior Resident in Dermatology
The Cleveland Clinic Foundation
Cleveland, Ohio

Anthony A. Gaspari, MD
Department of Dermatology
The Cleveland Clinic Foundation
Cleveland, Ohio

John K. Geisse, MD
Associate Clinical Professor
Departments of Dermatology and Pathology
University of California, San Francisco
San Francisco, California

Joel Gelfand, MD
Assistant Professor, Department of Dermatology
University of Pennsylvania
Philadelphia, Pennsylvania

Carlo Gelmetti, MD
Professor of Dermatology
Institute of Dermatological Sciences
Milan, Italy

Roy G. Geronemus, MD
Clinical Professor, The Ronald O. Perelman Department of Dermatology
New York University Medical Center
Laser and Skin Surgery Center of New York
New York, New York

Samer H. Ghosn, MD
Assistant Professor, Department of Dermatology
American University of Beirut Medical Center
Beirut, Lebanon

Lawrence E. Gibson, MD
Professor of Dermatology
Mayo Clinic College of Medicine
Consultant in Dermatology
Mayo Clinic
Rochester, Minnesota

Barbara A. Gilchrest, MD
Professor and Chair of Dermatology
Department of Dermatology
Boston University School of Medicine
Boston, Massachusetts

Richard G. Glogau, MD
Clinical Professor of Dermatology
University of California, San Francisco
San Francisco, California

Raphaela Goldbach-Mansky, MD
National Institute of Arthritis and Musculoskeletal and Skin Disease
National Institutes of Health
Bethesda, Maryland

Leonard H. Goldberg, MD
DermSurgery Associates, P.A.
Houston, Texas

Jonathan N. Goldfarb, MD
Division of Dermatology
Department of Internal Medicine
Southern Illinois University School of Medicine
Springfield, Illinois

Lowell A. Goldsmith, MD
Professor of Dermatology
University of North Carolina School of Medicine
Chapel Hill, North Carolina
Dean Emeritus
University of Rochester School of Medicine and Dentistry
Rochester, New York

Carmen E. Gota, MD
Staff, Department of Rheumatology
Center for Vasculitis Care and Research
The Cleveland Clinic Foundation
Cleveland, Ohio

Emmy M. Graber, MD
Chief Resident, Department of Dermatology
The Pennsylvania State University College of Medicine
Hershey, Pennsylvania

Robin A. C. Graham-Brown, MD
Consultant Dermatologist
Honorary Senior Lecturer, Department of Dermatology
Leicester Royal Infirmary
Leicester, England

Jane Margaret Grant-Kels, MD
Professor and Chair
Department of Dermatology
University of Connecticut Health Center
Farmington, Connecticut

Malcolm W. Greaves, MD, PhD, FRCP
Emeritus Professor of Dermatology
National Skin Centre
Singapore

Justin J. Green, MD
Department of Dermatology
University of Medicine and Dentistry of New Jersey–Robert Wood Johnson Medical School at Camden
Camden, New Jersey

Roy C. Grekin, MD
Clinical Professor of Dermatology
Dermatologic Surgery Unit
University of California, San Francisco
San Francisco, California

James M. Grichnik, MD, PhD
Associate Professor, Department of Dermatology
Duke University Medical Center
Durham, North Carolina

Douglas Grossman, MD, PhD
Associate Professor
Departments of Dermatology and Oncological Sciences
Huntsman Cancer Institute
University of Utah
Salt Lake City, Utah

Johann E. Gudjonsson, MD, PhD
Fellow, Department of Dermatology
University of Michigan
Ann Arbor, Michigan

Bridget C. Hackett, MRCPI
Regional Centre of Dermatology
Mater Misericordiae Hospital
Dublin, Ireland

Rebat M. Halder, MD
Professor and Chair, Department of Dermatology
Howard University Hospital
Washington, D.C.

Russell P. Hall III, MD
J. Lamar Callaway Professor of Dermatology
Chief, Division of Dermatology
Duke University Medical Center
Durham, North Carolina

Allan C. Halpern, MD
Dermatology Academic Offices
Memorial Sloan-Kettering Cancer Center
New York, New York

Analisa V. Halpern, MD
Department of Dermatology
University of Medicine and Dentistry of New Jersey–Robert Wood Johnson Medical School
Cooper University Hospital
Camden, New Jersey

C. William Hanke, MD, MPH, FACP
Laser and Skin Surgery Center of Indiana
Carmel, Indiana

Jon M. Hanifin, MD
Professor, Department of Dermatology
Oregon Health and Sciences University
Portland, Oregon

Mandy Harting, MD
Resident, Department of Dermatology
Baylor College of Medicine
Houston, Texas

Christina L. Haverstock, MD, MS
Resident, Department of Dermatology
Wake Forest University Medical Center
Winston-Salem, North Carolina

John L. M. Hawk, MD
Chair, Photobiology Unit
St. John's Institute of Dermatology
St. Thomas' Hospital
King's College London
London, England

Philip N. Hawkins, MD
National Amyloidosis Centre,
Department of Medicine
Royal Free Hospital
London, England

Christine M. Hay, MD
Infectious Diseases Division
University of Rochester Medical Center
Rochester, New York

Roderick J. Hay, MD
Faculty of Medicine and Health
Queen's University Belfast
Belfast, Northern Ireland

Michael P. Heffernan, MD
Associate Professor and Chief, Division of Dermatology
Wright State University
Boonshoft School of Medicine
Dayton, Ohio

Timothy Heffernan, PhD
Department of Medical Oncology
Dana Farber Cancer Institute
Harvard Medical School
Boston, Massachusetts

Stephen E. Helms, MD
Associate Professor of Internal Medicine, Dermatology Section
Northeastern Ohio University College of Medicine
Case Western Reserve College of Medicine
Warren, Ohio

Ulrich R. Hengge, MD
Professor, Department of Dermatology
Heinrich-Heine University
University Hospital of Duesseldorf
Duesseldorf, Germany

Frédérique Henry, MD
Dermatopathology Service
University Hospital of Liège
Liège, Belgium

Warren R. Heymann, MD
Department of Dermatology
University of Medicine and Dentistry of New Jersey–Robert Wood Johnson Medical School at Camden
Camden, New Jersey

M. John Hicks, MD, DDS, PhD
Professor, Department of Pathology
Director of Anatomic Pathology
Texas Children's Hospital
Baylor College of Medicine
Houston, Texas

Whitney A. High, MD
Assistant Professor, Dermatology & Dermatopathology
University of Colorado Health Sciences Center
Denver, Colorado

Steven M. Holland, MD
Chief, Laboratory of Clinical Infectious Diseases
National Institutes of Health
Bethesda, Maryland

Herbert Hönigsmann, MD
Professor and Chair, Department of Dermatology
Medical University of Vienna
Vienna, Austria

Thomas D. Horn, MD
Professor and Chair, Department of Dermatology
University of Arkansas for Medical Sciences
Little Rock, Arkansas

***Thomas J. Hornyak, MD, PhD**
Investigator, Dermatology Branch
Center for Cancer Research
National Cancer Institute
National Institutes of Health
Bethesda, Maryland

Elizabeth Bahar Houshmand, MD
Associate Professor and Chief, Division of Dermatology
Wright State University
Boonshoft School of Medicine
Dayton, Ohio

Alain Hovnanian, MD, PhD
Professor, Department of Medical Genetics
University Paul Sabatier
Purpan Hospital
Toulouse, France

Chung-Hong Hu, MD
Department of Dermatology
University of Wisconsin
Madison, Wisconsin

Linden Hu, MD
Division of Geographic Medicine and Infectious Disease
Tufts New England Medical Center
Boston, Massachusetts

***Sam T. Hwang, MD, PhD**
Senior Investigator
Dermatology Branch
Center for Cancer Research, National Cancer Institute
National Institutes of Health
Bethesda, Maryland

Gabor Illei, MD
Sjögren's Syndrome Clinic
Gene Therapy and Therapeutics Branch
National Institute of Dental and Craniofacial Research
National Institutes of Health
Bethesda, Maryland

Alan D. Irvine, MD, FRCPI, MRCP
Consultant Paediatric Dermatologist
Our Lady's Hospital for Sick Children
Dublin, Ireland

Peter H. Itin, MD
Professor and Head, Department of Dermatology
University Hospital Basel
Basel, Switzerland

Satori Iwamoto, MD, PhD
Department of Dermatology and Biochemistry
Boston University
Boston, Massachusetts

Sharon E. Jacob, MD
Assistant Professor, Department of Dermatology and Cutaneous Surgery
University of Miami Miller Medical School
Miami, Florida

Natalia Jaimes, MD
Resident in Dermatology
Universidad Pontificia Bolivariana
Medellín, Colombia

William D. James, MD, PhD
Department of Dermatology
University of Pennsylvania
Philadelphia, Pennsylvania

Matthew P. Janik, MD
Department of Dermatology
Wright State University and Boonshoft School of Medicine
Dayton, Ohio

Thomas Jansen, MD
Professor, Department of Dermatology, Venereology, and Allergology
University of Essen
Essen, Germany

Melinda Jen, MD
Resident, Department of Pediatrics
Section of Pediatric Dermatology
Children's Hospital of Philadelphia
Philadelphia, Pennsylvania

Jens-Michael Jensen, MD
Professor, Department of Dermatology
University of Kiel
University Hospitals of Kiel
Kiel, Germany

Richard Allen Johnson, MD
Instructor in Dermatology
Harvard Medical School
Clinical Associate in Dermatology
Massachusetts General Hospital
Boston, Massachusetts

Timothy M. Johnson, MD
Department of Dermatology
University of Michigan
Ann Arbor, Michigan

Graham A. Johnston, MB ChB, FRCP
Consultant Dermatologist, Department of Dermatology
Leicester Royal Infirmary
Leicester, England

Joseph L. Jorizzo, MD
Former (Founding) Chair, Department of Dermatology
Wake Forest University Medical Center
Winston-Salem, North Carolina

Marc A. Judson, MD
Professor, Division of Pulmonary and Critical Care Medicine
Medical University of South Carolina
Charleston, South Carolina

Steven Kaddu, MD
Department of Dermatology
Medical University of Graz
Graz, Austria

Andrea A. Kalus, MD
Acting Assistant Professor, Division of Dermatology
University of Washington
Seattle, Washington

Insoo Kang, MD
Associate Professor, Section of Rheumatology
Department of Medicine
Yale University School of Medicine
New Haven, Connecticut

Sewon Kang, MD
Professor, Department of Dermatology
University of Michigan
Ann Arbor, Michigan

Allen P. Kaplan, MD
National Allergy Asthma and Urticaria Centers of Charleston
Charleston, South Carolina

Julie K. Karen, MD
Resident, The Ronald O. Perelman Department of Dermatology
New York University School of Medicine
New York, New York

Daniel L. Kastner, MD
Chief, Genetics and Genomics Branch
National Institute of Arthritis and Musculoskeletal and Skin Disease
National Institutes of Health
Bethesda, Maryland

Kenneth A. Katz, MD
Department of Dermatology
University of Pennsylvania
Philadelphia, Pennsylvania

***Stephen I. Katz, MD, PhD**
Director, National Institute of Arthritis and Musculoskeletal and Skin Diseases
National Institutes of Health
Bethesda, Maryland

Lynda Kauls, MD
Assistant Professor, Department of Dermatology
Oregon Health and Science University
Portland, Oregon

Andrew Keat, MD
Consultant Physician
Northwick Park Hospital
Harrow, Middlesex, England

Dean L. Kellogg, Jr., MD, PhD
Associate Professor, Division of Geriatrics and Gerontology
Department of Medicine
University of Texas Health Science Center at San Antonio, Texas
San Antonio, Texas

David P. Kelsell, MD
The Royal London Hospital
London, England

Francisco A. Kerdel, MD
Voluntary Faculty
Department of Dermatology and Cutaneous Surgery
University of Miami Miller School of Medicine
Miami, Florida

Helmut Kerl, MD
Professor and Chairman, Department of Dermatology
Medical University of Graz
Graz, Austria

Abdul-Ghani Kibbi, MD, FACP
Professor and Chair, Department of Dermatology
American University of Beirut Medical Center
Beirut, Lebanon

Christina E. Killoran, MD
Department of Dermatology and Skin Surgery
Roger Williams Medical Center
Providence, Rhode Island

Jenny Kim, MD, PhD
Assistant Clinical Professor, Division of Dermatology
David Geffen School of Medicine
University of California at Los Angeles
Los Angeles, California

Alexa B. Kimball, MD, MPH
Department of Dermatology
Harvard Medical School
Boston, Massachusetts

John H. Klippel, MD
Arthritis Foundation
Atlanta, Georgia

Robert Knobler, MD
Associate Professor of Dermatology
Department of Dermatology
Division of Special & Environmental Dermatology
Medical University of Vienna
Vienna, Austria

Sandra R. Knowles, BScPhm
Division of Dermatology
Sunnybrook Health Sciences Center
University of Toronto
Toronto, Ontario, Canada

Irene E. Kochevar, PhD
Professor, Department of Dermatology
Harvard University School of Medicine
Wellman Center for Photomedicine
Massachusetts General Hospital
Boston, Massachusetts

Thomas Koenig, MD
Associate Dean for Student Affairs
Assistant Professor of Psychiatry and Behavioral Sciences
The Johns Hopkins University School of Medicine
Baltimore, Maryland

Nellie Konnikov, MD
Department of Dermatology
Boston Veterans Affairs Medical Center
Boston, Massachusetts

Kenneth H. Kraemer, MD
Researcher
National Institutes of Health
Center for Cancer Research
Bethesda, Maryland

Jean Krutmann, MD
Professor of Dermatology and Environmental Medicine
Director, Institut für Umweltmedizinische Forschung (IUF) at the Heinrich-Heine-University
Düsseldorf, Germany

Stéphane Kuenzli, MD
Uppsala, Sweden

Roopal V. Kundu, MD
Assistant Professor of Dermatology
Northwestern University
Director, Northwestern Center for Ethnic Skin
Feinberg School of Medicine
Northwestern University
Chicago, Illinois

Thomas S. Kupper, MD
Director, Harvard Skin Disease Research Center
Harvard Institute of Medicine
Brigham and Women's Hospital
Boston, Massachusetts

Amal K. Kurban, MD
Department of Dermatology
Boston University School of Medicine
Boston, Massachusetts

Razelle Kurzrock, MD, FACP
Director, Phase One Program
Division of Cancer Medicine
University of Texas
M.D. Anderson Cancer Center
Houston, Texas

Daniel Kusnir, MD
Director of the Multicultural Psychotherapy Training and Research Institute
Program Director
La Familia Children's Day Treatment
Hayward, California

Heinz Kutzner, MD
Dermatopathologische Gemeinschaftspraxis
Friedrichshafen, Germany

Helen J. Lachmann, MD
National Amyloidosis Centre
Department of Medicine
Royal Free and University College Medical School
London, England

Mario E. Lacouture, MD
Assistant Professor, Department of Dermatology
Feinberg School of Medicine
Northwestern University
Chicago, Illinois

Jürgen Lademann, MD
Dermatology Department
Charite Hospital/Humboldt University Berlin
Berlin, Germany

Jeffrey R. LaDuca, MD, PhD
Finger Lakes Dermatology
Auburn, New York

Jo Lambert, MD, PhD
Professor, Department of Dermatology
University Hospital Ghent
Ghent, Belgium

Sinéad Langan, MRCP
Center of Evidence-Based Dermatology
Nottingham University Hospitals NHS Trust
Nottingham, United Kingdom

Hilde Lapeere, MD
Department of Dermatology
University Hospital Ghent
Ghent, Belgium

Margarita M. Larralde, MD
Pediatric Dermatology Department
Hospital Ramos Mejía
Chief of Dermatology Department
Hospital Alemán
Buenos Aires, Argentina

Anne Laumann, MB ChB, MRCP
Associate Professor, Department of Dermatology
Feinberg School of Medicine
Northwestern University
Chicago, Illinois

Stephan Lautenschlager, MD
Head, Outpatient Clinic of Dermatology and Venereology
Triemli Hospital and University of Zurich
Zurich, Switzerland

Leslie P. Lawley, MD
Pediatric Dermatology Fellow
Division of Dermatology
Children's Memorial Hospital
Northwestern University
Chicago, Illinois

Thomas J. Lawley, MD
Department of Dermatology
Emory University School of Medicine
Atlanta, Georgia

Celeste Lebbé, MD
Service de Dermatologie
Hôpital Saint-Louis
Paris, France

Mark Lebwohl, MD
Professor and Chairman, Department of Dermatology
Mount Sinai School of Medicine
New York, New York

Jin Lee, MD, MBA
Resident, Department of Dermatology
Boston University
Boston, Massachusetts

Ken K. Lee, MD
Associate Professor, Department of Dermatology
Director of Dermatologic Surgery
Oregon Health and Science University
Portland, Oregon

Lela A. Lee, MD
Professor of Dermatology and Medicine
University of Colorado School of Medicine
Chief of Dermatology
Denver Health Medical Center
Denver, Colorado

Peter K. Lee, MD, PhD
Assistant Professor, Department of Dermatology
University of Minnesota
Minneapolis, Minnesota

Margaret S. Lee-Bellantoni, MD, PhD
Department of Dermatology
Boston University and Tufts–New England Medical Center
Boston, Massachusetts

David J. Leffell, MD
Professor of Dermatology and Surgery
Chief, Section of Dermatologic Surgery and Cutaneous Oncology
Department of Dermatology
Yale University School of Medicine
New Haven, Connecticut

Kristin M. Leiferman, MD
Professor, Department of Dermatology
University of Utah Health Sciences Center
Salt Lake City, Utah

Irene M. Leigh, MD
Centre for Cutaneous Research
St. Bartholomew's & the Royal London School of Medicine
Queen Mary & Westfield College
London, England

Aimee L. Leonard, MD
New England Dermatology and Laser Center
Springfield, Massachusetts

Donald Y. M. Leung, MD, PhD
Head, Division of Pediatric Allergy and Immunology
National Jewish Medical and Research Center
University of Colorado Medical School
Denver, Colorado

Nikki A. Levin, MD, PhD
Assistant Professor of Medicine
Division of Dermatology
University of Massachusetts Medical School
University of Massachusetts Memorial Health Care
Worcester, Massachusetts

Moise L. Levy, MD
Professor, Departments of Pediatrics and Dermatology
Baylor College of Medicine
Chief, Dermatology Service
Texas Children's Hospital
Houston, Texas

Ross M. Levy, MD
Chief Resident, Department of Dermatology
Feinberg School of Medicine
Northwestern University
Chicago, Illinois

Henry W. Lim, MD
Chairman, Department of Dermatology
Henry Ford Hospital
Detroit, Michigan

Susan L. Limb, MD
Johns Hopkins University School of Medicine
Baltimore, Maryland

Dan Lipsker, MD, PhD
Clinique Dermatologique
Hôpitaux Universitaires
Strasbourg Cedex, France

Robert Listernick, MD
Professor, Department of Pediatrics
Feinberg School of Medicine
Northwestern University
Divisions of General Academic Pediatrics
The Children's Memorial Hospital
Chicago, Illinois

Mayra E. Lorenzo, MD
Resident, Department of Dermatology
University of Massachusetts Medical School
Worcester, Massachusetts

James Loveless, MD
Dermatology Resident
Department of Dermatology
Johns Hopkins Medical Institutions
Baltimore, Maryland

Douglas R. Lowy, MD
Head, Signaling and Oncogenesis Section
Laboratory Chief, Laboratory of Cellular Oncology
National Cancer Institute
National Institutes of Health
Bethesda, Maryland

Anne W. Lucky, MD
Dermatology Research Associates, Inc.
Cincinnati, Ohio

Thomas A. Luger, MD
Professor and Chairman, Department of Dermatology
University of Münster
Münster, Germany

Paula C. Luna, MD
Dermatology Department
Churruca-Visca Hospital
Buenos Aires, Argentina

Calum C. Lyon, FRCP, MB BChir
Consultant Dermatologist and Honorary Clinical Tutor
Hull and York Medical School
York Hospital
York, United Kingdom

Catherine Maari, MD
Department of Dermatology
University of Montreal
Montreal, Quebec, Canada

Vandana K. Madkan, MD
Clinical Research Fellow
Center for Clinical Studies
University of Texas Health Science Center
Houston, Texas

Meera Mahalingam, MD, PhD, FRCPath
Associate Professor and Director, Dermatopathology
Division of Dermatology
University of Massachusetts Medical School
University of Massachusetts Memorial Health Care
Worcester, Massachusetts

Frederick D. Malkinson, MD
Department of Dermatology
University Hospital
Centre Hospitalier Universitaire Vaudois
Lausanne, Switzerland

Brian F. Mandell, MD, PhD, FACR
Vice Chairman, Division of Medicine
Staff, Department of Rheumatology
Center for Vasculitis Care and Research
The Cleveland Clinic Foundation
Cleveland, Ohio

Richard M. Marchell, MD
Assistant Professor, Department of Dermatology
Medical University of South Carolina
Charleston, South Carolina

M. Peter Marinkovich, MD
Associate Professor, Department of Dermatology
Program in Epithelial Biology
Stanford University School of Medicine
Stanford, California

Adriana R. Marques, MD
Laboratory of Clinical Infectious Diseases
National Institute of Allergy and Infectious Diseases
National Institutes of Health
Bethesda, Maryland

Dieter Maurer, MD
Professor
Department of Dermatology
Medical University of Vienna
Vienna, Austria

Theodora M. Mauro, MD
Associate Professor, Department of Dermatology
University of California, San Francisco
San Francisco Veterans Hospital
San Francisco, California

John A. McGrath, MD
Professor, Division of Skin Sciences
Kings College London
St. John's Institute of Dermatology
St. Thomas' Hospital
London, England

W. H. Irwin McLean, MD
Wellcome Trust Senior Research Fellow
Professor and Head, Human Genetics Research
Director, Epithelial Genetics Group
Human Genetics Unit
Division of Pathology and Neuroscience
Ninewells Hospital, University of Dundee
Dundee, Scotland

Darius R. Mehregan, MD
Assistant Professor of Dermatology
Wayne State University
Detroit, Michigan
Director of Dermatopathology
Pinkus Dermatopathology Laboratory, P.C.
Monroe, Michigan

David A. Mehregan, MD
Assistant Professor of Dermatology
Wayne State University
Detroit, Michigan
Director of Dermatopathology
Pinkus Dermatopathology Laboratory, P.C.
Monroe, Michigan

H. Cody Meissner, MD
Professor, Department of Pediatrics
Tufts New England Medical Center
Boston, Massachusetts

Natalie Mendoza, MD
Center for Clinical Studies
Houston, Texas

Andrew G. Messenger, MD
Honorary Senior Clinical Lecturer
University of Sheffield
Sheffield, England, U.K.

Dean D. Metcalfe, MD
Chief, Laboratory of Allergic Diseases
National Institute of Allergy and Infectious Diseases
National Institutes of Health
Bethesda, Maryland

Martin C. Mihm, Jr., MD
Clinical Professor of Pathology
Senior Dermatopathologist
Harvard Medical School
Massachusetts General Hospital
Boston, Massachusetts

Stanley J. Miller, MD
Associate Professor, Dermatology and Otolaryngology–Head and Neck Surgery
Johns Hopkins Hospital
Baltimore, Maryland

Tara Miller, MD
Dermatology Resident
University of California, San Francisco
San Francisco, California

Ginat Wintermeyer Mirowski, DMD, MD
Associate Professor, Department of Dermatology
Feinberg School of Medicine
Northwestern University
Chicago, Illinois
Adjunct Associate Professor
Department of Oral Pathology, Medicine, Radiology
Indiana University School of Dentistry
Indianapolis, Indiana

Robert L. Modlin, MD
Klein Professor and Chief, Department of Dermatology
Professor of Microbiology, Immunology, and Molecular Genetics
David Geffen School of Medicine
University of California, Los Angeles
Los Angeles, California

Megan M. Moore, MD
The Ronald O. Perelman Department of Dermatology
New York University School of Medicine
New York, New York

Akimichi Morita, MD, PhD
Professor and Chairman, Department of Geriatric and Environmental Dermatology
Nagoya City University Graduate School of Medical Sciences
Nagoya, Japan

Nico Mousdicas, MD
Departments of Dermatology, Pediatrics, Pharmacology and Toxicology
Indiana University School of Medicine
Indianapolis, Indiana

Ulrich Mrowietz, MD
Professor
Department of Dermatology
University of Kiel
Kiel, Germany

Sarah A. Myers, MD
Division of Dermatology
Duke University Medical Center
Durham, North Carolina

Jean-Marie Naeyaert, MD, PhD
Professor, Department of Dermatology
University Hospital Ghent
Ghent, Belgium

Amanda M. Nelson, PhD
Postdoctoral Scholar, Department of Dermatology
The Jake Gittlen Cancer Research Foundation
The Pennsylvania State University College of Medicine
Hershey, Pennsylvania

Isaac M. Neuhaus, MD
Assistant Professor of Clinical Dermatology
Department of Dermatology
University of California, San Francisco
San Francisco, California

Paul Nghiem, MD, PhD
Assistant Professor, Division of Dermatology
Affiliate Investigator, Fred Hutchinson Cancer Research Center
Seattle, Washington

Gerhard J. Nohynek, MD
Department of Dermatology
Charite Hospital/Humboldt University Berlin
Berlin, Germany

Scott A. Norton, MD, MPH
Professor, Department of Dermatology
Uniformed Services University of the Health Sciences
Bethesda, Maryland

Carlos H. Nousari, MD
Dermpath Diagnostics South Florida
Pompano Beach, Florida

Lilian M. Odo, MD
Department of Dermatology of Santo Amaro University
Odo Clinics of Dermatology
São Paulo, Brazil

John E. Olerud, MD
George F. Odland Professor
Department of Medicine
Head, Division of Dermatology
University of Washington
Seattle, Washington

Elise A. Olsen, MD
Professor of Medicine
Divisions of Dermatology and Oncology
Duke University Medical Center
Durham, North Carolina

Katia Ongenae, MD, PhD
Professor, Department of Dermatology
University Hospital Ghent
Ghent, Belgium

Grainne M. O'Regan, MRCPI
Our Lady's Children's Hospital
Dublin, Ireland

Seth J. Orlow, MD, PhD
Chairman, The Ronald O. Perelman Department of Dermatology
Samuel Weinberg Professor of Dermatology, Pediatrics, and Cell Biology
New York University School of Medicine
New York, New York

Anthony E. Oro, MD, PhD
Associate Professor, Department of Dermatology
Program in Epithelial Biology
Stanford University, School of Medicine
Stanford, California

Michael N. Oxman, MD
Professor of Medicine and Pathology
University of California at San Diego
Staff Physician (Infectious Diseases)
San Diego Veterans Affairs Healthcare System
San Diego, California

Nicole C. Pace, MD
Pediatric Dermatology Fellow
Dartmouth-Hitchcock Medical Center
Lebanon, New Hampshire

Sandra C. Paek, MD
Chief Resident, Department of Dermatology
University of Michigan
Ann Arbor, Michigan

Amy S. Paller, MD
Walter J. Hamlin Professor and Chair of Dermatology
Professor of Pediatrics
Feinberg School of Medicine
Northwestern University
Chicago, Illinois

Renato G. Panizzon, MD
Professor and Chairman, Department of Dermatology
University Hospital
Centre Hospitalier Universitaire Vaudois
University of Lausanne
Lausanne, Switzerland

Hee-Young Park, PhD
Associate Research Professor, Department of Dermatology
Boston University School of Medicine
Boston, Massachusetts

Eva Rawlings Parker, MD
Assistant Professor, Division of Dermatology
Loyola University Medical Center
Maywood, Illinois

Ralf Paus, MD
Professor and Head, Experimental Dermatology
University Hospital Schleswig-Holstein
Campus Luebeck
University of Luebeck
Luebeck, Germany

Michelle T. Pelle, MD
Assistant Clinical Professor, Division of Dermatology
University of California, San Diego
San Diego, California

Lisan S. Peng, MD
Interdepartmental Program in Vascular Biology and Transplantation
Yale University School of Medicine
New Haven, Connecticut

Brent Pennington, MD
Department of Dermatology
Yale University School of Medicine
New Haven, Connecticut

Jennifer B. Perone, MD
Assistant Professor, Department of Dermatology
University of Texas Southwestern Medical School
Dallas, Texas

Margot S. Peters, MD
Rochester, Minnesota

Peter Petzelbauer, MD
Professor, Department of Dermatology
Medical University of Vienna
Vienna, Austria

Tania J. Phillips, MD
Professor, Department of Dermatology
Boston University School of Medicine
Boston, Massachusetts

Gérald E. Piérard, MD, PhD
Chief, Dermatopathology Service
Department of Dermatology
University Hospital of Liège
Liège, Belgium

Claudine Piérard-Franchimont, MD, PhD
Laboratory Chief, Dermatopathology Service
University Hospital of Liège
Liège, Belgium

Bianca Maria Piraccini, MD
Department of Dermatology
University of Bologna
Bologna, Italy

Mark R. Pittelkow, MD
Consultant, Department of Dermatology
Mayo Clinic
Professor, Departments of Dermatology, Biochemistry, and Molecular Biology
Mayo Clinic College of Medicine
Rochester, Minnesota

Gerd Plewig, MD
Professor, Department of Dermatology
Ludwig-Maximilian-University of Munich
Munich, Germany

Jordan S. Pober, MD
Interdepartmental Program in Vascular Biology and Transplantation
Yale University School of Medicine
New Haven, Connecticut

Miriam Keltz Pomeranz, MD
Assistant Professor, The Ronald O. Perelman Department of Dermatology
New York University School of Medicine
New York, New York

Marinya Pongpudpunth, MD
Department of Dermatology
Boston University School of Medicine
Boston, Massachusetts

Frank C. Powell, MD
University College Dublin
Consultant Dermatologist
Mater Private Hospital
Dublin, Ireland

Julie Powell, MD
Professor, Department of Pediatrics
University of Montreal
Montreal, Quebec, Canada

Julie S. Prendiville, MD, MRCPI, FRCPC
Clinical Professor in Pediatrics
University of British Columbia
Head, Division of Pediatric Dermatology
British Columbia Children's Hospital
Vancouver, British Columbia, Canada

Howard Pride, MD
Department of Dermatology
Geisinger Medical Center
Danville, Pennsylvania

Charlotte Proby, MD
Centre for Cutaneaous Research
Barts and the London Queen Mary's School of Medicine and Dentistry
University of London
London, England

Ehrhardt Proksch, MD, PhD
Professor, Department of Dermatology
University of Kiel
University Hospitals of Kiel
Kiel, Germany

Caroline L. Rao, MD
Duke University Health System
Chapel Hill, North Carolina

Bina A. Rashid, MD
Division of Dermatology
Wright State University
Boonshoft School of Medicine
Dayton, Ohio

Thomas H. Rea, MD
Emeritus Professor of Dermatology
Keck School of Medicine
University of Southern California
Chief, Hansen's Disease Clinic
Los Angeles, California

Kalpana Reddy, BS
Fellow, Department of Dermatology
The Ohio State University College of Medicine
Atlanta, Georgia

Thomas E. Redelmeier, MD
Dermatology Department
Charite Hospital/Humboldt University Berlin
Berlin, Germany

Richard C. Reichman, MD
Infectious Diseases Division
School of Medicine and Dentistry
University of Rochester
Rochester, New York

Luis Requena, MD
Department of Dermatology
Fundación Jiménez Díaz
Universidad Autónoma
Madrid, Spain

Arthur R. Rhodes, MD, MPH
Professor of Dermatology
Rush Medical College
Senior Attending Physician
Rush University Medical Center
Chicago, Illinois

Benjamin E. Rich, PhD
Harvard School of Medicine
Brigham and Women's Hospital
Boston, Massachusetts

Stephen Richardson, MD
Instructor, Department of Dermatology
University of Pennsylvania Health System
Philadelphia, Pennsylvania

June K. Robinson, MD
Professor of Clinical Dermatology
Feinberg School of Medicine
Northwestern University
Chicago, Illinois

Maureen Rogers, MD
Honorary Consultant Dermatologist
The Children's Hospital at Westmead
Sydney, Australia

Marti J. Rothe, MD
Associate Professor, Department of Dermatology
University of Connecticut Health Center
Farmington, Connecticut

Jean-Claude Roujeau, MD
Department of Dermatology
Hôpital Henri Mondor
Université Paris XII Créteil
Paris, France

Thomas M. Rünger, MD
Professor, Department of Dermatology
Boston University School of Medicine
Boston, Massachusetts

Thomas Ruzicka, MD
Professor and Chairman, Department of Dermatology
Heinrich-Heine University
Ludwig-Maximilian-University of Munich
Munich, Germany

John G. Ryan, MB, MRCPI
Genetics and Genomics Branch
National Institute of Arthritis and Musculoskeletal and Skin Diseases
National Institutes of Health
Bethesda, Maryland

Arturo Saavedra, MD, PhD
Instructor in Medicine
Harvard Medical School
Staff in Dermatology, Dermatopathology, and Internal Medicine
Brigham and Women's Hospital
Boston, Massachusetts

Joni G. Sago, MD
Division of Dermatology
Department of Medicine
Duke University Medical Center
Durham, North Carolina

Fernanda H. Sakamoto, MD
Department of Dermatology
Massachusetts General Hospital
Harvard Medical School
Boston, Massachusetts

Miguel R. Sanchez, MD
Associate Professor, Department of Dermatology
New York University Medical Center
New York, New York

Andrea Sandoz, MD
Clinical Senior Instructor in Psychiatry, Child and Adolescent Psychiatry, and Pediatrics
University of Rochester School of Medicine and Dentistry
Rochester, New York

Kenzo Sato, MD, PhD
Professor of Dermatology
Human Gene Therapy Research Institute
Iowa Health System
Des Moines, Iowa

Jean-Hilaire Saurat, MD
Professor and Chairman
Department of Dermatology
Hôpital Cantonal Universitaire
Geneve, Switzerland

Hans Schaefer, MD
Professor of Biochemistry
Department of Dermatology
Charite Hospital/Humboldt University Berlin
Berlin, Germany

Mark Jordan Scharf, MD
Department of Dermatology
University of Massachusetts Medical School
University of Massachusetts Memorial Health Care
Worcester, Massachusetts

Kenneth E. Schmader, MD
Associate Professor of Medicine-Geriatrics
Vice Chief, Division of Geriatrics
Durham Veterans Affairs Medical Center GRECC
Duke University Medical Centers
Durham, North Carolina

Steven K. Schmitt, MD
Staff Physician, Department of Infectious Diseases
The Cleveland Clinic Foundation
Cleveland, Ohio

Theresa Schroeder-Devere, MD
Assistant Professor, Department of Dermatology
Oregon Health and Science University
Portland, Oregon

Robert A. Schwartz, MD, MPH
Department of Dermatology
University of Medicine and Dentistry of New Jersey
Newark, New Jersey

Alon Scope, MD
Dermatology Service
Memorial Sloan-Kettering Cancer Center
New York, New York

Kara N. Shah, MD, PhD, FAAP
Fellow, Department of Pediatrics and Dermatology
Children's Hospital of Philadelphia
The University of Pennsylvania School of Medicine
Philadelphia, Pennsylvania

Lori Shapiro, MD
Assistant Professor, Division of Dermatology
Sunnybrook Health Sciences Center
University of Toronto
Toronto, Ontario, Canada

Misty T. Sharp, MD
Department of Dermatology
University of Arkansas for Medical Sciences
Little Rock, Arkansas

Neil H. Shear, MD
Professor and Head, Division of Dermatology
Sunnybrook Health Sciences Center
University of Toronto
Toronto, Ontario, Canada

Meredith P. Sheedy, MD
Resident, Division of Dermatology
Duke University Medical Center
Durham, North Carolina

Robert L. Sheridan, MD
Chief, Burn Surgery Service
Shriner's Hospital for Children
Co-Director, Sumner Redstone Adult Burn Center
Massachusetts General Hospital
Boston, Massachusetts

Jeff K. Shornick, MD, MHA
Private Practice
Groton, Connecticut

Robert Sidbury, MD
Assistant Professor
Departments of Pediatrics and Immunology
Children's Hospital Boston
Harvard Medical School
Boston, Massachusetts

Daniel Asz Sigall, MD
Department of Dermatology
Mycology Section
Dr. Manuel Gea Gonzalez General Hospital
Mexico City, Mexico

Arthur J. Sober, MD
Professor of Dermatology
Harvard Medical School
Associate Chief of Dermatology
Massachusetts General Hospital
Boston, Massachusetts

Richard D. Sontheimer, MD
Professor and Vice-Chairman
Department of Dermatology
Richard and Adelaid Fleischaker Chair in Dermatology Research
University of Oklahoma Health Sciences Center
Oklahoma City, Oklahoma

Apra Sood, MD
Resident, Department of Dermatology
The Cleveland Clinic Foundation
Cleveland, Ohio

Nicholas A. Soter, MD
Professor, Department of Dermatology
New York University School of Medicine
New York, New York

John R. Stanley, MD
Milton B. Hartzell Professor and Chair
Department of Dermatology
University of Pennsylvania School of Medicine
Philadelphia, Pennsylvania

Christopher J. Steen, MD
Department of Dermatology
University of Medicine and Dentistry of New Jersey
Newark, New Jersey

Martin Steinhoff, MD, PhD
Professor, Department of Dermatology
Boltzmann Institute for Immunobiology of the Skin
University of Munster
Münster, Germany

Wolfram Sterry, MD
Professor and Chair, Department of Dermatology and Allergy
Charite University of Medicine
Berlin, Germany

Georg Stingl, MD
Professor of Dermatology
Head, Division of Immunology, Allergy, and Infectious Diseases (DIAD)
Medical University of Vienna
Vienna General Hospital
Vienna, Austria

Stephen P. Stone, MD
Professor, Division of Dermatology
Department of Internal Medicine
Southern Illinois University School of Medicine
Springfield, Illinois

Alan Storey, MD
Centre for Cutaneaous Research
Barts and the London Queen Mary's School of Medicine and Dentistry
University of London
London, England

Stephen E. Straus, MD
Chief, Laboratory of Clinical Investigation
National Institute of Allergy and Infectious Diseases
Director, National Center for Complementary and Alternative Medicine
National Institutes of Health
Bethesda, Maryland (d. 2007)

John S. Strauss, MD
Department of Dermatology
The Pennsylvania State University College of Medicine
Hershey, Pennsylvania

Bruce E. Strober, MD
Assistant Professor, The Ronald O. Perelman Department of Dermatology
New York University Medical Center
New York, New York

Tung-Tien Sun, MD
Rudolf L. Baer Professor of Dermatology
Professor, Cell Biology, Pharmacology and Urology
New York University Medical School
New York, New York

Neil A. Swanson, MD
Professor and Chair, Department of Dermatology
Oregon Health and Science University
Portland, Oregon

Morton N. Swartz, MD
Professor of Medicine
Harvard Medical School
Massachusetts General Hospital
Boston, Massachusetts

Susan M. Sweeney, MD
Assistant Professor of Medicine and Pediatrics
Division of Dermatology
University of Massachusetts Medical School
University of Massachusetts Memorial Health Care
Worcester, Massachusetts

Virginia P. Sybert, MD
Clinical Professor, Division of Medical Genetics
Department of Medicine
University of Washington School of Medicine
Staff Physician, Dermatology
Group Health Permanente
Seattle, Washington

Rolf-Markus Szeimies, MD
Associate Professor, Department of Dermatology
University of Regensburg
Regensburg, Germany

Moyses Szklo, MD, MPH, DrPH
Professor, Chronic Disease Immunology
Johns Hopkins University School of Hygiene and Public Health
Baltimore, Maryland

Sumayah J. Taliaferro, MD
Department of Dermatology
Howard University College of Medicine
Washington, D.C.

Elizabeth L. Tanzi, MD
Clinical Instructor, Department of Dermatology
Johns Hopkins Medical Center
Baltimore, Maryland
Washington Institute of Dermatologic Laser Surgery
Washington, D.C.

Gerhard Tappeiner, MD
Associate Professor
Department of Dermatology
Medical University of Vienna
Vienna, Austria

Francisco A. Tausk, MD
Professor, Departments of Dermatology and Psychiatry
University of Rochester School of Medicine
Rochester, New York

Charles R. Taylor, MD
Department of Dermatology
Massachusetts General Hospital
Harvard Medical School
Boston, Massachusetts

James S. Taylor, MD
Head, Section of Industrial Dermatology
Department of Dermatology
The Cleveland Clinic Foundation
Cleveland, Ohio

R. Stan Taylor, MD
Professor, Department of Dermatology
University of Texas Southwestern Medical Center
Dallas, Texas

Diane M. Thiboutot, MD
Vice-Chair, Research Affairs, Department of Dermatology
Jake Gittlen Cancer Research Foundation
The Pennsylvania State University College of Medicine
Hershey, Pennsylvania

Bruce Thiers, MD
Professor and Chair, Department of Dermatology
Medical University of South Carolina
Charleston, South Carolina

Valencia D. Thomas, MD
Assistant Professor, Department of Dermatology
Section of Dermatologic Surgery & Cutaneous Oncology
Yale University School of Medicine
New Haven, Connecticut

Wynnis Tom, MD
Chief Resident, Department of Dermatology
Saint Louis University
St. Louis, Missouri

Kenneth J. Tomecki, MD
Staff Physician, Department of Dermatology
The Cleveland Clinic Foundation
Cleveland, Ohio

Rochelle R. Torgerson, MD, PhD
Assistant Professor, Department of Dermatology
Mayo Clinic College of Medicine
Rochester, Minnesota

Antonella Tosti, MD
Professor, Department of Dermatology
University of Bologna
Bologna, Italy

Franz Trautinger, MD
Professor, Division of Dermatology
State Hospital of St. Pölten
St. Pölten, Austria

Jeffrey B. Travers, MD, PhD
Kampen-Norins Investigator and Chair of Dermatology
Professor, Departments of Dermatology, Pediatrics, Pharmacology and Toxicology
Indiana University School of Medicine
Indianapolis, Indiana

Hensin Tsao, MD, PhD
Associate Professor, Department of Dermatology
Harvard Medical School
Wellman Center for Photomedicine
Massachusetts General Hospital
Boston, Massachusetts

Erwin Tschachler, MD
Professor, Department of Dermatology and Venereology
Medical University of Vienna
Vienna, Austria

Margaret A. Tucker, MD
Director, Human Genetics Program
Division of Cancer Epidemiology and Genetics
National Cancer Institute
National Institutes of Health
Bethesda, Maryland

Stephen K. Tyring, MD, PhD, MBA
Professor of Dermatology, Microbiology/Molecular Genetics, and Internal Medicine
Director, Center for Clinical Studies
University of Texas Health Science Center
Houston, Texas

Jouni Uitto, MD, PhD
Professor and Chair, Department of Dermatology and Cutaneous Biology
Thomas Jefferson University
Philadelphia, Pennsylvania

Mark Unger, MD
Department of Dermatology
Mt. Sinai Medical School
New York, New York

Robin H. Unger, MD
Clinical Instructor, Department of Dermatology
Mt. Sinai Medical School
New York, New York

Walter P. Unger, MD, FRCP(C), FACP
Clinical Professor, Department of Dermatology
Mt. Sinai Medical School
New York, New York
Adjunct Professor, Dermatology
Johns Hopkins School of Medicine
Baltimore, Maryland

Anders Vahlquist, MD, PhD
Department of Medical Sciences
Uppsala University Hospital
Uppsala, Sweden

Isabel C. Valencia, MD
Assistant Professor
Department of Dermatology and Cutaneous Surgery
University of Miami Miller School of Medicine
Miami, Florida

L. Valeyrie-Allanore, MD
Department of Dermatology
Henri Mondor Hospital
Université Paris
Paris, France

Nanja Van Geel, MD, PhD
Professor, Department of Dermatology
University Hospital Ghent
Ghent, Belgium

Evelien Verhaeghe, MD
Department of Dermatology
University Hospital Ghent
Ghent, Belgium

Shannon Verma, MD
Resident, Department of Dermatology
Wright State University
Dayton, Ohio

Miikka Vikkula, MD, PhD
Maitre de Recherches du F.N.R.S., Human Molecular Genetics
Christian de Duve Institute & University of Louvain Medical School
Brussels, Belgium

John J. Voorhees, MD
Duncan & Ella Poth Distinguished Professor
Chair, Department of Dermatology
University of Michigan
Ann Arbor, Michigan

Justin J. Vujevich, MD
DermSurgery Associates, P.A.
Houston, Texas

Susan L. Walker, PhD
St. John's Institute of Dermatology
Division of Genetics and Molecular Medicine
King's College London School of Medicine
Guy's, King's College and St. Thomas' Hospitals
University of London
London, England

Tomi Wall, MD
Department of Dermatology
Massachusetts General Hospital
Harvard Medical School
Boston, Massachusetts

John S. Walsh, MD
Assistant Professor, Department of Dermatology
Mayo Medical School
Consultant in Dermatology and Dermatopathology
Mayo Clinic
Jacksonville, Florida

Roger H. Weenig, MD, MPH
Assistant Professor, Department of Dermatology
Mayo Clinic School of Medicine
Rochester, Minnesota

Arnold N. Weinberg, MD
Professor of Medicine
Massachusetts General Hospital
Harvard Medical School
Boston, Massachusetts

Martin A. Weinstock, MD, PhD
Director, Division of Dermatoepidemiology
Brown University
Chief of Dermatology
Veterans Affairs Medical Center
Providence, Rhode Island

Margaret A. Weiss, MD
Department of Dermatology
Johns Hopkins University School of Medicine
Baltimore, Maryland

Robert A. Weiss, MD
Department of Dermatology
Johns Hopkins University School of Medicine
Baltimore, Maryland

Victoria P. Werth, MD
Professor, Department of Dermatology
University of Pennsylvania
Philadelphia Veterans Affairs Medical Center
Philadelphia, Pennsylvania

Lucile E. White, MD
Assistant Professor, Department of Dermatology
Feinberg School of Medicine
Northwestern University
Chicago, Illinois

Hywel C. Williams, MSc, PhD, FRCP
Professor of Dermatoepidemiology
Center of Evidence-Based Dermatology
Nottingham University Hospitals NHS Trust
Nottingham, United Kingdom

Ifor R. Williams, MD, PhD
Department of Pathology
Emory University
Atlanta, Georgia

Mary Elizabeth Wilson, MD
Associate Clinical Professor of Medicine
Harvard Medical School
Associate Professor of Population and International Health
Harvard School of Public Health
Boston, Massachusetts

Robert Winchester, MD
Professor, Department of Pediatrics
Columbia Presbyterian Medical Center
Columbia University College of Physicians and Surgeons
New York, New York

Marni C. Wiseman, MD, FRCPC
University of Manitoba
Cancer Care Manitoba
Winnepeg, Canada

Karen M. Wiss, MD
Professor of Medicine and Pediatrics
Division of Dermatology
University of Massachusetts Medical School
University of Massachusetts Memorial Health Care
Worcester, Massachusetts

Klaus Wolff, MD, FRCP
Professor of Dermatology
Chairman Emeritus
Department of Dermatology
Medical University of Vienna
Vienna, Austria

Stephen E. Wolverton, MD
Professor of Clinical Dermatology
Vice Chair of Clinical Affairs
Indiana University
Indianapolis, Indiana

Gary S. Wood, MD
Professor and Chair, Department of Dermatology
University of Wisconsin
Madison, Wisconsin

Robert A. Wood, MD
Professor, Pediatric Allergy and Immunology
Division of Immunology & Allergy
Johns Hopkins University School of Medicine
Baltimore, Maryland

David T. Woodley, MD
Professor and Chair, Department of Dermatology
Keck School of Medicine
University of Southern California
Los Angeles, California

Mina Yaar, MD
Professor, Department of Dermatology
Boston University School of Medicine
Boston, Massachusetts

Albert C. Yan, MD
Assistant Professor
Director, Pediatric Dermatology
Children's Hospital of Philadelphia
The University of Pennsylvania
Philadelphia, Pennsylvania

Kim B. Yancey, MD
Professor and Chairman, Department of Dermatology
University of Texas Southwestern Medical Center at Dallas
Dallas, Texas

Gil Yosipovitch, MD
Professor, Department of Dermatology, and Neurobiology & Anatomy
Wake Forest Medical Center
Winston-Salem, North Carolina

Antony R. Young, PhD
Deputy Head, St. John's Institute of Dermatology
Division of Genetics and Molecular Medicine
King's College London School of Medicine
Guy's, King's College, and St. Thomas' Hospitals
University of London
London, England

Evaristo Sánchez Yus, MD
Department of Dermatology
Hospital Clínico San Carlos
Ciudad Universitaria
Madrid, Spain

Stuart H. Yuspa, MD
Chief, Laboratory of Cancer Biology and Genetics
Center for Cancer Research
National Cancer Institute
National Institutes of Health
Bethesda, Maryland

Andrea L. Zaenglein, MD
Department of Dermatology
The Pennsylvania State University College of Medicine
Hershey, Pennsylvania

Matthew T. Zipoli, MD
Dermatology Associates of Concord
Concord, Massachusetts

Christos C. Zouboulis, MD, PhD
Professor and Director
Departments of Dermatology and Immunology
Dessau Medical Center
Dessau, Germany

PREFACE

We are proud to present this Seventh Edition of *Fitzpatrick's Dermatology in General Medicine* (DIGM), which has been reorganized and substantially rewritten to reflect the current state of the science, practice, and art of dermatology. More than 50 percent of the text and figures of our 257 chapters are new to this edition, as are 50 percent of the authors. Integration of the basic and clinical science remains the DIGM signature, and the organization of the book is intended to promote understanding of the skin as an adaptive organ that changes throughout the life span. Clinical disease chapters are now grouped within sections by pathogenic and causative mechanism, and each section is introduced by the relevant basic science chapters.

To achieve the goal of making the text truly encyclopedic and readily accessible to readers at all levels of expertise, there are now two versions of the book, a concise printed version and an on-line version. Throughout the text, when additional on-line content is available, the following icon is present in the text to alert the reader:  To save space in print, the majority of references are available on-line only. The on-line edition and the on-line references can be found at www.digm7.com. Without sacrificing its focus on the skin as integral to and reflective of overall health, the new edition provides increased emphasis on therapy, dermatologic surgery, and cosmetic dermatology. The on-line edition provides additional detailed text for full and exhaustive coverage of each subject, many additional images, charts, and algorithms, and comprehensive up-to-date literature references.

The layout of DIGM has also changed. Readers will now find an "At a Glance" overview at the beginning of each chapter; algorithms for diagnosis and therapy to expedite decision making; boxes on differential diagnosis; and a wealth of diagrams, charts, and additional new images to enhance understanding of the text. Many more additional images can be found in the electronic version.

The new features and improved aspects of DIGM showcase the wealth of the contributing authors' knowledge. We have endeavored to integrate that knowledge into a single comprehensive and consistent reference that will serve the educational and reference needs of the entire dermatology community. We hope that you will find this goal achieved and use DIGM for this purpose for many years to come.

Klaus Wolff
Lowell A. Goldsmith
Stephen I. Katz
Barbara A. Gilchrest
Amy S. Paller
David J. Leffell

Copyright © 2008 by The McGraw-Hill Companies, Inc. Click here for terms of use.

This page intentionally left blank

ACKNOWLEDGMENTS

We are very grateful to the contributing authors who worked closely with us and one another under great time constraints to maintain the excellent standards of DIGM in a radically new format. We are also indebted to our families for their understanding and support, as well as the time with us they gave up during the development of the new edition. Support staff at our institutions who helped us with this edition—Renate Kosma, Jacy Bernal, and Grace Camire—deserve special recognition for their extraordinary level of assistance with manuscripts throughout the process of review and publication. The vibrancy of the new diagrams, algorithms, and charts is the work of Susan Gilbert, CMI, to whom we are grateful for her diligent efforts done within a very difficult schedule. Finally, we wish to acknowledge the excellent guidance and hard work of the McGraw-Hill team, especially Anne M. Sydor, Robert Pancotti, Sherri Souffrance, Charissa Baker, Armen Ovsepyan, Kevin Moran, Helen Parr, and Alexa Blondell.

Klaus Wolff
Lowell A. Goldsmith
Stephen I. Katz
Barbara A. Gilchrest
Amy S. Paller
David J. Leffell

Copyright © 2008 by The McGraw-Hill Companies, Inc. Click here for terms of use.

This page intentionally left blank



Introduction

Copyright © 2008 by The McGraw-Hill Companies, Inc. Click here for terms of use.



SECTION 1

GENERAL CONSIDERATIONS

CHAPTER 1

The Epidemiology and Burden of Skin Disease

Martin A. Weinstock
Mary-Margaret Chren

Scientists in health-related fields focus on phenomena at different levels. For laboratory scientists, the focus is at the molecular, cellular, or organ system level; for clinical scientists, the focus is on the patient; and for public health practitioners, the focus is on the population. Epidemiology is the basic science of public health.

Epidemiology has many subdivisions and offshoots. Often the *epidemiology of a disease* in a clinical review refers primarily to its frequency and distribution in the population and estimates of its morbidity and mortality. These data are derived by descriptive epidemiology. Case-control, cohort, and cross-sectional studies may seek to identify risk factors and causes of disease and form the core of analytical epidemiology. Evaluations of public health interventions (experimental epidemiology) constitute the third major branch of classic epidemiology. The basic principles of epidemiology have found broad application in many areas, including understanding the public health implications of naturally occurring and synthetic compounds (molecular epidemiology), the complex interactions of genetic and environmental factors in disease (genetic epidemiology), the formulation of better diagnostic and treatment strategies for patients based on available evidence (clinical epidemiology), and the structuring of health care delivery for better outcomes and greater efficiency (health services research). The reader is referred to other sources for a more detailed discussion of various topics in dermatoepidemiology.[1–3]

◀ Linear lesion. (Illustration by Glen Hintz, MS. Dermatology Lexicon Project. NIH-NIAMS Contract No. NO1-AR-1-2255.)

TYPES OF EPIDEMIOLOGIC STUDIES

Three of the many types of epidemiologic studies are mentioned here because of their prominence in epidemiologic research. The randomized, controlled trial is a particularly rigorous type of study appropriate to the evaluation of public health interventions. In general, the intervention is performed on a random sample of the study population, and the entire study population is then observed for the occurrence of the outcome in question. The random assignment of intervention allows the more rigorous application of many statistical techniques and reduces the potential for bias. Elimination of biases permits these studies to evaluate the efficacy and impact of an intervention more accurately than trials that do not assign the intervention randomly. Standards for reporting have been published[4] (http://www.consort-statement.org; last accessed June 29, 2006) and adopted by leading dermatology journals to improve assessment of their validity and their use in subsequent systematic reviews[5] (see Chap. 2).

When evaluating risk factors for disease, it is frequently impossible to assign the risk factor randomly. Hence, inference is based on observational studies. In classical cohort studies, a group with exposure to the risk factor and a group without are chosen and observed over time. Occurrences of the study outcome are counted and compared between groups. Although more vulnerable to bias than randomized trials, cohort studies, in which exposure to the risk factor is known well before the study outcome is knowable, avoid potentially serious biases. In a cohort study, the incidence of the study outcome can be measured directly in each group, and the relative risk can be measured directly as the ratio of the incidence between the two groups.

Cohort studies often are quite expensive to conduct because they require following a large population over time and may be impossible if the outcome being studied is uncommon. Hence, observational studies often use the case-control approach, in which cases with the outcome being studied and appropriate controls are investigated to determine their past exposure to the risk factor. Relative risks generally can be estimated by this approach, although incidence of the disorder cannot. Readers are referred to standard texts for more detail regarding epidemiologic study designs.[6] Case-control and cohort study methods in dermatology also have been reviewed.[7–9]

BIAS AND CONFOUNDING

The problem with inference from observational studies is that one may be led to draw erroneous conclusions. In particular, an association that is found between an exposure and a disease may be an artifact due to one or more of the many forms of bias or confounding. Proper inference regarding cause and effect requires understanding these possible artifacts and their potential impacts.[10]

Selection bias occurs when factors that lead to selection of the study population affect the likelihood of the outcomes or exposures evaluated. For example, a case-control study of cutaneous lymphoma may recruit its cases from sources that typically include a high proportion of referred patients. If controls are recruited from a local clinic population, their socio-

Copyright © 2008 by The McGraw-Hill Companies, Inc. Click here for terms of use.

economic status and location of residence may be substantially different from those of the cases simply due to the method of recruitment. Under these circumstances, an association of cutaneous lymphoma with occupation may be noted. It then becomes important to note that the observed association may be due not to a carcinogenic chemical in the workplace but rather to the method by which cases and controls were selected. Similarly, if one were conducting a cohort study of the effect of breast-feeding on the risk of atopic dermatitis, it would be important to select breast-fed and bottle-fed infants from similar environments.

Information bias occurs when the assessment of exposure or outcome may differ between the groups being compared. People who were exposed to a publicized environmental toxin may be more likely to seek care for minor symptoms or signs (and hence be more likely to be diagnosed and treated) than those who were not so exposed, even if the exposure had no biologic effect. Similarly, people who are diagnosed with a disease may be more likely to recall past exposures than healthy controls.

Confounding occurs when an observed association (or lack thereof) between exposure and disease is due to the influence of a third factor on both the exposure and the disease. For example, people who use sunscreens may have more intense sun exposure than those who do not, and intense sun exposure is one cause of melanoma. Hence, observational studies may mistakenly conclude that sunscreen use is a cause of melanoma when the observed association is due to sunscreen use serving as an indicator of a lifestyle involving intense sun exposure.

CAUSAL INFERENCE

Key issues in the public health arena often must rely on observational data for inferring cause and effect; in these situations, the validity and generalizability of the individual studies and of the totality of the evidence must be carefully examined. The following criteria generally are applied for causal inference when an association is found. Although they are described for inferring causality between an exposure and a disease, they are more generally applicable to epidemiologic causal inference.

Time Sequence

The exposure must precede the disease. This concept is simple and obvious in the abstract but sometimes difficult to establish in practice because the onset of disease may precede the diagnosis of disease by years, and the timing of exposure is often not well defined.

Consistency on Replication

Replication of the observed association is key and provides the strongest evidence if the replications are many and diverse and with consistent results. The diversity of the replications refers to varied contexts as well as to study designs with different potential weaknesses and strengths.

Strength of Association

True causal relationships may be strong (i.e., high relative risk) or weak, but artifactual associations are unlikely to have a high relative risk. If the association between factors x and y is due to the association of both with confounding variable z, the magnitude of the association between x and y always will be less than the magnitude of the association of either with z.

Graded Association

Also described as *biologic gradient*, this criterion refers to an association of the degree of exposure with occurrence of disease, in addition to an overall association of presence of exposure with disease. This dose-response relation may take many forms, as degree of exposure may, for example, refer to intensity, duration, frequency, or latency of exposure.

Coherence

Coherence refers to plausibility based on evidence other than the existence of an association between this exposure and this disease in epidemiologic studies. Coherence with existing epidemiologic knowledge of the disease in question (e.g., other risk factors for the disease and population trends in its occurrence) and other disorders (including but not limited to related disorders) supports inference. Coherence with existing knowledge from other fields, particularly those relevant to pathogenesis, is critically important when those fields are well developed. It may involve direct links, which are preferred, or analogy. Just as observations in the laboratory assume greater significance when their relevance is supported by epidemiologic data, the reverse is equally true.

Experiment

Experimental support is critical when feasible. As noted in Types of Epidemiologic Studies, the strongest inferences derive from results of randomized trials, although other experimental designs and quasi-experimental designs may contribute useful evidence.

More detailed discussions of these issues are available.[11,12]

INVESTIGATION OF DISEASE OUTBREAKS

Although outbreaks of disease vary tremendously, use of a standard framework for investigation is important to address the public health issues efficiently (see Chap. 3). The Centers for Disease Control and Prevention has outlined this framework as a series of 10 steps, which are described in more detail at http://www.cdc.gov.

1. *Preparation*. Before initiating fieldwork, background information on the disease must be gathered, and appropriate interinstitutional and interpersonal contacts should be made.
2. *Confirm the outbreak*. Publicity, population changes, or other circumstances may lead to an inaccurate perception that more cases than expected have occurred. Hence, local or regional data should be sought to confirm the existence of an increased frequency of disease.
3. *Confirm the diagnosis*. Symptoms and signs of persons affected should be determined and laboratory findings confirmed, perhaps with the assistance of reference laboratories.
4. *Establish a case definition, and find cases*. Careful epidemiologic investigation will involve precise and simple case definitions that can be applied in the field. Efforts to find and count additional cases beyond those reported initially is key to defining the scope of the outbreak.
5. *Establish the descriptive epidemiology*. The cases can now be characterized in terms of *time*, including development of an epidemic curve that describes the changes in magnitude of the outbreak; *place*, including mapping the distribution of cases; and *person*, the demographic and potential exposure characteristics of cases.
6. *Develop hypotheses*. On the basis of the data gathered in steps 1 through 5 and the input of other individuals, plausible hypotheses about causality can be developed for further evaluation.

7. *Conduct analytical epidemiologic investigations*. If the data gathered do not yet clearly prove a hypothesis, cohort and case-control investigations can be conducted to verify or disprove the hypotheses.
8. *Revise hypotheses and obtain additional evidence as needed*. Steps 6 and 7 are repeated, each building on prior iterations, to establish the causal chain of events.
9. *Implement control measures*. As soon as the causal chain of events is understood, prevention and control measures are initiated.
10. *Communicate results*. An outbreak investigation is not complete until the results have been appropriately communicated to the relevant communities.

DESCRIPTIONS OF DISEASE IN POPULATIONS: MEASURES OF DISEASE BURDEN

No single number can completely describe the burden of skin disease because that burden has many dimensions and because the term *skin disease* itself is rather ambiguous. Many disorders with substantial morbidity or mortality, such as melanoma or lupus erythematosus, affect multiple organ systems. The degree of skin involvement may vary widely from patient to patient and within the same patient from time to time. Diseases not typically treated by dermatologists, such as thermal burns, often are excluded from estimates of the burden of skin disease even though they primarily involve the skin. In addition, some diseases treated most often by dermatologists may be classified in a different category by funding agencies or others [e.g., melanoma is classified as an oncologic disorder as opposed to a disease of the skin by the National Institutes of Health and by the *International Classification of Diseases,* (http://www.who.int/classifications/apps/icd/icd10online/, accessed June 29, 2006) even though it almost always arises in the skin]. Organ systems are interrelated, and the overlap is sufficiently great that any definition of skin disease is necessarily arbitrary, and any global estimate of the public health burden of these diseases is therefore open to challenge. Typical measures of disease burden are discussed in the following sections.

Mortality

Mortality is a critical measure of disease impact. Death certification is universal in the United States, and the *International Classification of Diseases* code of the underlying cause of each death is recorded. For the year 2002, there were 14,968 deaths reported as due to "skin disease" in the United States, of which most were due to melanoma (Table 1-1). Additional major causes included other skin cancers (primarily keratinocyte carcinomas), infections of the skin, and skin ulcers (primarily decubitus ulcers). Bullous disorders represented about 1 percent of these deaths. The total number of skin disease deaths, of course, depends critically on the definition of skin disease, as noted in Descriptions of Disease in Populations: Measures of Disease Burden.

TABLE 1-1
Skin Disease Deaths, United States, 2002

DISEASE	DEATHS (N)
Cancers	11,031
Melanoma	7514
Genital	1017
Lymphoma	109
Other cancers	2391[a] (primarily basal and squamous cell carcinoma)
Ulcers	1671
Bacterial infections	1283
Bullous disorders	164
Other causes	819
Total	14,968

[a]We estimate that approximately one-half of these are misclassified squamous cell carcinomas arising from mucosal surfaces in the head and neck.[16]
Adapted from http://wonder.cdc.gov/mortICD10J.html (verified June 13, 2006).

In addition to the total number of deaths, mortality typically is expressed as an age-adjusted rate to facilitate comparisons among populations with different age distributions. Statements of age-adjusted rates of mortality (or other results standardized by age) should be accompanied by an indication of the standard used in the adjustment to avoid potentially misleading inferences. For example, when 1998 melanoma mortality rates are estimated using the 2000 U.S. population standard, the result is 50 percent higher than if the 1940 U.S. standard population is used (1.8 vs. 1.2 per 100,000 per year for women and 4.1 vs. 2.7 per 100,000 per year for men). Similarly, when years of potential life lost is reported, the reader must be wary of different definitions that may be applied. In one analysis, a decline in mortality from melanoma was noted by one definition that was not observed with another.[13]

Careful analyses of mortality include assessment of the validity of the data. Melanoma mortality statistics appear to be reasonably accurate.[14,15] However, deaths from keratinocyte carcinomas are overestimated by a factor of 2 (mostly due to the erroneous inclusion of mucosal squamous cell carcinomas of the head and neck region),[16,17] and deaths from cutaneous lymphoma are underestimated by about 40 percent.[15]

Incidence

Incidence refers to the number of new cases of a disorder. Mortality is low for most skin diseases; hence, incidence may be a more useful measure for the assessment of burden of skin disease. However, many features of skin diseases make their incidence difficult to measure. For example, for many skin disorders, there are no diagnostic laboratory tests, and, in fact, some disorders may evade physician diagnosis (e.g., allergic reactions). Incidence for reportable communicable diseases in the United States is published periodically based on reports to health departments, although under-reporting of skin diseases due to failure to present for medical care or to misdiagnosis is a concern (Table 1-2). Incidences of melanoma and cutaneous lymphoma have been published based on data from a system of nationwide cancer registries, yet under-reporting remains a potential concern with these data.[18,19] Special surveys have been conducted to estimate incidence of other disorders, such as keratinocyte carcinomas, although a system of sentinel registries would be required for nationwide assessment.[20] For some diseases unlikely to evade medical detection due to their severity, such as toxic epidermal necrolysis, efforts to estimate incidence have met with considerable success.[21,22] Specific contexts that permit more accurate incidence estimates include the workplace; for example, where occupational skin disease is a prevalent problem.[23]

Cohort Patterns

Cohort patterns of changes in mortality or incidence typically are observed when exposures determined in childhood predict frequency of disease throughout the life span. A classic example is melanoma mortality, for which sun exposure in childhood is an important determinant. A birth cohort is defined as the group of individuals born

TABLE 1-2
New Cases of Selected Reportable Diseases in the United States

	1940	1950	1960	1970	1980	1990	2000	2005
Acquired immunodeficiency syndrome	—	—	—	—	—	41,595	40,758	30,568
Anthrax	76	49	23	2	1	0	1	—
Congenital rubella	—	—	—	77	50	11	9	1
Congenital syphilis	—	—	—	—	—	3865	529	273
Diphtheria	15,536	5796	918	435	3	4	1	—
Gonorrhea	175,841	286,746	258,933	600,072	1,004,029	690,169	358,995	314,370
Hansen disease	—	44	54	129	223	198	91	89
Lyme disease	—	—	—	—	—	—	17,730	21,304
Measles	291,162	319,124	441,703	47,351	13,506	27,786	86	62[a]
Plague	1	3	2	13	18	2	6	7
Rocky Mountain spotted fever	457	464	204	380	1163	651	495	1843
Syphilis (primary and secondary)	—	23,939	16,145	21,982	27,204	50,223	5979	8020
Toxic shock syndrome	—	—	—	—	—	322	135	96
Tuberculosis[b]	102,984[c]	121,742[c]	55,494	37,137	27,749	25,701	16,377	11,547
U.S. population (millions)	132	151	179	203	227	249	281	296

— = data not available.
[a]Fifty-one indigenous cases.
[b]Reporting criteria changed in 1975.
[c]Data include newly reported active and inactive cases.
Adapted with permission from Weinstock MA, Boyle MM: Statistics of interest to the dermatologist, in *The Year Book of Dermatology and Dermatologic Surgery, 2006*, edited by Thiers BH, Lang PG Jr. Philadelphia, Elsevier Mosby, 2006, p 30.

within a defined (e.g., 10-year) period. Melanoma mortality generally increases as a power function of age within a birth cohort. Until recent decades, each successive birth cohort had higher risk than its predecessor; hence, the curves of mortality versus age were shifted upward. Thus the cross-sectional relationship of mortality versus age and the increase in mortality risk during most of the twentieth century followed a cohort pattern. For many countries in the past several decades a decline in melanoma mortality has been observed in younger age groups despite an increase in older age groups, suggesting a lower baseline in these mortality-versus-age curves for recent cohorts and hence a likely future decline in overall melanoma mortality.

Prevalence

Prevalence refers to the proportion of the population affected by a disorder. Because many skin diseases are nonlethal yet chronic, prevalence is a particularly important measure of frequency in dermatology. Population-based data on prevalence of skin disease for the United States were obtained in the first Health and Nutrition Examination Survey, which was conducted in the early 1970s.[24] Despite its limitations, this study was notable because the sample was representative of the general U.S. population, the number surveyed was large (over 20,000), and the entire surveyed population was examined by physicians (primarily dermatology residents), so the resulting estimates were not dependent on patients' ability or inclination to seek medical care. Indeed, one of the findings of the survey was that nearly one-third of those examined had one or more skin conditions judged to be significant enough to merit a visit to a physician. The most common conditions and their age- and gender-specific prevalences are indicated in Table 1-3 and Fig. 1-1. A similar survey in the United Kingdom of over 2000 Londoners in 1975 noted that almost one-quarter of adults had a skin condition serious enough to warrant medical care.[25] Other efforts have focused on obtaining prevalence estimates of specific conditions with special surveys.[26,27]

Lifetime Risk

Lifetime risks for certain disorders are quoted commonly, although their validity can be questioned. Lifetime risk can be measured only in retrospect, and even then it reflects competing causes of mortality in addition to incidence. It is commonly quoted for disorders such as cutaneous malignancies that are changing substantially in incidence, yet those changes are frequently ignored in its calculation, and, in any case, projections of future changes are quite speculative and may be misleading.[28]

Number of Physician Visits

Number of physician visits for a condition is one practical measure of its frequency that may reflect its incidence, prevalence, and severity, as well as access to health care. Table 1-4 lists frequencies of dermatologist and other physician outpatient visits for some of the most common skin conditions. A

TABLE 1-3
Prevalence of Skin Conditions—United States, 1971–1974[a]

	Male	Female	Both Sexes
• Dermatophytosis	131	34	81
• Acne (vulgaris and cystic)	74	66	70
• Seborrheic dermatitis	30	26	28
• Atopic dermatitis/eczema	20	18	19
• Verruca vulgaris	9	6	8
• Malignant tumors	6	5	6
• Psoriasis	6	5	6
• Vitiligo	6	4	5
• Herpes simplex	4	5	4

[a]Cases per 1000 population.
From Skin conditions and related need for medical care among persons 1–74 years, United States, 1971–1974. *Vital Health Stat* [11], no 212, U.S. Department of Health, Education, and Welfare, November 1978.

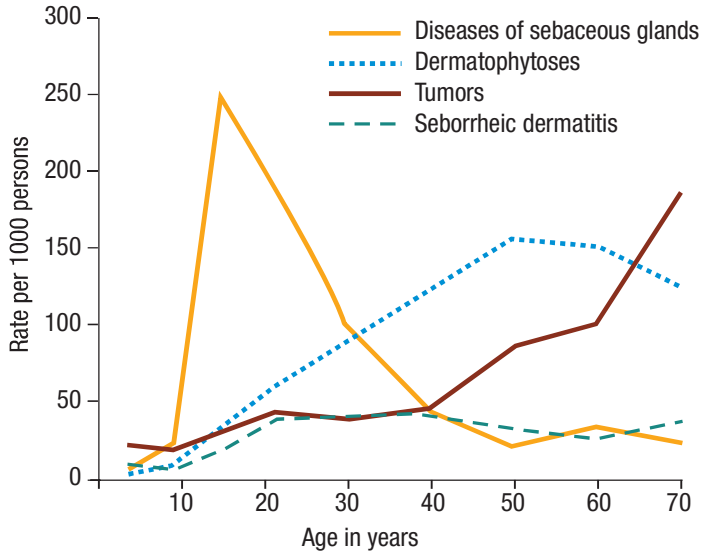

▲ **FIGURE 1-1** Prevalence rates for the four leading types of significant skin pathology among persons 1 to 74 years, by age, in the United States, 1971–1974.

feature of this measure of disease frequency is its direct relation to expenditures for care of the disease.

Other Measures of Morbidity: Conceptual Issues

The consequences of skin disease for a population may be difficult to determine comprehensively because these conditions most often do not affect survival.[29] Furthermore, the most important gauges of skin disease status and progression (i.e., the physical examination and patients' reports) are difficult to measure and compile. For example, a patient with psoriasis may have thickening and scaling of the palms (a bodily impairment), which affects his or her functioning (e.g., use of the hands), activities (role at work), and quality of life. Moreover, the challenges in measuring these complex constructs are further compounded because people understand and value these aspects of health very differently because of age, gender, cultural conceptions, or access to health care. In fact, the measurement of nonfatal consequences of disease is the subject of much international scientific and political attention (http://www3.who.int/icf/icftemplate.cfm, accessed July 3, 2006).

A crucial point for skin diseases is that a patient's experiences of effects of skin disease on his or her activities and well-being are important for determining the overall consequences of that disease. These experiences may not be assessed with global measures that focus on single aspects of health. For example, skin diseases that are visible and affect appearance may result in social stigma and mood changes, which would not be measured with metrics that are based on dysfunction.[30]

TABLE 1-4
Visits to Non-Federal Office-Based Physicians in the United States, 2003[a]

	Type of Physician		
Diagnosis	Dermatologist[b]	Other	All Physicians
Acne Vulgaris	3772 (12.7%)	[c]	4402 (0.5%)
Eczematous dermatitis	2452 (8.2%)	5676 (0.7%)	8128 (0.9%)
Warts	1400 (4.7%)	1567 (0.2%)	2967 (0.3%)
Skin cancer	2103 (7.1%)	1459 (0.2%)	3562 (0.4%)
Psoriasis	1100 (3.7%)	[c]	1268 (0.1%)
Fungal infections	[c]	2104 (0.2%)	2555 (0.3%)
Hair disorders	772 (2.6%)	[c]	1690 (0.2%)
Actinic keratosis	2653 (8.9%)	[c]	3031 (0.3%)
Benign neoplasm of the skin	2791 (9.4%)	[c]	3935 (0.4%)
All disorders	29,801 (100%)	876,222 (100%)	906,023 (100%)

[a]Estimates in thousands.
[b]Percentage of total visits is in parentheses.
[c]Figure does not meet standard of precision.
Adapted with permission from Weinstock MA, Boyle MM: Statistics of interest to the dermatologist, in *The Year Book of Dermatology and Dermatologic Surgery, 2006*, edited by Thiers BH, Lang PG Jr. Philadelphia, Elsevier Mosby, 2006, p 39.

Other Measures of Morbidity: Issues in Quantification

Like all assays, measures of the nonfatal consequences of diseases must have certain characteristics of accuracy.[31] For example, they must be *reliable* in that the variability in results among subjects who truly differ should be greater than the variability when a stable subject is examined repeatedly. The measures must have evidence of *validity*, which refers to the extent to which an instrument measures what it is supposed to measure and does not measure something else. Finally, health outcome measures also must demonstrate *responsiveness*, the ability to detect clinical change. In general, the accuracy of measures of disease status and morbidity in dermatology has not been evaluated adequately.[32] Furthermore, even when a validated instrument exists, the clinical significance of scores or changes in scores often cannot be judged until the tool is used widely and scores are available for many patients with disease of varying severity. Finally, a significant challenge is developing a consensus among dermatologists about the specific clinical features of an individual disease that are important to include in such measures. For example, criteria for clinically important improvement have been developed for some rheumatologic conditions[33] that, like skin diseases, are chronic and are best assessed using clinical rather than laboratory criteria.

Impairment

The extent to which a specific skin disease disrupts the skin itself is related both to the percentage of body surface area involved and to physical signs of the eruption, such as the amount of induration and the degree of scale. Given the pleomorphism of skin eruptions and lesions, most dermatologic severity-of-disease measures are disease-specific. Among the most studied instruments to measure clinical severity of disease are the Psoriasis Area and Severity Index (PASI)[34] and the Severity Scoring of Atopic Dermatitis (SCORAD) index.[35] With the PASI, severity of disease is assessed by judgment of the degree of involvement of four body regions with signs of erythema, induration, and des-

quamation. The SCORAD index combines an assessment of disease area with six clinical signs of disease intensity (scales to measure pruritus and sleep loss also can be included). These instruments share certain problems; for example, estimates of body surface area are often unreliable,[36] and investigators (and patients) may not agree that the selected clinical signs represent the important features of disease severity.[37]

Functioning and Quality of Life

Substantial progress has been made in the development and testing of patients' reports of the effects of their skin diseases on their activities and quality of life. Several generic instruments are available to measure skin-related quality of life associated with dermatologic disease of any sort.[38–41] Data continue to be accumulated about the performance of these instruments (including the use of sophisticated psychometric methods[42] and the interpretation of their scores.[43] An important conclusion from these studies is that correlations between the quality-of-life effects of skin diseases and their clinical severity as assessed by physicians are modest at best and may in fact be quite low. This finding is also typical of many nondermatologic diseases and implies that a comprehensive assessment of patients with skin disease should include measurement of clinical severity as well as its effects on quality of life.[44]

Utilities

A utility is a numeric measure of the value a patient places on a given health state compared with other health states. In the measurement of utilities, a variety of procedures are used (such as visual analog scales and time tradeoff exercises) to assign a numerical value (or utility) to health states. This value reflects patients' preferences for the health states, in which 1.0 represents perfect health and 0.0 represents death. Utilities are advantageous because they permit the incorporation of patient preferences into medical care decisions. Also, because they describe improvements in morbidity with a single weighted metric, utilities are used for the evaluation of complex tradeoffs such as the calculation of cost-effectiveness, in which the costs of treatments are compared with the values of the health states they make possible. Utilities are controversial, however, because they can be difficult to measure and can vary widely among patients in unpredictable ways. An increasing number of studies exist that formally measure utilities of patients with skin diseases.[45]

Costs

Costs of skin disease depend on the perspective from which they are measured, because the costs to insurers and patients may be quite different from the overall cost to society. Also, because most skin diseases are chronic and are cared for in the outpatient setting, estimation of both their monetary and intangible costs is difficult. A recent study estimated the overall direct and indirect cost to payers, patients, and society of 22 skin diseases.[46] In addition, costs for individual skin conditions have been calculated, and therapies have been evaluated in relation to their benefits and effectiveness.[47,48]

QUALITY OF CARE IN DERMATOLOGY

Health services research uses many of the scientific methods from epidemiology, clinical epidemiology, and the quantitative social sciences to study and improve the quality of health care. From the perspective of health services research, the processes involved in the provision of health care, as well as the particular therapeutic interventions and patient and provider characteristics, are all potentially important determinants of the quality of care. Dermatologic health services research is still new, and much attention has focused on studies of the effectiveness of care (i.e., outcomes of health care as it is usually practiced). To inform standard care, however, efficacy of interventions is also important (i.e., the results of interventions implemented in the idealized circumstances of a randomized clinical trial). Many of the examples cited earlier demonstrate a sharpened focus in dermatology on accurate measurement of the clinical encounter. This capacity to measure the progress of chronic diseases and their care will permit rigorous efforts to evaluate and improve the quality of that care.

KEY REFERENCES

The full reference list for all chapters is available at www.digm7.com.

1. Barzilai DA et al: Dermatoepidemiology. *J Am Acad Dermatol* **52**:559, quiz 574, 2005
2. Williams HC, Strachan DP: *The Challenge of Dermatoepidemiology.* Boca Raton, Florida, CRC Press, 1997
3. Weinstock MA: *Dermatoepidemiology.* Philadelphia, W.B. Saunders Company, 1995

45. Chen SC et al: A catalog of dermatology utilities: A measure of the burden of skin diseases. *J Investig Dermatol Symp Proc* **9**:160, 2004
46. Bickers DR et al: The burden of skin diseases: 2004. *J Am Acad Dermatol* **55**:490, 2006

CHAPTER 2

Evidence-Based Dermatology

Michael Bigby
Rosamaria Corona
Moyses Szklo

BRIEF HISTORY OF EVIDENCE-BASED MEDICINE

Hundreds of randomized controlled clinical trials were conducted between 1950 and the 1970s. However, their results were not catalogued or used systematically to inform medical decision making. In 1972 Archie Cochrane, a British epidemiologist and physician, published his response to being asked to evaluate the effectiveness of the British National Health Service in delivering health care to the population of the United Kingdom. In his analysis he concluded that medical science was poor at distinguishing interventions that were effective from those that were not and that physicians were not using available evidence from clinical research to inform their decision making.[6] See http://www.cochrane.org/cochrane/archieco.htm for more information on Archie Cochrane.

Groups of like-minded epidemiologists and physicians responded to Archie Cochrane's challenge by examining the methods by which medical decisions and conclusions were reached and proposed an alternative approach based on finding, appraising, and using available data from clinical research involving intact patients.[7] In 1985 Sackett et al. published *Clinical Epidemiology: A Basic Science for Clinical Medicine*, which detailed the rationale and techniques of this evidence-based approach.[7] These authors and others reduced the rules of evidence to a small subset of principles that were eas-

EVIDENCE-BASED MEDICINE AT A GLANCE

- Evidence-based medicine (EBM) is the use of the best current evidence in making decisions about the care of individual patients.
- EBM is predicated on asking clinical questions, finding the best evidence to answer the questions, critically appraising the evidence, applying the evidence to the treatment of specific patients, and saving the critically appraised evidence.
- The EBM approach is most appropriate for frequently encountered conditions.
- Results from well-designed clinical studies involving intact patients are at the pinnacle of the hierarchy of evidence used to practice evidence-based medicine.
- Recommendations about treatment, diagnosis, and avoidance of harm should take into account the validity, magnitude of effect, precision, and applicability of the evidence on which they are based.

ier to teach and to understand, and reintroduced the concept in 1992.[8] They named this technique *evidence-based medicine* (EBM). It was defined as the conscientious, explicit, and judicious use of the best current evidence in making decisions about the care of individual patients.[8] Whereas making decisions about therapy has been the primary focus of EBM, its principles have been extended to diagnosis, prognosis, avoidance of the harmful effects of interventions, determination of cost effectiveness, and economic analyses.

The introduction of EBM was met with considerable hostility. It was perceived as cookbook medicine, old hat, too restrictive, and an insult to those already trying to practice good medical care. The definition was softened to include the integration of independent clinical expertise, best available external clinical evidence from systematic research, and the patient's values and expectations.[2]

The Cochrane Collaboration was formed to some extent in response to Archie Cochrane's challenge to generate critical summaries, organized by specialty or subspecialty and updated periodically, of all relevant randomized controlled trials.[9] Created and maintained through the collaborative efforts of volunteers, the Cochrane Library is an impressive and useful compendium of systematic reviews, abstracts of systematic reviews, and the Cochrane Central Register of Controlled Trials, a database of over 473,000 controlled clinical trials (http://www3.interscience.wiley.com/cgi-bin/mrwhome/106568753/HOME). The Cochrane Library is the most complete and best index database of randomized controlled clinical trials and controlled clinical trials and is the best and most efficient place to find evidence about therapy.

The acceptance of EBM in the specialty of dermatology has been slow and reluctant. The term and principles are understood by few and misunderstood by many. EBM is perceived as an attempt to cut costs, impose rigid standards of care, and restrict dermatologists' freedom to exercise individual judgment. Practicing EBM in dermatology is hampered by the continued belief among dermatologists that clinical decisions can be guided by an understanding of the pathophysiology of disease, logic, trial and error, and nonsystematic observation.[1,10] It is hampered also by a lack of sufficient data in many areas. As with EBM in general, therapy is often primarily emphasized; however, evidence-based approaches to diagnosis and avoidance or evaluation of harm are also important considerations.

WHAT IS "THE BEST EVIDENCE"?

Practicing EBM is predicated on finding and using the best evidence. Potential sources of evidence include knowledge regarding the etiology and pathophysiology of disease, logic, personal experience, the opinions of colleagues or experts, textbooks, articles published in journals, and systematic reviews. An important principle of EBM is that the quality (strength) of evidence is based on a hierarchy. The precise hierarchy of evidence depends on the type of question being asked (Table 2-1).[11] This hierarchy consists of results of well-designed studies (especially if the studies have findings of similar magnitude and direction, and if there is statistical homogeneity among studies), results of case series, expert opinion, and personal experience, in descending order.[9,10] The hierarchy was created to encourage the use of the evidence that is most likely to be accurate and useful in clinical decision making. The ordering in this hierarchy has been widely discussed, actively debated, and sometimes hotly contested.[12]

A systematic review is an overview that answers a specific clinical question; contains a thorough, unbiased search of the relevant literature; uses explicit criteria for assessing studies; and provides a structured presentation of the results. A systematic review that uses quantitative methods to summarize results is a meta-analysis.[13,14] A meta-analysis provides an objective and quantitative summary of evidence that is amenable to statistical analysis.[13] Meta-analysis is credited with allowing the recognition of important treatment effects by combining the results of small trials that individually lacked the power to demonstrate differences among treatments. For example, the benefits of intravenous streptokinase in treating acute myocardial infarction were recognized by means of a cumulative meta-analysis of smaller trials at least a decade before this treatment was recommended by experts and before it was demonstrated to be efficacious in large clinical trials.[15,16] Meta-analysis has been criticized because of the discrepancies between the results of meta-analysis and those of large clinical trials.[16–19] For example, results of a meta-analysis of 14 small studies of the use of calcium to treat preeclampsia showed a benefit to treatment, whereas a large trial failed to show a treatment effect.[16] The frequency of such discrepancies ranges from 10 percent to 23 percent.[16] Discrepancies can often be explained by differences in treatment protocols, heterogeneity of study populations, or changes that occur over time.[16]

Publication bias is an important concern regarding systematic reviews. It results when factors other than the quality of the study are allowed to influence its acceptability for publication. Several studies have shown that factors such as sample size, direction and statistical significance of findings, and investigators' perceptions of whether the findings are "interesting" are related to the likelihood of publication.[20,21]

For example, in a study by Dickersin et al., the reasons given by investigators that results of completed studies were not published included "negative results" (28 percent), "lack of interest" (12 percent), and "sample size problems" (11 percent).[20] Results of studies with small samples are less likely to be published, especially if they have negative results.[20,21] This type of publication bias jeopardizes one of the main goals of meta-analysis (i.e., an increase in power through pooling of the results of small studies). Creation of study registers and advance publication of research designs have been proposed as ways to prevent publication bias.[22,23] Publication bias can be detected by using a simple

TABLE 2-1
Grades of Evidence[a,b]

Grade	Level of Evidence	Therapy/Harm	Diagnosis
A	1a	Systematic review (with homogeneity[c]) of RCTs	Systematic review (with homogeneity) of level 1 (see column 2) diagnostic studies, or a CPG validated on a test set.
	1b	Individual RCT (with narrow confidence intervals)	Independent blind comparison of an appropriate spectrum of consecutive patients, all of whom have been evaluated by both the diagnostic test and the reference standard.
	1c	All or none[d]	Very high sensitivity or specificity
B	2a	Systematic review (with homogeneity) of cohort studies	Systematic review (with homogeneity) of level 2 or better (see column 2) diagnostic studies
	2b	Individual cohort study [including low-quality RCT (e.g., < 80% follow-up)]	Independent blind comparison but either in non-consecutive patients or confined to a narrow spectrum of study individuals (or both), all of whom have been evaluated by both the diagnostic test and the reference standard or a diagnostic CPG not validated in a test set
	2c	"Outcomes" research[e]	
	3a	Systematic review (with homogeneity) of case-control studies	Systemic review (with homogeneity) of 3b (see column 2) and better studies
	3b	Individual case-control study	Independent blind comparison of an appropriate spectrum, but the reference standard was not applied to all study patients
C	4	Case series (and poor-quality cohort and case-control studies)	Reference standard was not applied independently or not applied blindly
D	5	Expert opinion without explicit critical appraisal, or based on physiology, bench research, or logical deduction	

CPG = clinical practice guideline, a systematically developed statement designed to help practitioners and patients make decisions about appropriate health care for specific clinical circumstances; RCT = randomized controlled trial.
[a]These levels were generated in a series of iterations among members of the NHS R&D Centre for Evidence-Based Medicine (Chris Ball, Dave Sackett, Bob Phillips, Brian Haynes, and Sharon Straus). For details see Levels of Evidence and Grades of Recommendation, http://www.cebm.net/levels_of_evidence.asp, May 2001.
[b]Recommendations based on this approach apply to "average" patients and may need to be modified in light of an individual patient's unique biology (e.g., risk, responsiveness) and preferences about the care he or she receives.
[c]*Homogeneity* means lacking variation in the direction and magnitude of results of individual studies.
[d]*All or none* means interventions that produced dramatic increases in survival or outcome, such as the use of streptomycin to treat tubercular meningitis.
[e]Outcomes research includes cost-benefit, cost-effectiveness, and cost-utility analysis.

graphic test (funnel plot) or by several other statistical methods."[24,25] In addition, for many diseases, the studies published are dominated by drug company–sponsored trials of new, expensive treatments. The need for studies to answer the clinical questions of most concern to practitioners is not addressed because sources of funding are inadequate.

Not all systematic reviews and meta-analyses are equal. A systematic review can be only as good as the clinical trials that it encompasses. The criteria for critically appraising systematic reviews and meta-analyses are shown in Table 2-2. Detailed explanations of each criterion are available.[13,26]

The type of clinical study that constitutes best evidence is determined by the category of question being asked. Questions about therapy and prevention are best addressed by randomized controlled trials.[13,26–28] Questions about diagnosis are best addressed by cohort studies.[13,26,29,30] Cohort studies, case-control studies, and post-marketing surveillance studies best address questions about harm.[13,26,31] Randomized controlled trials are a good source of evidence about the harmful effects of interventions for adverse events that occur frequently but not for rare adverse events. Case reports are often the first line of evidence regarding rare adverse events, and sometimes they are the only evidence. Methods for assessing the quality of each type of evidence are available.[13,26]

With regard to questions about therapy and prevention, the randomized controlled clinical trial has become the gold standard for determining treatment efficacy. Thousands of randomized controlled trials have been conducted. Studies have demonstrated that failure to use randomization or to provide adequate concealment of allocation resulted in larger estimates of treatment effects, caused predominantly by a poorer prognosis in non–randomly selected control groups than in randomly selected control groups.[32] However, studies comparing randomized and nonrandomized clinical trials of the same interventions have reached disparate and controversial results.[32–34] Some found that observational studies reported stronger treatment effects than randomized controlled trials.[32] Others found that the results of well-designed observational studies (with either a cohort or a case-control design) do not systematically overestimate the magnitude of the effects of treatment compared with randomized controlled trials on the same topic.[33,34] Examining the details of the controversy leads to the following limited conclusions. Trials using historical controls do yield larger estimates of treatment effects than do randomized controlled trials. Large, inclusive, fully blinded randomized controlled trials are likely to provide the best possible evidence about effectiveness.[12,35,36]

Although personal experience is an invaluable part of becoming a competent physician, the pitfalls of relying too heavily on personal experience have been widely documented.[7,37,38] Nisbett and Ross extensively reviewed people's ability to draw inferences from personal experience and describe several of these pitfalls.[39] These include the following:

- Overemphasis on vivid anecdotal occurrences and underemphasis on significant statistically strong evidence
- Bias in recognizing, remembering, and recalling evidence that supports pre-existing knowledge structures (e.g., ideas about disease etiology and pathogenesis) and parallel failure to recognize, remember, and recall evidence that is more valid

TABLE 2-2
Critical Appraisal of a Systematic Review

- Are the results of this systematic review valid?
  - Did the review address a focused clinical question?[a]
  - Were the criteria used to select articles for inclusion appropriate?[a]
  - Is it unlikely that important relevant studies were missed?[b]
  - Was the validity of the included studies appraised?[b]
  - Were assessments of studies reproducible?[b]
  - Were the results similar from study to study?[b]
- Are the valid results of this systematic review important?
  - What are the overall results of the review?
  - How precise were the results?
- Can you apply this valid, important evidence in caring for your patient?
  - Can the results be applied to your patient's care?
  - Were all clinically important outcomes considered?
  - Are the benefits worth the harms and costs?

[a]Primary guides.
[b]Secondary guides.
From Sackett D et al: *Evidence-Based Medicine: How to Practice and Teach EBM.* Edinburgh, Churchill Livingstone, 1996.

- Failure to accurately characterize population data because of ignorance of statistical principles, including sample size, sample selection bias, and regression to the mean
- Inability to detect and distinguish statistical association and causality
- Persistence of beliefs in spite of overwhelming contrary evidence

Nisbett and Ross provide examples from controlled clinical research. Simple clinical examples abound. Physicians may remember patients whose condition improved, often assume that patients who did not return for follow-up got better, and conveniently forget the patients whose condition did not improve. A patient treated with a given medication may develop a severe life-threatening reaction. On the basis of this single undesirable experience, the physician may avoid using that medication for many future patients, although on average it may be more efficacious and less toxic than the alternative treatments that the physician chooses. Few physicians keep adequate, easily retrievable records to codify results of treatments with a particular agent or treatments of a particular disease; and even fewer actually carry out analyses. Few physicians make provisions for tracking those patients who are lost to follow-up. Therefore, statements made about a physician's "clinical experience" may be biased. Finally, for many conditions, a single physician sees far too few patients with the given disorder to allow reasonably firm conclusions to be drawn about the response to treatments. For example, suppose that a physician has treated 20 patients with lichen planus using tretinoin and found that 12 (60 percent) had an excellent response. The confidence interval for this response rate (i.e., the true response rate for this treatment in the larger population from which this physician's sample was obtained) ranges from 36 percent to 81 percent. Thus the true response rate might well be substantially less (or more) than the physician concludes from personal experience.

Expert opinion can be valuable, particularly when the disorder is a rare condition in which the expert has the most experience or when other forms of evidence are not available. However, several studies have demonstrated that expert opinion often lags significantly behind conclusive evidence.[7] Experts suffer from relying on bench research, pathophysiology, and treatments based on logical deduction from pathophysiology as well as from the same pitfalls noted for reliance on personal experience. Experts should be aware of the quality of the evidence that exists.

It is widely believed that clinical decisions can be made on the basis of an understanding of the etiology and pathophysiology of disease and logic.[1,10] This paradigm is problematic because the accepted hypothesis regarding the etiology and pathogenesis of disease changes over time. Therefore, the logically deduced treatments change over time. For example, in the last 20 years, hypotheses about the cause of psoriasis have shifted from a disorder of keratinocyte proliferation and homeostasis, to abnormal signaling of cyclic adenosine monophosphate, to aberrant arachidonic acid metabolism, to aberrant vitamin D metabolism, to the current favorite, T-cell–mediated autoimmune disease. Each of these hypotheses spawned logically deduced treatments. The efficacy of many of these treatments has been substantiated by rigorous controlled clinical trials, but others are used even in the absence of systematically collected observations. Therefore, we have many options for treating patients with severe psoriasis (e.g., ultraviolet B radiation, narrow-band ultraviolet B radiation, Goeckerman treatment, psoralen plus ultraviolet A radiation, methotrexate, cyclosporin, and the biologics) and mild to moderate psoriasis (e.g., anthralin, topical corticosteroids, calcipotriene, and tazarotene) (see Chap. 18). However, we lack a clear sense of which is best, in what order they should be used, and in what combinations.[10,40] Treatments based on logical deduction from pathophysiology may have unexpected consequences. For example, the observation that antiarrhythmic drugs could prevent abnormal ventricular depolarization after myocardial infarction logically led to their use to prevent sudden death after myocardial infarction. However, a randomized controlled clinical trial showed increased mortality among patients treated with antiarrhythmic drugs than among those given a placebo.[28,41,42]

Textbooks can be valuable sources of evidence, particularly for rare conditions and for conditions for which the evidence does not change rapidly over time. However, textbooks have several well-documented limitations. They tend to reflect the biases and shortcomings of the experts who write them. Because of the way they are written, produced, and distributed, most are approximately 2 years out of date at the time of publication. Most textbook chapters are narrative reviews that do not consider the quality of the evidence reported.[7,13]

FINDING THE BEST EVIDENCE

The ability to find the best evidence to answer clinical questions is crucial for the practice of EBM. Finding evidence requires access to electronic search tools, searching skills, and availability of relevant data. Evidence about therapy is the easiest to find. The most useful sources for locating the best evidence about treatment include the following:

- The Cochrane Library
- The MEDLINE (Medical Literature Analysis and Retrieval System On-Line) and EMBASE (*Exerpta Medica Database*) databases
- Primary journals
- Secondary journals
- Evidence-based dermatology and EBM books
- The National Guideline Clearinghouse (http://www.guideline.gov/)

- The National Institute for Health and Clinical Excellence (http://www.nice.org.uk)

The Cochrane Library contains the Cochrane Database of Systematic Reviews, the Database of Abstracts of Reviews of Effectiveness, the Cochrane Central Register of Controlled Trials, and the Health Technology Assessment Database, among other databases (http://www3.interscience.wiley.com/cgi-bin/mrwhome/106568753/HOME). Volunteers write the systematic reviews in the Cochrane Library according to strict guidelines developed by the Cochrane Collaboration. Issue 1, 2007, of the Cochrane Library contained 4655 completed systematic reviews. The number of reviews of dermatologic topics is steadily increasing.

The Database of Abstracts of Reviews of Effectiveness contains abstracts of systematic reviews published in the medical literature. It provides abstracts and bibliographic details on 5931 published systematic reviews. The Database of Abstracts of Reviews of Effectiveness is the only database to contain abstracts of systematic reviews that have been assessed for quality. Each abstract includes a summary of the review together with a critical commentary about the overall quality. The Health Technology Assessment Database consists of completed and ongoing health technology assessments (studies of the medical, social, ethical, and economic implications of health care interventions) from around the world. The aim of the database is to improve the quality and cost effectiveness of health care.

The Cochrane Library is the best source for evidence about treatment. It can be easily searched using simple Boolean combinations of search terms as well as more sophisticated search strategies. The Cochrane Database of Systematic Reviews, Database of Abstracts of Reviews of Effectiveness, Central Register of Controlled Trials, and Health Technology Assessment Database can be searched simultaneously.

The Cochrane Library is available on CD-ROM by personal or institutional subscription and on the World Wide Web from Wiley InterScience (http://www3.interscience.wiley.com/cgi-bin/mrwhome/106568753/HOME). Subscribers to the Cochrane Library are provided with quarterly updates. The Cochrane Library is offered free of charge in many countries by national provision and by many medical schools in the United States. It should be available at your medical library.

The second best method for finding evidence about treatment and the most useful source for finding most other types of best evidence in dermatology is searching the MEDLINE database by computer.[44,45] MEDLINE is the National Library of Medicine's bibliographic database covering the fields of medicine, nursing, dentistry, veterinary medicine, the health care system, and the pre-clinical sciences. The MEDLINE database contains bibliographic citations and author abstracts from approximately 5000 current biomedical journals published in the United States and 80 foreign countries. The database contains approximately 15 million records dating back to the mid-1950s.[46]

MEDLINE searches have inherent limitations that make their reliability less than ideal.[45] Specific search strategies, or filters, have been developed to aid in finding relevant references and excluding irrelevant references to locate the best evidence about diagnosis, therapy, prognosis, harm, and prevention.[48]

These filters have been incorporated into the PubMed Clinical Queries search engine of the National Library of Medicine and are available at http://www.ncbi.nlm.nih.gov/entrez/query/static/clinical.shtml.[49]

The use of PubMed Clinical Queries (http://www.ncbi.nlm.nih.gov/entrez/query/static/clinical.shtml) is the preferred method for searching the MEDLINE database to locate the best clinically relevant evidence. It can be used freely by anyone with Internet access.

More than 20 vendors provide MEDLINE systems on-line and on CD-ROM. Haynes et al.[50] compared several vendors of MEDLINE on-line and on CD-ROM to determine which system was best in terms of locating relevant articles and excluding irrelevant articles. As assessed from combined rankings for the highest number of relevant and the lowest number of irrelevant citations retrieved, SilverPlatter MEDLINE clinical journal subset on CD-ROM performed best for librarian searches, whereas the PaperChase on-line system worked best for clinician searches. When judged by cost per relevant citation, Dialog's Knowledge Index performed best for both librarian and clinician searches.[50]

EMBASE is *Excerpta Medica*'s database covering pharmacology and biomedical specialties.[13] EMBASE has better coverage of European and non–English language sources and may be more up to date.[13] The overlap in journals covered by MEDLINE and EMBASE is approximately 34 percent (range, 10 percent to 75 percent depending on the subject).[51,52]

EMBASE is available on-line through the major database vendors [e.g., DataStar, Dialog, DIMDI (Deutschen Institut für Medizinische Dokumentation und Information), Ovid Online, and STN]. For more information, see http://www.elsevier.com/wps/find/bibliographicdatabasedescription.cws_home/523328/description#description. Personal and institutional subscriptions are available.

Structured abstracts of articles are published in secondary journals (e.g., the Evidence-Based Dermatology section of *Archives of Dermatology*). The articles are strictly selected on the basis of methodologic quality and are accompanied by commentary putting the information in clinical perspective. *Evidence-Based Dermatology* (Williams H et al., editors, Oxford, Blackwell Publishing Ltd., 2002) is a compendium of "mini" systematic reviews of the treatment of skin diseases. *Clinical Evidence* is a compendium of evidence on the effects of common clinical interventions that is updated every 6 months. It is available through the American College of Physicians and the British Medical Association.

Full-text versions of many primary journals are now available on the Internet. Available vendors include DataStar, Dialog, DIMDI, Ovid Online, and STN, among others. The National Guideline Clearinghouse maintains a database of guidelines for the treatment of disease written by panels of experts following strict criteria for evidence. The database is accessible through the Internet (http://www.guidelines.gov). Current coverage of dermatologic topics is limited.

The National Institute for Health and Clinical Excellence produces guidance on public health, health technologies, and clinical practice based on the best available evidence. It is accessible on-line at http://www.nice.org.uk.

CRITICALLY APPRAISING THE EVIDENCE

After evidence is found, the next step in practicing EBM is critically appraising the quality of the evidence and determining the magnitude of effects and the precision of the evidence. The criteria for critically appraising papers about treatment, diagnostic tests, and harmful effects of exposures are shown in Tables 2-3, 2-4, and 2-5, respectively.[13,26] Papers that meet

TABLE 2-3
Critical Appraisal of a Paper About Therapy

Are the results of this single preventive or therapeutic trial valid?
- Was the assignment of patients to treatments randomized and was the randomization list concealed?
- Were all patients who entered the trial accounted for at its conclusion and were their data analyzed in the groups to which they were randomly assigned?
- Were patients and clinicians kept blind as to which treatment was being received?
- Aside from the experimental treatment, were the groups treated equally?
- Were the groups similar at the start of the trial?

Are the valid results of this randomized trial important?
- Calculations:

Intervention Response Rate (IRR)	Comparison (Intervention) Response Rate (CRR)	Difference in Response Rates (DRR) (IRR – CRR)	Number Needed to Treat (NNT) (1/DRR)

- What is the 95% confidence interval of the difference in response rates (DRR)?[a]
- What is the 95% confidence interval of the NNT?[b]

Can you apply this valid, important evidence in caring for your patient?
- Do these results apply to your patient?
  - Is your patient so different from those in the trial that its results can't help you?
  - How great would the potential benefit of therapy actually be for your individual patient?
- Do the regimen and its consequences satisfy your patient's values and preferences?
  - Do your patient and you have a clear assessment of your values and preferences?
  - Are this regimen and its consequences consistent with them?

[a]The 95% confidence interval of the DRR is from

$$\text{DRR} - 1.96 \times \text{SE to DRR} + 1.96 \times \text{SE}$$

$$\text{where SE (standard error)} = \sqrt{\frac{IRR\ (1 - \text{IRR})}{\text{No. intervention patients}} + \frac{CRR\ (1 - CRR)}{\text{No. comparison patients}}}$$

[b]The 95% confidence interval of the NNT = 1/limits on the confidence interval of its DRR.
From Sackett D et al: *Evidence-Based Medicine: How to Practice and Teach EBM.* Edinburgh, Churchill Livingstone, 1996.

TABLE 2-4
Critical Appraisal of a Paper About a Diagnostic Test

Are the results of this diagnostic study valid?
- Was there an independent, blind comparison with a reference (gold) standard of diagnosis?
- Was the diagnostic test evaluated in an appropriate spectrum of patients (like those in whom it would be used in practice)?
- Was the reference standard applied regardless of the diagnostic test result?

Are the valid results of this diagnostic study important?
- Calculations:

		Target Disorder	
		Present	Absent
Diagnostic Test Result	Positive	a	b
	Negative	c	d

- Sensitivity = a/(a + c)
- Specificity = d/(b + d)
- Likelihood ratio for a positive test result = [a/(a + c)]/[b/(b + d)] = sensitivity/(1 – specificity)
- Likelihood ratio for a negative test result = [c/(a + c)]/[d/(b + d)] = (1 – sensitivity)/specificity

Can you apply this valid, important evidence about a diagnostic test in caring for your patient?
- Is the diagnostic test available, affordable, accurate, and precise in your setting?
- Can you generate a clinically sensible estimate of your patient's pre-test probability (from practice data, from personal experience, from the report itself, or from clinical speculation)?
- Will the resulting post-test probabilities affect your management and help your patient? (Could it move you across a test-treatment threshold? Would your patient be a willing partner in carrying out your recommendations?)
- Would the consequences of the test help your patient?

From Sackett D et al: *Evidence-Based Medicine: How to Practice and Teach EBM.* Edinburgh, Churchill Livingstone, 1996.

these criteria are more likely to provide information that is accurate and useful in the care of patients.[13,26] A detailed explanation of each criterion[13,26] and an example involving a patient with a dermatologic complaint are available.[45]

Critically appraising evidence consists of the three steps of determining whether the results have each of the following characteristics:

- Validity (i.e., they are as unbiased as possible)
- Clinical importance
- Applicability to the specific patient being seen

Determining the validity of evidence centers on ascertaining whether the evidence was produced in a manner most likely to eliminate and avoid bias. The critical questions to ask to determine the validity of papers about therapy, diagnostic tests, and harmful effects are shown at the tops of Tables 2-3, 2-4, and 2-5, respectively.

Evidence About Therapy and Prevention

Studies of therapy should randomly assign patients to treatment groups (using a table of random numbers or pseudo-random numbers generated by computer) and ensure concealed allocation (e.g., by using opaque envelopes so that the treating physician cannot guess to which treatment group the patient has been assigned). In addition, there should be nearly complete follow-up of all patients entered into the study; intention-to-treat analysis of results; masking of investigators, patients, and statisticians where possible; equal treatment of groups; and similarity between treatment groups with regard to the distributions of prognostic variables. These criteria represent only a small subset of the features of a well-designed and well-reported clinical trial.[37] A more complete set of criteria has been published, and adherence to these criteria is required by many of the leading medical journals.[53]

Important terms and concepts that must be understood to determine whether the results of a paper about therapy are clinically important include the following:

- The magnitude of the treatment effect
- The precision of this value
- The difference in response rates
- Its reciprocal, the number needed to treat (NNT)
- The confidence interval

TABLE 2-5
Critical Appraisal of a Paper About Harm

Are the results of this harm study valid?
- Were there clearly defined groups of patients, similar in all important ways other than exposure to the treatment or other cause?
- Were treatment exposures and clinical outcomes measured the same ways in both groups? [For instance, was the assessment of outcomes either objective (e.g., death) or blinded to exposure?]
- Was the follow-up of study patients complete and long enough?

Do the results satisfy some "diagnostic tests for causation"?
- Is it clear that the exposure preceded the onset of the outcome?
- Is there a dose-response gradient?
- Is there positive evidence from a "dechallenge-rechallenge" study?
- Is the association consistent from study to study?
- Does the association make biologic sense?

Are the valid results from this harm study important?

Calculations:

		Adverse Outcome	
		Present (Case)	Absent (Control)
Exposed to the Treatment	Yes (cohort)	a	b
	No (cohort)	c	d

- In a randomized trial or cohort study, relative risk = [a/(a + b)]/[c/(c + d)].
- In a case-control study, odds ratio (or relative odds) = ad/bc.

Should these valid, potentially important results of a critical appraisal about a harmful treatment change the treatment of your patient?
- Can the study results be extrapolated to your patient?
- What are your patient's risks of the adverse outcome?
- What are your patient's preferences, concerns, and expectations from this treatment?
- What alternative treatments are available?

From Sackett D et al: *Evidence-Based Medicine: How to Practice and Teach EBM.* Edinburgh, Churchill Livingstone, 1996.

In evaluating a clinical trial, the physician should look for clinical outcome measures that are clear-cut and clinically meaningful to the physician and his or her patients.[37] For example, in a study of a systemic treatment for warts, complete disappearance of warts is a meaningful outcome, whereas a decrease in the volume of warts is not. Historically, two principal methods have been used to determine patient outcomes in dermatologic clinical trials. The first involves examining the patient before, during, and at the conclusion of treatment and reporting how the patient appears at the various time points. The second involves determining the degree of improvement during treatment.[54] A third method, determining the impact of therapy on the quality of the patient's life, is being increasingly used in dermatologic trials.[37]

An example of the first method is commonly encountered in therapeutic trials of psoriasis. A common practice is to assign numerical values to the amount of erythema, the amount of scaling, the degree of infiltration, and the body surface area involved, and to formulate an "index" by calculating a derivative of some product of these four numbers.[55,56] The overall condition of the patient can then be represented by this index. A common index is the psoriasis area and severity index, which ranges from 0 to 72.[55] The major problem with indices is that they confound area of involvement with severity of disease.[54] For instance, a patient with thick plaque-type psoriasis of the knees, elbows, and scalp may have the same index as a patient with diffuse but minimal psoriasis of the trunk and arms. Whereas the former condition is notoriously difficult to treat, the latter will generally respond rapidly and easily to many forms of therapy.[54] The second problem with indices is that they lend an air of precision to the analysis and presentation of data that is not warranted.[54] For instance, Tiling-Grosse and Rees demonstrated that physicians and medical students were poor at estimating the area of involvement of skin disease, and therefore some of the components that make up indices may be inaccurate.[57] Finally, calculations of the means, differences in means, and percentages of change in indices in response to treatment often do not convey an accurate clinical picture of the changes that have occurred.[54]

The second method of assessment groups patients according to their degree of improvement. Treatments are then compared in terms of their ability to move patients into categories representing higher degrees of improvement. There are two major problems with this form of assessment. The first is that the categories of improvement are often not well defined. The second problem is that the categories are not additive.[54] That is, 60 percent to 80 percent improvement is often assumed to be twice as good as 20 percent to 40 percent improvement, but no such numerical relationship exists between these subjectively defined categories.

To be most useful, the outcome variables to be measured must be clearly defined, must be as objective as possible, and must have clinical and biologic significance.[37,54] The best indices and scales are the ones that accurately reflect the state of the disease and the ones whose validity and reliability have been verified by previous work.[37,54,58] The development of scales and indices for assessing cutaneous diseases and the testing of their validity, reproducibility, and responsiveness have been inadequate.[37,54,59] Therefore, a lack of clearly defined and useful outcome variables remains a major problem in interpreting dermatologic clinical trials.

Until better scales are developed, trials with the simplest and most objective outcome variables are the best. They lead to the least amount of confusion and support the strongest conclusions. Thus, trials in which a comparison is made between death and survival, recurrence of disease and no recurrence, or cure and lack of cure are studies whose outcome variables are easily understood and verified. For trials in which the outcomes are less clear-cut and more subjective, a simple ordinal scale is probably the best choice.[54] The best ordinal scales involve a minimum of human judgment, have a precision that is much smaller than the differences being sought, and are sufficiently standardized so that they can be used by others and produce similar results.[38]

In addition to being clearly defined, outcome variables should have clinical and biologic significance.[27,28] For example, in a therapeutic trial of patients with severe acne, treatment was associated with a decrease in lesion count from a mean of 400 to a mean of 350.

This numerical difference may be of statistical significance, but it does not convey the biologic significance of the change in lesion number.[54] This result may mean that some patients with severe acne experienced complete clearance, whereas in others the acne remained the same or got worse. It could also mean that in most patients the acne got slightly better. Furthermore, does an individual patient look better when the lesion number has been reduced from 400 to 350? Is there less scarring and fewer complications?

To strengthen clinical trials and help validate their conclusions, investigators should select only a few outcome variables and should choose them before initiation of the study. Measurement of many outcome variables increases the likelihood that spurious, chance differences will be detected. An ineffective treatment may be found efficacious when tested using poorly designed outcome assessment tools. Conversely, an effective therapy may be found ineffective when an insensitive scale is used.

Special precautions are recommended to recognize and remain skeptical of substitute or surrogate endpoints, especially when no differences are detected in clinically important outcomes.[28,60] Examples of such endpoints include CD4/CD8 ratios instead of survival rates in studies of treatments for acquired immunodeficiency syndrome, anti-nuclear antibody levels or sedimentation rates instead of clinical measures of disease activity in lupus erythematosus, and volume of warts instead of proportion of patients cleared of warts. The use of carefully chosen and validated surrogate endpoints often allows studies to provide answers to questions that would typically require much larger or longer trials if the targeted clinical endpoint were used. For example, a well-designed short clinical trial may be sufficient to demonstrate that a new drug effectively lowers serum cholesterol level or that a given drug is effective in controlling hypertension. In both cases, much longer and larger studies would be required to demonstrate that the cholesterol-lowering drug and the antihypertensive drug reduced morbidity and mortality from atherosclerotic and hypertensive cardiovascular diseases, respectively. Surrogate endpoints must correlate with clinical outcomes, however, and their validity must have been demonstrated in prior studies.

Once sound, clinically relevant outcome measures are chosen, the magnitude of the difference between the treatment groups in achieving these meaningful outcomes should be determined. The precision of the estimate of the differences among treatments should be assessed. Useful measures of the magnitude of the treatment effect are the difference in response rate and its reciprocal, the NNT.[13,26,45] The NNT represents the number of patients one would need to treat to achieve one additional cure.

The confidence interval provides a useful measure of the precision of the treatment effect.[13,26,45,61,62] The calculation and interpretation of confidence intervals have been extensively described.[63] In simple terms, the reported result (known as the *point estimate*) provides the best estimate of the treatment effect. Values become less and less likely as they move away from the reported result within the confidence interval.[13,26,45] The confidence interval provides a range of values in which the "population" or true response to treatment is likely to lie.

Examples of the application of the concepts of NNT and confidence interval are given in a paper identified through a search of the Cochrane Library that reported the results of a randomized controlled trial comparing the use of a placebo, acyclovir, prednisone, and acyclovir plus prednisone in the treatment of herpes zoster.[64] At day 30 of the trial, 48 of 52 patents treated with acyclovir experienced total healing compared with 22 of 52 patients who received a placebo. The response rates for acyclovir and placebo were 0.92 and 0.42, respectively, and the difference in response rates was 0.5. The NNT was 2 (1/0.5). This result means that for every two patients treated with acyclovir instead of placebo, one additional patient would show total healing by day 30. The 95 percent confidence interval for the difference in response rates is 0.35 to 0.65, and the 95 percent confidence interval for the NNT is 2 to 3.

What does it actually mean that the confidence interval for the difference in response rates in the foregoing example is 0.35 to 0.65? If the investigators in this study had the opportunity to repeat the study many times using the same design and procedures, sampling variability would prevent obtaining the same results in each study. Repeated trials were simulated using resampling (resampling is a computer-intensive method that uses the reported results of a trial to simulate the results that would be obtained if the trial were repeated a number of times).[45,65] The results when the trial was repeated 10 and 1000 times are shown in Fig. 2-1A and B, respectively. A 95 percent confidence interval of 0.35 to 0.65 means that if the trial is repeated many times and a confidence interval is calculated for each trial, the true result or response to treatment will be included in 95 percent of the confidence intervals so produced. Alternatively, if the trial were repeated multiple times, the results would lie within that interval (0.35 to 0.65) 95 percent of the time.

The population or true response to treatment will most likely lie near the middle of the confidence interval and will rarely be found at or near the ends of the interval. The population or true response to treatment has only a 1 in 20 chance of being outside of the 95 percent confidence interval. Unless a given patient is very different from the patients included in the study, his or her response will most likely lie near the middle of the confidence interval. If the 95 percent confidence interval of the difference in response rates excludes zero difference, one can reject the null hypothesis that the two treatments are the same.[26,45,61,62]

Misinterpreting trials that fail to show statistically significant differences among treatments is a common error in dermatologic clinical trials. It is important to remember that "not statistically significant" means that a difference has a reasonably high probability of having been due to chance; it does not mean that there is no difference or that treatment is necessarily ineffective.[37] Significant differences in treatment effects in comparison trials may be missed if the number of subjects tested is small. For example, in a 1978 survey of 71 published trials with negative results, Freiman et al. found that a 25 percent or 50 percent improvement in outcome might have been missed in 57 (80 percent) and 34 (48 percent) of the studies, respectively.[66] A follow-up study conducted by Moher, Dulberg, and Wells in 1994 indicated that a 25 percent or 50 percent improvement in outcome might have been missed in 84 percent and 64 percent, respectively, of 102 studies with negative results.[67] The sample sizes of many dermatologic trials are often inadequate to detect clinically important differences.

The acceptance of a significance level of .05 as the cutoff for rejecting the null hypothesis is a tradition based on quality control standards and is not an absolute truth. At times (e.g., when treatments have substantial side effects)

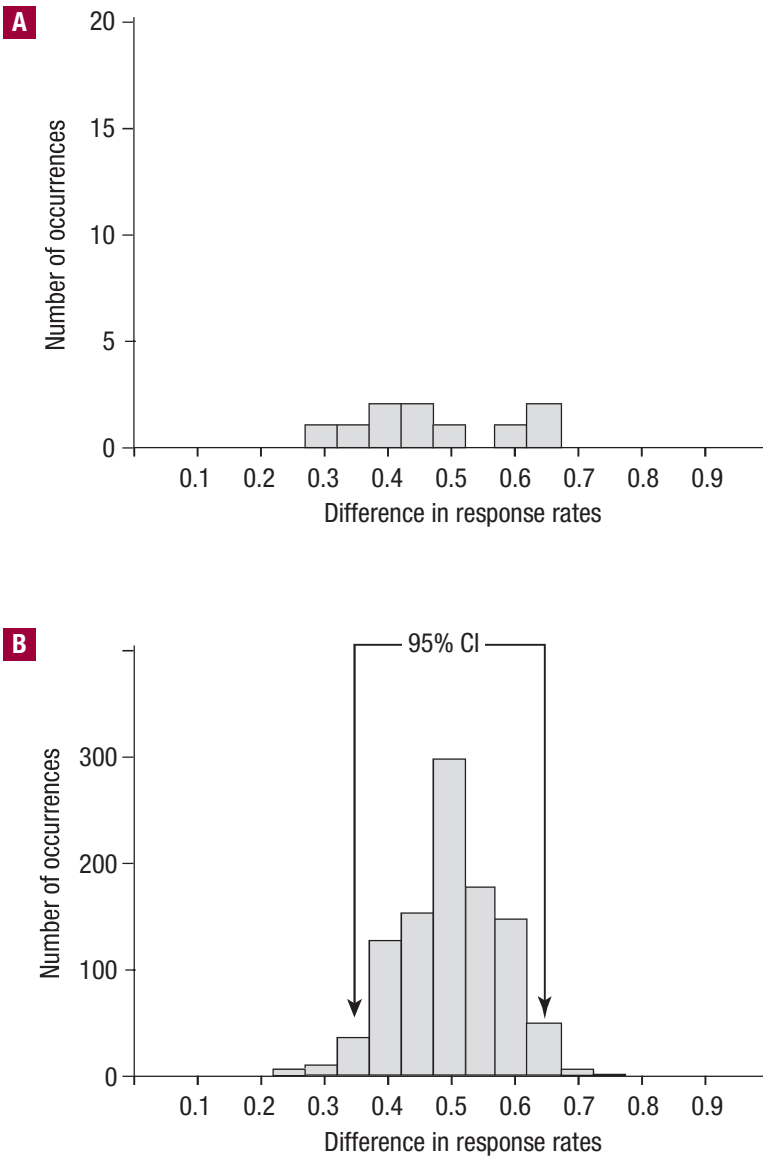

▲ **FIGURE 2-1** If the acyclovir trial were repeated 10 (**A**) or 1000 (**B**) times, the results in **A** and **B**, respectively, might be obtained. CI = confidence interval.

more stringent standards are required, and paradoxically, results that do not meet the p = 0.05 standard sometimes may be clinically significant. For example, consider a hypothetical trial of a new chemotherapeutic agent involving 30 patients with metastatic melanoma randomly assigned to treatment groups that produced a 5-year survival rate of 7 of 15 among patients treated with the new agent and 3 of 15 among control patients treated with conventional surgery, chemotherapy, and radiation. Whereas the result does not achieve statistical significance when analyzed by chi square testing (Yates corrected chi square = 1.35; p = 0.25), the result is nonetheless potentially significant. If the therapy is beneficial and the estimated difference in response rates is the true difference in response rates, it may result in the saving of 2400 lives annually (based on 7200 deaths from melanoma annually and the improvement in survival in this hypothetical example). Because of the biologic and clinical importance of the results suggested by the trial, the treatment should be investigated in a study that uses a larger patient group and has more power to detect a significant difference if one exists.[37]

The potential benefit of the treatment may be further revealed by the use of confidence intervals. To determine whether a treatment effect may have been missed in a study reporting negative (not statistically significant) results, one should look at the upper boundary of the 95 percent confidence interval. If this value would be clinically important if it were the true response, then an important treatment effect may have been missed in the study. Consider our hypothetical new treatment for metastatic melanoma. The cure rates for the new treatment and the conventional treatment were 47 percent and 20 percent, respectively, and the difference between them was thus 27 percent. The 95 percent confidence interval for the difference in cure rates was –10 percent to 51 percent. The upper boundary of the difference in cure rates was 51 percent. This difference would clearly have a significant impact on the treatment of patients with metastatic melanoma (the NNT is 2!), and therefore a significant treatment advance may have been missed in this study. Also note that the 95 percent confidence interval of the difference in cure rates includes zero difference; therefore, we cannot conclude with a high degree of confidence that the response rates of the two treatments are different. However, when zero is included as one of the values in the confidence interval, the inference that the therapy is not efficacious fails to consider the fact that the best estimate of effect is the point estimate (e.g., the observed difference in cure rates of 27 percent in our hypothetical example).[68] In other words, the values contained in the confidence interval are not equally likely and become less and less likely as they move away from the point estimate. Thus, in the example, a difference of 25 percent (close to the observed 27 percent) is much more likely than a difference of –5 percent (far from the observed 27 percent).[37]

Evidence About Diagnostic Tests

To be valid, studies of diagnostic tests should include blind comparison with a criterion (gold) standard, evaluation in an appropriate spectrum of patients, and consistent application of the criterion standard. Few studies in dermatology meet these criteria.

Important terms and concepts that must be understood to determine whether the results of a paper examining a diagnostic test are clinically important include the following:

- Likelihood ratio
- Pre-test probability
- Post-test probability
- Threshold for action

The likelihood ratio is the percentage of people with the given disease for whom the test result is positive divided

by the percentage of people who do not have the disease for whom the test result is positive.[45] The likelihood ratio is traditionally taught as the sensitivity divided by 1 minus the specificity [likelihood ratio = sensitivity/(1 – specificity)] and provides an estimation of how much higher the likelihood of the disease is, given a positive test result (post-test probability), compared with the probability before the test is done (pre-test probability).[13,26] An ideal test is one that will almost always yield positive results when the disease is present and negative results when the disease is absent. Thus, it is one with a high sensitivity and specificity. Such a test will have a very high likelihood ratio.

For the likelihood ratio to be useful, one must have an idea of how likely it is that the disease is present before the test is done (i.e., the pre-test probability) and a sense of how certain one needs to be to conclude that the patient has the disease and to act on this information (i.e., the threshold for action).[45,69] The pre-test probability is determined from available published data or based on physician experience and judgment.[26,45] Once the pre-test probability is known or estimated and the likelihood ratio is determined, a nomogram can be used to estimate the post-test probability (Fig. 2-2).[26]

If a nomogram is not available, the calculations can be done manually, but conversion of probabilities to odds is required. The odds of disease is defined as the probability of disease divided by 1 minus the probability [odds = probability/(1 – probability)]. For a defined group of individuals or patients, it can also be calculated as the ratio of the number of those with disease to those without disease. Thus, if the probability (proportion) of a disease is 0.20 (20 percent), the odds of that disease are 0.20/(1 – 0.20), or 0.20/0.80, or 1:4. This result means that for every person with the disease, there are four people without the disease. The post-test odds are equal to the pre-test odds times the likelihood ratio (post-test odds = pre-test odds × likelihood ratio).[26] The formula [probability = odds/(odds + 1)] is used to convert odds back to probability.

Whether formally or informally, physicians develop thresholds of certainty at or above which they are comfortable with establishing a diagnosis and acting on the diagnoses. Action may take the form of communicating the diagnosis or prognosis to the patient, prescribing treatment, or referring the patient. When

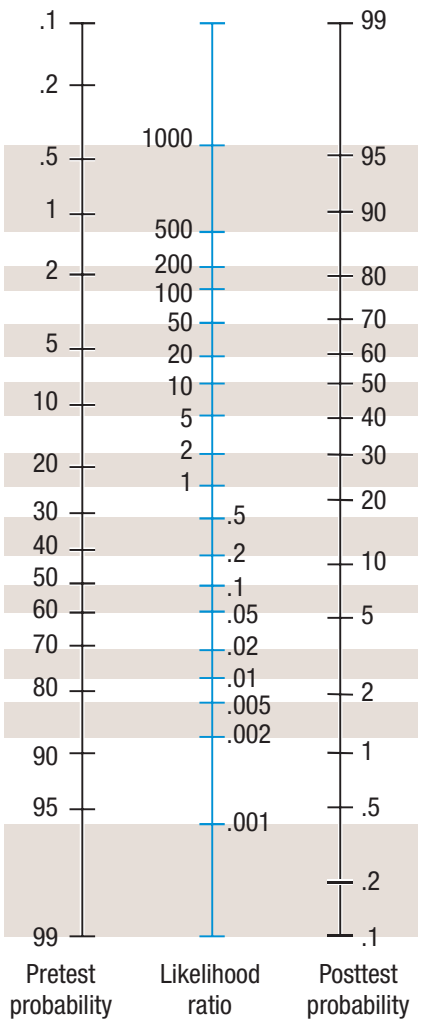

▲ **FIGURE 2-2** Nomogram for determining the post-test probability. To determine the post-test probability, draw a straight line through the pre-test probability and the likelihood ratio and read the post-test probability on the right.

historical and physical evidence leads a clinician to suspect a diagnosis but the degree of certainty does not exceed the threshold for establishing a diagnosis, a test is performed to raise the probability that the disease is present above the clinician's threshold for action.[69]

Evidence About Harm

To be valid, studies about the harmful effects of exposures should include cohorts with comparable groups of exposed and unexposed individuals, or cases and controls; objective outcome measures; and adequate follow-up. In addition, the results should make clinical and biologic sense.[13,26] Few dermatologic studies meet these criteria.

Important terms and concepts that must be understood to determine whether the results of a paper about harmful effects of exposures are clinically important include the following:

- Case-control and cohort studies
- Risk ratio
- Odds ratio

In a cohort study a group of individuals who are exposed to an agent is compared with an appropriately selected unexposed control group and both groups are followed until an event of interest occurs or for a pre-specified length of time. The association between exposure and the harmful outcome is expressed as the relative risk (see Table 2-5 for relative risk calculations). A relative risk of 1 implies no association. If the relative risk is greater than 1, then the result implies a positive association between exposure and the harmful outcome. If it is less than 1, then the implication is of an inverse association. However, to infer a causal association reflected by either an increase in risk (relative risk of more than 1) or a protective effect (relative risk less than 1), one must evaluate the validity and precision of the relative risk estimate. The precision can be readily assessed by means of the 95 percent confidence interval. A confidence interval that does not include 1.0 denotes a statistically significant association. Because the most likely result of a study is the point estimate (i.e., the reported result), the observed association (expressed by the point estimate) may be causal, even if the confidence interval includes 1.0 as a result of a small sample size.[13,26]

Case-control studies are used when the bad outcome is recognized and the causative agent is not yet discovered. They are also used when there is a very long time lag between exposure and outcome or when the frequency of adverse events is very small. In a case-control study, patients with a disease of interest are compared with appropriately selected controls. The odds of exposure to suspected etiologic agents are ascertained in cases and in controls (see Table 2-5). Recall that the odds of an event are calculated as the ratio of the number of events to the number of non-events.[70] Events are exposures to potentially harmful risk factors in case-control studies. The odds of exposure among cases are divided by the odds of exposure among controls to derive the odds ratio, which is a good estimate of the relative risk when the outcome (e.g., disease, death) is relatively rare (i.e., when it occurs in fewer than 5 percent of exposed subjects). The association between ex-

posure and outcome is expressed as the odds ratio in case-control studies. An odds ratio of 1 implies no association. If the odds ratio is higher than 1, then the result implies a positive association between exposure and the harmful outcome. If the odds ratio is less than 1, then the result implies a protective effect of the exposure.[13,26] As noted earlier, it is important to evaluate the validity and precision of the odds ratio estimate by examining the 95 percent confidence interval.

For example, suppose a case-control study was performed to study the relationship between limb deformity and exposure to thalidomide. The results of the study indicated that patients with limb deformities were more likely than controls to have been exposed to thalidomide in utero. The odds ratio for thalidomide exposure was 3.5 and the confidence interval was from 1.8 to 6.6. Thus the odds that patients with limb deformities were exposed to thalidomide in utero were 3.5 times the odds of thalidomide exposure in controls. Because the odds ratio is greater than 1 and its 95 percent confidence interval does not include 1, the result implies a positive association between thalidomide use and limb deformities not likely to have been due to random error. These results (an odds ratio of 3.5 and confidence interval of 1.8 to 6.6) were actually the findings of a study by Wolf et al., who studied the relationship between sunscreen use and melanoma in a case-control study in Austria.[71] Their results indicated that patients with melanoma were more likely than controls to have used sunscreen often. To infer causality it is important to assess whether the results could have occurred from bias and whether the results are biologically plausible.

To add confusion to an already difficult area, clinical researchers will often report results of meta-analyses, cohort studies, and randomized controlled trials using odds ratios. Odds ratios are used because they have stronger statistical properties than other measures.[70] For example, odds ratios can take any value between 0 and infinity, are symmetric in a log scale, and can be used to make adjustments for confounding factors using multiple regression.[70] Unfortunately, they are the measure of association least intuitively understood. If a meta-analysis, controlled trial, or cohort study is reported using odds ratios, the relative risk, difference in response rates, or NNT can often be calculated if the primary data are provided. Alternatively, these more readily understandable measures can be derived if the number of subjects in each group, odds ratio, and overall event rate are provided.

APPLYING EVIDENCE TO SPECIFIC PATIENTS

Applying the evidence to treatment of specific patients involves determining whether the evidence from studies is applicable to a given patient. This decision is based on the patient's condition and values. It involves asking a series of questions that are specific to the type of evidence being considered (see Tables 2-3, 2-4, and 2-5). When faced with the task of determining whether the results of a particular study are applicable to specific patients, physicians should determine whether there are any compelling reasons that the result should not be applied.[37] Applying evidence to specific patients always involves physician judgment.

SAVING THE CRITICAL APPRAISAL OF THE EVIDENCE

Once the physician has made the effort to ask a clinical question, find the best evidence, and critically appraise it, the physician should save the analysis in a place and format that allows it to be easily retrievable for future use. Worksheets for recording evidence from papers dealing with diagnosis, therapy and prevention, prognosis, and harm are available (http://www.cebm.utoronto.ca/teach/materials/caworksheets.htm).[26] These worksheets can be saved electronically or filed physically.

KEY REFERENCES

The full reference list for all chapters is available at www.digm7.com.

2. Sackett DL et al: Evidence based medicine: What it is and what it isn't. *BMJ* **312**:71, 1996
6. Cochrane A: *Effectiveness and Efficiency*. London, Royal Society of Medicine Press Ltd, 1999
7. Sackett DL et al: *Clinical Epidemiology: A Basic Science for Clinical Medicine*. Boston, Little, Brown and Company, 1991, p 441
13. Greenhalgh T: *How to Read a Paper: The Basics of Evidence Based Medicine*. London, BMJ Publishing Group, 1997, http://www.health.library.mcgill.ca/ebm/greenhalgh.htm, accessed April 2, 2007
26. Sackett D et al: *Evidence-Based Medicine: How to Practice and Teach EBM*. Edinburgh, Churchill Livingstone, 1996, p 250
37. Bigby M, Gadenne A-S: Understanding and evaluating clinical trials. *J Am Acad Dermatol* **34**:555, 1996
39. Nisbett R, Ross L: *Human Inference: Strategies and Shortcomings of Social Judgment*. Englewood Cliffs, NJ, Prentice-Hall, 1980, p 330
49. PubMed clinical queries using research methodology filters, http://www.ncbi.nlm.nih.gov/entrez/query/static/clinical.shtml, accessed January 2005
52. Higgins JPT, Green S, eds.: Cochrane handbook for systematic reviews of interventions 4.2.6 [updated September 2006], http://www.cochrane.org/resources/handbook/hbook.htm, accessed March 29, 2007
63. Gardner MJ, Altman DG, editors: *Statistics with Confidence,* 2nd ed. London, British Medical Journal, 2005

CHAPTER 3

Public Health in Dermatology

Hywel C. Williams
Sinéad Langan
Carsten Flohr

WHAT IS PUBLIC HEALTH MEDICINE ALL ABOUT?

Definition

The World Health Organization defines health as "a state of complete physical, mental and social well-being and not merely the absence of disease or infirmity."[1] The key message of this definition is that health is a holistic measure that is influenced by socioeconomic factors and inequality. Public health is a discipline in which the level of focus is on the health of populations as opposed to that of individuals, as is the case in clinical medicine. A useful definition of public health is as follows:

> *Public health is the science and the art of preventing disease, prolonging life, and promoting physical health and mental health and efficiency through organized community efforts*

PUBLIC HEALTH IN DERMATOLOGY AT A GLANCE



- Public health dermatology is about promoting skin health and not just treating skin disease.
- Despite strong historical origins, modern public health dermatology is still relatively underdeveloped.
- Doctors can do a lot to help individual patients but have little influence on the health of entire populations.
- Conversely, the impact of large population benefits are rarely appreciated by individuals.
- Prevention is often more logical than treating sick individuals who come for medical care.
- Sometimes a "low-risk" approach of reducing risk for diseases such as melanoma in the entire population can achieve more than a "high-risk" approach of targeting just those who have skin cancer or who are at high risk of developing skin cancer.
- When entire populations are considered, a little bit of harm affecting a lot of people can add up to more than a lot of harm affecting a few people in absolute terms.
- Modern public health dermatology has had some success in reduction of skin cancer incidence and control of infectious diseases.
- Sometimes, low-technology educational interventions directed at entire communities can result in more benefit than high-technology drugs targeted at a few ill individuals.

toward a sanitary environment, the control of community infections, the education of the individual in principles of personal hygiene, the organization of medical and nursing service for the early diagnosis and treatment of disease and the development of the social machinery to ensure to every individual in the community a standard of living adequate for the maintenance of health.[2]

This definition articulates some of the roles of public health practitioners in relation to society and health. It also highlights the four key areas of public health action: (1) preventing disease and promoting health, (2) improving medical care, (3) promoting health-enhancing behavior, and (4) modifying the environment.[3]

Historical Perspectives

Public health has played a key role in the prevention and treatment of dermatologic diseases. One of the first historical examples is scurvy. In 1746, James Lind discovered through observation, analysis, and performance of a controlled trial that scurvy in sailors was a dietary disease that could be cured by administration of oranges and lemons[5] (see eFigs. 3-0.1 and 3-0.2 in on-line edition). Lind's treatise preceded the discovery of vitamin C by more than a century. In 1775, Percivall Pott was the first to describe an occupationally induced cancer by noting that the mortality from scrotal cancer was 200 times higher in chimney sweeps than in other workers.[6] He attributed the excess mortality to tar and soot exposure in combination with poor personal hygiene. The first carcinogenic polycyclic aromatic hydrocarbon was not discovered until 1933. In the early twentieth century, pellagra was a major public health problem (see eFig. 3-0.3 in on-line edition). There were 100,000 deaths from the disease in a 40-year period and over 3 million sufferers in the United States at that time. In 1914 Dr. Joseph Goldberger noticed that inmates at the Georgia State Sanatorium developed high rates of pellagra whereas the nurses and attendants did not, and concluded that the origin of pellagra was probably a disease caused by a dietary deficiency. He confirmed his hypothesis with controlled clinical trials.[7] The deficient dietary factor, niacin, was discovered in 1937.

Collectively these examples illustrate the importance of public health in the prevention of disease. These examples also highlight the fact that knowledge of disease pathophysiology (i.e., mechanisms) is not always a prerequisite to determining the cause or risk factors for a disease and the potential for effective public health interventions.

HIGH-RISK AND LOW-RISK APPROACHES TO PUBLIC HEALTH

Traditionally, dermatology, like other branches of specialist medicine, has concentrated on the treatment of those who have fallen ill or those who believe they are ill or at high risk of developing disease. For instance, we prescribe topical corticosteroids for those with atopic dermatitis and we may give advice on sun protection to patients who previously had a malignant melanoma. We may see such melanoma patients on a regular basis in skin cancer follow-up clinics to monitor treatment success and to be able to detect recurrences or new early second melanomas. Doctors and patients alike tend to be highly motivated when such an approach is used. The potential benefits seem obvious, and although there may be side effects associated with the prescribed treatment, such as skin thinning with prolonged use of topical corticosteroids, or a scar from excision of a melanoma, many patients will accept such risks, because appropriate treatment leads to a significant improvement of symptoms and improved quality of life or survival. Such an approach to tackling disease has often been referred to in the literature as the *high-risk* approach, because it focuses on the treatment and detection of those at high risk of developing disease and those who have already fallen ill.[8]

In contrast to the high-risk approach, the ultimate aim of public health medicine and public health dermatology is to prevent the development of disease in the first place whenever possible, not only by forestalling it in those identified as being at high risk (e.g., because of a strong family history), but by shifting the entire distribution of a certain exposure in a healthier direction for the whole population (population strategy). Such a low-risk approach can be implemented through large-scale public health education campaigns aimed at fundamentally changing the entire population's behavior and lifestyle. For example, based on the data of the Framingham study one can extrapolate that a reduction of everybody's blood pressure by 10 mm Hg would result in an overall reduction in mortality from heart disease of around 30 percent.[8] In dermatology, a good example of a such a population strategy is attempts to change the general population's sun exposure behavior to reduce exposure to ultraviolet light and ultimately skin cancer incidence and mortality through public health education campaigns that are national (e.g., Australia) or international (e.g., the World Health Organization's INTERSUN program, http://www.who.int/uv/intersunprogramme/en/) in scope (Fig. 3-1). This makes sense particularly in a country like Australia, because a strong association between ultra-



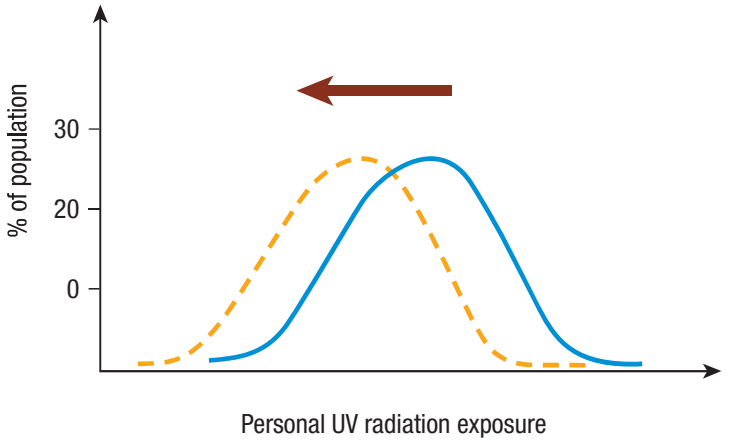

▲ **FIGURE 3-1** Distribution of ultraviolet (UV) radiation exposure before (*solid line*) and after (*dashed line*) implementation of a population strategy to reduce personal UV radiation exposure.



violet radiation and melanocytic and nonmelanocytic skin cancer is well established, and such risk is distributed widely through the predominantly fair-skinned population. Skin cancer is an important cause of death, and treatments for all forms of skin cancer pose an important burden on many countries' health care resources. Simple measures, such as avoiding sun exposure during peak hours of radiation and wearing suitable clothing, can provide adequate protection. The state of Victoria, Australia, has the most comprehensive population-based primary prevention campaign against skin cancer in the world (SunSmart campaign, http://www.sunsmart.com.au/), and it has been reported that this program's public investment was worthwhile. Not only has it resulted in a significant reduction in skin cancer incidence and mortality, but the returns from savings on skin cancer treatments have also exceeded the overall costs of the SunSmart campaign.[9]

It may seem obvious that upstream prevention is more desirable than treating sick individuals who come for treatment downstream after a long chain of pathologic events, some of which may be irreversible. Funding population prevention strategies may be difficult, yet the whole population will potentially benefit, as long as such interventions are evidence based and sustainable. However, it is generally more difficult to persuade healthy individuals to protect themselves against prolonged sun exposure than to persuade those who have already had a malignant melanoma excised. It is also worth pointing out that although a public health intervention such as vaccination against measles has dramatically reduced the incidence of disease at a population level, it is impossible to say which individuals have been helped by such a population intervention—a phenomenon known as the *prevention paradox*.

A population strategy is not suitable for trying to control all skin diseases at present, because such a strategy depends on knowledge of modifiable risk factors. In the many cases for which exposures that predispose to a particular skin condition are unknown, prevention through avoidance is not possible, and the only option available is treatment of disease rather than primary disease prevention.

A LOT OF HARM AFFECTING A FEW PEOPLE VERSUS A BIT OF HARM AFFECTING MANY

Making the conceptual jump from thinking about individual patients to thinking about entire populations can be challenging for practicing dermatologists, especially because such jumps can come up with some surprising results. For example, a dermatologist with an interest in contact dermatitis might see a case of severe hand dermatitis in a printer caused by allergic contact dermatitis from a chemical and then publicize such a case in a respected journal.[10] Another dermatologist reading such a case report might come to the conclusion that allergic contact dermatitis is an important cause of hand dermatitis in printers. Yet when this dermatologist visits the workplace to conduct a survey of all cases of hand eczema in printers, it becomes apparent that true allergic contact dermatitis is probably quite rare, and by far the most common cause of hand eczema is constant low-grade exposure to soap and water from repeated washing and friction from paper and dirt.[11] Thus, it is possible that a little bit of harm affecting a lot of individuals can add up to much more in absolute terms (the realm of the public health/occupational health physician) than a lot of harm affecting one or two workers (the realm of the dermatologist). Another well-known example of such a phenomenon is the effects of smoking on reduction in cardiovascular disease. Even though the association between tobacco smoking and lung cancer (relative risk of 14.0) is much stronger than that between smoking and cardiovascular disease (relative risk, 1.6), strategies for smoking cessation save around twice as many lives from cardiovascular disease than from lung cancer simply because heart disease is much more common than lung cancer.[12] From a public health perspective, therefore, the population-attributable risk (the proportion of the disease that may be attributable to a particular risk factor) is more important than other traditional measures of risk, such as the relative risk (whose magnitude may tell us something about the strength of a particular association). In a study of risk factors for psoriasis in Italy, Naldi et al. found that smoking accounted for up to 26 percent of all cases. In individuals with psoriasis who smoked who also had a family history of psoriasis, an increased body mass index might account for up to 48 percent of disease.[13] The fact that smoking and obesity are modifiable risk factors suggests that psoriasis is preventable, at least to some degree, in this population.

PUBLIC HEALTH APPROACH IN ACTION IN DERMATOLOGY

So far, we have illustrated the public health approach in dermatology using mainly historical examples. Yet although current dermatologic research is still relatively dominated by the pursuit of studies in which the unit of analysis is at a cellular or sub-cellular level, there are some good examples of public health dermatology in action.

One of the classic studies illustrating the public health approach in action for infectious skin disease was that conducted by Taplin and colleagues concerning scabies among Kuna Indians on the San Blas Archipelago.[14] These islands off the coast of Panama were plagued by very high rates of scabies in children in the 1980s, which led to misery and secondary bacterial infections. Despite the use of the best treatments available to combat the problem, the population burden of scabies remained largely unchanged. Only after the adoption of a public health approach in which everyone in defined areas was

treated did the prevalence of scabies fall dramatically from approximately 33 percent to approximately 1 percent. Similar dramatic decreases in scabies prevalence (from 25 percent to 1 percent) and in associated pyoderma and possibly post-streptococcal nephritis have been observed through the use of population-based treatment with ivermectin in the Solomon Islands.[15] Another example is the Global Alliance to Eliminate Lymphatic Filariasis (http://www.filariasis.org/), an alliance between the World Health Organization, ministries of health, and the private sector aimed at the worldwide eradication of this devastating disease. The Global Alliance to Eliminate Lymphatic Filariasis campaign is one of the most rapidly expanding public health programs in history and had regularly treated 25 million people in 12 countries by 2000 and 250 million in 39 countries by 2004. It is not restricted to mass treatment with antifilarial drugs but also includes public health education and advice on skin care of lymphedematous legs to prevent further morbidity.

Public health interventions are not restricted to administration of pharmaceutical drugs but can also include educational interventions such as the public education campaigns for reducing skin cancer through reduction in ultraviolet light exposure. One such successful program has been the introduction of basic dermatologic care in Mali through the development of a training program for general health care workers on the management of common skin diseases.[16] The proportion of patients with skin disease with a clear diagnosis and appropriate diagnosis increased from 42 percent before the training to 81 percent after it. Although such dramatic effects might be overestimated in a simple before-and-after study, the effects were sustained for up to 18 months after training. Paradoxically, these improvements in care were associated with a 25 percent reduction in prescription costs, which suggests that inappropriate empirical prescribing was a source of unnecessary expenditure before the training. Other researchers have also documented how scarce family income can be wasted on inappropriate treatment for skin diseases such as pyoderma and scabies in Mexico.[17] Ryan has described the role of educational clinics in the prevention of skin cancers as well as the management of early lesions in the albino population of 170,000 in Tanzania.[18]

Although many public health interventions may not sound as "high tech" as drugs targeted at specific biologic receptors, they may be more effective and appropriate for sick populations. The concept that a little bit of harm affecting a lot of people can add up to more than a lot of harm affecting a few people was developed earlier, but a similar maxim also holds true: sometimes a low-technology beneficial intervention that can be applied to a large population can add up to far greater benefit in population terms than a high-technology solution that will benefit only a few.

FUTURE OF PUBLIC HEALTH IN DERMATOLOGY

Some dermatologists have already conducted a population-based needs assessment for dermatologic care, followed by organization of the appropriate services at a population level, rather than just viewing the world of skin disease from within the narrow confines of a hospital-based practice. There are also increasing international collaborations to try to prevent and reduce the burden of skin diseases at a global level through health care planning and focused interventions. These are carried out through organizations such as the International Foundation for Dermatology (http://www.ifd.org/) in conjunction with the International League of Dermatological Societies (http://web.ilds.org/). The International League of Dermatological Societies is working to improve community dermatologic programs in developing countries, focusing on better diagnosis and clear evidence-based guidance for the management of common dermatoses. Training courses have been established, such as those at the Regional Dermatology Training Centre in Moshi, Tanzania (http://www.global-campus.org/rdtc) and short courses in Guerrero, Mexico and Mali. One of the key aims of these programs is to educate at the primary care level with the idea that the trainees will then multiply such knowledge by training others in their own countries. As Weinstock points out in Chapter 1, the burden of skin diseases is high. Many skin diseases can already benefit from a public health approach. What is needed to redress the relative paucity of public health dermatology is to understand the concept that populations are as important as individuals and to build on the sort of collaboration championed by the International Foundation for Dermatology.

KEY REFERENCES

The full reference list for all chapters is available at www.digm7.com.

2. Winslow CEA: The untilled field of public health. *Mod Med* **2**:183, 1920
7. Goldberger J, Wheeler GA, Syndenstricker E: A study of the diet of nonpellagrous and pellagrous households. *JAMA* **71**:944, 1918
8. Rose G: Sick individuals and sick populations. *Int J Epidemiol* **14**:32, 1985
9. Carter R, Marks R, Hill D: Could a national skin cancer primary prevention campaign in Australia be worthwhile? An economic perspective. *Health Promot Int* **14**:73, 1999
14. Taplin D et al: Community control of scabies: A model based on use of permethrin cream. *Lancet* **337**:1016, 1991
16. Mahé A et al: Integration of basic dermatological care into primary health care services in Mali. *Bull World Health Organ* **83**:935, 2005
18. Ryan TJ: Healthy skin for all. *Int J Dermatol* **33**:829, 1994



This page intentionally left blank

SECTION 2

APPROACH TO DERMATOLOGIC DIAGNOSIS

CHAPTER 4

Structure of Skin Lesions and Fundamentals of Clinical Diagnosis

Amit Garg
Nikki A. Levin
Jeffrey D. Bernhard

What is most difficult of all? It is what appears most simple: To see with your eyes what lies in front of your eyes.

—Goethe

THE ART OF DIAGNOSIS

The diagnosis and treatment of diseases that affect the skin rest on the physician's ability to use the lexicon of dermatology, to recognize the basic and sequential lesions of the skin, and to recognize the various patterns in which they occur in a variety of diseases and syndromes. In this chapter, we discuss a fundamental approach to the patient presenting with a skin problem. We introduce the technical vocabulary of dermatologic description, the "dermatology lexicon"—a set of terms that denote types of skin lesions. It is important to know and use this standard terminology, as it is the first step in generating a differential diagnosis. Once a lesion has been described as a pearly, flesh-colored, telangiectatic, ulcerated nodule, the experienced physician puts basal cell carcinoma at the top of the differential diagnosis. It is also important to use standard dermatologic terminology for consistency in clinical documentation, in research, and in communication with other physicians.

The process of examining and describing skin lesions may be likened to that of viewing a painting. First, one stands back and takes in the whole "canvas," analogous to viewing the patient from a few feet away at which distance an overall assessment of the patient's general and cutaneous health may be made. One may note such findings as skin color and turgor, presence of pallor or jaundice, degree of sun damage, and the overall number and location of lesions. Next, one looks more closely at the "trees" or "mountains" that make up the landscape, analogous to describing and categorizing the specific lesions on the patient. Finally, one may closely examine the details of the canvas, taking in the texture and brushstrokes, analogous to using magnification to see the borders of a nevus or compressing a lesion to see if it blanches. Just as a knowledgeable viewer of art may recognize a work of Georges Seurat by its tiny, dot-like brush strokes, an experienced observer of the skin can recognize a melanoma by its asymmetry, irregular borders and multiple colors. This chapter aims to introduce the reader to the art and science of dermatologic diagnosis.

APPROACH TO THE PATIENT

History

Dermatology is a visual specialty, and some skin lesions may be diagnosed at a glance. Nonetheless, the history is important and in complex cases, such as the patient with rash and fever or the patient with generalized pruritus, it may be crucial. Dermatologists vary in whether they prefer to take a history before, during, or after performing a physical examination. In practice, many perform a brief examination initially, obtain some history, then return to a more focused examination.

For the following reasons, it is often useful to at least briefly examine the patient before taking a lengthy history:

- Certain skin conditions, such as classic plaque-type psoriasis or molluscum contagiosum, for example, present with such distinctive morphologies

SKIN LESIONS AND DIAGNOSIS AT A GLANCE

- A patient and thorough approach to the evaluation decreases the risk of making an incorrect diagnosis or overlooking another diagnosis.
- Knowledge and appropriate use of dermatology terminology are fundamental.
- Recognition of disease patterns requires repeated patient encounters.
- The history is indispensable in elucidating complex diagnoses.
- The entire mucocutaneous surface, as well as the hair and nails, should be examined whenever reasonable.
- Morphologic characteristics derived from cell type in skin must be carefully scrutinized.
- Diseases have characteristic morphology and distribution.
- Common pitfalls in dermatologic diagnosis exist and can be avoided.



Copyright © 2008 by The McGraw-Hill Companies, Inc. Click here for terms of use.

TABLE 4-1
Approach to Dermatologic Diagnosis[a]

- Initial clinical impression: Does the patient appear ill?
- Physical examination: detailed examination of the skin, hair, nails, and mucous membranes
- Four cardinal features
  - Type of lesion: macule, papule, nodule, vesicle, etc. (see Table 4-2)
  - Shape of individual lesions: annular, iris, arciform, linear, round, oval, umbilicated, etc.
  - Arrangement of multiple lesions: isolated, scattered, grouped, linear, herpetiform, zosteriform, etc.
  - Distribution (be sure to examine scalp, mouth, palms, and soles)
    - Extent of involvement: circumscribed, regional, generalized, universal? What percentage of the body surface is involved?
    - Pattern: symmetry, exposed areas, sites of pressure, intertriginous areas?
- Characteristic locations: flexural, extensor, intertriginous, glabrous, palms and soles, dermatomal, trunk, lower extremities, exposed areas, etc.?
  - Three major characteristics
    - Color (see Table 4-3)
      - ~ If diffuse: red, brown, gray-blue, white, blue, orange-yellow, etc.; if circumscribed: red, violaceous, orange, yellow, lilac, livid, brown, black, blue, gray, white, etc.
      - ~ Does the color blanch with pressure (diascopy test)?
      - ~ Wood's lamp examination of pigmentary alterations: Is contrast enhanced?
    - Consistency and feel of lesion: soft, doughy, firm, hard, "infiltrated," dry, moist, mobile, tender, warm?
    - Anatomic components of the skin primarily affected: Is the process epidermal, dermal, subcutaneous, appendageal, or a combination of these?
- General physical examination as indicated by the clinical presentation and differential diagnosis, with particular attention to vital signs, lymphadenopathy, hepatomegaly, splenomegaly, joints, etc.
- History of a rash. Key questions:
  - When did it start?
  - Does it itch, burn, or hurt?
  - Where on the body did it start?
  - How has it spread (pattern of spread)?
  - How have individual lesions changed (evolution)?
  - Provocative factors?
  - Previous treatments and response?
- History of a growth. Key questions:
  - How long has the lesion been present?
  - Has it changed, grown, bled, itched, or failed to heal?
- General history of present illness as indicated by clinical situation, with particular attention to constitutional and prodromal symptoms
  - Acute illness syndrome (fever, sweats, chills, headache, nausea, vomiting, cough, runny nose, etc.)?
  - Chronic illness syndrome (fatigue, anorexia, weight loss, malaise)?
- Review of systems as indicated by clinical situation, with particular attention to symptoms indicating a possible connection between cutaneous signs and disease of other organ systems (e.g., rheumatic complaints: myalgias, arthralgias, Raynaud phenomenon, sicca symptoms)
- Review of systems for growths suspicious for, or associated with, malignancy: particular attention to symptoms of metastasis (weight loss, fevers, chills, night sweats, headache, swollen glands, abdominal pain, abnormal stooling, bone pain, etc.)
- Medication history: allergy; all prescription, nonprescription, and "complementary" medications, with particular attention to those that temporally correspond to the onset of the eruption
- Past medical history
  - Illnesses
  - Operations
  - Atopic history (asthma, hay fever, eczema)
  - Family medical history, particularly of skin disorders and of atopy
  - Family history of skin, or other, cancers
- Social history with particular reference to occupation, hobbies, sun exposure, pet exposure, tobacco smoking, alcohol consumption, recreational drugs, travel, sexual orientation and exposures
- Laboratory studies
  - Special procedures as determined by the individual clinical situation (see Chap. 5)
    - Dermatoscopy
    - Hand lens or 7× loupe magnification for identifying specific features
    - Biopsy for histopathologic and other analyses (e.g., electron microscopy, immunofluorescence, special stains) if indicated
    - Tissue to be minced for bacterial and fungal cultures
    - Gram stains of crust, scale, or exudates
    - Potassium hydroxide preparation for yeast or fungi
    - Cytologic preparation (Tzanck smear) in vesicular and bullous eruptions
    - Swab for bacterial, viral, and fungal cultures
    - Wood's lamp examination of urine for porphyrins and of hair and skin for fluorescence or for changes in pigmentation
    - Oil mount preparation of scraping for scabies mite
    - Patch testing for allergic contact dermatitis
  - General: hematology, chemistry, urinalysis, serologic tests (e.g., syphilis, antinuclear antibody), imaging studies, and others as indicated by the presentation
- Final diagnosis: re-examination over time and more than one biopsy may be required for definitive diagnosis

[a]This approach was developed by Thomas B. Fitzpatrick, Jeffrey D. Bernhard, and Harley A. Haynes. It has been modified by Amit Garg, Nikki Levin, and Jeffrey D. Bernhard.



that the diagnosis may be immediately obvious, rendering extensive history taking unnecessary.

- A patient's history may contain "red herrings," which lead the physician away from, rather than toward, the correct diagnosis. Examination of the patient before taking a history may yield a more complete and unbiased differential diagnosis.
- In certain situations, such as the evaluation of alopecia, initial examination of the patient to determine what type of hair loss is present allows the physician to pursue a line of questions pertinent to that type of alopecia.

In taking a history from a patient presenting with a new skin complaint, the physician's primary goal is to establish a diagnosis, with a secondary goal of evaluating the patient as a candidate for therapy. In patients whose diagnosis is already established, the physician's goals are to re-evaluate the original diagnosis, monitor disease progress and complications, and modify treatment accordingly. Table 4-1 is a guide useful in evaluating a patient with a rash or growth. The table is not an algorithmic

method of arriving at a diagnosis. Rather, it is meant to provide the learner with a fundamental and general approach to diagnosing an unknown.

Examination of the Dermatologic Patient

SCOPE OF THE COMPLETE CUTANEOUS EXAMINATION The complete cutaneous examination includes inspection of the entire skin surface, including often-overlooked areas such as the scalp, eyelids, ears, genitals, buttocks, perineal area, and interdigital spaces; the hair; the nails; and the mucus membranes of the mouth, eyes, anus, and genitals. In routine clinical practice, not all of these areas are examined unless there is a specific reason to do so, such as a history of melanoma or a particular localizing complaint.

ADVANTAGES TO PERFORMING A COMPLETE CUTANEOUS EXAMINATION Although it is not always essential or practical to perform a complete skin examination, there are many advantages to doing so, especially for new patients and challenging cases:

- Identification of potentially harmful lesions (e.g., skin cancers) of which the patient is unaware; any patient with a history of skin cancer or a chief complaint of a "new growth" deserves a full skin examination.
- Identification of benign lesions (e.g., seborrheic keratoses, angiokeratomas) that the patient was concerned about but reluctant to mention, thereby enabling the physician to provide reassurance.
- Finding hidden clues to diagnosis (e.g., scabies lesions on the penis, psoriatic plaques on the buttocks, Wickham striae of lichen planus on the buccal mucosa, nail pitting in alopecia areata).
- Opportunity for patient education (e.g., lentigines are a sign of sun damage and suggest the need for improved sun protection).
- Opportunity to convey the physician's concern about the patient's skin health as a whole. Patients appreciate this and also regard the physician as thorough.

BARRIERS TO PERFORMING A COMPLETE SKIN EXAMINATION Despite the advantages of performing a full cutaneous examination, numerous barriers exist that may prevent the dermatologist from performing such an evaluation for every patient. Understandably, patients may decline a full examination when their chief complaint is relatively minor or localized, such as a wart or acne. In other cases, patients may express resistance to disrobing for a full examination due to embarrassment, especially when the physician is of the opposite gender. Sometimes the physician is uncomfortable performing a complete skin examination with the concern that a patient may misinterpret the examination as improper. In many instances, time constraints and lack of personnel to serve as chaperones limit the ability to perform full skin examination.

IDEAL CONDITIONS FOR THE COMPLETE SKIN EXAMINATION A complete skin examination is most effective when performed under ideal conditions. It is most important to have excellent lighting, preferably bright, even light that simulates the solar spectrum. Without good lighting, subtle but important details may be missed. The patient should be fully undressed, wearing only a gown that is easily moved aside, with a sheet over the legs, if desired. Underwear, socks, and shoes should be removed, as should any makeup or eyeglasses. The examining table should be at a comfortable height, with a head that reclines, an extendable footrest, and gynecologic stirrups. The examining room should be at a comfortable temperature for the lightly dressed patient. It should contain a sink for hand washing and disinfecting hand foam, as patients are reassured by seeing their physician wash hands before the examination. If the patient and physician are of opposite genders, having a chaperone in the room can make the examination more comfortable for both.

RECOMMENDED TOOLS FOR THE COMPLETE SKIN EXAMINATION Although the physician's eyes and hands are the only essential tools for examination of the skin, the following are often useful and highly recommended:

- A magnifying tool such as a loupe, magnifying glass, or dermatoscope.
- A bright focused light such as a flashlight or penlight to sidelight lesions.
- Glass slides or a hand magnifier for diascopy.
- Alcohol pads to remove scale or surface oil.
- Gauze pads or tissues with water for removing makeup.
- Gloves to be used for examination when scabies or another highly infectious condition (secondary syphilis) is suspected, when examining mucus membranes, vulvar and genital areas, and when performing any procedure.
- A ruler for measuring lesions.
- Number 15 and number 11 scalpel blades for scraping or incising lesions, respectively.
- A camera for photographic documentation.
- A Wood's lamp (365 nm) for highlighting subtle pigmentary changes.

TECHNIQUE OF THE DERMATOLOGIC PHYSICAL EXAMINATION Just as there is no one correct way to perform a general physical examination, each physician approaches the complete skin examination with his or her own style. A common thread to effective styles of skin examination is consistency in the order of examining different body areas to ensure that no areas are overlooked. One approach to the complete skin examination is presented here. First, observe the patient at a distance for general impressions (e.g., asymmetry due to a stroke, obesity, pallor, fatigue, jaundice). Next, examine the patient in a systematic way, usually from head to toe, uncovering one area at a time to preserve patient modesty. Move the patient (e.g., from sitting to lying) and the illumination as needed for the best view of each body area. Palpate growths to determine whether they are soft, fleshy, firm, tender, or fluid-filled. Use of the hands to stretch the skin is especially useful in diagnosis of basal cell carcinoma, in which stretching skin reveals a "pearly" quality often not seen on routine inspection. A magnifier worn on the head leaves both hands free for palpation of lesions. Certain lesions, such as porokeratosis, are best examined with side lighting that reveals depth and the details of borders. During the examination, patients often find it reassuring for the physician to name and demystify benign lesions as they are encountered.

Special examination techniques for hair disorders are discussed in Chap. 86, but include having the patient sit in a chair so that the entire scalp is easily examined, parting the patient's hair at the front and occiput and gently tugging on hairs to determine the fraction of loose (telogen) hairs. Examination of the nails is discussed in Chap. 87.

After completing the examination, it is important to document the skin findings, including the type of lesions and their locations, either descriptively or on a body map. Careful documentation is



particularly important for suspicious lesions that are to be biopsied, so that the exact location may be found and definitively treated at a later date. Instant or digital photography is a useful adjunct for documentation.

INTRODUCTION TO MORPHOLOGY

Siemens (1891–1969) wrote, "he who studies skin diseases and fails to study the lesion first will never learn dermatology." His statement reinforces the notion that the primary skin lesion, or the evolution thereof, is the essential element on which clinical diagnosis rests. Joseph Jakob Edler von Plenck's (1738–1807) and Robert Willan's (1757–1812) work in defining basic morphologic terminology further permitted description and comparison of fundamental lesions, thereby facilitating characterization and recognition of skin disease. To read words, one must recognize letters; to read the skin, one must recognize the basic lesions. To understand a paragraph, one must know how words are put together; to arrive at a differential diagnosis, one must know what the basic lesions represent, how they evolve, and how they are arranged and distributed.

Variation and ambiguity in the morphologic terms generally accepted by the international dermatology community have engendered barriers to communication among physicians of all disciplines, including dermatologists. In dermatologic textbooks, the papule, for example, has been described as no greater than 1 cm in size, less than 0.5 cm, or ranging from the size of a pinhead to that of a split pea. Thus, in forming a mental image of a lesion or eruption after hearing its morphologic description, physicians sometimes remain irresolute. The mission of the Dermatology Lexicon Project is to create a universally accepted and comprehensive glossary of morphologic descriptive terms to support research, medical informatics, and patient care (http://www.DermatologyLexicon.org). Morphologic definitions in this chapter parallel and amplify those of the Dermatology Lexicon Project. In describing morphologic terms, our intent is simple: to provide the reader with a pure appreciation of the "letters that make up the alphabet" rather than detailing a "field guide" for diagnoses, which are covered in depth throughout the textbook. Table 4-2 is a summary of the lesions discussed.

TABLE 4-2
Morphologic Lesions

Raised	Depressed	Flat	Surface Change	Fluid Filled	Vascular
Papule	Erosion	Macule	Scale	Vesicle	Purpura
Plaque	Ulcer	Patch	Crust	Bulla	Telangiectasia
Nodule	Atrophy	Erythema	Excoriation	Pustule	Infarct
Cyst	Poikiloderma	Erythroderma	Fissure	Furuncle	
Wheal	Sinus		Lichenification	Abscess	
Scar	Striae		Keratoderma		
Comedo	Burrow		Eschar		
Horn	Sclerosis				
Calcinosis					

Raised Lesions

PAPULE A papule is a solid, elevated lesion less than 0.5 cm in size in which a significant portion projects above the plane of the surrounding skin. Oblique lighting with a flashlight in a darkened room is sometimes necessary to detect the slight elevation of embedded papules. Papules surmounted with scale are referred to as papulosquamous lesions. Sessile, pedunculated, dome-shaped, flat-topped, rough, smooth, filiform, mammillated, acuminate, and umbilicated constitute some common shapes and surfaces of papules. A clinical example is lichen planus (Fig. 4-1; see Chap. 26).

PLAQUE A plaque is a solid plateau-like elevation that occupies a relatively large surface area in comparison with its height above the normal skin level and has a diameter larger than 0.5 cm. The elevation need not be significant. Plaques, which may form by extension or confluence of papules, are further characterized by their size, shape, color, and surface change. A clinical example is psoriasis (Fig. 4-2; see Chap. 18).

NODULE Depending on the anatomic component(s) primarily involved, nodules are of five main types: (1) epidermal, (2) epidermal-dermal, (3) dermal, (4) dermal-subdermal, and (5) subcutaneous. On the skin, a nodule is a solid, round or ellipsoidal, palpable lesion that has a diameter larger than 0.5 cm. Size, however, is not the major consideration in the definition of nodule. Depth of involvement and/or substantive palpability, rather than diameter, differentiates a nodule from a large papule or plaque. *Tumor*, also sometimes included under the heading of nodule, is a general term for any mass, benign or malignant. A *gumma* is, specifically, the granulomatous nodular lesion of tertiary syphilis. For cases in which more than one term may be applicable, it is simply best to include measurements and descriptive terms that convey the important features of the lesion in question. Some additional features of a nodule that may help reveal a diagnosis include whether it is warm, hard, soft, fluctuant, movable, fixed, or painful. Similarly, different surfaces of nodules, such as smooth, keratotic, ulcerated, or fungating, also help direct diagnostic considerations. A clinical example is nodular basal cell carcinoma (Fig. 4-3; see Chap. 115).



▲ **FIGURE 4-1** Papule. Multiple, well-defined papules of varying sizes are seen. Flat tops and glistening surface are characteristic of lichen planus.



▲ **FIGURE 4-2** Plaque. Well-demarcated pink plaques with a silvery scale representing psoriasis vulgaris.





▲ **FIGURE 4-3** Nodule. A nodular basal cell carcinoma with well-defined, firm nodule with a smooth and glistening surface through which telangiectasia can be seen.

CYST A cyst is an encapsulated cavity or sac lined with a true epithelium that contains fluid or semisolid material (cells and cell products such as keratin). Its spherical or oval shape results from the tendency of the contents to spread equally in all directions. If the overlying skin is stretched enough by the cyst, follicular openings may be prominent. Sometimes, the cavity is so superficial that it gives the appearance of a vesicle that lacks encapsulation. A nodule or papule may be suspected of being a cyst if, on palpation, it is resilient; the eyeball, for example, feels similar to a cyst. Depending on the nature of the contents, cysts may be hard, doughy, or fluctuant. A clinical example is a cystic hidradenoma (Fig. 4-4; see Chap. 119).



▲ **FIGURE 4-4** Cyst. A bluish colored resilient cyst filled with a mucous-like material on the cheek is a cystic hidradenoma.

WHEAL A wheal is a swelling of the skin that is characteristically evanescent, disappearing within hours. These lesions, also known as *hives* or *urticaria*, are the result of edema produced by the escape of plasma through vessel walls in the upper portion of the dermis. Wheals may be tiny papules 2 mm to 4 mm in diameter or giant plaques measuring greater than 10 cm. Variable shapes (round, oval, serpiginous, or annular) may be noted, often in the same patient. Borders of a wheal, although sharp, are not stable and in fact move from involved to adjacent uninvolved areas over a period of hours. Wheals are pink to pale red in color. The flare, or ring of pink erythema, of a wheal may be intense if superficial vessels are dilated. If the amount of edema is sufficient to compress superficial vessels, wheals may in fact be white in the center or around the periphery, producing a zone of pallor. With associated inflammatory disruption of the vessels walls, wheals may have a deeper red color, may be purpuric, and are more persistent. Wheals are soft to firm depending on the extent of edema present.



▲ **FIGURE 4-5** Wheal. A sharply demarcated wheal with a surrounding erythematous flare occurring within seconds of the skin being stroked.

Angioedema is a deeper, edematous reaction that occurs in areas with very loose dermis and subcutaneous tissue such as the lip, eyelid, or scrotum. It may occur on the hands and feet as well, and result in grotesque deformity. A careful search for laryngeal edema should be made in cases of angioedema, as such cases may result in death from airway obstruction (see Chap. 37). A clinical example is dermatographism (Fig. 4-5; see Chap. 37).

SCAR A scar arises from proliferation of fibrous tissue that replaces previously normal collagen after a wound or ulceration breaches the reticular dermis. Scars have a deeper pink to red color early on before becoming hypo- or hyperpigmented. In most scars, the epidermis is thinned and imparts a wrinkled appearance at the surface. Adnexal structures, such as hair follicles, normally present in the dermis are destroyed. Hypertrophic scars typically take the form of firm papules, plaques, or nodules. Keloid scars are also elevated. Unlike hypertrophic scars (Fig. 4-6; see Chap. 64), keloids exceed,



▲ **FIGURE 4-6** Scar. A pink firm hypertrophic scar.







▲ **FIGURE 4-7** Comedo. Open and closed comedones on the face of this patient with acne.

with web-like extensions, the area of initial wounding. Atrophic scars are thin depressed plaques.

COMEDO A comedo is a hair follicle infundibulum that is dilated and plugged by keratin and lipids. When the pilosebaceous unit is open to the surface of the skin with a visible keratinaceous plug, the lesion is referred to as an *open comedo*. The black color of the comedo is due to the oxidized sebaceous content of the infundibulum ("blackhead"). A closed infundibulum in which the follicular opening is unapparent accumulates whitish keratin and is called a *closed comedo*. These lesions are common on the face and trunk. A clinical example is comedonal acne (Fig. 4-7; see Chap. 78).

HORN A horn is a conical mass of cornified cells arising over an abnormally differentiating epidermis. Associated underlying pathologic states may include human papilloma virus replication in keratinocytes of a wart or the clonal expansion of mutated keratinocytes in squamous cell carcinoma. A clinical example is verruca vulgaris (Fig. 4-8; see Chap. 196).

CALCINOSIS Deposits of calcium in the dermis or subcutaneous tissue may be



▲ **FIGURE 4-8** Horn. A conical column of hyperkeratosis overlying a pink papule. This cutaneous horn represents a verruca vulgaris.

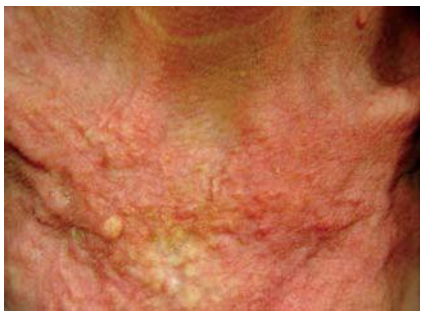

▲ **FIGURE 4-9** Calcinosis. Hard, whitish nodules on the chest representing dystrophic calcinosis in this patient with dermatomyositis.

appreciated as hard, whitish nodules or plaques, with or without visible alteration of the skin's surface. A clinical example is cutaneous calcinosis in dermatomyositis (Fig. 4-9; see Chap. 157).

Depressed Lesions

EROSION An *erosion* is a moist, circumscribed, depressed lesion that results from loss of a portion or all of the viable epidermal or mucosal epithelium. The defect extending to the most superficial part of the dermis may result in pinpoint bleeding in a sieve-like fashion. Erosions may result from trauma, detachment of epidermal layers with maceration, rupture of vesicles or bullae, or epidermal necrosis, for example. Extensive erosions may result in large areas of raw denudation. Unless they become secondarily infected, erosions do not scar. A clinical example is toxic epidermal necrolysis (Fig. 4-10; see Chap. 39).

ULCERS An ulcer is a defect in which the epidermis and at least the upper (papillary) dermis has been removed. Breach of the dermis and destruction of adnexal structures impede re-epithelialization, and the defect heals with scarring. There are numerous descriptive features helpful in determining the cause of ulcers. Location of the ulcer, such as on



▲ **FIGURE 4-10** Erosion. Sloughing of the skin in this patient with toxic epidermal necrolysis leaves behind a large erosion.



▲ **FIGURE 4-11** Ulcer. A large ulcer with a ragged base and heaped up pink erythematous border on the leg representing progressing pyoderma gangrenosum.

the medial aspect of the ankle or over pressure points, may be telling. Borders of the ulcer may be rolled, undermined, punched out, jagged, or angular. The base may be clean, ragged, or necrotic. Discharge may be purulent, granular, or malodorous. Surrounding skin may be red, purple, pigmented, reticulated, indurated, sclerotic, or infarcted. Other informative features include the presence of nearby nodules, surrounding excoriations, varicosities, hair, sweat, and the strength of adjacent pulses. A clinical example is pyoderma gangrenosum (Fig. 4-11; see Chap. 32).

ATROPHY *Atrophy* refers to a diminution in the size of a cell, tissue, organ, or part of the body. A decrease in the number of epidermal cells results in thinning of the epidermis. Atrophic epidermis is glossy, almost transparent, paper thin and wrinkled, and may not retain normal skin lines.

Epidermal atrophy may also be associated with similar alterations in the dermis. A decrease in the papillary or reticular dermal connective tissue manifests as a depression of the skin. In dermal atrophy occurring without epidermal involvement, the area of affected skin is normal in color and surface markings because the circumscribed depression is produced only by the decrease in dermal tissue.

Atrophy of the panniculus results in a more substantial depression of the skin. A thinned wrinkled surface indicates coexisting epidermal atrophy. Fig. 4-12 shows aged skin of the arm (see Chap. 108).

POIKILODERMA As a morphologic term, *poikiloderma* refers to the combination of atrophy, telangiectasia, and varied pigmentary changes (hyper- and hypo-) over an area of skin. This combination of features may give rise to a dappled appearance to the skin. The distribution



▲ **FIGURE 4-12** Atrophy. Thin, wrinkled atrophic skin that has lost its normal texture on the arm of this elderly woman.

of poikiloderma varies according to etiology. Because of some confusion in the past stemming from the use of the word *poikiloderma* in the naming of specific syndromes, it is probably best to restrict its use to a descriptive. A clinical example is chronic radiodermatitis (Fig. 4-13; see Chap. 95).

SINUS A sinus is a tract connecting deep suppurative cavities to each other or to the surface of the skin. The contents of the cavity, usually pus, fluid, or keratin, may drain to the surface when such communication exists. These tracts are usually noted on the scalp, neck, axillae, groin, and rectum. A clinical example is hidradenitis suppurativa (Fig. 4-14; see Chap. 83).



▲ **FIGURE 4-13** Poikiloderma. Poikiloderma with telangiectatic erythema, hyperpigmentation, hypopigmentation, and atrophy in chronic radiodermatitis.



▲ **FIGURE 4-14** Sinus. Suppurative communicating fibrous sinus tracts in the groin representing hidradenitis suppurativa.

STRIAE Striae are linear depressions of the skin that usually measure several centimeters in length and result from changes to the reticular collagen that occur with rapid stretching of the skin. The surface of striae may be thin and wrinkled. They may be pink to red in color and raised before becoming paler and flattened out. Striae are multiple and typically symmetrically distributed along lines of cleavage in the involved area. A clinical example is striae distensae (Fig. 4-15; see Chap. 107).

BURROW A burrow is a wavy, threadlike tunnel through the outer portion of the epidermis excavated by a parasite. Burrows measure only a few millimeters in length. A clinical example is scabetic burrow (Fig. 4-16; see Chap. 208).

SCLEROSIS *Sclerosis* refers to a circumscribed or diffuse hardening or induration in the skin that is a result of dermal fibrosis. It is detected more easily by palpation, on which the skin may feel board-like, immobile, and difficult to pick up. Hyperpigmentation or hypopigmentation may also distinguish the area of induration from normal skin. The epidermis overlying sclerotic dermis may be atrophic. Sclerosis may extend deep into the pannus, fascia, muscle, or bone with resulting musculoskeletal deformity and loss of function. A clinical example is morphea (Fig. 4-17; see Chap. 62).



▲ **FIGURE 4-15** Striae. Linear striae on the back of this woman who experienced a rapid growth spurt and weight gain.



▲ **FIGURE 4-16** Burrows. Several, slightly scaling, thread-like burrows on the medial aspect of the palm, associated with a more generalized eczematous process in this patient infested with scabies mites.

Flat and Macular Lesions

MACULE A macule is a flat lesion, even with the surface level of surrounding skin, perceptible as an area of color different from the surrounding skin or mucous membrane. Macules are non-palpable. Their shapes are varied and borders may be distinct or vague. Maculosquamous is a neologism invented to describe macules with fine non-palpable scaling, which may become apparent only after light scraping and scratching.

Perhaps the most important additional feature of a lesion other than primary morphology is color. Lesional color, which is often the first visual assessment made, is reliably reproducible with par-



▲ **FIGURE 4-17** Sclerosis. Firm, slightly depressed sclerotic plaque on the leg of a girl with morphea. The surface is atrophic and there are areas of hypo- and hyperpigmentation.



TABLE 4-3
Implications of Color Changes in Altered Skin

Color	Pathology	Diagnostic Consideration
Apple jelly	Granulomatous inflammation	Tuberculosis, sarcoidosis, leishmaniasis
Black	Melanin, necrosis	Melanoma, purpura fulminans, calciphylaxis
Blue	Deep dermal pigment, reduced hemoglobin, tattoo, medication	Blue nevus, amiodarone
Brown	Melanin, hemosiderin, chronic inflammation, post-inflammatory, dried serum	Nevus, melasma
Copper	Inflammation with plasma cells	Secondary syphilis
Green	Deep hemosiderin, pyocyanin pigment, tissue eosinophilia	*Pseudomonas* infection, tattoo, Wells syndrome
Grey	Deep melanin or other pigment deposition	Chloroquine toxicity, mongolian spot, erythema dyschromicum perstans
Lilac	Inflammation, dilatation of deep dermal blood vessels	Borders of evolving morphea, dermatomyositis
Orange	Granulomatous inflammation with histiocytes having abundant cytoplasm	Juvenile xanthogranuloma
Pearly	Epidermal proliferation without surface keratin	Basal cell carcinoma
Pink	Acute inflammation, dilatation of superficial dermal blood vessels, hemorrhage	Eczema
Red	Hemorrhage, acute inflammation, dilatation of blood vessels	Psoriasis, drug eruptions
Salmon pink	Inflammation with involvement of epidermis, dilatation of blood vessels inflammation with edema	Pityriasis rubra pilaris, psoriasis, urticaria
Violet	Hemorrhage, deep hemosiderin, lichenoid inflammation	Lichen planus, Kaposi sarcoma
White	Reduced or absent melanin synthesis, post-inflammatory	Tinea versicolor, albinism, vitiligo
Yellow	Superficial staphylococcus or streptococcus infection mixed with keratinized cells, carotenoids, hemosiderin, bile pigment, accumulated lipid	Impetigo, xanthomas, sebaceous hyperplasia, necrobiosis lipoidica diabeticorum, jaundice



ticular types of pathologies, such as destruction of melanocytes, dilatation of dermal blood vessels, or inflammation of vessel walls with extravasation of red blood cells. As such, color provides meaningful insight into pathologic processes of the skin and facilitates clinical diagnosis. Pigmentary changes represent an important and common type of macular color change and may be described as hyperpigmented (as in post-inflammatory hyperpigmentation), hypopigmented (as in tinea versicolor), or depigmented (as in vitiligo).

Table 4-3 describes characteristic colors that may be noted with inspection of altered skin. A clinical example is lentigo (Fig. 4-18; see Chap. 122).

PATCH A patch is similar to a macule; it is a flat area of skin or mucous membranes with a different color from its surrounding. A patch, however, is larger than 0.5 cm, and it may have a fine, very thin scale. Confluence of patches may cover large areas of the body. The term *patch* is also used to describe early lesions of cutaneous T-cell lymphoma that have a fine scale or are minimally atrophic. A clinical example is vitiligo (Fig. 4-19; see Chap. 72).



▲ **FIGURE 4-18** Macule. Uniform colored brown macule with slightly irregular, sharply defined borders representing a lentigo on the lip.

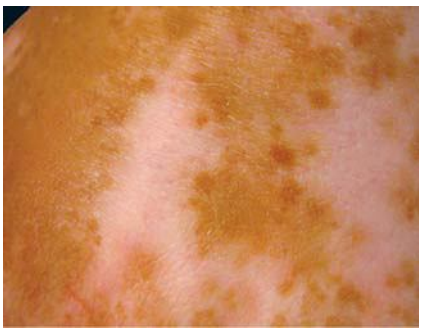

▲ **FIGURE 4-19** Patch. Depigmented patches within areas of normal skin tone representing vitiligo.

ERYTHEMA Erythema represents the blanchable change in color of skin or mucous membrane that is due to dilatation of arteries and veins in the papillary and reticular dermis. It exists in different colors, and to dub a primary lesion as *erythematous* alone is incomplete. Describing erythema with the color it most closely resembles provides a meaningful clue to diagnosis. For example, violaceous erythema brings to mind a differential unique from salmon pink–colored erythema, even if both types of erythema involve papules. A clinical example is dusky erythema, representing a fixed drug eruption (Fig. 4-20; see Chap. 40).

ERYTHRODERMA Erythroderma is a generalized deep redness of the skin involving more than 90 percent of the body surface within days to weeks. Scaling or desquamation generally follows establishment of the generalized erythema. The type of scale noted is suggestive of



▲ **FIGURE 4-20** Erythema. A large area of dusky red erythema in the gluteal region representing a fixed drug eruption.

TABLE 4-4
Types of Scale

Type of Scale	Description	Prototype Diagnosis
Crack-like/craquelé	Desquamation giving the appearance of dried, cracked skin.	Eczema craquelé
Exfoliative	Scales split of from the epidermis in finer scales or in sheets.	Drug reaction
Follicular	Scales appear as keratotic plugs, spines, or filaments.	Keratosis pilaris
Gritty	Densely adherent scale with a sandpaper texture.	Actinic keratosis
Ichthyosiform	Scales are regular polygonal plates arranged in parallel rows or diamond patterns (fish-like, tesselated).	Ichthyosis vulgaris
Keratotic	Scales appear as heaped up column of scale.	Cutaneous horn
Lamellar	Scales are thin large plates or shields attached in the middle and looser around the edges.	Lamellar ichthyosis
Pityriasiform	Scale is small and branny.	Pityriasis rosea
Psoriasiform (micaceous and ostraceous)	Scale is silvery and brittle and forms thin platelets in several loose sheets, like mica (micaceous scale). Large scales may accumulate in heaps, giving the appearance of an oyster shell (ostraceous scale).	Psoriasis vulgaris
Seborrheic	Scales are thick, waxy or greasy, yellow-to-brown, flakes.	Seborrheic dermatitis
Wickham striae	Scale appears as a lacy white pattern overlying violaceous flat-topped papules.	Lichen planus

the primary process (Table 4-4). A clinical example is Sézary syndrome (Fig. 4-21; see Chap. 23).



▲ **FIGURE 4-21** Erythroderma. Generalized red erythema and exfoliative scale in this erythrodermic patient.

Surface Change

SCALE, DESQUAMATION (SCALING) A scale is flat plate or flake arising from the outer-most layer of the stratum corneum. Groups of coherent cornified cells packed with filamentous proteins desquamate in scales imperceptibly from the skin's surface under normal circumstances on a regular basis as the epidermis is replaced completely every 27 days. When epidermal differentiation is disordered, accumulation and casting of stratum corneum become apparent as scale which ranges in size from fine dust-like particles to extensive parchment-like sheets. In some cases, scale is observed only after scratching the lesion, a phenomenon known as *latent desquamation*.

Not all scales are similar, and the expert dermatologist with the well-trained eye can obtain diagnostically useful information from close examinations of the type of scale present. Table 4-4 describes the types of scale one may encounter. A clinical example is psoriasis vulgaris (Fig. 4-22; see Chap. 18).

CRUSTS (ENCRUSTED EXUDATES) Crusts are hardened deposits that result when



▲ **FIGURE 4-22** Scale. Brittle silvery scales forming thin platelets in several loose sheets, like mica, on this plaque of psoriasis.

serum, blood, or purulent exudate dries on the surface of the skin. The appearance of crust is frequently heterogeneous and depends on the nature of secretion. The color of crust is a yellow-brown when formed from dried serous secretion; turbid yellowish-green when formed from purulent secretion; and reddish-black when formed from hemorrhagic secretion. Superficial crusts may be thin, delicate, and friable. Crusts may be thick and adherent when involving the entire thickness of the epidermis. Small or punctate crust may result from scratching, whereas larger, honey-colored moist crusts form with impetiginization, a secondary suppuration. Gentle maneuvering of crust may exude secretions from its base. Removal of the crust may reveal an underlying erosion or ulcer. A clinical example is impetigo (Fig. 4-23; see Chap. 177).

EXCORIATIONS Excoriations (Fig. 4-24) are surface excavations of epidermis that result from scratching and are frequent findings in patients experiencing pruritus. Rigorous or uncontrollable scratching may produce long, parallel, sometimes crossing, groups of excoria-



▲ **FIGURE 4-23** Crust. Glistening, honey-colored, delicate crusts under the nose representing impetigo.





▲ **FIGURE 4-24** Excoriation. Linear and punctate excoriations on the back induced by scratching.

tions which may be hemorrhagic when light bleeding is induced.

FISSURE A fissure is a linear loss of continuity of the skin's surface or mucosa that results from excessive tension or decreased elasticity of the involved tissue. Fissures frequently occur on the palms and soles where the thick stratum corneum is least expandable. Transitional areas between skin and mucosa and skin overlying joints are susceptible if elasticity is reduced. A clinical example is fissure on the palm associated with contact dermatitis (Fig. 4-25).

LICHENIFICATION Repeated rubbing of the skin may induce a reactive thickening of the epidermis, with changes in the collagen of the underlying superficial dermis. These changes produce a thickened skin with accentuated markings, which may resemble tree bark. Lichenified plaques may also show signs of scratching, such as excoriations and crusts. A clinical example is lichen simplex chronicus (Fig. 4-26; see Chap. 15).

KERATODERMA Keratoderma is an excessive hyperkeratosis of the stratum corneum that results in a yellowish thickening of the skin, usually on the palms or soles, that may be inherited (abnormal keratin formation) or acquired (mechanical stimulation). A clinical example is plantar keratoderma (Fig. 4-27; see Chap. 48).



▲ **FIGURE 4-25** Fissure. A linear loss of continuity of the skin on the palm representing a fissure.



▲ **FIGURE 4-26** Lichenification. An area of thickened skin with accentuated skin markings induced by repeated rubbing, representing lichenification noted in lichen simplex chronicus.

ESCHAR The presence of an eschar implies tissue necrosis, infarction, deep burns, gangrene, or other ulcerating process. It is a circumscribed, adherent, hard, black crust on the surface of the skin that is moist initially, protein rich, and avascular. This milieu fosters microbial growth. The eschar may slough naturally, or it may be débrided surgically to facilitate re-epithelialization and wound healing. A clinical example is thermal burn (Fig. 4-28; see Chap. 94).

Fluid-Filled Lesions

VESICLE AND BULLA A vesicle is a fluid-filled cavity or elevation smaller than or equal to 0.5 cm, whereas a bulla (blister) measures larger than 0.5 cm. The fluid in the cavity exerts equal pressure in all directions to give rise to a spherical shape. Vesicles may be non-palpable in areas of thicker stratum corneum such as the palm, where their presence may be suggested by a circumscribed translucency or



▲ **FIGURE 4-27** Keratoderma. Yellowish thickening of skin on the soles in this patient with an inherited keratoderma.



▲ **FIGURE 4-28** Eschar. Overlying eschars compromising peripheral perfusion in a burn victim.

a residual collarette of scale left behind after rupture. Mucosal vesicles rupture easily and may only be noted as an erosion or white thin plaque. Vesicles and bullae arise from cleavage at various levels of the epidermis (intraepidermal) or of the dermal-epidermal interface (sub-epidermal). The amount of pressure required to collapse the lesion may help predict whether the bulla is intraepidermal or sub-epidermal. Reliable differentiation, however, requires histopathologic examination of the blister cavity edge. Cleavage just beneath the stratum corneum produces a subcorneal vesicle or bulla. Intraepidermal vesiculation may result from spongiosis (widened intercellular spaces due to edema) or acantholysis (loss of cohesion between keratinocytes due to the loss of intercellular attachments). "Ballooning degeneration" (cytoplasmic swelling with loss of keratinocyte attachments) of epidermal cells noted in viral infections also results in epidermal vesiculation.

Because of their size, bullae are easily identifiable as tense or flaccid weepy blisters. Once collapsed or torn, blisters may leave behind erosions. The cavity wall is often thin and translucent enough to allow the visualization of contents, which may be clear, serous, hemorrhagic, or pus filled. Cleavage in tense bullae are commonly located at the dermal-epidermal junction. Sub-epidermal blisters are usually a result of mechanical fragility, or autoimmunity to or genetic alteration of a component of the basement membrane zone. A clinical example of vesicle is toxin-producing

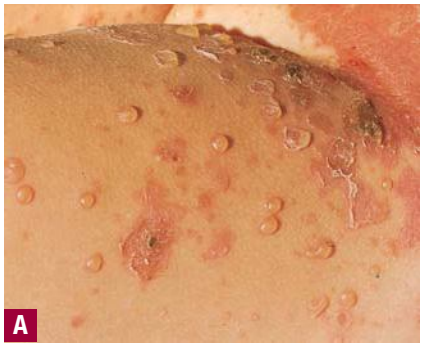



▲ **FIGURE 4-29** Vesicle (**A**) and bulla (**B**). Fragile sub-corneal translucent vesicles representing impetigo caused by a toxin-producing staphylococcus (**A**) and large tense sub-epidermal bullae filled with serous or hemorrhagic fluid in this patient with bullous pemphigoid (**B**).

staphylococcal impetigo (Fig. 4-29A; see Chap. 178). A clinical example of bulla is a bullous pemphigoid (Fig. 4-29B; see Chap. 54).

PUSTULE A pustule is a circumscribed, raised cavity in the epidermis or infundibulum containing pus. The purulent exudate, composed of leukocytes with or without cellular debris, may contain bacteria or may be sterile. A Gram stain and culture of the exudate from pustules should be performed when the potential for infection exists. Depending on its sterility, the exudate may be white, yellow, or greenish-yellow in color. Pustules may vary in size and, in certain situations, may coalesce to form "lakes" of pus. When associated with hair follicles, pustules may appear conical and contain a hair in the center. There may be an erythematous halo surrounding the pustule. Because of



▲ **FIGURE 4-30** Pustule. Two pustules representing superficial pyoderma.

their superficial location, pustules generally heal without scarring. A clinical example is superficial pyoderma (Fig. 4-30; see Chap. 177).

FURUNCLE A furuncle (Fig. 4-31; see Chap. 177) is a deep necrotizing folliculitis with suppuration. It presents as an inflamed follicle-centered nodule usually greater than 1 cm with a central necrotic plug and an overlying pustule. Several furuncles may coalesce to form a carbuncle.

ABSCESS An abscess (Fig. 4-32; see Chap. 179) is a localized accumulation of purulent material so deep in the dermis or subcutaneous tissue that the pus is usually not visible on the surface of the skin. An abscess is a pink erythematous, warm, tender, fluctuant nodule that may be associated with other signs of infection such as fever. It frequently begins as a folliculitis resulting from streptococcal or staphylococcal infection.

Purpura/Vascular Lesions

PURPURA Extravasation of red blood from cutaneous vessels into skin or mu-



▲ **FIGURE 4-31** Furuncle. An inflamed follicular-based nodule with a central necrotic plug that has come loose. There is crusting over the surface.



▲ **FIGURE 4-32** Abscess. A tender red erythematous fluctuant abscess on the leg.

cous membranes results in reddish-purple lesions included under the term *purpura*. The application of pressure with two glass slides or an unbreakable clear lens (diascopy) on a reddish-purple lesion is a simple and reliable method for differentiating redness due to vascular dilatation (erythema) from redness due to extravasated erythrocytes or erythrocyte products (purpura). If the redness is non-blanching under the pressure of the slide, the lesion is purpuric.

Petechiae are small, pinpoint purpuric macules. Ecchymoses are larger, bruise-like purpuric patches. These lesions correspond to a noninflammatory extravasation of blood. As extravasated red blood cells decompose over time, the color of purpuric lesions change from bluish-red to yellowish-brown or green. If a lesion is purpuric and palpable ("palpable purpura"), the suggestion of an inflammatory insult to the vessel wall as a cause of extravasation of blood and inflammatory cells exists. A clinical example is leukocytoclastic vasculitis (Fig. 4-33; see Chap. 164).

TELANGIECTASIA Telangiectasia (Fig. 4-34; see Chap. 173) are persistent dilatations of small capillaries in the superficial dermis that are visible as fine, bright, non-pulsatile red lines or net-like patterns on the skin. Telangiectasia may or may not disappear with diascopy.

INFARCT An infarct is an area of cutaneous necrosis resulting from a bland or inflammatory occlusion of blood vessels in the skin. A cutaneous infarct presents as a tender, irregularly shaped dusky reddish-gray macule or firm plaque that is sometimes depressed slightly below the plane of the skin. The demarcation of an infarct corresponds to the distribution of blood of the affected vessels. A pink zone of hyperemia often surrounds the area of infarction. A clinical example







▲ **FIGURE 4-33** Purpura. Non-blanching red erythematous papules and plaques (palpable purpura) on the legs, representing leukocytoclastic vasculitis.



▲ **FIGURE 4-34** Telangiectasia. Blanching dilated superficial capillaries representing telangiectasia.



▲ **FIGURE 4-35** Infarct. Dusky purple discoloration representing an area of infarction that eventuates in tissue necrosis. This patient had cholesterol emboli lodged in the distal end arteries of the toes.

is cholesterol emboli (Fig. 4-35; see Chap. 174).

Shape, Arrangement, and Distribution of Lesions

Once the type or types of lesions have been identified, one needs to describe their shape, arrangement, and pattern of distribution, all useful characteristics in morphologic diagnosis. For example, a single scaly plaque on a patient's trunk may have a broad differential diagnosis, but the same plaques symmetrically distributed on the elbows, knees, and umbilicus would be highly suggestive of psoriasis. The following descriptions of shapes and arrangements of skin lesions may be applied to single or multiple lesions. For example, a single lesion may be linear or multiple lesions may assume a linear pattern.

SHAPE OR CONFIGURATION OF SKIN LESIONS

- Annular (Fig. 4-36): ring-shaped; implies that the edge of the lesion differs from the center, either by being raised, scaly, or differing in color (e.g., granuloma annulare, tinea corporis, erythema annulare centrifugum).
- Round/nummular/discoid (Fig. 4-37): coin-shaped; usually a round to oval lesion with uniform morphology from the edges to the center (e.g., nummular eczema, plaque-type psoriasis, discoid lupus).
- Polycyclic (Fig. 4-38): formed from coalescing circles, rings, or incomplete rings (e.g., urticaria, subacute cutaneous lupus erythematosus).
- Arcuate (Fig. 4-39): arc-shaped; often a result of incomplete formation of an annular lesion (e.g., urticaria, subacute cutaneous lupus erythematosus).

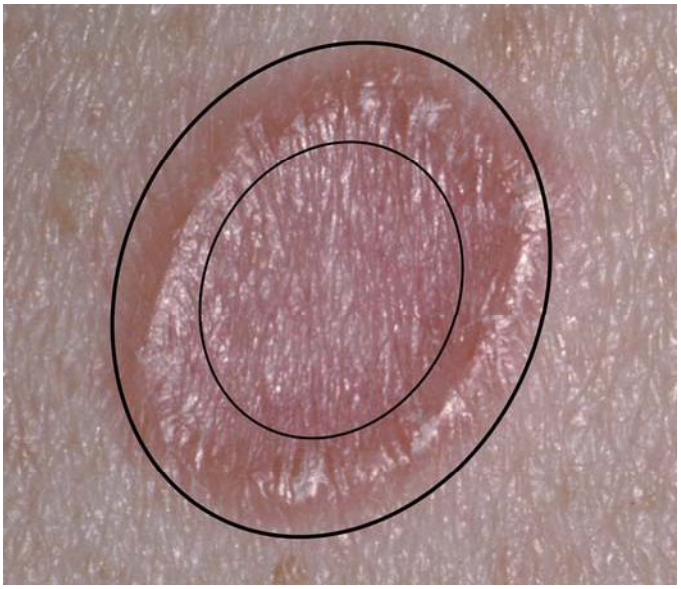

▲ **FIGURE 4-36** Annular lesion. (Illustration by Glen Hintz, MS. Dermatology Lexicon Project.)



▲ **FIGURE 4-37** Nummular lesion. (Illustration by Glen Hintz, MS. Dermatology Lexicon Project.)



▲ **FIGURE 4-38** Polycyclic lesion. (Illustration by Glen Hintz, MS. Dermatology Lexicon Project.)

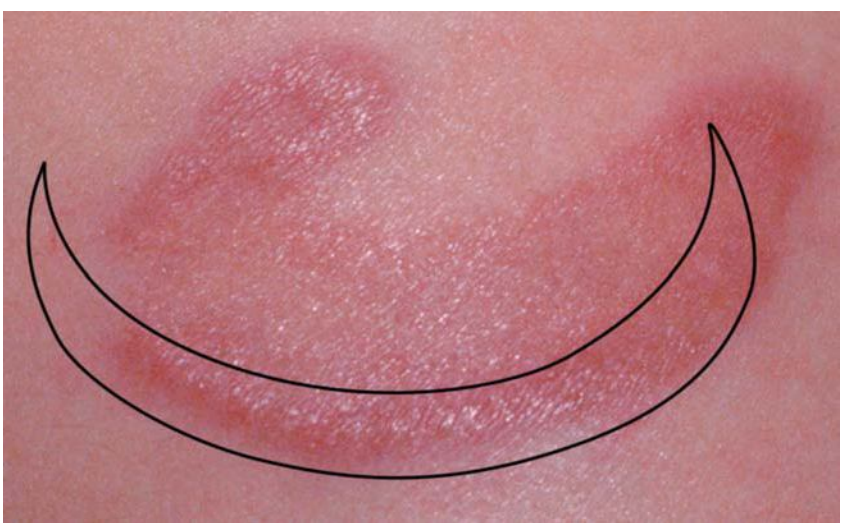

▲ **FIGURE 4-39** Arcuate lesion. (Illustration by Glen Hintz, MS. Dermatology Lexicon Project.)

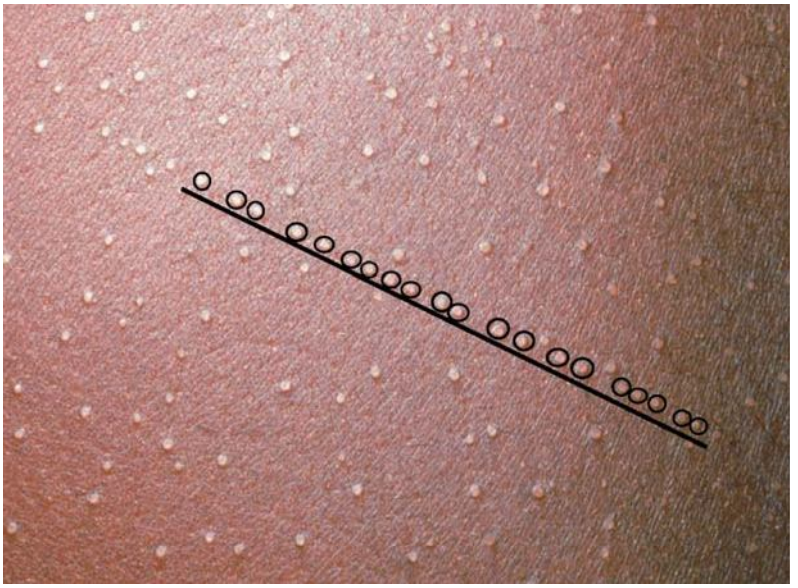

▲ **FIGURE 4-40** Linear distribution of lesions. (Illustration by Glen Hintz, MS. Dermatology Lexicon Project.)

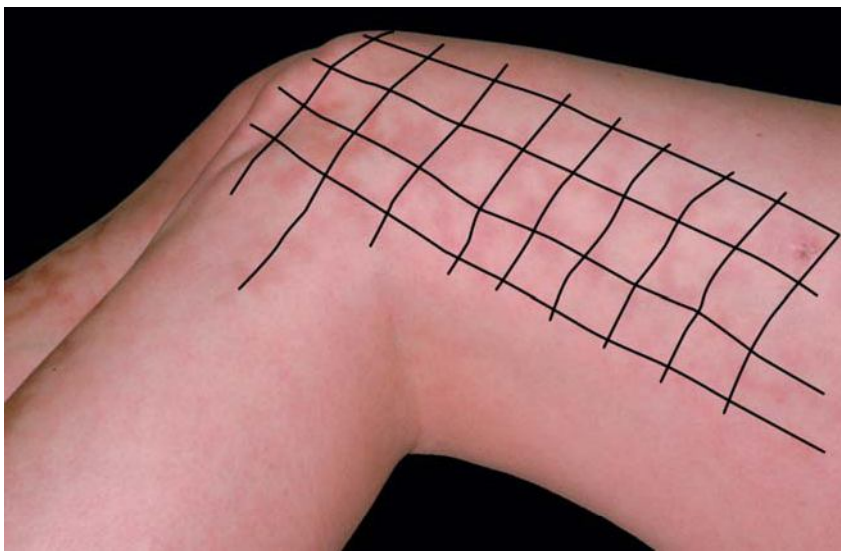

▲ **FIGURE 4-41** Reticular lesion. (Illustration by Glen Hintz, MS. Dermatology Lexicon Project.)



▲ **FIGURE 4-42** Serpiginous lesion. (Illustration by Glen Hintz, MS. Dermatology Lexicon Project.)

- Linear (Fig. 4-40): resembling a straight line; often implies an external contactant or Koebner phenomenon has occurred in response to scratching; may apply to a single lesion (e.g., a scabies burrow, poison ivy dermatitis, or bleomycin pigmentation) or to the arrangement of multiple lesions (e.g., lichen nitidus or lichen planus).
- Reticular (Fig. 4-41): net-like or lacy in appearance, with somewhat regularly spaced rings or partial rings and sparing of intervening skin (e.g., livedo reticularis, cutis marmorata).
- Serpiginous (Fig. 4-42): serpentine or snake-like (e.g., cutaneous larva migrans, in which the larva migrates this way and that through the skin in a wandering pattern).
- Targetoid (Fig. 4-43): target-like, with at least three distinct zones (e.g., erythema multiforme).
- Whorled (Fig. 4-44): like marble cake, with two distinct colors interspersed in a wavy pattern; usually seen in mosaic disorders in which cells of differing genotypes are interspersed (e.g., incontinentia pigmenti, hypomelanosis of Ito, linear and whorled nevoid hypermelanosis).

Arrangement of Multiple Lesions

- Grouped/herpetiform (Fig. 4-45): lesions clustered together (e.g., classic example is herpes simplex virus 1 reactivation noted as grouped vesicles on an erythematous base; also seen with certain arthropod bites).
- Scattered (Fig. 4-46): irregularly distributed.

Distributions of Multiple Lesions

- Dermatomal/zosteriform: unilateral and lying in the distribution of a single spinal afferent nerve root; the classic example is herpes zoster.
- Blaschkoid (Fig. 4-47): following lines of skin cell migration during embryogenesis; generally longitudinally oriented on the limbs and circumferential on the trunk, but not perfectly linear (see also Whorled in Shape and Configuration of Lesions); described by Alfred Blaschko and implies a mosaic disorder (e.g., incontinentia pigmenti, inflammatory linear verrucous epidermal nevus).
- Lymphangitic: lying along the distribution of a lymph vessel; implies an

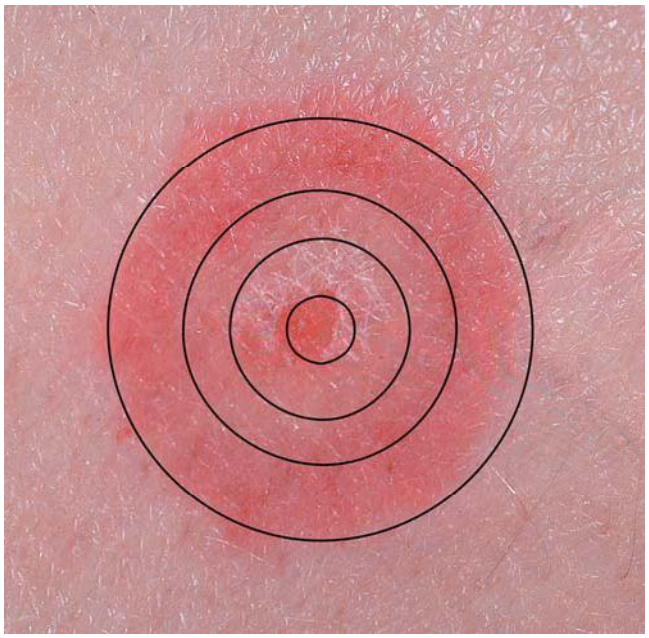

▲ **FIGURE 4-43** Targetoid lesion. (Illustration by Glen Hintz, MS. Dermatology Lexicon Project.)

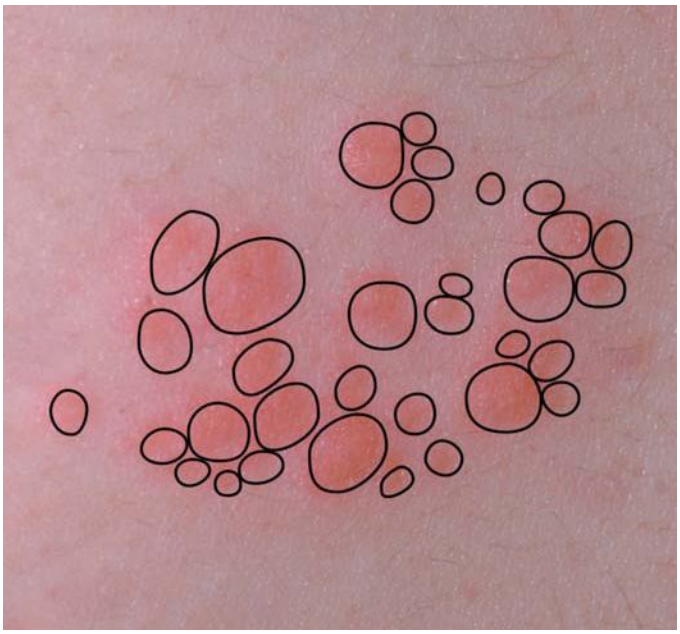

▲ **FIGURE 4-45** Grouped: clustered. (Illustration by Glen Hintz, MS. Dermatology Lexicon Project.)



▲ **FIGURE 4-44** Whorled: marbled appearance. (Illustration by Glen Hintz, MS. Dermatology Lexicon Project.)







▲ **FIGURE 4-46** Scattered lesion. (Illustration by Glen Hintz, MS. Dermatology Lexicon Project.)



▲ **FIGURE 4-47** Lesions in the distribution described by Blaschko for developmental lesions.

infectious agent that is spreading centrally from an acral site, usually a red streak along a limb due to a staphylococcal or streptococcal cellulitis.

- Sun exposed: occurring in areas usually not covered by clothing, namely the face, dorsal hands, and a triangular area corresponding to the opening of a V-neck shirt on the upper chest (e.g., photodermatitis, subacute cutaneous lupus erythematosus, polymorphous light eruption, squamous cell carcinoma).
- Sun protected: occurring in areas usually covered by one or more layers of clothing; usually a dermatosis that is improved by sun exposure (e.g., parapsoriasis, mycosis fungoides).
- Acral: occurring in distal locations, such as on the hands, feet, wrists, and ankles (e.g., palmoplantar pustulosis, chilblains).
- Truncal: occurring on the trunk or central body.
- Extensor: occurring over the dorsal extremities, overlying the extensor muscles, knees, or elbows (e.g., psoriasis).
- Flexor: overlying the flexor muscles of the extremities, the antecubital and popliteal fossae (e.g., atopic dermatitis).
- Intertriginous: occurring in the skin folds, where two skin surfaces are in contact, namely the axillae, inguinal folds, inner thighs, inframammary skin, and under an abdominal pannus; often related to moisture and heat generated in these areas (e.g., candidiasis).
- Localized: confined to a single body location (e.g., cellulitis).
- Generalized: widespread. A generalized eruption consisting of inflammatory (red) lesions is called an *exanthema* (rash). A macular exanthema consists of macules, a papular exanthema of papules, a vesicular exanthema of vesicles, etc. (e.g., viral exanthems, drug eruption).
- Bilateral symmetric: occurring with mirror-image symmetry on both sides of the body (e.g., vitiligo, plaque-type psoriasis).
- Universal: involving the entire cutaneous surface (e.g., erythroderma, alopecia universalis).

Table 4-5 describes some clinically relevant maneuvers and morphologic signs that point to particular integumentary or systemic diseases.

As the late Thomas B. Fitzpatrick often said, "dermatologists are physicians who can diagnose a rash!". They may also be internists, surgeons, biochemists,

TABLE 4-5
Selection of Cutaneous Signs[a]

Cutaneous Sign	Description	Significance
Apple jelly sign	A yellowish hue is produced from pressure on the lesion with a glass slide.	Noted in granulomatous processes.
Asboe-Hansen sign	Lateral extension of a blister with downward pressure.	Noted in blistering disorders in which the pathology is above the basement membrane zone.
Auspitz sign	Pinpoint bleeding at the tops of ruptured capillaries with forcible removal of outer scales from a psoriatic plaque.	Not entirely sensitive or specific for psoriasis.
Butterfly sign	Butterfly-shaped sparing from excoriations of the nonreachable interscapular region.	Noted in disorders associated with pruritus and implies that the physical findings are a consequence of rubbing and scratching.
Buttonhole sign	A flesh-colored, soft papule feels as though it can be pushed through a "buttonhole" into the skin.	Noted in a neurofibroma.
Carpet tack sign	Horny plugs at the undersurface of scale removed from a lesion.	Noted in lesions of chronic cutaneous lupus.
Crowe sign	Axillary freckling.	Noted in neurofibromatosis type I; may be seen as part of lentiginosis profuse.
Darier sign	Urticarial wheal produced in a lesion after it is rubbed with the rounded end of a pen. The wheal, which is strictly confined to the borders of the lesion, may not appear for several minutes.	Noted in urticaria pigmentosa and rarely with cutaneous lymphoma or histiocytosis.
Dermatographism	Firmly stroking unaffected skin produces a wheal along the shape of the stroke within seconds to minutes.	Symptomatic dermatographism represents a physical urticaria.
Pseudo-Darier sign	Transient induration of a lesion or piloerection after rubbing.	Noted in congenital smooth muscle hamartoma.
Fitzpatrick (dimple) sign	Dimpling of the skin with lateral compression of the lesion with the thumb and index finger produces dimpling due to tethering of the epidermis to the dermal lesion.	Characteristic of dermatofibroma.
Gottron sign	Raised or flat pink to violaceous erythema and/or papules of metacarpal or interphalangeal joints, olecranon, patellae, or malleoli.	Classically used in reference to dermatomyositis.
Hair collar	Ring of dark long scalp hair encircling a congenital lesion.	Associated with aplasia cutis, encephalocele, meningocele, or heterotopic brain tissue.
Heliotrope sign	Violaceous erythema over eyelids.	Noted in dermatomyositis.
Hertoghe sign	Thinning or loss of the outer third of the eyebrow.	May be associated with atopic dermatitis, hypothyroidism, systemic sclerosis.
Hutchinson nail sign	Periungual extension of pigment to the proximal and lateral nail folds.	Noted in subungual melanoma.
Hutchinson nose sign	Vesicles on the tip of the nose in a patient with herpes zoster of the face.	Due to the involvement of the nasociliary branch of ophthalmic nerve (V1) and indicates a higher likelihood of ocular disease.
Leser-Trélat sign	Sudden eruption of inflammatory seborrheic keratoses-like lesions.	Associated with systemic malignancy. Also reported with benign neoplasms, eczema, pregnancy, leprosy.
Nikolsky sign	Lateral pressure on unblistered skin with resulting shearing of the epidermis.	Noted in blistering disorders in which the pathology is above the basement membrane zone. Relevant entities include pemphigus vulgaris and toxic epidermal necrolysis.
Oil drop sign	Area of yellowish discoloration resembling an oil drop involving the nail bed distally (but not involving the free edge).	Indicates onycholysis noted in psoriatic nail disease.
Russell sign	Abrasions, lacerations, callosities of metacarpal and proximal interphalangeal joints.	Due to trauma from incisor teeth during self-induced vomiting in bulimia.
Shawl sign	Erythema over upper back and shoulders.	Classically used in reference to dermatomyositis.
Trousseau sign	Recurrent migratory superficial thrombophlebitis of small and large cutaneous veins.	Associated with internal malignancy (usually pancreatic), Behçet disease, rickettsial infections.
Ugly duckling sign	A pigmented lesion, among numerous atypical but clinically benign nevi, that stands out from the rest and may be a melanoma.	Helpful in screening numerous pigmented lesions in a low-risk individual. Once the lesion is distinguished from the others, it may be evaluated further for abnormal clinical features.

[a]Others are discussed in the chapters on diseases in which the signs occur.



TABLE 4-6
Ten Pointers and Pitfalls in Dermatologic Diagnosis

- Approach each and every evaluation with patience and thoroughness.
- Beware of "snap," "curbside," or "doorway" diagnoses.
- Examine the entire mucocutaneous surface, as well as the hair and nails.
- A new or changing mole should be carefully evaluated.
- Do not remove tissue without sending a portion for histologic examination.
- If the dermatopathologic findings are not consistent with the clinical impression, obtain another biopsy.
- If forced to choose between incongruent clinical and pathologic impression, follow clinical lead (cautiously).
- Generalized pruritus of more than 1 month's duration mandates a complete systemic workup.
- Seemingly non-specific rashes may just be camouflaged specific disorders.
- Drug-induced eruptions can mimic most skin conditions.
- Be wary of the "atypical" diagnosis. Atypical "this" may be "typical" that to someone who has seen it before.
- Consider all other reasonable possibilities before making a diagnosis of factitial disorder.

or immunologists; but without competency in dermatologic diagnosis they cannot qualify as dermatologists. This skill, however, is not specific to dermatologists. Any physician who makes the effort to study the skin and learn the dermatologic lexicon can develop a functional appreciation of the fundamentals of diagnosis. The advanced diagnostic eye can only be acquired by endlessly repeated encounters in which the physician is forced not only to look at, but also to observe, the rash while an experienced mentor points the way. The most common error in dermatologic diagnosis is to regard the lesions as non-specific "rashes" rather than as aggregates of specific individual lesions. As in surveying a blood smear, a "general impression" is not enough: The morphologic aspects of each individual cell must be carefully scrutinized and judged to be normal or abnormal. Too often, physicians adopt a speedy, superficial approach to the skin that they would not apply to any other organ that they examine (Table 4-6).

Lewis Thomas has said that "Medicine is no longer the laying on of hands, it is more like the reading of signals from machines." In dermatology, there can be no replacement for the laying on of hands, and the physician is repeatedly gratified by reading signals not from machines, but from people.

SUGGESTED READINGS

Bernhard JD et al: Maculopapularism. *Am J Dermatopathol* **8**:173, 1986

Bernhard JD (ed): *Itch: Mechanisms and Management of Pruritus*. New York, McGraw-Hill, 1994

Bolognia JL et al: Lines of Blaschko. *J Am Acad Dermatol* **31**:157, 1994

Dermatology Lexicon Project. http://www.futurehealth.rochester.edu/dlp2/aboutDLP/abtDLP.htm

Federman, DG et al: Full-body skin examinations: the patient's perspective. *Arch Dermatol* **140**:530, 2004

Feinstein AR: *Clinical Judgment*. Baltimore, Williams & Wilkins, 1967

Haxthausen H: How are dermatological diagnoses made? *Trans St Johns Hosp Dermatol Soc* **30**:3, 1951

Jackson R: The importance of being visually literate. *Arch Dermatol* **111**:632, 1975

Jackson R: *Morphological Diagnosis of Skin Disease*. Ontario, Grimsby, 1998

Leider M, Rosenblum M: *A Dictionary of Dermatological Words, Terms, and Phrases*. New York, McGraw-Hill, 1968

Thomas L: *The Youngest Science. Notes of a Medicine-Watcher*. New York, Viking Press, 1983, p 58

Winkelmann RK (chairman): The International League of Dermatologic Societies Committee on Nomenclature. Glossary of basic dermatologic lesions. *Acta Derm Venereol Suppl (Stockh)* **130**:1, 1987



CHAPTER 5

Diagnostic Procedures and Devices

Alon Scope
Allan C. Halpern

"Don't just stand there and look: do something"

—Shelley WB and Shelley ED[1]

With a clinically well-trained eye and appropriate patient history, the majority of skin lesions can be diagnosed with simple visual inspection. However, details seen by the naked eye are limited in magnification, depth, and contrast. In this chapter, we discuss procedures and devices that can aid the clinician in making the correct diagnosis. We present the diagnostic aids in an order that escalates in terms of invasiveness, cost, and technical complexity (see eFig. 5-0.1 in on-line edition).

ENHANCE YOUR LOOK: VISUAL AIDS TO INSPECTION

Magnifying Lens

Magnification of surface pathology can be achieved with a hand-held lens. Magnifying instruments with built-in lighting and a magnification of 2- to 10-fold are readily available. Swabbing the skin surface with alcohol or application of a drop of oil before magnification can eliminate dirt particles and enhance the transparency of the stratum corneum.

Diascopy

Diascopy is performed by firmly pressing a transparent, hard, flat object (such as two microscope slides) on the surface of the skin. The user should be careful not to injure the patient's or his or her own skin with the sharp edge of the slide. Diascopy can be useful in distinguishing erythema secondary to vasodilation, which is blanchable with pressure, from erythrocyte extravasation (purpura) which retains its red color. In nevus anemicus, in which the blood vessels in the lesion are vasoconstricted, pressure on the edge of the lesion makes the margins inapparent. Diascopy is also useful in detection of the yellowish-brown ("apple jelly") color in papules or nodules of granulomatous processes, such as sarcoidosis, granuloma annulare, and tuberculosis.

Wood's Light

The Wood's light ("black light"), first described in 1903, is a useful device for the clinical evaluation of varied cutaneous diseases such as pigment disorders, skin infections, and porphyrias. The Wood's

DIAGNOSTIC PROCEDURES AND TECHNIQUES

AT A GLANCE

- Diagnostic procedures and techniques can be ranked as a ladder that escalates in terms of invasiveness, cost, and technical complexity.
- The basis is clinical history and physical examination ("ask, look, manipulate"), but further diagnostic clues can be obtained from visual aids ("enhance your look"), such as Wood's light, digital photography, and dermoscopy.
- There are bedside and office procedures, short of a biopsy, that include microscopic and microbiologic evaluation of blisters, scales, discharged fluids, and hair ("scrape, pull, swab").
- Further laboratory and imaging evaluation may be required to assess for systemic involvement of disease.
- Results of diagnostic procedures, including biopsy, need to be interpreted in the context of the clinical assessment.

light is produced with a high pressure mercury lamp emitting through a "Wood's filter" made of silicate with nickel oxide, which is opaque to all radiation beyond a wavelength between 320 nm and 400 nm [ultraviolet A (UVA)], with peak emission at 365 nm. An examiner using Wood's light should use a completely dark room, allow time for accommodation of vision to see the contrasts clearly, hold the lamp at least 10 cm from the skin, and notify the patient to avoid looking directly at the light source.[2]

Wood's light is strongly absorbed by melanin, making it a useful tool in the evaluation of pigmented lesions.[3] A lesion with an increased concentration of epidermal melanin appears darker than surrounding normal skin, with more contrast than normally discernible by visible light examination. Thus, Wood's lamp can be helpful in determining the subtle clinical borders of a lentigo maligna.

The ability of Wood's light to produce characteristic fluorescence in pathologic conditions extends its application to skin infections and porphyria. The green fluorescence of ectothrix-type tinea capitis, as in *Microsporum* sp. infection, can help make the correct bedside diagnosis; it can also serve as a guide to the scalp site that has a higher likelihood of yielding a positive culture, although not all cases clearly fluoresce.[7] Typical fluorescence may also be seen in erythrasma ("coral red"), tinea versicolor (yellow to orange) and *Pseudomonas aeruginosa* infection in burn patients (green), particularly if the examined area has not been cleansed recently.[4] In porphyria cutanea tarda, Wood's light can be used to screen for pink-orange fluorescence in the urine.

The examiner should be aware of false-positive sources of fluorescence such as scales, ointments, dried soaps, threads of fiber, and scars.

Dermoscopy

Clinicians that use dermoscopy have come to appreciate sub-surface diagnostic cues. Thus enters a new set of primary morphology terms. Dermoscopy (reported in the literature under varied names, including *epiluminescence microscopy*, *dermatoscopy*, *skin surface microscopy*) is a non-invasive technique that uses a hand-held instrument (dermoscope) equipped with a light source and magnifying optics. The application of a liquid interface (usually oil, water, or alcohol) to the surface of the skin decreases light reflection by the epidermis. Thus, the dermoscope immersed in the fluid interface allows for the visualization of subsurface anatomic structures of the epidermis and papillary dermis that are otherwise invisible to the unaided eye (Fig. 5-1). A polarized-light dermoscope allows for comparable sub-surface visualization by absorbing surface backscatter, without the need for skin contact or liquid immersion.

Dermoscopy increases clinical diagnostic accuracy for melanoma diagnosis by approximately 10 percent to 20 percent.[8] Dermoscopy facilitates differentiating melanocytic lesions from other pigmented lesions such as seborrheic keratoses, hemangiomas, and pigmented basal-cell carcinomas.[9] A two-step algorithm has been developed to approach such differentiation.[10,11] In the first step, the observer decides whether the lesion is melanocytic or non-melanocytic by searching for a set of specific structures, such as pigment network and globules which connote melanocytic lesions. These specific dermoscopic structures have been correlated to known histopathologic features.[12] When a lesion is classified as melanocytic, the observer then continues to the second step, which involves assessment (see Chap. 124) of the lesion as benign or malignant. Several dermoscopic algorithms have been developed for the second step, including pattern analysis, the ABCD rule of dermoscopy (see Chap. 124), Menzies method, and the 7-point checklist of dermoscopy.[2] Dermoscopy may also be helpful in the diagnosis of nonmelanoma skin cancer. For example, arborizing (branching) blood vessels are typical of basal cell carcinomas; tortuous, glomerulus-like ("glomeruloid") blood vessels are seen in Bowen disease; and pin-point, dotted vessels in squamous cell carcinoma.

Dermoscopy has also been applied to evaluation of inflammatory lesions. Dermoscopy of the proximal nail folds can be used in place of bulky capillaroscopy to identify tortuous, dilated capillary loops and micro-hemorrhages in autoimmune diseases such as scleroderma and dermatomyositis.[13]

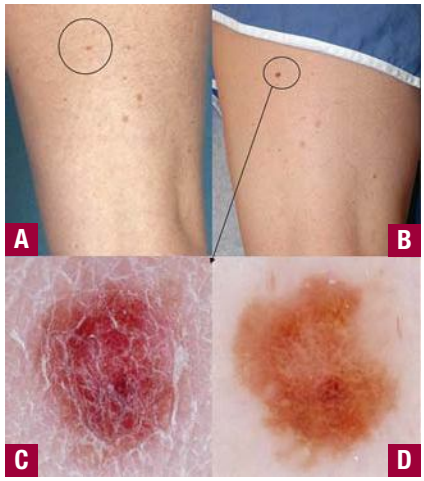

▲ **FIGURE 5-1** Visual aids to diagnosis: comparing baseline digital photography (**A**) to an image taken 3 years later (**B**), shows a lesion (*circles*) has become darker and larger. Clinical close-up image reveals a 7-mm brown-reddish papule not inherently concerning for malignancy (**C**). However, the degree of change along with dermoscopy (**D**) that shows a multi-component pattern with a negative network, irregular globules and regression, prompted an excisional biopsy. The lesion proved to be a malignant melanoma 0.5 in Breslow thickness.

Photography

One of the most important signs of skin cancer is a history of change. Physicians frequently encounter situations in which the clinical diagnosis of a cutaneous lesion is uncertain, and thus, the presence of baseline photographs for comparison can facilitate the decision whether to

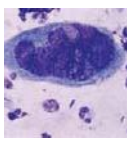

perform a biopsy. Those lesions that are new or have significantly changed may need to be biopsied (see Fig. 5-1), whereas if the lesion is found to be stable, the patient can be reassured that the lesion is unlikely to be cancerous.[17] A potential pitfall for photographically assisted follow-up is that reliance on monitoring lesions for change may reduce the sensitivity for diagnosis of skin cancer at the initial visit,[18] which could lead to untoward outcomes in patients who do not comply with the recommended follow-up.[19]

SCRAPE, PULL, SWAB

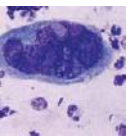

The scrape, pull, swab step of the diagnostic ladder considers sampling of cutaneous lesions short of performing a biopsy. Hair can be sampled by pulling or plucking for microscopic evaluation of fungal infection and hair disorders. Hair pulling, denoting gentle traction of hairs from the roots, is preferred over the hair plucking method (quick pulling with hand or clamp), because it is less painful and results in less hair shaft distortion.[23] A vesicular lesion can be scraped for Tzanck smear and the fluid sent, if appropriate, for culture or other microbial analysis methods, such as immunofluorescence or polymerase chain reaction. The lesion can be scraped with a scalpel or glass slide to sample scales in suspected fungal infection, burrows in scabies, and the base of an ulcer in genital lesions for direct microscopic identification of pathogens.[24] Mucosal surfaces, such as the nares, oropharynx, and urethra, can be swabbed for microbial cultures. For skin lesions, aspiration of pus/fluid collection and biopsy are better methods for pathogen identification than superficial swab sampling.[25] Fig. 5-2 depicts examples of infectious entities that can be readily diagnosed in the office setting.

BIOPSY THE LESION

Biopsy of the skin is a routine and essential diagnostic technique in dermatologic practice, as the skin is readily accessible to biopsy. The biopsy can be useful to confirm the clinical assessment when a definitive diagnosis is needed, add a diagnostic clue when clinical evidence is inconclusive, and occasionally uncover an unsuspected diagnosis. The biopsy may also be obtained to reassure the patient, and often the physician, that the diagnosis is correct despite suboptimal response to treatment. In case of lesions that are removed for cosmetic purposes, it is often prudent to submit the specimen for pathologic evaluation for medicolegal considerations.

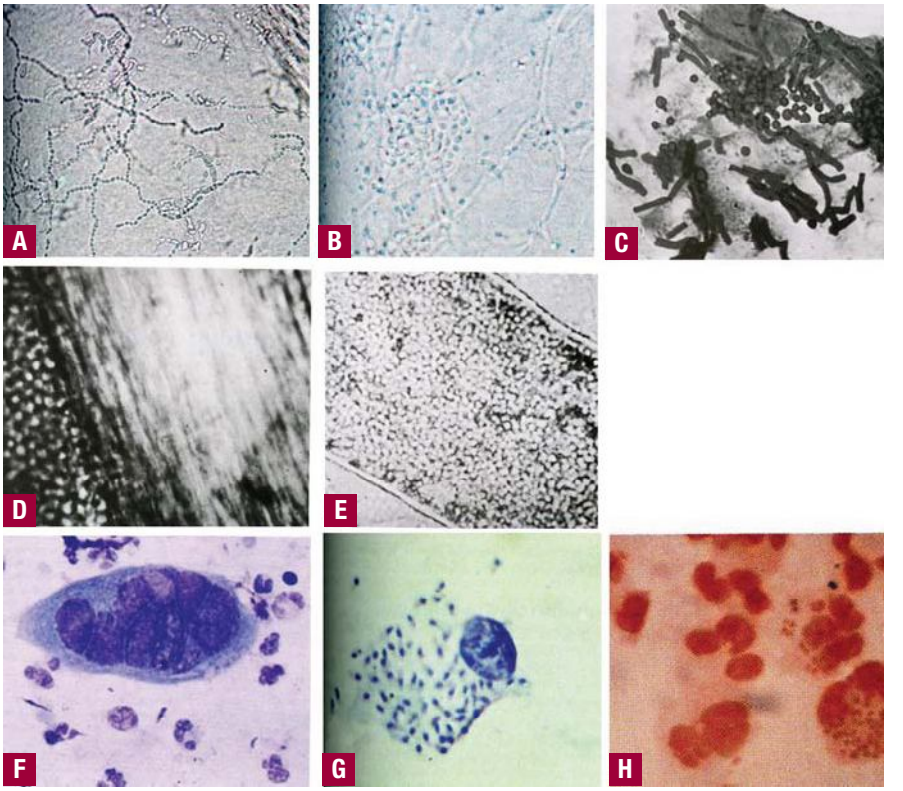

▲ **FIGURE 5-2** What to expect under the microscope: (**A**) septate hyphae in dermatophyte infection, (**B**) budding yeasts in *Candida*, (**C**) pityriasis versicolor demonstrating hyphae and spores ("spaghetti and meatballs"), (**D**) ectothrix-type tinea capitis, (**E**) endothrix-type tinea capitis, (**F**) multinucleated giant cell in herpetic infection (Tzanck smear), (**G**) *Leishmania* tissue amastigotes, and (**H**) diplococci within leukocytes in gonorrhea.

Selecting the appropriate biopsy technique requires an understanding of the sampling extent of each method weighed against the probable diagnosis.[6] In addition, the two opposing vectors in selecting the biopsy method are the wish to minimize scarring, gearing toward a smaller, more superficial biopsy, versus the limitations posed on the histopathologic analysis by inadequate sampling.[28] The flip side of the cosmetic advantage of small biopsies is that an insufficient biopsy may mandate a second procedure that could actually result in an inferior cosmetic outcome than if a proper biopsy had been done in the first place. A biopsy can completely remove the lesion, or in lesions with a large surface area, partially sample it. A shave biopsy usually transects the superficial to mid-dermis and thus is more appropriate to exophytic or warty processes or lesions limited to the epidermis or papillary dermis, such as seborrheic keratosis, solar keratosis, and epidermal nevus. A punch biopsy should be performed if the pathology lies in the dermis or subcutaneous fat. The punch can remove a small lesion in its entirety or sample a core of tissue in larger lesions. It is appropriate for most inflammatory processes, such as cutaneous vasculitis, or dermatoses associated with deposits, such as granuloma annulare. However, a punch biopsy, unless of sufficient bore to encompass the entire lesion, is not the method of choice for removal of most neoplastic processes, because there is a substantial rate of incomplete excision and diagnostic sampling error.

Pathology reports should not be accepted at face value when inconsistent with the clinical impression.[35] Clinical-pathology correlation should be pursued through further sectioning and re-evaluation of the specimen, performing additional biopsies, or by seeking a second pathologist's opinion. Finally, there are reaction patterns with similar histopathologic appearance despite distinct etiology, as is often the case with chronic dermatitis, and thus further evaluation, such as patch testing, is warranted to uncover the specific cause.

INVESTIGATE FURTHER

EVOLVING TECHNOLOGIES

Computer-assisted diagnostic systems are being applied primarily to the evaluation of pigmented lesions. Most systems analyze the dermoscopic image of a lesion, using a multitude of parameters such as dimensions, geometry, number of colors, hue, distribution of structures, texture, and gradient of change from the normal skin. Another strategy is multi-spectral imaging, which applies a range of visible-light and near infrared wavelengths to the lesion, variable in the depth of their skin penetration and their enhancement of tissue chromophores (such as melanin, collagen, and hemoglobin).[36] This provides the computer with a greater set of parameters for analysis than the standard dermoscopic image.

Sub-surface imaging modalities include cutaneous ultrasonography, reflectance confocal microscopy (RCM), and optical coherence tomography (OCT). Rules of thumb that apply to sub-surface imaging are that (1) the deeper one sees into the tissue, the lower the image resolution, and (2) longer wavelengths penetrate deeper. An inherent limitation of imaging is observer dependency.

Ultrasound imaging is based on the fact that tissue components impede and reflect acoustic waves differently.[38] Ultrasound systems produce a two-dimensional image ("B-scan") of the skin by displaying the magnitude of acoustic reflection as degree of brightness. Intermediate frequency ultrasound (7.5 to 10.0 MHz) is used to evaluate subcutaneous masses for size, extent, and consistency (solid versus cystic) and to monitor for the presence of regional lymph-node metastases in melanoma. High-frequency ultrasound (20 MHz) is currently under study as a means to assess tumor thickness preoperatively in melanoma and non-melanoma skin cancer. The hypoechogenicity of tumors compared with the surrounding dermis forms the basis for image contrast.

In contrast, OCT produces a two-dimensional vertical image of the skin that is analogous to the aforementioned B-mode ultrasound imaging, except that it uses light rather than sound waves.[48] Again, melanin produces increased backscatter of light making this modality potentially useful for pigmented lesion evaluation. Currently commercially available OCT systems do not deliver the cellular-detail resolution of RCM, limiting the ability to differentiate benign and malignant lesions, but images deeper into the tissue (up to 1 mm), allowing for assessment of the overall lesion architecture and depth of tumor invasion.[49]

KEY REFERENCES

The full reference list for all chapters is available at www.digm7.com.

3. Paraskevas LR, Halpern AC, Marghoob AA: Utility of the Wood's light: Five cases from a pigmented lesion clinic. *Br J Dermatol* **152**:1039, 2005
10. Braun RP, Saurat JH: Differential diagnosis of pigmented lesions of the skin, in *Atlas of Dermoscopy*, edited by AA Marghoob, RP Braun, AW Kopf. New York, Taylor & Francis, 2005, p 43
17. Marghoob AA et al: Instruments and new technologies for the in vivo diagnosis of melanoma. *J Am Acad Dermatol* **49**:777, 2003
24. Brodell RT, Helms SE: Bedside testing: the diagnostic cornerstone of dermatology. *Compr Ther* **23**:211, 1997
25. Gill VJ, Fedorko DP, Witebsky FG: The clinician and the microbiology laboratory, in *Principles and Practice of Infectious Diseases,* 6th ed., edited by GL Mandell, JE Bennet, R Dolin. Philadelphia, Elsevier Churchill Livingstone, 2005, p 203
31. Elenitsas R, Nousari CH, Seykora JT: Laboratory methods, in *Lever's Histopathology of the Skin,* edited by DE Elder, R Elenitsas, BL Johnson, et al. Philadelphia, Lippincott Williams and Wilkins, 2005, p 59
35. Soyer HP et al: Limitations of histopathologic analysis in the recognition of melanoma: a plea for a combined diagnostic approach of histopathologic and dermoscopic evaluation. *Arch Dermatol* **141**:209, 2005



CHAPTER 6

Basic Pathologic Reactions of the Skin

Martin C. Mihm, Jr.
Abdul-Ghani Kibbi
Klaus Wolff

The skin is composed of different tissue compartments that interconnect anatomically and interact functionally. It is difficult to envisage epidermal function without signals from the dermis or passenger leukocytes traveling to and from the skin. On the other hand, epidermis, dermis, and subcutaneous tissue are heterogeneous in nature and an analysis of pathologic processes involving the skin should therefore consider both this heterogeneity and the interactions of the individual cutaneous compartments; only then will it be understood why a few basic reactions lead to a multiplicity of reaction patterns within this tissue.

Pathophysiologically, the skin can be subdivided into three reactive units that extend beyond anatomic boundaries (Fig. 6-1); they overlap and can be divided into different subunits that respond to pathologic stimuli according to their inherent reaction capacities in a coordinated pattern.

The superficial reactive unit comprises the subunits epidermis, the junction zone, the subjacent loose connective tissue of the papillary body and its capillary network, and the superficial venular plexus (see Fig. 6-1, SRU). The reticular layer of the dermis represents another reactive unit and is composed of connective tissue and the deeper dermal vascular plexus (see Fig. 6-1, DRU). The third reactive unit, the subcutaneous tissue, is anatomically and functionally also heterogeneous; septal and lobular compartments may be involved either alone or together (see Fig. 6-1, S). Hair follicles and glands are a separate (fourth) reactive unit embedded in these three basic units.

SUPERFICIAL REACTIVE UNIT

Epidermis (See Fig. 6-1, E)

Keratinocytes, which have the capacity to keratinize, represent the bulk of the epidermis. The epidermis, an ectodermal epithelium, also harbors a number of other cell populations such as melanocytes, Langerhans cells, Merkel cells, and cellular migrants (see Chap. 7). The basal cells of the epidermis undergo proliferation cycles that provide for the renewal of the epidermis and, as they move toward the surface of the skin, undergo a differentiation process that results in keratinization. The epidermis is thus a dynamic tissue in which cells are constantly in nonsynchronized motion; the proliferation kinetics and the

BASIC PATHOLOGIC REACTIONS

AT A GLANCE



- Different tissue compartments interconnect anatomically and interact functionally. These are the reactive units of skin.
- The superficial reactive unit comprises the epidermis, the junction zone, and the papillary body with its vascular system.
- The reticular dermis with the deeper dermal vascular plexus is the second reactive unit.
- The third reactive unit is the subcutaneous tissue with its septal and lobular compartments.
- Hair follicles and glands are a fourth reactive unit embedded into these three units.
- Pathologic processes may involve these reactive units alone or several of them in a concerted fashion.
- The heterogenicity and interaction of these individual cutaneous compartments explain why a few basic pathologic reactions lead to a multiplicity of clinical and pathologic reaction patterns.



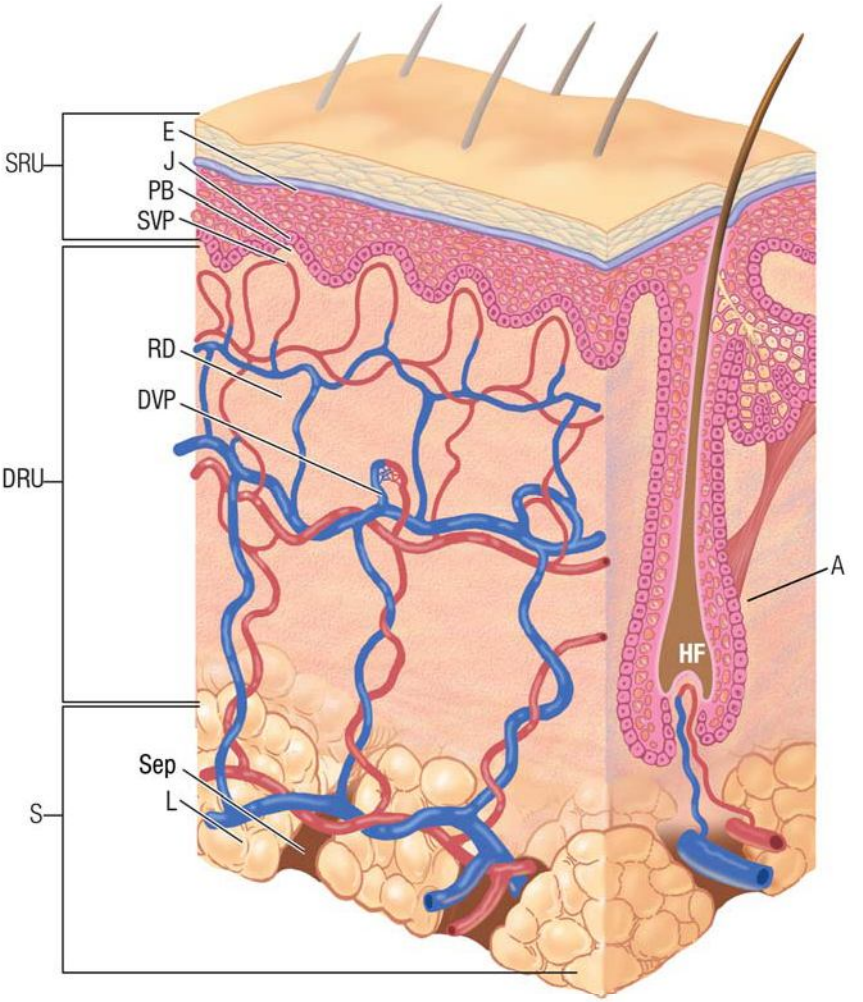

▲ **FIGURE 6-1** Reactive units of skin. The superficial reactive unit (SRU) comprises the epidermis (E), the junction zone (J), and the papillary body (PB) with the superficial microvascular plexus. The dermal reactive unit (DRU) consists of the reticular dermis (RD) and the deep dermal microvascular plexus (DVP). The subcutaneous reactive unit (S) consists of lobules (L) and septae (Sep). A fourth unit is the appendages (A; hair and sebaceous glands are the only appendages shown). HF = hair follicle.

direction and speed of migration of the individual cell populations differ from each other, so that keratinocytes not only pass each other but also pass melanocytes or Langerhans cells as they move toward the surface of the skin. At the same time they are interconnected through forces of cohesion that guarantee the continuity of the epithelium. Stability for this directional cellular flow is provided by the basal membrane complex (see Chap. 51), which anchors the epidermis to the dermis, and the stratum corneum, which encases the epidermis on the outside. It is here that individual cell migration ceases as the keratinizing cells are firmly interconnected by an intercellular cement-like substance (see Chap. 45). These forces of cohesion are finally lost at the surface of the epidermis where the individual cornified cells are desquamated. Pathologic changes within the epidermis may therefore relate to the kinetics of epidermal cells or their differentiation (see Chap. 44) and may involve transepidermal migration and intraepidermal cohesion; they also relate to peripatetic leukocytes and Langerhans cells trafficking to and from the epidermis and adhesion molecules facilitating and directing such cellular movements. For example, unless a Langerhans cell expresses the chemokine CCR6, it cannot migrate from the dermis to the epidermis. Without expression of CCR7, migration to the lymph node is not possible. Furthermore, many pathologic alterations are related to cytokines and hormones generated by keratinocytes, Langerhans cells, melanocytes, and peripatetic leukocytes. They may affect the entire cell population or individual cells, may be primarily targeted on keratinocytes, or may encompass the other epidermal cell populations as well.

DISTURBANCES OF EPIDERMAL CELL KINETICS The mitotic rate of germinative cells, the desquamation rate of corneocytes, and the generation time of epidermal cells determine the homeostasis of the epidermis (see Chap. 44). Under physiologic conditions, there is a balance among proliferation, differentiation, and desquamation. Enhanced cell proliferation accompanied by an enlargement of the germinative cell pool and increased mitotic rates lead to an increase of the epidermal cell population and thus to a broadening of the epidermis (*acanthosis*) (Fig. 6-2). A shift in the ratio of resting to proliferating cell as is the case in psoriasis (see Chap. 18) will lead to both an increase in the turnover of the entire epidermis and to a considerable increase of the volume of germinative cells that have to be accommodated at the dermal-epidermal junction.

This in turn results in an elongation of the rete ridges, which is accompanied by

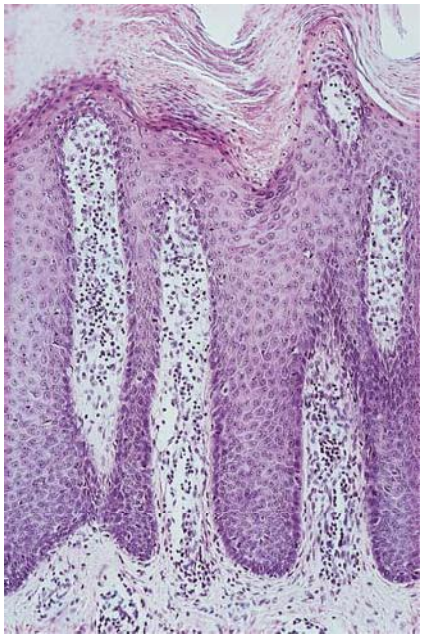

▲ **FIGURE 6-2** Acanthosis. This sign of increased epidermal kinetics is illustrated in a photomicrograph of psoriasis. Parakeratosis, the retention of nuclei in the horny layer, is evident.

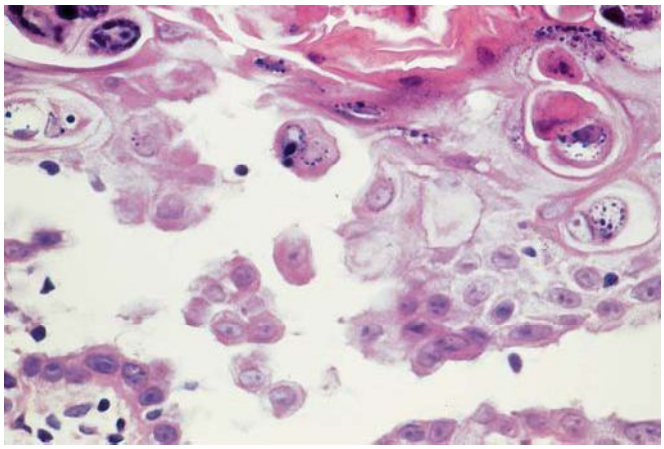

▲ **FIGURE 6-3** The association of dyskeratosis and acantholysis is seen in this high-power view of Darier disease, which also demonstrates the intraepidermal cleft formation resulting from these phenomena.

a compensatory elongation of the connective tissue papillae, resulting in an enlargement of the dermal-epidermal interface and, consequently, in an increased area for dermal-epidermal interactions (see Fig. 6-2).

DISTURBANCES OF EPIDERMAL CELL DIFFERENTIATION A simple example of disturbed epidermal differentiation is parakeratosis, in which faulty and accelerated cornification leads to a retention of pyknotic nuclei of epidermal cells (see Fig. 6-2). A parakeratotic stratum corneum is not a compact sheet of cornified cells but a loose structure with gaps between cells; these gaps lead to a loss of the barrier function of the epidermis.

Parakeratosis can be the result of incomplete differentiation in postmitotic germinative cells. Considering a transit time of 14 days for a postmitotic epidermal cell, a pathologic signal inducing parakeratosis in a cell early in differentiation requires almost 2 weeks to appear histologically in the stratum corneum. Alternatively, parakeratosis can also be the result of reduced transit time, which does not permit epidermal cells to complete the whole differentiation process, as for example in psoriasis. However, "parakeratosis" of cellophane-stripped epidermis becomes microscopically visible as early as 1 hour after trauma; here, parakeratosis does not represent disturbed differentiation; rather, it results from direct cellular injury to a viable epidermis deprived of its protective horny layer. Therefore, the morphologic term *parakeratosis* signifies both a programmed disturbance of differentiation and maturation and direct cellular injury.

Dyskeratosis is a term formerly used for premature cornification of individual cells within the viable layers of the epidermis. It is now understood that dyskeratosis represents the morphologic presentation of apoptosis of keratinocytes. Dyskeratotic cells have an eosinophilic cytoplasm and a pyknotic nucleus and are packed with keratin filaments arranged in perinuclear aggregates. Such a cell will tend to round up and lose its attachments to the surrounding cells. Dyskeratosis is therefore often associated with acantholysis (see Disturbances of Epidermal Cohesion) but not vice versa (Fig. 6-3).

In some diseases, dyskeratosis is the expression of a genetically programmed disturbance of keratinization as is the case in Darier disease (see Chap. 49). Dyskeratosis may occur in actinic keratosis and squamous cell carcinoma. Dyskeratosis may also be caused by direct physical and chemical injury. In the sunburn reaction, eosinophilic, apoptotic cells—so-called sunburn cells—are found within the epidermis within the first 24 hours after irradiation with UVB (see Chap. 89), and similar "dyskeratotic," that is, apoptotic, cells may occur after high dose systemic cytotoxic treatment. Individual cell death within the epidermis is a regular phenomenon in graft-versus-host reactions of the skin (see Chap. 28) and in erythema multiforme (see Chap. 38).

DISTURBANCES OF EPIDERMAL COHESION Epidermal cohesion is the result of a dynamic equilibrium of forming and dissociating intercellular contacts. Specific intercellular attachment devices (desmosomes) and the intercellular substance are responsible for intercellular cohesion. However, epidermal cohesion must permit epidermal cell motion. Desmosomes dissociate and re-form at new sites of intercellular contact as cells migrate through the epidermis. Intercellular cohesion forces are strong enough to guarantee the continuity of the epidermis as an uninterrupted epithelium but, on the other hand, are adaptable enough to permit locomotion, permeability of the intercellular space, and intercellular interactions.

The most common result of disturbed epidermal cohesion is the intraepidermal vesicle, a small cavity filled with fluid. A classification of intraepidermal blistering by anatomic level is shown in Table 6-1.

TABLE 6-1
Classification of Intraepidermal Blisters by Anatomic Level with Clinical Examples

Granular layer
Friction blister
Pemphigus foliaceus
Subcorneal pustular dermatosis
Staphylococcal scalded-skin syndrome/ bullous impetigo
Spinous layer
Eczematous dermatitis
Herpesvirus infection
Familial benign pemphigus
Suprabasal
Pemphigus vulgaris
Darier disease
Basal layer
Erythema multiforme
Lupus erythematosus
Lichen planus
Epidermolysis bullosa

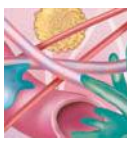

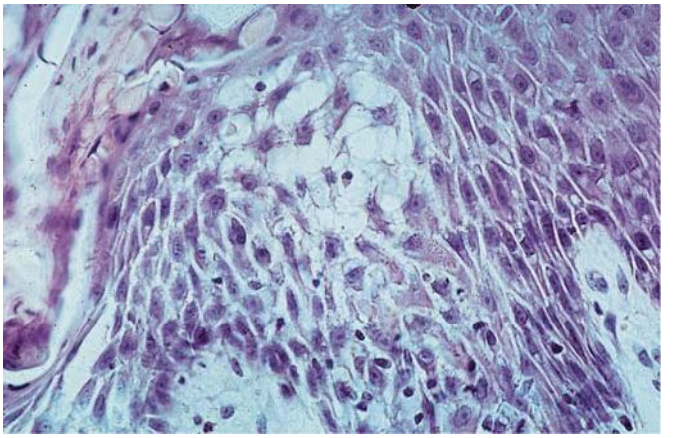

▲ **FIGURE 6-4** Spongiform vesicle resulting from edematous separation of keratinocytes. These are still partially attached to each other by desmosomes and have thus acquired a stellate appearance.



Three basic morphologic patterns of intraepidermal vesicle formation are classically recognized. *Spongiosis* is an example of the secondary loss of cohesion between epidermal cells due to the influx of tissue fluid into the epidermis. Serous exudate may extend from the dermis into the intercellular compartment of the epidermis; as it expands, epidermal cells remain in contact with each other only at the sites of desmosomes, acquiring a stellate appearance and giving the epidermis a spongelike morphology (spongiosis). As the intercellular edema increases, individual cells rupture and lyse, and microcavities (spongiotic vesicles) result (Fig. 6-4). Confluence of such microcavities leads to larger blisters. Epidermal cells may also be separated by leukocytes that disturb intraepidermal coherence; thus, the migration of leukocytes into the epidermis and spongiotic edema are often a combined phenomenon, best illustrated by acute contact dermatitis. The accumulation of polymorphonuclear leukocytes within the epidermis, the resulting separation of epidermal cells, and their subsequent destruction eventually lead to the formation of a spongiform pustule, one of the histopathologic hallmarks of psoriasis.

Acantholysis is a primary loss of cohesion of epidermal cells. This is initially characterized by a separation of the interdesmosomal regions of the cell membranes of keratinocytes, followed by splitting and a disappearance of desmosomes (see Chap. 52). The cells are intact but are no longer attached; they acquire their smallest possible surface and round up (Figs. 6-3 and 6-5). Intercellular gaps and slits result, and the influx of fluid from the dermis leads to a cavity, which may form in a suprabasal (Fig. 6-6), midepidermal, or even subcorneal location. Acantholytic cells can easily be demonstrated in cytologic smears (see Fig. 6-5) and in some conditions have diagnostic significance.

Acantholysis occurs in a number of different pathologic processes that do not have a uniform etiology and pathogenesis. Acantholysis may be a primary event leading to intraepidermal cavitation (primary acantholysis) or a secondary phenomenon in which epidermal cells are shed from the walls of established intraepidermal blisters (secondary acantholysis). Primary acantholysis is a pathogenetically relevant event in diseases of the pemphigus group (see Chap. 52), in which it results from the interaction of autoantibodies and antigenic determinants on the keratinocyte membranes and in the staphylococcal scalded-skin syndrome, where it is caused by a staphylococcal exotoxin (epidermolysin) (see Chap. 178). In familial benign pemphigus, it results from the combination of a genetically determined defect of the keratinocyte cell membrane and exogenous factors

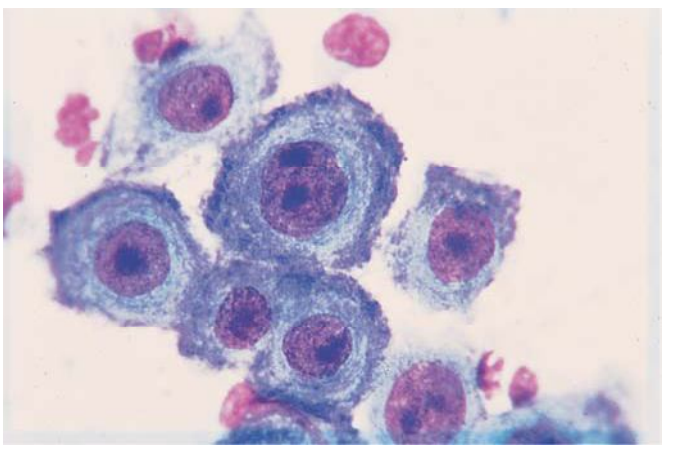

▲ **FIGURE 6-5** Acantholysis. Single as well as clusters of acantholytic cells are seen. The round shapes result from the loss of intercellular connections. Cytologic smear preparation of pemphigus vulgaris.

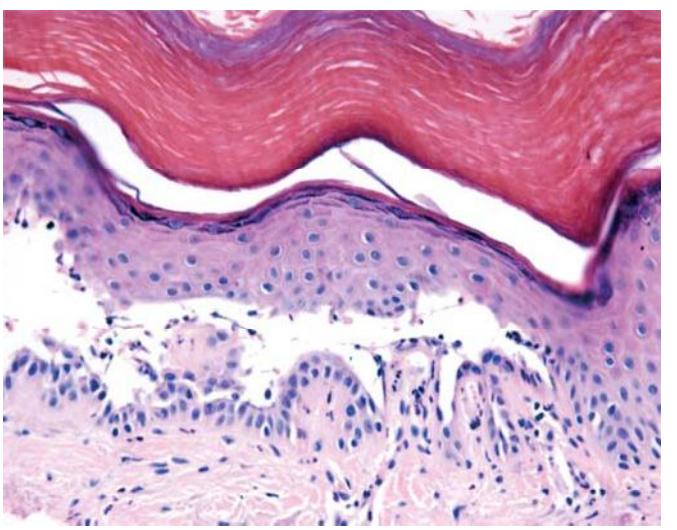

▲ **FIGURE 6-6** Pemphigus vulgaris. An intraepidermal suprabasal cleft is visible that has resulted from suprabasal acantholysis. It contains acantholytic and inflammatory cells.

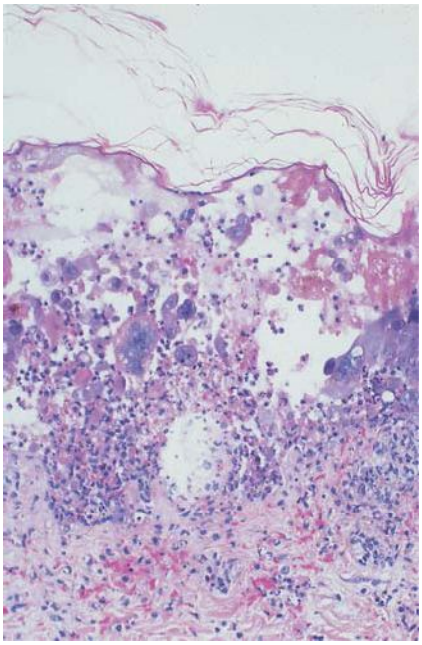

▲ **FIGURE 6-7** Herpes simplex infection. The epidermis shows marked ballooning degeneration, cytolysis, and intraepidermal vesiculation. Acantholytic and multinucleated epidermal giant cells are a clue to herpetic infection.

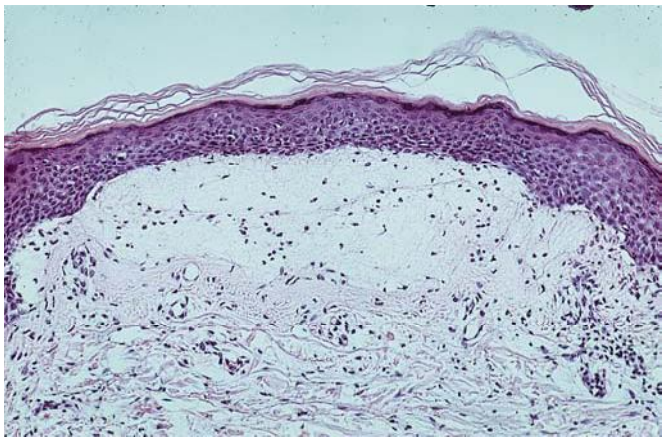

▲ **FIGURE 6-8** Bullous pemphigoid. Subepidermal (junctional) cleft formation and a perivascular and interstitial lymphoeosinophilic infiltrate are characteristic.

(see Chap. 49). A similar phenomenon, albeit more confined to the suprabasal epidermis, occurs in Darier disease, where it is combined with dyskeratosis in the upper epidermal layers (see Fig. 6-3) and a compensatory proliferation of basal cells into the papillary body (see Chap. 49). When acantholysis results from viral infection, it is usually combined with other cellular phenomena such as ballooning giant cells and cytolysis (Fig. 6-7; see Chaps. 193 and 194).

Indeed, a loss of epidermal cohesion can also result from a dissolution of cells (i.e., cytolysis). In the epidermolytic forms of epidermolysis bullosa, basal cells rupture as a result of trauma so that the cleft forms through the basal cell layer independently from preexisting anatomic boundaries (see Chap. 60). Cytolytic phenomena in the stratum granulosum are characteristic for epidermolytic hyperkeratosis, bullous congenital ichthyosiform erythroderma, ichthyosis hystrix, and some forms of hereditary palmoplantar keratoderma (see Chaps. 47 and 48).

Dermal-Epidermal Junction (See Fig. 6-1, J)

Epidermis and dermis are interlocked by means of the epidermal rete ridges and the corresponding dermal papillae and foot-like cytoplasmic microprocesses of basal cells that extend into corresponding indentations of the dermis. Dermal-epidermal attachment is enforced by hemidesmosomes that anchor basal cells on the basal lamina; this, in turn, is attached to the dermis by means of anchoring filaments and microfibrils (see Chap. 51). The basal lamina is not a rigid structure because leukocytes, Langerhans cells, or other migratory cells pass through it without causing a permanent breach in the junction. After being destroyed by pathologic processes, the basal lamina is reconstituted; this represents an important phenomenon in wound healing and other reparative processes. Functionally, the basal lamina is part of a unit that, by light microscopy, appears as the periodic acid-Schiff–positive "basal membrane" and, in fact, represents the entire junction zone. This consists of the lamina lucida, spanned by microfilaments, and subjacent anchoring fibrils, small collagen fibers, and extracellular matrix (see Chap. 51). The junction zone is a functional complex that is primarily affected in a number of pathologic processes.

DISTURBANCES OF DERMAL-EPIDERMAL COHESION The destruction of the junction zone or its components usually manifests as disturbance of dermal-epidermal cohesion and leads to blister formation. These blisters appear to be subepidermal by light microscopy (Fig. 6-8) but in reality may be localized at different levels and result from pathogenetically heterogeneous processes. A classification of blisters at the junction by anatomic level is given in Table 6-2. Subepidermal blister formation occurs in forms of epidermolysis bullosa (see Chap. 60) or can be the result of a complex inflammatory process that involves the entire junction zone, as is the case in lupus erythematosus, erythema multiforme, or lichen planus; therefore, it may be a phenomenon occurring in a group of etiologically and pathogenetically heterogeneous conditions. In bullous pemphigoid (see Fig. 6-8), cleft formation runs through the lamina lucida of the basal membrane and is caused by autoantibodies directed against specific antigens on the cytomembrane of basal cells (*junctional blistering*) (see Fig. 6-8; see Chap. 54). The presence of eosinophil granules that contain major basic protein that is toxic to keratinocytes also causes keratinocyte injury. Junctional blistering also occurs in the junctional forms of epidermolysis bullosa, but here it is due to the impairment or absence of molecules important for epidermal-dermal cohesion (see Chap. 60; see Table 6-2).

In sub-epidermal blistering, the target of the pathologic process is below the basal lamina (dermolytic blistering) (see Table 6-2). Reduced anchoring filaments and increased collagenase production result in dermolytic dermal-epidermal separation in recessive epidermolysis bullosa (see Chap. 60); circulating auto-

TABLE 6-2
Classification of Blisters at the Dermal-Epidermal Junction by Anatomic Level with Clinical Examples

Junctional (at the lamina lucida)
Junctional epidermolysis bullosa
Bullous pemphigoid
Dermolytic (below basal lamina)
Epidermolysis bullosa dystrophicans
Epidermolysis bullosa acquisita
Porphyria cutanea tarda
Dermatitis herpetiformis

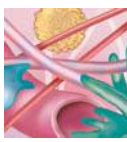

antibodies directed against type VII collagen in anchoring fibrils are the cause of dermolytic blistering in acquired epidermolysis bullosa (see Chap. 58). Other immunologically mediated inflammatory mechanisms result in dermolytic blistering in dermatitis herpetiformis (see Chap. 59), and physical and chemical changes in the junction zone and papillary body are the cause for a dermolytic cleft formation after trauma in porphyria cutanea tarda (see Chap. 132).

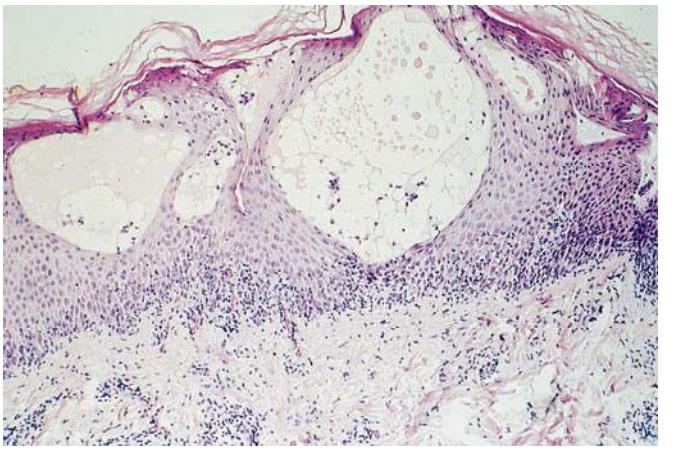

▲ **FIGURE 6-10** Contact dermatitis. Intraepidermal spongiotic vesicles and pronounced intercellular edema are present in the epidermis. The dermis contains perivascular aggregates of lymphocytes and histiocytes admixed with occasional eosinophils.

Pathologic Reactions of the Entire Superficial Reactive Unit (See Fig. 6-1, SRU)

Most pathologic reactions of the superficial skin involve the subunits of the superficial reactive unit jointly and thus include the papillary body of the dermis with the superficial microvascular plexus. This is a highly reactive tissue compartment consisting of capillaries, pre- and postcapillary vessels (see Chap. 163), fibroblasts, macrophages, dendritic cells, and peripatetic lymphocytes all embedded in a loose connective tissue and extracellular matrix (Fig. 6-9). The prominence of involvement of one of the components over the others may lead to the development of different clinical pictures. A few examples of such interactions are detailed below.

CONTACT DERMATITIS (See Chap. 13) In allergic contact dermatitis, there is an inflammatory reaction of the papillary body and superficial microvascular plexus and spongiosis of the epidermis (see Fig. 6-4) with signs of cellular injury and parakeratosis. Lymphocytes infiltrate the epidermis early in the process and aggregate around Langerhans cells, and this is followed by spongiotic vesiculation (Fig. 6-10). Parakeratosis develops as a consequence of epidermal injury, and the inflammation in the papillary body and around the superficial venular plexus stimulates mitotic processes within the epidermis, which, in turn, result in acanthosis and epidermal hyperplasia in chronic lesions.

PSORIASIS (See Chap. 18) The initial lesion of psoriatic lesions appears to be the perivascular accumulation of lymphocytes and monocytoid elements within the papillary body and superficial venules and focal migration of leukocytes into the epidermis. Acanthosis caused by increased epidermal proliferation, papillomatosis, and edema of the elongated dermal papillae together with vasodilatation of the papillary capillary loops and a denser perivascular infiltrate develop almost simultaneously (see Fig. 6-2); the disturbed differentiation of the epidermal cells results in parakeratosis, and neutrophils infiltrating the epithelium from tortuous capillaries (squirting capillaries) lead to spongiform pustules and, in the parakeratotic stratum corneum, to Munro's abscesses. The stimulus for increased epidermal proliferation follows signals released from T cells that are attracted to the epidermis by the expression of adhesion molecules at the keratinocyte surface and are maintained by cytokines released by keratinocytes (see Chap. 18). The composite picture characteristic of psoriasis, therefore, results from a combined pathology of the papillary body with the superficial venules, the epidermis, and circulating cells.

Psoriasis is a good example of the limited specificity of histopathologic reaction patterns within the skin because psoriasiform histologic features occur in a number of diseases unrelated to psoriasis.

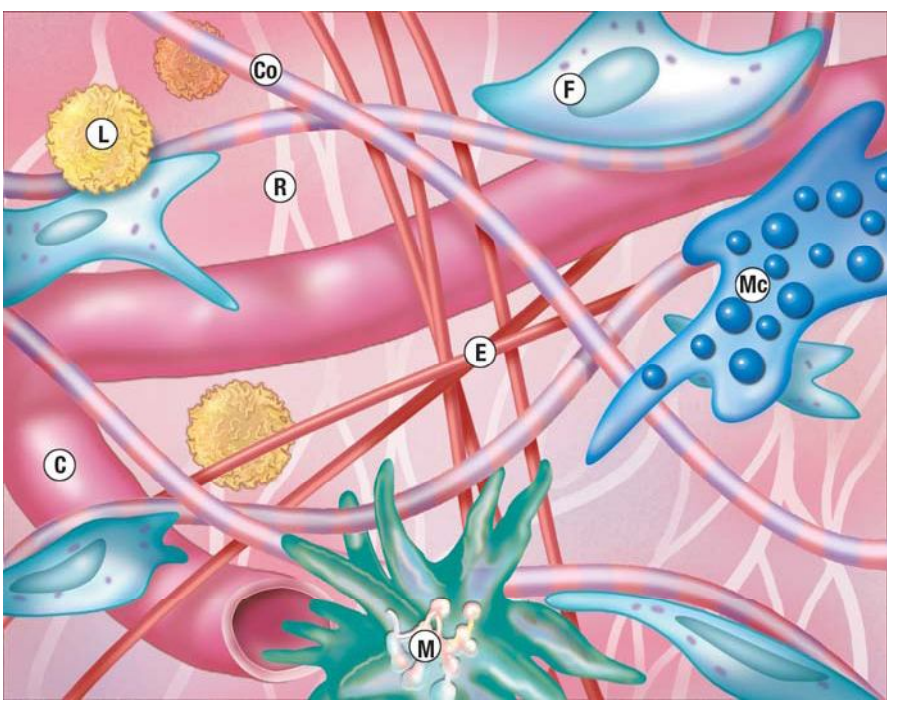

▲ **FIGURE 6-9** The compartment of the papillary body consists of capillaries (C), fibroblasts (F), macrophages and dendritic cells (M), peripatetic lymphocytes (L) and mast cells (Mc) all embedded in a loose connective tissue of extracellular matrix, thin collagen fibers (Co), elastic fibers (E) that are mostly oriented perpendicularly to the skin surface, and branched reticulin fibers (R).

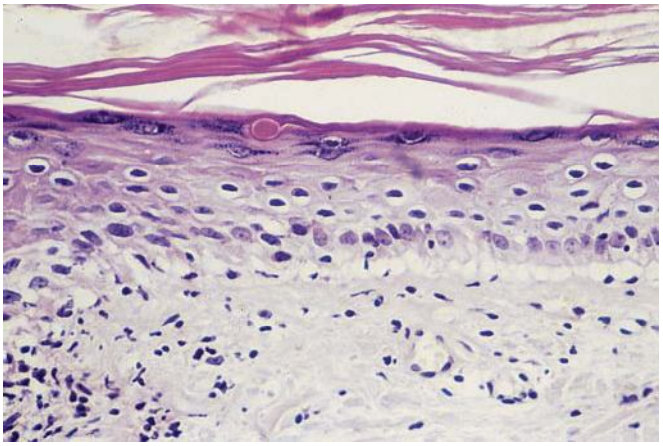

▲ **FIGURE 6-11** Lupus erythematosus. Hyperkeratosis, thinned epidermis devoid of rete ridges, and vacuolization of the basement membrane zone are present.

INTERFACE DERMATITIS Inflammation along the dermal-epidermal junction associated with vacuolation characterizes interface dermatitis. This common type of reaction may lead to papules or plaques in some skin diseases and bullae in others.

ERYTHEMA MULTIFORME (See Chap. 38) Two types of reactions occur. In both there is interface dermatitis characterized by lymphocytes scattered along a vacuolated dermal-epidermal junction.

LUPUS ERYTHEMATOSUS (See Chap. 156) Inflammation, edema, and a lymphocytic infiltrate in the papillary body and superficial venular plexus, as well as in the deeper layers of the dermis, are hallmarks of lupus erythematosus. The main target is the dermal-epidermal junction, where scattered lymphocytes appear and immune complex deposition leads to broadening of the PAS-positive basement membrane zone, accompanied by hydropic degeneration and destruction of basal cells and progressive atrophy (Fig. 6-11). Cytoid bodies result from apoptosis of individual epidermal cells that are infiltrated and coated by immunoglobulins. The changes in the junctional zone reflect on epidermal differentiation resulting in increased orthokeratosis and parakeratosis. Lupus erythematosus readily illustrates the heterogeneity, as well as the lack of specificity, of cutaneous reaction patterns: histologically, it is possible to distinguish between acute and chronic lesions but not between cutaneous and systemic lupus erythematosus. In chronic persisting lesions, the changes in the junctional zone initially associated with atrophy secondarily result in hyperplasia, hyperkeratosis, and an increased interdigitation between epidermis and connective tissue, whereas in acute cases, the destruction of the basal cell layer may lead to sub-epidermal blistering.

LICHEN PLANUS (See Chap. 26) This disease also exhibits a primarily junctional reaction pattern with accumulation of a dense lymphocytic infiltrate in the subepidermal tissue and cytoid bodies at the junction (Fig. 6-12). Lymphocytes encroach on the epidermis, destroying the basal cells, but they do not infiltrate the suprabasal layers and blister formation only rarely ensues. These alterations are accompanied by changes of epidermal differentiation—there is a widening of the stratum granulosum (*hypergranulosis*) and hyperkeratosis. Identical changes can be seen in graft-versus-host disease (see Chap. 28). Current thinking imputes a delayed hypersensitivity reaction to a keratinocyte antigen, the nature of which is unclear. The association of $CD8^+$ lymphocytes in apposition to apoptotic keratinocytes supports this view. The expression of Fas/FasL is also in favor of a role for apoptosis in the pathogenesis of these lesions.

DERMATITIS HERPETIFORMIS (See Chap. 59) This condition is usually included among the classic bullous dermatoses; however, it illustrates that the preponderance of one or several pathologic reaction patterns may obscure the true pathogenesis of the condition. The deposition of immunoglobulin A and complement on fibrillar and nonfibrillar sites within the tips of the dermal papillae, and the activation of the alternative pathway of the complement cascade, lead to an influx of leukocytes, which form small abscesses at the tips of the dermal papillae, as well as inflammation and edema (Fig. 6-13). This explains why the primary clinical lesion in dermatitis herpetiformis is urticarial or papular in nature, because only in the case of massive neutrophil infiltration will there be tissue destruction and cleft formation below the lamina densa that results in clinically visible vesiculation.

RETICULAR DERMIS (See Fig. 6-1, DRU)

The dermis represents a strong fibroelastic tissue with a network of collagen and elastic fibers embedded in an extracellular matrix with a high water-binding capacity (see Chap. 61). In contrast to the tightly interwoven fibrous components of this reticular layer of the dermis (Fig. 6-14), the previously described fibrous texture of the papillary body and the perifollicular and perivascular compartments is loose (see Fig. 6-9), and the orientation of the collagen bundles here follows the structures they surround.

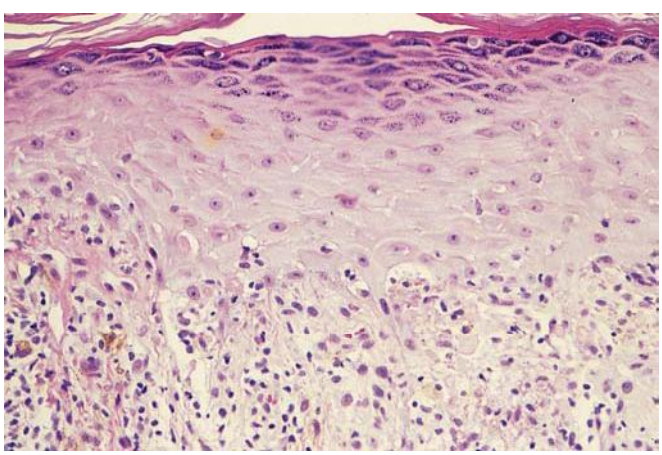

▲ **FIGURE 6-12** Lichen planus. There is hyperkeratosis, wedge-shaped hypergranulosis, basal cell vacuolization, and a lymphocytic infiltrate at the dermal-epidermal junction. This infiltrate "hugs" the basal cell layer and is associated with many cytoid bodies.

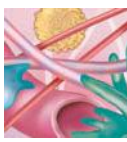

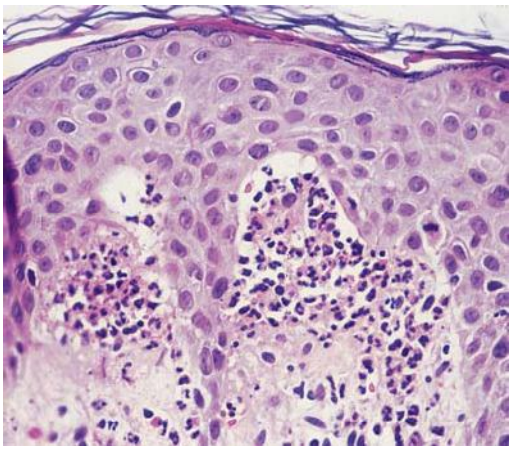

◀ **FIGURE 6-13** Dermatitis herpetiformis. Two papillae show microabscesses composed of neutrophils. Vacuolization and early cleft formation are evident in both papillae.



The dermis contains a superficial and deep vascular network. In the upper dermis, the superficial plexus supplies individual vascular districts consisting of several dermal papillae. Superficial and deep networks are connected so intimately that the entire dermal vascular system represents a single three-dimensional unit (see Chap. 163). On the other hand, there are profound functional differences between superficial and deep dermal vascular networks (see Chap. 163), which explain the differences of homing patterns of inflammatory cells to these sites.

As for the superficial microvascular system, two reaction patterns occur: (1) acute inflammatory processes in which the epidermis and junctional zone are often involved together with the vascular system, and (2) more chronic processes that often remain confined to the perivascular compartment. In this context, it should be noted that the cytologic composition of an inflammatory infiltrate within the skin does not always mirror the acuity of an inflammatory process. Polymorphonuclear leukocytic infiltrates are not always synonymous with an acute process; conversely, chronic processes are not always represented by a lymphohistiocytic infiltrate.

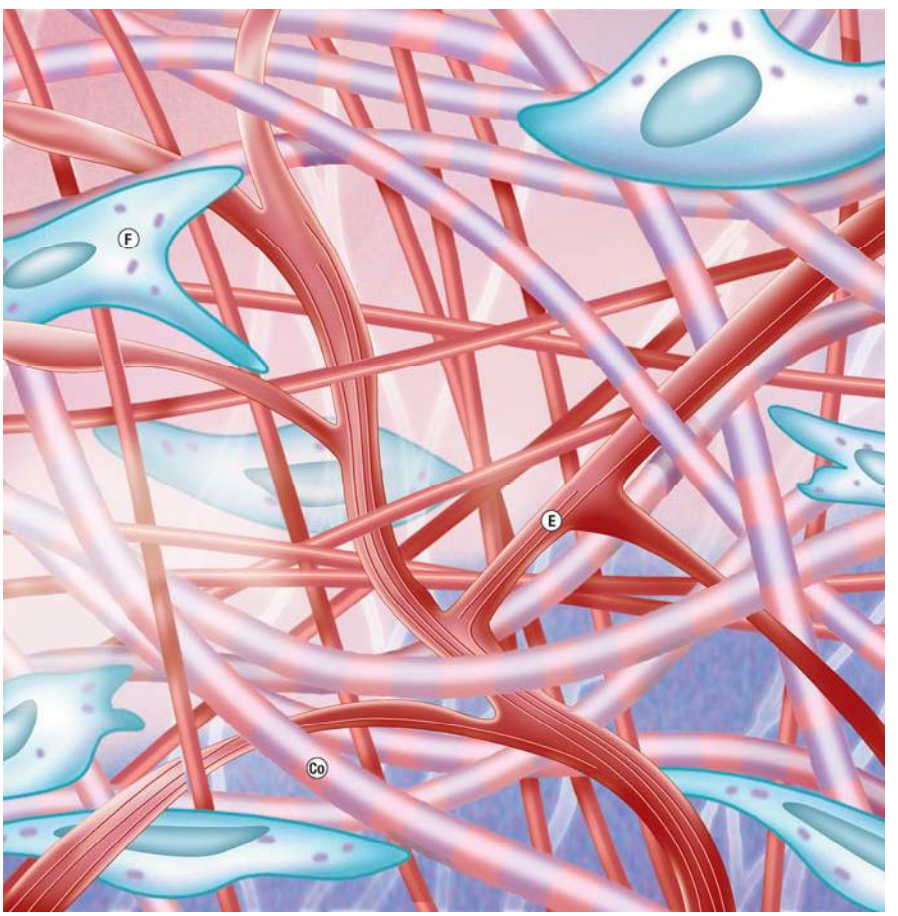

▲ **FIGURE 6-14** The reticular dermis is tightly woven fibroelastic tissue with a network of thick, banded collagen fibers (Co) and elastic (E) fibers embedded in an extracellular matrix. All are produced by fibroblasts (F). This tissue is much denser, relatively acellular, and has fewer capillary vessels than the papillary body (compare with Fig. 6-9).

Inflammation confined to the superficial connective tissue–vascular unit is characterized by endothelial activation, vascular dilatation, increased permeability, edema, a reduction of intravascular blood flow, an accumulation of red blood cells in the capillary loops, and cellular infiltration of the perivascular tissue. Depending on the degree of inflammation, the macroscopic corollary of the histologic changes represents erythematous, urticarial, and infiltrative (papular) lesions. The release of mediators from immunoglobulin E–laden mast cells in type I immune reactions, such as urticaria, is histologically manifested primarily as vasodilatation, edema of the papillary body, and a rather sparse infiltrate of leukocytes and histiocytic elements around the superficial venules (Fig. 6-15). These lesions usually resolve relatively rapidly without any residual pathology. More massive reactions, however, lead to a dense perivascular infiltrate (Fig. 6-16), and this may represent a transition to those processes where edema is less pronounced and where dense lymphocytic infiltrates surround the vessels in a sleevelike fashion, as is the case in cutaneous drug eruptions (see Fig. 6-16). More dramatic alterations occur when the vascular system itself is the target of the inflammatory process resulting in a destruction of at least some of the vessel components, as is the case in necrotizing vasculitis. These exudative changes result in clinical palpable purpura (Fig. 6-17; see Chap. 164).

Chronic inflammatory reactions of the superficial microvascular plexus usually reveal lymphocytic infiltrates in close association with the vascular walls clinical manifesting as erythema. In purpura simplex (see Chap. 169), damage to the vessel wall is much less evident than in necrotizing vasculitis, but the integrity of the vessels is also impaired as is evidenced by hemorrhage into the tissue. Lymphocytes and, as a secondary reaction, histiocytic elements partly laden with phagocytosed material including iron constitute the inflammatory infiltrate.

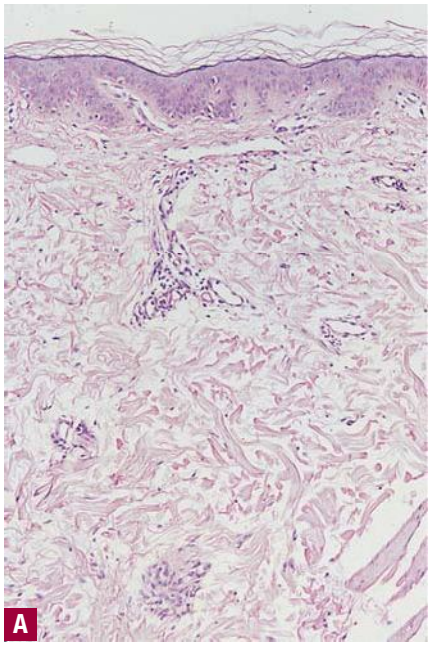

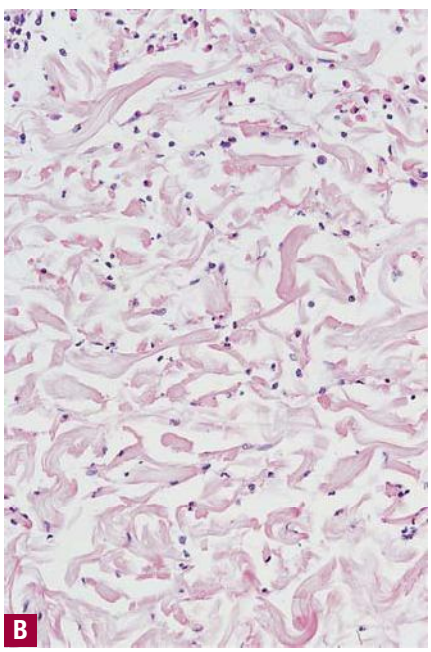

▲ **FIGURE 6-15** Urticaria. **A.** Characteristic of this reaction is a sparse, perivascular lymphocytic infiltrate with few eosinophils. Note the slight edema in the dermis and around the postcapillary venules. **B.** Higher magnification reveals separation of collagen bundles by edema and sparse interstitial inflammatory infiltrate with eosinophils.

The reaction patterns described for the vascular system of the papillary body and the superficial venular plexus also occur in the deep dermis, but there are morphologic and functional differences because here larger vessels are involved. Lymphocytic infiltrates surrounding the vessels in a sleevelike fashion lead to clinical signs only when they are substantial, and then they represent the histopathologic substrate for

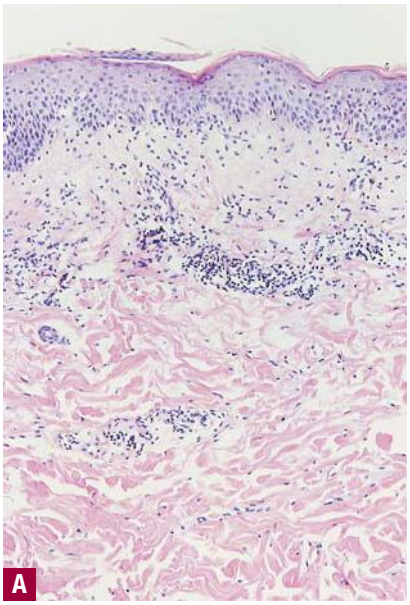

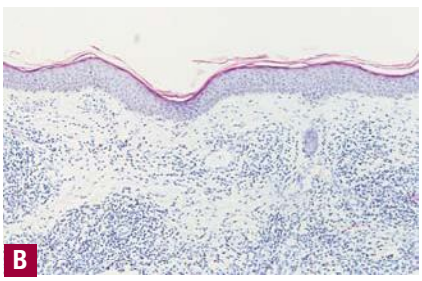

▲ **FIGURE 6-16** Drug eruption. **A.** Throughout the dermis, perivascular sleeves of mononuclear cells, mainly lymphocytes, are present about superficial and deep venules. There is slight edema in the papillary body and minimal interface dermatitis in this reaction to nifedipine. **B.** More pronounced, even nodular, mononuclear cell infiltrates around vessels in a drug reaction to a β blocker.

papular or nodular lesions. This is the case with drug eruptions (see Chap. 40; see Fig. 6-16B) and it is also true for deep-seated infiltrates in lupus erythematosus. In the case of necrotizing vasculitis of the medium-sized and larger vessels, there is usually a much more pronounced inflammatory infiltrate, clinically appearing as papular and nodular lesions, and secondary changes due to the interruption of the vascular flow are more pronounced: necrosis, blistering, and ulceration result as is the case in cutaneous panarteritis nodosa of the macroscopic type (see Chap. 165). In contrast to the macroscopic variant, microscopic polyarteritis nodosa affects vessels of varying sizes including venules and arterioles, affects lungs and kidneys, and is perinuclear neutrophil antibodies positive. Granulomatous vasculitis also leads to nodular lesions, whereas the hyalinizing vascular changes and vascular occlusion in livedoid vasculitis result in ischemic necrosis (see Chap. 164).

Lymphocytic Infiltrates

Although lymphocytic infiltrates occur in the majority of inflammatory dermatoses, there are a number of pathologic processes in which such infiltrates are the most prominent feature and thus determine the histologic picture. Lymphocytic infiltrates are formed in inflammatory or proliferative conditions and in the latter may represent a benign or malignant process. They may differ in their cytologic appearance and distribution, may be confined to the periadventitial compartments of the vascular system (superficial and deep perivascular dermatitis), or may occur diffusely throughout the collagenous tissue (diffuse dermatitis). They may be confined almost exclusively to the papillary dermis (interface dermatitis) and spare the sub-epidermal compartment or may exhibit pro-

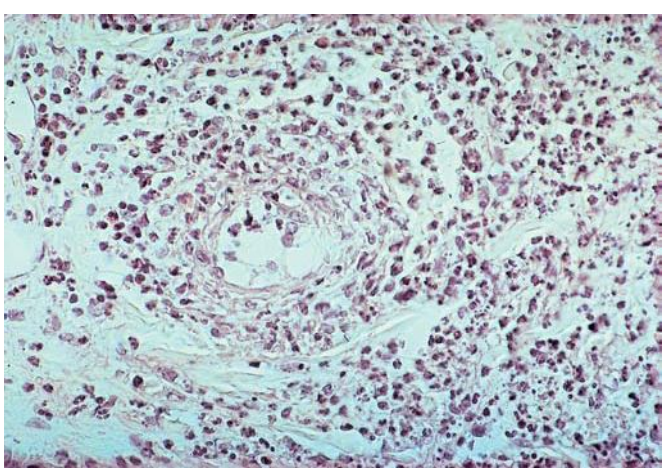

▲ **FIGURE 6-17** Necrotizing vasculitis. An inflammatory infiltrate composed mostly of neutrophils and nuclear dust is present both around and in the wall of a venule where fibrin is also deposited.

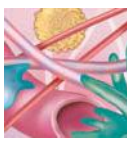

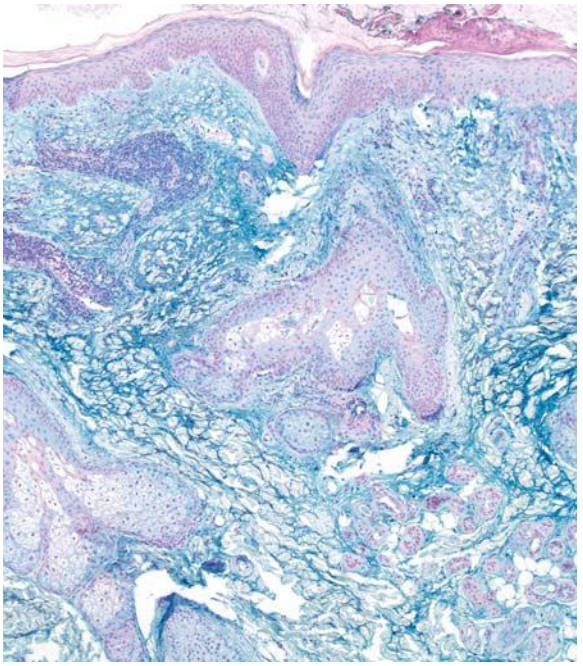

▲ **FIGURE 6-18** Mucinosis in lupus erythematosus. The prominent feature shown here is abundant mucin in the superficial and mid-dermis.



nounced epidermotropism. They may be independent of vessels, sparse (interstitial dermatitis) or nodular (nodular dermatitis). Because lymphocytes are a heterogeneous population of cells, the analysis of such infiltrates should take into account not only the cytomorphology and distribution pattern but histochemical properties and immunologic markers. The analysis of round cell infiltrates by monoclonal antibodies (immunophenotyping) and determination of their clonality are important aspects of dermatopathology (see Chap. 147).

Among the many possible reaction patterns characterized by lymphocytic infiltrates, several typical patterns can be distinguished.

- Superficial perivascular infiltrates are often accompanied by secondary reactions of the epidermis. Lymphoid cells surround the vascular channels in a sleevelike fashion but often extend diffusely to the epidermis, which may reveal focal parakeratosis in these areas. Clinically, these changes are often characterized as palpable figurate erythemas such as erythema annulare centrifugum, but polymorphic light eruption, drug eruptions (see Fig. 6-16A), or insect bites can produce a similar histopathologic picture.
- Lymphocytic cuffing of venules without involvement of the papillary body and the epidermis may occur in figurate erythemas and in drug eruptions (see Fig. 6-16B). The infiltrates of chronic lymphatic leukemia show a similar distribution pattern but are usually more pronounced.
- Perivascular lymphocytic infiltrates with a mucinous infiltration of the nonperivascular connective tissue may be found in lymphocytic infiltration of Jessner-Kanof, reticular erythematous mucinosis (see Chap. 147), or in lupus erythematosus (Fig. 6-18) and dermatomyositis (see Chaps. 156 and 157).
- Nodular lymphocytic infiltrates, which extend throughout the dermis exhibiting focal accumulations of histiocytic cells and thus acquiring the appearance of lymphoid follicles, are typical of lymphocytoma cutis (see Chap. 147). Phagocytosed polychrome bodies in histiocytic cells, mitoses in the center of the lymphoid follicles, and an admixture of eosinophils are characteristic features, as is the fact that the papillary body is usually spared so that a conspicuous grenz zone is found between the infiltrate and the epidermis.
- Non-follicular lymphocytic infiltrates sparing the superficial reactive unit may also occur in benign lymphoid hyperplasias, but in these cases, the differentiation from malignant lymphoma is very difficult. Polymorphic infiltrates showing histiocytes, plasma cells, and occasional eosinophils are usually benign, whereas most malignant non-Hodgkin lymphomas exhibit a more monomorphous picture.
- Nodular accumulations of lymphocytes with an admixture of plasma cells and eosinophils accompanied by vascular hyperplasia are characteristic of angiolymphoid hyperplasia (Fig. 6-19), in which blood vessel walls are thickened and the endothelial cells appear proliferated, swollen, and enlarged.
- Atypical lymphocytic infiltrates involving both the superficial and deeper dermis, and cytologically characterized by pronounced pleomorphism of the cellular infiltrate, are characteristic of lymphomatoid papulosis one of the spectrum of CD30$^+$ lymphoproliferative disorders (see Chap. 147). This condition exemplifies the problems that arise when the histopathology of a lesion is used alone to determine whether a process is benign or malignant. Without knowledge of the clinical features and the

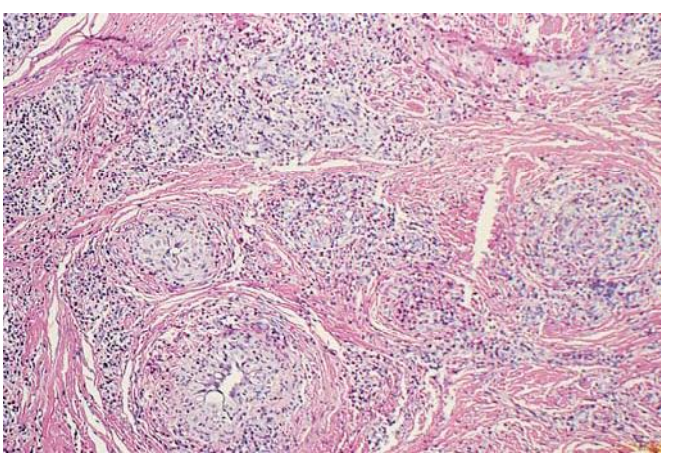

▲ **FIGURE 6-19** Angiolymphoid hyperplasia. Numerous vascular channels are surrounded by aggregates of inflammatory cells made up of lymphocytes and eosinophils. Note the protrusion of endothelial cells into the lamina of these vessels.

course of disease, a definite diagnosis is extremely difficult.

Polymorphonuclear Leukocytic Infiltrates

Although neutrophils are the classic inflammatory cells of acute bacterial infections, there are diseases in which neutrophils dominate the histopathology, even in the absence of a bacterial cause. In pyoderma gangrenosum, massive neutrophilic infiltration leads to sterile abscesses, breakdown of the tissue, and ulceration (see Chap. 32). In dermatitis herpetiformis, neutrophils accumulate in the tips of dermal papillae and form papillary abscesses (see Fig. 6-13) that precede the dermolytic blister formation described in Disturbances of Dermal-Epidermal Cohesion (see also Chap. 59). In erythema elevatum diutinum, neutrophils are the predominant cells centering around superficial and mid-dermal vessels, which exhibit fibrinoid homogenization of their walls (toxic hyalin) and signs of vasculitis (see Chap. 166). The neutrophil is also the predominant cell in the early stages of the more common necrotizing vasculitis (see Fig. 6-17). Neutrophils also represent the majority of the often massive inflammatory infiltrate in acute febrile neutrophilic dermatosis, which is accompanied by pronounced sub-epidermal edema (see Chap. 31).

Granulomatous Reactions

Skin is an ideal tissue for granuloma formation in which histiocytes play a key role. Although these cells are involved at one time or another in practically all inflammatory processes, it is only the proliferation and focal aggregation of histiocytic cells that may be termed a *granuloma*. When such cells are closely clustered they resemble epithelial tissue, hence the designation *epithelioid cells*. Development of giant cells, storage of phagocytosed material, and the admixture of inflammatory cells, such as lymphocytes, plasma cells, and eosinophils, may render the histologic picture of a granulomatous reaction more complex. To these have to be added vascular changes and alterations in the fibrous structure of the connective tissue. Granulomas almost always lead to destruction of pre-existing tissue, particularly elastic fibers, and in such instances result in atrophy, fibrosis, or scarring. Tissue damage or destruction manifests either as necrobiosis or fibrinoid or caseous necrosis, or it may result from liquefaction and abscess formation or from replacement of pre-existing tissue by fibrohistiocytic infiltrate and fibrosis.

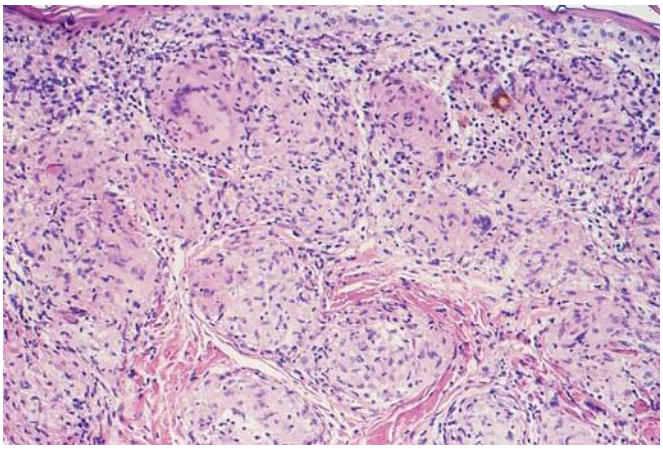

▲ **FIGURE 6-20** Sarcoidal granuloma. In the dermis, numerous "naked" tubercles consisting of epithelioid cells and scant lymphocytes are seen. The overlying epidermis is atrophic.

Sarcoidal granulomas (see Chap. 153) are typically characterized by naked nodules consisting of epithelioid cells, occasional Langhans giant cells, and only a small number of lymphocytes (Fig. 6-20). Silica, zirconium, and beryllium granulomas and a number of foreign-body granulomas may have such histopathologic features.

Granulomatous reactions of the skin comprise a large spectrum of histopathologic features. Palisading granulomas surround necrobiotic areas of the connective tissue with histiocytes in radial alignment (Fig. 6-21). Granuloma annulare, necrobiosis lipoidica, rheumatoid nodules, and the juxta-articular nodules of syphilis belong to this group. These reactions may have significance as signs of systemic disease. For example, when there are prominent neutrophils in the necrobiotic area of granuloma annulare or necrobiosis one may suspect an associated inflammatory bowel disease. Endocrinopathies can also be associated with these disorders, diabetes mellitus is a classic example associated with necrobiosis lipoidica. Of course, rheumatoid nodules can be associated with rheumatoid arthritis but can also occur as a result of trauma in some cutaneous locations. Drugs may also cause these reactions.

Infectious granulomas with a sarcoidal appearance may occur in tuberculosis, syphilis, leishmaniasis, leprosy, or fungal infections. Necrosis can also develop within the granuloma proper, as is the case for fibrinoid necrosis in sarcoidosis, caseation in tuberculosis, or the necrosis developing in mycotic granulomas. Many of the infectious granulomas are associated with epidermal hyperplasia, often exhibiting intraepidermal abscesses in which the causative organism

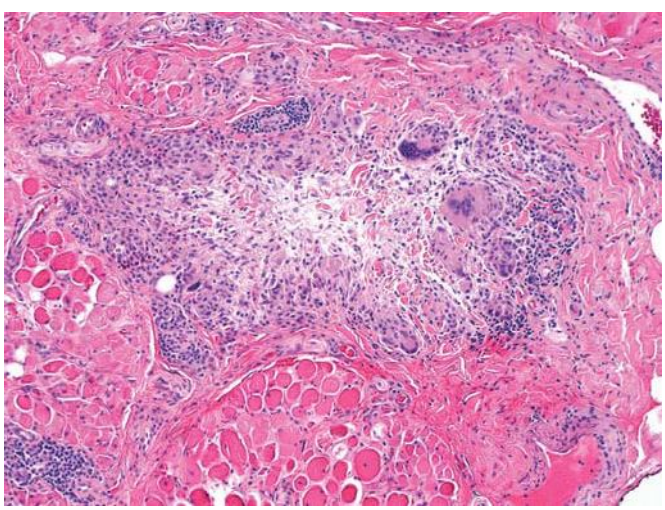

▲ **FIGURE 6-21** Granuloma annulare. A well-circumscribed palisading granuloma is seen in the dermis. Necrobiotic collagen is surrounded by histiocytes, lymphocytes, and a few scattered multinucleated giant cells.

can be found, often in a multinucleate giant cell. In the dermis there is a mixture of cells, including histocytes, epithelioid cells, eosinophils, neutrophils, and lymphocytes.

It is often difficult to classify granulomatous reactions within the skin by the histopathology alone, for even completely different etiologic conditions such as immunopathies and some forms of vasculitis may develop granulomas.

A specific form of granulomatous reaction results when the cellular infiltrate consists almost exclusively of the key granuloma cell, the *histiocyte*. One property of this cell is its capacity to store phagocytosed material. In xanthomatous reaction patterns, histiocytes take up and store fat and are thus transformed into foam cells. They are distributed either diffusely, as is the case in diffuse normolipemic xanthomatosis, or as an aggregate infiltrate mimicking a tumor, as in the xanthomas occurring in the hyperlipoproteinemias and xanthelasma (see Chap. 35).



Fibrous Dermis and Extracellular Matrix (See Fig. 6-1, DRU)

Sclerosing processes of the skin involve mainly the connective tissue of the dermis (see Figs. 6-1, DRU, and 6-14) but usually reflect dynamic changes of structure and function that involve practically all compartments of this organ. The hallmark of scleroderma (see Chap. 158) is the homogenization and dense packing of the collagen bundles, a narrowing of the interfascicular clefts within the reticular dermis, and the disappearance of the boundary between this portion of the dermis and the papillary body. There is also a diminution of the small papillary and subpapillary vessels, which appear narrowed, and, in the early stages, a perivascular lymphocytic infiltrate and edema. The impressive thickening of the dermis not only results from an increase of its fibrous components but is also caused by the fibrosis of the superficial layers of the subcutaneous fat that follows lymphocytic infiltration and a histiocytic reaction.

Sclerodermoid changes may be found in the toxic oil syndrome and L-tryptophan disease, eosinophilic fasciitis (see Chap. 35), and mixed connective tissue disease; they also occur in pachydermoperiostosis, where an increase of fibroblasts and ground substance accompany the sclerotic changes, and in porphyria cutanea tarda, which shows

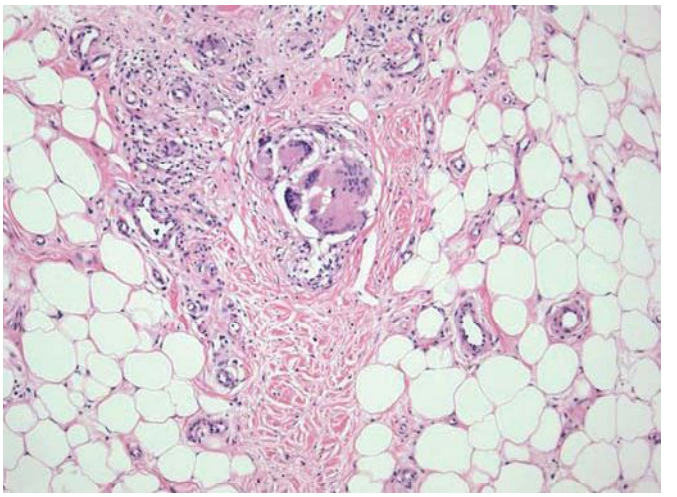

▲ **FIGURE 6-22** Erythema nodosum. A chronic granulomatous inflammatory infiltrate with giant cells extends along the thickened septum into the adjacent fat lobule.

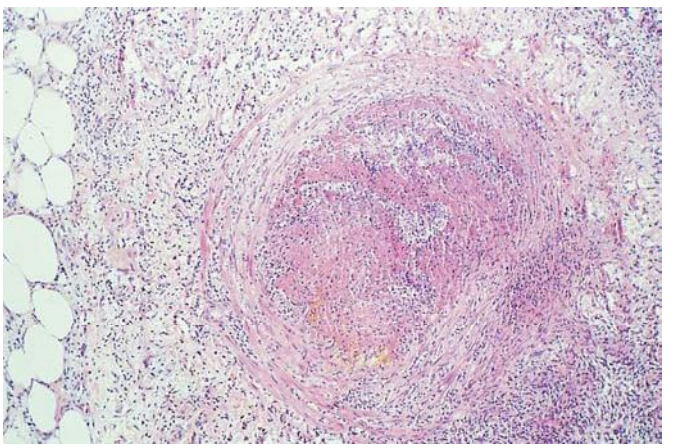

▲ **FIGURE 6-23** Nodular vasculitis. The characteristic features illustrated are severe vasculitis with necrosis of the large vessel wall and occlusion of the lumen. Necrosis of the fat lobules is present, as well as an acute and chronic inflammatory cell infiltrate.

typical hyalinization of the papillary vessels. In lichen sclerosus, there is a massive edema of the papillary body and a dense lymphocytic infiltrate that initially hugs the epidermis and later separates the edematous papillary body from the reticular dermis (see Chap. 63). As sclerosis sets in, there is also a disappearance of elastic tissue from the papillary body; the concomitant involvement of the epidermis includes hydropic degeneration of basal cells, atrophy, and, at the same time, hyperkeratosis. Changes in the junctional zone in this condition may occasionally lead to a separation of the epidermis from the dermis and thus to blister formation.

Faulty synthesis or cross-linking of collagen results in a number of well-defined diseases or syndromes but leads to relatively few characteristic histopathologic changes. In the different types of the Ehlers-Danlos syndrome (see Chap. 139), the faulty collagen cannot be recognized histopathologically, and only the relative increase of elastic tissue may indicate that something abnormal has occurred in the dermis. In generalized elastolysis, a fragmentation of elastic fibers is the histopathologic substrate of the clinical appearance of cutis laxa, and the fragmentation and curled and clumped appearance of elastic fibers are similarly diagnostic in pseudoxanthoma elasticum (see Chap. 139). On the other hand, in actinic elastosis, the histologic substrate of dermatoheliosis, all components of the superficial connective tissue are involved (see Chap. 89). Except for a narrow grenz zone below the epidermis, the papillary body and the superficial layers of the reticular dermis are filled with clumped and curled fibers that progressively become homogenized and basophilic. They are stained by dyes that have an affinity for

elastic tissue and thus histochemically behave similar to elastic fibers.

Such profound changes of dermal architecture become clinically apparent: The taut and firm connective tissue in scleroderma reflects the sclerotic texture and homogenization of the collagen bundles seen histologically; the loose folds of cutis laxa are a result of the fragmentation of elastic fibers; the cobblestone-like papules in pseudoxanthoma elasticum correspond to the focal aggregation of the pathologically altered elastic material; and the coarseness of skin lines and surface profile in dermatoheliosis are the clinical manifestations of the focal aggregation of elastotic material.

SUBCUTANEOUS FAT (See Fig. 6-1, S)

Inflammatory processes in the subcutaneous adipose tissue take a slightly different course than in the connective tissue of the dermis because of the specific anatomy of the subcutis (see Chaps. 7 and 68). Inflammation of subcutaneous fat reflects either an inflammatory process of the adipose tissue proper or the fat lobules (see Fig. 6-1, L) or a process arising in the septa (see Fig. 6-1, Sep); it can involve small venules and capillaries or arise from the larger muscular vessels. The histopathologic manifestations may vary accordingly. Small-vessel pathology is usually manifested locally, involving the neighboring fat lobules, whereas the destruction or occlusion of a larger vessel influences the entire tissue segment. Destruction of fat, be it of a traumatic or inflammatory nature, leads to the release of fatty acids that by themselves are strong inflammatory stimuli, attracting neutrophils and scavenger histiocytes and macrophages; phagocytosis of destroyed fat usually results in lipogranuloma formation.

Septal processes that follow inflammatory changes of the trabecular vessels are usually accompanied by edema, infiltration of inflammatory cells, and a histiocytic reaction. This is the classic appearance in erythema nodosum (Fig. 6-22; see Chap. 68). Recurring septal inflammation may lead to a broadening of the interlobular septa, fibrosis, the accumulation of histiocytes and giant cells, and may result in vascular proliferation. By contrast, in nodular vasculitis (Fig. 6-23), large-vessel vasculitis in the septal area is accompanied by necrosis of the fat, followed by histiocytic reactions, epithelioid cell granulomas within the fat lobules, and a fibrotic reaction sclerosing the entire subcutaneous fat. On the other hand, lobular panniculitis results from the necrosis of fat lobules as the primary event, as is the case in idiopathic nodular panniculitis (see Chap. 68), followed by an accumulation of neutrophils and leukocytoclasia. The lipid material derived from necrotic adipocytes contains free and esterified cholesterol, neutral fats, soaps, and free fatty acids, which, in turn, exert an inflammatory stimulus. Histiocytic cells migrate into the inflamed fat, and phagocytosis leads to foam cell formation. Epithelioid granulomas with giant cells may also result, and all types of fibrosis may develop. Fat necrosis is, therefore, the primary, and inflammation the secondary, event in this type of panniculitis.

The inherent capacity of the adipose tissue to respond to pathologic stimuli also holds true for disease conditions that affect the subcutaneous tissue only secondarily or result from exogenous factors. Traumatic panniculitis leads to necrosis of fat lobules and a reactive inflammatory and granulomatous tissue response. After the injection of oils or silicone, large cystic cavities may be formed, whereas after the injection of pentazocine, for instance, fibrosis and sclerosis dominate the histopathologic picture. Oily substances may remain within the adipose tissue for long periods without causing a significant tissue reaction; oil cysts evolve that are surrounded by multiple layers of residual connective tissue, so that the tissue acquires a "Swiss cheese" appearance. Animal or vegetable oils often lead to tuberculoid or lipophagic granulomas with massive histiocytic reactions, foam cells, and secondary fibrosis.

Panniculitis also occurs as a result of infectious agents (cocci, mycobacteria, and other bacterial and fungal organisms) or a specific disease process. In sarcoidosis, fat is gradually replaced by epithelioid cell nodules and, in lymphoma, by specific lymphomatous infiltrates. In lupus panniculitis, a dense lymphocytic infiltrate of the septal and lobular tissue determines the histopathologic picture, as does involvement of vessels manifesting as vasculitis. However, destruction of fat, liquefaction, and lipogranuloma may be so pronounced that the vascular component can hardly be recognized, and the histopathologic picture may resemble idiopathic nodular panniculitis.

SUGGESTED READINGS

Ackerman AB et al: *Histologic Diagnosis of Inflammatory Skin Diseases: An Algorithmic Method Based on Pattern Analysis*, 2nd ed. Baltimore, Williams & Wilkins, 1997

Bailey EA et al: Marginal zone lymphoma (low-grade B cell lymphoma of mucosa-associated lymphoid tissue type) of skin and subcutaneous tissue. *Am J Surg Pathol* **20**:1011, 1996

Biederman T, Rocken M, Carballido JM: TH1 and TH2 lymphocyte development and regulation of TH cell-mediated immune responses of the skin. *J Invest Dermatol Symp Proc* **9**:5, 2004

Cerroni L et al: *An Illustrated Guide to Skin Lymphoma*. Oxford, Blackwell Sciences Ltd, 1998

Crowson AN, Magro CM: The cutaneous pathology of lupus erythematosus: A review. *J Cutan Pathol* **28**:1, 2001

Crowson AN et al: Cutaneous vasculitis: A review. *J Cutan Pathol* **30**:161, 2003

Elder DE et al: *Lever's Histopathology of the Skin*, 8th ed. Philadelphia, Lippincott Williams and Wilkins, 2004

Magro CM et al: Granuloma annulare and necrobiosis lipoidica tissue reactions as a manifestation of systemic disease. *Hum Pathol* **27**:50, 1996

Magro CM et al: *The Lymphoid Proliferations*. New York, Wiley-Liss, Inc., 2006

McKee PH et al: *Pathology of the Skin*, 3rd ed. Philadelphia, Elsevier Mosby, 2005

Murphy GF, Mihm MC Jr: *Inflammatory Diseases of the Skin*, AFIP Fascicle, third series, AFIP September 2006

Schaerli P, Moser B: Chemokine: control of primary and memory T-cell traffic. *Immunol Res* **31**:57, 2005

Udey MC: Skin dendritic cells in immunity and autoimmunity. *J Investig Dermatol Symp Proc* **9**:1507, 2004

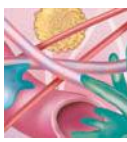

This page intentionally left blank

SECTION 3

OVERVIEW OF BIOLOGY, DEVELOPMENT, AND STRUCTURE OF SKIN

CHAPTER 7

Development and Structure of Skin

David H. Chu

SKIN: AN OVERVIEW

Skin is a complex organ that protects its host from its environment, at the same time allowing interaction with the environment. It is much more than a static, impenetrable shield against external insults. Rather, the skin is a dynamic, complex, integrated arrangement of cells, tissues, and matrix elements that mediates a diverse array of functions: skin provides a physical permeability barrier, protection from infectious agents, thermoregulation, sensation, ultraviolet (UV) protection, wound repair and regeneration, and outward physical appearance (Table 7-1). These various functions of skin are mediated by one or more of its major regions—the epidermis, dermis, and hypodermis (Fig. 7-1; see also Fig. 6-1, Chap. 6). These divisions are interdependent, functional units; each region of skin relies upon and is connected with its surrounding tissue for regulation and modulation of normal structure and function at molecular, cellular, and tissue levels of organization (see Chap. 6).

Whereas the epidermis and its outer stratum corneum provide a large part of the physical barrier provided by skin, the structural integrity of the skin as a whole is provided primarily by the dermis and hypodermis. Antimicrobial activities are provided by the innate immune system and antigen-presenting dendritic cells of the epidermis, circulating immune cells that migrate from the dermis, and antigen-presenting cells of the dermis (see Chap. 10). Protection from UV irradiation is provided in great measure by the most superficial cells of the epidermis. Inflammation begins with the keratinocytes of the epidermis or immune cells of the dermis, and sensory apparatus emanates from nerves that initially traverse the hypodermis to the dermis and epidermis, ending in specialized receptive organs or free nerve endings. The largest blood vessels of the skin are found in the hypodermis, which serve to transport nutrients and immigrant cells (see Fig. 6-1, Chap. 6). The cutaneous lymphatics course through the dermis and hypodermis, serving to filter debris and regulate tissue hydration. Epidermal appendages provide special protective or sensory functions. Skin also determines a person's physical appearance, influenced by pigmentation provided by melanocytes, with body contours, appearance of age, and actinic damage influenced by the epidermis, dermis, and hypodermis. The skin begins to be organized during embryogenesis, where intercellular and intracellular signals, as well as reciprocal crosstalk between different tissue layers, are instrumental in regulating the eventual maturation of the different components of skin.

What follows is an integrated description of the major structural features of the skin and how these structures allow the skin to achieve its major functions, followed by a review of their embryologic origins. Also highlighted are illustrative cutaneous diseases that manifest when these functions are defective. Understanding the genetic and molecular basis of skin disease has confirmed, and in some cases revealed, the many factors and regulatory elements that play critical roles in skin function.

STRUCTURE AND FUNCTION OF SKIN AT A GLANCE



- Three Major Layers—Epidermis, Dermis, Hypodermis:
  - Epidermis: major permeability barrier, innate immune function, adhesion, ultraviolet protection.
  - Dermis: major structural element, three types of components—cellular, fibrous matrix, diffuse and filamentous matrix. Also site of vascular, lymphatic, and nerve networks.
  - Hypodermis (subcutis): insulation, mechanical integrity, containing the larger source vessels and nerves.

EPIDERMIS

One of the most fundamental and visible features of skin is the stratified, cornified epidermis (Fig. 7-2). The epidermis is a continually renewing structure that gives rise to derivative structures called appendages (pilosebaceous units, nails, and sweat glands). The epidermis ranges in thickness from 0.4 to 1.5 mm, as compared with the 1.5- to 4.0-mm full-thickness skin. The majority of cells in the epidermis are keratinocytes that are organized into four layers, named for either their position or a structural property of the cells. These cells progressively differentiate from

Copyright © 2008 by The McGraw-Hill Companies, Inc. Click here for terms of use.

TABLE 7-1
Functions of Skin

Function	Tissue Layer	Some Associated Diseases
Permeability barrier	Epidermis	Atopic dermatitis
		Ectodermal dysplasias
		Ichthyoses
		Keratodermas
		Exfoliative dermatitis
		Bullous diseases
Protection from pathogens	Epidermis	Verruca vulgaris
	Dermis	Ecthyma
		Cellulitis
		Leishmaniasis
		Human immunodeficiency virus
		Tinea pedis/corporis
Thermoregulation	Epidermis	Ectodermal dysplasias
	Dermis	Raynaud
	Hypodermis	Hyperthermia
Sensation	Epidermis	Diabetic neuropathy
	Dermis	Leprosy
	Hypodermis	Pruritus
		Postherpetic neuralgia
Ultraviolet protection	Epidermis	Xeroderma pigmentosum
		Oculocutaneous albinism
Wound repair/regeneration	Epidermis	Keloid
	Dermis	Venous stasis ulcer
		Pyoderma gangrenosum
Physical appearance	Epidermis	Melasma
	Dermis	Vitiligo
	Hypodermis	Scleroderma
		Lipodystrophy

proliferative basal cells, attached to the epidermal basement membrane, to the terminally differentiated, keratinized stratum corneum, the outermost layer and barrier of skin (see Chap. 45). Intercalated among the keratinocytes at various levels are the immigrant resident cells—melanocytes, Langerhans cells, and Merkel cells. Other cells, such as lymphocytes, are transient inhabitants of the epidermis and are extremely sparse in normal skin. There are many regional differences in the epidermis and its appendages. Some of these differences are apparent grossly, such as thickness (e.g., palmoplantar skin vs. truncal skin, Fig. 7-3); other differences are microscopic.

Pathologic changes in the epidermis can occur as a result of a number of different stimuli: repetitive mechanical trauma (as in lichen simplex chronicus), inflammation (as in atopic dermatitis and lichen planus), infection (as in verruca vulgaris), immune system activity and cytokine abnormalities (as in psoriasis, Fig. 7-4), autoantibodies (as in pemphigus vulgaris and bullous pemphigoid), or genetic defects that influence differentiation or structural proteins [as in epidermolysis bullosa (EB) simplex, epidermolytic hyperkeratosis, the ichthyoses, and Darier disease].

Layers of the Epidermis

BASAL LAYER The keratinocyte is an ectodermally derived cell and is the primary cell type in the epidermis, accounting for at least 80 percent of the total cells. The ultimate fate of these cells is to contribute the components for the epidermal barrier as the stratum corneum. Thus, much of the function of the epidermis can be gleaned from the study of the structure and development of the keratinocyte.

Keratinocyte differentiation (keratinization) is a genetically programmed, carefully regulated, complex series of morphologic changes and metabolic events whose endpoint is a terminally differentiated, dead keratinocyte (corneocyte) that contains keratin filaments, matrix protein, and a protein-reinforced

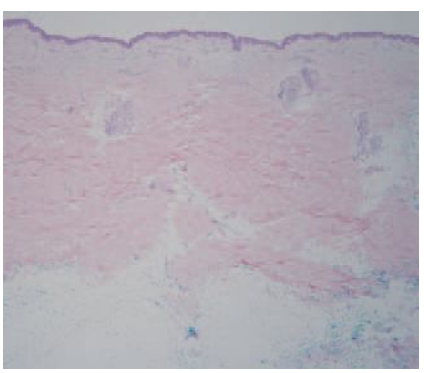

▲ **FIGURE 7-1** The major regions of skin. Skin is composed of three layers: (1) epidermis, (2) dermis, and (3) hypodermis. The outermost epidermis is separated from the dermis by a basement membrane zone, the dermal-epidermal junction. Below the dermis lies the subcutaneous fat (hypodermis). Epidermal appendages, such as hair follicles and eccrine and apocrine sweat glands, begin in the epidermis but course through the dermis and/or the epidermis. Blood vessels, lymphatics, and nerves course through the subcutaneous fat and emerge into the dermis. (Used with permission from O. Kovich, MD.)

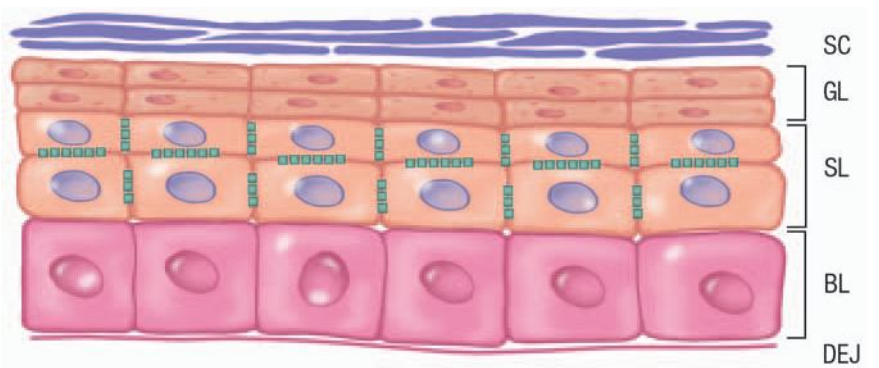

▲ **FIGURE 7-2** Schematic of epidermis. The epidermis is a stratified, cornified epithelium. The deepest layer consists of basal cells (BL) that rest upon the basement membrane of the dermal-epidermal junction (DEJ). These cells differentiate into the cells of the spinous layer (SL), characterized by abundant desmosomal spines. Spinous cells eventually become granular layer cells (GL), producing many of the components of the cornified envelope. Ultimately, the terminally differentiated keratinocytes shed their nuclei and become the stratum corneum (SC), a cross-linked network of protein and glycolipids.

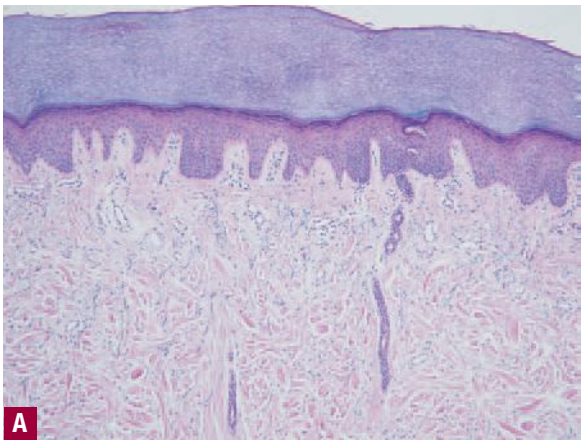

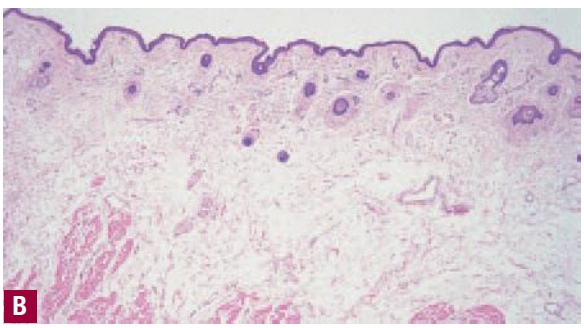

► **FIGURE 7-3** Anatomic variation in epidermal thickness. **A.** Acral skin. **B.** Eyelid skin. Note that the epidermis is considerably thicker in (**A**) than (**B**), including the compact layers of the stratum corneum, as well as the deeper epidermal layers. (Used with permission from O. Kovich, MD.)

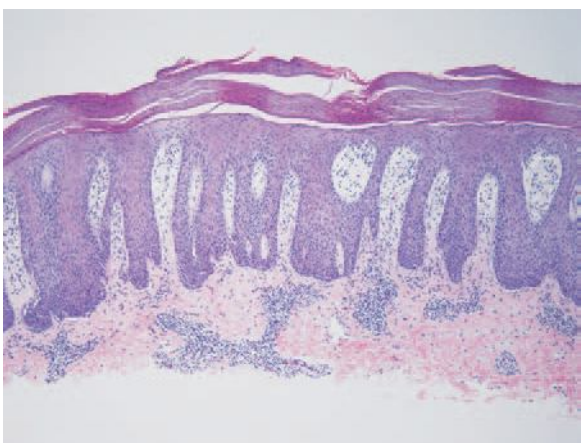

►**FIGURE 7-4** Epidermal hyperplasia. Hyperproliferation of the epidermis can occur due to a number of causes, as manifested in diseases such as psoriasis (pictured), as well as lichen simplex chronicus, atopic dermatitis, lichen planus, and verruca vulgaris. (Used with permission from O. Kovich, MD.)

plasma membrane with surface-associated lipids (see Chap. 44).

Keratins are a family of intermediate filaments and are the hallmark of all epithelial cells, including keratinocytes (reviewed in refs. 1 and 2). They serve a predominantly structural role in the cells. Fifty-four different functional keratin genes have been identified in humans—34 epithelial keratins and 17 hair keratins.[3] The co-expression of specific keratin pairs is dependent on cell type, tissue type, developmental stage, differentiation stage, and disease condition (Table 7-2). Furthermore, the critical role of these molecules is underscored by the numerous manifestations of disease that arise because of mutations in these genes (see Table 7-2). Thus, knowledge of keratin expression, regulation, and structure provides insight into epidermal differentiation and structure.

The basal layer (stratum germinativum) contains mitotically active, columnar-shaped keratinocytes that attach via keratin filaments (K5 and K14) to the basement membrane zone at hemidesmosomes (see Chap. 51), attach to other surrounding cells through desmosomes, and that give rise to cells of the more superficial, differentiated epidermal layers. Ultrastructural analysis reveals the presence of membrane-bound vacuoles that contain pigmented melanosomes transferred from melanocytes by phagocytosis.[4] The pigment within melanosomes contributes to the overall skin pigmentation perceived macroscopically.[5] The basal layer is the primary location of mitotically active cells of the epidermis. Cell kinetic studies suggest that the basal layer cells exhibit different proliferative potentials (stem cells, transit amplifying cells, and postmitotic cells), and in vivo and in vitro studies suggest that there exist long-lived epidermal stem cells[6] (see Chap. 44). Because basal cells can be expanded in tissue culture and used to reconstitute sufficient epidermis to cover the entire skin surface of burn patients,[7,8] such a starting population is presumed to contain long-lived stem cells with extensive proliferative potential.

A large amount of data supports the existence of multipotent epidermal stem cells within the bulge region of the hair follicle based on these traits.[9–17] Cells from this region are able to contribute to the formation not only of the entire pilosebaceous unit, but to the interfollicular epidermis as well.[14–17]

The existence of an additional progenitor population of cells, within the surface epidermal basal layer, is also supported by a number of lines of evidence, both in vitro and in vivo. These putative basal stem cells appear to be clonogenic, progress rapidly through S-phase of the cell cycle, and divide infrequently during stable self-renewal (retaining radiolabeled nucleotide label over long periods). Additionally, they are capable of cell division in response to exogenous and endogenous agents. Early lineage tracing experiments in the epidermis identified that keratinocytes are organized into vertical columns of progressively differentiating cells, termed *epidermal proliferating units*.[18–21]

The second type of cell, the transit amplifying cells of the basal layer, arises as a subset of daughter cells produced by the infrequent division of stem cells. These cells provide the bulk of the cell divisions needed for stable self-renewal and are the most common cells in the basal compartment. After undergoing several cell divisions, these cells give rise to the third class of epidermal basal cells, the postmitotic cells that undergo terminal differentiation. Although long believed to detach from the basal lamina to migrate to a more superficial (suprabasal) position in the epidermis, recent evidence has suggested that asymmetric division of basal cells relative to the basement membrane can directly give rise to a suprabasal differentiating daughter cell.[30] In humans, the normal transit time for a basal cell, from the time it loses contact with the basal layer to the time it enters the stratum corneum, is at least 14 days. Transit through the stra-

TABLE 7-2
Expression Patterns of Keratin Genes and Keratin-Associated Diseases

Basic	Acidic	Tissue Expression	Disease Association
1	10	Suprabasal keratinocytes	Bullous congenital ichthyosiform erythroderma; diffuse nonepidermolytic PPK (keratin 1)
1	9	Suprabasal keratinocytes (palmoplantar skin)	Epidermolytic PPK (epidermolytic hyperkeratosis)
2	10	Upper spinous and granular layers	Ichthyosis bullosa of Siemens
3	12	Cornea	Meesmann's corneal dystrophy
4	13	Mucosal epithelium	White sponge nevus
5	14	Basal keratinocytes	Epidermolysis bullosa simplex
6a	16	Outer root sheath, hyperproliferative keratinocytes, palmoplantar keratinocytes	Pachyonychia congenita type I; focal nonepidermolytic PPK
6b	17	Nail bed, epidermal appendages	Pachyonychia congenita type II; steatocystoma multiplex
8	18	Simple epithelium	Cryptogenic cirrhosis

PPK = palmoplantar keratoderma.

tum corneum and subsequent desquamation require another 14 days. These periods of time can be altered in hyperproliferative or growth-arrested states.

SPINOUS LAYER The shape, structure, and subcellular properties of spinous cells correlate with their position within the mid-epidermis. They are named for the spine-like appearance of the cell margins in histologic sections. Suprabasal spinous cells are polyhedral in shape with a rounded nucleus. As these cells differentiate and move upward through the epidermis, they become progressively flatter and develop organelles known as *lamellar granules* (see Granular Layer). Spinous cells also contain large bundles of keratin filaments, organized around the nucleus and inserted into desmosomes peripherally.

Spinous cells retain the stable K5/K14 keratins that are produced in the basal layer but do not synthesize new messenger RNA (mRNA) for these proteins, except in hyperproliferative disorders. Instead, new synthesis of the K1/K10 keratin pair occurs in this epidermal layer. These keratins are characteristic of an epidermal pattern of differentiation and thus are referred to as the *differentiation-specific* or *keratinization-specific keratins*. This normal pattern of differentiation is switched to an alternative pathway in hyperproliferative states, however. In conditions such as psoriasis, actinic keratoses, and wound healing, synthesis of K1 and K10 mRNA and protein is downregulated, and the synthesis and translation of messages for K6 and K16 are favored. Correlated with this change in keratin expression is a disruption of normal differentiation in the subsequent granular and cornified epidermal layers (see Granular Layer and Stratum Corneum). mRNA for K6 and K16 are present throughout the epidermis normally, but the message is only translated on stimulation of proliferation.

The "spines" of spinous cells are abundant desmosomes, calcium-dependent cell surface modifications that promote adhesion of epidermal cells and resistance to mechanical stress (reviewed in ref. 31; see also Chaps. 44 and 51). Within each cell is a desmosomal plaque, which contains the polypeptides plakoglobin, desmoplakins I and II, keratocalmin, desmoyokin, and plakophilin. Transmembrane glycoproteins—desmogleins 1 and 3 and desmocollins I and II, members of the cadherin family—provide the adhesive properties of the extracellular portion of the desmosomes, known as the *core*. Whereas the extracellular domains of the cadherins form part of the core, the intracellular domains insert into the plaque, linking them to the intermediate filament (keratin) cytoskeleton. Although desmosomes are related to adherens junctions, the latter associate with actin microfilaments at cell–cell interfaces, via a distinct set of cadherins (e.g., E-cadherin) and intracellular catenin adapter molecules.

That the desmosomes are integral mediators of intercellular adhesion is clearly demonstrated in diseases in which these structures are disrupted (Table 7-3).[32] The autoimmune bullous diseases pemphigus vulgaris and pemphigus foliaceus (see Chap. 52) are caused by antibodies that target the desmoglein proteins within the desmosomes. Loss of desmosomal adhesion results in the characteristic rounding and separation of keratinocytes (acantholysis), ultimately forming a blister within the epidermis. Strikingly, the clinical presentation of these diseases reflects the relative expression in the tissue of the desmoglein 1 and 3 proteins

TABLE 7-3
Disease Resulting from Disruption of Desmosomal Proteins

Protein	Diseases
Desmoglein 1	Pemphigus foliaceus Striate palmoplantar keratoderma Staphylococcal scalded-skin syndrome Bullous impetigo
Desmoglein 3	Pemphigus vulgaris
Desmoglein 4	Autosomal recessive hypotrichosis
Plakoglobin	Palmoplantar keratoderma with wooly hair and arrhythmogenic right ventricular cardiomyopathy (Naxos disease)
Plakophilin 1	Ectodermal dysplasia/skin fragility syndrome (skin erosions, dystrophic nails, sparse hair, and painful palmoplantar keratoderma)
Plakophilin 2	Arrhythmogenic right ventricular cardiomyopathy
Desmoplakin	Lethal acantholytic epidermolysis bullosa Striate palmoplantar keratoderma, type I Palmoplantar keratoderma with left ventricular cardiomyopathy and wooly hair Autosomal dominant arrhythmogenic right ventricular cardiomyopathy

(see Chaps. 51 and 52). Pemphigus vulgaris results from autoantibodies directed against desmoglein 3 and results in disruption of the epidermis between the basal and suprabasal layers (reviewed in ref. 33). On the other hand, desmoglein 1 is expressed in the upper epidermal layers, and antibodies to this protein in patients with pemphigus foliaceus result in blisters in the more superficial granular layer. Other diseases that target the same desmoglein 1 protein but by a different mechanism are staphylococcal scalded skin syndrome (see Chap. 178) and bullous impetigo, in which a bacterial protease cleaves and inactivates desmoglein 1, resulting in the same superficial blistering seen in pemphigus foliaceus.[34] Genetic mutations in other desmosomal components also reveal a role for these proteins in adhesion as well as cell signaling (see Table 7-3).[32]

The importance of calcium as a mediator of adhesion is well illustrated in the cases of two conditions that exhibit characteristic epidermal dyscohesion, Darier disease (keratosis follicularis) and Hailey-Hailey disease (benign chronic pemphigus) (see Chap. 49).[35,36] Both of these diseases are caused by mutations in genes that regulate calcium transport, SERCA2 (sarco/endoplasmic reticulum Ca^{2+}-ATPase type 2 isoform) in the case of Darier disease, and ATP2C1 (ATPase, Ca^{2+} transporting, type 2C, member 1, a regulator of cytoplasmic calcium concentration) in the case of Hailey-Hailey disease.

Lamellar granules are also formed in this layer of epidermal cells (Fig. 7-5). These secretory organelles deliver precursors of stratum corneum lipids into the intercellular space. Lamellar granules contain glycoproteins, glycolipids, phospholipids, free sterols, and a number of acid hydrolases, including lipases, proteases, acid phosphatases, and glycosidases. Glucosylceramides, the precursors to ceramides and the dominant component of the stratum corneum lipids, are also found within these structures (see Chap. 45). Genetic diseases demonstrate the importance of steroid and lipid metabolism for sloughing of cornified cells—in recessive X-linked ichthyosis, for example, mutation of steroid sulfatase results in a retention hyperkeratosis (see Chap. 47).[37,38]

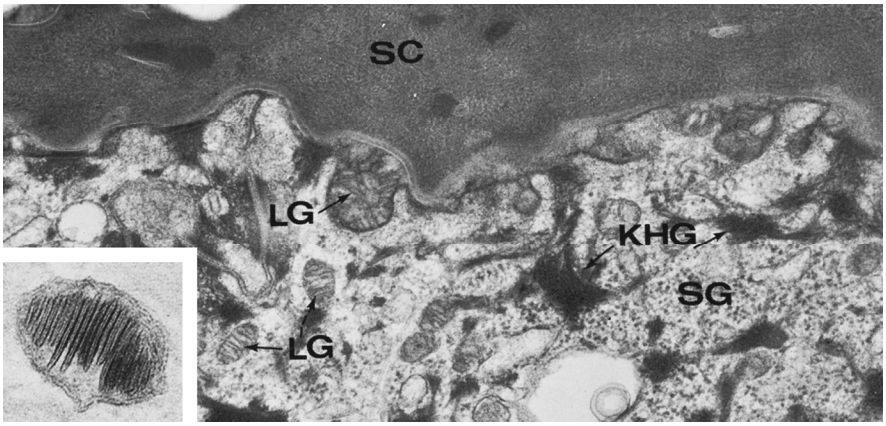

▲ **FIGURE 7-5** Junction of the stratum granulosum (SG) and stratum corneum (SC). Lamellar granules (LG) are in the intercellular space and cytoplasm of the granular cell. Keratohyalin granules (KHG) are also evident. *Inset:* Lamellar granule, ×28,750. (From Holbrook K: Structure and development of the skin, in *Pathophysiology of Dermatologic Disease*, 2nd ed., edited by Soter NA, Baden HP. New York, McGraw-Hill, 1991, p 7, with permission. Inset used with permission from EC Wolff-Schreiner, MD.)

GRANULAR LAYER Named for the basophilic keratohyalin granules that are prominent within cells at this level of the epidermis, the granular layer is the site of generation of a number of the structural components that will form the epidermal barrier, as well as a number of proteins that process these components (see Fig. 7-2) (reviewed in refs. 39 and 40). Keratohyalin granules (see Fig. 7-5) are composed primarily of profilaggrin, keratin filaments, and loricrin. It is in this layer that the cornified cell envelope begins to form. Release of profilaggrin from keratohyalin granules results in the calcium-dependent cleavage of the profilaggrin polymeric protein into filaggrin monomers. These filaggrin monomers aggregate with keratin to form macrofilaments. Eventually, filaggrin is degraded into molecules, including urocanic acid and pyrrolidone carboxylic acid, which contribute to hydration of the stratum corneum and help filter UV radiation. Loricrin is a cysteine-rich protein that forms the major protein component of the cornified envelope, accounting for more than 70 percent of its mass. Upon its release from keratohyalin granules, loricrin binds to desmosomal structures. Loricrin, along with involucrin, cystatin A, small proline-rich proteins (SPR1, SPR2, and cornifin), elafin, and envoplakin are all subsequently cross-linked to the plasma membrane by tissue transglutaminases (TGMs, primarily TGMs 3 and 1), forming the cornified cell envelope.

Mutations in the TGM1 gene have been shown to be the basis of some cases of lamellar ichthyosis, an autosomal recessive condition characterized by large scales and a disruption in the uppermost differentiating layers of the epidermis.[41,42] Another form of ichthyosis, ichthyosis vulgaris, is caused by mutations in the gene encoding filaggrin.[43,44] Loricrin abnormalities result in a form of Vohwinkel syndrome with ichthyosis and pseudoainhum, as well as the disease progressive symmetric keratodermia.[45–47] These findings emphasize the importance of proper formation of the cornified envelope in normal epidermal keratinization.

The final stage of granular cell differentiation involves the cell's own programmed destruction. During this process, in which the granular cell becomes a terminally differentiated corneocyte, an apoptotic mechanism results in the destruction of the nucleus and almost all cellular contents, with the exception of the keratin filaments and filaggrin matrix.

STRATUM CORNEUM (See Chap. 45) Complete differentiation of granular cells results in stacked layers of anucleate, flattened cornified cells that form the stratum corneum. It is this layer that provides mechanical protection to the skin and a barrier to water loss and permeation of soluble substances from the environment (reviewed in refs. 39 and 48). The stratum corneum barrier is formed by a two-compartment system of lipid-depleted, protein-enriched corneocytes surrounded by a continuous extracellular lipid matrix. These two compartments provide somewhat segregated but complementary functions that together account for the "barrier activity" of the epidermis. Regulation of permeability, desquamation, antimicrobial peptide activity, toxin exclusion, and selective chemical absorption are all primarily functions of the extracellular lipid matrix. On the other hand, mechanical reinforcement, hydration, cyto-

kine-mediated initiation of inflammation, and protection from UV damage are all provided by the corneocytes.

Nonkeratinocytes of the Epidermis

Melanocytes are neural crest-derived, pigment-synthesizing dendritic cells that reside primarily in the basal layer (see Chap. 70).[49] By light microscopy, these cells are recognized by their pale-staining cytoplasm, ovoid nucleus, and color of the pigment-containing melanosomes, the distinctive organelle of the melanocyte. The function of melanocytes has been highlighted by disorders in melanocyte number or function. The classic dermatologic disease, vitiligo, is caused by the autoimmune depletion of melanocytes.[50] Causes of other disorders of pigmentation are found in various defects in melanogenesis, including melanin synthesis, melanosome production, and melanosome transport and transfer to keratinocytes (see Chaps. 70 and 73). Regulation of melanocyte proliferation and homeostasis is under intensive study as well as a means to understanding melanoma (see Chap. 124).[4] Keratinocyte–melanocyte interactions are critical for melanocyte homeostasis and differentiation, influencing proliferation, dentricity, and melanization.

Merkel cells are slow-adapting type I mechanoreceptors located in sites of high-tactile sensitivity (see Chap. 120).[51] They are present among basal keratinocytes in particular regions of the body, including hairy skin and in the glabrous skin of the digits, lips, regions of the oral cavity, and the outer root sheath of the hair follicle. Like other nonkeratinocytes, Merkel cells have a pale-staining cytoplasm. Immunohistochemical markers of the Merkel cell include K8, K18, K19, and K20 keratin peptides. K20 is restricted to Merkel cells in the skin and thus may be the most reliable marker. Ultrastructurally, Merkel cells are easily identified by the membrane-bounded, dense-core granules that collect opposite the Golgi and proximal to an unmyelinated neurite (Fig. 7-6). These granules are similar to neurosecretory granules in neurons and contain neurotransmitter-like substances and markers of neuroendocrine cells, including metenkephalin, vasoactive intestinal peptide, neuron-specific enolase, and synaptophysin. Although increasingly more is being learned about the normal function of Merkel cells, they are of particular clinical note because Merkel cell-derived neoplasms are particularly aggressive and difficult to treat (see Chap. 120).

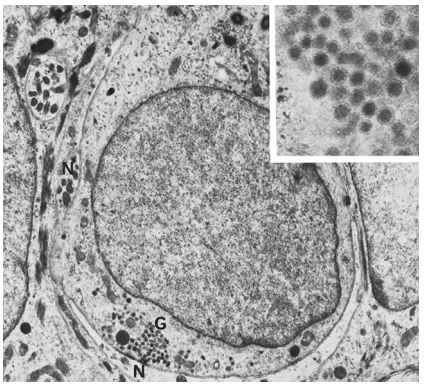

▲ **FIGURE 7-6** Merkel cells from the finger of a 130-mm CR (crown-rump) 21-week human fetus. Note nerve (N) in direct contact with the lateral and basal surfaces of the cell and dense core cytoplasmic granules (G). ×13,925. *Inset:* Merkel cell granules, ×61,450.

Langerhans cells are dendritic antigen-processing and -presenting cells in the epidermis (see Chap. 10).[52] Although they are not unique to the epidermis, they form 2 percent to 8 percent of the total epidermal cell population. They are mostly found in a suprabasal position but are distributed throughout the basal, spinous, and granular layers. In histologic preparations, Langerhans cells are pale-staining and have convoluted nuclei. The cytoplasm of the Langerhans cells contains characteristic small rod- or racket-shaped structures called *Langerhans cell granules* or *Birbeck granules* (Fig. 7-7). They principally function to sample and present antigens to T cells of the epidermis. Because of these functions, they are implicated in the pathologic mechanisms underlying allergic contact dermatitis, cutaneous leishmaniasis, and human immunodeficiency virus infection. Langerhans cells are reduced in the epidermis of patients with certain conditions, such as psoriasis, sarcoidosis, and contact dermatitis; they are functionally impaired by UV radiation, especially UVB.

Because of their effectiveness in antigen presentation and lymphocyte stimulation, dendritic cells and Langerhans cells have become prospective vehicles for tumor therapy and tumor vaccines. These cells are loaded with tumor-specific antigens, which will then stimulate the host immune response to mount an antigen-specific, and therefore tumor-specific, response.

DERMAL-EPIDERMAL JUNCTION

The dermal-epidermal junction (DEJ) is a basement membrane zone that forms the interface between the epidermis and dermis (see Chap. 51).[53,54] The major functions of the DEJ are to attach the epidermis and dermis to each other and to provide resistance against external shearing forces. It serves as a support for the epidermis, determines the polarity of growth, directs the organization of the cytoskeleton in basal cells, provides developmental signals, and serves as a semipermeable barrier.

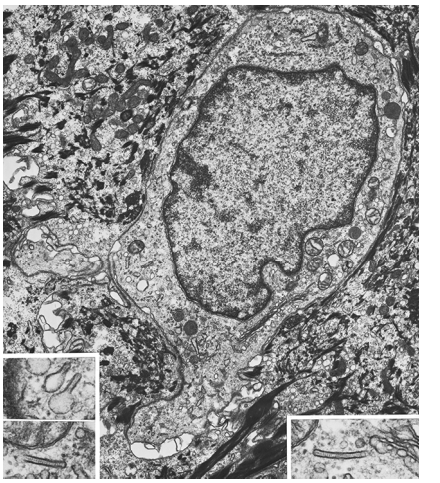

▲ **FIGURE 7-7** Langerhans cell. Note indented nucleus, lysosomes, as well as rod- and racket-shaped cytoplasmic granules (Birbeck granules), and the absence of keratin filaments. ×13,200. *Inset:* Birbeck granules ×88,000. (Used with permission from N. Romani, MD.)

The DEJ can be subdivided into three supramolecular networks: the hemidesmosome-anchoring filament complex, the basement membrane itself, and the anchoring fibrils. The critical role of this region in maintaining skin structural integrity is revealed by the large number of mutations in DEJ components that cause blistering diseases of varying severity, covered in detail in Chap. 60. These bullous diseases are grouped according to the level of the cleavage within the DEJ—the most superficial, EB simplex, involves basal keratinocyte cleavage. Junctional EB occurs within the lamina lucida and lamina densa regions. Dystrophic EB is the deepest level of blistering, within the sublamina densa/anchoring filaments. Chap. 51 provides a detailed discussion of the DEJ networks.

DERMIS

The dermis is an integrated system of fibrous, filamentous, diffuse, and cellular connective tissue elements that accommodates nerve and vascular networks, epidermally derived appendages, and contains many resident cell types, in-

cluding fibroblasts, macrophages, mast cells, and transient circulating cells of the immune system (see Figs. 6-9 and 6-14). The dermis makes up the majority of the skin and provides its pliability, elasticity, and tensile strength. It protects the body from mechanical injury, binds water, aids in thermal regulation, and includes receptors of sensory stimuli. The dermis interacts with the epidermis in maintaining the properties of both tissues, collaborates during development in the morphogenesis of the DEJ and epidermal appendages (see Development of Skin Appendages), and interacts in repairing and remodeling skin after wounding.

The dermis is arranged into two major regions, the upper papillary dermis and the deeper reticular dermis. These two regions are readily identifiable on histologic section, and they differ in their connective tissue organization, cell density, and nerve and vascular patterns. The papillary dermis abuts the epidermis, molds to its contours, and is usually no more that twice its thickness (see Fig. 6-9). The reticular dermis forms the bulk of the dermal tissue. It is composed primarily of large-diameter collagen fibrils, organized into large, interwoven fiber bundles, with branching elastic fibers surrounding the bundles (see Fig. 6-14). In normal individuals, the elastic fibers and collagen bundles increase in size progressively toward the hypodermis. The subpapillary plexus, a horizontal plane of vessels, marks the boundary between the papillary and reticular dermis. The lowest boundary of the reticular dermis is defined by the transition of fibrous connective tissue to adipose connective tissue of the hypodermis.

Fibrous Matrix of the Dermis

The connective tissue matrix of the dermis is comprised primarily of collagenous and elastic fibrous tissue.[55,56] These are combined with other, nonfibrous connective tissue molecules, including finely filamentous glycoproteins, proteoglycans (PGs), and glycosaminoglycans (GAGs) of the "ground substance."[57]

In terms of acellular components, collagen forms the bulk of the dermis, accounting for approximately 75 percent of the dry weight of skin, and providing both tensile strength and elasticity. (For details regarding the polypeptide structure and distribution of collagens, see Chap. 61.) The periodically banded, interstitial collagens account for the greatest proportion of collagen in adult dermis (type I, 80 percent to 90 percent; III, 8 percent to 12 percent; and V, < 5 percent). Although type V collagen accounts for a relatively small proportion of total collagen, it codistributes with both types I and III collagen to assist in regulating fibril diameter. It is located primarily in the papillary dermis and the matrix surrounding the basement membranes of vessels, nerves, and epidermal appendages, and at the DEJ. Type VI collagen is associated with fibril and in the interfibrillar spaces. Type IV collagen is confined to the basal lamina of the DEJ, vessels, and epidermal appendages. Type VII collagen forms anchoring fibrils at the DEJ.

Elastic connective tissue (see Chap. 61) is complex molecular mesh, assembled into a continuous network that extends from the lamina densa of the DEJ throughout the dermis and into the connective tissue of the hypodermis.[56] Elastic fibers return the skin to its normal configuration after being stretched or deformed. Elastic fibers are also present in the walls of cutaneous blood vessels and lymphatics and in the sheaths of hair follicles. By dry weight, elastic connective tissue accounts for approximately four percent of the dermal matrix protein. The components of elastic fibers include fibrillin-1, a 350-kd molecule, mutations in which cause Marfan syndrome (see Chap. 139). Elastin is the elastic fiber matrix component, and mutations in this protein cause the disease cutis laxa (see Chap. 139). Oxytalan fibers extend from the DEJ to the papillary/reticular dermal junction, where they merge with elaunin fibers. Elaunin fibers, in turn, evolve into mature elastic fibers of the reticular dermis. These fibers are normally located between bundles of collagen fibers, although in certain pathologic conditions, such as Buschke-Ollendorff syndrome, both elastic and collagen fibers become assembled within the same bundle. The importance of this elastic fiber network is clearly seen in the number of multisystem diseases that arise because of mutations in components of this network. Recently, the defect underlying pseudoxanthoma elasticum (PXE) was found to be mutation in ABCC6, a member of the large adenosine triphosphate-dependent transmembrane transporter family. Thus, this disease that is characterized by loss of skin elasticity and calcified elastic fibers is unlikely a primary defect in elastic tissue, but rather a metabolic disorder with secondary involvement of elastic fibers.[58–60] In addition to genetic mutations, solar radiation and aging also contribute to elastic fiber damage.[61]

Filamentous and Diffuse Matrix Components of the Dermis (See Chap. 61)

The fibrous and cellular matrix elements are embedded within more amorphous matrix components, which also are found in basement membranes.[62–64] PGs and GAGs surround and embed the fibrous components. PGs are large molecules consisting of a core protein that determines which GAGs will be incorporated into the molecule. The PG/GAG complex can bind water up to 1000 times its own volume and have roles in regulation of water-binding and compressibility of the dermis, as well as increasing local concentrations of growth factors through binding (e.g., basic fibroblast growth factor). They also link cells with the fibrillar and filamentous matrix, influencing proliferation, differentiation, tissue repair, and morphogenesis.

The major PGs in the adult dermis are chondroitin sulfates/dermatan sulfate, including biglycan, decorin, and versican; heparan/heparan sulfate PGs, including perlecan and syndecan; and chondroitin-6 sulfate PGs, which are components of the DEJ (see Chap. 61). The relative amounts of these different PGs change with age, as adult dermis after age 40 years generally has increases in dermatan sulfate, but decreases in chondroitin-6 sulfate and chondroitin sulfate.

Glycoproteins that are found in the dermis include fibronectin, thrombospondin, laminin, vitronectin, and tenascin. Like the PGs/GAGs, they interact with other matrix components via integrin receptors. These molecules facilitate processes of migration, cell adhesion, morphogenesis, and differentiation. Fibronectin is synthesized by both epithelial and mesenchymal cells, and it covers collagen bundles and the elastic network. Vitronectin is present on all elastic fibers except for oxytalan. Tenascin expression is found around the smooth muscle of blood vessels, arrector pili muscles, and appendages such as sweat glands.

Cellular Components of the Dermis

Fibroblasts, macrophages, and mast cells are the regular residents of the dermis,

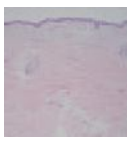

mostly found around the papillary region and surrounding vessels of the subpapillary plexus (see Fig. 6-20). They also occur in the reticular dermis in the interstices between collagen fiber bundles. The fibroblast is a mesenchymally derived cell that migrates through the tissue and is responsible for the synthesis and degradation of fibrous and nonfibrous connective tissue matrix proteins and a number of soluble factors. Fibroblasts provide a structural extracellular matrix framework as well as promote interaction between epidermis and dermis by synthesis of soluble mediators. Studies of human fibroblasts indicate that even within a single tissue, phenotypically distinct populations exist, some of which relate to regional anatomical differences.[65,66] They are also instrumental in wound healing and scarring, increasing their proliferative and synthetic activity during these processes.

The monocytes, macrophages, and dermal dendrocytes constitute the mononuclear phagocytic system of cells in the skin. Macrophages are derived from precursors in the bone marrow, differentiate into circulating monocytes, then migrate into the dermis to differentiate. These cells are phagocytic; process and present antigen to immunocompetent lymphoid cells; are microbicidal (producing lysozyme, peroxide, and superoxide), tumoricidal, secretory (growth factors, cytokines, and other immunomodulatory molecules), and hematopoietic (see Chap. 10); and are involved in coagulation, atherogenesis, wound healing, and tissue remodeling.

Mast cells (see Chap. 150) are specialized secretory cells that, in skin, are present in greatest density in the papillary dermis, near the DEJ, in sheaths of epidermal appendages, and around blood vessels and nerves of the subpapillary plexus. They are also common in the subcutaneous fat. Mast cells are identified histologically by a round or oval nucleus and abundant, darkly staining cytoplasmic granules. The surface of dermal mast cells is coated with fibronectin, which probably assists in securing cells within the connective tissue matrix. Mast cells can become hyperplastic and hyperproliferative in mastocytosis (see Chap. 150). Mast cells are secretory cells that are responsible for immediate-type hypersensitivity reaction in the skin and are involved in the production of subacute and chronic inflammatory disease. They synthesize secretory granules composed of histamine, heparin, tryptase, chymase, carboxypeptidase, neutrophil chemotactic factor, and eosinophilic chemotactic factor of anaphylaxis, which are mediators in these processes.

The dermal dendrocyte is a stellate, dendritic, or sometimes spindle-shaped, highly phagocytic fixed connective tissue cell in the dermis of normal skin. They are a subset of antigen-presenting macrophages or a distinct lineage that originates in the bone marrow. Similar to many other bone marrow-derived cells, dermal dendrocytes express factor XIIIa and CD45, and they lack typical markers of fibroblasts (e.g., Te-7). These cells are particularly abundant in the papillary dermis and upper reticular dermis, frequently in the proximity of vessels of the subpapillary plexus. Dermal dendrocytes function in the afferent limb of an immune response (see Chap. 10). They are also likely the cell of origin of a number of benign fibrotic proliferative conditions in the skin, such as dermatofibromas and fibroxanthomas (see Chap. 64).

CUTANEOUS VASCULATURE

Blood Vessels (See Chap. 163)

The blood vessels of the skin provide nutrition for the tissue, but in addition, they are involved in temperature and blood pressure regulation, wound repair, and numerous immunologic events.[67] The microcirculatory beds in skin progress from arterioles to precapillary sphincters. Extending from the sphincters are arterial and venous capillaries, which become postcapillary venules, and finally, collecting venules. When compared with vasculature of other organs, the vessels of skin are adapted to shearing forces, as they have thick walls supported by connective tissue and smooth muscle cells. Special cells, known as *veil cells*, surround the cutaneous microcirculation, defining a domain for the vessels within the dermis while remaining separate from the vessel walls.

The rich vascular network of the skin is located at boundaries within the dermis and supplies the epidermal appendages (see Fig. 163-2). The vessels that supply the dermis branch from musculocutaneous arteries that penetrate the subcutaneous fat and enter the deep reticular dermis. At this point, they are organized into a horizontal arteriolar plexus. From this plexus, ascending arterioles extend toward the epidermis. These arterioles contain two layers of smooth muscle cells, as well as pericytes, a second type of contractile cell of the vessel wall. At the junction between the papillary and reticular dermis, terminal arterioles form the subpapillary plexus. The arterioles at this level have only a single layer of smooth muscle cells, organized in a manner to suggest that they function as precapillary sphincters. Capillary loops then extend from the terminal arterioles of the plexus into the papillary dermis. At the apex of each capillary loop is the thinnest portion, in which both the endothelium and basal lamina of the vessels are attenuated, allowing for transport of material out of the capillary. The extrapapillary descending limbs of capillary loops are venous capillaries that drain into venous channels of the subpapillary plexus that lies above and below the arteriolar vascular plexus. The postcapillary venules of the subpapillary plexus are physiologically important components of the microcirculation. They are responsive to mediators such as histamine, developing gaps between adjacent endothelial cells that allow for the extravasation of fluid and cells, and are therefore often the sites of inflammatory cells during these responses.

Certain regions of the skin, such as the palms and soles, contain direct connections between arterial and venous circulation as potential shunts around congested capillary beds. These sites consist of an ascending arteriole (a glomus body), which is modified by three to six layers of smooth muscle cells and has associated sympathetic nerve fibers. The glomus can close completely when the blood pressure is below a critical level.

In the adult, the cutaneous vasculature normally remains quiescent, with the exception of certain hair cycle–dependent angiogenesis during anagen. Quiescence of vessels is in part due to inhibition of angiogenesis in the dermal matrix by factors such as thrombospondin. Pathogenic stimuli sometimes result in secondary angiogenesis, from tumors or during wounding. One of the key mediators of such angiogenesis is vascular endothelial growth factor (VEGF), often secreted by tumors or by keratinocytes (see Chap. 163).[68,69]

Numerous disorders can manifest themselves within the cutaneous vasculature. Leukocytoclastic vasculitis (cutaneous necrotizing venulitis) occurs within the venules in response to a number of potential pathogenic mechanisms (see Chap. 164). Stasis dermatitis,

urticaria, polyarteritis nodosa, thrombosis, and thrombophlebitis all affect vessels in the skin, of different sizes, some by occlusion of vessels (vasculopathy) and others by inflammation of the vessels (vasculitis).

Lymphatics

The lymph channels of the skin are important in regulating pressure of the interstitial fluid by resorption of fluid released from vessels and in clearing the tissues of cells, proteins, lipids, bacteria, and degraded substances.[70,71] The vessels begin in blind-ending initial lymphatics (also known as *lymphatic capillaries*, *prelymphatic tubules*, and *terminal* or *peripheral lymphatics*) in the papillary dermis. They drain into a horizontal plexus of larger lymph vessels located deep to the subpapillary venous plexus. A vertical system of lymphatics then carries fluid and debris through the reticular dermis to another deeper collecting plexus at the reticular dermis–hypodermis border.

Lymph flow within the skin depends on movements of the tissue caused by arterial pulsations and larger-scale muscle contractions and movement of the body, with backflow prevented by bicuspid-like valves within the vessels.

Although lymphatic vessels are only seen with difficulty on histologic section, because they are often collapsed in skin, they are composed of a large lumen and a thinner wall than blood vessels, with endothelium, discontinuous basal lamina, and elastic fibers. Molecular characterization of these vessels has identified Prox1, VEGFR-3, and LYVE-1 as specific markers of lymphatic character, and one of the most heavily-studied lymphangiogenic molecules is VEGF-C (see Chap. 163).

Certain pathologic conditions involve or highlight the lymphatic vessels, such as lymphedema, lymphangioma circumscriptum, and stasis dermatitis. The importance of lymphatics in the progression and spread of cancer is also becoming more clear, as melanoma cells destroy endothelial cells of the initial lymphatics to gain entry to the lymph circulation, and recent studies have shown that tumors themselves can promote lymphangiogenesis as part of their early program on the way to metastasis.[68] The discovery of the molecular defects in hereditary lymphedemas [type I Milroy disease VEGFR-3,[72–74] type II lymphedema praecox, lymphedema distichiasis, lymphedema and yellow nails, and lymphedema and ptosis MFH1 (forkhead transcription factor, FoxC2)[75]] has implicated the VEGFR-3 and FoxC2 in lymphatic development.

CUTANEOUS NERVES AND RECEPTORS

(See Chaps. 101 and 102) The nerve networks of the skin contain somatic sensory and sympathetic autonomic fibers.[76] The sensory fibers alone (free nerve endings) or in conjunction with specialized structures (corpuscular receptors) function as receptors of touch, pain, temperature, itch, and mechanical stimuli. The density and types of receptors are regionally variable, accounting for the variation in acuity at different sites of the body. Receptors are particularly dense in hairless areas such as the areola, labia, and glans penis. Sympathetic motor fibers are codistributed with the sensory nerves in the dermis until they branch to innervate the sweat glands, vascular smooth muscle, the arrector pili muscle of hair follicles, and sebaceous glands.

The nerves of skin branch from musculocutaneous nerves that arise segmentally from spinal nerves. The pattern of nerve fibers in skin is similar to the vascular patterns. That is, nerve fibers form a deep plexus, then ascend to a superficial, subpapillary plexus.

Free nerve endings include the penicillate and papillary nerve fibers and are the most widespread and important sensory receptors of the body. In humans, they are ensheathed by Schwann cells and a basal lamina. Free nerve endings are particularly common in the papillary dermis; the basal lamina of the fiber may merge with the lamina densa of the basement membrane zone.

The penicillate fibers are the primary nerve fibers found sub-epidermally in haired skin. These are rapidly adapting receptors that function in the perception of touch, temperature, pain, and itch. Because of overlapping innervation, discrimination tends to be generalized in these regions. On the other hand, free nerve endings present in non-haired, ridged skin, such as the palms and soles, project individually without overlapping distribution. These receptors are thought to function in fine discrimination.

Papillary nerve endings are found at the orifice of a follicle. These branches from nerves that innervate the deeper levels of the follicle are thought to be particularly receptive to cold sensation. Hair follicles also contain other receptors, from myelinated stem axons in the deep dermal plexus, thought to be slow-adapting receptors that respond to the bending or movement of hairs. Cholinergic sympathetic fibers en route to the eccrine sweat gland and adrenergic and cholinergic fibers en route to the arrector pili muscle are carried along with the sensory fibers in the hair basket.

Free nerve endings are also associated with individual Merkel cells. Merkel cell–nerve complexes are described by a variety of names (*touch domes*, *hederiform endings*, *Iggo's capsule*, *Pinkus corpuscles*, *Haarscheibe*), depending on their composition and location. In haired skin, touch domes are associated with hair follicles. In palmoplantar skin, these complexes are found at the site where the eccrine sweat duct penetrates a glandular epidermal papilla.

Corpuscular receptors, both Meissner's and Pacinian, contain a capsule and inner core and are composed of both neural and non-neural components. The capsule is a continuation of the perineurium, and the core includes the nerve fiber surrounded by lamellated wrappings of Schwann cells. Meissner's corpuscles are elongated or ovoid mechanoreceptors located in the dermal papillae of digital skin and oriented vertically toward the epidermal surface (Fig. 7-8). One to six axons enter the corpuscle, ramify extensively, and terminate in bulboid endings that are surrounded by lamellae.

The Pacinian corpuscle lies in the deep dermis and subcutaneous tissue of

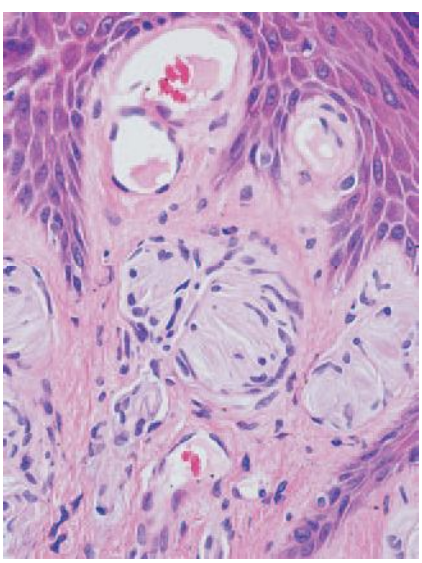

▲ **FIGURE 7-8** Meissner's corpuscle. Note the capsule and inner core located in the dermal papillae. These collections of cells serve as mechanoreceptors. (Used with permission from O. Kovich, MD.)

skin that covers weight-bearing surfaces of the body. It has a characteristic capsule and lamellar wrappings (Fig. 7-9). The perineural capsule is organized into 30 or more concentric layers of cells and fibrous connective tissue. The middle subcapsular zone is composed of collagen and fibroblasts, and the inner core consists of Schwann cell-derived hemilamellae: flattened semicircles that alternate with those of the opposite side. Pacinian corpuscles serve as rapidly adapting mechanoreceptors that respond to vibrational stimuli.

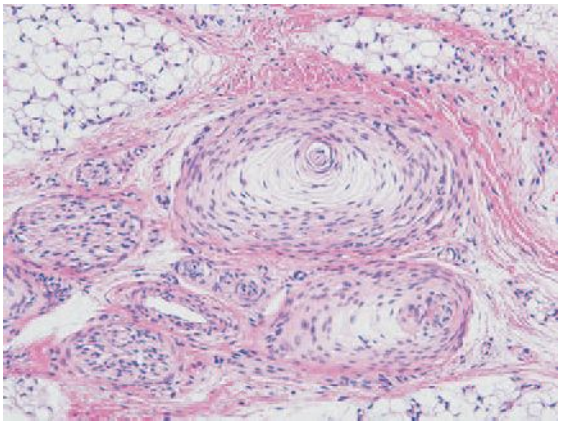

◀ **FIGURE 7-9** Pacinian corpuscle. Note the characteristic perineural capsule, likened to the appearance of an "onion-skin." Pacinian corpuscles serve as rapidly adapting mechanoreceptors that respond to vibrational stimuli. (Used with permission from O. Kovich, MD.)

HYPODERMIS (SUBCUTIS)

The tissue of the hypodermis insulates the body, serves as a reserve energy supply, cushions and protects the skin, and allows for its mobility over underlying structures. It has a cosmetic effect in molding body contours. The boundary between the deep reticular dermis and the hypodermis is an abrupt transition from a predominantly fibrous dermal connective tissue to a primarily adipose subcutaneous one (see Fig. 6-1, Chap. 6). Despite this clear distinction anatomically, the two regions are still structurally and functionally integrated through networks of nerves and vessels and through the continuity of epidermal appendages. Actively growing hair follicles span the dermis and extend into the subcutaneous fat, and the apocrine and eccrine sweat glands are normally confined to this depth of the skin.

Adipocytes form the bulk of the cells in the hypodermis.[77,78] They are organized into lobules defined by septa of fibrous connective tissue. Nerves, vessels, and lymphatics are located within the septa and supply the region. The synthesis and storage of fat continues throughout life by enhanced accumulation of lipid within fat cells, proliferation of existing adipocytes, or by recruitment of new cells from undifferentiated mesenchyme. The hormone leptin, secreted by adipocytes, provides a long-term feedback signal regulating fat mass. Leptin levels are higher in subcutaneous than omental adipose, suggesting a role for leptin in control of adipose distribution as well.

The importance of the subcutaneous tissue is apparent in patients with Werner syndrome (see Chap. 139), in which subcutaneous fat is absent in lesion areas over bone, or with scleroderma (see Chap. 158), where the subcutaneous fat is replaced with dense fibrous connective tissue. Such regions in Werner patients ulcerate and heal poorly. The skin of patients with scleroderma is taut and painful. In the hereditary and acquired lipodystrophies, loss of subcutaneous fat disrupts glucose, triglyceride, and cholesterol regulation, and causes significant cosmetic alteration, increasing the interest in possible hormonal therapy for these disorders (see Chap. 69).[79] The subcutaneous tissue is involved in different inflammatory conditions, and these are discussed in Chap. 68.

DEVELOPMENT OF SKIN

Significant advances in the understanding of the molecular processes responsible for the development of the skin have been made over the last several years. Such advances increase the understanding of clinicopathologic correlation among some inherited disorders of the skin and allow for the early diagnosis of such diseases.[80,81] The developmental progression of various components of the skin is well documented, and a time line indicating the events that occur during embryonic and fetal development is provided (Table 7-4).[82,83] Of note, the estimated gestational age (EGA) is used throughout this chapter; this system refers to the age of the fetus, with fertilization occurring on day 1. To avoid confusion, it should be pointed out that obstetricians and most clinicians define day 1 as the first day of the last menstrual period (menstrual age), in which fertilization occurs on approximately day 14. Thus, the two dating systems differ by approximately 2 weeks, such that a woman who is 14 weeks pregnant (menstrual age) is carrying a 12-week-old fetus (EGA).

Conceptually, fetal skin development can be divided into three distinct but temporally overlapping stages, those of specification, morphogenesis, and differentiation. These stages roughly correspond to the embryonic period (0 to 60 days), the early fetal period (2 to 5 months), and the late fetal period (5 to 9 months) of development. The earliest stage, specification, refers to the process by which the ectoderm lateral to the neural plate is committed to become epidermis, and subsets of mesenchymal and neural crest cells are committed to form the dermis. It is at this time that patterning of the future layers and specialized structures of the skin occurs, often via a combination of gradients of

TABLE 7-4
Timing of the Major Events in the Embryogenesis of Human Skin[a]

	First Trimester			Second Trimester			Third Trimester		
	1	2	3	4	5	6	7	8	9
Epidermis									
Appearance of epidermal cell layers									
Stratum basale	X								
Periderm	X								
Stratum intermedium		X							
Stratum granulosum						X			
Stratum corneum						X			
Periderm disappearance						X			

(continued)

TABLE 7-4
Timing of the Major Events in the Embryogenesis of Human Skin[a] (Continued)

	First Trimester			Second Trimester			Third Trimester		
	1	2	3	4	5	6	7	8	9
Epidermal cell junctions									
Desmosomes without associated keratin filaments	X								
Desmosomes with associated keratin filaments		X							
Tight junctions	X								
Hemidesmosomes			X						
Antigens									
Pemphigus and pemphigoid antigen			X						
A, B, H blood group antigens			X						
Immigrant cells									
Present, but type uncertain		X							
Melanocyte									
With premelanosomes		X							
With melanosomes that synthesize melanin				X					
Transfer of melanosomes to keratinocytes						X			
Langerhans cells			X						
Merkel cells				X					
Epidermal appendages									
Pilosebaceous apparatus									
Hair follicle development begins			X						
Hair exposed on skin surface and patterns established on the scalp			X						
Sebaceous gland primordium				X					
Sebaceous gland function				X					
Apocrine gland primordium						X			
Apocrine gland function							X		
Eccrine sweat glands (trunk)									
Duct and gland patent and functioning						X			
Nails									
Nail fold and establishment of matrix primordium			X						
Nail plate forms				X					
Keratinization of epidermis and appendages									
Dorsal ridge of presumptive nail			X						
Nail plate				X					
Palmar/plantar surface of digits				X					
Hair cone				X					
Hair tract				X					
Hair shaft					X				
Sebaceous duct					X				
Eccrine sweat gland duct (intraepidermal)						X			
Apocrine duct						X			
Dermis									
Structural organization									
Papillary and reticular regions established				X					
Dermal papillae established					X				
Dermal-subcutaneous boundary		X							
Panniculus adiposus established				X					
Connective tissue matrix proteins									
Collagen present by ultrastructural observation		X							
Collagen present by biochemical analysis									
Type I	?	X							
Type III	?	X							
Elastic microfibrils	?	X							
Elastic matrix				X					
Elastic fibrous networks						X			

[a]Data are representative of the trunk unless stated otherwise.

proteins and cell–cell signals. The second stage, morphogenesis, is the process by which these committed tissues begin to form their specialized structures, including epidermal stratification, epidermal appendage formation, subdivision between the dermis and subcutis, and vascular formation. The last stage, differentiation, denotes the process by which these newly specialized tissues further develop and assume their mature forms. Table 7-5 integrates specification, morphogenesis, and differentiation with skin morphology and genetic diseases.

For simplification and greater clarity, the stages of development of the epidermis—dermis and hypodermis, dermal–epidermal junction, and epidermal appendages—are presented sequentially.

Epidermis

EMBRYONIC DEVELOPMENT During the third week after fertilization, the human embryo undergoes gastrulation, a complex process of involution and cell redistribution that results in the formation of the three primary embryonic germ layers: ectoderm, mesoderm, and endoderm. Shortly after gastrulation, ectoderm further subdivides into neuroectoderm and presumptive epidermis. The specification of the presumptive epidermis is believed to be mediated by the bone morphogenetic proteins (BMPs). Later during this period, BMPs again appear to play a critical role, along with Engrailed-1 (En1), in specifying the volar versus interfollicular skin.[84–86] By 6 weeks EGA, the ectoderm that covers the body consists of basal cells and superficial periderm cells.

The basal cells of the embryonic epidermis differ from those of later developmental stages. Embryonic basal cells are more columnar than fetal basal cells, and they have not yet formed hemidesmosomes. Although certain integrins (e.g., $\alpha 6\beta 4$) are expressed in these cells, they are not yet localized to the basal pole of the cells. Before the formation of hemidesmosomes and desmosomes, intercellular attachment between individual basal cells appears to be mediated by adhesion molecules such as E- and P-cadherin, which have been detected on basal cells as early as 6 weeks EGA. Keratins K5 and K14, proteins restricted to definitive stratified epithelia, are expressed even at these early stages of epidermal formation.

At this stage, periderm cells form a "pavement epithelium." These cells are

TABLE 7-5
Proteins Involved in Cutaneous Development and Differentiation

	Epidermis	Dermis/SQ	DEJ	Appendages
Specification	• **BMPs** • **Engrailed-1** • (Aplasia cutis)	• **Lmx-1B** (Nail-patella syndrome) • **Engrailed-1** • **Wnt7a**	• Not known	• **Lmx-1B** • **Wnt7a** • **NGFR**
Morphogenesis	• **p63** • **Dlx-3** (Tricho-dento-osseous syndrome)	• **Lamin A/C, ZMPE STE24** (restrictive dermopathy) • **PTEN** (Proteus syndrome) • (Focal dermal hypoplasia/Goltz syndrome)	• **Laminin 1** • **Collagen IV** • **Heparin sulfate** • **Proteoglycans**	• **Ectodysplasin A (EDA)** (X-linked hypohidrotic ectodermal dysplasia) • **Connexin 30** (Autosomal hypohidrotic ectodermal dysplasia, type 2) • **EDA receptor** (Autosomal hypohidrotic ectodermal dysplasia, type 3) • **MSX1** (Witkop syndrome/tooth and nail syndrome) • **c-kit** (Piebaldism) • **PAX-3** (Waardenburg type 1,3) • **p63** (Hay-Wells/AEC, EEC) • **Beta-catenin** (pilomatricomas) • **Shh** • **Wnt** • **BMPs** • **FGF5** • **LEF1** • **Dlx-3**

Differentiation	• Structural proteins
	  • **K5, K14** (EB simplex)
	  • **Plectin** (EB with MD)
	  • **BPAG2** (GABEB)
	  • **α6β4 integrin** (EB with PA)
	  • **K1, K10** (BCIE)
	  • **K1, K9** (Vorner, Unna-Thost, Greither)
	  • **Loricrin** (NCIE, Vohwinkel, progressive symmetric erythrokeratodermia)
	  • **Filaggrin** (ichthyosis vulgaris)
	• Post-translational modifiers
	  • **LEKTI** (Netherton)
	  • **Transglutaminase 1** (lamellar ichthyosis; NCIE)
	  • **Phytanoyl CoA hydroxylase** (Refsum)
	  • **Fatty aldehyde dehydrogenase** (Sjögren-Larsson)
	  • **Steroid sulfatase/arylsulfatase** C (X-linked ichthyosis)
	• Transporter/channel proteins
	  • **ABCA12** (harlequin fetus)
	  • **Connexin 26** (KID syndrome, palmoplantar keratoderma with deafness)
	  • **Connexin 30.3** or **31** (erythrokeratoderma variabilis, progressive symmetric erythrokeratodermia)
	  • **SERCA2** (keratosis follicularis)
	  • **ATP2C1** (Hailey-Hailey disease)
	• Signal transduction proteins
	  • **Patched** (basal cell nevus syndrome)
		• **Capillary morphogenesis protein-2** (juvenile hyaline fibromatosis, infantile systemic hyalinosis)
		• **Collagen I, a1,** or **a2** (osteogenesis imperfecta)
		• **Collagen V, a1,** or **a2** (Ehlers-Danlos syndrome)
		• **Collagen VII** (dystrophic EB)
		• **Fibrillin** (Marfan syndrome)
		• **Elastin** (cutis laxa)
		• **MRP6** (PXE)
		• **Tie-2** (inherited venous malformations)
		• **Endoglin, activin receptor-like kinase 1** (HHT/Osler-Weber-Rendu)
		• **VEGF receptor-3** (hereditary lymphedema type I)
		• **MFH1** (hereditary lymphedema type II)
		• **Prox-1**
		• **LYVE-1**
			• **BPAG2**
			• **Collagen VII**
			• **α6β4 integrin**
			• **Laminin 5** (junctional EB)
				• Hair
				  • **BMPs**
				  • **Hoxc13**
				  • **Foxn1**
				  • **Plakoglobin** (Naxos disease)
				  • **Plakophilin/desmosomal band 6** (ectodermal dysplasia, skin fragility syndrome)
				  • **Hairless** (papular atrichia)
				• Nail
				  • **K6a, K16** (pachyonychia congenita type I)
				  • **K6b, K17** (pachyonychia congenita type II, steatocystoma multiplex)
				  • **Plakophilin**
				• Sebaceous gland
				  • **Blimp-1**
				  • **K6b, K17**

AEC = ankyloblepharon-ectodermal dysplasia-clefting; BCIE = bullous congenital ichthyosiform erythroderma; BMPs = bone morphogenetic proteins; BPAG = bullous pemphigoid antigen; EB = epidermolysis bullosa; EEC = ectrodactyly-ectodermal dysplasia-clefting; GABEB = generalized atrophic benign epidermolysis bullosa; HHT = hereditary hemorrhagic telangiectasia; K = keratin; KID = keratitis-ichthyosis-deafness; MD = multiple dystrophy; NCIE = non-bullous congenital ichthyosiform erythroderma; NGFR = nerve growth factor receptor; PA = pyloric atresia; PXE = pseudoxanthoma elasticum.
Protein names are indicated in **boldface**. Associated diseases/genodermatoses are listed in parentheses. Multiple names for the same protein or syndrome are separated by /. Genes and associated diseases can be found in Online Mendelian Inheritance in Man (OMIM) at http://www.ncbi.nlm.nih.gov/omim.

embryonic epidermal cells that are larger and flatter than the underlying basal cells. Apical surfaces contact the amniotic fluid and are studded with microvilli. Connections between periderm cells are sealed with tight junctions rather than desmosomes. By the end of the second trimester, these cells are sloughed and eventually form part of the vernix caseosa. Like stratified epithelial cells, periderm cells express K5 and K14, but they also express simple epithelial keratins K8, K18, and K19.

Aplasia cutis (see Chap. 106) may reflect focal defects in either epidermal specification or development caused by somatic mosaicism, or mutations that occur postzygotically. The molecular defect for this disorder is not known, however. The fact that few genetic diseases have been described in which epidermal specification or morphogenesis are defective likely reflects the fact that such defects would be incompatible with survival.

EARLY FETAL DEVELOPMENT (MORPHOGENESIS) By the end of 8 weeks of gestation, hematopoiesis has switched from the extraembryonic yolk sac to the bone marrow, the classical division between embryonic and fetal development. By this time, the epidermis begins its stratification and formation of an intermediate layer between the two pre-existing cell layers. The cells in this new layer are similar to the cells of the spinous layer in mature epidermis. Like spinous cells, they express keratins K1/K10 and the desmosomal protein desmoglein-3. The cells are still highly proliferative and, during this period of development, they evolve into a multilayer structure that will eventually replace the degenerating periderm.

Expression of the p63 gene plays a critical role in the proliferation and maintenance of the basal layer cells. Epidermal stratification does not occur in mice deficient for p63.[87–89] In humans, although no null mutations have been isolated, partial loss of p63 function mutations have been identified in ankyloblepharon, ectodermal dysplasia, and cleft lip/palate syndrome (Hay-Wells syndrome) as well as ectrodactyly, ectodermal dysplasia, and cleft lip/palate syndrome (see Chap. 143).[90–92] The pre-existing basal cell layer also undergoes morphologic changes at this time, becoming more cuboidal and expressing new keratin genes, K6, K8, K19, and K6/K16, that are usually expressed in hyperproliferative tissues. The basal layer also begins to elaborate proteins that will ultimately anchor them to the developing basal lamina (see Dermal-Epidermal Junction), including hemidesmosomal proteins BPAG1, BPAG2, and collagens V and VII (see Chaps. 51, 54, and 60).

Embryonic lines of ectodermal formation are revealed in mosaic disorders that follow the lines of Blaschko, including congenital, nevoid, and acquired conditions.[93–95] Molecular demonstration of genetic mosaicism has been reported for a number of X-linked disorders (reviewed in ref. 94), as well as epidermal nevi in epidermolytic hyperkeratosis.[96]

LATE FETAL DEVELOPMENT (DIFFERENTIATION) Late fetal development reveals the further specialization and differentiation of keratinocytes in the epidermis. It is at this time that the granular and stratum corneal layers are formed, and the rudimentary periderm is sloughed. Keratinization of the surface epidermis is a process of keratinocyte terminal differentiation which begins at 15 weeks EGA. The granular layer becomes prominent, and important structural proteins are elaborated in the basal layer cells. The hemidesmosomal proteins plectin and $\alpha 6\beta 4$ integrin are expressed and correctly localized at this time. Mutations in these genes result in various bullous genodermatoses (reviewed in Chap. 60). The more superficial cells undergo further terminal differentiation, and the keratin-aggregating protein filaggrin is expressed at this time.

The formation of the cornified envelope is a late feature of differentiating keratinocytes, and it relies on a number of different modifications to create an impermeable barrier. Enzymes such as transglutaminase, LEKTI (encoded by the gene SPINK-5), phytanoyl coenzyme A reductase, fatty aldehyde dehydrogenase, and steroid sulfatase are all important in the elaboration of the cornified envelope and mature lipid barrier, and defects in these enzymes can lead to abnormal epidermal barrier formation (see Chap. 47).

SPECIALIZED CELLS WITHIN THE EPIDERMIS The three major nonepidermal cell types—melanocytes, Langerhans cells, and Merkel cells—can be detected within the epidermis by the end of the embryonic period. Melanocytes are derived from the neural crest, a subset of neuroectoderm cells. Pigment mosaicism (formerly called *hypomelanosis of Ito* and *linear and whorled hypermelanosis*) (see Chap. 73) following the lines of Blaschko may reflect the migratory paths of melanoblasts, or alternatively, mosaic defects in pigment transfer from melanocytes to keratinocytes. The founders of each melanoblast clone originate at distinct points along the dorsal midline, traversing ventrally and distally to take up residence in the epidermis.

Melanocytes are first seen within the epidermis at 50 days EGA. Melanocytes express integrin receptors in vivo and in vitro and may use these to migrate to the epidermis during embryonic development. Migration, colonization, proliferation, and survival of melanocytes in developing skin depend on the cell surface tyrosine kinase receptor, *c-kit*, and its ligand, stem cell factor.[97,98] Melanin becomes detectable between 3 and 4 months EGA, and by 5 months, melanosomes begin to transfer pigment to keratinocytes. Many genetic disorders of pigmentation have been characterized and are presented in detail in Chaps. 71, 73, and 144. In the adult, a pool of melanocyte precursor cells resides in the upper permanent portion of the hair follicle, capable of producing mature melanocytes.[97,99,100]

Langerhans cells, another immigrant population, are detectable by 40 days EGA. They begin to express CD1 on their surface and to produce their characteristic Birbeck granules by the embryonic–fetal transition. By the third trimester, most of the adult numbers of Langerhans cells will have been produced.

Merkel cells, as described earlier in the chapter (see Nonkeratinocytes of the Epidermis), reside in the epidermis. They are first detectable in the volar epidermis of the 11- to 12-week EGA human fetus. The embryonic derivation of this population of cells is controversial. Evidence for in situ differentiation of Merkel cells from epidermal ectoderm versus immigration of Merkel cells from neural crest is supported by studies in which 8- and 11-week EGA fetal volar skin that lacked Merkel cells was transplanted to the nude mouse. Tissue harvested 8 weeks later contained an abundance of human K18-positive Merkel cells within the epidermis, suggesting that the cells differentiated within the grafted tissue.[101] On the other hand, more recent lineage tracing studies using a neural-crest specific label have suggested that Merkel cells indeed have a neural crest origin.[51]

Dermal and Subcutaneous Development

The origin of the dermis and subcutaneous tissue is more diverse than that of

the epidermis, which is exclusively ectodermally derived. The embryonic tissue that forms the dermis depends on the specific body site.[102,103] Dermal mesenchyme of the face and anterior scalp is derived from neural crest ectoderm. The limb and ventral body wall mesenchyme is derived from the lateral plate mesoderm. The dorsal body wall mesenchyme derives from the dermomyotomes of the embryonic somite. LIM homeobox transcription factor 1 beta (Lmx1B) and Wnt7a are important in the specification of the dorsal limb.[104–106] En1 and BMPs, on the other hand, specify the volar (ventral) limb mesenchyme (see Table 7-5).[88,105]

The embryonic dermis, in contrast to the mature dermis, is cellular and amorphous, with few organized fibers. The mature dermis contains a complex mesh of collagen and elastic fibers embedded in a matrix of PGs, whereas the embryonic mesenchyme contains a large variety of pluripotent cells in a hydrated gel that is rich in hyaluronic acid. These mesenchymal cells are thought to be the progenitors of cartilage-producing cells, adipose tissue, dermal fibroblasts, and intramembranous bone. Dermal fibers exist as fine filaments but not thick fibers. The protein components of the future elastin and collagen fibers are synthesized during this period but not assembled. At this point, there is no obvious separation between cells that will become musculoskeletal elements and those that will give rise to the skin dermis.

Although there is no known inherited disorder of dermal development, certain conditions, such focal dermal hypoplasia (Goltz syndrome) and Proteus syndrome, exhibit focal defects, probably a result of genetic mosaicism affecting genes important in this process (see Chap. 139). Mutations causing a global defect in this process would likely be incompatible with life.

The superficial mesenchyme becomes distinct from the underlying tissue by the embryonic–fetal transition (about 60 days EGA). By 12 to 15 weeks, the reticular dermis begins to take on its characteristic fibrillar appearance in contrast to the papillary dermis, which is more finely woven. Large collagen fibers continue to accumulate in the reticular dermis, as well as elastin fibers, beginning around mid-gestation and continuing until birth. By the end of the second trimester, the dermis has changed from a non-scarring tissue to one that is capable of forming scars. As the dermis matures, it also becomes thicker and well organized, such that at birth, it resembles the dermis of the adult, although it is still more cellular.

Many well-known clinical syndromes and molecules have been discovered that affect this final stage of dermal differentiation. These diseases include dystrophic EB (a collagen VII defect) (see Chap. 60), Marfan syndrome (a defect in fibrillin), Ehlers-Danlos syndrome (collagen V), cutis laxa (elastin), PXE, hereditary hemorrhagic telangiectasia (Osler-Weber-Rendu syndrome), and osteogenesis imperfecta (see Chap. 139). In many of these cases, the specific genetic defect helps to define the many different manifestations of these diseases, although in certain cases (e.g., PXE), the identity of the gene does not readily explain the mechanism of disease (see Chap. 139).

SPECIALIZED COMPONENTS OF THE DERMIS ***Blood Vessels and Nerves.*** Cutaneous nerves and vessels begin to form early during gestation, but they do not evolve into those of the adult until a few months after birth. The process of vasculogenesis requires the in situ differentiation of the endothelial cells at the endoderm–mesoderm interface. Originally, horizontal plexuses are formed within the subpapillary and deep reticular dermis, which are interconnected by groups of vertical vessels. This lattice of vessels is in place by 45 to 50 days EGA.

At 9 weeks EGA, blood vessels are seen at the dermal–hypodermal junction. By 3 months, the distinct networks of horizontal and vertical vessels have formed. By the fifth month, further changes in the vasculature derive from budding and migration of endothelium from pre-existing vessels, the process of angiogenesis. Depending on the body region, gestational age, and presence of hair follicles and glands, this pattern can vary with blood supply requirements.

Defects in vascular development have been described, as in the Klippel-Trénaunay and Sturge-Weber syndromes (see Chap. 173). In the Klippel-Trénaunay syndrome, unilateral cutaneous vascular malformations develop, with associated venous varicosities, edema, and hypertrophy of associated soft tissue and bone. In Sturge-Weber syndrome, many cutaneous capillary malformations are seen in the lips, tongue, nasal, and buccal mucosae. Some familial defects in vascular formation result from mutations in the gene encoding Tie-2 receptor tyrosine kinase. Capillary malformations seen in hereditary hemorrhagic telangiectasia have been linked to mutations in transforming growth factor-β–binding proteins, endoglin, and activin receptor-like kinase 1.

Lymphatics. Accumulating evidence suggests that lymphatics originate from endothelial cells that bud off from veins. The pattern of embryonic lymphatic vessel development parallels that of blood vessels. Detailed molecular studies into the development of lymphatics during embryogenesis and fetal development have long been hampered by the lack of lymphatic-specific markers. However, recent studies have identified new genes that appear to be specific for some of the earliest lymphatic precursors. LYVE-1 and Prox-1 are genes considered to be critical for earliest lymphatic specification, whereas VEGF-R3 and SLC may be important in later lymphatic differentiation.[107]

Nerves. The development of cutaneous nerves parallels that of the vascular system in terms of patterning, maturation, and organization. Nerves of the skin consist of somatic sensory and sympathetic autonomic fibers, which are predominantly small and unmyelinated. As these nerves develop, they become myelinated, with associated decrease in the number of axons. This process may continue as long as puberty.

Subcutis

As mentioned in Specialized Components of the Dermis, by 50 to 60 days EGA, the hypodermis is separated from the overlying dermis by a plane of thin-walled vessels. Toward the end of the first trimester, the matrix of the hypodermis can be distinguished from the more fibrous matrix of the dermis. By the second trimester, adipocyte precursors begin to differentiate and accumulate lipids. By the third trimester, fat lobules and fibrous septae are found to separate the mature adipocytes. The molecular pathways that define this process are currently an area of intense investigation. Although few regulators important in embryonic adipose specification and development have been identified, several factors critical for preadipocyte differentiation have been demonstrated, including leptin, a hormone important in fat regulation, and the peroxisome proliferator–activated receptor family of transcription factors.[77,108]

Dermal–Epidermal Junction

The dermal–epidermal junction is an interface where many inductive interactions occur that result in the specification or differentiation of the characteristics of the dermis and epidermis. This zone includes specialized basement membrane, basal cell extracellular matrix, the basalmost portion of the basal cells, and the superficial-most fibrillar structures of the papillary dermis. Both the epidermis and dermis contribute to this region.

As early as 8 weeks EGA, a simple basement membrane separates the dermis from the epidermis and contains many of the major protein elements common to all basement membranes, including laminin 1, collagen IV, heparin sulfate, and PGs. Components specific to the cutaneous basement membrane zone, such as proteins of the hemidesmosome and anchoring filaments, are first detected at the embryonic–fetal transition. By the end of the first trimester, or around the time of late embryonic development, all basement membrane proteins are in place. The α6 and β4 integrin subunits are expressed earlier than most of the other basement membrane components. However, they are not localized to the basal surface until 9.5 weeks EGA, coincident with the time that the hemidesmosomal proteins are expressed and hemidesmosomes are first observed. At the same time, anchoring filaments (laminin-332) and anchoring fibrils (collagen VII) begin to be assembled. The actual synthesis of collagen VII can be detected slightly earlier, at 8 weeks EGA.

Many congenital blistering disorders have been demonstrated to be a result of defects in proteins of the DEJ (for details, see Chaps. 51 and 60). The severity of the disease, plane of tissue separation, and involvement of non-cutaneous tissues depend on the proteins involved and the specific mutations. These genes are important candidates for prenatal testing.

DEVELOPMENT OF SKIN APPENDAGES

Skin appendages, which include hair, nails, and sweat and mammary glands, are composed of two distinct components: an epidermal portion, which produces the differentiated product, and the dermal component, which regulates differentiation of the appendage. During embryonic development, dermal–epidermal interactions are critical for the induction and differentiation of these structures (Fig. 7-10). Disruption of these signals often has profound influences on development of skin appendages. This discussion focuses on hair differentiation as a paradigm for appendageal development, because it is the appendage that has been studied most intensely.[6,109,110]

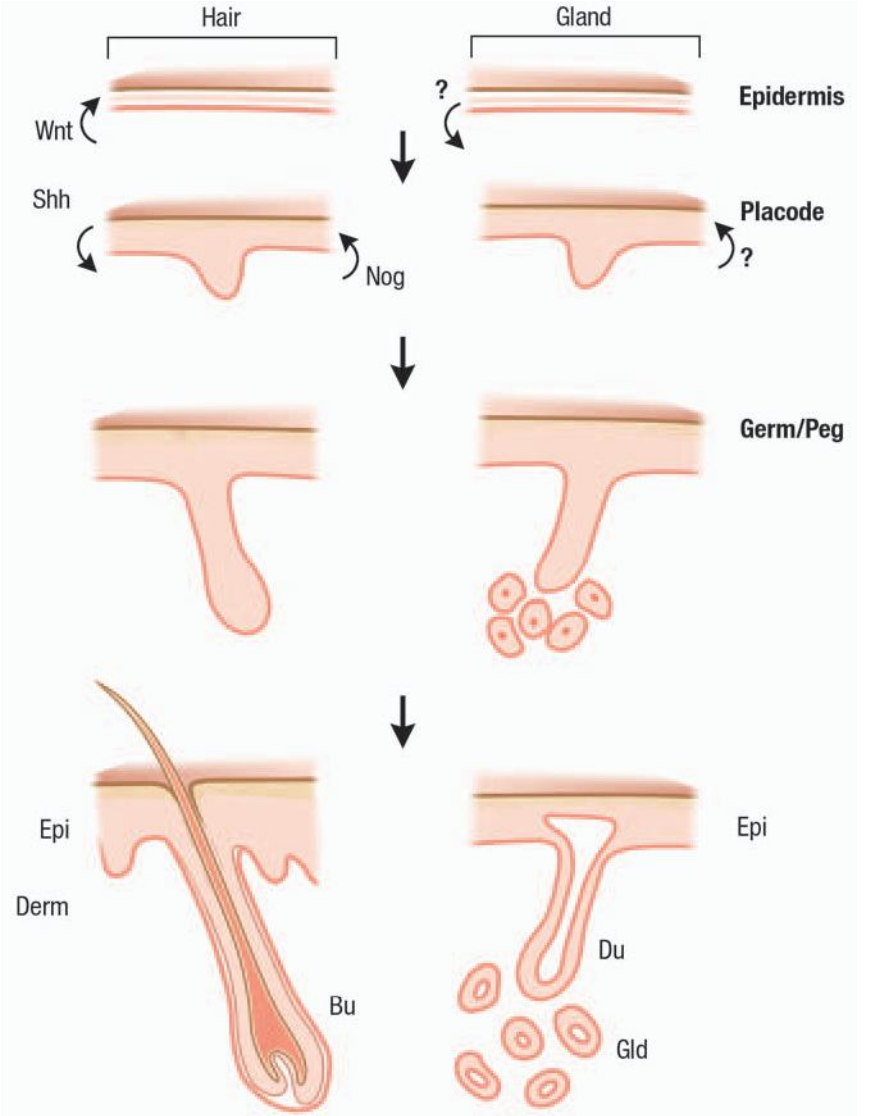

▲ **FIGURE 7-10** Appendageal morphogenesis. Through a series of reciprocal epithelial (epidermal)–mesenchymal (dermal) signals, including Wnt, sonic hedgehog (Shh), and Noggin (Nog), appendages such as the hair follicle and eccrine gland begin as epidermal invaginations (placodes), which signal the organization of specialized dermis (dermal condensate). This dermal condensate subsequently signals the differentiation of the epidermal downgrowth into the germ, peg, and mature appendageal structure. Bu = bulge; Derm = dermis; Du = duct; Epi = epidermis; Gld = gland.

Hair (See Chap. 84)

Dermal signals are initially responsible for instructing the basal cells of the epidermis to begin to crowd at regularly spaced intervals, starting between days 75 and 80 on the scalp. This initial grouping is known as the *follicular placode* or *Anlage*. Based on molecular localization of β-catenin, it has been implicated as a candidate for one of the effectors of this "dermal signal."

From the scalp, follicular placode formation spreads ventrally and caudally, eventually covering the skin. The placodes then signal back to the underlying dermis to form a "dermal condensate," which occurs at 12 to 14 weeks EGA. This process is thought to be a balance of placode promoters and placode inhibitors.[6,109,110] Wnt family signaling molecules are proposed to mediate placode promoting effects via the molecules LEF and β-catenin, as well as fibroblast growth factor, transforming growth factor-α, Msx1 and -2, ectodysplasin A (EDA), and EDAR (EDA receptor). BMP family molecules, on the other hand, act

as inhibitors of follicle formation. In model systems, ectopic expression of this family of molecules tends to suppress the formation of follicles. In mice, EDAR and β-catenin expression are required for expression of BMP4 and Sonic hedgehog (Shh), implicating these molecules in early follicular morphogenesis. Furthermore, EDAR may be important for lateral inhibition of cells surrounding the follicles.

Formation of the dermal papilla is thought to be initiated by the "first epithelial signal" that is transmitted from the follicle epithelium to the underlying mesenchyme. Molecules proposed to be involved in this signaling process include platelet-derived growth factor α polypeptide and Shh. After the follicular differentiation process begins, the dermis sends another signal to the epithelial placode cells to proliferate and invade the dermis. The dermal cells associated with the follicle then develop into the dermal papilla. The epithelial cells go on to form the inner root sheath and hair shaft of the mature hair follicle.

In addition to the widened bulge at the base, two other bulges form along the length of the developing follicle, termed the *bulbous hair peg*. The uppermost bulge is the presumptive sebaceous gland, whereas the middle bulge serves as the site for insertion of the arrector pili muscle. This middle bulge is also the location of the multipotent hair stem cells, which are capable of differentiating into any of the cells of the hair follicle, and also have the potential to replenish the entire epidermis, as has seen in cases of extensive surface wounds or burns.

By 19 to 21 weeks EGA, the hair canal has completely formed and the hairs on the scalp are visible above the surface of the fetal epidermis. They continue to lengthen until 24 to 28 weeks, at which time they shift from the active growth (anagen) phase to the degenerative phase (catagen), then to the resting phase (telogen) (see Chap. 84). This completes the first hair cycle. With subsequent hair cycles, hairs increase in diameter and coarseness. During adolescence, vellus hairs of androgen-sensitive areas mature to terminal-type hair follicles.

Sebaceous Glands (See Chap. 77)

Sebaceous glands mature during the course of follicular differentiation. This process begins between 13 and 16 weeks EGA, at which point the presumptive sebaceous gland is first visible as the most superficial bulge of the maturing hair follicle. The outer proliferative cells of the gland give rise to the differentiated cells that accumulate lipid and sebum. After they terminally differentiate, these cells disintegrate and release their products into the upper portion of the hair canal. Sebum production is accelerated in the second and third trimesters, during which time maternal steroids cause stimulation of the sebaceous glands. Hormonal activity is once again thought to influence the production of increased sebum during adolescence, resulting in the increased incidence in acne at this age.

Nail Development (See Chap. 87)

Presumptive nail structures begin to appear on the dorsal digit tip at 8 to 10 weeks EGA, slightly earlier than the initiation of hair follicle development. The first sign is the delineation of the flat surface of the future nail bed. A portion of ectoderm buds inward at the proximal boundary of the early nail field, and gives rise to the proximal nail fold. The presumptive nail matrix cells, which differentiate to become the nail plate, are present on the ventral side of the proximal invagination. At 11 weeks, the dorsal nail bed surface begins to keratinize. By the fourth month of gestation, the nail plate grows out from the proximal nail fold, completely covering the nail bed by the fifth month. Mutations in p63 affect nail development in syndromes such as ankyloblepharon, ectodermal dysplasia, and cleft lip/palate syndrome, as well as ectrodactyly, ectodermal dysplasia, and cleft lip/palate syndrome. Functional p63 is required for the formation and maintenance of the apical ectodermal ridge, an embryonic signaling center essential for limb outgrowth and hand plate formation. Wnt7a is thought to be important for dorsal limb patterning, and thus nail formation. In contrast to follicular development, Shh is not required for nail plate formation. Also similar to follicular differentiation, LMX1b and MSX1 are important for nail specification; LMX1b and MSX1 are mutated in nail-patella syndrome and Witkop syndrome, respectively.[111–113] Hoxc13 appears to be an important homeodomain-containing gene for both follicular and nail appendages, at least in murine models.[114]

Eccrine and Apocrine Sweat Gland Development (See Chap. 81)

Eccrine glands begin to develop on the volar surfaces of the hands and feet, beginning as mesenchymal pads between 55 and 65 days EGA. By 12 to 14 weeks EGA, parallel ectodermal ridges are induced, which overly these pads. The eccrine glands arise from the ectodermal ridge. By 16 weeks EGA, the secretory portion of the gland becomes detectable. The dermal duct begins around week 16, but the epidermal portion of the duct and opening are not complete until 2 weeks EGA.

Interfollicular eccrine and apocrine glands, in contrast, do not begin to bud until the fifth month of gestation. Apocrine sweat glands usually bud from the upper portion of the hair follicle. By 7 months EGA, the cells of the apocrine glands become distinguishable.

Although not much is known with regard to the molecular signals responsible for the differentiation of these structures, the EDA, EDAR, En1, and Wnt10b genes have been implicated. Hypohidrotic ectodermal dysplasia results from mutations in EDA or the EDAR (see Chap. 143).

KEY REFERENCES

The full reference list for all chapters is available at www.digm7.com.

6. Blanpain C, Fuchs E: Epidermal stem cells of the skin. *Annu Rev Cell Dev Biol* **22**:339, 2006
8. Pellegrini G et al: The control of epidermal stem cells (holoclones) in the treatment of massive full-thickness burns with autologous keratinocytes cultured on fibrin. *Transplantation* **68**:868, 1999
9. Cotsarelis G, Sun TT, Lavker RM: Label-retaining cells reside in the bulge area of pilosebaceous unit: Implications for follicular stem cells, hair cycle, and skin carcinogenesis. *Cell* **61**:1329, 1990
11. Rochat A, Kobayashi K, Barrandon Y: Location of stem cells of human hair follicles by clonal analysis. *Cell* **76**:1063, 1994
14. Tumbar T et al: Defining the epithelial stem cell niche in skin. *Science* **303**:359, 2004
16. Morris RJ et al: Capturing and profiling adult hair follicle stem cells. *Nat Biotechnol* **22**:411, 2004
22. Ghazizadeh S, Taichman LB: Multiple classes of stem cells in cutaneous epithelium: A lineage analysis of adult mouse skin. *EMBO J* **20**:1215, 2001
69. Detmar M: Molecular regulation of angiogenesis in the skin. *J Invest Dermatol* **106**:207, 1996
82. Holbrook KA: Structure and function of the developing human skin, in *Physiology, Biochemistry, and Molecular Biology of the Skin*, edited by Goldsmith LA. New York, Oxford Press, 1991, p 63
83. Loomis CA: Development and morphogenesis of the skin. *Adv Dermatol* **17**:183, 2001
87. Yang A et al: p63 is essential for regen-

erative proliferation in limb, craniofacial and epithelial development. *Nature* **398**:714, 1999
94. Happle R: X-chromosome inactivation: Role in skin disease expression. *Acta Paediatr Suppl* **95**:16, 2006
97. Nishimura EK et al: Dominant role of the niche in melanocyte stem-cell fate determination. *Nature* **416**:854, 2002
107. Oliver G, Detmar M: The rediscovery of the lymphatic system: Old and new insights into the development and biological function of the lymphatic vasculature. *Genes Dev* **16**:773, 2002
109. Millar SE: Molecular mechanisms regulating hair follicle development. *J Invest Dermatol* **118**:216, 2002

CHAPTER 8

Genetics in Relation to the Skin

John A. McGrath
W. H. Irwin McLean

THE HUMAN GENOME IN DERMATOLOGY

In the 30 years since the first human gene, placental lactogen, was cloned in 1977, huge investments in time, money, and effort have gone into disclosing the innermost workings of the human genome. The Human Genome Project, which began in 1990, has led to sequence information on more than 3 billion base pairs (bp) of DNA, with identification of most of the estimated 25,000 genes in the entire human genome.[1] Although a few relatively small gaps remain, the near completion of the entire sequence of the human genome is having a huge impact on both the clinical practice of genetics and on the strategies used to identify disease-associated genes. Laborious positional cloning approaches and traditional functional studies are gradually being transformed by the emergence of new genomic and proteomic databases.[2] Some of the exciting challenges that clinicians and geneticists now face are determining the function of these genes and defining disease associations, and, with relevance to patients, correlating genotype with phenotype. Nevertheless, many discoveries are already influencing how clinical genetics is practiced throughout the world, particularly for patients and families with rare, monogenic inherited disorders. The key benefits of dissection of the genome thus far have been the documentation of new information about disease causation, improving the accuracy of diagnosis and genetic counseling, and making DNA-based prenatal testing feasible.[3] Indeed, the genetic basis of more than 2000 inherited single gene disorders has now been determined, of which about 25 percent have a skin phenotype. These discoveries, therefore, have direct relevance to dermatologists and their patients. Recently, studies in rare inherited skin disorders have also led to new insight into the pathophysiology of more common complex trait skin disorders.[4] This new information is expected to have significant implications for the development of new therapies and management strategies for patients. For the dermatologist, therefore, understanding the basic language and principles of clinical and molecular genetics has become a vital part of day-to-day practice. The aim of this chapter is to provide an overview of key terminology in genetics that is clinically relevant to the dermatologist.

THE HUMAN GENOME

Normal human beings have a large complex genome packaged in the form of 46 chromosomes. These consist of 22 pairs of autosomes, numbered in descending order of size from the largest (chromosome 1) to the smallest (chromosome 22), in addition to two sex chromosomes, X and Y. Females possess two copies of the X chromosome, whereas males carry one X and one Y chromosome. The haploid genome consists of about 3.3 billion bp of DNA. Of this, only about 1.5 percent corresponds to protein-encoding exons of genes. Apart from genes and regulatory sequences, perhaps as much as 97 percent of the genome is of unknown function, often referred to as "junk" DNA. Caution should be exercised in labeling the non-coding genome as "junk," however, because other unknown functions may reside in these regions. Much of the non-coding DNA is in the form of repetitive sequences, pseudogenes ("dead" copies of genes lost in recent evolution) and transposable elements of uncertain relevance. Although initial estimates for the number of human genes was in the order of 100,000, current predictions, based on the essentially complete genome sequence, are in the range of 20,000 to 25,000.[1] Surprisingly, therefore, the human genome is comparable in size and complexity to primitive organisms such as the fruit fly. It is thought, however, that the generation of multiple protein isoforms from a single gene via alternate splicing of exons, each with a discrete function, is what contributes to increased complexity in higher organisms, including humans. In addition to protein-encoding genes, there are also many genes encoding untranslated RNA molecules, including transfer RNA, ribosomal RNA, and, as recently described, micro-RNA genes. Micro-RNA is thought to be involved in the control of a large number of other genes through the RNA inhibition pathway.

The draft sequence of the human genome was completed in 2003. Subsequently, small gaps have been filled, and the sequence has now been extensively annotated in terms of genes, repetitive elements, regulatory sequences, polymorphisms, and many other features recognizable by in silico data mining methods informed, wherever possible, by functional analysis. This annotation process will continue for some time as more features are uncovered. The human genome data, and that for an increasing number of other species, is freely available on websites (Table 8-1). Some regions of the genome, particularly near the centromeres, consist of long stretches of highly repetitive sequences that are difficult or impossible to clone and/or sequence. These heterochromatic regions of the genome are unlikely to be sequenced and are thought to be structural in nature, mediating the chromosomal architecture required for cell division, rather than contributing to heritable characteristics.

GENETIC AND GENOMIC DATABASES

Given the size and complexity of the human genome and other genomes now available, analysis of these enormous datasets in any kind of meaningful way is heavily reliant on computers. Even storage and retrieval of the sequence data associated with mammalian genome require considerable computer power, and memory and even the assembly of the raw sequence of any mammalian genome would have been unfeasible without computers. Many

TABLE 8-1
Websites for Accessing Human Genome Data

WEBSITE	URL
University of California, Santa Cruz	http://genome.ucsc.edu/
National Center for Biotechnology Information	http://www.ncbi.nlm.nih.gov
ENSEMBL	http://www.ensembl.org/
Online Mendelian Inheritance in Man	http://www.ncbi.nlm.nih.gov/entrez/query.fcgi?db=omim

web browsers for accessing genome data are available and the most useful of these are listed in Table 8-1. Each of these interfaces, which are the ones which the authors find most useful and user-friendly, contains a wide variety of tools for analysis and searching of sequences according to keyword, gene name, protein name, and homology to DNA or protein sequence data.

The main source of historical, clinical, molecular, and biochemical data relating to human genetic diseases is the Online Mendelian Inheritance in Man (OMIM) (see Table 8-1). All recognized genetic diseases and non-pathogenic heritable traits, including common diseases with a genetic component, as well as all known genes and proteins, are listed and reviewed by OMIM number with links to PubMed.

CHROMOSOME AND GENE STRUCTURE

Human chromosomes share common structural features (Fig. 8-1). All consist of two chromosomal arms, designated as "p" and "q." If the arms are of unequal length, the short arm is always designated as the "p" arm. Chromosomal maps to seek abnormalities are based on the stained, banded appearance of condensed chromosomes during metaphase of mitosis. During interphase, the uncondensed chromosomes are not discernible by normal microscopy techniques. Genes can now be located with absolute precision in terms of the range of bp that they span within the DNA sequence for a given chromosome. The bands are numbered from the centromere outwards using a system that has evolved as increasingly discriminating chromosome stains, as well as higher resolution light microscopes, became available. A typical cytogenetic chromosome band is 17q21.2, within which the type I keratin genes reside (see Fig. 8-1).

The ends of the chromosomal arms are known as *telomeres*, and these consist of multiple tandem repeats of short DNA sequences. In germ cells and certain other cellular contexts, additional repeats are added to telomeres by a protein-RNA enzyme complex known as *telomerase*. During each round of cell division in somatic cells, one of the telomere repeats is trimmed off as a consequence of the DNA replication mechanism. By measuring the length of telomeres, the "age" of somatic cells, in terms of the number of times they have divided during the lifetime of the organism, can be determined. Once the telomere length falls below a certain threshold, the cell undergoes senescence. Thus, telomeres contribute to an important biological clock function that removes somatic cells that have gone through too many rounds of replication and are at a high risk of accumulating mutations that could lead to tumorigenesis or other functional aberration.[5]

The chromosome arms are separated by the centromere, which is a large stretch of highly repetitious DNA sequence. The centromere has important functions in terms of the movement and interactions of chromosomes. The centromeres of sister chromatids are where the double chromosomes align and attach during the prophase and anaphase stages of mitosis (and meiosis). The centromeres of sister chromatids are also the site of kinetochore formation. The latter is a multi-protein complex to which microtubules attach, allowing mitotic spindle formation, which ultimately results in pulling apart of the chromatids during anaphase of the cell division cycle.

The majority of chromosomal DNA contains genes interspersed with non-coding stretches of DNA of varying sizes. The density of genes varies widely across the chromosomes so that there are gene-dense regions or, alternately, large areas almost devoid of functional genes. An example of a comparatively gene-rich region of particular relevance to inherited skin diseases is the type I keratin gene cluster on chromosome band 17q21.2 (see Fig. 8-1). This diagram also gives an idea of the sizes in bp of DNA of a typical chromosome and a typical gene located within it. This gene cluster spans about 900,000 bp of DNA and contains 27 functional type I keratin genes, several genes encoding keratin-associated proteins, and a number of pseudogenes (not shown). Because chromosome 17 is one of the smaller chromosomes, Fig. 8-1 starts to give some idea of the overall complexity and organization of the genome.

Protein-encoding genes normally consist of several exons, which collectively code for the amino acid sequence of the protein (or open reading frame). These are separated by non-coding introns. In human genes, few exons are much greater than 1000 bp in size, and introns vary from less than 100 bp up to more than 1 million bp. A typical exon might be 100 to 300 bp in size. The *KRT14* gene encoding keratin 14 or K14 protein is one of the genes in which mutations lead to epidermolysis bullosa (EB) simplex (see Chap. 60) and is illustrated in Fig. 8-1. *KRT14* is contained within about 7000 bp of DNA and consists of eight modestly sized exons interspersed by seven small introns. Although all genes are present in all human cells that contain a nucleus, not every gene is expressed in all cells of tissues. For example, the *KRT14* gene is only active in basal keratinocytes of the epidermis and other stratified epithelial tissues and is essentially silent in all other tissues. When a protein-encoding gene is expressed, the RNA polymerase II enzyme transcribes the coding strand of the gene, starting from the cap site and continuing to the end of the final exon, where various signals lead to termination of transcription. The initial RNA transcript, known as *heteronuclear RNA*, contains intronic as well as exonic sequences. This primary transcript undergoes splicing to remove the introns, resulting in the messenger RNA (mRNA) molecule.[6] In addition, the bases at the 5′ end (start) of the mRNA are chemically modified (capping) and a large number of adenosine bases are added at the 3′ end, known as the *poly-A tail*. These post-transcriptional modifications stabilize the mRNA and facilitate its transport within the cell. The mature mRNA undergoes a test round of translation which, if successful, leads to the transport of the mRNA to the cytoplasm, where it undergoes multiple rounds of translation by the ribosomes, leading to accumulation of the encoded protein. If the mRNA contains a nonsense mutation, otherwise known as a *premature termination codon mutation*, the

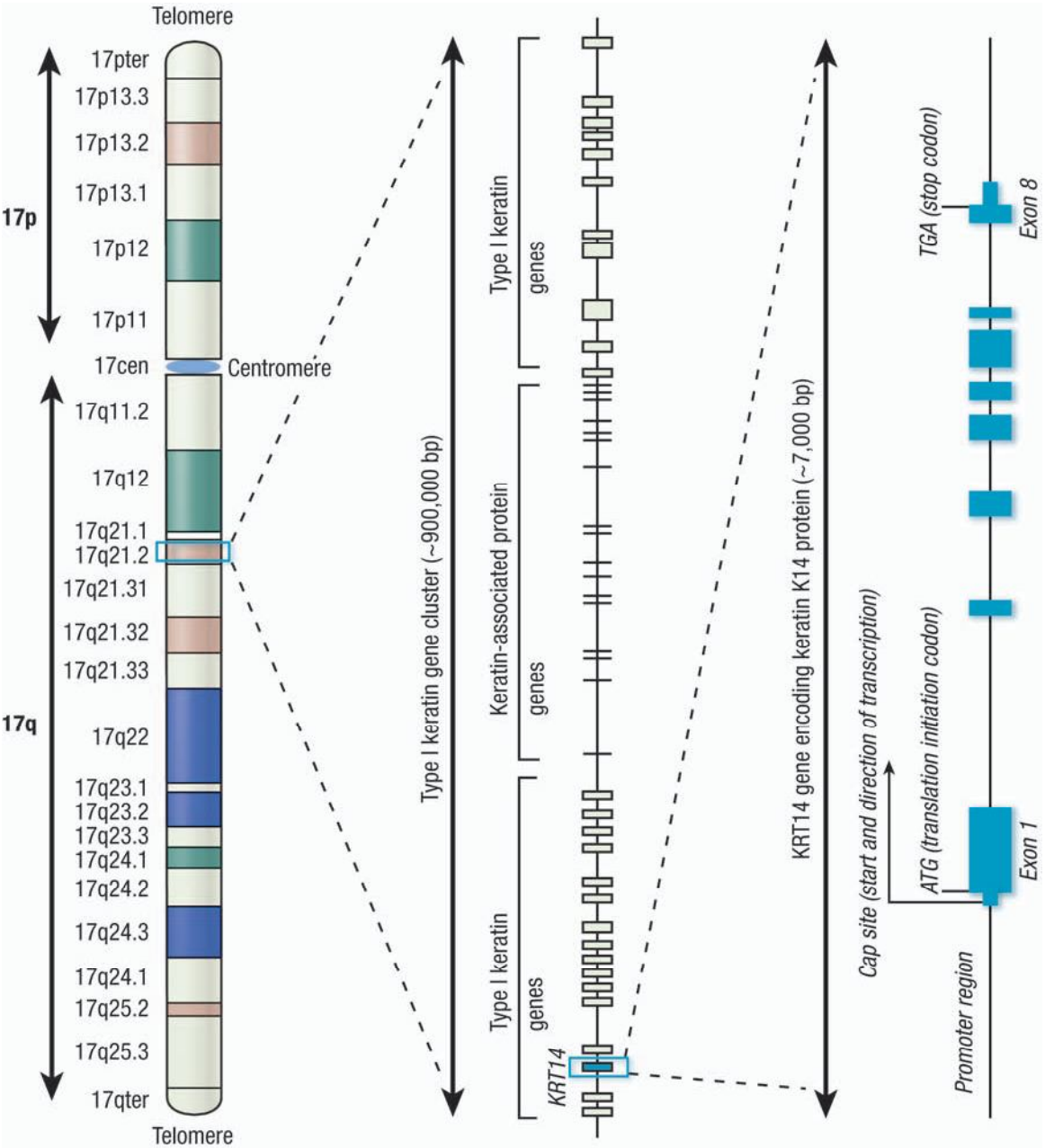

▲ **FIGURE 8-1** Illustration of the complexity of the human genome. On the left, the short (p) and long (q) arms of human chromosome 17 are depicted with their cytogenetic chromosome bands. One of these band regions, 17q21.2, is then highlighted to show that it is made up of approximately 900,000 base pairs (bp) and contains several genes, including 27 functional type I keratin genes. Part of this region is then further amplified to show one keratin gene, *KRT14*, encoding keratin 14, which is composed of 8 exons.

test round of translation fails, and the cell degrades this mRNA via the nonsense-mediated mRNA pathway.[7] This is a mechanism that the cell has evolved to remove aberrant transcripts, and it may also contribute to gene regulation, particularly when very low levels of a particular protein are required within a given cell.

Splicing out of introns is a complex process. The genes of prokaryotes, such as bacteria, do not contain introns, and so mRNA splicing is a process that is specific to higher organisms. In some more primitive eukaryotes, RNA molecules contain catalytic sequences known as *ribozymes*, which mediate the self-splicing out of introns without any requirement for additional factors. In mammals, splicing involves a large number of protein and RNA factors encoded by several genes. This allows another level of control over gene expression and also facilitates alternative splicing of exons, so that a single gene can encode several functionally distinct variants of a protein. These isoforms are often differentially expressed in different tissues. In terms of the gene sequences important for splicing, a few bp at the beginning and at the end of an intron, known as the 5′ splice site (or splice donor site) and the 3′ splice site (or splice acceptor site) are crucial. A few other bp within the intron, such as the branch point site located 18 to 100 bp away from the 3′ end, are also critical. Mutations affecting any of the invariant residues of these splice sites lead to aberrant splicing and either complete loss of protein expression or generation of a highly abnormal protein.

The mRNA also contains two untranslated regions, the 5′UTR upstream of the initiating ATG codon and the 3′UTR downstream of the terminator (or stop codon, which can be TGA, TAA or TAG). The 5′UTR can and often does possess introns, whereas the 3′UTR of more than 99 percent of mammalian genes does not contain introns. The nonsense-mediated mRNA decay pathway identifies mutant transcripts by means of assessing where the termination codon occurs in relation to introns. The natural stop codon is always followed immediately by the 3′UTR, which in turn does not normally possess any introns. If a stop codon occurs in an mRNA upstream of a site where an intron has been excised, this message is targeted for nonsense-mediated decay. The only genes that contain introns within their 3′UTR sequences are expressed at extremely low levels. This is one of the ways in which the cell can determine how much protein is made from a particular gene.

Gene complexity is widely variable and not necessarily related to the size of the protein encoded. Some genes consist of only a single small exon, such as those encoding the connexin family of gap junction proteins. Such single exon genes are rapid and inexpensive to analyze routinely. In contrast, the type VII collagen gene, *COL7A1*, in which mutations lead to the dystrophic forms of EB (see Chap. 60), has 118 exons, meaning that 118 different parts of the gene need to be isolated and analyzed for molecular diagnosis of each dystrophic EB patient. The filaggrin gene (*FLG*) on chromosome 1, recently shown to be the causative gene for ichthyosis vulgaris (see Chap. 47) and a susceptibility gene for atopic dermatitis (see Chap. 14), has only three exons. However, the third exon of *FLG* is more than 12,000 bp in size; is made up of repeats of a 1000-bp sequence; and varies in size from 12,000 to 14,000 bp between different individuals in the population. This unusual gene structure makes routine sequencing of genes such as *COL7A1* or *FLG* difficult, time consuming, and expensive.

GENE EXPRESSION

Each specific gene is generally only actively transcribed in a subset of cells or tissues within the body. Gene expression is largely determined by the promoter elements of the gene. In general, the most important region of the promoter is the stretch of sequence immediately upstream of the cap site. This proximal promoter region contains consensus binding sites for a variety of transcription factors, some of which are general in nature and required for all gene expression, others are specific to particular tissue or cell lineage, and some are absolutely specific for a given cell type and/or stage of development or differentiation. The size of the promoter can vary widely according to gene family or between the individual genes themselves. For example, the keratin genes are tightly spaced within two gene clusters on chromosomes 12q and 17q, but these are exquisitely tissue specific in two different ways. First, these genes are only expressed in epithelial cells, and therefore their promoters must possess regulatory sequences that determine epithelial expression. These regulatory elements are therefore specific for cells of ectodermal origin. Second, these genes are expressed in very specific subsets of epithelial cells, and so there must be a second level of control that specifies which epithelial cell layers express specific keratin genes. This is best illustrated in the hair follicle, where there are many different epithelial cell layers, each with a specific pattern of keratin gene expression (see Chap. 84).[8]

Transcription factors are proteins that either bind to DNA directly or indirectly by associating with other DNA-binding proteins. Binding of these factors to the promoter region of a gene leads to activation of the transcription machinery and transcription of the gene by RNA polymerase II. The transcription factor proteins are encoded by genes that are in turn controlled by promoters that are regulated by other transcription factors encoded by other genes. Thus, there are several tiers of control over gene expression in a given cell type, and the intricacies of this can be difficult to fully unravel experimentally. Nevertheless, by isolation of promoter sequences from genes of interest and placing these in front of reporter genes that can be assayed biochemically, such as firefly luciferase that can be assayed by light emission, the activity of promoters can be reproduced in cultured cells that normally express the gene. Combining such a reporter gene system with site-directed mutagenesis to make deletions or alter small numbers of bp within the promoter can help define the extent of the promoter and the important sequences within it that are required for gene expression. A variety of biochemical techniques, such as DNA footprinting, ribonuclease protection, electrophoretic mobility shift assays, or chromatin immunoprecipitation, can be used to determine which transcription factors bind to a particular promoter and help delineate the specific promoter sequences bound. Expression of reporter genes under the control of a cloned promoter in transgenic mice also helps shed light on the important sequences that are required to recapitulate the endogenous expression of the gene under study. Keratin promoters are unusual in that, generally, a small fragment of only 2000 to 3000 bp upstream of the gene can confer most of the tissue specificity. For this reason, keratin promoters are widely used in the dermatology field to drive exogenous transgene expression in the various specific cellular compartments of the epidermis and its appendages for a wide variety of experiments aimed at determining gene, cell, or tissue function.[9]

Some promoter or enhancer sequences act over very long distances. In some cases, sequences located millions of bp distant, with several other genes in the intervening region, somehow influence expression of a target gene. In some genetic diseases, mutations affecting such long-range promoter elements are now emerging. These types of mutations appear to be rare in the genetics field as a whole, but since they occur so very far away from the target gene and are therefore very difficult to find, this class of mutation may, in fact, be more common than is immediately obvious. In general, relatively few disease-causing mutations have been shown to involve promoters, but this class of defect is probably greatly under-represented because the promoters of most genes have been poorly characterized at the present time in terms of what sequences are truly important for promoter activity. Prediction of transcription factor binding sites by computer analysis remains an inexact science and is an area for further study in the future as the human genome sequence undergoes greater detailed scrutiny and annotation.

FINDING DISEASE GENES

In establishing the molecular basis of an inherited skin disease, there are two key steps. First, the gene linked to a particular disorder must be identified, and second, pathogenic mutations within that gene should be determined. Diseases can be matched to genes either by genetic linkage analysis or by a candidate gene approach.[10] Genetic linkage involves

studying pedigrees of affected and unaffected individuals and isolating which bits of the genome are specifically associated with the disease phenotype. The goal is to identify a region of the genome that all the affected individuals and none of the unaffected individuals have in common; this region is likely to harbor the gene for the disorder, as well as perhaps other non-pathogenic neighboring genes that have been inherited by linkage disequilibrium. Traditionally, genome-wide linkage strategies make use of variably-sized microsatellite markers scattered throughout the genome, although for recessive diseases involving consanguineous pedigrees, a more rapid approach may be to carry out homozygosity mapping using single nucleotide polymorphism (SNP) chip arrays. By contrast, the candidate gene approach involves first looking for a clue to the likely gene by finding a specific disease abnormality, perhaps in the expression (or lack thereof) of a particular protein or RNA, or from an ultrastructural or biochemical difference between the disease and control tissue. Nevertheless, the genetic linkage and candidate gene approaches are not mutually exclusive and are often used in combination. For example, to identify the gene responsible for the autosomal recessive disorder, lipoid proteinosis (see Chap. 137), genetic linkage using microsatellites was first used to establish a region of linkage on 1q21 that contained 68 genes.[11] The putative gene for this disorder, *ECM1* encoding extracellular matrix protein 1, was then identified by a candidate gene approach that searched for reduced gene expression (lack of fibroblast complementary DNA) in all these genes. A reduction in *ECM1* gene expression in lipoid proteinosis compared with control provided the clue to the candidate gene because there were no differences in any of the other patterns of gene expression.

Having identified a putative gene for an inherited disorder, the next stage is to find the pathogenic mutation(s). This can be done by sequencing the entire gene, a feat which is becoming easier as technologic advances make automated nucleotide sequencing faster, cheaper, and more accessible. However, the large size of some genes may make comprehensive sequencing impractical, and therefore initial screening approaches to identify the region of a gene that contains the mutation may be a necessary first step. There are many mutation detection techniques available to scan for sequence changes in cellular RNA or genomic DNA, and these include denaturing gradient gel electrophoresis, chemical cleavage of mismatch, single stranded conformation polymorphism, heteroduplex analysis, conformation sensitive gel electrophoresis, denaturing high-performance liquid chromatography and the protein truncation test.[12] The most critical factor that determines the success of any gene screening protocol is the sensitivity of the detection technique. In addition, when choosing a mutation screening strategy using genomic DNA, the size of the gene and its number of exons must be taken into account. The sensitivities of these methods vary greatly, depending on the size of template screened. For example, single-stranded conformation polymorphism has a sensitivity of > 95 percent for fragments of 155 bp, but this is reduced to only 3 percent for 600 bp. Once optimized, denaturing gradient gel electrophoresis has a sensitivity of about 99 percent for fragments of up to 500 bp, and conformation sensitive gel electrophoresis is expected to have a sensitivity of 80 percent to 90 percent for fragments of up to 600 bp. Chemical cleavage of mismatch, on the other hand, has a sensitivity of 95 percent to 100 percent for fragments > 1.5 kilobases (kb) in size and is ideal for screening compact genes where more than one exon can be amplified together using genomic DNA as the template. All these techniques detect sequence changes such as truncating and missense mutations as well as polymorphisms; however, the protein truncation test screens only for truncating mutations and is predicted to have a sensitivity of > 95 percent and can be used for RNA or DNA fragments in excess of 3 kb. Whichever approach is taken, having identified a difference in the patient's DNA compared with the control sample, the next stage is to determine how this segregates within a particular family and also whether it is pathogenic or not.

GENE MUTATIONS AND POLYMORPHISMS

Within the human genome, the genetic code of two healthy individuals may show a number of sequence dissimilarities that have no relevance to disease or phenotypic traits. Such changes within the normal population are referred to as *polymorphisms* (Fig. 8-2). Indeed, even within the coding region of the genome, clinically irrelevant substitutions of one bp, known as *SNPs*, are common and occur approximately once every 250 bp.[13] Oftentimes, these SNPs do not change the amino acid composition; for example, a C-to-T transition in the third position of a proline codon (CCC to CCT) still encodes for proline, and is referred to as a *silent mutation*. Some SNPs, however, do change the nature of the amino acid; for example, a C-to-G transversion at the second position of the same proline codon (CCC to CGC) changes the residue to arginine. It then becomes necessary to determine whether a missense change such as this represents a non-pathogenic polymorphism or a pathogenic mutation. Factors favoring the latter include the sequence segregating only with the disease phenotype in a particular family, the amino acid change occurring within an evolutionarily conserved residue, the substitution affecting the function of the encoded protein (size, charge, conformation, etc.), and the nucleotide switch not being detectable in at least 100 ethnically matched control chromosomes. Non-pathogenic polymorphisms do not always involve single nucleotide substitutions; occasionally, deletions and insertions may also be non-pathogenic.

A mutation can be defined as a change in the chemical composition of a gene. A missense mutation changes one amino acid to another. Mutations may also be insertions or deletions of bases, the consequences of which will depend on whether this disrupts the normal reading frame of a gene or not, as well as nonsense mutations, which lead to premature termination of translation (see Fig. 8-2). For example, a single nucleotide deletion within an exon causes a shift in the reading frame, which usually leads to a downstream stop codon, thus giving a truncated protein, or often an unstable mRNA that is readily degraded by the cell. However, a deletion of three nucleotides (or multiples thereof) will not significantly perturb the overall reading frame, and the consequences will depend on the nature of what has been deleted. Nonsense mutations typically, but not exclusively, occur at CpG dinucleotides, where methylation of a cytosine nucleotide often occurs. Inherent chemical instability of this modified cytosine leads to a high rate of mutation to thymine. Where this alters the codon (e.g., from CGA to TGA), it will change an arginine residue to a stop codon. Nonsense mutations usually lead to a reduced or absent expression of the mutant allele at the mRNA and protein levels. In the heterozygous state, this may have no clinical

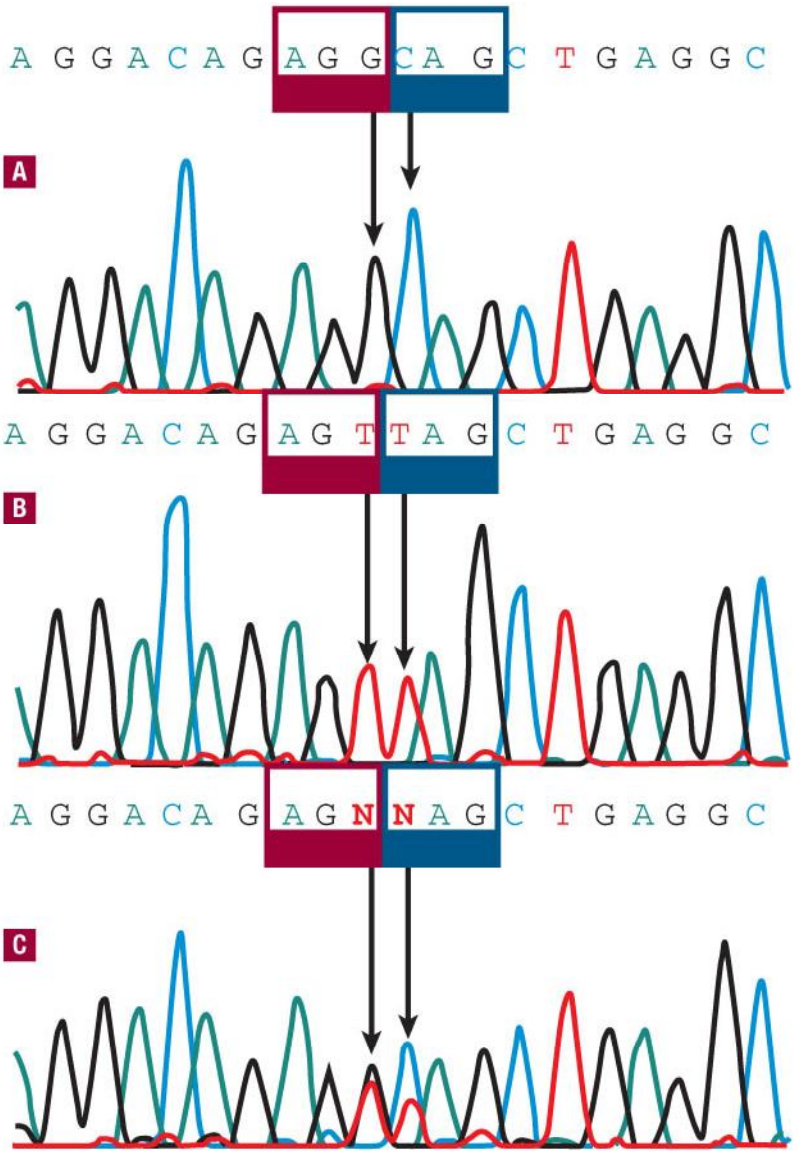

▲ **FIGURE 8-2** Examples of nucleotide sequence changes resulting in a polymorphism and a nonsense mutation. **A.** Two adjacent codons are highlighted. Outlined in purple, the AGG codon encodes arginine and the blue boxed codon, CAG encodes glutamine. **B.** The sequence shows two homozygous nucleotide substitutions. In the purple box, AGG now reads AGT (i.e., coding for serine rather than arginine). This is a common sequence variant in the normal population and is referred to as a *non-pathogenic missense polymorphism*. In contrast, in the blue box, the glutamine codon CAG now reads TAG, which is a stop codon. This is an example of a homozygous nonsense mutation. **C.** This sequence is from one of the parents of the subject sequenced in **B** and shows heterozygosity for both the missense polymorphism AGG > AGT and the nonsense mutation CAG > TAG, indicating that this individual is a carrier of both sequence changes.

effect [e.g., parents of individuals with Herlitz junctional EB are typically carriers of nonsense mutations in one of the laminin 332 (laminin 5) genes but have no skin fragility themselves; see Chap. 60], but a heterozygous nonsense mutation in the desmoplakin gene, for example, can result in the autosomal dominant skin disorder, striate palmoplantar keratoderma (see Chap. 48). This phenomenon is referred to as *haploinsufficiency* (i.e., half the normal amount of protein is insufficient for function).

Apart from changes in the coding region that result in frameshift, missense, or nonsense mutations, approximately 15 percent of all mutations involve alterations in the gene sequence close to the boundaries between the intron and exons, referred to as *splice site mutations*. This type of mutation may abolish the usual acceptor and donor splice sites that normally splice out the introns during gene transcription. The consequences of splice site mutations are complex; sometimes they lead to skipping of the adjacent exon, and other times they result in the generation of new mRNA transcripts through utilization of cryptic splice sites within the neighboring exon or intron.

Mutations within one gene do not always lead to a single inherited disorder. For example, mutations in the *ERCC2* gene may lead to xeroderma pigmentosum (type D), trichothiodystrophy, or cerebrofacioskeletal syndrome, depending on the position and type of mutation. Other trans-acting factors may further modulate phenotypic expression. This situation is known as *allelic heterogeneity*. Conversely, some inherited diseases can be caused by mutations in more than one gene (e.g., non-Herlitz junctional EB; see Chap. 60) and can result from mutations in either the *COL17A1*, *LAMA3*, *LAMB3*, or *LAMC2* genes. This is known as *genetic heterogeneity*. In addition, the same mutation in one particular gene may lead to a range of clinical severity in different individuals. This variability in phenotype produced by a given genotype is referred to as the *expressivity*. If an individual with such a genotype has no phenotypic manifestations, the disorder is said to be *non-penetrant*. Variability in expression reflects the complex interplay between the mutation, modifying genes, epigenetic factors, and the environment and demonstrates that interpreting what a specific gene mutation does to an individual involves more than just detecting one bit of mutated DNA in a single gene.

MENDELIAN DISORDERS

There are approximately 5000 human single-gene disorders and, although the molecular basis of less than one-half of these has been established, understanding the pattern of inheritance is essential for counseling prospective parents about the risk of having affected children. The four main patterns of inheritance are autosomal dominant, autosomal recessive, X-linked dominant, and X-linked recessive.

For individuals with an autosomal dominant disorder, one parent is affected, unless there has been a de novo mutation in a parental gamete. Males and females are affected in approximately equal numbers, and the disorder can be transmitted from generation to generation; on average, half the offspring will have the condition (Fig. 8-3). It is important to counsel affected individuals that the risk of transmitting the disorder is 50 percent for each of their

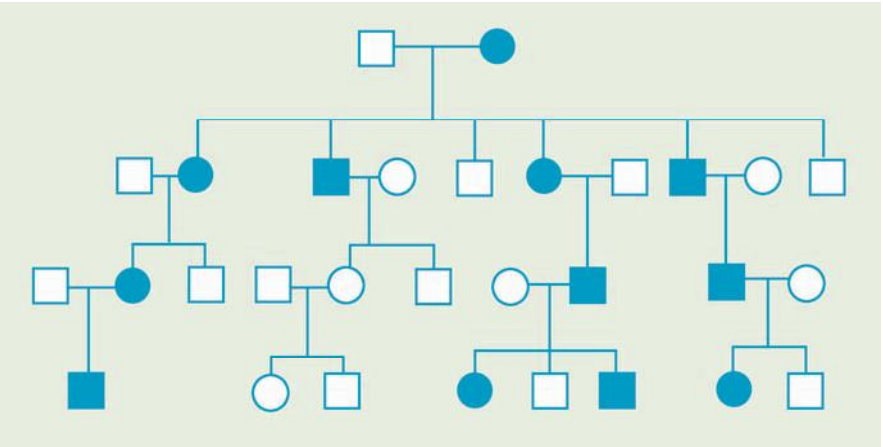

▲ **FIGURE 8-3** Pedigree illustration of an autosomal dominant pattern of inheritance. Key observations include: the disorder affects both males and females; on average, 50 percent of the offspring of an affected individual will be affected; affected individuals have one normal copy and one mutated copy of the gene; affected individuals usually have one affected parent, unless the disorder has arisen de novo. Importantly, examples of male-to-male transmission, seen here, distinguish this from X-linked dominant and are therefore the best hallmark of autosomal dominant inheritance. Filled circles indicate affected females; filled squares indicate affected males; unfilled circles/squares represent unaffected individuals.

children, and that this is not influenced by the number of previously affected or unaffected offspring. Any offspring that are affected will have a 50 percent risk of transmitting the mutated gene to the next generation, whereas for any unaffected offspring, the risk of the next generation being affected is negligible, providing that the partner does not have the autosomal dominant condition.

In autosomal recessive disorders, both parents are carriers of one normal and one mutated allele for the same gene and, typically, they are phenotypically unaffected (Fig. 8-4). If both of the mutated alleles are transmitted to the offspring, this will give rise to an autosomal recessive disorder, the risk of which is 25 percent. If one mutated and one wild-type allele is inherited by the offspring, the child will be an unaffected carrier, similar to the parents. If both wild-type alleles are transmitted, the child will be genotypically and phenotypically normal with respect to an affected individual. If the mutations from both parents are the same, the individual is referred to as a *homozygote*, but if different parental mutations within a gene have been inherited, the individual is termed a *compound heterozygote*. For someone who has an autosomal recessive condition, be it a homozygote or compound heterozygote, all offspring will be carriers of one of the mutated alleles but will be unaffected because of inheritance of a wild-type allele from the other, clinically and genetically unaffected, parent. This assumes that the unaffected parent is not a carrier. Although this is usually the case in nonconsanguineous relationships, it may not hold true in first-cousin marriages or other circumstances where there is a familial interrelationship. For example, if the partner of an individual with an autosomal recessive disorder is also a carrier of the same mutation, albeit clinically unaffected, then there is a 50 percent chance of the offspring inheriting two mutant alleles and therefore also inheriting the same autosomal recessive disorder. This pattern of inheritance is referred to as *pseudo-dominant*.

In X-linked dominant inheritance, both males and females are affected, and the pedigree pattern may resemble that of autosomal dominant inheritance (Fig. 8-5). There is, however, one important difference. An affected male transmits the disorder to all his daughters and to none of his sons. X-linked dominant inheritance has been postulated as a mechanism in incontinentia pigmenti (see Chap. 73), Conradi-Hünermann syndrome, and focal dermal hypoplasia (Goltz syndrome), conditions that are almost always limited to females. In most X-linked dominant disorders with cutaneous manifestations, affected males may be aborted spontaneously or die before implantation (for example, most male patients with incontinentia pigmenti have a postzygotic mutation in NEMO, and no affected mother; in this disorder, transmission tends to be female-to-female).

X-linked recessive conditions occur almost exclusively in males, but the gene is transmitted by carrier females, who have the mutated gene only on one X chromosome (heterozygous state). The sons of an affected male will all be normal (because their single X chromosome comes from their clinically unaffected mother) (Fig. 8-6). However, the daughters of an affected male will all be carriers (because all had to have received the single X chromosome that their father had, and that X chromosome carries the mutant copy of the corresponding gene). Some females show clinical abnormalities as evidence of the carrier state (such as in hypohidrotic ectodermal dysplasia;

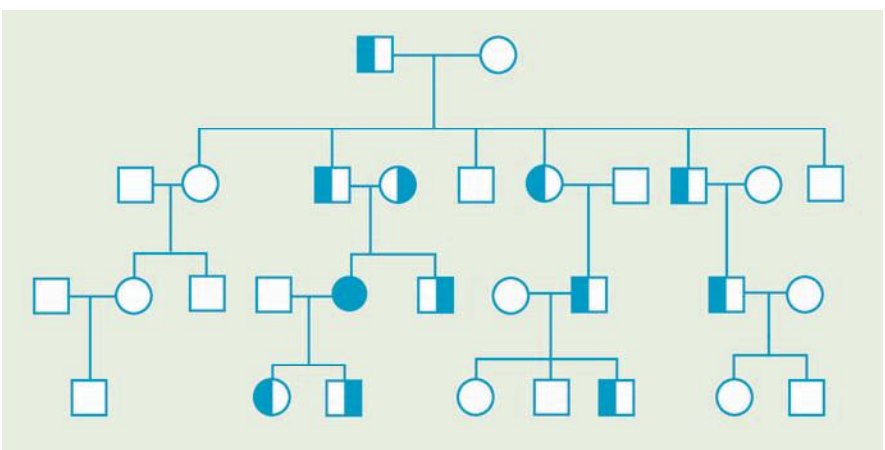

▲ **FIGURE 8-4** Pedigree illustration of an autosomal recessive pattern of inheritance. Key observations include: the disorder affects both males and females; there are mutations on both inherited copies of the gene; the parents of an affected individual are both heterozygous carriers and are usually clinically unaffected; autosomal recessive disorders are more common in consanguineous families. Filled circle indicates affected female; half-filled circles/squares represent clinically unaffected heterozygous carriers of the mutation; unfilled circles/squares represent unaffected individuals.

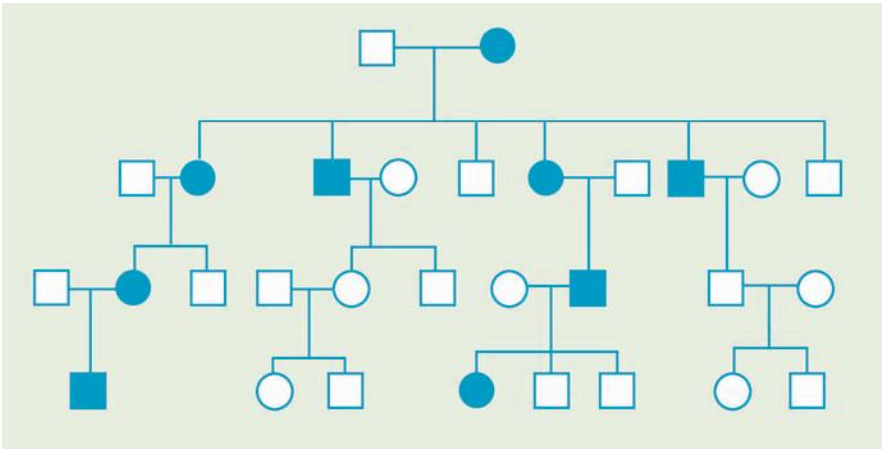

▲ **FIGURE 8-5** Pedigree illustration of an X-linked dominant pattern of inheritance. Key observations include: affected individuals are either hemizygous males or heterozygous females; affected males will transmit the disorder to their daughters but not to their sons (no male-to-male transmission); affected females will transmit the disorder to half their daughters and half their sons; some disorders of this type are lethal in hemizygous males and only heterozygous females survive. Filled circles indicate affected females; filled squares indicate affected males; unfilled circles/squares represent unaffected individuals.

see Chap. 143); the variable extent of phenotypic expression can be explained by lyonization, the normally random process that inactivates either the wild-type or mutated X chromosome in each cell during the first weeks of gestation and all progeny cells.[14] Other carriers may not show manifestations because the affected region on the X chromosome escapes lyonization (as in recessive X-linked ichthyosis) or the selective survival disadvantage of cells in which the mutated X chromosome is activated (as in the lymphocytes and platelets of carriers of Wiskott-Aldrich syndrome; see Mosaicism).

CHROMOSOMAL DISORDERS

Aberrations in chromosomes are common. They occur in about 6 percent of all conceptions, although most of these lead to miscarriage, and the frequency of chromosomal abnormalities in live births is about 0.6 percent. Approximately two-thirds of these involve abnormalities in either the number of sex chromosomes or the number of autosomes; the remainder are chromosomal rearrangements. The number and arrangement of the chromosomes is referred to as the *karyotype*. The most common numerical abnormality is trisomy, the presence of an extra chromosome. This occurs because of non-disjunction, when pairs of homologous chromosomes fail to separate during meiosis, leading to gametes with an additional chromosome. Loss of a complete chromosome, monosomy, can affect the X chromosome but is rarely seen in autosomes because of non-viability. A number of chromosomal disorders are also associated with skin abnormalities, as detailed in Table 8-2.

Structural aberrations (fragility breaks) in chromosomes may be random, although some chromosomal regions appear more vulnerable. Loss of part of a chromosome is referred to as a *deletion*. If the deletion leads to loss of neighboring genes this may result in a contiguous gene disorder, such as a deletion on the X chromosome giving rise to X-linked ichthyosis (see Chap. 47) and Kallman syndrome. If two chromosomes break, the detached fragments may be exchanged, known as *reciprocal translocation*. If this process involves no loss of DNA it is referred to as a *balanced translocation*. Other structural aberrations include duplication of sections of chromosomes, two breaks within one chromosome leading to inversion, and fusion of the ends of two broken chromosomal arms, leading to joining of the ends and formation of a ring chromosome.

A further possible chromosomal abnormality is the inheritance of both copies of a chromosome pair from just one parent (paternal or maternal), known as *uniparental disomy*.[15] *Uniparental heterodisomy* refers to the presence of a pair of chromosome homologs, whereas *uniparental isodisomy* describes two identical copies of a single homolog, and *meroisodisomy* is a mixture of the two. Uniparental disomy with homozygosity of recessive alleles is being increasingly recognized as the molecular basis for several autosomal recessive disorders, and there have been more than 35 reported cases of recessive diseases, including junctional and dystrophic EB (see Chap. 60), resulting from this type of chromosomal abnormality. For certain chromosomes, uniparental disomy can also result in distinct phenotypes depending on the parental origin of the chromosomes, a phenomenon known as *genomic imprinting*.[16,17] This parent-of-origin, specific gene expression is determined by epigenetic modification of a specific gene or, more often, a group of genes, such that gene transcription is

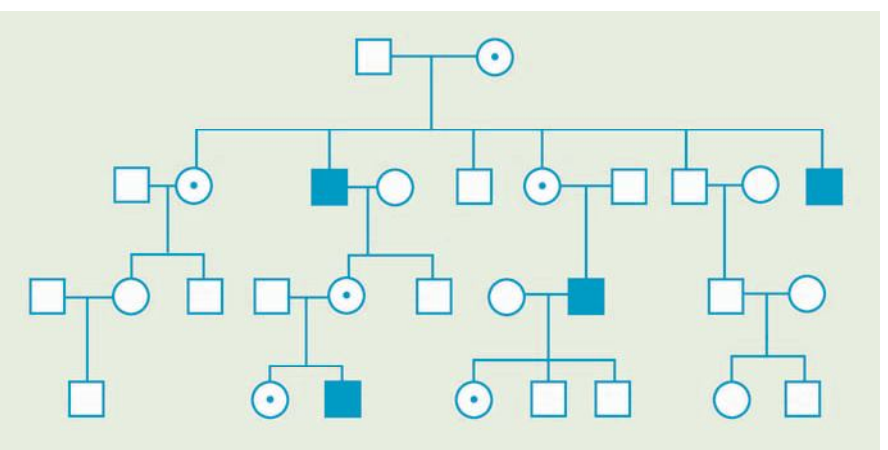

▲ **FIGURE 8-6** Pedigree illustration of an X-linked recessive pattern of inheritance. Key observations include: usually affects only males but females can show some features because of lyonization (X-chromosome inactivation); transmitted through female carriers, with no male-to-male transmission; for affected males, all daughters will be heterozygous carriers; female carrier will transmit the disorder to half her sons, and half her daughters will be heterozygous carriers. Dots within circles indicate heterozygous carrier females who may or may not display some phenotypic abnormalities; filled squares indicate affected males; unfilled circles/squares represent unaffected individuals.

TABLE 8-2
Chromosomal Disorders with a Skin Phenotype

Chromosomal Abnormality	Synonym	General Features	Skin Manifestations
Trisomy 21	Down syndrome	Small head with flat face Nose short and squat Ears small and misshapen Slanting palpebral fissures Thickened eyelids Eyelashes short and sparse Shortened limbs, lax joints Fingers short, sometimes webbed Hypoplastic iris, lighter outer zone (Brushfield's spots)	1–10 yr: dry skin, xerosis, lichenification 10+ yr: increased frequency of atopic dermatitis, alopecia areata, single crease in palm and fifth finger Other associations: skin infections, angular cheilitis, geographic tongue, blepharitis, red cheeks, folliculitis, seborrheic dermatitis, boils, onychomycosis, fine hypopigmented hair, vitiligo, delayed dentition and hypoplastic teeth, acrocyanosis, livedo reticularis, cutis marmorata, calcinosis cutis, palmoplantar keratoderma, pityriasis rubra pilaris, syringomas, elastosis perforans serpiginosa, anetoderma, hyperkeratotic form of psoriasis, collagenoma, eruptive dermatofibromas, urticaria pigmentosa, leukemia cutis, keratosis follicularis spinulosa decalvans
Trisomy 18	Edwards syndrome	Severe mental deficiency Abnormal skull shape Small chin, prominent occiput Low-set, malformed ears "Rocker bottom" feet Short sternum Malformations of internal organs Only 10% survive beyond first year	Cutis laxa (neck), hypertrichosis of forehead and back, superficial hemangiomas, abnormal dermatoglyphics, single palmar crease, hyperpigmentation, ankyloblepharon filiforme adnatum
Trisomy 13	Patau syndrome	Mental retardation Sloping forehead due to forebrain maldevelopment (holoprosencephaly) Microphthalmia or anophthalmia Cleft palate/cleft lip Low-set ears "Rocker bottom" feet Malformations of internal organs Survival beyond 6 mo is rare	Vascular anomalies (especially on forehead) Hyperconvex nails Localized scalp defects Cutis laxa (neck) Abnormal palm print (distal palmar axial triradius)
Chromosome 4, short arm deletion		Microcephaly Mental retardation Hypospadias Cleft lip/palate Low-set ears, preauricular pits	Scalp defects
Chromosome 5, short arm deletion		Mental retardation Microcephaly Cat-like cry Low-set ears, preauricular skin tag	Premature graying of hair
Chromosome 18, long arm deletion		Hypoplasia of mid-face Sunken eyes Prominent ear anti-helix Multiple skeletal and ocular abnormalities	Eczema in 25% of cases
45 XO	Turner syndrome	Early embryonic loss; prenatal ultrasound findings of cystic hygroma, chylothorax, ascites and hydrops Short stature, amenorrhea Broad chest, widely spaced nipples Wide carrying angle of arms Low misshapen ears, high arched palate Short fourth/fifth fingers and toes Skeletal abnormalities, coarctation of aorta	Redundant neck skin and peripheral edema Webbed neck, low posterior hairline Cutis laxa (neck, buttocks) Hypoplastic, soft up-turned nails Increased incidence of keloids Increased number of melanocytic nevi and halo nevi Failure to develop full secondary sexual characteristics Lymphatic hypoplasia/lymphedema
47 XXY	Klinefelter syndrome	No manifestations before puberty Small testes, poorly developed secondary sexual characteristics Infertility Tall, obese, osteoporosis	May develop gynecomastia Sparse body and facial hair Increased risk of leg ulcers Increased incidence of systemic lupus erythematosus

(continued)

TABLE 8-2
Chromosomal Disorders with a Skin Phenotype (Continued)

Chromosomal Abnormality	Synonym	General Features	Skin Manifestations
48 XXYY		Similar to Klinefelter syndrome	Multiple cutaneous angiomas Acrocyanosis, peripheral vascular disease
47 XYY		Phenotypic males (tall) Mental retardation Aggressive behavior	Severe acne
49 XXXXY		Low birth weight Slow mental and physical development Large, low-set, malformed ears Small genitalia	Hypotrichosis (variable)
Fragile X syndrome		Mental retardation Mild dysmorphism Hyperextensible joints, flat feet	—

altered, and only one inherited copy of the relevant imprinted gene(s) is expressed in the embryo. This means that, during development, the parental genomes function unequally in the offspring. The most common examples of genomic imprinting are Prader–Willi (OMIM #176270) and Angelman (OMIM #105830) syndromes, which can result from maternal or paternal uniparental disomy for chromosome 15, respectively. Three phenotype abnormalities commonly associated with uniparental disomy for chromosomes with imprinting are intrauterine growth retardation, developmental delay, and reduced stature.[18]

MITOCHONDRIAL DISORDERS

In addition to the 3.3 billion bp nuclear genome, each cell contains hundreds or thousands of copies of a further 16.5-kb mitochondrial genome, which is inherited solely from an individual's mother. This closed, circular genome contains 37 genes, 13 of which encode proteins of the respiratory chain complexes, whereas the other 24 genes generate 22 transfer RNAs and two ribosomal RNAs used in mitochondrial protein synthesis.[19] Mutations in mitochondrial DNA were first reported in 1988, and more than 250 pathogenic point mutations and genomic rearrangements have been shown to underlie a number of myopathic disorders and neurodegenerative diseases, some of which show skin manifestations, including lipomas, abnormal pigmentation or erythema, and hypo- or hypertrichosis.[20] Mitochondrial DNA has the capacity to form a mixture of both wild-type and mutant DNA within a cell, leading to cellular dysfunction only when the ratio of mutated to wild-type DNA reaches a certain threshold. The phenomenon of having mixed mitochondrial DNA species within a cell is known as *heteroplasmy*. Mitochondrial mutations can induce, or be induced by, reactive oxygen species, and may be found in, or contribute to, both chronologic aging and photoaging. Somatic mutations in mitochondrial DNA have also been reported in several premalignant and malignant tumors, including malignant melanoma, although it is not yet known whether these mutations are causally linked to cancer development or simply a secondary bystander effect as a consequence of nuclear DNA instability. Indeed, currently there is little understanding of the interplay between the nuclear and mitochondrial genomes in both health and disease. Nevertheless, it is evident that the genes encoded by the mitochondrial genome have multiple biologic functions linked to energy production, cell proliferation, and apoptosis.[21]

COMPLEX TRAIT GENETICS

For Mendelian disorders, identifying genes that harbor pathogenic mutations has become relatively straightforward, with hundreds of disease-associated genes being discovered through a combination of linkage, positional cloning, and candidate gene analyses. By contrast, for complex traits, such as psoriasis and atopic dermatitis, these traditional approaches have been largely unsuccessful in mapping genes influencing the disease risk or phenotype because of low statistical power and other factors.[22,23] Complex traits do not display simple Mendelian patterns of inheritance, although genes do have an influence, and close relatives of affected individuals may have an increased risk. To dissect out genes that contribute to, and influence susceptibility to, complex traits, several stages may be necessary, including establishing a genetic basis for the disease in one or more populations; measuring the distribution of gene effects; studying statistical power using models; and carrying out marker-based mapping studies using linkage or association. It is possible to establish quantitative genetic models to estimate the heritability of a complex trait, as well as to predict the distribution of gene effects and to test whether one or more quantitative trait loci exist. These models can predict the power of different mapping approaches, but often only provide approximate predictions. Moreover, low power often limits other strategies such as transmission analyses, association studies, and family-based association tests. Another potential pitfall of association studies is that they can generate spurious associations due to population admixture. To counter this, alternative strategies for association mapping include the use of recent founder populations or unique isolated populations that are genetically homogeneous, and the use of unlinked markers (so-called *genomic controls*) to assign different regions of the genome of an admixed individual to particular source populations. In addition, and relevant to several studies on psoriasis, linkage disequilibrium observed in a sample of unrelated affected and normal individuals can also be used to fine-map a disease susceptibility locus in a candidate region.

Recently, however, a conventional genetics approach has revealed fascinating new insight into the pathophysiology of one particular complex trait, namely

atopic dermatitis. This finding emanated from the discovery that the disorder ichthyosis vulgaris was due to loss-of-function mutations in the gene encoding the skin barrier protein filaggrin (see Chaps. 14 and 47).[24] To dermatologists, the clinical association between this condition and atopic dermatitis is well known, and the same loss-of-function mutations in filaggrin have subsequently been shown to be a major susceptibility risk factor for atopic dermatitis, as well as asthma associated with atopic dermatitis, but not asthma alone.[4] This suggests that asthma in individuals with atopic dermatitis may be secondary to allergic sensitization, which develops because of the defective epidermal barrier that allows allergens to penetrate the skin to make contact with antigen-presenting cells. Indeed, transmission-disequilibrium tests have demonstrated an association between filaggrin gene mutations and extrinsic atopic dermatitis associated with high total serum immunoglobulin E levels and concomitant allergic sensitizations.[25] These recent data on the genetics of atopic dermatitis demonstrate how the study of a "simple" genetic disorder can also provide novel insight into a complex trait. Mendelian disorders, therefore, may be useful in the molecular dissection of more complex traits.[26]

MOSAICISM

The presence of a mixed population of cells bearing different genetic or chromosomal characteristics leading to phenotypic diversity is referred to as *mosaicism*. There are several different types of mosaicism, including single gene, chromosomal, functional, and revertant mosaicism.[27]

Mosaicism for a single gene, referred to as *somatic mosaicism*, indicates a mutational event occurring after fertilization. The earlier this occurs, the more likely it is there will be clinical expression of a disease phenotype as well as involvement of gonadal tissue (gonosomal mosaicism); for example, when individuals with segmental neurofibromatosis subsequently have offspring with full-blown neurofibromatosis (see Chap. 142). However, in general, if the mutation occurs after generation of cells committed to gonad formation, then the mosaicism will not involve the germline, and the reproductive risk of transmission is negligible. *Gonosomal mosaicism* refers to involvement of both gonads and somatic tissue, but mosaicism can occur exclusively in gonadal tissue, referred to as *gonadal mosaicism*. Clinically, this may explain recurrences among siblings of autosomal dominant disorders such as tuberous sclerosis or neurofibromatosis, when none of the parents has any clinical manifestations and gene screening using genomic DNA from peripheral blood samples yields no mutation. Segmental mosaicism for autosomal dominant disorders is thought to occur in one of two ways: either there is a postzygotic mutation with the skin outside the segment and genomic DNA being normal (type 1), or there is a heterozygous genomic mutation that is then exacerbated by loss of heterozygosity within a segment or along the lines of Blaschko (type 2). This pattern has been described in several autosomal dominant disorders, including Darier disease, Hailey-Hailey disease (see Chap. 49), superficial actinic porokeratosis (see Chap. 50), and tuberous sclerosis (see Chap. 141).

The lines of Blaschko were delineated over 100 years ago; the pattern is attributed to the lines of migration and proliferation of epidermal cells during embryogenesis (i.e., the bands of abnormal skin represent clones of cells carrying a mutation in a gene expressed in the skin).[28] Apart from somatic mutations [either in dominant disorders, such as bullous ichthyosiform erythroderma leading to linear epidermolytic hyperkeratosis (see Chap. 47), or in conditions involving mutations in lethal dominant genes such as in McCune-Albright syndrome], mosaicism following Blaschko's lines is also seen in chromosomal mosaicism and functional mosaicism (random X-chromosome inactivation through lyonization). Chromosomal mosaicism results from nondisjunction events that occur after fertilization. Clinically, this is found in the linear pigmentary disorders hypomelanosis of Ito (see Chap. 73) and linear and whorled hyperpigmentation. It is important to point out that hypomelanosis of Ito is not a specific diagnosis but may occur as a consequence of several different chromosomal abnormalities that perturb various genes relevant to skin pigmentation. Functional mosaicism relates to genes on the X chromosome, because during embryonic development in females, one of the X chromosomes, either the maternal or the paternal, is inactivated. For X-linked dominant disorders, such as focal dermal hypoplasia (Goltz syndrome) or incontinentia pigmenti (see Chap. 73), females survive because of the presence of some cells in which the X chromosome without the mutation is active and able to function. For males, these X-linked dominant disorders are typically lethal, unless associated with an abnormal karyotype (e.g., Klinefelter syndrome; 47, XXY) or if the mutation occurs during embryonic development. For X-linked recessive conditions, such as X-linked recessive hypohidrotic ectodermal dysplasia (see Chap. 143), the clinical features are evident in hemizygous males (who have only one X chromosome), but females may show subtle abnormalities due to mosaicism caused by X-inactivation, such as decreased sweating or reduced hair in areas of the skin in which the normal X is selectively inactivated. There are 1317 known genes on the X chromosome, and most undergo random inactivation but a small percentage (approximately 27 genes on Xp, including the steroid sulfatase gene, and 26 genes on Xq) escape inactivation.

Revertant mosaicism, also known as *natural gene therapy*, refers to genetic correction of an abnormality by presence of a second mutation that either corrects a mutant gene or silences it.[29,30] Such events have been described in a few genes expressed in the skin, including the keratin 14, laminin 332, and collagen XVII genes in different forms of EB (Fig. 8-7; see Chap. 60). However, the clinical relevance of the conversion process depends on several factors, including the number of cells involved, how much reversal actually occurs, and at what stage in life the reversion takes place.

Apart from mutations in nuclear DNA, mosaicism can also be influenced by environmental factors, such as viral DNA sequences (retrotransposons) that can be incorporated into nuclear DNA, replicate, and activate or silence genes through methylation or demethylation. This phenomenon is known as *epigenetic mosaicism*; such events may be implicated in tumorigenesis but have not been associated with any genetic skin disorder.

EPIGENETICS

Disease phenotypes reflect the result of the interaction between a particular genotype and the environment, but it is evident that some variation, for example, in monozygotic twins, is attributable to neither. Additional influences at the biochemical, cellular, tissue, and organism levels occur, and these are referred to as *epigenetic phenomena*.[31] Single genes are



▲ **FIGURE 8-7** Revertant mosaicism in an individual with non-Herlitz junctional epidermolysis bullosa. The subject has loss-of-function mutations on both alleles of the type XVII collagen gene, *COL17A1*, but spontaneous genetic correction of the mutation in some areas has led to patches of normal-appearing skin (areas within black marker outline) that do not blister. (From Jonkman MF et al: Revertant mosaicism in epidermolysis bullosa caused by mitotic gene conversion. *Cell* **88**:543, 1997, with permission.)

not solely responsible for each separate function of a cell. Genes may collaborate in circuits, be mobile, exist in plasmids and cytoplasmic organelles, and can be imported by nonsexual means from other organisms or as synthetic products. Even prion proteins can simulate some gene properties. Epigenetic effects reflect chemical modifications to DNA that do not alter DNA sequence but do alter the probability of gene transcription. Analysis of these changes is known as *epigenomics*.[32] Examples of modifications include direct covalent modification of DNA by methylation of cytosines and alterations in proteins that bind to DNA. Such changes may affect DNA accessibility to local transcriptional complexes as well as influencing chromatin structure at regional and genome-wide levels, thus providing a link between genome structure and regulation of transcription. Indeed, epigenome analysis is now being carried out in parallel with gene expression to identify genome-wide methylation patterns and profiles of all human genes. For example, there is considerable interindividual variation in cytosine methylation of CpG dinucleotides within the major histocompatibility complex (MHC) region genes, although whether this has any bearing on the expression of skin disorders such as psoriasis remains to be seen. A further but as yet unresolved issue is whether there is heritability of epigenetic characteristics. Likewise, it is unclear whether environmentally induced changes in epigenetic status, and hence gene transcription and phenotype, can be transmitted through more than one generation. Such a phenomenon might account for the cancer susceptibility of grandchildren of individuals who have been exposed to diethylstilbestrol, but this has not been proved. Germline epimutations, however, have been identified in other human diseases, such as colorectal cancers characterized by microsatellite instability and hypermethylation of the *MLH1* DNA mismatch repair gene, although the risk of transgenerational epigenetic inheritance of cancer from such a mutation is not well established and probably small. Over the course of an individual's lifespan, epigenetic mutations may occur more frequently than DNA mutations, and it is expected that, over the next decade, the role of epigenetic phenomena in influencing phenotypic variation will gradually become better understood.[33]

HISTOCOMPATABILITY ANTIGEN DISEASE ASSOCIATION

HLA molecules are glycoproteins that are expressed on almost all nucleated cells. The HLA region is located on the short arm of chromosome 6, at 6p21, referred to as the *MHC*. There are three classic loci at HLA class I: HLA-A, -B, and -Cw, and five loci at class II: HLA-DR, -DQ, -DP, -DM, and -DO. The HLA molecules are highly polymorphic, there being many alleles at each individual locus. Thus, allelic variation contributes to defining a unique "fingerprint" for each person's cells, which allows an individual's immune system to define what is foreign and what is self. The clinical significance of the HLA system is highlighted in human tissue transplantation, especially in kidney and bone marrow transplantation, where efforts are made to match at the HLA-A, -B, and -DR loci. MHC class I molecules, complexed to certain peptides, act as substrates for $CD8^+$ T-cell activation, whereas MHC class II molecules on the surface of antigen-presenting cells display a range of peptides for recognition by the T-cell receptors of $CD4^+$ T helper cells (see Chap. 10). MHC molecules, therefore, are central to effective adaptive immune responses. Conversely, however, genetic and epidemiologic data have implicated these molecules in the pathogenesis of various autoimmune and chronic inflammatory diseases. Several skin diseases, such as psoriasis (see Chap. 18), psoriatic arthropathy (central and peripheral), dermatitis herpetiformis, pemphigus, reactive arthritis syndrome (see Chap. 20), and Behçet disease (see Chap. 167), all show an association with inheritance of certain HLA haplotypes (i.e., there is a higher incidence of these conditions in individuals and families with particular HLA alleles). However, the molecular mechanisms by which polymorphisms in HLA molecules confer susceptibility to certain disorders are still unclear. This situation is further complicated by the fact that, for most diseases, it is unknown which autoantigens (presented by the disease-associated MHC molecules) are primarily involved. For many diseases, the MHC class association is the main genetic association. Nevertheless, for most of the MHC-associated diseases, it has been difficult to unequivocally determine the primary disease-risk gene(s), owing to the extended linkage disequilibrium in the MHC region. However, recent genetic and functional studies support the long-held assumption that common MHC class I and II alleles themselves are responsible for many disease associations, such as the HLA cw6 allele in psoriasis.

GENETIC COUNSELING

In 2006, the National Society of Genetic Counselors (http://www.nsgc.org) defined genetic counseling as "the process of helping people understand and adapt to the medical, psychological and familial implications of genetic contributions to disease." Genetic counseling should include: (1) interpretation of family and medical histories to assess the chance of disease occurrence or recurrence; (2) education about inheritance, testing, management, prevention, resources, and research; and (3) counseling to promote informed choice and adaptation to the risk or condition.[34]

Genetic counseling is an integral part of the practice of dermatology. Once the diagnosis of an inherited skin disease is established and the mode of inheritance is known, every dermatologist should be able to advise patients correctly and appropriately, although additional support from specialists in medical genetics is often necessary. Genetic counseling must be based on an understanding of genetic principles and on a familiarity with the usual behavior of hereditary and congenital abnormalities. It is also important to be familiar with the range of clinical severity of a particular disease, the social consequences of the disorder, the availability of therapy (if any), and the options for mutation detection and prenatal testing in subsequent pregnancies at risk for recurrence (one useful site is http://www.genetests.com).

A key component of genetic counseling is to help parents, patients, and families know about the risks of recurrence or transmission for a particular condition. This information is not only practical but often relieves guilt and can allay rather than increase anxiety. For example, it may not be clear to the person that he or she cannot transmit the given disorder. The unaffected brother of a patient with an X-linked recessive disorder such as Fabry disease (see Chap. 136), X-linked ichthyosis (see Chap. 47), Wiskott-Aldrich syndrome (see Chap. 144), or Menkes syndrome (see Chap. 86) need not worry about his children being affected or even carrying the abnormal allele, but he may not know this.

Prognosis and counseling for conditions such as psoriasis in which the genetic basis is complex or still unclear is more difficult (see Chap. 18). Persons can be advised, for example, that if both parents have psoriasis, the probability is 60 percent to 75 percent that a child will have psoriasis; if one parent and a child of that union have psoriasis, then the chance is 30 percent that another child will have psoriasis; and if two normal parents have produced a child with psoriasis, the probability is 15 percent to 20 percent for another child with psoriasis.[35]

PRENATAL DIAGNOSIS

In recent years, there has been considerable progress in developing prenatal testing for severe inherited skin disorders (Fig. 8-8). Initially, ultrastructural examination of fetal skin biopsies was established in a limited number of conditions. In the late 1970s, the first diagnostic examination of fetal skin was reported for epidermolytic hyperkeratosis and Herlitz junctional EB (see Chap. 60).[36,37] These initial biopsies were performed with the aid of a fetoscope to visualize the fetus. However, with improvements in sonographic imaging, biopsies of fetal skin are now taken under ultrasound guidance. The fetal skin biopsy samples obtained during the early 1980s could be examined only by light microscopy and transmission electron microscopy. However, the introduction of a number of monoclonal and polyclonal antibodies to various basement membrane components during the mid-1980s led to the development of immunohistochemical tests to help complement ultrastructural analysis in establishing an accurate diagnosis, especially in cases of EB.[38] Fetal skin biopsies are taken during the mid-trimester. For disorders such as EB, testing at 16 weeks' gestation is appropriate. However, for some forms of ichthyosis, the disease-defining structural pathology may not be evident at this time, and fetal skin sampling may need to be deferred until 20 to 22 weeks of development.

Nevertheless, since the early 1990s, as the molecular basis of an increasing number of genodermatoses has been elucidated, fetal skin biopsies have gradually been superseded by DNA-based diagnostic screening using fetal DNA from amniotic fluid cells or samples of chorionic villi; the latter are usually taken at 10 to 12 weeks' gestation (i.e., at the end of the first trimester).[39,40] In addition, advances with in vitro fertilization and embryo micromanipulation have led to the feasibility of even earlier DNA-based assessment through preimplantation genetic diagnosis, an approach first successfully applied in 1990, for risk of recurrence of cystic fibrosis.[41] Successful preimplantation testing has also been reported for severe inherited skin disorders.[42] This is likely to become a more

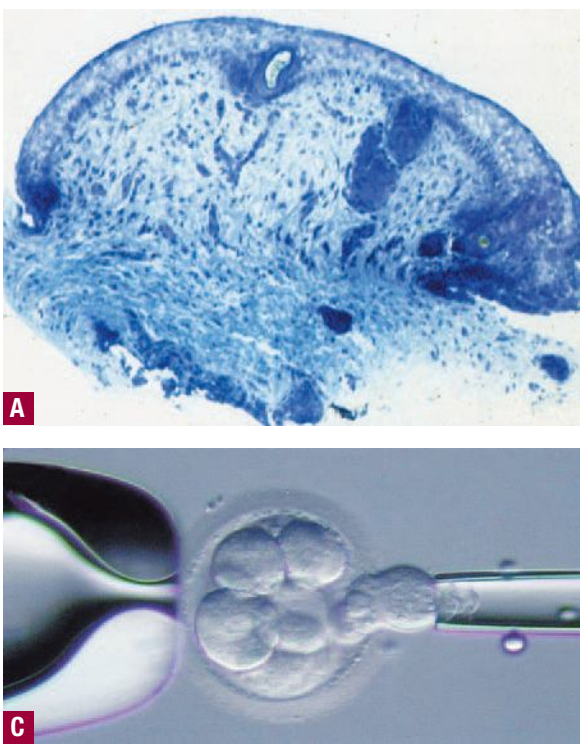

◀ **FIGURE 8-8** Options for prenatal testing of inherited skin diseases. **A.** Fetal skin biopsy, here shown at 18 weeks' gestation. **B.** Chorionic villi sampled at 11 weeks' gestation. **C.** Preimplantation genetic diagnosis. A single cell is being extracted from a 12-cell embryo using a suction pipette.

popular, though still technically challenging, option for some couples, in view of recent advances in amplifying the whole genome in single cells and the application of multiple linkage markers in an approach termed *preimplantation genetic haplotyping*.[43] For some disorders, alternative less invasive methods of testing are now also being developed, including analysis of fetal DNA from within the maternal circulation and the use of three-dimensional ultrasonography.

In the current absence of effective treatment for many hereditary skin diseases, prenatal diagnosis can provide much appreciated information to couples at risk of having affected children, although detailed and supportive genetic counseling is also a vital element of all prenatal testing procedures.

GENE THERAPY

The field of gene therapy can be subdivided in different ways.[44] First, there are approaches aimed at treatment of recessive genetic diseases where homozygous or compound heterozygous loss-of-function mutations lead to complete absence or complete functional ablation of a vital protein. These types of diseases are amenable to gene replacement therapy, and it is this form of gene therapy that has tended to predominate because it is generally technically more feasible than treatment of dominant genetic conditions.[45] In dermatology, these include diseases such as lamellar ichthyosis (see Chap. 47), where in most cases, there is hereditary absence of transglutaminase-1 activity in the outer epidermis, or the severe Hallopeau-Siemens form of recessive dystrophic EB, where there is complete absence of type VII collagen expression due to recessive mutations.[46]

The second form of gene therapy, in broad terms, is aimed at treatment of dominant-negative genetic disorders and is known as *gene inhibition therapy*. Here, there is a completely different type of problem to be tackled because these patients already carry one normal copy of the gene and one mutated copy. The disease results because an abnormal protein product produced by the mutant allele, dominant-negative mutant protein, binds to and inhibits the function of the normal protein produced by the wild-type allele. In many cases, it can be shown from the study of rare recessive variants of dominant diseases that one allele is sufficient for normal skin function, and so if a means could be found of specifically inhibiting the expression of the mutant allele, this should be therapeutically beneficial. However, finding a gene therapy agent that is capable of discriminating the wild-type and mutant alleles, which can differ by as little as one bp of DNA, is challenging , until recently, has resulted in little success. A typical dominant-negative genetic skin disease is EB simplex (see Chap. 60), caused by mutations in either of the genes encoding keratins 5 or 14. The vast majority of cases are caused by dominant-negative missense mutations, changing only a single amino acid, carried in a heterozygous manner on one allele.[47]

The other way that gene therapy approaches can be broadly subdivided is according to whether they involve in vivo or ex vivo strategies.[44] Using an in vivo approach, the gene therapy agent would be applied directly to the patient's skin or another tissue. In an ex vivo approach, a skin biopsy would be taken, keratinocytes or fibroblasts would be grown and expanded in culture, treated with the gene therapy agent, and then grafted onto or injected back into the patient. The skin is a good organ system for both these approaches because it is very accessible for in vivo applications. In addition, the skin can be readily biopsied, and cell culture and re-grafting of keratinocytes can be adapted for ex vivo gene therapy.

A disadvantage of the skin as a target organ for gene therapy is that it is a barrier tissue that is fundamentally designed to prevent entry of foreign nucleic acid in the form of viruses or other pathogenic agents. This is an impediment to in vivo gene therapy development but is not insurmountable due to developments in liposome technology and other methods for cutaneous macromolecule delivery.[48]

Gene replacement therapy systems have been developed for lamellar ichthyosis (see Chap. 47) and the recessive forms of EB (see Chap. 60), among other diseases. These mostly consist of expressing the normal complementary DNA encoding the gene of interest from some form of gene therapy vector adapted from viruses that can integrate their genomes stably into the human genome. Such viral vectors can therefore lead to long-term stable expression of the replacement gene.[49] Early studies tended to use retroviral vectors or adeno-associated viral vectors, but these have a number of limitations. For example, retroviruses only transduce dividing cells and therefore fail to target stem cells; consequently, gene expression is quickly lost due to turnover of the epidermis through keratinocyte differentiation. Furthermore, there have been some safety issues in small-scale human trials for both retroviral and adeno-associated viral vectors. Lentiviral vectors, derived from short integrating sequences found in a number of immunodeficiency viruses, have the advantage of being able to stably transduce dividing and non-dividing cells, with close to 100 percent efficiency and at low copy number. These may be the current vector of choice, but they also have potential problems because their preferred integration sites in the human genome are currently ill-defined and may lead to concerns about safety. However, with a wide variety of vectors under development and testing, it should become clear in future years which vectors are effective and safe for human use. Ultimately, like all novel therapeutics, animal testing can only act as a guide because the human genome is quite different and may react differently to foreign DNA integration, so that phase I, II, and III human trials or adaptations thereof will ultimately have to be performed to determine efficacy and safety. Currently, small-scale clinical trials are ongoing for junctional EB and are planned for a number of other genodermatoses, mainly concentrating on the more severe recessive conditions.

Treatment of dominant-negative disorders has recently started to receive a great deal of attention with the discovery of the RNA inhibition pathway in humans and the finding that small synthetic double-stranded RNA molecules of 19 to 21 bp, known as *short inhibitory RNA* (siRNA), can efficiently inhibit expression of human genes in a sequence-specific, user-defined manner.[47,50] There is currently a great deal of attention being focused on development of siRNA inhibitors to selectively silence mutant alleles in dominant-negative genetic diseases, such as the keratin disorders EB simplex or pachyonychia congenita. Because siRNAs can be designed against many different mRNA sequences with ease, and because they are much smaller molecules than gene therapy vectors, this new, rapidly evolving technology fits in between small molecule therapy and gene therapy. In a number of cases, siRNAs have been identified that can discriminate between normal and mutant alleles that differ by only a single bp mutation. In parallel, a number of groups are working on means of delivering siRNA to skin and other organ systems, and there is currently much optimism about these developing into clinically applicable agents in the near future. Some small scale clinical trials are under way and others are planned, including for keratinizing disorders. A number of animal models have shown positive results with low toxicity, including in non-human primates. However, at least one

study has shown liver toxicity with certain sequences but not others.

KEY REFERENCES

The full reference list for all chapters is available at www.digm7.com.

1. Hsu F et al: The UCSC known genes. *Bioinformatics* **22**:1036, 2006
2. Tsongalis GJ, Silverman LM: Molecular diagnostics: A historical perspective. *Clin Chim Acta* **369**:188, 2006
14. Happle R: X-chromosome inactivation: Role in skin disease expression. *Acta Paediatr Suppl* **95**:16, 2006
20. Schapira AH: Mitochondrial disease. *Lancet* **368**:70, 2006
26. Antonarakis SE, Beckmann JS: Mendelian disorders deserve more attention. *Nat Rev Genet* **7**:277, 2006
32. Callinan PA, Feinberg AP: The emerging science of epigenomics. *Hum Mol Genet* **15**:R95, 2006
34. Resta RG: Defining and redefining the scope and goals of genetic counseling. *Am J Med Genet C Semin Med Genet* **142**:269, 2006
44. Hengge UR: Progress and prospects of skin gene therapy: A ten year history. *Clin Dermatol* **23**:107, 2005
45. Ferrari S et al: Gene therapy in combination with tissue engineering to treat epidermolysis bullosa. *Expert Opin Biol Ther* **6**:367, 2006

CHAPTER 9

Basic Science Approaches to the Pathophysiology of Skin Disease

Paul R. Bergstresser

TOOLS TO INVESTIGATE SKIN DISEASE

Dermatologists and skin biologists, like scientists in other disciplines, use as many tools as possible to unravel mechanisms of disease. They even invent tools to address the unique features of skin. Contemporary medical science is virtually universal in its techniques, and investigators from diverse fields commonly use the same cutting-edge methods to address the pathogenesis of disease. A significant portion of ground-breaking activity does not occur in conventional basic science or clinical departments, but, rather, in department-independent "centers" (or "centers of excellence"), which combine the resources and special expertise of investigators from several disciplines.

BASIC SCIENCE APPROACHES: A HISTORICAL PERSPECTIVE

With this preamble about the universality of methods used by investigators, this chapter continues with a simple question: "How have *basic science approaches to the pathophysiology of skin disease* fit into contemporary models of biomedical investigation?" This question is addressed with an assertion and four principles (Table 9-1).

The best way to illustrate how new knowledge has been generated for skin disease is through examples of successful achievement. What follows are three examples of effective laboratory research, each with important contemporary effects. These examples begin 40 years ago, and they illustrate that the principles for scientific success have not changed.

Repair of Ultraviolet Radiation-Induced Damage: A Model of Discovery

BACKGROUND Treatment of skin cancer has occupied an increasingly large portion of dermatologists' clinical activity since the 1950s, as life expectancies have increased, and as leisure time has led to more outdoor recreation. Importantly, ultraviolet radiation (UVR) retains its position as the major relevant etiologic factor. Because of the central role of skin cancer and skin cancer therapy in dermatologic practice, detailed knowledge about the very rare genetic disorder xeroderma pigmentosum serves as a useful model for how basic science and clinical observations have come together.

KNOWLEDGE LINKS TO THE LABORATORY The seminal discovery in understanding the pathogenesis of xeroderma pigmentosum was made by James Cleaver who, as a Ph.D. scientist, headed a basic science laboratory at the University of California in San Francisco.[1] His work had included the development of techniques to study DNA repair in cells in vitro. Making use of the rich intellectual environment of an academic medical center, he introduced himself to one of the dermatologists, John Epstein, asking whether there might be a genetic human photosensitive skin disease in which there was excess of skin cancer. Dr. Epstein told him that xeroderma pigmentosum would be his best choice.

STUDIES IN HUMANS The advice to examine patients with xeroderma pigmentosum led to the first set of observations made in vitro, that the repair of UVR-induced damage in fibroblasts taken from patients with the disease was defective.[1] Cleaver's work was followed rapidly by a second paper from John Epstein and his associates, in which the repair of DNA after ultraviolet irradiation in vivo was observed to be defective in both keratinocytes and fibroblasts.[2] This work set the stage for a series of discoveries made by an increasingly large number of scientists, who demonstrated that the genetic error in xeroderma pigmentosum was a loss in the ability to excise DNA that had been damaged through irradiation.

SUBSEQUENT OBSERVATIONS Subsequently, cell fusion studies based on the concept of "complementation" demon-

TABLE 9-1
Assertion and Principles about Basic Science Approaches to Skin Disease

- Assertion: Basic science research in dermatology at academic medical centers is successful to the extent that it "fits" the resources and core values of that institution.
- Principle 1 (core values): Highly effective laboratory research in skin disease is more likely to occur when conducted in centers with core values and resources that promote research.
- Principle 2 (people): Institutions do not conduct research; people do. Well-trained, energetic, optimistic, and enthusiastic people do the best research, although intelligence helps as well.
- Principle 3 (collaboration): Research is now so complex that scientific collaboration is required. (Scientists work, not as individuals, but in groups. Many groups are international in scope.)
- Principle 4 (resources): It takes time to do research, and time costs money.



strated that there was a family of excision defects, any one of which could be responsible for the disease.[3] Complementation through cell fusion was an established genetic technique, and its use in defining xeroderma pigmentosum illustrated the application of a general genetic concept to skin disease. Tracking down the specific steps in the DNA excision process opened an entirely new field of DNA repair,[4] and a journal is now devoted entirely to this field.[5] An important intellectual circle has been closed recently: James Cleaver delivered the Lila Gruber Cancer Research Lecture at the Annual Meeting of the American Academy of Dermatology in 1976 in which he described his initial work, and in 2007 Errol Friedberg did so again, 31 years later, with a presentation entitled "DNA Repair and DNA Damage Tolerance: Fundamental Mechanisms That Protect Against Cancer."

These experiments were not conducted in a vacuum, without attention to the possibility of benefiting patients. In addition to preventing skin cancer through protection against UVR, pharmaceutical enhancement of DNA repair has now been developed.[6] It appears to diminish the rate of cancer development, at least in patients with xeroderma pigmentosum. This line of investigation began with a series of questions: (1) Is it possible for repair enzymes from a bacterial source to repair UVR-induced damage in human cells? (2) Is it possible to develop a liposome system that allows one to introduce the enzymes into cells? (3) Can one obtain an effect by topical application of liposomes containing the enzymes? (4) Is it possible to develop and manufacture a clinical product (drug) that repairs UVR-induced damage in humans? and (5) Does this product reduce the incidence of malignancy in patients with xeroderma pigmentosum? Through an extensive series of experiments and clinical trials, the answer to each question appears to be "yes."

Each of these developments was rooted in the original observation of James Cleaver, and returning to that observation, what were the critical elements?

Principle 1 (core values): The University of California in San Francisco has been an institution where basic science and clinical science have been valued and promoted for several generations.

Principle 2 (people): Dr. John Epstein studied photosensitive diseases, knew how to find patients with xeroderma pigmentosum, and had energy, inventiveness, and ability. James Cleaver then took the right questions to the laboratory, using contemporary genetic techniques.

Principle 3 (collaboration): Increasing numbers of investigators have been involved with each step of this process.

Principle 4 (resources): Talking, planning, thinking, and learning all take time. The amount of personal investment of time and talent has been considerable.

Recessive Dystrophic Epidermolysis Bullosa and Skin Cancer: A Second Model of Discovery

BACKGROUND A related sequence of observations may be found in a paper published, not 30 years ago, but 2 years ago, in which clinical insight led to a critical set of observations.[7] It began with studies of recessive dystrophic epidermolysis bullosa (RDEB), which is caused by any one of several collagen VII defects; some mutations produce no protein, and some produce a truncated protein. This work was derived from ongoing general studies of epidermolysis bullosa at Stanford University, with the ultimate goal of developing techniques of gene therapy.

THE PROBLEM OF CANCER It was also known that patients with RDEB commonly develop lethal squamous cell carcinomas. This clinical knowledge was key to the subsequent paper. However, this work could only be conducted in laboratories in which in vitro models of cutaneous carcinogenesis were already in development, as was happening in the department of dermatology at Stanford University.

THE CRITICAL EXPERIMENTS The investigators examined Ras-driven tumorigenesis in keratinocytes taken from patients with RDEB. It was noted that cells entirely devoid of collagen VII did not form tumors (in mice), whereas those retaining specific collagen VII fragments were tumorigenic. Importantly, the forced expression of fragments restored tumorigenicity to the collagen VII-null epidermis. Finally, fibronectin-like sequences in that portion of the fragment promoted tumor cell invasion. Thus, tumor-stroma interactions mediated by collagen VII appeared to promote neoplasia. The conclusion is that the retention of collagen VII sequences in a subset of RDEB patients may contribute to their increased susceptibility for squamous cell carcinoma.

But the critical issue was the intellectual context in which this work took place. Ultimately, it was the knowledge that carcinogenesis is common in patients with RDEB, combined with ongoing laboratory studies in cutaneous carcinogenesis and in the blistering diseases that led to this important discovery. Of course, one should not ignore the impact of energetic and inquisitive investigators.

Principle 1 (core values): Stanford University has been an institution where basic science and clinical science have been valued and promoted.

Principle 2 (people): Dating back to the 1980s, investigators at Stanford, led initially by Dr. Eugene Bauer, were interested in epidermolysis bullosa, stemming from his work on collagenase at Washington University in St. Louis. With the arrival of Drs. Khavari and Marinkovich, models of carcinogenesis and models of blistering skin diseases were developed. One of the investigators developed the idea that type VII might be a critical element in carcinogenesis.

Principle 3 (collaboration): Increasing numbers of investigators have been involved with each step of this process.

Principle 4 (resources): Talking, planning, thinking, and learning all take time.

Of course, success is not limited to laboratories in the San Francisco Bay area of California; similar events occur in academic medical centers around the world.

Pemphigus Vulgaris: One Observation Opens a New Field

BACKGROUND A landmark study in characterizing the pathogenesis of pemphigus vulgaris illustrates how one study can precipitate decades of investigation. In the early 1960s, under the leadership of Ernst Witebsky, Ernst Beutner and his colleagues at the University of Buffalo had been studying diseases in which circulating autoantibodies might cause injury to organs such as the thyroid. At the same time, the chair of dermatology at the medical center, James Jordon, oversaw the care of patients with pemphigus. It turned out that his son, Robert Jordan, worked as a medical student in Ernst Beutner's immunologic laboratory on diseases affecting organs other than skin. It should be noted that the observation that follows did not take place in a vacuum. Walter Lever had studied pemphigus for some time, and he had already



differentiated pemphigus and pemphigoid on the basis of classical histopathologic observations.[8] On the other hand, it was not an accident that the observation was made in Buffalo. Ernst Beutner had been interested in fundamental aspects of autoimmunity for many years, and he was a participant in an active group of investigators put together by Witebsky, beginning in 1935.

THE OBSERVATION Thus, given a convergence among clinical responsibilities (James Jordon), basic immunologic science (Ernst Beutner), and an enterprising medical student (Robert Jordon), the researchers demonstrated by direct immunofluorescence microscopy that patients with pemphigus possessed autoantibodies directed against an epidermal intercellular substance.[8,9] Antibodies were found precisely where the pathology develops.

SUBSEQUENT STUDIES This observation was followed over the next 40 years by a series of studies identifying the molecular characteristics of such antibodies, their specific targets, and increasingly novel therapies for patients with the disease. In fact, there are too many investigators who have played important roles in extending the original observation to recognize any one in particular, although the summary of a recent conference written in 2005 by Goldsmith,[10] as well as the relevant chapters in this text, are sufficient to assign credit appropriately.

So, how does this observation conform with the rules cited previously:

- Principle 1 (core values): In 1964, the University of Buffalo was a recognized center for immunologic research. Dr. Beutner had established a highly effective laboratory; Dr. James Jordon had access to a suitable cohort of patients with the disease, and the future Dr. Robert Jordon did the major portion of the work.
- Principle 2 (people): Drs. James Jordon and Ernst Beutner included all that was necessary, once the energy and enthusiasm of Robert Jordon were harnessed.
- Principle 3 (collaboration): Even 40 years ago, this work could not have been accomplished without the collaboration cited above.
- Principle 4 (resources): This work did take time, and the time of Robert Jordon was offered without compensation. Moreover, Dr. Beutner's laboratory was appropriately funded.

TABLE 9-2
Authors, Institutions, and Countries of Origin for Manuscripts[a]

	1956 (27:1–469, 1956) (JULY THROUGH DECEMBER)	2006 (126:1429–1921) (JULY AND AUGUST)
Manuscripts (total)	46	42
Authors		
Authors/manuscript (mean)	2.2	8.1
Single-author manuscripts	14	0
Origin of manuscripts		
One institution	40	11
Two institutions (one country)	6	15
Two or more countries (two continents)	0	16 (10)

[a]Published in two volumes of the *Journal of Investigative Dermatology*, separated by 50 years.

This last example introduces a more complicated set of issues, because the disease under study is not caused by a single gene defect. Rather, the example shows that investigators must address complex diseases, such as psoriasis, atopic dermatitis, cutaneous T-cell lymphoma, and toxic epidermolytic necrolysis, in which many genes play roles. Recent progress in all of these diseases will be found in the chapters that follow, and perhaps there will be even more to say in the next edition of this book.

These examples also presage a trend toward increased collaboration across laboratories and across cities and nations. As a result, contemporary cutaneous research has become international in scope. In the three examples cited above in the sections Repair of Ultraviolet Radiation-Induced Damage: A Model of Discovery; Recessive Dystrophic Epidermolysis Bullosa and Skin Cancer: A Second Model of Discovery; and Pemphigus Vulgaris: One Observation Opens a New Field; collaboration occurred primarily within one institution. It should be noted, however, that the expertise required for cutting-edge research now often requires collaboration by investigators in more than one institution and even among investigators in more than one country. This may be seen in the *Journal of Investigative Dermatology (JID)*, which has served as one of the preferred repositories of cutaneous research results for more than 50 years. Importantly, the extent of collaboration among investigators has increased substantially over that time. Two 6-month periods separated by 50 years in the *JID* were examined (Table 9-2). The unequivocal and dramatic results make two points. First, the number of authors per paper has increased four-fold in 50 years, reflecting the increasing requirement for collaboration among investigators. Second, collaboration now includes investigators located in different institutions, sometimes in the same country (36 percent) and often in different countries (38 percent), even from different continents (24 percent). Fully one-fourth of the manuscripts in 2006 included collaborating investigators from two different continents. The countries represented in 1956 were six in number: the United States, Israel, Brazil, Hungary, Spain, and the Netherlands. By 2006, 16 countries were represented (11 in Europe, 4 in Asia, and 1 in North America). The world of science is becoming smaller.

THE FUTURE OF LABORATORY INVESTIGATION IN DERMATOLOGY

A Resurgence of Clinical Science Can Be Anticipated

Although it is likely that the pace in the development of scientific technologies will only accelerate with time, access to such technologies may not be the rate-limiting step in cutaneous research. In fact, a strong case may be made that the limiting step will be the availability of well-characterized patient populations for study.[11]

In nearly 70 years of publication, one can observe in the *JID* several transitions in emphasis, each reflecting changes in the scientific communities that it represents. In the first half of its life, clinical observation was gradually replaced by experimentation. By the 1970s, there was increasing emphasis on laboratory investigation, as was required by the cutaneous scientists who laid the foundation of scientific dermatology. Of course, this was aided by knowledge that competition among the specialties for national and international funding required excellence in the laboratory. And, since the 1980s, one can observe continuing interest in biochemistry and physiology,



with a growing interest in genetics and bioinformatics. An astounding array of genetic characterizations and identifications have been reported, however primarily for single gene "defects."

More recently, however, there has been growing emphasis on clinical investigation and clinical science. These studies have required well-characterized and uniform patient populations, and the papers reveal a trend in which cohorts of patients are required for the cutting-edge laboratory studies that are now reported in the *JID*. It is not to say that biochemistry and physiology and single-patient studies have been abandoned; rather, this has been a process of supplementation. Four examples can be cited:

1. Winter and colleagues identified a single nucleotide polymorphism changing the sequence of keratin K6HF gene, which was "required" for the expression of pseudofolliculitis barbae in African American men.[12] Their discovery began with access to a well-defined population of American servicemen in Germany.
2. Alamartine and colleagues reported that interleukin 10 promoter polymorphisms conferred susceptibility to cutaneous squamous cell carcinomas in recipients of renal transplants.[13] This discovery required access to a well-defined cohort of renal transplant patients.
3. Warren and colleagues reported that autoantibodies to desmoglein 1 of the immunoglobulin G4 subclass alone were required for the expression of endemic pemphigus foliaceus in Brazil.[14] Access to multiple sera samples from patients and control subjects in a unique region of the world was required for this work.
4. Palmer and colleagues studied the effect of solar-simulated radiation on elicitation phases of contact sensitivity (contact allergic dermatitis).[15] These investigators tested the hypothesis that patients with polymorphic light eruption are resistant to the expected suppression of contact sensitivity elicitation reactions by UVR. Importantly, their hypothesis arose from the earlier observation that patients with this disease were resistant to the UVR-induced suppression that occurs normally during sensitization. Their ultimate conclusion that mechanisms of immunologic sensitization and elicitation diverge substantially depended on the availability of patients with a unique cutaneous disorder.

Impact of Priorities Set By the National Institutes of Health

The largest source of funding for skin research in the United States is the National Institute of Arthritis and Musculoskeletal and Skin Diseases (NIAMS), 1 of 27 institutes and centers under the umbrella of the National Institutes of Health. The leaders at NIAMS published recently a "Long-Range Plan for Research" (http://www.niams.nih.gov/an/stratplan/index.htm), which is useful in examining the future of basic science approaches to the pathophysiology of skin disease. Although other institutes within the National Institutes of Health, especially the National Cancer Institute, also fund cutaneous research, because of the size of its funding, NIAMS takes the lead in setting priorities. It should be noted that reports of this sort possess substantial influence on the direction of biomedical research, including the types of laboratory science that are funded and the priorities for funding. Although the entire report should be examined, a brief summary provides considerable insight into the future. Leaders of NIAMS anticipate the following:

1. New emphasis on biologic mechanisms of disease, genetic and environmental influences, and neuroimmune and neuroendocrine pathways;
2. A search for biomarkers of skin diseases;
3. Increasing emphasis on clinical research;
4. A search for complex genetic influences on disease;
5. Interest in new animal models;
6. Emphasis on research infrastructure; and
7. Emphasis on disease-specific research.

Finally, research needs and opportunities are predicted by NIAMS to be in the disciplines of:

- Developmental and molecular biology
- Percutaneous penetration and absorption
- Wound healing
- Inflammatory and immune skin diseases
- Molecular genetics of skin diseases
- Technology research
- Drug therapies and biologic agents for skin diseases
- Gene therapies for skin diseases or gene therapies that use skin
- Regenerative medicine
- Clinical and outcomes research
- Skin disease prevention and aging skin

Cutting-edge laboratory investigation today, and for the foreseeable future, will continue to follow the principles enumerated in Table 9-1. It will most likely be conducted in academic centers with core values and resources that promote research, by people who are motivated and well trained, commonly by investigators who collaborate with others, and where financial resources are available. Finally, clinicians who care for patients will have opportunities with increasing frequency to play critical roles in patient-centered investigation. National borders have virtually disappeared in cutaneous science, as investigators collaborate often, and with whomever they believe to be appropriate. Importantly, collaboration with scientists in other countries means that there is a chance for a lively exchange of personal and cultural information; simply put, doing science can be informative and rewarding.

REFERENCES

1. Cleaver JE: Xeroderma pigmentosum: A human disease in which the initial stage of DNA repair is defective. *Proc Natl Acad Sci U S A* **63**:428, 1969
2. Epstein JH et al: Defect in DNA synthesis in skin of patients with xeroderma pigmentosum demonstrated in vivo. *Science* **168**:1477, 1970
3. Robbins JH, Moshell AN: DNA repair processes protect human beings from premature solar skin damage—Evidence from studies on xeroderma pigmentosum. *J Invest Dermatol* **73**:102, 1979
4. Marchetto MCN et al: Gene transduction in skin cells: Preventing cancer in xeroderma pigmentosum mice. *Proc Natl Acad Sci U S A* **101**:17759, 2004
5. Friedberg EC: Growth of a journal. *DNA Repair* (Amst) **4**:1, 2005
6. Yarosh D et al: Effect of topically applied T4 endonuclease V in liposomes on skin cancer in xeroderma pigmentosum: A randomised study. Xeroderma Pigmentosum Study Group. *Lancet* **357**:926, 2001
7. Ortiz-Urda S et al: Type VII collagen is required for Ras-driven human epidermal tumorigenesis. *Science* **307**:1773, 2005
8. Levene GM: The treatment of pemphigus and pemphigoid. *Clin Exp Dermatol* **7**:643, 1982
9. Beutner EH, Jordon RE: Demonstration of skin autoantibodies in sera of pemphigus vulgaris patients by indirect immunofluorescent staining. *Proc Soc Exp Biol Med* **117**:505, 1965
10. Goldsmith LA: Pemphigus: Pathogenesis, pharmacology and progress. *J Invest Dermatol* **125**:vii, 2005
11. Bergstresser PR: Resurgent clinical science (and it's all about health). *J Invest Dermatol* **124**:xvii, 2005
12. Winter H et al: An unusual Ala12Thr polymorphism in the 1A alpha-helical segment of the companion layer-specific keratin K6hf: Evidence for a risk



factor in the etiology of the common hair disorder pseudofolliculitis barbae. *J Invest Dermatol* **122**:652, 2004
13. Alamartine E et al: Interleukin-10 promoter polymorphisms and susceptibility to skin squamous cell carcinoma after renal transplantation. *J Invest Dermatol* **120**:99, 2003
14. Warren SJP et al: The role of subclass switching in the pathogenesis of endemic pemphigus foliaceus. *J Invest Dermatol* **120**:104, 2003
15. Palmer RA et al: The effect of solar-simulated radiation on the elicitation phase of contact hypersensitivity does not differ between controls and patients with polymorphic light eruption. *J Invest Dermatol* **124**:1308, 2005



This page intentionally left blank



Disorders Presenting in Skin and Mucous Membranes

Copyright © 2008 by The McGraw-Hill Companies, Inc. Click here for terms of use.



SECTION 4

INFLAMMATORY DISORDERS BASED ON T-CELL REACTIVITY AND DYSREGULATION

CHAPTER 10

Innate and Adaptive Immunity in the Skin

Robert L. Modlin
Jenny Kim
Dieter Maurer
Christine Bangert
Georg Stingl

The human immune system is comprised of two distinct functional parts: innate and adaptive. These two components have different types of recognition receptors and differ in the speed in which they respond to a potential threat to the host (Fig. 10-1). Cells of the innate immune system, including macrophages and dendritic cells (DCs), use pattern recognition receptors encoded directly by the germline DNA, respond to biochemical structures commonly shared by a variety of different pathogens, and elicit a rapid response against these pathogens, although no lasting immunity is generated. In contrast, cells of the adaptive immune system, T and B lymphocytes, bear specific antigen receptors encoded by rearranged genes, and in comparison to the innate response, adaptive immunity develops more slowly. A unique feature of the adaptive immune response is its ability to generate and retain memory; thus, it has the capability of providing a more rapid response in the event of subsequent immunologic challenge. Although the innate and adaptive immune responses are distinct, they interact and can each influence the magnitude and type of their counterpart. Together, the innate and adaptive immune systems act in synergy to defend the host against infection and cancer. This chapter describes the roles of the innate and adaptive immune response in generating host defense mechanisms in skin.

◀ Psoriasis vulgaris: chronic stable type. Multiple large scaling plaques on the trunk, arm, buttocks, and abdomen. Lesions are polycyclic and confluent and form geographic patterns. This patient was cleared by acitretin/psoralen and ultraviolet A light combination treatment within 4 weeks.

INNATE IMMUNE RESPONSE

Immune mechanisms that are used by the host to immediately defend itself are referred to as *innate immunity*. These include physical barriers such as the skin and mucosal epithelium; soluble factors such as complement, antimicrobial peptides, chemokines, and cytokines; and cells, including monocytes/macrophages, DCs, natural killer cells (NK cells), and polymorphonuclear leukocytes (PMNs) (Fig. 10-2).

Physical and Chemical Barriers[1]

Physical structures prevent most pathogens and environmental toxins from harming the host. The skin and the epithelial lining of the respiratory, gastrointestinal, and the genitourinary tracts provide physical barriers between the host and the external world. Skin, once thought to be an inert structure, plays a vital role in protecting the individual from the external environment. The epidermis impedes penetration of microbial organisms, chemical irritants, and toxins; absorbs and blocks solar and ionized radiation; and inhibits water loss (see Chap. 45).

Molecules of the Innate Immune System

COMPLEMENT[2] (See eFig. 10-2.1 in online edition; see also Chap. 36) One of the first innate defense mechanisms that

INNATE AND ADAPTIVE IMMUNITY AT A GLANCE

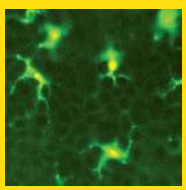

- Innate immune responses are
  - used by the host to immediately defend itself;
  - determine the quality and quantity of many adaptive immune responses;
  - are short lived;
  - have no memory;
  - include physical barriers (skin and mucosal epithelia);
  - include soluble factors such as complement, antimicrobial peptides, chemokines, and cytokines;
  - include cells such as monocytes/macrophages, dendritic cells, natural killer cells, and polymorphonuclear leukocytes.
- Adaptive immune responses
  - have memory;
  - have specificity;
  - are long-lasting;
  - in skin, are initiated by dendritic antigen-presenting cells in the epidermis (Langerhans cells) and by dermal dendritic cells;
  - are executed by T lymphocytes and antibodies produced by B lymphocytes.

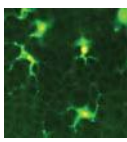

Copyright © 2008 by The McGraw-Hill Companies, Inc. Click here for terms of use.

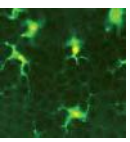

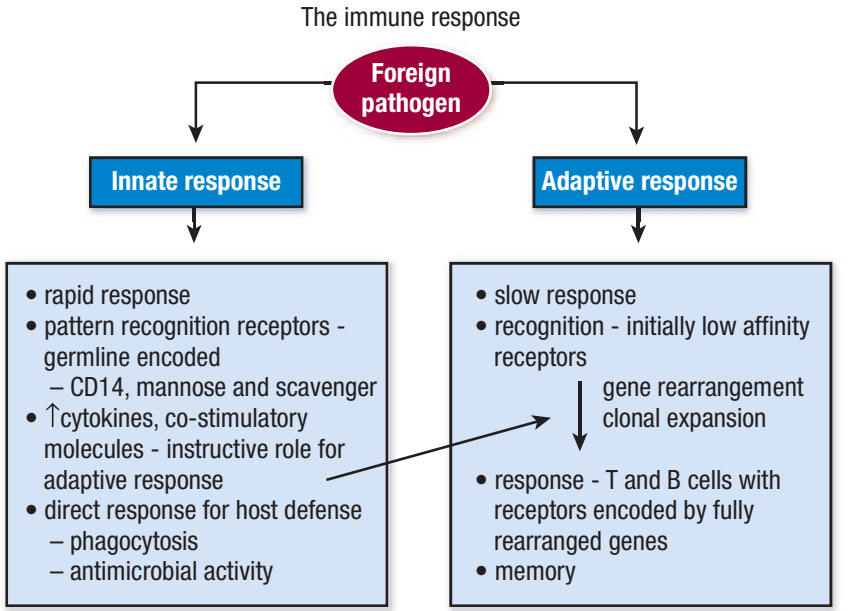

▲ **FIGURE 10-1** The immune system of higher vertebrates uses both innate and adaptive immune responses. These immune responses differ in the way they recognize foreign antigens and the speed with which they respond; yet, they complement each other in eradicating foreign pathogens.

awaits pathogens that overcome the epithelial barrier is the alternative pathway of complement. Unlike the classic complement pathway that requires antibody triggering, the lectin-dependent pathway as well as the alternative pathway of complement activation can be spontaneously activated by microbial surfaces in the absence of specific antibodies (see eFig. 10-2.1 in on-line edition). In this way, the host defense mechanism is activated immediately after encountering the pathogen without the 5 to 7 days required for antibody production.

NEUROPEPTIDES The skin is a rich source of neuropeptides, including neurotransmitters [e.g., calcitonin gene–related peptide (CGRP), substance P, somatostatin] and neurohormones (see Chap. 101). The inhibitory effects of CGRP and substance P on Langerhans cell (LC) antigen presentation function are discussed later. The neurohormone proopiomelanocortin (POMC) is produced by the pituitary gland as well as by a number of cell types, including keratinocytes.

ANTIMICROBIAL PEPTIDES[6] Antimicrobial peptides are an important evolutionarily conserved innate host defense mechanism in many organisms. Also, keratinocytes produce such peptides, including cathelicidins (LL-37) and β-defensins (BD-1, BD-2, BD-3). Their antimicrobial mechanism of action may relate to

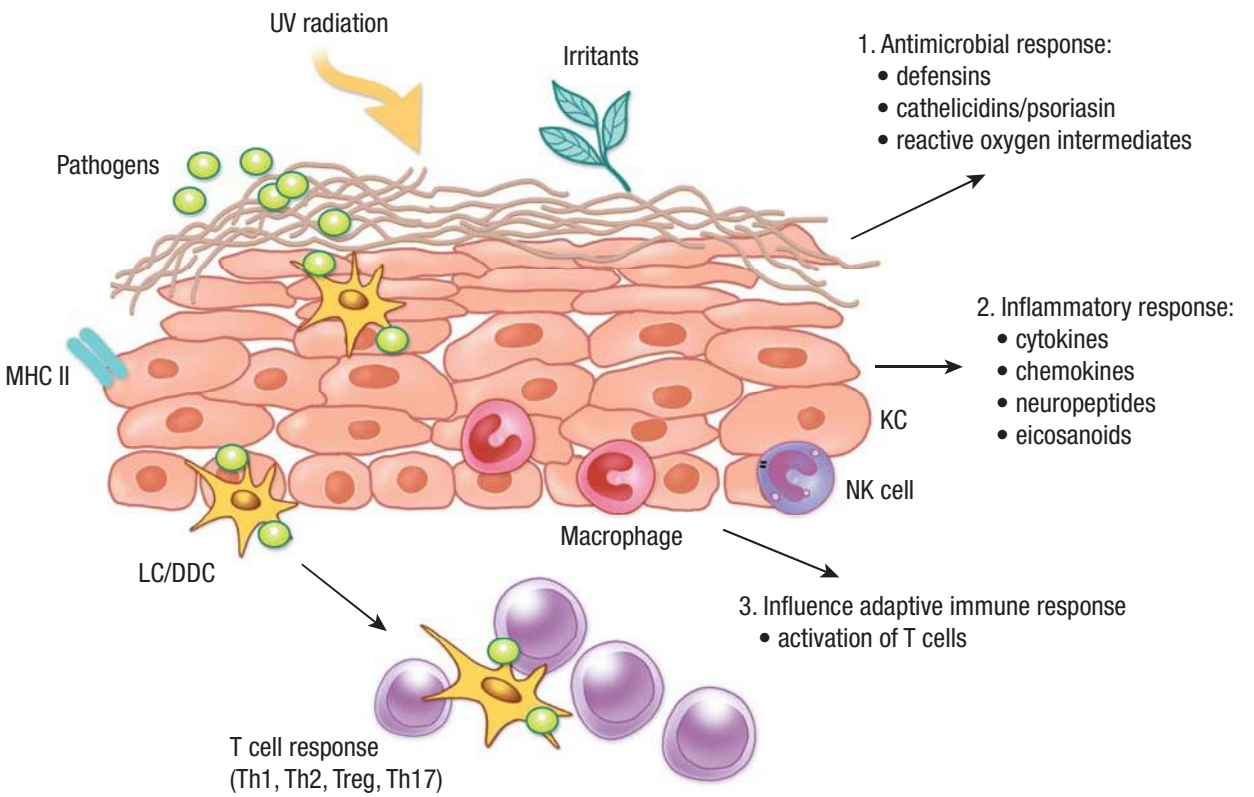

▲ **FIGURE 10-2** The innate immune response in skin. In response to exogenous factors, such as foreign pathogens, ultraviolet (UV) radiation, and chemical irritants, innate immune cells [granulocytes, mononuclear phagocytes, natural killer (NK) cells, keratinocytes] mount different types of responses including: (1) release of antimicrobial agents; (2) induction of inflammatory mediators, such as cytokines, chemokines, neuropeptides, and eicosanoids; and (3) initiation and modulation of the adaptive immune response. DDC = dermal dendritic cell; KC = keratinocyte; LC = Langerhans cell; MHC II = major histocompatibility complex class II; Th1, Th2, 17 = T helper 1, 2, Th17; Treg = T regulatory cell.

membrane insertion and pore formation. Adrenomedullin, members of the CGRP superfamily, α melanocyte-stimulating hormone, and secretory leukocyte protease inhibitor (antileukoprotease, human seminal inhibitor I) are among previously identified peptides whose antimicrobial activities were discovered later.

β-Defensins are cysteine-rich cationic low-molecular-weight antimicrobial peptides. The first human β-defensin, HBD-1, was isolated from human hemofiltrate obtained from a patient with end-stage renal disease. It is constitutively expressed in the epidermis and is not transcriptionally regulated by inflammatory agents. HBD-1 has antimicrobial activity against Gram-negative bacteria and appears to play a role in keratinocyte differentiation. A second human β-defensin, HBD-2, was discovered in extracts of lesions from psoriasis patients.[7] Unlike HBD-1 expression, HBD-2 expression is inducible by microbes, including *Pseudomonas aeruginosa*, *Staphylococcus aureus*, and *Candida albicans*.[7] Not only can microbes stimulate expression of HBD-2, but pro-inflammatory cytokines such as tumor necrosis factor-α (TNF-α) and interleukin 1 (IL-1) can also induce HBD-2 transcription in keratinocytes.[7] When tested for antimicrobial activity, HBD-2 showed effective activity against Gram-negative bacteria such as *Escherichia coli* and *P. aeruginosa* but not against Gram-positive bacteria such as *S. aureus*.[7] A third β-defensin, HBD-3, has now been isolated and characterized. Contact with TNF-α and with bacteria was found to induce HBD-3 messenger RNA expression in keratinocytes. In addition, HBD-3 demonstrated potent antimicrobial activity against *S. aureus* and vancomycin-resistant *Enterococcus faecium*. Therefore, HBD-3 is among the first human β-defensins in skin to demonstrate effective antimicrobial activity against Gram-positive bacteria. The localization of human β-defensins to the outer layer of the skin and the fact the β-defensins have antimicrobial activity against a variety of microbes suggest that human β-defensins are an essential part of cutaneous innate immunity. Furthermore, evidence indicating that human β-defensins attract DCs and memory T cells via CC chemokine receptor 6 (CCR6)[8] provides a link between the innate and the adaptive immunity in skin.

Cathelicidins are cationic peptides with a structurally variable antimicrobial domain at the C-terminus. Whereas in mammals like pigs or cattle a variety of cathelicidin genes exists, men (and mice) possess only one gene. The human precursor protein hCAP18 (human cathelicidin antimicrobial protein 18) is produced by skin cells, including keratinocytes, mast cells, neutrophils, and ductal cells of eccrine glands. Neutrophil proteases (i.e., proteinase 3) process hCAP18 into the effector molecule LL-37, which plays an important role in cutaneous host defense because of its pronounced antibacterial,[9,10] antifungal,[11] and antiviral[12,13] activities. LL-37 further contributes to innate immunity by attracting mast cells and neutrophils via formyl peptide receptor–like 1 and by inducing mediator release from the latter cells via a G protein–dependent, immunoglobulin E (IgE)–independent mechanism.[14] It has now been shown that LL-37 is secreted into human sweat, where it is cleaved by a serine protease–dependent mechanism into its peptides RK-31 or KS-30. Interestingly, these components display an even more potent antimicrobial activity than intact LL-37.[15]

In atopic dermatitis (see Chap. 14), LL-37 is downregulated, probably due to the effect of the T2 cytokines IL-4 and IL-13, which renders atopic skin more susceptible to skin infections with, for example, *S. aureus*, vaccinia virus (eczema vaccinatum), or herpes simplex virus (eczema herpeticum).[10,12,13]

Another important human antimicrobial peptide has now been identified, psoriasin (S100A7).[16] It is secreted predominantly by keratinocytes and plays a major role in killing the common gut bacterium *E. coli*. In fact, in vivo treatment of human skin with anti-psoriasin antibodies results in the massive growth of *E. coli*.[16]

OTHER MEDIATORS Other secreted protein mediators that can be synthesized and released from keratinocytes and that may play a role in host defense are the complement components C3 and factor B. Keratinocytes are among the cells that synthesize eicosanoids, an ensemble of lipid mediators regulating inflammatory and immunologic reactions. They can produce and release the cyclooxygenase product prostaglandin E_2, which has both pro-inflammatory and immunosuppressive properties and, when acting on DCs, promotes the development of IL-4–dominated type 2 T-cell responses.[17] Other keratinocyte-derived eicosanoids include the neutrophil chemoattractant leukotriene B_4, the pro-inflammatory 12-lipoxygenase product 12(s)-hydroxyeicosatetraenoic acid, and 15-hydroxyeicosatetraenoic acid, an anti-inflammatory and immunosuppressive metabolite of the 15-lipoxygenase pathway.

Another group of biologic response modifiers originating in keratinocytes and other epidermal cells is free radical molecules, now generally referred to as *reactive oxygen species*. These include the superoxide radical ($O_2^{\cdot -}$), hydrogen peroxide (H_2O_2), the hydroxyl radical ($OH^{\cdot}$), nitric oxide (NO), and others. These radicals are generally viewed as dangerously reactive entities threatening the integrity of many tissues. The skin is particularly at risk because it is exposed to oxygen from both inside and outside and because of the activation of oxygen by light (see Chaps. 88 and 89). Free radicals probably contribute to solar damage and photoaging of the skin. However, certain reactive oxygen species have potent inflammation-inducing properties (e.g., free oxygen radicals) as well as immunomodulatory properties (e.g., NO), and thus provide an important host defense mechanism against microbial invasion. For discussion of these molecules, the reader is referred to the review by Bickers and Athar.[18]

PATTERN RECOGNITION RECEPTORS How do the cells of the innate immune system recognize foreign pathogens? One way that pathogens can be recognized and destroyed by the innate immune system is via receptors on phagocytic cells. Unlike adaptive immunity, the innate immune response relies on a relatively small set of germline-encoded receptors that recognize conserved molecular patterns that are shared by a large group of pathogens. These are usually molecular structures required for survival of the microbes and therefore are not subject to selective pressure. In addition, pathogen-associated molecular patterns are specific to microbes and are not expressed in the host system. Therefore, the innate immune system has mastered a clever way to distinguish between self and nonself and relays this message to the adaptive immune system.

Of key importance was the discovery of the Toll-like receptors (TLRs), named after the *Drosophila* Toll gene whose protein product, Toll, participates in innate immunity and in dorsoventral development in the fruit fly.[19,20] The importance of Toll signaling in mammalian cells was confirmed by the demonstration that the transmembrane leucine-rich protein TLR4 is involved in lipopolysaccharide (LPS) recognition.[21]

In addition to TLRs, there exist a variety of other transmembrane molecules

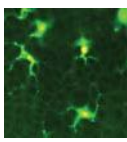

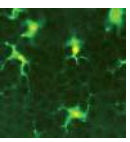

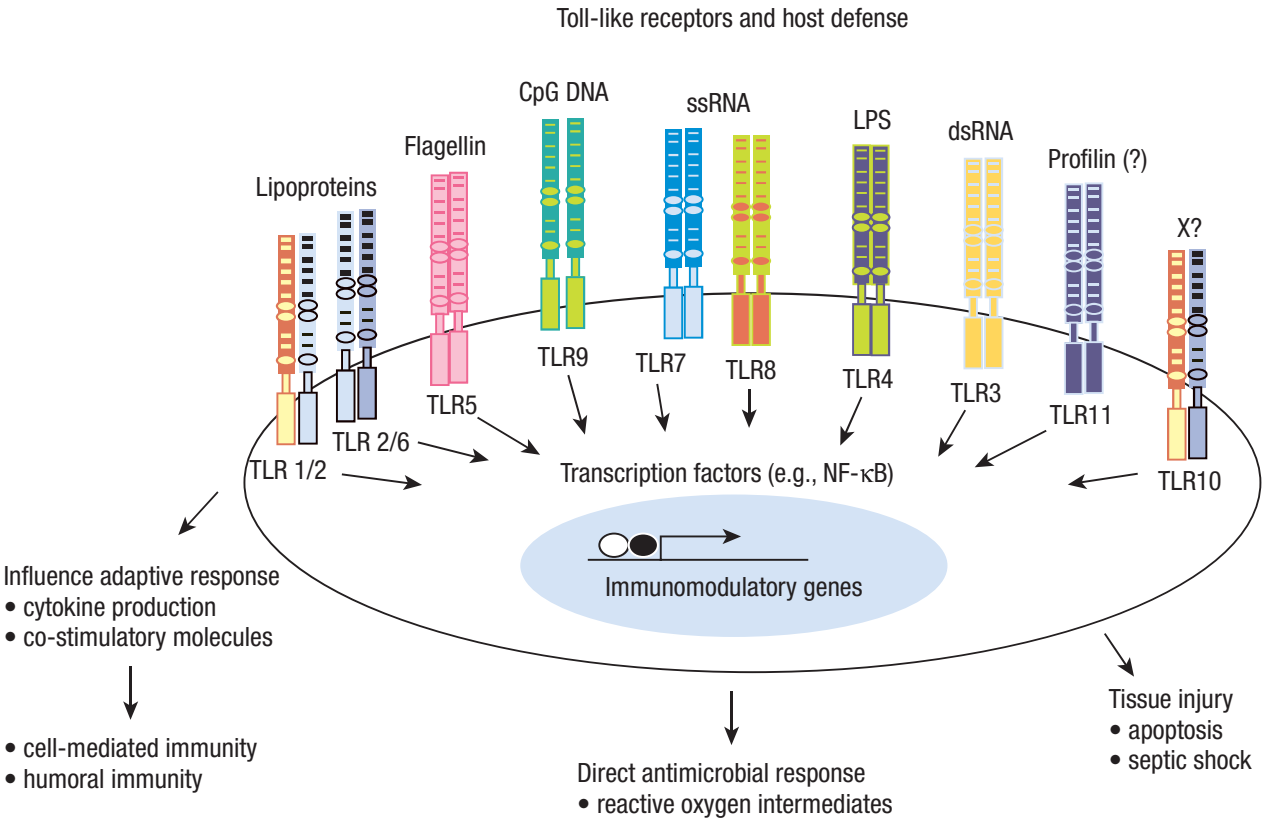

▲ **FIGURE 10-3** Toll-like receptors (TLRs) mediate innate immune response in host defense. Activation of TLRs by specific ligands induces (1) cytokine release and co-stimulatory molecules that instruct the type of adaptive immune response; (2) direct antimicrobial response; and (3) tissue injury. CpG DNA = immunostimulatory cytosine- and guanine-rich sequences of DNA; dsRNA = double-stranded RNA; LPS = lipopolysaccharide; NF-κB = nuclear factor κB; ssRNA = single-stranded RNA; X = ligand unknown.

that sense the presence of pathogens. These include the triggering receptors expressed on myeloid cells (TREM) proteins,[25] the family of Siglec molecules,[26] and a group of C-type lectin receptors.[27] The latter are prominently expressed on antigen-presenting cells (APCs) as, for instance, dectin-1 and DC-SIGN [DC-specific intercellular adhesion molecule 3 (ICAM-3) grabbing nonintegrin]. They are able to mediate efficient binding of microorganisms such as yeast and mycobacteria, respectively; achieve their phagocytosis; and induce activation of signaling pathways that result in the maturation of phagosomes as well as in the production of reactive oxygen and nitrogen derivatives.

Members of the TREM protein family function as amplifiers of innate responses. Extreme examples of the consequences of microbe activation of TREM proteins are life-threatening septicemia and the deadly hemorrhagic fevers caused by Marburg and Ebola virus infection.[28]

TOLL-LIKE RECEPTORS[29] There is now substantial evidence to support a role for mammalian TLRs in innate immunity (Fig. 10-3). First, TLRs recognize pathogen-associated molecular patterns present in a variety of bacteria, fungi, and viruses. Second, TLRs are expressed at sites that are exposed to microbial threats. Third, the activation of TLRs induces signaling pathways that, on the one hand, stimulate the production of effector molecules (reactive oxygen species, NO), and, on the other, promote the expression of co-stimulatory molecules and the release of cytokines and, as a result, the augmentation of the adaptive response. Fourth, TLRs directly activate host defense mechanisms that then combat the foreign invader.

TLRs were initially found to be expressed in all lymphoid tissues but were most highly expressed in peripheral blood leukocytes, including monocytes, B cells, T cells, granulocytes, and DCs. Certain TLRs (e.g., TLR2) are internalized after ligation. In such a situation, TLRs are recruited to the pathogen-containing phagosomes and discriminate between Gram-positive and Gram-negative bacteria,[31] thus surveying the intracellular compartments of the cells for microbial invaders.

The expression of TLRs on cells of the monocyte/macrophage lineage is consistent with the role of TLRs in modulating inflammatory responses via cytokine release. Because these cells migrate into sites that interface with the environment—lung, skin, and gut—the location of TLR-expressing cells would situate them to defend against invading microbes. TLR expression by adipocytes, intestinal epithelial cells, and dermal endothelial cells supports the notion that TLRs serve a sentinel role with regard to invading microorganisms. The regulation of TLR expression is critical to their role in host defense, yet few factors have been identified that modulate this process. IL-4 acts to downregulate TLR expression,[32] which suggests that T helper 2 (Th2) adaptive immune responses might inhibit TLR activation.

In *Drosophila*, Toll is critical for host defense. The susceptibility of mice with spontaneous mutations in TLRs to bacterial infection indicates that mammalian TLRs play a similar role. Activation of TLR2 by microbial lipoproteins induces activation of the inducible NO synthase (NOS-II or iNOS) promoter,[37] which leads to the production of NO, a known antimicrobial agent. There is strong evidence that TLR2 activation

leads to killing of intracellular *Mycobacterium tuberculosis* in both mouse and human macrophages.[38] In mouse macrophages, bacterial lipoprotein activation of TLR2 leads to a NO-dependent killing of intracellular tubercle bacilli. In human monocytes and alveolar macrophages, bacterial lipoproteins similarly activate TLR2 to kill intracellular *M. tuberculosis*; however, this occurs by an antimicrobial pathway that is NO independent, but dependent on the activation of the vitamin D receptor and potentially the induction of cathelicidin.[39] These data provide evidence that mammalian TLRs have retained not only the structural features of *Drosophila* Toll that allow them to respond to microbial ligands but also the ability to directly activate antimicrobial effector pathways at the site of infection.

The activation of TLRs can also be detrimental, leading to tissue injury. The administration of LPS to mice can result in manifestations of septic shock, which is dependent on TLR4.[21] Evidence suggests that TLR2 activation by *Propionibacterium acnes* induces inflammatory responses in acne vulgaris, which lead to tissue injury.[40] Aliprantis et al. demonstrated that microbial lipoproteins induce features of apoptosis via TLR2.[41] Thus, microbial lipoproteins have the ability to elicit both TLR-dependent activation of host defense and tissue pathology. This dual signaling pathway is similar to TNF receptor and CD40 signaling, which leads to both nuclear factor-κB activation and apoptosis.[42,43] In this manner, it is possible for the immune system to use the same molecules to activate host defense mechanisms and then, by apoptosis, to downregulate the response from causing tissue injury. Activation of TLR can lead to the inhibition of the major histocompatibility complex (MHC) class II antigen presentation pathway, which can downregulate immune responses leading to tissue injury but may also contribute to immunosuppression.[44] Finally, Toll activation has been implicated in bone destruction.[35]

The critical biologic role of TLRs in human host defense can be deduced from the finding that TLR4 mutations are associated with LPS hypo-responsiveness in humans.[45] By inference, one can anticipate that humans with genetic alterations in TLR may have increased susceptibility to certain microbial infections. Furthermore, it should be possible to exploit the pathway of TLR activation as a means to endorse immune responses in vaccines and treatments for infectious diseases as well as to abrogate responses detrimental to the host.

Cells of the Innate Immune System

PHAGOCYTES Two key cells of the innate immune system are characterized by their phagocytic function: macrophages and PMNs. These cells have the capacity to take up pathogens, recognize them, and destroy them. Some of the functions of these cells are regulated via TLRs and complement receptors as outlined earlier.

PMNs are normally not present in skin; however, during inflammatory processes, these cells migrate to the site of infection and inflammation, where they are the earliest phagocytic cells to be recruited. These cells have receptors that recognize pathogens directly (see Pattern Recognition Receptors), and due to their expression of FcγRIII/CD16 and C3bR/CD35, can phagocytose microbes coated with antibody and with the complement component C3b. As a consequence, granules (containing myeloperoxidase, elastase, lactoferrin, collagenase, and other enzymes) are released, and microbicidal superoxide radicals (O_2^-) are generated (see Chap. 30).

Effector Functions of Phagocytes. Activation of phagocytes by pathogens induces several important effector mechanisms, for example, triggering of cytokine production. A number of important cytokines are secreted by macrophages in response to microbes, including IL-1, IL-6, TNF-α, IL-8, IL-12, and IL-10. IL-1, IL-6, and TNF-α play a critical role in inducing the acute-phase response in the liver and in inducing fever for effective host defense. TNF-α induces a potent inflammatory response to contain infection. IL-8 is important as a mediator of PMN chemotaxis to the site of infection (see also Chap. 11 on cytokines).

Another important defense mechanism triggered in phagocytes in response to pathogens is the induction of direct antimicrobial responses. Phagocytic cells such as PMNs and macrophages recognize pathogens, engulf them, and induce antimicrobial effector mechanisms to kill the pathogens. PMNs generate oxygen-dependent or oxygen-independent killing. The release of toxic oxygen radicals, lysosomal enzymes, and antimicrobial peptides such as the human neutrophil defensins leads to direct killing of the microbial organisms.[6] Similarly, activation of TLRs on macrophages by microbial ligands upregulates iNOS (NOS-II), which results in rapid generation of NO and powerful microbicidal activity.[37] Macrophages use this mechanism to contain some infectious organisms not susceptible to PMN attack, such as mycobacteria, certain fungi, and parasites.

Phagocytic cells of the innate immune system can also be activated by cells of the adaptive immune system. CD40 is a 50-kd glycoprotein present on the surface of B cells, monocytes, DCs, and endothelial cells. The ligand for CD40 is CD40L, a type II membrane protein of 33 kd, preferentially expressed on activated $CD4^+$ T cells and mast cells. CD40-CD40L interaction plays a crucial role in the development of effector functions. $CD4^+$ T cells activate macrophages and monocytes to produce TNF-α, IL-1, IL-12, interferon-γ (IFN-γ), and NO via CD40-CD40L interaction. CD40L has also been shown to rescue circulating monocytes from apoptotic death, thus prolonging their survival at the site of inflammation. In addition, CD40-CD40L interaction during T-cell activation by APCs results in IL-12 production. Therefore, it can be concluded that CD40-CD40L interactions between T cells and macrophages play a role in maintenance of Th1-type cellular responses and mediation of inflammatory responses. Other studies have established a role for CD40-CD40L interactions in B-cell activation, differentiation, and Ig class switching.[55] In addition, CD40-CD40L interaction leads to upregulation of B7.1 (CD80) and B7.2 (CD86) on B cells. This co-stimulatory activity induced on B cells then acts to amplify the response of T cells. These mechanisms underscore the importance of the interplay between the innate and the adaptive immune system in generating an effective host response.

EOSINOPHILS (See Chap. 30) Eosinophils are a distinct class of bone marrow–derived granulocytes that normally constitute only a small fraction of peripheral blood leukocytes and occur in even smaller numbers in peripheral tissues. The cytokines granulocyte-macrophage colony-stimulating factor (GM-CSF), IL-3 and, most importantly, IL-5 are critical for their development and maturation.

NATURAL KILLER CELLS[58] NK cells appear as large granular lymphocytes. In humans, the vast majority of these cells exhibit the $CD3^-$, $CD56^+$, $CD16^+$, $CD94^+$, $CD161^+$ phenotype. Their function is to

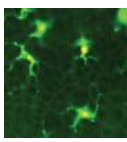

survey the body looking for altered cells, be they transformed or infected with viruses (e.g., cytomegalovirus), bacteria (e.g., *Listeria monocytogenes*), or parasites (e.g., *Toxoplasma gondii*). These pathogens are then killed directly via perforin/granzyme- or Fas/FasL-dependent mechanisms or indirectly via the secretion of cytokines (e.g., IFN-γ).

How do NK cells discriminate between normal and transformed or pathogen-infected tissue?

All nucleated cells express the MHC class I molecules. NK cells have receptors, termed *killer inhibitory receptors*, that recognize the self MHC class I molecules. This recognition results in the delivery of a negative signal to the NK cell that paralyzes it. If a nucleated cell loses expression of its MHC class I molecules, however, as often happens after malignant transformation or virus infection, the NK cell, on encountering it, will become activated and kill it.

In addition, NK cells have activating receptors that bind MHC-like ligands on target cells. One such receptor is NKGD2, which binds to the human non-classic MHC class I chain-related A and B molecules, MICA and MICB.[59] MICA and MICB are not expressed in substantial amounts on normal tissues but are overexpressed on carcinomas.[60] NK cells are able to kill MICA/MICB-bearing tumors, which suggests a role for NKGD2 in immune surveillance.

Another cell type that, at least in mice, could serve a similar function is the IFN-producing killer DC, which shares several features with DCs and NK cells.[61,62] Their human equivalent has yet to be identified.

KERATINOCYTES Once thought to be inert, keratinocytes, the predominant cells in the epidermis, can mount an immune and/or inflammatory response through secretion of cytokines and chemokines, arachidonic acid metabolites, complement components, and antimicrobial peptides.

Keratinocytes of unperturbed skin produce only a few of these mediators, such as the cytokines IL-1, IL-7, and transforming growth factor-β (TGF-β), constitutively. Resident keratinocytes contain large quantities of pre-formed and biologically active IL-1α as well as immature IL-1β in their cytoplasm.[63] The likely in vivo role of this stored intracellular IL-1 is that of an immediate initiator of inflammatory and repair processes after epidermal injury. IL-7 is an important lymphocyte growth factor that may have a role in the survival and proliferation of the T lymphocytes of human skin. Some evidence exists for the IL-7–driven propagation of lymphoma cells in Sézary syndrome.

TGF-β, in addition to its growth-regulating effects on keratinocytes and fibroblasts, modulates the inflammatory as well as the immune response[64] and is important for LC development (see further in Development, Maintenance, and Fate of Skin Dendritic Cells under Langerhans Cells and Other Dendritic Cells).[65] On delivery of certain noxious, or at least potentially hazardous, stimuli (e.g., hypoxia, trauma, non-ionizing radiation, haptens or other rapidly reactive chemicals like poison ivy catechols, silica, LPSs, and microbial toxins), the production and/or release of many cytokines is often dramatically enhanced. The biologic consequences of this event are manifold and include the initiation of inflammation (IL-1, TNF-α, IL-6, members of the chemokine family), the modulation of LC phenotype and function (IL-1, GM-CSF, TNF-α, IL-10, IL-15), T-cell activation (IL-15, IL-18),[66,67] T-cell inhibition (IL-10, TGF-β),[68] and skewing of the lymphocytic response in either the type 1 (IL-12, IL-18),[69] type 2 (thymic stromal lymphopoietin),[70] or Th17 (IL-23) direction.[71] In some cases, keratinocytes may also play a role in amplifying inflammatory signals in the epidermis originating from numerically minor epidermal cell subsets. One prominent example is the induction of pro-inflammatory cytokines such as TNF-α in keratinocytes by LC-derived IL-1β in the initiation phase of allergic contact dermatitis.[72] In the presence of a robust stimulus, keratinocyte-derived cytokines may be released into the circulation in quantities that cause systemic effects. During a severe sunburn reaction, for example, serum levels of IL-1, IL-6, and TNF-α are clearly elevated and probably responsible for the systemic manifestations of this reaction, such as fever, leukocytosis, and the production of acute-phase proteins.[73] There is also evidence that the ultraviolet (UV) radiation–inducible cytokines IL-6 and IL-10 can induce the production of autoantibodies and thus be involved in the exacerbation of autoimmune diseases such as lupus erythematosus. The fact that secreted products of keratinocytes can reach the circulation could conceivably also be used for therapeutic purposes. The demonstration by Fenjves et al.[74] that grafting of apolipoprotein E gene–transfected human keratinocytes onto mice results in the detection of apolipoprotein E in the circulation of the mouse supports the feasibility of such an approach.

Another important function of keratinocytes is the production/secretion of factors governing the influx and efflux of leukocytes into and out of the skin. Two good examples are the chemokines thymus and activation-regulated chemokine (TARC; CC chemokine ligand 17, or CCL17) and cutaneous T cell–attracting chemokine (CTACK)/CCL27 and their corresponding receptors CCR4 and CCR10, selectively expressed on skin-homing T lymphocytes. Blocking of both chemokines drastically inhibits the migration of T cells to the skin in a murine model of contact hypersensitivity (CHS).[75] Another more distinct function of a keratinocyte-derived chemokine in the recruitment of leukocyte sub-populations to the epidermis is suggested by the selective expression of the macrophage inflammatory protein 3α (MIP-3α)/CCL20 receptor, CCR6, on LCs and LC precursors[76] (see Development, Maintenance, and Fate of Skin Dendritic Cells and T Lymphocyte Sub-Populations).

The demonstration of cytokine receptors on and cytokine responsiveness by keratinocytes established that the functional properties of these cells can be subject to regulation by cells of the immune system. As a consequence, keratinocytes express or are induced to express immunologically relevant surface moieties that can be targeted by leukocytes for stimulatory or inhibitory signal transduction.

In addition to cytokines, keratinocytes secrete other factors such as neuropeptides, eicosanoids, and reactive oxygen species. These mediators have potent inflammatory and immunomodulatory properties and play an important role in the pathogenesis of cutaneous inflammatory and infectious diseases as well as in aging.

Keratinocytes can also synthesize complement and related receptors, including the C3b receptor [complement receptor 1 (CR1), CD35], the Epstein-Barr virus receptor CR2 (C3d receptor, CD21), the C5a receptor (CD88), the membrane co-factor protein (CD46), the decay-accelerating factor (CD55), and complement protectin (CD59). CD59 may protect keratinocytes from attack by complement. Its engagement by CD2 stimulates the secretion of pro-inflammatory cytokines from keratinocytes. Membrane co-factor (CD46) is reported to be a receptor for M protein of group A streptococci and for measles virus.[80] Its ligation induces pro-inflammatory cytokines in keratinocytes such as IL-1α, IL-6, and GM-CSF.

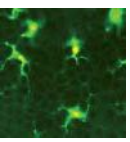

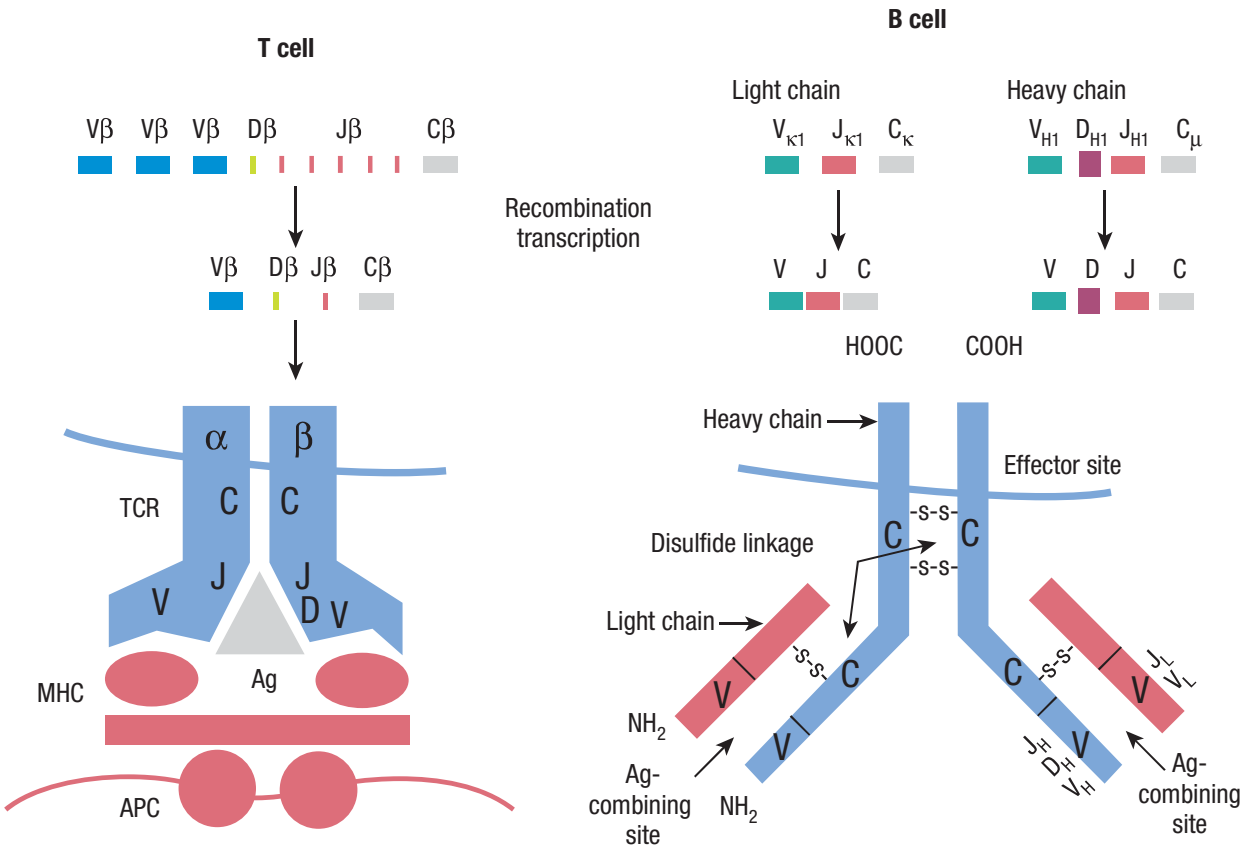

▲ **FIGURE 10-4** T-cell receptor (TCR) gene rearrangements. This diagram shows how diversity in TCRs and antibodies is generated by gene rearrangement. For the TCR, rearrangement of the β chain is shown, and for antibodies, that of immunoglobulin M heavy and light chains is depicted. The encoded antibody recognizes the nominal antigen per se, whereas the encoded TCR recognizes antigen in the context of an appropriate antigen-presenting molecule. Ag = antigen; APC = antigen-presenting cell; C = constant segment; D = diversity segment; J = joining segment; MHC = major histocompatibility complex; V = variable segment.

ADAPTIVE IMMUNE RESPONSE

The strength and the type of the innate response determines both the quantity and quality of an adaptive response initiated by dendritic APCs in the epidermis (LCs) and dermis (dermal DCs or DDCs) and executed by T lymphocytes and antibodies.

Lymphocytes

The adaptive immune response is mediated by T and B lymphocytes. The unique role of these cells is the ability to recognize antigenic specificities in all their diversity. All lymphocytes derive from a common bone marrow stem cell. This finding has been exploited in various clinical settings, with attempts to restore the entire lymphocyte pool by bone marrow or stem cell transplantation.

TYPES OF LYMPHOCYTES B cells mature in the fetal liver and adult bone marrow. They produce antibodies—protein complexes that bind specifically to particular molecules defined as antigens. As a consequence of recombinatorial events in different Ig gene segments (V or variable; D or diversity; J or joining), each B cell produces a different antibody molecule (Fig. 10-4). Some of this antibody is present on the surface of the B cell, conferring the unique ability of that B cell to recognize a specific antigen. B cells then differentiate into plasma cells, the actual antibody-producing and -secreting cells. The secreted antibody mediates humoral immune responses. In skin, humoral immunity contributes to the immune defense against extracellular pathogens. Antibodies bind to microbial agents and neutralize them or facilitate uptake of the pathogen by phagocytes that destroy them. Antibodies are also responsible for mediating certain pathologic conditions in skin. In particular, antibodies against self-antigens lead to autoimmune disease, typified in the pathogenesis of pemphigus and bullous pemphigoid. Furthermore, IgE antibodies to foreign substances elicit anaphylactic reactions (e.g., penicillin urticaria).

T cells mature in the thymus, where they are selected to live or to die. Those T cells that will have the capacity to recognize foreign antigens are positively selected and can enter the circulation. Those T cells that react to self are negatively selected and destroyed. If the immune system is envisioned as a bureaucracy, the T cell is the ideal bureaucrat. T cells have the unique ability to direct other cells of the immune system. They do this, in part, by releasing cytokines. For example, T cells contribute to cell-mediated immunity (CMI), required to eliminate intracellular pathogens, by releasing cytokines that activate macrophages and other T cells. T cells release cytokines that activate NK cells and also release cytokines that permit the growth, differentiation, and activation of B cells.

During their maturation in the thymus, thymocytes start to express the molecules that allow T cells to display their unique functional capacity, that is, to specifically recognize antigen in an MHC-restricted fashion (see General Principles of Antigen Presentation). These are the T-cell antigen receptor (TCR) and the accessory molecules CD4 and CD8. The vast majority of positively selected mature thymocytes are either $CD4^+/CD8^-$ (single positive) MHC class II–restricted cells or $CD8^+/$

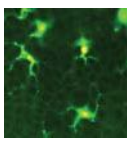

CD4⁻ (single positive) MHC class I–restricted cells, but some of them express the TCR but no accessory molecules (double-negative thymocytes). These mature thymocytes leave the thymus and migrate to the peripheral lymphoid tissues (lymph nodes, spleen, Peyer's patches, etc.). This process is most active in early infancy and childhood but continues with decreasing output well into adult life.

The TCR is a complex of molecules consisting of an antigen-binding heterodimer (α/β or γ/δ chains) that is noncovalently linked with five CD3 subunits (γ, δ, ε, ζ/η). TCR α/β or TCR γ/δ molecules must be paired with CD3 molecules to be inserted into the T-cell surface membrane[81] (see Fig. 10-4).

The TCR chains form the actual antigen-binding unit, whereas the CD3 complex mediates signal transduction, which results in either productive activation or nonproductive silencing of the T lymphocyte.

The TCR chains have amino acid sequence homology with and structural similarities to Ig heavy and light chains. The genes encoding TCR molecules are encoded as clusters of gene segments (V, J, D, C or constant) that rearrange during T-cell maturation. Together with the addition of nucleotides at the junction of rearranged gene segments, this recombinatorial process, which involves the enzymes recombinase activating gene 1 and 2, results in a heterogeneity and diversity of the antigen recognition unit that is broad enough to allow for a successful host defense.

The accessory molecules CD4 and CD8 stabilize the interaction of the TCR with the MHC-linked peptide antigen. Although CD4 binds to MHC class II molecules, CD8 acts as an adhesive by binding to MHC class I molecules.

T-LYMPHOCYTE SUB-POPULATIONS T cells can be classified and subdivided in different ways: (1) on the basis of the accessory molecules CD4 and CD8, (2) on the basis of their activation status (naive, memory, effector T cells), and (3) on the basis of their functional role in the immune response, which is often linked to the cytokine secretion property of the respective cell population.

As far as the activation status of T cells is concerned, it appears that the strength of the antigenic signal also determines the ultimate fate of a naive T cell. On robust activation, these cells differentiate into effector cells, which are then selected to enter the memory pool according to their capacity to access and use survival signals. Effector-memory cells home to peripheral tissues and are responsible for immediate protection against challenge. CCR7⁺ central-memory cells, on the other hand, home to secondary lymphoid organs and are responsible for secondary or long-term responses to antigen and might be involved in long-term maintenance of effector-memory cells.[82]

With regard to the functional capacities of various T-cell subsets, it was originally assumed that CD4⁺ cells predominantly subserve helper functions and that CD8⁺ cells act as killer cells. Many exceptions to this rule are now known to exist; for example, both CD4⁺ and CD8⁺ regulatory cells are found, but CD4⁺ cells are still commonly referred to as helper T cells (Th cells) and CD8⁺ cells as cytotoxic T cells.

Naive Th cells, so-called *Th0 cells*, can differentiate into several functional classes of cells during an immune response: (1) Th1 cells (type 1 T cells); (2) Th2 cells (type 2 T cells); (3) Th17 cells; (4) regulatory T cells (Treg); and (5) natural killer T cells (NKT).

T HELPER 1/T HELPER 2 PARADIGM T cells that produce IL-2, IFN-γ, and TNF are termed *Th1 cells*. They are the main carriers of CMI. Other T cells produce IL-4, IL-5, IL-6, IL-13, and IL-15. These are termed *Th2 cells* and are primarily responsible for extracellular immunity (see later).[83,84] Many factors influence whether an uncommitted Th cell develops into a mature Th1 or Th2 cell. The cytokines IL-12 and IL-4, acting through signal transducer and activator of transcription (STAT) 4 and 6, respectively, are key determinants of the outcome, as are antigen dose, level of co-stimulation, and genetic modifiers. Certain transcription factors have causal roles in the gene-expression programs of Th1 and Th2 cells. For example, the T-box transcription factor T-bet is centrally involved in Th1 development, inducing both transcriptional competence of the IFN-γ locus and selective responsiveness to the growth factor IL-12.[85] By contrast, the zinc-finger transcription factor GATA-3 seems to be crucial for inducing certain key attributes of Th2 cells, such as the transcriptional competence of the Th2 cytokine cluster, which includes the genes encoding IL-4, IL-5, and IL-13.[86,87]

In murine models of intracellular infection, resistant versus susceptible immune responses appear to be regulated by these two T-cell sub-populations.[50,51,88] Th1 cells, primarily by the release of IFN-γ, activate macrophages to kill or inhibit the growth of the pathogen and trigger cytotoxic T-cell responses, which results in mild or self-curing disease. In contrast, Th2 cells facilitate humoral responses and inhibit some cell-mediated immune responses, which results in progressive infection. These cytokine patterns are cross-regulatory. The Th1 cytokine IFN-γ downregulates Th2 responses. The Th2 cytokines IL-4 and IL-10 downregulate both Th1 responses and macrophage function. The result is that the host responds in an efficient manner to a given pathogen by making either a Th1 or Th2 response. Sometimes the host chooses an inappropriate cytokine pattern, which results in clinical disease.

The discovery that Th1/Th2 responses could contribute to the outcome of human disease due to a single antigen was first delineated by the study of leprosy. Because leprosy presents as a spectrum of clinical manifestations that correlate with the immune response to the pathogen, it provides an extraordinary window into immune regulation in humans. At one end of the spectrum, patients with tuberculoid leprosy typify the resistant response that restricts the growth of the pathogen. The number of lesions is few, although tissue and nerve damage is frequent. At the opposite end of this spectrum, patients with lepromatous leprosy represent extreme susceptibility to *M. leprae* infection. In lepromatous leprosy, the skin lesions are numerous and growth of the pathogen is unabated, which results in many viable *M. leprae* throughout the skin lesions. These clinical presentations correlate with the level of CMI against *M. leprae*. The standard measure of CMI to the pathogen is the Mitsuda reaction. Patients are challenged by intradermal injection of *M. leprae*, and induration is measured 3 weeks later. The test result is positive in tuberculoid patients and negative in lepromatous patients. It is widely agreed that T cells involved in CMI are pivotal in determining the outcome of infection with *M. leprae*, because, in correlation with skin test results, lymphocyte reactivity is positive in tuberculoid patients but is negative in lepromatous patients. Yet, there is an interesting paradox in that CMI and humoral responses exhibit an inverse relationship. Anti–*M. leprae* antibody levels are most elevated

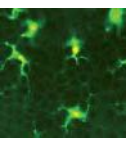

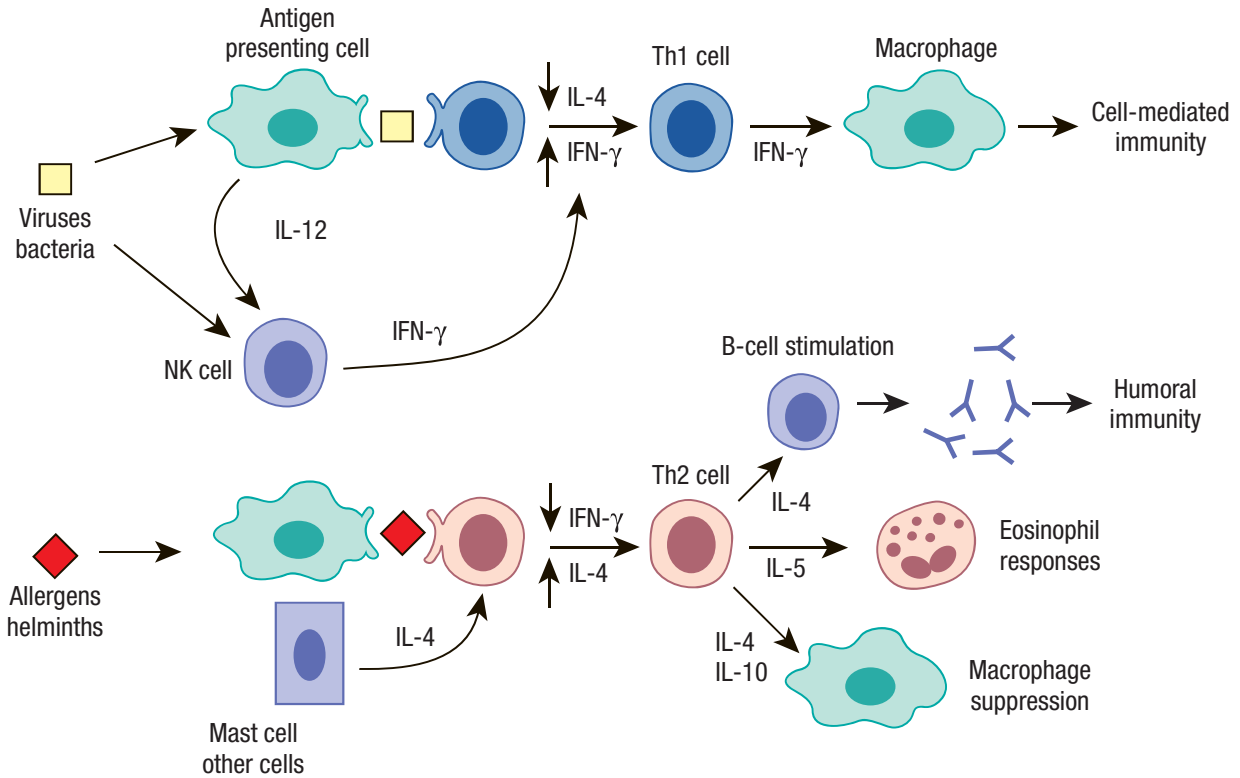

▲ **FIGURE 10-5** The role of innate immunity in determining the type of cytokine response. IFN = interferon; IL = interleukin; NK = natural killer; Th1, Th2 = T helper 1, 2.

in patients with the lepromatous form of the disease and therefore are not thought to play a role in protection.

This paradox can best be explained in terms of the patterns of cytokines in the lesions.[52,89] The Th1 cytokines, principally, IL-2 and IFN-γ, are more strongly expressed in tuberculoid lesions, whereas the Th2 cytokines, notably IL-4, IL-5, and IL-10, are characteristic of lepromatous lesions. These cytokine patterns can be assigned to the major T-cell subsets observed in the lesions: $CD4^+$ T cells predominate in tuberculoid lesions and $CD8^+$ T cells predominate in lepromatous lesions. All of the *M. leprae*–specific $CD4^+$ T cells derived from tuberculoid patients produce IL-2 and IFN-γ and are designated $CD4^+$ *type 1* cells. The $CD8^+$ T cells derived from lepromatous lesions produce high levels of IL-4 and low levels of IFN-γ and are designated $CD8^+$ *type 2* cells.

In terms of the immunopathogenesis of leprosy (see Chap. 186), the abundance of IL-2 and IFN-γ in tuberculoid lesions is likely to contribute to the resistant state of immunity in these patients. IL-2 may contribute to the host defense by inducing the clonal expansion of activated, cytokine-producing T cells and augments the production of IFN-γ. IFN-γ is well known to enhance production of reactive oxygen and nitrogen intermediates by macrophages and stimulates them to kill or restrict the growth of intracellular pathogens. The cytokines found to be increased in lepromatous lesions might be expected to contribute to the immune unresponsiveness and failure of macrophage activation in these individuals. IL-4 and IL-10 may contribute to the elevated anti–*M. leprae* antibodies in lepromatous patients via their role in differentiation and Ig class switching of B cells, but they also have a negative immunoregulatory effect on CMI, downregulating T-cell and macrophage function.

Of particular interest to immunologists is the delineation of factors that influence the T-cell cytokine pattern. The innate immune response is one important factor involved in determining the type of T-cell cytokine response (Fig. 10-5).

The ability of the innate immune response to induce the development of a Th1 response is mediated by release of IL-12, a 70-kd heterodimeric protein.[46] For example, in response to an intracellular pathogen, macrophages release IL-12, which acts on NK cells to release IFN-γ. The presence of IL-12, IL-2, and IFN-γ, with the relative lack of IL-4, facilitates Th1 responses. In contrast, in response to allergens or extracellular pathogen, mast cells or basophils release IL-4, which in the absence of IFN-γ leads to differentiation of T cells along the Th2 pathway. It is intriguing to speculate that keratinocytes may also influence the nature of the T-cell cytokine response. Keratinocytes can produce IL-10, particularly after exposure to UVB radiation.[68] The released IL-10 can specifically downregulate Th1 responses, thus facilitating the development of Th2 responses.

T HELPER 17 CELLS Not every T cell–mediated disease can be easily explained by the Th1/Th2 paradigm. Some T-cell sub-populations are characterized by the secretion of IL-17. These cells are therefore termed *Th17 cells*. IL-23, a member of the IL-12 family, is apparently of key importance for the development of Th17 cells,[90] which have been linked to a growing list of autoimmune and inflammatory diseases such as neuroinflammatory disorders, asthma, lupus erythematosus, rheumatoid arthritis, and, most notably, psoriasis.[71] IL-17 is believed to contribute to the pathogenesis of these diseases by acting as a potent pro-inflammatory mediator. It was originally assumed that Th1 and Th17 cells arise from a common Th1 precursor, but it now appears that Th17 cells are a completely separate and early lineage of effector $CD4^+$ Th cells produced directly from naive $CD4^+$ T cells.

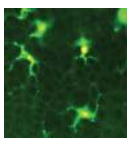

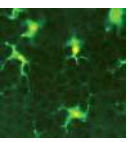

CYTOTOXIC T CELLS In responding to an intracellular pathogen (e.g., a virus) the T cell must lyse the infected cell. To do so, it must be able to recognize and respond to antigenic peptides encoded by this pathogen and displayed on the cell surface. For this to occur, antigens arising in the cytosol are cleaved into small peptides by a complex of proteases, called the *proteasome*. The peptide fragments are then transported from the cytosol into the lumen of the endoplasmic reticulum, where they associate with MHC class I molecules. These peptide–class I complexes are exported to the Golgi apparatus and then to the cell surface (see General Principles of Antigen Presentation for more details). The maturation of a $CD8^+$ T cell to a killer T cell requires not only the display of the antigenic signal but also the delivery of helper signals from $CD4^+$ T cells, for which the functional interaction between CD40 on the APC and CD40L on the $CD8^+$ T cell can substitute.

Two distinct subsets of cytotoxic T cells have been identified and can be differentiated by the mechanism by which they kill targets,[91] the end result being the induction of a programmed cell death known as *apoptosis*.[92,93] The first mechanism of cytotoxicity involves the interaction of two cell surface proteins, Fas ligand (CD95L) on the T cells and Fas (CD95) on the target. Ligation of these molecules delivers a signal through Fas that induces the apoptosis cascade in the target. The second mechanism involves the release of cytoplasmic granules present in such T cells. These granules contain perforin, which induces a pore in the target, and granzymes, serine esterases that, when injected into cells, trigger the apoptotic pathway. Such granules also contain granulysin, a protein with a broad spectrum of antimicrobial activity against bacteria, fungi, and parasites.[91,94] In this manner, cytotoxic T cells can directly kill microbial invaders. Besides contributing to host defense against infection and tumors, cytotoxic T cells can also contribute to tissue injury. For example, cytotoxic T cells recognize self-antigens of melanocytes and thus may contribute to the pathogenesis of vitiligo.[95]

REGULATORY T CELLS An important type of immunomodulatory T cells that controls immune responses is the so-called *regulatory T cells (Treg cells)*, formerly known as *T suppressor cells*.[96] Treg cells are induced by immature APCs/DCs and play key roles in maintaining tolerance to self-antigens in the periphery. Loss of Treg cells is the cause of organ-specific autoimmunity in mice that results in thyroiditis, adrenalitis, oophoritis/orchitis, and so on. Treg cells are also critical for controlling the magnitude and duration of immune responses to microbes. Under normal circumstances, the initial antimicrobial immune response results in the elimination of the pathogenic microorganism and is then followed by an activation of Treg cells to suppress the antimicrobe response and prevent host injury. Some microorganisms (e.g., *Leishmania* parasites, mycobacteria) have developed the capacity to induce an immune reaction in which the Treg component dominates the effector response. This situation prevents elimination of the microbe and results in chronic infection.

Regulatory functions are mediated by distinct groups of $CD4^+$, $CD8^+$, and NKT cells. The best-characterized Treg subset is the $CD4^+/CD25^+/CTLA\text{-}4^+/$GITR (glucocorticoid-induced TNF receptor family–related gene)$^+/FoxP3^+$ lymphocytes. The transcription factor FoxP3 is specifically linked to the suppressor function, as evidenced by the findings that mutations in the FoxP3 gene cause the fatal autoimmune and inflammatory disorder of scurfy in mice and IPEX (*i*mmune dysregulation, *p*olyendocrinopathy, *e*nteropathy, *X*-linked) in humans. The cytokines TGF-β and IL-10 are thought to be the main mediators of suppression.

$CD8^+$ cells can be activated to become suppressor cells by antigenic peptides that are presented in the context of an MHC class Ib molecule [Qa1 in mice; human leukocyte antigen E (HLA-E) in humans]. $CD8^+$ Treg cells suppress T cells that have intermediate affinity for self or foreign antigens and are primarily involved in self-nonself discrimination.

NKT cells are a distinctive population of T cells. They have properties of NK cells but, at the same time, express TCR α/β that consists of an invariant α chain (Vα24-JαQ) paired with various Vβ chains. These cells specifically recognize certain tumor cell–associated or bacterial glycolipids in the context of CD1 molecules and are therefore implicated in tumoricidal and bactericidal host responses (see CD1-Dependent Antigen Presentation). On antigenic stimulation, NKT cells produce large quantities of cytokines, particularly IL-4 and IL-10, and can use them to suppress Th1 responses. The biologic relevance of these in vitro data can be deduced from the observation that depletion of NKT cells can aggravate and accelerate Th1-mediated autoimmune diseases in mice, such as insulin-dependent diabetes, multiple sclerosis, and inflammatory bowel disease.[97]

LYMPHOCYTES OF THE SKIN Normal skin is the prototype of a nonlymphoid organ, that is, an organ in which primary lymphocyte responses are not initiated.

As opposed to normal mouse skin, in which a resident population of dendritic epidermal T cells uniformly equipped with a nonpolymorphic, canonical TCR γ/δ exists, normal human skin contains only small numbers of lymphocytes, the majority of which are located in the dermis and express TCR α/β rather than γ/δ.[98,99] These T cells of normal human dermis are preferentially clustered around postcapillary venules of the superficial plexus high in the papillary dermis and are often situated just beneath the dermal-epidermal junction and within, or in close proximity to, adnexal appendages such as hair follicles and eccrine sweat ducts. Most of them belong to the $CD45RO^+$ memory population—with the $CD4^+/CD8^-$ dominating over the $CD4^-/CD8^+$ phenotype—and express the skin-homing receptor cutaneous lymphocyte–associated antigen (CLA).[100]

At perivascular sites, most T cells stain positively for HLA-DR and CD25, which indicates that some of them represent effector cells and others perhaps Treg cells.

Epidermal T cells account for approximately 2 percent to 3 percent of all $CD3^+$ cells in normal human skin. They reside primarily in the basal and suprabasal layers, often in close apposition to LCs. Most of them are $CD8^+/CD4^-$ lymphocytes that bear TCR α/β dimers. There also exists a minor subset of double-negative ($CD4^-/CD8^-$) intraepidermal T cells with TCRs of either the α/β or the γ/δ phenotype. Their relationship, if any, to the murine dendritic epidermal T cell is not known.

The mechanism by which T lymphocytes traffic into skin depends on a chain of molecular events between cells. In skin-draining lymph nodes, the interaction of naive T cells with antigen-bearing cutaneous DCs (LCs, DDCs) results in the induction of the cell surface molecule CLA.[101]

CLA is a glycoprotein that defines a subset of memory T cells that home to skin. CLA is a glycosylated form of P-selectin glycoprotein ligand 1 that is expressed constitutively on all human peripheral blood T cells. The level of CLA

on cells is regulated by an enzyme, α(1,3)-fucosyl transferase VII, that modifies P-selectin glycoprotein ligand 1. In this manner, CLA^+ cells bind to both E-selectin and P-selectin, strengthening the interaction between circulating T cells and cutaneous endothelium, whereas CLA^- cells bind P-selectin but do not bind E-selectin.[102,103]

In patients with allergic contact dermatitis (see Chap. 13), the CLA^+ subset, but not the CLA^- subset, contains the T cells with the capacity to respond to the allergen.[104] Furthermore, more than 90 percent of T cells in inflammatory skin disease are CLA^+. CLA facilitates the entry of T lymphocytes into skin by mediating tethering and rolling of T cells on vascular endothelial cells through binding to E-selectin. Chemokines released by the endothelial cells increase the binding affinity of T-cell adhesion molecules. T cells firmly adhere to endothelium by the interaction of lymphocyte function–associated antigen 1 (LFA-1) with ICAM-1 and very late antigen 4 with vascular cell adhesion molecule. The interaction with the endothelial cells is now sufficiently strong to permit transmigration of the T cells into the skin and allow their participation in the inflammatory process.

A diversity of chemokines (see Chap. 12) contributes to tissue-specific T-cell homing. Leukocytes and nonleukocytes residing in the skin can produce chemokines with T-cell chemotactic properties, such as IL-8/CXC chemokine ligand 8 (CXCL8), Gro α/CXCL1, IFN-γ inducible protein-10/CXCL10, monokine induced by IFN-γ/CXCL9, macrophage chemoattractant protein-1 (MCP-1)/CCL2, MCP-2/CCL8, MCP-3/CCL7, regulated on activation normal T-cell expressed and secreted (RANTES)/CCL5, MIP-1α/CCL3, MIP-1β/CCL4, and lymphotactin/XCL1.

Of particular importance for skin homing of memory T cells is the interaction of TARC/CCL17 and CTACK/CCL27 with their corresponding chemokine receptors on CLA^+ T cells, CCR4 and CCR10, respectively.

The CC chemokine TARC/CCL17 is expressed by vascular endothelial cells of venules in normal and inflamed human skin[105] (see Chap. 163). CLA^+ memory T cells in peripheral blood displaying CCR4 adhere to cutaneous vessels via TARC/CCL17-induced binding to ICAM-1 and are thereby attracted to the skin. In addition, the recruitment of type 2 (Th2) T cells into diseased skin can be mediated by TARC/CCL17. In atopic dermatitis, a prominent example for a Th2-mediated immune response, this chemokine is known to be upregulated in basal keratinocytes.[106]

CTACK/CCL27, another CC chemokine, is also critically involved in the homing process under physiologic and inflammatory conditions.[75] It is constitutively produced by basal keratinocytes and is also displayed on the surface of dermal endothelial cells. Its expression is upregulated by IL-1β and TNF-α and downregulated by glucocorticosteroids. The receptor for CCL27, CCR10, is expressed on CLA^+ T cells, and in vivo experiments have demonstrated a pivotal role for CCL27-CCR10 interactions in T cell–mediated skin inflammation.[107]

Adhesion molecule interactions that help to anchor T cells in the epidermis include the attachment of LFA-1 (CD11a)–bearing T cells to $ICAM\text{-}1^+$ (CD54) keratinocytes in inflamed skin and, more physiologically, the $\alpha_E\beta_7$-E-cadherin–mediated binding of T cells to nonactivated keratinocytes.

The accumulation of T cells in skin is not stochastic. It is abundantly clear that specific populations of T cells, identified by cell surface determinants and their cytokine profile, localize to the skin. Various cell surface determinants on T cells allow detection of their presence. Initially, functional T-cell populations could be delineated in skin according to their expression of the CD4 and CD8 molecules. In the majority of inflammatory conditions studied, including lichen planus, psoriasis, and atopic dermatitis, $CD4^+$ T cells outnumber $CD8^+$ T cells, in proportions similar to or somewhat greater than those seen in the peripheral blood. However, in the study of the skin lesions of human leprosy, $CD4^+$ T cells were found to be predominant in the tuberculoid form of the disease, whereas $CD8^+$ T cells were found to be predominant in the lepromatous form of the disease.[108] Because all leprosy patients have an excess of $CD4^+$ T cells in their blood, the abundance of $CD8^+$ T cells in lepromatous skin lesions provides clear evidence for the specific accumulation of T-cell populations in skin.

A perhaps more relevant marker of T-cell populations is the diversity of their TCRs. The clearest example is the clonality of the T-cell population in cutaneous T-cell lymphoma, in which a single V gene usage is found to predominate in different skin lesions from the same individual[109,110] (see Chap. 146).

The dominant expression of several TCR V genes in an infiltrate is thought to indicate that a small number of antigens drive the local inflammatory response. Unlike in normal human skin whose TCR repertoire is rather divergent,[111] a limited TCR V gene usage has been reported to be present in the skin lesions of leprosy,[112] psoriasis,[113] basal cell carcinoma, and countless other reactions in which T cells are present. However, in no instance has the limited set of antigens been defined and correlated with the TCR usage.

The most direct indication of relevant T-cell populations in skin is determination of the number of T cells that recognize the antigen. It has been documented that 1 in 1000 to 1 in 10,000 T cells in the peripheral blood recognize a given antigen. In the skin, however, approximately 1 in 50 to 1 in 100 T cells recognize the antigen causing the disease.[114,115] Thus there is as much as a 100-fold enrichment of antigen-reactive T cells at the site of cutaneous inflammation.

With regard to survival and/or expansion of T cells of human skin/epidermis, it appears that IL-2, IL-7, and IL-15[111] play important roles. The latter two T-cell growth factors can be produced by human epidermal cells, and all are overexpressed in T cell–rich skin lesions of patients with tuberculoid leprosy.

The Th1/Th2 paradigm provides insight into the pathogenesis of many skin diseases in which T cells have an immunologic role. There is ample evidence that the Th1/Th2 paradigm is not rigid; there are situations in which a mixture of cytokines is found and examples of T-cell clones, known as *Th0 cells*, that secrete a combination of Th1 and Th2 cytokines. However, it has been possible to find a number of dermatologic conditions in which either a Th1 or Th2 cytokine pattern predominates. In the realm of cutaneous infection, leprosy (see T Helper 1/T Helper 2 Paradigm) and leishmaniasis are outstanding examples of diseases with a clinical spectrum in which Th1 and Th2 cytokines appear to have a pathogenic role. Leishmaniasis, like leprosy, is not a single disease entity but a set of clinical entities, each with a differing immunopathogenesis. As in leprosy, the type 1 cytokine pattern is characteristic of leishmaniasis lesions (see Chap. 206) in which CMI to the parasite is strong and the lesions self-cure; the type 2 pattern typifies lesions in which immunity to the parasite is weak and the cutaneous lesions are progressive.[117,118] Studies in animal models suggest that it may be possible to induce effective CMI by vac-

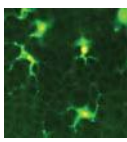

cination using a combination of parasite antigens and recombinant IL-12.[119] This immunotherapeutic strategy engenders a Th1 cytokine response. Th1 responses are involved in immunologic resistance to *Borrelia burgdorferi*[120] and *Treponema pallidum*,[121] the causative agents of Lyme disease and syphilis, respectively.

Concepts of the pathogenesis of atopic dermatitis (see Chap. 14) include a central role for allergen-specific T cells that produce Th2 or type 2 cytokines, including IL-4 and IL-5. Allergen-specific T cells with this cytokine profile have been demonstrated in the peripheral blood and skin lesions of subjects with active disease.[122–124] In addition, the lesions of atopic dermatitis contain abundant expression of IL-10, although the source of this cytokine is likely to be tissue macrophages and keratinocytes.[125] The Th2 pattern of cytokines together is thought to induce increased Ig production, particularly of IgE, mast cell growth, and the infiltration of eosinophils. These cytokines may also downregulate Th1 responses, which would account for the increased susceptibility to cutaneous bacterial infection.

Evidence suggests that pruritus, a key symptom of atopic dermatitis, may also be linked to the Th2 response. The cytokine IL-31 induces severe pruritus and dermatitis in mice and is preferentially expressed in Th2 cells. Human IL-31 is significantly upregulated in pruritic forms of skin inflammation (atopic dermatitis, prurigo nodularis) but not in non-pruritic forms (psoriasis), and circulating CLA^+ memory T cells of patients with atopic dermatitis produce higher levels of IL-31 that the T cells of donors with psoriasis.[126,127]

Clinical trials attempting to alter the Th2 response in atopic dermatitis through the administration of IFN-γ have shown that this treatment induces significant but modest clinical improvement but no reduction in IgE levels in some patients.[128] This was noteworthy, because Th2 cytokines help B cells produce autoantibodies in pemphigus vulgaris[129] (see Chap. 52). The beneficial effect of IFN-γ came as somewhat of a surprise in that a mediator shift has been described in atopic dermatitis, with Th2 cytokines dominating in acute lesions and Th1 cytokines in chronic lesions.[130]

In allergic contact dermatitis (see Chap. 13), sensitization involves the development of a Th1 response, as evidenced by the predominating IL-2 and IFN-γ production of murine T cells sensitized in vitro to haptenated APCs.[131] The situation in the elicitation phase is less clear. In nickel contact dermatitis, antigen-specific Th1-type T-cell clones were described,[132] as were Th2-type infiltrating T cells in lesional skin.[133]

Th1/Th2 responses may be involved in antitumor immunity. For example, IL-4 and IL-10 predominate in the lesions of basal cell and squamous cell carcinoma, whereas the Th1 response is present in benign neoplasms[54] (see Chaps. 114 and 115). The source of the IL-10 in these cutaneous carcinomas is the tumor itself, a mechanism by which the cancer can downregulate antitumor T-cell responses. Within the spectrum of cutaneous T-cell lymphoma, mycosis fungoides represents a Th1 cytokine response, whereas patients with the more progressive Sézary syndrome exhibit a Th2 cytokine response[134] (see Chap. 146). It was originally assumed that Th1 cytokine responses predominate in involved and, to a lesser extent, uninvolved skin of patients with psoriasis.[135] More recent evidence suggests that IL-23, rather than IL-12, is the key cytokine in this disease[136] and that it exerts its effects by triggering IL-22 production by Th17 cells, which results in dermal inflammation and acanthosis.[137] Although it is uncertain, these Th17 cells may be autoimmune, responding to self-antigens in the epidermis.

Whatever the role for the observed cytokine patterns in human disease, the Th1-Th2-Th17 paradigm exposes new targets for therapy. Trials are under way to exploit this knowledge through the use of cytokine agonists and antagonists to shift the balance between the different Th patterns for the benefit of the patient.

Langerhans Cells and Other Dendritic Cells

DEFINITION In 1868, the medical student Paul Langerhans, driven by his interest in the anatomy of skin nerves, identified a population of dendritically shaped cells in the suprabasal regions of the epidermis after impregnating human skin with gold salts.[138] These cells, which later were found in virtually all stratified squamous epithelia of mammals, are now eponymously referred to as *Langerhans cells*. There also exist substantial numbers of dendritic leukocytes in the dermis. Although some of them represent LCs on their way into or out of the epidermis, most of these cells are phenotypically slightly different from LCs and are generally referred to as *dermal dendritic cells*.[139] LCs and DDCs are lineage-negative (Lin^-), bone marrow–derived leukocytes endowed with exquisite migratory and antigen-presenting properties. Thus, they phenotypically and functionally resemble other DCs present in most, if not all, lymphoid and nonlymphoid tissues.[140] As the gatekeepers of the immune system, they control the response to events perturbing tissue homeostasis (Fig. 10-6A).

PHENOTYPIC PROPERTIES OF SKIN-BOUND LANGERHANS CELLS AND DERMAL DENDRITIC CELLS The expression of the Ca^{2+}-dependent lectin Langerin (CD207) is currently the single best feature discriminating LCs from other cells. Langerin is a transmembrane molecule associated with and sufficient to form Birbeck granules, the prototypic and cell type–defining organelles of LCs (see Fig. 10-6B). Birbeck granules are pentilaminar cytoplasmic structures frequently displaying a tennis racket shape at the ultrastructural level. The additional presence of Langerin on the LC cell surface coupled with its binding specificity for mannose suggests that Langerin is involved in the uptake of mannose-containing pathogens by LCs. However, the disruption of the Langerin gene in experimental animals does not result in a marked loss in LC functionality.[141] Notably, Langerin is expressed on virtually all LCs in stratified epithelia as well as on a major subset of DCs in the lung,[142] which may or may not be directly related to epidermal LCs.

The expression of additional molecules besides Langerin allows the identification of LCs within normal unperturbed epidermis. These include CD1a; the MHC class II antigens HLA-DR, HLA-DQ, and HLA-DP; and CD39, a membrane-bound, formalin-resistant, sulfhydryl-dependent adenosine triphosphatase (ATPase).

DDCs are phenotypically less well characterized. Their best markers are probably the molecules CD1b and CD1c as well as the subunit A of the clotting proenzyme factor XIII (factor XIIIa). DDCs can be distinguished from LCs by the absence of Langerin expression and Birbeck granules, and from macrophages by the abundant expression of MHC class II molecules, DEC205/CD205, and the absence of phagolysosomes at the ultrastructural level.

TISSUE DISTRIBUTION OF LANGERHANS CELLS AND DERMAL DENDRITIC CELLS In the epidermis, the density of the LC population varies regionally in human

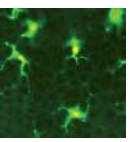

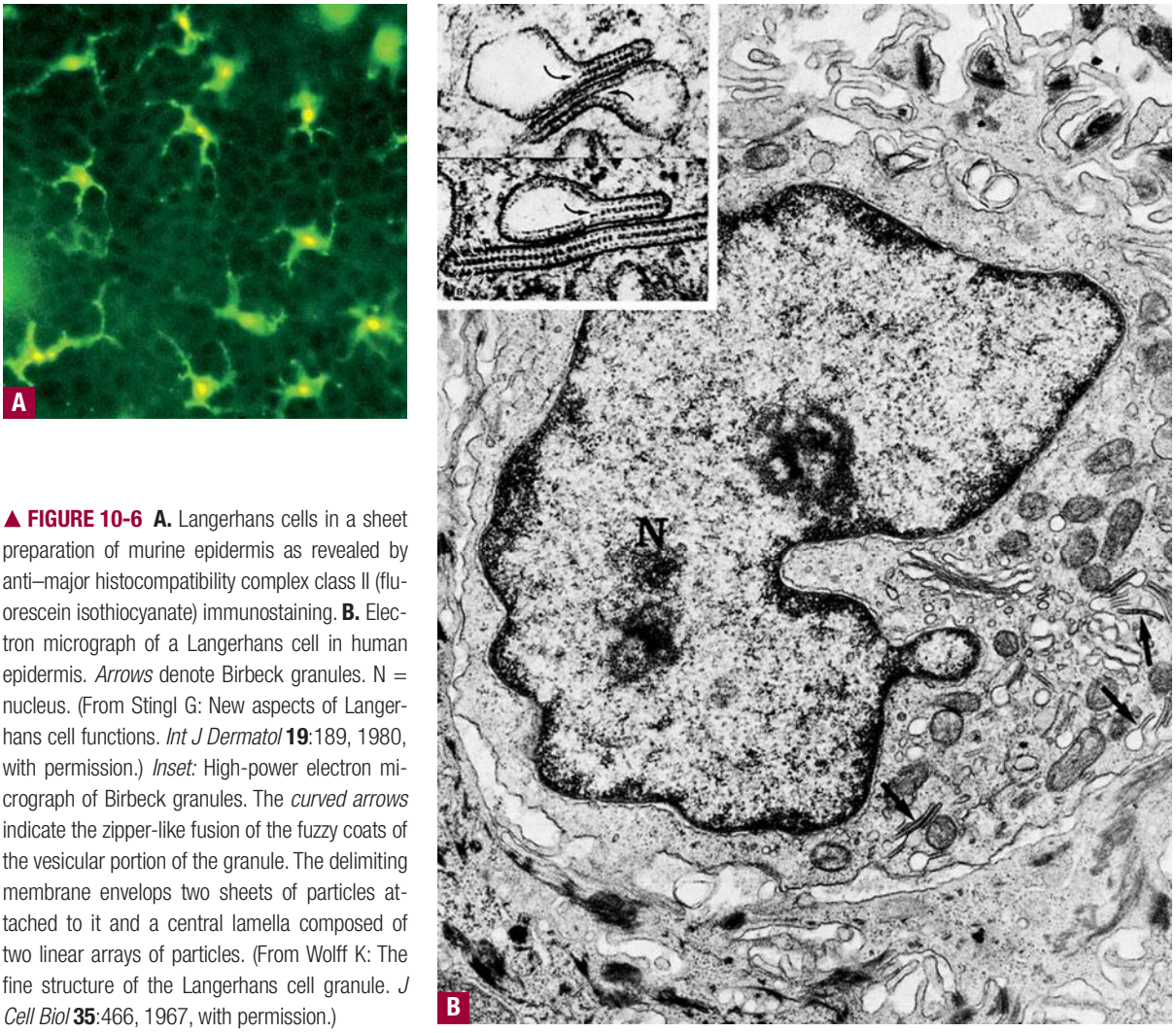

▲ **FIGURE 10-6** **A.** Langerhans cells in a sheet preparation of murine epidermis as revealed by anti–major histocompatibility complex class II (fluorescein isothiocyanate) immunostaining. **B.** Electron micrograph of a Langerhans cell in human epidermis. *Arrows* denote Birbeck granules. N = nucleus. (From Stingl G: New aspects of Langerhans cell functions. *Int J Dermatol* **19**:189, 1980, with permission.) *Inset:* High-power electron micrograph of Birbeck granules. The *curved arrows* indicate the zipper-like fusion of the fuzzy coats of the vesicular portion of the granule. The delimiting membrane envelops two sheets of particles attached to it and a central lamella composed of two linear arrays of particles. (From Wolff K: The fine structure of the Langerhans cell granule. *J Cell Biol* **35**:466, 1967, with permission.)

skin. On head, face, neck, trunk, and limb skin, the LC density ranges between 600 and 1000/mm^2. Comparatively low densities (approximately 200/mm^2) are encountered in palms, soles, anogenital and sacrococcygeal skin, and the buccal mucosa. The density of human LCs decreases with age, and LC counts in skin with chronic actinic damage are significantly lower than those in skin not exposed to UV light.

DDCs are located primarily in the vicinity of the superficial vascular plexus.

DEVELOPMENT, MAINTENANCE, AND FATE OF SKIN DENDRITIC CELLS (Fig. 10-7) HLA-DR$^+$/ATPase$^+$ DCs can be identified in the human epidermis by 6 to 7 weeks of estimated gestational age. These cells must originate from hemopoietic progenitor cells in the yolk sac or fetal liver, the primary sites of hemopoiesis during the embryonic period. Until the twelfth week of pregnancy, these cells are CD1a$^-$ and lack Birbeck granules. Thereafter, and coinciding with the initiation of bone marrow function, there occurs a dramatic increase in CD1a expression by epidermal DCs, which indicates the emergence of a true LC population. The relative numeric stability of LC counts during later life must be achieved by a delicate balance of LC generation and immigration into the epidermis and LC death and emigration from the epidermis.

Within the epidermis, LCs are anchored to surrounding keratinocytes by E-cadherin–mediated homotypic adhesion.[147] This anchoring and the display of TGF-β1 also prevent terminal differentiation and migration (see later), thus securing intraepidermal residence for the cells under homeostatic conditions.

Two non–mutually exclusive pathways of LC repopulation of the epidermis may exist: LC division within the epidermis, and the differentiation of LCs from skin-resident or blood-borne precursors. Evidence for the first possibility is the demonstration of cycling/mitotic LCs in the epidermis,[148] although it remains to be established whether this cell division alone suffices for maintaining the epidermal LC population. Notably, it has now been discovered that DDCs proliferate constitutively in situ in murine and human quiescent dermis,[149] which indicates that homeostatic cell division also contributes to the maintenance of this skin DC population.

The observation that the half-life of LCs within unperturbed murine epidermis is around 2 to 3 months[150] suggests a significant turnover of the epidermal LC population even under noninflammatory conditions. In seeming contradiction stands the observation that the LC population of human skin grafted onto a nude mouse remains rather constant for the life of the graft, despite epidermal proliferation and the absence of circulating precursors for human LCs. Moreover, epidermal LCs in mice whose bone marrow was lethally irradiated and subsequently transplanted are only partially replaced by LCs of donor origin,[151] whereas DCs in other organs are efficiently exchanged for donor DCs.[152] Together, these observations

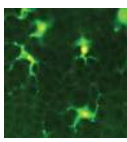

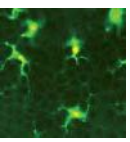

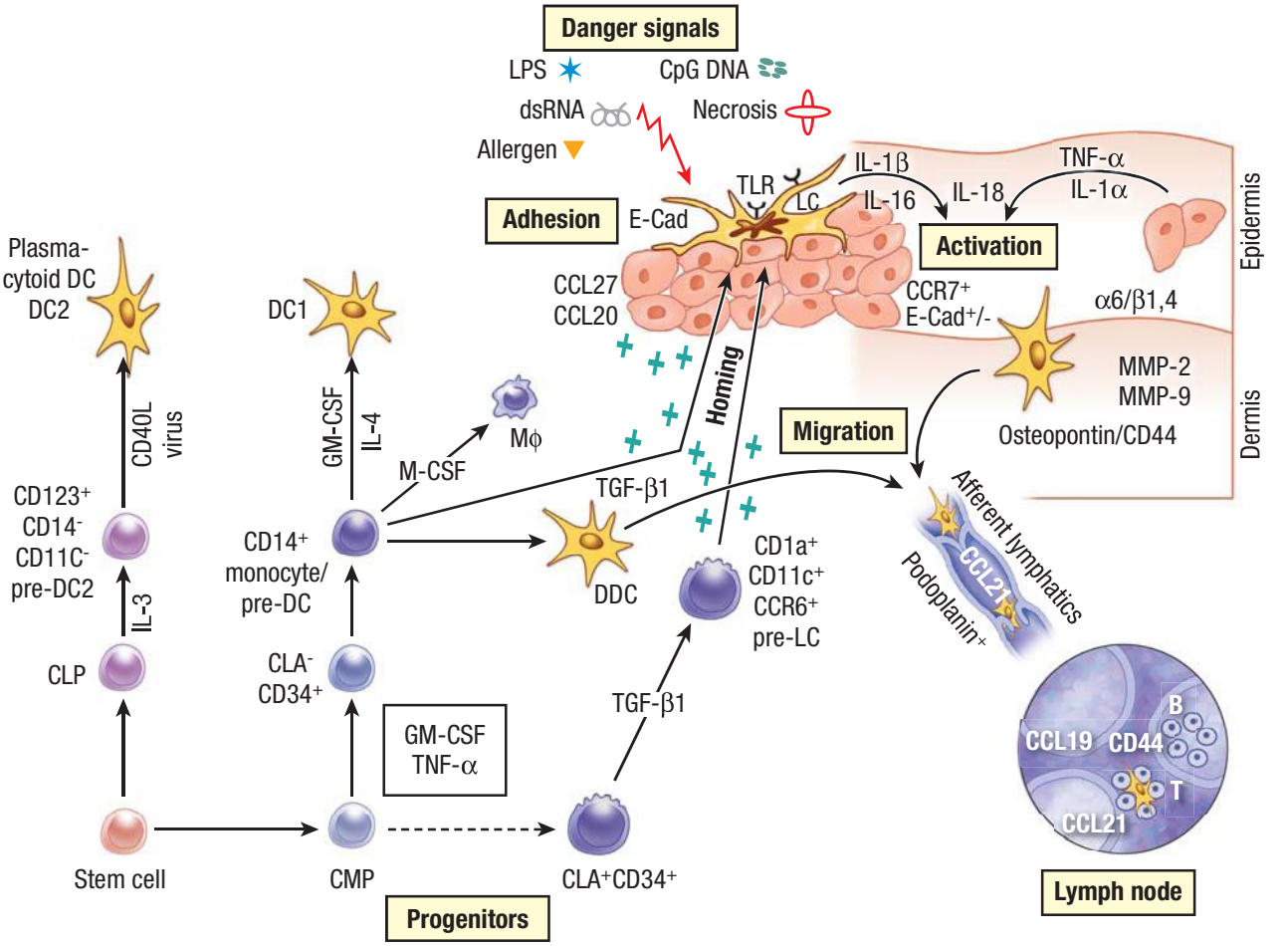

▲ **FIGURE 10-7** Schematic diagram of the ontogeny, migration, and maturation pathways of cutaneous dendritic leukocytes. $\alpha_6/\beta_{1,4}$ = $\alpha_6/\beta_{1,4}$ integrins; B = B cells; CCL = CC chemokine ligand; CCR = CC chemokine receptor; CD = cluster of differentiation-nomenclature of leukocyte antigens; CLA = cutaneous lymphocyte–associated antigen; CLP = common lymphoid progenitor cell; CMP = common myeloid progenitor cell; CpG DNA = immunostimulatory cytosine- and guanine-rich sequences of DNA; DC = dendritic cell; DDC = dermal dendritic cell; dsRNA = double-stranded RNA; E-Cad = E-cadherin; GM-CSF = granulocyte-macrophage colony-stimulating factor; IL = interleukin; LC = Langerhans cell; LPS = lipopolysaccharide; Mϕ = macrophage; M-CSF = macrophage colony-stimulating factor; MMP = matrix metalloproteinase; T = T cells; TGF-β1 = transforming growth factor-β1; TLR = Toll-like receptor; TNF-α = tumor necrosis factor-α.

suggest that a precursor cell population resides in the dermis that is engaged constantly in the self-renewal of the epidermal LC population under noninflammatory conditions. The prime candidate LC precursors are dermal $CD14^+$/$CD11c^+$ cells that have the potential to differentiate in vitro into LCs in a TGF-β1–dependent fashion.[153]

Under inflammatory conditions (e.g., UV radiation exposure, graft-versus-host disease), an additional pathway of epidermal LC recruitment becomes operative. In this situation, LC precursors enter the tissue, and their progeny populate the epidermis in a fashion dependent on chemoattraction mediated by LC-expressed chemokine receptors CCR2 and CCR6,[154] the ligands of which are secreted by endothelial cells and keratinocytes. Interestingly, a similar pathway of inflammation-dependent precursor recruitment exists for DDCs, which in contrast to that of LCs, relies on $CCR2^-$ but not CCR6-dependent cell migration.[149] Thus, CCR6 and its ligand MIP-3α/CCL20 may be essential for epidermal LC localization in vivo, as postulated previously in studies of LCs differentiated from human progenitor cells in vitro.[76] The action of MIP-3α/CCL20 may be assisted or replaced under noninflammatory situations by the chemokine BRAK/CXCL14, which is constitutively produced by keratinocytes.[155] The differentiation stage of the biologically relevant circulating LC precursors entering inflamed skin in vivo remains to be resolved. However, evidence exists that common myeloid progenitors, granulocyte-macrophage progenitors, monocytes, and even common lymphoid progenitors can give rise to the emergence of an epidermal LC population in experimental animals.[156,157]

Under inflammatory conditions, DC types that are not residents of the normal cutaneous environment appear in the skin. These include plasmacytoid DCs (pDCs) and DCs that phenotypically resemble myeloid DCs of the peripheral blood. The pDCs are DC precursors that are characterized by a highly developed endoplasmic reticulum, which results in their plasma cell-like appearance.[158] Functionally, pDCs display a unique ability to produce enormous amounts of natural IFNs in response to TLR ligands and thus were also named *principal type 1 IFN-producing cells*.[159] Under homeostatic conditions, pDCs are found in peripheral blood and T cell–rich areas of secondary lymphatic tissue. In certain types of skin inflammation (e.g., virus infection, lupus erythematosus, psoriasis, allergic contact dermatitis, atopic dermatitis), pDCs enter the skin in a fashion that engages the CXC chemokine receptor CXCR3.[160,161] Within the skin, pDCs localize in perivascular clusters with T cells and, on activation in situ, may contribute to antimicrobial

immune defense or (auto)immune-mediated tissue inflammation by the secretion of natural IFNs and other mechanisms that are still to be identified.

Another non-indigenous DC population originates from myeloid precursors and has been detected in inflammatory skin diseases such as atopic dermatitis and contact eczema. The so-called *inflammatory dendritic epidermal cells* are characterized by the expression of CD1a, CD1b, FcεRI, CD23, HLA-DR, and CD36.[162] Evidence exists that an immune response triggered by these cells is skewed in the Th1 direction.[163]

Finally, there remains the question as to the ultimate fate of the epidermal and dermal DC populations. Major perturbation of the cutaneous microenvironment (danger signal[164]) leads to their activation, which results either in their elimination via the stratum corneum in the case of LCs[165] or, more importantly, in the migration of LCs/DDCs to lymphoid tissues, where they initiate type 1 (Th1/cytotoxic T cell 1)–dominated T-cell responses (see The Skin–Initiation Site and Target of Immune Response). By contrast, it is less clear what happens in normal skin. Does LC shedding occur under physiologic (nondanger) conditions? Is there a natural flux of LCs/DDCs to the regional lymph nodes? If so, what are the functional consequences of such an occurrence? Evidence exists that melanin granules captured in the skin accumulate in the regional lymph nodes but not in other tissues. The further observation of only very few melanin granule–containing cells in TGF-$\beta1^{-/-}$ mice suggests that, under steady-state conditions, epidermal and/or dermal antigens are carried to the regional lymph nodes by TGF-β1–dependent cells (most likely LCs/DDCs) only. It appears that T lymphocytes encountering such APCs in vivo are rendered unresponsive in an antigen-specific manner.[166] It may therefore be assumed that absence of pathogenic T-cell autoimmunity and/or lack of reactivity against seemingly innocuous environmental compounds (e.g., aeroallergens) in the periphery is primarily the consequence of an active immune response rather than the result of its nonoccurrence.

On receipt of danger signals (e.g., TLR ligands, chemical haptens, hypoxia), the situation is quite different. After a few hours, LCs begin to enlarge, to display increased amounts of surface-bound MHC class II molecules, and to migrate downward in the dermis, where they enter afferent lymphatics and, finally, reach the T-cell zones of draining lymph nodes.[167] During this process, LCs undergo phenotypic changes similar to those that occur in single epidermal cell cultures[168]; that is, downregulation of molecules or structures responsible for antigen uptake and processing as well as for LC attachment to keratinocytes (e.g., Fc receptors, E-cadherin) and upregulation of moieties required for active migration and stimulation of robust responses of naive T cells (e.g., CD40, CD80, CD83, CD86). The mechanisms governing LC migration are becoming increasingly clear. TNF-α and IL-1β (in a caspase 1–dependent fashion) are critical promoters of this process, whereas IL-10 inhibits its occurrence. Increased cutaneous production and/or release of the pro-inflammatory cytokines is probably one of the mechanisms by which certain immunostimulatory compounds applied to or injected into the skin [e.g., imiquimod, unmethylated cytosine-phosphate-guanosine (CpG) oligonucleotides] accelerate LC/DDC migration. Interestingly enough, Cumberbatch et al.[169] reported that, in psoriasis, LCs are impaired in their migratory capacity. This was somewhat unexpected in view of the remarkable overexpression of TNF-α in psoriatic skin. These investigators also found that the failure of TNF-α and/or IL-1β to induce LC migration from uninvolved skin was not attributable to an altered expression of receptors for these cytokines. The nature of this LC migration inhibition factor is as yet unknown.

IL-16 also induces LC mobilization. This process could perhaps be operative in atopic dermatitis. In this disease, DCs of lesional skin exhibit surface IgE bound to high-affinity Fc receptors (FcεRI), and allergen-mediated receptor cross-linking results in enhanced IL-16 production.

An important hurdle for emigrating LCs is the basement membrane. During their downward journey, LCs probably attach to it via α_6-containing integrin receptors and produce proteolytic enzymes such as type IV collagenase (matrix metalloproteinase 9) to penetrate it and to pave their way through the dense dermal network into the lymphatic system. Evidence is accumulating that LC/DDC migration occurs in an active, directed fashion. Osteopontin is a chemotactic protein that is essential in this regard. It initiates LC emigration from the epidermis and attracts LCs/DDCs to draining nodes by interacting with an N-terminal epitope of the CD44 molecule.[170] The entry into and active transport of cutaneous DCs within lymphatic vessels appears to be mediated by MCPs binding to CCR2 and by secondary lymphoid-organ chemokine/CCL21 produced by lymphatic endothelial cells of the dermis and binding to CCR7 on maturing LCs and DDCs.[171,172] Interestingly, CCL21 expression is upregulated in irritant and allergic contact dermatitis, which implicates its regulated impact on DC emigration from the skin.[173]

FUNCTIONAL PROPERTIES OF DENDRITIC CELLS Like the other members of the DC family, LCs and DDCs are "professional" APCs, endowed with the unique capacity of stimulating antigen-specific responses in naive, resting T cells. To provide a better understanding of this functional property, the basic principles of antigen uptake, processing, and presentation are briefly reviewed.

GENERAL PRINCIPLES OF ANTIGEN PRESENTATION (Fig. 10-8) Unlike B cells, T cells cannot recognize soluble protein antigen per se; their antigen receptor TCR is designed to see antigen-derived peptides bound to MHC locus–encoded molecules expressed by APCs.[176] For the antigen-specific activation of Th cells, exogenous antigen–derived peptides are usually presented in the context of MHC class II molecules.[177] In this situation, peptides are generated in the endocytic, endosomal/lysosomal pathway and are bound to MHC class II molecules. The resulting MHC-peptide complex is expressed at the APC surface for encounter by the TCR of $CD4^+$ Th cells. In contrast, most $CD8^+$ T cells, destined to become cytotoxic T cells, recognize the endogenous antigen in association with MHC class I molecules.[177] Because most nucleated cells transcribe and express MHC class I genes and gene products, it is evident that many cell types can serve as APCs for MHC class I–restricted antigen presentation and/or as targets for MHC class I–dependent attack by T cells. In the MHC class II–dependent antigen-presentation pathway, DCs, including LCs and DDCs, B cells, and monocytes/macrophages, are the major APC populations.

Major Histocompatibility Complex Class I–Restricted Antigen Presentation[178]. **CLASSIC MAJOR HISTOCOMPATIBILITY COMPLEX CLASS I PRESENTATION PATHWAY.** Immediately after their biosynthesis, MHC class I heavy and light (β_2-microglobulin) chains are inserted

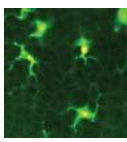

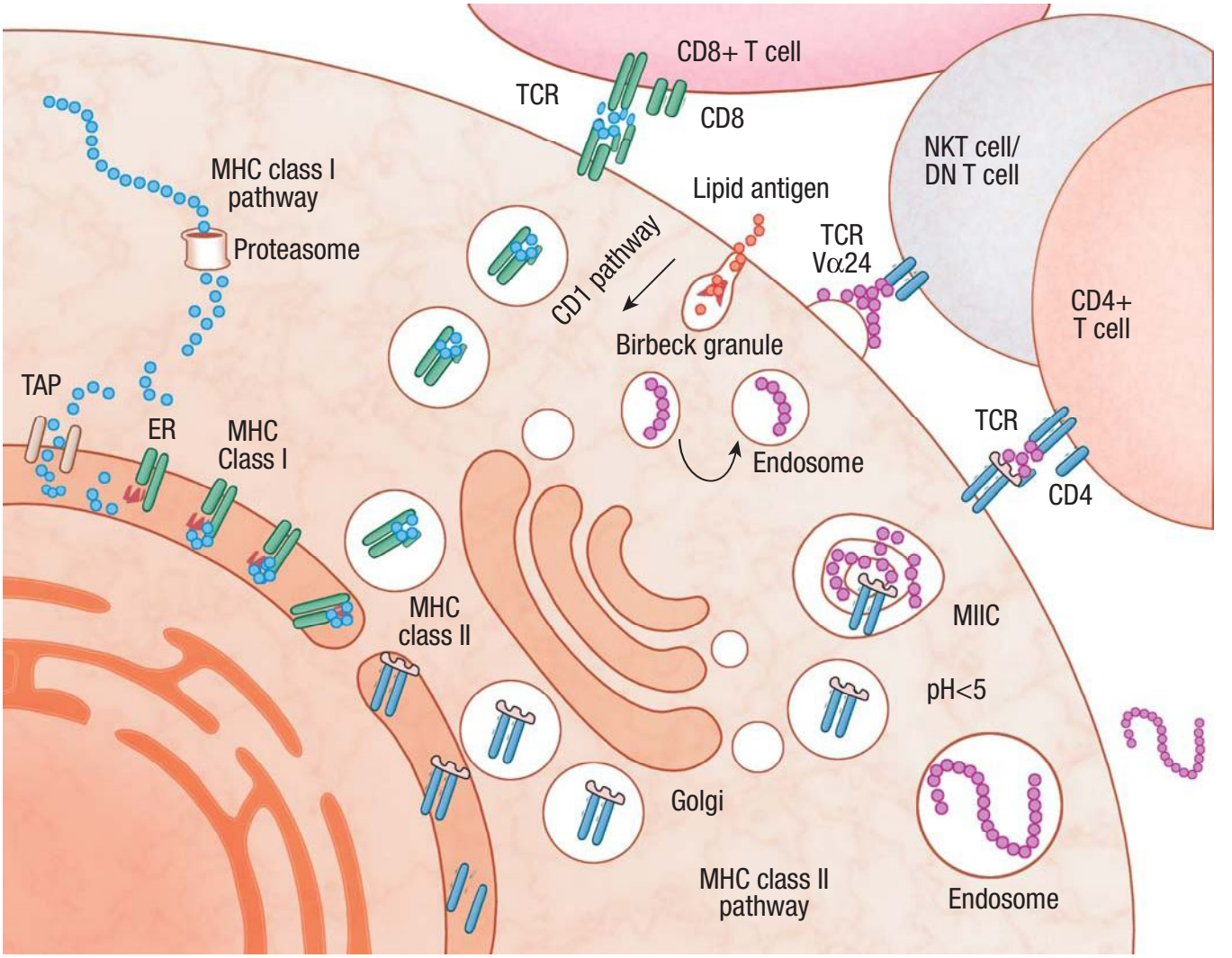

▲ **FIGURE 10-8** Antigen-processing pathways. The intracellular antigen-processing pathways for major histocompatibility complex (MHC) class I, MHC class II, and CD1 presentation are shown. The MHC class I pathway involves the processing of cytoplasmic proteins, whereas the MHC class II pathway involves the processing of exogenous proteins. The CD1 pathway regulates the processing and presentation of self-glycosphingolipids and bacterial lipoglycans. DN T cell = double-negative ($CD4^-/CD8^-$) T cell; ER = endoplasmic reticulum; MIIC = MHC class II lysosomal peptide-loading compartment; NKT cell = natural killer T cell; TAP = transporter associated with antigen processing; TCR = T-cell receptor.

into the membranes of the endoplasmic reticulum. The third subunit of the functional MHC class I complex is the peptide itself. The major sources of peptides for MHC class I loading are cytosolic proteins, which can be targeted for their rapid destruction through the catalytic attachment of ubiquitin. Cytosolic proteinaceous material undergoes enzymatic digestion by the proteasome to yield short peptide chains of 8 to 12 amino acids, an appropriate length for MHC class I binding. In its basic conformation, the proteasome is a constitutively active "factory" for self-peptides. IFN-γ, by replacing or adding certain proteasomal subunits, induces "immunoproteasomes," presumably to fine-tune the degradation activity and specificity to the demands of the immune response. The processed peptides are translocated to the endoplasmic reticulum by the transporter associated with antigen processing (TAP), an MHC-encoded dimeric peptide transporter. With the aid of chaperons (calnexin, calreticulin, tapasin), MHC class I molecules are loaded with peptides, released from the endoplasmic reticulum, and transported to the cell surface. Several infectious agents with relevance to skin biology have adopted strategies to subvert MHC class I presentation, and thus the surveillance of cell integrity, by interfering with defined molecular targets. Important examples of such interference are the inhibition of proteasomal function by the Epstein-Barr virus–encoded EBNA-1 protein, the competition for peptide-TAP interactions by a herpes simplex virus protein, and the retention or destruction of MHC class I molecules by adenovirus- and human cytomegalovirus-encoded products.

Alternative Major Histocompatibility Complex Class I Presentation Pathways (Cross-Presentation). Under certain conditions, exogenous antigen can reach the MHC class I presentation pathway. Significant evidence for this cross-presentation first came from in vivo experiments in mice demonstrating that viral, tumor, and MHC antigens can be transferred from MHC-mismatched donor cells to host bone marrow–derived APCs to elicit antigen-specific cytotoxic T-cell responses that are restricted to self MHC molecules.[179] In vitro studies have now defined that exosomes (i.e., small secretory vesicles of approximately 100 nm in diameter secreted by various cell types, including

tumor cells), heat shock proteins, immune complexes, and apoptotic cells (taken up via CD36 and αvβ3 or αvβ5 integrins) can all serve as vehicles for the delivery of antigen to DCs in a manner that permits the cross-presentation of antigen. In all in vitro systems in which a direct comparison has been made, DCs, including LCs, but not monocytes/macrophages, were capable of cross-presentation.[180,181] Three distinct pathways are currently exploited by which antigen can access MHC class I molecules of DCs: (1) a recycling pathway for MHC class I in which antigen is loaded in the endosome; (2) a pathway by which retrograde transport of the antigen from the endosome to the endoplasmic reticulum facilitates entry into the classic MHC class I antigen presentation pathway; and (3) an endosome to the cytosol transport pathway, which again allows antigen processing via the classic MHC class I antigen presentation pathway.

Major Histocompatibility Complex Class II–Restricted Antigen Presentation[177]. MHC class II molecules predominantly bind peptides within endosomal/lysosomal compartments. Sampling peptides in these sub-cellular organelles allow class II molecules to associate with a broad array of peptides derived from proteins targeted for degradation after internalization by fluid phase or receptor-mediated endocytosis, macropinocytosis, or phagocytosis. One of the striking structural differences between MHC class I and class II molecules is the conformation of their peptide-binding grooves. Whereas MHC class I molecules have binding pockets to accommodate the charged termini of peptides and thus selectively associate with short peptides, the binding sites of MHC class II molecules are open at both ends. Thus, MHC class II molecules bind peptides with preferred lengths of 15 to 22 amino acids but can also associate with longer moieties.

Newly synthesized MHC class II α and β subunits assemble in a stoichiometric complex with trimers of the type II transmembrane glycoprotein invariant chain (Ii). The association with Ii contributes in at least three different ways to the function of class II molecules: (1) Ii assembly promotes the proper folding of class II molecules in the endoplasmic reticulum; (2) the abluminal portion of Ii contains signal sequences that facilitate the export of MHC class II–Ii complexes through the Golgi system to endosomes/lysosomes; and (3) Ii prevents class II molecules from premature loading by peptides intended for binding to MHC class I molecules in the endoplasmic reticulum. The segment of Ii functioning as a competitor for peptide binding to class II is termed *class II–associated Ii peptide* (CLIP; residues 81 to 104 of Ii). Once the nascent MHC class IIα/β–Ii trimers arrive in the endosomal/lysosomal system, Ii is subject to proteolysis by acid hydrolases. The last proteolytic step, the generation of CLIP, is catalyzed by cathepsin S in DCs, by cathepsin L in thymic epithelial cells, and by cathepsin F in macrophages. On HLA-DM–chaperoned exchange of CLIP for exogenous antigen-derived peptide, fully assembled class II molecules are exported to the cell surface and acquire a stable conformation. Depending on the cell type and the activation status of a cell, the half-life of class II–peptide complexes varies from a few hours to days. It is particularly long (more than 100 hours) on DCs that have matured into potent immunostimulatory cells of lymphoid organs on encounter with an inflammatory stimulus in nonlymphoid tissues. The very long retention of class II–peptide complexes on mature DCs ensures that only those peptides generated at sites of inflammation will be displayed in lymphoid organs for T-cell priming. Cytokines have long been known to regulate antigen presentation by DCs. In fact, proinflammatory (TNF-α, IL-1, IFN-γ) and anti-inflammatory (IL-10, TGF-β1) cytokines regulate presentation in MHC class II molecules in an antagonistic fashion. Mechanistically, regulatory effects include the synthesis of MHC components and proteases, and the regulation of endolysosomal acidification.[182,183]

CD1-Dependent Antigen Presentation[184]. Besides peptides, self-glycosphingolipids and bacterial lipoglycans may also act as T cell–stimulatory ligands. Molecules that bind and present these moieties belong to the family of nonpolymorphic, MHC class I– and II–related CD1 proteins. In the skin, members of the CD1 family are expressed mainly by LCs and DDCs (see Development, Maintenance, and Fate of Skin Dendritic Cells). The CD1 isoforms CD1a, CD1b, CD1c, and CD1d sample both recycling endosomes of the early endocytic system and late endosomes and lysosomes to which lipid antigens are delivered. Unlike in the MHC class II pathway, antigen loading in the CD1 pathway occurs in a vacuolar acidification-independent fashion. T cells expressing a Vα24-containing canonic TCR, NKT cells, and $CD4^-/CD8^-$ T cells include the most prominent subsets of CD1-restricted T cells. CD1-restricted T cells play important roles in host defense against microbial infections. Accordingly, human subjects infected with *M. tuberculosis* showed stronger responses to CD1c-mediated presentation of a microbial lipid antigen than control subjects, and activation of CD1d-restricted NKT cells with a synthetic glycolipid antigen resulted in improved immune responses to several infectious pathogens. Thus, the CD1 pathway of antigen presentation and glycolipid-specific T cells may provide protection during bacterial and parasite infection, probably by the secretion of pro-inflammatory cytokines, the direct killing of infected target cells, and B-cell help for Ig production.

Compelling evidence exists that LCs and other skin DCs, as members of the family of professional APCs, play a pivotal role in the induction of adaptive immune responses against pathogens and neoantigens introduced into and/or generated in the skin (immunosurveillance). This is best illustrated by the early observation that LC-containing, but not LC-depleted, epidermal cell suspensions pulse-exposed to either soluble protein antigens or haptens elicit a genetically restricted, antigen-specific, proliferative in vitro response in naive T cells.[185] Although these observations imply that the LC/DC system is indispensable for the occurrence of antigen-specific skin immunity, it is equally clear that LCs/DCs as they occur in their tissue residence are poorly, if at all, stimulatory for naive T cells. Inaba et al.[186] found that freshly isolated LCs ("immature" LCs) can present soluble antigen to primed MHC class II–restricted T cells but are only weak stimulators of naive, allogeneic T cells. In contrast, LCs purified from epidermal cell suspensions after a culture period of 72 hours or LCs purified from freshly isolated murine epidermal cells and cultured for 72 hours in the presence of GM-CSF and IL-1 ("mature" LC) are extremely potent stimulators of primary T cell–proliferative responses to alloantigens,[186] soluble protein antigens,[187] and haptens.[187] The strong immunostimulatory potential of mature LCs for resting T cells does not mean that they are superior to freshly isolated, immature LCs in every functional aspect. In fact, immature LCs far excel cytokine-activated LCs in their capacity to take up and process native protein antigens.[188] Accordingly, immature rather than mature LCs/DCs ex-

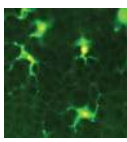

press antigen uptake receptors. Mature LCs, although fully capable of presenting pre-processed peptides, have lost their capacity to process and present native protein antigens.[188] This cytokine-induced/culture-induced switch from the processing/peptide loading to the presentation mode is a highly regulated LC/DC function attributable to fundamental molecular changes in protein synthesis and vesicle trafficking. LCs in their immature state display MHC class II antigens in lysosomal peptide-loading compartments (MIIC) and, to a much lesser extent, on the cell surface. When LCs mature in situ, MHC class II molecules are transferred to the plasma membrane. Likewise, MHC class I surface expression is upregulated during the process of DC maturation.

The display of MHC-peptide complexes on the DC surface delivers the "first signal" to T cells—that is, the triggering of the TCR by the APC-bound peptide-MHC complex. Although this event may be sufficient to induce the proliferation of primed T cells, it is insufficient for the productive activation of naive T cells. The occurrence of the latter requires the receipt of "second signals," which can be delivered by professional APCs. In fact, antigen-specific T cells that encounter MHC-expressing cells that cannot deliver second signals (e.g., MHC class II–induced keratinocytes, endothelial cells, fibroblasts) enter a state of anergy.[189] Second signals also determine the magnitude and quality of primary and secondary T-cell responses. In skin DCs, as well as in DCs from other locations, co-stimulatory molecules that deliver second signals are upregulated during maturation induced by surface receptors triggered by ligands secreted or presented by other somatic cells or, alternatively, by microbial products (danger or competence signals). Second signals include secreted cytokines and membrane-bound co-stimulators, the best defined of which are the two members of the B7 family, B7.1/CD80 and B7.2/CD86. LCs/DCs in situ do not express or express only minute amounts of these co-stimulatory molecules, but greatly upregulate these moieties during maturation. Other co-stimulatory molecules include the ICAM-1 that binds to LFA-1, and LFA-3, the ligand of T cell–expressed CD2. Other important ligand-receptor pairs that positively affect T-cell activation by DCs include heat-stable antigen (CD24)/CD24L, CD40/CD40L, CD70/CD27L, OX40 (CD134)/OX40L, and receptor activator of nuclear factor κB (RANK)/RANKL.

THE SKIN—INITIATION SITE AND TARGET OF IMMUNE RESPONSES (Fig. 10-9)

In 1983, Wayne Streilein coined the term *skin-associated lymphoid tissues*[191] to describe a functionally interactive circuit of cells and tissues (dendritic APCs, cytokine-producing keratinocytes, and skin-homing T cells originating in skin-draining peripheral lymph nodes) that provide the skin with unique immunosurveillance mechanisms for the successful prevention of or combat against cancer and infectious diseases. These cells and tissues also secure the homeostasis of the host by preventing the development or downregulating the expression of exaggerated tissue-destructive immune responses against per se innocuous moieties such as autoantigens and certain allergens.

Critical to the understanding of this yin-yang situation was the observation that, under homeostatic conditions, the overwhelming majority of antigen-presenting DCs are in an immature state that allows them to efficiently take up antigen with the help of specific receptor sites (e.g., Langerin, macrophage mannose receptor, C-type lectin receptor DEC-205, low-affinity IgG receptor CD32/FcγRII, high-affinity IgE receptor FcεRI, the thrombospondin receptor CD36, DC-SIGN), but does not endow them with immunostimulatory properties for naive resting T cells. On the delivery of danger signals,[164] however, DCs undergo a phenotypic and functional metamorphosis that enables them to elicit productive and, under optimal circumstances, protective primary immune responses.

It was originally assumed that the induction of antigen-specific non-responsiveness occurs when antigens are presented in the context of non-dendritic APCs (nonprofessional APCs). The early observation that the application of hapten to LC-deficient skin or mucosa results in hapten-specific tolerance[192] points in this direction.

More recent evidence now suggests that DCs/LCs themselves can actively induce immune tolerance. In vitro, immature DCs preferentially activate Treg cells.[193] In vivo, in the steady state, DCs induce tolerance to specific antigens targeted to these cells.[166,194,195] Mechanisms responsible for the tolerance-inducing property of nonactivated DCs, although not entirely understood, include (1) a reduced expression of MHC-antigen complexes[196] and co-stimulatory molecules[197] on the cell surface; (2) the secretion of immunosuppressive cytokines such as IL-10,[198] which fits well to the finding of Treg induction by UV-irradiated, IL-10–producing Treg cells[199]; (3) the expression of immunoinhibitory enzymes such as indoleamine 2,3-dioxygenase[200]; (4) the receipt of signals interfering with the maturation and migration of DCs, for example, neuropeptides such as CGRP[201] and vasoactive intestinal peptide,[202] the engagement of the CD47/SHPS-1 signal transduction cascade,[203] and others.

It appears that these different factors are not equally operative in all situations. LCs, for example, can activate self-antigen–specific CD8 T cells in the steady state, which leads to chronic skin disease,[204] and, at the same time, LCs are dispensable for[205] or can even downregulate[206] the induction of CHS.

Perturbation of tissue homoeostasis (i.e., the delivery of a danger signal) initiates a series of molecular events that allow peripheral DCs to rapidly migrate to secondary lymphoid organs, a journey during which they mature into potent immunostimulatory cells capable of sensitizing unprimed lymphocytes for productive responses. This can be well exemplified by a rather simple manipulation: culture of explanted skin for which hypoxia apparently suffices to trigger migration and maturation of cutaneous DCs.[167] Another example is the topical application of contact sensitizers (e.g., dinitrofluorobenzene), which leads to the activation of certain protein tyrosine kinases, the modification of cellular content and structure of intracytoplasmic organelles (increase in coated pits and vesicles, endosomes and lysosomes, Birbeck granules), and increased in situ motility of these cells.[207]

It appears that cytokines, released as a consequence of physicochemical or infection-associated tissue perturbation (e.g., keratinocyte-derived GM-CSF, TNF-α, IL-1) and/or ligation of CD40 molecules on DC/LC surfaces, provide the critical signal for the induction of LC maturation. But how do skin cells recognize a danger signal and translate it into increased cytokine production?

One biologically relevant pathway is certainly the maturation signal that is delivered to DCs/LCs by the uptake of necrotic cells. The fact that LCs are capable of cross-presentation[181,180] could make this an important mechanism in the generation of a protective antitumor immune response.

Successful defense against invading microorganisms involves the recognition of pathogen-associated molecular

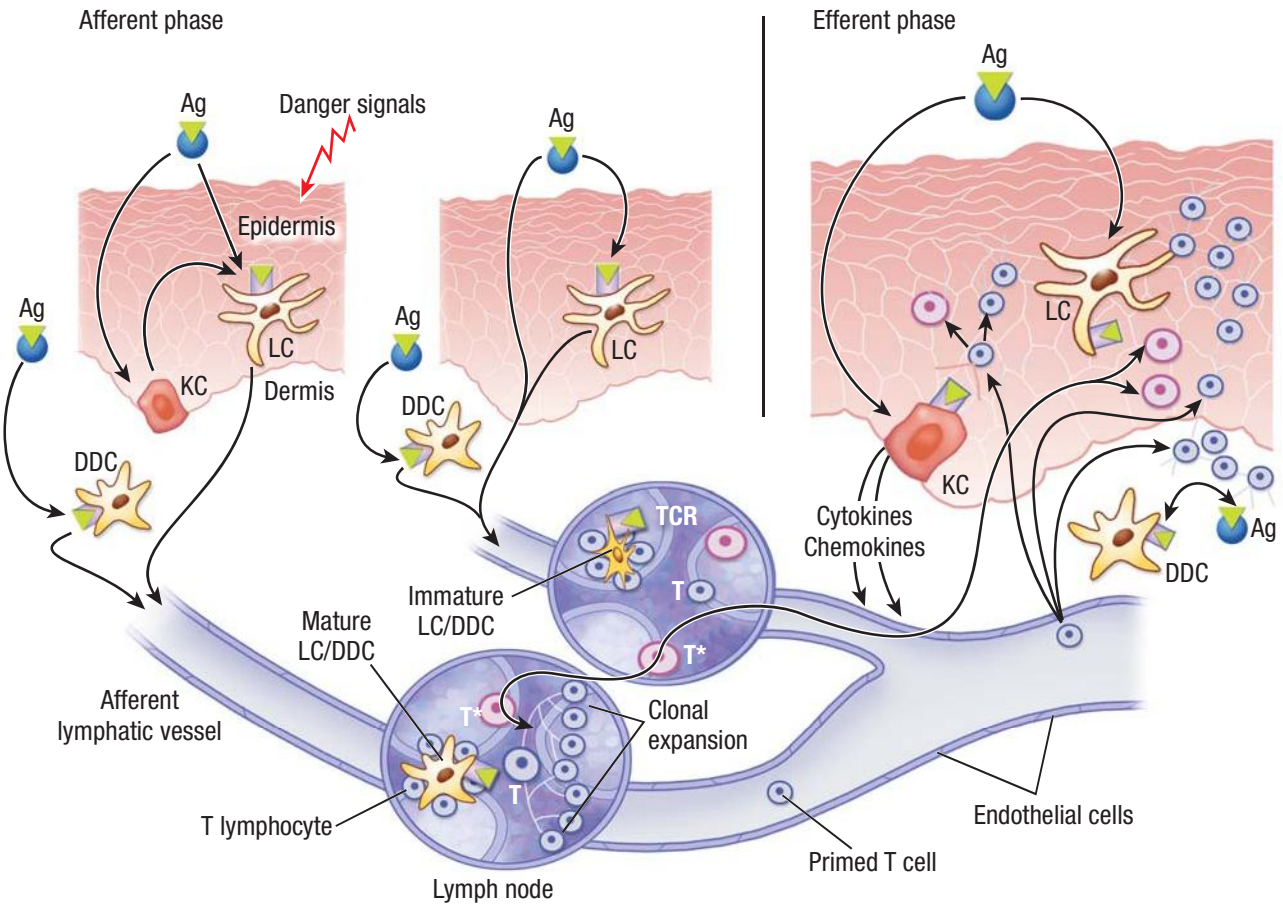

▲ **FIGURE 10-9** The mechanisms operative in the initiation, expression, and downregulation of cutaneous immune responses. Induction of productive T-cell immunity via the skin: The epicutaneous and/or intracutaneous de novo appearance of antigens (i.e., pathogens such as microorganisms and haptens) results in the elicitation of productive antigen-specific immunity when "danger signals" (i.e., bacterial DNA rich in unmethylated cytosine-phosphate-guanine repeats and other Toll-like receptor ligands) are present at the time of antigenic exposure. The receipt of danger signals leads to tissue perturbation, as evidenced by the increased secretion of granulocyte-macrophage colony-stimulating factor, tumor necrosis factor-α, and interleukin 1 (IL-1) by keratinocytes (KCs) and other skin cells. Antigen-presenting cells (APCs) [Langerhans cells (LCs), dermal dendritic cells (DDCs)] that pick up the antigen, process it, and re-express it as a peptide–major histocompatibility complex (MHC) product on the surface are also profoundly affected by danger signals or danger signal–induced cytokines. The alterations of LCs/DDCs include the increased expression of MHC antigens, co-stimulatory molecules, and cytokines (IL-1β, IL-6, IL-12), as well as the enhanced emigration of these cells from the skin to the paracortical areas of the draining lymph nodes. At this site, the skin-derived dendritic cells (DCs) provide activation stimuli to the naive resting T cells surrounding them. This occurs in an antigen-specific fashion and thus results in the expansion of the respective clone(s). These primed T cells begin to express skin-homing receptors (e.g., CLA) as well as receptors for various chemoattractants that promote their attachment to dermal microvascular endothelial cells of inflamed skin and, ultimately, their entry into this tissue. Elicitation of T cell–mediated tissue inflammation and pathogen defense: On receipt of a renewed antigenic stimulus by cutaneous APCs (LCs, DDCs), the skin-homing primed T cells expand locally and display the effector functions needed for the elimination, or at least the attack, of the pathogen. Alternatively, primed T cells may encounter the antigen on the surface of nonprofessional APCs (e.g., MHC class II–bearing KCs), a situation that conceivably results in a state of clonal T-cell anergy. Downregulation and prevention of cutaneous T-cell immunity: In the absence of danger signals (tissue homeostasis), antigen-loaded LCs/DDCs also leave the cutaneous compartment and migrate toward the draining lymph node. These cells or, alternatively, resident lymph node DCs that had picked up antigenic moieties from afferent lymphatics present this antigen in a nonproductive fashion—that is, they induce antigen-specific T-cell unresponsiveness or allow the responding T cell(s) to differentiate into immunosuppressive T regulatory cells. The latter may limit antigen-driven clonal T-cell expansion during primary immune reactions in lymph nodes and during secondary immune reactions at the level of the peripheral tissue. Such events can result in the downregulation of both desired (antitumor, antimicrobial) and undesired (hapten-specific, autoreactive) immune responses. Ag = antigen; T = T naive cell; T* = anergic T cell; TCR = T-cell receptor.

patterns through members of the TLR protein family, 11 members of which have been classified so far (see earlier). Evidence now exists that human LCs express messenger RNA encoding TLR1, TLR2, TLR3, TLR5, TLR6, and TLR10.[208] Ligands of TLR1, TLR2, and TLR6 include lipoproteins from *M. tuberculosis*, *B. burgdorferi*, *T. pallidum*, mycobacterial lipoarabinomannan, peptidoglycan, zymosan, and glycophosphatidyl inositol anchors from *T. pallidum* and *T. cruzi* lipoproteins. Whereas TLR5 detects bacterial flagellin, TLR3 is associated with the recognition of viral double-stranded RNA. LCs mount a particularly robust antiviral response to TLR3 agonists,[209] which implies that natural or synthetic ligands for TLR3 might prove useful in the treatment of viral skin infections.

For immunotherapeutic purposes, particular attention has also focussed on TLR7, TLR8, and TLR9, which are intracellular receptors for nucleic acids. TLR7 and TLR8 are engaged by viral single-stranded RNA and by synthetic small molecules mimicking features of nucleic

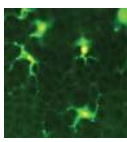

acids, such as imiquimod and R-848. TLR9, on the other hand, recognizes oligodeoxynucleotides (ODNs) containing unmethylated CpG motifs (CpG ODN), which are underrepresented in mammalian genomes but abundant in viral and bacterial DNA. Both TLR7 and TLR9 ligands have profound effects on the skin's immune system. Imiquimod and the other imidazoquinolines induce strong inflammation and, ultimately, regression of viral acanthomas and other superficial skin neoplasms.[210] CpG ODNs promote LC migration[211] and promote the development of Th1 responses.[212] It is still not clear how the topical application of TLR7 and TLR8 ligands could elicit such a robust inflammatory response, because the respective receptors are predominantly expressed on pDCs, which are the main producers of type I IFNs and are virtually absent in normal human skin.[213] The demonstration of TLR7 on suprabasal keratinocytes[208] could indicate that these cells, rather than LCs or DDCs, are the prime skin targets of topical imidazoquinolines and, by triggering the production of pro-inflammatory cytokines and chemokines in these cells, are responsible for the influx of different types of leukocytes, including plasmacytoid and myeloid inflammatory-type DCs. The role of these latter cells in the immune response has yet to be clarified. Evidence exists that inflammatory-type myeloid DCs skew the immune response in a Th1 direction[163] and that pDCs, depending on their state of activation, favor the activation of Th2 and Treg cells, respectively. When topical imiquimod treatment (see Chap. 221) results in the regression and, ultimately, resolution of skin neoplasms, these inflammatory-type DCs are abundantly present around regressing tumor cell islands[214] and can express molecules of the lytic machinery such as perforin, granzyme B, and TNF-related apoptosis-inducing ligand, which suggests their cytotoxic potential.

The induction of skin cell injury and/or demise by cells of the innate immune system should not detract from the fact that adaptive mechanisms are responsible for most of the desired immune reactions in the skin (i.e., the elimination of pathogenic microorganisms and neoplastic cells) as well as for immune-mediated injury of the skin. Examples of the latter are bullous diseases such as pemphigus and bullous pemphigoid. Although these entities are mediated by autoantibodies, other skin diseases are apparently the result of exaggerated and/or misdirected T-cell reactions.

The skin immune system is also affected by various immunomodulating compounds applied to or introduced into the skin. The efficacy of imidazoquinolines and CpG oligonucleotides in cutaneous neoplasms has already been discussed, and one would predict that a more selective targeting of LCs/DDCs will increase their efficacy, tolerability, and safety.

Corticosteroids, the most frequently used immunoinhibitory and anti-inflammatory substances in dermatology, have a profound influence on the phenotype and function of cutaneous leukocytes at both the topical and systemic levels. After topical application of betamethasone valerate for only a few days, apoptotic events are clearly visible in the epidermal LC population, and on continuation of this treatment the epidermis can be essentially depleted of these cells. The so-called *inflammatory-type DCs* (i.e., inflammatory dendritic epidermal cells and pDCs) are similarly susceptible to corticosteroids, which is one of the reasons for the excellent efficacy of topical corticosteroids in treating acute dermatitis/eczema.[220]

The effects of the topical calcineurin inhibitors tacrolimus and pimecrolimus are more selective. Their application to the skin of patients with atopic dermatitis leads to an apoptosis-induced depletion of T cells and to a gradual disappearance of inflammatory-type DCs but leaves the epidermal LC population essentially unaltered.[220] Time will tell whether the differential effects of topical corticosteroids and calcineurin inhibitors on the skin immune system will have an influence on the long-term safety of these compounds.

The entire field of topical immunomodulation is now advancing rapidly because of (1) an increasingly better understanding of the skin's immune function and, as a consequence, the identification of promising drug targets; (2) new computer-assisted methods of drug design; and (3) new technologies that allow for a better penetration of a given compound into the skin and its guidance to the desired target. These developments are heralding a new golden era of skin-based immunotherapy, and the skills of a well-trained dermatologist are required to use the therapy for the maximum benefit of patients.

KEY REFERENCES

The full reference list for all chapters is available at www.digm7.com.

2. Gasque P: Complement: A unique innate immune sensor for danger signals. *Mol Immunol* **41**:1089, 2004
6. Braff MH et al: Cutaneous defense mechanisms by antimicrobial peptides. *J Invest Dermatol* **125**:9, 2005
29. Akira S, Uematsu S, Takeuchi O: Pathogen recognition and innate immunity. *Cell* **124**:783, 2006
55. van Kooten C, Banchereau J: CD40-CD40 ligand. *J Leukoc Biol* **67**:2, 2000
71. Harrington LE, Mangan PR, Weaver CT: Expanding the effector CD4 T-cell repertoire: The Th17 lineage. *Curr Opin Immunol* **18**:349, 2006
81. von Boehmer H: Selection of the T-cell repertoire: Receptor-controlled checkpoints in T-cell development. *Adv Immunol* **84**:201, 2004
84. Abbas AK, Murphy KM, Sher A: Functional diversity of helper T lymphocytes. *Nature* **383**:787, 1996
92. Berke G: The binding and lysis of target cells by cytotoxic lymphocytes: Molecular and cellular aspects. *Annu Rev Immunol* **12**:735, 1994
101. Butcher EC, Picker LJ: Lymphocyte homing and homeostasis. *Science* **272**:60, 1996
115. Modlin RL et al: Learning from lesions: Patterns of tissue inflammation in leprosy. *Proc Natl Acad Sci U S A* **85**:1213, 1988
138. Langerhans P: Über die Nerven der menschlichen Haut. *Virchows Arch* **44**:325, 1868
140. Banchereau J, Steinman RM: Dendritic cells and the control of immunity. *Nature* **392**:245, 1998
159. Siegal FP et al: The nature of the principal type 1 interferon-producing cells in human blood. *Science* **284**:1835, 1999
164. Matzinger P: An innate sense of danger. *Ann N Y Acad Sci* **961**:341, 2002
184. Porcelli SA, Modlin RL: The CD1 system: Antigen-presenting molecules for T cell recognition of lipids and glycolipids. *Annu Rev Immunol* **17**:297, 1999
185. Stingl G, Tamaki K, Katz SI: Origin and function of epidermal Langerhans cells. *Immunol Rev* **53**:149, 1980
191. Streilein JW: Skin-associated lymphoid tissues (SALT): Origins and functions. *J Invest Dermatol* **80 Suppl**:12s, 1983
197. Lutz MB, Schuler G: Immature, semi-mature and fully mature dendritic cells: Which signals induce tolerance or immunity? *Trends Immunol* **23**:445, 2002
202. Kodali S et al: Vasoactive intestinal peptide modulates Langerhans cell immune function. *J Immunol* **173**:6082, 2004
210. Dockrell DH, Kinghorn GR: Imiquimod and resiquimod as novel immunomodulators. *J Antimicrob Chemother* **48**:751, 2001

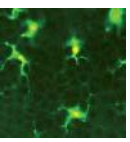

CHAPTER 11

Cytokines

Ifor R. Williams
Benjamin E. Rich
Thomas S. Kupper

THE CONCEPT OF CYTOKINES

When cells and tissues in complex organisms need to communicate over distances greater than one cell diameter, soluble factors must be employed. A subset of these factors is most important when produced or released transiently under emergent conditions. When faced with an infection- or injury-related challenge, the host must orchestrate a complex and carefully choreographed series of steps. It must mobilize certain circulating white blood cells precisely to the relevant injured area (but not elsewhere) and guide other leukocytes involved in host defense, particularly T and B cells, to specialized lymphatic tissue remote from the infectious lesion but sufficiently close to contain antigens from the relevant pathogen. After a limited period of time in this setting (i.e., lymph node), antibodies produced by B cells, and effector memory T cells, can be released into the circulation and will localize at the site of infection. Soluble factors produced by resident tissue cells at the site of injury, by leukocytes and platelets that are recruited to the site of injury, and by memory T cells ultimately recruited to the area, all conspire to generate an evolving and effective response to a challenge to host defense. Most important, the level of this response must be appropriate to the challenge and the duration of the response must be transient; that is, long enough to decisively eliminate the pathogen, but short enough to minimize damage to healthy host tissues. Much of the cell-to-cell communication involved in the coordination of this response is accomplished by cytokines.

General features of cytokines are their pleiotropism and redundancy. Before the advent of a systematic nomenclature for cytokines, most newly identified cytokines were named according to the biologic assay that was being used to isolate and characterize the active molecule (e.g., T-cell growth factor for the molecule that was later renamed *interleukin 2*, or IL-2). Very often, independent groups studying quite disparate bioactivities isolated the same molecule, which revealed the pleiotropic effects of these cytokines. For example, before being termed *interleukin 1*, this cytokine had been variously known as *endogenous pyrogen*, *lymphocyte-activating factor*, and *leukocytic endogenous mediator*. Many cytokines have a wide range of activities, causing multiple effects in responsive cells and a different set of effects in each type of cell capable of responding. The redundancy of cytokines typically means that in any single bioassay (such as induction of T-cell proliferation), multiple cytokines will display activity. In addition, the absence of a single cytokine (such as in mice with targeted mutations in cytokine genes) can often be largely or even completely compensated for by other cytokines with overlapping biologic effects.

CLASSIFICATIONS OF CYTOKINES

Primary and Secondary Cytokines

A simple concept that continues to be extremely useful for discussion of cytokine function is the concept of "primary" and "secondary" cytokines.[5] Primary cytokines are those cytokines that can, by themselves, initiate all the events required to bring about leukocyte infiltration in tissues. IL-1 (both α and β forms) and tumor necrosis factor (TNF; includes both TNF-α and TNF-β) function as primary cytokines, as do certain other cytokines that signal through receptors that trigger the nuclear factor κB (NF-κB) pathway. IL-1 and TNF are able to induce cell adhesion molecule expression on endothelial cells [selectins as well as immunoglobulin superfamily members such as intercellular adhesion molecule 1 (ICAM-1) and vascular cellular adhesion molecule 1 (VCAM-1)], to stimulate a variety of cells to produce a host of additional cytokines, and to induce expression of chemokines that provide a chemotactic gradient allowing the directed migration of specific leukocyte subsets into a site of inflammation (see Chapter 12). Primary cytokines can be viewed as part of the innate immune system (see Chap. 10), and in fact share signaling pathways with the so-called *Toll-like receptors (TLRs)*, a family of receptors that recognize molecular patterns characteristically associated with microbial products.[6] Although other cytokines sometimes have potent inflammatory activity, they do not duplicate this full repertoire of activities. Many qualify as secondary cytokines whose production is induced after stimulation by IL-1 and/or TNF family molecules. The term *secondary* does not imply that they are less important or less active than primary cytokines; rather, it indicates that their spectrum of activity is more restricted.

CYTOKINES AT A GLANCE

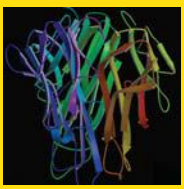

- Cytokines are polypeptide mediators that function in communication between hematopoietic cells and other cell types.
- Cytokines often have multiple biologic activities (pleiotropism) and overlapping biologic effects (redundancy).
- Primary cytokines, such as interleukin 1 and tumor necrosis factor-α, are sufficient on their own to trigger leukocyte influx into tissue.
- Most cytokines signal through either the nuclear factor κB or the Jak/STAT signaling pathways.
- Cytokine-based therapeutics now in use include recombinant cytokines, inhibitory monoclonal antibodies, fusion proteins composed of cytokine receptors and immunoglobulin chains, topical immunomodulators such as imiquimod, and cytokine fusion toxins.

T-Cell Subsets Distinguished by Pattern of Cytokine Production

Another valuable concept that has withstood the test of time is the assignment of many T cell–derived cytokines into groups based on the specific helper T-cell subsets that produce them (Fig. 11-1). The original two helper T-cell subsets were termed *Th1* and *Th2*. Commitment to one of these two patterns of cytokine secretion also occurs with CD8 cytotoxic T cells and γ/δ T cells. Dominance of type 1 or type 2 cytokines in a T-cell immune response has profound consequences for the outcome of immune responses to certain pathogens and extrinsic proteins capable of serving as allergens.[7] Nearly two decades after the original description of the Th1 and Th2 subsets, strong evidence has emerged that there are other function-

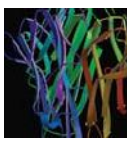

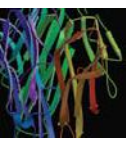

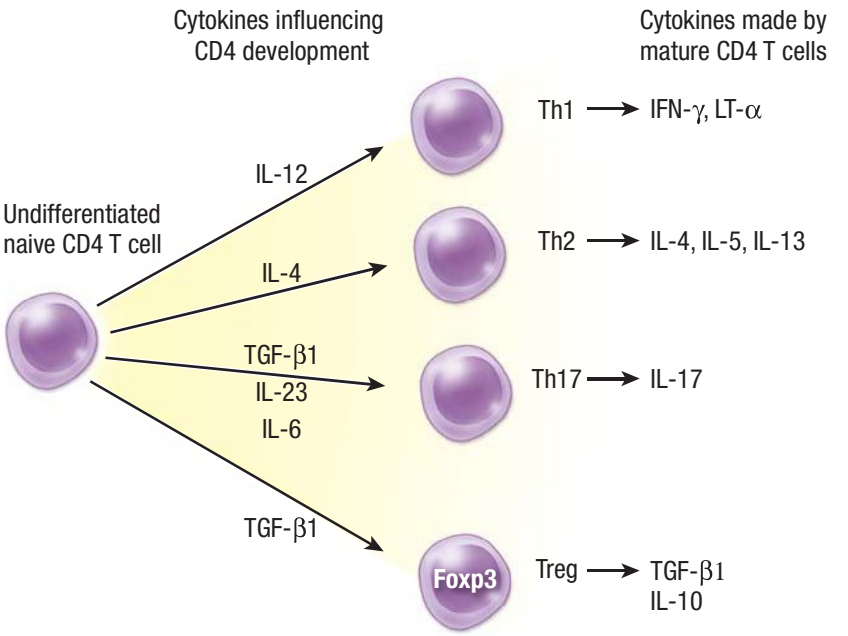

▲ **FIGURE 11-1** Cytokines control the development of specific CD4 helper T-cell subsets. The cytokine milieu at the time of activation of naive undifferentiated CD4 T cells has a profound influence on the ultimate pattern of cytokine secretion adopted by fully differentiated T cells. Subsets of effector CD4 T cells with defined patterns of cytokine secretion include T helper 1 (Th1), Th2, and Th17 cells. Regulatory CD4 T cells (Treg cells) express the FoxP3 transcription factor, and their effects are mediated in part by their production of transforming growth factor-β1 (TGF-β1) and/or interleukin 10 (IL-10). IFN = interferon; LT = lymphotoxin. (Adapted from Tato CM, O'Shea JJ: What does it mean to be just 17? *Nature* **441**:166, 2006.)

ally significant patterns of cytokine secretion by T cells. The Th17 subset is distinguished by production of a high level of IL-17, a member of a family of related cytokines (the other members are IL-17B through F) that had not yet been identified when the Th1 and Th2 subsets were first described. Th17 cells promote inflammation, and there is consistent evidence from human autoimmune diseases and mouse models of these diseases that IL-17–producing cells are critical effectors in autoimmune disease.[8] Another subset of T cells known as *regulatory T cells* (or *Treg cells* for short) has emerged as a crucial subset involved in the maintenance of peripheral self-tolerance.[9] Two of the most distinctive features of Treg cells are their expression of the FoxP3 transcription factor and production of transforming growth factor-β (TGF-β), a cytokine that appears to be required for Treg cells to limit the excess activity of the pro-inflammatory T-cell subsets.[10] IL-10 may also be required for the activity of Treg cells. Not only do each of these T-cell subsets exhibit distinctive patterns of cytokine production, cytokines are key factors in influencing the differentiation of naive T cells into these subsets. IL-12 is the key Th1-promoting factor, IL-4 is required for Th2 differentiation, and both IL-23 and TGF-β are involved in promoting Th17 development.

Structural Classification of Cytokines

Not all useful classifications of cytokines are based solely on analysis of cytokine function. Structural biologists, aided by improved methods of generating homogenous preparations of proteins and establishment of new analytical methods (e.g., solution magnetic resonance spectroscopy) that complement the classical x-ray crystallography technique, have determined the three-dimensional structure of many cytokines. These efforts have led to the identification of groups of cytokines that fold to generate similar three-dimensional structures and bind to groups of cytokine receptors that also share similar structural features. For example, most of the cytokine ligands that bind to receptors of the hematopoietin cytokine receptor family are members of the four-helix bundle group of proteins. Four-helix bundle proteins have a shared tertiary architecture consisting of four antiparallel α-helical stretches separated by short connecting loops. The normal existence of some cytokines as oligomers rather than monomers was discovered in part as the result of structural investigations. For example, interferon-γ (IFN-γ) is a four-helix bundle cytokine that exists naturally as a noncovalent dimer. The bivalency of the dimer enables this ligand to bind and oligomerize two IFN-γ receptor complexes, thereby facilitating signal transduction. TNF-α and TNF-β are both trimers that are composed almost exclusively of β-sheets folded into a "jelly roll" structural motif. Ligand-induced trimerization of receptors in the TNF receptor family is involved in the initiation of signaling.

SIGNAL TRANSDUCTION PATHWAYS SHARED BY CYTOKINES

To accomplish their effects, cytokines must first bind with specificity and high affinity to receptors on the cell surfaces of responding cells. Many aspects of the pleiotropism and redundancy manifested by cytokines can be understood through an appreciation of shared mechanisms of signal transduction mediated by cell surface receptors for cytokines. In the early years of the cytokine biology era, the emphasis of most investigative work was the purification and eventual cloning of new cytokines and a description of their functional capabilities, both in vitro and in vivo. Most of the cytokine receptors have now been cloned, and many of the signaling cascades initiated by cytokines have been described in great detail. The vast majority of cytokine receptors can be classified into a relatively small number of families and superfamilies (Table 11-1), the members of which function in an approximately similar fashion. Table 11-2 lists the cytokines of particular relevance for cutaneous biology, including the major sources, responsive cells, features of interest, and clinical relevance of each cytokine. Most cytokines send signals to cells through pathways that are very similar to those used by other cytokines binding to the same class of receptors. Individual cytokines often employ several downstream pathways of signal transduction, which accounts in part for the pleiotropic effects of these molecules. Nevertheless, we propose here that a few major signaling pathways account for most effects attributable to cytokines. Of particularly central importance are the NF-κB pathway and the Jak/STAT pathway, described in the following sections.

Nuclear Factor κB, Inhibitor of κB, and Primary Cytokines

A major mechanism contributing to the extensive overlap between the biologic

TABLE 11-1
Major Families of Cytokine Receptors

Receptor Family	Example	Major Signal Transduction Pathway(s) Leading to Biologic Effects
IL-1 receptor family	IL-1R, type I	NF-κB activation via TRAF6
TNF receptor family	TNFR1	NF-κB activation involving TRAF2 and TRAF5 Apoptosis induction via "death domain" proteins
Hematopoietin receptor family (class I receptors)	IL-2R	Activation of Jak/STAT pathway
IFN/IL-10 receptor family (class II receptors)	IFN-γR	Activation of Jak/STAT pathway
Immunoglobulin superfamily	M-CSF R	Activation of intrinsic tyrosine kinase
TGF-β receptor family	TGF-βR, types I and II	Activation of intrinsic serine/threonine kinase coupled to Smad proteins
Chemokine receptor family	CCR5	Seven transmembrane receptors coupled to G proteins

CCR = CC chemokine receptor; IFN = interferon; IL = interleukin; Jak = Janus kinase; M-CSF = macrophage colony-stimulating factor; NF-κB = nuclear factor κB; STAT = signal transducer and activator of transcription; TGF = transforming growth factor; TNF= tumor necrosis factor; TRAF = tumor necrosis factor receptor–associated factor.

activities of the primary cytokines IL-1 and TNF is the shared use of the NF-κB signal transduction pathway. IL-1 and TNF use completely distinct cell surface receptor and proximal signaling pathways, but these pathways converge at the activation of the NF-κB transcription factor. NF-κB is of central importance in immune and inflammatory processes because a large number of genes that elicit or propagate inflammation have NF-κB recognition sites in their promoters.[11] NF-κB–regulated genes include cytokines, chemokines, adhesion molecules, nitric oxide synthase, cyclooxygenase, and phospholipase A2.

In unstimulated cells, NF-κB heterodimers formed from p65 and p50 subunits are inactive because they are sequestered in the cytoplasm as a result of tight binding to inhibitor proteins in the IκB family (Fig. 11-2). Signal transduction pathways that activate the NF-

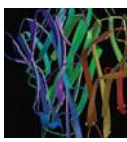

TABLE 11-2
Cytokines of Particular Relevance for Cutaneous Biology

Cytokine	Major Sources	Responsive Cells	Features of Interest	Clinical Relevance
IL-1α	Epithelial cells	Infiltrating leukocytes	Active form stored in keratinocytes	IL-1Ra used to treat rheumatoid arthritis
IL-1β	Myeloid cells	Infiltrating leukocytes	Caspase 1 cleavage required for activation	IL-1Ra used to treat rheumatoid arthritis
IL-2	Activated T cells	Activated T cells, Treg cells	Autocrine factor for activated T cells	IL-2 fusion toxin targets CTCL
IL-4	Activated Th2 cells, NKT cells	Lymphocytes, endothelial cells, keratinocytes	Causes B-cell class switching and Th2 differentiation	—
IL-5	Activated Th2 cells, mast cells	B cells, eosinophils	Regulates eosinophil response to parasites	Anti–IL-5 depletes eosinophils
IL-6	Activated myeloid cells, fibroblasts, endothelial cells	B cells, myeloid cells, hepatocytes	Triggers acute-phase response, promotes immunoglobulin synthesis	—
IL-10	T cells, NK cells	Myeloid and lymphoid cells	Inhibits innate and acquired immune responses	—
IL-12	Activated APCs	Th1 cells	Promotes Th1 differentiation, shares p40 subunit with IL-23	Anti-p40 inhibits Crohn disease and psoriasis
IL-13	Activated Th2 cells	Monocytes, keratinocytes, endothelial cells	Mediates tissue responses to parasites	—
IL-17	Activated Th17 cells	Multiple cell types	Mediates autoimmune diseases	Potential drug target in autoimmune disease
IL-23	Activated dendritic cells	Memory T cells, Th17 cells	Directs Th17 differentiation, mediates autoimmune disease	Anti-p40 inhibits Crohn disease and psoriasis
TNF-α	Activated myeloid, lymphoid, and epithelial cells	Infiltrating leukocytes	Mediates inflammation	Anti–TNF-α effective in psoriasis
IFN-α and IFN-β	Plasmacytoid dendritic cells	Most cell types	Major part of antiviral response	Elicited by topical imiquimod application
IFN-γ	Activated Th1 cells, CD8 T cells, NK cells, dendritic cells	Macrophages, dendritic cells, naive T cells	Macrophage activation, specific isotype switching	IFN-γ used to treat chronic granulomatous disease

APC = antigen-presenting cell; CTCL = cutaneous T-cell lymphoma; IFN = interferon; IL = interleukin; NK = natural killer; NKT = natural killer T cell; Th = T helper; TNF = tumor necrosis factor; Treg = T regulatory.

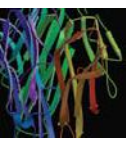

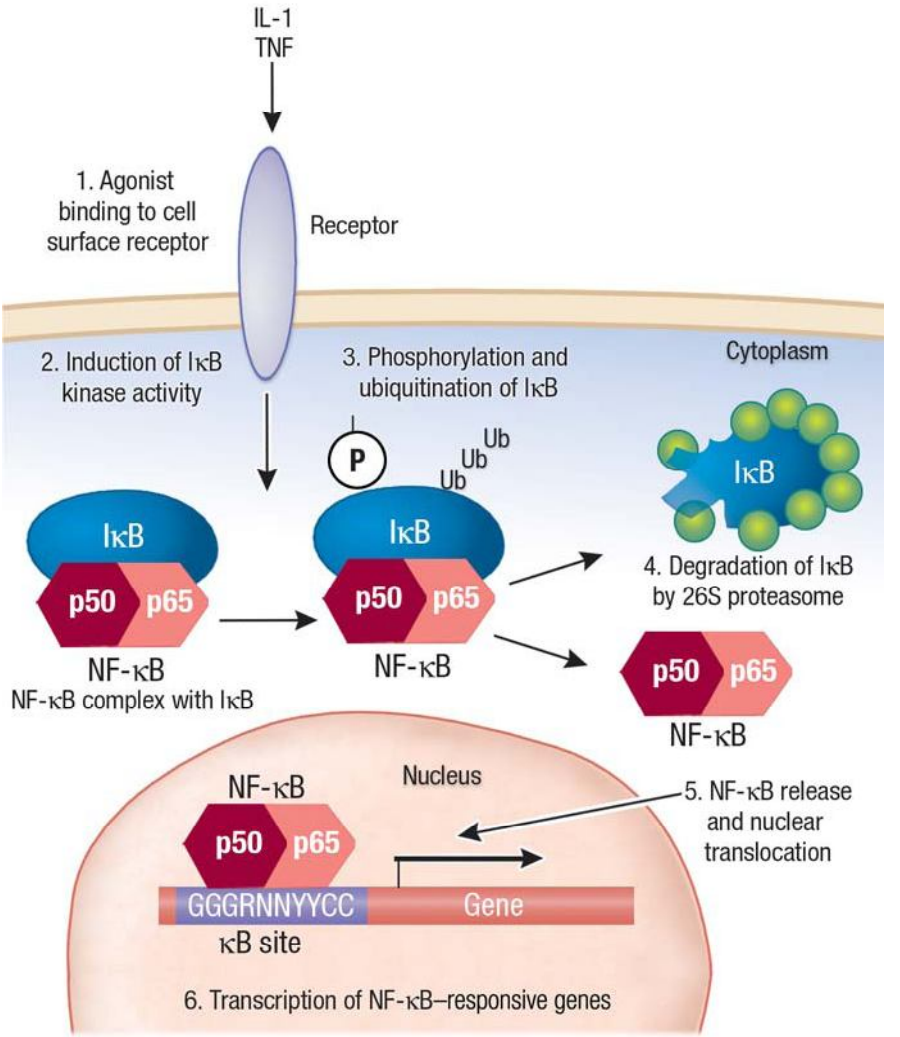

▲ **FIGURE 11-2** Activation of nuclear factor κB (NF-κB)–regulated genes after signaling by receptors for primary cytokines or by Toll-like receptors (TLRs) engaged by microbial products. Under resting conditions, NF-κB (a heterodimer of p50 and p65 subunits) is tightly bound to an inhibitor called *IκB* that sequesters NF-κB in the cytoplasm. Engagement of one of the TLRs or the signal transducing receptors for interleukin 1 (IL-1) or tumor necrosis factor (TNF) family members leads to induction of IκB kinase activity that phosphorylates IκB on critical serine residues. Phosphorylated IκB becomes a substrate for ubiquitination, which triggers degradation of IκB by the 26S proteasome. Loss of IκB results in release of NF-κB, which permits it to move to the nucleus and activate transcription of genes whose promoters contain κB recognition sites. Ub = ubiquitin.

κB system do so through the activation of an IκB kinase (IKK) complex consisting of two kinase subunits (IKKα and IKKβ) and a regulatory subunit (IKKγ). The IKK complex phosphorylates IκBα and IκBβ on specific serine residues, yielding a target for recognition by an E3 ubiquitin ligase complex. The resulting polyubiquitination marks this IκB for rapid degradation by the 26S proteasome complex in the cytoplasm. Once IκB has been degraded, the free NF-κB (which contains a nuclear localization signal) is able to pass into the nucleus and induce expression of NF-κB–sensitive genes. The presence of κB recognition sites in cytokine promoters is very common. Among the genes regulated by NF-κB are IL-1β and TNF-α. This endows IL-1β and TNF-α with the capacity to establish a positive regulatory loop that favors persistent inflammation. Cytokines besides IL-1 and TNF that activate the NF-κB pathway as part of their signal transduction mechanisms include IL-17 and IL-18.

Pro-inflammatory cytokines are not the only stimuli that can activate the NF-κB pathway. Bacterial products (e.g., lipopolysaccharide, or LPS), oxidants, activators of protein kinase C (e.g., phorbol esters), viruses, and ultraviolet (UV) radiation are other stimuli that can stimulate NF-κB activity. TLR4 is a cell surface receptor for the complex of LPS, LPS-binding protein, and CD14. The cytoplasmic domain of TLR4 is similar to that of the interleukin 1 receptor type 1 (IL-1R1) and other IL-1R family members and is known as the *TIR* domain (for Toll/IL-1 receptor).[12] When ligand is bound to a TIR domain–containing receptor, one or more adapter proteins that also contain TIR domains are recruited to the complex. MyD88 was the first of these adapters to be identified; the other known adapters are TIRAP (TIR domain–containing adapter protein), TRIF (TIR domain–containing adapter inducing IFN-β), and TRAM (TRIF-related adapter molecule).[13] Engagement of the adapter, in turn, activates one or more of the IL-1R–associated kinases (IRAK1 to IRAK4), which then signal through TRAF6, a member of the TRAF (TNF receptor–associated factor) family, and TAK1 (TGF-β–activated kinase) to activate the IKK complex.[14]

Jak/STAT Pathway

A major breakthrough in the analysis of cytokine-mediated signal transduction was the identification of a common cell surface to nucleus pathway used by the majority of cytokines. This Jak/STAT pathway was first elucidated through careful analysis of signaling initiated by IFN receptors (Fig. 11-3) but was subsequently shown to play a role in signaling by all cytokines that bind to members of the hematopoietin receptor family.[15] The Jak/STAT pathway operates through the sequential action of a family of four nonreceptor tyrosine kinases (the Jaks or *Ja*nus family *k*inases) and a series of latent cytosolic transcription factors known as *STATs* (*s*ignal *t*ransducers and *a*ctivators of *t*ranscription). The cytoplasmic portions of many cytokine receptor chains are noncovalently associated with one of the four Jaks [Jak1, Jak2, Jak3, and tyrosine kinase 2 (Tyk2)].

The activity of the Jak kinases is upregulated after stimulation of the cytokine receptor. Ligand binding to the cytokine receptors leads to the association of two or more distinct cytokine receptor subunits and brings the associated Jak kinases into close proximity with each other. This promotes cross-phosphorylation or autophosphorylation reactions that in turn fully activate the kinases. Tyrosines in the cytoplasmic tail of the cytokine receptor as well as tyrosines on other associated and newly recruited proteins are also phosphory-

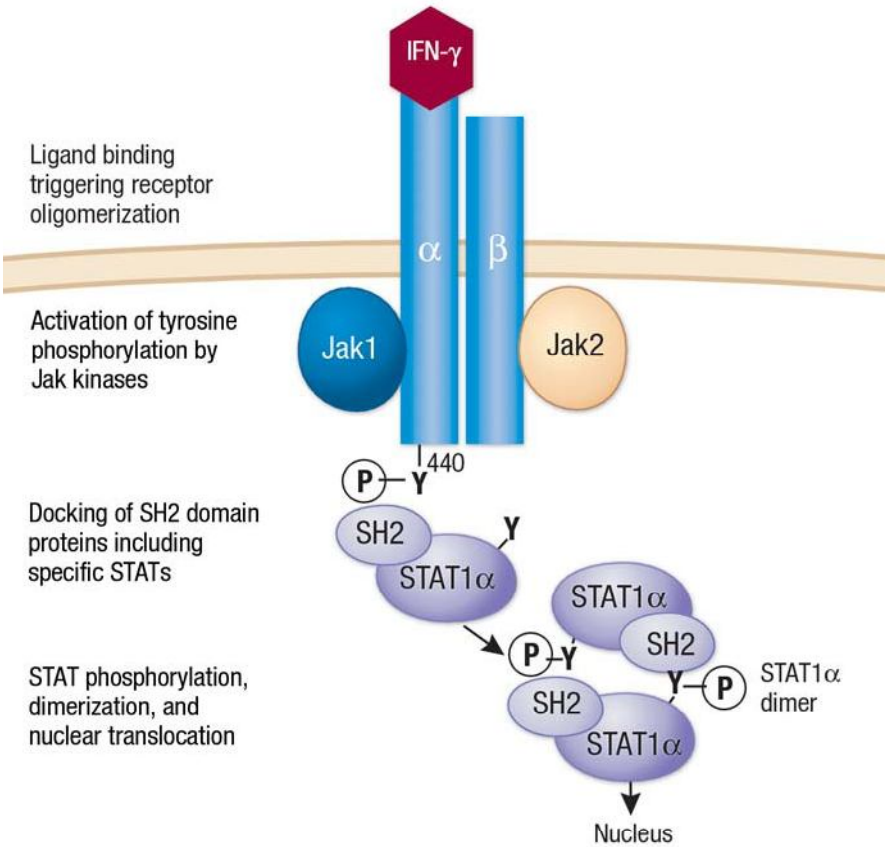

▲ **FIGURE 11-3** Participation of Jak (Janus kinase) and STAT (signal transducer and activator of transcription) proteins in interferon-γ (IFN-γ) signaling. Binding of human IFN-γ (a dimer) to its receptor brings about oligomerization of receptor complexes composed of α and β chains. The nonreceptor protein tyrosine kinases Jak1 and Jak2 are activated and phosphorylate critical tyrosine residues in the receptor such as the tyrosine at position 440 of the α chain (Y^{440}). STAT1α molecules are recruited to the IFN-γ receptor based on the affinity of their Src homology 2 (SH2) domains for the phosphopeptide sequence around Y^{440}. Receptor-associated STAT1α molecules then dimerize through reciprocal SH2-phosphotyrosine interactions. The resulting STAT1α dimers translocate to the nucleus and stimulate transcription of IFN-γ–regulated genes.

lated. A subset of the newly phosphorylated tyrosines can then serve as docking points for attachment of additional signaling proteins bearing Src homology 2 (SH2) domains. Cytoplasmic STATs possess SH2 domains and are recruited to the phosphorylated cytokine receptors via this interaction. Homodimeric or heterodimeric STAT proteins are phosphorylated by the Jak kinases and subsequently translocate to the nucleus. In the nucleus they bind recognition sequences in DNA and stimulate transcription of specific genes, often in cooperation with other transcription factors. The same STAT molecules can be involved in signaling by multiple different cytokines. The specificity of the response in these instances may depend on the formation of complexes involving STATs and other transcription factors that then selectively act on a specific set of genes.

INTERLEUKIN 1 FAMILY OF CYTOKINES (INTERLEUKINS 1α, 1β, 18, 33)

IL-1 is the prototype of a cytokine that has been discovered many times in many different biologic assays. Distinct genes encode the α and β forms of human IL-1, with only 26 percent homology at the amino acid level. Both IL-1s are translated as 31-kd molecules that lack a signal peptide, and both reside in the cytoplasm. This form of IL-1α is biologically active, but 31-kd IL-1β must be cleaved by caspase 1 (initially termed *interleukin-1β–converting enzyme*) to generate an active molecule.

In general, IL-1β appears to be the dominant form of IL-1 produced by monocytes, macrophages, Langerhans cells, and dendritic cells, whereas IL-1α predominates in epithelial cells, including keratinocytes. This is likely to relate to the fact that epithelial IL-1α is stored in the cytoplasm of cells that comprise an interface with the external environment. Such cells, when injured, release biologically active 31-kd IL-1α and, by doing so, can initiate inflammation.[5] If uninjured, however, these cells will differentiate and ultimately release their IL-1 contents into the environment. Leukocytes, including dendritic and Langerhans cells, carry their cargo of IL-1 inside the body, where its unregulated release could cause significant tissue damage. Thus, biologically active IL-1β release from cells is controlled at several levels: IL-1β gene transcription, caspase 1 gene transcription, and availability of the adapter proteins ASC and Ipaf that interact with caspase 1 in the inflammasome to allow the generation of mature IL-1β.[16] The role of IL-1β in the migration of Langerhans cells from the epidermis during the initiation of contact hypersensitivity is a pivotal event in the egress of Langerhans cells from the epidermis and the generation of successful sensitization. Studies of mice deficient in IL-1α and IL-1β genes suggest that both molecules are important in contact hypersensitivity but that IL-1α is more critical.

Active forms of IL-1 bind to the IL-1R1 or type 1 IL-1 receptor.[12] This is the sole signal-transducing receptor for IL-1, and its cytoplasmic domain has little homology with other cytokine receptors, showing greatest homology with the *Toll* gene product identified in *Drosophila*. A second cell surface protein, the IL-1R accessory protein, or IL-1RAcP, must associate with IL-1R1 for signaling to occur. When IL-1 engages the IL-1R1/IL-1RAcP complex, recruitment of the MyD88 adapter occurs, followed by interactions with one or more of the IRAKs. These kinases in turn associate with TRAF6. Stepwise activation and recruitment of additional signaling molecules culminate in the induction of IKK activity. The net result is the activation of a series of NF-κB–regulated genes.

A molecule known as the *IL-1 receptor antagonist*, or IL-1ra, can bind to IL-1R1 but does not induce signaling through the receptor. This IL-1ra exists in three alternatively spliced forms, and an isoform produced in monocytes is the only ligand for the IL-1R1 that both contains a signal peptide and is secreted from cells. Two other isoforms of IL-1ra, both lacking signal peptides, are contained within epithelial cells. The function of IL-1ra seems to be as a pure antagonist of IL-1 ligand binding to IL-1R1, and binding of IL-1ra to IL-1R1 does not in-

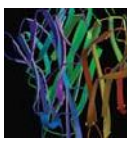

duce the mobilization of IL-1RAcP. Consequently, although both IL-1α/β and IL-1ra bind with equivalent affinities to IL-1R1, the association of IL-1R1 with IL-1RAcP increases the affinity for IL-1α/β manyfold while not affecting the affinity for IL-1ra. This is consistent with the observation that a vast molar excess of IL-1ra is required to fully antagonize the effects of IL-1. The biologic role of IL-1ra is likely to be in the quenching of IL-1–mediated inflammatory responses, and mice deficient in IL-1ra show exaggerated and persistent inflammatory responses.

A second means of antagonizing IL-1 activity occurs via expression of a second receptor for IL-1, IL-1R2. This receptor has a short cytoplasmic domain and serves to bind IL-1α/β efficiently, but not IL-1ra. This 68-kd receptor can be cleaved from the cell surface by an unknown protease and released as a stable, soluble 45-kd molecule that retains avid IL-1–binding function. By binding the functional ligands for IL-1R1, IL-1R2 serves to inhibit IL-1–mediated responses. It is likely that IL-1R2 inhibits IL-1 activity in another way, that is, by associating with IL-1RAcP at the cell surface and removing and sequestering it from the pool available to associate with IL-1R1. Thus, soluble IL-1R2 binds to free IL-1, whereas cell surface IL-1R2 sequesters IL-1RAcP. Expression of IL-1R2 can be upregulated by a number of stimuli, including corticosteroids and IL-4. However, IL-1R2 can also be induced by inflammatory cytokines, including IFN-γ and IL-1, probably as a compensatory signal designed to limit the scale and duration of the inflammatory response. Production of IL-1R2 serves to make the producing cell and surrounding cells resistant to IL-1–mediated activation. Interestingly, some of the most efficient IL-1–producing cells are also the best producers of the IL-1R2.

IL-18 was first identified based on its capacity to induce IFN-γ. One name initially proposed for this cytokine was IL-1γ, because of its homology with IL-1α and IL-1β. Like IL-1β, it is translated as an inactive precursor molecule of 23 kd and is cleaved to an active 18-kd species by caspase 1. It is produced by multiple cell types in skin, including keratinocytes, Langerhans cells, and monocytes. IL-18 induces proliferation, cytotoxicity, and cytokine production by Th1 and natural killer (NK) cells, mostly synergistically with IL-12. The IL-18 receptor bears striking similarity to the IL-1 receptor.[12] The binding chain (IL-18R) is an IL-1R1 homolog, originally cloned as IL-1Rrp1. IL-18R alone is a low-affinity receptor that must recruit IL-18RAcP (a homolog of IL-1RAcP). As for IL-1, both chains of the IL-18 receptor are required for signal transduction. Although there is no IL-18 homolog of IL-1ra, a molecule known as *IL-18–binding protein* binds to soluble mature IL-18 and prevents it from binding to the IL-18R complex.

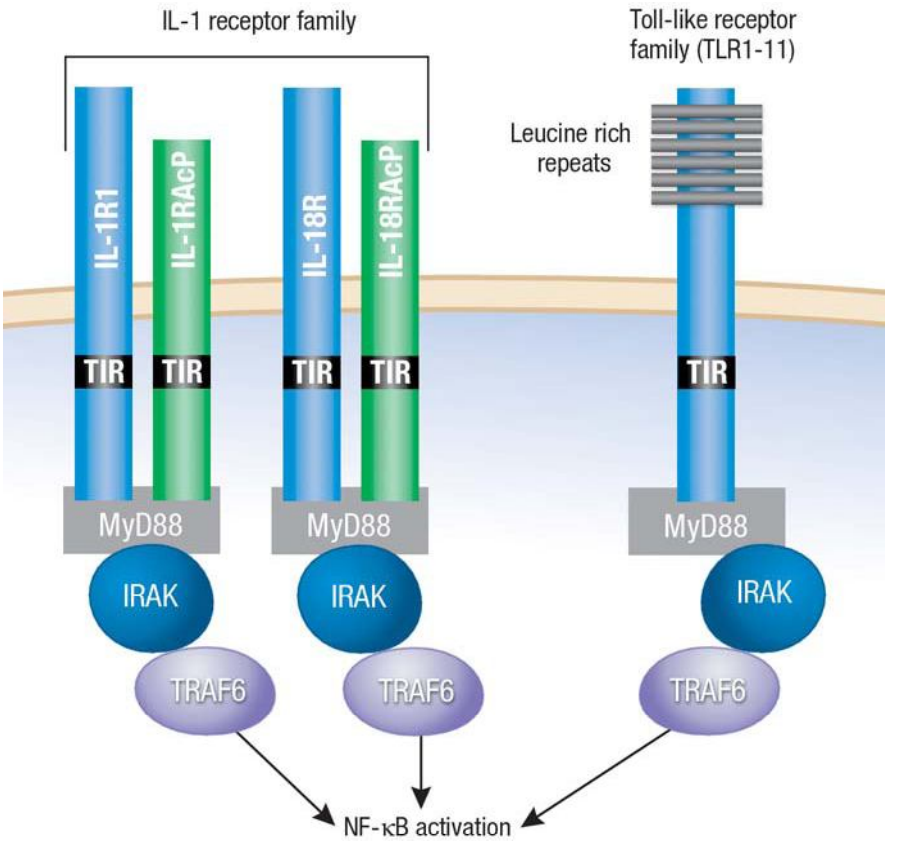

▲ **FIGURE 11-4** The interleukin 1 receptor (IL-1R) family and Toll-like receptors (TLRs) use a common intracellular signaling pathway. Receptors for cytokines in the IL-1 family (typified by the IL-1 and IL-18 receptors) share a common signaling domain with the TLRs (TLR1 to TLR11) called the *Toll/IL-1 receptor (TIR)* domain. The TIR domain receptors interact with TIR domain–containing adapter proteins such as MyD88 that couple ligand binding to activation of IL-1R–associated kinase (IRAK) and ultimately activation of nuclear factor κB (NF-κB). IL-1RAcP = IL-1R accessory protein; TRAF = tumor necrosis factor receptor–associated factor.

More recently, it has become clear that there is a family of receptors homologous to the IL-1R1 and IL-18R molecules,[12] having in common a TIR motif (Fig. 11-4). All of these share analogous signaling pathways initiated by the MyD88 adapter molecule. One of these receptors, originally known as *ST2*, was initially characterized as a gene expressed by Th2 cells, but not by Th1 cells. The description of a natural ligand for ST2 designated IL-33 has added a new member to the IL-1 family that shares characteristic features of other cytokines in the family, such as a requirement for processing by caspase 1 to release a mature form of the ligand. IL-33 stimulation of Th2 cells promotes their production of the characteristic Th2 cytokines IL-4, IL-5, and IL-10. IL-1R1, IL-18R, IL-33R (ST2), the TLRs, and their ligands are all best viewed as elements of the innate immune system that signal the presence of danger or injury to the host.[17]

When IL-1 produced by epidermis was originally identified, it was noted that both intact epidermis and stratum corneum contained significant IL-1 activity, which led to the concept that epidermis was a shield of sequestered IL-1 surrounding the host, waiting to be released on injury. More recently, it was observed that high levels of the IL-1ra co-exist within keratinocytes; however, repeated experiments show that in virtually all cases, the amount of IL-1 present is sufficient to overcome any potential for inhibition mediated by IL-1ra. Studies have now shown that mechanical stress to keratinocytes permits the release of large amounts of IL-1 in the absence of cell

death. Release of IL-1 induces expression of endothelial adhesion molecules, including E-selectin, ICAM-1, and VCAM-1, as well as chemotactic and activating chemokines. This attracts not only monocytes and granulocytes but a specific sub-population of memory T cells that bear cutaneous lymphocyte antigen on their cell surface. Memory T cells positive for cutaneous lymphocyte antigen are abundant in inflamed skin, comprising the majority of T cells present. Therefore, any injury to the skin, no matter how trivial, releases IL-1 and attracts this population of memory T cells. If they encounter their antigen in this microenvironment, their activation and subsequent cytokine production will amplify the inflammatory response. This has been proposed as the basis of the clinical observation of inflammation in response to trauma, known as the *Koebner reaction*.

TUMOR NECROSIS FACTOR: THE OTHER PRIMARY CYTOKINE

TNF-α is the prototype for a family of related signaling molecules that mediate their biologic effects through a family of related receptor molecules. TNF-α was initially cloned on the basis of its ability to mediate two interesting biologic effects: (1) hemorrhagic necrosis of malignant tumors, and (2) inflammation-associated cachexia. Although TNF-α exerts many of its biologically important effects as a soluble mediator, newly synthesized TNF-α exists as a transmembrane protein on the cell surface. A specific metalloproteinase known as *TNF-α–converting enzyme (TACE)* is responsible for most TNF-α release by T cells and myeloid cells. The closest cousin of TNF-α is TNF-β, also known as *lymphotoxin α (LT-α)*. Other related molecules in the TNF family include lymphotoxin β (LT-β), which combines with LT-α to form the LT-α1β2 heterotrimer; Fas ligand (FasL); TNF-related apoptosis-inducing ligand (TRAIL); TNF-related activation-induced cytokine (TRANCE); and CD40 ligand (CD154). Although some of these other TNF family members have not been traditionally regarded as cytokines, their structure (all are type II membrane proteins with an intracellular N-terminus and an extracellular C-terminus) and signaling mechanisms are closely related to those of TNF. The soluble forms of TNF-α, LT-α, and FasL are homotrimers, and the predominant form of LT-β is the membrane-bound LT-α1β2 heterotrimer. Trimerization of TNF receptor family members by their trimeric ligands appears to be required for initiation of signaling and expression of biologic activity.

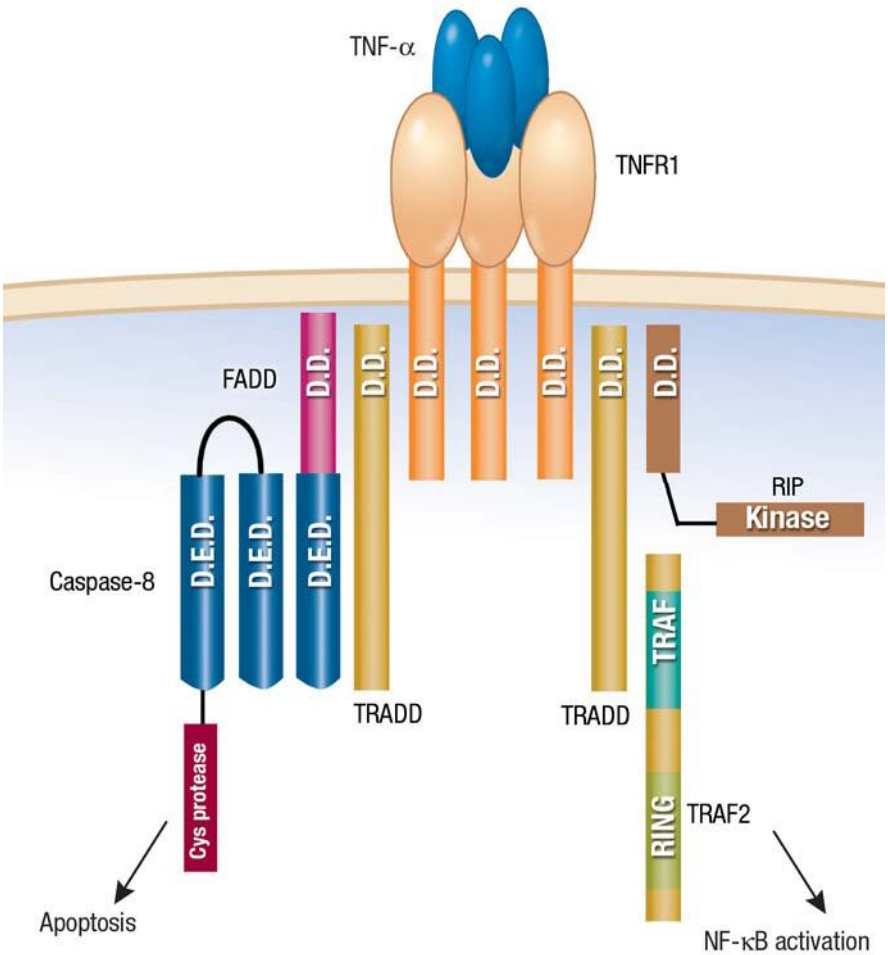

▲ **FIGURE 11-5** Two contrasting outcomes of signaling through tumor necrosis factor receptor 1 (TNFR1). Engagement of TNFR1 by trimeric tumor necrosis factor-α (TNF-α) can trigger apoptosis and/or nuclear factor κB (NF-κB) activation. Both processes involve the adapter protein TNFR-associated death domain (TRADD), which associates with TNFR1 via interactions between "death domains" (D.D.) on both proteins. For NF-κB activation, TNFR–associated factor 2 (TRAF2) and receptor-interacting protein (RIP) are required. Induction of apoptosis occurs when the death domain–containing protein Fas-associated death domain protein (FADD) associates with TRADD. FADD also contains a "death effector domain" (D.E.D.) that interacts with caspase 8 to initiate the apoptotic process. Cys = cysteine. (Adapted from Yuan J: Transducing signals of life and death. *Curr Opin Cell Biol* **9**:247, 1997; and Nagata S: Apoptosis by death factor. *Cell* **88**:355, 1997.)

The initial characterization of TNF receptors led to the discovery of two receptor proteins capable of binding TNF-α with high affinity. The p55 receptor for TNF (TNFR1) is responsible for most biologic activities of TNF, but the p75 TNF receptor (TNFR2) is also capable of transducing signals (unlike IL-1R2, which acts solely as a biologic sink for IL-1). TNFR1 and TNFR2 have substantial stretches of close homology and are both present on most types of cells. Nevertheless, there are some notable differences between the two TNFRs.

Unlike cytokine receptors from several of the other large families, TNF signaling does not involve the Jak/STAT pathway. TNF-α evokes two types of responses in cells: (1) pro-inflammatory effects, and (2) induction of apoptotic cell death (Fig. 11-5). The pro-inflammatory effects of TNF-α, which include upregulation of adhesion molecule expression and induction of secondary cytokines and chemokines, stem in large part from activation of NF-κB and can be transduced through both TNFR1 and TNFR2. Induction of apoptosis by signaling through TNFR1 depends on a region known as a *death domain* that is absent in TNFR2, as well as interactions with additional proteins with death domains within the TNFR1 signaling complex. Signaling initiated by ligand bind-

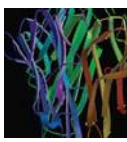

ing to TNFR1, Fas, or other death domain–containing receptors in the TNF family eventually leads to activation of caspase 8 or 10 and the nuclear changes and DNA fragmentation characteristic of apoptosis.

At least two TNFR family members (TNFR1 and the LT-β receptor) also contribute to the normal anatomic development of the lymphoid system. Mice deficient in TNF-α lack germinal centers and follicular dendritic cells. TNFR1 mutant mice show the same abnormalities plus an absence of Peyer's patches. Mice with null mutations in LT-α or LT-β have further abnormalities in lymphoid organogenesis and fail to develop peripheral lymph nodes.

TNF-α is an important mediator of cutaneous inflammation, and its expression is induced in the course of almost all inflammatory responses in skin. Normal human keratinocytes and keratinocyte cell lines produce substantial amounts of TNF-α after stimulation with LPS or UV light. Cutaneous inflammation stimulated by irritants and contact sensitizers is associated with strong induction of TNF-α production by keratinocytes. Exposure to TNF-α causes Langerhans cells to migrate to draining lymph nodes, which allows for sensitization of naive T cells. One molecular mechanism that may contribute to TNF-α–induced migration of Langerhans cells toward lymph nodes is reduced expression of the E-cadherin adhesion molecule after exposure to TNF-α. Induction of CC chemokine receptor 7 on both epidermal and dermal antigen-presenting cells correlates with movement into the draining lymphatics. The predominant TNFR expressed by keratinocytes is TNFR1. Autocrine signaling loops involving keratinocyte-derived TNF-α and TNFR1 lead to keratinocyte production of a variety of TNF-inducible secondary cytokines.

The central role of TNF-α in inflammatory diseases, including rheumatoid arthritis and psoriasis, has become evident from clinical studies. Clinical drugs that target the TNF pathway include the humanized anti–TNF-α antibody infliximab, the human anti–TNF-α antibody adalumimab, and the soluble TNF receptor etanercept. Drugs in this class are U.S. Food and Drug Administration (FDA) approved for the treatment of several autoimmune and inflammatory diseases, including Crohn disease and rheumatoid arthritis. All of these anti-TNF drugs are also FDA approved for the treatment of psoriatic arthritis, and etanercept is approved for use in treating chronic plaque psoriasis (see Chap. 235). This class of drugs also has the potential to be valuable in the treatment of other inflammatory dermatoses. Paradoxically, they are not effective against all autoimmune diseases—multiple sclerosis appears to worsen slightly after treatment with these agents. The TNF antagonists are powerful immunomodulating drugs, and appropriate caution is required in their use. Cases of cutaneous T-cell lymphoma initially thought to represent psoriasis have rapidly progressed to fulminant disease after treatment with TNF antagonists. TNF antagonists can also allow the escape of latent mycobacterial infections from immune control, with a potentially lethal outcome for the patient.

LIGANDS OF THE CLASS I (HEMATOPOIETIN RECEPTOR) FAMILY OF CYTOKINE RECEPTORS

The hematopoietin receptor family (also known as the *class I cytokine receptor family*) is the largest of the cytokine receptor families and comprises a number of structurally related type I membrane-bound glycoproteins. The cytoplasmic domains of these receptors associate with nonreceptor tyrosine kinase molecules, including the Jak kinases and src family kinases. After ligand binding and receptor oligomerization, these associated nonreceptor tyrosine kinases phosphorylate intracellular substrates, which leads to signal transduction. Most of the multiple-chain receptors in the hematopoietin receptor family consist of a cytokine-specific α chain subunit paired with one or more shared receptor subunits. Five shared receptor subunits have been described to date: the common γ chain (γ_c), the common β chain shared between the IL-2 and IL-15 receptors; a distinct common β chain shared between the granulocyte-macrophage colony stimulating factor (GM-CSF), IL-3, and IL-5 receptors; the IL-12Rβ2 chain shared by the IL-12 and IL-23 receptors; and finally the glycoprotein 130 (gp130) molecule, which participates in signaling by IL-6 and related cytokines.

Cytokines with Receptors That Include the γ_c Chain

The receptor complexes using the γ_c chain are the IL-2, IL-4, IL-7, IL-9, IL-13, IL-15, and IL-21 receptors. Two of these receptors, IL-2R and IL-15R, also use the IL-2Rβ_c chain. The γ_c chain is physically associated with Jak3, and activation of Jak3 is critical to most signaling initiated through this subset of cytokine receptors.[18]

INTERLEUKIN 2 AND INTERLEUKIN 15 IL-2 and IL-15 can each activate NK cells and stimulate proliferation of activated T cells. IL-2 is a product of activated T cells, and IL-2R is largely restricted to lymphoid cells. The IL-15 gene is expressed by nonlymphoid tissues, and its transcription is induced by UVB radiation in keratinocytes and fibroblasts and by LPS in monocytes and dendritic cells. Multiple isoforms of IL-15Rα are found in various hematopoietic and non-hematopoietic cells. The IL-2R and IL-15R complexes of lymphocytes incorporate up to three receptor chains, whereas most other cytokine receptor complexes have two. The affinities of IL-2R and IL-15R for their respective ligands can be regulated, and to some extent, IL-2 and IL-15 compete with each other. The highest-affinity receptor complexes for each ligand (approximately 10^{-11} *M*) consist of the IL-2Rβ_c and γ_c chains, as well as their respective α chains (IL-2Rα, also known as CD25, and IL-15Rα). γ_c and IL-2Rβ_c without the α chains form a functional lower-affinity receptor for either ligand (10^{-8} to 10^{-10} *M*). Although both ligands transmit signals through the γ_c chain, those signals elicit overlapping but distinct responses in various cells. Activation of naive CD4 T cells by T-cell receptor and co-stimulatory molecules induces expression of IL-2, IL-2Rα, and IL-2Rβ_c, which leads to vigorous proliferation. Prolonged stimulation of T-cell receptor and IL-2R leads to expression of FasL and activation-induced cell death. Although IL-2 signaling facilitates the death of CD4 T cells in response to sustained exposure to antigen, IL-15 inhibits IL-2–mediated activation-induced cell death as it stimulates growth. Similarly, IL-15 promotes proliferation of memory CD8 T cells, whereas IL-2 inhibits it. IL-15 is also involved in the homeostatic survival of memory CD8 T cells, NK cells, and NK T cells. These contrasting biologic roles are illustrated by mice deficient in IL-2 or IL-2Rα, which develop autoimmune disorders, and mice deficient in IL-15 or IL-15Rα, which have lymphopenia and immune deficiencies. Thus IL-15 appears to have an important role in promoting effector functions of antigen-specific T cells, whereas IL-2 is involved in reining in autoreactive T cells.[19]



INTERLEUKIN 4 AND INTERLEUKIN 13 IL-4 and IL-13 are products of activated Th2 cells that share limited structural homology (approximately 30 percent) and overlapping but distinct biologic activities. A specific receptor for IL-4, which does not bind IL-13, is found on T cells and NK cells. It consists of IL-4Rα (CD124) and γ_c and transmits signals via Jak1 and Jak3. A second receptor complex that can bind either IL-4 or IL-13 is found on keratinocytes, endothelial cells, and other nonhematopoietic cells. It consists of IL-13Rα1 (CD213a1) and IL-4Rα and transmits signals via Jak1 and Jak2. These receptors are expressed at low levels in resting cells, and their expression is increased by various activating signals. Curiously, exposure of monocytes to IL-4 or IL-13 suppresses expression of IL-4Rα and IL-13Rα1, whereas the opposite effect is observed in keratinocytes. Both signal transduction pathways appear to converge with the activation of STAT6, which is both necessary and sufficient to drive Th2 differentiation. Another cell surface molecule homologous to IL-13Rα1, termed *IL-13Rα2* (CD213a2), binds specifically to IL-13 but is not known to transmit any signals.[20]

The biologic effects of engagement of the IL-4 receptor vary depending on the specific cell type, but most pertain to its principal role as a growth and differentiation factor for Th2 cells. Exposure of naive T cells to IL-4 stimulates them to proliferate and differentiate into Th2 cells, which produce more IL-4, which in turn leads to autocrine stimulation that prolongs Th2 responses. Thus the expression of IL-4 early in the immune response can initiate a cascade of Th2 cell development that results in a predominately Th2 response. The genes encoding IL-4 and IL-13 are located in a cluster with IL-5 which undergoes structural changes during Th2 differentiation that are associated with increased expression. Although naive T cells can make low levels of IL-4 when activated, IL-4 is also produced by activated NK T cells. Mast cells and basophils also release preformed IL-4 from secretory granules in response to FcεRI-mediated signals. A prominent activity of IL-4 is the stimulation of class switching of the immunoglobulin genes of B cells. As critical factors in Th2 differentiation and effector function, IL-4 and IL-13 are mediators of atopic immunity. In addition to controlling the behavior of effector cells they also act directly on resident tissue cells, such as in inflammatory airway reactions.[21]

INTERLEUKIN 9 AND INTERLEUKIN 21 IL-9 is a product of activated Th2 cells that acts as an autocrine growth factor as well as a mediator of inflammation.[22] It is also produced by mast cells in response to IL-10 or stem cell factor. It stimulates proliferation of T and B cells and promotes expression of immunoglobulin E by B cells. It also exerts pro-inflammatory effects on mast cells and eosinophils. IL-9–deficient mice exhibit deficits in mast cell and goblet cell differentiation. IL-21 is also a product of Th2 T cells that signals through a receptor composed of a specific α chain (IL-21R) homologous to the IL-4R α chain and γ_c.[23] Absence of an intact IL-21 receptor is associated with impaired Th2 responses.[24] IL-9 and IL-21 can be grouped together with IL-4 and IL-13 as cytokines that function as effectors of allergic inflammatory processes and may play an important role in asthma and allergic disorders.

INTERLEUKIN 7 Mutations abrogating the function of IL-7, IL-7Rα (CD127), γ_c, or Jak3 in mice or humans cause profound immunodeficiency as a result of T- and NK-cell depletion.[18] This is principally due to the indispensable role of IL-7 in promoting the expansion of lymphocytes and regulating the rearrangement of their antigen receptor genes. IL-7 is a potent mitogen and survival factor for immature lymphocytes in the bone marrow and thymus. The second function of IL-7 is as a modifier of effector cell functions in the reactive phase of certain immune responses. IL-7 transmits activating signals to mature T cells and certain activated B cells. Like IL-2, IL-7 has been shown to stimulate proliferation of cytolytic T cells and lymphokine-activated killer cells in vitro and to enhance their activities in vivo. Monocytes exposed to IL-7 release IL-6, IL-1α, IL-1β, and TNF-α and exhibit enhanced tumoricidal activity in vitro. IL-7 is a particularly significant cytokine for lymphocytes in the skin and other epithelial tissues. It is expressed by keratinocytes in a regulated fashion, and this expression is thought to be part of a reciprocal signaling dialog between dendritic epidermal T cells and keratinocytes in murine skin. Keratinocytes release IL-7 in response to IFN-γ, and dendritic epidermal T cells secrete IFN-γ in response to IL-7.

An IL-7–related cytokine using one chain of the IL-7 receptor as part of its receptor is thymic stromal lymphopoietin (TSLP). TSLP was originally identified as a novel cytokine produced by a thymic stromal cell line that could act as a growth factor for B- and T-lineage cells. The TSLP receptor consists of the IL-7 receptor α chain and a second receptor chain homologous to but distinct from the γ_c chain. TSLP has attracted interest because of its ability to prime dendritic cells to become stronger stimulators of Th2 cells. This activity may permit TSLP to foster the development of some types of allergic diseases.[25]

Cytokines with Receptors Using the Interleukin 3 Receptor β Chain

The receptors for IL-3, IL-5, and GM-CSF consist of unique cytokine-specific α chains paired with a common β chain known as *IL-3Rβ* or β_c (CD131). Each of these factors acts on subsets of early hematopoietic cells.[26] IL-3, which was previously known as *multi-lineage colony-stimulating factor*, is principally a product of $CD4^+$ T cells and causes proliferation, differentiation, and colony formation of various myeloid cells from bone marrow. IL-5 is a product of Th2 $CD4^+$ cells and activated mast cells that conveys signals to B cells and eosinophils. IL-5 has a co-stimulatory effect on B cells in that it enhances their proliferation and immunoglobulin expression when they encounter their cognate antigen. In conjunction with an eosinophil-attracting chemokine known as *eotaxin*, IL-5 plays a central role in the accumulation of eosinophils that accompanies parasitic infections and some cutaneous inflammatory processes. IL-5 appears to be required to generate a pool of eosinophil precursors in bone marrow that can be rapidly mobilized to the blood, whereas eotaxin's role is focused on recruitment of these eosinophils from blood into specific tissue sites. GM-CSF is a growth factor for myeloid progenitors produced by activated T cells, phagocytes, keratinocytes, fibroblasts, and vascular endothelial cells. In addition to its role in early hematopoiesis, GM-CSF has potent effects on macrophages and dendritic cells. In vitro culture of fresh Langerhans cells in the presence of GM-CSF promotes their transformation into mature dendritic cells with maximal immunostimulatory potential for naive T cells. The effects of GM-CSF on dendritic cells probably account for the dramatic ability of GM-CSF to evoke therapeutic antitumor immunity when tumor cells are engineered to express it.[27]

Interleukin 6 and Other Cytokines with Receptors Using Glycoprotein 130

Receptors for a group of cytokines including IL-6, IL-11, IL-27, leukemia inhibitory factor, oncostatin M, ciliary

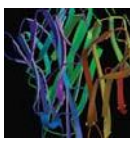

neurotrophic factor, and cardiotrophin-1 interact with a hematopoietin receptor family member, gp130, that does not appear to interact with any ligand by itself. The gp130 molecule is recruited into signaling complexes with other receptor chains when they engage their cognate ligands.

IL-6 is the most thoroughly characterized of the cytokines that use gp130 for signaling and serves as a paradigm for discussion of the biologic effects of this family of cytokines. IL-6 is yet another example of a highly pleiotropic cytokine with multiple effects. A series of different names (including *IFN-β2, B-cell stimulatory factor 2, plasmacytoma growth factor, cytotoxic T cell differentiation factor,* and *hepatocyte-stimulating factor*) were used for IL-6 before it was recognized that a single molecular species accounts for all of these activities. IL-6 acts on a wide variety of cells of hematopoietic origin. IL-6 stimulates immunoglobulin secretion by B cells and has mitogenic effects on B lineage cells and plasmacytomas. IL-6 also promotes maturation of megakaryocytes and differentiation of myeloid cells. Not only does it participate in hematopoietic development and reactive immune responses, but IL-6 is also a central mediator of the systemic acute-phase response. Increases in circulating IL-6 levels stimulate hepatocytes to synthesize and release acute-phase proteins.

There are two distinct signal transduction pathways triggered by IL-6. The first of these is mediated by the gp130 molecule when it dimerizes on engagement by the complex of IL-6 and IL-6Rα. Homodimerization of gp130 and its associated Jak kinases (Jak1, Jak2, Tyk2) leads to activation of STAT3. A second pathway of gp130 signal transduction involves Ras and the mitogen-activated protein kinase cascade and results in phosphorylation and activation of a transcription factor originally designated *nuclear factor of IL-6*.

IL-6 is an important cytokine for skin and is subject to dysregulation in several human diseases, including some with skin manifestations. IL-6 is produced in a regulated fashion by keratinocytes, fibroblasts, and vascular endothelial cells as well as by leukocytes infiltrating the skin. IL-6 can stimulate the proliferation of human keratinocytes under some conditions. Psoriasis is one of several inflammatory skin diseases in which elevated expression of IL-6 has been described. Human herpesvirus 8 produces a viral homolog of IL-6 that may be involved in the pathogenesis of human herpesvirus 8–associated diseases, including Kaposi sarcoma and body cavity–based lymphomas.

The other cytokines using gp130 as a signal transducer have diverse bioactivities. IL-11 inhibits production of inflammatory cytokines and has shown some therapeutic activity in patients with psoriasis. Exogenous IL-11 also stimulates platelet production and has been used to treat thrombocytopenia occurring after chemotherapy. IL-27 is discussed in the next section with the IL-12 family of cytokines.

Interleukin 12, Interleukin 23, and Interleukin 27: Pivotal Cytokines for T Helper 1 and T Helper 17 Responses

IL-12 is different from most other cytokines in that its active form is a heterodimer of two proteins, p35 and p40. IL-12 is principally a product of antigen-presenting cells such as dendritic cells, monocytes, macrophages, and certain B cells in response to bacterial components, GM-CSF, and IFN-γ. Activated keratinocytes are an additional source of IL-12 in skin. Human keratinocytes constitutively make the p35 subunit, whereas expression of the p40 subunit can be induced by stimuli including contact allergens, phorbol esters, and UV radiation.

IL-12 is a critical immunoregulatory cytokine that is central to the initiation and maintenance of Th1 responses. Th1 responses that are dependent on IL-12 provide protective immunity to intracellular bacterial pathogens. IL-12 also has stimulatory effects on NK cells, promoting their proliferation, cytotoxic function, and the production of cytokines, including IFN-γ. IL-12 has been shown to be active in stimulating protective antitumor immunity in a number of animal models.[27]

Two chains that are part of the cell surface receptor for IL-12 have been cloned. Both are homologous to other β chains in the hematopoietin receptor family and are designated β1 and β2. The β1 chain is associated with Tyk2 and the β2 chain interacts directly with Jak2. The signaling component of the IL-12R is the β2 chain. The β2 chain is expressed in Th1 but not Th2 cells and appears to be critical for commitment of T cells to production of type 1 cytokines. IL-12 signaling induces the phosphorylation of STAT1, STAT3, and STAT4, but it is STAT4 that is essential for induction of a Th1 response.

IL-23 is a heterodimeric cytokine in the IL-12 family that consists of the p40 chain of IL-12 in association with a distinct p19 chain. IL-23 has overlapping activities with IL-12 but also induces proliferation of memory T cells. Interest in IL-23 has been sparked by the observation that IL-23 is involved in the induction of T cells producing IL-17 (Th17 subset).[28] The IL-23 receptor consists of two chains: the IL-12Rβ1 chain that forms part of the IL-12 receptor and a specific IL-23 receptor encoded by a gene located near the IL-12Rβ2 gene.[29]

The newest member of the IL-12 family is IL-27. IL-27 is also a heterodimer and consists of a subunit called *EBI3* that is homologous to IL-12 p40 and a second subunit known as *p28* that is homologous to IL-12 p35. IL-27 plays a role in the early induction of the Th1 response.[30] The IL-27 receptor consists of a receptor called *WSX-1* that associates with the shared signal-transducing molecule gp130.[31]

The IL-12 family of cytokines has emerged as a promising new target for anti-cytokine pharmacotherapy. The approach that has been developed the furthest to date is targeting both IL-12 and IL-23 with monoclonal antibodies directed against the common p40 subunit. An anti–human p40 monoclonal antibody (CNTO 1275) was reported to show beneficial effects in phase I trials in psoriasis patients.[32] A similar therapeutic antibody (ABT-784) has demonstrated efficacy in Crohn disease.[33] The development of anti-p40 therapies is several years behind anti–TNF-α drugs, but p40 is an attractive target for future drug development efforts for some types of immune-mediated diseases.

LIGANDS OF THE CLASS II FAMILY OF CYTOKINE RECEPTORS

A second major class of cytokine receptors with common features includes two types of receptors for IFNs, IL-10R, and the receptors for additional IL-10–related cytokines including IL-19, IL-20, IL-22, and IL-24.

Interferons: Prototypes of Cytokines Signaling Through a Jak/STAT Pathway

IFNs were one of the first families of cytokines to be characterized in detail. The IFNs were initially subdivided into three classes: IFN-α (the leukocyte IFNs), IFN-β (fibroblast IFN), and IFN-γ

(immune IFN). The α and β IFNs are collectively called *type I IFNs*, and all of these molecules signal through the same two-chain receptor (the IFN-αβ receptor).[34] The second IFN receptor is a distinct two-chain receptor specific for IFN-γ. Both of these IFN receptors are present on many cell types within skin as well as in other tissues. Each of the chains comprising the two IFN receptors is associated with one of the Jak kinases (Tyk2 and Jak1 for the IFN-αβR and Jak1 and Jak2 for the IFN-γR). Only in the presence of both chains and two functional Jak kinases will effective signal transduction occur after IFN binding. A new class of IFNs known as *IFN-λ* or *type III IFNs* has now been identified that has a low degree of homology with both type I IFNs and IL-10.[35] The current members of this class are IL-28A, IL-28B, and IL-29. Although the effects of these cytokines are similar to those of the type I IFNs, they are less potent. These type III IFNs use a shared receptor that consists of the β chain of the IL-10 receptor associated with an IL-28 receptor α chain.

Viruses, double-stranded RNA, and bacterial products are among the stimuli that elicit release of the type I IFNs from cells. Plasmacytoid dendritic cells have emerged as a particularly potent cellular source of type I IFNs. Many of the effects of the type I IFNs directly or indirectly increase host resistance to the spread of viral infection. Additional effects mediated through IFN-αβR are increased expression of major histocompatibility complex (MHC) class I molecules and stimulation of NK cell activity. Not only does it have well-known antiviral effects, but IFN-α also can modulate T-cell responses by favoring the development of a Th1 type of T-cell response. Finally, the type I IFNs also inhibit the proliferation of a variety of cell types, which provides a rationale for their use in the treatment of some types of cancer. Forms of IFN-α enjoy considerable use clinically for indications ranging from hairy cell leukemia, various cutaneous malignancies, and papillomavirus infections (see Chap. 196). Some of the same conditions that respond to therapy with type I IFNs also respond to topical immunomodulatory agents like imiquimod. This synthetic imidazoquinoline drug is an agonist for the TLR7 receptor, whose natural ligand is single-stranded RNA. Imiquimod stimulation of cells expressing TLR7 elicits local release of large amounts of type I IFNs from plasmacytoid dendritic cells, which can trigger clinically useful antiviral and tumor inhibitory effects against genital warts, superficial basal cell carcinoma, and actinic keratoses. Resiquimod is a related synthetic compound that activates both TLR7 and TLR8, eliciting a slightly different spectrum of cytokines.[36]

Production of IFN-γ is restricted to NK cells, CD8 T cells, and Th1 CD4 T cells. Th1 cells produce IFN-γ after engagement of the T-cell receptor, and IL-12 can provide a strong co-stimulatory signal for T-cell IFN-γ production. NK cells produce IFN-γ in response to cytokines released by macrophages, including TNF-α, IL-12, and IL-18. IFN-γ has antiviral activity, but it is a less potent mediator than the type I IFNs for induction of these effects. The major physiologic role of IFN-γ is its capacity to modulate immune responses. IFN-γ induces synthesis of multiple proteins that play essential roles in antigen presentation to T cells, including MHC class I and class II glycoproteins, invariant chain, the Lmp2 and Lmp7 components of the proteasome, and the TAP1 and TAP2 intracellular peptide transporters. These changes increase the efficiency of antigen presentation to CD4 and CD8 T cells. IFN-γ is also required for activation of macrophages to their full antimicrobial potential, enabling them to eliminate microorganisms capable of intracellular growth. Like type I IFNs, IFN-γ also has strong antiproliferative effects on some cell types. Finally, IFN-γ is also an inducer of selected chemokines (CXC chemokine ligands 9 to 11) and an inducer of endothelial cell adhesion molecules (e.g., ICAM-1 and VCAM-1). Because of the breadth of IFN-γ's activities, it comes the closest of the T-cell cytokines to behaving as a primary cytokine.

Interleukin 10: An "Anti-Inflammatory" Cytokine

IL-10 is one of several cytokines that primarily exert regulatory rather than stimulatory effects on immune responses.[37] IL-10 was first identified as a cytokine produced by Th2 T cells that inhibited cytokine production after activation of T cells by antigen and antigen-presenting cells. IL-10 exerts its action through a cell surface receptor found on macrophages, dendritic cells, neutrophils, B cells, T cells, and NK cells. The ligand-binding chain of the receptor is homologous to the receptors for IFN-α/β and IFN-γ, and signaling events mediated through the IL-10 receptor use a Jak/STAT pathway. IL-10 binding to its receptor activates the Jak1 and Tyk2 kinases and leads to the activation of STAT1 and STAT3. The effects of IL-10 on antigen-presenting cells such as monocytes, macrophages, and dendritic cells include inhibition of expression of class II MHC and co-stimulatory molecules (e.g., B7-1, B7-2) and decreased production of T cell–stimulating cytokines (e.g., IL-1, IL-6, and IL-12). At least four viral genomes harbor viral homologues of IL-10 that transmit similar signals by binding to the IL-10R.

A major source of IL-10 within skin is epidermal keratinocytes. Keratinocyte IL-10 production is upregulated after activation; one of the best-characterized activating stimuli for keratinocytes is UV irradiation. UV radiation–induced keratinocyte IL-10 production leads to local and systemic effects on immunity. Some of the well-documented immunosuppressive effects that occur after UV light exposure are the result of the liberation of keratinocyte-derived IL-10 into the systemic circulation. IL-10 also plays a dampening role in other types of cutaneous immune and inflammatory responses, because the absence of IL-10 predisposes mice to exaggerated irritant and contact sensitivity responses.

Novel Interleukin 10–Related Cytokines: Interleukins 19, 20, 22, and 24

A series of cytokines related to IL-10 have been identified and shown to engage a number of receptor complexes with shared chains.[38] IL-19, IL-20, and IL-24 transmit signals via a complex consisting of IL-20Rα and IL-20Rβ. Transgenic mice overexpressing IL-20 develop severe cutaneous inflammation and altered epidermal proliferation and differentiation. Expression of the IL-20R chains is strongly induced when they are triggered, and they are only detected on keratinocytes, endothelial cells, and certain monocytes in association with inflammatory conditions such as psoriasis.[39] IL-22 activates a receptor consisting of IL-22R and IL-10Rβ, whereas IL-20 and IL-24 also engage a complex incorporating IL-20Rβ and IL-22R.[40,41] The profound effects of IL-20 expression in transgenic mice and the association of IL-20R expression with psoriasis point toward a significant role for these cytokines in the epidermal changes associated with cutaneous inflammation.

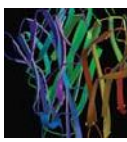

TRANSFORMING GROWTH FACTOR-β FAMILY AND ITS RECEPTORS

TGF-β1 was first isolated as a secreted product of virally transformed tumor cells capable of inducing normal cells in vitro to show phenotypic characteristics associated with transformation. Over 30 additional members of the TGF-β family have now been identified. They can be grouped into several families: the prototypic TGF-βs (TGF-β1 to TGF-β3), the bone morphogenetic proteins, the growth/differentiation factors, and the activins. The TGF name for this family of molecules is somewhat of a misnomer, because TGF-β has antiproliferative rather than proliferative effects on most cell types. Many of the TGF-β family members play an important role in development, influencing the differentiation of uncommitted cells into specific lineages. TGF-β family members are made as precursor proteins that are biologically inactive until a large pro-domain is cleaved. Monomers of the mature domain of TGF-β family members are disulfide linked to form dimers that strongly resist denaturation.

Participation of at least two cell surface receptors (type I and type II) with serine/threonine kinase activity is required for biologic effects of TGF-β.[42] Ligand binding by the type II receptor (the true ligand-binding receptor) is associated with the formation of complexes of type I and type II receptors. This allows the type II receptor to phosphorylate and activate the type I receptor, a "transducer" molecule that is responsible for downstream signal transduction. Downstream signal transmission from the membrane-bound receptors in the TGF-β receptor family to the nucleus is primarily mediated by a family of cytoplasmic Smad proteins that translocate to the nucleus and regulate transcription of target genes.

TGF-β has a profound influence on several types of immune and inflammatory processes. An immunoregulatory role for TGF-β1 was identified in part through analysis of TGF-β1 knockout mice that develop a wasting disease at 20 days of age associated with a mixed inflammatory cell infiltrate involving many internal organs. This phenotype is now appreciated to be a result in part of the compromised development of regulatory T cells when TGF-β1 is not available. Development of cells in the dendritic cell lineage is also perturbed in the TGF-β1–deficient mice, as evidenced by an absence of epidermal Langerhans cells and specific sub-populations of lymph node dendritic cells. A combination of effects of TGF-β on fibroblast function make it one of the most fibrogenic of all cytokines studied.[43] TGF-β–treated fibroblasts display enhanced production of collagen and other extracellular matrix molecules. In addition, TGF-β inhibits the production of metalloproteinases by fibroblasts and stimulates the production of inhibitors of the same metalloproteinases (tissue inhibitors of metalloproteinase, or TIMPs). TGF-β effects on fibroblasts may be important in promoting wound healing.

CHEMOKINES: SECONDARY CYTOKINES CENTRAL TO LEUKOCYTE MOBILIZATION

Chemokines are a large superfamily of small cytokines that have two major functions. First, they guide leukocytes via chemotactic gradients in tissue. Typically, this is to bring an effector cell to where its activities are required. Second, a subset of chemokines has the capacity to increase the binding of leukocytes via their integrins to ligands at the endothelial cell surface, which facilitates firm adhesion and extravasation of leukocytes in tissue. The activities of this important class of cytokines are sufficiently complex that they are the subject of a separate chapter (Chap. 12).

CYTOKINE NETWORK—THERAPEUTIC IMPLICATIONS AND APPLICATIONS

This chapter has attempted to bring some degree of order and logic to the analysis of a field of human biology that continues to grow at a rapid rate. Although many things may change in the world of cytokines, certain key concepts have stood the test of time. Principal among them is the idea that cytokines are emergency molecules, designed to be released locally and transiently in tissue microenvironments. When cytokines are released persistently, the result is typically chronic disease. One potential way to treat such diseases is with cytokine antagonists or other drugs that target cytokines or cytokine-mediated pathways.

Cytokines and cytokine antagonists are being used therapeutically by clinicians, and development of additional agents continues. With certain notable exceptions, systemic cytokine therapy has been disappointing and is often accompanied by substantial morbidity. In contrast, local and transient administration of cytokines may yield more promising results. An example of this approach is the transduction of tumor cells to express factors such as GM-CSF (GVAX vaccines) or IL-12 family members to enhance antitumor immune responses.[44] Conversely, agents that specifically block cytokine activity are also being developed. Antibodies and TNF receptor–Fc fusion proteins are FDA-approved antagonists of TNF-α activity that are highly effective at inducing durable remissions in psoriasis (see Chaps. 18, 235, and 236). Antibodies against the p40 subunit shared by IL-12 and IL-23 are also active in treating psoriasis. Anakinra is a formulation of recombinant IL-1Ra approved by the FDA as adjunct therapy or second-line monotherapy for the treatment of adult rheumatoid arthritis and has been shown to be very effective in patients with neonatal-onset multisystemic inflammatory disease (see Chap. 134). Other cytokines that have predominantly anti-inflammatory effects, such as IL-10 and IL-11, show some inhibitory activity in psoriasis, but are not currently being developed further for this indication. A class of pharmacologic agents that inhibits the production of multiple T cell–derived cytokines is the calcineurin inhibitors. Tacrolimus and pimecrolimus both bind to the immunophilin FK-506 binding protein-12 (FKBP-12), producing complexes that bind to calcineurin, a calcium-dependent phosphatase that acts on proteins in the nuclear factor of activated T cells' family to promote their nuclear translocation and activation of cytokine genes (including IL-2, IL-4, and IFN-γ)[45] (see Chap. 221). Finally, fusion toxins linked to cytokines, such as the IL-2 fusion protein denileukin diftitox, exploit the cellular specificity of certain cytokine-receptor interactions to kill target cells (see Chap. 235). Denileukin diftitox is FDA approved for the treatment of cutaneous T-cell lymphoma and has also shown therapeutic activity in psoriasis.[46] Each of the aforementioned approaches is still relatively new and open to considerable future development. An understanding of cytokines by clinicians of the future is likely to be central to effective patient care.

KEY REFERENCES

The full reference list for all chapters is available at www.digm7.com.

1. Oppenheim JJ: Cytokines: Past, present, and future. *Int J Hematol* **74**:3, 2001
3. Luger TA et al: Epidermal cell (keratinocyte)-derived thymocyte-activating factor (ETAF). *J Immunol* **127**:1493, 1981
4. Kupper TS: The activated keratinocyte: A model for inducible cytokine production by non–bone marrow–derived cells in cutaneous inflammatory and immune responses. *J Invest Dermatol* **94**:146S, 1990
5. Kupper TS: Immune and inflammatory processes in cutaneous tissues. Mechanisms and speculations. *J Clin Invest* **86**:1783, 1990

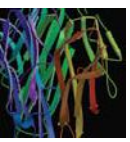

CHAPTER 12

Chemokines

Sam T. Hwang

The skin is an organ in which the migration, influx, and egress of leukocytes occurs in both homeostatic and inflammatory processes. Chemokines and their receptors are accepted as vital mediators of cellular trafficking. Since the discovery of the first chemoattractant cytokine, or chemokine, in 1977, 50 additional new chemokines and 17 chemokine receptors have been discovered. Most chemokines are small proteins with molecular weights in the 8 to 10 kd range and are synthesized constitutively in some cells and can be induced in many cell types by cytokines. Initially associated only with recruitment of leukocyte subsets to inflammatory sites,[1] it has become clear that chemokines play roles in angiogenesis, neural development, cancer metastasis, hematopoiesis, and infectious diseases. This chapter focuses primarily on the function of chemokines in inflammatory conditions, but also touches on the role of these molecules in other settings as well.

STRUCTURE OF CHEMOKINES

Chemokines are grouped into four subfamilies based on the spacing of amino acids between the first two cysteines. The CXC chemokines (also called *α-chemokines*) show a C-X-C motif with one nonconserved amino acid between the two cysteines. The other major subfamily of chemokines (called β-chemokines) lacks the additional amino acid and is termed the *CC subfamily*. The two remaining subfamilies contain only one member each: the C subfamily is represented by lymphotactin, and fractalkine is the only member of the CXXXC (or CX3C) subfamily. Chemokines can also be assigned to one of two broad and, perhaps, overlapping functional groups. One group [e.g., regulated on activation normal T-cell expressed and secreted (RANTES), macrophage inflammatory protein 1α/β, liver and activation-regulated chemokine (LARC)] mediates the attraction and recruitment of immune cells to sites of active inflammation, whereas others [e.g., secondary lymphoid-organ chemokine (SLC) and stromal cell–derived factor-1 (SDF-1)] appear to play a role in constitutive or homeostatic migration pathways.[2]

The complexity and redundancy in the nomenclature of chemokines have led to the proposal for a systematic nomenclature for chemokines based on the type of chemokine (C, CXC, CX3C, or CC) and a number based on the order of discovery as proposed by Zlotnik and Yoshie.[2] For example, SDF-1, a CXC chemokine, has the systematic name CXCL12. Because both nomenclatures are still in wide use, the original names (abbreviated in most cases) as well as systematic names are used interchangeably throughout the chapter. Table 12-1 provides a list of chemokine receptors of interest in skin that are discussed in this chapter as well as the major chemokine ligands that bind to them.

Chemokines are highly conserved and have similar secondary and tertiary structure. Based on crystallography studies, a disordered amino terminus followed by three conserved antiparallel β-pleated sheets is a common structural feature of chemokines. Fractalkine is unique in that the chemokine domain sits atop a mucin-like stalk tethered to the plasma membrane via a transmembrane domain and short cytoplasmic tail.[3] Although CXC and CC chemokines form multimeric structures under conditions required for structural studies, these associations may be relevant only when chemokines associate with cell-surface components such as glycosaminoglycans (GAGs) or proteoglycans. Because most chemokines have a net positive charge, these proteins tend to bind to negatively charged carbohydrates present on GAGs. Indeed, the ability of positively charged chemokines to bind to GAGs is thought to enable chemokines to preferentially associate with the lumenal surface of blood vessels despite the presence of shear forces from the blood that would otherwise wash the chemokines away.

CHEMOKINE RECEPTORS AND SIGNAL TRANSDUCTION

Chemokine receptors are seven transmembrane spanning membrane proteins that couple to intracellular heterotrimeric G proteins containing α, β, and γ subunits.[2] They represent a part of a large family of G protein coupled receptors (GPCRs), including rhodopsin, that have critical biologic functions. Leukocytes express several Gα protein subtypes: s, i, and q, whereas the β and γ subunits each have 5 and 11 known subtypes, respectively. This complexity in the formation of the heterotrimeric G protein may account for specificity in the action of certain chemokine receptors. Normally, G proteins are inactive when guanosine diphosphate (GDP) is bound, but they are activated when the GDP is exchanged for guanosine triphosphate (GTP) (Fig. 12-1). After binding to ligand, chemokine receptors rapidly associate with G proteins, which in turn increases the exchange of GTP for GDP. Pertussis toxin is a commonly used inhibitor of GPCR that irreversibly adenosine diphosphate-ribosylates Gα subunits of the α_i class and subsequently prevents most chemokine receptor–mediated signaling.

Activation of G proteins leads to the dissociation of the Gα and Gβγ subunits (see Fig. 12-1). The Gα subunit has been observed to activate protein tyrosine kinases and mitogen activated protein kinase, leading to cytoskeletal changes and gene transcription. The Gα subunit retains GTP, which is slowly hydrolyzed by the guanosine triphosphatase (GTPase) activity of this subunit. This GTPase activity is both positively and negatively regulated by GTPase-activating proteins

CHEMOKINES AT A GLANCE

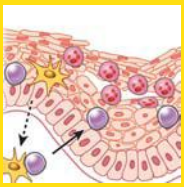

- Chemokines and their receptors are vital mediators of cellular trafficking.
- Most chemokines are small proteins with molecular weights in the 8- to 10-kd range.
- Chemokines are synthesized constitutively in some cells and can be induced in many cell types by cytokines.
- Chemokines play roles in inflammation, angiogenesis, neural development, cancer metastasis, hematopoiesis, and infectious disease.
- In skin, chemokines play important roles in atopic dermatitis, psoriasis, melanoma, melanoma metastasis, and some viral (including retroviral) infections.
- Promising therapeutic applications of chemokines include the prevention of T-cell arrest on activated endothelium or blocking infection of T cells by human immunodeficiency virus 1 using CC chemokine receptor 5 analogues.

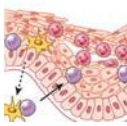

TABLE 12-1
Chemokine Receptors in Skin Biology

Chemokine Receptor (CCR)	Chemokine Ligand (CCL)	Expression Pattern	Comments	References
CCR1	MIP-1α (CCL3), RANTES (CCL5), MCP-3 (CCL7)	T, Mo, DCs, NK, B	Migration of DCs and Mo; strongly upregulated in T by IL-2	82
CCR2	MCP-1 (CCL2), -3, -4 (CCL13)	T, Mo	Migration of T to inflamed sites; replenish Langerhans cell precursors in epidermis; involved in skin fibrosis via MCP-1	32, 63, 82
CCR3	Eotaxin (CCL11) > RANTES, MCP-2 (CCL8), 3, 4	Eosinophils, basophils, Th2, NK	Migration of Th2, T, and "allergic" immune cells	22, 91
CCR4	TARC (CCL17), macrophage-derived chemokine (CCL22)	T (benign and malignant)	Expression in Th2 > Th1 cells; highly expressed on CLA+ memory T; TARC expression by keratinocytes may be important in atopic dermatitis; may guide trafficking of malignant as well as benign inflammatory T	10, 21, 44, 78, 92
CCR5	RANTES, MIP-1α,β (CCL3, 4)	T, Mo, DCs	Marker for Th1 cells; migration to acutely inflamed sites; may be involved in transmigration of T through endothelium; major HIV-1 fusion co-receptor	14, 82
CCR6	Liver and activation-regulated chemokine (CCL20)	T, DCs, B	Expressed by memory, not naive, T; possibly involved in arrest of memory T to activated endothelium and recruitment of T to epidermis in psoriasis	54, 55, 93
CCR7	Secondary lymphoid-organ chemokine (CCL21), Epstein-Barr virus–induced molecule-1 ligand chemokine (CCL19)	T, DCs, B, melanoma cells	Critical for migration of naive T and "central memory" T to secondary lymphoid organs; required for mature DCs to enter lymphatics and localize to lymph nodes; facilitates nodal metastasis	15, 34, 38, 74, 94
CCR9	Thymus-expressed chemokine (CCL25)	T, melanoma cells	Associated with melanoma small bowel metastases	75
CCR10	CTACK (CCL27)	T (benign and malignant), melanoma cells	Preferential response of CLA^+ T to CTACK in vitro; may be involved in T (benign as well as malignant) homing to epidermis, where CTACK is expressed; survival of melanoma in skin	9, 27, 76, 80
CXCR1, 2	IL-8 (CXCL8), MGSA/GRO α (CXCL1), ENA-78 (CXCL5)	Neutrophils, NK, En, melanoma cells	Recruitment of neutrophils (e.g., epidermis in psoriasis); may be involved in angiogenesis; melanoma growth factor	61, 96, 97
CXCR3	Interferon-inducible protein 10 (CXCL10), monokine induced by interferon-γ (CXCL9), interferon-inducible T cell α chemoattractant (CXCL11)	T	Marker for Th1 cells and may be involved in T recruitment to epidermis in cutaneous T-cell lymphoma; induces arrest of activated T on stimulated endothelium	18, 26
CXCR4	Stromal cell–derived factor-1α,β (CXCL12)	T, DCs, En, melanoma cells	Major HIV-1 fusion co-receptor; involved in vascular formation; involved in melanoma metastasis	73, 82
CX3CR1	Fractalkine (CX3CL1)	T, Mo, mast cells, NK	May be involved in adhesion on activated T, Mo, and NK cells to activated endothelium	3, 97

B = B cells; CLA = cutaneous lymphocyte–associated antigen; CTACK = cutaneous T cell–attracting chemokine; DCs = dendritic cells; En = endothelial cells; HIV-1 = human immunodeficiency virus 1; IL = interleukin; MCP = macrophage chemoattractant protein; MIP = macrophage inflammatory protein; Mo = monocytes; NK = natural killer cells; RANTES = regulated on activation normal T-cell expressed and secreted; T = T cells; TARC = thymus and activation-regulated chemokine; Th = T helper.

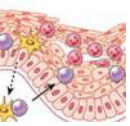

(also known as *regulator of G protein signaling proteins*). The Gβγ dimer initiates critical signaling events in regard to chemotaxis and cell adhesion. It activates phospholipase C,[4] leading to formation of diacylglycerol and inositol triphosphate [$Ins(1,4,5)P_3$]. $Ins(1,4,5)P_3$ stimulates Ca^{2+} entry into the cytosol, which along with diacylglycerol, activates protein kinase C isoforms. Although the Gβγ subunits have been shown to be critical for chemotaxis, the $G\alpha_i$ subunit has no known role in chemotactic migration. There is also evidence that binding of chemokine receptors results in the activation of other intracellular effectors including Ras and Rho, phosphatidylinositol-3-kinase.[5]

RhoA and protein kinase C appear to play a role in integrin affinity changes, whereas phosphatidylinositol-3-kinase may be critical for changes in the avidity state of lymphocyte function–associated antigen 1. Other proteins have been found that regulate the synthesis, expression, or degradation of GPCRs. For example, receptor-activity-modifying proteins act as chaperones of seven transmembrane spanning receptors and regulate surface expression as well as

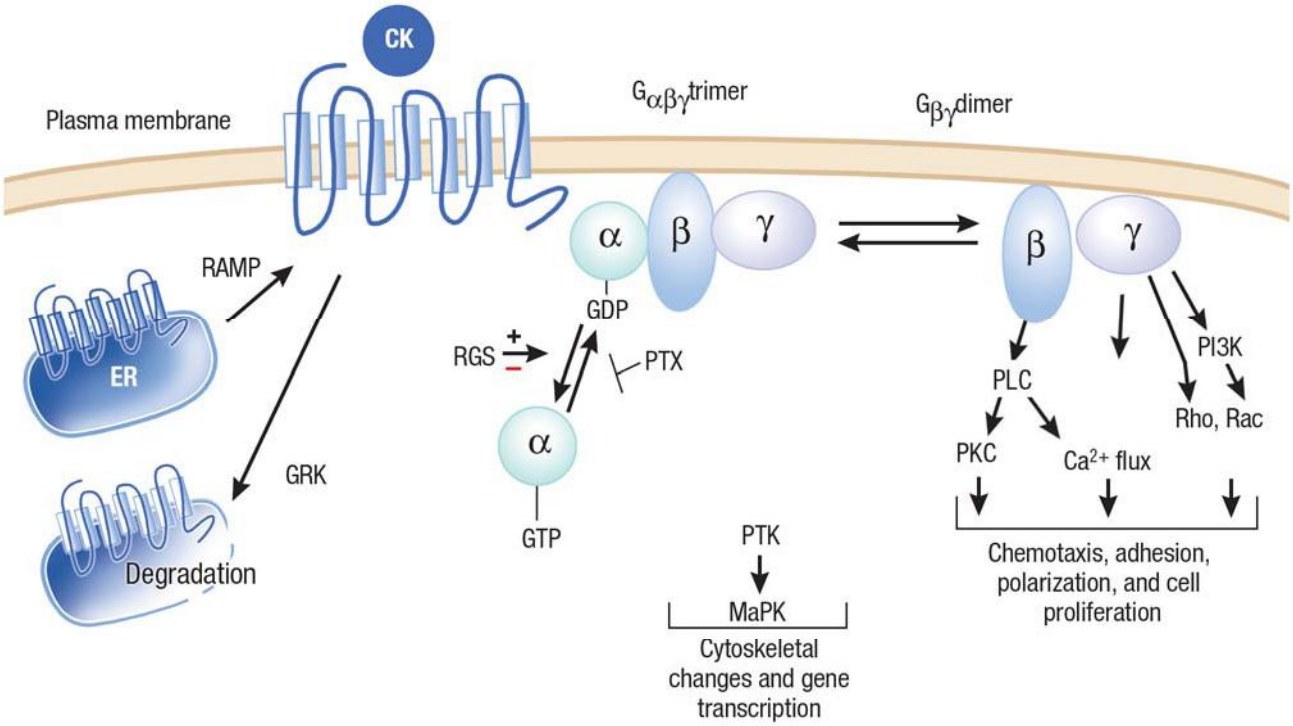

▲ **FIGURE 12-1** Chemokine receptor–mediated signaling pathways. CK = chemokine; ER = endoplasmic reticulum; GDP = guanosine diphosphate; GRK = G protein coupled receptor kinase; GTP = guanosine triphosphate; MaPK = mitogen-activated protein kinase; PKC = protein kinase C; PLC = phospholipase C; PTK = protein tyrosine kinase(s); PTX = pertussis toxin; RAMP = receptor–activity-modifying protein; RGS = regulator of G protein signaling protein.

the ligand specificity of chemokine receptors (see Fig. 12-1). Importantly, after chemokine receptors are exposed to appropriate ligands, they are frequently internalized, leading to an inability of the chemokine receptor to mediate further signaling. This downregulation of chemokine function, which has been termed *desensitization*, occurs because of phosphorylation of Ser/Thr residues in the C-terminal tail by proteins termed *GPCR kinases* and subsequent internalization of the receptor (see Fig. 12-1). Desensitization may be an important mechanism for regulating the function of chemokine receptors by inhibiting cell migration as leukocytes arrive at the primary site of inflammation.

CHEMOKINES AND CUTANEOUS LEUKOCYTE TRAFFICKING

Generally speaking, chemokines are thought to play at least three different roles in the recruitment of host defense cells, predominantly leukocytes, to sites of inflammation.[6] First, they provide the signal or signals required to cause leukocytes to come to a complete stop (i.e., arrest) in blood vessels at inflamed sites such as skin. Second, chemokines have been shown to have a role in the transmigration of leukocytes from the lumenal side of the blood vessel to the ablumenal side. Third, chemokines attract leukocytes to sites of inflammation in the dermis or epidermis after transmigration. Keratinocytes and endothelial cells are a rich source of chemokines when stimulated by appropriate cytokines. In addition, chemokines and their receptors are known to play critical roles in the emigration of resident skin dendritic cells (DCs) [i.e., Langerhans cells (LCs) and dermal DCs] from the skin to draining lymph nodes (LNs) via afferent lymphatic vessels, a process that is essential for the development of acquired immune responses (see Chap. 10).

This section is divided into three subsections. The first introduces basic concepts of how all leukocytes arrest in inflamed blood vessels before transmigration by introducing the multistep model of leukocyte recruitment. The second details mechanisms of T-cell migration, and the final subsection focuses on the mechanisms by which chemokines mediate the physiologic migration of DCs from the skin to regional LNs.

Multistep Model of Leukocyte Recruitment

For leukocytes to adhere and migrate to peripheral tissues, they must overcome the pushing force of the vascular blood stream as they bind to activated endothelial cells at local sites of inflammation. According to the multistep or cascade model of leukocyte recruitment (Fig. 12-2), one set of homologous adhesion molecules termed *selectins* mediates the transient attachment of leukocytes to endothelial cells while another set of adhesion molecules termed *integrins* and their receptors (immunoglobulin superfamily members) mediates stronger binding (i.e., arrest) and transmigration.[7] The selectins (E-, L-, and P-selectin) are members of a larger family of carbohydrate-binding proteins termed *lectins*. The selectins bind their respective carbohydrate ligands located on protein scaffolds and thus mediate the transient binding or "rolling" of leukocytes on endothelial cells.

The skin-associated vascular selectin known as *E-selectin* is upregulated on endothelial cells by inflammatory cytokines such as tumor necrosis factor (TNF)-α and binds to sialyl Lewis X–based carbohydrates. E-selectin ligands form distinct epitopes known as the *cutaneous lymphocyte–associated antigen* (CLA). CLA is expressed by 10 percent to 40 percent of memory T cells and has been suggested as a marker for skin-homing T cells.[8] At least two chemokine receptors [CC chemokine receptor 10 (CCR10) and CCR4] show preferential expression in CLA^+ memory T

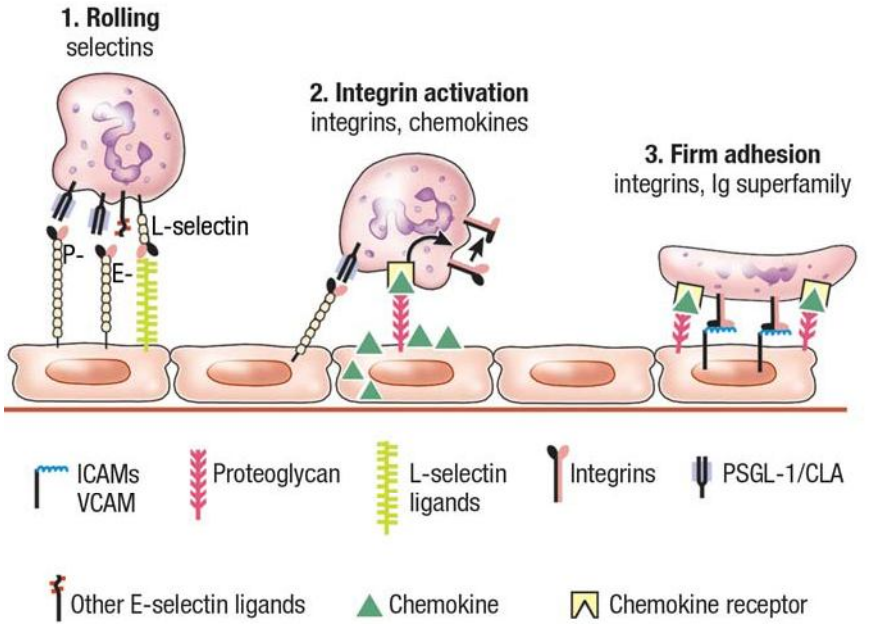

▲ **FIGURE 12-2** Multistep model of leukocyte recruitment. Leukocytes, pushed by the blood stream, first transiently bind or "roll" on the surface of activated endothelial cells via rapid interactions with P-, E-, or L-selectin. Chemokines are secreted by endothelial cells and bind to proteoglycans that present the chemokine molecules to chemokine receptors on the surface of the leukocyte. After chemokine receptor ligation, intracellular signaling events lead to a change in the conformation of integrins and changes in their distribution on the plasma membrane, resulting in integrin activation. These changes result in high affinity/avidity binding of integrins to endothelial cell intercellular adhesion molecules (ICAMs) and vascular cell adhesion molecule (VCAM)-1 in a step termed *firm adhesion*, which is then followed by transmigration of the leukocyte between endothelial cells and into tissue. CLA = cutaneous lymphocyte–associated antigen; Ig = immunoglobulin; PSGL-1 = P-selectin glycoprotein ligand 1.

cells.[9,10] Whereas E-selectin is likely to be an important component of skin-selective homing, there is also evidence to suggest that L-selectin is involved in T-cell migration to skin.[11,12]

In the second phase of this model, leukocyte integrins such as those of the β_2 family must be "turned on" or activated from their resting state to bind to their counter-receptors such as intercellular adhesion molecule 1 that are expressed by endothelial cells. A vast array of data suggest that the binding of chemokines to leukocyte chemokine receptors plays a critical role in activating both β_1 and β_2 integrins.[5,13] Activation of chemokine receptors leads to a complex signaling cascade (see Fig. 12-1) that causes a conformational change in individual integrins that leads to increases in the affinity and avidity of individual leukocyte integrins for their ligands. Furthermore, later steps of migration (i.e., transmigration or diapedesis) have been shown to be dependent on chemokines as well in selective cases.[14] In the case of neutrophils, their ability to roll on inflamed blood vessels likely depends on their expression of L-selectin and E-selectin ligands whereas their arrest on activated endothelia likely depends on their expression of CXCR1 and CXCR2 as described below for wound healing (see Chap. 163). Integrin activation via chemokine-mediated signals appears to be more complex in T cells, which appear to use multiple chemokine receptors, and is described in more detail in the following section.

Chemokine-Mediated Migration of T Cells

Antigen-inexperienced T cells are termed *naive* and can be identified by expression three cell surface proteins: CD45RA (an isoform of the pan-leukocyte marker), L-selectin, and the chemokine receptor CCR7. These T cells migrate efficiently to secondary LNs, where they may make contact with antigen-bearing DCs from the periphery. Once activated by DCs presenting antigen, T cells then express CD45RO, are termed *memory* T cells, and appear to express a variety of adhesion molecules and chemokine receptors which facilitate their extravasation from blood vessels to inflamed peripheral tissue. A specific subset of $CCR7^-$, L-$selectin^-$ memory T cells, has been proposed to represent an effector memory T-cell subset that is ready for rapid deployment at peripheral sites in terms of their cytotoxic activity and ability to mobilize cytokines.[15]

Although chemokines are both secreted and soluble, the net positive charge on most chemokines allows them to bind to negatively charged proteoglycans such as heparin sulfate that are present on the lumenal surface of endothelial cells, thus allowing them to be presented to T cells as they roll along the lumenal surface (see Fig. 12-2). After ligand binding, chemokine receptors send intracellular signals that lead to increases in the affinity and avidity of T-cell integrins such as lymphocyte function–associated antigen 1 and very late antigen 4 for their endothelial receptors intercellular adhesion molecule 1 and vascular cell adhesion molecule-1, respectively.[16] Only a few chemokine receptors (CXCR4, CCR7, CCR4, and CCR6) are expressed at sufficient levels on resting peripheral blood T cells to mediate this transition. With activation and interleukin (IL)-2 stimulation, increased numbers of chemokine receptors (e.g., CXCR3) are expressed on activated T cells, making them more likely to respond to other chemokines. In several different systems, inhibition of specific chemokines produced by endothelial cells or chemokine receptors found on T cells dramatically influences T-cell arrest in vivo and in vitro.[17]

CXCR3 serves as a receptor for chemokine ligands Mig (monokine induced by interferon-γ), interferon-inducible protein 10 (IP-10), and interferon-inducible T cell α chemoattractant. All three of these chemokines are distinguished from other chemokines by being highly upregulated by interferon-γ. Resting T cells do not express functional levels of CXCR3, but upregulate this receptor with activation and cytokines such as IL-2. Once expressed on T cells, CXCR3 is capable of mediating arrest of memory T cells on activated endothelial cells.[18] The expression of its chemokine ligands is strongly influenced by the cytokine interferon-γ, which synergistically works with proinflammatory cytokines such as TNF-α to increase expression of these ligands by activated endothelial cells[18] and epithelial cells.

In general, activation of T cells by cytokines such as IL-2 is associated with the enhanced expression of CCR1, CCR2, CCR5, and CXCR3. Just as T helper 1 (Th1) and Th2 (T cell) subsets have different functional roles, it might

have been predicted that these two subsets of T cells would express different chemokine receptors. Indeed, CCR4[19–21] and CCR3[22] are associated with Th2 cells in vitro, whereas Th1 cells are associated with CCR5 and CXCR3.[23]

In some instances, chemokine receptors may be regarded as functional markers that identify Th1- versus Th2-type lymphocytes while also promoting their recruitment to inflammatory sites characterized by "allergic" or "cell-mediated" immunity, respectively. When T cells are activated in vitro in the presence of Th1-promoting cytokines, CXCR3 and CCR5 appear to be highly expressed, whereas in the presence of Th2-promoting cytokines, CCR4, CCR8, and CCR3 expression predominates. In rheumatoid arthritis, a Th1-predominant disease, many infiltrating T cells express CCR5 and CXCR3[24] whereas, in atopic disease, CCR4 expressing T cells may be more frequent.[21] There is likely to be overlap as demonstrated under some conditions in which both Th1 and Th2 type T cells can express CCR4.[20]

The epidermis is a particularly rich source of chemokines, including RANTES, macrophage chemoattractant protein-1 (MCP-1), IP-10, IL-8, LARC, and thymus and activation-regulated chemokine (TARC), which likely contribute to epidermal T-cell migration. Keratinocytes from patients with distinctive skin diseases appear to express unique chemokine expression profiles. For instance, keratinocytes derived from patients with atopic dermatis (see Chap. 14) synthesized messenger RNA for RANTES at considerably earlier time points in response to IL-4 and TNF-α in comparison to unaffected and psoriatic patients.[25] Keratinocytes derived from psoriatic patients (see Chap. 18) synthesized higher levels of IP-10 with cytokine stimulation as well as higher constitutive levels of IL-8,[25] a chemokine known to recruit neutrophils. IL-8 may contribute to the large numbers of neutrophils that localize to the suprabasal and cornified layers of the epidermis in psoriasis. IP-10 may serve to recruit activated T cells of the Th1 helper phenotype to the epidermis and has been postulated to have a role in the recruitment of malignant T cells to the skin in cutaneous T-cell lymphomas.[26]

Cutaneous T cell–attracting chemokine (CTACK)/CC chemokine ligand 27 (CCL27) is selectively and constitutively expressed in the epidermis, and its expression is only marginally increased under inflammatory conditions.[27] Interestingly, CTACK has been reported to preferentially attract CLA$^+$ memory T cells in vitro[27] and has been demonstrated to play a role in the recruitment and function of skin-homing T cells in inflammatory disease models.[28,29]

Chemokines in the Trafficking of Dendritic Cells from Skin to Regional Lymph Nodes

Antigen-presenting cells, including DCs of the skin, are critical initiators of immune responses and their trafficking patterns are thought to influence immunologic outcomes. Their mission includes taking up antigen at sites of infection or injury and bringing these antigens to regional LNs where they both present antigen and regulate the responses of T and B cells. Skin-resident DCs are initially derived from hematopoietic bone marrow progenitors[30] and migrate to skin during the late prenatal and newborn periods of life. Under resting (steady state) conditions, homeostatic production by keratinocytes of CXCL14 (receptor unknown) may be involved in attracting CD14$^+$ DC precursors to the basal layer of the epidermis.[31] Under inflammatory conditions, when skin-resident DC and LC leave the skin in large numbers, keratinocytes release a variety of chemokines, including CCL2 and CCL7 (via CCR2)[32] and CCL20 (via CCR6),[33] which may attract monocyte-like DC precursors to the epidermis to replenish the LC population.

When activated by inflammatory cytokines (e.g., TNF-α, and IL-1β), lipopolysaccharide, or injury, skin DCs, including LCs, leave the epidermis, enter afferent lymphatic vessels, and migrate to draining regional LNs where they encounter both naive and memory T cells. Chemokines guide the DC on this journey. Activated DC specifically upregulate expression of CCR7, which binds to secondary lymphoid tissue chemokine (SLC/CCL21), a chemokine expressed constitutively by lymphatic endothelial cells (see eFig. 12-2.1 in on-line edition).[34,35] SLC guides DCs into dermal lymphatic vessels and helps retain them in SLC-rich regional draining LNs (Fig. 12-3).[36]

Interestingly, naive T cells also strongly express CCR7 and use this receptor to arrest on high endothelial venules.[37] The importance of the CCR7 pathway is demonstrated by LCs from CCR7 knockout mouse that demonstrate poor migration from the skin to regional LNs[38] and by the observation that antibodies to SLC block migration of DCs from the periphery to LNs.[34] Thus, CCR7 and its ligands facilitate the recruitment of at least two different kinds of cells—naive T cells and DCs—to the LNs through two different routes under both inflammatory[38] and resting conditions.[36]

After DCs reach the LN, they must interact with T cells to form a so-called *immunologic synapse* that is critical for T-cell activation. Activated DCs secrete a number of chemokines, including macrophage-derived chemokine,[39] which attracts T cells to the vicinity of DCs and promotes adhesion between the two cell types.[40,41] CCR5 (via CCL3/4) has also been identified as mediating recruitment of naive CD8$^+$ T cells to aggregates of antigen-specific CD4$^+$ T cells and DCs.[42] Therefore, chemokines orchestrate a complex series of migration patterns, bringing both DCs and T cells to the confines of the LN, where expression of chemokines by DCs themselves appears to be a direct signal for binding of the T cell (see Fig. 12-3).

CHEMOKINES IN DISEASE

Atopic Dermatitis (See Chap. 14)

Atopic dermatitis is a prototypical Th2-mediated, allergic skin disease (see Chap. 14) in which chemokines may play pathogenic roles.[43] The mechanism of lymphocyte homing to skin in the setting of atopic dermatitis has been elucidated by clinical data from humans as well as experimental data in the NC/Nga mouse model of atopic dermatitis, which suggest that the Th2-associated chemokine receptor, CCR4, in conjunction with its ligand, TARC/CCL17, may play a role in recruiting T cells to atopic skin. In human patients with atopic dermatitis, CLA$^+$CCR4$^+$ lymphocytes were found to be increased in the peripheral blood of atopic dermatitis patients compared to controls.[21] Moreover, serum levels of TARC in atopic dermatitis patients were 10-fold higher than concentrations found in unaffected individuals and correlated with disease severity, whereas psoriatics showed only a minimal elevation of TARC in the serum.[44] Interestingly, another chemokine, CCL18, whose receptor is currently unknown, is produced by LC (as well as other antigen-presenting cells) and shows selective expression in atopic skin relative to psoriatic skin. Similar to TARC, CCL18 at-

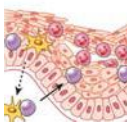

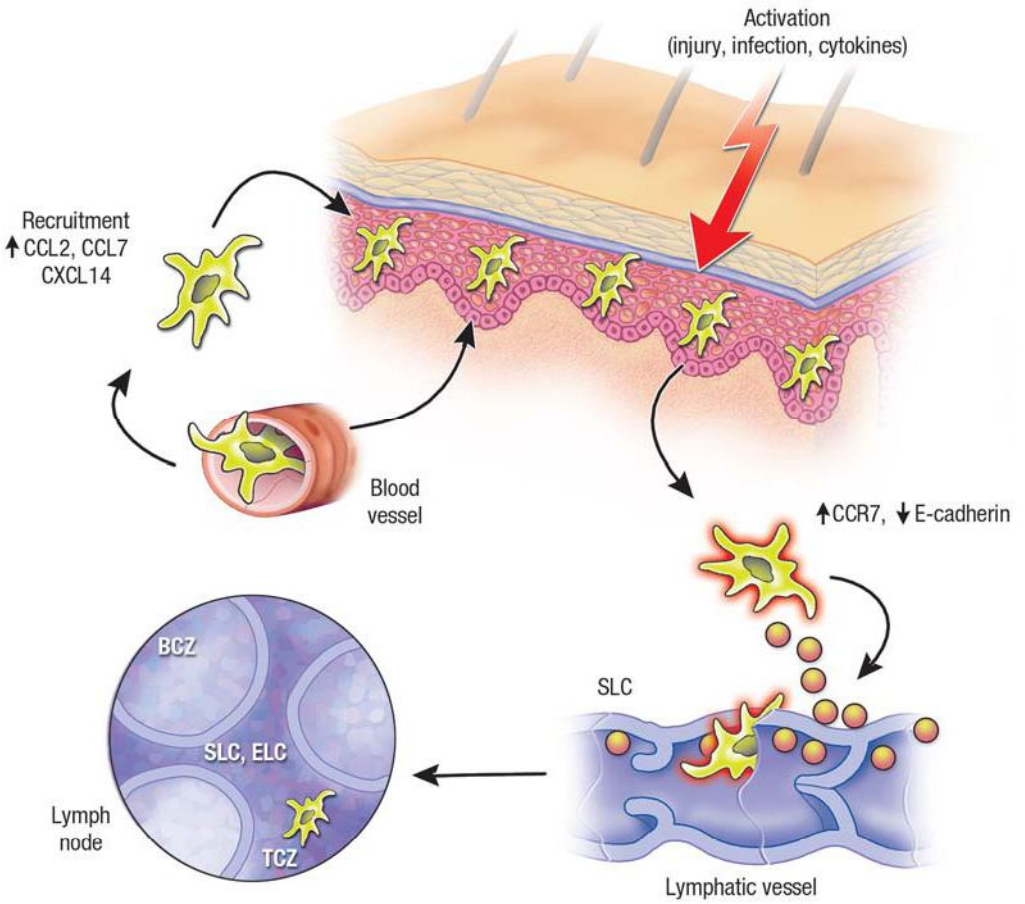

◀ FIGURE 12-3 Trafficking of epidermal Langerhans cells (LCs) to regional lymph nodes. LCs are activated by a variety of stimuli, including injury, infectious agents, and cytokines such as interleukin-1β and tumor necrosis factor-α. Having sampled antigens, the activated LCs downregulate E-cadherin and strongly upregulate CC chemokine receptor 7 (CCR7). Sensing the CCR7-ligand, secondary lymphoid-organ chemokine (SLC; ●), produced by lymphatic endothelial cells, the LCs migrate into lymphatic vessels, passively flow to the lymph nodes, and stop in the T-cell zones (TCZs) that are rich in two CCR7 ligands, SLC and Epstein-Barr virus–induced molecule-1 ligand chemokine (ELC). Note that chemokines also contribute to the recruitment of LCs under both resting and inflammatory conditions. BCZ = B-cell zone; CCL = CC chemokine ligand; CXCL = CXC chemokine ligand.

tracts CLA$^+$ memory T cells.[45] Perhaps of physiologic consequence, CCL18 expression is elicited in volunteer skin after topical challenge with dust mite allergen and staphylococcal superantigen.[46]

The recruitment of eosinophils to skin is a frequently observed finding in allergic skin diseases, including atopic dermatitis and cutaneous drug reactions, and likely is mediated by chemokines. Eotaxin/CCL11 was initially isolated from the bronchoalveolar fluid of guinea pigs after experimental allergic inflammation and binds primarily to CCR3, a receptor expressed by eosinophils,[47] basophils, and Th2 cells.[22] Injection of eotaxin into the skin promotes the recruitment of eosinophils whereas anti-eotaxin antibodies delay the dermal recruitment of eosinophils in the late-phase allergic reaction in mouse skin.[48] Immunoreactivity and messenger RNA expression of eotaxin and CCR3 are both increased in lesional skin and serum of patients with atopic dermatitis, but not in nonatopic controls.[49,50] Eotaxin has also been shown to increase proliferation of CCR3-expressing keratinocytes in vitro.[51] Finally, expression of eotaxin (and RANTES) by dermal endothelial cells has been correlated with the appearance of eosinophils in the dermis in patients with onchocerciasis that experience allergic reactions after treatment with ivermectin.[52] These observations suggest that production of eotaxin and CCR3 may contribute to the recruitment of eosinophils and Th2 lymphocytes in addition to stimulating keratinocyte proliferation.

Psoriasis (See Chap. 18)

Psoriasis, an inflammatory skin disorder characterized by thickened, pruritic plaques, does not have a clear etiology, although it is considered a Th1-mediated, autoimmune disease. As shown in Fig. 12-4 and reviewed by others,[53] there are multiple potential trafficking pathways that may be mediated by chemokines in psoriasis. Chemokines, including LARC/CCL20[54] and TARC/CCL17,[10] that are expressed by vascular endothelial cells mediate the arrest of effector memory T cells on endothelial cells.[55] In addition, both CCL17 and CCL20 can be synthesized by keratinocytes, possibly contributing to T-cell migration to the epidermis. Although the CCL17 receptor, CCR4, has been associated with Th2-type T cells,[19] there is also evidence suggesting that Th1-type T cells can express this receptor.[20]

Neutrophils found in the epidermis of psoriatic skin are likely to be attracted there by high levels of IL-8, which would act via CXCR1 and CXCR2. In addition to attracting neutrophils, IL-8 is an ELR$^+$ CXC chemokine that is known to be angiogenic, and it may also attract endothelial cells. This may lead to the formation of the long tortuous capillary blood vessels in the papillary dermis that are characteristic of psoriasis. Moreover, keratinocytes also express CXCR2 and thus may be auto-regulated by the expression of CXCR2 ligands in the skin. Of note, an IL-8/CXCL8–producing population of memory T cells that express CCR6 has been isolated from patients with acute generalized exanthematous pustulosis, a condition induced most commonly by drugs (e.g., aminopenicillins) and characterized by small intraepidermal or subcorneal sterile pustules (see Chap. 40).[56] Similar T cells have been isolated from patients with Behçet disease and pustular psoriasis.[57] It is possible that this subpopulation of T cells contributes to neutrophil accumulation in the stratum corneum (Munro abscesses) in psoriasis and other inflammatory skin disorders characterized by neutrophil-rich infiltrates in the absence of frank infection.

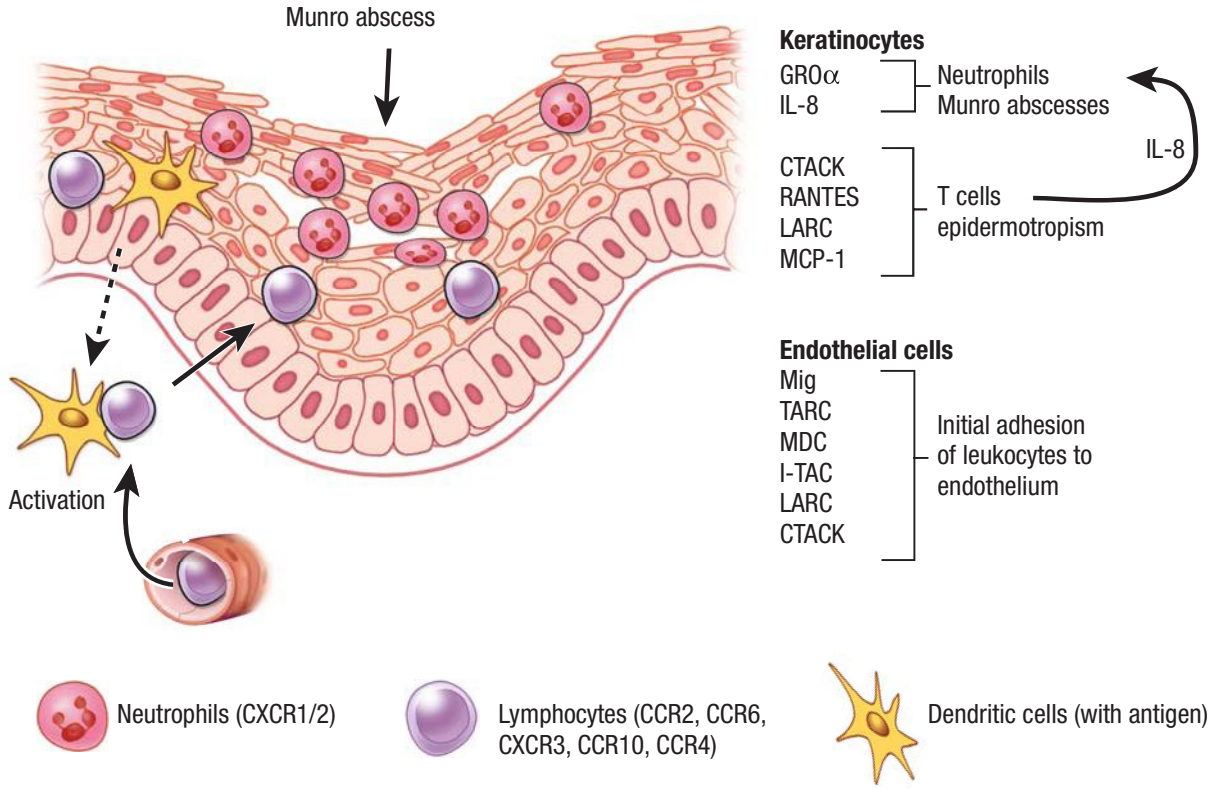

▲ FIGURE 12-4 Possible sites of actions of chemokines in psoriasis. Chemokines attract both neutrophils (to form Munro abscesses) and lymphocytes via attachment to endothelial cells and then migrate to the epidermis (epidermotropism). Specific chemokines tend to attract either neutrophils or lymphocytes, but generally not both. A newly identified subset of T cells can secrete interleukin-8 and attract neutrophils in conditions such as acute generalized exanthematous pustulosis.[58] Dendritic cells may also secrete chemokines, attract T cells, and stimulate conjugate formation that activates T cells. CCR = CC chemokine receptor; CTACK = cutaneous T cell–attracting chemokine; CXCR = CXC chemokine receptor; IL-8 = interleukin 8; I-TAC = interferon-inducible T cell α chemoattractant; LARC = liver and activation-regulated chemokine; MCP-1 = macrophage chemoattractant protein-1; MDC = macrophage-derived chemokine; Mig = monokine induced by interferon-γ; RANTES = regulated on activation normal T-cell expressed and secreted; TARC = thymus and activation-regulated chemokine.

Although the aforementioned chemokines have been shown to be expressed in psoriatic epidermis, they may also be found in a variety of skin diseases, including cutaneous T-cell lymphoma and atopic dermatitis. It is becoming apparent that multiple, rather than single, chemokines and their receptors likely contribute to the fine-tuning of T-cell migration in the skin.

Cancer

Chemokines may play a role in tumor formation and immunity in several distinct ways, including the control of angiogenesis and the induction of tumor immune responses.[58] CXC chemokines that express a three amino acid motif consisting of glu-leu-arg (ELR) immediately preceding the CXC signature are angiogenic, whereas most non-ELR CXC chemokines, except SDF-1, are angiostatic. Interestingly, it is not clear that ELR⁻ chemokines actually bind to chemokine receptors to reduce angiogenesis. It has been proposed that they act by displacing growth factors from proteoglycans. In any event, the balance between ELR⁺ versus ELR⁻ chemokines is thought to contribute to the complex regulation of angiogenesis at tumor sites. IL-8, a prototypical ELR⁺ chemokine, can be secreted by melanoma cells and has been detected in conjunction with metastatic dissemination of this cancer.[59] IL-8 may also act as an autocrine growth factor for melanoma[60] as well as several other types of cancer. Although CXCR1 and CXCR2 bind IL-8 in common, several other ELR⁺ CXC chemokines, including growth regulated oncogene α and epithelial-neutrophil–activating peptide-78, bind primarily to CXCR2. CXCR2 appears, in most instances, to be associated with both the angiogenic and growth regulatory properties of tumors.[61]

Tumors, including melanoma, have long been known to secrete chemokines that can attract a variety of leukocytes. The question arises as to why this is not deleterious to the tumor itself. Breast cancers, for instance, are known to secrete MCP-1, a chemokine that attracts macrophages through CCR2. Higher tissue levels of MCP-1 correlate with increasing numbers of macrophages within the tissue. Although chemokines secreted by tumor cells do lead to recruitment of immune cells, this does not necessarily lead to increased clearance of the tumor.[62]

Inflammatory cells such as macrophages may actually play a critical role in cancer invasion and metastasis. First, MCP-1 may increase expression of macrophage IL-4 through an autocrine feedback loop and possibly skew the immune response from Th1 to Th2. Interestingly, MCP-1–deficient mice show markedly reduced dermal fibrosis after dermal challenge with bleomycin, a finding of possible relevance to the pathogenesis of conditions such as scleroderma.[63] Secondly, macrophages may promote tumor invasion and metastasis.[64] The antitumor effects of specific chemokines may occur by a variety of mechanisms. ELR⁻ CXCR3 ligands such as IP-10 are potently anti-angiogenic and may act as downstream effectors of IL-12–induced, natural killer cell–dependent angiostasis.[65] Of note, some cancer cells can synthesize

LARC, attracting immature DCs that express CCR6.[66] Experimentally, LARC has been transduced into murine tumors, where it attracts DCs in mice and suppresses tumor growth in experimental systems.[67] Last, chemokines produced by tumor cells may attract $CD4^+CD25^+$ T regulatory cells that suppress host anti-tumor cytolytic T cells.[68]

Tumor metastasis is the most common source of mortality and morbidity in cancer. With skin cancers such as melanoma, there is a propensity for specific sites such as brain, lung, and liver, as well as distant skin sites. Cancers may also metastasize via afferent lymphatics and eventually reach regional draining LNs. The discovery of nodal metastasis often portends a poor prognosis for the patient. In fact, the presence of nodal metastases is one of the most powerful negative predictors of survival in melanoma.[69]

Chemokines may play an important role in the site-specific metastases of cancers of the breast and of melanoma (Fig. 12-5).[70] Human breast cancer as well as melanoma lines expressed the chemokine receptors CXCR4 and CCR7, whereas normal breast epithelial cells and melanocytes do not appear to express these receptors.[71] CXCR4 is expressed in over 23 different solid and hematopoietic cancers. Broad expression of this receptor may be due to its regulation by hypoxia, a condition common to growing tumors, via the hypoxia inducible factor-1α transcription factor.[72] In several different animals of breast cancer[71] and melanoma metastasis,[73] inhibition of CXCR4 with antibodies or peptides resulted in dramatically reduced metastases to distant organs. Expression of CCR7 by cancer cells, including gastric carcinoma and melanoma, appears to be critical for invasion of afferent lymphatics and LN metastasis. CCR7-transfected B16 murine melanoma cells were found to metastasize with much higher efficiency to regional LNs compared to control B16 cells after inoculation into the footpad of mice.[74] CCR9 may also play a role in melanoma metastasis to the small bowel, which shows high expression of the CCR9 ligand, CCL25.[75]

CCR10 is highly expressed by melanoma primary tumors[76] and is correlated with nodal metastasis in melanoma patients[77] and in experimental animal models (see eFig. 12-5.1 in online edition).[76] Engagement of CCR10 by CTACK results in activation (via phosphorylation) of the phosphatidylinositol 3-kinase and Akt signaling pathways, leading to anti-apoptotic effects in melanoma cells.[76] Because CTACK is constitutively produced by keratinocytes, it may act as a survival factor for both primary as well as secondary (metastatic) melanoma tumors that express CCR10. In fact, CCR10-activated melanoma cells become resistant to killing by melanoma antigen-specific T cells.[76] Interestingly, CCR4[78] and CCR10[79,80] have been implicated in the trafficking and/or survival of malignant T (lymphoma) cells to skin. Thus, a limited number of specific chemokine receptors appear to play distinct, nonredundant roles, in facilitating cancer progression and metastasis (summarized in Fig. 12-5).

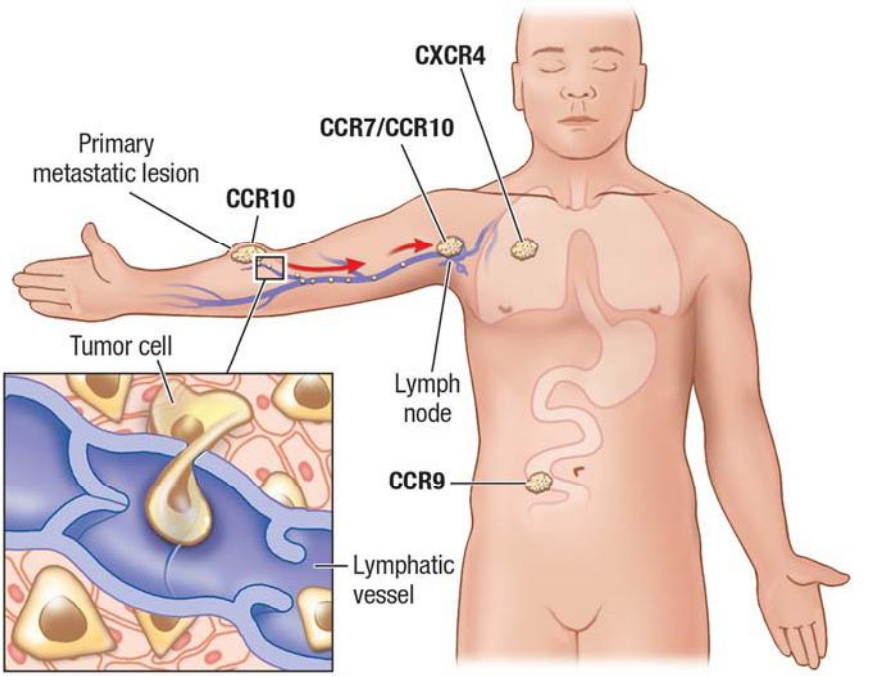

▲ **FIGURE 12-5** Chemokine receptors in melanoma progression and metastasis. Chemokine receptors play distinct roles in melanoma metastasis.[71] CC chemokine receptor 10 (CCR10) may enhance survival of primary melanoma tumors and skin metastases. CCR7, CCR10, and, possibly, CXC chemokine receptor 4 (CXCR4) may contribute to lymph node metastasis. CXCR4 appears to be involved in primary tumor development and metastasis at distant organ sites such as the lungs. CCR9 has been implicated in melanoma small bowel metastasis in patients.

Infectious Diseases

Although chemokines and chemokine receptors may have evolved as a host response to infectious agents, recent data suggest infectious organisms may have co-opted chemokine- or chemokine receptor–like molecules to their own advantage in selected instances. A variety of microorganisms express chemokine receptors, including US28 by cytomegalovirus (see Chap. 193) and Kaposi sarcoma herpesvirus (or human herpesvirus-8) GPCR. In the case of Kaposi sarcoma herpesvirus GPCR, this receptor is able to promiscuously bind several chemokines. More important, it is constitutively active and may work as a growth promoter in Kaposi sarcoma (see Chap. 128).[81]

Human immunodeficiency virus 1 (HIV-1), the causative agent of acquired immunodeficiency syndrome, is an enveloped retrovirus that enters cells via receptor-dependent membrane fusion (see Chap. 198). CD4 is the primary fusion receptor for all strains of HIV-1 and binds to HIV-1 proteins, gp120 and gp41. However, different strains of HIV-1 have emerged that preferentially use CXCR4 (T-tropic) or CCR5 (M-tropic) or either chemokine receptor as a co-receptor for entry. Although other chemokine co-receptors can potentially serve as co-receptors, most clinical HIV-1 strains are primarily dual-tropic for either CCR5 or CXCR4.[82]

The discovery of a 32–base pair deletion (Δ32) in CCR5 in some individuals that leads to low levels of CCR5 expression in T cells and DCs and correlates with a dramatic resistance to HIV-1 infection demonstrated a clear role for CCR5 in the pathogenesis of HIV-1 in-

fection.[83] Interestingly, the frequency of Δ32 mutations in humans is surprisingly high, and the complete absence of CCR5 in homozygotes has only been associated with a more clinically severe form of sarcoidosis. Otherwise, these individuals are healthy. In fact, there is an association of less severe autoimmune disease with this mutation.[84]

LCs reside in large numbers in the genital mucosa and may be one of the first initial targets of HIV-1 infection.[85] Because infected (activated) LCs likely enter dermal lymphatic vessels and then localize to regional LNs, the physiologic migratory pathway of LCs may also coincidentally lead to the transmission of HIV-1 to T cells within secondary lymphoid organs. CCR5 is expressed by immature or resting LCs in the epidermis and is the target of CCR5 analogues of RANTES that block HIV infection,[86] suggesting possible therapeutic strategies in the treatment or prevention of HIV-1 disease.[87] CXCR4 antagonists may also be of clinical utility with T- or dual-tropic viruses.[88]

A newly described autosomal dominant genetic syndrome comprised of warts (human papilloma virus–associated), hypogammaglobulinemia, infections, and myelokathexis is the result of an activating mutation (deletion) in the cytoplasmic tail of the CXCR4 receptor or in yet unidentified downstream regulators of CXCR4 function.[89,90] Bacterial infections are common because myelokathexis is associated with neutropenia and abnormal neutrophil morphology. The nearly universal presence of human papilloma virus infections associated with this syndrome can involve multiple common, as well as genital, wart subtypes (see eFig. 12-5.2 in on-line edition) and suggest a critical role for normal CXCR4 function in immunologic defense against this common human pathogen.

Thus, the skin is rich in cells (keratinocytes, fibroblasts, endothelial cells, and immune cells) that are able to produce chemokines. Chemokines not only orchestrate the migration of inflammatory cells, but also play roles in angiogenesis, cancer metastasis, and cellular proliferation. Other unanticipated biologic roles may ultimately be discovered. Just two of the promising therapeutic applications of chemokines (or molecules that mimic chemokines) may be in (1) preventing undesirable migration into the skin by preventing arrest of T cells or other inflammatory cells on activated endothelium and (2) blocking the infection of DCs and T cells by HIV-1 virus using CCR5 analogues. Signaling pathways are just beginning to be understood, and further work needs to be done to understand the regulation of these receptors, the specificity of intracellular activities, and the mechanism by which chemokine receptors work in the face of multiple chemokines present in many inflammatory sites.

KEY REFERENCES

The full reference list for all chapters is available at www.digm7.com.

1. Charo IF, Ransohoff RM: The many roles of chemokines and chemokine receptors in inflammation. *N Engl J Med* **354**:610, 2006
2. Zlotnik A, Yoshie O: Chemokines: A new classification system and their role in immunity. *Immunity* **12**:121, 2000
6. Homey B: Chemokines and inflammatory skin diseases. *Adv Dermatol* **21**:251, 2005
36. Ohl L et al: CCR7 governs skin dendritic cell migration under inflammatory and steady-state conditions. *Immunity* **21**:279, 2004
77. Simonetti O et al: Potential role of CCL27 and CCR10 expression in melanoma progression and immune escape. *Eur J Cancer* **42**:1181, 2006
90. Diaz GA, Gulino AV: WHIM syndrome: A defect in CXCR4 signaling. *Curr Allergy Asthma Rep* **5**:350, 2005



CHAPTER 13

Allergic Contact Dermatitis

David E. Cohen
Sharon E. Jacob

As the primary interface with the environment, the skin is placed in the precarious position of routine exposure and assault from exogenous chemicals and physical agents. Fortunately, most of these exposures result in no clinically apparent disease. However, in some circumstances, a panoply of immunologic events results in the sensitization and subsequent elicitation of allergic contact dermatitis (ACD).

The classic interpretation of the skin as a simple barrier to penetration by exogenous agents underestimates the immunologic capacity of the integument. Modern concepts have divulged the finely orchestrated interplay of host defenses that cope with these onslaughts. In the 1950s, Landsteiner and Chase[1] firmly established ACD as a form of cell-mediated hypersensitivity. It was not until the latter half of the twentieth century, however, that the fundamental role of intact lymphatic systems, cellular elements (Langerhans cells, keratinocytes, and lymphoid cells), and specific cytokines in the sensitization and elicitation phases of ACD became recognized (see Chap. 10).[1]

Today we understand that these complex T-cell–mediated events are specifically and sensitively targeted to one or more chemical entities. When the level of exposure exceeds the thresholds of sensitization and elicitation, immunologic memory of the event is generated. That being said, the frequent lack of an obvious causative culprit or temporal relationship between the allergen and dermatitis leads to an intense detective and analytic exercise of determining and subsequently avoiding the offending chemical entity.

EPIDEMIOLOGY

Much of the epidemiologic data regarding ACD has been extrapolated or inferred from government reports on the prevalence and economic impact of occupational skin diseases. A basic assumption in many studies is that most occupational dermatitis is irritant in nature. More recent evidence, however, suggests that there is a larger proportion of allergic occupational dermatosis than previously thought. Of the 5839 patients patch-tested for contact dermatitis by the North American Contact Dermatitis Group between 1998 and 2000, 1097 (19 percent) were deemed to have occupationally related disease. In this occupational cohort, 60 percent of cases were of allergic and 32 percent were of irritant origin. Of note, the hands were primarily affected in two-thirds of allergic occupational cases and four-fifths of irritant occupational cases[2] (Fig. 13-1; see Chap. 211).

In 2001, 4714 cases of occupational dermatitis were reported to the Bureau

CONTACT DERMATITIS AT A GLANCE



- Allergic contact dermatitis (ACD) is the classic presentation of delayed-type hypersensitivity responses to exogenous agents.
- Over 3700 allergens have been reported to cause ACD in humans.
- ACD may clinically present acutely after allergen exposure and initial sensitization or after elicitation in a previously sensitized individual.
- The acute phase is characterized by the development of erythematous, indurated, scaly plaques, with severe cases demonstrating vesiculation and bullae in exposed areas. Affected sites often mimic the pattern of exposure and may provide insight into the allergen source and elicitor of disease.
- Repeated or continuous exposure of sensitized individual to allergens results in chronic disease, which is usually marked by lichenified erythematous plaques with variable hyperkeratosis, scale, and fissuring.
- The hands, feet, eyelids, and lips, which commonly come in contact with the environment, are likely sites for ACD.
- Histopathologic presentation consists of epidermal spongiosis with a superficial, perivascular, lymphohistiocytic dermal infiltrate.



TABLE 13-1
Prevalence/Percentage of Subjects Showing Positive Reactions to Allergens Tested by the North American Contact Dermatitis Group

1. Nickel sulfate (2.5%)[a]	**16.7**	31. EU/MF resin (5%)	2.3
2. Neomycin (20%)	**11.6**	**32. Lanolin (30%)**	**2.2**
3. Balsam of Peru (25%)	**11.6**	**33. p-tert-Butylphenol formaldehyde resin (1%)**	**1.9**
4. Fragrance mix (8%)	**10.4**		
5. Thimerosal (0.1%)[b]	**10.2**	34. Glyceryl thioglycolate (1%)	1.9
6. Sodium gold thiosulfate (0.5%)[a]	10.2	**35. Benzocaine (5%)**	**1.7**
7. Quaternium-15 (2%)[b]	**9.3**	36. Tolsylamide formaldehyde resin (10%)	1.6
8. Formaldehyde (1% aqs)[b]	**8.4**	37. Methyl methacrylate (2%)	1.4
9. Bacitracin (20%)	7.9	38. Glutaraldehyde (1%)[b]	1.4
10. Cobalt chloride (1%)[a]	**7.4**	39. Ethyl acrylate (0.1%)	1.3
11. MDGN/PE (2.5%)[b]	5.8	40. dl-α-Tocopherol	1.1
12. Carba mix (30%)[c]	**4.9**	41. Budesonide (0.1%)	1.1
13. Para-phenylenediamine (1%)	**4.8**	42. DMDHEU (4.5% aqs)	1.1
14. Thiuram (1%)[c]	**4.5**	43. Ylang-ylang oil (2%)	1.1
15. Potassium dichromate (0.25%)[a]	**4.3**	**44. Black rubber mix (6%)[c]**	**1.0**
16. Benzalkonium chloride (1% aqs)[b]	4.3	45. Compositae mix (6%)	1.0
17. Propylene glycol (30% aqs)	4.2	**46. Mercaptobenzothiazole (1%)[c]**	**0.9**
18. 2-Bromo-2-nitropropane-1,3-diol (0.5%)[b]	3.3	47. Dibucaine (2.5%)	0.9
		48. Thioureas (1%)	0.8
19. Diazolidinylurea (1% aqs)[b]	3.2	49. Jasmine absolute (2%)	0.7
20. Imidazolidinylurea (2%)[b]	3.0	**50. Mercapto mix (1%)[c]**	**0.7**
21. Tixocortol-21-pivalate (1%)	3.0	51. Lidocaine (15%)	0.7
22. Disperse Blue 106 (1%)	3.0	**52. Paraben mix (1%)[b]**	**0.6**
23. Ethylenediamine dihydrochloride (1%)	**2.8**	53. Sesquiterpene lactone (0.1%)	0.6
		54. Benzophenone (3%)	0.6
24. DMDM hydantoin (1%)[b]	2.8	55. PCMX (1%)[b]	0.6
25. Cocamidopropyl betaine (1% aqs)	2.8	56. Tetracaine (1%)	0.6
26. MDGN/PE (4%)[b]	2.7	57. Hydrocortisone-17-butyrate (1%)	0.5
27. Colophony (20%)	**2.6**	58. dl-α-Tocopherol acetate	0.5
28. Epoxy resin (1%)	**2.3**	59. IPBC (0.1%)	0.3
29. MCI/MI (100 ppm aqs)[b]	**2.3**	60. PE (1%)[b]	0.2
30. Amidoamine (0.1% aqs)	2.3	61. Prilocaine (2.5%)	0.1

aqs = aqueous; DMDHEU = dimethyloldihydroxyethyleneurea; DMDM = dimethylol-dimethyl; EU/MF = ethyleneurea/melamine formaldehyde; IPBC = iodopropynyl butyl carbamate; MCI/MI = methylchloroisothiazolinone/methylisothiazolinone; MDGN = methyldibromo glutaronitrile; PCMX = parachlorometaxylenol; PE = phenoxyethanol.
[a]Metal allergen.
[b]Biocides/preservatives.
[c]Rubber additive.
Bold indicates components of T.R.U.E. (Thin-layer Rapid Use Epicutaneous) Test. (T.R.U.E. Test uses caine mix instead of benzocaine.)
North American Contact Dermatitis Group. *Am J Contact Dermatol* **15**:176, 2004.



▲ **FIGURE 13-1** Allergic contact dermatitis to epoxy. This patient was occupationally exposed.

of Labor Statistics, down 50 percent from the 9472 cases registered just 10 years earlier. The substantial drop over that decade in both the rate and absolute number of cases of occupational dermatitis may reflect improved work conditions and may explain the observed relative decrease in irritant contact dermatitis (ICD) and proportional increase in ACD. It is important to note that the prevalence of ACD in the general population is often extrapolated from the data gleaned from occupational dermatitis studies or from centers and groups that patch-test patients who already have dermatitis.

Because few cross-sectional general population-based studies regarding the prevalence and incidence of ACD have ever been performed, the remainder of available epidemiologic data is generally obtained from retrospective studies reviewing specific body sites of involvement. These data are marred to varying extents by the selection bias inherent in referral to a patch test center and may not be representative of the general population. Nevertheless, such data permit recognition of allergens with high sensitizing potential and strategies for their replacement by substances with low sensitizing potential. Table 13-1 lists many common allergens that elicited positive test results in a group of individuals who were patch-



◀ **FIGURE 13-2** This patient was found to have clinically relevant positive reactions to balsam of Peru and bromonitropropane.

tested by the North American Contact Dermatitis Group.

In two cross-sectional studies, 769 randomly selected 15- to 41-year-old patients from the western part of Copenhagen County, Denmark, were patch-tested in 1990 and 1998 to evaluate the point prevalence of ACD in this population. The rate of positive reactions to at least one allergen was 15.9 percent and 18.6 percent, respectively. Nickel was the most common allergen. Furthermore, the investigators noted a statistically significant increase in allergy to cosmetic agents over the time interval between studies.[3]

These same investigators completed another cross-sectional study in those same years. They randomly patch-tested 567 patients aged 15 to 69 years from western Copenhagen in 1990. In 1998, they re-tested 365 of the same patients in an effort to observe incident cases. Of the individuals who previously had negative patch test results in 1990, 12 percent showed one or more positive patch test results (incident contact allergy). Notably, 6 percent and 8 percent of the re-tested patients who previously had negative patch test results developed incident allergy to nickel and haptens other than nickel, respectively. Female gender, young age, and prior ear piercing (before 1990) were risk factors for the development of nickel allergy.[4]

In a United States–based study, Templet, Hall, and Belsito noted that hand dermatitis was one of the most frequently cited reasons for referral to a patch-testing center. Of the 1034 patients who had been patch-tested over an 8-year period, 32 percent had hand dermatitis; 54 percent were diagnosed with ACD, whereas only 27 percent received a diagnosis of ICD. A gender difference was seen: the peak prevalence in men was in the fifth decade, whereas no specific peak was seen in women.[5]

Another United States–based study found that 17 percent of a U.S. managed care insured population experienced hand dermatitis, with one in six affected patients not seeking medical attention. The effect of chronic hand disease was estimated to increase total medical costs by 25 percent or $70 per month based on medical care delivery and prescription costs.[6]

With the high incidence of hand and face exposure to the environment, one would anticipate a comparable prevalence of hand and face dermatitis. Absolute prevalence data on facial and eyelid dermatitis in the general population is not available, however. Rather, scant prevalence data are available from tertiary care referral centers, which represent only approximately 17 percent of all patch-tested individuals. Of the individuals with eyelid dermatitis referred for patch testing, approximately 50 percent to 75 percent were reported to have at least one positive patch test reaction.[7,8] Few data are available for source-based epidemiology. U.S. population studies of cosmetic allergy prevalence are nearly 20 years old and, given the dynamic nature of product development, no longer provide the data accuracy they once did. One study in India demonstrated a 66 percent rate of positive reactions to cosmetics in patch testing. The allergic individuals tended to be young (mean age, 27.5 years), with dermatitis affecting the face, neck, and scalp. Fragrances, preservatives, and para-phenylenediamine (PPD) were the most common provocative agents.[9]

Age

Although the subject of ACD in pediatric patients has received substantial attention in Europe, it has not enjoyed the same level of attention in North America. Despite this, ample evidence suggests that even young children have rather substantial prevalence rates when they are patch-tested under appropriate conditions[10] (Fig. 13-2). In Italy, of 1094 consecutively patch-tested children, 570 proved to be allergic (52.1 percent). In this cohort of children younger than 12 years of age, the highest sensitization rate was observed in those 7 months to 3 years of age (63.4 percent allergic). Metals, mercury derivatives (thimerosal and metallic mercury), neomycin, wool alcohols, methylchloroisothiazolone-methylisothiazolinone (Kathon CG), and fragrance mix were the most frequent contact allergens. Girls showed a greater propensity for nickel allergy than boys. The neck and antecubital/popliteal fossae were more frequently involved in individuals allergic to nickel and Kathon CG, and sensitization was more frequently seen in atopic than in non-atopic patients.[11]

Clinically, individuals older than 65 years have various defects in the induction and/or elicitation of ACD.[13] In studies of *Rhus* reactivity, younger individuals (18 to 25 years) had a more rapid onset and resolution of the dermatitis than did older persons. When sensitization rates to standard allergens were analyzed as a function of age, incidence rates were found to be significantly lower in individuals older than 70 years.[14] When 1444 elderly subjects with suspected ACD were compared to a control group aged 20 to 40 years, the prevalence of allergic reactivity was found to be significantly lower in the elderly group compared with younger adult patients (40.7 percent vs. 47.8 percent, $p < 0.0001$). The clinical relevance of this difference is debatable, however, and may reflect a need to modify the allergens selected in keeping with age-appropriate exposures or to allow a longer time between patch removal and the delayed reading. Allergens used with greater frequency in this population, such as neomycin, lanolin alcohols, paraben mix, and methyl dibromoglutaronitrile/phenoxyethanol (Euxyl K400) showed a higher sensitization rate in elderly patients than in younger adult patients[15] (Fig. 13-3).

Gender and Race

Gender differences in the development of ACD are largely unknown, because few studies have looked at induction of sensitization in men and women under controlled circumstances. When the human repeat-insult patch-testing method was used to assess induction rates for 10 common allergens, women were found to be more often sensitized to 7 of the







▲ **FIGURE 13-3** Allergic contact dermatitis to aminoglycoside antibiotics. The patient used a neomycin-containing topical antibiotic and a tobramycin-containing eyedrop.

10 allergens studied.[16] In maximization studies that looked at allergens of different potencies, women reacted more frequently to the weakest sensitizers.[17]

The role of race, if any, in the development of ACD to potent allergens such as dinitrochlorobenzene paraphenylenediamine remains controversial.[18,19] Goh found no differences in the incidence of ACD among the indigenous (Malay, Chinese, and Indian) sub-populations in Singapore.[20] Limited studies suggest lower sensitization rates to nickel and neomycin in African Americans than in Caucasians.[14] In addition, erythema evaluation becomes increasingly difficult with ascending order in Fitzpatrick's skin typing, which makes this evaluation variable and requires that greater importance be given to changes in edema and induration. Additional studies evaluating racial influences on immunologic and nonimmunologic (e.g., barrier function) factors and ethnic influences affecting ACD development are needed.

ETIOLOGY AND PATHOGENESIS

ACD represents a delayed (type IV) hypersensitivity reaction to the over 3700 exogenous chemicals that have been described to provoke this reaction.[21] Because this represents a true allergy with immunologic sequelae, only minute quantities of a given chemical are necessary to elicit overt allergic reactions. Evidence dating back to the 1940s indicates that the ability to be sensitized to specific agents has a genetic component. Research has now linked the presence of specific human leukocyte antigen alleles to allergy to nickel, chromium, and cobalt.[22,23]

To mount an immune reaction to an allergen, the individual must be genetically susceptible, have sufficient contact with a sensitizing chemical, and then have repeated contact with the substance later. This is in distinction to ICD, in which no immunologic reaction takes place and the intensity of the reaction is proportional to the dose of the chemical applied (which is directly related to chemical concentration, duration of exposure, and general skin integrity).

Thus ACD is a systemic disease defined by hapten-specific T cell–mediated skin inflammation and characterized by three phases: sensitization, elicitation, and resolution.[24] In the sensitization phase, low-molecular-weight electrophilic or hydrophilic hapten chemicals (usually less than 500 to 1000 d) penetrate the skin and form hapten-protein complexes with epidermal carrier proteins, which produces a complete allergen. These binding proteins are likely cell surface molecules on the Langerhans cell, such as class I and II major histocompatibility complex molecules. For a detailed description of the mechanisms involved in the generation and perpetuation of ACD, see Chap. 10.

The linkage between haptens and epidermal proteins is usually covalent, although metallic haptens may form stable noncovalent linkages with carrier proteins, such as cobalt in vitamin B_{12}.[25] Some of these hapten chemicals are not inherently allergenic (pro-haptens) and must undergo metabolic biotransformation to be able to participate in an allergic response.[26] Because the skin has substantial metabolic capabilities, including many phase I and phase II enzymes, such biotransformation may occur in the skin at the site of contact with the chemical. The importance of the relationship between the carrier and the hapten cannot be underestimated, because potent contact sensitizers, when complexed to nonimmunogenic carriers, can induce tolerance rather than sensitization.

CLINICAL APPROACH

An algorithmic approach to the patient is described in the following sections.

Consideration of the Diagnosis

ACD should be considered in the differential diagnosis of a wide range of eczematous dermatoses (Box 13-1). For example, a patient who has a geometric or pattern-specific dermatitis after an exposure to an exogenous agent should be suspected of having ACD. In addition, the diagnosis should be considered in individuals whose dermatitis is persistent despite appropriate standard therapies. This also pertains to patients with confounding skin disorders, such as atopic dermatitis and psoriasis, who have classic presentations.

Construction of the Exposure Montage

Sensitization and subsequent elicitation of a dermatitis are a direct consequence of exposure to a specific chemical in a susceptible person. There are many variables that factor into the susceptibility of a given individual. For example, an alteration in the inherent skin barrier function or repair mechanism, which may be affected by genetics, age, gender, customs, and psychosocial influences, can increase the predisposition. The geographic location in which the patient resides may also be important, because it may, for example, increase the probability of encountering region-specific botanical allergens. Finally, incidental random exposures must be considered; for instance, a Floridian family's excursion to poison ivy–laden Pennsylvania. Thus, it may be considered that for every chemical there is a predetermined dose (threshold of sensitization) in every person that under optimal circumstances could potentially result in sensitization and the subsequent clinical outcome of ACD.

History Taking

The paradox of patch testing is the deceptive simplicity of application versus the required expertise necessary for allergen selection and interpretation and recognition of clinical significance.[27] Expertise in patch testing starts with obtaining a comprehensive multi-year history from the patient regarding the present illness. An algorithmic approach is again necessary. Information regarding the patient's demographic characteristics, personal and family medical histories, and occupational and home environment, as well as a dermatitis-specific history including prior use of over-the-counter and prescription medications must be obtained (Table 13-2).

Investigation of Exposure Patterns

Patterns of exposure direct the physician to the likely cause(s) of the erup-

Box 13-1

Differential Diagnosis of the Eczematous Dermatoses

DIFFERENTIAL DIAGNOSIS	GEOGRAPHIC-MORPHOLOGIC DISTRIBUTION	DIAGNOSTIC CLUES
Allergic contact dermatitis	Eczematous, scaly edematous plaques with vesiculation	Primary lesions in distribution of contactant; pruritus
Asteotic dermatitis	Crackled parchment-like patches, absent edema and vesiculation	Lower legs
Atopic dermatitis	Eczematous, honey-crusted, scaled plaques; chronic lesions may be lichenified	Flexural areas in children and neck predominance
Autosensitization reaction	Eczematous, poorly defined patches of vesiculation	History of chronic dermatitis or infection with new widespread, less-defined patches
Dyshidrotic eczema	Deep-seated papulovesicles on palmar-plantar surfaces and volar edges	Palm and sole typically dorsal involvement
Irritant contact dermatitis	Sharply demarcated macular erythema, hyperkeratosis, absence of vesiculation	Burning exceeds itching
Mycosis fungoides (patch to plaque stage)	Poorly demarcated, atrophic, scaly pink patches and plaques	Torso predominance
Nummular dermatitis	Coin-shaped, well demarcated plaques with scale and vesiculation; variably exudative	Legs, dorsal hands, extensor surfaces
Psoriasis	Sharply demarcated papulosquamous plaques with no vesiculation	Scalp, retro-auricular area, elbows, knees, genitalia, nails; predominance in areas of trauma (Koebnerization); pustules may be acutely present, particularly on palms and soles; concomitant arthritis
Seborrheic dermatitis	Papulosquamous greasy, scaly plaques	Hair-bearing regions, glabella, and nasolabial folds
Stasis dermatitis	Papulosquamous plaques with dyschromia	Shins and medial surfaces, lower legs, concomitant varicosities

From Rietschel RL: Clues to an accurate diagnosis of contact dermatitis. *Dermatol Ther* **17**:224, 2004.

tion. One must not only consider the potential exposure variables for each patient but also must cross-reference these allergen exposures to arrive at the most likely suspect allergen list for that individual. As a case in point, a patient with a persistent post–hair dye hairline and eyelid dermatitis should be investigated for current use of hair dye products, black henna tattoo preparations, para-aminobenzoic acid–based sunscreens, ester anesthetics, and cross-reacting medications (e.g., hydrochlorothiazide, sulfonylureas, and cyclooxygenase 2 inhibitors). Furthermore, a 2-year-old with concomitant hand and facial dermatitis would more likely be sensitized to balsam of Peru–based fragrances or preservatives in baby washes and diaper balms. It is important to focus on the most likely substances but also to include high-probability alternatives.

Of note, each algorithm is as specific to the patient as the patient's environment is to him or her. Potential new allergens are frequently entering the individual's immediate and global environment. For example, betaine detergent technology was first incorporated into personal care and hygiene products (e.g., low-irritancy baby shampoo) in the late 1960s. In 1983, the first case of cocamidopropyl betaine allergy was noted; since then there has been an upward trend toward its ever-increasing inclusion in personal care products.[28] Almost two decades later, the increasing incidence of cocamidopropyl betaine allergy led to the inclusion of this allergen in comprehensive standard screening trays and the designation of co-

TABLE 13-2
History Taking in Allergic Contact Dermatitis

Demographics and occupational history	Age, gender, race, ethnicity, religion, social aspects (marital status), job title, job description, regular and occasional chemical exposures and sources, location of employment, time at current job, previous occupations
Family medical history	Genetic factors, predispositions
Personal medical history	Drug allergies, concomitant diseases, medications, surgeries
Dermatitis-specific history	Onset, location, temporal associations (waxings/wanings), treatments

camidopropyl betaine as allergen of the year by the American Contact Dermatitis Society. Although there are inherent limitations and biases in the data tracked by the members of tertiary referral groups that report epidemiologic data, the importance of these data cannot be overemphasized, because they also increase awareness of rising chemical allergies previously thought to be rare (e.g., to corticosteroids, gold, and amide anesthetics).

CLINICAL MANIFESTATIONS

Cutaneous Findings

Given the wide array of potential allergens and the inherent uniqueness of every person's skin, it stands to reason that there should be an equally wide variation in the clinical presentation of ACD. However, certain aspects are less variable and tend to follow rather reproducible patterns. In general, once sensitization has been established, acute ACD progresses from erythema to edema to papulovesiculation, with escalating responses (see Figs. 13-2 and 13-3). One exception may be the areas of thin skin with higher absorption coefficients, such as the eyelids, mucosal surfaces, and genitalia. These areas may quickly become edematous, which leads the individual to avoid behaviors or to seek medical attention, and thus the more developed stage may be interrupted. Second, ACD usually occurs in the distribution of the contactant. For example, an arm that has brushed against poison ivy may demonstrate a linear vesicular edematous plaque. In situations in



which the allergen exposure is persistent, however, lichenification and scale predominate. Concurrent with this evolution comes the possibility of more widespread eruptions in non-distinct patterns. Given this, early diagnosis is of utmost importance.

Morphologic Approach

Once a comprehensive history has been obtained, the second step is a complete dermatologic assessment of the patient. This is especially helpful because the patient may be aware of only the most prominent site of dermatitis, and a concurrent dermatitis at a remote site may provide integral clues to the diagnosis. Knowledge of the shape, character, and location of the dermatitis heightens the probability that the culprit allergen will be accurately chosen for testing.



Regional Dermatitis Algorithm

SCALP Despite the great potential for allergen exposure, the scalp remains relatively resistant to allergic dermatitis. Possible reasons for this decreased reactivity may be increased skin thickness, alterations in cellular milieu because of the follicular hair units, variations in vascularity, and dilutional effects of perspiration. Often allergens that are applied the scalp and hair, for example, hair dye (PPD) and shampoos (fragrances, preservatives, and surfactants), may elicit dermatitis in the adjacent areas, such as the hairline, eyelids, and postauricular areas. In the patient with scalp dermatitis, consideration should be given to alternative diagnoses such as seborrheic dermatitis and ICD.

FACE AND EYELIDS The face is always exposed to a great number of potential allergens (see Figs. 13-2 and 13-3). Incidental exposures to aeroallergens can lead to severe consequences, for example, blistering dermatitis after fall burning of leaves accidentally contaminated with poison ivy or chronic photo contact dermatitis from feverfew or other sesquiterpene lactone–containing plants. Furthermore, inadvertent transmission from the hands is frequent to this area, and dermatitis can be seen despite lack of any evidence of allergy on the hands (ectopic contact dermatitis). Because the face is the most likely area to encounter a myriad of grooming tools such as eyelash curlers, makeup sponges, and toothbrushes (rubber additives) and personal hygiene products and cosmetics (fragrances, emulsifiers, preservatives), a wide range of allergens must be considered. Vehicle-based preservatives are a significant source of facial dermatitis.

NECK Like the face, the neck is subject to numerous direct environmental encounters as well as indirect exposure from the hands. Given the repeated insult from a wide variety of fragrance-based chemicals (perfume, eau de toilette, scents), the neck and wrists are especially prone to and may eventually develop a *berloque* dermatitis (*berloque* is French for "trinket-like," and refers to the pendant-like pigmentation seen on the neck and chest). Metal allergy may manifest as chronic dermatitis from exposure to necklaces and jewelry clasps that contain nickel or cobalt.

TORSO The relatively protected condition of the torso alters the list of potential allergen sources. Although it also encounters the fragrances, preservatives, and detergents of daily personal hygiene products (body washes, soaps, lotions), it is also susceptible to textile allergens (dyes and formaldehyde resins.) The most significant textile-associated allergens are the disperse dyes (azoanilines) and urea formaldehyde resins (in wrinkle-resistant, colorfast clothing). Specifically, the heat, humidity, and friction of the body fold (periaxillary and pericrural) areas may contribute to the leaching of the textile resins and dyes and the observed dermatitis accentuation in these areas.[29]

AXILLAE The axillary compartment is subject to many of the same exposures as the trunk, with one major distinction being the use of deodorants and antiperspirants (Fig. 13-4). The formulations of these products use a wide variety of constituents, such as fragrances [balsam of Peru, Lyral (hydroxyisohexyl 3-cyclohexene carboxaldehyde)], preservatives (formaldehyde releasers, parabens), and other excipients (lichen extract, vitamin E, propylene glycol). A commonly observed effect is the sparing of the vault, secondary to the perspirational dilution of the allergens. Furthermore, aerosolized exposure of the allergens may lead to a scattering array pattern with satellite papules.

HANDS AND FEET The high incidence of hand dermatitis (see Epidemiology) is a direct consequence of the fact that the hands are our most important tools in our interactions with the environment. In fact, hand dermatitis can account for as much as 80 percent of the occupationally related skin diseases, especially in certain "wet work" occupations (health care, food handling, cosmetology, etc.).[30] Careful consideration should be given to occupation-specific exposures in the evaluation of hand dermatitis. For example, a construction worker may be sensitized to chromium from cement exposure, whereas a hairdresser may be allergic to paraphenylenediamine (dyes), cocamidopropyl betaine (surfactant-detergent), or glycerol monothioglycolate (permanent wave and straightening solutions).



▲ **FIGURE 13-4** Allergic contact dermatitis to aerosol deodorant. This patient was allergic to Lyral.

The multifactorial etiology of hand dermatitis adds to the complexity of both the diagnosis and treatment (see Fig. 13-1).[31] Co-existent disorders, such as atopy, dyshidrosis, psoriasis, and dermatophytosis, may be encountered in these patients. At times, an underlying endogenous dermatosis may even become unmasked or worsened by a secondary contact dermatitis (either allergic or irritant). For example, cases of iatrogenic contact dermatitis to either the rubber additive in gloves (thiuram, carbamate) or topical therapeutics (preservatives and corticosteroids) may be encountered. Clinical clues that the physician should have a higher index of suspicion of ACD include involvement of the finger web spaces and dorsal hands, and pruritus.

As are the palms, the volar foot surfaces are relatively resistant to development of ACD, and the investigator must consider co-morbidities and the possibility of confounding disorders (psoriasis, dyshidrosis, juvenile plantar dermatosis, etc.) to

comprehensively evaluate the patient with such manifestations. The dorsum of the foot, on the other hand, is frequently involved. Complete evaluation should include testing with the principal allergens generally associated with foot dermatitis, including rubber accelerators (present in rubber-based liners and/or glues), isocyanates (in foam rubber), *p*-tert-butylphenol formaldehyde resin (in glue), potassium dichromate (in tanned leather), antibiotic creams and topical corticosteroids (from prescription and over-the-counter self-treatment), in addition to suspect source component testing using a 8–10 mm punch biopsy swatch of the shoe. Often, extended contact with the shoe component is necessary to elicit a reaction.

Perioral and Perianal Mucosal Exposures

Mucosal ACD, such as aphthae and lingual erosions caused by contact with allergens in toothpaste, is a rare but perhaps under-reported phenomenon. More commonly, patients have persistent perioral dermatitis rather than intra-oral lesions. Flavorants, detergents (cocamidopropyl betaine), and whiteners (peroxides) are frequently encountered in dental hygiene products. Fortunately, only rarely do individuals react to dental amalgam metals (nickel, cobalt, mercury, and gold) with oral lichen planus–like dermatoses, stomatitis, or systematic symptoms. The low reaction rates may reflect a dilutional effect of the mucosal secretions or inherent differences in mucosal immunity. Furthermore, studies have shown that primary mucosal exposure to an allergen may lead to tolerance. For example, the frequency of nickel sensitivity is lower in individuals who undergo orthodontic treatment before ear piercing.[32]

With an increasing number of older persons (older than 65 year of age) in our society, age-associated changes such as mucosal dryness, incontinence, and inability to cleanse properly have resulted in increasing use of genital and perianal hygiene products and exposure to related allergens, such as moistened toilet tissue (methylchloroisothiazolinone and methyldibromoglutaronitrile) and suppositories (fragrances and parabens). Although lower or slower reactivity is reported in the aged population, studies suggest that ACD continues to occur in this population.[33–35] Thus, increased vigilance will be required to discover new allergen associations involving these and other products used by this population.

Paradoxical Dermatoses

The quintessential allergen inducing a paradoxical dermatitis is gold. It is important to note that allergic reactions to gold very rarely involve the contact site of the offending jewelry, such as a watch or a ring. Reactions may be seen on the eyelids, cheeks, or bridge of the nose, however, where gold (e.g., in glasses) has come into contact with a harder metal such as titanium dioxide or zinc oxide in a sunscreen, cosmetic cream, or foundation.[36]

Several other allergens (e.g., lanolin and paraben) are also noted for their paradoxical induction of ACD because they are too weak to elicit a response on intact skin but may give rise to ACD when they are applied to a damaged epidermis (e.g., atopy, stasis dermatitis)—thus the terms *paraben paradox* and *lanolin paradox*.[37] Furthermore, corticosteroids, which were designated the allergens of the year in 2005 by the American Contact Dermatitis Society, because of their intrinsic anti-inflammatory properties, require a delayed patch test reading (at 96 hours) to capture allergic reactions. In cases of treatment-resistant dermatitis or cases in which clinical progression occurs despite the use of increasingly potent corticosteroids, corticosteroid allergy should be suspected. One must be aware of the five structural classes of corticosteroids (A, B, C, D1, and D2; see Chap. 216) and the inherent potential cross-reactivities between the classes.[38]

Systemic Manifestations and Generalized Dermatitis

Systemic contact dermatitis is a relatively uncommon and poorly understood aspect of ACD that highlights the potential for long-lasting immunologic memory in previously sensitized areas of skin. This phenomenon occurs primarily in individuals who are initially sensitized topically to an allergen and then subsequently exposed systemically, which results in a wide array of outcomes, from a recall reaction (dermatitis at the site of original sensitization) to extensive, bizarre-appearing dermatitis and erythroderma.

The more ubiquitous the allergen in nature and the patient's environment, the less obvious the temporal associations will be between the exposures and the dermatitis. One particularly notorious allergen is balsam of Peru, derived from the post-wounding exudates of the bark of the El Salvadoran *Myroxylon pereirae* tree (see Figs. 13-2, 13-5).[39] It is encountered in early infancy in baby washes and diaper salves and again daily in adulthood a wide range of substances from fragranced personal hygiene products to denture adhesives. Furthermore, the balsam itself—or, more typically, modified fractions of it—are frequently used as fragrance and flavoring additives (e.g., in lozenges, cough syrups, children's antibiotic suspensions, and colas). Importantly, because these chemicals (cinnamic acid, cinnamyl cinnamate, benzyl benzoate, benzoic acid, and benzyl alcohol and esterified polymers of coniferyl alcohol) are naturally derived, they have a number of natural cross-reactants (cinnamon, clove, eugenol). In one report special analyses proved that tomatoes contained cinnamic alcohol and coniferyl alcohol, two main allergens in the balsam of Peru mixture.[40] Consumption of these allergens may result in a recall reaction topically at other sites where similar chemicals were previously applied or in a systemic flare (see Fig. 13-5). Of note, 47 percent of patients allergic to balsam of Peru and/or other fragrance agents required dietary modification to control their dermatitis; 18 percent of patients who failed to modify their diets had persistent disease, and only 36 percent improved without some form of dietary modification.[39]



▲ **FIGURE 13-5** Allergic contact dermatitis to fragrances. This patient had a systemic flare reaction.

The metals are a group of frequently encountered ubiquitous allergens (nickel, cobalt, and chromium). They are present in a wide range of metallic objects (jewelry, tweezers, clothing snaps, paperclips, and coins) in addition to unexpected sources such as cigarette smoke, vitamins, water, and foodstuffs.

Another frequently and unexpectedly encountered allergen is formalde-



hyde. It has a variety of industrial applications, including in plastics and glues, and is commonly used as a broad-spectrum biocide. Thus sources of exposure can range from insulation materials, shoe glues, paper products, nail hardeners, clothing resins, and cigarette smoke to commonly used personal hygiene products and medical creams. The formaldehyde-releasing preservatives (FRPs) include quaternium-15 (Dowicil), imidazolidinyl urea (Germal I), diazolidinyl urea (Germal II), 2-bromo-2-nitropropane-1,3-diol (Bronopol), dimethylol-dimethyl hydantoin (Glydant), and *tris*-(hydroxy-methyl)-nitro-methane (Tris Nitro). A staggering number of leave on and wash on/wash off cosmetics and creams include these common allergenic preservatives. Of note, some topical steroid preparations contain fairly high amounts of FRPs, and failure to improve warrants patch testing with both corticosteroid and preservatives. Furthermore, corticosteroids containing FRPs should not be used by patients hypersensitive to formaldehyde.[41]



For many patients, the diagnosis of rubber allergy comes with a cumbersome list of substances to avoid, because both natural and synthetic rubber chemicals are ubiquitous. Frequent sites of allergen contact and subsequent reaction are the face (makeup sponges), ear canals (earplugs, ear phones), periocular area (goggles, eyelash curlers), brassiere and/or waistline areas (elasticized undergarments), genital areas (condoms, diaphragms, pessaries), hands (gloves, rubber bands), feet (shoes), and/or joints (orthopedic braces). It is important to note that for every 100 lb of rubber, there are 4 to 5 lb of rubber additives (90 percent of which constitute the accelerators and antidegradants), and these additives are responsible for a majority of the reactions.[42] Sensitization is typical to either the accelerants (thiurams, carbamates, guanidines, and/or benzothiazoles) or the antioxidants (black rubber mix/PPD derivatives) that are found in both natural and synthetic rubber, with thiuram mix (62 percent) and black rubber mix (38 percent) being the most common offenders.[43]

NONECZEMATOUS VARIANTS OF ALLERGIC CONTACT DERMATITIS ACD, like syphilis, is a great mimicker with multiple noneczematous variants, including but not limited to lichenoid contact dermatitis, erythema multiforme (EM), cellulitis-appearing dermal contact hypersensitivity, contact leukoderma, contact purpura, and erythema dyschromicum perstans.[44] Of these, the lichenoid and EM-like variants are most common.

Lichenoid allergic contact reactions are usually secondary to exposure and sensitization to metals, substituted PPD color developers, and flavoring agents. Metals, in particular, have been linked to oral lichen planus. Many drugs can also cause a systemic lichenoid hypersensitivity, the most notorious being the quinine derivatives, hydroxyurea, angiotensin-converting enzyme inhibitors, β blockers, and anti-epileptic agents. EM-like ACD reactions are most frequently seen after contact with exotic woods, common plants, and topical medications. The other noneczematous variants of ACD are quite rare. Of note, most cases of contact leukoderma are due to either post-inflammatory hypopigmentation or direct chemical toxicity (e.g., hydroquinones, catechols, phenols, mercaptoamines).[45] Granulomatous dermatitis has been reported in response to metals, including mercury, chromates, cobalt, beryllium, gold, and palladium (Fig. 13-6).

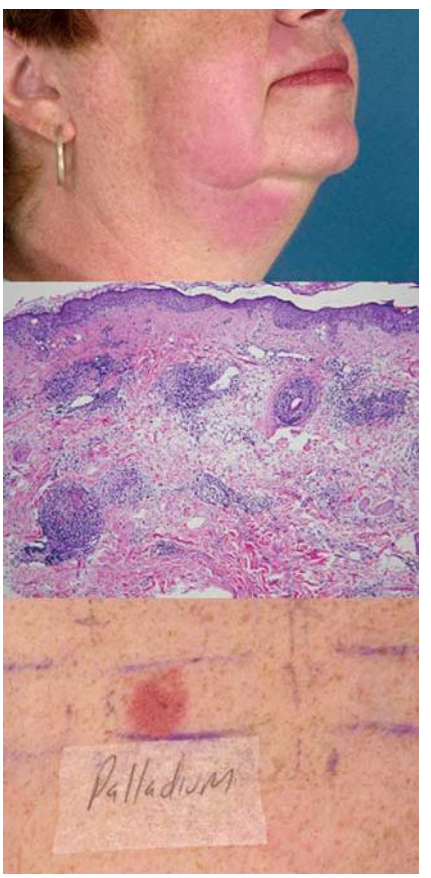

▲ **FIGURE 13-6** Granulomatous contact dermatitis in a patient with palladium allergy. A palladium-containing dental post was implanted on the affected side just before the onset of the eruption. Improvement was effected by its removal.

ALLERGIC CONTACT URTICARIA Allergic contact urticaria (ACU) represents one of the least common forms of contact dermatitis. ACU is an immunoglobulin E–mediated immediate-type hypersensitivity reaction that is distinct from the T cell–mediated type IV hypersensitivity reaction of ACD. Importantly, ACU has been reported in response to a number or agents that are also capable of eliciting a type IV reaction, for example, bacitracin (antibiotic), mercaptobenzothiazole (rubber accelerator), and colophony (adhesive).

The most notorious allergen to cause ACU worldwide is natural rubber latex. The incidence in the United States is largely unknown; however, estimates suggest that less than 1 percent to 2 percent of the general population is affected.[46] Among hospital workers most likely to be exposed to natural rubber latex gloves, the rate of latex ACU has been reported to range from a low of 5.5 percent[47] to as high as 38 percent.[48] Furthermore, comorbid conditions requiring hospitalizations and medical care in early life, such as moderate to severe atopic dermatitis, spina bifida, or meningomyelocele, predispose to the development of ACU, as does mucosal exposure to latex.

ACU from latex may present as immediate symptoms (such as burning, stinging, or itching with or without localized urticaria on contact with latex proteins) or, with aerosolization exposure, may include disseminated urticaria, allergic rhinitis, and/or anaphylaxis. Latex-allergic patients may also develop a type IV delayed hypersensitivity reaction to nonlatex components of the gloves, usually on the dorsal aspect of the hands; for example, to a rubber additive (thiuram) that may be found in latex, nitrile, and vinyl gloves. In contrast to ACD, ACU in response to latex gloves may present with palmar involvement, which may relate to solubilization of the latex proteins or the lipid content of the hyperkeratotic volar surface caused by normal hidrosis.

Although there are over 250 separate natural rubber latex proteins, only approximately 25 percent show reactivity with immunoglobulin E autoantibodies.[46] As of 2003, the International Union of Immunological Societies Committee on Nomenclature listed 13 *Hevea brasiliensis* (Hev b) protein allergens. Significant advances in DNA technology and cloning have allowed for purification and characterization of these allergens. It is now known that the most important Hev b allergens are Hev b 1 to 3

for children with spina bifida and Hev b 2 and 5 to 7 for health care workers.[46]

A diagnosis of latex allergy should be considered in any patient with a history of urticaria or angioedema when donning condoms or gloves, or inflating balloons. In vitro radioallergosorbent testing and enzyme-linked immunosorbent assay are commercially available and should be performed as the initial diagnostic step. Three in vitro serologic assays have U.S. Food and Drug Administration (FDA) approval for diagnostic purposes: ImmunoCAP (Pharmacia-Upjohn, Uppsala, Sweden), AlaSTAT FEIA (Diagnostic Products Corp., Los Angeles, CA), and HY-TEC EIA (Hycor Biomedical, Inc., Garden Grove, CA).

Although skin prick testing is the gold standard, it should be noted that there is currently no FDA-approved, commercially available, standardized latex allergen preparation. The stability profile and quality controllability of non-ammoniated latex make it the current top candidate for FDA licensure.[46] Currently, extemporaneous extracts or elutes made by soaking high-allergen gloves in water at room temperature are used.[49] In most but not all cases, these crude eluates are sufficient to allow prick test confirmation of ACU. It must be emphasized that in vivo testing can potentiate anaphylactic reactions.

LABORATORY FINDINGS

In Vivo Patch Test

The gold standard method for the diagnosis of ACD remains the patch test. Details on the patch test procedure are beyond the scope of this chapter but may be found in a number of standard texts.[50] It must be noted that only 23 commercially prepared allergens are currently FDA approved in the United States for use in a preloaded system. A perusal of Table 13-1 makes it apparent that nearly half of the top 25 allergens in North America are not available on the commercially made trays in the United States. The T.R.U.E. (Thin-layer Rapid Use Epicutaneous) Test has 2 panel trays. Thus, investigators who intend to fully evaluate their patients must prepare allergen trays with worldwide standardized commercially available allergens and add patient-specific test materials for completeness. Compounding reference texts outlining appropriate allergen concentrations and vehicles are available.[50]

TRUE-POSITIVE AND TRUE-NEGATIVE RESULTS The identification of true-positive reactions with clinical relevance is the primary goal of the patch test and is best achieved with a high pre-test probability.[51] That being said, one major challenge in patch testing is obtaining a true-positive result (true sensitization) with no clinical relevance to the patient's current dermatologic problem and assuming they are related. Attempts to assign relevance to such an allergen may lead to consequences that are cumbersome and distressing to both the physician and the patient. Assigning clinical relevance to a true-positive patch test result requires correlation between the involved areas of skin and the patient's environmental exposures, and notation of significant improvement on avoidance of the allergen or recurrence with its reintroduction.

The North American Contact Dermatitis Group frequently reports their prevalence data with relevance assignments, and continued failure of relevance marks the allergen for removal from the standard screening series. A good example of this is thimerosal. Many patients with positive patch test results to thimerosal have been sensitized by vaccines but are asymptomatic.[52] It should be noted that lack of relevance does not mean the patient is not allergic to the chemical in question, but more specifically that this chemical is not the causal agent for the dermatitis currently being evaluated.

True-negative results are an equally important component of the patch test, because they provide some assurance that a chemical in question is not causing the dermatitis. If a question arises as to whether a true-negative result is truly irrelevant, provocative repeat open application testing can be an invaluable diagnostic tool. The patient is taught to repeatedly apply the commercial product to intact normal skin (same site) several times daily for 1 to 2 weeks to elicit a reaction.

FALSE-POSITIVE AND FALSE-NEGATIVE RESULTS No in vivo test is infallible, and investigative patch testers must always take into consideration the possibility of false-positive and false-negative reactions when performing the patch test.

Because there are more than 3700 potential human allergens, and because of the obvious limitation of the commercially available screening trays such as T.R.U.E. Test (Kabi Pharmacia Service A/S, Hillerod, Denmark) and Allergen Patch Test Kit (Hermal Laboratories, Delmar, NY–American Academy of Dermatology), it stands to reason that a high number of clinically relevant allergens go unidentified. In an analysis of the North American Contact Dermatitis Group data for 1994 to 1996 on 3120 patients[53] it was found that 62 percent had at least one positive reaction to an allergen present on the T.R.U.E. Test, of which 45 percent were relevant to the current dermatitis. In their study of 732 patients over 5.5 years, Cohen et al.[54] found that only 23 percent of patients reacted exclusively to allergen(s) in the Allergen Patch Test standard series, 37 percent reacted to allergens in both the standard series and other supplementary tests, and 40 percent reacted only to supplementary allergens.

In Vitro Tests for Allergic Contact Dermatitis

In vitro and animal tests for the diagnosis of ACD such as the lymphocyte transformation and macrophage migration inhibition tests have been in development for the last decade. One major obstacle in developing in vitro systems is the lack of specificity to detect the antigenic moiety of a particular chemical. Lymphocyte transformation tests performed on blood cells from patients who had a positive patch test reaction to thiuram mix and/or showed sensitization to tetramethylthiuram monosulfide or to tetramethylthiuram monosulfide and tetramethylthiuram disulfide demonstrated significant proliferation of peripheral blood mononuclear cells in response to hapten-protein conjugates, whereas cells from patients with negative patch test reactions to thiuram and control donors with no history of ACD failed to mount a significant response.[58] The local lymph node assay, which uses a mouse model, allows quantitative assessment of the sensitizing potency of allergens.[59] However, patch testing remains the only reliable bioassay to ascertain sensitization to exogenous chemicals.

DIFFERENTIAL DIAGNOSIS

Eczematous Dermatoses

The differential diagnosis of ACD includes a wide range of inflammatory skin disorders (see Box 13-1). The presence of eosinophilic spongiosis and multinucleate dermal dendritic fibrohistiocytic cells is especially suggestive of ACD when encountered in the presence of acanthosis, lymphocytic infiltrate, dermal eosinophils, and hyperkeratosis.[60]



Noneczematous Variants

The pathologic findings of the noneczematous variants of ACD may be nearly identical to those of the diseases they simulate. Lichenoid ACD does have some features that help to distinguish it from idiopathic lichen planus, including a less intense lichenoid infiltrate with more eosinophils and neutrophils, less epidermal hyperplasia with fewer necrotic keratinocytes, and some degree of epidermal spongiosis.[61] In contrast, EM-like ACD has no epidermal spongiosis, and the findings are indistinguishable from those of EM from other causes. Dermal contact hypersensitivity also lacks spongiosis but has the characteristic lymphohistiocytic, perivascular infiltrate that often goes deeper in the dermis (mid-dermal) than eczematous ACD. The histopathologic features of acute allergic contact leukoderma have not been studied. In the best-documented cases, eczematous patch test reactions to PPD subsequently depigmented, at which time the biopsy specimen was indistinguishable from that for chemically induced vitiligo. Allergic contact purpura is pathologically similar to the eczematous variant of ACD but with a capillaritis that results in extravasation of red blood cells.[62] It is difficult to separate from the other pigmented purpuric dermatoses.

In all of the noneczematous and eczematous variants of ACD, patch testing is the only means for accurate diagnosis. The history, physical examination, and/or pathology are usually not diagnostic.



COMPLICATIONS

Complications of Not Patch Testing

In 2004 the American Academy of Dermatology and the Society for Investigative Dermatology determined that 72 million Americans were living with contact dermatitis and that it was the third most common reason for patients to seek consultation with the dermatologist. It accounted for 9.2 million visits that year, at a cost of $1.9 billion.[63] In 1989, Rietschel determined that patch testing the 5.7 million persons estimated to have dermatitis/eczema translated into a positive cost-benefit ratio of $40 million to $90 million per year, when the expense of patch testing was compared with the cost of treatment.[64] Furthermore, Van Der Valk, Devos, and Coenraads reported that patch testing was even more cost effective when the test was performed on patients for whom there was a high index of suspicion for the diagnosis of ACD, because increased likelihood of detecting a clinically relevant allergen correlates with a significantly better clinical outcome.[65]

Complications of Patch Testing

Patient disappointment is a significant problem with patch testing, because there is no guarantee of detection of a clinically relevant allergen or of subsequent skin improvement with avoidance of a given allergen. These outcomes are anticipated and expected, but not guaranteed. Furthermore, there are small risks of causing a flare of the dermatitis and, although remote, of inducing sensitization to one of the allergens. Patients should be made aware that positive test reactions may persist for several weeks, and in the case of gold, sometimes longer. Post-inflammatory hyperpigmentation or hypopigmentation may occur at positive patch test reaction sites.

PROGNOSIS

It is difficult to assess the actual prognosis of ACD, because there is no standardized instrument for such an evaluation. Quality-of-life questionnaires (which measure symptom, emotional, and functional parameters), number of outpatient dermatology visits, and subjective evaluations have all been used. In fact, much of the information on prognosis is extrapolated from data on occupational contact dermatitis, because of the important implications for worker's compensation. It is important to note that these data are subject to selection bias, because most studies are investigating patients who are being evaluated at a tertiary care contact dermatitis referral clinic.[67]

Almost two decades ago, the prognosis for occupational contact dermatitis was relatively poor, with only 30 percent to 50 percent of patients demonstrating improvement.[68] Fortunately, more recent reviews demonstrate that with early intervention and appropriate management over 75 percent of patients recover without permanent impairment.[69] This upward trend toward a positive prognosis may relate to better identification of allergens, improved standardization of the diagnostic tools, increased preventive efforts, and patient education.[70]

Cahill et al. performed an extensive review of the literature to identify common variables that influence prognosis.[71] They specifically looked at the effects of age, sex, atopy, patient knowledge, disease etiology, duration of symptoms, and change of vocation and found no differences related to these factors. Change of work conditions is not always associated with an improved prognosis, because patients may still not appropriately avoid the inducing allergen. Furthermore, change of employment, although it may improve ACD, may have a direct negative impact on quality of life.[72]

Although assessment of the patient's knowledge base is a difficult task, it is generally accepted that greater knowledge correlates with better clinical outcomes. In a follow-up study by Agner, Flyvholm, and Menne, patients diagnosed with formaldehyde allergy were rigorously informed about their diagnosis and the culprit allergen, and given an exposure assessment for their products. At 1- and 5-year post–patch test follow-up, the patients were interviewed and examined by the dermatologist, and given further exposure assessment for their current products. As expected, patients who reported not paying attention to their allergens when buying or using consumer products were exposed to formaldehyde in their current products. Furthermore, patients who reportedly paid attention to avoiding their allergens had statistically fewer flares of their dermatitis.[73]

Use of the Contact Allergen Replacement Database tool allowed for a lower mean counseling time and higher levels of patient satisfaction, although no statistically significant differences were noted on clinical measures of disease activity.[74]

Nielsen et al. performed a cross-sectional study on a random sample of 567 persons (aged 15 to 69 years) and a subsequent repeat patch study on 365 (68 percent) of the original population. Positive patch test results were re-confirmed in 71 percent of the subjects (37 out of 52) 8 years after the baseline study. Nickel provoked the highest frequency of positive reactions at 79 percent (19 out of 24 subjects), whereas cosmetic ingredients produced the lowest frequency, 50 percent (5 out of 10 subjects). Of note, 60 percent (21 out of 35 subjects) had a positive patch test reaction to one or more allergens. This study confirmed the continued need for allergen avoidance to prevent elicitation of ACD.[75] Unfortunately, there are factors that are beyond the ability of the patient to control to become symptom free. These include the nature (ubiquity) of the allergen itself or the inability to

shield the skin from the environment (e.g., the face and hands are always exposed). Reports indicate that sensitization to nickel, chromium, and epoxy are specifically associated with a less favorable prognosis, especially if contact is occupationally related, even when continued exposure ceases.[76,77]

Meding, Wrangsjo, and Jarvholm evaluated the long-term course, occupational relevance, and medico-social implications of hand dermatitis in patients diagnosed through a prior population-based study.[78] Patients were evaluated using two questionnaires, one administered at baseline and one administered 15 years later. Of the patients who completed both questionnaires, 66 percent reported periodic exacerbations of their chronic hand eczema (44 percent of which had been within the previous year), whereas 12 percent experienced continuous symptoms. These findings underscore the overwhelming chronicity of most hand dermatitis cases. Predictive factors for hand eczema severity were also assessed using a logistic regression model.[79] The most important predictive factors for persistence of disease were a history of childhood eczema, a greater extent of eczema involvement at initial presentation, and an age younger than 20 years at onset of the hand eczema. In addition they found that hand dermatitis was associated with considerable alteration of psychosocial function, for example, sleep disturbances (36 percent) and hampered leisure activities (72 percent). In the 3 percent of patients who reported a necessary occupational change secondary to their hand dermatitis, this change did correlate with clinical improvement.

TREATMENT

The fundamental management of patients with ACD relies on both treatment of symptoms and avoidance of additional encounters with allergic contactants.

Pharmacologic Intervention

In the face of acute or symptomatic chronic contact dermatitis, pharmacologic intervention is necessary to alleviate the symptoms and physical limitations imposed by the eruption. The impact of the dermatitis on the activities of daily living and the ability to perform work functions must not be underestimated.

Acute vesicular, weeping eruptions may benefit from the use of drying agents such as topical aluminum sulfate/calcium acetate. Chronic, lichenified eruptions are best treated with emollients. Pruritus can be controlled with topical antipruritics or oral antihistamines, but topical antihistamines and anesthetics are best avoided because of the risk of inducing a secondary allergy in already dermatitic skin.

Despite the drawbacks associated with their long-term use, corticosteroids remain the gold standard and the mainstay for alleviating symptoms and hastening the recovery from ACD (see Chap. 216). Topical corticosteroids (divided into five stereochemical structural classes, each with similarly broad mechanisms of action and effectiveness[38]) have been shown in a number of models to reduce the signs and symptoms of ACD.[80] Furthermore, they are generally well tolerated when used short term. Long-term and widespread use of topical steroids, however, can result in cutaneous atrophy, hirsutism, hypopigmentation, folliculitis, acne, and systemic absorption. The use of systemic corticosteroids, on the other hand, is warranted only in moderate to severe acute cases and in cases of refractory ACD.

In the past decade, calcineurin inhibitors have been used as treatment options for many inflammatory skin disorders. Their mechanism of action is elaborated in Chap. 221. Oral cyclosporine and topical tacrolimus and pimecrolimus have demonstrated efficacy in the treatment of eczematous dermatitides, including atopic dermatitis predominantly, as well as contact dermatitis. Cyclosporine has been used orally to treat ACD, but limited penetration has hindered its topical use. In addition, tacrolimus and pimecrolimus (which share a macrolactam structure) have proved efficacious as topical anti-inflammatory drugs.

Phototherapy

Phototherapy has been reserved for patients with refractory ACD who are unresponsive to corticosteroids and for patients who are unable to avoid all provoking factors in their daily environment. Several studies have demonstrated the effectiveness of ultraviolet light (oral psoralen plus ultraviolet A photochemotherapy, and therapy with shortwave ultraviolet B light), due to its intrinsic immunosuppressive properties, in the treatment of both chronic ACD and ICD of the hands. Furthermore, ultraviolet B light therapy was said to produce an excellent effect in 7 of 10 patients with hand ACD.[81] Notably, the treatment duration was lengthy (5 months), maintenance therapy was required, and controls were not performed.

TABLE 13-3
Foods and Topical Items Reported to Provoke Reactions in Persons Allergic to Fragrance and Balsam of Peru

- Tomatoes
- Citrus fruits
- Spices such as cinnamon, cloves, vanilla, nutmeg, curry, allspice, paprika, anise, and ginger
- Chocolate
- Chili
- Beer and wine
- Vinegar
- Dairy products
- Coffee
- Baked goods
- Hemorrhoidal suppositories
- Fragranced personal hygiene products and cosmetics
- Flavored teas, coffee, and tobacco
- Deodorants
- After-shave lotions
- Confectionary
- Tincture of benzoin
- Colas and other soft drinks
- Wound spray
- Medicinal creams
- Calamine lotion
- Baby powder
- Dental cement
- Sunscreens
- Cough medicine
- Lozenges
- Suntan lotions
- Lip preparations

Data from Srivastava D, Chang YT, Kumar S, Cohen DE. Identification of the constituents of balsam of Peru in tomatoes. *Dermatitis* **16**:091, 2005. Oral presentation, abstract; and Salam TN, Fowler JF: Balsam-related systemic contact dermatitis *J Am Acad Dermatol* **45**:377, 2001.

PREVENTION

Prevention rests on the avoidance of allergens.

At times, the sensitization to allergens such as nickel and fragrance chemicals like balsam of Peru can induce non-localized reactions through their systemic absorption (Table 13-3). In some circumstances, the avoidance of these allergens in the diet can result in clinical improvement. In any event, the treatment of ACD is simply allergen avoidance. It is the process of elucidating and implementing this treatment plan that can be so arduous. This concept is reinforced by the results of one study of 230 workers,[82] in which only one-third of study participants accurately recalled their diagnoses and treatment regimens, and persistent dermatitis was three times more likely in those workers who could not remember this information than in those who did. The benefit of allergen avoidance and the consequences of not doing so are discussed in the Prognosis section.

For certain allergens found in topical preparations (e.g., vehicles, preservatives, stabilizers, and emulsifiers), it is important to impress upon patients the



need to read labels. In addition, a periodically updated electronic database of ingredients in cosmetics and over-the-counter and prescription topical preparations (Contact Allergen Replacement Database) is available on the Internet (http://www.contactderm.org) and allows practitioners to generate a unique list of topical preparations appropriate for the individual with specific allergies.

Patients with allergies to preservatives (e.g., methylchloroisothiazolone) must be aware that these materials can be found in any water-based formulation, such as latex paint. Furthermore, the name given a chemical used in a cosmetic or pharmaceutical product is frequently changed when it is used in an industrial product. For instance, the cosmetic preservative quaternium-15, when used in industry, is referred to as Dowicil 100 or Dowicil 200. Practitioners guiding patients through the synonymic jungle of these chemicals are advised to consult standard texts on the subject.

Unfortunately for patients and physicians alike, the allergenic components of many materials will fail to be labeled (e.g., rubber-, textile-, and metal-related allergens, to name a few). In counseling patients with reactions to these materials, the physician must provide information about what kinds of products are likely to contain the allergens, as well as appropriate replacements. Such information can be found in standard texts.[50]

Furthermore, some allergens may be incompletely labeled; for example, given the proprietary nature of a fragrance formulation, individual fragrances combined in a product may go unlisted. Patients with an allergic reaction to a fragrance should be advised to use fragrance-free materials, which include not only topical preparations but also a variety of other products such as toilet paper, sanitary napkins, and diapers.

Because many allergens share common antigenic moieties, the patient needs to be instructed not only about the known allergen but also about possible cross-reacting allergens. For example, the individual allergic to benzocaine must be aware of the many potentially cross-reacting substances, which include agents as diverse as other ester anesthetics (e.g., procaine), certain medications (e.g., sulfonamides), hair dyes (e.g., PPD), textile dyes (e.g., aniline dyes), some sunscreens (e.g., para-aminobenzoic acid), and other products.

To date, hyposensitization or tolerance induction has remained an elusive method for coping with ACD.

KEY REFERENCES

The full reference list for all chapters is available at www.digm7.com.

4. Nielsen NH et al: Incidence of allergic contact sensitization in Danish adults between 1990 and 1998; the Copenhagen Allergy Study, Denmark. *Br J Dermatol* **147**:487, 2002
12. Heine G et al: Frequency of contact allergy in German children and adolescents patch tested between 1995–2002: Results from the Information Networks of the Departments of Dermatology and the German Contact Dermatitis Research Group. *Contact Dermatitis* **51**:111, 2004
21. de Groot AC: *Patch testing: Test Concentrations and Vehicles for 3700 Allergens*, 2nd ed. Amsterdam, Elsevier, 1994
38. Jacob SE, Steele T: Corticosteroid classes: A quick reference guide including patch test substances and cross reactivity. *J Am Acad Dermatol* **54**:723, 2006
39. Veien NK: Ingested food in systemic allergic contact dermatitis. *Clin Dermatol* **15**:547, 1997
44. Belsito DV: The diagnostic evaluation, treatment, and prevention of allergic contact dermatitis in the new millennium. *J Allergy Clin Immunol* **105**:409, 2000
46. Taylor JS, Erkek E: Latex allergy: Diagnosis and management. *Dermatol Ther* **7**:289, 2004
53. North American Contact Dermatitis Group patch test results for the detection of delayed-type hypersensitivity to topical allergens. *Am J Contact Dermatol* **15**:176, 2004
54. Cohen DE et al: Utility of a standard allergen series alone in the evaluation of allergic contact dermatitis: A retrospective study of 732 patients. *J Am Acad Dermatol* **36**:914, 1997
74. Kist JM et al: The Contact Allergen Replacement Database and treatment of allergic contact dermatitis. *Arch Dermatol* **140**:1448, 2004



CHAPTER 14

Atopic Dermatitis (Atopic Eczema)

Donald Y. M. Leung
Lawrence F. Eichenfield
Mark Boguniewicz

Atopic dermatitis (AD) is a chronically relapsing skin disease that occurs most commonly during early infancy and childhood. It is frequently associated with abnormalities in skin barrier function and allergen sensitization. There is no single distinguishing feature of AD or a diagnostic laboratory test. Thus, the diagnosis is based on the constellation of clinical findings described by Hanifin and Rajka[1] and listed in Table 14-1.

EPIDEMIOLOGY

Since the 1960s, there has been a greater than threefold increase in the prevalence of AD.[2] Indeed, the most recent estimates indicate that AD is a major public health problem worldwide, with a prevalence in children of 10 percent to 20 percent in the United States, northern and western Europe, urban Africa, Japan, Australia, and other industrialized countries.[3] The prevalence of AD in adults is approximately 1 percent to 3 percent. Interestingly, the prevalence of AD is much lower in agricultural countries such as China and in Eastern Europe, rural Africa, and Central Asia. There is also a female preponderance for AD, with an overall female/male ratio of 1.3:1.0.

The basis for this increased prevalence of AD is not well understood. However, wide variations in prevalence have been observed within countries inhabited by similar ethnic groups, suggesting that environmental factors are critical in determining disease expression.[4] Some of the potential risk factors that have received attention as being associated with the rise in atopic disease include small family size, increased income and education both in whites and blacks, migration from rural to urban environments, and increased use of antibiotics, that is, the so-called *Western lifestyle*.[5,6] This has resulted in the "hygiene hypothesis" that allergic diseases might be prevented by "infection in early childhood transmitted by unhygienic contact with older siblings."[7]

ETIOLOGY AND PATHOGENESIS

AD is a highly pruritic inflammatory skin disease that results from complex interactions between genetic susceptibility genes resulting in a defective skin barrier, defects in the innate immune system,

ATOPIC DERMATITIS AT A GLANCE




- Prevalence peak of 15 percent to 20 percent in early childhood in industrialized countries.
- A chronic or chronically relapsing disorder with major features of:
  - Pruritus
  - Eczematous dermatitis (acute, subacute, or chronic) with typical morphology and age-specific patterns
  - Facial and extensor involvement in infancy
  - Flexural eczema/lichenification in children and adults.
- Commonly associated with:
  - Personal or family history of atopy (allergic rhinitis, asthma, atopic dermatitis)
  - Xerosis/skin barrier dysfunction
  - Immunoglobulin E reactivity.
- Genetic basis influenced by environmental factors with alterations in immunologic responses in T cells, antigen processing, inflammatory cytokines, host defense proteins, allergen sensitivity, and infection.

and heightened immunologic responses to allergens and microbial antigens.[8]

Decreased Skin Barrier Function

AD is associated with a marked decrease in skin barrier function due to the downregulation of cornified envelope genes (filaggrin and loricrin), reduced ceramide levels, increased levels of endogenous proteolytic enzymes, and enhanced trans-epidermal water loss.[9,10] Addition of soap and detergents to the skin raises its pH, thereby increasing activity of endogenous proteases, leading to further breakdown of epidermal barrier function. The epidermal barrier may also be damaged by exposure to exogenous proteases from house dust mites and *Staphylococcus aureus*. This is worsened by the lack of certain endogenous protease inhibitors in atopic skin. These epidermal changes likely contribute to increased allergen absorption into the skin and microbial colonization. Because epicutaneous, as compared to systemic or airway, sensitization to allergen results in higher level allergic immune responses, decreased skin barrier function could act as a site for allergen sensitization and predispose such children to the development of respiratory allergy later in life.[11]

TABLE 14-1
Features of Atopic Dermatitis

- Major features
  - Pruritus
  - Rash on face and/or extensors in infants and young children
  - Lichenification in flexural areas in older children
  - Tendency toward chronic or chronically relapsing dermatitis
  - Personal or family history of atopic disease: asthma, allergic rhinitis, atopic dermatitis
- Other common findings
  - Dryness
  - Dennie-Morgan folds (accentuated lines or grooves below the margin of the lower eyelid)
  - Allergic shiners (darkening beneath the eyes)
  - Facial pallor
  - Pityriasis alba
  - Keratosis pilaris
  - Ichthyosis vulgaris
  - Hyperlinearity of palms and soles
  - White dermatographism (white line appears on skin within 1 minute of being stroked with blunt instrument)
  - Conjunctivitis
  - Keratoconus
  - Anterior subcapsular cataracts
  - Elevated serum immunoglobulin E
  - Immediate skin test reactivity

Immunopathology of Atopic Dermatitis

Clinically unaffected skin of AD patients manifests mild epidermal hyperplasia and a sparse perivascular T-cell infiltrate.[8] Acute eczematous skin lesions are characterized by marked intercellular edema (spongiosis) of the epidermis. Dendritic antigen-presenting cells [e.g., Langerhans cells (LCs), macrophages] in lesional and, to a lesser extent, in nonlesional skin of AD exhibit surface-bound immunoglobulin E (IgE) molecules. A sparse epidermal infiltrate consisting primarily of T lymphocytes is also frequently observed. In the dermis of the acute lesion, there is an influx of T cells with occasional monocyte-macrophages. The lymphocytic infiltrate consists predominantly of activated memory T cells bearing CD3, CD4, and CD45 RO (suggesting previous encounter with antigen). Eosinophils are rarely present in acute AD. Mast cells are found in normal numbers in different stages of degranulation.

Chronic lichenified lesions are characterized by a hyperplastic epidermis with elongation of the rete ridges, prominent hyperkeratosis, and minimal spongiosis. There is an increased number of IgE-bearing LCs in the epidermis, and macrophages dominate the dermal mononuclear cell infiltrate. Mast cells are increased in number but are generally fully granulated. Neutrophils are absent in AD skin lesions even in the setting of increased *S. aureus* colonization and infection. Increased numbers of eosinophils are observed in chronic AD skin lesions. These eosinophils undergo cytolysis with release of granule protein contents into the upper dermis of lesional skin. Eosinophil-derived extracellular major basic protein can be detected in a fibrillar pattern associated with the distribution of elastic fibers throughout the upper dermis. Eosinophils are thought to contribute to allergic inflammation by the secretion of cytokines and mediators that augment allergic inflammation and induce tissue injury in AD through the production of reactive oxygen intermediates and release of toxic granule proteins.

Cytokines and Chemokines

Atopic skin inflammation is orchestrated by the local expression of pro-inflammatory cytokines and chemokines.[12] Cytokines such as tumor necrosis factor-α (TNF-α) and interleukin 1 (IL-1) from resident cells [keratinocytes, mast cells, dendritic cells (DCs)] bind to receptors on the vascular endothelium, activating cellular signaling pathways, which leads to the induction of vascular endothelial cell adhesion molecules. These events initiate the process of tethering, activation, and adhesion to vascular endothelium followed by extravasation of inflammatory cells into the skin. Once inflammatory cells have infiltrated into the skin, they respond to chemotactic gradients established by chemokines which emanate from sites of injury or infection.

Acute AD is associated with the production of T helper 2 type (Th2) cytokines, notably IL-4 and IL-13,[13] which mediate immunoglobulin isotype switch-



ing to IgE synthesis, and upregulate expression of adhesion molecules on endothelial cells. In contrast, IL-5, is involved in eosinophil development and survival, and predominates in chronic AD.[13] The important role that Th2 cytokines play in the skin's inflammatory response is supported by the observation that transgenic mice genetically engineered to overexpress IL-4 in their skin develop inflammatory pruritic skin lesions similar to AD, suggesting that local skin expression of Th2 cytokines plays a critical role in AD.[14] Allergen-sensitized skin from IL-5–deficient mice has been found to have no detectable eosinophils and exhibits decreased thickening, whereas skin from IL-4–deficient mice displays normal thickening of the skin layers, but has a reduction in eosinophils.[15] Increased production of granulocyte macrophage colony-stimulating factor in AD is reported to inhibit apoptosis of monocytes, thereby contributing to the persistence of AD.[16] The maintenance of chronic AD also involves production of the Th1-like cytokines IL-12 and IL-18, as well as several remodeling-associated cytokines, including IL-11 and transforming growth factor-β1.[17]

The skin-specific chemokine, cutaneous T cell–attracting chemokine [CTACK; CC chemokine ligand 27 (CCL27)], is highly upregulated in AD and preferentially attracts skin homing cutaneous lymphoid antigen $(CLA)^+$ CC chemokine receptor 10^+ ($CCR10^+$) T cells into the skin.[12] CCR4 expressed on skin homing CLA^+ T cells can also bind to CCL17 on the vascular endothelium of cutaneous venules. Selective recruitment of CCR4-expressing Th2 cells is mediated by macrophage-derived chemokine and thymus and activation-regulated cytokine, both of which are increased in AD. Severity of AD has been linked to the magnitude of thymus and activation-regulated cytokine levels. In addition, chemokines such as fractalkine, interferon (IFN)-γ–inducible protein 10, and monokine induced by IFN-γ are strongly upregulated in keratinocytes and result in Th1-cell migration toward epidermis, particularly in chronic AD. Increased expression of the CC chemokines, macrophage chemoattractant protein-4, eotaxin, and RANTES (regulated on activation normal T-cell expressed and secreted) contribute to infiltration of macrophages, eosinophils, and T cells into both acute and chronic AD skin lesions. See Chaps. 11 and 12 for a more detailed review of cytokines and chemokines in skin inflammation.



Key Cell Types in Atopic Dermatitis Skin

ANTIGEN-PRESENTING CELLS AD skin contains two types of high-affinity, IgE-receptor–bearing myeloid DCs: (1) LCs and (2) inflammatory dendritic epidermal cells (IDECs), IgE-bearing LCs that appear to play an important role in cutaneous allergen presentation to IL-4–producing Th2 cells.[18] In this regard, IgE-bearing LCs from AD skin lesions, but not LCs that lack surface IgE, are capable of presenting inhalant allergens to T cells. These results suggest that cell-bound IgE on LCs facilitates capture and internalization of allergens into LCs before their processing and antigen presentation to T cells. IgE-bearing LCs that have captured allergen likely activate memory Th2 cells in atopic skin, but they may also migrate to the lymph nodes to stimulate naive T cells there to further expand the pool of systemic Th2 cells. Stimulation of FcεRI on the surface of LCs by allergens induces the release of chemotactic signals and recruitment of precursor cells of IDECs and T cells in vitro. Stimulation of FcεRI on IDECs leads to the release of high amounts of pro-inflammatory signals, which contribute to the amplification of allergic immune response.

In contrast to other inflammatory skin diseases, such as allergic contact dermatitis or psoriasis vulgaris, very low numbers of plasmacytoid DCs (pDCs), which play an important role in host defense against viral infections, can be detected within the AD skin lesion.[19] pDCs in the peripheral blood of patients with AD have been shown to bear the trimeric variant of FcεRI on their cell surface, which is occupied by IgE molecules. The modified immune function of pDCs of patients with AD after FcεRI-mediated allergen stimulation might contribute to a local deficiency of type I IFNs, thereby contributing to increased susceptibility of AD patients toward viral skin infections such as eczema herpeticum.[20]

T CELLS Skin homing memory T cells play an important role in the pathogenesis of AD, particularly during the acute phase of illness. This concept is supported by the observation that primary T-cell immunodeficiency disorders are frequently associated with eczematous skin lesions that clear after successful bone marrow transplantation.[21] Furthermore, in animal models of AD, the eczematous rash does not occur in the absence of T cells.[15] In addition, treatment with topical calcineurin inhibitors, which specifically target activated T cells, significantly reduces the clinical skin rash of AD.[22]

Several studies have demonstrated, in acute AD, the presence of Th2-like T cells that produce cytokines that enhance allergic skin inflammation. During the chronic phase of AD, there is a switch to Th1-like cells which primarily produce IFN-γ. These Th2-like cells induce the activation and apoptosis of keratinocytes.[23] Recently, T regulatory (Treg) cells have been described as a further subtype of T cells that have immunosuppressive function and cytokine profiles distinct from either Th1 and Th2 cells.[24] Treg cells are able to inhibit the development of both Th1 and Th2 responses. Mutations in a nuclear factor expressed in Treg cells, FoxP3, result in IPEX (*i*mmune dysregulation, *p*olyendocrinopathy, *e*nteropathy, *X*-linked) syndrome characterized by elevated serum IgE, food allergy, and eczema.[25] Interestingly, staphylococcal superantigens subvert Treg cell function and may thereby augment skin inflammation.[26]

KERATINOCYTES Keratinocytes play a critical role in the augmentation of atopic skin inflammation. AD keratinocytes secrete a unique profile of chemokines and cytokines after exposure to pro-inflammatory cytokines. This includes high levels of RANTES after stimulation with TNF-α and IFN-γ.[27] They are also an important source of thymic stromal lymphopoietin (TSLP), which activates DCs to prime naive T cells to produce IL-4 and IL-13 (i.e., Th2 cell differentiation).[28] The importance of TSLP in AD pathogenesis is supported by the observation that mice genetically manipulated to overexpression TSLP in the skin develop AD-like skin inflammation.

Keratinocytes also play a key role in the skin's innate immune responses via the expression of Toll-like receptors, production of pro-inflammatory cytokines and antimicrobial peptides (such as human β defensins and cathelicidins) in response to tissue injury or invading microbes.[29] Several studies have now demonstrated that AD keratinocytes produce reduced amounts of antimicrobial peptides and this may predispose such individuals to skin colonization and infection with *S. aureus*, viruses, and fungi. This defect, however, appears to be acquired as the result of Th2-cytokine (IL-4, IL-10, and IL-13)–mediated inhibi-

tion of TNF- and IFN-γ–induced antimicrobial peptide generation.

Genetics

AD is familially transmitted with a strong maternal influence. Genome screens of families with AD have implicated chromosomal regions that overlap with other inflammatory skin diseases such as psoriasis. Together with candidate gene studies, these have provided interesting insights into the pathogenesis of AD. Although many genes are likely to be involved in the development of AD, there has been particular interest in the potential role of skin barrier/epidermal differentiation genes and immune response/host defense genes.

Loss-of-function mutations of the epidermal barrier protein, filaggrin, have been demonstrated to be a major predisposing factor for AD[30] as well as ichthyosis vulgaris, a common keratinizing disorder associated with AD. Of note, the filaggrin gene is found on chromosome 1q21 which contains genes (including loricrin and S100 calcium binding proteins) in the epidermal differentiation complex, which are known to be expressed during terminal differentiation of the epidermis. DNA microarray analyses have demonstrated upregulation of S100 calcium binding proteins and downregulation of loricrin and filaggrin in AD. Candidate gene approaches have also implicated variants in the *SPINK5* gene, which is expressed in the uppermost epidermis where its product, LEKT1, inhibits two serine proteases involved in desquamation and inflammation (stratum corneum tryptic enzyme and stratum corneum chymotryptic enzyme). Stratum corneum tryptic enzyme and stratum corneum tryptic enzyme expression is increased in AD, suggesting that an imbalance of protease versus protease inhibitor activity may contribute to atopic skin inflammation. These observations establish a key role for impaired skin barrier function in the pathogenesis of AD, as impaired skin barrier formation allows increased transepidermal water loss and, importantly, increased entry of allergens, antigens, and chemicals from the environment resulting in skin inflammatory responses. It is important to note that these filaggrin mutations, and likely other mutations affecting the skin barrier, can occur in unaffected individuals, patients with ichthyosis vulgaris who do not have AD, and that the majority of patients with AD outgrow their inflammatory skin disease. Thus, other gene products must also be involved in AD pathology.

Chromosome 5q31-33 contains a clustered family of functionally related cytokine genes—IL-3, IL-4, IL-5, IL-13, and granulocyte macrophage colony-stimulating factor—which are expressed by Th2 cells. A case control comparison has suggested a genotypic association between the T allele of the 590C/T polymorphism of the IL-4 gene promoter region with AD. Because the T allele is associated with increased IL-4 gene promoter activity when compared to the C allele, this suggests that genetic differences in transcriptional activity of the IL-4 gene influence AD predisposition. In addition, an association of AD with a gain-of-function mutation in the α subunit of the IL-4 receptor has been reported, providing further support of the concept that IL-4 gene expression plays a role in AD. Functional mutations in the promoter region of the C-C chemokines, RANTES and eotaxin, as well as variants in IL-13, the β subunit of the high affinity cell surface receptor for IgE (FcεR1) found on basophils and mast cells suggest an overlapping genetic basis with other atopic diseases. The involvement of T-cell immunoglobulin- and mucin-domain–containing molecule-1 and IL-18 genes support the role of $CD4^+$ T cells and dysregulation of Th1 genes in the pathophysiology of AD. As well, reports of AD association with polymorphisms of the NOD1 gene, which encodes cytosolic pathogen recognition receptor and Toll-like receptors, suggest an important role for host defense genes in the pathogenesis of AD. The reader is referred to Chap. 8 and reference 31 for a detailed discussion of the genetics of AD.

Role of Pruritus in Atopic Dermatitis

Pruritus is a prominent feature of AD, manifested as cutaneous hyperreactivity and scratching following exposure to allergens, changes in humidity, excessive sweating, and low concentrations of irritants.[32] Control of pruritus is important because mechanical injury from scratching can induce pro-inflammatory cytokine and chemokine release, leading to a vicious scratch-itch cycle perpetuating the AD skin rash. The mechanisms of pruritus in AD are poorly understood. Allergen-induced release of histamine from skin mast cells is not an exclusive cause of pruritus in AD, because antihistamines are not effective in controlling the itch of AD.[33] The observation that treatment with topical corticosteroids and calcineurin inhibitors is effective at reducing pruritus suggests that the inflammatory cells play an important role in pruritus.[34,35] Molecules that have been implicated in pruritus include T-cell–derived cytokines such as IL-31, stress-induced neuropeptides, proteases such as proteases which can act on protease-activated receptors, eicosanoids, and eosinophil-derived proteins.[36–38] The reader is referred to Chap. 102 for a detailed discussion of the pathophysiology of pruritus.

CLINICAL FINDINGS

The diagnosis of AD is based on the constellation of clinical features summarized in Table 14-1. AD typically begins during infancy. Approximately 50 percent of patients develop this illness by the first year of life and an additional 30 percent between the ages of 1 and 5 years. Between 50 percent and 80 percent of patients with AD develop allergic rhinitis or asthma later in childhood. Many of these patients outgrow their AD as they are developing respiratory allergy.

Cutaneous Lesions

Intense pruritus and cutaneous reactivity are cardinal features of AD. Pruritus may be intermittent throughout the day but is usually worse in the early evening and night. Its consequences are scratching, prurigo papules (Fig. 14-1), lichenification (Fig. 14-2), and eczematous skin lesions. Acute skin lesions are characterized by intensely pruritic, erythematous papules associated with excoriation, vesicles over erythematous skin, and serous exudate (Fig. 14-3). Subacute dermatitis is characterized by erythematous, excoriated, scaling papules (Fig.



▲ **FIGURE 14-1** Prurigo papules in a patient with atopic dermatitis.







▲ **FIGURE 14-2** Lichenification of the neck and shoulders in an adult with atopic dermatitis.

14-4). Chronic AD is characterized by thickened plaques of skin, accentuated skin markings (lichenification), and fibrotic papules (prurigo nodularis; Fig. 14-5). In chronic AD, all three stages of skin reactions frequently co-exist in the same individual. At all stages of AD, patients usually have dry, lackluster skin (Fig. 14-6).

The distribution and skin reaction pattern vary according to the patient's age and disease activity. During infancy, the AD is generally more acute and primarily involves the face, scalp, and the extensor surfaces of the extremities (Fig. 14-7). The diaper area is usually spared. In older children, and in those who have long-standing skin disease, the patient develops the chronic form of AD with lichenification and localization of the rash to the flexural folds of the extremities (Fig. 14-8). AD often subsides as the patient grows older, leaving an adult with skin that is prone to itching and inflammation when exposed to exogenous irritants. Chronic hand eczema may be the primary manifestation of many adults with AD (Fig. 14-9). Other associated features of AD are listed in Table 14-1.



▲ **FIGURE 14-4** Erythematous papules in a patient with subacute atopic dermatitis.



▲ **FIGURE 14-5** Severe lichenification and hyperpigmented prurigo papules seen in a patient with chronic atopic dermatitis.

Laboratory Tests

Laboratory testing is not needed in the routine evaluation and treatment of uncomplicated AD. Serum IgE levels are elevated in approximately 70 percent to 80 percent of AD patients. This is associated with sensitization against inhalant and food allergens and/or concomitant allergic rhinitis and asthma.[39,40] In contrast, 20 percent to 30 percent of AD patients have normal serum IgE levels. This subtype of AD has a lack of IgE sensitization against inhalant or food allergens. However, some of these patients may possess IgE sensitization against microbial antigens such as *S. aureus* toxins, and *Candida albicans* or *Malassezia sympodialis* can be detected. As well, some of these patients show positive reactions using the atopy patch test despite negative immediate skin tests.

The majority of patients with AD also have peripheral blood eosinophilia. Patients with AD have increased spontaneous histamine release from baso-





◀ **FIGURE 14-3** **A.** Pronounced weeping and crusting of eczematous lesions in childhood atopic dermatitis. **B.** Excoriated papules and crusting in an acute flare of atopic dermatitis.



▲ **FIGURE 14-6** Infiltrated, erythematous facial skin with scaliness in an adolescent with atopic dermatitis. Note lateral thinning of eyebrows and intra-ocular (Dennie-Morgan) fold.

phils. These findings likely reflect a systemic Th2 immune response in AD especially those patients who have elevated serum IgE levels. Importantly, the peripheral blood skin homing CLA^+ T cells in AD expressing either CD4 or CD8 spontaneously secrete IL-5 and IL-13, which functionally prolong eosinophil survival and induce IgE synthesis.

DIAGNOSIS AND DIFFERENTIAL DIAGNOSIS

Table 14-1 lists the clinical features of AD. Of the major features, pruritus and chronic or remitting eczematous dermatitis with typical morphology and distribution are essential for diagnosis. Other features, including exogenous allergy or elevated IgE, are variable, and some of the "associated features" in the table may not be useful discriminators of individuals with AD from the unaffected general population. Various diagnostic criteria have been proposed to assist with clinical diagnosis, definition of patients for clinical studies, and epidemiologic population studies.[41] A refined list of diagnostic criteria suitable for epidemiologic studies has been derived and validated by workers in the United Kingdom.[42]



▲ **FIGURE 14-7** Itching infant with atopic dermatitis. (Used with permission from Oholm Larsen, MD.)



▲ **FIGURE 14-8** Childhood atopic dermatitis with lichenification of antecubital fossae and generalized severely pruritic eczematous plaques.

Box 14-1 lists a number of inflammatory skin diseases, immunodeficiencies, skin malignancies, genetic disorders, infectious diseases, and infestations that share symptoms and signs with AD. These should be considered and ruled out before a diagnosis of AD is made. Infants presenting in the first year of life with failure to thrive, diarrhea, a generalized scaling erythematous rash, and recurrent cutaneous and/or systemic infections should be evaluated for severe combined immunodeficiency syndrome. Wiskott-Aldrich syndrome is an X-linked recessive disorder characterized by cutaneous findings almost indistinguishable from AD. It is associated with thrombocytopenia, variable abnormalities in humoral and cellular immunity, and recurrent severe bacterial infections. The hyper-IgE syndrome is characterized by elevated serum IgE levels, defective T-cell function, recurrent deep-seated bacterial infections, including cutaneous abscesses due to *S. aureus* and/or pruritic skin disease due to *S. aureus* pustulosis, or by recalcitrant dermatophytosis. A papulopustular eruption of the face and scalp may be seen in early life.[43] Although *S. aureus* is an important pathogen in this disorder, infection with other bacteria, viruses, and fungi may occur, particularly when patients are on chronic antistaphylococcal antibiotic prophylaxis. Other features of hyper-IgE syndrome include pneumonia with pneumatocele formation, dental anomalies with retained primary teeth, bone fractures, and osteopenia.

It is important to recognize that an adult who presents with an eczematous dermatitis with no history of childhood eczema, respiratory allergy, or atopic family history may have allergic contact dermatitis. A contact allergen should be considered in any patient whose AD does not respond to appropriate therapy. Of note, contact allergy to topical glucocorticoids and topical calcineurin inhibitors has been reported in patients with chronic dermatitis. In addition, cutaneous T-cell lymphoma must be ruled out in any adult presenting with chronic dermatitis poorly responsive to topical glucocorticoid therapy. Ideally, biopsies should be obtained from three separate sites, because the histology may show spongiosis and cellular infiltrate similar to AD. Eczematous dermatitis has been also reported with human immunodeficiency virus as well as with a variety of infestations such as scabies. Other conditions that can be confused with AD include psoriasis, ichthyoses, and seborrheic dermatitis.



▲ **FIGURE 14-9** Typical papules, vesicles, and erosions seen in atopic hand dermatitis.



Box 14-1

Differential Diagnosis of Atopic Dermatitis

Most Likely

- Contact dermatitis (allergic and irritant)
- Seborrheic dermatitis
- Scabies
- Psoriasis
- Ichthyosis vulgaris
- Keratosis pilaris
- Dermatophytosis

Consider

- Asteatotic eczema
- Lichen simplex chronicus
- Nummular dermatitis
- Juvenile palmar-plantar dermatosis
- Impetigo
- Drug eruptions
- Perioral dermatitis
- Pityriasis alba
- Photosensitivity disorders (hydroa vacciniforme; polymorphous light eruption, porphyrias)
- Molluscum dermatitis

LESS COMMON/RARE DISORDERS PREDOMINANTLY IN ADOLESCENTS AND ADULTS

- Cutaneous T-cell lymphoma (mycosis fungoides or Sézary syndrome)
- Human immunodeficiency virus–associated dermatoses
- Lupus erythematosus
- Dermatomyositis
- Graft-versus-host disease
- Pemphigus foliaceus
- Dermatitis herpetiformis
- Photosensitivity disorders (hydroa vacciniforme, polymorphous light eruption, porphyrias)

LESS COMMON/RARE DISORDERS PREDOMINANTLY IN INFANTS/CHILDREN

- Metabolic/nutritional
  - Phenylketonuria
  - Prolidase deficiency
  - Multiple carboxylase deficiency
  - Zinc deficiency (acrodermatitis enteropathica; prematurity; deficient breast milk zinc; cystic fibrosis)
  - Others: biotin, essential fatty acids, organic acidurias
- Primary immunodeficiency disorders
  - Severe combined immunodeficiency disorder
  - DiGeorge syndrome
  - Hypogammaglobulinemia
  - Agammaglobulinemia
  - Wiskott-Aldrich syndrome
  - Ataxia-telangiectasia
  - Hyperimmunoglobulin E syndrome
  - Chronic mucocutaneous candidiasis
  - Omenn syndrome
- Genetic syndromes
  - Netherton syndrome
  - Hurler syndrome
- Inflammatory, autoimmune disorders
  - Eosinophilic gastroenteritis
  - Gluten-sensitive enteropathy
  - Neonatal lupus erythematosus
- Proliferative disorders
  - Langerhans cell histiocytosis



COMPLICATIONS

Ocular Problems

Eye complications associated with severe AD can lead to significant morbidity. Eyelid dermatitis and chronic blepharitis are commonly associated with AD and may result in visual impairment from corneal scarring. Atopic keratoconjunctivitis is usually bilateral and can have disabling symptoms that include itching, burning, tearing, and copious mucoid discharge. Vernal conjunctivitis is a severe bilateral recurrent chronic inflammatory process associated with papillary hypertrophy, or cobblestoning of the upper eyelid conjunctiva. It usually occurs in younger patients and has a marked seasonal incidence, often in the spring. The associated intense pruritus is exacerbated by exposure to irritants, light, or sweating. Keratoconus is a conical deformity of the cornea believed to result from chronic rubbing of the eyes in patients with AD and allergic rhinitis. Cataracts were reported in the early literature to occur in up to 21 percent of patients with severe AD. However, it is unclear whether this was a primary manifestation of AD or the result of the extensive use of systemic and topical glucocorticoids, particularly around the eyes. Indeed, more recent studies suggest that routine screening for cataracts in patients with AD may not be productive unless there is concern about potential side effects from steroid therapy.

Infections

AD can be complicated by recurrent viral skin infections that may reflect local defects in T-cell function. The most serious viral infection is herpes simplex (see Chap. 193), which can affect patients of all ages, resulting in Kaposi varicelliform eruption or eczema herpeticum. After an incubation period of 5 to 12 days, multiple, itchy, vesiculopustular lesions erupt in a disseminated pattern; vesicular lesions are umbilicated, tend to crop, and often become hemorrhagic and crusted (Fig. 14-10). Punched out and extremely painful erosions result. These lesions may coalesce to large, denuded, and bleeding areas that can extend over the entire body.

Although smallpox infections have been eradicated worldwide since the late 1970s, threats of bioterrorism (with smallpox and other infectious agents) have made nations reconsider their policies toward initiating vaccination programs. In AD patients, smallpox vaccination (or even exposure to vaccinated individuals) (see Chap. 195) may cause a severe widespread eruption (called *eczema vaccinatum*) that appears very similar to eczema herpeticum. Thus, in patients with AD, vaccination is contraindicated unless there is a clear risk of smallpox. In addition, decisions regarding vaccination of family members should take into consideration the potential of eczema vaccinatum in household contacts.

Superficial fungal infections are also more common in atopic individuals and may contribute to the exacerbation of AD. Patients with AD have an increased prevalence of *Trichophyton rubrum* infections compared to nonatopic controls. There has been particular interest in the role of *M. furfur* (*Pityrosporum ovale* or *P. orbiculare*) in AD. *M. furfur* is a lipophilic yeast (see Chap. 189) commonly present in the seborrheic areas of the skin. IgE antibodies against *M. furfur* are commonly found in AD patients and most frequently in patients with head and neck dermatitis. In contrast, IgE sensitization to *M. furfur* is rarely observed in normal controls or asthmatics. Positive allergen patch test reactions to this yeast have also been demonstrated. The potential importance of *M. furfur* as well as other dermatophyte infections is further supported by the reduction of AD skin severity in such patients after treatment with antifungal agents.

S. aureus is found in more than 90 percent of AD skin lesions. Honey-colored crusting, folliculitis, and pyoderma are indicators of secondary bacterial skin infection, usually due to *S. aureus,* that requires antibiotic therapy. Regional lymphadenopathy is common in such patients. The importance of *S. aureus* in AD is supported by the observation that patients with severe AD, even those without overt infection, can show clini-



▲ **FIGURE 14-10** Eczema herpeticum. Typical vesicles and crusting in a patient with disseminated disease.

cal response to combined treatment with antistaphylococcal antibiotics and topical glucocorticoids. Although recurrent staphylococcal pustulosis can be a significant problem in AD, deep-seated *S. aureus* infections occur rarely and should raise the possibility of an immunodeficiency syndrome such as hyper-IgE syndrome. Methicillin-resistant staphylococcus may be an important pathogen in some patients.

Hand Dermatitis

Patients with AD often develop nonspecific, irritant hand dermatitis. It is frequently aggravated by repeated wetting and by washing of the hands with harsh soaps, detergents, and disinfectants. Atopic individuals with occupations involving wet work are prone to develop an intractable hand dermatitis in the occupational setting. This is a common cause of occupational disability.

Exfoliative Dermatitis

Patients with extensive skin involvement may develop exfoliative dermatitis (see Chap. 23). This is associated with generalized redness, scaling, weeping, crusting, systemic toxicity, lymphadenopathy, and fever. Although this complication is rare, it is potentially life threatening. It is usually due to superinfection, for example, with toxin-producing *S. aureus* or herpes simplex infection, continued irritation of the skin, or inappropriate therapy. In some cases, the withdrawal of systemic glucocorticoids used to control severe AD may be a precipitating factor for exfoliative erythroderma.

PROGNOSIS AND CLINICAL COURSE

The natural history of AD is not completely known because studies have been flawed in terms of inadequate sample size, an unclear definition of remission, inadequate length of follow up, selection bias in the initial cohort, and excessive loss of patients to follow up. Nevertheless, although the outcome of AD may be difficult to predict in any given individual, the disease generally tends to be more severe and persistent in young children. Periods of remission appear more frequently as the patient grows older. Spontaneous resolution of AD has been reported to occur after age 5 years in 40 percent to 60 percent of patients affected during infancy, particularly if their disease is mild. Although earlier studies suggested that approximately 84 percent of children outgrow their AD by adolescence, more recent studies have reported that AD disappears in approximately 20 percent of children followed from infancy until adolescence, but becomes less severe in 65 percent. In addition, more than one-half of adolescents treated for mild dermatitis may experience a relapse of disease as adults.

Importantly for occupational counseling, adults whose childhood AD has been in remission for a number of years may present with hand dermatitis, especially if daily activities require repeated hand wetting. The following predictive factors correlate with a poor prognosis for AD: widespread AD in childhood, associated allergic rhinitis and asthma, family history of AD in parents or siblings, early age at onset of AD, being an only child, and very high serum IgE levels.

TREATMENT

Successful treatment of AD requires a systematic, multipronged approach that incorporates skin hydration, pharmacologic therapy, and the identification and elimination of flare factors such as irritants, allergens, infectious agents, and emotional stressors (Fig. 14-11).[44] Many factors lead to the symptom complex characterizing AD. Thus, treatment plans should be individualized to address each patient's skin disease reaction pattern, including the acuity of the rash, and the trigger factors that are unique to the particular patient. In patients refractory to conventional forms of therapy, alternative anti-inflammatory and immunomodulatory agents may be necessary.

Topical Therapy

CUTANEOUS HYDRATION Patients with AD have reduced skin barrier function and dry skin (xerosis) contributing to disease morbidity by the development of microfissures and cracks in the skin, which serve as portals of entry for skin pathogens, irritants, and allergens. This problem can become aggravated during the dry winter months and in certain work environments. Lukewarm soaking baths for at least 20 minutes followed by the application of an occlusive emollient to retain moisture can give such patients excellent symptomatic relief. Use of an effective emollient combined with hydration therapy helps to restore and preserve the stratum corneum barrier, and may decrease the need for topical glucocorticoids. Moisturizers are available in the form of lotions, creams, or ointments. Some lotions and creams may be irritating due to added preservatives, solubilizers, and fragrances. Lotions containing water may be drying due to an evaporative effect. Hydrophilic ointments can be obtained in varying degrees of viscosity according to the patient's preference. Occlusive ointments are sometimes not well tolerated because of interference with the function of the eccrine sweat ducts and the induction of folliculitis. In these patients, less occlusive agents should be used.

Topical therapy to replace abnormal epidermal lipids, improve skin hydration, and decrease skin barrier dysfunction may be useful therapeutically. Studies have shown benefits of topical preparations with distinct compositions of lipids and ceramides, as well as a nonsteroidal cream containing palmitamide MEA, an essential fatty acid, and





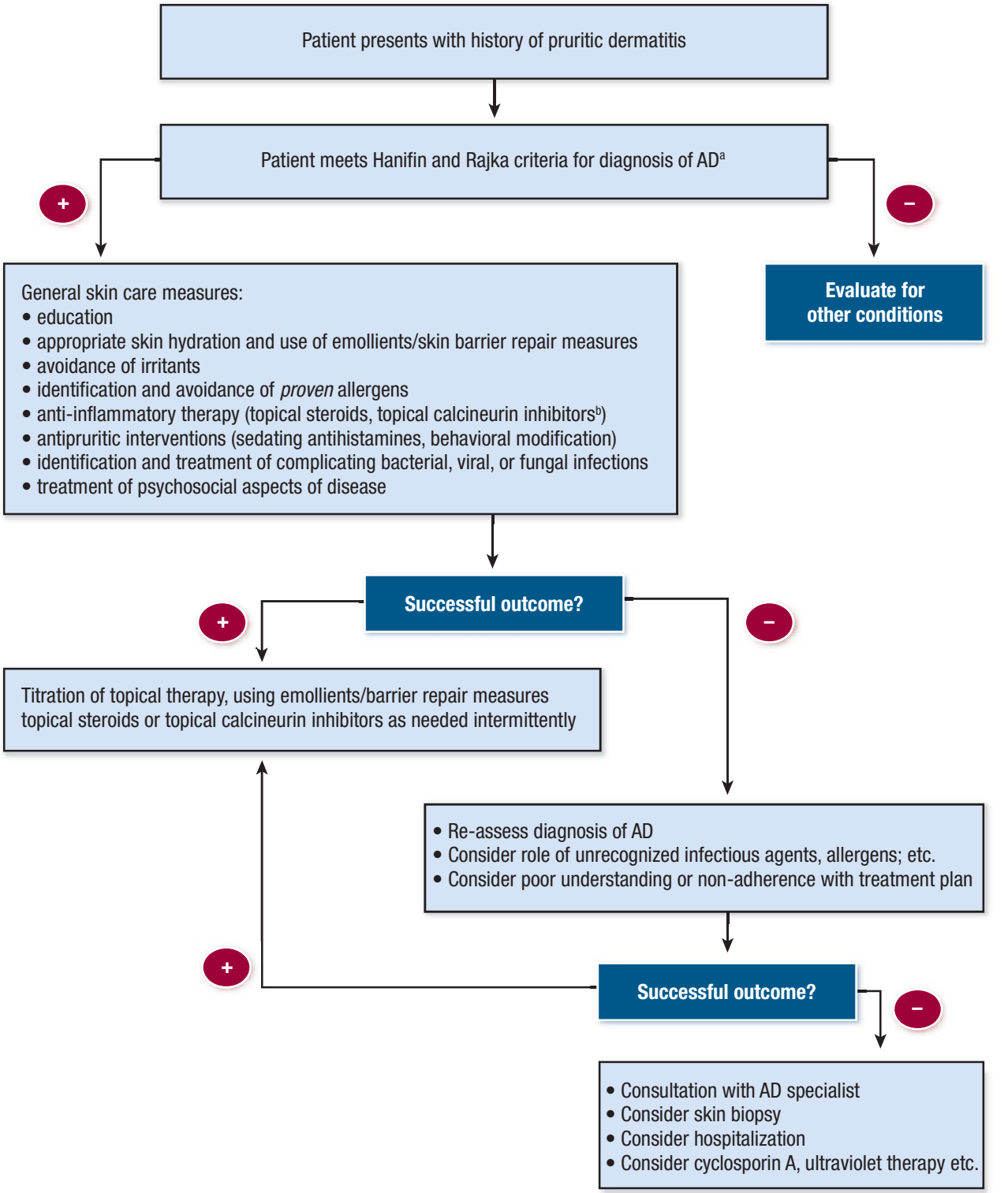

▲ **FIGURE 14-11** Approach to patient with atopic dermatitis (AD). [a]See Table 14-1. [b]Second-line therapy per black box warning.

a hydrolipidic cream with glycyrrhetinic acid (MAS063ADP).[45,46] Further clinical studies to define the benefits relative to traditional moisturizers and topical anti-inflammatory agents will be helpful.

Hydration, by baths or wet dressings, promotes transepidermal penetration of topical glucocorticoids. Dressings may also serve as an effective barrier against persistent scratching, allowing more rapid healing of excoriated lesions. Wet dressings are recommended for use on severely affected or chronically involved areas of dermatitis refractory to therapy. However, overuse of wet dressings may result in maceration of the skin complicated by secondary infection. Wet dressings or baths also have the potential to promote drying and fissuring of the skin if not followed by topical emollient use. Thus, wet dressing therapy is reserved for poorly controlled AD and should be closely monitored by a physician.

TOPICAL GLUCOCORTICOID THERAPY Topical glucocorticoids are the cornerstone of treatment for anti-inflammatory eczematous skin lesions. Because of potential side effects, most physicians use topical glucocorticoids only to control acute ex-

acerbations of AD. However, recent studies suggest that once control of AD is achieved with a daily regimen of topical glucocorticoid, long-term control can be maintained in a subset of patients with twice weekly applications of topical fluticasone to areas that have healed but are prone to developing eczema.[47]

Patients should be carefully instructed in the use of topical glucocorticoids to avoid potential side effects. The potent fluorinated glucocorticoids should be avoided on the face, the genitalia, and the intertriginous areas. A low-potency glucocorticoid preparation is generally recommended for these areas. Patients should be instructed to apply topical glucocorticoids to their skin lesions and to use emollients over uninvolved skin. Failure of a patient to respond to topical glucocorticoids is sometimes due in part to an inadequate supply. It is important to remember that it takes approximately 30 g of cream or ointment to cover the entire skin surface of an adult once. To treat the entire body twice daily for 2 weeks requires approximately 840 g (2 lb) of topical glucocorticoids.

There are seven classes of topical glucocorticoids, ranked according to their potency based on vasoconstrictor assays. Because of their potential side effects, the ultrahigh-potency glucocorticoids should be used only for very short periods of time and in areas that are lichenified but not on the face or intertriginous areas. The goal is to use emollients to enhance skin hydration and low-potency glucocorticoids for maintenance therapy. Midpotency glucocorticoids can be used for longer periods of time to treat chronic AD involving the trunk and extremities. Glucocorticoids in gels are often in a propylene glycol base and may be irritating to the skin in addition to promoting dryness, thus limiting their use to the scalp and beard areas.

Factors which influence topical glucocorticoid potency and side effects include the molecular structure of the compound, the vehicle, the amount of medication applied, the duration of application, occlusion, as well as host factors, including age, body surface area and weight, skin inflammation, anatomic location of treated skin, and individual differences in cutaneous or systemic metabolism. Side effects from topical glucocorticoids are directly related to the potency ranking of the compound and the length of use, so it is incumbent on the clinician to balance the need for a more potent steroid with the potential for side effects. In addition, ointments have a greater potential to occlude the epidermis, resulting in enhanced systemic absorption when compared to creams. Side effects from topical glucocorticoids can be divided into local side effects and systemic side effects resulting from suppression of the hypothalamic-pituitary-adrenal axis. Local side effects include the development of striae, skin atrophy, perioral dermatitis, and acne rosacea. The potential for potent topical glucocorticoid to cause adrenal suppression is greatest in infants and young children. Of note, a study of children as young as 3 months of age found that fluticasone propionate 0.05 percent cream, a midpotency formulation, was safe and effective even when applied on the face and over significant areas of the body for up to 1 month[48] and fluticasone 0.05 percent cream has been approved for use in children as young as 3 months for up to 4 weeks with fluticasone lotion approved for use in children 12 months and older. Mometasone cream and ointment are approved for children ages 2 years and older.

Because normal-appearing skin in AD shows evidence of immunologic dysregulation, the use of topical corticosteroids as maintenance therapy has been reported in several controlled studies.[49] Once control of AD with a once daily regimen was achieved, long-term control could be maintained with twice weekly application of fluticasone to previously involved areas.

TOPICAL CALCINEURIN INHIBITORS Topical tacrolimus and pimecrolimus have been developed as nonsteroidal immunomodulators.[50] Tacrolimus ointment 0.03 percent has been approved for intermittent treatment of moderate to severe AD in children aged 2 years and older, with tacrolimus ointment 0.1 percent approved for use in adults; whereas pimecrolimus cream 1 percent is approved for treatment of patients aged 2 years and older with mild-moderate AD. Both drugs have proven to be effective with a good safety profile for treatment up to 4 years with tacrolimus ointment[51] and up to 2 years with pimecrolimus cream.[52] A frequently observed side effect with topical calcineurin inhibitors is a transient burning sensation of the skin. Importantly, treatment with topical calcineurin inhibitors is not associated with skin atrophy,[53] thus they are particularly useful for the treatment of areas such as the face and intertriginous regions. Ongoing surveillance and recent reports have not shown a trend for increased frequency of viral superinfections especially eczema herpeticum.[54] The long-term safety of topical calcineurin inhibitors has not been established. Rare cases of skin malignancy and lymphoma have been reported with topical tacrolimus, though the level of data quality and applicability of these reports was judged low in the report of a scientific consensus conference.[55]

Identification and Elimination of Triggering Factors

GENERAL CONSIDERATIONS Patients with AD are more susceptible to irritants than are unaffected individuals. Thus, it is important to identify and eliminate aggravating factors that trigger the itch-scratch cycle. These include soaps or detergents, contact with chemicals, smoke, abrasive clothing, and exposure to extremes of temperature and humidity. Alcohol and astringents found in toiletries are drying. When soaps are used, they should have minimal defatting activity and a neutral pH. New clothing may be laundered before wearing to decrease levels of formaldehyde and other added chemicals. Residual laundry detergent in clothing may be irritating. Using a liquid rather than powder detergent and adding a second rinse cycle facilitates removal of the detergent.

Recommendations regarding environmental living conditions should include temperature and humidity control to avoid problems related to heat, humidity, and perspiration. Every attempt should be made to allow children to be as normally active as possible. Certain sports, such as swimming, may be better tolerated than other sports involving intense perspiration, physical contact, or heavy clothing and equipment, but chlorine should be rinsed off immediately after swimming and the skin lubricated. Although ultraviolet (UV) light may be beneficial to some patients with AD, sunscreens should be used to avoid sunburn. However, because sunscreens can be irritants, care should be used to identify a nonirritating product.

SPECIFIC ALLERGENS Foods and aeroallergens such as dust mites, animal danders, molds, and pollens have been demonstrated to exacerbate AD. Potential allergens can be identified by taking a careful history and carrying out selective skin-prick tests or specific serum IgE levels. Negative skin tests or serum tests for allergen-specific IgE have a high predictive value for ruling out suspected allergens. A normal total serum IgE



level, however, does not rule out the possibility of allergen-specific IgE being present. Positive skin or in vitro tests, particularly to foods, often do not correlate with clinical symptoms and should be confirmed with controlled food challenges and elimination diets. Avoidance of foods implicated in controlled challenges results in clinical improvement. Extensive elimination diets, which in some cases can be nutritionally deficient, are rarely, if ever, required, because even with multiple positive skin tests, the majority of patients react to three or fewer foods on controlled challenge. In dust mite–allergic patients with AD, prolonged avoidance of dust mites has been found to result in improvement of their skin disease. Avoidance measures include use of dust mite–proof encasings on pillows, mattresses, and box springs; washing bedding in hot water weekly; removal of bedroom carpeting; and decreasing indoor humidity levels with air conditioning. Because there are many triggers contributing to the flares of AD, attention should be focused on identifying and controlling the flare factors that are important to the individual patient. Infants and young children are more likely to have food allergies, whereas older children and adults are more likely to be sensitive to environmental aeroallergens.



EMOTIONAL STRESSORS Although emotional stress does not cause AD, it often exacerbates the illness. AD patients often respond to frustration, embarrassment, or other stressful events with increased pruritus and scratching. In some instances, scratching is simply habitual and less commonly associated with significant secondary gain. Psychological evaluation or counseling should be considered in patients who have difficulty with emotional triggers or psychological problems, contributing to difficulty in managing their disease. It may be especially useful in adolescents and young adults who consider their skin disease disfiguring. Relaxation, behavioral modification, or biofeedback may be helpful in patients with habitual scratching.

INFECTIOUS AGENTS Anti-staphylococcal antibiotics are very helpful in the treatment of patients who are heavily colonized or infected with *S. aureus*.[56] Cephalosporins or penicillinase-resistant penicillins (dicloxacillin, oxacillin, or cloxacillin) are usually beneficial for patients who are not colonized with resistant *S. aureus* strains. Because erythromycin-resistant staphylococci are common, erythromycin and newer macrolide antibiotics are usually of limited utility. Topical mupirocin offers some utility in the treatment of impetiginized lesions; however, in patients with extensive superinfection, a course of systemic antibiotics is most practical. Methicillin-resistant staphylococci may require culture and sensitivity testing to assist in appropriate antibiotic selection.

Herpes simplex can provoke recurrent dermatitis and may be misdiagnosed as *S. aureus* infection. The presence of punched-out erosions, vesicles, and/or infected skin lesions that do not respond to oral antibiotics should initiate a search for herpes simplex. This can be diagnosed by a Giemsa-stained Tzanck smear of cells scraped from the vesicle base, direct immunofluorescence assay, polymerase chain reaction identification of herpes genetic material, or by viral culture. For infection suspected to be caused by herpes simplex, topical anti-inflammatory agents might be discontinued, at least temporarily. Antiviral treatment for cutaneous herpes simplex infections is of critical importance in the patient with widespread AD because life-threatening dissemination has been reported. Acyclovir, 400 mg three times daily for 10 days or 200 mg four times daily for 10 days by oral administration (or an equivalent dosage of one of the newer antiherpetic medications), is useful in adults with herpes simplex confined to the skin. Intravenous treatment may be necessary for severe disseminated eczema herpeticum. The dosage should be adjusted according to weight in children.

Dermatophyte infections can complicate AD and may contribute to exacerbation of disease activity. Patients with dermatophyte infection or IgE antibodies to *Malassezia* may benefit from a trial of topical or systemic antifungal therapy.

PRURITUS The treatment of pruritus in AD should be directed primarily at the underlying causes. Reduction of skin inflammation and dryness with topical glucocorticoids and skin hydration, respectively, often symptomatically reduce pruritus. Inhaled and ingested allergens should be eliminated if documented to cause skin rash in controlled challenges. Systemic antihistamines act primarily by blocking the H_1 receptors in the dermis, thereby ameliorating histamine-induced pruritus. However, histamine is only one of many mediators that can induce pruritus of the skin. Therefore, certain patients may derive minimal benefit from antihistaminic therapy. Some antihistamines are also mild anxiolytics and may offer symptomatic relief through tranquilizing and sedative effects. Studies of newer, non-sedating antihistamines show variable results in the effectiveness of controlling pruritus in AD, although they may be useful in the subset of AD patients with concomitant urticaria or concurrent allergic rhinitis.

Because pruritus is usually worse at night, the sedating antihistamines, for example, hydroxyzine or diphenhydramine, may offer an advantage with their soporific side effects when used at bedtime. Doxepin hydrochloride has both tricyclic antidepressant and H_1- and H_2-histamine receptor–blocking effects. It can be used in doses of 10 to 75 mg orally at night or up to 75 mg bid in adult patients. If nocturnal pruritus remains severe, short-term use of a sedative to allow adequate rest may be appropriate. Treatment of AD with topical antihistamines is generally not recommended because of potential cutaneous sensitization. However, short-term (1 week) application of topical 5 percent doxepin cream has been reported to reduce pruritus without sensitization. Of note, sedation is a side effect of widespread application of doxepin cream, and allergic contact dermatitis has been reported.

Tar Preparations

Coal tar preparations may have antipruritic and anti-inflammatory effects on the skin although usually not as pronounced as those of topical glucocorticoids.[57] Tar preparations may be useful in reducing the potency of topical glucocorticoids required in chronic maintenance therapy of AD. Newer coal tar products have been developed that are more acceptable with respect to odor and staining of clothes than some older products. Tar shampoos can be beneficial for scalp dermatitis and are often helpful in reducing the concentration and frequency of topical glucocorticoid applications. Tar preparations should not be used on acutely inflamed skin, because this often results in skin irritation. Side effects associated with tars include folliculitis and photosensitivity. There is a theoretic risk of tar being a carcinogen based on observational studies of workers using tar components in their occupations.

Phototherapy

Natural sunlight is frequently beneficial to patients with AD. However, if the

sunlight occurs in the setting of high heat or humidity, thereby triggering sweating and pruritus, it may be deleterious to patients. Broadband UVB, broadband UVA, narrowband UVB (311 nm), UVA-1 (340 to 400 nm), and combined UVA-B phototherapy can be useful adjuncts in the treatment of AD. Investigation of the photoimmunologic mechanisms responsible for therapeutic effectiveness indicates that epidermal LCs and eosinophils may be targets of UVA phototherapy with and without psoralen, whereas UVB exerts immunosuppressive effects via blocking of function of antigen-presenting LCs and altered keratinocyte cytokine production. Photochemotherapy with psoralen and UVA light may be indicated in patients with severe, widespread AD, although studies comparing it with other modes of phototherapy are limited. Short-term adverse effects with phototherapy may include erythema, skin pain, pruritus, and pigmentation. Long-term adverse effects include premature skin aging and cutaneous malignancies (see Chaps. 238 and 239 for detailed discussion of phototherapy and photochemotherapy).

Hospitalization

AD patients who appear erythrodermic or who have widespread severe skin disease resistant to outpatient therapy should be hospitalized before considering systemic alternative therapies (see Systemic Therapy). In many cases, removing the patient from environmental allergens or emotional stresses, intense patient education, and assurance of compliance with therapy results in a sustained improvement in their AD. Clearing of the patient's skin during hospitalization also allows the patient to undergo allergen skin testing and appropriately controlled provocative challenges to correctly identify or rule out potential allergens.

Systemic Therapy

SYSTEMIC GLUCOCORTICOIDS The use of systemic glucocorticoids, such as oral prednisone, is rarely indicated in the treatment of chronic AD. Some patients and physicians prefer the use of systemic glucocorticoids to avoid the time-consuming skin care involving hydration and topical therapy. However, the dramatic clinical improvement that may occur with systemic glucocorticoids is frequently associated with a severe rebound flare of AD after the discontinuation of systemic glucocorticoids. Short courses of oral glucocorticoids may be appropriate for an acute exacerbation of AD whereas other treatment measures are being instituted. If a short course of oral glucocorticoids is given, it is important to taper the dosage and to begin intensified skin care, particularly with topical glucocorticoids and frequent bathing followed by application of emollients, to prevent rebound flaring of AD.

CYCLOSPORINE Cyclosporine is a potent immunosuppressive drug that acts primarily on T cells by suppressing cytokine transcription. The drug binds to cyclophilin, an intracellular protein, and this complex, in turn, inhibits calcineurin, a molecule required for initiation of cytokine gene transcription. Multiple studies demonstrate that both children and adults with severe AD, refractory to conventional treatment, can benefit from short-term cyclosporine treatment. Various oral-dosing regimens have been recommended: 5 mg/kg has generally been used with success in short-term and long-term (1 year) use, whereas some authorities advocate body-weight–independent daily dosing of adults with 150 mg (low dose) or 300 mg (high dose) daily of cyclosporine microemulsion. Treatment with cyclosporine is associated with reduced skin disease and an improved quality of life (see Chap. 234 for further discussion). Discontinuation of treatment may result in rapid relapse of skin disease, although some patients may have sustained remission. Elevated serum creatinine or more significant renal impairment and hypertension are specific side effects of concern with cyclosporine use.

ANTIMETABOLITES Mycophenolate mofetil is a purine biosynthesis inhibitor used as an immunosuppressant in organ transplantation, that has been used for treatment of refractory inflammatory skin disorders (see Chap. 228). Open-label studies report that short-term oral mycophenolate mofetil, 2 g daily, as monotherapy results in clearing of skin lesions in adults with AD resistant to other treatment, including topical and oral steroids and psoralen and UVA light. The drug has generally been well tolerated with the exception of one patient developing herpes retinitis that may have been secondary to this immunosuppressive agent. Dose-related bone marrow suppression has also been observed. Similar results were previously reported in another open study of ten patients with a mean reduction in the SCORAD (SCORing Atopic Dermatitis) index of 68 percent in all ten patients. Of note, not all patients benefit from treatment. Therefore the medication should be discontinued if patients do not respond within four to eight weeks. Dose finding and well-controlled studies are needed for this drug.

Methotrexate is an antimetabolite with potent inhibitory effects on inflammatory cytokine synthesis and cell chemotaxis. Methotrexate has been used for AD patients with recalcitrant disease, although controlled trials are lacking. Dosing is more frequent than the weekly dosing used for psoriasis. Azathioprine is a purine analog with anti-inflammatory and antiproliferative effects; azathioprine has been used for severe AD, although no controlled trials have been reported. Myelosuppression is a significant adverse effect, and thiopurinemethyl transferase levels may predict individuals at risk.

Unproven Therapies

INTERFERON-γ IFN-γ is known to suppress IgE responses and downregulate Th2 cell proliferation and function. Several studies of patients with AD, including a multicenter, double-blind, placebo-controlled trial[58] and two long-term open trials,[59,60] have demonstrated that treatment with recombinant human IFN-γ results in clinical improvement. Reduction in clinical severity of AD correlated with the ability of IFN-γ to decrease total circulating eosinophil counts. Influenza-like symptoms are commonly observed side effects early in the treatment course.

OMALIZUMAB Treatment of patients with severe AD and elevated serum IgE levels with monoclonal anti-IgE has shown lack of efficacy in three adult patients[61] and significant improvement in three adolescent patients.[62]

ALLERGEN IMMUNOTHERAPY Unlike allergic rhinitis and extrinsic asthma, immunotherapy with aeroallergens has not proven to be efficacious in the treatment of AD. There are anecdotal reports of both disease exacerbation and improvement. A recent study of specific immunotherapy over 12 months in adults with AD sensitized to dust mite allergen showed improvement in SCORAD as well as reduction in topical steroid use.[63] However, well-controlled studies are still required to determine the role for immunotherapy with this disease.



EXTRACORPOREAL PHOTOPHERESIS Extracorporeal photopheresis consists of the passage of psoralen-treated leukocytes through an extracorporeal UVA light system. Clinical improvement in skin lesions associated with reduced IgE levels has been reported in a few patients with severe, resistant AD who were treated with extracorporeal photopheresis and topical glucocorticoids.

PROBIOTICS Perinatal administration of the probiotic *Lactobacillus rhamnosus* strain GG was shown to reduce the incidence of AD in at-risk children during the first 2 years of life.[64] Mothers were given either placebo or lactobacillus GG daily for 4 weeks before delivery and then either the mother (if breast feeding) or the infant continued with daily therapy for 6 months. In a follow-up study, the same group assessed the persistence of potential to prevent AD at 4 years.[65] The results suggest that the preventive effect of *Lactobacillus* GG on AD could extend beyond infancy. In a second study, children with AD treated with two *Lactobacillus* strains for 6 weeks experienced improvement of their eczema compared to placebo treated patients, although their SCORAD index did not change significantly.[66] The treatment response was found to be more pronounced in patients with positive skin-prick tests and elevated IgE levels. Another study of children with moderate to severe AD treated for 8 weeks with *L. fermentum* in a placebo-controlled study showed persistent improvement in SCORAD at 16 weeks.[67] These studies suggest that probiotics, or at least some lactobacillus strains, may have preventative, lasting effects on the incidence of AD in a subset of patients. More research into subgroups of responders, optimal therapy [route (i.e., directly to infant or via mother's milk); length of treatment; strain of lactobacillus], as well as mechanisms involved is clearly needed.[68]

CHINESE HERBAL MEDICATIONS Several placebo-controlled clinical trials have suggested that patients with severe AD may benefit from treatment with traditional Chinese herbal therapy (see Chap. 242). They had significantly reduced skin disease and decreased pruritus. The beneficial response of Chinese herbal therapy, however, is often temporary, and effectiveness may wear off despite continued treatment. The possibility of hepatic toxicity, cardiac side effects, or idiosyncratic reactions remains a concern. The specific ingredients of the herbs also remain to be elucidated and some preparations have been found to be contaminated with corticosteroids. At present, Chinese herbal therapy for AD is considered investigational.

KEY REFERENCES

The full reference list for all chapters is available at www.digm7.com.

1. Hanifin JM, Rakja G: Diagnostic features of atopic dermatitis. *Acta Derm Venereol* **92**:44, 1980
8. Leung DY et al: New insights into atopic dermatitis. *J Clin Invest* **113**:651, 2004
9. Cork MJ et al: New perspectives on epidermal barrier dysfunction in atopic dermatitis: Gene-environment interactions. *J Allergy Clin Immunol* **118**:3, 2006
10. Sugiura H et al: Large-scale DNA microarray analysis of atopic skin lesions shows overexpression of an epidermal differentiation gene cluster in the alternative pathway and lack of protective gene expression in the cornified envelope. *Br J Dermatol* **152**:146, 2005
12. Homey B et al: Cytokines and chemokines orchestrate atopic skin inflammation. *J Allergy Clin Immunol* **118**:178, 2006
29. McGirt LY, Beck LA: Innate immune defects in atopic dermatitis. *J Allergy Clin Immunol* **118**:202, 2006
31. Morar N et al: The genetics of atopic dermatitis. *J Allergy Clin Immunol* **118**:7, 2006
32. Leung DY, Bieber T: Atopic dermatitis. *Lancet* **361**:151, 2003
34. Eichenfield LF et al: Safety and efficacy of pimecrolimus (ASM 981) cream 1% in the treatment of mild and moderate atopic dermatitis in children and adolescents. *J Am Acad Dermatol* **46**:495, 2002
35. Van Der Meer JB et al: The management of moderate to severe atopic dermatitis in adults with topical fluticasone propionate. The Netherlands Adult Atopic Dermatitis Study Group. *Br J Dermatol* **140**:1114, 1999
37. Bilsborough J et al: IL-31 is associated with cutaneous lymphocyte antigen-positive skin homing T cells in patients with atopic dermatitis. *J Allergy Clin Immunol* **117**:418, 2006
38. Sonkoly E et al: IL-31: A new link between T cells and pruritus in atopic skin inflammation. *J Allergy Clin Immunol* **117**:411, 2006
44. Hoare C, Li Wan Po A, Williams H: Systematic review of treatments for atopic eczema. *Health Technol Assess* **4**:1, 2000
55. Berger TG et al: The use of topical calcineurin inhibitors in dermatology: safety concerns. Report of the American Academy of Dermatology Association Task Force. *J Am Acad Dermatol* **54**:818, 2006



CHAPTER 15

Nummular Eczema and Lichen Simplex Chronicus/Prurigo Nodularis

Susan Burgin

NUMMULAR ECZEMA

Epidemiology

Nummular eczema (also nummular dermatitis) is predominantly a disease of adulthood. Men are more frequently affected than women. The peak incidence in both males and females is around 50 to 65 years of age. There is a second peak in women around 15 to 25 years of age. Nummular eczema is rare in infancy and childhood. The peak age of onset in childhood is 5 years.[1]

Etiology and Pathogenesis

The pathogenesis of nummular eczema is unknown. The vast majority of patients with nummular eczema do not have a personal or family history of atopy,[2,3] although nummular plaques may be seen in atopic eczema. Numerous factors have been implicated as causal. The state of hydration of the skin in elderly patients has been shown to be decreased.[4] The role of infection previously received much attention in the literature. An internal focus of infection, including teeth, upper respiratory tract, and lower respiratory tract, was found in 68 percent of patients in one study.[5] A role for environmental allergens, such as the house dust mite and *Candida albicans* has also been touted.[4] Nummular eczema has been reported during therapy with isotretinoin and gold.[6,7] Generalized nummular eczema is seen in patients with hepatitis C undergoing combination therapy with interferon-α 2b and ribavirin.[8,9] Mercury amalgam was implicated as a cause in two patients.[10]

NUMMULAR ECZEMA

AT A GLANCE



- Also known as *discoid eczema.*
- A chronic disorder of unknown etiology.
- Papules and papulovesicles coalesce to form nummular plaques with oozing, crust, and scale.
- Most common sites of involvement are upper extremities, including the dorsal hands in women, and the lower extremities in men.
- Pathology may show acute, subacute, or chronic eczema.

Clinical Findings

Well-demarcated, coin-shaped plaques form from coalescing papules and papulovesicles. Pinpoint oozing and crusting eventuate and are distinctive (Fig. 15-1). Crust may however cover the entire surface (Fig. 15-2). Plaques range from 1 to 3 cm in size. The surrounding skin is generally normal, but may be xerotic. Pruritus varies from minimal to severe. Central resolution may occur, leading to annular forms. Chronic plaques are dry, scaly, and lichenified. The classic distribution of lesions is the extensor aspects of the extremities. In women, the upper extremities, including the dorsal aspects of the hands, are more frequently affected than the lower extremities.[2] Exudative discoid and lichenoid dermatitis of Sulzberger-Garbe may represent a variant of nummular eczema.[11]



▲ **FIGURE 15-1** Nummular eczema. Coin-shaped plaques with pinpoint erosions and excoriations. (Image from Division of Dermatology, University of the Witwatersrand, Johannesburg, South Africa, with permission from Professor D. Modi.)



▲ **FIGURE 15-2** Nummular eczema in a child. Crusted plaques. (Used with permission from P. Lio, M.D., Beth Israel Deaconess Medical Center, Boston, Massachusetts.)

Laboratory Tests

Patch testing may be useful in chronic recalcitrant cases to rule out a superimposed contact dermatitis. In a series from India, just under one-half of 50 patients had positive patch tests to colophony, nitrofurazone, neomycin sulfate, and nickel sulfate.[12] Serum immunoglobulin E levels are normal.

Special Tests

Histopathologic changes are reflective of the stage at which the biopsy is performed. Acutely, there is spongiosis, with or without spongiotic microvesicles. In subacute plaques, there is parakeratosis, scale-crust, epidermal hyperplasia, and spongiosis of the epidermis (Fig. 15-3). There is a mixed cell infiltrate in the dermis. Chronic lesions may resemble lichen simplex chronicus microscopically.

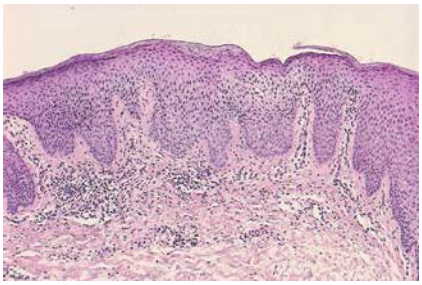

▲ **FIGURE 15-3** Histopathology of nummular eczema. Parakeratosis containing plasma and neutrophils (scale-crust) and psoriasiform epidermal hyperplasia with spongiosis are present, with a superficial dermal perivascular infiltrate of lymphocytes, macrophages, and eosinophils.

Differential Diagnosis

See Box 15-1.

Complications

Nummular eczema may be complicated by secondary bacterial infection.

Prognosis and Clinical Course

The course is usually chronic. Recurrence at prior sites of involvement is a feature of the disease.[5]

Treatment

Topical steroids in the mid- to high-potency range are the mainstay of treatment. The calcineurin inhibitors, tac-

Box 15-1

Differential Diagnosis of Nummular Eczema

Most Likely

- Allergic contact dermatitis
- Stasis dermatitis
- Atopic dermatitis
- Tinea corporis

Consider

- Impetigo
- Psoriasis (long-standing plaques)
- Mycosis fungoides (long-standing plaques)
- Paget disease, when there is unilateral involvement of nipple/areola
- Other nummular dermatoses
  - Fixed drug eruption
  - Pityriasis rotunda

Always Rule Out

- Tinea corporis



rolimus and pimecrolimus, and tar preparations are also effective. Emollients can be added adjunctively if there is accompanying xerosis. Oral antihistamines are useful if pruritus is severe. Oral antibiotics are indicated when secondary infection is present. For widespread involvement, phototherapy with broad or narrow band ultraviolet B may be beneficial.

LICHEN SIMPLEX CHRONICUS AND PRURIGO NODULARIS

Epidemiology

Lichen simplex chronicus affects adults, predominantly from ages 30 to 50 years. Females are affected more commonly than males. Prurigo nodularis may occur at any age, but most patients are between 20 and 60 years old.[13] Men and women are equally affected. Patients with co-existent atopic dermatitis have been found to have an earlier age of onset (mean: 19 years) as compared to the non-atopic group (mean: 48 years).[14]

Etiology and Pathogenesis

Lichen simplex chronicus is induced by rubbing and scratching secondary to itch. The prurigo nodule is induced by picking and scratching most commonly, but not always, in response to itch. Various factors incite itch in both disorders, and not all are well understood. A variable association between lichen simplex chronicus and atopic disorders has been reported, ranging from approximately 26 percent to 75 percent.[15,16] Similarly, a subset of patients with prurigo nodularis has coexistent atopic eczema. Here, prurigo nodules occur in concert with subacute prurigo, lichenification, and xerosis. "Besnier prurigo" refers to the pruriginous nodules seen in atopic dermatitis. In the non-atopic nodular prurigo group, systemic causes of pruritus, including renal insufficiency, hyper- or hypothyroidism, liver failure, human immunodeficiency virus disease, parasitic infection, or an underlying malignancy, must be excluded. Hepatitis B and C have been reported as associations without liver failure.[17] Prurigo nodularis has also been reported to occur in the setting of celiac disease in the presence or absence of dermatitis herpetiformis.[18,19]

Environmental factors have been implicated in inducing itch, such as heat, sweat, and irritation associated with anogenital lichen simplex chronicus.[16] The presence of emotional or psychological factors in patients with prurigo nodularis and lichen simplex chronicus has been alluded to in the literature. One study of prurigo nodularis patients found that approximately one-half of 46 patients had a history of depression, anxiety, or other treatable psychological disorders.[20] Lichen simplex chronicus patients also had higher depression scores in one study.[21] Whether these emotional factors are secondary to the primary dermatologic disease, or whether they are primary and causative (altering perception of itch) is unclear. It has been postulated that neurotransmitters that affect mood, such as dopamine, serotonin, or opioid peptides, modulate perception of itch via descending spinal pathways.[13] Obsessive-compulsive disorder has also been associated with picking in these disorders.[22]

At a microscopic level, increased numbers of Merkel cells are also seen adjacent to the dermal nerve fibers and mast cells in prurigo nodularis. It is thought that this complex may mediate the abnormally heightened perception of touch and itch in these patients. Nerve growth factor is overexpressed in prurigo nodularis lesions and it has been implicated in the pathogenesis of the characteristic cutaneous neural hyperplasia seen.[23] Nerve growth factor is produced and released by mast cells, which are increased in number and size on histologic sections. It upregulates the expression of neuropeptides, such as calcitonin gene–related peptide and substance P. These are thought to mediate inflammation and itch.[17]

Clinical Findings

HISTORY Severe itching is the hallmark of lichen simplex chronicus. Itching may be paroxysmal, continuous, or sporadic. Rubbing and scratching may be conscious and to the point of replacing the sensation of itch with pain, or may be unconscious, occurring during sleep. Itch severity is worse with sweating, heat, or irritation from clothing. Itching is also worse in times of psychological distress.[16]

CUTANEOUS LESIONS In lichen simplex chronicus, repeated rubbing and scratching gives rise to a lichenified (thickened skin with accentuated skin markings), scaly plaque with excoriations. Hyper- and hypopigmentation are seen with chronicity. Usually, only one plaque is present; however, more than one site may be involved. The most common sites of involvement are the scalp, the nape of the neck (especially in women), the ankles, the extensor aspects of the extremities, and the anogenital region.[24] The labia majora in women and the scrotum in men (Fig. 15-4) are the most common sites of genital involvement.[16] The upper inner thighs may also be affected.

Prurigo nodules vary in size from 0.5 to 3.0 cm and are firm to hard on palpation. The surface may be hyperkeratotic or crateriform. There is often overlying

LICHEN SIMPLEX CHRONICUS AND PRURIGO NODULARIS AT A GLANCE




Lichen Simplex Chronicus

- Also known as *neurodermatitis circumscripta* or *circumscribed neurodermatitis*.
- A chronic, severely pruritic disorder characterized by one or more lichenified plaques in which the skin is thickened and there are accentuated skin markings.
- Most common sites of involvement are scalp, nape of neck, extensor aspects of extremities, ankles, and anogenital area.
- Pathology consists of hyperkeratosis, hypergranulosis, psoriasiform epidermal hyperplasia, and thickened papillary dermal collagen.

Prurigo Nodularis

- Described by Hyde in 1909; also known as *nodular prurigo*.
- A pruritic disorder that runs a chronic course.
- Hyperkeratotic, firm nodules vary in size from 0.5 to 3.0 cm and may be excoriated.
- Associations include atopic dermatitis or systemic causes of pruritus.
- Pathology consists of hyperkeratosis, hypergranulosis, and psoriasiform epidermal hyperplasia. Dermal changes include thickened papillary dermal collagen and characteristic neural hyperplasia.





▲ **FIGURE 15-4** Lichen simplex chronicus of the scrotum: lichenification, hyper- and hypopigmentation with excoriation. (Image from Division of Dermatology, University of the Witwatersrand, Johannesburg, South Africa, with permission from Professor D. Modi.)

excoriation. Pruritus is usually severe. Limbs are affected in most cases, especially the extensor aspects (Fig. 15-5). The abdomen and sacrum were the next most common sites of involvement in one study.[20] Face and palms are rarely involved; however, nodules may occur on any site that can be reached by the patient. Lesions may vary in number from few to more than 100. Nodules resolve with post-inflammatory hyper- or hypopigmentation with or without scarring.



▲ **FIGURE 15-5** Prurigo nodularis. (Used with permission from Professor D. Modi, Division of Dermatology, University of the Witwatersrand, Johannesburg, South Africa.)

RELATED PHYSICAL FINDINGS In patients with atopic eczema, the intervening skin is often lichenified and xerotic. In non-atopic patients, cutaneous signs of underlying systemic disease or lymphadenopathy, signifying lymphoma, may be present.

Laboratory Tests

In patients with prurigo nodularis in whom an underlying systemic cause of pruritus is suspected, a complete blood count with differential count, renal, liver, and thyroid function tests may be ordered. A chest x-ray may be obtained to screen for lymphoma. Human immunodeficiency virus testing may also be indicated. The need for a more extensive evaluation may be individualized based on patient history and results of the aforementioned tests.

Special Tests

On histopathologic sections, lichen simplex chronicus shows varying degrees of hyperkeratosis with para- and orthokeratosis, hypergranulosis, and psoriasiform epidermal hyperplasia. The papillary dermis shows thickening of collagen with coarse collagen bundles and vertical streaks. There is a variable inflammatory infiltrate around the superficial vascular plexus with lymphocytes, histiocytes, and eosinophils. A biopsy may also reveal a primary pruritic disorder that has led to secondary lichenification, such as psoriasis.

The epidermal findings in prurigo nodularis are similar to lichen simplex chronicus. The lesion is more papular with bulbous epidermal hyperplasia. Papillary dermal changes also resemble lichen simplex chronicus. There is cutaneous neural hyperplasia with thickened nerve bundles and an increase in nerve fibers by S-100 staining. This is not seen in other pruritic disorders, including lichen simplex chronicus.

Differential Diagnosis

See Boxes 15-2 and 15-3.

Complications

Sleep studies have shown that disturbances in the sleep cycle in patients with lichen simplex chronicus are present. Non–rapid eye movement sleep is disturbed, and patients have an increased arousal index (brief awakenings from sleep) caused by scratching.[25]

Box 15-2

Differential Diagnosis of Lichen Simplex Chronicus

Most Likely
- Lichenified atopic eczema
- Lichenified psoriasis
- Hypertrophic lichen planus

Consider
- Genital: Extramammary Paget disease

Always Rule Out
- Vulva, perianally: Underlying lichen sclerosus, HPV, or tinea cruris
- Scrotum: Underlying HPV or tinea cruris

HPV = human papillomavirus.

Prognosis and Clinical Course

Both diseases run a chronic course with persistence or recurrence of lesions. Exacerbations may occur in response to emotional stress.

Treatment

Treatment is aimed at interrupting the itch-scratch cycle. Both components should be addressed. Systemic causes of itch should be identified and addressed. In both conditions, first-line measures to control itch include potent topical steroids, best under occlusion, as well as nonsteroidal antipruritic preparations such as menthol, phenol, or pramoxine. Emollients are an important adjunct. Intralesional steroids, such as triamcinolone acetonide, given in varying concentrations according to the thickness of the plaque or nodule, are beneficial. Sedating antihistamines, such as hydroxyzine, or tricyclic antidepressants, such as doxepin, may be used to abolish nighttime itch in both conditions. Selective serotonin reuptake inhibitors have

Box 15-3

Differential Diagnosis of Prurigo Nodularis

Most Likely
- Perforating disease
- Hypertrophic lichen planus
- Pemphigoid nodularis
- Actinic prurigo
- Multiple keratoacanthomas

Consider
- Nodular scabies
- Dermatitis herpetiformis



been recommended for relief of daytime pruritus or in patients with obsessive-compulsive disorder.[16]

Capsaicin, calcipotriene, topical tacrolimus, and cryotherapy, with or without intralesional steroid injections, have all been successfully used in prurigo nodularis. Both broad- and narrowband ultraviolet B, as well as topical or oral psoralen and ultraviolet A light, show efficacy and are indicated in widespread cases. Thalidomide and cyclosporine have also been shown to be beneficial. Naltrexone has shown efficacy in a small series.[26]

The importance of avoiding scratching should be addressed with the patient. Nails should be kept short and occlusive measures, such as plastic films, topical steroid tape, or Unna boots in widespread cases, may be needed.

KEY REFERENCES

The full reference list for all chapters is available at www.digm7.com.

8. Moore MM, Elpern DJ, Carter DJ: Severe, generalized nummular eczema secondary to interferon alfa-2b plus ribavirin combination therapy in a patient with chronic hepatitis C virus infection. *Arch Dermatol* **140**:215, 2004
13. Wallengren J: Prurigo: Diagnosis and management. *Am J Clin Dermatol* **5**:85, 2004
14. Tanaka M et al: Prurigo nodularis consists of two distinct forms: Early-onset atopic and late-onset non-atopic. *Dermatology* **190**:269, 1995
16. Lynch PJ: Lichen simplex chronicus (atopic/neurodermatitis) of the anogenital region. *Dermatol Ther* **17**:8, 2004
17. Lee MR, Shumack S: Prurigo nodularis: A review. *Australas J Dermatol* **46**:211, 2005
23. Johansson O, Liang Y, Emtestam L: Increased nerve growth factor- and tyrosine kinase A-like immunoreactivities in prurigo nodularis skin—An exploration of the cause of neurohyperplasia. *Arch Dermatol Res* **293**:614, 2002
25. Koca R et al: Sleep disturbance in patients with lichen simplex chronicus and its relationship to nocturnal scratching: A case control study. *South Med J* **99**:482, 2006



CHAPTER 16

Vesicular Palmoplantar Eczema

Daven N. Doshi
Alexa B. Kimball

Vesicular palmoplantar eczema is a dermatitis of the hands and feet characterized by small to large blisters clinically and spongiotic vesicles histologically. It can manifest as either an acute or a chronic dermatitis, or both. Because clinical and histologic presentations of the variants of hand dermatitis, including vesicular palmoplantar eczema, often overlap, rendering the formulation of precise diagnostic categories can be difficult. For example, patients with pompholyx, the most acute form of vesicular palmoplantar eczema, have been noted to have higher incidence rates of both atopy and contact dermatitis than controls.

With the preceding caveat in mind, vesicular palmoplantar eczema can be divided into four categories: pompholyx, chronic vesiculobullous hand dermatitis, hyperkeratotic hand dermatitis, and id reactions. These conditions can be grouped under the category of endogenous hand dermatitis, in contrast to dermatitis clearly caused by exogenous factors such as contact allergy or irritation.

Pompholyx is a term best reserved for acute explosive outbreaks of small to large vesicles and bullae on the palms and soles. It tends to occur more often in the spring and fall, and may be associated with stress. Other etiologic factors are less well established. *Cheiropompholyx* and *podopompholyx* are terms occasionally used to describe cases affecting the palms or soles, respectively.

Chronic vesiculobullous hand dermatitis, also known as *dyshidrotic hand eczema* or *dyshidrotic hand dermatitis*, is usually characterized by small vesicles on the lateral aspects of the fingers. "Dyshidrosis," a dysfunction of the sweat gland, was long postulated to be a cause, but its role has been subsequently disproved. However, the terminology persists and is commonly used.

A third category is chronic hyperkeratotic hand dermatitis, an entity that generally occurs on the central palms. Unlike the other classifications of vesicular palmoplantar eczema, vesicles do not dominate the clinical presentation. However, the spongiosis observed histologically is indistinguishable from the other categories.

An id reaction is a vesiculobullous dermatitis, generally appearing on the lateral aspects of the fingers, elicited by an infection elsewhere in the body. The most common cause is a fungal infection. Treatment of the underlying causative factor usually leads to resolution. Endogenous hand dermatitis can, of course, be exacerbated by exogenous factors, most notably irritant dermatitis and allergic contact dermatitis. In addition, atopy may in some cases predispose to the development of vesicular palmoplantar eczema.

VESICULAR PALMOPLANTAR ECZEMA AT A GLANCE



- An acute and/or chronic dermatitis clinically characterized by small to large blisters on the palms and soles.
- Histopathology characterized by spongiotic vesicles.
- Considered an endogenous dermatitis, distinct from dermatitis caused by exogenous factors such as contact, allergy, or irritation.
- Can be divided into four categories: pompholyx, chronic vesiculobullous hand dermatitis, hyperkeratotic hand dermatitis, and id reactions.
- Does not respond well to treatment.

EPIDEMIOLOGY

Differences in classification and definition have made it difficult to assess the true incidence of the endogenous hand disorders. Most studies have focused on the prevalence of exogenous hand disorders as seen in occupational settings.

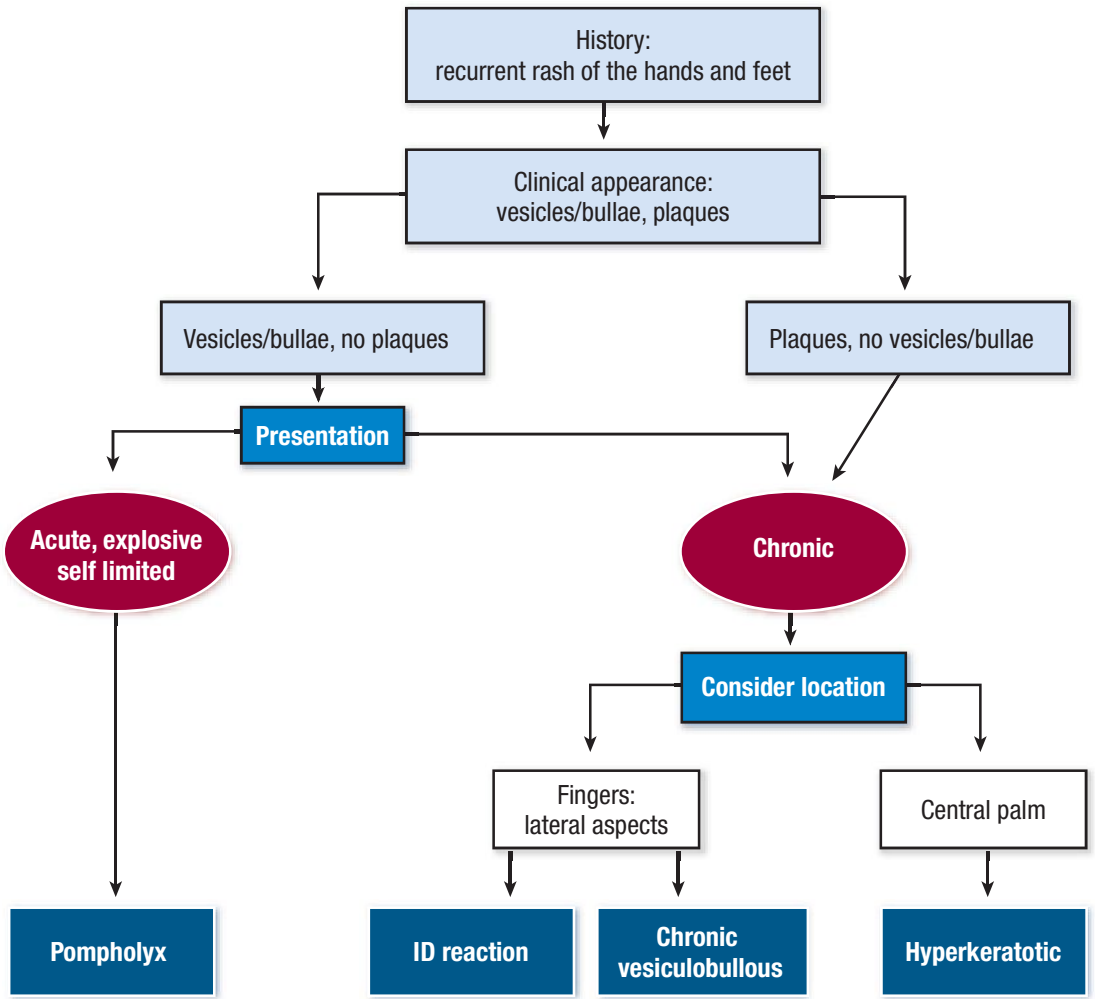

▲ **FIGURE 16-1** Approach to the patient with vesicular palmoplantar eczema.

Pompholyx is the least common presentation of hand dermatitis; in one population study, the 1-year prevalence of pompholyx was estimated to be 0.5 percent.[1] In the same study, hyperkeratotic hand dermatitis represented 2 percent of all hand dermatoses.[1]

ETIOLOGY AND PATHOGENESIS

With the exception of the id reaction, a direct cause of vesicular palmoplantar eczema is rarely identified. A number of etiologic factors have been associated with pompholyx, including atopy (see Chap. 14), contact allergy (see Chap. 13), psychological stress, and hot weather.[1] Pompholyx has also been reported after intravenous immunoglobulin therapy,[3] ingestion of piroxicam,[2] and after ingestion of certain metals in predisposed or sensitized patients.[2] More recently, there has been a report of five cases of photo-induced pompholyx[2]; patients with a reported history of photo-induced disease were challenged by ultraviolet A (UVA). Histologic evaluation confirmed the diagnosis of pompholyx and a true photosensitivity rather than photoaggravation.

EXACERBATING FACTORS

Contact allergy is common in patients affected with vesicular palmoplantar eczema, especially the chronic type, but the causal relationship is not always clear. There are cases in which contact allergy has exacerbated pre-existing hand dermatitis and also reports that ingestion of certain metals, including nickel, cobalt, and chromium, have caused flares. However, in other cases, the causal relationship may be the reverse. The skin's impaired barrier function in vesiculobullous hand dermatitis (see Chap. 46) may in some cases lead to sensitization and a higher prevalence of contact dermatitis in the affected population.

Investigations into the role of atopy (see Chap. 14) have yielded mixed results. Some studies have shown levels of personal or familial atopy as high as 50 percent in affected subjects, compared to 11.5 percent of controls, but other studies have demonstrated no difference in the prevalence in people with vesiculobullous hand dermatitis versus controls.[4]

CLINICAL FINDINGS

Pompholyx

Fig. 16-1 is an algorithm showing the approach to the patient with vesicular palmoplantar eczema. The severity of pompholyx can range from the inconvenient to the severe and can even be serious enough to necessitate hospitalization. In true acute pompholyx, there is an explosive outbreak of deep-seated vesicles on the palms, the lateral aspects of the fingers (Fig. 16-2), and sometimes the soles, usually in a symmetric pattern. Discomfort and itching usually precede the development of the blisters, which have been described as having a "tapioca" appearance (see Fig. 16-2). Blisters may coalesce then desiccate and resolve without rupture (Fig. 16-3). Intact, large blisters can be drained, but should not be un-



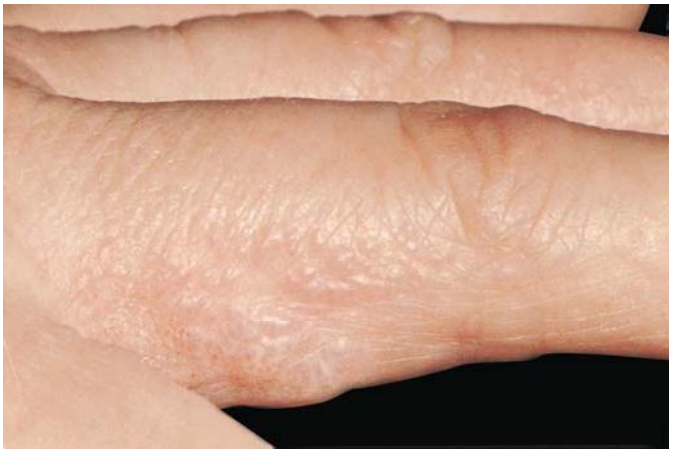

▲ **FIGURE 16-2** Chronic vesiculobullous hand dermatitis. There is a vesicular dermatitis on the lateral sides of the fingers. Note the tapioca-like, deep seated vesicles.



▲ **FIGURE 16-4** Podopompholyx. Large blisters have ruptured leaving erosions that are drying up. Note large bulla on the arch of the right foot: The roof of the blister still contains tapioca-like vesicles. This is characteristic.

roofed. However, large blisters may rupture spontaneously, leaving oozing or dried up erosions (Fig. 16-4).

This acute phase is generally followed by desquamation of the affected areas. Individual outbreaks are usually self-limited over 2 to 3 weeks, although they may recur. Secondary bacterial infection is common, often resulting in a local cellulitis, and can sometimes potentiate the development of lymphatic damage, resulting in lymphedema. Attacks are most common among adolescents and young adults and seem to be more common in the spring and summer months.

Chronic Vesiculobullous Dermatitis

Chronic vesiculobullous hand dermatitis is more common than true pompholyx and more difficult to manage because of its relapsing course. The clinical presentation includes small 1- to 2-mm vesicles filled with clear fluid localizing to the lateral aspects of the fingers, palms, and soles as in pompholyx (see Fig. 16-2). As the condition becomes more chronic, the clinical appearance may evolve and subsequently appear more fissured and hyperkeratotic (as in Fig. 16-5). A clear history of vesicles or exacerbations characterized by blistering may help to narrow the classification of a given presentation of hand dermatitis.

Hyperkeratotic Hand Dermatitis

Patients with hyperkeratotic hand dermatitis are usually male and generally present with chronic keratotic pruritic plaques, sometimes with fissures on the central palm (see Fig. 16-5). This condition may be the end result of contact allergy, excoriation, and irritation, but generally the cause is not identifiable, and contact allergy does not seem to play an important role. This hand dermatitis commonly occurs in middle-aged to elderly men and is normally very refractory to treatment. Frictional factors of lichen simplex chronicus may be an important factor in some cases. Plantar involvement is present in a minority of cases.

Id Reaction

In an id reaction, erythematous vesicles usually are seen on the lateral aspects of the fingers and the palms and are typically pruritic (Fig. 16-6). This eruption of vesicles is usually sudden and classically occurs in response to an intense inflammatory process, especially fungal infections, taking place somewhere else on the body. The id reaction is thought to be an allergic reaction to fungi or to some antigen created during the inflammatory process. Treatment of the underlying infection results in resolution of the vesicular eruption.

LABORATORY FINDINGS

There are no distinctive laboratory findings characteristic of vesicular palmoplantar eczema, although immuno-



▲ **FIGURE 16-3** Cheiropompholyx. Apart from small vesicles, there are large bullae, some purulent; others have collapsed and are drying up.



▲ **FIGURE 16-5** Hyperkeratotic hand dermatitis. There are pruritic keratotic plaques on the central palm: Occasional vesiculation and fissuring may occur.



▲ **FIGURE 16-6** Id reaction to tinea pedis. Erythematous, partially dried up vesicles on the foot. Lesions are very pruritic.

globulin E levels may be elevated in atopic patients.

PATHOLOGY

The histology of these entities depends on the chronicity of the disease. The primary vesicle appears as an intraepidermal spongiotic vesicle that does not involve the acrosyringia on either conventional and electron microscopy. Lymphocytic infiltration is common in the epidermis, with a mixed infiltrate observed in the dermis. In more chronic cases, the epidermis may show hyperproliferation, hyperkeratosis, or even psoriasiform epidermal hyperplasia. Periodic acid-Schiff staining can be helpful in excluding fungal elements.

DIAGNOSIS

The diagnosis of vesiculobullous hand dermatitis is usually made on the basis of clinical presentation, history, and sometimes histology. Patch testing may be useful in helping to distinguish this entity from other palmoplantar disorders or in eliminating other exacerbating factors such as irritant exposure and contact allergy.

There are many other skin conditions of the hands and feet that can be difficult to distinguish from vesiculobullous hand dermatitis. Several of the diagnoses may also co-exist.

DIFFERENTIAL DIAGNOSIS (Box 16-1)

Allergic contact dermatitis (see Chap. 13) may be clinically indistinguishable from constitutional forms of hand eczema, and patch testing should always be considered for those with recurrent, atypical, or persistent forms of the disease. Common allergens include nickel, thimerosal, neomycin sulfate, formaldehyde, *p*-phenylenediamine, quaternium-15, colophony, potassium dichromate, benzoyl peroxide, fragrances, rubber, and lanolin. Although frequently considered, laundry detergents are a rare cause of allergic contact dermatitis.

Irritant contact dermatitis (see Chap. 46) is by far the most common hand dermatitis and is often exacerbated by occupational exposures. It is usually symmetric, chronic, and affects the dorsal fingertips and web spaces.

Atopic hand dermatitis (see Chap. 14) is associated with a number of factors: hand dermatitis before age 15 years, persistent eczema on the body, dry or itchy skin in adult life, and widespread atopic dermatitis in childhood. The backs of the hands, particularly the fingers, are affected with erythema, vesiculation, crusting, excoriation, and scale.

Infections, most commonly from tinea, can mimic endogenous hand dermatitis. In cases of asymmetric or atypical cases, or in cases of small vesicles confined to the feet, a potassium hydroxide examination may be useful in ruling out primary tinea infection. In chronic cases of hand dermatitis, fungal and bacterial infections may be superimposed, and treatment may result in improvement of clinical symptoms.

Herpes simplex may, in unusual cases, present as blisters on the hands.

Psoriasis and psoriasiform hand dermatitis (see Chap. 18) are most prominent over pressure points. Psoriasis can normally be distinguished by its sharply marginated, nummular, or circinate scaly plaques; relative lack of itching; silvery scales; and the presence of psoriasis elsewhere. Psoriasiform hand dermatitis can occur without a family or personal history of psoriasis. It is a diagnosis made primarily on clinical and histologic presentation. At times, however, it appears as though eczematous, hyperkeratotic, and psoriatic diatheses co-exist. Repeated pressure or friction may cause hyperkeratosis in some individuals.

Pustular eruptions of palms and soles (see Chap. 21) is generally easy to distinguish because, unlike the presentation of clear fluid-filled blisters and bullae of hand dermatitis, pustules are the primary lesion. For example, in pustular psoriasis, the vesicles are cloudy and painful.

Keratolysis exfoliativa (recurrent focal palmar peeling) is a chronic, asymptomatic, noninflammatory peeling of the palms and soles, most commonly seen during the summer months. It is thought to occur more frequently in people with hyperhidrosis in these areas. Scaling usually starts from one to two fine points and expands outward to larger circular areas. The condition is usually self-limited and asymptomatic, requiring only emollients.

Bazex acrokeratosis paraneoplastica is a rare, acute, erythematous, scaling, vesiculobullous hand dermatitis with nail dystrophy associated with neoplasia, usually squamous carcinomas of the upper digestive and respiratory tracts, although there have been some reports of similar findings in patients with colon cancer and genitourinary tumors.

Other blistering diseases, such as pemphigoid, pemphigus, or epidermolysis bullosa, may affect the hands and feet, but usually do so in the setting of blisters elsewhere on the body.

Box 16-1

Differential Diagnosis of Vesicular Palmoplantar Eczema

Most Likely

- Allergic contact dermatitis
- Irritant contact dermatitis
- Atopic hand dermatitis
- Infections, commonly from tinea

Consider

- Bazex acrokeratosis paraneoplastica
- Psoriasis
- Psoriasiform hand dermatitis
- Pustular eruption of palms and soles
- Keratolysis exfoliativa
- Bullous disorders
- Herpes simplex (never bilateral)

COMPLICATIONS

Secondary bacterial infection of the vesicles can result in cellulitis, lymphangitis, and, in rare instances, septicemia.



PROGNOSIS AND CLINICAL COURSE

Pompholyx tends to occur as intermittent explosive outbreaks and becomes less frequent with middle age. The more chronic forms of vesicular palmoplantar eczema, however, are much more persistent and frustrating to manage and often require multiple therapeutic approaches over time.

TREATMENT (Box 16-2)

Treatment of vesiculobullous hand dermatitis should be based on the acuity of the condition, the severity of the disease, the prominence of blisters versus chronic changes, and any relevant history that reveals possible co-factors.



Topical Therapy

Topical steroids, typically high potency, are usually first-line agents. They are often more effective if used under occlusion, although this approach may increase the chance of infection. Topical drying agents, such as Domeboro soaks, Burow's solutions (aluminum subacetate), or dilute potassium permanganate solution (1 to 8000) may be useful in acute forms with a predominance of vesicles.

Nonsteroidal topical immunomodulating agents, such as tacrolimus and pimecrolimus, have been studied for treatment of individuals with mild to moderate chronic hand dermatitis. The majority of these studies, however, did not limit study subjects to those with vesicular palmoplantar eczema; patients with atopic, allergic, and irritant dermatitis were included. With this in mind, statistically significant improvements from baseline were observed for erythema, scaling, induration, fissuring, and pruritus, but not for vesiculation.[2]

Hyperkeratotic palmar eczema is notoriously difficult to manage. Topical retinoids and calcipotriene, both of which act to regulate epidermal cell maturation, have anecdotally been shown to improve this category of hand dermatitis.[1]

Systemic Therapy

For recurrent pompholyx and chronic vesicular dermatitis, oral prednisone may be required and is often effective if treatment is initiated early, at the onset of the itching prodrome. However, because of significant side effects, systemic glucocorticoids are typically inappropriate for long-term management.

Cyclosporine has been studied at dosing levels of 3 mg/kg/day and 5 mg/kg/day in the treatment of chronic vesicular dermatitis. Although patients showed improvement with treatment, relapses occurred shortly after discontinuation of cyclosporine.[5]

Mycophenolate mofetil has been used in the treatment of chronic vesicular dermatitis at dosing levels of 2 to 3 g/day (in divided doses). It has been anecdotally shown to improve chronic vesicular dermatitis that has been otherwise recalcitrant to corticosteroids, iontophoresis, and phototherapy. However, it has also been anecdotally shown to induce biopsy-proven dyshidrotic eczema.

Methotrexate has proven a useful therapy of a wide range of skin diseases. In chronic vesicular eczema, it has been reported to partially or completely clear lesions at low doses ranging from 12.5 to 22.5 mg/week.[5] However, its wide spectrum of potential side effects remains a limiting factor to its use in this particular skin disease.

Alitretinoin, 9-*cis*-retinoic acid, in preliminary studies has been reported to be successful in the treatment of chronic hyperkeratotic hand eczema. Patients refractory to treatments with corticosteroids, radiation therapy, tretinoin, isotretinoin, and acitretin reported "good" to "very good" responses to alitretinoin.[2]

Box 16-2

Treatments for Vesicular Palmoplantar Eczema

	TOPICAL	PHYSICAL	SYSTEMIC
First line	Corticosteroids	Ultraviolet A-1 Psoralen and ultraviolet A light Narrowband ultraviolet B	Prednisone Cyclosporine Mycophenolate mofetil Methotrexate Alitretinoin
Second line	Drying agents Tacrolimus Pimecrolimus Retinoids Calcipotriene	Grenz ray Iontophoresis Intradermal botulinum toxin Sympathectomy	

Radiation Therapy

Superficial radiotherapy (Grenz ray) is still sometimes used at a few centers. This condition may be one of the last indications for this treatment modality, although it is one of the few therapies tested successfully in a double-blind study.[5]

UVB, systemic, topical and bath water psoralen and UVA light (PUVA) have been used in severe cases of chronic vesicular hand eczema. Recent studies have evaluated the use of UVA-1; one study compared localized high-dose UVA-1 irradiation against topical cream psoralen UVA for the treatment of dyshidrotic eczema.[6] This study demonstrated that UVA-1 irradiation and topical PUVA showed similar beneficial responses. In addition, the potential side effects noted with PUVA, such as phototoxic reactions and long-term carcinogenic risk, are at least theoretically reduced with UVA-1 therapy.

Other Therapies

Iontophoresis, sympathectomy, and intradermal botulinum toxin are effective therapies for hyperhidrosis and have been studied as treatments for chronic vesicular dermatitis.[5] Tap water iontophoresis with pulsed direct current showed no benefit for subjects with hand dermatitis over controls in time to improvement, but those who were treated had much longer remissions, by a factor of months.[3] In one study, intradermal botulinum toxin A was shown to have good effect in treating patients with treatment-refractory vesicular dermatitis, especially those patients whose condition was aggravated by hyperhidrosis and during summer months.[7]

Two severity indices, the dyshidrosis area and severity index and the total sign and symptoms score, have been validated and may prove useful in clinical trials to better assess the effectiveness of some of these approaches.

PREVENTION

Prevention is a critical part of therapy in most cases, especially when known exacerbating factors are present. Avoidance of commonly encountered allergens, such as foods and plants, and irritants, such as soaps, solvents, acids, and alkalis, can be helpful. Vinyl gloves, rather than latex, are recommended because of the risk of either having an underlying allergy or of developing one in the setting of impaired barrier function. Modification of environmental exposure to exacerbating factors, such as friction and cold

air, may also help with persistent or refractory disease. For maintenance, frequent use of emollients, such as ointments, helps to preserve normal skin-barrier function.

REFERENCES

1. Meding B, Swanbeck G: Epidemiology of different types of hand eczema in an industrial city. *Acta Derm Venereol* **69**:227, 1989
2. Man I, Ibbotson SH, Fergusonn J: Photoinduced pompholyx: A report of 5 cases. *J Am Acad Dermatol* **50**:55, 2004
3. Ikeda K et al: Pompholyx after IV immunoglobulin therapy for neurologic disease. *Neurology* **54**:1879, 2000
4. Lehucher-Michel MP et al: Dyshidrotic eczema and occupation: A descriptive study. *Contact Derm* **43**:200, 2000
5. Warshaw EM: Therapeutic options for chronic hand dermatitis. *Dermatol Ther* **17**:240, 2004
6. Petering H et al: Comparison of localized high-dose UVA1 irradiation versus topical cream psoralen-UVA for treatment of chronic vesicular dyshidrotic eczema. *J Am Acad Dermatol* **50**:68, 2003
7. Swartling C et al: Treatment of dyshidrotic hand dermatitis with intradermal botulinum toxin. *J Am Acad Dermatol* **47**:667, 2002

CHAPTER 17

Autosensitization Dermatitis

Donald V. Belsito

EPIDEMIOLOGY

Autosensitization dermatitis refers to a phenomenon in which an acute dermatitis develops at cutaneous sites distant from an inflammatory focus, and where the secondary acute dermatitis is not explained by the inciting cause of the primary inflammation. The classic presentation of autosensitization is that seen in patients with venous stasis disease,[1] where as many as 37 percent of patients have been reported to develop at least one episode of autosensitization.[2]

ETIOLOGY AND PATHOGENESIS

The term *autosensitization dermatitis* was coined in 1921 by Whitfield to describe reaction patterns ranging from a generalized, erythematous, morbilliform, and urticarial eruption after blunt trauma to a generalized, petechial, papulovesicular dermatitis after the acute irritation of chronic stasis dermatitis.[3] Subsequently, the vesicular id reactions associated with infections caused by tuberculosis,[4] histoplasmosis,[5] dermatophytes,[6] and bacteria[7] were included under this rubric.[8–10] Other precipitating factors for this phenomenon have included the application of irritant or sensitizing chemicals,[11] ionizing radiation,[12,13] and retained suture material.[14]

Although the disease was originally thought to be due to autosensitization to epidermal antigens,[10] this concept has not been experimentally verified. In murine studies designed to determine whether keratinocyte-derived proteins can serve as antigenic carriers for hapten, Fehr et al.[15] derived major histocompatibility complex–restricted, T-cell receptor α/β, $CD4^+$ T-cell clones that proliferated in response to keratinocyte extracts unconjugated to hapten. In these studies, such autoreactive T-cell clones could not be derived after treatment with irritants. Nonetheless, the authors speculated that T cells autoreactive to keratinocyte antigens may be generated during the course of contact hypersensitivity and lead to the development of an id reaction.

In the most extensive study to date,[1] only 4 of 81 patients with autosensitization dermatitis had serum antibodies cytotoxic to autologous or homologous skin. However, the role of such autoantibodies in mediating the disorder, even in these four patients, must be interpreted cautiously, given the high frequency of epidermal autoantibodies in the normal adult population.[16]

In an experiment in which guinea pigs were injected with autologous skin, Wilhelmj et al.[17] reported dermatitis in 2 of 11 guinea pigs, but it was not clear whether these reactions were immunologic and, if so, what the causal allergen(s) was. Other investigators using similar techniques have been unable to induce cutaneous disease in animals by means of epidermal extracts.[18] In contrast, 19 of 24 patients with active autosensitization who were intradermally challenged with water-soluble extracts of autologous epidermal scale developed a reaction.[19]

The term *autosensitization* is probably a misnomer. The disease is more likely due to a hyperirritability of the skin induced by either immunologic or nonimmunologic stimuli. Factors such as irritation, sensitization, infection, and wounding, which are known to precipitate autosensitization, have been reported to release a variety of epidermal cytokines.[20,21] Once hematogenously disseminated in sufficient amounts, these cytokines could heighten the sensitivity of skin to a variety of non-specific, but otherwise innocuous, stimuli, producing a pattern of "spillover" reactions[22] that have been classically termed *autosensitization*. Such a hypothesis would account for (1) the results in humans of delayed-type hypersensitivity testing with autologous epidermal scale,[19] (2) the histopathologic findings noted in the disease (see the section Clinical Findings), and (3) the activated T lymphocytes occasionally observed in the blood of patients with autosensitization.[23] The characteristic distribution of the disease

AUTOSENSITIZATION DERMATITIS AT A GLANCE



- An acute disorder triggered by infection, stasis and contact dermatitides, ionizing radiation, blunt trauma, and retained suture material.
- Widespread, pruritic, papulovesicular eruption, most frequently affecting the extremities.
- Related features are those of the precipitating disorder.
- Pathology is non-diagnostic and consistent with an acute spongiotic process of the epidermis with a superficial, perivascular, lymphohistiocytic infiltrate of the dermis containing occasional eosinophils.





▲ **FIGURE 17-1** Stasis dermatitis with autosensitization. An elderly woman with a long-standing history of stasis dermatitis presented with gradual worsening of the edema; pruritus; and multiple, punctate, superficial, excoriated ulcers overlying the medial malleoli (**A**). Nine days after the ulcers appeared, she developed an acute, extremely pruritic, erythematous, papulovesicular eruption over the forearms (**B**), which progressively involved the upper arms, upper torso, and hands. The acute papulovesicular dermatitis also involved the lower extremities and can be noted overlying the chronic stasis dermatitis (**A**).

might perhaps be explained if the skin overlying the arms and legs was found to contain increased numbers of, or more avid receptors for, various cytokines than the skin of the face or hands. Such a geographic variation in the distribution of bullous pemphigoid antigen has been observed and hypothesized to account for the clinical patterns of this autoimmune disease.[24] Application of modern biotechnological tools should provide insight into the mysteries of autosensitization.

CLINICAL FINDINGS

Typically, 1 to 2 weeks after an acute inflammation, an extremely pruritic, symmetric, scattered, erythematous eruption with macules, papules, and vesicles develops (Fig. 17-1). The eruption involves the forearms, thighs, legs, trunk, face, hands, neck, and feet in descending order of frequency.[2,10] During the evolution of the dermatitis, its morphology may change in a manner consistent with the chronicity (i.e., vesicles to scale). Histopathologically, the findings are not pathognomonic: spongiotic epidermal vesicles associated with a superficial, perivascular lymphohistiocytic infiltrate of the dermis, which may contain scattered eosinophils.[25] Immunophenotypic studies of skin have revealed that most of the lymphocytes in the epidermis are $CD3^+$ and $CD8^+$ T cells, whereas those in the dermis are primarily $CD4^+$.[22] In the majority of individuals with autosensitization,[1] deposition of antibody or complement in affected skin is not detected.

DIFFERENTIAL DIAGNOSIS

See Box 17-1.

PROGNOSIS AND CLINICAL COURSE

The rash often persists and spreads until the underlying causative primary site of inflammation is treated.

Box 17-1

Differential Diagnosis of Autosensitization Dermatitis

Most Likely

- Allergic contact dermatitis
- Irritant contact dermatitis
- Atopic dermatitis
- Nummular dermatitis

Consider

- Polymorphous light eruption

Always Rule Out

- Infectious processes
  - Dermatophyte infections
  - Scabies and other mite infestations
  - Viral exanthems
- Drug eruptions

TREATMENT

Treatment is best directed toward the inciting disease. The frequently weeping, vesicular eruption of autosensitization benefits from drying agents such as aluminum sulfate and calcium acetate. Given the likely involvement of cytokines and inflammatory mediators sensitive to glucocorticoids[26] or macrolactams,[27] systemic and/or topical treatment with these drugs may be helpful. To prevent the secondary effects of excoriation, pruritus must be controlled with topical antipruritic agents or oral antihistamines. However, one must remain alert to the possibility of inducing an allergy in existing dermatitic skin with topical medicaments.

KEY REFERENCES

The full reference list for all chapters is available at www.digm7.com.

1. Parish WE et al: A study of auto-allergy in generalized eczema. *Br J Dermatol* **77**:479, 1965
2. Haxthausen H: Generalized "ids" ("autosensitization") in varicose eczema. *Acta Derm Venereol (Stockh)* **35**:271, 1955
13. Linn J et al: Radiotherapy-induced id reaction. *Am J Clin Oncol* **28**:105, 2005
15. Fehr BS et al: T cells reactive to keratinocyte antigens are generated during induction of contact hypersensitivity in mice. A model for autoeczematization in humans? *Am J Contact Dermat* **11**:145, 2000
20. Williams IR, Kupper TS: Immunity at the surface: Homeostatic mechanisms of the skin immune system. *Life Sci* **58**:1485, 1996

CHAPTER 18

Psoriasis

Johann E. Gudjonsson
James T. Elder

EPIDEMIOLOGY

Prevalence

Psoriasis is universal in occurrence. However, its prevalence in different populations varies from 0.1 percent to 11.8 percent, according to published reports.[1] The highest reported incidences in Europe have been in Denmark (2.9 percent) and the Faeroe Islands (2.8 percent), with the average for northern Europe being around 2 percent. Prevalences ranging from 2.2 percent to 2.6 percent have been measured in the United States, with approximately 150,000 newly diagnosed cases per year. A higher prevalence in East Africans as opposed to West Africans may explain the relatively low prevalence of psoriasis in African Americans (1.3 percent vs. 2.5 percent in white Americans[2]). The incidence of psoriasis is also low in Asians (0.4 percent), and in an examination of 26,000 South American Indians, not a single case was seen. Psoriasis is equally common in males and females.[3,4]

Age of Onset

Psoriasis may begin at any age, but it is uncommon under the age of 10 years. It is most likely to appear between the ages of 15 and 30 years. Possession of certain HLA class I antigens, particularly HLA-Cw6, is associated with an earlier age of onset and with a positive family history. This finding led Henseler and Christophers[5] to propose that two different forms of psoriasis exist: type I psoriasis, with age of onset before 40 years and HLA-associated, and type II, with age of onset after 40 years and lacking HLA associations, although many patients do not fit into this classification. There is no evidence that type I and type II psoriasis respond differently to different therapies.

ETIOLOGY AND PATHOGENESIS

Psoriasis is a chronic inflammatory skin disease, with a strong genetic basis, characterized by complex alterations in epidermal growth and differentiation and multiple biochemical, immunologic, and vascular abnormalities, and a poorly understood relationship to nervous system function. Its root cause remains unknown. Historically, psoriasis was widely considered to be a primary disorder of keratinocytes. With the discovery that the T-cell specific immunosuppressant cyclosporin A (CsA) was highly active against psoriasis, most researchers have focused on the immune system.

Genetics of Psoriasis

The genetic basis of psoriasis has been appreciated for nearly 100 years.[6] However, as Gunnar Lomholt lamented in 1963 in his classic study of psoriasis in the Faeroe Islands[7]: "That psoriasis is genetically conditioned is beyond doubt. But when the mode of inheritance appears to have been almost demonstrated, it again slips out of the fetters of fixed rules!" Over the years, based on some very large pedigrees and population surveys, single-gene recessive, two-gene recessive, dominant with reduced penetrance, and polygenic models have been suggested. Analysis of the population-based studies of Lomholt[7] and Hellgren[8] utilizing recurrence risk analysis[9] demonstrated that λ_r-1, the excess recurrence risk for relatives of degree r, dropped by a factor of 6 to 7 as r increased from 1 to 2, as opposed to the factor of 2 predicted for monogenic disorders. This analysis favors a polygenic model.[10] Based on population studies, the risk of psoriasis in an offspring has been estimated to be 41 percent if both parents are affected, 14 percent if one parent is affected, and 6 percent if one sibling is affected, compared to 2 percent when no parent or sibling is affected.[11]

Concordance for psoriasis in monozygotic twins ranged from 35 percent to 73 percent in various studies.[12–14] This variability, and the fact that these rates do not approach 100 percent, supports a role for environmental factors. Interestingly, concordance in both monozygotic and dizygotic twins decreases as one moves closer to the equator.[14] Given the strong therapeutic effects of ultraviolet (UV) light on psoriasis (see Treatment, below), these data suggest that UV exposure may be a major environmental factor interacting with genetic factors in psoriasis.

The search for the involvement of specific genes in psoriasis began over a decade ago with studies of genetic linkage (i.e., the co-transmission of marker and disease alleles within families).

PSORIASIS AT A GLANCE



- World-wide occurrence: Affects approximately 2 percent of Americans; prevalence ranges from 0.1 percent to 3 percent in various populations.
- A chronic disorder with polygenic predisposition combined with triggering environmental factors such as trauma, infection, or medication.
- Erythematous scaly papules and plaques; pustular and erythrodermic eruptions occur.
- Most common sites of involvement are scalp, elbows and knees, hands, feet, trunk, and nails.
- Psoriatic arthritis occurs in 10 percent to 25 percent of patients; pustular and erythrodermic forms may be associated with fever.
- Pathology is characterized by uniform elongation of the rete ridges, with dilated blood vessels, thinning of the suprapapillary plate, and intermittent parakeratosis. Epidermal and perivascular dermal infiltrates of lymphocytes, with neutrophils occasionally in aggregates in the epidermis.

However, despite multiple genome-wide linkage studies, only one locus, termed *psoriasis susceptibility 1* (PSORS1), has been consistently confirmed.[16] PSORS1 is located in the major histocompatibility complex (MHC, chromosome 6p21.3), home of the HLA) genes.[17] Multiple HLA alleles have been associated with psoriasis, particularly HLA-B13, HLA-B37, HLA-B46, HLA-B57, HLA-Cw1, HLA-Cw6, HLA-DR7, and HLA-DQ9.[10] Many of these alleles are in linkage disequilibrium with HLA-Cw6 (i.e., found together on the same chromosome more often than would be predicted by chance). HLA-Cw6 has consistently demonstrated the highest relative risk for psoriasis in Caucasian populations.[10]

HLA-Cw6 is also associated with psoriatic arthritis, with a tendency for early onset of skin lesions.[24] HLA-B27, HLA-B38, and HLA-B39 are also associated with psoriatic arthritis,[25] with HLA-B27 being most strongly associ-



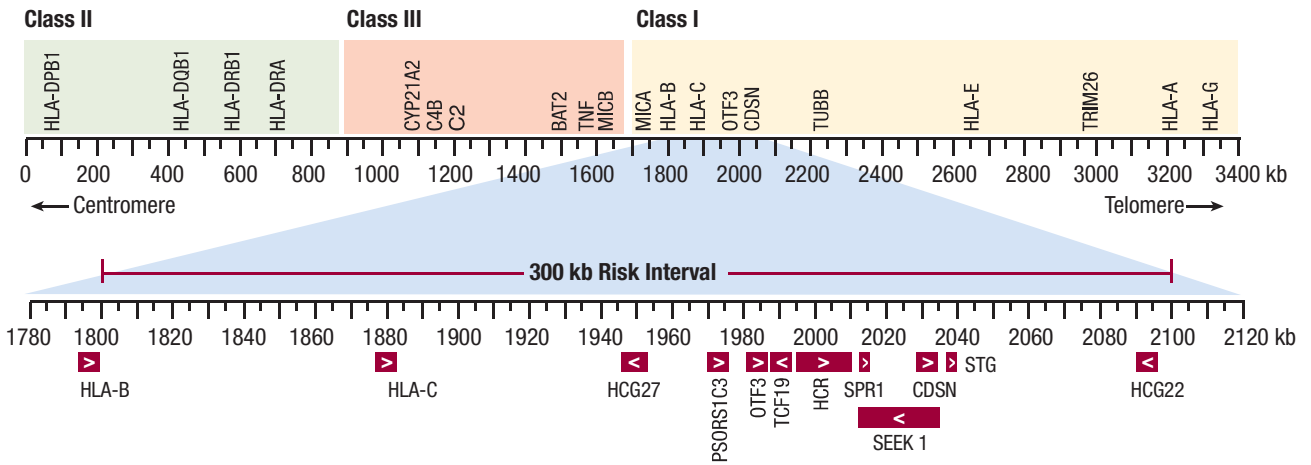



▲ **FIGURE 18-1** Map of the major histocompatibility complex (MHC) and psoriasis susceptibility 1 (PSORS1). The upper panel depicts the entire MHC; only a few of the over 200 genes contained in this interval are shown. The lower panel depicts the gene content of the PSORS1 risk interval determined by several independent studies. The 10 genes extending from HLA-C to STG reside in a region of strong linkage disequilibrium in the genome, and each of these genes has been associated with psoriasis. Of these, only HLA-C and CDSN have protein-altering (missense) variants unique to psoriasis-risk haplotypes (HLA-Cw6 and CDSN*TTC), and in a sample of 76 haplotypes in which these putative risk alleles were separated from each other, only those haplotypes carrying HLA-Cw6 carried risk for psoriasis. See on-line text for details.

ated with the axial variant (see Chap. 19).

HLA-Cw6 remains strongly associated with psoriasis when found together with several different HLA-B alleles,[27] suggesting that the PSORS1 gene must reside telomeric to HLA-B (Fig. 18-1).

Only about 10 percent of HLA-Cw6 carriers develop psoriasis, and it has been estimated that PSORS1 accounts for only one-third to one-half of the variation in genetic liability to psoriasis.[32] Therefore, it is highly likely that additional non-MHC genes are also involved. In addition to PSORS1, linkage studies have identified 18 potential susceptibility loci.[16,33] However, many of these have proven difficult to replicate. After PSORS1, the second-most replicated psoriasis susceptibility locus is PSORS2 (17q24-q25),[34] with four independent studies providing confirmatory evidence ($p < 0.01$) in support of the original report.[35–38] It has been reported recently that this locus contributes to psoriasis by influencing the expression of the SLC9A3R1, NAT1, and/or RAPTOR genes involved in immunologic regulation,[39] but others have been unable to confirm these findings.[40,41] Other loci showing evidence of reproducibility include PSORS4 (1q21.3),[42–44] PSORS5 (3q21),[45–47] PSORS8 (16q12-q13),[48] and PSORS9 (4q28-q31).[49,50] PSORS4 resides in the epidermal differentiation complex, the location of at least 58 genes involved in epidermal differentiation, including the loricrin, involucrin, filaggrin, small proline rich region, S100, and late cornified envelope genes.[51] The PSORS5 locus (3q21) was originally linked to psoriasis in Swedish families[46]; the evidence for replication is based on two association studies.[46,47] The PSORS8 locus overlaps with a known susceptibility gene for Crohn disease (NOD2/CARD15) and has been implicated in psoriatic arthritis.[48] The PSORS9 locus was originally identified in a Chinese population, but also provided some evidence for linkage in four other genome-wide linkage scans involving largely Caucasian populations.[50]

Pathogenesis of Psoriasis

DEVELOPMENT OF LESIONS Detailed light, electron microscopic, immunohistochemical, and molecular studies of involved and uninvolved skin of both newly appearing and established psoriatic lesions provide a useful framework for cause-and-effect relationships between the many cellular events that take place in a psoriatic lesion. They are illustrated schematically in Fig. 18-2 and with actual photomicrographs in Fig. 18-3.

Initial Lesion. In the initial pinhead-sized macular lesions there is marked edema, and mononuclear cell infiltrates are found in the upper dermis.[52] These findings are usually confined to the area of one or two papillae. The overlying epidermis soon becomes spongiotic, with focal loss of the granular layer. The venules in the upper dermis dilate and become surrounded by a mononuclear cell infiltrate.[53] Similar findings have been described in early macules and papules of psoriasis[54] and in clinically normal-appearing skin 2 to 4 cm away from any active lesion in patients undergoing an acute flare of guttate psoriasis.[55] These findings are suggestive of a "pre-psoriatic state," which could be related to underlying genetic factors.

Developing Lesion. Studies of the clinical margins of somewhat larger lesions (0.5 to 1.0 cm) reveal an approximately 50 percent increase in epidermal thickening in the "normal-appearing" skin immediately adjacent to lesions.[53] There is a large increase in the metabolic activity of epidermal cells, including the stratum corneum, increased DNA synthesis, an increased number of mast cells and dermal macrophages, and increased mast cell degranulation.[53,56,57] Subsequent studies revealed increased numbers of dermal T cells[58] and dendritic cells (DCs)[59] in both uninvolved and involved psoriatic skin relative to normal skin. Toward the center of the lesion, a "marginal zone" can be identified, with increasing band-like epidermal thickness, increasing parakeratosis and capillary elongation, and perivascular infiltration of lymphocytes and macrophages, without exudation into the epidermis. More centrally, rete ridges begin to develop in the marginal zone, before finally transitioning into the fully developed psoriatic plaque. Squamous cells manifest enlarged extracellular spaces with only a few desmosomal connections. Parakeratosis is typically mounded or spotty.

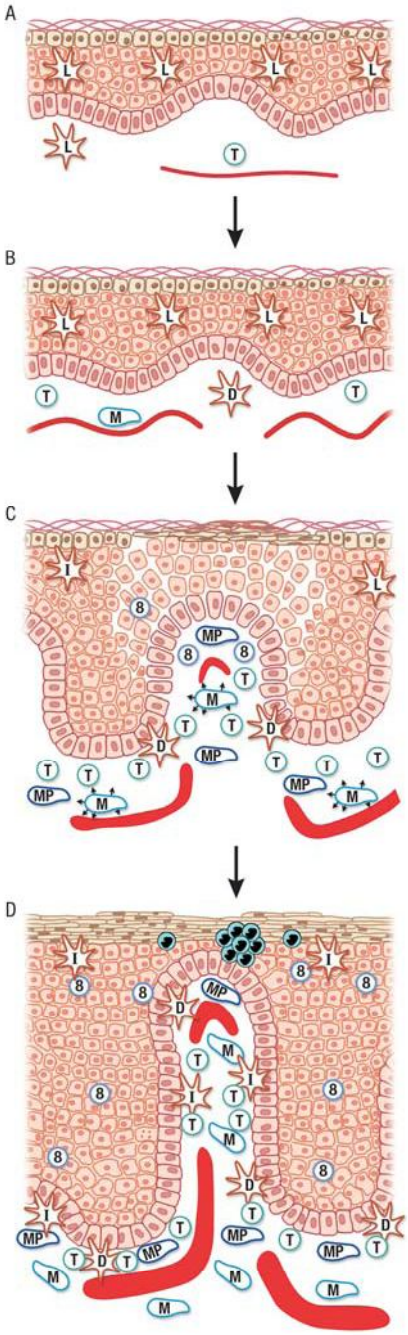

▶ **FIGURE 18-2** Development of psoriatic lesions. This figure depicts the transition from normal skin to fully developed lesion described in the text. Normal skin from a healthy individual (*panel A*) contains epidermal Langerhans cells, scattered immature dendritic cells (D), and skin-homing memory T cells (T) in the dermis. Normal-appearing skin from a psoriatic individual (*panel B*) manifests slight capillary dilatation and curvature, and a slight increase in the numbers of dermal mononuclear cells and mast cells (M). A slight increase in epidermal thickness is usually present. In chronic plaque psoriasis, the intensity of these changes may depend on distance from an established lesion. The transition zone of a developing lesion (*panel C*) is characterized by progressive increases in capillary dilatation and tortuosity, numbers of mast cells, macrophages (MP), and T cells, and mast cell degranulation (*arrowheads*). In the epidermis, there is increasing thickness with increasingly prominent rete pegs, widening of the extracellular spaces, transient dyskeratosis, spotty loss of the granular layer, and parakeratosis. Langerhans cells (L) begin to exit the epidermis, and inflammatory dendritic epidermal cells (I) and $CD8^+$ T cells (8) begin to enter the epidermis. The fully developed lesion (*panel D*) is characterized by fully developed capillary dilatation and tortuosity with a 10-fold increase in blood flow, numerous macrophages underlying the basement membrane, and increased numbers of dermal T cells (mainly $CD4^+$) making contact with maturing dermal dendritic cells (D). The epidermis of the mature lesion manifests markedly increased (approximately 10-fold) keratinocyte hyperproliferation extending to the lower suprabasal layers, marked but not necessarily uniform loss of the granular layer with overlying compaction of the stratum corneum and parakeratosis, increased numbers of $CD8^+$ T cells, and accumulation of neutrophils in the stratum corneum (Munro's microabscesses).

Mature Lesion. Mature lesions of psoriasis are characterized by uniform elongation of rete ridges, with thinning of the epidermis overlying the dermal papillae.[53,54] Epidermal mass is increased three to five times, and there are many more mitoses observed frequently above the basal layer. About 10 percent of basal keratinocytes are cycling in normal skin, whereas this value rises to 100 percent in lesional psoriatic skin.[60] Widening of the extracellular spaces between keratinocytes persists but is less prominent than in developing lesions and is more uniform than the typical spongiosis of eczematous skin lesions. The tips of the rete ridges are often clubbed or fused with adjacent ones, with thin, elongated, edematous papillae containing dilated, tortuous capillaries. Parakeratosis, with accompanying loss of the granular layer, is often horizontally confluent but may alternate with orthokeratosis,[61] and hyperkeratosis is more extensive than in the transitional zone. The inflammatory infiltrate around the blood vessels in the papillary dermis becomes more intense but still consists of lymphocytes, macrophages, DCs, and mast cells. Unlike the initial lesion and the transitional zone, lymphocytes are observed in the epidermis of the mature lesion. Neutrophils exit from the tips of a subset of dermal capillaries (the "squirting papillae"), leading to their accumulation in the overlying parakeratotic stratum corneum (Munro's microabscesses) and, less frequently, in the spinous layer (spongiform pustules of Kogoj). Collections of serum can also be seen in the epidermis and the stratum corneum.[53,54]

CELLULAR PARTICIPANTS IN PSORIASIS

T Cells[39,62,63]***.*** In 1984, it was demonstrated that the eruption of psoriatic skin lesions coincided with epidermal influx and activation of T cells,[58] and shortly thereafter it was further shown that resolution of psoriasis during phototherapy was preceded by depletion of T cells, predominantly from the epidermis.[64] CsA was highly effective in psoriasis,[65,66] and this effect was demonstrated to be primarily through blockade of T cells rather than keratinocytes.[67] Furthermore, psoriasis has been triggered or cured by bone marrow transplantation, depending on whether the donor or the host was psoriatic.[68,69] The role of T cells in psoriasis was functionally demonstrated in 1996 when it was shown that the psoriasis process could be induced by injecting activated autologous T cells into uninvolved psoriatic skin transplanted onto severe combined immunodeficient mice.[70]

The best-characterized T cells are the $CD4^+$ and $CD8^+$ subsets. Predominantly of the memory phenotype ($CD45RO^+$), these cells express the cutaneous lymphocyte antigen (CLA), a ligand for E-selectin, which is selectively expressed on skin capillaries and therefore provides them with access to the skin.[75] $CD8^+$ T cells are predominantly located in the epidermis, whereas $CD4^+$ T cells are predominantly located in the upper dermis.[76,77] The cytokine profile of psoriatic lesions is rich in interferon (IFN)-γ,[78] indicative of T helper 1 (Th1) polarization of $CD4^+$ cells, and T cytotoxic 1 (Tc1) polarization of $CD8^+$ cells.[79] However, a novel subset of $CD4^+$ T cells, stimulated by interleukin (IL)-23 and characterized by IL-17 production, was recently described and may play an important role in maintaining chronic inflammation in psoriasis and other autoinflammatory conditions.[80–82]

Regulatory T Cells. Several different populations of regulatory T cells (Tregs) exist but the best characterized one is the $CD4^+CD25^+$ subset.[83] A recent study of this subset in psoriasis demonstrated impaired inhibitory function and failure to suppress effector T-cell proliferation.[84]



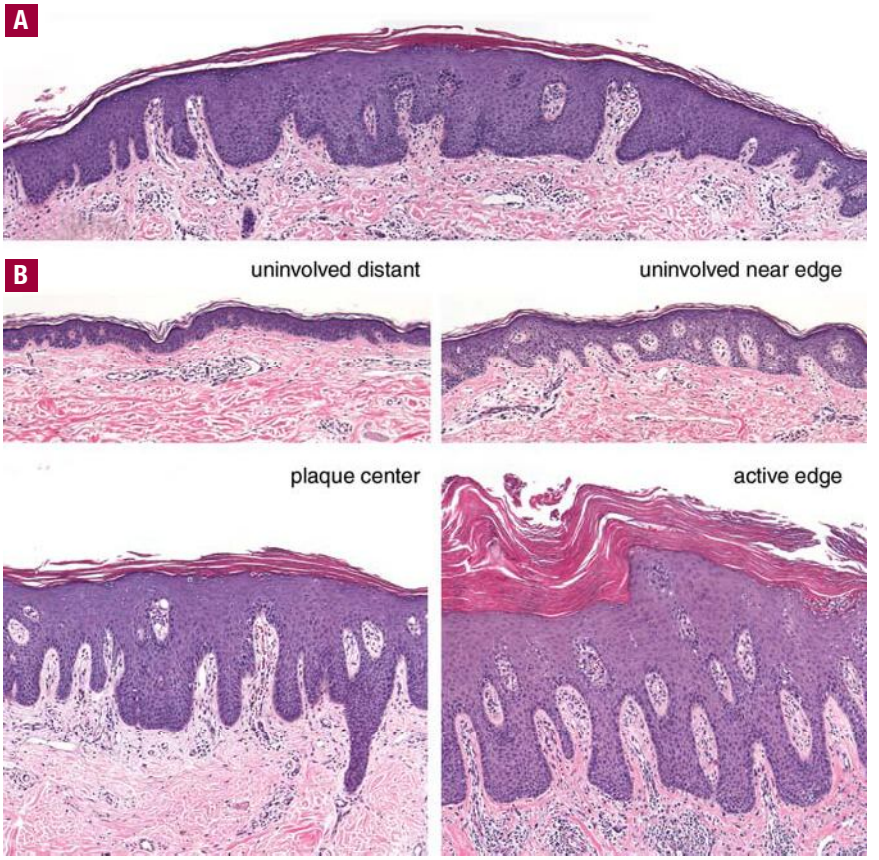

▲ **FIGURE 18-3** Histopathology of psoriasis. **A.** Pinpoint papule of psoriasis. In the transition from the edges to the center of the lesion, note progressive thickening of epidermis with elongation of rete pegs, increasing dilatation and tortuosity of vessels, and increasing mononuclear cell infiltrate. Also note the transition from basket-weave to compact stratum corneum with loss of granular layer in the center of the lesion. (4-mm punch biopsy, hematoxylin and eosin, scale bar = 100 μM.) **B.** Comparison of uninvolved versus involved skin. Four 4-mm biopsies were taken from the same individual sampled in **A** on the same day. "Uninvolved distant" skin was taken from the upper back 30 cm from the nearest visible lesion of psoriasis. "Uninvolved near edge" skin was taken 0.5 cm from the edge of a 20-cm plaque, which had been present for several years, according to the patient. "Center plaque" skin was taken from a relatively inactive (less red and scaly) area in the center of this plaque. "Involved edge" skin was taken from an active (more red and scaly) area about 1 cm inside the edge of the same plaque. In comparing "uninvolved distant" to "uninvolved near edge" skin, note that the latter manifests increased thickness and early elongation of the rete pegs, dilatation and early tortuosity of blood vessels, and increased numbers of mononuclear cells in the upper dermis, many of which are in a perivascular location. In this patient, "uninvolved near edge" skin also manifests an increased frequency of dyskeratotic keratinocytes, a finding that has been noted previously at the periphery of psoriatic lesions.[53] In comparing less active to more active areas of the plaque, note that the more active area manifests increased dermal mononuclear infiltrate, increased hyperkeratosis and parakeratosis, and Munro's microabscesses. (4-mm punch biopsies, hematoxylin and eosin, scale bar = 100 μM.)

Natural Killer and Natural Killer T Cells. Natural killer (NK) cells are major producers of IFN-γ and serve as a bridge between innate and acquired immunity. NK cells are present in psoriasis,[85,86] and can trigger the formation of psoriasis lesions in a xenograft model system.[87] NK cells are regulated in part by killer immunoglobulin-like receptors (KIRs), which recognize HLA-C and other MHC class I molecules. KIRs are a family of ~15 closely linked genes located on chromosome 19q13.4,[88] some of which stimulate and others of which inhibit NK cell activation. Recently, KIR genes have been associated with psoriasis[89–91] and psoriatic arthritis.[92,93]

Dendritic Cells. Treatments directed primarily against key co-stimulatory molecules expressed by "professional" antigen-presenting DCs markedly improve psoriasis.[39] This suggests that T cells in psoriatic lesions are in constant communication with DCs, which have a role in both the priming of adaptive immune responses and the induction of self-tolerance[95] (see Chap. 10). Several subsets of DCs have been defined, and many of these are found in a mature state within psoriatic lesions[96,97] (see Fig. 18-2). Although these cells are believed to be central to the pathogenesis of psoriasis, the specific role of each subset is still unclear.

LANGERHANS CELLS. (See Chap. 10) Langerhans cells (LCs) are considered to be immature DCs (iDCs). LCs have a well-defined role as antigen-presenting cells (APCs) in contact dermatitis,[98] but their role in psoriasis, in which their numbers are characteristically decreased,[96,99] is unclear. DCs lacking the characteristic Birbeck granule but positive for the maturation molecule DC-LAMP are found in the dermis of psoriatic lesions, suggesting that these cells mature and exit the epidermis during the course of lesion formation[100] (see Fig. 18-2). Interestingly, migration of LCs in response to inflammatory cytokines is markedly impaired in uninvolved psoriatic epidermis.[101]

INFLAMMATORY DENDRITIC EPIDERMAL CELLS. (See Chap. 10) Thought to be monocyte-derived iDCs,[102] inflammatory dendritic epidermal cells (IDECs) are distinguished from LCs by the lack of Birbeck granules and lower expression of CD1a. Unlike LCs, IDECs are nearly absent in normal skin, and their numbers are markedly increased in the epidermis of active psoriasis lesions, as well as a large number of other inflammatory dermatoses[96,99] (see Fig. 18-2).

DERMAL DENDRITIC CELLS. Identified initially by strong expression of MHC class II or factor XIIIa, dermal DCs do not express activation markers in resting normal skin and can be considered another type of iDC that is similar to myeloid iDCs found in other tissues.[103] Psoriasis lesions demonstrate a marked increase in the number and maturation state of these cells[96,104,105] (see Fig. 18-2).

PLASMACYTOID DENDRITIC CELLS. Plasmacytoid DCs (pDCs) are inefficient presenters of antigens to T cells. However, they regulate inflammation and link innate with adaptive immunity, producing large amounts of IFN-α when activated[106] (see Chap. 10). Absent from normal skin, pDCs are significantly increased in both uninvolved and involved psoriatic skin,

but activated only in involved skin.[96,107] Interestingly, inhibition of pDCs was shown to prevent development of psoriasis in a mouse xenograft model.[107] Conversely, imiquimod, which has been reported to exacerbate psoriasis,[108] likely acts through this type I IFN system by binding to Toll-like receptor 7 on pDCs.[109]

Mast Cells and Macrophages. Mast cells and macrophages are prominent in initial and developing psoriasis lesions (see Fig. 18-2). Many of the macrophages lie scattered just under the basement membrane, subadjacent to proliferating keratinocytes expressing the macrophage chemokine MCP-1.[110–112] These phagocytically active cells could be involved in generating fenestrations (holes) in the epidermal basement membrane.[113] Recent studies in two different mouse models of psoriasis, one dependent on and the other independent of T cells, showed that selective elimination of macrophages led to prompt improvement of lesions. These new findings suggest that macrophages may play a key role in the pathogenesis of psoriasis, at least in part via production of tumor necrosis factor (TNF)-α.[114–116]

Neutrophils. Although neutrophils are commonly seen in the upper epidermis of psoriatic lesions, they appear late during the development of lesions, their number is quite variable, and their role in the pathogenesis of psoriasis is unclear. Recent studies in one of the same mouse models used to implicate macrophages indicate that neutrophils are probably unnecessary for lesional development.[116]

Keratinocytes. Keratinocytes are a major producer of pro-inflammatory cytokines, chemokines, and growth factors,[117] as well as other inflammatory mediators such as eicosanoids[118] and mediators of innate immunity such as cathelicidins, defensins, and S100 proteins.[119] Psoriatic keratinocytes are engaged in an alternative pathway of keratinocyte differentiation called *regenerative maturation*.[120] Regenerative maturation is activated in response to immunologic stimulation in psoriasis,[121] but the mechanism by which this occurs is presently unknown.

Other Cell Types. Other cell types, such as endothelial cells and fibroblasts, are also likely to be participants in the pathogenic process. Endothelial cells are strongly activated in developing and mature lesions of psoriasis[53,54] and in addition to delivering a 10-fold increase in blood flow to the lesion, they play a major role in controlling the flux of leukocytes and serum proteins into psoriatic tissue.[122–124] Fibroblasts support keratinocyte proliferation in a paracrine manner,[125] and this process is exaggerated in psoriasis.[126] Fibroblasts produce many chemotactic factors and support the migration of T cells out of psoriatic lesions.[127] Thus, fibroblasts may also be intimately involved in psoriasis by directing the localization of T cells.

SIGNALING MOLECULES IN PSORIASIS

Cytokines and Chemokines. The cytokine network in psoriasis is extremely complex, involving the actions and interactions of multiple cytokines, chemokines, and growth factors and their receptors in addition to other mediators produced by multiple cell types.[63] Combinations of cytokines and growth factors can result in effects that are not seen when these factors are studied individually. For example, T-cell clones isolated from psoriatic skin lesions are able to promote keratinocyte proliferation in an IFN-γ–dependent manner,[128,129] but by itself, IFN-γ has an antiproliferative effect on cultured keratinocytes.[130]

Besides IFN-γ, a plethora of cytokines and chemokines are upregulated in psoriasis, including the cytokines TNF-α,[131] IL-2,[78] IL-6,[132] IL-8,[133] IL-15,[134] IL-17,[135] IL-18,[136] IL-19, IL-20, and IL-22[137] and the chemokines MIG/CXCL9, IP-10/CXCL10, I-TAC/CXCL11, and MIP3α/CCL20.[39,63] More complex abnormalities have been observed for other immunomodulatory cytokines and their receptors, including IL-1 and transforming growth factor-β.[138–140] The psoriatic plaque is characterized by the predominance of cytokines produced by Th1 cells (IFN-γ, IL2, and TNF-α) over those produced by Th2 cells (IL-4, IL-5, and IL-10). DCs also contribute cytokines to the environment, including IL-18, IL-20, IL-23, and TNF-α. IL-18 and IL-23 stimulate production of IFN-γ, and it is now clear that IL-23 and not IL-12 (which shares the p40 subunit with IL-23) is the predominant source of upregulated p40 expression in psoriatic lesions.[141] As mentioned earlier, IL-23 supports chronic inflammation by maintaining a separate $CD4^+$ T-cell subset characterized by IL-17 production.[80] Recently, this Th17 subset has been shown to elaborate IL-22, which mediates IL-23–induced dermal inflammation and epidermal hyperplasia in mice.[141a] The most prominent cytokines currently thought to be involved in the pathogenesis of psoriasis are summarized in Fig. 18-4.

Innate Immune Mediators. In addition to cytokines and chemokines, several mediators of innate immunity are abnormally expressed in psoriasis.[119] Prominent among the innate immune mediators are the antimicrobial peptides human β-defensin-2 (HBD-2) and cathelicidin (LL-37), both of which are increased in psoriasis but not in atopic dermatitis.[142] Notably, expression of HBD-2 and LL-37 is increased in response to pro-inflammatory and type I cytokines (TNF-α, IL-1, and IFN-γ) and suppressed by type II cytokines (IL-4, IL-10, and IL-13).[142] These differences in antimicrobial peptide expression help to explain why approximately 30 percent of patients with atopic dermatitis have bacterial or viral infections, as opposed to only 7 percent of psoriasis patients, even though both conditions have a defective skin barrier.[143] They may also explain why psoriasis patients, though frequently colonized with *Staphylococcus aureus*, are not markedly improved by antibiotic treatment, whereas atopic dermatitis patients often obtain dramatic benefit from antibiotic therapy. The S100 proteins are a large family of dimeric low-molecular-weight proteins that bind calcium and other divalent cations. S100A2, S100A7 (psoriasin), and the S100A8/A9 heterodimer (calprotectin) are markedly overexpressed in psoriasis lesions.[144] These proteins exert chemotactic and antimicrobial activity, the latter through sequestration of zinc ions.[145,146] Nitric oxide is produced in large amounts by DCs in psoriasis via the enzyme inducible nitric oxide synthase, where it appears to trigger multiple signal transduction events.[104] Finally, the complement component C5a is a potent chemoattractant for neutrophils and may contribute to the accumulation of neutrophils in the stratum corneum of psoriasis.[147] Interestingly, it is also the most potent chemoattractant for DCs in psoriatic scale extracts.[148] Many of these mediators are regulated in response to Toll-like receptors, providing a mechanism whereby the innate immune system can rapidly recognize a wide variety of pathogens according to their pathogen-associated molecular patterns[149] (see Chap. 10).

Eicosanoids. The role of eicosanoids in psoriasis remains unclear.[150] Levels of free arachidonic acid, leukotriene B4, 12-hydroxyeicosatetraenoic acid, and 15-hydroxyeicosatetraenoic acid are





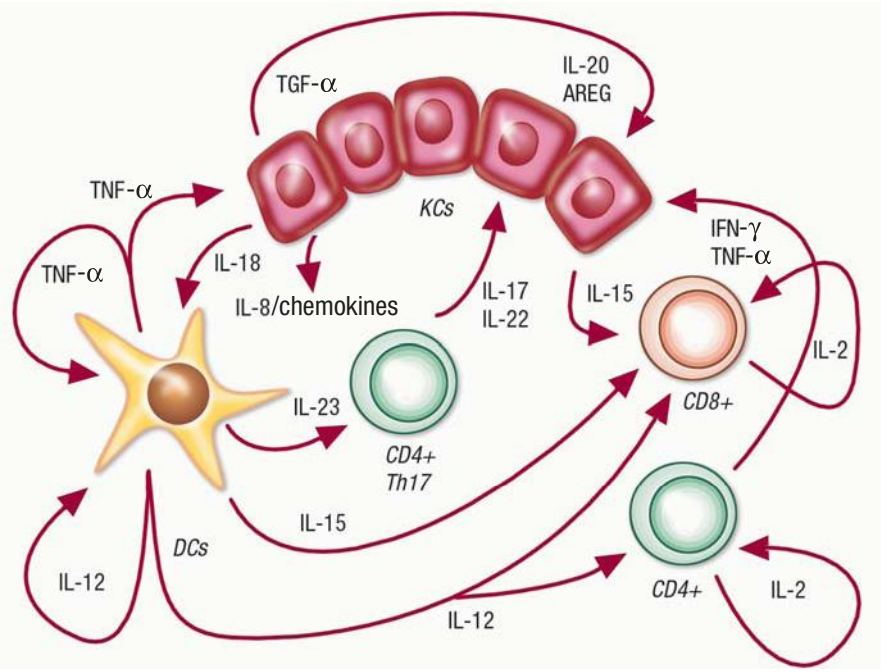

▲ **FIGURE 18-4** Key cytokine interactions in psoriatic lesions. The cytokine network in psoriasis is extremely complex with interactions of multiple cytokines, chemokines, and growth factors involving multiple positive and negative feedback cycles. Only key cytokines are depicted in this figure. T helper 1 (Th1) cytokines such as interferon (IFN)-γ and tumor necrosis factor (TNF)-α are characteristic, and interleukin (IL)-23 was recently implicated in the pathogenesis.[82,141] IL-23 is thought to maintain and expand a specific subset of $CD4^+$ T cells, named Th17, which is characterized by production of IL-17 and IL-22. Other major cytokine producers in the lesional skin are dendritic cells (DCs), $CD4^+$, and $CD8^+$ T cells and keratinocytes (KCs). IFN-γ and TNF-α induce KCs to produce IL-7, IL-8, IL-12, IL-15, IL-18, and TNF-α besides a multitude of other cytokines, chemokines, and growth factors. IL-18 acts on DCs synergistically with IL-12 to further increase the production of IFN-γ. IL-7 and IL-15 are important for the proliferation and homeostatic maintenance of the $CD8^+$ T cells. IL-17 synergizes with IFN-γ to elicit further production of pro-inflammatory cytokines and chemokines by the KCs. TGF-α = transforming growth factor-α.

markedly increased in lesional skin, whereas levels of prostaglandins E and F2α are increased less than two-fold.

Growth Factors. Multiple growth factors are overexpressed in psoriasis.[151] Members of the epidermal growth factor (EGF) family induce their own production in keratinocytes, including transforming growth factor-α, amphiregulin (ARE6), and heparin-binding EGF-like growth factor.[152] Recent studies in xenografted mice found a reduction in epidermal hyperplasia after antibody-mediated neutralization of ARE6.[153] Activation of the EGF receptor stimulates keratinocyte production of vascular endothelial growth factor (VEGF),[122] perhaps accounting for the long-standing observation that the angiogenic properties of normal and psoriatic skin associate with the epidermis.[154] Polymorphisms in the VEGF gene have also been reported to be associated with psoriasis.[155] Nerve growth factor (NGF) is also overexpressed by keratinocytes in psoriatic skin, and NGF receptors are increased in the peripheral nerves of lesional skin. Paracrine growth factors produced outside the epidermal compartment may also play an important role in stimulating epidermal hyperplasia in psoriasis, including insulin-like growth factor-1[159] and keratinocyte growth factor.[160]

Proteases and Their Inhibitors. The psoriatic lesion is characterized by marked overexpression of multiple classes of proteinases by both keratinocytes and leukocytes. Metalloproteinases release TNF-α, several EGF-like growth factors, and many other cytokines and growth factors from their membrane-anchored precursors.[161] Leukocyte-derived elastase has also been implicated in the release of EGF-like growth factors.[162] Serine proteases directly activate protease-activated receptors.[163] Each of these mechanisms may contribute to stimulation of keratinocyte proliferation. The protease inhibitors elafin, serpinB3, and serpinB13 (hurpin) are among the most markedly overexpressed genes in psoriatic lesions,[164,165] suggesting that homeostatic mechanisms are strongly engaged in an effort to regulate the proteolytic environment of psoriatic lesions.

Integrins. Several observations suggest an early role for α5 integrins and their ligand fibronectin in psoriasis. Fibronectin is increased in psoriatic epidermis,[166] and it has been suggested that fibronectin gains access to the epidermis via fenestrations in the epidermal basement membrane.[167]

Signal Transduction. As would be expected given this plethora of intercellular signaling alterations, multiple signal transduction mechanisms are dysregulated in psoriatic epidermis, including receptor tyrosine kinase, mitogen-activated protein kinase, Akt, STAT, Src family kinase, and NF-κB pathways. These abnormalities affect immunocyte activation and trafficking as well as keratinocyte responses of proliferation, differentiation, and survival.

PSORIASIS AS AN AUTOIMMUNE DISEASE: INTEGRATING GENETICS AND IMMUNOLOGY $CD8^+$ T cells comprise at least 80 percent of the T cells in the epidermis of psoriatic lesions,[171] and their invasion into the epidermis correlates with lesional development.[77,172,173] Because it presents antigens to $CD8^+$ T cells, HLA-Cw6 is an excellent candidate for functional involvement in psoriasis. Fig. 18-5 is a model of the transition from guttate to chronic plaque psoriasis and of the role of HLA-Cw6 in the pathogenesis of psoriasis. Many aspects of this working model remain to be verified experimentally.

CLINICAL FINDINGS

Fig. 18-6 is an algorithm showing clinical findings and treatment for psoriasis.

History

It is useful to determine the age at onset and the presence or absence of a family history of psoriasis, as younger age of onset and positive family history have been associated with more widespread and recurrent disease.[5,27] In addition, the physician should inquire about the prior course of the disease, as major differences exist between "acute" and "chronic" disease. In the latter form, lesions may persist unchanged for months or even years, whereas acute disease

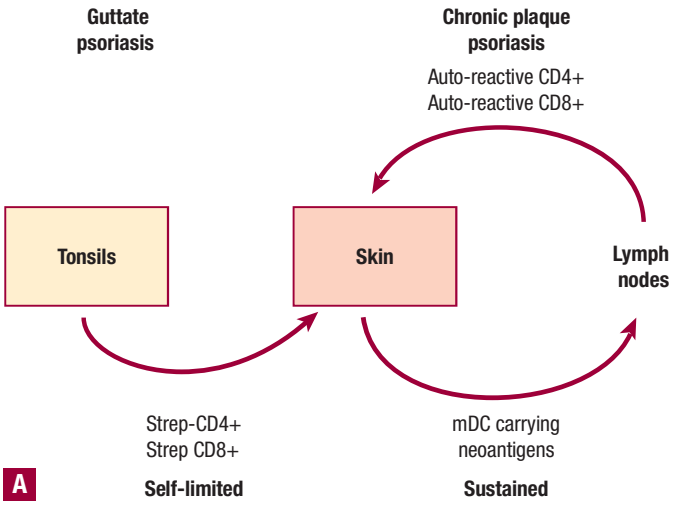

A

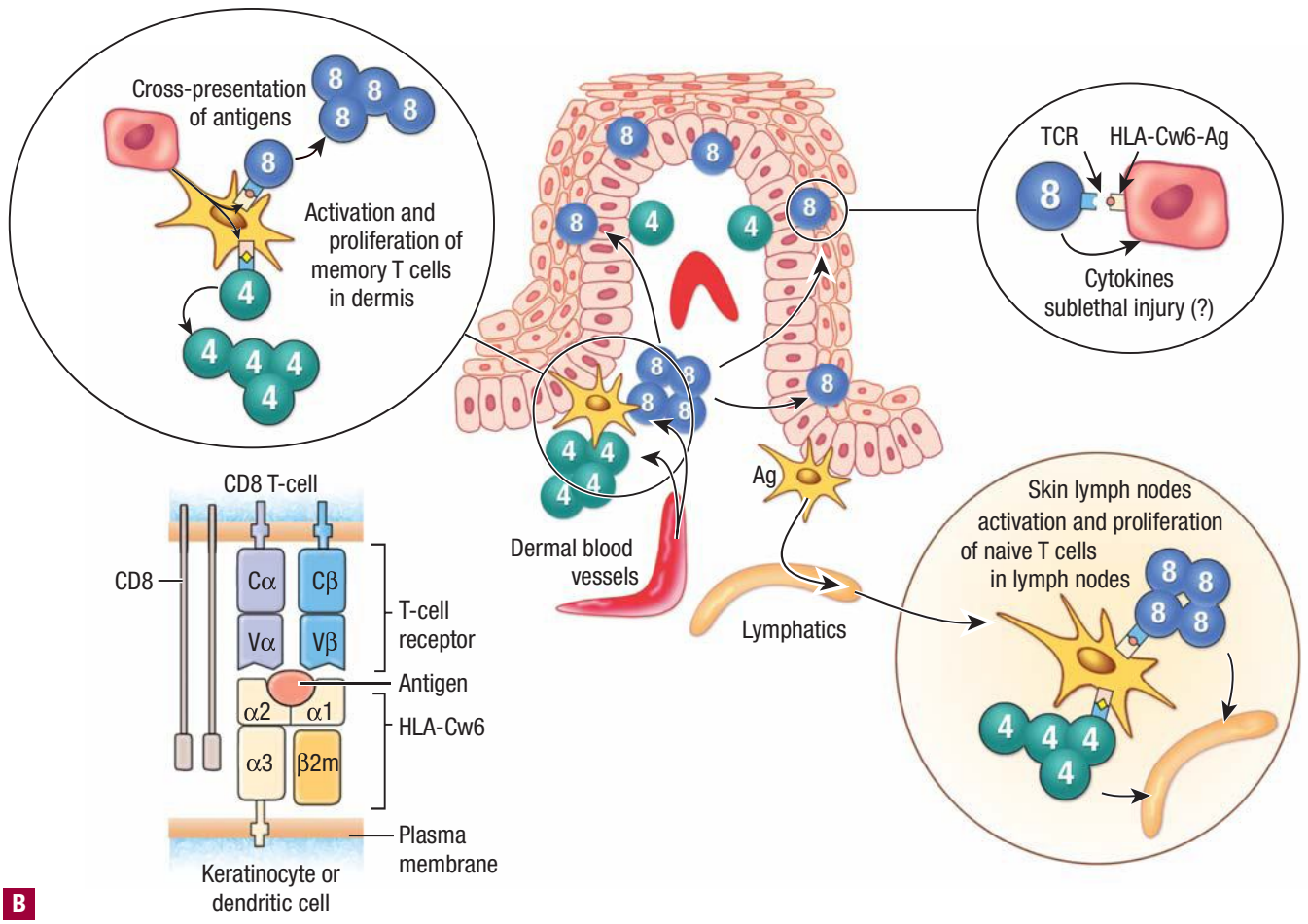

B



▲ **FIGURE 18-5** **A.** Proposed model for transition from guttate to chronic plaque psoriasis. It is envisaged that *Streptococcus*-specific T cells migrate from the tonsils into the skin where the T cells recognize cross-reactive antigens derived from keratinocytes with resulting inflammatory activity (guttate lesions). If effective cross-presentation does not occur, the disease process is self-limited. If effective cross-presentation is established in secondary skin lymphoid tissue, generation and recruitment of auto-reactive T cells occurs, with resulting chronicity of the process. **B.** Proposed role of HLA-Cw6 in the pathogenesis of psoriasis. The antigen in the binding pocket of HLA-C (in this case HLA-Cw6) interacts with a T-cell receptor (TCR). The region of the TCR that interacts directly with the antigen is the complement-determining region 3 (CDR3). Oligoclonality of the CDR3 region has been demonstrated for psoriatic $CD8^+$ T cells, strongly suggesting that psoriasis is an antigen-driven process. The role of HLA-Cw6 in psoriasis is likely to be two-fold. HLA-Cw6 is active in cross-presenting peptides on the surface of dendritic cells, allowing activation and clonal expansion of antigen-specific $CD8^+$ T cells. This process is dependent on $CD4^+$ T-cell help and is likely to happen both in the dermis (activation of memory resident T cells) and local lymph nodes (activation of naive T cells). Subsequently, the $CD8^+$ T cells are able to migrate into the epidermis where they encounter HLA-Cw6 on the surface of the keratinocytes presenting those same pathogenic peptides. This leads to release of inflammatory mediators by the $CD8^+$ T cells and activation of the keratinocytes, with the resulting development of psoriatic lesions. mDC = mature dendritic cells.



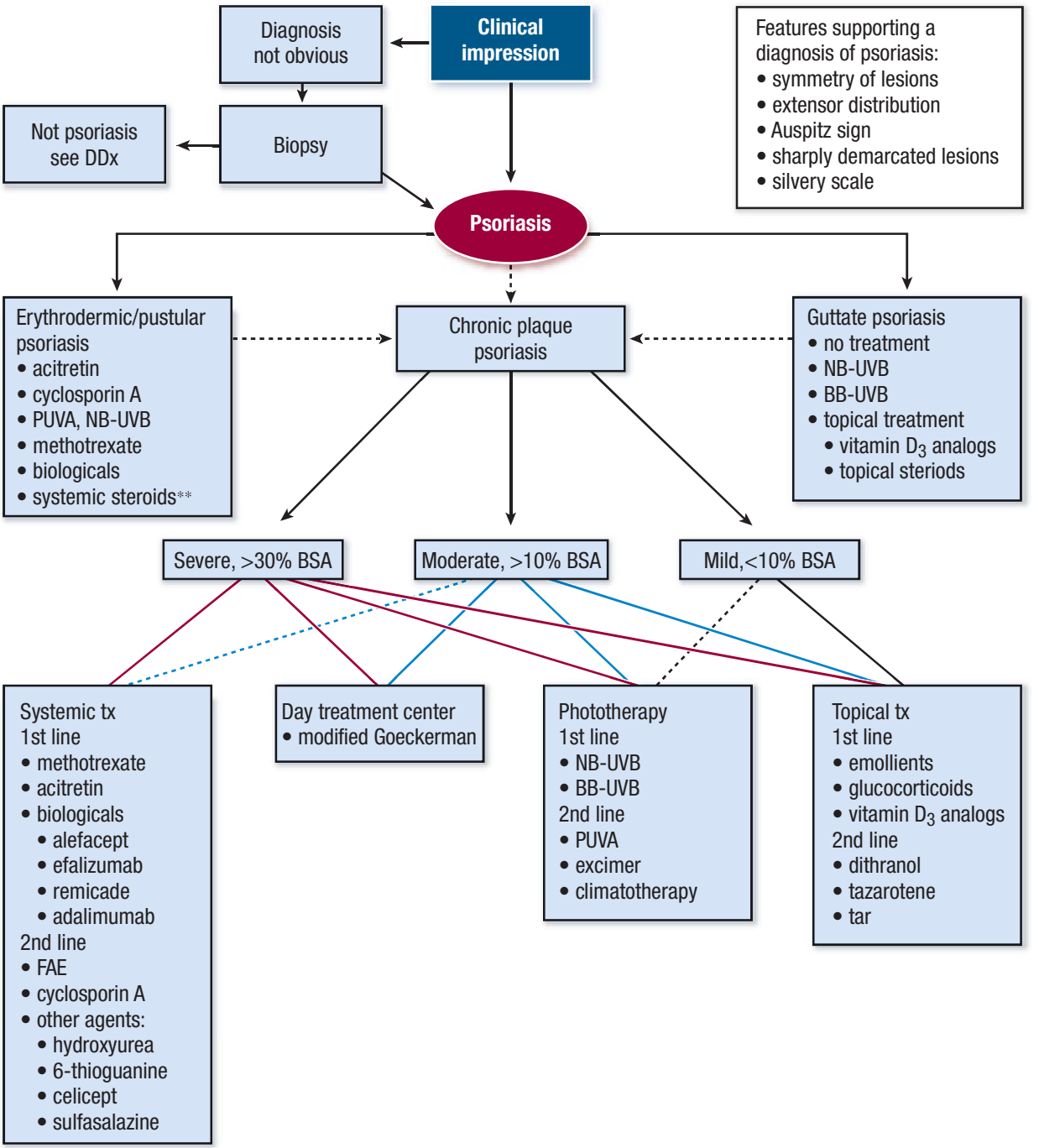

▲ **FIGURE 18-6** Diagnosis and treatment algorithm for psoriasis. The diagnosis of psoriasis is usually based on clinical features. In those few cases in which clinical history and examination is not diagnostic, biopsy is indicated to establish the correct diagnosis. The majority of psoriasis cases fall into three major categories; guttate, erythrodermic/pustular, and chronic plaque, of which the latter is by far the most common. Guttate psoriasis is often a self-limited disease with spontaneous resolution within 6 to 12 weeks. In mild cases of guttate psoriasis, treatment may not be needed, but, with widespread disease, ultraviolet B (UVB) phototherapy in association with topical therapy is very effective. Erythrodermic/pustular psoriasis is often associated with systemic symptoms and necessitates treatment with fast-acting systemic medications. The most commonly used drug for erythrodermic and pustular psoriasis is acitretin. In occasional cases of pustular psoriasis, systemic steroids may be indicated (**). *Dotted arrows* indicate that guttate, erythrodermic, and pustular forms often evolve into chronic plaque psoriasis. Therapeutic choices for chronic plaque psoriasis are typically based on the extent of the disease. Among the main treatment regimens (topical treatment, phototherapy, day treatment centers, and systemic treatments), first-line and second-line modalities are indicated by the *solid* and *dashed lines*, respectively. Individuals with conditions that limit their activities, including painful palmoplantar involvement and psoriatic arthritis, may require more potent treatments irrespective of the extent of affected body surface area. Likewise, psychological issues and the impact on quality of life should be taken into consideration. Within each treatment regimen, first-line and second-line choices are grouped. Cyclosporin A is not considered a first-line, long-term systemic treatment due to its side effects, but short-term treatment can be helpful for induction of remission. If patients have incomplete response to or are unable to tolerate individual first-line systemic medications, combination regimens (Table 18-5), rotational treatments, or use of biologic therapies should be considered. BB-UVB = broadband UVB; BSA = body surface area; DDx = differential diagnosis; FAE = fumaric acid ester; NB-UVB = narrowband UVB; PUVA = psoralen and UVA light; tx = therapy.



▲ **FIGURE 18-7** **A–F.** Chronic plaque psoriasis located at typical sites. Note marked symmetry of lesions. (Photos used with permission from Mr. Harrold Carter.)

shows sudden outbreak of lesions within a short time (days). Likewise, patients have great variability in regard to relapses. Some patients have frequent relapses occurring weekly or monthly, whereas others have more stable disease with only occasional recurrence. The frequently relapsing patients tend to develop more severe disease with rapidly enlarging lesions covering significant portions of the body surface[204] and may require more rigorous treatment compared to those with more stable disease. Certain medications may worsen psoriasis (see Treatment). The physician should also inquire about joint complaints. Although osteoarthritis is extremely common and can co-exist with psoriasis, a history of onset of joint symptoms before the fourth decade and/or a history of warm, swollen joints should raise the suspicion of psoriatic arthritis (see Chap. 19).

Cutaneous Lesions[205]

The classic lesion of psoriasis is a well-demarcated, raised, red plaque with a white scaly surface (Fig. 18-7). Lesions can vary in size from pinpoint papules to plaques that cover large areas of the body. Under the scale, the skin has a glossy homogeneous erythema, and bleeding points appear when the scale is removed, traumatizing the dilated capillaries below (the Auspitz sign) (Fig. 18-8).[205] Psoriasis tends to be a symmetric eruption, and symmetry is a helpful feature in establishing a diagnosis. Unilateral involvement can occur, however. The psoriatic phenotype may present a changing spectrum of disease expression even within the same patient.

Koebner phenomenon (also known as the *isomorphic response*) is the traumatic induction of psoriasis on nonlesional skin; it occurs more frequently during flares of disease and is an all-or-none phenomenon (i.e., if psoriasis occurs at one site of injury it will occur at all sites of injury) (Fig. 18-9). The Koebner reaction usually occurs 7 to 14 days after injury, and approximately 25 percent of patients may have a history of trauma-related Koebner phenomenon at some point in their lives.[206] Estimates of lifetime prevalence rise as high as 76 percent when factors such as infection, emotional stress, and drug reactions are included.[3] The Koebner phenomenon is not specific for psoriasis but can be helpful in making the diagnosis when present.



▲ **FIGURE 18-8** Auspitz sign. Note point of bleeding after scale is removed. (Photos used with permission from Dr. Johann Gudjonsson and Ms. Laura Vangoor.)





▲ **FIGURE 18-9** Koebner phenomenon. **A.** Psoriasis appearing in keratome biopsy sites 4 weeks after biopsy. (Photo used with permission from Mr. Harrold Carter.) **B.** Flare of psoriasis on the back after a sunburn. Note sparing of sun-protected areas. (Photo used with permission from Dr. James Rasmussen.)

Clinical Patterns of Skin Presentation[205]

PSORIASIS VULGARIS, CHRONIC STATIONARY PSORIASIS, PLAQUE-TYPE PSORIASIS Psoriasis vulgaris is the most common form of psoriasis, seen in approximately 90 percent of patients. Red, scaly, symmetrically distributed plaques are characteristically localized to the extensor aspects of the extremities, particularly the elbows and knees, along with scalp, lower lumbosacral, buttocks, and genital involvement (see Fig. 18-7). Other sites of predilection include the umbilicus and the intergluteal cleft. The extent of involvement varies widely from patient to patient. There is constant production of large amounts of scale with little alteration in shape or distribution of individual plaques. Single small lesions may become confluent, forming plaques in which the borders resemble a land map (psoriasis geographica). Lesions may extend laterally and become circinate because of the confluence of several plaques (psoriasis gyrata). Occasionally, there is partial central clearing, resulting in ring-like lesions (annular psoriasis) (Fig. 18-10). This is usually associated with lesional clearing and portends a good prognosis. Other clinical variants of plaque psoriasis have been described, depending on the morphology of the lesions, particularly those associated with gross hyperkeratosis (see Fig. 18-10). *Rupioid psoriasis* refers to lesions in the shape of a cone or limpet. *Ostraceous psoriasis*, an infrequently used term, refers to a ring-like, hyperkeratotic concave lesion, resembling an oyster shell. Finally, elephantine psoriasis is an uncommon form characterized by thickly scaling, large plaques, usually on the lower extremities. A hypopigmented ring (Woronoff ring) surrounding individual psoriatic lesions may occasionally be seen and is usually associated with treatment, most commonly UV radiation or topical corticosteroids (see Fig. 18-10). The pathogenesis is not well understood but may result from inhibition of prostaglandin synthesis.[207]

GUTTATE (ERUPTIVE) PSORIASIS Guttate psoriasis (from the Latin *gutta*, meaning "a drop") is characterized by eruption of small (0.5 to 1.5 cm in diameter) papules over the upper trunk and proximal extremities (Fig. 18-11). It typically manifests at an early age and as such is found frequently in young adults. This form of psoriasis has the strongest association to HLA-Cw6,[22] and streptococcal throat infection frequently precedes or is concomitant with the onset or flare of guttate psoriasis.[208] However, antibiotic treatment has not been shown to be beneficial or to shorten the disease course.[209] Patients with a history of chronic plaque psoriasis may develop



▲ **FIGURE 18-10** Unusual forms of plaque-type psoriasis **A.** Annular psoriasis on the flank. **B.** Rupioid psoriasis in an infant. Note cone-shaped lesions. **C.** Psoriatic patient undergoing modified Goeckerman therapy (ultraviolet B light, coal tar, and topical steroid), demonstrating Woronoff rings. **D.** Elephantine psoriasis of the lower extremities. Note psoriatic involvement of toenails. (Photographs used with permission from Dr. Johann Gudjonsson, Mr. Harrold Carter, and Ms. Laura Vangoor.)



▲ **FIGURE 18-11** Guttate psoriasis, involving thigh (**A**), hands (**B**), and back (**C** and **D**). The patient in **D** went on to develop chronic plaque psoriasis. (Photos used with permission from Drs. Johann Gudjonsson and Trilokraj Tejasvi, Mr. Harrold Carter, and Ms. Laura Vangoor.)

guttate lesions, with or without worsening of their chronic plaques.

SMALL PLAQUE PSORIASIS Small plaque psoriasis resembles guttate psoriasis clinically, but can be distinguished by its onset in older patients, by its chronicity, and by having somewhat larger lesions (typically 1 to 2 cm) that are thicker and scalier than in guttate disease. It is said to be a common adult-onset presentation of psoriasis in Korea and other Asian countries.[210]

INVERSE PSORIASIS Psoriasis lesions may be localized in the major skin folds, such as the axillae, the genito-crural region, and the neck. Scaling is usually minimal or absent, and the lesions show a glossy sharply demarcated erythema, which is often localized to areas of skin-to-skin contact (Fig. 18-12). Sweating is impaired in affected areas.[211]

ERYTHRODERMIC PSORIASIS Psoriatic erythroderma represents the generalized form of the disease that affects all body sites, including the face, hands, feet, nails, trunk, and extremities (Fig. 18-13). Although all the symptoms of psoriasis are present, erythema is the most prominent feature, and scaling is different compared with chronic stationary psoriasis. Instead of thick, adherent, white scale there is superficial scaling. Patients with erythrodermic psoriasis lose excessive heat because of generalized vasodilatation, and this may cause hypothermia. Patients may shiver in an attempt to raise their body temperature. Psoriatic skin is often hypohidrotic due to occlusion of the sweat ducts,[212] and there is an attendant risk of hyperthermia in warm climates. Lower extremity edema is common secondary to vasodilatation and loss of protein from the blood vessels into the tissues. High-output cardiac failure and impaired hepatic and renal function may also occur. Psoriatic erythroderma has a variable presentation, but two forms are thought to exist.[213] In the first form, chronic plaque psoriasis may worsen to involve most or all of the skin surface, and patients remain relative responsive to therapy. In





▲ **FIGURE 18-12** Inverse psoriasis. Note the well-demarcated, beefy-red, shiny plaques in **A**. The patient in **B** has atrophy and purpura of the upper inner arm, secondary to chronic topical corticosteroid treatment. (Photos used with permission from Mr. Harrold Carter.)





▲ **FIGURE 18-13** Erythrodermic psoriasis. The patient in **A** had chronic plaque psoriasis that progressed to near-complete involvement. The patient in **B** rapidly developed near-complete involvement and complained of fatigue and malaise. In both panels, note islands of sparing. (Photos used with permission from Mr. Harrold Carter.)

the second form, generalized erythroderma may present suddenly and unexpectedly or result from non-tolerated external treatment (e.g., UVB, anthralin), thus representing a generalized Koebner reaction. Generalized pustular psoriasis [see Generalized Pustular Psoriasis (von Zumbusch)] may revert to erythroderma with diminished or absent pustule formation. Occasional diagnostic problems may arise in differentiating psoriatic erythroderma from other causes (see Chap. 23).

PUSTULAR PSORIASIS Several clinical variants of pustular psoriasis exist: generalized pustular psoriasis (von Zumbusch type), annular pustular psoriasis, impetigo herpetiformis, and two variants of localized pustular psoriasis—pustulosis palmaris et plantaris and acrodermatitis continua. In children, pustular psoriasis can be complicated by sterile, lytic lesions of bones[214,215] and can be a manifestation of the SAPHO syndrome (synovitis, acne, pustulosis, hyperostosis, osteitis).[216]

Generalized Pustular Psoriasis (von Zumbusch). Generalized pustular psoriasis (von Zumbusch) is a distinctive acute variant of psoriasis. It is usually preceded by other forms of the disease. Attacks are characterized by fever that lasts several days and a sudden generalized eruption of sterile pustules 2 to 3 mm in diameter (Fig. 18-14). The pustules are disseminated over the trunk and extremities, including the nail beds, palms, and soles. The pustules usually arise on highly erythematous skin, first as patches (Fig. 18-15) and then becoming confluent as the disease becomes more severe. With prolonged disease, the fingertips may become atrophic. The erythema that surrounds the pustules often spreads and becomes confluent, leading to erythroderma. Characteristically, the disease occurs in waves of fevers and pustules. The etiology of generalized psoriasis von Zumbusch type is unknown. Various provoking agents include infections, irritating topical treatment (Koebner phenomenon), and withdrawal of oral corticosteroids.[217] This form of psoriasis is usually associated with prominent systemic signs and can potentially have life-threatening complications such as bacterial superinfection, sepsis, and dehydration.[218] Severe pustular psoriasis can be difficult to control and requires a potent treatment regimen with rapid onset of action to avoid life-threatening complications. Drugs commonly used include etretinate, methotrexate (MTX), cyclosporin, or oral corticosteroids.[219] Cases of acute respiratory distress syndrome associated with generalized pustular psoriasis have been reported.[220]

Exanthematic Pustular Psoriasis. Exanthematic pustular psoriasis tends to occur after a viral infection and consists of widespread pustules with generalized plaque psoriasis. However, unlike the von Zumbusch pattern, there are no constitutional symptoms, and the disorder tends not to recur.[205] There is an overlap between this form of pustular psoriasis and acute generalized exanthematous pustulosis, a type of drug eruption.

Annular Pustular Psoriasis. Annular pustular psoriasis is a rare variant of pustular psoriasis. It usually presents in an annular or circinate form. Lesions may appear at the onset of pustular psoriasis, with a tendency to spread and form enlarged rings, or they may develop during the course of generalized pustular psoriasis. The characteristic features are pustules on a ring-like erythema that sometimes resembles erythema annulare centrifugum. Identical lesions are found in patients with impetigo herpetiformis, an entity defined by some as a variant of pustular psoriasis occurring in pregnancy.[221] Onset in pregnancy is usually early in the third trimester and persists until delivery.[222] It tends to develop earlier in subsequent pregnancies. Impetigo herpetiformis is often associated with hypocalcemia.[217,223] There is usually no personal or family history of psoriasis.[224]

Localized Pustular Psoriasis Variants. Localized pustular psoriasis variants, including pustulosis palmaris et plantaris and acrodermatitis continua (of Hallopeau), are discussed in Chap. 21.

SEBOPSORIASIS A common clinical entity, sebopsoriasis presents with erythematous plaques with greasy scales localized to seborrheic areas (scalp, glabella, nasolabial folds, perioral and presternal areas, and intertriginous areas). In the absence of typical findings of psoriasis elsewhere, distinction from seborrheic dermatitis is difficult. Sebopsoriasis may represent a modification of seborrheic dermatitis by the genetic background of psoriasis and is relatively resistant to treatment. Although an etiologic role of *Pityrosporum* remains unproven, antifungal agents may be useful.[225]

NAPKIN PSORIASIS Napkin psoriasis usually begins between the ages of 3 and 6 months and first appears in the diaper (napkin) areas as a confluent red area with appearance a few days later of small red papules on the trunk that may also involve the limbs. These papules have the typical white scales of psoriasis. The face may also be involved with red scaly eruption. Unlike other forms of psoriasis, the rash responds readily to treatment and tends to disappear after the age of 1 year.

LINEAR PSORIASIS Linear psoriasis is a very rare form. The psoriatic lesion presents as linear lesion most commonly on the limbs but may also be limited to a dermatome on the trunk. This may be an underlying nevus, possibly an inflammatory linear verrucous epidermal ne-

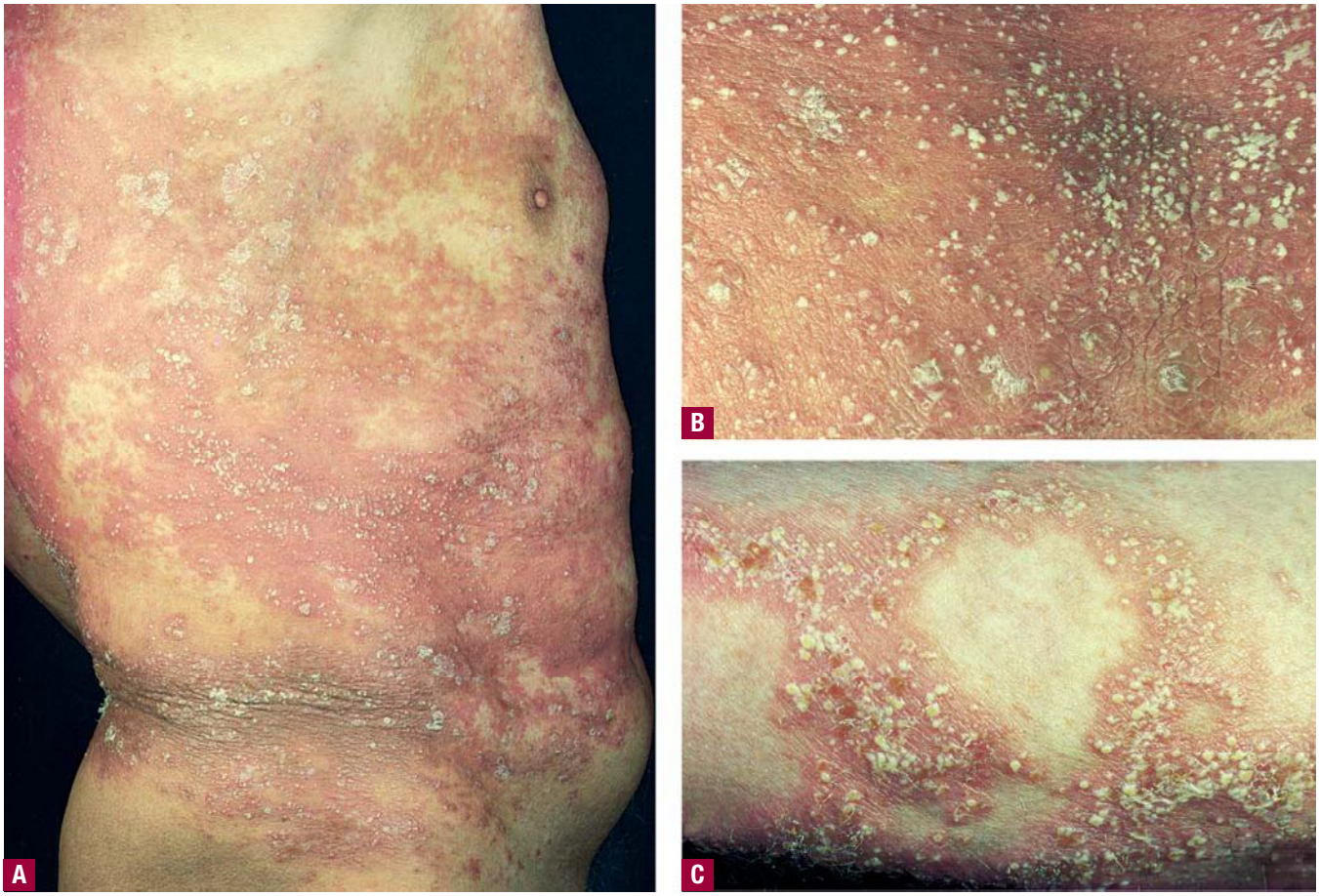

▲ **FIGURE 18-14** **A–C.** Generalized, von Zumbusch-type pustular psoriasis. Tiny pustules, 1 to 2 mm in diameter on erythematous skin.

vus (ILVEN), as these lesions resemble linear psoriasis both clinically and histologically. The existence of a linear form of psoriasis distinct from ILVEN is controversial.[226]



▲ **FIGURE 18-15** Pustular psoriasis. Panel **B** is a close-up of the cluster of pustules in the left half of panel **A**. (Photo used with permission from Drs. Trilokraj Tejasvi and Neena Khanna.)

Related Physical Findings

NAIL CHANGES IN PSORIASIS (See also Chap. 87) Nail changes are frequent in psoriasis, being found in up to 40 percent of patients,[27] and are rare in the absence of skin disease elsewhere. Nail involvement increases with age, with duration and extent of disease, and with the presence of psoriatic arthritis. Several distinct changes have been described and can be grouped according to the portion of the nail that is affected (Table 18-1).[227–229]

Nail pitting is one of the commonest features of psoriasis, involving the fingers more often than the toes (Fig. 18-16). Pits range from 0.5 to 2.0 mm in size and can be single or multiple. The proximal nail matrix forms the dorsal (superficial) portion of the nail plate, and psoriatic involvement of this region results in pitting due to defective keratinization. Other alterations in the nail matrix resulting in deformity of the nail plate (onychodystrophy) include leukonychia, crumbling nail, and red spots in the lunula. Onychodystrophy has a stronger association with psoriatic arthritis than other nail changes.[27] Oil spots and salmon patches are translucent, yellow-red discolorations observed beneath the nail plate often extending distally toward the hyponychium, due to psoriasiform hyperplasia, parakeratosis, microvascular changes, and trapping of neutrophils in the nail bed.[228,229] Unlike pitting, which is also seen in alopecia areata and other disorders, oil spotting is considered to be nearly specific for psoriasis. Splinter hemorrhages result from capillary bleeding underneath the thin suprapapillary plate of the psoriatic nail bed. Subungual hyperkeratosis is due to hyperkeratosis of the nail bed and is often accompanied by onycholysis (separation of the nail plate from the nail bed), which usually involves the distal aspect of the nail. Anonychia is total loss of the nail plate. Although nail changes are rarely seen in the localized pustular variant of pustulosis palmaris et plantaris, anonychia can be seen in other forms of pustular psoriasis.

GEOGRAPHIC TONGUE Geographic tongue, also known as *benign migratory glossitis* or *glossitis areata migrans*, is an idiopathic inflammatory disorder resulting in the local loss of filiform papillae. The condition usually presents as asymptomatic ery-



TABLE 18-1
Nail Changes in Psoriasis

Nail Segment Involved	Clinical Sign
Proximal matrix	Pitting, onychorrhexis, Beau's lines
Intermediate matrix	Leukonychia
Distal matrix	Focal onycholysis, thinned nail plate, erythema of the lunula
Nail bed	"Oil drop" sign or "salmon patch," subungual hyperkeratosis, onycholysis, splinter hemorrhages
Hyponychium	Subungual hyperkeratosis, onycholysis
Nail plate	Crumbling and destruction plus other changes secondary to the specific site
Proximal and lateral nail folds	Cutaneous psoriasis

Modified from Del Rosso JQ et al: Dermatologic diseases of the nail unit, in *Nails: Therapy, Diagnosis, Surgery,* edited by Scher RK, Daniel CR. Philadelphia, W.B. Saunders, 1997, p 172, with permission.

thematous patches with serpiginous borders, resembling a map. These lesions characteristically have a migratory nature. Geographic tongue has been postulated to be an oral variant of psoriasis, as these lesions show several histologic features of psoriasis, including acanthosis, clubbing of the rete ridges, focal parakeratosis, and neutrophilic infiltrate. In addition, the prevalence of geographic tongue is increased in psoriatic patients.[230] However, geographic tongue is a relatively common condition and is seen in many non-psoriatic individuals, so its relationship to psoriasis needs further clarification.

PSORIATIC ARTHRITIS Arthritis is a common extra-cutaneous manifestation of psoriasis seen in up to 40 percent of patients. It has a strong genetic component, and several overlapping subtypes exist. This condition is discussed in Chap. 19.

Laboratory Tests

Although histopathologic examination is rarely necessary to make the diagnosis, it can be helpful in difficult cases. The histopathologic findings of guttate and chronic plaque psoriasis have already been described (see Development of Lesions). In early lesions of pustular psoriasis, the epidermis is usually only slightly acanthotic, whereas psoriasiform hyperplasia is seen in older and persistent lesions. Neutrophils migrate from dilated vessels in the upper dermis into the epidermis where they aggregate beneath the stratum corneum and in the upper Malpighian layer to form the spongiform pustules of Kogoj.

Other laboratory abnormalities in psoriasis are usually not specific and may not be found in all patients. In severe psoriasis vulgaris, generalized pustular psoriasis, and erythroderma, a negative nitrogen balance can be detected, manifested by a decrease of serum albumin.[231]

Psoriasis patients manifest altered lipid profiles, even at the onset of their skin disease.[232] Patients had 15 percent higher levels of high-density lipoproteins, and their cholesterol-triglyceride ratio for very low-density lipoprotein particles was 19 percent higher. Furthermore, plasma apolipoprotein-A1 concentrations were 11 percent higher in psoriasis patients. Whether these differences in lipid profile can explain or are contributing to an increased incidence of cardiovascular events in psoriasis remains to be seen.

Serum uric acid is elevated in up to 50 percent of patients and is mainly correlated with the extent of lesions and the activity of disease. There is an increased risk of developing gouty arthritis. Serum uric acid levels usually normalize after therapy.

Markers of systemic inflammation can be increased, including C-reactive protein, α_2-macroglobulin, and erythrocyte sedimentation rate. However, such elevations are rare in chronic plaque psoriasis uncomplicated by arthritis. Increased serum immunoglobulin (Ig) A levels and IgA immune complexes, as well as secondary amyloidosis, have also been observed in psoriasis, and the latter carries a poor prognosis.[233]

Special Tests

Immunostaining techniques, fluorescence-activated cell sorting of dissociated cell suspensions, and assessment of



▲ **FIGURE 18-16** Nail psoriasis. Panel **A** demonstrates distal onycholysis and oil drop spotting. Panel **B** demonstrates distal onycholysis, salmon-patch discoloration, and pitting. Panel **C** demonstrates splinter hemorrhages and pitting. Panel **D** demonstrates onychodystrophy and loss of nails in a patient with psoriatic arthritis. (Photos **A**, **C**, **D** used with permission from Drs. Johann Gudjonsson and Trilokraj Tejasvi, and Mr. Harrold Carter.)

Box 18-1

Differential Diagnosis of Psoriasis

PSORIASIS VULGARIS

Most Likely

- Discoid/nummular eczema
- Cutaneous T-cell lymphoma (CTCL)
- Tinea corporis

Consider

- Pityriasis rubra pilaris
- Seborrheic dermatitis
- Subacute cutaneous lupus erythematosus
- Erythrokeratoderma (the fixed plaques of keratoderma variabilis and/or progressive symmetric erythrokeratoderma
- Inflammatory linear verrucous epidermal nevus
- Hypertrophic lichen planus
- Lichen simplex chronicus
- Contact dermatitis
- Chronic cutaneous lupus erythematosus/discoid lupus erythematosus
- Hailey-Hailey disease (flexural)
- Intertrigo (flexural)
- *Candida* infection (flexural)

Always Rule Out

- Bowen disease/squamous cell carcinoma in situ
- Extramammary Paget disease

GUTTATE

Most Likely

- Pityriasis rosea
- Pityriasis lichenoides chronica
- Lichen planus

Consider

- Small plaque parapsoriasis
- PLEVA
- Lichen planus
- Drug eruption

Always Rule Out

- Secondary syphilis

ERYTHRODERMIC

Most Likely

- Drug-induced erythroderma
- Eczema
- CTCL/Sézary syndrome
- Pityriasis rubra pilaris

PUSTULAR

Most Likely

- Impetigo
- Superficial candidiasis
- Reactive arthritis syndrome
- Superficial folliculitis

Consider

- Pemphigus foliaceus
- Immunoglobulin A pemphigus
- Sneddon-Wilkinson disease (subcorneal pustular dermatosis)
- Migratory necrolytic erythema
- Transient neonatal pustular melanosis
- Acropustulosis of infancy
- Acute generalized exanthematous pustulosis

T-cell receptor gene rearrangements have been of major importance in elucidating the pathogenesis of psoriasis and in characterizing the response to antipsoriatic therapies, but are generally not required for diagnosis or management.

DIFFERENTIAL DIAGNOSIS (Box 18-1)

COMPLICATIONS

Patients with psoriasis have an increased morbidity and mortality from cardiovascular events, particularly those with severe and long duration of psoriasis skin disease.[234,235] Risk of myocardial infarction is particulary elevated in younger patients with severe psoriasis.[236]

Psoriasis patients have also been shown to have increased relative risk of lymphoma, particularly in patients with more severe disease.[237]

Psoriasis is emotionally disabling, carrying with it significant psychosocial difficulties. Emotional difficulties arise from concerns about appearance, resulting in lowered self-esteem, social rejection, guilt, embarrassment, emptiness, sexual problems, and impairment of professional ability.[238] The presence of pruritus and pain can aggravate these symptoms. Psychological aspects can modify the course of illness; in particular, feeling stigmatized can lead to treatment noncompliance and worsening of psoriasis.[239] Likewise, psychological stress can also lead to depression and anxiety.[240] The prevalence of suicidal ideation and depression in patients with psoriasis is higher than that reported in other medical conditions and the general population.[241] Thus, although the disease is not threatening to life itself, psoriasis can very significantly impair quality of life.[242] A comparative study reported reduction in physical and mental functioning comparable with that seen in cancer, arthritis, hypertension, heart disease, diabetes, and depression.[243] According to a recent survey, 79 percent of patients with severe psoriasis reported a negative impact on their lives.[244]

PROGNOSIS AND CLINICAL COURSE

Natural History[205]

Guttate psoriasis is often a self-limited disease, lasting from 12 to 16 weeks without treatment.[205] It has been estimated that one-third to two-thirds of these patients later develop the chronic plaque type of psoriasis.[4,174] In contrast, chronic plaque psoriasis is in most cases a lifelong disease, manifesting at unpredictable intervals. Spontaneous remissions, lasting for variable periods of time, may occur in the course of psoriasis in up to 50 percent of patients. The duration of remission ranges from 1 year to several decades. In two separate studies, remission ranged from 17 percent to 55 percent. In another study of patients followed for 21 years, 71 percent had persistent lesions, 13 percent were free of the disease, and 16 percent had intermittent lesions.[205] The cause of spontaneous remission is unknown, but could reflect successful generation of self-tolerance under the model of immunologic self-reactivity discussed earlier (see Psoriasis as an Autoimmune Disease).

Erythrodermic and generalized pustular psoriasis have a poorer prognosis, with the disease tending to be severe and persistent.[205]

Modifying Factors

OBESITY It has been demonstrated that obese individuals are more likely to present with severe psoriasis (defined as > 20 percent body surface area involvement).[244] However, obesity does not appear to have a role in defining the onset of psoriasis.[245]

SMOKING Smoking (more than 20 cigarettes daily) has also been associated with more than a twofold increased risk of severe psoriasis.[246] Unlike obesity, smoking



TABLE 18-2
Topical Treatments for Psoriasis

	Topical Steroids	Vitamin D Analogues	Tazarotene	Calcineurin Inhibitors
Mechanism of action	Bind to glucocorticoid receptors, inhibiting the transcription of many different AP-1– and NF-κB–dependent genes, including IL-1 and tumor necrosis factor-α.	Bind to vitamin D receptors, influencing the expression of many genes. Promote keratinocyte differentiation.	Metabolized to tazarotenic acid, its active metabolite,[358] which binds to retinoic acid receptors. Normalizes epidermal differentiation, exhibits a potent antiproliferative effect, and decreases epidermal proliferation.	Bind to FK506-binding protein (FKBP) and inhibit calcineurin, decreasing the activation of the transcription factor, NF-AT, with resultant decrease in cytokine transcription, including IL-2.
Dosing	10,000-fold range of potency. High-potency steroids are applied to affected areas twice daily for 2–4 wk and then intermittently (weekends).	Calcipotriene, 0.005%, to affected areas twice daily. Often used alternating with topical steroids (i.e., vitamin D analogues on weekdays, topical steroids on weekends).	Available in 0.05% and 0.1% formulations, both as cream and gels. Apply every night to affected area.	Application to affected areas twice daily.
Efficacy	Very effective as short-term treatment.	Efficacy is increased by combination with topical steroids. Can be combined with various other therapies.	Efficacy is increased by combination with topical steroids.[359]	Effective for treatment of facial and flexural psoriasis[268] but minimally for chronic plaque psoriasis.[267]
Safety	Suppression of the hypothalamic-pituitary-adrenal axis (higher risk in children). Atrophy of the epidermis and dermis. Formation of striae. Tachyphylaxis.[257]	Development of irritation at the site of application is common.[257] Isolated reports of hypercalcemia in patients who applied excessive quantities.[360]	When used as monotherapy, significant proportion of patients develop irritation at the site of application.[361]	Burning sensation at the site of application. Case reports of development of lymphoma.
Contraindications	Hypersensitivity to the steroid, active skin infection.	Hypercalcemia, vitamin D toxicity.	Pregnancy, hypersensitivity to tazarotene.	Use only with caution for treatment of children younger than the age of 2 yr.
Remarks/long-term use	Long-term use increases risk of side effects.	Calcipotriol is well tolerated and continues to be clinically effective with minimum of adverse effects in long-term use.[362,363]	Combination of steroid with tazarotene may reduce atrophy seen with super-potent topical steroids.[359] If added during phototherapy, the ultraviolet doses should be reduced by one-third.[257]	Due to anecdotal reports of association with malignancy, this class of medications recently received a black-box warning by the U.S. Food and Drug Administration.
Pregnancy category	C	C	X	C

AP = activator protein; IL = interleukin; NF = nuclear factor; NF-AT = nuclear factor of activated T cells.



appears to have a role in the onset of psoriasis.[245] Recently, a gene-environment interaction has been identified between low activity of the cytochrome P_{450} gene CYP1A1 and smoking in psoriasis.[247]

INFECTION An association between streptococcal throat infection and guttate psoriasis has been repeatedly confirmed.[208,248] Streptococcal throat infections have also been demonstrated to exacerbate preexisting chronic plaque psoriasis.[175]

Severe exacerbation of psoriasis can be a manifestation of human immunodeficiency virus (HIV) infection.[249] Like psoriasis in general, HIV-associated psoriasis has a strong association with HLA-Cw6.[250] Interestingly, the prevalence of psoriasis in HIV infection is no higher than in the general population (1 percent to 2 percent of patients[249,250]), indicating that this infection is not a trigger for psoriasis but rather a modifying agent. Psoriasis is increasingly more severe with progression of immunodeficiency but can remit in the terminal phase.[251,252] This paradoxical exacerbation of psoriasis may be due to loss of regulatory T cells and increased activity of the CD8 T-cell subset.[171] Psoriasis exacerbation in HIV disease may be effectively treated with antiretroviral therapy.[253,254]

DRUGS Medications that exacerbate psoriasis include antimalarials, β blockers, lithium, nonsteroidal anti-inflammatory drugs, IFNs-α and -γ, imiquimod, angiotensin-converting enzyme inhibitors, and gemfibrozil.[255] Imiquimod acts on pDCs and stimulates IFN-α production,[107] which then strengthens both innate and Th1 immune responses. Lithium has been proposed to cause exacerbation by interfering with calcium release within keratinocytes, whereas β blockers are thought to interfere with intracellular cyclic adenosine monophosphate levels.[255] The mechanisms by which the remaining medications exacerbate psoriasis are largely unknown. Patients with active or unstable psoriasis should receive advice when traveling to countries where antimalarial prophylaxis is needed.

TREATMENT

General Considerations

A broad spectrum of anti-psoriatic treatments, both topical and systemic, is available for the management of psoriasis. As detailed in Tables 18-2 to 18-6, it is notable that most if not all of these treatments are immunomodulatory. When choosing

TABLE 18-3
Phototherapy of Psoriasis

	Narrowband UVB (NB-UVB; 310–331 nm)	Broadband UVB (BB-UVB)	Psoralen and UVA Light (PUVA)	Excimer Laser (308 nm)
Dosing	Determine MED. Initial treatment at 50% of MED followed by three to five treatments weekly. Lubricate before treatment. Advance treatment by at least 10% of the MED.[364] (Fitzpatrick skin types I–III, 10%–15%; skin types IV–VI, 15%–20%).[365]	Determine MED. Initial treatment often at 75% of MED. Advance treatment by at least 10% of MED (Fitzpatrick skin types I–III, 10%–15%; skin types IV–VI, 15%–20%).[365]	Dose based on MPD is recommended. If MPD testing is impractical, a regimen based on skin type may be used. Initial dose 0.5–2.0 J/cm^2, depending on skin type (or MPD). Treat twice weekly, increments of 40% per week until erythema, then maximum 20% per week. No further increments once 15 J/cm^2 is reached.[366]	Up to 6 MED (2–6 MED), twice weekly.
Efficacy	> 70% improvement in a split body study after 4 wk of treatment. Nine out of eleven patients showed clearance.[365] More effective than BB-UVB.[273,274,365]	47% improvement in a split body study after 4 wk, only 1 out of 11 patients showed clearance.[365]	Induces remission in 70%–90% of patients.[367–369] Less convenient than NB-UVB but may be more effective.[277]	Seventy-five percent improvement in Psoriasis Area and Severity Index in 72% of patients in an average of 6.2 treatments.[370]
Safety	Photodamage, polymorphic light eruption, increased risk of skin aging and skin cancers although lower than that for PUVA.[371]	Photodamage, polymorphic light eruption, increased risk of skin aging and skin cancers.	Photodamage, premature skin aging, increased risk of melanoma and nonmelanoma skin cancers, ocular damage. Eye protection required with oral psoralens.	Erythema, blisters, hyperpigmentation, and erosions. Long-term side effects not yet clear but likely similar to NB-UVB.
Contraindications	Absolute: Photosensitivity disorders. Relative: Photosensitizing medications, melanoma, and nonmelanoma skin cancers.	Absolute: Photosensitivity disorders. Relative: Photosensitizing medications, melanoma, and nonmelanoma skin cancers.	Absolute: Light-sensitizing disorder, lactation, melanoma. Relative: Age < 10 yr, pregnancy, photosensitizing medications, nonmelanoma skin cancers, severe organ dysfunction.	Absolute: Photosensitivity disorders. Relative: Photosensitizing medications, melanoma, and nonmelanoma skin cancers.
Remarks	Effective as a monotherapy, but coal tar (Goeckerman regimen), anthralin (Ingram regimen), or systemic therapies may increase effectiveness in resistant cases.[364]	Coal tar (Goeckerman regimen), anthralin (Ingram regimen), or systemic therapies may increase effectiveness in resistant cases.	< 200 total treatments (or < 2000 J/cm^2 UVA) are recommended.[372] Combination with oral retinoids can reduce cumulative UVA exposure.	Normal skin is spared from unnecessary radiation exposure, as therapy is selectively directed toward lesional skin.[282]

MED = minimal erythema dose; MPD = minimal phototoxic dose; UVB = ultraviolet B; UVA = ultraviolet A.



a treatment regimen (see Fig. 18-6) it is important to reconcile the extent and the measurable severity of the disease with the patient's own perception of his or her disease. In this context, it is notable that a recent study found that 40 percent of patients felt frustrated with the ineffectiveness of their current therapies, and 32 percent reported that treatment was not aggressive enough.[244] As psoriasis is a chronic condition, it is important to know the safety of a treatment during long-term use. In most treatments, the duration of a treatment is restricted because of the cumulative toxicity potential of an individual treatment, and, in some instances, treatment efficacy may diminish with time (tachyphylaxis). Some treatments, such as calcipotriol, MTX, and acitretin, can be regarded as appropriate for continuous use.[256] These treatments maintain efficacy and have low cumulative toxicity potential. In contrast, topical corticosteroids, dithranol, tar, photo(chemo)therapy, and cyclosporin are not indicated for continuous chronic use, and combinatorial or rotational treatments[256] are suggested. However, patients with stable chronic plaque psoriasis who respond well to local treatments may not require a change of treatment.[256] In cases of itchy/pruritic psoriasis, treatments with an irritative potential, such as dithranol, vitamin D_3 analogues, and photo(chemo)therapy, should be used cautiously, whereas treatments with potent anti-inflammatory effects, such as topical corticosteroids, are more appropriate.[256]

In patients with erythrodermic and pustular psoriasis, treatments with an irritant potential should be avoided, and acitretin, MTX, or short-course cyclosporin are the treatments of first choice.[256]

See Boxes 18-2 and 18-3 for special considerations in the treatment of women of child-bearing potential and pregnancy and children.

Topical Treatments (see Table 18-2)[257,258]

Most cases of psoriasis are treated topically. As topical treatments are often cosmetically unacceptable and time-consuming to use, non-compliance is on the order of 40 percent.[259] In most cases, ointment formulations are more effective than creams but are less cosmetically acceptable. For many patients, it is worth prescribing both cream and ointment formulations; cream for use in the morning and ointment for nighttime.[260]

CORTICOSTEROIDS Glucocorticoids exert many if not all of their myriad effects by stabilizing and causing nuclear translocation of glucocorticoid receptors, which are members of the nuclear hormone receptor superfamily. Topical glucocorticoids are commonly first-line therapy in mild to moderate psoriasis and in sites such as the flexures and genitalia, where other topical treatments can induce irritation. Improvement is usually achieved within 2 to 4 weeks, with maintenance treatment consisting of intermittent applications (often restricted to the weekends). Tachyphylaxis to treatment with topical corticosteroids is a well-estab-

TABLE 18-4
Systemic Treatments for Psoriasis

	Cyclosporin A	Methotrexate	Acitretin	Fumaric Acid Esters
Mechanism of action	Binds cyclophilin, and the resulting complex blocks calcineurin, reducing the effect of the NF-AT in T cells, resulting in inhibition of interleukin 2 and other cytokines.	Blocks dihydrofolate reductase, leading to inhibition of purine and pyrimidine synthesis. Also blocks AICAR transformylase, leading to accumulation of anti-inflammatory adenosine.[373]	Binds to retinoic acid receptors. May contribute to improvement by normalizing keratinization and proliferation of the epidermis.	Interferes with intracellular redox regulation, inhibiting NF-κB translocation. Skews the T-cell response toward a Th2-like pattern.[374]
Dosing	High-dose approach: 5 mg/kg daily, then tapered. Low-dose approach: 2.5 mg/kg daily, increased every 2–4 wk up to 5 mg/kg daily.[375] Tapering is recommended on discontinuation.	Start with a test dose of 2.5 mg and then gradually increase dose until a therapeutic level is achieved (average range, 10–15 mg weekly; maximum, 25–30 mg weekly).[375]	Initiate at 25–50 mg daily and escalate and titrate to response.[375]	Initiate at low dose, and escalate dose weekly. After treatment response is achieved, the dose should be individually adjusted. The maximum dose is 1.2 g/day.[299]
Efficacy	Very effective, up to 90% of patients achieve clearance or marked improvement.[376,377]	May reduce the severity of psoriasis by at least 50% in more than 75% of patients.[260]	Modestly effective as monotherapy.[260]	80% Mean reduction in Psoriasis Area and Severity Index.[378]
Safety	Nephrotoxicity, HTN, immunosuppression. Increased risk of malignancy if before PUVA.	Hepatotoxicity, chronic use may lead to hepatic fibrosis. Fetal abnormalities or death, myelosuppression, pulmonary fibrosis, severe skin reactions. Rarely, severe opportunistic infections.	Hepatotoxicity, lipid abnormalities, fetal abnormalities or death, alopecia, mucocutaneous toxicity, hyperostosis.	GI symptoms, including diarrhea. Flushing ± headaches. Lymphopenia, acute renal failure.[299,378]
Monitoring	BP. Obtain baseline CBC, CMP, magnesium, uric acid, lipids, UA. Repeat tests every 2–4 wk, then every month along with BP.[285]	Baseline CBC and LFTs. Monitor CBC and LFTs weekly until target dose is achieved, then every 4–8 wk.[285] Liver biopsy every 1.5 g of cumulative dose or use procollagen III assay.	Baseline LFTs, CBC, lipids, pregnancy test. Repeat LFTs, CBC, lipids every week for 1 mo then every 4 wk. Pregnancy test every month for females. Spinal x-rays if symptoms.	Baseline CBC, CMP, UA. Repeat tests every month for the first 6 mo and bi-monthly thereafter.[299]
Contraindications	Absolute: Uncontrolled HTN, abnormal renal function, history/current malignancy.	Absolute: Pregnancy, lactation. Relative: Hepatic dysfunction, hepatitis, renal insufficiency.	Absolute: Pregnancy during or within 3 years after termination of acitretin, lactation.	Absolute: Patients with chronic disease of the GI tract or renal disease. Pregnant or lactating women. Malignancy (or history of).[299]
Remarks/ long-term use	Intermittent short-course treatments appear to be safer than chronic long-term use.[377,379]	With appropriate monitoring, long-term use appears to be safe.	Retinoids have been combined with PUVA and occasionally with UVB in an attempt to minimize the side effects and to improve therapeutic response.[260]	Not U.S. Food and Drug Administration-approved for psoriasis but widely used in Europe. New formulations may reduce risk of GI symptoms.
Pregnancy category	C	X	X	C
	Hydroxyurea	**6-Thioguanine**	**Mycophenolate Mofetil**	**Sulfasalazine**
Mechanism of action	Inhibits ribonucleotide diphosphate reductase, which converts ribonucleotides to deoxyribonucleotides, thus selectively inhibiting DNA synthesis in proliferating cells.	Purine analog that interferes with purine biosynthesis, thereby inducing cell cycle arrest and apoptosis.	A noncompetitive inhibitor of inosine monophosphate dehydrogenase, blocking de novo purine biosynthesis. Selectively cytotoxic for cells that rely on de novo purine synthesis (i.e., lymphocytes).	Anti-inflammatory agent, inhibits 5-lipoxygenase, molecular mechanism unclear.
Dosing	500 mg daily, increased to 1.0–1.5 g daily based on response and tolerance.[285]	Starting dose is 80 mg twice weekly, with 20-mg increments every 2–4 weeks. Maximum dose, 160 mg three times weekly.[285]	Doses often initiated at 500–750 mg bid and then increased to 1.0–1.5 g bid.	Starting dose: 500 mg tid. If tolerated after 3 days, increase dose to 1 g tid. If tolerated after 6 wk, increase dose to 1 g qid.[285]

(continued)



TABLE 18-4
Systemic Treatments for Psoriasis (Continued)

	Hydroxyurea	6-Thioguanine	Mycophenolate Mofetil	Sulfasalazine
Efficacy	In a study of 85 patients with extensive chronic plaque psoriasis, 61% had satisfactory remission.[380]	A small retrospective cohort study demonstrated > 90% improvement in up to 80% of patients.[303]	Appears to be only moderately effective for treatment of psoriasis.[381,382]	Appears to be moderately effective treatment for severe psoriasis.[383]
Safety	Bone marrow suppression, macrocytosis. Teratogenicity and mutagenicity. Dermatologic side effects: lichen planus–like eruptions, exacerbation of post-irradiation erythema, leg ulcers, and dermatomyositis changes.	Bone marrow suppression; GI complaints, including nausea and diarrhea; hepatic dysfunction. Instances of hepatovenous-occlusive disease have been reported.[304]	GI, including constipation, diarrhea, nausea and vomiting, bleeding. Myelosuppression, leukopenia. Headaches, HTN, peripheral edema. Infectious disease, lymphoma.	Headache, nausea and vomiting, which occur in approximately one-third of patients. Rashes, pruritus, and hemolytic anemia (associated with G6PD deficiency).
Monitoring	Baseline CBC, CMP, LFTs. Repeat baseline tests weekly for 4 wk then every 2–4 wk for at least 12 wk. Then repeat tests every 3 mo.[285] Hold dosage if WBC $< 2.5 \times 10^9$/L, platelet count is $< 100 \times 10^9$/L or severe anemia.	Baseline CBC, CMP, LFTs. Repeat baseline tests weekly during dose escalation, then every 2 wk. Hold if WBC $\leq 4.0 \times 10^9$/L, platelet count is $< 125 \times 10^9$/L, or hemoglobin < 110 g/L.[285]	Baseline CBC and CMP. Repeat laboratory tests weekly × 6 wk, then every 2 wk × 2 mo, and then monthly. Monitor BP.	Baseline CBC, CMP, and G6PD. Repeat CBC and CMP weekly for 1 mo, then every 2 wk for 1 mo, then monthly for 3 mo, and then every 3 mo.
Contraindications	Absolute: Prior bone marrow depression (leukopenia, thrombocytopenia, anemia), pregnancy, lactation. Relative: Renal abnormalities.	Absolute: Patients with inherited deficiency of thiopurine methyltransferase enzyme have increased risk of myelosuppression. Liver toxicity. Pregnancy.	Absolute: Patients with severe infections, malignancy.[285]	Absolute: Hypersensitivity to sulfasalazine, sulfa drugs, salicylates, intestinal or urinary obstruction, porphyria. Precaution in patients with G6PD deficiency.
Remarks/ long-term use	Limited experience with long-term treatment.	Patients have been effectively maintained on treatment for up to 33 mo.[384]	Limited experience with long-term treatment.	Limited experience with long-term treatment.
Pregnancy category	D	D	C	B

AICAR = 5-Aminoimidazole-4-carboxamide ribonucleotide; BP = blood pressure; CBC = complete blood cell count; CMP = comprehensive metabolic panel; G6PD = glucose-6-phosphate dehydrogenase; GI = gastrointestinal; HTN = hypertension; LFTs = liver function tests; NF = nuclear factor; NF-AT = nuclear factor of activated T cells; PUVA = psoralen and UVA light; Th = T helper; UA = urinalysis; UV = ultraviolet; WBC = white blood cell count.

TABLE 18-5
Combination Treatments for Psoriasis

	Topical Vitamin D_3	Topical Corticosteroids	Dithranol	Coal Tar	Tazarotene	Ultraviolet B (UVB)	Psoralen and UVA Light (PUVA)	Methotrexate (MTX)	Cyclosporin A (CsA)
Acitretin	++	+	+	+	+	++	++	−	±
CsA	++	+	+	+	+	±	−	±	
MTX	+	+	+	+	+	±	±		
PUVA	++	+	+	−	++	±			
UVB	+/++	+	+/++	+/++	++				
Tazarotene	+	++	+	+					
Coal tar	+	+	+/++						
Dithranol	+	+							
Topical corticosteroids	+/++								

− = contraindicated combination; ± = insufficient evidence; + = recommended combination; ++ = strongly recommended combination.
Reasons for contraindicated combinations: CsA with PUVA; increased risk of squamous cell carcinoma. Coal tar with PUVA, severe phototoxic responses. Acitretin with MTX, hepatotoxicity.
Adapted from van de Kerkhof PC: Therapeutic strategies: Rotational therapy and combinations. *Clin Exp Dermatol* **26**:356, 2001, with permission.



TABLE 18-6
Biologic Treatments for Psoriasis

	ALEFACEPT	EFALIZUMAB	ETANERCEPT	INFLIXIMAB	ADALIMUMAB
Mechanism	Binds CD2 on T cells, blocking the CD2-LFA3 interaction, thus interfering with T-cell activation and causing T-cell apoptosis.	Binds CD11a (α subunit of LFA-1). Blocks the interaction of LFA-1 with intercellular adhesion molecule-1. Inhibits T-cell activation, trafficking, and adhesion to keratinocytes.	Human recombinant, soluble TNF-α receptor. Binds TNF-α and neutralizes its activity.	Chimeric monoclonal antibody that has high specificity, affinity, and avidity for TNF-α.	Fully human recombinant monoclonal antibody that specifically targets TNF-α.
Dosing	15 mg IM once weekly.	Subcutaneous injections. Conditioning: 0.7 mg/kg. Maintenance: 1 mg/kg weekly.	25- to 50-mg injections subcutaneously twice weekly.	Intravenous infusions over 2 h. 5–10 mg/kg at weeks 0, 2, and 6.	40-mg injections subcutaneously every other week.
Efficacy	PASI-75 at 14 wk (2 wk after last dose) 24%. Patients who respond maintain improvement for extended periods of time. Repeat courses are safe and well tolerated.[385]	PASI-75 at 12 wk, 22%–41%;[386–388] at 24 wk, 44%;[389] and at 27 mo of extended treatment, 56%.[388]	PASI-75 at 12 wk, 34% and at 24 wk, 44%.[390]	PASI-75 at 10 wk, 82% (5 mg/kg) and 91% (10 mg/kg).[391] At wk 26 (following a single course), 57% of patients maintained PASI-50, and 50% maintained PASI-75.[391]	PASI-75 at 24 weeks 59%.[392]
Safety	Lymphopenia, malignancy, serious infections. Not recommended for human immunodeficiency virus–positive patients. Effects of live vaccines not studied.	Serious infections, thrombocytopenia, exacerbation of psoriasis. Live vaccinations not recommended.	Serious infections, exacerbation of MS, pancytopenia, malignancy. Worsening congestive heart failure. Lupus-like symptoms (anti-dsDNA positive). Live vaccinations should not be given.	Infusion-related reactions, infections, worsening of MS, malignancy or lymphoproliferative disease, worsening heart failure. Lupus-like symptoms (anti-dsDNA positive). Live vaccinations should not be given.	Injection site reactions, infections, lupus-like syndrome, worsening heart failure, cytopenias, neurologic events.[393] Live vaccinations should not be given.
Monitoring	$CD4^+$ T-cell counts every 2 wk during treatment.	Regular platelet counts.	Baseline PPD.	Baseline PPD.	Baseline PPD.
Long-term administration	Up to nine courses have been administered over 4–5 yr in small number of patients with incremental benefits.	PASI responses continue to increase to wk 24 and are maintained in patients receiving long-term continuous therapy (up to 24 mo).	PASI response continues to increase to wk 24. Large databases in patients with other immunologic diseases indicate safety.	As intermittent therapy. Large databases in patients with other immunologic diseases indicate relative safety.	Expected to be similar to other TNF-α inhibitors.
Pregnancy category	B	C	B	B	B

dsDNA = double-stranded DNA; LFA = lymphocyte function–associated antigen; MS = multiple sclerosis; PASI-50 = 50% improvement in Psoriasis Area and Severity Index; PASI-75 = 75% improvement in Psoriasis Area and Severity Index; PPD = purified protein derivative (of tuberculin); TNF = tumor necrosis factor.



lished phenomenon in psoriasis.[261] Long-term topical corticosteroids may cause striae (Fig. 18-17) and adrenal suppression. This class of agents is discussed in detail in Chap. 225.

VITAMIN D_3 AND ANALOGUES[262] Vitamin D exerts its actions by binding to the vitamin D receptor, another member of the nuclear hormone receptor superfamily. Vitamin D_3 acts to regulate cell growth, differentiation, and immune function, as well as calcium and phosphorous metabolism. Vitamin D has been shown to inhibit the proliferation of keratinocytes in culture and to modulate epidermal differentiation. Furthermore, vitamin D inhibits production of several pro-inflammatory cytokines by psoriatic T-cell clones, including IL-2 and IFN-γ.[263]

Analogues of vitamin D that have been used for the treatment of skin diseases are calcipotriene, (calcipotriol), tacalcitol, and maxacalcitol. In short-term studies, potent topical corticosteroids were found to be superior to calcipotriene. When compared with short-contact anthralin or 15 percent coal tar, calcipotriene was the more effective agent. The efficacy of calcipotriene is not reduced with long-term treatment.[264] Calcipotriene applied twice daily is more effective than once-daily use. Hypercalcemia is the only major concern with the use of topical vitamin D preparations. When the amount used does not exceed the recommended 100 g/week, calcipotriene can be used with a great margin of safety.[265] Vitamin D analogues are often used in combination with or in rotation with topical corticosteroids in an effort to maximize therapeutic effectiveness while minimizing steroid-related skin atrophy.

ANTHRALIN (DITHRANOL) Dithranol (1,8-dihydroxy-9-anthrone) is a naturally oc-

Box 18-2

Treatment of Women of Child-Bearing Potential and during Pregnancy

- Special caution needs to be exercised when treating women of child-bearing potential and during pregnancy.
- Medications such as methotrexate and oral retinoids should be avoided or used with extreme caution and then only along with appropriate contraception.
- In selected cases, isotretinoin rather than acitretin may be the preferred agent due to its much shorter half-life.
- As methotrexate is fetotoxic and an abortifactant and retinoids are potent teratotoxins, the use of these agents is absolutely contraindicated in pregnancy.
- Many women experience improvement or remission during periods of pregnancy, thus decreasing the need for the more potent agents.
- If treatment is needed, emollients and other topical agents are first line agents, often in association with ultraviolet B phototherapy.
- Many of the topical agents, such as topical steroids and calcipotriene, are pregnancy category C agents, and caution should be exercised with their use.
- Several of the biologic agents are category B and can be used in pregnancy. Likewise, cyclosporin A may be considered, as it is pregnancy category C and is nonteratogenic.
- Systemic psoralen and ultraviolet A light has been used on occasion in selected cases and appears to be safe.

curring substance found in the bark of the araroba tree in South America. It can also be synthesized from anthrone. Dithranol is made up in a cream, ointment, or paste.

Box 18-3

Treatment of Children

- Children represent a large fraction of psoriasis patients, as the disease commonly presents during childhood or adolescence.
- As for adults, first line treatment is with topical agents, often in association with ultraviolet B phototherapy.
- Due to its carcinogenic risk and opportunity for long-term exposure, psoralen and ultraviolet A light is generally contraindicated in childhood.
- Likewise, the decision to treat with systemic agents should be carefully assessed, as the long-term potential side-effect profile of many of the systemic agents is still unknown. However, many of the systemic agents have been used successfully in severe recalcitrant cases.



▲ **FIGURE 18-17** Positive and negative outcomes of psoriasis treatment. Panel **A** illustrates near-complete improvement of psoriasis after 10 weeks of infliximab therapy. Panel **B** illustrates marked improvement after 28 days of oral cyclosporin A treatment. Panel **C** illustrates marked reduction in nail dystrophy after 16 weeks of cyclosporin A treatment. Panel **D** illustrates severe atrophy with striae distensae after several years of treatment with potent topical steroid creams. (Photos used with permission from Mr. Harrold Carter.)

Dithranol is approved for the treatment of chronic plaque psoriasis. Its most common use has been in the treatment of psoriasis, particularly on plaques resistant to other therapies. It can be combined with UVB phototherapy with good results (the Ingram regimen). Most common side effects are irritant contact dermatitis and staining of clothing, skin, hair, and nails. Anthralin possesses antiproliferative activity on human keratinocytes along with potent anti-inflammatory effects. Classic anthralin therapy starts with low concentrations (0.05 to 0.1 percent) incorporated in petrolatum or zinc paste and given once daily. To prevent auto-oxidation, salicylic acid (1 percent to 2 percent) should be added. The concentration is increased weekly in individually adjusted increments up to 4 percent until the lesions resolve. Scalp psoriasis should be treated with great caution as anthralin can stain hair purple to green.

COAL TAR The use of tar to treat skin diseases dates back nearly 2000 years. In 1925, Goeckerman introduced the use of crude coal tar and UV light for the treatment of psoriasis. Tar is the dry distillation product of organic matter heated in the absence of oxygen. Its mode of action is not understood, and, because of its inherent chemical complexity, tar is not pharmacologically standardized, and the specific therapeutic activity of its components is not known. Tar appears to exert its action through suppression of DNA synthesis and consequent reduction of mitotic activity in the basal layer of the epidermis, and some components in tar appear to have anti-inflammatory activity. Coal tar, in concentrations up to 20 percent (5 percent to 20 percent) can be compounded in creams, ointments, and pastes. It is often combined with sali-



cylic acid (2 percent to 5 percent), which by its keratolytic action leads to better absorption of the coal tar.[205] Occasionally, patients become sensitive to the coal tar and develop allergic reactions. A folliculitis may occur after the use of coal tar. Furthermore, it has an unwelcome smell and appearance and can stain clothing and other items. Coal tar is carcinogenic.

TAZAROTENE Tazarotene is a third-generation retinoid for topical use that reduces mainly scaling and plaque thickness, with limited effectiveness on erythema. It is thought to act by binding to retinoic acid receptors, but its molecular targets are unknown. It is available in 0.05 percent and 0.1 percent gels, and a cream formulation has been developed. When this drug is used as a monotherapy, a significant proportion of patients develop local irritation. This retinoid dermatitis is worse with the 0.1 percent formulation. Efficacy of this drug can be enhanced by combination with mid- to high-potency glucocorticoids or UVB phototherapy. When used in combination with phototherapy, it lowers the minimal erythema dose (MED) for both UVB and UVA. It has been recommended that UV doses be reduced by at least one-third if tazarotene is added in the middle of a course of phototherapy.[266]

TOPICAL CALCINEURIN INHIBITORS (See Chap. 221) Tacrolimus (FK-506) is a macrolide antibiotic, derived from the bacteria *Streptomyces tsukubaensis* that, by binding to immunophilin (FK506 binding protein), creates a complex that interacts and inhibits calcineurin, thus blocking both T-lymphocyte signal transduction and IL-2 transcription. Pimecrolimus is also a calcineurin inhibitor and works in a manner similar to tacrolimus and CsA.

In a study of 70 patients with chronic plaque psoriasis treated with topical tacrolimus, there was no improvement beyond that seen for placebo.[267] However, for treatment of inverse and facial psoriasis, these agents appear to provide effective treatment.[268,269] The main side effect of these medications is a burning sensation at application site. Anecdotal reports of lymph node or skin malignancy require further evaluation in controlled studies, and these drugs have a U.S. Food and Drug Administration (FDA) "black box warning."

BLAND EMOLLIENTS Between treatment periods, skin care with emollients should be performed to avoid dryness. Emollients reduce scaling, may limit painful fissuring, and can help control pruritus. They are best applied immediately after bathing or showering. The addition of urea (up to 10 percent) is helpful to improve hydration of the skin and remove scaling of early lesions. The use of liberal bland emollients over a thin layer of topical prescription treatments improves hydration while minimizing treatment costs.

Phototherapy[270] (See Table 18-3) (See Chap. 238)

The mechanism of action of phototherapy appears to involve selective depletion of T cells, predominantly those that reside in the epidermis.[121,171] The mechanism of depletion appears to involve apoptosis[271] and is accompanied by a shift from a Th1 immune response toward a Th2 response in the lesional skin.[272]

ULTRAVIOLET B LIGHT (290 TO 320 NM) The initial therapeutic UVB dose lies at 50 percent to 75 percent of the MED. Treatments are given two to five times per week. As peak UVB erythema appears within 24 hours of exposure, increments can be performed at each successive treatment. The objective is to maintain a minimally perceptible erythema as a clinical indicator of optimal dosing. Treatments are given until total remission is reached or until no further improvement can be obtained with continued treatment. The main side effects of UVB phototherapy are summarized in Chap. 238.

Narrowband (312 nm) UVB (NB-UVB) phototherapy is superior to conventional broadband UVB (290 to 320 nm) with respect to both clearing and remission times[273,274] (see Table 18-3). Although early studies found NB-UVB to be as effective as psoralen and UVA light (PUVA),[275,276] a recent controlled trial found that PUVA was more effective, albeit less convenient.[277] On clearing, treatment is either discontinued or patients are subjected to maintenance therapy for 1 or 2 months. During this period, the frequency of UVB treatments is reduced while maintaining the last dose given at the time of clearing.[270]

Systemic drugs, such as retinoids, increase the efficacy of UVB light, particularly in patients with chronic and hyperkeratosis plaque–type psoriasis.[278,279] Because they are known to inhibit carcinogenesis in experimental animals, retinoids may possibly reduce the carcinogenic potential of UVB phototherapy.

PSORALEN AND ULTRAVIOLET A LIGHT (See Chap. 239) PUVA is the combined use of psoralens (P) and long-wave ultraviolet A radiation (UVA). The combination of drug and radiation results in a therapeutic effect, which is not achieved by the single component alone. Remission is induced by repeated controlled phototoxic reactions (see Table 18-3). A detailed account of PUVA therapy and its short-term and long-term side effects is to be found in Chap. 239.

EXCIMER LASER[280] (See Chap. 240) Supra-erythemogenic fluences of UVB and PUVA are known to result in faster clearing of psoriasis,[281] however, the limiting factor for the use of such high fluences lies with the intolerance of the uninvolved surrounding skin as psoriatic lesions can often withstand much higher UV exposures.[282] The monochromatic 308-nm excimer laser can deliver such supra-erythemogenic doses of light (up to 6 MED, usually in the range of 2 to 6 MEDs) focally to lesional skin (see Table 18-3). In a study on 124 patients, 72 percent of study subjects achieved at least 75 percent clearing in an average of 6.2 treatments delivered twice weekly.[282] The role of this treatment seems to be indicated for patients with stable recalcitrant plaques particularly in the elbows and knee region.

PHOTODYNAMIC TREATMENT[283] (See Chap. 239) Photodynamic therapy has been tried for several inflammatory dermatoses, including psoriasis. In a randomized study on the effect of topical aminolevulinic acid–based photodynamic therapy, 29 patients demonstrated unsatisfactory clinical response and frequent occurrence of pain during and after treatment, prompting the authors to declare this as an inadequate treatment option for psoriasis.

CLIMATIC THERAPY[284] It is well known that going to a sunny climate can improve psoriasis, although a small proportion of patients actually deteriorate. Patients should be warned not to overexpose themselves in the first few days, as sunburn may actually progress to psoriasis (Koebner phenomenon). The best-studied effects are from the Dead Sea area, and those therapeutic effects may be attributed, at least partially, to the unique climatic characteristic of that location. As it is situated 400 m below sea level, the evaporation of the sea forms an aerosol that stays in the atmosphere above the sea and surround-



ing beaches. This aerosol screens out the majority of the UVB rays but not the UVA. This mixture of UV light appears to be sufficient to clear psoriasis but without sunburn. Thus, patients can stay on the shores of the Dead Sea for long periods of time with greatly reduced risk of sunburn. This treatment is carried out over a period of 3 to 4 weeks, and improvements comparable to NB-UVB or PUVA treatments are observed. The main disadvantages of this treatment are time and expense.

Systemic Oral Agents[285,286] (See Table 18-4)

METHOTREXATE MTX is highly effective for chronic plaque psoriasis[286] and is also indicated for the long-term management of severe forms of psoriasis, including psoriatic erythroderma and pustular psoriasis[285] (see Table 18-4). For mechanisms of action, see Chap. 228. When first used for the treatment of psoriasis, MTX was thought to act directly to inhibit epidermal hyperproliferation via inhibition of dihydrofolate reductase (DHFR). However, it was found to be effective at much lower doses (0.1 to 0.3 mg/kg weekly) in the management of psoriasis, psoriatic arthritis, and other inflammatory conditions such as rheumatoid arthritis. At these concentrations, MTX inhibits the in vitro proliferation of lymphocytes, but not proliferation of keratinocytes.[286] It is now thought that the inhibition of DHFR is not the main mechanism of anti-inflammatory action of MTX, but rather the inhibition of an enzyme involved in purine metabolism [AICAR (5-aminoimidazole-4-carboxamide ribonucleotide) transformylase]. This leads to accumulation of extracellular adenosine, which has potent anti-inflammatory activities, particularly for neutrophils.[287] Consistent with a DHFR-independent mechanism of action, concomitant administration of folic acid (1 to 5 mg/day) reduces certain side effects, such as nausea and megaloblastic anemia, without diminishing the efficacy of antipsoriatic treatment.[288] The cellular targets of MTX action in psoriasis are still under investigation, but its mechanism of action may involve modulation of adhesion molecules, such as intercellular adhesion molecule 1, rather than induction of lymphocyte apoptosis.[289]

The very long half-life of MTX may account for its efficacy after weekly administration and may also help to explain why its onset of action is rather slow (therapeutic effects usually require 4 to 8 weeks to become evident). MTX is renally excreted and should therefore not be administered to patients with impairment in renal function, as MTX side effects are generally dose-related. Short-term toxicity and long-term concerns are discussed in Chap. 228.

In the most recent guidelines,[290] patients with normal liver function tests and without a history of liver disease or alcoholism are not asked to undergo liver biopsy until they have been treated with a cumulative MTX dose of 1.0 to 1.5 g. Repeat biopsies are done approximately 1.0 to 1.5 g thereafter if liver function test and biopsy findings are normal. Some groups have recommended the use of amino terminal type III procollagen peptide (PIIINP) assay for screening of liver fibrosis.[291] Specific guidelines have been developed for monitoring PIIINP levels in psoriatic patients,[291] but the FDA has not yet approved the use of this assay for diagnostic use within the United States.

Another well-known side effect of MTX is myelosuppression, especially pancytopenia, which usually occurs in the setting of folate deficiency. Leucovorin calcium (folinic acid) is the only antidote for the hematologic toxicity of MTX. When an overdose is suspected, an immediate leucovorin dose of 20 mg should be given parenterally or orally, and subsequent doses should be given every 6 hours.[292] Pneumonitis can develop, and mucosal and skin ulcerations have also been reported in patients treated with MTX.[293,292]

Discontinuation of MTX treatment is required in the event of hepatotoxicity, hematopoietic suppression, active infections, nausea, and pneumonitis. MTX is also teratogenic and should therefore not be prescribed for women who are pregnant. Several classes of drugs, including nonsteroidal anti-inflammatory drugs and sulfonamides, may interact with MTX to increase toxicity.

ACITRETIN[294] Acitretin is a second-generation, systemic retinoid that has been approved for the treatment of psoriasis since 1997 and is discussed in Chap. 229.

The clinical forms most responsive to etretinate or acitretin as monotherapy include generalized pustular and erythrodermic psoriasis. Acitretin induces clearance of psoriasis in a dose-dependent fashion. Overall, higher starting doses appeared to clear psoriasis faster.[295] The mechanism of action of retinoids for psoriasis is not fully understood.

The optimal initial dose of acitretin for psoriasis is reported at 25 mg/day, with a maintenance dose of 20 to 50 mg/day (see Table 18-4). Adverse effects, such as hair loss and paronychia, occur more frequently with higher initial dose (i.e., ≥ 50 mg/day). Most patients relapse within 2 months after discontinuing etretinate or acitretin. Acitretin should be discontinued if liver dysfunction, hyperlipidemia, or diffuse idiopathic hyperostosis develops.

CYCLOSPORIN A CsA is a neutral cyclic undecapeptide derived from the fungus *Tolypocladium inflatum gams*. Its mechanism of action and side effects are discussed in Chap. 234. The only formulation approved for treatment of psoriasis is available as an oral solution or in capsules. It is highly effective for cutaneous psoriasis and can also be effective for nail psoriasis (see Fig. 18-17). CsA is particularly useful in patients who present with widespread, intensely inflammatory, or frankly erythrodermic psoriasis. Dosage ranges from 2 to 5 mg/kg/day (see Table 18-4).[296] Because the nephrotoxic effects of CsA are largely irreversible, CsA treatment should be discontinued if kidney dysfunction and/or hypertension occur. CsA-induced hypertension may be treated with calcium antagonists such as nifedipine.[297] The most common adverse effects noted in patients using CsA for short periods of time are neurologic, including tremors, headache, paresthesia, and/or hyperesthesia. Long-term treatment of psoriasis with low-dose CsA was found to increase risk of non-melanoma skin cancers.[298] However, unlike organ transplant patients treated with higher doses of CsA, there is little or no increased risk of lymphoma.

FUMARIC ACID ESTERS Fumaric acid was first reported in 1959 to be beneficial in the systemic treatment of psoriasis[299] and is licensed in Germany for treatment of psoriasis. Because fumaric acid itself is poorly absorbed after oral intake, esters are used for treatment. The esters are almost completely absorbed in the small intestine, and dimethylfumarate is rapidly hydrolyzed by esterases to monomethylfumarate, which is regarded as the active metabolite. The mode of action of fumaric acid esters (FAEs) in the treatment of psoriasis is not fully understood, but experimental data point toward a skewing of the Th1-dominated T-cell response in psoriasis to a Th2-like pattern and inhibition of keratinocyte proliferation.[299] Patients with severe concomitant disease, chronic disease of the



gastrointestinal tract, chronic kidney disease, or with bone marrow disease leading to leukocytopenias or leukocyte dysfunction should not be treated. Likewise, pregnant or lactating women and patients with malignant disease (including positive history of malignancy) should be excluded from treatment. Prolonged therapy (up to 2 years) to prevent relapse in psoriasis patients with high disease activity is possible. Another therapeutic option is short-course intermittent therapy. FAEs are given until a major improvement is achieved and are then withdrawn (see Table 18-4). If a patient remains lesion-free during prolonged treatment, the FAE dose should be gradually decreased to reach the individual's threshold.[299] Therapy with FAEs can be stopped abruptly. Rebound phenomena have not been observed.[299]



SULFASALAZINE Sulfasalazine is an uncommonly used systemic agent in the management of psoriasis. In the only prospective double-blind study on the efficacy of sulfasalazine in psoriasis, moderate effects were seen, with 41 percent of the patients showing marked improvement, 41 percent with moderate, and 18 percent with minimal improvement after 8 weeks of treatment.[300]

SYSTEMIC STEROIDS (See Chap. 225) In general, systemic steroids should not be used in the routine care of psoriasis. When systemic steroids are used, clearance of psoriasis is rapid, but the disease usually breaks through, requiring progressively higher doses to control symptoms. If withdrawal is attempted, the disease tends to relapse promptly and may rebound in the form of erythrodermic and pustular psoriasis.[301] However, systemic steroids may have a role in the management of persistent, otherwise uncontrollable, erythroderma and in fulminant generalized pustular psoriasis (von Zumbusch type) if other drugs are ineffective.

MYCOPHENOLATE MOFETIL (See Chap. 228) Mycophenolate mofetil is a prodrug of mycophenolic acid, an inhibitor of inosine-5′-monophosphate dehydrogenase. Mycophenolic acid depletes guanosine nucleotides preferentially in T and B lymphocytes and inhibits their proliferation, thereby suppressing cell-mediated immune responses and antibody formation. The drug is usually well tolerated with few side effects. Few studies have been done on this medication for psoriasis, but, in a prospective open-label trial on 23 patients with dosage between 2 to 3 g daily, a 24 percent reduction of the Psoriasis Area and Severity Index (PASI) was seen after 6 weeks, with 47 percent improvement at 12 weeks.[302]

6-THIOGUANINE 6-Thioguanine is a purine analog that has been highly effective for psoriasis.[303] Apart from bone marrow suppression, gastrointestinal complaints including nausea and diarrhea can occur, and elevation of liver function tests is common.[285] Isolated instances of hepatic veno-occlusive disease have been reported.[304]

HYDROXYUREA Hydroxyurea is an antimetabolite that has been shown to be effective as monotherapy, but nearly 50 percent of patients who achieve marked improvement develop bone marrow toxicity with leukopenia or thrombocytopenia. Megaloblastic anemia is also common but rarely requires treatment.[285] Cutaneous reactions affect most patients treated with hydroxyurea, including leg ulcers, which are the most troublesome.[305]

Combination Treatments (See Table 18-5)

Combination treatment may increase efficacy and reduce side effects, and so may result in a more substantial improvement, or alternatively, may permit reduced doses to reach the same improvement as compared with monotherapy.[256] Data on combination of biologics with other systemic or topical agents are not yet widely available, but some combinations commonly used in the treatment of inflammatory arthritides, such as a combination of MTX and anti-TNF agents,[306] may be appropriate for treatment of recalcitrant psoriatic disease.

Biologic Treatments[307–310] (See Table 18-6) (See also Chap. 235)

Based on the continuous progress in psoriasis research and advances in molecular biology, a new class of agents—targeted biologic therapies—has emerged.[307,308] These agents are designed to block specific molecular steps important in the pathogenesis of psoriasis or have been transferred to the psoriasis arena after being developed for other inflammatory diseases. Currently, three types of biologics are approved or are in development for psoriasis: (1) recombinant human cytokines, (2) fusion proteins, and (3) monoclonal antibodies, which may be chimeric or humanized (see Table 18-6). Due to the risk of the development of antibodies to mouse sequences, humanized or fully human antibodies are preferred for clinical use.

Using internationally acknowledged safety and efficacy endpoints, the overall utility and benefit of biologics have been demonstrated based on the percentage of patients achieving at least a 50 percent improvement in PASI (PASI-50), a 75 percent improvement in PASI (PASI-75), the impact of treatment on quality of life, and safety and tolerability.[310] In general, these agents have antipsoriatic activity roughly comparable to that of MTX and lack its risk of hepatotoxicity. However, they are far more expensive, carry risks of immunosuppression, infusion reactions, and antibody formation, and their long-term safety remains to be evaluated. In the opinion of the authors, use of biologic agents should be reserved for treatment of severe psoriasis that is either unresponsive to MTX or in patients for whom the use of MTX is contraindicated.

ALEFACEPT Alefacept is a human lymphocyte function–associated antigen (LFA)-3-IgG1 fusion protein designed to prevent the interaction between LFA-3 and CD2. The LFA-3-CD2 signal plays an important role in activation of T cells. The LFA-3 portion of alefacept binds to the CD2 receptor on T cells, blocking the interaction between LFA-3 and CD2, thus interfering with the activation of T cells, inducing apoptosis and modifying the inflammatory process. CD2 is upregulated on memory effector T cells, explaining the preferential depletion of these cells by alefacept.[311] One-third to one-half of psoriatic patients do not respond to alefacept; the reasons for this remain unclear. However, evidence indicates that repeated administration of alefacept leads to improved response, and that responses to alefacept are durable.[308]

EFALIZUMAB Efalizumab (anti-CD11a) is a humanized monoclonal antibody developed for treatment of plaque psoriasis. It is directed against CD11a, the α subunit of LFA-1, and thus blocks the interaction of LFA-1 with its ligand intercellular adhesion molecule 1. This blockade inhibits T-cell activation, cutaneous T-cell trafficking, and T-cell adhesion to keratinocytes.[312,313] Some patients have shown evidence of exacerbation of the disease at the end of the dosing period.[314] Studies are currently evaluating

the safety and tolerability of long-term treatment with efalizumab.

TUMOR NECROSIS FACTOR-α ANTAGONISTS

The clinical application of TNF antagonists in inflammatory diseases has exploded on the clinical realm in a manner reminiscent of the discovery of the activity of corticosteroids.[315] TNF-α is a homotrimeric protein that exists in both transmembrane and soluble forms, the latter resulting from proteolytic cleavage and release. It is still unclear which form is more important in mediating its pro-inflammatory activities or the relative importance of the two p55- and p75-kd TNF-α–binding receptors.[316]

Currently, three anti-TNF biologics are available in the United States. Infliximab is a chimeric monoclonal antibody that has high specificity, affinity, and avidity for TNF-α. An example of an excellent treatment outcome with infliximab is shown in Fig. 18-17. Etanercept is a human recombinant, soluble, TNF-α receptor-FcIgG fusion protein that binds TNF-α and neutralizes its activity. Adalimumab is the first fully human recombinant IgG1 monoclonal antibody and specifically targets TNF-α. Currently, infliximab and adalimumab are only FDA-approved for psoriatic arthritis. However, clinical trials have shown that each of these agents is well tolerated and appears suitable for long-term use in chronic plaque psoriasis. However, like all the targeted biologic therapies, they carry risks of immunosuppression (see Table 18-6), and their long-term safety requires further study.

Clinical studies have found infliximab and adalimumab to be slightly more effective than etanercept in the treatment of psoriasis (see Table 18-6). It is likely that the differential effects of these agents are associated with selectivity in their ability to perturb these receptor ligand interactions. It is known that infliximab, adalimumab, and etanercept bind TNF differently; infliximab and adalimumab bind to both soluble and membrane-bound TNF, whereas etanercept binds primarily to soluble TNF.[317] Binding to membrane-bound TNF can induce a dose-dependent increase in apoptosis of T cells, but the relevance of this mechanism in psoriasis has not been evaluated.

ANTI-INTERLEUKIN 12/INTERLEUKIN 23 P40

A recently developed agent has been developed and tested for treatment of chronic plaque psoriasis and has shown promising efficacy in phase I trials. This agent is a human IgG1 κ monoclonal antibody that binds to the common p40 subunit of human IL-12 and IL-23 and prevents its interaction with its receptor.[318] Besides blocking IL-12, which is critical for Th1 differentiation of T cells, blockade of IL-23 may be even more important in the treatment of chronic plaque psoriasis, as this cytokine supports chronic inflammation by maintaining a separate $CD4^+$ T-cell subset characterized by IL-17 production.[80–82] A phase I trial testing various treatment doses showed clear correlation between the anti-IL-12 p40 dose and the proportion of subjects achieving at least a 75 percent improvement in PASI score.[318]

Numerous new drugs are currently in clinical trials for treatment of psoriasis as outlined in a comprehensive review.[319]

PREVENTION

There is no known prevention for psoriasis.

KEY REFERENCES

The full reference list for all chapters is available at www.digm7.com.

3. Farber EM, Nall ML: The natural history of psoriasis in 5,600 patients. *Dermatologica* **148**:1, 1974
10. Elder JT et al: The genetics of psoriasis. *Arch Dermatol* **130**:216, 1994
16. Sagoo GS et al: Genome-wide studies of psoriasis susceptibility loci: A review. *J Dermatol Sci* **35**:171, 2004
39. Bowcock AM, Krueger JG: Getting under the skin: The immunogenetics of psoriasis. *Nat Rev Immunol* **5**:699, 2005
54. Ragaz A, Ackerman AB: Evolution, maturation, and regression of lesions of psoriasis. New observations and correlation of clinical and histologic findings. *Am J Dermatopathol* **1**:199, 1979
62. Gaspari AA: Innate and adaptive immunity and the pathophysiology of psoriasis. *J Am Acad Dermatol* **54**:S67, 2006
63. Nickoloff BJ, Nestle FO: Recent insights into the immunopathogenesis of psoriasis provide new therapeutic opportunities. *J Clin Invest* **113**:1664, 2004
70. Wrone-Smith T, Nickoloff BJ: Dermal injection of immunocytes induces psoriasis. *J Clin Invest* **98**:1878, 1996
84. Sugiyama H et al: Dysfunctional blood and target tissue $CD4^+CD25$ high regulatory T cells in psoriasis: Mechanism underlying unrestrained pathogenic effector T cell proliferation. *J Immunol* **174**:164, 2005
107. Nestle FO et al: Plasmacytoid predendritic cells initiate psoriasis through interferon-α production. *J Exp Med* **202**:135, 2005
114. Clark RA, Kupper TS: Misbehaving macrophages in the pathogenesis of psoriasis. *J Clin Invest* **116**:2084, 2006
116. Stratis A et al: Pathogenic role for skin macrophages in a mouse model of keratinocyte-induced psoriasis-like skin inflammation. *J Clin Invest* **116**:2094, 2006
119. Braff MH et al: Cutaneous defense mechanisms by antimicrobial peptides. *J Invest Dermatol* **125**:9, 2005
167. Bata-Csorgo Z et al: Fibronectin and α5 integrin regulate keratinocyte cell cycling. A mechanism for increased fibronectin potentiation of T cell lymphokine-driven keratinocyte hyperproliferation in psoriasis. *J Clin Invest* **101**:1509, 1998
171. Gudjonsson JE et al: Immunopathogenic mechanisms in psoriasis. *Clin Exp Immunol* **135**:1, 2004
232. Mallbris L et al: Psoriasis is associated with lipid abnormalities at the onset of skin disease. *J Am Acad Dermatol* **54**:614, 2006
236. Gelfand JM et al: Risk of myocardial infarction in patients with psoriasis. *JAMA* **296**:1735, 2006
237. Gelfand JM et al: The risk of lymphoma in patients with psoriasis. *J Invest Dermatol* **126**:2194, 2006
238. Fortune DG, Richards HL, Griffiths CE: Psychologic factors in psoriasis: Consequences, mechanisms, and interventions. *Dermatol Clin* **23**:681, 2005
244. Krueger G et al: The impact of psoriasis on quality of life: Results of a 1998 National Psoriasis Foundation patient-membership survey. *Arch Dermatol* **137**:280, 2001
255. O'Brien M, Koo J: The mechanism of lithium and β-blocking agents in inducing and exacerbating psoriasis. *J Drugs Dermatol* **5**:426, 2006
256. van de Kerkhof PC: Therapeutic strategies: Rotational therapy and combinations. *Clin Exp Dermatol* **26**:356, 2001
257. Lebwohl M, Ali S: Treatment of psoriasis. Part 1. Topical therapy and phototherapy. *J Am Acad Dermatol* **45**:487; quiz 499–502, 2001
262. Lehmann B: The vitamin D_3 pathway in human skin and its role for regulation of biological processes. *Photochem Photobiol* **81**:1246, 2005
285. Lebwohl M, Ali S: Treatment of psoriasis. Part 2. Systemic therapies. *J Am Acad Dermatol* **45**:649; quiz 662–644, 2001
290. Roenigk HH, Jr. et al: Methotrexate in psoriasis: Revised guidelines. *J Am Acad Dermatol* **19**:145, 1988
299. Mrowietz U, Christophers E, Altmeyer P: Treatment of severe psoriasis with fumaric acid esters: Scientific background and guidelines for therapeutic use. The German Fumaric Acid Ester Consensus Conference. *Br J Dermatol* **141**:424, 1999
308. van de Kerkhof PC: Consistent control of psoriasis by continuous long-term therapy: The promise of biological treatments. *J Eur Acad Dermatol Venereol* **20**:639, 2006



CHAPTER 19

Psoriatic Arthritis

Robert Winchester



DEFINITION AND CLASSIFICATION

Psoriatic arthritis is a clinically distinctive autoimmune inflammation of the musculoskeletal system that occurs in persons with psoriasis or with a strong family history of psoriasis. The inflammation underlying psoriatic arthritis is apparently driven by CD8 T cells and is based on the entrance and activation of T cells in three target sites: the entheses (fibrocartilage insertions of ligaments, tendons, and fascia), the synovium of peripheral synovial joints, and the spine and sacroiliac joints. The activated T cell releases cytokines and chemokines that directly affect target tissues, activate macrophages to secondarily release additional cytokines and chemokines and, result in the recruitment of additional inflammatory leukocytes.

Of the three target sites, the inflammation of the entheses, enthesitis,[1] and the spine, spondyloarthritis, are distinctive features of psoriatic arthritis. In contrast, the development of arthritis, synovitis, or non-specific musculoskeletal symptoms in a person with psoriasis does not, per se, make the diagnosis of psoriatic arthritis and requires exclusion of the coincident occurrence of psoriasis with other inflammatory arthritides or musculoskeletal conditions such as fibromyalgia, seronegative or seropositive rheumatoid arthritis, Lyme disease, repetitive motion injuries, or osteoarthritis. Although the large majority of cases of psoriatic arthritis are readily identified, precise and sensitive diagnostic criteria for psoriatic arthritis are not yet fully developed and validated, which complicates the study of the disease. The criteria for case classification for study purposes also are improving. Table 19-1 summarizes some distinguishing features of psoriatic arthritis that are useful for its diagnosis. These distinguishing features reflect increased emphasis on the presence of enthesitis and spondyloarthritis as specific elements of psoriatic arthritis.

Psoriatic arthritis develops in approximately 10 percent to 15 percent of those with psoriasis. In approximately one-half of those affected with psoriatic arthritis, the musculoskeletal involvement appears an average of a decade after the onset of psoriasis, whereas in the remainder the onset is roughly contemporaneous or even precedes the development of skin disease.[2] Psoriatic arthritis is, intriguingly, more likely to be found in individuals with psoriasis who lack HLA-Cw6, *Psors 1*, consistent with some genetic heterogeneity. Unlike most autoimmune diseases, psoriatic arthritis does not appear to involve B cells or autoantibody production or be critically dependent on CD4 T cells as is indicated by the increase in prevalence and severity of psoriatic arthritis in those with advancing and poorly treated human immunodeficiency virus-1 (HIV-1) infection, where special concerns exist about its therapy.

The rapid development of potent new pharmacologic agents and improved regimens for their use has substantively improved the treatment of psoriatic arthritis. This is particularly the case in more severe forms of psoriatic arthritis where in view of the role of T cells and macrophages in disease pathogenesis, new immunobiologics, such as tumor necrosis factor (TNF) blockers, offer the potential of targeting and interdicting specific stages or events in the mechanism of disease, and indeed are very effective disease-modifying antirheumatic drugs (DMARDs), at least in subsets of individuals.

TABLE 19-1
Diagnostic Clinical Features of Psoriatic Arthritis

- Characteristic features
  - Psoriasis present
  - Enthesitis
  - Dactylitis
  - Onychodystrophy
  - Distal interphalangeal joint involvement
  - Juxta-articular new bone formation
  - Sacroiliitis and/or spondyloarthritis
  - Isolated involvement of the joints of one ray (e.g., distal interphalangeal, proximal interphalangeal, monocyte chemotactic protein)
  - Insidious appearance of ankylosed joints (e.g., hallux rigidus)
- Supporting features
  - In the absence of documented psoriasis, a convincing history of psoriasis and/or a family history positive for psoriasis
  - Peripheral arthritis, often asymmetrical or oligoarticular at onset
- Exclusions
  - Fibromyalgia
  - Seronegative or seropositive rheumatoid arthritis
  - Intercurrent arthritides (e.g., Lyme disease)
  - Repetitive motion–induced musculoskeletal syndromes

PSORIATIC ARTHRITIS AT A GLANCE



- Psoriatic arthritis is a member of the seronegative spondyloarthritis group of disorders and affects three principal target sites: the entheses, the synovium, and the spine and sacroiliac joints.
- Occurs in 10 percent to 15 percent of those with psoriasis. In one-half, psoriasis appears an average of a decade earlier than the arthritis; in the rest arthritis is roughly contemporaneous or even precedes the skin disease.
- Strong genetic predisposition: susceptibility associated with HLA-Cw6 and other class I major histocompatibility complex alleles including HLA-B27 and HLA-B39.
- The pathogenesis appears to involve activation of CD8 T cells, which release inflammatory mediators that affect the target tissues.
- The most distinctive features of psoriatic arthritis are distal interphalangeal joint arthritis, dactylitis, enthesitis, periosteal new bone formation, and asymmetric oligoarthritis and spondylitis.
- A severe syndrome with features of psoriasis, psoriatic arthritis, and reactive arthritis may occur with advanced fulminant untreated human immunodeficiency virus-1 infection.
- Therapy is determined by the balance of the severity of the skin and musculoskeletal disease. Nonsteroidal anti-inflammatory drugs are the mainstay of therapy in concert with physical therapy; methotrexate is usually the initial choice for more severe involvement. In the event of failure, a growing number of second-line disease-modifying agents are often effective, but with an attendant increased risk of untoward effects.

Psoriatic arthritis is classified as one of the seronegative spondyloarthritis group of disorders that also includes ankylosing spondylitis, undifferentiated spondylitis, Reiter syndrome, reactive arthritis, and enteropathic arthritis. The term *seronegative* refers to the absence of rheumatoid factor or other autoantibodies, and the

absence of these autoantibodies is one of the essential laboratory features of psoriatic arthritis. The seronegative spondyloarthritis disorders share involvement of the spine (spondylo), sacroiliac joints, and some degree of genetic susceptibility associated with HLA-B27. In addition, each of the entities in the spondyloarthritis group of disorders has the singularly distinctive feature of enthesitis that may either involve peripheral joints or the spine. This results in tendinitis, fasciitis, and some of the deep inflammatory back pain of spondyloarthritis. Common to the spondyloarthritis group of disorders is juxta-articular new bone formation, which results from the cytokine-induced activation and modulation of mesenchymal or periosteal cells to an osteogenic program. It is typically found around the entheses and accounts for bone spurs. Perhaps related to this pattern of mesenchymal cell activation is the characteristic development of joint fibrosis and ankylosis (see Table 19-1).

Some clinical and pathogenic features of psoriatic arthritis are similar to those of Reiter syndrome and reactive arthritis. In the setting of advancing HIV-1 infection, the arthrocutaneous syndrome that may develop often has considerable clinical overlap in both the skin and musculoskeletal findings of psoriatic arthritis and Reiter syndrome.

Psoriatic arthritis is distinguished from ankylosing spondylitis by the confinement of spinal involvement to a few vertebrae and from all the other spondyloarthritides by the predominance of more distal peripheral joint involvement. A distinctive and diagnostically specific feature of psoriatic arthritis is acral inflammatory involvement of the skin, nail matrix, periosteum, enthuses, and synovium of one or more digits with the complex of onychodystrophy, periungual erythrodermia, and distal interphalangeal joint (DIP) involvement (Fig. 19-1; see Table 19-1). Dactylitis, sometimes graphically termed *sausage digits*, is a characteristic inflammation of one or more digits with a high specificity for psoriatic arthritis characterized by inflammatory edema of the entire digit due to extensive enthesitis, DIP and proximal interphalangeal synovitis, tenosynovitis often focused on flexor tendons, and periosteitis. Similar to the acral dystrophy, dactylitis is also a diagnostic feature of psoriatic arthritis.

The relationship to the presence of psoriasis is of course a hallmark of psoriatic arthritis. However, the presence of psoriasis is not an absolute requirement



▲ **FIGURE 19-1** Psoriatic arthritis. Striking joint swelling of the distal interphalangeal joints with associated psoriasis of the skin and psoriatic nail involvement reflecting acral inflammatory involvement.

for the diagnosis of psoriatic arthritis and a history of prior psoriasiform lesions or a family history of psoriasis suffices (see Table 19-1). Except for the absence of psoriasis, some cases of the spondyloarthritis disorder undifferentiated spondylitis are indistinguishable from the joint involvement of psoriatic arthritis and this has sometimes been termed *psoriatic arthritis sine psoriasis*.

In psoriatic arthritis, the peripheral joints are involved in a variety of patterns of arthritic involvement at presentation, often affecting only one or a few joints in an asymmetric manner (Table 19-2). These patterns are sometimes useful diagnostically as originally emphasized by Moll and Wright in their classic paper on patterns of joint involvement.[3] For example, DIP arthritis in an individual with psoriasis immediately suggests the diagnosis of psoriatic arthritis and essentially requires only the exclusion of osteoarthritis, the other entity that commonly affects the DIP joint. However, it is now recognized that some of these patterns of arthritis onset are neither stable nor highly specific for psoriatic arthritis. Over time with the accumulative involvement of different peripheral joints by the disease, the asymmetric features of psoriatic arthritis often become less apparent. For these reasons, with the exception of the characteristic DIP arthritis or spondyloarthritis, less emphasis is now being placed on the other patterns of arthritis for diagnosis, other than classifying the arthritis as axial or peripheral.

TABLE 19-2
Patterns of Psoriatic Arthritis Joint Involvement

- Asymmetric or symmetric peripheral joint involvement
  - Distal interphalangeal joint involvement
  - Small joints of hands and feet
  - Large joints
- Axial disease
  - Spondyloarthritis with vertebral squaring affecting one or a few vertebrae, often asymmetrically
  - Sacroiliitis

HISTORICAL ASPECTS

The recent identification of psoriatic arthritis in skeletal remains of individuals who sought refuge in ancient Middle Eastern Byzantine monasteries in Biblical times suggests that psoriasis with psoriatic arthritis was one of the forms of biblical leprosy, attesting to the severe and ancient nature of this condition. The association of arthritis with psoriasis was first formally described in 1818 by Alibert and was designated *psoriasis arthritique* by Bazin in 1860. The notion of a distinctive arthritis associated with psoriasis became widely accepted, but in the decades after World War II psoriatic arthritis was grouped with rheumatoid arthritis as a "rheumatoid variant" or "rheumatoid spondylitis." Subsequently, the distinct nature of psoriatic arthritis was again emphasized, using as criteria the clinical pattern of joints affected, spondylitis, and the absence of rheumatoid factor. The observation of an elevated frequency of HLA-B27 provided a strong immunogenetic basis for the entity. The central importance of enthesitis has been recognized, along with the development of more prevalent and intense disease with advancing HIV infection.

EPIDEMIOLOGY

Despite the problems in diagnostic and classification criteria of psoriatic arthritis, considering the frequency of psoriasis to be between 1 percent and 3 percent, and using the 10 percent to 15 percent value for the prevalence of psoriatic arthritis in those with psoriasis, the prevalence of psoriatic arthritis in the different populations would be expected to range from 0.10 percent to 0.45 percent, a value approaching half that of the prevalence of seropositive rheumatoid arthritis and in agreement with recent prevalence studies.[4,5] Reports of much higher prevalence in some series ascertained clinically or by newer imaging modalities, such as magnetic resonance imaging (MRI), may reflect the absence of specific or fully developed criteria for excluding other forms of common joint or musculoskel-



etal diseases, and one should await their full validation.

PATHOGENESIS AND PATHOLOGY

Two lines of evidence strongly implicate lymphocytes in the pathogenesis of psoriatic arthritis: the presence and activated state of both CD8 T cells and natural killer (NK) cells in lesional sites and the response of the disease to immunomodulatory therapy directed at these cells or pathways triggered by them. The inflammatory infiltrate in the synovitis of fully developed psoriatic arthritis has been well studied because of its accessibility and contains a small number of very large CD8 T-cell clonal expansions.[6,7] The T-cell receptors of these clones often appear structurally related and manifest the same CDR3 length and the same or homologous CDR3 amino acid sequences, structural features that strongly imply the clones are driven by an antigen, the identity of which remains unknown. The CD8 T-cell clones in the synovial tissue and fluid are derived from clonal precursor pools that are also highly expanded in blood (> 20 cell divisions). Their activation in the tissue is presumably the basis of the arthritis and enthesitis through the release of chemokines and cytokines as illustrated by the hypothetical scheme in Fig. 19-2. Their phenotype is predominantly that of memory effector CD8 T cells that have lost the co-stimulatory CD28 molecule, but gained various receptors that are typically expressed on, and regulate the activation of, NK cells.

The synovium in active psoriatic arthritis also contains a preponderant infiltrate of polyclonal, non-antigen–specific CD4 T cells, as shown by analysis of the T-cell repertoire.[6,7] These appear to arise via a chemokine-mediated recruitment of non-antigen specific T cells. Other types of bystander type clonal expansions are also found in the joint fluid and synovium, which appear to be directed to diverse viral and other antigens unrelated to the presumed autoantigens driving the joint disease. These are presumably attracted to the inflammatory milieu and by their activation in the tissue may secondarily contribute to the intensification of arthritis.

Cytokines that have been implicated in the pathogenic process of psoriatic arthritis include macrophage-derived TNF-α, interleukin (IL)-6, IL-1α, and lymphocyte-derived IL-2 and interferon-γ, although compared with rheumatoid arthritis synovium, the psoriatic arthritis synovium has less interferon-α and IL-1.[8–10] Infiltrating T cells elaborate chemokines, including RANTES (regulated on activation, normal T cell expressed and secreted). The chemokine IL-8 is expressed at a high level by the synovial lining cells and to a lesser extent in cells located in the perivascular areas and likely mediates attraction of neutrophils to the joint fluid, a characteristic feature of psoriatic arthritis. Lining cells also elaborate the chemokine monocyte chemotactic protein 1 (CCL2), a chemotactic factor that attracts and activates monocytes but not neutrophils. Macrophages in the lining produce chemokines such as GRO-α (growth-regulated protein α precursor, CXCL1), which also has chemotactic activity for neutrophils. Vascular abnormalities are prominent in the psoriatic synovium both at the gross level and immunopathologically with a transformation to an activated endothelium. These changes are likely to reflect specific cytokine profiles augmented in the psoriatic patient. The destruction of cartilage differs from that seen in rheumatoid arthritis by minimally elevated levels of aggrecan and greatly increased concentrations of cartilage oligomeric matrix protein.[11]

The role of dendritic cells in the initiation of the inflammation has not been well delineated. These are the likely candidate cells to mediate the response to physical stress, microbial infection, cytokines including interferon-α, and other danger signals that can initiate the process of arthritis in predisposed individuals.

Theoretic scenarios to explain the immune drive underlying inflammation: The nature of the immunologic recognition events responsible for the CD8 clonal expansion remains completely unknown. Two potential scenarios could account for the immune drive in psoriatic arthritis because they each illuminate dif-



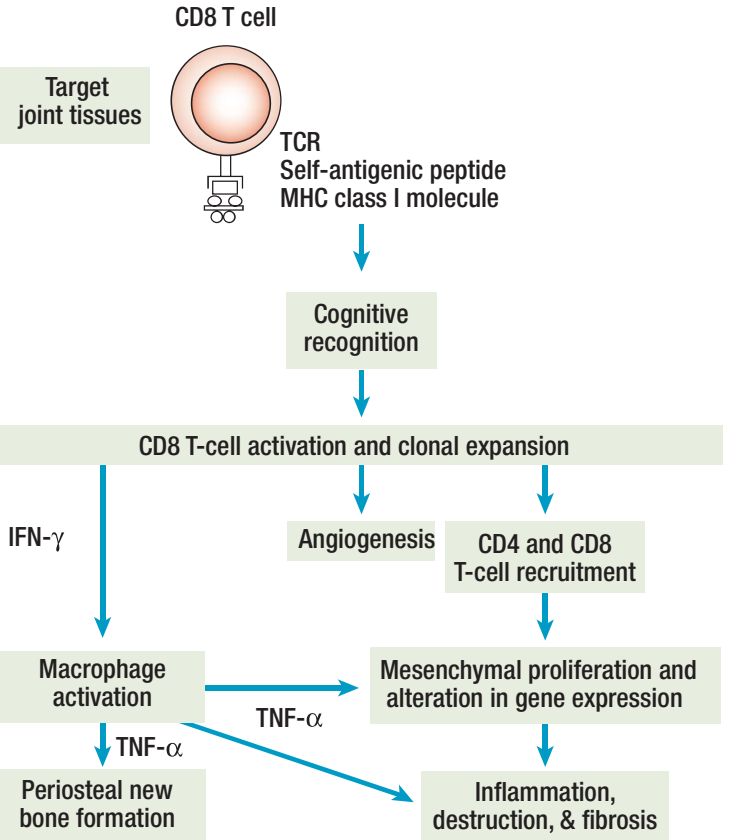

▲ **FIGURE 19-2** A scheme for pathogenesis of inflammation and tissue destruction summarizing the mechanisms of inflammation in psoriatic arthritis. The process is driven by cognitive recognition of a self-peptide presented to a CD8 T cell by a major histocompatibility complex (MHC) class I molecule on a joint cell. The ensuing T-cell activation and clonal expansion initiates non-antigen–specific recruitment of CD4 and CD8 T cells, angiogenesis, and monocyte recruitment by the release of cytokines and chemokines. Activation of macrophages occurs through cytokines such as interferon (IFN)-γ. The activated macrophages release cytokines such as tumor necrosis factor (TNF)-α, interleukin-1, and interleukin-6. These products alter patterns of gene expression in cells comprising the joint and related structures, resulting in inflammation, fibrosis, new bone formation, erosions, and osteolysis. TCR = T-cell receptor.

ferent aspects of immune response mechanisms relevant to psoriatic arthritis.

Scenario 1, adaptive immune drive (see Fig. 19-2): The first and more classic view is that the clonal expansion reflects a typical specific peptide antigen-triggered adaptive immune response mediated by CD8 T cells to a particular autoantigen. Ongoing activation of the CD8 T-cell clones by the unlimited reservoir of self-antigen drives the clonal expansion and sustains the attack on the target cells expressing the autoantigen. The primary defects responsible for this scenario are expression of the autoantigen, binding of autoantigen peptides by major histocompatibility complex (MHC) class I allelic molecules associated with susceptibility, and provision of initial clonal activation in an adaptive immune response by activated dendritic cells.

Scenario 2, innate immune activation of preexisting memory/effector T cells: This alternative scenario is based on the predominant memory-effector phenotype of the expanded CD8 T cells in the inflammatory sites. Their CD28-negative status reflects the fact that as memory effector cells they do not require engagement of this receptor by counter-receptors on activated dendritic cells to provide a signal two by this pathway, and instead, the activating NK receptors expressed by these cells provide a surrogate signal two on recognition of molecules expressed on stressed or injured cells. In this scenario, the engagement of receptors that recognize innate immune response ligands is the central recognition event, and the clonal specific adaptive immune response T-cell receptors provide a low affinity recognition signal.

DISEASE PATHOGENESIS AND STAGES

In common with other autoimmune diseases, the development of psoriasis and subsequently psoriatic arthritis can be considered to occur in stages, beginning with a genetically defined predisposition and ending with a final stage of overt joint disease (Fig. 19-3). The following sections group some of the information about the predisposition and pathogenesis of psoriatic arthritis according to these stages and the preceding two scenarios.

Genetic Predisposition: Stage 1

FAMILIAL AGGREGATION The family history of the patient provides an important clue to diagnosis. More than 40 percent of patients with psoriatic arthritis have a

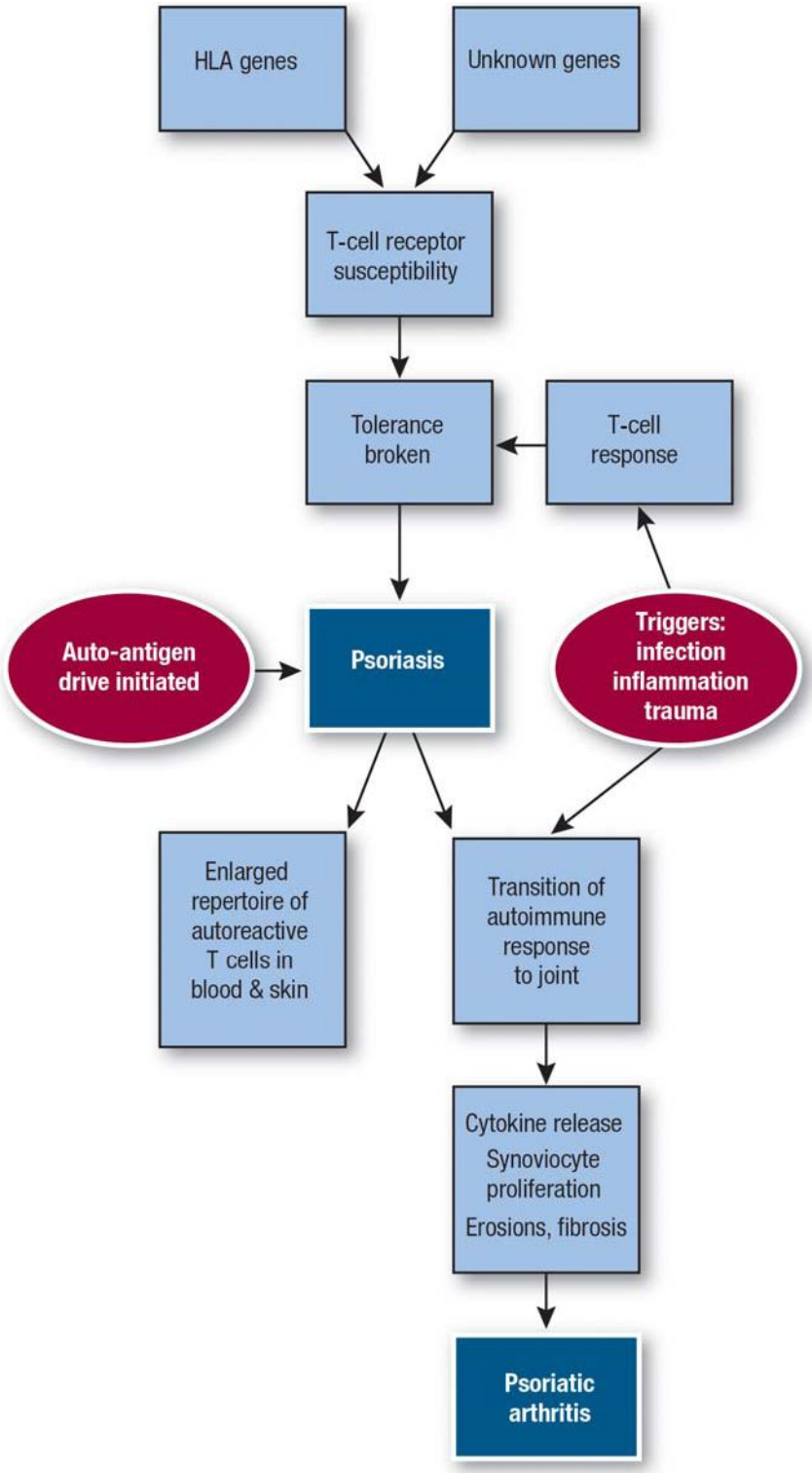

▲ **FIGURE 19-3** Hypothetical stages in the development of psoriasis or psoriatic arthritis. The first stage is one of genetically defined susceptibility illustrated in the first compartment. Major histocompatibility complex class I molecules, self-peptides, and other still unknown genes interact to select a T-cell repertoire that has the property of recognizing a self-peptide critical to pathogenesis of psoriasis or psoriatic arthritis. The second compartment depicts several possible initiation events in which the T-cell clones selected in stage one are triggered to recognize a self-peptide. This physiologic adaptive immune response is initiated by a specific microorganism or by non-antigen–specific inflammation or trauma. In the third stage, the unlimited amount of self-peptide autoantigen drives the immune response to clonal expansion and an effector phenotype that results in psoriasis. In the fourth phase, these T-cell clones acquire the ability to respond to a self-antigen of the joint. In a final phase, these clones acquire the potential to injure the joint by the release of chemokines that recruit and activate monocytes and non-antigen–specific T cells. Multiple inflammatory mechanisms characterize this stage.



family history that includes one or sometimes multiple cases of psoriatic arthritis, psoriasis, or seronegative spondyloarthritis in their blood relatives, a likelihood 40-fold greater than that of their unaffected spouses.[12–14] This, along with high twin concordance rates, establishes that germline genes importantly contribute to the definition of the predisposition to develop psoriatic arthritis. Despite this strong familial aggregation, a little more than one-half of patients with psoriatic arthritis are sporadic cases with a negative family history. In the classic studies of Moll and Wright,[3] among 88 probands that fulfilled their criteria for psoriatic arthritis, 12.5 percent had at least one first- or second-degree relative with psoriatic arthritis that also met these criteria, with a psoriatic arthritis prevalence of 5.5 percent among 181 first-degree relatives. Rahman and Elder[2] reanalyzed these data and estimated the magnitude of the genetic contribution for psoriatic arthritis from the relative proportion of disease in the first-degree relatives compared with the prevalence of disease in the general population using the λ_R formulation by Risch.[15] Assuming the prevalence of psoriatic arthritis is 0.1 percent, this yields a risk λ_R for first-degree relatives of 55. Even assuming a highest prevalence of psoriatic arthritis in the population of 0.45 percent, the λ_R would decrease only to 12.2, a notably high recurrence ratio for a complex disease, implying a very strong genetic contribution to susceptibility. In a more recent study, Myers et al.[16] reported essentially similar findings. The concordance rate among siblings for all types of psoriatic arthritis was 14 percent including enthesitis and for psoriasis 21 percent. If enthesitis is excluded, the resulting values resemble the 12.5 percent frequency of affected siblings observed by Moll and Wright, who did not include enthesitis in their original criteria. The inheritance of psoriatic arthritis has a mixed multifactorial pattern found in many autoimmune diseases that either simulates a partially dominant mode of inheritance that is incompletely penetrant,[3] or a recessive mode.[17] As might be expected, affected sibling pairs are usually discordant for their patterns of joint involvement. The most common symptom in affected siblings was enthesitis.



HLA CLASS I GENES INVOLVED IN DETERMINING SUSCEPTIBILITY Because the highly polymorphic MHC genes have an important role in regulating immune responsiveness, they were the first candidate genes to be examined for a role in determining genes involved in psoriatic arthritis susceptibility. Association studies with candidate genes with psoriatic arthritis began with Brewerton's identification of a significantly increased frequency of HLA-B27 in individuals with psoriatic arthritis.[18] There is considerable heterogeneity in the reported frequency of HLA-B27 in psoriatic arthritis, ranging from 39 percent in Taiwan,[19] 17 percent to 34 percent in different studies from northern Spain,[20,21] through 20 percent in Great Britain,[22–24] 4 percent in Israel,[25] and to series in which HLA-B27 was not detected.[26] These variations partially reflect the diagnostic criteria used and the geographic distribution of HLA-B27 alleles that increase in circumpolar populations. In addition, the influence of immunogenetic factors on the pattern of joint involvement in psoriatic arthritis was shown by an increase of the frequency of HLA-B27 to approximately 70 percent with spine involvement. HLA-B39 and to a lesser extent HLA-B38 (both splits of the specificity termed *HLA-B16* in the very old nomenclature) have been identified as elevated in psoriatic arthritis in multiple independent studies, but with divergence between different reports, in part because of the differences in ethnic distribution. HLA-B*3801 differs from HLA-B*3901 because the former, similar to HLA-B27, bears a strong ligand for the KIR3DL1 NKR receptor, whereas the latter is nonreactive. HLA-B38 and HLA-B39 do not share ancestral haplotypes or HLA-C alleles with HLA-B27 alleles.

As anticipated from the relationship of psoriatic arthritis to psoriasis, psoriatic arthritis is also associated with an elevated frequency of *HLA-Cw6* as first reported in a study using serologic techniques by Murray et al.,[25] where it was identified in 34.6 percent of psoriatic arthritis, 50.0 percent of psoriasis, and 13.5 percent of controls. Interestingly, the HLA-Cw6 allele, related to *Psors1*, is found in strong linkage disequilibrium with HLA-B57 and HLA-B13, but not with HLA-B27, HLA-B38, or HLA-B39. Alleles encoding HLA-B13 and HLA-B57 are also in strong linkage disequilibrium with the HLA-DR7 and the DQA1*0201 alleles, emphasizing the large genomic distances over which these ancestral haplotypes extend, and as expected HLA-DR7 and the DQA1*0201alleles have also been reported at increased frequency in psoriatic arthritis and psoriasis.[27,28]

There are four general lessons about HLA associations in psoriatic arthritis: First, the genetic effect of HLA susceptibility alleles is evident in both simplex "sporadic" psoriatic arthritis as well as in multiplex families, demonstrating that both sporadic and multiplex forms of psoriatic arthritis are likely determined by the same genes. Second, even in multiplex families the inheritance of HLA alleles associated with susceptibility does not account for all affected individuals. Third, the greater increase in the frequency of the HLA-Cw6 allele in psoriasis without psoriatic arthritis and the greater increase in HLA-B27, HLA-B38, or HLA-B39 in psoriatic arthritis provide molecular evidence of genetic heterogeneity in psoriatic arthritis and psoriasis. Fourth, in comparison to psoriasis, the role of HLA alleles in determining susceptibility to psoriatic arthritis is less conclusively etched and seemingly more intricate. These findings strongly suggest that other non-MHC genes play an important role in specifying psoriatic arthritis susceptibility.

Triggering of T Cells: Stage 2

HLA class I molecules have two different functions. First, they specifically bind and present peptides that are recognized by the clonally specific T-cell receptors on CD8 T cells, a recognition event central to the adaptive immune response to intracellular pathogens. Second, they engage a variety of NK receptors expressed by NK cells or memory/effector CD8 T cells in an innate immune system surveillance process that in part detects reduction in expression of self-MHC, missing self, found on transformed or pathogen-infected cells, and also detects aberrant increases in class I or related molecules induced by stress and injury. One set of either activating or inhibiting NK receptors that interact with particular allelic HLA-B or HLA-C allelic molecules is the killer inhibitor receptor (KIR) system. Alleles of the KIR system have been shown to interact epistatically with HLA alleles in determining susceptibility to psoriatic arthritis.[29,30] The interpretation of the meaning of the association of HLA-B27 and the second group of HLA class I alleles including HLA-B13, HLA-B57, and HLA-Cw6 with susceptibility to develop psoriatic arthritis is compatible with both scenarios of pathogenesis described above. In the first scenario, these HLA molecules are envisioned to act to select a particular repertoire of CD8 T cells by binding and presenting certain self-peptides during the phase of positive thymic selection of the T-cell repertoire. In

the second scenario, these particular allelic HLA molecules interact differently with various NK receptors (e.g., KIR receptors on the memory-effector population).

The second stage of the disease involves activation of the CD8 T-cell clones and the pathways involved differ in each of the two potential scenarios. In the first scenario, during T-cell repertoire formation all T cells are selected on self-peptides and the individuals with psoriatic susceptibility alleles are left with certain potentially self-reactive CD8 T-cells in their repertoire. These may be in a state termed *clonal ignorance* rather than tolerance, and the provision of appropriate co-stimulatory signals to the T-cell by accessory molecules on activated dendritic cells is the critical event that results in the activation of these T-cell clones. In the innate immune scenario, activation is accomplished by either self- or non-self-antigens that are not identical to peptides found in the entheses or joints. The CD8 T cells directed to putative keratinocyte peptides that expand for a decade while mediating psoriasis until the phase of overt psoriatic arthritis appears might suffice to account for this clonal expansion. Alternatively, the clones may expand in an adaptive immune response to a pathogen. The HLA susceptibility alleles could play a role in developing a primed memory–effector cell repertoire.

Events Resulting in Overt Joint Inflammation and Injury: Stage 3

The development of joint inflammation requires a pool of expanded antigen-reactive CD8 T-cell clones with an effector cell phenotype that can be triggered by the joint environment. In the adaptive immune response scenario, there is a phase of substantive CD8 T-cell clonal expansion and differentiation to an effector phenotype driven by psoriatic self-antigens as depicted in the third compartment in Fig. 19-3. In the second scenario, this expansion has been accomplished. The critical event in the innate immune scenario is the provision of a clonal attracting and activating stimulus in the joint that initiates the localization and in situ activation of the memory-effector T cells through engagement of their NK and other receptors acquired as the cell enters the memory-effector stage of development. It is the analogue of the activation of the dendritic in the innate scenario. Engagement of these NK receptors by ligands induced in the joint tissues provides abundant co-stimulation to activate the memory-effector CD8 T-cell clone with minimal clonal T-cell receptor engagement.

Both scenarios then merge in terms of the consequence of T-cell activation. A cascade of secondary immune responses occurs in the joint tissue as a result of this drive. Chemokines and cytokines, including interferon-γ released by T-cell activation (see Chaps. 11 and 12), activate vascular endothelium and monocyte-macrophages. The activated macrophages release additional chemokines and cytokines such as IL-1, IL-6, and TNF-α. The cytokines affect the pattern of gene expression in target mesenchymal cells resulting in injury and loss of function, whereas the chemokines instigate the non-antigen–specific recruitment of other CD8 T cells and CD4 T cells into the site of inflammation, as well as additional leukocytes. These recruited bystander T cells, in turn, release additional cytokines that act on synovial lining cells, cells of the entheses, and other cells in the fibroblast lineage to alter their pattern of gene expression, proliferate, and preside over cartilage erosion or induce new bone formation. Similarly, these immunoreactants act on vascular endothelium to alter its functional state toward one that supports inflammation and recruits additional leukocytes. The combination of cytokines, chemokines, and other pro-inflammatory factors from all of these cell types results in the distinctive picture of joint and tendon inflammation, cartilage destruction, and mesenchymal activation characterized by fibrosis and new bone formation.

CLINICAL MANIFESTATIONS

Onset and Occurrence

Psoriatic arthritis characteristically develops between 25 and 45 years of age, an average of 10 years after appearance of psoriasis, but can occur at nearly any age. Onset earlier in adulthood or in childhood is associated with a heightened likelihood of developing destructive arthritis. Typically, early onset psoriatic arthritis occurs in a setting of a strong family history of the disease.[31] The sex ratio parallels that of psoriasis, with an excess of females in early childhood but an essentially equivalent incidence in both sexes in adults.

The onset of arthritis is usually insidious, but occasionally is abrupt, sometimes seeming to following a joint injury. Whether the injury precipitates the process or simply draws attention to an ongoing process is unclear. The intensity of the disease and the abrupt onset may suggest reactive arthritis (see Chap. 20) syndrome or gout (see Chap. 161). Dactylitis and pitting edema of the hands or feet, sometimes asymmetric, secondary to enthesitis and tenosynovitis may be the first manifestation of psoriatic arthritis and emphasizes the tendency for acral involvement of the limbs in psoriatic arthritis. The development of insidious inflammatory back pain is an important clue to the recognition of axial disease and this may be the initial manifestation of psoriatic arthritis (Table 19-3). Constitutional features, including fever and malaise, are uncommon, usually evident only in a fulminant onset with widespread joint disease. However, the erythrocyte sedimentation rate, C-reactive protein, and the serum complement levels are commonly elevated, reflecting activation of acute phase reactants by cytokines.

TABLE 19-3
Inflammatory Back Pain from Initial Inflammation of Spondylitis, Sacroiliitis, or Axial Enthesitis

- Onset before age 40 yr
- Insidious dull deep buttock or low back pain
- Poorly localized, does not follow nerve root
- Persists > 3 mo
- Stiffness/pain on arising in the morning, or during sleep
- Improvement with exercise
- Differential diagnosis from mechanical or degenerative spine disease

Skin Disease

Susceptibility to the development and severity of arthritis loosely correlates with the severity of cutaneous involvement. However, remissions and exacerbations of the joint disease correlate only poorly with similar changes in the skin disease.

Tenosynovitis and Enthesitis

Enthesitis and dactylitis are hallmarks of psoriatic arthritis. Enthesitis may be quite subtle and can sometimes be relatively easy to overlook, or it may be fulminant with intense tenosynovitis. Enthesitis may present only as non-specific foot pain, tennis elbow in the non-dominant hand, or isolated posterior tibial tendonitis; these symptoms are not considered by the patient to be part of the illness. Enthesitis is sometimes widespread and symmetric, a distribution that differentiates it from post-traumatic or



occupational tendon injury that tends to affect the dominant hand and arm. Advances in imaging greatly aid in the identification of enthesitis and other features of psoriatic arthritis.[32,33] The property of magnetic resonance to image ligaments and cartilage is a particular strength, as is its ability to identify tissue edema or small effusions by various types of signal weighting. MRI showed the inflammation of the bone adjacent to the insertion as well as the soft tissue changes. Ultrasonography was shown to delineate the swelling of the entheses and the peritendinous soft tissues as well as the distension of adjacent bursae by fluid collections. Bone scintigraphy is often useful in identifying the precise nature and location of the sometimes confounding development of enthesitis that may simulate infection.



Nail Disease

The nail matrix is frequently affected in psoriatic arthritis, resulting in a variety of manifestations, including nail pitting, subungual hyperkeratosis and onycholysis, nail crumbling, Beau's lines (ridging), leukonychia, salmon patches, erythematous patches of the lunula, and ectatic tortuous capillaries that resemble splinter hemorrhages. Nail matrix disease is more strongly associated with psoriatic arthritis than with psoriasis alone, being found in 80 percent to 85 percent of those with arthritis versus 20 percent to 30 percent of those with the isolated cutaneous form of the disease.[34] Nail disease and paronychia is especially related to involvement of the DIP of the same digit reflecting the acral dystrophic state (see Fig. 19-1).

JOINT DISEASE PATTERNS AND RADIOLOGY The pattern of peripheral joint involvement[35] and the associated findings of nail disease, tenosynovitis, enthesitis, ankylosis, periosteal new bone formation, erosions, osteolysis, and axial involvement provide radiologic hallmarks for the recognition of psoriatic arthritis (see Tables 19-1 and 19-2). Approximately 75 percent of persons diagnosed with psoriatic arthritis manifest peripheral, usually asymmetric, oligoarthritis that involves the small joints of the hands and feet (Fig. 19-4), the large joints of the legs, or a combination of both small and large joints. When only a few joints are involved, the distribution often appears asymmetric. The hand involvement can include stiffness and dactylitis that are attributable to enthesitis



▲ **FIGURE 19-4** Radiograph revealing juxta-articular osteoporosis and erosions at all metacarpophalangeal, distal, and proximal interphalangeal joints in a 30-year-old man with human immunodeficiency virus-1–associated psoriatic arthritis.

as well as synovitis. Deformity secondary to fibrosis and contractures may occur. The classic pencil-in-cup joint of psoriatic arthritis is sometimes seen, consisting of symmetric and conical osteolysis of the proximal head, with enlargement of the base of the distal head by new bone formation. Acral osteolysis and erosions at the tip of the tuft of the digit are characteristic, especially when they involve the hallux. Ankylosis of one or more isolated joints is another distinctive feature due to fibrosis and new bone formation. Sometimes the initial or only manifestation of psoriatic arthritis is hallux rigidus, implying the subtle nature of joint inflammation and the need for its earlier recognition.

Inflammation of one or many of the DIPs is virtually pathognomonic for psoriatic arthritis or reactive arthritis; it need only be distinguished from Heberden's nodes, which occur in a form of osteoarthritis infection, or, rarely, crystalline arthritides such as gout. The points of distinction concerning rheumatoid arthritis versus psoriatic arthritis are summarized in Table 19-4, and it is important to emphasize that the DIP is rarely, if ever, affected by rheumatoid arthritis. In some instances, the joint involvement in the hands and feet is widespread (see Fig. 19-4).

The large joints that are affected in psoriatic arthritis include the hips, knees, and ankles. Often only a single hip or knee joint is involved; the dominant diagnostic considerations in adults include degenerative osteoarthritis or post-traumatic arthritis rather than psoriatic arthritis. Post-traumatic forms of psoriatic arthritis in athletes are particularly challenging to distinguish from purely mechanical injuries. In approximately 5 percent of persons with psoriatic arthritis, the character of the joint injury becomes profoundly destructive with marked osteolysis, resulting in what is sometimes referred to as *arthritis mutilans*. In rare instances, this process is generalized, but much more commonly one or a few joints in the hands or feet are characterized by destruction out of proportion to the remainder of the illness. *Opera glass hand* refers to the osteolytic shortening of digits or the wrist

TABLE 19-4
Contrasts between Psoriatic Arthritis and Rheumatoid Arthritis

	Psoriatic Arthritis	Rheumatoid Arthritis
Elevated erythrocyte sedimentation rate, C-reactive protein	Yes	Yes
Susceptibility alleles	MHC class I	MHC class II
Amelioration with progressive HIV infection	No	Yes
Implied class of lymphocytes driving inflammation	CD8	CD4
Autoantibodies (e.g., rheumatoid factor)	No	Yes
Immune complexes	No	Yes
Small vessel vasculitis	No	Yes
Fibroblastic response	Yes	Rare
Sacroiliitis	Yes	No
Enthesitis, dactylitis	Yes	No
Erosions	Yes	Yes
Juxta-articular osteopenia on x-ray	Uncommon	Yes
Juxta-articular new bone	Yes	No

HIV = human immunodeficiency virus; MHC = major histocompatibility complex.

bones surrounded by redundant folds of skin. Pustular psoriasis or erythroderma is more common among this group.[36] In occasional patients the sternomanubrial and temporomandibular joints may become involved, in association with extensive typical psoriatic arthritis.

The synovitis of psoriatic arthritis is accompanied by the formation of joint fluid with features that reflect the pathogenesis of the disease. The fluid is dominated by polymorphonuclear leukocytes, with levels that may reach 25,000 per mm^3, presumably recruited by IL-8. The number of lymphocytes is often substantially elevated and consists mainly of T cells and NK cells, with a preponderance of CD8 T cells.[37] The T-cell phenotype reflects their activated state with expression of HLA-DR, CD25, and CD69 and their predominant memory-effector differentiation, being $CD28^-$, $CD45RA^+$, and expressing various NK receptors.

Certain syndromes simulate psoriatic arthritis but increasingly appear to be distinct entities; these include the anterior chest wall syndrome of sternomanubrial or costoclavicular involvement, where sternomanubrial disease occurs in isolation; the so-called *SAPHO syndrome* and recurrent multifocal osteomyelitis. See reference 38 for a brief review of these entities.

The axial involvement occurs in just over one-third of cases and is often most evident in the lower spine and sacroiliac joints. The predisposition to axial involvement is strongly influenced by the presence of HLA-B27. The axial involvement is often heralded by inflammatory back pain (see Table 19-4). The spinal involvement differs from the uniform ascending pattern that characterizes ankylosing spondylitis. Scattered submarginal syndesmophytes and apophyseal or odontoid erosions are found without widespread vertebral squaring, apophyseal joint involvement, or ligamentous calcification. Sometimes the nonmarginal syndesmophytes become bulky broad paravertebral excrescences that contrast with the vertically oriented outgrowths of bone in the outer margins of the annulus fibrosus in ankylosing spondylitis.[39,40] Vertebral squaring from new bone formation, apophyseal joint involvement, and ligamentous calcification in the lumbar spine are similar to that found in ankylosing spondylitis. Sacroiliitis is more often asymmetric rather than the symmetric involvement of ankylosing spondylitis. MRI is the most sensitive and specific modality for identifying sacroiliitis and other changes in the axial skeleton.[41]

Whether current ascertainment of joint involvement by clinical and classic x-ray procedures in those with psoriasis is adequate has been the subject of several studies using newer imaging modalities such as radionuclide scanning, ultrasonography, or nuclear MRI. In a study using MRI to examine the frequency of hand involvement in patients with nummular psoriasis, plaque psoriasis, or both, free from arthritic symptoms, Offidani et al. found 68 percent of psoriasis patients had at least one arthritic sign by MRI, such as soft tissue swelling, periarticular effusion, joint effusion-synovial pannus, tendon sheath effusion, bone erosion, subluxation, bone cysts, and subchondral signal intensity abnormalities, whereas standard x-rays revealed joint abnormalities in 32 percent.[32] Further investigation of these observations is warranted, including the determination of the specificity of these findings.

Other Manifestations

Apart from cutaneous and musculoskeletal involvement, ocular involvement occurs in approximately one-fourth of those with psoriatic arthritis. Conjunctivitis is the most prevalent condition and usually responds to symptomatic therapy. Iritis develops in approximately 5 percent of those with psoriatic arthritis. It is uncertain whether this reflects the presence of HLA-B27, because uveal tract inflammation is strongly associated with the presence of this allele, or whether it is an intrinsic feature of psoriatic arthritis. Because of the serious inflammatory consequences of synechiae and glaucoma, it is important to detect the development of iritis and initiate appropriate therapy. Cutaneous vasculitis, a feature of many autoimmune rheumatic diseases, is absent from psoriatic arthritis.

PEDIATRIC PSORIATIC ARTHRITIS There are two syndromes currently classified as juvenile psoriatic arthritis distinguished by age of onset and other features. The onset of juvenile psoriatic arthritis shows a peak incidence, with female preponderance, between 2 and 4 years and a second peak beginning at age 11 to 12 years in both sexes that extends into adulthood and in most respects resembles the disease in adults. The subset of children between 2 and 4 years of age currently diagnosed with juvenile psoriatic arthritis is predominantly female, has positive anti-nuclear antibodies, and has potentially ominous chronic anterior uveitis, indistinguishable from that seen in young (2 to 4 years of age) girls with pauciarticular juvenile arthritis.[42] They have much lower frequencies of HLA-B27 and HLA-Cw6 than the older onset subset. This interesting early onset form of juvenile psoriatic arthritis may be a variant form of pauciarticular juvenile arthritis that is characterized by psoriasis and dactylitis and be a fundamentally different entity from psoriatic arthritis as it is currently understood. In contrast to the usual sequence in adults, almost one-half of juvenile patients presented with arthritis before skin disease, with the interval between the onset of arthritis and psoriasis as long as 8 years.[43] Psoriasis, or a positive family history of psoriasis, usually provides the diagnosis, but if it is absent diagnosis is often delayed due to the similarities of the disorder with pauciarticular or oligoarticular juvenile arthritis. Axial involvement, when found, is usually associated with the presence of HLA-B27. Therapy is analogous to that of the adult disease, with the added concern that chronic inflammation in a joint may enhance the maturation of the epiphyses resulting in limb asymmetry and deformity. Additionally, management is complicated because Reye syndrome in young children may be seen with salicylate administration.

The long-term course of juvenile psoriatic arthritis results in a polyarticular pattern with asymmetric involvement of both upper and lower extremities and prominent digital involvement. Criteria have been developed for the classification of childhood psoriatic arthritis where, in addition to the presence of arthritis and psoriasis or a positive family history thereof, emphasis is placed on dactylitis, nail pitting, symmetry of arthritis, disease course (oligoarthritis or polyarthritis), anti-nuclear antibodies, and uveitis.[44] Interestingly, emphasizing the interplay between various events that precipitate reactive arthritis or reactive arthritis syndrome and the development of psoriatic arthritis of five HLA-B27–positive children reported with what was termed *juvenile reactive arthritis* following *Salmonella enteritidis* infection, three developed typical psoriasis in the months after the arthritis.[45]

PSORIATIC ARTHRITIS AND HUMAN IMMUNODEFICIENCY VIRUS INFECTION In North America and most of Europe, the con-



siderable earlier problem of extraordinarily severe psoriasis, psoriatic arthritis, and reactive syndrome occurring in the setting of advanced fulminant HIV-1 infection has abated due to better antiretroviral therapy and management of other infections, but in some regions of the world these complications of HIV remain a very substantive problem.[38] The onset of de novo psoriasis and psoriatic arthritis in HIV-infected individuals may be explosive with many features indistinguishable from Reiter syndrome. It can be triggered by an antecedent infection with an arthritogenic Gram-negative organism or appear in a more insidious manner.[46–49] Almost invariably, the psoriasiform skin disease is very severe with pronounced acral involvement (see Fig. 19-1). Alternatively, in an individual with pre-existing mild psoriasis, the development of acquired immunodeficiency syndrome (AIDS) can be signaled by an abrupt increase in severity of the skin disease and development of psoriatic arthritis.



The progression of the arthritis takes two general forms: an accumulative pattern evolving to full intensity over several weeks to months, or the more common milder, intermittent pattern of recrudescences and remissions. The accumulative form is often associated with widespread polyarticular (but asymmetric) arthritis and is characterized by synovial thickening, erosions, and juxtaarticular osteoporosis. Hand and upper extremity involvement predominates in the accumulative pattern. The intermittent form usually has oligoarticular knee or ankle joint involvement. Severe enthesopathy of the Achilles tendon, plantar fascia, and anterior or posterior tibial tendons may cause some patients to exhibit a characteristic broad-based "AIDS" gait, walking with the feet in inversion and extension in an attempt to diminish pain by distributing weight on the lateral margins. Multidigit dactylitis frequently occurs and, in combination with plantar fasciitis and extensor tenosynovitis, may simulate cellulitis or pedal edema. Although synovitis of the knee is prominent, hip disease and shoulder-girdle involvement are uncommon, emphasizing the acral component of involvement. The prevalence of axial involvement appears to be distinctly uncommon, with sacroiliitis only occasionally seen.

The cutaneous manifestations of HIV-associated psoriatic arthritis overlap with those of HIV-associated reactive arthritis syndrome. The eruption often resembles widespread pustular psoriasis with a greater tendency for involvement of the groin and intertriginous regions (inverse or sebopsoriasis). A progressive intensification of changes in the distal digits is often very prominent. Acrokeratosis is very common, often associated with erythema and periungual pseudoparonychia formation. Severe alterations in the nails of the hands and feet often accompany DIP joint involvement and are manifested clinically as onychodystrophy with or without subungual hyperkeratoses.

COURSE AND PROGNOSIS

For most patients with psoriatic arthritis, the musculoskeletal manifestations are relatively milder than those of rheumatoid arthritis. However, the subset of psoriatic arthritis cases with arthritis mutilans have catastrophic joint destruction that often proceeds more rapidly than joint injury in rheumatoid arthritis. After 8 years of disease, two-thirds of patients with psoriatic arthritis are effectively employed,[50,51] roughly one-half develop significant deformity of one or more joints, and approximately 1 in 10 progress to an advanced stage of musculoskeletal impairment.[52] Severe and sustained joint involvement or enthesitis is especially evident in the HIV-associated form. Persons with hip or knee involvement may ultimately require joint replacement. However, despite a much greater degree of vitality among the majority of those with psoriatic arthritis, quality of life evaluation was equivalently diminished to that of rheumatoid arthritis.[53]

Several patterns of disease progression are evident. For most, the enthesitis arthritis waxes and wanes in severity, but remains persistently active. Approximately one-fifth of prospectively followed patients experience sustained remissions that last an average of 2.6 years.[54] Among the remainder with persistently active disease, mild but sometimes troublesome localized disease, such as the foot pain or recurrent tendinitis of enthesitis, forms a dominant pattern of involvement. For these individuals the overall prognosis is very good. Other patients with psoriatic arthritis progress to fibrous or bony ankylosis of one or a few joints, which may be unnoticed if there are no occupational demands. In yet another pattern, largely asymptomatic axial joint involvement not ameliorated by any of the specific therapeutic measures progresses independently of the state of the skin or peripheral joint disease.[55]

TREATMENT

The induction treatment algorithm summarized in Fig. 19-5 is a modification of the algorithm initially proposed by the British Society of Rheumatology.[56] This is an idealized way of approaching treatment choices that apply to an average patient, but certainly not to all patients. Because either skin or musculoskeletal disease may be the dominating feature, the choices summarized in the algorithm should be further modified for treating the skin lesions if they are the preponderant process. For example, an individual with mutilans arthritis would likely be a candidate for immunobiologic therapy in combination with a DMARD and move directly to the bottom of the algorithm. In the algorithm, patients with peripheral psoriatic arthritis involving entheses, joints, or both are subsetted according to disease severity into three initial treatment groups, mild, moderate, and severe, that receive nonsteroidal anti-inflammatory drugs (NSAIDs) alone or in combination with the first line DMARDs, sulfasalazine or methotrexate (MTX), with those at the more severe end of the spectrum begun on a combination of MTX and sulfasalazine. The following section expands on the nature and effects of these and related agents. Each of these therapies may be combined as appropriate with administration of local corticosteroids into one or a few sites of enthesitis or synovitis. Local therapy of a localized disease process is preferable to systemic therapy. Objective failure of an adequate trial of this regimen moves the patient to the second-line DMARDs such as the cyclosporine class of calcineurin blockers and the leflunomide class of DNA/RNA antimetabolites including azathioprine (Imuran), with an attendant increased risk from side and untoward effects. Objective failure is a difficult concept to define comprehensively, but should include both worsening of patient and physician global assessment and documented evidence of persisting or progressive synovitis or enthesitis; development of cartilage or bone erosions; and progression of joint fibrosis or ankylosis. The British Society of Rheumatology criterion for treatment failure is ≥ 3 tender and ≥ 3 swollen joints on two occasions 1 month apart. Objective failure of an adequate trial of second-line DMARDs moves the patient to the use of immunobiologics, such as a TNF blocker. Response moves the patient to a maintenance regimen.

In the case of mild disease, a maintenance regimen is a continuation of the

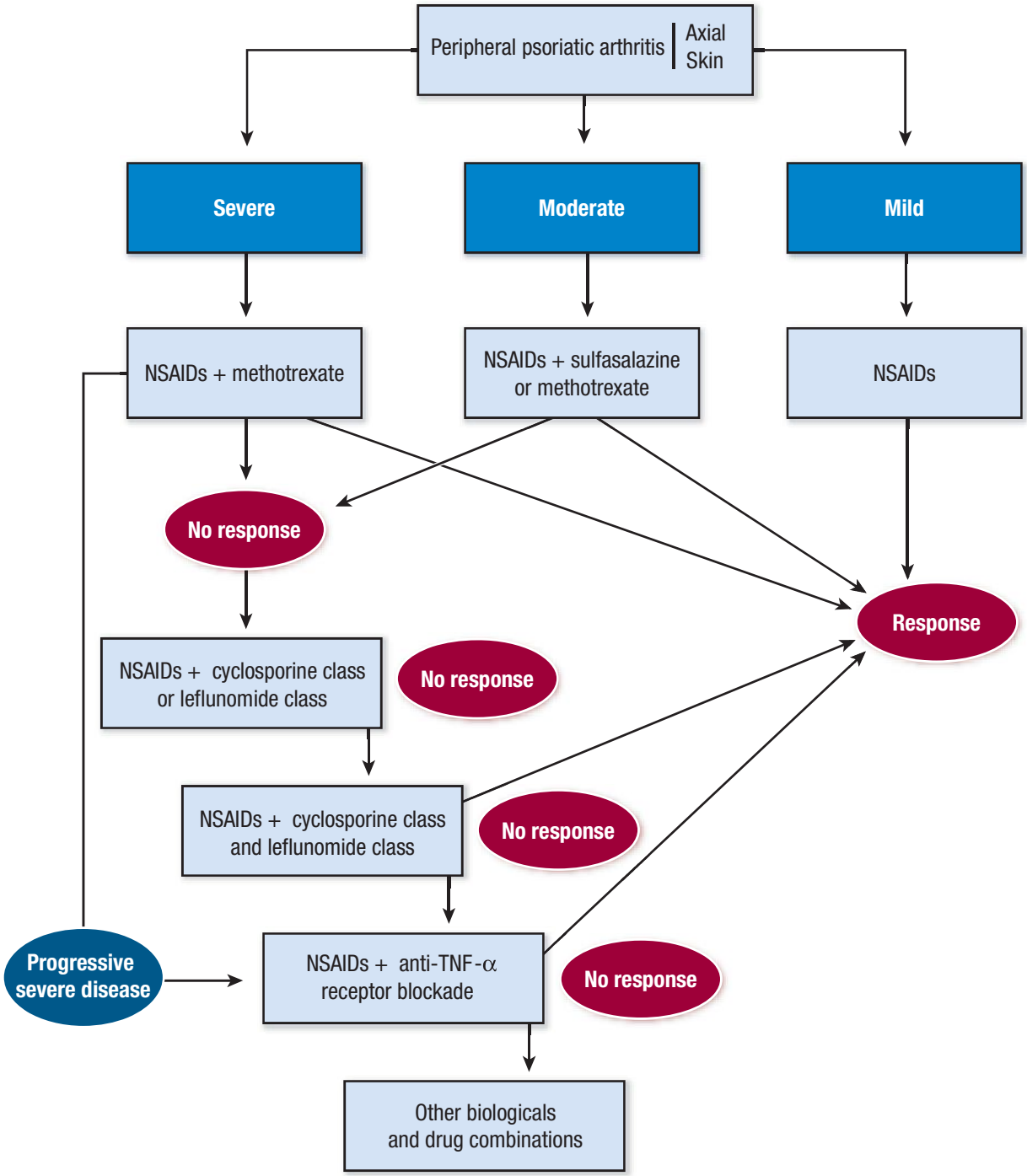

▲ **FIGURE 19-5** An algorithm summarizing choices for the induction of treatment of psoriatic arthritis involving the peripheral joints according to response or no response. NSAIDs = nonsteroidal anti-inflammatory drugs; TNF = tumor necrosis factor.

NSAID administration. For more severe psoriatic arthritis, the choices of maintenance therapy are more complex and guidelines less established, though based on the principles of drug action as outlined below for induction, and involve stepping back through the scheme.

Mild Joint Involvement

For most patients with mild joint involvement or enthesitis, the goals of therapy are the control of pain and inflammation by using traditional NSAIDs or analgesics, the maintenance of joint range of motion and function by physical therapy, local therapy for isolated areas of involvement, and the avoidance of potentially injurious extreme joint stress through counseling against repetitive injury. The patient should be monitored for progression in the severity of joint involvement.

NSAIDs act late in the inflammatory cascade by altering lipid remodeling in prostaglandin and leukotriene pathways and do not greatly alter the natural history of psoriatic arthritis. However, they do lessen stiffness, tissue edema, overall inflammation and pain, and thus increase mobility and function. Several biochemical families of NSAIDs or analgesics are available for therapy and although they have some differences in anti-inflammatory efficacy and toxicity, choosing which NSAID to start is mainly dictated by physician experience



and the individual response of a patient. Naproxen and indomethacin are traditionally considered representative of NSAIDs with the greatest efficacy in treating spondyloarthritis. Adverse effects shared by all NSAIDs include gastric and renal toxicity; hypersensitivity reactions; central nervous system effects, in particular tinnitus and headache; and coagulation abnormalities. In some patients with psoriasis the use of NSAIDs induces an idiosyncratic flare of the psoriatic skin lesions, the result of enhanced production of leukotrienes that occurs with cyclooxygenase inhibition. Most patients have had experience of self-prescribed drugs of this class and before initiating NSAID therapy patients should be asked whether aspirin or other NSAIDs caused a flare of psoriasis, and this class of drug should be avoided in that instance.



Lack of adequate response to NSAIDs usually requires additional drug therapy. If the involvement is limited to one or two sites, local intra-articular steroid injections may relieve an isolated episode of severe synovitis, whereas enthesitis and tendinitis respond to injections into the tendon sheaths that may be performed under ultrasound imaging to assure delivery of the drug to the proper site.

Systemic steroid is not commonly administered because of its much lower efficacy in psoriatic arthritis compared to other autoimmune diseases, coupled with the risks of inciting a transition to pustular psoriasis, a rebound of the skin disease on withdrawal, and the well-known complications of steroid therapy. Similarly, parenteral or oral gold salts are not therapies of choice because of their limited efficacy in treating psoriatic arthritis.[57]

Moderate Joint Disease

Patients with moderate joint disease are optimally first treated by combining NSAID administration with sulfasalazine. Double blind trials have shown sulfasalazine is moderately effective in reducing clinical parameters of joint disease activity and laboratory indices of inflammation in approximately 30 percent to 40 percent of patients,[57] especially in those with spondylitis.[58] Sulfasalazine has no effect on skin disease. In those with more severe disease who cannot tolerate MTX, a trial of sulfasalazine may be warranted before administering the more potent DMARDs discussed below. A low incidence of untoward reactions to sulfasalazine have been noted, mainly hypersensitivity dermatitis or gastrointestinal intolerance.

Severe Psoriatic Arthritis

For severe joint involvement, enthesitis, and axial disease, NSAIDs are supplemented with a more potent anti-inflammatory agent with immunomodulatory properties, such as the first-line DMARD MTX, or if there is no objectively satisfactory response, to second-line DMARDs such as cyclosporine A class drugs or antimetabolites such as leflunomide either separately or in combination. TNF blockers are at the third level of therapy. These, and more newly developed second- and third-generation DMARDs, offer a variety of strategies to rationally downmodulate the immune response in difficult cases. As emphasized above, these guidelines summarized in Fig. 19-5 are an idealized flow diagram, but individual cases raise therapeutic challenges not encapsulated in the algorithm and these require individual solutions based on the knowledge of the patient, the disease, and the drugs.

The improved benefit of these new agents comes with a variety of new risks, and the risk-to-benefit ratio of each of these agents agent should be carefully weighed. Special concerns also exist about their use in children or during pregnancy. In addition to untoward responses unique to each agent there is an overarching potential for untoward suppression of the immune response with each of these agents and attention should be given to identifying patients that are persistently infected with pathogens, such as *Mycobacterium tuberculosis*, or HIV-1 that may contraindicate their use. Additional strategies of particular DMARD combinations for induction or rotational therapies for maintenance that reduce risk and gain benefit are currently being developed.

METHOTREXATE (See Chap. 228) MTX is currently the initial drug of choice for therapy of severe psoriatic arthritis in those with either mild to severe skin disease. Both parenteral and oral MTX are effective in psoriatic arthritis. The efficacy of parenteral MTX suggests that this route of administration may have some advantages for the induction phase of therapy especially in instances of particularly severe disease.[57] Maintenance MTX therapy may be administered by the oral route. The untoward effects of MTX are discussed in Chap. 228. Minimal immune impairment is sometimes encountered and the uncommon possibility of developing opportunistic infections such as *Pneumocystis carinii* should be kept in mind in the differential diagnosis of pneumonitis developing during MTX therapy.

Although in higher doses MTX is a DNA antimetabolite, MTX therapy in psoriatic arthritis and rheumatoid arthritis appears to act by increasing the release of adenosine, which engages adenosine receptors 2A and 2B, which in turn inhibit the release of pro-inflammatory cytokines and chemokines by macrophages.[59] MTX also enhances the production of anti-inflammatory cytokines, such as IL-10, by macrophages and appears to modulate the macrophages from a pro- to an anti-inflammatory differentiation state. Supporting the conclusion that the anti-inflammatory effect is not a consequence of the antifolate action of this compound is the recommendation that it be given together with folic acid.

The action of MTX on the inflammatory T cell infiltrate in the synovitis of psoriatic arthritis is consistent with the hypothesized mode of drug action.[7] The drug reduces the polyclonal infiltration of predominantly CD4 T cells but has little effect on the CD8 antigen–driven oligoclonal expansions over 12 to 18 months of therapy. The inability of MTX therapy to eliminate the expanded CD8 clones suggests that the MTX is suppressive rather than curative, and that these clones may be the basis of recrudescent disease that appears after cessation of the drug.

OTHER NONBIOLOGIC AGENTS (See Chap. 228)

Cyclosporine. Cyclosporine A is considered to be equivalent in efficacy to MTX; however, more serious untoward effects limit its use. Cyclosporine A improves both the psoriatic skin and joint disease in approximately 50 percent of patients. Improvement in skin disease occurs after 2 to 6 weeks of treatment, whereas the joint involvement takes up to 24 weeks to improve.[58,60] However, as with MTX and TNF inhibitors, within 4 weeks of discontinuing the drug exacerbations of both skin and joint disease were seen. Cyclosporine binds to cyclophilin and blocks the function of the serine-threonine phosphatase calcineurin. Consequently, the cytoplasmic component of the nuclear factor of activated T cells is not dephosphorylated and cannot enter the T-cell

nucleus, bind to the IL-2 gene promoter, and activate IL-2 synthesis. Cyclosporine inhibits T-cell activation and clonal expansion, acting at a different point in the pathogenesis of psoriatic arthritis than MTX and combinations of the two drugs may offer advantages. Untoward effects of cyclosporine A include renal toxicity, hypertension, and azotemia and the potential for the development of Epstein Barr virus–related B-cell lymphomas. Newer drugs of this class have improved safety profiles and appear to offer an improved benefit risk ratio, but extensive trials of their use have not been conducted in psoriatic arthritis.

DNA and RNA Antimetabolites. With the exception of leflunomide, a more recently introduced agent that inhibits de novo ribonucleotide synthesis, the place of DNA and RNA antimetabolites in the therapy of psoriatic arthritis has received less extensive recent analysis, compared to the immunobiologic agents, but antimetabolites appear to have a role in the therapy of this disease, especially in the maintenance phase of therapy. These agents have the potential to directly affect the lymphocyte populations that putatively drive the disease. As with the immunobiologics discussed in Immunobiologic Agents, there is a class risk of immunosuppression, but the emergence of autoimmunity has not been reported.

Leflunomide inhibits de novo ribonucleotide synthesis. The low levels of ribonucleotides trigger p53 to block entrance of lymphocytes into S phase and inhibit cytokine release. The therapeutic effect takes 2 to 3 months to be manifest and the drug persists for long periods, requiring chelation by cholestyramine for its elimination in the event of adverse responses. In a 24-week double-blind trial, 36.3 percent of patients with psoriatic arthritis that were treated with leflunomide achieved American College of Rheumatology 20 percent improvement criteria (ACR20) responses compared to 20.0 percent of placebo-treated controls.[61] Leflunomide is a moderately effective second-line DMARD for psoriatic arthritis. The spectrum of untoward effects and contraindications should be consulted.

Azathioprine, studied in a randomized trial, was comparable in efficacy to MTX on psoriatic arthritis, but had little effect on skin disease, limiting its potential use to those with disproportionally severe musculoskeletal disease.[57] Bone marrow suppression is the primary untoward effect. Mycophenolate mofetil has not been studied in a randomized trial, but appears efficacious in open label studies, with less potential for marrow suppression.[62] It has also been used to treat uveitis. A single report of the efficacy of 6-thioguanine in the treatment of psoriasis, associated with the depletion and induction of apoptosis in activated T lymphocytes, suggests that this compound could be beneficial in severe psoriatic arthritis as a complement to the mode of action of MTX and TNF blockers.[63]

IMMUNOBIOLOGIC AGENTS (See Chap. 235) Immunobiologic drugs offer new, incisive, but expensive approaches to interdicting some pathways in the pathogenesis of psoriatic arthritis (see Fig. 19-2). The first important advance in this area was inactivation of effector cytokines secreted by activated monocytes. Because of the important role of TNF-α as an effector of inflammation in psoriatic arthritis, the anti-TNF agents infliximab and etanercept are taking an important place in the therapy of severe destructive psoriatic arthritis, especially in individuals who do not respond to MTX.[64] Etanercept is a receptor fusion protein that binds circulating TNF-α, whereas infliximab is a chimeric monoclonal antibody that binds TNF-α both in circulating and receptor-bound form. Adalimumab is a fully humanized monoclonal antibody that similarly binds circulating and receptor-bound TNF-α.

Etanercept. Of 86 patients completing a double-blind trial randomized to etanercept given subcutaneously twice weekly at 48 weeks of therapy, 59 percent exhibited a sustained ACR20 improvement compared to 13 percent in the placebo group. Maximal clinical improvement occurred between 4 and 12 weeks. Radiographic progression was inhibited during treatment. At 24 weeks, 47 percent of treated patients achieved a Psoriasis Area and Severity Index (PASI)-50 compared to 18 percent in the placebo group, whereas only 23 percent of patients had a PASI-75 response.[65] Etanercept as a monotherapy at 50 mg twice weekly does not provide increased efficacy when compared to the standard dose of 25 mg twice weekly.[66]

Infliximab. Infliximab, administered intravenously at weeks 0, 2, 6, and 14 in a placebo-controlled double blind study, yielded a 65 percent ACR20 in the treated group and 10 percent in the placebo group when evaluated at week 16.[67] Forty-six percent and 29 percent, respectively, achieved ACR50 and ACR70 responses, with 0 percent responses in the placebo group. Clinical responses appear within the first weeks of therapy and were maximal by week 12. Sixty-eight percent of those with skin involvement achieved a PASI-75, versus 0 percent in the placebo group. Skin and musculoskeletal improvement persisted through week 50 of therapy. Infliximab appears to be the most potent of the three agents, perhaps because of its intravenous route of administration, and this suggests it would be the agent of choice in very severe and rapidly progressing psoriatic arthritis.

Adalimumab. Adalimumab administered subcutaneously biweekly in a placebo-controlled double blind study yielded a 57 percent ACR20 in the treated group and 15 percent in the placebo group when evaluated at week 24. Thirty-nine percent and 23 percent, respectively, achieved ACR50 and ACR70 responses, with 6 percent and 1 percent, respectively, responding in the placebo group.[68] Maximal responses were achieved by week 12. Fifty-nine percent of those with skin involvement achieved a PASI-75, versus 1 percent in the placebo group. Skin and musculoskeletal improvement persisted through week 50 of therapy.

Anti–TNF-α therapy results in reduction in lining layer thickness, vascularity, and infiltration with neutrophils and macrophages. It appears that TNF blockade therapy has an action similar to that of MTX on eliminating major components of the effector pathways of joint inflammation, without significantly acting directly on the lymphocyte populations underlying the autoimmune drive of psoriatic arthritis.[69] In view of the good responses of many patients to these agents, a perplexing feature of their pharmacology is that at least one-third of patients with severe disease do not have satisfactory responses. It is presumed that their disease does not use pathways involving TNF-α. Importantly, little or no added efficacy was seen in each of the studies when the TNF blocker was combined with MTX, perhaps because they interdict the same pathways of macrophage-mediated inflammation. There is cautious support for the combination of leflunomide or other antimetabolites with infliximab, reflecting the complementarity of mechanisms of action, but in some units a high rate of adverse events has led to frequent treatment discontinuation.[70] This combination therapy is considered justified for treatment of patients diag-



nosed early who are at risk for rapid progression and for patients who do not respond to monotherapy; it is suggested to add biologic agents to a previously established leflunomide monotherapy rather than starting both treatments simultaneously.[70] At this stage of knowledge, there is little information from rigorous clinical trials to guide the physician in when to stop TNF blockade therapy and the choice of a subsequent maintenance drug. MTX is commonly used in this situation, but a rationale could be made for using agents that target T cells.

Considering the central role of TNF-α in the effector arm of the adaptive and innate immune response, an anticipated class effect of blockade of this pathway is the potential to impair overall immune function. This is reflected by instances of activation of latent *M. tuberculosis* infection with therapy, the appearance of opportunistic infections, and the development of B-cell lymphoma. The risk of reactivation of latent *M. tuberculosis* infection is greater with infliximab than with the etanercept, possibly because infliximab and adalimumab reduced the proportion of tuberculosis-responsive $CD69^+$ CD4 cells by 70 percent and 49 percent, respectively, and suppressed antigen-induced interferon-γ production by 70 percent and 64 percent; in contrast, etanercept produced no significant effect.[71] An unanticipated untoward class effect of these agents is the development of certain autoimmune diseases during therapy, including lupus-like disorders, leukocytoclastic vasculitis, and Guillain-Barré or multiple sclerosis–like demyelinating diseases.[72] Combination therapy with leflunomide may increase the likelihood of the autoimmune diseases developing. The development of anti-nuclear and anti-DNA antibodies and other serologic evidence of autoimmunity, including anticardiolipin antibodies and antineutrophil cytoplasmic antibodies, commonly occurs during treatment. These are mainly of the immunoglobulin M (IgM) or IgA class and usually decline in titer or disappear after treatment is stopped. Most, but not all, of the autoimmune diseases are mild and usually remit on discontinuation of the biologic. The mechanism responsible for this autoimmune state induced by TNF blockade is unclear. The evolving guidelines for use of these agents should be consulted before therapy is considered.

Alefacept. Another group of more recently introduced immunobiologics block the induction or maintenance of T-cell activation in psoriatic arthritis. Alefacept is a LFA3-Ig fusion protein that specifically targets T cells by blocking the LFA3-CD2 interactions, that provide a component of signal 2 in lymphocyte activation. Alefacept also triggers apoptosis or killing of activated memory T cells expressing high levels of CD2 through binding to FcRIII IgG receptors on NK cells and macrophages. Alefacept in combination with MTX for the treatment of psoriatic arthritis gave an ACR20 response at week 24 in 54 percent of patients, compared with 23 percent in the placebo plus MTX control group. Fifty-three percent of patients receiving alefacept plus MTX had a 50 percent reduction in their PASI at week 14 compared with 17 percent of those receiving placebo plus MTX.[73]

Other intriguing biologics, such as anakinra, an IL-1 receptor antagonist (IL-1ra) or abatacept, a CTLA4-Ig reagent that blocks CD28 from receiving a costimulatory signal 2, have not had clinical trials in psoriatic arthritis. Efalizumab is a recombinant humanized monoclonal antibody against the CD11a that blocks the LFA-1/intercellular adhesion molecule does not appear to ameliorate the joint disease.

Therapies for Axial Disease

The management of axial disease in psoriatic arthritis is not well delineated. Intensive physiotherapy and adequate NSAID administration are the cornerstones of treatment. There is no evidence for an effect of sulfasalazine on axial disease. MTX is demonstrated to be effective in double-blind studies in ankylosing spondylitis,[74] and by extension of its beneficial effect on peripheral joints in psoriatic arthritis, is likely to be the DMARD of first choice in treating axial disease. In unresponsive patients, TNF blockade is the next step, but there are only limited data supporting an effect on axial disease in psoriatic arthritis.

Therapy in Human Immunodeficiency Virus Infection

In psoriatic arthritis associated with HIV infection, NSAIDs such as naproxen are the first line of therapy; however, in many patients this drug does not adequately control inflammation, especially the very disabling enthesitis. Etretinate therapy (see Chap. 229) may be particularly useful in this form of psoriatic arthritis because it lacks immunosuppressive effects.[75] MTX, although effective for HIV-associated psoriatic arthritis, has been associated with the abrupt development of opportunistic infection and death in individuals with advanced HIV infection.[48] Therefore, MTX and similar potentially immunosuppressive agents are to be used with very considerable caution. Exquisite attention should be directed to monitoring HIV-1 virion levels and overall immunologic competency during such therapy by closely following absolute numbers of CD4 and CD8 T cells. An increase in virion level or a notable decline in CD4 count not controlled by antiviral therapy is an indication to withhold immunosuppressive therapy. A report on the use of Etanercept in psoriatic arthritis associated with HIV infection noted excellent clinical response of the skin and joint manifestations, but the drug had to be discontinued because of the development of multiple infections.[76] These observations emphasize the need for considering the presence of HIV infection when instituting immunosuppressive therapy in an individual with recent onset severe psoriatic arthritis.

Surgery and Related Techniques

Reconstructive surgery for severely damaged joints is highly successful. Arthroscopic synovectomy or intra-articular injection of short-lived radioactive isotopes of elements, such as Ytterbium, is an experimental approach that has been effective in treating instances of severe chronic monoarticular synovitis. Because of the enhanced tendency to fibrosis associated with these therapies, anti-inflammatory and physical therapy measures aimed at improving range of motion are important adjuncts to these interventions. Joint replacement and forms of reconstructive therapy are appropriate in situations of advanced joint destruction.

KEY REFERENCES

The full reference list for all chapters is available at www.digm7.com.

3. Moll JMH, Wright V. Familial occurrence of psoriatic arthritis. *Ann Rheum Dis* **22**:181, 1973
7. Curran SA et al: Nucleotide sequencing of psoriatic arthritis tissue before and during methotrexate administration reveals a complex inflammatory T cell infiltrate with very few clones exhibiting features that suggest they drive the inflammatory process by recognizing autoantigens. *J Immunol* **172**:1935, 2004



18. Brewerton DA et al: HL-A 27 and arthropathies associated with ulcerative colitis and psoriasis. *Lancet* **1**:956, 1974
26. Murray C et al: Histocompatibility alloantigens in psoriasis and psoriatic arthritis. Evidence for the influence of multiple genes in the major histocompatibility complex. *J Clin Invest* **66**:670, 1980
30. Nelson GW et al: Cutting edge: Heterozygote advantage in autoimmune disease: Hierarchy of protection/susceptibility conferred by HLA and killer Ig-like receptor combinations in psoriatic arthritis. *J Immunol* **173**:4273, 2004
31. Rahman P et al: Comparison of clinical and immunogenetic features in familial versus sporadic psoriatic arthritis. *Clin Exp Rheumatol* **18**:7, 2002
32. Offidani A et al: Subclinical joint involvement in psoriasis: Magnetic resonance imaging and X-ray findings. *Acta Derm Venereol* **78**:463, 2002
38. Winchester R: Psoriatic arthritis and the spectrum of syndromes related to the SAPHO syndrome. *Curr Opin Rheumatol* **11**:251, 1999
56. Kyle S et al: Guideline for anti-TNF-alpha therapy in psoriatic arthritis. *Rheumatology (Oxford)* **44**:390, 2005

CHAPTER 20

Reactive Arthritis

Andrew Keat

EPIDEMIOLOGY

Reactive arthritis appears to affect all populations world-wide though with varying prevalence and clinical associations. The epidemiology of these urethritis-associated and gastrointestinal forms of reactive arthritis is distinct. The former predominantly affects males and occurs sporadically, whereas the latter affects males and females equally and occurs either in outbreaks or sporadically. The possibility that reactive arthritis may also follow respiratory tract infections is unresolved.

Accurate measures of the incidence or prevalence of reactive arthritis are not available. There are several reasons for this, notably the wide variability in clinical practice of the application of this diagnosis, linked with variations in recognition and demonstration of precipitating infections. Moreover, many cases are mild and go unrecognized. It is clear that the prevalence of reactive arthritis correlates with the prevalence of HLA-B27 and with exposure to known initiating infections.[1,2] In Finland, the annual incidence of reactive arthritis after bowel or genitourinary infections was found to be approximately 30/100,000,[3] whereas German figures estimate a prevalence figure of 10/100,000.[4] A Norwegian study found the annual incidence of postenteric reactive arthritis to be 5/100,000 and of postchlamydial reactive arthritis to be 4.6/100,000,[5] whereas in the United States, the annual age-adjusted incidence has been reported to be 3.5/100,000.[6] It is more common in some circumpolar and North American populations,[7] and in some black African populations it has been linked with human immunodeficiency virus (HIV) infection.[8] Inevitably, some other cases identified only as seronegative oligoarthritis are probably reactive arthritis, so that the true incidence and prevalence are probably underestimated.

Reactive arthritis occurs at any age, but typically is a disorder of young adults aged between 20 and 40 years, being rare in young children and in older populations. Children appear to be less likely than adults to develop reactive arthritis even after apparently provocative enteric infections,[9,10] although reactive arthritis in children is well recognized.

In outbreaks of bacterial enteric infections caused by *Salmonella, Shigella,* and *Campylobacter* reactive arthritis has been reported in 1 percent to 4 percent.[11] In some outbreaks, the incidence of arthritis is higher[12] and in others no cases are detected in spite of involvement of apparently "arthritogenic" infections.[13] Some outbreaks of yersiniosis have been associated with a high prevalence of reactive arthritis whereas in others arthritis has not been recorded.[12,13] It is unclear to what extent this variability is attributable to bacterial, other environmental, and to host factors.

Among men with non-gonococcal genitourinary infections, reactive arthritis develops in approximately 1 percent to 3 percent;[14,15] no accurate prevalence or incidence data are available for women with genitourinary infections, though reactive arthritis is probably underrecognized in this group.

ETIOLOGY

Concept of Reactive Arthritis

The term *reactive arthritis* implies a clinically characteristic reaction to a precipitating infection. For practical purposes, the clinical entity is the same as Reiter syndrome. The term was introduced by Ahvonen and colleagues in 1974[16] to indicate the likely, if hypothetic, link between an initiating infection and the subsequent aseptic arthritis. The condition may best be defined by a modification of their description as "arthritis as-

REACTIVE ARTHRITIS AT A GLANCE



- Reactive arthritis is one of the spondyloarthropathy group of arthritides. Its defining feature is initiation by infection, usually in the genitourinary or gastrointestinal tract.
- Key clinical features are asymmetric arthritis at a few joints, most often the knee, ankle, or metatarsophalangeal joints, enthesitis typically at the Achilles tendon or plantar fascia attachments to the calcaneum and sacroiliitis.
- Psoriasiform lesions on the soles—keratoderma blenorrhagicum—or penis—circinate balanitis—occur in one-third of patients and inflammatory eye disease is present in a similar proportion. Urethritis may occur with or without urogenital infection.
- The presence of HLA-B27 predisposes to the development of reactive arthritis.
- *Salmonella*, *Campylobacter*, *Shigella*, *Yersinia*, and *Chlamydia* infections are particularly thought to trigger reactive arthritis, but other infections may also act as initiators.
- Most episodes of reactive arthritis resolve spontaneously within 12 months, with minimal sequelae, but up to one-half of those affected may develop a recurrence.



sociated with infection elsewhere in the body but without viable microorganisms in the joint." *Reiter syndrome* has been redefined more recently as "an episode of peripheral arthritis of more than 1 month's duration occurring in association with urethritis and/or cervicitis."[17] When only two of the three features of the classic Reiter syndrome triad are present, the term *incomplete Reiter syndrome* is sometimes used.[18] Both complete and incomplete Reiter syndrome should be considered to be inseparable from reactive arthritis.

Reactive arthritis has been subdivided into sexually acquired reactive arthritis (SARA)[19] and post-dysenteric arthritis or enteric reactive arthritis. *Chlamydia-induced arthritis* has been used to refer specifically to reactive arthritis thought to be triggered specifically by a chlamydial infection[20] and *post-streptococcal reactive arthritis* has been used to describe arthritis, with features resembling reactive arthritis, associated with streptococcal throat infection.[21]

The term *post-infective arthritis* is also used to refer to aseptic arthritis after a defined episode of infection, and includes some forms of meningococcal arthritis. Reactive arthritis is associated with characteristic clinical and genetic features and so is separated from post-infective arthritis on that basis. However, there is no clear separation between reactive and post-infective arthritis. Similarly, some conditions, notably Lyme arthritis, appear to share features with reactive and post-infective arthritis but, at least in some cases, are associated with viable microorganisms in the joint. Thus, such conditions should be regarded as primarily infective or low-grade septic arthritis. The term *microseptic arthritis* has been used.

In spite of the confusing plethora of terms, it is inescapable that reactive arthritis represents an overarching, if variable, condition with characteristic clinical and genetic features and established linkage with infection. Observations of familial clustering and shared clinical and genetic features justifies the inclusion of reactive arthritis within the spondyloarthritis family.

Initiating Infections

The understanding of reactive arthritis as a disease caused by certain bacterial infections is based on observations of associations, not on clear understanding of pathogenetic mechanisms. Studies of outbreaks have identified *Shigella, Campylobacter, Salmonella,* and *Yersinia* bacteria as being likely causes of reactive arthritis.[22–30] Small studies and anecdotal reports have also implicated a wide range of other bacteria and, occasionally, other microorganisms in the causation of reactive arthritis,[31] though their true role is not established. Chief among these are diarrhea-associated illnesses, including antibiotic associated colitis due to overgrowth of *Clostridium difficile,* though traveler's diarrhea, in which no specific microorganism is implicated, has also been linked with episodes of reactive arthritis.[32] Bacteria strongly linked to reactive arthritis share the property of persisting in macrophage endosomes. These include *Salmonella enteritidis, S. typhimurium,* and *S. heidelberg; Shigella flexneri* types 1b and 2a, and *S. dysenteriae* but not *S. sonnei; Yersinia enterocolitica* and *Y. pseudotuberculosis; Campylobacter fetus;* and *C. difficile*. Among the *Salmonella* and *Shigella* infections that result in Reiter syndrome there is a reported connection between the ability to induce Reiter syndrome and the presence of a distinctive plasmid.[33] Extensive studies of genital-tract infection have also indicated a likely similar role for *Chlamydia trachomatis* which can be isolated from the genital tract in 35 percent to 50 percent of cases,[34–37] as in uncomplicated non-gonococcal urethritis. Several studies have implicated other genitourinary pathogens, particularly *Neisseria gonorrhoeae*[38,39] and possibly mycoplasmas[40,41] in the causation of reactive arthritis and other inflammatory arthritides but the nature of the link remains uncertain.

Septic arthritis caused by microorganisms also associated with reactive arthritis, notably *Salmonella*, *Campylobacter,* and *Neisseria gonorrhoeae* must be distinguished from aseptic disease.

Reactive arthritis may occur linked to infective symptoms, but without identified pathogens. In some instances, evidence of infection may be absent because the symptoms of infection were mild or trivial so that the patient was not aware of them. Nevertheless, care should be taken to restrict the use of the term to episodes of arthritis conforming to a spondyloarthropathy temporally associated with a recognized initiating infectious event.

Human Immunodeficiency Virus Infection

Reactive arthritis and other forms of inflammatory arthritis may occur in HIV-infected individuals even in the presence of marked immunosuppression.[46,47] The prevalence of reactive arthritis appears to vary among different populations: in some black African populations, the high prevalence of HIV infection has been linked with an increased prevalence of reactive arthritis.[8] In North American and European populations, clinical features of the arthritis are typical of that found in HIV-negative individuals although psoriasis may be especially extensive and severe. Among HIV-infected black Africans, clinical characteristics may be atypical in that more joints tend to be affected and the course may be accelerated with rapid joint destruction.[48] Whether HIV infection actually contributes directly to the development of reactive or any form of aseptic arthritis remains uncertain; however, evidence that the incidence of arthritis is reduced by highly active antiretroviral therapy[49] is consistent with a direct effect of HIV on the development of arthritis. As in non–HIV-associated cases, it may be impossible to differentiate between reactive arthritis, psoriatic arthritis, and undifferentiated spondyloarthropathy.[50]

Genetic Factors

Although most patients do not give a family history of reactive arthritis or a related disease, genetic susceptibility to reactive arthritis conferred by HLA-B27 is well recognized. There is some correlation between the prevalence of HLA-B27 in a population and the prevalence of reactive arthritis and other spondyloarthropathies, though HLA-B27 is not essential for disease.

The prevalence of HLA-B27 and reactive arthritis varies around the world.[7,51] In healthy Caucasian populations, HLA-B27 is present in 7 percent to 9 percent; the gene being detected in 45 percent to 80 percent of those with reactive arthritis. Where the prevalence of HLA-B27 is low, as in some native populations of South America, Australia, and Southern Africa, the likelihood of reactive arthritis is also low. Conversely, groups with a high HLA-B27 prevalence, such as some Eskimo, Native American, and Melanesian (e.g., Papua New Guinean) populations, reactive arthritis, and other spondyloarthropathies are more common. Nonetheless, some HLA-B27 positive individuals do not develop arthritis even during a known trigger infection.[52]

Among the many HLA-B27 subgroups, not all have been detected among reactive arthritis patients. However, there is no clear linkage between



any individual B27 subgroup and reactive arthritis.

In addition to HLA-B27, other incompletely defined genes appear to be involved. In some families with HLA-B27, there is a strong familial aggregation of Reiter syndrome without ankylosing spondylitis, whereas in other families, the opposite is the case.[7] A similar divergence between Reiter syndrome and ankylosing spondylitis is evident among certain groups of American Indians and Inupiat Eskimos, in whom HLA-B27 is prevalent. Reiter syndrome/reactive arthritis, but not ankylosing spondylitis, is common among Navajo and Inupiat Indians, whereas the Haida and Pima have a high frequency of ankylosing spondylitis but not reactive arthritis.

HLA-B27 is associated with disease severity. Many patients, especially those with short-lived or mild disease, are HLA-B27 negative. HLA-B27 positivity is associated with more severe symptoms and joint damage, prolonged course, greater risk of chronicity, and the subsequent development of ankylosing spondylitis.[53]

HIV-infected Caucasians with reactive arthritis are usually HLA-B27 positive, whereas non-Caucasians tend to be HLA-B27 negative.[49,54]

TABLE 20-1
Characteristics of Spondyloarthropathy[a]

MUSCULOSKELETAL	GENETIC	EXTRA-ARTICULAR
Inflammatory oligoarthritis		Skin/mucosal psoriasis
Enthesitis		Genitourinary inflammation
Sacroiliitis	HLA-B27	Inflammatory bowel disease
Spondylitis		Inflammatory eye disease
Dactylitis		Carditis

[a]One or more musculoskeletal lesions often occurring in association with one or more characteristic extra-articular lesions, which may be subclinical, with negative tests for autoantibodies, including rheumatoid factor.

PATHOGENESIS

Although a number of microorganisms have been strongly linked with the cause of reactive arthritis and many others weakly associated, there are no adequate guiding principles to help to establish or refute a role for any specific microorganism as a causal agent. Criteria for inferring causality in reactive arthritis have been proposed[55] but further work is needed to clarify the situation. A temporal relationship between infection and arthritis may provide strong evidence of causality in some outbreaks but cannot be seen as such in sporadic cases. The isolation of *Chlamydia trachomatis* from joint samples in early studies[31] and the subsequent identification of chlamydial membrane proteins, genomic and plasmid DNA and RNA in synovium and synovial fluid from patients with reactive arthritis[56–60] strongly suggested that the microorganisms identified could be presumed to cause the arthritis. It is possible that intra-articular chlamydiae are viable.[61] Similarly, identification of membrane protein and lipopolysaccharide antigens from *Yersinia* and *Salmonella* bacteria in joint material supported the same conclusion.[62–64] Moreover, the presentation of bacterial antigens by antigen presenting cells within the joint[65] and the presence of sensitized T lymphocytes in the joint[66–68] have all been cited as supporting causal roles of specific bacteria in individual cases.[69,70] Suggestive as these pieces of evidence are, however, they leave the key issues unresolved. It seems likely that bacterial components in the circulation may enter inflamed joints non-specifically[71] and that many bacteria found within joints may be non-specific.[72,73]

Understanding of pathogenetic mechanisms in reactive arthritis is, in spite of the tantalizing prospects offered by HLA-B27 and specific bacteria, far from complete. Numerous studies have addressed the processing and presentation of bacterial antigens and the responses of CD8-positive lymphocytes, which processes appear to play critical roles in the pathogenesis of reactive arthritis and, perhaps, other spondyloarthropathies. The potential of various bacterial preparations to induce arthritis experimentally is well demonstrated in animal systems and more recent studies with HLA-B27 transgenic animals[74,75] have amplified, but not clarified, the case for a direct role for bacteria in arthritis in the context of HLA-B27.

Currently no "front-runner" theory seems able to explain all the features of reactive arthritis. There is evidence, however, to implicate arthritogenic peptides, molecular mimicry between bacterial antigens and the HLA-B27 molecule, aberrant or misfolded forms of HLA-B27, as well as aspects of non-antigen-presenting functions of the HLA-B27 molecule, including altered intracellular bacterial killing and/or processing. The influence of non-HLA genes may also be important.

CLINICAL FINDINGS

History and Presenting Features

The characteristic features of reactive arthritis are those of spondyloarthropathy (Table 20-1) in general, temporally linked to a recognized precipitating infection. The interval between the onset of symptoms of infection and the onset of symptoms of arthritis may be up to 3 months but is typically less than 1 month. The condition usually evolves rapidly over 1 to 3 weeks, varying in severity from mild arthralgia to severely disabling polyarthritis.

Acute pain and swelling at a knee or metatarsophalangeal joint is the most common presentation. Dactylitis at a toe (sausage toe; Fig. 20-1) or heel pain due to enthesitis at the plantar fascia or Achilles tendon insertion (Fig. 20-2) is also a common presenting feature. Upper limb arthritis is rare and involvement of only one or a few joints contrasts with the picture of typical rheumatoid disease. A past history of eye or joint problems or a family history of spondyloarthropathy-related features, including inflammatory eye disease and ankylosing spondylitis, gives vital clues to the diagnosis. Reactive arthritis is a systemic

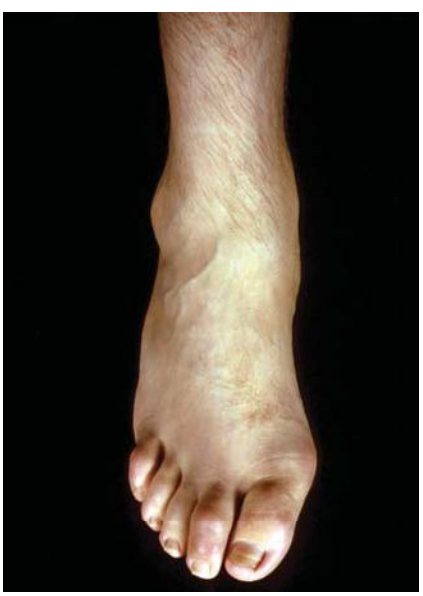

▲ **FIGURE 20-1** Dactylitis of second toe (sausage toe).





▲ **FIGURE 20-2** Achilles tendon bursitis.



disease, although the severity varies greatly. Malaise, fatigue, and low-grade fever or feverishness are common. Uncommonly, arthritis may be accompanied by high fever with a marked acute phase response suggestive of sepsis.

Symptoms of infection may be prominent, mild, or absent. Hence, men with urethritis may present to genitourinary medicine physicians being unaware of the significance of rheumatic symptoms and vice versa. In men with SARA, an urethral discharge, with or without dysuria, is usually present and most patients are able to give an accurate history of recent exposure to infection, if asked directly. However, genital tract infections in women are more often asymptomatic. Diarrhea and abdominal pain associated with an episode of arthritis are usually, but not always, mild. There may be symptomatic infection in family members, close contacts, or sexual contacts. Uncommonly, features of infection are highly atypical; gut infection, especially by *Yersinia*, may mimic appendicitis or salpingo-oophoritis. More commonly, symptoms are mild or absent, so that infection is overlooked.

Skin and Mucous Membrane Lesions

Psoriasiform skin and mucous membrane lesions occur in up to one-third of patients with SARA but in fewer of those with other forms of reactive arthritis. Circinate balanitis (Fig. 20-3) has been described in up to 36 percent of patients. It may accompany the acute episode or occur in isolation. The lesion is initially vesicular with little or no surrounding erythema. Irregular, moist, superficial ulcers form in the uncircumcised male and may coalesce to give a circinate distribution (see Fig. 20-3). These ulcers may occasionally become secondarily infected. In the circumcised male, the lesions evolve to form hard crusts and plaques. Circinate vulvitis has also been described.[83]



▲ **FIGURE 20-3** Circinate balanitis.

Examination of the soles of the feet may reveal keratoderma blenorrhagicum (Fig. 20-4), which is similar to palmoplantar pustulosis (see Chap. 21), in up to 15 percent of patients with SARA. The initial lesions are small vesicles or erythematous macules surrounded by an erythematous base, which may coalesce. The vesicle wall becomes progressively thickened, forming a small papule, nodule, or even a horny excrescence. The appearance of the lesions varies from a scaling plaque-like process that resembles pustular psoriasis to combinations of crusting, exudation, and erosion associated with erythema. Lesions on the soles may be markedly hyperkeratotic. Oral psoriasiform lesions (geographic tongue) occur uncommonly and painless mucosal ulcers may occur on the tongue, palate, buccal mucosa, and lips; they are usually transient and cause little or no morbidity. Histologically, keratoderma blennorrhagicum is indistinguishable from pustular psoriasis, being characterized by hyperkeratosis and parakeratosis, elongation and hypertrophy of the rete pegs, general epidermal hyperplasia, and extensive neutrophilic infiltration with formation of microabscesses and spongiform pustules (see Chap. 21). The histologic appearance of circinate balanitis is similar though the moist lesion in uncircumcised males is not keratinized. Mouth ulcers are similarly unkeratinized.

In the presence of HIV infection, keratoderma blennorrhagicum may be distributed over the entire body, also involving the digits, in a pattern that resembles that of pustular psoriasis and in the groin in the pattern of inverse psoriasis or sebopsoriasis. The keratoderma blennorrhagicum lesions may last for weeks to months, disappear, and then recur.[84] In patients with HIV infection, arthritis may begin as typical reactive arthritis but gradually transform into chronic psoriatic arthritis.

Typical psoriatic nail lesions may be seen and typical psoriatic plaques may occur elsewhere on the body.

Erythema nodosum may occur uncommonly after enteric infections, especially *Yersinia* infection, but is not associated with HLA-B27.

Joint and Enthesis Lesions

The musculoskeletal picture of reactive arthritis may be indistinguishable from psoriatic arthritis (see Chap. 19).



▲ **FIGURE 20-4** Keratoderma blennorrhagicum.

Monoarthritis or asymmetric oligoarthritis affecting knees, ankles, and subtalar and metatarsophalangeal joints are typical. The clinical picture contrasts with rheumatoid disease by predominantly affecting leg joints in an asymmetric fashion; however, small joint disease, especially at the metatarsophalangeal joints, may be erosive. In severe cases, extensive erosive damage produces severe, rheumatoid-like deformity, with marked subluxation and valgus deformity at the metatarsophalangeal joints. Other large joints, such as the hips and shoulders, may also be involved and persistent arthritis at the knee may be associated with huge effusions and the formation of a Baker's cyst. Rupture of a Baker's cyst may mimic deep vein thrombosis.

Pain in the buttock, often described as in the "hip," may be due to acute sacroiliitis. Sacroiliitis is difficult to diagnose acutely, as similar symptoms may be referred from non-inflammatory lesions in the lumbosacral spine. Radiographs are likely to be normal at this stage unless a previous episode of sacroiliitis has occurred and isotope bone scanning is often unhelpful. Magnetic resonance imaging (MRI) and computerized tomography scanning may, however, demonstrate early evidence of acute sacroiliitis. In reactive arthritis, this is often unilateral in contrast to the bilateral involvement in ankylosing spondylitis (see eFig. 20-4.1 in on-line edition).

Inflammation at entheses—sites of bony attachments of ligaments and tendons—is highly characteristic of all the spondyloarthropathies, including reactive arthritis.[6,85,86] Pain at the ankle region may be due to enthesitis at the Achilles tendon or plantar fascia attachments to the calcaneus. Achilles tendonitis may be associated with characteristic bursitis. Painful enthesopathy may also occur at costochondral junctions and at ischial tuberosities and iliac crests. Acute enthesopathic lesions may be well shown by MRI or by ultrasound scanning; plain radiographs demonstrate bony spurs, especially at the plantar fascia attachment, but these are late signs that often reflect previous disease rather than the current episode.

Genitourinary Features

Urogenital inflammation may occur either as a feature of initiating sexually transmitted infection or as a sterile reactive lesion. Thus, urethritis has been included in the triad classically recognized as Reiter syndrome irrespective of the presumed initiating event. Cystitis and prostatitis may be present and can sometimes lead to complications such as shrinking of the bladder. Furthermore, pelvic inflammatory disease, including salpingitis, may arise in women with reactive arthritis.[87,88] Inflammation of the urogenital tract has a tendency to relapse with or without apparent reinfection.

Gastrointestinal Involvement

Acute infective enteritis or colitis may, similar to urogenital infections, be the etiologic triggering event. It has become apparent, however, that, as in the urogenital system, the epithelium of the intestine may form part of the reactive disease itself. Ileocolonoscopic studies have demonstrated that in some patients with established reactive arthritis, irrespective of the presumed precipitating infection, macroscopic or microscopic inflammatory lesions in the small or large intestine, resembling ulcerative colitis or Crohn disease are present.[89,90] This is similar to findings in other spondyloarthropathies, especially ankylosing spondylitis, though the significance of these findings is unclear.

Ocular Lesions

One-third of patients with reactive arthritis develop unilateral or bilateral inflammatory eye lesions, which form a classic part of the clinical picture. Conjunctivitis with sterile discharge occurs in one-third of patients. It usually subsides spontaneously but may progress to episcleritis, keratitis, or even corneal ulceration. Acute anterior uveitis (iritis) occurs only in 4 percent to 5 percent of patients during an episode of reactive arthritis but is more usually asynchronous, a history of iritis supporting the rheumatic diagnosis.[91] Both conjunctivitis and iritis have a strong tendency to recur. Although iritis is more often associated with severe ocular pain, redness, lacrimation, photophobia, and visual impairment,[92] conjunctivitis and iritis are often indistinguishable without specialist assessment. Thus, the development of ocular pain and/or redness warrants urgent ophthalmologic examination to prevent permanent visual impairment.

Cardiac Lesions

Symptomatic heart disease is rare in reactive arthritis. Palpitations and pericardial type chest pain, occasionally with a pericardial rub, have been described.[93] However, electrocardiographic abnormalities are not uncommon early in disease with changes including first-, second-, and third-degree heart block, ST-segment and T- and Q-wave changes and significant dysrhythmias occurring in approximately 5 percent of patients.[94,95] These are usually without clinical sequelae.

As in other spondyloarthropathies, aortic root inflammation with or without aortic valve disease is an important, if uncommon, feature.[96,97] Symptomatic aortic valve disease, generally incompetence, occurs in 1 percent of patients and is an important cause of morbidity and mortality.

Other Systemic Manifestations

Numerous other lesions have been described anecdotally in patients with reactive arthritis or Reiter syndrome. These include glomerulonephritis and immunoglobulin A nephropathy, which seldom leads to permanently impaired renal function, peripheral neuropathy, pleurisy, pulmonary parenchymal inflammation, and amyloidosis.

DIFFERENTIAL DIAGNOSIS

In many patients, the disease features are typical and the diagnosis is easy; however, in practice, the differential diagnosis is wide and misdiagnosis is common. Reactive arthritis has to be differentiated from other forms of inflammatory arthritis, including other spondyloarthropathies, rheumatoid arthritis, gout, sarcoidosis, and septic arthritides and from systemic vasculitides, which may present in their early stages in young adults with joint pain and fever, thus entering the differential diagnosis, albeit briefly. In addition, reactive arthritis must be differentiated from non-specific symptoms in patients who present with arthralgia and symptoms suggestive of infection, usually genitourinary but in whom a clear diagnosis of infection cannot be made. Inevitably, in some instances, the true diagnosis, especially rheumatoid arthritis, psoriatic arthritis, and ankylosing spondylitis, only becomes clear with clinical follow-up.

The diagnosis of reactive arthritis is reached in two stages: the recognition of a spondyloarthropathy and the establishment of a link with a "triggering" infection (Fig. 20-5).

Is It a Spondyloarthropathy?

There are no confirmatory tests for the diagnosis of spondyloarthropathy. Po-





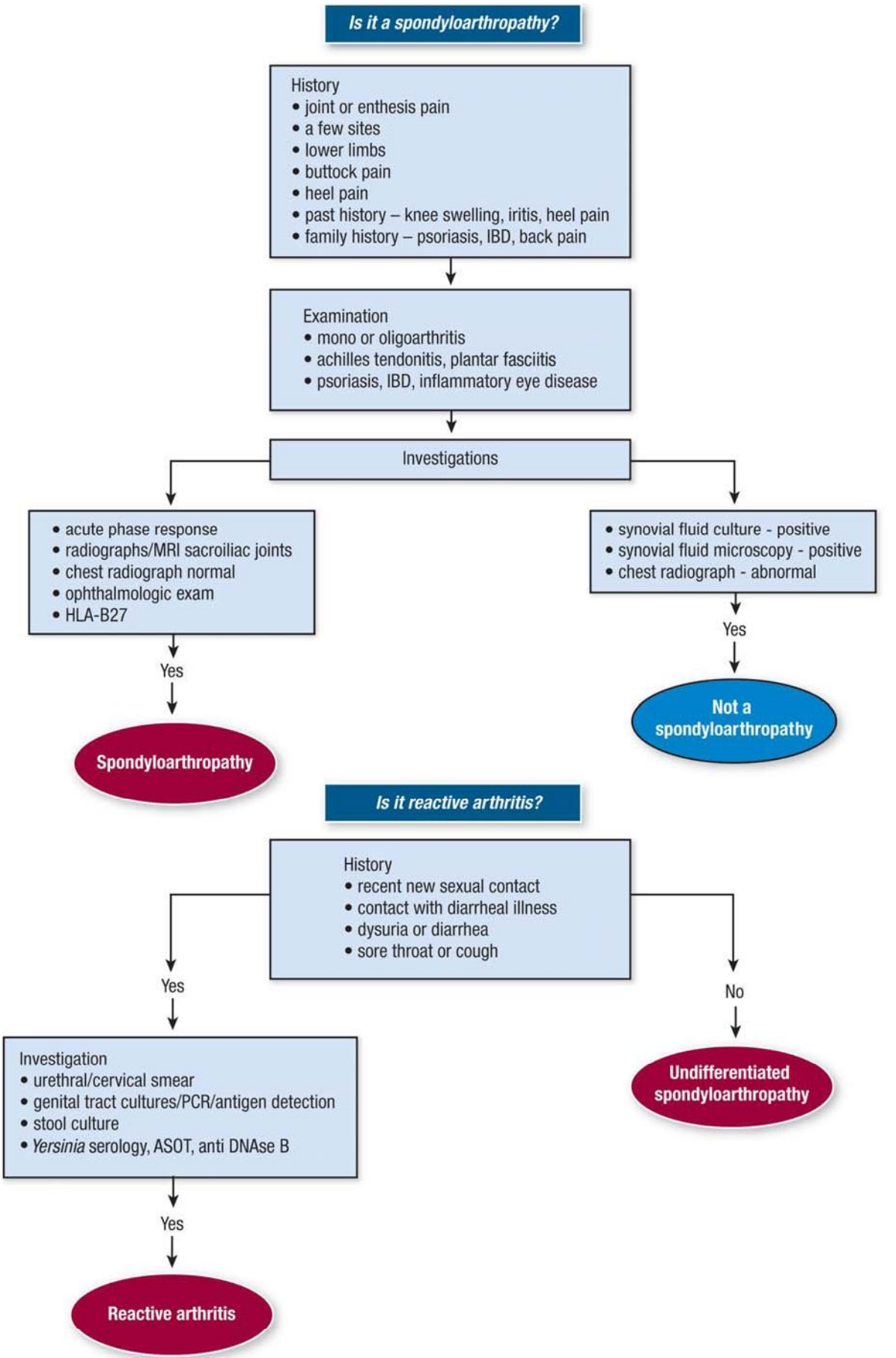

▲ **FIGURE 20-5** Diagnostic algorithm "making the diagnosis." anti DNAse B = antideoxyribonuclease B; ASOT = antistreptolysin O titer; IBD = inflammatory bowel disease; MRI = magnetic resonance imaging; PCR = polymerase chain reaction.

tential diagnostic criteria have been put forward[98,99] and the characteristic clinical features of spondyloarthropathy, particularly lower limb mono- or oligoarthritis; enthesitis, especially at the heel, and buttock pain, often in a young adult, are readily recognized. A family history of spondyloarthropathy features, including inflammatory bowel disease and iritis, is suggestive. Presentation in the context of infection, whether in the presence of a known sporadic genitourinary or gut infection or during an outbreak of diarrhea, raises suspicion of the diagnosis, although gastrointestinal symptoms in cases of enteric reactive arthritis are often mild or even absent. Even isolated monoarthritis at a lower limb joint, such as a single swollen knee, should raise suspicion of a spondyloarthropathy.

Investigations serve to confirm the presence of inflammatory arthritis and demonstrate the presence or likely recent presence of an associated infection. Acute phase reactions, whether measured by C-reactive protein, erythrocyte sedimentation rate or plasma viscosity, are usually elevated. In patients with substantial systemic upset and fever, the C-reactive protein may be very high, suggesting sepsis, which is also a key differential diagnosis. With persistent, active disease, non-specific normochromic anemia and leukocytosis may also develop. Urinalysis should be carried out at diagnosis and should be repeated during the follow-up, as pyuria indicative of urethritis and proteinuria may indicate renal involvement. Tests for rheumatoid factor and other autoantibodies are usually negative.

An essential component of this initial diagnostic stage is the exclusion of alternative differential diagnoses. Septic arthritis attributable to both acute pyogenic organisms and to *Mycobacterium tuberculosis* needs to be excluded, especially in children. Hence, joint aspiration and occasionally synovial biopsy are important investigations. Blood cultures are also essential if sepsis is suspected. Arthroscopy and synovial biopsy may also be useful to exclude or confirm the diagnosis of pigmented villonodular synovitis, though otherwise findings are non-specific. Similarly, crystal synovitis occasionally presents with intense effusion at a knee or ankle in a young adult. This requires exclusion by examination of synovial fluid for crystals. Sarcoidosis and *Mycoplasma pneumoniae* infection should also be considered within the differential diagnosis and should necessitate chest x-ray with or without further investigations.

In those with eye symptoms, urgent assessment by an ophthalmologist is important as uveitis requires prompt and correct treatment if eyesight is to be protected. When cardiac abnormalities are detected clinically or rheumatic fever is suspected, electrocardiography and echocardiography may be helpful. In those with severe or prolonged episodes of reactive arthritis, however, conduction disturbances are common, though generally benign.

Is It Reactive Arthritis?

The diagnosis of reactive arthritis and its designation according to putative infectious cause are dependent on demonstrating a temporal relationship with a specific bacterial infection. A clear history of potentially infective symptoms, such as abdominal pain, diarrhea, dysuria, urethral or vaginal discharge, or possibly of other infective symptoms such as sore throat is important, though not essential. So too is a history of likely exposure to infection, including sexual intercourse with (a) new sexual partner(s) and the presence of other contacts with abdominal symptoms, including family members, who may also have eaten contaminated food. Sometimes the clue to a point source of bacterial food poisoning may come from public health services rather than the patient. The timing of contact with potential sources of infection should be carefully documented and contacts traced if appropriate. For some patients, evidence of a potentially initiating infection only emerges from a "blind" search in the absence of infective symptoms when other features raise this diagnostic possibility.

Once a probable trigger infection is identified, effort should be made to confirm the infective diagnosis and identify the putative causal microorganism. Specialist genitourinary examination may confirm the presence of urethritis or cervicitis; culture for appropriate pathogens can be taken along with immunodetection tests for *Chlamydia trachomatis.*

PROGNOSIS AND CLINICAL COURSE

Most episodes of reactive arthritis resolve within 3 to 5 months, with a mean episode duration of 19 weeks.[11,53] Sixty percent to 80 percent of patients are in remission at 12 months[101] and 75 percent to 100 percent have remitted by 2 years, those with enteric reactive arthritis faring slightly better than those with SARA.[11,53]

HLA-B27–positive individuals are more likely to develop sacroiliitis and subsequent ankylosing spondylitis,[53,102] and, in hospital-based studies, HLA-B27–positive individuals are likely to have longer episode duration, more extra-articular features, especially iritis, and erosive joint damage. Within spondyloarthropathies, male gender, a positive family history, the presence of chronic gut lesions detected endoscopically and hip involvement predict long episode duration.[102] Recurrent episodes and chronic disease are also linked to HLA-B27 positivity. A weighted risk analysis for severe prognosis in spondyloarthropathy has been proposed.[102] Each feature is scored and a total score is calculated. A poor outcome is predicted if hip arthritis is present or if more than three factors are present.

It appears that HLA-B27–negative individuals are largely, if not entirely, protected from developing sacroiliitis, destructive peripheral arthritis, iritis and subsequent ankylosing spondylitis. The identity of the triggering agent does not appear to influence the episode duration.

Back pain, whether inflammatory of non-specific, persists beyond the acute episode in up to 25 percent of patients.[103] Sacroiliitis, on plain radiography, has been reported in 14 percent to 49 percent of patients attending hospital. The issue as to whether reactive arthritis promotes the subsequent development of ankylosing spondylitis is unresolved but it is likely that the overall incidence of ankylosing spondylitis in individuals who have had reactive arthritis is significantly higher than the background prevalence among unselected HLA-B27–positive individuals.[104] The presence of chronic gut lesions on endoscopy is also a predictor of the development of chronic spondyloarthropathy, including ankylosing spondylitis; conversely, absence of such gut lesions or possession of HLA-Bw62 correlates positively with remission of arthritis without sequelae.[105]

Recurrence and Persistence

Between 30 percent and 50 percent of patients with SARA have a relapse; in contrast, relapse is less common in the enteric forms. Recurrences may be triggered by new infections but may also occur without evident provoking factors. Conversely, individuals with a past history of reactive arthritis may have a new infection by a bacterium known to trigger the disease without developing a recurrence. Iritis and psoriasiform rashes are particularly prone to recurrence independent of arthritis without recognizable triggers. Such recurrences tend to become less common with advancing age.



Persistence of arthralgia, fatigue, and pain resulting from joint damage is not uncommon for 2 or 3 years despite quiescence of the arthritis. Joints that have been affected by reactive arthritis may be prone to later osteoarthritis.

Work Disability

Work disability is difficult to analyze usefully because it has been addressed in rather disparate studies as social and unemployment support systems differ between countries. It seems likely that work disability is rare after outbreaks of enteric infection, but among hospital attenders some patients are unable to continue working, usually because of persistent disease, painful foot joint damage, or spondylitis. In North America and Canada, up to 16 percent of this latter group changes their work or becomes unemployable, and this figure may rise with late follow-up.[106,107] The presence of heel disease predicts poor outcome.

Mortality

Death is an extremely uncommon outcome of reactive arthritis. Anecdotally, occasional deaths have been attributed to carditis, cardiac valvular disease, amyloidosis, and complications of surgery. It is likely that mortality of patients with reactive arthritis does not differ from that of the healthy population.

TREATMENT

Skin and Mucosal Lesions

Skin and mucosal lesions are essentially psoriasis and should be managed accordingly (see Chap. 18). In mild cases, keratinolytic agents such as salicylic acid ointment or topical treatments, including vitamin D analogues and corticosteroids may be used; in more severe cases, methotrexate or retinoids are often beneficial.

Arthritis and Enthesitis

In most patients, episodes of reactive arthritis resolve spontaneously and treatment needs to recognize the likely natural course. It is also the case, however, that many patients are at a stage of life in which tolerance of even temporary disruption of occupational and recreational activities is low so that enthusiasm for restorative treatment is high. Thus, treatment decisions should seek to balance these conflicting facets of the condition. Treatment guidelines for SARA have been published.[108]

Making and explaining the diagnosis and its implications is the cornerstone of treatment. The role of infection also raises important issues that have to be anticipated and managed: Chief among these issues are the role, protection, and potential culpability of sexual partners and the public health and legal issues arising from the consumption of contaminated food.

Treatment of peripheral joint and enthesis lesions is exactly as for other inflammatory arthritides, with analgesics, nonsteroidal anti-inflammatory drugs, antitumor necrosis factor-α biologics, local steroid injections for individual lesions, physiotherapy and attention to footwear all playing important roles.

In nonsteroidal anti-inflammatory drug–resistant disease, with marked systemic features or prolonged active phase, systemic corticosteroids may be helpful. Steroids may be administered as a single intramuscular dose of depot methylprednisolone (80 to 120 mg), especially to "buy time" if a second-line drug is being introduced, or as a course of oral prednisolone (15 to 30 mg once daily), the dose being tapered according to response. Corticosteroid therapy should be used for the minimum possible period and accompanied by appropriate bone protective treatment.

In recurrent, chronic or erosive disease, second-line agents may be used as in rheumatoid arthritis. Of these, sulphasalazine is the best studied and shown to be well tolerated and probably effective for peripheral joint disease.[109,110] Treatment should be started at low dose, increasing to 2 to 3 g a day if tolerated by the patient, as in the treatment of rheumatoid arthritis. Gastrointestinal intolerance may limit dose escalation.

Other agents, including methotrexate, azathioprine, and leflunomide, may be effective though formal evidence for this in reactive arthritis is limited.[111,112]

Antitumor necrosis factor therapy has been used successfully on an anecdotal basis in a few patients with severe, chronic disease. The place of such biologic therapy in this condition is, however, far from established.

Treatment of arthritis in the context of HIV infection is as in HIV-negative patients but with the additional need for appropriate antiviral therapy. Local corticosteroid injections may also be used as in non-HIV cases. In long-standing cases, sulfasalazine may be beneficial.[113] Immunosuppressive agents should be used with great care, if at all, in individuals with HIV infection.[114]

Eye inflammation must be diagnosed and treated promptly if irreversible damage to eyesight is to be avoided. Treatment of iritis consists of corticosteroids in the form of eye drops, local injection or even systemically, and of mydriatics. The patient should be informed about the strong possibility of recurrence.

Antimicrobial Therapy

Appropriate antibiotic treatment of acute genitourinary infection, along with contact tracing and treatment of sexual partners is essential. Conversely, antibiotic treatment of bacterial diarrhea, other than in exceptional circumstances, is best avoided. It is unclear whether antibiotic treatment of acute sexually transmitted infections reduces the likelihood of reactive arthritis developing but there is some evidence that this may be so.[115] It is clear that many patients develop arthritis in spite of completing a course of antibiotics sufficient to clear their genitourinary infection. Short courses of antibiotics of 1 or 2 weeks do not appear to influence the course or duration of either SARA or enteric reactive arthritis.[116,117] Numerous studies have addressed the potential value of medium- to long-term (3 to 12 months) antimicrobial mtherapy in reactive arthritis but have been unable to demonstrate any convincing evidence of efficacy.

It is clear that medium- to long-term antibiotic treatment of patients with reactive arthritis is not justified by current evidence.[118]

KEY REFERENCES

The full reference list for all chapters is available at www.digm7.com.

49. Calabrese LH, Kirchner E, Shrestha R: Rheumatic complications of human immunodeficiency virus infection in the era of highly active anti-retroviral therapy: Emergence of a new syndrome of a new reconstitution and changing patterns of disease. *Semin Arthritis Rheum* **35**:166, 2005
51. Reveille JD, Ball EJ, Khan MA: HLA-B27 and genetic predisposing factors in spondyloarthropathies. *Curr Opin Rheumatol* **13**:265, 2001
53. Leirisalo-Repo M: Prognosis, course of disease and treatment of the spondyloarthropathies. *Rheum Dis Clin Amer* **24**:737, 1998
82. Vahamiko S, Penttinen MA, Granfors K: Aetiology and pathogenesis of reactive arthritis: role of non-antigen-presenting effects of HLA-B27. *Arthritis Res Ther* **7**:136, 2005
85. McGonagle D: Diagnosis and treatment of enthesitis. *Rheum Dis Clin North Am* **29**:549, 2003
108. Carlin EM, Keat AC: European guidelines for the management of sexually acquired reactive arthritis. *Int J STD AIDS* **12**:94, 2001

CHAPTER 21

Pustular Eruptions of Palms and Soles

Ulrich Mrowietz

Pustular eruptions of the palms and soles include palmoplantar pustulosis (PPP), acrodermatitis continua (Hallopeau disease), and infantile acropustulosis (Table 21-1). The entities present with chronic and persistent eruptions of sterile, purulent vesicles.

PALMOPLANTAR PUSTULOSIS

PPP is a chronic pustular dermatosis localized on the palms and soles only. High resistance to treatment and a high recurrence rate are characteristic. Histologically, it is characterized by intraepidermal vesicles filled with neutrophils.

Previously, PPP was classified as a form of pustular psoriasis and many textbooks describe PPP in their respective chapter of psoriasis. Today, PPP is regarded as its own entity.

The involvement of palms and soles has a great impact on life quality and the ability to work.

Epidemiology

PPP has a worldwide distribution. It is a rare condition, but the exact incidence is not known.

Females show a higher prevalence than males, with a ratio of approximately 3:1. Onset of the disease occurs mostly between the ages of 20 and 60 years; rarely, the condition occurs after the sixth decade of life, and in 10 percent of the patients the onset is before the age of 20 years.

PALMOPLANTAR PUSTULOSIS AT A GLANCE



- Chronic inflammatory disorder with sterile pustule formation.
- Affects only palms and soles.
- Disabling in severe cases.
- High rate of recurrence.
- Often resistant to treatment.
- Can be part of SAPHO (synovitis, acne, pustulosis, hyperostosis, osteitis) syndrome.

Genetics

HLA typing of patients with PPP reveals no increased frequency of any of the known psoriasis-linked alloantigens.[1] In a direct comparison among chronic-plaque psoriasis, guttate psoriasis, and PPP, the three major candidate genes within the PSORS1 region (HLA-Cw*6, HCR*WWCC, and CDSN*5) showed a high association to guttate and chronic plaque psoriasis, not, however, to PPP.[2] Investigation of the apolipoprotein E alleles e2, e3, and e4 in chronic plaque and guttate psoriasis as well as in PPP in acitretin responders and nonresponders showed that the frequency of the e4 allele was significantly higher in the psoriasis groups but not in PPP patients as compared to healthy controls.[3] In chronic plaque psoriasis and psoriatic arthritis an association with tumor necrosis factor (TNF)-α–238 and –308 promotor polymorphisms have been found; however, the association has not been found in PPP.[4]

Studies from Japan provide evidence for phenotypic and genetic heterogeneity of PPP according to its association/provocation with tonsillitis. In patients in which PPP was not associated with tonsillitis, the phenotype frequency of the TNF-β2 allele of the TNF-β gene and of the allele B of the TNF-α gene (TNF-α pB) was significantly higher as compared to controls.[5]

These findings further substantiate the notion that PPP and psoriasis represent different entities.

Etiology

The cause of PPP is not known. An imbalance of the protease/antiprotease system in the skin consisting of decreased antileukoprotease (elafin/SKALP) activity in pustular psoriasis has been discussed as a possible mechanism of pustule formation.[6] Exacerbation of PPP has been observed after patch testing with metals and was accompanied by elevated leukotriene B4 levels in plasma and pustules.[7]

In a long-term survey from Japan, the incidence of PPP was found to be positively correlated to heavy smoking (more than 20 cigarettes per day), tonsillitis, and seasonal factors such as high humidity and high temperature.[8,9]

The most striking association in PPP is smoking. In two Swedish surveys, 95 percent of PPP patients were smokers at onset of disease and cessation of smoking was the most important measure to treat the disease.[10,11] There is evidence from immunohistochemical studies that nicotinic acetylcholine receptors are modulated in lesional skin from smoking PPP patients when compared to smokers and healthy controls suggesting an abnormal response to nicotine in PPP.[12]

Case reports have revealed multiple provocation factors of PPP including thyroid-diseases,[13] *Helicobacter pylori* infection,[14] and psychologic factors such as anxiety.[15]

TABLE 21-1
Pustular Eruptions of Palms and Soles

	Sterile Pustules on Palms and Soles	Age	Cutaneous Atrophy	Associated Disease	Histology
Palmoplantar pustulosis	Yes	Adults	Absent	Psoriasis, SAPHO (synovitis, acne, pustulosis, hyperostosis, osteitis) syndrome	Spongiform pustule, neutrophils, some eosinophils
Acrodermatitis continua (Hallopeau)	Yes	Adults	Present	Pustular psoriasis, Zumbusch type	Spongiform pustule, neutrophils
Infantile acropustulosis (see Chap. 106)	Yes	Infants	Absent	Absent	Subcorneal pustule, neutrophils, some eosinophils

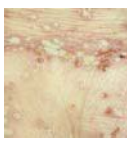

Clinical Features

The primary lesions are pustules of nearly equal size measuring two to four mm in diameter. Crops of pustules usually arise within a few hours on the typical-appearing palmar and plantar skin (Fig. 21-1). Involvement usually is symmetric but unilateral location on palms and/or soles is seen. Single lesions then become surrounded by an erythematous ring. Sometimes, the pustules extend to the dorsa of the fingers, the feet, or over the volar wrists (see Fig. 21-1C). Episodes of new pustular eruptions occur at varying intervals and remain strictly confined to the sites of predilection.

As pustules become older, their yellow color changes to dark brown, so that in untreated PPP, the lesions show various shades of color (see Fig. 21-1C and D). Dried pustules are shed within approximately 8 to 10 days.

There are no symptoms other than itching or a burning sensation, which may precede new crops of lesions. However, in severe eruptions, pain and the inability to stand, walk, or do manual work may greatly reduce the quality of life. As remission begins, fewer pustules are produced, but the skin may remain erythematous and hyperkeratotic, resembling eczema. Remissions last for days, weeks, or months until pustulation again occurs.

Disease Associations

An association of PPP and osteoarthritis of the anterior chest wall was first described in Japan.[16] As reported by Swedish authors, involvement of the manubriosternal joint is present in 6 percent and of the sternoclavicular joints in 10 percent of patients.[17] Scintigraphic investigations showed sternocostoclavicular joint involvement to be present in 16 of 73 (22 percent) patients.[18] For this condition, the term *SAPHO* (synovitis, acne, pustulosis, hyperostosis, osteitis) has been established.[19] Clinical manifestations of SAPHO syndrome are similar whether they occur in relation to severe acne (mostly acne conglobata) or PPP (see Chap. 78). The primary lesion consists of a sterile abscess containing neutrophils. The site of predilection is the anterior chest wall. SAPHO syndrome can be associated with pseudoinfectious arthritis. Involvement of the sacroiliacal joints may be present.[20]

PPP is also seen in patients with chronic recurrent multifocal osteomyelitis as well as with noninfectious inflammatory bone lesions.



▲ **FIGURE 21-1** Palmoplantar pustulosis. **A** and **B.** Groups of pustules measuring 2 to 3 mm in diameter occur on erythematous skin on palms and soles. Both feet and both hands are normally affected symmetrically. **C** and **D.** Lesions may occasionally spread beyond the predilection sites, and pustules may appear on the wrists. Within several days after pustule formation, lesions dry, flatten, and acquire a brownish color. This may be followed by eczematous changes with scaling and fissuring.

Histopathology

Histologically, there is an intraepidermal cavity filled with polymorphonuclear leukocytes associated with spongiform changes within the surrounding epidermis (Fig. 21-2). Eosinophils and mast cells are present in increased numbers in PPP biopsies from lesional skin. Another hallmark is the inability to visualize the epidermal part of the eccrine duct in PPP specimens indicating an involvement of the acrosyringium.[21]

Laboratory Findings

The lesions of PPP are sterile; a moderately increased white blood cell count may occasionally be observed, but all other laboratory tests are usually normal. In patients with an infectious trigger, infection-associated laboratory parameters, such as C-reactive protein, may be increased. Increased levels of anti-gliadin antibodies may occasionally be found.

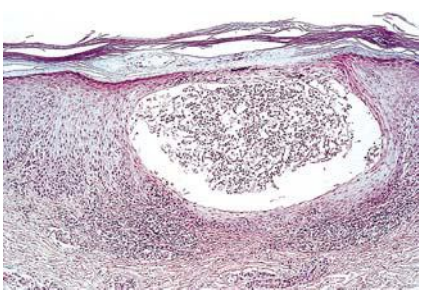

▲ **FIGURE 21-2** Histologically, there is a spongiform pustule and a moderate lymphohistiocytic infiltrate.

Box 21-1

Differential Diagnosis

Most Likely

- Dyshidrotic eczema with secondary bacterial infection
- Tinea of palms and soles with pustules

Consider

- Keratoderma blenorrhagicum in Reiter disease
- Involvement of palms and soles in generalized pustular psoriasis
- Infected scabies with pustulation
- Vesicopustular mycosis fungoides of palms and soles
- Pustular localized vasculitis

Diagnosis and Differential Diagnosis (Box 21-1)

PPP is a distinct entity. The course of the disease, together with the characteristic morphology, permits the proper diagnosis. The disease must be differentiated from "dyshidrotic" eczematous dermatitis (pompholyx), especially when pustules due to secondary infection are present (see Chap. 16). In that condition, the onset is also acute, but clear vesicles of various sizes are scattered on the palms, soles, and volar and interdigital aspects of the fingers. These may coalesce and secondarily become pustular because of secondary bacterial infection.

Pustular variants of tinea of the palms and soles or pustules developing in infected scabies may resemble PPP. Bacterial cultures or demonstration of hyphae or mites clearly separate these entities from PPP.

Rare clinical variants such as vesicopustular mycosis fungoides palmaris et plantaris,[22] pustular localized vasculitis,[23] or palmoplantar involvement of generalized pustular psoriasis may also resemble PPP.

Treatment

PPP is difficult to treat and all reported treatments have a high recurrence rate. The management of PPP is summarized in Box 21-2.

The first measure in the management of PPP is cessation of smoking. In patients with proven gluten intolerance, a gluten-free diet was found to have a beneficial effect on lesions in psoriasis and PPP.[24]

Among topical treatments only a few procedures have been identified as being of therapeutic benefit.[25] Unilateral involvement and/or PPP with a limited effect on daily living activities should be treated with topical agents. Due to the fact that skin penetration through palmar and plantar skin is highly restricted even in acute disease with focal skin barrier disruption only certain drugs can be used effectively. Potent and superpotent steroids are the drugs of choice and may be used under plastic film or hydrocolloid occlusion, particularly in the beginning of therapy.

Subsequent topical therapy with vitamin D_3-analogues such as calcipotriol/calcipotriene, tazarotene, or anthralin may prevent a quick relapse in some patients. However, every prolonged topical steroid use is usually needed to maintain a therapeutic effect, particularly when combined with these compounds on an every second- or third-day basis; this may also delay cutaneous side effects.

Psoralen and ultraviolet A light (PUVA) treatment has been used alone or in combination with systemic retinoids and found to be effective.

PUVA bath or PUVA with application of the photosensitizer in an ointment or gel formulation showed beneficial effects in case-controlled studies.[26]

In disabling PPP and in PPP with a high frequency of relapse systemic therapy is preferred. A systematic review found retinoids to be the only drugs with proven efficacy. However, as there is a female preponderance in PPP, the use of systemic retinoids is restricted at least in women with childbearing potential. Other systemic agents with efficacy are methotrexate (10 to 25 mg/week) and cyclosporine. It has been shown that cyclosporine is effective in a low-dose regimen (1 to 2 mg/kg/day) over a 1-year period.[27] Systemic steroids are of questionable value. Withdrawal is usually followed by a rebound. Efficacy of fumaric acid ester therapy in PPP has been decribed.[28]

There is debate as to whether TNF-α antagonists may be beneficial in PPP. Whereas in chronic plaque type psoriasis and generalized pustular psoriasis the anti-TNF α monoclonal antibody infliximab was found to be highly effective, this agent was found to be both of beneficial effect and to worsen PPP.[29,30] In the SAPHO syndrome, infliximab led to a complete remission of osteoarticular disease but PPP deteriorated during treatment.[31] Efalizumab, an anti-CD11a monoclonal antibody, seems to be beneficial in PPP, but experience is limited.

ACRODERMATITIS CONTINUA (HALLOPEAU)

Acrodermatitis continua is a rare, sterile, pustular eruption of the fingers or toes that slowly extends proximally. Continuous pustulation leads to nail destruction and atrophy of the distal phalanx.

In 1888, Crocker[32] described a relapsing bullous and pustular eruption on hands and feet; this was further delineated by Hallopeau.[33] Acrodermatitis continua is now classified as a form of acropustular psoriasis.

Clinical Features

Acrodermatitis continua most often begins at the tips of one or two fingers (Fig.



Box 21-2

Treatments for Palmoplantar Pustulosis and Acrodermatitis Continua

	TOPICAL		PHYSICAL		SYSTEMIC	
First line	Potent and superpotent steroids Calcipotriol	bid, plastic film occlusion bid	Bath-psoralen and ultraviolet light	4/wk	Acitretin	0.5 mg/kg/bw/day
Second line	Anthralin Tazarotene	Once daily bid			Methotrexate Cyclosporine	10–25 mg/wk 3–5 mg/kg/bw, when effective individual titration of dose
					Fumaric acid esters[a]	According to dose-escalation scheme, corresponding to a maximum of 720 mg of dimethylfumarate/day
Third line					Efalizumab	1 mg/kg/bw/wk

[a]Registered in Germany only.

21-3), less often on the toes. The nail folds are affected very early, and trauma is thought to play an initiating role. The first signs consist of small pustules, which, on bursting, leave an erythematous, shiny area in which new pustules develop. These then tend to coalesce, forming polycyclic lakes of pus. As the disease extends proximally, the affected area shows either glossy erythema or a crusted, keratotic, and fissured surface with newly formed pustules underneath (see Fig. 21-3). Pustulation of the nail bed and the nail matrix almost always occurs and quite often leads to loss of the nail plate or severe onychodystrophy (see Fig. 21-3). Acrodermatitis continua of long duration may show complete destruction of the nail matrix and thus lead to anonychia. The skin becomes shiny and severely atrophic, and there is atrophic thinning of the distal part of the phalanx.





▲ **FIGURE 21-3** **A.** Acrodermatitis continua demonstrating acral pustule formation and subungual lakes of pus with destruction of the nail plate. **B.** Repeated eruptions lead to nail loss and severe atrophy. Note pustulation within the atrophic epidermis of the distal phalanges.

The disease may remain confined to the original site, sometimes up to several years, but more often it spreads proximally to cover the hand, dorsum of forearm, or foot. In such instances more than one extremity is involved. Acrodermatitis continua may be associated with generalized pustular psoriasis of the Zumbusch type (see Chap. 18).

Histopathology

The main histopathologic feature of acrodermatitis continua is a subcorneal cavity filled with neutrophils. Epidermal cell necrosis and spongiosis does not occur, but the roof and shoulder zones adjacent to the pustule show aggregated leukocytes between the epidermal cells, forming spongiform pustules. There is a moderate lymphohistiocytic infiltrate in the upper dermis, together with focal edema.

Lesions of long duration show severe atrophy of the papillary dermis and thinning of the epidermis.

Laboratory Findings

Systemic abnormalities are absent, and laboratory tests are usually within normal ranges. The pustules are sterile. In advanced cases, x-ray may reveal atrophy of the distal phalanx and arthropathy of the interphalangeal joints.

Diagnosis and Differential Diagnosis

Acrodermatitis continua at an early stage must be differentiated from acute paronychia caused by bacteria or fungi. Cultures and smears help rule out infectious causes. The distal localization and the tendency of the pustules to become confluent, forming denuded, erythematous, or crusted lesions, distinguishes acrodermatitis continua from PPP or pustular dyshidrotic eczema. Atrophy and loss of nails do not occur in these conditions. Contact dermatitis with secondary infection and pustulation has less clearly defined margins, runs a different clinical course, and lacks the persistence typical for acrodermatitis continua.

Treatment

As in pustular psoriasis, no specific drug is able to induce lasting remissions. Potent or superpotent topical steroids, preferentially under occlusion, are useful in blocking pustulation. Caution is advised in cases already showing atrophy. PUVA suppresses the eruption of new pustules and can be employed for long periods as maintenance treatment (see Chap. 239).

Treatment with a combination of systemic acitretin and local calcipotriol/calcipotriene was successful in one patient in a left-right comparison.[34] In recalcitrant patients, dapsone may be tried.[35] Recently, topical treatment with tacrolimus 0.1 percent ointment alone or in sequential combination with calcipotriol was found successful.[36,37] In more severe cases, TNF-α antagonists infliximab, etanercept, and adalimumab, the latter two in combination with acitretin, have been successfully used.[38–40]

In principle, regimens used for treatment of PPP may also be used for therapy of acrodermatitis continua (see Box 21-2). The therapeutic result lasts as long as the drugs are given, and relapses occur after withdrawal.

Course and Prognosis

Acrodermatitis continua shows a chronic course with a tendency of the lesions to spread proximally. Spontaneous improvement is rare, and episodes of acute pustulation occur without apparent cause. The development of pustules at other sites, or even the eruption of generalized pustular psoriasis, supports the idea that acrodermatitis continua is a variant of psoriasis.

INFANTILE ACROPUSTULOSIS

Infantile acropustulosis is discussed in Chap. 106.

KEY REFERENCES

The full reference list for all chapters is available at www.digm7.com.

2. Asumalahti K et al: Genetic analysis of PSORS1 distinguishes guttate psoriasis and palmoplantar pustulosis. *J Invest Dermatol* **120**:627, 2003
4. Mössner R et al: Association of TNF-238 and -308 promotor polymorphisms with psoriasis vulgaris and psoriatic arthritis but not with pustulosis palmoplantaris. *J Invest Dermatol* **124**:282, 2005
10. Hagforsen E et al: Palmoplantar pustulosis: An autoimmune disease precipitated by smoking? *Acta Derm Venereol* **82**:341, 2002
20. Kahn MF, Chamot AM: SAPHO syndrome. *Rheum Dis Clin North Am* **18**:225, 1992
21. Eriksson MO et al: Palmoplantar pustulosis: a clinical and immunohistochemical study. *Br J Dermatol* **138**:390, 1998
25. Marsland AM et al: Interventions for chronic palmoplantar pustulosis. *Cochrane Database Syst Rev* **CD001433**, 2006
33. Hallopeau H: Sur une asphyxie locale des extrémités avec polydactylite suppurative chronique et pussées éphémères des dermatite pustuleuse disséminées et symmétriques. *Ann Dermatol Syphiligr* (Paris) **1**:420, 1890

CHAPTER 22

Seborrheic Dermatitis

Gerd Plewig
Thomas Jansen

Seborrheic dermatitis is a common chronic papulosquamous dermatosis that is usually easily recognized. It affects infants and adults and is often associated with increased sebum production (seborrhea) of the scalp and the sebaceous follicle–rich areas of the face and trunk. The affected skin is pink, edematous, and covered with yellow-brown scales and crusts. The disease varies from mild to severe, including psoriasiform or pityriasiform patterns and erythroderma.[1] Seborrheic dermatitis is one of the most common skin manifestations in patients with human immunodeficiency virus (HIV) infection and acquired immunodeficiency syndrome (AIDS).[2] Consequently, it is included in the spectrum of premonitory lesions and should be carefully evaluated in high-risk patients.

EPIDEMIOLOGY

Seborrheic dermatitis has two age peaks, one in infancy within the first 3 months of life and the second around the fourth to the seventh decades of life. No data are available on the exact incidence of seborrheic dermatitis in infants, but the disorder is common. The disease in adults is believed to be more common than psoriasis, for example, affecting at least 3 percent to 5 percent of the population in the United States.[3] Men are affected more often than women in all age groups. There does not appear to be any racial predilection. Seborrheic dermatitis is found in up to 85 percent of patients with HIV infection and AIDS.[2]

ETIOLOGY AND PATHOGENESIS

Although many theories abound, the cause of seborrheic dermatitis remains unknown.

SEBORRHEA

Seborrhea is associated with oily-looking skin (seborrhea oleosa), although an increased sebum production cannot always be detected in these patients.[4] Even if seborrhea does provide a predisposition, seborrheic dermatitis is not a disease of the sebaceous glands. The high incidence of seborrheic dermatitis in newborns parallels the size and activity of the sebaceous glands at this age. It has been shown that newborns have large sebaceous glands with high sebum secretion rates similar to adults.[5] In childhood, sebum production and seborrheic dermatitis are closely connected. In adulthood, however, they are not, as the sebaceous gland activity peaks in early puberty and decades later seborrheic dermatitis may occur.

The sites of predilection—face, ears, scalp, and upper part of the trunk—are particularly rich in sebaceous follicles. Two diseases are prevalent in these regions: seborrheic dermatitis and acne. In patients with seborrheic dermatitis, the sebaceous glands are often particularly large on cross-sectional histologic specimens. In one study, skin surface lipids were not elevated but the lipid composition was characterized by an increased proportion of cholesterol, triglycerides, and paraffin, and a decrease in squalene, free fatty acids, and wax esters.[6] However, mild abnormalities in the skin surface lipids could well result from the ineffective keratinization, which is often demonstrable histopathologically. Seborrheic dermatitis seems to be more frequent in patients with parkinsonism and other neurologic disorders, in whom sebum secretion is increased. Similarly, after reduction of sebum production induced by levodopa and by promestriene, seborrheic dermatitis may improve.

The synonym *eczéma flannelaire* stems from the idea that a retention of skin surface lipids by clothing and rubbing of rough textiles on the skin (flannel), or synthetic underwear promotes or aggravates seborrheic dermatitis.

MICROBIAL EFFECTS

Unna and Sabouraud, who were among the first to describe the disease, favored an etiology involving bacteria, yeasts, or both. This hypothesis has remained unsupported, although bacteria and yeasts can be isolated in great quantities from affected skin sites.

In infancy, *Candida albicans* is often found in dermatitic skin lesions and in stool specimens. Although intracutaneous tests with candidin, positive agglutinating antibodies in serum, and positive lymphocyte-transformation tests in affected infants revealed sensitization to *C. albicans,* this yeast cannot be convincingly linked to the pathogenesis.

Aerobic bacteria were recovered from the scalp of patients with seborrheic dermatitis (140,000 bacteria/cm^2 vs. 280,000 in unaffected individuals and 250,000 in persons with dandruff). In contrast, *Staphylococcus aureus* was rarely seen in unaffected persons or those with dandruff. *Staphylococcus* was recovered in approximately 20 percent of patients with seborrheic dermatitis, accounting for an average of approximately 32 percent of the total skin flora.[7]

Propionibacterium acnes counts were low in patients with seborrheic dermatitis (7550 bacteria/cm^2 in those without dandruff). The small quantities of *P. acnes* in patients with seborrheic dermatitis may explain the low yield of free fatty acids from their skin surfaces.

The lipophilic yeast *Malassezia furfur* (also known as *Pityrosporum*) is abundant in normal skin (504,000 organisms/cm^2 vs. 922,000 in individuals with dandruff and 665,000 in patients with seborrheic dermatitis).[7] Some authors claim strong evidence in favor of a pathogenic role for these microbes, whereas others do not share this view. Their argument is that *M. furfur* is not the causative organism, but is merely present in large numbers. In patients with pityriasis versicolor[8] and *Malassezia* folliculitis,[9] seborrheic dermatitis has been found in a higher percent-

SEBORRHEIC DERMATITIS AT A GLANCE



- Infantile and adult forms exist.
- Characterized by erythema and greasy scaling.
- Lesions favor scalp, ears, face, chest, and intertriginous areas.
- Generalized and even erythrodermic forms may occur.
- Etiology unknown but may be related to increased sebum secretion, abnormal sebum composition, certain drugs, or *Malassezia* yeasts.
- May be a cutaneous marker of human immunodeficiency virus infection and acquired immunodeficiency syndrome, especially when severe, atypical, and therapy resistant.



age than expected. Clearing of seborrheic dermatitis by selenium sulfide and continued suppression of *M. furfur* with topical amphotericin B caused a relapse of the disease on inflamed scalp skin.[10] In seborrheic dermatitis, both normal and high levels of serum antibodies against *M. furfur* have been demonstrated. A cell-mediated immune response to *M. furfur* has been found in normal individuals using *Malassezia* extracts in lymphocyte-transformation studies.[11] Overgrowth of *M. furfur* may lead to inflammation, either through introduction of yeast-derived metabolic products into the epidermis or as a result of the presence of yeast cells on the skin surface. The mechanism of production of inflammation would likely then be through Langerhans cell and T lymphocyte activation by *Malassezia* or its by-products. When *M. furfur* comes into contact with serum, it can activate complement via the direct and alternative pathways and this may play some part in the introduction of inflammation.[12] A possible role for this yeast in the pathogenesis of seborrheic dermatitis is supported by the fact that seborrheic dermatitis–like lesions have been shown to be reproducible in animal models by inoculation of *M. furfur*.[13]

MISCELLANEOUS

Drugs

Several drugs have been reported to produce seborrheic dermatitis–like lesions, including arsenic, gold, methyldopa, cimetidine, and neuroleptics.

Neurotransmitter Abnormalities

Seborrheic dermatitis is often associated with a variety of neurologic abnormalities, pointing to a possible influence of the nervous system. These neurologic conditions include postencephalitic parkinsonism, epilepsy, supraorbital injury, facial paralysis, unilateral injury to the trigeminal ganglion, poliomyelitis, syringomyelia, and quadriplegia. Emotional stress seems to aggravate the disease; a high rate of seborrhea is reported among combat troops in times of war.

Physical Factors

It has been suggested that cutaneous blood flow and skin temperature may be responsible for the distribution of seborrheic dermatitis.[14] Seasonal variations in temperature and humidity are related to the course of the disease. Low fall and winter temperatures and low humidity in centrally heated rooms are known to worsen the condition. Seborrheic dermatitis of the face was observed in 8 percent of 347 patients receiving psoralen and ultraviolet A light therapy for psoriasis and occurred within a few days to 2 weeks after the beginning of treatment;[15] the patients had no previous history of facial psoriasis or seborrheic dermatitis. Lesions were avoided by masking the face during irradiation.

Aberrant Epidermal Proliferation

Epidermal proliferation is increased in seborrheic dermatitis, similar to psoriasis, explaining why cytostatic therapeutic modalities may improve the condition.[16]

Nutritional Disorders

Zinc deficiency in patients with acrodermatitis enteropathica and acrodermatitis enteropathica-like conditions may be accompanied by dermatitis mimicking seborrheic dermatitis of the face. Seborrheic dermatitis is, however, not associated with zinc deficiency nor does it respond to supplementary zinc therapy.

Seborrheic dermatitis in infancy may have a different pathogenesis. Biotin deficiency, whether secondary to holocarboxylase or biotinidase deficiency, and abnormal metabolism of essential fatty acids have been proposed as possible mechanisms.[17] However, biotin has been subsequently shown to have no more than placebo effect when studied in a double-blind manner.[18] Although one study suggested the possible role of food allergy in seborrheic dermatitis of infancy,[19] this has not been confirmed.

Genetic Factors

Recently, a condition considered to be seborrheic dermatitis with a gene defect in a zinc finger protein has been described.[20]

IMMUNODEFICIENCY AND SEBORRHEIC DERMATITIS

The development of seborrheic dermatitis either de novo or as a flare of preexisting disease also may serve as a clue to the presence of HIV infection and AIDS. The first report of this association in 1984 was followed by observations from all parts of the world.[2]

The increased incidence and severity of seborrheic dermatitis in HIV seropositive individuals has led to speculation that unchecked growth of *Malassezia* in immunosuppressed patients is responsible. However, a study that compared quantitative *Malassezia* cultures in AIDS patients with and without seborrheic dermatitis did not demonstrate increased yeast colonization in patients with seborrheic dermatitis.[21]

PSORIASIS AND SEBORRHEIC DERMATITIS

In patients with a psoriatic predisposition, particularly adults, seborrheic dermatitis is said to evolve into psoriasis. The term *sebopsoriasis* is sometimes used for these overlapping conditions. It should be used with caution because psoriasis, especially of the scalp, is clinically and histopathologically almost indistinguishable from seborrheic dermatitis.

CLINICAL FINDINGS

In all patients with seborrheic dermatitis there is a so-called *seborrheic stage*, which is often combined with a gray-white or yellow-red skin discoloration, prominent follicular openings, and mild to severe pityriasiform scales. Several forms can be distinguished (Table 22-1).

SEBORRHEIC DERMATITIS IN INFANTS

The disease occurs in infants predominantly within the first months of life as an inflammatory disease mainly affecting the hairy scalp and intertriginous folds with greasy-looking scales and crusts (Fig. 22-1). Other regions such as the center of the face, chest, and neck may also be affected. Scalp involvement

TABLE 22-1
Clinical Patterns of Seborrheic Dermatitis

- Infantile
  - Scalp (cradle cap)
  - Trunk (including flexures and napkin area)
  - Leiner's disease
    - Nonfamilial
    - Familial C5 dysfunction
- Adult
  - Scalp
  - Face (may include blepharitis)
  - Trunk
    - Petaloid
    - Pityriasiform
    - Flexural
    - Eczematous plaques
    - Follicular
  - Generalized (may be erythroderma)



▲ **FIGURE 22-1** Seborrheic dermatitis in an infant. Widespread pattern of seborrheic dermatitis with psoriasiform lesions on the trunk and groin.

is fairly characteristic. The frontal and parietal scalp regions are covered with an oily-looking, thick, often fissured crust (*crusta lactea*, *milk crust*, or *cradle cap*). Hair loss does not occur and inflammation is sparse. In the course of the disease, the redness increases and the scaled areas form clearly outlined erythematous patches topped by a greasy scale. Extension beyond the frontal hairline occurs. The retroauricular folds, the pinna of the ear, and the neck may also be involved. Otitis externa is often a complicating factor. Semiocclusive clothing and diapers favor moisture, maceration, and intertriginous dermatitis, particularly in the folds of the neck, axillae, anogenital area, and groin. Opportunistic infection with *C. albicans*, *S. aureus*, and other bacteria occurs. The clinical aspect reminds one of psoriasis, hence the expressions *psoriasoid* or *napkin psoriasis.*

Prognosis and Clinical Course

The disease is usually protracted over weeks to months. Exacerbation and, rarely, generalized exfoliating dermatitis may occur. The prognosis is good. There is no indication that infants with seborrheic dermatitis are more likely to suffer from the adult form of the disease.

Differential Diagnosis (See Box 22-1)

The most useful distinguishing feature between atopic dermatitis and seborrheic dermatitis is the increased number of lesions on the forearms and shins in the former and in the axillae in the latter. The development of skin lesions solely in the diaper area favors a diagnosis of infantile seborrheic dermatitis. Radioallergosorbent assay test screening to egg white and milk antibodies or other geographically or ethnically relevant allergens (e.g., soybean), and, to a lesser extent, total immunoglobulin E levels, may be useful in diagnosing atopic dermatitis at an early stage and distinguishing it from infantile seborrheic dermatitis. Absent to mild pruritus is considered a significant feature of infantile seborrheic dermatitis. Some authors believe that infantile seborrheic dermatitis is a clinical variant of atopic dermatitis rather than a separate entity.[22]

Box 22-1

Differential Diagnosis of Infantile Seborrheic Dermatitis

Most Likely

- Atopic dermatitis

Consider

- Scabies, psoriasis

Rule Out

- Langerhans cell histiocytosis

ERYTHRODERMA DESQUAMATIVUM (LEINER DISEASE)

Erythroderma desquamativum is a complication of seborrheic dermatitis in infants (dermatitis seborrhoides infantum) and was described in 1908 by Leiner.[23] There is usually a sudden confluence of lesions, leading to a universal scaling redness of the skin (erythroderma). The young patients are severely ill with anemia, diarrhea, and vomiting. Secondary bacterial infection is common. The prognosis is very good unless proper intensive care and skin care are not provided. The disease is both a familial and a nonfamilial form. The former is noted for having a functional deficiency of C5 complement, resulting in defective opsonization. These patients respond to antibiotics and infusions of fresh frozen plasma or whole blood. The true nature of this disease remains obscure.

SEBORRHEIC DERMATITIS IN ADULTS

The clinical picture and course of seborrheic dermatitis in adults differs from that of infants.

Seborrheic eczematid is the mildest form of the disease (eczematid = eczema-like, dermatitis-like). It is associated with seborrhea, scaling, mild redness, and often pruritus of the scalp, eyebrows, nasolabial folds, and retroauricular area, as well as over the sternum and the shoulder blades. Asymptomatic fluffy, white dandruff of the scalp represents the mild end of the spectrum of seborrheic dermatitis and has been referred to as *pityriasis sicca*. Nasolabial erythema, more common in young women than men, may be part of this disease spectrum.

Patchy seborrheic dermatitis is the classic, well-known disease with chronic recurrent lesions. Lesions have a predilection for scalp, temples, inner parts of the eyebrows and glabella with nasolabial folds (Figs. 22-2 and 22-3), retroauricular folds and external ear canal (Fig. 22-4) and V-shaped areas of the chest and back (Fig. 22-5). Less frequently, intertriginous areas, such as the side of the neck, axillae, submammary region, umbilicus, and genitocrural folds, are involved.

Clinical Findings

Skin lesions are characterized by a yellow color, mild to severe erythema, mild inflammatory infiltrate, and oily, thick scales and crusts. This has occasionally been referred to as *pityriasis steatoides*. Patients report pruritus, particularly on the scalp and in the ear canal. The lesions start with follicular and perifollicular redness and mounds; they spread until they form clearly outlined, round to circinate (petaloid) patches (Greek *petalon,* a thin plate or leaf). The pityriasiform type of seborrheic dermatitis is seen on the trunk and mimics the



▲ **FIGURE 22-2** Seborrheic dermatitis with involvement of nasolabial folds, cheeks, eyebrows, and nose.





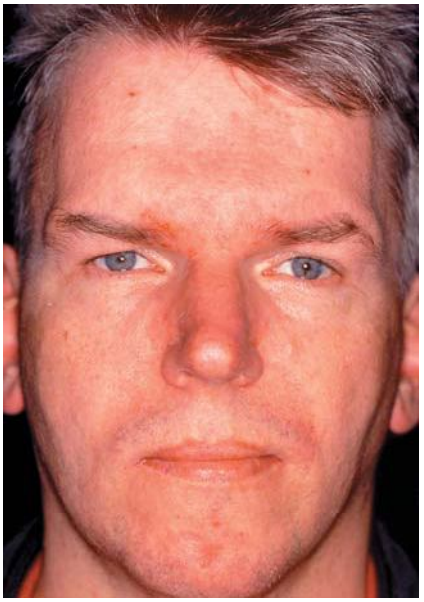

▲ **FIGURE 22-3** Seborrheic dermatitis of the forehead and centrofacial region.

lesions of pityriasis rosea, producing oval scaly lesions whose long axes tend to parallel the ribs. In some individuals, only one or two sites are involved. Chronic dermatitis of the ear canal may be the sole manifestation of seborrheic dermatitis, often mistaken for fungal infections. Another possible manifestation is blepharitis with honey-colored crusts along the rim of the eyelid and casts of horny cell debris around the eyelashes. In men, a more follicular type of seborrheic dermatitis may extend over large parts of the back, flanks, and abdomen.

Prognosis and Clinical Course

Usually, the disease lasts for years to decades with periods of improvement in warmer seasons and periods of exacerbation in the colder months. Widespread lesions may occur as a result of improper topical treatment or sun exposure. The extreme variant of the disease is generalized exfoliative erythroderma (seborrheic erythroderma). Onychodystrophy, electrolyte imbalance, and thermal dysregulation are additional features sometimes found in these patients.



▲ **FIGURE 22-4** Seborrheic dermatitis of the earlobe and ear.



▲ **FIGURE 22-5** Seborrheic dermatitis of the upper back.

PITYRIASIS AMIANTACEA

Pityriasis amiantacea (synonyms: tinea amiantacea, asbestos scalp, porrigo amiantacea, tinea asbestina, keratosis follicularis amiantacea) is the name given to a disease of the scalp in which heavy scales extend onto the hairs and separate and bind together their proximal portions. See Box 22-2 for site-specific differential diagnosis of seborrheic dermatitis.

Pityriasis amiantacea is a reaction of the scalp, often without evident cause, that may occur at any age. It may be observed as a complication or sequel of streptococcal infection, seborrheic dermatitis, atopic dermatitis, lichen simplex, and it also occurs in psoriasis, of which it may be the first clinical manifestation.[24]

The process may be circumscribed or diffuse. It is only slightly inflammatory with dry, micaceous scales, or markedly inflammatory with admixture of a crust (Fig. 22-6). Removal of the scales reveals normal or erythematous edematous epidermis. The process is not followed by atrophy, scarring, or alopecia. If scarring alopecia occurs, it may be related to secondary infection. A common form complicates chronic or recurrent fissuring behind one or both ears, mostly in young girls. The sticky scales extend several centimeters into the neighboring scalp. Another form extends from patches of lichen simplex and is seen mainly in middle-aged women.



▲ **FIGURE 22-6** Pityriasis amiantacea. Masses of sticky silvery scales adhere to the scalp and are attached in layers to the shafts of the hairs that they surround.

SEBORRHEIC DERMATITIS IN HUMAN IMMUNODEFICIENCY VIRUS–INFECTED INDIVIDUALS

The expression of seborrheic dermatitis differs in several aspects from its classic form seen in HIV seronegative individuals: The distribution is extensive, severity is marked (Fig. 22-7), and treatment often difficult. Even the histopathologic changes differ somewhat from those seen in commonly encountered seborrheic dermatitis (Table 22-2).

HISTOPATHOLOGY

The histopathologic picture varies according to the stage of the disease: acute, subacute, or chronic.[25,26] In acute and subacute seborrheic dermatitis,

Box 22-2

Site-Specific Differential Diagnosis of Seborrheic Dermatitis

Scalp	Dandruff, psoriasis, atopic dermatitis, impetigo
Face	Psoriasis, rosacea, contact dermatitis, impetigo
Ear canal	Psoriasis, contact dermatitis
Eyelids	Atopic dermatitis, psoriasis, *Demodex folliculorum* infestation
Chest and back	Pityriasis rosea, pityriasis versicolor
Intertriginous areas	Psoriasis, candidiasis
All sites, rule out	Secondary syphilis, pemphigus foliaceus



▲ **FIGURE 22-7** Widespread unusual distribution pattern of seborrheic dermatitis in a patient with acquired immunodeficiency syndrome (AIDS). **A.** Moist patches on the centrofacial region and hairy scalp. **B.** Moist lesions on the chest. In patients with AIDS, the disease responds poorly to conventional therapy.

there is a sparse superficial perivascular infiltrate of lymphocytes and histiocytes, slight to moderate spongiosis, slight psoriasiform hyperplasia, follicular plugging by orthokeratosis and parakeratosis, and scale-crusts containing neutrophils at the tips of the follicular ostia (see Table 22-2). In chronic seborrheic dermatitis, there are markedly dilated capillaries and venules in the superficial plexus, in addition to the above-mentioned features.

Clinically and histopathologically the lesions of chronic seborrheic dermatitis are psoriasiform and often difficult to distinguish from those of psoriasis.[25] Abortive forms of psoriasis share many features with seborrheic dermatitis. There are lesions that resemble psoriasis and may persist over many years before they finally turn into overt psoriasis. The most important diagnostic signs of seborrheic dermatitis are mounds of scale-crust–containing neutrophils at the tips of the dilated horn-filled follicular infundibula. Acrosyringia and acroinfundibula may be plugged by corneocyte casts.

The most consistent findings in pityriasis amiantacea are spongiosis, parakeratosis, migration of lymphocytes into the epidermis, and a variable degree of acanthosis.[27] The essential features responsible for the asbestosis-like scaling are diffuse hyperkeratosis and parakeratosis together with follicular keratosis in which each hair is surrounded by a sheath of corneocytes and debris.

Cytologic abnormalities of superficial horny cells (corneocytes) including ortho- and parakeratotic (nucleated) cells, horny cells in different stages of nuclear decomposition (halo cells), and masses of leukocytes can be evaluated by exfoliative cytology. Seborrheic dermatitis and psoriasis, however, present similar findings compared with other conditions of the dermatitis-eczema group.[28] The histopathology of AIDS-associated seborrheic dermatitis is more severe and differs in some respects from the classical form (see Table 22-2).

TREATMENT

General Considerations

In general, therapy is directed toward loosening and removal of scales and crusts, inhibition of yeast colonization, control of secondary infection, and reduction of erythema and itching. Adult patients should be informed about the chronic nature of the disease and understand that therapy works by controlling the disease rather than by curing it. The prognosis of infantile seborrheic dermatitis is excellent because the condition is benign and self-limited.

Infants

SCALP Treatment consists of the following measures: removal of crusts with 3 percent salicylic acid in olive oil or a water-soluble base; warm olive oil compresses; application of low-potency glucocorticosteroids (e.g., 1 percent hydrocortisone) in a cream or lotion for a few days; topical antifungal agents such as imidazoles (in a shampoo); mild baby shampoos; proper skin care with emollients, creams, and soft pastes.

INTERTRIGINOUS AREAS Treatment measures include drying lotions, such as 0.2 percent to 0.5 percent clioquinol in zinc lotion or zinc oil. In cases of candidiasis, nystatin or amphotericin B lotion or cream can be applied followed by soft and stiff pastes. In cases of oozing der-

TABLE 22-2
Histopathologic Differences Between Acquired Immunodeficiency Syndrome–Associated Seborrheic Dermatitis and Classic Seborrheic Dermatitis

Classic Seborrheic Dermatitis	Acquired Immunodeficiency Syndrome–Associated Seborrheic Dermatitis
Epidermis	
Limited parakeratosis	Widespread parakeratosis
Rare necrotic keratinocytes	Many necrotic keratinocytes
No interface obliteration	Focal interface obliteration with clusters of lymphocytes
Prominent spongiosis	Sparse spongiosis
Dermis	
Thin-walled vessels	Many thick-walled vessels
Rare plasma cells	Increased plasma cells
No leukocytoclasis	Focal leukocytoclasis

From Soeprono FF et al: Seborrheic-like dermatitis of acquired immunodeficiency syndrome: A clinicopathologic study. *J Am Acad Dermatol* **14**:242, 1986, with permission.

matitis, application of 0.1 percent to 0.25 percent gentian violet where still available in combination with cotton or muslin diapers is often helpful. Imidazole preparations (e.g., 2 percent ketoconazole in soft pastes, creams, or lotions) may also be effective.

DIET Milk-free and high-protein, low-fat diets have not been shown to be of value, nor has the efficacy of oral or intramuscular biotin, vitamin B complex, or essential fatty acids been established.

Adults



Because the disease runs an unpredictably long course, careful and mild treatment regimens are recommended. Anti-inflammatory agents and, when indicated, antimicrobial or antifungal agents have to be used.

SCALP Frequent shampooing with shampoos containing 1.0 percent to 2.5 percent selenium sulfide, imidazoles (e.g., 2 percent ketoconazole), zinc pyrithione, benzoyl peroxide, salicylic acid, coal or juniper tar where still available, or detergents is recommended. Crusts or scales can be removed by overnight application of glucocorticosteroids or salicylic acid in water-soluble bases or, when necessary, under occlusive dressings. Tinctures, alcoholic solutions, hair tonics, and similar products usually aggravate the inflammatory state and should be avoided.

In pityriasis amiantacea, scales should be removed by the use of cade oil ointment or a topical tar/salicylic ointment. Either preparation should be washed out of the scalp after 4 to 6 hours with a suitable shampoo (e.g., tar or imidazole shampoo). Potent topical corticosteroid scalp creams or liquids may be beneficial in some cases, preferably under plastic occlusion in the initial phase. If topical treatment does not work, systemic glucocorticosteroids (e.g., 0.5 mg prednisolone/kg body weight/day for approximately 1 week) in combination with topical treatment (steroid under occlusion, followed by open application) should be considered. Concomitant antimicrobial treatment (e.g., macrolides, sulfonamides) is reserved for stubborn cases, especially if bacterial co-infection of the scalp is proven or suspected. Of course, the underlying condition must be treated. Treatment remains difficult, and relapses occur frequently.

FACE AND TRUNK Patients should avoid greasy ointments and reduce or omit the use of soaps. Alcoholic solutions or pre- or aftershave lotions should not be recommended. Low-potency glucocorticosteroids (1 percent hydrocortisone is usually sufficient) are helpful early in the course of the disease. Uncontrolled long-term applications lead to side effects such as steroid dermatitis, steroid rebound phenomenon, steroid rosacea, and perioral dermatitis.

SEBORRHEIC OTITIS EXTERNA Seborrheic otitis externa can be best treated with a low-potency glucocorticosteroid cream or ointment. Many otic preparations (solutions) that contain neomycin and other antibiotics, often in combination, are strong sensitizers and should be avoided. Once dermatitis is under control, the glucocorticosteroid should be discontinued and a solution containing aluminum acetate should be applied once or twice daily to maintain control. This acts as a drying agent and reduces the microbial flora. Basic ointments or plain petroleum jelly, gently applied into the ear canal (without cotton tips), are often helpful to maintain satisfaction of the patient. Topical pimecrolimus is effective.

SEBORRHEIC BLEPHARITIS Special consideration is given to the treatment of seborrheic blepharitis. The use of hot compresses with gentle débridement with a cotton-tipped applicator and baby shampoo one or more times daily is recommended. Stubborn cases may require the use of a topical antibiotic such as sodium sulfacetamide ophthalmic ointment. The use of ocular preparations containing glucocorticosteroids should be deferred to an ophthalmologist. If *Demodex folliculorum* mites occur in large numbers, a trial with antiparasitic drugs such as crotamiton, permethrin, or benzyl benzoate is worthwhile.

Antifungals

Good results are achieved with topical application of antifungal agents, especially imidazoles. Clinical studies have reported response rates ranging from 63 percent[29] up to 90 percent[30] after 4 weeks. In these trials, imidazoles such as itraconazole, miconazole, fluconazole, econazole, bifonazole, climbazole, ciclopirox, and ciclopiroxolamine were studied. The imidazole compound that has been mostly used is ketoconazole. In several clinical studies, 2 percent ketoconazole cream has been found as effective as glucocorticosteroid creams, and this often results in more prolonged remissions.[29,31] Comparative studies of topical antifungal agents, however, are lacking. Personal experience, though based on open uncontrolled studies only, favors 2 percent ketoconazole cream. Other antifungal agents may also be effective. In a limited trial, 1 percent butenafine cream, a benzylamine derivative, demonstrated efficacy in the topical treatment of seborrheic dermatitis.

Oral antifungal agents such as ketoconazole, itraconazole, and terbinafine are also effective, but because of potential side effects and pharmacoeconomic considerations, should probably be limited to severe or refractory cases. Antifungal agents have a wide spectrum of effects, including anti-inflammatory properties and inhibition of cell wall lipid synthesis. This efficacy is not proof of a causal relationship between *M. furfur* and seborrheic dermatitis.

Metronidazole

Topical metronidazole is a worthwhile alternative in the treatment repertoire of seborrheic dermatitis. It has been used successfully in patients with rosacea. Extemporaneous formulations (1 percent to 2 percent in a cream base) or commercial products (0.75 percent gel, cream, or lotion; 1 percent cream) are used once or twice daily. Recently, a significant benefit of using 1 percent metronidazole gel over placebo in the treatment of seborrheic dermatitis was demonstrated.[32] Conversely, 0.75 percent metronidazole gel was shown to have similar efficacy than placebo in the treatment of seborrheic dermatitis.[33]

Lithium

Other topical agents that are effective in the treatment of seborrheic dermatitis are lithium succinate[34] and lithium gluconate,[35] which possess antifungal properties.

Calcineurin Inhibitors

Topical tacrolimus[36] and pimecrolimus[37] may be superior alternatives to corticosteroids as they both have anti-inflammatory properties but do not have long-term side effects. Tacrolimus also exhibits antifungal properties.

Vitamin D_3 Analogues

Vitamin D_3 analogues (calcipotriol cream or lotion, calcitriol ointment, or tacalcitol

ointment) are also recommended and useful in selected patients.[38] Their anti-inflammatory and antifungal properties may be responsible for their efficacy in seborrheic dermatitis.

Isotretinoin

Oral isotretinoin (13-*cis*-retinoic acid) is a useful, although not officially approved, drug for this indication. Low doses (0.05 to 0.10 mg/kg body weight daily) given for several months clear stubborn seborrheic dermatitis in many cases. In women of child-bearing age, all precautions must be met (see Chap. 229).

Phototherapy

Narrow-band ultraviolet B phototherapy appears to be an effective and safe treatment option for patients with severe and refractory seborrheic dermatitis.[39] Psoralen and ultraviolet A light therapy has been used successfully in the erythrodermic form of the disease.[40]

KEY REFERENCES

The full reference list for all chapters is available at www.digm7.com.

20. Birnbaum RY et al: Seborrhea-like dermatitis with psoriasiform elements caused by a mutation in ZNF750, encoding a putative C2H2 zinc finger protein. *Nat Genet* **38**:749, 2006
21. Wikler JR et al: Quantitative skin cultures of *Pityrosporum* yeasts in patients seropositive for the human immunodeficiency virus with and without seborrheic dermatitis. *J Am Acad Dermatol* **27**:37, 1992
28. Goldschmidt H, Thew MA: Exfoliative cytology of psoriasis and other common dermatoses: Quantitative analysis of parakeratotic horny cells in 266 patients. *Arch Dermatol* **106**:476, 1972
30. Green CA et al: Treatment of seborrhoeic dermatitis with ketoconazole: II. Response of seborrheic dermatitis of the face, scalp and trunk to topical ketoconazole. *Br J Dermatol* **116**:217, 1987
31. Katsambas A et al: A double-blind trial of treatment of seborrheic dermatitis with 2% ketoconazole cream compared with 1% hydrocortisone cream. *Br J Dermatol* **121**:353, 1989
36. Nakayama J: Four cases of sebopsoriasis or seborrheic dermatitis of the face and scalp successfully treated with 1α-24 (R)-dihydroxycholecalciferol (tacalcitol) cream. *Eur J Dermatol* **10**:528, 2000
37. Braza TJ et al: Tacrolimus 0.1% ointment for seborrhoeic dermatitis: An open-label pilot study. *Br J Dermatol* **148**:1242, 2003
38. Rigopoulos D et al: Pimecrolimus cream 1% vs. betamethasone 17-valerate 0.1% cream in the treatment of seborrhoeic dermatitis. A randomized open-label clinical trial. *Br J Dermatol* **151**:1071, 2004

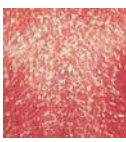

CHAPTER 23

Exfoliative Dermatitis

Jane Margaret Grant-Kels
Megan L. Bernstein
Marti J. Rothe

EPIDEMIOLOGY

The incidence of exfoliative dermatitis (ED) has varied widely in studies from 0.9 to 71.0 per 100,000 outpatients.[1–4] Males are affected more commonly than females with a 2:1 to 4:1 male-to-female ratio. The average age of disease onset varies from 41 to 61, with the majority of studies excluding children.

Preceding skin disease plays a role in more than one-half of the cases of ED. Psoriasis is the leading underlying skin disease identified in almost one-fourth of the cases. Recently, ED was reported in 87 of 160 cases of severe psoriasis.[5]

ETIOLOGY AND PATHOGENESIS

ED can be caused by a wide range of cutaneous and systemic diseases (Table 23-1). Data from 18 published studies on ED were compiled to assess etiology.[1,2,4,6–20] Pre-existing skin disease plays a role in approximately 52 percent (range, 27 percent to 68 percent) of ED cases. ED is most commonly caused by psoriasis (23 percent), spongiotic dermatitis (20 percent), drug hypersensitivity reactions (15 percent), and cutaneous T-cell lymphoma (CTCL) or Sézary syndrome (5 percent). In approximately 20 percent of ED cases (range, 7 percent to 33 percent), no underlying etiology is identified and these cases are classified as idiopathic. Less common causes of ED in adults include immunobullous disease; connective tissue disease; infections, including scabies and dermatophytes; pityriasis rubra pilaris (PRP) (4 percent of dermatoses); and underlying malignancy. In neonates and infants, the differential diagnosis includes dermatoses (such as psoriasis, atopic dermatitis, and seborrheic dermatitis), drugs, and infection (particularly staphylococcal scalded-skin syndrome). In addition, several congenital disorders including the ichthyoses, both bullous and non-bullous congenital ichthyosiform erythroderma, Netherton syndrome, and immunodeficiencies should be considered (Box 23-1).

Drugs are implicated in a significant percentage (mean, 15 percent; range, 4 percent to 39 percent) of ED cases, and the list is constantly expanding. Table 23-2 is a listing of drugs reported to cause ED. However, many of these drugs are reported in single case notes. The most commonly implicated drugs include calcium channel blockers, antiepileptics, antibiotics (penicillin family, sulfonamides, vancomycin), allopurinol, gold, lithium, quinidine, cimetidine, and dapsone.

EXFOLIATIVE DERMATITIS AT A GLANCE



- Exfoliative dermatitis (ED) is diffuse erythema and scaling of the skin involving more than 90 percent of the total body skin surface area.
- Common underlying etiologies are psoriasis, atopic dermatitis and other spongiotic dermatoses, drug hypersensitivity reactions, and cutaneous T-cell lymphoma.
- The cause of ED is unknown in approximately 20 percent of cases (idiopathic ED).
- Diagnostic workup includes a complete history, physical examination, dermatohistopathology, and other laboratory work up determined by clinical clues.
- Systemic complications include fluid and electrolyte imbalance, thermoregulatory disturbance, fever, tachycardia and high-output failure, hypoalbuminemia, and peripheral edema.
- Treatment addresses the underlying etiology, symptomatic relief, and potential systemic complications.

TABLE 23-1
Diseases Associated with Exfoliative Dermatitis

DERMATOSES
- Spongiotic dermatitis
  - Atopic dermatitis[a]
  - Seborrheic dermatitis[2]
  - Contact dermatitis
  - Stasis dermatitis
- Bullous
  - Pemphigus foliaceus
  - Paraneoplastic pemphigus
  - Bullous pemphigoid
  - Hailey-Hailey[73]
- Papulosquamous
  - Psoriasis[a]
  - Pityriasis rubra pilaris[a]
  - Impetigo herpetiformis[74]
- Photosensitive
  - Chronic actinic dermatitis
  - Actinic reticuloid [75]
- Adverse drug[a]
- Other
  - Pseudolymphoma[76]
  - Erythema gyratum repens[77]
  - Perforating folliculitis[78]
  - Radiation recall dermatitis[79]
  - Senile erythroderma with hyperIgE[80]

SYSTEMIC
- Dermatomyositis[81–84]
- Subacute cutaneous lupus[85,86]
- Acute graft-versus-host disease[87,a]
- Postoperative transfusion induced[88]
- Thyrotoxicosis[89]
- Sarcoidosis[90–92]
- Hypercalcitonemia [93]
- Idiopathic hypereosinophilic syndrome[94]

INFECTIONS
- Bacterial
  - Tuberculosis[95]
  - Congenital syphilis[96]
- Viral
  - Hepatitis C[97]
  - Human immunodeficiency virus
  - Human herpesvirus 6[98]
- Fungal
  - Dermatophyte[14,18]
  - Histoplasmosis[99–101]
  - Congenital cutaneous candidiasis[102]
- Parasite
  - Norwegian scabies
  - Toxoplasmosis[103]
  - Leishmaniasis[104]
- Toxin-mediated infections
  - Staphylococcal scalded-skin syndrome[a]
  - Toxic shock syndrome

MALIGNANCY
- Solid tumors
  - Lung[14,17,18,105]
  - Prostate[14,18,106]
  - Thyroid[14]
  - Liver[14,107]
  - Gallbladder[108]
  - Melanoma[18,109]
  - Breast[18]
  - Ovary[18]
  - Fallopian tube[110]
  - Esophagus[111]
  - Stomach[17,112]
  - Rectum[18]
  - Buschke-Loewenstein tumor[113]
- Lymphoproliferative
  - Cutaneous T-cell lymphoma[a]
  - Sézary syndrome
  - Papuloerythroderma of Ofuji
  - Hodgkin lymphoma[11,14,15,114]
  - B-cell lymphoma[115]
  - (Cutaneous) anaplastic large cell lymphoma[116,117]
  - Angioimmunoblastic T-cell lymphoma[118]
  - Castleman disease[119]
  - Acute myeloid leukemia M6[120]
  - Acute myelomonocytic leukemia[121]
  - Adult T-cell leukemia[122]
  - Chronic lymphocytic leukemia[11]
  - Chronic eosinophilic leukemia[123]
  - Myelodysplasia[124]
  - Multiple myeloma[23]
  - Reticulum cell sarcoma[6]
  - Angioimmunoblastic lymphadenopathy[125]
  - Cutaneous lymphoid hyperplasia
  - Hypereosinophilic syndrome[126,127]
  - Mastocytosis (type II-IV)[128,129]
  - Histiocytosis[130]
  - Rosai-Dorfman disease

CONGENITAL
- Immunodeficiency
  - Common variable hypogammaglobulinemia[131]
  - Wiskott-Aldrich syndrome
  - Severe combined immunodeficiency
  - Omenn syndrome
  - Leiner disease
  - Hyperimmunoglobulin-E (hyperIgE) syndrome[132]
  - Secretory IgA deficiency
- Metabolic
  - Maple syrup urine disease
  - Neutral lipid storage disease
  - Essential fatty acid deficiency
  - Holocarboxylase synthetase deficiency[133]
- Ichthyosis
  - Bullous congential ichthyosiform erythroderma
  - Non-bullous congenital ichthyosiform erythroderma
  - Netherton syndrome
  - Conradi-Hünermann syndrome[134]
  - Epidermolytic hyperkeratosis
  - Keratitis, ichthyosis, and deafness[135]
  - Lamellar ichthyosis
  - Lethal congenital erythroderma[136]
  - Sjögren-Larsson syndrome

[a]Most common diseases.

ED can result from an exacerbation of previously localized disease in more than one-half of patients.[9] Possible triggers for psoriatic ED include:

- Discontinuation of potent topical or oral corticosteroids, methotrexate, or biologics (efalizumab)[21]
- Medications, such as lithium, terbinafine, and antimalarials
- Topical irritants including tars
- Systemic illness
- Infection including human immunodeficiency virus
- Phototherapy burns
- Pregnancy
- Emotional stress

It is critical to consider other possible etiologies, even in patients with pre-existing dermatoses or with evidence of an underlying dermatosis on skin examination. In one case series, malignancy-related ED was identified in seven patients, five of whom had a pre-existing dermatosis.[9]

Some patients with chronic idiopathic ED have been reported to develop CTCL. This has led to the concern that patients with chronic idiopathic ED may be at increased risk for progression to mycosis fungoides or Sézary syndrome.[18,22] Some theories propose that the chronic T-cell stimulation in chronic ED (atopic ED) may promote the development of CTCL.[23–27] A monoclonal expansion of $CD4^+CD7^-CD26^-$ lymphocytes was recently noted in elderly patients with chronic or relapsing ED without progression to hematologic malignancy, CTCL, or Sézary syndrome. Therefore, the term *monoclonal T-cell dyscrasia of undetermined significance*, a T-cell equivalent to monoclonal gammopathy of undetermined significance, was pro-

Box 23-1

Differential Diagnosis

Most Likely

- Spongiotic dermatitis (20%–24%) (atopic, 9%; contact dermatitis, 6%; seborrheic dermatitis, 4%; chronic actinic dermatitis, 3%)
- Psoriasis (23%)
- Drug hypersensitivity reaction (15%)
- Cutaneous T-cell lymphoma (5%)
- Idiopathic (approximately 20%)

Consider

- Contact dermatitis
- Immunobullous disease (superficial pemphigus, bullous pemphigoid, paraneoplastic pemphigus)
- Infection (scabies, dermatophytosis)
- Toxin-mediated (toxic shock syndrome, staphylococcal scalded-skin syndrome)
- Chronic actinic dermatitis
- Pityriasis rubra pilaris
- Collagen vascular disease
- Paraneoplastic (solid tumors and hematologic)
- Primary immunodeficiency
- Congenital ichthyoses

Always Rule Out

- Cutaneous T-cell lymphoma
- Drug-induced hypersensitivity syndrome
- Paraneoplastic

TABLE 23-2
Drugs Implicated in Exfoliative Dermatitis

Antibiotics
- Aztreonam
- Cefoxitin[137,138]
- Doxycycline[125]
- Gentamicin[71]
- Isoniazid[2,11,15]
- Minocycline
- Neomycin
- Penicillin[6,11,14,15]
- Ribostamycin[139]
- Rifampin
- Streptomycin[2,14]
- Sulfasalazine[36]
- Sulfonamides[11,14]
- Teicoplanin[140]
- Thiacetazone[2]
- Tobramycin[141]
- Trimethoprim[1]
- Vancomycin[142,143]

Antivirals
- Dideoxyinosine[144]
- Indinavir[145]
- Interferon α[146]
- Zidovudine[147]

Anti-lepromatous
- Clofazimine[148]
- Dapsone[149–154]

Anti-epileptics
- Carbamazepine[8,17,155,156]
- Lamotrigine[157]
- Phenytoin[11,17,37,158]
- Phenobarbital[159]

Anti-inflammatory
- Aspirin
- Celecoxib[160]
- Diflunisal[161]
- Metamizole[162]
- Phenylbutazone[2]
- Piroxicam[163]

Cardiac drugs
- Amiodarone
- Captopril[164]
- Diltiazem[165,166]
- Isosorbide dinitrate[11]
- Mexiletine
- Nifedipine[167]
- Practolol[1]
- Quinidine[6,17]

Chemotherapy
- Carboplatin[168]
- Cisplatin[169]
- Doxorubicin[170]
- Fluorouracil
- Imatinib[171,172]
- Mitomycin C[173]
- Pentostatin[174]
- Vinca alkaloids[175]

Diabetic
- Sulfonylureas
- Chlorpropamide[176]

Psychiatric
- Barbiturates
- Bupropion[177]
- Chlorpromazine[1]
- Etumine[8]
- Lithium[178]
- Phenothiazines

Other
- Allopurinol[1,8,11,17]
- Antimalarials[6,11,14,45,179]
- Arsenicals
- Bacille Calmette-Guérin immunization[180]
- Bromodeoxyuridine[181]
- Cimetidine[182]
- Clodronate[183]
- Codeine[14,184]
- Ephedrine[185]
- Epoprostenol[186]
- Erythropoietin[187,188]
- Ethylenediamine[189]
- Fluindione[190]
- Gold[1,6,14,17]
- *Hypericum* (St. John's wort)[191]
- Interleukin 2[192]
- Iodine[14]
- Leflunomide[193]
- Mercurials[14,15]
- Nystatin [194]
- Omeprazole[195,196]
- Phenolphthalein[14]
- Propolis[197]
- Pseudoephedrine[72]
- Ranitidine
- Retinoids[198]
- *Rhus* (lacquer)[199,200]
- Roxatidine acetate hydrochloride[201]
- Terbinafine[202]
- Terbutaline[11]
- Tetrachloroethylene[14]
- Thalidomide[203–205]
- Thiazide[11]
- Timolol eye drops[206]
- Tramadol
- Tumor necrosis factor-α[192]

posed to indicate a possible pre-malignant or pre–Sézary-like condition.[23] On the other hand, chronic idiopathic ED may also represent primary chronic, undiagnosed CTCL.

The pathogenesis of ED is related to the pathogenesis of the underlying disorders which are covered in their respective chapters. The mechanisms by which an underlying disease manifests as ED, a pre-existing dermatosis explodes into ED, or the de novo development of idiopathic ED are not well understood.

Recent research on the immunopathogenesis of toxin-mediated infection demonstrates staphylococcal pathogenicity islands encoding superantigens (see Chap. 178). These islands carry the genes for the toxins of toxic shock syndrome and staphylococcal scalded-skin syndrome.[28] It has been theorized that possibly *Staphylococcus aureus* colonization or another antigen, such as toxic shock syndrome toxin-1, may play a role in the pathogenesis of ED.[29,30] Patients with ED were noted to have *S. aureus* colonization in the nares in 83 percent, and in the skin and nares in 17 percent[30]; however, only one in six patients was *S. aureus* enterotoxin positive.[30]

Cytokine profiles in dermal infiltrates may be different depending on the underlying cause of ED. Benign ED demonstrates a T helper 1 cytokine profile; in contrast, Sézary syndrome shows a T helper 2 cytokine profile pointing to a different pathophysiologic mechanism.[31]

Elevations in immunoglobulin E (IgE) are noted in many types of ED and, again, the mechanism may be different in different types of ED. For example, it has been theorized that elevations in IgE in psoriatic ED may point to a change from a T helper 1 cytokine profile in psoriasis to a T helper 2 cytokine in psoriatic ED.[32] This secondary mechanism is different than the primary overproduction of IgE in atopic dermatitis. HyperIgE syndrome is an immune deficiency that has been associated with ED, and has high IgE production due to selective insufficient interferon-γ secretion.[33] The mechanisms related to this elevation of IgE may be related to the underlying disease process or to the manifestation of the disease as ED.

ED secondary to atopic dermatitis, psoriasis, and CTCL is associated with increased circulating levels of adhesion molecules: intercellular adhesion molecule 1, vascular cell adhesion molecule 1, and E-selectin. In contrast, there are no differences in expression of adhesion molecules (vascular cell adhesion molecule 1, intercellular adhesion molecule 1, P-selection, E-selectin) on endothelial cells in different types of ED. Similarities in adhesion molecule profile in different types of ED may reflect similarities in end-stage immunologic pathways, which in turn result in the similar clinical examination observed in patients with diverse etiologies of ED.[34]

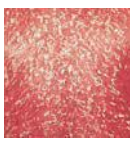

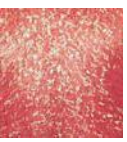

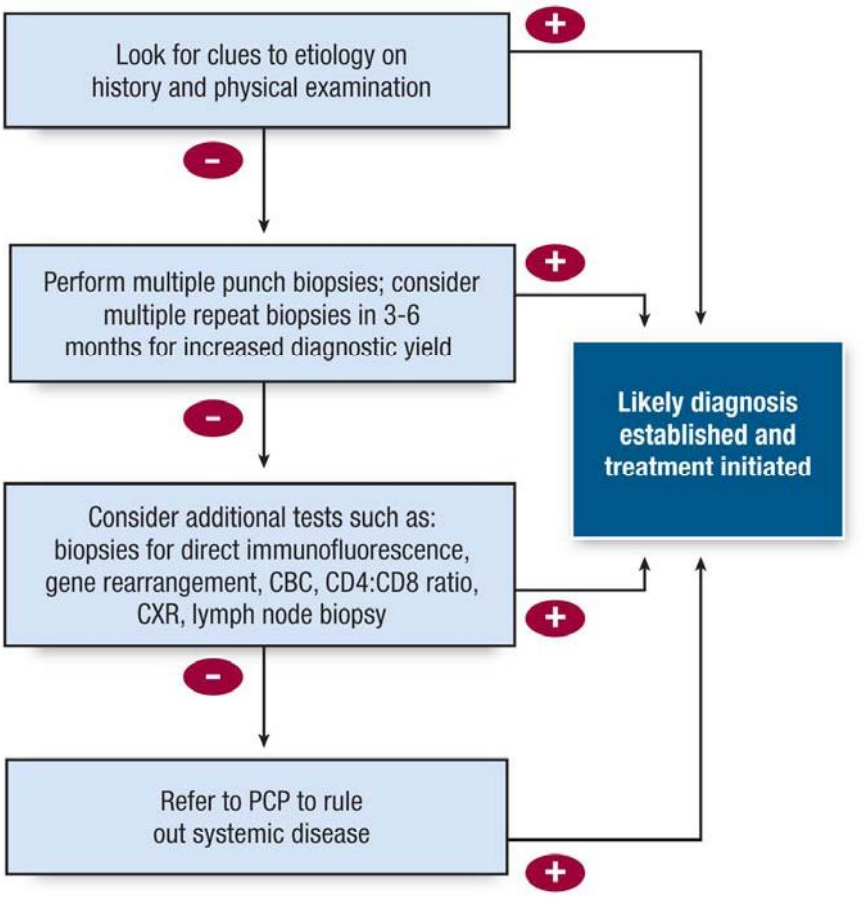

▲ **FIGURE 23-1** Approach to the patient with exfoliative dermatitis. CBC = complete blood cell count; CXR = chest x-ray; PCP = primary care physician.

Mitotic rate, and thus number of germ cells, is increased in the skin of ED. The significant scaling of ED skin reflects decreased transit time through the epidermis. This scaling also leads to loss of protein, amino acids, and nucleic acids. Protein loss may increase by 25 percent to 30 percent via scaling in psoriatic ED, and 10 percent to 15 percent in nonpsoriatic ED.[35] Additionally, protein-losing enteropathy may contribute to hypoalbuminemia.

CLINICAL FINDINGS

Fig. 23-1 is an algorithm showing the approach to a patient with ED.

History

Obtaining a detailed history of a patient who presents with ED is critical to the determination of the etiology. The history can uncover possible precipitating causes including relevant past medical history (history of dermatoses, systemic medical conditions), family history, and medication use. Patients with history of psoriasis and atopic dermatitis should be queried specifically regarding use of topical and systemic corticosteroids, methotrexate, and other systemic medications; topical irritants; systemic illness; infection; phototherapy burns; pregnancy; and emotional stress. Thermoregulatory disturbance, malaise, fatigue, and pruritus are commonly reported by ED patients; these symptoms are not specific to any etiology.

Time of onset is important to assess possible etiologies of ED. Onset of ED due to drug reactions is classically rapid, and resolution is also faster than other causes of ED. One exception is ED in association with drug hypersensitivity reactions due to anticonvulsants, antibiotics, and allopurinol. This reaction develops in 2 to 5 weeks after medication is started and may remain ongoing after discontinuation of the medication. Associated signs of a possible drug etiology include fever, lymphadenopathy, organomegaly, edema, leukocytosis with eosinophilia, and liver and renal dysfunction.[36,37]

History of transplant should raise suspicion of CTCL, as it has been found that there is a higher frequency of ED secondary to CTCL in post-transplant patients.[38]

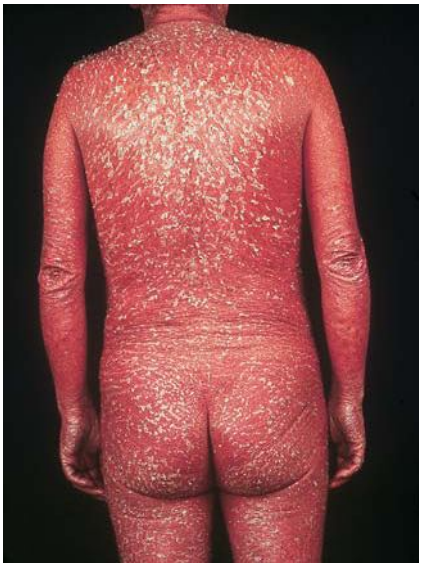

▲ **FIGURE 23-2** Exfoliative dermatitis in psoriasis. There is universal erythema, thickening of the skin, and heavy scaling. The patient had fatigue, malaise, and was shivering.

Cutaneous Lesions

ED, by definition, is generalized erythema and scaling of the skin involving more than 90 percent of the patient's skin surface (Fig. 23-2). The initial presentation is erythematous patches that progress to generalized red erythema with a shiny appearance. Fine white or yellow scaling begins a few days after onset of erythema, classically arising in the flexures. Plate-like scaling may occur acutely and on the palms and soles. The scaling progresses further with the skin appearing dull red.

Areolar sparing has been noted in some cases of CTCL, drug reactions, eczema, psoriasis, photosensitivity, and PRP.[39] Typically, there is not mucosal involvement.

With chronicity, edema and lichenification lead to skin induration. Ectropion and epiphora may develop secondary to chronic periorbital involvement (Fig. 23-3). Palmoplantar keratoderma (Fig. 23-4) has been noted in up to 80 percent of patients with chronic ED.[18]

Chronic ED also manifests with scaling of the scalp and, in some cases, diffuse effluvium. Nail changes may include onycholysis, subungual hyperkeratosis, splinter hemorrhages, paronychia, Beau's lines, and, occasionally, onychomadesis.[2] Shore-line nails with alternating bands of nail plate discontinuity represent drug-induced ED reflecting the periods of time the drug was used[40] (see Chap. 87).



▲ **FIGURE 23-3** Blepharitis, epiphora, and ectropion in exfoliative dermatitis of atopic dermatitis.

Eruptive seborrheic keratoses may arise in patients with ED.[41–43] The keratoses often resolve spontaneously as the ED subsides.

Specific Features of Underlying Diseases

Features of underlying diseases may aid in diagnosis and are listed in Table 23-3 (see eFigs. 23-4.1–4.4 in on-line edition).

Related Physical Findings

Related physical findings due to ED of any etiology may include the following:

- Thermoregulatory disturbances can result in hyperthermia or less commonly hypothermia; however, most patients complain of feeling chilly.
- Tachycardia due to increased blood flow to the skin and fluid loss due to disrupted epidermal barrier.
- High-output cardiac failure has been infrequently reported secondary to the high flow state in ED.[44]
- Peripheral pedal or pretibial edema may occur in up to 54 percent of patients.[15,22] Rarely, facial edema has been reported in drug-induced ED.
- Generalized lymphadenopathy occurs in more than one-third of patients.[2,11,15] The clinician must distinguish between dermatopathic lymphadenopathy and lymphoma. If lymphadenopathy is prominent, a lymph node biopsy may be required.
- Hepatomegaly may occur in about one-third of patients[2,11,15] and is more commonly seen in drug-induced ED.
- Splenomegaly has also been rarely reported[11] and is most commonly associated with lymphoma.

Laboratory Tests

Laboratory tests are most often nonspecific. The most common laboratory abnormalities include anemia, leukocytosis, lymphocytosis, eosinophilia, increased IgE, and an elevated erythrocyte sedimentation rate. Fluid loss may lead to electrolyte abnormalities and abnormal renal function (elevated creatinine level). Elevated IgE levels have been noted in patients with ED unrelated to atopic dermatitis,[8,11,18] including in 81.3 percent of psoriatic ED patients.[32] Eosinophilia is non-diagnostic and has been found in 20 percent of ED patients.[17] However, when highly elevated eosinophil counts are noted, the possibility of associated Hodgkin disease must be investigated. Decreased serum albumin can also be noted in ED.[2,8,15,45]



▲ **FIGURE 23-4** Exfoliative dermatitis in pityriasis rubra pilaris. Note keratoderma with an orange hue and thickening of the thumb nails.

Sézary cell count may be used for differentiation of Sézary syndrome from other benign causes of ED. Greater than 20 percent circulating Sézary cells is diagnostic for Sézary syndrome, whereas less than 10 percent is non-specific.[17,22] Sézary cells may be found in numbers less than 10 percent in several benign dermatoses, including psoriasis, atopic dermatitis, discoid lupus, lichen planus, and "parapsoriasis."[46] In addition, quantitative real-time polymerase chain reaction assay for five genes may be used for molecular diagnosis of Sézary syndrome[47] (see Chap. 146). Immunophenotyping of skin lymphocytes may be a useful adjunct study in differentiation of Sézary syndrome from actinic reticuloid. In patients with underlying actinic reticuloid,[48] there is a $CD8^+$ lymphocyte predominance, in contrast to Sézary patients with clonal CD4+ predominance. More specifically, $CD28^+/CD5^+/NKa^-/CD4^+$ T cells with reduction of CD3, CD4, CD7, CD2, and/or T-cell receptor α/β supports the diagnosis of Sézary syndrome in ED patients.[49]

Histopathology

Clinical evaluation in conjunction with multiple skin punch biopsies over time are required. The histopathology differs depending on the underlying diagnosis. However, there are often many nonspecific features seen in ED, including hyperkeratosis, parakeratosis, acanthosis, and a chronic inflammatory infiltrate, that may mask features of the underlying etiology. In addition, the histologic features of the underlying diagnosis may be more subtle than usually seen in that disease entity when unassociated with ED.[50] One-third of biopsy specimens of erythroderma fail to reveal the underlying diagnosis.[50] An accurate diagnosis was made 50% of the time when dermatopathologists blinded to clinical information reviewed biopsies of erythroderma.[51] Therefore, multiple punch biopsies obtained simultaneously and repeated over time are recommended to maximize the possibility of histopathologic diagnosis. In addition to standard hematoxylin and eosin–stained sections evaluated with routine microscopy, various special stains, immunoperoxidase studies, gene rearrangement studies, and direct immunofluorescence may be helpful in determining the underlying cause.

The histologic clues of underlying disease are found in the on-line version of this book.

TABLE 23-3
Specific Features of Underlying Disease Process

Underlying Disease Process	Clinical Clues	
Idiopathic erythroderma ("red man syndrome")	Elderly men Chronic and relapsing course Dermatopathic lymphadenopathy	Pruritus Palmoplantar keratoderma
Psoriasis (see Chap. 18)	History of localized disease[10] Personal or family history of psoriasis Classic psoriasiform plaques on elbows, knees, sacrum, etc. Well-circumscribed plaques at margins of erythroderma	Large lamellar scales Psoriatic nail changes: pits, oil drop sign, onycholysis, subungual hyperkeratosis Collarettes of scale suggestive of ruptured pustules of pustular psoriasis Psoriatic arthritis
Atopic dermatitis (see Chap. 14)	History of localized disease,[10] most often moderate to severe Personal or family history of atopy (atopic dermatitis, asthma, rhinoconjunctivitis) Marked pruritus	Classic atopic lesions in antecubital and popliteal fossae Lichenification and prurigo nodularis Excoriations Focal skin atrophy from years of use of potent topical steroids
Spongiotic dermatitis of other etiologies, such as contact dermatitis (see Chap. 13) or stasis dermatitis (see Chap. 17)	Distribution of original skin lesions History of contactant History of pre-existing venous disease	
Drug reaction (see Chap. 40)	Recent start of new drug, or use of frequently implicated drug Rapid onset of rash and progression to exfoliative dermatitis	Lymphadenopathy Organomegaly Fever
Cutaneous T-cell lymphoma (see Chap. 146)	Severe debilitating pruritus Fissured, painful keratoderma Hepatosplenomegaly	Lymphadenopathy Alopecia Leonine facies
Immunobullous disease		
Pemphigus foliaceus and fogo selvagem (see Chap. 52)	Flaccid blisters Collarettes of scale at sites of previous blisters Superficial erosions and crusts	
Bullous pemphigoid (see Chap. 54)	Tense blisters (early lesions) Deep erosions and superficial ulcers Urticarial plaques	Pruritus Elderly patient
Paraneoplastic pemphigus (see Chap. 53)	Mucosal erosions and crusting prominent Rash resembles erythema multiforme Failure to thrive (i.e., cachexia)	
Paraneoplastic ED	Failure to thrive (i.e., cachexia)	
Pityriasis rubra pilaris (see Chap. 24)	Initial lesion: Seborrheic dermatitis-like eruption of the scalp Worsening post-sun exposure Generalized salmon-colored slightly infiltrated erythema	Islands of sparing Palmoplantar keratoderma, often orange Follicular pink papules of elbows, wrists, dorsal fingers or in skin spared from ED
Chronic actinic dermatitis (see Chap. 91)	Photo-accentuation	
Acute graft-versus-host disease (see Chap. 28)	History of bone marrow transplantation or blood transfusion	Initial lesion: palmar erythema Progression to toxic epidermal necrolysis
Dermatomyositis (see Chap. 157)	Gottron papules Heliotrope sign Poikiloderma	Periungual telangiectasia Muscle weakness
Sarcoidosis (see Chap. 153)	Apple jelly papules, plaques, and/or nodules	
Norwegian scabies (see Chap. 208)	Down syndrome or nursing home patient Burrows	Massively thickened nails Keratoderma

ED = exfoliative dermatitis.

Special Tests

Laboratory testing is driven by the patient's medical history and clinical presentation. In addition to multiple skin biopsies, lymph node biopsies may be indicated if the lymph node enlargement is prominent and the clinical scenario suggests the possibility of lymphoma rather than dermatopathic lymphadenopathy. If the condition is thought to be paraneoplastic, radiologic workup should be undertaken. CD4:CD8 ratios and immunophenotyping of skin and blood should be considered if a lymphoproliferative disease is considered a possible cause of the ED.

COMPLICATIONS

Systemic complications of ED include fluid and electrolyte imbalances, thermoregulatory disturbance, infection, high-output cardiac failure,[44] cardiogenic shock,[52] acute respiratory distress syndrome,[53] decompensation of chronic liver disease,[54] and gynecomastia.[55]

Fluid and electrolytes are lost from leaky capillaries, which leads to fluid and electrolyte imbalances. Protein loss increases in ED via scaling by 10 percent to 15 percent in nonpsoriatic ED and up to 25 percent to 30 percent in psoriatic ED.[35] This significant protein loss leads to a negative nitrogen balance and may cause edema, muscle wasting, and hypoalbuminemia.

High-output cardiac failure may occur due to increased blood flow to the skin, and is of particular concern in patients with cardiac conditions and the elderly.[44] This shunting of blood, in conjunction with increased transepithelial water loss secondary to vasodilatation, leads to temperature dysregulation. The capillaries cannot respond appropriately to temperature changes via vasoconstriction and vasodilation.[56] The basal metabolic rate is also increased, which also elevates the skin temperature.[57]

Increased susceptibility to bacterial colonization occurs due to inflammation, fissuring, and excoriation of the skin. Sepsis may occur occasionally. Patients with CTCL and human immunodeficiency virus–positive ED are at increased risk for staphylococcal sepsis.[29,53,58]

PROGNOSIS AND CLINICAL COURSE

The clinical course and prognosis of ED vary depending on the underlying etiology. Drug-induced ED improves with discontinuation of the offending drug.[1] An important exception to this is with severe systemic hypersensitivity reactions in which the ED may persist for weeks after discontinuation of the drug, and is seen in association with liver and renal dysfunction. Psoriatic and atopic ED typically improves in weeks to months; however, chronic and persistent cases occur. Recurrence of psoriatic ED occurs in 15 percent of patients after initial resolution.[45]

Malignancy-related ED (including CTCL) is most often chronic and refractory. Positive prognostic factors for mycosis fungoides and Sézary syndrome–related ED include age younger than 65 years, symptom duration of greater than 10 years before diagnosis, absence of evidence of lymphoma involving a lymph node, and the absence of circulating Sézary cells in mycosis fungoides.[59] Mean survival ranges from 1.5 to 10.2 years based on these prognostic indicators.[59] Complete remission occurs in one-third of idiopathic ED patients and partial remission occurs in one-half of patients.[18,22] Patients with chronic idiopathic ED are at increased risk of evolution to the diagnosis of CTCL.[8,11,18,22] The proposed monoclonal T-cell dyscrasia of undetermined significance is intended to indicate this possible pre-malignant or pre–Sézary-like condition.[24]

The mortality rate for ED has varied from 3.75 percent to 64.00 percent in six series over 51 years.[4,8,11,14,16,20] Early series of ED reported high mortality rates due to severe drug reactions, lymphoproliferative malignancy, pemphigus foliaceus, and idiopathic ED.[6] These deaths were due to complications such as sepsis, pneumonia, and cardiac failure.[6,14,20] More recent studies have shown lower mortality rates with most deaths occurring in patients with malignancy-associated ED,[1,11,17] usually due to underlying disease progression, treatment complications, or sepsis.[11] A recent study demonstrated a death rate of 3.75 percent (3 of 80 patients) in a 30-month follow-up with deaths due to pneumonia in patients with pemphigus foliaceus and Sézary syndrome.[16] High-output cardiac failure has also been reported as a cause of death.[8]

TREATMENT

Initial treatment of ED of any etiology involves fluid and electrolyte replacement. Although most patients can be managed on an outpatient basis, patients with significant fluid and electrolyte imbalance or cardiovascular or respiratory compromise require inpatient management. Possible offending drugs should be discontinued, including drugs such as lithium and antimalarials that may trigger a flare in patients with underlying psoriasis. Folate supplementation and a diet of 130 percent of normal dietary requirements for protein aids in replacing nutrient losses.[35,60]

The treatment of ED is summarized in Box 23-2. The environment should be warm and humid for patient comfort and skin moisture, as well as preventing hypothermia. Gentle local skin care, including oatmeal baths and wet dressings to weeping or crusted lesions, bland emollients, and low-potency topical steroids should be started. High-potency topical steroids[61] and topical immunomodulators, such as tacrolimus,[62] should be avoided as systemic absorption may occur due to the increased skin permeability and large surface area involved. In addition, topical irritants, such as anthralin and tar, should be avoided. Symptomatic treatment includes sedating antihistamines for pruritus, and diuretics for leg edema refractory to leg elevation. Systemic antibiotics are required for patients with evidence of localized and systemic secondary infection. Patients without evidence of secondary infection may also benefit from systemic antibiotic therapy as bacterial colonization may exacerbate ED.

ED refractory to local therapy may require systemic dermatologic therapy with therapy tailored to the underlying etiology, if known. Systemic corticosteroids should be avoided in patients with possible underlying psoriasis. Psoriatic ED may be responsive to methotrexate, cyclosporine, acitretin, mycophenolate mofetil, and biologics. Intravenous infliximab of 5 to 10 mg/kg has been prescribed with complete remission of psoriatic ED.[63,64] Lower doses of infliximab (2.7 to 4.4 mg/kg) have been used in combination with methotrexate with good clinical response.[65]

Etanercept has been used as a steroid-sparing agent with relief of pruritus in Sézary syndrome in two patients.[66] However, etanercept should be used with caution in these patients because of risk of further immunosuppresion. CTCL may be treated with topical corticosteroids, psoralen plus ultraviolet A, total skin electron beam irradiation, systemic chemotherapy including CHOP-like regimens (*c*yclophosphamide, *h*ydroxydaun*o*mycin, vincristine, and *p*rednisone), interferon-α, extracorporeal photochemotherapy, and biologics such as monoclonal antibodies (alemtuzumab),[67] bexarotene (selective retinoic X receptor retinoid),[68,69] and denileukin diftitox.

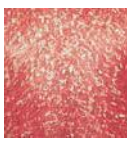

Box 23-2

Therapy

	TOPICAL	SYSTEMIC	DOSAGE
First line	Oatmeal baths Wet dressings Bland emollients Low-potency corticosteroids	Sedating antihistamines Systemic antibiotics if secondary infection Diuretics for peripheral edema Fluid and electrolyte replacement	
Second line (once etiology established)		Corticosteroids for drug hypersensitivity reactions, immunobullous disease, atopic dermatitis. Cyclosporine for psoriasis, atopic dermatitis Methotrexate for psoriasis, atopic dermatitis, pityriasis rubra pilaris Acitretin (Soriatane) for psoriasis, pityriasis rubra pilaris Mycophenolate mofetil for psoriasis, atopic dermatitis, immunobullous disease Infliximab for psoriasis	1–2 mg/kg/day with taper 4–5 mg/kg/day 5–25 mg qwk depending on renal function and response to treatment 25–50 mg qd 1–3 g qd 5–10 mg/kg

Systemic corticosteroids are useful for drug hypersensitivity reactions. Cyclosporine, methotrexate, azathioprine, mycophenolate mofetil, and systemic corticosteroids may be helpful for spongiotic (eczematous) dermatitis. PRP usually responds to systemic retinoids or methotrexate. Papuloerythroderma of Ofuji has been treated with topical and systemic corticosteroids, cyclosporine, interferon, etretinate, and most recently with a combination of retinoid plus psoralen and ultraviolet A light.[70]

Empiric therapy with systemic agents including methotrexate, cyclosporine, acitretin, mycophenolate mofetil, and systemic corticosteroids have been used when the underlying cause of ED is not known. It should be emphasized that a strong suspicion for psoriatic ED precludes systemic corticosteroid use due to risk for a rebound flare. Immunosuppressive drugs should not be used until CTCL has been ruled out with the most current laboratory testing.

PREVENTION

Prevention of ED may be aided by avoidance of medications that have previously caused ED. Careful records of allergies should be maintained by the patient. This should include potentially cross-reactive medications, including topical agents (examples: ED occurring secondary to systemic gentamicin use in a patient with known contact allergy to neomycin,[71] ED secondary to pseudoephedrine use in a patient with a contact allergy to phenylephrine).[72] Avoidance of systemic steroids by clinicians in patients with psoriasis aids in prevention of rebound flares.

KEY REFERENCES

The full reference list for all chapters is available at www.digm7.com.

1. Hasan T, Jansen CT: Erythroderma: A follow-up of fifty cases. *J Am Acad Dermatol* **8**:836, 1983
2. Sehgal VN, Srivastava G: Exfoliative dermatitis. A prospective study of 80 patients. *Dermatologica* **173**:278, 1986
3. Sigurdsson V, Steegmans PH, van Vloten WA: The incidence of erythroderma: A survey among all dermatologists in The Netherlands. *J Am Acad Dermatol* **45**:675, 2001
4. Wong KS et al: Generalised exfoliative dermatitis—A clinical study of 108 patients. *Ann Acad Med Singapore* **17**:520, 1988
16. Rym BM et al: Erythroderma in adults: A report of 80 cases. *Int J Dermatol* **44**:731, 2005
24. Gniadecki R, Lukowsky A: Monoclonal T-cell dyscrasia of undetermined significance associated with recalcitrant erythroderma. *Arch Dermatol* **141**:361, 2005
35. Kanthraj GR et al: Quantitative estimation and recommendations for supplementation of protein lost through scaling in exfoliative dermatitis. *Int J Dermatol* **38**:91, 1999
51. Walsh NM et al: Histopathology in erythroderma: Review of a series of cases by multiple observers. *J Cutan Pathol* **21**:419, 1994

CHAPTER 24

Pityriasis Rubra Pilaris

Daniela Bruch-Gerharz
Thomas Ruzicka

EPIDEMIOLOGY

Pityriasis rubra pilaris is a rare chronic disorder with an estimated incidence ranging from 1 in 5000 to 1 in 50,000 dermatology patients. The age distribution is bimodal with peak incidences in the first and fifth decades of life. The disease occurs in all races and affects the sexes equally.[1]

ETIOLOGY AND PATHOGENESIS

Although an underlying dysfunction in vitamin A metabolism has been suggested as a cause, the etiology and pathogenesis of pityriasis rubra pilaris are poorly understood. The role of vitamin A deficiency remains uncertain, because attempts to produce keratotic lesions by vitamin A deprivation have been unsuccessful. Moreover, a deficiency of retinol-binding protein as an underlying pathogenic mechanism resulting in inadequate transport of vitamin A to the skin has yet to be ascertained. Larregue et al. reported that a previous upper respiratory tract episode appeared to trigger the onset of the disease.[2] A report of an acute exanthematous form of juvenile pityriasis rubra pilaris that followed an upper respiratory tract infection and initially resembled Kawasaki disease supports the hypothe-

PITYRIASIS RUBRA PILARIS AT A GLANCE





- A papulosquamous disorder of unknown etiology that often progresses to erythroderma and a disabling keratoderma.
- The disease is subclassified into six types, including both hereditary and acquired forms.
- Typically, pityriasis rubra pilaris includes follicular hyperkeratosis and a reddish orange, scaling dermatitis with islands of normal skin.
- Confusion with psoriasis is the major problem in diagnosis.
- Histopathologic examination reveals hyperkeratosis, alternating vertical and horizontal parakeratosis, and a mild superficial perivascular lymphocytic infiltrate.
- No single therapy is effective; most effective are retinoids, psoralen plus ultraviolet A phototherapy, and methotrexate.

sis of a superantigen-mediated process.[3] Finally, genetic factors with an autosomal dominant pattern of inheritance have been believed to play a critical role in the induction of pityriasis rubra pilaris. Nevertheless, affected relatives are not observed in the classical acute-onset disease and are found infrequently with other variants.

CLINICAL FINDINGS

Cutaneous Lesions

Pityriasis rubra pilaris is generally believed to comprise more than a single entity, and a classification scheme based on clinical characteristics and course has been proposed by Griffiths[1] (Table 24-1).

Type I (classic adult) is the most common subtype, accounting for more than 50 percent of all cases. Characteristically, patients show an eruption of follicular hyperkeratotic papules that spread in a cephalocaudal direction (Fig. 24-1). As the disease further evolves, a reddish orange, scaling dermatitis appears that often progresses to a generalized erythroderma over a period of 2 to 3 months (Fig. 24-2). A diagnostic hallmark of pityriasis rubra pilaris is sharply demarcated islands of unaffected skin ("nappes claires") in a random distribution (see Fig. 24-2B). Many patients develop a waxy, diffuse, yellowish keratoderma of the palms and soles (Fig. 24-3). Peripheral edema is common. Nail changes are not uncommon and include distal yellow-brown discoloration, nail plate thickening, splinter hemorrhages, and subungual hyperkeratosis. Eventually, the mucous membranes may be affected with a diffuse whitish appearance of the buccal mucosa as well as lacy white plaques and erosions. Hair and teeth are normal.

Type II is an atypical variant with onset in adulthood. Areas of follicular hyperkeratosis as well as ichthyosiform scaling, especially on the legs, dominate the clinical picture. This variant lacks the typical cephalocaudal progression observed in type I, and there is less tendency for patients to become erythrodermic. Sparseness of the scalp hair is occasionally seen.

Type III (classic juvenile) typically begins in year 1 or 2 of life and shows all the morphologic features of type I (Fig. 24-4).

Type IV (circumscribed juvenile) affects approximately 25 percent of patients. This type usually presents several years after birth and is characterized by well-demarcated hyperkeratotic erythematous plaques on the elbows and knees, resembling localized psoriasis. According to Griffiths,[1] these lesions do not progress to the widespread types I and III. Yet, some cases show marked palmoplantar keratoderma.

Type V is an atypical variant of juvenile pityriasis rubra pilaris that usually presents in the first few years of life and has a more chronic course. This type is distinguished by follicular hyperkeratosis with only minimal erythema and a scleroderma-like appearance of the hands and feet. Most cases of familial pityriasis rubra pilaris belong to this type, which may even represent a different clinical entity sharing features with several poorly defined ichthyotic disorders such as follicular ichthyosis and the erythrokeratodermas.



TABLE 24-1
Classification Scheme for Pityriasis Rubra Pilaris (Types I–VI According to Griffiths[1] and Gonzáles-López[4])

Type	Description	%	Clinical Characteristics	Distribution	Course
I	Classic adult	> 50	Erythroderma with islands of normal skin ("nappes claires"), follicular hyperkeratosis, waxy diffuse palmoplantar keratoderma	Generalized, beginning on the head and neck, then spreading caudally	Often resolves within an average of 3 y
II	Atypical adult	5	Combination of follicular hyperkeratosis and ichthyosiform lesions on the legs, sparse scalp hair	Generalized	Long duration (> 20 y)
III	Classic juvenile	10	Similar to type I but appears in year 1 or 2 of life	Generalized	Often resolves within an average of 1–2 y
IV	Circumscribed juvenile	25	Prepubertal children; well-demarcated scaly, erythematous plaques on the elbows and knees, resembling localized psoriasis	Localized	Uncertain, some cases clear in the late teens
V	Atypical juvenile	5	Begins in first few years, accounts for most familial cases; follicular hyperkeratosis, scleroderma-like appearance of the hands and feet	Generalized	Chronic course, improves with retinoids but relapses when they are stopped
VI	Human immunodeficiency virus infection associated	NA	Similar to type I with variable beginning; associated with acne conglobata, hidradenitis suppurativa, and lichen spinulosus	Generalized	May respond to antiretroviral triple therapy

NA = data not available.

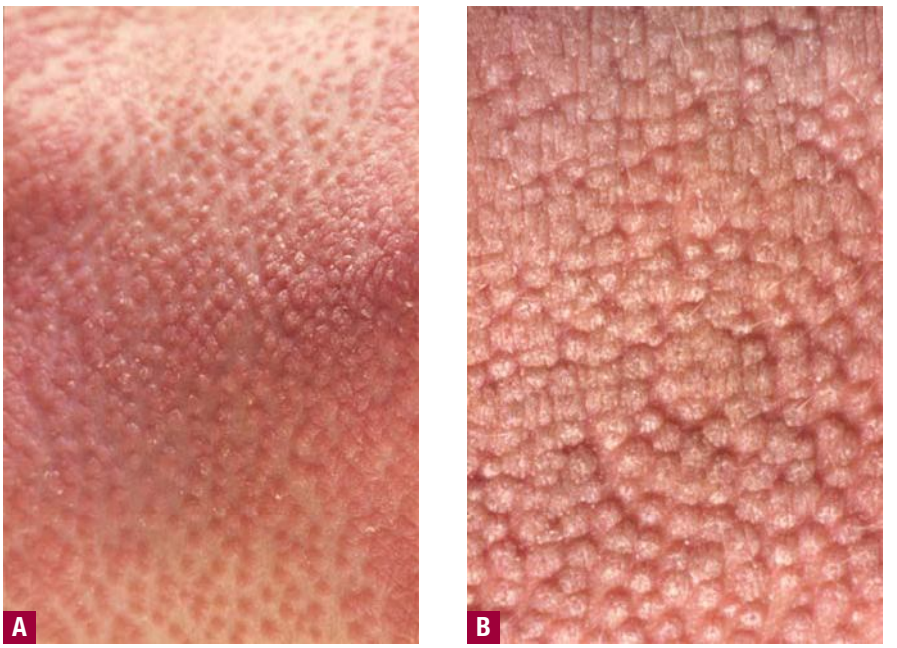

▲ **FIGURE 24-1** Acuminate follicular papules of pityriasis rubra pilaris. Close-ups of discrete (**A**) and confluent (**B**) lesions.

Some reports have described a type VI variant associated with human immunodeficiency virus (HIV) infection.[4] The clinical features of this variant are similar to those of type I but with increased severity and additional manifestations of acne conglobata, hidradenitis suppurativa, and lichen spinulosus.

Related Findings

There have been rare cases of a pityriasis rubra pilaris–like eruption, clinically and histologically, in patients with dermatomyositis, often associated with internal neoplasia. Concomitant rheumatologic disorders, mainly inflammatory polyarthritis, have also been reported. In addition, numerous other non-cutaneous diseases have been considered to be related to pityriasis rubra pilaris, which in all cases probably occurred fortuitously.

PATHOLOGY

Pathologic findings in pityriasis rubra pilaris vary according to the duration of the disease. The findings are most likely to be diagnostic in the acute phase, when hyperkeratosis, acanthosis with broad short rete ridges, and alternating orthokeratosis and parakeratosis oriented in both horizontal and vertical directions can be observed (see Pityriasis Rubra Pilaris At a Glance). Usually, there is a sparse superficial, perivascular lymphocytic infiltrate in the underlying dermis. Keratinous plugs of the follicular infundibula as well as perifollicular areas of parakeratosis may also be present. A prominent granular layer and dilated, but not tortuous, capillaries are features that help to distinguish pityriasis rubra pilaris from psoriasis, the most important differential diagnosis.



▲ **FIGURE 24-2** Generalized pityriasis rubra pilaris. Reddish orange, scaling dermatitis (**A**) with islands of normal skin ("nappes claires") (**B**).

DIFFERENTIAL DIAGNOSIS

See Box 24-1.

COMPLICATIONS

Systemic symptoms are uncommon except when generalized erythroderma occurs, and then they are comparable to those seen in exfoliative dermatitis. Occasionally, a mild ectropion may develop when the face becomes uniformly erythematous. Although they are rare, moderate to severe pruritus or burning sensations may occur.

PROGNOSIS AND CLINICAL COURSE

The classic adult disease (type I) usually remits completely within an average of 3 years (see Table 24-1). Recurrences are recognized in up to 20 percent of patients, however, sometimes after long periods of subclinical disease. In the classic juvenile variant (type III), spontaneous clearing is commonly observed in 1 to 2 years. The atypical variants (type II and IV), however, have a less favorable prognosis for remission, although some cases of type IV improve in the late teens. There is little or no tendency for type V to resolve spontaneously; improvement with administration of systemic retinoids has been described, but relapses occurred when treatment was withdrawn. Clinical manifestations in the HIV infection–associated type VI are severe and occasionally fatal, with death occurring due to complications of cutaneous sepsis.

TREATMENT

Patients with pityriasis rubra pilaris are often unresponsive to multiple therapies, both topical and systemic.[5] Because of the relative rarity of the disease and its variable course, the chances for





▲ **FIGURE 24-3** Keratoderma in pityriasis rubra pilaris. Palmar (**A**) and plantar (**B**) erythema and waxy hyperkeratosis are frequent manifestations. Sometimes, there is an orange-yellow tint.

clinical trials to assess treatment options are limited. Previous treatment strategies, which relied on megadoses of oral vitamin A or the anabolic steroid stanozolol, proved to be largely ineffective.

Currently, oral retinoids are the first line of therapy in patients with pityriasis rubra pilaris. Isotretinoin has been reported to be of value, although a comprehensive review suggests that acitretin may be more effective in clearing lesions. Accordingly, most patients are treated first with acitretin today. Therapy with methotrexate, using the guidelines established for psoriasis has shown variable rates of success. Some cases respond well to photochemotherapy (psoralen with ultraviolet A phototherapy), some may flare, and others require combination treatment with retinoids or methotrexate. In patients with severe symptoms, effective amelioration of the disease may require extracorporeal photopheresis. Immunosuppressive agents are of inconsistent benefit. Thus, controversy persists about the role of cyclosporine in the treatment of pityriasis rubra pilaris. Although most studies show lack of efficacy, several cases of adult-type pityriasis rubra pilaris showed significant clearance in 2 to 4 weeks with this therapy. Some patients are helped by azathioprine, but this effect is also inconsistent. The use of glucocorticosteroids in the management of pityriasis rubra pilaris has been studied, but there is no evidence to suggest a beneficial effect. Whether phototherapy can be effective is controversial. Ultraviolet B irradiation, which is efficiently used for psoriasis, has not been helpful or has even worsened pityriasis rubra pilaris.[6] Ultraviolet A1 phototherapy may be a satisfactory alternative.

When conventional treatment strategies fail, new therapeutic approaches may include the use of immunomodulatory drugs. Fumaric acid esters were reported as successful in inducing remission in a patient with juvenile pityriasis rubra pilaris unresponsive to the usual treatment options.[7] Moreover, there is some evidence indicating that blockade of tumor necrosis factor-α, which is beneficial in psoriasis and psoriatic arthritis, is effective in the adult-onset type I of pityriasis rubra pilaris.[8]

Topical treatment with keratolytics (when possible, under an occlusive plastic dressing) has proved a valuable mode of adjuvant therapy in pityriasis rubra pilaris. For symptomatic relief, emollients and antihistamines provide significant benefit. Topical therapy with calcipotriol showed encouraging results. Its disadvantage is that total body treatment for the erythrodermic patient can be toxic. Success has been reported with topical aminonicotinamide 1 percent, although it is not commonly used.[5]

Pityriasis rubra pilaris associated with HIV infection has responded to triple antiretroviral therapy.[4]

Current therapeutic options for pityriasis rubra pilaris used in adults and children (including drug doses) are listed in Box 24-2.





▲ **FIGURE 24-4** Juvenile pityriasis rubra pilaris: **A.** Confluence of lesions leads to extensive erythroderma. **B.** Characteristic scattered islands of unaffected skin are evident. So is the plantar hyperkeratosis.

Box 24-1

Differential Diagnosis of Pityriasis Rubra Pilaris

Most Likely

- Localized
  - Psoriasis
  - Follicular ichthyosis
- Generalized
  - Psoriasis
  - Erythrokeratodermia variabilis

Consider

- Localized
  - Follicular eczema
  - Lichen ruber acuminatus
  - Keratosis pilaris
- Generalized
  - Pityriasis lichenoides chronica
  - Nonbullous ichthyosiform erythroderma

Always Rule Out

- Generalized (therapy-resistant cases)
  - Human immunodeficiency virus infection
  - Cutaneous T-cell lymphoma

PREVENTION

Pityriasis rubra pilaris is a rare but socially and psychologically disabling condition, occurring in children and adults of both sexes. Suicide remains a risk in patients with generalized disease. Knowledge of the clinical pattern and cutaneous findings, therefore, is crucial to permit early therapeutic intervention and may allow prevention of protracted illness and serious complications in this clinically challenging condition.



Box 24-2

Treatments for Pityriasis Rubra Pilaris

FIRST LINE

- Topical
  - Emollients (water in oil emulsion)
  - Keratolytics (salicylic acid, urea)
  - Vitamin D_3 (calcipotriol)
- Physical
  - Photochemotherapy (topical or systemic psoralen plus ultraviolet A)
  - Extracorporeal photopheresis
- Systemic
  - Retinoids (0.5 to 0.75 mg/kg acitretin per day)
  - Methotrexate (10 to 25 mg weekly, intramuscularly or orally, in divided doses, once a week)
  - Triple antiretroviral therapy (for human immunodeficiency virus–associated variant)

SECOND LINE

- Topical
  - Glucocorticoids (medium to high potency)
  - Vitamin A analogues (tazarotene)
- Physical
  - Ultraviolet A1 phototherapy
  - Narrowband ultraviolet B phototherapy
  - Ultraviolet B phototherapy
- Systemic
  - Azathioprine (100 to 150 mg/day)
  - Cyclosporine A (5 mg/kg/day)
  - Fumaric acid esters[7]
  - Tumor necrosis factor-α antagonists[8]



KEY REFERENCES

1. Griffiths WAD: Pityriasis rubra pilaris. *Clin Exp Dermatol* **5**:105, 1980
2. Larregue M et al: Acute pityriasis rubra pilaris in the child. *Ann Dermatol Venereol* **110**:221, 1983
3. Betlloch I et al: Acute juvenile pityriasis rubra pilaris: A superantigen mediated disease. *Pediatr Dermatol* **18**:411, 2001
4. González-López A et al: HIV-associated pityriasis rubra pilaris responsive to triple antiretroviral therapy. *Br J Dermatol* **140**:931, 1999
5. Clayton BD et al: Adult pityriasis rubra pilaris: A 10-year case series. *J Am Acad Dermatol* **36**:959, 1997
6. Iredale HE, Megitt SJ: Photosensitive pityriasis rubra pilaris. *Clin Exp Dermatol* **31**:36, 2006
7. Coras B et al: Fumaric acid esters therapy: A new treatment modality in pityriasis rubra pilaris? *Br J Dermatol* **152**:388, 2005
8. Liao WC, Mutasim DF: Infliximab for the treatment of adult-onset pityriasis rubra pilaris. *Arch Dermatol* **141**:423, 2005

CHAPTER 25

Parapsoriasis and Pityriasis Lichenoides

Gary S. Wood
Chung-Hong Hu
Andrea L. Garrett

PARAPSORIASIS

Historical Aspects

As shown in Table 25-1, the currently accepted classification of parapsoriasis includes large and small-plaque forms of parapsoriasis en plaques (often referred to simply as *parapsoriasis*) as well as acute and chronic forms of pityriasis lichenoides [known today as *pityriasis lichenoides et varioliformis acuta* (PLEVA) and *pityriasis lichenoides chronica* (PLC), respectively].[1] Pityriasis lichenoides was first described in 1894 by Neisser[7] and Jadassohn.[8] In 1899 Juliusberg delineated the chronic form and named it PLC.[9] Mucha redescribed the acute form in 1916 and distinguished it from the chronic form.[10] Habermann named the acute variant PLEVA in 1925.[11] Mucha-Habermann disease is synonymous with PLEVA. Some authors regard lymphomatoid papulosis as a variant of pityriasis lichenoides, whereas others consider it to be a separate disease.[1,12–14] Lymphomatoid papulosis is discussed in Chap. 146 as part of the spectrum of $CD30^+$ cutaneous lymphoproliferative disorders.

TABLE 25-1
Classification of Parapsoriasis

1. Parapsoriasis en plaques
   - A. Large-plaque parapsoriasis
     Variants: poikilodermatous, retiform
   - B. Small-plaque parapsoriasis
     Variant: digitate dermatosis
2. Pityriasis lichenoides
   - A. Pityriasis lichenoides chronica (Juliusberg)
   - B. Pityriasis lichenoides et varioliformis acuta (Mucha-Habermann)

Epidemiology

Large-plaque parapsoriasis (LPP) and small-plaque parapsoriasis (SPP) are, in general, diseases of middle-aged and older people, with a peak incidence in the fifth decade. Occasionally, lesions arise in childhood and may be associated with pityriasis lichenoides. SPP shows a definite male predominance of approximately 3:1. LPP is probably more common in males, but the difference is not as striking as in SPP. Both occur in all racial groups and geographic regions.

Etiology and Pathogenesis

It is likely that a complete understanding of the pathogenesis of parapsoriasis will develop with our understanding of the pathogenesis of both chronic dermatitis and mycosis fungoides (MF), because parapsoriasis appears to bridge these disorders. The T cells that mediate most inflammatory skin diseases belong to the skin-associated lymphoid tissue (SALT).[15] These T cells express the cutaneous lymphocyte-associated antigen and traffic between the skin and the T-cell domains of peripheral lymph nodes via the lymphatics and bloodstream. MF (see Chap. 146) has been shown to be a neoplasm of SALT T cells. Sensitive polymerase chain reaction (PCR)–based tumor clonality assays have underscored the SALT nature of MF tumor clones by showing that they can continue to traffic after neoplastic transformation[16] and can even participate in delayed-type hypersensitivity reactions to contact allergens.[17] This implies that rather than being a skin lymphoma per se, MF is actually a SALT lymphoma; that is, a malignancy of a T-cell circuit rather than of one particular tissue. Trafficking of MF tumor cells has been detected even in patients with very early stage disease whose lesions were consistent clinicopathologically with LPP.[16,18] Therefore, it can be said that at least in some cases LPP is a monoclonal proliferation of SALT T cells that have the capacity to traffic between the skin and extracutaneous sites.

This view is also supported by the presence of structural and numerical chromosomal abnormalities in the peripheral blood mononuclear cells of pa-

PARAPSORIASIS AT A GLANCE



- Also known as *parapsoriasis en plaques.*
- Parapsoriasis occurs worldwide and affects mainly adults.
- Large-plaque parapsoriasis (LPP) and small-plaque parapsoriasis (SPP) are recognized.
- Large and small "plaque" lesions actually present as flat patches rather than infiltrated plaques.
- Lesions are chronic and favor non–sun-exposed skin; LPP may be poikilodermatous.
- Pathology consists of superficial, mostly $CD4^+$ T-cell infiltrate; dominant clonality is more common in LPP than in SPP.
- LPP appears to exist on a continuum with patch-stage mycosis fungoides (MF) and progresses to overt MF at a rate of approximately 10 percent per decade.
- SPP has minimal risk of progression to overt MF in the experience of most experts.
- Treatment options include topical corticosteroids; ultraviolet B irradiation, and psoralen and ultraviolet A irradiation; and topical cytotoxic drugs.

tients with LPP.[19] In this context, LPP can be regarded as the clinically benign end of the MF disease spectrum, which eventuates in transformed large cell lymphoma at its malignant extreme. To say that these diseases belong to the same disease spectrum is not to say that they are biologically equivalent disorders. To lump them all together simply as "MF" would be to ignore their distinctive clinicopathologic features, which are likely due to genetic and/or epigenetic differences, such as the *p53* gene somatic mutations observed in some cases of large cell transformation of MF.[20–22] It is likely that several such differences separate these clinicopathologically defined disorders in a stepwise fashion analogous to the sequential acquisition of somatic mutations that occurs in the colon cancer disease spectrum as colonic epithelial cells progress through normal, hyperplastic, in situ carcinoma, invasive carcinoma, and metastatic carcinoma stages.[23,24]

A unifying feature of the parapsoriasis group of diseases is that all of them appear to be cutaneous T-cell lymphoproliferative disorders: LPP,[16,25–33] SPP,[26,33,34] pityriasis lichenoides,[33,35–37] and lymphomatoid papulosis[26,38–40] have all been shown to be monoclonal disorders in many cases.[5] These relationships suggest that progression from LPP through the various stages of the MF disease spectrum is accompanied by an increasing gradient of dominant T-cell clonal density resulting from mutations that confer increasing growth autonomy to the neoplastic T-cell clone.[41] Interestingly, analysis of peripheral blood has demonstrated that clonal T cells are often detectable in patients with LPP/early MF[31,33] or SPP,[33,42] which again supports the systemic SALT nature of these "primary" skin disorders.

Dominant clonality as seen in the parapsoriasis disease group, follicular mucinosis, pagetoid reticulosis, and certain other disorders does not equate to clinical malignancy. In fact, most patients with these diseases experience a benign clinical course, and in some cases the disease resolves completely. In addition, other types of chronic cutaneous T-cell infiltrates sometimes exhibit dominant clonality, including primary (idiopathic) erythroderma and non-specific chronic spongiotic dermatitis. This has given rise to the concept of clonal dermatitis,[18,28] originally described in the context of clonal non-specific chronic spongiotic dermatitis but later expanded to include other nonlymphomatous cutaneous T-cell infiltrates that harbor occult monoclonal T-cell populations. Several cases of clonal dermatitis, some of which have progressed to MF, have been identified.[18,28,32] We suspect that for each disease with a potential for progression to MF, the principal risk may reside in the subset showing clonal dermatitis, because this is the subset in which dysregulation has begun to occur.

The postulated relationships among MF, clonal dermatitis, and selected types of chronic dermatitis are depicted in Fig. 25-1. Each of the entities shown is postulated to be at risk for MF through a clonal dermatitis intermediate. In this model, MF becomes the final common pathway for the clonal evolution of neoplastic T cells emerging from the polyclonal SALT T-cell populations present in each of the various precursor diseases.

Clinical Findings

CUTANEOUS LESIONS LPP lesions are either oval or irregularly shaped patches

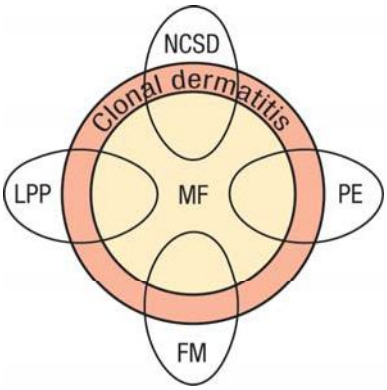

▲ **FIGURE 25-1** The relationship of clonal dermatitis to mycosis fungoides (MF) and various types of chronic dermatitis. The proportions of each entity that represent clonal dermatitis and mycosis fungoides vary with each disease and are not drawn to scale. FM = follicular mucinosis; LPP = large-plaque parapsoriasis; NCSD = nonspecific chronic spongiotic dermatitis; PE = primary erythroderma.

or very thin plaques that are asymptomatic or mildly pruritic. They are usually well marginated but may also blend imperceptibly into the surrounding skin. The size is variable, but typically most lesions are larger than 5 cm, often measuring more than 10 cm in diameter. Lesions are stable in size and may increase in number gradually. They are found mainly on the "bathing trunk" and flexural areas (Fig. 25-2). Extremities and the upper trunk, especially the breasts in women, also may be involved. They are light red-brown or salmon pink, and their surface is covered with small and scanty scales. Lesions may appear finely wrinkled—"cigarette paper" wrinkling. Such lesions exhibit varying degrees of epidermal atrophy. Telangiectasia and mottled pigmentation also are observed when the atrophy becomes prominent (Fig. 25-3). This triad of atrophy, mottled pigmentation, and telangiectasia defines the term *poikiloderma* or *poikiloderma atrophicans vasculare*, which also may be seen in other conditions (Box 25-1).



▲ **FIGURE 25-2** Large-plaque parapsoriasis. Irregularly shaped patches of variable size on the arm of a 16-year-old girl.





▲ **FIGURE 25-3** Large-plaque parapsoriasis. Poikilodermatous variant.

Retiform parapsoriasis refers to a rare variant of LPP that presents as an extensive eruption of scaly macules and papules in a net-like or zebra-stripe pattern that eventually becomes poikilodermatous (Fig. 25-4).

SPP characteristically occurs as round or oval discrete patches or very thin plaques, mainly on the trunk (Fig. 25-5). The lesions measure less than 5 cm in diameter; they are asymptomatic and covered with fine, moderately adherent scales. The general health of the patient is unaffected. A distinctive variant with lesions of a finger shape, known as *digitate dermatosis*,[3] has yellowish or fawn-colored lesions (Fig. 25-6). It follows lines of cleavage of the skin and gives the appearance of a hug that left fingerprints on the trunk. The long axis of these lesions often measures greater than 5 cm. Chronic superficial dermatitis is a synonym for SPP.[43] Digitate lesions with a yellow hue were referred to in the past as *xanthoerythrodermia perstans*.[1]

Box 25-1

Differential Diagnosis of Poikiloderma

- Large-plaque parapsoriasis
- Dermatomyositis
- Lupus erythematosus
- Chronic radiation dermatitis
- Bloom syndrome
- Rothmund-Thomson syndrome
- Dyskeratosis congenita
- Xeroderma pigmentosum



▲ **FIGURE 25-4** Large-plaque parapsoriasis. Retiform variant.

Laboratory Tests

HISTOPATHOLOGY In early LPP lesions, the epidermis is mildly acanthotic and slightly hyperkeratotic with spotty parakeratosis. The dermal lymphocytic infiltrate tends to be perivascular and scattered (Fig. 25-7). In the more advanced lesions one observes an interface infiltrate with definite epidermotropism. These invading lymphocytes may be scattered singly or in groups, sometimes associated with mild spongiosis. In addition, the poikilodermatous lesions show atrophic epidermis, dilated blood vessels, and melanophages (Fig. 25-8). Immunohistologic studies have revealed similar features in LPP and early MF, including a predominance of $CD4^+$ T-cell subsets, frequent CD7 antigen deficiency, and widespread epidermal expression of class II HLA (HLA-DR).[25–27,44–47]



▲ **FIGURE 25-5** Small-plaque parapsoriasis. Small, discrete patches less than 5 cm in diameter.



▲ **FIGURE 25-6** Small-plaque parapsoriasis. Digitate dermatosis variant. Typical "fingerprint" patches on the flank. Note that their length often exceeds 5 cm.

SPP exhibits mild spongiotic dermatitis with focal areas of hyperkeratosis, parakeratosis, scale crust, and exocytosis. In the dermis, there is a mild superficial perivascular lymphohistiocytic infiltrate and dermal edema (Fig. 25-9). There is no progression of the histologic features with time. Immunohistologic studies reveal a predominantly $CD4^+$ T-cell infiltrate with non-specific features resembling those seen in various types of dermatitides.[45]

Diagnosis and Differential Diagnosis

LPP is distinguished from SPP by the larger size, asymmetric distribution, and irregular shape of its lesions, which are

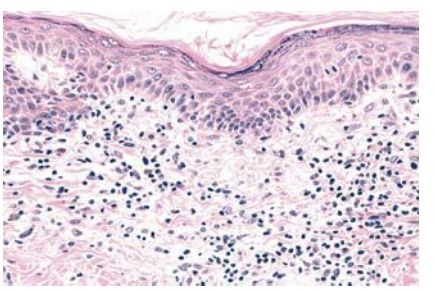

▲ **FIGURE 25-7** Large-plaque parapsoriasis. Mildly hyperkeratotic and focally parakeratotic epidermis with moderately dense superficial perivascular infiltrate. Lymphoid cells are mostly small, cytologically normal lymphocytes, and there is focal single-cell epidermotropism. (Used with permission from Helmut Kerl, M.D.)

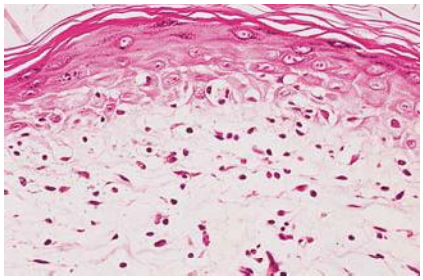

▲ **FIGURE 25-8** Large-plaque parapsoriasis. Atrophic variant. Sparse superficial lymphoid infiltrate with mild epidermotropism and epidermal atrophy.

less discrete and often poikilodermatous. LPP may be clinically and histopathologically indistinguishable from the patch stage of MF. Both LPP and SPP are readily distinguished from more advanced infiltrated plaques of MF because parapsoriasis lesions are, by definition, not thicker than patches or at most very thin plaques. This is so because the English equivalent of the French term *plaques* is *patches*, that is, lesions that are essentially flat and devoid of induration or palpable infiltration.[48] Failure to appreciate this important distinction has led to considerable confusion and misuse of the terms *large-plaque* and *small-plaque parapsoriasis* by some individuals. These designations more appropriately might be thought of as *large-patch* and *small-patch parapsoriasis*.

The degree to which LPP is differentiated from early MF depends primarily on the histopathologic criteria used to diagnose the latter disorder. Unfortunately, there are no universally accepted minimal criteria for the diagnosis of MF; however, one set proposed by the International Society for Cutaneous Lymphoma is presented in Table 25-2.[49] This algorithm is based on a holistic integration of clinical, histopathologic, immunopathologic, and clonality data. It differs significantly from many prior approaches because it does not rely solely on histopathologic features.[50] Assuming that histopathologic examination does not disclose features diagnostic of some other dermatosis, these criteria allow lesions to be classified as either patch-stage MF or not. For the practical purposes of clinical management, patients presenting clinically with patch lesions whose features result in a score of 4 points or more are considered to have unequivocal MF. Obviously, the more liberal the criteria, the more cases could be considered to be MF. However, there will always be some cases that fail to meet any specific set of criteria, and the designation *LPP* is a useful term to apply to them because it guides treatment and follow-up and conveys an understanding that the risk of dying from lymphoma is small.

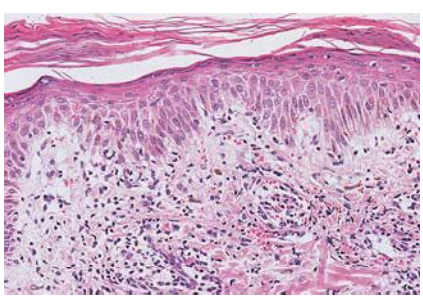

▲ **FIGURE 25-9** Small-plaque parapsoriasis. Superficial perivascular lymphoid infiltrate, mild spongiosis, parakeratosis, and focal scale crust.

TABLE 25-2
Algorithm for the Diagnosis of Patch-Stage Mycosis Fungoides (Four Points Are Required)

PARAMETER	2 POINTS	1 POINT
Clinical:	Any two	Any one
Persistent, progressive patches and plaques ±		
Non–sun-exposed distribution		
Variation in size and shape		
Poikiloderma		
Histopathologic:	Both	Either
Superficial dermal T-cell infiltrate ±		
Epidermotropism		
Nuclear atypia		
Immunopathologic:	Not applicable	Any one
CD2, CD3, or CD5 < 50%		
CD7 < 10%		
Epidermal-dermal discordance		
Molecular biologic:	Not applicable	Present
Dominant T-cell clonality		

Note: Epidermotropism implies the lack of significant spongiosis (intraepidermal lymphoid cells associated with spongiosis is termed *exocytosis* rather than *epidermotropism*). Discordance refers to differential antigen expression between the epidermis and dermis, as opposed to the biopsy specimen as a whole.
From Pimpinelli N et al: Defining early mycosis fungoides. *J Am Acad Dermatol* **53**:1053, 2005, with permission.

The clinical and/or histopathologic differential diagnosis of LPP also includes those collagen vascular diseases and genodermatoses exhibiting poikilodermatous features, lichenoid drug eruptions, secondary syphilis, chronic radiodermatitis, and occasionally several other diseases tabulated in Box 25-2. These generally can be distinguished by their associated clinical findings. Histopathologic differentiation among these diseases is covered largely in the discussion of pseudo-MF in Chap. 147.

SPP, when it presents with its distinctive digitate dermatosis lesions parallel to skin lines in a truncal distribution, stands out from other types of parapsoriasis. Individual SPP lesions may show some superficial resemblance to PLC. SPP is distinguished from psoriasis by the absence of the Auspitz sign (see Chap. 18), micaceous scale, nail pits, and typical psoriatic lesions involving the scalp, elbows, and knees. Histologically, its mild spongiotic dermatitis and absence of other characteristic features distinguish it from PLC, psoriasis, and several of the other entities listed in Box 25-2. Clinical features are also important, such as the herald patch of pityriasis rosea and the papulovesicular coin-shaped patches favoring the lower extremities in nummular dermatitis.

Sometimes patients with MF may exhibit small patches of disease at presentation; however, these lesions typically have histopathologic features at least consistent with MF and generally are associated with larger, more classic lesions of MF elsewhere on the skin. They also may show poikilodermatous features not seen in SPP. Furthermore, the presence of well-developed, moderate to thick small plaques, as seen in some MF patients, is incompatible with the diagnosis of SPP because the latter disorder includes only lesions that are no more than patches or very thin plaques. It is also important to recognize that partially treated or early relapsing lesions of MF may show only non-specific features that should not be taken as evidence of a pathogenetic link to SPP or any other dermatosis.

Complications

LPP can be associated with other forms of parapsoriasis and overt cutaneous





Box 25-2

Differential Diagnosis of Large-Plaque Parapsoriasis (LPP) and Small-Plaque Parapsoriasis (SPP)

Most Likely

- LPP
  - Tinea corporis
  - Plaque-type psoriasis
  - Contact dermatitis
  - Subacute cutaneous lupus erythematosus
- SPP
  - Nummular dermatitis
  - Pityriasis rosea
  - Plaque and guttate psoriasis
  - Pigmented purpuric dermatoses
  - Pityriasis lichenoides chronica

Consider

- LPP
  - Xerotic dermatitis
  - Atopic dermatitis
  - Dermatomyositis
  - Drug eruption
  - Erythema dyschromicum perstans
  - Pigmented purpuric dermatoses
  - Early inflammatory morphea
  - Atrophoderma of Pasini-Pierini
  - Erythema annulare centrifugum
  - Pityriasis rubra pilaris
  - Genodermatoses with poikiloderma
  - Chronic radiodermatitis
- SPP
  - Tinea versicolor
  - Seborrheic dermatitis
  - Drug eruption

Always Rule Out

- LPP
  - Mycosis fungoides
- SPP
  - Mycosis fungoides
  - Secondary syphilis

lymphomas as detailed elsewhere in this chapter. Both LPP and SPP occasionally can develop areas of impetiginization secondary to excoriation.

Prognosis and Clinical Course

Both LPP and SPP may persist for years to decades with little change in appearance clinically or histopathologically. Approximately 10 to 30 percent of cases of LPP progress to overt MF.[1,51] In this context, LPP represents the clinically benign end of the MF disease spectrum, with transformation to large cell lymphoma at the opposite extreme. The rare retiform variant is said to progress to overt MF in virtually all cases.[1]

In contrast to LPP with its malignant potential, SPP is a clinically benign disorder in the experience of most experts. Patients with this disease as defined in this chapter rarely, if ever, develop overt MF.[15,43,52] Despite this fact and what most observers consider to be its nonspecific histopathologic features, some authors favor lumping SPP within the MF disease spectrum as a very early, nonprogressive variant.[53] This issue has been debated at length.[36,54,55]

Box 25-3

Treatment of Large-Plaque Parapsoriasis and Small-Plaque Parapsoriasis

FIRST LINE

- Emollients
- Topical corticosteroids
- Topical tar products
- Sunbathing
- Broadband ultraviolet B phototherapy
- Narrowband ultraviolet B phototherapy

SECOND LINE

(Mainly for large-plaque parapsoriasis cases considered to be early mycosis fungoides)

- Topical bexarotene
- Topical imiquimod
- Psoralen and ultraviolet A phototherapy
- Topical mechlorethamine
- Topical carmustine (BCNU)

Treatment

Patients with SPP should be reassured and may forego treatment. The disease may be treated with emollients, topical tar preparations, topical corticosteroids, and/or broadband or narrowband ultraviolet B (UVB) phototherapy (Box 25-3).[56] Response to therapy is variable. Patients should initially be examined every 3 to 6 months and subsequently every year to ensure that the character of the process is stable.

LPP requires more aggressive therapy: high-potency topical corticosteroids with phototherapy such as broadband UVB, narrowband UVB, or psoralen and ultraviolet A (PUVA). The goal of treatment is to suppress the disorder to prevent possible progression to overt MF. Other methods of treatment, such as topical nitrogen mustard, have been used, particularly for the poikilodermatous type. The patient should be examined carefully every 3 months initially and every 6 months to 1 year subsequently for evidence of progression. Repeated multiple biopsies of suspicious lesions should be performed. Cases that satisfy the clinicopathologic criteria for early MF can be treated with broadband UVB, narrowband UVB, PUVA, topical nitrogen mustard, topical bexarotene gel, topical imiquimod, or topical carmustine (BCNU).[57] Electron-beam radiation therapy generally is reserved for more advanced, infiltrated lesions of MF.

Prevention

Because LPP and SPP are uncommon diseases that appear to affect patients randomly, there are no known preventive measures.

PITYRIASIS LICHENOIDES

Epidemiology

Pityriasis lichenoides affects all racial and ethnic groups in all geographic regions. It is more common in children and young adults but can affect all ages. There is a male predominace of 1.5:1 to 3:1.[58,59] PLC is three to six times more common than PLEVA.

Etiology and Pathogenesis

The etiology of pityriasis lichenoides is unknown. Some cases have been associated with infectious agents such as *Toxoplasma gondii*,[60,61] Epstein-Barr virus,[62,63] cytomegalovirus,[62] parvovirus B19,[62,64,65] and human immunodeficiency virus.[66,67] At least one case was linked repeatedly with estrogen-progesterone therapy and another with chemotherapy drugs.[68] It is uncertain whether these agents are actively involved in disease pathogenesis or merely coincidental bystanders; however, several cases associated with toxoplasmosis have cleared fairly quickly in response to specific therapy.[61]

Immunohistologic studies have shown a reduction in $CD1a^+$ antigen–presenting dendritic (Langerhans) cells within the central epidermis of pityriasis lichenoides lesions.[69] Keratinocytes and endothelial cells are $HLA\text{-}DR^+$, which suggests activation by T-cell cytokines.[69] $CD8^+$ T cells predominate in PLEVA, whereas either $CD8^+$ or $CD4^+$ T cells predominate in PLC.[69–71] Many of these T cells express memory proteins (CD45RO) and cytolytic proteins (TIA-1 and granzyme B).[64,72] Dominant T-cell clonality has been demonstrated in about half of PLEVA cases and a minority of PLC cases.[35–37,73] In aggregate, these findings raise the possibility that pityriasis lichenoides is a variably clonal cytolytic memory T-cell lymphoproliferative response to one or more foreign antigens. Deposition of immunoglobulin M, C3, and fibrin in and around blood vessels and along the dermoepi-

PITYRIASIS LICHENOIDES AT A GLANCE

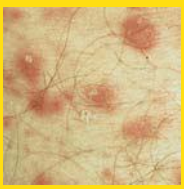


- Pityriasis lichenoides et varioliformis acuta (PLEVA) and pityriasis lichenoides chronica (PLC) represent two ends of a disease spectrum; both entities and intermediate forms can coexist.
- All forms are characterized by spontaneously resolving, temporally overlapping crops of papules.
- PLEVA papules last for weeks and may develop crusts, vesicles, pustules, or ulcers.
- PLC papules persist for months and develop scales.
- All forms contain interface, cytolytic T-cell infiltrates with variable epidermal destruction.
- In PLEVA, $CD8^+$ cells predominate.
- In PLC, $CD8^+$ or $CD4^+$ cells predominate.
- Dominant T-cell clonality can be detected in all forms, more often in PLEVA than in PLC.
- Treatment depends on severity and ranges from topical steroids, systemic antibiotics, ultraviolet irradiation, and psoralen and ultraviolet A to systemic immunosuppressants.

dermal junction in early acute lesions suggests a possible concomitant humoral immune response, although this could be a secondary phenomenon.

The relationship of pityriasis lichenoides to lymphomatoid papulosis remains controversial[14,50,69] (see also Chaps. 146 and 147). Common features include dominant T-cell clonality and spontaneous resolution of papular, predominantly lymphoid lesions. Furthermore, individual lesions with the clinicopathologic characteristics of either pityriasis lichenoides or lymphomatoid papulosis can co-exist in the same patient, either concurrently or serially. It remains to be determined whether this can be explained as an artifact of sampling lymphomatoid papulosis lesions at various stages of their evolution. The presence of large $CD30^+$ atypical lymphoid cells is the hallmark of lymphomatoid papulosis (at least types A and C).[74] Furthermore, these cells are typically $CD4^+$ and often lack one or more mature T-cell antigens such as CD2, CD3, and CD5. These features serve to distinguish lymphomatoid papulosis from pityriasis lichenoides. Although occasional $CD30^+$ cells can be seen in a wide variety of dermatoses, the presence of any appreciable number should favor lymphomatoid papulosis over pityriasis lichenoides as a matter of definition. It may be that the "PLC-PLEVA" and "lymphomatoid papulosis–$CD30^+$ anaplastic large cell lymphoma" disease spectra are intersecting rather than overlapping entities; that is, although pityriasis lichenoides is a distinct cutaneous T-cell disorder, it is possible that it may sometimes serve as fertile soil for the development of the $CD30^+$ T-cell clone characteristic of lymphomatoid papulosis.

Clinical Findings

CUTANEOUS LESIONS PLC and PLEVA exist on a clinicopathologic continuum.[1,50] Therefore, individual patients may exhibit a mixture of acute and chronic lesions sequentially or concurrently. In addition, lesions representing clinical or histopathologic intergrades between the extremes may also occur at any time.

Lesions are often asymptomatic but can be pruritic or burning, especially in the more acute cases. PLC typically presents as recurrent crops of erythematous scaly papules that spontaneously regress over several weeks to months (Fig. 25-10). PLEVA manifests as recurrent crops of erythematous papules that develop crusts, vesicles, pustules, or erosions before spontaneously regressing within a matter of weeks (Fig. 25-11). The more severe ulcerative variant is known as *pityriasis lichenoides with ulceronecrosis and hyperthermia (PLUH)* or *febrile ulceronecrotic Mucha-Habermann disease*. It presents as purpuric papulonodules with central ulcers up to a few centimeters in diameter (Fig. 25-12). Some have proposed that this severe variant is actually an overt T-cell lymphoma.[75] Pityriasis lichenoides lesions tend to concentrate on the trunk and proximal extremities,



▲ **FIGURE 25-10** Pityriasis lichenoides chronica. Polymorphous appearance ranging from early erythematous papules to scaling brown-red lesions and tan-brown involuting, flat papules and macules.







▲ **FIGURE 25-11** Pityriasis lichenoides et varioliformis acuta. **A.** Adolescent with multiple erythematous papules and crusted lesions in various stages of evolution. **B.** Larger papulovesicular and hemorrhagic, crusted lesions in an adult. Note varioliform scars adjacent to active lesions on posterior thigh and leg. **C.** Pustules, crusts, and necrotic-centered papules with erythematous, indurated base.





▲ **FIGURE 25-12** Pityriasis lichenoides, ulceronecrotic, hyperacute variant. Large necrotic eschar with halo erythema developing in febrile patient with antecedent pityriasis lichenoides et varioliformis acuta.



but any region of the skin and even mucous membranes can be involved. Rare regional or segmental lesion distributions have been described.[76,77] Although there are usually numerous co-existent lesions, occasionally only a small number of lesions will be present at any one time. All forms of pityriasis lichenoides can result in post-inflammatory hypopigmentation or hyperpigmentation. Chronic lesions can resolve with post-inflammatory hypopigmentation, sometimes presenting as idiopathic guttate hypomelanosis. Chronic lesions rarely lead to scars. In contrast, acute lesions result in deeper dermal injury and consequently often resolve leaving varioliform (smallpox-like) scars. The presence of lesions in various stages of evolution imparts a polymorphous appearance that is characteristic of pityriasis lichenoides.

Laboratory Tests

Miscellaneous non-specific abnormalities in blood test results occur but are of little practical value. Leukocytosis and a decreased CD4/CD8 ratio can occur.

HISTOPATHOLOGY As with the morphology of the clinical lesions, pityriasis lichenoides can exhibit a range of histopathologic features encompassing acute, chronic, and intermediate lesional variants (Figs. 25-13 and 25-14). All cases of pityriasis lichenoides contain an interface dermatitis that is denser and more wedge shaped in the acute lesions. The infiltrate is composed mainly of lymphocytes with a variable admixture of neutrophils and histiocytes. There is exocytosis, parakeratosis, and extravasation of erythrocytes. Epidermal damage ranges from intercellular and extracellular edema in less severe cases to extensive keratinocyte necrosis, vesicles, pustules, and ulcers. The acute variants can exhibit lymphocytic vasculitis with fibrinoid degeneration of blood vessel walls.

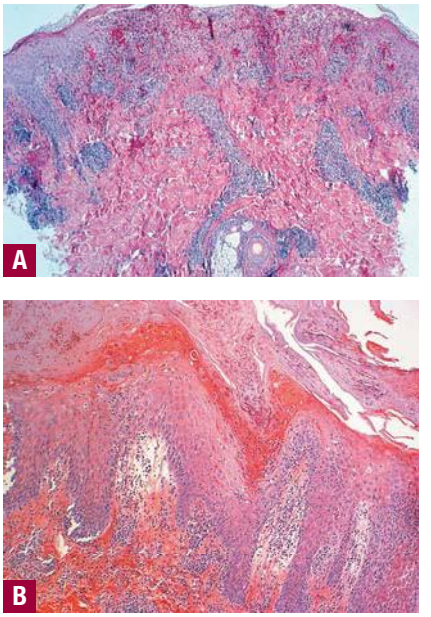

▲ **FIGURE 25-13** Pityriasis lichenoides et varioliformis acuta. **A.** Ulcerated papule with epidermal necrosis, hemorrhage, and superficial and deep perivascular lymphocytic infiltrate. Hematoxylin and eosin (H&E) stain. **B.** Parakeratosis and crust with marked spongiosis and epidermal necrosis. Lymphocyte exocytosis and basal hydropic changes. H&E stain.

Occasional CD30$^+$ lymphoid cells and occasional atypical lymphoid cells may be seen as a non-specific finding in many cutaneous lymphoid infiltrates. The presence of an appreciable numbers of these cells is not consistent with classic pityriasis lichenoides of any type and should raise concern for the lymphomatoid papulosis–CD30$^+$ anaplastic large cell lymphoma disease spectrum.[74] Other immunohistologic features and the clonality of pityriasis lichenoides are discussed in Etiology and Pathogenesis.

Differential Diagnosis

The differential diagnosis of pityriasis lichenoides includes many papular eruptions (Box 25-4). Those that develop crusts, vesicles, pustules, or ulcers are grouped with PLEVA, whereas those that form predominantly scaly papules are grouped with PLC. Most of them can be excluded based on history and typical clinicopathologic features. A few, such as secondary syphilis and viral-associated lesions, also can be excluded based on serologic tests. Among the most challenging diseases to distinguish from pityriasis lichenoides are lymphomatoid papulosis and macular or papular variants of MF.[78] As detailed earlier, the presence of large atypical lymphoid cells (often CD30$^+$) differentiates lymphomatoid papulosis from pityriasis lichenoides.[74] Macular or papular variants of MF are rare. They exhibit classic features of MF, including small atypical epidermotropic lymphoid cells with convoluted nuclei and a band-like superficial dermal lymphoid infiltrate.[78]

Complications

Secondary infection is the most common complication of pityriasis lichenoides. PLEVA may be associated with low-grade fever, malaise, headache, and arthralgia. Patients with PLUH can develop high fever, malaise, myalgia, arthralgia, and gastrointestinal and central nervous system symptoms. Occasionally, debilitated patients may die. PLC has been associated uncommonly with LPP in children.[79] Despite

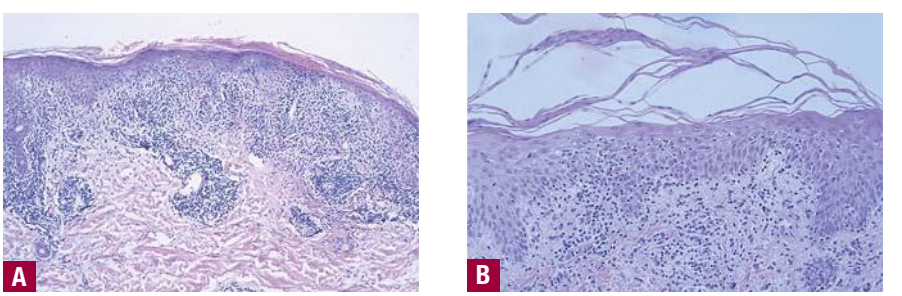

▲ **FIGURE 25-14** Pityriasis lichenoides chronica. **A.** Compact parakeratosis, lymphocytic exocytosis, occasional eosinophilic necrotic keratinocytes, edema, and diffuse lymphocytic infiltrate localizing to epidermal-dermal interface and perivascular sites within the dermis. Hematoxylin and eosin (H&E) stain. **B.** Parakeratosis, spongiosis, and a predominant mononuclear cell infiltrate in the epidermis and dermis with papillary edema. H&E stain.

Box 25-4

Differential Diagnosis of Pityriasis Lichenoides et Varioliformis Acuta (PLEVA) and Pityriasis Lichenoides Chronica (PLC)

Most Likely

- PLEVA
  - Arthropod bites, stings, infestations
  - Leukocytoclastic vasculitis
  - Viral exanthem (e.g., varicella-zoster, herpes simplex)
- PLC
  - Pityriasis rosea
  - Drug eruption
  - Guttate psoriasis

Consider

- PLEVA
  - Folliculitis
  - Rickettsiosis
  - Erythema multiforme
  - Dermatitis herpetiformis
- PLC
  - Spongiotic dermatitis, papular variant
  - Small-plaque parapsoriasis
  - Lichen planus
  - Gianotti-Crosti syndrome

Always Rule Out

- PLEVA
  - Lymphomatoid papulosis
  - Secondary syphilis
- PLC
  - Lymphomatoid papulosis
  - Mycosis fungoides (papular variant)
  - Secondary syphilis

their sometimes dominant T-cell clonal nature, PLC and PLEVA are considered clinically benign disorders without significant linkage to lymphomas or other malignancies.

Prognosis and Clinical Course

Pityriasis lichenoides has a variable clinical course characterized by recurrent crops of lesions that spontaneously resolve. The disorder may resolve spontaneously within a few months or, less commonly, persist for years. PLEVA usually has a shorter duration than PLC.

Box 25-5

Treatment of Pityriasis Lichenoides et Varioliformis Acuta and Pityriasis Lichenoides Chronica

FIRST LINE

- Topical corticosteroids
- Antibiotics (erythromycin 500 mg PO 2–4× daily[80]; tetracycline 500 mg PO 2–4× daily,[81] minocycline 100 mg PO twice daily)
- Phototherapy (sunbathing, ultraviolet B,[82] ultraviolet A + ultraviolet B,[83] narrowband ultraviolet B[84])

SECOND LINE

- Topical tacrolimus[85,86]
- Prednisone (60/40/20 mg PO taper, 5 days each)[87]
- Methotrexate (10–25 mg PO weekly)[88,89]
- Phototherapy (ultraviolet AI, psoralen plus ultraviolet A)
- Cyclosporin (2.5–4 mg/kg/day total dose divided into twice-daily PO doses; use the minimum)[66]
- Retinoids (e.g., acitretin 25–50 mg PO daily)[90]

Although the conclusion was not confirmed by subsequent investigation, one report suggested that the duration of pityriasis lichenoides in children correlated better with its clinical distribution than with the relative abundance of acute and chronic lesions, which often co-existed.[59] From longest to shortest duration, the distribution of lesions ranged from peripheral (distal extremities) to central (trunk) to diffuse.

Treatment

The mainstay of traditional therapy has been a combination of topical corticosteroids and phototherapy (Box 25-5). Systemic antibiotics in the tetracycline and erythromycin families are used primarily for their anti-inflammatory rather than antibiotic effects. Cases with minimal disease activity may not require any treatment. The more acute the clinical course and the more severe the individual lesions, the more systemic therapy is indicated. Methotrexate is often effective in relatively low doses. Calcineurin inhibitors and retinoids may also be beneficial. Severe cases of PLEVA and PLUH often require systemic corticosteroids or similar drugs to gain control of systemic symptoms. Topical and systemic antibiotics may be needed to treat secondary infections complicating ulcerated skin lesions. These agents are often selected initially to cover Gram-positive pathogens, but subsequent use should be guided by culture results.

Prevention

There are no known preventive measures.

KEY REFERENCES

The full reference list for all chapters is available at www.digm7.com.

1. Lambert WC, Everett MA: The nosology of parapsoriasis. *J Am Acad Dermatol* **5**:373, 1981
3. Hu CH, Winkelmann RK: Digitate dermatosis. A new look at symmetrical, small plaque parapsoriasis. *Arch Dermatol* **107**:65, 1973
5. Montgomery H, ed: *Parapsoriasis in Dermatopathology*. New York, Harper & Row, 1967
28. Wood GS et al: Detection of clonal T-cell receptor gamma gene rearrangements in early mycosis fungoides/Sézary syndrome by polymerase chain reaction and denaturing gradient gel electrophoresis (PCR/DGGE). *J Invest Dermatol* **103**:34, 1994
43. Samman PD: The natural history of parapsoriasis en plaques (chronic superficial dermatitis) and prereticulotic poikiloderma. *Br J Dermatol* **87**:405, 1972
48. Burg G et al: Cutaneous lymphomas consist of a spectrum of nosologically different entities including mycosis fungoides and small plaque parapsoriasis. *Arch Dermatol* **132**:567, 1996
50. Wood G: *The Benign and Malignant Cutaneous Lymphoproliferative Disorders Including Mycosis Fungoides*. Baltimore, Williams & Wilkins, 2001
54. Burg G, Dummer R: Small plaque (digitate) parapsoriasis is an "abortive cutaneous T-cell lymphoma" and is not mycosis fungoides. *Arch Dermatol* **131**:336, 1995



CHAPTER 26

Lichen Planus

Mark R. Pittelkow
Mazen S. Daoud



Lichen planus (Greek *leichen*, "tree moss"; Latin *planus*, "flat") is a unique, common inflammatory disorder that affects the skin, mucous membranes, nails, and hair. The appearance of lichen planus and lichen planus–like or lichenoid dermatoses has been likened to the scurfy, finely furrowed, dry excrescences of the symbiotic vegetation known as *lichen*. Although this morphologic comparison may be antiquated, lichen planus is a distinctive entity with prototypic "lichenoid" papules that show distinctive color and morphology, develop in typical locations, and manifest characteristic patterns of evolution. Microscopic features, similar to the gross morphology, are distinctive although the microscopic pattern of inflammation and skin response is shared by several dermatoses. The term *lichenoid reaction* is the histologic description used to capsulize the pathologic characteristics of skin diseases resembling lichen planus.

The four Ps—purple, polygonal, pruritic, papule—is the mnemonic device often used to recall the constellation of symptoms and skin findings that characterize lichen planus.

HISTORICAL ASPECTS

EPIDEMIOLOGY

The exact incidence and prevalence of lichen planus are unknown, but the overall prevalence is believed to be somewhat less than 1 percent of the general population. Estimates between 0.14 percent and 0.80 percent have been reported worldwide and approximately 0.44 percent in the United States. No racial predilection has been observed.[2]

At least two-thirds of cases occur between the ages of 30 and 60 years of age. No sexual predilection is evident. Females are usually affected in their fifties and sixties, whereas males develop lichen planus at a somewhat earlier age. The disease is less common in the very young and the elderly. The development of lichen planus may be affected by seasonal or environmental factors.[2]

Fewer than 100 cases of familial lichen planus have been reported. The familial form tends to be more protracted and severe and presents in erosive, linear, or ulcerative patterns or with atypical features affecting young adults and children.[3] Some believe that the familial form represents a separate, unique dermatosis. Different HLA haplotypes were reported in familial lichen planus, including HLA-B7, -Aw19, -B18, and -Cw8. In non-familial lichen planus, HLA-A3, -A5, -A28, -B8, -B16, and -Bw35 are more common.[4] HLA-B8 is more common in patients with oral lichen planus as a sole manifestation, and HLA-Bw35 is more strongly associated with cutaneous lichen planus.

ETIOLOGY AND PATHOGENESIS

It is evident that immunologic mechanisms almost certainly mediate the development of lichen planus. No consistent alterations in immunoglobulins (Igs) have been shown in lichen planus, and humoral immunity most likely is a secondary response in the immunopathogenesis.

Cell-mediated immunity, on the other hand, plays the major role in triggering the clinical expression of the disease. Both $CD4^+$ and $CD8^+$ T cells are found in lesional skin of lichen planus. Progression of disease may lead to preferential accumulation of $CD8^+$ cells. The majority of the lymphocytes in the infiltrate of lichen planus are $CD8^+$ and CD45RO (memory) positive cells and express the α-β T-cell receptor (TCR), and in a minority, the γ-δ receptor. This later cell subtype is not normally found in healthy skin. These cells are considered responsible for the development of the most characteristic change observed in the lichenoid reaction, namely, apoptosis. The inflammatory process that leads to apoptosis is complex and not fully understood. The epithelial-lymphocyte interaction can be divided into three major stages: antigen recognition, lymphocyte activation, and keratinocyte apoptosis.

Lichen Planus–Specific Antigen Recognition

It is evident that the majority of T cells in the infiltrate of lichen planus, both within the epithelium and adjacent to damaged basal keratinocytes, are activated $CD8^+$ cytotoxic lymphocytes. Evidence from oral lichen planus suggests that $CD8^+$ lesional T cells recognize a lichen planus–specific antigen associated with major histocompatibility complex (MHC) class I on lesional keratinocytes. The nature of this antigen is unknown. Theoretically, the antigen may be an autoreactive peptide, thus classifying lichen planus as an autoimmune disease. Alternatively, it may represent an exogenous antigen such as an altered protein, drug, contact allergen, viral or infectious agent, or an unidentified immunogenic target.[5]

The role of T-helper (CD4) cells in the pathogenesis of lichen planus is not fully defined. T cells may become activated via antigen-presenting cells such as Langerhans cells or accessory cells such as epidermal keratinocytes in association with members of the MHC II and specific cytokines. T-helper lymphocytes may also propagate $CD8^+$ cytotoxic lymphocytes through cellular cooperation and release of cytokines.

The nature of antigenic stimulation is not known. Contact sensitizers such as metals could act as haptens and elicit an immunologic response. Enhanced lymphocyte reactivity to inorganic mercury, a component of dental amalgam, has been found in patients with oral lichenoid reactions. Low-grade chronic exposure to mercury, and possibly to other metals such as gold, may stimulate a lymphocytic reaction that manifests as lichen planus. A list of contact chemicals and drugs that can elicit lichenoid reactions is discussed in Drug-Induced Lichen Planus. The role of infection in the development of lichen

LICHEN PLANUS AT A GLANCE



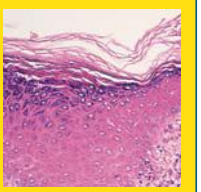

- Worldwide occurrence: Less than 1 percent.
- Lesions: Symmetric, grouped, erythematous to violaceous, flat-topped, polygonal papules.
- Distribution: Widespread, predilection for flexural aspects of arms and legs.
- Variants: Based on configuration, morphology of lesion, and site of involvement.
- Pathology: Basal epidermal keratinocyte damage and lichenoid interface lymphocytic reaction.

planus has been repeatedly raised over the years. Though provocative, no conclusive evidence has molecularly linked lichen planus to any of the following infections or microorganisms: syphilis, herpes simplex virus 2, human immunodeficiency virus (HIV), amebiasis, chronic bladder infections, hepatitis C virus (HCV), *Helicobacter pylori*, or human papillomavirus.

Cytotoxic Lymphocyte Activation

Following antigen recognition, $CD8^+$ T cells are activated. Activated cytotoxic lymphocytes undergo lesional tissue clonal expansion, leading to oligoclonal and occasionally to monoclonal proliferation as detected by analysis of the TCR-γ chain gene products.[6]

Activated lymphocytes, both by helper subsets (Th1 and Th2) and cytotoxic-suppressor cells, release soluble mediators (cytokines and chemokines), such as interleukin (IL)-2, IL-4, IL-10, interferon (IFN)-γ, tumor necrosis factor (TNF)-α, and transforming growth factor-β1, that attract lymphocytes and regulate their biologic activities within and adjacent to the epithelium. Both pro- and anti-inflammatory cytokines, that is, mixed Th1 and Th2 cytokine products, are generated simultaneously. The balance between lymphocytic activation and downregulation determines the clinical behavior of the disease.[7] IFN-γ, produced by T-helper cells during the antigen recognition stage, induces keratinocytes to produce lymphotoxin-α and TNF-α, and to upregulate MHC class II, thus increasing interactions with T-helper cells. Furthermore, IFN-γ upregulates the expression of intercellular adhesion molecule-1 and vascular cell adhesion molecule-1 by basal keratinocytes, Langerhans cells, and other macrophage-dendritic cells.[8] Intercellular adhesion molecule-1 is a ligand for the β_2-integrin, leukocyte function–associated antigen-1, on the surface of lymphocytes, which further enhances the interaction of these lymphocytes with the antigen-presenting cells.[9] Laminin-5 and collagen types IV and VII are increased in lesional lichen planus and serve as ligands for β1-integrin on the surface of lymphocytes, thus allowing for enhanced association of lymphocytes with the basement membrane. Integrin α3 is present on activated, skin-homing T cells and may localize these effector cells to the epidermal-dermal interface and basement membrane, which contain epiligrin/laminin-5, a ligand for this integrin.[10] This close interaction between lymphocytes and basement membrane targets metalloproteinases produced by lymphocytes to alter extracellular matrix proteins and integrins, and the process eventuates in apoptosis, basement membrane disruption, reduplication, and subepidermal cleft formation (see Pathology). TNF-α upregulates the expression of matrix metalloproteinase (MMP)-9 mRNA in lesional T lymphocytes, thus further enhancing basement membrane disruption (see Keratinocyte Apoptosis).[11]

Keratinocytes also participate in the response by producing IL-1β, IL-4, IL-6, granulocyte-macrophage colony-stimulating factor, and TNF-α. These cytokines further activate tissue macrophages and peripheral blood mononuclear cells[12] and upregulate expression of cell surface adhesion molecules and migration activity. Keratinocyte-produced cytokines also upregulate expression of specific keratin genes. Keratin (K) 17, usually restricted to adnexal structures, is variably expressed in the basal and suprabasal layers of the interfollicular epithelium of affected epidermis. K6 and K16 also become detectable in the basal and suprabasal layers. K4 and K13 are reduced in the suprabasal compartment in areas with orthokeratosis, associated with increased production of K1 and K10.[13]

Keratinocyte Apoptosis

The exact mechanisms used by activated cytotoxic T cells to trigger apoptosis of keratinocytes is not completely known. Possible mechanisms include: (1) T-cell secreted TNF-α binding to the TNF-α R1 receptor on the keratinocyte surface, (2) T-cell surface CD95L (Fas ligand) binding CD95 (Fas) on the keratinocyte, and (3) T-cell secreted granzyme B entering the keratinocyte via perforin-induced membrane pores. All these mechanisms may activate the keratinocyte caspase cascade, resulting in keratinocyte apoptosis.[5]

Recruited lymphocytes may further contribute to apoptosis via a different mechanism, the loss of a basement membrane–derived cell survival signal that normally prevents the onset of apoptosis. Hence, basement membrane disruption may trigger apoptosis. Principle mediators are the MMPs, a family of zinc-containing endoproteinases that primarily function to degrade connective tissue matrix proteins. The action of these enzymes is also regulated by inhibitors such as tissue inhibitors of metalloproteinases (TIMPs) (see Chap. 61). It has been shown that lesional T cells in lichen planus have higher MMP-9 levels than peripheral blood T cells. Lesional T-cell MMP-9 activity increases following stimulation with TNF-α, but not TIMP-1, an inhibitor for MMP-9.[5] These observations suggest that T-cell secreted MMP-9 disrupts epithelial basement membranes, blocking cell survival signals to keratinocytes and inducing apoptosis.

Various other environmental, behavioral, or infectious factors have been observed on occasion to be associated with the development or exacerbation of lichen planus. However, no well-established association has been documented between emotional stress, tobacco use, or oral or gastrointestinal candidiasis and development of lichen planus.

CLINICAL FINDINGS

Cutaneous Lesions

The classic cutaneous lesion of lichen planus is a faintly erythematous to violaceous, flat-topped, polygonal papule, sometimes showing a small central umbilication (Fig. 26-1). Papules are grouped and tend to coalesce. A thin, transparent, and adherent scale may be discerned atop the lesion. Fine, whitish puncta or reticulated networks referred to as *Wickham striae* are present over the surface of many well-developed papules (see Fig. 26-1). These are considered to be highly characteristic and are more easily observed after applying oil, xylene, or water and visualizing the lesions with a magnifying lens or a handheld dermatoscope. The surface alteration may result from localized thickening of the keratohyalin-containing cell layers of the stratum granulosum, although a focal increase in the activity of lichen planus may account for the morphologic alteration of Wickham striae.



▲ **FIGURE 26-1** Flat-topped, polygonal, sharply defined papules of violaceous color, grouped and confluent. Surface is shiny and reveals fine white lines (Wickham striae). Note pigmentation of resolving lesions.







▲ **FIGURE 26-2** Generalized lichen planus. Small, flat-topped violaceous papules, some grouped, some disseminated, becoming confluent on the trunk.

Lichen planus begins as faintly erythematous macules that form purplish papules over several weeks. Sometimes multiple lesions develop rapidly over a short time, with dissemination following the initial appearance of only a few papules. Further spread of lesions after the initial limited expression occurs in approximately one-third of cases. In generalized disease (Fig. 26-2), the eruption often spreads within 1 to 4 months from onset. The initial lesions almost always appear on the extremities, with the lower extremities being somewhat more common.

The lesions are usually distributed symmetrically and bilaterally over the extremities. Lichen planus tends to involve the flexural areas of the wrists, arms, and legs (see Fig. 26-1). The thighs, lower back, trunk, and neck may also be affected. Oral mucous membranes (Fig. 26-3) and the genitalia (Fig. 26-4) are additional sites of involvement. The face is usually spared in typical cases, and palmoplantar involvement is unusual. Inverse lichen planus usually affects the axillae, groin, and inframammary areas.

Lichen planus tends to be quite pruritic, although some patients are completely asymptomatic. The degree of pruritus is generally related to the extent of involvement, with more intense pruritus in generalized cases. An exception is hypertrophic lichen planus, which is more localized but extremely pruritic. Oral involvement is generally asymptomatic unless erosions or ulcers developed. Erosive oral lichen planus is usually extremely painful. In the acute, evolving stages of the disease, scratching, injury, or trauma may induce an isomorphic (Koebner) response (Fig. 26-5). Lichen planus usually heals with hyperpigmentation (see Fig. 26-1), which is more prominent among patients with darker skin color. Hypopigmentation uncommonly develops after resolution of lesions.

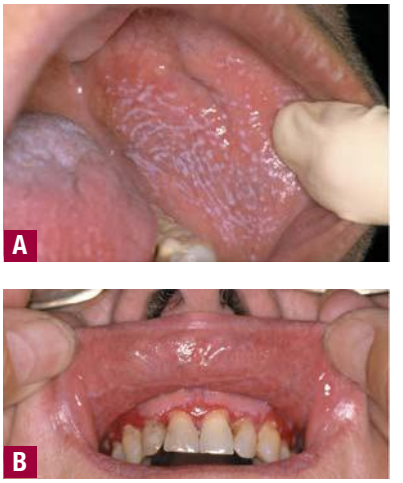

▲ **FIGURE 26-3** Mucosal lichen planus. **A.** A typical lace-like whitish reticulated pattern of oral lesions is seen on the buccal mucosa. **B.** Erosive gingivitis. Here lichen planus manifests as painful erosions on the gingiva.

Although the clinical and pathologic features of childhood lichen planus are similar to those in adults, scalp, nail, and hair involvement are not common. Mucous membrane involvement, thought to be rare, may occur in up to one-third of patients. The hypertrophic variant occurs in one-fourth of children with lichen planus.

Clinical Variants

Many variations in the clinical presentation have been described and are generally categorized according to (1) the configuration of lesions, (2) the morphologic appearance, or (3) the site of involvement. These variations are patterned by subtle or unknown properties of the disease. The prototypic papule can be altered or modified in configuration, morphology, or anatomic distribution.



▲ **FIGURE 26-4** Lichen planus on the penis. Agminate pattern of lesions involving the glans, sulcus, and meatus (not seen) of the penis.



▲ **FIGURE 26-5** Lichen planus. Linear pattern with Koebner response adjacent to clustered papules on the flexural wrist.

CONFIGURATION OF LESIONS ***Annular Lichen Planus.*** Annular lesions occur in approximately 10 percent of cases and commonly develop as arcuate groupings of individual papules that develop rings or peripheral extension of clustered papules with central clearing. They tend to occur in blacks and are more common on the penis and scrotum (see Fig. 75-9, Chap. 75).[2] Another form of annular lichen planus occurs when larger lesions reach 2 to 3 cm in diameter and become hyperpigmented with a raised outer rim. This form may occur on the trunk or extremities. Actinic lichen planus, seen in subtropical zones on sun-exposed, dark-skinned young adults and children, is frequently annular in shape.

Linear Lichen Planus. Papules of lichen planus may develop a linear pattern secondary to trauma (koebnerization) (see Fig. 26-5) or, uncommonly, as a spontaneous, isolated eruption, usually on the extremities, and rarely on the face. This linear pattern should be differentiated from nevus unius lateris and lichen striatus. A zosteriform pattern has also been described.[14] Lichen planus can develop in the site of healed herpes zoster.



▲ **FIGURE 26-6** Hypertrophic lichen planus in the pretibial region of a dark-skinned individual. Lesions are almost nodular and very dark with the violaceous sheen of lichen planus. Lesions may later become hyperkeratotic.

MORPHOLOGY OF LESIONS ***Hypertrophic Lichen Planus.*** Hypertrophic lichen planus (lichen planus verrucosus) usually occurs on the extremities, especially the shins and interphalangeal joints, and tends to be the most pruritic variant (Fig. 26-6). Lesions are thickened and elevated, purplish or reddish-brown in color, and hyperkeratotic. Occasionally, verrucous plaques develop. Lesions may show accentuated and elevated follicular induration and chalk-like scale. This variant usually heals with scar formation and hyper- or hypopigmentation. Chronic venous insufficiency is frequently present.

Atrophic Lichen Planus. The atrophic variant is rare and is characterized by the presence of a few well-demarcated, white-bluish papules or plaques with central superficial atrophy.[2] Sometimes the lesions show more erythema. The lesions are a few millimeters wide but may coalesce to form larger plaques. They are most common on the lower extremities or trunk. The lesions often resemble lichen sclerosus et atrophicus. However, the histologic features are diagnostic.

Vesiculobullous Lichen Planus. Bullous lichen planus is a rare variant of the disease characterized by the development of vesicles and bullae within the lesions (Fig. 26-7). The bullae, which appear most commonly on the extremities, arise from papules of lichen planus and rarely from normal-appearing skin.



▲ **FIGURE 26-7** Vesiculo-bullous lichen planus. Vesicles and bullae with violaceous-erythematous papules and plaques on the foot.

They may appear suddenly during an acute flare of disease and are usually associated with mild constitutional symptoms. These lesions usually resolve in a few months. Bulla arising in oral lichen planus can lead to painful erosions. Histologically, the typical changes of lichen planus are seen in conjunction with subepidermal separation. The duration of this variant is no different from that of classic lichen planus. Bullae arising from normal skin are more characteristic of lichen planus pemphigoides and should be differentiated from bullous lichen planus by direct and indirect immunofluorescence (see below).

Erosive and Ulcerative Lichen Planus. Ulcerative lichen planus is a rare variant presenting with chronic, painful bullae and ulcerations of the feet. Often, cicatricial sequelae are evident (Fig. 26-8). This variant is usually associated with more typical lesions of the nails, mucosal surfaces, and skin, which often aids in establishing the diagnosis. Permanent loss of toenails and cicatricial alopecia of the scalp are common. Because squamous cell carcinoma (SCC) may develop in lesions of ulcerative lichen planus, persistent ulceration should raise suspicions of malignancy, and this potential complication should be ruled out by biopsy. Excision and skin grafting should be considered if conservative therapy is ineffective.[15]



▲ **FIGURE 26-8** Erosive-ulcerative lichen planus showing erosions, ulcers, and granulation tissue and scarring of toes, interdigital web spaces, and soles.

Erosive to ulcerative lesions of lichen planus are also seen with greater frequency in more severe cases of oral lichen planus. Lesions may involve the buccal mucosa, alveolar epithelium, and sulci, and may extend to the posterior pharynx and laryngeal area. Though rare, erosive esophageal disease may result in dysphagia and stenosis.

Follicular Lichen Planus. Follicular lichen planus may occur alone or in association with other forms of cutaneous or mucosal lichen planus.[16] The term *lichen planopilaris* has been used to describe this distinctive variant, but other terms include *lichen planus follicularis*, *peripilaris*, and *acuminatus*. Individual keratotic follicular papules and studded plaques are seen. Sites of predilection include the trunk and medial aspects of the proximal extremities. Follicular lichen planus may affect the scalp[2] with the development of cicatricial alopecia (see Lichen Planus of the Scalp; Fig. 26-9). The triad of follicular lichen planus of skin (lichen planus spinulosus) and/or scalp, multifocal cicatricial alopecia of the scalp, and nonscarring alopecia of the axillary and pubic areas, has been described as Graham-Little-Piccardi-Lassueur (or Graham-Little-Feldman) syndrome. Sometimes more typical lesions of the skin and nails are seen. Other variants of follicular lichen planus include the pseudopeladic form of Brocq, the lichen planus follicularis tumidus form with oval pseudotumoral plaques of the mastoid area, post-menopausal frontal fibrosing alopecia, and lichen planoporitis, with the lichenoid reaction centered over the acrosyringium and eccrine ducts entering the epidermis.[17]

Lichen Planus Pigmentosus. Lichen planus pigmentosus is characterized by hyperpigmented, dark-brown macules in sun-exposed areas and flexural folds. This entity tends to occur in Latin Americans and other patients with darker-pigmented skin. Histologically, an atrophic epidermis, a vacuolar alteration of the basal cell layer with a scarce lymphohistiocytic lichenoid infiltrate, and pigment incontinence are seen. This variant of lichen planus bears significant similarity to ashy dermatosis or erythema dyschromicum perstans and may represent overlap in the phenotypic spectrum of lichenoid inflammation in darkly pigmented skin, with ethnic and genetic factors influencing the expression of disease (see Chap. 73).[18] There are similar histopathologic findings among these diseases. However, distinct clinical, his-







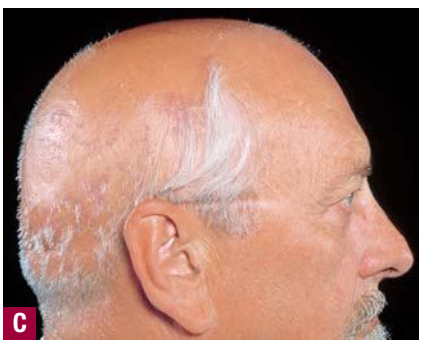

▲ **FIGURE 26-9** Lichen planus. **A.** Irregular patches of alopecia with violaceous papules and coalescing plaque of lichen planus within scalp. **B.** Lichen planopilaris resulting in atrophic, scarred, porcelain-colored area centrally with bordering follicular involvement consisting of dusky erythema, perifollicular hyperkeratosis and scale, and follicular convergence resulting in doll's hair formation. **C.** Extensive hair loss leading to pseudopelade of Brocq appearance. Several remaining tufts of hair showing violaceous erythema and disease activity.

tologic, and immunopathologic differences among these three conditions have been emphasized by some investigators. Erythema dyschromicum perstans may be strongly influenced by environmental agents as well.

The sequela of healing (late waning, resolving) is often slightly atrophic, hyperpigmented skin. In cases where the inflammatory phase was minimal, such as lichen planus "invisible de Gougerot," the pigmentation may be long-lasting and one of the few signs of previously active disease.

Actinic Lichen Planus. Actinic lichen planus is also known as *lichen planus subtropicus, lichen planus tropicus, summertime actinic lichenoid eruption, lichen planus actinicus, lichen planus atrophicus annularis,* and *lichenoid melanodermatosis*. Actinic lichen planus is more common in Middle Eastern countries in spring and summer, where sunlight appears to have a precipitating effect. Exposed areas of the face, dorsal hands and arms, and the nape of the neck are usually affected. Papules are hyperpigmented with violaceous-brown color and a thready, rolled edge showing well-defined borders. Typical lichen planus lesions may be present over the extremities. Pruritus and scaling are minimal.

Other Variants. A perforating variant has been described. Transepidermal elimination of lichen planus–like inflammatory tissue is observed. Guttate lichen planus is another variant that resembles guttate psoriasis but with the characteristic lichenoid histology. Exfoliative and exanthematous forms are very rare and may represent manifestations of lichenoid drug reactions (Fig. 26-10). The rare entity of invisible lichen planus describes lesions that are not perceptible with visible light illumination but become apparent with Wood's lamp examination. Pruritus is present and biopsy evaluation shows lichenoid histology. This entity may be a minimal variant of lichen planus "invisible de Gougerot."

SITE OF INVOLVEMENT ***Lichen Planus of the Scalp.*** Lichen planopilaris or follicular lichen planus may affect the scalp in a distinctive clinical and histologic pattern.[16–18] Individual keratotic follicular papules that coalesce and merge over the scalp to form patches are typically seen. Cutaneous, nail, or mucous membrane involvement with lichen planus may also be present. This condition affects women more than men. Patients present with uni- or multifocal hair loss that may be extensive and involve the entire scalp (see Fig. 26-9). Perifollicular erythema and acuminate keratotic plugs are characteristic features. Follicular-centered lesions are usually observed under close inspection of the scalp and orifices, particularly at the margins of the alopecic area or within patches still bearing hair.

End-stage disease is characterized by a nondescript scarring alopecia that has led to the use of several clinical terms describing the entity: *lichen planopilaris, folliculitis decalvans et atrophicus, lichen spinulosus at follicultis decalvans,* and *Graham-Little syndrome* are different terms that likely describe the same entity.[16]



▲ **FIGURE 26-10** Lichen planus–like eruption. Generalized violaceous papules with superficial scale coalescing to form erythematous variant. History of associated drug exposure leading to lichenoid reaction.

Pseudopelade of Brocq is a rare clinical syndrome of scarring alopecia and fibrosis, in which distinct pathologic features are absent. It is generally accepted that pseudopelade of Brocq is the end stage of follicular fibrosis caused by a primary inflammatory dermatosis such as lichen planus, lupus erythematosus, pustular-scarring forms of folliculitis, or fungal infections, including favus, scleroderma, and sarcoidosis.

Mucosal Lichen Planus. Lichen planus can affect the mucosal surfaces of mouth, vagina, esophagus, conjunctiva, urethra, anus, nose, and larynx. Its prevalence is estimated at approximately 1 percent of the adult population. Oral involvement occurs in approximately 60 percent to 70 percent of patients with lichen planus. It may be the only manifestation in 20 percent to 30 percent of patients.

Different types of oral lichen planus have been described, including reticular, plaque-like, atrophic, papular, erosive-ulcerative, and bullous forms of the disease (see Fig. 26-3).[19] The reticular pattern is considered the most common, but in oral medicine clinics, erosive forms predominate as a consequence of the symptomatology and chronicity. Erosive lichen planus is more common in the elderly and tends to cause a painful, burning sensation. The buccal, gingival, and glossal mucosae are the most commonly affected areas. The palate, floor of the mouth, retromolar pads, and lips may also be affected. Gingival involvement may take the form of gingival stomatitis or desquamative gingivitis, and as a sole presentation, represents 8 percent to 10 percent of oral lichen planus. Oral lichenoid reaction may be seen on the buccal mucosa adjacent to amalgam dental fillings. Patch tests frequently show

positive reactions to mercury, gold, and other metals.[20,21] Because of the prolonged course and associated pain and discomfort, patients with oral lichen planus tend to be depressed, and psychological help should be offered to them.

Bilateral reticular keratotic or atrophic changes of the buccal mucosa and lichenoid atrophic patches over the dorsal tongue have been described in patients with HIV infection. The eruptions usually follow zidovudine or ketoconazole intake. Histologically, liquefaction degradation of basal keratinocytes and epithelial atrophy with lichenoid lymphocytic infiltrate are seen.

Male genitalia are involved in 25 percent of cases, and the glans penis is most commonly affected, with annular lesions frequently present (see Fig. 26-4). Female genital involvement consists of patches of leukoplakia or erythroplakia, sometimes with erosions, and, occasionally, as a more generalized desquamative vaginitis. Vaginal adhesions and labial agglutination may result. Anal lesions of mucosal lichen planus present with leukokeratosis, hyperkeratosis, fissuring, and erosions (Fig. 26-11).

A special form of mucosal lichen planus characterized by involvement of vulvar and gingival tissues has been described.[22] The characteristic features include erythema and erosions of the gingivae and tongue and, occasionally, white reticulated plaques, in association with pain and discomfort. Desquamation and erosions of vulva and vagina in association with burning pain, dyspareunia, and vaginal discharge mirror the oral findings.

Conjunctival lichen planus may manifest as cicatricial conjunctivitis. Histologically, irregular thickening with reduplication of the basement membrane is seen. Direct immunofluorescence distinguishes ophthalmic lichen planus from cicatricial pemphigoid.



▲ **FIGURE 26-11** Lichen planus. Perianal leukoand hyperkeratosis with hypertrophic, folded violaceous epithelium, fissures, and healing biopsy site.

Lichen Planus of the Nails. (See also Chap. 87) Nail involvement occurs in 10 percent to 15 percent of patients.[23] Lichen planus limited to the nails is uncommon, and the initial involvement is followed, in many cases, by the development of typical lesions elsewhere. Lichen planus of nails is infrequent in children. Thinning, longitudinal ridging, and distal splitting of the nail plate (onychoschizia) are the most common findings. Onycholysis, longitudinal striation (onychorrhexis), subungual hyperkeratosis, or even absence (anonychia) of the nail plate can also be seen. Twenty-nail dystrophy (trachyonychia) may represent an isolated nail finding of lichen planus. Psoriasis and alopecia areata can also lead to these distinctive nail changes. Nail loss may result from ulcerative lichen planus involving the nail unit. Pterygium or forward growth of the eponychium with adherence to the proximal nail plate is a classic finding of lichen planus of the nail (Fig. 26-12). An atrophic cicatrizing form of lichen planus with random and progressive nail loss in Asians and blacks has also been reported. The tenting or pup-tent sign is observed as a result of nail bed involvement that elevates the nail plate and may cause longitudinal splitting.[2]

Inverse Lichen Planus. The inverse pattern occurs only rarely and is characterized by red-brownish, discrete papules and nodules. The eruption occurs mainly in the flexural areas such as axillae, inframammary, groin, and, less likely, the popliteal and antecubital areas. koebnerized lesions are occasionally present.

Palmoplantar Lichen Planus. Palmoplantar lichen planus, an acral, localized variant, is rare and may create difficulty in diagnosis if it is present as an isolated finding. Very pruriginous, erythematous, scaly plaques with or without hyperkeratosis are characteristic. Lesions are often seen on the internal plantar arch.[24] Yellowish, compact keratotic papules or papulonodules are seen on the lateral margins of the fingers and hand surfaces; however, they are less likely to affect the fingertips. They appear like callosities with an inflammatory, erythematous halo. The lesions resemble psoriasis vulgaris, warts, calluses, porokeratosis, hyperkeratotic eczema, tinea, or secondary syphilis. Histologically, findings are identical to those of classic lichen planus.[24] Palmoplantar lichen planus may also present as erosive-ulcerative type (see the section Erosive and Ulcerative Lichen Planus).



▲ **FIGURE 26-12** Lichen planus. Classic pterygium formation and tenting of several fingers with loss of nail plates.

SPECIAL FORMS OF LICHEN PLANUS OR LICHENOID ERUPTIONS

Drug-Induced Lichen Planus. Lichen planus–like or lichenoid eruptions describe a group of cutaneous reactions identical or similar to lichen planus (see Fig. 26-10).[25] Lichenoid drug eruptions have been reported after ingestion, contact, or inhalation of certain chemicals (Table 26-1).

A lichenoid drug eruption may be typical or atypical for classic lichen planus, with localized or generalized eczematous papules and plaques and variable desquamation. Lichenoid drug eruptions typically manifest post-inflammatory hyperpigmentation and alopecia, and do not exhibit classic Wickham striae. The eruptions usually appear symmetrically on the trunk and extremities, unlike the flexural distribution of classic lichen planus. A photodistributed pattern is often found, and several drugs frequently induce this reaction. Mucous membrane involvement is less common and is often associated with specific drugs and chemicals.

The latency period for development of a lichenoid drug eruption by these agents varies from months to a year or more based on the dosage, host response, previous exposure, and concomitant drug administration. Resolution of the eruptions is quite variable, but most disappear in 3 to 4 months. Resolution of a gold-induced lichenoid eruption may require up to 2 years after discontinuation of the drug. For many inciting drugs, the severity and extent of the eruption influences the rate of clearance. Occasionally, the lichenoid drug eruption disappears or may recur intermittently despite continuation of treatment.

Lichenoid contact dermatitis may result from contact with compounds such as color film developers, dental restoration materials, metals (e.g., mercury, silver, and gold), and aminoglycoside antibiotics.[25] Oral lichenoid drug eruptions





TABLE 26-1
Agents Inducing Lichen Planus and Lichenoid Reactions

Common inducers
- Gold salts
- β blockers
- Antimalarials
- Thiazide diuretics
- Furosemide
- Spironolactone
- Penicillamine

Less common
- ACE inhibitors
- Calcium channel blockers
- Sulfonylurea
- Nonsteroidal anti-inflammatory drugs
- Ketoconazole
- Tetracycline
- Phenothiazine
- Sulfasalazine
- Carbamazepine
- Lithium
- Antituberculosis
- Iodides
- Radiocontrast media
- Methyldopa (Aldoclor)
- Heavy metals

Inducers of lichen planus by contact
- Color film developers
- Dental restorative materials
- Musk ambrette
- Nickle
- Gold

Inducers of photodistributed lichenoid eruption
- 5-Fluorouracil (Efudex)
- Carbamazepine (Tegretol)
- Chlorpromazine (Compazine, Thorazine)
- Diazoxide (Proglycem)
- Ethambutol
- Pyritinol
- Quinine
- Quinidine (Quinaglute)
- Tetracycline
- Thiazide
- Furosemide (Lasix)

Inducers of oral lichen planus and lichenoid eruption
- Allopurinol (Zyloprim)
- ACE inhibitors
- Cyanamide
- Dental restorative materials
- Gold salts
- Ketoconazole (Ketoconazole)
- Nonsteroidal anti-inflammatory drugs
- Penicillamines (Cuprimine)
- Sulphonylurea

ACE = angiotensin-converting enzyme.

related to amalgam seem to be caused by mercury, although gold may be the more common metal sensitizer in oral lichenoid eruptions.

Lichen Planus–Lupus Erythematosus Overlap Syndrome. Lichen planus–lupus erythematosus overlap syndrome, a rare variant, is characterized by lesions that share features of lichen planus and lupus erythematosus. Atrophic plaques and patches with hypopigmentation and a livid red to blue-violet color with telangiectasia and minimal scaling are characteristic. Transient bullae may develop. Classic lesions of lichen planus are not usually seen. Photosensitivity, pruritus, and follicular plugging are also not common. Lesions may develop anywhere, but are most common on the extremities (Fig. 26-13). Some patients with this overlap syndrome may progress to systemic lupus erythematosus. In other instances, laboratory evaluation may reveal only a weak-positive antinuclear antibody. This disease variant is characterized by a prolonged course and lack of response to treatment. Histologically, a lichenoid reaction typical for lichen planus and histologic features of lupus erythematosus are usually present in the same biopsy.[26] By direct immunofluorescence, the most common finding is the presence of cytoid bodies staining with IgG, IgM, and C3 intraepidermally or at the dermal-epidermal junction, as seen in classic lichen planus. Linear to granular deposition of IgM and C3 (as seen in lupus erythematosus, but not in lichen planus) has been observed occasionally. Shaggy deposition of fibrinogen at the basement membrane zone, typical of lichen planus, is sometimes found.[26]

Lichen Planus Pemphigoides. Lichen planus pemphigoides is characterized by the development of tense blisters atop lesions of lichen planus or the development of vesicles de novo on uninvolved skin (Fig. 26-14). It is important to differentiate this entity from bullous lichen planus, in which blisters develop in lesions of long-standing lichen planus as a result of intense lichenoid inflammation and extensive liquefaction degeneration of basal keratinocytes. The etiology of this variant is not clear. It was proposed that basal cell keratinocyte damage by lymphocytes in lichen planus may unmask hidden antigenic determinants and lead to autoantibody formation and induction of bullous lesions. Histologic findings resemble those of lichen planus. Direct immunofluorescence shows linear deposition of IgG and C3 at the dermal-epidermal junction. Sera from these patients react with the epidermal side of NaCl-split human skin. Circulating IgG autoantibodies react to the major noncollagenous extracellular domain (NC16A) of the 180-kd bullous pemphigoid antigen within the basement membrane zone. Further mapping showed that lichen planus pemphigoides serum reacts with amino acids 46 to 59 of domain NC16A, a protein segment that was previously



▲ **FIGURE 26-13** Lichen planus–lupus erythematosus overlap syndrome. Lichenoid lesions involving dorsal hand and forearm with direct immunofluorescence evidence of lupus erythematous.



▲ **FIGURE 26-14** Lichen planus pemphigoides. Lichenoid maculopapular erythema, erosions, and bullae with direct immunofluorescence showing features of bullous pemphigoid. Indirect immunofluorescence also was positive.

shown to be unreactive with bullous pemphigoid sera. This newly described epitope is designated *MCW-4*.[27]

Keratosis Lichenoides Chronica (Nekam Disease)

Lichenoid Reaction of Graft-Versus-Host Disease. (see Chap. 28) Chronic graft-versus-host disease (GVHD) (occurring 100 days after transplant) may present as a lichenoid eruption indistinguishable clinically and histologically from lichen planus. Lichenoid GVHD favors the trunk, buttocks, hips, thighs, palms, and soles. In oral mucosa, xerostomia and oral ulcerations are occasionally seen. Histologically, the findings in lichen planus and oral GVHD are similar, although infiltrating $CD3^+$ T lymphocytes are present in larger numbers in oral lichen planus than in lichenoid lesions of oral GVHD.[29] In a comparative study between those two entities, the number of natural killer cells, Leu-8–positive T cells (homing receptor: CD62L, LECAM), CD25-positive lymphocytes, and the CD4:CD8 ratio were not different. Langerhans cells are often increased in both conditions.

Lichenoid Keratosis. Lichenoid keratoses are brown to red, scaling maculopapules found on sun-exposed skin of extremities. Histologic features of lichen planus are present, with the additional finding of focal parakeratosis. They frequently occur with solar lentigo, seborrheic keratosis, and actinic keratosis and likely represent an "involuting lichenoid plaque."[30]

Lichenoid Dermatitis

Related Findings

Lichen planus is seen with increased frequency in association with liver diseases such as autoimmune chronic active hepatitis, primary biliary cirrhosis, and postviral chronic active hepatitis.[32] The association with primary biliary cirrhosis is observed regardless of treatment with D-penicillamine, a drug that may cause an exacerbation of lichen planus.

The role of infection in development of lichen planus has been repeatedly raised over the years. Association of lichen planus with syphilis, herpes simplex virus 2, HIV, amebiasis, and chronic bladder infections has been reported.[2] HCV has also been implicated in triggering lichen planus.[7] The prevalence of HCV infection varied between 16 percent and 29 percent in southern European patients with lichen planus.[33,34] On the other hand, many studies from northern Europe and the United States did not substantiate any link.[35,36] Genetic factors controlling disease susceptibility and prevalence of certain HCV genotypes in certain geographic areas may have significantly influenced these results.

Recently, several reports described lichen planus–like eruptions after hepatitis B vaccination.[37]

There is no evidence to link lichen planus to diabetes mellitus, autoimmune diseases, or internal malignancies. Cases of severe erosive gingivitis and stomatitis with histologic appearance of lichen planus in association with internal malignancies may represent cases of paraneoplastic pemphigus (see Chap. 53). The pathologic spectrum of findings and target organ involvement in this condition is broad, ranging from lichenoid dermatitis to frank acantholysis, such that a preferred term is *paraneoplastic autoimmune multiorgan syndrome*.[38]

Lichen Planus and Malignant Transformation

There has been considerable controversy as to whether oral lichen planus inherently harbors malignant potential.[39] It is currently believed that the risk of malignant transformation is fairly low (Fig. 26-15). Risk factors that increase the likelihood of developing oral cancer are long-standing disease, erosive or atrophic types, and tobacco use. It is generally accepted that 0.5 percent to 5.0 percent of patients with oral lichen planus develop SCC. The majority of these cases are in situ carcinoma or with microinvasive pattern. The most common site for malignant transformation is the tongue, followed by buccal mucosa, gingiva, and, rarely, the lip. Clinically, the lesions appear as indurated, non-healing ulcers or exophytic lesions with a keratotic surface in the majority of cases. Red atrophic plaques could also be seen and often correlate with SCC in situ. Advanced cases could result in nodal metastases and occasionally death.[39]



▲ **FIGURE 26-15** Lichen planus and squamous cell carcinoma. Long-standing oral lichen planus with scarring changes of tongue. Circumscribed erythroplakia and erosions of the right lateral tongue was biopsied and confirmed squamous cell carcinoma.

The risk of skin malignancy in cutaneous lichen planus is extremely low. Most patients developing SCC in cutaneous lichen planus had a history of either arsenic or x-ray exposure.

Laboratory Tests

No specific abnormalities of laboratory analyses are seen in lichen planus. The total white blood cell count and lymphocytes may be decreased. This could be related to cytokine activation and local trafficking of cells to skin or other tissue compartments.

Patch tests in patients with oral or cutaneous lichen planus usually reveal positive results in a majority of patients.[5] Sensitivity to mercury and gold is often positive in one-half of the cases. Chromate, flavoring agents, acrylate, and thimerosal are common sensitizers.[20,21]

Pathology

The two major pathologic findings in lichen planus are basal epidermal keratinocyte damage and lichenoid-interface lymphocytic reaction. The epidermal changes include hyperkeratosis, wedge-shaped areas of hypergranulosis, and elongation of rete ridges that resemble a sawtooth pattern (Fig. 26-16). Multiple apoptotic cells or colloid-hyaline (Civatte) bodies are seen at the dermal-epidermal junction. Eosinophilic colloid bodies are present in the papillary dermis. They are periodic acid-Schiff–positive and measure approximately 20 μm in diameter. A band-like lymphocytic infiltrate is seen in the papillary dermis that abuts the epidermis. Many histiocytes and few plasma cells are seen. Plasma cells are more prominent in mucous membrane specimens. Few eosinophils are seen in drug-induced lichen planus or lichenoid drug eruptions. Melanin pigmentation is invariably present and is more pronounced in older, waning lesions and in dark-skinned individuals. Separation of the epidermis in small clefts (Max Joseph cleft formation) is occasionally seen (Fig. 26-17).



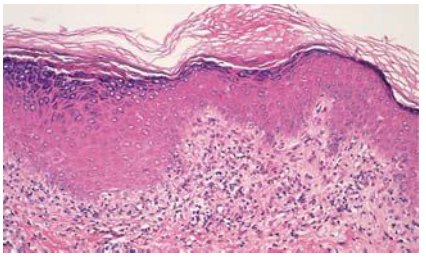

▲ **FIGURE 26-16** Lichen planus. Typical hyperkeratosis, hypergranulosis, early sawtooth changes, and lichenoid interface reaction of classic lichen planus.



Direct immunofluorescence shows numerous apoptotic cells at the dermal-epidermal junction staining with IgM and, occasionally, with IgG and IgA. Shaggy deposition of fibrinogen at the dermal-epidermal junction is characteristic of lichen planus (Fig. 26-18). Immunocytochemical studies show that the majority of the cells in the infiltrate are T lymphocytes, with scattered B lymphocytes. An increased density of Langerhans cells, dermal dendritic cells, and histiocytes have also been seen, especially in early active lesions.

Features that may be seen in lichenoid drug eruptions, but not in lichen planus, include the presence of abundant plasma cells and eosinophils in the infiltrate, focal parakeratosis and hypogranulosis, and the presence of cytoid bodies high in the stratum corneum. Furthermore, lymphocytic infiltration is less dense and not as band-like as that seen in classic lichen planus.

The differential diagnosis of lichen planus is shown in Boxes 26-1 and 26-2.

PROGNOSIS AND CLINICAL COURSE

Lichen planus is an unpredictable disease that typically persists for 1 to 2 years, but which may follow a chronic, relapsing course over many years. The duration varies according to the extent and site of involvement and morphology of lesions. Generalized eruptions tend to have a rapid course and heal spontaneously faster than limited cutaneous disease. Lichen planopilaris is one of the most chronic and often progressive disease variants with little potential for hair regrowth after follicular inflammation and destruction.[16] Hypertrophic lichen planus typically follows a protracted, unremitting course.[2] Spontaneous regression is also an uncommon feature of oral lichen planus. The mean duration for oral lichen planus is 5 years. The reticular variant has a better prognosis than erosive disease that does not heal spontaneously. Generally, the duration of disease conforms to the following order, from shortest duration to longest duration: (1) generalized, (2) cutaneous, (3) cutaneous + mucous membrane, (4) mucous membrane, and (5) hypertrophic = lichen planopilaris.

Relapse of disease occurs in 15 percent to 20 percent of cases and tends to occur in the same area as the initial episode. Recurrences are more common in generalized lichen planus and are usually of shorter duration.

Malignant transformation may occur, and SCC usually develops in fewer than 1 percent of persistent oral-mucous lesions on long-term follow-up.[41]

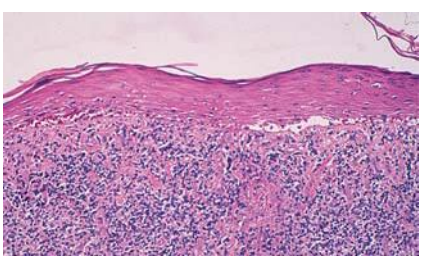

▲ **FIGURE 26-17** Lichen planus. More extensive epidermal alterations with hydropic changes, thinned epidermis, focal wedge-shaped hypergranulosis, compact orthokeratosis, and pronounced lichenoid inflammation with focal hemorrhage.

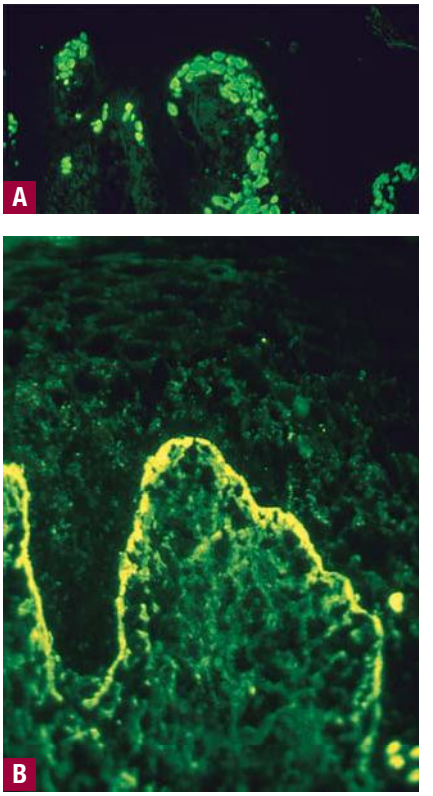

▲ **FIGURE 26-18** Lichen planus. Direct immunofluorescence examination of involved skin. **A.** Numerous immunoglobulin M–positive cytoids at the dermal-epidermal junction. **B.** Fibrinogen/fibrin, shaggy pattern at the dermal-epidermal junction.

Box 26-1

Differential Diagnosis of Lichen Planus

Classic	Psoriasis
	Drug eruption
	Lichen simplex chronicus
Annular	Granuloma annulare
	Tinea
Linear	Nevus unius lateris
	Lichen striatus
	Linear epidermal nevus
Hypertrophic	Lichen simplex chronicus
	Prurigo nodularis
	Lichenoid cutaneous amyloidosis
	Kaposi sarcoma
Atrophic	Lichen sclerosus
Follicular	Lichen nitidus
	Lichen spinulosus
Childhood	Lichen nitidus
	Lichen striatus
	Pityriasis lichenoides
	Papular acrodermatitis of childhood

Box 26-2

Differential Diagnosis of Site-Specific Lichen Planus

Nail	Psoriasis
	Onychomycosis
	Alopecia areata
Genital	Psoriasis
	Seborrheic dermatitis
Palms and soles	Secondary syphilis
Lichen planopilaris	Cicatricial alopecia
	Lupus erythematosus
	Inflammatory folliculitis
	Alopecia areata
	Cicatricial pemphigoid
	Keratosis follicularis spinulosa decalvans
Mucosal	Paraneoplastic pemphigus
	Candidiasis
	Lupus erythematosus
	Leukokeratosis
	Secondary syphilis
	Traumatic patches

TREATMENT

Management of lichen planus can be challenging and discouraging for both the patient and physician. Lichen planus may be associated with only minor symptoms or may cause considerable

Box 26-3

Treatment for Oral Lichen Planus

	TOPICAL		PHYSICAL	SYSTEMIC	
First line	Topical steroids	4–6 times daily		Anti-candidal systemic steroids	30–80 mg/day
	Lidocaine	prn		Etretinate	75 mg/day
	Intralesional steroids	5–40 mg/mL		Acitretin	30 mg/day
	Tretinoin gel	2/day		Isotretinoin	20–40 mg/day
	Isotretinoin gel	2/day			
	Tacrolimus (Protopic)	1–4/day			
	Pimecrolimus (Elidel)	1–4/day			
Second line	Cyclosporine mouthwash	2–4 daily	Extracorporeal photochemotherapy[a]	Cyclosporine	3–10 mg/kg/day
			Photodynamic therapy[a]	Griseofulvin	200–400 mg/day
				Hydroxychloroquine	50–200 mg/day
				Thalidomide	Variable
				Azathioprine, cyclophosphamide, mycophenolate, mofetil	Variable

[a]Experimental.

discomfort and disability. Hence, treatment options should be assessed for attendant risks and benefits and tailored to the extent and severity of disease. Avoidance of exacerbating drugs, unless necessary, and minimizing trauma to skin and mucosal tissues are routinely recommended.

Various drugs have been proposed for the treatment of oral[42–52] and cutaneous lichen planus[53–66] and the majority of these consist of small series of patients or anecdotes. Many of the advocated treatments lack conclusive evidence for efficacy.[67]

Oral Lichen Planus (Box 26-3)

GENERAL MEASURES For oral lichen planus, good oral hygiene and regular personal and professional dental care need to be encouraged. Several treatment approaches are useful for oral or mucous membrane lichen planus. Replacement of amalgam or gold dental restorations with composite material is frequently of considerable benefit in patients with oral lichenoid reactions, even in the apparent absence of relevant patch test results. Chronic lesions on the buccal mucosa in contact with metal or other contact sensitizers frequently heal promptly after replacement,[20,21] and, occasionally, lesions at sites distant to oral lesions may also clear after removal of metal restorations. Gingival lesions may respond less favorably. The decision to undergo removal and restoration is often difficult and usually depends on the chronicity, severity, and clinical and patch test evidence for involvement by the metal/prosthesis as well as the level of frustration of the patient.

Topical Steroids. Topical steroids are the first-line therapy in mucosal lichen planus.[44] A variety of topical glucocorticoids have been shown to be effective. Use of occlusive materials suitable for mucous membranes, such as Orabase, may provide protection and sustained tissue contact with the glucocorticoid, as well as alleviate the discomfort associated with erosive lesions. Fluocinonide in an adhesive gel or base, 0.1% fluocinolone acetonide, and 0.05% clobetasol propionate in Orabase showed good results. Application four to six times/day is recommended. Treatment may be complicated by frequent infections with oral candidiasis. The use of chlorhexidine gluconate mouthwashes and topical anti-candidal medications is recommended during therapy.

In some situations where secondary irritation and inflammation of oral tissues appear to be related to colonization of the mouth by candida, an antifungal treatment course (troche or oral) may be indicated.

Topical anesthetics also provide symptomatic benefit for patients with difficulty eating and chewing. It is often compounded with topical corticosteroids. Glucocorticoids containing vaginal and rectal suppositories are usually helpful for mucosal involvement in these areas.

Glucocorticoids can be administered by intralesional injection. Triamcinolone acetonide 40 mg/mL or at diluted concentrations if effective and safe.[68]

SYSTEMIC GLUCOCORTICOIDS. Systemic glucocorticoids provide effectiveness in erosive oral and vulvovaginal lichen planus. Systemic dosing can be used alone, or, more commonly, in conjunction with topical glucocorticoids. A dose range from 30 to 80 mg/day, tapered over 3 to 6 weeks, shows benefit. Relapses are common after dose reduction or discontinuation. Higher doses are often needed for esophageal lichen planus. Oral candidiasis is a common complication.

RETINOIDS. Topical retinoic acid (tretinoin gel) has been shown to be effective in erosive as well as plaque-like oral lesions. Irritation often makes this localized approach to therapy less attractive. Isotretinoin gel is also effective, especially in nonerosive oral lesions. Improvement is usually noted after 2 months; however, recurrence is common after discontinuation of therapy.[69] Topical retinoids are often used in conjunction with topical glucocorticoids. Although not proven in clinical trials, this may improve the efficacy and lessen the side effects.

Etretinate orally has been used at 75 mg/day (0.6 to 1.0 mg/kg/day) in erosive oral lichen planus with significant improvement in the majority of patients. Relapses are common after discontinuation of medication.[45] Two-thirds of patients showed marked improvement or complete remission within 8 weeks of instituting acitretin, 30 mg/day.[46] Only the aromatic retinoid acitretin is currently available by prescription after the removal of etretinate from the U.S. market. There is no conclusive data on the efficacy of oral tretinoin or isotretinoin.

CYCLOSPORINE, TACROLIMUS, AND PIMECROLIMUS. Topical application of cyclosporine, 100 mg/mL, 5 mL three times daily has shown benefit for oral li-



Box 26-4

Treatment for Cutaneous Lichen Planus

	TOPICAL		PHYSICAL	SYSTEMIC	
First line	Topical steroids	1–2/day	Psoralen and ultraviolet A light	Systemic steroids	30–80 mg/day
	Intralesional steroids	5–20 mg/mL		Etretinate	10–75 mg/day
	Tacrolimus	Variable		Acitretin	30 mg/day
	Pimecrolimus	Variable		Isotretinoin	20–40 mg/day
Second line				Cyclosporine	3–10 mg/kg/day
				Dapsone	200 mg/day
				Hydroxychloroquine	200–400 mg/day
				Azathioprine mycophenolate mofetil	1500 mg bid
Special forms				Doxycycline, tetracycline, and nicotinamide	Lichen planus pemphigoides
				Interferon-α 2b	Generalized
				Metronidazole	Generalized
				Cyclophosphamide	Refractory lichen planus
				Methotrexate	Refractory lichen planus



chen planus. Application modalities include mouthwashes and manual administration with local massage. Topical cyclosporine washes seem to be effective in oral lichen planus, especially the severe erosive forms,[47] but they do not appear to be better than local glucocorticoid therapy. Lack of effectiveness in a few cases[48] and the high cost of this medication, as well as the lack of a commercial formulation for topical application limit its use. Availability of alternate topical immunosuppressive agents, tacrolimus and pimecrolimus, currently provides useful substitutes to topical cyclosporine.[70–72] Tacrolimus, a member of the immunosuppressive macrolide family that suppresses T-cell activation is effective in erosive mucosal disease, providing rapid relief from pain and burning with minimal side effects.[49] Oral cyclosporine at dose regimens of 3 to 10 mg/kg/day has been used for severe ulcerative disease.

Miscellaneous. The polyene antifungal griseofulvin lacks clear effectiveness. Newer antifungal agents (e.g., fluconazole, itraconazole) may be useful in oral lichen planus with evidence of candida overgrowth, especially concomitantly with systemic glucocorticoids.

Hydroxychloroquine at 200 to 400 mg/day for at least 6 months is also used cautiously because antimalarials are implicated as possible inducers of lichen planus.[50]

Thalidomide should be reserved for cases recalcitrant to other remedies. The dose could be started at 50 mg/day and increased gradually to 200 mg/day.[51]

Dapsone can be used orally at 100 to 200 mg daily and has proved effective in two-thirds of patients with cutaneous and oral disease.

Extracorporeal photochemotherapy twice a week for 3 weeks and then tapered has had favorable results.[52] Other experimental therapies include efalizumab,[73] alefacept,[74] and even low-dose excimer 308-nm laser[75] and photodynamic therapy.[76] Azathioprine, cyclophosphamide, and mycophenolate mofetil have shown benefit in oral lichen planus, but randomized clinical trials are lacking.

Cutaneous Lichen Planus (Box 26-4)

TOPICAL GLUCOCORTICOIDS A large variety of topical and systemic therapies are available for the treatment of cutaneous lichen planus, and this range of options may be attributed to the chronicity, symptomatology, and variable responsiveness of the dermatosis. Topical glucocorticoids are typically used for limited cutaneous disease. Potent topical glucocorticoids, with or without occlusion, are occasionally beneficial in cutaneous lichen planus.

Intralesional triamcinolone acetonide (5 to 10 mg/mL) is effective in treating oral and cutaneous lichen planus. This may also be used in lichen planus of the nails with injection of the proximal nail fold every 4 weeks. Regression of lesions occurs within 3 to 4 months. For hypertrophic lichen planus, higher concentrations of intralesional glucocorticoid (10 to 20 mg/mL) may be required. Regular and close observation should be performed to monitor for any signs of atrophy or localized hypopigmentation that may develop; treatment should be discontinued promptly with development of these complications.

Systemic glucocorticoids are often useful and effective in doses greater than 20 mg/day (e.g., 30 to 80 mg prednisone) for 4 to 6 weeks with subsequent taper over 4 to 6 weeks. Other regimens include prednisone 5 to 10 mg/day for 3 to 5 weeks. Symptoms are often alleviated, and patients in the early stages of evolution or experiencing a flare have marked benefit and attenuation or aborted progression of disease. However, the rate of relapse after termination of therapy is unknown. In lichen planopilaris, potent topical glucocorticoids in conjunction with oral glucocorticoids, 30 to 40 mg/day, for at least 3 months, seems to be successful; however, relapse typically occurs following discontinuation. Long-term, chronic continuation of oral or injected glucocorticoids is contraindicated in most cases because of the high risk of complications.

RETINOIDS The systemic retinoids demonstrate anti-inflammatory activity and have been used in the treatment of lichen planus. Remission and marked improvement was achieved with 30 mg/day of acitretin for 8 weeks.[46] Oral tretinoin is used at 10 to 30 mg/day with marked improvement and mild side effects.[53] Low-dose etretinate (10 to 20 mg/day) use has been associated with complete remission of cutaneous, oral, and nail lichen planus after 4 to 6 months of treatment. Prompt beneficial response was noted with the use of 75 mg/day of etretinate,[54] but side effects of retinoids are dose related and may limit use of higher dose therapeutic regimens.

PHOTOCHEMOTHERAPY Psoralen and ultraviolet A (UVA) light photochemotherapy is usually successful in generalized cutaneous lichen planus. It has been used in conjunction with oral glucocorticoids to hasten the response. Bath psoralen and UVA light therapy

with 50 mg trioxsalen, added to 150 L of water, then exposing the patients to UVA after 10 minutes of bathing gave good results.[55] Recurrence of disease was noted. UVA-1 phototherapy may also benefit more protracted lichen planus.[77] Narrowband UVB is also beneficial in the treatment of disseminated cutaneous lichen planus.[56,78]

IMMUNOSUPPRESIVE AGENTS Systemic cyclosporine has been used successfully in recalcitrant lichen planus.[57] The administered dose can range from 3 to 10 mg/kg/day. Pruritus usually disappears after 1 to 2 weeks. Clearance of the rash is seen in 4 to 6 weeks. Low doses (1.0 to 2.5 mg/kg/day) are probably sufficient to achieve remission. Adverse effects on renal function, development of hypertension, and other significant side effects, as well as relapse after discontinuation of the drug, limit its use to severe cases.[58]

Azathioprine is useful in recalcitrant, generalized cutaneous lichen planus and in lichen planus pemphigoides.[59] Similar results are seen with mycophenolate mofetil at a dose of 1500 mg twice daily.[60]

MISCELLANEOUS Antimalarials, especially hydroxychloroquine at 200 to 400 mg/day, have been reported to be particularly useful in actinic lichen planus.[61]

IFN-α2b has been administered for treatment of generalized lichen planus with improvement, but this biologic response modifier also has been implicated in development or exacerbation of lichen planus.[62]

Thalidomide can be used in lichen planus unresponsive to other therapies.[63] Oral metronidazole 500 mg twice daily for 1 to 2 months also reportedly clears the majority of cases of generalized lichen planus.[64]

Based on the benefit in bullous pemphigoid, combination therapy with tetracycline or doxycycline and nicotinamide has been reported as useful in the treatment of lichen planus pemphigoides.[65]

Low molecular weight heparin in low doses has lymphoid antiproliferative and immunomodulatory properties.[66,79] At a dose of 3 mg weekly, heparin injections have been reported to significantly improve the symptoms of pruritus and activity of the disease. Four to six injections of heparin induced complete regression of lesions within 4 to 10 weeks. Cutaneous involvement and reticulated oral lesions had the best response. Oral lichen planus showed minimal improvement with this regimen.

Skin grafting has been beneficial in the management of ulcerative lichen planus of the feet that is recalcitrant to other treatments. Cyclophosphamide, methotrexate, and phenytoin reportedly are useful but should be reserved for cases refractory to less toxic drugs.

KEY REFERENCES

The full reference list for all chapters is available at www.digm7.com.

2. Boyd AS, Nelder KH: Lichen planus. *J Am Acad Dermatol* **25**:593, 1991
5. Sugerman PB et al: Oral lichen planus. *Clin Dermatol* **18**:533, 2000
16. Mehregan DA et al: Lichen planopilaris: clinical and pathologic study of forty-five patients. *J Am Acad Dermatol* **27**:935, 1992
19. Silverman S, Bahl S: Oral lichen planus update: Clinical characteristics, treatment responses, and malignant transformation. *Am J Dent* **10**:259, 1997
20. Rogers RS III, et al. Lichenoid contact stomatitis: is inorganic mercury the culprit? *Arch Dermatol* **140**:1524, 2004
25. Ellgehausen P et al: Drug-induced lichen planus. Clin Dermatol **16**:325, 1998
32. Palekar NA et al: Extrahepatic manifestations of hepatitis C. *South Med J* **98**:1019, 2005
41. Eisen D: The clinical features, malignant potential, and systemic associations of oral lichen planus: a study of 723 patients. *J Am Acad Dermatol* **46**:207, 2002
42. McCreary CE, McCartan BE: Clinical management of oral lichen planus. *Br J Oral Maxillofac Surg* **37**:338, 2001
43. Popovsky JL, Camisa C: New and emerging therapies for diseases of the oral cavity. *Dermatol Clin* **18**:113, 2000
44. Lozada-Nur F, Miranda C: Oral lichen planus: topical and systemic therapy. *Semin Cutan Med Surg* **16**:295, 1997
56. Habib F et al: Narrow band UVB phototherapy in the treatment of widespread lichen planus. *Ann Dermatol Venereol* **132**:17, 2005
67. Zakrzewska JM et al: A systematic review of placebo-controlled randomized clinical trials of treatments used in oral lichen planus. *Br J Dermatol* **153**:336, 2005
68. Xia J et al: Short term clinical evaluation of intralesional triamcinolone acetonide injection for ulcerative oral lichen planus. *J Oral Pathol Med* **35**:327, 2006
70. Byrd JA et al: Response of oral lichen planus to topical tacrolimus in 37 patients. *Arch Dermatol* **140**:1508, 2004



CHAPTER 27

Lichen Nitidus

Mark R. Pittelkow
Mazen S. Daoud

Lichen nitidus (Latin nitidus, "shiny" or "glistening") is an uncommon, usually asymptomatic cutaneous eruption first described by Felix Pinkus in 1901 and further characterized by him in 1907.[1,2] The dermatosis consists of small, glistening, flesh-colored to pink or reddish-brown papules that may be limited to the penis, genitalia, abdomen, and extremities or, less frequently, may occur as a generalized condition. The histopathologic findings are characteristic. Although the condition is often chronic, the prognosis is good, and no clearly associated systemic illnesses have been documented.

EPIDEMIOLOGY

Because the disease is uncommon, accurate epidemiologic characteristics of lichen nitidus have not yet been defined. Lichen nitidus is a dermatosis that occurs infrequently and has been reported to affect blacks more than Caucasians, although no strong predisposition for any race is clearly evident. Perhaps the relative prominence of pale lesions on dark skin accounts for the reported increased incidence in blacks. A predilection for children, young adults, and males has also been reported, but, again, these data are not well established. The incidence is estimated to be approximately 3.4 cases/10,000 population, based on a 25-year survey of skin diseases in African Americans.[3] Compared to the more common lichen planus, the crude ratio of lichen nitidus to lichen planus is 1.7:100, based on pathologic diagnosis of cases evaluated over several decades at the Mayo Clinic.

ETIOLOGY AND PATHOGENESIS

Once considered a tuberculoid reaction, lichen nitidus is currently regarded as a disorder of unknown etiology. The relationship between lichen nitidus and lichen planus has been debated for many

LICHEN NITIDUS AT A GLANCE


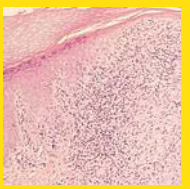

- Small, glistening, flesh-colored to pink or reddish-brown papules of unknown etiology.
- Distinctive, circumscribed infiltrate of lymphocytes and histiocytes in papillary dermis situated directly beneath thinned epidermis.
- There is no associated systemic disease.
- Prognosis is good.



TABLE 27-1
Comparison of Features between Lichen Nitidus and Lichen Planus

	Lichen Nitidus	Lichen Planus
Incidence	Rare	Common
Lesion		
Size	Usually 1–2 mm	Variable, usually larger
Shape	Round	Polygonal
Color	Flesh, pink, red-brown	Erythematous to violaceous
Wickham striae	Absent	Present
Mucosal changes	Rare	Variably present
Pruritus	Uncommon	Usually present, marked
Histopathology		
Hyperkeratosis	Variable and focal	Usually present
Parakeratosis	Mostly present	Not found
Infiltrate	Focal in one to three papillary bodies	Band-like, extends through many rete ridges
Lymphocytes	Variable	Vast majority of cells
Histiocytes	Variable, almost always present	Almost none
Giant cells	Occasional	None
Dyskeratotic	Occasional	Very common
Immunopathology		
Cytoids	Usually negative	Immunoglobulin M and other conjugates
Basement membrane	Usually negative	Fibrinogen, other conjugates
Immunohistochemistry		
$CD4^+$ lymphocytes	Majority of cells	Majority of cells
$CD68^+$ cells	Common	Uncommon

years.[4] The co-existence of both diseases in some patients and the observation that the discrete, tiny papules of lichen planus are indistinguishable from those of lichen nitidus were used to support the view that lichen nitidus is a variant of lichen planus. However, most experienced clinicians, as well as research studies, favor the separation of these two diseases as distinct entities based on both clinical and immunodermatopathologic differences and the characteristic and distinctive histologic changes. Table 27-1 summarizes some of these differences and similarities. Another etiologic theory of lichen nitidus proposes that an allergen may cause epidermal and dermal antigen-presenting cells (e.g., Langerhans cells) to activate a cell-mediated response, initiate lymphocyte accumulation, and form discrete inflammatory papules. The presence of large numbers of Langerhans cells in the infiltrate supports this theory.[5] Specific cytokines produced by the inflammatory cells influence the immune response and may shift the T lymphocyte response toward the T helper 2 subset that has the potential to produce the superficial dermal granulomas seen in lichen nitidus.[6] Functional impairment in cellular immunity has been reported in generalized lichen nitidus,[7] and lichenoid photoeruptions similar to lichen nitidus were seen in a patient with HIV infection.[8] Rare cases of lichen nitidus associated with atopic dermatitis, Crohn disease, and juvenile chronic arthritis have been reported. Induction of allergic contact dermatitis by topical application of dinitrochlorobenzene in a patient with lichen nitidus cleared the eruption, presumably by altering the cellular immunity, cellular infiltration, and cytokine expression.[6]

A rare familial presentation of lichen nitidus has been reported, although no genetic factors of the disease have been identified.[9]

CLINICAL FINDINGS

Lichen nitidus is composed of multiple, discrete, smooth, flat, round papules. Individual papules are 1 to 2 mm in size, flesh-colored to slightly pink or, in blacks, hypopigmented, with a glistening appearance (Fig. 27-1). Sometimes, minimal scale is present or can be elicited by rubbing the surface of the papules. Occasionally, the papules are grouped and the isomorphic or Koebner phenomenon is observed. Lesions may occur anywhere over the skin surface; however, the most frequent sites of predilection are the flexural surfaces of the arms and the wrists, lower abdomen, breasts, the glans and shaft of the penis, and other areas of the genital region. Rare sites of involvement include mucous membranes, nails, palms, and soles. Rare clinical variants include vesicular, hemorrhagic, spinous follicular, linear, generalized, and actinic types.[10–16]

Palmo-plantar involvement may manifest several morphologic forms. Bilateral hyperkeratosis of palms and soles with erythema, fissuring, and a texture resembling fine sandpaper has been observed.[13,14] Occasionally, minute keratotic spicules on the palmar surfaces or multiple pinpoint papules that extend to the dorsa of the extremities occur (Fig. 27-2). Nail abnormalities usually manifest as longitudinal, beaded ridging, and terminal splitting with or without irregular pitting. Lesions of lichen planus may infrequently be present simultaneously.[17] Lichen nitidus is usually asymptomatic; however, pruritus is occasionally present and sometimes intense. There are no constitutional symptoms or systemic abnormalities associated with the disease. Lichen nitidus has been reported after hepatitis B vaccination.[18]

PATHOLOGY

A dense mass of infiltrating lymphohistiocytic cells is situated immediately below the epidermis and results in widening of the papillary dermis with elongation and the appearance of embracement by neighboring rete ridges (Fig. 27-3). Occasionally, two or three papillary spaces merge together as part of the inflamma-

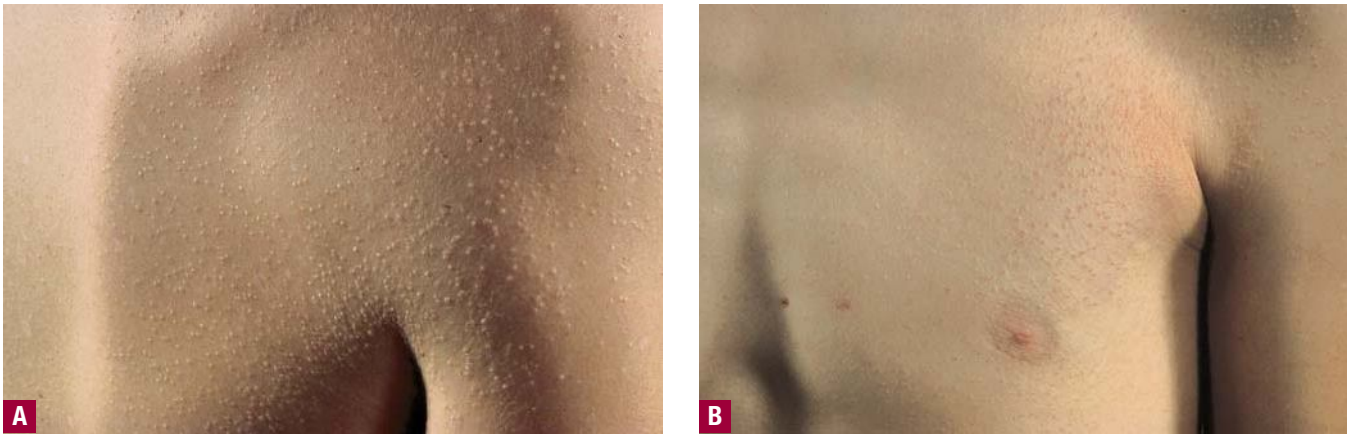

▲ **FIGURE 27-1** Lichen nitidus. **A.** Pinpoint to pinhead, discrete, dome-shaped papules over upper back, shoulder, and arm. Side-lighting, as performed here, enhances visualization of multiple small lesions. **B.** Individual papules, flesh- to pink-colored over chest and arm, becoming more grouped over anterior axilla.



tory infiltrate. The overlying epidermis is thinned and occasionally demonstrates central parakeratosis without hypergranulosis. This is a characteristic diagnostic finding, when observed (see Fig. 27-3B). Minimal hydropic degeneration with few dyskeratotic cells is usually observed within the basal epidermal layer adjacent to the papillary dermal infiltrate. With the development of hydropic degeneration, basal cell disruption, and epidermal thinning, the epidermis may partially detach from the dermis. Colloid bodies are rarely seen in lichen nitidus, in contrast to their frequent occurrence in lichen planus. The dermal infiltrate is well circumscribed and composed of closely associated histiocytes, lymphocytes, and occasional foreign body or Touton-type giant cells. Usually, no plasma cells or eosinophils are seen. In some cases, the majority of the cells in the infiltrate are histiocytic. Palmar lesions may show a deep parakeratotic plug. Transepithelial elimination of the inflammatory infiltrate has been described.[5] Purpuric or hemorrhagic lesions are associated with capillary wall degeneration and red blood cell extravasation.[11]

The majority of the cells in the infiltrate are T lymphocytes intermixed



▲ **FIGURE 27-2** Lichen nitidus. Wrist and palmar involvement with development of hyperkeratotic lesions.

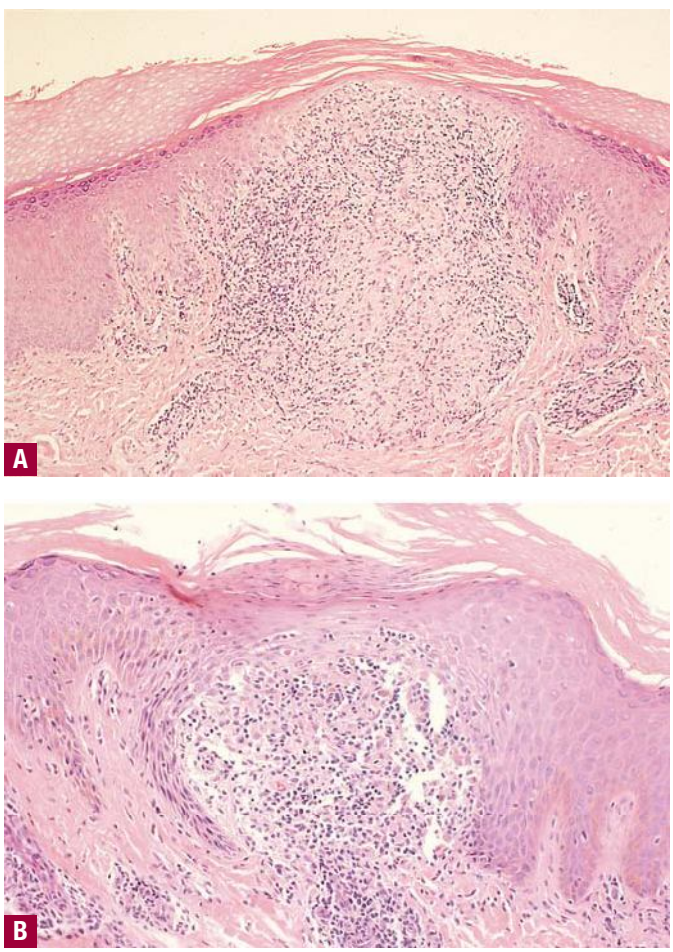

▲ **FIGURE 27-3** Lichen nitidus. **A.** Distinctive, circumscribed infiltrate of papillary dermis situated directly beneath thinned epidermis. Many histiocytes mingle with lymphocytes that are enveloped by bordering rete ridges. (Hematoxylin and eosin.) **B.** Central parakeratosis, epidermal thinning, and loss of granular layer with focus of granuloma-appearing, inflammatory cells and reactive, finger-like extensions of epidermis. (Hematoxylin and eosin.)

with few to many histiocyte–macrophages that stain with CD68, as well as epidermal Langerhans cells and indeterminate cells that express S100 protein. $CD4^+$ cells predominate over $CD8^+$ T lymphocytes. Many cells in the infiltrate express HLA-DR antigen, which implicates them as antigen-presenting cells.[5]

Direct immunofluorescence examination of lichen nitidus is usually negative for deposition of immunoglobulins at the dermal-epidermal junction, in contrast to the vast majority (95 percent) of cases of lichen planus (see Table 27-1).[19] Cytoids are also not usually observed in lichen nitidus. The results of ultrastructural studies coincide with light microscopic findings and also show activated lymphocyte morphology with convoluted nuclei, resembling Sézary cells.[20]



DIFFERENTIAL DIAGNOSIS

Differential diagnosis of lichen nitidus is summarized in Box 27-1. The most important differential diagnosis is lichen planus and is detailed in Table 27-1.

PROGNOSIS AND CLINICAL COURSE

Lichen nitidus is typically a focal, asymptomatic, chronic inflammatory reaction that eventually resolves spontaneously after months to 1 year in two-thirds of patients or, less frequently, over a few years. Rarely, the eruption may persist indefinitely. New lesions may continue to develop as older lesions resolve. Lesions heal without scar formation or pigmentary abnormalities.

Box 27-1

Differential Diagnosis of Lichen Nitidus

Most Likely

- Lichen planus
  - CD8 lymphocytes predominate
  - No granulomatous inflammation
- Psoriasis
  - Plaques has silvery scale
- Verruca plana
  - Variable in size
  - Verrucous surface
  - Fewer lesions than lichen nitidus
  - Less likely to involve multiple anatomic areas
- Keratosis pilaris
  - More keratotic and scaling
  - Hand dermatitis
  - Palmo-plantar involvement of lichen nitidus

Consider

- Lichen spinulosus
- Papular eczema
- Lichen scrofulosorum
- Lichenoid syphilitic lesions
- Bowenoid papulosis
- Sarcoidosis
- Lichen amyloidosus

TREATMENT

Because the disease is asymptomatic and self-limiting, no intervention is required in most cases. Treatment of lichen nitidus is warranted when it is associated with protracted pruritus or when the appearance interferes with the patient's daily activities and outlook. Topical glucocorticoids may yield favorable results. A short course of oral glucocorticoids may also be helpful and hasten resolution of more extensive, generalized, or symptomatic disease.[22] Psoralen and ultraviolet A light,[21] ultraviolet A and B phototherapy,[22] astemizole,[23] acitretin or etretinate,[14,17] low-dose cyclosporine,[24] and oral itraconazole[25] have also been used successfully when indicated for more problematic disease.

Narrowband ultraviolet B could be a safe and effective treatment in generalized lichen nitidus.[26,27] Tacrolimus ointment was also reported to be effective after 1 month of therapy.[28] History of exposure to tuberculosis in the setting of lichen nitidus should be investigated and when appropriate treated with antituberculous medications. Complete clearance of lichen nitidus was seen in one case.[29]

KEY REFERENCES

The full reference list for all chapters is available at www.digm7.com.

4. Smoller BR, Flynn TC: Immunohistochemical examination of lichen nitidus suggests that it is not a localized papular variant of lichen planus. *J Am Acad Dermatol* **27**:232, 1992
5. Wright AL et al: An immunophenotypic study of lichen nitidus. *Clin Exp Dermatol* **15**:273, 1990
14. Lucker GP et al: Treatment of palmoplantar lichen nitidus with acitretin. *Br J Dermatol* **130**:791, 1994
19. Waisman M et al: Immunofluorescent studies in lichen nitidus. *Arch Dermatol* **107**:200, 1973
22. Chen W et al: Generalized lichen nitidus. *J Am Acad Dermatol* **36**:630, 1997
27. Park JH et al: Treatment of generalized lichen nitidus with narrowband ultraviolet *Br J Am Acad Dermatol* **54**:545, 2006

CHAPTER 28

Graft-Versus-Host Disease

Misty T. Sharp
Thomas D. Horn

Dermatologists play an important role in the evaluation and management of patients at risk for or diagnosed with graft-versus-host disease (GVHD). Of all organs that may be affected in GVHD, the skin is the earliest and most frequent target. To evaluate patients optimally, the dermatologist must know the type of marrow transplant, any manipulation of marrow before infusion, the preparative regimen used, the date of marrow infusion, the peripheral white blood cell count, the medications administered, and the course of hospitalization.

The clinical manifestations, histopathologic features, treatment, and pathogenesis of GVHD with emphasis on the skin are considered in this chapter. Table 28-1 provides definitions for several commonly used terms.

ERUPTION OF LYMPHOCYTE RECOVERY

The concept of development of cutaneous eruptions at the time of peripheral recovery of lymphocytes after marrow-ablative therapy unifies all diagnoses considered in this chapter.[4] As defined initially, the eruption of lymphocyte recovery occurred with the earliest return of lymphocytes to the peripheral circulation of patients with acute leukemia who did not receive a marrow transplant.[5] The eruptions consisted of erythematous coalescing macules, predominantly on the trunk and proximal extremities. Skin biopsy specimens revealed non-specific changes, with an upper dermal perivascular infiltrate of lymphocytes and variable epidermal spongiosis but no significant epidermal cell necrosis. An acute elevation in temperature accompanied the cutaneous eruptions. Resolution of the eruption occurred with multi-line hematologic recovery.

GRAFT-VERSUS-HOST DISEASE AT A GLANCE



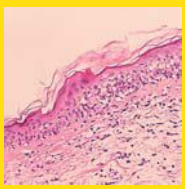

- Acute cutaneous graft-versus-host reaction (GVHR) develops in 20 percent to 80 percent of patients undergoing allogeneic bone marrow transplantation, usually 10 to 30 days after infusion.
- Skin is the earliest and most frequent target. Liver and gastrointestinal disease are also common; the presence of elevated total bilirubin levels and diarrhea can aid in establishing the diagnosis.
- Predisposing factors include mismatch in major histocompatibility complex antigens, transplantation between unrelated individuals, older age, and certain prophylactic regimens, among others.
- The eruptions of acute GVHR consist of faint, erythematous macules on any skin surface, which may begin in a perifollicular pattern (early stages) and progress to erythroderma (later stages) or bullae (stage 4).
- Pathologic features of acute GVHR consist of an infiltrate of lymphocytes in the dermis, basal vacuolar alteration, and necrosis of epidermal cells at a frequency of at least four per linear millimeter of epidermis (grade 2).
- Chronic GVHR generally occurs longer than 60 days after allogeneic marrow transplantation at an incidence of roughly 25 percent; it is divided into lichenoid and sclerodermoid forms.
- Cutaneous eruptions simulating acute allogeneic GVHRs occur after autologous and syngeneic transplantation in up to 10 percent of patients.

This concept of lymphocyte recovery eruption has application to the field of stem cell transplantation, because graft-versus-host reactions (GVHRs) develop at the time of peripheral lymphocyte recovery and represent this phenomenon with immunologic differences between donor and recipient or in the setting of some immunologic manipulation. Indeed, some histologically non-specific cutaneous eruptions among patients at risk for GVHD may represent an eruption of lymphocyte recovery rather than a true GVHR, because acute cutaneous GVHR requires the epidermis to be targeted for cytotoxic damage by an effector lymphocyte population.

EPIDEMIOLOGY AND INCIDENCE

Marrow-ablative regimens vary. Combinations of cyclophosphamide, busulfan, total-body exposure to ionizing radiation, methotrexate, and thiotepa are used. Acute cutaneous GVHR develops in 20 percent to 80 percent of patients, usually 10 to 30 days after stem cell infusion. Factors that predispose to the occurrence of GVHD include mismatch in major histocompatibility complex (MHC) antigens, transplantation between unrelated individuals (Table 28-2), older age, and prophylactic regimen, among others. Patients receive cyclosporine in high doses at the time of stem cell infusion to promote engraftment and prevent maximal expression of GVHD. Other modalities used to diminish the severity of GVHD require the use of various antibodies to remove putative effector cell populations from the graft.

Chronic GVHD is categorized into lichenoid and sclerodermoid forms. The lichenoid phase generally develops earlier than the sclerodermoid phase, and both usually occur longer than 60 days after transplantation. Some patients experience both forms of the disease sequentially or concurrently. The greatest predictor for the development of chronic GVHR is prior acute GVHD.[6] The incidence of chronic cutaneous GVHR is roughly 25 percent. Rare reports of chronic GVHR after autologous transplantations exist.[7]

Cutaneous eruptions simulating acute allogeneic GVHRs occur after autologous and syngeneic transplants in up to 10 percent of patients.[8] Prospective evaluation of eruptions in patients receiving peripheral stem cell transplants has not been undertaken, but mild eruptions do occur at the time of peripheral lymphocyte recovery. The long-term administration of low-dose cyclosporine in the setting of autologous marrow transplantation promotes a graft-versus-host (GVH)–like eruption in roughly 60 percent of patients. Theoretically, cyclosporine, given in low dosage, promotes escape from thymic and peripheral mechanisms regulating expression of self-targeted mechanisms and thus allows expression of autoimmunity.[9] This autoimmunity resembles a mild acute cutaneous allogeneic GVHR. Again with the goal of enhancing graft-versus-tumor effect, protocols exist that add interferon-γ (IFN-γ) and interleukin 2 to cyclosporine regimens. These cytokines support general immunologic reactions and expand T-cell populations, and it is hoped they will prime any graft-versus-tumor effect that may accrue with autologous transplantation. Eruptions in this setting are more common and more severe, leading to erythroderma (stage 3 disease), an otherwise uncommon finding after autologous transplantation.[10]

Whether these eruptions are truly GVHRs as seen after allogeneic transplantation is uncertain. Because autologous marrow and peripheral stem cell transplant programs increasingly are performed outside university centers, dermatologists will encounter these eruptions more frequently. To assess clinical trial outcomes adequately, dermatologists and pathologists in academic centers must assess the occurrence of GVH-like reactions accurately.

ETIOLOGY AND PATHOGENESIS

Acute Cutaneous Graft-Versus-Host Reaction after Allogeneic Stem Cell Transplantation

The precise pathophysiology of GVHD is not known. A distillation of many lines of evidence implicates allostimulation of donor lymphocytes by major and/or minor

TABLE 28-1
Terms and Definitions

TERM	DEFINITION
• Allogeneic	Between two individuals
• Autologous	From the same person
• Syngeneic	Between two individuals with identical genetic material
• Xenograft	Transplanted tissue from another species
• Graft-versus-host disease (GVHD)	The totality of organ dysfunction attributable to the targeting of the recipient's tissues by immunocompetent lymphocytes
• Graft-versus-host reaction (GVHR)	The expression of GVHD in a specific organ (e.g., cutaneous GVHR)
• Stage	A term referring to clinical findings
• Grade	A term referring to histopathologic findings

TABLE 28-2
Overview of Acute Graft-Versus-Host Disease (GVHD) by Type of Transplant

Marrow Transplant	Incidence and Severity of GVHD	Cutaneous Manifestations	Treatment	Histopathology
Allogeneic, matched	++	Erythematous macules and papules, variable distribution; bullae rare	Prednisone FK-506 Anti-thymocyte globulin Monoclonal antibodies	Dermal infiltrate of lymphocytes, more than four necrotic epidermal cells per linear millimeter, sub-epidermal bulla
Allogenic, mismatched	+++	Generally greater distribution and intensity than for allogeneic, matched	Same	Same
Allogenic, unmatched	++++	Generally greater distribution and intensity than for allogeneic, matched	Same	Same
Allogenic, unmatched, unrelated	++++	Generally greater distribution and intensity than for allogeneic, matched	Same	Same
Syngeneic	+	Generally less widely distributed than for allogeneic, matched	Usually none	Fewer lymphocytes, fewer necrotic keratinocytes than for allogeneic, matched
Autologous	+	Generally less widely distributed than for allogeneic, matched	Usually none	Changes resemble eruption of lymphocyte recovery
Autologous with cyclosporine	++	Generally less widely distributed than for allogeneic, matched	Usually none	Fewer lymphocytes, fewer necrotic keratinocytes than for allogeneic, matched
Autologous with cyclosporine and interferon-γ	++	Eruption more widespread, erythroderma more common than for autologous with or without cyclosporine	Prednisone rarely for erythroderma	Spongiosis often a prominent feature with fewer necrotic epidermal cells than for allogenic, matched

+ to ++++ = less common/severe to most common/severe.



transplantation antigens, with subsequent targeting of host tissues, mostly epithelial, for cytotoxic damage. It is unclear whether direct lymphocyte-mediated damage occurs via molecules such as granzyme and perforin, whether cytokines are the main mediators of cell death, or whether both mechanisms are operative.[11] Epithelial cell death ensues by apoptosis, with evidence implicating T cell–mediated mechanisms as well as noncellular triggers.[12,13]

It is unlikely that a specific lymphocyte subset consistently mediates GVHD. Many epitopes on major and minor histocompatibility antigens are likely to promote allostimulation, resulting in numerous populations of effector lymphocytes in target organs. Indeed, several cytotoxic T-cell clones have been isolated and identified from the skin of a single patient.[14] $CD4^+$ and $CD8^+$ cell lines are capable of mediating epidermal damage. In a murine model of GVHD, the effector population mediating the cutaneous GVHR varied with the strains used in the transplant,[15] which suggests that among humans each donor-recipient pair is nearly unique, with the potential to use different lymphocyte subsets in subsequent GVHD. Evidence exists to implicate $CD4^+$ T cells as major mediators of human disease.[16] These considerations are likely to explain the variability of disease expression, irrespective of MHC match or mismatch.

Other cell types are likely involved in mediating GVHD. The presence of numerous natural killer cells in the dermal and epidermal infiltrates of cutaneous GVHRs suggests that these cells are recruited once the antigen-specific recognition phase of the immunologic reaction has occurred in a target tissue.[17] Mast cells and dermal dendrocytes increase in number in the superficial dermis during acute phases of the disease.[18]

Why cutaneous involvement in GVHD is so frequent and early compared with liver and gastrointestinal disease is unknown.

Chronic Cutaneous Graft-Versus-Host Reaction after Allogeneic Stem Cell Transplantation

Chronic GVHD in the skin bears great similarity to various diseases presumed to be autoimmune in origin. Empirical observation suggests the connection between lichen planus, scleroderma, and Sjögren's syndrome with phases of cutaneous GVHR. Improper regulation of autoreactive elements of the immune system is proposed as an explanation for the development of these disorders.[19] Strong evidence links transforming growth factor-β to the development of skin and visceral changes in sclerodermoid GVHD, with neutralizing antibodies capable of reversing the fibrosis in a mouse model.[20] In women with scleroderma, persistent chimerism of male fetal tissue is identified. A fetal antimaternal immunologic reaction is proposed as the GVH-like mechanism mediating the disease.[21] Cutaneous fibroblasts in sclerodermatous skin express MHC class II molecules and make abnormally large amounts of type I collagen.

As the use of peripheral blood stem cell transplantation increases, it is important to note a possible higher associated incidence of chronic GHVD.[22]

Acute Cutaneous Graft-Versus-Host Reaction after Autologous and Syngeneic Marrow and Peripheral Stem Cell Transplantation

In rodents and humans, evidence exists that autoimmunity is directed against one or more epitopes on the MHC class II molecule.[23] Because IFN-γ upregulates MHC class II expression (ideally on tumor cells), and because cyclosporine promotes MHC class II–reactive T lymphocytes, this therapy combined with the dose intensification of autologous transplants leads to enhanced GVH-like cutaneous reactions and possibly the beneficial graft-versus-tumor effect.





▲ **FIGURE 28-1** Acute cutaneous graft-versus-host reaction (GVHR). Erythematous macules involving the pinna (**A**), palms (**B**), and soles are typical in early stages of cutaneous GVHR after allogeneic and autologous marrow transplantation.



▲ **FIGURE 28-3** Acute cutaneous graft-versus-host reaction (GVHR). Diffuse erythema may evolve in acute cutaneous GVHR and is often faint.

CLINICAL FINDINGS

History

The optimal evaluation of a patient with suspected GVHD should begin with the identification of certain key factors in the patient's history. The type of stem cell transplantation, any manipulation of stem cells before infusion, the preparative regimen used, the date of stem cell infusion, the white blood cell count, any medications administered, and the hospitalization course are all important aspects of the history to consider. Although the most common clinical scenario resulting in an acute cutaneous GVHR is allogeneic stem cell transplantation, an acute cutaneous GVHR may arise after maternal-fetal transfer of lymphocytes[24] as well as after blood transfusion[25] and solid organ transplantation, most commonly of a liver containing numerous immunocompetent lymphocytes.[26]

The presence of any signs indicative of extracutaneous GVHD, such as diarrhea, can be helpful. However, the absence of such signs should not dissuade the clinician from a diagnosis of GVHD given the proclivity for early, isolated skin involvement. These things, coupled with the clinical and histologic findings, as discussed later, can aid the dermatologist in establishing a diagnosis of either acute or chronic GVHD, which facilitates early intervention.

Cutaneous Lesions

ACUTE CUTANEOUS GRAFT-VERSUS-HOST REACTION AFTER ALLOGENEIC TRANSPLANTATION The eruption of an acute GVHR generally begins with faint erythematous macules on any skin surface but often the palms, soles, and pinnae (stage 1) (Fig. 28-1). The specificity of palmoplantar erythema in the diagnosis of a cutaneous GVHR is questionable because chemotherapy alone, in the absence of stem cell support, may cause acral erythema.[27] Edema and tenderness often accompany the erythema regardless of cause. Pruritus is an uncommon complaint. As the acute GVHR evolves, the distribution of erythematous macules increases, and they become confluent over broad surfaces, commonly the upper back (stages 2 to 3). On the trunk, the erythematous macules may be observed in a perifollicular array at a very early stage (Fig. 28-2). At later stages, erythroderma may ensue (Fig. 28-3). Development of bullae (stage 4) portends a poor prognosis. These bullae are sub-epidermal with a necrotic roof and greatly resemble toxic epidermal necrolysis (Fig. 28-4). The staging scheme is detailed in Table 28-3. This progression of acute cutaneous GVHR generally occurs over several weeks. An explosive variant is described in which erythroderma evolves rapidly, with subsequent quick evolution to a lichen planus–like eruption resembling chronic disease.[28] Factors predisposing to this form of acute cutaneous GVHR are not known.

With successful treatment, the eruption resolves with desquamation in the same general progression as its appearance. A brown-gray discoloration of the skin may evolve as a post-inflammatory change with very slow or, in some cases, no resolution.

Differential Diagnosis of Acute Cutaneous Graft-Versus-Host Reaction after Allogeneic Transplantation. The clinical differential diagnosis of acute cutaneous GVHR includes drug hypersensitivity eruption, viral exanthem, transient acantholytic dermatosis, and, in the presence of bullae, toxic epidermal necrolysis. Findings in a



▲ **FIGURE 28-2** Follicular graft-versus-host reaction (GVHR). In some patients, the earliest manifestation of acute cutaneous GVHR is perifollicular erythema, as seen in this photograph at day 15 after marrow transplantation.



▲ **FIGURE 28-4** Stage 4 graft-versus-host reaction showing ruptured bullae, erosions, and crusts resembling toxic epidermal necrolysis.

TABLE 28-3
Clinical Staging Scheme for Acute Cutaneous Graft-Versus-Host Reaction

STAGE	DESCRIPTION
1	Cutaneous eruption involving less than 25% of body surface area
2	Cutaneous eruption involving 25%–50% of body surface area
3	Erythroderma
4	Vesicles and bullae

Adapted from Glucksberg H et al: Clinical manifestations of graft-versus-host disease in human recipients of marrow from HLA-matched sibling donors. *Transplantation* **18**:295, 1974.

skin biopsy specimen may help to differentiate a GVHR from a drug eruption or a viral exanthem. Transient acantholytic dermatosis is an incidental finding in febrile patients receiving antineoplastic chemotherapy, with or without stem cell support.[29] Sampling of more palpable lesions predisposes to obtaining this spurious diagnosis. Confident differentiation between stage 4 acute cutaneous GVHR and toxic epidermal necrolysis generally is not possible, although dermatologists are often asked to try. Affected patients have received numerous medications known to cause toxic epidermal necrolysis, but rational criteria to exclude a GVHR in this setting do not exist.

Histopathology of Acute Cutaneous Graft-Versus-Host Reaction after Allogeneic Transplantation. The changes of an interface dermatitis appear in all phases of a cutaneous GVHR, including chronic sclerodermoid disease. The grading scheme for the histopathologic features of acute cutaneous GVHR is given in Table 28-4. Minimal criteria for the diagnosis include an infiltrate of lymphocytes in the dermis, basal vacuolar alteration, and necrosis of epidermal cells at a frequency of at least four per linear millimeter of epidermis (grade 2).[30] Extension of lymphocytes into the epidermis is common (Fig. 28-5). The direct apposition of a lymphocyte to a necrotic keratinocyte is known as *satellite cell necrosis* and may occur in many types of interface dermatitis in which cell death is mediated by lymphocytes. Some quantitation of necrotic epidermal cells is advised, because changes referable to the preparative regimen clearly include this finding, but numbers are lower than in a GVHR.[30] Other histologic findings attributable to marrow-ablative measures include loss of polarity of keratinocytes, large and bizarrely shaped keratinocytes with unusual mitotic figures, and irregular nuclear forms.[31] This "dysmaturation" should be ignored when seeking to establish the diagnosis of a GVHR because it may prevent adequate assessment of the specimen. Significant infiltration by lymphocytes typically does not accompany changes due to the preparative regimen, provided there is no erosion or ulceration.

TABLE 28-4
Histologic Grading Scheme for Acute Cutaneous Graft-Versus-Host Reaction

GRADE	DESCRIPTION
0	Normal skin or changes not referable to graft-versus-host disease
1	Basal vacuolization of the dermal-epidermal junction
2	Basal vacuolization, necrotic epidermal cells, lymphocytes in the dermis and/or epidermis
3	Sub-epidermal cleft formation plus grade 2 changes
4	Separation of epidermis from dermis plus grade 2 changes

Adapted from Lerner KG et al: Histopathology of graft-versus-host reaction (GVHR) in human recipients of marrow from HLA-matched sibling donors. *Transplantation* **18**:367, 1974.

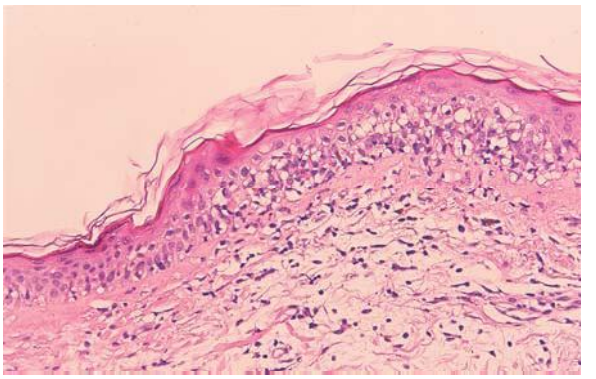

◀ **FIGURE 28-5** Histopathologic features of acute cutaneous graft-versus-host reaction, grade 2. Inflammation of the upper dermis is evident, with extension of lymphocytes into the epidermis and interface change.

Evaluations of the immunologic changes in the skin during acute cutaneous GVHD document upregulation of keratinocyte expression of MHC class II molecules and intercellular adhesion molecule 1. Inflammatory infiltrates contain a mixture of $CD4^+$ (helper/inducer), $CD8^+$ (cytotoxic/suppressor), and $CD56^+$ natural killer cell lymphocytes with extension of all subsets into the epidermis.[33] After the preparatory regimen, the number of Langerhans cells gradually diminishes over 1 to 4 weeks to undetectable levels.[34] Repopulating cells are derived from the donor. In a murine model, Langerhans cell number and function decreased more in animals developing GVHD than in those undergoing the preparative regimen alone.[35]

CHRONIC CUTANEOUS GRAFT-VERSUS-HOST REACTION AFTER ALLOGENEIC TRANSPLANTATION The lichenoid form of GVHD greatly resembles lichen planus, with erythematous to violaceous polygonal, variably keratotic papules arising on flexor surfaces. Subsequent greater distribution occurs in some patients (Fig. 28-6). The lichenoid phase resolves with post-inflammatory hyperpigmentation.

The sclerodermoid phase greatly resembles scleroderma in that variably distributed plaques of thickened skin arise that have a shiny, somewhat atrophic appearance and varied hyperpigmentation and hypopigmentation (Fig. 28-7A). The plaques display erythema and progressive loss of the pilosebaceous apparatus. Some patients develop very few sclerodermoid plaques and do not require therapy. Other patients develop widespread disease associated with joint contractures, chronic cutaneous ischemia with erosion (see Fig. 28-7B), alopecia, and a syndrome of general wasting. Bacterial skin infections recur, consonant with the general immunodeficiency that characterizes chronic GVHD. This immunocompromise pro-



▲ **FIGURE 28-6** Chronic graft-versus-host disease. Violaceous to brownish lichen planus–like, perifollicular papules that are becoming confluent on the trunk, occurring 3 months after allogeneic bone marrow transplantation.





▲ **FIGURE 28-7** **A.** Sclerodermoid graft-versus-host reaction. Shiny bound-down skin with variable pigmentation is evident. **B.** Chronic graft-versus-host disease, sclerodermoid type. There is sclerosis and poikiloderma involving the entire skin. The porcelain white areas reflect sclerosis, the red is massive telangiectasias and erosions, and the brown is residual pigmentation after a lichenoid eruption with which the whole condition started. Sclerosis of the tissue now supervenes and the skin feels bound down on palpation, similar to progressive systemic sclerosis (diffuse systemic scleroderma).

motes sepsis, a common cause of death in these patients.

The sharp separation between the lichenoid and sclerodermoid phases of chronic GVHD is artificial. The two forms of disease clearly overlap in many patients. Furthermore, lichen planus–like forms of GVHD occur soon after transplantation.[36] Because immunomodulation and variability in histocompatibility are likely to result in differing clinical expression of all forms of cutaneous GVHR, rigid adherence to the concept of time as an accurate discriminant of the phases of GVHD may not be appropriate.

Histopathology of Chronic Cutaneous Graft-Versus-Host Reaction after Allogeneic Transplantation. Fully evolved histologic features of lichen planus may occur in lichenoid chronic GVHR. In general, the degree of inflammation is less in GVHR, but acanthosis, orthohyperkeratosis, wedge-shaped hypergranulosis, sharply pointed rete ridges, basal vacuolization, necrotic epidermal cells, and melanophages in the upper dermis characterize the fully evolved lesion (Fig. 28-8A). The only distinction between a lichenoid chronic GVHR and acute GVHR lies in recognition of the lichen planus–like epidermal changes, because

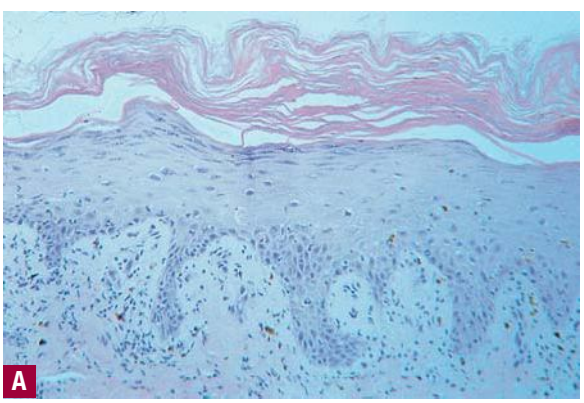

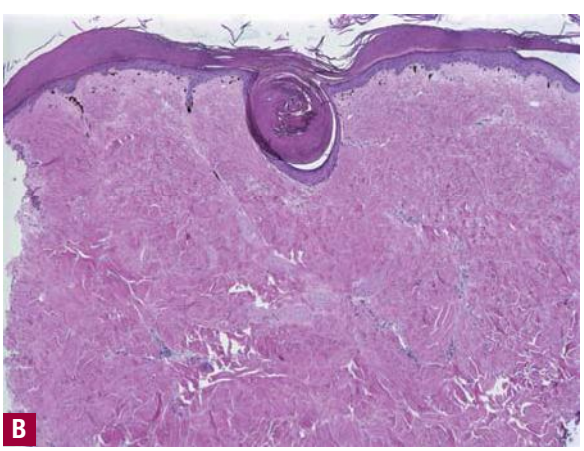

◀ **FIGURE 28-8** **A.** Histopathologic features of lichenoid graft-versus-host reaction (GVHR). Epidermal features of lichen planus are present with acanthosis, hypergranulosis, hyperkeratosis, and pointed rete ridges. The inflammatory infiltrate in the upper dermis is less intense than in the typical case of idiopathic lichen planus. **B.** Histopathologic features of sclerodermoid GVHR. The epidermis shows mild, compact hyperkeratosis and keratotic plugging. There is hyalinization of the collagen throughout the dermis with loss of the appendageal structures.

both entities are considered to represent interface dermatitides.

Sclerodermoid chronic GVHR displays thickened bundles of collagen with loss of interstices, entrapment of eccrine coils, and progressive loss of pilosebaceous units (see Fig. 28-8B). The dermal-epidermal junction is ill defined with basal vacuolization and melanophages. Necrotic epidermal cells are rare. Unlike in scleroderma, the progression of collagen alteration in sclerodermoid GVHR is from the papillary dermis downward.[9] Panniculitis is an uncommon finding.

Mucosal Histopathology of Chronic Cutaneous Graft-Versus-Host Reaction after Allogeneic Transplantation. Specimens of oral mucosa and minor salivary glands may aid in the diagnosis of chronic GVHD.[37] Interface changes along the epithelium may occur, but generally without associated acanthosis and other epidermal features of lichenoid chronic GVHR in the skin. Similar to the changes in Sjögren's syndrome, lymphocytes infiltrate glandular elements of the salivary glands, with progressive destruction and loss of acini. Lacrimal glands are sampled less often but show similar changes.

ACUTE CUTANEOUS GRAFT-VERSUS-HOST REACTION AFTER AUTOLOGOUS AND SYNGENEIC MARROW AND PERIPHERAL STEM CELL TRANSPLANTATION Erythematous macules and papules appear in variable locations and distributions at the time of peripheral lymphocyte recovery and are self-limited. Resolution with desquamation occurs without therapy. Stage 1 and stage 2 disease is most common after the administration of cyclosporine, whereas stage 3 disease is common after the addition of IFN-γ and is accompanied by significant pruritus. Stage 4 disease, manifestations of chronic GVHD, and extra-cutaneous involvement are exceedingly rare. Erythroderma with histologic features of spongiotic dermatitis occurs uncommonly after infusion of unmodified transplants but is generally persistent and difficult to treat.

Infusion of unmodified autologous transplants result in eruptions that are histologically indistinguishable from those of lymphocyte recovery.[38] The administration of cyclosporine results in some cutaneous eruptions that histopathologically resemble grade 2 acute cutaneous GVHR after allogeneic transplantation, but the findings are usually mild without evolution to grade 3 or grade 4 GVHR. Use of transplants modified by the administration of cyclosporine and IFN-γ results in eruptions that combine the histologic features of a GVHR and eczematous dermatitis, as evidenced by more marked exocytosis and intercellular edema.[10]

Related Physical Findings

Although the skin is the earliest and most commonly involved organ in GVHD, liver and gastrointestinal disease are frequent; the presence of elevated total bilirubin levels and diarrhea often aids in establishing the diagnosis when skin findings are not specific. Isolated liver or gastrointestinal involvement is uncommon. Retrospective analysis of a large series of patients revealed that the extent of the cutaneous eruption, total bilirubin value, and stool output per day provided significant prognostic information when considered separately or together.[39]

Ocular and oral involvement may occur in the acute phase but is less common than in chronic GVHD. Oral involvement is typical in chronic cutaneous GVHD, characterized by white lacy patches on the buccal mucosa. Rare patients display oral changes only. Sicca symptoms resembling Sjögren's syndrome often accompany the sclerodermoid phase because of diminished lacrimal and salivary output. In certain patients with the chronic form of cutaneous GVHD, the main anatomic site of collagen alteration is fascial. This fasciitis is similarly debilitating and is suggested in patients in whom the skin seems supple but the deeper soft tissue is hard. Joint contracture is quite common in this group of patients.

DIAGNOSIS AND DIFFERENTIAL DIAGNOSIS

An algorithm outlining an approach to the patient with cutaneous GVHD is shown in Fig. 28-9.

The diagnosis of acute cutaneous GVHR rests on the combination of clinical findings, including the onset of variably distributed erythematous macules and papules at the time of peripheral lymphocyte recovery (generally longer than 10 to 14 days after transplantation), and a minimum of grade 2 histopathologic changes. Because stage 1 disease generally is not treated, eruptions with limited distribution may not warrant sampling. If eruptions persist or progress despite initial non-specific histopathologic changes, resampling is very helpful, because diagnostic changes evolve as the rash evolves.

Despite some distinguishing clinical features, acute allogeneic cutaneous GVHR lacks absolutely specific findings. Other diagnostic considerations include a drug hypersensitivity reaction and a viral exanthem. Differentiation of stage 4 cutaneous GVHR from toxic epidermal necrolysis was discussed earlier. In addition, in some patients a poorly characterized cutaneous eruption seems to occur at the time of marrow engraftment but before the appearance of peripheral lymphocytes. This eruption develops before day 14 after transplantation and consists of variably distributed erythematous macules. It should not be confused with a GVHR, because this "engraftment" or "cytokine-release" eruption clearly occurs very early and without a discernible rise in the number of peripheral leukocytes (Box 28-1).

What is the role of the biopsy specimen? It is easier to establish a diagnosis of GVHR than to exclude drug eruption and viral exanthem from consideration. The causes that may underlie grade 1 changes generally defy identification. It is sufficient to report "not GVHD" rather than to speculate about the cause when objective criteria are lacking. Holding to the standard of an infiltrate of lymphocytes, basal vacuolization, and at least four necrotic epidermal cells per millimeter of epidermis helps to diminish the effects of the preparative regimen and heighten the specificity, and thus the significance, of the histologic changes. This standard should be used in diagnostic dermatopathology as well as in prospective and retrospective investigations of the specificity of the histologic changes of acute cutaneous GVHR. Although it is not documented in the literature, rare patients display early clinical and histologic features of a drug hypersensitivity reaction, including eosinophils in the tissue, only to manifest typical histopathologic features of grade 2 GVHR 7 to 10 days later, after engraftment. Once allogeneic lymphocytes predominate and infiltrate the site of prior inflammation, effector function changes, which allows expression of GVHR.

Controversy exists regarding the use and timing of skin biopsy to aid in the diagnosis of acute cutaneous GVHD. Some clinicians feel that withholding treatment while awaiting results of a biopsy can potentially lead to rapid progression of

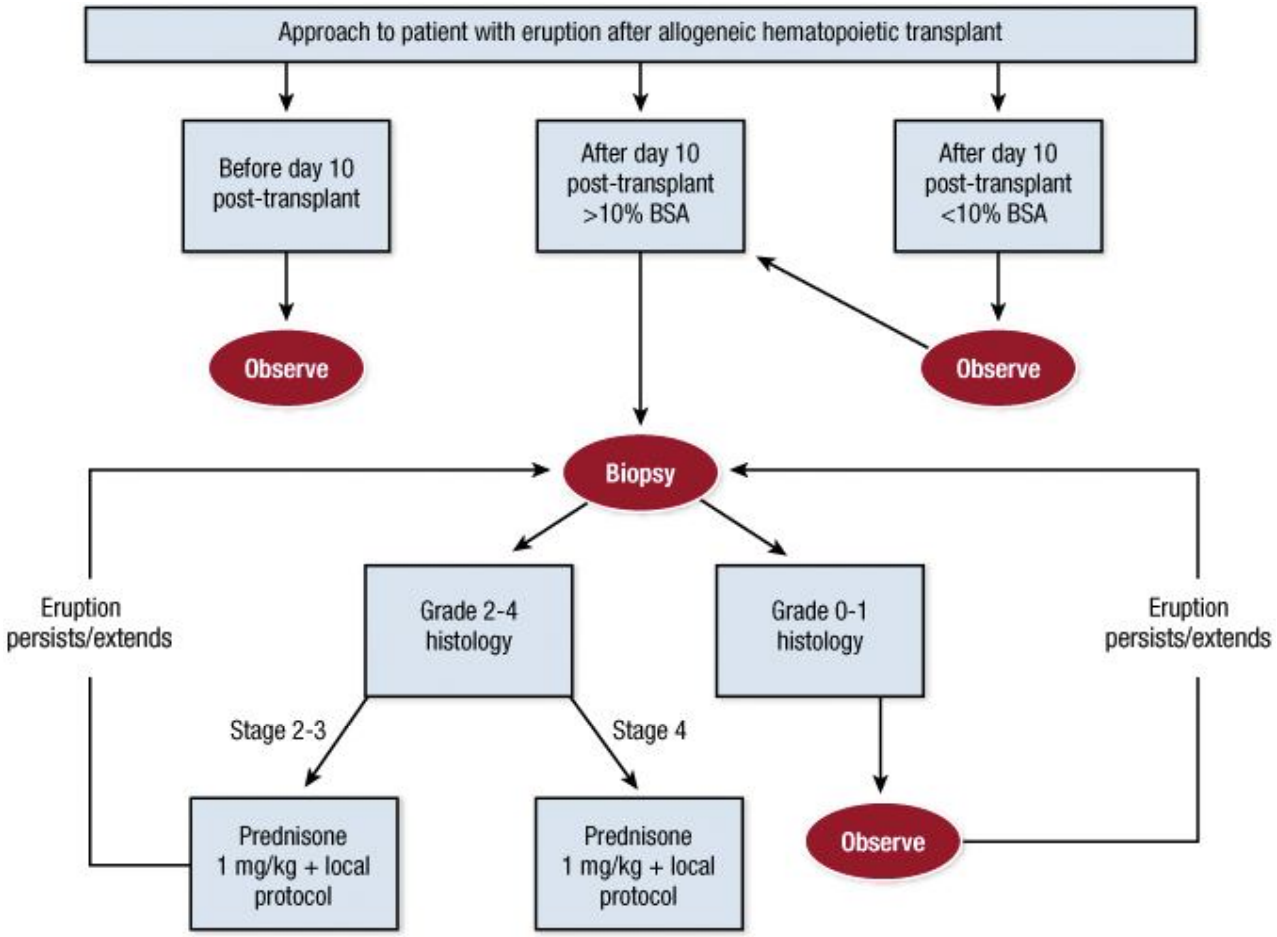

▲ **FIGURE 28-9** Approach to the patient with eruption after allogeneic hematopoietic transplantation. BSA = body surface area.

disease and adverse outcomes. Others maintain that immunosuppressive therapy must be used cautiously in the stem cell transplant population given the high risk of sepsis in these patients. The absence of specific histopathologic changes in early GVHD adds to the confusion. A published decision analysis used expert opinion to estimate the sensitivity and specificity of skin biopsy results to help determine relative benefit-risk ratios of appropriate versus inappropriate treatment of GVHD. This model predicted that in patient populations with a prevalence of GVHD of 30 percent or higher, as is typical for patients receiving allogeneic stem cell transplants, the best outcomes were reached with empiric treatment of GVHD without obtaining results of a skin biopsy. However, when prevalence of GVHD was 30 percent or less, it was advisable to await results of a skin biopsy to help guide treatment.[40]

The diagnosis of sclerodermoid GVHR is generally apparent on the basis of the clinical and histologic findings detailed earlier. If superficial biopsy specimens fail to show changes consistent with sclerodermatous disease, then consideration should be given to fascial involvement, which requires incisional sampling. Distinguishing between acute cutaneous GVHR and some cases of lichenoid chronic GVHR is more challenging. Rigid adherence to time after transplantation as a reliable discriminant between the two phases results in confusion.[36] Clinical and histologic features resembling lichen planus should lead to the diagnosis of lichen planus–like GVHR, with less emphasis placed on whether the disease is necessarily acute or chronic. Separation of autologous GVHR from the eruption of lymphocyte recovery may be difficult. Applying the same histologic criteria as for acute allogeneic GVHR is recommended.

LABORATORY TESTS

As previously discussed in Diagnosis and Differential Diagnosis, the diagnosis of acute cutaneous GVHD rests predominantly on the combination of characteristic cutaneous lesions appearing within the appropriate clinical setting (typically longer than 10 to 14 days after transplantation) and a minimum of grade 2 histologic changes. A peripheral white blood cell count can be helpful in determining whether peripheral lymphocyte recovery has occurred, which makes the diagnosis of acute GVHD more likely. Evaluation of liver function test results and total bilirubin levels helps to determine the presence and extent of liver involvement.

In rare circumstances, rapid histologic confirmation of acute GVHD may be warranted. In these cases, skin biopsy with frozen tissue diagnosis may be necessary to help guide patient management and treatment decisions.

COMPLICATIONS

In patients with acute GVHD, the risk of sepsis is high as a result of profound immunosuppression from pre-transplant preparative regimens or from immunosuppressive treatment in the setting of a GVHR. Significant blister formation in some patients may result in widespread denudation with exposed dermis, which places the patient at an even greater risk of sepsis as well as fluid and electrolyte imbalance. The risk of systemic infec-

Box 28-1

Differential Diagnosis of Graft-Versus-Host Disease

Most Likely

- Acute graft-versus-host reaction (GVHR)
  - Eruption of lymphocyte recovery
  - Drug eruption
  - Radiation effect
  - "Engraftment" or "cytokine-release" eruption (before day 14)
- Chronic GVHR
  - Lichenoid
    Lichenoid drug reaction
  - Sclerodermoid
    Radiation dermatitis

Consider

- Acute GVHR
  - Viral exanthem
  - Transient acantholytic dermatosis
  - Toxic epidermal necrolysis (stage IV disease)
- Chronic GVHR
  - Lichenoid
    Lichen planus
    Pityriasis lichenoides chronica
  - Sclerodermoid
    Morphea
    Scleroderma
    Lichen sclerosus
    Eosinophilic fasciitis
    Nephrogenic fibrosing dermopathy
    Sjögren's syndrome (with sicca symptoms)

Always Rule Out

- Acute GVHR
  - Sepsis
- Chronic GVHR
  - Bacterial, fungal, or viral skin infections
  - Sepsis
  - Squamous cell carcinoma (oral or cutaneous)

tion is also high in patients with chronic GVHD and represents the most common cause of death in these patients. In long-term survivors with chronic GVHD, the incidence of cutaneous and oral mucosal squamous cell carcinoma is increased in the presence of risk factors that include older age, treatment with cyclosporine, and prior administration of ionizing radiation.[41,42]

PROGNOSIS

A graft-versus-tumor effect is recognized in patients who develop GVHD.[43] The incidence of tumor relapse is reduced, which results in a dichotomous view of the disease. GVHD is the most common cause of morbidity and mortality after allogeneic stem cell transplantation, yet mild disease modulated by immunosuppression increases the chance of cure. As previously stated, systemic infection is the most common cause of death in patients with chronic GVHD. Patients with sclerodermoid disease demonstrate better survival than patients with lichenoid disease because they have overcome the earlier phases of acute and chronic GVHD and have lived longer, on average. Patients with skin biopsy specimens showing fully evolved features of lichenoid disease have a 5.6-fold increased risk for death due to GVHD.[36] No other histologic finding is known to correlate with outcome, specifically not in the early phases of GVHD. Degree of organ involvement in acute GVHD has been used to create a clinical staging system [grades 0 (best) to IV (worst)]. This system has been used as a prognostic indicator.[44]

TREATMENT

Acute Cutaneous Graft-Versus-Host Reaction after Allogeneic Transplantation

Standard therapies are listed in Box 28-2. Anti–tumor necrosis factor-α drugs, such as etanercept and infliximab, have been used with some success.[45,46] Dosages and specific regimens vary among transplantation centers.

Ultraviolet radiation must be administered cautiously to avoid increasing the erythema of the GVHR and thereby inciting more inflammation. One study found phototherapy with long-wavelength ultraviolet A light (340 to 400 nm) to be a safe, effective adjunct treatment for cutaneous manifestations of both acute and chronic GVHD.[47] There are no published data regarding the use of narrow-band ultraviolet B therapy in GVHD. Extracorporeal photopheresis has reported benefit in acute disease, including steroid-refractory GVHD, possibly by promoting a shift from a T helper 1 to T helper 2 lymphocyte distribution.[48–50] Pre-treatment of the graft with ultraviolet A radiation prevented disease in a murine model of transfusion GVHD.[51]

Chronic Cutaneous Graft-Versus-Host Reaction after Allogeneic Transplantation

Although most chronic GVHR is manifested only in the skin, oral immunosuppressive therapy is used because the disease is considered to be systemic (Box 28-3).

Intermittent cultures for bacteria and fungi should be performed as necessary. Long-term administration of antibiotics becomes necessary in cases of recurrent pyoderma.

For the lichenoid manifestations, ultraviolet light therapy generally controls widespread disease effectively.[52,53] Tapering phototherapy is recommended after several months of clearance. Therapies claiming efficacy in treating sclerodermoid GVHR are difficult to evaluate because the disease is relatively rare and remits spontaneously in some cases. It is unclear whether ultraviolet irradiation is able

Box 28-2

Treatment of Acute Graft-Versus-Host Disease

	TOPICAL	PHYSICAL		SYSTEMIC	
First Line	Corticosteroids	Psoralen plus ultraviolet A		Corticosteroids-Methylprednisolone	2 mg/kg/day[56]
Second Line		Extracorporeal photopheresis	2 consecutive days q2wk	Tacrolimus	4–20 mg/day[57]
		Ultraviolet A1 (340–400 nm)		Cyclosporine	12–15 mg/kg/day PO or 3–5 mg/kg/day IV[58]
				Mycophenolate mofetil	2 g/day[59]
				Antithymocyte globulin	15 mg/kg/day[60]
				Etanercept	25 mg biw[45]
				Infliximab	10 mg/kg/wk[46]
				OKT3 (anti CD3 mAb)	5 mg/day[61]

Box 28-3

Treatment of Chronic Graft-Versus-Host Disease

	TOPICAL	PHYSICAL		SYSTEMIC	
First Line	Corticosteroids	Psoralen plus ultraviolet A		Prednisone	1 mg/kg qd–qod[62]
				Cyclosporine	10 mg/kg in 2 divided doses qd-qod[62]
Second Line	Tacrolimus	Ultraviolet A1 (340–400 nm)	20 J/cm^2 qiw[63]	Methotrexate	7.5 mg/m^2/wk[64]
		Ultraviolet B		Mycophenolate mofetil	2 g/day
		Extracorporeal photopheresis	2 consecutive days q2wk[65]	Tacrolimus	0.05 mg/kg IV or 0.15mg/kg PO bid[66]
				Thalidomide	200–800 mg/day[67]
				Azathioprine	1.5 mg/kg/day[68]
				Hydroxychloroquine	800 mg/day (12 mg/kg/day)[69]
				Acitretin[62]	

to reverse the cutaneous changes in sclerodermoid disease. Extracorporeal photopheresis has proven beneficial in both lichenoid and sclerodermoid steroid-resistant chronic GVHD.[54,55]

Acute Cutaneous Graft-Versus-Host Reaction after Autologous and Syngeneic Transplantation

No significant morbidity is associated with autologous GVHR, and the cutaneous eruptions resolve without therapy. Patients with erythroderma after autologous stem cell transplantation may require systemic glucocorticoids to control the intense itching that accompanies the eczematous changes seen histologically.

PREVENTION

Attempts to prevent acute GVHD are essential, because treatment of established disease is difficult, and, as previously mentioned, prior acute GVHD is the greatest predictor for the development of chronic GVHD.[6] Three prophylactic strategies are used: optimal donor selection, pre-treatment manipulation of donor marrow or stem cells, and pharmacoprophylaxis. Ideally, the donor should be a young, sex-matched, human leukocyte antigen–identical sibling or monozygotic twin. Prophylactic treatment of allogeneic donor marrow to deplete effector T cells is also effective in preventing and reducing the severity of acute GVHD; however, this manipulation has been associated with an elevated risk of tumor recurrence and graft failure. Various pharmacologic prophylactic regimens are generally used in the post-transplantation period, including combinations of methotrexate, tacrolimus, cyclosporine, and cyclophosphamide. Because of improved treatment of GVHD, there is increasing use of MHC-mismatched and unrelated donors.

KEY REFERENCES

The full reference list for all chapters is available at www.digm7.com.

3. Miller KB et al: A novel reduced intensity regimen for allogeneic hematopoietic stem cell transplantation associated with a reduced incidence of graft-versus-host disease. *Bone Marrow Transplant* **33**:881, 2004
5. Horn TD et al: Cutaneous eruptions of lymphocyte recovery. *Arch Dermatol* **105**:1512, 1989
8. Hood AF et al: Acute graft-versus-host disease: Development following autologous and syngeneic bone marrow transplantation. *Arch Dermatol* **123**:745, 1987
12. Gilliam AC et al: Apoptosis is the predominant form of epithelial target cell injury in acute experimental graft-versus-host disease. *J Invest Dermatol* **107**:377, 1996
30. Horn TD et al: Reappraisal of histologic features of the acute cutaneous graft-versus-host reaction based upon an allogeneic rodent model. *J Invest Dermatol* **100**:546a, 1993
47. Wetzig T et al: Medium dose long-wavelength ultraviolet A (UVA1) phototherapy for the treatment of acute and chronic graft-versus-host disease of the skin. *Bone Marrow Transplant* **35**:515, 2005



CHAPTER 29

Skin Disease in Acute and Chronic Immunosuppression

Lynda Kauls
Andrew Blauvelt

This chapter focuses on dermatologic manifestations in immunosuppressed patients without human immunodeficiency virus (HIV) disease, predominantly immunosuppression induced by drugs, conditions surrounding bone marrow transplantation, and hematologic malignancy. Skin manifestations of HIV disease are described in Chap. 198. Other chapters cover graft-versus-host disease (see Chap. 28), skin signs associated with primary immunodeficiency disorders (see Chap. 144), and side effects of cancer chemotherapeutic agents and cytokines (see Chaps. 228, 234, and 235). Because relatively few skin diseases manifest exclusively in immunosuppressed hosts, many conditions discussed in this chapter occur in immunocompetent individuals as well. Salient clinical features particularly associated with immunosuppression are emphasized here.

The diversity of cutaneous infections that occur in immunosuppressed patients can pose a significant diagnostic challenge. To aid in evaluation, it is helpful to understand the underlying immune defects associated with the medical conditions of each patient (Table 29-1), which helps to focus the history taking and physical examination toward skin manifestations of specific pathogens. This chapter is divided into two major subsections based on this concept: acute immunosuppression and chronic immunosuppression. When patients are acutely immunosuppressed, usually from iatrogenic ablation of the immune system or from acute leukemia, infections occur that are normally controlled by neutrophils and macrophages.

SKIN DISEASE IN ACUTE AND CHRONIC IMMUNOSUPPRESSION

AT A GLANCE





- Skin manifestations in patients who have hematologic malignancies, have undergone bone marrow transplantation, or are immunosuppressed by drugs are common and varied.
- Many of these skin diseases occur in immunocompetent individuals as well.
- In patients with acute immunosuppression, infections occur that are normally controlled by neutrophils and macrophages.
- In patients who have long-term immunosuppression, T-cell function is impaired and skin diseases are often similar to those seen in patients with human immunodeficiency virus infection.
- Salient dermatologic features particularly associated with immunosuppression are important diagnostic signs and indicators for therapy.

In chronically immunosuppressed individuals, such as transplant patients and those taking corticosteroids on a long-term basis, T-cell function is impaired, and diseases will often be similar to those observed in HIV disease.

In ill immunosuppressed patients a disease often manifests in the skin. Appropriate evaluation and diagnosis of skin lesions are critical to the overall health of these individuals, because the skin is often a window to more severe systemic infections or illnesses. In particular, in these patients, unusual presentations of infection with typical pathogens and infections with rare opportunistic pathogens are common. Diagnosis is also made more difficult by the variety of organisms that share similar morphologies and the wide variety of morphologic presentations of a single organism (Table 29-2). This makes prompt clinical evaluation and extensive use of skin biopsy and culture necessary to make an accurate diagnosis and initiate prompt treatment to obviate significant morbidity and mortality.

ACUTE IMMUNOSUPRESSION

The prototype of an acutely immunosuppressed patient needing dermatologic evaluation is a neutropenic patient undergoing chemotherapy or transplantation. Neutropenia and resultant opportunistic infection are side effects of many cancer therapies that often pose a more immediate threat to survival than the malignancy itself. Moreover, individuals with cancer often have immune system defects before aggressive cytotoxic, radiation, or surgical therapy.[1] For example, tumors can secrete immunosuppressive factors (e.g., transforming growth factor-β1 and interleukin 10) that help them evade normal immune responses and lead to further systemic immunosuppression. In the past two decades, overall mortality due to infection among patients undergoing hematopoietic transplantation has decreased significantly, but it still represents an ongoing risk to survival. The causes of infection-related death have remained relatively stable, with death due to bacterial infections being the most common (36 percent), followed by deaths due to infection or infestation by viruses (31 percent), fungi (28 percent), and parasites (5 percent).[2,3]

Bacterial Infections

Empiric therapy for fever and neutropenia was first introduced in the 1970s when 60 percent to 70 percent of infections were due to Gram-negative bacteria such as *Escherichia coli*, *Pseudomonas aeruginosa*, and *Klebsiella* species. Since that time, bacteremia caused by Gram-positive organisms has become more prevalent.[4] Acutely immunocompromised hosts are at risk for becoming bacteremic from skin and soft-tissue infections such as folliculitis, furuncles, and wound infections. The use of indwelling intravascular catheters is also thought to play a role in the shift to Gram-positive organisms, such as coagulase-negative staphylococci and methicillin-resistant *Staphylococcus aureus*.[5] Rapid empiric therapy is typically instituted in these patients. Bone marrow transplant patients and other patients with neutropenia are prone to streptococcal bacteremia and may develop facial flushing, a widespread erythematous eruption of macules and papules, and desquamation of the palms and soles. Staphylococcal scalded-skin syndrome, which typically occurs in children (see Chap. 178), can occur in immunosuppressed adults.[6]

Ecthyma gangrenosum is the most characteristic lesion of *Pseudomonas* septicemia. Patients with neutropenia, cystic fibrosis, or extensive burns are particularly susceptible to systemic *P. aeruginosa* infection (see Chap. 180).[7] Ecthyma gangrenosum appears as a painful erythematous to dusky nodule or plaque that rapidly develops a central pustule or hemorrhagic vesicle, followed by a central area of necrosis (Fig. 29-1). The classic and most common form is due to hematogenous spread of *Pseudomonas*, but similar-appearing lesions can represent primary cutaneous infection, usually at the site of a medical procedure. As is common with other infections in neutropenic hosts, primary lesions can lead to bacteremia and should be treated aggressively. The groin, perianal area, and axillae are the most common locations for ecthyma gangrenosum. There may be one or many lesions. Other bacterial organisms are also capable of causing ecthyma gangrenosum–like lesions, including *S. aureus*, *Aeromonas hydrophilia*, *Serratia marcescens*, *K. pneumoniae*, and *E. coli*. Fungal organisms such as *Aspergillus* can also cause similar lesions. These organisms should be ruled out by culture. Other cutaneous manifestations of *Pseudomonas* septicemia may appear initially as grouped vesicles, cellulitis, subcutaneous nodules, petechiae, purpura, or folliculitis.[8] All these types of lesions can progress to ulcerative and necrotic lesions that are more characteristic of ecthyma gangrenosum. Necrosis is secondary to underlying focal vasculitis, which can be observed in skin biopsy specimens. Diagnosis is made by culture of the organism from skin or blood. The mortality rate of *P. aeruginosa* bacteremia is high at 33 percent to 75 percent.[9] Better outcomes have been shown with the initial use of combination antimicrobial therapy until susceptibilities can be identified, such as an antipseudomonal β-lactam antibiotic or a carbapenem in combination with an aminoglycoside or a fluoroquinolone.[10]

Fungal Infections

Candidiasis and aspergillosis represent the two most common fungal infections

TABLE 29-1
Opportunistic Infections That Are Commonly Associated with Specific Underlying Immune Defects

Immune Defect	Usual Conditions	Common Bacterial Pathogens	Common Viral Pathogens	Common Fungal Pathogens
Defective cell-mediated immunity	Organ transplantation, metastatic cancer, Hodgkin disease, glucocorticoid or cyclosporine therapy	*Listeria, Salmonella, Nocardia, Mycobacterium avium-intracellulare, M. tuberculosis, Legionella*	Cytomegalovirus, herpes simplex virus, varicella-zoster virus	*Candida, Cryptococcus, Histoplasma, Coccidioides*
Defective humoral immunity	Multiple myeloma, chronic lymphocytic leukemia	*Streptococcus pneumoniae, Haemophilus influenzae, Neisseria meningitidis*	Enteroviruses	—
Neutropenia	Cancer chemotherapy, acute leukemia, adverse drug reaction	Aerobic Gram-negative bacteria; *Staphylococcus aureus, Streptococcus viridans, Staphylococcus epidermidis*	Herpes simplex virus	*Candida, Aspergillus*
Defective neutrophil function	Chronic granulomatous disease, myeloperoxidase deficiency	Catalase-positive bacteria: *S. aureus, Escherichia coli*	—	*Candida*
Defective chemotaxis	Diabetes, alcoholism, renal failure, systemic lupus, trauma	*S. aureus, Streptococcus*	—	*Candida*
Hyposplenism	Splenectomy, hemolytic anemia	*S. pneumoniae, H. influenzae*	—	—
Defective complement components	Congenital or acquired deficiencies	*S. pneumoniae* (C2, C3, C5 alternate), *H. influenzae* (C2, C3, alternate), *S. aureus* (C5), Enterobacteriaceae (C5), *Salmonella* (alternate), *N. meningitidis* (C6–C8)	—	—
Skin barrier disruption	Intravascular catheters, decubitus ulcers, burns	*Staphylococcus, M. fortuitum,* Gram-negative bacteria, anaerobes	—	*Candida, Aspergillus, Mucor*

that occur in patients who are undergoing cytotoxic chemotherapy or stem cell transplantation or who have acute myeloproliferative disorders. They are not unique to the neutropenic patient, however, and are encountered in settings such as surgical and neonatal intensive care units, and in patients with cell-mediated immune dysfunction such as those undergoing long-term immunosuppression after solid organ transplantation. Additional risk factors for opportunistic fungal infection include hyperalimentation, antibiotic use, hyperglycemia, and central venous catheter use. Mortality rates for fungal bloodstream infections are highest in neutropenic hosts and range from 40 percent to 90 percent.[11] Recovery from disseminated fungal infections is rare unless neutropenia resolves. Other fungal organisms causing infection in hosts with acute neutropenia include *Trichosporum* species, *Fusarium* species, and organisms in the Zygomycetes class.

TABLE 29-2
Cutaneous Morphologies and Associated Organisms in Immunosuppression[a]

Organism	Ecthymatous Lesions	Morbilliform Eruption	Vesicles	Erythemas (Cellulitic Patches and Plaques)	Ulcers
Bacteria					
Pseudomonas aeruginosa	X		X		
Streptococcus viridans		X		X (facial)	
Staphylococcus sp.	X	X			
Aeromonas hydrophilia	X				
Nocardia spp.				X	
Vibrio vulnificus				X	X
Fungi					
Aspergillus sp.	X		X (hemorrhagic)		X (necrotic)
Zygomycetes organisms	X			X (facial)	X (necrotic)
Fusarium sp.	X				
Cryptococcus neoformans				X	X
Histoplasma capsulatum				X	X (mucosal)
Coccidioides immitis		X			
Viruses					
Herpes simplex virus			X	X	X
Varicella-zoster virus			X	X	X
Cytomegalovirus					X (mucosal)

[a]Each organism has a wide variety of presentations, and not all are included in this table.

CANDIDIASIS (See Chap. 189) Candidiasis is the most common fungal infection in immunosuppressed patients.[12] His-



▲ **FIGURE 29-1** Ecthyma gangrenosum secondary to *Pseudomonas aeruginosa* infection in the groin area.



torically, most candidal infections were due to *Candida albicans*, but there has been an emergence of other organisms in recent years, including *C. glabrata*, *C. krusei,* and *C. tropicalis*.[11,12]

The classic triad of fever, myalgias, and erythematous skin lesions in a septic patient not responding to antibiotic therapy is highly suggestive of disseminated candidiasis. Fungi may seed numerous organs, causing myositis, meningitis, endocarditis, pneumonitis, cerebritis, esophagitis, bursitis, osteomyelitis, arthritis, and endophthalmitis. Cutaneous lesions are present in only 5 percent to 10 percent of individuals with disseminated candidiasis. *C. tropicalis* is more likely than other strains to cause skin lesions (up to 25 percent of patients). Lesions are characteristically non-painful, non-blanching, discrete, erythematous macules, papules, or nodules (Fig. 29-2) and may become purpuric, pustular, or necrotic within the centers of the lesions. They are usually generalized, but occasionally patients have very few lesions limited to the proximal extremities. The major clinical differential diagnosis includes infections caused by other opportunistic pathogens and drug eruptions. Histologically, periodic acid-Schiff–positive yeast forms are seen in the dermis, usually in association with vascular damage and mild inflammation. *Candida* can be grown from skin lesion samples in approximately 50 percent of patients. Tissue scrapings from dermal skin can be obtained at the time of biopsy with a scalpel or small-diameter curette for slide examination and can be an invaluable aid in making a rapid diagnosis in an acutely ill patient.

The treatment of choice for disseminated candidiasis is intravenous amphotericin B, which is less toxic when liposomal and lipid-complex forms are used. *C. glabrata*, *C. albicans*, *C. tropicalis*, and *C. parapsilosis* are showing resistance to fluconazole, and *C. krusei* is naturally resistant.[13,14] Newer antifungals including voriconazole and caspofungin are effective against *Candida* species, although breakthrough infections with resistant *C. glabrata* have already been reported with voriconazole[15] (see Chap. 233).

ASPERGILLOSIS After candidiasis, aspergillosis is the most common opportunistic fungal infection in immunosuppressed patients.[8,11] Persistent neutropenia and neutrophil dysfunction is a risk factor for disseminated infection, and patients with acute leukemia have the highest incidence of infection.[16] Infection rates are also high for patients undergoing allogeneic stem cell transplantation, although risk factors in this group are expanded to include immunosuppression for graft-versus-host disease prophylaxis, graft-versus-host disease itself, and other infectious diseases, especially cytomegalovirus (CMV) infection. Systemic infection is classically seen during the period of neutropenia caused by the conditioning regimen, whereas invasive infection is more common 30 to 40 days after transplantation. This observation emphasizes that immune defenses other than those mediated by granulocytes are important for protection against invasive fungal infections, and against *Aspergillus* infections in particular. The incidence of invasive aspergillosis is also increasing in non-classic immunocompromised hosts such as critically ill patients in the intensive care unit. Environmental factors also clearly contribute to the development of aspergillosis, especially in primary cutaneous disease. These include hospital construction (which increases spore counts in ventilation systems), the use of indwelling catheters (which provide portals of entry for organisms), and contamination of tape and arm boards used to secure catheters.



▲ **FIGURE 29-2** Early cutaneous lesion of disseminated candidiasis in a neutropenic patient after chemotherapy for non-Hodgkin lymphoma.



▲ **FIGURE 29-3** Ecthymatous lesion of primary cutaneous aspergillosis under tape occlusion from previous central line in an oncology patient.

A. fumigatus is the most common cause of disseminated infections, whereas *A. flavus* is associated most commonly with primary cutaneous disease.[17] Emerging strains are evolving in aspergillosis as in candidiasis. *A. terreus* is more likely to be health care associated, more resistant to amphotericin B, and has a lower response rate to antifungal therapy than *A. fumigatus*.[16]

Primary cutaneous aspergillosis often develops at sites of intravenous catheters or under areas of occlusion. Lesions initially appear as small cellulitic areas and progress quickly to necrotic ulcers with black eschars (Fig. 29-3). In patients with *Aspergillus* sinusitis, necrotic ulcers with black eschars can occur in the anterior nares and on the nasal septum, palate, and skin overlying the nasal bridge. Cutaneous necrosis caused by *Aspergillus* is secondary to invasion of fungi within deep blood vessels.

Primary cutaneous, pulmonary, or sinus infection can easily become invasive and lead to disseminated disease in immunocompromised hosts. Patients with disseminated aspergillosis often present with unremitting fever despite antibiotic use. The central nervous system, heart, kidneys, and gastrointestinal tract also may be involved. Cutaneous manifestations of disseminated aspergillosis are uncommon, occurring in 5 percent to 10 percent of patients.[17] Lesions begin as single or multiple painful, erythematous papules, nodules, or plaques. They rapidly expand and develop central hemorrhagic vesicles or bullae, which in turn quickly progress to central ulcers with black eschars. In disseminated disease, the prognosis is very poor (usually higher than 90 percent mortality). In tissue sections, diagnosis can be made by demonstration of nonpigmented septated hyphae that branch at acute angles. Blood culture results often are not positive or reliable because *Aspergillus* is found commonly as a laboratory contaminant. Traditionally, the treatment of choice has been liposomal amphotericin B, although studies now show that voriconazole and, to a lesser degree, caspofungin may be more effective and better tolerated.[18] Surgical removal of isolated lesions of primary cutaneous aspergillosis can be attempted, although this may not necessarily prevent secondary disseminated infection in patients with persistent neutropenia.



ZYGOMYCOSIS (See Chap. 190) Zygomycosis is the third most common opportunistic fungal infection in immunosuppressed hosts, accounting for 5 percent to 15 percent of all fungal infections.[19] The term *zygomycosis* is used to describe a group of fungal infections caused by ubiquitous Zygomycetes found in soil and decaying matter. Infections in humans are mostly caused by the order Mucorales (mucormycosis) and include the genuses of *Mucor*, *Rhizopus*, *Absidia*, *Mortierella*, and *Cunninghamella*. The term *zygomycosis* is now preferred over *mucormycosis* because it is broader and more relevant when organisms are not identifiable. Like aspergillosis, zygomycosis is rare in individuals without underlying immunodeficiency or predisposing conditions. Host defenses usually prevent the germination of the spore unless the inoculation is too great, as in trauma or surgical wounds. Chronic medical conditions that affect macrophage function, such as diabetes or corticosteroid-induced immunosuppression, lead to an inability to inhibit spore germination, and these patients are at increased risk of infection. Additional risk factors besides immunosuppression include iron overload, burns, intravenous illicit drug use, and malnourishment.

Primary infection can occur by inhalation, by direct inoculation into damaged skin, or by ingestion. Patients with prolonged neutropenia present most often with pulmonary disease and dissemination. The mortality rate in these individuals is very high. Diabetic patients with sustained hyperglycemia and metabolic acidosis are predisposed to primary rhinocerebral (66 percent) and pulmonary (16 percent) infections.[19] Malnutrition and gastrointestinal disease predispose patients to primary gastrointestinal tract infection. Wounds and burn injuries predispose to primary cutaneous infection. Each type of primary infection can lead to hematogenous spread and disseminated infection of numerous organs (especially the brain).

The clinico-pathologic hallmarks of cutaneous zygomycosis are vascular invasion, ischemic infarction, and necrosis, which result in painful erythematous nodules and plaques that ulcerate rapidly and form central black eschars.[20] Rhinocerebral zygomycosis typically begins with facial edema and erythema (Fig. 29-4), bloody nasal discharge, and ulceration of the palate or nasal septum. Within a few days, necrotic skin lesions, headache, focal neurologic defects, exophthalmos, and altered vision develop and can progress to seizures, stupor, coma, and death. Clinical manifestations of primary cutaneous disease range from necrotic papules to cellulitis, subcutaneous nodules, bullae, and eschars. Diagnosis of zygomycosis usually is made by demonstration of non-septated hyphae (with branching at right angles) within infected tissue. The treatment of choice for disseminated disease is lipid preparations of intravenous amphotericin B and surgical débridement. If possible, reversal or removal of underlying predisposing conditions should be attempted.



▲ **FIGURE 29-4** Rapidly progressing zygomycosis in a man with diabetes.

FUSARIOSIS *Fusarium* is a filamentous mold found in soil and plants. Disseminated infections are found in severely immunocompromised individuals, whereas immunocompetent patients have localized lesions at areas of skin breakdown. Neutropenic patients are particularly susceptible to infection and rapid dissemination.[21] The source of infection in patients undergoing acute immunosuppressive therapy is often the skin, especially from cellulitis developing at the site of onychomycosis, local trauma, or insect bites. Nasal sinuses are another source of primary infection that can lead to dissemination after acute immunosuppression. In disseminated disease, patients present with multiple painful erythematous papules and nodules, some with central necrosis. Lesions are often at different stages of development, and a specific presentation of papules evolving into target-like lesions with a ring of normal-appearing skin and an outer rim of erythema has been observed. Skin lesions often precede fungemia and are the single source of diagnosis in a majority of patients.[22] The mortality rate in patients who are persistently neutropenic is 100 percent, compared with 30 percent in patients whose immune systems recover. Newer triazole antifungals such as voriconazole have some efficacy against infection with *Fusarium* sp., for which treatment options have traditionally been limited. Granulocyte transfusions may also play a role in treatment.

TRICHOSPORONOSIS *Trichosporon beigelii*, a yeast-like organism that causes white piedra in the tropics, may produce acute systemic infection in immunosuppressed patients, most commonly in the setting of neutropenia.[23] Patients with disseminated trichosporonosis are acutely ill. They may have fever, hypotension, pulmonary infiltrates, renal involvement, and hepatosplenomegaly. Skin lesions occur in 30 percent of patients and appear similar to cutaneous lesions of disseminated candidiasis. Definitive diagnosis is made by culture, and the treatment of choice is fluconazole; amphotericin B resistance is common.

Viral Infections

Viral infections are predominantly associated with defects in cellular immune function and are not typically expected to cause problems in patients whose main immunologic defect is neutropenia.[24] The most common viral infection that occurs in patients who are undergoing induction chemotherapy for lymphoma or an acute leukemia or who are in the first few weeks after a bone marrow transplantation is reactivation of latent herpes simplex virus (HSV) infection (see Chap. 193). Clinical presentations in acutely immunosuppressed patients include an increased severity of oral mucositis, intra-oral ulcers outside of the gingival margin, and necrotizing gingivitis.[24] Pneumonitis can occur from either contiguous spread from the oropharynx or from viremia. Antiviral prophylaxis is approximately 90 percent effective in preventing disease during chemotherapy or hematologic transplantation. When disease does occur in transplant patients, 5 percent to 10 percent of cases are resistant to acyclovir because of mutation in the gene coding for thymidine kinase, which is the enzyme required for efficacy of acyclovir, valacyclovir, and famciclovir (see Chap. 232). The treatment of choice in these patients is foscarnet.

Reactivation of varicella-zoster virus (VZV) (see Chap. 194) usually occurs 3 months or longer after transplantation and is relatively rare in the acutely immunosuppressed patient. VZV infection in adults with leukemia or after solid organ





▲ **FIGURE 29-5** Disseminated varicella in a patient after induction chemotherapy.



transplantation is rarely primary but more often represents reactivation of latent virus. In this setting, patients are at increased risk for both skin and systemic dissemination of virus (Fig. 29-5). Of note, before the use of antiherpesvirus prophylaxis in children who had lymphoma or acute leukemia or underwent bone marrow transplantation, primary varicella was a classic opportunistic infection associated with mortality rates of 7 percent to 30 percent.

CHRONIC IMMUNOSUPPRESSION

Patients with chronic immunosuppression include those that are iatrogenically immunosuppressed because they are taking medications that impair the immune system and those with chronic diseases that are associated with immune dysfunction, such as diabetes mellitus. The population of patients who are taking immunosuppressive medications over the long term is growing as solid organ transplantation becomes a therapeutic option for many human diseases. The overall incidence of solid organ transplantation continues to increase, and the survival of patients in the short and long term has improved. These individuals require lifelong therapy with immunosuppressive drugs to maintain function of the transplanted organ. Cyclosporine, tacrolimus, sirolimus, prednisone, mycophenolate mofetil, and azathioprine (see Chaps. 228 and 234) are the drugs used most commonly to prevent graft-versus-host disease, predominately by inhibiting cell-mediated immunity (i.e., T-cell function).[25] Humoral immunity (i.e., B-cell function) remains relatively intact in these patients. Thus, opportunistic diseases in most transplant patients are dominated by viral and fungal infections, intracellular bacterial infections, and virus-associated malignancies, conditions that are controlled predominantly by cell-mediated immune mechanisms in immunocompetent hosts.

Bacterial Infections

MYCOBACTERIAL INFECTIONS (See Chap. 184) Atypical mycobacteria are ubiquitous organisms found in soil and water. The most common organisms in this group include *Mycobacterium marinum*, *M. chelonae*, *M. fortuitum*, *M. kansasii*, *M. haemophilum*, and *M. avium-intracellulare*. Before the epidemic of acquired immunodeficiency syndrome (AIDS), most cases occurred in persons with underlying pulmonary disease. However, mycobacterial infections after transplantation are increasing in frequency and severity, with the highest incidence in recipients of hematopoietic stem cell transplants. These patients usually present with catheter-related infections, although skin lesions are rare in this population. Skin involvement is the most commonly reported manifestation of nontuberculous mycobacterial infections in solid organ recipients except lung transplant recipients, who are more likely to have pulmonary involvement. Manifestations include both localized and disseminated cutaneous disease.[26] Atypical mycobacterial infections in the skin are characterized by diverse morphologies, including reddish brown nodules and plaques (Fig. 29-6), abscesses (Fig. 29-7), and ulcers.[26] *M. avium-intracellulare* and *M. haemophilum* commonly cause disseminated infection, which can involve the lungs, lymph nodes, liver, spleen, bone marrow, and skin. Organisms can be identified by special stains or by culture of specimens from affected skin. Specific antimycobacterial antibiotic treatment regimens are complex and depend on the mycobacterial species, results of sensitivity testing, extent and severity of disease, and presence or absence of underlying immune defects.



▲ **FIGURE 29-6** Cutaneous *Mycobacterium avium-intracellulare* infection in a child with an inherited interleukin 12 receptor deficiency.



▲ **FIGURE 29-7** *Mycobacterium chelonae* infection in a patient receiving long-term, high-dose glucocorticoid treatment.

M. tuberculosis infection is a common worldwide problem, especially in individuals with impaired immunity. For example, individuals receiving high-dose corticosteroids are prone to active pulmonary tuberculosis. Cutaneous tuberculosis is usually more common in the setting of immunosuppression. Specifically, scrofuloderma (tuberculous lymphadenitis with extension to overlying skin) and numerous cutaneous lesions of miliary tuberculosis may occur more commonly in patients with underlying immune defects.

NOCARDIOSIS (See Chap. 185) *Nocardia* sp. are ubiquitous filamentous bacteria found in soil. *N. asteroides* is the most common species associated with human disease; however, *N. brasiliensis* can be seen in the southern United States and is more often associated with primary cutaneous disease. *N. farcinica* is less commonly isolated but is more likely to cause disseminated disease and has a higher risk of drug resistance.[27] Infection can be seen in immunocompetent hosts, but the majority of infections involve patients with immune compromise, particularly solid organ or bone marrow transplant recipients, those receiving long-term corticosteroid therapy, AIDS patients, intravenous drug users, and individuals with chronic pulmonary disease. In particular, long-term corticosteroid use doubles the risk of infection in susceptible individuals.[27] In transplant patients, the mean onset of infection is 9 months after transplantation, although it can occur as early as 1 month afterward. Before the use of cyclosporine to prevent rejection, infection rates were much



◀ **FIGURE 29-8** Nocardiosis in a man with glioblastoma.

higher in transplant recipients, and this decline is attributed to decreased use of corticosteroids. Most cases of nocardiosis in transplant patients (80 percent to 90 percent) present as primary pulmonary disease and dissemination occurs in up to 40 percent of cases. The skin is involved as a focus in one-third of cases with disseminated infection. More rarely, the skin is the primary location of infection.

Several types of skin lesions have been described, including abscesses with sinus tract formation, subcutaneous nodules with pustules (Fig. 29-8), mycetoma, sporotrichoid nodules, and cellulitis.[28] Diagnosis is based on demonstration of Gram-positive, partially acid-fast, branching bacilli in tissue or tissue exudate or is determined by tissue culture, although it often takes several weeks for organisms to grow. The treatment of choice is trimethoprim-sulfamethoxazole. Numerous other antibiotics have been reported to be efficacious as well, such as minocycline, carbapenems, and amikacin. Transplant patients may require long-term prophylactic therapy to prevent recurrent disease. In addition, incision and drainage of cutaneous abscesses should be performed.

BACILLARY ANGIOMATOSIS (See Chap. 182) Bacillary angiomatosis is caused by infection with the bacterium *Bartonella henselae* or *B. quintana* and usually occurs in AIDS patients and other immunocompromised hosts.[29] Cutaneous lesions appear as painful, dome-shaped vascular papules and nodules (often resembling pyogenic granulomas) (see Fig. 182-3). Disseminated infection may occur and involve the liver, spleen, bone marrow, and brain. Patients often have a history of scratches or bites by cats, the natural reservoir for *B. henselae* and *B. quintana*. Diagnosis is made by demonstration of pleomorphic bacilli in tissue specimens with Warthin-Starry silver stain. Preferred treatments include oral erythromycin and doxycycline.

OTHER BACTERIAL INFECTIONS (See Chaps 179, 180, and 183) Cellulitis caused by *Streptococcus pyogenes*, *Streptococcus pneumoniae*, or *S. aureus* may progress rapidly and cause necrotizing fasciitis in immunosuppressed patients (Fig. 29-9). Solid organ recipients also may develop recurrent cellulitis of the elbow, a condition termed *transplant elbow* that has been attributed to staphylococcal infection.

Individuals with underlying complement deficiencies (loss of late-phase components C5 to C9) or alcoholism are susceptible to infection with *Neisseria meningitidis*.[30] Patients have acute septicemia, meningitis, disseminated intravascular coagulation, and widespread petechiae and purpura (Fig. 29-10).

Persons with underlying hepatic disease (commonly alcoholic cirrhosis or hemochromatosis) are prone to infection with *Vibrio vulnificus*, a Gram-negative bacillus commonly found in seawater, shellfish, clams, and oysters.[31] Infection occurs by ingestion of contaminated seafood or by direct cutaneous inoculation after contact with contaminated seawater. Patients classically present with rapidly evolving septicemia and painful cellulitis, bullae, or ulcers on the lower extremities (Fig. 29-11).

Capnocytophaga canimorsus is a commensal bacterium found in the saliva of dogs and cats that is transmitted to humans by bites or scratches.[32,33] Hosts particularly susceptible to septicemia and widespread organ involvement include alcoholics, asplenic patients, and those taking glucocorticosteroids.[32] Skin lesions occur commonly and include macules, papules, purpura, and gangrene. In immunosuppressed patients, *Salmonella enteritidis* has been associated with cutaneous abscesses of the head and neck.[34]

Fungal Infections

CANDIDIASIS (See Chap. 189) Although mucocutaneous candidiasis is less serious than disseminated candidiasis in the setting of acute immunosuppression (as described in the earlier Candidiasis section), it is the most common complication observed in hosts with chronic cell-mediated immune dysfunction.[35] Approximately 10



▲ **FIGURE 29-9** Early (**A**) and late (after surgical débridement, **B**) lesions of necrotizing fasciitis caused by *Streptococcus pyogenes* in an intravenous drug abuser with underlying Job syndrome.





▲ **FIGURE 29-10** Acute meningococcemia in a man with acquired complement deficiency.



▲ **FIGURE 29-12** White superficial onychomycosis in a renal transplant patient receiving cyclosporine.

percent of patients with organ transplants exhibit oral candidiasis.[36] Patients with chronic mucocutaneous candidiasis have specific underlying immune deficits in fighting candidal infections and usually have chronic widespread disease without systemic involvement.

Patients with oral mucosal candidiasis most commonly have pseudomembranous, white, friable plaques that leave a raw, erythematous undersurface when scraped. Less common oral lesions include erythematous or atrophic plaques as well as angular cheilitis. Esophageal involvement should be suspected in any patient with oral candidiasis complaining of pain or difficulty swallowing. Moist intertriginous areas are common locations of cutaneous lesions and are characterized by tender erythematous papules and plaques, often with satellite pustules. Onychomycosis and paronychia caused by *Candida* sp. are common in patients with chronic mucocutaneous candidiasis. For mucocutaneous disease, topical therapy with nystatin or clotrimazole and oral fluconazole are the treatments of choice. Prophylactic treatment with fluconazole is often recommended for patients at high risk for infection, such as those who have recently undergone organ transplant surgery.

DERMATOPHYTOSIS (See Chap. 188) Dermatophytoses are common uncomplicated infections in normal hosts, but immunosuppressed patients may have widespread, aggressive infection that can be resistant to topical and systemic therapy.[37,38] Interestingly, the incidence of dermatophyte infection was not found to be higher in renal transplant patients than in normal hosts in one study.[39] Specific presentations seen in immunocompromised patients include multiple lesions, a wide distribution, and Majocchi granuloma. Manifestations more suggestive of immunosuppression include both white superficial onychomycosis and proximal subungual onychomycosis. In the former, the surfaces of affected nails have a white, chalky appearance (Fig. 29-12), and hyphae are observed readily in superficial nail plate scrapings. These conditions should prompt a search for underlying immune deficiency.

CRYPTOCOCCOSIS (See Chap. 190) *Cryptococcus neoformans* is a yeast-like encapsulated fungus that is ubiquitous and is found commonly in soil enriched with bird feces. Primary infection is acquired via the respiratory tract by inhalation of airborne spores and usually is asymptomatic in healthy individuals. Organ transplant recipients are now the population at highest risk of developing disseminated disease, because improved antiretroviral agents have decreased the incidence in those with HIV disease.[40] Other immunosuppressed patients, particularly those receiving high-dose systemic corticosteroids, are susceptible to hematogenous spread and disseminated infection.[41] Also at increased risk include those with diabetes mellitus, chronic lymphocytic leukemia, chronic myeloid leukemia, multiple myeloma, and Hodgkin disease. The central nervous system is most commonly involved, although infection may occur throughout the body, including the lungs, bone marrow, heart, liver, spleen, kidneys, thyroid, lymph nodes, and adrenal glands. The skin is the most commonly affected site in disseminated disease in those with organ transplants receiving systemic tacrolimus.[40]

Classically, cutaneous lesions occur in up to 15 percent of patients with disseminated infection; however, skin lesions are manifest in 67 percent of patients receiving tacrolimus. In transplant patients, erythematous, edematous, warm, painful plaques on the extremities (clinically indistinguishable from bacterial cellulitis) have been reported most frequently.[40] Umbilicated papules (resembling mollus-



▲ **FIGURE 29-11** *Vibrio vulnificus* infection in an alcoholic patient after minor trauma sustained while swimming in the ocean.



▲ **FIGURE 29-13** Molluscum-like lesions of cutaneous cryptococcosis. (Used with permission from Yale Residents' slide collection.)

cum contagiosum), nodules, pustules, vesicles, and ulcers also may occur (Fig. 29-13). Oral mucosal cryptococcal nodules and ulcerations also have been described. Lesions may be isolated or multiple and can be quite painful. Although any area of the skin and oral mucosa may be affected, there is a predilection for disseminated disease to involve the head and neck region.

Although primary skin disease may occur in the absence of pulmonary infection, diagnosis of cutaneous cryptococcosis always warrants an investigation for systemic infection, especially because disseminated disease may not always be evident clinically. This is usually accomplished by examining cerebrospinal fluid for cryptococcal polysaccharide antigens. For skin lesions, budding encapsulated yeasts can be identified readily in tissue biopsy specimens as well as in material obtained by a scraping of skin lesions. The yeast stain red with periodic acid-Schiff and mucicarmine stains and black with methenamine silver stain. India ink can be used to accentuate the capsule in a skin scraping (Fig. 29-14). *Cryptococcus* can be isolated in culture of cutaneous tissue. The treatment of choice for cryptococcosis is intravenous amphotericin B with or without flucytosine. Fluconazole is used as alternative primary treatment and is the treatment of choice for prophylaxis in individuals at high risk for primary or recurrent infection.

HISTOPLASMOSIS (See Chap. 190) *Histoplasma capsulatum* is a dimorphic fungus that is found commonly in soil in central and eastern regions of the United States. As with cryptococcosis, inhalation of airborne spores causes primary pulmonary infection that usually leads to self-limited disease in otherwise healthy individuals. Disseminated disease most often occurs in individuals with deficiencies in cell-mediated immunity.[42] In addition to pneumonia, immunosuppressed hosts may show fever, renal failure, central nervous system involvement, hepatosplenomegaly, lymphadenopathy, and myelosuppression.

Skin lesions occur in 5 percent to 25 percent of patients with disseminated infection and may be an initial sign of disease.[43] Mucocutaneous lesions commonly manifest as painful nodules or plaques that progress to ulcers with indurated borders. Numerous other morphologic forms have also been described, including molluscum-like papules, acneiform papules and pustules, and cellulitis. In addition, as with cryptococcosis, the head and neck region is involved most frequently. In fact, the oropharynx is the most common site for lesions of mucocutaneous histoplasmosis. Because the organism grows very slowly in culture, histoplasmosis is best diagnosed by direct examination of tissue. Numerous small, oval, yeast-like fungi can be seen within the cytoplasm of dermal macrophages. Antigen testing is also available, but cross-reaction can occur with blastomycosis and other fungal infections (though not with cryptococcus). The treatment of choice for disseminated histoplasmosis in an immunosuppressed host is intravenous amphotericin B. For patients who are not acutely ill, oral itraconazole may be used; itraconazole is also recommended for immunosuppressed patients to prevent recurrent disease.

COCCIDIOIDOMYCOSIS (See Chap. 190) *Coccidioides immitis*, the causative agent of coccidioidomycosis, is endemic to soil in the southwestern United States, and infection is usually acquired through inhalation of spores, which causes pulmonary disease.[44] Although progressive primary infection may occur in immunosuppressed patients, reactivation of a prior, clinically unapparent infection appears to be more common. The risks of dissemination and fatal infection are greater among pregnant women, non-Caucasians, and immunosuppressed patients with defects in cell-mediated immunity. Thus, disseminated coccidioidomycosis can occur in any immunocompromised patient who lives or has lived previously in an endemic area.

Immunosuppressed patients with disseminated disease may have fever, pneumonia, bone involvement, and meningitis. Mortality is high. Skin lesions are varied, but include multiple verrucous papules, abscesses, and ulcerated papules and plaques. Distinguishing primary cutaneous lesions (which are rare) from disseminated disease is important and may require serologic testing.[45] Primary cutaneous lesions usually resolve in healthy individuals, whereas lesions persist in immunocompromised patients. Other cutaneous lesions seen in systemic disease include erythema multiforme, urticaria, a maculopapular rash, and erythema nodosum. Definitive diagnosis of coccidioidomycosis is made by demonstrating characteristic endosporulating spherules in smears or biopsy specimens or by culture of infected tissue. In disseminated infections in immunosuppressed hosts, treatments for life-threat-

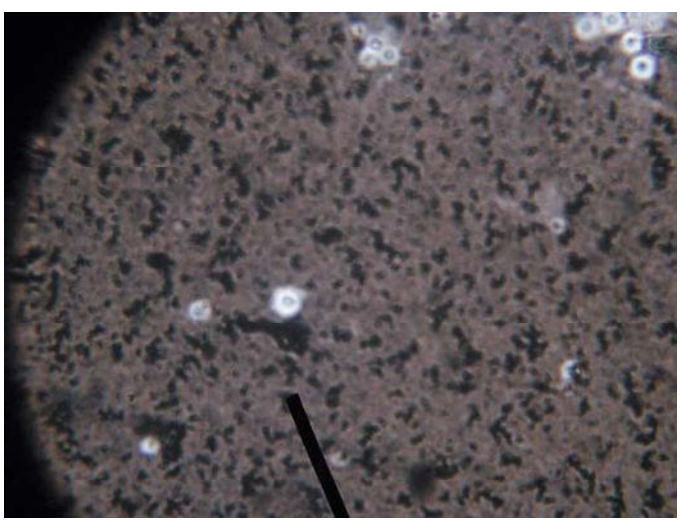

▲ **FIGURE 29-14** Low-power microscopic examination of a skin scraping from the patient in Fig. 29-13 stained with India ink. The capsule resists the stain and appears as a halo around the organism. Slide preparations can help confirm the diagnosis rapidly. (Used with permission from Yale Residents' slide collection.)



ening disease include amphotericin B until infection is controlled, followed by itraconazole or fluconazole. Immunosuppressed patients with meningeal disease may require lifelong therapy.[46]

BLASTOMYCOSIS (See Chap. 190) *Blastomyces dermatitidis* is endemic to the soil of the Ohio and Mississippi river valleys. Infection is acquired through inhalation of spores. Immunosuppressed patients are prone to disseminated disease involving the lungs, bone, genital tract, and skin. Skin is the most common extrapulmonary site of involvement.[47,48] Lesions appear as verrucous or ulcerated plaques with serpiginous borders located on the head, neck, or distal extremities. Ulcerative lesions begin as subcutaneous nodules and pustular lesions. Subcutaneous, tender lesions can also occur that mimic panniculitis.[47] Diagnosis is made on demonstration of broad-based, budding, thick-walled yeasts in exudates or skin scrapings from the edges of lesions or by tissue culture. In life-threatening disseminated infection, intravenous amphotericin B is the treatment of choice, whereas less severe disease is treated with oral itraconazole.

OTHER FUNGAL INFECTIONS *Alternaria* is a common saprophytic fungus that can cause opportunistic infection in the setting of organ transplantation, Cushing syndrome, autoimmune bullous disease, and lymphoproliferative disorder. Over half of the patients reported to have cutaneous alternariosis were taking systemic corticosteroids, and secondary increased skin fragility has been implicated as a risk factor. There are two routes of infection: traumatic inoculation and secondary colonization of a pre-existing skin lesion.[49]

Penicillium marneffei is a dimorphic fungus that is common in Southeast Asia (see Chap. 190). Most infections are associated with HIV disease, although disseminated infection has been reported in immunosuppressed travelers to endemic areas.[50] Tinea versicolor and folliculitis caused by *Pityrosporum ovale* (also known as *Malassezia furfur*) (see Chap. 189) may be widespread and persistent in immunosuppressed hosts. In addition, *Malassezia* has been reported to cause indwelling catheter–associated fungemia in immunosuppressed hosts, especially in those receiving parenteral lipid preparations.

Viral Infections

HERPESVIRUS INFECTION (See Chaps. 192, 193, and 194) Herpesviruses include HSV-1, HSV-2, VZV, human herpesvirus 6 (HHV-6), HHV-7, Epstein-Barr virus (EBV), and Kaposi sarcoma–associated herpesvirus (KSHV). Infections are most prevalent in patients with acquired defects in cell-mediated immunity. Herpesviruses infect hosts for life and remain dormant in the nuclei of latently infected cells. Suppression of immunity often leads to reactivation (i.e., a latent to lytic switch).

Recurrent HSV-1, HSV-2, and VZV infections are common in cancer and post-transplant patients, with 70 percent to 80 percent experiencing reactivation with at least one of these three viruses. Herpes zoster (recurrent VZV infection) is most likely to occur during the first year after transplantation, and the incidence ranges from close to 6 percent in liver transplant recipients to 16 percent in heart transplant patients.[51] Although presentations can be identical to those in immunocompetent hosts, presentations atypical in morphology and distribution can occur. For example, in immunosuppressed hosts recurrent lesions due to HSV or VZV may be isolated, nondermatomal, disseminated, necrotic, ulcerative, or verrucous (Figs. 29-15 and 29-16). In the mouth, chronic recurrent HSV infection can form white plaques and can be confused clinically with candidiasis. Lesions can occur in atypical locations, such as the tongue. Severe pain often is associated with both skin and oral lesions, and postherpetic pain is common. Protracted clinical courses of recurrent HSV or VZV infection are also more common in the setting of immunosuppression. In short, any painful, eroded lesion in an immunocompromised patient, regardless of its distribution or age, should be evaluated for both HSV and VZV by Tzanck preparation, immunofluorescence testing for viral antigen, polymerase chain reaction testing, and/or viral culture. Importantly, systemic infection involving the lungs, central nervous system, liver, heart, and gastrointestinal tract may occur. Treatment with systemic acyclovir or a related antiherpesvirus drug is always necessary. Prophylactic treatment to prevent recurrent episodes should be considered for individual patients if warranted. Foscarnet is the drug of choice for acyclovir-resistant viruses.



▲ **FIGURE 29-15** Severe chronic herpes simplex infection in a patient receiving long-term, high-dose glucocorticoids for autoimmune disease.



▲ **FIGURE 29-16** Severe recurrent varicella-zoster virus infection in a child with acute lymphocytic leukemia.

Reactivation and recurrent disease associated with CMV (see Chap. 192) are major causes of morbidity and mortality in patients with marked immunosuppression, occurring in up to one-third of transplant patients.[52] In this population, disease is most commonly caused by reactivation of pre-existing CMV infection, although CMV may be transmitted from donor to host via the transplanted organ. CMV retinitis, gastroenteritis, hepatitis, and pneumonitis are the most common clinical disease manifestations. Cutaneous lesions are varied and non-specific, including ulcers, papules, vesicles, petechiae, and morbilliform eruptions. Oral ulcers caused by CMV, particularly on the lateral aspects of the tongue, are most common. Painful, punched-out perianal ulcers have been reported and are probably the most specific type of skin lesion attributable to CMV infection. Tzanck preparations of specimens



from the bases of ulcers may show multinucleated giant cells, and CMV-infected dermal endothelial cells may be seen in tissue sections by routine microscopy, appearing as large cells with intranuclear inclusions surrounded by clear halos (owl-eye nuclei). In addition, CMV can be cultured from infected skin. Ulcers containing both CMV and HSV also have been reported. The treatment of choice for systemic CMV disease is intravenous ganciclovir, although intravenous foscarnet, cidofovir, or CMV immunoglobulin also may be effective. HHV-6 and HHV-7, herpesviruses closely related to CMV, also can cause widespread multiorgan infection in immunosuppressed individuals.

EBV and KSHV infections (see Chaps. 128 and 192) are distinguished from the other herpesviruses infections in that they are associated with malignancies in the setting of immunosuppression. Specifically, chronic reactivated EBV infection is associated with non-Hodgkin lymphoma and other lymphoproliferative disorders, whereas chronic KSHV infection is associated with Kaposi sarcoma (KS), primary effusion lymphoma, and the plasmablastic variant of Castleman disease. Their neoplastic potential is discussed further later. Oral hairy leukoplakia is a unique presentation of EBV reactivation within oral mucosal epithelial cells, classically seen in patients with AIDS but also seen in other immunosuppressed individuals (see Chap. 198).[52] Lesions appear as adherent, white, corrugated plaques on the lateral aspects of the tongue. Histologically, there is hyperkeratosis and vacuolated suprabasal epithelial cells. Oral hairy leukoplakia may respond to topical podophyllin or high-dose acyclovir; however, it is usually asymptomatic and does not require treatment. Although it has been regarded as a poor prognostic indicator in HIV-infected individuals, the clinical significance of oral hairy leukoplakia in transplant patients is not known.

HUMAN PAPILLOMAVIRUS INFECTION (See Chap. 196) Warts caused by human papillomavirus (HPV) infection are a common problem in post-transplant patients and in others receiving long-term immunosuppressive drug therapy. The prevalence of warts is higher in patients taking cyclosporine-based regimens than in immunosuppressed patients not taking cyclosporine. In addition, the prevalence of warts increases with longer duration of immune compromise, with up to 95 percent of individuals affected 5 years after transplant surgery. In this setting, lesions are numerous, persistent, and difficult to eradicate. The morphology of the lesions may be typical or atypical. Atypical lesions appear as scaly macules and plaques, occur more commonly in sun-exposed areas, and are associated with HPV types observed in patients with epidermodysplasia verruciformis (e.g., HPV types 5 and 8). Several studies have reported that systemic retinoids (i.e., isotretinoin or acitretin) can prevent or decrease wart formation and prevent a variety of pre-malignant and malignant cutaneous lesions in post-transplant patients. In these patients, the association between HPV infection and cutaneous genital and non-genital squamous cell carcinoma (SCC) is complex, as discussed in Non-Melanoma Skin Cancer.



▲ **FIGURE 29-17** Norwegian (crusted) scabies in a man with non-Hodgkin lymphoma.

Parasitic Infestations: Norwegian Scabies (See Chap. 208)

Norwegian (or keratotic or crusted) scabies infection typically occurs in the settings of mental deficiency, malnutrition, or immunosuppression. Clinically, patients present with multiple widespread, thick, gray or yellowish scaly plaques (Fig. 29-17), with numerous mites present within lesions. Unlike in common scabies, pruritus may be minimal. Several courses of treatment with topical permethrin, as well as keratolytics, may be necessary to cure patients. Oral ivermectin is useful in these patients.

Cancer

NON-MELANOMA SKIN CANCER (See Chaps. 114 and 115) Non-melanoma skin cancer is the most common malignancy in adult solid organ transplant patients and causes significant morbidity and mortality. The overwhelming majority of these neoplasms are SCCs; however, the incidences of basal cell carcinomas and other cutaneous malignancies are also increased.[53] For SCC, the risk is at least 65 times higher in transplant patients than in the general population and increases exponentially with length of immunosuppression.[53,54] The cumulative incidence is a staggering 80 percent after 20 years of immunosuppressive therapy in renal transplant patients.[55] The incidence of other epithelial proliferative diseases, including actinic keratoses, keratoacanthomas, porokeratosis, appendageal tumors, and sebaceous carcinomas, is greatly increased as well.

The pathogenesis of non-melanoma skin cancers in post-transplant patients is multifactorial and has been studied and reviewed extensively.[53,56,57] The distribution of lesions and the populations at highest risk suggest that sun exposure is one of the most important risk factors.[58] Risk also increases with age and is greater for those with fair skin type, those living near the equator, and those with documented histories of significant sun exposure. In addition, gene mutations in tumor suppressor gene p53 characteristic of those caused by ultraviolet radiation are found within non-melanoma skin cancers in transplant patients.[59,60] The role of immunosuppressive medications is dual. Some of the most common agents (azathioprine and cyclosporine) are directly carcinogenic, and their additional effects on the immune system diminish immune surveillance mechanisms that potentially serve to eradicate pre-cancerous lesions. The role of HPV infection in organ transplant recipients is unclear. HPV is known to cause cervical SCC and can be detected in cutaneous cancers of transplant patients. Furthermore, epidermodysplasia verruciformis–associated HPV types (5, 8, and others) have been detected in cutaneous SCC, and there is suspicion that in-



fections by these viruses may occur at an increased rate in immunosuppressed patients. Asymptomatic infection has been identified in the general population, however, and thus it is unclear whether these HPV types are transcriptionally active and pathogenic in forming skin cancers in the setting of immunosuppression.[61–63]

Importantly, SCC in post-transplant patients can be clinically aggressive. Local invasion, recurrence after primary treatment, and distant metastases are not uncommon and are all associated with a higher rate of mortality in organ transplant recipients.[56,64] The mortality rate from skin cancers in this population should not be underestimated. Skin cancers accounted for up to 27 percent of deaths in heart transplant recipients after the fourth year post-transplantation.[65]



Oral mucosal leukoplakia and oral SCC also occur more commonly in immunocompromised individuals.[66] Lip lesions are particularly common, which suggests a pathogenic role for sunlight in lesion formation.

The incidence of Merkel cell carcinoma (see Chap. 120) is increased and the cancer presents at a younger age in transplant recipients. Sentinel lymph node biopsy has become the standard of care in this population due to the high rate of lymph node metastases.[67,68] The mortality rate is high at 56 percent 2 years after diagnosis, which is nearly twice the rate for immunocompetent individuals.

Careful and regular examination of skin and oral mucosa by both patients and dermatologists is required for all transplant patients, with an emphasis on monitoring of potentially pre-malignant lesions (e.g., actinic keratoses, porokeratosis, leukoplakia) for morphologic changes and initiation of treatment as indicated. Ideally, patients would be treated for pre-cancerous lesions before transplant surgery. All transplant patients should be advised to maximize sun precautions. Oral retinoids, especially acitretin, have been used successfully to decrease the occurrence of new SCCs and actinic keratoses in transplant patients but can be difficult to tolerate.[69] A range of dosages has been used, and good effects with minimal side effects have been reported at daily dosages of 0.2 to 0.4 mg/kg/day.[70] It is a common clinical observation that when the medication is discontinued, numerous cancerous lesions arise (described as a rebound effect).[71] Thus, when retinoids are considered for prophylaxis of non-melanoma skin cancers, they should be considered as a long-term treatment.

MELANOMA (See Chap. 124) The incidence of melanoma and widespread atypical melanocytic nevi may be increased in transplant recipients and in other immunosuppressed patients.[72] In particular, children who have had transplants appear to be at higher risk for the development of melanoma (14 percent of all skin cancers) compared with adults (5 percent of skin all cancers).[73] Most melanomas arise from precursor nevi in these patients. Melanomas have also been reported to originate from donor organs causing metastatic disease in graft recipients.[74]

LYMPHOMA (See Chap. 146) Lymphoproliferative disorders are common after transplantation and are often related to EBV-mediated proliferation of B cells. Extra-nodal involvement is common, including involvement of the gastrointestinal tract, lungs, central nervous system, the transplanted organ, and skin.[75,76] Lesions present as violaceous macules to firm papules and plaques, similar to presentation in immunocompetent individuals. Lymphoma with purely cutaneous involvement is rare after transplantation. Most reported cases represent lymphomas of B-cell origin and are occasionally $CD30^+$. The presence of EBV is often detected. Prognosis is generally better if there is cutaneous involvement alone, perhaps due to the ease of detection. Cutaneous T-cell lymphomas account for 30 percent of cases of cutaneous lymphomas in transplant patients. EBV is not associated with development in these patients. Clinical presentation is similar to that in non-transplant patients, except that there is an increased incidence of erythroderma. Prognosis is also worse than for cutaneous T-cell lymphoma in the general population.[77]

KAPOSI SARCOMA (See Chap. 128) The occurrence of KS is increased in patients receiving immunosuppressive therapy after organ transplantation, with an incidence of 0.5 percent to 5.0 percent. Risk factors in transplant recipients include male sex and Mediterranean, Jewish, Arabic, Caribbean, or African descent, as in the classic form of the disease.[78,79] All cases of KS, regardless of clinical or geographic setting, are associated with KSHV infection.[80] The vast majority of patients with post-transplant KS are KSHV seropositive before transplantation. Rarely, post-transplant KS can occur when KSHV-infected organs are transplanted into KSHV seronegative recipients.[81,82]

Clinically, skin lesions of post-transplant KS are identical to other forms of KS. As in classic KS, transplant-associated disease is found most commonly on the lower legs and feet, although the groin and oral cavity are also common locations. Typically, early KS lesions are deep red to violaceous macules or patches. With time, lesions develop into papules, plaques, nodules, or tumors. Visceral involvement occurs in 25 percent of renal transplant patients and 50 percent of those with heart or lung transplants.[83] Reduction in immunosuppressive treatment often causes disease regression, although these patients remain at risk for developing KS at a later time if immunosuppressive therapy is reinstituted. Additional treatments include local excision or radiation therapy, intralesional therapy, and systemic chemotherapy.

KEY REFERENCES

The full reference list for all chapters is available at www.digm7.com.

3. Leather HL, Wingard JR: Infections following hematopoietic stem cell transplantation. *Infect Dis Clin North Am* **15**:483, 2001
8. Lopez FA, Sanders CV: Dermatologic infections in the immunocompromised (non-HIV) host. *Infect Dis Clin North Am* **15**:671, 2001
14. Giamarellou H, Antoniadou A: Infectious complications of febrile leukopenia. *Infect Dis Clin North Am* **15**:457, 2001
23. Rolston K: Overview of systemic fungal infections. *Oncology (Williston Park)* **15**:11, 2001
26. Doucette K, Fishman JA: Nontuberculous mycobacterial infection in hematopoietic stem cell and solid organ transplant recipients. *Clin Infect Dis* **38**:1428, 2004
38. Conant MA: Fungal infections in immunocompromised individuals. *Dermatol Clin* **14**:155, 1996
44. Virgili A, Zampino MR, Mantovani L: Fungal skin infections in organ transplant recipients. *Am J Clin Dermatol* **3**:19, 2002
52. Tan HH, Goh CL: Viral infections affecting the skin in organ transplant recipients: Epidemiology and current management strategies. *Am J Clin Dermatol* **7**:13, 2006
53. Euvrard S, Kanitakis J, Claudy A: Skin cancers after organ transplantation. *N Engl J Med* **348**:1681, 2003
83. Farge D: Kaposi's sarcoma in organ transplant recipients. The Collaborative Transplantation Research Group of Ile de France. *Eur J Med* **2**:339, 1993

SECTION 5

INFLAMMATORY DISEASES BASED ON NEUTROPHILS AND EOSINOPHILS

CHAPTER 30

Regulation of the Production and Activation of Neutrophils and Eosinophils

Steven M. Holland
James Loveless
Lisa A. Beck

NEUTROPHILS

This section presents an overview of neutrophil biology and function and uses a few well-characterized defects of myeloid function as illustrations.

Ontogeny and Development

Similar to the other components of the hematopoietic system, the neutrophil is ultimately derived from a pluripotent hematopoietic stem cell. The development of the myeloid stem cell is largely determined by ambient cytokines and reflected in its surface markers, morphology, and functional characteristics. The myeloblast is fully committed to the neutrophil lineage and is the first morphologically distinct cell in neutrophil development. Subsequent stages of neutrophil development occur under the influence of granulocyte colony-stimulating factor (G-CSF) and granulocyte-macrophage colony-stimulating factor (GM-CSF). Four to six days are required for maturation through the mitotic phase to the myelocyte, and 5 to 7 days more for the myelocyte to develop into a mature neutrophil, including the metamyelocyte and band stages, before emerging as a fully developed neutrophil. Development of neutrophils through the myelocyte stage normally occurs exclusively in the bone marrow, which is composed of approximately 60 percent developing neutrophils. The mature neutrophil measures 10 to 12 μm and has a highly condensed, segmented, multi-lobulated nucleus, usually with three to five lobes. Although 10^{11} neutrophils are generated daily, this number can rise 10-fold in the setting of infection. The calculated circulating granulocyte pool is 0.3×10^9 cells/kg blood and the marginated pool is 0.4×10^9 cells/kg blood, comprising only 3 percent and 4 percent of the total granulocyte pool, respectively. The bone marrow releases 1.5×10^9 cells/kg blood/day to this pool but keeps 8.8×10^9 cells/kg blood in the marrow in reserve. An additional reserve of immature and less competent neutrophils, 2.8×10^9 cells/kg blood, is also available.

G-CSF is critically important for neutrophil production.[1] Mice deficient in G-CSF show reduced neutrophil numbers and cannot upregulate neutrophil numbers in response to infection.

Biologic Functions

GRANULE CONTENT AND FUNCTION (Table 30-1) Neutrophils are characterized by cytoplasmic granules and partially condensed nuclei. Granules are first found at the promyelocyte stage.[2] Primary (azurophilic) granules are the first to arise, measure approximately 0.8 μm in diameter, and contain numerous antimicrobial products including lysozyme, myeloperoxidase, and defensins.[3] Primary granules are only synthesized at the promyelocyte stage. The promyelocyte gives rise to the myelocyte, the last cell of the neutrophil lineage with proliferative potential. Therefore, cytokines or agents which increase total neutrophil production must act at or before the myelocyte stage. The smaller eosinophilic secondary (specific) granules appear during the myelocyte stage. These granules measure about 0.5 μm in diameter and contain lactoferrin, collagenase, gelatinase, vitamin B_{12}–binding protein, and complement receptor 3 (CR3; CD11b/CD18). $gp91^{phox}$ and $p22^{phox}$ comprise the specific granule component cytochrome b_{558}, defects in which cause chronic granulomatous disease

NEUTROPHILS AT A GLANCE



- Human bone marrow commits enormous resources to the creation of neutrophils, producing approximately 10^{11} daily with a circulating half-life of approximately 7.5 hours and tissue survival for 1 to 2 days.
- Neutrophils are absolutely required for the prevention of infection and are not yet amenable to significant external replacement therapy.
- The neutrophil not only plays a central role in host defense, it can be responsible for significant tissue damage as well.
- The pathophysiology of the neutrophil indicates pathways, which can be exploited to enhance protection from infection. Selective abrogation of those pathways that are injurious in certain settings is also possible.
- Regulation of neutrophil responses in the skin is a major concern.



Copyright © 2008 by The McGraw-Hill Companies, Inc. Click here for terms of use.

TABLE 30-1
Human Neutrophil and Eosinophil Components

Primary Granules	Secondary Granules	Other Cytoplasmic Organelles
Neutrophil		
• Galactin-10		
Enzymes		
• Bactericidal/permeability-increasing protein		
• Defensins	• p15s	
• Lysozyme	• Lysozyme	
• Myeloperoxidase		
• Elastase		
• Cathepsin G		
• Proteinase 3	• Proteinase 3	
• Azurocidin		
• Phospholipase A2		
• 5-Lipoxygenase		
• Cyclooxygenase		
Acid hydrolases		
• Cathepsin B	• Cathepsin B	Cathepsin B
• Cathepsin D	• Cathepsin D	Cathepsin D
• β-Glycerophosphatase		β-Glycerophosphatase
• β-Glucuronidase		β-Glucuronidase
• *N*-acetyl-β-glucosamine		*N*-acetyl-β-glucosamine
• α-Mannosidase		α-Mannosidase
Eosinophil	Cationic proteins	
• Galactin-10	• Major basic protein	
• α-Mannosidase	• Eosinophil cationic protein	
	• Eosinophil-derived neurotoxin	
	• Eosinophil peroxidase	
	Enzymes	Acid hydrolases
	Cytokines	β-Glucuronidase
	Growth factors	Arylsulfatase B
	Chemokines	Acid phosphatase
		Catalase
		Histaminase
		Collagenase
		Matrix metalloproteinase 9
		Enzymes
		Phospholipase A2
		Cyclooxygenases
		5-Lipoxygenase
		15-Lipoxygenase
		Leukotriene C_4 synthase



(CGD), characterized by infections with particular catalase-producing bacteria. Gelatinase also cleaves and potentiates the activity of the chemokine interleukin 8 (IL-8). Because primary granules are synthesized early and distributed to daughter cells during division, they are eventually outnumbered by about 3:1 by the specific granules, which are produced throughout the myelocyte stage.

Granules fuse in a sequential fashion with incoming phagocytic vacuoles, such as those containing ingested bacteria. Secondary granules fuse to the phagosome within the first 30 seconds after ingestion and release their enzymes, many of which function best at neutral or alkaline pH. By 3 minutes after ingestion, the primary granules have fused to the phagolysosome leading to rapid lowering of the intravacuolar pH. For objects too large to be ingested, or certain stimuli, degranulation to the cell surface occurs with release of granule contents into the surrounding environment. This can be inferred by detection of lactoferrin levels in blood.

An example of disordered granule biogenesis is Chédiak-Higashi syndrome (CHS), a rare autosomal recessive disorder with abnormal pigmentation due to a generalized abnormality of primary granule and lysosome formation (see Chap. 144).

NEUTROPHIL-SPECIFIC GRANULE DEFICIENCY

Neutrophil-specific granule deficiency is a rare, autosomal recessive condition clinically characterized by a profound susceptibility to bacterial infections. There is a paucity or absence of neutrophil-specific granules, specific granule proteins (e.g., lactoferrin), and their respective messenger RNAs, and very low levels of the primary granule products defensins and their messenger RNAs. Specific granule deficiency is due to loss of the transcriptional factor CCAAT/enhancer binding protein e (CEBPe), which is essential in normal myeloid development. Acquired abnormalities of neutrophil granules are seen in some myeloid leukemias, in which primary granule contents may be aberrantly accumulated (e.g., Auer rods in acute myelogenous leukemia).

Tissue Trafficking

CHEMOATTRACTANTS AND CHEMOTAXIS

Metchnikoff discovered over a century ago that neutrophils move toward very slight gradients of chemical signals, now termed *chemoattraction*. The "classic" chemoattractants are *N*-formyl-methionyl-leucyl-phenylalanine, complement factor 5a (C5a), leukotriene B_4, and platelet-activating factor (PAF). More recently, chemokines (*chemo*attractant cyto*kines*), a class of small (< 10 kd) extremely active chemoattractant proteins have been identified (see Chap. 12).

IL-8 is a potent chemoattractant and neutrophil activator (see Chap. 11). Its blockade by neutralizing antibody in rabbit models of pulmonary inflammation prevented neutrophil accumulation and reperfusion injury, confirming its central role in neutrophil recruitment to sites of inflammation. Cellular sources for IL-8 include neutrophils, monocytes, T cells, B cells, natural killer cells, basophils, eosinophils, fibroblasts, endothelial cells, keratinocytes, and smooth muscle. Exudative neutrophils are particularly effective at synthesizing IL-8, probably through a calcium-regulated mechanism.

Exuberant neutrophil function is implicated in Sweet syndrome (acute febrile neutrophilic dermatosis) as shown by the frequent association of the syndrome with hematologic malignancies, dysmyelopoiesis, and sometimes with the use of G-CSF (see Chap. 31).

The classic chemoattractants and chemokines use similar receptors that have in common seven transmembrane regions, an extracellular amino terminal domain, and transduce their signals through pertussis-toxin sensitive heterotrimeric G proteins. These are the same type of receptors through which light, neuropeptides, and neurotransmitters signal. Chemoattractant receptor signaling entails exchange of bound guanine diphosphate for guanine triphosphate by the α subunit of the heterotrimeric G protein, which in turn leads to the dissociation of the β-γ subunit of the complex, stimulation of phospholipase C, and generation of inositol triphosphate and diacylglycerol from phosphatidylinositol bisphosphate. Inositol triphosphate stimulates the release of calcium from intracellular "calciosomes," whereas diacylglycerol activates protein kinase C. Extracellular calcium also enters the cell, preparing it for subsequent movement, generation of oxidants, and secretion of vesicles.

Ras-related guanosine triphosphatases of the rho superfamily are also involved in actin cytoskeletal regulation and adhesion. Phosphatidylinositol 3-kinase is activated by rho and ras and is necessary for the neutrophilic respiratory burst, adhesion, endothelial transmigration, and chemotaxis. Mitogen-activated protein (MAP) kinases are serine/threonine kinases that include p38, Erk1, Erk2, and Jnk and are involved in neutrophil signaling and adhesion. Inhibition of p38 impairs chemotaxis and tumor necrosis factor (TNF)-α–mediated superoxide production, adhesion, and release of secondary granules. Erk activation is required for neutrophil homotypic aggregation. Salicylates also inhibit neutrophil adhesion through Erk inhibition.

Several chemokine receptors also function as necessary human immunodeficiency virus (HIV) co-receptors. Mutations in the chemokine receptor CCR5 that are protective against HIV infection have spawned investigation into chemokine receptor blockade for prevention of HIV infection.

ADHESION Neutrophils exist as free-flowing (those which are sampled on blood drawing) and marginated cells (those which are attached to the endothelium or are traversing the lung, skin, or other tissues). Neutrophils rolling along the endothelium recognize sites of activation (e.g., chemokine expression), adhere to those sites, and traverse the endothelium to enter the tissue and fight infection. Leukocyte physical interaction with endothelium and other leukocytes is mediated by integrins, selectins, and intercellular adhesion molecules (ICAMs; Fig. 30-1).

Elaboration of chemoattractants or display of activation markers on endothelium triggers leukocyte high affinity binding by β_2 integrins, heterodimeric surface molecules largely stored in the secondary granules of neutrophils that are displayed on the cell surface upon leukocyte activation. There are three β_2 integrin heterodimers comprised of different α chains, CD11a, -b, and -c, and a common β chain, CD18. Each CD11/CD18 complex has separate and overlapping activities. CD11a/CD18 [leukocyte function–associated molecule 1 (LFA-1)] binds to other leukocytes and mediates tight adhesion to the endothelium through ICAM-1 and ICAM-2. CD11b/CD18 (Mac-1, Mo-1, or CR3) binds to the inactivated form of the third component of complement (C3bi) and thereby facilitates complement-mediated phagocytosis. CD11b/CD18 also binds to bacteria directly, to fibrinogen, and to endothelium through ICAM-1. The divalent cations Ca^{2+} and Mg^{2+}/Mn^{2+} mediate adhesion through β_2 integrin "A" domains containing a metal ion-dependent adhesion site. CD11b/CD18 may also induce the expression of the β_1 integrin very late antigen 6 [VLA-6 (CD49f/CD29)], derived from neutrophilic granules, to aid in tissue infiltration. The integrin-associated protein (CD47), expressed on neutrophils and endothelial and epithelial cells, is also involved in the transendothelial and transepithelial migration of neutrophils.[4] Metalloproteinases may be involved in cleavage of L-selectin, allowing neutrophil migration through the basement membrane.

Absence of CD18 causes lack of the CD18/CD11 heterodimers and is called *leukocyte adhesion deficiency type 1* (LAD1). Neutrophils lacking CD18 roll normally along the endothelium but are unable to stick to the vessel wall or exit the circulation after chemotactic stimulation. Absence of LFA-1 (CD11a/CD18) makes neutrophils unable to bind tightly to and traverse activated endothelium to infected areas. Therefore, affected patients have chronic neutrophil leukocytosis, presumably from inability of neutrophils to bind tightly to endothelium and exit the circulation, thus leading to a reduction in the marginated pool and an increase in the circulating pool. Poor neutrophil penetration to sites of bacterial invasion leads to necrotic ulcers that lack neutrophils on biopsy. Absence of Mac-1 (CD18/CD11b or CR3) leads to inability to perform complement-mediated phagocytosis, although antibody-mediated phagocytosis remains intact.

Severe LAD-1 (< 0.5 percent of normal protein expression) is a disorder manifested by delayed umbilical stump separation, umbilical stump infection, persistent leukocytosis in the absence of active infection (> 15,000/μL), and severe, destructive periodontitis with loss of teeth and alveolar bone. Recurrent infections of the skin, upper and lower airway, bowel, perirectal area, and septicemia are common and usually due to *Staphylococcus aureus* or Gram-negative rods. Severe LAD-1 patients should receive bone marrow transplantation in early childhood. Moderate LAD-1 (2.5 percent to 10.0 percent of normal protein expression) tends to be diagnosed later in life and is less commonly associated with life-threatening infections. Leukocytosis, delayed wound healing, and periodontal disease are still common. Fluorescent-activated cell sorting shows reduction or absence of CD18 and the co-expressed molecules CD11a, CD11b, and CD11c.

Neutrophil "rolling" along the endothelium is mediated through selectins, surface glycoproteins on the endothelium, and sialyl-Lewis X (CD15s), a surface glycoprotein on neutrophils (see Fig. 30-1). Endothelial cells express E-selectin (CD62E) and P-selectin (CD62P), whereas leukocytes express L-selectin (CD62L). Although endothelial E-selectin and P-selectin bind to the sialyl-Lewis X (CD15s) antigen on neutrophils, the neutrophil molecule L-selectin probably binds to distinct antigens on endothelium, including CD34, and is highly sensitive to glycosylation. L-selectin is shed by neutrophils on activation, thereby allowing neutrophil migration into sites of inflammation. Cross-linking of L-selectin on neutrophils results in superoxide generation and may result in upregulation of TNF-α, IL-8, and tyrosine phosphorylation and activation of MAP kinase. LAD2 occurs in the absence of properly fucosylated CD15s, leading to neutrophilia, recurrent pulmonary, periodontal, and cutaneous infections, and abnormal chemotaxis. The defect is in the gene FUCT1, which is a fucosyl transferase. Because the product of FUCT1 is a GDP-fucose transporter, this disease is now classified as a congenital disorder of glycosylation (CDG), and known as *CDG-IIc*. Interestingly, although infections are common early in life, LAD-2 (CDG-IIc) patients appear to improve with age. Administration of oral fucose to some patients with LAD-2 has



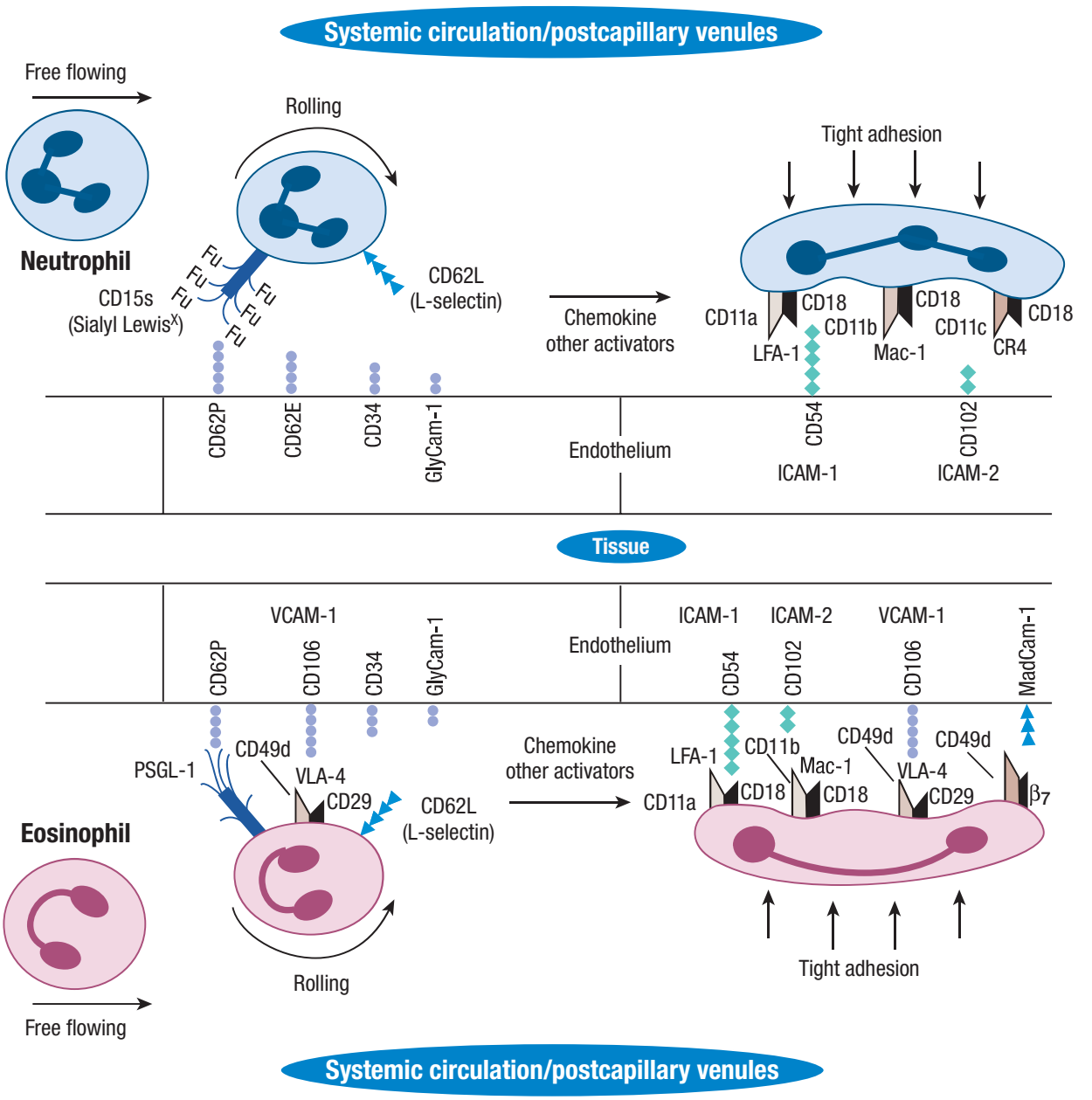

▲ **FIGURE 30-1** Tissue trafficking of neutrophils and eosinophils. The interaction of selectins and integrins on the leukocyte surface with their endothelial addressins is depicted (neutrophils on the top and eosinophils on the bottom). The majority of leukocytes are in a laminar flow pattern. Following tissue signals that activate endothelial selectins and glycoproteins, a subset of leukocytes begin to roll along the vascular wall. For the neutrophil, this typically involves the interaction of CD15s with CD62P (P-selectin) and CD62E (E-selectin) on the endothelial cell or CD62L (L-selectin) with CD34 or glycosylation-dependent cell adhesion molecule 1 (GlyCAM-1) on the endothelial cell. Eosinophil rolling primarily uses P-selectin glycoprotein ligand 1 (PSGL-1) and its counter-ligand on the endothelium, P-selectin, with a more minor role played by CD62L [very late antigen 4 (VLA-4)] and their endothelial addressins, CD34/GlyCAM-1 and vascular cellular adhesion molecule-1 (VCAM-1), respectively. Abnormalities in fucosylation of CD15s cause leukocyte adhesion deficiency 2. Activation of leukocytes by the requisite chemoattractant leads to the expression of integrins with higher avidity conformations. In the case of the neutrophil, the relevant integrins are the β_2 family members [lymphocyte function–associated antigen 1 (LFA-1), Mac-1, and CR4]; whereas eosinophils express a more limited number of β_2 family members (LFA-1 and Mac-1), but also express a β_1 integrin VLA-4 and β_7 integrin ($\alpha_4\beta_7$). The β_2 integrins bind to endothelial intercellular adhesion molecule 1 (ICAM-1) and ICAM-2, whereas the β_1 and β_7 integrins bind VCAM-1 and mucosal addressin cell adhesion molecule-1 (MadCAM-1), respectively. Defects in CD18, the β chain of the β_2 integrins, lead to the inability of neutrophils to exit the circulation at sites of infection and is called *leukocyte adhesion deficiency 1*. Interestingly, eosinophils, monocytes, and lymphocytes are observed at sites of infection in these patients, as these cells can use β_1 integrins to mediate the firm adhesion step required for leukocyte transendothelial migration.

been reported to be therapeutic, but this has not been consistent. Most patients also have mental retardation, short stature, distinctive facies, and the Bombay (hh) blood phenotype, indicating the multiple systems in which fucosylation is critical.

The CD18 integrin pathway is critical for inflammation in the skin, but not necessary for accumulation of neutrophils in the lung or peritoneum. Therefore, although CD18-dependent pathways are critical for cutaneous inflammation, CD18-independent pathways exist for pulmonary and peritoneal inflammation. Further, in the setting of congenital absence of CD18, compensatory pathways exist in the mouse to respond to peritoneal inflammation.

PHAGOCYTOSIS Phagocytosis is the culmination of object recognition, binding, signaling, adherence, cytoskeletal remodeling, engulfment, and membrane fusion. Two mechanisms are well characterized, one mediated by immunoglobulin and one mediated by complement.

Receptors for the Fc portions of immunoglobulin G [IgG (FcγR)] are present on many components of the cellular immune response, including neutrophils, monocytes, macrophages, eosinophils, and basophils. FcγRI (CD64) is a receptor for IgG1 and IgG3 on monocytes, macrophages, and eosinophils and is upregulated on neutrophils after interferon-γ (IFN-γ) stimulation. FcγRII (CD32) binds IgG with rather low affinity, and prefers IgG1 and IgG3. FcγRIII (CD16) binds IgG1 and IgG3 with intermediate affinity. Neutrophil FcγRIIIB, is bound to the membrane through a glycan phosphatidyl inositol linkage, which is largely cleavable by phosphatidyl inositol-specific phospholipase C. As FcγRIIIB has no cytoplasmic domain, its role in signal transduction may be through association with FcγRII. Cross-linking of these receptors by antibody leads to rapid engulfment of targets with release of granule contents and oxygen metabolites into the phagolysosome. If the target is too large, degranulation occurs against the antibody-coated surface.

The complement receptors CR1 and CR3 are expressed on the surfaces of neutrophils, eosinophils, and basophils. Complement receptor 1 is designated *CD35* and is found on many cell types. It binds C3b and enhances its degradation to C3dg by factor I, thereby removing that molecule from further activation of the alternative pathway. CR3, CD11b/CD18, binds iC3b and fibrinogen as well as certain bacteria, parasites, and fungi. CR1 and CR3 are not per se able to stimulate phagocytosis, but in the presence of a second signal, such as one given through FcγR or by cytokines, phagocytosis proceeds.

MECHANISMS OF KILLING Neutrophil granules contain enzymes and proteins for killing ingested bacteria and fungi. Some of these bactericidal mechanisms are dependent on the generation of oxygen metabolites for microbicidal activity, but others are not. In addition to mobilizing their own resources, neutrophils produce a multitude of cytokines that stimulate and attract other phagocytes as well as lymphocytes.

OXYGEN-INDEPENDENT PATHWAYS Bactericidal/permeability-increasing protein (BPI) is a highly potent antibacterial granule protein synthesized and stored in the primary granules. It is a highly basic (isoelectric point > 9.6) protein of 452 amino acids and approximately 58 kd. Sequence homology to lipopolysaccharide (LPS)-binding protein, a critical endotoxin binding acute-phase reactant, suggests that it acts by directly binding to LPS. BPI is cytotoxic to Gram-negative bacteria at concentrations as low as 10^{-9} *M*, but much less effective against Gram-positive organisms. Binding to LPS leads to insertion of BPI into the outer membrane of the organism and eventual insertion into the inner membrane. Arrest of bacterial growth is solely dependent on the N-terminal half of the molecule. The C-terminal fragment serves as an anchor to the membrane. BPI appears to act inside the phagolysosome. Not all Gram-negative rods are sensitive to BPI, especially *Burkholderia (Pseudomonas) cepacia* and *Serratia marcescens*, pathogens in patients who lack oxidative killing.

Defensins are small (< 4 kd) cationic proteins in the primary granules of neutrophils involved in killing ingested Gram-positive and Gram-negative bacteria. Defensins are synthesized during the promyelocyte/myelocyte stage as prepropeptides, stored predominantly in a dense subset of the primary granules as propeptides, and released during neutrophil degranulation. Defensins prefer an actively metabolizing target and can kill transformed mammalian cells as well as prokaryotes and yeasts. Defensins and BPI act synergistically against Gram-negative bacteria. Defensins are reduced in the CHS but absent in specific granule deficiency.

Proteinase 3 is the antigen against which the antineutrophil cytoplasmic antibody is directed in Wegener granulomatosis (see Chap. 165). It is found predominantly in primary granules but is also in secondary and secretory granules. Synthesis and surface display are upregulated by cytokines such as TNF-α. Elastase is a myeloid serine protease in primary granules that has remarkable roles in host defense. Mice with elastase defects have decreased resistance to Gram-negative bacteria. However, human neutrophil elastase deficiency causes severe congenital neutropenia and cyclic neutropenia. Phospholipase A2 is also found in neutrophil granules, where its various isoforms act both directly and synergistically with BPI to kill intracellular bacteria.

Lactoferrin is an iron-binding protein present in specific granules and in mucosal secretions. When released into the phagolysosome, lactoferrin binds iron and inhibits the growth of phagocytosed bacteria and some fungi. The mechanisms through which lactoferrin exerts its antimicrobial action probably include the depletion of iron from an organism's environment, but iron-binding–independent antimicrobial activities and direct immunomodulatory effects are also reported. Lactoferrin is readily released into the circulation after burns and experimental endotoxemia, presumably from neutrophil degranulation.

OXYGEN-DEPENDENT PATHWAYS Neutrophils can produce toxic oxygen metabolites through the reduced nicotinamide dehydrogenase phosphate (NADPH) oxidase complex, which typically is assembled in the wall of the phagolysosome. The NADPH oxidase catalyses the addition of an electron to molecular oxygen, leading to the formation of superoxide anion. Superoxide in turn is converted to hydrogen peroxide by superoxide dismutase. Inside the phagolysosome, the primary granule component myeloperoxidase converts the hydrogen peroxide to hypohalous acid by the addition of a halogen (bleach when the halide is chloride in neutrophils, bromide in eosinophils). The NADPH oxidase is a multiprotein complex, which is maintained in separate membrane-bound and cytosolic compartments. On cell activation, the cytosolic components translocate to the phagolysosome membrane, resulting in an active NADPH oxidase, which can produce the respiratory burst.

The components of the NADPH oxidase are named *phox* (*ph*agocyte *ox*idase) proteins. $p22^{phox}$ and $gp91^{phox}$ are the α and β chains, respectively, of the cytochrome b558 complex, which resides in the wall of the secondary granule. The cytosolic compartment contains three factors, $p47^{phox}$, $p67^{phox}$, $p40^{phox}$ and the small guanine nucleotide (guanine triphosphate) binding protein *rac*. Assembly of the NADPH complex is caused by diverse stimuli. $p47^{phox}$ and $p67^{phox}$ contain *src*-homology type 3 domains (SH3 boxes), which bind to proline-rich targets in themselves and other members of the NADPH complex. Stimulation leads to structural changes in $p47^{phox}$ that promote its interaction with $p22^{phox}$ through $p47^{phox}$ SH3 domains and $p22^{phox}$ C-terminal proline-rich sequences.

Pathologic mutations in the four required components impair the generation of phagocyte superoxide and cause



CGD, a disease characterized by recurrent life-threatening infections with bacteria and fungi and exuberant granuloma formation (see Chap. 144).[5]

Pharmacologic Manipulation

When neutrophils are over-recruited into neutrophilic dermatoses, they can produce reactive oxygen intermediates, activate proteinases, and release chemotactic cytokines, which can contribute to tissue injury and inflammation. Therefore, it makes sense to aim treatment to suppress the generation of reactive oxygen intermediates, to inhibit neutrophil adhesion and chemotaxis, and to suppress the release of lysosomal enzymes and chemotactic factors.

Dapsone is often used for chronic neutrophilic dermatoses such as dermatitis herpetiformis, sub-corneal pustular dermatosis, or erythema elevatum diutinum (see Chap. 226). Dapsone suppresses neutrophil adherence and subsequent migration, is a successful scavenger of reactive oxygen intermediates, and interferes with the myeloperoxidase-halide system and leukocyte-mediated cytotoxicity. Thalidomide reduces inflammation through inhibition of TNF-α and subsequent neutrophil-endothelial adhesion and reactive oxidant generation (see Chap. 236). Dapsone and thalidomide both inhibit the pro-inflammatory cytokine TNF-α, which activates neutrophils through upregulation of complement receptors (CR3, CR4) and endothelial adhesion molecules, ICAM-1, and E-selectin. Colchicine inhibits neutrophil chemotaxis, release of lysosomal enzymes, and production of reactive oxidants and is therefore considered for Sweet syndrome and neutrophilic bullous dermatoses. Antibiotics such as tetracyclines, macrolides, and metronidazole also have antioxidant properties and interfere with neutrophil chemotaxis. In addition to its antioxidant activity, sulfasalazine induces neutrophil apoptosis and enhances adenosine release at sites of inflammation, making it especially useful in pyoderma gangrenosum.

EOSINOPHILS

Ontogeny and Development

Eosinophils develop and mature in the bone marrow from $CD34^+$ hematopoietic progenitor cells and are released into the circulation as mature cells. Eosinophils share this progenitor with basophils, defined as the eosinophil/basophil colony forming unit. This hybrid cell, which has been found in the circulation of subjects with atopic dermatitis, is characterized by granule contents that have features of both cell types as well as by the expression of the IL-5 receptor and the CC chemokine receptor, CCR3.[6] Several investigators have also found eosinophil/basophil colony forming unit in inflamed tissues of subjects with allergic diseases.[7] Because these tissues produce many of the eosinophilopoietins, it has been proposed that extramedullary hematopoiesis may occur at sites of inflammation. IL-5, the most selective eosinophil-active cytokine, induces the differentiation and proliferation of eosinophil precursors in the bone marrow. Allergen challenge induces production of eosinophil precursors in the bone marrow and release of mature eosinophils, which is due to the endocrinologic actions of tissue-derived IL-5 with a modest contribution by the CCR3 ligand, CCL11 (eotaxin). IL-3 and GM-CSF have also been shown to stimulate eosinophil production by the bone marrow and, interestingly, bind to receptors that share a common β chain (with IL-5) but have unique α chains.[8]

Mouse studies have corroborated the primary importance of the cytokines, IL-5, and the CC chemokine, CCL11.[9] For example, IL-5 transgenic mice develop peripheral blood and tissue eosinophilia, whereas the administration of neutralizing anti–IL-5 antibodies in wild-type mice leads to a significant reduction in baseline levels of circulating eosinophils and diminished tissue eosinophilia in response to infection with various parasites or allergen challenge.[10] It is important to note that despite the massive eosinophilia observed in IL-5 transgenic mice, these mice do not develop the tissue damage observed in eosinophilic diseases. This is probably because eosinophils must also be activated to degranulate and/or release their inflammatory mediators. Not surprisingly, mice deficient in both CCL11 and IL-5 have the greatest reduction in tissue eosinophils in asthma models.[10] The human correlate to this would be the recently recognized variant of idiopathic hypereosinophilic syndrome (IHES) referred to as the *lymphocytic variant* (see Chap. 35), where a clonal population of T cells producing IL-5 is responsible for the profound eosinophilia as demonstrated by the dramatic clinical response to an anti–IL-5 (mepolizumab) therapy.[11]

EOSINOPHILS AT A GLANCE



- Eosinophils are bone marrow–derived cells that normally account for 1 percent to 3 percent of peripheral blood leukocytes or less than 350 cells/mm^3 of blood.
- As pro-inflammatory cells, their presence within tissue sites is usually associated with diseased states that can be divided into: Parasitic infections, atopic diseases, fibrotic disorders, reactive eosinophilias, and hypereosinophilic syndromes.
- They play a role in innate and adaptive immune responses, which may explain why they are present in normal, noninflamed tissues such as the gastrointestinal tract and lymphoid tissues.
- This section reviews the biologic actions of eosinophils with particular focus on what controls eosinophil production, activation, and tissue trafficking.
- Pharmacologic manipulation of eosinophilic inflammation is possible but mostly non-specific; however, new, more specific strategies are emerging.

Biologic Functions

Both intact and degranulated eosinophils are a significant component of the inflammatory infiltrate in many cutaneous diseases such as urticaria, bullous pemphigoid, herpes gestationis, drug eruptions, incontinentia pigmenti, arthropod bite in this location, Wells syndrome, and atopic dermatitis.[12–16] Furthermore, evaluations of a variety of tissue samples have demonstrated that eosinophils can be found in lymph nodes and spleen and are especially prominent after allergen or microbial insults.[10] This observation, coupled with evidence that eosinophils can process and present a variety of antigens, has led to the speculation that eosinophils are recruited to secondary lymphoid structures to promote the proliferation of effector T cells. Under more unique situations, eosinophils also home to the thymus, mammary glands, and uterus. It has been suggested based on the localization of eosinophils within the thymus

and the timing of their migration, namely during the neonatal period, that they may be important for thymocyte deletion. Murine models also suggest that eosinophils are important for postnatal mammary gland development and their recruitment into the uterus heralds estrus.[17] Interestingly, eosinophils are resident cells in the lamina propria of much of the gastrointestinal tract and it is thought that reactions play a role in host defense. The recruitment of eosinophils to the gastrointestinal, thymic, and mammary areas appears to be under the control of the CC chemokine, CCL11. There are many pathologic states in the gastrointestinal tract where eosinophil numbers are substantially increased such as drug reactions, helminthic infections, inflammatory bowel disease, gastroesophageal reflux, eosinophilic gastroenteritis, and eosinophilic esophagitis; in the latter condition, there is a report suggesting that tissue eosinophilia and disease manifestations can be treated with an anti–IL-5 therapy (mepolizumab).[10,18–20] The skin, in contrast to these other tissues, is devoid of eosinophils except during pathologic conditions.

EOSINOPHIL ULTRASTRUCTURE AND GRANULE CONTENT (See Table 30-1) Eosinophils are approximately 8 μm in diameter and have a bilobed nucleus and distinctive cytoplasmic granules. Each cell contains approximately 20 membrane-bound, core-containing, secondary granules, which contain the basic proteins.[21] These granules avidly take up acidic dyes such as eosin to give the eosinophils their characteristic microscopic appearance. Four highly basic proteins are found within these granules: major basic protein (MBP), eosinophil cationic protein (ECP), eosinophil peroxidase (EPO), and eosinophil-derived neurotoxin (EDN). Other proteins have been found in the secondary granules, including enzymes, cytokines, growth factors, and chemokines. In addition, the cells contain a number of primary granules, which lack a core and are of variable size. These granules contain Charcot-Leyden crystal protein (also known as *galectin-10*) that is a characteristic feature of asthmatic sputum and can be found in both eosinophils and neutrophils. Normal eosinophils contain five non-membrane–bound lipid bodies, which are the principal stores of arachidonic acid. They also contain the enzymes cyclooxygenase and 5- and 15-lipoxygenase, which are required to synthesize prostaglandins and leukotrienes.[22,23]

FUNCTION OF GRANULE PROTEINS AND RELEASED PRODUCTS Eosinophils contain many substances (cationic granule proteins, arachidonic acid–derived lipids, hydrolytic enzymes, neuropeptides, reactive oxygen species, and cytokines/chemokines) that mediate inflammation (see Table 30-1), probably the best characterized of these are the cationic proteins.[21] All of these proteins have been shown to induce direct tissue damage to both host cells (myocytes, endothelial cells, neurons, epithelial cells, and smooth muscles cells) and microbes (parasites and some bacteria).[18,24] For example, MBP, ECP, or EPO application to airway epithelium in primates produces ciliostasis, desquamation, and hyperreactivity of respiratory smooth muscle.[25] The damage to the endothelium in IHES is thought to be the initiating factor in the cardiomyopathy observed in these subjects.

All four of the cationic granule proteins likely contribute to the edema observed in many eosinophilic diseases, in part due to the release of histamine from mast cells and basophils. This is further supported by the observation that MBP injected into the skin of humans causes a dose-dependent wheal-and-flare response.[21] NERDS (nodules, eosinophilia, rheumatism, dermatitis and swelling), bullous pemphigoid, herpes gestationis, episodic angioedema with eosinophilia (Gleich syndrome), urticaria, eosinophilic cellulitis (Wells syndrome), and even insect bite reactions demonstrate variable degrees of edema that are probably explained at least in part by this mechanism (see Chap. 35).[26]

There is evidence to show that eosinophils from both healthy and diseased subjects produce several neuro-active mediators, including MBP, EDN, nerve growth factor, vasoactive intestinal peptide, and substance P. This, coupled with the fact that eosinophils (both intact and degranulated) are often observed in close proximity to nerve endings, suggests some cross-talk.[27] Eosinophil-induced nerve dysfunction is thought to be responsible for the gastric dysmotility observed in subjects with food allergies or the dysfunction of vagal muscarinic M2 receptors observed in asthmatics.[10]

ECP and EDN are ribonucleases and as such have been thought to play a role in viral host defense. Coupling this finding with the evidence that eosinophils express Toll-like receptors 7 and 8 (which bind single-stranded RNA from viral replication) makes it credible that these cells are important in viral host defense.[28]

MBP and ECP are thought to have procoagulant activity due in part to their ability to neutralize heparin and their effects on platelet activation.[21] Thrombosis has been noted in IHES, including several case reports of hepatic vein obstruction (Budd-Chiari syndrome). The etiology of this thrombosis is not completely clear. It could be the result of direct endothelial damage or due to the procoagulant activity of MBP and ECP.[29] Additionally, MBP and ECP neutralize heparin and MBP is a strong platelet agonist. Last, PAF, which is released by eosinophils, can cause platelet aggregation.

Eosinophils produce several arachidonic acid metabolites, and the best characterized of those are from the 5-lipoxygenase pathway [leukotriene C_4 (LTC_4), LTD_4, and LTE_4] and the cyclooxygenase pathway (thromboxane B_2, prostaglandin E_2, and prostaglandin $F_1\alpha$).[22,23] LTC_4 is the only leukotriene produced intracellularly by eosinophils. LTD_4 and LTE_4 are metabolites of LTC_4 produced by extracellular cleavage. LTC_4, LTD_4, and LTE_4 are called *cysteinyl leukotrienes* and have several biologic effects, including bronchoconstriction, increased airway reactivity, increased vascular permeability, and leukocyte recruitment. The cysteinyl leukotrienes elaborated at least in part by eosinophils are major mediators of asthma and allergic rhinitis, and this is further demonstrated by the clinical improvement observed with the leukotriene antagonists (montelukast, zafirlukast, and zileuton). Whether leukotrienes play a role in eosinophilic disorders of the skin is less clear. The predominant cyclooxygenase product of eosinophils is thromboxane B_2, but this and the other mediators produced through this pathway are minor compared to those produced by the 5- and 15-lipoxygenase pathways.

Many hydrolytic enzymes have been identified in human eosinophils, but their role in disease remains largely speculative (see Table 30-1). Arylsulfatase B, β-glucuronidase, acid phosphatase, catalase, and histaminase are present in the eosinophil. On stimulation with IL-5 or PAF, eosinophils have been shown to release matrix metalloproteinase 9 (MMP-9), which is thought to be important for their migration through basement membranes. Collagenase, which degrades type I and type III collagen, may play a role in tissue remodeling.

Reactive oxygen species are important in tissue injury induced by eosinophils. The reactive oxygen species produced include superoxide and hydrogen peroxide. These are produced by NADPH oxi-



dase during the respiratory burst initiated on eosinophil activation. Hydrogen peroxide can generate hypohalous acids through the action of EPO, which are also cytotoxic. Reactive oxygen species can also propagate the inflammatory response by inducing gene expression and T-cell proliferation.

A variety of cytokines and chemokines are produced by eosinophils.[21] Tumor growth factor (TGF)-α, TGF-β, fibroblast growth factor-2, vascular endothelial growth factor, nerve growth factor, platelet-derived growth factor-β, TNF-α, IL-1α, IL-2 through -6, IL-10, IL-12, IL-16, GM-CSF, IL-8, CCL3 (MIP-1α), lymphocyte chemoattractant factor, CCL5 (RANTES), and CCL11.

The release of TGF-α, TGF-β, fibroblast growth factor-2, vascular endothelial growth factor, MMP-9 and inhibitors of MMPs from eosinophils and the ability of eosinophil mediators to induce platelet release of TGF-β, suggests that they are important inducers of fibroblast proliferation and extracellular matrix proteins.[30] After intradermal eosinophilic infiltration, there is production of the extracellular proteins tenascin and procollagen 1 and myofibroblast formation.[28] Eosinophil-induced fibrosis is observed in the lungs and heart of IHES patients and in the skin of subjects with eosinophilic fasciitis (Shulman syndrome), eosinophilia myalgia syndrome, or toxic oil syndrome (see Chaps. 35 and 158).

Products released by eosinophils (chemoattractants, colony-stimulating factors, and endothelial-activating cytokines) facilitate further leukocyte recruitment to sites of inflammation. Additionally, some investigators have suggested that eosinophils present antigen to T cells.[31] For example, eosinophils have been shown to express some of the requisite co-stimulatory molecules characteristic of the T-cell–antigen presenting cells synapse, such as the IL-2 receptor (CD25), B7 homologs, and HLA-DR (major histocompatibility complex class II). GM-CSF stimulated eosinophils induce T-cell proliferation in response to staphylococcal superantigens (*Staphylococcus* enterotoxins A, B, and E).

Eosinophils have also been found in a variety of cancers, particularly in lymphomas, leukemias, and colon cancer. Numerous clinical studies suggest that tumors associated with tissue and/or peripheral eosinophilia have a more favorable prognosis.[6] Whereas in other tumors, they are thought to confer a poor prognosis, such as nodular sclerosing Hodgkin disease, Sézary syndrome, and gastric carcinomas, in Sézary syndrome (see Chap. 146), the tumor cells produce IL-5 and are therefore responsible for the eosinophilia. Therefore, in this tumor, the eosinophilia is a reflection of tumor burden.[32] In the case where eosinophilia is a good prognostic factor, the eosinophils may be a host response to the tumor.[33,34] The specific nature of eosinophil-dependent antitumor activity has not been sufficiently explored but may include direct cytotoxic effects on tumor cells by ECPs, antigen presentation, vascular compromise via microthrombi formation (secondary to release of heparinases and PAF), or synergism with the antitumor response of other leukocytes.

Thus, the actions of these granule proteins and released cytokines/chemokines derived from activated eosinophils are numerous and include direct cytotoxic effects on structural cells and microbes, increased vascular permeability, procoagulant effects, immediate host response to some parasites, viruses, and tumor cells, enhanced leukocyte migration, amplification of effector T-cell responses and possibly even mammary gland development. Collectively, these varied biologic actions provide the explanation for most of the signs and symptoms observed in eosinophilic skin diseases (see Chap. 35).

ACTIVATION OF EOSINOPHILS A variety of inflammatory mediators have been shown to activate eosinophils. These include cytokines (TNF-α, GM-CSF, and IL-3 and -5), complement components (C3a and C5a), lipid mediators (LTC_4 and PAF), chemokines as well as engagement of IgA and IgG Fc receptors. Several members of the CC chemokine subfamily [CCL5, CCL7 (MCP-3), CCL11, CCL14 (MCP-4), CCL24 (eotaxin-2)] that bind to the chemokine receptor CCR3 are also potent activators of eosinophils.[35] Activated eosinophils develop a number of phenotypic changes, including a reduction in granules, vacuolization, and an expansion of their cytoplasm, leading to a reduction in cell density and are referred to as *hypodense*. The number of hypodense cells predicts allergic disease severity. A cell surface marker that can distinguish hypodense from normodense eosinophils has not been identified, but there are several surface markers with enhanced expression on in vitro or in vivo activated or hypodense cells: αM integrin (CD11b), αX integrin (CD11c), FcγR111 (CD16), hyaluronic acid receptor (CD44), ICAM-1 (CD54), CD69, and HLA-DR.[36]

SURFACE RECEPTORS There is a large variety of receptors present on the surface of eosinophils but no single surface protein is uniquely expressed on eosinophils. These receptors have either been identified by flow cytometry or by functional assays, and can be grouped as follows: chemotactic factor receptors (chemokine, complement, and others), immunoglobulin and other immunoglobulin supergene family members, cytokine receptors, adhesion molecule receptors, and a variety of receptors involved in apoptosis.

Chemotactic Factor Receptors. Chemotactic factors are thought to be important in orchestrating cellular trafficking to sites of inflammation as well as physiologic homing (e.g., gastrointestinal tract). Many chemotactic agents [leukotriene B_4, PAF, bacterial products (fMLP), and C5a] have quite potent effects on eosinophils but are non-selective in that they recruit most leukocytes. Because many eosinophilic diseases are characterized by tissue eosinophilia with little to no neutrophilia, the identification of more selective chemotaxins, such as CCR3 ligands, was an important breakthrough.

As with neutrophils, specific members of the chemokine family are thought to be essential for the cellular trafficking of eosinophils. The binding of chemokines to their respective receptors on the eosinophil mediates many biologic effects in addition to cell shape change and migration such as cell activation, receptor internalization, induction of the respiratory burst, and transient activation of integrin adhesiveness.

It has become increasingly clear that the chemokine receptor CCR3 and its major ligands (CCL5, CCL11, CCL13, CCL24, CCL26) play a critical role in both the homeostatic and inflammation-induced recruitment of eosinophils to tissue sites.[10,35] Not surprisingly, the most highly expressed chemokine receptor on human eosinophils is CCR3.

Immunoglobulin Receptors and Members of the Immunoglobulin Supergene Family. In the immunoglobulin family, the receptor most highly expressed on eosinophils is FcγR11 (CD32), which binds aggregated IgG, particularly of the subclass IgG_1 and IgG_3. The binding of IgG to this receptor can alter eosinophil survival. There is conflicting evidence



concerning the presence of the high affinity IgE receptor FcεR1 on the surface of eosinophils. FcαRI (CD89), the IgA receptor, is present on the surface of eosinophils and the binding of IgA opsonized particles to this receptor triggers a variety of immune effector functions. This, coupled with the fact that there are many eosinophils found in the gastrointestinal tract, suggest that eosinophils play an important role in mucosal immunity.

Members of the immunoglobulin superfamily are type I transmembrane molecules that share common structural characteristics of the globular domains found in immunoglobulins. ICAM-1 (CD54) and ICAM-3 (CD50) are expressed on eosinophils and are thought to be important in leukocyte-leukocyte and leukocyte-tissue cell adhesion using LFA-1(αLβ2; CD11a) as its counterligand (see Fig. 30-1).

Cytokine Receptors. Cytokine receptors are present at low levels on the surface of eosinophils. Receptors for IL-3 (CD123), IL-5 (CD125), and GM-CSF (CD116) are most readily detectable and all share a common β chain (CD132). Eosinophil activation has been noted by a variety of other cytokines despite the fact that their receptors are not readily detected by flow cytometry. These include: stem cell factor (c-kit receptor; CD117), IFN-γ (CD119), TNF-α (CD120), IL-4 (CD124), IL-9 (CD129 and CD132), IL-13β (gp65), IL-2 (CD25), and TGF-β receptors.

Receptors Involved in Apoptosis. Apoptosis plays a role in many biologic processes. Diseases characterized by eosinophilia are thought to result in part from a delayed or defective apoptotic pathway. Eosinophils from atopic dermatitis patients have markedly reduced death kinetics compared to those isolated from non-atopic and even airway allergic donors.[10] Eosinophils express several "death receptors," such as Fas receptor (CD95), Siglec-8, CD30, CD45, Campath (CD52), and CD69 and important intracellular regulators of eosinophil apoptosis such as the members of the B-cell leukemia/lymphoma (Bcl)-2 and inhibitor of apoptosis families.[37] Eosinophil apoptosis is one mechanism by which glucocorticoids lower eosinophil counts and this effect can be overcome by the actions of IL-3, IL-5, and GM-CSF.[38] Interestingly, lidocaine and sulfonylureas (such as glyburide) can also inhibit this cytokine-induced eosinophil survival and may have some anti-eosinophilic effects clinically.[28]

Adhesion Molecule Receptors. Adhesion molecule receptors are expressed on the eosinophil cell surface to mediate trafficking to tissues and within tissues, and for general cell-cell interactions (see Fig. 30-1).[39] These receptors fall into three groups: IgSF, selectins and their glycoprotein counterligands, and integrins. L-selectin (CD62L) and P-selectin glycoprotein ligand-1 (PSGL-1, CD162) are expressed at high levels, whereas E-selectin ligands [e.g., sialyl-Lewis X (CD15s)] are expressed at very low levels. P-selectin and PSGL-1 are the most important selectin pair in eosinophil migration into tissues.[8]

Eosinophils express a variety of integrins (β_1, β_2, and β_7) on their surface, which facilitate their adhesion to extracellular matrix proteins, vascular cellular adhesion molecule 1 (VCAM-1) (CD106) on activated endothelium or ICAM-1 present on resting or activated epithelium and activated endothelium. Integrins are composed of two subunits that exist as noncovalently associated heterodimers, with an α and a β subunit. The β_1 integrins expressed on eosinophils include α4β1 (VLA-4), which binds to VCAM-1 found on activated endothelium and the extracellular matrix protein, fibronectin. Eosinophil adhesion to fibronectin induces the autocrine production of eosinophil survival cytokines (IL-3, IL-5, and GM-CSF). The only other β_1 integrin expressed on eosinophils is $\alpha_6\beta_1$, which mediates the binding to another matrix protein, laminin. Four β_2 integrins are found on eosinophils: αLβ2 (LFA-1), αMβ2 (Mac-1), αXβ2, and αDβ2. These integrins bind to ICAM-1, -2, and -3; VCAM-1; fibrinogen; and the complement fragment, C3bi. Last, eosinophils also express α4β7, which is the ligand for the gut mucosal addressin cell adhesion molecule-1 thought to be important in homing of eosinophils to gastrointestinal mucosa. $\alpha_4\beta_7$ also mediates adhesion to fibronectin and VCAM-1.

Tissue Trafficking

The selective recruitment of eosinophils into sites of inflammation is largely a function of eosinophil-activating cytokines, endothelial-activating cytokines, and chemokines (see Fig. 30-1).

EOSINOPHIL-ACTIVATING CYTOKINES The eosinophil-activating cytokines (IL-3, IL-5, and GM-CSF) enhance cell survival, eosinophil maturation, chemotactic responses, and leukotriene production. Eosinophils from subjects with atopic dermatitis have increased migratory responses in vitro to several common chemotaxins (*N*-formylmethionyl-leucyl-phenylalanine, IL-4, and PAF) in comparison to eosinophils from unaffected individuals, suggesting that they were exposed to one of these activating cytokines in vivo.[3] In fact, IL-5 treatment of eosinophils from normal donors induced the migratory responses observed in eosinophils from atopic dermatitis subjects.[40] Similarly, we have observed that the kinetics of eosinophil recruitment in response to intradermal RANTES challenge are profoundly faster in allergic subjects.[41] Eosinophils from atopic dermatitis donors also have prolonged cell survival ex vivo compared with normal controls providing further evidence that they have been primed by activating cytokines like IL-5 in vivo.[42] Although eosinophil-activating cytokines can be produced by many cell types (keratinocytes, endothelial cells, monocytes, and T cells) there is some evidence that eosinophils themselves may be a major source and therefore suggests that there may be an autocrine feedback loop.[42] Interestingly, the local reactions observed in response to subcutaneous GM-CSF administration given as an adjunct to chemotherapy demonstrate both intact and degranulated eosinophils, suggesting that eosinophil activation by GM-CSF coupled with cutaneous trauma may be sufficient to get tissue recruitment.[43]

ENDOTHELIAL-ACTIVATING CYTOKINES (See Chap. 163) There are at least three types of endothelial activations that occur. The first is the expression of P-selectin, which occurs when endothelial cell Weibel-Palade bodies are transported to the cell surface extremely quickly after exposure of endothelial cells to histamine, leukotrienes, and a host of other inflammatory mediators. Expression of P-selectin on the endothelial surface initiates leukocyte rolling (via PSGL-1), which is an important initial step before firm adhesion and transendothelial migration. A second type of endothelial activation is that induced by nonspecific activators such as IL-1 and TNF-α. These cytokines stimulate endothelial expression of E-selectin, ICAM-1, and VCAM-1. They also induce production of chemokines by endothelial cells. The third type of endothelial activation is that induced by IL-4 and IL-13. These cytokines selectively



induce VCAM-1, which is centrally involved in the recruitment of VLA-4–positive cells, including eosinophils, basophils, and lymphocytes into sites of allergic inflammation.

The initial step of eosinophil recruitment involves rolling on endothelial selectins (and perhaps the L-selectin counterligand or VCAM-1). This is followed by a firm adhesion, or "tethering," of the eosinophil. Recent in vitro studies have shown that tethering or firm adhesion of eosinophils to VCAM-1 or ICAM-1 is a process which is substantially increased by CCR3 ligands (CCL5, CCL7, and CCL11).



CHEMOKINES The transition from rolling on the endothelial surface to firm adherence is mediated by chemokines on the endothelial surface. Induction of the expression of chemokines by activated endothelial cells results in higher levels of chemokines on or near the endothelial surface, which transiently affect β_1 and β_2 integrin avidity, resulting in firm adhesion of the eosinophil to the endothelial cell. Chemokines produced by structural cells such as fibroblasts, smooth muscle cells, and epithelium are probably more important in directing migration and activation of eosinophils within tissues.[44]

Pharmacologic Manipulation

Many available therapies (glucocorticoids, calcineurin antagonists, myelosuppressive drugs, IFN-α, IFN-γ, leukotriene antagonists, and possibly even antihistamines) inhibit eosinophilic inflammation; however, none is specific for eosinophils. Glucocorticoids are the most effective. They are thought to affect tissue eosinophil infiltration by three mechanisms: induction of eosinophil apoptosis, reduction of eosinophil production by bone marrow, and inhibition of the production of the cytokines and chemokines important in eosinophil trafficking.[38,45] Steroids also suppress the production of several cytokines important for the induction of adhesion molecules on endothelial cells (IL-1, TNF-α, IL-4, and IL-13) and the release of eosinophil-active chemokines (CCL5, CCL7, and CCL11). The immediate (within 3 hours) reduction in circulating eosinophils observed after systemic administration of steroids is thought to occur as a consequence of sequestration into extramedullary organs (liver, spleen, and lymph node) as has been shown in rodents.

Several myelosuppressive drugs [hydroxyurea, interferons (IFN) and calcineurin antagonists] are beneficial in eosinophilic disorders alone or as steroid-sparing agents.[2] IFNs are thought to act by inhibiting eosinophil degranulation and inflammatory mediator release. IFN-α is primarily used as a steroid-sparing agent in subjects with the myeloproliferative variant of hypereosinophilic syndrome (see Chap. 35). Calcineurin antagonists (cyclosporin, FK506, and pimecrolimus) are thought to act by inhibiting T-cell cytokine release including cytokines that induce eosinophilic inflammation (IL-4, IL-5, and GM-CSF). Topical tacrolimus has been shown to decrease the expression of CCL5, CCL11, and IL-5 in atopic dermatitis, which was observed in conjunction with a decrease in tissue eosinophil counts.[46] Leukotriene antagonists, including 5-lipoxygenase inhibitors (zileuton) and cysLT$_1$ receptor antagonists (zafirlukast and montelukast) have been shown to decrease tissue eosinophils in allergic subjects and may diminish the biologic actions of eosinophil-derived leukotrienes. Lastly, there have been conflicting reports regarding the ability of the newer generation antihistamines (cetirizine and fexofenadine) to inhibit eosinophil recruitment in allergen challenge models of the skin or airways.

New, more specific strategies have emerged: for example, mepolizumab (a humanized monoclonal antibody to IL-5) decreases peripheral eosinophil counts in the majority of hypereosinophilic subjects and demonstrated a moderate improvement in small trial in subjects with atopic dermatitis.[8,47] Imatinib mesylate, a tyrosine kinase inhibitor U.S. Food and Drug Administration–approved for the treatment of chronic myelogenous leukemia, has produced complete or near complete remissions for hypereosinophilic cases associated with platelet-derived growth factor receptor rearrangement which has kinase activity (see Chap. 35). In these subjects, the clinical responses are rapid, with normalization of eosinophil counts generally occurring within 1 week of initiation of treatment and reversal of signs and symptoms within 1 month.[11] There is limited evidence that alemtuzumab, a monoclonal antibody to CD52, which is U.S. Food and Drug Administration–approved for B-cell lymphocytic leukemia may also be useful for this group of hypereosinophilic disorders.[11] CCR3-blocking antibodies have been shown to inhibit allergen-induced eosinophil recruitment in human skin xenografts from allergic subjects. Two companies (Glaxo-SmithKline and Bristol-Myers Squibb) have CCR3 antagonists in phase I or II studies for use in atopic airway diseases.[48]

The eosinophil is clearly a multifunctional cell whose original function was primarily to fight parasitic infections. As this function is largely unnecessary in developed countries, the eosinophil has likely evolved to respond to other environmental insults, leading to the rise of eosinophilic diseases such as atopy.[24] It has become clear that eosinophils play a role in allergic diseases, fibrotic diseases, and antitumor host response.[30] Only recently has it been recognized that it is present under "normal" conditions in parts of the gastrointestinal tract and lymphoid organs, suggesting that it may have a homeostatic function as well. A better understanding of the relevant inflammatory versus homeostatic functions of this leukocyte will likely yield therapies for eosinophilic diseases with improved risk/benefit ratios.

KEY REFERENCES

The full reference list for all chapters is available at www.digm7.com.

1. Nathan C: Neutrophils and immunity: Challenges and opportunities. *Nat Rev Immunol* **6**:173, 2006
2. Faurschou M, Borregaard N: Neutrophil granules and secretory vesicles in inflammation. *Microbes Infect* **5**:1317, 2003
3. Pham CT: Neutrophil serine proteases: Specific regulators of inflammation. *Nat Rev Immunol* **6**:541, 2006
4. Zen K, Parkos CA: Leukocyte-epithelial interactions. *Curr Opin Cell Biol* **15**:557, 2003
5. Segal BH et al: Genetic, biochemical, and clinical features of chronic granulomatous disease. *Medicine (Baltimore)* **79**:170, 2000
6. Baatjes AJ et al: Anti-allergic therapies: Effects on eosinophil progenitors. *Pharmacol Ther* **95**:63, 2002
8. Simon D, Braathen LR, Simon HU: Eosinophils and atopic dermatitis. *Allergy* **59**: 561, 2004.
10. Rothenberg ME, Hogan SP: The eosinophil. *Annu Rev Immunol* **24**:147, 2006.
11. Klion AD et al: Approaches to treatment of hypereosinophilic syndromes: A workshop summary report. *J Allergy Clin Immunol* **117**:1292, 2006
21. Gleich GJ, Adolphson CR: The eosinophilic leukocyte: Structure and function. *Adv Immunol* **39**:177, 1986
28. Munitz A, Levi-Schaeffer F: Eosinophils; "new" roles for "old" cells. *Allergy* **59**:268, 2004

CHAPTER 31

Acute Febrile Neutrophilic Dermatosis (Sweet Syndrome)

Philip R. Cohen
Herbert Hönigsmann
Razelle Kurzrock

HISTORY

EPIDEMIOLOGY

The distribution of Sweet syndrome cases is worldwide, and there is no racial predilection.[1,2,12,16–20,30,31] The dermatosis presents in three clinical settings (Table 31-1).[13,15] Classic or idiopathic Sweet syndrome may be associated with infection (upper respiratory tract or gastrointestinal tract), inflammatory bowel disease, or pregnancy.[13,15] It most commonly occurs in women between the ages of 30 years to 60 years. However, classic Sweet syndrome also occurs in younger adults and children.[32–48] The youngest Sweet syndrome patients are brothers who developed the dermatosis at 10 and 15 days of age.[46]

Several investigators consider it appropriate to distinguish between the classic form and the malignancy-associated form of this disease because the onset or recurrence of many of the cases of Sweet syndrome are temporally associated with the discovery or relapse of cancer.[15,49–60] Malignancy-associated Sweet syndrome does not have a female predominance and is most often associated with acute myelogenous leukemia.[61,62] In Sweet syndrome patients with dermatosis-related solid tumors, carcinomas of the genitourinary organs, breast, and gastrointestinal tract are the most frequently occurring cancers.[1,2,63–66]

A drug-induced variant of the dermatosis has also been described.[13,67,68] It has most frequently been observed to occur in association with the administration of granulocyte-colony stimulating factor (G-CSF).[1,2] However, several other medications have also been implicated in eliciting drug-induced Sweet syndrome.[11,13,17,39,41,69–124]

ETIOLOGY AND PATHOGENESIS

The pathogenesis of Sweet syndrome may be multifactorial and remains to be definitively determined. A septic process is suggested by the accompanying fever and peripheral leukocytosis. Indeed, a bacterial infection may have a causative role because most patients with classic Sweet syndrome have a febrile upper respiratory tract infection or tonsillitis that precedes their skin lesions by 1 to 3 weeks. Also, Sweet syndrome patients with culture-confirmed and serology-confirmed *Yersinia enterolitica* intestinal infection improve with systemic antibiotics.[2,77,125–127]

Sweet syndrome may result from a hypersensitivity reaction to an eliciting bacterial, viral, or tumor antigen. The appearance, histopathology, and course of the skin lesions suggest this concept. In addition, the prompt response of both the symptoms and the lesions to corticosteroids supports this hypothesis.[2,127]

Leukotactic mechanisms, dermal dendrocytes, circulating autoantibodies, immune complexes, HLA serotypes, and cytokines have all been postulated to contribute to the pathogenesis of Sweet syndrome. Complement does not appear to be essential to the disease process. In some patients antibodies to neutrophilic cytoplasmic antigens have been demonstrated; however, these are likely to represent an epiphenomenon.[2]

On the other hand, cytokines—directly and/or indirectly—may have an etiologic role in the development of Sweet syndrome symptoms and lesions.[2,21–23]

G-CSF, granulocyte macrophage–colony-stimulating factor, interferon-γ, interleukin 1, interleukin 3, interleukin 6, and interleukin 8 are potential cytokine candidates in the pathogenesis.[2,13,21–23,44,128–132]

CLINICAL FINDINGS

History

Sweet syndrome patients may appear dramatically ill. The skin eruption is usually accompanied by fever and leukocytosis. However, the skin disease can follow the fever by several days to weeks or be concurrently present with the fever for the entire episode of the dermatosis. Arthralgia, general malaise, headache, and myalgia are other Sweet syndrome–associated symptoms.[1,2,23]

ACUTE FEBRILE NEUTROPHILIC DERMATOSIS (SWEET SYNDROME)

AT A GLANCE


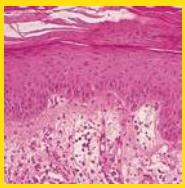

- A constellation of symptoms and findings: the acute onset of fever, neutrophilia, erythematous, and tender skin lesions that typically show an upper dermal infiltrate of mature neutrophils.
- Cardiovascular, central nervous system, gastrointestinal, hepatic, musculoskeletal, ocular, oral, otic, pulmonary, renal, and splenic organs can be involved.
- Classic Sweet syndrome may be associated with infection of the upper respiratory and/or gastrointestinal tract, inflammatory bowel disease, and pregnancy.
- Malignancy-associated Sweet syndrome occurs in individuals with previously undiagnosed or relapsing hematologic malignancies and solid tumors; in these patients, Sweet syndrome appears as a cutaneous paraneoplastic syndrome.
- Drug-induced Sweet syndrome describes the onset of the dermatosis in patients after the initiation of certain medications—most commonly granulocyte-colony stimulating factor.
- Cytokines may have an important role in the pathogenesis.
- The first-line oral systemic agents for treating Sweet syndrome are corticosteroids, potassium iodide, and colchicine.
- Topical application of high potency corticosteroids or intralesional corticosteroids may be efficacious for treating localized lesions.

Cutaneous Lesions

Skin lesions of Sweet syndrome typically appear as tender, red, or purple-red papules or nodules. The eruption may present as a single lesion or multiple lesions which are often distributed asymmetrically (Fig. 31-1). The pronounced



TABLE 31-1
Clinical Features in Patients with Sweet Syndrome

Characteristic	Clinical Form			
	Classic[a] (%)	Hematologic Malignancy[a] (%)	Solid Tumor[a] (%)	Drug-Induced[b] (%)
Epidemiology				
• Women	80	50	59	71
• Prior upper respiratory tract infection	75–90	16	20	21
• Recurrence[c]	30	69	41	67
Clinical symptoms				
• Fever[d]	80–90	88	79	100
• Musculoskeletal involvement	12–56	26	34	21
• Ocular involvement	17–72	7	15	21
Lesion location				
• Upper extremities	80	89	97	71
• Head and neck	50	63	52	43
• Trunk and back	30	42	33	50
• Lower extremities	Infrequent	49	48	36
• Oral mucous membranes	2	12	3	7
Laboratory findings				
• Neutrophilia[e]	80	47	60	38
• Elevated erythrocyte sedimentation rate[f]	90	100	95	100
• Anemia[g]	Infrequent	82	83	100
• Abnormal platelet count[h]	Infrequent	68	50	50
• Abnormal renal function[i]	11–50	15	7	0

[a]Percentages for classic, hematologic malignancy, and solid tumor associated with Sweet syndrome adapted with permission from Cohen PR, Kurzrock R: Sweet's syndrome and cancer. *Clin Dermatol* **11**:149, 1993.
[b]Percentages for drug-induced Sweet syndrome adapted with permission from Walker DC, Cohen PR: Trimethoprim-sulfamethoxazole-associated acute febrile neutrophilic dermatosis: Case report and review of drug induced Sweet's syndrome. *J Am Acad Dermatol* **34**:918, 1996.
[c]Recurrence after oral rechallenge testing in the patients with drug-induced Sweet syndrome.
[d]Temperature > 38°C (100°F).
[e]Neutrophil count > 6000 cells/μL.
[f]Erythrocyte sedimentation rate > 20 mm/h.
[g]Hemoglobin < 13 g/dL in men and < 12 g/dL in women.
[h]Platelet count < 150,000/μL or > 500,000/μL.
[i]This includes hematuria, proteinuria, and renal insufficiency.





▲ **FIGURE 31-1** Unilateral lesions of Sweet syndrome around the eye and upper lip consisting of plaques and pseudovesicular papules suggesting herpes simplex.



▲ **FIGURE 31-2** Multiple confluent papules and plaques of Sweet syndrome that at first sight give the illusion of vesiculation, but are solid on palpation. (From Hönigsmann et al: Akute febrile neurtophile Dermatose. *Wien Klin Wochenschr* **91**:842, 1979, with permission.)

edema in the upper dermis of the lesions results in their transparent, vesicle-like appearance and has been described as an *illusion of vesiculation* (Fig. 31-2). In later stages, central clearing may lead to annular or arcuate patterns. The lesions may appear bullous, become ulcerated, and/or mimic the morphologic features of pyoderma gangrenosum in patients with malignancy-associated Sweet syndrome.[133,134] The lesions enlarge over a period of days to weeks. Subsequently, they may coalesce and form irregular sharply bordered plaques (Fig. 31-3). They usually resolve, spontaneously or after treatment, without scarring. Lesions associated with recurrent episodes of Sweet syndrome occur in one-third to two-thirds of patients.[1,2,135,136]

Cutaneous pathergy, also referred to as *skin hypersensitivity*, is a dermatosis-associated feature.[1,2] It occurs when Sweet syndrome skin lesions appear at sites of cutaneous trauma. These include the locations where procedures have been performed such as biopsies,[20] intravenous catheter placement,[20] and venipuncture.[12,17,20,37,137,138] They also include sites of insect bites and cat scratches,[20] areas that have received radiation therapy,[139–141] and places that have been contacted by sensitizing antigens.[137,142] In addition, in some Sweet syndrome patients, lesions have been photodistributed or localized to the site of a prior phototoxic reaction (sunburn).[13,20,98,143–145] Sweet syndrome lesions have also rarely been located on the arm affected by postmastectomy lymphedema.[100,146]

Sweet syndrome can present as a pustular dermatosis.[147] The lesions appear as tiny pustules on the tops of the red papules or erythematous-based pustules. Some of the patients previously described as having the "pustular eruption of ulcerative colitis" are perhaps more appropriately included in this clinical variant of Sweet syndrome.[1,148]

Neutrophilic dermatosis of the dorsal hands or *pustular vasculitis of the dorsal hands* refers to a localized, pustular variant of Sweet syndrome when the clinical lesions are predominantly restricted to the dorsal hands.[3,149–154] The lesions from this latter group of individuals are similar to those of Sweet syndrome in morphology and rapidly resolve after systemic corticosteroids and/or dapsone therapy is initiated. In addition, many of the individuals with this form of the disease also had concurrent lesions located on either their oral mucosa, arm, leg, back, and/or face.[3,155–163]

The cutaneous lesions of subcutaneous Sweet syndrome usually present as erythematous, tender dermal nodules



▲ **FIGURE 31-3** Acute febrile neutrophilic dermatosis. Typical lesion consisting of coalescing, plaque-forming papules. **A.** Bright-red lesions on the neck. **B.** Lesion on the dorsum of the right hand exhibiting the "relief of a mountain range" feature. [From Hönigsmann H, Wolff K: Acute febrile neutrophilic dermatosis (Sweet syndrome), in *Major Problems in Dermatology*, vol. 10, edited by Wolff K, Winkelmann RK. London, Lloyd-Luke, 1980, p 307, with permission.]

on the extremities.[4,8,12,17,99,119,164–185] When the lesions are located on the legs, they often mimic erythema nodosum (see Chap. 69).[170] Because Sweet syndrome can present concurrently[21,125,187–189] or sequentially[170] with erythema nodosum,[17,21,187,190] tissue evaluation of one or more new dermal nodules may be necessary to establish the correct diagnosis—even in a patient whose Sweet syndrome has previously been biopsy confirmed.[1,2,4] Diagnostic criteria are summarized in Table 31-2.

Related Physicial Findings

EXTRACUTANEOUS MANIFESTATIONS (Table 31-3) Extracutaneous manifestations of Sweet syndrome can affect bones, central nervous system, ears, eyes, kidneys, intestines, liver, heart, lung, mouth, muscles, and spleen.[12,16,17,20,25,26,32,33,44,73,75,101,117,138,139,165,202,203,205,212–257]

In children, dermatosis-related sterile osteomyelitis has been reported. Ocular manifestations of Sweet syndrome may be the presenting feature of the condition. However, the incidence of ocular involvement (such as conjunctivitis) is variable in classic Sweet syndrome and uncommon in the malignancy-associated and drug-induced forms of the dermatosis. In contrast, mucosal involvement of the mouth, presenting as oral ulcers, occurs more frequently in Sweet syndrome patients with hematologic disorders and is uncommon in patients with classic Sweet syndrome.[23,26,102,117,203,252] The oral lesions typically resolve after initiation of treatment with systemic corticosteroids, similar to extracutaneous manifestations of Sweet syndrome occurring at other sites.[1,2]

ASSOCIATED DISEASES Several conditions have been observed to occur either before, concurrent with, or after the diagnosis of Sweet syndrome. Hence, the appearance of Sweet syndrome may be etiologically related to the development of some of these conditions. Specifically, the association between Sweet syndrome and the other condition is probably bona fide, possibly bona fide, or remains to be established.[1,2,5,11–20,30,36–43,69–126,158–161,164,166,186–190,195,214,231,236,259–339]

ASSOCIATED NEUTROPHILIC DERMATOSES The unifying characteristic of neutrophilic dermatoses of the skin and mucosa is their inflammatory infiltrate: mature polymorphonuclear leukocytes. Several of these conditions can display similar clinical and pathologic features. However, the location of the neutrophilic infiltrate helps to differentiate these dermatoses.[6,120] Concurrent or sequential occurrence of Sweet syndrome and the following additional neutrophilic dermatoses have been observed: erythema elevatum diutinum (see Chap. 166),[340] neutrophilic eccrine hidradenitis

TABLE 31-2
Diagnostic Criteria for Classic Sweet Syndrome versus Drug-Induced Sweet Syndrome

Classic[a]	Drug-Induced[b]
Major	• Abrupt onset of painful erythematous plaques or nodules
• Abrupt onset of painful erythematous plaques or nodules	• Histopathologic evidence of a dense neutrophilic infiltrate without evidence of leukocytoclastic vasculitis
• Histopathologic evidence of a dense neutrophilic infiltrate without evidence of leukocytoclastic vasculitis	• Pyrexia > 38°C (100°F)
Minor	• Temporal relationship between drug ingestion and clinical presentation, or temporally related recurrence after oral challenge
• Pyrexia > 38°C (100°F)	• Temporally related resolution of lesions after drug withdrawal or treatment with systemic corticosteroids
• Association with an underlying hematologic or visceral malignancy, inflammatory disease, or pregnancy, or preceded by an upper respiratory or gastrointestinal infection or vaccination	
• Excellent response to treatment with systemic corticosteroids or potassium iodide	
• Abnormal laboratory values at presentation (three of four): Erythrocyte sedimentation rate > 20 mm/h, positive C-reactive protein, > 8000 leukocytes, > 70% neutrophils	

[a]The presence of both major criteria and two of the four minor criteria is required to establish the diagnosis of classic Sweet syndrome; the patients with malignancy-associated Sweet syndrome are included with the patients with classic Sweet syndrome in this list of diagnostic criteria.
[b]All five criteria are required for the diagnosis of drug-induced Sweet syndrome.
Adapted with permission from Walker DC, Cohen PR: Trimethoprim-sulfamethoxazole-associated acute febrile neutrophilic dermatosis: Case report and review of drug induced Sweet syndrome. *J Am Acad Dermatol* **34**:918, 1996.

TABLE 31-3
Extracutaneous Manifestations of Sweet Syndrome

- Bone: Acute sterile arthritis, arthralgias, focal aseptic osteitis, pigmented villonodular synovitis, sterile osteomyelitis (chronic recurrent multifocal osteomyelitis)[12,32,44,164,212–215]
- Central nervous system: Acute benign encephalitis, aseptic meningitis, brain single-photon emission computed tomography abnormalities, brainstem lesions, cerebrospinal fluid abnormalities, computed axial tomography abnormalities, electroencephalogram abnormalities, encephalitis, Guillain-Barré syndrome, idiopathic hypertrophic cranial pachymeningitis, idiopathic progressive bilateral sensorineural hearing loss, magnetic resonance imaging abnormalities, neurologic symptoms, "neuro-Sweet disease," pareses of central origin, polyneuropathy, psychiatric symptoms[33,68,212–229]
- Ears: Tender red nodules and pustules that coalesce to form plaques in the external auditory canal and the tympanic membrane[230]
- Eyes: Blepharitis, conjunctival erythematous lesions with tissue biopsy showing neutrophilic inflammation, conjunctival hemorrhage, conjunctivitis, dacryoadenitis, episcleritis, glaucoma, iridocyclitis, iritis, limbal nodules, ocular congestion, periocular swelling, peripheral ulcerative keratitis, retinal vasculitis, scleritis, uveitis[12,20,26,101,185,202,214,229,231–239]
- Kidneys: Mesangiocapillary glomerulonephritis, urinalysis abnormalities (hematuria and proteinuria)[16,17,25,26,73]
- Intestines: Intestine with extensive and diffuse neutrophilic inflammation, neutrophilic ileal infiltrate, pancolitis (culture-negative)[36,203,240,241]
- Liver: Hepatic portal triad with neutrophilic inflammation, hepatic serum enzyme abnormalities, hepatomegaly[12,16,17,20,25,26,212,224,242]
- Heart: Aortic stenosis (segmental), aortitis (neutrophilic and segmental), cardiomegaly, coronary artery occlusion, heart failure, myocardial infiltration by neutrophils, vascular (aorta, brachiocephalic trunk and coronary arteries) dilatation[243–247]
- Lung: Bronchi (main stem) with red-bordered pustules, bronchi with neutrophilic inflammation, pleural effusion showing abundant neutrophils without microorganisms, chest roentgenogram abnormalities: corticosteroid-responsive culture-negative infiltratives, pulmonary tissue with neutrophilic inflammation[17,20,73,101,138,139,165,205,212,246–251]
- Mouth: Aphthous-like superficial lesions (buccal mucosa, tongue), bullae and vesicles (hemorrhagic: labial and gingival mucosa), gingival hyperplasia, necrotizing ulcerative periodontitis, nodules (necrotic: labial mucosa), papules (macerated: palate and tongue), pustules (individual and grouped: palate and pharynx), swelling (tongue), ulcers (buccal mucosa and palate)[26,75,102,117,203,249,252–254]
- Muscles: Magnetic resonance imaging (T1-weighted and T2-weighted) abnormalities: high signal intensities due to myositis and fasciitis, myalgias (in up to one-half of the patients with idiopathic Sweet syndrome), myositis (neutrophilic), tendinitis, tenosynovitis[73,75,244,255–257]
- Spleen: Splenomegaly[212]

From Cohen PR, Kurzrock R: Sweet's syndrome revisited: A review of disease concepts. *Int J Dermatol* **42**:761, 2003, with permission.



(see Chap. 82),[6] pyoderma gangrenosum (see Chap. 32),[231,269,341,342] sub-corneal pustular dermatosis (see Chap. 34),[6] and vasculitis (see Chap. 164).[3,192,231]

CONCURRENT LEUKEMIA CUTIS In patients with hematologic disorders, such as leukemia, Sweet syndrome may present as either a paraneoplastic syndrome (signaling the initial discovery of an unsuspected malignancy), a drug-induced dermatosis (after treatment with either all-*trans* retinoic acid, bortezomib, G-CSF, or imatinib mesylate), or a condition whose skin lesions concurrently demonstrate leukemia cutis.[1] In the third setting of hematologic dyscrasia-associated Sweet syndrome, there is the coincident presence of leukemia cutis (characterized by abnormal neutrophils) and Sweet syndrome (consisting of mature polymorphonuclear leukocytes) within the same skin lesion.[1,70,71,93,109,165,205–211] Acute leukemia (myelocytic and promyelocytic) is the most frequent hematologic malignancy associated with this unique presentation of Sweet syndrome. Myelodysplastic syndrome and myelogenous leukemia (either chronic or not otherwise specified) are the other associated hematologic disorders that have been associated with concurrent Sweet syndrome and leukemia cutis.[109] "Secondary" leukemia cutis, in which the circulating immature myeloid precursor cells are innocent bystanders that have been recruited to the skin as the result of an inflammatory oncotactic phenomenon stimulated by the Sweet syndrome lesions has been suggested as one of the hypotheses to explain concurrent Sweet syndrome and leukemia cutis in the same lesion.[165,206,207] Alternatively, "primary" leukemia cutis, in which the leukemic cells within the skin constitutes the bonified incipient presence of a specific leukemic infiltrate is another possibility.[207] Finally, it is possible that the atypical cells of leukemia cutis developed into mature neutrophils of Sweet syndrome as a result of G-CSF therapy–induced differentiation of the sequestered leukemia cells in patients with "primary" leukemia cutis who were being treated with this agent.[205]

LABORATORY TESTS

Histopathology

Evaluation of a lesional skin biopsy is helpful when the diagnosis of Sweet syndrome is suspected. Lesional tissue should also be submitted for bacterial, fungal, mycobacterial, and possibly viral cultures because the pathologic findings of Sweet syndrome are similar to those observed in cutaneous lesions caused by infectious agents.[1,2]

A diffuse infiltrate of mature neutrophils and edema are characteristically present in the upper dermis (Fig. 31-4). Swollen endothelial cells, dilated small blood vessels, and fragmented neutrophil nuclei (referred to as *karyorrhexis* or *leukocytoclasia*) may also be present (Fig. 31-5). Fibrin deposition or neutrophils within the vessel walls (changes of "primary" leukocytoclastic vasculitis) are usually absent and the overlying epidermis is normal.[1,2,23,167,168] However, the spectrum of pathologic changes described in cutaneous lesions of Sweet syndrome has expanded to include concurrent leukemia cutis, vasculitis, and variability of the composition or the location of the inflammatory infiltrate.[3,191]

The inflammatory infiltrate in Sweet syndrome is typically located in the papillary and upper reticular dermis; however, it can also involve the epidermis or adipose tissue. Although the dermal inflammation is usually dense and diffuse, it can also be perivascular or demonstrate "secondary" changes of leukocytoclastic vasculitis believed to be occurring as an epiphenomenon and not representative of a "primary" vasculitis.[3,192,193] Neutrophilic spongiotic vesicles[194] or sub-corneal pustules[12,80,167,195,196] result from exocytosis of neutrophils into the epidermis.[12,17,80,167,194,195,197] When the neutrophils are located either entirely or only partially in the subcutaneous fat, the condition is referred to as *subcutaneous Sweet syndrome*.[4,8,12,17,99,119,164–184]

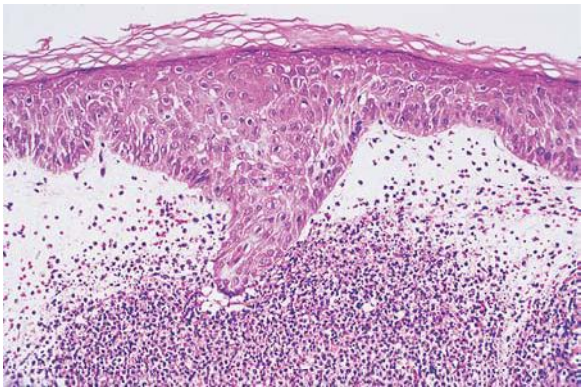

▲ **FIGURE 31-4** Histopathologic presentation of acute febrile neutrophilic dermatosis (Sweet syndrome) demonstrates massive edema of the papillary dermis and a dense diffuse infiltrate of mature neutrophils throughout the upper dermis (hematoxylin and eosin stain). (From Cohen PR et al: Sweet's syndrome in patients with solid tumors. *Cancer* **72**:2723, 1993, with permission.)

Other Laboratory Tests

Peripheral leukocytosis with neutrophilia and an elevated erythrocyte sedimentation rate are the most consistent laboratory findings in Sweet syndrome.[23] However, leukocytosis is not always present in patients with biopsy-confirmed Sweet syndrome.[26] For example, anemia, neutropenia, and/or abnormal platelet counts may be observed in some of the patients with malignancy-associated Sweet syndrome. Therefore, a complete blood cell count with leukocyte differential and platelet count, evaluation of acute phase reactants (such as the erythrocyte sedimentation rate or C-reactive protein), serum chemistries (evaluating hepatic function and renal function), and a urinalysis should be performed. It is also reasonable to perform a serologic evaluation of thyroid function because there appears to be a bona fide association between thyroid disease and Sweet syndrome.[1,2]

Special Tests

EVALUATION FOR EXTRACUTANEOUS MANIFESTATIONS Extracutaneous manifestations of Sweet syndrome may result in other laboratory abnormalities. Patients with central nervous system involvement may have abnormalities on brain single photon emission computed tomography, computerized axial tomography, electroencephalograms, magnetic resonance imaging, and cerebrospinal fluid analysis. Patients with kidney and liver involvement may demonstrate urinalysis abnormalities (hematuria and proteinuria) and hepatic serum enzyme elevation. In addition, patients with pulmonary involvement may have pleural effusions and corticosteroid-responsive culture-negative infiltrates on their chest roentgenograms.[2,343]

MALIGNANCY WORKUP

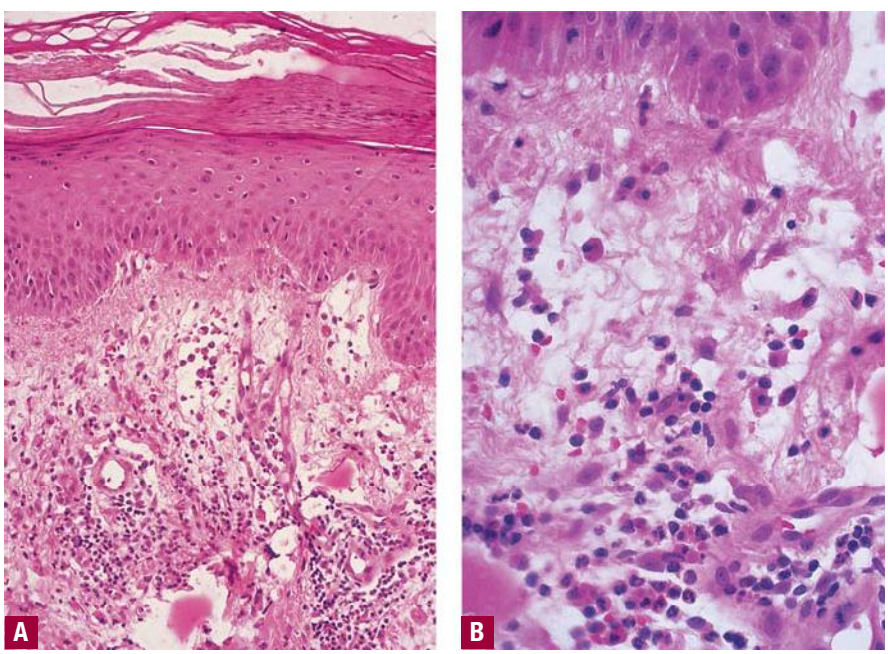

▲ **FIGURE 31-5** Characteristic histopathologic features of Sweet syndrome are observed at low (**A**) and high (**B**) magnification: papillary dermal edema, swollen endothelial cells, and a diffuse infiltrate of predominantly neutrophils with leukocytoclasia, yet no evidence of vasculitis (hematoxylin and eosin stain). (From Cohen PR, Holder WR, Rapini RP: Concurrent Sweet's syndrome and erythema nodosum: A report, world literature review and mechanism of pathogenesis. *J Rheumatol* **19**:814, 1992, with permission.)

DIFFERENTIAL DIAGNOSIS

Clinical Differential Diagnosis (Box 31-1)

Sweet syndrome skin and mucosal lesions mimic those of other conditions. Therefore, infectious and inflammatory disorders, neoplastic conditions, reactive erythemas, vasculitis, other cutaneous conditions, and other systemic diseases are included in the clinical differential diagnosis of Sweet syndrome (see Box 31-1).[2,15,23,148,165,202,220,344,345]

Histologic Differential Diagnosis (Box 31-2)

The histologic differential diagnosis of Sweet syndrome includes conditions microscopically characterized by either neutrophilic dermatosis or neutrophilic panniculitis.[2–4,6,12,193,346–353] The pathologic changes associated with Sweet syndrome are similar to those observed in an abscess or cellulitis; therefore, culture of lesional tissue for bacteria, fungi, and mycobacteria should be considered to rule out infection.[23] Leukemia cutis not only mimics the dermal changes of Sweet syndrome, but can potentially occur within the same skin lesion as Sweet syndrome; however, in contrast to the mature polymorphonuclear neutrophils found in Sweet syndrome, the dermal infiltrate in leukemia cutis consists of malignant immature leukocytes.[354] The pathologic changes in the adipose tissue of subcutaneous Sweet syndrome lesions can be found in either the lobules, the septae, or both; therefore, conditions characterized by a neutrophilic lobular panniculitis (see Chap. 68) also need to always be considered and ruled out.[2,4]





Box 31-1

Clinical Differential Diagnosis of Sweet Syndrome

Most Likely

- Drug eruptions
- Cellulitis
- Chloroma
- Erysipelas
- Erythema nodosum
- Leukemia cutis
- Leukocytoclastic vasculitis
- Panniculitis
- Pyoderma gangrenosum

Consider

- Acral erythema
- Erythema elevatum diutinum
- Erythema multiforme
- Halogenoderma
- Lymphoma
- Neutrophilic eccrine hidradenitis
- Periarteritis nodosa
- Urticaria
- Viral exanthema

Always Rule Out

- Bacterial sepsis
- Behçet disease
- Bowel bypass syndrome
- Dermatomyositis
- Familial Mediterranean fever
- Granuloma faciale
- Leprosy
- Lupus erythematosus
- Lymphangitis
- Metastatic tumor
- Rheumatoid neutrophilic dermatitis
- Syphilis
- Systemic mycosis
- Thrombophlebitis
- Tuberculosis

Adapted from Cohen PR, Kurzrock R: Sweet syndrome and cancer. *Clin Dermatol* **11**:149, 1993.

COMPLICATIONS

Complications in patients with Sweet syndrome can be directly related to the mucocutaneous lesions or indirectly related to the Sweet syndrome–associated conditions. Skin lesions may become secondarily infected and antimicrobial therapy may be necessary. In patients with malignancy-associated Sweet syndrome, reappearance of the dermatosis may herald the unsuspected discovery that the cancer has recurred. Systemic manifestations of Sweet syndrome–related conditions—such as inflammatory bowel disease, sarcoidosis, and thyroid diseases—may warrant disease-specific treatment.

PROGNOSIS AND CLINICAL COURSE

The symptoms and lesions of Sweet syndrome eventually resolve without any therapeutic intervention in some patients with classic Sweet syndrome. However, the lesions may persist for weeks to months.[10,23,254,355] In patients with malignancy-associated Sweet syndrome, successful management of the cancer occasionally results in clearing of the related dermatosis.[13,15,23] Similarly, discontinuation of the associated medication in patients with drug-induced Sweet syndrome is typically followed by spontaneous improvement and subsequent resolution of the syndrome.[13,15,23] Surgical intervention has also resulted in the resolution of Sweet syndrome in some of the patients who had associated tonsillitis, solid tumors, or renal failure.[1,2,19,315,356,357]

Sweet syndrome may recur after either spontaneous remission or therapy-induced clinical resolution.[10] The duration of remission between recurrent episodes of the dermatosis is variable. Sweet syndrome recurrences are more common in cancer patients; in this patient population, the reappearance of dermatosis-associated symptoms and lesions may represent a paraneoplastic syndrome which is signaling the return of the previously treated malignancy.[1,2,15,135]

TREATMENT

Systemic corticosteroids are the therapeutic mainstay for Sweet syndrome.[7,8,10,12,16,17,19,20,23,36,49,50,70,184,223,233,240,250,284,358–361] Initiation of therapy promptly results in improvement of the symptoms and resolution of the mucocutaneous lesions. Daily pulse methylprednisolone administered intravenously may be necessary in patients with refractory disease. Topical (such as 0.05 percent clobetasol propionate)[13,19–21,30,234,362–365] or intralesional (such as triamcinolone acetonide at a dose between 3.0 mg/cc to 10.0 mg/cc)[362,366,367] corticosteroids may be effective for treating localized Sweet syndrome lesions.[1,2,7]

Other first-line (potassium iodide and colchicine) and second-line (indomethacin, clofazimine, cyclosporine, and dapsone) systemic treatments for Sweet syndrome are summarized in Box 31-3.[10,12,17,20,23,30,49,70,143,184,198,203,221,223,231,240,245,250,259,261,281,284,294,296,329,359–363,368–384]

Vasculitis and hypothyroidism are potential drug-induced side effects of potassium iodide.[385] Gastrointestinal symptoms, such as diarrhea, abdominal pain, and nau-

Box 31-2

Histologic Differential Diagnosis of Sweet Syndrome

Most Likely

- Abscess/cellulitis: Positive culture for infectious agent
- Leukemia cutis: Dermal infiltrate consists of immature neutrophils
- Leukocytoclastic vasculitis: Vessel wall destruction—extravasated erythrocytes, fibrinoid necrosis of vessel walls, karyorrhexis, and neutrophils in the vessel wall
- Pyoderma gangrenosum: Ulcer with overhanging, undermined violaceous edges

Consider

- Erythema elevatum diutinum: Erythematous asymptomatic plaques often located on the dorsal hands and elbows; younger lesions have microscopic features of leukocytoclastic vasculitis, whereas older lesions have dermal fibrosis and mucin
- Granuloma faciale: Yellow to red to brown indurated asymptomatic facial plaques; there is a grenz zone of normal papillary dermis beneath which there is a dense diffuse inflammatory infiltrate of predominantly neutrophils (with microscopic features of leukocytoclastic vasculitis) and numerous eosinophils
- Neutrophilic eccrine hidradenitis: Neutrophils around eccrine glands, often in patients with acute myelogenous leukemia receiving induction chemotherapy

Always Rule Out

- Bowel (intestinal) bypass syndrome: History of jejunal-ileal bypass surgery for morbid obesity
- Halogenoderma: Neutrophilic dermal infiltrate with necrosis and pseudoepitheliomatous hyperplasia with intraepidermal abscesses; history of ingestion of bromides (leg lesions), iodides (facial lesions), or topical fluoride gel to teeth during tumor radiation therapy to face
- Lobular neutrophilic panniculitides: In addition to subcutaneous Sweet syndrome, these include α_1-antitrypsin deficiency syndrome, factitial panniculitis (secondary to the presence of iatrogenic or self-induced foreign bodies), infectious panniculitis (secondary to either a bacterial, fungal, mycobacterial, or protozoan organism), pancreatic panniculitis, rheumatoid arthritis–associated panniculitis
- Rheumatoid neutrophilic dermatitis: History of rheumatoid arthritis, nodules, and plaques

Adapted from Cohen PR: Paraneoplastic dermatopathology: Cutaneous paraneoplastic syndromes. *Adv Dermatol* **11**:215, 1995.

Box 31-3

Systemic Treatments for Sweet Syndrome

LINE	MEDICATION	DOSE
First	Prednisone	1 mg/kg/day (usually ranging from 30–60 mg) as a single oral morning dose. Within 4–6 wk, taper dose to 10 mg/day; however, some patients may require 2–3 mo of treatment or intravenous therapy.
	Methylprednisolone sodium succinate	Intravenously administered (up to 1000 mg/day) over 1 or more hours daily for 3–5 days. This is followed by a tapering oral dose of corticosteroid or another immunosuppressant agent.
	Potassium iodide	Administered orally as 300-mg enteric-coated tablets, three times each day (for a daily dose of 900 mg) or as a saturated solution (1 g/mL of water) of potassium iodide (saturated solution of potassium iodide, also referred to as *Lugol's solution*), beginning at a dose of 3 drops three times each day (9 drops/day = 450 mg/day) and increasing by 1 drop three times/day, typically to a final dose of 21 drops/day (1050 mg) to 30 drops/day (1500 mg).[a]
	Colchicine	Administered orally at a dose of 0.5 mg three times each day (for a daily dose of 1.5 mg).
Second	Indomethacin	Administered at an oral daily dose of 150 mg for 7 days, and then 100 mg/day for 14 days.
	Clofazimine	Administered orally at a daily dose of 200 mg for 4 wk, and then 100 mg/day for 4 wk.
	Cyclosporine	As monotherapy or as a second-line agent (after failure of first-line therapy or as a corticosteroid-sparing agent). Initial oral daily dose ranged from 2 mg/kg/day[380] to 4 mg/kg/day[231] to 10 mg/kg/day; in the latter patient, from the eleventh day the dose was reduced by 2 mg/kg/day every 2 days and discontinued on day 21.
	Dapsone	As either monotherapy or in combination therapy. Initial oral dose ranged from 100 mg/day to 200 mg/day; the latter dose was either administered as a single dose or divided into two equal doses.

[a]One drop = 0.05 mL (or 50 mg when the concentration of potassium iodide is 1000 mg/mL) when a "standard" medicine dropper (which dispenses 20 drops/mL) is used.
From Cohen PR, Kurzrock R: Sweet's syndrome revisited: A review of disease concepts. *Int J Dermatol* **42**:761, 2003.

sea and vomiting, are potential adverse effects from colchicine that may improve after lowering the daily dose of the drug.[2]

Second-line systemic agents for Sweet syndrome have all been used as monotherapy either in the initial management of the patient or after first-line therapies have failed. In addition, cyclosporine and dapsone have been used in combination therapy either as a corticosteroid-sparing agent or with other drugs.[1,2,7,303]

There are certain patients whose Sweet syndrome lesions have improved after receiving systemic antibiotics.[7] For example, these include individuals with *Staphylococcus aureus* secondarily impetiginized lesions (treated with an antimicrobial agent to which their bacterial strain is susceptible),[23] patients with inflammatory bowel disease (treated with metronidazole),[267,387] and persons with dermatosis-related yersinia[125,126] or chlamydia[306,307] infection (treated with either doxycycline,[125,389] minocycline,[30,126] or tetracycline[306,307,388]). In addition, effective treatment of Sweet syndrome has also been described, predominantly in case reports, with other drugs: cytotoxic chemotherapies and antimetabolites (chlorambucil and cyclophosphamide),[30,39,148,200,251,360,390] immunoglobulin,[303] interferon alpha,[202,366] etretinate,[361] and tumor necrosis factor antagonists (etanercept,[392] infliximab,[264,265,278,266] and thalidomide[5,393]). Pentoxifylline was hypothesized to be beneficial for treating Sweet syndrome[394,395]; however, when used as monotherapy, it was not found to be efficacious.[1,2,7,295,362]

KEY REFERENCES

Complete References Available on CD-ROM and On-Line Version

1. Cohen PR, Kurzrock R: Sweet's syndrome revisited: A review of disease concepts. *Int J Dermatol* **42**:761, 2003
2. Cohen PR: Sweet's syndrome. *Orphanet Encyclopedia*. http://www.orpha.net/data/patho/GB/uk-Sweet.pdf, accessed October 2003
3. Cohen PR: Skin lesions of Sweet syndrome and its dorsal hand variant contain vasculitis: An oxymoron or an epiphenomenon? *Arch Dermatol* **138**:400, 2002
4. Cohen PR: Subcutaneous Sweet's syndrome: A variant of acute febrile neutrophilic dermatosis that is included in the histologic differential diagnosis of neutrophilic panniculitis. *J Am Acad Dermatol* **52**:927, 2005
5. Cohen PR: Sweet's syndrome and relapsing polychondritis: Is their appearance in the same patient a coincidental occurrence or a bonified association of these conditions? *Int J Dermatol* **43**:772, 2004
6. Cohen PR: Neutrophilic dermatoses occurring in oncology patients. *Int J Dermatol* **46**:106, 2007
7. Cohen PR, Kurzrock R: Sweet's syndrome: A review of current treatment options. *Am J Clin Dermatol* **3**:117, 2002
8. Sweet RD: An acute febrile neutrophilic dermatosis. *Br J Dermatol* **76**:349, 1964

67. Saez M et al: Drug-induced Sweet's syndrome. *J Eur Acad Dermatol Venereol* **18**:233, 2004

103. White JM et al: Cutaneous manifestations of granulocyte colony-stimulating factor. *Clin Exp Dermatol* **31**:206, 2006

106. Kumar G et al: Sweet's syndrome associated with sargramostim (granulocyte-macrophage colony stimulating factor) treatment. *Am J Hematol* **76**:283, 2004



CHAPTER 32

Pyoderma Gangrenosum

Frank C. Powell
Bridget C. Hackett



EPIDEMIOLOGY

The prevalence of pyoderma gangrenosum (PG) is unknown. Estimates have suggested that approximately three cases of PG per million of the population occur per year, with most large referral centers seeing one to two cases per year.[1] It has been reported in all age groups but mainly affects adults between the ages of 40 and 60 years.[2] Most reported series of patients with PG indicate a moderate preponderance of females. PG often occurs in patients who have other diseases (arthritis, inflammatory bowel disease, hematologic dyscrasias, etc.) but is not a manifestation or complication of these diseases and its clinical course is usually unrelated to their severity or activity.[3]

ETIOLOGY AND PATHOGENESIS

The etiology of PG is unknown, and its pathogenesis poorly understood. Because a lymphocytic infiltrate is prominent at the advancing border of active lesions, it has been postulated that lymphocyte antigenic stimulation takes place in the skin with subsequent clonal proliferation in lymph nodes and recirculation to the skin with cytokine release and neutrophil recruitment. The predominance of neutrophils in the infiltrate of established lesions of PG (both in the skin and sometimes other organs) has suggested to others that a defect in neutrophil chemotaxis or reactivity is the basic pathologic problem in PG. Abnormal immune reactivity and cross-reacting autoantibodies directed at antigens common to the skin and intestine or joints are other proposed pathogenic mechanisms. Several studies have shown positive direct immunofluorescent findings in the vessels adjacent to active PG lesions.[4]

CLINICAL FINDINGS

The approach to an individual suspected of having PG is outlined in the patient algorithm (Fig. 32-1). The clinical presentation of PG may be diverse and there is neither a diagnostic laboratory test nor pathognomonic histopathologic findings. It is therefore important to avoid misdiagnosing other diseases as PG.[5] The most important considerations are the exclusion of vascular disease (stasis, occlusion, and vasculitis), infection (bacterial and deep fungal infection), and malignancy (primary or secondary cutaneous malignancy) in every patient. Close follow-up and re-evaluation (with repeated skin biopsies, tissue and swab cultures, and blood tests as indicated) is an important part of the ongoing evaluation of patients with suspected PG, particularly those who show a poor response to therapy.

History

A patient with PG usually complains of severe pain related to the cutaneous lesion but out of proportion to its clinical appearance. Approximately 25 percent of patients note the onset of PG at sites of minor cutaneous trauma (needle stick, inoculation site, insect bites), called the *pathergic phenomenon* (Fig. 32-2). Lesions progress rapidly (with the exception of vegetative PG), and cutaneous destruction evolves over days rather than weeks. Special inquiry regarding drug intake (especially iodides/bromides, hydroxyurea); exposure to and symptoms of infectious diseases (Box 32-1); symptoms relating to the musculoskeletal system (joint pains, swelling etc), the gastrointestinal tract (abdominal pain, diarrhea, constipation, etc.), hematologic disease (tiredness, anemia, bruising, blood clotting disorders, etc.), and non-specific but potential malignancy-related symptoms, such as weight loss and fatigue, should be made.

Cutaneous Lesions

PG is protean in its clinical expression with extreme variability according to the type and stage of disease. Lesions can be classified morphologically as being ulcerative, bullous, pustular, or vegetative. Usually one variant of PG dominates the clinical picture, but some patients show more than one type (isolated pustular lesions frequently occur in patients with ulcerative PG).

The most common initial lesion in a patient with ulcerative PG is an inflammatory pustule or furuncle (usually single but sometimes multiple) which appears on normal appearing skin (most commonly the leg), sometimes at the site of minor trauma. This develops a surrounding areola or zone of erythema that broadens into the normal skin ahead of the enlarging inflammatory lesion (Fig. 32-3). As it enlarges, the center degenerates, crusts, and erodes, converting it into an eroding ulcer the development of which is accompanied by an alarming increase in the severity of the pain. The ulcer has a bluish edge (due to undermining by the necrotizing inflammatory process) and the base is covered with purulent material. Exposure of muscle or tendon occurs in some cases. Control of

PYODERMA GANGRENOSUM AT A GLANCE



- Pyoderma gangrenosum (PG) is a rare inflammatory disease of unknown etiology characterized by neutrophilic infiltration of the dermis and destruction of tissue.
- PG is more frequent in female patients and occurs at any age, usually between 40 and 60 years.
- The majority of patients with PG have other systemic diseases (such as arthritis, inflammatory bowel disease, hematologic dyscrasias, malignant disease, etc.), but PG also occurs independently of these disorders.
- PG may present as ulceration, bullous lesions, or pustular or vegetative lesions. Clinical features sometimes overlap in individual patients.
- There is no laboratory test or investigation that establishes the diagnosis of PG.
- Specified criteria suggest the diagnosis of PG, but other conditions (particularly infection, vascular disease, and malignancy) must be excluded.
- The mainstays of management are systemic immunosuppressive agents together with appropriate local and topical therapy.
- The disease in most patients is chronic. Remission usually requires months of therapy; maintenance therapy is necessary in many and relapses occur in many patients. Significant morbidity and mortality are experienced by patients with ulcerative and bullous PG.

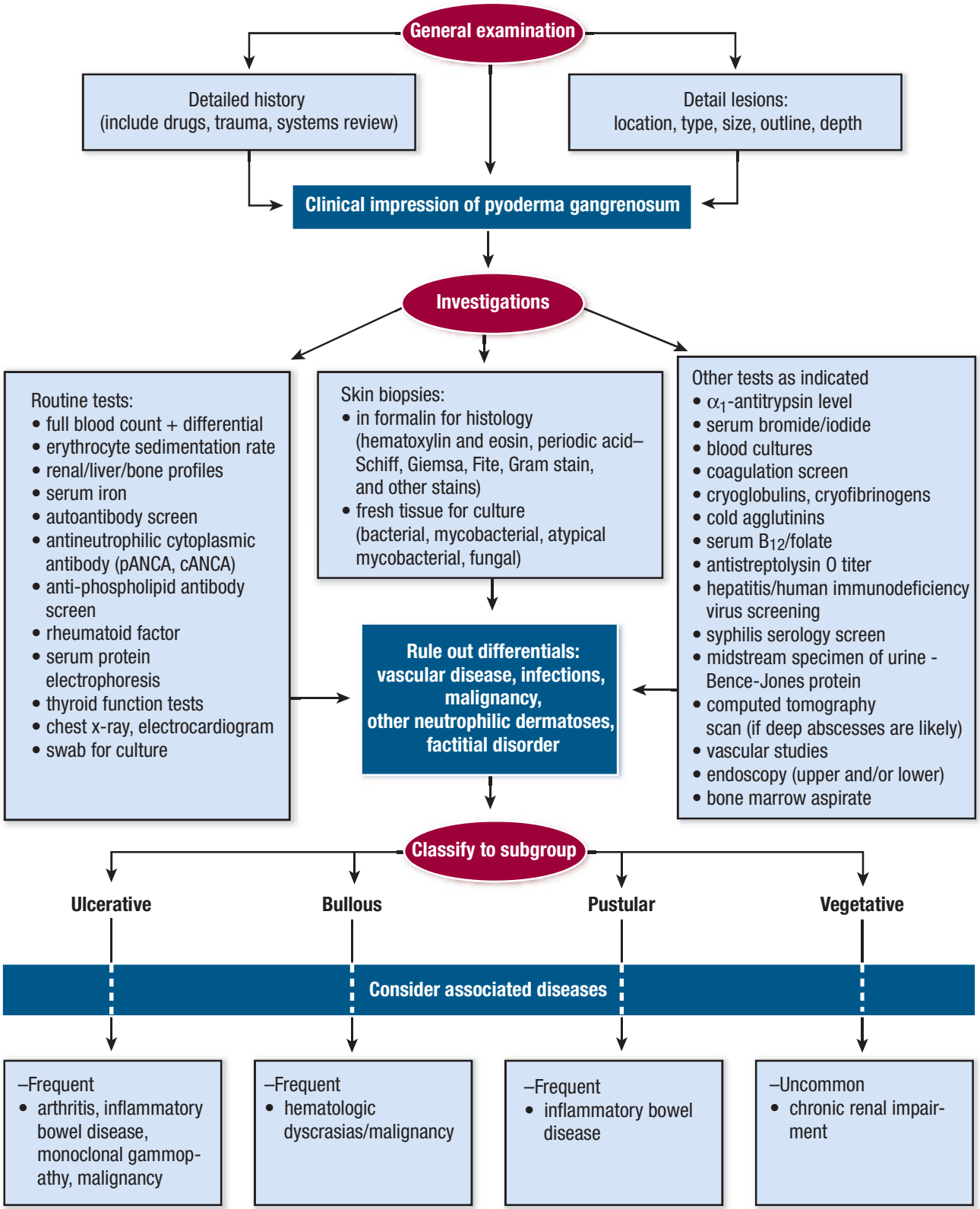

▲ **FIGURE 32-1** Approach to the patient with pyoderma gangrenosum.

ulcerative PG usually requires systemic immunosuppressive therapy.

Bullous PG (or atypical PG) usually presents as a painful, rapidly expanding superficial inflammatory erosion. In the early acute stage the bullous nature of the lesion is evident, but because the roof of the blister necroses rapidly, close inspection of the border of established lesions is necessary to reveal its bullous nature (Fig. 32-4). Bullous PG is commonly associated with hematologic disease and most often appears on the upper limbs.[2] It usually requires systemic immunosuppressive therapy for control.

Pustular PG (also called the *pustular eruption of inflammatory bowel disease*) is a generalized eruption that occurs almost exclusively in the setting of acute inflammatory bowel disease. Its onset is dramatic, with the rapid development







▲ **FIGURE 32-2** Several pathergic pyoderma gangrenosum lesions occurring along a thoracotomy scar site. Note central ulceration, violaceous borders, and peripheral rim of erythema.

of multiple, large, circular-to-oval, painful pustules on the trunk and, to a lesser extent, the face and limbs (Fig. 32-5). Control of this eruption is difficult without controlling the bowel disease. Vegetative PG (or superficial granulomatous pyoderma) usually presents as a single furunculoid nodule, abscess, plaque, or ulcer, typically on the trunk (Fig. 32-6). In contrast to other variants, it is gradual in its onset, mild in the discomfort it generates, and not usually associated with the presence of systemic disease. This form of PG is usually more responsive to localized or mild forms of systemic therapy than the other variants.[6]

Related Physical Findings

Because PG involvement of internal organs (especially the lungs, liver, and spleen) with sterile neutrophilic abscesses can occur and because many patients with PG have diseases of other systems, a thorough physical examination is mandatory with particular search for clinical manifestations of inflammatory bowel disease, arthritis, vasculitis (leukocytoclastic/granulomatous/cryoglobulinemic/Takayasu arteritis), hematologic disease and internal malignancy.

LABORATORY TESTS

Routine Investigations (See Fig. 32-1)

All patients with PG should have the following tests carried out: Full blood cell count with differential white cell count and erythrocyte sedimentation rate (anemia, leukocytosis, and elevated erythrocyte sedimentation rate may be seen); renal, liver, and bone profiles; autoantibody screen (including anti-Ro/La antibodies, antineutrophilic cytoplasmic antibodies, anti-phospholipid antibodies, rheumatoid factor); serum protein electrophoresis (monoclonal gammopathy occurs in 10 percent of patients); thyroid function studies; chest x-ray, electrocardiogram, and midstream specimen of urine; and swabs from lesions sent for bacterial, fungal, and viral cultures. An incisional, wedge skin biopsy should be taken from the edge of the lesion sampling a portion of normal skin progressing through the border into the area of active inflammation to allow the various histologic patterns to be discerned. The excised tissue should then be divided with one section (fresh tissue) sent for bacterial, mycobacterial, and fungal culture, and another portion sent in formalin for histologic evaluation requesting hematoxylin and eosin and periodic acid-Schiff, Giemsa, Fite, Gram, and other stains considered relevant. Although immunofluorescent studies may show positive vascular staining in perilesional skin, this is not essential for diagnostic purposes and can be omitted unless vasculitis is suspected.

Histopathology

The histopathology is non-specific. The histopathologic changes seen in the skin depend on the clinical type of PG (ulcerative, bullous, pustular, or vegetative) and the timing and site of the biopsy relative to the inflammatory process.[7] In general, biopsies taken from the center of established PG lesions show marked neutrophilic infiltration with abscess formation, whereas those taken from peripheral areas show a mixed or predominantly lymphocytic inflammatory infiltrate.

A marked perivascular lymphocytic infiltration is seen in biopsies taken from the "zone" or area of erythema which surrounds active lesions of ulcerative PG. Lymphocytes may be seen to infiltrate vessel walls with intramural and intravascular fibrin deposition indicative of vascular damage (lymphocytic vasculitis).[8] Biopsies taken from the edge of an ulcer show a transition in the cellular infiltrate from lymphocytes and some histiocytes to a predominance of polymorphonuclear leukocytes and early abscess formation. Abscess formation with intense dermal neutrophilic infiltration extending to the panniculus and areas of tissue necrosis dominates the histologic findings in biopsies taken from central areas of ulcerative PG lesions. Leukocytoclasis is not a prominent finding and although occasionally evidence of leukocytoclastic vasculitis is seen close to the abscess center, this is a minor feature and considered secondary to the intense inflammatory changes. Histologic examination of lesional skin from a patient with bullous PG shows a poorly defined sub-epidermal or intra-epidermal bulla with epidermal necrosis and marked upper dermal edema with prominence of neutrophils. Biopsy of pustular PG shows a dense dermal neutrophilic infiltration (often centered about a follicle) with sub-epidermal edema and infiltration of neutrophils into the epidermis with sub-corneal aggregations, whereas vegetative PG is characterized histologically by the presence of pseudoepitheliomatous hyperplasia, sinus tract formation, and the presence of palisading granulomas in the setting of focal dermal neutrophilic abscesses.

The predominance of the neutrophilic infiltrate in established lesions of PG have led to its classification as one of the neutrophilic dermatoses. Clinical (and to an extent histologic) overlap occurs with the other dermatoses in this category, especially atypical or bullous forms of Sweet syndrome (see Chap. 31). Several of the neutrophilic dermatoses (Sweet syndrome, erythema elevatum diutinum, sub-corneal pustular dermatosis, and PG) share an association with immunoglobulin A mono-

Box 32-1

Differential Diagnosis of Pyoderma Gangrenosum (PG)

VARIANT SPECIFIC

Ulcerative PG

Most Likely

- Vascular
  - Venous stasis ulceration
  - Occlusive disease/Arteritis
  - Vasculitis
  - Anti-phospholipid-antibody syndrome
- Malignancy
  - Primary or secondary
- Infection
  - Bacterial
  - Mycobacterial/Atypical mycobacterial
  - Viral (herpes simplex)
  - Deep fungal infection (*Sporotrichosis*, *Aspergillus*, *Cryptococcus*)
- Other
  - Drugs (halogenoderma/hydroxyurea, etc.)

Consider

- Infection
  - Necrotizing fasciitis
  - Syphilis/Amebiasis/Mucormycosis
  - Histoplasmosis/Rhizopus
- Other
  - Dermatitis artefacta
  - Calciphylaxis/Insect bite (spider)

Bullous PG

Most Likely

- Infection
  - Bacterial (cellulitis/impetigo)
  - Viral (in immunocompromised)
  - Fungal (mucormycosis in diabetics)
- Other
  - Sweet syndrome/Behçet disease

Consider

- Bullous dermatoses
  - Erythema multiforme/Bullous pemphigoid
- Other
  - Insect/Arthropod bite/Malignancy

Pustular PG

Most Likely

- Infection
  - Bacterial/Viral/Fungal
- Vasculitis
  - Pustular vasculitis

Consider

- Other
  - Pustular psoriasis
  - Sneddon-Wilkinson disease
  - Pustular drug eruption
  - Bowel bypass syndrome
  - Pyostomatitis vegetans

Vegetative PG

Most Likely

- Infection
  - Bacterial/Viral/Fungal
  - Mycobacterial/Atypical mycobacterial
  - Leishmaniasis

Consider

- Blastomycosis-like pyoderma
- Dermatitis artefacta/Malignancy
- Pyoderma vegetans

SITE-SPECIFIC[a]

Parastomal

Most Likely

- Dermatoses
  - Irritant/Allergic contact dermatitis
  - Other (e.g., psoriasis)
- Infection
  - Bacterial (*Staphylococcus*/*Streptococcus*)/Cellulitis
  - Fungal (*Candida*)
- Other
  - Extra-intestinal inflammatory bowel disease
  - Malignancy

In wounds

Most Likely

- Infection
  - Bacterial/Cellulitis
  - Fungal (e.g., mucormycosis)
- Breakdown
  - Suture allergy
  - Mechanical

Consider

- Malignancy

Genital

Most Likely

- Infection
  - Bacterial/Viral infection (herpes simplex virus, Epstein-Barr virus, cytomegalovirus)
  - Tuberculosis/Tuberculide
  - Fournier gangrene
- Malignancy
  - Squamous cell/Extramammary
  - Paget disease

Consider

- Infection
  - Syphilis/Lymphogranuloma venereum/Histoplasmosis
  - Leishmaniasis/Granuloma inguinale
- Other
  - Dermatitis artefacta
  - Behçet disease

Head and neck

Most Likely

- Infection
  - Bacterial/Viral/Fungal
  - Dissecting cellulitis of the scalp
- Malignancy
  - Squamous cell carcinoma
  - Basal cell carcinoma

Consider

- Vasculitis
  - Wegener granulomatosis
  - Malignant pyoderma
- Other
  - Dermatitis artefacta

[a]The differential diagnosis of lower limb PG is essentially that delineated for variant-specific ulcerative PG.

clonal gammopathy, and diseases such as inflammatory bowel disease and hematologic disorders occur more frequently than expected in these patients.

Special Investigations

In patients in whom the clinical history or examination indicates further testing is necessary, the following additional tests should be considered: endoscopy (upper and/or lower gastrointestinal); vascular studies; bone marrow aspirate examination; ultrasound of abdomen (including liver/spleen/aorta); computed tomography of the thorax, abdomen, or brain; and other directed investigations as indicated in Fig 32-1.



DIFFERENTIAL DIAGNOSIS

The differential diagnosis to be considered in a patient with PG is extensive.[5] Different variants of PG (ulcerative, bullous, vegetative, pustular) suggest alternative diagnoses and the occurrence of PG at certain cutaneous sites raises further diagnostic issues for the clinician, as shown in Box 32-1.

Because there is no confirmatory diagnostic test for PG, the following major criteria are proposed. The diagnosis of PG is likely in a patient with:

- Sudden onset of a painful lesion fitting the morphologic criteria (ulcerative, bullous, pustular, or vegetative) in a (usually middle-aged) patient without significant toxemia or relevant drug intake, *and*
- Histologic evidence of marked tissue neutrophilia in the absence of leukocytoclastic vasculitis and exclusion of malignancy and infective organisms by special studies and negative tissue culture, *and*
- Exclusion of vascular stasis/occlusion/vasculitis by appropriate studies.

The following minor criteria provide supportive evidence of the diagnosis or raise suspicion of PG in patients who do not fulfil all the major criteria above:

- Localization at a characteristic site (ulcerative PG on the legs, vegetative on the trunk, bullous PG on the upper limb, pustular PG on the trunk or face) or at a site of cutaneous trauma (ulcerative PG) or in a peristomal site.
- Rapid progression of the inflammatory lesion with escalating pain severity (except vegetative PG).
- Occurrence in an individual with systemic disease, such as arthritis, inflam-



▲ **FIGURE 32-3** Established lesion of ulcerative pyoderma gangrenosum showing well-defined ulceration with surrounding zone of erythema.

matory bowel disease, or hematologic dyscrasias (except vegetative PG).
- Rapid reduction of pain and inflammation on initiation of systemic steroid therapy.

COMPLICATIONS

Active or poorly controlled PG causes significant morbidity (loss of mobility, pain, exposure to secondary infection, anemia of chronic disease, etc.). Many of the treatments for PG have significant side effects and have to be administered for many months. Frequent monitoring and follow-up of patients are necessary.

PROGNOSIS AND CLINICAL COURSE

The prognosis depends on the PG variant; the age and sex of the patient; presence of other systemic disease; and the type, dosage, and duration of therapy required to bring the disease under control. Patients with vegetative PG generally have a good prognosis and the skin lesions often heal within 6 months of the initiation of relatively mild forms of treatment.[6] Patients with pustular PG often have complete remission of their cutaneous lesions if they gain control of the severe inflammatory bowel disease that usually accompanies this variant. Ulcerative PG is a chronic recurrent disease with a significant morbidity and mortality.[2,4] Patients older than 65 years of age and male patients seem to have a worse prognosis. Patients with bullous PG who have an associated hematologic disorder also have a poor prognosis. The onset of bullous PG in a patient with stable polycythemia rubra vera appears to herald the onset of leukemic change in some patients.[9]



▲ **FIGURE 32-5** Pustular pyoderma gangrenosum lesions of the penis in a patient who also had ulcerative pyoderma gangrenosum.

TREATMENT

General Measures

The age, mobility, social support networks, pain threshold, extent and severity of disease, and ability to comply with



▲ **FIGURE 32-4** Bullous pyoderma gangrenosum lesion showing collapsed roof of blister and superficial erosive quality of the subsequent ulceration.



▲ **FIGURE 32-6** Vegetative pyoderma gangrenosum—an indolent area of chronic inflammation and ulceration that was present for months.

therapeutic measures should be evaluated for each patient and the treatment adapted accordingly. The patient should be given realistic expectations of the speed of recovery likely in this disease. Thus, although lesions develop and evolve within days, the healing process usually takes weeks or months. Adequate bed rest, efficient pain relief, correction of anemia, and appropriate therapy of any associated disease are pivotal in the overall management strategy of a patient with PG.[10] If other systemic illnesses are present, cooperation with a general physician is important, and if surgery is anticipated appropriate measures (such as the use of subcuticular sutures and systemic steroid cover) adopted to avoid precipitating new PG lesions.

The location, morphology, size, and outline of each lesion should be recorded (by photography and by using a calibrated transparent plastic sheet placed over lesions on which the outline is traced) on presentation and subsequent review.

Wound Care

The cutaneous lesions of PG are usually extremely tender so cleansing should be carried out daily with tepid sterile saline or a mild antiseptic solution. Potassium permanganate solution diluted 1:2000 is helpful if there is marked exudation. Silver sulphadiazine 1 percent cream is usually soothing when applied to the ulcerated lesions of PG and may facilitate granulation tissue formation as well as inhibiting bacterial growth. A non-adhesive dressing should be applied over the lesion and held in place with a crêpe elasticized bandage wound firmly, but not tightly, over it. Some patients, particularly those with superficial lesions, obtain significant easing of discomfort with the use of hydrocolloid dressings, which can be left on for 2 to 3 days and "melt" into the lesion. Careful instruction is important to ensure compliance and to avoid the use of irritants such as chemical de-sloughing agents, caustics (such as silver nitrate), or dressings (such as gauze impregnated with soft paraffin and/or antibacterial agents), which may adhere to the ulcer base.

Topical Treatments

Topical treatments are important adjuncts to the systemic treatment needed for the management of most PG patients, and may be sufficient to bring the condition under control in those who have vegetative or mild ulcerative PG. Fluorinated topical corticosteroid ointment applied to the periphery of an active PG lesion can reduce inflammation and may be sufficient as a monotherapy to heal vegetative or superficial peristomal PG.[11] Topical disodium cromoglycate (with or without occlusion), benzoyl peroxide, nicotine cream or patches, hyperbaric oxygen, and radiotherapy have all been reported as being effective in individual patients with PG. Topical tacrolimus (with or without occlusion) seems to be particularly effective for isolated pustular lesions and for peristomal PG.

Box 32-2

Systemic Treatments for Pyoderma Gangrenosum

MEDICATION	DOSAGE
Prednisone	0.5–1.5 mg/kg/day PO
Methylprednisolone (pulsed dose)	500 mg–1 g IV
Dapsone	50–200 mg/day PO
Clofazimine	200–400 mg/day PO
Minocycline	50–100 mg twice daily PO
Cyclosporine	3–6 mg/kg/day PO
Tacrolimus	0.1–0.3 mg/kg PO
Mycophenolate mofetil	500 mg–1 g bid PO
Infliximab	5 mg/kg IV

Intralesional Treatments

Intralesional triamcinolone acetonide (5 to 10 mg/mL) injected twice weekly into the border of a vegetative PG lesion may lead to healing and can be useful in a patient with ulcerative PG if one section of the ulcer is proving recalcitrant to other therapies. Intralesional cyclosporine and tacrolimus have also been reported to be effective in some PG patients.

Systemic Treatments

Because PG is a rare disease, most treatment recommendations are based on experience gained from small series of patients studied.[12] The treatments of PG with suggested doses are listed in Box 32-2. As experience with newer agents is gained, it is likely these recommendations will change. Systemic steroid treatment is probably the initial treatment of choice for most patients with PG. It is important to initiate systemic steroids at a sufficiently high dose to control the disease. Rapid diminution of pain is often recorded by the patient after initiation of therapy and steroids should be continued at this dosage until lesions show evidence of healing, after which gradual tapering of the dose can be undertaken. A steroid-sparing agent should be added as soon as possible as prolonged therapy is anticipated in most patients, as well as bone protective measures to diminish the risk of osteoporosis. Intravenous corticosteroids in pulsed doses have also been used to induce remission, but serious potential adverse effects limit their use to exceptional circumstances. Dapsone has been traditionally used in the treatment of PG and remains a useful drug, particularly when used in conjunction with systemic corticosteroids. Dapsone is generally well tolerated, but hematologic complications (including agranulocytosis, hemolysis and hemolytic anemia, and methhemoglobulinemia) as well as other potentially serious side effects may occur. Other antimicrobial agents reported as successful in the treatment of PG patients include rifampicin, tetracyclines, vancomycin, mezlocillin, clofazimine, and minocycline. These have usually been prescribed in combination with other systemic therapies and seem to work in PG patients by mechanisms other than their antibacterial properties. Most experience has been with clofazimine and minocycline (100 to 200 mg daily). The latter is well tolerated and often allows for a reduction in systemic corticosteroid dosage and appears to prolong remission in some patients.

Cyclosporine is an alternative first-line therapy of PG[13] or may be used in combination with systemic corticosteroids to achieve rapid control of disease. Doses of 3 to 6 mg/kg/day have shown efficacy and continued treatment is usually required for 3 to 4 months. Less risk of serious side effects (such as impairment of renal function and hypertension) is seen at these low doses, but careful monitoring of patients is required and attention should paid to the possibility of other drugs interacting with this medication.

Tacrolimus (FK-506) and mycophenolate mofetil have also been used successfully in the treatment of PG either as monotherapies or in combination with systemic corticosteroids or cyclosporine.[14]



Both drugs cause significant immunosuppression with resultant susceptibility of the patient to infection and malignant disease and can have other potentially serious side effects. Infliximab, an antitumor necrosis factor antibody, has been used successfully to treat patients with inflammatory bowel disease and has been reported to be effective in some patients with PG.[15] Other similar drugs that have been reported to be efficacious in the treatment of patients with PG include etanercept and adalimumab. The role of these agents in the management of PG has yet to be fully defined and susceptibility to reactivation of tuberculosis infection and other significant side effects remain a concern in patients treated with these agents. The use of thalidomide in the treatment of PG has probably been superseded by the development of these agents. Other drugs which have been reported to be helpful in the treatment of PG include azathioprine (thiopurine methyl transferase levels should be checked pre-treatment), colchicine,[16] cyclophosphamide, chlorambucil, and melphalan. These agents can have toxic effects and experience of their efficacy is limited.

Other modalities which have been reported to be useful in the treatment of individual patients or small series of patients with PG include human intravenous immunoglobulin,[17] interferon-α, nicotine,[18] potassium iodide, leukocytapheresis,[19] and plasma exchange. Skin grafting should be avoided if possible because of the risk of inducing new PG lesions at the donor sites, but cultured tissue allografts/autografts and the use of bovine collagen matrix have been reported to be useful in patients in whom the disease is controlled but re-epithelialization incomplete.[20]

The unpredictable nature of PG and its variable aggressiveness in individual patients mean that a flexible approach to treatment is required and the use of therapeutic agents have to be adapted to the patient's physiologic state (childhood, pregnancy, old age). By whichever modality control of PG is achieved, maintenance therapy should be continued until there is complete wound healing. Patients with ulcerative PG have a significant risk of relapse, so long-term follow up is required.

PREVENTION

A patient who has had a history of PG should be advised to avoid trauma to the skin as there is the possibility of precipitating a new lesion (the pathergic phenomenon). If such patients have to undergo surgery, they should have close supervision by a dermatologist of their postoperative course. Patients with a history of aggressive PG may warrant a course of systemic steroids during and for a period (2 weeks or longer) postoperatively to prevent the development of new PG lesions and subcuticular sutures should be used where possible. Patients with a history of PG and Crohn disease who are to have an ileostomy should be warned about the possible development of peristomal PG lesions.

KEY REFERENCES

The full reference list for all chapters is available at www.digm7.com.

1. Powell FC, Su WP, Perry HO: Pyoderma gangrenosum: Classification and management. *J Am Acad Dermatol* **34**:395, 1996
2. Bennett ML et al: Pyoderma gangrenosum. A comparison of typical and atypical forms with an emphasis on time to remission. Case review of 86 patients from 2 institutions. *Medicine (Baltimore)* **79**:37, 2000
3. Powell FC et al: Pyoderma gangrenosum: A review of 86 patients. *Q J Med* **55**:173, 1985
4. Von den Driesch P: Pyoderma gangrenosum: A report of 44 cases with follow-up. *Br J Dermatol* **137**:1000, 1997
5. Weenig RH et al: Skin ulcers misdiagnosed as pyoderma gangrenosum. *N Engl J Med* **347**:1412, 2002
7. Crowson AN, Mihm MC Jr, Magro CM: Pyoderma gangrenosum: A review. *J Cutan Pathol* **30**:97, 2003
8. Su WP et al: Histopathologic and immunopathologic study of pyoderma gangrenosum. *J Cutan Pathol* **13**:323, 1986



CHAPTER 33

Granuloma Faciale

Darius R. Mehregan
David A. Mehregan

HISTORICAL ASPECTS

EPIDEMIOLOGY

Granuloma faciale[3] occurs predominantly in adult men and women. There is a slight male predominance, and mean age at presentation is 52 years.[4,5] Granuloma faciale can occur in individuals of any race; however, it is more common in Caucasians. The disease presents most commonly with a single lesion on the face, but extra-facial lesions have been described.[6] Patients with multiple lesions have also been reported.[7] A rare mucosal variant has been described as eosinophilic angiocentric fibrosis, which typically involves the upper respiratory tract.[8]

ETIOLOGY AND PATHOGENESIS

The etiology of granuloma faciale is unknown. The disease can be considered a localized chronic fibrosing vasculitis.[9] Immunofluorescence studies have revealed deposition of immunoglobulins and complement factors in the vessel walls consistent with a type III immunologic response, marked by deposition of circulating immune complexes in vascular lumina.[10] However, other authors have described negative results with immunofluorescence.[11]

CLINICAL FINDINGS

Granuloma faciale is characterized by solitary papules, plaques, or nodules. The lesions are typically asymptomatic red, brown, or violaceous plaques that are soft

GRANULOMA FACIALE AT A GLANCE



- Granuloma faciale is an uncommon inflammatory dermatosis characterized clinically by reddish brown papules and plaques primarily involving the face.
- The pathology shows changes of a chronic leukocytoclastic vasculitis with a mixed infiltrate containing eosinophils, extensive perivascular fibrin deposition, and dermal fibrosis.
- Etiology is unknown.



◀ **FIGURE 33-1** Granuloma faciale. Raised edematous plaques on cheek showing prominent follicular ostia.

and well circumscribed (Figs. 33-1 and 33-2). Lesions are most common on the face. Sites of predilection include the nose, preauricular area, cheeks, forehead, eyelids, and ears.[4,11] Rarely, patients may present with multiple lesions or lesions on the trunk or extremities. Extra-facial lesions have been reported both as isolated findings and in conjunction with facial lesions. Lesions may be present for weeks or months and tend to follow a chronic course. The plaques typically have a smooth surface and show dilated follicular ostia (see Fig. 33-1). Ulceration is rare. Lesions are typically asymptomatic; however, patients may complain of tenderness, burning, or pruritus.[4] Photo-exacerbation of lesions has been reported.[12]

LABORATORY FINDINGS

An extensive laboratory evaluation is not required. Peripheral blood eosinophilia is occasionally detected.



▲ **FIGURE 33-2** Granuloma faciale. Single plaque on the nose showing prominent follicular ostia and central dell.

The diagnosis may be established by a combination of clinical findings and confirmatory tissue biopsy results. A punch biopsy that includes the full thickness of the dermis is recommended. Histologic examination shows a normal-appearing epidermis, which may be separated from the underlying inflammatory infiltrate by a narrow grenz zone (Fig. 33-3). Within the dermis is a dense and diffuse infiltrate of lymphocytes, plasma cells, eosinophils, and neutrophils with evidence of leukocytoclasis (Fig. 33-4). The inflammatory infiltrate surrounds the blood vessels, which show evidence of fibrin deposition. In later stages, the perivascular fibrin deposition becomes extensive and dominates the histologic picture. Deposition of hemosiderin may contribute to the brown color seen clinically. Electron microscopic studies confirm the presence of an extensive eosinophilic infiltrate with Charcot-Leyden crystals and numerous histiocytes filled with lysosomal vesicles; however, cases with few eosinophils in the infiltrate have also been described.[13] Immunoglobulins, fibrin, and complement can be found deposited along the dermo-epidermal junction in a granular pattern and around blood vessels by direct immunofluorescence.[10]

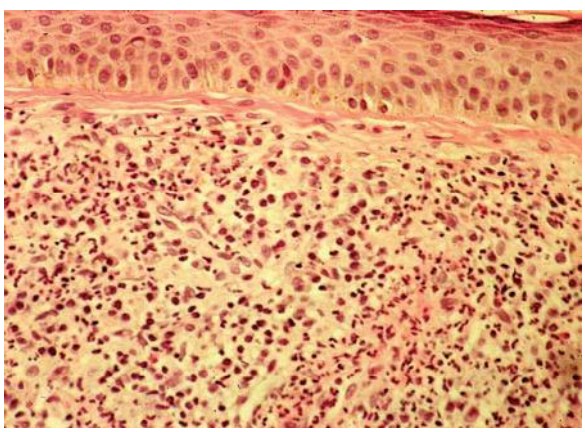

▲ **FIGURE 33-3** Granuloma faciale. This low-power histologic section shows a mixed infiltrate of lymphocytes, histiocytes, neutrophils, plasma cells, and eosinophils. There is sparing of a narrow grenz zone between the inflammatory infiltrate and the overlying epidermis.

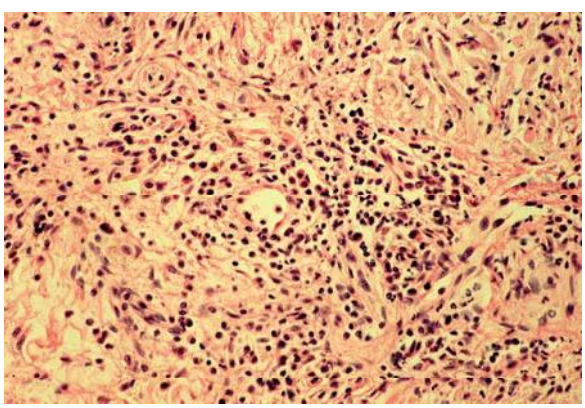

▲ **FIGURE 33-4** Granuloma faciale. This histologic section shows perivascular deposition of fibrin and a mixed infiltrate of lymphocytes, neutrophils, and eosinophils. There are scattered macrophages containing hemosiderin.



Box 33-1

Differential Diagnosis of Granuloma Faciale

Most Likely

- Face
  - Sarcoidosis
  - Granuloma annulare
  - Lymphocytic infiltration of Jessner
  - Rosacea
- Extrafacial
  - Erythema elevatum diutinum

Consider

- Face
  - Discoid lupus erythematosus
  - Lymphoma cutis
  - Angiolymphoid hyperplasia with eosinophilia
  - Tinea faciei
  - Basal cell carcinoma
  - Xanthogranuloma
  - Mastocytoma
- Extrafacial
  - Granuloma annulare
  - Benign lymphocytic infiltrate of Jessner
  - Fixed drug eruption

Always Rule Out

- Face
  - Discoid lupus erythematosus
- Trunk
  - Erythema elevatum diutinum

Box 33-2

Treatments for Granuloma Faciale

	TOPICAL	PHYSICAL	SYSTEMIC
First-line therapy	Topical corticosteroids	Cryotherapy Intralesional steroids Pulsed dye laser	Dapsone, 50–100 mg/day
Second-line therapy	Topical tacrolimus ointment	Surgical excision	



DIFFERENTIAL DIAGNOSIS

The clinical differential diagnosis for granuloma faciale includes discoid lupus erythematosus, polymorphous light eruption, fixed drug eruption, benign lymphocytic infiltrate of Jessner, lymphoma cutis, pseudo-lymphoma, sarcoidosis, granuloma annulare, tinea faciei, insect bite reaction, xanthogranuloma, mastocytoma, basal cell carcinoma, Langerhans cell histiocytosis, and rosacea (Box 33-1). The diagnosis can be reliably made by analysis of a punch biopsy specimen. Absence of serologic evidence of lupus erythematosus helps to differentiate these lesions from the lesions of discoid lupus erythematosus.

The primary histologic differential diagnosis is erythema elevatum diutinum (EED). Both diseases represent chronic forms of fibrosing small vessel vasculitis and may be related. However, there are several clinical and histologic differences. EED is characterized by multiple lesions, primarily located on extensor surfaces of the extremities in a symmetric acral distribution. The trunk and face are typically spared in EED. Histologically, both show a chronic fibrosing vasculitis.[14] However, a grenz zone of normal collagen beneath the epidermis is not typical of EED. EED may be associated with systemic conditions, primarily monoclonal gammopathies, and shows an excellent response to dapsone.[15,16] The histologic and clinical differential may also include angiolymphoid hyperplasia with eosinophilia. However, the lesions of angiolymphoid hyperplasia with eosinophilia contain blood vessels with prominent "hobnail" endothelial cells that protrude into the vascular lumina rather than perivascular fibrin deposition. One case of tinea faciei caused by *Trichophyton rubrum* has been described with clinical and histologic changes consistent with granuloma faciale.[17]

COMPLICATIONS

Granuloma faciale is rarely associated with systemic toxicity.[18]

PROGNOSIS AND CLINICAL COURSE

Lesions tend to be chronic and resistant to treatment.

TREATMENT

A variety of medical and surgical therapies have been used in the treatment of granuloma faciale (Box 33-2). Because of the small number of patients involved, randomized trials to evaluate these treatments are lacking. Resistance to therapy and cosmetic complications should be discussed with the patient before initiation of therapy. Topical and intralesional steroids have been administered with modest improvement.[4,19] Cryosurgery has been applied with effective results.[20,21] Because the disease is known to be a variant of chronic leukocytoclastic vasculitis, dapsone 25 to 100 mg/day has been used with benefit in a number of patients.[22,23] Topical tacrolimus ointment 0.1 percent also has been used with success.[24]

Surgical excision may be an option for small lesions. Lesions of granuloma faciale have been treated with a variety of medical lasers. In one study, the Candela Vbeam pulsed dye laser at 595 nm provided resolution in two of four patients.[25] A variety of pulsed dye lasers have been used with similar results.[26–29] A carbon dioxide laser has also been applied with varying success.[30] The use of an argon laser resulted in total resolution of the granuloma faciale with subsequent scarring. The lesions in two patients were reported to respond to the Laserscope potassium-titanyl-phosphate 532-nm laser in combination with tacrolimus ointment 0.1 percent.[31]

KEY REFERENCES

The full reference list for all chapters is available at www.digm7.com.

3. Cobane JH, Straith CL, Pinkus H: Facial granulomas with eosinophilia: Their relation to other eosinophilic granulomas of the skin and to reticulogranuloma. *Arch Derm Syphilol* **61**:442, 1950
4. Radin DA, Mehregan DR: Granuloma faciale: Distribution of the lesions and review of the literature. *Cutis* **72**:213, 2003
9. Carlson JA, LeBoit PE: Localized chronic fibrosing vasculitis of the skin: An inflammatory reaction that occurs in settings other than erythema elevatum diutinum and granuloma faciale. *Am J Surg Pathol* **21**:698, 1997
10. Nieboer C, Kalsbeek GL: Immunofluorescence studies in granuloma eosinophilicum faciale. *J Cutan Pathol* **5**:68, 1978
11. Ortonne N et al: Granuloma faciale: A clinicopathologic study of 66 patients. *J Am Acad Dermatol* **53**:1002, 2005
16. Crowson AN, Mihm MC Jr, Magro CM: Cutaneous vasculitis: A review. *J Cutan Pathol* **30**:161, 2003
19. Dowlati B, Firooz A, Dowlati Y: Granuloma faciale: Successful treatment of nine cases with a combination of cryotherapy and intralesional corticosteroid injection. *Int J Dermatol* **36**:548, 1997

CHAPTER 34

Sub-Corneal Pustular Dermatosis (Sneddon-Wilkinson Disease)

Franz Trautinger
Herbert Hönigsmann

Sub-corneal pustular dermatosis (SPD) is a rare, chronic, recurrent, pustular eruption characterized histopathologically by sub-corneal pustules that contain abundant neutrophils. The condition was originally described in 1956 by Sneddon and Wilkinson,[1] who separated SPD from other previously unclassified pustular eruptions. Until 1966, when the first comprehensive review appeared, more than 130 cases had been reported, but not all fulfilled the clinical and histopathologic criteria required for this diagnosis.[2] A considerable number of additional cases have since appeared in the literature, and a sub-type with intraepidermal deposits of immunoglobulin A (IgA) directed against desmocollin 1 has been recognized.[3] Today, these cases are usually classified as SPD-type IgA pemphigus and it is a matter of debate whether the finding of epidermal IgA deposits define a subset of SPD or a new pemphigus variant that is otherwise indistinguishable from "classic" SPD.

EPIDEMIOLOGY

There is no racial predilection. Most of the reported cases have been in whites, but the disease has also been observed in Africans, Japanese, and Chinese. The condition is more common in women and in persons older than 40 years of age, but SPD may occur at any age.[2] A pustular eruption that is clinically and histologically similar to the human disease, which also responds to dapsone treatment, has been observed in dogs.[4]

ETIOLOGY AND PATHOGENESIS

The cause of SPD is unknown. Cultures of the pustules consistently do not reveal bacterial growth. The role of trigger mechanisms such as preceding or concomitant infections, though repeatedly discussed, has remained speculative. Immunologic mechanisms have been implicated in the pathogenesis, and in a subset of patients, whose disease clinically resembled SPD, intraepidermal IgA deposits have been detected. Some of these patients also had circulating IgA antibodies against the same sites within the epidermis. Desmocollin 1 has been described as an autoantigen in these cases and the disease has been classified as a rare pemphigus variant (SPD-type IgA pemphigus).[3,5,6] The pathogenetic role of these antibodies is still to be demonstrated.[7]

The occasional association of SPD with certain other diseases may represent more than a mere coincidence. Increased serum IgA has been detected in a number of patients, and the disease has been reported to occur in cases of IgA-paraproteinemia and IgA multiple myeloma.[8–11] In addition, SPD is associated with pyoderma gangrenosum,[12,13] ulcerative colitis,[14] and Crohn disease.[15] On the other hand, pyoderma gangrenosum is not uncommon in patients with inflammatory bowel disease, paraproteinemia, and myeloma (see Chap. 32). Whether or not the co-existence of these conditions reflects common pathogenetic mechanisms remains to be clarified, but an additional common denominator linking these disorders is their response to sulfone and sulfonamide therapy.

Further associations reported to date include IgG paraproteinemia,[16,17] CD30+ anaplastic large-cell lymphoma,[18] non-small cell lung cancer,[19] apudoma,[20] rheumatoid arthritis,[21,22] hyperthyroidism,[23] and mycoplasma pneumoniae infection.[24]

CLINICAL FINDINGS

The primary lesions are small, discrete, flaccid pustules or vesicles that rapidly turn pustular and usually arise in crops within a few hours on clinically normal or slightly erythematous skin (Fig. 34-1). In dependent regions, pus characteristically accumulates in the lower half of the pustule (see Fig. 34-1B); as the pustules usually have the tendency to coalesce, they often, but not always, form annular, circinate, or bizarre serpiginous patterns. After a few days, the pustules rupture and dry up to form thin, superficial scales and crusts, closely resembling impetigo. Peripheral spreading and central healing leave polycyclic, erythematous areas in which new pustules arise as others disappear (see Fig. 34-1A). There is no atrophy or scarring, but an occasional brownish hyperpigmentation may mark previously affected sites. Variable intervals of quiescence, lasting from a few days to several weeks, may be followed by the sudden development of new lesions. The eruptions tend to occur symmetrically, affecting mainly the axillae, groin, abdomen, submammary areas, and the flexor aspects of the limbs. In rare cases, the face,[25] palms, and soles[26] may be involved. Scalp and mucous membranes invariably remain free of lesions. Episodic itching and burning represent subjective symptoms in a small number of patients, but there are no systemic symptoms or abnormalities in routine laboratory parameters.

HISTOPATHOLOGY

The hallmark of the disease is a strictly sub-corneal pustule filled with polymorphonuclear leukocytes,[1] with only an occasional eosinophil.[2] Acantholysis is not involved in pustule formation, but a few acantholytic cells may be found in older lesions (secondary acantholysis). Surprisingly, the epidermal layers underlying the pustule exhibit little pathology, and, apart from a variable number of migrating leukocytes, there is little evidence of spongiosis or cytolytic damage to the epidermal cells. The dermis contains a perivascular infiltrate com-

SUB-CORNEAL PUSTULAR DERMATOSIS AT A GLANCE



- A rare condition with worldwide occurrence.
- A chronic recurrent disorder with a benign course, frequently associated with various forms of immune dysfunction [most commonly immunoglobulin A (IgA) monoclonal gammopathy]. Occurrence of intraepidermal deposits of IgA indicate a relationship with IgA pemphigus.
- Crops of flaccid, coalescing pustules; often in annular or serpiginous patterns.
- Usually distributed symmetrically in the axillae, groins, submammary, the flexor aspects of the limbs, and on the abdomen.
- Pathology: Sub-corneal pustules filled with polymorphonuclear leukocytes.





▲ **FIGURE 34-1** Sub-corneal pustular dermatosis. **A.** Typical distribution. Note accentuated involvement of groin and abdomen. Hyperpigmented macules mark previously affected areas. **B.** Close-up showing coalescence of pustules, which form annular and circinate patterns. Lesions of different developmental stages are seen side by side. At the lower right, newly formed pustule with characteristic hypopyon formation.

posed of neutrophils and rarely mononuclear cells and eosinophils (Fig. 34-2).

In a subset of patients, direct immunofluorescence reveals intraepidermal IgA deposits.[16] In these cases, IgA is usually present in a pemphigus-like intercellular pattern, either in the entire epidermis or confined to its upper layers. By indirect immunofluorescence, circulating IgA antibodies directed against the intercellular substance of the epidermis were detected in single cases. Today these cases are usually diagnosed as SPD-type IgA pemphigus (see Chap. 52).

Ultrastructural examination of paralesional skin has shown cytolysis of keratinocytes confined to the granular layer;[27] the formation of pustules has been regarded as a secondary event caused by invasion and sub-corneal accumulation of leukocytes.

DIFFERENTIAL DIAGNOSIS (Box 34-1)

An early localized eruption of SPD may be clinically and histologically indistinguishable from impetigo, but the distribution pattern of the lesions, the absence of bacteria in the pustules, the ineffectiveness of topical and systemic antibiotic therapy suggest the correct diagnosis. Dermatitis herpetiformis is also highly pruritic, affecting primarily the extensor surfaces and is sub-epidermal with IgA.

Pemphigus foliaceus has acantholysis and atypical immunofluorescence pattern. Generalized pustular psoriasis (von Zumbusch's type) presents with systemic symptoms (fever, malaise, leukocytosis), and spongiform pustules within the epidermis. The necrolytic migratory eruption of glucagonoma syndrome can be differentiated by its distribution, lack of actual pustule formation, erosions of the lips and oral mucosa, and, histologically, necrobiosis of the upper epidermis. Biochemically, excess levels of glucagon are diagnostic. Acute generalized pustulosis is widespread with predilection of the distal parts of the extremities, and histologically may exhibit leukocytoclastic vasculitis.

Box 34-1

Differential Diagnosis of Sub-Corneal Pustular Dermatosis

- Bacterial impetigo
- Dermatitis herpetiformis
- Pemphigus foliaceus
- Immunoglobulin A pemphigus/intraepidermal immunoglobulin A pustulosis
- Pustular psoriasis
- Necrolytic migratory erythema
- Acute generalized exanthematous pustulosis

PROGNOSIS AND CLINICAL COURSE

SPD is a benign condition. Without treatment, attacks recur over many years and remissions are variable, lasting from a few days to several weeks. Despite the protracted course the general health of the patient is usually not impaired. However, one of our own cases who had SPD, pyoderma gangrenosum, and IgA paraproteinemia of more than 20 years' duration died of septicemia with staphylococcal abscesses in the lungs, liver, and spleen.

TREATMENT

The drugs of choice are the sulfones (Box 34-2), such as dapsone in a dose of 50 to 150 mg daily. The response is slower and less dramatic than in dermatitis herpetiformis, but complete remission is most often obtained. In some patients, the treatment may be withdrawn after several months, although in others it may have to be continued for years; the minimal effective dose to suppress disease should be determined in these patients. Sulfapyridine (1.0 to 3.0 g daily) is also beneficial; systemic corticosteroids are less effective, although they can suppress generalized flares when given in high doses. Retinoids, phototherapy, and ultraviolet B have been reported to induce remissions, but this awaits confirmation.[28–30] Responses to colchicine, cyclosporine, and topical tacalcitol (1α-24R-dihydroxyvitamin D_3) have been anecdotally re-

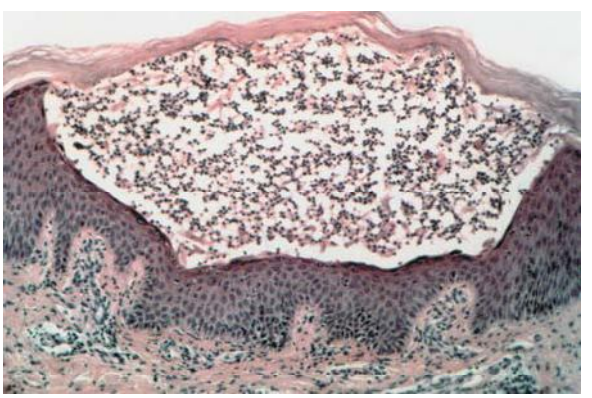

▲ **FIGURE 34-2** Sub-corneal pustular dermatosis. Strictly sub-corneal pustule filled with polymorphonuclear leukocytes, with the underlying epidermal layers exhibiting only slight edema and some migrating leukocytes. There is a mild inflammatory infiltrate around dermal blood vessels.

Box 34-2

Treatments for Sub-Corneal Pustular Dermatosis

First line	Sulfones	50–150 mg/day
	Corticosteroids	As required
Second line (anecdotally reported beneficial responses)	Retinoids, photochemotherapy, ultraviolet B, colchicine, cyclosporine, infliximab	

ported. In two recalcitrant cases, rapid initial responses have been observed to infliximab.[32,33] In one patient, remission could be maintained with acitretin, whereas the other relapsed despite continuation of infliximab.

KEY REFERENCES

The full reference list for all chapters is available at www.digm7.com.

1. Sneddon IB, Wilkinson DS: Subcorneal pustular dermatosis. *Br J Dermatol* **68**:385, 1956
3. Robinson ND et al: The new pemphigus variants. *J Am Acad Dermatol* **40**:649, 1999
6. Ishii N et al: Immunolocalization of target autoantigens in IgA pemphigus. *Clin Exp Dermatol* 29:62, 2004.
10. Vaccaro M et al: Subcorneal pustular dermatosis and IgA lambda myeloma: An uncommon association but probably not coincidental. *Eur J Dermatol* **9**:644, 1999
33. Bonifati C et al: Early but not lasting improvement of recalcitrant subcorneal pustular dermatosis (Sneddon-Wilkinson disease) after infliximab therapy: Relationships with variations in cytokine levels in suction blister fluids. *Clin Exp Dermatol* **30**:662, 2005.



CHAPTER 35

Eosinophils in Cutaneous Diseases

Kristin M. Leiferman
Margot S. Peters

Peripheral blood eosinophilia and/or infiltration of tissues by eosinophils occur in a variety of common and unusual diseases, including those of infectious, immunologic, and neoplastic etiology. Eosinophils are conspicuous in tissue sections stained with hematoxylin and eosin because of their intense avidity for eosin dye. Eosinophils have myriad phlogistic activities that implicate them in disease.[1–3] Common dermatoses associated with eosinophils in lesional tissues include arthropod bites and drug eruptions. Parasitic infections, especially those due to ectoparasites and helminths, typically have a marked eosinophilic host response.[4,5] Autoimmune blistering diseases, such as bullous pemphigoid and the various forms of pemphigus, often have prominent eosinophilic infiltrates, including histologic presentation as eosinophilic spongiosis.[6,7] Infiltration of eosinophils in the subcutaneous tissues (eosinophilic panniculitis) does not represent a specific diagnosis but rather is a manifestation of a diverse selection of entities, including erythema nodosum.[8,9] Eosinophils may be found in Langerhans cell histiocytosis, cutaneous neoplasms, and lymphoproliferative malignancies.[10] Although eosinophils constitute one of the histologic features in numerous cutaneous diseases, they represent a criterion for histologic diagnosis in relatively few entities (Table 35-1). They also play a role in certain categories of clinical reactions, particularly those characterized by edema.[11]

HYPEREOSINOPHILIC SYNDROMES

History

Epidemiology

The hypereosinophilic syndromes (HES) occur worldwide and span all age groups. Over 90 percent of patients with myeloproliferative HES and the mutant gene Fip1-like 1/platelet-derived growth factor receptor-α (*FIP1L1-PDGFRA*) are men, but lymphocytic HES shows equal gender distribution. The relative frequencies of the sub-types are unknown, although up to 25 percent of HES patients may have lymphocytic HES. Rare familial cases have been reported. A mini-epidemic has been observed over the last decade in eosinophilic esophagitis, a subset of overlap HES with organ-restricted disease, with prevalence estimates as high as 1:2500 among children and 1:4000 among adults.[25,26]

Etiology

Eosinophils are implicated as the cause of most end-organ damage in all HES subtypes. Clinical improvement usually parallels a decrease in eosinophil count. Patients with lymphocytic HES have abnormal T-cell clones with unusual surface phenotypes, including $CD3^+CD4^-CD8^-$ and $CD3^-CD4^+$. These T cells display activation markers, such as CD25, and secrete T helper 2 cytokines, including high levels of interleukin 5 (IL-5).[27] An 800-kilobase deletion on chromosome band 4q12 that codes for a tyrosine kinase has been found in myeloproliferative HES.[28] Patients with the *FIP1L1-PDGFRA* gene mutation, but without clinical manifestations of systemic mastocytosis, have elevated serum tryptase levels and increased atypical spindle-shaped mast cells in bone marrow.[29,30] Although they do not exhibit all its immunologic markers, these patients satisfy criteria for mastocytosis but are considered to form a distinct subset of HES, with cardiomyopathy and endomyocardial fibrosis, that responds to imatinib. The *FIP1L1-PDGFRA* gene is detected in mast cells, eosinophils, neutrophils, and mononuclear cells. Many HES patients have marked neutrophilia, likely due to the aberrant gene in the neutrophil lineage. Thus, alteration of several cell lines probably contributes to the pathogenesis of myeloproliferative HES. Multiple other chromosomal abnormalities have been identified in myeloproliferative HES, including translocations, partial and complete chromosomal deletions, and trisomies 8, 15, and 21.[31] The etiology of the other HES variants is not well understood, although patients with episodic angioedema and eosinophilia [Gleich syndrome[32]; see Episodic Angioedema Associated with Eosinophilia (Gleich Syndrome)] and the nodules, eosinophilia, rheumatism, dermatitis, and swelling (NERDS) syndrome[33] have developed T-cell clones.

Clinical Findings and Course

Patients satisfying HES diagnostic criteria (Table 35-2) present with signs and symptoms related to the organ systems infiltrated by eosinophils. HES may

EOSINOPHILS IN CUTANEOUS DISEASES

AT A GLANCE



- Eosinophils may be seen in skin biopsy specimens from a broad range of cutaneous diseases but are not pathognomonic for any dermatosis.
- Eosinophils are an important component of the characteristic histologic pattern in a limited number of diseases, including the following:
  - Hypereosinophilic syndromes
  - Wells syndrome (eosinophilic cellulitis)
  - Angiolymphoid hyperplasia with eosinophilia
  - Kimura disease
  - Eosinophilic pustular folliculitis
  - Granuloma faciale
  - Eosinophilic ulcer of the oral mucosa
- Clinical reaction patterns with eosinophil involvement include diseases in which eosinophils probably play a pathogenic role and are a component of the histologic pattern but are not important for diagnosis.
- Evidence for involvement of eosinophils in cutaneous diseases is provided by observation of intact eosinophils in lesional tissue sections and/or by immunostains for their toxic granule proteins, which are deposited in tissues.

present with cutaneous disease,[34] and pruritic erythematous macules, papules, plaques, wheals, or nodules[35] are present in over 50 percent of patients. Lesions may involve the trunk and extremities. Urticaria and angioedema occur in all HES sub-types and are characteristic of certain variant sub-types. Erythema annulare centrifugum,[36–38] purpuric papules,[39] livedo reticularis, and Wells syndrome (eosinophilic cellulitis)[40,41] also may be seen in patients with HES.

Lymphocytic HES commonly is associated with severe pruritus, eczema, erythroderma, urticaria, and angioedema, as well as lymphadenopathy and, rarely, endomyocardial fibrosis. In myeloproliferative HES, the usual presenting complex includes fever, weight loss, fatigue, malaise, skin lesions, and hepatosplenomegaly.[42] Mucosal ulcers of the oropharynx or anogenital region (Fig. 35-1) portend an aggressive clinical course; death is likely within 2 years of presentation if the disorder is untreated.[43,44] Cardiac disease occurs frequently. Eosinophils adhere to endocardium and release granule proteins onto endothelial cells, thrombus formation follows, and, finally, subendocardial fibrosis with restrictive cardiomyopathy occurs. Mitral or tricuspid valvular insufficiency results from tethering of chordae tendineae. Cardiac abnormalities that are essentially identical to those of HES but are confined to the in-

TABLE 35-1
Eosinophils in Cutaneous Diseases

- Diseases characterized by tissue eosinophils
  - Hypereosinophilic syndromes
  - Wells syndrome (eosinophilic cellulitis)
  - Angiolymphoid hyperplasia with eosinophilia
  - Kimura disease
  - Eosinophilic pustular folliculitis
    - Classic (Ofuji disease)
    - Human immunodeficiency virus–associated
    - Infantile/neonatal
  - Granuloma faciale
  - Eosinophilic ulcer of oral mucosa
- Diseases typically associated with tissue eosinophils
  - Arthropod bites and sting reactions
  - Infestations/parasitic diseases
  - Bullous dermatoses
    - Pemphigoid
    - Pemphigus
    - Incontinentia pigmenti
  - Drug reactions
  - Urticaria and angioedema
  - Dermatoses of pregnancy
  - Histiocytic diseases
    - Langerhans cell histiocytosis
    - Juvenile xanthogranuloma
  - Vasculitis
    - Churg-Strauss syndrome
    - Eosinophilic vasculitis
- Histologic reaction patterns associated with a variety of diseases
  - Eosinophilic spongiosis
    - Immunobullous diseases
      - ~ Pemphigoid
      - ~ Pemphigus
    - Incontinentia pigmenti
    - Arthropod bite
    - Acute dermatitis
  - Eosinophilic panniculitis
    - Erythema nodosum
    - Wells syndrome
    - Vasculitis
    - Arthropod bite
    - Injection granuloma
    - Gnathostomiasis
    - Infection
    - Lymphoma

HYPER-EOSINOPHILIC SYNDROMES

AT A GLANCE



- Spectrum of entities defined by inclusive criteria (Table 35-2).
- Cutaneous lesions are common and may be the presenting sign.
- Two major hypereosinophilic syndromes (HES) sub-types and several variants.
  - Lymphocytic characterized by T-cell clones that produce interleukin 5.
  - Myeloproliferative associated with a deletion on chromosome 4 that produces a tyrosine kinase fusion gene Fip1-like 1/platelet-derived growth factor receptor-α.
    - Responsive to imatinib
    - Severely debilitating mucosal ulcers portend a grim prognosis unless HES is treated
    - Overlap with mastocytosis
  - Other variant HES sub-types may evolve into lymphocytic HES.
    - Familial
    - Organ-restricted
    - Associated with specific disorders such as Churg-Strauss syndrome
    - Undefined with benign, complex, and episodic presentations
- Associated embolic events constitute a medical emergency.
- Eosinophilic endomyocardial disease occurs in HES and in patients with prolonged peripheral blood eosinophilia from any cause.

TABLE 35-2
Diagnostic Criteria for Hypereosinophilic Syndromes

- Peripheral blood eosinophilia of at least 1500 eosinophils/μL
  - Longer than 6 mo or
  - Less than 6 mo with evidence of organ damage
- Signs and symptoms of multiorgan involvement
- No evidence of parasitic or allergic disease or other known causes of peripheral blood eosinophilia

tramural regions can occur without appreciable peripheral blood eosinophilia.[45,46] Splinter hemorrhages and/or nail fold infarcts may herald the onset of thromboembolic disease. The central and peripheral nervous system, lungs, and, rarely, kidneys may be affected. In contrast to myeloproliferative HES, lymphocytic HES generally follows a benign course, and T-cell clones can remain stable for years. Patients should be observed closely and regarded as having pre-malignant or malignant T-cell proliferation,[27] because the disease may evolve into lymphoma.

Patients with myeloproliferative HES frequently present with clinical features resembling those of chronic myelogenous leukemia and sometimes are regarded as having chronic eosinophilic leukemia. Although the disease may evolve into frank leukemia, the relatively mature nature of the eosinophils and lack of evidence for clonal expansion generally preclude such classification. During the decade or more after diagnosis, HES may evolve into acute leukemia and, less commonly, has been associated with B-cell lymphomas.

Churg-Strauss syndrome (see Chap. 165) is a variant HES sub-type. Other variant HES types include Gleich syndrome[32] [see Episodic Angioedema Associated with Eosinophilia (Gleich Syndrome)], in which eosinophil counts fluctuate with extreme angioedema. The overall 5-year survival rate for HES patients is 80 percent; congestive heart failure from the restrictive cardiomyopathy of eosinophilic endomyocardial disease is a major cause of death, followed by sepsis.

Laboratory Tests

A key criterion for diagnosis is marked, prolonged peripheral blood eosinophilia (see Table 35-2). Other causes of eosinophilia, including allergic and parasitic diseases, should be excluded. Tests to detect organ involvement, particularly measurement of liver enzyme levels, are important. Because eosinophilic endomyocardial disease can develop in any patient with prolonged peripheral blood eosinophilia, patients should undergo periodic echocardiography. Increased serum levels of immunoglobulin E (IgE) are often present in lymphoproliferative HES, and levels of vitamin B_{12} and tryptase are increased in myeloproliferative HES. The Chic2 fluorescent in situ hybridization assay detects the deletion that produces the *FIP1L1-PDGFRA* gene product and should be performed, because patients with this mutation respond to treatment with imatinib.[29,47] Alternatively, the mutant gene can be detected by a polymerase chain reaction assay. Both tests are available commercially. In patients who lack the fusion gene, testing for other clonal cytogenetic abnormalities or abnormal clonal T-cell populations is warranted. Cytoflow of peripheral blood lymphocytes and immunophenotyping of tissue lymphocytes should be performed for the diagnosis of lymphocytic HES and repeated periodically to look for transformation from a variant HES type to lymphocytic HES or to T-cell lymphoma.

The cutaneous histopathologic features of HES vary with the type of lesion. Skin biopsy specimens from urticarial lesions resemble idiopathic urticaria, with generally mild, non-specific perivascular and interstitial infiltration of lymphocytes, eosinophils, and, occasionally, neutrophils. Immunostaining reveals extensive deposition of eosinophil granule proteins in the absence of intact eosinophils in episodic angioedema with eosinophilia and HES with mucosal ulcers, and in synovial tissues in NERDS. Other than in Churg-Strauss syndrome, vasculitis is only rarely associated with HES.[39]

Differential Diagnosis

Clinically, parasitic infections and infestations may closely resemble HES. A history of travel to endemic areas or certain dietary exposure implicates helminthiasis. Along with eosinophilia, total serum IgE levels higher than 500 IU/mL commonly are found in helminthic infections. Examination of stool samples for ova and parasites and serologic testing for *Strongyloides* antibodies should be performed. In patients with isolated urticarial plaques with or without angioedema, the differential diagnosis includes urticaria, but demonstration of multiorgan involvement supports HES. HES with episodic angioedema may resemble hereditary angioedema clinically, although patients with hereditary angioedema often have a family history of the disease, rarely have the markedly elevated eosinophil counts that characterize HES, and may be distinguished by complement abnormalities. Pruritic eczematoid lesions of lymphocytic HES may resemble those of atopic dermatitis, contact dermatitis, drug reaction,

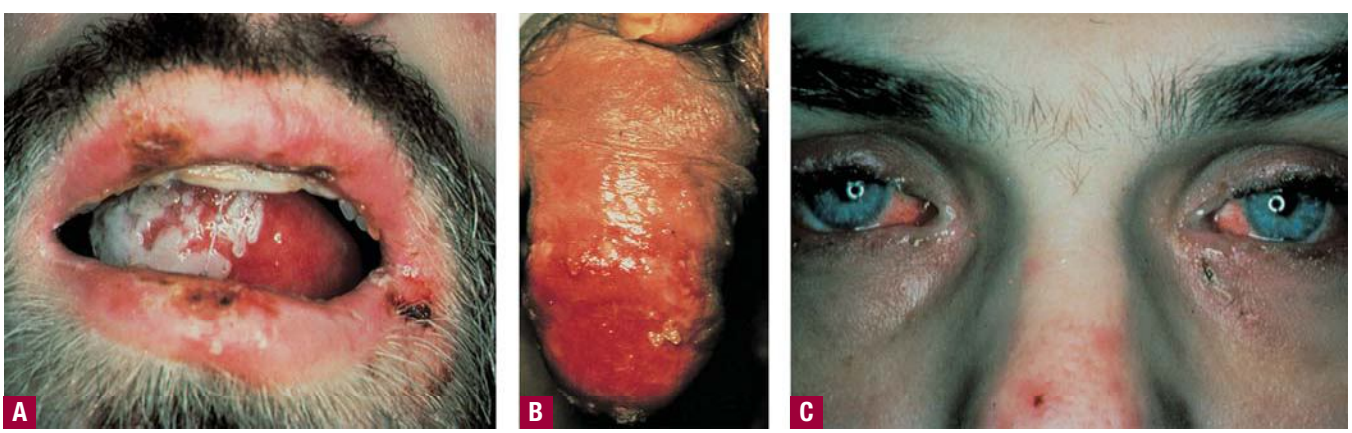

▲ **FIGURE 35-1** Hypereosinophilic syndrome. Mucosal erosions and ulcers of the mouth (**A**) and glans penis (**B**); conjunctival irritation (**C**).

fungal infection, and T-cell lymphoma. There are multiple diseases in the differential diagnosis of patients with orogenital ulcers,[44] including those associated with thrombosis, such as Behçet syndrome, Crohn disease, ulcerative colitis, and Reiter syndrome. Others considerations are recurrent aphthous stomatitis, immunobullous diseases, erythema multiforme, lichen planus, herpes simplex infection, and syphilis.

Treatment

The goal of treatment is to relieve symptoms and improve organ function while keeping peripheral blood eosinophils at 1000 to 2000/μL and minimizing treatment side effects (Fig. 35-2).[24] Myeloproliferative HES is very responsive to imatinib. In patients with the mutant gene *FIP1L1-PDGFRA*, administration of imatinib mesylate is indicated and usually induces hematologic remission, but endomyocardial disease may worsen during the first several days of treatment. Troponin levels should be monitored before and during imatinib therapy. To improve cardiac function, glucocorticoids should be given before and with initiation of imatinib therapy.[12,38] Imatinib resistance can develop.[48,49] In the absence of the gene mutation, after *Strongyloides* infection has been excluded,[50] first-line therapy is prednisone. Approximately 70 percent of patients will respond, with peripheral eosinophil counts returning to normal. Patients for whom glucocorticoid monotherapy fails have a worse prognosis generally; in such cases, or when long-term side effects become problematic, other treatments should be used. Patients who have features of myeloproliferative HES but who lack *FIP1L1-PDGFRA* still may respond to imatinib.[22] Interferon-α (IFN-α) has been beneficial in treating myeloid and lymphocytic HES.[51] In one patient, loss of the *FIP1L1–PDGFRA* mutation after several years of IFN-α therapy was associated with complete remission.[52] Other treatments with reported benefit include hydroxyurea, dapsone, vincristine sulfate, cyclophosphamide, methotrexate, 6-thioguanine, 2-chlorodeoxyadenosine and cytarabine combination therapy, pulsed chlorambucil, etoposide, cyclosporine, intravenous immunoglobulin, alemtuzumab, and psoralen plus ultraviolet A phototherapy.[53] Extracorporeal photopheresis alone or in combination with IFN-α or other therapies, as well as bone marrow and peripheral blood stem cell allogeneic transplantation,[54,55] represent additional options. Two monoclonal antibodies against human IL-5 have been associated with clinical improvement and reductions in peripheral blood and dermal eosinophils, particularly in patients with lymphocytic HES.[56]

WELLS SYNDROME

History

Epidemiology

Wells syndrome is primarily a disease of adults, but approximately 30 pediatric patients have been reported.[57,59–69] Familial eosinophilic cellulitis has been described.[70] The disease has no gender predilection.

Etiology

Whether Wells syndrome is a specific entity that is triggered by factors including underlying disease, infection, and drugs, or whether it is merely a reaction pattern may be difficult to discern from some of the reported cases and in practice.[71] Association of eosinophilic cellulitis with a range of disorders (Table 35-3), including arthropod bites,[60,66,72] myeloproliferative disease,[72] colon cancer,[73] reaction to thimerosal-containing vaccination,[74] Churg-Strauss syndrome,[65] hypereosinophilic syndromes,[40,41] dermographism,[75] onchocerciasis,[61] herpes simplex infection,[76] immunobullous disease,[60,77] and drug reactions[78,79] suggests that it is a reactive or allergic hypersensitivity phenomenon, although the pathogenesis is unknown.[80]

Deposition of toxic granule proteins in lesional tissues, revealed by immunofluorescence testing, provides evidence that eosinophil degranulation contributes to flame figure formation in Wells syndrome.[68] Indeed, Wells and Smith postulated that infiltration of phagocytic histiocytes between collagen bundles may be a response to collagen damage induced by eosinophil cytotoxicity.[60] The severity of Wells syndrome has been correlated with serum levels of IL-5 and eosinophil cationic protein,[81] and IL-5 is implicated in the development of hereditary eosinophilic cellulitis.[70]

Clinical Findings and Course

Cutaneous edema was the common clinical thread in the first four cases reported by Wells.[57] After prodromal burning or itching, lesions begin with erythema and edema (Fig. 35-3A), sometimes in the form of annular or arcuate plaques or nodules. Over a period of days, they evolve into large edematous plaques with violaceous borders. Bullae may develop. Individual lesions gradually change from bright red to brown-red and then to blue-gray or greenish gray, resembling morphea (Fig. 35-3B). Less common clinical presentations include papules, vesicles (Fig. 35-4), and hemorrhagic bullae. The cutaneous lesions may be single or multiple and may be located at any site, but typically involve the extremities and less often the trunk. The most frequent systemic complaint in patients with Wells syndrome is malaise; fever occurs in a minority of cases. Lesions resolve without scarring, usually within weeks to months, but multiple recurrences are common.

WELLS SYNDROME (EOSINOPHILIC CELLULITIS) AT A GLANCE



- Single or multiple lesions commonly located on the extremities or trunk.
- Lesions may be painful or pruritic.
- Sometimes associated with general malaise but only uncommonly with fever.
- Edematous and erythematous lesions evolve into plaques with violaceous borders.
- Blisters may be a prominent feature.
- Individual lesions persist for weeks and gradually change from red to blue-gray or greenish gray, resembling morphea.
- Multiple recurrences.
- Peripheral blood eosinophilia common.
- Histologic pattern characterized by dermal infiltration with eosinophils, and flame figures surrounded by histiocytes.
- Systemic glucocorticoids usually beneficial.



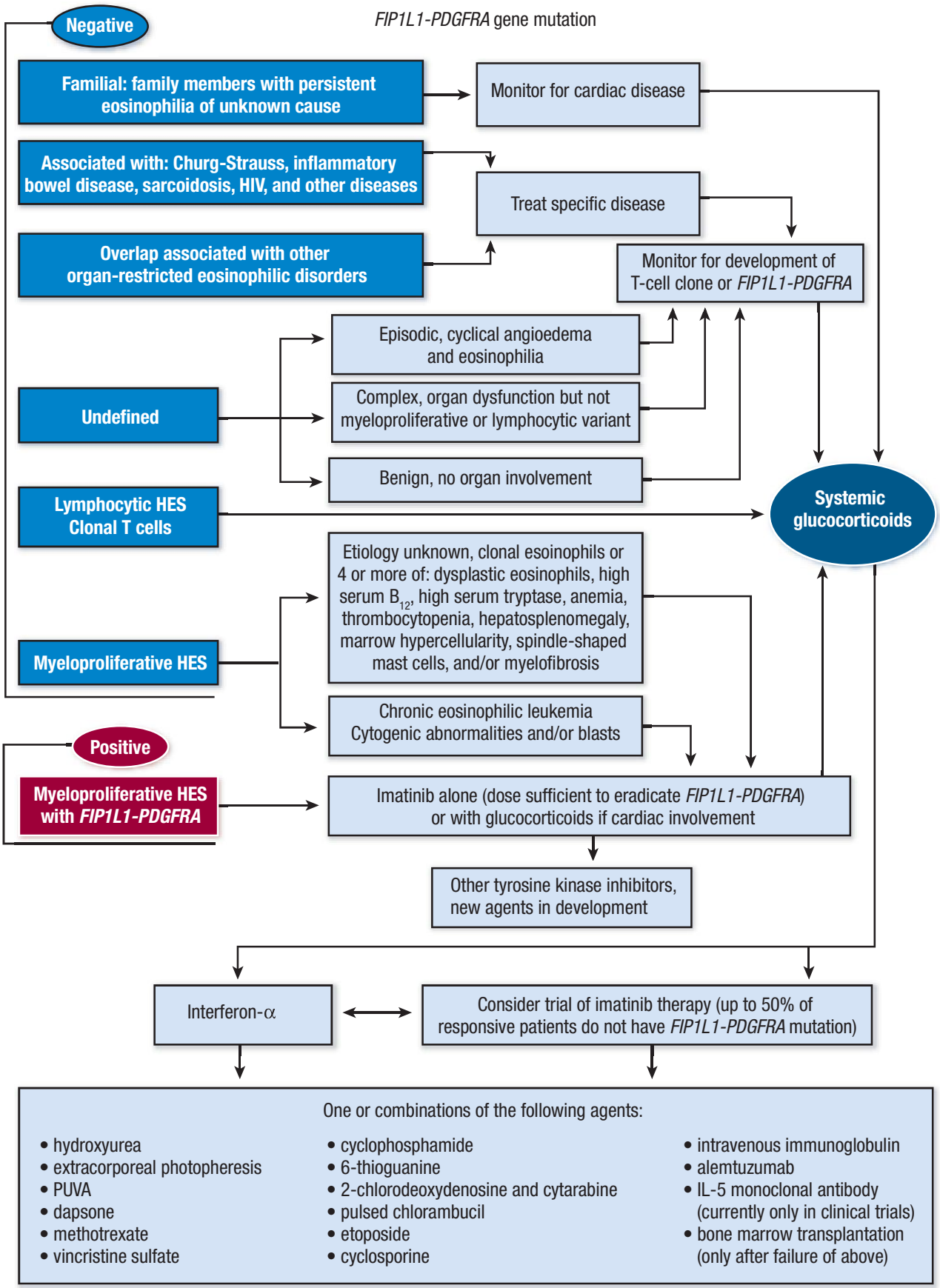

▲ **FIGURE 35-2** Hypereosinophilic syndromes (HES): classification and treatment. *FIP1L1-PDGFRA* = Fip1-like 1/platelet-derived growth factor receptor-α; HIV = human immunodeficiency virus; IL-5 = interleukin 5; PUVA = psoralen plus ultraviolet A phototherapy. (Modified from Klion AD et al: Approaches to the treatment of hypereosinophilic syndromes: A workshop summary report. *J Allergy Clin Immunol* **117**:1292, 2006; and Stetson CL, Leiferman KM: Eosinophilic dermatoses, in *Dermatology*, 2nd ed, edited by Bolognia JL, Jorizzo JL, Rapini RR. Elsevier, in press, Fig. 27-2.)

TABLE 35-3
Conditions Associated with Wells Syndrome and/or Flame Figures

- Arthropod bites
- Ascariasis
- Churg-Strauss syndrome
- Colonic adenocarcinoma
- Dental abscess
- Dermographism
- Drug reactions
- Eczema
- Eosinophilic pustular folliculitis
- Herpes gestationis
- Herpes simplex infection
- Hypereosinophilic syndromes
- Immunobullous diseases
- Mastocytoma
- Myeloproliferative disease
- Onchocerciasis
- Vaccination containing thimerosal
- Tinea
- Toxocariasis
- Urticaria

Laboratory Tests and Histopathology

Peripheral blood eosinophilia is observed in approximately 50 percent of patients.[77] Skin lesions are characterized histologically by diffuse dermal infiltration with eosinophils, histiocytes, and foci of amorphous and/or granular material associated with connective tissue fibers, which Wells termed *flame figures*.[57] In the early stages, there also is dermal edema. Later, histiocytes palisade around flame figures. In addition to eight patients with the syndrome, the 1979 report of Wells and Smith includes nine patients with the typical histologic features of eosinophilic cellulitis but in association with a variety of clinical diagnoses, including pemphigoid, eczema, and tinea.[60] This and subsequent reports of flame figures in lesions from patients with a wide spectrum of diseases (see Table 35-3),[60,66,72,78,82] indicate that the flame figure is characteristic for, but not diagnostic of, Wells syndrome.[71] When examined for eosinophil granule major basic protein by immunofluorescence, flame figures show bright extracellular staining (Fig. 35-5), indicating that extensive eosinophil degranulation has occurred.[68]



▲ **FIGURE 35-3** Wells syndrome. **A.** Early lesion with erythema and edema. **B.** Late lesion resembling morphea.



▲ **FIGURE 35-4** Familial Wells syndrome. Plaques with erythema, edema, vesicles, and bullae resembling acute dermatitis or pemphigoid. (From Davis MD et al: Familial eosinophilic cellulitis, dysmorphic habitus, and mental retardation. *J Am Acad Dermatol* **38**:919, 1998, with permission.)

Differential Diagnosis

Urticaria, erysipelas, and acute cellulitis should be considered in the differential diagnosis of the early stages of Wells syndrome (see Fig. 35-3A). Later, plaques may resemble morphea (see Fig. 35-3B). The presence of blisters may suggest pemphigoid (see Fig. 35-4). Flame figures are the hallmark of Wells syndrome, but because they have been identified in biopsy specimens from other dermatoses, they are not alone sufficient for the diagnosis. However, a diagnosis of Wells syndrome in the absence of flame figures should be met with skepticism, even in the presence of dermal infiltration with eosinophils and histiocytes.[71]

Treatment

Wells syndrome usually improves dramatically after administration of sys-

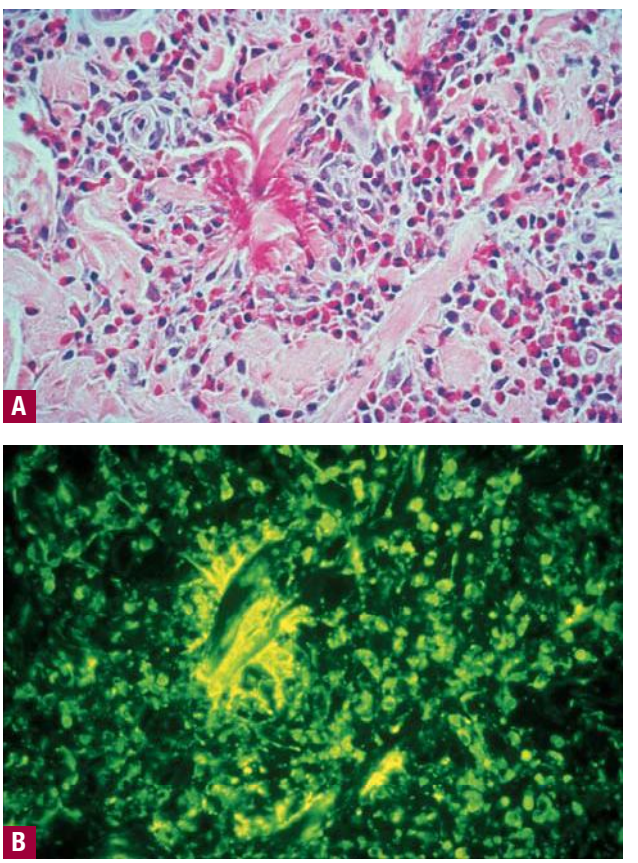

◀ **FIGURE 35-5** Flame figure in familial Wells syndrome. **A.** Hematoxylin and eosin–stained section. **B.** Eosinophil granule major basic protein immunostain (of serial section to **A**) shows extensive granule protein deposition localized to the flame figure. (Original magnification ×400.)

ANGIOLYMPHOID HYPERPLASIA WITH EOSINOPHILIA AND KIMURA DISEASE

AT A GLANCE



- Kimura disease (KD) occurs mainly in Asian males; angiolymphoid hyperplasia with eosinophilia (ALHE) occurs in all races with a female predominance.
- KD is found in a somewhat younger age group than ALHE.
- Characterized by recurrent dermal and/or subcutaneous lesions, primarily of the head and neck area.
  - ALHE lesions tend to be smaller, more superficial, and more numerous than those of KD.
  - KD tends to involve subcutaneous tissues, regional lymph nodes, and salivary glands.
- ALHE may be painful, pruritic, or pulsatile, whereas KD is generally asymptomatic.
- Peripheral blood eosinophilia is seen in both diseases.
- Increased immunoglobulin E levels are found only in KD.
- Renal disease is associated only with KD (reported incidence of 10 percent to 20 percent).
- Histopathologic features:
  - Dominant feature of KD is lymphoid proliferation, often with germinal centers, whereas ALHE is characterized by vascular proliferation with numerous large epithelioid or histiocytoid endothelial cells.
  - Fibrosis is characteristic of KD and is limited or absent in ALHE.
  - Inconspicuous to numerous eosinophils in ALHE.
  - Eosinophil abscesses may occur in KD.

temic glucocorticoids, and tapering of steroid dose over 1 month is well tolerated in most patients. Recurrences may be treated with additional courses of systemic glucocorticoids. For patients who fail to respond, or who experience relapse often enough to raise concerns about the long-term side effects of systemic glucocorticoid therapy, other options such as minocycline, dapsone, griseofulvin, and antihistamines may be beneficial. Cyclosporine and IFN-α also have been used with success. For treatment of mild disease, topical glucocorticoids may be sufficient.

ANGIOLYMPHOID HYPERPLASIA WITH EOSINOPHILIA

History

Epidemiology

Angiolymphoid hyperplasia with eosinophilia (ALHE) occurs in both males and females, but the literature indicates a slight female predominance. Patients are generally in the third to fifth decade of life. In contrast to Kimura disease (KD), which develops mainly in patients from Asia, ALHE has no racial predilection and is typically seen in Westerners.

Etiology

The pathogenesis of ALHE is unknown, but it is considered to be a reactive phenomenon, possibly arising in response to or in association with an underlying vascular malformation. There is a history of trauma in some cases. ALHE has been reported to occur in pregnancy, which suggests that sex hormones may be a factor in its development.[88]

Clinical Findings and Course

ALHE shows a predilection for the head and neck area and is characterized by solitary, few, or multiple, sometimes grouped, erythematous, violaceous or brown papules, plaques, or nodules of the dermis and/or subcutaneous tissues (Fig. 35-6; see also Fig. 147-11 in Chap. 147). Lesions may be associated with pruritus or pain, or may pulsate. Although they are confined to the skin in most patients, mucosal involvement may occur. ALHE tends to be chronic and nonremitting over months to years.

Laboratory Tests and Histopathology

Approximately 20 percent of patients have peripheral blood eosinophilia, but IgE levels are unremarkable. There is no association with renal disease. The dominant histologic feature is a well-defined area, in the dermis and/or subcutis, of prominent vascular proliferation with large epithelioid or histiocytoid endothelial cells that contain abundant eosinophilic cytoplasm, often with cytoplasmic vacuoles (see Fig. 147-11 in Chap. 147). There are variable numbers of eosinophils and lymphocytes,[89] with an occasional finding of lymphoid nodules. In their report of 116 patients with ALHE, Olsen and Helwig found 53 cases in which "an arterial structure" appeared to be associated with venules or "was the area of endothelial proliferation," which provided evidence that these lesions represent a form of arteriovenous shunt.[87] The stroma typically is myxoid, and fibrosis is minimal or ab-



▲ **FIGURE 35-6** Angiolymphoid hyperplasia with eosinophilia. **A.** Forehead nodule. **B.** Recurrence of lesions in skin graft and adjacent sites 6 years after surgical removal of lesion in **A**.

sent. Mast cells may be a component of the histologic picture.

Differential Diagnosis

Lesions of ALHE generally are smaller, more superficial, and more numerous than those of KD, and often are symptomatic. Although lymphoid follicles may occur in ALHE, they represent the dominant characteristic of KD (Table 35-4). Although KD may exhibit some vascularity, it lacks the large epithelioid endothelial cells that are a key feature of ALHE (see Table 35-4). ALHE should be distinguished from a variety of benign and malignant vascular proliferations, including pyogenic granuloma, epithelioid hemangioendothelioma, and Kaposi sarcoma—all of which lack a noticeable eosinophil infiltrate.

Treatment

Intervention is dictated in part by the number, location, and size of lesions. Patients with solitary or a few small lesions may benefit from excision or Mohs surgery.[90] There may be recurrence at the surgical site (see Fig. 35-6). A variety of other treatment modalities have been used with success, including systemic and intralesional steroid administration, IFN therapy,[91] cryotherapy,[92] laser therapy,[93] and topical application of tacrolimus.[94]

KIMURA DISEASE

History

Epidemiology

KD occurs predominantly in young adult Asian males. It also has been reported in children.

Etiology

KD is an idiopathic inflammatory disorder. The combination of peripheral blood eosinophilia, increased serum IgE levels, and histologic pattern of lymphoid nodules with germinal centers and numerous eosinophils suggests that KD represents an allergic hypersensitivity reaction. The pathogenic stimulus for the hypersensitivity response is unknown. Association with glomerulonephritis raises the possibility that KD has an autoimmune basis.

Clinical Findings and Course

Patients typically have one or a few asymptomatic, non-tender, slowly enlarging subcutaneous nodules. Lesions characteristically involve the head and neck region but may be localized to the extremities, axilla, groin, or trunk. There often is associated regional lymphadenopathy and sometimes more widespread lymph node enlargement.[96–98] The overlying skin appears normal. KD is typically chronic and recurrent.

TABLE 35-4
Comparison of Angiolymphoid Hyperplasia with Eosinophilia (ALHE) and Kimura Disease (KD)

	ALHE	KD
Gender	Typically middle-aged females	Predominantly young adult males
Symptoms	Pruritus, pain, pulsation	Asymptomatic
Lesion type and location	Small and superficial, with overlying erythema; head and neck region	Large, mainly subcutaneous; overlying skin normal; head and neck region; may involve regional lymph nodes and salivary glands
Lymphoid follicles	Uncommon	Prominent lymphoid follicles with germinal centers
Vascular proliferation	Prominent vascular proliferation with large epithelioid/histiocytoid endothelial cells; evidence of underlying vascular malformation may be evident	Some stromal vascularity with unremarkable endothelial cells
Fibrosis	Absent or limited	Prominent
Serum immunoglobulin E level	Normal	Increased
Nephropathy	Absent	Present in up to 20% of patients

Laboratory Tests and Histopathology

Peripheral blood eosinophil counts and serum IgE levels are elevated in most patients. Evaluation of renal function is indicated, because KD is associated with glomerulonephritis and nephrotic syndrome.[99,100] Histologically, lesions are characterized by lymphoid aggregates, usually in the form of lymphoid follicles with germinal centers, numerous eosinophils (see eFig. 35-6.1 in online edition), and fibrosis. Other features may include eosinophil abscesses and stromal vascularity, without the epithelioid or histiocytoid endothelial cells that are typical of ALHE.

Differential Diagnosis

Because lesions of KD are usually subcutaneous, with normal-appearing overlying skin and are associated with lymphadenopathy, the possibility of lymphoma or metastatic carcinoma should be considered in the clinical differential diagnosis. Historically, there has been debate about whether ALHE and KD represent separate entities or are part of a single disease spectrum, a confusion that may be furthered by a report of KD and ALHE occurring in the same patient.[101] Both ALHE and KD are characterized by persistent and recurrent lesions, primarily involving the head and neck areas. However, there are distinct clinical and histologic differences between the two disorders (see Table 35-4), particularly the lymphoid follicles with germinal centers that dominate KD in contrast to the vascular proliferation with large epithelioid endothelial cells that characterizes ALHE. Lesional tissue and peripheral blood eosinophilia are more pronounced in KD.

Treatment

Surgical excision is the treatment of choice when feasible in patients with a single or a limited number of nodules, but lesions may recur.[102] Other therapeutic options include systemic glucocorticoids, radiation therapy, and cyclosporine.[103] The presence of renal disease may influence or dictate the therapeutic regimen.

EOSINOPHILIC PUSTULAR FOLLICULITIS

History

Epidemiology

Predominantly a disease of males, eosinophilic pustular folliculitis (EPF) is now considered to encompass three clinical

EOSINOPHILIC PUSTULAR FOLLICULITIS

AT A GLANCE



- Three clinical types, characterized by follicular papules and pustules that may involve the head, trunk, and extremities
  - Classic eosinophilic pustular folliculitis (Ofuji disease)
    - Typically occurs in Japanese patients, who have chronic, recurrent follicular pustules, with a tendency to form circinate plaques, in a seborrheic distribution
  - Eosinophilic pustular folliculitis associated with immunosuppression
    - Most often occurs in patients with human immunodeficiency virus infection, who have severely pruritic papules of the face and upper trunk
  - Eosinophilic pustular folliculitis of infancy/neonatal period
    - Follicular pustules of the scalp
- Tendency for recurrences and chronicity (except eosinophilic pustular folliculitis of infancy)
- Characterized by follicular and perifollicular eosinophil infiltration
- Associated with peripheral blood eosinophilia

types.[108] Classic EPF is not racially restricted but typically occurs in Japanese adults in the third and fourth decades of life.[109] EPF associated with human immunodeficiency virus (HIV) infection is now the most common type and may develop in the setting of antiretroviral therapy.[107,110,111] EPF occurs infrequently in association with other types of immunosuppression.[112] EPF of infancy presents during the first year of life,[106,108] including the neonatal period. The number of patients reported to have HIV-associated EPF far exceeds those in the other two categories. EPF associated with immunosuppression has been observed in HIV-negative patients who have hematologic or lymphoproliferative disease, including lymphoma, leukemia, or polycythemia vera. Drug-induced EPF[112–114] and EPF associated with myelodysplastic syndrome[115] also have been described.

Etiology

Although a variety of theories concerning the pathogenesis of EPF have been proposed, the etiology is unknown. Immune dysfunction and allergic hypersensitivity are considered to play a role.

Clinical Findings and Course

Classic EPF presents as recurrent crops or clusters of follicular papules and pustules, which may form an annular pattern and usually resolve in 7 to 10 days. Lesions predominantly involve the face and trunk but also may affect the extremities, with involvement of the palms and soles in approximately 20 percent of patients.[109] In contrast, HIV-associated EPF tends to manifest as extremely pruritic discrete follicular papules, typically involving the head and neck and often the proximal extremities (see Fig. 198-3, Chap. 198). Rosenthal et al. emphasized the urticarial quality of such lesions.[110] In EPF of infancy, lesions typically are located on the scalp but also may be found on the face and extremities. In some neonates who have pustular eruptions that clinically resemble EPF and typically have peripheral blood eosinophilia, the disorder may be classified more appropriately under the term *eosinophilic pustulosis* because the cutaneous infiltrates are not folliculocentric (see Chap. 106).[116] EPF of infancy has a good prognosis, whereas classic and HIV-associated EPF are characterized by recurrences. Post-inflammatory pigmentation may be seen as lesions resolve, but scarring does not occur.

Laboratory Tests and Histopathology

Patients suspected of having EPF should be evaluated for underlying immune deficiency, particularly HIV infection. Peripheral blood eosinophilia is a component of all three types of EPF. Although patients with classic EPF usually have eosinophilia with leukocytosis, HIV-positive patients often exhibit eosinophilia with lymphopenia. Low CD4 cell counts and high IgE levels are typical of HIV-associated EPF.[110] Histologically, the most striking feature is the infiltration of eosinophils into hair follicles and perifollicular areas (see eFig. 35-6.2 in on-line edition), sometimes with follicular damage. The infiltrates also may contain lymphocytes and neutrophils, and may be perivascular as well as follicular. Follicular mucinosis (see Chap. 146) has been noted in association with EPF.

Differential Diagnosis

Folliculitis secondary to bacterial or fungal infection must be kept in mind, particularly in immunosuppressed patients. Because of the distribution of lesions, seborrheic dermatitis should be considered, as should lupus erythematosus, particularly when lesions are more maculopapular than pustular. Acneiform eruptions may resemble EPF. Erythema toxicum neonatorum, acropustulosis, and acne neonatorum also should be considered in infants.

Treatment

Topical glucocorticoids generally are the first approach to the treatment of all types of EPF. Nonsteroidal anti-inflammatory drugs, particularly indomethacin, also have been suggested as first-line therapy; clinical improvement may be observed within 2 weeks and is associated with a decrease in peripheral blood eosinophil counts.[117] Ultraviolet light therapy (ultraviolet B or psoralen and ultraviolet A) may be beneficial. Topical tacrolimus is a treatment option, particularly for facial lesions.[118] Topical permethrin, systemic retinoids, systemic glucocorticoids, cyclosporine, itraconazole, metronidazole, cetirizine, minocycline, dapsone, and IFNs have been tried with success.[119] Antiretroviral treatment that results in an increase in CD4 cell counts often is associated with improvement in HIV-associated EPF.

EOSINOPHILIC ULCER OF THE ORAL MUCOSA

Eosinophilic ulcer of the tongue, now referred to as *eosinophilic ulcer of the oral mucosa*, is a self-limited disease of the tongue, oral mucosa, or lips, manifested as a 1- to 2-cm ulcer with the histopathologic pattern of massive eosinophil infiltration extending into underlying muscle.[120–122] The infiltrate often contains lymphocytes, histiocytes, plasma cells, neutrophils and mast cells. The finding of large CD30$^+$ lymphocytes in eosinophilic ulcer of the oral mucosa suggests that it may be a lymphoproliferative disorder.[123]

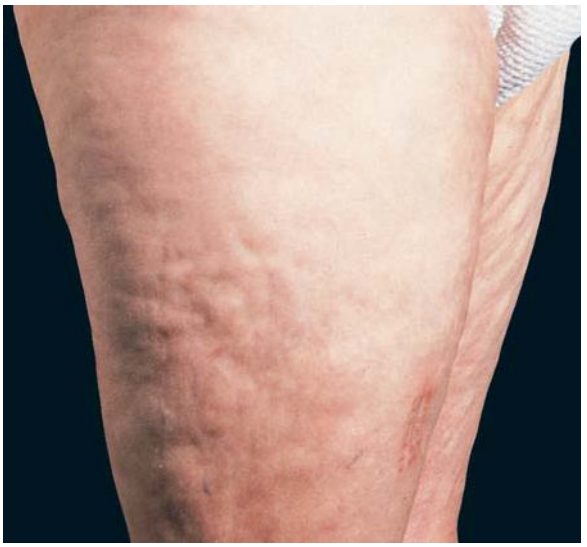

◀ **FIGURE 35-7** Eosinophilic fasciitis. Puckered skin of the thighs.



CLINICAL REACTION PATTERNS WITH EOSINOPHIL INVOLVEMENT

There are a variety of diseases in which eosinophils may be present in cutaneous lesions, with or without associated peripheral blood eosinophilia, but either the histologic pattern is unremarkable or eosinophils are not critical for the histologic diagnosis of the given entity (see Table 35-1). In many of these dermatoses, the eosinophil loses its morphologic integrity after disruption through cytolysis and is not identifiable histologically.[124] However, toxic granule proteins and other eosinophil products are deposited in skin and persist for extended periods of time.[125]

Edema

Prominent among the eosinophil-associated skin reactions are those manifesting edema. In addition to the presence of cationic granule proteins in lesions, the ability of eosinophils to elaborate vasoactive mediators, induce histamine release from mast cells and basophils, and elicit a cutaneous wheal-and-flare reaction supports a role for the eosinophil as a primary participant in the edema associated with certain cutaneous diseases (see Chap. 37).[11]

EPISODIC ANGIOEDEMA ASSOCIATED WITH EOSINOPHILIA (GLEICH SYNDROME) Episodic angioedema associated with eosinophilia is characterized by recurrent angioedema (with up to 30 percent increase in body weight), urticaria, fever, increased serum IgM levels, and leukocytosis as high as 100,000 cells/mm^3 with up to 90 percent eosinophils; disease activity fluctuates with the peripheral eosinophil count.[32,131] Skin biopsy specimens from this disorder[32] and its localized variant, recurrent facial edema with eosinophilia,[132] show few eosinophils, but immunofluorescence staining reveals extracellular deposition of eosinophil granule proteins around collagen bundles and blood vessels. The syndrome is associated with a number of immunologic abnormalities, including increased activated T cells[132a] and increased serum IL-5 levels.[133] Capillary leak syndromes, due to administration of IL-2[134] and granulocyte-macrophage colony-stimulating factor,[135] also are associated with peripheral blood eosinophilia, increased serum IL-5 levels, and eosinophil degranulation.

Chronic Dermatitis/Pruritus

Although infestations typically are associated with eosinophils, the histologic pattern is non-diagnostic unless a specific organism is identified in tissue sections.[5,136]

Blisters

Autoimmune blistering diseases often are associated with prominent infiltration of eosinophils, including presentation as eosinophilic spongiosis (see Chaps. 52 and 54).

In addition to pemphigoid gestationis (which may exhibit eosinophilic spongiosis), several other pruritic dermatoses of pregnancy (see Chap. 107) may contain tissue eosinophilia.[156–159]

Fibrosis

Eosinophils are found in association with fibrotic reactions, including those resulting from parasitic infections, pulmonary and hepatic drug sensitivity reactions, and HES.[161] Eosinophils elaborate mediators that degrade collagen and stimulate dermal fibroblast DNA synthesis and matrix production.[162] Eosinophilic fasciitis usually presents with pain, erythema, swelling, and induration of the extremities, as well as peripheral blood eosinophilia and hypergammaglobulinemia.[163] Contractures and rippling of the skin may develop (Fig. 35-7). There is infiltration of lymphocytes, plasma cells, mast cells, and eosinophils, as well as increased thickness of the fascia.

Eosinophilia-myalgia syndrome (EMS), historically related to ingestion of certain lots of L-tryptophan, is characterized by marked peripheral eosinophilia, disabling generalized myalgias, pneumonitis, myocarditis, neuropathy, encephalopathy, and fibrosis,[164] a constellation of features that are similar to but distinguishable from eosinophilic fasciitis.[165,166] Cutaneous abnormalities of EMS include edema, pruritus, a faint erythematous rash, hair loss, and *peau d'orange* or morphea-like skin lesions.[167] Lungs, heart, and nervous system may be affected.[168] There is a prominent inflammatory infiltrate in the perimysium and fascia, and striking evidence of eosinophil granule protein deposition in skin and around muscle bundles.[169]

Toxic oil syndrome (TOS), which resembles EMS, was linked to consumption of adulterated rapeseed oil distributed in the industrial belt around Madrid.[170] Patients experienced acute respiratory symptoms followed by intense myalgias, thromboembolism, weight loss, sicca syndrome, and then a chronic phase characterized by eosinophilic fasciitis–like lesions, peripheral neuropathy, muscle atrophy, and pulmonary hypertension. The cutaneous manifestations of TOS were a non-specific pruritic, erythematous rash that persisted up to 4 weeks, followed over the next 2 months by subcutaneous edema, mainly of the extremities, accompanied by myalgias, arthralgias, contractures, and peripheral blood eosinophilia. Over many years, patients developed indurated plaques of the pretibial areas and occasionally the forearms and abdomen,[170] with marked fibrosis extending into subcutaneous fat. Eosinophil infiltration and degranulation were especially prominent in the acute phase of TOS, and serum eosinophil granule protein levels were elevated during all phases.[171]

Vasculitis

Eosinophils often are associated with cutaneous lesions that represent allergic

drug reactions. There is evidence that, when eosinophils are part of the histologic pattern in leukocytoclastic vasculitis, the eruption is probably drug induced[172] (see Chap. 164). In 1951, Churg and Strauss described the complex of systemic vasculitis, asthma, and eosinophilia as *allergic granulomatosis*.[173] Cutaneous lesions are characterized by eosinophil infiltration, necrotizing vasculitis, and extravascular granulomas (see Chap. 165).

Malignancy

Eosinophils may be observed in a variety of cutaneous and extracutaneous neoplasms. Their presence in tumors appears to be independent of immune surveillance and likely is part of an early inflammatory reaction at the site of tumorigenesis.[178]

KEY REFERENCES

The full reference list for all chapters is available at www.digm7.com.

1. Leiferman KM: A current perspective on the role of eosinophils in dermatologic diseases. *J Am Acad Dermatol* **24**:1101, 1991
2. Gleich GJ: Mechanisms of eosinophil-associated inflammation. *J Allergy Clin Immunol* **105**:651, 2000
4. Klion AD, Nutman TB: The role of eosinophils in host defense against helminth parasites. *J Allergy Clin Immunol* **113**:30, 2004
30. Gleich GJ, Leiferman KM: The hypereosinophilic syndromes: Still more heterogeneity. *Curr Opin Immunol* **17**:679, 2005
80. Moossavi M, Mehregan DR: Wells' syndrome: A clinical and histopathologic review of seven cases. *Int J Dermatol* **42**:62, 2003
83. Wells GC, Whimster IW: Subcutaneous angiolymphoid hyperplasia with eosinophilia. *Br J Dermatol* **81**:1, 1969
101. Chong WS, Thomas A, Goh CL: Kimura's disease and angiolymphoid hyperplasia with eosinophilia: Two disease entities in the same patient: Case report and review of the literature. *Int J Dermatol* **45**:139, 2006
102. Yuen HW et al: Kimura's disease: A diagnostic and therapeutic challenge. *Singapore Med J* **46**:179, 2005
108. Nervi SJ, Schwartz RA, Dmochowski M: Eosinophilic pustular folliculitis: A 40 year retrospect. *J Am Acad Dermatol* **55**:285, 2006
119. Ellis E, Scheinfeld N: Eosinophilic pustular folliculitis: A comprehensive review of treatment options. *Am J Clin Dermatol* **5**:189, 2004
125. Davis MD et al: Interactions of eosinophil granule proteins with skin: Limits of detection, persistence, and vasopermeabilization. *J Allergy Clin Immunol* **112**:988, 2003
178. Cormier SA et al: Pivotal advance: Eosinophil infiltration of solid tumors is an early and persistent inflammatory host response. *J Leukoc Biol* **79**:1131, 2006

This page intentionally left blank

SECTION 6

INFLAMMATORY DISEASES BASED ON ABNORMAL HUMORAL REACTIVITY AND OTHER INFLAMMATORY DISEASES

CHAPTER 36

Humoral Immunity and Complement

Lela A. Lee

During evolution, jawed vertebrates developed the capacity to respond with exquisite specificity to foreign organisms.[1] Specific immunity is characterized by an enormous diversity of possible responses and by refinement in the immune response with successive exposures to the organism.[2] The cells that can discriminate with fine specificity through their vast repertoire of receptors are lymphocytes. Specific immunity, also called *adaptive immunity* because it develops as an adaptation to infection, can be segregated into humoral immunity, mediated by antibodies produced by B lymphocytes, and cellular immunity, mediated by T lymphocytes. These two forms of specific immunity developed to serve different functions. Humoral immunity is directed primarily toward extracellular antigens such as circulating bacteria and toxins. Cellular immunity is directed primarily toward antigens that infect or inhabit cells (for cellular immunity, see Chap. 10). To combat extracellular pathogens, the defending agent needs to be abundant and widely distributed in the body, particularly at its interfaces with the environment. Antibodies fulfill these characteristics by being capable of being secreted in great quantity from the cells that produce them and by being distributed in blood, mucosa, and interstitial fluid. In addition, antibodies can attach through Fc receptors (FcRs) to the surface of certain other cells of the immune system, such as mast cells, conferring antigen specificity to cells that do not have their own endogenously produced antigen-specific receptors.

ANTIBODY STRUCTURE

Antibodies, or immunoglobulins (Ig), are a family of glycoproteins that share a common structure.[2–4] The antibody molecule has a symmetric Y-shape consisting of two identical light chains, each about 24 kd, that are covalently linked to two identical heavy chains, each about 55 or 70 kd, that are covalently linked to one another (Fig. 36-1). Within the light and heavy chains are variable and constant regions. The major function of the variable region is to recognize antigen, whereas the constant region mediates effector functions. The light and heavy chains contain a series of repeating, homologous units of about 110 amino acids that assume a globular structure and are called *Ig domains*. The Ig domain motif is found not only in antibody molecules but also in a variety of other molecules of the Ig "superfamily," including the T cell receptor, the major histocompatibility complex (MHC), CD4, CD8, intercellular adhesion molecule 1, among other molecules. The light chain has two major domains, a variable (V_L) and a constant (C_L) domain. The heavy chains have four or five domains, a variable (V_H) and three (in IgA, IgD, and IgG) or four (in IgM and IgE) constant (C_H1-4) domains. In IgA, IgD, and IgG, there is a hinge region between C_H1 and C_H2 that confers additional flexibility to the molecule. The variable domains are at the N-terminus. At the C-terminus are the constant domains and, in the heavy chains of membrane-bound antibodies, the transmembrane and cytoplasmic domains.

Within the variable regions of the light and heavy chains are three areas of intense variability called *hypervariable regions*. These three regions, which are in proximity to one another in the three-dimensional structure of the antibody, are the areas most responsible for binding antigen. Because the hypervariable

HUMORAL IMMUNITY AND ANTIBODY STRUCTURE AT A GLANCE

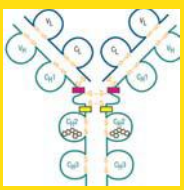

- Humoral immunity, mediated by antibodies produced by B lymphocytes, is a form of specific immunity directed primarily toward extracellular antigens.
- Antibody molecules consist of two identical light chains covalently linked to two identical heavy chains. The variable region of the antibody molecule is responsible for antibody binding, and the constant region mediates most effector functions.
- The five antibody classes serve distinct functions. Immunoglobulin M (IgM) is involved in primary antibody responses, IgD is an antigen receptor on naive B cells, IgA is critical for mucosal immunity, IgG is the major Ig in the circulation and is important in secondary antibody responses, and IgE mediates immunity to parasites.
- An individual is capable of generating millions of distinct antibodies in millions of distinct B-cell clones through the processes of gene rearrangement and junctional diversity.

Copyright © 2008 by The McGraw-Hill Companies, Inc. Click here for terms of use.

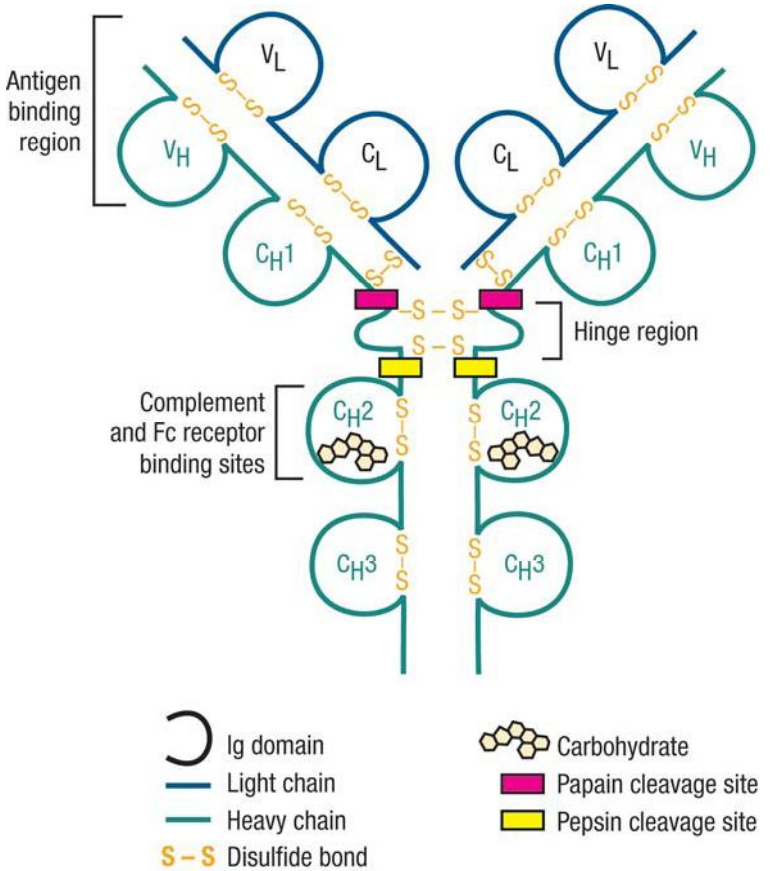

▲ **FIGURE 36-1** Schematic representation of an immunoglobulin G (IgG) molecule.

regions form a shape complementary to that of the antigen, the hypervariable regions are also called the *complementarity-determining regions*. The unique areas formed by the hypervariable regions are present in too low an amount in the individual to generate self-tolerance. Thus, the immune system may not distinguish the unique portion of the antibody as self and may produce antibodies to that region of the antibody. The area of the antibody capable of generating an immune response is called an *idiotope*, and antibody responses to idiotopes result in a network of idiotypic–anti-idiotypic interactions that may help regulate the humoral immune response.[5]

There are two types of light chains, κ and λ, each encoded on different chromosomes. Each antibody molecule has either two κ or two λ chains, never one of each. The functional differences, if any, between κ and λ are not known. There are five types of heavy chains, α, δ, ε, γ, and μ, corresponding to the antibody classes IgA, IgD, IgE, IgG, and IgM, respectively. The different heavy chain classes have significantly different functions, as discussed in Antibody Classes. The IgA and IgG classes contain closely related subclasses, consisting of IgA1 and IgA2, and IgG1, IgG2, IgG3, and IgG4 (Table 36-1).

Enzymatic digestion of IgG molecules by papain results in three cleavage products, two identical Fab fragments consisting of a light chain bound to the V-C_H1 region of the heavy chain and an Fc portion consisting of two C_H2-C_H3 heavy chains bound to each other. *Fab* was so named for its property of antigen binding, and *Fc* was so named for its property of crystallizing. When IgG is digested by pepsin, the C-terminal region is digested into small fragments. The remaining product consists of the Fab region along with the hinge region. Fab fragments containing the hinge region are termed Fab′. When the two Fab′ fragments in an antibody molecule remain associated, the fragment is called $F(ab')_2$.

ANTIBODY CLASSES (See Table 36-1)

Immunoglobulin M

IgM is the first Ig molecule to be expressed during B-cell development. Its secretory form is a pentamer consisting of five IgM molecules joined at their C-termini by tail pieces and stabilized by a molecule called a *joining (J) chain*. The engagement of membrane-bound IgM by antigen results in the activation of naive B cells. Secreted IgM recognizes antigen, usually through low-affinity interactions, and it can activate complement. IgM is the major effector of the primary antibody response. Although IgM interactions are typically low affinity, IgM can be very effective in responding to a polyvalent antigen (such as a polysaccharide with repeating epitopes) because its pentameric structure allows for multiple low-affinity interactions, resulting in a high-avidity interaction. (*Avidity* refers to the overall strength of attachment, whereas *affinity* refers to the strength of attachment at a single antigen-binding site.)

Immunoglobulin D

The IgD molecule exists primarily in a membrane-bound form and is the second antibody class to be expressed during B-cell development. Its function is not completely understood, but in its membrane-bound form it can serve as an antigen receptor for naive B cells.[6]

Immunoglobulin A

IgA is the most abundant Ig in the body, being present in large quantity at mucosal sites. It is responsible for mucosal immunity and is secreted in breast milk, thus contributing to neonatal immunity. In its secreted form, it exists as a monomer, dimer, or trimer, with the multimers being formed by interactions between tail pieces and stabilized by the J chain. For transport across epithelial surfaces, IgA dimers attach to a type of FcR called the *polymeric Ig receptor*.[7] Once the transport process is complete, the IgA dimers remain attached to the extracellular portion of the receptor, called the *secretory component*, which protects the IgA from proteolysis. Cells of the immune system that have receptors for IgA include neutrophils, eosinophils, and monocytes.

Immunoglobulin G

IgG is the most abundant Ig in the circulation. Its secreted form is a monomer. IgG plays an important role in secondary antibody responses, and its interactions with antigen tend to be high-affinity, particularly as the immune response ma-

TABLE 36-1
Immunoglobulin Classes and Their Functions

A	Subtypes	Secreted Form	Approximate Molecular Weight of Secreted Form (kD)	Serum Concentration (mg/mL)	Serum Half-Life (Days)	Functions
IgM	None	Pentamer	970	1.5	5	Primary antibody response; antigen receptor on naive B cells; complement activation
IgD	None	Monomer[a]	180[a]	Trace	3	Antigen receptor on naive B cells
IgA	IgA1	Monomer, polymer (usually dimer)	160 (monomer), 390 (secretory IgA)	3	6	Mucosal immunity; neonatal immunity
	IgA2	Monomer, polymer (usually dimer)	160 (monomer), 390 (secretory IgA)	0.5	6	
IgG	IgG1	Monomer	150	9	23	Neonatal immunity; opsonization; complement activation (except IgG4); phagocytosis; antibody-dependent cell-mediated cytotoxicity; feedback inhibition of B cells
	IgG2	Monomer	150	3	23	
	IgG3	Monomer	170	1	7	
	IgG4	Monomer	150	0.5	23	
IgE	None	Monomer	190	0.05	2	Immediate hypersensitivity; defense against parasites

Ig = immunoglobulin.
[a]IgD is not a secreted molecule, but trace amounts can be found in serum.

tures. A number of cells have FcRs for IgG, including monocytes, neutrophils, eosinophils, natural killer (NK) cells, and B cells. IgG opsonizes (coats) antigen, allowing phagocytosis of the antigen, and activates complement. An exception is IgG4, which does not activate complement. IgG is important in neonatal immunity, as it is the only Ig class to cross the placenta, and it is secreted in breast milk. The interaction of IgG with the MHC class I-related receptor FcRn is involved in the delivery of IgG across the placenta as well as in prolonging its level in the circulation.[8] The serum half-life of IgG is 23 days, considerably longer than that of the other Ig classes.

Immunoglobulin E

IgE is found in very small amounts in the circulation. High-affinity receptors for the Fc portion of IgE are present on mast cells, basophils, and eosinophils, and low-affinity receptors are present on B cells and Langerhans cells. In mast cells, basophils, and eosinophils, IgE engagement with antigen activates the cells. IgE mediates immediate hypersensitivity, but its principal protective role may be to combat parasites.

MECHANISMS FOR THE GENERATION OF ANTIBODY DIVERSITY

The information encoded by an individual's DNA is limited by the need for the DNA to fit into a package the size of a cell. This space is far too small for sufficient DNA to encode billions of different lymphocyte receptors if the genes were encoded separately. Lymphocytes have adapted to this limitation by special mechanisms that increase by orders of magnitude the number of different possible antigen receptors.[9] Each clone of B cells produces identical antigen receptors (i.e., antibodies) with unique specificity. It is estimated that an individual has approximately 10^9 different B-cell clones, resulting in 10^9 distinct antibodies. A major mechanism for generating this enormous diversity is gene rearrangement, whereby segments of DNA within a lymphocyte undergo somatic recombinations.[10] Light chain genes contain three regions, V (variable), J (joining), and C (constant), and heavy chain genes contain four regions, V, D (diversity), J, and C. Within each region are many gene segments from which to select for the final antibody product, which is comprised of one gene segment from each region. The initial event in antibody formation is the joining of one D and one J segment from a heavy chain gene, with subsequent deletion of the DNA between the two segments. Next, a V segment is selected to join to the DJ segment, and any remaining D segments are deleted. The VDJ complex has attached 3′ to it any remaining J segments plus the C region. The unused J segments are removed during RNA processing. A similar process occurs in light chain loci; because there are no D segments in light chain loci, a VJ rather than a VDJ complex is formed.

The ability to select one segment each from the many segments available in the V, D, and J regions leads to a vast increase in the repertoire of possible antibodies. Additional diversity is generated by the juxtaposition of a rearranged light chain to a rearranged heavy chain and by the addition, deletion, or transposition of nucleotides at the junctions between V and D, D and J, and V and J segments, a phenomenon called *junctional diversity*.

B-CELL MATURATION

Bone marrow and fetal liver stem cells that give rise to B cells are initially pluripotent.[2,11] The stem cells may proceed to develop in the lymphocytic pathway, where they can give rise to B, T, or NK cells. The earliest cell committed to the B-cell lineage is called a *pro-B cell*. At the pro-B cell stage, the cell expresses recombination, activating gene and terminal deoxyribonucleotidyl transferase proteins, which will be needed subsequently for somatic recombination and nucleoside transfers involved in junctional diversity, respectively. At the pro-B-cell stage, limited somatic recombination has taken place, and Ig is not yet expressed.

The next stage of B-cell maturation is represented by the *pre-B cell* and is marked by the synthesis of a cytoplas-

B-CELL MATURATION AT A GLANCE



- The pro-B cell expresses enzymes needed for gene rearrangement and junctional diversity, but neither heavy nor light chains are expressed.
- The pre-B cell expresses μ heavy chains in the cytoplasm. On the cell surface, the heavy chains associate with surrogate light chains to form pre-B cell receptors.
- The immature B cell produces light chains and can therefore express antibody molecules on the cell surface. If antigen exposure occurs at this stage, negative selection may take place.
- The mature B cell expresses both immunoglobulin M and immunoglobulin D and is competent to respond to antigen.

mic μ heavy chain. Because light chains are not yet expressed at this stage, surface Ig is not present. Some of the μ heavy chains associate with invariant molecules called *surrogate light chains* to form complexes called *pre-B cell receptors*. These receptors are then expressed on the pre-B cell surface and provide important signals for the proliferation and maturation of the developing B cell.

The formation of light chains marks the next stage in B-cell maturation, the immature B cell. When light chains join with the μ heavy chains, an IgM molecule results and can be expressed on the cell surface. The cytoplasmic tails of IgM molecules are too short to transduce signals. Signal transduction is rather a function of two other molecules, called Ig α and Ig β, associated with IgM in a B-cell receptor complex on the cell surface. Although the presence of a B-cell receptor complex confers the ability to recognize specific antigens, at this stage such recognition does not result in proliferation or differentiation. Rather, the cells may undergo negative selection when antigen is encountered. Immature B cells recognizing self-antigen may be deleted through apoptosis[12] or may undergo receptor editing, a process by which a new, nonself specificity is acquired.[13]

Acquisition of the ability to express IgD as well as IgM is the hallmark of the next stage, the mature B cell. The cell is naive because it has not been activated by antigen, but it is competent to respond to antigen. Mature B cells exit the bone marrow and migrate to blood and lymphoid tissues, where they constitute the majority of B cells in those locations.

The encounter of antigen by mature naive B cells leads to B-cell activation, proliferation, and differentiation. A subset of B cells become memory B cells, which are then activated if the antigen is encountered subsequently.[14] Another subset of B cells differentiates into cells that make progressively less membrane-bound Ig and more secreted Ig. These cells can undergo class switching from IgM and IgD to IgA, IgE, or IgG.[15] The terminally differentiated B cells committed to the production of secreted Ig are plasma cells and have abundant rough endoplasmic reticulum, consistent with the function of the cells as antibody factories.

ANTIGENS BOUND BY B CELLS

B cells recognize a variety of macromolecules, including proteins, lipids, and nucleic acids. The portion of the macromolecule recognized by the antibody is called an *epitope* or *determinant*. B cells recognize both linear epitopes (epitopes formed by several adjacent amino acids) and, quite commonly, conformational epitopes (epitopes present as a result of folding of the macromolecule).[16] In contrast to B cells, T-cell responses are almost entirely restricted to linear epitopes of peptides.

Macromolecules, particularly large proteins, may contain several different epitopes, and a humoral response to a macromolecule typically is comprised of multiple different antibodies. Although each different antibody is specific for a given epitopic configuration, similarities in epitopes may exist such that an antibody to a given epitope on a given macromolecule also may be able to bind a different epitope on a different macromolecule. This phenomenon is called *cross-reactivity*, and may be important in the genesis of autoimmune antibody responses.

Macromolecules that have multiple identical epitopes are classified as being polyvalent or multivalent. Antibodies to these macromolecules or aggregates of macromolecules may form complexes called *immune complexes* with the antigen. At a particular concentration of antibody and antigen, called the zone of equivalence, a large network of linked antigens and antibodies forms. At lower or higher concentrations of antibody or antigen, the complexes are much smaller. Immune complexes, formed in the circulation or in tissue, may be responsible for disease through the initiation of an inflammatory response.

B-CELL ACTIVATION AND ANTIBODY FUNCTION

On engagement of the mature B-cell receptor by antigen, clustering of receptors initiates signaling transduced by Ig α and Ig β. The resulting signaling cascade eventuates in the expression of genes involved in B-cell activation. B-cell activation is facilitated by second signals, one of which is provided by the complement protein C3d.[17] Complement fragment C3d is formed as a result of complement activation through any of the complement activation pathways (see Complement System later in this chapter). The B-cell surface contains a co-receptor complex consisting of complement receptor 2 (CR2), CD19, and CD81. Simultaneous binding of antigen by antibody on the B-cell surface and of C3d by CR2 leads to markedly increased B-cell activation.

The subsequent response to an antigen often involves a complex interaction between B cells and T cells, leading to a fine-tuning of the immune response.[18] B cells are capable of functioning as antigen-presenting cells. In a response to a protein antigen, B cells take up the antigen, process it, and present peptide–class II MHC complexes to $CD4^+$ T cells. T cells recognizing the peptide–class II MHC complexes receive a primary signal from the complex and a secondary signal from co-stimulatory interactions, notably binding of B7-1 and B7-2 on B cells to CD28 on T cells.[19] These T cells are activated, and their activation, in turn, provides signals to the B cells through the actions of cell surface molecules (in particular, CD40 on B cells and CD40 ligand on T cells) and cytokines [e.g., interleukin 2 (IL-2), IL-4, IL-5, and IL-6].[2] The overall effects on B cells are activation, proliferation, and differentiation.

Class switching from IgM to IgA, IgE, or IgG occurs as a result of T cell–B cell interactions.[15,20] The determination of the antibody class selected is based on the location and cytokine milieu in which the interaction occurs. For example, B-cell responses to antigens encountered on mucosal surfaces characteristically result in class switching to IgA,

B-CELL ACTIVATION AND ANTIBODY FUNCTION AT A GLANCE



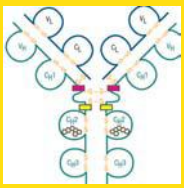

- When the B-cell receptor (surface antibody) binds antigen, a second signal provided by C3d engagement with complement receptor 2 significantly augments B-cell activation.
- B-cell responses to protein antigens typically involve T-cell help, with resultant antibody class switching and affinity maturation.
- Effector functions of antibodies include neutralization of antigen, complement activation, cell activation, phagocytosis, and antibody-dependent, cell-mediated cytotoxicity. Most of these are mediated through the binding of immunoglobulin (Ig) to Fc receptors containing an immunoreceptor tyrosine-based activation motif.
- Negative signaling to B cells is provided by binding of IgG to a B-cell Fc receptor that contains an immunoreceptor tyrosine-based inhibition motif. The availability of excess IgG to bind this receptor is an indication that antigen is being successfully eliminated and the immune response is no longer required.

and transforming growth factor-β is an important contributing cytokine.

T-cell interaction with B cells also results in affinity maturation, whereby the affinity of antibodies for the antigen progressively increases. During affinity maturation, somatic hypermutations in antibody genes result in antibodies with both greater and lesser affinity for the antigen.[21,22] Those antibodies with greater affinity confer a survival advantage on the B cells that produce them. Progressively, the population of B cells evolves in favor of those producing higher-affinity antibodies for the antigen. Both class switching and affinity maturation require the expression of an enzyme called *activation-induced cytosine deaminase*.[23]

As noted in the section Antigens Bound by B Cells, T-cell responses are limited almost entirely to peptides. Thus, B-cell responses to non-protein antigens may not result in T-cell help through the mechanisms described earlier.[24] One type of T-cell–independent B-cell response produces so-called *natural antibodies*—IgM antibodies that are largely anticarbohydrate antibodies produced without apparent antigen exposure.[25] These natural antibodies are characterized by a limited repertoire and are produced by B1 peritoneal cells either spontaneously or in response to bacteria that colonize the gut.

Antigen occupation of antibody-binding sites leads to functional results, called *effector functions*. With the exception of direct neutralization of antigen by antibody binding, effector functions are typically mediated through the binding of Ig to FcRs.[26,27] FcRs generally are divided into those that trigger cell activation and those that do not. Those that can trigger activation contain one or more motifs called *immunoreceptor tyrosine-based activation motifs*. Of those that do not trigger activation, some can inhibit cell activation and contain a motif called *immunoreceptor tyrosine-based inhibition motif*. FcRs that neither activate nor inhibit cell activation are involved in the transport of Ig through epithelia and the prolongation of the half-life of IgG.

The effector functions of antibodies serve to eliminate the antigen that initiated the immune response and also to downregulate the immune response when activation is not required. Effector functions of antibodies include neutralization of antigen, complement activation, cell activation (of monocytes, neutrophils, eosinophils, and B cells), phagocytosis (by monocytes and neutrophils), and antibody-dependent cell-mediated cytotoxicity (mediated by NK cells and eosinophils). In addition, engagement of IgG by antigen provides a negative signal to B cells, mediated through the binding of the antigen-antibody complex to an immunoreceptor tyrosine-based inhibition motif-containing Fcγ receptor, FcγIIB, on the B cell.[28]

B CELLS AND ANTIBODIES IN DISEASE

Disorders of B cells or antibodies cause or contribute to many diseases of dermatologic relevance.[29–34] Immunodeficiency diseases may result from abnormalities of B-cell development or activation or from abnormalities in effector function pathways. B-cell lymphomas may result from failure to regulate proliferation, differentiation, or programmed cell death. Antibodies may initiate an inflammatory response that results in injury, as in IgE-mediated allergic reactions or immune-complex diseases. In some cases, the antigen may not be obviously harmful, but the response to the antigen is. In other cases, the antigen may be pathogenic, but the character or magnitude of the immune response is inappropriate or inadequately controlled. The regulatory systems that protect an organism from attack by its own immune system occasionally fail. In some cases, autoimmunity may be initiated as a result of an immune response to a pathogen. The pathogen may act as a non-specific activator of the immune system, or may activate the immune response specifically (e.g., by containing an epitope or epitopes that are cross-reactive with an autoepitope). These responses may be particularly difficult to control because the major stimulus for the immune response, the antigen, is a normal component of "self" and cannot be eliminated. Thus, through many mechanisms, the normal protective B-cell response, which developed as an elegant means to discriminate very finely among various potential pathogens, can be subverted to result in harm to the organism.

COMPLEMENT SYSTEM

The complement system was discovered through its ability to contribute to, or "complement," bacterial cell lysis by antibodies.[35,36] At physiologic temperatures, serum containing antibacterial antibodies lysed bacteria effectively, whereas serum heated to 56°C (133°F) lost its ability to lyse bacteria. Because antibodies are quite stable at 56°C (133°F), it was postulated that the loss of lytic ability was due to the degradation of heat-labile non-antibody molecules.

Although the complement system was first identified through its role in humoral immunity, it evolved rather early as a component of innate immunity (see Chap. 10) and has multiple functions in immune defense. The complement system is constituted in part by a set of plasma proteins that are normally inactive or minimally active.[2] The initial steps of activation involve the cleavage of an inactive protein into a smaller and a larger fragment. The larger fragment, then, is itself able to cleave other proteins in the cascade. Because an activated molecule in one step is capable of generating

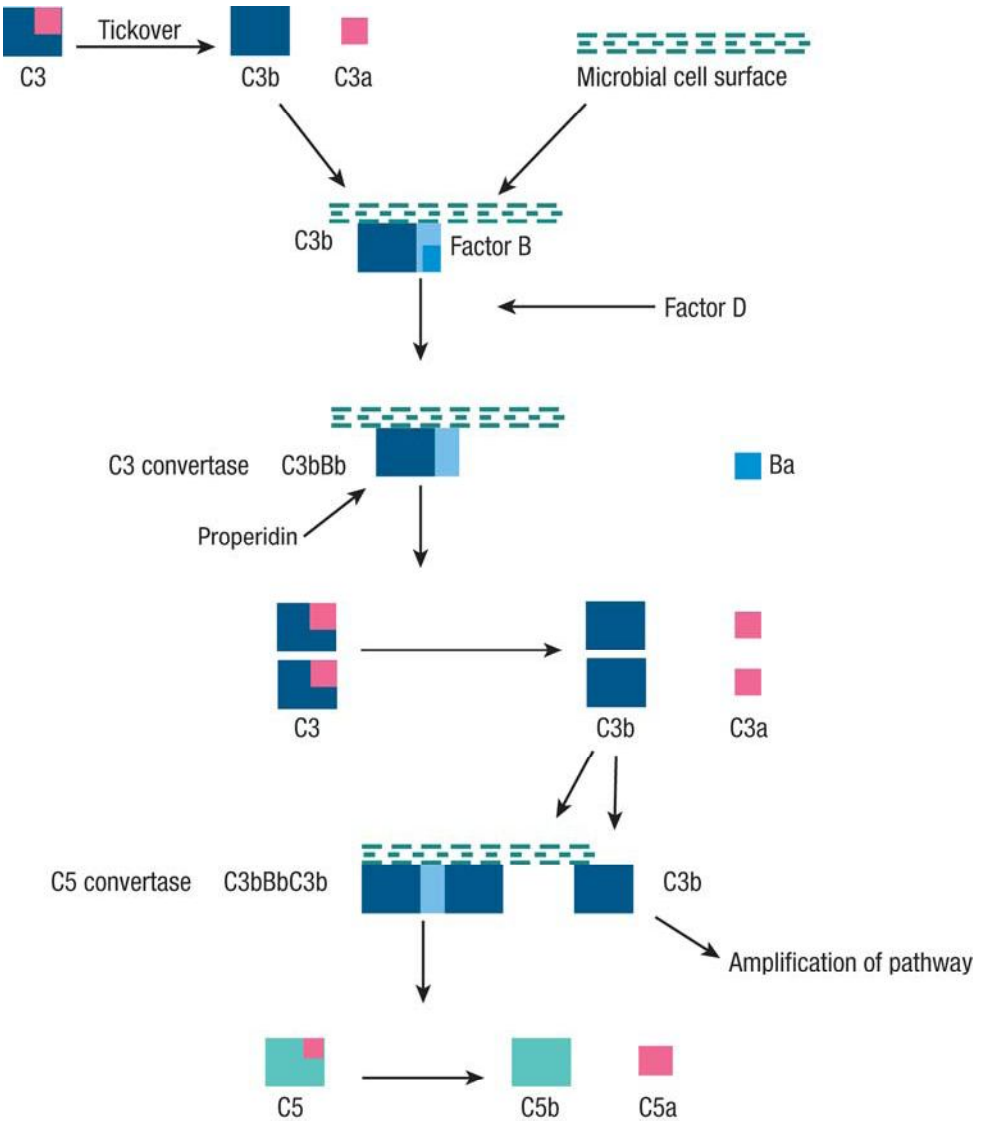

◀ **FIGURE 36-2** The alternative pathway of complement activation. Shown are the steps from the initial attachment of C3b to a microbial cell surface through the cleavage of C5 into C5a and C5b. The final steps of complement activation are shown in Fig. 36-4. See Alternative Pathway for details.

many activated molecules in the following step, the sequential cleavage and activation of complement proteins result in amplification of the cascade.

PATHWAYS OF COMPLEMENT ACTIVATION

The early stages of the activation of complement ultimately result in cleavage of the complement protein C3. This is followed by the cleavage of C5 and initiation of the final steps of complement activation. There are three distinct pathways that lead to the cleavage of C3, the classical, the alternative, and the lectin pathways. Although the classical pathway was the first to be described, the alternative pathway is evolutionarily older.[37]

Alternative Pathway (Fig. 36-2)

The first step in the activation of the alternative pathway is the binding of C3b to a cell surface such as a bacterial cell surface. Intact C3 is an inactive molecule, but there is a low-level spontaneous cleavage of C3, called *tickover*, which results in the continuous availability of the C3b fragment. C3b can bind stably to a cell surface through an interaction between a thioester group of C3b and a hydroxyl group of the cell surface. In intact C3, the thioester domain is covered by hydrophobic residues that prevent hydrolysis of the thioester bond. The anaphylatoxin (ANA) domain of C3 stabilizes this inactive conformation. Once the ANA domain is cleaved to release C3a, the thioester group is exposed, and conformational change results in its ability to bond to the cell surface.[38,39] If this chemical bonding does not occur, the thioester group is hydrolyzed and C3b is inactivated.

Once stable attachment of C3b to the cell surface takes place, a plasma protein called *Factor B* binds to C3b. Factor B is in turn cleaved by Factor D, generating Bb and Ba. The complex of C3b and Bb, stabilized by the plasma protein properidin, is the alternative pathway C3 convertase (i.e., it cleaves C3 into C3a and C3b). The addition of further C3b to the complex results in C3bBbC3b, which constitutes the alternative pathway C5 convertase. The late steps of complement activation, after the cleavage of C5, are common to the three pathways and are described in Final Steps of Complement Activation.

Thus, the low level of C3b in the plasma acts as a sentinel for microbes. Once C3b is bound to the cell surface, subsequent molecular interactions result in a substantial amplification of the alternative pathway and cleavage of C5. The requirement for binding of C3b to a structural element serves to limit the effect of complement activation to the area where complement activation is needed. The alternative pathway of complement activation does not require finely specific recognition of antigen and so is considered a component of innate

COMPLEMENT SYSTEM AND ACTIVATION PATHWAYS AT A GLANCE

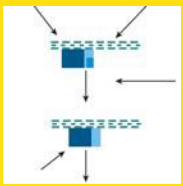

- The complement system functions to kill microbes via lysis or phagocytosis, to clear immune complexes and apoptotic debris from the circulation, to promote inflammation, and to stimulate humoral immunity.
- The three pathways of complement activation are the alternative, classical, and lectin pathways.
- The early steps in complement activation are triggered enzyme cascades in which cleavage of an inactive protein into fragments results in cleavage of subsequent proteins in the cascade.
- The alternative and lectin pathways are primarily pathways of innate immunity; the classical pathway is a pathway characteristically initiated by humoral immunity.
- The complement pathways converge at the cleavage of C3 and subsequent cleavage of C5. The final steps of activation consist of the addition of C6–8 to C5b, and polymerization of C9 to form the membrane attack complex.

immunity. It follows that if specific recognition is not required, C3b can bind to human cells as well as microbes. However, activation on human cells is generally prevented by the intervention of regulatory proteins present on the surface of human cells, protecting these cells from inappropriate and harmful attack by the complement system.[40]

Classical Pathway (Fig. 36-3)

The initial step in the activation of the classical pathway is characteristically the binding of the portion of the C1 complex called *C1q* to IgG or IgM antibodies.[36] The C1q molecule consists of six identical arms attached to a central trunk. The globular ends of the arms attach to the complement-binding regions of the heavy chains of certain Ig classes. In order for C1q to be activated, it must bind simultaneously to at least two Ig heavy chains. This means, in effect, that the Ig must have bound antigen. In the case of IgG, binding of multiple epitopes by antibodies results in close proximity of the antibodies and thus the proper configuration for C1q activation. (As mentioned in Immunoglobulin G, IgG4 is an exception, in that it does not bind C1q or activate complement.) Because IgM exists as a pentamer, theoretically IgM without bound antigen could activate complement. However, when IgM is not bound by antigen, the C1q binding site is not accessible. When antigen is bound, a conformational change results in exposure of the C1q binding site.

The complement component C1 is a complex of C1q, C1r, and C1s. Binding of two or more of the globular heads of C1q results in activation of C1r. Activated C1r is a protease that cleaves and activates C1s, and activated C1s, in turn, cleaves C4 into C4a and C4b. (The numbering of the complement proteins differs from their positions in the activation sequence, as components were discovered before the elucidation of their positions in the pathway.) C4b, like C3b, contains a thioester group that can form stable bonds with hydroxyl groups on a particular structure. Bound C4b is then bound by C2, which is cleaved into C2a and C2b. The C4bC2a complex is the classical pathway C3 convertase. (Note: Typically, suffix "a" denotes the smaller and "b" the larger complement fragment. The nomenclature of C2, with C2a being the larger fragment and C2b the smaller, is contradictory to that of the rest of the complement system.)

The cleavage of C3 results in C3a and C3b. The C3b fragment may then go on to activate complement by the alternative pathway, or act in concert with C4bC2a to form C4bC2aC3b, the classical pathway C5 convertase.

The major characteristics of the classical pathway are much the same as those of the alternative pathway. Activation of the pathway requires attachment of a complement protein to a structure such as a cell surface or immune complex, so that the effects of complement activation are spatially limited. Initial activation steps result in the formation of a C3 convertase that cleaves C3. Cleavage of C3 leads to the formation of a C5 convertase that cleaves C5 into C5a and C5b. A major difference is the initiation of the classical pathway by specific recognition of antigen by antibodies, in contrast to the rather non-specific binding that occurs to initiate the alternative pathway.

Lectin Pathway

The lectin pathway is very similar to the classical pathway, with the exception of the initiating steps. The first step is the binding of a plasma lectin, mannose-binding protein (MBP), to polysaccharides on microbial cell surfaces.[41] MBP, a member of the collectin (collagenous lectin) family, is structurally similar to C1q and can associate with C1r and C1s. MBP attachment to a microbe can begin the cascade through the activation of C1r and C1s. MBP also interacts with MBP-associated serine proteases, which are analogous to C1r and C1s. Binding of MBP to microbial cell surfaces results in cleavage of MBP-associated serine protease and thence cleavage of C4.[42] In either case, the effect is the formation of C4b and its stable binding to a cell surface. As is the case for the alternative pathway, the lectin pathway is a component of innate immunity.

Final Steps of Complement Activation (Fig. 36-4)

The alternative, classical, and lectin pathways converge at the cleavage of C5. The C5b fragment remains surface-bound. The next steps do not involve enzymatic cleavage, but rather the sequential binding of C6, C7, and C8 to C5b. The C5b-8 complex stably bound to a cell membrane becomes an active membrane attack complex (MAC) through the addition of C9. C9 polymerizes around the complex and forms pores in cell membranes. These pores may result in cell death through osmotic rupture, particularly in non-nucleated erythrocytes.

Nucleated cells are more resistant to lysis, but may still exhibit effects attributable to MAC binding.[43] It is quite possible that the non-lytic changes induced by MAC are of more functional and pathologic significance overall than is MAC-induced cell lysis.[44] These non-lytic effects may differ depending on cell type and milieu, and similar effects may lead to different outcomes. For example, MAC insertion into phagocyte cell membranes can lead to the production of inflammatory mediators such as reactive oxygen species and prostaglandins, resulting in phagocyte activation.[45] Glomerular epithelial cells may also exhibit inflammatory mediator production, but, in that setting, the inflammatory media-

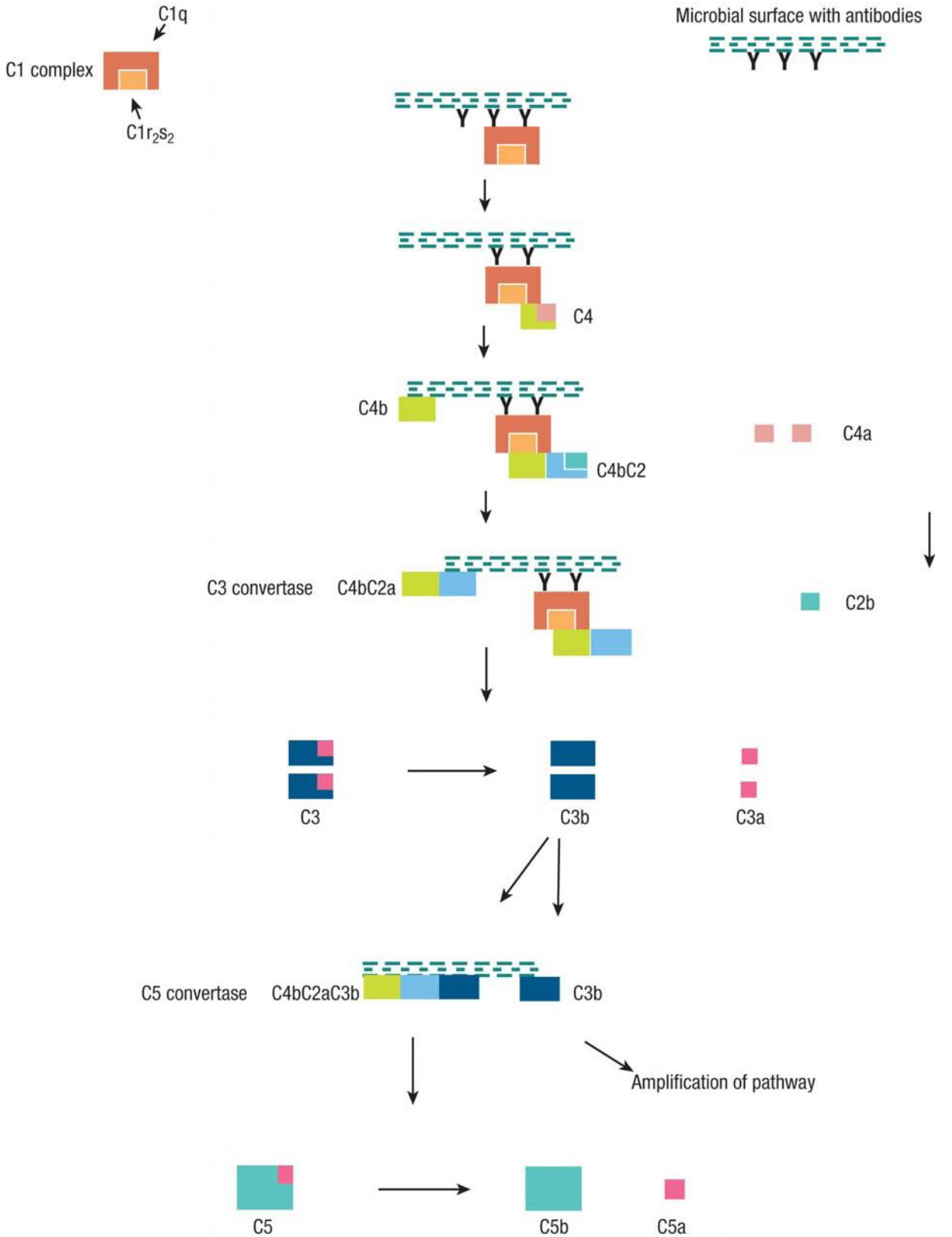

▲ **FIGURE 36-3** The classical pathway of complement activation. Shown are the steps from the initial binding of C1q to antibody-antigen complex through the cleavage of C5 into C5a and C5b. The final steps of complement activation are shown in Fig. 36-4. See Classical Pathway for details.

tors may lead to tissue injury.[46] MAC has also been reported to cause proliferation of certain cells, and MAC has been reported to have both apoptotic and anti-apoptotic properties.[43]

Additional Initiators of Complement Activation

In addition to the characteristic initiators of the three pathways, certain additional structures can trigger complement activation.[47] These include, among others, the following: in the alternative pathway, IgA immune complexes and endotoxin; in the classical pathway, C-reactive protein, ap-

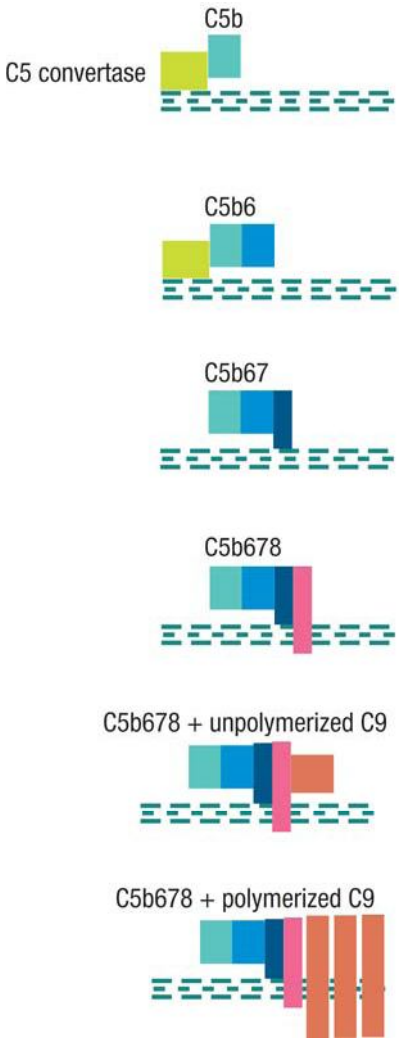

▲ **FIGURE 36-4** Formation of the membrane attack complex. The alternative, classical, and lectin pathways converge at the formation of C5b and its sequential attachment to C6, C7, C8, and C9. The polymerization of C9 results in tubular structures on the cell membrane.

optotic bodies, and serum amyloid P; and in the lectin pathway, serum ficolin.[41,48]

FUNCTIONS OF COMPLEMENT PROTEINS

As mentioned earlier, the earliest function of the complement system to be discovered was the lysis of bacteria. Killing of microbes through direct lysis is mediated by the MAC, C5b-9. Microbes may also be destroyed through coating, or opsonization, by complement and phagocytosis of the opsonized particles by phagocytic cells. The processes of opsonization and phagocytosis are also mechanisms for another important function of complement—the clearance of immune complexes and apoptotic debris from the circulation.

An ancillary function of complement activation is the induction of inflammation. Inflammation, characterized by vascular changes and ingress and activation of leukocytes and inflammatory proteins, serves to augment the localized immune response in tissue. Three mediators of inflammation initiated by complement activation are the complement fragments C3a, C4a, and C5a. These are called *anaphylatoxins* because of their ability to induce degranulation of mast cells.[49] The most potent of these ANAs is C5a. Receptors for C5a are expressed on endothelial cells, mast cells, eosinophils, basophils, monocytes, neutrophils, smooth muscle cells, and epithelial cells. Binding of C5a to endothelial cells results in increased vascular permeability and expression of P-selectin, both of which promote leukocyte accumulation in tissue. Binding to neutrophils results in increased neutrophil motility, adhesion to endothelial cells, and production of reactive oxygen species. The overall result is the accumulation of cells at local sites in tissue where they can phagocytose and efficiently kill microbes.

The activation of complement also results in stimulation of the humoral immune system through the generation of C3d. B cells whose cell surface antibodies recognize complement-bound antigen are upregulated by the concurrent binding of C3d to CR2 on the B-cell surface. Opsonization by complement also facilitates antigen presentation to B cells by follicular dendritic cells.

COMPLEMENT RECEPTORS

There are several proteins that interact with complement and serve to mediate or regulate its functions. One set of these proteins is the complement receptors.

The type 1 complement receptor, CR1 (CD35), is a member of a family of proteins called *regulators of complement activation* (RCA), which share a common structure consisting of multiple short consensus repeats, also known as *complement control protein repeats*.[40] CR1 binds C3b or C4b and is expressed on peripheral blood cells, including monocytes, B and T lymphocytes, neutrophils, eosinophils, and erythrocytes, on follicular dendritic cells, and on keratinocytes.[50] On phagocytic cells, binding of CR1 to C3b or C4b results in phagocytosis of particles opsonized by complement fragments, as well as activation of microbicidal mechanisms in the phagocytic cells. On erythrocytes, binding of CR1 to C3b- or C4b-coated immune complexes results in transport of the complexes to the spleen and liver, where they are cleared from the circulation by phagocytes. Thus, CR1 serves as an important mediator of complement function. It also can serve as a downregulator of complement activation, as it is involved in the dissociation of C3 convertase complexes.

The type 2 complement receptor, CR2 (CD21), is also a member of the RCA family.[47] CR2 binds C3 fragments iC3b, C3dg, and C3d, as well as Epstein-Barr virus, interferon-α, and the immunoregulatory protein CD23. CR2 is expressed on subsets of B and T lymphocytes, basophils, mast cells, follicular dendritic cells, and some epithelial cells. On B cells, CR2 serves as a co-receptor for B-cell activation. When CR2 is bound by C3d, the level of B-cell activation is increased by orders of magnitude.[51] On dendritic cells, CR2 engagement results in a trapping of immune complexes in germinal centers. CR2 also appears to play a role in antigen presentation to T cells.

The type 3 complement receptor, CR3 (CD11b/CD18, Mac-1), is an integrin cell surface molecule expressed on monocytes, neutrophils, NK cells, and mast cells.[52] It functions to promote phagocytosis of microbes through binding to iC3b and through direct binding to microbes. It interacts with intercellular adhesion molecule 1 expressed endogenously on endothelial cells to stabilize the adhesion of leukocytes to endothelium, facilitating the recruitment of leukocytes from the circulation into tissue. It also may play a role in neutrophil apoptosis.

The type 4 complement receptor, CR4 (CD11c/CD18), is also an integrin cell surface molecule. It is expressed on monocytes, neutrophils, NK cells, and dendritic cells, and probably functions similarly to CR3.

REGULATION OF COMPLEMENT ACTIVATION

Molecules involved in the regulation of complement activation serve to downregulate the immune response once an immune response is no longer needed and to limit the immune response to the sites required, specifically protecting self from complement attack.

The C1 inhibitor (C1 INH) is a protease inhibitor that inhibits certain plasma serine proteases, including C1, kallikrein, and factor XII.[36] C1 exists as a complex of C1q and a tetramer of two C1r and two C1s fragments. When C1q

COMPLEMENT RECEPTORS AND REGULATORY PROTEINS

AT A GLANCE

- Some of the important effects of complement are mediated through binding of complement proteins to complement receptors. CR1 functions in phagocytosis, immune complex clearance, and down-regulation. CR2 is important in stimulation of humoral immunity. CR3 and -4 promote phagocytosis.
- Regulation of complement activation is provided by certain serum and cell surface proteins. Many of the regulatory cell surface proteins are expressed on human cells but not microbes, thus protecting human cells from complement damage.
- Some of the regulatory proteins downregulate complement activation by displacing components of the early steps of the cascade. These include C1 inhibitor, factor H, C4 binding inhibitor, decay accelerating factor, membrane co-factor protein, and CR1.

binds antibody, C1 INH can act to limit complement activation by binding to the C1rC1s tetramer, dissociating it from C1q and preventing downstream activation of the pathway.

Another major point of interaction of regulatory proteins is with bound C3b or C4b.[40] As mentioned earlier, the thioester group of unbound C3b or C4b is rapidly hydrolyzed, rendering these molecules inactive. For surface-bound C3b or C4b, inactivation occurs through the displacement of components of the alternative or classical pathway C3 convertase from C3b or C4b or through proteolysis of C3b or C4b. In the alternative pathway, inactivation of the C3 convertase complex, C3bBb, can take place through the displacement of Bb from C3b by the plasma protein factor H or the cell surface proteins decay accelerating factor (DAF, CD55), membrane co-factor protein (MCP, CD46), and CR1. These three cell surface proteins, all members of the RCA family, are expressed on human cells but not microbes, thereby allowing complement activation to proceed on microbes while protecting human cells from injury. Factor H preferentially binds cell surfaces with high levels of sialic acid, and the relative abundance of sialic acid on human cells but not microbes further focuses the downregulation of complement activation on human cells. In the classical and lectin pathways, the C3 convertase is C4bC2b. DAF, MCP, and CR1 can displace C2b from C4b, as can the plasma protein C4-binding protein (C4BP). Thus, the cell surface proteins DAF, MCP, and CR1 can dissociate the C3 convertases of both the alternative and the classical/lectin pathways, whereas the plasma proteins factor H and C4BP are specific for alternative or classical/lectin, respectively. Proteolysis of C3b or C4b is mediated by factor I, a plasma protein that requires co-factors for its activity. MCP, CR1, factor H, and C4BP can all serve as co-factors for factor I.

Regulation of complement at the late steps is mediated in part by CD59, a cell surface protein expressed on human cells but not microbes. It binds the C5b-8 complex and inhibits addition of C9, blocking formation of the MAC. Plasma S protein binds the C5b-7 complex and blocks its insertion into the cell membrane and also inhibits C9 polymerization.[53] Intact MACs may be removed from cells through shedding on membrane vesicles or by internalization and degradation.[43]

Carboxypeptidase N can remove the terminal arginine of C3a, C4a, and C5a and has been referred to as *ANA inactivator*.[54] Carboxypeptidase R has also been shown to remove the terminal arginine of C3a and C5a.[55]

COMPLEMENT AND DISEASE

Genetic Abnormalities of the Complement System

Deficiencies of complement cascade proteins, complement receptors, or complement regulatory proteins can lead to a variety of diseases.[56] Genetic deficiencies of complement have been associated primarily with increased risk for infection or autoimmunity. As examples, deficiencies of many complement components, particularly the early complement components C1–C4, have been associated with early-onset systemic lupus erythematosus (SLE), C3 deficiency has been associated with life-threatening pyogenic infections, and C5–C9 deficiencies have been associated with neisserial infections (reviewed in Chap. 144). Genetic deficiency of mannose-binding lectin is relatively common, with significantly low levels occurring in about 10 percent of Caucasians, and is associated with increased risk for infection and autoimmunity, including SLE.[57,58]

Altered expression of CR3 (CD11b/CD18) and CR4 (CD11c/CD18) occurs in leukocyte adhesion deficiency-1, a congenital disorder resulting from mutations in the gene encoding CD18. Mutation in CD18 also affects expression of CD11a/CD18 (leukocyte function–associated antigen-1). Patients with leukocyte adhesion deficiency-1 exhibit significant abnormalities of leukocyte adhesion and have recurrent infections (see Chap. 144).

Deficiency of the complement regulatory protein C1 INH causes angioneurotic edema as a result both of poorly regulated classical pathway activation and of excess bradykinin due to the actions of

COMPLEMENT AND DISEASE

AT A GLANCE



- Genetic deficiencies of complement components have been associated primarily with susceptibility to infection or autoimmunity. Genetic deficiencies of regulatory complement proteins may result in inappropriately prolonged complement activation, such as occurs with C1 inhibitor deficiency.
- Complement is associated with systemic lupus erythematosus through several possible mechanisms. These include increased risk of autoimmunity conferred by certain complement deficiencies, tissue damage resulting from autoantibody-induced complement activation, ineffective clearance of autoimmunity-promoting apoptotic debris, and failure to eliminate self-reactive B cells.
- Complement activation has been implicated in the pathogenesis of atherosclerosis, diabetic microvascular disease, and rejection of xenotransplants.
- Certain infectious agents have evolved mechanisms for evasion of destruction by complement, and some use complement receptors or regulatory proteins to gain entry into the cell.

kallikrein and factor XII. Angioedema may also occur if one has markedly reduced levels of the ANA inactivator, carboxypeptidase N[59] (see Chap. 37).

Deficiency of a protein required for the proper expression of DAF and CD59 on the cell surface is associated with paroxysmal nocturnal hemoglobinuria, a disease characterized by complement-mediated erythrocyte lysis.[60] Hemolytic-uremic syndrome has been associated with mutations in MCP, factor H, and factor I.[61] Factor H deficiency has also been associated with membranoproliferative glomerulonephritis.

Complement, Systemic Lupus Erythematosus, and Autoantibodies

Complement has been closely associated with SLE (see also Chap. 156), albeit in seemingly paradoxical ways.[62,63] Genetic deficiencies of complement components are associated with SLE, but some of the tissue injury seen in SLE appears to be mediated in part by complement activation. Thus, complement seems to be simultaneously protective and deleterious. These observations underscore the protean roles of complement in the immune system. Complement activation has the potential for causing tissue injury, but complement components may be important in clearance of immune complexes and apoptotic debris. Apoptotic bodies that are not cleared effectively may be able to trigger autoimmunity through presentation of normally sequestered autoantigens to the immune system. It has also been suggested that complement participates in eliminating self-reactive immature B cells, a further mechanism for a protective effect of complement in SLE.[63]

Altered expression of both CR1 and CR2 has been observed in patients with SLE.[64] In murine models of lupus, knockout mice lacking expression of CR1 and CR2 (located on the same gene in mice and produced through alternative splicing) have accelerated autoimmunity if the mice otherwise have the optimal genetic background. These findings indicate that the interaction of CR2 and C3d, important in B-cell response to antigen, is another factor that determines susceptibility to SLE.

Autoantibodies to complement components can result in or exacerbate disease.[65] Autoantibodies to C1q are relatively common in SLE and have been associated with more severe renal disease, possibly through an adverse affect on the clearance of immune complexes or apoptotic bodies.[66] C3 nephritic factor is an autoantibody to the C3 convertase, C3bBb, which acts to stabilize the complex. Its clinical significance is its association with membranoproliferative glomerulonephritis type II and partial lipodystrophy.

Complement and Vascular Disease

Complement activation has been implicated in the pathogenesis of atherosclerosis, as well as myocardial reperfusion injury after myocardial ischemia.[67,68] In the microvascular proliferative disease associated with diabetes, glycation, and thereby inactivation of CD59, may result in cellular proliferation due to nonlytic proliferative effects of MAC.[69] Complement activation has also been implicated in hyperacute rejection of xenotransplants due to the presence of natural antibodies to components of the endothelial cells of the transplanted organ, with resultant complement activation, endothelial cell injury, and intravascular coagulation. Pigs genetically engineered to overexpress MCP, DAF, or CD59 have been developed to circumvent this problem.[40]

Evasion or Subversion of Complement by Microbes

The observation that individuals with deficiencies of components of the late stages of complement activation are at increased risk for only a limited set of infections illustrates that infectious agents have evolved means of evading destruction by complement. Gram-positive bacteria have thick cell walls that are difficult to penetrate by MAC.[36] Group A streptococcus M protein binds factor H, which downregulates complement activation. A protein of vaccinia virus acts as a cofactor for factor I, leading to proteolysis of C3b and C4b. In human immunodeficiency virus (HIV) infection, the inclusion of downregulatory molecules of the complement system into the viral or host cell membrane allows HIV to evade complement-mediated destruction.[70] DAF can be subsumed into the HIV virus membrane upon budding from infected human cells, and factor H can bind to HIV surface glycoproteins on infected human cells.

The complement system has been subverted by certain infectious agents for entry into the cell. Epstein-Barr virus penetrates B cells via binding to CR2 on the B-cell surface.[36] Measles virus binds to cells via MCP. Mycobacteria make C4-like molecules that bind C2a and then cleave C3. The deposition of C3b on the mycobacterial cell membrane leads to its uptake into macrophages, where it exists as an intracellular parasite.

KEY REFERENCES

The full reference list for all chapters is available at www.digm7.com.

1. Litman GW, Anderson MK, Rast JP: Evolution of antigen binding receptors. *Annu Rev Immunol* **17**:109, 1999
2. Abbas AK, Lichtman AH: *Cellular and Molecular Immunology*, 5th ed. Philadelphia, Elsevier Saunders, 2005
11. Hardy RR, Hayakawa K: B cell development pathways. *Annu Rev Immunol* **19**:595, 2001
15. Stavnezer J, Amemiya CT: Evolution of isotype switching. *Semin Immunol* **16**:257, 2004
18. Mills DM, Cambier JC: B lymphocyte activation during cognate interactions with $CD4^+$ T lymphocytes: molecular dynamics and immunologic consequences. *Semin Immunol* **15**:325, 2003
36. Walport MJ: Complement. First of two parts. *N Engl J Med* **344**:1058, 2001
38. Janssen BJ et al: Structures of complement component C3 provide insights into the function and evolution of immunity. *Nature* **437**:505, 2005
40. Kim DD, Song WC: Membrane complement regulatory proteins. *Clin Immunol* **118**:127, 2006
43. Cole DS, Morgan BP: Beyond lysis: How complement influences cell fate. *Clin Sci (Lond)* **104**:455, 2003
47. Holers VM. Complement receptors and the shaping of the natural antibody repertoire. *Springer Semin Immunopathol* **26**:405, 2005

CHAPTER 37

Urticaria and Angioedema

Allen P. Kaplan



Urticaria is defined as a skin lesion consisting of a wheal-and-flare reaction in which localized intracutaneous edema (wheal) is surrounded by an area of redness (erythema) that is typically pruritic. Individual hives can last from as briefly as 30 minutes to as long as 36 hours. They can be as small as a millimeter or 6 to 8 inches in diameter (giant urticaria). They blanch with pressure as the dilated blood vessels are compressed, which also accounts for the central pallor of the wheal. The dilated blood vessels and increased permeability that characterize urticaria are present in the superficial dermis and involve the venular plexus in that location. Angioedema can be caused by the same pathogenic mechanisms as urticaria, but the pathology is in the deep dermis and subcutaneous tissue and swelling is the major manifestation. The overlying skin may be erythematous or normal. There is less pruritus (fewer type C nerve endings at the deeper cutaneous levels), but pain or burning may be present.

EPIDEMIOLOGY

Urticaria and angioedema are common. Age, race, sex, occupation, geographic location, and season of the year can be implicated in urticaria and angioedema only insofar as they may contribute to exposure to an eliciting agent. Of a group of college students, 15 percent to 20 percent reported having experienced urticaria, whereas 1 percent to 3 percent of the patients referred to hospital dermatology clinics in the United Kingdom noted urticaria and angioedema. In the National Ambulatory Medical Care Survey data for 1990 to 1997 in the United States, women accounted for 69 percent of patient visits. There was a bimodal age distribution among patients, with peaks at birth to 9 years and at 30 to 40 years.[1]

Urticaria/angioedema is considered to be acute if the condition lasts less than 6 weeks. Most acute episodes are due to adverse reactions to medications or foods or, in children, to viral illnesses. Episodes of urticaria/angioedema persisting beyond 6 weeks are considered chronic and are divided into two major subgroups, chronic autoimmune urticaria (45 percent) and chronic idiopathic urticaria (55 percent), which have a combined incidence in the general population of 0.5 percent.[2] Physically induced urticaria/angioedema is not included in the definition. Various types of physical urticaria/angioedema may last for years, but the individual lesions last fewer than 2 hours (except in delayed pressure urticaria) and are intermittent. Whereas 85 percent of children experience urticaria in the absence of angioedema, 40 percent of adult patients with urticaria also experience angioedema.

Approximately 50 percent of patients with chronic urticaria (with or without angioedema) are free of lesions within 1 year, 65 percent within 3 years, and 85 percent within 5 years; fewer than 5 percent have lesions that last for more than 10 years. Angioedema alters the natural history, and only 25 percent of patients who also have angioedema experience resolution of lesions within 1 year. There are no data regarding the remission rate in patients with only angioedema. The hereditary group of disorders is considered to be lifelong once the diagnosis becomes clinically manifest.

PATHOGENESIS

Mast Cell and Histamine Release

The mast cell is the major effector cell in most forms of urticaria and angioedema, although other cell types undoubtedly contribute. Cutaneous mast cells adhere to fibronectin and laminin through the very late activation (VLA) β_1 integrins VLA-3, VLA-4, and VLA-5 and to vitronectin through the $\alpha_v\beta_3$ integrin. Cutaneous mast cells, but not those from other sites, release histamine in response to compound 48/80, C5a, morphine, and codeine. The neuropeptides substance P (SP), vasoactive intestinal peptide (VIP), and somatostatin (but not neurotensin, neurokinins A and B, bradykinin, or calcitonin gene-related peptide), activate mast cells for histamine secretion. Dermal microdialysis studies of the application of SP on skin indicate that it induces histamine release only at 10^{-6} *M*, which suggests that after physiologic nociceptor activation, SP does not contribute significantly to histamine release.[3] Not all potential biologic products are generated when cutaneous mast cells are stimulated. For example, SP releases histamine from cutaneous mast cells above 10^{-6} *M* but does not induce prostaglandin D_2 (PGD_2). Vascular permeability in skin is produced predominantly by H_1 histamine receptors (85 percent); H_2 histamine receptors account for the remaining 15 percent.

The current hypothesis regarding cellular infiltration that follows mast cell degranulation suggests that the release of mast cell products (histamine, leukotrienes, cytokines, chemokines) leads to alterations in vasopermeability, upregulation of adhesion molecules on endothelial cells, and rolling and attachment of blood leukocytes, followed by chemotaxis and transendothelial cell migration.

Various forms of physical urticaria/angioedema have provided experimental models for the study of urticaria/

URTICARIA AND ANGIOEDEMA AT A GLANCE



- Occurs acutely at some time in 20 percent of the population; incidence of chronic urticaria/angioedema is approximately 0.5 percent.
- Acute urticaria/angioedema is caused by drugs, foods, occasionally infection in association with immunoglobulin E–dependent mechanisms (allergy), or metabolic factors.
- Chronic urticaria/angioedema is an autoimmune disorder in 45 percent of patients.
- In the absence of urticaria, angioedema can be due to overproduction or impaired breakdown of bradykinin.
- Treatment of acute urticaria/angioedema relies on antihistamines and short courses of corticosteroids, and identification and elimination of endogenous and exogenous causes.
- Treatment of C1 inhibitor deficiency includes androgenic agents, antifibrinolytic agents, and C1 inhibitor (C1 INH) concentrates. Fresh frozen plasma and C1 INH concentrate can abort acute episodes.
- Treatment of physical urticaria/angioedema includes high-dose antihistamine prophylaxis, except for delayed-pressure urticaria.
- Treatment of chronic idiopathic or autoimmune urticaria/angioedema includes antihistamines (non-sedating and sedating preparations), low-dose daily or alternate day corticosteroids, or cyclosporine.

angioedema by allowing the observation of the elicited clinical response, examination of lesional and normal skin biopsy specimens, assay of chemical mediators released into the blood or tissues, and characterization of peripheral leukocyte responses.[6,7] The intracutaneous injection of specific antigen in sensitized individuals has provided an experimental model for analysis of the role of immunoglobulin E (IgE) and its interaction with the mast cell. In many subjects, the challenged cutaneous sites demonstrate a biphasic response, with a transient, pruritic, erythematous wheal-and-flare reaction followed by a tender, deep, erythematous, poorly demarcated area of swelling that persists for up to 24 hours. This is the late-phase response with recruitment of variable numbers of neutrophils, prominent eosinophils, monocytes, small numbers of basophils, and $CD4^+$ T lymphocytes of the T helper 2 (Th2) subclass.[8]

Autoimmunity and Chronic Urticaria

The first suggestion that patients with chronic urticaria and angioedema might have an autoimmune diathesis was the observation that there is an increased incidence of antithyroid antibodies in such patients relative to the incidence in the population at large.[9] These include antimicrosomal (peroxidase) and antithyroglobulin antibodies, as seen in patients with Hashimoto thyroiditis.[10] Patients may have clinical hypothyroidism, but a small number might be hyperthyroid if inflammation is at an early stage when thyroid hormone is released into the circulation. This atypical presentation should be distinguished from the occasional case of Graves disease. Nevertheless, most patients are euthyroid. The incidence of antithyroid antibodies in patients with chronic urticaria, as reported in the literature, varies between 15 percent and 24 percent,[11,12] but the most recent data are closer to the latter figure[12] and demonstrate segregation of antithyroid antibodies with chronic autoimmune urticaria rather than chronic idiopathic urticaria. The association is, however, not absolute. The incidence in the autoimmune subgroup was 27 percent and the incidence in the chronic idiopathic urticaria subgroup was 11 percent, whereas the incidence in the population at large is 7 percent to 8 percent. Gruber et al. (1988)[13] considered the possibility that patients might have circulating anti-IgE antibodies that are functional and did indeed find these in 5 percent to 10 percent of patients. Grattan et al.[14,15] sought antibodies reactive with skin mast cells by performing an autologous skin test and found a 30 percent incidence of positive reactions in patients with chronic urticaria. There were only rare positive reactions in healthy control subjects or patients with other forms of urticaria. Subsequently, this level of positivity was shown by Hide et al.[16] to be due to an IgG antibody reactive with the α subunit of the IgE receptor; in addition, a 5 percent to 10 percent incidence of functional anti-IgE antibodies was confirmed.[17]

Functional Assays of the Anti–Immunoglobulin E Receptors

Assays for anti-IgE receptor antibody have included in vivo methods and in vitro assays. The autologous skin test,[14,18] provided one of the first clues that a subset of patients with chronic urticaria have an autoimmune disorder. Basophils are frequently used as an in vitro surrogate for mast cells, and secretion of histamine as a result of incubation with patient sera or purified IgG was readily demonstrated[19–21] but was not observed if the source of basophils was a "nonreleaser"—that is, basophils with an abnormality in the signal transduction molecules lyn or syc, which are unresponsive to signals through the IgE receptor but are normally responsive to other secretagogues, such as the cytokine monocyte chemoattractant protein-1.[22] The incidence of a positive assay result was generally higher than that observed with the autologous skin test; reported values varied between 35 percent and 50 percent.[19,21,23] Absorption of sera with cloned α subunit decreased the percentage of histamine release as the amount of added α subunit was increased,[22] which confirmed reactivity with this receptor subunit. The assay could be made more sensitive by preincubating basophils with interleukin 3 (IL-3),[24] although the percentage of positive reactions was not significantly affected. Release of leukotriene C4 and IL-3 along with histamine was also demonstrable.[25,26] Although more cumbersome, activation of cutaneous mast cells could also be performed in vitro by using either thin skin slices[27] or partially purified mast cells derived from foreskin samples.[28]

Binding Assays for Antireceptor Antibody

Attempts to quantitate IgG antibody to the α subunit have, in general, been unsuccessful. Initial attempts to demonstrate the presence of antibody by means of immunoblotting[23,29] have not proved useful, because positive reactions can be seen in other autoimmune disorders[29] or occasionally in sera[23] from subjects with no history of urticaria. In addition, studies of the relationship of a positive immunoblot result with histamine release did not yield a significant correlation[22]; sera with a positive blot result but negative histamine release were frequently seen. However, sera with positive histamine release and a negative blot result did have demonstrable IgG anti-α because absorption of such sera with the α subunit inhibited histamine release. Thus lack of sensitivity of the immunoblot explained part of the discrepancy, but the cause of the false-positive blot results was not apparent.

Subclass analysis of the pathogenic IgG has been helpful in further delineating the relationship (or lack thereof) between binding assays and functional methods. An early report suggested that much of the antireceptor antibody exists within the IgG1 and IgG3 subclasses, but these data were based on immunoblot analysis.[29] Thus, we used affinity chromatography to purify IgG subclasses from the sera of patients with chronic urticaria to determine which have functional antireceptor antibody. When we isolated IgG2 antibody from nine patients with chronic urticaria, none of them released histamine from human basophils, irrespective of whether a positive IgG2 anti-α antibody immunoblot result was seen. Much of the histamine release does appear to be due to IgG1 and IgG3, and rarely to IgG4.[30]

Role of Complement

The notion that complement might contribute to the histamine release observed with sera from patients with chronic urticaria was suggested by studies in which complement depletion or inactivation appeared to diminish histamine release.[20,29] A series of reports[22,28,34] documented not only a role for complement but also more specifically activation of the classical pathway and generation of C5a. First, we demonstrated that the addition of purified patient IgG to normal serum (as a source of complement) but not sera deficient in C2 or C5 augmented cutaneous mast cell histamine release.[28] This was confirmed with basophils.[22,34] We could also reconstitute C5-deficient serum with purified C5 to recover the augmentation of histamine release provided by serum. Then we





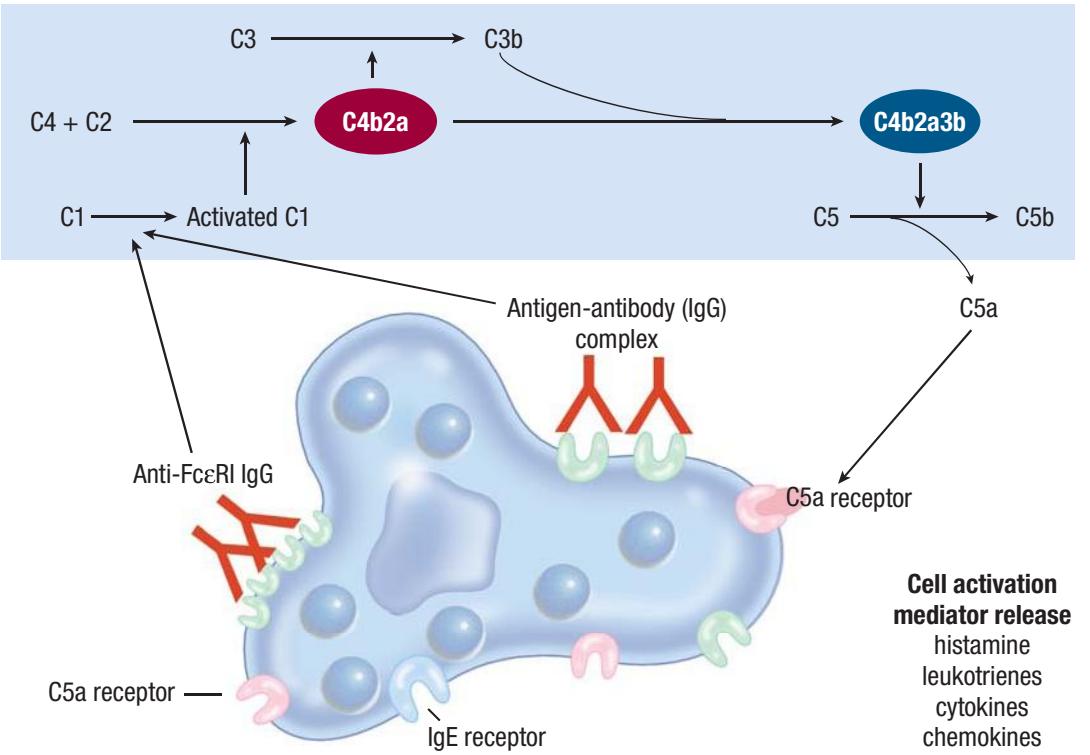

▲ **FIGURE 37-1** Schematic diagram of the activation of cutaneous mast cells by immunoglobulin G (IgG) antireceptor antibody, followed by activation of complement, release of C5a, and augmentation of mast cell release.

demonstrated inhibition of the complement contribution to histamine release by using an antibody to the C5a receptor.[34] It is not clear why the presence of a functional anti-IgE receptor would cause symptoms limited to the skin, but among the differences between pulmonary and cutaneous mast cells is the absence of C5a receptors on lung mast cells. On the other hand, it is also not clear why the IgG2 anti-IgE receptor antibody, which is often demonstrable by means of immunoblotting, does not activate basophils or cutaneous mast cells, because IgG2 anti-FcεRIα should cross-link α subunits, as might any IgG subclass antibody directed to the α subunit. The difference might have to do with antibody affinity or differing α subunit epitopes with which these antibodies react. The geometry of binding is also a factor, because the Fc regions of two adjacent IgG molecules must each be able to bind to one of the globular heads of C1Q to initiate complement activation (Fig. 37-1). It is theoretically possible to have binding of IgG to the IgE receptor in the absence of cross-linking (e.g., the receptors are too far apart) and still observe histamine release if the two Fc regions are sufficiently close together to activate C1. If receptors are sparse, the antibody can bind without activating either the cells or complement, whereas receptor saturation with IgE might preclude binding. These considerations may account for the marked heterogeneity in patient manifestations and severity.

Cellular Infiltrate

Mast cell degranulation initiates the inflammatory process in autoimmune chronic urticaria and is assumed also to do so in idiopathic chronic urticaria. Evidence for increased numbers of mast cells in chronic urticaria has been presented,[35,36] but there are also publications indicating no significant differences from normal[37]; these studies did not discriminate the autoimmune from the idiopathic groups. However, no alternative mechanisms for mast cell degranulation in the idiopathic groups have been suggested to date. Yet the histology of the lesions in the two groups differs in only minor ways. Common to all biopsy specimens is a perivascular infiltrate that surrounds small venules within the superficial and deep venular plexus, with a prominence of $CD4^+$ T lymphocytes and monocytes and virtually no B cells.[35,38] Granulocytes are quite variable but are plentiful if the lesion undergoes biopsy early in its development. Neutrophils and eosinophils are both present,[39,40] although the degree of eosinophil accumulation varies greatly.[38] Even when eosinophils are not evident, major basic protein can be identified within lesions (in at least two-thirds of patients), which most likely represents evidence of prior eosinophil degranulation.[41] The presence of basophils has also been demonstrated by using an antibody (BB1) that is specific for this cell type.[40] Thus the infiltrate resembles that of an allergic late-phase reaction, as suggested previously.[42] Endothelial cell activation is suggested by the presence of intercellular adhesion molecule 1 and E-selectin in biopsy specimens of urticarial lesions.[43] Sources of chemokines include the mast cell and the activated endothelial cell; the latter cells are stimulated not only by cytokines or monokines, such as IL-4, IL-1, and tumor necrosis factor-α (TNF-α) but also by the vasoactive factors—for example, histamine and leukotrienes released from activated mast cells.[44]

Basophil Releasability

The basophils of patients with chronic urticaria have been shown to be hyporesponsive to anti-IgE, an observation made by Kern and Lichtenstein[47] long before there were any clues to the pathogenesis of this disorder. These findings were confirmed[48] and appeared to be associated with basopenia[49] and to segregate to the autoimmune subgroup. One obvious interpretation is that there is in vivo desensitization of

basophils in the presence of circulating anti-IgE receptor. However, we have found a paradoxical result when the isolated basophils of patients with chronic urticaria were activated and compared with the basophils of healthy control subjects. Although the basophils of the patients with urticaria were clearly less responsive to anti-IgE, they demonstrated augmented histamine release when incubated with serum, and it did not matter whether the serum was taken from normal individuals, from other patients with chronic urticaria, or was their own (autologous).[50]

Bradykinin: Role in Angioedema

Kinins are low-molecular-weight peptides that participate in inflammatory processes by virtue of their ability to activate endothelial cells and, as a consequence, lead to vasodilatation, increased vascular permeability, production of nitric oxide, and mobilization of arachidonic acid. Kinins also stimulate sensory nerve endings, causing a burning dysesthesia. Thus the classical parameters of inflammation (i.e., redness, heat, swelling, and pain) can all result from kinin formation. Bradykinin is the best characterized of this group of vasoactive substances.

There are two general pathways by which bradykinin is generated. The simpler of the two has only two components: an enzyme tissue kallikrein[52] and a plasma substrate, low-molecular-weight kininogen.[53,54] Tissue kallikrein is secreted by many cells throughout the body; however, certain tissues produce particularly large quantities. These include glandular tissues (salivary and sweat glands and pancreatic exocrine gland) and the lung, kidney, intestine, and brain.

The second pathway for bradykinin formation is far more complex and is part of the initiating mechanism by which the intrinsic coagulation pathway is activated (see eFig 37-1.1 in online edition).[55] Factor XII is the initiating protein that binds to certain negatively charged macromolecular surfaces and autoactivates (autodigests) to form factor XIIa.[56,57] This is synonomous with Hageman factor as designated in the figure. There are two plasma substrates of factor XIIa—namely, prekallikrein[58] and factor XI[59,60]—and each of these circulates as a complex with high-molecular-weight kininogen (HK).[61,62] These complexes also attach to initiating surfaces, and the major attachment sites are on two of the domains of HK, which thereby places both prekallikrein and factor XI in optimal conformation for cleavage to kallikrein (plasma kallikrein) and factor XIa, respectively. It is important to note that plasma kallikrein and tissue kallikrein are separate gene products and have little amino acid sequence homology, although they have related functions (i.e., cleavage of kininogens). Tissue kallikrein prefers low-molecular-weight kininogen but is capable of cleaving HK, whereas plasma kallikrein cleaves HK exclusively. The two kininogens have an identical amino acid sequence starting at the N-terminus and continuing to 12 amino acids beyond the bradykinin moiety[54] but differ in C-terminal domains because of alternative splicing at the transcription level.[63,64]

CLINICAL FINDINGS

Circumscribed, raised, erythematous, usually pruritic, evanescent areas of edema that involve the superficial portion of the dermis are known as *urticaria* (Fig. 37-2); when the edematous process extends into the deep dermis and/or subcutaneous and submucosal layers, it is known as *angioedema*. Urticaria and angioedema may occur in any location together or individually. Angioedema commonly affects the face or a portion of an extremity, may be painful but not pruritic, and may last several days. Involvement of the lips, cheeks, and periorbital areas is common, but angioedema also may affect the tongue, pharynx, or larynx. The individual lesions of urticaria arise suddenly, rarely persist longer than 24 to 48 hours, and may continue to recur for indefinite periods. They are highly pruritic.



▲ **FIGURE 37-2** Urticaria and angioedema. This patient has urticaria occurring on the face, neck, and upper trunk with angioedema about the eyes.

Immunologic: Immunoglobulin E– and Immunoglobulin E Receptor–Dependent Urticaria/Angioedema

ATOPIC DIATHESIS Episodes of acute urticaria/angioedema that occur in individuals with a personal or family history of asthma, rhinitis, or eczema are presumed to be IgE dependent. In clinical practice, however, urticaria/angioedema infrequently accompanies an exacerbation of asthma, rhinitis, or eczema. The prevalence of chronic urticaria/angioedema is not increased in atopic individuals.

SPECIFIC ANTIGEN SENSITIVITY Common examples of specific antigens that provoke urticaria/angioedema are foods such as shellfish, nuts, milk, eggs, and chocolate; drugs and therapeutic agents, notably penicillin; aeroallergens; and Hymenoptera venom (see Fig. 37-2). Urticaria in patients with helminthic infestations has been attributed to IgE-dependent processes; however, proof of this relationship is often lacking. Specific allergens and non-specific stimuli may activate local reactions termed *recall urticaria* at sites previously injected with allergen immunotherapy.

Physical Urticaria/Angioedema[6,7]

DERMOGRAPHISM Dermographism is the most common form of physical urticaria and is the one most likely to be confused with chronic urticaria. A lesion appears as a linear wheal with a flare at a site at which the skin is briskly stroked with a firm object (Fig. 37-3). A transient wheal appears rapidly and usually fades within 30 minutes; however, the patient's normal skin is typically pruritic, so that an itch-scratch sequence may appear. The prevalence of



▲ **FIGURE 37-3** Topical dermatographic response to scratching the skin.





dermographism in the general population was reported as 1.5 percent and 4.2 percent, respectively, in two studies, and its prevalence in patients with chronic urticaria is 22 percent. It is not associated with atopy. The peak prevalence occurs in the second and third decades. In one study, the duration of dermographism was found to be longer than 5 years in 22 percent of individuals and longer than 10 years in 10 percent.

Elevations in blood histamine levels have been documented in some patients after experimental scratching, and increased levels of histamine,[74] tryptase, SP, and VIP, but not calcitonin gene–related peptide, have been detected in experimental suction-blister aspirates. The dermographic response has been passively transferred to the skin of normal subjects with serum or IgE.[75]

In delayed dermographism lesions develop 3 to 6 hours after stimulation, either with or without an immediate reaction, and last 24 to 48 hours. The eruption is composed of linear red indurated wheals. This condition may be associated with delayed pressure urticaria, and these two may, in fact, represent the same entity. Cold-dependent dermographism is a condition characterized by marked augmentation of the dermatographic response when the skin is chilled.[76]

PRESSURE URTICARIA Delayed pressure urticaria appears as erythematous, deep, local swellings, often painful, that arise from 3 to 6 hours after sustained pressure has been applied to the skin.[77,78] Spontaneous episodes are elicited on areas of contact after sitting on a hard chair, under shoulder straps and belts, on the feet after running, and on the hands after manual labor. The peak prevalence occurs in the third decade. Delayed pressure urticaria may occasionally be associated with fever, chills, arthralgias, and myalgias, as well as with an elevated erythrocyte sedimentation rate and leukocytosis. In one study, it accompanied chronic urticaria in 37 percent of patients. This is far more commonly seen than pressure urticaria with no spontaneously occurring hives. An IgE-mediated mechanism has not been demonstrated; however, histamine and IL-6 have been detected in lesional experimental suction-blister aspirates and in fluid from skin chambers, respectively.[4,79,80]

VIBRATORY ANGIOEDEMA Vibratory angioedema may occur as an acquired idiopathic disorder, in association with cholinergic urticaria, or after several years of occupational exposure to vibration.[81] It has been described in families with an autosomal dominant pattern of inheritance.[82] The heritable form often is accompanied by facial flushing. An increase in the level of plasma histamine was detected during an experimental attack in patients with the hereditary form and in patients with acquired disease.[81,82] A typical symptom is hives across the back when toweling off after a shower (in the absence of dermatographism).

COLD URTICARIA There are both acquired and inherited forms of cold urticaria/angioedema; however, the familial form is rare. Idiopathic or primary acquired cold urticaria may be associated with headache, hypotension, syncope, wheezing, shortness of breath, palpitations, nausea, vomiting, and diarrhea. Attacks occur within minutes after exposures that include changes in ambient temperature and direct contact with cold objects. The elicitation of a wheal after the application of ice has been called a diagnostic cold contact test (Fig. 37-4). If the entire body is cooled, as in swimming, hypotension and syncope, which are potentially lethal events (causing drowning), may occur. In rare instances, acquired cold urticaria has been associated with circulating cryoglobulins, cryofibrinogens, cold agglutinins, and cold hemolysins, especially in children with infectious mononucleosis.[83–85]

Passive transfer of cold urticaria by intracutaneous injection of serum or IgE to the skin of normal recipients has been documented.[86,87] Histamine, chemotactic factors for eosinophils and neutrophils, PGD_2, cysteinyl leukotrienes, platelet-activating factor, and TNF-α have been released into the circulation after experimental challenge.[88–94] Histamine, SP, and VIP, but not calcitonin gene–related peptide, have been detected in experimental suction-blister aspirates. Histamine has been released in vitro from chilled skin biopsy specimens that have been re-warmed.[95] Neutrophils harvested from the blood of an experimentally cold-challenged arm manifested an impaired chemotactic response suggesting in vivo desensitization. Whereas complement has no role in primary acquired cold urticaria, cold challenge of patients with cold urticaria who have circulating immune complexes (such as cryoglobulins) can provoke a cutaneous necrotizing venulitis with complement activation.[96–99]



▲ **FIGURE 37-4** Positive ice cube test results in a patient with cold urticaria. The peaked left corner of the urticarial lesion is the track of ice water running down the arm.

Rare forms of acquired cold urticaria that have been described mainly in case reports include systemic cold urticaria,[76] localized cold urticaria,[100] cold-induced cholinergic urticaria, cold-dependent dermographism,[76] and localized cold reflex urticaria.[101,102] Two forms of dominantly inherited cold urticaria have been described. Familial cold urticaria has been termed *familial cold autoinflammatory syndrome* and is considered a type of periodic fever.[103] It is a disorder showing an autosomal dominant pattern of inheritance with a genetic linkage to chromosome band 1q44. The responsible gene has been identified as CIASI, which codes for a protein involved in regulation of inflammation and apoptosis.[104] The eruption occurs as erythematous macules and infrequent wheals and is associated with burning or pruritus. Fever, headaches, conjunctivitis, arthralgias, and a neutrophilic leukocytosis are features of attacks. The delay between cold exposure and onset of symptoms is 2.5 hours, and the average duration of an episode is 12 hours. Renal disease with amyloidosis occurs infrequently. Skin biopsy specimens show mast cell degranulation and an infiltrate of neutrophils. Results of the cold contact test and passive transfer with serum have been negative. Serum levels of IL-6 and granulocyte colony-stimulating factor were elevated in one patient. Other studies suggest a pathogenic role for IL-1. Delayed cold urticaria occurs as erythematous, edematous, deep swellings that appears 9 to 18 hours after cold challenge. Lesional biopsy specimens show edema with minimal numbers of mononuclear cells; mast cells are not degranulated; and neither complement proteins nor immunoglobulins are detected. Cold immersion does not release histamine, and the condition cannot be passively transferred.

CHOLINERGIC URTICARIA Cholinergic urticaria develops after an increase in core



▲ **FIGURE 37-5** Lesions of cholinergic urticaria observed in a patient after 15 minutes of exercise in a warm room.

body temperature, such as during a warm bath, prolonged exercise, or episodes of fever.[105] The highest prevalence is observed in individuals aged 23 to 28 years. The eruption appears as distinctive, pruritic, small, 1- to 2-mm wheals that are surrounded by areas of erythema (Fig. 37-5). Occasionally, the lesions may become confluent, or angioedema may develop. Systemic features include dizziness, headache, syncope, flushing, wheezing, shortness of breath, nausea, vomiting, and diarrhea. An increased prevalence of atopy has been reported. The intracutaneous injection of cholinergic agents, such as methacholine chloride, produces a wheal with satellite lesions in approximately one-third of patients.[106,107] Alterations in pulmonary function have been documented during experimental exercise challenge[108] or after the inhalation of acetylcholine, but most patients are asymptomatic.

A major sub-population of patients with cholinergic urticaria have a positive skin test result and in vitro histamine release in response to autologous sweat.[109] It is not clear whether or not this is IgE mediated, and any antigen present in sweat is unidentified. This is the same sub-population with a positive methacholine skin test result with satellite lesions and a non-follicular distribution of the wheals. The remaining patients had negative results on autologous sweat skin tests and no in vitro histamine release. Results of the methacholine skin test are negative for satellite lesions and the hives tend to be follicular in distribution.

Familial cases have been reported only in men in four families.[110] This observation suggests an autosomal dominant or sex-linked pattern of inheritance. One of these individuals had co-existing dermographism and aquagenic urticaria.

After exercise challenge, histamine and factors chemotactic for eosinophils and neutrophils are released into the circulation.[88,108] Tryptase has been detected in lesional suction-blister aspirates. The urticarial response has been passively transferred on one occasion; however, most other attempts to do so have been unsuccessful.

Cold urticaria and cholinergic urticaria are not uncommonly seen together,[111,112] and cold-induced cholinergic urticaria represents an unusual variant in which typical "cholinergic"-appearing lesions occur with exercise, but only if the person is chilled, for example, with exercise outside on a winter's day. The ice cube test and methacholine skin test both yield negative results.[113]

LOCAL HEAT URTICARIA Local heat urticaria is a rare form of urticaria in which wheals develop within minutes after exposure to locally applied heat. An increased incidence of atopy has been reported. Passive transfer has been negative. Histamine, neutrophil chemotactic activity, and PGD_2 have been detected in the circulation after experimental challenge.[114] A familial delayed form of local heat urticaria in which the urticaria occurred in 1 to 2 hours after challenge and lasted up to 10 hours has been described.

SOLAR URTICARIA Solar urticaria occurs as pruritus, erythema, wheals, and occasionally angioedema that develop within minutes after exposure to sun or artificial light sources. Headache, syncope, dizziness, wheezing, and nausea are systemic features. Most commonly, solar urticaria appears during the third decade.[115] In one study, 48 percent of patients had a history of atopy. Although solar urticaria may be associated with systemic lupus erythematosus and polymorphous light eruption, it is usually idiopathic. The development of skin lesions under experimental conditions in response to specific wavelengths has allowed classification into six sub-types; however, individuals may respond to more than one portion of the light spectrum. In type I, elicited by wavelengths of 285 to 320 nm, and in type IV, elicited by wavelengths of 400 to 500 nm, the responses have been passively transferred with serum, which suggests a role for IgE antibody. In type I, the wavelengths responsible are blocked by window glass.[116,117] Type VI, which is identical to erythropoietic protoporphyria, is due to ferrochelatase (heme synthase) deficiency (see Chap. 132).[118] There is evidence that an antigen on skin may become evident once the skin is irradiated with the appropriate wavelength of light, followed by complement activation and release of C5a.[119–121]

Histamine and chemotactic factors for eosinophils and neutrophils have been identified in blood after exposure of the affected individuals to ultraviolet A, ultraviolet B, and visible light.[122,123] In some individuals, uncharacterized serum factors with molecular weights ranging from 25 to 1000 kd, which elicit cutaneous wheal-and-erythema reactions after intracutaneous injection, have been implicated in the development of lesions.

EXERCISE-INDUCED ANAPHYLAXIS Exercise-induced anaphylaxis is a clinical symptom complex consisting of pruritus, urticaria, angioedema respiratory distress, and syncope that is distinct from cholinergic urticaria.[124–127] In most patients, the wheals are not punctate and resemble the hives seen in acute or chronic urticaria. The symptom complex is not readily reproduced by exercise challenges as is cholinergic urticaria. There is a high prevalence of an atopic diathesis. Some cases are food dependent—that is, exercise will lead to an anaphylaxis-like episode only if food was ingested within 5 hours of the exercise. The food dependency is subdivided into two groups; in the first the nature of the food eaten is not relevant, whereas in the second a specific food to which there is IgE-mediated hypersensitivity must be eaten for hives to appear.[128–131] Yet in these cases, eating the food without exercise does not result in urticaria. The food-dependent group is easier to treat because avoidance of food (or a specific food) for 5 to 6 hours before exercise prevents episodes. Cases not related to food require therapy for acute episodes and attempts to prevent episodes with high-dose antihistaminics or avoidance of exercise. Results of a questionnaire study of individuals who had had exercise-induced anaphylaxis for more than a decade[132] disclosed that the frequency of attacks had decreased in 47 percent and had stabilized in 46 percent. Forty-one percent had been free of attacks for 1 year. Rare familial forms have been described. In exercise-induced anaphylaxis, baseline pulmonary function test results are normal. Biopsy specimens show mast cell degranulation, and histamine and tryptase are released into the circulation when symptoms appear.



ADRENERGIC URTICARIA Adrenergic urticaria occurs as wheals surrounded by a white halo that develop during emotional stress. The lesions can be elicited by the intracutaneous injection of norepinephrine.

AQUAGENIC URTICARIA AND AQUAGENIC PRURITUS Contact of the skin with water of any temperature may result in pruritus alone or, more rarely, urticaria. The eruption consists of small wheals that are reminiscent of cholinergic urticaria. Aquagenic urticaria has been reported in more than one member in five families.[133] Aquagenic pruritus without urticaria is usually idiopathic but also occurs in elderly persons with dry skin and in patients with polycythemia vera, Hodgkin disease, myelodysplastic syndrome, and hypereosinophilic syndrome. Patients with aquagenic pruritus should be evaluated for the emergence of a hematologic disorder. After experimental challenge, blood histamine levels were elevated in subjects with aquagenic pruritus and with aquagenic urticaria. Mast cell degranulation was present in lesional tissues. Passive transfer was negative.



Contact Urticaria

Urticaria may occur after direct contact with a variety of substances. It may be IgE mediated or nonimmunologic. The transient eruption appears within minutes, and when it is IgE mediated, it may be associated with systemic manifestations. Passive transfer has been documented in some instances. Proteins from latex products are a prominent cause of IgE-mediated contact urticaria.[134] Latex proteins also may become airborne allergens, as demonstrated by allergen-loaded airborne glove powder used in inhalation challenge tests. These patients may manifest cross-reactivity to fruits, such as banana, avocado, and kiwi.[135] Associated manifestations include rhinitis, conjunctivitis, dyspnea, and shock. The risk group is dominated by biomedical workers and individuals with frequent contact with latex, such as children with spina bifida. Agents such as stinging nettles, arthropod hairs, and chemicals may induce release of histamine directly from mast cells.

Papular Urticaria

Papular urticaria occurs as episodic, symmetrically distributed, pruritic, 3- to 10-mm urticarial papules that result from a hypersensitivity reaction to the bites of insects such as mosquitoes, fleas, and bedbugs. This condition occurs mainly in children. The lesions tend to appear in groups on exposed areas such as the extensor aspects of the extremities.[136]

Urticaria/Angioedema Mediated by Bradykinin, the Complement System, or Other Effector Mechanisms

KININS AND C1 INHIBITOR DEFICIENCY C1 inhibitor (C1 INH) is the sole plasma inhibitor of factor XIIa and factor XIIf,[137,138] and it is one of the major inhibitors of kallikrein[139] as well as factor XIa.[140] Thus, in the absence of C1 INH, stimuli that activate the kinin-forming pathway will do so in a markedly augmented fashion; the amount of active enzyme and the duration of action of the enzymes are prolonged. C1 INH deficiency can be familial, in which there is a mutant C1 INH gene, or it can be acquired. Both the hereditary and acquired disorders have two sub-types. For the hereditary disorder, type 1 hereditary angioedema (HAE) (85 percent) is an autosomal dominant disorder with a mutant gene (often with duplication, deletions, or frameshifts) that leads to markedly suppressed C1 INH protein levels as a result of abnormal secretion or intracellular degradation.[141] Type 2 HAE (15 percent) is also a dominantly inherited disorder, typically with a point (missense) mutation that leads to synthesis of a dysfunctional protein.[142] The C1 INH protein level may be normal or even elevated, and a functional assay is needed to assess activity. The acquired disorder also has two forms, although they may overlap in some patients. One group is associated with B-cell lymphoma[143–145] or connective tissue disease,[146] in which there is consumption of C1 INH. Examples are systemic lupus erythematosus and cryoglobulinemia, in which complement activation is prominent, and B-cell lymphomas, in which immune complexes are formed by anti-idiotypic antibodies to monoclonal immunoglobulin expressed by the transformed B lymphocytes.[147] The second form is an autoimmune disorder with a circulating IgG antibody to C1 INH itself.[148–150] Acquired types have depressed C1q levels, whereas hereditary types do not, and depressed C4 levels characterize all forms of C1 INH deficiency. The acquired autoimmune subgroup shows a circulating 95-kd cleavage product of C1 INH because the antibody depresses C1 INH function yet allows cleavage by enzymes with which it usually interacts.[150–152] Research data indicate the presence of acquired type II C1 INH deficiency in patients usually considered to have acquired type 1 C1 INH deficiency; hence, an overlap syndrome occurs.

It is now clear that depletion of C4 and C2 during episodes of swelling[153,154] is a marker of complement activation but does not lead to release of a vasoactive peptide responsible for the swelling. Bradykinin is, in fact, the mediator of the swelling,[155–157] and the evidence in support of this conclusion is summarized below. Patients with HAE are hyper-responsive to cutaneous injection of kallikrein.[158] They have elevated bradykinin levels and low prekallikrein and HK levels during attacks of swelling.[159–161] The augmentation in complement activation seen at those times may be due to activation of C1r and C1s by factor XIIf.[162] The presence of kallikrein-like activity in induced blisters of patients with HAE also supports this notion,[163] as does the progressive generation of bradykinin on incubation of HAE plasma in plastic (non–contact-activated) tubes[155,156] as well as the presence of activated factor XII and cleaved HK levels seen during attacks.[164] One unique family has been described in which there is a point mutation in the C1 INH (A1a 443→Val) leading to an inability to inhibit complement but normal inhibition of factor XIIa and kallikrein.[165,166] No family member with this type 2 mutation has had angioedema,[165] although complement activation is present. In some studies plasma bradykinin levels have been shown to be elevated during attacks of swelling in both hereditary and acquired C1 INH deficiency,[160] and local bradykinin generation has been documented at the sites of swelling.[167] It is not known whether bradykinin generation is predominantly seen in the fluid phase, occurs along cell (endothelial) surfaces, or both. Fig. 37-6 depicts a patient with facial swelling due to HAE. Fig. 37-7 is a diagram depicting the steps in the bradykinin-forming cascade that are inhibitable by C1 INH.

An estrogen-dependent form of HAE has been recognized. One of the first reports involved a single family with seven affected individuals in three generations, which suggests a hereditary (autosomal dominant) pattern.[168] Clinical features include angioedema without urticaria, laryngeal edema, and abdominal pain with vomiting. Attacks occur during pregnancy and with the administration of exogenous estrogens.



▲ **FIGURE 37-6** Hereditary angioedema. Extensive involvement (**A**) is to be contrasted with the patient's normal facies (**B**).

ANGIOTENSIN-CONVERTING ENZYME INHIBITORS Angioedema has been associated with the administration of angiotensin-converting enzyme (ACE) inhibitors.[169] The frequency of angioedema occurring after ACE inhibitor therapy is 0.1 percent to 0.7 percent. Angioedema develops during the first week of therapy in up to 72 percent of affected individuals and usually involves the head and neck, including the mouth, tongue, pharynx, and larynx. Urticaria occurs only rarely. Cough and angioedema of the gastrointestinal tract are associated features. It has been suggested that therapy with ACE inhibitors is contraindicated in patients with a prior history of idiopathic angioedema, HAE, and acquired C1 INH deficiency.[170] It appears that this swelling is also a consequence of elevated levels of bradykinin[160]; however, the accumulation of bradykinin is due to a defect in degradation rather than excessive production. ACE, being identical to kininase II, is the major enzyme responsible for bradykinin degradation (see eFig. 37-1.1 in on-line edition), and although it is present in plasma, the vascular endothelium of the lung appears to be its major site of action.[171] The action of ACE always leads to the formation of degradation products with no activity, whereas kininase I alone yields the des-arg products, which are capable of stimulating B1 receptors.

The excessive accumulation of bradykinin implies that production is ongoing, for example, that some event leads to activation of the plasma cascade, or that release of tissue kallikrein is present so that faulty inactivation of bradykinin leads to swelling. Continuous turnover of the cascade is implied by data demonstrating activation along the surface of cells and cellular expression or secretion of a prekallikrein activator other than factor XIIa.[172,173]

Urticarial Vasculitis

Chronic urticaria and angioedema may be manifestations of cutaneous necrotizing venulitis, which is known as *urticarial venulitis* (see Chap. 164).[174,175] Associated features include fever, malaise, arthralgia, abdominal pain, and less commonly conjunctivitis, uveitis, diffuse glomerulonephritis, obstructive and restrictive pulmonary disease, and benign intracranial hypertension.



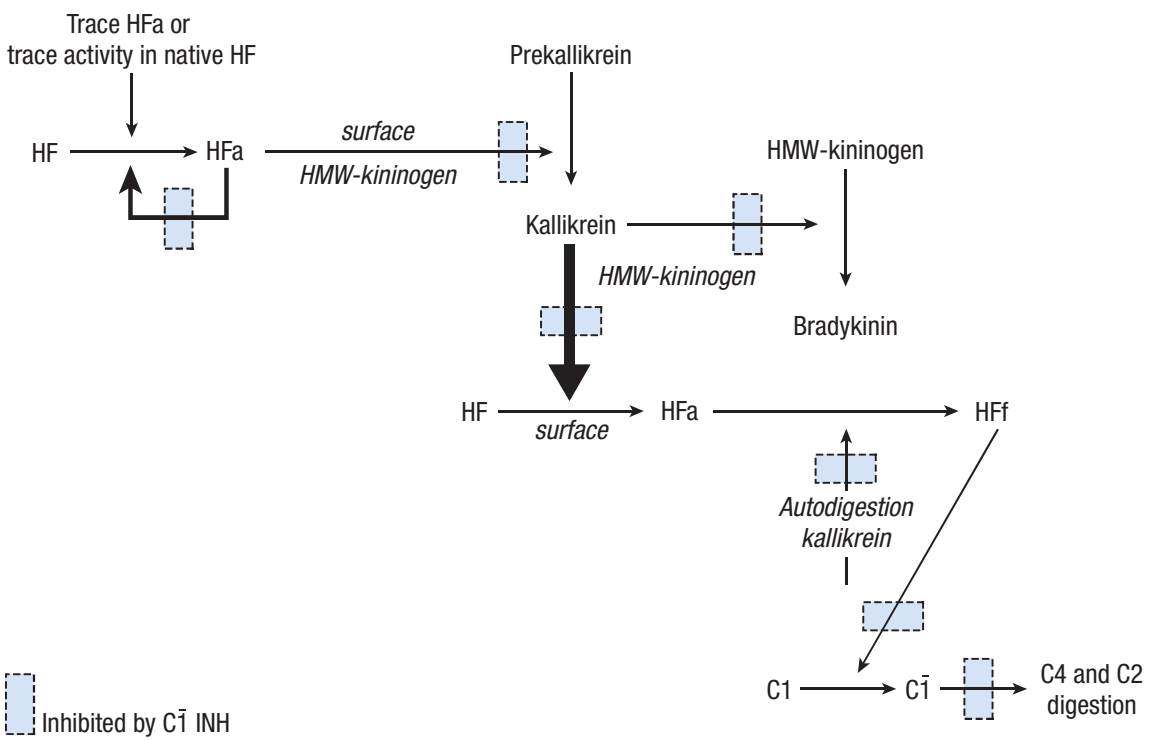

▲ **FIGURE 37-7** Pathways for the formation of bradykinin, with indication of all steps inhibitable by C1 inhibitor (INH) as well as complement activation by means of Hageman factor fragment (factor XIIf) (HFf). HF = Hageman factor (factor XII); HFa = activated Hageman factor (factor XIIa); HMW = high-molecular-weight.

Serum Sickness

Serum sickness, which was defined originally as an adverse reaction that resulted from the administration of heterologous serum to humans, may similarly occur after the administration of drugs. Serum sickness occurs 7 to 21 days after the administration of the offending agent and is manifested by fever, urticaria, lymphadenopathy, myalgia, arthralgia, and arthritis. Symptoms are usually self-limited and last 4 to 5 days. More than 70 percent of patients with serum sickness experience urticaria, which may be pruritic or painful. The initial manifestation of urticaria may appear at the site of injection.



Reactions to the Administration of Blood Products

Urticaria/angioedema may develop after the administration of blood products. It usually is the result of immune complex formation and complement activation that leads directly to vascular and smooth muscle alterations and indirectly via anaphylatoxins to mast cell mediator release. Aggregated IgG may also be responsible for human reactions to immunoglobulins as evidenced by the fact that the administration of IgG from which aggregates have been removed is not associated with urticaria or anaphylaxis.

An uncommon mechanism for the development of urticaria after the administration of blood products is the transfusion of IgE of donor origin directed toward an antigen to which the recipient is subsequently exposed. Another mechanism may be the transfusion of a soluble antigen present in the donor preparation into a previously sensitized recipient.

Infections

Episodes of acute urticaria can be associated with upper respiratory tract viral infections, most commonly in children.[185] The acute urticaria resolves within 3 weeks. Hepatitis B virus infection has been associated with episodes of urticaria lasting up to 1 week that are accompanied by fever and arthralgias as part of the prodrome. The mechanism is analogous to that seen in serum sickness–like reactions with viral-antibody immune complexes.

Urticaria/Angioedema after Direct Mast Cell Degranulation

Various therapeutic and diagnostic agents have been associated with urticaria/angioedema. Up to 8 percent of patients receiving radiographic contrast media experience such reactions, which occur most commonly after intravenous administration. Decreased serum alternative pathway complement protein levels and increased serum histamine levels have been detected in patients receiving radiocontrast media. Opiate analgesics, polymyxin B, curare, and D-tubocurarine induce release of histamine from mast cells and basophils.

Urticaria/Angioedema Related to Abnormalities of Arachidonic Acid Metabolism

Intolerance to aspirin manifested as urticaria/angioedema occurs in otherwise normal individuals or in patients with allergic rhinitis and/or bronchial asthma. Urticaria/angioedema in response to aspirin and nonsteroidal anti-inflammatory drugs (NSAIDs) occurred in approximately 10 percent to 20 percent of individuals referred to a hospital dermatology clinic in the United Kingdom. Patients intolerant of aspirin also may react to indomethacin and to other NSAIDs.

Reactions to aspirin are shared with other NSAIDs because they reflect inhibition of prostaglandin endoperoxide synthase 1 (PGHS-1, cyclooxygenase 1)[186] as well as inhibition of the inducible PGHS-2 (cyclooxygenase 2). Sodium salicylate and choline salicylate generally are well tolerated because of their weak activity against PGHS-1. PGHS-2 inhibitors are generally well tolerated in those with NSAID-induced urticaria.[187,188] Reactions to NSAIDs increase the levels of cysteinyl leukotrienes,[189] which may relate to the appearance of urticaria, although their role in NSAID-induced asthma is better characterized. Prick skin tests are of no diagnostic value, passive transfer reaction results are negative, and neither IgG nor IgE antibodies have been associated with clinical disease. The clinical manifestations elicited by aspirin challenge of aspirin-intolerant patients are blocked when such patients are protected with a cysteinyl leukotriene receptor blocker or biosynthetic inhibitor; this finding confirms a pathobiologic role for the cysteinyl leukotrienes.

Chronic Idiopathic Urticaria and Idiopathic Angioedema

Because the clinical entity of chronic idiopathic urticaria and idiopathic angioedema is frequently encountered and in fact represents the most common form of chronic urticaria, has a capricious course, and is recognized easily, it is frequently associated with concomitant events. Such attributions must be interpreted with caution. Although infections, food allergies, adverse reactions to food additives, metabolic and hormonal abnormalities, malignant conditions, and emotional factors have been claimed as causes, proof of their etiologic relationship often is lacking. The latest consideration is chronic urticaria as a consequence of infection with *Helicobacter pylori*. Articles both supporting[190–192] and denying[193–196] such a relationship are numerous, and a definite answer is not available. However the *H. pylori* infection rate in the population at large is far greater than the incidence of chronic urticaria, and in the opinion of this author, the association is spurious. The controversy has been put in perspective by M. Greaves.[197] Idiopathic angioedema is diagnosed when angioedema is recurrent, when urticaria is absent, and when no exogenous agent or underlying abnormality is identifiable. An extensive review of angioedema has been published.[170]

Cyclic episodic angioedema has been associated with fever, weight gain, absence of internal organ damage, a benign course, and peripheral blood eosinophilia.[198] Biopsy specimens of tissues show eosinophils, eosinophil granule proteins, and CD4 lymphocytes exhibiting HLA-OR. Blood levels of IL-1, soluble IL-2 receptor, and IL-5 are elevated.

Miscellaneous

Muckle-Wells syndrome consists of urticaria, amyloidosis, and nerve deafness and is due to the same gene defect as that seen in familial cold urticaria.[104] Schnitzler syndrome is a chronic urticaria associated with IgM monoclonal protein and osteosclerosis, and antibody to IL-1α has been shown to be present.[199]

APPROACH TO THE PATIENT

The evaluation of patients with urticaria/angioedema (Fig. 37-8) begins with a comprehensive history taking, with particular emphasis on the recognized causes, and a physical examination. Some varieties of urticaria may be identified by their characteristic appearance, such as the small wheals with a large erythematous flare of cholinergic urticaria, the linear wheals in dermographism, and the localization of lesions

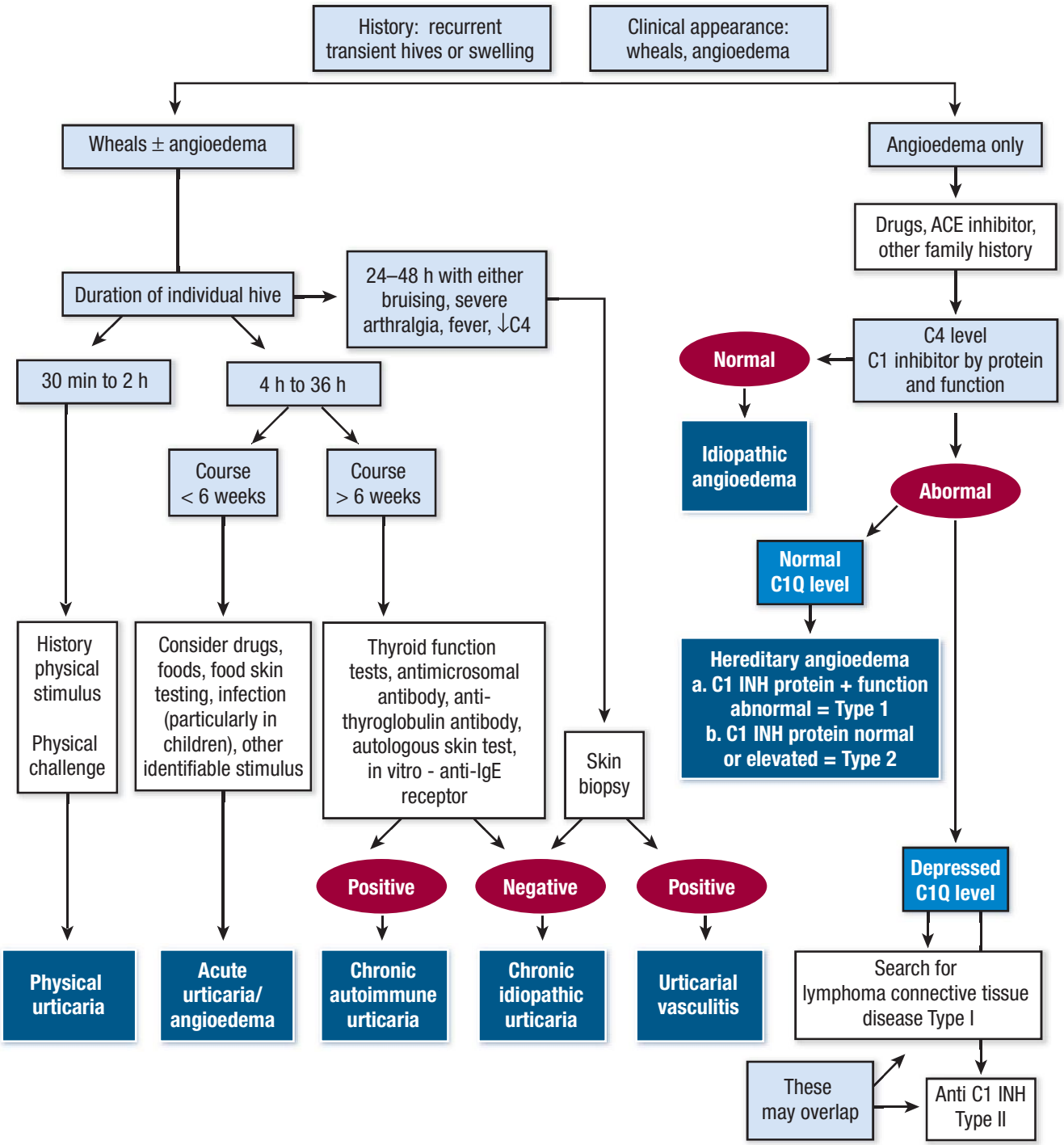

▲ **FIGURE 37-8** Approach to the patient with urticaria/angioedema. ACE = angiotensin-converting enzyme; IgE, immunoglobulin E; INH = inhibitor; ↓ = decreased.

to exposed areas in light- or cold-induced urticaria. If suggested by the history, the physical examination in all patients with urticaria should include tests for physical urticaria, such as a brisk stroke to elicit dermographism, the use of a weight to elicit delayed pressure urticaria, and application of a cold or warm stimulus to identify cold-induced urticaria and localized heat urticaria, respectively. Exercise, such as running in place, may elicit cholinergic urticaria and, in some instances, exercise-induced anaphylaxis. Phototests to elicit solar urticaria usually are performed in referral centers, as are challenges for exercise-induced anaphylaxis.

When urticaria has been present for days or weeks at a time (but less than 6 weeks) or occurs recurrently for similar intervals, the main considerations are allergic reactions (IgE mediated) to food or drugs. A careful history regarding possibilities is essential. Skin testing can corroborate IgE-mediated hypersensitivity to foods or can provide suspects when the history is unrevealing. Double-blind placebo-controlled food challenge can demonstrate clinical relevance in cases in which the role of a food is uncertain. Non–IgE-mediated causes of urticaria include adverse reactions to NSAIDs and opiates. Any of these can be associated with concomitant angioedema or, less commonly, present as angioedema in the absence of urticaria. Children may have acute urticaria in association with viral illnesses; it is unclear whether infection with bacteria



Box 37-1

Differential Diagnosis of Urticaria/Angioedema

ACUTE (< 6 WK)
- Drug reaction
  - Immunoglobulin E (IgE) mediated
  - Metabolic—idiosyncratic
  - Cellular immunity
- Food reactions
  - IgE mediated
  - Non–IgE mediated (e.g., scombroid poisoning)
- Intravenous administration
  - Blood products
  - Contrast agents
  - Intravenous γ globulin
- Infection
  - Viral in children
  - Infectious mononucleosis or hepatitis B prodrome
  - ? Bacterial in children

PHYSICAL
- Individual lesions last < 2 h
  - Cold urticaria
  - Cholinergic urticaria
  - Dermatographism
  - Local heat urticaria
  - Aquagenic urticaria
  - Cold-induced cholinergic urticaria
  - Cold-dependent dermatographism
- Lesions last > 2 h
  - Delayed pressure urticaria
  - Vibratory angioedema
  - Familial cold-induced syndromes, usually with fever

CHRONIC (> 6 WK)
- Autoimmune, often with antithyroid antibodies
- Idiopathic
- Urticarial vasculitis
  - Idiopathic—skin only
  - Associated with other connective tissue disease
- Familial febrile syndromes with urticaria-like rash
- Schnitzler syndrome



such as *Streptococcus* can induce urticaria as well, but neither form occurs in adults with the exception of urticaria in association with infectious mononucleosis (Epstein-Barr virus) or as a prodrome to hepatitis B infection. In each of these circumstances, individual lesions last anywhere from 4 hours to 24 hours and fade without associated purpura. If hives last less than 2 hours, the cause is usually a physical urticaria, the most common being dermatographism, cholinergic urticaria, and cold urticaria. The main exception is delayed pressure urticaria, in which lesions typically last 12 to 36 hours and first appear 3 to 6 hours after the initiating stimuli. Once urticaria continues for longer than 6 weeks (particularly if present for many months or years) chronic urticaria is present. Chronic urticaria is now divided into chronic idiopathic urticaria for which a cause has not yet been found and chronic autoimmune urticaria. Angioedema accompanies chronic urticaria in 40 percent of cases and is more problematic in the autoimmune subgroup. Swelling in association with chronic urticaria can affect hands, feet, eyes, cheeks, lips, tongue, and pharynx, but not the larynx. When angioedema is present in the absence of an identifiable antigen or exogenous stimulus, the main entities to consider are C1 INH deficiency (hereditary or acquired) and idiopathic angioedema. Approximately 0.5 percent of patients have an urticarial vasculitis with palpable purpura or other stigmata of a possible vasculitis, such as fever, elevated sedimentation rate, petechiae or purpura, elevated white blood cell count, or lesions of unusual duration (36 to 72 hours). The differential diagnosis of acute, chronic, and physical urticaria/angioedema is summarized in Box 37-1.

LABORATORY FINDINGS

In most patients with chronic urticaria/angioedema, no underlying disorders or causes can be discerned. Diagnostic studies should be based on findings elicited by the history and physical examination. Evaluation of chronic urticaria/angioedema should include thyroid function tests and assays for antimicrosomal and antithyroglobulin antibodies, and the autologous skin test can be done, even in an office setting.[200] Routine screening laboratory tests are of little value. The histamine release assays for anti-IgE receptor or anti-IgE antibodies remain a research tool. Serum hypocomplementemia is not present in chronic idiopathic urticaria or chronic autoimmune urticaria, and mean levels of serum IgE in these patients are not different from those in the general population, in which the incidence of atopy is 20 percent.

Cryoproteins should be sought in patients with acquired cold urticaria. An anti-nuclear antibody test should be performed in patients with solar urticaria. Assessment of serum complement proteins may be helpful in identifying patients with urticarial venulitis or serum sickness (C4, C3, C1q binding assay for circulatory immune complexes) as well as those with hereditary and acquired forms of C1 INH deficiency (C4, C1 INH by protein and function, C1q level).

Skin biopsy of chronic urticarial lesions should be undertaken to identify urticarial venulitis or to assess rashes for which the urticarial nature is not clear.

There is little role for routine prick skin testing or the radioallergosorbent test in the diagnosis of specific IgE-mediated antigen sensitivity in chronic urticaria/angioedema. Inhalant materials are uncommon causes of urticaria/angioedema, and food skin tests may be difficult to interpret. The tests for drugs are limited to penicillin but cannot be performed in patients with dermographism. The radioallergosorbent test should be reserved for those in whom skin testing is contraindicated, unavailable, or unrevealing despite a history provoking high suspicion of such a disorder.

A finding of the release of histamine from peripheral basophilic leukocytes has supported the diagnosis of anaphylactic sensitivity to a variety of antigens, which include pollens and insect venom.

Histopathology

Edema involving the superficial portion of the dermis is characteristic of urticaria, whereas angioedema involves the deeper dermis and subcutaneous tissue. Both disorders are associated with dilation of the venules.

In chronic urticaria, the dermal infiltrating inflammatory cells may be sparse or dense and include more CD4 than CD8 T lymphocytes, neutrophils, eosinophils, and basophils[45,201] without B lymphocytes or natural killer cells. NKT cells have not been assessed. Increased expression of TNF-α and IL-3 on endothelial cells and perivascular cells was detected in the upper dermis of patients with acute urticaria, chronic idiopathic urticaria, and delayed pressure urticaria and in one patient with cold urticaria.[202] TNF-α also was detected on epidermal keratinocytes in lesional and non-lesional biopsy specimens. In chronic idiopathic urticaria,

CD11b and CD18 cells were detected about the blood vessels in the superficial and deep dermis. Direct immunofluorescence tests for immunoglobulins and complement proteins were negative.

Major basic protein and eosinophil cationic protein, which are derived from the eosinophil granule, are present around blood vessels and are dispersed in the dermis in lesions of acute urticaria, chronic idiopathic urticaria, delayed pressure urticaria, cholinergic urticaria, and solar urticaria. In chronic idiopathic urticaria, free eosinophil granules in the dermis were increased in wheals of longer than 24 hours' duration compared with wheals lasting fewer than 24 hours. The secreted form of eosinophil cationic protein and eosinophil-derived neurotoxin were detected on cells in greater amounts in biopsy specimens from patients with chronic urticaria without autoantibodies than in those with autoantibodies. P-selectin, E-selectin, intercellular adhesion molecule 1, and vascular cellular adhesion molecule 1 have been demonstrated on the vascular endothelium of patients with chronic idiopathic urticaria and dermographism. Major histocompatability complex class II antigen also is upregulated on the endothelial cells of patients with chronic urticaria, and the peripheral blood lymphocytes have increased CD40 ligand expression and higher Bcl-2 expression; these observations suggest an augmentation of autoimmune phenomena.[203]

In papular urticaria, the epidermis is thick, with intercellular edema and lymphocytes. In the dermis, there is edema with an infiltrate containing T lymphocytes, macrophages, eosinophils, and neutrophils without B lymphocytes or the deposition of immunoglobulins, fibrin, or C3.

TREATMENT

Therapy for acute urticaria uses antihistamines as described in Fig. 37-9; however, the rash can be severe and generalized, and angioedema may be present as well. Thus, if relief provided by nonsedating antihistamines appears insufficient, one can use hydroxyzine or diphenhydramine at 25 to 50 mg qid. A course of corticosteroid can be used, for example, 60 to 80 mg/day for 3 days followed by a taper by 5 to 10 mg/day. Epinephrine can relieve severe symptoms of urticaria or angioedema (generalized urticaria, severe pruritus, accelerating angioedema) and is indicated if laryngeal edema is present. Edema of the posterior tongue and/or pharyngeal edema can be confused with it.

The ideal treatment for urticaria/angioedema is identification and removal of its cause. Many patients with acute urticaria and angioedema probably are not treated by physicians because the cause in identified by the individual or the course is limited. Treatment of chronic urticaria focuses on measures that provide symptomatic relief. The physician should provide not only medications but also support and reassurance. In a questionnaire study, patients with chronic idiopathic urticaria considered the worst aspects to be pruritus and the unpredictable nature of the attacks. The presence of facial angioedema can be particularly disconcerting, and tongue and/or pharyngeal edema is often considered life threatening. This is not the case and is confused with the potential for laryngeal edema seen with anaphylaxis or anaphylaxis-like reactions, C1 INH deficiency, or reactivity to ACE inhibitors. Affected individuals reported sleep disturbances, diminished energy, social isolation, and altered emotional reactions as well as difficulties in relation to work, home activities, social life, and sex life.[204,205] Another study showed a correlation between the severity of chronic idiopathic urticaria and depression. In a questionnaire study, individuals with delayed pressure urticaria and cholinergic urticaria had the most quality-of-life impairment.[206] Those with cholinergic urticaria suffered in relation to their sporting activities and sexual relationships. Although urticaria/angioedema may be a source of frustration to both physicians and patients, most individuals can achieve acceptable symptomatic control of their disease without identification of the cause. In some individuals it is important to avoid aspirin and other NSAIDs. Antipruritic lotions, cool compresses, and ice packs may provide temporary relief. H_1-type antihistaminic drugs are the mainstays in the management of urticaria/angioedema. The older H_1-type antihistaminics are known as *classic*, *traditional*, or *first-generation* H_1-type antihistamines. Newer low-sedating or second- and third-generation H_1-type antihistamines with reduced sedative and anticholinergic side effects have become the initial therapeutic agents of choice. The drug should be taken on a regular basis and not as needed. If the initial drug chosen is ineffective, an agent from a different pharmacologic class should be used, and non-sedating antihistaminics can be combined. When this is ineffective, doses of hydroxyzine or diphenhydramine in the range of 25 to 50 mg qid may be needed. The same is true for the treatment of dermatographism when it is particularly severe. It should be noted that if the molar release of histamine in the skin exceeds that of the delivered antihistamine (as can be seen with dermatographism), the histamine will keep the receptors to which it is bound in the active conformation, and therapeutic efficacy with the antihistamine will be achieved only when its molar concentration is much greater than that of histamine. Diphenhydramine is an alternative to hydroxyzine or cetirizine for dermatographism but not for cholinergic urticaria.[207,208] Cold urticaria can be treated with most antihistaminics, but cyproheptadine (Periactin) at 4 to 8 mg tid or qid seems to be particularly effective.[209–212] Local heat urticaria is treated with antihistaminics; no regimen is particularly favored. Although anecdotal reports suggest that delayed pressure urticaria will respond to NSAIDs, dapsone, cetirizine, or sulfasalazine, most require corticosteroids (used as in chronic urticaria) to control symptoms, and cyclosporine can be a particularly effective alternative. Familial cold autoinflammatory sydrome (urticaria) responds to parenteral IL-1 receptor antagonist (anakinra)

Treatment choices for chronic urticaria (idiopathic or autoimmune) have been reviewed[213] and are summarized in Fig. 37-9. It is important to use first-generation antihistamines at a maximal dose if non-sedating antihistamines have not been helpful before resorting to corticosteroids or cyclosporine. H_2-receptor antagonists may yield some additional histamine receptor blockade, although their contribution is usually modest. The efficacy of leukotriene antagonists is controversial, with equal numbers of articles pro and con. If steroids are used, this author recommends not exceeding 25 mg qod or 10 mg daily. With either approach, attempts to slowly taper the dose should be made every 2 to 3 weeks. One-mg prednisone tablets can be very helpful when the daily dose is less than 10 mg. Double-blind, placebo-controlled studies of cyclosporine indicate that it is a good alternative to corticosteroid[214,215] and can be safer when used appropriately. Measurement of blood pressure, blood urea nitrogen level, and creatinine level, and a urinalysis should be performed every 6 to 8 weeks. The starting adult dosage is 100 mg bid; it can be slowly advanced to 100 mg tid, but no higher. The response rate is 75 percent in





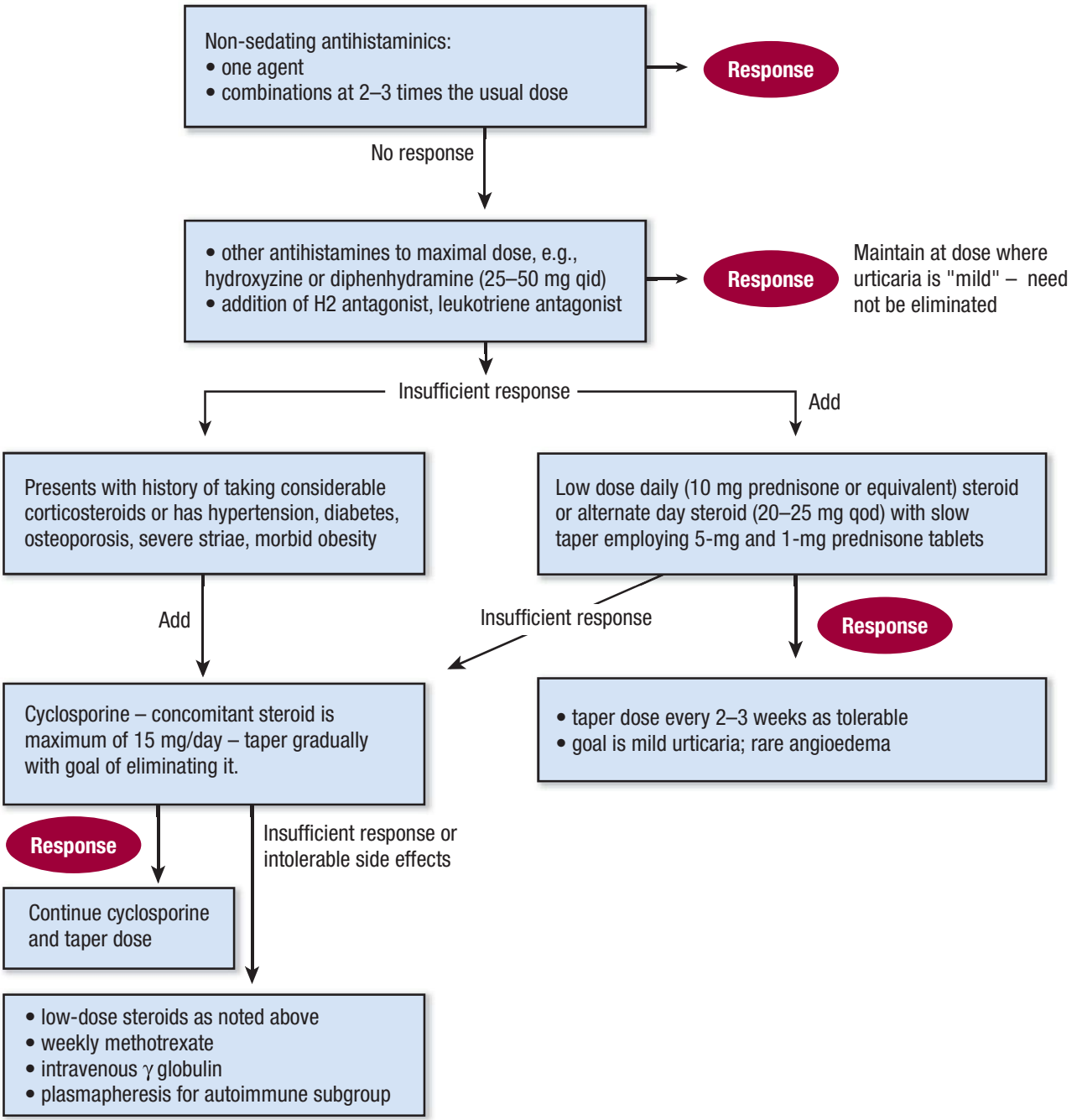

▲ **FIGURE 37-9** Treatment of chronic idiopathic or autoimmune urticaria/angioedema. Note that the following agents are expected to be effective rarely, if ever: hydroxychloroquine, cholchicine, dapsone, sulfasalazine, mycophenolate mofetil. Hydroxychloroquine is, however, the drug of choice for the hypocomplementemic urticarial vasculitis syndrome. Urticarial vasculitis may respond to dapsone or colchicine.

the autoimmune groups and 50 percent in the idiopathic group. No comparable studies have been performed (or clinical effects obtained) with dapsone, hydroxychloroquine, colchicine, sulfasalazine, or methotrexate, and only small numbers of cases have been treated successfully with intravenous γ globulin or phasmapheresis.[216,217]

Urticarial vasculitis is treated with antihistamines and, if severe, low-dose corticosteroid. Here dapsone or hydroxychloroquine may be steroid sparing. When urticarial vasculitis is part of a systemic disease, the treatment will focus on what is needed for the underlying disorder. The drug of choice for the hypocomplementemic urticarial vasculitis syndrome (with circulating immune complexes due to IgG anti-C1q)[179] is hydroxychloroquine.[218]

Angioedema caused by ACE inhibitors can be an acute emergency with laryngeal edema or tongue or pharyngeal edema that is so extensive the patient cannot manage secretions, and intubation is necessary. Supportive therapy, epinephrine, and time are needed; there is no response to antihistamines or corticosteroids. Other antihypertensive agents can be substituted, including those that block angiotensin II receptors.

Acute attacks of HAE are treated with epinephrine, intubation, or tracheostomy when severe laryngeal edema is encountered, and fresh frozen plasma or C1 inhibition concentrate is given to abort episodes. Prophylaxis uses androgens such as danazol (200-mg tab-

lets)[219,220] or stanozolol (2-mg tablets),[221,222] or antifibrinolytics[223–225] such as ε-aminocaproic acid or tranexamic acid (not available in the United States). The androgens are more commonly used—one watches for hirsutism, irregular menses, or abnormal liver chemistry test results as potential side effects. Increased dosages may be used when the patient undergoes elective surgical procedures (e.g., three tablets per day for 2 or 3 days before the procedure, the day of the procedure, and 1 day after). A C1 INH concentrate (or cloned material) is not available in the United States but is routinely used to treat acute episodes in Europe and Australia. Inhibitors of kallikrein (for acute episodes) are in clinical trials. Acquired C1 INH deficiency can be treated with low-dose androgens in addition to therapy of the underlying condition. Plasmapheresis and/or cytotoxic agents may be needed in type II acquired C1 INH deficiency.

ACKNOWLEDGMENT

I wish to thank Dr. Nicholas Soter, who reviewed this manuscript, made many helpful suggestions, and donated two of the photographs.

KEY REFERENCES

The full reference list for all chapters is available at www.digm7.com.

6. Gorevic P, Kaplan A: The physical urticarias. *Int J Dermatol* **19**:417, 1980
13. Gruber B et al: Prevalence and functional role of anti-IgE autoantibodies in urticarial syndromes. *J Invest Dermatol* **90**:213, 1988
14. Grattan C et al: A serological mediator in chronic idiopathic urticaria—a clinical, immunological and histological evaluation. *Br J Dermatol* **114**:583, 1986
34. Kikuchi Y, Kaplan A: A role for C5a in augmenting IgG-dependent histamine release from basophils in chronic urticaria. *J Allergy Clin Immunol* **109**:114, 2002
40. Sabroe R et al: Cutaneous inflammatory cell infiltrate in chronic idiopathic urticaria: Comparison of patients with and without anti-FcepsilonRI or anti-IgE autoantibodies. *J Allergy Clin Immunol* **103**:484, 1999
55. Kaplan AP et al: Pathways for bradykinin formation and inflammatory disease. *J Allergy Clin Immunol* **109**:195, 2002
155. Fields T et al: Kinin formation in hereditary angioedema plasma: Evidence against kinin derivation from C2 and in support of "spontaneous" formation of bradykinin. *J Allergy Clin Immunol* **72**:54, 1983
170. Kaplan A, Greaves M: Angioedema. *J Am Acad Dermatol* **53**:373, 2005
197. Greaves M: Chronic idiopathic urticaria and *Helicobacter pylori*—not directly causative but could there be a link. *Allergy Clin Immun Int* **13**:23, 2001
200. Sabroe R et al: The autologous serum skin test: A screening test for autoantibodies in chronic idiopathic urticaria. *Br J Dermatol* **140**:446, 1999
213. Kaplan A: Clinical practice. Chronic urticaria and angioedema. *N Engl J Med* **346**:175, 2002
219. Gelfand J et al: Treatment of hereditary angioedema with danazol. Reversal of clinical and biochemical abnormalities. *N Engl J Med* **295**:1444, 1976



CHAPTER 38

Erythema Multiforme

Jean-Claude Roujeau

Erythema multiforme (EM) is an acute self-limited, usually mild, and often relapsing mucocutaneous syndrome. The disease is usually related to an acute infection, most often a recurrent herpes simplex virus (HSV) infection. EM is defined only by its clinical characteristics: target-shaped plaques predominant on the face and extremities.

The absence of specific pathology, specific cause, and biologic markers contribute to a confusing nosology. The definition of EM in this chapter is based on the classification proposed by Bastuji-Garin et al.[1] The principle of this classification is to consider Stevens-Johnson syndrome (SJS) as a minor form of toxic epidermal necrolysis (TEN) and to separate these two diseases from EM (see Chap. 39). The validity of this classification has been challenged by some studies, especially for cases in children and cases related to *Mycoplasma pneumoniae*. It has been confirmed by several others studies, however, especially the prospective international Severe Cutaneous Adverse Reactions study.[2] That study demonstrated that, compared with SJS patients, EM patients were younger, more often male, had a 10-fold higher rate of recurrence, and less frequently had a body temperature higher than 38.5°C (101.3°F) and involvement of two or more mucous membranes.

The original name proposed by von Hebra was *erythema exudativum multiforme*. The term *erythema multiforme* has now been universally accepted (Table 38-1).

EPIDEMIOLOGY

EM is considered relatively common, but its incidence is unknown. Evaluations have been limited to cases severe enough to require hospitalization. Such cases are definitely rare, with figures in the range of 1 to 6 per million per year. Minor forms of EM are certainly more frequent, but the diagnosis of EM is nonetheless too often made.

TABLE 38-1
Erythema Multiforme Sub-Types

- Erythema multiforme minor: Skin lesions without involvement of mucous membranes
- Erythema multiforme major: Skin lesions with involvement of mucous membranes
- Herpes-associated erythema multiforme
- Mucosal erythema multiforme (Fuchs syndrome, ectodermosis pluriorificialis): mucous membrane lesions without cutaneous involvement

ERYTHEMA MULTIFORME AT A GLANCE



- Rare cutaneous and/or mucocutaneous eruption characterized by target lesions.
- Benign course but frequent recurrences.
- Most cases related to herpes simplex virus (HSV) infection.
- Frequent recurrences can be prevented by long-term use of anti-HSV medications.

EM occurs in patients of all ages, but mostly in adolescents and young adults. There is a slight male preponderance (male-female sex ratio of approximately 3:2). EM is recurrent in at least 30 percent of patients.

There is no established underlying disease. Infection with human immuno-

deficiency virus and autoimmune disorders do not increase the risk of EM, and this contrasts with SJS. Cases may occur in clusters, which suggests a role for infectious agents. There is no indication that the incidence may vary with ethnicity or geographic location.

Predisposing genes have been reported, with 66 percent of EM patients having HLA-DQB1*0301 allele, compared with 31 percent of controls.[3] The association was even stronger in patients with herpes-associated EM. Because of the weakness of this association, familial cases remain very rare.



ETIOLOGY

Most cases of EM are related to infections. Herpes virus is definitely the most common cause, principally in recurrent cases. Proof of causality of herpes is firmly established from clinical experience, epidemiology,[2] detection of HSV DNA in the lesions of EM,[4,5] and prevention of EM by suppression of HSV recurrences.[6] Clinically, a link with herpes can be established in about one-half of cases. In addition 10 percent to 40 percent of cases without clinical suspicion of herpes were also demonstrated to be herpes related, because HSV DNA was detected in the EM lesions by polymerase chain reaction (PCR) testing. EM eruptions begin on average 7 days after a recurrence of herpes. The delay can be substantially shorter. Not all symptomatic herpes recurrences are followed by EM, and asymptomatic ones can induce EM. Therefore, this causality link can be overlooked by both patients and physicians. HSV-1 is usually the cause, but HSV-2 can also induce EM. The proportion probably reflects the prevalence of infection by HSV subtypes in the population.

M. pneumoniae is the second major cause of EM and may even be the major cause in pediatric cases.[7–9] In cases related to *M. pneumoniae* the clinical presentation is often less typical and more severe than in cases associated with HSV. The relationship to *M. pneumoniae* is often difficult to establish. Clinical and radiologic signs of atypical pneumonia can be mild, and *M. pneumoniae* is usually not directly detected. PCR testing of throat swabs is the most sensitive technique. Serologic results are considered diagnostic in the presence of immunoglobulin M antibodies or a more than twofold increase in immunoglobulin G antibodies to *M. pneumoniae*. *M. pneumoniae*–related EM can recur.

Many other infections have been reported to be causes of EM in individual cases or small series, but the evidence for causality of these other agents is only circumstantial. Published reports have implicated infection with orf virus, varicella-zoster virus, parvovirus B19, and hepatitis B and C viruses, as well as infectious mononucleosis and a variety of other bacterial or viral infections. Immunization has been also implicated as a cause in children.

Drugs are a rare cause of EM with mucous membrane lesions. It may be argued whether these eruptions are truly EM or mere imitators, for example, annular urticaria or maculopapular eruption with some lesions resembling targets.

Idiopathic cases are those in which neither HSV infection nor any other cause can be identified. Such cases are fairly common under routine circumstances. But HSV has been found in situ by PCR in up to 40 percent of "idiopathic" recurrent cases.[10] Some such cases respond to prophylactic antiviral treatment and are thus likely to have been triggered by asymptomatic HSV infection; others are resistant.

EM-like dermatitis may result from contact sensitization. These rashes should be viewed as imitators of EM, despite their clinical and histopathologic similarities.

PATHOGENESIS

Mechanisms have been investigated in depth in herpes-associated EM.[5] It is not known whether similar pathophysiologic mechanisms apply to EM due to other causes.

Complete infective HSV has never been isolated from lesions of herpes-associated EM. The presence of HSV DNA in EM lesions has been reported in numerous studies using the PCR assay. These studies demonstrated that keratinocytes did not contain complete viral DNA but only fragments, always including the viral polymerase (Pol) gene. HSV Pol DNA is located in basal keratinocytes and in lower spinous cell layers. The viral Pol protein is synthesized in epidermal cells. HSV-specific T cells, including cytotoxic cells, are recruited, and the virus-specific response is followed by a non-specific inflammatory amplification by autoreactive T cells. These cells and the cytokines they produce induce the delayed hypersensitivity-like appearance of the pathology of EM lesions.

HSV is present in the blood for a few days around an overt recurrence of herpes. If keratinocytes were infected in that way, one would expect disseminated herpes rather than EM. It has been shown that HSV DNA is transported to the epidermis by cells that engulf the virus and fragment the DNA. These cells are monocytes, macrophages, and especially $CD34^+$ Langerhans cell progenitors harboring the skin homing receptor cutaneous lymphocyte-associated antigen. Upregulation of adhesion molecules greatly increases binding of HSV-containing mononuclear cells to endothelial cells. HLA-class I and adhesion molecule upregulation in endothelial cells may account for the dermal inflammatory response. When reaching the epidermis the cells transmit the viral Pol gene to keratinocytes. The genes may persist for a few months, but the synthesis and expression of the Pol protein will last for only a few days. This may explain the transient character of clinical lesions.

Incomplete fragmentation of viral DNA, increased number of circulating $CD34^+$ cells, and/or increased immune response to Pol protein may explain why only a small proportion of persons with recurrent herpes develop EM.

CLINICAL FINDINGS

The first step is to suspect EM, based on clinical features. A skin biopsy and laboratory investigations are useful mainly if the diagnosis is not definite clinically. The second step is to determine whether hospitalization is needed when EM major (EMM) occurs with oral lesions that impair feeding, when a possible diagnosis of SJS is suspected, or when severe constitutional symptoms are present. The third step is to establish the cause of EM by identifying a history of recurrent herpes, performing chest radiography, or documenting *M. pneumoniae* infection (Fig. 38-1).

History

Prodromal symptoms are absent in most cases. If present, they are usually mild, suggesting an upper respiratory infection (e.g., cough, rhinitis, low-grade fever).

In EMM, fever higher than 38.5°C (101.3°F) is present in one-third of cases.[2]

A history of previous attack(s) is found in at least one-third of patients and thus helps with the diagnosis. The events of the preceding 3 weeks should be reviewed for clinical evidence of any

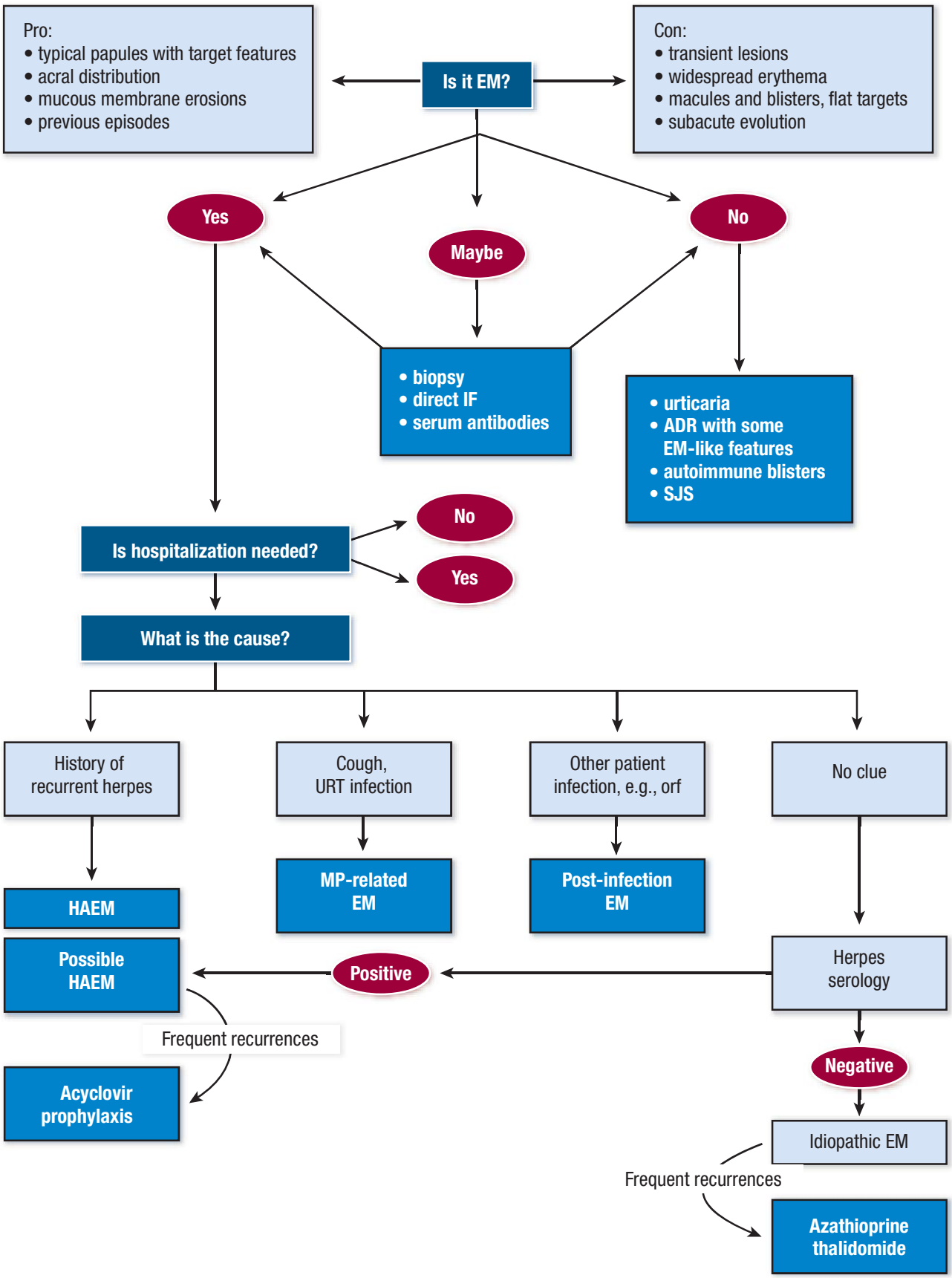

▲ **FIGURE 38-1** Approach to the patient with erythema multiforme (EM). ADR = adverse drug reaction; HAEM = herpes-associated erythema multiforme; IF = immunofluorescence; MP = *Mycoplasma pneumoniae*; SJS = Stevens-Johnson syndrome; URT = upper respiratory tract.

precipitating agent, with a special focus on recurrent herpes.

Cutaneous Lesions

The skin rash arises abruptly. In most patients, all lesions appear within 3 days, but in some, several crops follow each other during one episode of EM.

Often there are a limited number of lesions, but up to hundreds may form. Most occur in a symmetric, acral distribution on the extensor surfaces of the extremities (hands and feet, elbows, and knees), face, and neck and appear less frequently on thighs, buttocks, and trunk. Lesions often first appear acrally and then spread in a centripetal manner. Mechanical factors (Koebner phenomenon) and actinic factors (predilection of sun-exposed sites) appear to influence the distribution of lesions. Although patients occasionally report burning and itching, the eruption is usually asymptomatic.

The diversity in clinical pattern implied by the name *multiforme* is mainly due to the findings in each single lesion; most lesions are usually rather similar in a given patient at a given time. The typical lesion is a highly regular, circular, wheal-like erythematous papule or plaque that persists for 1 week or longer (Fig. 38-2). It measures from a few millimeters to approximately 3 cm and may expand slightly over 24 to 48 hours. Although the periphery remains erythematous and edematous, the center becomes violaceous and dark; inflammatory activity may regress or relapse in the center, which gives rise to concentric rings of color (see Fig. 38-2). Often, the center turns purpuric and/or necrotic or transforms into a tense vesicle or bulla. The result is the classic target or iris lesion.



▲ **FIGURE 38-2** Typical target lesions on the palm.



▲ **FIGURE 38-3** Erythema multiforme major. Involvement of the lips with a target pattern.

According to the proposed classification, typical target lesions consist of at least three concentric components: (1) a dusky central disk, or blister; (2) more peripherally, an infiltrated pale ring; and (3) an erythematous halo. Not all lesions of EM are typical; some display two rings only ("raised atypical targets"). However, all are papular, in contrast with macules, which are the typical lesions in SJS-TEN. In some patients with EM, most lesions are livid vesicles overlying a just slightly darker central portion, encircled by an erythematous margin (Fig. 38-3). Larger lesions may have a central bulla and a marginal ring of vesicles (herpes iris of Bateman) (Fig. 38-4).

Unusual presentations include cases in which recurrent EM in the same patient produces typical target lesions in one instance but plaques in a subsequent event. Mucous membranes can be severely involved in some episodes and spared in others (see Mucous Membrane Lesions).



▲ **FIGURE 38-4** Multiple concentric vesicular rings (herpes iris of Bateman). This pattern may be more frequent in *Mycoplasma pneumoniae*–related cases of erythema multiforme major.

In most cases, EM affects well under 10 percent of the body surface area. In 88 hospital cases of EMM prospectively included in the Severe Cutaneous Adverse Reactions study, the median involvement was 1 percent of the body surface area.[2] Very rare instances of extensive skin lesions with "giant" targets and prominent involvement of several mucous sites may be difficult to distinguish from SJS.

The duration of an individual lesion is shorter than 2 weeks, but residual pigmentation may remain for months. There is no scarring.

Mucous Membrane Lesions

Mucosal lesions are present in up to 70 percent of patients, most often limited to the oral cavity.

Predilection sites for mucosal lesions are the lips, on both cutaneous and mucosal sides; non-attached gingivae; and the ventral side of the tongue. The hard palate is usually spared, as are the attached gingivae. On the cutaneous part of the lips, identifiable target lesions may be discernible (see Fig. 38-3). On the mucosa proper there are erosions with fibrinous deposits, and occasionally intact vesicles and bullae can be seen (Fig. 38-5). The process may rarely extend to the throat, larynx, and even the trachea and bronchi.

Eye involvement begins with pain and bilateral conjunctivitis in which vesicles and erosions can occur (Fig. 38-6).

The nasal, urethral, and anal mucosae also may be inflamed and eroded.

Ectodermosis pluriorificialis is a rare occurrence characterized by severe involvement of two or three mucosal sites in the absence of skin lesions. Its often relapsing nature suggests that it is HSV related. Moreover, typical target lesions may arise on the skin with new attacks.

Relationship to Recurrent Herpes

In more than 70 percent of patients with recurrent EM, an episode of recurrent HSV infection precedes the rash; the association with herpes labialis predominates over that with genital herpes or herpes in other locations. EM usually follows recurrent herpes but may also occur after primary HSV infection. The average interval is 7 days (range, 2 to 17 days); the duration of the lag period appears to be specific for individual patients. In a



▲ **FIGURE 38-5** Erythema multiforme major (EMM). Mouth lesions of EMM usually manifest as erosions.

small number of patients, HSV recrudescence and EM may occur simultaneously. Not all episodes of EM are preceded by clinically evident HSV infection, and not all HSV episodes are followed by EM. Episodes of recurrent HSV infection may precede the development of HSV-related EM by many years.

Related Physical Findings

Fever and other constitutional symptoms are usually absent in EM minor, and the physical examination is normal. Fever higher than 38.5°C (101.3°F) is present in 32 percent of cases of EMM. Mouth erosions may be very painful and may impair alimentation. The patient may be unable to close the mouth and may constantly drool blood-stained saliva. Cervical lymphadenopathy is usually present in these patients. The pain of genital erosions may lead to reflex urinary retention. Cough, polypnea, and hypoxia may occur in *M. pneumoniae*–related cases.



▲ **FIGURE 38-6** Erythema multiforme major. Eye lesions. Conjunctivitis with erosions.

LABORATORY FINDINGS

Histopathologic Analysis

Early lesions of EM exhibit lymphocyte accumulation at the dermal-epidermal interface, with exocytosis into the epidermis, lymphocytes attached to scattered necrotic keratinocytes (satellite cell necrosis), spongiosis, vacuolar degeneration of the basal cell layer, and focal junctional and sub-epidermal cleft formation (Fig. 38-7). The papillary dermis may be edematous but principally contains a dense mononuclear cell infiltrate, which is more abundant in older lesions. The vessels are ectatic with swollen endothelial cells; there may be extravasated erythrocytes and eosinophils. Immunofluorescence findings are negative or non-specific. In advanced lesions sub-epidermal blister formation may occur, but necrosis rarely involves the entire epidermis (see eFig. 38-7.1 in on-line edition). In late lesions, melanophages may be prominent.

The histopathologic appearance of EM lesions is different from that of SJS-TEN lesions, in which dermal inflammation is moderate to absent and epidermal necrosis much more pronounced (see Chap. 39). Still, the histopathologic appearances are somewhat overlapping and do not allow the distinction of EM from SJS-TEN in all instances. The main reason for performing a biopsy is to rule out other diagnoses.

Other Laboratory Tests

There are no specific laboratory tests for EM. In more severe cases, an elevated erythrocyte sedimentation rate, moderate leukocytosis, increased levels of acute-phase proteins, and mildly elevated liver aminotransferase levels may occur. In the presence of respiratory symptoms a chest radiograph is needed, and documentation of *M. pneumoniae* infection by PCR assay of a throat swab and serologic testing (a pair at a 2- or 3-week interval) should be sought. Investigations to document causality are important in cases with frequent recurrences when prevention with long-term antiviral treatment is considered and when there is no clinical evidence of association with herpes. HSV can sometimes be isolated from the initial lesion of labial herpes. Amplification of HSV Pol gene from biopsy samples of EM lesions is not done routinely. A negative result on serologic testing for HSV may be helpful to exclude the possibility of herpes-associated EM. The positive predictive value of the presence of HLA-DQB1*0301 is too low to have any clinical value.

DIFFERENTIAL DIAGNOSIS (Box 38-1)

In a retrospective analysis of 66 pediatric cases discharged from hospital with a diagnosis of EM 24 (36 percent) were clearly not EM or SJS.[7] Diseases that had been frequently erroneously called EM were urticaria and maculopapular drug eruption.

The designation of *Rowell syndrome*[11] is used for a variety of cutaneous lupus erythematosus with lesions resembling those of EM. Subacute evolution, a positive result on direct fluorescence testing, and the presence of anti-nuclear antibodies exclude EM.

Sweet syndrome can mimic EM minor; biopsy easily distinguishes the two. Paraneoplastic pemphigus and more rarely other autoimmune blistering diseases occasionally present with target-like lesions that can be confused with those of EM.

One of these has been reported as EMM with antidesmoplakin antibodies.[12] It resembles EMM in its acute and recurrent course, but the presence of acantholysis, deposits of immunoglobulin G around basal cells, and serum antibodies against desmoplakin distinguish it from EM.

Whether considered a variant of EMM or a separate disease, SJS should be recognized promptly for three reasons: (1) the possibility of life-threatening complications, (2) the risk of progression to TEN, and (3) the need for urgent withdrawal of suspected causative drug(s). Pain, constitutional symp-



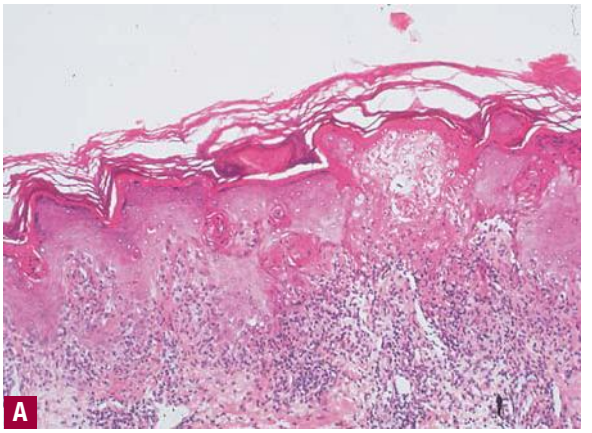

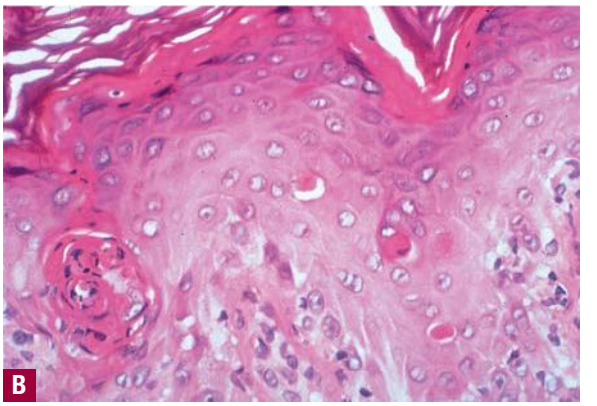

▲ **FIGURE 38-7** Histopathologic features of erythema multiforme (early lesion). **A.** An intense lymphohistiocytic infiltrate fills the mid-dermis and obliterates many blood vessels. The dermal papillae are edematous and contain material with the staining properties of fibrin. There is sub-epidermal cleft formation and circumscribed necrosis of the epidermis. **B.** High-power magnification of scattered keratinocyte necrosis.



toms, severe erosions of mucosae, rapid progression, and dusky or violaceous skin lesions are alerting features.

COURSE AND COMPLICATIONS

EM runs a mild course in most cases, and each individual attack subsides within 1 to 4 weeks. Recovery is complete, and there are usually no sequelae, except for transient hypopigmentation or hyperpigmentation in some cases.

In rare instances the ocular erosions of EMM may cause severe residual scarring of the eye. *M. pneumoniae*–related EMM may be associated with severe erosive bronchitis.

Recurrences are common and may characterize the majority of cases. In one report of a large series of patients with recurrent EM, the mean number of attacks was 6 per year (range, 2 to 36), and the mean total duration of disease was 9.5 years. In 33 percent, the condition persisted for more than 10 years.[13] Up to 50 recurrences have been described in a single patient. The severity of episodes in patients with recurrent EM is highly variable and unpredictable. The frequency of episodes and cumulative duration of disease are not correlated with the severity of attacks. The frequency and severity of recurrent EM tend to decrease spontaneously over time (after 2 years or longer), parallel with the improvement of recurring HSV infection.

A small fraction of patients experience a prolonged series of overlapping attacks of EM; this has been labeled *continuous EM* or *persistent EM*.[13]

TREATMENT

The aims of treatment are to reduce the duration of fever, eruption, and hospitalization. Based on retrospective series or small controlled trials, the use of systemic corticosteroids seems to shorten the duration of fever and eruption but may increase the length of hospitalization because of complications. However,

Box 38-1

Differential Diagnosis of Erythema Multiforme (EM)

	MUCOUS MEMBRANE LESIONS	CLINICAL PATTERN	PATHOLOGIC FINDINGS	LABORATORY TESTING	COURSE
Urticaria	No	Circinate, transient	Edema		More acute than EM
Maculopapular drug eruption	Rare (lips)	Widespread polymorphous target-like lesions, macules, papules, plaques	Most often non-specific		
Lupus (Rowell syndrome)	Possible (mouth)	Face and thorax Large target-like lesions, annular plaques	Interface dermatitis Positive result on DIF ("lupus band")	Anti-nuclear antibodies present	Subacute
Paraneoplastic pemphigus	Constant; always early and severe	EM-like lesion plus lichenoid papules Positive Nikolsky sign	Acantholysis Positive result on DIF	Antibodies present	Chronic
Pemphigoid	Rare	Circinate erythematous patches	Sub-epidermal blister	Antibodies present	Chronic
Antidesmoplakin "EM major"	Constant	EM-like lesions	Basal acantholysis Positive result on DIF	Antibodies present	Acute relapsing
Stevens-Johnson syndrome	Constant	Widespread small blisters Atypical targets Constitutional symptoms	Interface dermatitis Epidermal necrosis		Acute

DIF = direct immunofluorescence testing.

the methodology of most studies was poor, with small series often mixing the various forms of idiopathic and viral-associated EM and drug-induced SJS.

Several series indicate that administering anti-HSV drugs for the treatment of full-blown postherpetic EM is useless. When symptomatic, *M. pneumoniae* infection should be treated with antibiotics (macrolides in children, macrolides or quinolone in adults). There is no evidence indicating whether it improves the evolution of the associated EM. Therefore, when asymptomatic infection is suggested by serologic testing, treatment is not mandatory.

Liquid antacids, topical glucocorticoids, and local anesthetics relieve symptoms of painful mouth erosions.

PREVENTION

Continuous therapy with oral anti-HSV drugs (see Chap. 232) is effective to prevent recurrences of herpes-associated EM with or without clinical evidence that herpes is the precipitating factor.[6] Topical acyclovir therapy used in a prophylactic manner does not prevent recurrent herpetic EM.

In a series of 65 patients with recurrent EM, 11 were treated with azathioprine when all other treatments had failed. Azathioprine was beneficial in all 11 patients.[13]

Retrospective uncontrolled analyses of thalidomide therapy have indicated that it is moderately effective for the treatment of EM.[14] In one randomized controlled trial, levamisole appeared useful. Because agranulocytosis is a severe and not exceptional adverse effect, levamisole use is permitted in only a few countries. The benefit-risk ratio is probably too low to support its use in the treatment of EM.

KEY REFERENCES

The full reference list for all chapters is available at www.digm7.com.

1. Bastuji-Garin S et al: A clinical classification of cases of toxic epidermal necrolysis, Stevens-Johnson syndrome and erythema multiforme. *Arch Dermatol* **129**:92, 1993
2. Auquier-Durant A et al: Correlations between clinical patterns and causes of erythema multiforme majus, Stevens-Johnson Syndrome and toxic epidermal necrolysis. *Arch Dermatol* **138**:1019, 2002
4. Weston WL: Herpes-associated erythema multiforme. *J Invest Dermatol* **124**:xv, 2005
6. Tatnall FM, Schofield JK, Leigh IM: A double-blind, placebo-controlled trial of continuous acyclovir therapy in recurrent erythema multiforme. *Br J Dermatol* **132**:267, 1995
8. Forman R, Koren G, Shear NH: Erythema multiforme, Stevens-Johnson syndrome and toxic epidermal necrolysis in children: A review of 10 years' experience. *Drug Saf* **25**:965, 2002
13. Schofield JK, Tatnall FM, Leigh IM: Recurrent erythema multiforme: Clinical features and treatment in a large series of patients. *Br J Dermatol* **128**:542, 1993
14. Wu JJ et al: Thalidomide: Dermatological indications, mechanisms of action and side-effects. *Br J Dermatol* **153**:254, 2005



CHAPTER 39

Epidermal Necrolysis (Stevens-Johnson Syndrome and Toxic Epidermal Necrolysis)

L. Valeyrie-Allanore
Jean-Claude Roujeau

Toxic epidermal necrolysis (TEN) and Stevens-Johnson syndrome (SJS) are acute life-threatening mucocutaneous reactions characterized by extensive necrosis and detachment of the epidermis. Stevens and Johnson first reported two cases of disseminated cutaneous eruptions associated with an erosive stomatitis and severe ocular involvement.[1] In 1956, Lyell described patients with epidermal loss secondary to necrosis and first introduced the term *toxic epidermal necrolysis*.[2] Both SJS and TEN are characterized by skin and mucous membrane involvement. Erythematous macules, mainly localized on the trunk and proximal limbs, evolve progressively to confluent flaccid blisters leading to epidermal detachment. Because of the similarities in clinical and histopathologic findings, drug etiology, and mechanisms, these two conditions represent severity variants of an identical process that differs only in the percentage of body surface involved.[3–5] It is therefore better to use the designation *epidermal necrolysis* for both, as proposed by Ruiz-Maldonado (acute disseminated epidermal necrosis)[6] and Lyell (exanthematic necrolysis).[7]

EPIDEMIOLOGY

Epidermal necrolysis (EN) is rare. The overall incidence of SJS and TEN was estimated at 1 to 6 cases per million person-years and 0.4 to 1.2 cases per million person-years, respectively.[8,9] EN can occur at any age, with the risk increasing with age after the fourth decade, and more frequently affects women, showing a sex ratio of 0.6. Patients infected with human immunodeficiency virus and to a lesser degree patients with collagen vascular disease and cancer are at increased risk.[10–12] The overall mortality associated with EN is 20 percent to 25 percent, varying from 5 percent to 12 percent for SJS to more than 30 percent for TEN. Increasing age, significant co-morbidity, and greater ex-

EPIDERMAL NECROLYSIS AT A GLANCE



- Rare and life-threatening reaction, mainly drug-induced.
- Widespread apoptosis of keratinocytes provoked by the activation of a cell-mediated cytotoxic reaction.
- Confluent purpuric and erythematous macules evolving to flaccid blisters and epidermal detachment predominating on the trunk and upper limbs and associated with mucous membrane involvement.
- Pathologic analysis shows full-thickness necrosis of epidermis associated with mild mononuclear cell infiltrate.
- Early identification and withdrawal of suspect drugs are essential for good patient outcome.
- Treatment is mainly symptomatic.



TABLE 39-1
SCORTEN: A Prognostic Scoring System for Patients with Epidermal Necrolysis

SCORTEN PROGNOSTIC FACTORS	POINTS
• Age > 40 yr	1
• Heart rate > 120 beats/min	1
• Cancer or hematologic malignancy	1
• Body surface area involved > 10 percent	1
• Serum urea level > 10 m*M*	1
• Serum bicarbonate level < 20 m*M*	1
• Serum glucose level > 14 m*M*	1

SCORTEN	MORTALITY RATE (%)
0–1	3.2
2	12.1
3	35.8
4	58.3
> 5	90

Data from Bastuji-Garin S et al: SCORTEN: A severity-of-illness score for toxic epidermal necrolysis. *J Invest Dermatol* **115**:149, 2000.

tent of skin involvement correlate with poor prognosis.

A prognosis score (SCORTEN) has been constructed for EN,[13] and its usefulness has been confirmed by several teams.[14,15] The performance of the score is at its best on day 3 of hospitalization[16] (Table 39-1).

ETIOLOGY

The pathophysiology of EN is still unclear; however, it is now established that drugs are the most important etiologic factors.[17–19] More than 100 different drugs have been reported as possible causes.[17–20] The importance of one medication can be established in approximately 70 percent of cases.[21] Retrospective population-based studies or case series were not accurate enough to quantify the risk of medications.[22] A multinational case-control study analyzed the association of EN with specific drugs along other epidemiologic co-factors.[20] Fewer than a dozen "high-risk" medications were implicated in one-half of cases of EN in Europe (Table 39-2). These high-risk drugs are antibacterial sulfonamides, aromatic anticonvulsants, allopurinol, oxicam nonsteroidal anti-inflammatory drugs, lamotrigine, and nevirapine.[20–25] The risk seems confined to the first 8 weeks of treatment. Slow dose escalation decreases the rate of rash with lamotrigine and nevirapine,[26,27] but there is no evidence that it decreases the risk of EN.[24] Oxcarbazepine, a 10-keto derivative of carbamazepine, which was considered to carry a lower risk, seems to significantly cross-react with carbamazepine.[28] Many nonsteroidal anti-inflammatory drugs are suspected to be associated with EN,[12,29–30] but primarily oxicam derivatives and diclofenac.[31] A significant but much lower risk has also been reported for non-sulfonamide antibiotics such as aminopenicillins, quinolones, cephalosporins, and tetracyclines. The role of corticosteroids in the induction of EN is still unclear. In a case-control study, corticosteroids were found to be associated with a high relative risk, independent of underlying disease.

The role of infectious agents in the development of EN is much less prominent than for erythema multiforme. However, a few cases of EN associated with *Mycoplasma pneumoniae* infection, viral disease, and immunization have been reported.[32,33] These rare observations underscore the fact that medications are not the only cause of EN, but there is still little evidence that infections can explain more than a very small percentage of cases.

Cases of EN have been reported after bone marrow transplantation. Some are an extreme form of acute graft-versus-host disease (see Chap. 28); others could be drug induced. The relationship between EN and graft-versus-host disease is difficult to assess because skin lesions and skin histologic features are nearly indistinguishable.[34]

Finally, physical mechanisms such as radiotherapy in addition to treatment with anti-epileptic drugs such as phenytoin, phenobarbital, or carbamazepine can trigger EN on radiation sites.[35,36]

PATHOGENESIS

Even if the precise sequence of molecular and cellular events is incompletely understood, several studies provide important clues to the pathogenesis of EN. The immunologic pattern of early lesions suggests a cell-mediated cytotoxic reaction against keratinocytes leading to massive apoptosis.[37,38] Immunopathologic studies have demonstrated the presence of $CD8^+$ T killer lymphocytes in the epidermis and dermis in bullous adverse reactions, with some natural killer cell–like features, during the initial phase of EN, whereas monocytes are present more during the late phase.[39,40] These cytotoxic $CD8^+$ T cells express α-β T-cell receptors and are able to kill through perforin and granzyme B but not through Fas or Trail.[40]

TABLE 39-2
Medications and the Risk of Epidermal Necrolysis

HIGH RISK	LOWER RISK	DOUBTFUL RISK	NO EVIDENCE OF RISK
Allopurinol	Acetic acid NSAIDs (e.g., diclofenac)	Paracetamol (acetaminophen)	Aspirin
Sulfamethoxazole	Aminopenicillins	Pyrazolone analgesics	Sulfonylurea
Sulfadiazine	Cephalosporins	Corticosteroids	Thiazide diuretics
Sulfapyridine	Quinolones	Other NSAIDs (except aspirin)	Furosemide
Sulfadoxine	Cyclins	Sertraline	Aldactone
Sulfasalazine	Macrolides		Calcium channel blockers
Carbamazepine			β Blockers
Lamotrigine			Angiotensin-converting enzyme inhibitors
Phenobarbital			Angiotensin II receptor antagonists
Phenytoin			Statins
Phenylbutazone			Hormones
Nevirapine			Vitamins
Oxicam NSAIDs			
Thiacetazone			

NSAIDs = nonsteroidal anti-inflammatory drugs.

Approach to patient with EN

- early suspicion of diagnosis
- rapid confirmation (examination of frozen biopsy speciman may help)
- elimination of differential diagnoses (biopsy and direct immunofluorescence testing)
- evaluation of disease severity with special attention to respiratory function
- prompt referral to a specialized ward
- avoidance of a specific treatment of unproven value
- re-evaluation at discharge and a few weeks later
  - –appropriate documentation of the case
  - –determination of causality
  - –notification to regulatory agency
  - –evaluation and prevention of sequelae
  - –recommendations for future use of drugs

▲ **FIGURE 39-1** Approach to the patient with epidermal necrolysis.

It is now well established that this oligoclonal $CD8^+$ expansion corresponds to a drug-specific, major histocompatibility complex–restricted cytotoxicity against keratinocytes. Furthermore, regulatory $CD4^+CD25^+$ T cells have been demonstrated to be potentially important in the prevention of severe epidermal damage induced by reactive cytotoxic T lymphocytes.[41] Important cytokines such as interleukin 6, tumor necrosis factor-α (TNF-α), and Fas ligand (Fas-L) are also present in the lesional skin of EN patients. Viard et al. suggested that keratinocyte apoptosis in lesional skin was associated with increased expression of Fas on their membranes and was blocked by high concentrations of human immunoglobulins that interfere with the interaction of Fas and Fas-L.[42] TNF is probably also important. This molecule is present in lesional epidermis, in blister fluid, and in peripheral mononuclear cells and macrophages.[43,44]

Slow acetylation was found in patients with sulfonamide-induced TEN, which suggests an increased production of reactive metabolites.[45] However, the immunologic response is directed against the parent drug rather than reactive metabolites.[40]

Finally, genetic susceptibility could play an important role. A strong association was observed in Han Chinese between the human leukocyte antigen HLA-B1502 and SJS induced by carbamazepine and between HLA-B5801 and SJS induced by allopurinol.[46,47] However, the association between carbamazepine-induced EN and HLA-B1502 is not present in European patients who do not have Asian ancestry.[48]

CLINICAL FINDINGS

Even in cases requiring immediate referral to specialized wards, the dermatologist will have a specific role in the management of patients with EN (Fig. 39-1).

History

EN clinically begins within 8 weeks (usually 4 to 30 days) after the onset of drug exposure. Only in very rare cases with prior reaction and inadvertent rechallenge with the same drug does it appear more rapidly, within a few hours. Nonspecific symptoms such as fever, headache, rhinitis, and myalgias may precede the mucocutaneous lesions by 1 to 3 days. Pain on swallowing and burning or stinging of the eyes progressively develop, heralding mucous membrane involvement. About one-third of cases begin with non-specific symptoms, one-third with symptoms of mucous membrane involvement, and one-third with an exanthema. Whatever the initial symptoms are, their rapid progression, the addition of new signs, severe pain, and constitutional symptoms should alert one to the onset of a severe disease.

Cutaneous Lesions

The eruption is initially symmetrically distributed on the face, the upper trunk, and the proximal extremities. The distal portions of the arms as well as the legs are relatively spared, but the rash can rapidly extend to the rest of the body within a few days and even within a few hours. The initial skin lesions are characterized by erythematous, dusky red, purpuric macules, irregularly shaped, which progressively coalesce. Atypical target lesions with dark centers are often observed (Fig. 39-2A). Confluence of

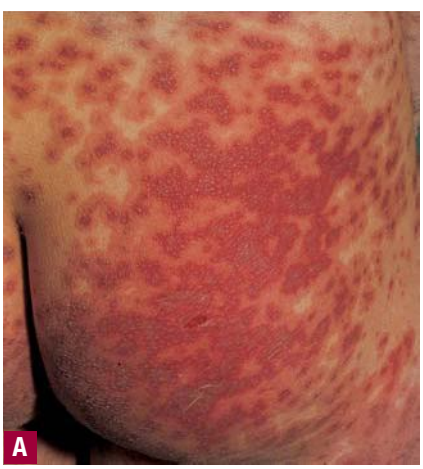



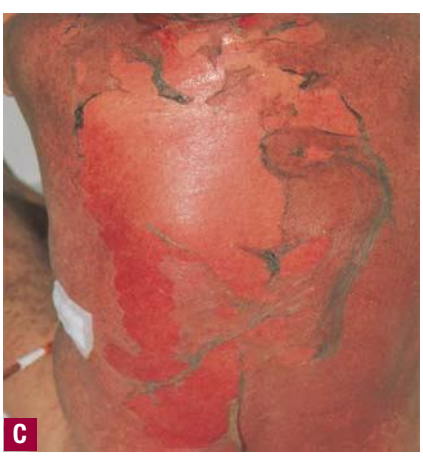

▲ **FIGURE 39-2** **A.** Early eruption. Erythematous dusky red macules (flat atypical target lesions) that progressively coalesce and show epidermal detachment. **B.** Advanced eruption. Blisters and epidermal detachment have led to large confluent erosions. **C.** Full-blown epidermal necrolysis characterized by large erosive areas reminiscent of scalding.

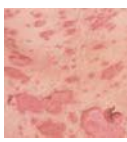

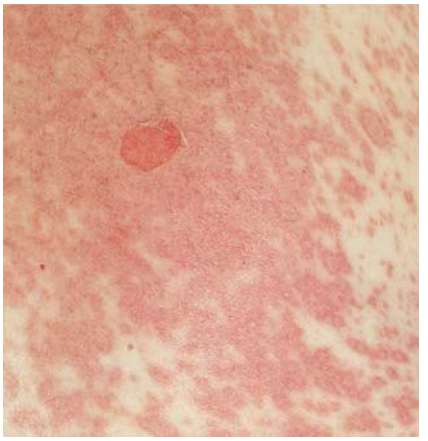

▲ **FIGURE 39-3** Early exanthematous phase with Nikolsky sign.

necrotic lesions leads to extensive and diffuse erythema. Nikolsky sign, or dislodgement of the epidermis by lateral pressure, is positive on erythematous zones (Fig. 39-3). At this stage, the lesions evolve to flaccid blisters, which spread with pressure and break easily (see Fig. 39-2B). The necrotic epidermis is easily detached at pressure points or by frictional trauma, revealing large areas of exposed, red, sometimes oozing dermis (see Fig. 39-2C). In other areas, epidermis may remain.

Patients are classified into one of three groups according to the total area in which the epidermis is detached or "detachable" (positive Nikolsky): SJS, less than 10 percent of body surface area (BSA); SJS/TEN overlap, between 10 percent and 30 percent; TEN, more than 30 percent of BSA. Correct evaluation of the extent of lesions is difficult, especially in zones with spotty lesions. It is helpful to remember that the surface of one hand (palm and fingers) represents a little less than 1 percent of the BSA.

Mucous Membrane Involvement

Mucous membrane involvement (nearly always on at least two sites) is observed in approximately 90 percent of cases and can precede or follow the skin eruption. It begins with erythema followed by painful erosions of the buccal, ocular, and genital mucosa. This usually leads to impaired alimentation, photophobia, conjunctival synechiae, and painful micturition. The oral cavity and the vermilion border of the lips are almost invariably affected and feature painful hemorrhagic erosions coated by grayish white pseudomembranes and crusts of the lips (Fig. 39-4A and B). Approximately 85 percent of patients have

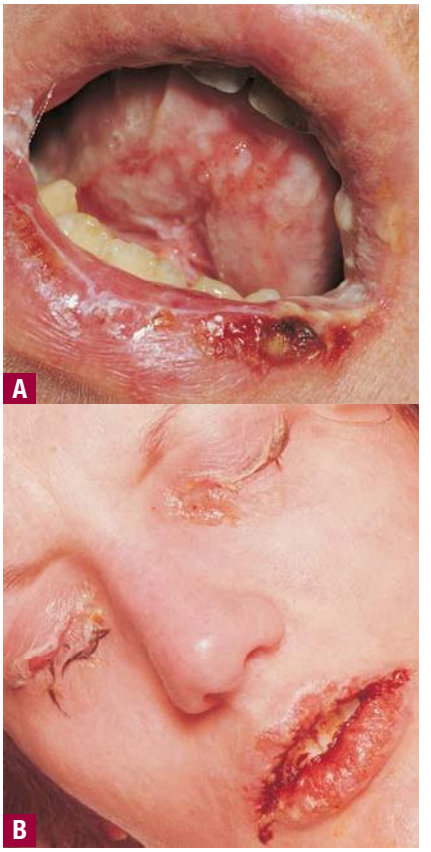

▲ **FIGURE 39-4** **A.** Extensive erosions and necroses of the lower lip and oral mucosa. **B.** Massive erosions covered by crusts on the lips. Note also shedding of eyelashes.

conjunctival lesions, mainly manifested by hyperemia, erosions, chemosis, photophobia, and lacrimation. There may be shedding of eyelashes (see Fig. 39-4B). Severe forms may lead to corneal ulceration, anterior uveitis, and purulent conjunctivitis. Synechiae between eyelids and conjunctiva often occur. Shedding of nails occurs in severe forms.

Extra-Cutaneous Symptoms

EN is associated with high fever, pain, and weakness. Visceral involvement is also possible, particularly with pulmonary and digestive complications. Early pulmonary complications occur in approximately 25 percent of patients and are essentially manifested by dyspnea, bronchial hypersecretion, and hypoxemia but also by hemoptysis and expectoration of bronchial mucosal casts.[49,50] Bronchial involvement in EN is not correlated with the extent of skin lesions or with the related offending agent. In most cases chest radiographs are normal on admission but can rapidly reveal interstitial syndrome. In all reported cases, when acute respiratory failure developed rapidly after the onset of skin involvement, it was associated with poor prognosis. In the case of respiratory abnormalities, fiberoptic bronchoscopy appears to be a simple procedure to distinguish a specific epithelial detachment in the bronchi from an infectious pneumonitis, which has a much better prognosis.

Gastrointestinal tract involvement is less commonly observed, with epithelial necrosis of the esophagus, small bowel, or colon manifesting as profuse diarrhea with malabsorption, melena, and even colonic perforation.[51,52]

Renal involvement has been reported. Proteinuria, microalbuminuria, hematuria, and azotemia are not rare. Proximal tubule damage can result from necrosis of tubule cells by the same process that destroys epidermal cells. The involvement of glomerular structures is also possible.[53,54]

LABORATORY TESTS

Laboratory Values

Evaluation of respiratory rate and blood oxygenation are among the first steps to take in the emergency room. Any alteration should be checked through measurement of arterial blood gas levels. Serum bicarbonate levels below 20 m*M* indicate a poor prognosis. They usually result from respiratory alkalosis related to the specific involvement of bronchi and more rarely from metabolic acidosis.

Massive transdermal fluid loss is responsible for electrolyte imbalances, hypoalbuminemia, and hypoproteinemia, and mild and transient renal insufficiency and prerenal azotemia are common. Raised blood urea nitrogen level is one marker of severity. Anemia is usual, and mild leukocytosis as well as thrombocytopenia may occur. Neutropenia is often considered to be an unfavorable prognostic factor but is too rare to have a significant impact on SCORTEN. Transient peripheral $CD4^+$ lymphopenia is nearly always seen constant and is associated with decreased T-cell functions. Mild elevation in levels of hepatic enzymes and amylase (most probably of salivary origin) are frequent but without impact on prognosis. A hypercatabolic state is responsible for inhibition of insulin secretion or insulin resistance, which results in hyperglycemia and occasionally overt diabetes. A blood glucose level above 14 m*M* is one marker of severity. Other abnormalities in laboratory values may occur, indicating involvement of other organs and complications such as sepsis.

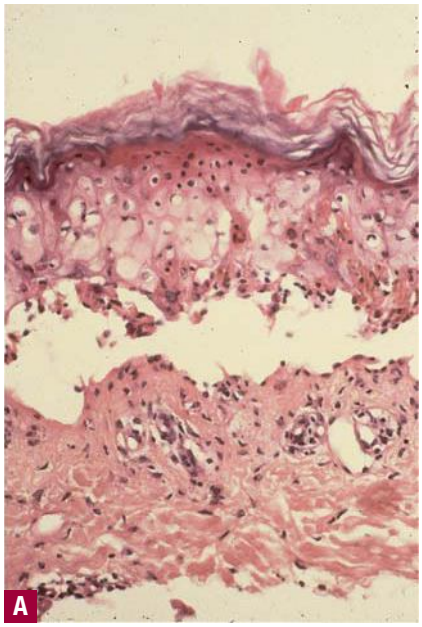

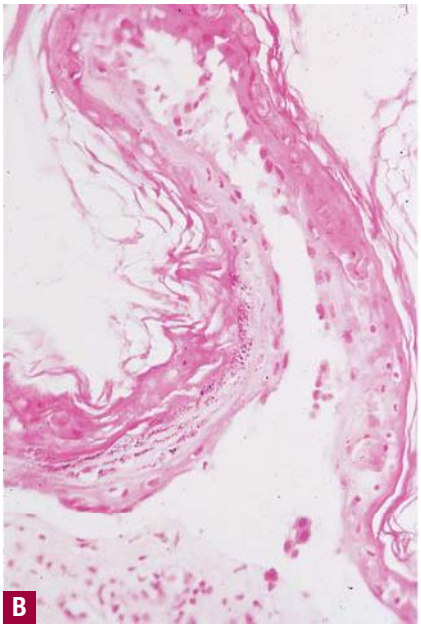

▲ **FIGURE 39-5** Histologic appearance of toxic epidermal necrolysis. **A.** Eosinophilic necrosis of the epidermis in the peak stage, with little inflammatory response in the dermis. Note cleavage in the junction zone. **B.** The completely necrotic epidermis has detached from the dermis and folded like a sheet.

Histopathology

Skin biopsy for routine histologic and immunofluorescence studies must be performed in every case of EN, even if the diagnosis is clinically obvious, because of a high probability of future legal actions and because it is the only way to exclude most differential diagnoses.

In the early stages, epidermal involvement is characterized by sparse apoptotic keratinocytes in the suprabasal layers, which rapidly evolves to a full-thickness EN and sub-epidermal detachment (Fig. 39-5). A moderately dense mononuclear cell infiltrate of the papillary dermis is observed, mainly represented by lymphocytes and macrophages. Among the T-cell population, $CD8^+$ lymphocytes with phenotypic features of cytotoxic cells are clearly represented, which suggests a cell-mediated immunologic reaction.[37,55] Eosinophils seems to be less common in patients with the most severe form of EN.[56,57] Results of direct immunofluorescence study are negative.

DIFFERENTIAL DIAGNOSIS (Box 39-1)

The absence of mucous membrane involvement or its restriction to a single site must always raise the suspicion of an alternative diagnosis: staphylococcal scalded skin syndrome in infants; purpura fulminans in children and young adults; acute generalized exanthematous pustulosis, thermal burns, phototoxicity, or pressure blisters in adults. Linear immunoglobulin A bullous disease and paraneoplastic pemphigus present with a less acute progression. Pathologic findings and a positive result on direct immunofluorescence testing are important for these diagnoses.

Early EN cases are often initially diagnosed as varicella. The rapid progression of skin lesions and the severity of mucous membrane involvement should raise the probability of EN.

In all aspects, including pathology, generalized bullous fixed drug eruption (GBFDE) resembles EN. It may have a similar drug-related mechanism. The distinction is worthwhile, however, because GBFDE has a much better prognosis, probably because of the mild involvement of mucous membranes and the absence of visceral complications. Prior attacks, rapid onset after drug intake, and very large, well-demarcated blisters are the hallmarks of GBFDE.

Thermal burns or scalding are occasionally an issue when a transient loss of consciousness occurs.

Destruction of epithelia by toxins, whether through contact (fumigants) or ingestion (colchicine poisoning, methotrexate overdose), may result in clinical features of EN. In these rare cases causality is generally obvious.

Overreporting of SJS is common. It usually arises from confusion between desquamation and detachment of epidermis and also between mucous membranes and periorificial skin. Because of such confusion, patients with a desquamative rash and scaly lips are occasionally diagnosed with and reported as having SJS.

Box 39-1

Differential Diagnosis of Epidermal Necrolysis (EN)

Most Likely

- ☐ Limited EN (Stevens-Johnson syndrome)
  - • Erythema multiforme major
  - • Varicella
- ☐ Widespread EN
  - • Acute generalized exanthematous pustulosis
  - • Generalized bullous fixed drug eruption

Consider

- ☐ Paraneoplastic pemphigus
- ☐ Linear immunoglobulin A bullous disease
- ☐ Pressure blisters after coma
- ☐ Phototoxic reaction
- ☐ Graft-versus-host disease

Always Rule Out

- ☐ Staphylococcal scalded skin syndrome
- ☐ Thermal burns
- ☐ Skin necrosis from disseminated intravascular coagulation or purpura fulminans
- ☐ Chemical toxicity (e.g., colchicine intoxication, methotrexate overdose)

COMPLICATIONS

During the acute phase, the most common complication of EN is sepsis. The epithelial loss predisposes these patients to bacterial or fungal infections, which are the main causes of mortality. Multisystem organ failure and pulmonary complications are observed in more than 30 percent and 15 percent of cases, respectively.[58] Late ophthalmic complications are seen in 20 percent to 75 percent of patients with EN.[59–61] The relationship between the initial severity of ocular involvement and the development of late complications seems now to be well established. Late ophthalmic complications are mainly due to functional alteration of the conjunctival epithelium with dryness and abnormal lacrimal film.[60] This leads to chronic inflammation, fibrosis, entropion, trichiasis, and symblepharon. Long-term irritation and deficiency of stem cells in the limbus may result in metaplasia of corneal epithelium with painful ulcerations and altered vision.

Hypopigmentation and/or hyperpigmentation are frequently observed, but rarely associated with hypertrophic or

atrophic scars. Nail changes, including change in pigmentation of the nail bed, ridging, dystrophic nails, and permanent anonychia, occur in more than 50 percent of cases.

Vulvar and vaginal complications of EN have been underestimated.[62] Dyspareunia is not rare and is related to vaginal dryness, itching, pain, and bleeding. Genital adhesions may lead to the requirement for surgical treatment. Esophageal, intestinal, bronchial, urethral, and anal strictures may also develop in rare cases.

Because these late complications and sequelae may develop insidiously, it is strongly suggested that all patients surviving EN have a clinical follow-up a few weeks after discharge, including examination by an ophthalmologist.

Symptoms suggesting post-traumatic stress disorder are not rare, and psychiatric consultation may be necessary.



PROGNOSIS AND CLINICAL COURSE

The epidermal detachment progresses for 5 to 7 days. Then, patients enter a plateau phase, which corresponds to progressive re-epithelialization. This can take a few days to several weeks, depending on the severity of the disease and the prior general condition of the patient. During this period, life-threatening complications such as sepsis or systemic organ failure may occur. The mortality rate is 5 percent to 12 percent for SJS and more than 30 percent for TEN. The prognosis is not affected by the type or dose of the responsible drug or the presence of human immunodeficiency virus infection (see Table 39-1).[13]

TREATMENT

EN is a life-threatening disease that requires optimal management: early recognition and withdrawal of the offending drug(s) and supportive care in an appropriate hospital setting.

Prompt withdrawal of offending agents is associated with an increased rate of survival in patients with EN induced by drugs with short elimination half-lives.[63] On the other hand, it is preferable to continue every important and non-suspected medication. That will avoid reluctance on the part of the patient's physicians to prescribe them in the future. In case of doubt, all non–life-sustaining drugs should be stopped, and particularly those administered within the previous 8 weeks.

Symptomatic Treatment

Only patients with limited skin involvement and a SCORTEN score of 0 or 1 can be treated in non-specialized wards. Others should be transferred to intensive care units or burn centers.

Supportive care consists of maintaining hemodynamic equilibrium and preventing life-threatening complications. The aims are basically the same as for extensive burns.

EN is associated with significant fluid loss from erosions, which results in hypovolemia and electrolyte imbalance. Fluid replacement must be started as soon as possible and adjusted daily. Volumes of infusions are usually less than for burns of similar extent, because interstitial edema is absent. Peripheral venous lines are preferred when possible, because the sites of insertion of central lines are often involved in detachment of epidermis and prone to infection.

The environmental temperature should be raised to 28°C to 30°C (82.4°F to 86°F). The use of an air-fluidized bed improves patient comfort.

Early nutritional support is preferentially provided by nasogastric tube to promote healing and to decrease the risk of bacterial translocation from the gastrointestinal tract.

To reduce the risk of infection, aseptic and careful handing is required. Skin, blood, and urine specimens should be cultured for bacteria and fungi at frequent intervals.

Prophylactic antibiotics are not indicated. Patients should receive antibiotics when clinical infection is suspected. Prophylactic anticoagulation is provided during hospitalization.

Extensive and aggressive débridement of necrotic epidermis is not recommended in EN because the superficial necrosis is not an obstacle to re-epithelialization, and might even accelerate the proliferation of stem cells due to the inflammatory cytokines.

There is no standard policy on wound dressings and the use of antiseptics. It is a matter of experience for each center. Skillfulness on the part of specialized nurses, careful manipulation, and an aggressive protocol of prevention and treatment of pain are essential.

Eyes should be examined daily by an ophthalmologist. Artificial tears, antibiotic or antiseptic eyedrops, and vitamin A are often used every 2 hours in the acute phase, and mechanical disruption of early synechiae is indicated. The mouth should be rinsed several times a day with antiseptic or antifungal solution.

Specific Treatment

Because of the importance of immunologic and cytotoxic mechanisms, a large number of immunosuppressive and/or anti-inflammatory therapies have been tried to halt the progression of the disease. None has clearly proved its efficacy. The low prevalence of the disease makes randomized clinical trials hard to perform.

CORTICOSTEROIDS The use of systemic corticosteroids is still controversial. Some studies found that such therapy could prevent the extension of the disease when given during the early phase.[64,65] Other studies concluded that steroids did not stop the progression of the disease and were even associated with increased mortality and adverse effects, particularly sepsis.[66,67] Furthermore, many cases have been reported in patients already treated with corticosteroids,[68,69] which may increase the risk of EN.[20] Thus, systemic corticosteroids cannot be recommended as the mainstay treatment of EN.

INTRAVENOUS IMMUNOGLOBULIN The proposal to use high-dose intravenous immunoglobulin was based on the demonstration that Fas-mediated cell death can be abrogated by the anti-Fas activity present in commercial batches of normal human immunoglobulins.[42] Benefits have been claimed by several studies and case reports[70,71] but refuted by several others.[72–74] Thus, intravenous immunoglobulin cannot be considered the standard of care, but if it is used, a minimal precaution is to avoid preparations that are potentially nephrotoxic.

CYCLOSPORIN A Cyclosporin is a powerful immunosuppressive agent associated with biologic effects that may theoretically be useful in treatment of EN: activation of T helper 2 cytokines, inhibition of $CD8^+$ cytotoxic mechanisms, and anti-apoptotic effect through inhibition of Fas-L, nuclear factor κ B, and TNF-α. Several case reports and series suggest the efficacy of cyclosporin A.[75,76] However, prospective studies are needed to confirm its benefits and the absence of significant adverse effects.

PLASMAPHERESIS OR HEMODIALYSIS The rationale for using plasmapheresis or hemodialysis is to prompt the removal of the offending medication, its metabolites, or inflammatory mediators such as cytokines. Small series reported their efficacy and safety in treating EN.[77–79] Considering the absence of evidence and the risks associated with intravascular catheters, however, these treatments cannot be recommended.

ANTI–TUMOR NECROSIS FACTOR AGENTS
Anti-TNF monoclonal antibodies have been successfully used to treat a few patients. Because a prior randomized controlled trial of thalidomide, an anti-TNF agent, had to be interrupted due to significantly increased mortality,[44] extreme caution is suggested in the use of anti-TNF agents to treat EN.

PREVENTION

The most important issue is to evaluate drug causality. In vitro tests or patch tests to medications occasionally can be useful in the exploration of drug allergy. When used in EN patients, their sensitivity was too low.[80,81]

Careful inquiry into all exposures to medications in the few weeks preceding the onset of the reaction leads to the identification of a probable culprit drug in approximately 70 percent of cases. The most useful clinical criteria are duration of treatment before onset (typically 4 to 30 days), absence of prior intake, and use of a drug known for being associated with a high risk.

The few published cases of recurrent SJS or TEN were always due to inadvertent re-administration of the same or a very closely related medication. Epidemiology and in vitro studies suggest that the list of possible cross-reactive medications is rather narrow, based on close chemical similarities. As an example, there is no evidence that patients who experienced SJS or TEN in reaction to an anti-infectious sulfonamide are at increased risk for reaction to sulfonamide-related diuretics or antidiabetic medications. Only anti-infectious sulfonamides should be contraindicated in this situation.

A list of the suspected medication(s) and molecules of the same biochemical structure must be given to the patient on a personal "allergy card." It is also very useful to provide a list of drugs of common use that cannot be suspected. Because of recent indications of genetic susceptibilities to the development of EN, prescription of the offending agent to family members should also be avoided.

Finally, prolonged ophthalmologic follow-up should be recommended for patients with eye symptoms. Very promising treatments have now been developed for the ocular sequelae of EN, including special scleral lenses and grafting of stem cells from contralateral limbus or mouth mucosa.[82–84]

Restriction of sun exposure may help resolve the pigmentation changes.

KEY REFERENCES

The full reference list for all chapters is available at www.digm7.com.

16. Guégan S et al: Performance of the SCORTEN during the first five days of hospitalisation to predict the prognosis of epidermal necrolysis. *J Invest Dermatol* **126**:272, 2006
20. Roujeau JC et al: Medication use and the risk of Stevens-Johnson syndrome or toxic epidermal necrolysis. *N Engl J Med* **333**:1600, 1995
21. Auquier-Dunant A et al: Correlation between clinical patterns and causes of erythema multiforme major, Stevens Johnson and toxic epidermal necrolysis. *Arch Dermatol* **138**:1019, 2002
25. Mockenhaupt M et al: Risk of Stevens-Johnson and toxic epidermal necrolysis in new users of antiepileptics. *Neurology* **64**:1134, 2005
31. Mockenhaupt M et al: The risk of Stevens-Johnson syndrome and toxic epidermal necrolysis associated with nonsteroidal antiinflammatory drugs: A multinational perspective. *J Rheumatol* **30**:2234, 2003
40. Nassif A et al: Drug specific cytotoxic T-cells in the skin lesions of a patient with toxic epidermal necrolysis. *J Invest Dermatol* **118**:728, 2002
46. Chung WH et al: Medical genetics: A marker for Stevens Johnson syndrome. *Nature* **428**:486, 2004
55. Chave TA et al: Toxic epidermal necrolysis: Current evidence, practical management and future directions. *Br J Dermatol* **153**:241, 2005
58. Palmieri T et al: A multicenter review of toxic epidermal necrolysis treated in U.S. burn centers at the end of the twentieth century. *J Burn Care Rehabil* **23**:87, 2002
84. Nishida K et al: Corneal reconstruction with tissue engineered cell sheets composed of autologous oral epithelium. *N Engl J Med* **351**:1187, 2004



CHAPTER 40

Cutaneous Reactions to Drugs

Neil H. Shear
Sandra R. Knowles
Lori Shapiro

Complications of drug therapy are a major cause of patient morbidity and account for a significant number of patient deaths.[1] Drug eruptions range from common nuisance eruptions to rare or life-threatening drug-induced diseases. Drug reactions may be solely limited to the skin, or they may be part of a systemic reaction, such as drug hypersensitivity syndrome or toxic epidermal necrolysis (TEN) (see Chap. 39).

Drug eruptions are distinct disease entities and must be approached as any other cutaneous disease. A precise diagnosis of the reaction pattern can help narrow possible causes, because different drugs are more commonly associated with different types of reactions.

EPIDEMIOLOGY

In the Boston Collaborative Drug Surveillance Program, the prevalence of cutaneous adverse drug reactions (ADRs) in hospitalized patients was 2.2 percent. Antibiotics were responsible for 7 percent of detected reactions.[2] The Harvard Medical Practice Study showed that approximately 14 percent of ADRs in hospital patients are cutaneous or allergic in nature.[3]

ETIOLOGY

In the evaluation of patients with a history of an ADR, it is important to obtain a detailed medication history, including use of over-the-counter preparations and herbal and naturopathic remedies. New drugs started within the preceding 6 weeks are potential causative agents for most cutaneous eruptions (exceptions include drug-induced lupus and drug-induced cutaneous pseudolymphoma), as are drugs that have been used intermittently.

PATHOGENESIS OF DRUG ERUPTIONS

Constitutional factors influencing the risk of cutaneous eruption include pharmacogenetic variation in drug-metabolizing enzymes and human leukocyte antigen (HLA) associations. Acetylator phenotype alters the risk of developing drug-induced lupus due to hydralazine, procainamide, and isoniazid. HLA-DR4 is significantly more common in individuals with hydralazine-related drug-

CUTANEOUS ADVERSE DRUG ERUPTIONS

AT A GLANCE



- Drug-induced cutaneous eruptions are common.
- They range from common nuisance rashes to rare life-threatening diseases.
- The spectrum of clinical manifestations includes exanthematous, urticarial, pustular, bullous, and erythema multiforme–like eruptions.
- These reactions may mimic other cutaneous diseases such as acne, porphyria, lichen planus, and lupus.
- Fixed drug eruptions are usually solitary dusky macules that recur at the same site.
- Drug reactions may be limited solely to skin or may be part of a severe systemic reaction, such as drug hypersensitivity syndrome or toxic epidermal necrolysis.

induced lupus than in those with idiopathic systemic lupus erythematosus.[4] HLA factors may also influence the risk of reactions to nevirapine, abacavir, carbamazepine, and allopurinol.[5–8]

Many drugs associated with severe idiosyncratic drug reactions are metabolized by the body to form reactive, or toxic, drug products.[9] These reactive products comprise only a small proportion of a drug's metabolites and are usually rapidly detoxified. However, patients with drug hypersensitivity syndrome, TEN, and Stevens-Johnson syndrome (SJS) resulting from treatment with sulfonamide antibiotics and the aromatic anticonvulsants (e.g., carbamazepine, phenytoin, phenobarbital, primidone, and oxcarbazepine) show greater sensitivity in in vitro assessments to the oxidative, reactive metabolites of these drugs than do control subjects.[10,11]

Acquired factors also alter an individual's risk of drug eruption. Active viral infection and concurrent use of other medications have been shown to alter the frequency of drug-associated eruptions. Drug–drug interactions may also alter the risk of cutaneous eruption. Valproic acid increases the risk of severe cutaneous adverse reactions to lamotrigine, another anticonvulsant.[12] The basis of these interactions and reactions is unknown, but they may represent a mixture of factors, including alterations in drug metabolism, drug detoxification, antioxidant defenses, and immune reactivity.

The course and outcome of drug-induced disease are also influenced by host factors. Older age may delay the onset of drug eruptions and has been associated with a higher mortality rate in some severe reactions. A higher mortality rate is also observed in patients with severe reactions who have underlying malignancy.[13] Reactivation of latent viral infection with human herpesvirus 6 also appears common in drug hypersensitivity syndrome and may be partially responsible for some of the clinical features and/or course of the disease.[14] Viral infections may act as, or generate the production of, danger signals that lead to damaging immune responses to drugs, rather than immune tolerance.

The pathogenesis of most drug eruptions is not understood, although the clinical features of most drug reactions are consistent with immune-mediated disease. The immune system may target the native drug, its metabolic products, altered self, or a combination of these factors.

MORPHOLOGIC APPROACH TO DRUG ERUPTIONS

The morphology of cutaneous eruptions may be exanthematous, urticarial, blistering, or pustular. The extent of the reaction is variable. For example, once the morphology of the reaction has been documented, a specific diagnosis [e.g., fixed drug eruption (FDE) or acute generalized exanthematous pustulosis (AGEP)] can be made. The reaction may also present as a syndrome (e.g., serum sickness–like reaction or hypersensitivity syndrome reaction). Fever is associated with the more serious cutaneous ADRs.

Exanthematous Eruptions

Exanthematous eruptions, known also as *morbilliform* or *maculopapular*, are the most common form of drug eruptions, accounting for approximately 95 percent of skin reactions[2] (Fig. 40-1). Simple exanthems are erythematous changes in the skin without evidence of blistering or pustulation. The eruption typically starts on the trunk and spreads peripherally in a symmetric fashion. Pruritus is almost always present. These eruptions usually occur within 1 week of initiation of therapy and resolve within 7 to 14 days. Resolution occurs with a change in color from bright red to a brownish red, which may be followed by scaling or desquamation. The differential diagnosis in these patients includes a viral exanthem, collagen vascular disease, and bacterial and rickettsial infections.



▲ **FIGURE 40-1** Exanthematous drug eruption: Ampicillin. Symmetrically arranged, brightly erythematous macules and papules, which are discrete in some areas and confluent in others on the trunk and discrete on the extremities.

Exanthematous eruptions can be caused by many drugs, including the penicillins, sulfonamides, nonnucleoside reverse transcriptase inhibitors (e.g., nevirapine), and anti-epileptic medications.[2] Studies have shown that drug-specific T cells play a major role in exanthematous, bullous, and pustular drug reactions.[15] In patients who have concomitant infectious mononucleosis, the risk of developing an exanthematous eruption while being treated with an aminopenicillin (e.g., ampicillin) increases from 3 percent to 7 percent to 60 percent to 100 percent.[16] A similar drug-viral interaction has been observed in 50 percent of patients infected with human immunodeficiency virus (HIV) who are exposed to sulfonamide antibiotics.[17]

An exanthematous eruption in conjunction with fever and internal organ involvement (e.g., liver, kidney, central nervous system) signifies a more serious reaction, known as the *hypersensitivity syndrome reaction* (HSR) (Table 40-1). It occurs in approximately 1 in 3000 exposures to agents such as aromatic anticonvulsants, lamotrigine, sulfonamide antibiotics, dapsone, nitrofurantoin, nevirapine, minocycline, and allopurinol (Fig. 40-2). HSR occurs most frequently on first exposure to the drug, with initial

TABLE 40-1
Clinical Features of Selected Cutaneous Reactions to Drugs

Clinical Presentation	Drug Eruption	Fever	Internal Organ Involvement	Arthralgia	Lymphadenopathy	Implicated Drugs
Hypersensitivity syndrome reaction	Exanthem, exfoliative dermatitis, pustular eruptions, SJS/TEN	Present	Present	Absent	Present	Aromatic anticonvulsants (e.g., phenytoin, phenobarbital, carbamazepine), sulfonamide antibiotics, dapsone, minocycline, allopurinol, lamotrigine
Serum sickness–like reaction	Urticaria, exanthem	Present	Absent	Present	Present	Cefaclor, cefprozil, bupropion, minocycline, infliximab, rituximab
Drug-induced lupus	Usually absent	Present/absent	Present/absent	Present	Absent	Procainamide, hydralazine, isoniazid, minocycline, acebutolol
Drug-induced subacute cutaneous lupus erythematosus	Papulosquamous or annular cutaneous lesion (often photosensitive)	Absent	Absent	Absent	Absent	Thiazide diuretics, calcium channel blockers, ACE inhibitors
Acute generalized exanthematous pustulosis	Non-follicular pustules on an edematous erythematous base	Present	Absent	Absent	Absent	β Blockers, macrolide antibiotics, calcium channel blockers

ACE = angiotensin-converting enzyme; SJS = Stevens-Johnson syndrome; TEN = toxic epidermal necrolysis.

symptoms starting 1 to 6 weeks after exposure. Fever and malaise are often the presenting symptoms. Atypical lymphocytosis with subsequent eosinophilia may occur during the initial phases of the reaction in some patients. Although most patients have an exanthematous eruption, more serious cutaneous manifestations may be evident (Fig. 40-3). Internal organ involvement can be asymptomatic. Some patients may become hypothyroid approximately 2 months after the first symptoms appear.[18]

The formation of toxic metabolites by the aromatic anticonvulsants may play a pivotal role in the development of HSR.[11] In most individuals, the chemically reactive metabolites that are produced are detoxified by epoxide hydroxylases. If detoxification is defective, however, one of the metabolites may act as a hapten and initiate an immune response, stimulate apoptosis, or cause cell necrosis directly. Approximately 70 percent to 75 percent of patients who develop anticonvulsant HSR in response to one aromatic anticonvulsant show cross-reactivity to the other aromatic anticonvulsants. In addition, in vitro testing shows that there is a familial occurrence of HSR induced by anticonvulsants.[11] Thus, counseling of family members and disclosure of risk is essential.

Sulfonamide antibiotics are also metabolized to toxic metabolites, namely, hydroxylamines and nitroso compounds. In most people, the metabolite is detoxified. However, HSRs may occur in patients who are unable to detoxify this metabolite. Because siblings and other first-degree relatives are at an increased risk (perhaps as high as 1 in 4) of developing a similar adverse reaction, counseling of family members is essential.

Other aromatic amines, such as procainamide, dapsone, and acebutolol, are also metabolized to chemically reactive compounds. It is recommended that patients who develop symptoms compatible with a sulfonamide HSR avoid these aromatic amines, because the potential exists for cross-reactivity. However, cross-reactivity should not occur between sulfonamides and drugs that are not aromatic amines (e.g., sulfonylureas, thiazide diuretics, furosemide, and acetazolamide).[19]

Allopurinol is associated with the development of serious drug reactions, including HSR. In a patient who developed HSR with hepatitis, reactivation of human herpesvirus 6 occurred.[20] Allo-





▲ **FIGURE 40-2** Drug hypersensitivity syndrome: Phenytoin. Symmetric, bright red, exanthematous eruption, confluent in some sites; the patient had associated lymphadenopathy.



▲ **FIGURE 40-3** Hypersensitivity syndrome reaction, characterized by fever, a pustular eruption, and hepatitis, in a 23-year-old man after 18 days of treatment with minocycline.

purinol-induced adverse reactions, including HSR, SJS, and TEN, have been strongly associated with a genetic predisposition in Han Chinese; presence of the HLA-B*5801 allele was found to be an important genetic risk factor.[5]

Urticarial Eruptions

Urticaria is characterized by pruritic red wheals of various sizes. Individual lesions generally last for less than 24 hours, although new lesions can commonly develop. When deep dermal and subcutaneous tissues are also swollen, the reaction is known as *angioedema*. Angioedema is frequently unilateral and non-pruritic and lasts for 1 to 2 hours, although it may persist for 2 to 5 days.[21]

Urticaria and angioedema, when associated with drug use, are usually indicative of an immunoglobulin E (IgE)–mediated immediate hypersensitivity reaction. This mechanism is typified by immediate reactions to penicillin and other antibiotics (see Chap. 37). Signs and symptoms of IgE-mediated allergic reactions typically include pruritus, urticaria, cutaneous flushing, angioedema, nausea, vomiting, diarrhea, abdominal pain, nasal congestion, rhinorrhea, laryngeal edema, and bronchospasm or hypotension or both.

Serum sickness–like reactions (see Table 40-1) are defined by the presence of fever, rash (usually urticarial), and arthralgias 1 to 3 weeks after initiation of drug therapy. Lymphadenopathy and eosinophilia may also be present; however, in contrast to true serum sickness, immune complexes, hypocomplementemia, vasculitis, and renal lesions are absent.

Cefaclor is associated with an increased relative risk of serum sickness–like reactions. The overall incidence of cefaclor-induced serum sickness–like reactions has been estimated to be 0.024 percent to 0.2 percent per course of cefaclor prescribed. In genetically susceptible hosts, a reactive metabolite is generated during the metabolism of cefaclor that may bind with tissue proteins and elicit an inflammatory response manifesting as a serum sickness–like reaction.[24]

Other drugs that have been implicated in serum sickness–like reactions are cefprozil, bupropion, minocycline, and rituximab[25] as well as infliximab.[26] The incidence of serum sickness–like reactions caused by these drugs is unknown.

Pustular Eruptions

Acneiform eruptions are associated with the use of iodides, bromides, adrenocorticotropic hormone, glucocorticoids, isoniazid, androgens, lithium, actinomycin D, and phenytoin. Drug-induced acne may appear in atypical areas, such as on the arms and legs, and is most often monomorphous. Comedones are usually absent. The fact that acneiform eruptions do not affect prepubertal children indicates that previous hormonal priming is a necessary prerequisite. In cases in which the offending agent cannot be discontinued, topical tretinoin may be useful.[27]

AGEP is an acute febrile eruption that is often associated with leukocytosis[28] (Fig. 40-4 and Table 40-1). After initiation of the implicated drug, 1 to 3 weeks may elapse before skin lesions appear. The lesions often start on the face or main skin creases. Generalized desquamation occurs approximately 2 weeks later. The estimated incidence of AGEP is approximately 1 to 5 cases per million per year.[29] AGEP is most commonly associated with β-lactam and macrolide antibiotics and calcium channel blockers. Differential diagnosis includes pustular psoriasis, HSR with pustulation, sub-corneal pustular dermatosis (Sneddon-Wilkinson disease), pustular vasculitis, or TEN, especially in severe cases of AGEP. The typical histopathologic analysis of AGEP lesions shows spongiform sub-corneal and/or intraepidermal pustules, an often marked edema of the papillary dermis, and perivascular infiltrates with neutrophils and exocytosis of some eosinophils.[29] Discontinuance of therapy is usually the extent of treatment necessary in most patients, although some patients may require the use of corticosteroids. Positive results on patch tests and lymphocyte transformation tests suggest involvement of T cells in AGEP.[30]

Bullous Eruptions (Table 40-2)

Pseudoporphyria is a cutaneous phototoxic disorder that can resemble either porphyria cutanea tarda in adults or erythropoietic protoporphyria in children (see Chap. 132). Pseudoporphyria of the porphyria cutanea tarda variety is characterized by skin fragility, blister formation, and scarring in photodistribution; it occurs in the presence of normal porphyrin levels. The other clinical pattern mimics erythropoietic protoporphyria and manifests as cutaneous burning, erythema, vesiculation, angular chickenpox-like scars, and waxy thickening of the skin. The eruption may begin within 1 day of initiation of therapy or may be delayed for as long as 1 year. The course



▲ **FIGURE 40-4** Acute generalized exanthematous pustulosis in a 48-year-old man who developed non-follicular pustules and fever after 7 days of treatment with diltiazem.

is prolonged in some patients, but most reports describe symptoms that disappear several weeks to several months after the offending agent is withdrawn. Because of the risk of permanent facial scarring, the implicated drug should be discontinued if skin fragility, blistering, or scarring occurs.[31] In addition, the use of broad-spectrum sunscreen and protective clothing should be recommended.

Both idiopathic and drug-induced linear IgA disease (see Chap. 56) are heterogeneous in clinical presentation. Cases of the drug-induced type have morphologies resembling erythema multiforme, bullous pemphigoid, and dermatitis herpetiformis. The drug-induced disease may differ from the idiopathic entity in that mucosal or conjunctival lesions are less common, spontaneous remission occurs once the offending agent is withdrawn, and immune deposits disappear from the skin once the lesions resolve.

Biopsy specimens are necessary for diagnosis. Histologically, the two entities are similar. A study suggests that, as in the idiopathic variety, the target antigen is not unique in the drug-induced disease. Although 13 percent to 30 percent of patients with sporadic linear IgA have circulating basement membrane zone antibodies, these antibodies have not been reported in drug-induced cases.[32] In patients with linear IgA bullous disease proven by direct immunofluorescence, the index of suspicion of drug induction should be higher in cases with only IgA and no IgG in the basement membrane zone.

Pemphigus may be considered as drug induced or drug triggered (i.e., a la-



TABLE 40-2
Drug Eruptions Mimicry

Clinical Presentation	Pattern and Distribution of Skin Lesions	Mucous Membrane Involvement	Implicated Drugs	Treatment
Stevens-Johnson syndrome	Atypical targets, widespread	Present	Aromatic anticonvulsants,[a] lamotrigine, sulfonamide antibiotics, allopurinol, piroxicam, dapsone	IVIg, cyclosporine, supportive care
Toxic epidermal necrolysis	Epidermal necrosis with skin detachment	Present	As above	IVIg, cyclosporine, supportive care
Pseudoporphyria	Skin fragility, blister formation in photodistribution	Absent	Tetracycline, furosemide, naproxen	Supportive care
Linear IgA disease	Bullous dermatosis	Present/absent	Vancomycin, lithium, diclofenac, piroxicam, amiodarone	Supportive care
Pemphigus	Flaccid bullae, chest	Present/absent	Penicillamine, captopril, piroxicam, penicillin, rifampin, propranolol	Supportive care
Bullous pemphigoid	Tense bullae, widespread	Present/absent	Furosemide, penicillamine, penicillins, sulfasalazine, captopril	Supportive care

IVIg = intravenous immunoglobulin.
[a]Aromatic anticonvulsants = phenytoin, carbamazepine, phenobarbital, oxcarbazepine, primidone.



tent disease that is unmasked by the drug exposure; see Chap. 52). Drug-induced pemphigus caused by penicillamine and other thiol drugs tends to remit spontaneously in 35 percent to 50 percent of cases, presents as pemphigus foliaceus, has an average interval to onset of 1 year, and is associated with the presence of anti-nuclear antibodies in 25 percent of patients.

Most patients with nonthiol drug-induced pemphigus manifest clinical, histologic, immunologic, and evolutionary aspects similar to those of idiopathic pemphigus vulgaris with mucosal involvement and show a 15 percent rate of spontaneous recovery after drug withdrawal. Treatment of drug-induced pemphigus begins with drug cessation. Systemic glucocorticoids are often required until all symptoms of active disease disappear. Vigilant follow-up is required after remission to monitor the patient and the serum for autoantibodies to detect an early relapse.[33]

Drug-induced bullous pemphigoid (see Chap. 54) can encompass a wide variety of presentations, ranging from the classic features of large, tense bullae arising from an erythematous, urticarial base with moderate involvement of the oral cavity, through mild forms with few bullous lesions, to scarring plaques and nodules with bullae.[33] In contrast to patients with the idiopathic form, patients with drug-induced bullous pemphigoid are generally younger. In addition, the histopathologic findings are of a perivascular infiltration of lymphocytes with few eosinophils and neutrophils, intraepidermal vesicles with foci of necrotic keratinocytes, thrombi in dermal vessels, and a possible lack of tissue-bound and circulating antibasal membrane zone IgG.

In the acute, self-limited condition, resolution occurs after the withdrawal of the culprit agent, with or without glucocorticoid therapy. In some patients, however, the drug may actually trigger the idiopathic form of the disease.

Erythema multiforme major, SJS, and TEN represent variants of the same disease process. Differentiation between the two patterns depends on the nature of the skin lesions and the extent of body surface area involvement[34,35] (see Chaps. 38 and 39).

The pathogenesis of severe cutaneous ADRs is unknown, although a metabolic basis has been hypothesized.[36] In addition, the detection of drug-specific T-cell proliferation provides evidence that T cells are involved in severe skin rashes.[37]

Treatment of erythema multiforme, SJS, and TEN includes discontinuance of the suspected drug(s) and supportive measures such as careful wound care, hydration, and nutritional support. The use of corticosteroids in the treatment of SJS and TEN is controversial.[38,39] Intravenous immunoglobulin (IVIg, 0.4 to 1.0 g/kg/day for 2 to 4 days) has been shown in most reports to halt progression of TEN, especially when IVIg is started early.[40,41] However, some studies have not found an improved outcome in patients with TEN who are treated with IVIg.[42] Patients who have developed a severe cutaneous ADR should not be rechallenged with the drug or undergo desensitization therapy with the medication.

Fixed Drug Eruptions

FDEs usually appear as solitary, erythematous, bright red or dusky red macules that may evolve into an edematous plaque; bullous-type lesions may be present. FDEs are most commonly found on the genitalia and in the perianal area, although they can occur anywhere on the skin surface (Fig. 40-5). Some patients may complain of burning or stinging, and others may have fever,



▲ **FIGURE 40-5** Fixed drug eruption: Tetracycline. A well-defined plaque on the knee, merging with three satellite lesions. The large plaque exhibits epidermal wrinkling, a sign of incipient blister formation. This was the second such episode after ingestion of a tetracycline. No other lesions were present.

malaise, and abdominal symptoms. FDE can develop from 30 minutes to 8 to 16 hours after ingestion of the medication. After the initial acute phase lasting days to weeks, residual grayish or slate-colored hyperpigmentation develops. On rechallenge, not only do the lesions recur in the same location, but also new lesions often appear.

More than 100 drugs have been implicated in causing FDEs, including ibuprofen, sulfonamides, naproxen, and tetracyclines. A haplotype linkage in trimethoprim-sulfamethoxazole–induced FDE has been documented.[43]

A challenge or provocation test with the suspected drug may be useful in establishing the diagnosis. Patch testing at the site of a previous lesion yields a positive response in up to 43 percent of patients. Results of prick and intradermal skin tests may be positive in 24 percent and 67 percent of patients, respectively.[45]

Anticoagulant-Induced Skin Necrosis

Anticoagulant-induced skin necrosis begins 3 to 5 days after initiation of treatment. Both coumarin and heparin (unfractionated and low molecular weight) can induce skin necrosis (Fig. 40-6). Early red, painful plaques develop in adipose-rich sites such as breasts, buttocks, and hips. These plaques may blister, ulcerate, or develop into necrotic areas. It is estimated that 1 in 10,000 persons who receive the drug is at risk of this adverse event.[46] The incidence is four times higher in women, especially in obese women, with a peak incidence in the sixth and seventh decades of life. Affected patients often have been given a large initial loading dose of coumarin in the absence of concomitant heparin therapy. An accompanying infection such as pneumonia, viral infection, or erysipelas may be seen in up to 25 percent of patients. An association with protein C and protein S deficiencies exists, but pre-treatment screening is not warranted. An association with heterozygosity for the factor V Leiden mutation has been reported.[47]



▲ **FIGURE 40-6** Skin necrosis in a patient after 4 days of warfarin therapy.

Treatment involves the discontinuation of coumarin, administration of vitamin K, and infusion of heparin at therapeutic dosages. Fresh frozen plasma and purified protein C concentrates have been used.[48] Supportive measures for the skin are a mainstay of therapy. The morbidity rate is high; 60 percent of affected individuals require plastic surgery for remediation of full-thickness skin necrosis by skin grafting. These patients may be treated with coumarin in the future, but small dosages (2 to 5 mg daily) are recommended, with initial treatment under heparin coverage.

The pathogenesis of this adverse event is the paradoxical development of occlusive thrombi in cutaneous and subcutaneous venules due to a transient hypercoagulable state. This results from the suppression of the natural anticoagulant protein C at a greater rate than the suppression of natural procoagulant factors.

Drug-Induced Lichenoid Eruptions

Drug-induced lichen planus produces lesions that are clinically and histologically indistinguishable from those of idiopathic lichen planus (see Chap. 26); however, lichenoid drug eruptions often appear initially as eczematous with a purple hue and involve large areas of the trunk. Usually the mucous membranes and nails are not involved. Histologically, focal parakeratosis, focal interruption of the granular layer, cytoid bodies in the cornified and granular layers, the presence of eosinophils and plasma cells in the inflammatory infiltrate, and an infiltrate around the deep vessels favor a diagnosis of lichenoid drug eruption.[49] Many drugs, including β blockers, penicillamine, and angiotensin-converting enzyme (ACE) inhibitors, especially captopril, reportedly produce this reaction. The mean latent period is between 2 months and 3 years for penicillamine, approximately 1 year for β-adrenergic blocking agents, and 3 to 6 months for ACE inhibitors. The latent period may be shortened if the patient has been previously exposed to the drug.[49] Resolution usually occurs with 2 to 4 months. Rechallenge with the culprit drug has been attempted in a few patients, with reactivation of symptoms within 4 to 15 days.[50]

Drug-Induced Cutaneous Pseudolymphoma

Pseudolymphoma is a process that simulates lymphoma but has a benign behavior and does not meet the criteria for malignant lymphoma. Drugs are a well-known cause of cutaneous pseudolymphomas (see Chap. 147), but the condition may also be induced by foreign agents such as insect bites, infections (e.g., HIV), and idiopathic causes.[51]

Anticonvulsant-induced pseudolymphoma generally occurs after 1 week to 2 years of exposure to the drug. Within 7 to 14 days of drug discontinuation, the symptoms usually resolve. The eruption often manifests as single lesions but can also be widespread erythematous papules, plaques, or nodules. Most patients also have fever, marked lymphadenopathy and hepatosplenomegaly, and eosinophilia.[52] Mycosis fungoides–like lesions are also associated with these drugs.[53]

Drug-Induced Vasculitis

Drug-induced vasculitis represents approximately 10 percent of the acute cutaneous vasculitides and usually involves small vessels[54] (see Chap. 164). Drugs that are associated with vasculitis include propylthiouracil, hydralazine, granulocyte colony-stimulating factor, granulocyte-macrophage colony-stimulating factor, allopurinol, cefaclor, minocycline, penicillamine, phenytoin, and isotretinoin.[55] The average interval from initiation of drug therapy to onset of drug-induced vasculitis is 7 to 21 days.[56]

The clinical hallmark of cutaneous vasculitis is palpable purpura, classically found on the lower extremities. Urticaria can be a manifestation of small vessel vasculitis, with individual lesions remaining fixed in the same location for more than 1 day. Other features include hemorrhagic bullae, ulcers, nodules, Raynaud disease, and digital necrosis.[57] The same vasculitic process may also affect internal organs such as the liver, kidney, gut, and central nervous system and can be potentially life threatening.

Drug-induced vasculitis can be difficult to diagnose and is often a diagnosis of exclusion. In some cases, serologic testing has revealed the presence of perinuclear-staining antineutrophil cytoplasmic autoantibodies against myeloperoxidase.[58] Alternative causes for cutaneous vasculitis such as infection or autoimmune disease must be eliminated. Tissue eosinophilia may be an indicator of drug induction in cutaneous

small vessel vasculitis.[59] Treatment consists of drug withdrawal. Systemic glucocorticoids may be of benefit.

Drug-Induced Lupus (See Chap. 156)

Drug-induced lupus is characterized by frequent musculoskeletal complaints, fever, weight loss, pleuropulmonary involvement in more than half of patients, and in rare cases renal, neurologic, or vasculitic involvement[60] (see Table 40-1). Most patients have no cutaneous findings of lupus erythematosus. The most common serologic abnormality is positivity for anti-nuclear antibodies with a homogenous pattern. Although antihistone antibodies are seen in up to 95 percent of drug-induced lupus, they are not specific for the syndrome and are found in 50 percent to 80 percent of patients with idiopathic lupus erythematosus. Unlike in idiopathic lupus erythematosus, antibodies against double-stranded DNA are typically absent, whereas anti–single-stranded DNA antibodies are often present.[61] Genetic factors may also play a role in the development of drug-induced lupus. HLA-DR4 is present in 73 percent of the patients with hydralazine-induced lupus and in 70 percent of patients with minocycline-induced lupus.[62] Evidence now suggests that abnormalities during T-cell selection in the thymus initiate lupus-like autoantibody induction.[63]

The identification of minocycline as a cause of drug-induced lupus makes it important for dermatologists to recognize this syndrome. Minocycline-induced lupus typically occurs after 2 years of therapy. The patient presents with a symmetric polyarthritis. Hepatitis is often detected on laboratory evaluation.[64] Cutaneous findings include livedo reticularis, painful nodules on the legs, and nondescript eruptions. Antihistone antibodies are seldom present. A study of HLA class II alleles revealed the presence of HLA-DR4 or HLA-DR2 in many of the patients.[62]

In contrast, drug-induced subacute cutaneous lupus erythematosus is characterized by a papulosquamous or annular cutaneous lesion, which is often photosensitive, and absent or mild systemic involvement. Circulating anti-Ro (Sjögren syndrome A) antibodies have also been identified in many patients. The most commonly reported causative agents are thiazide diuretics, calcium channel blockers, and ACE inhibitors. The number of patients who develop subacute cutaneous lupus erythematosus during treatment with these medications is very small, and these drugs are thought to have a low risk for causing or exacerbating cutaneous lupus.[65]

DIAGNOSIS AND MANAGEMENT

The iatrogenic disorders described here are distinct disease entities, although they may closely mimic many infective or idiopathic diseases. A drug cause should be considered in the differential diagnosis of a wide spectrum of dermatologic diseases, particularly when the presentation or course is atypical.

The diagnosis of a cutaneous drug eruption involves the precise characterization of reaction type. A wide variety of cutaneous drug-associated eruptions may also warn of associated internal toxicity (Table 40-3). Even the most minor cutaneous eruption should trigger a clinical review of systems, because the severity of systemic involvement does not necessarily mirror that of the skin manifestations.[66] Hepatic, renal, joint, respiratory, hematologic, and neurologic changes should be sought, and any systemic symptoms or signs investigated. Fever, malaise, pharyngitis, and other systemic symptoms or signs should be investigated. A usual screen would include a full blood count, liver and renal function tests, and a urine analysis.

Skin biopsy should be considered for all patients with potentially severe reactions, such as those with systemic symptoms, erythroderma, blistering, skin tenderness, purpura, or pustulation, as well as in cases in which the diagnosis is uncertain. Some cutaneous reactions, such as FDE, are virtually always due to drug therapy, and nearly 90 percent of TEN cases are also drug related.[35] Other more common eruptions, including exanthematous or urticarial eruptions, have many nondrug causes.

There is no gold standard investigation for confirmation of a drug cause. Instead, diagnosis and assessment of cause involve analysis of a constellation of features such as timing of drug exposure and reaction onset, course of reaction with drug withdrawal or continuation, timing and nature of a recurrent eruption on rechallenge, a history of a similar response to a cross-reacting medication, and previous reports of similar reactions to the same medication. Investigations to exclude nondrug causes are similarly helpful.

Several in vitro investigations can help to confirm causation in individual cases, but their exact sensitivity and specificity remain unclear. Investigations include the lymphocyte toxicity and lymphocyte transformation assays.[11,12] Penicillin skin testing with major and minor determinants is useful for confirmation of an IgE-mediated immediate hypersensitivity reaction to penicillin.[67] Patch testing has been used in patients with ampicillin-induced exanthematous eruptions[68] and in the ancillary diagnosis of FDEs. Patch testing has greater sensitivity if performed over a previously involved area of skin.[69]

Cutaneous drug eruptions do not usually vary in severity with dose. Less severe reactions may abate with continued drug therapy (e.g., transient exanthematous eruptions associated with commencement of a new HIV antiretroviral regimen). However, a reaction suggestive of a potentially life-threatening situation should prompt immediate discontinuation of the drug, along with discontinuation of any interacting drugs that may slow the elimination of the suspected causative agent. Although the role of corticosteroids in the treatment of serious cutaneous reactions is controversial, most clinicians choose to start prednisone at a dosage of 1 to 2 mg/kg/day when symptoms are severe, except in patients with SJS or TEN. Antihistamines, topical corticosteroids, or both can be used to alleviate symptoms. Resolution of the reaction over a reasonable time frame after the drug is discontinued is consistent with a drug cause but also occurs for many infective and other causes of transient cutaneous eruptions. Patients should not be rechallenged if they have suffered a potentially serious reaction.

TABLE 40-3
Clinical Features That Warn of a Potentially Severe Drug Reaction

- Systemic
  - Fever and/or other symptoms of internal organ involvement such as pharyngitis, malaise, arthralgia, cough, and meningism
  - Lymphadenopathy
- Cutaneous
  - Evolution to erythroderma
  - Prominent facial involvement ± edema or swelling
  - Mucous membrane involvement (particularly if erosive or involving conjunctiva)
  - Skin tenderness, blistering or shedding
  - Purpura

PREVENTION

Cutaneous reactions to drugs are largely idiosyncratic and unexpected; serious



reactions are rare. Once a reaction has occurred, however, it is important to prevent future similar reactions in the patient with the same drug or a cross-reacting medication. For patients with hypersensitivity and severe reactions, wearing a bracelet (e.g., MedicAlert) detailing the nature of the reaction is advisable, and patient records should be appropriate labeled.

Host factors appear important in many reactions. Some of these can be inherited, which places first-degree relatives at a greater risk than the general population for a similar reaction to the same or a metabolically cross-reacting drug. This finding appears to be important in SJS, TEN, and drug hypersensitivity syndrome.

Reporting reactions to the manufacturer or regulatory authorities is important. Post-marketing voluntary reporting of rare, severe, or unusual reactions remains crucial to enhance the safe use of pharmaceutical agents.

KEY REFERENCES

The full reference list for all chapters is available at www.digm7.com.

15. Pichler W et al: Cellular and molecular pathophysiology of cutaneous drug reactions. *Am J Clin Dermatol* **3**:229, 2002
21. Tan E, Grattan C: Drug-induced urticaria. *Expert Opin Drug Saf* **3**:471, 2004
30. Britschgi M, Pichler W: Acute generalized exanthematous pustulosis, a clue to neutrophil-mediated inflammatory processes orchestrated by T cells. *Curr Opin Allergy Clin Immunol* **2**:325, 2002
34. Wolf R et al: Life-threatening acute adverse cutaneous drug reactions. *Clin Dermatol* **23**:171, 2005
35. Roujeau J et al: Medication use and the risk of Stevens-Johnson syndrome or toxic epidermal necrolysis. *N Engl J Med* **333**:1600, 1995
57. Roujeau JC, Stern R: Severe adverse cutaneous reactions to drugs. *N Engl J Med* **331**:1272, 1994
66. Sullivan J, Shear N: The drug hypersensitivity syndrome: What is the pathogenesis? *Arch Dermatol* **137**:357, 2001



CHAPTER 41

Pityriasis Rosea

Andrew Blauvelt

The term *pityriasis rosea* (PR) was first used by Gibert in 1860 and means pink (rosea) scales (pityriasis).[1] PR is a common acute, self-limited skin eruption that typically begins as a single thin oval scaly plaque on the trunk ("herald patch") and is typically asymptomatic. The initial lesion is followed several days to weeks later by the appearance of numerous similar-appearing smaller lesions located along the lines of cleavage of the trunk (a so-called *Christmas tree* pattern). PR most commonly occurs in teenagers and young adults, and is most likely a viral exanthem associated with reactivation of human herpesvirus 7 (HHV-7) and sometimes HHV-6.[1–4] Possible treatment may focus on associated pruritus. One study suggests that administration of high-dose acyclovir for 1 week hastens recovery from PR.[5]

EPIDEMIOLOGY

PR is reported in all races throughout the world, irrespective of climate.[6–8] The average annual incidence at one center was reported to be 0.16 percent (158.9 cases per 100,000 person-years).[8] Although PR is usually considered to be more common in the spring and fall months in temperate zones, seasonal variation has not been borne out in studies performed in other parts of the world. Clustering of cases can occur and has been used to support an infectious etiology for PR, although this is not a consistent feature observed in all communities.[7] Most studies have shown a slight female preponderance of approximately 1.5:1.[6,8] PR most commonly occurs between the ages of 10 and 35 years.[8] It is rare in both the very young (defined as less than 2 years) and the elderly (defined as older than 65 years). Recurrences of PR are rare, which suggests lasting immunity after an initial episode of PR.

ETIOLOGY AND PATHOGENESIS

Historically, PR has been considered to be caused by an infectious agent, given (1) the resemblance of the rash to known viral exanthems, (2) rare recurrences of PR that suggest lifelong immunity after one episode, (3) occurrence of seasonal variation in some studies, (4) clustering in some communities, and (5) the appearance of flu-like symptoms in a subset of patients. Numerous studies over the past 50 years have explored various pathogens as possible causes of PR. These pathogens have included numerous bacteria, fungi, and, most notably, viruses. Beginning with a study by Drago and colleagues in 1997,[2] most recent PR etiologic and pathogenetic studies have been focused on two ubiquitous HHVs, HHV-7 and HHV-6. Critical evaluation of the medical and scientific literature on PR reveals neither credible nor reproducible evidence that PR is associated with any pathogen other than HHV-7 and HHV-6.

PITYRIASIS ROSEA AT A GLANCE



- Common acute papulosquamous eruption normally lasting 4 to 10 weeks.
- Most often begins as a single 2- to 4-cm thin oval plaque with a fine collarette of scale located inside the periphery of the plaque ("herald patch"). Similar-appearing, but smaller, lesions then appear several days to weeks later and are typically distributed along the lines of cleavage on the trunk (in a "Christmas tree" pattern).
- Usually asymptomatic, but sometimes associated with pruritus and mild flu-like symptoms.
- Occurs most commonly in teenagers and young adults.
- Best scientific evidence supports the theory that pityriasis rosea represents a viral exanthem associated with reactivation of human herpesvirus 7 and sometimes human herpesvirus 6.
- Treatment is usually supportive, although mid-potency topical corticosteroids can be used for associated pruritus. One report suggests that administration of high-dose acyclovir for 1 week may hasten recovery from the disease.

The best scientific evidence suggesting that PR is a viral exanthem associated with reactivation of either HHV-7 or HHV-6 (and sometimes with both viruses) is strong.[2–4,9–11] In fact, the most definitive and compelling study on herpesviruses and PR was by Broccolo and colleagues in 2005.[3] Using sensitive and quantitative techniques, investigators have collectively shown that (1) HHV-7 DNA, and less commonly HHV-6 DNA, can be readily detected in cell-free plasma or serum samples from many patients with PR but not in serum or plasma from healthy individuals or patients with other inflammatory skin diseases; (2) HHV-7 messenger RNA and protein, and less commonly HHV-6 messenger RNA and protein, can be detected in scattered leukocytes found in perivascular and perifollicular regions within PR lesions but not in normal skin or skin from patients with other inflammatory skin diseases; (3) HHV-7– and HHV-6–specific immunoglobulin M antibody elevations in the absence of virus-specific immunoglobulin G antibodies do not occur in PR patients, whereas in primary viral infections elevation of immunoglobulin M antibodies alone is typical; and (4) HHV-7 and HHV-6 DNA are present in saliva of individuals with PR, which is not observed in those with a primary infection with these viruses. Taken together, these data strongly suggest that PR is a viral exanthem associated with systemic reactivation of HHV-7 and, to a lesser extent, HHV-6. Patients are viremic, which may explain associated flu-like symptoms in some patients, and they generally do not have infected epithelial cells or large viral loads within skin lesions, which explains the difficulty in detecting these viruses by electron microscopy and by non-nested polymerase chain reaction testing.

Despite these findings, there is still controversy over the role of HHV-7 and HHV-6 in the etiology of PR, because a number of studies with "negative" results have failed to support a causative role for HHV-7 and HHV-6 in this disease.[12–14] Whereas the studies with positive results have used the most sensitive, specific, and calibrated techniques for virologic studies and reports have been published in high-quality journals, the studies with negative results either used laboratory methods that were not particularly sensitive, calibrated, or quantifiable, or focused on peripheral blood mononuclear cells rather than cell-free plasma or serum.

Correct interpretation of the recent viral literature on PR also requires proper understanding of the biology of HHV-7 and HHV-6. HHV-7 and HHV-6 are closely related β-herpesviruses, and the clinical diseases and biology associated with this group of herpesviruses are not as well studied as those of the α-herpesviruses (herpes simplex virus 1 and 2, varicella-zoster virus) and the γ-herpesviruses (Epstein-Barr virus and Kaposi sarcoma–associated herpesvirus). HHV-6 and HHV-7 are ubiquitous, with 90 percent of the U.S. population infected with HHV-6 by the age of 3 years[15] and 90 percent of the U.S. population infected with HHV-7 by the age of 5 years.[16] Unlike the α-herpesviruses, HHV-7 and HHV-6 do not infect keratinocytes but instead infect $CD4^+$ T cells within blood and are retained within these cells in a latent form in most individuals.[15–17] These cells are the likely source of cell-free viral DNA found in plasma or serum samples of patients with PR. They are also the likely source of the scattered perivascular and perifollicular virus-positive cells observed within some lesions of PR.[3,4]

It is important to note that the concept that PR represents a reactive viral exanthem containing few infected cells within skin lesions and viral reactivation within circulating blood $CD4^+$ T cells is perfectly analogous to that of the disease roseola, which is well accepted to be caused by primary infection with either HHV-6 or HHV-7[18,19] (see Chap. 192). In roseola, children are viremic and skin lesions generally do not contain infected cells.[20] Complete understanding of the role of HHV-7 and HHV-6 in the pathogenesis of PR is lacking at this time. For example, the mechanisms by which HHV-7 and HHV-6 are reactivated are unknown. As well, the characteristic distribution of lesions and differences in lesional and non-lesional skin are unexplained.

CLINICAL FINDINGS

History

In classic PR, patients usually describe the onset of a single truncal skin lesion followed several days to weeks later by the onset of numerous smaller lesions on the trunk. Pruritus is severe in 25 percent of patients with uncomplicated PR, slight to moderate in 50 percent, and absent in 25 percent. In a minority of patients, flu-like symptoms have been reported, including general malaise, headache, nausea, loss of appetite, fever, and arthralgias.

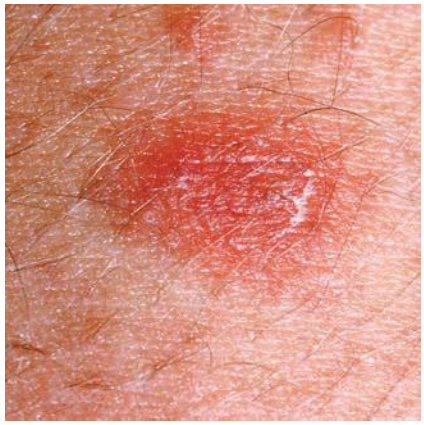

▲ **FIGURE 41-1** A typical primary plaque (herald patch) of pityriasis rosea, demonstrating an oval shape and fine scale inside the periphery of the plaque.

Cutaneous Lesions

The primary plaque of PR, or herald patch (Figs. 41-1, 41-2, 41-3 and see eFigs. 41-3.1 and 41-3.2 in on-line edition), is seen in 50 percent to 90 percent of cases. It is normally well demarcated; 2 to 4 cm in diameter; oval or round; salmon colored, erythematous, or hyperpigmented (especially in individuals with darker skin); and demonstrates a fine collarette of scale just inside the periphery of the plaque. When the plaque is irritated, it may have an eczematous papulovesicular appearance (see eFig. 41-3.3 in on-line edition). The primary plaque is usually located on the trunk in areas covered by clothes, but sometimes it is on the neck or proximal extremities. Localization on the face or penis is rare. The site of the primary lesion does not differ in males and females.

The interval between the appearance of the primary plaque and the secondary eruption can range from 2 days to 2



▲ **FIGURE 41-2** A non-scaly purpuric primary plaque (herald patch) of pityriasis rosea.





▲ **FIGURE 41-3** A double herald patch of pityriasis rosea.



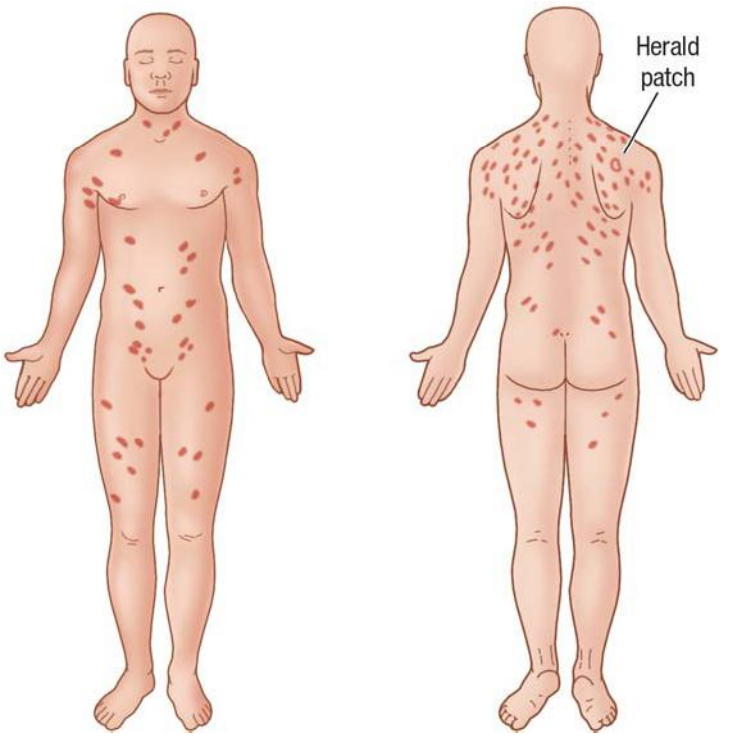

▲ **FIGURE 41-4** Schematic diagram of the primary plaque (herald patch) and the typical distribution of secondary plaques along the lines of cleavage on the trunk in a Christmas tree pattern.

months, but the secondary eruption typically occurs within 2 weeks of the appearance of the primary plaque. At times, the primary and secondary lesions may appear at the same time. The secondary eruption occurs in crops at intervals of a few days and reaches its maximum in approximately 10 days. Occasionally, new lesions continue to develop for several weeks. The symmetric eruption is localized mainly to the trunk and adjacent regions of the neck and proximal extremities (Fig. 41-4). The most pronounced lesions extend over the abdomen and anterior surface of the chest as well as over the back (Figs. 41-5, 41-6, 41-7 and see eFigs. 41-6.1 and 41-6.2 in on-line edition). Lesions distal to the elbows and knees can occur but are less common. Two main types of secondary lesions occur: (1) small plaques resembling the primary plaque in miniature aligned with their long axes along lines of cleavage and distributed in a Christmas tree pattern, and (2) small, red, usually non-scaly papules that gradually increase in number and spread peripherally. Both types of lesions may exist concomitantly.

In approximately 20 percent of patients, the clinical picture diverges from the classic one described earlier. The primary plaque may be missing or present as double or multiple lesions (see Fig. 41-3 and see eFig. 41-3.1 in on-line edition), often close together. The primary plaque may be the sole manifestation of the disease or only one of two lesions (see eFig. 41-3.2 in on-line edition). The distribution of the secondary eruption may be exclusively peripheral. Facial involvement has been reported and occurs mainly in children. Localized forms of disease may involve certain body regions such as the scalp, axillae, vulva, and groin (see eFigs. 41-3.3 and 41-6.1 in on-line edition) and also may be localized to one side of the body.

The morphology of the secondary lesions may be atypical, and in these cases, the diagnosis of PR can be more challenging. Macules may occur and lack scaling, papules may be follicular, and typical plaques may be absent or resemble psoriasis (see eFig. 41-7.1 in on-line edition). The palms and soles are involved at times, and the clinical picture in these patients may simulate a widespread eczematous eruption. A vesicular type of PR (see eFig. 41-3.3 in on-line edition) is uncommon and usually affects children and young adults. Urticarial, pustular, purpuric (see Fig. 41-2 and see eFig. 41-7.2 in on-line edition), and erythema multiforme–like variants of PR also exist. These atypical forms of PR are not uniformly difficult to diagnose, because many patients will have classic plaques admixed with various atypical lesions, such as vesicles, follicular papules, and purpura.



▲ **FIGURE 41-5** Typical distribution of secondary plaques along the lines of cleavage on the back in a Christmas tree pattern.



▲ **FIGURE 41-6** Typical distribution of secondary plaques along the lines of cleavage on the chest of a black individual.



▲ **FIGURE 41-7** Vesicular pityriasis rosea, showing typical primary plaque and secondary papulovesicles. Note Christmas tree distribution.

Related Physical Findings

In rare cases enanthema may occur with hemorrhagic macules and patches, bullae on the tongue and cheeks, or lesions that resemble aphthous ulcers. Nail dystrophy after PR has also been reported. Lymphadenopathy may occur in patients with PR, especially early in the course of the disease and in association with flu-like symptoms.

LABORATORY TESTS

In cases of classic PR, most patients do not require skin biopsies because the diagnosis is straightforward on clinical grounds and the histologic findings are nonspecific. Typical histopathologic features include focal parakeratosis, a reduced or absent granular cell layer, mild acanthosis, mild spongiosis, papillary dermal edema, a perivascular and superficial dermal interstitial infiltrate of lymphocytes and histiocytes, and focal extravasation of erythrocytes (Fig. 41-8). Similar histologic findings are observed in both primary and secondary plaques. The histologic picture is indistinguishable from that of superficial gyrate erythema.

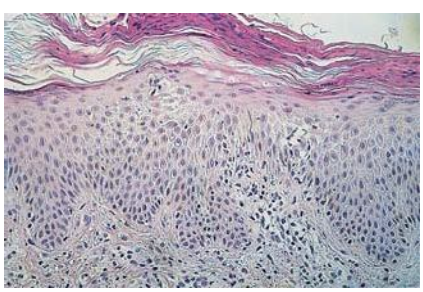

▲ **FIGURE 41-8** Typical nonspecific histologic features of pityriasis rosea, including patchy parakeratosis, absence of a granular cell layer, slight acanthosis, spongiosis, and a lymphohistiocytic infiltrate in the superficial dermis.

In older lesions, the perivascular infiltrate is often both superficial and deep, with less spongiosis and more pronounced acanthosis. These late lesions may be difficult to distinguish from psoriasis and lichen planus.

Routine blood studies usually give normal results and are not recommended. However, leukocytosis, neutrophilia, basophilia, lymphocytosis, and slight increases in erythrocyte sedimentation rate and levels of total protein, α_1- and α_2-globulins, and albumin have been reported.

DIFFERENTIAL DIAGNOSIS (Box 41-1)

Secondary syphilis may present with slightly scaly lesions and can mimic papular PR with no primary plaque. Mucosal lesions and lymphadenopathy may occur in both PR and syphilis, but as with involvement of the palms and soles, these findings are much more common in the latter. Serologic tests for syphilis will differentiate the two. Tinea corporis may resemble PR, especially when PR occurs as only a primary plaque or when it is localized to the groin area. Scaling will be at the periphery of the plaques in tinea corporis as opposed to inside the periphery of plaques in PR. Mycologic investigation is often necessary to rule out dermatophyte infection. The lesions of nummular dermatitis are usually round, not oval, and pinpoint papules and vesicles are more prominent than in PR. Guttate psoriasis may cause difficulties in diagnosing PR when only a few lesions are present, when lesions follow lines of cleavage, and when the disease course is chronic. Histologic examination may be useful in these cases. Pityriasis lichenoides chronica may present with a Christmas tree pattern on the trunk, but as a rule, typical lesions will be found on the extremities.

Box 41-1

Differential Diagnosis of Pityriasis Rosea (PR)

- **Secondary syphilis:** history of primary chancre, no herald patch is present, lesions typically involve palms and soles, condyloma lata may be present, usually more systemic complaints and lymphadenopathy, presence of plasma cells on histology. When in doubt, serologically test patient for syphilis (e.g., perform a Venereal Disease Research Laboratory test).
- **Tinea corporis:** scale is usually at periphery of plaques, plaques usually not oval and distributed along lines of cleavage. When in doubt, perform a KOH examination.
- **Nummular dermatitis:** plaques usually circular and not oval, no collarettes of scale, tiny vesicles common. When in doubt, perform a biopsy.
- **Guttate psoriasis:** plaques usually smaller than PR plaques and do not follow lines of cleavage, scale is thick and not fine. When in doubt, perform a biopsy.
- **Pityriasis lichenoides chronica:** longer disease course, smaller lesions, thicker scale, no herald patch is present, more common on extremities. When in doubt, perform a biopsy.
- **PR-like drug eruption:** see text for extensive list. When in doubt, obtain a drug history.

Many drugs have been reported to cause PR-like rashes. Thus, it is always important to obtain a drug history to investigate this possibility. These include arsenic, barbiturates, bismuth, captopril, clonidine, gold, interferon-α, isotretinoin, ketotifen, labetalol, organic mercurials, methoxypromazine, metronidazole, omeprazole, D-penicillamine, salvarsan, sulfasalazine, terbinafine, and tripelene amine hydrochloride. Of note, a more recent addition to this list is imatinib,[21] a drug used in the treatment of chronic myeloid leukemia. Drug-induced PR may be of the classic type, but it often shows atypical features, a protracted course, large lesions, subsequent marked hyperpigmentation, and transformation to lichenoid dermatitis.

COMPLICATIONS

Patients may experience flu-like symptoms, but these are relatively mild if they occur. No serious complications occur in PR patients.

PROGNOSIS AND CLINICAL COURSE

All patients with PR have complete spontaneous resolution of their disease. The disease duration normally varies between 4 and 10 weeks, with the first few weeks associated with the most new inflammatory skin lesions and the greatest likelihood of flu-like symptoms. Both post-inflammatory hypopigmentation and hyperpigmentation can follow PR. As with other skin diseases, this occurs more commonly in individuals with darker skin color, with hyperpigmentation predominating. Treatment with ultraviolet light phototherapy may also worsen post-inflammatory hyperpigmentation and



should be used with caution. Otherwise, patients have no residual effects secondary to the occurrence of PR. Recurrent disease is possible, but it is rare.

TREATMENT

Because PR is self-limited, there is no need for active treatment in uncomplicated cases. Patient education and reassurance is warranted in all cases. Midpotency topical corticosteroids may be used for symptomatic relief of pruritus. Interestingly, Drago and colleagues have reported that patients given high-dose acyclovir (i.e., 800 mg five times daily for 1 week) experienced more rapid resolution of PR than patients treated with placebo for 1 week.[5] Specifically, 79 percent of 42 patients had complete resolution of PR within 2 weeks of starting acyclovir therapy, whereas 4 percent of 45 patients treated with placebo experienced resolution of their disease at 2 weeks. Although patients were blinded to the type of treatment they received, the trial was limited in that the investigators were not blinded and the patients were not randomly assigned to one of the two treatment groups. Given that acyclovir and its derivatives are relatively inexpensive and well-tolerated drugs, this form of therapy should be considered in PR patients presenting early in their disease course who demonstrate associated flu-like symptoms and/or extensive skin disease. Several years ago, erythromycin was reported to be of benefit to patients with PR,[22] but clinical experience and a more recent report showing no efficacy of azithromycin in PR have not confirmed this initial result.[23] Some patients with PR may benefit from phototherapy,[24] although this should be used with caution given that it can increase the risk of post-inflammatory hyperpigmentation after disease resolution (Box 41-2).

Box 41-2

Treatment of Pityriasis Rosea

- For all patients: education about the disease process and reassurance
- For patients with associated pruritus: midpotency topical corticosteroids
- For patients early in the disease course who demonstrate associated flu-like symptoms and/or extensive skin disease: oral acyclovir 800 mg five times daily for 1 week (or equivalent acyclovir derivative) may hasten recovery from disease
- For selected patients: phototherapy may be useful

PREVENTION

There are no data on how PR can be prevented.

KEY REFERENCES

The full reference list for all chapters is available at www.digm7.com.

2. Drago F et al: Human herpesvirus 7 in pityriasis rosea. *Lancet* **349**:1367, 1997
3. Broccolo F et al: Additional evidence that pityriasis rosea is associated with reactivation of human herpesvirus-6 and -7. *J Invest Dermatol* **124**:1234, 2005
4. Watanabe T et al: Pityriasis rosea is associated with systemic active infection with both human herpesvirus-7 and human herpesvirus-6. *J Invest Dermatol* **119**:793, 2002
5. Drago F, Vecchio F, Rebora A: Use of high-dose acyclovir in pityriasis rosea. *J Am Acad Dermatol* **54**:82, 2006
7. Chuh AA et al: Temporal case clustering in pityriasis rosea: A regression analysis on 1379 patients in Minnesota, Kuwait, and Diyarbakir, Turkey. *Arch Dermatol* **141**:767, 2005
14. Chuh AA, Chan HH, Zawar V: Is human herpesvirus 7 the causative agent of pityriasis rosea?—a critical review. *Int J Dermatol* **43**:870, 2004
21. Brazzelli V et al: Pityriasis rosea–like eruption during treatment with imatinib mesylate: Description of 3 cases. *J Am Acad Dermatol* **53**:S240, 2005



CHAPTER 42

Erythema Annulare Centrifugum and Other Figurate Erythemas

Walter H. C. Burgdorf

The figurate erythemas include a variety of eruptions characterized by annular and polycyclic lesions. Classification of this group has always been controversial; the literature abounds with contradictions, uncertainties and a bewildering array of synonyms. Darier in 1916 was the first to use the term *erythema annulare centrifugum* (EAC), although similar lesions had been described previously under other names.[1] Table 42-1 lists the figurate erythemas and the differential diagnoses to consider.

EPIDEMIOLOGY

EAC is an uncommon disorder. No epidemiologic data are available. There are only two large series in the literature: 66 cases identified clinically[2] and 73 first diagnosed histologically.[3] EAC appears to have no predilection for either sex or for any age group. Erythema gyratum perstans is an older synonym for familial EAC.

ETIOLOGY AND PATHOGENESIS

Almost certainly EAC is not a single disease but a clinical finding with many causes. Both the annularity and the peripheral spread of EAC have attracted speculation as to a possible mechanism. Most hypotheses have centered around interactions among inflammatory cells, their mediators, and ground substance as foreign antigens diffuse through the skin.[4,5]

ERYTHEMA ANNULARE CENTRIFUGUM AT A GLANCE



- Clinical pattern of annular expanding erythematous rings, which enlarge rapidly, fade, and then disappear, as new lesions appear.
- Diagnosis of erythema annulare centrifugum is one of exclusion.
- Superficial and deep variants can be separated clinically and histologically. Deep form is often lupus tumidus.
- No single cause.

TABLE 42-1
Migrating Erythemas

Disorder	Key Features	Chapter
Erythema annulare centrifugum (EAC)	Slowly migrating lesions; often idiopathic.	This chapter
Erythema gyratum repens	Rapidly moving; usually cancer mark.	154
Erythema migrans	Annular lesions originating from tick bite; skin sign of Lyme borreliosis.	187
Annular urticaria	Giant urticaria is annular and overlaps with EAC; patients have ordinary urticaria elsewhere and more pruritus.	37
Bullous pemphigoid	Early lesions often urticarial and may be annular.	54
Erythema multiforme	Target lesions, usually acral, often mucosal disease; some lesions annular.	38
Dermatophyte infections and tinea versicolor	Many fungal infections are annular (ringworm); they resemble superficial EAC but the scale contains hyphae or spores.	188, 189
Annular psoriasis	Pustular and occasionally ordinary psoriasis may have annular lesions.	18
Annular lupus erythematosus	Most common in neonatal form; Ro/La antibodies should be sought; overlaps with Sjögren syndrome (especially in Asians).	156
Erythema marginatum	Transient, rapidly spreading annular erythema; specific for rheumatic fever.	161
Necrolytic migratory erythema	Marker for glucagonoma; erosive perioral and acral lesions, but truncal lesions may be polycyclic.	154
Carrier state chronic granulomatous disease	Female carriers may have annular lupus erythematosus–like rash.	144
Hereditary lactate dehydrogenase M-subunit deficiency	Another rare genodermatosis with annular erythematous and scaly lesions.	This chapter
Familial annular erythema	Extremely rare.	This chapter
Annular erythema of infancy	Many different disorders; must rule out neonatal lupus erythematosus.	This chapter

The cause of most cases of EAC is unknown. In one series, 24 patients were closely evaluated, and in none of the cases was any definite cause found.[6] Bacterial or candidal infections are most often suspected as triggers.[7,8] Autoimmune diseases are also occasionally associated.[9] The hormonal changes of menses[10] or pregnancy have been implicated as well.[11] Although medications are often identified as causing EAC in case reports, none regularly induces such lesions.[12] EAC may be coupled with malignant neoplasms, with the eruption disappearing after treatment of the tumor and often returning as the tumor recurs.[13] This paraneoplastic marker must be distinguished from metastatic tumors with an annular pattern.[14]

CLINICAL FINDINGS

History

The history is most important in exploring the differential diagnostic considerations. In general the lesions are asymptomatic but may be cosmetically disturbing.

Cutaneous Lesions

EAC presents as one or more lesions that begin as erythematous macules or urticarial papules and enlarge by peripheral extension to form ringed, arcuate, or polycyclic figures (Fig. 42-1). They spread gradually to form large rings with central clearing, with the edges of the lesions often advancing several millimeters a day (see eFig. 42-1.1 in on-line edition). After a variable period of time, the lesions disappear, often to be replaced by new ones. In some cases annual recurrence has been described.[15]



▲ **FIGURE 42-1** Superficial erythema annulare centrifugum. A large annular plaque with trailing scale behind the advancing erythematous edge.

Two sub-types of EAC can be identified both clinically and histologically[16]:

1. Superficial gyrate erythema has an indistinct border and trailing scale and may be pruritic (see Fig. 42-1, also see eFig. 42-1.1 in on-line edition).
2. Deep gyrate erythema has a firm yet indurated border, lacks scale, and is less often pruritic (Fig. 42-2, see eFig. 42-2.1 in on-line edition).

Additional findings may point to an underlying disorder, but most patients have no systemic signs or symptoms.



▲ **FIGURE 42-2** Deep erythema annulare centrifugum. Annular, slowly spreading lesions without scale, similar to urticaria but more long lived.

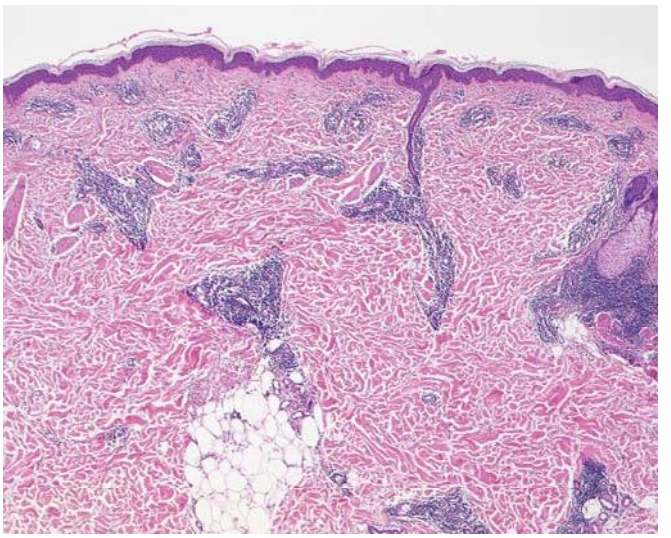



▲ **FIGURE 42-3** Deep erythema annulare centrifugum with normal epidermis and lymphocytic infiltrates about vessels of superficial and deep dermis. Many such lesions are lupus tumidus, so a careful search for mucin is mandatory. None is seen here. (Used with permission from Heinz Kutzner, Friedrichshafen, Germany.)

LABORATORY TESTS

Histopathology

Superficial EAC has epidermal changes of parakeratosis and spongiosis, with a superficial perivascular infiltrate (see eFigs. 42-2.2 and 42-2.3 in on-line edition). Deep EAC lacks epidermal damage and has intense lymphohistiocytic cuffing about both the superficial and deep vessels (Fig. 42-3). There is minimal papillary dermal edema and no spongiosis. One should search carefully for mucin as a clue to lupus erythematosus.

Other Laboratory Tests

There are no other laboratory tests diagnostic for EAC.

DIFFERENTIAL DIAGNOSIS (Box 42-1)

The differential diagnostic challenge in EAC is twofold. First one must exclude other eruptions that can appear similar, such as erythema migrans as the first sign of borreliosis (see Chap. 187) or erythema gyratum repens, which is generally more rapidly moving and usually reflects an underlying malignancy (see Chap. 154). In addition, there are diseases that can clinically present as EAC, but biopsy will provide a different answer. Included in this group are leukocytoclastic vasculitis, granulomatous disorders, metastases, and eosinophilic infiltrates.[17]

Then comes the problem of the many odd disorders that cause confusion, because they seem to have distinctive features but are rarely encountered (see Table 42-1). Prime examples are annular erythemas associated with the carrier state of chronic granulomatous disease[18] or a lactate dehydrogenase M-subunit deficiency.[19] There are also neutrophilic and lichenoid[20] variants of EAC. Familial EAC, originally described as erythema gyratum perstans, is rare.[21] Finally, there is the broad spectrum of annular erythemas of infancy,[22] including neonatal lupus erythematosus, *Malassezia furfur* infections, and the idiopathic variants which themselves may show eosinophilic or neutrophilic infiltrates,[23] as well as atrophy.[24]

Box 42-1

Differential Diagnosis of Erythema Annulare Centrifugum (EAC)

Most Likely

- Dermatophyte infections
- Tinea versicolor
- Erythema migrans
- Annular urticaria
- Lupus erythematosus
  - Lupus tumidus for deep EAC
  - Subacute lupus erythematosus for superficial EAC
- Annular psoriasis

Consider

- Erythema multiforme
- Granulomatous diseases (granuloma annulare, actinic granuloma, sarcoidosis)
- Bullous pemphigoid (urticarial phase)
- Leukocytoclastic vasculitis (especially in children)
- Erythema marginatum
- Erythema gyratum repens
- Necrolytic migratory erythema
- Hypereosinophilic syndrome
- Carrier state chronic granulomatous disease
- Hereditary lactase dehydrogenase M-subunit deficiency
- Familial annular erythema
- Annular erythemas of infancy

Always Rule Out

- Lupus erythematosus
- Underlying tumor or annular metastasis

PROGNOSIS AND CLINICAL COURSE

EAC tends to be a chronic disease, which waxes and wanes. The course is determined by associated diseases or triggers.

TREATMENT

Although an assiduous search for the underlying cause is the primary goal of treatment, only symptomatic relief is available. Systemic glucocorticoids usually suppress EAC, but recurrence is common when these drugs are stopped. Systemic therapy with antipruritics may help. Topical vitamin D analogues, perhaps combined with ultraviolet irradiation, are another option.[25,26] Empiric use of antibiotic, antifungal, or anti-candidal agents has sometimes been useful.[27] Biologics may represent yet another option.[28] In general, most of the therapeutic approaches used for chronic urticaria can also be tried for EAC.

KEY REFERENCES

The full reference list for all chapters is available at www.digm7.com.

2. Kim KJ et al: Clinicopathologic analysis of 66 cases of erythema annulare centrifugum. *J Dermatol* **29**:61, 2002
3. Weyers W, Diaz-Cascajo C, Weyers I: Erythema annulare centrifugum: Results of a clinicopathologic study of 73 patients. *Am J Dermatopathol* **25**:451, 2003
6. Mahood JM: Erythema annulare centrifugum: A review of 24 cases with special reference to its association with underlying disease. *Clin Exp Dermatol* **8**:383, 1983
15. Garcia Muret MP et al: Annually recurring erythema annulare centrifugum: A distinct entity? *J Am Acad Dermatol* **54**:1091, 2006
25. Gniadecki R: Calcipotriol for erythema annulare centrifugum. *Br J Dermatol* **146**:317, 2002
27. De Aloe G et al: Erythema annulare centrifugum successfully treated with metronidazole. *Clin Exp Dermatol* **30**:583, 2005
28. Minni J, Sarro R: A novel therapeutic approach to erythema annulare centrifugum. *J Am Acad Dermatol* **54**:S134, 2006

CHAPTER 43

Granuloma Annulare

Julie S. Prendiville

Granuloma annulare is a benign self-limited disease, first described by Colcott-Fox[1] in 1895 and Radcliffe-Crocker[2] in 1902.

EPIDEMIOLOGY

Granuloma annulare is a relatively common disorder.[3] It occurs in all age groups but is rare in infancy.[3–5] The localized annular and subcutaneous forms occur more frequently in children and young adults. The generalized variant is more common in adults. Many studies report a female preponderance,[3] but some have found a higher frequency in males.[6] Granuloma annulare does not favor a particular race or geographic area, with the possible exception of the perforating type, which may be more common in Hawaii.[7]

Most cases of granuloma annulare are sporadic. Occasional familial cases are described with occurrence in twins, siblings, and members of successive generations.[3,8,9] Attempts to identify an associated HLA sub-type have yielded disparate results in different population groups.[10,11]

ETIOLOGY AND PATHOGENESIS

The etiology of granuloma annulare is unknown, and the pathogenesis is poorly understood. Most cases occur in otherwise healthy children. A variety of predisposing events and associated systemic diseases is reported, but their significance is unclear. It is possible that granuloma annulare represents a phenotypic reaction pattern with many different initiating factors.[12]

Predisposing Events

Non-specific mild trauma is considered a possible triggering factor because of the frequent location of lesions on the distal extremities of children. An early study of subcutaneous granuloma annulare found a history of trauma in 25 percent of children,[3] but this observation has not been replicated. Trauma is also a suspected factor in auricular lesions.[13] Granuloma annulare has occurred after a cat bite[14] and an octopus bite,[15] and insect bite reactions have been implicated.[3] There is a report of perforating granuloma annulare in long-standing tattoos.[16] Widespread lesions have developed after waxing-induced pseudofolliculitis[17] and erythema multiforme minor,[18] and in association with systemic sarcoidosis.[3,19] Severe uveitis without other evidence of sarcoidosis was found in eight patients with granuloma annulare.[20]

INFECTIONS AND IMMUNIZATIONS There are several reports of the development of granuloma annulare within herpes zoster scars, sometimes many years after the active infection.[21] It is also described after chickenpox.[22] Generalized, localized, and perforating forms of granuloma annulare may occur in association with human immunodeficiency virus (HIV) infection (see eFig. 43-0.1 in online edition).[23–28] Adenovirus was isolated from a lesion in one HIV-positive patient.[29] Epstein-Barr virus was excluded as a causative agent in these cases.[23,24] However, in other instances generalized granuloma annulare has been linked to viral infections, including Epstein-Barr virus infection,[30] chronic hepatitis B,[31] and hepatitis C.[32] Vaccinations for tetanus,[33] diphtheria toxoid,[34] and hepatitis B vaccination[35] have been implicated as triggering factors, although vaccination sites were spared in one case of generalized granuloma annulare.[36]

Lesions compatible with granuloma annulare may occur in patients with active tuberculosis.[12] There are also reports of granuloma annulare after tuberculin skin tests[3] and bacille Calmette-Guérin immunization.[37] Evidence of *Borrelia burgdorferi* infection was detected in two reports,[38,39] but this association was not confirmed in a serologic study.[40] A case in which chronic relapsing granuloma annulare flared during scabies infestation was attributed to the Koebner phenomenon.[41]

SUN EXPOSURE Granuloma annulare with a predilection for sun-exposed areas[42–44] and seasonal recurrence[42] has been described. Photosensitive granuloma annulare has been observed in patients with HIV infection.[45] One patient developed generalized disease after psoralen plus ultraviolet A light therapy,[46] but it is of note that phototherapy and psoralen/ultraviolet A phototherapy have also been used to treat generalized granuloma annulare.[47–50]

Actinic granuloma, also known as *annular elastolytic giant cell granuloma*, develops on photodamaged skin and is believed to represent a granulomatous reaction to actinic elastosis.[51] Its relationship to granuloma annulare is debated.

DRUGS Granuloma annulare–like drug reactions are reported for gold therapy and treatment with allopurinol, diclofenac, quinidine, intranasal calcitonin, and amlodipine.[52] An interstitial granulomatous drug reaction linked to the use of angiotensin-converting enzyme inhibitors, calcium channel blockers, and other medications is considered a distinct entity but may mimic granuloma annulare.[53,54]

DIABETES MELLITUS AND THYROID DISEASE Development of granuloma annulare in patients with diabetes mellitus is extensively documented. Whether this is a true relationship has long been debated. The link is primarily with type 1 insulin-dependent diabetes,[55] but cases are also reported with type 2 non–insulin-dependent disease.[56–58] Localized[55] and generalized[43,58,59] as well as subcutaneous nodular[56,60,61] and perforating[5,7] forms of granuloma annulare have been observed. Granuloma annulare rarely pre-dates the onset of diabetes.[55,61] The histopathologic similarity between granuloma an-

GRANULOMA ANNULARE AT A GLANCE


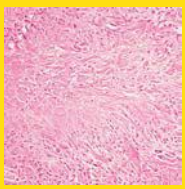

- Relatively common disorder; exact prevalence is unknown; favors children and young adults.
- A localized ring of beaded papules on the extremities is typical; generalized, subcutaneous, perforating, and patch subtypes also occur.
- The cause is unknown, and the pathogenesis is poorly understood.
- Pathologic features consist of granulomatous inflammation in a palisaded or interstitial pattern associated with varying degrees of connective tissue degeneration and mucin deposition.
- Most cases resolve spontaneously within 2 years.





▲ **FIGURE 43-1** **A.** Typical annular lesion of granuloma annulare on a finger. **B.** A larger annular lesion of granuloma annulare on the dorsum of the hand.



nulare and necrobiosis lipoidica diabeticorum and the co-existence of both conditions in occasional diabetic patients[57] suggest a true association. However, most patients with granuloma annulare do not have diabetes mellitus. Studies attempting to establish a causal correlation have yielded conflicting results.[55,62,63]

Granuloma annulare has also occurred in a number of patients with thyroiditis, hypothyroidism, and thyroid adenoma.[59,64–67]

MALIGNANCY An association between granuloma annulare and malignancy in adult patients is reported primarily with Hodgkin and non-Hodgkin lymphoma, including mycosis fungoides, Lennert lymphoma, B-cell disease,[68–71] and T-cell large cell lymphocytic leukemia.[72] It is reported less commonly with solid tumors, particularly of the breast.[43,68] The skin lesions of cutaneous lymphoma and other hematologic malignancies may mimic granuloma annulare both clinically and histopathologically.[73,74] It may be difficult to distinguish whether they represent true granuloma annulare with atypical lymphocytes, or cutaneous lymphoma obscured by a granulomatous infiltrate.[70,71]

Pathogenetic Mechanisms

The pathogenetic mechanisms that result in foci of altered connective tissue surrounded by a granulomatous inflammatory infiltrate are not understood. Proposed mechanisms include (1) a primary degenerative process of connective tissue initiating granulomatous inflammation,[75] (2) a lymphocyte-mediated immune reaction resulting in macrophage activation and cytokine-mediated degradation of connective tissue,[27,76–80] and (3) a subtle vasculitis or other microangiopathy leading to tissue injury.[76]

CLINICAL FINDINGS

History

The typical history is of one or more papules with centrifugal enlargement and central clearing. These annular lesions are often misdiagnosed as tinea corporis and treated unsuccessfully with topical antifungal agents. Subcutaneous nodules may raise suspicion about malignancy or rheumatoid disease.

Granuloma annulare is usually asymptomatic. Mild pruritus may be present, but painful lesions are rare.[81,82] Nodular lesions on the feet may cause discomfort from footwear.[83] Cosmesis is often a concern for adolescent and adult patients, particularly with generalized disease.

Cutaneous Lesions

Clinical variants of granuloma annulare include the localized, generalized, subcutaneous, perforating, and patch types. Linear granuloma annulare,[84] a follicular pustular form,[85] and papular umbilicated lesions in children[86] have also been described. There is overlap between the different variants, and more than one morphologic type may co-exist in the same patient.

LOCALIZED TYPE The most common form of granuloma annulare is an annular or arcuate lesion. It may be skin colored, erythematous, or violaceous. It usually measures 1 to 5 cm in diameter.[3] The annular margin is firm to palpation and may be continuous or consist of discrete or coalescent papules in a complete or partial circle (Fig. 43-1). The epidermis is usually normal, but surface markings may be attenuated over individual papules. Within the annular ring, the skin may have a violaceous or pigmented appearance. Solitary firm papules or nodules may also be present. Papular lesions on the fingers may appear umbilicated.

The dorsal hands and feet, ankles, lower limbs, and wrists are the sites of predilection (see Figs. 43-1, 43-2). Less commonly, lesions occur at other sites, including the eyelids.[87] The palms and soles are occasionally involved.[81,82] Localized annular lesions may co-exist with the subcutaneous or patch forms.

GENERALIZED TYPE The generalized form of granuloma annulare is said to comprise 8 percent to 15 percent of cases.[3,43] The majority of patients are adult, but it may be seen in childhood.[43,88] Unlike in localized disease, the trunk is frequently involved, in addition to the neck and extremities. The face, scalp, palms, and soles may also be affected.[43]

Generalized granuloma annulare presents as widespread papules (Fig. 43-3A), some of which coalesce to form small annular plaques or larger discolored patches with raised arcuate and serpiginous margins (see Fig. 43-3B). Lesions may be skin colored, pink, violaceous, tan, or yellow. An annular or non-annular morphology may predominate.[43] A generalized form of perforating granuloma annulare has also been described.[5,7]

SUBCUTANEOUS TYPE The subcutaneous form of granuloma annulare occurs



▲ **FIGURE 43-2** Localized granuloma annulare with nodule on the hand of a child.



▲ **FIGURE 43-3** **A.** Generalized granuloma annulare. Small papular lesions that are too small to exhibit annular configuration. **B.** Multiple annular lesions on the lower arm.

predominantly in children[89,90] but is also described in adult patients.[91–93] It is characterized by firm to hard, usually asymptomatic nodules located in the deep dermis and subcutaneous tissues. They may extend to underlying muscle, and nodules on the scalp and orbit are often adherent to the underlying periosteum.

Individual lesions measure from 6 mm to 3.5 cm in diameter.[90,94] They are distributed most often on the anterior lower legs in a pretibial location.[89] Other sites of predilection are the ankles, dorsal feet, buttocks, and hands.[93,95] Nodules on the scalp,[94,96] eyelids,[97–99] and orbital rim[60,100,101] may present a diagnostic challenge. Subcutaneous granuloma annulare may also be found on the penis.[102]

PERFORATING TYPE The perforating type of granuloma annulare is a rare variant characterized by trans-epidermal elimination of the necrobiotic collagen. It may be localized, usually to the dorsal hands and fingers (see eFig. 43-3.1 in on-line edition), or generalized over the trunk and extremities.[5,7] It has been described on the ears[103] and within herpes zoster scars and tattoos.[16] Superficial small papules develop central umbilication or crusting, and there may be discharge of a creamy fluid. Lesions heal with atrophic or hyperpigmented scars. In one series, 24 percent of patients complained of pruritus and 21 percent of pain.[104] Papular umbilicated granuloma annulare on the hands of children[86] and a generalized follicular pustular type of granuloma annulare[85] may be clinical variants.

PATCH TYPE Macular lesions that present as erythematous, red-brown, or violaceous patches without an annular rim are reported in adult women.[80,105] An arcuate dermal erythema is also observed. Generalized confluent erythema has been described in an HIV-positive patient.[27]

Related Physical Findings

Most patients with granuloma annulare are healthy and have no other abnormal physical findings. Arthralgia is reported in association with painful lesions on the hands.[82] Granuloma annulare–like skin lesions and joint disease characterize a multisystem disorder described as interstitial granulomatous dermatitis with arthritis.[106]

Oral involvement was observed in one patient with HIV-associated disease.[24]

LABORATORY TESTS

A diagnosis of localized annular granuloma annulare is made on clinical examination, and further evaluation is rarely indicated. Biopsy to obtain a specimen for histopathologic examination is necessary when the presentation is atypical, when lesions are symptomatic, and when the diagnosis is otherwise in doubt. Histopathologic analysis may be required to confirm a diagnosis of generalized granuloma annulare or subcutaneous nodular disease on the head and orbital region.

Histopathologic Findings

The diagnosis is best made at low magnification. Changes are usually observed in the upper and middle dermis, although any part of the dermis or subcutis can be involved. The characteristic histopathologic finding is a lymphohistiocytic granuloma associated with varying degrees of connective tissue degeneration and mucin deposition. The inflammatory infiltrate may have a palisaded or interstitial pattern, or a mixture of both patterns.[107–109] Occasionally, a sarcoid-like pattern with large epithelioid histiocytes is seen.[107]

The typical appearance is of single or multiple foci of inflammation with a central core of altered collagen (necrobiosis) surrounded by a wall of palisaded histiocytes (Fig. 43-4). The necrobiotic centers are usually oval, slightly basophilic, devoid of nuclei, and marked by a loss of definition of the collagen bundles and diminished or absent elastic tissue fibers. Stains for mucin and lipid often give positive results.

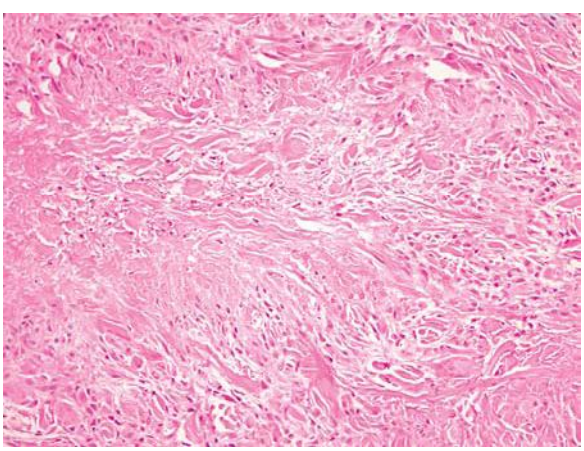

◀ **FIGURE 43-4** Palisading granulomatous inflammation surrounding degenerating collagen within the dermis. (Hematoxylin and eosin stain, ×200.) (Used with permission from Dr. Richard Crawford.)





Box 43-1

Differential Diagnosis of Granuloma Annulare

ANNULAR TYPE

Consider

- Tinea corporis
- Subacute cutaneous lupus erythematosus
- Neonatal lupus erythematosus
- Annular lichen planus
- Acute febrile neutrophilic dermatosis
- Erythema chronicum migrans
- Actinic granuloma
- Necrobiosis lipoidica diabeticorum

Rule Out

- Infections (e.g., tuberculosis, atypical mycobacteria, syphilis)
- Interstitial granulomatous dermatitis with arthritis
- Interstitial granulomatous drug reaction
- Annular sarcoidosis
- Lymphoma

GENERALIZED TYPE

Consider

- Lichen planus
- Lichen nitidus
- Molluscum contagiosum

Rule Out

- Lichenoid and granulomatous dermatitis of acquired immunodeficiency syndrome
- Infections (e.g., tuberculosis, atypical mycobacteria, syphilis)
- Sarcoidosis
- Blau syndrome (familial granulomatous arthritis, skin eruption, and uveitis)
- Interstitial granulomatous drug reaction
- Lymphoma

SUBCUTANEOUS TYPE

Consider

- Erythema nodosum
- Dermoid cyst
- Rheumatoid nodules

Rule Out

- Epithelioid sarcoma
- Benign or other malignant tumors
- Deep infections

PERFORATING TYPE

Consider

- Molluscum contagiosum
- Insect bites
- Pityriasis lichenoides
- Perforating collagenosis and other perforating disorders
- Foreign body granuloma
- Papulonecrotic tuberculid
- Palisaded neutrophilic and granulomatous dermatitis of immune complex disease

PATCH TYPE

Consider

- Morphea
- Erythema annulare centrifugum
- Parapsoriasis

Rule Out

- Lymphoma

Immunofluorescence testing may show deposition of fibrin, immunoglobulin M, and C3 as a variable finding around vessel walls or at the basement membrane zone; immunoglobulin M cytoid bodies are also reported.[106] Ultrastructural changes in the connective tissue and capillaries have been described.[75]

Special Tests

A diagnosis of granuloma annulare is made clinically or by skin biopsy. Special investigations are usually not necessary. Further evaluation to rule out systemic disease such as infection, sarcoidosis, or malignancy may be required in atypical cases of granuloma annulare.[12,72–74,82,105] Investigation for endocrine disease is indicated if the patient has signs or symptoms of diabetes or thyroid dysfunction.

Imaging studies may be performed in subcutaneous granuloma annulare when the clinical features are not recognized or when the presentation is atypical with rapid enlargement or pain.[112] Radiographs show a non-specific soft tissue mass without calcification or bone involvement. Ultrasonographic examination reveals a hypoechoic area in the subcutaneous tissues. Magnetic resonance imaging shows a mass with indistinct margins, isointense or slightly hyperintense to muscle with T1-weighted images and with a heterogeneous but predominantly high signal intensity on T2-weighted images.[112]

DIFFERENTIAL DIAGNOSIS

See Box 43-1.

TREATMENT

See Box 43-2.

Box 43-2

Treatment Options for Granuloma Annulare

- Await spontaneous resolution
- Apply topical corticosteroid with or without occlusion
- Administer intralesional triamcinolone 2.5 mg/mL[113]

ANECDOTAL REPORTS OF BENEFIT

- Topical
  - Tacrolimus 0.1% ointment[114]
  - Pimecrolimus cream[115]
  - Imiquimod 5% cream[116,117]
- Intralesional
  - Interferon-γ[118]
  - Interferon-β[118]
  - Sterile water or saline[113]
- Systemic
  - Antimalarials[88]
  - Retinoids[119–123]
  - Corticosteroids[83,98]
  - Cyclosporin[72,124]
  - Zileuton with vitamin E[125]
  - Chlorambucil, niacinamide, potassium iodide, fumaric acid esters, dapsone[3,43,83]
  - Etanercept[126]
  - Infliximab[127]
  - Efalizumab[128]
- Other
  - Phototherapy[47–50]
  - Skin biopsy[129]
  - Cryotherapy[130]
  - Pulsed dye or CO_2 laser[131,132]

CLINICAL COURSE AND PROGNOSIS

Most cases of localized granuloma annulare resolve spontaneously without sequelae. Lesions may clear within a few weeks or persist for several years. The majority disappear within 2 years.[83] Recurrent lesions may develop months or even years later, frequently at the same site. Generalized granuloma annulare often runs a more protracted course.[43] Perforating granuloma annulare results in scarring.[104] There is one report of anetoderma and mid-dermal elastolysis after generalized granuloma annulare.[44]

KEY REFERENCES

The full reference list for all chapters is available at www.digm7.com.

3. Muhlbauer JE: Granuloma annulare. *J Am Acad Dermatol* **3**:217, 1980
43. Dabski K, Winkelmann RK: Generalized granuloma annulare: Clinical and laboratory findings in 100 patients. *J Am Acad Dermatol* **20**:39, 1989

75. Hanna WM, Moreno-Merlo F, Andrighetti L: Granuloma annulare: An elastic tissue disease? Case report and literature review. *Ultrastructural Pathol* **23**:33, 1999
76. Dahl MV: Speculations on the pathogenesis of granuloma annulare. *Australas J Derm* **26**:49, 1985
77. Mempel M et al: T-cell receptor repertoire and cytokine pattern in granuloma annulare: Defining a particular type of cutaneous granulomatous inflammation. *J Invest Dermatol* **118**:957, 2002
78. Fayyazi A et al: Expression of IFN-gamma, coexpression of TNFalpha and matrix metalloproteinases and apoptosis of T lymphocytes and macrophages in granuloma annulare. *Arch Dermatol Res* **292**:384, 2000
90. Felner EI, Steinberg JB, Weinberg AG: Subcutaneous granuloma annulare: A review of 47 cases. *Pediatrics* **100**:965, 1997



This page intentionally left blank

SECTION 7

DISORDERS OF EPIDERMAL DIFFERENTIATION AND KERATINIZATION

CHAPTER 44

Epidermal Growth and Differentiation

Stanley J. Miller
Tung-Tien Sun
Pierre A. Coulombe

THE EPIDERMIS: AN OVERVIEW

The lifelong proliferation of the epidermis and its long-term maintenance require interfollicular stem cells and molecular regulators of epidermal growth and differentiation. This chapter focuses on epidermal stem cells, keratin filaments that are synthesized as major epidermal specialization products, keratohyalin granules, and the cornified envelope (CE).

EPIDERMAL GROWTH

Epidermal Stem Cells

Like all epithelia, the epidermis undergoes a constant process of self-renewal. Proliferation is initiated by a stem cell and occurs primarily in the basal layer.[1] A highly orchestrated program of terminal differentiation begins with keratinocytes exiting into the suprabasal layers, culminating in the production of superficially located cornified cells, which, in essence, consist largely of highly disulfide–cross-linked and aggregated keratin fibers wrapped in an impenetrable CE. This outermost cell layer, the stratum corneum, is the ultimate product of interfollicular epidermal differentiation, and is largely responsible for the skin's barrier function against water loss and environmental insults.

In all epithelia, an underlying homeostatic system exists to replace terminally differentiated cells and tissue loss after injury. This hierarchical system typically involves several stages of cells that have decreasing reproductive capacity and increasing commitment to differentiation (Fig. 44-1). The most primordial cell in the hierarchy, the stem cell, has the ability to reproduce for the entire life span of the organism. It is relatively undifferentiated, divides infrequently, and often resides in a specialized physical locale termed a *niche*. After division, a stem cell gives rise to, on average, one daughter stem cell that remains in the stem cell niche and another, termed a *transit-amplifying (TA) cell*, that leaves the stem cell niche. These rapidly proliferating cells undergo further reproductive divisions, and their offspring both expand the population of cells arising from the initial stem cell mitosis and progressively commit irreversibly to differentiation along one or several lineages. Our knowledge of stem and TA cell location and functioning in the interfollicular epidermis is incomplete. Nevertheless, there exists a framework of understanding,[1,2] which will undoubtedly be revised and clarified by future studies.

Epidermal Proliferative Units

Interfollicular epidermal stem cells reside at the base of organized, hexagonal columns of cells designated *epidermal proliferative units* (EPUs) (Fig. 44-2). The interdigitating, repetitive columnar organization of mouse skin was first noted by Mackenzie in 1970,[3] and our understanding of EPU structure has changed little since its initial description by Potten in 1974.[4] The basal layer of each functionally independent and self-renewing EPU consists of approximately 10 cells. A single epidermal stem cell lies at the center, with TA cells surrounding it. Under normal homeostatic conditions, epidermal proliferation occurs in this basal layer, and exit of TA cells into the suprabasal layer is accompanied by their commitment to terminal differentiation. The presence of EPUs has been described in the skin of some body sites for both mouse[5–7] and human[8–10] skin. The existence of functional differences between the centrally located stem cells and the peripherally located TA cells within individual EPUs[11,12] has been demonstrated by a variety of techniques. At a macroscopic

EPIDERMAL GROWTH AND DIFFERENTIATION AT A GLANCE



- The interfollicular epidermis is maintained by a population of stem cells.
- Slow-cycling stem cells give rise to transit-amplifying cells, which yield terminally differentiated cells.
- Abnormalities in epidermal stem cells may be involved in pathogenesis of skin cancers and other proliferative epidermal diseases.
- Epidermal differentiation is accompanied by orchestrated expression of keratins and subunits of cornified envelope.
- Keratins contribute to the mechanical stability and pliability of the epidermis.
- Mutations in major epidermal differentiation products are underlying causes of important skin diseases.

Copyright © 2008 by The McGraw-Hill Companies, Inc. Click here for terms of use.

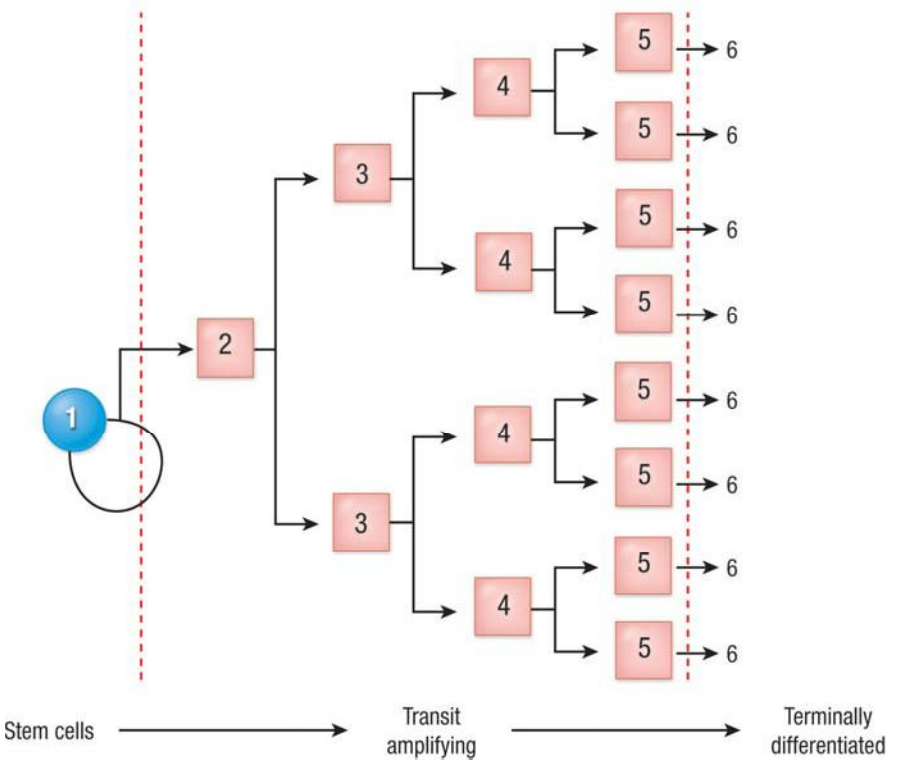

▲ **FIGURE 44-1** The proliferative hierarchy in epithelia: the stem cell concept. The ultimate progenitor cells are termed *stem cells*. They are slow cycling, long-lived, phenotypically undifferentiated, reside in specialized microenvironments, and constitute only a small percentage of the total epithelial cell population. Stem cell division produces transit amplifying or committed progenitor cells, which cycle rapidly and produce a clonal expansion of the offspring arising from an initial stem cell division. These cells eventually become the mature, terminally differentiated cells that constitute the bulk of a given epithelial population. Numbers indicate generation.

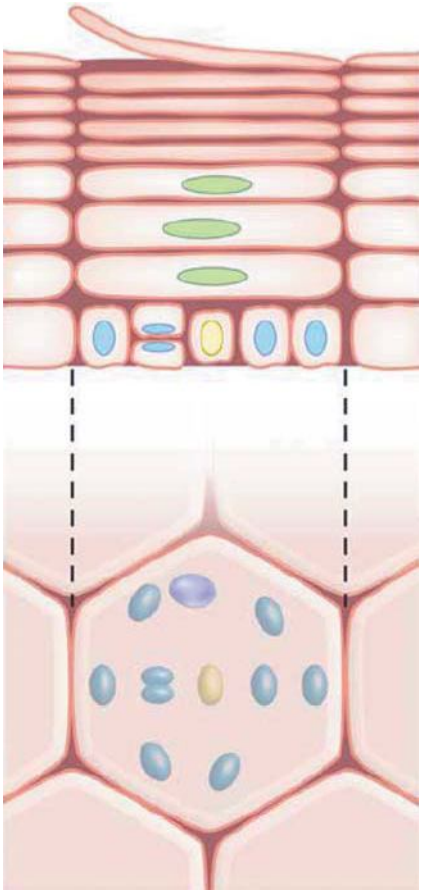

▲ **FIGURE 44-2** Functional organization of interfollicular epidermis: the epidermal proliferative unit (EPU) concept. Interfollicular epidermis of the skin of certain body sites is histologically organized into columns termed *EPUs*; each consists of approximately 10 basal cells, including a single putative stem cell (*yellow*), its immediate transit-amplifying cell progeny (*blue*), and early-differentiating cells (*purple*). More differentiated keratinocytes (*green*) and then mature enucleated squames lie directly above them, in an ordered stack rising above the basal layer. EPUs represent functionally independent packets of self-renewing interfollicular epidermis that are ultimately dependent on a single putative stem cell for lifelong cell production. Constant self-renewal within the basal layer of skin compensates for the continual loss of differentiated squames from its surface. (Reprinted/adapted from Kaur P: Interfollicular epidermal stem cells: Identification, challenges, potential. *J Invest Dermatol* **126**:1452, 2006.)

level, EPU size in human skin has been suggested be approximately 2 mm.[13]

Relative Location of Epidermal Stem Cells in the Rete Ridges

Whether epidermal stem cells are uniformly dispersed (as single cells at the bottom of EPU, or as clusters; see Lateral Migration), or concentrated in certain areas of the skin is controversial. Initial studies of monkey palm epidermis by Lavker and Sun in 1982 suggest an enrichment of putative stem cells at the base of rete ridges,[14] whereas later examination of the expression of β1-integrin (a putative stem cell marker; see Markers for the Interfollicular Epidermal Stem and Transit Amplifying Cells) in human foreskin and scalp localized the presumptive stem cells to the tops of dermal papillae.[8] A recent study using retroviral transduction of fluorescent marker protein into human foreskin xenografts grown on the backs of athymic mice found epidermal stem cells located at all levels throughout the undulating basal layer.[10] It is therefore possible that, in human skin, regional differences exist in the relative distribution of interfollicular epidermal stem cells.

Asymmetric versus Symmetric Division of the Epidermal Stem Cells

The logistics of epidermal cell division are still not clearly understood. Within the scheme of "stem cell → TA cell → terminally differentiated cell," epidermal proliferation is initiated by the division of a stem cell and then expanded by subsequent divisions of TA cells. The initial stem cell division may be asymmetric, yielding one stem cell and one TA cell that is destined to exit from the stem cell niche, or symmetric, yielding two identical stem cell or TA cell progeny. Invariant, asymmetric stem cell division is more common in unicellular organisms and invertebrates. A structured three-dimensional niche (a so-called *lineage niche*[15]) is typically required to partition the two different offspring. For example, in the Drosophila ovary, the daughter stem cell remains associated with somatic ("cap") cells of the basal terminal filament, whereas the committed daughter cell is displaced from the niche and differentiates into a mature egg.[16] Symmetric division is more common in mammals, with extrinsic stimuli regulating the final size of stem and committed progenitor populations.[17] Recent research suggests that asymmetric division may also occur in the basal cell layer of epidermis.[18] One interesting implication is that, during each round of asymmetric stem cell division, selective segregation of the original DNA

into the daughter cell that is destined to remain a stem cell may provide a mechanism to protect the stem cell genome from accumulating mutations and subsequent cancer formation.[19] It has therefore been suggested that epidermal stem cells have the ability to divide in both an asymmetric and symmetric fashion. During development, when an increased number of stem cells are required—and perhaps during wound healing in adult life as well—epidermal stem cells follow a symmetric program of division that expands their population.[13] During times of homeostasis in mature epidermis, asymmetric division may predominate.[18] TA cells are generally thought to divide symmetrically, producing either two daughter TA cells or two postmitotic cells, but they may have the ability to alter their divisional programs as well.[20] A complex regulatory system could use these two modes of division, frequency of stem cell division, total number of TA cell divisions, and duration of both stem and TA cell cycle times to maintain the integrity of epidermis and other stratified squamous epithelia in the face of various physiologic requirements[21] (see eFig. 44-2.1 in on-line edition).

Lateral Migration

Although the epidermis is traditionally thought of as consisting of vertically oriented, self-contained columns or units of replication,[5,10] some studies suggest that lateral movement between and beyond these individual columns may occur. In sun-exposed skin, Brash and colleagues[22] have identified clonal patches of keratinocytes, each containing a single p53 mutation, that are many cells in size. During wound healing, an organized lateral migration of proliferating cells occurs, that is then followed, once healing is completed, by reconstitution of new epidermal columns and re-establishment of a program of vertical differentiation.

Stratification

Under normal homeostatic conditions, the process of differentiation begins at the time of exit from the basal layer. Approximately 8 percent of basal cells are positive for markers of differentiation (such as keratins 1/10),[24] and these cells are usually connected to the basement membrane by a thin stalk and are mushroom-shaped in cross-section[12] indicating they are in the process of exiting vertically from the basal layer compartment. The mechanisms that initiate the processes of differentiation and stratification are unclear. Stratification, which begins with exit from the basal layer, may be initiated by the onset of differentiation[25] and assisted by actin dynamics within the cytoskeletal architecture of the overlying suprabasal layers.[26] It appears from whole-mount labeling experiments that the process of differentiation, as evidenced by K10 keratin expression, begins within the TA compartment.[24] Recently, it has been suggested that oriented, asymmetric division within the basal cell layer initiates both stratification and differentiation in mammalian epidermis.[18]

Relationship between Stem Cells in Various Compartments in Skin Epithelia

Follicular stem cells are located in the region of the bulge (see Chap. 84)[27] and were initially hypothesized to serve as an "ultimate reservoir" of stem cells for the interfollicular epidermis.[28] However, it is now clear that the interfollicular epidermis and hair follicle bulge contain separate and distinct stem cell populations, each responsible for the maintenance of their terminally differentiated keratinocyte populations. Bulge stem cells do not appear to contribute to the interfollicular epidermis during periods of homeostasis.[7,29,30] Progenitor cells migrate from the follicular bulge to sites of interfollicular epidermal wounding, but the migration appears to involve TA cells,[7] and their presence in the new epidermis appears to be temporary and short-lived. It has also recently been shown that bone marrow–derived stem cells do not function adequately as a source of interfollicular keratinocytes during steady-state homeostasis or after wounding.[31]

Markers for the Interfollicular Epidermal Stem and Transit Amplifying Cells

Unfortunately, reliable markers for interfollicular stem and TA cells do not yet exist. Recent work has identified many candidate markers for follicular bulge stem cells (see Chap. 84)[32,33] but their applicability to interfollicular epidermal stem cells remains unknown. This is an area of intense, ongoing research. Even the precise number of stem cells present in the interfollicular epidermis remains uncertain; original kinetic studies in mice indicated that stem cells represent approximately 10 percent of the basal cell layer,[4] whereas more recent label-retaining[11] and transgenic mouse[7] studies suggest a 1 percent presence. Of interest is a recent study that performed single cell gene expression profiling of interfollicular stem and TA cells.[36] Fourteen putative stem cell markers were discovered, including an epidermal growth factor receptor antagonist named *Lrig1*.

Regulatory Mediators

As with stem cell markers, the study of regulatory mediators of interfollicular epidermal homeostasis is the focus of ongoing research efforts.[37] Although frequently complex and overlapping, regulatory mediators may be somewhat artificially divided into four broad categories. First are the stimuli that direct progenitor cells towards specific terminal differentiation pathways (e.g., follicular vs. interfollicular vs. sebaceous structures; stratified squamous vs. simple columnar epithelium). Second are the microenvironmental features of the niche that maintain stem cell presence. Third are mediators that alter proliferation, often through focal and differing effects on the stem and TA cell populations. Fourth are regulators that stimulate or inhibit a commitment to terminal differentiation.

Several pathways appear to be involved in stem cell homeostasis and function. p63 has been suggested to be involved in epidermal stem cell maintenance,[47] although the details are not yet clear.

Diseases Related to Proliferative Dysfunction

A number of skin diseases appear to be related to stem or TA cell dysfunction. One example of an epidermal stem cell–related disease is skin cancer.[59] A stem cell model of cancer views tumor growth as an aberrant version of normal tissue homeostasis.[60] Although the end product is not a normally differentiated cell, owing to the multiple genetic mutations present, the process of cancerous growth appears in many instances to recapitulate the "stem cell → TA cell → differentiated cell" procession that occurs during normal tissue homeostasis. As in normal tissues, only a small percentage of the tumor population (the "cancer stem cells") maintain the capacity for long-term proliferation.[60] Cancer stem cells arise slowly from normal stem cells over time, because they are the only cells that per-

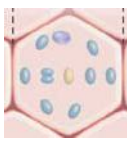

TABLE 44-1
Human Keratins and Their Distribution

Type I Keratins			Type II Keratins		
Old Name	New Name	Main Site(s) of Expression	Old Name	New Name	Main Site(s) of Expression
K9	K9	Epidermis (suprabasal)	K1	K1	Epidermis (suprabasal)
K10	K10	Epidermis (suprabasal)	K2e	K2	Epidermis (suprabasal)
K12	K12	Cornea	K3	K3	Cornea (suprabasal)
K13	K13	Oral mucosa	K4	K4	Oral mucosa (suprabasal)
K14	K14	Complex epithelia	K5	K5	Complex epithelia (basal layer)
K15	K15	Complex epithelia	K6a	K6a	Epithelial appendages
K16	K16	Epithelial appendages	K6b	K6b	Epithelial appendages
K17	K17	Epithelial appendages	K6e/h	K6c	Skin (needs confirmation)
K18	K18	Simple epithelia	K7	K7	Simple epithelia
K19	K19	Broad distribution	K8	K8	Simple epithelia
K20	K20	Gut epithelium			
K23	K23	Pancreas (needs confirmation)			
K24	K24	Unknown			
K25irs-4	K25-K28	Inner root sheath (hair follicles)	K6irs1-4	K71-K74	Inner root sheath (hair follicles)
			K6hf	K75	Companion layer (hair follicles)
			K2p	K76	Oral mucosa
			K1b	K77	Sweat gland ducts
			K5b	K78	Tongue
			K6l	K79	Skin
			Kb20	K80	Tongue
Ha1-Ha8	K31-K38	Hair shaft (hair follicle)	Hb1-Hb6	K81-K86	Hair shaft (hair follicles)
K39	K39	Hair shaft (hair follicle)			
K40	K40	Hair shaft (hair follicle)			

Note: A revised keratin nomenclature has been published. See ref. 65.

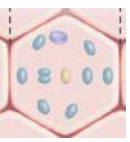

sist in an organ for the months and years necessary to acquire the multiple genetic mutations required to produce a malignancy (see Chap. 112).[59]

An epidermal disease that may represent an example of TA cell dysfunction is psoriasis (see Chap. 18). In addition to inflammatory and dermal changes, there appears to be a large increase in the β1-integrin–dim (TA cell) keratinocyte population in psoriasis, extending up into the suprabasal layers, with greatly increased proliferative activity as measured by Ki67 expression.[61,62] Further, C-myc, which is thought to stimulate conversion of epidermal stem to TA cells,[48] is upregulated in psoriasis.[63]

Gene Therapy

Because it is so accessible, the epidermis is an attractive target for gene therapy. This field of endeavor has tremendous potential but is still in its infancy. A number of technical issues remain unresolved.[64] The organization of skin into vertical proliferative units poses potential limits to the lateral spread of genetic manipulation, and to be long lasting, the epidermal stem cells must be the ultimate targets of therapy. Nevertheless, many advances in this arena are likely in the coming years.

KERATINS AND EPIDERMAL DIFFERENTIATION

Keratins and Their Classification

Keratins (also known as *cytokeratins*) are structural proteins that belong to the superfamily of intermediate filament (IF) proteins. They are heterogeneous in size (40 to 70 kd) and charge (isoelectric point, 4.7 to 8.4), and notoriously insoluble. Sequencing the human genome revealed the presence of 54 functional keratin genes that are nearly perfectly conserved in many other mammals.[65] The tremendous diversity of keratin genes had not been fully appreciated until the advent of database mining and genomics and could not be accommodated in the original nomenclature system aptly devised by Roland Moll, Werner Franke, and colleagues in 1982.[66] An international effort recently yielded a revised nomenclature (Table 44-1) that accommodates the newly discovered keratins, adheres to the guidelines of the Human and Mouse Gene Organization Gene Nomenclature Committee, and maintains the designation of keratins originally devised by Moll and colleagues.[65]

Sequence homology and gene substructure (number and position of introns) reveal two distinct groups of keratins of roughly equal size, designated types I and II IF genes (Fig. 44-3A).[65,67] In *Homo sapiens*, functional type I and type II keratin genes are clustered on the long arms of chromosomes 17 (see Fig. 44-3B) and 12 (see Fig. 44-3C), respectively.[65,68] Keratin genes are highly conserved across mammals, at the level of their organization, structure, sequence, and regulation.[69] Mature filaments contain types I and II keratins in a 1:1 molar ratio.[67,70] This requirement underlies the coordinated transcription of types I and II keratin genes. Remarkably, most types I and II keratin genes are regulated in a pair wise, tissue type–, and differentiation-related fashion.[71–73] This is illustrated particularly well in stratified epithelia such as epidermis (Fig. 44-4). Given their large number, differential regulation, and ease of detection (owing to abundance), keratin messenger RNAs and proteins represent unparalleled markers for staging the fate and differentiation of epithelial cells, under healthy and diseased conditions.

Keratin Proteins Form the Intermediate Filament Network of Epithelial Cells

Despite sequence differences, all keratins display the tripartite domain structure

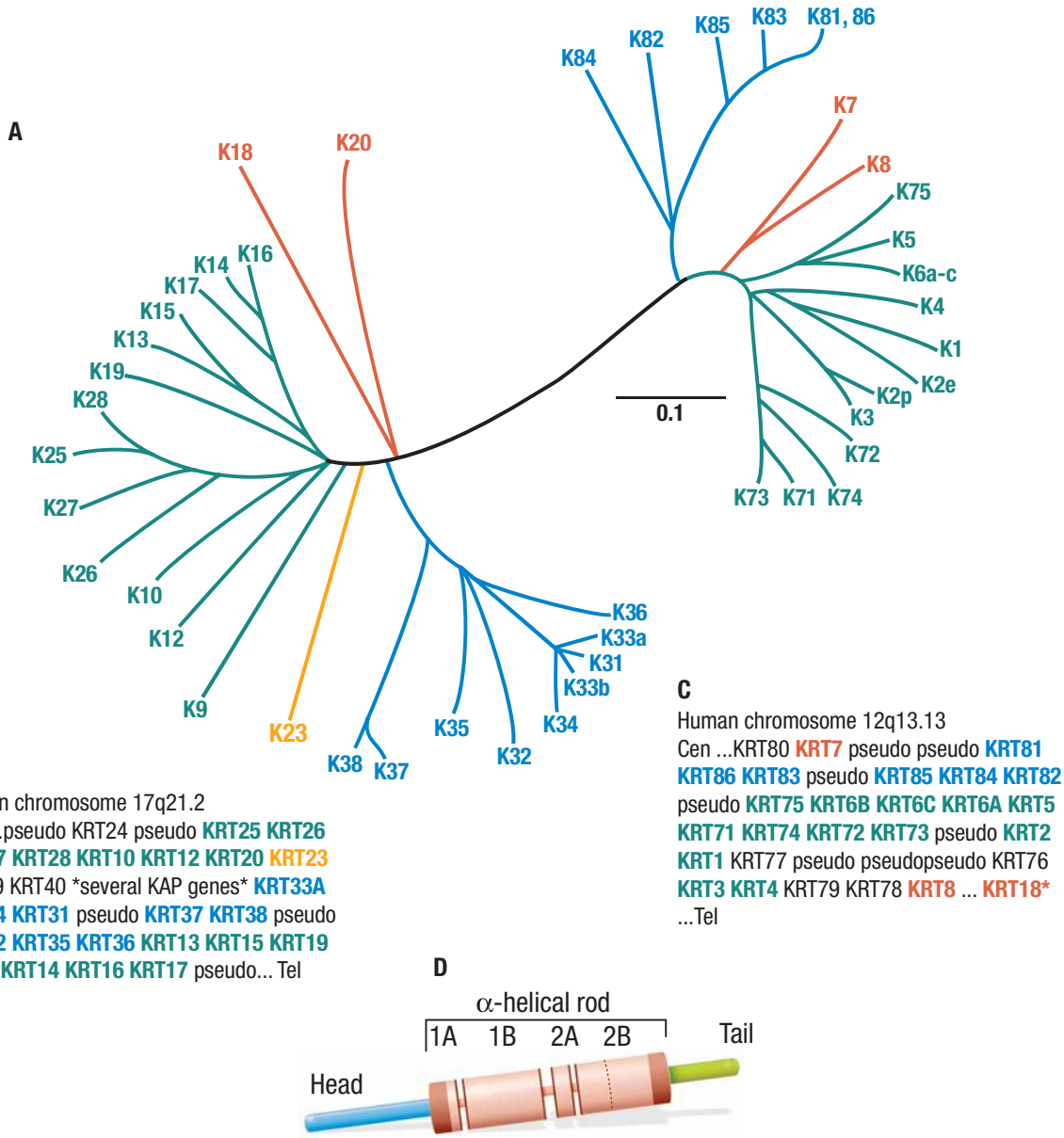

▲ **FIGURE 44-3** The human keratin gene family. **A.** Comparison of the primary structure of human keratins using the publicly available ClustalW and TreeView software. Sequence relatedness is inversely correlated with the length of the lines connecting the various sequences, and to the number and position of branch points. This comparison makes use of the sequences from the head and central rod domain for each keratin. A few keratins were left out for clarity purposes. Two major branches are seen in this tree display, corresponding to type I and type II sequences. Beyond this dichotomy, each subtype is further segregated into major subgroupings (denoted by different colors). **B.** Organization of functional type I keratin genes, all of which are clustered on human chromosome 17, with the only exception being K18 (see *asterisk* in **C**), which is located at the telomeric (Tel) boundary of the type II gene cluster. A large number of genes encoding keratin-associated proteins (KAPs) interrupts the type I gene cluster, between KRT40 and KRT33A. **C.** Organization of functional type II keratin genes, which are clustered on human chromosome 12. The K8 and K18 genes are separated by 450,000 base pairs. **D.** Schematic representation of the tripartite domain structure shared by all keratin and other intermediate filament proteins. A central α-helical "rod" domain acts as the major determinant of self-assembly. This rod domain is partitioned into subdomains 1A, 1B, 2A, and 2B, and flanked by non-helical "head" and "tail" domains at the N- and C-termini, respectively. Both ends of the rod domain contain 15 to 20 amino-acid regions (*red*) that are highly conserved among all intermediate filament proteins. Cen = centromere; pseudo = pseudogene (non-functional). (Adapted from Coulombe PA, Bernot K: Keratins and the skin, in *Encyclopedia of Biological Chemistry*, Vol. 2, Elsevier Inc., 2004, with permission.)

that is typical of IF-forming proteins (see Fig. 44-3D). The central domain consists of an extended α helix featuring long-range heptad repeats that mediate coiled-coil dimerization. This "rod" domain is approximately 310 amino acids long and is flanked by highly variable sequences at the N-terminal head and C-terminal tail domains (see Fig. 44-3D).[67] Neither terminal domain exhibits known motifs other than the glycine loops seen in epidermal keratins.[74] The head and tail domains are readily protease accessible at the surface of the filament, where they can foster interactions with neighboring filaments, other proteins, or serve as substrates for post-translational modifications involved in their regulation.[68] Given their heterogeneity of size and primary structure, the head and tail domains are expected to make key contributions to the differential function and regulation of keratin proteins in vivo.[75]

The central rod domain of keratins is the main determinant of self-assembly, with important contributions from the head domain as well.[76] The ex-

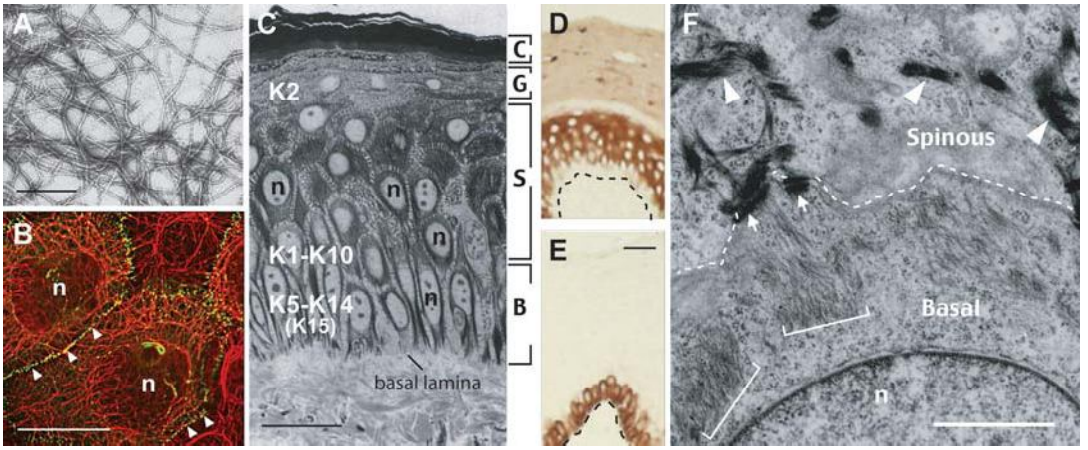

▲ **FIGURE 44-4** Keratin filaments and interfollicular epidermis. **A.** Visualization of filaments, reconstituted in vitro from purified human K5 and K14, by negative staining and electron microscopy. (Bar = 150 nm.) **B.** Double-labeling for keratin (*red chromophore*) and desmoplakin, a desmosome component (*green chromophore*), by indirect immunofluorescence of human epidermal cells in culture. Keratin intermediate filaments are organized in a network that spans the entire cytoplasm and are attached at desmosomal cell–cell contacts (*arrowheads*) between cells. (Bar = ~50 μm.) **C.** Histologic cross-section of resin-embedded human trunk epidermis, revealing the basal (B), spinous (S), granular (G), and cornified (C) cell layers. (Bar = ~50 μm.) **D** and **E.** Differential distribution of keratin epitopes on human skin tissue cross-sections (similar to frame **E**) as visualized by an antibody-based detection method. **D.** K10 is primarily concentrated in the differentiating, suprabasal layers of epidermis. *Dashed line* indicates the basal lamina. **E.** K14 occurs in the basal layer, where the epidermal progenitor cells reside. (Bar = ~50 μm.) **F.** Ultrastructure of the boundary between the basal and suprabasal cells in mouse trunk epidermis, as seen by routine transmission electron microscopy. The sample, from which this micrograph was taken, is oriented in the same manner as frame **C.** Organization of keratin filaments as loose bundles correlates with the expression of K5-K14 in basal cells (*brackets*), whereas the formation of denser, electron-dense filament bundles reflects the onset of K1-K10 expression in early differentiating cells (*arrowheads*). *Arrows* point to desmosomes connecting the two cells. (Bar = 2 μm.) n = nucleus. (**B** used with permission from Dr. Kathleen Green, Northwestern University; **C–F** reproduced from Coulombe PA, Bernot K: Keratins and the skin, in *Encyclopedia of Biological Chemistry*, Vol. 2, Elsevier Inc., 2004, with permission.)

traordinary stability of keratin subunits reflects the tightness of interactions between type I and type II keratins.[77] Most of the intracellular pool of keratin proteins (> 95 percent) is polymerized.[68] There is evidence that keratin IF assembly begins at the cell periphery, near the cortical F-actin cytoskeleton, in cultured epithelial cells.[78]

Keratins form the major IF network in almost all epithelial cells.[66,67,73] The abundance and organization of keratin IFs in vivo differ among epithelia. Keratin proteins are highly abundant (10 percent to 80 percent of total cellular proteins) in surface-exposed stratified squamous epithelia (e.g., epidermis, oral mucosa, corneal epithelium, etc.).[71] In epithelial cells of such tissues, keratin IFs are organized in a pan-cytoplasmic network extending from the surface of the nucleus to the cytoplasmic periphery, where they are membrane-anchored at sites of cell-matrix and cell-cell adhesion (hemidesmosomes, desmosomes) (Fig. 44-4B). In simple epithelia (e.g., liver, gut, pancreas, etc.), keratins are less abundant. In such tissues, polarized epithelial cells often feature asymmetrically organized keratin IFs concentrated mostly at the cytoplasmic periphery and, particularly, the apical pole.[68] Several associated proteins contribute to the organization and regulation of keratin IFs in these various settings.[79] Some of these proteins promote the bundling of keratin IFs (e.g., filaggrin, trichohyalin), and their association with microtubules and microfilaments (e.g., plectin, BPAG isoforms) and/or with desmosomes or hemidesmosomes (desmoplakin, plakophilin, BPAG isoforms, etc.) (see Fig. 44-4). Other partners, e.g., TRADD, 14-3-3, Akt, reflect the newly discovered participation of keratin IFs in signaling roles.[80]

Keratin Gene Expression Mirrors Epithelial Differentiation: The Case of Epidermis

Skin provides a beautiful example of the tight relationship that has evolved between keratin gene regulation and epithelial differentiation. More than one-half of all known keratin genes are expressed in mature mammalian skin tissue alone. The architectural complexity of adult skin epithelia is achieved through a temporally and spatially regulated expression of keratin and a number of other epithelial differentiation-related genes.[71,81] In the clinical setting, keratin typing is often exploited in diagnosing cancer type, its differentiation status (and therefore prognosis), as well as the origin of the cells forming metastatic foci. This strategy is also applied for diseases other than cancer.[68]

In "thin" interfollicular epidermis (e.g., trunk; see Fig. 44-4), mitotically active cells of the basal layer act as progenitors, and consistently express K5 and K14 as their main keratin pair, along with lower levels of K15. Onset of differentiation coincides with the appearance of the K1/K10 pair through a robust transcriptional induction that occurs at the expense of the K5/K14 genes, which are downregulated.[71,81] Accordingly, K1/K10 keratins are readily detectable in the lowermost suprabasal layer of epidermis (see Fig. 44-4D). The appearance of K1 and K10 correlates with a sudden and dramatic shift in the organization of keratin IFs, which now exhibit significant bundling.[82] Another type II gene, K2, is expressed at a later stage of differentiation (i.e., the granular layer).[83]

The epidermis of palm and sole skin is specialized for resisting a high degree of mechanical stress, and thus is markedly thicker. This function is reflected in its architecture of alternating stripes of primary and secondary ridges,[14] and again, in keratin expression. In the thick, stress-bearing, primary ridges, the major differentiation-specific (type I) K9 is presumed to foster a more resilient cytoskeleton. In the thinner secondary ridges, postmitotic keratinocytes preferentially express the (type II) K6a and (type I) K16 and K17.[84] Relative to K1, K9, and K10, the properties of K6a, K16, and K17 likely foster greater cellular pliability, thereby providing flexible "hinge" regions between the more rigid,

K1/K9-rich primary ridges.[84] Although this attractive model remains to be supported by direct experimentation, it is consistent with the dramatic upregulation of K6a, K6b, K16, and K17 that occurs in keratinocytes recruited from wound margins to participate in the restoration of the epidermal barrier after injury.[80,85]

Function of Keratin in the Epidermis and Other Skin Epithelia

A major function fulfilled by keratins and all other IF proteins is to enhance the cell's ability to withstand trauma. This structural support function[67,68] is made possible by the unique mechanical properties exhibited by IF networks.[80] This function is enhanced by attachment of IFs to adhesion complexes (desmosomes, hemidesmosomes) and to F-actin and microtubules.[67,68,79] Partial or complete loss of this function, e.g., through inherited mutations, underlies a wide variety of rare diseases that render cells fragile and unable to sustain mechanical stress (see Chap. 60). In vivo, the mechanical properties of IF networks likely need to be modulated, in a dynamic fashion, to meet the demands placed on cells by changing physiological circumstances. To a degree, varying needs along a continuum of viscoelastic properties likely account for the dynamic regulation of keratin IF genes and their proteins in vivo.[80]

The recent discovery of nonmechanical functions for keratin proteins has placed the field on an exciting new path.[80] In hair follicles, K17 promotes the anagen (growth) phase by attenuating TNF-α–induced apoptosis in matrix keratinocytes.[90] In the epidermis, the suprabasally expressed K10 regulates proliferation in the basal layer of epidermis and in sebaceous glands, likely through a non–cell-autonomous mechanism,[91,92] whereas K17 cell-autonomously regulates protein synthesis and cell size in wound-proximal keratinocytes.[93] Keratins influence the melanin pigment distribution and, thus, skin pigmentation.[94–96] In polarized epithelia, keratin IFs impact the distribution of organelles, routing of specific outer membrane proteins, and response to stress.[97] These newly defined keratin functions, which are just beginning to be understood, involve regulated interactions between keratin proteins and non-cytoskeletal proteins, many exerting key roles in specific signaling pathway.[79,80,97] Interference with these functions could play a role in the pathogenesis of disorders linked to IF gene mutations.[68] The discovery of these novel keratin functions provides an opportunity to better understand the diversity and context-dependent regulation of IF genes and their proteins.

Mutations in Epidermal Keratins Underlie Several Inherited Skin Blistering Diseases (See Chap. 60)

The following general principles can be drawn from the large body of data accumulated to date while studying keratin-based disorders (see Chaps. 47, 48, and 60). The majority of cases involve single missense mutations acting in a dominant-negative fashion. Small insertions and deletions are also seen with some frequency.[110] In this setting, dominance implies that disease-causing mutant keratin proteins do not markedly alter the early stages of assembly (dimer, tetramer formation) up to the step(s) involving subunit incorporation in a growing IF polymer.[68] Depending on their nature and location within the keratin protein backbone, these mutations exert a wide range of effects on the assembly or organization of IFs in keratinocytes, with a corresponding impact on the severity of clinical presentation.

CORNIFIED ENVELOPE

Alongside the substantial buildup in keratin IFs inside keratinocytes, two specializations allow the epidermis to build a remarkably effective and mechanically resilient barrier: the CE, a covalently cross-linked protein polymer that forms underneath the plasma membrane, and an extracellular hydrophobic phase that is made up of specialized lipids synthesized by terminally differentiating keratinocytes.[116] Epidermal lipids are discussed in detail in Chap. 45.

The CE represents a complex assembly of covalently cross-linked proteins that forms underneath, and eventually replaces, the keratinocyte membrane in the granular layer of epidermis, as part of the final push to complete terminal differentiation. This 20-nm thick sheath, which is so insoluble and stable it resists extended boiling in the presence of strong denaturants, encased the cell's interior and significantly contributes to the physicochemical properties of the stratum corneum compartment.[117] The extraordinary stability of the CE results in large part from the large number of ε-(γ-glutamyl)-lysine isopeptide bonds between its primary constituents, which are further reinforced by disulfide bridges. These isopeptide bonds are catalyzed by transglutaminases, a family of calcium-dependent enzymes.[118] The outer aspect of the CE is covalently linked to ceramides and other specialized lipids that are produced by, and secreted from, differentiated granular keratinocytes, whereas large bundles of tightly packed keratin IFs are cross-linked to its inner aspect.

The major protein constituents of the CE are loricrin, involucrin, filaggrin, elafin, cystatin A, cornifelin, several small-proline rich proteins and calcium-binding S-100 proteins, and "late-envelope proteins." In addition to these proteins, key components of desmosomes (e.g., desmoplakin, envoplakin, and periplakin) and several type II keratins (K1, K2, K5) are also cross-linked into the CE (Table 44-2).[117–119] CE proteins have several interesting features in common. First, many CE proteins are encoded by genes clustered as part of the epidermal differentiation complex locus on human chromosome 1q21. In addition to obvious evolutionary implications, this genomic clustering brings up the distinct possibility of coordinated regulation through cis-acting determinants.[116,119] Second, many of these proteins are made as precursors that are activated by proteolytic cleavage, calcium binding, or other modifications at the time of CE formation. Third, many CE proteins are made of repeated units that lack an intrinsically defined three-dimensional structure. Fourth, virtually all CE proteins are transglutaminase substrates.[116,118]

Involucrin, loricrin, and filaggrin, in particular, are well characterized components of the CE.[117,118] Involucrin biosynthesis is initiated in the spinous compartment, soon after the onset of K1/K10 keratin expression, in differentiating epidermal keratinocytes. It is the first major component to be activated and cross-linked into the emerging CE, possibly reflecting a scaffolding role, and is concentrated on the outermost aspect of the mature CE. Profilaggrin and loricrin are synthesized in precursor forms and stored in keratohyalin granules. Loricrin is the major structural component of the CE (approximately 80 percent by weight)—this largely unstructured but highly flexible protein features glycine loops as described for type II keratins. Once activated via dephosphorylation and proteolytic cleavage, filaggrin participates in the bundling of keratin IFs in the late granular compartment of epidermis (hence accounting for its incorporation into the CE) and also is degraded to free amino acids that contribute to the cornified cell's ability to re-

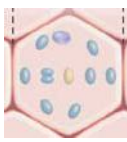

TABLE 44-2
Protein Composition of the Cornified Envelope

Protein	Molecular Weight (kD) (Precursor Form)	Chromosome Location	Cornified Envelope (CE) Percent Contribution	Comments/Disease Association
Loricrin	26	1q21	80	Rich in Gly, Ser, Cys residues; contains glycine loops; flexible; stored in keratohyalin granules; mutated in Vohwinkel syndrome, a mutilating keratoderma with ichthyosis, and in progressive symmetric erythrokeratodermia, a related condition.
Involucrin	65	1q21	5	Made up of repeated units; highly α-helical; Gly-, Asp-rich; early TG substrate; may act as a scaffold during CE assembly.
Small proline-rich proteins	6–18	1q21	3–5	Encoded by 15 genes that are differentially regulated in various stratified epithelia. Great transglutaminase substrates; influence CE's mechanical properties.
Cystatin A	12	3cen-q21	2–5	Cysteine protease inhibitor; also stored in keratohyalin granules; mutations in cystatin M/E cause harlequin ichthyosis.
Late CE proteins	9–12	1q21	Unknown	Encoded by 18 genes; synthesized and incorporated at a late stage of CE formation.
Profilaggrin/ filaggrin	> 400; 36	1q21	< 1	Also bundles keratin filaments; degraded to single amino acids, which markedly contribute to retain water, in stratum corneum layers; mutated in ichthyosis vulgaris, a mild but very common condition; risk factor in individuals with atopic dermatitis and asthma.
S-100A	10–14	1q21	< 1	Family of EF-hand-containing, calcium-binding proteins; believed to transmit calcium-dependent signals.
Proelafin	10	20q12-q13	< 1	Elafin is the active entity and acts as a serine protease inhibitor.
Annexin 1	36	9q12-q21	< 1	Also known as *lipocortin*; interacts with S-100A11.
Keratins (K1, K2, K5, K10, K14)	56–70	12q13	< 1	Type II keratins are transglutaminase substrates; keratin intermediate filaments become covalently linked to the inner aspect of the CE.
Desmosomal proteins	195–330	Various	< 1	Includes desmoplakin, envoplakin, periplakin, and others. Assembly of CE is initiated at desmosome cell–cell contacts.

Note: A review article by Eckert RL et al: Transglutaminase function in epidermis. *J Invest Dermatol* **124**:481, 2005, served as a direct inspiration for this table.

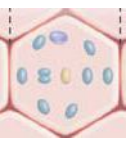

tain water. Basic information about other CE components is provided in Table 44-2.[117,118] The protein composition and fine structure of the epidermal CE differs to a degree from those of the other stratified squamous epithelia; the underlying significance of this CE heterogeneity is unclear.[117,118] The important contribution of the CE towards proper barrier function in epidermis is reflected in the clinical symptoms associated with mutations altering their primary constituents in the context of human diseases (see Table 44-2).[116]

CONCLUDING REMARKS

In this chapter, we have discussed the concept of stem cells, which play key roles in the epidermis, hair follicles, and all other self-renewing tissues. Although follicular epithelial stem cells can give rise to TA cells that participate in epidermal repair, the epidermis seems to have its own stem cell population distinct from that of the follicle. We also discussed the changes of keratins during epidermal differentiation. It is well appreciated that specific type I and type II keratins are co-expressed as pairs associated with various stages of normal and pathologic epidermal differentiation, and that mutations of major epidermal keratins cause various forms of skin blistering diseases; however, the functional implications of these different keratins, not only in terms of structural roles, but also in terms of their novel involvements in signal transduction and organelle transport, is just beginning to be understood. Additional studies are needed to better understand the roles of stem and TA cells in epidermal proliferation and homeostasis; how the niche microenvironment maintains epidermal stem cells; the detailed relationship between epidermal and hair follicular epithelial stem cells and their relative contributions to skin diseases such as psoriasis and skin neoplasms such as basal and squamous cell carcinoma; and how the keratin filaments function, at the atomic level, in normal and diseased epidermis. These future studies should lead to new modalities, including cell and gene therapies, for a better treatment of some of the devastating skin diseases.

KEY REFERENCES

The full reference list for all chapters is available at www.digm7.com.

1. Blanpain C, Fuchs E: Epidermal stem cells of the skin. *Annu Rev Cell Dev Biol* **22**:339, 2006
2. Kaur P: Interfollicular epidermal stem cells: Identification, challenges, potential. *J Invest Dermatol* **126**:1450, 2006

36. Jensen KB, Watt FM: Single-cell expression profiling of human epidermal stem and transit-amplifying cells: Lrig1 is a regulator of stem cell quiescence. *Proc Natl Acad Sci U S A* **103**:11958, 2006
37. Dai X, Segre JA: Transcriptional control of epidermal specification and differentiation. *Curr Opin Genet Dev* **14**:485, 2004

59. Miller SJ, Lavker RM, Sun TT: Interpreting epithelial cancer biology in the con-

text of stem cells: Tumor properties and therapeutic implications. *Biochim Biophys Acta* **1756**:25, 2005
65. Schweizer J et al: New consensus nomenclature for mammalian keratins. *J Cell Biol* **174**:169, 2006
67. Fuchs E, Weber K: Intermediate filaments: Structure, dynamics, function, and disease. *Annu Rev Biochem* **63**:345, 1994
68. Omary MB, Coulombe PA, McLean WH: Intermediate filament proteins and their associated diseases. *N Engl J Med* **351**:2087, 2004
71. Fuchs E: Keratins and the skin. *Annu Rev Cell Dev Biol* **1995**;11:123, 1995
80. Coulombe PA, Wong P: Cytoplasmic intermediate filaments revealed as dynamic and multipurpose scaffolds. *Nat Cell Biol* **6**:699, 2004
117. Candi E, Schmidt R, Melino G: The cornified envelope: A model of cell death in the skin. *Nat Rev Mol Cell Biol* 6:328, 2005

CHAPTER 45

Skin as an Organ of Protection

Ehrhardt Proksch
Jens-Michael Jensen

The skin's most important function is to form an effective barrier between the "inside" and the "outside" of the organism. Life on dry land requires the presence of a barrier to regulate water loss and prevent desiccation, commonly referred to as the *inside-outside barrier*. The skin also provides an *outside-inside barrier* to protect against mechanical, chemical, and microbial assaults from the external environment (Fig. 45-1). To perform these functions, the epidermis undergoes keratinization, a process in which epidermal cells progressively mature from basal cells with proliferative potential to the lifeless, flattened squames of the stratum corneum (SC) (Fig. 45-2). Both the SC and the deeper skin layers protect the skin from ultraviolet (UV) radiation, mechanical forces, and cold and hot temperatures. To effectively perform this multiplicity of functions, the skin contains different types of barriers. The physical barrier consists mainly of the SC, but the nucleated

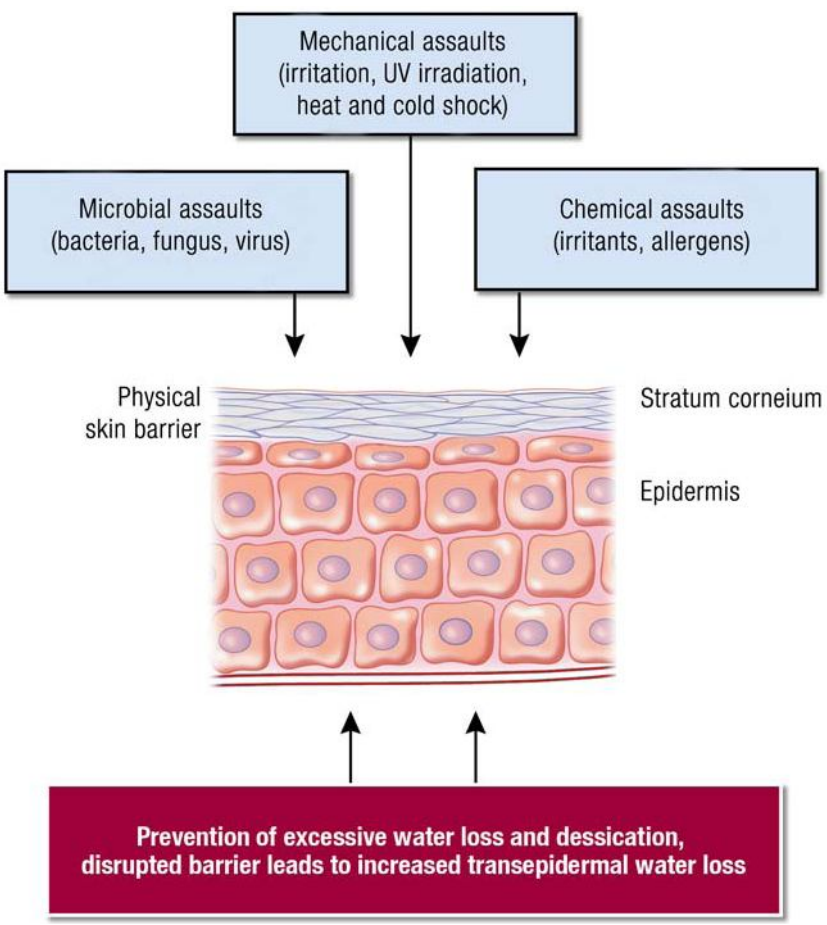

▲ **FIGURE 45-1** Functions of the epidermal "inside-outside" and "outside-inside" barrier. UV = ultraviolet.

SKIN BARRIER AT A GLANCE

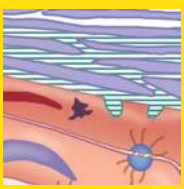

- The most important function of the skin is to form a barrier between the organism and the environment.
- The skin barrier prevents excessive water loss (inside-outside barrier) and the entry of harmful substances from the environment (outside-inside barrier).
- The physical barrier is predominantly located in the stratum corneum.
- The stratum corneum barrier is composed of corneocytes and intercellular lipids, cholesterol, free fatty acids, and ceramides.
- Keratins and cornified envelope proteins are important for the mechanical stability of the corneocytes.
- The cornified envelope protein involucrin binds ceramides covalently, forming a backbone for the subsequent attachment of free ceramides.
- The nucleated epidermis through tight junctions and desmosomes also contributes to the barrier.
- Experimental barrier disruption increases epidermal lipids and changes in epidermal differentiation.
- The signals for barrier recovery are cytokines and the calcium ion gradient.
- Several diseases are characterized by a probably genetically disturbed barrier function. The disturbed barrier function contributes to disease pathology, in particular in contact dermatitis, atopic dermatitis, forms of ichthyosis, and psoriasis.
- Lipid or lipid-like creams and ointments can repair disturbed barrier function.

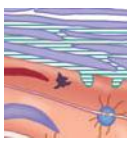

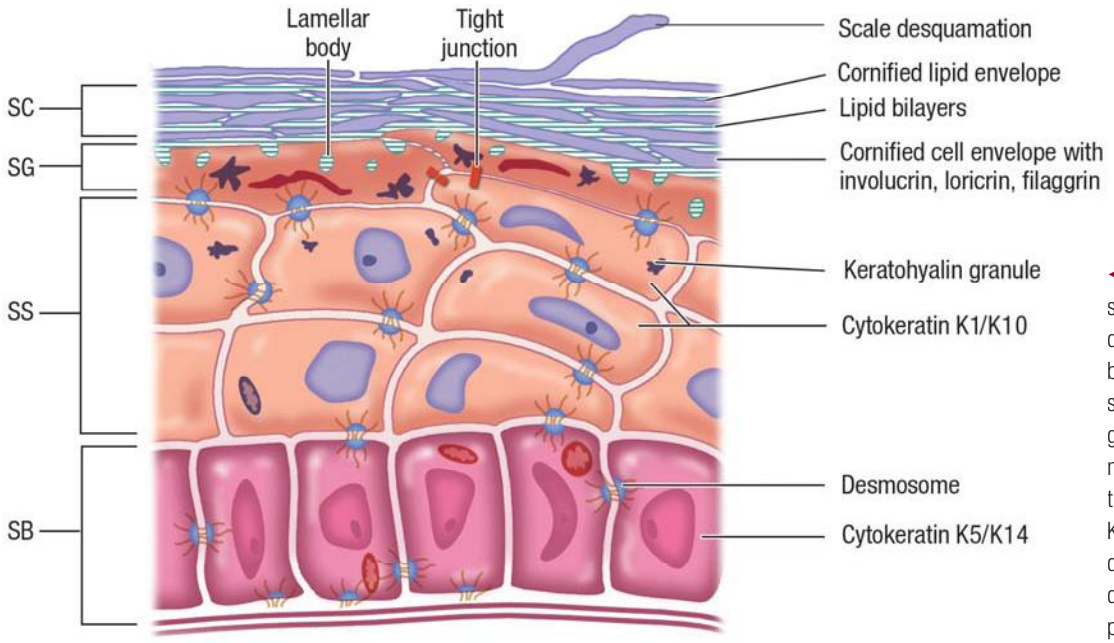

◀ **FIGURE 45-2** Progressive maturation of the epidermis from the stratum basale (SB), via the stratum spinosum (SS) and stratum granulosum (SG) to the terminal differentiated layer, the stratum corneum (SC). Key molecules of the epidermal structure are derived during the differentiation process.

epidermis, in particular the tight junctions, provides another important barrier component. The chemical-biochemical (antimicrobial) barrier consists of lipids, acids, lysozymes, and antimicrobial peptides. The humoral and cellular immune system provides a barrier to infectious disease (see Chap. 10), but immune hyperactivity may lead to allergy (Table 45-1).

Although the skin is of central importance for preventing water loss in a dry environment, aquatic animals also require a skin barrier to protect them from the high salinity of their surrounding environment. Terrestrial mammals with dense fur have much thinner skin than animals without this protective coat, demonstrating that fur itself is a considerable barrier. The relatively hairless skin of pigs shows much similarity to human skin and is therefore a good model for skin research.

In addition to the SC, the entire skin, as a whole, serves a protective function. The innermost region of human skin, the subcutaneous fat layer, offers mechanical shock protection, insulates the body against external heat and cold, and is active in general energy metabolism and storage. The dermis is composed of collagen bundles and elastic fibers and is very important for the mechanical strength of the skin. The epidermis, the skin's outer layer, consisting primarily of stratified nucleated keratinocytes and the SC, is most important for skin protection and the focus of this chapter. Sweat glands and blood vessels regulate body temperature. Sebaceous glands secrete sebaceous lipids to protect the hair from the environmental stress. In animals, sebaceous lipids serve as a water repellent for the fur, aiding in buoyancy and temperature regulation, and also preventing desiccation of the body and UV damage. The role of sebaceous lipids for SC barrier function and for dry skin is still a matter of discussion.[1] Sebaceous glands also transport glycerol to the skin surface, which is important for SC hydration.[2] Nerve fibers are chemosensitive and act as a warning system against external trauma.

STRUCTURE OF THE STRATUM CORNEUM: PHYSICAL PERMEABILITY BARRIER

The SC is the specific location of the physical barrier.[3,4] The typical basket-weave appearance of the SC in routine formalin-embedded sections does not give the impression that it could function as an effective barrier. With the advent of electron microscopy and ruthenium tetroxide fixation, the structure of the SC barrier can now be visualized (Fig. 45-3). The barrier regulating water permeation is not absolute. The normal movement of water from the SC into the atmosphere is known as *trans-epidermal water loss* (TEWL). The SC also serves as the principal barrier against the percutaneous penetration of chemical substances and microbial assaults and is capable of withstanding mechanical forces.[5]

The 10 to 20 μm thick SC forms a continuous sheet of protein-enriched cells, embedded in an intercellular matrix, enriched in nonpolar lipids, and organized as lamellar lipid layers. The viable epidermis is a stratified squamous epithelium, consisting of basal, spinous, and granular cell layers. Each layer is defined by its position, shape, morphology, and the differentiation status of its keratinocytes. On leaving the basal layer, keratinocytes begin to differentiate and undergo a number of changes in both structure and composition during the apical migration into the stratum spinosum and stratum granulosum. Keratinocytes synthesize and express numerous structural proteins and lipids during their maturation. The final steps in keratinocyte differentiation are associated with profound changes in their structure, resulting in their transformation into flat and anucleated squamous cells of the SC, acting mainly with keratin filaments and surrounded by a cell envelope composed of cross-linked proteins (cornified envelope proteins) as well as a covalently bound lipid envelope (see Fig. 45-2). Extracellular nonpolar lipids surround the corneocytes to form a hydro-

TABLE 45-1
Different Skin Barriers

Physical barrier	Stratum corneum, nucleated epidermis (desmosomes, tight junctions)
Chemical/biochemical (antimicrobial) barrier (innate immunity)	Lipids, organic acids, lysozymes, antimicrobial peptides
Immune barrier humoral and cellular immune system	Lymphocytes, neutrophils, monocytes, Langerhans cells

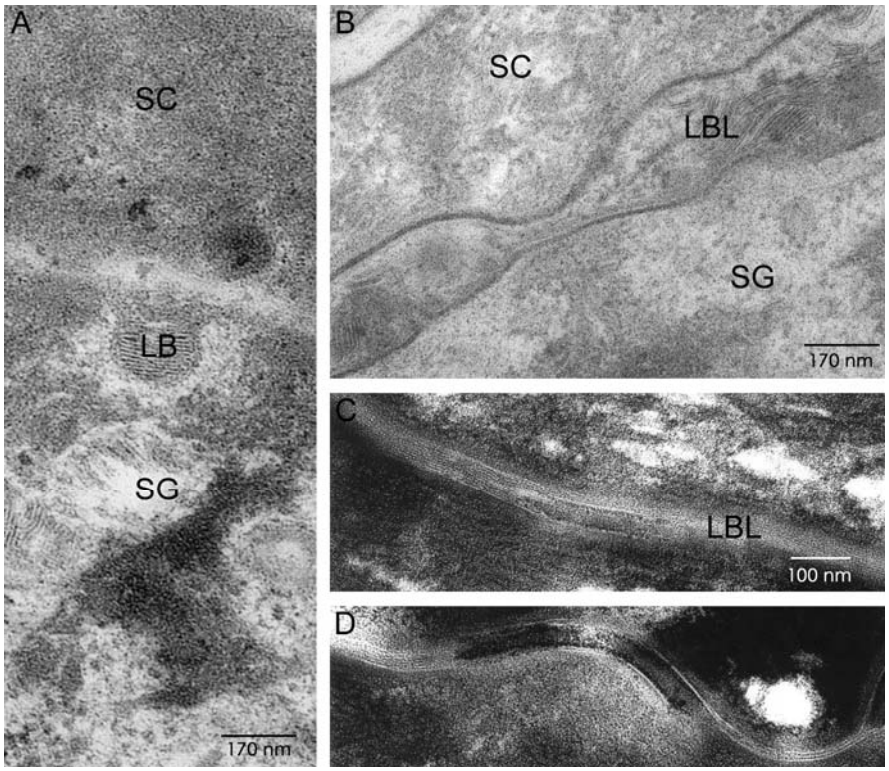

▲ **FIGURE 45-3** Electron microscopy revealed that in the stratum granulosum (SG)/stratum corneum (SC) interface the lamellar bodies (LB) content is extruded to the interface (**A**), thus forming continuous lipid bilayers (LBL) (**B** then **C**). Desmosomes are becoming corneosomes in the process of cornification (**D**).

phobic matrix. The cornified envelope proteins as well as the covalently bound lipid envelope are thought to be important for the chemical resistance of the corneocytes (Fig. 45-4). Desmosomes, which interconnect adjacent keratinocytes, are important for SC cohesion and are shed during the desquamation process in the SC. In the upper spinous and granular layers, characteristic lamellar vesicles appear, which are called *epidermal lamellar bodies* (Figs. 45-3 and 45-5). These are enriched in polar lipids, glycosphingolipids, free sterols, phospholipids, and catabolic enzymes, which deliver the lipids required for the SC's extracellular layers. The lamellar bodies may also contain proteins such as human β-defensin 2.[6] In response to certain signals, probably an increase in calcium concentration during the transition from the granular layers to the SC, the lamellar bodies move to the apex of the upper-most granular cells, fuse with the plasma membrane, and secrete their content into the intercellular spaces through exocytosis. The lipids derived from the lamellar bodies are subsequently modified and rearranged into intercellular lamellae positioned approximately parallel to the cell surface. The covalently bound lipid envelope acts as a scaffold for this process. After the extrusion of the lamellar bodies into the stratum granulosum-SC interface, the polar lipids are enzymatically converted into nonpolar products. Hydrolysis of glycosphingolipids generates ceramides while phospholipids are converted into free fatty acids. These changes in lipid composition and cell structure result in the formation of a very dense structure packed into the interstices of the SC (Table 45-2).[7]

Lipid Composition and Role of Lipids in the Stratum Corneum

Confocal laser scanning microscopy and X-ray microanalysis studies have shown that the major route of penetration results in the tortuous halfway between the corneocytes, confirming that intercellular lipids play an irreplaceable role in regulating skin barrier function.[7] The major lipid classes in the SC are cholesterol, free fatty acids, and ceramides (Fig. 45-6).[8-10]

CHOLESTEROL Cholesterol is probably the most abundant lipid in the entire body and part of the plasma membrane, and part of the intercellular lipid lamellae in the SC. Although basal cells are capable of resorbing cholesterol from circulation, most cholesterol in the epidermis is synthesized in situ from acetate.[11] The epidermal keratinocyte, the main cell type in the epidermis, is highly active in the synthesis of several lipids, including cholesterol and free fatty acids. The rate-limiting step in cholesterol biosynthesis is catalyzed by hydroxymethylglutaryl CoA reductase (Fig. 45-7). Epidermal cholesterol synthesis is regulated by these enzymes and increased during permeability barrier repair.[12]

FREE FATTY ACIDS The skin contains free fatty acids as well as fatty acids bound in triglycerides, phospholipids, glycosylceramides, and ceramides. The chain length of free fatty acids in the epidermis ranges from C12 to C24. The rate-limiting enzymes acetyl-CoA carboxylase and fatty acid synthase in the epidermis are largely autonomous (Figs. 45-7 and 45-8).[13] Saturated and monounsaturated fatty acids are synthesized in the epidermis, in contrast to di- and polyunsaturated acids. The nomenclature of the fatty acids is determined from the position of the first double bond in the molecule, starting from the terminal methyl group. In particular, the essential ω-6-unsaturated acids must be obtained from food and the circulation or can be obtained by topical treatment. The non-essential monounsaturated fatty acid, the oleic acid, is an ω-9 fatty acid. The most important double unsaturated fatty acid, linoleic acid, is an ω-6 fatty acid. Also of importance is α-linoleic acid (ω-3). No skin changes due to an ω-3 fatty acid deficiency are currently known; however, it has been proposed that these fatty acids are important for the resolution of inflammation. ω-3 fatty acids are obtained from fish,

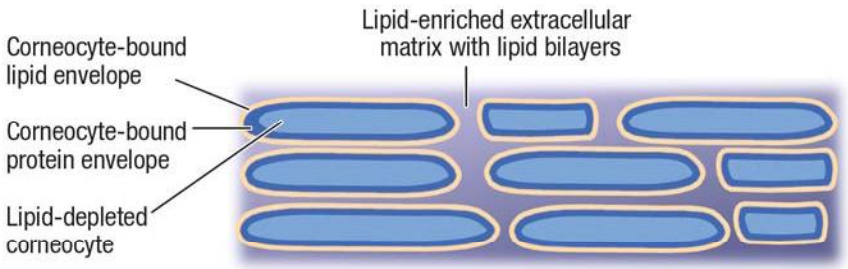

▲ **FIGURE 45-4** The lipid-depleted corneocyte is surrounded by an inner protein envelope and an outer lipid envelope. Special ceramides are covalently bound to cornified envelope proteins, particularly to involucrin.

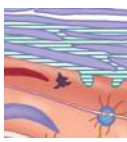

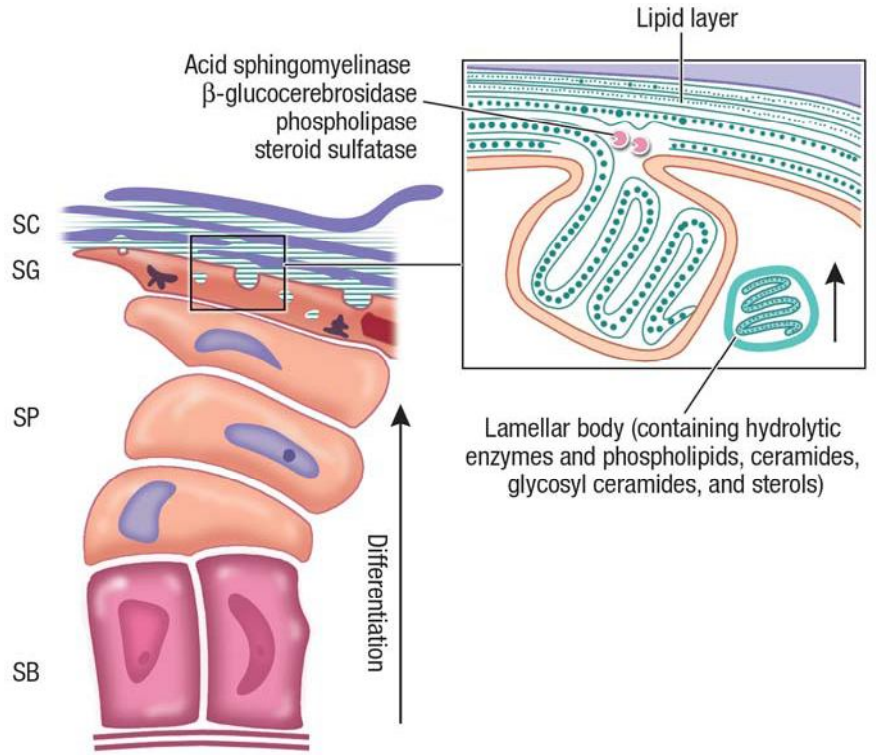

▲ **FIGURE 45-5** During differentiation, the upper stratum spinosum (SP) and the stratum granulosum (SG) cells generate lamellar bodies containing preformed lipid structures and hydrolytic enzymes. Their content is extruded into the SG-stratum corneum (SC) interface and undergoes profound remodelling. SB = stratum basale.

whereas ω-6 fatty acids are obtained from plant oils.[14,15] Essential fatty acid deficiency (EFAD) caused by unusual human diets or malabsorption or experimentally induced in rats and mice leads to the EFAD syndrome, characterized by profound changes in epithelia including the epidermis.[16] In this condition, the epidermis is rough, scaly, and red and shows a severely disturbed permeability barrier function. In addition, severe bacterial infection, impaired wound healing, and alopecia may occur. Linoleic acid is part of phospholipids, glucosylceramides, ceramide 1, ceramide 4, and ceramide 9.[17] It has been proposed that the linoleic acid metabolite γ-linoleic acid is of special importance for atopic eczema.

CERAMIDES Ceramide is an amide-linked fatty acid containing a long-chain amino alcohol called *sphingoid base*. The carbon chain lengths of amide-linked fatty acids and sphingoid bases in most mammalian tissues are 16 to 26 and 18 to 20, respectively (see Fig. 45-6). Although sphingolipids, including glycosphingolipids and phosphosphingolipids, are ubiquitously distributed in mammalian tissues, tissue-specific molecular distribution has been described. Glucosylceramide is enriched in the epidermis and spleen whereas galactosylceramide is enriched in the brain but is not detected in keratinocytes. Whereas ceramide is a minor lipid component, comprising less than 10% of cholesterol or phospholipids in other mammalian tissues, ceramide is a major lipid component in the SC, accounting for 30 to 40 percent of lipids by weight. Moreover, such a high content of ceramides in the SC is not observed in the epidermal stratum granulosum, stratum spinosum, or stratum basale. This also suggests that terminal differentiation is a key factor in accumulating ceramide. The SC contains at least nine different ceramides.[17] In addition, there are two protein-bound ceramides, ceramide A and ceramide B (see Fig. 45-6).[7] These ceramides are covalently bound to cornified envelope proteins, most importantly to involucrin.

Ceramides are synthesized by serine-palmitoyl transferase as rate-limiting enzyme and by hydrolysis of both glucosylceramide (by β-glucocerebrosidase)[18] and sphingomyelin (by acid sphingomyelinase) (Figs. 45-8 and 45-9).[19] Whereas all kinds of ceramides are derived by synthesis from serine-palmitoyl transferase and from β-glucocerebrosidase, only ceramide 2 and ceramide 5 are obtained from sphingomyelinase because sphingomyelin contains nonhydroxy acids.[20]

Lipid Transport

Keratinocytes require abundant cholesterol for cutaneous permeability barrier function. ABCA1 is a membrane transporter responsible for cholesterol efflux and plays a pivotal role in regulating cellular cholesterol levels. It was demonstrated that ABCA1 is expressed in cultured human keratinocytes and murine epidermis. Liver X receptor activation and activation of peroxisome proliferator-activated receptor (PPAR)-α, PPAR-ss/δ and retinoid X receptor increased ABCA1

TABLE 45-2
Protective Functions of the Stratum Corneum

Functions	Structural Bases	Biochemical Mechanisms
Permeability barrier	Lamellar bilayers	Hydrophobic lipids
Mechanical integrity/ resilience	Cornified envelope, cytosolic filaments	Cross-linked peptides (e.g., involucrin, loricrin), keratin filaments
Hydration	Lamellar bilayers; corneocyte cytosolic matrix	Sebaceous gland-derived glycerol, filaggrin break-down amino acids, natural moisturizing factors
Cohesion/desquamation	Corneodesmosomes	Serine proteases
Antimicrobial defense	Lamellar bilayers, extracellular matrix	Free fatty acids, antimicrobial peptides
UV protection	Corneocyte cytosol	Structural proteins, trans-urocanic acid
Antioxidant defense	Corneocytes, extracellular matrix	Keratins, sebaceous gland-derived vitamin E and other antioxidants
Waterproofing/repellence	Lamellar bilayers	Keratinocyte and sebum-derived lipids
Cytokine signalling	Corneocyte cytosol	Storage and release of pro-IL-α, serine proteases
Xenobiotic defense	Lamellar bilayers	Lipid solubility, cytochrome p_{450} system (outer epidermis)

IL = interleukin; UV = ultraviolet.

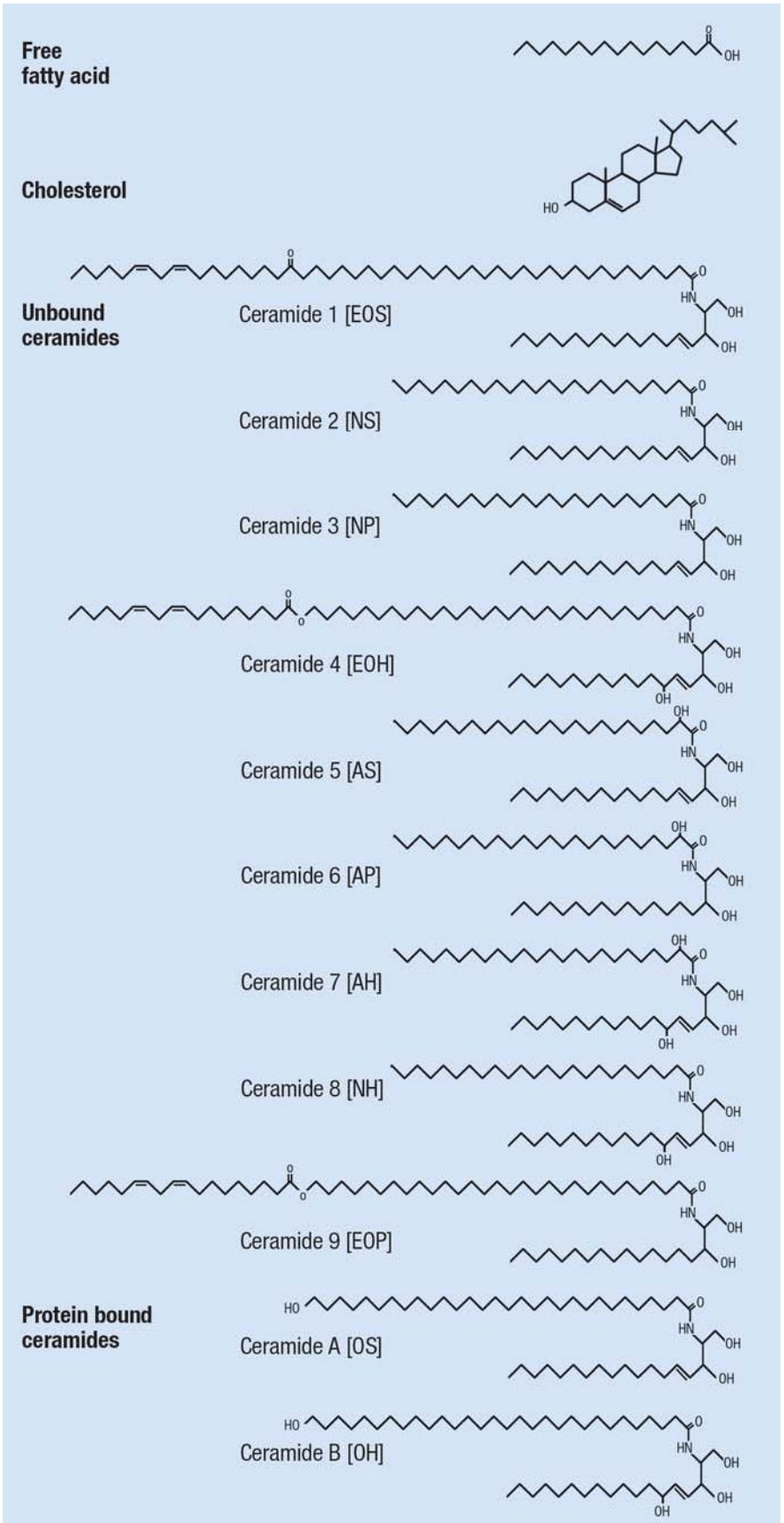

▲ **FIGURE 45-6** The stratum corneum lipid barrier contains free fatty acids, cholesterol, and different ceramide sub-types. Protein-bound ceramides and very-long-chain ceramides provide an anchor between the protein envelope proteins and the free intercellular lipids.

expression in keratinocyte cultures. Thus cholesterol levels for permeability barrier function are regulated by ABCA1, liver X receptor, and PPARs.[21] The cellular fatty acid transport and metabolism is regulated by fatty acid-binding proteins.[22]

EPIDERMAL PROLIFERATION AND DIFFERENTIATION IN SKIN BARRIER FUNCTION

To provide this physical barrier of the SC, not only intercellular lipids, but also the corneocytes are of crucial importance.[23,24] The epidermis undergoes keratinization in which epidermal cells progressively mature from basal cells with proliferative potential to lifeless flattened squames of the SC (see Fig. 45-2). Keratinocytes arise from stem cells in the basal layers and transient amplification cells and move to a series of differentiation events until they are finally brought to desquamation.[25] Thus, in the normal epidermis, there is a balance between the processes of proliferation and desquamation that results in a complete renewal approximately every 28 days (see Chap. 6). In some of the ichthyoses, the rate of desquamation may be decreased, leading to epidermal cell retention (retention hyperkeratosis) (see Chap. 47).[26] In inflammatory skin diseases like psoriasis, there is an increase in proliferation resulting in a disturbance in differentiation and parakeratotic squames (hyperproliferative hyperkeratosis) (see Chap. 18).[27]

Keratins are major structural proteins synthesized in keratinocytes (see Chap. 44). They assemble into a web-like pattern of intermediate filaments that emanate from a perinuclear ring, extend throughout the cytoplasm, and terminate at junctional desmosomes and hemidesmosomes. During the final stages of normal differentiation, keratins are aligned into highly ordered and condensed arrays through interactions with filaggrin, a matrix protein. In keratin disorders, the filament networks collapse around the nucleus, preventing attachment with the filament-matrix complex and the inner surface of squames and alter interaction between neighboring cells, thereby affecting desquamation. Filaggrin aggregates the keratin filaments into tight bundles. This promotes the collapse of the cell into a flattened shape, which is characteristic of corneocytes in the cornified layer. Together, keratins and filaggrin constitute 80 to 90 percent of the protein mass of mammalian epidermis.[23,24]

The structural proteins involucrin, loricrin, trichohyalin, and the class of small proline-rich proteins are synthesized and

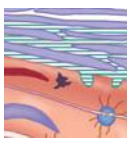

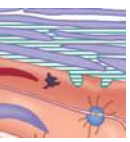

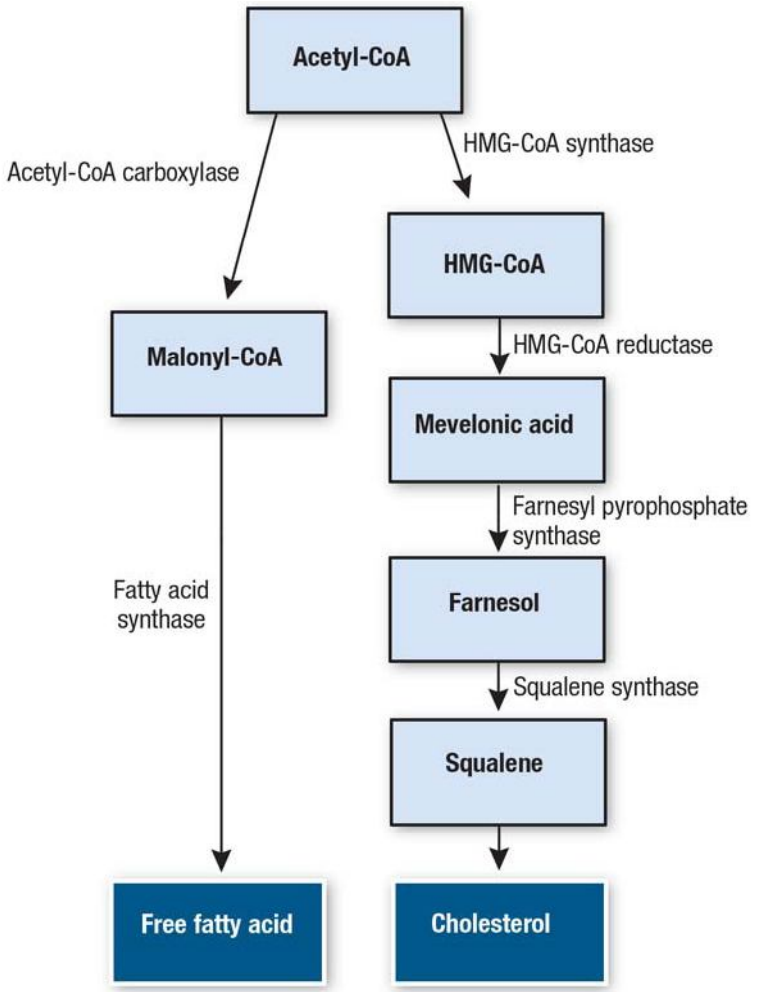

▲ **FIGURE 45-7** Synthetic pathways and key enzymes for stratum corneum free fatty acids and cholesterol. CoA = coenzyme A; HMG-CoA = hydroxymethylglutaryl CoA.

subsequently cross-linked by transglutaminases to reinforce the cornified envelope just beneath the plasma membrane. The proteins of the cornified envelope constitute approximately 7 to 10 percent of the mass of the epidermis. These corneocytes provide the bulwark of mechanical and chemical protection, and together with their intercellular lipid surroundings, confer water impermeability. The cornified cell envelope is a tough protein-lipid polymer structure formed just below the cytoplasmic membrane and subsequently resides on the exterior of the corneocytes (see Fig. 45-4). It is resistant to 10 percent potassium hydroxide and is the rigid structure seen on potassium hydroxide skin scrapings (see Chap. 188). It consists of two parts: a protein envelope and a lipid envelope. The protein envelope contributes to the biomechanical properties of the cornified envelope as a result of cross-linking of specialized cornified envelope structural proteins by both disulfide bonds and N(ε)-(γ-glutamyl)lysine isopeptide bonds formed by transglutaminases.[24,28] The isopeptide bonds are resistant to most common proteolytic enzymes. The corneocyte-bound lipid envelope is plasma membrane-like structure, which replaces the plasma membrane on the external aspect of mammalian corneocytes.[29] Involucrin, envoplakin, and periplakin serve as substrates for the covalent attachment ω-hydroxyceramides with very long chain N-acyl fatty acids of by ester linkage.[30] These not only provide a coating to the cell, but also interdigitate with the intercellular lipid lamellae (Table 45-3).[24]

EXPERIMENTAL BARRIER DISRUPTION AND GENE MODIFICATION IN EPIDERMAL DIFFERENTIATION

Experimental barrier disruption leads to changes in epidermal keratin and cornified envelope protein expression and, vice versa, overexpression and deficiency of these proteins in mice result in barrier defects. A number of diseases displaying defective epidermal barrier function are also the result of genetic defects in the synthesis of either keratins, cornified envelope proteins, or the transglutaminase 1 cross-linking enzyme.

Inhibition of hydroxymethylglutaryl CoA reductase by topical application of the lipid lowering drug lovastatin results in a disturbed barrier function and in epidermal hyperproliferation. Therefore, the specific relationship between barrier function and epidermal DNA synthesis was examined. After acute skin barrier

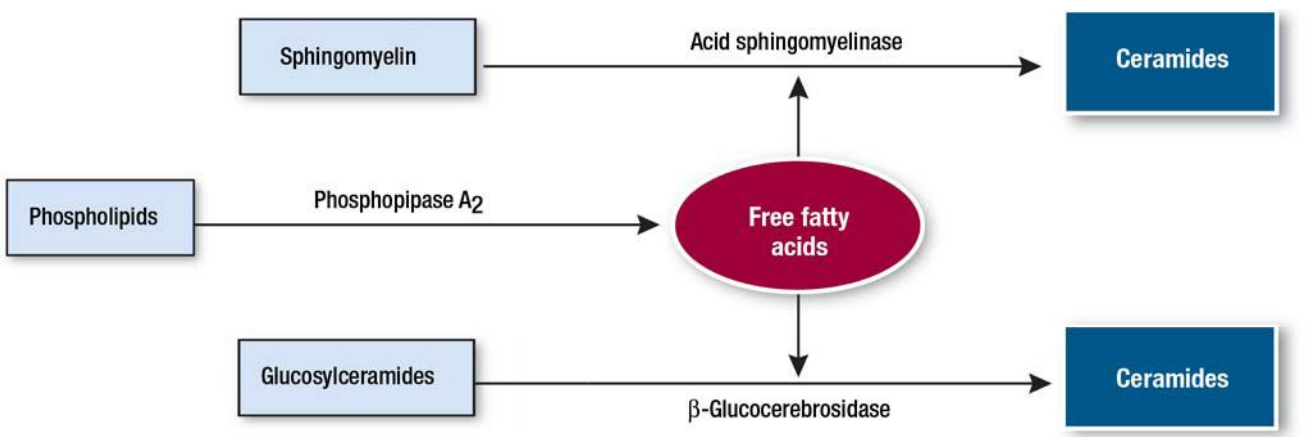

▲ **FIGURE 45-8** Sphingomyelin and glycosylceramides are precursor for ceramide generation, whereas phospholipids are precursors of fatty acids.

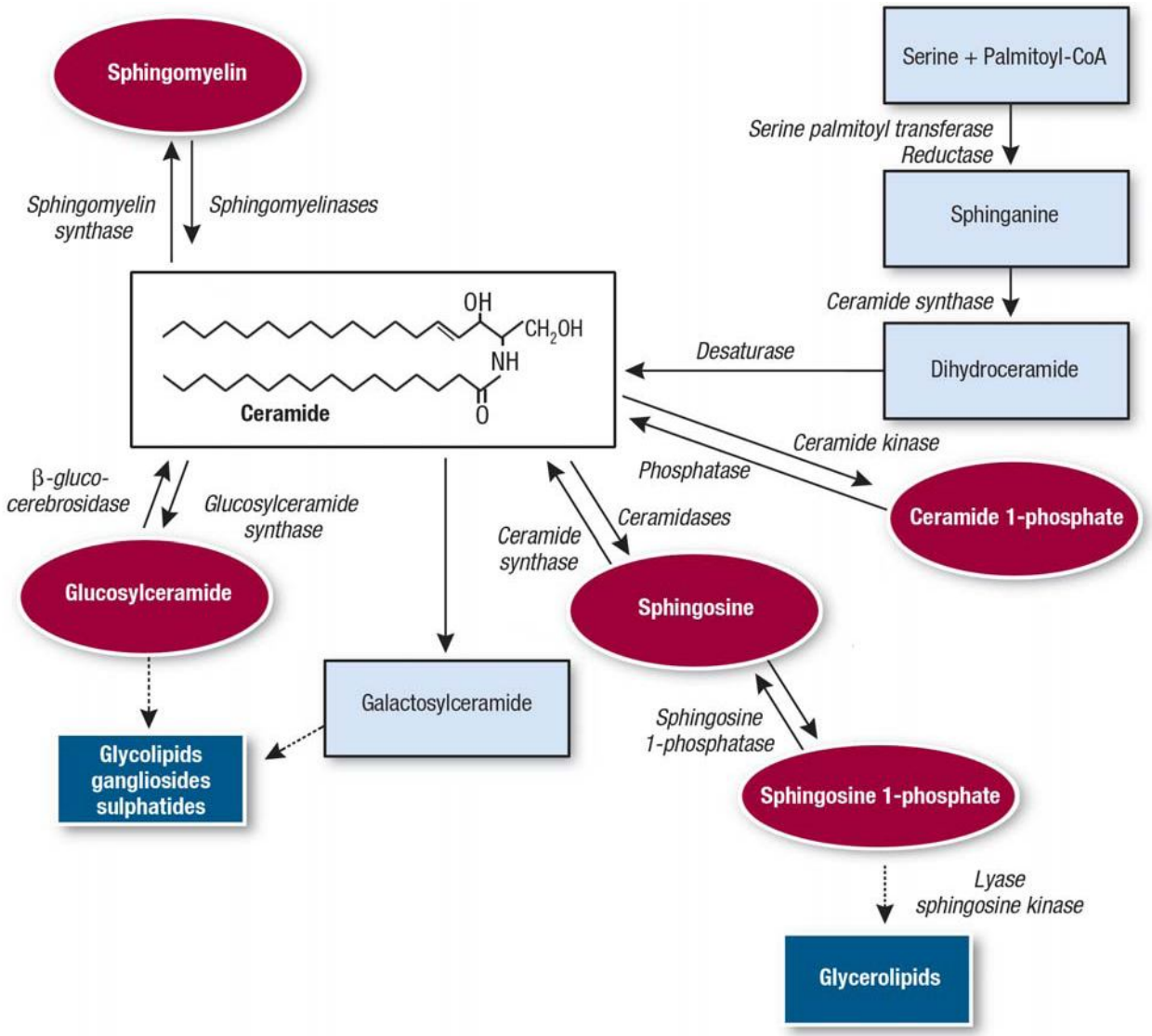

▲ **FIGURE 45-9** Generation and degradation of ceramides.

disruption (local acetone treatment or by tape-stripping) (Fig. 45-10) and in a model of chronic barrier disruption (EFAD diet), an increase in DNA synthesis leading to epidermal hyperplasia was noticed.[31] The increase in DNA and lipid synthesis was partially prevented by occlusion.[14,31,32]

Also, the described acute or chronic barrier disruption leads to specific changes in epidermal keratin and cornified envelope protein expression (see Chap. 44). Increased expression of the basal keratins K5 and K14 and a reduction of the differentiation-related keratins K1 and K10 was noted. In addition, there was expression of the proliferation-associated keratins K6 and K16 as well as the inflammation-associated keratin K17 (Fig. 45-11).[33] The importance of keratins for skin barrier function was supported by studies in K10-deficient mice. Heterozygotes and homozygotes showed a mild or severe permeability barrier disruption, respectively. Importantly, homozygous neonatal K10-deficient mice exhibited an extremely delicate epidermis and died a few hours after birth. Heterozygous littermates showed a normal skin at birth but developed increasing hyperkeratosis as they grew up.[34] Barrier repair in heterozygous K10-deficient mice was delayed and skin hydration was impaired.[35] Changes in ceramide composition, a reduced amount of glucosylceramide and sphingomyelin, and reduced acid sphingomyelinase activity as well as increased involucrin content was also noted.[36] This shows that genetically determined changes in structural proteins lead to an impaired skin barrier function, changes in differentiation and lipid composition, but the detailed mechanisms remain to be determined.

The importance of keratins for skin barrier function is further supported by studies in diseases that are caused by monogenetic defects of these structural

TABLE 45-3
Additional Protective Functions of the Nucleated Epidermis

FUNCTIONS	BIOCHEMICAL CORRELATES
Antimicrobial systems	Antimicrobial peptides and lipids, iron-binding proteins, complement
Antioxidants	Glutathione, oxidases, catalase, cytochrome P_{450} system, vitamins C and E
Inflammatory mediators	Prostaglandins, eicosanoids, leukotrienes, histamine, cytokines
UV-absorbing molecules	Melanin, trans-urocanic acid, vitamin D, vitamin C metabolites
Xenobiotic-metabolizing enzymes	Glucuronidation, sulfation, hydroxylation mechanisms

UV = ultraviolet

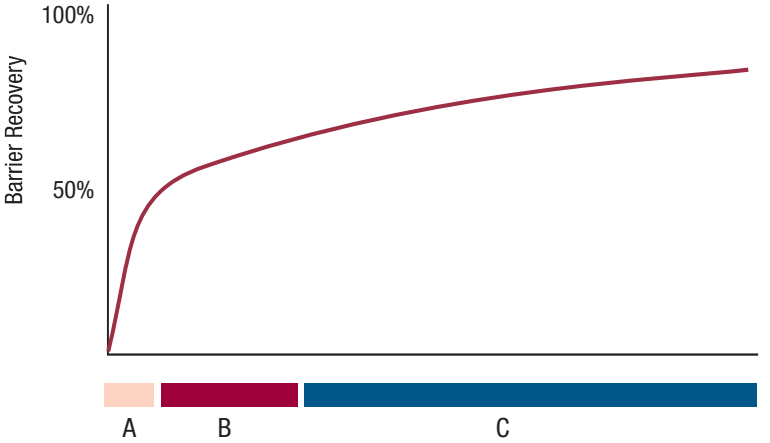

▲ **FIGURE 45-10** Three phases of barrier recovery with distinct metabolic activities occurring after acute barrier disruption. A = Secretion of preformed pool of lamellar bodies (0 to 30 minutes). B = Increased lipid synthesis (free fatty acids, ceramide, and cholesterol) (30 minutes to 6 hours), accelerated lamellar body formation and secretion (2 to 6 hours). C = Increased glucosylceramide processing (9 to 24 hours), increased keratinocyte proliferation and differentiation (16 to 24 hours).

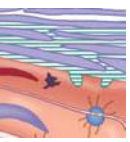

proteins. Epidermolysis bullosa simplex shows mutation in the basal layer keratins K5 or K14 (see Chap. 60). Genetic defects in the suprabasal keratins results in hyperkeratosis and a mild barrier defect (see Chaps. 47 and 48). Epidermolytic hyperkeratosis has spinous layer K1 or K10 defects, epidermolytic palmoplantar keratoderma has granular layer K9 defects (because this keratin is expressed only in palmar and plantar skin the disease is restricted to that area), and ichthyosis bullosa of Siemens has granular layer defects K2 (formerly K2e) defects (reviewed in ref. 23).

Experimental permeability barrier disruption leads to a premature expression of involucrin, but not loricrin.[33] Overexpression of filaggrin in mice in the suprabasal epidermis resulted in a delay in barrier repair.[37] Loss of normal profilaggrin and filaggrin causes flaky tail (ft/ft), an autosomal recessive mutation in mice that results in dry, flaky skin, and annular tail and paw constrictions, in the neonatal period. Targeted ablation of the murine involucrin gene did not show changes in skin barrier function under basal conditions[38] but did demonstrate a reduced ability for barrier repair. Loricrin-deficient mice did not show a disturbed barrier function, but demonstrated a greater susceptibility to mechanical stress, which may alter skin barrier function secondarily.[39,40]

Changes in epidermal proliferation and differentiation are also seen in inflammatory skin diseases with a disturbed skin barrier function (see Fig. 45-11). Increased proliferation is one of the main characteristics of psoriasis, but also in atopic dermatitis lesional skin there is a considerable increase in epidermal proliferation. Also, changes in keratins and cornified envelope proteins occur in inflammatory skin diseases.[41] Overall, this shows that there is undoubtedly a connection between epidermal proliferation, differentiation, and skin barrier function.

FUNCTIONS OF THE SUB-CORNEAL EPIDERMAL LAYERS

Although the SC is recognized as the most important physical barrier, the lower epidermal layers are also significant in barrier function. A low to moderate increase in TEWL occurs after removal of the SC by tape stripping, whereas loss of the entire epidermis through suction blisters leads to a severe disturbance in barrier function. Loss of the SC and parts of the granular layers in staphylococcal scalded-skin syndrome, are not usually life-threatening (see Chap. 178).[42] In contrast, suprabasal and sub-epidermal blistering diseases pemphigus vulgaris, toxic epidermal necrolysis (Lyell syndrome), and severe burns, respectively, are life-threatening when large areas of the body are involved (see Chaps. 39 and 94). Patients die because of extensive water loss or sepsis induced by external bacteria infection; outcomes directly resulting from perturbed barrier function. Survival rates can be greatly improved with application of an artificial barrier in the form of a foil or a grease ointment, often containing active antimicrobial substances. These clinical observations confirm the importance of the nucleated epidermal layers in skin barrier function in both directions, both in preventing excessive water loss and the entry of harmful substances into the skin.[43]

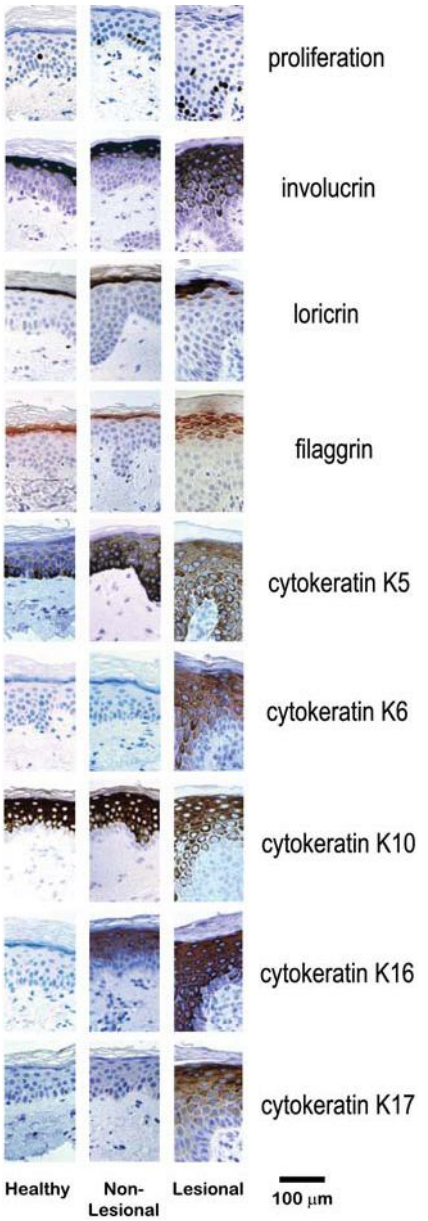

▲ **FIGURE 45-11** Skin diseases with a disturbed skin barrier function show changes in epidermal differentiation. In atopic dermatitis, these changes are already present in non-lesional and are more pronounced in lesional epidermis. The proliferation rate is significantly increased. A premature, but reduced, expression of involucrin occurs. The loricrin shows gaps in the stained band. Reduced filaggrin expression is in particular noted in non-lesional skin. Basal cytokeratin K5 expression is found in suprabasal cells in non-lesional skin and even in the entire nucleated epidermis in lesional atopic epidermis. Proliferation-associated K6 appears in lesional epidermis only. Expression of suprabasal cytokeratin K10 is found in the entire suprabasal epidermis in normal and non-lesional skin, but staining was reduced in diseased skin. K16 labelling is already found in non-lesional skin and more pronouncedly in lesional skin in atopic dermatitis, whereas inflammation-associated K17 shows immunostaining in lesional epidermis only.

Tight Junctions: A Second Line Epidermal Barrier

Tight junctions are cell junctions sealing neighboring cells and controlling the paracellular pathway of molecules, separating the apical from the basolateral parts of a cell (fence function) (see Fig. 45-2). The most important tight junction proteins in the human epidermis are occludin, claudins, and zonal occluding proteins. Localization of occludin is restricted to the stratum granulosum, zonal occluding protein-1 and claudin-4 are found in suprabasal layers, and claudins-1 and -7 are found in all epidermal layers. In various diseases with perturbed SC barrier function, such as psoriasis vulgaris, lichen planus, acute and chronic eczema, and ichthyosis vulgaris, tight junction proteins that were formerly restricted to the stratum granulosum and upper stratum spinosum were also found in deeper layers of the epidermis. Claudin-1–deficient mice die within 1 day of birth due to tremendous water loss.[44] Altered barrier function of the skin has also been demonstrated in mice overexpressing claudin-6 in the epidermis.[45,46]

Desmosomal and Adherence Junction Proteins: Structural Cell-Cell Interfaces

A perturbation in SC barrier function has also been found after the alteration of desmosomal proteins. Desmogleins are desmosomal cadherins that play a major role in stabilizing cell-cell adhesion in the living layers of the epidermis (see Fig. 45-2; see Chap. 51). Autoantibodies against these transmembrane glycoproteins cause blisters in pemphigus vulgaris due to loss of keratinocyte adhesion. In acute eczema, which shows disturbed skin barrier function, a reduction in keratinocyte membrane E-cadherin in areas of spongiosis has been found.[47,48] In transgenic mice in which the distribution of desmoglein 3 in epidermis was similar to that in mucous membrane, a highly increased TEWL resulted in lethality during the first week of life due to dehydration.[49] Mice conditionally inactivated in E-cadherin in the epidermis died perinatally due to the inability to retain a functional epidermal water barrier. Absence of E-cadherin leads to improper localization of key tight junctional proteins and in permeable tight junctions and thus altered epidermal barrier function.[50]

Connexins: Intercellular Gatekeepers

Connexins are transmembrane proteins that homo- or heteromerize on the plasma membrane to form a connexon. Connexons on adjoining cells associate to form gap junctions and allow the passage of ions and small molecules between cells. Connexin-26 is one of the most highly upregulated genes in psoriatic plaques. Missense mutations in connexin-26 result in five distinct ichthyosis-like skin disorders (see Chap. 47). In mice overexpressing connexin-26, a hyperproliferative state, infiltration of immunocells, and a delayed epidermal barrier recovery were noted.[51]

Proteases

Proteases are important for epidermal differentiation. The characteristic resistance of the cornified envelope is based on the formation of very stable isopeptide bonds that are catalyzed by transglutaminase 1, 3, and 5. Transglutaminase 1-deficient mice showed a defective SC and early neonatal death.[52] Mutations in transglutaminases 1 have been found to be the defect in lamellar ichthyosis (see Chap. 47).[53] Cathepsin D is involved in the processing of transglutaminase 1. Cathepsin D-deficient mice expressed a defect in barrier function and hyperproliferation.[54]

Netherton syndrome, a severe autosomal recessive genodermatosis, is caused by mutations in SPINK5, encoding the serine protease inhibitor LEKTI (see Chap. 47). In Netherton syndrome, often an atopic eczema-like skin disease with a disrupted permeability barrier is found. SPINK 5-/- mice replicate key features of Netherton syndrome, including altered desquamation, impaired keratinization, hair malformation, and a skin barrier defect. LEKTI deficiency causes abnormal desmosome cleavage in the upper granular layer through degradation of desmoglein 1 due to SC chymotryptic enzyme-like hyperactivity. This leads to defective SC adhesion and results in loss of skin barrier function.[55]

Cytokine Signaling: Regulation of Epidermal Homeostasis and Repair

Cytokines are very important for the regulation of wound healing in which re-epithelization and differentiation to form a competent barrier is the last step (see Chap. 249). Besides the immune cells, keratinocytes are able to produce a large variety and amount of cytokines (Fig. 45-12; see Chap. 11). Of special importance are the so-called *primary* cytokines tumor necrosis factor (TNF), interleukin (IL)-1, and IL-6. The cytokines IL-1α and IL-1β are among the few that are present in the SC under basal conditions. In response to all forms of acute barrier disruption, the preformed pool of IL-1α is released.[57] IL-1, TNF, and IL-6 are potent mitogens and stimulators of lipid synthesis in cutaneous and extracutaneous tissues. After acute permeability barrier disruption an increase in the expression of TNF, IL-1, and IL-6 on the messenger RNA and the protein level occurs.[19,58,59] There is a delay in barrier repair in several genetically engineered mice, including those deficient in TNF-α receptor 1, IL-1 receptor 1 TNF-α receptor 1-double knock-out mice, and in IL-6.[19,59] Moreover, topical application of TNF enhances permeability barrier repair, and topical application of IL-6 in IL-6-deficient mice restores the normal speed in permeability barrier (see Fig. 45-12). In TNF receptor 1-deficient mice, the generation of lipids for skin barrier repair is delayed and the activity of acid sphingomyelinase, which generates ceramides for skin barrier repair, is reduced.[19] STAT3 tyrosine phosphorylation was induced after barrier disruption in wild type, but markedly reduced in IL-6-deficient mice. The acute increase in TNF, IL-1, and IL-6 after barrier disruption is crucial for skin barrier repair. However, if barrier disruption is prolonged and a chronic increase in cytokine production occurs, it could have a harmful effect leading to inflammation and epidermal proliferation. Disrupted permeability barrier, epidermal hyperproliferation, and inflammation is well known in several diseases like irritant and allergic contact dermatitis, atopic dermatitis, and psoriasis, and could aggravate the disease.

Ionic Modulations: Epidermal Calcium and Potassium Levels

A perturbed barrier recovers normally when exposed to an isotonic, hyper- or hypotonic external solution instead of air. If the solution contains both calcium and potassium the barrier recovery is inhibited. There is a calcium gradient in the epidermis with a relatively low calcium concentration in the basal epidermis, and an even lower concentration in the spinous layers, while the highest calcium concentrations are found in the granular layers. Calcium in the SC is very low because the relatively dry SC with extracellular lipids is not able to solve the high polar ions. After disruption of the permeability barrier there is influx of water into the SC and the ion gradient is lost

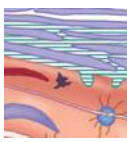

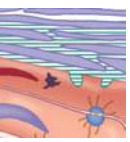

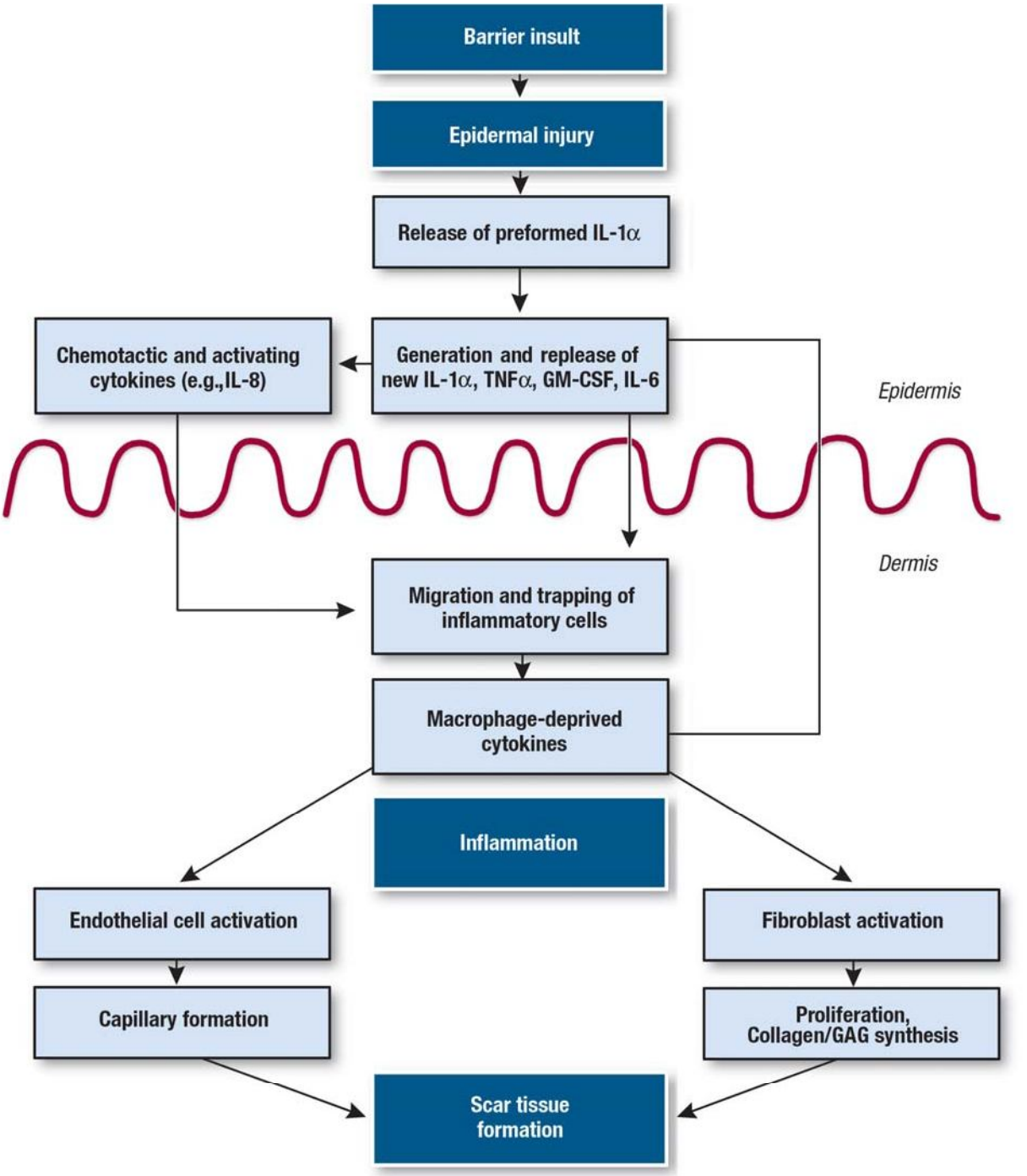

▲ **FIGURE 45-12** A barrier insult from the outside results not only in the release of cytokines for epidermal cell signaling, but also interacts with dermal processes, which may result in inflammation and ultimately scar tissue formation in case of destruction of the dermis. GAG = glycosaminoglycan; GM-CSF = granulocyte macrophage-colony stimulating factor; IL = interleukin; TNF = tumor necrosis factor.

(Fig. 45-13). This depletion of calcium regulates lamellar body exocytosis.[60-62] Calcium is a very important regulator of protein synthesis in the epidermis, including regulation of transglutaminase 1 activity.[63] Furthermore, extracellular calcium ions are important for cell to cell adhesion and epidermal differentiation. Intracellular calcium is controlled by more than one mechanism as demonstrated by two genetic diseases: Disturbed regulation of calcium metabolism and increased TEWL[64] occur in Darier disease, characterized by loss of adhesion between suprabasal epidermal cells associated with abnormal keratinization, and in Hailey-Hailey disease, which shows loss of epidermal cell to cell adhesion. The gene for Darier disease (*ATP2A2*) encodes a calcium transport adenosine triphosphatase of the sarco (endo)plasmic reticulum (SERCA2),[65,66] whereas the gene for Hailey-Hailey (*ATP2C1*) codes for a secretory pathway for calcium and manganese transport adenosine triphosphatase of the Golgi apparatus (SPCA1).[67]

Neurotransmitters in the Keratinocytes: Common Origins of the Brain and Skin

Neurotransmitters are found in keratinocytes and may regulate skin permeability barrier function. The receptors can be categorized in two groups, that is, ionotro-

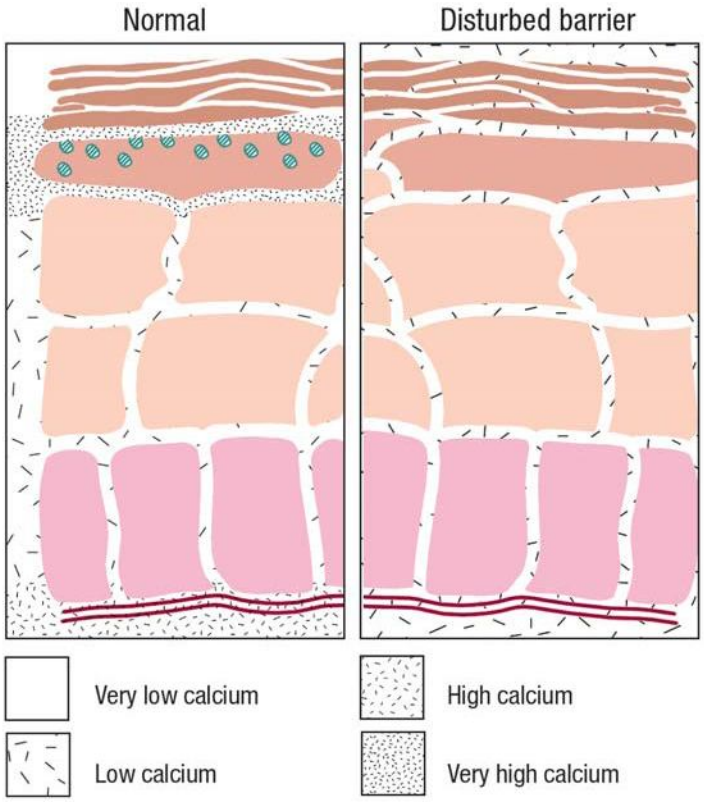

▲ **FIGURE 45-13** Changes in calcium gradient after barrier disruption regulates lamellar body secretion and epidermal differentiation.

pic (calcium or chloride ion) receptors and G protein-coupled receptors. Topical application of calcium channel agonists delays the barrier recovery whereas antagonists accelerate barrier repair.

The G protein-coupled receptors modulate intracellular cyclic adenosine monophosphatase (cAMP) level, increase of intracellular cAMP in epidermal keratinocytes delays barrier recovery, whereas cAMP antagonists accelerate the barrier recovery. Activation of dopamine 2–like receptors, melatonin receptors, or serotonin receptor (type 5-HT 1) decreases intracellular cAMP and consequently accelerates barrier recovery, whereas activation of adrenergic β_2 receptors increases intracellular cAMP and delays the barrier repair. Many agonists or antagonists of neurotransmitter receptors are used clinically to treat nervous disorders. Some of them might also be effective for treating skin diseases.[68]

PATHOLOGIC SKIN BARRIERS: SKIN BARRIER FUNCTION IN DERMATOSES

A mild impairment of the skin barrier is found in monogenetic diseases expressing an impaired epidermal differentiation or lipid composition without inflammation, such as ichthyosis vulgaris, X-linked recessive ichthyosis (see Chap. 47), and Darier disease (see Chap. 49).[64] The diseases with a more pronounced barrier disruption are inflammatory diseases, such as irritant and allergic contact dermatitis (see Chaps. 211 and 13), atopic dermatitis (see Chap. 14), seborrheic dermatitis (see Chap. 22), psoriasis (see Chap. 18), and T-cell lymphoma (see Chap. 146). Also, blistering diseases, most of them inflammatory-related, show an increase in TEWL especially after loosening of the blister roof and the development of erosions (Table 45-4).

Most inflammatory skin lesions are covered with dry scales or scale-crusts due to the disturbed epidermal differentiation and an SC with poor water-holding capacity. Inflammatory skin diseases can be produced by either exogenous or endogenous causes. In contact dermatitis, disruption of the barrier by irritants and allergens is the primary event, followed by sensitization, inflammation, increased epidermal proliferation, and changes in differentiation. In T-cell lymphoma (mycosis fungoides), an endogenous cause for barrier disruption, changes in epidermal proliferation, and differentiation, by expansion of clonal malignant $CD4^+$ T cells is obvious.[69] In atopic dermatitis and in psoriasis, it is debatable whether permeability barrier disruption is followed by inflammation or whether inflammation leads to epidermal changes including barrier dysfunction. The vast majority of reports on the pathogenesis of atopic dermatitis and even more on psoriasis focused on the primary role of abnormalities in the immune system.[70] However, others have proposed an "outside-inside" pathogenesis for atopic dermatitis and other inflammatory dermatoses with barrier abnormalities,[71,72] as an alternative to the current "inside-outside" paradigm.

Atopic Dermatitis: Consequence of a Chronically Disturbed Barrier

The existence of a defective permeability barrier function in atopic dermatitis is now widely accepted. A genetically impaired skin barrier function is already present in non-lesional and more pronounced in lesional skin in atopic dermatitis. Increased epidermal proliferation and disturbed differentiation, including changes in keratins and cornified envelope proteins involucrin, loricrin, and filaggrin, and in lipid composition, cause impaired barrier function in atopic dermatitis (see Figs. 45-11 and 45-14).[73] Recently, two mutations in the filaggrin gene have been described[74] and immediately confirmed.[75,76] Two loss-of-function genetic variants in the gene encoding filaggrin are strong predispos-

TABLE 45-4
Potential Role of the Cutaneous Barrier in the Pathophysiology of Skin Disorders

- Barrier abnormality represents a primary or intrinsic process:
  - Irritant contact dermatitis
  - Allergic contact dermatitis
  - Burns
  - Ulcers (ischemic, vascular, diabetic)
  - Bullous disorders by friction or keratin abnormalities
  - Premature infant's skin
  - Ichthyosis, Gaucher disease (II), Niemann-Pick disease (I)
- A primary barrier abnormality triggers immunologic reactions, but vice versa primary immunologic reactions may trigger barrier abnormalities in yet unknown subgroups of the diseases
  - Atopic dermatitis
  - Psoriasis
- Immunologic abnormality triggers barrier abnormality
  - T-cell lymphoma (mycosis fungoides)
  - Autoimmune bullous diseases
  - Lichen planus

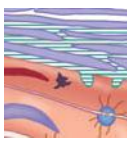

ing factors for atopic dermatitis in atopic kindreds of European origin.[77] These mutations were also significantly associated with asthma, independent of atopic dermatitis, that means that genetic factors that compromise the epidermal barrier could also underlie mucosal atopic diseases (filaggrin is a protein that is unique to keratinizing epithelia). The atopic syndrome represents a genetically impaired skin barrier function as well as impaired nasal, bronchial, and intestinal mucous membranes leading to atopic dermatitis, allergic rhinitis, bronchial asthma, or aggravation of atopic dermatitis. Defective permeability barrier function enables penetration of environmental allergens into the skin and initiates immunological reactions and inflammation (Fig. 45-15). Filaggrin mutation is the first strong genetic factor identified in this complex disease. Filaggrin hydrolysis generates amino acids in their deaminated products, which serve as endogenous humectants.[78] This may explain the dry skin well known in atopic dermatitis. Also, gene polymorphisms in the gene for SPINK5, which encodes the serine protease inhibitor LEKTI, have been reported[79] and variations within two serine proteases of the kallikrein family, the SC chymotryptic enzyme which degrades corneodesmosomal proteins, involved in the cohesion between the corneocytes of the SC, have been found in some cohorts with atopic dermatitis.

The impaired skin barrier function in atopic dermatitis is also caused by reduced lipid content or impaired lipid composition in atopic dermatitis. In particular, a decreased content for the total amount and for certain types of ceramides has been described.[72] A decrease in covalently bound ceramides[80] and a reduced sphingomyelinase activity has been found in atopic dermatitis. Also, decreased secretion of lamellar bodies, which are predominantly composed of lipids, with subsequent entombment of lamellar bodies within corneocytes, has been reported.[81]

Psoriasis: Epidermal Hyperproliferation and the Skin Barrier (See Chap. 18)

Psoriasis is a chronic, generalized, and scaly erythematous dermatosis that is primarily localized in the epidermis, showing highly enhanced proliferation and disturbed differentiation, which leads to hyperkeratosis and parakeratosis. In addition, there is a neutrophilic infiltrate in the beginning and in particular in severe cases of psoriasis; later a moderate T-lymphocytic infiltrate is present. Because of this

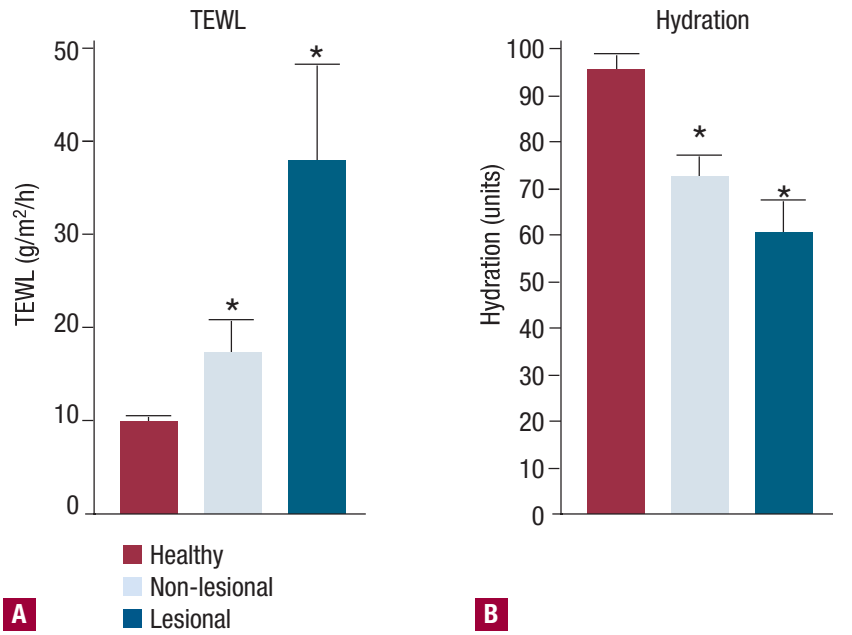

▲ **FIGURE 45-14** Transepidermal water loss (TEWL) (**A**) and stratum corneum hydration (**B**) are impaired in atopic dermatitis. Reduced stratum corneum hydration and enhanced TEWL are already seen in non-lesional and are more pronounced in lesional skin in atopic dermatitis.

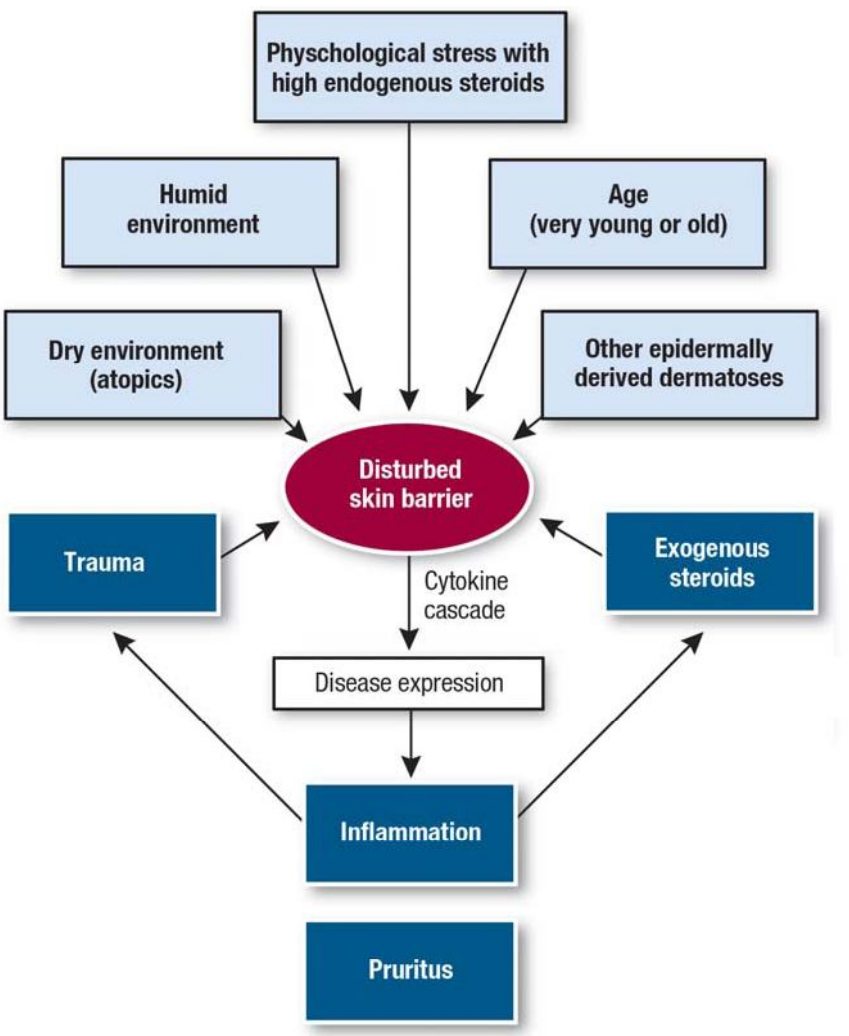

▲ **FIGURE 45-15** Endogenous and exogenous insults lead to a disturbance in skin barrier function, thus inducing or maintaining inflammatory skin diseases in atopic dermatitis.

severely disturbed proliferation and epidermal differentiation, there is an impaired barrier function.[82] The level of TEWL is directly related to the clinical severity of the lesion: high TEWL in acute exanthematous psoriasis; a moderate increase in TEWL in the chronic plaque type of the disease. Abnormalities in the SC intercellular lipids, especially a significant reduction in ceramide 1 have been found.[83] Electron microscopy studies disclosed severe structural alteration of the intercellular lipid lamellae.[84] A genetic linkage of psoriasis to the epidermal differentiation complex 1q21 has been found. Within the epidermal differentiation complex the small proline-rich proteins are highly upregulated in psoriasis plaques.[85] Also, the association of psoriasis with cytokeratin K17 has been discussed.

Ichthyosis: Pathologic Lack of Moisture in the Epidermis (See Chap. 47)

Ichthyosis comprises a group of monogenetic diseases expressing a disturbed desquamation resulting in scales and a mild to moderate barrier defect. They are caused either by changes in epidermal lipids or by changes in epidermal differentiation. X-linked recessive ichthyosis is relative mild noncongenital ichthyosis, consisting of a generalized desquamation of large, adherent, and dark brown scales. The metabolic basis of XLRI is an enzymatic lysosomal deficiency of steroid sulfatase or arylsulfatase C. Complete deletions of the *STS* gene mapped to the Xp22.3-pter region have been found in up to 90 percent of patients. The reduced cholesterol sulfatase activity leads to accumulation of cholesterol sulfate and a reduction of cholesterol and consequent abnormality in the structural organization of the intercorneocyte lipid lamellae.[86-88]

Ichthyosis vulgaris is the most common monogenetic skin disease. Recently, loss-of-function mutations in the gene encoding filaggrin that cause ichthyosis vulgaris have been described. During terminal differentiation, profilaggrin is cleaved into multiple filaggrin peptides that aggregate keratin filaments. The resultant matrix is cross-linked to form a major component of the cornified cell envelope. Reduction of this major structural protein leads to an impaired keratinization and to a moderate defect in skin barrier function.[89]

Transglutaminase 1 is responsible for the cross-link of several cornified envelope proteins. Therefore, deficiency in transglutaminase 1[53] leads to lamellar ichthyosis, which is a more severe disease than ichthyosis vulgaris with a defect in filaggrin only.

TREATMENT IMPLICATIONS AND APPROACHES: RESTORING THE SKIN'S PROTECTIVE FUNCTION

Treatment strategies in inflammatory diseases often address immunogenic abnormalities and barrier function. Treatment with corticosteroids, cyclosporin, tacrolimus, pimecrolimus, and UV light has been shown to reduce cell inflammation as well as to improve barrier function, thus helping to normalize proliferation and differentiation. However, because of side effects, these treatments should be used for a short time only. In contrast, application of bland creams and ointments containing lipids and lipid-like substances, hydrocarbons, fatty acids, cholesterol esters, and triglycerides can be used without side effects for long-term treatment of mild to moderate inflammatory diseases. Creams and ointments partially correct or stimulate barrier repair and increase SC hydration,[41,90–92] thus influencing epidermal proliferation and differentiation.[14] It has been proposed that a lipid mixture containing the three key lipid groups (ceramides, cholesterol, and free fatty acids) is able to improve skin barrier function and SC hydration in atopic dermatitis.[93] Also, the efficacy of ceramide 3 in a nanoparticle cream in atopic dermatitis has been described.[94] However, because several research groups and companies report that creams containing ceramides and a mixture of the three key lipids are not superior to "classical" cream or ointment preparations, such preparations have not yet been widely used. More research is necessary to determine the significance of ceramides and the composition of creams and ointments with the most therapeutic benefit.

KEY REFERENCES

The full reference list for all chapters is available at www.digm7.com.

7. Bouwstra JA, Pilgrim K, Ponec M: Structure of the skin barrier, in *Skin Barrier*, edited by PM Elias, KR Feingold. New York, Taylor and Francis, 2006, p 65
23. Roop D: Defects in the barrier. *Science* **267**:474, 1995
28. Candi E, Schmidt R, Melino G: The cornified envelope: A model of cell death in the skin. *Nat Rev Mol Cell Biol* **6**:328, 2005
46. Brandner JM, Proksch E: Epidermal barrier function: Role of tight junctions, in *Skin Barrier*, edited by PM Elias, KR Feingold. New York, Taylor and Francis, 2006, p 191
73. Proksch E, Foelster-Holst R, Jensen JM: Skin barrier function, epidermal proliferation and differentiation in eczema. *J Dermatol Science* **43**:159-169, 2006
77. Irvine AD, McLean WH: Breaking the (un)sound barrier: Filaggrin is a major gene for atopic dermatitis. *J Invest Dermatol* **126**:1200, 2006



CHAPTER 46

Irritant Contact Dermatitis

Antoine Amado
James S. Taylor
Apra Sood

Dermatitis or eczema is a pattern of cutaneous inflammation that presents with erythema, vesiculation, and pruritus in its acute phase. Its chronic phase is characterized by dryness, scaling, and fissuring. Irritant contact dermatitis (ICD) is a cutaneous response to contact with an external chemical, physical, or biologic agent; endogenous factors such as skin barrier function and pre-existing dermatitis also play a role. The spectrum of presentation after contact with an irritant varies from overt dermatitis to subjective contact reaction, contact urticaria, caustic and necrotic reactions as well as pigmentary changes and other dermatoses.

EPIDEMIOLOGY

In contrast to allergic contact dermatitis (ACD), no previous exposure to the irritant is necessary in eliciting irritant reactions.[1] ICD accounts for 80 percent of all cases of contact dermatitis,[2,3] and is often occupation-related. ICD caused by personal-care products and cosmetics is also common; however, very few of these patients with these irritant reactions seek medical help because they manage by avoiding the offending agent.[4]

The incidence of ICD is difficult to determine because the accuracy of the

IRRITANT CONTACT DERMATITIS

AT A GLANCE





- Irritant contact dermatitis (ICD) is a nonimmunologic inflammation of the skin caused by contact with a chemical, physical, or biologic agent.
- Up to 80 percent of contact dermatitis is irritant and is commonly related to occupation.
- The most important exogenous factor for ICD is the inherent toxicity of the chemical for human skin.
- Endogenous factors, such as skin barrier function and pre-existing dermatitis, play an important role in the pathogenesis of ICD.
- Atopic dermatitis is a major risk factor for irritant hand dermatitis because of impaired barrier function and a lower threshold for skin irritation.
- Patch testing should be performed in cases with suspected chronic irritant dermatitis to exclude an allergic contact dermatitis.
- Identification and avoidance of the potential irritant is the mainstay of treatment.



epidemiologic data is limited. European cross-sectional studies for eczema due to all causes in the general population have shown point prevalence rates of 0.7 percent to 40 percent and 1-year to lifetime prevalence rates of 7.2 percent to 11.8 percent.[5] Data from the U.S. Bureau of Labor Statistics show that of the 249,000 cases of nonfatal occupational illnesses reported in 2004 for both genders, 15.6 percent (38,900 cases) were skin diseases, the second most frequent cause of all occupational diseases reported.[6] Based also on annual surveys of the Bureau of Labor Statistics incidence rates of occupational diseases in the American working population, contact dermatitis constitutes 90 percent to 95 percent of all occupational skin diseases, and ICD constitutes about 80 percent of occupational contact dermatitis.[7]

ETIOLOGY AND PATHOGENESIS

Four interrelated mechanisms have been associated with ICD: (1) removal of surface lipids and water-holding substances, (2) damage to cell membranes, (3) epidermal keratin denaturation,[8–11] and (4) direct cytotoxic effects.[11] There is a clearly demonstrated immunologic-like component to the irritant response,[12] which is characterized by the release of proinflammatory mediators, particularly cytokines, from nonimmune cutaneous cells (keratinocytes) in response to chemical stimuli. This is a process that does not require previous sensitization.[10] Disruption of the skin barrier leads to release of cytokines such as interleukin 1α (IL-1α), IL-1β, and tumor necrosis factor-α (TNF-α). A 10-fold increase in the levels of TNF-α and IL-6, and a threefold increase in the levels of granulocyte-macrophage colony-stimulating factor and IL-2 have been observed in ICD. TNF-α is one of the key cytokines in irritant dermatitis, leading to the increased expression of major histocompatibility complex class II and intracellular adhesion molecule 1 on keratinocytes.[10,13]

INFLUENCING FACTORS

ICD is a multifactorial disease where both exogenous (irritant and environmental) and endogenous (host) factors play a role. Occupational ICD is discussed in more detail in Chap. 211.

Exogenous Factors (Table 46-1)

Other than with strong acids and alkalis, it has not been possible to predict the irritant potential of a chemical based on molecular structure. The irritant potential of compounded formulations may be more difficult to predict. Factors to be considered include: (1) chemical properties of the irritant: pH, physical state, concentration, molecule size, amount, polarization, ionization, vehicle, solubility; (2) characteristics of exposure: amount, concentration, duration, and type of contact, simultaneous exposure to other irritants, and interval after previous exposure[4,14]; and (3) environmental factors: body region and temperature, and mechanical factors such as pressure, friction, or abrasion.[2] Low ambient humidity and cold temperature decrease the water content of the stratum corneum, making it more permeable to irritants.

When one or more irritants are combined or used simultaneously, a synergistic or antagonistic effect may occur as a consequence of specific cellular interactions between the compounds, or an alteration in the skin permeability by one or more of the compounds, that would not occur when an irritant is used alone.[4,12] This is known as the *crossover phenomenon*. In a study by Wigger-Alberti et al.,[15] concurrent application of sodium lauryl sulphate and toluene twice daily for 30 minutes to the volar forearms of healthy volunteers induced significantly stronger irritant reactions than those caused by twice-daily application of each chemical alone. This study suggests a crossover phenomenon between the two compounds by which one irritant caused an increased susceptibility to the other irritant.

TABLE 46-1
Exogenous Factors Influencing Cutaneous Irritation

- Type of irritant (pH, chemical activity)
- Cutaneous penetration of irritant
- Body temperature
- Mechanical factors (pressure, friction, abrasion)
- Environment (temperature, humidity)
- Other exposure factors: duration, prior or simultaneous exposures, direct versus airborne

Adapted from Denig NI, Hoke AW, Maibach HI. Irritant contact dermatitis. Clues to causes, clinical characteristics, and control. *Postgrad Med* **103**:199, 207, 212; 1998; and Frosch PJ, John SM: Clinical aspects of irritant contact dermatitis, in *Contact Dermatitis*, 4th edition, edited by Frosh PJ, Menné T, Lepoittevin J-P. Germany, Springer-Verlag Berlin Heidelberg, 2006, p 255.

Endogenous Factors (Table 46-2)

GENETIC FACTORS It has been hypothesized that an individual's ability to quench free radicals, to change the levels of antioxidant enzymes, and the ability to form protective heat shock proteins may all be under genetic control. These factors also determine the variability in responsiveness to irritants.[16] Additionally, a genetic predisposition to irritant susceptibility may be specific for each irritant.[17]

GENDER The majority of clinical ICD affects the hands, and women account for a majority of these patients.[18] Rather than a gender-related skin susceptibility, women have more extensive exposure to irritants and wet work and are more likely to seek treatment than men.[4,14,19] No gender difference for ICD has been established experimentally.

TABLE 46-2
Endogenous Factors Influencing Cutaneous Irritation

- Atopic dermatitis
- Skin permeability
- Individual susceptibility
- Primary sensitive (hyperirritable) skin
- Lack of hardening
- Secondary hyperirritability of the skin (status eczematicus)
- Race
- Age
- Sensitivity to ultraviolet light

Adapted from Denig NI, Hoke AW, Maibach HI. Irritant contact dermatitis. Clues to causes, clinical characteristics, and control. *Postgrad Med* **103**:199, 207, 212; 1998; and Frosch PJ, John SM: Clinical aspects of irritant contact dermatitis, in *Contact Dermatitis*, 4th edition, edited by Frosh PJ, Menné T, Lepoittevin J-P. Germany, Springer-Verlag Berlin Heidelberg, 2006, p 255.

AGE Children younger than 8 years of age are more susceptible to percutaneous absorption of chemicals and irritant reactions.[4] Most studies show no compromise in skin barrier permeation with increasing age. Data on the influence of aging on experimental skin irritation are conflicting. Visible skin irritation (erythema) is decreased in older persons while invisible skin irritation (barrier damage) might be increased in the elderly.[20]

ETHNICITY There are no studies that demonstrate that skin types significantly influence the development of ICD.[21,22] Because erythema is difficult to measure in dark skin, early studies[23] using erythema as the only parameter to quantify irritation may have led to an erroneous interpretation that black skin is more resistant to irritation than white skin. It is also possible that variations among individuals rather than ethnicity play a role in the intensity of an irritant response.[24]

SKIN SITE There are significant site differences in barrier function, making the skin of the face, neck, scrotum, and dorsal hands more susceptible to ICD. The palms and soles are comparatively more resistant.[25]

ATOPY A history of atopy is a well-known predisposing factor for irritant hand dermatitis (see Chap. 14). A history of atopic dermatitis seems to be linked to an increased susceptibility to irritant dermatitis because of a lower threshold for skin irritation, impaired skin barrier function, and slower healing process.[26]

Thus, the most important exogenous factor is the inherent toxicity of the chemical for human skin and its penetration.[27] The most important endogenous factors are atopic history and skin barrier function.[20]

TABLE 46-3
Types of Irritant Contact Dermatitis (ICD)

IRRITATION	ONSET	PROGNOSIS
Acute ICD	Acute, often single exposure	Good
Delayed acute ICD	Delayed 12–24 h or longer	Good
Irritant reaction	Acute, often multiple exposures	Good
Chronic ICD	Slowly developing (weeks to years)	Variable
Traumatic ICD	Slowly developing after preceding trauma	Variable
Acneiform ICD	Moderately slowly developing (weeks to months)	Variable
Nonerythematous (suberythematous) irritation	Slowly developing	Variable
Subjective (sensory) irritation	Acute	Excellent
Friction dermatitis	Slowly developing	Variable
Asteatotic irritant eczema	Slowly developing	Variable
Other clinical subtypes of acute and chronic ICD		
Interdigital	Slowly developing (days to weeks)	Variable
Frictional melanosis	Slowly developing (months to years)	Poor
Diaper dermatitis	Acute or delayed	Variable
Chemical burns	Acute or delayed	Variable
Nonimmunologic contact urticaria	Acute	Variable
Airborne	Acute	Variable
Scalp irritation	Acute or delayed	Variable
Nail irritation	Delayed to slow	Variable
Tandem[a]	Acute or delayed	Variable
Photoirritation[a]	Acute	Variable

[a]Personal communication H. I. Maibach, June, 2005.
Adapted from Chew AL, Maibach HI. Ten genotypes of irritant contact dermatitis, in *Irritant Dermatitis*, edited Chew AL, Maibach HI, Lepoittevin J-P. Germany, Springer-Verlag Berlin Heidelberg, 2006, p 6.

CLINICAL TYPES OF IRRITANT CONTACT DERMATITIS

ICD has a spectrum of clinical features, which can be divided into several different categories, depending on the irritant and its exposure pattern.[28] But these manifestations also depend on mechanical, thermal, climatic, and constitutional factors.[14] The clinical types of ICD vary according to the irritant in question: ulceration (e.g., strong acids or alkalis), folliculitis (e.g., oils and greases), miliaria (e.g., aluminum chloride), hyperpigmentation (e.g., heavy metals), and hypopigmentation (e.g., *p*-tert-butylphenol).[10]

At least 10 clinical types of ICD have been described. They are listed in Table 46-3 along with a number of clinical sub-types of acute and chronic ICD.

1. *Irritant reaction:* An irritant reaction clinically presents as an acute monomorphic reaction that includes scaling, low-grade erythema, vesicles, or erosions and is usually localized on the dorsum of the hands and fingers. It is often seen in individuals who are exposed to wet work. An irritant reaction can resolve or progress to cumulative irritant dermatitis.[10,12]
2. *Acute ICD:* Acute ICD usually results from a single skin exposure to a strong irritant or caustic chemical, such as alkalis and acids, or as a result of a series of brief chemical or physical contacts. Most cases of acute irritant dermatitis are a consequence of accidents at work. A sensation of burning, itching, or stinging may occur immediately after the exposure to the irritant. The patient may present with erythema, edema, and vesiculation and with exudation, bullae formation, and tissue necrosis in more severe cases. The healing process of acute ICD occurs



TABLE 46-4
Airborne Irritants

- Acids and alkalis
- Ammonia
- Anhydrous calcium sulfate
- Arsenic
- Calcium silicate
- Cement
- Dichlorvos
- Domestic cleaning products
- Epoxy resins
- Formaldehyde
- Fiberglass
- Industrial solvents
- Metallic oxide powders
- Paper
- Phenol formaldehyde resins
- Sawdust from toxic trees
- Silver
- Sodium sesquicarbonate
- Urea-formaldehyde insulating foam, dust foam
- Wool dust (in atopic patients)

Adapted from Denig NI, Hoke AW, Maibach HI. Irritant contact dermatitis. Clues to causes, clinical characteristics, and control. *Postgrad Med* **103**:199, 207, 212; 1998.

TABLE 46-5
Chemicals Causing Delayed Irritant Reactions

- Acrylates (certain)
  - Butanediol diacrylate
  - Hexanediol diacrylate
  - Tetraethylene glycol diacrylate
- Anthralin (Dithranol)
- Benzalkonium chloride
- Benzoyl peroxide
- Bis (2-chloroethyl) sulfide
- Calcipotriol
- Dichlor (2-chlorovinyl) arsine
- Diclofenac
- Epichlorhydrine
- Ethylene oxide
- Fluorohydrogenic acid
- Nonanoic acid
- Octyl gallate
- Podophyllin
- Propylene glycol
- Sodium lauryl sulfate
- Tretinoin

Adapted from Denig NI, Hoke AW, Maibach HI. Irritant contact dermatitis. Clues to causes, clinical characteristics, and control. *Postgrad Med* **103**:199, 207, 212; 1998; and Frosch PJ, John SM: Clinical aspects of irritant contact dermatitis, in *Contact Dermatitis*, 4th edition, edited by Frosh PJ, Menné T, Lepoittevin J-P. Germany, Springer-Verlag Berlin Heidelberg, 2006, p 255.



as a decrescendo phenomenon, where the irritant reaction quickly peaks and then immediately begins to heal upon removal of the irritant. Complete healing may take 4 weeks, with a good prognosis.[4,12,14]

Other forms of acute irritant reaction have been also described (see Table 46-3), such as airborne contact dermatitis resulting from exposure to irritant fumes or dusts (Table 46-4).[4,14] Irritant cheilitis may result from lip licking or use of cosmetics and medication. Diaper dermatitis and perianal dermatitis may be the result of prolonged or too frequent contact with urine or fecal residues.[14] Dermatitis resulting from sodium azide released by airbag deployment has also been described,[29] causing an alkaline chemical burn; the accompanying talc powder may also contribute to the dermatitis.

3. *Delayed acute irritancy:* The delayed irritant reaction is acute but without visible signs of inflammation appearing until 8 to 24 hours or more after exposure. Otherwise, the clinical appearance and course are similar to those of an acute ICD.[4,12] The delayed presentation may simulate that of an ACD, sometimes making differentiation of the two disorders difficult, even with patch testing. Substances causing delayed irritancy are listed in Table 46-5. Delayed acute irritancy in general has a good prognosis.[10,12,14]
4. *Chronic cumulative ICD:* This is the most frequent type of contact dermatitis encountered in clinical practice. Also called *traumiterative ICD*, cumulative ICD develops as a result of repeated insults to the skin, where the chemicals involved are often multiple and weak and would not in themselves be strong enough to cause irritant dermatitis.[10,12,14] The most common marginal irritants include soap, detergents, surfactants, organic solvents, and oils,[2] which may also act as perpetuating factors once the dermatitis has become established. Cosmetic cumulative ICD is not infrequent in women, particularly in the eyelids.[14]

   Initially, cumulative contact dermatitis can appear with itch, pain, and a few localized patches of dry skin; then erythema, hyperkeratosis, and fissuring can develop.[2,4,12,14] The symptoms do not immediately follow exposure to the irritant, appearing after days, months, or years of exposure. With extensive and frequent exposure to some irritants, the skin becomes hardened, with better resistance to future irritant exposures. Hardened skin appears coarse and lichenified, which may contribute to further resistance. However, even brief periods away from exposure lower the resistance, and with re-exposure, patients are once again at risk for irritation. Chronic cumulative ICD can be confused with ACD because of the delayed and variable presentation, and appropriate diagnostic patch testing is indicated to exclude ACD. The prognosis of cumulative ICD is variable.[4,12]
5. *Subjective (symptomatic, sensory) irritancy:* Patients complain of itching, tingling, stinging, burning, or smarting sensation within minutes of contact with an irritant, but without visible cutaneous changes.[12,28] Subjective irritancy usually occurs on the face, head, and neck. Cosmetics, sunscreens, and woolen garments are commonly implicated.[3,4,28] Other common sensory irritants include lactic acid (a model for this phenomenon), propylene glycol, and aluminum salts. Stimulation of cutaneous type C nociceptors has been implicated in this form of irritancy,[12] although recently changes in cutaneous vasculature have been implicated. Some sensory irritation may be nonimmunologic contact urticaria. Screening raw ingredients or final formulations with the guinea pig ear swelling test or the human forehead assay may allow one to minimize sub-clinical contact urticaria.[30]
6. *Nonerythematous (suberythematous) irritation:* This is a state in which the irritation is not visually apparent, but is histologically visible. Common symptoms include burning, itching, or stinging. Sub-erythematous irritation has been linked with the use of consumer products containing significant amounts of surfactant.[4,12]
7. *Frictional dermatitis:* Mechanical irritation can result from repeated microtrauma and friction. Nipple dermatitis in patients with ill-fitting bras, and dermatitis from prosthetic limbs, mechanical injury from thorns and spines in plants, adhesive tape, or from handling coarse paper, glass, and rock wool fiber are only some.[10,14] This type of contact irritation usually leads to dry, hyperkeratotic abraded skin, making it more vulnerable to the effects of irritants.[4]
8. *Traumatic reactions:* Traumatic reactions can develop after acute skin trauma as

burns or lacerations and most commonly occurs on the hands and persists for about 6 weeks or longer. The healing process in this type of dermatitis is prolonged, and erythema, scaling, papules, or vesicles can appear. The clinical course can resemble that of nummular dermatitis.[4,12]

9. *Pustular or acneiform reactions:* Pustular or acneiform reactions are usually seen after occupational exposures to oils, tars, heavy metals, and halogens but also after the use of some cosmetics. The pustular lesions are sterile and transient and may develop several days after exposure. This type of dermatitis is seen especially among atopic and seborrheic patients.[4,9,12]
10. *Exsiccation eczematid:* Exsiccation eczematid usually occurs in elderly patients who frequently shower without reapplying moisturizers to their skin. Intense itching, dry skin, and ichthyosiform scaling are clinical features that characterize this irritant reaction.[12]

COMMON IRRITANTS (Table 46-6)

Water is a hypotonic element that acts as a cytotoxic agent on eroded skin.[14] Hard water has been found to be more irritating than soft water.[31] Skin cleansers cause irritation depending on the chemistry of their constituents. They remove surface lipid film, denature proteins, and damage the cell membrane. Soaps, detergents, and waterless cleansers are the most common irritants. Preservatives, especially quaternary ammonium compounds, have an irritant effect. Foods, such as citrus peels, garlic, flour, and spices, can act as irritants.[14] Capsaicin produces hand irritation after handling hot peppers and is also present in some personal defense sprays used by police or by civilians.[1] Pineapple juice contains bromelain, an irritating proteolytic enzyme.[32]

Other potential irritants include: Animal products from seafood and meat, from caterpillars, carpet beetles, and moths; topical medicaments, such as occlusive transdermal drug delivery systems, gentian violet, tar, potassium permanganate, mercury, hexachlorophene, etc.[14]; cosmetics, especially when applied to the eyelids; and alkalis, present in soap, bleaches, detergents, oven cleansers, and toilet bowl cleaners.[1] Fiberglass dermatitis can develop from wearing clothes that have been washed together with fiberglass-contaminated work clothes or with fiberglass curtains.[33] Other tear gases, [e.g., 2-chlorobenzylidene malononitrile, known as *CS* (pepper spray) and, rarely, 1-chloroacetophenone, known as *CN* (Mace)] are present in a variety of self-defense or riot-control sprays[1] and cause lacrimation, sternutation, and, occasionally, cutaneous irritation and sensitization.

TABLE 46-6
Causes of Irritant Contact Dermatitis

- Animal products
- Cosmetics
- Degreasing agents
- Detergents
- Dusts/friction
- Foods
- Low humidity
- Metal working fluids
- Tear gases
- Topical medicaments
- Solvents
- Water/wet work

Adapted from Contact dermatitis and drug eruptions, in *Andrews' Diseases of the Skin. Clinical Dermatology*. 10th edition, edited by James WJ, Berger TG, Elston DM. Philadelphia, Elsevier Inc, 2006, p 91; Wilkinson SM, Beck MH: Contact dermatitis: Irritant, in *Rook's Textbook of Dermatology*. 7th edition, vol 1, edited by Burns T et al. Oxford, Blackwell Publishers, 2004. p 19.1; and English JS: Current concepts of irritant contact dermatitis. *Occup Environ Med* **61**:722, 674, 2004.

DIAGNOSIS

Differential Diagnosis (Boxes 46-1 and 46-2)

ICD is often diagnosed by excluding other causes for the dermatitis, including ACD.[2] A detailed inquiry, including occupational, recreational (hobbies), and past medical histories, and a meticulous clinical examination are important for making the correct diagnosis. History of exposure to friction, wet work, soaps, and detergents or exposure to organic or alkaline solvents; and/or an environmental relative humidity of less than 35 percent are key factors that support a diagnosis of irritancy.[34] When an allergic component is considered, diagnostic patch testing should be performed.[26] A biopsy often cannot differentiate allergic, irritant, or atopic dermatitis, but may be helpful in excluding psoriasis, in the case of palmar involvement. Measuring trans-epidermal water loss (TEWL) can indicate barrier impairment but cannot distinguish between ACD and ICD. Rietschel [11] has proposed criteria with subjective and objective features, each with major and minor findings for the diagnosis of ICD. The more features identified, the stronger the case for ICD (Table 46-7).

In their review of pre-market predictive tests for irritants, Basketter and Kimber[35] conclude that except where appropriate human tests, such as the 4-hour prophetic patch test, can be conducted, skin irritation tests, especially in animals, are of only limited value in the characterization of the potential effects associated with actual exposure of humans to irritants. In the clinical setting there is likely to be exposure to multiple irritants.

Box 46-1
Differential Diagnosis of Irritant Contact Dermatitis (Major Types)

Most Likely

Localized
- Seborrheic dermatitis
- Stasis dermatitis
- Atopic eczema
- Tinea
- Asteatosis

Disseminated
- Atopic eczema
- Asteatosis
- Autoeczematization
- Tinea corporis

Consider

Localized
- Lichen simplex chronicus
- Herpes simplex
- Herpes zoster
- Steroid acne
- Rosacea
- Factitial dermatitis

Disseminated
- Psoriasis
- Polymorphous light eruption
- Nummular eczema
- Parapsoriasis
- Lyme disease
- Drug eruption
- Secondary syphilis

Always Rule Out

Localized
- Allergic contact dermatitis
- Bowen disease

Disseminated
- Allergic contact dermatitis
- Secondary syphilis
- Cutaneous T-cell lymphoma

Adapted from Denig NI, Hoke AW, Maibach HI. Irritant contact dermatitis. Clues to causes, clinical characteristics, and control. *Postgrad Med* **103**:199, 207, 212; 1998; and Rietschel RL: Clues to an accurate diagnosis of contact dermatitis. *Dermatol Ther* **17**:224, 2004.



Box 46-2

Differential Diagnosis of Irritant Contact Dermatitis (CD; Site Specific)

Most Likely

- Face
  - Seborrheic dermatitis
  - Atopic eczema
  - Allergic CD
- Hand
  - Atopic eczema
  - Allergic CD
  - Tinea manuum
  - Dyshidrotic dermatitis

Consider

- Face
  - Atopic eczema
  - Photoallergic CD
  - Systemic CD
  - Steroid acne
  - Herpes simplex
  - Herpes zoster
  - Rosacea
  - Psoriasis
- Hand
  - Psoriasis
  - Nummular eczema
  - Lichen simplex chronicus

Always Rule Out

- Face
  - Allergic CD
  - Systemic CD
  - Airborne CD
  - Direct/indirect CD
  - Ectopic CD
  - Photodermatitis
- Hand
  - Bowen disease
  - Dyshidrotic dermatitis
  - Psoriasis
  - Tinea manuum

Adapted from Denig NI, Hoke AW, Maibach HI. Irritant contact dermatitis. Clues to causes, clinical characteristics, and control. *Postgrad Med* **103**:199, 207, 212; 1998; and Rietschel RL: Clues to an accurate diagnosis of contact dermatitis. *Dermatol Ther* **17**:224, 2004.



TABLE 46-7
Diagnostic Criteria of Irritant Contact Dermatitis

MAJOR	MINOR
Subjective	
• Onset of symptoms within minutes to hours of exposure	• Onset of dermatitis within 2 wk of exposure
• Pain, burning, stinging, or discomfort exceeding itching early in the clinical course	• Many people in the environment affected similarly
Objective	
• Macular erythema, hyperkeratosis, or fissuring predominating over vesiculation	• Sharp circumspection of the dermatitis
• Glazed, parched, or scalded appearance of the epidermis	• Evidence of gravitational influence, such as dripping effect
• Healing process begins promptly on withdrawal of exposure to the offending agent	• Lack of tendency of the dermatitis to spread
• Patch testing is negative	• Morphologic changes suggesting small concentration differences or contact time produce large differences in skin damage

Adapted from Rietschel RL: Clues to an accurate diagnosis of contact dermatitis. *Dermatol Ther* **17**:224, 2004.

In attempts to predict individual susceptibility to irritants, a number of tests have been studied, including alkali resistance with sodium hydroxide, ammonium hydroxide, dimethyl sulfoxide, threshold response to various irritants (sodium lauryl sulfate, nonanoic acid, benzalkonium chloride, kerosene, croton oil, and anthralin), lactic acid stinging, minimal erythema dose with ultraviolet B (UVB), and measurement of TEWL. In their review, Frosch and John[27] conclude that none is so simple and reliable that it can be used on a large scale. A number of these procedures have been used experimentally, usually with individual chemicals, with the results having limited applicability, but they may be of some value in predicting thresholds of irritation. Of the bioengineering methods used, TEWL measurement is the most frequently used procedure to quantify impaired functions of the stratum corneum. Clinically invisible subtle damage, such as by detergents, can be reliably detected by an increase in TEWL.

Patch Testing

Patch testing is often essential to help distinguish ACD from ICD or to diagnose concomitant ICD and ACD. Negative patch tests may favor a diagnosis of ICD "by exclusion" of ACD. A diagnosis of ACD may be missed with false-negative patch test results (see Chaps. 13 and 211).[11,26] Conversely, patch testing with obvious irritants, or non-standard chemicals or mixtures can lead to false-positive patch test results. Irritant patch test reactions may present as erythema with or without papules and often remain confined to the test site and are sharply demarcated. These irritant reactions also show a decrescendo pattern, in which a decreasing severity is seen, although this is not always a reliable indicator.[3,26] Irritant patch test reactions do not equate with ICD but only reflect the irritating patch test concentration or procedure. It is important to perform comprehensive patch testing with the appropriate substances and concentrations to prevent incorrect conclusions.[11]

TREATMENT

Identification and elimination of the irritants and protection from further exposure are important in the management of ICD.[4] Once dermatitis develops, use of topical treatment is helpful. The role of topical corticosteroids in the management of ICD is controversial, but they may be helpful because of their anti-inflammatory effect.[4,36] Prolonged use of topical corticosteroids may lead to epidermal atrophy and increased susceptibility to irritants. Emollients or occlusive dressings may improve barrier repair in dry, lichenified skin.[4,14] Traditional petrolatum-based emollients are accessible, inexpensive, and have been shown to be as effective as emollient containing skin-related lipids.[37] Other "barrier creams" are of limited value.[38] Topical calcineurin inhibitors (e.g., pimecrolimus) may be used as an alternative to low-potency topical corticosteroids in chronic ICD.[39]

In severe or chronic cases, phototherapy (psoralens with UVA or UVB) or systemic drugs, such as azathioprine and cyclosporine, may be effective.[14,36] Grenz radiotherapy is a potential third-line adjunctive treatment. Bacterial superinfection can be treated with topical or systemic antibiotics.[14] In sensory irritation, strontium salts act by selectively blocking the activation of cutaneous type C nociceptors.[12]

PREVENTION

ICD is a risk factor for the development of ACD because the impaired skin barrier may increase the potential for the induction and elicitation of ACD. Thus, the prevention of irritant dermatitis means simultaneous prevention of ACD.[10,40]

Although behavior patterns that have become a matter of routine for years[40] may be difficult to change, once an irritant

has been identified as the causal factor, patients should be educated about irritant avoidance, including everyday practices that may cause or contribute to the ICD.

The use of personal protective equipment, especially in high-risk jobs, is very important. Protective gloves should be worn for any wet work. However, patients should avoid wearing waterproof gloves for long periods of time to help reduce sweating. In this case, gloves should have a fabric lining or alternatively, thin cotton gloves can be worn inside waterproof gloves.[3]

Substitution of less irritating substances, such as emollients and soap substitutes, should be used rather than soap when washing. Moisturizers are thought to increase hydration or prevent TEWL, thereby maintaining skin barrier function and reducing the risk of ICD. Care should be taken for several months after the dermatitis has healed, as the skin remains vulnerable to flares of dermatitis for a prolonged period.[3,26,28]

PROGNOSIS

The prognosis for acute ICD is good if the causative irritant can be identified and eliminated. The prognosis for cumulative or chronic irritant dermatitis is guarded and may be worse than that of ACD.[41] An atopic background, lack of knowledge about the disease, and/or a delayed diagnosis and treatment are factors that lead to a worse prognosis.[14] Persistent post-occupational dermatitis has been seen in 11 percent of individuals.[42]

KEY REFERENCES

The full reference list for all chapters is available at www.digm7.com.

2. Taylor JS: Contact dermatitis and related disorders, in *ACP Medicine Online*. 2005 edition, section 2, edited by Dale DC, Federman DD. WebMD Inc. Retrieved May 22, 2006, from http://www.acpmedicine.com/cgi-bin/publiccgi.pl?loginOP
6. US Department of Labor, Bureau of Labor Statistics. *Occupational Injuries and Illnesses: Industry Data, 2004*. Retrieved August 15, 2006, from http://data.bls.gov/cgi-bin/surveymost?ii
10. Smith HR, Basketter DA, McFadden JP: Irritant dermatitis, irritancy and its role in allergic contact dermatitis. *Clin Exp Dermatol* **27**:138, 2002
11. Rietschel RL: Clues to an accurate diagnosis of contact dermatitis. *Dermatol Ther* **17**:224, 2004
22. Basketter DA et al: Individual, ethnic and seasonal variability in irritant susceptibility of skin: The implications for a predictive human patch test. *Contact Dermatitis* **35**:208, 1996
27. Frosch PJ, John SM: Clinical aspects of irritant contact dermatitis, in *Contact Dermatitis*, 4th edition, edited by Frosch PJ, Menné T, Lepoittevin J-P. Germany, Springer-Verlag Berlin Heidelberg, 2006, p 255
35. Basketter D, Kimber I: Predictive tests for irritants and allergens and their use in quantitative risk assessment, in *Contact Dermatitis*, 4th edition, edited by Frosch PJ, Menné T, Lepoittevin J-P. Germany, Springer-Verlag Berlin Heidelberg, 2006, p 179



CHAPTER 47

The Ichthyoses

Philip Fleckman
John J. DiGiovanna

The ichthyoses are a heterogeneous group of skin diseases characterized by generalized scaling. Scaling reflects altered differentiation of the epidermis. In this chapter, the terms *epidermal differentiation*, *keratinization*, and *cornification* will be used synonymously. The name *ichthyosis* is derived from the Greek *ichthys*, meaning "fish," and refers to the similarity in appearance of the skin to fish scales. Both inherited and acquired forms are found. Early reports of ichthyosis in the Indian and Chinese literature date back to several hundred years B.C., and the condition was discussed by Willan in 1808.[1]

Ichthyosis can present at birth or develop later in life. It can occur as a disease limited to the skin or in association with abnormalities of other organ systems. A number of well-defined types of ichthyosis with characteristic features can be reliably diagnosed. However, because of the great clinical heterogeneity and the profound effect of the environment on scaling, a specific diagnosis can be challenging in certain patients and families.

Siemens introduced genetic concepts into the ichthyoses.[2]

Genetic approaches to understanding the ichthyoses have revealed the gene defects underlying many of these genodermatoses.[9–11] A new classification is evolving based on the underlying molecular and genetic bases of these disorders. Knowing which gene is mutated directs us to the underlying pathophysiologic process. Understanding and describing these disorders on the basis of common molecular processes lead to more rational approaches to understanding their pathophysiology and treatment. A listing of the more common and the better understood hereditary ichthyoses according to pattern of inheritance and clinical features is shown in Table 47-1. Grouping these disorders according to underlying abnormality (Table 47-2) facilitates understanding of the clinical phenotypes in terms of underlying mechanism. However, further work is necessary to clearly understand how the gene mutations and resultant protein disruptions result in clinical disease, and, furthermore, how therapeutic interventions can be creatively developed.

ICHTHYOSES AT A GLANCE



- A heterogenous group of skin diseases characterized by generalized scaling and, often, areas of thickened skin.
- Most types are inherited, and these usually present at birth. However, some forms are acquired.
- Scales may vary in size, color, and body site.
- May be accompanied by erythema, abnormalities in other parts of skin, and adnexal structures.
- May be associated with systemic findings, such as failure to thrive, increased susceptibility to infection, atopic dermatitis, neurosensory deafness, neurologic and other disease.
- Pathology is usually non-specific with the exception of epidermolytic hyperkeratosis, neutral lipid storage disease, Refsum disease, and acquired ichthyosis associated with sarcoidosis.



TABLE 47-1
Features of Selected Ichthyoses

Diagnosis	Onset	Characteristic Clinical Features	Associated Features	Gene	Protein	Function	Skin Histopathology
Autosomal semidominant[a]							
Ichthyosis vulgaris (OMIM #146700)	Infancy/childhood	Fine or centrally tacked-down scale with superficial fissuring. Relative flexural sparing; worse on lower extremities. Hyperlinear palms/soles.	Keratosis pilaris; atopy.	*FLG*	Absence of filaggrin	Uncertain	Hyperkeratosis; reduced or absent granular layer.
Autosomal dominant[a]							
EHK (bullous CIE; OMIM #113800)	Birth	Heterogeneous. May have verrucous, firm, hyperkeratotic (hystrix) spines, often linearly arrayed in flexural creases; blisters; may have erythroderma and/or palmar/plantar keratoderma.	Frequent skin infections; characteristic pungent odor.	*KRT1*, *KRT10*; in Vörner type (confined to palms/soles) *KRT9*	Keratin 1 or 10; in Vörner type, keratin 9	Structural protein abnormality leading to keratin intermediate filament dysfunction—epidermal fragility	Hyperkeratosis; vacuolar degeneration of the epidermal granular (and often deeper) layer; large, irregular keratohyalin granules.
Ichthyosis bullosa of Siemens (OMIM #146800)	Birth	Redness and blistering at birth. Later develop hyperkeratosis, accentuated over flexures. Mauserung (molting): Collarette-like lesion where uppermost epidermis has been lost.	—	*KRT2*	Keratin 2, which is expressed in superficial epidermis	As above for EHK	Hyperkeratosis and epidermal vacuolization, similar to EHK but confined to the upper spinous and granular layer.
Ichthyosis hystrix of Curth and Macklin (OMIM #146590)	Birth	Resembles EHK, varies from palmar/plantar keratoderma to generalized. Thick "porcupine-like" spines. No blistering.	—	*KRT1*—mutation in variable region	Keratin 1	As above for EHK	Upper epidermal keratinocytes have perinuclear vacuolization/perinuclear shells of tonofilaments.
Annular epidermolytic erythema (OMIM #607602)	Birth/infancy Annular plaques develop later	Severe, intermittent scaling with blisters or pustules. Evolves to widespread, migratory, annular plaques.	—	*KRT1*, *KRT10*	Keratin 1 or 10	As above for EHK	As above for EHK.
Erythrokeratodermia variabilis (OMIM #133200)							
Generalized type	Birth	Generalized hyperkeratosis and figurate, migratory red patches.	Red patches move over minutes to hours; may be triggered by changes in temperature.	*GJB3* or *GJB4*	Connexin 31 or 30.3; connexins form gap junction channels between cells	Abnormal intercellular communication	Hyperkeratosis, acanthosis, papillomatosis, capillary dilatation; epidermis may have "church spire" appearance.
Localized type	Variable	Localized hyperkeratotic plaques with figurate, migratory red patches.	Hyperkeratotic plaques may be induced by trauma. Considerable intrafamilial variability.				

Progressive symmetric erythrokeratodermia (OMIM #602036)	Shortly after birth	Erythematous, scaly plaques, symmetrically distributed over extremities, buttocks, and face; stabilize in early childhood. Trunk tends to be spared.	—	*LOR*	Loricrin	Cornified envelope formation	Non-specific.
Keratitis, ichthyosis, and deafness syndrome; recessive has been reported (OMIM #148210)	Birth/infancy	Progressive corneal opacification; either mild generalized hyperkeratosis or discrete erythematous plaques, which may be symmetric; neurosensory deafness.	Follicular hyperkeratosis, scarring alopecia, dystrophic nails, susceptibility to infection.	*GJB2*, *GJB6*	Connexins-26, -30; connexins form gap junction channels between cells	Abnormal intercellular communication	Non-specific.
X-linked							
X-linked recessive ichthyosis (OMIM #08100)	Birth/infancy	Fine to large scales; comma-shaped corneal opacities on posterior capsule.	Cryptorchidism; female carriers may have corneal opacities and delay of onset or progression of labor in affected pregnancies.	*STS*	Steroid sulfatase	Lipid metabolism—abnormal cholesterol metabolism with accumulation of cholesterol sulfate	Hyperkeratosis, may have hypergranulosis; non-specific.
Chondrodysplasia punctata X-linked recessive (CDPX; OMIM #302950)	Birth	May begin as erythroderma, linear or whorled atrophic or hyperkeratosis, alopecia, skeletal abnormalities, short stature.	Cataracts, deafness.	*ARSE*	Arylsulfatase E	Lipid metabolism—ill-defined: Failure of hydrolysis of sulfate ester bonds	—
X-linked dominant chondrodysplasia punctata (Conradi-Hünermann-Happle syndrome; CDPX2; OMIM #302960)	Birth	CIE at birth, clears and is replaced by linear hyperkeratosis, follicular atrophoderma and pigmentary abnormalities; stippled calcifications on radiographs.	Occurs almost exclusively in females; hair shaft abnormalities, short stature, cataracts.	*EBP*	EBP—also known as 3β-hydroxysteroid-δ8-δ7-isomerase	Lipid metabolism—post-squalene cholesterol biosynthesis	—
CHILD syndrome X-linked dominant (OMIM #308050)	Birth	Congenital hemidysplasia, ichthyosiform erythroderma, limb defects.	Almost exclusively in females.	*NSDHL*; *EBP* also reported	NSDHL (3 β-hydroxysteroid dehydrogenase); EBP also reported	Lipid metabolism—post-squalene cholesterol biosynthesis	—

(continued)





TABLE 47-1
Features of Selected Ichthyoses (Continued)

Diagnosis	Onset	Characteristic Clinical Features	Associated Features	Gene	Protein	Function	Skin Histopathology
Autosomal recessive							
ARCI							
ARCI/LI	Birth; often collodion presentation	Large, plate-like, brown scale over most of the body; accentuated on lower extremities. Ectropion; eclabium; alopecia. Palmar/plantar involvement varies.	Heat intolerance.	Various (see Table 47-3)	Various (see Table 47-3)	Various (see Table 47-3)	Hyperkeratosis, acanthosis, may show parakeratosis. Non-specific.
ARCI/CIE	Birth; often collodion presentation	Fine, white scale; generalized erythroderma. Palmar/plantar involvement varies.	Heat intolerance.	Various (see Table 47-3)	Various (see Table 47-3)	Various (see Table 47-3)	Hyperkeratosis, acanthosis, may show parakeratosis. Non-specific.
ARCI/overlap	Birth; often collodion presentation	Varies between "lamellar" and "CIE." Considerable overlap may exist.	Heat intolerance.	Various (see Table 47-3)	Various (see Table 47-3)	Various (see Table 47-3)	Hyperkeratosis, acanthosis, may show parakeratosis. Non-specific.
Harlequin ichthyosis (OMIM #242500)	Birth	Markedly thickened skin with geometric, deep fissures. Survivors develop severe CIE phenotype.	Restricted respiration, poor feeding; neonatal sepsis; often leads to neonatal death. Failure to thrive.	*ABCA12*	ATP-binding cassette, subfamily A, member 12	Lipid metabolism—membrane transport, abnormality of lipid metabolism	Massively thickened, orthokeratotic stratum corneum; variable acanthosis; granular layer variably decreased.
Netherton syndrome (OMIM #256500)	Birth	Ichthyosis linearis circumflexa or similar to CIE; trichorrhexis invaginata.	Atopy; high serum levels of immunoglobulin E; may have aminoaciduria; failure to thrive.	*SPINK-5*	LEKTI (a serine protease inhibitor)	Protein metabolism—may result in premature desmosomal degradation in stratum corneum	Non-specific.
Sjögren-Larsson syndrome (OMIM #270200)	Ichthyosis apparent at birth	Generalized fine scale to coarse hyperkeratosis; spastic diplegia; mental retardation; retinal glistening white dots.	Short stature, seizures.	*FALDH* (*ALDH10*, *ALDH3A2*)	Fatty aldehyde dehydrogenase	Lipid metabolism—fatty aldehyde metabolism	Non-specific.
Refsum disease (OMIM #266500)	Ichthyosis develops in adulthood	Progressive neurologic dysfunction; skeletal, cardiac, and renal abnormalities. Retinitis pigmentosa.	Elevated plasma phytanic acid.	Most *PAHX*; *PEX7* also reported (see RCDP below)	Phytanoyl-CoA hydroxylase	Peroxisome abnormality—deficiency of phytanic acid catabolism; results in phytanic acid accumulation	Lipid-containing vacuoles in basal keratinocytes.
RCDP (OMIM #215100)	Birth	Dwarfism, stippled cartilage calcifications, joint contractures, cataracts, ichthyosis, mental retardation.	Low levels of red cell plasmalogens; accumulation of phytanic acid.	*PEX7*	Peroxin 7 (peroxisomal protein)	Peroxisome abnormality—failure of receptor targeting enzymes to peroxisomes	—

Trichothiodystrophy [Tay syndrome; *PIBI(D)S*, *IBI(D)S*, *BI(D)S)*; OMIM #278730, #601675, #234050]	Some have ichthyosis, which may be apparent at birth; may have collodion presentation	*B*rittle hair, *p*hotosensitivity, *s*hort stature, *i*chthyosis, *i*ntellectual impairment, microcephaly, recurrent infections.	Abnormally low sulfur content of hair.	Majority have defect in *ERCC2* (XPD). A few have mutations in *ERCC3* (XPB), *GTF2H5* (TTDA), or *TTDN1*	Most XPD. XPB, TTDA, or TTDN1 in a few	Components of transcription factor TFIIH	Tiger-tail banding of hair shafts under polarizing microscopy; hair shaft abnormalities (trichoschisis, trichorrhexis nodosa-like fraying; ribboning).
Chanarin-Dorfman syndrome (neutral lipid storage disease; OMIM #275630)	Birth; may be collodion	Generalized scaling, resembles CIE; variable extra-cutaneous involvement: cataracts, decreased hearing, psychomotor delay.	Severe pruritus; neurologic abnormalities; hepatic abnormalities; lipid droplets in circulating leukocytes.	*CGI-58*	Unknown	Lipid metabolism—activates adipose-triglyceride lipase for lipolysis of triglycerides	Lipid droplets in dermal and epidermal cells, and acrosyringia of eccrine ducts.
Multiple sulfatase deficiency (OMIM #272200)	Birth	Ichthyosis resembling X-linked recessive.	Neurologic deterioration; skeletal abnormalities; facial dysmorphism.	*SUMF1*	C_{α}-formylglycine generating enzyme	Generates catalytic residue in active site of eukaryotic sulfatases	Non-specific.
Peeling skin syndrome							
Type A (noninflammatory; OMIM #270300)	Birth	Generalized peeling in superficial, thin flakes.	—	Unknown	Unknown	Unknown	Intracellular split within corneocytes in stratum corneum.
Type A—acral variant (OMIM #609796)	Birth	Limited to over hands and feet.	—	*TGM5*	Transglutaminase 5	Protein cross-linking	Non-specific.
Type B (inflammatory)	Birth	Presents as CIE; evolves to migratory, scaling patches.	Pruritus, elevated immunoglobulin E, aminoaciduria, short stature.	Unknown	Unknown	Unknown	Intercellular split between stratum corneum and granular layer; between keratinocytes.

ARCI = autosomal recessive congenital ichthyosis; ATP = adenosine triphosphate; CIE = congenital ichthyosiform erythroderma; CHILD syndrome = *c*ongenital *h*emidysplasia with *i*chthyosiform erythroderma and *l*imb *d*efects syndrome; CoA = coenzyme A; EBP = emopamil-binding protein; EHK = epidermolytic hyperkeratosis; LEKTI = *l*ympho-*e*pithelial *K*azal-*t*ype related *i*nhibitor; LI = lamellar ichthyosis; NSDHL = *N*AD(P)H *s*teroid *de*h*y*drogenase-*l*ike protein; OMIM = Online Mendelian Inheritance in Man; RCDP = *R*hizomelic *c*hondro*d*ysplasia *p*unctata; SPINK-5 = *s*erine *p*rotease *in*hibitor, *K*azal type *5*; TFIIH = transcription factor IIH.
[a]These are the predominant modes of inheritance.



TABLE 47-2
Ichthyoses Organized by Pathophysiology

Disorder	Protein/Function Abnormality
Structural Proteins	
• Ichthyosis vulgaris	Filaggrin
• Cytoskeleton	
• Epidermolytic hyperkeratosis	Keratins
• Palmar/plantar keratoderma[a]	
• Ichthyosis bullosa of Siemans	
• Annular epidermolytic ichthyosis	
• Ichthyosis hystrix	
• Palmar/plantar epidermolytic hyperkeratosis[a]	
• Pachyonychia congenita[a]	
• Cornified envelope formation	
• ARCI/lamellar ichthyosis	Transglutaminase 1
• Progressive symmetric erythrokeratodermia	Loricrin
• Mutilating keratoderma with ichthyosis[a] (loricrin keratoderma, Vohwinkel syndrome without deafness)	
Lipid Metabolism	
• ARCI	12-R lipoxygenase pathway
• Chanarin-Dorfman syndrome	Function unknown
• CHILD syndrome	Steroid dehydrogenase Sterol isomerase
• Conradi-Hünermann-Happle syndrome	Sterol isomerase
• Refsum disease	Phytanic acid catabolism
• Sjögren-Larsson syndrome	Fatty alcohol metabolism
• X-linked recessive ichthyosis	Steroid sulfatase
Intercellular Communication	
• Erythrokeratodermia variabilis	Gap junction proteins: *Connexins*
• Keratitis, ichthyosis, deafness syndrome	
• Vohwinkel syndrome (classic)	
• PPK with deafness[a]	
Protein Metabolism	
• Netherton syndrome	Protease inhibitor
• Papillon-Lefèvre syndrome[a]	Protease
Calcium Homeostasis[b]	
• Darier disease	Ca^{2+}-dependent ATPase
• Hailey-Hailey disease	
Nucleotide excision repair/transcription	
• Trichothiodystrophy	Transcription

ARCI = autosomal recessive congenital ichthyosis; ATPase = adenosine triphosphatase; CHILD syndrome = *c*ongenital *h*emidysplasia with *i*chthyosiform erythroderma and *l*imb *d*efects syndrome; PPK = palmoplantar keratoderma.
[a]Discussed in Chap. 48.
[b]Discussed in Chap. 49.



Online Mendelian Inheritance in Man (OMIM),[12] a catalog of human genes and genetic disorders, is a useful reference with links to additional resources.

CLINICAL PRESENTATION

A specific diagnosis in an individual or family with ichthyosis can help to predict prognosis and is important for genetic counseling. Several features are useful in distinguishing different forms of ichthyosis. These include the age of onset, presence of collodion membrane at birth, quality of scale, presence/absence of erythroderma, abnormalities in other parts of the skin (e.g., palms and soles, ectropion, eclabium) and adnexal structures (e.g., alopecia, hair follicle or shaft abnormality), and involvement of other organ systems. In different types of ichthyosis, the appearance of the surface of the skin may vary. Visible scaling (see Chapter 4) may be seen in some patients, with flakes of stratum corneum varying in size from fine to coarse. There may also be a thickening of the skin with or without visible scale. The term *hyperkeratosis* has been used clinically to describe thickened skin, with or without scale, that reflects thickening of the stratum corneum. A family pedigree may clarify the pattern of inheritance. The presence of parental consanguinity may suggest autosomal recessive inheritance. However, many autosomal dominant diseases (e.g., epidermolytic hyperkeratosis) have a high frequency of spontaneous mutation, and the lack of a positive family history does not rule out autosomal dominant inheritance. Light microscopic features are usually diagnostic in epidermolytic hyperkeratoses and can be helpful in selected ichthyoses (e.g., Refsum disease, neutral lipid storage disease, acquired ichthyosis of sarcoidosis), but histopathologic examination may not be useful to distinguish other ichthyoses. In many cases, the clinical diagnosis may be clarified by genetic analysis. The development of ichthyosis in adulthood may be a marker of systemic disease.

ETIOLOGY AND PATHOGENESIS

The fully differentiated end product of the epidermis is the stratum corneum, which is composed of terminally differentiated keratinocytes, corneocytes ("bricks"), surrounded by an intercellular matrix ("mortar") (see Chap. 45). The corneocyte bricks are protein-enriched, and the intercellular mortar is composed of hydrophobic, lipid-enriched membrane bilayers.[8] The keratin-laden corneocytes are thought to be primarily responsible for the resilience and water retention properties of the stratum corneum, while the matrix forms most of the permeability barrier to water loss. The normal stratum corneum undergoes desquamation in an organized and invisible manner, with individual corneocytes separating from each other and shedding as single cells. Ichthyotic skin has an abnormal quality and quantity of scale, the barrier function of the stratum corneum is compromised, and there may be alterations in the kinetics of epidermal cell proliferation (see Chap. 44). The stratum corneum can be viewed as a compartment, with thickening of the stratum corneum being the result of cells entering the compartment at an increased rate, or leaving (corneocyte desquamation) too slowly, or both.

The process of epidermal differentiation is complex and not completely understood. Defects in many different aspects and steps of this process can lead to a similar end result: abnormal stratum corneum and scale. In some of these dis-

orders, the underlying abnormality has been identified. For example, mutations in the genes that encode the suprabasal epidermal keratins, keratins-1 and -10, cause epidermolytic hyperkeratosis.[13] Mutations in the gene encoding transglutaminase 1, an enzyme that catalyzes the cross-linking of proteins and attachment of ceramides during the formation of corneocytes, cause lamellar ichthyosis, one form of autosomal recessive congenital ichthyosis (ARCI).[14–16] The observation that key components of this process cause ichthyosiform disorders highlights the importance and complexity of normal keratinocyte differentiation.

Steroid sulfatase controls the hydrolysis of cholesterol sulfate in corneocytes and is thought to be important in the regulation of corneocyte desquamation. Deficiency of steroid sulfatase causes X-linked recessive ichthyosis.[17,18] The observation that several drugs that lower serum cholesterol (e.g., nicotinic acid, triparanol) can induce ichthyotic skin changes indicates the importance of lipid homeostasis in normal keratinization.[19] Further evidence is the identification of mutations in the genes encoding cholesterol biosynthetic enzymes as a cause of X-linked dominant chondrodysplasia punctata and *c*ongenital *h*emidysplasia with *i*chthyosiform erythroderma and *l*imb *d*efects (CHILD) syndrome and genes encoding other aspects of lipid biosynthesis in the autosomal recessive congenital ichthyoses.[20] The recent identification of mutations in *SPINK-5* (serine *p*rotease *in*hibitor, *K*azal type *5*), encoding a serine protease inhibitor, confirms a role for protease inhibitors in normal epidermal differentiation.[21] The discoveries of connexin abnormalities as causes for erythrokeratodermia variabilis; keratitis, ichthyosis, and deafness (KID) syndrome; and other disorders involving ectodermal tissues highlight the role of intercellular communication for properly functioning skin.[10,22]

These examples highlight the complexity of the process of forming a normally functioning stratum corneum and demonstrate that diverse abnormalities can result in similar clinical phenotypes of thickened stratum corneum and scaling. How do diverse processes result in similar phenotypes? The answers are unclear, although studies suggest that defects in the barrier may result in inflammation and hyperproliferation.[23] Furthermore, our evolving understanding of these mechanisms continues to clarify the multisystem, clinical phenotypes observed in several ichthyosiform disorders.



◀ **FIGURE 47-1** Ichthyosis vulgaris. Full presentation of ichthyosis vulgaris in individuals with mutations in both profilaggrin genes (**A**, **C**, **E**); milder presentation in an individual with a profilaggrin mutation in a single allele (**B**, **D**, **F**). **A and B.** Fine, white scale on lower abdomen. **C–F.** Hyperlinear palms. (From Smith FJ et al: Loss-of-function mutations in the gene encoding filaggrin cause ichthyosis vulgaris. *Nat Genet* **38**:337, 2006, with permission.)

ICHTHYOSIS VULGARIS

Ichthyosis vulgaris (OMIM #146700), the most common ichthyosis, is relatively mild. Although infants usually have normal skin, the disease often manifests within the first year. The scale of ichthyosis vulgaris is usually most prominent on the extensor surfaces of the extremities, with flexural sparing (Fig. 47-1). The diaper area tends to be spared. There may be fine, white scale over large areas. Particularly on the lower extremities, which are often the most severely involved area, the scale may be centrally attached, with "cracking" (superficial fissuring through the stratum corneum) at the edges. This turning up at the edges can lead to the skin feeling rough.

A number of other findings are commonly observed in association with ichthyosis vulgaris.[24] Hyperlinear palms are usually present, and some patients may have palmar/plantar thickening approaching a keratoderma. Keratosis pilaris (a follicular spine–like hyperkeratosis) is common, even in individuals with mild ichthyosis vulgaris, and usually involves the outside of the arms, extensor thighs, and buttocks (see eFig 47-1.1 in on-line edition). Atopy is also frequently observed and can manifest as hay fever, eczema, or asthma. These findings can confound an accurate diagnosis, because hyperlinear palms and keratosis pilaris may be seen in atopic individuals who do not have ichthyosis vulgaris. Rarely, individuals with ichthyosis vulgaris may have hypohidrosis with heat intolerance. There is great variation in the severity of clinical manifestations between affected individuals in the same family. The condition usually worsens in climates that are dry and cold and improves in warm, humid environments, where the disease may clear dramatically.

The disease was thought to be autosomal dominant.[4] Recently, mutations in the gene encoding profilaggrin (*FLG*) have been found to cause ichthyosis vulgaris. This finding clarifies the inheritance pattern as semi-dominant. Individuals who are homozygotes or compound heterozygotes for the mutations (i.e., those with mutations in both profilaggrin alleles) manifest a severe clinical phenotype. Individuals with mutations in one profilaggrin allele (heterozygotes) manifest a mild phenotype with ~60 percent penetrance (see Fig. 47-1). The prevalence of the mutations is ~9 percent, and that of homozygotes is ~1 in 400 in the Anglo European population.[25,26]

It is difficult to distinguish some patients with mild ichthyosis vulgaris from simple dry skin (xerosis). Evolving understanding of this very common condition is beginning to clarify how a spectrum of underlying mutations can cause the diverse clinical severity of dry skin from xerosis to severe ichthyosis vulgaris. In addition, on the basis of skin findings alone, males with severe ichthyosis vulgaris may be difficult to differentiate from those affected with X-linked recessive ichthyosis.[24,27] The histopathologic findings of ichthyosis vulgaris (Fig. 47-2A) may be distinctive in specimens taken





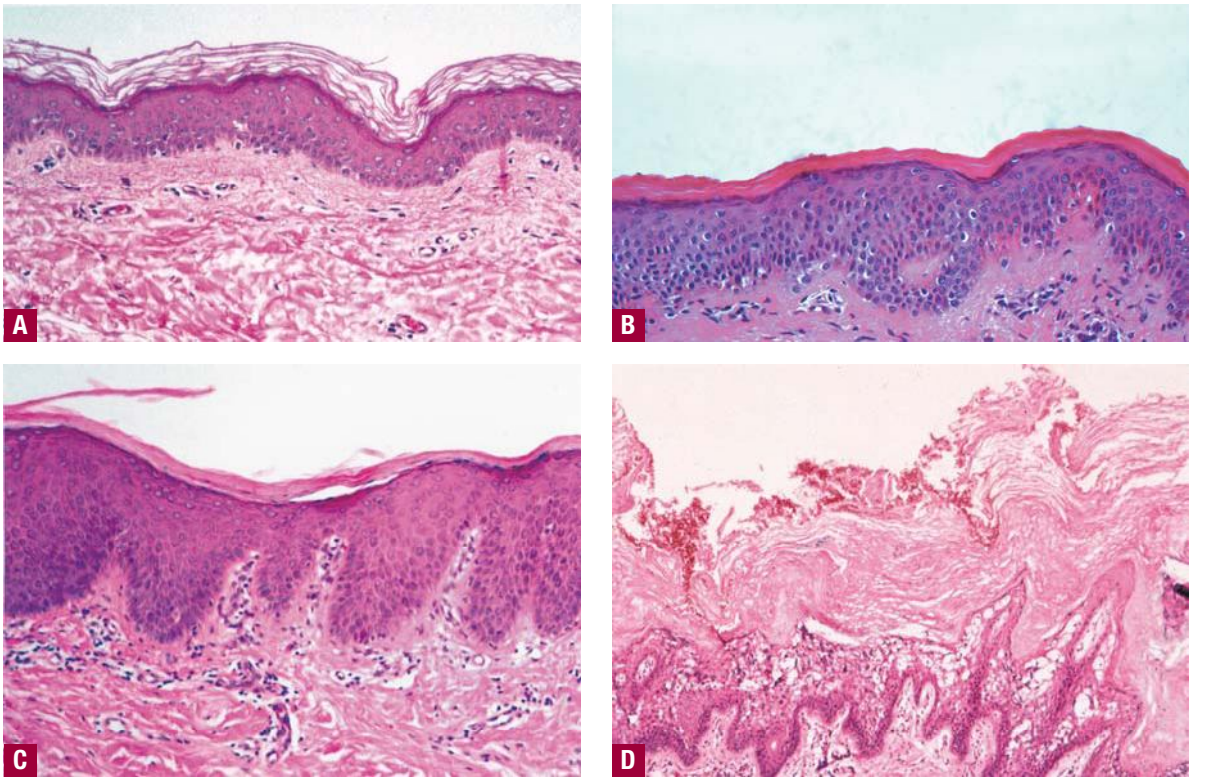

▲ **FIGURE 47-2** Histopathology. **A.** Ichthyosis vulgaris. Note absent granular layer. **B.** X-linked recessive ichthyosis. Note compact hyperkeratosis and accentuated granular layer. (Used with permission from Rob McFarlane, MD.) **C.** Autosomal recessive congenital ichthyosis. Thickened stratum corneum composed of compact hyperkeratosis with foci of parakeratosis. **D.** Epidermolytic hyperkeratosis. The stratum corneum is thickened (hyperkeratosis), and there is prominent vacuolar degeneration of suprabasalar epidermis most marked at the granular layer.

from homozygotes, showing mild hyperkeratosis and absent granular layer. In heterozygotes, even when the granular layer is present on light microscopy, examination by electron microscopy can show keratohyalin granules that are small, abnormally shaped, and crumbly in appearance.[28]

Filaggrin is an epidermal protein that is thought to be important in the aggregation of keratin intermediate filaments[29] and retention of moisture in the stratum corneum.[30] Keratin filaments form a network, or cell matrix, that gives structural integrity to the epidermal keratinocytes. Filaggrin is synthesized as a high-molecular weight precursor, profilaggrin, that contains multiple filaggrin molecules and is localized to keratohyalin granules. Biochemical studies of epidermis from patients with ichthyosis vulgaris have shown absence or decrease of filaggrin and its precursor, profilaggrin.[31] The defective profilaggrin expression is maintained in keratinocytes cultured from subjects with ichthyosis vulgaris.[32] In the Anglo-European population, mutations in *FLG* are very strong predisposing factors for atopic dermatitis. A strong association is also found with individuals who have both asthma and atopic dermatitis.[26]

X-LINKED RECESSIVE ICHTHYOSIS

In the 1960s, X-linked recessive ichthyosis (OMIM #308100) was distinguished clinically from other ichthyoses.[4] Shortly thereafter, the syndrome of placental steroid sulfatase deficiency was described in pregnancies with failure to initiate labor in association with low maternal urinary estrogens. Because the majority of maternal urinary estrogens are derived from the fetal adrenal and are metabolized by the placenta, low levels can reflect fetal abnormalities or death. However, in this condition, low levels do not indicate severe fetal morbidity. The association between failure to initiate or progress labor and ichthyosis in the male offspring was not appreciated until later.[17,18] Steroid sulfatase hydrolyzes sulfate esters, which include cholesterol sulfate and sulfated steroid hormones.[33] Sulfated fetal adrenal hormones undergo desulfation to estrogens, which are excreted in maternal urine. The absence of steroid sulfatase enzyme in the fetal placenta leads to low maternal urinary estrogens and, in some pregnancies, to a failure of labor to initiate or to progress normally. In males with X-linked recessive ichthyosis, steroid sulfatase enzyme activity is decreased or absent in many tissues, including epidermis, stratum corneum, and leukocytes, and in cultured fibroblasts.[34] In addition, cholesterol sulfate, an enzyme substrate, accumulates in serum and in scale. Carrier females have been found to have leukocyte steroid sulfatase levels intermediate between those observed in normal individuals and those in affected males.

X-linked recessive ichthyosis occurs in approximately 1 in 2000 to 6000 males.[4,35] Scaling may begin in the newborn period and is usually most prominent on the extensor surfaces, although there is significant involvement of the flexural areas. Although the extent and degree of scaling are variable, X-linked ichthyosis can usually be distinguished from ichthyosis vulgaris on clinical criteria.[4,36] The latter tends to be associated with hyperlinear palms and soles, keratosis pilaris, and a family history of atopy. X-linked ichthyosis tends to have more severe involvement with larger scale, and comma-shaped, corneal opacities may be present in one-half of adult patients (Fig. 47-3).[37,38] Corneal opacities do not affect vision and may be present in female carriers.[38] Affected males have an increased risk of cryptorchidism and, independently, they are



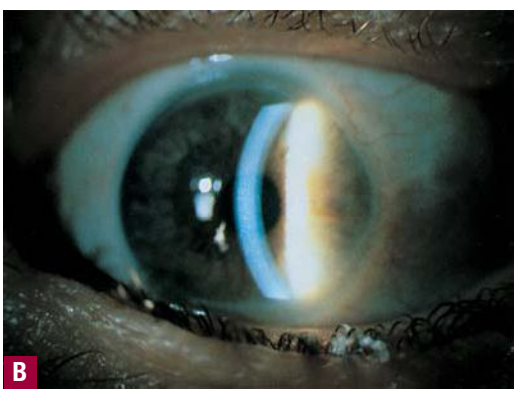

◀ **FIGURE 47-3** X-linked recessive ichthyosis. **A.** The scales are large and dark and most evident on the flexural areas in this patient. **B.** The blue arc is a cross-section of the cornea as seen by slit-lamp examination. The opacities appear white.

at increased risk for the development of testicular cancer.[39] Histopathologic examination shows compact orthohyperkeratosis, acanthosis, and papillomatosis. The granular layer is usually thickened (see Fig 47-2B).

Cholesterol sulfate levels are elevated in the serum, epidermis, and scale,[40] and there is increased mobility of β-lipoproteins (low-density lipoproteins) on electrophoresis, a feature that can suggest the diagnosis. Steroid sulfatase is one of a group of arylsulfatases located on chromosome Xp22. More than 90 percent of the mutations in X-linked ichthyosis are deletions, explaining the failure to find immunologically detectable enzyme protein in some patients. Deletions can often be detected by fluorescence in situ hybridization, available in many clinical laboratories. Confirmation of the diagnosis can also be made by finding an elevation in serum cholesterol sulfate levels (normal is 80 to 200 μg/dL; X-linked ichthyosis is 2000 to 9000 μg/dL). Unfortunately, cholesterol sulfate determination in serum and scale may not be readily available for laboratory confirmation of the clinical diagnosis. In the rare case in which deletions are not detected and a clinical diagnosis is necessary, arylsulfatase C (steroid sulfatase) enzyme activity can be measured in cultured fibroblasts. Deletions that include adjacent sulfatases explain the overlap syndromes involving chondrodysplasia punctata and X-linked ichthyosis.[41] The X-linked form of Kallmann syndrome, in which hypogonadotrophic hypogonadism and anosmia are found, often with renal abnormalities, obesity, synkinesis (mirror image movements of the extremities), cleft palate, and spastic paraplegia, can also be seen in association with X-linked recessive ichthyosis as part of a contiguous gene deletion syndrome.[42] Because of this, and because of the association with testicular carcinoma, patients with X-linked recessive ichthyosis should be queried about anosmia and have periodic testicular examination.[43.]

In the epidermis, steroid sulfatase catalyzes the hydrolysis of cholesterol sulfate. The identification of steroid sulfatase deficiency in X-linked ichthyosis supports the importance of cholesterol sulfate hydrolysis in normal desquamation. Topical application of cholesterol sulfate in mice can induce a scaling disorder, further supporting the role of cholesterol sulfate hydrolysis in corneocyte desquamation.

A family was described with an ichthyosis inherited in an X-linked pattern but with normal steroid sulfatase activity and the absence of corneal opacities.[44] This demonstrates heterogeneity within X-linked ichthyosis. Because of its frequent occurrence, steroid sulfatase deficiency accounts for most cases of X-linked ichthyosis, but a normal steroid sulfatase level in a male with ichthyosis does not rule out an X-linked pattern of inheritance.

AUTOSOMAL RECESSIVE CONGENITAL ICHTHYOSIS

The term *autosomal recessive congenital ichthyosis* is useful to describe a heterogeneous group of disorders that present at birth with generalized involvement of the skin. ARCI can be syndromic, when accompanied by manifestations in other organ systems, or nonsyndromic. Autosomal recessive ichthyosis is rare and has been estimated to occur in about 1 in 300,000 persons.[4]

In older literature, non-bullous congenital ichthyosiform erythroderma (NCIE, lamellar ichthyosis, with autosomal recessive inheritance) was distinguished from bullous congenital ichthyosiform erythroderma (epidermolytic hyperkeratosis, with autosomal dominant inheritance) based on clinical appearance (bullae) and pattern of inheritance.[6,45] That the term *lamellar ichthyosis* was used interchangeably with NCIE and included a spectrum of phenotypes has led to some confusion. Williams and Elias distinguished lamellar ichthyosis from NCIE [usually called *congenital ichthyosiform erythroderma* (CIE)], a milder erythrodermic form.[46] Some patients with lamellar ichthyosis can be clearly distinguished from those with CIE on the basis of clinical features. In lamellar ichthyosis, one sees large, dark, plate-like scale, and although infants may be red at birth, adults





▲ **FIGURE 47-4** Classic lamellar ichthyosis phenotype. **A.** Ectropion. **B and C.** Large, brown, plate-like scale. (From Russell LJ et al: Linkage of autosomal recessive lamellar ichthyosis to chromosome 14q. *Am J Hum Genet* **55**:1146, 1994, with permission.)

have little to no erythroderma (Fig. 47-4). In the more severe, classic presentation of lamellar ichthyosis, tautness of the facial skin leads to traction on the eyelids and lips, leading to ectropion and eclabium. Scarring alopecia, most prominent at the periphery of the scalp, may be partly due to traction at the hair line. In contrast, CIE has generalized redness and fine, white scale (Fig. 47-5). Patients with classic CIE have little to no ectropion, eclabium, or alopecia. However, many patients do not fit neatly into these two clinical descriptions,[47] in that they have features of both lamellar ichthyosis and CIE and a clinical phenotype intermediate between both disorders. Therefore, it can be useful to consider these two distinctive presentations as ends of a spectrum, between which lie a gradation of clinical phenotypes with variable degrees of erythema and coarseness of scale. Individual features, such as collodion membrane (discussed in Collodion Baby under Ichthyosis in the Newborn), ectropion, and alopecia, can occur across the spectrum. The collodion presentation may, over time, evolve into a disease that falls anywhere within the clinical spectrum of severity and can develop into lamellar ichthyosis, CIE, or have minimal involvement (self-healing collodion baby).[48] Although attempts to refine the categorization of these disorders by using biochemical and ultrastructural observations have failed to yield a consistent and replicable classification scheme,[5] identification of the spectrum of specific molecular defects underlying these conditions will undoubtedly help.

Most patients with lamellar ichthyosis or CIE inherit the disease in an autosomal recessive pattern. Rarely, families have been described with similar phenotypes, where the disease is inherited as an autosomal dominant trait.[5] This is an important consideration for genetic counseling.

LAMELLAR ICHTHYOSIS

Lamellar ichthyosis is apparent at birth, and the newborn usually presents encased in a collodion membrane. At this time, the skin may be red. Over time, the skin develops large, plate-like scales, which appear to be arranged in a mosaic pattern (see Fig. 47-4). In some areas, the scales are centrally attached with raised borders. The scales tend to be largest over the lower extremities, where the large, plate-like scale separated by superficial fissuring can lead to an appearance similar to that of a dry riverbed. During childhood and into adulthood the degree of erythema may vary, but the severe presentation of classic lamellar ichthyosis usually has minimal to no erythroderma. Involvement of the palms and soles in lamellar ichthyosis is variable and ranges from minimal hyperlinearity to severe keratoderma.

The lips and mucous membranes tend to be spared in lamellar ichthyosis, but the adnexal structures may be compromised by the adherent, firm scale. Thick stratum corneum on the scalp tends to encase hairs, and in conjunction with the tautness of the skin, may lead to a scarring alopecia, most marked at the periphery of the scalp. The hyperkeratosis can interfere with normal sweat gland function, resulting in hypohidrosis, but the degree of impairment varies between patients. Some patients have severe heat intolerance and must be vigilant to avoid overheating. Treatment with oral retinoids can improve or prevent some sequelae of lamellar ichthyosis. Patients frequently notice an increase in sweating, with improved heat tolerance. Although retinoid therapy can cause blepharitis or even conjunctivitis, it is usually well tolerated by patients with lamellar ichthyosis. Moreover, the ability of systemic retinoid (and in some cases, topical retinoid) therapy to decrease thick periocular scale can decrease the tendency to develop ectropion. Nevertheless, patients with severe, classic lamellar ichthyosis usually require careful eye maintenance. Because of the ectropion (see Fig. 47-4), the lids may fail to close fully, particularly during sleep; hydration with liquid tears during the day and ophthalmic lubricants at night can prevent exposure keratitis.

Histopathologic examination typically shows orthokeratotic hyperkeratosis with



▲ **FIGURE 47-5** Congenital ichthyosiform erythroderma. Bright, red erythroderma with fine, white scale.

TABLE 47-3
Genes Identified in Autosomal Recessive Congenital Ichthyosis

Gene[a]	Protein	Function	Systemic Findings
TGM1	Transglutaminase 1	Cornified envelope formation	—
ABCA12	ATP-binding cassette, subfamily A, member 12	Membrane transport/lipid metabolism	—
ALOXE3	Arachidonate lipoxygenase 3	Hydroperoxide isomerase	—
ALOX12B	Arachidonate 12-lipoxygenase, R type	Lipoxygenase	—
ICHYN	Ichthyin	Trioxilin A3 receptor? Hepoxylin pathway?	—
FLJ39501 (CYP4F22)	Cytochrome P_{450}, family 4, subfamily F, polypeptide 2	LTB4-omega-hydoxylase?	—
SNAP29	SNAP receptor (SNARE)	Vesicle transport	CEDNIK syndrome
ABHD5 (CGI58)	Abhydrolase domain containing 5 comparative gene identification-58	Member of esterase/lipase/thioesterase subfamily	Chanarin-Dorfman syndrome

ATP = adenosine triphosphate; CEDNIK = *ce*rebral *d*ysgenesis, *n*europathy, *i*chthyosis, and palmoplantar *k*eratoderma; LTB4 = leukotriene B4; SNAP = soluble N-ethylmaleimide–sensitive factor attachment protein.
[a]The same gene may have more than one name.



mild to moderate acanthosis (see Fig. 47-2C). Rates of epidermal proliferation are normal or only slightly elevated in patients with lamellar ichthyosis, in contrast to those with CIE, which has significantly greater labeling indices.[49]

Genetic linkage studies performed on a group of families affected with the severe phenotype of classic lamellar ichthyosis (large, plate-like scale; ectropion; and minimal to no erythema) found linkage to markers on chromosome 14 in the region of the transglutaminase 1 gene locus.[50] Subsequently, mutations in *TGM1*, the gene encoding transglutaminase 1, were found in several families with lamellar ichthyosis, solidifying the role for transglutaminase 1 in the formation of a normal stratum corneum and its role as a cause of lamellar ichthyosis.[14,15] The transglutaminases catalyze calcium-dependent cross-linking of proteins through the formation of ε-(γ-glutamyl) lysine isodipeptide bonds. During the formation of the stratum corneum, transglutaminase catalyzes the cross-linking of cellular proteins, mostly involucrin, loricrin, and small proline-rich proteins. The resulting protein complex is deposited on the inner side of the plasma membrane to form the cornified envelope. Transglutaminase also attaches ceramides to cornified envelope proteins, notably involucrin, and thereby is important in the formation of both the protein and lipid components of the stratum corneum.[16]

Bathing suit ichthyosis is an unusual form of lamellar ichthyosis in which affected individuals develop the scaling typical of lamellar ichthyosis, but limited to the bathing suit area.[51] The distribution correlates with warmer areas of skin. Decreased transglutaminase is found in these areas, and unique, temperature-sensitive mutations in *TGM1* have been identified in affected individuals.[52]

In a human skin/immunodeficient mouse xenograph model, transfer of a transglutaminase 1 gene into transglutaminase 1–deficient keratinocytes from lamellar ichthyosis patients resulted in normalization of transglutaminase expression and epidermal architecture, in addition to restoration of cutaneous barrier function.[53] Additional disease-causing loci have been found (see Congenital Ichthyosiform Erythroderma).

CONGENITAL ICHTHYOSIFORM ERYTHRODERMA

As with lamellar ichthyosis, CIE is apparent at birth, and the newborn usually presents with a taut, shiny, collodion membrane. After shedding of the membrane, the skin of infants with CIE remains red, usually with a fine, white, generalized scale (see Fig. 47-5). On the lower legs, the scale may be larger and darker. In contrast to lamellar ichthyosis, the classic presentation of CIE has little to no ectropion, eclabium, or alopecia. As in lamellar ichthyosis, there is a wide variation in the ability to sweat, and patients with CIE may have minimal sweating with severe heat intolerance. Mucous membranes are usually spared. Palm/sole involvement is variable. Nails may have ridging, but they are often spared. As with all the ichthyoses, dermatophyte infection of the skin and nails is common.

Histopathologic examination shows hyperkeratosis, acanthosis, and often parakeratosis (see Fig. 47-2C). Studies of epidermal proliferation have shown markedly increased epidermal cell turnover, in contrast to lamellar ichthyosis.[49]

A small subset of patients with CIE have been found to have mutations in *TGM1*, and two siblings with a collodion presentation, CIE, and palmoplantar keratoderma had an autosomal dominant mutation in the cornified envelope protein, loricrin.[54] Further genetic heterogeneity within ARCI has been demonstrated, with exclusion of *TGM1* as the disease-causing gene in families with phenotypes within the spectrum of classic lamellar ichthyosis and CIE and identification of mutations in other genes. To date, mutations have been identified in five additional genes in nonsyndromic ARCI, and in two additional genes in two forms of syndromic ARCI. In addition, two other genetic loci (12p11.2-q13 and 19p13.1-13.2) have been found to be associated with ARCI; the responsible genes have not been identified (Table 47-3). A newly described, lipoxygenase pathway has been hypothesized as a common pathway linking many of the ARCIs.[20] This hypothesis remains to be tested, and how the most common mutation in ARCI, that of *TGM1*, might relate to lipid abnormalities is unclear.

EPIDERMOLYTIC HYPERKERATOSIS

In 1902, Brocq described bullous ichthyotic erythroderma and distinguished the blistering type from the nonblistering type of congenital ichthyotic erythroderma.[55] The original description included three unrelated patients whose clinical manifestations varied. However, this was probably the first description of

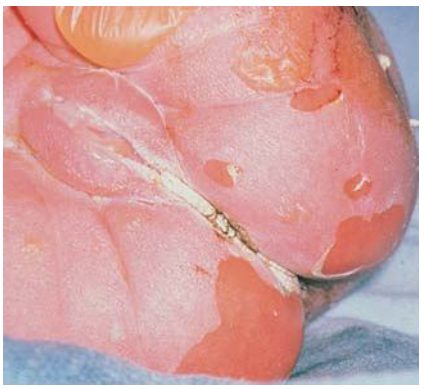

▲ **FIGURE 47-6** Epidermolytic hyperkeratosis. Newborn showing blistering and erosions.



epidermolytic hyperkeratosis (OMIM #113800). Today, the disease is named for the distinctive histopathologic features of vacuolar degeneration of the epidermis (i.e., epidermal lysis) and associated hyperkeratosis. Epidermolytic hyperkeratosis is also known as *bullous congenital ichthyosiform erythroderma*, an earlier descriptive name signifying the blistering, neonatal presentation, scaling, and redness.

Epidermolytic hyperkeratosis is transmitted as an autosomal dominant trait with a prevalence of approximately 1 in 200,000 to 300,000 persons. However, there is a high frequency of spontaneous mutation, and as many as one-half of the cases have no family history and represent new mutational events.[45] The disease usually presents at birth with blistering, redness, and peeling (Fig. 47-6). With time, generalized hyperkeratosis may develop, which may or may not be associated with erythroderma. Epidermolytic hyperkeratosis skin usually has a characteristic pungent odor, thought to be related to superinfection by mixed flora.

In contrast to most other ichthyoses, the histopathologic picture of epidermolytic hyperkeratosis is distinctive. There are a tremendously thickened stratum corneum and vacuolar degeneration of the upper epidermis, leading to the histologic term *epidermolytic hyperkeratosis* (see Fig. 47-2D). The vacuolar degeneration usually involves the upper epidermis and occasionally all of the suprabasilar keratinocytes. Granular cells exhibit dense, enlarged, irregularly shaped masses that appear to be keratohyalin granules.[6] On electron-microscopic examination, clumping of filaments is observed to begin in the first suprabasal layer. These aggregated filaments are clumps of keratin intermediate filaments that contain the terminal differentiation-specific keratin-1 and keratin-10.[56]

There is striking clinical heterogeneity between epidermolytic hyperkeratosis families. Six distinctive clinical phenotypes have been described.[57] Several clinical features can be useful to distinguish between the different sub-types, including the presence versus absence of severe palmar/plantar hyperkeratosis and of erythroderma, quality of scale, extent of involvement, presence of digital contractures, and gait abnormality (Table 47-4). Three types with no severe palm/sole hyperkeratosis are called *NPS types*. Patients with the NPS-1 clinical phenotype have generalized involvement with thick, brown verrucous hyperkeratosis, most prominent over joints. Palms and soles are spared. Cobblestone or hystrix (porcupine-like) spiny papules are characteristic; this severe clinical presentation is one of the more commonly recognized types of epidermolytic hyperkeratosis (Fig. 47-7A). NPS-2 is similar, but much milder, without the hystrix spines and with relative sparing of the skin between joints (see Fig. 47-7B). Generalized exfoliative erythroderma is found in NPS-3 (see Fig. 47-7C). Three types with severe palm/sole hyperkeratosis are called *PS types*. Patients with the PS-1 type have a smooth palmar/plantar hyperkeratosis with a sharp border, often delineated by a red halo. Blisters may be present at the border. There may be limited involvement of the trunk, usually confined to areas over joints (see Fig. 47-7D). The PS-2 type is characterized by generalized erythroderma and scaling. Volar involvement may be severe, with contractures of the digits and ainhum-like constricting digital bands (see Fig. 47-7E). The PS-3 type has generalized skin involvement with a pebbly hyperkeratosis that is arrayed in a distinctive, cerebriform pattern on the palms and soles (see Fig 47-7F).

Sporadic epidermolytic hyperkeratosis due to a postzygotic, spontaneous mutation during embryogenesis can present in a mosaic pattern of skin involvement. Areas of hyperkeratosis alternating with normal skin are often distributed in streaks along Blaschko's lines (Fig. 47-8A). These may be limited to a few streaks, or there may be many, with widespread, patchy involvement. Unilateral localization can also occur. This clinical mosaic pattern correlates with underlying genetic mosaicism in that keratin mutations characteristic of epidermolytic hyperkeratosis, which were found in lesional skin, were absent in normal skin.[58,59] If the germline is involved, individuals with mosaic epidermolytic hyperkeratosis can transmit the mutation, which leads to generalized epidermolytic hyperkeratosis in affected offspring (see Fig. 47-8B).[59]

TABLE 47-4
Characteristics of Epidermolytic Hyperkeratosis

	NPS-1	NPS-2	NPS-3	PS-1	PS-2	PS-3
Palm/sole hyperkeratosis	–	–	–	+	+	+
Palm/sole surface	Normal	Normal	Hyperlinear, minimal scale	Smooth	Smooth	Cerebriform
Digital contractures	–	–	–	–	+	–
Scale	Hystrix	Brown	Fine, white	Mild	White scale to peel	Tan
Distribution	Generalized	Generalized	Generalized	Localized	Generalized	Generalized
Erythroderma	–	–	+	–	+	–
Blistering	+	+	+	Localized	+	Neonatal
Most common mutation	Keratin-10			Keratin-1		

NPS = types without severe palm/sole hyperkeratosis; PS = types with severe palm/sole hyperkeratosis; – = absent; + = present.



▲ **FIGURE 47-7** Clinical phenotypes of epidermolytic hyperkeratosis. NPS (no severe palm/sole hyperkeratosis) types are shown in **A–C**. **A.** NPS-1. Generalized involvement with thick, brown verrucous hyperkeratosis. Palms are spared. Over the dorsal foot, hyperkeratosis is arrayed in a characteristic cobblestone or hystrix (porcupine-like) pattern. **B.** NPS-2. Brown hyperkeratosis over the trunk and accentuated over joints. Palms are spared. Compared with the verrucous hyperkeratosis in NPS-1, involvement is much milder. On the lower legs, note the blistering, hypertrichosis, and relative sparing of the skin between the joints. **C.** NPS-3. Generalized erythroderma with white scale and hyperkeratosis. PS (severe palm/sole hyperkeratosis) types are shown in the lower section. **D.** PS-1. Palmar and plantar hyperkeratosis with sharp border delineated by a red halo. Blisters are present at the border. Note the relatively smooth surface. There is characteristic involvement at the joints sparing most of the trunk and extremities. **E.** PS-2. Hands (*left* and *center*) of a 15-year-old patient with severe palmar hyperkeratosis and contractures. Flank of same patient (*lower right*) exhibiting generalized erythroderma and scaling. Palms (*upper right*) of a 36-year-old patient with severe palmar hyperkeratosis, contractures, and ainhum-like constricting digital bands. The palmar hyperkeratosis limits spreading of the fingers. **F.** PS-3. Hyperkeratosis in a cobblestone pattern on the knees. Four-year-old patient with hyperkeratosis in a distinctive cerebriform pattern on the palms and soles (not shown). (Adapted from DiGiovanna JJ, Bale SJ: Clinical heterogeneity in epidermolytic hyperkeratosis. *Arch Dermatol* **130**:1026, 1994,with permission.)





▲ **FIGURE 47-8** Mosaic epidermolytic hyperkeratosis. **A.** Streaks of hyperkeratosis distributed along Blaschko's lines in a sporadic case due to postzygotic occurrence of new mutation. **B.** Grandchild of patient shown in **A**. If the germ line is involved generalized involvement can be transmitted to subsequent generations in an autosomal dominant inheritance pattern.

Within keratinocytes, keratin intermediate filaments form an elaborate network that confers structural stability to the cells. In the suprabasilar differentiating keratinocytes of interfollicular epidermis, this network is formed by keratin-1 and keratin-10. In epidermolytic hyperkeratosis, failure of this network leads to keratinocyte fragility (particularly of the upper epidermis), easy blistering, abnormal epidermal kinetics (hyperproliferation), and thickened stratum corneum (hyperkeratosis). Keratin-10 is the co-expressed partner of keratin-1, both of which are required to form keratin intermediate filaments in the cells of the suprabasal layers of the epidermis (see Chap. 44). Genetic linkage studies[60] and sequencing of the keratin-1 and keratin-10 genes of a number of epidermolytic hyperkeratosis families have identified mutations in either keratin-1 or keratin-10.[56,57] In most cases, palmar plantar involvement implies mutations in keratin-1; this may reflect the "redundancy" of keratin-9 (a keratin that occurs only in the suprabasal epidermis of palmar and plantar skin) and keratin-10 in palmar/plantar epithelium. Mutations in keratin-9 have been found in families with the type of epidermolytic hyperkeratosis limited exclusively to the palms and soles (Vörner) (see Chap. 48).[61]

DISORDERS RESEMBLING EPIDERMOLYTIC HYPERKERATOSIS

Ichthyosis Bullosa of Siemens

Ichthyosis bullosa of Siemens (OMIM #146800) is a rare autosomal dominant genodermatosis that is similar in clinical appearance to epidermolytic hyperkeratosis. Patients are born with redness and blistering. The redness subsides over the subsequent weeks to months while the skin develops dark gray hyperkeratosis, particularly over flexural areas. In some areas, there may be a lichenified appearance to the skin. As with epidermolytic hyperkeratosis, the epidermis is fragile; however, the fragility is more superficial. This can result in loss of the uppermost epidermis (predominantly stratum corneum), yielding a characteristic, collarette-like depressed area that has been described as "mauserung" (molting). Histologically, the epidermis shows hyperkeratosis and vacuolization similar to epidermolytic hyperkeratosis, but it may be confined to the granular layer. In four families with ichthyosis bullosa of Siemens and two originally diagnosed with epidermolytic hyperkeratosis but who lacked mutations in keratin-1 and keratin-10, mutations were found in the gene encoding keratin-2 a differentiation-specific keratin of the suprabasilar epidermis that is expressed in the more superficial epidermal layers.[62]

Ichthyosis Hystrix of Curth and Macklin

Ichthyosis hystrix of Curth and Macklin (OMIM #146590) is a rare, autosomal dominant disorder that clinically resembles epidermolytic hyperkeratosis. Clinical expression varies, even within families, from palmoplantar keratoderma to a severe generalized involvement. There can be widespread patchy, thick, gray-brown hyperkeratosis, most marked on the extensor arms and legs. Patients with extensive involvement resemble those with severe epidermolytic hyperkeratosis without palmar/plantar involvement, with verrucous or porcupine-like (hystrix) hyperkeratosis. However, in contrast to epidermolytic hyperkeratosis, blistering does not occur. Histologic examination of the epidermis shows acanthosis, papillomatosis, and severe orthokeratotic hyperkeratosis, with frequent binucleate cells. Keratinocytes within the granular and upper spinous layers may have perinuclear vacuolization, and some have prominent perinuclear shells. On electron microscopy, there are concentric, unbroken shells of tonofilaments surrounding the nucleus. Study of a three-generation family with ichthyosis hystrix of Curth and Macklin identified a mutation in the variable tail domain (V2) of the keratin-1 gene. Structural analyses of the resulting keratin-1 abnormality showed a failure of keratin intermediate filament bundling, retraction of the cytoskeleton from the nucleus, and failure of localization of loricrin to desmosomal plaques.[63]

Annular Epidermolytic Erythema

Annular epidermolytic erythema (cyclic ichthyosis with epidermolytic hyperkeratosis) (OMIM #607602) presents at birth or in the first few months afterward with severe, intermittent scaling and blistering that resolves during puberty.[64] Residual, limited thickened



▲ **FIGURE 47-9** Collodion baby. The infant is 36 hours old and is covered with a macerated membrane that shows fissures; note ectropion and eclabium. The condition may develop over time into various clinical phenotypes, including autosomal recessive congenital ichthyosis and self-healing collodion baby (see Table 47-5).

plaques of verrucous scale in linear rows can be seen in flexural and intertriginous skin. In some cases, explosive bouts of widespread erythema with blisters and pustules are seen.[65] Patients subsequently develop widespread, migratory, polycyclic, and annular scaling plaques. Light and electron microscopy reveals findings of epidermolytic hyperkeratosis. Mutations in the rod portion of keratin-10[66] and the helix termination of keratin-1[65] have been found.

ICHTHYOSIS IN THE NEWBORN

Collodion Baby

A collodion baby is the usual presentation of ARCI (Fig. 47-9). Less commonly, a collodion presentation can also be seen in infants with several other forms of ichthyosis and, rarely, Gaucher disease (Table 47-5). The child is born encased in a translucent, parchment-like membrane that is taut and may impair respiration and sucking. The spectrum of involvement is probably variable, but has not been well characterized. In addition, the birth is often premature, which adds to morbidity. During the first 2 weeks of life, the membrane breaks up and peels off, often leaving fissures, with impairment of the barrier to infection and water loss. This can lead to difficulties in thermal regulation, an increased risk of infection, and hypernatremic dehydration.[67] Newborn care should include careful monitoring of temperature, hydration, electrolytes, and for infection. Measures to keep the peeling membrane soft and lubricated to facilitate flexibility and desquamation should be used. Appropriate pain management and eye care should be employed, when indicated. These newborns usually benefit from a humidified incubator where the air is saturated with water; wet compresses followed by bland lubricants can be used to further hydrate the membrane and achieve maximum pliability.[68] If, during peeling, residual areas of the membrane are allowed to dry and harden in areas such as the extremities, the taut membrane can constrict and lead to distal swelling. Collodion presentation can develop into a wide spectrum of ichthyotic phenotypes as the child grows (see Table 47-5). In addition, an autosomal recessive, self-healing collodion baby has been described, where the skin clears within the first few weeks and transitions into normal skin thereafter.[48] A *TGM1* mutation sensitive to increase hydrostatic pressure (such as might be found in utero) has been found in one family with two affected children with a history of self-healing collodion membranes.[69]

TABLE 47-5
Disorders Associated with Collodion Membrane

- AEC syndrome
- Autosomal recessive congenital ichthyosis (lamellar ichthyosis, congenital ichthyosiform erythroderma, overlap)
- Chondrodysplasia punctata
- Gaucher disease
- Loricrin keratoderma[a]
- Neutral lipid storage disease
- Self-healing collodion baby
- Sjögren-Larsson syndrome
- Trichothiodystrophy
- X-linked hypohidrotic ectodermal dysplasia
- Other

[a]Mutilating keratoderma with ichthyosis (Vohwinkel syndrome without deafness).
AEC = *a*nkyloblepharon-*e*ctodermal defect-*c*left lip and/or palate.
Note: This table does not distinguish the frequency in which collodion membrane is found in the different disorders listed. In some cases, severe peeling may be mistaken for collodion membrane.[167]

The newborn affected with one of the more severe, generalized types of epidermolytic hyperkeratosis usually has erythema, blistering, widespread erosions, and denuded skin. Because there is a high frequency of new mutations, the disease may be unexpected, and the diagnosis may be unknown. Epidermolysis bullosa or staphylococcal scalded-skin syndrome may be suspected, and the infant treated with antibiotics. The newborn may require intensive care with fluid and electrolyte monitoring. Specialized skin care can minimize blistering and enhance healing of erosions and should include lubrication (to decrease friction as well as mechanical trauma), protective padding, and specialized wound dressings. The newborn with extensive erosions is prone to bacterial infection and sepsis, and carefully chosen topical and systemic antibiotics can minimize the extent of infection.

Harlequin Ichthyosis

A dramatic, severe, and often fatal presentation of ichthyosis is that of harlequin ichthyosis (OMIM #242500, Fig. 47-10). The child is often premature and born with massive, shiny plates of stratum corneum separated by deep, red fissures that tend to form geometric patterns, as seen in the patched costumes of the harlequin clowns from the Italian Commedia dell'Arte dating from the sixteenth and seventeenth centuries. There are poorly developed or absent ears and marked ectropion and eclabium. The first report is from the diary of Rev. Oliver Hart, of Charleston, South Carolina, who described these features in 1750.[70] These children are at great risk during the neonatal period and often die shortly after birth. Abnormal water loss through the skin and poor temperature regulation lead to risk of fluid and electrolyte imbalance. The infants are also at risk for infection beginning in the skin, but at the same time (because of poor temperature regulation) do not show the usual signs of infection. Normal respiration may be restricted by the taut skin. Treatment





▲ **FIGURE 47-10** Harlequin ichthyosis. Note rudimentary ears and the distorted appearance as a result of the thick "plates" of stratum corneum. This baby died a few days after birth.



with systemic retinoids during the newborn period can facilitate desquamation of the membrane.[71,72] Advances in neonatal intensive care, together with facilitating desquamation by judicious use of systemic retinoid therapy, have led to improvements in survival and to the use of the name *harlequin baby* rather than *harlequin fetus*. Some babies have suffered from failure to thrive and require tube feeding. The skin of those who survive the newborn period usually resembles a severe phenotype of CIE.[71,72]

In harlequin ichthyosis, normal lamellar granules are not found; instead, there are small vesicles that lack internal structure. There is also no evidence of the lipid lamellae that form between granular and cornified cells as a result of discharge of lamellar granule contents into the intercellular space.[73] Occurrence of harlequin ichthyosis in consanguineous families suggests autosomal recessive inheritance.[74] Mutations in *ABCA12*, which codes for an adenosine triphosphate-binding cassette transporter involved in lamellar granule secretion and epidermal lipid transport, have been shown to underlie harlequin ichthyosis.[75–77] Mutations in *ABCA12* have also been identified in a subset of individuals with ARCI (see Table 47-3).[78]

LESS-COMMON ICHTHYOSES

Netherton Syndrome

Netherton syndrome (OMIM #256500) is a rare, autosomal recessive disorder characterized by the concurrence of ichthyosis, a structural hair shaft abnormality, and atopy.[79,80] The usual cutaneous manifestation is ichthyosis linearis circumflexa, a distinctive condition of generalized hyperkeratosis and polycyclic and serpiginous erythematous plaques with a characteristic, migratory, double-edged scale at the margins (Fig. 47-11A). At birth, affected children may present with generalized erythroderma. Infants and children may have feeding problems, with poor absorption and failure to thrive.[81] With atopic dermatitis, there may be pruritus, and scratching can lead to lichenification at the flexures. In some patients, the ichthyosis resembles lamellar ichthyosis or CIE.[5,79] Histopathologic examination is not specific and may show features of hyperkeratosis, psoriasis, and atopic dermatitis. Most patients have a specific hair shaft abnormality called *trichorrhexis invaginata*, in which the distal hair segment is telescoped into the proximal one, forming a ball-and-socket–like deformity on microscopic examination (see Fig. 47-11B). This is also known as "bamboo hair" and is due to abnormal cornification of the internal root sheath. Hair from multiple areas should be examined, because only 20 percent to 50 percent of hair may be affected, and the characteristic abnormality may be (see Chap. 86) more commonly observed on eyebrow hair.[82] Trichorrhexis nodosa and pili torti may also occur. The hair defects may not be detectable at birth, and may disappear with age. Atopy in these patients may manifest as atopic dermatitis, asthma, or severe food allergy (particularly to nuts), and marked elevations of serum immunoglobulin E may occur. In some patients, a generalized aminoaciduria, mild developmental delay, and impaired cellular immunity may also be present. Netherton syndrome has been found to be due to mutations in *SPINK-5*, a gene encoding LEKTI (*l*ympho-*e*pithelial *K*azal-*t*ype related *i*nhibitor).[21] LEKTI is a serine protease inhibitor that is predominantly expressed in epithelial and lymphoid tissues, and may be important in the downregulation of inflammatory pathways. This discovery highlights the importance of the regulation of proteolysis in the overlap between epithelial barrier function and the hypersensitivity of atopy. Subsequently, LEKTI was associated with common atopy and atopic dermatitis.[83] Prenatal testing for Netherton syndrome using molecular data has been successfully accomplished.[84] Tacrolimus ointment, a topical immunosuppressant, is effective in common atopic dermatitis with minimal systemic absorption. However, Netherton syndrome is complicated by an abnormal skin barrier, allowing increased percutaneous absorption and associated risk for systemic toxic effects. This should be considered when using topical agents such as tacrolimus, where monitoring of serum levels may be necessary,[85] and topical steroids, where iatrogenic Cushing syndrome has been reported.[86]

Sjögren-Larsson Syndrome

In 1957, Sjögren and Larsson reported on 13 families from north Sweden with a syndrome of congenital ichthyosis, spastic paralysis, and mental retardation. Sjögren-Larsson syndrome (SLS; OMIM #270200) is a rare, autosomal recessive disorder that presents at birth with an ichthyosis that may range from fine scaling to generalized hyperkeratosis. Erythema may be present at birth but tends to gradually clear by 1 year of age. Collodion-like membranes are rarely seen. The ichthyosis manifests as fine scale, large scale, or a thickening of the stratum corneum without scale and may be pruritic. Thickened areas may be yellow to brown in color and have a lichenified appearance with accentuated skin markings. The most involved areas are the sides and back of the neck, lower abdomen, and flexures. Hair, nails, and the ability to sweat are generally normal.[87] During the first 2 to 3 years, neurologic manifestations of spastic diplegia or tetraplegia and mental retardation develop and can be accompanied by speech defects and seizures. A characteristic ophthalmologic finding is the presence of glistening white dots in the macula of the retina; these occur after 1 year of age and may not be present in all patients. Histologic findings of hyperkeratosis, papillomatosis, acanthosis, and a mildly thickened granular layer are non-specific. Electron-microscopic examination of the skin shows lamellar membranous inclusions in the granular and cornified cells.



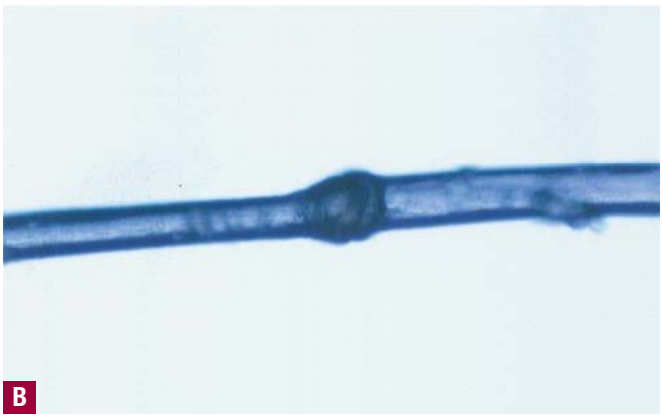

▲ **FIGURE 47-11** Netherton syndrome. **A.** Ichthyosis linearis circumflexa showing typical annular lesions. (Used with permission from James Stroud, MD.) **B.** Bamboo hair shaft shows features of trichorrhexis invaginata.



Rizzo et al. linked SLS to fatty alcohol: NAD oxidoreductase (FAO) deficiency. FAO is a complex enzyme with two separate proteins that sequentially catalyze the oxidation of fatty alcohol to fatty aldehyde and subsequently to fatty acid. Further work identified the fatty aldehyde dehydrogenase (FALDH) activity in cultured fibroblasts from patients with SLS component as the affected component of FAO in SLS. FALDH is a microsomal enzyme that catalyzes the oxidation of medium- and long-chain aliphatic aldehydes derived from metabolism of fatty alcohol, phytanic acid, ether glycerolipids, and leukotriene B4.[88] Mutations found in the FALDH gene (*ALDH10*, recently renamed *ALDH3A2*) of three unrelated SLS patients confirmed the role for this enzyme in the etiology of this disorder and the importance of this pathway for normal desquamation.[89] Most mutations are specific to families, although several common mutations suggest founder effect or favored sites for mutation.[90]

The identification of decreased fibroblast FAO activity in a family with atypical cutaneous findings (lack of ichthyosis or discrete plaques rather than generalized ichthyosis) has expanded the spectrum of clinical phenotypes associated with abnormal FAO activity.[91]

Erythrokeratodermias

The erythrokeratodermias are a clinically and genetically heterogeneous group of disorders characterized by hyperkeratosis and localized erythema. Within a broad spectrum of phenotypes, at least two disorders can be delineated: erythrokeratodermia variabilis and progressive symmetric erythrokeratodermia. There are overlapping clinical features and phenotypic variability within these two designations.[92]

ERYTHROKERATODERMIA VARIABILIS Erythrokeratodermia variabilis (OMIM #133200), described by Mendes da Costa in 1925, is a rare disorder that usually presents at birth or during the first year of life. Both autosomal dominant and recessive inheritance have been described.[93] At least two distinct clinical presentations can be distinguished. One type (Fig. 47-12) is characterized by generalized, persistent, red-brown hyperkeratotic plaques and accentuated skin markings. A second, localized type has involvement that is limited in extent and characterized by sharply demarcated, hyperkeratotic plaques; these are symmetrically arrayed and remain relatively fixed for months to years. In the localized type, there may be considerable variability between affected family members, and the disorder may not be apparent until later in life. Both types are characterized by striking, sharply demarcated, migratory red patches, which vary in size from a few to many centimeters and appear or regress over minutes to hours; some individuals complain of burning at these sites, although in others, they are asymptomatic. Both types of skin lesions may be triggered by trauma to the skin or change in temperature. Palmoplantar hyperkeratosis may be present in either type, but hair, nails, and mucous membranes are unaffected. Histopathologic features are non-specific and include hyperkeratosis, acanthosis, papillomatosis, and capillary dilatation. Epidermis involved with severe papillomatosis and suprapapillary thinning may result in a "church spire" appearance.

Several variants have been described. Erythrokeratodermia en cocardes was described in a family in which the erythematous component was in a target-like configuration.[94] In a possible clinical variant of erythrokeratodermia en cocardes, erythema gyratum repens–like erythema (see Chap. 154) was described in a large kindred.[95] Another family with erythema annulare centrifugum–like lesions (see Chap. 42) has also been described.[96] A child with atypical erythrokeratodermia with neurosensory deafness, bilateral talipes (clubfoot) deformity, and neuropathy was described in which the erythematous component changed only slowly over the year.[97] Erythrokeratodermia with ataxia (Giroux-Barbeau type) is an autosomal dominant disorder that presents during infancy with well-defined, symmetric hyperkeratotic plaques and underlying erythema distributed over the extensor surface of the extremities.[98] Skin lesions regress during adulthood while a progressive spinocerebellar ataxia develops.

Both the localized type of erythrokeratodermia variabilis and erythrokera-

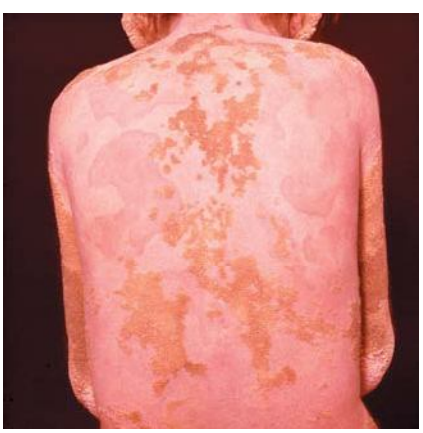

▲ **FIGURE 47-12** Erythrokeratodermia variabilis. Generalized type with widespread hyperkeratosis and migratory, figurate, red patches.

todermia with ataxia have been mapped to a common region (chromosome 1p34-35).[99] Subsequently, Richard et al. found mutations in *GJB3*, the gene encoding connexin-31, in four families with erythrokeratodermia variabilis.[100] Connexins are a family of proteins that form gap junctions, which are important channels for intercellular communication. This intercellular signaling system is crucial for maintaining tissue homeostasis, growth control, development, and synchronized response of cells to stimuli. The identification of connexin mutations as the cause of erythrokeratodermia variabilis implicates this pathway in epidermal differentiation and in the mechanism of skin response to external factors. Different mutations in the same connexin-31 gene (*GJB3*) have been found in other patients with deafness and also in some with peripheral neuropathy. Mutations in the related connexin-30.3 (*GJB4*) have been found in other families with erythrokeratodermia variabilis[101]; in the variants with erythema gyratum repens-like erythema that have been studied, connexin-30.3 mutations appear to be found exclusively.[93]

PROGRESSIVE SYMMETRIC ERYTHROKERATODERMIA Progressive symmetric erythrokeratodermia (OMIM #602036), first definitively described by Darier in 1911,[102] is characterized by well-demarcated, erythematous, hyperkeratotic plaques that are symmetrically distributed over the extremities and buttocks, and often the face.[103] The trunk tends to be spared, but palms and soles may be involved. The plaques appear shortly after birth, progress slowly during the first few years, and then stabilize in early childhood. The plaques usually remain stable in location and appearance but may undergo partial regression at puberty. The variable, migratory erythema that defines erythrokeratodermia variabilis is absent. The disorder is inherited in an autosomal dominant pattern but with incomplete penetrance and variable expressivity. A mutation in the cornified envelope protein loricrin was found in one family,[104] although the diagnosis (and the distinction from erythrokeratodermia variabilis) has been disputed.[105]

Keratitis, Ichthyosis, and Deafness Syndrome

KID syndrome (OMIM #148210) is a rare disorder characterized by *k*eratitis (with progressive corneal opacification), *i*chthyosis, and *d*eafness (neurosensory). Involvement of multiple ectodermal tissues qualifies KID syndrome as an ectodermal dysplasia. Most cases are compatible with autosomal dominant inheritance. However, occurrence in an inbred sibship suggests the existence of an autosomal recessive form. The disease is characterized by discrete erythematous plaques, and there may be a mild, generalized hyperkeratosis. The distinctive plaques may have a discrete border and a verrucous appearance with crusting and may be conspicuously figurate and symmetric on the face (Fig. 47-13). Furrowing about the mouth results in characteristic faces. There may be prominent follicular hyperkeratosis, which can result in a scarring alopecia of the scalp. "Leather-like" palmar/plantar keratoderma is almost always seen (see eFig. 47-13.1 in on-line edition).[106] Several authors have suggested that because the plaques do not scale, this disorder is more accurately designated an erythrokeratodermia rather than an ichthyosis.[5,106] Descriptions of nail changes vary from absent, delayed appearance after birth, atrophic, or brittle to thickened, with loss of or "rough" cuticles, subungual hyperkeratosis, and leukonychia. The teeth may be small. Auditory evoked potential studies allow detection of the hearing deficit in infancy. Affected individuals can have an increased susceptibility to bacterial, fungal, or viral infections. Squamous cell carcinoma of the skin and tongue has also been reported. In contrast to many other ichthyotic conditions, treatment of these patients with oral retinoids has been reported to be of little benefit and possibly to exacerbate the corneal neovascularization.

Richard et al. discovered dominant mutations in *GJB2*, the gene encoding connexin-26, in eight sporadic cases and one family with KID syndrome. Functional studies of cells expressing mutated connexin-26 demonstrated failure of a fluorescent tracer to pass through gap junction channels to neighboring cells, consistent with disruption of intercellular communication.[22] Different mutations in the same gene (*GJB2*) encoding connexin-26 have also been found in a family with a mutilating palmoplantar keratoderma (Vohwinkel syndrome) and deafness (without ichthyosis)[107] (discussed in Chap. 48), and a mutation in *GJB6*, the gene for connexin-30, has been demonstrated in one child with KID syndrome.[108] Connexin proteins aggregate to form gap junction channels, which span the cell membrane between adjacent cells. These channels are flexible structures that are constantly remodeled, and enable a direct cytoplasmic connection that allows the passage of a variety of small molecules between cells. The identification of mutations in the genes encoding a variety of connexin proteins has highlighted the role of connexin-mediated intercellular communication through gap junctions in the development and maintenance of ectodermal tissues. Connexins-26, -30, and -31 are expressed in the stratified epithelia of the cochlea and epidermis, and abnormalities in these proteins can cause sensorineural hearing impairment and/or skin disorders.[10]



▲ **FIGURE 47-13** Keratitis, ichthyosis, and deafness syndrome. Discrete, symmetric hyperkeratotic plaques are present on the cheeks and nose.

Refsum Disease

Refsum disease (heredopathia atactica polyneuritiformis) (OMIM #266500) is a rare, progressive, degenerative disorder of lipid metabolism resulting from the failure to break down dietary phytanic acid and its subsequent accumulation in tissues. This autosomal recessive condition affects mostly the Scandinavians and populations originating from northern Europe. Clinical manifestations include retinitis pigmentosa, peripheral neuropathy, cerebellar ataxia, cranial nerve dysfunction (neural deafness, anosmia), miosis, electrocardiographic abnormalities, cardiomyopathy, renal tubular dysfunction, and skeletal abnormalities (epiphyseal dysplasia). Ichthyosis, which is variable, generally develops in adulthood after the neurologic and ophthalmologic manifestations. Often, there are small white scales over the trunk and extremities resembling ichthyosis vulgaris. Routine hematoxylin and eosin histologic examination shows variably sized vacuoles in the epidermal basal and suprabasal cells, which corre-



spond to lipid accumulation seen with lipid stains of frozen sections.[109]

Phytanic acid (a 20-carbon, branched-chain fatty acid) is derived from a variety of dietary sources, including dairy products, ruminant fats, and chlorophyll-containing foods; although chlorophyll-bound phytol cannot be absorbed in humans. The disease is caused by a deficiency of phytanoyl-coenzyme A hydroxylase (PhyH), a peroxisomal protein that catalyzes the α-oxidation of phytanic acid. This is the first step in the breakdown of phytanic acid, and PhyH deficiency leads to the accumulation of phytanic acid in the serum and tissues, where it substitutes for the fatty acids normally present. Although mutations in *PAHX*, the gene encoding PhyH, are responsible for most cases of Refsum disease[110] there is genetic heterogeneity.[111] Some affected patients have mutations in the *PEX7* gene, which is the same gene mutated in rhizomelic chondrodysplasia punctata (RCDP; see Rhizomelic Chondrodysplasia Punctata). Refsum disease is distinguished from infantile Refsum disease, a fulminant generalized peroxisomal biogenesis disorder in which young children present with severe neurologic abnormalities, mental retardation, hepatomegaly, and dysmorphic features in addition to the other signs of adult Refsum disease.[112]

The diagnosis can be made by detection of elevated levels of plasma phytanic acid. In children who do not have elevated plasma levels of phytanic acid, the diagnosis may be made by measuring PhyH activity in cultured fibroblasts.[112] Treatment includes dietary restriction of foods containing phytanic acid and its precursors and can include plasmapheresis or lipapheresis. In the clinical setting of a delayed onset of ichthyosis in association with neurologic impairment, this disease should be considered because therapy can arrest progression.

Chondrodysplasia Punctata

Chondrodysplasia punctata is a clinically and genetically diverse group of rare diseases, first described by Conradi, that share the features of stippled calcification of the epiphyses and skeletal changes. They are characterized by abnormal deposition of calcium in the areas of enchondral bone formation during fetal development and early infancy. Several forms also include ichthyosiform changes. Clinical severity ranges from severe dwarfism and death during infancy to a self-limited radiographic abnormality in others. An autosomal recessive (rhizomelic) type and both X-linked dominant[114] and recessive forms[115] have been described. The validity of the originally described autosomal dominant Conradi-Hünermann type has been questioned, because some reported cases were later shown to belong to the X-linked dominant type, and occurrences previously considered sporadic have subsequently been recognized as resulting from warfarin (Coumadin) anticoagulant embryopathy.[114,116]

RHIZOMELIC CHONDRODYSPLASIA PUNCTATA RCDP (autosomal recessive; OMIM #215100) is also known as *peroxisomal biogenesis disorder complementation group 11*. It is a rare, multisystem developmental disorder characterized by dwarfism due to symmetric shortening of the proximal long bones (i.e., rhizomelia), specific radiologic abnormalities (i.e., the presence of stippled calcifications of cartilage, vertebral body clefting), joint contractures, congenital cataracts, ichthyosis, and severe mental retardation. Skin changes are present in approximately 25 percent of patients. Patients have low levels of red cell plasmalogens and accumulation of phytanic acid, starting with normal levels at birth and increasing to more than 10 times normal by age 1 year.

X-LINKED RECESSIVE CHONDRODYSPLASIA PUNCTATA X-linked recessive chondrodysplasia punctata (OMIM #302950) can involve skin (linear or whorled atrophic or ichthyosiform hyperkeratosis, follicular atrophoderma; may begin as erythroderma; Fig. 47-14), hair (coarse, lusterless, cicatricial alopecia), short stature and skeletal abnormalities, cataracts, and deafness. Curry et al. studied a family who had atypical ichthyosis and elevated cholesterol sulfate in two affected males and identified an X chromosomal deletion (Xp22) that included the gene for steroid sulfatase.[115] There is a cluster of arylsulfatase genes at this location. Mutations in *ARSE*, the gene encoding the enzyme arylsulfatase E, were found in five patients; however, it is possible that the disorder may also be caused by mutations in adjacent arylsulfatase genes.[118] The similarity to warfarin embryopathy suggests that warfarin embryopathy may be due to drug-induced inhibition of the same enzyme.

X-LINKED DOMINANT CHONDRODYSPLASIA PUNCTATA Happle and co-workers identified X-linked dominant chondrodysplasia punctata (CDPX2; Conradi-Hünermann-Happle syndrome; OMIM #302960) as a distinct variant characterized by a mosaic pattern of skin involvement and occurrence almost exclusively in females, with loss of the gene function hypothesized to be lethal to males.[114] Affected females have a normal life expectancy, and there may be increased disease expression in successive generations (anticipation). Occurrence in a male has been observed in association with a 47,XYY karyotype. CDPX2 presents at birth as a CIE that clears over months and is replaced by linear hyperkeratosis, follicular atrophoderma, and pigmentary abnormalities. Happle hypothesized that the linear involvement is due to mosaic X-chromosome inactivation (lyonization). Hair shaft abnormalities and cicatricial alopecia can also occur. Stippled calcifications are seen in radiographs of areas of endochondral bone formation during childhood but may no longer be visible after puberty. Stature may be short, with asymmetric shortening of the legs. Cataracts occur, usually asymmetrically, in about two-thirds of patients. Histochemical staining for calcium may show calcifications within the epidermis, especially within hair follicles in young children, which may not be present in older children.[119] Mutations in the gene encoding the emopamil-binding protein (EBP) cause the Conradi-Hünermann-Happle syndrome. EBP was first identified as a binding target for the drug emopamil, a calcium-channel blocker. It was later found to be 3β-hydroxysteroid-δ8-δ7-isomerase that catalyzes an intermediate step in the conversion of lanosterol to cholesterol.[120] How this defect causes clinical manifestations is unclear.



▲ **FIGURE 47-14** Chondrodysplasia punctata. Newborn child. Generalized erythroderma with scales forming a whorled pattern.

CHILD Syndrome

The CHILD syndrome (OMIM #308050) is a rare disorder that is found almost ex-



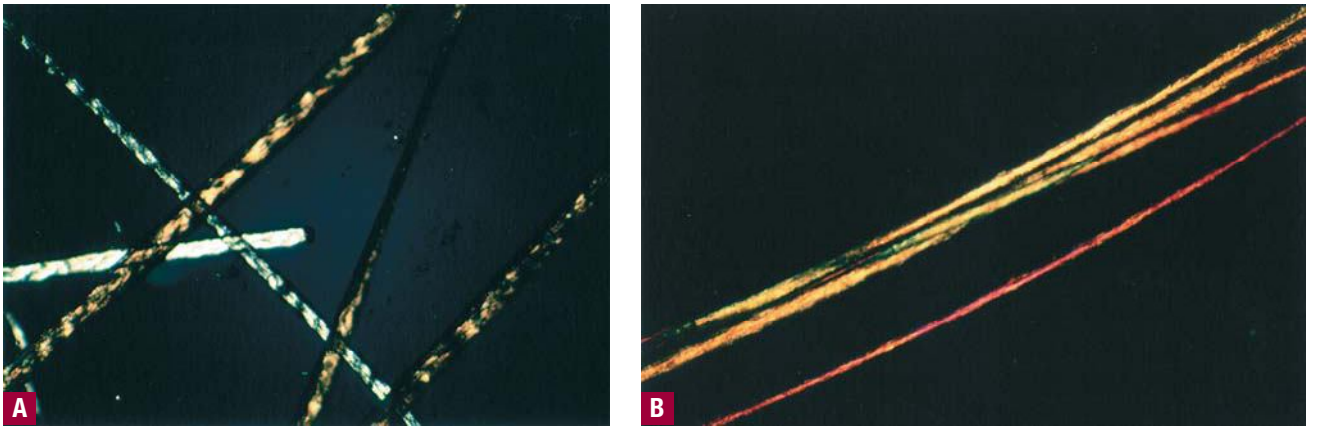

▲ **FIGURE 47-15** Trichothiodystrophy hair shows tiger-tail banding (**A**) under polarization, which is not observed with normal hair (**B**).



clusively in females.[121] The disorder is related to CDPX2 and also has skin and skeletal abnormalities. The ichthyosiform erythroderma has a psoriasiform morphology (see eFig. 47-14.1 in on-line edition) distinguished by a sharp midline demarcation with minimal linear or segmental contralateral involvement. Involvement of the right side occurs more frequently than the left. There may be bands of normal skin on the affected side. A case with bilateral involvement has been described. Limb defects occur ipsilateral to the ichthyosis and range from digital hypoplasia to agenesis of the extremity. There may be punctate calcification of cartilage. Unilateral hypoplasia can involve the central nervous system and cardiovascular, pulmonary, renal, endocrine, and genitourinary systems. The inheritance pattern is thought to be X-linked dominant, with the condition being lethal in males. Peroxisomal deficiency has been described in a study that showed fibroblasts from involved skin had fewer peroxisomes and accumulated cytoplasmic lipid; ultrastructurally, they accumulated lamellated membrane and vacuolar structures. Subsequently, mutations in either of two peroxisomal genes were found to cause CHILD syndrome. One patient was found to have a mutation in the gene encoding EBP (3β-hydroxysteroid-δ8-δ7-isomerase) (the gene underlying CDPX2)[122] and six patients (including one boy) were found to have mutations in NSDHL [*N*AD(P)H *s*teroid *deh*ydrogenase-*l*ike protein] encoding a 3β-hydroxysteroid dehydrogenase.[123] Each enzyme functions in the post-squalene cholesterol biosynthetic pathway, catalyzing intermediate steps in the conversion of lanosterol to cholesterol.[124]

Trichothiodystrophy

Trichothiodystrophy (TTD; OMIM #601675) is an autosomal recessive disorder that includes a broad spectrum of clinical phenotypes linked by the characteristic features of sulfur-deficient, brittle hair that exhibits tiger tail banding when viewed under polarizing microscopy (Fig. 47-15; see Chap. 140).[125] TTD hair shafts exhibit a variety of structural abnormalities related to a decrease in high sulfur matrix proteins and associated reduction in the ratio of strong to weak disulfide bonds within the hair shafts.[126–128] The disorder is reviewed in Chap. 140. Patients may have photosensitivity, ichthyosis, intellectual impairment, short stature, microcephaly, characteristic facial features (protruding ears, micrognathia) and decreased fertility.[125–130] The spectrum of clinical involvement is broad, ranging from only hair to severe multisystem abnormalities. Roughly one-half of TTD patients have clinical photosensitivity that ranges from subtle to severe. A similar number have ichthyosis, which also varies in severity from mild to severe. Newborns may have a collodion presentation, followed by decreasing erythema over weeks and evolution into a generalized ichthyosis, usually without erythema, which varies from fine, translucent scaling to large, dark yellow-brown hyperkeratosis (Fig 47-16B).[131,132] There may be flexural sparing, palmoplantar keratoderma, and dystrophic nails (ridging, splitting) (see Fig. 47-16A). Ectropion usually does not occur. There can be low birth weight, lack of subcutaneous fat (progeria-like facies), short stature, and delayed psychomotor development. Hypogonadism manifests as cryptorchidism in males and impaired sexual maturation in females.

A series of mnemonics have been used to describe the constellation of findings as BIDS (*b*rittle hair, *i*ntellectual impairment, *d*ecreased fertility, and *s*hort stature); when patients also have *i*chthyosis, IBIDS has been used; with the addition of *p*hotosensitivity, PIBI(D)S has been used.[133] However, these terms do not account for the other multisystem findings commonly present.

The majority of TTD patients have a defect in XPD (*ERCC2*). A few have mutations in XPB (*ERCC3*) or TTDA (*GTF2H5*), genes that are components of the transcription factor IIH (TFIIH) that regulates both DNA repair and transcription. Some TTD patients have mutations in *TTDN1*.[134] Although many TTD patients have photosensitivity, in contrast to xeroderma pigmentosum, these photosensitive patients have not been observed to be at high risk for the development of skin cancer. Nucleotide excision repair is one normal cellular mechanism by which structural DNA damage (e.g., ultraviolet-induced cyclobutane pyrimidine dimers) is removed and repaired (see Chaps. 109 and 140). TFIIH is involved in the initiation of transcription and also in nucleotide excision repair, and consists of a complex of proteins including the XPD and XPB proteins. In the vicinity of the damage, these two helicase subunits of TFIIH unwind the DNA in opposite directions.

Chanarin-Dorfman Syndrome

Chanarin-Dorfman syndrome (neutral lipid storage disease; OMIM #275630) is an autosomal recessive disorder characterized by accumulation of triglycerides in the cytoplasm of leukocytes, muscle, liver, fibroblasts, and other tissues. Blood lipid levels, however, are normal. To date, approximately 30 patients have been reported, mainly from the Mediterranean basin. The ichthyosis is a generalized fine scaling with variable erythema, resembling CIE. Presentation is often that of a collodion baby with ectropion and eclabium. Skin changes may evolve to orange-red with brown scale and are associated with pruritus. Extra-cutaneous involvement, which is vari-



▲ **FIGURE 47-16** Trichothiodystrophy. **A.** The nails are thinned and brittle, with onychoschizia, cracking, and irregular transverse depressions of the dorsal surface. **B.** Skin involvement in trichothiodystrophy can vary from absent to severe ichthyosis. This patient has a more severe ichthyotic involvement with dark-colored, adherent scale.

able and may be mild, includes cataracts, decreased hearing, hepatosplenomegaly with abnormal liver enzymes and fatty liver, psychomotor delay, myopathy with elevations in serum muscle enzymes, and neurologic abnormalities.

Multiple Sulfatase Deficiency

Multiple sulfatase deficiency (OMIM #272200) is a rare autosomal recessive disorder that is characterized by a deficiency of several sulfatases, which results in the accumulation of sulfatides, glycosaminoglycans, sphingolipids, and steroid sulfates in tissues and body fluids.[139] The activity of both lysosomal (arylsulfatases A and B) and microsomal (arylsulfatase C/steroid sulfatase of X-linked ichthyosis) arylsulfatases is impaired. The disorder is a composite of the clinical features of both metachromatic leukodystrophy and of a mucopolysaccharidosis.

Peeling Skin Syndrome

Peeling skin syndrome (OMIM #270300) is an autosomal recessive disorder characterized by lifelong peeling of the stratum corneum. It may be associated with pruritus, short stature, and easily removed anagen hairs. Low plasma tryptophan levels and aminoaciduria have also been reported.[143] Traupe suggested that there are two types of peeling skin syndromes.[5] Type A, which is noninflammatory and asymptomatic, is characterized by generalized peeling in thin superficial flakes of differing size and shape. In contrast, type B presents with congenital ichthyotic erythroderma and evolves into erythematous, scaling, migratory patches. This type is pruritic and may be associated with elevated levels of immunoglobulin E, aminoaciduria, and short stature. The stratum corneum is easily separated mechanically from the lower epidermis, and histologically the split, which occurs intercellularly, is seen between the stratum corneum and the granular layer.

Rud Syndrome

Rud syndrome (OMIM #308200) is a poorly characterized disorder, probably of recessive inheritance, that includes epilepsy, mental retardation, infantilism, congenital ichthyosis, and retinitis pigmentosa. Steroid sulfatase deficiency has been reported in some patients. Traupe critically reviewed the literature and suggested that the clinical constellation usually labeled Rud syndrome is associated with steroid sulfatase deficiency (X-linked recessive ichthyosis) and likely reflects a heterogenous group of disorders; because both the neurologic involvement and the ichthyosis are ill defined, the term *Rud syndrome* should be abandoned.[5]

ACQUIRED ICHTHYOSIS

The development of ichthyosis in adulthood can be a manifestation of systemic disease and has been described in association with malignancies, drugs, endocrine and metabolic disease, human immunodeficiency virus (HIV) and other infections, and autoimmune conditions.[149] The granular layer is often attenuated in this disorder, and the scale often resembles that seen in mild ichthyosis vulgaris. Although Hodgkin disease is the most common malignancy reported with acquired ichthyosis, non-Hodgkin lymphomas and a variety of other malignancies have also been observed.[150] Skin involvement may follow the course of malignancy and clear with effective cancer treatment. Acquired ichthyosis is commonly seen in association with acquired immunodeficiency syndrome; ichthyotic or xerotic skin has been observed in up to 30 percent of acquired immunodeficiency syndrome patients (see Chap. 198).[151] A study of HIV-1-positive intravenous drug users found acquired ichthyosis occurred only after profound helper T-cell depletion, more frequently with co-infection with human T-cell leukemia/lymphoma virus type 2, and suggested that it may be a marker for concomitant infection with HIV-1 and human T-cell leukemia/lymphoma virus type 2.[152]

In acquired ichthyosis occurring in association with sarcoidosis, skin biopsy can be diagnostic, showing noncaseating granulomas in the dermis (see Chap. 153).[153] Acquired ichthyosis may be a marker of autoimmune disease, occurring with systemic lupus erythematosus, dermatomyositis, mixed connective tissue disease, and eosinophilic fasciitis (see Chaps. 30, 156, 157).[154,155] It has been described in bone marrow transplant recipients, where it may be related to graft-versus-host disease (see Chap. 28).[156]

Although occurrence in association with cholesterol-lowering agents (nico-



tinic acid, triparanol) highlights the relationship between cholesterol metabolism and normal desquamation, acquired ichthyosis has been observed with a variety of drugs, including butyrophenone (antipsychotic), dixyrazine (major tranquilizer), and nafoxidine (estrogen antagonist).[19] Kava is a psychoactive beverage made from the root of a pepper plant and used for thousands of years by Pacific Islanders. Heavy kava drinkers can acquire a reversible ichthyosiform eruption called *Kava dermopathy*. In Western nations, kava is sold in health food stores as a relaxant.[157]



Confluent and Reticulated Papillomatosis of Gougerot and Carteaud

Confluent and reticulated papillomatosis of Gougerot and Carteaud is an uncommon but distinctive acquired ichthyosiform dermatosis seen in young adults and characterized by persistent brown, scaly macules, papules, patches, and plaques. Lesions tend to be localized predominantly on the neck, upper trunk (intermammary and interscapular regions), and axillae where they tend to be confluent and become reticulated towards the periphery (Fig. 47-17). The lesions bear a clinical resemblance to tinea versicolor, a skin infection with *Pityrosporum* sp. A variety of treatment approaches have been reported, including topical (keratolytics, derivatives of vitamins A and D, antimicrobials) and systemic (antibiotics, retinoids) agents. Minocycline has been suggested as a first-line treatment; successful retreatment of recurrences supports the concept that this condition is an abnormal response to an infection or inflammation.[158,159]

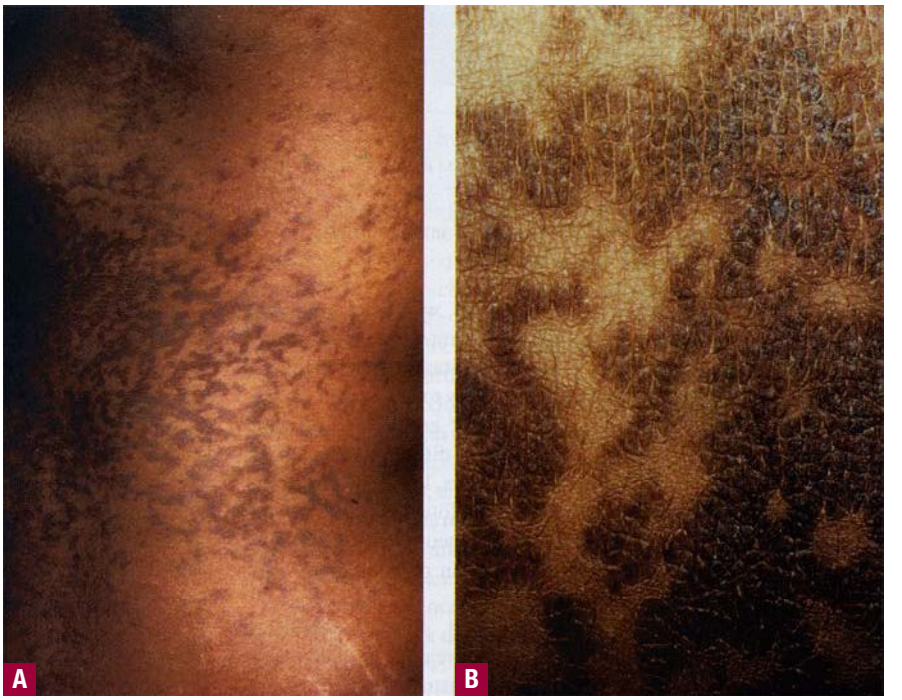

▲ **FIGURE 47-17** Confluent and reticulated papillomatosis of Gougerot and Carteaud. **A.** Dark, scaly papules and plaques on the trunk, which become reticulated toward the periphery. **B.** Close-up view of the distinctive, scaly, reticulated papules and plaques. (Used with permission from Andrew Montemarano, DO, and Stephen Krivda, MD.)

TREATMENT

Current therapies for the inherited ichthyoses are symptomatic and focus on hydration, lubrication, and keratolysis.[160,161] Ichthyotic skin, even if thickened, has a decreased barrier function and increased transepidermal water loss. Because pliability of the stratum corneum is a function of its water content, hydration can soften the surface of the skin. In moist, humid climates, most ichthyoses improve, and mild ichthyoses (e.g., ichthyosis vulgaris) may undergo extensive clearing. Moistening the skin with, for example, long baths can hydrate it. Well-hydrated areas of hyperkeratosis can more easily be thinned with mild abrasives (sponges, buff puffs, pumice stones, etc.). Addition of bath oils or application of lubricants before drying can prolong the hydration and softening. Depending on the ichthyosis and environmental conditions, individual patients may prefer specific lubricating agents, which can take the form of lotions, creams, oils, ointments, or petrolatum. In dry climates and winter months, humidifiers can be used to create a more hospitable environment.

Keratolytic agents are used to enhance corneocyte desquamation and thereby remove scale and thin hyperkeratotic stratum corneum. There are many commercially available keratolytic creams and lotions containing urea, salicylic acid, or α-hydroxy acids (e.g., lactic acid, glycolic acid). Urea may function by its capacity to bind water. Propylene glycol (40 percent to 60 percent in water), with or without occlusion, can also be effective in scale removal. Occlusion can effectively increase skin hydration and facilitate desquamation; it can also enhance the effect of keratolytic agents. Special care should be taken when using extensive areas of occlusion with keratolytic agents and in individuals who may be heat intolerant. Topical retinoid or vitamin D preparations may also be effective but can be irritating in some patients. The markedly impaired barrier function in ichthyosis should be considered when using topical preparations over large areas of body surface. For example, widespread use of topical salicylic acid preparations can lead to significant absorption, intoxication (e.g., nausea, tinnitus, dyspnea, hallucinations), and even death.[162] Children are at greater risk because they have a greater body surface area per unit weight than adults, a situation that effectively heightens the possibility of developing systemic toxicity from topicals. The abnormal skin barrier should be considered when treating concomitant dermatoses in ichthyosis patients. Topical 0.1 percent tacrolimus ointment is effective in atopic dermatitis with minimal systemic absorption. However, the atopic dermatitis of Netherton syndrome is complicated by a defective ichthyotic skin barrier. The defective barrier is associated with increased percutaneous absorption and risk for systemic toxic effects. This should be considered when using topical agents such as tacrolimus or topical steroids, where increased systemic absorption has been observed and monitoring of serum levels may be necessary.[85,86]

Another risk to children is that in several types of ichthyosis, nutritional requirements may be high, and inadequate

nutrition can lead to failure to thrive. This was thought to be related to the large turnover of scale; however, recent studies suggest energy loss from impaired barrier function is the cause.[163] Some patients with ichthyosis (particularly lamellar ichthyosis and CIE) have decreased sweating with heat intolerance. It is important for the parents of a newborn with ichthyosis to be aware of the possibility of decreased sweating and to be attentive for signs of heat intolerance, such as flushing and lethargy, particularly during hot weather, and, as the child grows, during exercise. Avoiding hot environments, carrying spray bottles with water to moisten the skin and cool it through evaporation, and cooling vests can minimize heat stress.

Systemic retinoid therapy with isotretinoin or acitretin can induce dramatic improvement in many ichthyoses and is particularly useful in lamellar ichthyosis, CIE, and erythrokeratodermia variabilis. The decision to initiate systemic retinoid therapy should be weighed carefully, because once the drug is started, continued benefit usually requires chronic therapy. Treatment of the harlequin newborn with systemic retinoid therapy during the newborn period can be lifesaving due to enhanced desquamation of a constricting membrane.

Fungal infections are common, both of skin and nails, and are often undiagnosed because of the generalized scaling. A high index of suspicion can help diagnose tinea corporis, capitis, or versicolor, where the only symptom may be localized pruritus and the only sign a difference in the character of scale or a localized area of alopecia.

The management of epidermolytic hyperkeratosis has acute and chronic aspects and varies with the clinical type. Areas of thick, hard hyperkeratosis, which are not pliable and have a hard rough surface, are prone to mechanical trauma. In patients with the hystrix type of porcupine-like hyperkeratosis, the rough surface causes high traction with objects moving across the skin surface, which tend to catch on the hyperkeratotic horn and peel it off. Topical agents such as lubricants and keratolytics can reduce the thickened, rough areas and help to minimize blistering and erosion. Bacterial infection of the skin is common, often leads to enhanced blistering, and may require frequent therapy with topical and oral antibiotics. In patients with extensive involvement, systemic retinoid therapy can be dramatically effective in decreasing the hyperkeratosis and the frequency of infections. Because these drugs can enhance blistering in epidermolytic hyperkeratosis patients, they should be administered carefully and started at low doses.

Box 47-1

Ichthyosis Resources

- **The Foundation for Ichthyosis and Related Skin Types** provides support and information for affected individuals, family members, friends, and health care providers—F.I.R.S.T., 1364 Welsh Road G2, North Wales, PA 19454 Tel: 215-619-0670; http://www.scalyskin.org/; e-mail: info@scalyskin.org.
- **GeneTests** (http://www.genetests.org) provides disease reviews, genetic testing resources, and educational materials.
- **Online Mendelian Inheritance in Man, OMIM,** (http://www.ncbi.nlm.nih.gov/entrez/query.fcgi?db=OMIM) (trademark, Johns Hopkins University), a catalog of human genes and genetic disorders, is a useful reference with links to additional resources.
- **The National Registry for Ichthyosis and Related Disorders** is a resource for investigators to improve diagnosis and treatment of these disorders—University of Washington, Dermatology, Box 356524, 1959 NE Pacific St., Seattle, WA 98195-6524 Tel: 1-800-595-1265; http://www.skinregistry.org; e-mail: info@skinregistry.org.

PRENATAL DIAGNOSIS

Molecular diagnosis is preferred when possible. Alternative methods, including fetoscopy and fetal skin biopsy, have the disadvantage of not being able to be performed early in pregnancy. Both harbor a risk of fetal mortality. For these and other reasons, fetal skin biopsy is rarely performed, and expert interpretation is almost impossible to obtain. In the past, fetal skin biopsy at approximately 20 to 22 weeks' gestation was performed in lamellar ichthyosis, CIE, epidermolytic hyperkeratosis, and SJS. In harlequin ichthyosis, prenatal diagnosis has been successfully performed by fetal skin biopsy[164] and ultrasonography.[165] When it is possible to do prenatal diagnosis by molecular analysis of a fetal sample, it is optimally performed early in pregnancy. This can be done with chorionic villous sampling or by amniocentesis in disorders where the underlying genetic defect is known, and the specific mutation in the family has been identified. If a specific mutation has not been identified, in some circumstances where there is an appropriate family structure, prenatal diagnosis can be done using linkage analysis. Prenatal diagnosis by mutational analysis has been accomplished in epidermolytic hyperkeratosis[166]; lamellar ichthyosis (*TGM1*); SJS (*FALDH*); ichthyosis bullosa of Siemens (*keratin 2*); PIBI(D)S (*ERCC2/XPD*, *ERCC3/XPB*); autosomal recessive RCDP(*PEX7*); X-linked chondrodysplasia punctata (arylsulfatase gene cluster at Xp22); Netherton syndrome (*SPINK-5*)[84]; and harlequin ichthyosis (*ABCA12*) (personal communication, David Kelsell, 7.26.06). In SJS, the diagnosis can be made by assay of enzyme activity in cultured amniocytes, even if the mutation in FALDH is undefined. For autosomal recessive disorders where the mutation is known (e.g., lamellar ichthyosis and SJS), carrier detection may be performed for at-risk relatives.

See Box 47-1 for more information on the ichthyoses.



KEY REFERENCES

The full reference list for all chapters is available at www.digm7.com.

5. Traupe H: *The Ichthyoses: A Guide to Clinical Diagnosis, Genetic Counseling, and Therapy*. Berlin, Springer-Verlag, 1989
8. Williams ML, Elias PM: Genetically transmitted, generalized disorders of cornification. The ichthyoses, in *Dermatologic Clinics. The Genodermatoses*, edited by Alper JC. Philadelphia, W.B. Saunders Co, 1987, p 155
9. Bale SJ, DiGiovanna JJ: Genetic approaches to understanding the keratinopathies. *Adv Dermatol* **12**:99, 1997
10. Richard G: Connexins: A connection with the skin. *Exp Dermatol* **9**:77, 2000
11. Arin MJ, Hohl D, Roop DR: Disorders of keratinization, in *Connective Tissue and Its Heritable Disorders: Molecular, Genetic, and Medical Aspects*, 2nd ed, edited by Royce PM, Steinmann B. New York, Wiley-Liss, 2002, p 1025
12. Online Mendelian Inheritance in Man, http://www3.ncbi.nlm.nih.gov/entrez/query.fcgi?db=OMIM
20. Lefevre C et al: Mutations in a new cytochrome P450 gene in lamellar ichthyosis type 3. *Hum Mol Genet* **15**:767, 2006
25. Smith FJ et al: Loss-of-function mutations in the gene encoding filaggrin cause ichthyosis vulgaris. *Nat Genet* **38**:337, 2006
57. DiGiovanna JJ, Bale SJ: Clinical heterogeneity in epidermolytic hyperkeratosis. *Arch Dermatol* **130**:1026, 1994
77. Thomas AC et al: ABCA12 is the major harlequin ichthyosis gene. *J Invest Dermatol* **126**:2408, 2006
84. Sprecher E et al: The spectrum of pathogenic mutations in SPINK5 in 19 families with Netherton syndrome: Implications for mutation detection and first case of prenatal diagnosis. *J Invest Dermatol* **117**:179, 2001

92. Rogers M: Erythrokeratodermas: A classification in a state of flux? *Australas J Dermatol* **46**:127, 2005
124. Herman GE: Disorders of cholesterol biosynthesis: Prototypic metabolic malformation syndromes. *Hum Mol Genet* **12 Spec No 1**:R75, 2003
126. Liang C et al: Characterization of tigertail banding and hair shaft abnormalities in trichothiodystrophy. *J Am Acad Dermatol* **52**:224, 2005
149. Okulicz JF, Schwartz RA: Hereditary and acquired ichthyosis vulgaris. *Int J Dermatol* **42**:95, 2003
159. Davis MD, Weenig RH, Camilleri MJ: Confluent and reticulate papillomatosis (Gougerot-Carteaud syndrome): A minocycline-responsive dermatosis without evidence for yeast in pathogenesis. A study of 39 patients and a proposal of diagnostic criteria. *Br J Dermatol* **154**:287, 2006
161. DiGiovanna JJ, Robinson-Bostom L: Ichthyosis: Etiology, diagnosis, and management. *Am J Clin Dermatol* **4**:81, 2003
163. Moskowitz DG et al: Pathophysiologic basis for growth failure in children with ichthyosis: An evaluation of cutaneous ultrastructure, epidermal permeability barrier function, and energy expenditure. *J Pediatr* **145**:82, 2004



CHAPTER 48

Inherited Keratodermas of Palms and Soles

David P. Kelsell
Irene M. Leigh

EPIDEMIOLOGY

All these conditions are rare.

ETIOLOGY AND PATHOGENESIS

Palmoplantar keratodermas (PPKs) are a heterogeneous group of disorders characterized by abnormal thickening of the palms and soles.[1] Autosomal recessive, X-linked, and dominant modes of inheritance as well as acquired forms have all been described. The palmoplantar epidermis is a specialized epidermis. Many of the PPKs arise due to inherited gene defects encoding the structural components of the keratinocyte.[2] The most abundant proteins of the keratinocyte are the keratins, of which eight keratin genes are mutated in a wide spectrum of the keratodermas.[3] The keratin intermediate filaments (IFs) are attached at the plasma membrane to the main cell junction of the epidermis, the desmosome. Desmosomal proteins mutated in the keratodermas include desmoplakin, plakoglobin, plakophilin, and desmosomal cadherins (see Chap. 44).[4] Mutations in other junctional proteins of the adherens junction and gap junctions are also implicated in these skin diseases. These three cell junction types have key roles in keratinocyte adhesion and cell–cell communication.

Although many of the structural proteins found in the palmoplantar epidermis are not palmoplantar-specific, others, such as keratin 9 (K9), are unique to this site. K6a and K16 are found in the palmoplantar epidermis, nail plate, hair follicle, oral mucosa, sweat gland, and larynx, but not in normal skin. Thus, abnormalities of these keratins are likely to be distributed clinically in these sites. K17 has a limited basal expression in the palmoplantar epidermis but is extensively expressed in the outer hair root sheath and the nails; abnormalities of this keratin are likely in these sites. Mutations in the keratin genes lead to an unstable filament network. The codistribution of certain structural proteins with other tissues (for example, muscle, nerve, and brain) may explain some genetic diseases associated with multiple organ involvement, such as desmoplakin and plakoglobin mutations with cardiocutaneous syndromes and connexin mutations associated with PPK, deafness, and neuropathy.

Desmoplakin is the most abundant of the desmosomal proteins and attaches the IF network, particularly the type II keratins, to the cell membrane. It also binds other desmosomal proteins such as plakoglobin and plakophilin. Desmoplakin is linked to the desmosomal cadherins (the desmocollins and desmogleins) indirectly via the binding of plakoglobin and plakophilin. The desmogleins and desmocollins are the cell–cell adhesive proteins of the desmosome. Plakoglobin is also a component of adherens junctions that bind actin filaments rather than IFs (see Chap. 51).

Connexins are the major protein components of the gap junction. Four connexins are implicated in skin diseases, often in syndromic forms associated with hearing loss or neuropathy.[5,6] Gap junctions, formed from aqueous connexin channels, facilitate intercellular communication, allowing the exchange of small molecules between cells. This, in turn, leads to coordination within the tissue, mediating differentiation and response to cellular damage.

Non-structural proteins are also involved in the pathogenesis of the kerato-

INHERITED KERATODERMAS OF PALMS AND SOLES AT A GLANCE



- Palmoplantar keratodermas form a rare but highly diverse group of hereditary skin disorders.
- Chronic thickening of palms and soles may be found alone (simple), in combination with skin lesions elsewhere (complex), or in association with complex syndromes (syndromic), including ectodermal dysplasia where hair, teeth, and nails may be affected.
- Examination will subclassify keratodermas according to whether they affect the whole palm and sole (diffuse), or are restricted to more limited areas (focal) or bead-like tiny lesions (punctate).
- Complications include severe pain, difficulty in walking, and secondary infection.
- The genetic basis of many keratodermas particularly involves mutations in genes encoding keratins, connexins, and desmosomal components.
- Associated cardiomyopathies, deafness, cancer, musculoskeletal and neurologic disorders can, in part, be explained by the underlying biology and tissue expression of affected genes.
- Treatments target removal of hyperkeratotic material by keratolytics and systemic retinoids; appropriate footwear is helpful.

dermas, including the SLURP1 protein, which is secreted and involved in cell signaling and adhesion. A metabolic defect in tyrosine aminotransferase leading to increased serum tyrosine and phenolic acid metabolites also results in keratoderma. Table 48-1 provides an overview of the different keratodermas, their mode of inheritance, and underlying gene defects discussed in this chapter.

CLINICAL FINDINGS

General

Three distinct clinical patterns of PPK may be identified:

- *Diffuse PPK*, which is characterized by an even, thick, symmetric hyperkeratosis over the whole of the palm and sole. This pattern is usually evident at birth or in the first few months of life.
- *Focal PPK*, in which large, compact masses of keratin develop at sites of recurrent friction, principally on the feet, although also on the palms and other sites. The pattern of calluses in this focal group may be either discoid (nummular) or linear.
- *Punctate PPK*, in which multiple tiny "raindrop" keratoses involve the palmoplantar surface. They may involve the whole of the palmoplantar surface or may be more restricted in their distribution (i.e., palmar creases).

Considerable intra- and interfamily variation is often seen. Historically, emphasis in clinical diagnosis has been placed on the extent of spread (transgrediens) of the keratoderma onto the wrists, dorsa of the hands, knuckles, elbows, and knees. However, transgrediens is a highly variable feature, even within the same family, and probably represents little more than the normal variation in the extent of ridged skin in that particular patient. Similarly, the progression with age (progrediens) is unhelpful because many of the keratodermas are induced by physical trauma; thus the severity of the keratoderma may reflect the physical activity and weight of that patient.

The keratodermas can additionally be classified into three further subgroups

- *Simple* keratodermas with only PPK
- *Complex* keratodermas with PPK associated with lesions of nonvolar skin, hair, teeth, nails, and/or sweat glands, including the ectodermal dysplasias
- *Syndromic* keratodermas with PPK associated with abnormalities of other organs, including deafness, cardiomyopathy, and cancer

TABLE 48-1
Genes in Palmoplantar Keratoderma (PPK)

Keratoderma Type	Mode of Inheritance	Underlying Gene Defect
EPPK	AD	K9/K1
Pachyonychia congenital types I and II	AD	K6a, K6b, K16, and K17
Ichthyosis hystrix	AD	K1
Vohwinkel syndrome	AD	Cx26
KID syndrome	AD	Cx26/Cx30
PPK and hearing loss	AD	Cx26
EKV	AD/AR	Cx31/Cx30.3
HED	AD	Cx30
Bart-Pumphrey syndrome (hearing loss, PPK, knuckle pads, and leukonychia)	AD	Cx26
Oculo-dento-digital dysplasia (development of the face, eyes, skeletal system, heart, and dentition, plus keratoderma)	AD	Cx43
Diffuse NEPPK	AD	12q11-q13 or Desmoglein 1
Striate keratoderma	AD	Desmoplakin, Desmoglein 1, or K1
Skin fragility-ectodermal dysplasia syndrome	AR	Plakophilin 1
SPPK or EPPK, woolly hair/cardiomyopathy	AD/AR	Desmoplakin
Lethal acantholytic epidermolysis bullosa	AR	Desmoplakin
NEPPK, woolly hair, and ARVC (Naxos disease)	AR	Plakoglobin
Papillon-Lefèvre/Haim-Munk syndrome	AR	Cathepsin C
Mal de Meleda	AR	Slurp1
Camisa disease (honeycomb palmoplantar keratoderma with ichthyosis)	AD	Loricrin
CEDNIK syndrome	AR	SNAP29 (vesicle fusion)
Oculocutaneous tyrosinemia	AR	Tyrosine aminotransferase
NEPPK and sensorineural deafness		Mitochondrial (A7445G)
Huriez syndrome	AD	4q23
KLICK syndrome	AR	13q
Punctate PPK	AD	15q22.2–15q22.31
Focal PPK with esophageal cancer	AD	17q25

AD = autosomal dominant; AR = autosomal recessive; ARVC = arrhythmogenic right ventricular cardiomyopathy; CEDNIK = *ce*rebral *d*ysgenesis, *n*europathy, *i*chthyosis, and *k*eratoderma; Cx = connexin; EPPK = epidermolytic palmoplantar keratoderma; EKV = erythrokeratodermia variabilis; HED = hidrotic ectodermal dysplasia; K1 etc. = keratin 1; KID = keratitis, ichthyosis, and deafness; KLICK = *k*eratosis *l*inearis with *i*chthyosis *c*ongenita and sclerosing *k*eratoderma; NEPPK = nonepidermolytic palmoplantar keratoderma; Slurp1 = secreted LY6/PLAUR domain containing 1; SNAP29 = synaptosomal-associated protein 29; SPPK = striate palmoplantar keratoderma.

DIFFUSE PALMOPLANTAR KERATODERMA

Diffuse Epidermolytic PPK [PPK Cum Degeneratione Granulosa Vörner, Vörner's Epidermolytic Palmoplantar Keratoderma (Simple)]. Diffuse epidermolytic PPK is one of the most common patterns of PPK. It is an autosomal dominant condition that presents within the first few months of life. The keratoderma presents as a well-demarcated, symmetric thickening of palms and soles and often has a "dirty" snakeskin appearance due to the underlying epidermolysis that produces a very characteristic fissuring





▲ **FIGURE 48-1** Diffuse epidermolytic palmoplantar keratoderma. A "dirty" keratoderma involving the entire palmar surface is demonstrated. (Used with permission from Barts and the London NHS Trust, United Kingdom.)

(Fig. 48-1). Knuckle pads have been reported rarely, and there may be minimal involvement of the elbows and knees.

Diffuse Nonepidermolytic PPK [Unna-Thost Disease, Diffuse Orthohyperkeratotic Keratoderma, Tylosis, Keratosis Palmoplantaris Diffusa Circumscripta, Keratosis Extremitatum Progrediens (Simple)]. Diffuse nonepidermolytic PPK is inherited as an autosomal dominant condition and is present from infancy. Clinically, there is a well-demarcated, symmetric, often "waxy" keratoderma involving the whole of the palms and soles (Fig. 48-2) with a sharp cutoff at the wrist. Spread of the hyperkeratosis to the dorsa of the hands and wrists is a variable feature within most pedigrees but a "cobblestone" hyperkeratosis of the knuckles may be seen. The dorsa of the fingers are often involved, with a scleroderma-like thickening of the skin distal to the proximal interphalangeal joint. Elbows and knees are rarely involved "Parrot beaking" of the fingernails and widening of the onychocorneal band are characteristic. Secondary dermatophyte infection, leading to maceration and peeling of the palms and soles, is a common complication. It is of note that re-examination of the histology of the index family of Unna-Thost disease, has shown that this family had epidermolytic PPK rather than nonepidermolytic.



▲ **FIGURE 48-2** Diffuse nonepidermolytic palmoplantar keratoderma. Note the waxy keratoderma involving the entire plantar surface with involvement of the non–weight-bearing digits. (Used with permission from Barts and the London NHS Trust, United Kingdom.)

Huriez Syndrome [PPK with Sclerodactyly, Scleroatrophic and Keratotic Dermatosis of Limbs, Sclerotylosis (Syndromic)]. Huriez syndrome is an autosomal dominant keratoderma with sclerodactyly that presents from birth with a diffuse symmetric keratoderma of the palms and soles. The fingers have a pseudoscleroderma tous appearance. Atrophic fibrosis of limb skin also may be seen. Variable nail features have been described, with longitudinal ridging hypoplasia and clubbing. Squamous cell carcinoma develops in the atrophic skin in the third to fourth decades, and bowel cancer also has been described in association with this phenotype.

Mal de Meleda [Mutilating PPK of the Gamborg-Nielsen Type, Acral Keratoderma, Palmoplantar Ectodermal Dysplasia Type VIII (Complex)]. Mal de Meleda is an autosomal recessive keratoderma that presents at birth or in early infancy. The keratoderma is diffuse, symmetrically involving the palms and soles with spread to the dorsa of the hands in a glove-and-stocking distribution. Knuckle pads with elbow and knee hyperkeratosis have been described. Constricting bands (pseudoainhum) around the digits may develop (see Chap. 66), resulting in loss of function and autoamputation of digits. Koilonychia, subungual hyperkeratosis, longitudinal grooving, onychogryphosis, and leukokeratosis also have been described. Other associations include angular cheilitis, hyperhidrosis, and poor physical development with electroencephalographic anomalies and brachydactyly.

PPK of Sybert [Greither Palmoplantar Keratoderma, Keratosis Palmoplantaris Transgrediens et Progrediens, Keratosis Extremitatum Hereditaria Progrediens (Complex)]. PPK of Sybert is an extremely rare autosomal dominant keratoderma with symmetric severe involvement of the whole palmoplantar surface in a glove-and-stocking distribution. Spread of the keratoderma involves elbows and knees. Pseudoainhum formation with amputation of the digits has been described.

Olmsted Syndrome [Mutilating Palmoplantar Keratoderma with Periorificial Keratotic Plaques, Polykeratosis of Touraine (Syndromic)]. With the exception of one family in which a mother and son were affected, suggesting autosomal dominant transmission, all cases of Olmsted syndrome appear to be sporadic. Diffuse mutilating keratoderma of the palms and soles with flexion deformity of the digits begins in infancy. Constricting bands around the digits lead to autoamputation of the digits. There are progressive perioral, perianal, and perineal hyperkeratotic plaques that may extend to the inner thigh and groin. Alopecia, deafness, nail dystrophy, and dental loss have all been reported. Corneal epithelial dysplasia, leading to corneal scarring and visual impairment, has been reported in one patient, and leukokeratosis has been reported in two patients. Acrodermatitis enteropathica needs to be excluded by measurement of serum zinc levels.

Congenital Poikiloderma with Traumatic Bulla Formation, Anhidrosis, and Keratoderma [Naegeli-Franceschetti-Jadassohn Syndrome (Complex)]. Congenital poikiloderma with traumatic bulla formation, anhidrosis, and keratoderma is an autosomal dominant condition, with onset within the first few years of life, which presents with reticulate pigmentation that may be extensive and not preceded by any inflammation. The pigmentation particularly involves the neck and axilla. A diffuse keratoderma with punctiform and linear accentuations is usually seen, and adermatoglyphia occurs. The hair is normal, but variable nail changes have been described, from almond nails to onychodystrophy. The teeth have enamel defects, are abnormally shaped, and are lost early. Hypohidrosis or anhidrosis is the principal problem, leading to heat intolerance. Because this disorder was considered initially to be a noninflammatory variant of incontinentia pigmenti, transitional cases between the two syndromes have been described.



▲ **FIGURE 48-3** Striate keratoderma. Linear calluses extend up the fingers; this phenotype is highly variable even within the same family. (Used with permission from Barts and the London NHS Trust, United Kingdom.)

FOCAL PALMOPLANTAR KERATODERMA

Striate PPK [Brünauer-Fuhs-Siemens Type, Keratosis Palmoplantaris Varians, Wachters PPK, Acral Keratoderma (Simple)]. Striate PPK is an autosomal dominant keratoderma that principally involves the soles with onset in infancy or the first few years of life. The hands may show minimal callous formation; however, with manual labor, a striate pattern of PPK is seen over the palmar aspects of the digits (Fig. 48-3). Elbow and knee involvement is seen variably. Patients also report increased skin fragility, with the skin splitting following trauma, but blistering does not occur. Nails and hair may be variably involved, with ridging of the nails and cuticular hyperkeratosis; woolly hair has been reported in a few individuals.

Pachyonychia Congenita Type I [Jadassohn-Lewandowsky Syndrome (Complex)]. Pachyonychia congenita type I is an autosomal dominant keratoderma that principally involves the plantar surfaces (Fig. 48-4). Onset of plantar calluses may be delayed up to 7 years of age. Nail changes may be evident at birth but more commonly develop within the first few months of life. They are characterized by an upward angulation of the distal end of the nail as a result of subungual hyperkeratosis, giving the characteristic "door wedge" distal hyperkeratosis (see eFig. 48-4.1 in on-line edition; see Chap. 87).[6] Calluses develop over the plantar pressure points (see Fig. 48-4); palmar calluses are not seen except in manual workers. Blistering may occur on walking. Hair abnormalities and oral, laryngeal, and follicular hyperkeratosis have all been described.

Focal Palmoplantar Keratoderma with Oral Mucosal Hyperkeratosis [Keratosis Palmoplantaris Nummularis, Hereditary Painful Callosity Syndrome, Keratosis Follicularis (Complex)]. Focal PPK with oral mucosal hyperkeratosis represents a clinical overlap syndrome with pachyonychia congenita type I but without the classic nail involvement. It is an autosomal dominant keratoderma in which calluses develop over plantar pressure points. Sparing of palms occurs except in manual workers. Oral hyperkeratosis is seen, particularly involving the labial attached gingiva. The follicular hyperkeratosis evident over the arms and legs becomes less prominent with age. Nail changes range from widening of the onychocorneal band with splinter hemorrhages to the door-wedge subungual hyperkeratosis characteristic of pachyonychia type I. Blistering may occur on walking, thus limiting physical activity. Epidermolysis is a variable feature.



▲ **FIGURE 48-4** Pachyonychia congenita type I. This figure demonstrates a focal palmoplantar keratoderma involving most of the plantar surface but with sparing of the non–weight-bearing digits. (Used with permission from Barts and the London NHS Trust, United Kingdom.)

Pachyonychia Congenita Type II [Jackson-Sertoli Syndrome, Jackson-Lawler Pachyonychia Congenita (Complex)]. Pachyonychia congenita type II is an autosomal dominant keratoderma presenting with a limited focal plantar keratoderma that may be very minor. Nail changes may be evident at birth but more commonly develop within the first few months of life. The nail changes are characterized by an upward angulation of the distal end of the nail as a result of subungual hyperkeratosis to give the characteristic door-wedge distal hyperkeratosis. Multiple epidermal cysts and steatocystoma are seen. All individuals have woolly scalp hair, and the eyebrows grow straight out, giving a bushy appearance. Natal teeth are seen variably.

Papillon-Lefèvre Syndrome (Syndromic). Papillon-Lefèvre syndrome is an autosomal recessive disease that develops within the first few months of life. The pattern is focal and involves most of the palmoplantar surface with punctiform accentuation in some areas, particularly along the palmoplantar creases (Fig. 48-5). Spread of the keratoderma to the dorsa of the hands and to the Achilles tendons, elbows, and knees is found in some cases. Severe periodontitis occurs following



▲ **FIGURE 48-5** Papillon-Lefèvre syndrome. A complex pattern of keratoderma with focal and punctate lesions involving the sole is demonstrated. (Used with permission from Barts and the London NHS Trust, United Kingdom.)



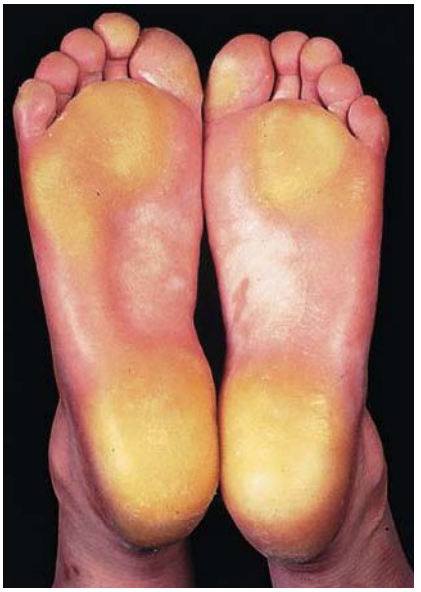

▲ **FIGURE 48-6** Palmoplantar keratoderma associated with esophageal malignancy. Note the focal palmoplantar keratoderma involving most of the plantar surface but with sparing of the non–weight-bearing digits. (Used with permission from Barts and the London NHS Trust, United Kingdom.)

eruption of deciduous dentition and recurs with permanent dentition. A subtle, generalized, whitish opalescence of the oral mucosa has been described. Transverse ridging of nails, onychogryphosis, and sheeted follicular hyperkeratosis have all been described. A proneness to infections also has been reported.

Palmoplantar Keratoderma Associated with Esophageal Cancer [Palmoplantar Ectodermal Dysplasia Type III, Tylosis (Syndromic)]. PPK associated with esophageal cancer is an autosomal dominant keratoderma that occurs with late onset. The keratoderma principally is of the focal type involving the plantar pressure points. More diffuse patterns may be seen in some patients, but the non–weight-bearing digits are always spared (Fig. 48-6). The age of onset is usually between 7 and 8 years of age. The palms are usually not involved, but there may be callus formation in manual workers. Oral leukokeratosis often predates the onset of the PPK and involves the buccal mucosa more than the labial attached gingival mucosa. Widespread follicular hyperkeratosis is evident, particularly in children. The nails are normal, and this is an important differentiating feature from focal PPK with oral hyperkeratosis. Associated features: the risk of developing esophageal squamous cell carcinoma in these families has been reported as between 40 percent and 90 percent of those affected by age 65. Oral squamous cell carcinomas also have been reported, and there may be an increased incidence of other tumors.

Oculocutaneous Tyrosinemia [Tyrosinemia Type II, Richer-Hanhart Syndrome (Syndromic)]. (See Chap. 131) Oculocutaneous tyrosinemia is an autosomal recessive condition, with onset between ages 2 and 4 years when painful, circumscribed callosities develop on the pressure points of the palm and sole. Occasionally, calluses also may develop on the elbows and knees. Photophobia and corneal erosions develop within the first few months of life. The corneal erosions may progress to corneal ulceration and glaucoma. Mental retardation develops if patients are not treated. When patients are placed on a low-tyrosine, low-phenylalanine diet, the cutaneous and ocular manifestations disappear.

Vohwinkel Syndrome [Keratoma Hereditarium Mutilans (Syndromic)]. Vohwinkel syndrome is an autosomal dominant keratoderma with onset in early infancy that presents with a honeycombed keratoderma involving the palmoplantar surfaces. Flexion contractures and constricting bands of digits, particularly of the fifth digit, result in autoamputation (Fig. 48-7). Spread of the keratoderma occurs with linear and/or starfish keratoses on the extensor surfaces of the elbows, knees, and knuckles. Mild to moderate sensorineural hearing loss is often associated. A diffuse, generalized ichthyosiform dermatosis may be seen in some affected individuals and is specific to the form associated with normal hearing, which is due to loricrin mutations. Nail dystrophy, alopecia, onychogryphosis, and a variety of neurologic abnormalities other than sensorineural hearing loss, such as spastic paraplegia and myopathy, have been described.

PUNCTATE PALMOPLANTAR KERATODERMA

Keratosis Punctata Palmaris et Plantaris [Buschke-Fischer-Brauer Disease, Keratosis Papulosa, Papulotranslucent Acrokeratoderma, Keratoderma Punctatum, Maculosa Disseminata, Davis Colley Disease (Simple)]. Keratosis punctata palmaris et plantaris is an autosomal dominant PPK





◀ **FIGURE 48-7** Vohwinkel syndrome. **A.** Note the diffuse pattern of keratoderma with pseudoainhum formation and (**B**) autoamputation of fifth digits. Note also starfish keratoses on knuckles (**A**). (Used with permission from Department of Dermatology, University of Heidelberg, Germany.)



▲ **FIGURE 48-8** Punctate keratoderma of palms (**A**) and soles (**B**).

with variable penetrance that develops at 12 to 30 years of age. Clinically, there are multiple, tiny, punctate keratoses over the entire palmoplantar surfaces, but they begin over the lateral edge of the digits (Fig. 48-8). Lesions are induced by physical trauma and made worse by paring and/or chiropody. The punctate keratoses coalesce into a more diffuse pattern over the pressure points of the sole. Variable nail changes have been described but are an inconsistent part of the phenotype. An association with diverse malignancies in a few families is likely to have occurred by chance.

Spiny Keratoderma [Punctate Keratoderma, Punctate Porokeratosis of the Palms and Soles, Porokeratosis Punctata Palmaris et Plantaris (Complex)]. Spiny keratoderma is an autosomal dominant keratoderma of late onset that develops in patients aged 12 to 50 years. Multiple tiny keratotic plugs, mimicking the spines on a music box, involve the entire palmoplantar surfaces. It may be associated with facial sebaceous hyperplasia.

Focal Acral Hyperkeratosis [Acrokeratoelastoidosis Lichenoides, Degenerative Collagenous Plaques of the Hands (Simple)]. Focal acral hyperkeratosis is a late-onset keratoderma, inherited as an autosomal dominant condition, that presents with oval or polygonal crateriform papules developing along the border of the hands, feet, and wrists. These concentrate in skin creases but occasionally a more confluent pattern is seen over the palms or soles to give a diffuse pattern. The disease is principally found in black races. Elastorrhexis has been reported but is probably not a characteristic feature.

ECTODERMAL DYSPLASIAS AND ERYTHROKERATODERMAS ***Hidrotic Ectodermal Dysplasia [Fischer-Jacobsen-Clouston Syndrome, Alopecia Congenita with Keratosis Palmoplantaris, Keratosis Palmaris with Drumstick Fingers, PPK and Clubbing (Complex)].*** This entity is discussed in Chap. 143.

Erythrokeratodermia Variabilis [Progressive Symmetric Erythrokeratoderma, Keratosis Palmoplantaris Transgrediens et Progrediens, Keratosis Extremitatum Progrediens (Complex)]. (See Chap. 47) Erythrokeratodermia variabilis is a keratoderma that is usually inherited in an autosomal dominant fashion, although recessive cases have been reported. The PPK is evident in infancy and increases in severity throughout childhood. Sharply outlined geographic areas of erythrokeratoderma are distributed symmetrically over the body. Erythematous desquamation of the palms and soles with hyperhidrosis is characteristic, but the disease is not palmoplantar-specific. Spread of the keratoderma to the dorsa of the hands and feet is seen commonly. Associated defects are rare in erythrokeratodermia variabilis; however, neurologic anomalies (deafness, peripheral neuropathy, decreased tendon reflexes, nystagmus, dysarthria, and cerebellar ataxia) and onychodystrophy have been described.

KERATODERMAS AND ASSOCIATED SYNDROMES ***Diffuse Palmoplantar Keratoderma, Woolly Hair and Arrhythmogenic Right Ventricular Cardiomyopathy [Naxos Disease (Syndromic)].*** Both recessive and dominant conditions of diffuse PPK have been described. The recessive disorder (Naxos disease) has a clear association with cardiomyopathy. The disorder is characterized by the development, during infancy, of a diffuse keratoderma over the plantar pressure points. Other cutaneous anomalies include acanthosis nigricans of the axilla and groin, diffuse xerosis, follicular hyperkeratosis over the zygoma, and palmoplantar hyperhidrosis. Woolly hair over the scalp and short, scanty eyebrows, eyelashes, beard, and axillary and pubic hair are seen. Nails, teeth, and sweat gland function are all normal. Endomyocardial fibrodysplasia with ventricular tachycardia and right ventricular dilatation with right ventricular bands have been reported.

Striate Palmoplantar Keratoderma, Woolly Hair and Left Ventricular Dilated Cardiomyopathy [Carvajal Syndrome (Syndromic)]. Both dominant and recessive forms of striate PPK, woolly hair, and left ventricular dilated cardiomyopathy have been described, with a clear association with cardiomyopathy. The skin disease presents as a striate PPK with some non-volar involvement, particularly at sites of pressure or abrasion. Cardiologic investigation of a number of affected family members with the recessive form has been reported, with the diagnosis of a left ventricular dilated cardiomyopathy, often resulting in heart failure during adolescence. Cardiac manifestations are variable, with some cases having arrhythmogenic right ventricular cardiomyopathy or both ventricles involved.

Keratitis, Ichthyosis, and Deafness Syndrome [Ichthyosiform Erythroderma, Corneal Involvement, and Deafness; Desmons Syndrome (Syndromic)]. (See Chap. 47) Keratitis, ichthyosis, and deafness syndrome is an autosomal dominant disorder with profound sensorineural deafness that presents from birth. Ichthyosiform erythroderma develops with a well-marginated serpiginous outline. Follicular hyperkeratosis, perioral furrowed plaques, and oral leukokeratosis have been described. Other changes include a diffuse keratoderma with a reticulate surface, recurrent infections, sensorineural deafness, keratoconjunctivitis and photophobia, hepatitis, mental retardation, and skeletal abnormalities with short stature and pes cavus. Hypotrichosis and nail dystrophy may occur. Multiple cutaneous squamous cell carcinomas are seen.

Palmoplantar Keratoderma and Spastic Paraplegia [Charcot-Marie-Tooth Disease with PPK and Nail Dystrophy (Syndromic)]. PPK and spastic paraplegia is an autosomal dominant or X-linked dominant keratoderma that begins in early childhood with a thick focal keratoderma over the soles and, to a lesser extent, the palms. Punctate keratoderma has been described



in one family. Pes cavus, frontal balding, spastic paraplegia (motor and sensory neuropathy), and mental retardation are reported. Muscular atrophy that develops at approximately 40 years of age starts in the lower legs, with weakness, progressive gait difficulties, and stumbling. Nail dystrophy is an inconsistent feature.

Eyelid Cysts, Palmoplantar Keratosis, Hypodontia, and Hypotrichosis [Schöpf-Schulz-Passarge Syndrome (Syndromic)]. Eyelid cysts, palmoplantar keratosis, hypodontia, and hypotrichosis is an autosomal recessive condition with diffuse symmetric PPK. PPK and fragility of the nails begin around age 12 years. Hair becomes sparse by age 25, and cysts of the eyelid margins occur at age 60. Other changes include facial telangiectasia, early loss of teeth, generalized hypotrichosis, and longitudinal and oblique furrows in nails. Multiple squamous cell carcinomas in the area of the PPK are reported, as well as eccrine poromas, hypernephroma, and basal cell carcinoma. Apocrine hidrocystoma of the eyelid margins is one manifestation.



HISTOPATHOLOGY

1. Epidermolytic hyperkeratosis (EHK) is found in epidermolytic PPK and other diseases characterized by keratin mutations with keratoderma [such as bullous ichthyosiform erythroderma (see Chap. 47) and the Dowling-Meara form of epidermolysis bullosa simplex (see Chap. 60)], including pachyonychia congenita type I. EHK is characterized by marked hyperkeratosis, acanthosis, and papillomatosis. The keratinocytes throughout the spinous and granular cell layers show epidermolysis at light microscopic level, with keratin aggregates and cytolysis seen readily by electron microscopy. Because epidermolysis is easily missed if the biopsy is performed from the edge of the palm or sole, it is important to biopsy a weight-bearing area or the thenar or hypothenar eminence. In pachyonychia congenital type II, keratin filament aggregation is restricted in the nonvolar epidermis to sites of keratin K17 and K6b expression, particularly the deep outer hair root sheath and ducts of the sebaceous glands. The exact histology of the cysts seen in both pachyonychia congenita type II and steatocystoma multiplex depends on the part of the pilosebaceous unit involved. Most consist of vellus hair cysts, but epidermal cysts, keratin-filled cysts, and steatocysts also may be seen.
2. Striate keratodermas. The skin lesions are often but not always characterized by filament aggregates close to the cell membrane with widened intercellular spaces and attenuated desmosomal connections.
3. Non-specific changes. Many keratodermas are difficult to distinguish histologically in the absence of epidermolytic change, and a clear differential diagnosis is difficult. Generally, non-epidermolytic keratodermas show orthohyperkeratosis and acanthosis, with a well-preserved granular cell layer. There are a number of subtle distinguishing features in some keratodermas.
   i. Erythrokeratodermas: Electron microscopy shows abnormalities in the stratum granulosum, where a prominent tonofilament-keratohyalin complex envelops a clear cytoplasmic halo around an often crenelated nucleus.
   ii. PPK of Sybert: In involved skin, lipid-laden cells accumulate in the stratum corneum, giving the cells a clear, punctate profile. Amyloid deposition has been noted in the superficial zone of the papillary dermis after treatment with retinoids.
   iii. Naegeli-Franceschetti-Jadassohn syndrome: Typically shows patchy hyperpigmentation of the epidermis and marked secondary pigmentary incontinence, with numerous melanophages, containing melanin granules, in the upper dermis. Eccrine glands appear normal in size and number.
   iv. Papillon-Lefèvre syndrome: The skin lesions show hyperkeratosis with occasional parakeratotic patches, acanthosis, and slight perivascular infiltrates. The periodontal lesions are characterized by pocket formation, with secondary ulceration of the pocket epithelium and a mixed inflammatory cell infiltrate.
   v. Oculocutaneous tyrosinemia: Histology of the palmoplantar lesions may be helpful diagnostically in demonstrating eosinophilic cytoplasmic inclusions.
   vi. Vohwinkel disease: Histopathology demonstrates the characteristic feature of hyperkeratosis with "round" retained nuclei with hypergranulosis.
   vii. Punctate porokeratosis: Histology shows columnar parakeratosis, which resembles the cornoid lamella of porokeratosis, with a poorly developed granular cell layer.

DIFFERENTIAL DIAGNOSIS

The diagnosis is initially made on the clinical distribution of lesions, associated features, and the presence of a family history. Histopathology is helpful to confirm the presence of EHK and to exclude other possible diagnoses, particularly in late onset cases. However, the majority of disease phenotypes are present at birth or in early life and therefore, the presence of a genetically determined disease should be the primary consideration. Knowledge of the molecular basis of these diseases can now lead to the screening of candidate genes as an aid to diagnosis. These genetic tests can be provided by commercial, academic, or health service organizations (see Table 48-1).

Most likely differential diagnoses in late-onset PPKs are shown in Box 48-1.

COMPLICATIONS OF KERATODERMAS

- Pain: This is a particular problem in focal keratodermas with accentuation of lesions on the weight-bearing areas, such as pachyonychia congen-

Box 48-1

Differential Diagnosis of Late-Onset Palmoplantar Keratoderma

- Hyperkeratotic eczema: Tends to be focal, highly pruritic; can be suppressed by treatment and varies in site
- Palmoplantar psoriasis: Tends to produce silvery scale and focal hyperkeratosis not limited to the weight-bearing areas often in association with nail/joint involvement and typical lesions in other skin sites
- Acquired punctate keratoses: Punctate keratoses appearing later in life; can be associated with malignancy, usually in middle age
- Arsenical keratoses: Bead-like palmoplantar keratoses in chronic arsenical ingestion in association with raindrop pigmentation, and susceptibility to non-melanoma skin cancer in those living in areas with ground contamination of drinking water
- Chronic tinea pedis: Can produce extensive hyperkeratosis together with powdery scaling, but clears completely with appropriate antifungal therapy, unlike the secondary infection of palmoplantar keratodermas

ita type 1 (painful callosity syndrome), and is largely due to the pain of walking on pebble-like masses. However, it does not appear greatly improved by removal of hyperkeratotic material, and the fragility of the skin may be exacerbated. Therefore, patients may need additional pain-relieving medication, including analgesics and drugs for neuropathic pain. Specialized footwear to disseminate weight can also help to make the patients more comfortable.

- Difficulty in walking: Secondary to pain on walking, patients may require aids for walking, such as crutches and wheelchairs.
- Use of hands for work and fine movements: Thickening of the palmar epidermis produces a gauntlet-like stiffness in the hands and fingers, which blunts sensation and makes fine movements more difficult, which limits available occupations.
- Secondary infections: Particularly when hyperhidrosis or maceration of the skin are found, there is a tendency to secondary infection, particularly tinea pedis and pitted keratolysis. The inflammatory response may exacerbate the skin thickening, and such patients may be helped by the intermittent use of systemic antifungal drugs, particularly terbinafine, and topical agents countering yeasts, corynebacteria, and dermatophytes.
- Some keratodermas are complicated by progressive disabilities of other organs, which may require specific therapies, including treatment of cardiac dysrhythmias, hearing aids, etc.

TREATMENT

- Physical débridement: Regular chiropody can help to reduce keratotic masses, and patients are often expert at self-treatment in this area
- Topical keratolytic agents: Salicylic acid ointment (5 percent to 20 percent), corn plasters (20 percent to 40 percent salicylic acid), and benzoic acid compound ointment all help to soften the hyperkeratotic materials and aid removal of hyperkeratotic debris with a foot file. The use of 40 percent to 60 percent propylene glycol in aqueous cream under occlusion at night can also soften and assist removal of callosities.
- Treatment of hyperhidrosis: Hyperhidrosis may be a separate requirement, which can be helped by regular potassium permanganate soaks or aluminium chloride hexahydrate lotion. Other physical treatments, such as iontophoresis and Botox injections, are difficult in the presence of gross skin thickening.
- Antifungal creams and systemic antifungal agents may need repeated intermittent courses (e.g., terbinafine initially full treatment and then 1 week per month).
- Retinoids: Acitretin 10 to 20 mg/day (isotretinoin in women of childbearing age) may have a direct benefit in normalizing hyperkeratotic skin, particularly in diseases caused by keratin or connexin mutations. However, treatment is required lifelong and then complications such as periosteal hyperostosis become a significant risk. In addition, the removal of the hyperkeratosis may increase the sensitivity and fragility of the underlying epidermis, and this limits their usefulness.
- Genetic therapies: As the genetic basis of the different diseases become apparent, the mechanisms of manipulating gene expression by small molecules or gene therapy become possible.[7] However, given the diversity of the biologic basis and the rarity of the diseases, this is unlikely to be a global cure. Early studies suggesting the use of small interfering RNA for dominant mutations, for example, pachyonychia congenita type I, will require delivery systems that penetrate palmoplantar epidermis. The knowledge about the genetic basis does, however, permit the development of prenatal diagnosis in severe or life-threatening cases.

REFERENCES

1. Itin PH, Fistarol SK: Palmoplantar keratodermas. *Clin Dermatol* **23**:15, 2005
2. Irvine AD, McLean WH: The molecular genetics of the genodermatoses: Progress to date and future directions. *Br J Dermatol* **148**:1, 2003
3. Irvine AD: Inherited defects in keratins. *Clin Dermatol* **23**:6, 2005
4. McGrath JA: Inherited disorders of desmosomes. *Australas J Dermatol* **46**:221, 2005
5. Richard G: Connexin disorders of the skin. *Clin Dermatol* **23**:23, 2005
6. Laird DW: Life cycle of connexins in health and disease. *Biochem J* **394**:527, 2006
7. Lewin AS, Glazer PM, Milstone LM: Gene therapy for autosomal dominant disorders of keratin. *J Investig Dermatol Symp Proc* **10**:47, 2005



CHAPTER 49

Acantholytic Disorders of the Skin: Darier-White Disease, Acrokeratosis Verruciformis, Grover Disease, and Hailey-Hailey Disease

Alain Hovnanian



Acantholytic disorders of the skin are a heterogenous group of diseases characterized by loss of intraepidermal coherence with breakdown of intercellular contacts. Several of these conditions are genetically determined, including Darier-White disease (DD) and Hailey-Hailey disease (HHD). The identification of their defective genes as a calcium pump of the sarco/endoplasmic reticulum in DD and a calcium pump of the Golgi apparatus in HHD represents a major breakthrough in the understanding of their pathogenesis. These discoveries have highlighted the key role of Ca^{2+} signaling in intercellular adhesion and differentiation of the epidermis and have significantly improved diagnostic procedures and genetic counseling for patients with these conditions. Although the precise mechanisms remain to be understood, these results open new avenues for research and treatment of these distressing conditions. These advances have also allowed a better classification of related localized acantholytic conditions, namely, epidermal dyskeratotic acantholytic nevi, which are a localized form of DD caused by somatic mosaicism, and acrokeratosis verruciformis (AKV) of Hopf, which was found to be allelic to DD. Thus, defects in the same gene encoding this calcium pump of the endoplasmic reticulum (ER) underlie three related conditions. Unlike for these genetically determined conditions, the pathogenesis of transient acantholytic dermatosis or Grover disease (GD), which does not show a genetic predisposition, remains unknown.

DARIER-WHITE DISEASE

Etiology and Pathogenesis

DD is a rare autosomal dominant disease affecting both sexes and all ethnic groups. Its prevalence has been estimated at 1 in 26,300 in Slovenia,[1] 1 in 30,000 in Scotland,[2] 1 in 36,000 in northeast England,[3] and 1 in 100,000 in Denmark.[4,5] Penetrance of the disease is complete, and expression is highly variable between and within affected families. Spontaneous mutations are frequent.

The gene for DD was mapped by linkage analysis to chromosome band 12q23-24 in 1993, with no evidence for genetic heterogeneity in affected families.[6] *ATP2A2* was identified as the defective gene in 1999 using a candidate positional cloning approach.[7] *ATP2A2* encodes sarco/endoplasmic reticulum Ca^{2+} adenosine triphosphatase (ATPase) isoform 2 (SERCA2), a calcium pump transporting Ca^{2+} from the cytosol to the lumen of the ER. The identification of a Ca^{2+} pump as the defective protein in DD came as a surprise and shed light on the key role of Ca^{2+} signaling in the homeostasis of the epidermis.[8]

ATP2A2 spans 76 kilobases (kb), is organized in 21 exons, and encodes a 4.4-kb transcript, which is alternatively spliced into three isoforms: SERCA2a, SERCA2b, and SERCA2c.[9,10] SERCA2a is expressed in the heart and slow-twitch skeletal muscles. SERCA2b and SERCA2c are ubiquitously expressed. SERCA2b is the major isoform detected in the human epidermis.[11] SERCA2 pumps belong to the P-type Ca^{2+} ATPase family, defined by the highly conserved phosphorylation sequence DKTGT. They catalyze the hydrolysis of adenosine triphosphate (ATP) coupled with the translocation of 2 Ca^{2+} ions from the cytosol (100 n*M*) to the ER lumen, where Ca^{2+} is stored at high concentrations (500 μ*M*).[12] SERCA pumps comprise three cytoplasmic domains (the actuator, the phosphorylation, and the ATP-binding domains) linked by five stalk domains to 10 or 11 transmembrane domains anchored in the ER membrane. After binding of two Ca^{2+} ions, SERCA pumps undergo trans-phosphorylation from ATP, which leads to conformational changes and the release of Ca^{2+} ions into the ER lumen. This complex cycle involves critical interactions between cytoplasmic and transmembrane domains, four of which form the two Ca^{2+} ions binding pockets of the molecule. More than 130 ATP2A2 mutations have now been reported in DD patients, the majority of which are different from family to family[7,13–27] (http://www.hgmd.cf.ac.uk/ac/gene.php?gene=ATP2A2). Mutations are distributed across the entire molecule. They disrupt critical functional domains of SERCA2 and show no evidence of clustering or mutation hot spots.

DARIER-WHITE DISEASE (OMIM #124200)

AT A GLANCE



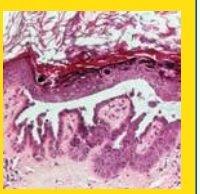

- Also called *Darier disease* or *keratosis follicularis*.
- Late-onset genetic disorder of keratinization.
- First described independently by Darier and White in 1889.
- Clinical features consist of warty papules and plaques in seborrheic areas, specific nail changes, palmo-plantar pits, and papules on the dorsum of the hands and feet.
- Histologic examination of skin lesions shows suprabasal acantholysis in the epidermis with dyskeratotic cells.
- Caused by loss-of-function mutations in the *ATP2A2* gene encoding sarco/endoplasmic reticulum calcium adenosine triphosphatase isoform 2 (SERCA2), which impair intracellular Ca^{2+} signaling.

The majority of the mutations are missense mutations (50 percent) or in-frame deletions or insertions (8 percent), which predict the synthesis of a structurally abnormal protein. Other mutations include nonsense mutations (12 percent) and frameshift mutations (23 percent), which lead to a premature termination codon (PTC) and predict loss of protein expression through nonsense messenger RNA (mRNA) decay. The remaining mutations are splice site mutations (7 percent), the effects of which on the mutated protein remain to be documented. Genotype-phenotype comparison initially suggested that ATP2A2 missense mutations are more frequent in severe or atypical forms, but this has not been confirmed in other studies.[22] However, considerable inter- and intrafamilial variability in the disease phenotype indicates that additional factors influence disease expression.[7,18,23] Three mutations identified in patients with classic DD are of specific interest because they occur in a region of exon 20 that is specific for SERCA2b isoform.[13,28] Each of

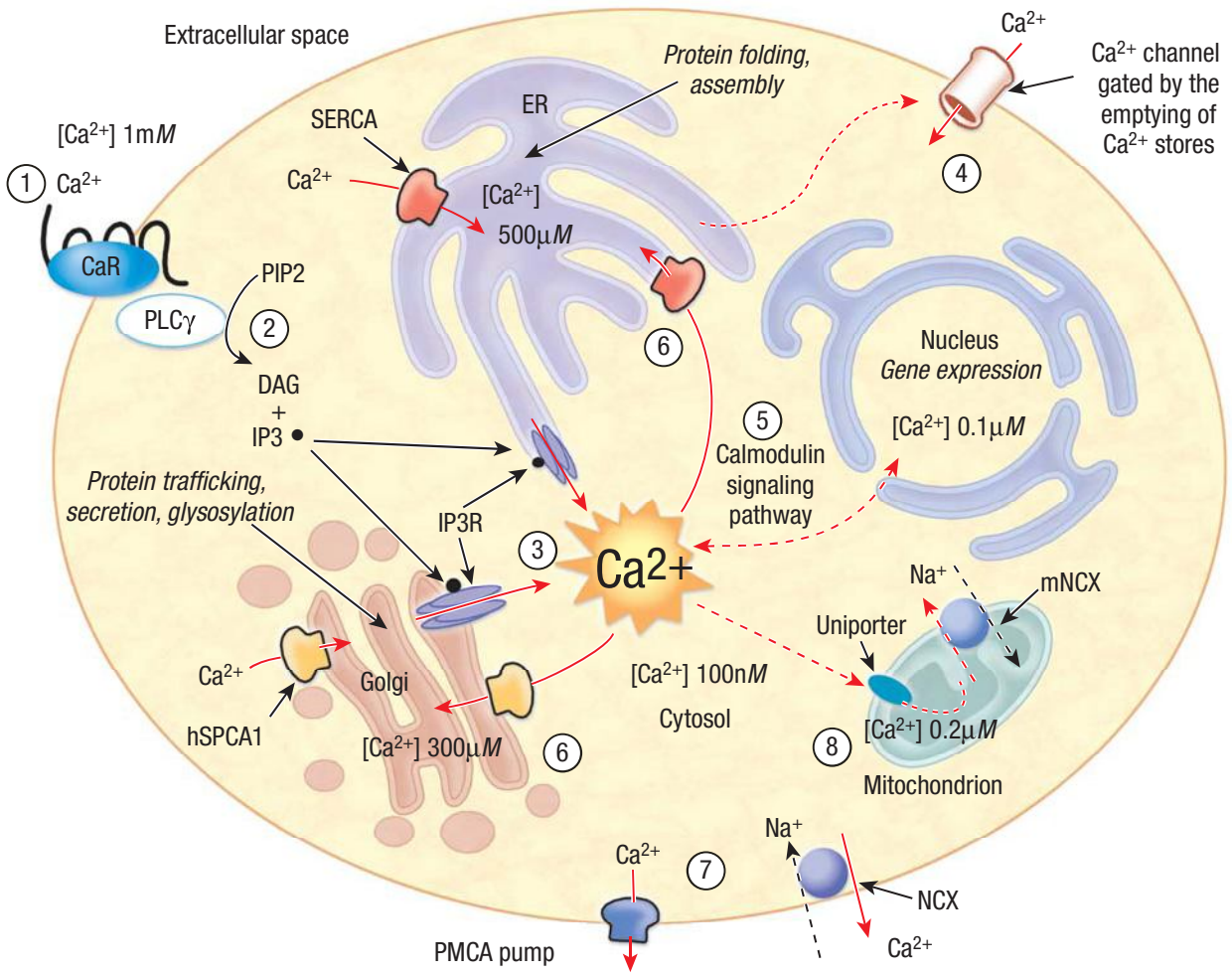

▲ **FIGURE 49-1** A simplified representation of Ca^{2+} signaling in keratinocytes. 1. Ca^{2+} binding to its plasma membrane receptor (CaR) activates phospholipase Cγ (PLCγ). 2. This causes the hydrolysis of phosphatidylinositol 4,5-bisphosphate (PIP2) into inositol 1,4,5-tris-phosphate (IP3) and diacylglycerol (DAG). 3. IP3 binds to its receptor (IP3R) at the surface of the endoplasmic reticulum (ER) and Golgi apparatus, which causes the depletion of intracellular stores and induces an increase in intracellular Ca^{2+} levels. 4. This increase triggers the opening of Ca^{2+} release–activated channels in the plasma membrane, which leads to a sustained increase in Ca^{2+} intracellular levels. 5. Ca^{2+} binds to calmodulin; this activates calcineurin and calmodulin-dependent protein kinases, which regulate gene transcription through phosphorylation/dephosphorylation of transcription factors. 6. Active Ca^{2+} transport by the different sarco/endoplasmic reticulum calcium adenosine triphosphatase (ATPase) pumps (SERCA1 to SERCA3) and human secretory pathway Ca^{2+}/Mn^{2+}-ATPase (hSPCA1) pump is essential to replenish ER and Golgi Ca^{2+} stores, respectively. hSPCA1 is also required for Mn^{2+} influx into the Golgi apparatus (not indicated here). 7. Ca^{2+} efflux to the extracellular space involves plasma membrane Ca^{2+}–ATPases (PMCA) and Na^{+}/Ca^{2+} exchangers (NCX). 8. Mitochondria take up Ca^{2+} released from the internal stores during Ca^{2+} signaling via the Ca^{2+} uniporter and return it to the cytosol through an NCX. Thus, Ca^{2+} homeostasis requires differential Ca^{2+} concentrations in the cytosol, the sarco/endoplasmic reticulum, the Golgi apparatus, the mitochondria, and the nucleus of the cell. The largest store of cellular Ca^{2+} is located in the ER lumen and in Ca^{2+}-binding proteins. Ca^{2+} signaling is highly regulated and generated by influx through Ca^{2+} receptors, release from internal stores (ER, Golgi apparatus, mitochondrion), and sequestration by Ca^{2+} pumps (SERCAs, hSPCA1) and Ca^{2+} exchangers. mNCX = mitochondria Na^{2+}/Ca^{2+} exchanger.

these mutations leads to a PTC, which indicates that loss of SERCA2b expression is sufficient to cause DD and that SERCA2a isoform cannot compensate for it. This finding is consistent with the fact that the most prominent expression of SERCA2b is in the epidermis, although both isoforms are expressed in cultured keratinocytes.[11,23]

The role of extracellular Ca^{2+} in keratinocyte adhesion and differentiation has been well documented, but the key function of SERCA2b in intracellular Ca^{2+} homeostasis in the epidermis was unsuspected. In normal keratinocytes, there is an increasing epidermal gradient in the normal skin, from the basal layer to the superficial layers. High extracellular concentrations are required for epidermal intercellular adhesion, differentiation, and cornification. Ca^{2+} signaling involves binding of raised extracellular Ca^{2+} to a Ca^{2+} plasma membrane receptor, which activates phospholipase C and generates inositol 1,4,5-tris-phosphate (IP3) and diacylglycerol from phosphatidylinositol bisphosphate (Fig. 49-1). IP3 in turn acts as a second messenger, binding to its receptors on the ER (and Golgi apparatus) to trigger release of Ca^{2+} from the intracellular stores into the cytoplasm. Emptying of ER Ca^{2+} stores activates an influx of extracellular Ca^{2+} through plasma membrane Ca^{2+} channels, which function like store-operated channels (capacitive entry mechanism).[32] The molecular identity of these channels that amplify the Ca^{2+} response has not been clearly established, but they could include transient receptor potential channels.[33] The SERCA2 pump plays a key role in Ca^{2+} signaling by refilling the internal Ca^{2+} reservoir of the ER, which is considered the major intracellular Ca^{2+} store. On stimulation, the release of Ca^{2+} from the



ER store will lead to specific cellular responses, depending on the amplitude, frequency, and sub-cellular location of the Ca^{2+} signal. Ca^{2+} triggers the switch between keratinocyte proliferation and differentiation. The increase of intracellular Ca^{2+} levels activates calmodulin, a major Ca^{2+}-binding protein that plays a key role in the control of gene transcription by Ca^{2+}. This results in the activation of the cytosolic calmodulin-dependent phosphatase calcineurin and the family of Ca^{2+}/calmodulin-dependent protein kinases. Both types of enzymes contribute to the regulation of cell division and differentiation. Calcineurin dephosphorylates the cytoplasmic NFAT (nuclear factor of activated T cells) proteins, which allows their translocation into the nucleus and the induction of their downstream target genes. It is of interest to note that cyclosporin A, tacrolimus, and pimecrolimus are calcineurin inhibitors (see Chap. 221). Activation of the Ca^{2+}/calmodulin-dependent protein kinase cascade involves three distinct kinases that regulate transcription through phosphorylation of nuclear factors and histone acetylation, which leads to transcriptional activation or inhibition. By keeping appropriate Ca^{2+} concentrations in the ER lumen, SERCA2 also plays an essential role in protein synthesis, chaperone-dependent processing, and post-translational modification of membrane and secreted proteins, which require a unique calcium-rich environment.[34] Ca^{2+} is required for the assembly of desmosomes and adherens junctions as well as actin polymerization.[35]

A change in the Ca^{2+} ER luminal content is likely to have a major effect on Ca^{2+} signaling, protein post-translational modifications, and trafficking. Although no glycosylation defect of the desmosomal proteins was detected in DD keratinocytes, in culture trafficking of desmoplakin to the membrane is significantly hindered.[42] Defective expression of this key molecule that links the cytoskeleton to the desmosomal complexes could contribute to impaired cell-to-cell adhesion in the epidermis in DD. Finally, Ca^{2+} plays a key role in the transcriptional regulation of a wide range of genes that are essential for epidermal cell-to-cell adhesion and terminal differentiation, which suggests that abnormal Ca^{2+} signaling could have a profound impact on the transcription of these genes.

The observation that exposure to ultraviolet B (UVB) irradiation, heat, and infection triggers disease manifestations indicates the role of external factors in unmasking the basic defect in DD. In the absence of stress, SERCA2 deficiency can be compensated by increased expression of the normal allele and/or other regulatory systems. Triggering factors would disrupt this subtle balance by downregulating ATP2A2 or increasing the requirement for SERCA2 to maintain a unique Ca^{2+} content in the lumen. Because only one copy of ATP2A2 is functional, reduction of SERCA2 levels would be excessive, or compensation would not reach adequate levels. Consistent with this possibility, UVB irradiation and pro-inflammatory cytokines have been shown to downregulate ATP2A2 as well as ATP2C1 mRNA expression.[43] Reduced levels of SERCA2 would result in inappropriate Ca^{2+} concentrations in the lumen, causing dysfunction of calcium-dependent chaperone molecules that leads to impair folding, assembly, and/or trafficking of proteins. Whether this preferentially affects proteins playing a key role in cell-to-cell adhesion and/or differentiation or affects protein processing in general remains to be determined.





▲ **FIGURE 49-2** Hyperkeratotic papules coalescing into plaques in seborrheic areas of the upper chest in a patient with Darier-White disease.



▲ **FIGURE 49-4** Macerated plaques of confluent and keratotic papules in the axillae.

Clinical Findings

Onset of the disease is usually around puberty. The majority of patients develop the first lesions between 10 and 20 years of age. Typical lesions are greasy keratotic papules, skin-colored, yellow-brown or brown, which may be isolated or may form relatively large, crusted, and confluent plaques. The sites of predilection are the seborrheic areas of the trunk (Figs. 49-2, 49-3) and face: the upper chest, the back, the sides of the neck, the forehead, the ears, and the scalp. The groin, axillae (Fig. 49-4), and anogenital region are also frequently involved. The skin lesions can become vegetating in the folds and are often infected, malodorous, and responsible for major discomfort. They can be limited or form extensive plaques during acute phases. Careful examination of the palms and soles will frequently reveal small pits or punctuated keratoses, which are highly suggestive of DD (Fig. 49-5). Hands and feet can also show discrete flat, skin-colored papules on the dorsal areas, similar to AKV of Hopf.[4]

Nail abnormalities are an almost constant feature and are highly specific for



◀ **FIGURE 49-3** Inflammatory plaques in the submammary region, with fissures and maceration. Note that the fingernails are dystrophic.



▲ **FIGURE 49-5** Plane keratotic papules of the palms.

the disease. The nails are fragile and split easily. They show a combination of red and white longitudinal stripes, have a V-shaped nick at the free margin of the nail, and show subungual hyperkeratosis (Fig. 49-6).

The mucous membranes also can be affected. The hard palate, oral mucosa, gingivae, esophagus, vulva, and rectum may be sites of whitish small papules, often densely grouped (leukoplakia).[44] Blockage of the salivary glands has been reported. Intrafamilial differences in disease severity have been described in several studies, which indicates that additional genetic and/or environmental factors influence disease expression.[18]

Histopathology

Histologic examination shows hyperkeratosis, focal dyskeratosis (premature and abnormal keratinization of single keratinocytes) associated with suprabasal acantholysis leading to suprabasal clefts (Fig. 49-7). The rounded eosinophilic dyskeratotic cells are called *corps ronds* in the stratum spinosum, and *grains* in the upper layers of the epidermis. They are thought to correspond to apoptotic keratinocytes. Electron microscopy has revealed separation of the keratin filaments from the desmosomes with clumping of perinuclear tonofilaments.[45]



▲ **FIGURE 49-6** Dystrophic fingernails showing fragility, splitting, and red and white longitudinal stripes.

Associated Manifestations

Behavior and learning difficulties have been observed in patients with DD, but they may be, at least in part, secondary to the social handicap caused by the disease. Neuro-psychiatric abnormalities have also been reported in families with DD.[46] These include seizures, mild mental retardation, bipolar disease, and schizophrenia. Familial co-segregation of DD and bipolar disorder has been reported in several families and strongly supports the existence of a bipolar disorder susceptibility gene in the DD region.[47] However, ATP2A2 has been excluded as a common susceptibility gene for bipolar disease.[48] These observations, together with the finding of SERCA2b expression in the brain[49] and the importance of calcium signaling in neurons, raise the question of whether skin and neuro-psychiatric conditions are occurring independently or represent expression of the same genetic defect affecting both skin and brain.[17]

Clinical Forms

Some patients develop erosive or bullous forms; others have malodorous, vegetating lesions in the flexures. Pruritic and papulovesicular lesions can be seen in some DD patients, similar to those in GD (see Grover Disease). Rare clinical variants include cornifying forms on the legs,[50] comedone-like lesions,[51] and hemorrhagic macules on palms and soles.[52] In pigmented skin, DD may present as hypopigmented macules and papules.[53]

Two particular forms of the disease should be distinguished. In the first,

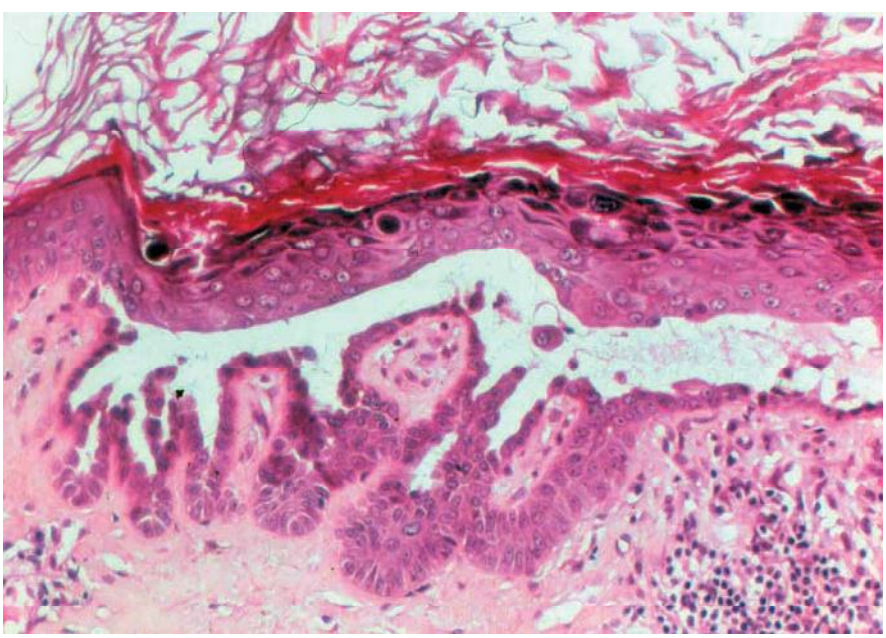

▲ **FIGURE 49-7** Histologic preparation of affected skin in Darier-White disease showing suprabasal cleft of the epidermis containing acantholytic cells, associated with rounded dyskeratotic cells with a dark nucleus ("corps ronds" or "grains") and hyperkeratosis.





▲ **FIGURE 49-8** Acantholytic epidermal nevi (segmental Darier-White disease). Limited and unilateral distribution of keratotic and inflammatory papules following Blaschko's lines on the breast and axillary region.



acantholytic dyskeratotic epidermal nevi, the localized and unilateral keratotic papules of DD follow Blaschko's lines[54,55] (Fig. 49-8). Molecular analysis in these patients has shown that they represent mosaic forms of DD, carrying a postzygotic ATP2A2 mutation in affected areas only.[26,56] There has been no report of patients with segmental DD having a child with generalized DD, and the risk of transmission of a generalized form remains unknown.

Acral forms are difficult to distinguish from AKV of Hopf, which could be considered a clinical variant of DD, because both diseases are due to ATP2A2 mutations (see Acrokeratosis Verruciformis).[14,57]

Differential Diagnosis

The classic form of DD is highly suggestive of the condition. However, DD can be misdiagnosed as seborrheic dermatitis or acne in the initial stages. The diagnosis of clinical variants can sometimes be challenging (Box 49-1). Acral forms resemble plane warts. Erosive or bullous forms predominating in the folds may be difficult to distinguish from HHD[58] (see Hailey-Hailey Disease) and pemphigus vulgaris (see Chap. 52). However, HHD usually presents later in the third decade and shows painful flexural erosions with rhagades and no keratotic papules. Vegetating forms need to be distinguished from pemphigus vegetans (see Chap. 52). Pruritic and papulovesicular forms resemble GD. However, GD occurs in patients with long-term sun damage and is usually transient, although chronic forms have been described.[59]

Course

The skin lesions generally appear between early childhood and the age of 20 years. The condition runs a chronic relapsing course, with exacerbations throughout life. Some patients will have relatively mild disease, whereas others, sometimes within the same family, will develop a more severe form. In particular, the skin lesions are exacerbated by exposure to sunlight or artificial UVB radiation, heat, sweating, friction, and infections. Patients with DD appear to have an increased susceptibility to herpes simplex and chronic pyogenic infections. Rare cases of recurrent corneal ulcerations with perforation have been reported.[60]

Treatment

Patients with mild disease will benefit from advice about sun protection (sun avoidance and use of sunscreens in the summer) and avoidance of heat. When skin lesions are limited, emollients containing urea or lactic acid can reduce crusting. Topical applications of tretinoin or isotretinoin improve the hyperkeratosis of localized lesions, although irritation limits their value. Topical steroids may help in reducing irritation but are not effective alone. New retinoids such as tazarotene are somewhat effective and are tolerated better than first-generation retinoids. Antiseptics (topical or in the bath), antibiotics, and antifungal medications are helpful to prevent or treat pyogenic and fungal infection. Herpes infection should be suspected when lesions are painful and exacerbated and requires antiviral treatment with acyclovir.

Box 49-1

Differential Diagnosis of Darier Disease

- Classic form
  - Seborrheic dermatitis
  - Seborrheic keratoses
  - *Candida* infection (submammary)
- Papular vesicular form
  - Grover disease
- Erosive, bullous form
  - Hailey-Hailey disease
  - Pemphigus vulgaris
  - Langerhans cell histiocytosis
  - *Candida* infection
  - Impetigo
- Vegetating form
  - Pemphigus vegetans
- Acral form
  - Verrucae planae

For those with more severe disease, oral retinoids such as acitretin are the most effective treatment. Their efficacy lasts only as long as the treatment is continued. The initial dose is usually 25 to 30 mg per day for 2 to 4 weeks, and if the drug is well tolerated, the dose can be increased up to 60 mg for 2 months. The patient must be monitored carefully for possible side effects (see Chap. 229). After initial clearing of the lesions, the dosage should be reduced progressively and stopped (in winter) or maintained at as low a level as possible to avoid relapse.[4] Topical tacrolimus has been used successfully to treat extensive DD.[61]

The disease can cause a considerable social handicap and can require specific psychological support by a medical psychologist. Genetic counseling should be offered, although prenatal diagnosis of the disease should be restricted to extremely disabling forms.

ACROKERATOSIS VERRUCIFORMIS

Genetics

AKV is inherited in an autosomal dominant fashion, but sporadic cases have been reported. A heterozygous Pro602Leu missense mutation in the ATP2A2 gene in a large British family affected with AKV has been identified.[14] This mutation is located in the ATP-binding domain of SERCA2 and has not been reported in patients with classic DD. Functional analysis showed that it abolishes Ca^{2+} transport. These results established that AKV and DD can be due to mutations in the same gene (i.e., are allelic disorders). However, one study in a large Chinese family did not find evidence for the involvement of ATP2A2, which raises the possibility of genetic heterogeneity in AKV.[62]

Clinical Manifestations

The onset of AKV is early in life, often at birth or later in infancy. The disease is characterized by multiple small, flat, flesh-colored, warty papules typically located on the dorsum of the hands and feet[63] (Fig. 49-9). Grouped or isolated papules can also develop on the knees, elbows, extensor aspects of lower legs, forearms, and wrists. Punctate keratoses and pits on the palms and soles can be present and can interrupt the dermal ridges in the finger pads and palms. Palmar skin may be thickened. Varying de-

ACROKERATOSIS VERRUCIFORMIS (OMIM #101900)

AT A GLANCE



- Rare, heritable disorder of keratinization, originally described by Hopf in 1931.
- Usually presents with multiple small flat-topped papules predominantly on the dorsum of the hands and feet.
- Histopathologic analysis shows hyperkeratosis, hypergranulosis, and acanthosis with "church spikes," circumscribed elevations of the epidermis, without acantholysis or dyskeratosis.
- Allelic with Darier-White disease: Both are due to defects in ATP2A2.

grees of nail involvement have been reported, including longitudinal striations, splitting, and subungual hyperkeratosis with V-shaped nicks at their free margins. The rest of the skin is clear, with no involvement of seborrheic areas.

Histopathology

The classic histopathologic findings of AKV include hyperkeratosis, hypergranulosis, and acanthosis with papillomatosis. Localized elevations of the epidermis resembling "church spikes" are frequent and typical of AKV (but not constant) (Fig. 49-10). There are no features of dyskeratosis or acantholysis, which are classic features of DD lesions.

Clinical Forms

A rare linear variant with persistent localized unilateral lesions has been reported in two unrelated Saudi patients.[64]

Differential Diagnosis

AKV should be distinguished from plane warts and epidermodysplasia verruciformis (see Chap. 196) by histopathologic features.

Course

Lesions tend to persist throughout life, increase slowly in number, and become more prominent after sun exposure. Transformation to squamous cell carcinoma has been reported in two cases.[62,65,66]

Treatment

Superficial ablation is the most effective treatment. Applications of retinoic acid, cryotherapy, and carbon dioxide laser ablation have been effective.



▲ **FIGURE 49-9** Small, flesh-colored papules over the dorsum of the hand in a patient with acrokeratosis verruciformis of Hopf.

GROVER DISEASE

Etiology and Pathogenesis

GD is not a rare disease and shows no evidence for genetic predisposition.[67]

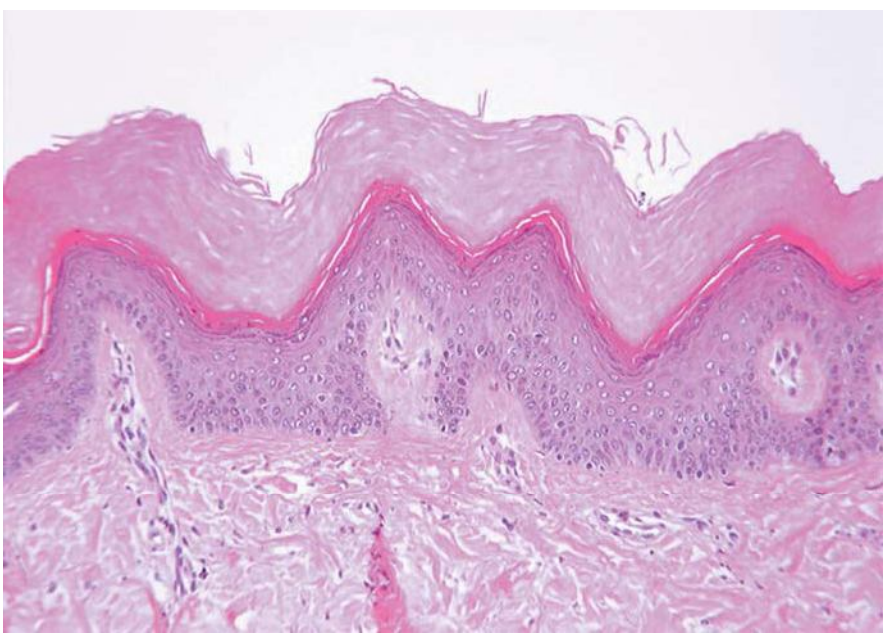

▲ **FIGURE 49-10** Histopathologic features of Hopf disease showing acanthosis and hyperkeratosis with "church spike" elevations of the epidermis, but no acantholysis or dyskeratosis. (Used with permission from Dr. Laurence Lamant, Department of Pathology, Purpan Hospital, Toulouse, France.)

GROVER DISEASE (TRANSIENT ACANTHOLYTIC DERMATOSIS)

AT A GLANCE



- First described in 1970.
- Pruritic, polymorphic, cutaneous papulovesicular eruption on the trunk.
- Occurs in adults after long-term sun damage.
- Histologic examination shows variable focal acantholytic dyskeratosis.
- Classic (transient) form resolves within a few months, but a persistent form has been recognized.
- There is no evidence for genetic predisposition.

The cause of the disease is unknown. The majority of patients are white males older than 40 years, with solar damage. Electron microscopy shows clumping of keratin filaments and loss



of desmosomes. Immunohistologic staining reveals internalization and redistribution of desmosomal attachment plaques.[68] Because GD shares several clinical, histologic, and ultrastructural features with DD, mutations in ATP2A2, the defective gene in DD, have been sought in patients with persistent GD.[59] No ATP2A2 mutation was identified in the skin (lesional and normal) or in leukocytes in four patients, which indicates that GD is not allelic to DD. Thus, although DD and GD share striking clinical and histopathologic features, the mechanism underlying acantholytic dyskeratosis in GD remains unknown.



Clinical Findings

The disease onset is around 40 years of age. The typical patient is a male with fair skin and a history of habitual sun exposure. GD presents with an acute eruption with pronounced itching often disproportionate to the eruption. Red papules, papulovesicles, and eczematous plaques with erosions and crusts are scattered, or rarely grouped (Figs. 49-11, 49-12). The lesions are disseminated on the trunk and can extend to the neck and proximal limbs.[69–71] Excessive sun exposure, heat, sweating, and exposure to ionizing radiation are precipitating factors.[72] There are usually no associated findings.

Histopathology

Four histologic types have been described in GD, with different patterns of acantholysis.[69,71,73] They comprise a DD type with suprabasal cleft and dyskeratotic cells; a pemphigus-like type with acantholytic cells within suprabasal cleft; an HHD-like type with acantholysis of most of the stratum malpighii; and a spongiotic form with acantholytic cells within vesicles (Fig. 49-13). These patterns are frequently in combination and may correspond to various stages of the disease. The histologic changes are often localized, so that multiple biopsies and sections are required. The dermis often shows an inflammatory cell infiltrate. Indirect immunofluorescence testing gives negative results.

Clinical Forms

A bullous form has been described.[74] More recently, a widespread form of GD with lentiginous sun-induced "freckling" was reported in two females.[75] Many cases clear within a few months (transient acantholytic dermatosis), whereas others persist for years (persistent acantholytic dermatosis), especially in elderly patients. Persistent disease runs a chronic relapsing course and is often associated with asteotic eczema, atopic dermatitis, and contact dermatitis. Some patients complain of weakness, and cancers have been associated.



▲ **FIGURE 49-11** Grover disease. Pruriginous papules on the trunk resembling folliculitis in a 60-year-old man.

Differential Diagnosis

Prurigo simplex, folliculitis, papular eczema, scabies, papular urticaria, miliaria rubra, and dermatitis herpetiformis should be excluded (Box 49-2). GD should also be distinguished from other acantholytic diseases, including pemphigus vulgaris, DD, and HHD. A unilateral transient acantholytic dermatosis (GD) along Blaschko's lines has been reported, although the differential diagnosis with linear DD remains difficult.[76,77]



▲ **FIGURE 49-12** Grover disease. Discrete papulovesicular lesions of the supermammary region with crusts in a 53-year-old man.

Box 49-2

Differential Diagnosis of Grover Disease

Consider

- Prurigo simplex
- Folliculitis
- Papular eczema
- Scabies
- Miliaria rubra

Rule Out

- Dermatitis herpetiformis
- Darier-White disease
- Hailey-Hailey disease
- Pemphigus vulgaris

Course

In the transient form, the course is transitory, and spontaneous healing often occurs within a few weeks or 2 months. In older patients, the disease may last longer (persistent GD) and can continue for years. The prognosis is variable, but the disease is usually chronic, and the severity of the condition fluctuates.

Treatment

The effectiveness of treatments is difficult to assess because of the variable course. Precipitating factors, including UV radiation, heat, sweating, and topical irritants, should be avoided. In mild cases, topical corticosteroids, emollients, calcipotriol, urea, lactic acid, and zinc oxide are useful in relieving irritation and controlling the pruritus. In more severe or persistent cases, isotretinoin (40 mg/day), acitretin, oral corticosteroids, and psoralen plus UVA therapy can be effective.[78–83]

HAILEY-HAILEY DISEASE

Genetics

HHD is a rare blistering disease inherited in an autosomal dominant manner. Its incidence has been suggested to be 1 in 50,000. Penetrance in adults is complete, but expressivity is variable. Some forms present with mild lesions resembling eczema, whereas other forms are characterized by severe widespread disease.[84]

The identification of ATP2A2 as the defective gene in DD has guided the search for the gene for HHD. HHD had been linked to chromosome region 3q21-24, with no evidence for locus heterogeneity. Because HHD and DD are very similar both clinically and histologically, the discovery of the crucial role of SERCA2 in cell-to-cell adhesion and differentiation of the epidermis raised the

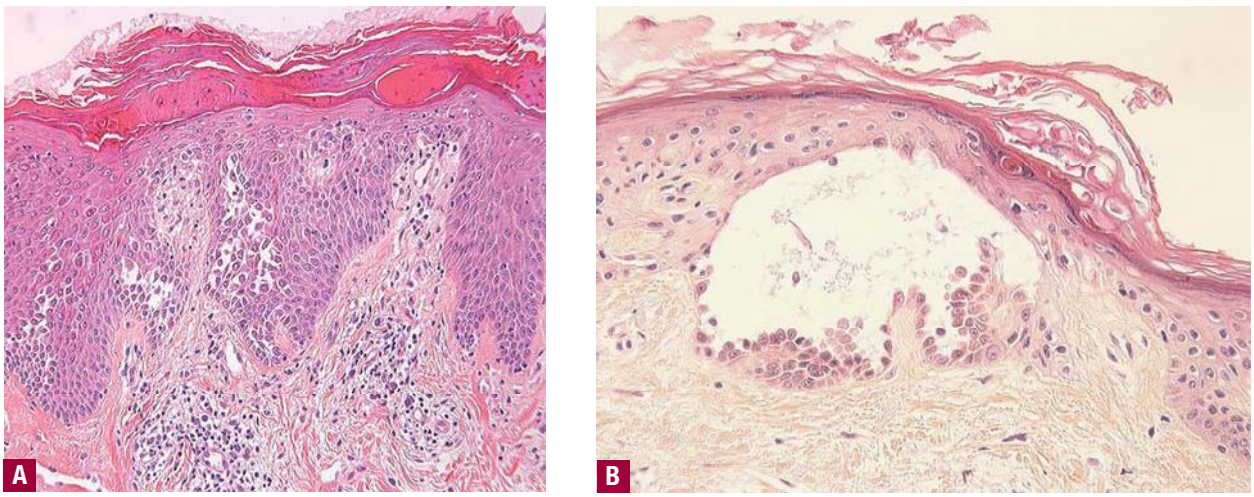

▲ **FIGURE 49-13** **A.** Hailey-Hailey–like pattern in Grover disease with areas of detached keratinocytes (acantholysis), focal spongiosis, and epidermal hyperplasia. **B.** Pemphigus-like pattern in Grover disease with suprabasal acantholytic cleavage.

possibility that defects in another calcium pump could underlie HHD. This led to the identification of a new gene in the HHD region, ATP2C1, which encodes the related human secretory pathway Ca^{2+}/Mn^{2+} ATPase (hSPCA1), as the defective gene in HHD.[58,85]

The gene spans approximately 30 kb on 3q21 and comprises 28 exons encoding a 4.5-kb transcript. The predicted protein is approximately 115 kd in size. Alternative splicing of ATP2C1 primary transcripts in keratinocytes leads to four splice variants, ATP2C1a to ATP2C1d, which differ by different splicing of exon 27 and/or 28. ATP2C1d is the largest variant, containing exons 27 and 28 in their entirety. ATP2C1 mRNA is ubiquitously expressed. It is highly expressed in human epidermal keratinocytes and at variable levels in other human tissues. Behne and colleagues have shown that human keratinocyte SPCA1 localizes to the Golgi apparatus.[86]

SPCA1 belongs to the SPCA (secretory pathway calcium ATPase) class, which like PMCA (plasma membrane calcium ATPase) possesses only one of the two high-affinity Ca^{2+}-binding sites present in SERCA. On the basis of amino acid sequence alignment, the structure of the SPCA family is thought to be similar to that of the SERCA family, but the single Ca^{2+}-binding site transports a single Ca^{2+} or Mn^{2+} ion. SPCA1 has been shown to transport both ions in the Golgi lumen and therefore plays a major role in cytosolic and intra-Golgi Ca^{2+} and Mn^{2+} homeostasis.[87] SPCA1 has the same apparent transmembrane organization and contains all of the conserved domains found in P-type ion transport ATPases. It exhibits 97 percent amino acid identity to the rat SPLA Ca^{2+} pump of the Golgi apparatus, 49 percent identity to the yeast secretory pathway PMR1 pump, 37 percent identity to human SERCA2, and 31 percent identity to human plasma membrane Ca^{2+} ATPase PMCA2.[85,88]

HHD is caused by mutations inactivating one ATP2C1 allele.[89] More than 80 pathogenic ATP2C1 mutations have been reported to date. The studies have revealed that mutations did not cluster but were scattered across the ATP2C1 gene and show substantial allelic heterogeneity.[28,58,85,90–98] Several recurrent mutations have been identified, some of which result from a founder effect in patients of British extraction.[90] Of these mutations, 20 percent are nonsense mutations and 30 percent are frameshift mutations, which indicates that at least 50 percent of ATP2C1 mutations reported so far lead to PTCs. These mutations predict loss of expression or marked reduction of mutated ATP2C1 via nonsense-mediated mRNA decay, which further supports the possibility that haploinsufficiency of ATP2C1 is a prevalent mechanism for the dominant inheritance of HHD. Nineteen percent of the mutations affect splice sites, but their effects on splicing remains to be determined. Twenty-eight percent of the mutations are missense mutations, whereas the remaining 3 percent are in-frame mutations. These mutations lead to amino acid changes in highly conserved critical functional domains of the Golgi Ca^{2+} pumps in different species (rat, yeast), and between SERCA and PMCA pumps. Some of these mutations occur at amino acid residues, which by site-directed mutagenesis have been shown to abrogate SERCA1 function.[99]

Comparison between genotype and phenotype, however, fails to detect any clear correlation between the nature of the mutation and the clinical features of HHD (age of onset, severity, progression). Extensive inter-familial and intra-familial variation in clinical features has also been

HAILEY-HAILEY DISEASE (OMIM #169600)

AT A GLANCE


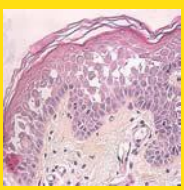

- Also called *familial benign chronic pemphigus.*
- Late-onset blistering dermatosis.
- First described by the Hailey brothers in 1939.
- Presents after the third of fourth decade with painful erosions and fissures (rhagades) in the flexures.
- Histologic examination of skin lesions shows extensive loss of intercellular contacts (acantholysis) of suprabasal and upper layers of the epidermal keratinocytes, which gives the appearance of a "dilapidated brick wall."
- Caused by loss-of-function mutations in the ATP2C1 gene encoding the human secretory pathway calcium/manganese adenosine triphosphatase (hSPCA1) of the Golgi apparatus, which impair intracellular Ca^{2+} signaling.



noted, as well as variation between families sharing the same mutation.[90]

Etiology and Pathogenesis

The majority of mutations result in protein instability, whereas others cause lack of Ca^{2+} and/or Mn^{2+} ion transport through different alterations of the catalytic cycle of the SPCA1 pump.[91,92,100] Studies highlight the crucial role of specific residues in the binding of Ca^{2+} and Mn^{2+} to hSPCA1. They also further support the theory of haploinsufficiency as a prevalent mechanism for the dominant inheritance of HHD, which suggests that the level of functional hSPCA1 in epidermal cells is critical.

In view of the ubiquitous expression of ATP2C1, it is not clear why defects in ATP2C1 result in a disease restricted to the skin, and why the disorder is limited to certain areas of the skin. The mechanism by which mutant ATP2C1 cause acantholysis is also unknown. HHD keratinocytes in culture display elevated resting cytosolic Ca^{2+} levels, abnormally low Golgi Ca^{2+} levels, and impaired regulation of excess cytosolic Ca^{2+} in vitro.[58,86] Abnormal Ca^{2+} signaling in HHD keratinocytes correlates with decreased protein levels of ATP2C1. In vivo, clinically normal HHD contains lower Ca^{2+} stores and displays an abnormal Ca^{2+} gradient.[86] Elevated cytosolic Ca^{2+} levels could influence gene expression or alter post-translational modification of target proteins (activation of protein kinase C). Alternatively, low Ca^{2+} or Mn^{2+} concentrations in the Golgi lumen could impair post-translational modifications (proteolytic processing, glycosylation, trafficking, or sorting) of membrane (associated) proteins important in epidermal cell-to-cell adhesion, such as desmosomal components. This may impair desmosome formation and/or stability, leading to the acantholysis characteristic of HHD. It has been suggested that desmosomal glycoproteins differ in their extent of glycosylation among different cell types. Thus, the reason why clinical signs are restricted to the epidermis could be related to a particular glycosylation state that leaves epidermal cells more prone to Ca^{2+} changes. It is also possible that non-cutaneous tissues have compensatory mechanisms to overcome ATP2C1 dysfunction that are missing in the skin. The demonstration of loss of expression and/or function of mutant SPCA1 proteins identified in HHD suggests that epidermal cells are sensitive to levels of hSPCA1 (gene dosage), which may not be the case for other tissues. This could explain why lesions are exacerbated by external factors (sun exposure, sweating, friction) that would place epidermal cells under stress and disrupt a subtle balance maintained in the steady state. In support of this possibility, UVB irradiation and pro-inflammatory cytokines have been shown to downregulate ATP2C1 as well as ATP2A2 mRNA expression.[105] Finally, defective actin reorganization and a marked decrease in cellular ATP have been reported in HHD keratinocytes in vitro, which suggests an additional mechanism in the pathogenesis of HHD.[106]



▲ **FIGURE 49-14** Hailey-Hailey disease (familial benign pemphigus). Hypertrophic and macerated plaque of the axilla with painful fissures (rhagades).

Clinical Manifestations

The disease often manifests in adulthood (30s and 40s) and is characterized by vesicular lesions, painful erosions, and scaly erythematous plaques that occur at sites of friction and flexures (neck, axillae, submammary region, groin, and perineum) (Figs. 49-14, 49-15). Painful fissures (rhagades) in flexures are common and very suggestive of the disease. The lesions are often itchy but painful when scratched. Mucosal involvement is rare, but oral, esophageal, and vulvar lesions are possible. Longitudinal white lines on the fingernails can be seen and are helpful in diagnosing the disease (Fig. 49-16). Penetrance in adults is complete, but expressivity is variable between and within affected families (see Clinical Forms). Flexural forms may become hypertrophic and malodorous.



▲ **FIGURE 49-15** Focal erosive plaque with fissures in the axilla of a patient with Hailey-Hailey disease.



▲ **FIGURE 49-16** White longitudinal stripes on the fingernails of a patient with Hailey-Hailey disease.

Histopathology

Histopathologic examination of skin lesions shows widespread loss of cohesion between suprabasal keratinocytes (acantholysis), giving the appearance of a "dilapidated brick wall" (Fig. 49-17). Vesicle formation or epidermal clefting is possible. Dyskeratosis, when present, is mild. Ultrastructural studies of acantholytic cells have shown perinuclear aggregates of keratin filaments that have retracted from desmosomal plaques.[68]

Clinical Forms

Expressivity of the disease can vary greatly. Mild forms may be limited to nail changes or mild lesions resembling eczema, whereas severe forms display widespread flexural disease, with hypertrophic and malodorous plaques and painful fissures. This can cause considerable pain and distress and can limit patient mobility. There are no extracutaneous manifestations.[84] Two types of mosaicism are seen in patients with HHD. Type 1 segmental manifestation of mosaicism presumably reflects a localized postzygotic mutation.[107] This manifests as a streak or multiple localized streaks of disease along Blaschko's lines in a patient without evidence of the disorder elsewhere. Type 2 mosaicism is

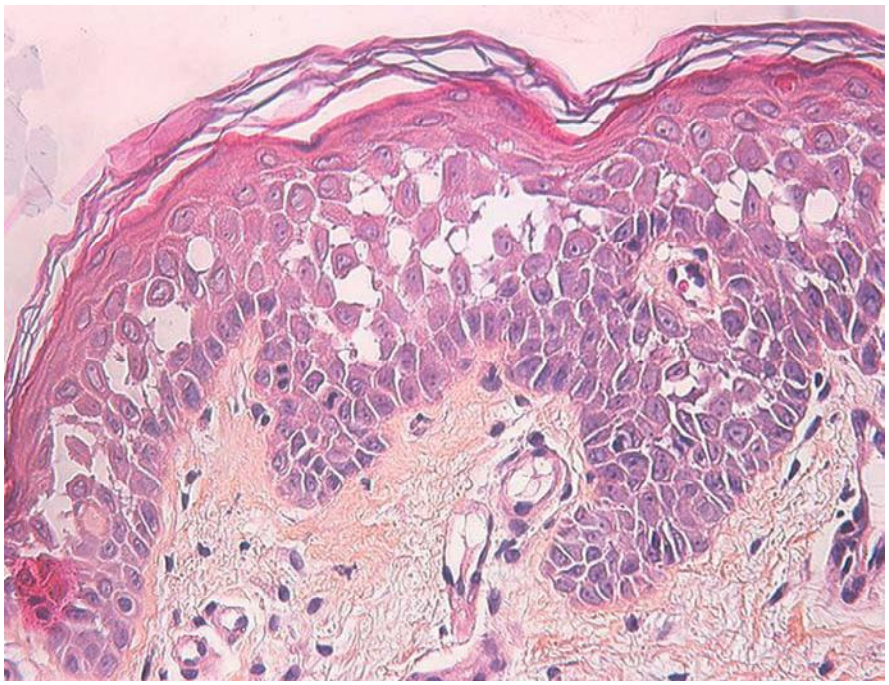

▲ **FIGURE 49-17** Hailey-Hailey disease. Extensive loss of intercellular contacts within the suprabasal and upper layers of the epidermis giving the appearance of a "dilapidated brick wall."

characterized by severely affected unilateral segmental areas along Blaschko's lines superimposed on classic disease,[108] which suggests postzygotic loss of heterozygosity at the ATP2C1 locus.

Differential Diagnosis

HHD shows considerable clinical and histologic overlap with DD, although acantholysis is more widespread in HHD, whereas dyskeratosis is a predominant feature of DD. Because lesions can vary considerably, the disease can be misdiagnosed as eczema; bacterial, fungal, or viral infection; or pemphigus (Box 49-3).

Course

Lesions are frequently induced or exacerbated by UV exposure, sweating, friction, and skin infection. The disease has a chronic fluctuating course, and patients undergo recurrent exacerbations and remissions that can last months to years. The disease can severely affect the quality of life.[109] The development of squamous cell carcinomas on HHD skin lesions has been reported in rare cases.[110]

Box 49-3

Differential Diagnosis of Hailey-Hailey Disease

Consider

- Darier-White disease
- Eczema
- *Candida* infection
- Intertrigo

Rule Out

- Pemphigus vulgaris

Treatment

HHD is a difficult disease to treat, and various therapeutic modalities must be considered. The use of topical corticosteroids in association with antibacterial agents can result in transient improvement. More widespread flares may require systemic antibiotics (erythromycin and tetracyclines). Bacterial culture and sensitivity testing are useful to determine appropriate antibiotics. In patients with refractory disease, the response to dapsone, systemic corticosteroids, retinoids (acitretin or isotretinoin), and immunomodulators (methotrexate, thalidomide, cyclosporine) is usually poor. Treatment with systemic or topical calcipotriol was reported to be efficient.[61,111–113] The exact mechanism of action of vitamin D_3 in treating HHD is unknown, but it could involve an increase in Ca^{2+} intracellular concentration as shown in cultured keratinocytes.[114] More recently, topical application of tacrolimus was also found to be effective.[115] Because this molecule is a calcineurin inhibitor, this raises the question of the role of its signaling pathway in the disease. Finally, topical application of gentamicin was used in an HHD patient harboring a nonsense mutation in ATP2C1 because of the potential of aminoglycosides to induce read-through of nonsense mutations in human cells. This led to a significant improvement in the patient's lesions, which indicates the potential value of this approach for patients with a nonsense ATP2C1 mutation.[116] Surgery remains an option in the absence of response to these treatments.

Diet and activity advice is also useful. To help minimize friction, patient weight should be maintained at appropriate levels, and comfortable clothing should be worn to prevent heat, moisture, and friction.

KEY REFERENCES

The full reference list for all chapters is available at www.digm7.com.

4. Cooper SM, Burge SM: Darier's disease: Epidemiology, pathophysiology, and management. *Am J Clin Dermatol* **4**:97, 2003
7. Sakuntabhai A et al: Mutations in ATP2A2, encoding a Ca^{2+} pump, cause Darier disease. *Nat Genet* **21**:271, 1999
8. Hovnanian A: Darier's disease: From dyskeratosis to endoplasmic reticulum calcium ATPase deficiency. *Biochem Biophys Res Commun* **322**:1237, 2004
14. Dhitavat J et al: Acrokeratosis verruciformis of Hopf is caused by mutation in ATP2A2: Evidence that it is allelic to Darier's disease. *J Invest Dermatol* **120**:229, 2003
15. Godic A et al: P160L mutation in the Ca(2+) ATPase 2A domain in a patient with severe Darier disease. *Dermatology* **209**:142, 2004
56. Sakuntabhai A et al: Mosaicism for ATP2A2 mutations causes segmental Darier's disease. *J Invest Dermatol* **115**:1144, 2000
58. Hu Z et al: Mutations in ATP2C1, encoding a calcium pump, cause Hailey-Hailey disease. *Nat Genet* **24**:61, 2000
62. Wang PG et al: Genetic heterogeneity in acrokeratosis verruciformis of Hopf. *Clin Exp Dermatol* **31**:558, 2006
63. Rallis E et al: Acrokeratosis verruciformis of Hopf (Hopf disease): Case report and review of the literature. *Dermatol Online J* **11**:10, 2005
67. Parsons JM: Transient acantholytic dermatosis (Grover's disease): A global perspective. *J Am Acad Dermatol* **35**:653, 1996; quiz 667
84. Burge SM: Hailey-Hailey disease: The clinical features, response to treatment and prognosis. *Br J Dermatol* **126**:275, 1992
85. Sudbrak R et al: Hailey-Hailey disease is caused by mutations in ATP2C1 encoding a novel Ca(2+) pump. *Hum Mol Genet* **9**:1131, 2000
87. Missiaen L et al: SPCA1 pumps and Hailey-Hailey disease. *Biochem Biophys Res Commun* **322**:1204, 2004
89. Foggia L, Hovnanian A: Calcium pump disorders of the skin. *Am J Med Genet C Semin Med Genet* **131C**:20, 2004
91. Fairclough RJ et al: Effect of Hailey-Hailey disease mutations on the func-



tion of a new variant of human secretory pathway Ca^{2+}/Mn^{2+}-ATPase (hSPCA1). *J Biol Chem* **278**:24721, 2003
107. Hwang LY et al: Type 1 segmental manifestation of Hailey-Hailey disease. *J Am Acad Dermatol* **49**:712, 2003
108. Poblete-Gutierrez P et al: Allelic loss underlies type 2 segmental Hailey-Hailey disease, providing molecular confirmation of a novel genetic concept. *J Clin Invest* **114**:1467, 2004

CHAPTER 50

Porokeratosis

Grainne M. O'Regan
Alan D. Irvine



Porokeratosis is a morphologically distinct disorder of keratinization, characterized clinically by hyperkeratotic papules or plaques surrounded by a thread-like elevated border that expands centrifugally. Histologically, a thin column of parakeratotic cells extends throughout the stratum corneum and is seen in all variants. This distinctive histopathologic feature, known as the *cornoid lamella*, corresponds to the raised hyperkeratotic border evident clinically.

Several clinical variants of porokeratosis have been described, some with overlapping features (Box 50-1). Although various forms are recognized, the clinical distinction between the different variants may not be justified, because overlap occurs among the varieties. Reports of one type of porokeratosis co-existing with other forms and different types developing in multiple members of an affected family suggest more similarities than disparities, particularly in the disseminated forms.[1,2]

Box 50-1

Clinical Variants of Porokeratosis

Porokeratosis of Mibelli	OMIM #175800
Disseminated superficial actinic porokeratosis (DSAP)	OMIM #175900 and #607728
Disseminated superficial porokeratosis (DSP)	
Porokeratosis palmaris et plantaris disseminata (PPPD)	OMIM #175860
Punctate porokeratosis (PP)	
Linear porokeratosis (LP)	
Syndromic form: CAP (*c*raniosynostosis, *a*nal anomalies, and *p*orokeratosis) syndrome	OMIM #603116

OMIM = Online Mendelian Inheritance in Man.

HISTORICAL ASPECTS

ETIOLOGY AND PATHOGENESIS

Porokeratosis is a genetically heterogeneous disorder with several loci identified to date; however, the pathogenetic mechanisms remain elusive. Loci at chromosome bands 12q23.2-24.1 and 15q25.1-26 (DSAP1 and DSAP2) have been reported in familial disseminated superficial actinic porokeratoses; a further locus has been identified for disseminated superficial porokeratosis (DSP) at 18p11.3.[10–12] The locus at DSAP1 corresponds to a candidate gene, *SART3*, that encodes a tumor rejection antigen and is thought to be involved in the regulation of messenger RNA splicing. Mutations in *SART3* may thus result in altered proliferation and transformation of epithelial cells. Fine mapping of the locus at DSAP1 has also revealed mutations in another potential candidate gene, *SSH1*, which encodes a phosphatase that plays a key role in actin dynamics.[13,14] Porokeratosis punctata palmaris et plantaris maps to a 6.9-centimorgan region at chromosome band 12q24.1-24.2 that overlaps with the region identified for DSAP1, which suggests that the two forms are allelic.[15]

The centrifugal expansion of individual lesions is postulated to reflect the migration of a mutant clone of keratinocytes.[16] Supporting this mutant clone theory are findings of abnormal DNA ploidy and chromosomal abnormalities in lesional keratinocytes.[17] The tumor suppressor proteins p53 and pRb are overexpressed in keratinocytes immediately beneath and adjacent to the cornoid lamella, although to date p53 mutations have not been identified.[18–22] Cytogenetic abnormalities in fibroblasts, particularly on chromosome 3, have also been documented.[23,24] Decreased mdm2, abnormal expression of psi-3, cytokeratins, filaggrin, and involucrin have also been reported.[25,26] The increased prevalence of porokeratosis in immunosuppressed patients suggests that impaired immunity may be permissive in genetically predisposed individuals.[27–30] Other reported triggering factors such as exposure to ultraviolet light, together with the increased potential for malignant transformation, highlight the

POROKERATOSIS AT A GLANCE





- A chronic progressive disorder of keratinization, characterized clinically by hyperkeratotic papules or plaques surrounded by a thread-like elevated border that expands centrifugally.
- At least six clinical variants of porokeratosis have been described.
- The classic form, porokeratosis of Mibelli, presents in infancy or childhood as asymptomatic small brown to skin-colored annular papules with a characteristic raised border.
- Disseminated superficial actinic porokeratosis is the most common type, with multiple papules distributed symmetrically on sun-exposed areas.
- Linear porokeratosis presents at birth or in childhood with lesions distributed along Blaschko's lines.
- Punctate porokeratosis appears during or after adolescence as 1- to 2-mm papules on the palms or soles.
- Histologically, a thin column of parakeratotic cells termed the *cornoid lamella*, corresponding to the hyperkeratotic border, extends throughout the stratum corneum and is seen in all variants.
- A genetically heterogeneous disorder; the majority of forms may be inherited as an autosomal dominant trait.
- Malignant epithelial neoplasms are reported in all sub-types except the punctate variety.



▲ **FIGURE 50-1** Porokeratosis of Mibelli is characterized by a single large lesion with a clearly defined edge. The scaling is not clearly seen at the border because of the interdigital location of this lesion.

dysplastic potential of affected keratinocytes. Malignant degeneration has been described in all variants of porokeratosis, with the exception of the punctate variety.[31–33]

CLINICAL FINDINGS

Porokeratosis of Mibelli

Classic porokeratosis of Mibelli begins during infancy or childhood as asymptomatic small brown to skin-colored annular papules with a characteristic annular border (Fig. 50-1). The well-demarcated hyperkeratotic border is usually more than 1 mm in height, with a characteristic longitudinal furrow. The center of the lesion may be hyperpigmented, hypopigmented, depressed, atrophic, or anhidrotic. Lesions range in diameter from millimeters to several centimeters, but giant lesions measuring up to 20 cm may occur. Such giant porokeratoses are rare and occur predominantly on the lower leg and foot. Large lesions are associated with a higher malignant potential.[33] Multiple lesions may arise; however, they are usually regionally localized and unilateral. The condition may be familial and inherited as an autosomal dominant trait. Lesions persist indefinitely.

Disseminated Superficial Actinic Porokeratosis

Disseminated superficial actinic porokeratosis (DSAP) is the most common of the porokeratoses. Lesions are characteristically uniformly small, annular, asymptomatic or mildly pruritic papules ranging from 2 to 5 mm in diameter, distributed symmetrically on the extremities. Lesions are more generalized than other forms of porokeratosis, with typically in excess of 50 lesions located predominantly in sun-exposed sites (Fig. 50-2A and B). A history of increased prominence with sun exposure is usually reported. Although widespread, lesions typically spare palms, soles, and mucous membranes. Compared with porokeratosis of Mibelli, the hyperkeratotic border is characteristically more subtle. As the lesions progress, the older, central area becomes atrophic and anhidrotic. DSAP tends to be inherited as an autosomal dominant disorder, with the earliest reported age of onset at 7 years, and is usually fully penetrant by the third or fourth decade of life.[11] Initial reports of induction of lesions by exposure to ultraviolet light and hypersensitivity of DSAP-derived fibroblasts to x-rays have not been consistently reproduced, and the pathogenesis of DSAP remains unknown.[18,34–36]

Disseminated Superficial Porokeratosis

DSP also shows an autosomal dominant pattern of inheritance and has its onset in the third or fourth decade of life. Lesions primarily are morphologically identical to those of DSAP, occur on the extremities, and are typically distributed symmetrically, but do not spare sun-protected areas as in DSAP. As with DSAP, in excess of 100 lesions may be disseminated, with a predilection for the extensor surfaces of the extremities. Notably, involvement of the face is rare in both DSAP and DSP. In both disseminated forms, there is a reported female predominance, with a female-male ratio of 3:1.

Disseminated Superficial Porokeratoses of Immunosuppression

Disseminated superficial porokeratoses of immunosuppression are recognized after renal, hepatic, and cardiac transplantation, electron beam irradiation,[37] immunosuppressive chemotherapy, and the use of systemic corticosteroids; with hematopoietic malignancies[38]; and in the setting of human immunodeficiency virus infection.[39] Porokeratosis has also been reported after bone marrow transplantation in the absence of ongoing immunosuppressive therapy, which suggests a more complex association than immunosuppression alone.[40] The distribution and morphology of DSP of immunosuppression are similar to those of DASP, but a history of sun exposure is less evident.

Linear Porokeratosis

Linear porokeratosis is an uncommon variant that usually presents in early childhood, although congenital presenta-



▲ **FIGURE 50-2** **A.** Disseminated superficial actinic porokeratosis with multiple lesions on the forearm in this severely affected individual. **B.** The characteristic furrowing (*arrows*) is clearly demonstrated on the forearm of this patient.





▲ **FIGURE 50-3** Linear porokeratosis showing the characteristic distribution along Blaschko's lines.



tions have been reported.[41] Two distinct clinical variants have been described. The more common presentation consists of a unilateral lesion confined to an extremity following Blaschko's lines (Fig. 50-3). In the rare generalized form, multiple lesions affect several extremities and may involve the trunk. Linear porokeratosis is thought to represent a mosaic form of classic porokeratosis of Mibelli, resulting from a postzygotic mutation. Linear variants have the highest potential for malignant degeneration of all the porokeratoses. It has been postulated that this association can be attributed to allelic loss due to mutation or overexpression of p53.[42] There are also reports of the co-existence of linear porokeratosis and DSAP in the same patient or a first-degree family member.[43,44] These findings may be explained by the loss of heterozygosity for the DSAP allele and provides an example of the type 2 segmental manifestations of an autosomal dominant disorder.[45,46]

Porokeratosis Palmaris et Plantaris Disseminata

Porokeratosis palmaris et plantaris disseminata (porokeratosis punctata palmaris et plantaris) is a genodermatosis with an autosomal dominant inheritance pattern characterized by small, relatively uniform lesions (Fig. 50-4) that initially appear on the palms and soles. Subsequently, lesions spread to involve other parts of the body, including the mucous membranes and non–sun-exposed sites. The palmar and plantar lesions are generally more hyperkeratotic, and the characteristic longitudinal furrow along this ridge may be quite pronounced (Fig. 50-5). Typically the lesions appear in during adolescence or early adulthood and are bilateral and distributed symmetrically. Porokeratosis palmaris et plantaris disseminata affects males twice as often as females.



▲ **FIGURE 50-4** Porokeratosis palmaris et plantaris disseminata showing multiple superficial lesions on the calf. Note the similarity to disseminated superficial actinic porokeratosis shown in Fig. 50-2A.

Punctate Porokeratosis

Punctate porokeratosis usually appears during adolescence or adulthood and may be seen concomitantly with other types of porokeratosis. Multiple minute and discrete punctate, hyperkeratotic lesions surrounded by a thin, raised margin are present on the palms and soles. Lesions may occur in a linear arrangement, or they may aggregate to form plaques. Punctate porokeratosis must be differentiated clinically and histologically from punctate keratoderma, also referred to as punctate porokeratotic keratoderma or as porokeratosis punctata palmaris et plantaris (see Chap. 48).

CDAGS Syndrome

CDAGS syndrome (*c*raniosynostosis and clavicular hypoplasia, *d*elayed closure of the fontanel, *a*nal anomalies, *g*enitourinary malformations, *s*kin eruption), also referred to as *CAP syndrome* (*c*raniosynostosis, *a*nal anomalies, *and* p*o*rokeratosis), is a rare genodermatosis reported in four ethnically diverse families to date.[47,48] The main phenotypic features consist of craniosynostosis and clavicular hypoplasia, anal anomalies, and porokeratosis. It appears to segregate as an autosomal recessive trait, with possible linkage to chromosome band 22q12-13. The cutaneous manifestations are strikingly consistent, with the development of small, widespread porokeratotic papules from 1 month of age in affected individuals, predominantly affecting the face and extremities, with reported photoaggravation of lesions. It is postulated that dysregulation of multiple signaling pathways during embryogenesis is causative; however, no unifying pathogenetic mechanism has been identified.

HISTOPATHOLOGY

Histopathologic patterns are similar in all forms of porokeratosis, with the characteristic changes evident at the raised and advancing edge of the lesion. The stratum corneum is hyperkeratotic, with a thin column of poorly staining parakeratotic cells, the cornoid lamella, running through the surrounding normal-staining cells (Fig. 50-6). The underlying keratinocytes are edematous with spongiosis and shrunken nuclei, and a striking dermal lymphocytic pattern may be evident. Underlying the cornoid lamella, the granular layer is either absent or markedly reduced but is of nor-

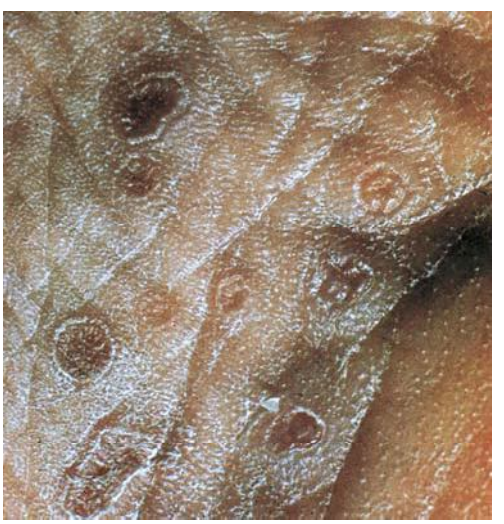

◀ **FIGURE 50-5** Sole of the foot in a patient with porokeratosis palmaris et plantaris disseminata. The ridge and furrow are clearly seen.

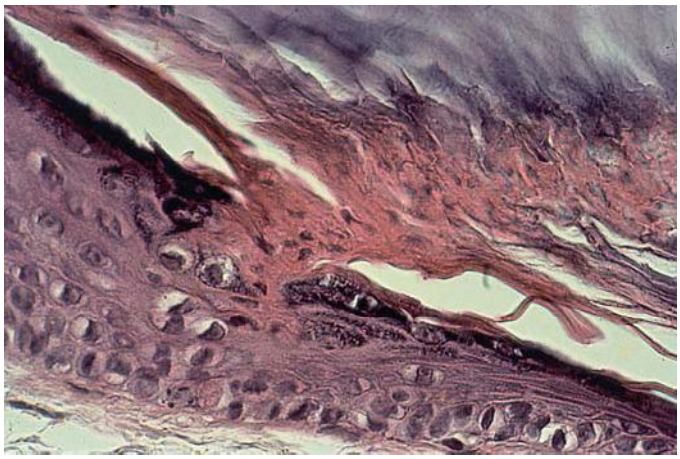

▲ **FIGURE 50-6** The cornoid lamella arises from an indentation of the epidermis and extends as a thin column throughout the stratum corneum. The underlying granular layer is absent or reduced.

mal thickness in other areas of the lesion. The epidermis in the central portion of porokeratosis may be normal, hyperplastic, or atrophic. Although characteristic of porokeratosis, the cornoid lamella is not pathognomonic and may also be found in other conditions, such as viral warts, some ichthyoses, and nevoid hyperkeratoses.

DIFFERENTIAL DIAGNOSIS

The classic lesions of porokeratosis are clinically distinctive, and the diagnosis is usually clinically apparent. Atypical lesions, however, may require differentiation (Box 50-2). A cornoid lamella may be found in actinic keratoses but in actinic keratosis is distinguished by the presence of cytologic atypia. Verruca vulgaris often shows mounds of parakeratosis that are sometimes identical to cornoid lamellae, but koilocytosis is usually present. Linear porokeratosis may be clinically confused with other linear lesions, such as linear inflammatory verrucous epidermal nevus, incontinentia pigmenti (stage II), and lichen planus, none of which has a cornoid lamella.

Box 50-2

Differential Diagnosis of Porokeratosis

LOCALIZED LESIONS

Most Likely

- Granuloma annulare
- Tinea corporis
- Actinic keratosis
- Viral warts

Consider

- Elastosis perforans
- Lichen planus
- Goltz syndrome

LINEAR

Consider

- Linear inflammatory verrucous epidermal nevus
- Incontinentia pigmenti (stage II)
- Lichen planus
- Ichthyosis linearis circumflexa

TREATMENT

Lesions of porokeratosis are chronic, slowly progressive, and relatively asymptomatic, although intense pruritus has been reported.[49] Intervention is usually unnecessary, and disease surveillance is standard. If the lesions are problematic or cosmetically unacceptable, however, treatment with potent topical steroids, keratolytics, topical retinoids, topical 5-fluorouracil,[50] imiquimod 5 percent, calcipotriol,[51] anthralin,[52] cryotherapy,[53] carbon dioxide laser,[54] pulsed dye laser,[55] or neodymium:yttrium-aluminum-garnet laser may be considered (Box 50-3). Treatment outcomes are variable and treatments are poorly standardized. Ablative techniques, such as curettage, excision, and dermabrasion,[56] have also been used with variable degrees of success. Oral retinoids have been shown to give the most reproducible results, with reduction in the size and thickness of extensive lesions, although the disease typically recurs after their discontinuation. Given the association with malignancy, closer disease surveillance and a lower threshold for biopsy of suspicious lesions may be warranted in cases of giant porokeratoses and linear lesions, and in immunosuppressed individuals.

Box 50-3

Treatment for Porokeratosis

	TOPICAL	SURGICAL	SYSTEMIC
First line	Photoprotection 5-Fluorouracil	Cryotherapy	
Second line	Calcipotriol Imiquimod Topical corticosteroids Topical retinoids	CO_2 laser vaporization	Oral retinoids
Third line	Dermabrasion Neodymium:yttrium-aluminum-garnet laser Grenz ray	Surgical excision	

COURSE AND PROGNOSIS

The porokeratoses are generally chronic and progressive, with lesions increasing in size and number with time. Typically, this process occurs over decades in porokeratosis of Mibelli but may be rapid in DSAP, particularly after sun exposure. In cases of immunocompromise, fluctuations in severity may parallel the state of immunocompetence, and there are reports of remission after removal of primary malignancy.[30] The disease is generally considered a benign process; however, malignant degeneration may occur. Malignancy is thought to arise in 7 percent to 11 percent of individuals, although these figures are likely overestimated. Squamous cell carcinoma is the most frequently associated tumor and may be invasive. Bowen disease and basal cell carcinoma have also been reported. Spontaneous resolution of lesions has been reported, although it is exceptionally rare.[57]

KEY REFERENCES

The full reference list for all chapters is available at www.digm7.com.

1. Lin JH et al: Coexistence of three variants of porokeratosis with multiple squamous cell carcinomas arising from lesions of giant hyperkeratotic porokeratosis. *J Eur Acad Dermatol Venereol* **20**:621, 2006



11. Wu LQ et al: Confirmation and refinement of a genetic locus for disseminated superficial actinic porokeratosis (DSAP1) at 12q23.2-24.1. *Br J Dermatol* **150**:999, 2004
15. Wei SC et al: Identification of a locus for porokeratosis palmaris et plantaris disseminata to a 6.9-cM region at chromosome 12q24.1-24.2. *Br J Dermatol* **149**:261, 2003
28. Herranz P et al: High incidence of porokeratosis in renal transplant recipients. *Br J Dermatol* **136**:176, 1997
31. Maubec E et al: Common skin cancers in porokeratosis. *Br J Dermatol* **152**:1389, 2005
41. Zhang ZH et al: Congenital facial linear porokeratosis. *Clin Exp Dermatol* **30**:361, 2005
47. Flanagan N et al: Familial craniosynostosis, anal anomalies, and porokeratosis: CAP syndrome. *J Med Genet* **35**:763, 1998



SECTION 8

DISORDERS OF EPIDERMAL AND DERMAL-EPIDERMAL COHESION AND VESICULAR AND BULLOUS DISORDERS

CHAPTER 51

Epidermal and Epidermal-Dermal Cohesion

Leena Bruckner-Tuderman
John R. Stanley

The cell-cell and cell–basement membrane adhesion in the epidermis provides the skin with its resistance against environmental influences; epidermal integrity is required for protection of the entire organism against mechanical, physical, or microbial noxae. The major cellular structures involved are the desmosomes at cell-cell junctions in the epidermis and the hemidesmosome–basement membrane adhesion complexes and related structures at the epidermal-dermal junction. Ultrastructurally, the hemidesmosome closely resembles one-half of the desmosome; however, at the molecular level, these two structures are distinct. Both represent specifically organized assemblies of intracellular and transmembrane molecules, which on one hand anchor cytoskeletal filaments to the cell plasma membrane and on the other hand the plasma membrane to extracellular structures, i.e., another cell or the extracellular matrix. Our knowledge of the desmosomal, hemidesmosomal, and basement membrane molecules has expanded drastically in the last 10 to 15 years due to the great power of both molecular genetics and proteomics. After some of the proteins were initially identified as autoantigens in pemphigus and pemphigoid, a multitude of molecules have now been characterized at both protein and gene levels, and their expression, regulation, and functions have been discerned. The antigenic epitopes in different autoimmune blistering skin diseases have been carefully mapped and, to date, mutations in at least 18 different genes have been shown to underlie heritable disorders of epidermal or epidermal-dermal adhesion in humans and mice. Morphologic, molecular and functional aspects of these adhesion structures are delineated in this chapter.

EPIDERMAL COHESION

Ultrastructure of Desmosomes

Desmosomes (also called *maculae adhaerentes*) are the major cell adhesion junction of epithelial tissues; however, they are also found in myocardium and a few other tissues.[1–3] Not only do they serve as a sort of spot weld of the keratinocytes but they also anchor intermediate filaments (keratin in the case of epidermis and mucous membranes) to the cell surface. In serving these functions, they form a three-dimensional scaffolding of the intermediate filaments that are stretched from the nuclear envelope to the cell surface.[4] This scaffolding is critical to stabilize epidermal structure in the face of external trauma, and its collapse results in cytolysis of keratinocytes (see Chaps. 47 and 60).

Ultrastructural cross-section of the desmosome shows a symmetric structure consisting of two apposing dense plaques inside the membranes that are themselves separated by approximately 30 nm (Fig. 51-1A).[5] This intercellular center has been called the *desmoglea* (from Greek, "desmosomal glue"), because it is thought to provide the adhesion that keeps cells together at this junction.[6] In high resolution, there is a thin electron dense midline in the center of the desmoglea. The dense plaque inside the cell actually is formed of an outer very dense plaque bordering the membrane, and an inner less dense plaque that intertwines with keratin intermediate filaments.

Biochemical Characterization of Desmosomes

The molecular components of the various desmosomal substructures have been biochemically characterized and cloned (see Fig. 51-1B).[4] These proteins fall into three major gene families: plakins (e.g., desmoplakin), armadillo proteins (e.g., plakoglobin and plakophilins), and desmosomal cadherins (desmogleins and desmocollins). Plakins and armadillo proteins are in the plaque, and desmosomal cadherins are transmembrane proteins whose extracellular amino-termini comprise the desmoglea. The major inner plaque component is *desmoplakin*, which exists in two RNA splice variants, desmoplakin I and II.[7,8] Desmoplakin is part of the plakin gene family,[9] which includes bullous pemphigoid antigen 1 and plectin, plaque proteins of the hemidesmosome, as well as envoplakin and periplakin, whose functions in the desmosome are not as yet well defined. Similar to other desmosomal components, desmoplakin is a modular protein, with different modules fulfilling different functions. The central part of one desmoplakin molecule coils around the central part of another to form a rod-like center. The carboxy-terminus binds to keratin filaments,[10] and the amino terminus binds to plakoglobin.[11] Desmoplakin, therefore, provides the major link between the keratin filaments and the desmosomal plaque.

Plakoglobin is the second major protein in desmosomal plaques.[12] A member of the armadillo gene family that also includes plakophilins,[13] it is a modular protein with repeating homologous units.

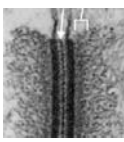

Copyright © 2008 by The McGraw-Hill Companies, Inc. Click here for terms of use.

EPIDERMAL AND EPIDERMAL-DERMAL COHESION

AT A GLANCE

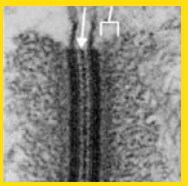

- Desmosomes, hemidesmosomes, and the epidermal basement membrane are providers of epidermal and epidermal-dermal cohesion.
- They represent distinct molecular adhesion complexes.
- The major components of desmosomes belong to three major gene families: the plakins, armadillo proteins, and desmosomal cadherins.
- The hemidesmosomal components comprise plakin homologues, integrins, and collagenous transmembrane proteins.
- All basement membranes contain collagen IV, laminins, nidogens, and perlecan.
- Functional specificity of basement membranes is provided by additional tissue-specific glycoproteins.
- In addition to their structural roles, desmosomes, hemidesmosomes, and the epidermal basement membrane are biologically active in cellular signaling.
- Mutations in the genes encoding the above proteins cause hereditary skin diseases; ranging from hypotrichosis and keratoderma to epidermolysis bullosa and Kindler syndrome.
- Protein components of desmosomes, hemidesmosomes, and epidermal basement membrane are targeted in autoimmune skin blistering diseases of the pemphigus or pemphigoid group and in epidermolysis bullosa acquisita.

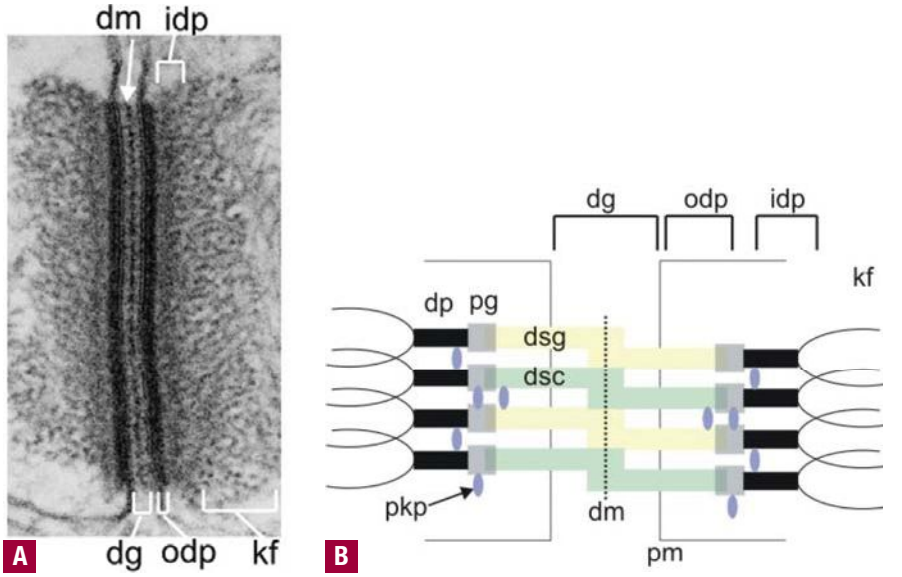

▲ **FIGURE 51-1** Electron microscopic image (**A**) and simplified schematic diagram (**B**) of a desmosome (not drawn to scale). dg = desmoglea; dm = dense midline; dp = desmoplakin; dsc = desmocollins; dsg = desmoglein; idp = inner dense plaque; kf = keratin filaments; odp = outer dense plaque; pg = plakoglobin; pkp = plakophilins; pm = plasma membrane. (Electron micrograph used with permission from Kathleen Green and with permission of Elsevier, adopted from Yin T, Green KJ: Regulation of desmosome assembly and adhesion. *Semin Cell Develop Biol* **15**:665, 2004.)

The first indication of plakoglobin binding to a desmosomal protein (desmoglein) came from studies with pemphigus (see Chap. 52) sera in which plakoglobin was co-precipitated with desmoglein by both pemphigus vulgaris and foliaceus sera.[14] *Desmoglein* 3 and 1 are the pemphigus vulgaris and foliaceus antigens, respectively, that the sera bound, and plakoglobin was co-precipitated because of its binding to these desmogleins. Various domains of plakoglobin modulate its binding to desmogleins and desmocollins.[15–17] Other domains bind to desmoplakin, thus linking desmogleins and desmocollins to desmoplakin.[11] *Plakophilins*, additional plakin proteins in the desmosome, bind various desmosomal components, and may aid in clustering and stabilizing them.[18,19]

Finally, desmogleins and desmocollins provide the link between the extracellular desmoglea and the intracellular plaque.[20–22] These glycoproteins are in the cadherin supergene family, and, similar to other members of this family, are thought to mediate calcium-dependent adhesion. In humans, there are four genes encoding desmogleins 1, 2, 3, and 4. The desmoglein 3 gene was actually discovered and cloned because it was the antigen in pemphigus vulgaris (see Chap. 52).[23] These isoforms have different tissue distributions with desmogleins 1 and 3 being predominant in epidermis and mucous membranes. Within these tissues, the desmogleins also have unique distributions, which has major implications for understanding the pathophysiology of pemphigus (see Chap. 52). Similarly, there are four genes encoding desmocollins I, II, III, and IV, which in addition have alternative RNA splice variants, and, similar to desmogleins, each have unique tissue specific distributions.[21,24–26] These desmosomal cadherins play a major role in providing cell adhesion in the epidermis and mucous membranes. Similar to the other desmosomal components, desmosomal glycoproteins are modular with different parts of the molecules providing different functions. Their cytoplasmic tails bind plakoglobin and other armadillo proteins and their extracellular domains provide adhesion with desmosomal cadherins expressed on apposing cells.

Function and Pathology of Desmosomes

As described in Biochemical Characterization of Desmosomes, the major function of desmosomes is thought to be cell adhesion. Animal models, autoimmune skin diseases, and the blisters caused by exfoliative toxin from staphylococci confirm this function (Table 51-1; see Chaps. 52 and 178).[27] For example, a mouse genetically engineered with a targeted deletion of desmoglein 3 develops mucous membrane and skin blisters from loss of cell adhesion in the deep epidermis, similar to pemphigus vulgaris patients.[28] Patients with pemphigus vulgaris and foliaceus develop loss of cell adhesion and resultant blisters in the epidermis due to anti-desmoglein 3 and 1 antibodies, respectively (Fig. 51-2).

TABLE 51-1
Desmosomal Targets in Skin Disease

	Desmosome Component	Autoimmune Target	Genetic Target
Desmosomal cadherins	Desmoglein 1[a]	PF	SPPK (AD)
	Desmoglein 3	PV, PNP	
	Desmoglein 4	PF,[b] PV[b]	AR hypotrichosis
	Desmocollins	SPD[47]	
Desmosomal plaque proteins	Desmoplakin	PNP	SPPK (AD); keratoderma, woolly hair, left ventricular cardiomyopathy (AR)
	Other plakins[c]	PNP	
	Plakoglobin		Naxos disease: keratoderma, woolly hair, right ventricular cardiomyopathy (AR)
	Plakophilins		Plakophilin 1: skin fragility and ectodermal dysplasia (AR)
Stratum corneum desmosome protein	Corneodesmosin		Hypotrichosis simplex of the scalp (AD)[47]

[a]Also targeted by exfoliative toxin in bullous impetigo and staphylococcal scalded-skin syndrome.
[b]Anti-desmoglein 1 in these sera cross-react with desmoglein 4.
[c]Including envoplakin, periplakin, and bullous pemphigoid antigen 1.
AD = autosomal dominant; AR = autosomal recessive; PF = pemphigus foliaceus (see Chap. 52); PNP = paraneoplastic pemphigus (see Chap. 53); PV = pemphigus vulgaris (see Chap. 52); SPD = subcorneal pustular dermatosis (see Chap. 34); SPPK = striate palmoplantar keratoderma (see Chap. 48).

Exfoliative toxins from staphylococci specifically cleave desmoglein 1 to cause blisters from loss of cell adhesion in the superficial epidermis in bullous impetigo and staphylococcal scalded skin syndrome (see Chap. 178).[29]

More recent data suggests that the function of desmosomes is much more complicated than simple cell adhesion. For example, desmosomal molecules are important in development and differentiation.[30,31] A targeted genetic deletion of desmoglein 2 causes early embryonic lethality in mice, and prevents proliferation of embryonic stem cells.[32] Inappropriate expression of desmoglein 3 in the upper epidermis results in hyperproliferation, abnormal differentiation, and barrier defects.[33,34] Mice with a targeted deletion of desmocollin I also have abnormal differentiation and a defective epidermal barrier.[35] In addition, the armadillo components of the desmosome may mediate or modulate signal transduction.[31] The original member of the armadillo family, *Armadillo*, was discovered in Drosophila as a member of the Wnt signaling pathway. Another member of the family, β-catenin, is both a component of the adherens junction, another cell adhesion junction, and plays a critical role in Wnt signaling in epithelial cells. β-Catenin, in this later function, translocates to the nucleus and complexes with other molecules to form a transcription factor. Plakoglobin, a member of this family, may also serve a similar dual role (adhesion and signaling), but exactly how remains to be determined. Similarly, plakophilins may localize to both desmosomes and translocate to the nucleus, suggesting they also may be involved in signaling and transcription.[36–38]

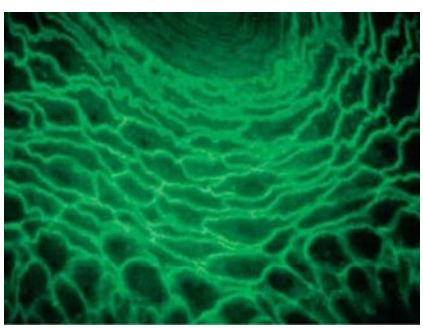

▲ **FIGURE 51-2** Indirect immunofluorescence staining of human epidermis with pemphigus serum that contains autoantibodies to desmoglein 3.

These complexities of the function of desmosomal components may account for the various disease manifestations of patients with mutations in desmosome genes (see Table 51-1).[39,40] Desmoglein 1 and desmoplakin mutations are associated with striate palmar plantar keratoderma.[41,42] Desmoglein 4 mutations are found in autosomal recessive hypotrichosis.[43] Autosomal recessive desmoplakin mutations can cause not only keratoderma but woolly hair and left ventricular cardiomyopathy.[44] Plakoglobin mutations result in Naxos disease, keratoderma, woolly hair, and arrhythmogenic right ventricular cardiomyopathy.[45] Plakophilin 1 mutations result in a disease that includes skin fragility and ectodermal dysplasia.[46] Interestingly, some of these genetic diseases of different desmosomal components have overlapping clinical features, suggesting that they may share certain final common pathophysiologic pathways.

The exact pathophysiologic mechanisms relating the mutations in these genetic diseases to the phenotypes have not been well worked out. However, these diseases clearly indicate the importance of desmosomes and their components beyond just cell adhesion.

EPIDERMAL-DERMAL COHESION

Structural and Functional Characteristics of Basement Membranes

Basement membranes underlie epithelial and endothelial cells and separate them from each other or from the adjacent stroma. Another form of basement membrane surrounds smooth muscle or nerve cells. The physiologic functions of basement membranes are diverse: In the various organ systems they provide support for differentiated cells, maintain tissue architecture during remodeling and repair, and, in some cases, acquire specialized functions, including the ability to serve as selective permeability barriers (e.g., the glomerular basement membrane or the blood-brain barrier) or acquire strong adhesive properties, like the basement membrane at the dermal-epidermal junction, or that surrounding smooth muscle cells, which provide the tissues resistance against shearing forces. All of these characteristics of basement membranes are also used during development and differentiation of multicellular organisms (Box 51-1).

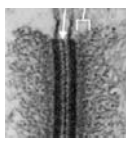

Box 51-1

Major Functions of Basement Membranes

- Scaffold for tissue organization and template for tissue repair.
- Selective permeability barriers. The renal basement membranes serve for the ultrafiltration of plasma, and other basement membranes also demonstrate selective filtration.
- Physical barriers between different types of cells or between cells and their underlying extracellular matrix.
- Firmly link an epithelium to its underlying matrix or to another cell layer and provide polarity.
- Regulate cellular functions.

Ultrastructurally, basement membranes most often appear as trilaminar structures, consisting of a central electron-dense region, known as the *lamina densa*, adjacent on either side to an apparently less-dense area, known as the *lamina lucida* or *lamina rara*. The lamina lucida directly abuts the plasma membranes of the adherent cells. The relative size of each of these regions varies among basement membranes of different tissues, among the basement membranes of the same tissue at different ages, and as a consequence of diseases. For example, the trilaminar glomerular basement membrane in humans varies from 240 nm to 340 nm in width, whereas the bilaminar basement membrane of the dermal-epidermal junction measures 50 nm to 90 nm. This ultrastructure demonstrates that basement membranes serve as substrates for the attachment of cells and fix their polarity. Their continuity throughout the various organ systems stabilizes the established tissue orientations and provides a template for orderly repair after traumatic injury. Major disruptions in the basement membrane result in the formation of scar tissue and the loss of function in that area.

Different basement membranes contain both common and unique components. All share a basic network structure to which specific macromolecules have been appended. These molecules are responsible for the specialized structures and functions of different basement membranes. The basic constituents of these structures are collagen IV, laminins, nidogens, and proteoglycans of the perlecan type, which all are highly conserved, although the isoforms, the number of the polypeptide subunits, and their individual structures vary among species.[47,48] The nearly ubiquitous distribution of heparan sulfate proteoglycans in all basement membranes suggests that these serve as selective permeability barriers in multiple locations, including the kidney and the blood-brain barrier. Ultrafiltration may be especially important during development and morphogenesis of all tissues.

Basement membranes also provide physical separation between epithelia and their underlying extracellular matrices. This barrier is especially important in the containment of tumors. With the exception of certain cells of the immune system, non-malignant cells seldom cross a basement membrane. Benign tumor cells, when placed on isolated amniotic basement membranes, are unable to cross this barrier in vitro. In contrast, malignant cells bind the basement membrane, regionally disrupt its structure at the site of the attachment, and migrate through the rupture. Laminins and integrins mediate the tumor-cell binding, and the basement membrane dissolution is catalyzed by metalloproteases produced by the tumor cell. The absence of distinguishable basement membranes in tumor biopsies has been an indicator of malignancy, and there appears to be a high correlation between metastasis and basement membrane degradation. These observations underline the importance of the basal lamina as an obstacle to cell migration.

By binding biologically active signaling molecules, basement membranes regulate a multitude of biologic events. The constituent proteoglycans can bind growth factors that can be released from the complexes by tissue proteinases. Thus, the basement membranes are potent regulators of cell adhesion and migration, cytoskeleton and cell form, cell division, differentiation and polarization, and apoptosis.[49]

ULTRASTRUCTURE OF THE DERMAL-EPIDERMAL JUNCTION

The dermal-epidermal junction is an example of a highly complex form of basement membrane,[50,51] which underlies the basal cells and extends into the upper layers of the dermis (Fig. 51-3A). This basement membrane is continuous along the epidermis and skin appendages, including sweat glands, hair follicles, and sebaceous glands. The dermal-epidermal junction can be divided into three distinct zones. The first zone contains the keratin filament-hemidesmosome complex of the basal cells and extends through the lamina lucida to the lamina densa. The plasma membranes of the basal cells in this region contain numerous electron-dense plates known as hemidesmosomes. The intracellular architecture and organization of the basal cells are maintained by keratin intermediate filaments, 7 to 10 nm in diameter that course through the basal cells and insert into the desmosomes and hemidesmosomes. External to the plasma membrane is a 25- to 50-nm–wide lamina lucida that contains anchoring filaments, 2 to 8 nm in diameter, originating in the plasma membrane and inserting into the lamina densa. The anchoring filaments can be seen throughout the lamina lucida but they are concentrated in the regions of the hemidesmosomes. Ultrastructurally, the anchoring filaments appear to secure the epithelial cells to the lamina densa.

The existence of the lamina lucida in vivo has been questioned. When the ultrastructure of the basement membrane is evaluated after high-pressure preservation techniques, the lamina densa ap-

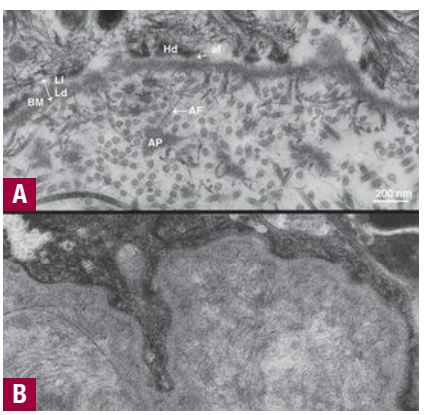

▲ **FIGURE 51-3** **A.** Ultrastructure of the human dermal-epidermal junction as visualized by transmission electron microscopy after standard fixation and embedding protocols. af = anchoring filament; AF = anchoring fibril; AP = anchoring plaque; BM = basement membrane; Hd = hemidesmosome; Ld = lamina densa; Ll = lamina lucida. (Bar = 200 nm.) **B.** Ultrastructure of the human dermal-epidermal junction by transmission electron microscopy following protocols using high-pressure fixation and embedding techniques. Note the dense character of both the basement membrane and the subjacent papillary dermis. Anchoring filaments, anchoring fibrils, and anchoring plaques are not distinguishable. (Both photos used with permission from Douglas R. Keene, MD, Shriners Hospital, Portland, Oregon.)

pears intimately associated with the epithelial cell surface.[50,52] When the dermal-epidermal junction is similarly prepared, no distinct lamina lucida is seen (see Fig. 51-3B). This suggests that the lamina lucida may result from shrinkage of the cell surface away from the lamina densa due to dehydration. The appearance of anchoring filaments spanning the lamina lucida may then result from the firm attachment of constituents of the lamina densa at the hemidesmosome that is subsequently pulled from the lamina densa by shrinkage. Other components that are also tightly fixed to the keratinocyte plasma membrane, either at the hemidesmosomes or at other sites along the membrane between the hemidesmosomes, may similarly become displaced into the shrinkage space. Regardless of its actual occurrence in vivo, the evaluation of the lamina lucida by standard electron microscopy techniques has allowed identification of specific structures that would otherwise have been difficult to detect. In addition, the morphologic term *lamina lucida* remains practical in the scientific communication and continues to be used.

The second zone, the lamina densa, appears as an electron-dense amorphous structure 20 nm to 50 nm in width. The dermal-epidermal lamina densa is similar in appearance to analogous structures in other organs. At high magnification, it has a granular-fibrous appearance.[50] The major molecular components of the lamina densa are collagen IV, nidogen-entactin, perlecan, and laminins, which all can polymerize to networks of variable thickness.[53]

The subbasal lamina contains microfibrillar structures. Two of these are readily distinguishable. The first structure, known as *anchoring fibrils*, appears as condensed fibrous aggregates 20 nm to 75 nm in diameter.[54] At high resolution, they appear to have a nonperiodic cross-striated banding pattern (see Fig. 51-3A). The length of the anchoring fibril is difficult to measure because of its random orientation in relation to the plane of the section. In toad skin, these structures have lengths of approximately 800 nm. The anchoring fibrils in human skin appear to be somewhat shorter. The ends of the anchoring fibrils appear less tightly packed, giving a somewhat frayed appearance. The proximal end inserts into the basal lamina, and the distal end is integrated into the fibrous network of the dermis.[55] Many of the anchoring fibrils originating at the lamina densa loop back into the lamina densa in a horseshoe-like manner; others insert their opposite ends into amorphous-appearing structures, termed *anchoring plaques*.[55] These structures are believed to be independent "islands" of electron-dense material, although some controversy exists in the literature.[56] Anchoring fibrils are primarily aggregates of collagen VII.[57]

Tubular fibrillin-containing microfibrils, 10 nm to 12 nm in diameter, are also localized in the sublamina densa region. These are elastic-related fibers, because elastic components of the dermis are formed from microfibrillar and amorphous components.[58] The microfibrillar component in the presence of abundant amorphous component is known as the *elastic fiber*. In the papillary dermis, the microfibrils insert into the basal lamina perpendicular to the basement membrane and extend into the dermis, where they gradually merge with the elastic fibers to form a plexus parallel to the dermal-epidermal junction. These two elastic components appear to be continuous with the elastic fibers present deep within the reticular dermis.[58] The gradient of an increasing amorphous component from the basal lamina into the reticular dermis may represent a system of increasingly mature elastic fibers.

In summary, the ultrastructure of the dermal-epidermal junction strongly suggests that the lamina densa functions as a structural scaffold for the attachment of the epidermal cells at one surface, secured by anchoring filaments extending from the lamina densa to the hemidesmosomes. The latter also serve as insertion points for intracellular keratin filaments that form scaffolding for the basal cells. On the opposite surface, the extracellular matrix suprastructures of the dermis are firmly attached to the lamina densa. The interaction of different dermal fibers with the basal lamina appears to be mediated by the anchoring fibrils. The elastic system of the dermis inserts directly into the basal lamina via the microfibrils. Thus, the dermal-epidermal junction provides a continuous series of attachments between the reticular dermis and the cytoskeleton of the basal cells. These observations suggest four major functions for the epidermal basement membrane: (1) a structural foundation for the secure attachment and polarity of the epidermal basal cells; (2) a barrier function, separating the components of the epidermis and the dermis; (3) firm attachment of the dermis to the epidermis through a continuous system of structural elements; and (4) modification of cellular functions, such as organization of the cytoskeleton, differentiation, or rescue from apoptotic signaling via outside-in signalling mechanisms.

Box 51-2

Ubiquitous Components of Basement Membranes

- Collagen IV
- Laminins
- Nidogens
- Perlecan

BIOCHEMICAL CHARACTERIZATION OF THE BASEMENT MEMBRANE

Basement membranes contain collagenous and non-collagenous glycoproteins and proteoglycans. The unusual amino acids hydroxyproline and hydroxylysine are found almost exclusively in collagens;[59] the hydroxyproline content suggests that collagens account for 40 percent to 65 percent of the total basement membrane protein. All basement membranes contain collagen IV as the major collagen, laminin, nidogen, and the heparan sulfate proteoglycan perlecan, irrespective of tissue source (Box 51-2). In addition, many other tissue specific glycoproteins have been found in basement membranes, including different laminins, fibulins, and fibronectin.[47–49]

In contrast to the ubiquitous components within all basement membranes, some molecules demonstrate a restricted distribution. Certain collagen IV isoforms, collagens VII and XVII, or several laminins, are not ubiquitous. For example, the α3 chain of collagen IV is localized in the basement membrane of the kidney and lung, but not in those of the skin and blood vessels. In contrast, collagens VII and XVII are associated with the squamous epithelia of skin but are not found in glomerular and alveolar basement membranes. Differences in macromolecular composition are responsible for morphologic and functional variance of basement membranes.

Ubiquitous Components of Basement Membranes

COLLAGEN IV Collagen IV is a heterotrimer of three α chains.[48,59] Each of these contains three distinct domains (Fig. 51-4A): the N-terminal cysteine-rich (7-S)

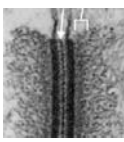

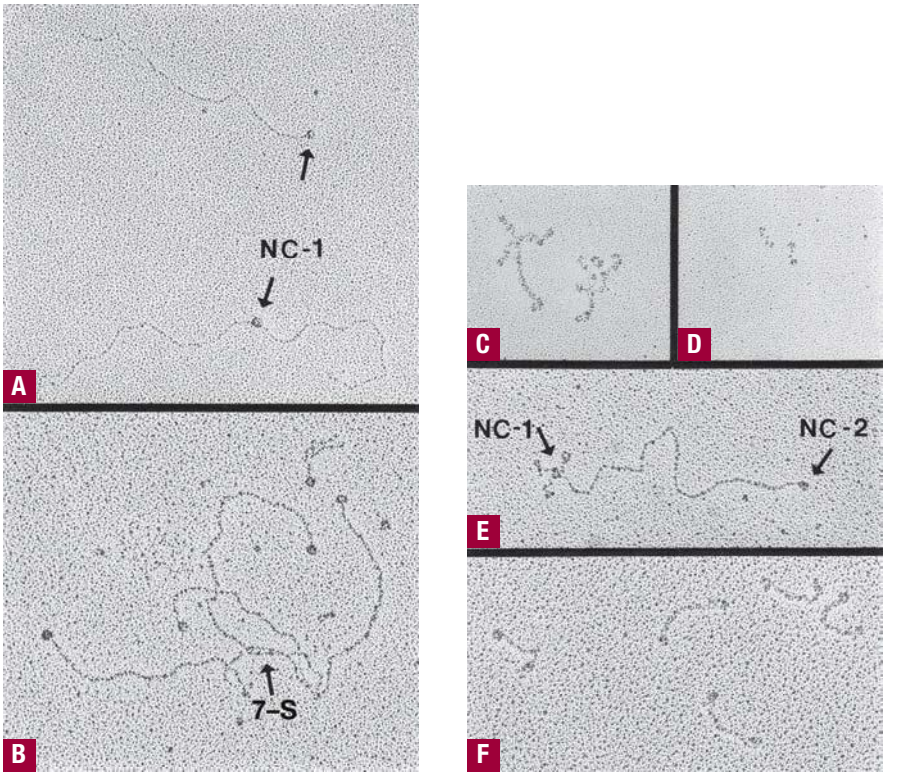

▲ **FIGURE 51-4** Images of basement membrane molecules visualized by rotary shadowing. **A.** Collagen IV monomer and a dimer resulting from aggregation of C-terminal NC-1 domains. **B.** Collagen IV tetramer ("spider") demonstrating the 7-S domain with the four protruding molecules and their large terminal NC-1 domains. **C.** Laminin 1 (laminin 111) molecules. **D.** Nidogen molecules. **E.** Procollagen VII. The NC-1 and NC-2 regions are indicated. **F.** Laminin 5 (laminin 332) molecules. (All micrographs were provided by Douglas R. Keene, MD, Shriners Hospital, Portland, Oregon.)



▲ **FIGURE 51-5** **A.** Representation of the networks formed by the ubiquitous components of the basement membranes. Monomeric collagen IV (Col-IV) self-assembles into dimers and tetramers that further aggregate into a complex lattice. Laminins self-polymerize into networks. Perlecan can oligomerize in vitro, and the glycosaminoglycan side chains interact with the Col-IV framework. Nidogen-entactin is thought to bind components of all three networks and also fibulins. Nidogen therefore plays a central role as a stabilizer of the lamina densa framework. Individual molecules are not drawn to scale. (Drawing used with permission from Peter Yurchenco, MD, Robert Wood Johnson Medical School, Piscataway, N.J, U.S.A.) **B.** Rotary shadowing image of a quick-freeze, deep-etch replica of Col-IV polymers. The replica shows an extensive, branching and anastomosing network with occasional globular structures (*arrowhead*), which can be visualized as a model for the structure of the lamina densa. (Photo provided by Toshihiko Hayashi, PhD, University of Tokyo, Japan. See also Nakazato K et al: Gelation of lens capsule type IV collagen solution at a neutral pH. *J Biochem* 120:889, 1996.)

domain, a central triple-helical domain, and a C-terminal globular domain (NC-l). The trimer composition is determined by the NC-l domains, and the α chains are linked to each other by covalent interactions through these domains.[60] The triple helix of collagen IV is long and contains several sites at which glycine is not present in every third position.[59] These discontinuities result in increased flexibility in the collagen IV helix, but also render it susceptible to a variety of proteases.

The characteristic fibril structure of the interstitial collagens results from aggregation of molecules in a staggered array, producing a cross-banding pattern in electron microscope after appropriate staining. In contrast, the ultrastructure of the lamina densa indicates no periodic cross-striations, suggesting that the aggregates of collagen IV are different. The suprastructure of collagen IV has been partially elucidated by rotary shadowing electron microscopy that indicated that the major interactions among collagen IV molecules occur at their amino- and carboxyl-terminal domains, and by lateral association of their triple helices (see Fig. 51-4A).[47,48,59] Covalent interactions among 7-S regions of different molecules are the basis for the specialized network characteristic of basement membranes (see Fig. 51-4B). The individual 7-S regions overlap in both the parallel and antiparallel directions, producing a characteristic four-legged "spider" form. The NC-l domains at the end of each leg of the spider interact with the NC-l domain of the adjacent aggregates (see Fig. 51-4B). Association is stabilized by covalent bonds. These end-to-end interactions result in an extended two-dimensional network that is the basis of basement membrane organization.

The high flexibility of the basement membrane network structure makes the possibility of interactions with other collagens or noncollagenous molecules very attractive. An open meshwork of collagen IV with, for example, laminins or perlecan, can be easily visualized (Fig. 51-5).[49] The implied porosity of this structure would then be limited by the size of the pores in the collagen network and by structural elements associated with it. This model of the basement membrane structure allows considerable mechanical stability while retaining physiologic flexibility. These properties of strength and elasticity would be expected for a dynamic surface, such as that seen in the epidermal-dermal junction and surrounding blood vessels.

Collagen IV molecules in different basement membranes contain genetically distinct but structurally homologous

α chains. The α1 and α2 chains are ubiquitous, but the α3, α4, α5, and α6 chains show restricted distribution among tissues.[61] The chain organization and discriminatory interactions between the NC-1 domains govern network assembly in the basement membranes.[60] Two networks, namely α1-α2–containing and α3-α4-α5–containing networks, exist in the glomerular basement membrane. Smooth muscle basement membranes have an α1-α2-α5-α6–containing network in addition to the classic α1-α2 network. In the skin, the α1-α2–containing collagen IV network dominates within the dermal-epidermal junction, but α1-α2-α5-α6–containing network is also likely to be present.[62] Taken together, the six chains of collagen IV are distributed in three major networks, α1-α2, α3-α4-α5, and α1-α2-α5-α6, whose chain composition is determined by the NC-l domains.

The α3(IV) chain is the antigen recognized by the circulating autoantibodies in the Goodpasture syndrome,[61] and autoantibodies directed against the NC-l domain of the α5(IV) collagen chain were reported in a case with sub-epidermal bullous eruptions and renal insufficiency.[63] Structural aberrations in the genes encoding the α3, α4, α5, and α6 chains cause different forms of Alport syndrome, a genetic disease characterized by nephritis and deafness.[61] Recent analyses of mouse mutants revealed unexpected phenotypes of mutations in the mouse *Col4α1* and *Col4α2* genes encoding the α1 and α2 chains (i.e., abnormalities of the kidney, the brain, and the eye). Peripheral glomerulopathy in the kidney, porencephaly, a rare neurologic disease characterized by degenerative cavities in the brain, intracerebral hemorrhages, and a spectrum of eye abnormalities affecting the iris, cornea, retinal arterioles, and optic nerve were observed.[64,65] Subsequently, a *Col4α1* mutation was identified in a human family with small-vessel disease, which often underlies ischemic strokes and intracerebral hemorrhages.[66] Interestingly, despite the ubiquitous presence of the α1 and α2 chains of collagen IV in basement membranes, aberrations did not occur in all basement membranes, suggesting varying roles for collagen IV in different basement membranes.

Laminins. Laminins are very large glycoproteins (600 to 950 kd) within the lamina lucida/lamina densa of all basement membranes.[49] Three types of subunit chains have been designated α (200 kd to 400 kd), β (220 kd), and γ (155 kd to 200 kd) chains, and each laminin is a trimeric aggregate of one α, β, and γ chain. The trimers have semirigid and extended structures, which appear as an asymmetric cross in rotary shadowing electron microscopy (see Fig. 51-4C). The long arm of the cross is approximately 125 nm in length; the short arms are variable. Each laminin molecule is divided into globular and rod-like domains that have been individually implicated in various functions, such as aggregation with itself and with other components of the lamina densa (Fig. 51-6), cell attachment and spreading, neurite outgrowth, or cellular differentiation.[49,67] The C-terminal LG domain of the α chain, at the foot of the long arm of the laminin cross, harbors the binding site for integrins.[49,67]

To date, 15 laminin isoforms have been identified. These represent different trimeric combinations of five distinct α chains, three β chains and three γ chains known so far. Historically, laminins were named as *laminin-1* to *laminin-15*, in the order of their discovery, but this classification had grown quite impractical, with the need to memorize the numbers. A new, simplified nomenclature is based on the chain composition and the number of each α, β, and γ chain (Table 51-2).[68] For example, the classic "prototype" laminin-1, with α chain composition α1β1γ1, is now called *laminin 111*. The major laminin of the epidermal basement membrane, the previous laminin-5, with α chain composition α3β3γ2, is now called *laminin 332*.

The α2 chain containing laminins are present primarily within the basement membranes of the muscle fibers, nerves, neuromuscular junction, and glomerulus. Mutations in the α2 chain cause progressive muscular dystrophy and a significant decrease in the amount of basement membrane accumulated surrounding muscle cells.[67] The absence of the basement membrane leads to progressive degeneration of the muscle due to cell death. Therefore, the prediction is that laminins, and basement membranes in general, are required to prevent apoptosis by the cell types they surround.[67] The α3 chain is involved in epithelial adhesion (see Epithelial-Specific Basement Membrane Components), and the α4 and α5 chains are found in a variety of tissues including endothelia, epithelia, neuromuscular junction, and glomerulus.[69] Laminin 511 is present in the basement membrane of the epidermis and the hair follicles, where it is believed to be involved in developmental signaling.[70] The distribution of the β2 chain is largely restricted to the neuromuscular junction, but it is also found in nonmuscle tissues such as

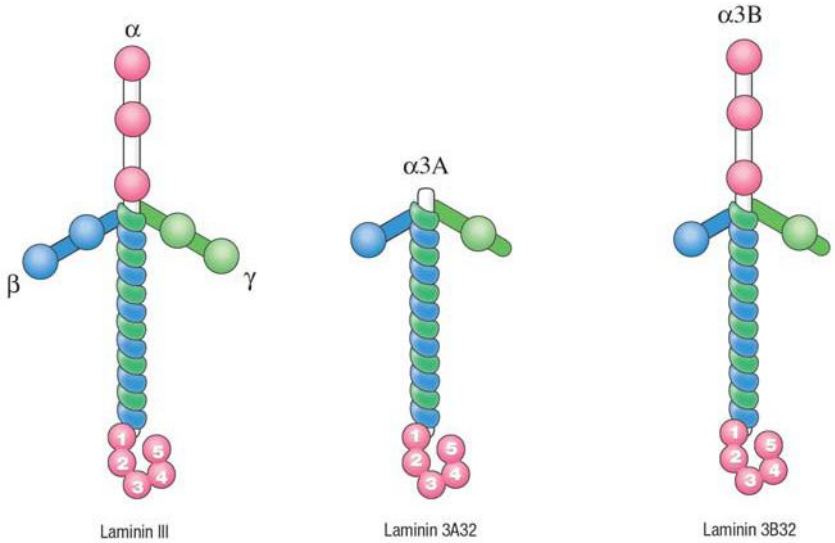

▲ **FIGURE 51-6** A schematic representation of laminin molecules. Each laminin is a heterotrimer of an α, a β, and a γ chain. On the left, the classic prototype laminin 111 consisting of α1β1γ1 chains is shown. The N-terminal short arm of each chain is free, the long C-termini fold to a coiled-coil and form the long arm. The distal C-terminus of the α chain contains five globular LG domains, which harbor the integrin-binding site. Laminin 332, the previous laminin 5, exists in two forms, 3A32 and 3B32. These represent splice variants of the α chain, the short variant is 3A and the "full length" chain 3B. The N-termini of the β3 and γ2 chains are proteolytically processed to yield mature laminin 332.

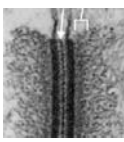

TABLE 51-2
New Laminin Nomenclature[a]

Old Name	Chain Composition	New Name	Tissue Distribution
Laminin-1	α1β1γ1	Laminin 111	Developing epithelia
Laminin-2	α2β1γ1	Laminin 211	Muscle, nerves
Laminin-3	α1β2γ1	Laminin 121	Myotendinous junction
Laminin-4	α2β2γ1	Laminin 221	Neuromuscular junction, glomerulus
Laminin-5	α3β3γ2	Laminin 332A	Stratified epithelia
Laminin-6	α3β1γ1	Laminin 311A	Stratified epithelia
Laminin-7	α3β2γ1	Laminin 321A	Amnion, maybe other stratified epithelia
Laminin-8	α4β1γ1	Laminin 411	Endothelia, nerves, smooth muscle, adipose tissue
Laminin-9	α4β2γ1	Laminin 421	Endothelia, neuromuscular junction, smooth muscle, glomerulus, adipose tissue
Laminin-10	α5β1γ1	Laminin 511	Mature epithelia and endothelia, smooth muscle
Laminin-11	α5β2γ1	Laminin 521	Mature epithelia and endothelia, smooth muscle, neuromuscular junction, glomerulus
Laminin-12	α2β1γ3	Laminin 213	Muscle
Laminin-14	α4β2γ3	Laminin 423	Retina, central nervous system, kidney, testis
Laminin-15	α5β2γ3	Laminin 523	Retina, central nervous system, muscle, kidney

[a]See references 68 and 69.

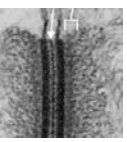

the kidney glomerulus and the capillary basal lamina.[67] The β3 chain is involved in epithelial adhesion (see Epithelial-Specific Basement Membrane Components). Three γ chain variants—γ1, γ2, and γ3—are known. The γ2 chain is found only in laminin 332 in the skin (see Epithelial-Specific Basement Membrane Components). The γ3 chain, a component of laminins 423 and 523, binds nidogens 1 and 2 and is localized in basement membrane zones of adult and embryonic brain, kidney, skin, muscle, and testis. It is present in much lower concentrations than the γ1 chain, a fact that may indicate highly specialized functions.[71] The functions of all laminins are not yet fully understood, but by interacting with integrins and other cell surface components laminins control cellular activities such as adhesion, migration, proliferation, and polarity in a wide variety of organs.[67,68]

Nidogens. Two nidogens, nidogen 1 and 2, also known as *entactin 1* and *2*, are distinct gene products. Both are relatively small molecules (see Fig. 51-4D), which bind laminins at a specific site within the γ1 and the γ3 chain,[71] but also collagen IV, perlecan, and fibulins. It has been proposed that nidogens act as connecting elements between the collagen IV and laminin networks and integrate other basement membrane components into this specialized extracellular matrix.[47,48] Targeted ablation of nidogens in mice showed that the loss of either isoform has no effect on basement membrane formation and organ development, but lack of both results in severe defects of the lung and the heart[72] that are not compatible with life. Interestingly, despite the ubiquitous presence of nidogens in basement membranes, aberrations did not occur in all basement membranes, suggesting distinct roles for nidogens in different basement membranes.[72]

Heparan Sulfate Proteoglycans. Another class of ubiquitous integral basement membrane constituents are the proteoglycans.[73] Three proteoglycans are characteristically present in vascular and epithelial basement membranes: perlecan, agrin, and bamacan. They consist of a core protein of various lengths, and the first two carry primarily heparan sulfate side chains, whereas the latter carries primarily chondroitin sulfate. The name *perlecan* is derived from its rotary shadowing appearance reminiscent of a string of pearls. Perlecan represents a complex multidomain proteoglycan with enormous dimensions and a number of post-translational modifications.[74] Knockout mice lacking perlecan exhibited abnormalities in many tissues, including basement membranes, and embryonic lethality. The basement membranes deteriorated in regions under increased mechanical stress, such as myocardium or skin, resulting in lethal cardiac abnormalities and skin blistering.[73,74] Agrin is a major heparan sulfate proteoglycan of neuromuscular junctions and renal tubular basement membranes. Bamacan is likely to be the chondroitin sulphate proteoglycan previously identified in many basement membranes. The proteoglycans are capable of interactions with several other basement membrane components and are believed to contribute to the overall architecture of the basement membrane as well as provide tissue-specific functions. The high sulfate content of the proteoglycans makes them highly negatively charged and hydrophilic, and the charge density is responsible for providing the selective permeability of the glomerular basement membrane.

Syndecans are transmembrane heparan sulfate proteoglycans present on most cell types, including basal keratinocytes of the epidermis. The extracellular domains have affinity for laminins and, presumably through these interactions, they regulate a variety of biologic processes, ranging from growth factor signaling, cell adhesion, and cytoskeletal organization, to infection of cells with microorganisms.[75]

Fibulins. Fibulins are a family of six highly conserved, calcium-binding extracellular matrix proteins. They are located in vessel walls, basement membranes, and microfibrillar structures and they have overlapping binding sites for a variety of ligands, both basement membrane proteins and components of the interstitial connective tissues.[76] Therefore, fibulins are believed to function as intermolecular bridges that stabilize the supramolecular organization of extracellular membrane structures, such as elastic fibers and basement membranes. Genetic defects of the genes encoding fibulin 4 and 5 cause different forms of cutis laxa.[77]

EPITHELIAL-SPECIFIC BASEMENT MEMBRANE COMPONENTS

The dermal-epidermal junction of skin is an excellent example of specific divergence in basement membrane structure. The structural components of hemidesmosomes, anchoring filaments, and anchoring fibrils in the basement mem-

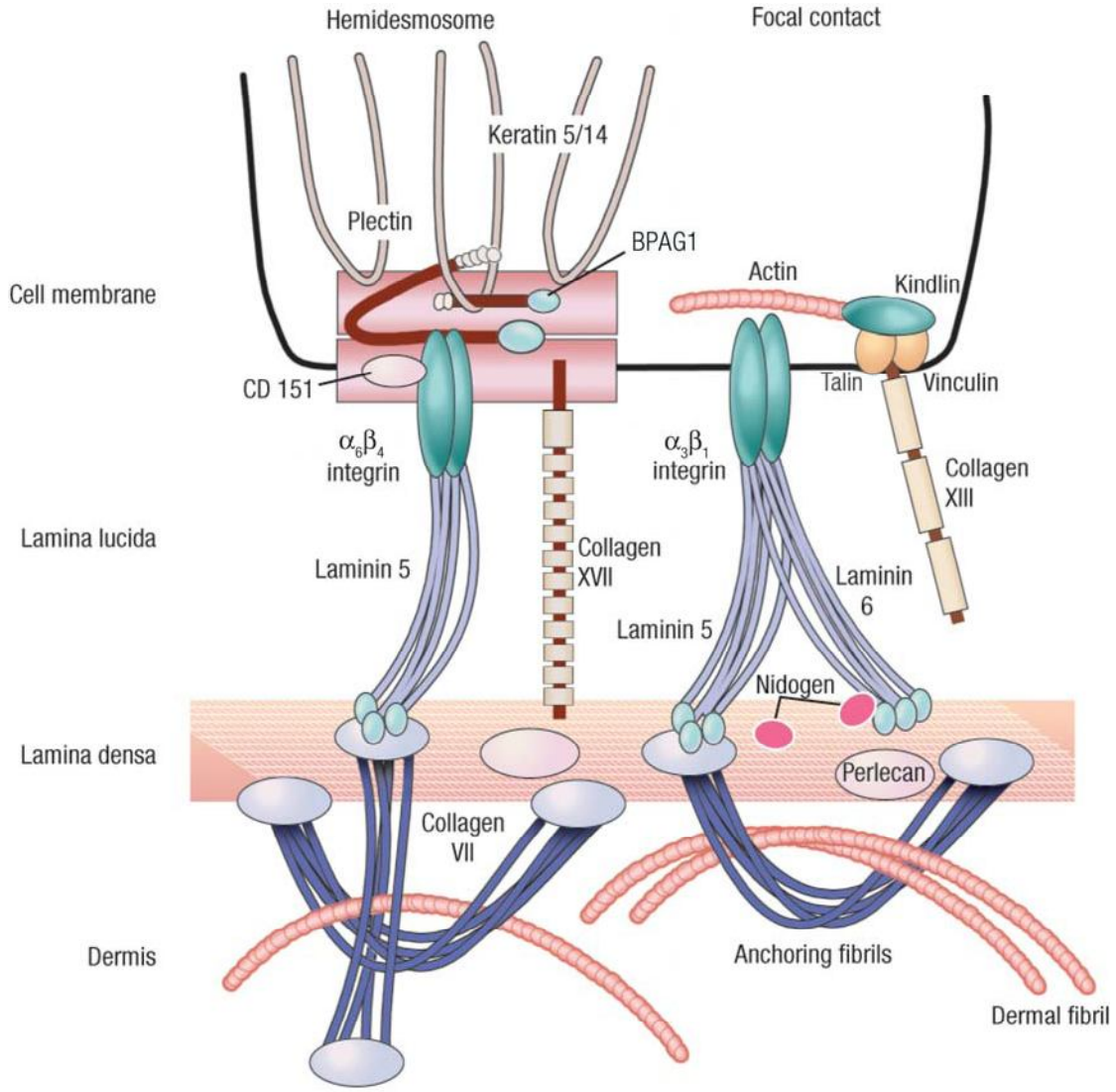

▲ **FIGURE 51-7** Model of the hypothetical relationships of molecules within the dermal-epidermal junction basement membrane. The illustration depicts laminin 332 as the bridge between the transmembrane hemidesmosomal integrin $\alpha_6\beta_4$ and the collagen VII NC-1 domain. The tight binding of laminin 332 to $\alpha_6\beta_4$ and to collagen VII provides the primary resistance to frictional forces. The transmembrane collagen XVII also participates in this stabilization, because its extracellular domain also binds laminin 332. Within the epithelial cell, the transmembrane elements bind the proteins of the hemidesmosomal dense plaque, bullous pemphigoid antigen (BPAG)1 and plectin, which then associate with the keratins. Collagen XVII binds BPAG1, integrin $\alpha_6\beta_4$, and plectin, and integrin $\alpha_6\beta_4$ binds plectin. The laminin 5-6 complex is shown within the basement membrane between hemidesmosomes, bound by integrin $\alpha_3\beta_1$, and associated with the intracellular proteins kindlin, talin, and vinculin. This complex presumably maintains basement membrane stability. In vitro, integrin $\alpha_3\beta_1$, kindlin, talin, and vinculin, and another transmembrane collagen, type XIII, are localized to the focal contacts, which may function as the link between the basement membrane and the epithelial cortical actin network. In the lamina densa, collagen IV and perlecan networks are stabilized by nidogen. Anchoring fibrils are secured to the lamina densa by the NC-1 domain of collagen VII. The fibrils project into the dermis and either terminate in anchoring plaques or loop back to the lamina densa. The anchoring fibril network entraps dermal fibrils, thus securing the adhesion of the lamina densa to the papillary dermis. None of the molecules is drawn to scale.

brane zone are quite well characterized (for review, see refs. 47–51, 78, 79). A cartoon depicting the relative locations of the proteins found at the dermal-epidermal junction is shown in Figure 51-7. These proteins are listed in Table 51-3 and discussed in the following sections.

Hemidesmosomes

Ultrastructurally, the hemidesmosome closely resembles one-half of the desmosome at cell-cell junctions in the epidermis. However, the components of these two structures are distinct. Characterization of the hemidesmosomal proteins was initially aided by the use of autoantibodies in serum of patients with bullous pemphigoid (Fig. 51-8), which recognized antigens with a mass from 120 kd to 230 kd.[27,80,81] Cloning of the cDNAs for the molecules helped identify three distinct polypeptide chains: 230 kd, 180 kd, and 120 kd. The 230-kd protein, *BPAG1* (bullous pemphigoid antigen 1, or BP230), is a coiled-coil dimeric protein with homology to plakins, which bind intermediate filaments.[80,82] BPAG1 is the major component of the hemidesmosomal inner dense plaque. In a transgenic mouse model, deletions in BPAG1 caused epidermolysis bullosa simplex[78] but no human mutations have been found so far.[83] The 180-kd protein, previously called *BPAG2* or *BP180*, and the major

TABLE 51-3
Hemidesmosomal and Basement Membrane Zone (BMZ) Targets in Skin Disease

	Hemidesmosome/BMZ Component	Autoimmune Target	Genetic Target
Cytoskeletal proteins	Keratin 5 and 14		EBS
Hemidesmosomal plaque proteins	Bullous pemphigoid antigen 1/BP230	BP	
	Plectin	BP, CP	EBS-MD
Other intracellular adhesion complex proteins	Kindlin-1		KS
Hemidesmosomal transmembrane components	Collagen XVII/BP180	BP, CP, LAD, PG	JEB-non-Herlitz
	$\alpha_6\beta_4$ integrin	BP, CP	JEB-PA
	CD151		Pretibial EB, nephritis, deafness, β-thalassemia minor
Anchoring filament proteins	Laminin 332/laminin-5	CP	JEB-Herlitz JEB–non-Herlitz
	Ectodomain of collagen XVII	LAD, BP	JEB-non-Herlitz
Anchoring fibril proteins	Collagen VII	EBA	DEB

BP = bullous pemphigoid (see Chap. 54); CP = cicatricial pemphigoid (see Chap. 55); DEB = dystrophic EB (see Chap. 60 for all); EB = epidermolysis bullosa; EBA = EB acquisita (see Chap. 58); EBS = EB simplex; EBS-MD = EBS with muscular dystrophy; JEB= junctional EB; JEB-PA = JEB with pyloric atresia; KS = Kindler syndrome; LAD = linear immunoglobulin A dermatosis (see Chap. 56); PG = pemphigoid gestationis (see Chap. 57).

antigen in bullous pemphigoid, is a transmembrane collagen now known as *collagen XVII*, where the collagenous domain is extracellular.[84–87] In fact, collagen XVII is a prototype of the novel protein family of collagenous transmembrane proteins, type II transmembrane molecules with one or more collagenous stretches in the extracellular domain.[88] Mutations in collagen XVII cause junctional epidermolysis bullosa (see Chap. 60), indicating that it stabilizes interactions of basal keratinocytes with the basement membrane. Its intracellular ligands are plectin, BPAg-1 and β_4 integrin, and the extracellular ligands α_6 integrin and laminin 332.[78,79] The 120-kd protein is the ectodomain of collagen XVII,[85,87,88] which is shed from the cell surface by proteinases of the ADAM (A disintegrin-like and metalloproteinase-containing) family[89] through cleavage within the juxtamembranous NC-16 domain (Fig. 51-9). Plectin, another dimeric plakin homologue, is also a component of the hemidesmosome.[78] However, its tissue distribution is not limited to hemidesmosome-containing basement membranes. Mutations of plectin result in epidermolysis bullosa simplex and progressive muscular dystrophy and, in some cases, junctional epidermolysis bullosa with pyloric atresia (see Chap. 60), indicating a role for plectin in the stability of cell-basement membrane adhesion in a variety of tissues.

One key component of the hemidesmosome is the integrin $\alpha_6\beta_4$.[78] It has a high affinity for laminin 332, and therefore is essential to integration of the hemidesmosome with the underlying basement membrane and stroma.[78,79] Mutations in either the α6 or β4 chains result in dermal-epidermal instability. In mice, null mutations cause severe junctional epidermolysis bullosa.[78] In humans, different mutations in the α6 or β4 chains are associated with variably severe skin blistering associated with pyloric atresia.[79,83]

A member of the widely expressed cell surface transmembrane proteins of the tetraspanin family, CD151, is also a component of the hemidesmosome. It forms complexes with $\alpha_3\beta_1$ and $\alpha_6\beta_4$ integrins at the basolateral surface of basal keratinocytes and stabilizes their functions by pro-



▲ **FIGURE 51-8** **A.** Skin blisters in bullous pemphigoid result from antibody-mediated loss of function of the adhesion molecule collagen XVII. **B.** Indirect immunofluorescence staining of human skin with a pemphigoid serum that contains autoantibodies to collagen XVII.

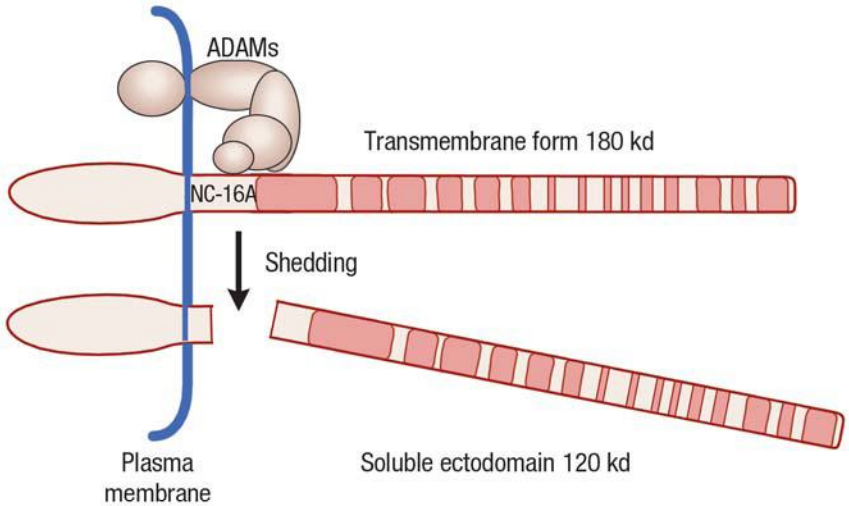

▲ **FIGURE 51-9** Schematic representation of collagen XVII and its ectodomain shedding. Collagen XVII is a hemidesmosomal transmembrane protein with an intracellular N-terminus. The extracellular C-terminus (ectodomain) contains several collagenous subdomains (*brown*) and intervening non-collagenous sequences (*beige*). The ectodomain can be shed from the cell surface by proteinases of the ADAMs (A disintegrin-like and metalloproteinase-containing) family, themselves transmembrane proteins. Thus, the 180-kd full-length molecule yields a shorter soluble ectodomain of 120 kd. The 180-kd full-length molecule is the classic bullous pemphigoid antigen-2, and the ectodomain is the 120-kd linear immunoglobulin A (IgA) dermatosis antigen. Further degradation of the C-terminus of the ectodomain results in the 97-kd linear IgA dermatosis antigen.

viding a framework for the spatial organization of the different components.[90] Dissociation of the CD151-integrin complexes permits remodeling of epithelial cell interactions with the basement membrane and cell migration.[91,92] CD151-null mice have apparently normal tissue morphology, including hemidesmosomes, but exhibit some functional aberrations, e.g., poor keratinocyte migration in explant cultures.[93] A rare human genetic condition delivered indirect information on the functions of CD151. In addition to the expression of CD151 in several tissues like the kidney and the skin, its gene also encodes the MER2 blood group antigen on erythrocytes. Homozygous CD151-null mutations were identified in three MER2-negative patients, who also presented with hereditary nephritis, sensorineural deafness, pretibial epidermolysis bullosa, and β-thalassemia minor.[94] These symptoms suggest that CD151 is important for the assembly of the basement membrane in the kidney, skin, and inner ear and plays a role in erythropoiesis.

Other Epidermal Adhesion Complexes

In addition to the hemidesmosomal components, other adhesion molecules are known to be present at the basolateral aspect of basal keratinocytes, for example integrin $\alpha_3\beta_1$, the receptor for the laminin 332–311 complex in the basement membrane between the hemidesmosomes,[95] and another transmembrane collagen, type XIII.[96] Since these proteins are localized to focal contacts in vitro, together with vinculin and talin, they are predicted to function as the link between the basement membrane and the epithelial cortical actin network. Recently, a novel intracellular component of this complex, kindlin-1, was identified by the genetic studies. The kindlin-1 gene, KIND1, is mutated in the Kindler syndrome,[97–99] a disorder with skin blistering in infancy, progressive poikiloderma, skin atrophy, pigment anomalies, and, occasionally, skin cancer. In the epidermis, kindlin-1 is expressed at the basolateral surface of basal keratinocytes, and in cultivated epithelial cells it co-localizes with vinculin, a marker of integrin-mediated cell-matrix adhesions, and actin microfilaments.[97,100] These observations suggest that kindlin-1 is necessary for the stability of the dermal-epidermal junction and that, in addition to hemidesmosomes, tethering the actin cytoskeleton to cell-matrix adhesions offers alternative means to anchor basal epithelial cells to the basement membrane.[79]

Anchoring Filaments

The anchoring filaments contain laminin 332 and the ectodomain of collagen XVII,[67,68,79] two ligands that interact with each other through noncovalent bonds.[101] The ectodomain of collagen XVII, which protrudes from the plasma membrane into the lamina lucida, has a loop structure consistent with its role as an anchoring filament protein.[102] The molecular characteristics of this collagen are delineated in Hemidesmosomes.[84–88] Laminin 332 is a disulfide-bonded complex of α3, β3, and γ2 chains. The two splice variants of the α3 chain, α3A and α3B, associate with the α3 and γ2 chains to form laminin 3A32 and 3B32 (see Fig. 51-6), previously known as *laminin-5*.[68] Rotary shadowing imaging indicates that laminin 332 has a rod-like structure terminating in the globular regions (see Fig. 51-4F), a shape consistent with its role as an anchoring filament protein. The individual chains are considerably truncated relative to other laminin chains, and this truncation is reflected in the loss of the structures equivalent to the short arms of other laminins. Additionally, the α3 and γ2 chains are proteolytically processed after secretion from the keratinocyte, further trimming the short arms.[103,104] The C-terminus of the α chain, longer than that of the β and γ chains, comprises five globular LG modules, LG1 through LG5, which interact with cell surface receptors. The $\alpha_3\beta_1$ and $\alpha_6\beta_4$ integrins have affinity for the LG1-3 domains,[105] whereas the LG4-5 tandem has affinity for syndecans and β-dystroglycan on the keratinocyte surface.[106] The LG4-5 modules are proteolytically cleaved in most laminins, a process which may modulate interactions with cell surface receptors.[67,68] Laminin 332 forms covalent complexes with laminin 311 (α3β1γ1), binds to the NC-1 domain of collagen VII, the anchoring fibril protein[79] and to the distal ectodomain of collagen XVII.[101] Genetic evidence demonstrates that laminin 332 is essential in keratinocyte adhesion, as null mutations in any of its component α3, β3, or γ2 chains result in severe Herlitz junctional epidermolysis bullosa (see Chap. 60).[83] Targeted disruption of the mouse lama3 gene prevented the synthesis of both laminin 332 and 311 molecules and resulted in abnormal hemidesmosomes, lack of survival of mutant epithelial cells, severe junctional blistering, abnormalities of ameloblast differentiation in developing teeth, and perinatal lethality.[107] Therefore, the severity of the laminin 332 null phenotype reflects the loss of its ability to bridge the hemidesmosomes and the anchor-

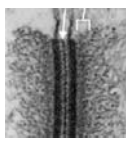

ing fibrils, resulting in a separation within the lamina lucida.

Epithelial Lamina Densa

The basement membrane beneath and between the hemidesmosomes contains the α1-α2–containing collagen IV network, probably some α1-α2-α5-α6–containing collagen IV network, as well as nidogen, perlecan, and laminin α3 and α5-containing molecules.[47–49,61] The N-terminus of the α3 chain lacks the so-called *LN modules*, which allow self-polymerization of other laminin isoforms. However, the α3 chain can associate with the β1 and γ1 chains of laminin 311, previously laminin-6, which has the unique property of forming disulfide-bonded dimers with laminin 332.[67,68] It is probable that the major α3-containing laminin in the lamina densa between hemidesmosomes is the laminin 332-311 complex.[67,68,79] As the laminin α3 chain is a ligand for integrin $\alpha_3\beta_1$ present between hemidesmosomes, binding of laminin 332-311 complex to the intracellular actin cytoskeleton is likely to be mediated by integrin $\alpha_3\beta_1$. This is consistent with studies in mice in which targeted ablation of the integrin α_3 chain causes loss of the basement membrane between hemidesmosomes but not beneath them.[108] The N-termini of laminin 332 bind to collagen VII, a component of the anchoring fibrils located in the sub-lamina densa, so that anchoring filaments and fibrils are directly connected.[109] The laminin 332-311 complex and laminin 511 (α5β1γ1), previously laminin-10, contain a γ1 chain and can therefore bind nidogen 1 and 2 and the collagen IV network.[70,71] Further, nidogen 1 and fibulin 1 and 2 were shown to be ligands for recombinant N-terminal γ2 chain of laminin 332.[110] These interactions are important for the integration of laminin 332 into the extracellular matrix before the maturation of the γ2 chain,[103] as a substantial portion of N-terminus of the γ2 chain is cleaved in human adult skin.[79] Yet another link, which strengthens dermal-epidermal cohesion, is provided by molecular interactions between perlecan within the lamina densa and fibrillin 1 in the microfibrils.[111]

Anchoring Fibrils

Collagen VII is the major component of the anchoring fibrils.[55,57,112] The collagen VII molecule is distinguished from other collagens in that it has a very long triple-helical domain, 450 nm in length. Globular domains exist at both ends of the triple helix, and the N-terminal domain NC-1 is very large and trident-like (see Fig. 51-4E). The smaller C-propeptide, NC-2, is believed to facilitate the formation of the antiparallel, centrosymmetric dimers,[113] before it is removed by the metalloproteinase bone morphogenetic protein 1[114] to yield a mature collagen VII. The dimers are covalently cross-linked through disulfide bonds at the carboxy terminus, and they aggregate laterally to form the anchoring fibrils.[112] The fibrils are further stabilized by tissue transglutaminase, which catalyzes the formation of covalent γ-glutamyl-ε-lysine cross-links.[115]

The NC-1 domain of collagen VII binds to laminin-5 and collagen IV within the lamina densa (see Fig. 51-3A).[116] The triple helical domains of an antiparallel collagen VII dimer make the length of the anchoring fibril. It extends perpendicularly from the lamina densa and either loops back into the lamina densa or inserts into the anchoring plaques.[55–57] The anchoring plaques are electron-dense structures that contain collagen IV and laminin 332, and perhaps other basement membrane components, but which are believed to be independent of the lamina densa itself.[55] They are distributed randomly in the papillary dermis below the lamina densa and are interrelated by additional anchoring fibrils. The anchoring fibril network forms a scaffold that entraps large numbers of dermal fibrils, securing the lamina densa to the subjacent dermis.[55–57,112] In the acquired form of epidermolysis bullosa, epidermolysis bullosa acquisita (see Chap. 58), and in bullous systemic lupus erythematosus (see Chap. 156), autoantibodies target mainly the NC-1 domain of collagen VII.[117,118]

Mutations in *COL7A1*, the gene encoding collagen VII, result in dystrophic epidermolysis bullosa (see Chap. 60). As of 2006, more than 300 *COL7A1* mutations have been found in both recessive and dominant forms of dystrophic epidermolysis bullosa (Fig. 51-10), and the spectrum of biologic and clinical phenotypes is much broader than anticipated.[79,83,119] In two different mouse models, complete or partial deficiency of collagen VII recapitulated the clinical and morphologic characteristics of recessive dystrophic epidermolysis bullosa in humans.[120,121] These mice will be useful for testing of molecular therapy strategies for dystrophic epidermolysis bullosa. A number of such therapies, ranging from protein[122] therapy to transposon-mediated gene transfer,[123] have been considered. Gene augmentation in an ex vivo approach currently seems to be most promising as a first step, in particular for recessive dystrophic epidermolysis bullosa.[124–127] This strategy comprises genetic correction of patient keratinocytes in vitro,



▲ **FIGURE 51-10** Skin fragility and blistering in dystrophic epidermolysis bullosa. Functional deficiency of collagen VII as a result of mutations in the *COL7A1* gene leads to trauma-induced separation of the epidermis and the dermis. The blister roof is below the lamina densa, leading to scar formation on healing of the blisters.

and their cultivation into epithelial sheets for grafting onto the patient's skin. Results with a canine dystrophic epidermolysis bullosa model seem promising: transduction of epidermal cells with a retroviral vector containing the entire collagen VII cDNA enhanced expression and deposition of collagen VII at the dermal-epidermal junction.[126] In another approach, nonviral gene transfer using cotransfection of C31 integrase and human collagen VII resulted in the expression of the protein in collagen VII–deficient DEB keratinocytes.[124] As fibroblasts also contribute to the synthesis of collagen VII, their suitability for gene therapy approaches is under investigation.[128,129]

Cellular Origin of the Dermal-Epidermal Basement Membrane

The basement membrane constituents are products of both epithelial and mesenchymal cells. In vitro modeling of basement membrane formation clearly shows that, under at least some conditions, the dermal-epidermal junction basement membrane is contributed to by both tissue compartments, and it has been proposed that differentiated fibroblasts exist adjacent to epithelial tissues in vivo, which produce basement membrane components and assist in basement membrane assembly.[130,131] Of the known basement membrane components, only laminins 332 (laminin-5) and 311A (laminin-6) are exclusively produced by the epidermis. Epithelial cells also manufacture most of collagen VII, whereas mainly mesenchymal cells synthesize collagen IV, nidogen, perlecan, and the laminin α2 chain.[131] Because the mesenchymal products are translocated to the basolateral epithelial surface where they condense, that surface must provide the localization cues. Integrins $\alpha_6\beta_4$ and $\alpha_3\beta_1$ and collagen XVII have been implicated in this process, suggesting that the laminins coordinate basement membrane polymerization.[67,68,101] As nidogen is required for stabilization of the basement membrane, and because it is a mesenchymal product, it is likely that the dermis is essential to development of basement membranes.[133] Studies using different skin equivalent culture models have demonstrated that a tight interplay between fibroblasts and keratinocytes, in terms of both their matrix production and secretion of soluble signals, regulates the formation of the dermal-epidermal basement membrane.[132,134] An interesting regulatory step may be added by dermal enzymes (e.g., bone morphologic protein 1), which process epithelial cell products, such as laminin 332 and procollagen VII, to mature basement membrane molecules.[103,104,114]

KEY REFERENCES

The full reference list for all chapters is available at www.digm7.com.

4. Yin T, Green KJ: Regulation of desmosome assembly and adhesion. *Semin Cell Develop Biol* **15**:665, 2004
27. Payne AS et al: Desmosomes and disease: pemphigus and bullous impetigo. *Curr Opin Cell Biol* **16**:536, 2004
39. McGrath JA: Keratinocyte adhesion and the missing link: from Dowling-Meara to Hay-Wells. *Clin Exp Dermatol* **26**:296, 2001
48. Timpl R: Macromolecular organization of basement membranes. *Curr Opin Cell Biol* **8**:618, 1996
61. Hudson BG et al: Alport's syndrome, Goodpasture's syndrome, and type IV collagen. *N Engl J* Med **348**:2543, 2003
68. Aumailley M, et al: A simplified laminin nomenclature. *Matrix Biol* **24**:326, 2005
73. Iozzo RV: Basement membrane proteoglycans: from cellar to ceiling. *Nat Rev Mol Cell Biol* **6**:646, 2005
78. Koster J, Borradori L, Sonnenberg A: Biology of the hemidesmosomes, in *Handbook of Experimental Pharmacology*, vol 165, edited by J Behrens, WJ Nelson. Berlin, Springer, 2004, p 243
80. Yancey KB: The pathophysiology of autoimmune blistering diseases. *J Clin Invest* **115**:825, 2005
83. Has C, Bruckner-Tuderman L: Molecular and diagnostic aspects of genetic skin fragility. *J Dermatol Science* **44**:129, 2006



CHAPTER 52

Pemphigus

John R. Stanley

The term *pemphigus* refers to a group of autoimmune blistering diseases of skin and mucous membranes that are characterized histologically by intraepidermal blisters due to acantholysis (i.e., separation of epidermal cells from each other) and immunopathologically by in vivo bound and circulating immunoglobulin G (IgG) directed against the cell surface of keratinocytes.[1] The nosology of this group of diseases is outlined in Table 52-1. Essentially, pemphigus can be divided into four major types: vulgaris, foliaceus, paraneoplastic (see Chap. 53), and IgA pemphigus (see Chap. 34). In pemphigus vulgaris (PV), the blister occurs in the deeper part of the epidermis, just above the basal layer, and in pemphigus foliaceus (PF), also called *superficial pemphigus*, the blister is in the granular layer.[2]

The history of the discovery of pemphigus, and its various forms, is covered in Lever's classic monograph *Pemphigus and Pemphigoid*.[2] Both PV and PF display a spectrum of disease. Various points along these spectra have been given unique names, but because the presentation of these diseases is fluid, patients' disease usually crosses these artificial designations over time. Thus, patients with PV may present with more localized disease, one form of which is called *pemphigus vegetans of Hallopeau*. This may become slightly more extensive and may merge into pemphigus vegetans of Neumann. Finally, with more severe disease, full-blown PV may appear. Similarly, patients with PF may present with more localized disease, represented by pemphigus erythematosus. However, these patients often go on to more widespread PF.

TABLE 52-1
Classification of Pemphigus

TYPE	FORM
Pemphigus vulgaris	Pemphigus vegetans: Localized Drug-induced
Pemphigus foliaceus	Pemphigus erythematosus: Localized Fogo selvagem: Endemic Drug-induced
Paraneoplastic pemphigus	
IgA pemphigus	Sub-corneal pustular dermatosis Intraepidermal neutrophilic IgA dermatosis

IgA = immunoglobulin A.

PEMPHIGUS AT A GLANCE


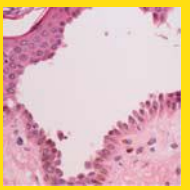

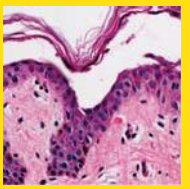
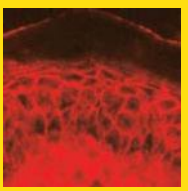

- Two major types: Vulgaris and foliaceus.
  - Pemphigus vulgaris: Erosions on mucous membranes and skin; flaccid blisters on skin
  - Pemphigus foliaceus: Crusted, scaly skin lesions
- Pathology.
  - Pemphigus vulgaris: Suprabasilar acantholysis
  - Pemphigus foliaceus: Sub-corneal acantholysis
- Direct immunofluorescence shows immunoglobulin G (IgG) on the keratinocyte cell surface of the patient's skin; indirect immunofluorescence shows IgG in patient's serum that binds the cell surface of normal keratinocytes.
- Autoantigens are desmogleins, transmembrane desmosomal adhesion molecules.
- Therapy includes topical and systemic corticosteroids and immunosuppressives.

The discovery by Beutner and Jordon in 1964 of circulating antibodies against the cell surface of keratinocytes in the sera of patients with PV pioneered our understanding that PV is a tissue-specific autoimmune disease of skin and mucosa. Ultimately, their work led the way to the discoveries of autoantibodies in other autoimmune bullous diseases of the skin.[3]

EPIDEMIOLOGY

Several retrospective surveys of patients with PV, PF, or both clearly indicate that the epidemiology of pemphigus is dependent on both the area in the world that is studied as well as the ethnic population in that area.[2,4–12] The prevalence of pemphigus of both types in men and women is nearly equal in most areas; however, notable exceptions are the predominance of women in an endemic focus of PF in Tunisia, and a predominance of men in an endemic focus of PF in Colombia.[8,13] The mean age of onset of disease is approximately 40 to 60 years of age; however, the range is broad, and disease may start in the elderly and in children.

Incidence and Prevalence

PEMPHIGUS VULGARIS PV is more common in Jews and probably in people of Mediterranean descent and from the Middle East. This same ethnic predominance does not exist for PF. Therefore, in areas where the Jewish, Middle Eastern, and Mediterranean population predominates, the ratio of PV to PF cases tends to be higher. For example, in New York, Los Angeles, and Croatia, the ratio of PV to PF cases is approximately 5:1; in Iran the ratio is 12:1; whereas in Finland, it is only 0.5:1.0, and in Singapore it is 2:1. Similarly, the incidence of pemphigus is variable depending on location: In Jerusalem, the incidence of PV has been estimated to be 1.6 per 100,000 population per year and in Iran approximately 10.0 per 100,000 per year; in Finland, the incidence is much lower, 0.76 per million population. In France and Germany, the incidence of PV is approximately 1.0 case per million population per year and that of PF is 0.5 cases per million per year. The prevalence and incidence of PF are also very dependent on its location, as best exemplified by fogo selvagem and other forms of endemic PF in Colombia and Tunisia.

FOGO SELVAGEM The first recognition of endemic PF was in Brazil and is called *fogo selvagem*, which means "wild fire" in Portuguese. It is a disease that is clinically, histologically, and immunopathologically the same as sporadic PF in any individual patient, but its epidemiology is unique.[14,15] Fogo selvagem is endemic in the rural areas of Brazil, especially along inland riverbeds. The geographic distribution of disease clustering is similar to that of a black fly, *Simulium nigrimanum*, thought by natives to be a vector of this disease. A study of potential environmental risk factors has also implicated the bite of this black fly, showing it to be significantly more frequent among those with the disease compared to an age-, sex-, and occupation-matched control population with unrelated dermatoses.[16] The prevalence on some well-studied Indian reservations in rural Brazil can be as high as 3.4 percent, with the incidence up to 0.8 to 4.0 new cases per 1000 people per year.[15,17] On the reservation in Limao Verde, up to 55 percent of unaffected individuals have a low-level IgG1 antibody response against desmoglein 1, the PF autoantigen (see Pemphigus Antigens), which becomes an IgG4 response of higher titer against a more pathogenic epitope in disease.[15] These results suggest that some environmental agent (e.g., insects or other infectious disease agent) may trigger a low-level autoantibody response that becomes more generalized by intramolecular epitope spreading in genetically susceptible individuals. With this theory in mind, it is interesting that 40 percent to 80 percent of patients from Brazil with the insect-borne diseases onchocerciasis, leishmania, and Chagas disease have low-level anti-desmoglein 1 antibodies, but patients with other infectious diseases from Brazil rarely have such antibodies.[18]

Fogo selvagem occurs often in children and young adults, unlike sporadic PF, which is a disease of mostly middle-aged and older patients (although rare cases in children have been reported[19]). Also unlike PF, fogo selvagem occurs not infrequently in genetically related family members, although it is not contagious. This fact probably implies a common exposure, as well as susceptibility. There is no known racial or ethnic predominance, and anyone moving into an endemic area may be susceptible to disease. Finally, the development of the rural endemic areas of Brazil decreased the incidence of disease. Certainly, this fascinating disease holds clues to understanding how this autoimmune response is triggered.

ETIOLOGY AND PATHOGENESIS

Electron Microscopy

Ultrastructural studies of the blisters in pemphigus have focused on the appearance of desmosomes, because these are the most prominent cell-to-cell adhesion junctions in stratified squamous epithelia. Early studies of PV lesions seemed to demonstrate early dissolution of cell-to-cell membrane contacts between intact desmosome junctions, with later separation and disappearance of the desmo-

somes.[20] In acantholytic cells, separation of the opposing desmosomal plaques was seen, leaving half-desmosomes with the tonofilaments still inserted into the plaque. Such observations of acantholysis with half-desmosomes without tonofilament collapse have also been reported in a mouse model of PV.[21,22] In contrast, the addition of PV serum to cultured keratinocytes affects desmosome structure by causing the retraction of the tonofilaments that normally attach to desmosomal plaques.[23] Biopsies of uninvolved skin from patients with PV show disruption of desmosomes and decreased numbers of desmosomes.[24] All these data confirm that at various time points during acantholysis, the desmosome is affected and ultimately destroyed, consistent with the cell biologic data discussed in Pathophysiology of Acantholysis.

Similarly, in lesions of PF, electron microscopy was reported to show abnormalities in desmosome structure in early acantholysis and in the mucosa, which binds autoantibodies but does not undergo gross acantholysis.[25,26] The earliest of these changes may be retraction of tonofilaments from the desmosome-dense plaque. Later, there may be a decrease or absence of desmosomes. These electron microscopic studies are difficult to interpret regarding the time course of events, but they all indicate that, at least in some stage of acantholysis, desmosomes are destroyed.

Immunopathology

IMMUNOFLUORESCENCE The hallmark of pemphigus is the finding of IgG autoantibodies against the cell surface of keratinocytes. These autoantibodies were first discovered in patients' sera by indirect immunofluorescence and soon thereafter were discovered by direct immunofluorescence of patients' skin.[27] Essentially all patients with active PV or PF have a positive finding on a direct immunofluorescence test for IgG on the cell surface of keratinocytes in perilesional skin (Fig. 52-1A).[28] The diagnosis of pemphigus should be seriously questioned if the test result of direct immunofluorescence is negative. Depending on the substrate used for indirect immunofluorescence, more than 80 percent of patients with pemphigus have circulating antiepithelial cell surface IgG (Fig. 52-1B).[29] Patients with early localized disease and those in remission are most likely to have negative findings on an indirect immunofluorescence test.

Patients with PV and those with PF usually display similar direct and indirect immunofluorescence findings with IgG on the cell surface of epidermal cells throughout the epidermis. Therefore, it is usually not possible to differentiate the two diseases by the pattern of immunofluorescence. The substrate used to detect pemphigus antibody binding in indirect immunofluorescence greatly influences the sensitivity of the test, however. In general, monkey esophagus is more sensitive for detecting PV antibodies and guinea pig esophagus is a superior substrate for detecting PF antibodies.[29]

There is a positive, but imperfect, correlation between the titer of circulating anti–cell surface antibody and the disease activity in PV and in PF.[30] Although this correlation may hold in general, and although patients in remission often show serologic remission with negative direct and indirect immunofluorescence findings,[31,32] disease activity in individual patients does not necessarily correlate with antibody titer. Therefore, in the day-to-day management of these patients, following disease activity is much more important than following antibody titer.

Pemphigus erythematosus is a localized form of PF with a characteristic direct immunofluorescence finding of immunoreactants, usually IgG and C3, at the basement membrane zone of erythematous facial skin. These immunoreactants are in addition to the epidermal cell surface IgG.[33]

PEMPHIGUS ANTIGENS Immunologic evidence and molecular cloning have demonstrated that pemphigus antigens are desmogleins, transmembrane glycoproteins of desmosomes (cell-to-cell adhesion structures).[34,35] Immunoelectron microscopy has localized both PV and PF antigens to the cell surface of keratinocytes in desmosomal junctions.[36–38]

Characterization of pemphigus antigens at a molecular level has confirmed that they are molecules in desmosomes. Immunoprecipitation and immunoblotting studies with extracts from cultured keratinocytes or epidermis have demonstrated that PF antigen (as well as the fogo selvagem antigen) is desmoglein 1, a 160-kd transmembrane glycoprotein of desmosomes.[39–41]

Molecular cloning of the complementary DNA that encodes PV antigen identified it as desmoglein 3, another desmoglein isoform encoded by a separate gene.[42] All patients with PV have anti–desmoglein 3 antibodies, and some of these patients also have anti–desmoglein 1 antibodies.[43,44] Patients with PV that affects predominantly mucous membranes tend to have only anti–desmoglein 3 antibodies, whereas those with mucocutaneous disease usually have both anti–desmoglein 3 and anti–desmoglein 1 antibodies.[45–47] The dual antibody status of some patients with PV is in contrast to the single antibody status of PF patients, who have antibodies against only desmoglein 1.

Desmogleins 1 and 3 are closely related members of the cadherin supergene family. The original members of this family (e.g., E-cadherin) have been shown to be transmembrane, calcium-dependent, homophilic cell adhesion molecules. Presumably, the desmogleins fulfill similar functions in desmosomes. PF and PV sera bind calcium-sensitive, conformational epitopes on desmogleins 1 and 3, respectively, suggesting that they might interfere with a calcium-sensitive adhesion function.[48,49]

Although other cell surface molecules, such as acetylcholine receptors, may modulate adhesion, their direct involvement in the pathophysiology of pemphigus is controversial.[50–52]

ENZYME-LINKED IMMUNOSORBENT ASSAY FOR IMMUNODIAGNOSIS For diagnosis of disease, antigen-specific enzyme-linked

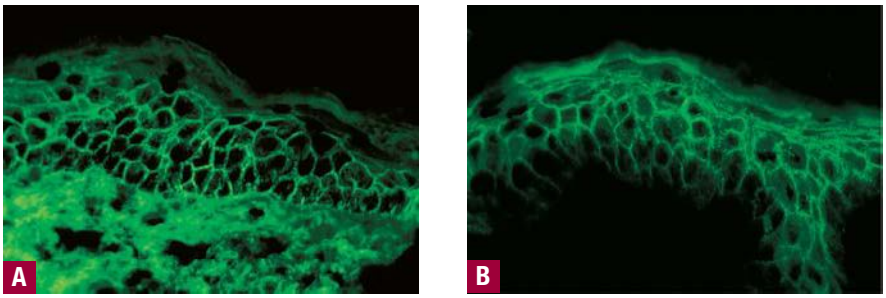

▲ **FIGURE 52-1** Immunofluorescence in pemphigus. **A.** Direct immunofluorescence for immunoglobulin G (IgG) of perilesional skin from a patient with pemphigus vulgaris. Note cell surface staining throughout the epidermis. **B.** Indirect immunofluorescence with the serum from a patient with pemphigus foliaceus on normal human skin. Note IgG on the cell surface throughout the epidermis.



immunosorbent assays have been shown to be more sensitive and specific (e.g., they can differentiate PV from PF) than immunofluorescence, and their titer correlates better than that of indirect immunofluorescence with disease activity.[43,53] These assays use desmogleins 1 and 3 bound to plates, which are then incubated with patient sera and developed with anti-human IgG reagents. Such assays can differentiate between PV and foliaceus.[43,49,53,54] In most cases, enzyme-linked immunosorbent assay is positive for desmoglein 3 (but not desmoglein 1) in mucosal PV, is positive for both desmogleins 3 and 1 in PV with both mucosal and significant skin involvement, and is positive for only desmoglein 1 in PF.



Pathophysiology of Acantholysis (See Chap. 51)

Pemphigus autoantibodies both from patients with PV and from those with PF are pathogenic. The occurrence of neonatal PV demonstrates that maternal IgG can cross the placenta and cause disease.[55] However, neonatal PF is very rare.[56]

Essentially, neonatal PV results from the passive transfer of IgG to the fetus. Similar experimental passive transfer studies show that PV and PF IgG cause acantholysis at the suprabasilar and granular layers of the epidermis, respectively, when added to skin in organ culture.[57,58] Antibody-induced acantholysis in this system occurs without the participation of complement or inflammatory cells.

Further compelling evidence of autoantibody-mediated pathology in pemphigus comes from studies of the passive transfer of PV and PF IgG to neonatal mice. These mice develop blisters and erosions that clinically and histologically mimic the corresponding type of pemphigus.[59,60] Complement fixation is not necessary to produce disease, and, consistent with this observation, even monovalent Fab′ immunoglobulin fragments are pathogenic in these mice.[60,61]

The pathology-causing autoantibodies in pemphigus are those directed against desmogleins 1 and 3.[35,36] IgG that is affinity purified from PV sera on the extracellular domain of desmoglein 3 can cause suprabasilar acantholysis, the typical histologic finding of PV lesions, when injected into neonatal mice.[62,63] Furthermore, the extracellular domain of desmoglein 3 can adsorb out of PV sera antibodies pathogenic in neonatal mice.[64] Similarly, the extracellular domain of desmoglein 1 can adsorb out all pathogenic antibodies from PF sera, and antibodies affinity purified on desmoglein 1 are pathogenic.[65] Finally, an active animal model of PV has been established by immunizing mice that are not tolerant of desmoglein 3 (i.e., mice whose desmoglein 3 gene has been deleted) to generate an immune response against desmoglein 3.[66] After the passive transfer of lymphocytes from these immunized mice to normal mice, the latter develop clinically and histologically typical lesions of PV and have anti–desmoglein 3 antibodies in their skin and sera.

These data strongly suggest that PV and PF autoantibodies against desmogleins 3 and 1, respectively, cause the blister formation in these diseases. They may do so by interfering with a cell-to-cell adhesion function of these desmogleins or with their role in desmosome assembly. If indeed the pathophysiology of pemphigus arises from such antibodies directly inhibiting the function of desmoglein, interfering with the function of the desmoglein in some other way should result in a process that mimics pemphigus. This hypothesis was tested by genetically engineering a mouse with a targeted deletion of the desmoglein 3 gene.[67] The phenotype of this knockout mouse was very similar to that of patients with PV, with suprabasilar blisters developing in the oral mucosa and skin. These data, then, are consistent with the idea that autoantibodies directly cause a loss of adhesion of keratinocytes.

Another line of evidence that inactivation of desmogleins causes the blistering of pemphigus comes from studies of bullous impetigo and staphylococcal scalded-skin syndrome, which are caused by exfoliative toxin released by *Staphylococcus aureus*. Desmoglein 1 is the specific target for exfoliative toxin. The enzyme proteolytically cleaves desmoglein 1, resulting in blisters identical to those seen in PF.[68] Thus, inactivation of desmoglein 1 can cause blisters identical to those seen in PF, which suggests that the anti–desmoglein 1 antibodies in PF patients also inactivate desmoglein 1. Finally, in a mouse model of PV, anti–desmoglein 3 antibodies appear to directly interfere with desmoglein function within the desmosome, causing split desmosomes, without keratin retraction, in areas of acantholysis.[22]

If inactivation of desmoglein isoforms results in blistering, then why do blisters in PV and PF have specific tissue localizations that do not necessarily correlate with the sites at which the antibodies bind by immunofluorescence? In PF, for example, the anti–desmoglein 1 antibodies bind throughout the epidermis and mucous membranes,[69] yet blisters occur only in the superficial epidermis. This apparent paradox has been explained by desmoglein compensation, as outlined in Fig. 52-2. The concept of desmoglein compensation originates in the assumption that autoantibodies against one desmoglein isoform inactivate only that isoform and that another isoform co-expressed in the same area can compensate in adhesion.[70,71] Desmoglein compensation also explains why neonatal PF is so unusual, even though the anti–desmoglein 1 antibodies cross the placenta; in neonatal skin, as opposed to adult skin, desmoglein 3 is co-expressed with desmoglein 1 in the superficial epidermis.[72] The validity of desmoglein compensation has been proven by the demonstration that transgenic mice with forced expression of desmoglein 3 in the superficial epidermis are protected against blistering by passive transfer of PF IgG.[72] Further evidence for desmoglein compensation has been obtained on the genetic level.[73] Specifically, transgenic expression of desmoglein 1 can compensate for genetic loss of desmoglein 3 in knockout mice.

Recently it has been shown that another desmoglein, desmoglein 4, which is in the developing hair cortex and is mutated in some types of autosomal recessive hypotrichosis, is also present in the superficial epidermis, and is a target of some pemphigus antibodies.[74–77] However, the anti-desmoglein 4 antibodies in mucocutaneous PV and in PF also bind desmoglein 1 and do not seem to be sufficient or necessary for acantholysis.[78]

Although the anti-desmoglein antibodies in pemphigus may directly inactivate desmogleins in desmosomes, thereby causing loss of cell adhesion, it is also possible that they deplete the desmosome of desmoglein.[79–82] This effect may occur by depletion of desmoglein from the cell surface before it becomes incorporated into the desmosome, thus decreasing the precursor pool. Another possibility is that pemphigus antibodies might cause depletion of desmoglein directly from the desmosomes. In either case, PV antibodies have been shown to target desmoglein 3 (together with plakoglobin) for endocytosis and lysosomal degradation. It has been shown that adhesion on the cell surface is necessary to prevent endocytosis of organizing desmosomes,[83] therefore desmoglein inter-

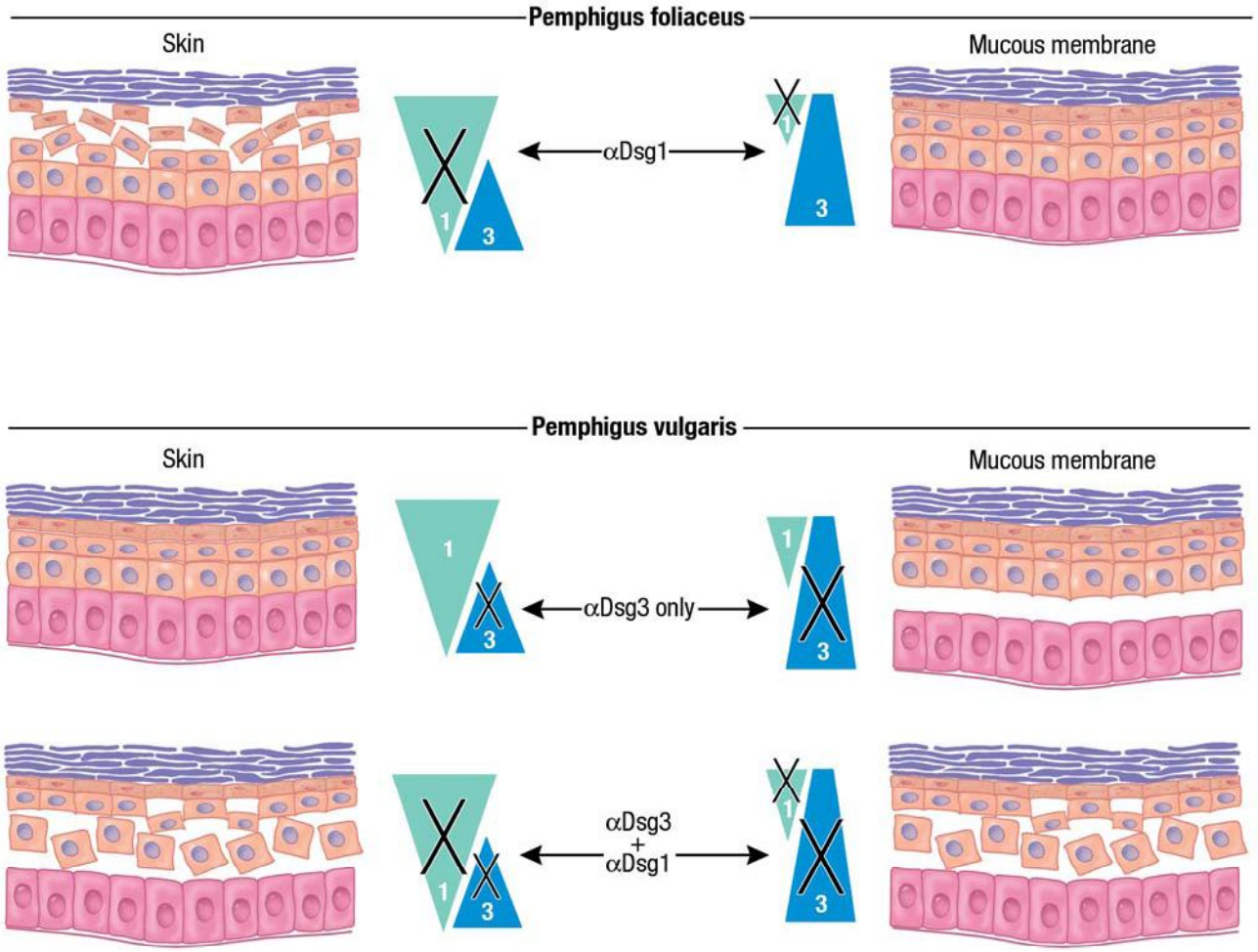

▲ **FIGURE 52-2** Desmoglein (Dsg) compensation. Triangles represent the distribution of Dsg 1 and 3 in skin and mucous membranes. Anti-Dsg 1 antibodies in pemphigus foliaceus cause acantholysis only in the superficial epidermis of skin. In the deep epidermis and in mucous membranes, Dsg3 compensates for antibody-induced loss of function of Dsg 1. In early pemphigus vulgaris, antibodies are present only against Dsg 3, which cause blisters only in the deep mucous membrane where Dsg 3 is present without compensatory Dsg 1. However, in mucocutaneous pemphigus, antibodies against both Dsg 1 and Dsg 3 are present, and blisters form in both mucous membrane and skin. The blister is deep probably because antibodies diffuse from the dermis and interfere first with the function of desmosomes at the base of the epidermis.

nalization and degradation may reflect the pemphigus antibody-induced loss of adhesion function. However, depletion, acantholysis, or both may also be dependent on antibody-mediated intracellular signaling that may or may not depend on loss of adhesion.[84] Various observations have implicated signaling, which may simply be associated with acantholysis or may be causal. Some examples follow: PV added to keratinocytes causes phosphorylation of desmoglein 1, which in turn is associated with its dissociation from plakoglobin.[85] Plakoglobin itself, which may be part of some signaling pathways, is necessary in culture for PV IgG to cause retraction of keratin filaments, which may be a marker for early acantholysis.[23] Phosphorylation of heat shock protein 27 in cells treated with PV IgG has implicated the p38MAPK signaling pathway, and inhibition of this pathway prevents cytoskeletal reorganization, presumably associated with loss of cell adhesion, in these cells.[86] Finally, blocking various signaling pathways prevents acantholysis caused by PV IgG in neonatal mice.[87] Which, if any, of these signaling mechanisms is necessary or sufficient for acantholysis, their exact involvement in causing acantholysis or whether they are activated as a result of acantholysis, remains to be determined.

Genetic Restriction of the Pemphigus Immune Response

Compared to a matched population, patients with PV have a markedly increased frequency of certain class II major histocompatibility complex (MHC) antigens. Among Ashkenazi Jews with PV, the serologically defined HLA-DR4 haplotype is predominant, whereas in other ethnic groups with PV, the DQ1 allele is more common.[88] However, the association with disease susceptibility becomes even more striking in an analysis of these MHC alleles at a genetic level to determine the amino acid sequence of the cell surface molecules that they encode. Patients with the DR4 serotype almost all have an unusual allele called *DRB1*0402*, and patients with the DQ1 serotype almost all have a rare allele called *DQB1*0503*. The protein chains encoded by these alleles vary from those encoded by the alleles found in HLA-DR4 and DQ1 controls without disease in only a few amino acids.

These MHC alleles encode cell surface molecules that are necessary for antigen presentation to the immune system; therefore, it is hypothesized that the disease-associated MHC class II molecules allow presentation of desmoglein 3 peptides to T cells.[89] Consistent with this hypothesis is the finding that certain peptides from desmoglein 3, predicted to



fit into the DRB1*0402 peptide-binding pocket, were able to stimulate T cells from patients.[90] Furthermore, in this binding pocket, if one of the negatively charged amino acids specific for the DRB1*0402 subtype of DR4 was changed to a positively charged amino acid (characteristically present in other sub-types of DR4) by site-directed mutagenesis, then the desmoglein 3 peptide could no longer be effectively presented to the T cells. Other studies have confirmed that the immune response in pemphigus is restricted to certain desmoglein peptides and immune response genes coding for antigen presentation molecules.[91–93] These studies suggest that certain populations are susceptible to PV because of the genetics of their immune response genes. However, an unexpected observation was that T cells of normal people with the DRB1*0402 or DQB1*0503 respond just as well as those of pemphigus patients to the same desmoglein 3 peptides.[89,94] Therefore, to stimulate T cells in pemphigus certain immune response genes are necessary but are not sufficient. The factor that may determine who gets pemphigus and who does not is the presence of regulatory T cells that can suppress the autoimmune response in those who do not.[89,95]

Similar, but less restricted, HLA-DR alleles are associated with PF.[96]

As opposed to the antigen-presenting immune response genes discussed above, there is more heterogeneity of the T-cell receptor variable gene usage, although there may be some restriction.[94,97]

A mouse model of PV supports the importance of both T and B cells in inducing active disease. Loss of tolerance of both the B and T cell, in this model, is necessary for disease activity to develop.[98] These findings are consistent with the importance of antigen presentation to T cells discussed above.

Finally, genetic cloning of monoclonal anti-desmoglein antibodies from a PV patient shows a marked genetic restriction in antibody gene usage in the anti-desmoglein antibodies.[99] This restriction is most marked for the heavy chain variable gene.

CLINICAL MANIFESTATIONS

Pemphigus Vulgaris

SKIN The skin lesions in PV are rarely pruritic, but are often painful.[1] The primary lesion of PV is a flaccid blister, which may occur anywhere on the skin surface (Fig. 52-3). Usually, the blister arises on normal-appearing skin, but it may develop on erythematous skin. Even new blisters are usually flaccid or become so within a short time. Because these blisters are fragile, intact blisters may be sparse. The most common skin lesions that occur in these patients are erosions, often painful, subsequent to broken blisters. These erosions are often quite large, as they have a tendency to spread at their periphery (Fig. 52-4). This characteristic finding can be elicited in pemphigus patients with active blistering by applying lateral pressure to normal-appearing skin at the periphery of active lesions. The result is a shearing away of the epidermis in normal-appearing areas, a phenomenon known as the *Nikolsky sign.*[100] This sign helps differentiate pemphigus from other blistering diseases of the skin (Box 52-1).

In certain patients, erosions have a tendency to develop excessive granulation tissue and crusting (Fig. 52-5); that is, these patients display more vegetating lesions. This type of lesion tends to occur more frequently in intertriginous areas, in the scalp, or on the face (see Fig. 52-5A). In pemphigus vegetans of Hallopeau, vegetating lesions are present from the outset of disease (see Fig. 52-5B). Before the advent of effective therapy for pemphigus, the prognosis for these patients was not as grave as that for patients with the more usual type of PV. In other patients (e.g., those with pemphigus vegetans of Neumann), ordinary PV erosions may tend to develop vegetations. The vegetating type of response may also appear in certain lesions that tend to be resistant to therapy and remain for long periods of time in one place. Thus, vegetating lesions seem to be one reactive pattern of the skin to the autoimmune insult of PV, with certain areas of the skin showing more of a tendency to form vegetations.

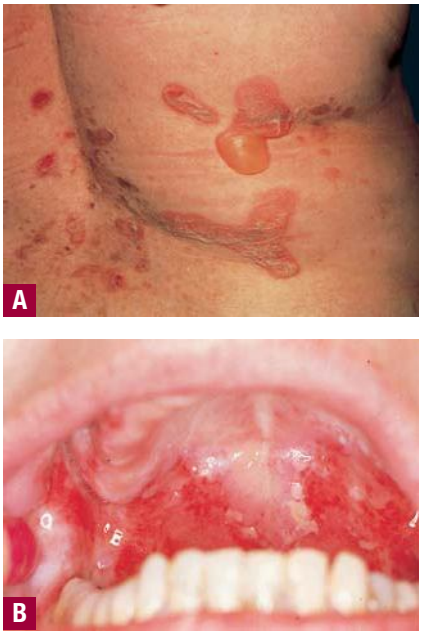

▲ **FIGURE 52-3** Pemphigus vulgaris. **A.** Flaccid blisters. (Used with permission from Lawrence Lieblich, MD.) **B.** Oral erosions.



▲ **FIGURE 52-4** Pemphigus vulgaris. Extensive erosions due to blistering. Almost the entire back is denuded. Note intact, flaccid blisters at the lower border of eroded lesions.

MUCOUS MEMBRANES In the majority of patients, painful mucous membrane erosions are the presenting sign of PV and may be the only sign for an average of 5 months before skin lesions develop (see Fig. 52-3B).[4] However, the presenting symptoms may vary according to geographic area; for example in a study from Croatia, painful oral lesions were the presenting symptom in only 32 percent of patients. Most of these patients progressed to a more generalized eruption in 5 months to 1 year; however, some had oral lesions for more than 5 years before generalization.[11] On the other hand, in Tehran, 62 percent of patients presented with oral lesions.[9] The mucous membranes most often affected are those of the oral cavity, which is involved in almost all patients with PV and is often the only mucous membrane involved (see Fig. 52-3B). Intact blisters are rare, probably because they are fragile and break easily. Scattered and often extensive erosions may appear on any part of the oral cavity, although they perhaps occur most frequently on the buccal mucosa. These erosions may spread to involve the pharynx

Box 52-1

Differential Diagnosis of Pemphigus

PEMPHIGUS SUBTYPES
- Pemphigus vulgaris
  - Pemphigus vegetans
- Pemphigus foliaceus
  - Pemphigus erythematosus
  - Endemic pemphigus foliaceus (e.g., fogo selvagem)
- Immunoglobulin A (IgA) pemphigus
  - Subcorneal pustular dermatosis
  - Intraepidermal neutrophilic dermatosis
- Paraneoplastic pemphigus

INTRAEPIDERMAL BLISTERING DISEASES WITHOUT AUTOANTIBODIES
- Familial benign pemphigus (Hailey-Hailey disease)
- Bullous impetigo, staphylococcal scalded-skin syndrome
- Blisters from herpes simplex and zoster
- Allergic contact dermatitis (e.g., rhus dermatitis)
- Epidermolysis bullosa simplex
- Incontinentia pigmenti

MOUTH ULCERS/EROSION WITHOUT AUTOANTIBODIES
- Aphthous ulcers
- Candidiasis
- Lichen planus
- Behçet disease

SUB-EPIDERMAL BLISTERING DISEASES WITH AUTOANTIBODIES
- Bullous pemphigoid
- Herpes gestationis
- Cicatricial pemphigoid
- Epidermolysis bullosa acquisita
- Linear IgA disease and chronic bullous disease of childhood
- Dermatitis herpetiformis
- Bullous lupus erythematosus

SUB-EPIDERMAL BLISTERING DISEASES WITHOUT AUTOANTIBODIES
- Erythema multiforme
- Toxic epidermal necrolysis
- Porphyria
- Epidermolysis bullosa

and larynx with subsequent hoarseness. Often, these erosions are so uncomfortable and, in fact, painful that the patient is unable to eat or drink adequately.

Mucous membranes in other areas may also be involved with painful erosions; these include nasal mucosa, conjunctiva, anus, penis, vagina, and labia.[9,101,102] Even the esophagus has been reported to be involved in unusual cases.[103]

Skin involvement without mucous membrane involvement in PV is unusual and accounts in one study for only 11 percent of cases.[9,104]

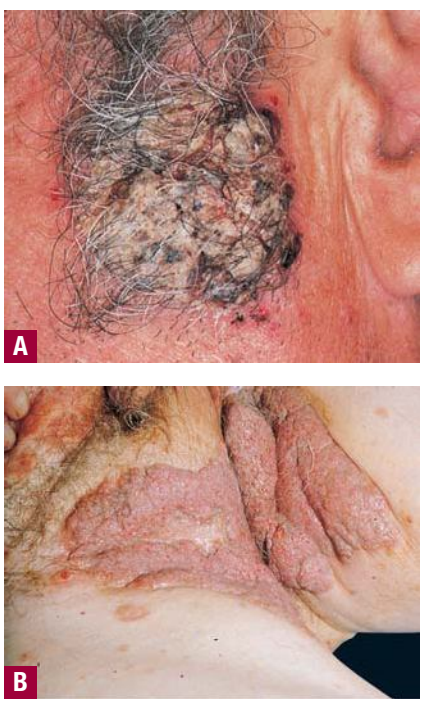

▲ **FIGURE 52-5** **A.** Crusted, vegetating lesions in pemphigus vulgaris. **B.** Extensive, vegetating granulomatous lesions in pemphigus vegetans.

Pemphigus Foliaceus

SKIN The characteristic clinical lesions of PF are scaly, crusted erosions, often on an erythematous base.[2,105] In more localized and early disease, these lesions are usually well demarcated and scattered in a seborrheic distribution, including the face, scalp, and upper trunk (Fig. 52-6A). The primary lesions of small flaccid blisters are often inconspicuous and difficult to find. Disease may stay localized for years, or it may rapidly progress to sometimes generalized involvement, resulting in an exfoliative erythroderma (Fig. 52-6B). Exposure to sun, heat, or both may exacerbate disease activity. Patients with PF often complain of pain and burning in the skin lesions. In contrast to patients with PV, those with PF only very rarely, if ever, have mucous membrane involvement, even with widespread disease.

The colloquial term for Brazilian endemic pemphigus, fogo selvagem (Portuguese for "wild fire"), takes into account many of the clinical aspects of this disease: the burning feeling of the skin, the exacerbation of disease by the sun, and the crusted lesions that make the patients appear as if they had been burned.

PEMPHIGUS ERYTHEMATOSUS Also known as *Senear-Usher syndrome*, pemphigus erythematosus is simply the localized form of PF. Typical scaly and crusted lesions of PF occur across the malar area of the face and in other seborrheic areas. Pemphigus erythematosus may remain localized for years, or it may evolve into more generalized PF. If there is a unique aspect of pemphigus erythematosus, it is the immunofluorescence findings noted in Immunopathology.

In addition, many patients with pemphigus erythematosus show serologic findings suggestive of systemic lupus erythematosus, especially the presence of anti-nuclear antibodies, although few patients have been reported to actually have the two diseases concurrently.[106]

Neonatal Pemphigus

Infants born to mothers with PV may display clinical, histologic, and immunopathologic signs of pemphigus.[55,107] The degree of involvement varies from none to severe enough to result in a stillbirth. If the infant survives, disease tends to remit as maternal antibody is catabolized. Mothers with PF may also transmit their autoantibodies to the fetus, but, as discussed in Pathophysiology of Acantholysis, neonatal PF occurs only rarely.[108–110] Neonatal pemphigus should be distinguished from PV and PF that occur in childhood, which are similar to the autoimmune diseases seen in adults.[111]

Drug-Induced Pemphigus

Although there are sporadic case reports of pemphigus associated with the use of several different drugs, the association with penicillamine, and perhaps captopril, is the most significant.[112] The prevalence of pemphigus in penicillamine users is estimated to be approximately 7 percent. PF (including pemphigus erythematosus) is more common than PV in these penicillamine-treated patients, although either may occur. The findings of direct and indirect immunofluorescence are positive in most of these patients. Three patients with drug-induced PF and one with drug-induced PV have been shown to have autoantibodies to the same molecules involved in sporadic pemphigus, namely, desmoglein 1 and desmoglein 3, respectively.[113] Therefore, by immunofluorescence and immu-





▲ **FIGURE 52-6** Pemphigus foliaceus. **A.** Scaly, crusted lesions on upper back. **B.** Exfoliative erythroderma due to confluent lesions.



nochemical determinations, these patients with drug-induced pemphigus resemble those with sporadic disease.

Both penicillamine and captopril contain sulfhydryl groups that may interact with the sulfhydryl groups in desmoglein 1, 3, or both, thereby causing pemphigus either by directly interfering with these adhesion molecules or, more likely, by modifying them so that they become more antigenic. The use of these drugs may also lead to a more generalized dysregulation of the immune response, allowing production of other autoantibodies such as those resulting in myasthenia gravis. Most, but not all, patients with drug-induced pemphigus go into remission after they stop taking the offending drug.

Associated Diseases

Myasthenia gravis, thymoma, or both have been associated with PV and PF.[114] Approximately one-half of associated pemphigus cases are vulgaris; one-half, foliaceus or erythematosus. Most of these data, however, were reported before the recognition of paraneoplastic pemphigus as a distinct entity. Therefore, although thymoma may clearly be associated with PV and PF, it may also be associated with paraneoplastic pemphigus (see Chap. 53). The course of myasthenia gravis and the course of pemphigus seem independent of each other. Likewise, the thymic abnormality may either precede or follow the onset of pemphigus. Thymic abnormalities include benign or malignant thymoma and thymic hyperplasia. Irradiation of the thymus or thymectomy, although clearly beneficial for myasthenia gravis, may not improve the pemphigus disease activity. Although this association is reported in at least 30 cases, the finding of thymoma or myasthenia gravis in a patient with PV or PF is still unusual.

Although very uncommon, PV or PF has been associated with bullous pemphigoid in the same patient.[115] Finally, PV has rarely evolved into PF, and vice versa, as determined by clinical, histologic, and immunochemical criteria.[116–118]

HISTOPATHOLOGY

Pemphigus Vulgaris

The characteristic histopathologic finding in PV is a suprabasilar blister with acantholysis (Fig. 52-7). Just above the basal cell layer, epidermal cells lose their normal cell-to-cell contacts and form a blister. Often, a few rounded up (acantholytic) keratinocytes are in the blister cavity. The basal cells stay attached to the basement membrane, but may lose the contact with their neighbors; as a result, they may appear to be a "row of tombstones." Usually, the upper epidermis (from one or two cell layers above the basal cells) remains intact, as these cells maintain their cell adhesion. Pemphigus vegetans shows not only suprabasilar acantholysis, but also papillomatosis of the dermal papillae and downward growth of epidermal stands into the dermis, with hyperkeratosis and scale-crust formation. In addition, pemphigus vegetans lesions may show intraepidermal abscesses composed of eosinophils.[1] Early PV lesions may show eosinophilic spongiosis.[119]

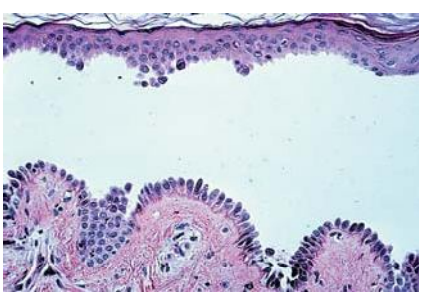

▲ **FIGURE 52-7** Histopathology of pemphigus vulgaris. Suprabasilar acantholysis. The row of tombstones.

Pemphigus Foliaceus

The histopathology of early blisters in PF patients demonstrates acantholysis (loss of cell-to-cell contact) just below the stratum corneum and in the granular layer (Fig. 52-8A). The stratum corneum is often lost from the surface of these lesions. The deeper epidermis, below the granular layer, remains intact. Another frequent finding is sub-corneal pustules, with neutrophils and acantholytic epidermal cells in the blister cavity (Fig. 52-8B). These histologic findings are indistinguishable from those seen in bullous impetigo. Pemphigus erythematosus has histologic findings identical to those of PF. As in PV lesions, very early PF lesions may show eosinophilic spongiosis.[119]

PROGNOSIS AND CLINICAL COURSE

Before the advent of glucocorticoid therapy, PV was almost invariably fatal, and PF was fatal in approximately 60 percent of patients. PF was almost always fatal in elderly patients with concurrent medical problems; however, in other patients its prognosis, without therapy, was much better than PV.[120,121]

The systemic administration of glucocorticoids and the use of immunosuppressive therapy have dramatically improved the prognosis for patients with pemphigus; however, pemphigus is still a disease associated with a significant morbidity and mortality.[122,123] Infection is often the cause of death, and by causing the immunosuppression necessary in the treatment of active disease, therapy is frequently a contributing factor.[124] With glucocorticoid and immunosuppressive therapy, the mortality (from disease or therapy) of PV patients followed from 4 to 10 years is ap-

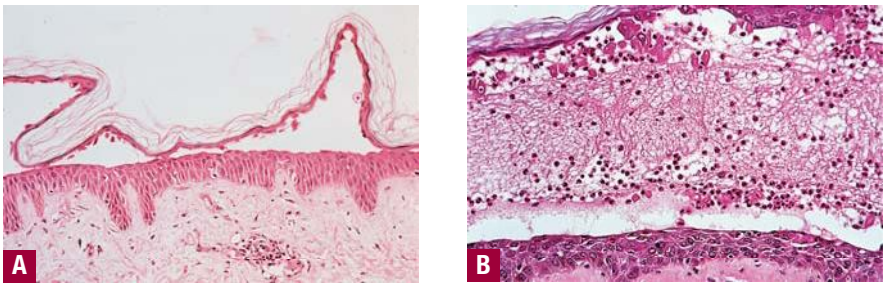

▲ **FIGURE 52-8** Histopathology of pemphigus foliaceus. **A.** Acantholysis in the granular layer. **B.** Subcorneal pustule with acantholysis.

proximately 10 percent or less, whereas that of PF is probably even less. In a more recent study of 40 patients with PV, 2 patients (5 percent) died of sepsis and 17 percent, after an average of 18 months of therapy, went into a complete and long-lasting (> 4 years, average, thought to be permanent) remission requiring no further therapy.[125] Another 37 percent of patients achieved remission but relapsed at times after therapy was stopped; most of these also eventually achieved long-lasting remissions. The remainder of patients required continual therapy. In a group of 159 patients with PV from Croatia, only approximately 12 percent went into long-term remission after therapy with glucocorticoids and immunosuppressives, but most relapsed.[11] In a study from Tehran of 1206 pemphigus patients seen over 20 years, 6.2 percent of PV and 0.2 percent of PF patients died, mostly of septicemia; only 9.3 percent were in complete remission without therapy.[9]

TREATMENT

Approach to therapy of pemphigus varies widely, even among experts.[126] It is generally agreed that PV, even if initially limited in extent, should be treated at its onset, because it will ultimately generalize and the prognosis without therapy is very poor. In addition, it is probably easier to control early disease than widespread disease, and mortality may be higher if therapy is delayed.[127]

Because PF may be localized for many years, and the prognosis without systemic therapy may be good, patients with this type of pemphigus do not necessarily require treatment with systemic therapy; the use of topical glucocorticoids may suffice. When the disease is active and widespread, however, the therapy for PF is, in general, similar to that for PV.

The systemic administration of glucocorticoids, usually prednisone, is the mainstay of therapy for pemphigus. At one time, primarily before adjuvant immunosuppressive therapy was available, very high initial doses of prednisone were recommended for therapy. Now, however, few authorities recommend such high doses, and many feel that intermediate or low doses, especially if used in combination with immunosuppressive therapy and, if necessary, with tolerance of some residual disease activity, result in fewer complications and decreased mortality.[7,124,128,129] However, some experts in pemphigus still recommend controlling active disease initially with escalating doses of prednisone.[121,130] Once disease activity is controlled, tapering prednisone to as low a dose as possible should be the goal.

Interestingly, prednisone can control blistering in as few as several days, at a time when the autoantibody titer would be unchanged. How, then, could it work to control disease? One possibility is that it may increase the synthesis of desmogleins or change their post-transcriptional modification to prolong their half-life.[131] If, as discussed in Pathophysiology of Acantholysis, pemphigus IgG depletes desmosomes of desmogleins, then prednisone could counteract this effect.

Although there are few controlled studies, most authors feel that immunosuppressive agents, such as mycophenolate mofetil (CellCept), azathioprine (Imuran), and cyclophosphamide (Cytoxan), have a steroid-sparing effect, decrease the incidence of side effects of therapy, and may increase the numbers of remissions.[32,120,122,127,132] Usually, mycophenolate mofetil or azathioprine, which has less potential adverse effects than cyclophosphamide, is the initial immunosuppressive agent.[133,134] Treatment regimens often begin with both an immunosuppressive agent and prednisone in moderate to intermediate doses, depending on disease activity, although some authors suggest first determining if the disease responds to a course of glucocorticoids alone.[32,123,129] In any case, if there are contraindications to glucocorticoid use, if the glucocorticoids do not control the disease, or if a dosage low enough to minimize the risk of steroid complications is not effective, the patient should receive adjuvant therapy, usually consisting of immunosuppressive agents.

Results obtained by using prednisone and immunosuppressive agents to treat patients with PV, although not controlled, have been impressive. For example, in a series of 29 patients treated with prednisone and azathioprine, approximately 50 percent went into clinical and serologic remission and continued off therapy for a mean follow-up of 4 years.[32] Many of these patients were considered cured. Only one patient in this study died because of complications of therapy. The disease activity of most of the other patients was well controlled.

Mycophenolate mofetil has been shown to have a rapid effect in lowering pemphigus antibody titers and to decrease disease activity, even in patients whose disease is unresponsive to azathioprine.[132–134] As it probably has fewer adverse reactions than azathioprine, it has, in some centers, replaced azathioprine as a first-line agent in treating these patients.

Cyclophosphamide, although more toxic than azathioprine or mycophenolate mofetil, is thought to be very effective in controlling severe disease, with one report of 19 of 23 patients with pemphigus achieving complete remission in a median time of 8.5 months.[135]

Early localized PV may be treated with relatively low-dose prednisone (e.g., 20 mg), often with an immunosuppressive agent.[136] The decision to use immunosuppressive agents in young patients must take into account the potential increased incidence of malignancies that might be associated with the use of these drugs, as well as the risks of infertility (especially associated with cyclophosphamide) and teratogenicity. In some patients, especially those who are elderly with limited disease or those in whom glucocorticoids are contraindicated, immunosuppressive agents alone may be used.[137] Because patients may die from complications of therapy, it is important to monitor all patients closely for potential side effects, such as infection, diabetes, leukopenia, thrombocytopenia, anemia, gastrointestinal ulcer disease, bleeding, liver and renal function abnormalities, high blood pressure, electrolyte disturbances, and osteoporosis.

There are additional, innovative therapies that are usually used when more standard treatment is not effective. For example, the intravenous, pulse administration of methylprednisolone, 250 to 1000 mg given over approximately 3 hours q24h for 4 to 5 consecutive days, can result in long-term remissions and decrease the total dose of glucocorticoids necessary to control disease.[138] Although the purpose of this therapy is to decrease the incidence of complications



of long-term steroid use, it can result in all the usual glucocorticoid complications, as well as cardiac arrhythmias with sudden death, and its use is controversial.[139] Furthermore, a controlled trial found that adjuvant oral dexamethasone pulse therapy in addition to standard therapy with prednisolone and azathioprine for PV is not beneficial.[140] It may be that simply giving divided lower doses of prednisone could accomplish the same result with fewer side effects. Intravenous pulse therapy with cyclophosphamide, with or without pulse therapy with glucocorticoids, has also been reported to result in remissions of PV.[141,142] The advantage of this therapy over that of daily cyclophosphamide has not been clearly established.



Another method of decreasing serum autoantibodies is the intravenous use of γ-globulin in high doses. It may be useful as adjuvant therapy in those whose condition does not respond to more conventional therapy.[143,144] It is thought to function by increasing catabolism of the patient's antibodies, which include the pathogenic autoantibody.[145] It seems to be effective for therapy but is expensive and requires many intravenous infusions for remission and continued infusions for maintenance of remission. There can also be significant side effects with this therapy.[146]

Another potentially very effective therapy for pemphigus that is refractory to more standard therapy is a monoclonal anti-CD20 antibody [rituximab (Rituxan)], mostly used and approved for therapy of B-cell malignancies.[147–149] In pemphigus patients, this monoclonal antibody would also presumably target B cells, the precursors of antibody-producing plasma cells. The B cell also acts to process autoantigen and present it to T cells that provide "help" in stimulating the autoantibody response. Rituximab is given as intravenous therapy once a week for 4 weeks, and such a course can be repeated in approximately 6 months. Improvement is usually seen within 1 to 2 months after the course of therapy. Most patients show at least partial remission and some show dramatic complete remissions; however, serious infections and other adverse effects may be seen, some of which may be due to concomitant use of other immunosuppressives.

Plasmapheresis is sometimes used, in combination with cyclophosphamide or another immunosuppressive agent, for severe pemphigus, or for pemphigus which is unresponsive to a combination of prednisone and immunosuppressive agents. Although one controlled study found it to be ineffective,[150] other studies have found that it both reduces serum levels of pemphigus autoantibodies and controls disease activity.[151] For maximum effectiveness, it is probably necessary to perform plasmapheresis on patients taking immunosuppressive agents to prevent the antibody-rebound phenomenon that can follow the removal of IgG.

Other potential therapies for pemphigus, used less frequently than those that have been discussed, include immunoablative therapy without stem cell rescue; the administration of cyclosporine, gold, antimalarials, or dapsone; and extracorporeal photochemotherapy.[113,152–154]

All in all, there has been a tremendous advance in the armamentarium of therapies for pemphigus since the time before the development of glucocorticoids when PV was a fatal disease. Thanks to these advances, the "row of tombstones" seen in the pathology of PV no longer alludes to its prognosis.

KEY REFERENCES

The full reference list for all chapters is available at www.digm7.com.

15. Aoki V et al: Environmental risk factors in endemic pemphigus foliaceus (fogo selvagem). *J Investig Dermatol Symp Proc* **9**:34, 2004
27. Beutner EH et al: Autoantibodies in pemphigus vulgaris. *JAMA* **192**:682, 1965
35. Stanley JR, Amagai M: Pemphigus, bullous impetigo, and staphylococcal scalded-skin syndrome. *N Engl J Med* **355**:1800, 2006
40. Stanley JR et al: A monoclonal antibody to the desmosomal glycoprotein desmoglein 1 binds the same polypeptide as human autoantibodies in pemphigus foliaceus. *J Immunol* **136**:1227, 1986
42. Amagai M et al: Autoantibodies against a novel epithelial cadherin in pemphigus vulgaris, a disease of cell adhesion. *Cell* **67**:869, 1991
46. Amagai M et al: The clinical phenotype of pemphigus is defined by the anti-desmoglein autoantibody profile. *J Am Acad Dermatol* **40**:170, 1999
53. Amagai M et al: Usefulness of enzyme-linked immunosorbent assay using recombinant desmogleins 1 and 3 for serodiagnosis of pemphigus. *Br J Dermatol* **140**:351, 1999
57. Schiltz JR, Michel B: Production of epidermal acantholysis in normal human skin in vitro by the IgG fraction from pemphigus serum. *J Invest Dermatol* **67**:254, 1976
59. Anhalt GJ et al: Induction of pemphigus in neonatal mice by passive transfer of IgG from patients with the disease. *N Engl J Med* **306**:1189, 1982
71. Mahoney MG et al: Explanation for the clinical and microscopic localization of lesions in pemphigus foliaceus and vulgaris. *J Clin Invest* **103**:461, 1999
89. Hertl M, Eming R, Veldman C: T cell control in autoimmune bullous skin disorders. *J Clin Invest* **116**:1159, 2006
129. Fine JD: Management of acquired bullous skin diseases. *N Engl J Med* **333**:1475, 1995
132. Enk AH, Knop J: Mycophenolate mofetil is effective in the treatment of pemphigus vulgaris. *Arch Dermatol* **135**:54, 1998

CHAPTER 53

Paraneoplastic Pemphigus

Grant J. Anhalt
Carlos H. Nousari

Paraneoplastic pemphigus (PNP) is an autoimmune disorder that is almost always linked to an underlying lymphoproliferative disorder. These features define it: (1) Painful stomatitis and a polymorphous cutaneous eruption with lesions that may be blistering, lichenoid, or resemble erythema multiforme. (2) Histologic findings that reflect the variability of the cutaneous lesions, showing acantholysis, lichenoid, or interface change. (3) Direct immunofluorescence demonstrating deposition of immunoglobulin G (IgG) and complement in the epidermal intercellular spaces, and often granular/linear complement deposition along the epidermal basement membrane zone. (4) Serum autoantibodies that bind the cell surface of skin and mucosae in a pattern typical for pemphigus, but in addition, bind to simple, columnar, and transitional epithelia. (5) These serum autoantibodies identify desmogleins 1 and 3, but additionally identify members of the plakin family of epithelial proteins, such as desmoplakins, envoplakin, and periplakin.[1] The disease is associated, in the majority of cases, with non-Hodgkin lymphoma (NHL), chronic lymphocytic leukemia (CLL), and Castleman disease. There is no regularly effective treatment and most patients die from complications of the disease, including pulmonary involvement with respiratory failure.

PARANEOPLASTIC PEMPHIGUS AT A GLANCE



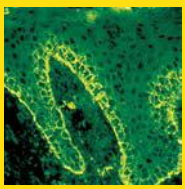

- Rare complication of malignancy, most commonly non-Hodgkin lymphoma, chronic lymphocytic leukemia, or Castleman disease.
- Painful, erosive stomatitis and polymorphous cutaneous lesions that may be blistering and erosive (resembling erythema multiforme), morbilliform, or lichenoid.
- Serum autoantibodies directed against plakin proteins that are detected by indirect immunofluorescence against rodent bladder epithelium.
- High mortality rate, with death due to sepsis, complications of treatment, or bronchiolitis obliterans.
- No consistently effective therapy, but some success with the combined use of rituximab, systemic corticosteroids, and other immunosuppressive agents.

EPIDEMIOLOGY

The incidence of the disease is unknown, but it is less common than pemphigus vulgaris or foliaceus (see Chap. 52). In an analysis of adverse event reporting in 100,000 patients with known NHL and CLL, there were 12 cases of PNP. Of note, only three of these cases were identified by the reporting physician as such, and the remainder were identified only by retrospective data analysis. That implies that the majority of cases are still not properly diagnosed. The most common misdiagnoses applied in this series were erythema multiforme, Stevens-Johnson syndrome, toxic epidermal necrolysis (TEN), and drug reaction.

ETIOLOGY AND PATHOGENESIS

In almost all cases, this syndrome is associated with a limited number of lymphoproliferative neoplasms. The approximate frequency of specific neoplasms has been estimated, based on 140 cases of PNP diagnosed and confirmed by immunoprecipitation demonstration of the characteristic autoantibody profile, to be 44 percent NHL, 19 percent CLL, 16 percent Castleman disease (giant follicular hyperplasia), 8 percent thymoma (malignant and benign), 7 percent sarcomas that are retroperitoneal and often poorly differentiated, 4 percent Waldenström macroglobulinemia, and in 2 percent the neoplasms were too poorly differentiated to categorize (Fig. 53-1). The majority of cases are associated with NHL and CLL, but the disproportionate representation of Castleman disease is notable because of the rarity of this disorder. The association with Castleman is even more striking in pediatric cases, where it is the underlying neoplasm in almost all cases.[2] Before the description of PNP there were many cases of Castleman disease associated with atypical forms of pemphigus, and we suspect most were cases of PNP. Archived clinical material was available from one such case, which subsequently confirmed that the patient had autoantibodies specific for PNP.

With very rare exceptions, more common cancers, such as adenocarcinomas of breast, bowel, and lung, or basal cell and squamous cell carcinoma of skin have not been associated with PNP. There are a few reports of PNP occurring with tumors such as squamous cell carcinoma, but most of these diagnoses have not been confirmed by immunochemical testing, so the association remains unproven.

The mechanisms by which these tumors induce autoimmunity against epithelial proteins remains speculative. One hypothesis states that the tumors constitutively or anomalously express epithelial proteins. These proteins are targeted by the antitumor immune response that cross-reacts with normal constitutive epithelial proteins of the host. This mechanism occurs in several neurologic paraneoplastic syndromes.[3] This antitumor immune response may be initiated by reactivity against plakin proteins, and the antitumor immune response may cross-react with normal constitutive proteins of epithelia. To date, there is no evidence to support this hypothesis.

It is more likely that this autoimmune disease is a result of more complex interactions between the tumor cells and the immune system. There is some evidence that dysregulated cytokine production by tumor cells drives the development of autoimmunity. Patients with PNP have evidence of markedly elevated levels of interleukin 6 (IL-6).[4] It has been observed that in a subset of cases of NHLs,[5] CLL, and Castleman tumors, the tumor cells secrete massive amounts of IL-6 in vitro. IL-6 is known to promote B-cell differentiation and to drive immunoglobulin production, and dysregulated IL-6 production has been implicated in certain autoimmune diseases. Castleman tumors are known to be associated with other autoimmune phenomena such as myasthenia gravis and autoimmune cytopenias, and these patients also have high serum levels of IL-6. Symptoms attributable to Castleman tumors are routinely reversed by complete excision of the affected node(s), and, coincidentally, serum IL-6 levels revert to normal. Administration of anti–IL-6 monoclonal antibodies also effectively reverses systemic manifestations of Castleman disease and is currently being studied in clinical trials.[5]

It had also been proposed that the lymphoid tumor itself may produce autoantibody. Cultures of Castleman tumors have been shown to contain B cells that produce specific autoantibody.[6] However, Castleman tumors are unique in that they are nonclonal neoplasms,

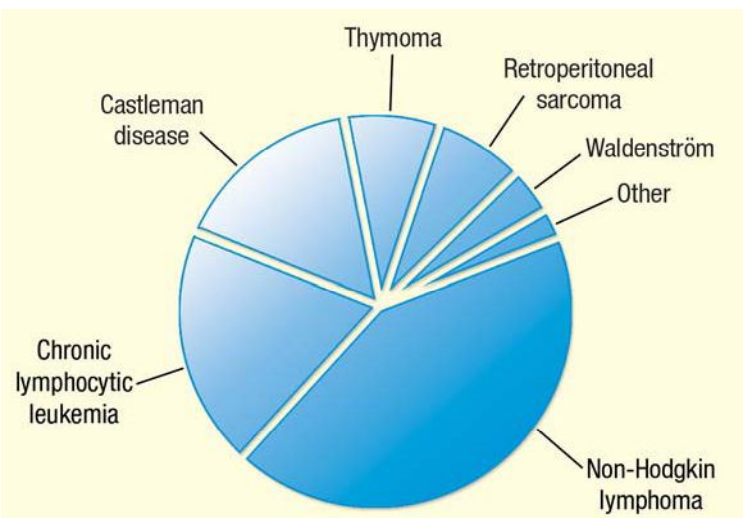

▲ **FIGURE 53-1** Tumors associated with paraneoplastic pemphigus.



and these studies showed the expansion of several immunologically active B-cell clones within the tumors. In Waldenström macroglobulinemia, the autoantibody is not of IgM origin, but is polyclonal and IgG, showing that the tumor cells do not produce the autoantibody.

Almost all patients have autoantibodies against desmogleins, demonstrable by enzyme-linked immunosorbent assay, and when the desmoglein autoantibodies from these patients are injected into neonatal mice, acantholytic skin lesions are induced.[7] However, none of features of the disease that suggest cell-mediated autoimmunity is recreated by immunoglobulin injections. No other internal organs are involved, and there is no lymphocyte-mediated cell damage. This is also an indication that humoral immunity alone reproduces features of acantholysis, but passive transfer of autoimmune cells from these patients may be necessary to reproduce the complete spectrum of the disease in animals.



CLINICAL FINDINGS

History

Cutaneous Lesions

The most constant clinical feature of the disease is the presence of intractable stomatitis (Fig. 53-2A,B). This is the earliest presenting sign, and after treatment it is the one feature that persists throughout the course of the disease and is extremely resistant to therapy. This finding is so consistent that the diagnosis should not be considered if stomatitis is absent.

This stomatitis consists of erosions and ulcerations that can affect all surfaces of the oropharynx. The lesions differ from those seen in pemphigus vulgaris in that they show more necrosis and lichenoid change. They also preferentially localize to the lateral borders of the tongue, and characteristically extend onto and involve the vermilion of the lips. Occasionally, oral lesions are the only manifestation of the disease.

The cutaneous lesions of PNP are quite variable, and different morphologies may occur in an individual patient according to the stage of the disease (see Fig. 53-2C,D). The initial patients reported with the syndrome had episodes of waves of blistering affecting the upper trunk, head and neck, and proximal extremities. These lesions consisted of blisters that ruptured easily, leaving erosions. The blisters on the extremities were sometimes quite tense, resembling those seen in bullous pemphigoid, or they had surrounding erythema, clinically resembling erythema multiforme (see Fig. 53-2D). On the upper chest and back, confluent erosive lesions can develop, producing a picture resembling TEN. The similarity of the mucocutaneous features to erythema multiforme and TEN explains why this is the most common differential diagnosis for PNP. However, it is important to note that erythema multiforme and TEN are self-limited events that evolve and resolve over several weeks, whereas PNP is a relentlessly progressive disease that continuously evolves over months.



▲ **FIGURE 53-2** **A.** Extensive erosions involving the vermillion of the lips in a patient presenting with paraneoplastic pemphigus and an occult lymphoma. The characteristic severe stomatitis, accompanied by polymorphous cutaneous lesions, is the most consistent feature of the disease. **B.** Painful ulcerations tend to localize to the lateral border of the tongue. **C.** Lesions of the trunk from the same patient pictured in **A**. Erythematous macules and papules coalesce and become erosive on the upper chest as the cutaneous lesions evolve. **D.** Lesions from the forearm of the same patient. These lesions clinically resemble erythema multiforme, but biopsy shows a mix of individual cell necrosis, interface change, and acantholysis.

Cutaneous lichenoid eruptions are very common, and they may be the only cutaneous signs of the disease or may develop in lesions that had previously been blistered. When cutaneous lichenoid lesions are present, severe stomatitis is also invariably present. In the chronic form of the disease and after treatment, this lichenoid eruption may predominate over blistering on the cutaneous surface. Both blisters and lichenoid lesions affecting the palms and the soles as well as the paronychial tissues are common and help to distinguish this from pemphigus vulgaris, in which acral and paronychial lesions are uncommon.

There are a small number of patients who appear to have PNP but who do not have demonstrable circulating autoantibodies.[8] These patients tend to have predominantly lichenoid skin and mucosal lesions, but behave in every other way like antibody-positive patients. They have the same underlying neoplasms, and frequently develop bronchiolitis obliterans. Because the definition of the disease relies so heavily on demonstration of the specific autoantibody markers, further study is required to know how to classify these patients. For now, they are called the *lichenoid variant of paraneoplastic pemphigus*.

The disease has also been identified in a horse and two dogs. In animal spe-

cies, the disease has the same associated neoplasms and clinical outcomes.[9]

Related Clinical Findings

PNP is the only form of pemphigus that has involvement of non-stratified squamous epithelium. Approximately 30 percent to 40 percent of cases develop pulmonary injury, often with a fatal outcome.[10] The earliest symptoms are progressive dyspnea associated initially with an absence of findings on chest radiography. Pulmonary functions studies show airflow obstruction, involving large and small airways. Inflammation of the large airways evolves and is evidenced by endoscopic biopsy showing acantholysis of bronchial respiratory epithelium. Pulmonary function deteriorates in most cases despite immunosuppressive therapy, and radiologic, histologic, and functional changes characteristic of bronchiolitis obliterans develop.

LABORATORY TESTS

The key finding is the serologic identification of polyclonal IgG autoantibodies against plakin proteins and, in most cases, desmogleins 1 and 3. The plakins are a group of sequence-related proteins that form the intracellular plaque of desmosomes and hemidesmosomes, and mediate attachment of cytoskeletal intermediate filaments to transmembrane adhesion molecules such as the desmogleins (see Chap. 51). Autoantibodies against these proteins are the most characteristic surrogate markers for the disease. The pattern of antigens recognized by individual patients shows considerable variability, but the most characteristic and consistently recognized plakin antigens are envoplakin[11] and periplakin[12] (210 and 190 kd, respectively; Fig. 53-3). The next most frequently detected are antibodies against desmoplakin I and desmoplakin II (250 and 210 kd, respectively). Less commonly, patients recognize bullous pemphigoid Ag 1 (230 kd), plectin, and plakoglobin. The identity and frequency of an antigen band at 170 kd are not well defined. PNP patients may also have clinical and serologic evidence of other autoimmune phenomena such as myasthenia gravis and autoimmune cytopenias (see Fig. 53-3).

To screen for PNP autoantibodies, one can test for IgG autoantibodies by indirect immunofluorescence reactive with rodent urinary bladder epithelium. A positive result implies the presence of plakin autoantibodies; however, the sensitivity and specificity of this serologic test are only approximately 75 percent and 83 percent, respectively.[13] More specific and sensitive tests include immunoblotting against epidermal cell extracts that can effectively detect antibodies against envoplakin, periplakin, desmoplakin, and immunoprecipitation, using radiolabeled keratinocyte extracts, which can detect antibodies against any of the plakin proteins.

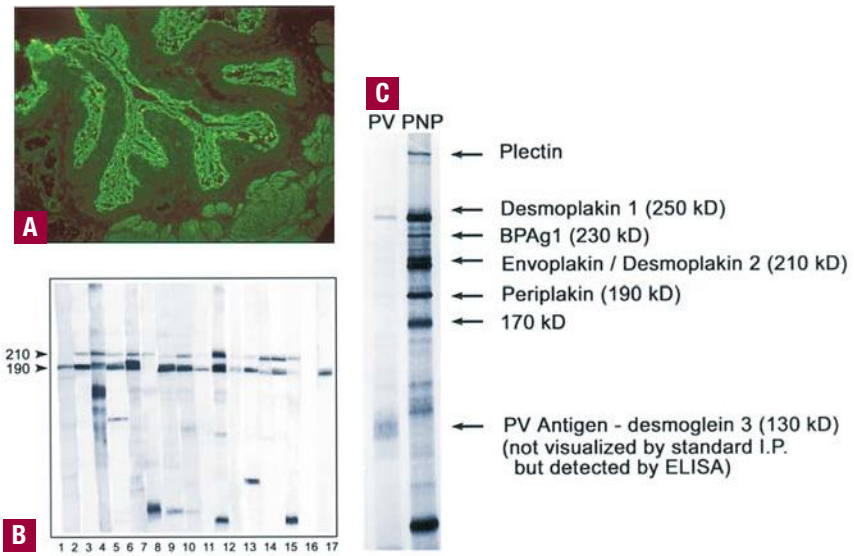

▲ **FIGURE 53-3** Diagnosis of paraneoplastic pemphigus (PNP) depends on the demonstration of antiplakin antibodies. **A.** This can be accomplished by indirect immunofluorescence of patient serum on rodent urinary bladder demonstrating binding of immunoglobulin G to the cell surface of transitional epithelial cells. A positive result implies the presence of anti-plakin antibodies. This technique, although easily performed, has the lowest sensitivity and specificity. **B.** Immunoblotting against epidermal cell extracts is much more sensitive and specific. This shows detection of envoplakin (210 kd) and/or periplakin (190 kd) in 15 patients with PNP. Lane 16 is a normal control, and lane 17 shows a monoclonal antibody against periplakin. This technique uses denatured antigen extracts, so it does not reliably detect some of the PNP antigens, but antibodies against the most characteristic plakin antigens, envoplakin and periplakin, are easily detected. **C.** Immunoprecipitation using radiolabeled, nondenatured epidermal extracts and serum from a patient with PNP and pemphigus vulgaris (PV). In this case, the PNP patient's serum identifies all of the plakin antigens. Envoplakin and desmoplakin II migrate as a doublet at 210 kd. This technique is the most sensitive and specific test for demonstration of anti-plakin antibodies in PNP, but has limited availability. Although this technique readily detects the anti-plakin antibodies, desmoglein 3 is not always efficiently identified, and this is best shown by using enzyme-linked immunosorbent assay (ELISA).

The PNP autoantibody profile is more complex than that observed in pemphigus vulgaris or foliaceus, where there are autoantibodies produced only against the desmogleins. The humoral immunity in PNP may represent an example of epitope spreading in which patients develop autoantibodies against structurally related plakin proteins and structurally unrelated transmembrane cell surface proteins (the desmogleins) that are physically linked to the plakin proteins in the desmosome and hemidesmosome.

Histopathology

The histopathology of PNP is distinctive from pemphigus vulgaris and foliaceus for two reasons. First, because the lesions can be clinically very polymorphous, there is substantial variability in the histologic findings.[14] Second, findings due to cell-mediated cytotoxicity are frequently observed.

Because of the severe mucositis, many biopsies of oral lesions yield non-specific changes of inflammation and ulceration. If one can biopsy perilesional epithelium, a lichenoid mucositis with variable degrees of individual cell necrosis and suprabasilar acantholysis can be observed.

When evaluating biopsies from skin lesions, one must recognize that lesions with different clinical morphologies yield differing histologic findings. In noninflammatory cutaneous blisters, suprabasilar acantholysis is expected to be more prominent than the interface/lichenoid change (Fig. 53-4A). When erythematous macules and papules are sampled, interface and lichenoid dermatitis is predominant (see Fig. 53-4B,C). Lesions with a mixed clinical pattern also show mixed histologic features of concomitant suprabasi-





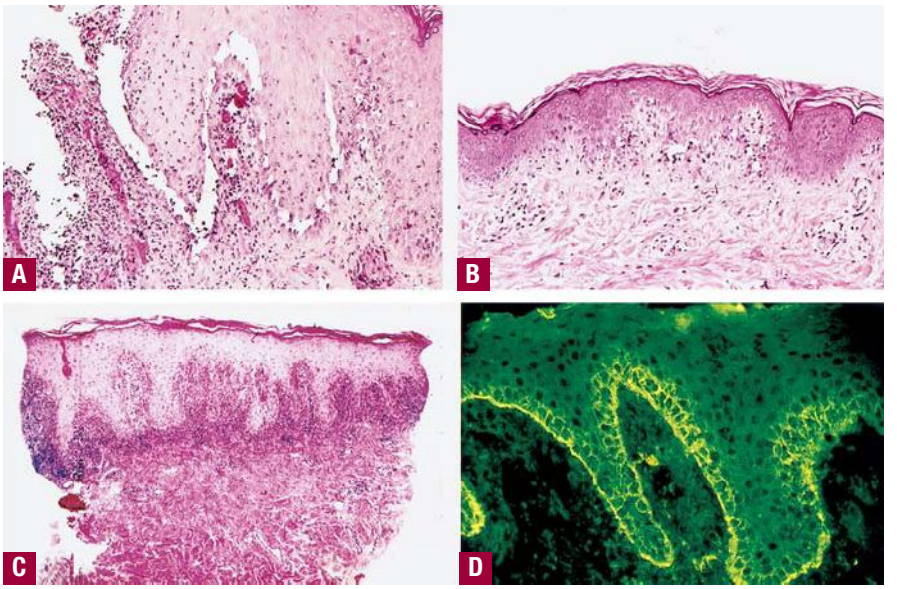

▲ **FIGURE 53-4** **A.** Histopathology of a blistering cutaneous lesion in paraneoplastic pemphigus. This demonstrates the characteristic presence of vacuolar interface change and suprabasilar acantholysis. [Hematoxylin and eosin (H&E), 200×.] **B.** Macular and papular lesions may show just vacuolar interface change. (H&E, 100×.) **C.** Lichenoid lesions demonstrate lichenoid infiltrates on histologic examination. (H&E, 40×.) The presence of these varied histologic findings help differentiate paraneoplastic pemphigus from pemphigus vulgaris. **D.** Direct immunofluorescence can be negative in a significant number of cases, but when positive, the most characteristic changes are those of deposition of immunoglobulin G and complement components on both the surface of basilar and suprabasilar keratinocytes and along the epidermal basement membrane zone. (Immunofluorescence with fluoresceinated anti-immunoglobulin G, 200×.)

lar acantholysis and interface/lichenoid dermatitis.

There is also observed variability of the interface and lichenoid dermatitis. The spectrum of changes can include: (1) individual keratinocyte necrosis with lymphocytic infiltration into the epidermis, reminiscent of that seen in erythema multiforme or graft-versus-host disease; (2) vacuolar interface change with sparse lymphocytic infiltrate of the basilar epithelium, resembling cutaneous lupus erythematosus or dermatomyositis; and (3) a thick lichenoid band along the dermal-epidermal junction similar to that seen in lichen planus. Although most of the specimens show a complex overlap of histologic patterns, there is a relatively good correlation between the clinical and the predominant histologic pattern.

The histopathologic variability of this disease may be related to the fact that it is a presumed antitumor immune response. If this speculation is correct, one would expect to observe a combination of both humoral and cell-mediated immunity that is aberrantly directed against normal epithelium. In such a setting, one would expect to see changes of the sort described in the previous paragraph. This degree of cell-mediated immunity is not seen in pemphigus vulgaris or foliaceous (see Chap. 52); hence the unique histopathologic features, and, presumably, the unique clinical features as well. The presence of T-cell mediated epithelial cytotoxicity has been recently demonstrated in histologic studies.[15]

Immunopathology

Patients should have evidence of IgG autoantibodies bound to the cell surface of affected epithelium by direct immunofluorescence. However, false negatives are more common in PNP than in pemphigus vulgaris and repeated biopsies may be necessary to demonstrate this finding. In a minority of cases, one might also see a combination of both cell surface and basement membrane zone deposition of IgG and complement components, but the absence of this combined cell surface/basement membrane zone staining does not negate the diagnosis (see Fig. 53-4D).

Special Tests

Approximately one-third of patients have an occult malignancy at the time they develop PNP. Neoplasms that would not be detected by routine complete blood count, serum chemistries, and physical examination are most likely to be intra-abdominal lymphoma, intrathoracic or retroperitoneal Castleman tumors, or retroperitoneal sarcomas. The most effective and efficient method for screening for these tumors is either computer-aided tomography or magnetic resonance imaging of the body from the neck to the base of the bladder. Other studies, such as endoscopy, are not required.

DIAGNOSIS AND DIFFERENTIAL DIAGNOSIS

The diagnosis can best be made if the algorithm shown in Fig. 53-5 is followed. The clinical differential diagnosis is summarized in Box 53-1.

PROGNOSIS AND CLINICAL COURSE

It is not known why PNP is so refractory to the type of immunosuppressive treatments that are usually effective in pemphigus vulgaris and other autoimmune diseases.

In those patients who do succumb, death has been attributed in individual cases to multiple factors, including sepsis, gastrointestinal bleeding, "multiorgan failure," and respiratory failure. Patients with autoimmune disease associated with B-cell neoplasms are known to have a high frequency of autoimmune cytopenias, and some fatal episodes of sepsis are suspect to have occurred because of sudden and unexplained neutropenia, possibly due to this mechanism. Respiratory failure is a common terminal event. The development of shortness of breath with obstructive disease progressing to bronchiolitis obliterans is a terminal pathway in most cases. Because these patients have autoantibodies that react with desmoplakins, and because desmoplakins are present in respiratory epithelium, respiratory failure may be due to autoantibody-mediated injury to bronchial epithelium, with plugging of terminal bronchioles, resulting in airflow obstruction and ventilation/perfusion abnormalities. Additionally, direct damage to alveolar epithelium could cause a diffusion barrier and subsequent intractable hypoxia. One autopsy study showed an absence of autoantibodies and a marked infiltration of bronchioles with cytotoxic T cells in a patient who died from PNP and bronchiolitis obliterans. This shows that there may be similar complex humoral and cell-mediated autoimmune injury to the lung, similar to what is seen in the skin. The pulmonary injury does not respond well to medical treatment, and

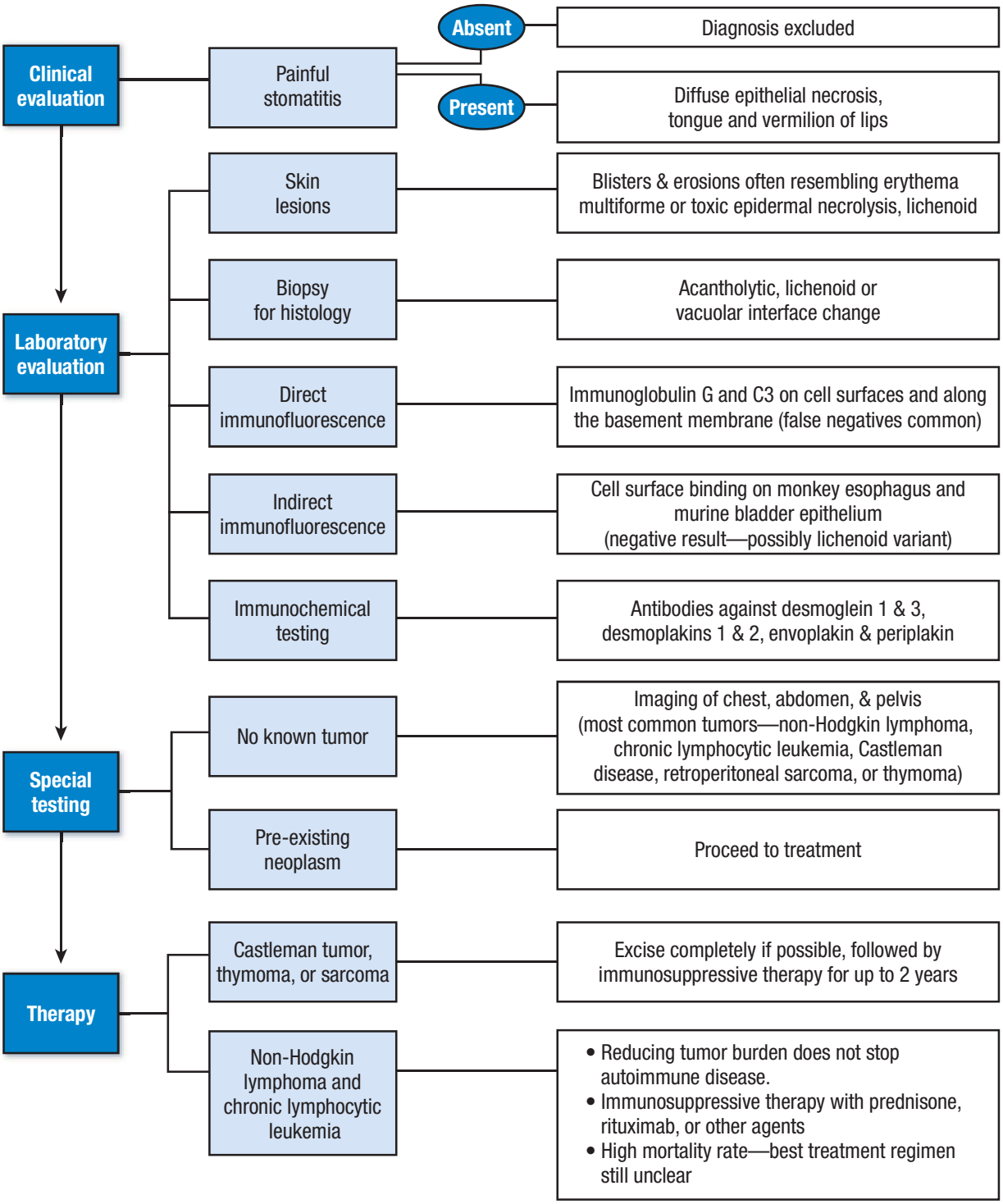

▲ **FIGURE 53-5** Approach to a patient with paraneoplastic pemphigus.

the development of shortness of breath and hypoxia in a patient with this syndrome is an ominous prognostic sign.

In patients with malignant neoplasms there is no definite correlation between tumor burden and the activity of the autoimmune syndrome. Treatment of the primary malignancy does not affect the activity of the autoimmune disease. It seems that once the process is initiated by the malignancy, the autoimmunity progresses independently. An example of the disconnect between tumor burden and autoimmunity is found in the case reported by Fullerton et al.,[16] in which PNP occurred after successful autologous bone marrow transplantation for NHL. This patient was free of detectable tumor burden at the time of his death, but died from pulmonary injury secondary to PNP. It is notable that the patient underwent autologous bone marrow transplantation, and therefore received his own memory T cells, or possibly individual malignant lymphoid cells that were not detectable by routine autopsy methods.

TREATMENT (Box 53-2)

Individuals with benign or encapsulated tumors such as Castleman tumors or thymoma should have them surgically



Box 53-1

Differential Diagnosis of Paraneoplastic Pemphigus

- Oral lesions
  - Pemphigus vulgaris
  - Stevens-Johnson syndrome
  - Mucous membrane pemphigoid
  - Oral lichen planus
  - Chemotherapy-induced stomatitis
  - Major aphthous stomatitis
- Cutaneous lesions
  - Erythema multiforme/Stevens-Johnson syndrome/toxic epidermal necrolysis
  - Pemphigus vulgaris
  - Drug eruption
  - Lichen planus
  - Sub-epidermal blistering disorders

Box 53-2

Treatments for Paraneoplastic Pemphigus

	DRUG	USUAL DOSE	OTHER DOSING
First line	Prednisone	0.5–1.0 mg/kg	Methylprednisolone, 1000 mg IV daily × 3 days
	Rituximab	375 mg/m^2 IV weekly × 4 wk	1000 mg IV weekly × 2 wk
	Daclizumab	2 mg/kg IV weekly × 4 wk, then every other week indefinitely	
Second line	Cyclosporine	5 mg/kg daily	
	Cyclophosphamide	2.5 mg/kg daily	
	Mycophenolate mofetil	1500 mg PO bid	
	High-dose IV immunoglobulin	2 g/kg IV, repeat q 3–4 wk	
	Plasmapheresis	Every other day for six total treatments	



excised. If the entire lesion is removed, the disease generally improves substantially or goes into complete remission. The remission of the autoimmune disease may take 1 to 2 years after surgery, so continued immunosuppression during this period is required. The usual treatment involves combined use of prednisone and rituximab.[17] In pediatric cases with respiratory disease, the persistent autoimmunity immediately postsurgery can cause ongoing pulmonary injury, and lung transplantation might be required for long-term survival.[18]

In patients with malignant neoplasms, there is no consensus regarding a therapeutic regimen that is consistently effective. Although there are a couple of individual reports of long-term survivors, almost all patients with NHL or CLL succumb in a period of 1 month to 2 years after diagnosis. Oral corticosteroids in a dose of 0.5 to 1.0 mg/kg produce partial improvement, but not complete resolution of lesions. Although cutaneous lesions respond more quickly to therapy, the stomatitis is generally quite refractory to any form of therapy. In addition to corticosteroids, many other agents have been tried in individual cases, but none has proven to be particularly effective. Methods that have been tried and that have frequently been unsuccessful include immunosuppression with cyclophosphamide, mycophenolate mofetil or azathioprine, gold, dapsone, plasmapheresis, and photopheresis. A small number of patients have shown a good response to combination treatment directed at both humoral and cell-mediated autoimmunity. These patients received oral prednisone, rituximab, and daclizumab, a monoclonal antibody against CD 25, the high affinity IL-2 receptor. This appears to be a less toxic way of downregulating both humoral and cell-mediated autoimmunity, with promising early results.

PREVENTION

There is no known intervention that may prevent the development of PNP in a patient with a known lymphoid malignancy. Although there have been individual case reports of PNP perhaps being triggered by certain drugs, radiation therapy, or cytokine administration, it is still not clear that any of these treatments triggered the autoimmune disease, and it appears more likely that the neoplasm itself triggers the autoimmunity.

KEY REFERENCES

The full reference list for all chapters is available at www.digm7.com.

1. Anhalt GJ et al: Paraneoplastic pemphigus: An autoimmune mucocutaneous disease associated with neoplasia. *N Engl J Med* **323**:1729, 1990
3. Posner JB. Immunology of paraneoplastic syndromes: Overview. *Ann N Y Acad Sci* **998**:178, 2003
4. Nousari HC et al: Elevated levels of interleukin-6 in paraneoplastic pemphigus. *J Invest Dermatol* **112**:396, 1999
8. Cummins DL, et al. Lichenoid paraneoplastic pemphigus in the absence of detectable antibodies. *J Am Acad Dermatol* **56**:153, 2007
10. Nousari HC et al: The mechanism of respiratory failure in paraneoplastic pemphigus. *N Engl J Med* **340**:1406, 1999
11. Kim SC et al: cDNA cloning of the 210-kDa paraneoplastic pemphigus antigen reveals that envoplakin is a component of the antigen complex. *J Invest Dermatol* **109**:365, 1997
17. Borradori L et al: Anti-CD20 monoclonal antibody (rituximab) for refractory erosive stomatitis secondary to CD20(+) follicular lymphoma-associated paraneoplastic pemphigus. *Arch Dermatol* **137**:269, 2001

CHAPTER 54

Bullous Pemphigoid

John R. Stanley

Walter Lever was a pioneer in classifying bullous pemphigoid as a disease different from pemphigus with its own distinctive clinical and histologic features.[1] This was important because at the time pemphigus vulgaris usually was fatal, whereas bullous pemphigoid had a comparatively good prognosis. This classification of bullous pemphigoid and pemphigus was confirmed and fully justified by the distinctive immunopathologic features of these diseases discovered approximately 12 years later.[2,3]

EPIDEMIOLOGY

The majority of patients with bullous pemphigoid are older than 60 years old at the age of onset, with a peak incidence in the 80s and older.[4,5] Although bullous pemphigoid does occur rarely in children,[6] reports earlier than approximately 1970 (when the use of immunofluorescence for diagnosis became more widespread) were inaccurate because these most likely included children with chronic bullous disease of childhood, which is now differentiated from bullous pemphigoid by the presence of immunoglobulin A (IgA), rather than IgG, at the basement membrane zone. There is no known ethnic, racial, or sexual predilection for developing bullous pemphigoid. The incidence of bullous pemphigoid is estimated to be seven per million per year in both France and Germany, and 14 per million per year in Scotland.[5,7,8] However, the incidence in Scottish men older than 85 years old is reported as 472 cases per million per year.

BULLOUS PEMPHIGOID AT A GLANCE



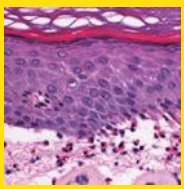

- Usually occurs in elderly patients.
- Mortality 6 percent to 40 percent in 1 year.
- Pruritic urticarial lesions and tense large blisters. Oral mucous membrane erosions in minority of patients.
- Pathology shows sub-epidermal blisters with eosinophils.
- Direct immunofluorescence shows C3 and immunoglobulin G at epidermal basement membrane, indirect immunofluorescence shows anti–basement membrane immunoglobulin G in serum.
- Autoantigens are proteins in the keratinocyte hemidesmosome, a basal cell-basement membrane adhesion structure.
- Therapy includes topical and systemic corticosteroids and immunosuppressives.

ETIOLOGY AND PATHOGENESIS

Electron Microscopy

Ultrastructural studies demonstrate that early blister formation in bullous pemphigoid occurs in the lamina lucida, between the basal cell membrane and the lamina densa.[9] With blister formation, there is loss of anchoring filaments and hemidesmosomes. With degranulation of infiltrating leukocytes, there is fragmentation and ultimate loss of the lamina densa.[10] In addition, degranulation of mast cells near the epidermal basement membrane has been observed both by light and electron microscopy.[11]

Immunopathology

Direct immunofluorescence of perilesional skin from pemphigoid patients reveals immunoreactants deposited in a linear pattern at the epidermal basement membrane.[2,3] C3 is detected in almost all patients, sometimes as the sole immunoreactant; however, IgG is also detected in most patients (Fig. 54-1A).[12–14]

Indirect immunofluorescence indicates that approximately 70 percent to 80 percent of patients with bullous pemphigoid have circulating IgG that binds to the basement membrane of normal stratified squamous epithelia, such as human epidermis or monkey esophagus (see Fig. 54-1B).[12–15] Most patients with circulating anti–basement membrane IgG also have anti–basement membrane IgE in their sera.[16–18] If the immunofluorescence substrate is incubated first in 1 *M* NaCl to separate the epidermis from the dermis at the lamina lucida, then an even higher percentage of patients will have detectable circulating antibody.[19,20] In addition to being more sensitive, the other advantage of this 1 *M* NaCl-split substrate is that bullous pemphigoid antibodies bind to the roof of the artificially induced blister (i.e., the bottom of the basal cells) and thus can be differentiated from the antibodies of patients with epidermolysis bullosa acquisita (EBA); their antibodies bind the base (i.e., dermal side; Fig. 54-2). In contrast to pemphigus, in bullous pemphigoid the indirect immunofluorescence



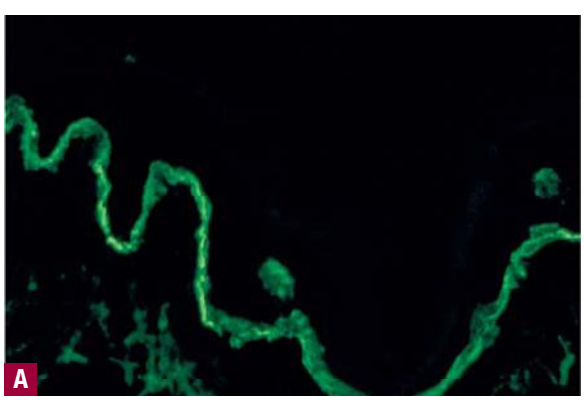

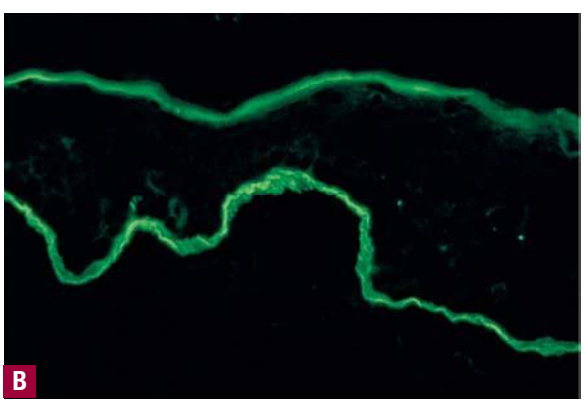

▲ **FIGURE 54-1** Immunofluorescence in bullous pemphigoid. **A.** Direct immunofluorescence of perilesional skin shows a linear band of C3 (×340). **B.** Indirect immunofluorescence shows a linear pattern of immunoglobulin G binding to the epidermal basement membrane of normal skin (×340).

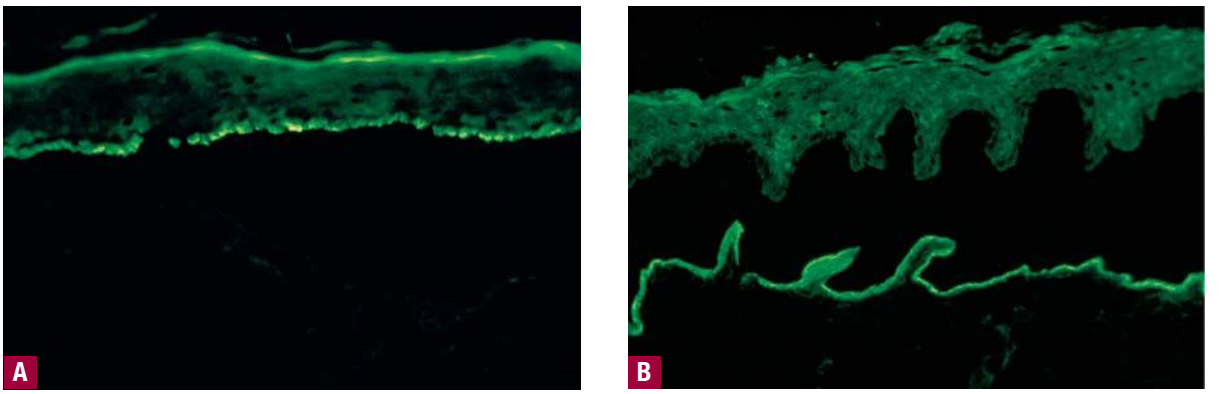

▲ **FIGURE 54-2** Indirect immunofluorescence on normal skin previously incubated in 1 *M* NaCl. **A.** Immunoglobulin G (IgG) from bullous pemphigoid serum binds to the roof of the artificial blister (×330). **B.** IgG in epidermolysis bullosa acquisita serum binds to the base (×215).



antibody titer does not usually correlate with disease extent or activity.[21]

In addition to C3, other components of both the classical and alternative complement pathways and the complement regulatory protein β1H are deposited at the epidermal basement membrane zone in bullous pemphigoid patients.[22–24] Activated complement components are found in the blister fluid of these patients, and in vitro complement fixation immunofluorescence assays indicate the ability of bullous pemphigoid sera to fix complement components of the classical and alternative pathways to the epidermal basement membrane. These studies suggest that bullous pemphigoid IgG causes complement activation by the classic pathway, with activation of the alternative pathway by the C3 amplification mechanism.

Pemphigoid Antigens

Immunoelectron microscopic studies have localized bullous pemphigoid antigen in the hemidesmosome, an adhesion junction important in anchoring the basal cell to the basement membrane.[25,26] Autoantibodies bind both inside the cell to the plaque of the hemidesmosome and outside the cell to the extracellular face of the hemidesmosome.

Molecular characterization of bullous pemphigoid antigen by immunochemical methods revealed the unexpected finding that autoantibodies from these patients bind two distinct molecules.[27] Most bullous pemphigoid patients have antibodies against a 230-kd molecule.[28–30] Cloning of the complementary DNA encoding this molecule (now called *BPAG1* or *BPAG1e*) indicated that it belongs to a gene family that includes desmoplakin I, a desmosome plaque protein that is important in anchoring keratin intermediate filaments to the desmosome (see Chap. 51).[31,32] BPAG1e has been localized ultrastructurally to the plaque of the hemidesmosome, exactly where keratin intermediate filaments insert.[33] Further proof that the function of BPAGle is to anchor keratin intermediate filaments to the hemidesmosome was obtained by analysis of a mouse that was genetically engineered with a targeted deletion of this molecule.[34] This mouse showed fragility of basal cells due to collapse of the keratin filament network but no epidermal-dermal adhesion defect, suggesting that bullous pemphigoid antibodies do not act by inhibiting the function of BPAG1e. In fact, because BPAG1e is inside the cell, it is unclear if patient autoantibodies normally have access to it. Interestingly, an alternatively spliced form of BPAG1e is expressed in neural tissue. Now termed *BPAG1n*, this form stabilizes the cytoskeleton of sensory nerves,[35,36] just as BPAG1e stabilizes the cytoskeleton of epidermal cells.

Immunochemical studies have also revealed that almost all patients with bullous pemphigoid, as well as patients with herpes gestationis, have autoantibodies against a 180-kd molecule now called *BPAG2* or *type XVII collagen*.[37–39] The complementary DNA encoding the BPAG2 molecule has been cloned, and the expressed protein is a transmembrane molecule with a collagenous extracellular domain.[40] Antibodies against BPAG2 localize it as a transmembrane molecule at the hemidesmosome, and cell biologic studies indicate that its cytoplasmic domain targets it to that location.[41,42] The extracellular domain of BPAG2 has been localized to anchoring filaments.[43] The autoantibodies from most patients with bullous pemphigoid (as well as those from patients with pemphigoid gestationis; see Chap. 57) recognize a particular epitope (called *NC16a*) in a small noncollagenous region of BPAG2 that is just outside the membrane.[44,45] As discussed in Pathophysiology of Lesion Production, antibodies against this epitope are capable of mediating sub-epidermal blister formation in neonatal mice. At initial presentation, enzyme-linked immunosorbent assay to measure reactivity of patient sera against the NC16a domain of BPAG2 is both sensitive and specific for a diagnosis of bullous pemphigoid.[46–48] In addition, antibody titers against this epitope, as determined by enzyme-linked immunoassay, correlate with disease activity.[49] Further evidence that BPAG2 mediates epidermal-dermal adhesion comes from analysis of the gene defect in patients with the genetic sub-epidermal blistering disease generalized atrophic benign epidermolysis bullosa. These patients have recessively inherited mutations in the *BPAG2* gene that result in a missing or dysfunctional protein (see Chap. 60).[50]

Not only patients with bullous pemphigoid and herpes gestationis but also patients with linear IgA disease, cicatricial pemphigoid, and lichen planus pemphigoides have antibodies against BPAG2 or its metabolic products.[51]

Pathophysiology of Lesion Production

Autoantibodies, particularly those against BPAG2, detected in patients with bullous pemphigoid are probably pathogenic. Bullous pemphigoid IgG injected into rabbit cornea fixes to the basement membrane and causes subepithelial blister formation.[52] In vitro studies with normal human skin sections indicate that the bullous pemphigoid IgG is capable of activating complement by the classical pathway, thereby causing leu-

kocyte adherence to the basement membrane, with degranulation and resulting dermal-epidermal separation.[53] Almost all patients with active bullous pemphigoid have anti-BPAG2 IgG1, a subclass capable of complement fixation, whereas most patients in remission have anti-BPAG2 IgG4, which does not fix complement.[54]

In an elegant and informative animal model, it has been demonstrated that antibodies against BPAG2 can induce disease by passive transfer to neonatal mice.[55] In these studies, antibodies were raised in rabbits against the epitope on mouse BPAG2 that corresponds to the epitope that most human bullous pemphigoid and pemphigoid gestationis sera recognize. Passive transfer of these rabbit antibodies to neonatal mice induces blisters with histology very similar to that of bullous pemphigoid lesions. In this model, complement, neutrophils, and neutrophil elastase are necessary for anti-BPAG2 induction of blister formation.[56–59] Further observations with this model show that mast cell deficient, matrix metalloproteinase-9–deficient, and gelatinase B–deficient mice are resistant to anti-BPAG2 blistering.[60–63] Matrix metalloproteinase-9 and gelatinase B are thought to degrade antiproteinase 1 and decrease its inhibition of neutrophil elastase.[62,63]

IgE anti-BPAG2 antibodies may also play a role in blister formation.[17,18] The antibodies not only bind to the epidermal basement membrane, but also, through their Fc tail, bind the surface of mast cells. BPAG2 fragments, either released during the normal remodeling of the basement membrane or from protease degradation in bullous pemphigoid, or both, may bind these IgE antibodies, thereby causing degranulation of mast cells.

The preceding immunopathologic observations are consistent with a proposed pathophysiologic explanation for blister formation in bullous pemphigoid (Fig. 54-3).[63] The initial step in blister formation is postulated to be antibody binding to the bullous pemphigoid antigen. Fixation of IgG to the basement membrane activates the classic complement cascade and probably also the C3 amplification mechanism. Activated complement components cause chemotaxis of leukocytes as well as degranulation of mast cells. Anti-BPAG2 IgE may also contribute to mast cell degranulation. Mast cell products cause chemotaxis of eosinophils through mediators such as eosinophil chemotactic factor of anaphylaxis. Finally, leukocyte and mast cell proteases result in dermal-epidermal separation. For example, eosinophils, the predominant inflammatory cell at the basement membrane in bullous pemphigoid lesions, produce a gelatinase that cleaves the collagenous extracellular domain of BPAG2, probably contributing to blister formation.[64] In mice, neutrophil elastase is critical for blister formation, as discussed earlier in this section. Various other proteases may also be involved in regulating this cascade of events as shown in Fig. 54-3. The relative importance of each of these pathways in blister formation in humans remains to be determined.

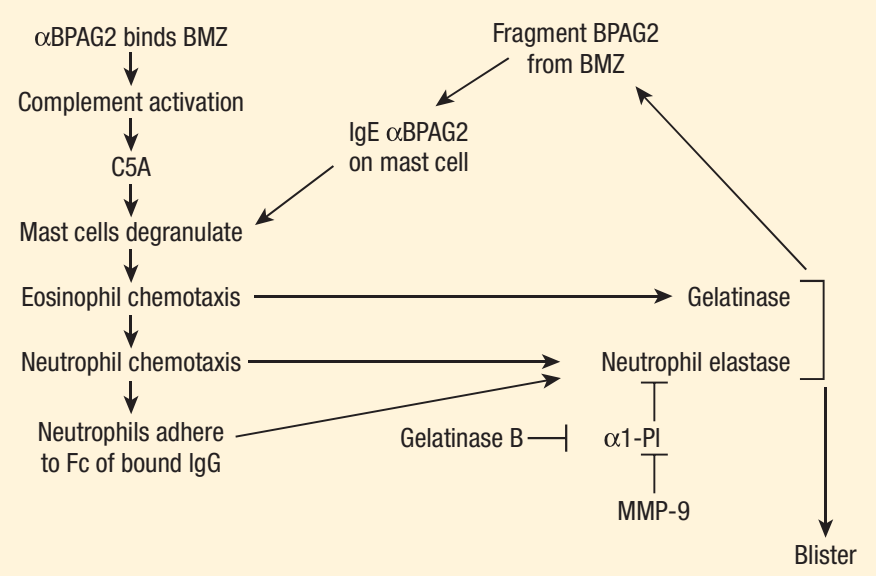

▲ **FIGURE 54-3** Simplified schematic for one model of the pathophysiology of blister formation in bullous pemphigoid. BMZ, basement membrane zone; Ig = immunoglobulin; MMP-9 = matrix metalloproteinase 9.

In light of identification of the bullous pemphigoid antigens as components of the hemidesmosome, it also must be considered that antibodies may interfere directly with the function of this adhesion junction thought to be important in anchoring the basal cells to the basement membrane. In this regard, a mechanism of blister formation in which antibodies against BPAG2 interfere with hemidesmosome formation has been proposed.[65]

The involvement of antibodies against BPAG1, as opposed to BPAG2, in causing blisters is not as well established. A few experimental animal models suggest that these antibodies may be involved, especially after basement membrane damage, but the evidence not as convincing for primary causation as that for anti-BPAG 2 antbiodies.[66,67]

As in most autoimmune diseases, the cause of the induction of autoantibody production in bullous pemphigoid remains obscure, although the overexpression of the class II major histocompatability complex allele *DQbeta1*0301* in bullous pemphigoid patients suggests that presentation of BPAG2 peptides to the immune system in a way that causes disease is restricted to individuals with certain immune response genes.[68]

CLINICAL FINDINGS

Skin and Mucous Membrane Involvement

The skin lesion characteristic of bullous pemphigoid is a large, tense blister arising on normal skin or on an erythematous base (Fig. 54-4).[4] These lesions are most common on the lower abdomen, inner or anterior thighs, and flexor forearms, although they may occur anywhere. The bullae usually are filled with clear fluid but may be hemorrhagic. Eroded skin from ruptured blisters usually shows a good tendency to reepithelialize, and, unlike pemphigus vulgaris, these erosions do not tend to expand at the periphery. However, new, discrete vesicles may form at the edge of old, resolving lesions. The lesions of bullous pemphigoid do not scar. There is usually, but not always, marked pruritus.

Sometimes the erythematous component predominates, and patients may present with urticarial lesions, especially early in the course of disease (see Fig. 54-4B). The erythematous component also can appear serpiginous, with peripheral blisters, and may be quite ex-







▲ **FIGURE 54-4** Bullous pemphigoid. **A.** Large, tense bullae and erythematous macules on the thighs and lower legs. (Used with permission from James Fitzpatrick, MD.) **B.** Urticarial lesions of bullous pemphigoid.

tensive (Fig. 54-5). Resolution usually occurs from the center and may be accompanied by hyperpigmentation.

Mucous membrane lesions occur in approximately 10 percent to 35 percent of patients and are almost always limited to the oral mucous membranes, especially the buccal mucosa.[4,12] Intact blisters or, more usually, erosions are seen. These do not scar and usually are not extensive. Unlike erythema multiforme, the vermillion border of the lips is involved rarely.

In addition to the characteristic clinical findings, there have been descriptions of bullous pemphigoid with unusual presentations.[69] In all these cases, the diagnosis has been confirmed by immunofluorescence findings. For example, lesions in bullous pemphigoid sometimes are localized, most commonly to the lower legs.[70] These patients with localized disease have antibodies against the same pemphigoid antigens described in Pathophysiology of Lesion Production[71,72] and they may go on to generalized bullous pemphigoid or remain localized for years. There is a specific type of localized pemphigoid described in young girls in which blisters and erosions are limited to the vulvar and perivulvar area.[73] As in other forms of localized pemphigoid and childhood pemphigoid, antibodies from this disease bind the pemphigoid antigens.[6,73] Not infrequently, especially early in disease, patients may have only urticarial and eczematous lesions without bullae. Other less usual presentations include erythroderma, prurigo nodularis–like or vegetating lesions, and dyshidrotic dermatitis–like lesions. Again, the antibodies from these patients show typical immunofluorescence localization and bind the pemphigoid antigens.[74–77]

Precipitating Factors

Most cases of bullous pemphigoid occur sporadically without any obvious precipitating factors. However, there are several reports of precipitation of bullous pemphigoid by ultraviolet (UV) light, either UVB or psoralens with UVA, and radiation therapy.[78–81]

Laboratory Abnormalities

In addition to the immunopathologic features described earlier, almost one-half of patients will have elevated total serum IgE, levels of which are positively correlated with IgG anti–basement membrane zone immunofluorescence titers.[14,82,83] Furthermore, elevated levels of IgE correlate with the presence of pruritus.[14] Finally, approximately one-half of patients have peripheral blood eosinophilia, sometimes marked, but not correlated with serum IgE levels.[14,84]

HISTOPATHOLOGY

Biopsy of an early small blister is most diagnostic. Histology of such a biopsy shows a sub-epidermal blister without epidermal necrosis and with a superficial dermal infiltrate consisting characteristically of lymphocytes, histiocytes, and eosinophils (Fig. 54-6A).[4] The degree of the infiltrate ranges from intense to sparse, but it characteristically contains





▲ **FIGURE 54-5** Bullous pemphigoid. **A.** Extensive urticarial, inflammatory plaques with central regression and hyperpigmentation. **B.** Large, tense bullae and erythematous urticarial-type lesions.

some eosinophils. Biopsies from blisters arising on erythematous bases tend to have more extensive infiltrates. Eosinophils are also seen often in the blister cavity. Neutrophils may be seen in the infiltrate, but in contrast to histologic findings in dermatitis herpetiformis, they seldom form microabscesses in the papillary tips. Urticarial lesions may show only a superficial dermal infiltrate of lymphocytes, histiocytes, and eosinophils with papillary dermal edema. Histology of these urticarial lesions also may display degranulating eosinophils at the dermal-epidermal junction, with early separation of individual basal cells from the basement membrane and/or eosinophilic spongiosis (see Fig. 54-6B).[85]

ASSOCIATED DISEASES

There have been many case reports of bullous pemphigoid associated with malignancy. However, bullous pemphigoid occurs in elderly patients, as does malignancy, and case-control studies suggest that there is no increase, or a very small increase, in the incidence of malignancy in patients compared with age-matched controls.[86–88] However, there may be an increased incidence of malignancy in bullous pemphigoid patients



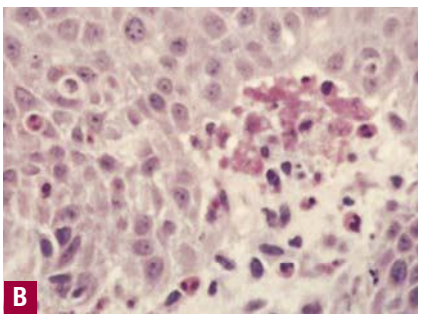

▶ **FIGURE 54-6** Histopathology of bullous pemphigoid. **A.** Sub-epidermal blister with an inflammatory cell infiltrate, containing eosinophils, in the superficial dermis. **B.** Degranulating eosinophils at the epidermal basement membrane and eosinophilic spongiosis.

with negative indirect immunofluorescence as compared with those with positive indirect immunofluorescence.[12,89] Whether this increase means that in indirect immunofluorescence–negative patients with bullous pemphigoid there is an overall increased incidence of malignancy compared with age-matched controls is not known. Most authors agree that, other than a general physical examination and good review of systems, an extensive screening workup for an asymptomatic malignancy is not indicated for a bullous pemphigoid patient.

The coexistence of bullous pemphigoid and lichen planus (see Chap. 26), referred to as *lichen planus pemphigoides*, has been well documented.[90] These cases show typical clinical, histologic, and immunopathologic features of both diseases. It is postulated that anti–basement membrane zone antibodies develop as a consequence of the damage induced by the T-cell lymphocytic infiltrate at the basement membrane in lichen planus. Some authors have reported an association of bullous pemphigoid with various other autoimmune diseases, including pemphigus.[91–94] These associations occur only rarely. Finally, there may be a slight increased incidence of psoriasis in bullous pemphigoid patients as compared with age-matched controls.[95,96]

DIFFERENTIAL DIAGNOSIS

Bullous pemphigoid can be differentiated easily from most other blistering diseases, such as linear IgA disease, chronic bullous disease of childhood, dermatitis herpetiformis, erythema multiforme, and pemphigus, by histology and immunofluorescence (Box 54-1). The most difficult diseases to differentiate from bullous pemphigoid are EBA and cicatricial pemphigoid.[97,98] EBA usually can be distinguished by clinical criteria if it presents as a noninflammatory mechanobullous disease (see Chap. 58). However, occasionally it may present as an inflammatory disease that may be similar clinically and histologically to bullous pemphigoid.[97] By routine direct and indirect immunofluorescence, these diseases also may show indistinguishable findings. However, EBA may be distinguished from bullous pemphigoid by indirect or direct immunofluorescence on skin incubated in 1 *M* sodium chloride to cause a split in the lamina lucida, as discussed in Immunopathology (see Fig. 54-2).[99] Immunoelectron microscopy also distinguishes these diseases because the IgG in EBA is below the lamina densa on the anchoring fibrils,[100] whereas the IgG in bullous pemphigoid is closely associated with the basal cell hemidesmosomes. Finally, autoantibodies from EBA patients bind type VII collagen.[101]

As opposed to bullous pemphigoid, cicatricial pemphigoid usually manifests clinical activity predominantly, if not exclusively, on mucous membranes (see Chap. 55). Cicatricial pemphigoid is characterized by desquamative gingivitis as well as inflammation and scarring of conjunctiva. If there is blistering of the skin, it may be transient or may result in scarring. Large, tense blisters, which are characteristic of bullous pemphigoid, are usually not seen in cicatricial pemphigoid.

Box 54-1

Differential Diagnosis of Bullous Pemphigoid

- Sub-epidermal blistering diseases with autoantibodies
  - Pemphigoid gestationis
  - Cicatricial pemphigoid
  - Epidermolysis bullosa acquisita
  - Linear immunoglobulin A disease and chronic bullous disease of childhood
  - Dermatitis herpetiformis
  - Bullous lupus erythematosus
  - Very rare diseases with not fully characterized basement membrane antigens (a, b)
- Sub-epidermal blistering diseases without autoantibodies
  - Erythema multiforme
  - Toxic epidermal necrolysis
  - Porphyria
  - Epidermolysis bullosa
- Intraepidermal blistering diseases with autoantibodies
  - Pemphigus
- Intraepidermal blistering diseases without autoantibodies
  - Allergic contact dermatitis (e.g., rhus dermatitis)
  - Bullous impetigo, staphylococcal scalded-skin syndrome
  - Friction blister
  - Hailey-Hailey disease
  - Incontinentia pigmenti

Adapted from Zillikens D et al: A novel subepidermal blistering disease with autoantibodies to a 200-kDa antigen of the basement membrane zone. *J Invest Dermatol* **106**:1333, 1996; and Egan CA et al: Anti-p200 pemphigoid: diagnosis and treatment of a case presenting as an inflammatory subepidermal blistering disease. *J Am Acad Dermatol* **46**:786, 2002.

PROGNOSIS AND CLINICAL COURSE

Bullous pemphigoid, even without therapy, may be a self-limited disease, but it may last from several months to many years. Lever[4] reported that 8 of 30 adults with bullous pemphigoid, before the advent of glucocorticoid therapy, went into remission after approximately 15 months (range, 3 to 38 months) of active disease. The 1-year mortality of patients with bullous pemphigoid has been reported to be between 19 percent and 40 percent in Europe, but lower (less than 6 percent to 12 percent) in the United



States.[6,102–106] Old age and poor general health were associated with poor prognosis, as might be expected.[103] Thus, bullous pemphigoid is a potentially fatal disease mostly in the elderly, whose health already may be fragile.

Approximately one-half of treated patients go into remission within approximately 2.5 to 6.0 years; however, in individual patients, disease may continue for 10 years or more.[12,14] Clinical remission with reversion of direct and indirect immunofluorescence to negative has been noted in patients, even those with severe generalized disease, treated with oral corticosteroids alone or with azathioprine.[13,14]



TREATMENT

Localized bullous pemphigoid often can be treated successfully with topical corticosteroids alone (Box 54-2).[13,14,107] Topical tacrolimus has also been reported to be useful in a few cases of localized pemphigoid.[107–111]

More extensive disease, which may be more difficult to control than less extensive disease,[13] is usually treated with oral prednisone.[107,112] However, a randomized controlled clinical trial from France has shown that potent topical steroids are effective in both moderate and severe bullous pemphigoid, and in patients with extensive disease, but not moderate disease, topical therapy with 40 g/day of clobetasol propionate cream 0.05 percent, applied twice a day, was safer and more effective than oral prednisone starting at 1 mg/kg/day once a day.[113] This topical therapy did result in significant systemic absorption and may be effective through a combination of local and systemic effects.[114] Such therapy may not be practical in the United States.

In elderly patients, the complications of systemic glucocorticoid therapy (such as osteoporosis, diabetes, and immunosuppression) may be especially severe.[115] Therefore, it is important to try to minimize the total dose and duration of therapy with oral glucocorticoids. Starting doses of prednisone of 0.75 mg/kg/day or even less may be adequate for disease control.[116] In addition, immunosuppressive agents such as azathioprine (and less often methotrexate or cyclophosphamide) often are used for their potential steroid-sparing effects,[107,112,117–119] although very few controlled trials have addressed this common approach to therapy.[112,116] One of the few controlled trials for therapy of bullous pemphigoid found that if systemic corticosteroids are given at rather high dosage for 4 weeks without taper, the addition of azathioprine does not add appreciable benefit.[120] Therefore, the beneficial effects of azathioprine may reside in its steroid-sparing effects.[117] In elderly patients, these immunosuppressives may be used during initial therapy and even may be used without accompanying prednisone in limited disease. However, to bring widespread disease under rapid control, systemic or intensive topical corticosteroids are often necessary because their effect is usually rapid (within days), whereas immunosuppressives may take at least 4 to 6 weeks to show a salutary effect. High-dose "pulse" therapy with intravenous methylprednisolone also has been reported to be effective in rapidly controlling active blister formation in bullous pemphigoid.[121]

Sulfones may be effective in a minority of patients. Dapsone and sulfapyridine have been reported to control disease activity in 15 percent to 44 percent of bullous pemphigoid patients.[107,122–124]

Reports have described successful treatment of some bullous pemphigoid patients with tetracycline and nicotinamide or variations on this theme, such as erythromycin and nicotinamide or tetracycline alone.[125–127] In small numbers of patients, other therapies reported to be effective include mycophenolate mofetil (which may provide a less toxic alternative for azathioprine),[107,128,129] plasmapheresis,[130] intravenous γ globulin,[131–133] methotrexate,[134] leflunomide,[135] and chlorambucil.[136]

Box 54-2

Treatments for Bullous Pemphigoid

- Corticosteroids
  - High potency topical
  - Prednisone
- Other immunosuppressive agents
  - Azathioprine
  - Mycophenolate mofetil
- Modulators of antibody levels
  - Intravenous gammaglobulin
  - Plasmapheresis
- Other
  - Tetracycline or erythromycin and nicotinamide
  - Dapsone
  - Topical tacrolimus

KEY REFERENCES

The full reference list for all chapters is available at www.digm7.com.

9. Lever WF: Pemphigus and pemphigoid. *J Am Acad Dermatol* **1**:2, 1979
15. Beutner EH et al: The immunopathology of pemphigus and bullous pemphigoid. *J Invest Dermatol* **51**:63, 1968
31. Stanley JR et al: Isolation of cDNA for bullous pemphigoid antigen by use of patients' autoantibodies. *J Clin Invest* **82**:1864, 1988
40. Giudice GJ et al: Cloning and primary structural analysis of the bullous pemphigoid autoantigen BP180. *J Invest Dermatol* **99**:243, 1992
63. Liu Z. Bullous pemphigoid: Using animal models to study the immunopathology. *J Investig Dermatol Symp Proc* **9**:41, 2004
103. Joly P et al: Prediction of survival for patients with bullous pemphigoid: a prospective study. *Arch Dermatol* **141**:691, 2005
107. Fine JD: Management of acquired bullous skin diseases (see comments). *N Engl J Med* **333**:1475, 1995
112. Wojnarowska F et al: Guidelines for the management of bullous pemphigoid. *Br J Dermatol* **147**:214, 2002

CHAPTER 55

Cicatricial Pemphigoid

Kim B. Yancey

Cicatricial pemphigoid (alternate designation: mucous membrane pemphigoid) is a rare chronic autoimmune subepithelial blistering disease characterized by erosive lesions of mucous membranes and skin that result in scarring of at least some sites of involvement.[1–6]

EPIDEMIOLOGY

Cicatricial pemphigoid has been estimated to occur in approximately 1 person per million annually; females are affected 1.5 to 2.0 times as often as males.[7–9] Cicatricial pemphigoid has a mean age of onset of the early to middle 60s.[9] Although there is no known racial or geographic predilection, the *HLA-DQB1*0301* allele has been shown to be significantly increased in frequency in patients with oral, ocular, and generalized bullous pemphigoid; amino acid residues at positions 57 and 71 to 77 of the DQB1 protein may represent a disease susceptibility marker.[1,10–14]

ETIOLOGY AND PATHOGENESIS

Autoantibodies directed against autoantigens in epidermal basement membrane are held responsible for the pathogenesis of cicatricial pemphigoid (Fig. 55-1). A variety of different autoantigens are recognized by circulating autoantibodies from these patients.[1,15–29] These and other findings have led to the idea that cicatricial pemphigoid is not a single nosologic entity but rather a disease phenotype. Autoantigens recognized by immunoglobulin G (IgG) autoantibodies from patients with cicatricial pemphigoid are summarized in Table 55-1. Bullous pemphigoid antigen 2 (BPAG2) appears to represent a major cicatricial pemphigoid autoantigen; other autoantigens of particular interest include laminin 5, integrin subunit β_4, integrin subunit α_6, type VII collagen, and bullous pemphigoid antigen 1. Other patients with cicatricial pemphigoid have IgA anti–basement membrane autoantibodies (alone or in conjunction with IgG anti–basement membrane autoantibodies); the best characterized IgA autoantigen linked to the cicatricial pemphigoid phenotype is bullous pemphigoid antigen 2.[1,30–32]

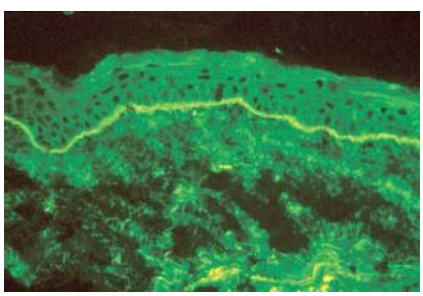

▲ **FIGURE 55-1** Direct immunofluorescence microscopy of normal-appearing perilesional skin from a patient with cicatricial pemphigoid shows continuous linear deposits of C3 in the epidermal basement membrane.

CICATRICIAL PEMPHIGOID AT A GLANCE



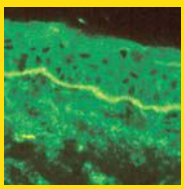

- A chronic autoimmune subepithelial blistering disease characterized by erosive lesions of mucous membranes and skin that result in scarring.
- Lesions commonly involve the oral and ocular mucosae; other sites that may be involved include the nasopharyngeal, laryngeal, esophageal, genital, and rectal mucosae.
- A rare disorder, occurring in 1 person per million annually; females are affected 1.5 to 2.0 times as often as males.
- A progressive disorder that may result in serious complications (e.g., blindness, loss of the airway, esophageal stricture formation).
- Immunopathologic studies of perilesional mucosa and skin demonstrate in situ deposits of immunoreactants in epithelial basement membranes; circulating anti–basement membrane autoantibodies are detected in sera of some but not all patients.
- A variety of different autoantigens are recognized by autoantibodies from patients, which suggests that cicatricial pemphigoid is not a single nosologic entity but rather a disease phenotype.

CLINICAL FINDINGS

History

Patients typically describe the onset of painful, erosive, and/or blistering lesions on one or more mucosal surfaces. A few skin lesions on the upper body are also sometimes noted. Associated symptoms are site specific as detailed later.

Mucosal and Cutaneous Lesions

The mouth is the most frequent site of involvement in patients with cicatricial pemphigoid; it is often the first (and only) site affected. Lesions often involve the gingiva, buccal mucosa, and palate (Figs. 55-2 and 55-3); other sites such as the alveolar ridge, tongue, and lips are also susceptible.[9,33] A frequent oral manifestation is desquamative gingivitis. Other lesions may present as tense blisters that rupture easily or as mucosal erosions that form as a consequence of epithelial fragility. Lesions in the mouth may result in a delicate white pattern of reticulated scarring. In severe disease, adhesions may develop between the buccal mucosa and the alveolar process, around the uvula and tonsillar fossae, and between the tongue and the floor of the mouth. Gingival involvement can result in tissue loss and dental complications (e.g., caries, periodontal ligament damage, and loss of bone mass and teeth).

Ocular involvement in patients with cicatricial pemphigoid is common and may become sight threatening (Fig. 55-4).[34,35] Ocular lesions typically manifest as conjunctivitis that progresses insidiously to scarring. Early ocular disease can be quite subtle and nonspecific. Although disease is usually bilateral, it often begins unilaterally and progresses to both eyes within several years. Patients may complain of burning, dryness, or a foreign-body sensation in one or both eyes; frank blisters on conjunctival surfaces are rarely seen. Early disease is best appreciated by slit-lamp examination. Because disease may be localized to the upper tarsal conjunctiva, it may escape detection without eversion of the eyelids. Chronic ocular involvement can result in scarring characterized by shortened fornices, symblepharons (i.e., fibrous tracts between bulbar and palpebral conjunctival surfaces), and, in severe disease, ankyloblepharons (i.e., fibrous tracts fusing the superior and



TABLE 55-1
Major Cicatricial Pemphigoid Autoantigens

Autoantigen	MW (kd)	Location SSS/Ultra	Passive Transfer Studies
BPAG1	230	Epid/HD	
BPAG2	180	Epid/HD-af	Exp IgG vs. the NC16A domain of BPAG2 creates subepid blisters in newborn mice that resemble those seen in patients with BP.[75]
Integrin β_4	~205	Epid/HD-af	
Integrin α_6	~120	Epid/HD-af	
Laminin 5	400–440	Derm/LL-LD interface	Exp IgG vs. laminin 5 creates subepid blisters in newborn and adult mice that resemble those seen in patients with AECP.[76] Patient IgG creates subepid blisters in human skin grafts on immunodeficient adult mice that resemble those seen in patients with AECP.[77]
Type VII collagen	290	Derm/AF	Exp and patient IgG vs. the NC1 domain of type VII collagen create subepid blisters in adult mice that resemble those seen in patients with EBA.[78–80]

AECP = anti-epiligrin cicatricial pemphigoid; AF = anchoring fibril; BP = bullous pemphigoid; BPAG1 = bullous pemphigoid antigen 1; BPAG2 = bullous pemphigoid antigen 2; Derm = dermal; EBA = epidermolysis bullosa acquisita; Epid = epidermal; Exp = experimental; HD = hemidesmosome; HD-af = hemidesmosome-anchoring filament complexes; IgG = immunoglobulin G; LL-LD interface = lamina lucida–lamina densa interface; Location SSS/Ultra = localization in 1 *M* NaCl–split skin/ultrastructural localization in epidermal basement membrane; MW (kd) = molecular weight in kilodaltons; subepid = sub-epidermal.



inferior palpebral conjunctivae with obliteration of the conjunctival sac). Conjunctival scarring also can cause entropion and trichiasis (i.e., in-turning of the eyelashes) that result in corneal irritation, superficial punctate keratinopathy, corneal neovascularization, corneal ulceration, and/or blindness. Additional ocular complications include scarring of the lacrimal ducts, decreased tear secretion, and loss of mucosal goblet cells leading to decreased tear mucus content and unstable tear films. It is very important for patients with suspected ocular involvement to be examined by an ophthalmologist, because early disease may be subtle, is only identified by slit-lamp examination, and can result in severe complications. Cicatricial pemphigoid may be limited to the eyes.

Other sites that may be affected by cicatricial pemphigoid include the nasopharyngeal, laryngeal, esophageal, and anogenital regions. Nasopharyngeal lesions can result in discharge, epistaxis, excessive crust formation, impaired airflow, chronic sinusitis, scarring, and tissue loss. Laryngeal involvement may present as hoarseness, sore throat, or loss of phonation. Chronic laryngeal erosions, edema, and scarring may result in supraglottic stenosis and airway compromise that eventually necessitates tracheostomy.[36] Esophageal involvement may result in stricture formation, dysphagia, odynophagia, weight loss, and/or aspiration. Moreover, it has been suggested that esophageal dysfunction and gastroesophageal reflux may elicit or exacerbate laryngeal disease and/or bronchospasm in such patients. Although involvement of the genital and/or rectal mucosae in patients with cicatricial pemphigoid is rare, it can be a source of substantial pain and morbidity. Rare cases of urethral stricture, vaginal stenosis, and anal narrowing have developed as a consequence of this disease.

The skin is involved in 25 percent to 35 percent of patients with cicatricial pemphigoid. The most frequently affected areas are the scalp, head, neck, and upper trunk (Fig. 55-5). Lesions typically consist of small vesicles or bullae situated on erythematous and/or urticarial bases. Lesions rupture easily and are



▲ **FIGURE 55-2** Cicatricial pemphigoid. Denuded sites on the buccal mucosa extend into the maxillary sulcus.



▲ **FIGURE 55-3** Cicatricial pemphigoid. Erosive lesions on the hard palate.



▲ **FIGURE 55-4** Cicatricial pemphigoid. Ocular involvement has resulted in conjunctivitis, a shortened conjunctival fornix, and symblepharon formation.



▲ **FIGURE 55-5** Cicatricial pemphigoid. The scalp displays scarring alopecia and a focal hemorrhagic crust as a consequence of involvement with cicatricial pemphigoid.

often seen as small, crusted papules or plaques. The extent and number of cutaneous lesions are generally small; lesions sometimes recur in the same areas.

Related Physical Findings

SYSTEMIC ASSOCIATIONS A cohort of 35 patients with anti-epiligrin cicatricial pemphigoid was shown to have an increased relative risk for cancer.[37,38] Ten patients in this cohort had solitary solid cancers (three lung, three gastric, two colon, two endometrial); eight patients developed cancer after the onset of cicatricial pemphigoid (six within a year, seven within 14 months). The time between blister onset and cancer diagnosis was approximately 14 months in 9 of the 10 patients. Eight patients in this cohort died as a consequence of their cancer. All deaths occurred within 21 months. This form of cicatricial pemphigoid appears to have a relative risk for malignancy that approximates that for adults with dermatomyositis; as is true for the latter, the risk for cancer appears to be particularly high in the first year of disease. Other patients with anti-epiligrin cicatricial pemphigoid and cancer have been described more recently.[39–42]

BRUNSTING-PERRY PEMPHIGOID In 1957, Brunsting and Perry described seven patients with locally recurrent and scarring sub-epidermal blistering lesions of the head or neck that for many years was thought to be a form of cicatricial pemphigoid.[43] Although these patients are typically elderly and demonstrate deposits of immunoreactants in epidermal basement membranes like other patients with cicatricial pemphigoid, Brunsting-Perry pemphigoid predominates in men and lacks mucous membrane involvement. More recently, patients with the same clinical, histologic, and immunopathologic features have been reported to have autoantibodies directed against type VII collagen (or rarely to bullous pemphigoid antigens).[3,44] Identification of similar patients with blister planes beneath the lamina densa further suggests that individuals with this phenotype usually have localized forms of epidermolysis bullosa acquisita.

LABORATORY TESTS

Light Microscopy

Although the findings of light microscopy studies of lesional skin or mucosa from patients with cicatricial pemphigoid often are nonspecific, they characteristically show a sub-epidermal blister and a dermal leukocytic infiltrate composed of lymphocytes and histiocytes as well as variable numbers of neutrophils and eosinophils.[2,3,45] Plasma cells often are seen in mucosal lesions, whereas eosinophils and neutrophils are seen most commonly in skin lesions. Biopsy specimens of older lesions may be relatively "cell poor" and show features that correlate with the noninflammatory character of such sites clinically. Light microscopy studies of older lesions often show fibroblast proliferation and lamellar fibrosis (i.e., fibrosis characterized by collagen bundles ordered parallel to the surface epithelium).

Electron Microscopy

Ultrastructural studies of lesional skin or mucosa from patients with cicatricial pemphigoid show that blisters typically develop within the lamina lucida and eventuate in partial or complete destruction of the basal lamina in older lesions.[45–48] A generally held impression is that blisters form below those of bullous pemphigoid, because scarring is more common in patients with this disease. Reports of patients with blisters in the sublamina densa region are thought to represent mucosa-predominant forms of epidermolysis bullosa acquisita.

Immunofluorescence Microscopy

Direct immunofluorescence microscopy of normal-appearing perilesional tissue from patients with cicatricial pemphigoid shows continuous deposits of immunoreactants in epithelial basement membranes.[5,48] The most commonly detected immunoreactants are IgG and C3 (see Fig. 55-1); the predominant subclass of these autoantibodies is IgG4.[49] IgA, IgM, and/or fibrin are found in some patients.[50] One study of skin and mucosal samples from 10 patients found immunoreactants more commonly in perilesional mucosal biopsy specimens, which suggests that mucous membranes are the preferred biopsy site for direct immunofluorescence microscopy studies.[48] Splitting tissue samples with 1 *M* NaCl increases the sensitivity of direct immunofluorescence microscopy and facilitates identification of immunoreactants as well as their relative distribution within epithelial basement membranes.[51,52]

Indirect immunofluorescence microscopy studies using intact skin or mucosa often find low-titer IgG (and/or IgA) anti–basement membrane autoantibodies in patients with cicatricial pemphigoid.[1,3,5,53] The use of 1 *M* NaCl–split skin as a test substrate in these studies substantially increases the detection of such autoantibodies.[26,54,55] In such studies, IgG (and/or IgA) binding is usually directed against the epidermal side of 1 *M* NaCl–split skin, although combined epidermal and dermal or exclusively dermal binding can occur. In fact, this heterogeneity in autoantibody binding patterns was one of the first clues that cicatricial pemphigoid is a disease phenotype that is associated with different autoantigens (see Table 55-1). Although some studies have suggested that the use of human mucosal tissue substrates increases the likelihood of detecting autoantibodies in patients with cicatricial pemphigoid, other studies have not obtained similar results.[6,48] Patients with both IgG and IgA anti–basement membrane autoantibodies appear to have a worse prognosis as defined by requirements for medications to control disease as well as overall clinical severity score.[30,32]

Specialized Tests

Selected cases may require specialized immunochemical studies (e.g., immunoblot studies of keratinocyte or skin extracts, immunoprecipitation studies of biosynthetically radiolabeled keratinocytes) to identify the autoantigen targeted by patient anti–basement membrane autoantibodies. Perilesional tissue from seronegative patients may be further characterized by immunoelectron microscopy studies to determine if in situ deposits of immunoreactants reside above or below the lamina densa of epidermal basement membrane.

DIFFERENTIAL DIAGNOSIS

The diagnosis of cicatricial pemphigoid is suggested when patients present with bullous or erosive lesions of mucous membranes and continuous deposits of immunoreactants are demonstrated in epithelial basement membranes of perilesional tissue. Distinguishing cicatricial pemphigoid from other autoimmune bullous diseases can be difficult and may require specialized immunopathologic studies and/or immunoelectron microscopy. Disorders that must be differentiated from cicatricial pemphigoid include lichen planus, erythema multiforme, lupus erythematosus, lichen sclerosus, and—in the case of ocular disease—cicatrizing or inflammatory conjunctivitis that results from long-term use



Box 55-1

Differential Diagnosis of Cicatricial Pemphigoid

Most Likely

- Pemphigus
  - Pemphigus vulgaris
  - Paraneoplastic pemphigus
- Other sub-epidermal immunobullous diseases
  - Epidermolysis bullosa acquisita
  - Bullous pemphigoid
  - Linear immunoglobulin A dermatosis
- Erythema multiforme
- Lupus erythematosus
- Lichen planus

Consider

- Drug-induced hypersensitivity reaction
- Lichen sclerosus (especially in the anogenital area)

Always Rule Out

- Pemphigus (specifically, pemphigus vulgaris, paraneoplastic pemphigus)
- Other sub-epidermal immunobullous diseases
- Erythema multiforme
- Lupus erythematosus
- Lichen planus



of certain ophthalmologic preparations (e.g., pilocarpine, guanethidine, or ephedrine used in the treatment of glaucoma or idoxuridine used as an antiviral) or biologics that inhibit epidermal growth factor receptor tyrosine kinase (Box 55-1).[34,56] It also has been reported that some cases of ocular cicatricial pemphigoid develop after an acute episode of severe ocular inflammatory injury secondary to Stevens-Johnson syndrome[57] (see Chap. 39). Interestingly, the time between the appearance of Stevens-Johnson syndrome and the onset of ocular cicatricial pemphigoid in these patients can range from a few months to more than 30 years.

COMPLICATIONS

Site-specific complications of cicatricial pemphigoid were outlined earlier and are summarized in Table 55-2.

PROGNOSIS AND CLINICAL COURSE

Cicatricial pemphigoid is typically a chronic and progressive disorder, although involvement may be limited to a given anatomic site (e.g., the mouth, the conjunctivae) for many years. Cicatricial pemphigoid rarely goes into spontaneous remission; its treatment is largely determined by its severity and sites of involvement. Scarring can only be prevented in these patients; it cannot be completely reversed.

TABLE 55-2
Potential Complications of Cicatricial Pemphigoid

SITE	POTENTIAL COMPLICATIONS
Mouth	
Mucosa	Painful, erosive scarring lesions; adhesions between the buccal mucosa and the alveolar process; the uvula and the tonsillar fossae; the tongue and the floor of the mouth
Gingiva	Loss of gingival tissue, caries, periodontal ligament damage, loss of alveolar bone, loss of teeth
Eyes	
Conjunctivae	Painful, erosive conjunctivitis; foreign-body sensations; photophobia; scarring; shortened fornices; loss of goblet cells; decrease in tear mucus content, unstable tear film; symblepharons; ankyloblepharons
Eyelids	Ectropion, trichiasis, ankyloblepharons
Cornea	Corneal irritation, superficial punctate keratinopathy, corneal neovascularization, corneal ulcers, blindness
Tear ducts	Scarring, occlusion, secondary infection
Nose	Discharge, epistaxis, excessive crust formation, impaired airflow, recurrent and chronic sinusitis, scarring, tissue loss
Larynx	Hoarseness, impaired phonation, loss of voice, scarring, supraglottic stenosis, airway compromise and loss
Esophagus	Dysphagia, odynophagia, impaired swallowing, aspiration, stricture formation, weight loss
Anogenital region	Painful erosions, stenosis, stricture, secondary infection

TREATMENT

The following overview (Box 55-2) is representative of most treatment regimens.[4,58–60]

Mild lesions of the oral mucosa and skin can often be treated effectively with topical glucocorticoids (or calcineurin inhibitors such as tacrolimus) in a gel or ointment base applied two to four times each day.[59,61,62] These agents are particularly effective before bed, because oral secretions diminish during sleep. Because it is difficult to maintain contact of topical agents with mucous membranes (and because lesions often are localized to the gingiva), customized delivery trays to occlude topical glucocorticoids over lesional sites in the mouth are also useful.[63] This approach also facilitates interactions with professionals who can manage other complications in these patients (e.g., dental complications). Mouthwash (dexamethasone 100 µg/mL, 5 mL per rinse) used in a "swish-and-spit" regimen for 5 minutes two to three times each day represents another approach for topical therapy. For oral disease resistant to topical glucocorticoids, these agents can (in some instances) be administered intralesionally. In addition to these measures, patients should follow a strict regimen of oral hygiene that includes regular brushing, flossing, and cleaning of teeth. Use of toothpastes and mouthwashes that lack sodium lauryl sulfate and alcohol, respectively, often facilitates patient compliance with such activities.

A number of reports have suggested that dapsone (50 to 200 mg by mouth daily) may be effective.[35,64] Others have found that cicatricial pemphigoid does not respond to this agent. Systemic glucocorticoids can be administered alone (e.g., 20 to 60 mg of prednisone by mouth each morning) or in combination with dapsone. Because of potentially severe complications, ocular, laryngeal, and/or esophageal involvement requires aggressive management by teams of physicians familiar with specialized care of these organ systems. For mild or moderate ocular involvement, systemic glucocorticoids (e.g., 20 to 60 mg of prednisone by mouth each morning) alone or in conjunction with daily dapsone may be effective. Patients whose ocular disease is complicated by trichiasis may benefit from epilation, although this decision is best made by an ophthalmologist. For severe disease affecting the ocular, pharyngeal, or urogenital epithelia, a combination of systemic glucocorticoids and an additional immunosuppressive is indicated. In such cases, azathioprine (2.0 to 2.5 mg/kg/day), mycophenolate mofetil (1.0 to 2.5 g/day), or cyclophosphamide (1 to 2 mg/kg/day) are often used in conjunction with daily prednisone (1 mg/kg/day).[59,65–68] In this regimen, daily prednisone is tapered gradually over approxi-

Box 55-2

Treatments for Cicatricial Pemphigoid

MILD INVOLVEMENT

Sites	*Local Care Measures*
Mouth	Topical corticosteroid (gels or ointments) bid/qid; topical corticosteroids under occlusion (e.g., dental trays); topical calcineurin inhibitors; intralesional corticosteroids
Nose	Irrigation with isotonic saline bid/tid; nasal lubricants; topical corticosteroids (e.g., via sprays, inhalers)
Anogenital region	Topical corticosteroids; topical calcineurin inhibitors
Skin	Topical corticosteroids; topical calcineurin inhibitors

MODERATE INVOLVEMENT

Sites	*Therapeutic Options*
Mouth, eyes, nose, larynx, esophagus, anogenital region	Local care measures outlined above plus dapsone 50–200 mg daily, prednisone 20–60 mg each morning, or both of these agents simultaneously

SEVERE INVOLVEMENT

Sites	*Therapeutic Options*
Mouth, eyes, nose, larynx, esophagus, anogenital region	Local care measures outlined above plus prednisone (1 mg/kg each morning), intravenous immunoglobulin (2 g/kg body weight over 2–3 days every 2–6 wk for 4–6 mo), or both of these agents simultaneously in conjunction with azathioprine (2–2.5 mg/kg/day), mycophenolate mofetil (1–2.5 g/day), cyclophosphamide (1–2 mg/kg/day), or rituximab (375 mg/m^2 weekly × 4 then every 4–6 mo as needed)

mately 6 months, and the patient is maintained on the alternate agent alone for an additional 6 to 12 months. Such combined regimens have had success in halting the progression of severe ocular disease, limiting scarring, and producing long-term remissions. In an effort to avoid adverse effects and complications produced by prolonged treatment with immunosuppressive agents, some groups treat patients with intravenous immunoglobulin (i.e., intravenous immunoglobulin 2 g/kg of body weight administered over 2 to 3 days every 2 to 6 weeks for 4 to 6 months).[69–72] Another emerging trend in the management of patients with particularly severe disease is the use of biologic agents that antagonize tumor necrosis factor-α (e.g., etanercept, infliximab) or bind CD20 (rituximab).[73,74]

Involvement of the nasopharynx or esophagus potentially has severe complications and requires aggressive and specialized care. Nasal lesions often benefit from twice-daily irrigation of the nasal passages with saline or tap water as well as the use of topical emollients. Esophageal involvement requires medical management to avert dysphagia, pain, tissue loss, and secondary complications such as gastroesophageal dysfunction and reflux, stricture formation, aspiration, laryngeal irritation, or bronchospastic pulmonary disease. All patients with cicatricial pemphigoid require long-term follow-up because of the possibility for this chronic disease to relapse.

KEY REFERENCES

The full reference list for all chapters is available at www.digm7.com.

2. Chan LS et al: The first international consensus on mucous membrane pemphigoid: Definition, diagnostic criteria, pathogenic factors, medical treatment, and prognostic indicators. *Arch Dermatol* **138**:370, 2002
3. Fleming TE, Korman NJ: Cicatricial pemphigoid. *J Am Acad Dermatol* **43**:571, 2000
4. Yancey KB, Egan CA: Pemphigoid: Clinical, histologic, immunopathologic, and therapeutic considerations. *JAMA* **284**:350, 2000
37. Egan CA et al: Anti-epiligrin cicatricial pemphigoid: Clinical findings, immunopathogenesis, and significant associations. *Medicine (Baltimore)* **82**:177, 2003
58. Kirtschig G et al: Interventions for mucous membrane pemphigoid/cicatricial pemphigoid and epidermolysis bullosa acquisita: A systematic literature review. *Arch Dermatol* **138**:380, 2002

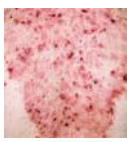

CHAPTER 56

Linear Immunoglobulin A Dermatosis and Chronic Bullous Disease of Childhood

Caroline L. Rao
Russell P. Hall III

Linear immunoglobulin A (IgA) dermatosis is a rare immune-mediated blistering skin disease that is defined by the presence of homogeneous linear deposits of IgA at the cutaneous basement membrane (Fig. 56-1). Although in the original description of patients with linear IgA dermatosis it was considered to be a manifestation of dermatitis herpetiformis (DH), it has now been clearly separated from DH on the basis of its immunopathology, immunogenetics, and lack of consistent association with a gluten-sensitive enteropathy.[1–4] Patients with linear IgA dermatosis can present with lesions suggestive of epidermolysis bullosa acquisita (EBA), DH, bullous pemphigoid (BP), lichen planus, or cicatricial pemphigoid.[1–5] These different clinical presentations appear to result from the IgA binding to different epidermal antigens.

Chronic bullous disease of childhood (CBDC) is a rare blistering disease that occurs predominantly in children younger than 5 years of age and has an identical pattern of homogeneous linear IgA deposits at the epidermal basement membrane.[6,7] Recent studies have demonstrated that in some patients CBDC and linear IgA dermatosis represent different presentations of the same disease process.[8,9]

EPIDEMIOLOGY

Linear IgA dermatosis occurs most often after puberty, with most patients presenting after the fourth decade of life.[2,10,11] A slight predominance of females has been noted in several studies.[2,10,11] In contrast, CBDC presents most often before the age of 5 years.[10] As in patients with linear IgA dermatosis, there is a slight female predominance in patients with CBDC.[7,10]

LINEAR IMMUNOGLOBULIN A DERMATOSIS

AT A GLANCE


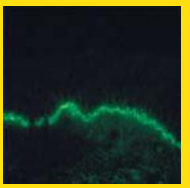

- Rare blistering disease with onset typically after fourth decade of life.
- Linear band of immunoglobulin A at the dermal epidermal basement membrane.
- Clinical presentations may mimic dermatitis herpetiformis, bullous pemphigoid, and cicatricial pemphigoid.
- May occur in association with many drugs, including vancomycin.
- May occur in association with inflammatory bowel disease but only rarely associated with gluten sensitive enteropathy.
- Rarely seen in association with malignancy, specifically lymphoid.
- Histology shows sub-epidermal collection of neutrophils at the basement membrane, often collecting in papillary tips with sub-epidermal blisters.
- Most patients respond dramatically to treatment with dapsone; some require adjunctive systemic corticosteroids.
- Prognosis variable with both spontaneous remissions and long-standing disease.

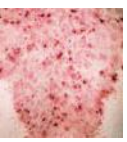

Evaluation of the HLA association in patients with linear IgA dermatosis and CBDC has yielded conflicting results. Some investigators have found an increased frequency of the human histocompatibility antigen HLA-B8 in patients with linear IgA dermatosis, whereas others have found no increased frequency.[12–14] In CBDC, an increased frequency of HLA-B8 has been noted, with up to 76 percent of patients expressing HLA-B8.[10] Collier et al. demonstrated an increased frequency of HLA-B8, -DR3, and -DQ2 in CBDC that was not seen in adults with linear IgA dermatosis.[12] These authors suggested that these haplotypes may have a role in earlier disease presentation. In addition, the *TNF2* allele was found with increased frequency in both adults and children with linear IgA disease when compared with unaffected subjects. There was, however, no increase seen in either adults or children when compared with HLA-DR3+ controls.

ETIOLOGY AND PATHOGENESIS: IMMUNOPATHOLOGY

Linear IgA dermatosis and CBDC are defined by the presence of a homogeneous linear band of IgA at the dermal-epidermal basement membrane zone. A minority of patients in both groups have additional deposits of other immunoreactants, most often IgG and occasionally the third component of complement (C3).[10] Because IgA is the predominant Ig of the secretory immune system, numerous investigators have attempted to determine if the IgA present in the skin of these patients is of mucosal origin. Characterization of the IgA subclass in the skin has revealed almost exclusively IgA1 and not the subclass most often associated with mucosa, IgA2.[15–17] In addition, neither secretory piece nor J chain, both of which are present in secretory IgA, have been found in the IgA present in the skin of patients with linear IgA deposits.[18]Although these data have led to suggestions that the IgA is not of mucosal origin, the true origin of the IgA deposits in the skin of these patients is not known.

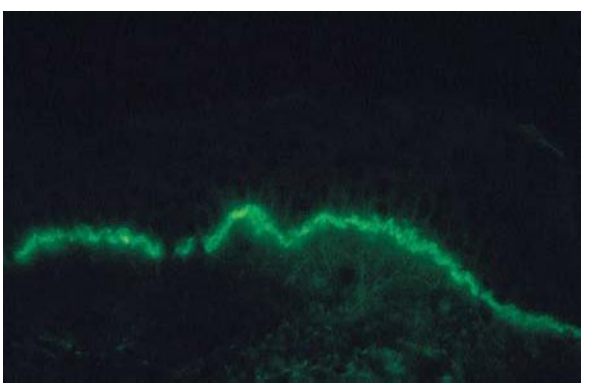

◀ FIGURE 56-1 Direct immunofluorescence of normal-appearing perilesional skin from a patient with linear immunoglobulin A dermatosis. A homogeneous band of immunoglobulin A is present at the dermal-epidermal junction.

CHRONIC BULLOUS DISEASE OF CHILDHOOD

AT A GLANCE



- Rare blistering disorder of childhood presenting predominantly in children less than 5 years of age.
- Linear immunoglobulin A at the dermal epidermal basement membrane.
- Clinical presentation of tense bullae, often in perineum and perioral regions, giving a "cluster of jewels" appearance. New lesions sometimes appear around the periphery of previous lesions with a collarette of blisters.
- Histology shows sub-epidermal collection of neutrophils at the basement membrane, similar to linear immunoglobulin A bullous dermatosis.
- Most patients respond dramatically to treatment with dapsone.
- Spontaneous remissions, often within 2 years, are frequent.

Initially it was thought that patients with linear IgA dermatosis and CBDC rarely had circulating IgA antibodies against the epidermal basement membrane. Indirect immunofluorescence, using 1 *M* NaCl-split normal human skin as a substrate, demonstrates that the majority of patients with CBDC have low-titer circulating antibodies against the epidermal side of the split skin.[10,19] Circulating low-titer IgA antibodies directed against the epidermal basement membrane also have been found in adults with linear IgA dermatosis.[10,19] Others have reported binding of IgA antibodies from some patients to the dermal side of normal human split skin, suggesting that more than one antigen may be the target for the IgA anti–basement membrane antibodies.[19] Immunoelectron microscopic studies have been performed to determine the exact location of the IgA in the skin of patients with both linear IgA dermato-

sis and CBDC. Immunoelectron microscopy of the skin of patients with linear IgA deposits has revealed three distinct patterns of immunoreactants. In some patients with linear IgA dermatosis, the IgA deposits are found in the lamina lucida region of the basement membrane zone, similar to the location of immunoreactants present in the skin of patients with BP.[20,21] A second pattern of IgA deposition has been detected in which the IgA deposits are present at and below the lamina densa in a pattern similar to that seen in EBA.[20–22] Prost et al. have described a third pattern of immunoreactants in some patients with linear IgA dermatosis in which the IgA deposits are found both above and below the lamina densa.[21] In a similar manner, immunoelectron microscopic studies of skin of patients with CBDC have shown the IgA immunoreactants to be in either the lamina lucida or a sublamina densa location.[22,23] These findings further support the probability that multiple antigens may be involved as the targets in both adults and children with linear IgA deposits in the skin.

Although the relatively low titer of IgA antibodies against the basement membrane present in the sera of patients with both linear IgA dermatosis and CBDC has complicated the search for specific antigenic targets for the IgA, several investigators have made significant observations regarding the antigenic targets in these diseases. Zone et al.[24] studied sera from patients who had circulating IgA antibodies that bound to the epidermal side of 1 *M* NaCl-split normal human skin, as shown by indirect immunofluorescence. They found that serum IgA from patients with either CBDC or linear IgA dermatosis bound to a 97-kd protein. Immunoelectron microscopy revealed that the 97-kd antigen is present in the lamina lucida, below the hemidesmosome of normal human skin, in a location similar to where the IgA is localized in patients with CBDC and linear IgA dermatosis.[25] Subsequently, Zone et al. determined that the 97-kd linear IgA bullous disease antigen is identical to a portion of the extracellular domain of the 180-kd BP antigen (BPAG2 or collagen XVII), which is essential in anchoring basal keratinocytes to the epidermal basement membrane.[26] The BP antigen (BPAG2) consists of a 180-kd transmembrane protein and 120-kd portion that corresponds to the collagenous ectodomain. Roh et al. and Schumann et al. have reported that autoantibodies in patients with linear IgA dermatosis recognize the soluble 120-kd ectodomain of type XVII collagen[27,28] The 120-kd antigen target is not unique to linear IgA dermatosis because it is also the antigen targeted by autoantibodies in some patients with cicatricial pemphigoid and BP.[27,28] Furthermore, IgA antibodies and T cells from patients with linear IgA bullous dermatosis have been found to be directed against the NC-16A region of collagen type XVII, which is the same region against which the IgG and T cells from patients with BP are directed.[29,30] This may explain in part the overlap in clinical and histologic features of these conditions. Wojnarowska et al. have identified another possible target antigen in patients with linear IgA dermatosis and CBDC. Using sera from patients in whom the IgA bound to the epidermal side of 1 *M* NaCl-split skin on routine indirect immunofluorescence. They found that IgA in the sera of some patients with these diseases bound to a 285-kd protein (LAD 285) that was not the 230-kd BP antigen or type VII collagen, the EBA antigen.[31] Allen and Wojnarowska have analyzed the sera of over 70 patients with both linear IgA dermatosis and CBDC and found that the predominant antigenic target in these patients is the BP180 antigen (collagen XVII), but that some patients react with multiple antigens including the BP230, LAD 285, and other yet to be identified proteins.[32] In many patients, IgA appears to bind to several different antigenic targets, suggesting the possibility that there is epitope spreading. The clinical significance of these findings however, has not been established.[32]

CLINICAL FINDINGS

Cutaneous Manifestations

The clinical manifestations of linear IgA dermatosis are heterogeneous and often indistinguishable from those seen in patients with DH.[2,10,11,35] Patients may present with combinations of annular or grouped papules, vesicles, and bullae (Figs. 56-2 and 56-3). Typically, these lesions are distributed symmetrically on extensor surfaces, including elbows, knees, and buttocks. Lesions most often are very pruritic, resulting in numerous crusted papules (Fig. 56-4). The clinical presentation can be difficult to distinguish from that seen in patients with DH. However, the degree of pruritus seen in patients with linear IgA dermatosis is variable and, in general, less severe than that seen in patients with DH. Some patients with linear IgA dermatosis present with larger bullae, in a pattern more consistent with that seen in patients with BP, or occasionally with cutaneous findings similar to those seen in patients with EBA. Patients with drug-induced linear IgA bullous dermatosis have been reported with erythema multiforme–like findings and a toxic epidermal necrolysis–like presentation, with widespread bullae and mucosal involvement. Recovery has been reported with discontinuation of the offending agent alone, but these patients may benefit from dapsone therapy (see Treatment).[36–38]

The clinical presentation of CBDC is characterized most often by the development of tense bullae, often on an in-



▲ **FIGURE 56-2** Patient with linear immunoglobulin A dermatosis with crusted erosions, papules, and vesicles on the back and neck.



▲ **FIGURE 56-3** Patient with linear immunoglobulin A dermatosis with annular erythematous plaques on the thighs.





▲ **FIGURE 56-4** Patient with linear immunoglobulin A dermatosis with grouped urticarial papules on the back with scattered crusted erosions.



flammatory base.[6] These lesions occur most frequently in the perineum and perioral region and often may occur in clusters, giving a "cluster of jewels" appearance (Figs. 56-5, 56-6, and 56-7). New lesions sometimes appear around the periphery of previous lesions, with a resulting "collarette" of blisters. Patients often report significant pruritus and/or a burning of the skin with the development of skin lesions. Patients with CBDC often present with the acute development of large numbers of tense blisters, which may rupture and become secondarily infected.

Rarely, patients with linear IgA dermatosis may present with an acute febrile illness with arthritis, arthralgias, and generalized malaise.[39,40] The presence of multiple papules and vesicles in a patient with systemic signs and symptoms has led to the evaluation of these patients for systemic infections, including viral infections. Routine direct immunofluorescence, however, has revealed linear deposits of IgA, and these patients have responded to conventional therapy.



▲ **FIGURE 56-5** Patient with chronic bullous disease of childhood. Tense bullae and crusted papules are present on the abdomen, with a clustering of bullae noted in the perineal region.



▲ **FIGURE 56-6** Chronic bullous disease of childhood. Tense blisters on erythematous bases in the pubic and inguinal areas.

Mucosal Involvement

Mucosal involvement is an important clinical manifestation seen in patients with linear IgA dermatosis and CBDC. This involvement can range from largely asymptomatic oral ulcerations and erosions to severe oral disease alone as well as to severe conjunctival and oral disease typical of that seen in cicatricial pemphigoid.[10,41,42] Oral lesions may occur in up to 70 percent of patients with linear IgA disease.[10] Although most patients with linear IgA dermatosis and mucosal involvement have significant cutaneous disease, cases have been reported in the literature in which the presenting and predominant clinical manifestations are lesions of the mucous membranes.[42,43] These patients may present with desquamative gingivitis and oral lesions consistent with those seen in patients with cicatricial pemphigoid (see Chap. 54). Patients also may present with conjunctival disease and scar formation typical of that seen in patients with cicatricial pemphigoid (see Chap. 55). Patients with linear IgA bullous dermatosis have also been reported to present with severe laryngeal and pharyngeal involvement before the development of more typical cutaneous manifestitations.[44]



▲ **FIGURE 56-7** Extensive chronic bullous disease of childhood. Note tense and flaccid blisters without notable inflammation.

Disease Associations

The similar clinical presentation of many patients with linear IgA disease to that seen in patients with DH led to the investigation of patients with linear IgA disease for an associated gluten-sensitive enteropathy. Although some investigators have found evidence of minimal inflammatory changes in the small bowel of patients with linear IgA disease, numerous investigators have been unable to show that the majority of patients with linear IgA disease have significant evidence of the villous atrophy characteristically seen in patients with DH.[1,45] In addition, the clinical manifestations of linear IgA disease have not been controlled by the use of a gluten-free diet.[46] Circulating autoantibodies against tissue transglutaminase, which occur in high frequency in patients with untreated gluten-sensitive enteropathy and DH, have not been found in most patients with linear IgA diseases.[47]

Other conditions have been reported in association with linear IgA disease. One example is ulcerative colitis (UC), which can result in a clinical syndrome where the activity of both diseases is linked (i.e., as one disease flares, so does the other). Paige and co-workers reviewed 70 patients with linear IgA bullous dermatosis and found 7.1 percent had associated UC. The extent and reason for this association has yet to be established. Perhaps, the abnormal mucosal IgA1 production seen in patients with UC may play a role.[46,48,49] Baldari et al. reported a case of CBDC occurring after acute mononucleosis.[50] These authors suggest that this virus may have a role in initiation of the disease through immune stimulation. CBDC also has been reported in association with chronic granulomatous disease in the setting of *Paecilomyces* lung infection.[51] The relationship between these conditions and CBDC has yet to be established.

The relatively acute onset of clinical, histologic, and immunopathologic find-

ings consistent with linear IgA disease has been seen in patients who have been taking a variety of drugs, including vancomycin, lithium phenytoin, sulfamethoxazole/trimethroprin, furosemide, atorvastatin, captopril, and diclofenac.[36,38,52,53] Vancomycin is the most common drug that is associated with the development of linear IgA bullous dermatosis. The mechanism of this interaction is not known; however, a small number of patients with vancomycin-induced linear IgA disease have been reported to have circulating IgA antibodies directed against the BP180, BP230, and LAD 285 antigens.[54,55] In one case of vancomycin-induced linear IgA bullous dermatosis, rechallenge with vancomycin in a gradual manner did not result in a recurrence of the eruption.[56]

Linear IgA disease also has been associated rarely with a variety of malignancies. Patients with linear IgA disease have been reported with both lymphoid and nonlymphoid malignancies.[57,58] Godfrey et al. reported three cases of lymphoid malignancies in 70 patients with linear IgA disease followed for a mean of 8.5 years. This represented an increase over the predicted number of 0.2 cases in an age- and sex-matched population.[57] No increase in the rate of nonlymphoid malignancies was seen. These findings suggest a small risk of lymphoid malignancy in these patients. However, larger population-based studies need to be done to confirm these findings.

HISTOPATHOLOGY

Routine histopathology of an early lesion in patients with linear IgA dermatosis and CBDC reveals a sub-epidermal bulla with collections of neutrophils along the basement membrane, often accumulating at the papillary tips (Fig. 56-8). A mild lymphocytic infiltrate may be present around the superficial dermal blood vessels without any evidence of neutrophilic vasculitis. Occasionally, the inflammatory infiltrate is composed of eosinophils, but most frequently neutrophils are the major component of the sub-epidermal inflammation.[10,59,60] Electron microscopic examination of the blisters found in patients with both linear IgA dermatosis and CBDC has revealed that the blister forms either within the lamina lucida or in a sublamina densa location.[20,23] Most often the histopathology seen in linear IgA disease is difficult to distinguish from that seen in patients with DH. Smith et al.[60] reported that patients with linear IgA disease tended to have fewer papillary microabscesses and a more diffuse infiltrate of neutrophils at the basement membrane zone. However, Blenkinsopp et al. found no significant difference between the histopathology found in patients with linear IgA disease and those with DH.[59] In general, the histopathology of blisters in linear IgA disease, CBDC, and DH is virtually indistinguishable.

DIFFERENTIAL DIAGNOSIS

Linear IgA dermatosis often closely mimics the clinical pattern seen in patients with DH. Some patients may have findings that resemble those seen in patients with BP, cicatricial pemphigoid, EBA, and, rarely, toxic epidermal necrolysis. In a similar manner, patients with CBDC must be differentiated from those with DH of childhood and childhood BP. The findings of linear IgA deposits at the basement membrane by direct immunofluorescence, most often in the absence of IgG and the third component of complement, can distinguish this disease from BP, cicatricial pemphigoid, and EBA, whereas granular IgA deposits are found at the basement membrane in patients with DH (Box 56-1).

Box 56-1

Linear Immunoglobulin A Bullous Dermatosis Differential Diagnosis

- Dermatitis herpetiformis
- Bullous pemphigoid
- Epidermolysis bullosa acquisita
- Bullous eruption of systemic lupus erythematosus
- Cicatricial pemphigoid
- Lichen planus
- Toxic epidermal necrolysis

TREATMENT AND PROGNOSIS

Adults with linear IgA dermatosis have an unpredictable course.[2,10] Many patients have disease that continues for years, with few, if any, episodes of remission. Occasionally, patients may have a spontaneous remission with loss of clinical features of the disease and disappearance of the linear IgA deposits in the skin. Patients with severe mucosal disease, especially of the eyes, may have persistent problems with symblepharon formation and resulting structural problems with the eyelids and cornea, even after active blistering has remitted.

Patients with linear IgA disease most often respond dramatically to dapsone or sulfapyridine. This response usually occurs within 24 to 48 hours, in a manner similar to that seen with DH; as such, it is not a helpful diagnostic sign for linear IgA disease.[2,10,11] Although most patients are well controlled with dapsone or sulfapyridine alone, some patients require low-dose prednisone therapy to suppress blister formation.[9,10] The majority of patients with linear IgA disease cannot control their skin disease with a gluten-free diet.[42]

CBDC is most often a self-limited disease, with most children going into remission within 2 years of the onset of the disease.[6,7,10] Occasionally, the disease persists well into puberty but often is less severe than the initial eruption. Patients with CBDC respond in a similar dramatic fashion to dapsone or sulfapyridine.[6,7,10] Many children, however, require the addition of relatively small doses of prednisone to bring the disease under control.[6,7] Mycophenolate mofetil has been used as a steroid-sparing agent in isolated cases.[61] Intravenous immunoglobulins have also been proposed in the rare patient not responding to, or intolerant of, dapsone therapy.[62,63] Several case reports suggest that some patients with CBDC may respond to antibiotics, including sulfonamides, dicloxacillin, and erythromycin.[64, 65] In a recent case series, seven children with linear IgA disease treated with flucloxacillin demonstrated im-

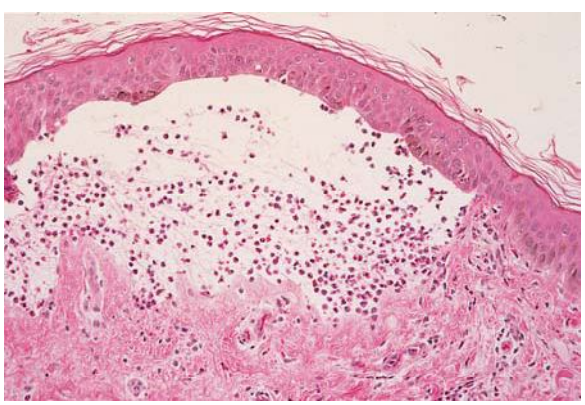

◀ **FIGURE 56-8** Histopathology of lesional skin from a patient with linear immunoglobulin A dermatosis showing a subepidermal blister filled with neutrophils. (Used with permission from Kim B. Yancey, MD.)



provement, with four achieving remission within 3 months.[66] However, spontaneous remission in these patients cannot be ruled out.

KEY REFERENCES

The full reference list for all chapters is available at www.digm7.com.

1. Lawley TJ et al: Small intestinal biopsies and HLA types in dermatitis herpetiformis patients with granular and linear IgA skin deposits. *J Invest Dermatol* **74**:9, 1980
7. Jablonska S et al: Linear IgA bullous dermatosis of childhood (chronic bullous dermatosis of childhood). *Clin Dermatol* **9**:393, 1992
10. Wojnarowska F et al: Chronic bullous disease of childhood, childhood cicatricial pemphigoid and linear IgA disease of adults: A comparative study demonstrating clinical and immunopathologic overlap. *J Am Acad Dermatol* **19**:792, 1988
24. Zone JJ et al: Identification of the cutaneous basement membrane zone antigen and isolation of antibody in linear immunoglobulin A bullous dermatosis. *J Clin Invest* **85**:812, 1990
26. Zone JJ et al: The 97 kDa linear IgA bullous disease antigen is identical to a portion of the extracellular domain of the 180 kDa bullous pemphigoid antigen, BPAg2. *J Invest Dermatol* **110**:207, 1998
39. Leigh G, Marsden RA, Wojnarowska F: Linear IgA dermatosis with severe arthralgia. *Br J Dermatol* **119**:789, 1988
46. Leonard JN et al: Experience with a gluten free diet in the treatment of linear IgA disease. *Acta Derm Venerol (Stockh)* **67**:145, 1987



CHAPTER 57

Pemphigoid Gestationis (Herpes Gestationis)

Jeff K. Shornick

EPIDEMIOLOGY

Pemphigoid gestationis (PG) is the least common, yet best-characterized, dermatitis specific to pregnancy.[1] It classically presents as an intensely itchy, urticarial rash during the later part of pregnancy or the immediate postpartum period, then rapidly progresses to a pemphigoid-like, vesiculo-bullous eruption. The rash may wax and wane during pregnancy, only to flare during labor and delivery. PG appears to be mediated by a specific immunoglobulin G (IgG) directed against the cutaneous basement membrane zone (BMZ).

PG occurs in approximately 1 in 50,000 pregnancies.[2,3] It is associated with HLA-DR3 and DR4, and it appears likely that the incidence in various ethnic groups parallels the frequency of these genes in different populations.[4]

ETIOLOGY AND PATHOGENESIS

PG appears to be caused by an anti-BMZ antibody that induces C3 deposition along the dermal-epidermal junction. The PG autoantibody is an IgG that is infrequently found by direct immunofluorescence (IF), although indirect, complement-added IF reveals the circulating IgG in the majority of patients. In salt-split skin, staining remains with the epidermal fragment. An enzyme-linked immunosorbent assay (ELISA) for the PG antibody is now commercially available, and when this highly sensitive test is used, antibody titers appear to correlate with disease activity.[5] The PG autoantibody belongs to the IgG1 subclass and fixes complement via the classical complement pathway.[6] T cells also show selective NC16A reactivity in PG, although their role in disease development remains to be elucidated.[7]

Nearly all patients with PG [and most patients with bullous pemphigoid (BP)] have demonstrable antibodies to BP180 (type XVII collagen), a 180-kd transmembrane protein with its N-terminal end embedded within the intracellular component of the hemidesmosome and its C-terminal end located extracellularly (see Chap. 51). The extracellular section contains a series of 15 collagenous components alternating with 16 short, non-collagenous domains. The sixteenth non-collagenous segment closest to the plasma membrane of the basal keratinocyte is designated NC16A and contains the immunoreactive site.[8,9] The PG autoantibody is assumed to be pathogenic for several reasons: (1) It is found in essentially all patients. (2) In vitro, purified antibodies to BP180 from patients with BP cause chemoattraction to the dermal-epidermal junction with subsequent degranulation and dermal-epidermal separation.[10] (3) Rabbit antibodies to BP180 in animal models induce sub-epidermal blisters when infused into neonatal mice or hamsters.[11,12]

The BP180 protein differs significantly from the BP230 protein recognized by the majority of BP sera.[13,14] The 230-kd protein is coded for on the short arm of chromosome 6.[15] Its complementary DNA (cDNA) has been sequenced[16] and codes for an intracellular protein[17] that shows considerable homology with desmoplakin I.[18] The 180-kd protein is coded for on the long arm of chromosome 10.[19] Its cDNA shows no homology with the 230-kd cDNA but rather encodes a protein with two domains showing the primary structure of tri-helical collagen.[20]

What initiates the production of autoantibody remains unclear, but because gestational pemphigoid is exclusively a disease of pregnancy, attention has fo-

PEMPHIGOID GESTATIONIS AT A GLANCE



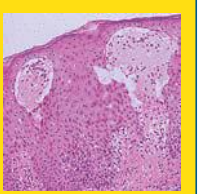

- Acute-onset, intensely pruritic, vesiculobullous eruption of pregnancy or the immediate postpartum period.
- Rare, occurring in roughly 1 in 50,000 pregnancies.
- Histopathology: dermal-epidermal separation with numerous eosinophils.
- Direct immunofluorescence: linear deposition of C3, with or without immunoglobulin G, along the basement membrane zone of the epidermal fragment of salt-split skin.
- Enzyme-linked immunosorbent assay for pemphigoid gestationis antibody (BP180) commercially available.
- No significant maternal morbidity or mortality.
- Associated with a slight increase in premature and small-for-gestational-age births.

cused on immunogenetics and potential cross-reactivity between placental tissue and skin.

Immunogenetic studies reveal an increase in HLA antigens DR3 or DR4, and curiously, nearly 50 percent of patients have the simultaneous presence of both.[21] The extended haplotype HLA-A1, B8, DR3 is known to be in linkage disequilibrium with a deletion of C4A (the C4 null allele or C4QO). Indeed, 90 percent of patients have either a C4AQO or a C4BQO.[22] Whether the C4QO association is the primary genetic marker for PG or whether the presence of a C4QO is even clinically relevant to complement function, however, remains to be shown.

It is worth noting that patients with neither DR3 nor DR4 may have clinically indistinguishable disease; the presence of the characteristic HLA antigens alone is not sufficient to produce disease.[21]

Essentially, 100 percent of women with a history of PG have demonstrable anti-HLA antibodies.[23,24] Because the only source of disparate HLA antigens is typically the placenta (which is primarily of paternal origin), the universal finding of anti-HLA antibodies implies a high frequency of immunologic insult during gestation. Indeed, a slight increase in HLA-DR2 in the husbands of women with PG has been reported.[23] It has been suggested that immunologically primed women may simply react more strongly to tissue with disparate HLA antigens. Whether anti-HLA antibodies represent phenomenon or epiphenomenon, remains to be clarified.

The autoantibody of gestational pemphigoid binds to amniotic basement membrane, a structure derived from fetal ectoderm and antigenically similar to skin.[25,26] Women with PG also show an increased expression of major histocompatibility complex class II antigens (DR, DP, DQ) within the villous stroma of chorionic villi but not skin.[27,28] It has therefore been proposed that PG is a disease initiated by the aberrant expression of major histocompatibility complex class II antigens (of paternal haplotype) within the placenta that serves to initiate an allogeneic response to placental BMZ, which then cross-reacts with skin.[29]

On the other hand, PG has also been reported in association with hydatidiform moles[30] and choriocarcinomas.[31] This is an intriguing clinical observation, because most hydatidiform moles are produced by a diploid contribution of paternal chromosomes and contain neither fetal tissue nor amnion. There are no case reports of a PG-like rash in males with choriocarcinoma. Unlike its counterpart in women, choriocarcinoma in males is strictly syngeneic tissue. Because choriocarcinoma in women is entirely derived from placental tissue (which is largely of paternal derivation), the suggestion is that the development of PG is somehow dependent on the state of partial allograph, not necessarily on the presence of amnion.

CLINICAL FINDINGS

PG is exclusively associated with pregnancy. It typically presents during late pregnancy with the abrupt onset of intensely pruritic urticarial lesions. Fifty percent of patients experience first onset on the abdomen, often within or immediately adjacent to the umbilicus. The other half present with typical lesions, but in an atypical distribution (extremities, palms, or soles). Rapid progression to a generalized, pemphigoid-like eruption, sparing only the face, mucous membranes, palms, and soles is the rule (although any site may be involved). Flares occur with delivery in approximately 75 percent of patients and may be dramatic. The explosive onset of blistering may occur within hours of delivery, either as a flare of pre-existing disease or as presentation de novo. Up to one-quarter of patients initially present during the immediate postpartum period.

Newborns may be affected up to 10 percent of the time, but the disease is typically mild and self-limited. IF of newborn skin may yield positive findings despite a lack of clinically apparent disease, which suggests that more than C3 deposition alone is required to induce lesions.[32]

Because of clinical and IF similarities with BP, and because of the considerable confusion over the term *herpes gestationis* (particularly outside dermatology), most authors have accepted the revised terminology of PG.[33] However, there are several differences worth bearing in mind: (1) BP is a disease of the elderly and shows no gender bias. PG is exclusively associated with pregnancy. (2) PG shows a strong association with HLA-DR3, -DR4, and a C4 null allele. BP does not. (3) Indirect IF in BP yields positive results in the majority of patients, and the titer of anti-BMZ antibody is often high. The titer of anti-BMZ antibody in PG is usually so low that antibody cannot be detected without the use of complement-added or ELISA techniques. (4) The majority of BP sera react to an intracellular 230- to 240-kd component of the hemidesmosome. Sera from most PG patients react to a 180-kd transmembrane protein with a collagenous domain coded for on a different chromosome. Until such time as nosology is driven by pathologic mechanism instead of clinical observation, naming is likely to remain fungible.



▲ **FIGURE 57-1** Pemphigoid gestationis. Polymorphic lesions on dorsa of feet.

Cutaneous Lesions

The typical lesions of PG are urticarial or arcuate plaques that rapidly progress toward a mixed dermatitis, including tense, pemphigoid-like blisters (Figs. 57-1, 57-2, and 57-3). Blisters may arise within urticarial plaques or on otherwise normal-appearing skin. Pruritic urticarial papules and plaques of pregnancy (see Chap. 107) can show microvesiculation but not the tense, sub-epidermal blisters of PG.

Related Physical Findings

PG is seen exclusively in women and only in the presence of pregnancy (or trophoblastic tissue). Any other setting is inconsistent with this diagnosis.

LABORATORY TESTS

Results of routine laboratory investigations are normal. Histopathology classically reveals a sub-epidermal vesicle with a perivascular infiltrate of lymphocytes and eosinophils (Fig. 57-4). Eosinophils may be lined up along the dermal-epidermal junction and typically fill the vesicular space. Classic findings, however, are seen only in the minority of cases. A nonspecific mixed cellular infiltrate containing a variable number of





▲ **FIGURE 57-2** Pemphigoid gestationis. Erythematous urticarial and bullous lesions on the chest and shoulders.



eosinophils is more common. The presence of eosinophils is the most constant feature of PG.

Special Tests

The sine qua non for a diagnosis of PG is the finding of C3, with or without IgG, in a linear band along the BMZ of perilesional skin (Fig. 57-5). In salt-split skin specimens, antibody deposition is found along the bottom of the epidermal fragment, a finding similar to that seen in BP. Indirect IF only occasionally detects circulating IgG deposition. However, complement-added indirect IF reveals the circulating anti-BMZ IgG in nearly all patients. The PG ELISA now available will likely replace IF.



▲ **FIGURE 57-3** Pemphigoid gestationis. Urticarial papules and plaques on the trunk.

Anti-BMZ antibody titers correlate with the extent and severity of disease, but only if ELISA tests are used.[5] There is no apparent correlation between HLA type and clinical activity.[21] An increased incidence of antithyroid antibodies has been documented, but clinically apparent thyroid dysfunction appears rare.[34] Antinuclear antibodies are not seen, and serum complement levels are normal.

DIFFERENTIAL DIAGNOSIS

Since early lesions of PG can be urticarial, the most frequent frustration is differentiating PG from pruritic urticarial papules and plaques of pregnancy, otherwise known as *polymorphous eruption of pregnancy* (see Chap. 107). PG usually progresses rapidly, which makes the clinical diagnosis apparent. Allergic contact dermatitis and drug eruptions might also be difficult to distinguish. Where doubt exists, IF (or ELISA) is the key to differentiation and is particularly relevant in helping patients plan for future pregnancies (Fig. 57-6 and Box 57-1).

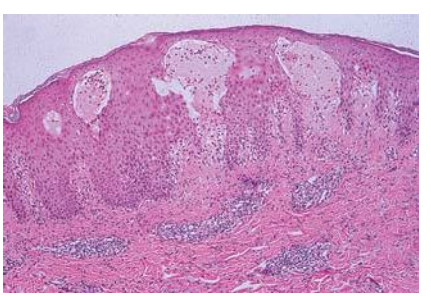

▲ **FIGURE 57-4** Pemphigoid gestationis. Subepidermal vesicle formation; dermal edema; infiltrate consisting of lymphocytes, histiocytes, eosinophils, and a few neutrophils; and focal basal cell necrosis. Note bulbous, teardrop-like vesicles.

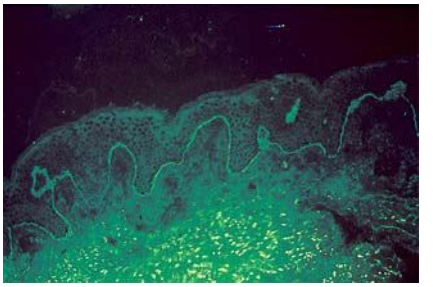

▲ **FIGURE 57-5** Pemphigoid gestationis. Linear deposition of C3 along the basement membrane zone.

COMPLICATIONS

No increase in maternal morbidity or mortality has been documented, although the impression of such an increase remains from a review of individual case reports. Cutaneous disease in the newborn is typically self-limited and rarely requires intervention. Although there is an increased risk of premature and small-for-gestational-age births,[32] there are no data to suggest that treatment with systemic corticosteroids alters the risk of premature delivery. That being the case, it is imperative that the risks of therapy be balanced against the severity of the symptoms.

Women with a history of PG appear to be at increased risk for the subsequent development of Graves disease.[34]

PROGNOSIS AND CLINICAL COURSE

The clinical presentation and course of disease may be extremely variable. Many patients experience spontaneous resolution during the later part of gestation only to experience a flare, sometimes dramatically, at the time of delivery. Others develop relatively trivial urticarial lesions during one pregnancy, only to suffer characteristic blistering during a subsequent gestation. Still others develop classic disease during one pregnancy, then no disease during the next. The frequency of such "skip pregnancies" approximates 5 percent to 10 percent.[35] Recurrences associated with menstruation are common, and flares during the subsequent use of oral contraceptives occur in at least 25 percent of patients.

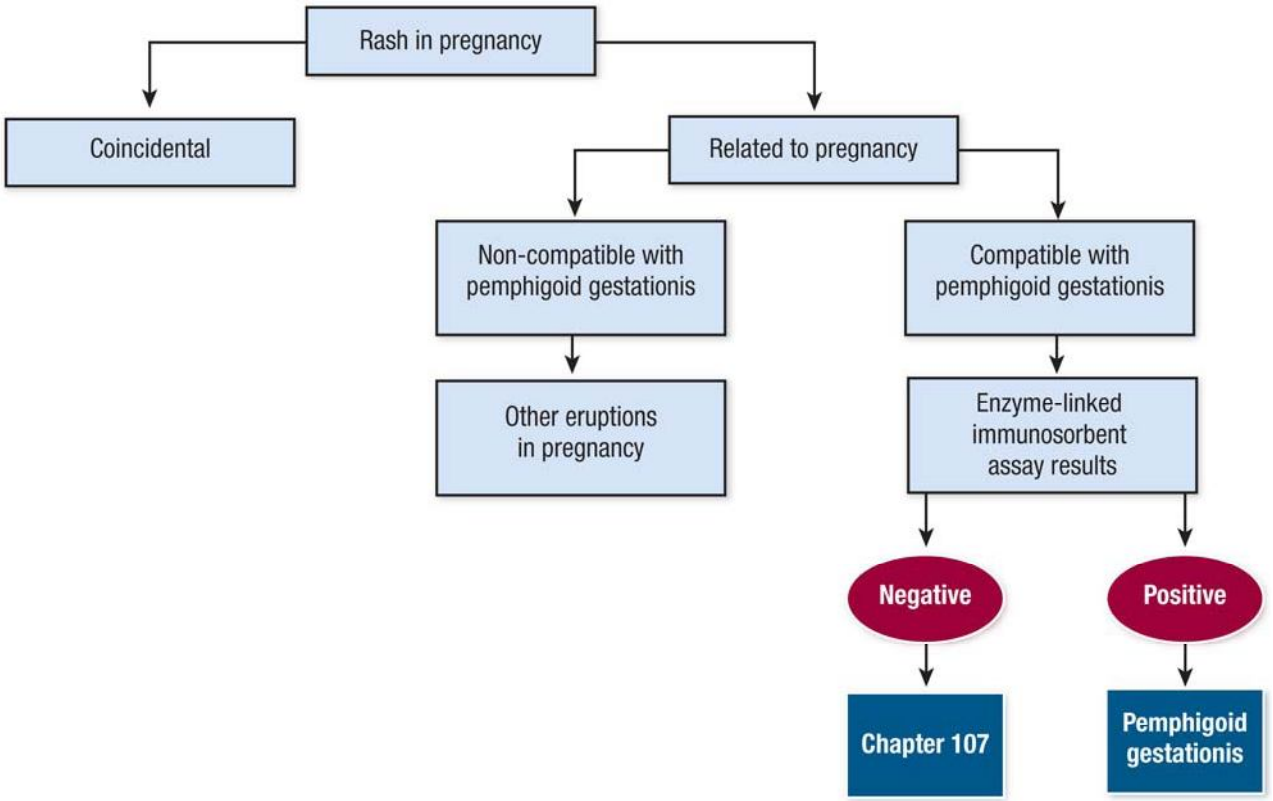

▲ **FIGURE 57-6** Approach to the patient with pemphigoid gestationis.

Most disease spontaneously remits over weeks to months following delivery, although there are isolated reports of protracted postpartum involvement. It has often been said that once gestational pemphigoid develops, it tends to occur earlier and with greater severity during subsequent gestations, but there are no data to support this contention.

No clear pattern of paternal contribution, if there is one, has yet been elucidated. First onset during both primiparous and multiparous pregnancies has been reported, with and without a change in partners.

Box 57-1

Differential Diagnosis of Pemphigoid Gestationis

Most Likely

- Urticarial pemphigoid gestationis
- Pruritic urticarial papules and plaques of pregnancy
- Other eruptions of pregnancy (see Chap. 107)
- Contact dermatitis
- Drug eruption

Consider

- Urticaria
- Erythema multiforme
- Dermatitis herpetiformis

Rule Out

- Pemphigus vulgaris
- Varicella

TREATMENT

Gestational pemphigoid is sufficiently rare that no controlled studies are available. Nonetheless, there is general consensus that treatment with topical corticosteroids and antihistamines is ineffective. Systemic corticosteroids remain the cornerstone of therapy. Most patients respond to 0.5 mg/kg of prednisone (prednisolone) daily. Maintenance therapy, generally at a lower dosage, may or may not be required throughout gestation. As noted earlier, many patients experience spontaneous disease regression during the third trimester, only to experience flare during parturition.

In individual cases, alternatives to corticosteroids (dapsone, pyridoxine, cyclosporine) or adjuvants (gold, methotrexate, cyclophosphamide, plasmapheresis) have been tried. None, with the possible exception of cyclosporine, is useful prior to term, and the experience with each has been variable at best. There are obvious concerns with the use of any of these alternatives during pregnancy.

PREVENTION

Only a small percentage of women who express DR3, DR4, or the combination of DR3 and DR4 ever develop PG, and the role of the paternal tissue in the development of disease (if any) is far from clear. With no predictive test available, prevention is not possible.

Those with a history of PG face the likelihood (but not the assurance) of recurrent involvement during subsequent gestations and are likely to develop symptoms during the use of oral contraceptives. Women who have experienced PG need not avoid additional pregnancies. They should, however, be counseled that recurrent disease is the rule.

KEY REFERENCES

The full reference list for all chapters is available at www.digm7.com.

1. Ambros-Rudolph C et al: The specific dermatoses of pregnancy revisited and reclassified: Results of a retrospective two-center study on 505 pregnant patients. *J Am Acad Dermatol* **54**:395, 2006
29. Kelly SE, Black MM, Fleming S: Pemphigoid gestationis: A unique mechanism of initiation of an autoimmune response by MHC class II molecules? *J Pathol* **158**:81, 1989



CHAPTER 58

Epidermolysis Bullosa Acquisita

David T. Woodley
Mei Chen



EPIDEMIOLOGY

Epidermolysis bullosa acquisita (EBA) is a sporadic autoimmune bullous disease of unknown etiology and with no gender, ethnic, or geographic predisposition. Although EBA does not have a Mendelian pattern type of inheritance, there may be some genetic predisposition to EBA and autoimmunity in African Americans who live in the southeastern part of the United States.[1] African American patients in the southeastern part of the United States who have either EBA or bullous systemic lupus erythematosus (SLE) have a high incidence of the HLA-DR2 phenotype. The calculated relative risk for EBA in HLA-DR2+ individuals is 13.1 in these patients. These results also suggest that EBA and bullous SLE are immunogenetically related and that either the HLA-DR2 gene is involved with autoimmunity to anchoring fibril collagen or is some sort of a marker for some other gene that exists in linkage disequilibrium with it.[1]

ETIOLOGY AND PATHOGENESIS

EBA is a chronic, sub-epidermal blistering disease associated with autoimmunity to the collagen (type VII collagen) within anchoring fibril structures that are located at the dermal-epidermal junction (DEJ). Although the precise etiology of EBA is unknown, most of the evidence suggests an autoimmune etiology. The immunoglobulin G (IgG) autoantibodies to type VII collagen are associated with a paucity of normal anchoring fibrils at the basement membrane zone (BMZ) separating the epidermis from the dermis and poor epidermal-dermal adherence. Although it is an acquired disease that usually begins in adulthood, it was placed in the category epidermolysis bullosa (EB) approximately 100 years ago because physicians were struck by how similar the clinical lesions of EBA were to those seen in children with hereditary dystrophic forms of EB. Direct immunofluorescence (DIF) of perilesional skin biopsies from EBA patients reveals IgG deposits at the DEJ.[2] EBA antibodies bind to type VII collagen within anchoring fibrils (see Chap. 51).[3,4]

Anchoring fibrils anchor the epidermis and its underlying BMZ to the papillary dermis. Patients with hereditary forms of dystrophic EB (see Chap. 60) and EBA have decreased numbers of anchoring fibrils in their DEJ. This paucity of anchoring fibrils is associated with two similar clinical phenotypes, EBA and dystrophic forms of hereditary EB, because both diseases are characterized by skin fragility, sub-epidermal blisters, milia formation, and scarring. Although both EBA and hereditary forms of dystrophic EB are etiologically unrelated in terms of their underlying pathogenesis, they share the common feature of decreased anchoring fibrils. In the case of dystrophic forms of hereditary EB, the cause of decreased or absent anchoring fibrils is a genetic defect in the gene that encodes for type VII collagen α chains that ultimately results in small, nonfunctional or decreased anchoring fibrils.[5,6] The gene coding for type VII collagen is located on the short arm of chromosome 3, approximately 21 cm from zero.[7] The gene defects involved in hereditary forms of dystrophic EB have been identified at variable locations, but the severity of the disease appears to correlate with the degree of type VII collagen and anchoring fibril perturbations.[6] In EBA, the IgG autoantibodies binding to the type VII collagen α chains result in decreased anchoring fibrils, but the pathway leading to this reduction is unknown. It may be that type VII collagen α chains that are newly synthesized but decorated with EBA autoantibodies cannot form triple-helical structures and stable anchoring fibrils. Healed burn wounds that have been covered with cultured keratinocyte sheets also have decreased numbers of anchoring fibrils within the first year after transplantation, and this is associated with spontaneous blister formation, shortened suction blistering times, and skin fragility.[8] These observations provide indirect evidence that anchoring fibrils play a role in maintaining adherence between the epidermis and dermis.

The type VII collagen α chain has a molecular mass between 250 and 320 kd, and the collagen consists of a homotrimer of three identical α chains (see Chap. 51). Each α chain consists of a large globular noncollagenous amino terminus called the *non-collagenous 1* (NC-1) *domain* that is approximately one-half the entire mass of the α chain. Next, there is a helical domain with typical glycine-X-Y repeats. At the carboxyl terminus is a second globular noncollagenous domain, NC-2, that is much smaller than NC-1.[9] Most EBA autoantibodies recognize four predominant antigenic epitopes within the NC-1 domain and do not recognize the helical or NC-2 domains.[10,11] There may be something intrinsically "antigenic" about the NC-1 domain because the available monoclonal antibodies that have been generated against type VII collagen (anti–C-VII antibodies) specifically recognize only NC-1 subdomains.

A reduction in the number of anchoring fibrils is seen in lesional and perilesional skin of EBA patients, but the pathway leading to this reduction is unknown.

Several independent lines of evidence have implicated autoimmune responses

EPIDERMOLYSIS BULLOSA ACQUISITA AT A GLANCE



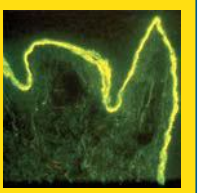

- Rare, autoimmune sub-epidermal bullous disease due to immunoglobulin G autoantibodies to type VII collagen.
- Etiology is unknown.
- Skin fragility, sub-epidermal blisters, residual scarring, and milia formation. Common sites are trauma-prone areas such as hands, feet, elbows, knees, sacrum, nails, and mouth.
- Related features may include an underlying systemic disease such as inflammatory bowel disease. May have erosions of the mucosa and esophageal stenosis.
- Pathology shows sub-epidermal bulla, fibrosis, milia formation, and positive direct immunofluorescence for immunoglobulin G deposits at the epidermal-dermal junction.
- Treatment options limited and often difficult.

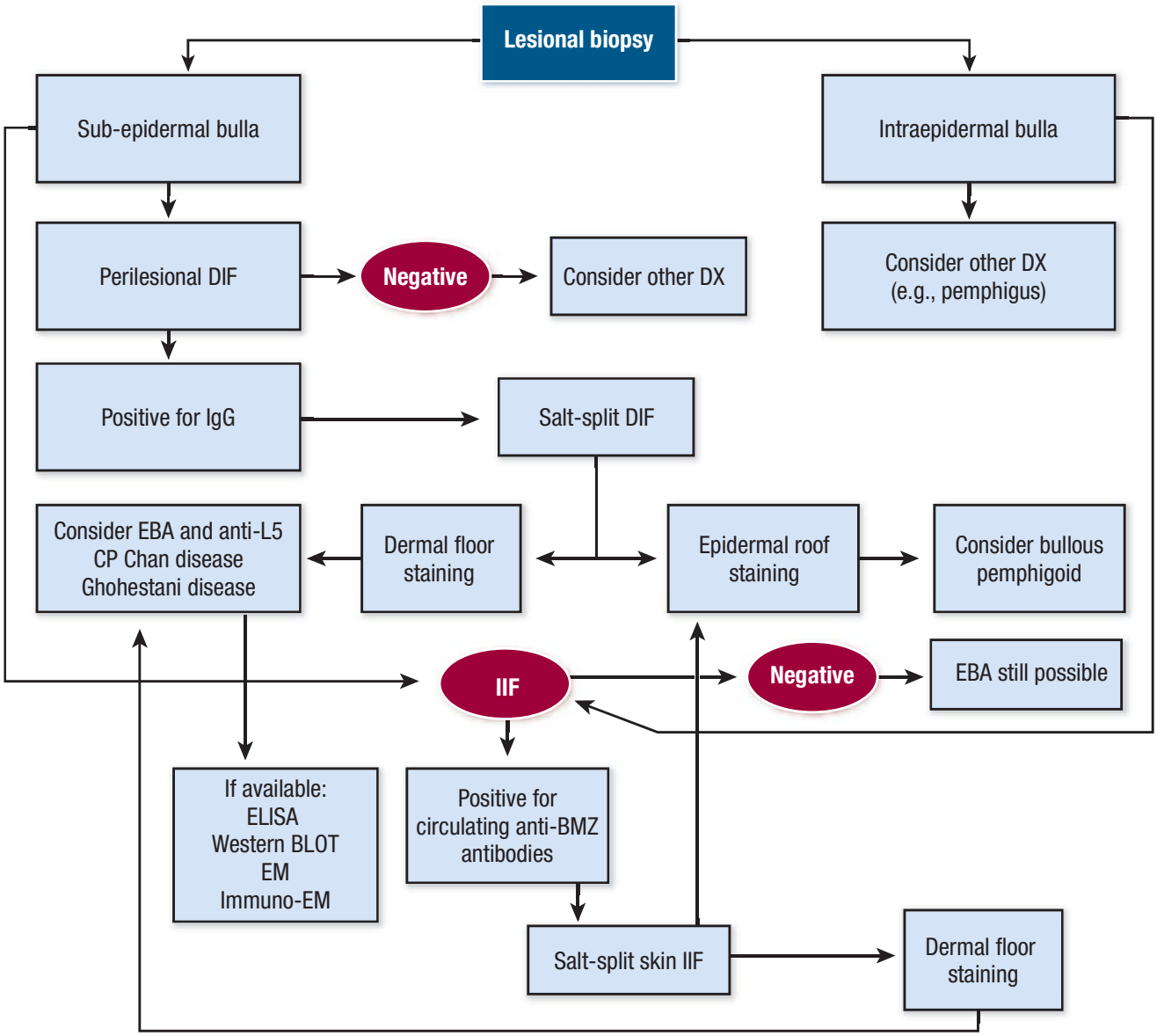

▲ **FIGURE 58-1** Approach to the patient with epidermolysis bullosa acquisita (EBA). BMZ = basement membrane zone; DIF = direct immunofluorescence; DX = diagnosis; ELISA = enzyme-linked immunosorbent assay; IgG = immunoglobulin G; IIF = indirect immunofluorescence.

as a key element in the pathogenesis of EBA. First, the pathogenic role of EBA antibodies is suggested by the observation that when patients with SLE develop autoantibodies to the EBA antigen, they develop widespread skin blisters and fall into a subset of SLE called *bullous SLE*.[16] This "experiment of nature" suggests that EBA autoantibodies are pathogenic and capable of inducing disadherence between the epidermis and dermis. Secondly, direct proof that EBA autoantibodies are pathogenic comes from recent passive transfer studies. We immunized rabbits and raised a high titer antiserum to the NC-1 domain of human type VII collagen. We injected this antibody into hairless immune competent mice, and the mice developed bullous skin disease with many of the features of EBA in humans.[17] The mice developed subepidermal blisters and lost nails on their feet. They also had circulating NC-1 antibodies in their blood and anti–NC-1 IgG antibody deposits at their DEJ. In addition, the mice had murine complement deposits at the DEJ induced by the autoantibody-antigen complex.[17] Another study by Sitaru and colleagues[18] showed that the injection of rabbit polyclonal antibodies to the NC-1 domain of mouse type VII collagen into mice also induced sub-epidermal skin blisters that were reminiscent of human EBA.[18] Further, we have also affinity purified human EBA autoantibodies against an NC-1 column and injected them into mice. The mice then developed clinical, histologic, immunologic and ultrastructural features akin to human EBA.[19] Taken together, these successful passive transfer experiments and the observations with bullous SLE strongly suggest that EBA autoantibodies are "pathogenic" and capable of causing epidermal-dermal separation in skin.

CLINICAL FINDINGS (Fig. 58-1)

If a patient presents with bullae on the skin with no reasonable explanation despite a thorough history and physical examination, three tests should be done: a skin biopsy for routine hematoxylin and eosin histology, a second biopsy juxtaposed to a lesion but on normal-appearing skin for DIF and a blood draw to test for antibodies against the BMZ and/or type VII col-



lagen by indirect immunofluorescence (IIF) or enzyme-linked immunosorbent assay (ELISA).

History

Cutaneous Lesions

The cutaneous lesions of EBA can be quite varied and can mimic other types of acquired autoimmune bullous diseases. The common denominator for patients with EBA is autoimmunity to type VII (anchoring fibril) collagen. Although the clinical spectrum of EBA is still being defined, there are at least five clinical presentations: (1) a classic presentation, (2) a bullous pemphioid (BP)-like presentation, (3) a cicatricial pemphigoid (CP)–like presentation, (4) a presentation reminiscent of Brunsting-Perry pemphigoid with scarring lesions and a predominant head and neck distribution, and (5) a presentation reminiscent of linear IgA bullous dermatosis or chronic bullous disease of childhood.

Classic Presentation

The classic presentation (Figs. 58-2 and 58-3A) is of a noninflammatory bullous disease with an acral distribution that heals with scarring and milia formation. This presentation is reminiscent of porphyria cutanea tarda (PCT; see Chap. 132) when it is mild and of the hereditary form of recessive dystrophic EB when it is severe (see Chap. 60). The classic form of EBA is thus a mechanobullous disease marked by skin fragility. These patients have erosions, tense blisters within noninflamed skin, and scars over trauma-prone surfaces such as the backs of the hands, knuckles, elbows, knees, sacral area, and toes (see Figs. 58-2, 58-3A, and 58-4). Some blisters may be hemorrhagic or develop scales, crusts, or erosions. The lesions heal with scarring and frequently with the formation of pearl-like milia cysts within the scarred areas (see Fig. 58-3A). Although this presentation may be reminiscent of PCT, these patients do not have other hallmarks of PCT, such as hirsutism, a photodistribution of the eruption, or scleroderma-like changes, and their urinary porphyrins are within normal limits. A scarring alopecia and some degree of nail dystrophy may be seen.

Although the disease is usually not as severe as that of patients with hereditary forms of recessive dystrophic EB, EBA patients with the classic form of the disease may have many of the same sequelae, such as scarring, loss of scalp hair, loss of nails, fibrosis of the hands and fingers, and esophageal stenosis.[23]





◀ **FIGURE 58-2** Patient with epidermolysis bullosa acquisita who has severe blistering, erosions, scarring, and milia formation on trauma-prone areas of her skin. This is the classic presentation.

Bullous Pemphigoid–Like Presentation (See Chap. 54)

A second clinical presentation of EBA is of a widespread, inflammatory vesiculobullous eruption involving the trunk, central body, and skin folds in addition to the extremities.[15] The bullous lesions are tense and surrounded by inflamed or even urticarial skin. Large areas of inflamed skin may be seen without any blisters and only erythema or urticarial plaques. These patients often complain of pruritus and do not demonstrate prominent skin fragility, scarring, or milia formation. This clinical constellation is more reminiscent of BP (see Figs. 58-3B and 58-4) than a mechanobullous disorder. Similar to BP, the distribution of the lesions may show an accentuation within flexural areas and skin folds.

Cicatricial Pemphigoid–Like Presentation (See Chap. 55)

Both the classic and BP-like forms of EBA may have involvement of mucosal surfaces. However, EBA also may present with such predominant mucosal involvement that the clinical appearance is reminiscent of CP (see Fig. 58-3C).[24] These patients usually have erosions and scars on the mucosal surfaces of the mouth, upper esophagus, conjunctiva, anus, or vagina with or without similar lesions on the glabrous skin.

Brunsting-Perry Pemphigoid–Like Presentation (See Chap. 55)

Brunsting-Perry cicatricial BP is a chronic, recurrent vesiculobullous eruption localized to the head and neck and characterized by residual scars, subepidermal bullae, IgG deposits at the DEJ, and minimal or no mucosal involvement. The antigenic target for the IgG autoantibodies, however, has not been defined. Nevertheless, a patient reported with this constellation of findings had IgG autoantibodies directed to anchoring fibrils below the lamina densa.[25] We have seen three additional patients with the features of Brunsting-Perry pemphigoid and autoantibodies directed to type VII collagen (unpublished observations). Therefore, it appears that EBA patients may present with a clinical phenotype of Brunsting-Perry pemphigoid (see Fig. 58-3D).

Immunoglobulin A Bullous Dermatosis–Like Presentation (See Chap. 56)

IgA bullous dermatosis–like presentation of EBA is manifested by a subepidermal bullous eruption, a neutrophilic infiltrate, and linear IgA deposits at the BMZ when viewed by DIF. It may resemble linear IgA bullous dermatosis (LABD), dermatitis herpetiformis, or chronic bullous disease of childhood and may feature tense vesicles arranged in an annular fashion and involvement of mucous membranes.[26] The autoantibodies are usually IgA, IgG, or both.

The diagnosis of these sub-epidermal blistering cases with IgA anti-type VII collagen antibodies showing linear IgA deposition at the BMZ is disputable. Some clinicians regard the patients as having purely LABD, whereas others regard them as having a subset of EBA. Further, the majority of EBA patients have low titer IgA antibodies in their blood directed against type VII collagen.

Childhood EBA is a rare disease. It has a variable presentation, including an LABD-like disease, a BP-like disease, and the classic mechanobullous EBA presentation. Although mucosal involvement is frequent and severe in



▲ **FIGURE 58-3** **A.** Classic presentation of epidermolysis bullosa acquisita with scarring and milia over trauma-prone areas of skin. **B.** Bullous pemphigoid–like presentation of epidermolysis bullosa acquisita with a widespread inflammatory vesiculobullous dermatosis. **C.** Cicatricial pemphigoid–like presentation of epidermolysis bullosa acquisita with a mucosal-centered bullous scarring eruption. **D.** Brunsting-Perry pemphigoid–like presentation of epidermolysis bullosa acquisita with bullous and scarring lesions predominantly on the head and neck.

childhood EBA, the overall prognosis is more favorable than in adult EBA.

Incidence of the Clinical Presentations of Epidermolysis Bullosa Acquisita

According to the authors' experience, approximately 25 percent of patients with EBA may present with a BP-like clinical appearance. The disease of some of these patients eventually smolders into a more noninflammatory mechanobullous form. However, both the classic and BP-like forms of the disease may co-exist in the same patient (Fig. 58-5). The clinical phenotype of EBA that is reminiscent of pure CP occurs in fewer than 10 percent of all EBA cases.

Related Physical Findings

EBA patients may have many physical findings similar to patients with hereditary dystrophic EB due to gene defects in the type VII collagen gene. These include oral erosions, esophageal strictures, hypo- and hyperpigmentation skin mottling, nail loss, milia formation, scarring, and a degree of fibrosis of the hands.

A number of published reports suggest that EBA may be associated with various systemic diseases[20] such as inflammatory bowel disease, SLE, amyloidosis, thyroiditis, multiple endocrinopathy syndrome, rheumatoid arthritis, pulmonary fibrosis, chronic lymphocytic leukemia, thymoma, diabetes, and other diseases in which an autoimmune pathogenesis has been implicated. At the University of North Carolina, Stanford, Northwestern, and University of Southern California, with a combined experience of following over 62 EBA pa-



▲ **FIGURE 58-4** An epidermolysis bullosa acquisita patient with involvement of the leg. Note bullae, erosions, and crusts.



▲ **FIGURE 58-5** An epidermolysis bullosa acquisita patient demonstrating two presentations of the disease: The classic mechanobullous presentation with erosions, scarring, and milia over the elbows and the more inflammatory bullous pemphigoid–like lesions on her trunk.



tients, it appears that inflammatory bowel disease is the systemic disease most frequently associated with EBA.

LABORATORY TESTS

Histopathology

Routine histologic examination of lesional skin obtained from EBA patients shows a sub-epidermal blister and a clean separation between the epidermis and dermis. The degree of inflammatory infiltrate within the dermis usually reflects the degree of inflammation of the lesion observed by the clinician. Lesions that are reminiscent of recessive dystrophic EB or PCT usually have a notable scarcity of inflammatory cells within the dermis. Lesions that are clinically reminiscent of BP usually have significantly more inflammatory cells within the dermis, and these cells may be a mixture of lymphocytes, monocytes, neutrophils, and eosinophils. The histology of EBA skin specimens obtained from BP-like lesions may be difficult to distinguish from BP itself.

Immunofluorescence

Patients with EBA have IgG deposits within the DEJ of their skin.[3,23] This is best detected by DIF of a biopsy specimen obtained from a perilesional site (Fig. 58-6). IgG is the predominant immunoglobulin class, but deposits of complement, IgA, IgM, factor B, and properdin also may be detected. The DIF staining demonstrates an intense linear fluorescent band at the DEJ. Yaoita et al.[2] have suggested that a positive DIF and IgG deposits within the sub-lamina densa zone are necessary criteria for the diagnosis of EBA.

Patients with PCT, which may mimic EBA clinically, frequently have IgG and complement deposits at the DEJ similar to those of EBA patients (see Chap. 132). However, the DIF feature that distinguishes PCT from EBA is that PCT skin also demonstrates immune deposits around the dermal blood vessels.

Patients with EBA may have autoantibodies in their blood directed against the DEJ.[3] These antibodies can be detected by IIF of the patient's serum on a substrate of monkey or rabbit esophagus or human skin and stain the DEJ in a linear fashion that may be indistinguishable from BP sera.[19]

Immunoelectron Microscopy

The localization of the immune deposits within the DEJ of the skin of EBA patients by immunoelectron microscopy is the "gold standard" for the diagnosis. As demonstrated by Nieboer et al.[22] and Yaoita et al.,[2] patients with EBA have immune deposits within the sub-lamina densa zone of the cutaneous BMZ. This localization is clearly distinct from the deposits in BP, which are higher up in the hemidesmosome area or lamina lucida area of the basement membrane. It is also distinct from CP, which has antigenic targets confined to the lamina lucida (see Chaps. 54 and 55).

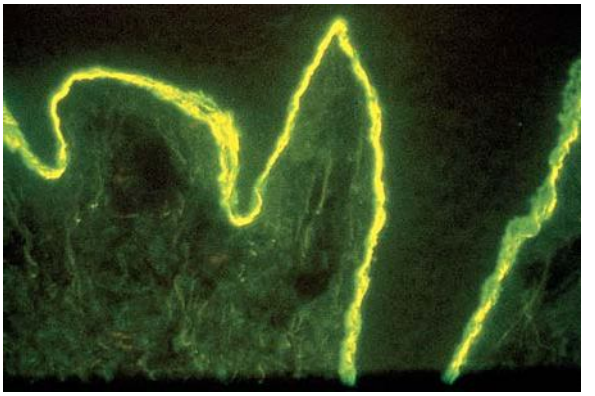

◀ **FIGURE 58-6** Direct immunofluorescence staining for immunoglobulin G deposits in perilesional skin of an epidermolysis bullosa acquisita patient. Note the dense deposits within the dermal-epidermal junction (the epidermis is on top in this section).

Indirect Salt-Split Skin Immunofluorescence

When human skin is incubated in 1 *M* NaCl, the DEJ fractures cleanly through the lamina lucida zone. This fracture places the BP antigen on the epidermal side of the split and all other basement membrane structures on the dermal side of the separation. Salt-split skin substrate can be used to distinguish EBA and BP sera.[3]

If the serum antibody is IgG and labels the epidermal roof, the patient does not have EBA, and BP should be considered. If, on the other hand, the antibody labels the dermal side of the separation, the patient usually has either EBA or bullous SLE. The latter can be ruled out by other serology and by clinical criteria.

Direct Salt-Split Skin Immunofluorescence

Perilesional skin incubated in cold 1 *M* NaCl is fractured through the DEJ, which effectively places the BP antigen (and any associated immune deposits) on the epidermal roof and the EBA antigen (and any associated immune deposits) on the dermal floor of the separation.[23] If the patient has EBA, immune deposits are detected on the dermal side of the separation by a routine DIF method using fluorescein-conjugated anti-human IgG.

Western Immunoblotting

Antibodies in EBA sera bind to a 290-kd band in Western blots of human skin basement membrane proteins containing type VII collagen, whereas sera from all other primary blistering diseases do not.[3] This band is the α chain of type VII collagen. Often, a second band of 145 kd is labeled with EBA antibodies. This band is the amino-terminal globular NC-1 domain of the type VII collagen α chain, which is rich in carbohydrate and contains the antigenic epitopes of EBA autoantibodies, bullous SLE autoantibodies, and monoclonal antibodies against type VII collagen.[10]

Enzyme-Linked Immunosorbent Assay

Chen et al.[32] have produced milligram quantities of recombinant, purified, post-translationally modified NC-1 in stably transfected human cells and have used this NC-1 to develop an ELISA for autoantibody detection in EBA patients and in patients with bullous SLE. This new ELISA is more sensitive than immunofluorescence and Western blotting, and yet it is very specific for antibodies to type VII collagen.

DIFFERENTIAL DIAGNOSIS (Box 58-1)

Because EBA has been described in infants and children, it is worth considering that a patient thought to have genetic dystrophic EB just might be a rare childhood patient with EBA. This can be ruled out by the antibody tests out-

Box 58-1

Differential Diagnosis of Epidermolysis Bullosa Acquisita

Most Likely

- Porphyria cutanea tarda
- Pseudo-porphyria cutanea tarda
- Bullous pemphigoid
- Cicatricial pemphigoid

Consider

- Linear immunoglobulin A bullous disease
- Brunsting-Perry pemphigoid
- Bullous systemic lupus erythematosus

lined in the section Laboratory Tests. PCT can look clinically very much like classic EBA and can be ruled out by a urine or plasma test for uroporphyrins. Pseudo-PCT, usually caused by drugs such as nonsteroidal anti-inflammatory agents, can look similar to EBA with skin fragility, erosions, and blisters over trauma-prone areas, scarring, and milia formation. Nevertheless, the DIF appears different in that pseudo-PCT, like PCT, shows IgG deposits at both the BMZ at the DEJ and around dermal blood vessels (which are not stained in EBA).

The BP-like EBA can be eliminated by several methods listed above, but the first-line test would be indirect and direct salt-split immunofluorescence.

DIAGNOSIS

The diagnostic criteria developed by Yaoita et al.[2] for the diagnosis of EBA still stand. These criteria, with slightly updated modifications, are shown in Table 58-1.

Alternatives for the last item are indirect or direct salt-split skin immunofluorescence, Western blotting, and ELISA.

COMPLICATIONS

The complications caused by EBA include secondary skin infections, usually due to *Staphylococcus* or *Streptococcus*, because the blisters and erosions compromise the skin's barrier. Scarring and milia formation are naturally occurring complications or sequelae of the deep blistering process. Severe EBA patients may develop significant fibrosis of the hands with decreased range of motion of the palm and digits. Because of wounds and fibrosis of the soles of the feet and toes, some EBA patients have difficulty walking. Many patients with EBA lose their fingernails. EBA patients with significant mucosal involvement may develop esophageal strictures.

TABLE 58-1

Diagnostic Criteria for Epidermolysis Bullosa Acquisita

- A bullous disorder within the clinical spectrum outlined earlier (see Clinical Findings).
- No family history of a bullous disorder.
- Histology showing a sub-epidermal blister.
- Deposition of immunoglobulin G deposits within the dermal-epidermal junction (i.e., a positive direct immunofluorescence of perilesional skin).
- Immunoglobulin G deposits localized to the lower lamina densa and/or sub-lamina densa zone of the dermal-epidermal junction when perilesional skin is examined by direct immunoelectron microscopy.

TREATMENT

EBA usually responds poorly to treatment. Supportive therapy is warranted in all patients with EBA. This includes instruction in open wound care and strategies for avoiding trauma. Patients should be warned not to overwash or overuse hot water or harsh soaps and to avoid prolonged or vigorous rubbing of their skin with a washcloth or towel. In some patients, it appears that prolonged sun exposure may aggravate or promote new lesions on the dorsal hands and knuckles. Thus, avoidance of prolonged sun exposure and the use of sunscreens are helpful. The patient should be educated to recognize localized skin infections and to seek medical care and antibiotic therapy promptly when they occur.

EBA patients are often refractory to high doses of systemic glucocorticoids, azathioprine, methotrexate, and cyclophosphamide, especially when they have the classic mechanobullous form of the disease. These agents may be somewhat helpful in controlling EBA when it appears as an inflammatory BP-like disease. Some EBA patients improve on dapsone, especially when neutrophils are present in their dermal infiltrate.

Cyclosporine has been shown to be beneficial in EBA.[33] However, the long-term toxicity of this drug limits its use.

There are also independent reports of EBA patients responding to high doses of colchicine.[34] This is often used as a first-line drug because its side effects are relatively benign compared with other therapeutic choices. Diarrhea is a common side effect of colchicine, however, which makes it difficult for many patients to achieve a high enough dose to control the disease. Moreover, because of this side effect, we are hesitant to use colchicine in EBA patients who also have inflammatory bowel disease. In addition, there are patients who do not respond to colchicine. Colchicine is a well-known microtubule inhibitor, but it also appears to have properties that have the potential to inhibit antigen presentation to T cells, which could downregulate autoimmunity.

Photopheresis has been used in Sézary syndrome, mycosis fungoides, and a variety of autoimmune bullous diseases (see Chap. 239). Photopheresis improves the clinical features of EBA and remarkably lengthens the suction blistering times of the patients, suggesting an improvement in their dermal-epidermal adherence.[35]

Intravenous Ig has been used in dermatomyositis, an entity in which autoimmunity may play a role. Intravenous Ig has been reported to be effective in some patients with EBA.[36] The mechanism by which γ globulin may invoke a positive response in EBA is unknown.

The anti–TNF-α biologics (such as infliximab; see Chap. 235) and anti CD antibodies against B cells have been tried in EBA with some success in limited open trials. Box 58-2 outlines treatment options in EBA that have some support in the medical literature.

Box 58-2

Treatments for Epidermolysis Bullosa Acquisita (EBA)

MEDICATION	DOSE RANGE
Colchicine[a]	0.6–3.0 mg/day
Cyclosporine A	6 mg/kg/day
Dapsone[b]	100–300 mg/day
Cytoxan	50–200 mg/day
Prednisone[c]	1.0–1.5 mg/kg
Intravenous immunoglobulin[d]	3 g/kg divided over 5 days
Infliximab	5 mg/kg at 0, 2, 4, and 6 wk

[a]Must start with 0.4–0.6 mg/day and each 1–2 wk double this dose as tolerated. When patient develops diarrhea, back off 1 tablet (0.4–0.6 mg).
[b]Begin at 25 mg/day and double each week after the complete blood count and liver function tests. Most patients need between 100–250 mg/day. Increasing the dose slowly helps the patient tolerate the anemia that develops (i.e., less orthostatic lightheadedness, etc.). Expect a 1- to 2-g drop in the patient's hemoglobin on therapeutic doses.
[c]Usually does not help the classic, mechanobullous type of EBA with minimal inflammation. However, it may be somewhat helpful in the bullous pemphigoid–like type of EBA.
[d]Intravenous immunoglobulin is given over 4–5 days every month for 5 or 6 mo to give it an adequate trial.



KEY REFERENCES

The full reference list for all chapters is available at www.digm7.com.

2. Yaoita H et al: Epidermolysis bullosa acquisita: Ultrastructural and immunological studies. *J Invest Dermatol* **76**:288, 1981
3. Woodley DT et al: Identification of the skin basement membrane autoantigen in epidermolysis bullosa acquisita. *N Engl J Med* **310**:1007, 1984
15. Gammon WR et al: Epidermolysis bullosa acquisita: A pemphigoid-like disease. *J Am Acad Dermatol* **11**:820, 1984
16. Gammon WR et al: Evidence that antibasement membrane zone antibodies in bullous eruption of systemic lupus erythematosus recognize epidermolysis bullosa acquisita autoantigens. *J Invest Dermatol* **84**:472, 1985
17. Woodley DT et al: Evidence that antitype VII collagen antibodies are pathogenic and responsible for the clinical, histological, and immunological features of epidermolysis bullosa acquisita. *J Invest Dermatol* **124**:958, 2005
18. Sitaru C et al: Induction of dermal-epidermal separation in mice by passive transfer of antibodies specific to type VII collagen. *J Clin Invest* **115**:870, 2005
19. Woodley DT et al: Induction of epidermolysis bullosa acquisita in mice by passive transfer of autoantibodies from patients. *J Invest Dermatol* **126**: 1324, 2006
22. Nieboer C et al: Epidermolysis bullosa acquisita: Immunofluorescence, electron microscopic and immunoelectron microscopic studies in four patients. *Br J Dermatol* **102**:383, 1980



CHAPTER 59

Dermatitis Herpetiformis

Russell P. Hall III
Stephen I. Katz

EPIDEMIOLOGY

Dermatitis herpetiformis (DH) is characterized by an intensely itchy, chronic papulovesicular eruption that usually is distributed symmetrically on extensor surfaces. The disease can be clearly distinguished from the other sub-epidermal blistering eruptions by histologic, immunologic, and gastrointestinal criteria. The prevalence of DH in various Caucasian populations varies between 10 and 39/100,000 persons.[1–3] It may start at any age, including childhood; however, the second, third, and fourth decades are the most common. After presentation, DH persists indefinitely, although with varying severity. Patients with DH have an associated gluten-sensitive enteropathy (GSE) that is usually asymptomatic.

HISTORY

ETIOLOGY AND PATHOGENESIS

In 1999, Dieterich et al. identified antibodies to tissue transglutaminases (Tgases) in the sera from DH patients.[18] Distinguishing between various types of Tgases enabled Sardy et al. in 2002 to demonstrate that epidermal Tgase is the dominant autoantigen in DH.[19]

Gluten, a protein found in wheat, barley, and rye, plays a critical role in the pathogenesis of DH. Oats, long thought to contain gluten and play a role in inducing DH lesions, have been shown to be devoid of toxicity in patients with DH.[20,21] In 1966, Marks et al. first noted a gastrointestinal abnormality in patients with DH.[11] Shortly thereafter, it was shown that the lesion was reversible by avoidance of the dietary protein gluten.[13,22] Initially, the intestinal abnormality was thought to be present in 60 percent to 75 percent of DH patients. However, this view has been modified in two ways. First, the diagnostic criteria for DH have been delineated more precisely, and second, it can be shown that certain patients without apparent gastrointestinal pathology can be "induced" to develop gastrointestinal lesions by subjecting them to a large gluten intake; such patients have been said to have latent celiac sprue.[23] Thus, most patients with DH have a gastrointestinal abnormality similar (if not identical) to celiac disease, however minimal that may be when the patient is ingesting a normal gluten load. As in celiac disease, there is an increased density of small bowel intraepithelial T cells with a γ/δ T-cell receptor in the jejunum of patients with DH.[24] The finding that T-cell lines from patients with DH produce significantly more interleukin 4 (IL-4) than those from patients with GSE and that gut biopsies from symptomatic patients with isolated GSE showed increased expression of interferon-γ suggests that different cytokine patterns may play a role in the varied clinical manifestations of these two diseases.[25,26] Systemic evidence of the gut mucosal immune response has also been found in the serum and the skin of patients with DH. Patients with DH on regular gluten-containing diets have been found to have increased serum IL-2 receptor levels and serum IL-8 levels,[27,28] increased endothelial cell E-selectin expression in skin and an increased expression of CD11b on circulating neutrophils.[25,27,29] These systemic manifestations of the gut mucosal immune response may play a role in creating the pro-inflammatory environment in the skin necessary for the development of skin lesions.

The GSE seen in DH patients probably relates to the immunoglobulin A (IgA) deposits that are found in the skin of these patients, although a direct relationship has not been demonstrated. It is known that patients with both GSE and DH have antibodies to Tgases that are thought to be the major autoantigens in these diseases.[18,30] There appears to be a predilection for the autoantibodies to bind to epidermal Tgase in DH, whereas the predilection is for autoantibodies to bind tissue Tgase in patients with isolated GSE.[19] The mechanism whereby IgA anti-epidermal Tgase deposits in DH skin is not known. One

DERMATITIS HERPETIFORMIS AT A GLANCE



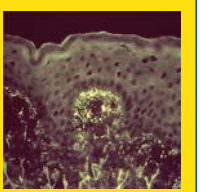

- Intensely itchy, chronic papulovesicular eruption distributed symmetrically on extensor surfaces.
- Characterized histologically by dermal papillary collections of neutrophils (microabscesses).
- Granular immunoglobulin A deposits in normal-appearing skin are diagnostic for dermatitis herpetiformis.
- Most, if not all, dermatitis herpetiformis patients have an associated gluten-sensitive enteropathy.
- The rash responds rapidly to dapsone therapy and, in many patients, to strict adherence to a gluten-free diet.

long-standing hypothesis has been that IgA containing circulating immune complexes are responsible for the IgA deposits in DH skin. The recent discovery of IgA anti-epidermal Tgase antibodies has suggested that IgA-epidermal Tgase immune complexes may be depositing in the skin of DH patients. Only a minority of DH patients, however, have been found to have IgA and epidermal tissue Tgase deposits co-localized in a perivascular pattern.[31,32] In addition, perivascular neutrophil deposits that are typically found with the perivascular deposition of immune complexes rarely occur in patients with DH.[33] These findings suggest an alternative hypothesis that IgA anti-epidermal Tgase may directly bind in the skin to epidermal tissue Tgase. The exact mechanism of IgA binding in the skin of patients with DH, however, remains unknown.

Whether the IgA skin deposits play a role in the pathophysiology of blister formation is not known. The finding of IgA and complement in almost all skin sites, not only in lesional skin, makes one postulate that if IgA (either alone or as a part of an immune complex) does play a role, additional factors are still needed to explain the initiation of lesions. Takeuchi et al. have demonstrated that minor trauma to skin results in increased expression of IL-8 and E-selectin, both of which may predispose to a neutrophilic inflammatory infiltrate.[34] These findings, coupled with the typical appearance of DH lesions on extensor surfaces at sites of trauma, suggest local cytokine/chemokine production after trauma may be one of the inciting factors of DH skin lesions. It may be that after the initial neutrophilic infiltrate binds to the cutaneous IgA, factors such as cytokines, chemokines, and proteases are released that both directly result in blister formation and induce basal keratinocytes to produce collagenases or stromelysin-1 that further contributes to the formation of blisters.[35,36] Other studies have suggested that T cells may play a role in the pathogenesis of the skin lesions; however, no specific T-cell responses to gluten have been detected.[37,38]

It has been known for some time that iodides, administered orally, can exacerbate or elicit eruptions of DH, and this has, in former times, been used for diagnostic purposes. The availability of immunopathologic techniques for the detection of IgA deposits in skin has made such provocation tests obsolete.

The absence of animal models of DH, either naturally occurring or developed in the laboratory, has limited advances in our understanding of the pathogenesis of DH. Recently, Marietta and coworkers reported a new mouse model for DH. They reported an HLA-DQ8 transgenic non-obese diabetic mouse that when immunized with gluten developed neutrophilic skin lesions along with cutaneous deposits of IgA. In addition, withdrawal of dietary gluten resulted in resolution of the skin lesions.[39] Further investigation of this mouse model may provide important information regarding the pathogenesis of DH.



▲ **FIGURE 59-1** Dermatitis herpetiformis. Extensive eruption with grouped papules, vesicles, and crusts on the back.

CLINICAL MANIFESTATIONS

The primary lesion of DH is an erythematous papule, an urticaria-like plaque, or, most commonly, a vesicle (Figs. 59-1, 59-2, and 59-3). Large bullae occur infrequently. Vesicles, especially if they occur on the palms, may be hemorrhagic. The continual appearance and disappearance of lesions may result in hyperpigmentation and hypopigmentation. Patients may present with only crusted lesions, and a thorough search may not reveal a primary lesion. The herpetiform (herpes-like) grouping of lesions is often present in some areas (see Figs. 59-1 and 59-3), but patients also may have many individual nongrouped lesions.

Symptoms vary considerably from the usually severe burning and itching in most patients to the almost complete lack of symptoms in a rare patient. Most patients usually can predict the eruption of a lesion as much as 8 to 12 hours before its appearance because of localized stinging, burning, or itching.



▲ **FIGURE 59-2** Dermatitis herpetiformis. Papules, vesicles, and crusts on knees.

The usual symmetric distribution of lesions on elbows, knees, buttocks, shoulders, and sacral areas is seen in most patients at one time or another (see Figs. 59-1 to 59-4). Although these regions are affected most commonly, most patients have scalp lesions and/or lesions in the posterior nuchal area. Another commonly affected area is the face and facial hairline. Mucous membrane lesions are uncommon, as are lesions on the palms and soles.

LABORATORY TESTS

In Vivo–Bound Immunoglobulin A and Complement

After Cormane demonstrated that both perilesional and uninvolved skin of patients with DH contained granular (or fibrillar) Ig deposits located in dermal papillary tips, van der Meer found that the most regularly detected Ig class in DH skin



▲ **FIGURE 59-3** Dermatitis herpetiformis. This patient has many firm-topped vesicles and bullae, some erosions, and residual hyperpigmentation. Some of the vesicles are arranged in an annular pattern.





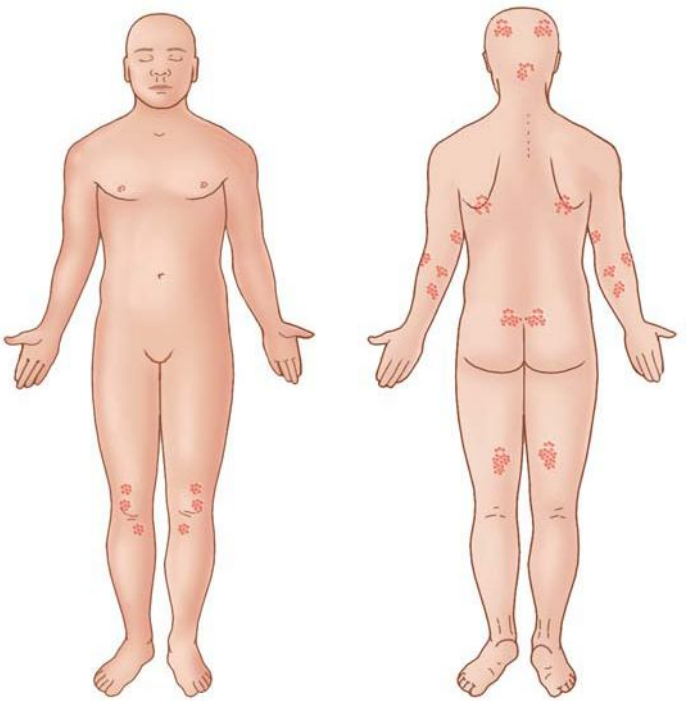

▲ **FIGURE 59-4** Dermatitis herpetiformis. Pattern of distribution.

was IgA (Fig. 59-5).[9,10] IgA deposits have, however, not been seen in the skin of patients with isolated GSE (celiac disease).[40]

Finding granular IgA deposits in normal-appearing skin is the most reliable criterion for the diagnosis of DH.[33,41] These IgA deposits are unaffected by treatment with drugs but may decrease in intensity or disappear after long-term adherence to a gluten-free diet.[42,43] The IgA deposits are not uniformly intense throughout the skin and may be detected more easily in normal-appearing skin near active lesions.[44] In DH, other immunoglobulins sometimes are bound to the skin in the same areas as the IgA.[41] IgA deposits also may be seen in the skin of patients with bullous pemphigoid, scarring pemphigoid, Henoch-Schönlein purpura, and alcoholic liver disease, although in different patterns of distribution than those seen in DH.

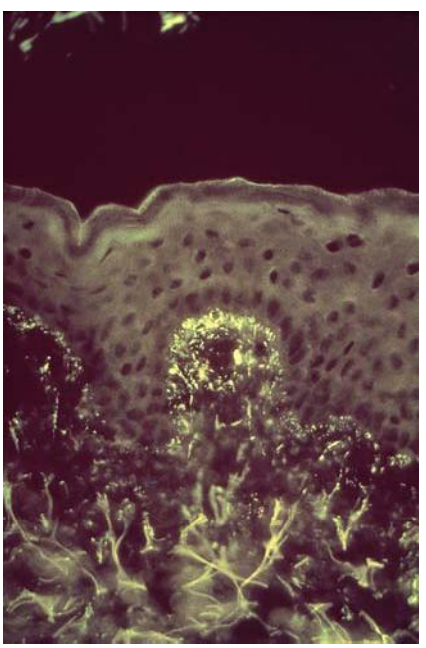

▲ **FIGURE 59-5** Dermatitis herpetiformis. Direct immunofluorescence showing granular dermal papillary deposits of immunoglobulin A.

Because of the IgA skin deposits and the association between DH and GSE (celiac disease), several groups have studied the IgA subclasses in DH. IgA1 is the predominant (or exclusive) subclass that has been identified in the skin of DH patients.[45,46] Most IgA1 is produced in the bone marrow, whereas most IgA2 is produced at mucosal sites. This does not negate the possibility that the IgA1 in skin may still be of mucosal origin because IgA1 is the predominant IgA subclass of IgA antibodies directed against dietary proteins produced in gut secretions in patients with DH.[47,48]

The third component of complement (C3) is frequently found in the same location as IgA. The presence of C3 in both perilesional and normal-appearing skin is not affected by treatment with dapsone (diaminodiphenyl sulfone), but C3 may not be detectable after treatment with a gluten-free diet.[43,49,50] C5 and components of the alternative complement pathway also may be seen in areas corresponding to the IgA deposits. The C5-C9 membrane attack complex, which is formed as the terminal event in complement activation, is also seen in normal-appearing and perilesional skin of patients.[51]

The exact site of the IgA deposits in DH skin has been studied by immunoelectron microscopy. Early studies indicated that IgA is preferentially associated with bundles of microfibrils and with anchoring fibrils of the papillary dermis immediately below the basal lamina.[52,53] More recent studies, however, have indicated that some or almost all of the IgA deposits are related to nonfibrillar components of skin and other connective tissues.[52–56] There is also no agreement as to whether the IgA deposits in DH co-localize to fibrillin, a major component of the elastic microfibrillar bundles.[56,57]

Serum Studies

Antireticulin antibodies of the IgA and IgG classes have been detected in the sera of 17 percent to 93 percent of patients with DH and in higher percentages of patients with other diseases, especially celiac disease.[58] Thyroid microsomal antibodies and anti-nuclear antibodies also have been detected in increased incidence in the sera of patients with DH.[59,60] Putative immune complexes have been detected in the sera of 25 percent to 40 percent of patients.[61,62]

Chorzelski et al. have described an IgA antibody that binds to an intermyofibril substance (endomysium) of smooth muscle.[63] The nature of this antigen has been identified recently by the studies of Sardy et al., who showed that these IgA autoantibodies have specificity for Tgases, particularly epidermal-specific Tgases.[19]

Immunogenetic Findings

There is a marked increase in the incidence of certain major histocompatibility complex antigens in patients with DH. Worldwide studies have found that 77 percent to 87 percent of DH patients have HLA-B8 (compared with 20 percent to 30 percent of unaffected individuals).[15,64–66] In addition, the class II major histocompatibility complex antigens HLA-DR and -DQ are associated with DH even more frequently than is HLA-B8.[67,68] Park et al. reported that more than 90 percent of patients expressed Te24, which was later shown to be similar to HLA-DQw2, and this finding has been confirmed by others.[69] Molecular studies indicate that susceptibility to DH is not associated with a

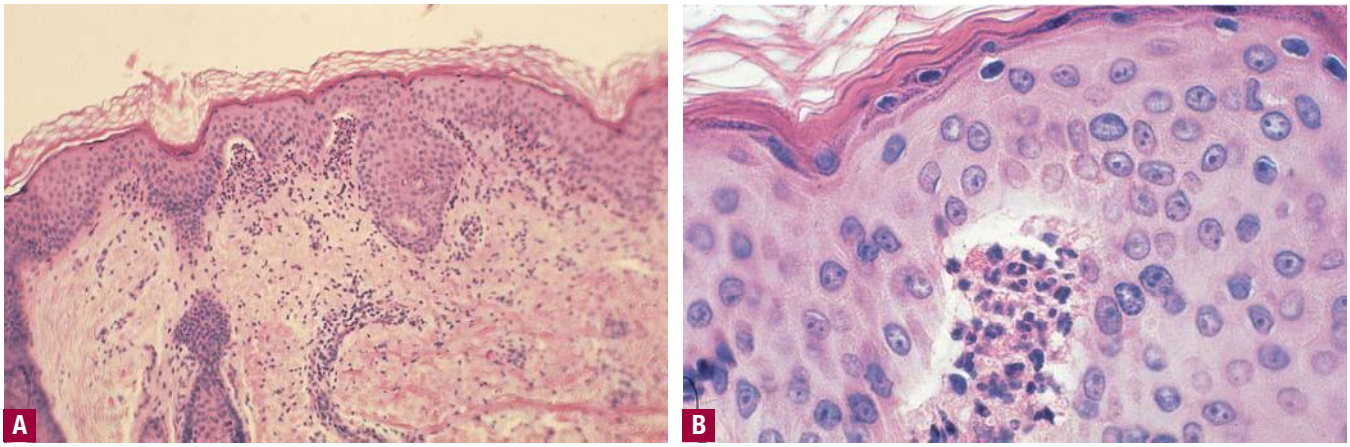

▲ **FIGURE 59-6** Dermatitis herpetiformis. Biopsy of an early lesion showing dermal papillary collections of neutrophils and eosinophils and sub-epidermal vesiculation at low (**A**) and high (**B**) magnification.

unique HLA-DQw2 molecule.[70] Virtually all patients with DH have genes that encode the HLA-DQ (α1*0501, β1*02) or the HLA-DQ (α1*03, β1*0302) heterodimers, a pattern identical to that seen in celiac disease.[70,71] This strong association between susceptibility genes and DH and GSE is important clinically and pathophysiologically in that there is a strong concordance of these two diseases in monozygotic twins.[72] Furthermore, first-degree relatives of both DH and GSE patients are often (4 percent to 5 percent) affected with one or the other of these diseases.[73]

Histopathology

The histology of an early skin lesion (clinically nonvesicular) is characterized by dermal papillary collections of neutrophils (microabscesses), neutrophilic fragments, varying numbers of eosinophils, fibrin, and, at times, separation of the papillary tips from the overlying epidermis (Fig. 59-6). In addition, in such early lesions, the upper and middle dermal blood vessels are surrounded by a lymphohistiocytic infiltrate as well as some neutrophils and an occasional eosinophil.[7,8] At times, early lesions may be difficult or impossible to differentiate from those of linear IgA disease (see Chap. 56), the bullous eruption of lupus erythematosus (see Chap. 156), bullous pemphigoid (see Chap. 54), or the neutrophil-rich form of epidermolysis bullosa acquisita (see Chap. 58). The histology of older lesions shows subepidermal vesicles that may be impossible to differentiate from other subepidermal bullous eruptions, such as bullous pemphigoid, erythema multiforme, bullous drug eruption, and pemphigoid gestationis. Immunofluorescent localization and ultrastructural studies of the site of blister formation in DH have demonstrated that the blister forms above the lamina densa—within the lamina lucida. This is thought to occur because the lamina lucida is the most vulnerable component of the dermal-epidermal junction.[74,75]

ASSOCIATED PROBLEMS

Gastrointestinal Manifestations

It is now well accepted that most, if not all, DH patients have an associated gastrointestinal abnormality that is caused by gluten sensitivity.[12,13,65] The pathology of the GSE associated with DH and that in isolated GSE (GSE unassociated with DH) is essentially the same, although the lesion in the latter is usually much more severe; this applies to the epithelial cell derangement as well as to the character of the lymphoplasmacytic infiltrate. In addition, the distribution of the gastrointestinal lesion in the small intestine is, as a general rule, more widespread in celiac disease. The functional changes in the bowel and clinical sequelae encountered in the GSE associated with DH and those encountered in celiac disease are similar but again differ in degree, those in the latter being more severe. Thus, in DH one observes steatorrhea (20 percent to 30 percent of patients), abnormal D-xylose absorption (10 percent to 33 percent of patients), and occasional anemia secondary to iron or folate deficiency. In patients not taking dapsone or related drugs, the latter is usually due to malabsorption. Studies using elemental diets (see Elemental and Other Diet Therapy) in the treatment of DH have questioned the critical role attributed to gluten in the pathogenesis of this disease. In addition to the small intestinal lesion, patients with DH have an increased incidence of achlorhydria and atrophic gastritis.[76,77] Reports of pernicious anemia and antibodies to gastric parietal cells are thus likely to be due to more than chance.

Malignancy

Leonard et al. have reported an increased frequency of malignancies, especially gastrointestinal lymphomas, and Collin et al. have reported a significant increase in non-Hodgkin lymphomas in patients with DH.[78,79] A combined retrospective study from both these groups suggests a protective role for a gluten-free diet against gastrointestinal lymphomas.[80] Hervonen and co-workers reported that 1 percent of 1104 patients with DH developed a lymphoma from 2 to 31 years after the diagnosis of DH. Of interest, only two lymphomas were of the enteropathy-associated type, whereas eight were B-cell type lymphomas and one was unclassified. The patients with DH that developed lymphoma had adhered to a gluten-free diet less strictly than patients without lymphoma.[81] Recently, Viljamaa and coworkers reported on the rate of malignancies and mortality in patients with DH with a 30-year population-based study.[82] They reported no difference in overall malignancy rate in patients with DH from the general population; however, there was an increase in non-Hodgkin lymphomas. Of interest, the mortality rate for patients with DH was lower than in the general population. In total, these studies suggest that patients with DH are at increased, albeit low, risk for lymphoma and that this risk is not restricted to enteropathy-associated lymphomas.

Other Diseases

In addition to celiac disease, atrophic gastritis, and pernicious anemia (see Gas-



trointestinal Manifestations), DH patients have a higher incidence of other autoimmune diseases such as thyroid disease, insulin-dependent diabetes, lupus erythematosus, Sjögren syndrome, and vitiligo.[60,83,84] This predilection for associated autoimmune diseases may be due to the high frequency of the 8.1 ancestral haplotype in these DH patients.[85]

Neurologic disease has been reported in patients with isolated celiac disease, including epilepsy, ataxia, and dementia; however, confirmation of these findings awaits confirmation with large epidemiologic studies.[86] Some authors have proposed that patients with DH may be at higher risk for these neurologic complications due to long-standing ingestion of gluten; however, Wills and co-workers found no evidence of immune-mediated neurologic disease in their evaluation of patients with DH.[87]

Patients with untreated celiac disease have also been found to have an increased frequency of bone loss.[88] Patients with DH frequently continue on gluten-containing diets with a long-standing, albeit low grade, malabsorption. Di Stefano demonstrated a significantly reduced bone mineral density in patients with DH on gluten-containing diets.[89] These findings suggest that patients with DH be followed closely and those on gluten-containing diets be screened for potential decrease in bone density. If decreased bone mineral density is found, patients should be encouraged to begin a gluten-free diet.

DIFFERENTIAL DIAGNOSIS

DH may be confused with numerous other conditions because of its pleomorphic manifestations and the occasional lack of diagnostic lesions (Box 59-1). Neurotic excoriations, eczema, papular urticaria, transient acantholytic dermatosis, pemphigoid, pemphigoid gestationis, erythema multiforme, and various other dermatoses can be differentiated easily on the basis of histologic and immunologic criteria. Linear IgA disease may be more difficult to differentiate clinically and histologically, but it is distinctive immunologically. A high index of suspicion is very helpful in that even in the absence of primary lesions, DH can be diagnosed based on the typical in vivo–bound granular IgA deposits in normal-appearing skin.

Box 59-1

Differential Diagnosis of Dermatitis Herpetiformis

Consider

- Eczema
- Atopic dermatitis
- Papular urticaria
- Neurotic excoriations
- Bullous pemphigoid
- Pemphigoid gestationis
- Linear immunoglobulin A dermatosis
- Atopic dermatitis

Rule Out

- Scabies

TREATMENT

Sulfones

Diaminodiphenyl sulfone (dapsone), sulfoxone (diasone—not available in the United States), and sulfapyridine provide prompt improvement in symptoms and signs of the disease. Symptoms may abate in as few as 3 hours or as long as a few days after the first pill is taken, and new lesions no longer erupt after 1 to 2 days of treatment. Exacerbations occur from hours to days after cessation of treatment. This response to therapy was, for a long time, the most important element in making a diagnosis. The preferred treatment for an adult is dapsone at an initial dosage of 100 to 150 mg/day (this usually can be taken once a day). An occasional patient may require 300 to 400 mg of dapsone for initial improvement. Patients should be instructed to take the minimal dose required to suppress signs and symptoms. Not all patients require daily treatment; in rare cases, 25 mg weekly is sufficient. Sulfapyridine, in a dosage of 1.0 to 1.5 g daily, is particularly useful in patients intolerant of dapsone, in elderly patients, and in those with cardiopulmonary problems. The pharmacology, mechanism(s) of action, adverse effects, and monitoring of dapsone are discussed in Chap. 226. It is important to know that nonsteroidal anti-inflammatory drugs often exacerbate DH, even in patients taking dapsone.[90]

Gluten-Free Diet

EFFECT ON THE SMALL INTESTINE There is no doubt that the intestinal lesion in DH responds to dietary gluten withdrawal. The time course of the response in adults with DH is the same as that in adults with celiac disease.

EFFECT ON THE SKIN DISEASE Strict adherence to a gluten-free diet will, after variable periods of time (from 5 months to 1 year), reduce or completely eliminate the requirement for medication in most, but not all, patients. The most extensive early study by Fry et al. has been confirmed by several groups.[14] However, it is only the very highly motivated patient who can adhere to the diet, which requires counseling by an individual who is very familiar with its use.

Elemental and Other Diet Therapy

Studies in small numbers of DH patients have indicated that elemental diets (composed of free amino acids, short-chain polysaccharides, and small amounts of triglycerides) can be very beneficial in alleviating the skin disease within a few weeks.[91,92] The beneficial effect on the skin disease may be achieved even if the patient ingests large amounts of gluten.[91] Unfortunately, elemental diets are difficult to tolerate for long periods. Interestingly, complete resolution of the skin lesions of DH has also been reported by adherence to the high-protein, unlimited fat, low-carbohydrate diet popularized as the "Atkins Diet."[93] Further studies are needed to confirm this report.

KEY REFERENCES

The full reference list for all chapters is available at www.digm7.com.

4. Duhring LA: Dermatitis herpetiformis. *JAMA* **3**:225, 1893
9. van der Meer JB: Granular deposits of immunoglobulins in the skin of patients with dermatitis herpetiformis: An immunofluorescent study. *Br J Dermatol* **81**:493, 1969
11. Marks J, Shuster S, Watson AJ: Small bowel changes in dermatitis herpetiformis. *Lancet* **2**:1280, 1966
14. Fry L et al: Clearance of skin lesions in dermatitis herpetiformis after gluten withdrawal. *Lancet* **1**:288, 1973
15. Katz SI et al: HL-A8: A genetic link between dermatitis herpetiformis and gluten-sensitive enteropathy. *J Clin Invest* **51**:2977, 1972
19. Sardy M et al: Epidermal transglutaminase (TGase 3) is the autoantigen of dermatitis herpetiformis. *J Exp Med* **195**:747, 2002
39. Marietta E et al: A new model for dermatitis herpetiformis that uses HLA-DQ8 transgenic NOD mice. *J Clin Invest* **114**:1090, 2004
42. Leonard J et al: Gluten challenge in dermatitis herpetiformis. *N Engl J Med* **308**:816, 1983
81. Hervonen KF et al: Lymphoma in patients with dermatitis herpetiformis and their first-degree relatives. *Br J Dermatol* **152**:82, 2005

82. Viljamaa M et al: Malignancy and mortality in patients with coeliac disease and dermatitis herpetiformis: 30-year population based study. *Dig Dis Sci* **38**:374, 2006
89. Di Stefano M et al: Bone mass and metabolism in dermatitis herpetiformis. *Dig Dis Sci* **44**:2139, 1999
91. Kadunce DP et al: The effect of an elemental diet with and without gluten on disease activity in dermatitis herpetiformis. *J Invest Dermatol* **97**:175, 1991

CHAPTER 60

Inherited Epidermolysis Bullosa

M. Peter Marinkovich
Eugene A. Bauer

Inherited epidermolysis bullosa (EB) is a family of diseases that have the common feature of blistering in response to mild trauma.[1] Patients with EB can show blistering in the form of small vesicles or larger bullae, which can occur on both the cutaneous surfaces as well as on the mucosal tissues. The fragility of the skin and mucosa and the traumatic production of painful blisters are shared by all EB cases. However, the distribution of the involvement, the depth of blister formation, and the severity of the blistering process varies with the different EB subtypes and depends on the underlying heritable molecular defect. EB diseases also vary in the way in which blistered areas heal. The wound repair responses are often abnormal and can eventuate into chronic erosions, hypertrophic granulation tissue, scarring, or even invasive carcinoma. Although the milder EB subtypes are associated with a normal lifespan and little or no internal involvement, the most severe, recessively inherited forms are mutilating, multiorgan disorders that threaten both the quality and length of life.[2,3]

ETIOLOGY AND PATHOGENESIS

Overview

EB arises from defects of attachment of basal keratinocytes to the underlying dermis (see Chap. 51). These defects can arise from inside the keratinocyte plasma membrane or extracellularly in the dermal-epidermal basement membrane zone (BMZ). The etiology and pathogenesis of EB cannot be understood without an appreciation of the organization of the dermal-epidermal BMZ. Many tissues, such as the skin and cornea, which are subjected to external disruptive forces, contain a complex BMZ composed of a group of specialized components that combine together to form anchoring complexes (Fig. 60-1). At the most superior aspect of the BMZ, keratin-containing intermediate filaments of the basal cell cytoskeleton insert upon electron dense condensations of the basal cell plasma membrane, termed *hemidesmosomes*. Anchoring filaments span the lamina lucida connecting hemidesmosomes with the lamina densa and anchoring filaments. At the most inferior aspect of the BMZ, type VII collagen-containing, anchoring fibrils extend from the lamina densa into the papillary dermis and combine with the lamina densa and anchoring plaques, trapping interstitial collagen fibrils. Thus, the cutaneous BMZ connects the extensive basal cell cytoskeletal network with the abundant network of interstitial collagen fibrils in the dermis.[19,20]

CLINICAL FINDINGS

A classification of EB is made based on the ultrastructural level within which the cleavage plane of the blister occurs. EB has been traditionally classified according to the level of BMZ separation on transmission electron microscopy (TEM) into simplex, junctional, and dystrophic sub-types (Fig. 60-2). However, a fourth category has been proposed, hemidesmosomal EB, which takes into account patients who show intraepidermal blistering just above the basal plasma membrane (see Fig. 60-2E).[67] Although traditionally the diagnostic "gold standard" for grouping EB has been electron microscopy, immunomapping of basement membrane antigens as viewed by indirect immunofluorescence (IDIF) can also be quite useful in distinguishing sub-types of EB. Within each of these groups, there are several distinct types of EB based on clinical, genetic, histologic, and biochemical evaluation.[68] These findings are summarized in the following sections (Table 60-1).

EPIDERMOLYSIS BULLOSA AT A GLANCE




- Family of inherited genodermatoses characterized by blistering in response to minor trauma.
- Blistering level categorizes as simplex, hemidesmosomal, junctional, and dystrophic sub-types.
- Cutaneous involvement varies from localized to widespread blistering, depending on sub-type.
- Extra-cutaneous involvement varies from none to severely debilitating or lethal.
- Oropharynx, trachea, esophagus, eyes, teeth, nails, and hair can be involved, depending on sub-type.
- Diagnosis is made by immunofluorescence and/or electron microscopy followed by DNA analysis.

Epidermolysis Bullosa Simplex

EBS is a group characterized by intraepidermal blistering and is associated with keratin gene mutations. The disease phenotypes range from mild to severe among different subgroups.[69] The three most common EBS types are dominantly inherited and include generalized (Koebner), localized (Weber-Cockayne), and herpetiform (Dowling-Meara). There are several uncommon varieties, which include the EBS Ogna variant, EBS superficialis, and EBS with mottled pigmentation (see Table 60-1).

GENERALIZED EPIDERMOLYSIS BULLOSA SIMPLEX Also known as the *Koebner variant*, generalized EBS shows an onset of blistering at birth or at latest during early infancy. The hands, feet, and extremities usually show the most involvement. Lesions often heal with post-inflammatory





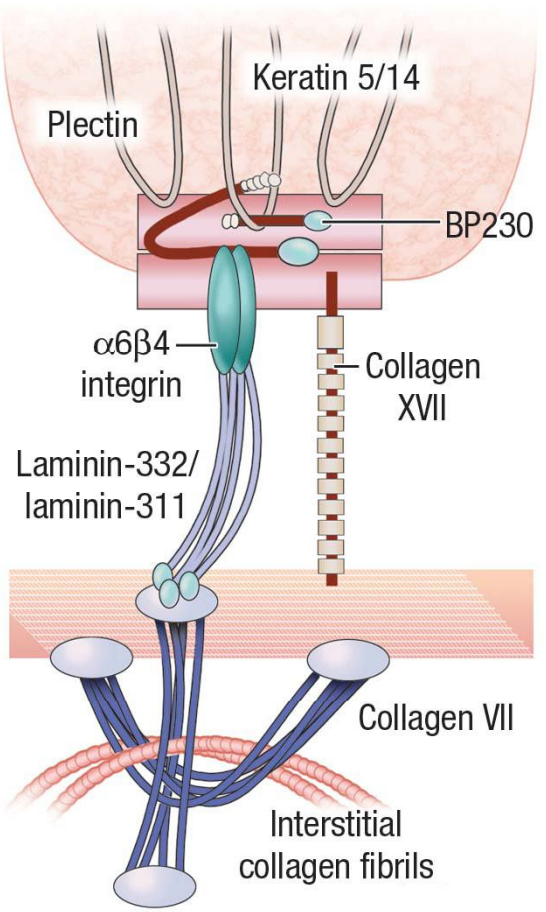



◀ **FIGURE 60-1** Schematic of the components of the dermal-epidermal basement membrane on the left compared with ultrastructural appearance of basement membrane morphologic entities on the right. BP230 = bullous pemphigoid antigen 230 KD.

hyper- or hypopigmentation and, although occasional atrophy and milia can occur, they are rare and much less frequent than in EB herpetiformis. Palmar-plantar hyperkeratosis and erosions may be present (Fig. 60-3). Thickening of the soles is common but often does not present until later childhood. The oral mucosa sometimes shows mild erosive activity, but this usually improves with increasing age. There is not severe growth retardation in this EB sub-type.

EPIDERMOLYSIS BULLOSA HERPETIFORMIS EB herpetiformis is also known as the *Dowling-Meara form of EBS*. It presents at birth and, like the Koebner variant, it has a generalized distribution. The Dowling-Meara form is regarded as the most severe of the EBS sub-types (Fig. 60-4). It differs from the Koebner variant, however, in that the oral mucosa is more often involved, occasionally showing extensive erosions. Milium formation may sometimes occur in infancy in patients with this sub-type. However, this post-wound phenomenon usually resolves later in childhood. The disease received its name due to the spontaneous appearance of grouped or "herpetiform" blisters. These occur on the trunk and proximal extremities and heal without scarring. It should be noted that when patients are young and show a generalized blistering, this herpetiform pattern may not be seen. Therefore, its absence should not be used as a basis to exclude this EB sub-type. EB herpetiformis often shows nail involvement, and blistering is not uncommonly hemorrhagic. In this disease, nails may become shed and may re-grow with dystrophy. Interestingly, although heat exacerbates the blistering in other EBS subtypes, it does not appear to have a major impact in EB herpetiformis. Hyperkeratosis of the palms and soles often develops beginning in early childhood and can progress to confluent keratoderma of the palms and soles. These can be quite painful, and, occasionally, interference with ambulation has led to flexural contractures. Occasionally, involvement of the esophagus in EB herpetiformis, ranging from erosions to pyloric atresia,[70] has been reported. The upper respiratory tract can also be affected, including laryngeal involvement.[71] Natal teeth have been described in a few patients with EB herpetiformis.

LOCALIZED EPIDERMOLYSIS BULLOSA SIMPLEX Localized EBS is the mildest form of EB and is often referred to as the *Weber-Cockayne sub-type of EBS* (Fig. 60-5). This disease is the most common form of EB and often presents during infancy or childhood. Occasionally, it presents in early adulthood, such as when blisters are noted on the feet after marching during military service. It is speculated that there are a number of undiagnosed cases of this form of EB, as it can be mild enough to escape reporting or detection during clinical visits. Hyperhidrosis of the palms and soles is a common association. Blisters can occasionally become secondarily infected. Post-inflammatory pigmentary abnormalities occur with this variant, but milia and scarring as a rule are absent. Blistering activity usually follows areas of trauma, with hands and feet being the most common, and the scalp being the least common. Mild oral erosions are present only rarely and usually resolve with increasing age. Nail involvement is rare with this EB sub-type.

ADDITIONAL VARIANTS OF EPIDERMOLYSIS BULLOSA SIMPLEX (See Table 60-1)

Epidermolysis Bullosa Simplex of Ogna. Onset of EBS of Ogna in infancy is common with seasonal blistering (summer) on the acral areas. Small hemorrhagic and serous blisters occur primarily on the extremities. Healing occurs without

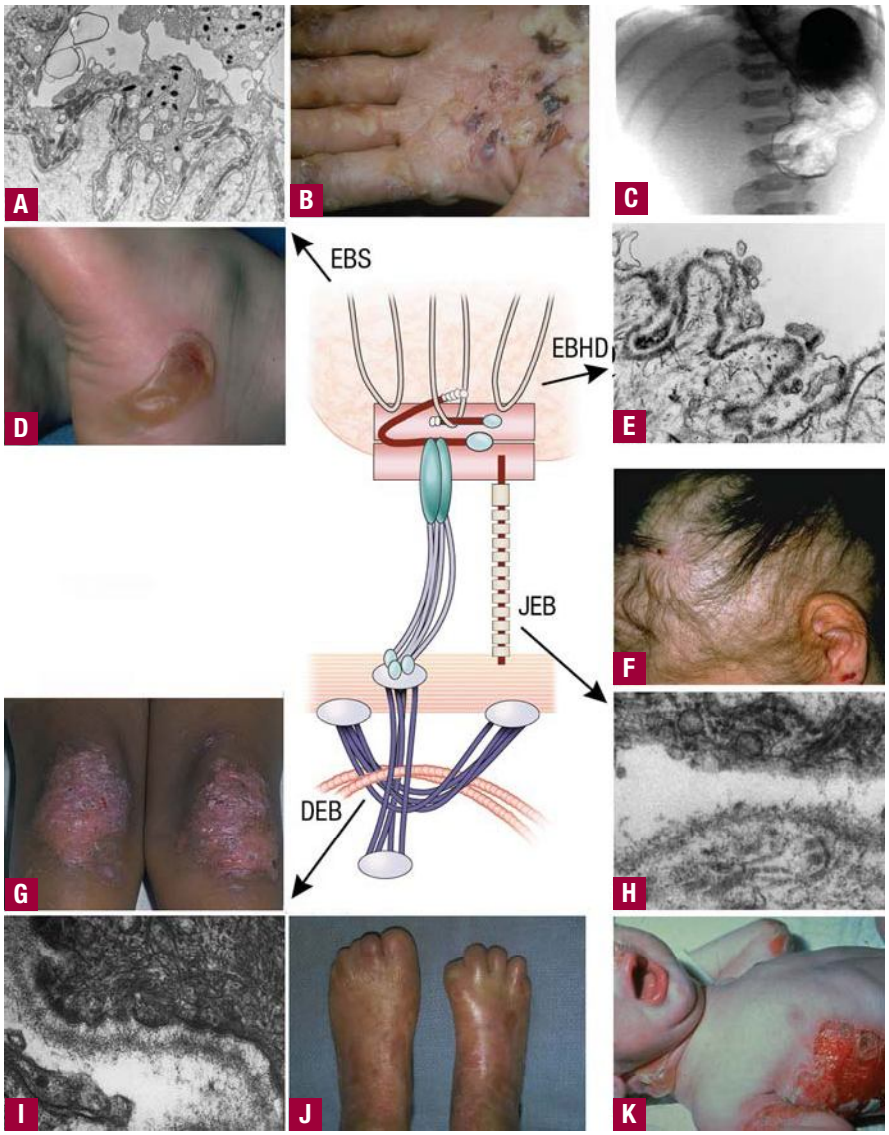

▲ **FIGURE 60-2** Comparison of levels of skin separation in epidermolysis bullosa (EB) with clinical findings. **A.** Transmission electron micrograph showing typical intraepidermal separation in EB simplex (EBS). **B.** Palmar hyperkeratosis and erosions in EB herpetiformis. **C.** Radiograph showing pyloric atresia associated with EB. **D.** Localized blister on heel in EBS Weber-Cockayne. **E.** Transmission electron micrograph showing hemidesmosomal separation in EB (EBHD) with pyloric atresia. **F.** Non-scarring, diffuse alopecia and scalp erosions in generalized atrophic benign epidermolysis bullosa. **G.** Localized dystrophic changes with milia in dominant dystrophic epidermolysis bullosa (DEB). **H.** Transmission electron microscopy showing typical intralamina lucida separation in junctional EB (JEB). **I.** Transmission electron microscopy showing typical sublamina densa separation in DEB. **J.** Pseudosyndactyly in recessive DEB. **K.** Generalized blistering in Herlitz JEB.

scarring. All patients described thus far have come from Norway. These patients also show a characteristic onychogryphosis of the great toenails.

Epidermolysis Bullosa Simplex Superficialis. EBS superficialis is an uncommon form of EBS that is named after the subcorneal separation that produces the blisters in this disease. Erosions and crusts, rather than intact bullae, are usually seen in these patients, who heal with post-inflammatory pigmentary changes. Despite the superficial cleavage plane, oral erosions, nail involvement, and milia have been observed in this disease.

Epidermolysis Bullosa Simplex with Mottled Pigmentation. EBS with mottled pigmentation, as its name implies, is characterized by mottled hyperpigmentation of the trunk and proximal extremities. There is blistering in a generalized distribution beginning at birth or early infancy. Blistering may improve with increasing age, and it is the pigment abnormalities that tend to progress during childhood, leading families to seek medical attention. Small, acral verrucous papules are also characteristic. Mild oral mucosal involvement may be present in infancy. This condition is distinct from the large melanocytic nevi, which can be seen in all three EB types.[72]

MOLECULAR PATHOLOGY OF EPIDERMOLYSIS BULLOSA SIMPLEX Most of the patients with EBS analyzed at the genetic level have been found to be associated with mutations of the genes coding for K5 and K14 keratins.[73] The level of separation of the skin in these patients is at the mid-basal cell, shown in Fig. 60-2A, associated with variable intermediate filament clumping. Hemidesmosomes and other BMZ structures are normal by electron microscopy. The majority of keratin gene mutations associated with EBS are dominantly inherited due to abnormalities in the multimeric assembly of keratin filaments. There is a smaller subset of patients with recessively inherited disease of varying severity.[74,75]

Mutations coding for the most conserved regions of K5 and K14 keratins, the helix boundary domains,[76] correlate with the most severe forms of EBS, such as the Dowling-Meara sub-type, which exhibits intermediate filament clumping seen by TEM. On the other hand, milder types of disease, such as the Weber-Cockayne sub-type, are associated with mutations coding for regions of K5 and K14 keratins that are less conserved. Mutations that code for a specific region of the amino terminus of K5 keratin are present in patients having EBS with mottled pigmentation.[77] Although the significance of this type of mutation and its association with pigmentary abnormalities remain unclear,[78,79] it has been suggested that the K5 keratin globular head domain is responsible for keratin filament insertion onto melanosomes.

Hemidesmosomal Epidermolysis Bullosa

Historically, EB has been subclassified according to the level of skin separation noted in biopsies of skin blisters by transmission electron microscopic analysis. Although EB has traditionally been classified into simplex, junctional, and dystrophic categories, two more rare forms of EB have been more recently described, which form a distinct level of skin separation. Hemidesmosomal EB consists of blistering skin disease with a level of separation that is intermediate between that of EBS and junctional EB (JEB). Ultrastructurally, the level of skin



TABLE 60-1
Classification of Epidermolysis Bullosa

Level of Separation	Disease	Defect
Simplex	Generalized/Koebner	KRT5/KRT14
Simplex	Herpetiformis/Dowling-Meara	KRT5/KRT14
Simplex	Localized/Weber-Cockayne	KRT5/KRT14
Simplex	Ogna	KRT5/KRT14
Simplex	Superficialis	KRT5/KRT14
Simplex	Mottled pigmentation	KRT5
Hemidesmosomal[a]	EB with muscular dystrophy	PLEC1
Hemidesmosomal[b]	EB with pyloric atresia	ITGB4/ITGA6
Junctional	Gravis/Herlitz	LAMB3/LAMA3/LAMG2
Junctional	Mitis	LAMB3/LAMA3/LAMG2
Junctional[c]	Generalized atrophic benign	COL17A1/LAMB3
Junctional	Localized	COL17A1
Dystrophic	Pasini	COL7A1
Dystrophic	Cockayne-Touraine	COL7A1
Dystrophic	Localized RDEB	COL7A1
Dystrophic	Hallopeau-Siemens	COL7A1
Variable	Kindler syndrome	KIND1
Desmosomal	Ectodermal dysplasia-skin fragility	PKP1

COL7A1 = collagen, type VII, α_1; EB = epidermolysis bullosa; ITGB = integrin β; KRT = keratin; LAMA = laminin α; LAMB = laminin β; PKP = plakophilin; PLEC = plectin; RDEB = recessive dystrophic epidermolysis bullosa.
[a]Alternatively classified as simplex.
[b]Alternatively classified as junctional.
[c]Case with type XVII collagen cytoplasmic deletion showed both junctional and hemidesmosomal levels of skin separation.[120]



separation, while intraepidermal, is localized at the inferior aspect of basal keratinocytes, at the point of insertion of keratin filaments onto the hemidesmosome (see Fig. 60-2E). Typically, small fragments of basal cell plasma membrane are present, often with electron dense hemidesmosome fragments, atop the dermal side of the skin separation.[67] Of the two diseases that form this type of separation, one is associated with muscular dystrophy; the other is associated with pyloric atresia.

EPIDERMOLYSIS BULLOSA WITH MUSCULAR DYSTROPHY EB with muscular dystrophy is a rare clinical entity that is an autosomal recessive disorder that consists of generalized blistering of the skin at birth or shortly thereafter. This is accompanied by a progressive muscular dystrophy.[80] It presents with generalized blistering similar to EBS of Koebner, clinically. These patients have been shown to harbor mutations in the gene coding for HD1/plectin.[81–83] The mutations associated with this disease produce premature termination codons that result in lack of expression of plectin. Plectin is normally expressed in a wide range of tissues, including muscle. Although the mechanism of muscular dystrophy in plectin-deficient patients is unknown, it has been observed that disorganization of muscle sarcomeres occurs in the absence of plectin. It is possible that absence of plectin's spectrin-like domain, which may normally interact with actin filaments in muscle, may be a key factor in the muscle pathology.[84]

EPIDERMOLYSIS BULLOSA WITH PYLORIC ATRESIA Patients with EB with pyloric atresia exhibit extreme mucosal and cutaneous fragility and may also have various urologic abnormalities, including hydronephrosis and nephritis. Mutations of the genes coding for the β_4 and α_6 integrins have also been associated with EB.[85–91] In this group of diseases, pyloric atresia is present. Although pyloric stenosis is relatively more common, the distinct association of pyloric atresia, a relatively rare condition, with EB makes this disease particularly unique. In these patients, hemidesmosomes are almost absent or rudimentary at best, and the level of separation is such that fragments of the basal cell plasma membrane remain adherent to the base of the blister. The skin ultrastructure in patients with $\alpha_6\beta_4$ defects is remarkably similar to the β_4 integrin knockout mice described in the section Anchoring Filaments in on-line edition; however, the mice do not show pyloric atresia. These studies illustrate well that there are limitations in the utility of animal models of EB. Most cases of this disease are quite severe and lethal in infancy due to extensive extra-cutaneous epithelial sloughing in addition to wide-



▲ **FIGURE 60-3** Widespread blistering in an infant with generalized epidermolysis bullosa simplex.



◀ **FIGURE 60-4** Characteristic blister formation on trunk and arm in patient with epidermolysis bullosa simplex herpetiformis.



▲ **FIGURE 60-5** Trauma-induced blistering from clothing in a patient with localized epidermolysis bullosa simplex.

spread blistering of the skin and mucosa. Rare, nonlethal cases of this disease have been characterized, which appear to result from a partial loss of function of β_4 integrin.[92] Interestingly, nonlethal JEB can sometimes ameliorate itself through alterations in messenger RNA splicing.[93,94]

Junctional Epidermolysis Bullosa (See Table 60-1)

All patients with JEB share the common histopathologic feature of blister formation within the lamina lucida of the BMZ due to defects of anchoring filaments. This group of diseases is inherited in an autosomal recessive manner, and there is considerable variation of the individual clinical phenotypes, depending on the molecular defect. Three principal forms of JEB are most common. *Herlitz disease*, *JEB gravis*, or *lethal JEB* are each used to describe patients presenting with the most severe phenotypic disease.[17,95] It is unfortunate that this most severe sub-type of JEB is also the most common. A more indolent form of JEB is termed *mitis JEB*, and a third relatively mild form is called *generalized atrophic benign EB*.



◀ **FIGURE 60-7** Periorificial erosions and hypertrophic granulation tissue in a patient with junctional epidermolysis bullosa mitis.

JUNCTIONAL EPIDERMOLYSIS BULLOSA GRAVIS Lethal JEB or Herlitz JEB patients typically do not survive infancy, and death rates are estimated at 40 percent in the first year of life. Of those that survive infancy, most die before 5 years of age. This disease is characterized by generalized and often extensive blistering at birth (Fig. 60-6). Later during infancy, a distinctive periorificial granulation tissue manifests. This can occur around the mouth, eyes, and nares most commonly, but also can be present in the scalp, around the ears, and, less frequently, in other locations besides the head and neck (see eFig. 60-6.1 in on-line edition). This hypertrophic granulation tissue can also occur in nonlethal sub-types. Nails are usually severely affected and often are lost during infancy. When nails are still present, they are usually dystrophic and often associated with hypertrophic granulation tissue. Dental defects are present in this disease, characterized by pitting of the tooth enamel. Oropharyngeal mucosal erosions are usually present and may be widespread. Erosions of all stratified squamous epithelial tissues, including nasal, conjunctival, esophageal, tracheal, laryngeal, rectal, and urethral mucosa, can be affected. Associated systemic findings in severe cases are important factors in the lethality of this disease. Involvement of the large airways, including tracheolaryngeal stenosis or obstruction, is commonly associated with Herlitz disease, and hoarseness in early infancy is an ominous sign. There is a characteristic failure to thrive and growth retardation in this disease, often with a mixed anemia. Sepsis is a common and often lethal complication.

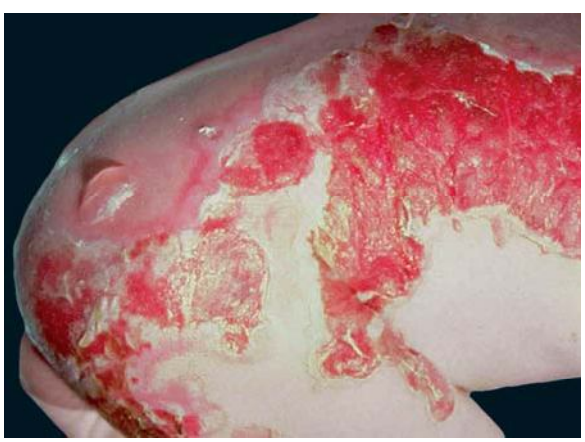

◀ **FIGURE 60-6** Widespread blistering at birth in a patient with Herlitz junctional epidermolysis bullosa.

JUNCTIONAL EPIDERMOLYSIS BULLOSA MITIS Sometimes, patients initially presenting with a Herlitz-like phenotype will survive infancy and clinically improve with age. These patients eventually prove to have a severity of blistering and oral erosions less than the lethal form. In particular, a lack of significant hoarseness is regarded as a favorable prognostic sign, indicative of less severe internal disease manifestations. Scalp and nail lesions, as well as periorificial non-healing erosions, are among the most common findings in these patients during childhood (Fig. 60-7). Despite the lack of lethality in infancy, these patients, nonetheless, can have severe epithelial adhesion abnormalities, and tracheostomies or gastrostomy tubes may help in patient survival (see Fig. 60-7). The nonlethal status of these patients distinguishes them from the Herlitz group, and the terms *nonlethal JEB* or *JEB mitis* have been used to describe these patients. They are much less common than Herlitz EB patients. There are other rare variants of nonlethal JEB that present with localized junctional blistering of the extremities or intertriginous areas.

GENERALIZED ATROPHIC BENIGN EPIDERMOLYSIS BULLOSA Generalized atrophic benign EB also presents at birth with generalized cutaneous involvement.[96] These patients have features that distinguish them from Herlitz and mitis/nonlethal sub-types described above in Junctional Epidermolysis Bullosa Gravis and





▲ **FIGURE 60-8** Loss of nails and skin atrophy in a patient with generalized atrophic benign epidermolysis bullosa.



Junctional Epidermolysis Bullosa Mitis. Despite the widespread cutaneous blistering, there is a relative paucity of oral erosions. Although enamel pitting is present, resulting in extensive dental caries, and nail dystrophy can often be severe (Fig. 60-8), there is little other extracutaneous involvement noted in these patients. The blisters in these patients, which heal with a characteristic atrophic scarring, are debilitating and can be widespread, but nonetheless, these patients generally have a normal lifespan. Blistering improves with age, growth is normal, and anemia is rarely seen. Some patients with this disease have undergone normal, uncomplicated pregnancies and deliveries. One peculiar characteristic of these patients is a progressive alopecia of the scalp and terminal hairs elsewhere in the body (see eFig. 60-8.1 in online edition). The hair loss starts to become severe after the onset of puberty, and although patchy hair loss associated with atrophic scarring has been described, often the alopecia is quite diffuse and scarring is subtle or non-existent.

LOCALIZED JUNCTIONAL EPIDERMOLYSIS BULLOSA A very rare sub-type of JEB is the localized variant, also known as *minima JEB*. These patients generally show mild disease that can be accentuated in localized areas, most often the hands, feet, and pretibial regions. Nails can sometimes be shed or become dystrophic, and enamel pitting can occur. Oral or nasal erosions can also occur; however, there is an absence of any internal involvement. These patients generally have a favorable prognosis and a normal lifespan.

MOLECULAR PATHOLOGY OF JUNCTIONAL EPIDERMOLYSIS BULLOSA JEB can be associated with mutations of the genes coding for either the α_3, β_3, or γ_2 subunits of laminin-332 (i.e., LAMA3, LAMB3, LAMG2, respectively).[97–102] Absence of any of the three chains results in a lack of trimeric laminin-332 assembly and secretion, which results in a similar blistering phenotype. Patients with mutations of genes coding for the β_3 or γ_2 laminin subunits will still show normal expression of laminin-311, which contains α_3, β_1, and γ_1 chains. Therefore, positive linear BMZ staining of JEB skin for α_3 chain on IDIF with absent expression of the other chains is an indication of either a β_3 or γ_2 chain defect. Conversely, absence of α_3 staining on IDIF can be indicative of a mutation of the α_3 gene. About 80 percent of laminin-332 mutations can be traced to one of two recurrent nonsense mutations in the LAMB3 gene, making prenatal testing for laminin-332 lesions easier than other EB candidate genes.[103] In the letalis patients, all of the mutations so far detected have been those producing premature termination codons, resulting in absence of expression of laminin-332. Although Herlitz cases generally show a complete lack of expression of laminin-332, nonlethal/mitis patients often show reduced expression of laminin-332. This is due to expression of a molecule with deletions or missense mutations, resulting in partial loss of laminin-332 function. This can lead to cases clinically classified as mitis or generalized atrophic benign JEB (GABEB).[97,104–108] In some cases, spontaneous amelioration of blistering in severe JEB cases has taken place that has been associated with genetic mechanisms, which result in the re-expression of laminin-332.[94]

In the JEB variant, GABEB, blistering occurs in the lamina lucida region, and abnormalities of hemidesmosomes/anchoring filaments are usually present (see Fig. 60-2H). Although laminin-332 mutations underlie a subset of GABEB patients, the majority of these patients have abnormalities of the hemidesmosomal protein type XVII collagen (also known as BP180 or BPAG2).[109] A number of mutations of the gene coding for type XVII collagen[110–119] have been described in GABEB patients, including premature termination codon mutations, missense mutations, splice site mutations, truncations, and a glycine substitution mutation. Although intralaminin lucida/junctional skin separation has been shown in all patients with this disease, one patient was described with a cytoplasmic deletion of type XVII collagen who had both hemidesmosomal as well as junctional skin separation.[120] Localized JEB has been shown to be associated with COL17A1 mutations.[115] Of interest, one mosaic GABEB patient was identified who demonstrated well-defined areas of blistering associated with absence of type XVII collagen expression as well as areas of nonblistering skin associated with normal type XVII collagen expression. Careful analysis of the patient's keratinocytes revealed reversion of one of the two alleles of the mutation (revertant mosaicism), most likely due to a mitotic gene conversion involving non-reciprocal exchange of parental allele DNA.[121] This has also been demonstrated in another case.[122] It is possible that this phenomenon of mutational rescue of genes affecting recessive cases of EB is more widespread than currently reported, and more careful examination of involved and uninvolved regions of EB skin undoubtedly will reveal more cases. Understanding how EB can undergo spontaneous molecular correction in these cases could help in the design of future exogenously based molecular therapies.

Dystrophic Epidermolysis Bullosa (See Table 60-1)

DEB, also termed *dermolytic EB*, is characterized by blisters that heal with scarring and milium formation. DEB can be inherited either in an autosomal recessive or dominant fashion. Regardless of the mode of inheritance, DEB is derived from defects of the ultrastructural entity known as the *anchoring fibril*, which results in sublamina densa separation. There are four primary sub-types of DEB but several additional rare forms also exist. The main sub-types are differentiated by clinical criteria and include dominant DEB of Cockayne-Touraine, dominant DEB of the albopapuloid or Pasini variant, localized recessive DEB (RDEB), and generalized RDEB.

DOMINANT DYSTROPHIC EPIDERMOLYSIS BULLOSA The Cockayne-Touraine subtype of dominant DEB can present at birth, but, occasionally, it is not appreciated until childhood. Although generalized blistering can sometimes take place, especially early in life, the blistering usually becomes localized to repetitively traumatized areas such as knees, sacrum, and acral surfaces (Fig. 60-9). These areas show a characteristic scarred, dystrophic appearance. Often the scarring is hypertrophic. Milia are common accompanying features of the healing process in



▲ **FIGURE 60-9** Localized trauma-induced blistering with secondary milia in a patient with dominant dystrophic epidermolysis bullosa.

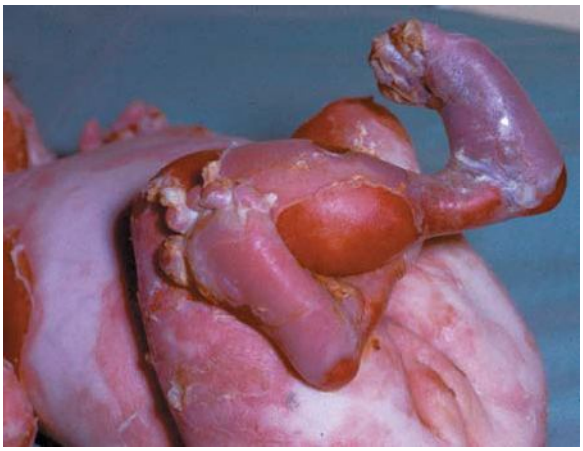

◀ **FIGURE 60-10** Widespread blistering with localized absence of skin at birth in a patient with recessive dystrophic epidermolysis bullosa.

these patients. Nail dystrophy or nail loss with atrophic scarring of the distal digits are common. Oral lesions are not common, and teeth are usually unaffected. These patients have a good prognosis and a normal lifespan.

The Pasini sub-type of DEB presents at birth with a generally more severe and widespread blistering phenotype compared with the Cockayne-Touraine variant. Blisters in the Pasini sub-type heal with scarring plaques and milia in a fashion similar to other DEB sub-types. In addition, this disease is characterized by the spontaneous appearance of distinctive, scar-like, flesh-colored papules on the trunk. These albopapuloid lesions are characteristic of the Pasini subtype but not pathognomonic, as these lesions can also be seen in other EB subtypes. As the patients get older, the generalized blistering may eventually localize to the extremities. Patients often show dystrophic or absent nails. Oral erosions can often be present, but usually are not extensive, and enamel defects can be seen in some patients.

RECESSIVE DYSTROPHIC EPIDERMOLYSIS BULLOSA RDEB can be quite variable in its severity. Although the severe sub-type is the most common, a localized form can occasionally be seen, which has been termed *RDEB mitis*. Similar to the Cockayne-Touraine DEB, localized RDEB is usually confined to repetitively traumatized skin surfaces, most often in an acral distribution. Scarring and milium formation accompany the healing of blisters. Mucosal involvement, if present, is mild.

Severe RDEB, also known as the *Hallopeau-Siemens* (HS) variant, is a devastating disease (Fig. 60-10). This disease presents with generalized blistering at birth. Occasionally, there is extensive denudation of an entire region of skin at birth, often involving one of the limbs. This congenital absence of skin is sometimes termed *Bart syndrome*. Healing and blistering cycles occurring during infancy can lead to progressive ulcerations and scarring that can become quite extensive (see eFig. 60-10.1 in on-line edition). Pseudosyndactyly resulting from a closure of the digits in a "mitten" of skin is extremely common in this disease (see Fig. 60-2J). Scarring can lead to flexion contracture of the hands as well as the limbs. In contrast to the severe JEB patients, these patients do not show significant periorificial involvement. Instead, the scalp is the most commonly affected area on the head and neck of these patients.

The oropharynx can be extensively involved in both dominant and RDEB (Fig. 60-11), with generalized erosions evolving into a scarring that limits the movement of the tongue and narrows the opening of the oral cavity. The teeth can show significant enamel pitting, and caries can be extensive, leading to loss of teeth. Involvement of the trachea or larynx can lead to a narrowing of the airway that could require intervention with a tracheostomy. Mucosal erosions of the esophagus can lead to stricture formation and webbing. The combination of oral lesions, dental caries, esophageal strictures, and increased caloric needs from extensive wound healing can lead these patients toward malnutrition and growth retardation. These patients usually have problems with anemia and may show a deficiency of iron absorption.

In the more distant past, most severe RDEB patients died in infancy of sepsis and other complications of extensive blistering. More recently, with improved nutritional and wound care support, these patients usually can survive into their teens or into adulthood. However, after puberty, another devastating complication, squamous cell carcinoma (SCC), can, and often does, appear. It is estimated that 50 percent to 80 percent of HS-RDEB patients eventually develop these carcinomas, and many of these die of metastatic disease. RDEB-associated carcinomas are extremely aggressive, with strong tendencies for invasion and metastasis.

MOLECULAR PATHOLOGY OF DYSTROPHIC EPIDERMOLYSIS BULLOSA Abnormalities of anchoring fibrils in DEB patients range from subtle changes in some patients with dominant disease, to absence of anchoring fibrils in patients with the severe recessive form, and a sublamina densa plane of blister cleavage is also present (see Fig. 60-2I). These observations correlate with IDIF microscopic analysis of DEB patients, which demonstrates varying degrees of linear basement membrane staining in dominant patients and totally absent staining in severe recessive patients. In some patients, there is a cytoplasmic retention of type VII collagen that can be demonstrated in patient biopsy sections and analysis of patient keratinocytes.[123]



▲ **FIGURE 60-11** Oral erosions in a patient with dominant dystrophic epidermolysis bullosa.



DEB has been shown to be associated in all cases thus far with mutations of the gene coding for type VII collagen (COL7A1). In the recessive forms, mutations usually cause premature termination codons that result in lack of type VII collagen in tissue. It is known that messenger RNAs bearing premature stop codons show accelerated turnover.[124] In addition, truncated proteins that are not secreted or not assembled into anchoring fibrils may also show accelerated turnover. Either or both of these mechanisms can explain the lack of detectable type VII collagen in the tissue of individuals with severe RDEB associated with mutations that produce premature termination codons.[60,125,126]



Generally, COL7A1 mutations that do not cause premature termination codons produce less severe disease.[60,127–135] For example, mutations that produce glycine substitutions of the triple helical region interfere with triple helical assembly of the type VII collagen molecule. These types of mutations are present in many patients with milder dominant forms of this disease. In these patients, type VII collagen molecules may not be able to assume the proper conformation needed to polymerize into anchoring fibrils. Other COL7A1 mutations have been shown to be associated with impaired secretion of type VII collagen, resulting in intracellular accumulation of this molecule.[133,136–138] In one study, DEB patient mutations that involve the area of the gene coding for the type VII collagen NC-2 domain were shown to interfere with NC-2 processing and the assembly of anchoring fibrils.[139]

Other Inherited Skin Disorders Related to Epidermolysis Bullosa

New advances in our understanding of the molecular pathology of the skin have brought to light the underlying pathophysiology of two diseases that are related to EB—Kindler syndrome and ectodermal dysplasia/skin fragility syndrome.

KINDLER SYNDROME Kindler syndrome was first described by Theresa Kindler in 1954.[140] It is characterized by EB-like, trauma-induced blistering at birth and during infancy, with atrophic changes during healing reminiscent of junctional or dystrophic EB.[141–147] However, in late childhood, the blistering usually subsides and gives way to a progressive poikiloderma that distributes to sun-exposed areas. The poikiloderma may show areas of atrophy and hyperkeratosis, as well as hypopigmentation, hyperpigmentation, and telangiectasias. These patients often show photosensitivity. Nail changes and webbing of the toes and fingers are also sometimes present. Internal complications include oral inflammation, esophageal or ureteral strictures, and ectropion. Ultrastructurally, these patients show reduplication of the basement membrane, which is the most consistent feature seen. Although there is often a sublamina densa split with anchoring fibril abnormalities, sometimes lamina lucida or intraepidermal separation can be seen, associated with the blistering phenotype. Molecular investigation of this disease led to the discovery of a new epidermal protein, kindlin-1, which shows decreased expression by immunofluorescent microscopy in this disease.[148–151] Kindlin-1 appears to have some homology to signaling proteins such as talin, which suggests a signaling function, but its role in Kindler syndrome remains unclear. A number of mutations of the gene coding for kindlin-1, KIND1, have been described.[148,149,151–156] These include nonsense, frameshift, and splice site mutations that underlie the observed decreased kindlin-1 expression in affected skin. Why the disease evolves from a blistering to a poikilodermatous phenotype and the exact function of kindlin-1 in epidermal homeostasis remain to be fully elucidated.

ECTODERMAL DYSPLASIA-SKIN FRAGILITY SYNDROME Ectodermal dysplasia-skin fragility syndrome is a rare disorder characterized by skin erosions, skin fragility, and peeling beginning at birth or infancy.[157] Alopecia is also very common, as are palmoplantar keratoderma, painful fissures, and nail dystrophy. Patients may sometimes demonstrate failure to thrive, cheilitis, hypohidrosis, and pruritus as well. The underlying molecular defect has been shown to be loss of function of the desmosomal protein plakophilin 1.[158] Plakophilin is expressed mainly in suprabasilar keratinocytes and outer root sheath cells. Microscopic findings in this disease usually show intraepidermal acantholysis located in the areas where plakophilin 1 is normally expressed. The molecular defect involves loss of function mutations in the PKP1 gene coding for plakophilin 1.[159–164]

DIAGNOSIS

The first step toward making the diagnosis of EB begins with a thorough history and physical examination (Fig. 60-12). Useful historical information includes the age of onset of blistering and the presence of blistering in other family members. A review of gastrointestinal (GI), respiratory, ocular, dental, and genitourinary systems is important as is evaluation of general growth and development. Physical examination requires not only a complete skin examination, but a thorough evaluation of mucosal tissues, hair, nails, and teeth. Laboratory measurements of importance in the initial visit include evaluation for anemia and for measures of nutrition, such as serum albumin.

Skin biopsy is another important diagnostic step. Routine histologic analysis cannot be used to diagnose EB but can be useful for excluding other causes of blistering. The dermal-epidermal BMZ is simply too small to be visualized by light microscopy. To differentiate levels of BMZ separation in skin biopsies, TEM and/or IDIF microscopy must be used. The interior of blisters rapidly reepithelialize, which can obscure correct determination of blister levels. For this reason, it is critical to biopsy a blister that is as fresh as possible. One way to ensure a fresh blister is for the clinician to induce it in the office. This can be accomplished by gently rotating a pencil eraser over an intact area of patient's skin until separation of the epidermis from the dermis can be observed.

TEM has been regarded for many years as the gold standard for determining the level of blistering in EB subtypes. In addition to determining the level of blistering, ultrastructural entities can also be analyzed by TEM for characteristic alterations. For example, clumping of keratin intermediate filaments in basal keratinocyte cytoplasm is a pathognomonic finding for Dowling-Meara EBS. Rudimentary hemidesmosomes can be an important clue to the diagnosis of JEB. Absent or altered anchoring fibrils often occur in DEB subtypes, especially the recessive forms.

IDIF microscopy can provide additional information on the level of blistering as well as important clues to the underlying molecular defects. In this technique, a panel of antibodies against known BMZ antigens is applied to frozen sections of blistered patient skin. The localization of the antigens to the epidermal or dermal portion of the blister indicates the level of skin separation in the BMZ. In EBS samples, for example, intracellular hemidesmosomal components, such as BP230, and a lamina densa protein, such as type IV collagen, would each localize to the floor of the blister. In JEB cases, BP230 would localize to the roof of the blister, whereas

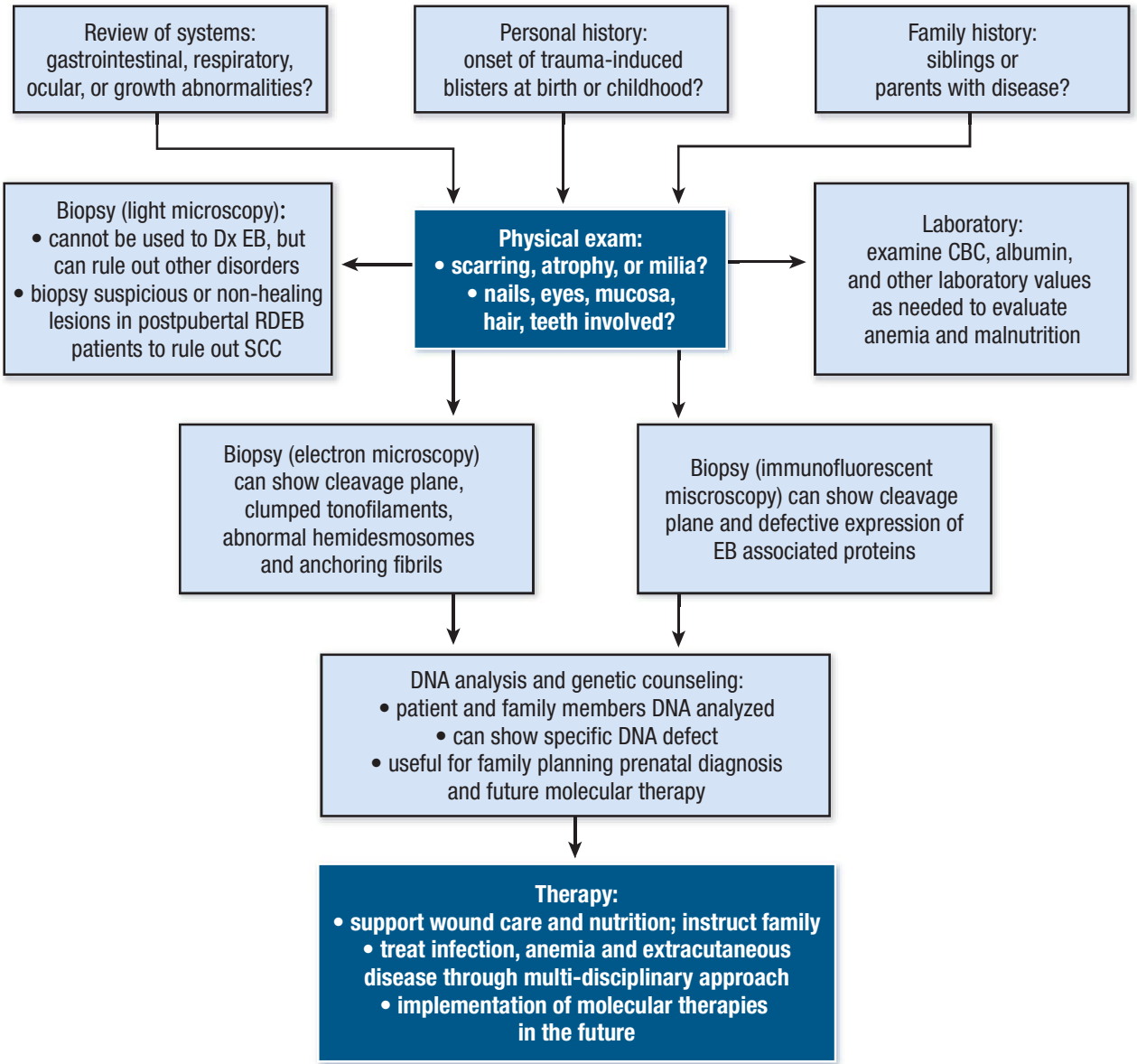

▲ FIGURE 60-12 Approach to epidermolysis bullosa (EB) patients. A complete history, including family history and review of systems, is essential. Physical examination can provide important clues, and laboratory values can help identify associated anemia and malnutrition. Electron microscopy and/or indirect immunofluorescence microscopy is required for diagnosis. DNA analysis is helpful for determining prognosis and family planning. Therapy is mainly supportive. Teaching and working with nursing staff and especially families is critical, as is interdisciplinary interactions with other specialties in the treatment of extra-cutaneous complications. CBC = complete blood cell count; Dx = diagnosis; RDEB = recessive dystrophic epidermolysis bullosa; SCC = squamous cell carcinoma.

type IV collagen would localize to the floor. In DEB, type VII collagen and BP230 would localize to the roof of the blister. The specific absence or presence of staining with a particular antibody in frozen sections of intact portions of patient skin gives important clues to the specific molecular defect. Samples that lack staining with antibodies specific to laminin-332 would further support a JEB diagnosis, whereas a lack of staining for type VII collagen would support a DEB diagnosis. Absence of staining for BP180 would support a GABEB diagnosis.

Gene mutation analysis has revolutionized our understanding of the EB family of diseases. Concurrent advances in our knowledge of the biochemical structure and supramolecular assembly of BMZ proteins have both facilitated and complemented the molecular biology studies. Despite these advances, a complete correlation of molecular and clinical phenotypes has not yet been achieved. Thus, EB patient diagnosis requires both clinical and molecular information. Blood samples or buccal swabs are taken from the patient as well as the parents and siblings for genetic analysis.

Differential Diagnosis (See Box 60-1)

Genetic Counseling

DNA mutation analyses can be extremely helpful to EB patients. The prognostic benefit to the patient can often be highly significant. For example, RDEB cases may have equivalent blistering activity compared with the more severe dominant cases, but their risk of invasive SCC is much greater. Through DNA diagnosis, these two groups can be distinguished, thereby identifying patients potentially at risk for invasive SCC.

Prenatal diagnosis of EB in affected families can be an extremely accurate technique, especially if the original pro-



Box 60-1

Differential Diagnosis of Epidermolysis Bullosa

Most Likely

- Pompholyx
- Insect bites
- Friction blisters
- Thermal burns
- Bullous impetigo
- Bullous congenital ichthyosiform erythroderma (neonate)
- Aplasia cutis (neonate)

Consider

- Chronic bullous dermatosis of childhood (linear immunoglobulin A disease)
- Bullous pemphigoid
- Epidermolysis bullosa acquisita
- Bullous systemic lupus erythematosus
- Cicatricial pemphigoid
- Pemphigus vulgaris

Always Rule Out

- Stevens-Johnson syndrome
- Toxic epidermal necrolysis



band has previously had mutational analysis or identification of the defective gene. Fetal skin biopsies and fetoscopy with their increased risk of pregnancy loss can now be avoided by analysis of either chorionic villus sampling as early as 8 to 10 weeks[165] or amniocentesis in the second trimester.[166] The development of highly informative intragenic and flanking polymorphic DNA markers in EB candidate genes together with rapid screening of genetic "hotspots" makes genetic screening of at-risk pregnancies a viable option.[3,103,167] Coupling of the technique of in vitro fertilization with EB prenatal diagnosis, preimplantation diagnosis has now been successfully performed for EB cases.[159,165,168] Another promising area of prenatal diagnosis with potential future applications to EB is the detection and analysis of fetal cells in the maternal circulation.[169]

TREATMENT

Therapy for EB is by necessity supportive, as currently available therapies cannot correct the underlying molecular defect. The regimen is tailored to the severity and extent of skin and systemic involvement and usually entails a combination of wound management, infection control, surgical management as needed, and nutritional support. Skin care and supportive care for other organ systems in certain EB sub-types is most optimally coordinated through a multidisciplinary approach.[170,171] Comprehensive topical therapy is a mainstay of treatment in EB, with avoidance of trauma as a primary goal. Wound healing is impaired by endogenous factors, including foreign bodies, bacteria, nutritional deficiencies, anemia, and repeated trauma. Therefore, optimizing wound healing in EB patients involves control of all of these factors.[172]

Supportive Skin Care

Extensive areas of denuded skin can result in the loss of the barrier provided by the stratum corneum. Subsequent microbial penetration can result in the accumulation of serum and moisture that further enhances bacterial propagation. The above factors combined with immunosuppressive therapy facilitate development of infections. Prevention of infection is obviously the preferred strategy.

A modified Dakin's solution (0.025 percent weight per volume sodium hypochlorite) can be helpful in reducing the bacterial load in patient skin.[173,174] Soaking wounds in this solution for 20 minutes before dressing changes also helps to free adherent bandages that have dried onto the wound bed. After soaking, wounds can be dressed with mupirocin or other topical antibiotics and covered with semiocclusive nonadhesive dressings. Tape causes further blistering and peeling of the skin; thus it is essential to use self-adhering (clinging) gauze to hold non-adherent dressings in place.

For patients with most sub-types of EBS, such as Koebner and Weber-Cockayne EBS, avoiding exposure to heat is key to controlling blister formation. Advising patients to use soft, well-ventilated shoes is also recommended. Herlitz JEB patients, lacking functional laminin-332, an extracellular matrix protein shown to be involved in keratinocyte adhesion and migration, may have especially difficult problems with wound healing. In JEB patients with chronic hypertrophic granulation tissue in the periorificial regions of the face, keratinocyte autografts have been used.[175,176] For DEB patients, use of finger splinting or diligent hand wrapping and appropriate hand protection against trauma are helpful, especially after hand surgery (see Surgical Treatment).

Treatment of Infection

Management of skin infections is a critical part of EB patient care. Large areas of denuded skin, a common finding in EB patients, provides an inadequate barrier to microbial penetration. Patients with severe EB sub-types, such as RDEB, may also have immunologic abnormalities, including decreased lymphocyte production due to poor nutritional status that lower a patient's resistance to infection. *Staphylococcus aureus* and *Streptococcus pyogenes* are common infectious agents. Gram-negative infections with *Pseudomonas aeruginosa* can also occur. Sepsis is a common cause of death in JEB letalis patients. Skin cultures and the use of the appropriate systemic antibiotics are indicated for wound infection. To prevent infections in chronic wounds, a regimen entailing regular whirlpool therapy followed by topical antibiotics is the preferred strategy. Rotation of topical antibiotics is also a helpful way to combat resistant bacteria.

Surgical Treatment

Among the EB patient population, those with the severe HS-RDEB variant are generally the most in need of surgical intevention.[177] Mitten pseudosyndactyly in these patients can be surgically released; however, this procedure may have to be repeated periodically due to the strong tendency of this condition to recur.[178–181] Splinting after surgery is essential to reducing recurrence of hand deformities. Surgery may also be used to correct limb, perioral, and perineal contracture deformities; but, unfortunately, recurrence is common.[177,182,183] Extra care must be taken to minimize trauma to the oral mucosa in EB patients during intubation.[184,185]

In the case of tissue-engineered skin, application of allogeneic skin equivalents has recently demonstrated some promise in wound healing and improvement of quality of life[186] and thus represents an area of future investigation. Although long-term benefit or persistence of allografted cells has not been demonstrated, this therapy nonetheless appears to be a helpful short-term therapy to help chronic EB wounds to heal.

Treatment of Tumors

SCC often arises after puberty in patients with RDEB.[187,188] SCC may arise in multiple primary sites, especially in nonhealing areas. Careful surveillance of non-healing areas is of utmost importance because patients often die from metastatic disease. Surgical excision using either Mohs or non-Mohs ap-

proaches is an important first-line modality, with radiation therapy limited by poor tumor response and impaired site healing.[189] Isotretinoin has been used for RDEB patients for chemoprevention of SCC. Although it appears well tolerated, it is not clear whether it can increase the overall survival rate of these patients.[190]

Care for Extra-Cutaneous Involvement

GASTROINTESTINAL MANAGEMENT Esophageal lesions are often the most disabling complication found in RDEB and JEB of both the Herlitz and non-Herlitz varieties.[191–194] Esophageal strictures usually respond to dilatation; however, recurrence of strictures after dilation is common.[195] Colonic interposition has proved effective in advanced cases. Gastrostomy tube insertion has been effective in providing nutrition to individuals with esophageal strictures.[193] Increased fluid and fiber intake and stool softeners may also be of value in EB patients who suffer from constipation.

EYE LESIONS EBS patients, particularly those with the Dowling-Meara subtype, can experience recurrent inflammation of the eyelid, with bullous lesions in the conjunctivae. JEB and RDEB patients can experience corneal ulcerations with scarring, obliteration of tear ducts, and eyelid lesions.[196] Cicatricial conjunctivitis can also occur in RDEB patients. Corneal erosions are treated supportively with application of antibiotic ointments and use of cycloplegic agents to reduce ciliary spasms and provide comfort. Moisture chambers and ocular lubricants are also commonly used. Severely affected upper eyelids may be surgically managed with full-thickness skin grafting. Complete correction of any eye disorder in EB patients is difficult to achieve. Proper management of eye lesions in EB patients must include the assistance of an ophthalmologist to prevent serious visual compromise.[197,198]

OROPHARYNGEAL LESIONS Good dental hygiene is essential for EB patients, and regular visits to the dentist are especially important. Enamel defects in JEB and DEB patients often lead to dental carries.[199,200] The softest brush available should be used for regular cleansing. Oral mucosal blistering may also accompany forms of JEB and DEB. Normal saline rinses are effective for gentle cleaning of the mucosal surfaces. Mouthwashes containing alcohol or other harsh agents should be avoided. Erosions and scarring involving the trachea and larynx with resultant narrowing of the airway can occur both in JEB and DEB patients and should be evaluated by gentle endoscopy with an otolaryngologist or other surgical specialist. In patients with airway involvement, there is danger of pulmonary aspiration.[182]

NUTRITION AND ANEMIA Nutritional assessment and support can be critical in EB patients[201] for several reasons. Extensive cutaneous injury is associated with marked alterations in hemodynamic and metabolic responses, with increased caloric and protein requirements. Oropharyngeal as well as GI lesions provide the greatest overall threat to nutritional well-being. These include oral blistering, abnormal esophageal motility, strictures, dysphagia, diarrhea, malabsorption, and dental problems. Nutritional assessment must take into account the preceding factors to develop a supplemental regimen to replenish nutritional deficiencies. Patients are often unable to increase their food intake to balance this increased caloric need. For example, hypoplastic enamel formation in certain sub-types of EB such as GABEB may lead to tooth decay, mucosal blistering, and oral candidiasis. All of these potential complications may compromise a patient's ability to eat. Extensive internal mucosal disadhesion in the GI tract may cause abnormal GI motility, strictures, and diarrhea, complications that may lead to malabsorption of iron and other nutrients. Anemia of chronic disease can certainly affect all severe EB sub-types. RDEB patients often show a particularly severe defect of iron absorption from the GI tract. Often in these patients, an iron-deficient anemia can develop, which is not responsive to oral supplementation. For these patients, parenteral iron can be helpful. Furthermore, if a lack of a reticulocyte response to iron supplementation is seen in iron-deficient patients, it is helpful to assess the erythropoietin level and to treat with recombinant erythropoietin, if necessary.[202] Transfusion is also useful in the treatment of anemia in EB, especially when symptoms require a rapid correction.

TREATMENT OF PSYCHOLOGICAL ASPECTS OF EPIDERMOLYSIS BULLOSA Patients with EB, especially the severe sub-types, can be plagued with chronic pain and debilitation.[203] Although many, despite extremely adverse conditions, seem to find a way to maintain a surprisingly positive outlook on life, others lapse into depression.[204] Severe EB patients can also create stress for their families and loved ones.[205,206] Thus, it is important to identify the warning signs of depression when they arise and to work in a multi-disciplinary approach with psychiatrists and clinical psychologists, as needed. Supportive psychotherapy and patient support group meetings can help patients and their families in this regard. An additional source of support for patients and families includes several important lay person organizations that assist with patient education and support, including the Dystrophic Epidermolysis Bullosa Research Association of America (http://www.debra.org) and the Epidermolysis Bullosa Medical Research Foundation (http://www.ebkids.org).



Systemic Therapies

Systemic therapies are not effective in ameliorating the fundamental blistering tendencies in EB patients. Tetracycline and phenytoin have been used in the past for EB but are not currently indicated treatment.[207,208] Corticosteroids, either topical or systemic, have no beneficial, long-term use in inherited EB.

Future Directions In Molecular Therapy

A number of pre-clinical models have facilitated the study and development of therapy for EB. Some of these models use mouse genetic approaches to produce entirely murine tissue models.[209] These include transgenic mouse models with skin-targeted expression of transdominant molecules,[210] such as inducible dominant-negative mutations in basal cell keratins in models of EBS.[211] Murine knockout models have also been used, including knockout of basal keratin genes in a model of recessive EBS and of the α_6 and β_4 integrins, laminin-332, and type VII collagen.[212,213] These targeted gene disruptions in mice have accurately recapitulated the blistering phenotype of the corresponding human disorders. These murine genetic models have been of great use in clarifying our understanding of the pathogenesis of this group of disorders and in providing disease models for development of potential future therapies. Other animal models have also been shown to have the potential to study EB pathophysiology and therapy in a pre-clinical

setting. Canine, equine, and feline forms of a number of sub-types of EB show promise as pre-clinical models of molecular therapy.[214–220]

In addition to such pure animal models, human skin/mouse chimeras have been generated in an attempt to produce true human tissue models of EB. These chimeras have either used full-thickness grafting of EB patient skin or epidermis regenerated on skin composites and sheets from EB keratinocytes grown in culture.[221] Immune-deficient severe combined immune deficiency and nude mice readily accept such xenografts and the grafted EB skin retains the clinical and molecular characteristics of the patient donor. This immunodeficient mouse models can be extended to study injections of human cells or proteins as well. This approach has been reported for RDEB due to mutations in type VII collagen and for benign JEB due to mutations in type XVII collagen. Because human epidermis differs dramatically from mouse epidermis in tissue architecture, these in vivo models of human tissue in EB may be of special use in development of models for gene therapy of these disorders.

Future potential therapies for EB include protein and gene therapy. In the former case, the missing or defective protein is produced by recombinant methods and applied or injected directly to intact or blistered skin. Recent studies of type VII collagen protein transfer into RDEB-derived skin equivalents has showed successful incorporation of this molecule into anchoring fibrils combined with clinical improvement of skin separation. Type VII collagen has a longer in vivo half-life than most molecules. This suggests that protein application or injection could take place at extended intervals, perhaps greater than 3 months, as persistence of exogenous type VII collagen protein was detected in animal models for at least this long. In the case of gene therapy, delivery of genes targeted to restore normal protein expression is the goal.[222] Successful corrective gene delivery has recently been achieved in human EB tissue in the immune-deficient model system described below for both laminin-332 and Type XVII collagen.[223,224] Thus, genetic therapies may be of significant use in the future. More recently, both viral and nonviral methods of gene transfer have demonstrated successful expression of type VII collagen in RDEB skin equivalents on immunodeficient mice[225–228] as well as in a canine animal model.[219] Genomic DNA therapeutic approaches have also been studied in EB keratinocytes with some success, but still at the in vitro stage.[229,230] Dermal fibroblasts have long been appreciated to be a main contributor of type VII collagen to the dermal-epidermal basement membrane.[231] Recently, approaches that inject type VII collagen-expressing fibroblasts have proved successful in restoring type VII collagen expression and reversing the blistering phenotype in RDEB skin equivalents on immunodeficient mice.[226,232] These studies suggest that molecular therapy of EB can produce durable and effective remission of blistering in vivo, which leads to a way toward future clinical applications.



KEY REFERENCES

The full reference list for all chapters is available at www.digm7.com.

1. *Epidermolysis Bullosa: Clinical, Epidemiologic, and Laboratory Advances and the Findings of the National Epidermolysis Bullosa Registry*, edited by Fine JD et al. Baltimore, John Hopkins University Press, 1999
2. McAllister JC, Peter Marinkovich M: Advances in inherited epidermolysis bullosa. *Adv Dermatol* **21**:303, 2005
3. Uitto J, Richard G: Progress in epidermolysis bullosa: From eponyms to molecular genetic classification. *Clin Dermatol* **23**:33, 2005

68. Fine JD et al: Revised classification system for inherited epidermolysis bullosa: Report of the Second International Consensus Meeting on diagnosis and classification of epidermolysis bullosa. *J Am Acad Dermatol* **42**:1051, 2000
69. Horn HM, Tidman MJ: The clinical spectrum of epidermolysis bullosa simplex. *Br J Dermatol* **142**:468, 2000

141. Ashton GH: Kindler syndrome. *Clin Exp Dermatol* **29**:116, 2004

165. Fassihi H et al: Prenatal diagnosis for severe inherited skin disorders: 25 years' experience. *Br J Dermatol* **154**:106, 2006

182. Travis SP et al: Oral and gastrointestinal manifestations of epidermolysis bullosa. *Lancet* **340**:1505, 1992

187. McGrath JA et al: Epidermolysis bullosa complicated by squamous cell carcinoma: report of 10 cases. *J Cutan Pathol* **19**:116, 1992

222. Ferrari S et al: Gene therapy approaches for epidermolysis bullosa. *Clin Dermatol* **23**:430, 2005

SECTION 9

DISORDERS OF THE DERMAL CONNECTIVE TISSUE

CHAPTER 61

Collagen, Elastic Fibers, and Extracellular Matrix of the Dermis

Jouni Uitto
Mon-Li Chu
Richard Gallo
Arthur Z. Eisen

COLLAGEN

Structure

The closely related proteins of the collagen family are the main fibrillar components of the connective tissues and the major extracellular proteins of the human body.[1–4] The physiologic role of collagen fibers in the skin is to provide tensile properties that allow the skin to serve as a protective organ against external trauma. In human skin, collagen fibers form the bulk of the extracellular matrix and comprise approximately 80 percent of the dry weight of the dermis. The bulk of collagen in dermis is deposited as large bundles of regularly oriented fibers composed of fibrils that are aligned in a parallel manner, which results in a pattern of cross-striations that can be visualized by electron microscopy (Fig. 61-1). The most prominent cross-striations appear as repeating bands spaced approximately 70 nm apart.

The prototype of the collagens is type I collagen, the most abundant collagen in the dermis and in most other connective tissues (Fig. 61-2). The type I collagen molecule has an approximate molecular mass of 290 kd and is composed of three polypeptide chains, each approximately 94 kd. These three polypeptides, known as the *α chains*, are coiled around each other much like strands of rope, so that the collagen monomer has a triple-helical structure. This conformation gives the molecule a rigid, rod-like shape with approximate dimensions of 1.5 × 300 nm (see Fig. 61-2).

The special structure of the collagen triple helix is largely explainable by the unusual amino acid composition of the α chains. Specifically, each α chain of type I collagen has approximately 1000 amino acids, and glycine (Gly), the smallest amino acid, accounts for approximately one-third of the total number of amino acids, evenly distributed in the collagenous portion of the polypeptide. Consequently, the polypeptide chains of collagen can be described as repeating triplets represented as $(Gly\text{-}X\text{-}Y)_{333}$ (see Fig. 61-2). The X and Y positions of the repeating sequence can be occupied by a variety of amino acids, but the X position is often occupied by proline and the Y position by hydroxyproline. These two amino acids account for approximately 22 percent of the to-

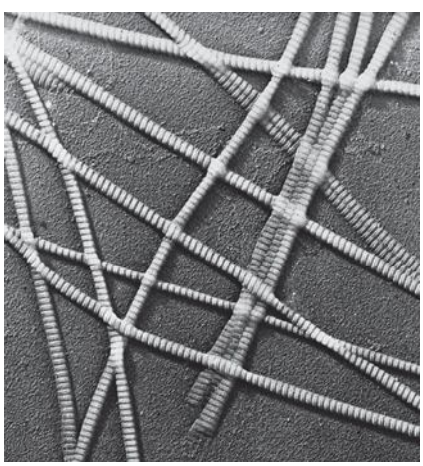

▲ **FIGURE 61-1** Electron micrograph of collagen fibers demonstrating the regular banding pattern at approximately 70-nm intervals. (×45,000.)

COLLAGEN, ELASTIC FIBERS, AND EXTRACELLULAR MATRIX AT A GLANCE

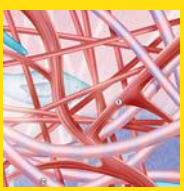

- The maintenance of tissue architecture and the physiologic properties of skin are attributable to the extracellular matrix of connective tissues.
- The connective tissue network comprises a large number of extracellular matrix components, including the collagens, elastic fibers, proteoglycan/glycosaminoglycan macromolecules, and several non-collagenous glycoproteins.
- The ability of resident cells, such as fibroblasts and smooth muscle cells, to synthesize and assemble the extracellular matrices is critical for morphogenesis, angiogenesis, and wound healing of the skin.
- In a number of pathologic situations, the dynamic balance between extracellular matrix synthesis and degradation is deranged, as exemplified by tumor invasion and metastasis, fibrotic skin diseases, and inflammatory processes.

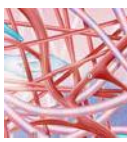

Copyright © 2008 by The McGraw-Hill Companies, Inc. Click here for terms of use.



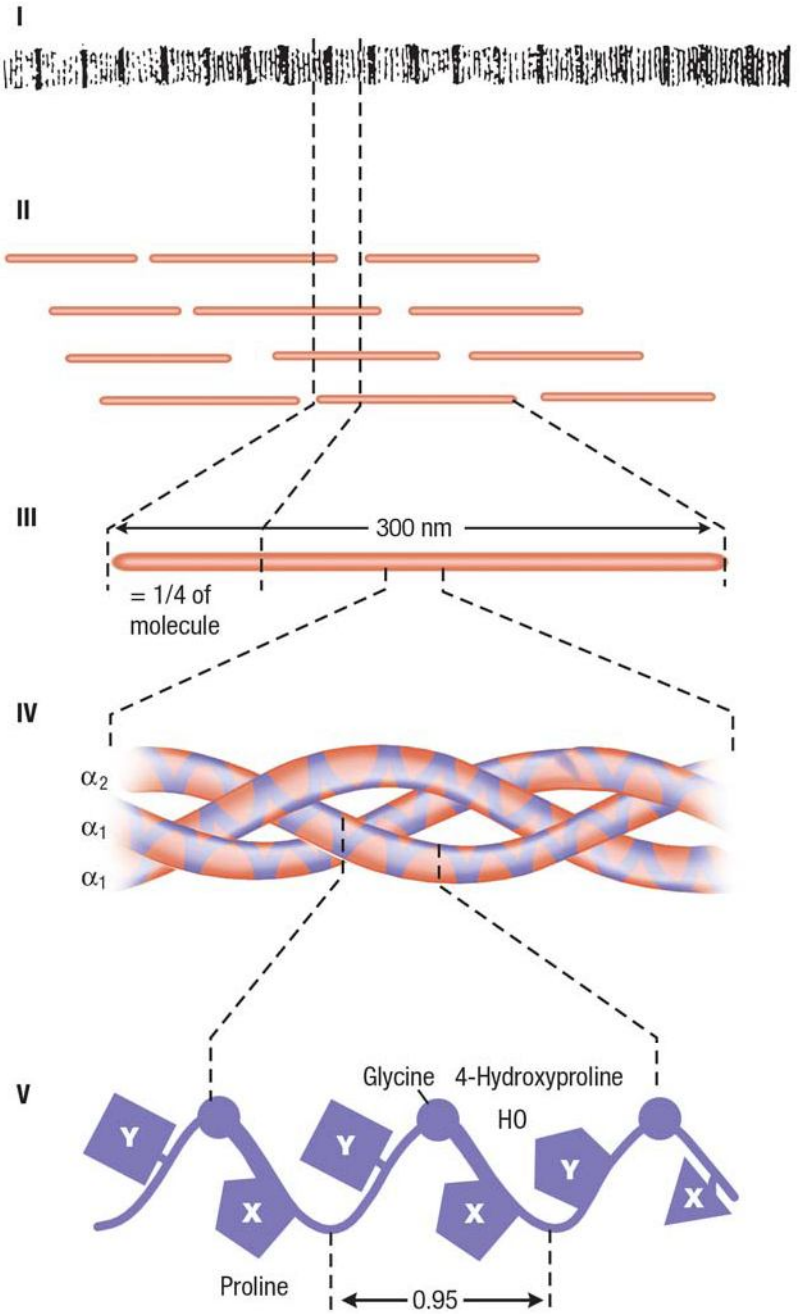

▲ **FIGURE 61-2** Schematic representation of the structure of type I collagen. The collagen fibers (I), which on electron microscopy demonstrate a repeating periodicity (see Fig. 61-1), are composed of individual collagen molecules aligned in a quarter-stagger arrangement (II). Each type I collagen molecule is an approximately 300-nm-long rod-like structure (III) consisting of three individual polypeptides, known as *α chains*, which are twisted around each other in a right-handed triple helix (IV). Each chain is composed of amino acids in a repeating Gly-X-Y sequence (V); as indicated, the X position is frequently occupied by a prolyl residue, and the Y position is frequently occupied by a 4-hydroxyprolyl residue. The individual α chains have a left-handed helical secondary structure with a pitch of 0.95 nm. (From Uitto J et al: Collagen structure, function, and pathology, in *Progress in Diseases of the Skin*, vol 1, edited by Fleischmajer R. New York, Grune & Stratton, 1981, p 103, with permission.)

tal amino acid composition of type I collagen. The relatively high contents of these amino acids and the characteristic distribution of glycine in every third position are necessary for the triple-helical conformation of the collagen molecule, and hydroxyproline plays a critical role in stabilizing the triple helix at body temperature. The triple-helical conformation gives collagen many of its unique properties and is essential for normal fibrillogenesis. Mutations that affect the formation of the stable triple helix prevent collagen from forming fibers, which results in serious defects of connective tissue function and a spectrum of clinical phenotypes.[1–5]

Genetic Heterogeneity

Collagens comprise a family of closely related yet genetically distinct proteins. In the human genome there are as many as 42 different genes encoding α chains with variable amino acid sequences. These α chains correspond to at least 28 different types of collagen, which have been assigned Roman numerals I to XXVIII (Table 61-1). In addition to well-characterized collagens, short, triple-helical collagenous segments are present in other proteins, including acetylcholinesterase, the C1q component of the complement system, pulmonary surfactant proteins, macrophage scavenger receptors, emilins (elastin microfibril interface–located glycoproteins), and ectodysplasin A, a product of the gene mutated in X-linked anhidrotic ectodermal dysplasia.[6,7] These proteins are not included in the collagen family, however, because the collagenous domains are not a predominant part of the molecules, and the proteins do not function primarily as structural components of the extracellular matrix of connective tissue.

On the basis of the fiber architecture in tissues, the genetically distinct collagens can be divided into different classes (see Table 61-1). Collagen types I, II, III, V, and XI align into relatively large fibrils and are therefore designated *fibril-forming collagens*. Type IV is arranged in an interlacing network within the basement membranes, whereas type VI is a distinct microfibril-forming collagen and type VII collagen forms anchoring fibrils. *FACIT* (fibril-associated collagens with interrupted triple helices) collagens[8] include types IX, XII, XIV, XVI, XIX, XX, XXI, XXII, and XVI. Many of these collagens are associated with larger collagen fibers and may serve as molecular bridges important for the organization and stability of the extracellular matrices. Type XIII and XVII collagens are transmembrane proteins. Collagen types XX through XXVIII have been described more recently, and their supramolecular structures remain unknown. An overview of the major collagen types contributing to skin physiology and pathology is presented in the following paragraphs. Other collagen types are not discussed in detail because they do not appear to be present in the skin in significant quantities or they seem not to contribute to the physiologic properties of dermis.

TABLE 61-1
Genetic Heterogeneity of Collagen

Collagen Type	Chain Composition[a]	Molecular Characteristics/ Supramolecular Assembly	Tissue Distribution/Cell Source[b]
I	$[\alpha1(I)]_2\alpha2(I)$	Fibrillar	Skin, bone, tendon
I-trimer	$[\alpha1(I)]_3$	Fibrillar	Tumors, skin
II	$[\alpha1(II)]_3$	Fibrillar	Cartilage
III	$[\alpha1(III)]_3$	Fibrillar	Fetal skin, blood vessels, gastrointestinal tract
IV	$[\alpha1(IV)]_2\alpha2(IV)$[c]	Basement membrane	Ubiquitous
V	$[\alpha1(V)]_2\alpha2(V)$; $[\alpha1(V)]_3$[c]	Fibrillar	Ubiquitous
VI	$\alpha1(VI)\alpha2(VI)\alpha3(VI)$	Microfibril	Ubiquitous
VII	$[\alpha1(VII)]_3$	Anchoring fibril	Papillary dermis of the skin and other epithelial tissues (gastrointestinal tract, trachea, esophagus)
VIII	$[\alpha1(VIII)]_3$	Network forming	Endothelial cells
IX	$\alpha1(IX)\alpha2(IX)\alpha3(IX)$	FACIT	Cartilage
X	$[\alpha1(X)]_3$	Network forming	Hypertrophic cartilage
XI	$\alpha1(XI)\alpha2(XI)\alpha3(XI)$	Fibrillar	Cartilage
XII	$[\alpha1(XII)]_3$	FACIT	Tendons, ligaments, perichondrium, periosteum, cornea
XIII	$[\alpha1(XIII)]_3$	Transmembrane	Ubiquitous including epidermis (17 splice combinations known)
XIV	$[\alpha1(XIV)]_3$	FACIT	Skin, tendons, cornea
XV	$[\alpha1(XV)]_3$	Basement membrane	Ubiquitous
XVI	$[\alpha1(XVI)]_3$	FACIT	Skin, internal organs, cartilage
XVII	$[\alpha1(XVII)]_3$	Transmembrane	Hemidesmosomes of basal keratinocytes in dermal-epidermal junction of the skin
XVIII	$[\alpha1(XVIII)]_3$	Basement membrane	Ubiquitous
XIX	$[\alpha1(XIX)]_3$	FACIT	Basement membrane
XX	Unknown	FACIT	Corneal epithelia, embryonic skin, sternal cartilage, tendon, lung
XXI	Unknown	FACIT	Smooth muscle cell in blood vessel walls, developing heart
XXII	Unknown	FACIT	Tissue junctions
XXIII	Unknown	Transmembrane	Metastatic tumor cells
XXIV	Unknown	Fibrillar	Developing bone and cornea
XXV	Unknown	Transmembrane	Neurons
XXVI	Unknown	FACIT	Testis, ovary
XXVII	Unknown	Fibrillar	Cartilage, eye, ear, lung
XXVIII	Unknown	Basement membrane	Peripheral nerves

FACIT = fibril-associated collagens with interrupted triple helices.
[a]The precise chain composition of some of the recently described collagens is not known.
[b]The predominant tissue distribution is indicated; lesser amounts may be present in other tissues.
[c]Additional α chains exist (see text).

Type I collagen, the most widely distributed and most extensively characterized form of collagen, is found predominantly in bone and tendon and accounts for approximately 80 percent of the total collagen of adult human dermis. The type I collagen molecule contains two identical α chains, designated *α(I)*, and a third chain, called *α2(I)*, that is clearly different in its amino acid composition. Thus, the chain composition of type I collagen is $[\alpha1(I)]_2\alpha2(I)$.

Type III collagen, another genetically distinct form of collagen, predominates in gastrointestinal and vascular connective tissues, but it also represents approximately 10 percent of the total collagen in the adult human dermis.[9] Type III collagen is composed of three identical α chains, α1(III), distinguished from the chains of type I collagen by a relatively high content of hydroxyproline and glycine and the presence of a cysteine residue. Collagen types I and III form the relatively broad extracellular fibers that are primarily responsible for the tensile strength of the human dermis. Mutations in the type I and III collagen genes can result in connective tissue abnormalities in the skin and joints, among other tissues, in different forms of Ehlers-Danlos syndrome and fragility of bones in osteogenesis imperfecta.[1,3,5]

Type IV collagen is abundantly present in basement membranes.[10] In the skin, type IV collagen is found in the

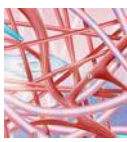

basement membrane at the dermal-epidermal junction, primarily within the lamina densa, where it forms a lattice rather than the fibers characteristic of dermal collagens. The type IV collagen present in human skin is predominantly a heterotrimer, $[\alpha1(IV)]_2\alpha2(IV)$, although, occasionally, the homopolymers $[\alpha1(IV)]_3$ and $[\alpha2(IV)]_3$ may be assembled. The type IV collagen molecule is characterized by the presence of noncollagenous interruptions within the triple-helical domain, which confer flexibility on the molecule. More recently, four additional α chains—α3(IV), α4(IV), α5(IV), and α6(IV)—have been identified.[11] The type IV collagen molecules containing these subunit polypeptides appear to be expressed primarily in glomerular basement membranes, and their importance for renal physiology is indicated by the fact that mutations in the gene encoding the α5(IV) polypeptide result in Alport syndrome,[12] an X-linked renal disease. Furthermore, autoantibodies recognizing the α3(IV) chains underlie Goodpasture syndrome.[13] Finally, the α5 chain of type IV collagen has been shown to be a target of circulating immunoglobulin G autoantibodies in a novel autoimmune disease characterized by sub-epidermal blisters and renal insufficiency.[14]

Type V collagen consists of a subfamily of similar interrelated collagens that contain four different types of α chains. The predominant form in the skin is $[\alpha1(V)]_2\alpha2(V)$. Type V collagen is present in most connective tissues. In the skin type V collagen represents less than 5 percent of the total collagen. In dermis, type V collagen is associated with major collagen fibers consisting of type I and III collagens, and type V collagen has been postulated to regulate the fiber diameter during fibrillogenesis. The importance of type V collagen has been demonstrated by discovery of mutations in the type V collagen genes in patients with classical autosomal dominant forms (types I and II) of Ehlers-Danlos syndrome.[15,16] It is of interest that a clinically similar, classical type of Ehlers-Danlos syndrome can be based on absence of tenascin-X expression, which leads to an autosomal recessive form of the disease.[17,18] Tenascin-X is developmentally associated with collagen fibrillogenesis, and its absence could explain the presence of defective collagen fibers similar to those found in patients with mutations in the type V collagen genes.

Type VI collagen is a relatively abundant component in a variety of tissues, including skin.[19] The type VI collagen molecules consist of three distinct α chains—α1(VI), α2(VI), and α3(VI)—which fold into a triple-helical domain of approximately 100 nm in length, with globular domains at both ends of the molecule.[20] Type VI collagen assembles into relatively thin microfibrils that form a network independent of the previously mentioned broad collagen fibers, which consist of type I, III, and V collagens. The microfibrillar network of type VI collagen may perform an anchoring function by stabilizing the assembly of the broad collagen fibers as well as basement membranes. Studies have now demonstrated that mutations in each of the three type VI collagen genes can lead to different forms of congenital muscular dystrophy, with multiple joint contractures, laxity of distal joints, and characteristic skin involvement.[21]

Type VII collagen—the major, if not the exclusive, component of the anchoring fibrils at the dermal-epidermal basement membrane zone—was originally designated as long-chain collagen because it has an unusually long triple-helical region of approximately 450 nm.[22] It has only one type of α chain, α1(VII), and the triple-helical collagenous domain is flanked by a large, nonhelical (noncollagenous) domain (NC-1) at the amino terminus and a shorter carboxyl-terminal nonhelical domain (NC-2). Type VII collagen molecules become organized into anchoring fibrils, which extend from the lower part of the lamina densa to the papillary dermis, through the formation of antiparallel dimers linked through their carboxyl-terminal ends. The large amino-terminal, non-collagenous domains of type VII collagen interact with type IV collagen and laminin-5 components of the dermal-epidermal basement membrane, and it has been suggested that most anchoring fibrils form U-shaped loops that entrap broad dermal collagen fibers consisting of type I and III collagens.[23] Thus, alterations in the expression, structure, or molecular interactions of type VII with other basement membrane components could result in skin fragility. Such a situation is exemplified by dystrophic epidermolysis bullosa (DEB), a group of mechanobullous diseases characterized by blistering of the skin after minor trauma[24,25] (see Chaps. 51, 60). In fact, distinct mutations in the type VII collagen gene, COL7A1, have been demonstrated in more than 400 families with different forms of DEB, and none of the families with DEB studied so far has revealed mutations in genes other than that encoding the α1(VII) polypeptide of type VII collagen.[25] Furthermore, type VII collagen serves as the autoantigen in the acquired form of epidermolysis bullosa, an autoimmune disorder with circulating anti–type VII collagen antibodies[26] (see Chap. 58).

Type XVII collagen was initially identified as the 180-kd bullous pemphigoid antigen *(BPAG2)*, which was recognized by circulating autoantibodies in the sera of patients with bullous pemphigoid or herpes gestationis. This antigen, which is synthesized by basal keratinocytes, was localized by immunoelectron microscopy to the hemidesmosomes at the dermal-epidermal basement membrane zone of human skin. Type XVII collagen is a transmembrane protein in type 2 topography; that is, the amino-terminal end is intracellular, whereas the carboxy-terminal ectodomain is in the extracellular space.[27] The ectodomain consists of 15 collagenous domains with the characteristic repeating Gly-X-Y sequences that form triple helices.[28] These collagenous domains are separated by non-collagenous segments of variable sizes, and consequently type XVII collagen is a protein characterized by alternating collagenous and non-collagenous segments.[27] The type XVII collagen gene was mapped to the long arm of human chromosome 10. This location is distinct from any previously mapped collagens and also distinguishes BPAG2 from BPAG1, the 230-kd bullous pemphigoid antigen, which has been mapped to the short arm of chromosome 6.[29] The importance of the type XVII collagen was also shown by mutations in the corresponding gene *(COL17A1)* that underlie a nonlethal variant of junctional epidermolysis bullosa, generalized atrophic benign epidermolysis bullosa (see Chap. 60).[27,30] These patients have protracted, lifelong blistering of the skin, atrophic scarring, alopecia, and nail dystrophy.

Collagen Gene Structure

The collagen genes, like most eukaryotic genes, are large, multiexon genes interrupted at several points by noncoding DNA sequences called *introns*.[31] Thus, the prototypic eukaryotic gene coding for a protein is much larger than would be predicted from the amino acid sequences of the final protein. An example of the complexity of collagen genes is the intron-exon organization of the type VII collagen gene *(COL7A1)* (Fig. 61-3), which consists of 118 exons, one of the largest numbers in any published gene.[32]



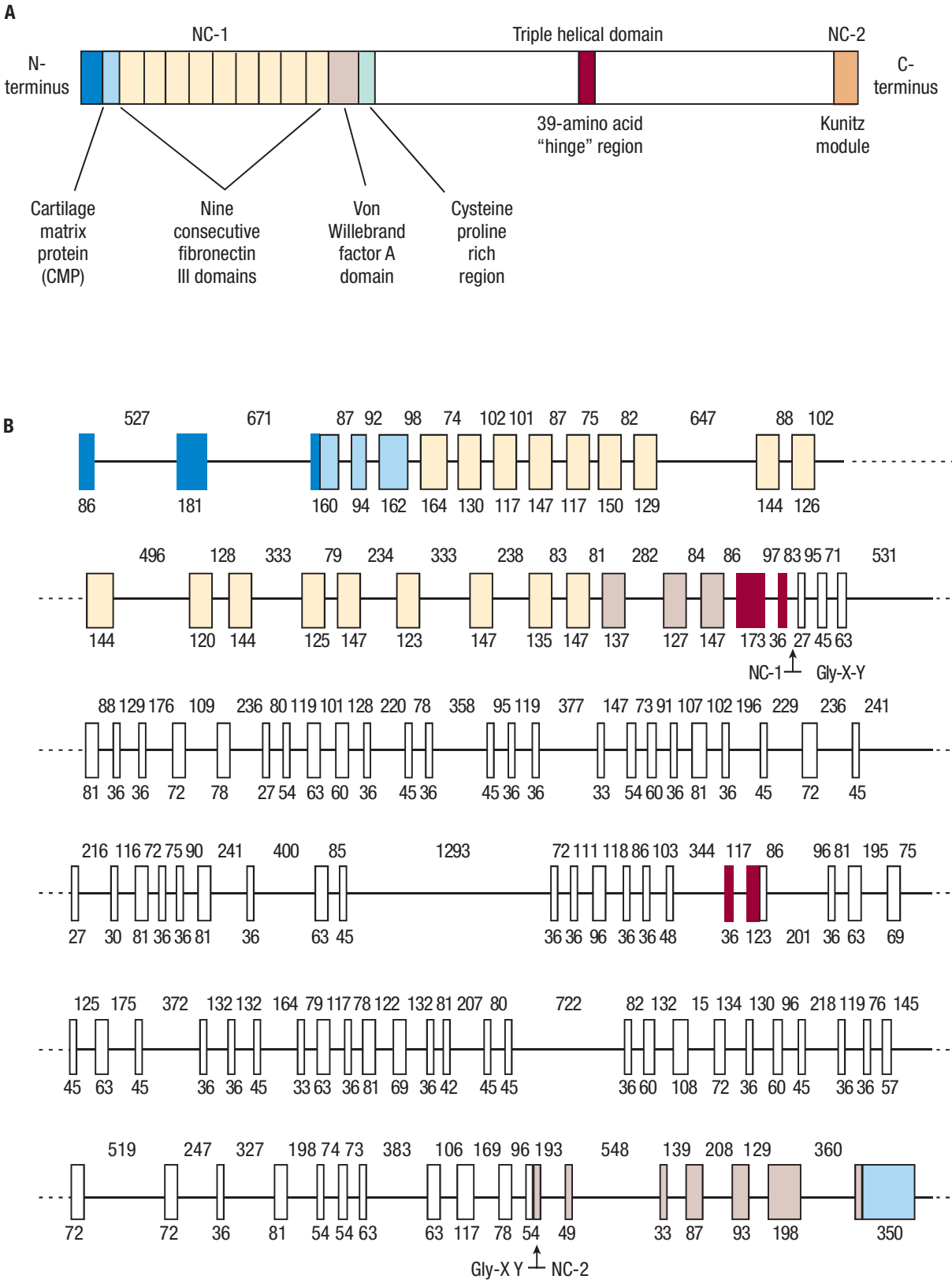

▲ **FIGURE 61-3** Structural organization of the type VII collagen polypeptide, the α1(VII) chain, as deduced from molecular cloning, and the intron-exon organization of the corresponding gene, *COL7A1*. **A.** The α1(VII) polypeptide consists of a triple-helical domain that contains imperfections or interruptions in the Gly-X-Y repeat sequence, including a 39–amino acid "hinge" region. The central collagenous domain is flanked by non-collagenous segments, the amino-terminal NC-1 domain, and the carboxyl-terminal NC-2 domain. The NC-1 domain consists of submodules with homology to known adhesive proteins, as indicated below the molecule. The NC-2 domain has a segment of homology with the Kunitz proteinase inhibitor molecule. **B.** The type VII collagen gene consists of a total of 118 exons (*vertical blocks*), which are separated from each other by intervening noncoding intronic sequences (*horizontal lines*). The sizes (in base pairs) of the introns (above the lines) and the exons (*below the blocks*) are indicated. Gly = glycine. [Modified from Christiano AM et al: Structural organization of the human type VII collagen gene (COL7A1), composed of more exons than any previously characterized gene. *Genomics* **21**:169, 1994, with permission.]

During the early stages of gene expression, the entire gene is transcribed into a high-molecular-weight precursor messenger RNA (mRNA), which is a complementary copy of the coding strand of the double-helical DNA. The precursor mRNA undergoes post-transcriptional modifications, such as capping and polyadenylation, and the introns are removed by splicing to yield a linear, uninterrupted coding sequence with 5′ and 3′ untranslated flanking regions. The mature mRNA is then transported into the cytoplasm and translated in cells, such as dermal fibroblasts, to the corresponding polypeptide.

With few exceptions, the collagen genes are widely scattered throughout the human genome.[1] For example, the genes coding for the two constituent polypeptide chains of type I collagen, α1(I) and α2(I), are located on separate chromosomes, 17 and 7, respectively. Knowledge of the precise chromosomal location of the genes coding for collagens in human skin has allowed identification of polymorphic markers within the genes and in the flanking DNA for use in genetic linkage studies. In addition, sophisticated mutation detection strategies, based on scanning of the genes, have led to identification of a large number of mutations in different collagen genes with characteristic phenotypic consequences.[1]

Translation of Collagen Polypeptides

Under physiologic conditions, fibril-forming collagen molecules spontaneously assemble into insoluble fibers. This observation presented a logistic problem, because it was difficult to visualize how a collagen molecule could be synthesized inside the cell and then secreted into the extracellular space without premature assembly of the molecules into insoluble fibers. The solution to this problem was found in the demonstration that collagen is initially synthesized as a larger precursor molecule, procollagen, that is soluble under physiologic conditions.

The precursor polypeptides of procollagen, so-called *pre-proα chains*, are synthesized on the ribosomes of the rough endoplasmic reticulum in fibroblasts and related cells (Fig. 61-4). This initial translation product, the pre-proα chain, contains an amino-terminal signal (or leader) sequence, a characteristic feature of many secreted proteins. The signal sequence is rich in hydrophobic amino acids and probably serves as a signal for attachment of the ribosomes to the membranes of the rough endoplasmic reticulum and vectorial release of the nascent polypeptides into the cisternae of the rough endoplasmic reticulum. During the transmembrane transport of the polypeptides, the signal sequence is enzymatically removed in a reaction catalyzed by signal peptidase (Table 61-2). The polypeptides released inside the lumen of the rough endoplasmic reticulum are termed *proα chains* and are larger than collagen α chains because they contain additional peptide sequences at both ends of the molecule. These non-collagenous extension peptides are different from the collagenous portion of the molecule in that they do not have glycine in every third position and often contain motifs homologous with sequences found as building blocks in other extracellular matrix proteins, such as the fibronectin III domain, von Willebrand factor A domain, and thrombospondin N-terminal domain sequences. It should be noted that, in spite of their homology, these domains do not have the functional characteristics of the original proteins.

Post-Translational Modifications of Polypeptide Chains

After the assembly of amino acids into pre-proα chains on the ribosomes, the polypeptides undergo several modifications before the completed collagen molecules are deposited into extracellular fibers (see Fig. 61-4). Most of these modification reactions are catalyzed by specific enzymes, and many of the modifications are characteristic of the biosynthesis of collagen (Tables 61-2 and 61-3). The post-translational modification reactions of collagen include (1) synthesis of hydroxyproline by hydroxylation of selected prolyl residues; (2) synthesis of hydroxylysine by hydroxylation of selected lysyl residues; (3) attachment of carbohydrates, galactose or glucosylgalactose, onto certain hydroxylysyl residues; (4) chain association, disulfide bonding, and triple-helix formation; (5) proteolytic conversion of procollagen to collagen; and (6) fiber formation and cross-linking. Current evidence indicates that modification reactions (1) to (4) are intracellular events, whereas proteolytic conversion, fiber formation, and cross-linking probably take place extracellularly (see Fig. 61-4).

SYNTHESIS OF HYDROXYPROLINE A characteristic feature of collagen is the presence of relatively large amounts of hydroxyproline (Fig. 61-5). Small amounts of hydroxyproline are also found in elastin, as well as in some proteins in which the collagenous domains are a minor portion of the molecule, such as acetylcholinesterase, the C1q component of the complement system, the macrophage scavenger proteins, and ectodysplasin A (see refs. 1, 6, and 7). The hydroxyproline in collagen is found in two isomeric forms. *Trans*-4-hydroxy-L-proline accounts for more than 95 percent of the total hydroxyproline in type I and type III collagens. The minor form is *trans*-3-hydroxy-L-proline, which is found in greater amounts in type IV collagen. A critical amount of *trans*-4-hydroxy-L-proline is a prerequisite for the folding of α chains into the triple helix, the conformation required for the normal secretion of procollagen molecules out of the cells (Fig. 61-6). Thus, in the absence of hydroxyproline, collagen polypeptides would not form the critical triple-helical structure under physiologic conditions, and no functional collagen fibers would appear in the extracellular space.

The hydroxyprolines are synthesized by hydroxylation of certain prolyl residues that are already in the newly produced collagen polypeptides (see Fig. 61-5). The formation of *trans*-4- and *trans*-3-hydroxy-L-proline is catalyzed by two separate enzymes—prolyl-4-hydroxylase and prolyl-3-hydroxylase, which both require molecular oxygen, ferrous iron, α-ketoglutarate, and a reducing agent, such as ascorbate as co-substrates or co-factors for the reactions (see Fig. 61-5 and Table 61-2).

The hydroxylation of appropriate prolyl residues begins while the proα chains are growing on the ribosomes, and the hydroxylation is completed soon after the release of full-length polypeptide chains from the ribosomes. The enzyme prolyl-4-hydroxylase has been localized to the rough endoplasmic reticulum (see Fig. 61-6). Prolyl hydroxylases do not hydroxylate prolyl residues if the collagen substrate is in a triple-helical conformation. Because triple-helix formation takes place in the cisternae of the rough endoplasmic reticulum hydroxyproline formation must be completed before the procollagen molecules leave this cellular compartment.

Prolyl hydroxylase requires a reducing agent, such as ascorbate, for its activity. Therefore, ascorbic acid deficiency leads to a decreased formation of collagen fibers. This explains some of the clinical manifestations in scurvy, such as poor wound healing and decreased tensile strength of



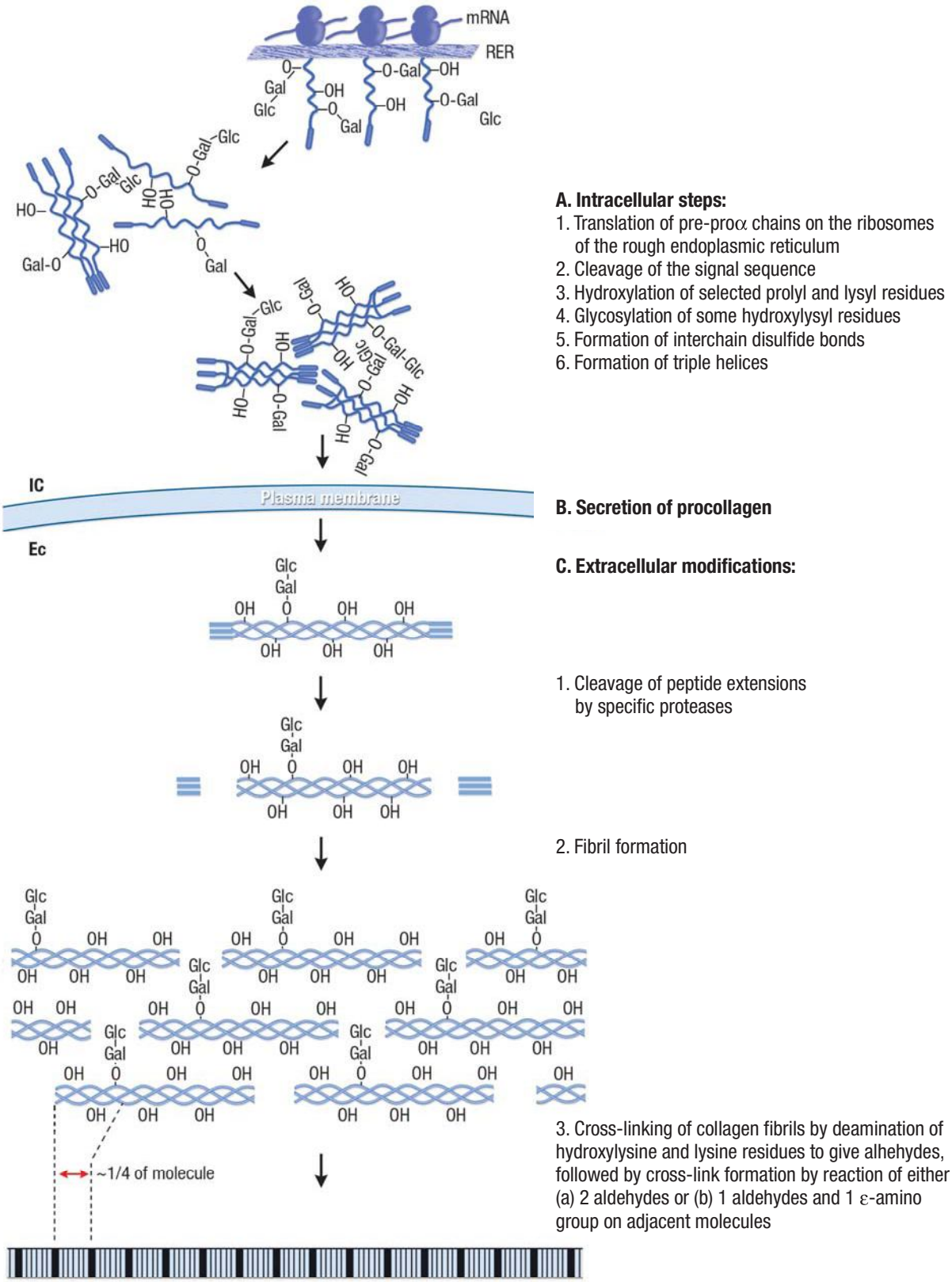

A. Intracellular steps:

1. Translation of pre-proα chains on the ribosomes of the rough endoplasmic reticulum
2. Cleavage of the signal sequence
3. Hydroxylation of selected prolyl and lysyl residues
4. Glycosylation of some hydroxylysyl residues
5. Formation of interchain disulfide bonds
6. Formation of triple helices

B. Secretion of procollagen

C. Extracellular modifications:

1. Cleavage of peptide extensions by specific proteases
2. Fibril formation
3. Cross-linking of collagen fibrils by deamination of hydroxylysine and lysine residues to give alhehydes, followed by cross-link formation by reaction of either (a) 2 aldehydes or (b) 1 aldehydes and 1 ε-amino group on adjacent molecules

▲ **FIGURE 61-4** Biosynthesis of procollagen and the assembly of collagen molecules into the extracellular fibers. EC = extracellular; Glc-Gal = glucosylgalactose attached to a hydroxy-lysyl residue; IC = intracellular; mRNA = messenger RNA; –OH = hydroxyl group of hydroxy-proline or hydroxylysine; RER = rough endoplasmic reticulum.

the connective tissues.[33] An analogous situation may exist in tissues with relative anoxia, because molecular oxygen is a specific requirement for the formation of hydroxyl groups in hydroxyproline. Studies in animal models demonstrate that wound healing is relatively poor under hypobaric conditions, and in such situations the low oxygen levels may limit the synthesis of hydroxyproline.[34] This observation may also explain the decreased healing tendency of wounds and ulcers in peripheral

TABLE 61-2
Characteristics of Enzymes Participating in the Biosynthesis of Collagen

Enzyme[a]	Substrate	Product	Co-Factors and Co-Substrates
Signal peptidase	Nascent pre-proα chains	Proα chains	None known
Prolyl-4-hydroxylase	Prolyl residue in X-Pro-Gly sequence in proα chains[b]	4-Hydroxyproline	O_2, Fe^{2+}, α-ketoglutarate, ascorbic acid
Prolyl-3-hydroxylase	Prolyl residue in Pro-Hyp-Gly sequence in proα chains[b]	3-Hydroxyproline	O_2, Fe^{2+}, α-ketoglutarate, ascorbic acid
Lysyl hydroxylase	Lysyl residue in Lys-Gly, Lys-Ser, or Lys-Ala sequence in proα chains[b]	Hydroxylysine	O_2, Fe^{2+}, α-ketoglutarate, ascorbic acid
Collagen galactosyl transferase	Hydroxylysine in proα chains[b]	Gal-*O*-hydroxylysine	Mn^{2+}, UDP-galactose
Collagen glucosyl transferase	Galactosyl-*O*-hydroxylysine in proα chains[b]	Glc-Gal-*O*-hydroxylysine	Mn^{2+}, UDP-glucose
Protein disulfide isomerase[c]	Cysteine residues in the extensions of proα chains	S-S bonds stabilizing the correct protein conformation	Thiols
Procollagen N-proteinase (ADAMTS-2)	Procollagen or p_n-collagen	P_c-collagen or collagen[d]	Ca^{2+}
Procollagen C-proteinase	Procollagen p_c-collagen	P_n-collagen or collagen[d]	Ca^{2+}
Lysyl oxidases	Lysyl or hydroxylysyl residue in fibrillar collagen	Aldehyde derivatives of lysine or hydroxylysine	Cu^{2+}, O_2

ADAMTS = a disintegrin and metalloprotease with thrombospondin motifs; Ala = alanine; Gal = galactose; Glc = glucosyl; Gly = glycine; Hyp = hydroxyproline; Lys = lysine; p_c-collagen = collagen molecule with the C-terminal propeptide still attached whereas the N-propeptide has been removed; p_n-collagen = collagen molecule with the N-terminal propeptide still attached whereas the C-propeptide is cleaved off; Pro = proline; Ser = serine; UDP = uridine diphosphate.
[a]The action of these enzymes (with the exception of signal peptidase) is relatively specific to collagen; the complete sequences of procollagen synthesis and collagen degradation involve additional, less-specific enzymes, such as those of transcription and translation.
[b]These reactions are terminated when the proα chains fold into the triple-helical conformation.
[c]It has not been established whether the formation of interchain disulfides in procollagen involves enzymatic catalysis, as occurs in some other proteins, or whether their synthesis takes place spontaneously.
[d]If intact procollagen is used as a substrate, partially modified products are formed; however, if the partially cleaved proteins (p_n-collagen, p_c-collagen) serve as substrates, collagen is produced.



tissues that are anoxic due to relatively poor blood supply.

SYNTHESIS OF HYDROXYLYSINE Hydroxylysine is another amino acid characteristic of collagen (Fig. 61-7). During the intracellular synthesis of procollagen, hydroxylysine serves as an attachment site for the sugar residues and is critical to the formation of cross-links that stabilize the extracellular collagen matrix. Free hydroxylysine is not incorporated into nascent polypeptide chains, but certain lysyl residues in peptide linkages are converted to hydroxylysine. The hydroxylation reaction is catalyzed by an enzyme, lysyl hydroxylase, that, like the prolyl hydroxylases, requires oxygen, Fe^{2+}, α-ketoglutarate, and ascorbate as co-factors and co-substrates. The critical importance of lysyl hydroxylation of collagen can be seen from the effects of the deficiency of lysyl hydroxylase in patients with the scoliotic form (type VI) of Ehlers-Danlos syndrome, characterized by hyperextensible skin, loose-jointedness, severe kyphoscoliosis, and ocular fragility.

GLYCOSYLATION Collagen is a glycoprotein that contains galactosyl and glucosylgalactosyl residues attached to the molecule. These residues are attached to collagen polypeptides during intracellular biosynthesis in a sequential manner, so that a galactosyl residue is first added to the molecule and then a glucose moiety is attached to some of the galactosyl residues (see Figs. 61-4 and 61-5). The link between the carbohydrate unit and the polypeptide is an *O*-glycosidic bond through the hydroxyl group of hydroxylysine. Therefore, the synthesis of hydroxylysine is a prerequisite for the glycosylation of collagen. The two glycosylation reactions are catalyzed by separate, specific enzymes called *collagen galactosyl transferase* and *collagen glucosyl transferase* (see Table 61-2). These enzymes have been extensively purified from a variety of sources. Both of them use uridine diphosphate sugars as a source of the carbohydrate and require Mn^{2+} as a co-factor. Not only are sugars attached to the hydroxylysyl residues in the triple-helical portion of the molecule, but the nonhelical extension peptides contain complex carbohydrates, consisting mainly of mannose. The function of the sugar residues in collagen and also in the extension peptides is not known.

Chain Association, Disulfide Bonding, and Triple-Helix Formation

A critical step in the intracellular biosynthesis of procollagen is the association of three proα chains and subsequent folding of the collagen portion of the polypeptides into a triple helix (see Fig. 61-6). The non-collagenous peptide extensions on the individual proα chains assume globular conformations soon after their translation, and this conformation contains the specific information that directs the correct association of the three proα chains. Such a mechanism might explain the association of proα1 and proα2 chains in a proper 2:1 ratio during the synthesis of type I procollagen. It would also explain the rapid and efficient association of the proα chains and folding of the molecule into the triple helix. The association of the extensions at the carboxyl-terminal ends of the polypeptide chains appears to facilitate folding of the molecules into the triple helix, perhaps by providing a nucleation site from which the formation of the triple helix is propagated throughout the collagenous portion of the molecule.

TABLE 61-3
Major Steps in the Biogenesis and Degradation of Collagen and Their Functional Significance

STEP[a]	FUNCTIONAL SIGNIFICANCE
I. Expression of genes coding for collagen polypeptides	
a. Gene selection	Determines the collagen isotype to be synthesized
b. Transcription	Formation of mRNA precursor
c. Processing of mRNA precursor	Formation of functional mRNA
d. Translation	Assembly of polypeptide chains
e. Control of the rate of transcription, mRNA processing, or translation	Determines the amount of polypeptide synthesized
II. Intracellular co-translational and post-translational modifications	
a. Removal of the signal sequence	May be necessary for secretion
b. Synthesis of 4-hydroxyproline	Stabilization of triple helix
c. Synthesis of 3-hydroxyproline	Unknown
d. Synthesis of hydroxylysine	Stabilization of covalent cross-links; attachment site for glycosylation
e. Synthesis of hydroxylysine-*O*-glycosides	May influence cross-link formation and determine the morphology and stability of the fibers
f. Glycosylation of the extension peptides	Unknown
g. Degradation of nonhelical chains	Removal of defective polypeptides and modulation of collagen production
h. Chain association and disulfide bonding	Facilitation of triple-helix formation
i. Triple-helix formation	Prerequisite for proper secretion
III. Secretion	Transport of procollagen through Golgi apparatus to the extracellular space
IV. Extracellular modifications	
a. Removal of the extension peptides from procollagen	Necessary for fiber formation
b. Deamination of certain lysine and hydroxylysine residues	Necessary for cross-link formation
c. Nonenzymatic glycosylation	May interfere with fiber formation
V. Fiber formation	
a. Alignment of the molecules	Formation of microfibrils
b. Formation of cross-links	Stabilization of the fiber structures
c. Supramolecular assembly	Architectural organization of collagen in tissues
d. Interactions with other extracellular macromolecules	Determine the physiologic properties of tissues
VI. Extracellular degradation	
a. Cleavage by specific collagenases	Rate-limiting step in degradation
b. Further degradation by peptidases and enzymes metabolizing free amino acids	Removal of degradation products

mRNA = messenger RNA.
[a]These are the major steps in the sequence in which they are likely to occur under physiologic conditions in vivo; however, some of the reactions can occur simultaneously or in reverse order.

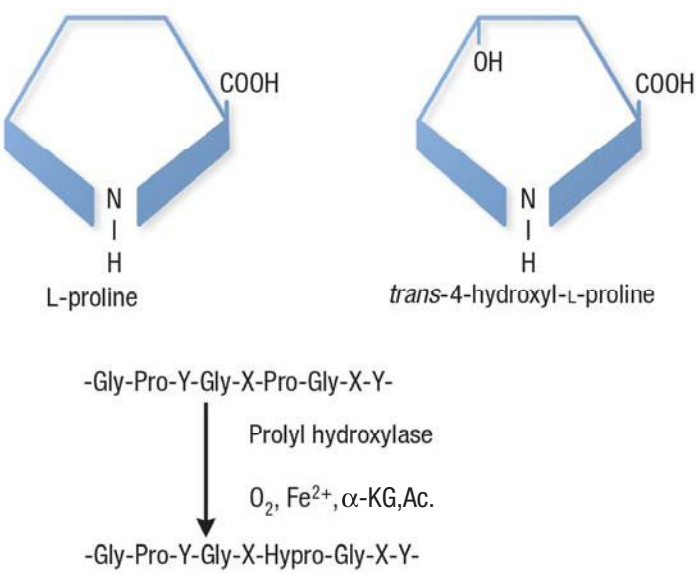

◀ **FIGURE 61-5** Structures of proline (Pro) and hydroxyproline (Hypro), and schematic representation of the enzymatic hydroxylation of prolyl residues in the Y position of the repeating Gly-X-Y sequence of collagen polypeptides. Ac = ascorbic acid; Gly = glycine; α-KG = α-ketoglutarate. (From Uitto J, Prockop DJ: Inhibition of collagen accumulation by proline analogues: The mechanism of their action, in *Collagen Metabolism in the Liver*, edited by Popper H, Becker K. New York, Stratton Intercontinental, 1975, p 139, with permission.)

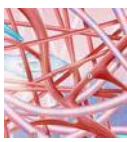

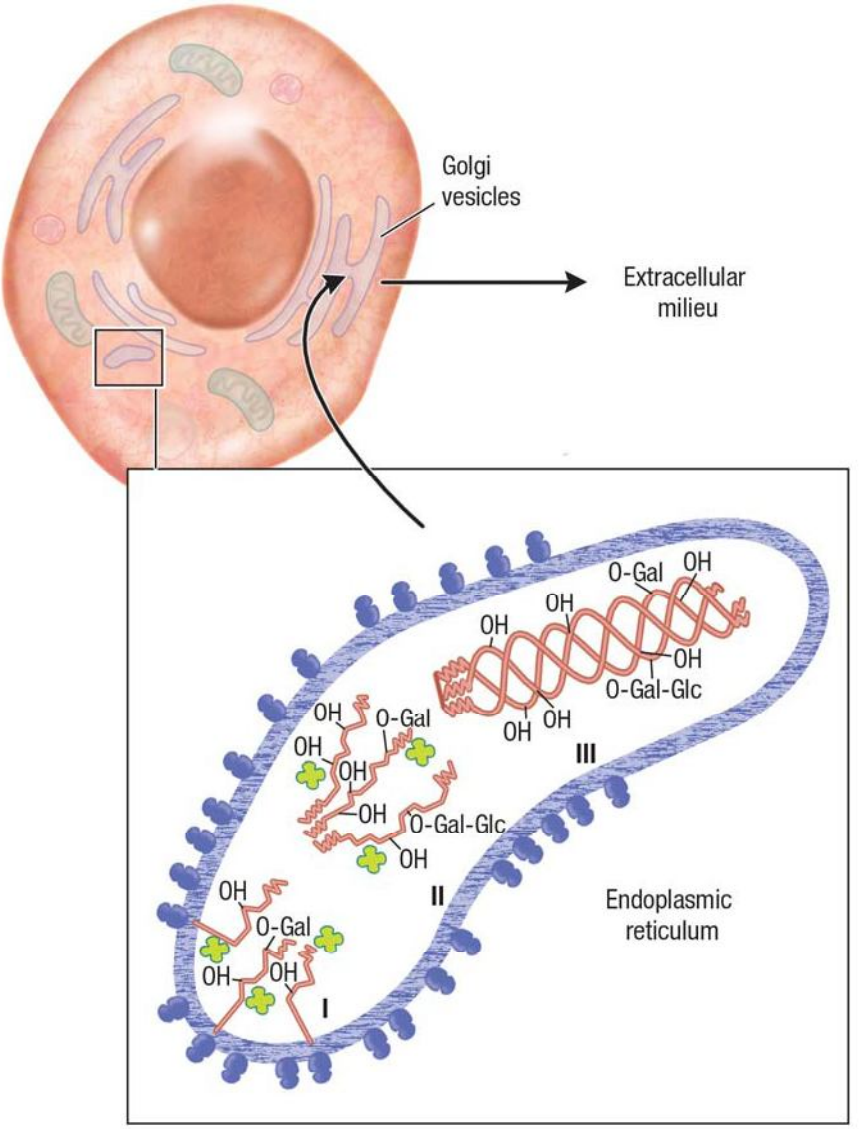

▲ **FIGURE 61-6** Representation of the synthesis and secretion of procollagen by a fibroblast. The enlarged area demonstrates events taking place in the rough endoplasmic reticulum of the cells during the synthesis of procollagen. In the first stage (I), the polypeptide chains of procollagen are synthesized on the membrane-bound ribosomes, and the nascent chains are fed into the cisternae of the rough endoplasmic reticulum. Hydroxylation of prolyl and lysyl residues and glycosylation of hydroxylysyl residues are initiated on the growing polypeptide chains, and these reactions are completed soon after release of full-size chains from ribosomes (II). Three proα chains are linked together by the formation of interchain disulfide bonds, and the collagenous portions of the polypeptides assume a triple-helical conformation (III). The procollagen molecules are then transferred from the rough endoplasmic reticulum to Golgi vesicles and are secreted from these vesicles into the extracellular milieu. –OH = hydroxyl groups of hydroxyproline and hydroxylysine; –Gal = galactosyl residue attached to hydroxylysine; –Gal-Glc = glucosylgalactosyl residue attached to hydroxylysine in O-glycosidic linkage; the cloverleaf-like structures signify the hydroxylating and glycosylating enzymes. (After Prockop DJ et al: Intracellular steps in the biosynthesis of collagen, in *Biochemistry of Collagen*, edited by Ramachandran GN, Reddi AH. New York, Plenum, 1976, p 163, with permission.)

Conversion of Procollagen to Collagen

After secretion into the extracellular space, procollagen molecules are converted to collagen by limited proteolysis, which removes the extension peptides on the molecule.[35] The conversion of type I procollagen to collagen is catalyzed by two specific enzymes, procollagen N-proteinase and procollagen C-proteinase, that separately remove the amino-terminal and carboxyl-terminal extensions, respectively (see Table 61-2). Furthermore, the N-proteinase catalyzing the conversion of type III procollagen to collagen is a separate, specific enzyme.

The N-proteinase capable of cleaving type I procollagen belongs to the ADAMTS (a disintegrin and metalloprotease with thrombospondin motifs) family of extracellular proteases, and is specifically ADAMTS-2.[36,37] The activity of this enzyme is dependent on the native conformation of the amino-terminal propeptides in procollagen, because it does not catalyze the removal of the extension peptides from isolated proα chains. Furthermore, partially purified N-proteinase is inhibited by metal chelators, which suggests a requirement for divalent cations.

C-proteinase is required for removal of the carboxyl-terminal extension from types I, II, III, and V procollagens, which allows the fully processed molecules to form functional fibers.[35] Cloning of type I procollagen C-proteinase revealed that it is identical to bone morphogenic protein-1, a metalloprotease implicated in pattern formation during development of diverse organisms and also capable of inducing ectopic bone formation.[38,39] The activity of C-proteinase/bone morphogenic protein-1 is stimulated by procollagen C-proteinase enhancers, glycoproteins that bind to the C-terminal propeptide of type I procollagen.[40,41] Thus, the conversion of procollagen to collagen is a complex, carefully controlled process, and lack of removal of either the amino- or the carboxyl-terminal extensions results in impaired tensile strength of collagen fibers in the skin. Specifically, deficiency in the removal of the amino-terminal propeptide of type I collagen in vivo causes dermatosparaxis, a disease of fragile skin, originally recognized in various animal species, and more recently recognized in humans.[42,43] Specifically, the human counterpart is the dermatosparaxis type of Ehlers-Danlos syndrome (type VIIc), caused by deficiency in N-proteinase activity. It should be noted that a phenotypically similar disease, the arthrochalasia type of Ehlers-Danlos syndrome (types VIIa and VIIb), can be caused by mutations in the type I collagen genes (COL1A1 or COL1A2, respectively) at the cleavage site for the N-proteinase.[44]

Fiber Formation and Cross-Linking

After removal of the extension peptides in the extracellular space, the collagen molecules spontaneously align to form fibers. These fibers, however, do not attain the necessary tensile strength until

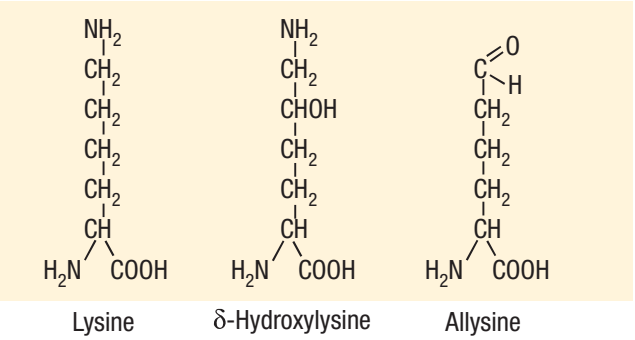

▲ **FIGURE 61-7** Structures of lysine, hydroxylysine, and allysine, the aldehyde derivative of lysine. (From Uitto J, Lichtenstein JR: Defects in the biochemistry of collagen in diseases of connective tissue. *J Invest Dermatol* **66**:59, 1976, with permission.)

the molecules are linked together by specific covalent bonds known as *cross-links*.[45] The most common forms of cross-links in collagen are derived from lysine or hydroxylysine. The first step in the cross-linking of collagen is the enzymatic conversion of some of the lysyl and hydroxylysyl residues to corresponding aldehyde derivatives by removal of the epsilon-amino groups (see Figs. 61-4 and 61-6). The aldehydes then form cross-links by two kinds of reactions. One reaction involves condensation of an aldehyde with an epsilon-amino group still present in another unmodified lysine or hydroxylysine to form a Schiff base–type of covalent cross-link (Fig. 61-8). The second type of reaction is an aldol condensation between two aldehydes. In addition to these cross-links, collagen contains several more complex cross-links that also involve lysyl or hydroxylysyl residues. The lysine- and hydroxylysine-derived cross-links can be either intramolecular, occurring between two adjacent α chains in the same collagen molecule, or intermolecular, stabilizing the alignment of neighboring collagen molecules along microfibril structures.

The first step in collagen cross-linking, the oxidative deamination of certain lysyl and hydroxylysyl residues, is catalyzed by lysyl oxidase. This enzyme requires copper as a co-factor, and its activity is readily inhibited by nitriles, such as β-amino-propionitrile, which produce lathyrism in animals. Because the cross-links of collagen provide the tensile strength required in certain tissues, a defect in the formation of these covalent bonds can lead to a disturbance in connective tissue function. An example is occipital horn syndrome (previously known as *Ehlers-Danlos syndrome type IX*), which results from reduced lysyl oxidase activity (see Chap. 139). The primary defect resides in perturbed copper metabolism caused by mutations in a copper transport enzyme protein, an adenosine triphosphatase encoded by the gene MNK-1 that is also involved in Menkes syndrome.[46] As a result, serum copper levels are reduced, which leads to reduced lysyl oxidase activity.

Control of Collagen Production

A major question in collagen biology concerns the mechanisms that control the deposition of collagen in tissues. Such control must exist in vivo, because the consequences of uncontrolled collagen accumulation are demonstrated by diseases such as progressive systemic sclerosis and various other fibrotic conditions.[47]

The accumulation of collagen in tissues can be controlled at several different levels of biosynthesis and degradation. Several observations suggest that an important control mechanism acts at the level of mRNA formation through regulation of the transcriptional activity of gene expression.[48] The transcriptional regulation of collagen gene expression involves both *cis*-acting elements and *trans*-acting factors. The *cis*-acting elements are nucleotide sequences in the promoter region of the gene that serve as binding sites for *trans*-acting cellular proteins, which can upregulate or downregulate the transcriptional promoter activity. Some of the *trans*-acting factors are nuclear receptors, such as the retinoic acid receptors (RAR and RXR)[49] that form a complex with the ligand (a retinoid) and then bind to the retinoic acid–responsive elements (RARE) in the target gene. Retinoids, such as all-*trans*-retinoic acid, modulate type I collagen gene expression both in vitro and in vivo. In particular, quiescent nonproliferating cells can be stimulated by retinoic acid to activate collagen gene expression. This may have rele-

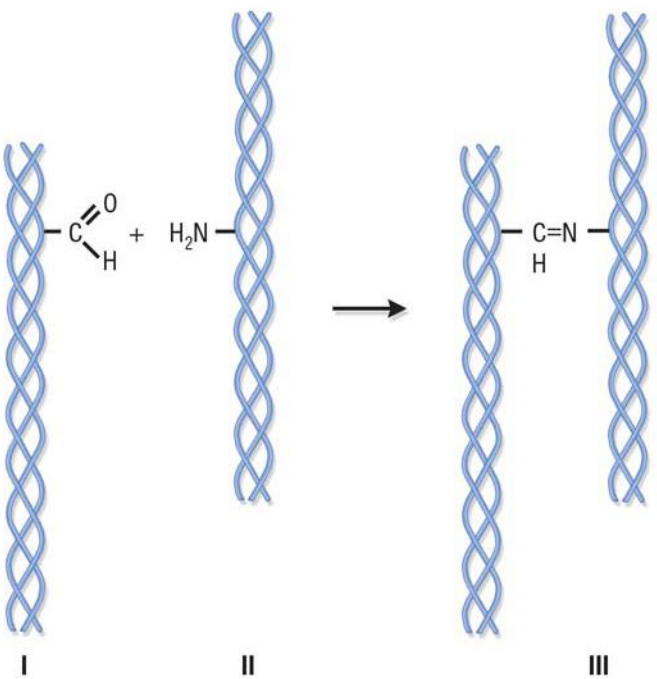

▲ **FIGURE 61-8** Representation of the formation of intermolecular cross-links of collagen. The cross-linking is initiated by oxidative deamination of either a lysyl or hydroxylysyl residue to form a corresponding aldehyde derivative (I). The aldehyde then reacts with an epsilon-amino group on an unmodified lysyl or hydroxylysyl residue in an adjacent collagen molecule (II), and they form a Schiff base–type covalent cross-link. (From Uitto J, Lichtenstein JR: Defects in the biochemistry of collagen in diseases of connective tissue. *J Invest Dermatol* **66**:59, 1976, with permission.)

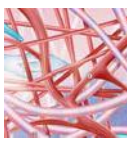

vance to the elevated collagen synthesis observed in photodamaged dermis after topical application of all-*trans*-retinoic acid (see Chap. 108).[50]

One of the most powerful modulators of connective tissue gene expression is transforming growth factor-β (TGF-β), a member of a family of growth factors that upregulate the expression of several extracellular matrix protein genes, including those encoding collagen types I, III, IV, V, VI, and VII.[51]

Degradation and Turnover

Extracellular matrix remodeling is a cooperative multi-step process involving localized degradation of the existing matrix components, followed by cytoskeletal rearrangement, cell translocation, and the deposition of new extracellular matrix components. Although each of these steps is controlled by a variety of molecular mechanisms, the initial step depends on the presence of proteinases capable of initiating the degradation of the matrix macromolecules. These enzymes comprise the matrix metalloproteinase (MMP) gene family,[52–54] which includes the collagenases, the gelatinases, the stromelysins, the matrilysins, metalloelastase, enamelysin, and the membrane-type MMPs (Fig. 61-9 and Table 61-4).

Interstitial collagenase (MMP-1) was the first enzyme of the MMP family to be discovered and was defined by its ability to break down triple-helical collagen that is resistant to most proteases. Human skin collagenase was initially isolated in active form from culture medium of skin explants[55] and subsequently as a proenzyme from monolayer fibroblast cultures.[56] Many other cell types, including keratinocytes, synovial cells, and monocytes-macrophages, express an identical enzyme. Interstitial collagenase, like the other MMPs, contains intrinsic zinc in the active site and requires calcium for its activity and thermostabilization.

Interstitial collagenase degrades collagen types I, II, III, VII, and X (but does not degrade collagen type IV and V). At physiologic pH and temperature the enzyme catalyzes a single cleavage three-quarter of the distance from the amino terminus in each of the three polypeptide chains comprising the triple-helical, native collagen monomer. Collagenase specifically cleaves the α1(I) chains at a Gly-Ile (glycine-isoleucine) bond (residues 775 and 776) and the α2(I) chain at a Gly-Leu (glycine-leucine) bond in the homologous region. Ten other Gly-Ile or Gly-Leu bonds within the triple-helical domain of the interstitial collagens are not cleaved, which suggests that the local conformation of the collagenase cleavage site is a major factor in determining substrate specificity. This region is more hydrophobic than other parts of the collagen molecule and lacks hydroxyproline residues that stabilize the triple helix. Indeed, human fibroblast collagenase catalyzes multiple cleavages in the denatured chains of all collagen types at Gly-Ile and Gly-Leu bonds. Thus it appears that the triple helix of native collagen can drastically alter the ability of human fibroblast collagenase to catalyze cleavages that would be permissible from primary sequence consideration alone. Moreover, even under optimal conditions of cleavage, collagen degradation by human fibroblast collagenase proceeds slowly for an enzymatic process, with a turnover number of approximately 25 molecules of fibrillar collagen degraded per molecule of collagenase per hour.

Human neutrophil interstitial collagenase (MMP-8) attacks collagens at the same site as does fibroblast collagenase to produce the characteristic three-quarter/one-quarter collagen fragments. The cloned enzyme is highly homologous to fibroblast collagenase but has a molecular mass of 75 kd due to a high degree of glycosylation. It is not immediately secreted but is stored in neutrophil granules and released on stimulation. Although both fibroblast and neutrophil collagenases have similar affinities for types I and III collagen, fibroblast collagenase degrades soluble type III collagen with a higher turnover rate, whereas neutrophil collagenase degrades soluble type I collagen more rapidly.[56] For both enzymes, the differences in specificity against monomeric collagens are largely abolished when the substrates are reconstituted into the insoluble fibrillar forms found in tissues.

Important mechanistic information on collagen degradation has recently emerged, and specifically, it has been shown[57] that activated collagenase (MMP-1) moves processively on collagen fibrils in which the mechanism of movement is a biased diffusion with the biased component of the motion depending on the proteolysis of collagen and not on ATP hydrolysis. Most importantly, the closely related matrix metalloproteinases, MMP-2 (gelatinase), MMP-9, and the extracellular portion of the membrane associated metalloproteinase, MT1-MMP can also diffuse on collagen fibrils. These studies also show that a collagenolytic MT1-MMP complex exists at the cell surface. The MT1-

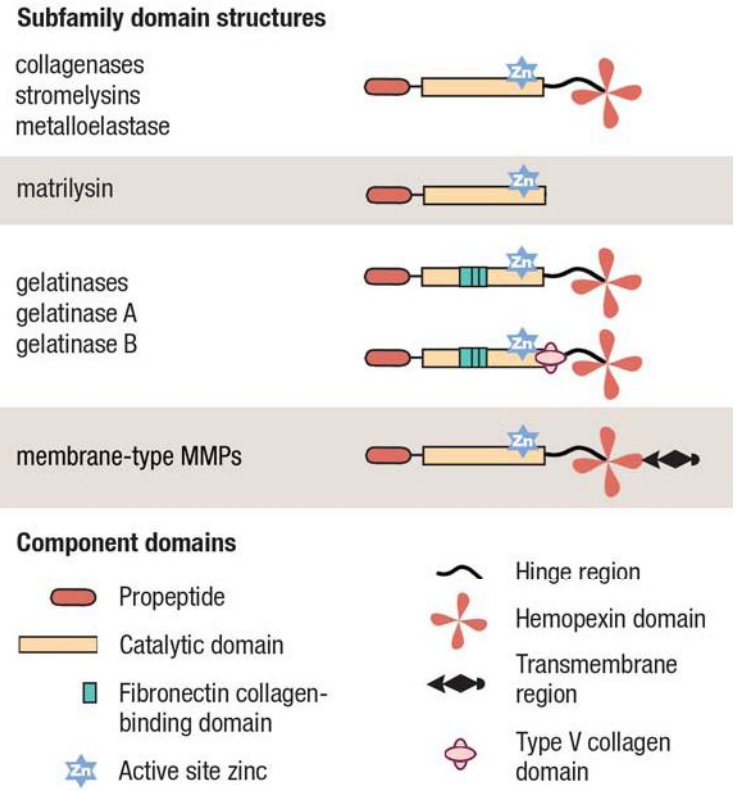

▲ **FIGURE 61-9** Domain structure of matrix metalloproteinases (MMPs).

TABLE 61-4
Matrix Metalloproteinases (MMPs)

Enzyme	MMP Number	Alternate Name	Proenzyme Molecular Weight	Known Matrix Substrates
Interstitial collagenase	MMP-1	Type I collagenase	52,000	Collagens I, II, III, VII, VIII, X, entactin, tenascin, aggrecan, denatured collagens, interleukin-1β, myelin basic protein, L-selectin
Neutrophil collagenase	MMP-8	—	75,000	Collagens I, II, III, V, VII, VIII, X, gelatin, aggrecan, fibronectin
Collagenase-3	MMP-13	—	52,000	Collagens I, II, IV, IX, X, XIV, aggrecan
Gelatinase A	MMP-2	72-kd type IV collagenase	72,000	Denatured collagens, collagens IV, V, VII, X, XI, XIV; collagen I, species dependent; elastin; fibronectin; laminin; aggrecan; myelin basic protein
Gelatinase B	MMP-9	92-kd type IV collagenase	92,000	Denatured collagens, collagens IV, V, VII, X, XIV, elastin, entacin, aggrecan, fibronectin, osteonectin, interleukin-1β, plasminogen, myelin basic protein
Stromeylsin-1	MMP-3	Proteoglycanase	57,000	Proteoglycan core protein, laminin, fibronectin, collagens I, IV, V, IX, X, XI, gelatin, elastin, tenascin, aggrecan, myelin basic protein, entactin, decorin, osteonectin
Stromelysin-2	MMP-10	Transin-2	55,000	Proteoglycan core protein, collagens III, IV, V, laminin, fibronectin, elastin, aggrecan
Stromelysin-3	MMP-11	—	61,000	α1-proteinase inhibitor
Matrilysin	MMP-7	PUMP, matrilysin-1	28,000	Collagen IV, denatured collagens, laminin, fibronectin, elastin, aggrecan, tenascin, myelin basic protein
Matrilysin-2	MMP-26	Endometase	28,000	Gelatin, α1-proteinase inhibitor
Membrane-type MMP-1	MMP-14	MTI-MMP	63,000	Progelatinase A, denatured collagen, fibronectin, laminin, vitronectin, entactin, proteoglycans
Membrane-type MMP-2	MMP-15	MT2-MMP	72,000	Progelatinase A
Membrane-type MMP-3	MMP-16	MT3-MMP	64,000	Progelatinase A
Membrane-type MMP-4	MMP-17	MT4-MMP	70,000	Unknown
Membrane-type MMP-5	MMP-24	MT5-MMP	73,000	Progelatinase A
Membrane-type MMP-6	MMP-25	MT6-MMP	63,000	Unknown
Metalloelastase	MMP-12	—	54,000	Elastin, collagen IV, vitronectin, plasminogen, laminin, entactin, fibrinogen, fibrin, fibronectin
Enamelysin	MMP-20	—	54,000	Amelogenin, aggrecan
MMP-19	MMP-19	RASI-1	57,000	Gelatin, aggrecan, fibronectin
MMP-21	MMP-21	—	Unknown	Unknown
MMP-22	MMP-22	—	Unknown	Unknown
MMP-23	MMP-23	—	44,000	Unknown
Epilysin	MMP-28	—	56,000	Unknown

PUMP = punctuated metalloproteinase.

MMP complex anchored at the cell surface has profound implications concerning the generation of the forces required for cell locomotion, not only in the normal physiologic processes of tissue remodeling but also in pathologic processes, such as tumor invasion.

Collagenase-3 (MMP-13), first cloned from breast carcinoma, is homologous to rodent collagenase. The purified recombinant enzyme cleaves triple-helical collagens, giving the characteristic three-quarter/one-quarter fragments. Unlike interstitial and neutrophil collagenases, however, collagenase-3 acts 5 to 10 times more rapidly on soluble type II collagen, a cartilage-specific collagen, than on types I and III. Because of its preferential cleavage of type II collagen, and because it is made by both normal and osteoarthritic chondrocytes, collagenase-3 is thought to play an important role in osteoarthritis.

At physiologic temperature, the collagen cleavage products (i.e., the three-quarter/one-quarter fragments), which are initially triple helical, become soluble, are thermally unstable, and denature spontaneously, forming gelatin (denatured collagen). These denatured gelatin polypeptides are then susceptible to attack by other proteinases. Thus, the interstitial collagenases stand at a key point in connective tissue metabolism: They initiate the proteolytic events that result in the degradation of collagen and overall turnover of the extracellular matrices.

Collagen Diseases

The term *collagen disease* implies that a clinical condition involves an abnormality in the structure, synthesis, or degra-

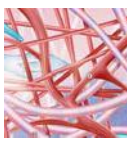

dation of collagen. This term is frequently used to characterize a clinically heterogeneous group of inflammatory diseases, including lupus erythematosus, scleroderma, and dermatomyositis. In the classic nomenclature, the use of the term in these diseases was based on morphologic changes, known as *fibrinoid degeneration*, that have been interpreted to represent changes in collagen fibers. However, there is currently no conclusive evidence that fibrinoid degeneration of collagen fibers is indicative of a primary defect in collagen. On the basis of available biochemical evidence, scleroderma is the only clinical condition among the classic collagen diseases that involves any detectable abnormality in the structure or metabolism of collagen (see also Chaps. 62 and 158).



Collagen is an unusual protein in many respects, and its structure and metabolism involve a number of special features that are critical for deposition of normal collagen fibers. Based on our understanding of the biochemistry of normal collagen, it is now possible to identify discrete points at which defects could be introduced into collagen molecules or mature fibers. In a primary collagen disease, such a defect could be an inherited abnormality in the structure of the collagen or procollagen or in the enzymes participating in the biosynthesis and degradation of collagen.[1] In a secondary, acquired type of collagen disease, changes in collagen may be a consequence of initially unrelated metabolic changes. According to these definitions, several clinical disorders that are true collagen diseases are currently known. Indeed, there are many diseases in which a basic biochemical defect in collagen has been described, and several heritable connective tissue diseases with cutaneous involvement are now known to result from specific molecular defects in collagen genes (Table 61-5; see Chap. 139). Many of these diseases involve insertions, deletions, or single-base substitutions in the genes that alter the primary structure of the protein. In several acquired diseases, the regulation of collagen gene expression is disturbed, which leads to altered deposition of collagen in tissues. The diversity of collagen pathology is exemplified by Ehlers-Danlos syndrome and fibrotic skin diseases (see Chaps. 139 and 158). Ehlers-Danlos syndrome comprises a group of phenotypically similar conditions that frequently result from abnormalities in the structure of collagen or in enzymes modifying collagen molecules. In contrast, the fibrotic skin diseases exemplify conditions with altered regulation of collagen gene expression that leads to excessive accumulation of collagen in tissues.

TABLE 61-5
Heritable Connective Tissue Diseases with Cutaneous Involvement

Disease	Inheritance	Mutated Genes[a]	Affected Protein
Ehlers-Danlos syndrome	AD, AR	COL1A1, COL1A2, COL3A1, COL5A1, COL5A2	α chains of types I, III, and V collagens
		PLOD1, PLOD2	Procollagen-lysine, 2-oxoglutarate 5-dioxygenase (lysyl hydroxylase)
		ADAMTS-2	Procollagen N-peptidase
		TNX	Tenascin-X
		B4GALT-7	Xylosylprotein 4-β-galactosyl-transferase
Osteogenesis imperfecta	AD, AR	COL1A1, COL1A2	α1 and α2 chains of type I collagen
Cutis laxa	AD, AR, XR[b]	ELN	Elastin
		MNK-1 (ATP7A)	ATP-dependent copper transporter
		FBLN4	Fibulin-4
		FBLN5	Fibulin-5
Homocystinuria	AR	CBS	Cystathionine β-synthase
Menkes syndrome	XR	MNK-1 (ATP7A)	ATP-dependent copper transporter
Focal dermal hypoplasia	XD	ND	
Tuberous sclerosis (shagreen patches)	AD	TSK-1	Hamartin 1
Familial cutaneous collagenoma	AD	ND	
Epidermolysis bullosa	AD, AR	COL7A1, COL17A1	α1 chains of types VII and XVII collagen

AD = autosomal dominant; AR = autosomal recessive; ATP = adenosine triphosphate; XD = X-linked dominant; XR = X-linked recessive; ND = not determined.
[a]For detailed discussion of these genes, see refs. 4 and 87.
[b]Most cases involve abnormalities in the elastic fibers, and in some cases, mutations in the elastin gene (ELN) have been disclosed. Occipital horn syndrome, a copper deficiency syndrome, allelic to the Menkes syndrome gene (MNK-1), was previously known as *X-linked cutis laxa* and also *Ehlers-Danlos syndrome type IX* (see Chap. 139).

ELASTIC FIBERS

Structure and Development of the Elastic Fibers

Elastic fibers of the connective tissue form a network responsible for the resilient properties of various organs.[58–60] The distribution of elastic fibers is variable in different tissues: their relative concentration is highest in the aorta and arterial blood vessels, but they are also abundant in the lungs. Elastic fibers are also present in the skin, although they are only a minor component (Fig. 61-10). Specifically, in sun-protected adult human skin, the elastin content is 1 percent to 2 percent of the total dry weight of dermis.[61] In the papillary dermis, elastic fibers are present either as bundles of microfibrils (oxytalan fibers) or with small amounts of cross-linked elastin (elaunin fibers). In the reticular dermis, the elastic fibers, which consist primarily of elastin, are oriented horizontally in a network with vertical extensions to the papillary dermis in the form of oxytalan fibers.

Examination of elastic connective tissues by transmission electron microscopy has demonstrated that mature elastic fibers consist of two distinct components (Fig. 61-11). The major component is a well-characterized connective tissue protein, elastin, and this amorphous, electron-lucent core, when visualized by transmission electron microscopy, is surrounded by distinct microfibrillar structures that have a regular diameter of 10 to 12 nm (see Fig. 61-11). The microfibrillar component is composed of a variety of proteins that have now been characterized.[58,60]

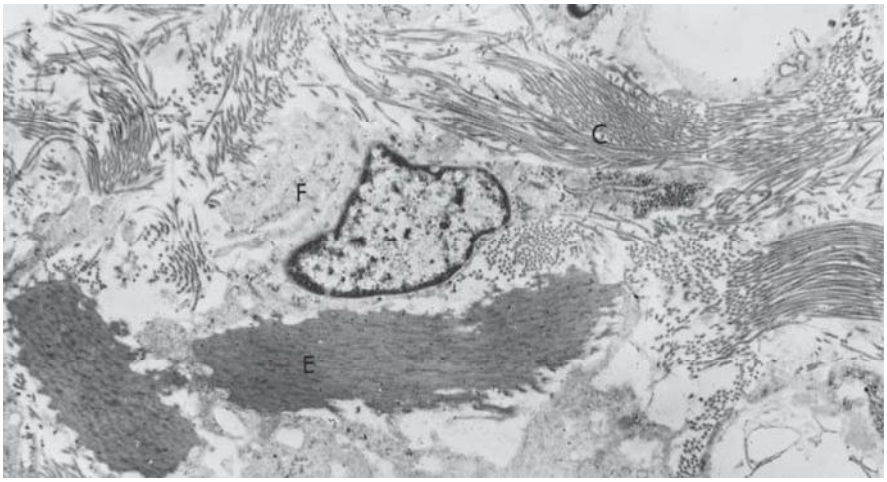

▲ **FIGURE 61-10** Transmission electron microscopy of human skin demonstrating a fibroblast (F) surrounded by elastic structures (E) and collagen fibers (C).

Elastin and the microfibrils exist in close association in various connective tissues; however, the relative proportions of these components vary during embryonic development. The first elements of elastic fibers that form during fetal development consist of bundles of microfibrils that can be visualized by electron microscopy early in the first trimester of gestation. It has been postulated that the microfibrils form a scaffold into which the elastin molecules align. During the second trimester, the elastic fibers remain relatively immature in structure and composition, but with increasing fetal age and maturation of the fibers, the amorphous elastin component becomes more prominent. Fully developed elastic fibers consist of a central amorphous core surrounded by an envelope of microfibrils, and electron microscopic estimations of the fully matured elastic fibers suggest that the elastin protein represents well over 90 percent of the total content of such fibers (see Fig. 61-11). It should be noted, however, that skin as well as other tissues contain microfibrils devoid of elastin.

Biology of the Elastic Fibers

ELASTIN ***Protein Structure.*** The fibers composed of elastin, when visualized by scanning electron microscopy, appear as amorphous, branching structures forming continuous sheets in some connective tissues (Fig. 61-12). The isolation and characterization of the basic polypeptide unit of elastin were hindered for a long time by the extreme insolubility of elastin in mature animal tissues. It was discovered, however, that this insolubility is attributable to the presence of complex covalent cross-links, known as *desmosines* (see Fibrillogenesis and Cross-Linking), whose formation can be prevented by maintaining the animals on a copper-deficient diet or by feeding them lathyrogens, such as β-aminopropionitrile, which inhibit elastin and collagen cross-linking. Once the formation of the cross-links is prevented, a large fraction of newly synthesized elastin can be extracted from the tissues. By these methods, large quantities of soluble elastin were initially purified from porcine aorta, and short peptide fragments were sequenced.[62] The precise amino acid sequence of human elastin has now been deduced from cloned complementary DNAs (cDNAs).[63,64]

The basic molecular unit of elastin is a linear polypeptide, known as *tropoelastin*, that consists of approximately 800 amino acids with a molecular mass of approximately 70 kd. The amino acid composition of elastin is similar to that of collagen in that about one-third of the total number of amino acid residues consist of glycine. However, glycine is not evenly distributed in elastin, as it is in a typical collagen sequence. Instead, the glycine residues are grouped in valine- and proline-rich regions, which are interspersed with alanine-rich sequences. Elastin also contains some hydroxyproline, but the relative content of this amino acid is considerably lower than that in collagen, and the values for hydroxyproline are variable. Elastin does not contain hydroxylysine or carbohydrate moieties covalently linked to the polypeptide chain.

A characteristic feature of elastic fibers is the presence of cross-links that covalently bind elastin polypeptide chains into a fiber network. The two major cross-link compounds, desmosine and its isomer, isodesmosine, are structures that appear to be unique to elastin[65] (Fig. 61-13). The content of desmosines in various elastin preparations has been shown to be fairly constant, approximately 1.5 residues per 1000 amino acids. Consequently, assay of desmosine and isodesmosine can provide a quantitative measure of the elastin content in tissues.[66]

Gene Structure. Cloning of cDNAs corresponding to the human elastin mRNA, approximately 3.5 kilobases (kb) in size, has allowed elucidation of the entire primary sequence of tropoelastin[64] (Fig. 61-14). The deduced amino acid sequence depicts alternating segments of cross-link domains, characterized by the presence of lysyl residues separated by two or three alanine residues, and hydrophobic domains. The cross-link domains and the hydrophobic regions are en-



▲ **FIGURE 61-11** Transmission electron microscopy of the elastic fibers in normal human skin. Elastin, the electron-lucent core of the fiber, is surrounded by thin, electron-dense microfibrils. (Original magnification ×16,000.)

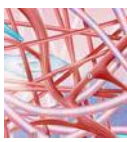

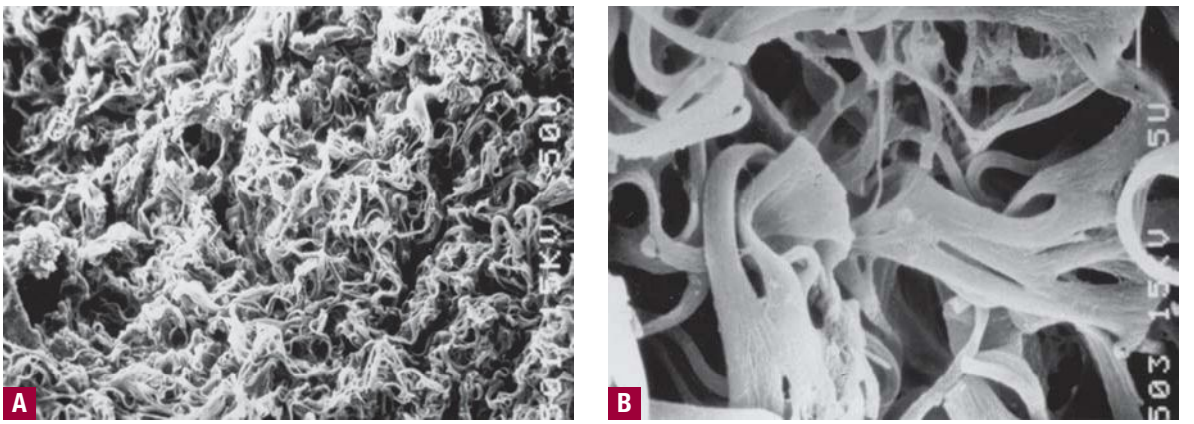

▲ **FIGURE 61-12** Scanning electron micrographs of the elastic fibers in human skin. (Original magnifications: **A.** ×2000. **B.** ×5000.)



coded by separate exons.[67] The human elastin gene consists of 34 separate exons spanning a total of 45 kb of genomic DNA (see Fig. 61-14).

Constitutive and Alternative Splicing. The information stored in the DNA sequence of the elastin gene is transcribed in the nucleus of the cells to a large mRNA precursor, which undergoes several post-transcriptional modifications, including splicing and polyadenylation. The processed molecules are then transported to the cytoplasm, where the functional mRNAs serve as templates for the synthesis of elastin polypeptides during translation. Several lines of evidence suggest that the rate of elastin biosynthesis is largely regulated by the abundance of the functional mRNA, and consequently, assay of elastin mRNA levels allows measurements of the rate of elastin biosynthesis in tissues and cells.

An early observation during the isolation of human elastin cDNAs was that several overlapping clones were identical, with the exception of short sequences that were absent in some clones but present in others.[63,64,68] Comparison of these sequences in the cDNAs with the corresponding genomic DNA segments indicated that the differences were due to alternative splicing of certain exons during post-transcriptional processing of the elastin pre-mRNA. In fact, at least six exons in the human gene have been reported to be subject to alternative splicing, and several of the variant mRNAs are translated into protein. This mechanism can provide significant variation in the amino acid composition of individual elastin polypeptides and presumably in the function of the elastic fibers in different tissues. However, the developmental significance and tissue specificity of alternative splicing has not been elucidated in detail.

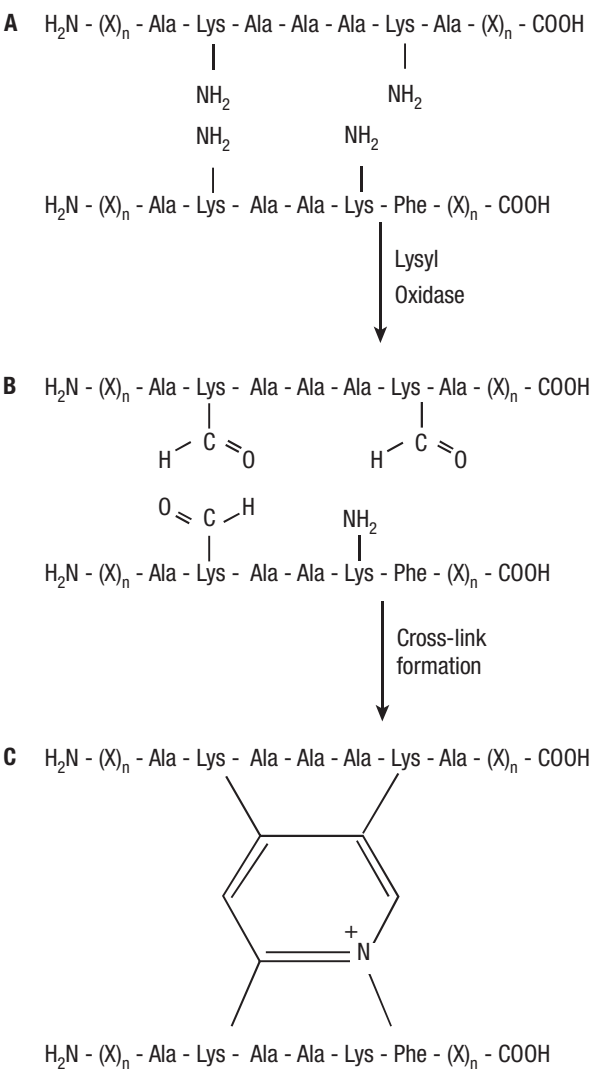

◀ **FIGURE 61-13** Formation of intermolecular cross-links, desmosine and isodesmosine, between two tropoelastin polypeptides. **A.** Amino acid sequences of a potential cross-link region within the tropoelastin polypeptides. Note the ε-amino group (NH_2) of the four contributing lysyl residues. **B.** Three of the lysyl residues undergo oxidative deamination catalyzed by lysyl oxidase to yield corresponding aldehyde derivatives, allysines. **C.** Three of the allysines and the fourth unmodified lysyl residue, still containing an epsilon-amino group, fuse into a stable desmosine cross-link. Ala = alanine; Lys = lysine; Phe = phenylalanine. (From Uitto et al: Elastic fibers of the connective tissue, in *Biochemistry and Physiology of Skin*, 2nd ed, edited by Goldsmith L. New York, Oxford University Press, 1991, with permission.)

Regulation of Elastin Gene Expression. The elastin promoter contains a remarkable constellation of potential binding sites for transcriptional regulatory factors indicative of complex transcriptional regulation. These include multiple *Sp1* and *AP2* binding sites, putative glucocorticoid-responsive elements, and TPA (phorbol ester tumor promoter, 12-O-tetradecanoylphorbol and cyclic adenosine monophosphate–responsive elements. The absence of a TATA box in the promoter region suggests that there may be multiple sites of transcriptional initiation, and various molecular tests confirm this fact.[67] Functional analyses

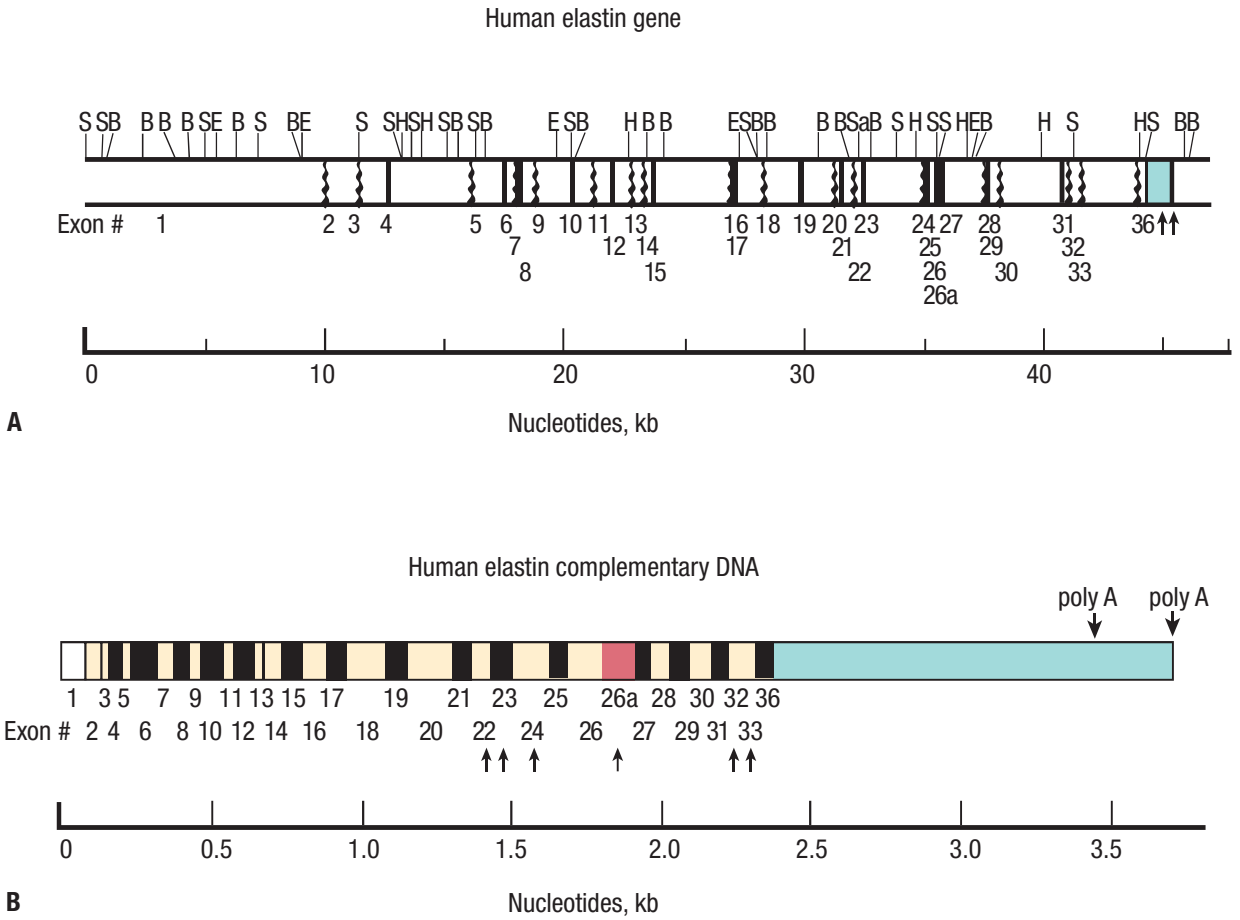

▲ **FIGURE 61-14** Representation of the human elastin gene (**A**) and the corresponding complementary DNA (cDNA) (**B**). **A.** The exons have been numbered starting from the 5′ end of the gene and correspond to those shown in the cDNA (see **B**). The presence of restriction endonuclease cleavage sites: *BamHI* (B), *EcoRI* (E), *HindIII* (H), *SacI* (S) is noted on top. **B.** The cDNA, approximately 3.5 kilobases (kb) in size, is divided into separate exons that are numbered from 1 to 36 and drawn to scale. Note that the human elastin gene contains only 34 exons; however, to maintain a consistent numbering system between the bovine and human elastin genes, the last exon is designated as number 36; thus, the human gene is missing the counterparts of bovine exons 34 and 35. The *arrows* indicate the exons that have been shown to be subject to alternative splicing. The arrows with poly A indicate the polyadenylation sites. (From Uitto et al: Elastic fibers of the connective tissue, in *Biochemistry and Physiology of Skin*, 2nd ed, edited by Goldsmith L. New York, Oxford University Press, 1991, with permission.)

of the human elastin promoter segment have been carried out by constructing a panel of promoter-reporter gene (such as chloramphenicol acetyl transferase) constructs.[69] These constructs have been used in transient transfections with a variety of cultured cells, including human skin fibroblasts. These studies indicate that the core promoter necessary for basal expression of the gene is contained within the region –128 to –1 (in reference to translation initiation site –1, +1), and the upstream sequences contain several upregulatory and downregulatory elements. Development of transgenic mice expressing the human elastin promoter has revealed that 5.2 kb of DNA flanking the human elastin gene contains the elements necessary for tissue-specific expression.[70] In addition to the 5′ upstream sequences, the first introns of both the bovine and human elastin genes contain regions of extremely strong sequence homology. Because it has been demonstrated that the first intron of three different collagen genes contains segments that act as enhancer elements of the promoter activity,[71] the strong conservation within intron 1 of the elastin gene suggests the possible presence of an enhancer in this gene as well.

Cytokine and Hormonal Regulation. The presence of multiple *cis*-acting elements in the elastin promoter region suggests that elastin gene expression is subject to modulation at the transcriptional level by *trans*-acting factors. For example, previous studies have indicated that tumor necrosis factor-α decreases elastin mRNA abundance primarily by suppressing promoter activity.[72] In other studies, TGF-β has been shown to upregulate the abundance of human elastin mRNA by up to approximately 30-fold,[73] but evidence from transient transfection assays suggests that this upregulation is, at least in part, post-transcriptional. In fact, assay of elastin mRNA half-life suggests that TGF-β stabilizes the elastin mRNA, which leads to elevated steady-state levels. These observations collectively suggest that mediators released from inflammatory cells can modulate elastin gene expression, and such modulation may play a role in diseases characterized by altered accumulation of elastic fibers in tissues.

Vitamin D_3 also modulates elastin gene expression. Specifically, incubation of fibroblasts with vitamin D_3 results in an 80 percent to 90 percent decrease in total accumulation of tropoelastin, accompanied by a parallel decrease in steady-state levels of the corresponding mRNA.[74] At the same time, insulin-like growth factor-1 enhances elastin gene expression at the transcriptional level.[75] Although there is preliminary evidence for modulation of elastin gene expression by selective growth factors and

hormone-like substances, the precise details are largely unknown.

Elastin Biosynthesis. Elastin biosynthesis involves several specific steps necessary for the assembly of elastic fibers. Several studies show that smooth muscle cells in culture synthesize relatively large quantities of elastin, which suggests that they may be the major source of elastin in tissues rich in elastic fibers, such as vascular connective tissue.[76] In addition to smooth muscle cells, human dermal fibroblasts in culture also express the elastin gene. The amount of elastin synthesized by cultured human skin fibroblasts is relatively small; nonetheless, fibroblasts may be the primary source of elastin in the dermis. Elastin gene expression has also been suggested to occur in cultured epidermal keratinocytes, although the level of expression in keratinocytes is very low in comparison to that in dermal fibroblasts, and the biologic significance of elastin gene expression in keratinocytes is unclear.[77]

After the completion of translation, newly synthesized polypeptides are translocated into the cisternae of the rough endoplasmic reticulum, in a manner similar to that occurring during the biosynthesis of collagen and other proteins destined for export from the cell. The polypeptides are then transferred from the rough endoplasmic reticulum into the extracellular space by transport mechanisms whose functioning, in the case of elastin, is not completely understood. It has been demonstrated, however, that incubation of cells synthesizing elastin with colchicine decreases the rate of elastin secretion and that the polypeptides accumulate intracellularly.[78,79] These observations suggest that the secretion of elastin polypeptides is a process that involves the microtubules of the cells and that the molecules may be transferred out of the cells packaged in Golgi vacuoles or related vesicles.

An interesting feature of elastin is the presence of 4-hydroxyproline. However, the relative hydroxyproline concentration in various elastin preparations is considerably lower than that in collagen. Amino acid analyses of elastin isolated from various sources indicate that the hydroxyproline content of the protein can vary from 7 to 25 residues per 1000 amino acids, and that hydroxyproline accounts for approximately 10 percent to 20 percent of the total imino acid (proline plus hydroxyproline) content of the molecule.[78,80] Previous studies clearly demonstrated that hydroxyproline plays an important functional role in the synthesis and secretion of collagen. In contrast, the presence of hydroxyproline is not required for the synthesis and secretion of elastin. This conclusion is based on studies in which cells synthesizing both elastin and procollagen are incubated with α,α-dipyridyl, an inhibitor of prolyl hydroxylase, which prevents the formation of hydroxyproline. Under such conditions, the cells continue to synthesize and secrete tropoelastin at the normal rate, whereas no intact triple-helical procollagen is recovered in the medium. The hydroxyproline found in elastin, therefore, appears to be a coincidental feature of the molecule in terms of synthesis and secretion of this protein.

Fibrillogenesis and Cross-Linking. The formation of desmosines occurs in the extracellular space, and the first step is the oxidative deamination of lysyl residues to corresponding aldehydes, known as *allysines*. This conversion is catalyzed by copper-requiring enzymes, lysyl oxidases.[81,82] The desmosines are formed by the fusion of three allysines and a fourth unmodified lysyl residue in two adjacent tropoelastin chains. Thus, the desmosines link the individual elastin polypeptides into an insoluble network (see Fig. 61-13).

Lysyl oxidases, a group of closely related enzymes, require copper and molecular oxygen as co-factors. It has been shown that in copper-deficient animals the activity of lysyl oxidases is reduced and the newly synthesized elastic fibers are not stabilized by the formation of desmosines.[83] Consequently, the individual tropoelastin polypeptides remain soluble and the elastin-rich tissues are fragile. Because lysyl oxidases are synthesized and secreted by human skin fibroblasts in culture,[84] these cells are presumably one source of the enzyme in vivo.

Degradation and Remodeling. Although the metabolic turnover of elastin is very slow compared with that of proteins in general, a portion of the body's elastin is continuously degraded and may partly be replaced by newly synthesized fibers.[85] In addition, degradation of elastin is markedly increased in a variety of pathologic conditions.[86] Thus, the tissues containing elastin must contain proteolytic enzymes that are capable of degrading elastic fibers.

Evidence for elastase, a specific elastolytic enzyme, was first obtained from study of the pancreas, and since then elastolytic enzymes have been detected in several other tissues, as well as in a variety of cell types, including polymorphonuclear leukocytes, monocytes/macrophages, and platelets.[87] However, elastases from different sources (pancreas versus polymorphonuclear leukocytes) have different cleavage specificities, as shown by peptide mapping of degradation products.[88]

The classic elastases are serine proteases that degrade insoluble elastic fibers at neutral or slightly alkaline pH. The activity of these enzymes is inhibited by serum factors, such as α_1-antitrypsin and α_2-macroglobulin. In addition to the classic elastases, which are serine proteases, others were shown to be metalloenzymes requiring calcium for their activity. One such enzyme is secreted by macrophages isolated from human alveolar macrophage exudates.[89]

Of particular dermatologic interest is the demonstration of elastase activity in the blister fluid from lesions of dermatitis herpetiformis and bullous pemphigoid (see Chaps. 59 and 54, respectively).[90,91] The elastase activity in the lesions of dermatitis herpetiformis is due to a serine protease and probably originates from polymorphonuclear leukocytes abundantly present in the lesions. The activity in the bullous pemphigoid lesions is caused by a metalloenzyme of unknown cellular origin. Regardless of the origin of the elastase activity, these enzymes could play a role in the development of the blisters by degrading the elastic fibers and other structures in the dermal-epidermal junction.

MICROFIBRILLAR PROTEINS Microfibrils consist of apparently tubular structures approximately 10 to 12 nm in diameter. Their staining properties and susceptibilities to enzymatic digestion differ from those of the amorphous elastin. At high resolution, the microfibrils appear in cross-section as an outer electron-dense shell surrounding an inner lucid core and in longitudinal section as a beaded chain, which suggests that they may be composed of more than one protein. Apparently similar microfibrils are present in many tissues, including those containing abundant elastin and those in which there is no visible or immunoreactive elastin, such as the ocular ciliary zonule and the periodontal ligament. In the dermis, the microfibrillary bundles that connect the deep dermal elastic plexus with the dermal-epidermal junction region consist of microfibrils indistinguishable from those associated with elastic fibers. In their



superficial distribution, no immunoreactive elastin is associated with them; but as they traverse the dermis, they are associated with an increasing amount of amorphous elastin.

Because of their insolubility and apparent complexity, chemical characterization of the microfibrils progressed slowly until recently. These structural proteins can now be divided into several groups based on their molecular characteristics. Table 61-6 lists these proteins and provides some distinguishing features, including their human chromosomal localizations. These groups include several gene families that share protein domain motifs.

Fibrillins. The largest of the microfibrillar proteins, and quantitatively and functionally perhaps the most important ones, are the fibrillins, 350-kd glycoproteins that form an integral part of the microfibril structure.[92,93] Electron microscopic images of human monomeric fibrillin synthesized by fibroblasts in culture show an extended flexible molecule approximately 148 nm long and 2.2 nm wide. Multiple fibrillin molecules align in a parallel head-to-tail fashion to form microfibrils. Molecular cloning studies have so far identified two distinct homologous human genes encoding fibrillins: fibrillin-1 (FBN1) and fibrillin-2 (FBN2).[93] Analysis of the fibrillin amino acid sequences, deduced from cloned cDNAs, showed that these proteins contain multiple repeats of a sequence motif previously observed in epidermal growth factor (EGF) precursor molecule, with each motif having six conserved cysteines.[92] Many of these repeats contain consensus sequences that have been associated with calcium binding. A second motif containing eight cysteines, originally found in latent TGF-β–binding proteins (LTBPs) has also been identified in the fibrillins (Fig. 61-15 provides a comparison of the structures of the fibrillins and LTBPs). Of interest is the report of a protein in jellyfish that has extensive homology to mammalian fibrillin; this thus identifies fibrillin as a very ancient protein that evolved well before elastin.[94]

Latent Transforming Growth Factor-β–Binding Proteins. Several members of the LTBP family have been cloned and shown to contain repeating domains similar to those found in FBN1 and FBN2 (see Fig. 61-15). TGF-β is always secreted as a latent complex, and this complex is bound to a LTBP.[95] To date, four distinct LTBPs (LTBP1 to LTBP4) have been cloned and characterized, ranging in size from 125 to 310 kd. Although LTBPs may facilitate the secretion of TGF-β or binding of the inactive complex to the cell surface where activation takes place, they are also found as free proteins associated with components of the extracellular matrix. Development of an LTBP3 knockout mouse has revealed craniofacial malformations, perturbed ossification, and development of osteosclerosis and osteoarthritis in deficient animals.[96] These observations were interpreted to mean that LTBP3 is important for the control of TGF-β action and, specifically, that LTBPs may modulate TGF-β bioavailability.

Immunohistologic studies have localized LTBP1 to microfibrils in elastic fibers, which strongly suggests that one or more of the LTBPs may be a component of these fibrils. Furthermore, levels of LTBP1 are altered in a number of

TABLE 61-6
Microfibrillar Component Proteins

Microfibrillar Protein	Characteristic Features	Human Chromosomal Locus
Fibrillins (FBNs)	350 kd Contain EGF- and TGF-β–binding protein motifs	
FBN1	Mutations in Marfan syndrome	15q15-q21
FBN2	Mutations in congenital contractural arachnodactyly	5q23-q31
FBN3		19p13.3-13.2
Latent TGF-β–binding proteins (LTBPs)	125 to 310 kd Contain EGF- and TGF-β–binding protein motifs Secreted as a complex with latent TGF-β but also found as a free protein	
LTBP1		2p22-24
LTBP2		14q22-q33
LTBP3		11q12
LTBP4		19q13.1-13.2
Fibulins (FBLNs)	60 to 240 kd Contain EGF and anaphylatoxin motifs	
FBLN1		22q13.3
FBLN2		3p24-p25
FBLN3		2p16
FBLN4	Mutations in cutis laxa	11q13
FBLN5	Mutations in cutis laxa	14q32.1
Microfibril-associated glycoproteins (MAGPs)		
MAGP1	31 kd; widely distributed in microfibrils	1p36.1-p35
MAGP2	25 kd	12p12.3-p13.1
Microfibril-associated proteins (MFAPs)		
MFAP1	Very acidic	15q15-q21
MFAP2		1p36.1-p35
MFAP3		5q32-q33.2
MFAP4	Frequently deleted in Smith-Magenis syndrome	17p11.2
βig-h3		5q31
Lysyl oxidases (LOXs)	Probably not structural components	
LOX		5q23-q31
LOXL1		15q24-q25
LOXL2		8p21.3-p21.2
LOXL3		2p13
LOXL4		10q24
Emilins		
Emilin1 (gp115)		2p23
Emilin2		18p11.3

EGF = epidermal growth factor; TGF-β = transforming growth factor-β.

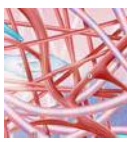



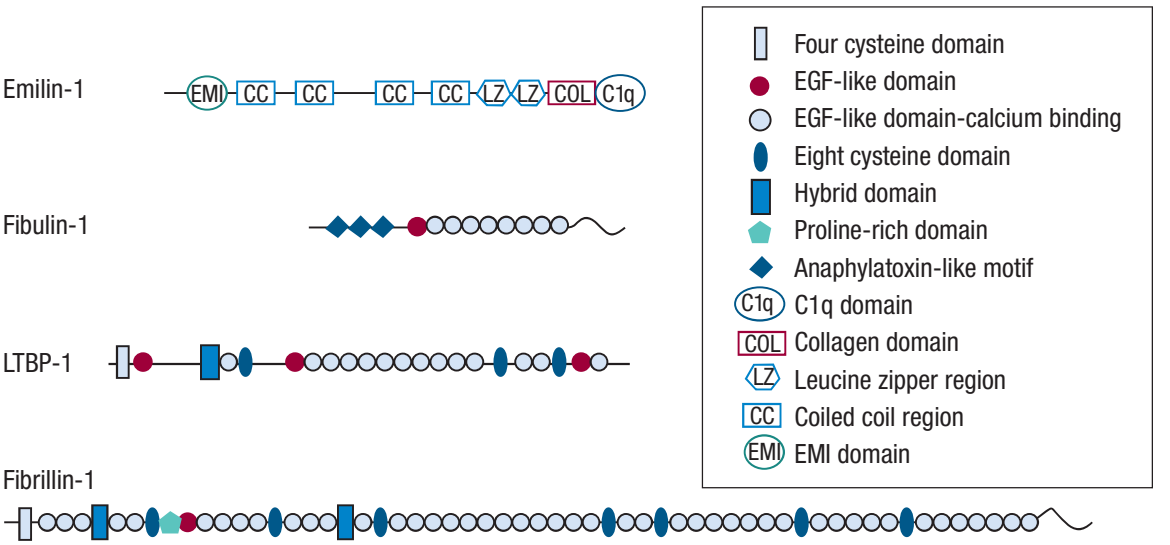

▲ **FIGURE 61-15** Modular domain structures of selected elastin-associated microfibrillar proteins, including fibrillin (FBN), latent transforming growth factor-β–binding protein (LTBP), fibulin (FBLN), and emilin. The first member of each gene family is represented. The FBN, LTBP, and FBLN families are related because they share common protein motifs. EGF = epidermal growth factor; EMI = emilin-specific domain. (Adapted from Rosenbloom J, Abrams WR: Elastin and the microfibrillar apparatus, in *Connective Tissue and Its Heritable Disorders*, 2nd ed, edited by Royce RM, Steinmann B. New York, Wiley-Liss, 2002; Pan T-C et al: Structure and expression of fibulin-2, a novel extracellular matrix protein with multiple EGF-like repeats and consensus motifs for calcium binding. *J Cell Biol* **123**:1269, 1993; and Colombatti A et al: The EMILIN protein family. *Matrix Biol* **19**:289; 2000.)

pathologic conditions, including solar elastosis.[97]

Fibulins. The fibulins are a family of extracellular matrix glycoproteins that contain tandem EGF-like repeats similar to fibrillins and LTBPs.[98] Molecular cloning has identified as many as five distinct fibulin genes (see Table 61-6). The deduced amino acid sequences reveal that the molecules are modular and have the EGF-like repeats and a common carboxyl-terminal globular domain (see Fig. 61-15). Fibulin proteins are widely distributed in connective tissues, including the skin, and enriched in developing elastin-containing tissues. Fibulins 1, 2, 4, and 5 are located within the elastic fibers. FBLN5 binds both smooth muscle cells and elastin, thus facilitating the cell-matrix interactions. FBLN4- and FBLN5-deficient mice, developed by targeted ablation of the corresponding genes, demonstrate marked reduction in elastogenesis. FBLN4-deficient mice have a severe phenotype that leads to perinatal death, primarily due to pulmonary and cardiovascular abnormalities.[99] Particularly interesting is the clinical phenotype of FBLN-5 knockout mice, which show progressive laxity of skin in addition to vascular abnormalities and emphysematous lung changes.[100,101] The skin changes are reminiscent of those noted in patients with congenital cutis laxa. In fact, mutations in the FBLN4 and FBLN5 genes have been documented in some cases of cutis laxa.[102–104]

Other Microfibrillar Proteins. A number of other proteins unrelated to the fibrillins, LTBPs, and fibulins are constituents of the microfibrils. Such microfibrillar components include the lysyl oxidases,[81,82] interface proteins called *emilins*,[105] and several proteins belonging to the families of microfibril-associated proteins or microfibril-associated glycoproteins (see Table 61-6).[106–108] Among the latter, microfibril-associated protein 1 is remarkable in that it is extremely acidic, with glutamic acid comprising 23 percent and aspartic acid 6 percent of the residues. The extremely acidic nature of the protein suggests that it may have an important function in the assembly of the very basic tropoelastin molecules. Finally, lysyl oxidases are critical for the cross-linking and stabilization of the elastic fiber structures.

Pathology of the Elastic Fibers in Cutaneous Diseases

Several heritable and acquired connective tissue diseases have been shown to be associated with aberrations in the elastic fibers, including pseudoxanthoma elasticum, cutis laxa, and Buschke-Ollendorff syndrome (Table 61-7; see Chap. 139). In addition, clinically distinct entities with phenotypes closely resembling pseudoxanthoma elasticum (e.g., elastoderma) or cutis laxa (e.g., wrinkly skin syndrome) can be recognized.

PROTEOGLYCANS AND GLYCOSAMINOGLYCANS

Proteoglycans and their glycosaminoglycan components constitute an important portion of the cellular membrane and extracellular matrix of the skin. Their ability to bind proteins and alter protein-protein interactions or enzymatic activities has identified them as important determinants of cellular responsiveness in development, homeostasis, and disease. Because proteoglycans are a structurally unique and highly diverse group of macromolecules, it is important to become familiar with their structure and organization in order to understand their function. The most distinguishing structural characteristic of proteoglycans is that they comprise both a core protein and covalently linked linear carbohydrate chains known as *glycosaminoglycans* (GAGs). GAGs are highly polyanionic and bear a high charge density. It has long been recognized that GAGs are a critical component of the skin, and more recently it has been appreciated that the content and composition of GAGs in the skin changes during development and in a variety of pathologic processes, and that both core protein and GAGs impart a unique set of functions that are critical to a large number of biologic processes.

TABLE 61-7
Clinical Features, Histopathology, Inheritance, Associated Biochemical Findings, and Predisposing Clinical Conditions in Cutaneous Diseases with Elastic Fiber Abnormalities[a]

Disease	Inheritance	Clinical Manifestations	Skin Histopathologic Findings	Biochemical Findings[b] Related to Elastic Fibers and Predisposing Clinical Conditions
Pseudoxanthoma elasticum	AR, sporadic[c]	Yellowish papules coalescing into plaques Inelastic skin Cardiovascular and ocular abnormalities	Accumulation of pleomorphic and calcified elastic fibers in the mid-dermis	Deposition of calcium apatite crystals, excessive accumulation of glycosaminoglycans on elastic fibers; D-penicillamine treatment; mutations in the *ABCC6* gene
Buschke-Ollendorff syndrome	AD	Dermatofibrosis lenticularis disseminata and osteopoikilosis	Accumulation of interlacing elastic fibers in the dermis	Increased desmosine content in the skin; mutations in *LEMD3*
Cutis laxa	AR, AD, or NH	Loose, sagging, inelastic skin Pulmonary emphysema Tortuosity of aorta Urinary and gastrointestinal tract diverticuli	Fragmentation and loss of elastic fibers	Decreased desmosine content and reduced elastin mRNA levels; increased elastase activity in some cases; D-penicillamine treatment, inflammatory and urticarial skin lesions (e.g., drug reaction); mutations in the *ELN, EBLN4,* or *FBLN5* gene in limited cases
DeBarsy syndrome	AR	Cutis laxa–like skin changes Mental retardation Dwarfism	Rudimentary, fragmented elastic fibers	Reduced elastin mRNA levels
Wrinkly skin syndrome	AR	Decreased elastic recoil of the skin Increased number of palmar and plantar creases	Decreased number and length of elastic fibers	—
Mid-dermal elastolysis	NH	Fine wrinkling of the skin, primarily in exposed areas	Fragmentation and loss of elastin in the mid-dermis	Inflammatory; sun exposure
Anetoderma	NH	Localized areas of atrophic, sac-like lesions	Loss and fragmentation of elastic fibers in the dermis	Reduced desmosine content in the lesions; often secondary to inflammatory lesions
Elastosis perforans serpiginosa	NH	Hyperkeratotic papules, commonly on the face and neck	Accumulation and trans-epidermal elimination of elastic fibers	D-penicillamine–induced abnormalities in elastin cross-linking
Elastoderma	Unknown	Loose and sagging skin with loss of recoil	Accumulation of pleomorphic elastotic material without calcification in the mid and lower dermis and the subcutaneous tissue	—
Isolated elastomas	NH	Dermal papules or nodules	Accumulation of thick elastic fibers in the dermis	—
Elastofibroma dorsi	NH	Deep subcutaneous tumor, usually on subscapular area	Accumulation of globular elastic structures encased in collagenous meshwork	Trauma on the lesional area
Actinic elastosis	NH	Thickening and furrowing of the skin	Accumulation of irregularly thickened elastic fibers in upper dermis	Long-term sun exposure
Marfan syndrome	AD	Skeletal, ocular, and cardiovascular abnormalities Hyperextensible skin Striae distensae	Fragmentation of the elastic structures in the aorta	Mutations in the *FBN1* gene
Congenital contractural arachnodactyly	AD	Camptodactyly and joint contractures		Mutations in the *FBN2* gene
Williams syndrome	AD	Supravalvular aortic stenosis Velvety skin Dysmorphic facies	Disruption of smooth muscle and matrix relationship affecting blood vessels	Allelic deletion of the *ELN* gene; contiguous gene deletion syndrome

AD = autosomal dominant; AR = autosomal recessive; NH = not a heritable disease; mRNA = messenger RNA.
[a]Most of these conditions represent a group of diseases with clinical, genetic, and biochemical heterogeneity.
[b]The biochemical abnormalities have been demonstrated in only a limited number of patients in each group, and it is not known whether the biochemical changes are the same in each patient with any given disease.
[c]Rare cases with a distinct acquired form of pseudoxanthoma elasticum have been described.

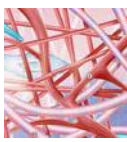

Structure

Historically, terms such as *ground substance* or *mucopolysaccharides* were used to describe proteoglycans because of their histologic appearance and their thick and mucinous nature when isolated. Because of these physical properties, proteoglycans were difficult to study and poorly understood. More recently, glycobiology has clearly defined proteoglycans as essential regulatory molecules that control many cellular functions. To attain this understanding, important advances have been made in the identification of specific proteoglycan core proteins and the assembly of their GAG side chains.

Proteoglycans are recognized as members of specific gene families based on amino acid sequence information derived from their core proteins and carbohydrate compositional analysis of their GAG side chains. The prototypical proteoglycan consists of a single core protein linked to one or more GAGs (Fig. 61-16A). Each core protein has the capacity to accept a variety of GAG chains. Consequently, the nomenclature for proteoglycans is complicated in that individual molecules must be defined based on the core protein and the associated GAGs.



Glycosaminoglycan Chain

The GAG chain is defined based on the assembly of essential sugar residues. These sugars are organized as disaccharide pairs that usually consist of an acidic sugar that is either an iduronic acid or glucuronic acid alternating with a hexosamine that is either glucosamine or galactosamine. When the chains are assembled as disaccharides, the choice of sugars and the linkage between them is used to assign a name to the GAG chain. Thus, several terms are used to define GAGs (see Fig. 61-16B), including *hyaluronic acid*, which contains a glucuronic acid alternating with *N*-acetylglucosamine–linked β1–3 and β1–4; *heparan sulfate*, containing iduronic or glucuronic acids alternating with *N*-acetylglucosamine–linked β1–4; *chondroitin sulfate*, containing glucuronic acid alternating with *N*-acetylgalactosamine–linked β1–3 and β1–4; and *keratan sulfate*, containing galactose alternating with *N*-acetylglucosamine–linked β1–4 and β1–3. A fifth general term used to describe GAGs, and of particular importance to cutaneous biology, is *dermatan sulfate*. This form of GAG (also known as *chondroitin sulfate B*) is similar to other chondroitin sulfates except that it contains a high proportion of iduronic acids in place of glucuronic acid and has more variable sulfation. Dermatan sulfate shares features of both chondroitin sulfate (*N*-acetylgalactosamine) and heparan sulfate (iduronate) (see Fig. 61-16B).

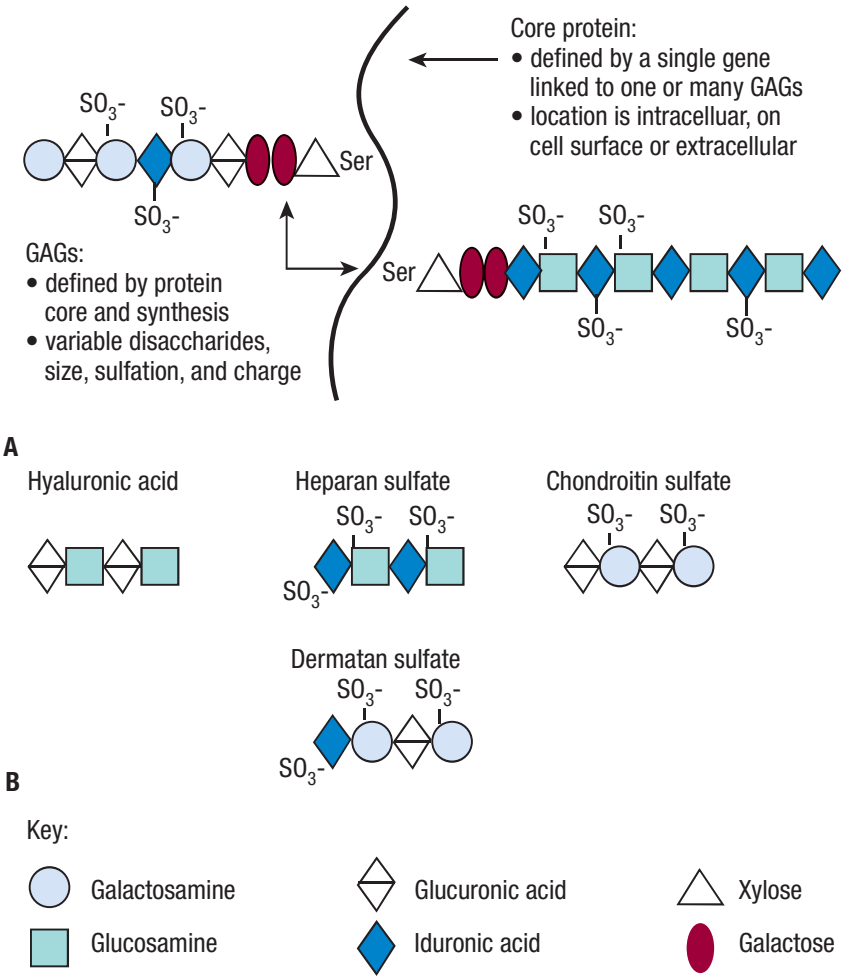

▲ **FIGURE 61-16** **A.** Prototype of proteoglycan structure. Core proteins may contain from 1 to 100 glycosaminoglycan (GAG) chains, depending on the core protein sequence. Two different GAG chains are shown: dermatan sulfate (*top left*) and heparan sulfate (*bottom right*). Sites of potential sulfation are indicated. *Ser* represents a serine amino acid residue in the core protein to which GAGs are attached. **B.** Disaccharide repeating units of GAGs shown as tetrasaccharides. Structures of heparan sulfate, dermatan sulfate, chondroitin sulfate A (chondroitin 4-sulfate)/C (chondroitin-6 sulfate), and hyaluronan are shown. Sulfation can vary in heparan sulfate and dermatan sulfate.

The linear chains of linked disaccharide units in a GAG are highly variable in size, ranging from as few as 10 disaccharides to several thousand. Thus, the mass of naturally occurring GAGs typically ranges between 5×10^3 d and 5×10^7 d for hyaluronic acid. Further variability is introduced into the GAG chain by epimerization reactions and sulfation reactions. The control of these reactions depends on the nature of the GAG, the core protein to which it may be attached, the cell type, and the cell environment. For example, the simplest GAG, hyaluronic acid, is never sulfated, whereas other GAGs can be sulfated to varying degree. The highly sulfated sugars tend to occur in specific regions of the GAG chain and are interspersed with areas of low sulfation. Such discrete domains of low or high sulfation are believed to determine the interactions between proteoglycans and GAGs and their many binding partners.

The size, disaccharide composition, and sulfation are of critical importance in understanding GAGs. These parameters influence function and are the mechanism by which instructions are defined within the molecule. Thus, the linear GAG should be considered as a molecule containing information, just as information is encoded in a protein. Synthesis of

GAGs (with the exception of hyaluronan) occurs in the Golgi apparatus, and the sequence information is determined by the activity and location of multiple specific enzymes along this pathway. Today, many of the synthetic enzymes that control heparan sulfate synthesis and those enzymes responsible for postsynthetic modifications have been identified and characterized.[109] The sulfated GAGs are all synthesized on core proteins. The tetrasaccharide xylose–galactose–galactose–glucuronic acid is first assembled on the core protein by beginning with a xylosyltransferase that forms a linkage between xylose and a serine residue in the core protein. Subsequent elongation reactions that occur in the Golgi apparatus define the nature of the GAG chain. It is appreciated that part of the information necessary to direct synthesis of the GAG is encoded within the core protein sequence itself. The final product, core protein with attached GAG, defines the proteoglycan (see Fig. 61-16A). Hyaluronan, the only GAG produced without attachment to a core protein, is synthesized by an enzyme complex at the plasma membrane and then extruded into the extracellular space.

Core Protein

Our understanding of proteoglycans has markedly advanced as a result of increased information about their core proteins and the subsequent use of molecular tools to study the expression and function of both the protein core and GAG components. Many specific proteoglycans can now be defined and studied based on their core protein sequences. For purposes of organization, it is useful to group proteoglycans according to their site of expression by the cell. Specific proteoglycan core proteins have been identified within the cell, attached to the cell surface, bound within the extracellular matrix, and released in soluble form (Table 61-8).

Serglycin is the best-known intracellular proteoglycan and is found within the secretory granules of hematopoietic cells, including mast cells, leukocytes, and eosinophils. This core protein is processed further to contain either heparan sulfate or chondroitin sulfate GAG. The heparan sulfate form is found in serosal mast cells and is a major source from which heparin is pharmacologically derived. The serglycin peptide core is composed primarily of tandem serine-glycine repeats and has an estimated mass of 16 to 18 kd before GAG addition and 60 to 750 kd after the addition of multiple heterogenous GAG chains.[110] Thus, serglycin is a unique proteoglycan because of its distinctive core protein sequence, and intracellular localization. In the skin, serglycin is found whenever mast cells or eosinophils enter the dermal stroma. On release, serglycin becomes a major source for the delivery of highly sulfated heparan sulfate GAG.

Several cell surface proteoglycans have been identified and are the subject of interest because of their ability to function at the interface between the plasma membrane and the extracellular environment. These cell proteoglycans can be found attached to the cell surface either by a phospholipid anchor (e.g., glypican family) or as membrane-spanning core proteins (e.g., syndecan family). The glypican family of core proteins shares the glycophosphatidyl inositol anchorage mechanism and a unique cysteine motif that is likely to impart a compact tertiary structure to the proteoglycans. Consequently, glypicans can be visualized as a compact protein presenting GAG chains in close proximity to the outer surface of the plasma membrane.

The surfaces of most cells contain another important family of proteoglycans known as the *syndecans*. Syndecans, like glypicans, are found in a wide variety of cells and tissues. The structure of these cell surface proteoglycans differs from that of the glypicans, however, in that syndecan core proteins consist of a short C-terminal cytoplasmic region, a transmembrane domain, and an extracellular region containing attachment sites for

TABLE 61-8
Core Proteins of Proteoglycans

Core Protein	Location	Usual GAG Component
Intracellular		
Serglycin	Mast cells, basophils	HS, CS
Cell surface		
Syndecan-1	Keratinocytes, other epithelia	HS, CS
Syndecan-2	Fibroblasts, endothelia, bone	HS
Syndecan-3	Neural cells, limbs	HS
Syndecan-4	Ubiquitous, lymphoid	HS, CS
NG-2	Neural, melanoma	CS
Glypican (GPC-1)	Brain, vascular endothelia	HS
Cerebroglycan (GPC-2)	Brain only	HS
OCI-5 (GPC-3)	Intestine and mesenchymal	HS
K-glypican (GPC-4)	Kidney, brain	HS
Glypican-5 (GPC-5)	Brain, kidney, bone	HS
Glypican-6 (GPC-6)	Intestine, kidney, lung	HS
Epican	Keratinocytes	HS, CS, KS
Betaglycan	Fibroblasts, epithelia	HS
Endocan	Endothelia	DS
Thrombomodulin	Endothelia	DS
Extracellular matrix		
Aggrecan	Cartilage	KS, CS
Versican	Fibroblasts	CS, DS
Brevican	Brain	CS
Neurocan	Brain	CS
Phosphocan	Brain	CS, KS
Decorin	Fibroblasts, others	DS
Biglycan	Bone	DS
Epiphycan	Cartilage	DS
OIF	Cartilage	
Fibromodulin	Fibroblasts	KS
Lumican	Cornea	KS
Agrin	Brain	HS
Perlecan	Basement membranes	HS
Bamacan	Basement membranes	CS

CS = chondroitin sulfate; DS = dermatan sulfate; GAG = glycosaminoglycan; HS = heparan sulfate; KS = keratan sulfate; NG-2 = NG2 proteoglycan; OIF = osteoinductive factor.

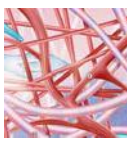

GAG chains. Unlike glypicans, syndecans span the plasma membrane and extend beyond the surface of the cell. In this way, syndecans are in a unique position to connect extracellular GAG to structures within the cytoplasmic space. The cytoplasmic domain imparts the ability of syndecans to participate in intracellular signal transduction via the protein kinase C pathway. Expression of syndecans is abundant in skin. Syndecan transcripts and proteins are expressed in distinct patterns during development[111] and in mature tissues.[112] Syndecan-1 is particularly abundant on keratinocytes and can vary the nature of attached GAG chains as keratinocytes differentiate.[113] During wound repair, syndecan-1 and syndecan-4 are highly induced in the dermis and granulation tissue.[114] Deletion of syndecan-4 from mice greatly decreases the rate of wound repair.[115] During malignant transformation, syndecan-1 expression decreases in the epidermis,[116] and expression can alter malignant behavior in select cell types.[117] Thus, syndecans have received particular attention as proteoglycans that modify cell function. Because syndecans and other proteoglycans can contain more than one GAG species, either simultaneously or under different cellular circumstances, GAG expression provides another mechanism of regulation in addition to protein expression.

The extracellular matrix contains multiple proteoglycans that have now been identified and studied. Aggrecan, a large proteoglycan found in cartilage, has been studied extensively. This core protein contains a region with over 100 serine-glycine dipeptides that serve as attachment sites for chondroitin sulfate GAG. The approximately 230-kd core protein can be modified to contain up to 130 GAG chains and have a final mass of approximately 2200 kd.[118] This densely packed multiple-GAG configuration has been described as a "bottle brush" to indicate the predicted structure. The aggrecan core protein also contains sites for keratan sulfate attachment and a domain for noncovalent binding to hyaluronic acid. As many as 100 aggrecan molecules can bind to a single hyaluronic acid molecule. Thus, the overall proteoglycan aggregate (from which the name *aggrecan* is derived) can have a mass near 200,000 kd.[118]

In the skin, fibroblasts produce large aggregating proteoglycans similar to aggrecan. The best known of these large proteoglycans is *versican*. The core protein of versican contains attachment sites for 12 to 15 GAG chains, which are primarily chondroitin sulfate or dermatan sulfate. Versican, like aggrecan, also binds hyaluronic acid, which enables it to form large aggregates. In skin, versican has been identified in the dermis (fibroblasts) and epidermis (keratinocytes) and demonstrates selective upregulation in response to TGF-β.[119] Thus, the size, distribution, and abundance of versican in the skin suggest that it is an important molecule in the regulation of the behavior of the skin.

In addition to the genes encoding large aggregating extracellular matrix proteoglycans represented by aggrecan and versican, several genes encoding smaller proteoglycans have been identified in the extracellular matrix as well. One family of the proteoglycans is characterized by a leucine-rich repeat motif. The prototype of this family is decorin, an approximately 36-kd secreted proteoglycan. Decorin is found in abundance in skin and cartilage and is thought to be a ubiquitous component of connective tissue. The relatively small decorin core protein has a single dermatan sulfate chain covalently bound to a serine residue at amino acid position 4 and, like many other proteoglycans, also has *N*-linked oligosaccharides. Thus, after GAG addition, decorin can have a mass of 80 kd. Decorin received its name from observations that this molecule closely associates with collagen fibrils and can be seen to "decorate" the fibrils in vivo. This interaction is attributed to the ability of the decorin core protein to directly bind to collagen type I.[120] The single GAG chain of decorin also binds to tenascin-X, another extracellular matrix protein that colocalizes with collagen fibrils in connective tissues.[121] These binding interactions contribute to collagen fibril formation and influence function. Interestingly, similar phenotypes showing abnormal collagen morphology are seen in a patient deficient in tenascin-X and in the murine decorin knockout model.[122]

Function

To understand how proteoglycans function in the skin it is essential to appreciate the basics of their organization: (1) proteoglycans are part protein and part GAG; (2) GAGs are heterogeneous but encode specific information; (3) proteoglycan core proteins are expressed in different cellular compartments; and (4) proteoglycan expression and GAG composition vary according to cellular context. These characteristics are important, because the fundamental influence dictating proteoglycan function is the ability to bind to other molecules in its environment. Therefore, the sequences (both amino acid sequence and disaccharide sequence) of the core protein and GAG control proteoglycan function by influencing binding.

Similar GAGs can be found on multiple core proteins. This ability to interchange GAGs among cores adds complexity to the study of proteoglycan function. Therefore, in many cases, proteoglycan function is discussed purely in terms of the function of GAG chains. This implies that a number of genes encoding core proteins containing these GAGs may have a similar function. Fig. 61-17 illustrates some of the functions attributed to proteoglycans containing heparan sulfate and dermatan sulfate. The functions proposed for proteoglycans containing these GAGs derive from the ability of these molecules to bind to other components of the extracellular environment and mediate assembly of larger molecular complexes.

The list of molecules to which the major skin proteoglycans heparan sulfate and dermatan sulfate bind is quite extensive (Table 61-9). Therefore, several functions for proteoglycans have been proposed that include the particular biologic system in which the ligand is involved. Some of the most compelling experimental evidence for the functions of heparan and dermatan sulfate proteoglycans identifies the ability to bind several growth factors, cytokines, and components of the extracellular matrix.[123,124] Numerous laboratories have shown that heparan sulfate is required for the function of several growth factors, including several members of the fibroblast growth factor family,[125,126] hepatocyte growth factor/scatter factor,[127] and vascular endothelial growth factor.[128] In this model, the heparan sulfate proteoglycan can be found either at the cell surface or in a soluble form. The molecules then assemble to form a ternary complex at the cell surface between the growth factor, its specific high-affinity signaling receptor, and the proteoglycan (see Fig. 61-17).[129] Only after this ternary complex is formed does the cell receive the growth factor signal to begin to proliferate, differentiate, or migrate. The ability of dermatan sulfate to participate in these interactions has been demonstrated,[130,131] and the significance of this assembly to skin biology is apparent during wound repair. Heparan sulfate–dependent growth factors, such as members of the fibroblast growth factor family, are induced



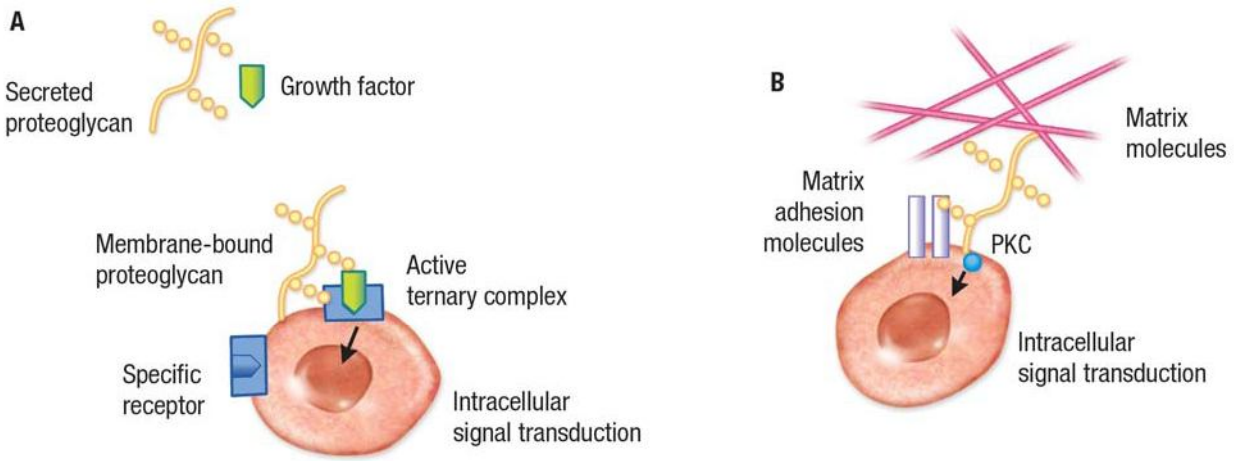

▲ **FIGURE 61-17** Theoretical models for proteoglycan function. **A.** Proteoglycans as co-receptors for growth factors. Proteoglycan, growth factor, and specific receptor must all assemble at the cell surface before growth factor can activate the cell. Secreted extracellular proteoglycans may sequester and stabilize growth factors. **B.** Proteoglycans as extracellular matrix receptors. Proteoglycan can assemble with other matrix adhesion receptors (e.g., integrins) to aid in cell adherence. The proteoglycan syndecan-4 also interacts and signals through protein kinase C (PKC) to enable cell activation by matrix adhesion.

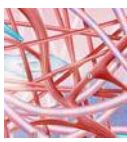

in a healing wound[132] and influence the wound repair process through the stimulation of keratinocyte proliferation, fibroblast growth, and angiogenesis. Heparan sulfate proteoglycans such as syndecan-1 and syndecan-4 are also induced at these sites[133] and enable activity of the growth factor. Because dermatan sulfate is the predominant GAG in wound fluid and because it can bind a variety of growth factors, cytokines, and extracellular matrix proteins, the further study of this GAG and the proteoglycans it comprises promises to be an exciting area for future investigation.

The influence of the proteoglycan core protein on cell behavior is thought to relate to the ability of the core protein to influence the amount and localization of GAG expression. In the example of wound repair, heparan and dermatan sulfate expression is influenced by the expression of the syndecan core proteins to which the GAGs are covalently attached. Other molecules, such as the syndecan inducer PR-39,[133] the syndecan inhibitor tumor necrosis factor-α,[134] and TGF-β, can have significant influence on the wound repair process by controlling GAG and proteoglycan expression.[135]

Study of the expression of proteoglycans has expanded the direct evidence for a function for these molecules. In addition to binding to growth factors, heparan sulfate proteoglycans play an important role in adhesion to the extracellular matrix. In the current model, cell surface proteoglycans, in conjunction with other matrix-binding molecules such as the integrins, help the cell adhere to the extracellular matrix (see Fig. 61-17). Syndecan-4 is selectively enriched in dermal fibroblasts at sites consistent with this function. Furthermore, the formation of these focal adhesions requires heparan sulfate and the subsequent activation of protein kinase C by a domain in the syndecan-4 core protein cytoplasmic tail.[136] In this setting, both the extracellular GAG and intracellular core protein of the proteoglycan have demonstrable function.

Other proteoglycans also interact with matrix molecules. Chondroitin sulfate and dermatan sulfate bind fibronectin and laminin.[137] As mentioned earlier, decorin, to which dermatan sulfate is typically attached, is known to associate primarily with type I collagen via its core protein.[120] In mice, selective disruption of the decorin gene leads to abnormal collagen morphology and increased skin fragility.[122] Thus, through targeted disruption of the gene in the mouse, the function of decorin as a stabilizer of collagen fibrils has been directly confirmed.

The function of the large extracellular matrix proteoglycans in skin is thought to relate primarily to the physical properties inherent in their large mass and charge density. Hyaluronan has been studied extensively from this perspective because of its extreme hydrophilicity and viscosity in dilute solution. As discussed earlier, hyaluronic acid is pure GAG and is synthesized extracellularly without a core protein. The genes for human hyaluronan synthase have been cloned and identified.[138,139] The expression of hyaluronan is developmentally regulated in skin and changes during wound repair. It has been proposed that the physicochemical properties of hyaluronan serve to expand the matrix and thus aid cell movements. Other physical properties attributed to GAG and large proteoglycan complexes, such as those formed with versican or basement membrane proteoglycans, include their ability to act as anionic filters and elastic cushions and their function in salt and water balance. In fetal skin, the high relative content of hyaluronan has been associated with the ability of fetal skin to heal without scar.

Multiple cutaneous disorders are associated with abnormal proteoglycan synthesis or deposition. A deficiency of decorin core protein has been described as the cause of a variant form of Ehlers-Danlos syndrome. Infectious disease is influenced by proteoglycan expression. For example, decorin-deficient mice are somewhat resistant to infection with *Borrelia burgdorferi*. Presumably this resistance is caused by a partial dependence of the organism on decorin for binding in the dermis.[140] During aging, the composition of GAG in the skin undergoes a marked change.[141,142] It has been proposed that the observed decrease in hyaluronic acid can explain diminished skin turgor in aged skin. Retinoids also effect this response.[143] In keloids, hyaluronic acid synthesis is elevated.[144] Thyroid hormone also has a marked effect on the synthesis of proteoglycans and GAGs. The manifestation of this response is seen in pretibial myxedema, in which the mucinous material deposited is predominantly hyaluronic acid and chondroitin sulfate. Other pathologic skin conditions, including pseudoxanthoma elasticum,

TABLE 61-9
Binding Interactions of Heparan Sulfate, Dermatan Sulfate, and Heparin

CATEGORY	LIGAND
Extracellular matrix components	Collagen types I, III, IV, V Fibronectin Laminin Pleiotrophin Tenascin-X Thrombospondin Vitronectin wnt-I wnt-induced secretory protein
Growth factors (GFs)	Fibroblast GF family Hepatocyte GF/scatter factor Heparin-binding epidermal GF Platelet-derived GF Schwannoma-derived GF Vascular endothelial GF
Growth factor binding proteins (BPs)	Follistatin Insulin-like GF BP-3 Transforming GF-β BP
Cytokines	Transforming GF-β Interleukin 8 Interferon-γ–inducible protein-10 Interferon-γ Macrophage inhibitory protein-1α
Cell adhesion molecules (CAMs)	CD45 L-selectin Mac-1 Neural cell adhesion molecule Platelet/endothelial CAM
Proteases/antiproteases	Elastase Thrombin Tissue plasminogen activator Antithrombin III Heparin co-factor II Leuserpin Plasminogen activator inhibitor-I Protein C inhibitor Protease nexin I
Pathogens	gC and gB of herpes simplex virus gC-11 of cytomegalovirus gp 120 of human immunodeficiency virus *Staphylococcus aureus* surface proteins Penetrin of *Trypanosoma cruzi* *Streptococcus mutans* surface proteins *Neisseria gonorrhoeae* surface proteins Mycobacterial surface proteins Adhesin proteins of *Borrelia burgdorferi*

scleroderma, psoriasis, a variant form of Ehlers-Danlos syndrome, lichen myxedema, and ultraviolet B–irradiated skin, have also been reported to be characterized by abnormal amounts of proteoglycans. These associations do not imply that abnormal proteoglycan metabolism is responsible for these disorders, but they suggest that much of the pathophysiology of skin disease can be influenced by the function of cutaneous proteoglycans.

KEY REFERENCES

The full reference list for all chapters is available at www.digm7.com.

1. Myllyharju J, Kivirikko KI: Collagens, modifying enzymes and their mutations in humans, flies and worms. *Trends Genet* **20**:33, 2004.
2. Franzke CW, Bruckner P, Bruckner-Tuderman L: Collagenous transmembrane proteins: Recent insights into biology and pathology. *J Biol Chem* **280**:4005, 2005.
18. Bristow J, Carey W, Egging D, Schalkwijk J: Tenascin-X, collagen, elastin, and the Ehlers-Danlos syndrome. *Am J Med Genet C Semin Med Genet* **139**:24, 2005.
21. Lampe AK, Bushby KM: Collagen VI related muscle disorders. *J Med Genet* **42**:673, 2005.
25. Varki R et al: Epidermolysis bullosa. II. Type VII collagen mutations and phenotype/genotype correlations in the dystrophic subtypes. *J Med Genet* **44**:181,2007
37. Flannery CR: MMPs and ADAMTSs: Functional studies. *Front Biosci* **11**:544, 2006.
52. Lemaitre V, D'Armiento J: Matrix metalloproteinases in development and disease. *Birth Defects Res C Embryo Today* **78**:1, 2006.
58. Kielty C et al: Elastic fibers. *J Cell Sci* **115**:2817, 2002
82. Molnar J et al: Structural and functional diversity of lysyl oxidase and the LOX-like proteins. *Biochim Biophys Acta* **1647**:220, 2003.
86. Uitto J, Pulkkinen L: Heritable diseases affecting the elastic tissues: Cutis laxa, pseudoxanthoma elasticum and related disorders, in *Emery and Rimoin's Principles and Practice of Medical Genetics*, 4th ed, edited by Rimoin DL et al. New York, Churchill Livingstone, 2002, p 4044
93. Ramirez F et al: Fibrillin microfibrils: Multipurpose extracellular networks in organismal physiology. *Physiol Genomics* **19**:151, 2004
95. Rifkin DB: Latent transforming growth factor-beta (TGF-beta) binding proteins: Orchestrators of TGF-beta availability. *J Biol Chem* **280**:7409, 2005
98. Timpl R et al: Fibulins: A versatile family of extracellular matrix proteins. *Nat Rev Mol Cell Biol* **4**:479, 2003.
105. Colombatti A et al: The EMILIN protein family. *Matrix Biol* **19**:289, 2000
124. Iozzo RV: Basement membrane proteoglycans: From cellar to ceiling. *Nat Rev Mol Cell Biol* **6**:646, 2005



CHAPTER 62

Morphea

Vincent Falanga
Christina E. Killoran

MORPHEA

Localized scleroderma (LS), or morphea, differs from systemic sclerosis (scleroderma) by the presence of various cutaneous morphologic variants and the absence of clinically detectable systemic involvement. There may be overlaps in the pathogenesis of fibrosis in the localized and systemic forms.

Epidemiology

LS has been reported to have an incidence of 2.7 per 100,000.[1] There is a male–female ratio of 1:2 to 3, and the condition is more common in Caucasians and Asians than in African Americans.[2–4] All variants occur in adults and children and can occur at any age. Linear scleroderma is more common in children and can present in the first or second decade, whereas morphea and generalized morphea are more common in adults and usually present in midlife.[3–5] The relative frequency of the different morphologic variants is not clear, and reported studies have found different rates. In affected adults, 35 percent to 65 percent have plaque-type morphea, 8 percent to 9 percent generalized morphea, 6 percent to 46 percent linear scleroderma, 3.5 percent en coup de sabre, 3.5 percent morphea profunda, and less than 1 percent guttate, bullous morphea, and Parry-Romberg syndrome.[2,6] One study, which included 126 children, found that 48 percent of patients had plaque-type morphea, 17.5 percent linear, 14 percent mixed morphologic type, 8 percent Parry-Romberg, 3 percent generalized morphea, 3 percent en coup de sabre, 2 percent a keloidal form, and less than 1 percent had pansclerotic morphea of childhood, morphea profunda, or bullous morphea.[6]

The average duration of clinically active disease ranges from 3 to 6 years.[2,6] In chronic cases, slow clinical progression may persist for decades. Most patients will have a clinical remission of disease. Patients with plaque-type morphea are most likely to have the shortest disease duration. Rare patients, especially those with generalized morphea, morphea profunda, or linear scleroderma, will have a chronic course with several relapses, sometimes barely detectable clinically.[6]

Etiology and Pathogenesis

The etiology of LS is unknown. There are reports of morphea after infection with measles, varicella, and *Borrelia burgdorferi*. Other suggested triggers include trauma, bacille Calmette-Guérin vaccination, vitamin B injection, radiation therapy, penicillamine, and bromocriptine. However, no direct etiology has ever been proved. Suggested pathogenic events are similar to those hypothesized for systemic sclerosis. Endothelial cell damage, inflammation and release of cytokines that stimulate collagen production by fibroblasts, and an imbalance of extracellular matrix turnover in the skin seem likely. The reason for the limited distribution of LS is unclear, but the patterning suggests that mosaic genetic changes may contribute (see eFig. 62-0.1 in on-line edition).

Many studies have suggested a pathogenic role for transforming growth factor-β (TGF-β). TGF-β stimulates fibroblasts to produce increased amounts of glycosaminoglycans, fibronectin, and collagen; decreases extracellular matrix breakdown; and it diminishes fibroblast susceptibility to apoptosis. TGF-β has been found to be increased in lesions of LS as well as in the skin and fibrotic lungs of patients with systemic sclerosis.[7–11] Some work suggests that, at least in systemic sclerosis, TGF-β receptor expression in dermal fibroblasts is increased. There are also data supporting the possibility that alterations in the Smad protein pathway, which is important in TGF-β signal transduction, may play a role in collagen overproduction.[12–18] Fibroblast cultures derived from systemic sclerosis and LS produce increased amounts of connective tissue components, including collagen type I in vitro. Skin biopsies have shown a greater capacity for collagen overproduction and sub-population of fibroblasts with activation of type I collagen expression; these fibroblasts co-localize with inflammatory mononuclear cells that express TGF-β.[9,19] Biopsies of sclerotic lesions also show expression of different isoforms of TGF-β, as well as tissue metalloproteinase-3 (TIMP-3) in sub-populations of fibroblasts cultured from LS lesions.[8–10] TGF-β enhances TIMP-3 expression, and TIMP-3 inhibits breakdown of collagen.[19] It should be noted that three different isoforms of TGF-β (1, 2, and 3) are present in humans; TGF-β1 is the best studied.

Some evidence suggests that the fibrotic response may be driven predominantly by $CD4^+$ T cells. Plasma cells and histiocytes can probably contribute to the stimulation of dermal fibroblasts. Inflammatory cells found in the dermis of scleroderma lesions are primarily T lymphocytes, mainly T helper cells. There is also increased interleukin 2 (IL-2) and IL-4 production.[20] At least in the systemic form of scleroderma, connective tissue growth factor has also been implicated.[11,21,22] A pathogenic role for dermal dendrocytes has also been suggested. The presence of $CD34^+$ and of factor $XIIIa^+$ dermal dendrocytes correlates with active inflammation and sclerosis in LS.[9] The pathogenic role of mast cells in LS has not been clearly elucidated, but mast cells may be a component of sclerodermatous skin, especially in the inflammatory and early stages.[23,24] Mast cell granules contain chemical mediators and proteolytic enzymes that can stimulate fibroblasts and even activate profibrotic cytokines, (i.e., TGF-β); histamine may also stimulate collagen production.[24]

Clinical Findings

There are three main variants of LS: morphea (Fig. 62-1), generalized morphea (see eFig. 62-1.1 in on-line edition), and linear scleroderma (Fig. 62-2, 62-3). Morphea and generalized morphea have a slow and insidious onset and typically affect the trunk.[2] Other less frequent variants include bullous, keloidal, guttate, and subcutaneous morphea (Fig. 62-4). Linear scleroderma is more common in children younger than



▲ **FIGURE 62-1** Morphea: A typical morphea plaque. At an earlier stage, one might see a violaceous border and more edema.







▲ **FIGURE 62-2** Linear scleroderma. **A.** Linear indurated plaques extending from the dorsal aspect of the right hand onto the third digit and involving the proximal and distal interphalangeal joints with contracture. **B.** Older morphea lesions on the foot.

the age of 10 years,[2] with the extremities most commonly affected. With the exception of en coup de sabre (Fig. 62-5; see eFig. 62-5.1 in on-line edition) and progressive facial hemiatrophy, the face and acral areas are typically spared; these areas are usually affected in systemic sclerosis.[2] Patients do not have Raynaud phenomenon or sclerodactyly, and progression to systemic sclerosis is rare.

CUTANEOUS LESIONS ***Morphea.*** Morphea presents with a single or a few circumscribed indurated patches or plaques generally with hypo- or hyperpigmentation (see Fig. 62-1). Early lesions present with edema with or without surrounding erythema. Pain occasionally is present for weeks before becoming clinically apparent. Active lesions can become indurated and maintain an erythematous or violaceous border. With progression, lesions often become whitened or yellow (see Fig. 62-2B), especially centrally. Plaques vary in size from 0.5 to 30 cm.[2] Sub-morphologic variants of morphea include guttate, bullous, keloidal, and morphea profunda (see Figs. 62-4, 62-5).[4] Some authors suggest that lichen sclerosus is a superficial or early form of morphea (see Chap. 63)[25,26]; indeed, the white, atrophic lesions of morphea may resemble lichen sclerosus. Chronic sclerodermoid graft-versus-host disease (see Chap. 28) can have clinically



▲ **FIGURE 62-3** Linear scleroderma: Late stage linear involvement of the knee and contracture. Note the atrophy of the tissue surrounding the patella.



▲ **FIGURE 62-4** Subcutaneous morphea: Involved areas on the thighs have minimal surface changes.



▲ **FIGURE 62-5** Linear scleroderma, en coup de sabre: Oblique view.

and histologically overlapping features of lichen sclerosus, morphea, and eosinophilic fasciitis (EF), suggesting that these disorders may be part of a spectrum of fibrotic disease.[27,28]

Generalized Morphea. Generalized morphea is a more severe form of morphea characterized by multiple lesions, often showing confluence and involving a larger body surface area (see Fig. 62-2). Some patients may have a subcutaneous form with little surface involvement (see Fig. 62-4).

Linear Scleroderma. Linear scleroderma is characterized by a band-like skin induration often with pigment changes, which may cross joint lines and sometimes leads to contractures (see Fig. 62-2A). This form of LS occurs more commonly in children and on the extremities. The fibrotic process often may extend to the subcutaneous tissue, including fascia and muscle (see Figs. 62-3, 62-5).[2] Joint contractures can be a significant cause of morbidity and deformities (see Fig. 62-2A). In very young children, the process may affect bone growth and disrupt development of tissues. A "pansclerotic" process involving the entire extremity is seen in very severe cases. Pansclerotic morphea in children has been associated with an increased risk of cutaneous squamous cell carcinoma, particularly in ulcerated areas of affected skin.[29,30]

Linear scleroderma occurring on the face may present either as a purplish-brown streak or as a single white, atrophic band running vertically on the forehead, generally known as *en coup de sabre* (see Fig. 62-5, see eFig. 62-5.1 in on-line edition). Progression to involve the scalp is common (see eFig. 62-5.1 in on-line edition). If only the subcutaneous tissue, muscle, and, occasionally, bone are involved, this ipsilateral form

of LS is known as *progressive facial hemiatrophy* or *Parry-Romberg syndrome* (see eFig. 62-5.2 in on-line edition).[2] The extent of skin involvement and the development of facial hemiatrophy are not always directly correlated. Patients affected with facial lesions and Parry-Romberg syndrome fall within a spectrum of disease severity. Mildly affected patients may have only a single linear atrophic band. Severely affected patients may have facial hemiatrophy with loss of subcutaneous tissue, muscle, and bone as well as atrophy of the tongue and salivary glands on the same side. Severely affected patients may also have central nervous system involvement of the meninges and brain with the potential for seizures, headaches, and vision changes.

Eosinophilic Fasciitis. EF, or Shulman syndrome, is a related disorder that presents with the rapid onset of symmetric areas of edema on the extremities (see Chap. 35; see also Deep Morphea in Chap. 68). The condition progresses over several weeks to cutaneous induration and contractures, with features similar to those of subcutaneous forms of LS.[2] Up to 30 percent to 40 percent of patients with EF have lesions indistinguishable from LS.

Atrophoderma of Pasini and Pierini. Atrophoderma of Pasini and Pierini is present in many patients with LS and presents with oval blue to dark brown hyperpigmented atrophic and slightly depressed areas. There is generally no induration or violaceous border in these lesions, in contrast to plaque-type morphea. The borders of the atrophoderma lesions have a "cliff-drop" appearance (see Fig. 65-4). Some consider atrophoderma to be an aborted, superficial form of LS (see Chap. 65).[4,5,31,32]

RELATED PHYSICAL FINDINGS Typically, LS patients have no signs beyond the cutaneous lesions. Initially, before the development of LS, patients may present with arthralgia and, occasionally, frank arthritis. These findings tend to resolve with progression of the cutaneous lesions, but may cause clinicians to consider systemic rheumatologic conditions. Other uncommon findings include fever, regional lymphadenopathy, migraines, abdominal pain, tinnitus, neuralgias, and spina bifida.[2,4] En coup de sabre has been associated with neurologic abnormalities, including seizures, uveitis, and inflammatory lesions of cortical and subcortical regions of the brain. However, there is no recognized internal organ involvement in LS.

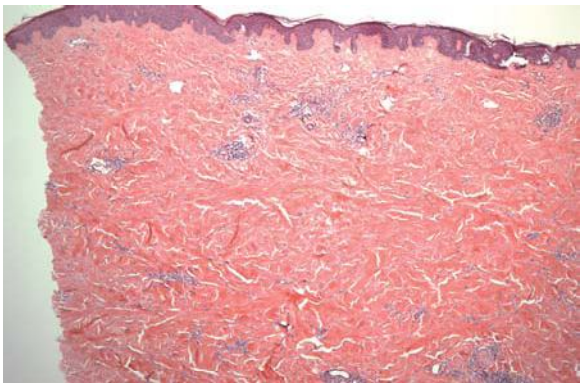

▲ **FIGURE 62-6** Morphea, histopathology: Note the squared-off edge of the biopsy specimen with mild superficial and deep inflammatory infiltrate and broadened compact collagen fibers, generally parallel to the epidermis.

LABORATORY ABNORMALITIES ***Serum Autoantibodies.*** Serum autoantibodies have been found with variable frequency in patients with LS. The most commonly found autoantibodies are antinuclear antibodies in up to 46 percent to 80 percent of patients,[5,6,33,34] usually with a homogenous immunofluorescence pattern. With extensive involvement, 36 percent to 53 percent of cases have anti–single stranded DNA and/or antihistone antibodies.[33,35,36] Typically, patients with generalized morphea have a higher frequency of antibody positivity than other subsets of LS, and autoantibodies correlate with a more severe clinical presentation, greater number of lesions, more sclerotic lesions, and a longer duration of clinical course.[2,5]

Other Serum Abnormalities. Blood eosinophilia has been described in 6 percent to 50 percent of patients with LS.[6,34] Levels of eosinophilia appear to correlate with disease activity. Declining levels of eosinophilia may coincide with a decrease in activity of the cutaneous lesions. Elevated immunoglobulins, particularly serum immunoglobulin G levels, have been associated with active, more extensive disease and joint contractures. A positive rheumatoid factor is seen in 26 percent of patients, and the erythrocyte sedimentation rate is elevated in 25 percent.

Histopathology. Early lesions may not have obvious or specific histologic changes. Vacuolization and destruction of endothelial cells with basal lamina reduplication have been reported.[2] Typically, in advanced indurated lesions, one sees a squared-off edge to the biopsy specimen (Fig. 62-6). Superficial and deep inflammatory infiltrates may occasionally be present. Very early lesions may demonstrate an inflammatory infiltrate in the deep dermis and subcutaneous tissue (see eFig 62-6.1 in on-line edition). Lymphocytes, macrophages, plasma cells, eosinophils, and mast cells are also seen. Deposition of glycosaminoglycans may be detected in the early stages of LS, particularly if care is taken to preserve this matrix component during histologic processing.[40]

Differential Diagnosis (Box 62-1)

Complications

Subcutaneous and muscle tissue atrophy and joint contractures are mainly seen in linear scleroderma (see Figs. 62-2,

Box 62-1

Differential Diagnosis of Morphea

Most Likely
- Systemic sclerosis (scleroderma)
- Eosinophilic fasciitis

Consider
- Lichen sclerosus
- Lupus profundus
- Connective tissue nevi
- Morpheaform basal cell carcinoma
- Toxic oil syndrome
- Chronic graft-versus-host
- Lipodermatosclerosis

Always Rule Out
- Lyme disease, acrodermatitis chronica atrophicans
- Phenylketonuria
- Porphyria cutanea tarda
- POEMS syndrome

POEMS = *p*olyneuropathy, *o*rganomegaly, *e*ndocrinopathy, *M* protein, and *s*kin changes.

62-3), generalized morphea (see eFig. 62-1.1 in on-line edition), and subcutaneous morphea (morphea profunda), and can cause significant impairment of mobility. Contractures are frequently seen in linear scleroderma involving limbs and crossing joint lines (see Fig. 62-2A). Children are more commonly affected by linear scleroderma than adults. In rare and severe cases, pansclerotic morphea may require amputation of the involved limbs because of their impaired growth. Patients with linear craniofacial involvement (see Fig. 62-5), such as en coup de sabre and facial hemiatrophy, may have neurologic, ophthalmologic, and oral abnormalities.[2,6] Severe cases of LS characterized by hyper- or hypopigmentation, contractures, and underlying tissue atrophy can be devastating. These complications lead to functional, cosmetic, and psychological difficulties.[2,5]



Prognosis and Clinical Course

In spite of the common presence of serum autoantibodies, LS typically does not have a recognized systemic involvement, although a rare overlap with other connective tissue disorders has been reported. Most cases of LS are self-limited, with clinical activity apparent for an average of 3 to 5 years. Some patients may have re-activation of apparently inactive lesions. In up to 13 percent of patients with linear scleroderma, one sees re-activation after several years of remission. En coup de sabre may have an insidious course lasting for decades. It may be that LS remains a chronic process with a low level of activity over many years. Slight atrophy with or without hyperpigmentation may be the only persistent sign of disease.

Treatment

In many cases, LS lesions become inactive spontaneously; however, more severe cases can cause irreversible fibrosis/sclerosis of the skin and subcutaneous tissues. Treatment is directed at the inflammatory component, cytokine release, and activation and collagen deposition. Many therapies have been used in the treatment of LS with variable success. Topical and systemic steroids, oral and topical vitamin D analogues, methotrexate, cyclophosphamide, azathioprine, hydroxychloroquine, intralesional interferon-γ, penicillin and D-penicillamine have all been tried.[41–47] Physical therapy is of the greatest importance in patients with contractures to preserve or improve limb function. Treatments that have been reported to be successful include D-penicillamine,[45] topical tacrolimus under occlusion,[48] oral calcitriol,[47] topical calcipotriene,[47–49] methotrexate alone[42] or combined with pulsed corticosteroids,[44] topical imiquimod,[50] topical tretinoin with ammonium lactate,[51] and N-(3′, 4-dimethoxycinnamoyl) anthralinic acid—an antiallergy medication that inhibits passive cutaneous anaphylaxis.[52] In pediatric cases with impaired growth of the affected extremity, timely surgical intervention and "stapling" of the epiphyseal plates of the normal side may be effective. This will result in slower, but continued, growth of the affected extremity and may lead to a lesser degree of limb disparity.

PHOTOTHERAPY Several studies have demonstrated marked improvement in a majority of LS patients using psoralen and ultraviolet A light, broad band ultraviolet A (UVA), or UVAI phototherapy.[3,55–60]

PRACTICAL APPROACH In the absence of truly randomized and prospective clinical trials, the approach to patients is often highly individualized. For limited involvement with one or few morphea lesions, one can use topical treatments such as calcipotriene, tacrolimus, retinoids, or no treatment at all. On the other hand, lesions of en coup de sabre can lead to considerable disfigurement. Our approach to those facial lesions has been the use of either hydroxychloroquine or perhaps methotrexate in combination with small doses (5 to 10 mg) of systemic corticosteroids. For more generalized involvement, we usually use phototherapy. If that approach is not successful, or if there is substantial subcutaneous involvement, a useful medication is methotrexate. Beyond these approaches, one is left with even more anecdotal experience. D-penicillamine, cyclosporine, and other immunosuppressive agents have been used.

KEY REFERENCES

The full reference list for all chapters is available at www.digm7.com.

4. Yu BD, Eisen AZ: Scleroderma, in *Fitzpatrick's Dermatology in General Medicine*, edited by Freedberg et al. New York, McGraw-Hill, Medical Pub. Division, 2003 p 1709
5. Falanga V: Localized scleroderma. *Med Clin North Am* **73**:1143, 1989
9. Kawakami T et al: Immunohistochemical analysis of transforming growth factor beta 3 expression in solitary morphoea profunda with histological membranocystic changes. *Br J Dermatol* **146**:171, 2002
41. Sapadin AN, Fleischmajer R: Treatment of scleroderma. *Arch Dermatol* **138**:99, 2002
42. Seyger MM et al: Low-dose methotrexate in the treatment of widespread morphea. *J Am Acad Dermatol* **39**:220, 1998
44. Kreuter A et al: Pulsed high-dose corticosteroids combined with low-dose methotrexate in severe localized scleroderma. *Arch Dermatol* **141**:847, 2005

CHAPTER 63

Lichen Sclerosus

Ulrich R. Hengge

Lichen sclerosus (LS) is a chronic inflammatory dermatosis of the anogenital area that affects quality of life due to the severe itching. LS may also present with extragenital manifestations that are generally non-pruritic. Of note, vulvar disease seems to have an increased risk of squamous cell carcinoma, but the role of additional co-factors (e.g., human papillomavirus infection or prior radiotherapy) has not been defined.

EPIDEMIOLOGY

The incidence of LS has not been precisely determined. It has been estimated to be in the order of 14 per 100,000 persons per year.[1] LS is more prevalent in females, accounting for a 5:1 gender ratio. It preferentially affects women in the fifth or sixth decade of life and children younger than the age of 10 years.[1,2] Up to 15 percent of LS cases occur in children, particularly in girls, and one study reported a prevalence of 1 in 900 premenarchal girls.[3] A 0.07 percent incidence in males has recently been determined in a study of 153,432 male soldiers.[4] Among blacks and Hispanics, the incidence in this group was 1.06 percent, whereas the

LICHEN SCLEROSUS AT A GLANCE




- Infrequent chronic inflammatory dermatosis with anogenital and extragenital manifestations.
- Preferentially affects women in the fifth or sixth decade of life and children younger than the age of 10 years; gender ratio 5:1 female–male.
- Antibodies to extracellular matrix protein-1 and T cells with receptor rearrangement point to an autoimmune pathogenesis.
- Anogenital manifestations cause severe discomfort (pruritus, dyspareunia, dysuria, and painful defecation) and present with polygonal papules and porcelain-white plaques, erosions, and various degrees of sclerosis.
- Vulvar lichen sclerosus is associated with an increased risk of squamous cell carcinoma; the role of human papillomavirus infection or prior radiotherapy remains to be elucidated.
- Potent topical corticosteroids and skin care are the most successful therapeutics; calcineurin antagonists have also recently demonstrated benefit.
- Interdisciplinary management is essential for long-term control.

incidence was only 0.051 percent in white soldiers.[4] LS seems to be a prominent cause of phimosis; in one study, 14 percent of adolescent boys had LS, whereas 40 percent of phimosis cases in adult men were associated with LS.[5] Similarly, a recent study of foreskins examined after therapeutic circumcision for phimosis confirmed many cases of unrecognized LS.[6] As genital LS in males is almost exclusively seen in uncircumcised men, the rate of circumcision in a given population has a strong impact on the occurrence of the disease.

ETIOLOGY AND PATHOGENESIS

The cause of LS is unknown. There is no genetic predisposition.[7] Evidence for the presumed infectious cause, such as acid-fast rods, spirochetes, or *Borrelia*, has not been found.[7] Serologic and clinical evidence of thyroid disease, alopecia areata, pernicious anemia, and vitiligo suggested an association with LS. Extragenital LS is commonly seen in association with plaque-type morphea, and some authors have suggested a common pathomechanism. Recently, low-titer autoantibodies against the extracellular matrix protein-1 (ECM-1) and collagen XVII have been identified in 67 percent of LS.[8,9] ECM-1 (see Chap. 137) may be involved in basement membrane and interstitial collagenous fiber assembly and growth-factor binding,[10] and may also regulate blood vessel function.[11] Local irritation also seems to play a role in some cases. The disturbed function of fibroblasts with increased production of collagen has been demonstrated in LS.[12,13]

CLINICAL FINDINGS

Cutaneous Lesions

Polygonal papules and porcelain-white plaques with atrophic fragile skin, fissures, telangiectasias, purpura, erythema, erosions, and different degrees of sclerosis are present in the anogenital area (Fig. 63-1A to F); sometimes the classical figure-8 pattern of the vulva and anus may be observed (see Fig. 63-1E). Blisters (occasionally hemorrhagic) may develop when the lichenoid infiltrate separates epidermis from the sclerotic dermis. The size of LS lesions may vary from a few millimeters to large portions of the trunk. Anogenital LS frequently causes intractable itching and soreness, dyspareunia, dysuria, discomfort with defecation, or genital bleeding and, with time, may lead to destructive scarring (see Fig. 63-1F). Gradual obliteration or synechiae of the labia minora and clitoris, as well as stenosis of the introitus, may also result (see Chap. 76). Male genital LS is usually confined to the glans penis, prepuce, or foreskin remnants (see Fig. 63-1A to C). Penile shaft involvement is less common, whereas scrotal involvement is rare. Many male genital LS cases are simply diagnosed as phimosis. In severe cases, erections may become painful (see Chap. 75). Extragenital manifestations typically affect the thigh, the neck, and trunk; lesions are usually asymptomatic (Fig. 63-2). Rarely the oral mucosa may also be involved.

Related Physical Findings

Except for the association with autoimmune thyroid disease, alopecia areata, pernicious anemia, morphea, and vitiligo, which should be ruled out, no additional related findings have been reported. In particular, genital infections by herpes simplex virus or *Candida* do not seem to be increased in LS patients.

LABORATORY TESTS

Histopathology

Classical LS shows an atrophic epidermis and a lichenoid infiltrate at the dermal-epidermal junction.[14] Papillary edema is usually seen in early LS but is gradually replaced by fibrosis with homogenization of acid mucopolysaccharides as the lesion matures (Fig. 63-3). The lymphocytic infiltrate in LS contains abundant T cells, B cells, and antigen-presenting dendritic cells that are major histocompatibility complex class II^+, $CD8^+$, and $CD57^+$.[15,16] A monoclonal T-cell receptor γ-chain rearrangement has alluded to the existence of an LS antigen, potentially the ECM-1 protein, which is also recognized by the recently described autoantibodies.[8,17] Epidermal hyperplasia and/or dysplasia associated with LS on vulvar specimens are associated with an increased risk of malignant transformation, especially in conjunction with infection by high-risk papillomaviruses.

Special Tests

Imaging studies are only needed in special situations (e.g., urinary obstruction secondary to stenosing genital LS). High-resolution ultrasound is occasionally used to document the depth of sclerosis.

DIAGNOSIS AND DIFFERENTIAL DIAGNOSIS

A skin punch biopsy of a mature lesion will confirm the diagnosis if the diagnosis is not obvious by clinical examination. ECM-1 autoantibodies may be detected by specialized laboratories; a commercial enzyme-linked immunosorbent assay has recently become available.[18] Despite the described association with autoimmune diseases, an autoimmune workup (e.g., anti-nuclear antibody, parietal cell antibody, vitamin B_{12} levels, thyroid function tests) is not generally recommended due to their relatively low occurrence.[19] For the same reason, *Borrelia* antibody titers should not be analyzed, as they are not associated with LS.[20] To exclude squamous cell carcinoma, repetitive biopsies may be indicated.



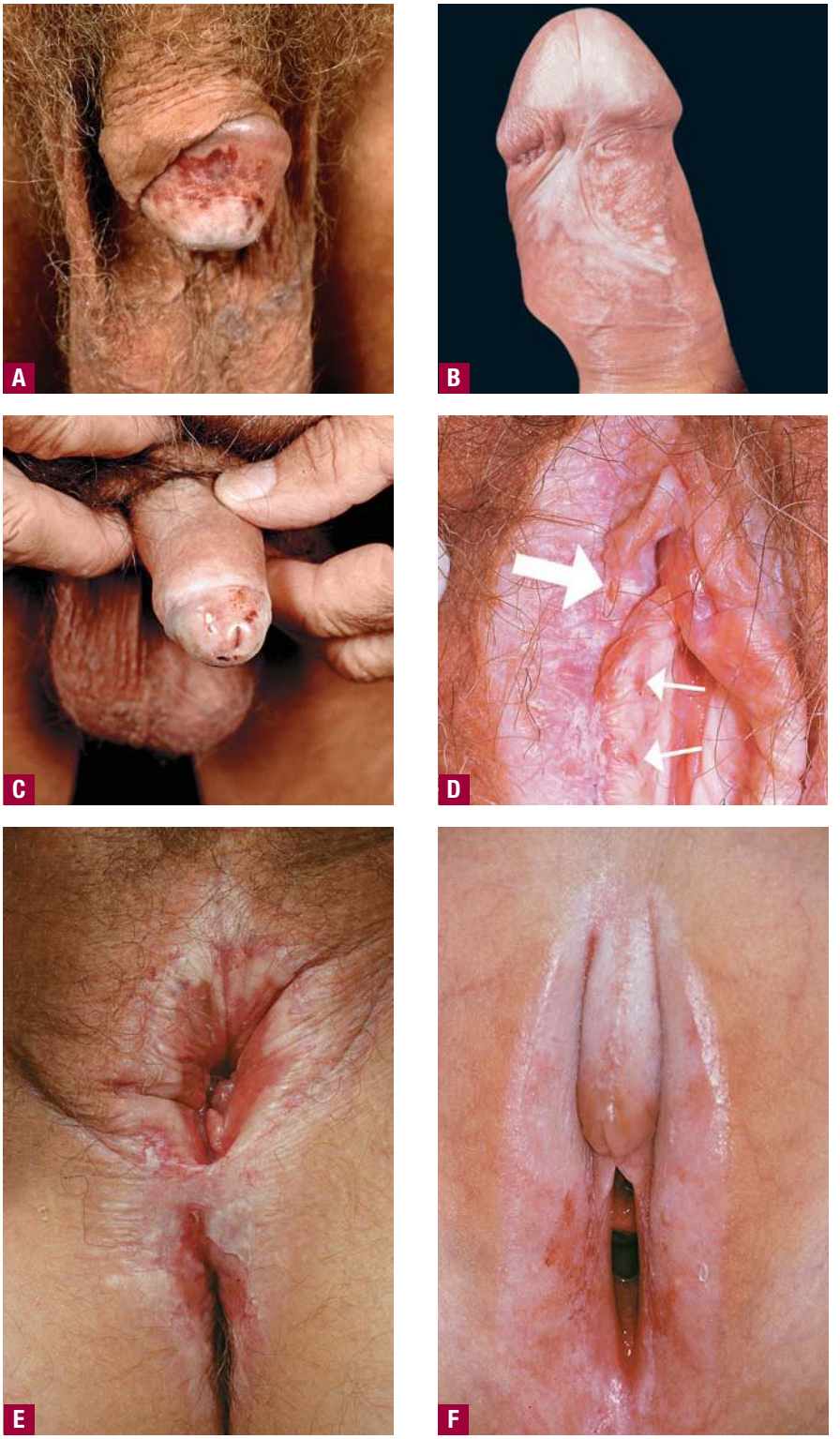

▲ **FIGURE 63-1** **A.** Early sclerosis and significant hemorrhage on the glans in early lichen sclerosus. **B.** Sclerosis of the frenulum and increased vulnerability with bleeding upon sexual intercourse. **C.** Significant sclerosis of the glans and conglutination with the preputium in advanced lichen sclerosus. Note narrowing of the urethral orifice and hemorrhage. **D.** In addition to the well-demarcated white vulvar plaque that is classic for lichen sclerosus, the waxy and crinkled texture, purpura (*small arrows*), and erosions (*large arrow*) are diagnostic. **E.** Sclerotic vulva with disappearance of the smaller labia and shrinkage of the introitus. Significant erythema and erosions are seen on the vulva and the anus in a figure-8 configuration. The patient complained of severe pruritus and dyspareunia. **F.** Erosive, sclerotic vulva in an 8-year-old girl.



▲ **FIGURE 63-2** Extragenital lichen sclerosus with confluent whitish papules and plaques on the skin over the thoracic and lumbar spine.

The differential diagnosis of LS and localized scleroderma (morphea) may be difficult (Box 63-1; see Fig. 63-2). Clinically, morphea may be confused with extragenital LS. Morphea represents a circumscribed connective tissue disease with a number of different presentations. Typical early plaque-type lesions show a lilac ring with progressive central induration and whitening and peripheral hyperpigmentation (see Chap. 62). Histologically, early morphea presents as a dense lymphocytic, superficial, and deep perivascular infiltrate with degeneration of collagen fibers. In later stages, inflammation is replaced by dermal fibrosis much like the changes seen in LS. Patients have been described with lesions typical of

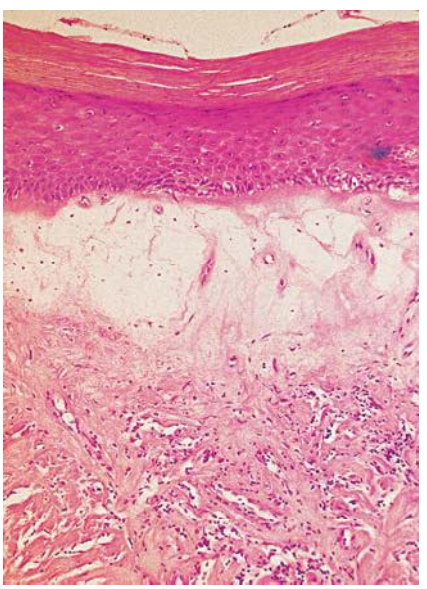

▲ **FIGURE 63-3** Hyperkeratotic epithelium without rete ledges and basal degeneration of keratinocytes. Collagen fibers are homogenized in the papillary dermis, and a lichenoid lymphocytic infiltrate is present. The dermal vessels are dilated.

Box 63-1

Differential Diagnosis of Lichen Sclerosus

GENITAL MANIFESTATIONS

Consider

- Balanitis plasmacellularis (Zoon disease)
- Child abuse (sexual)
- Complications of dermatologic laser surgery
- Contact dermatitis, including excessive genital hygiene
- Lichen planus
- Lichen simplex chronicus
- Vitiligo

Rule Out

- Cicatricial (scarring) pemphigoid
- Erythroplasia of Queyrat (Bowen disease)
- Leukoplakia
- Squamous cell carcinoma
- Paget disease

EXTRAGENITAL MANIFESTATIONS

Consider

- Anetoderma
- Atrophoderma of Pasini and Pierini
- Idiopathic guttate hypomelanosis
- Lipoid proteinosis (mild forms, see Chap. 137)
- Lichen nitidus
- Lichen planus
- Morphea
- Pinta
- Tinea versicolor

Rule Out

- Discoid lupus erythematosus
- Graft-versus-host disease (scleroderma-like)
- Extramammary Paget disease
- Squamous cell carcinoma

both plaque-type morphea and the chalky white, atrophic plaques of LS, suggesting that morphea and LS may share a common pathomechanism.[21] Anti-nuclear antibodies may be positive in either morphea or LS.

Constipation is a common complication in children with anogenital LS.[22] The associated purpura and discoloration often raise concern about child abuse, especially if LS is not recognized (see Chap. 105). LS in children has occasionally been associated with a perineal pyramidal protrusion, a common lesion that can be confused with condyloma and is also associated with constipation. This association further (erroneously) increases the suspicion of sexual abuse.[23,24] It should be noted, however, that LS and child abuse may co-exist[25] and that some cases of LS have been linked with trauma of the anogenital region (see Chap. 105). See Box 63-2 for pitfalls in the diagnosis of LS.

Box 63-2

Pitfalls in the Diagnosis of Lichen Sclerosus

- Wrong/incomplete diagnosis in the case of squamous cell carcinoma.
- Lichen sclerosus, especially when bullous, hemorrhagic, or erosive; may be confused with child abuse.
- Inappropriate surveillance for steroid adverse effects.
- Irritant dermatitis due to overwashing of the anogenital area may imitate lichen sclerosus and facilitate the occurrence of contact dermatitis.

COMPLICATIONS

Besides dyspareunia, urinary obstruction, constipation, secondary infection related to ulceration, and steroid use, squamous cell carcinoma represents the main complication in females (Fig. 63-4). The lifetime risk of developing squamous cell cancer as a complication of long-standing LS has been estimated in the order of 4 percent to 6 percent.[1,26] Age, long duration of LS, human papillomavirus infection, and evidence of hyperplastic changes represent significant risk factors.[27,28] In males, painful erections and urinary obstruction represent the most frequent complications.

PROGNOSIS AND CLINICAL COURSE

The prognosis of LS is good for most anogenital cases, especially for those in prepubertal children that may resolve spontaneously or may be healed after treatment with ultrapotent topical steroids.[29] The disease is usually self-limiting, but requires treatment due to the severity of patient discomfort. Recalcitrant chronic LS causing erosions and progressive scarring may result in severe sexual dysfunction. Cosmetic improvement for extragenital cases and for chronic atrophic genital disease is rather poor.

TREATMENT

Various attempts to treat LS have been undertaken. The single most effective treatment of LS is ultrapotent topical corticosteroids such as clobetasol.[17,29–38] However, there is no systematic trial to support this common practice. Due to corticosteroid adverse effects, the treatment period with ultrapotent steroids should be limited, generally to less than 4 weeks. Treatment should be continued, when necessary, with less potent corticosteroids or calcineurin inhibitors (see below).



▲ **FIGURE 63-4** **A.** A 1.5-cm, sharply demarcated ulcer of long-standing lichen sclerosus on the right major labium. **B.** Histology reveals squamous cell carcinoma.

Case series using topical tacrolimus and pimecrolimus have shown clinical effectiveness.[40–44] Although many of the effects of topical tacrolimus parallel those of corticosteroids,[45] adverse effects such as atrophy, telangiectasias, and pigment changes do not occur. A recent multicenter, phase II trial has assessed the safety and efficacy of twice-daily application of tacrolimus ointment 0.1 percent in 84 patients (49 women, 32 men, and 3 girls) with long-standing LS (mean duration, 5.8 years),



with a follow-up period of 18 months.[46] Clearance of active LS was reached by 42.9 percent of patients, with at least 50 percent improvement in an additional 34.3 percent of patients. However, the duration of treatment to achieve an optimal response was up to 24 weeks.

Systemic therapy with retinoids, including isotretinoin, etretinate, and acitretin and oral tacrolimus, have been useful in small trials. Systemic antibiotics against borreliosis and penicillamine have not proved effective.

Destructive surgical therapies, such as cryotherapy, the tissue-vaporizing carbon dioxide lasers, and non-ablative lasers such as the pulsed dye and Erb: YAG lasers, have been reported to work in LS but should only be used with caution. Vulvectomy should be limited to cases in which squamous cell carcinoma has been detected.

Female LS patients should be particularly monitored for any sign of secondary genital malignancy. Prepubertal LS in girls may resolve spontaneously; however, some of these patients may eventually suffer from vulvodynia in adulthood. In case of LS-associated dyspareunia that interferes with sexual activity, the use of topical anesthetics should be considered.

Circumcision will generally resolve male genital LS and the associated phimosis, although potent topical steroids may obviate the need for surgery. Asymptomatic extragenital LS usually requires no treatment other than cover makeup in selected cases.

PREVENTION

No truly preventive measures of LS have been reported. An interdisciplinary management is essential for the long-term control of LS. Specialists from gynecology, urology, pediatrics, and psychosomatic medicine should be involved in patient care and collaborate to prevent significant complications, including the monitoring for squamous cell cancer and corticosteroid adverse events. It has also been helpful to circulate information via patient organizations for LS.

KEY REFERENCES

The full reference list for all chapters is available at www.digm7.com.

1. Powell JJ, Wojnarowska F: Lichen sclerosus. *Lancet* **353**:1777, 1999
3. Powell JJ, Wojnarowska F: Childhood vulvar lichen sclerosus: An increasingly common problem. *J Am Acad Dermatol* **44**:803, 2001
8. Oyama N et al: Autoantibodies to extracellular matrix protein 1 in lichen sclerosus. *Lancet* **362**:118, 2003
15. Farrell AM et al: Lichen sclerosus: Evidence that immunological changes occur at all levels of the skin. *Br J Dermatol* **140**:1087, 1999
27. von Krogh G, Dahlman-Ghozlan K, Syrjanen S: Potential human papillomavirus reactivation following topical corticosteroid therapy of genital lichen sclerosus and erosive lichen planus. *J Eur Acad Dermatol Venereol* **16**:130, 2002
34. Dahlman-Ghozlan K, Hedblad MA, von Krogh G: Penile lichen sclerosus et atrophicus treated with clobetasol dipropionate 0.05 percent cream: A retrospective clinical and histopathological study. *J Am Acad Dermatol* **40**:451, 1999
46. Hengge UR et al: Multicenter, phase-II trial on the safety and efficacy of topical tacrolimus ointment for the treatment of lichen sclerosus. *Br J Dermatol* **155**:1021, 2006



CHAPTER 64

Dermal Hypertrophies

Mandy Harting
M. John Hicks
Moise L. Levy

DERMAL HYPERTROPHIES AND BENIGN DERMAL TUMORS

Dermal tumors and proliferations represent an often encountered and clinically bewildering group of disorders. This chapter reviews several of the benign dermal tumors. Some of these present clinically in a fashion that can offer clues diagnostically. Histopathology is key to the ultimate diagnosis and proper management of several of these conditions. Malignant fibrous tumors of the dermis are discussed in Chap. 125.

FIBROMATOSES

Fibromatoses are proliferations composed of fibrous tissue, fibroblastic cells, or spindled stromal cells with varying degrees of cellularity, and often exhibiting myofibroblastic or fibroblastic differentiation. Although on occasion the fibromatoses of childhood may spontaneously regress, those occurring in adults usually behave much more aggressively. Generally, fibromatoses are considered benign conditions; however, rare malignant transformation occurs in some tumors.

CHILDHOOD FIBROMATOSES

Solitary Lesions

FIBROMATOSIS COLLI (STERNOMASTOID TUMOR OF INFANCY) Fibromatosis colli (sternomastoid tumor of infancy) is a self-limiting disorder that is characterized by a benign proliferation of fibroblasts in the lower one-third of the sternocleidomastoid muscle. Fibromatosis colli usually appears in the first few weeks of life and can grow rapidly. This condition may clinically and radiographically mimic other tumors, such as rhabdomyosarcoma or neuroblastoma, due to its rapid growth and marked expansion of the sternocleidomastoid.[1] It is the most common cause of neonatal torticollis,[2] although other causes of tor-

DERMAL HYPERTROPHIES AT A GLANCE



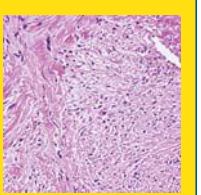

- There are childhood and adult variants of dermal hypertrophies, which can be indolent or aggressive in their behavior.
- Desmoid tumors are locally aggressive and infiltrative, deep-seated tumors characterized by high recurrence rates after surgical excision.
- Hypertrophic scars and keloids remain very common dermal hypertrophies, which are often difficult in their management.
- Other dermal hypertrophies include solitary lesions, such as dermatofibromas and acrochordons, hamartomas, and connective tissue nevi.



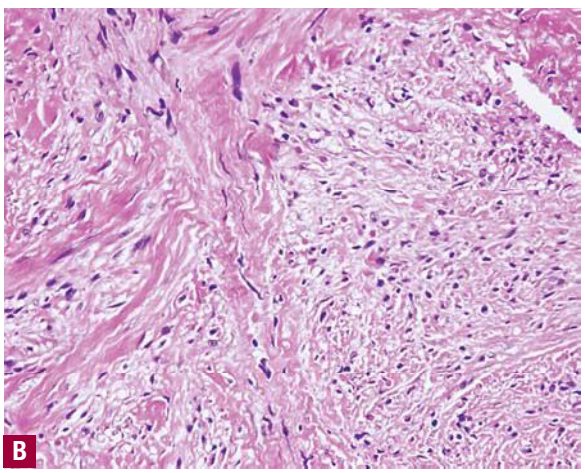

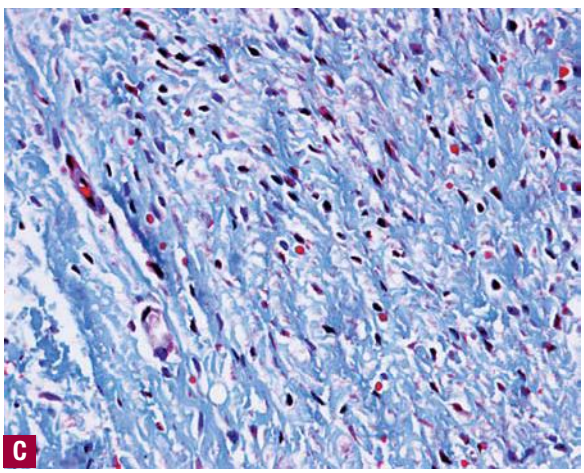

◀ **FIGURE 64-1** **A.** Well-defined pink nodule of infantile digital fibromatosis. Usually the third to fifth digits are affected; here, the tumor is found on the second digit of an infant. **B.** Infantile digital fibromatosis possesses poorly circumscribed interlacing bundles of myofibroblasts embedded in a modest background of collagen (hematoxylin and eosin 100× magnification A). **C.** The defining characteristic is densely eosinophilic, cytoplasmic inclusion bodies in fibroblasts that also stain red with Masson trichrome (100× magnification).



ticollis, such as vertebral anomalies, ocular muscle disorders, Sandifer syndrome, and superficial and deep cervical infections, must be considered.[1] This condition usually resolves within the first year of life.[1]

Invasive diagnostic and therapeutic interventions are not necessary, and excisional biopsy should be reserved for cases in which malignancy is highly suspected.[3] Fine-needle aspiration reveals clusters of benign, spindled, plump fibroblasts with ovoid to elongated nuclei. It is the preferred technique in diagnosing fibromatosis colli.[2]

INFANTILE DIGITAL FIBROMATOSIS (INCLUSION BODY FIBROMATOSIS, REYE TUMOR) Infantile digital fibromatosis was first described by Reye in 1965 as a rare form of superficial juvenile fibromatosis presenting as an asymptomatic, flesh-colored, firm nodule on the fingers and toes, primarily in infants and less commonly in children. This tumor is a benign fibroblastic proliferation that appears in the first year of life and may be present at birth in one-third of cases.[4] The tumor almost always affects the third to fifth digits, rarely the second digits, and never the thumb or hallux (Fig. 64-1A).

Histologically, poorly circumscribed, interlacing bundles of myofibroblasts are observed. The pathognomonic finding is eosinophilic, paranuclear inclusion bodies in the fibroblasts, which stain red with Masson trichrome stain and purple with phosphotungstic acid-hematoxylin (see Fig. 64-1B, C).[5] These inclusions are actin filaments arranged in a whorled pattern on electron microscopic study, and they immunoreact with smooth muscle and vimentin. At times, these inclusions may be sparse, but their presence may eliminate infantile myofibromatosis and congenital infantile fibrosarcoma from the differential diagnosis. It should also be realized that digital fibromas may comprise one component of a syndrome. Digital fibromas have occasionally been associated with facial pigmentary dysplasia, focal dermal hypoplasia, metacarpal and metatarsal disorganization, and limb malformations.[6,7]

At one time, infantile digital fibromatosis was considered a potentially malignant disease. However, malignant transformation or metastatic disease has never been reported to date; thus, conservative therapy with simple surgical excision of the nodule only is recommended.[8] Although spontaneous regression over years has been observed in some cases, surgical intervention has been used because residual deformities of the digit and contractures can occur with larger lesions.[4] Up to 60 percent of cases recur even after wide local excision.[8] Intralesional fluorouracil has been used with good clinical outcome in one case.[8] Some have used intralesional triamcinolone for recurrences after shave biopsy, with good results.

CALCIFYING APONEUROTIC FIBROMA Calcifying aponeurotic fibroma is an uncommon, benign, fibrous tumor that was first described by Keasbey in 1953.[9] It is most commonly found on the palms and soles of children and young adults. However, it can present in any area that is closely related to aponeuroses, such as the neck, forearm, popliteal fossa, lower back, and thigh. It is a very slow growing, deep-seated firm proliferation that presents as an asymptomatic infiltrative soft tissue mass, usually measuring less than 3 cm in diameter.[10] Its peak incidence is between the ages of 8 and 14.[11]

Surgical excision is the current recommendation. However, 50 percent of the tumors recur locally, usually within 3 years of diagnosis, and rare cases of malignant transformation have been reported.[11,12] Due to calcifications, calcific stippling may be seen by x-ray. Because of the tendency to recur, magnetic resonance imaging has been used to deter-

mine the extent of the tumor and best surgical strategy.[13] Local recurrence is more common in children younger than 5 years of age.

Multifocal Lesions

AGGRESSIVE INFANTILE FIBROMATOSIS Aggressive infantile fibromatosis presents as rapidly growing nodules on the trunk, with a high potential for local invasiveness. This tumor rarely spontaneously regresses.[14] Histologically, the tumor is variable, including an immature mesenchymal pattern, a collagenous pattern, and a desmoid pattern. Distant metastasis rarely occurs. Whether this represents metastatic disease versus multifocal lesions is difficult to determine from a clinical and radiographic standpoint. Cytogenic and molecular pathology analyses are important.



INFANTILE MYOFIBROMATOSIS First described by Enzinger in 1981, infantile myofibromatosis is the most frequent fibromatosis in childhood and consists of a benign proliferation of fibroblasts and myofibroblasts.[16] Solitary or multiple nodules involving the skin, striated muscles, bones, and viscera may be seen. Three types exist: solitary, multicentric, and generalized. Patients that have generalized disease often have visceral involvement, and may have a 75 percent mortality rate.[17,18] Although most cases are sporadic, a familial pattern of inheritance has been reported in few cases.[17]

Extensive surgical therapy is reserved for patients with multicentric or generalized disease because solitary lesions may spontaneously regress. Close clinical follow-up of solitary lesions with excision when they affect function or are of a cosmetic concern would be indicated. Due to the increased mortality rate of patients with multicentric and generalized disease, chemotherapy and radiotherapy have been used in these cases.[17]

JUVENILE HYALINE FIBROMATOSIS Juvenile hyaline fibromatosis (JHF) was first reported by Murray in 1873 as molluscum fibrosum, but the current name in use was provided by Kitano in 1976.[19] It is a rare, autosomal recessive condition, characterized by the onset, at ages 2 months to 4 years, of subcutaneous, pearly papules and firm, large nodules that progressively enlarge and tend to ulcerate.[20] Recently, a defect on chromosome 4q21 associated with the locus of the capillary morphogenesis gene-2 (CMG2) has been demonstrated. This gene encodes a protein that is upregulated during capillary formation. The resulting protein binds to laminin and collagen IV via von Willebrand's factor type A domain. CMG2 also acts as a cellular receptor for anthrax toxin. How absence of CMG2 protein leads to JHF is not clear, but perturbation of basement–membrane matrix assembly likely contributes to the characteristic perivascular hyaline deposition.[6,7,19,20]

The most commonly affected areas include the nose, chin, ears, scalp, back, and knees.[19] Patients tend to have gingival hypertrophy, which can result in periodontal disease and caries due to problems maintaining adequate oral hygiene. Deposition of hyaline material is found in various organs, including the skin.[20,21] Progressive joint contractures, osteolysis, and muscular weakness can result in severe debilitation.[19]

Histologically, cords of spindled myofibroblasts, often with cytoplasmic vacuoles, occur in hyalinized and chondroid stroma. Calcospherules have been demonstrated and are helpful diagnostic markers.[19] Ultrastructural analysis shows amorphous, fine fibrillar material with the banding pattern of type VI collagen.

The differential diagnosis of JHF includes infantile systemic hyalinosis (ISH), which is now known to be allelic. Currently, no widely accepted effective treatment exists for JHF or ISH. Surgical excision is often not feasible due to the number and size of the tumors, and anesthesia can be complicated because of the oral and dental issues. Administration of interferon-α 2b over 2 years led to significant improvement in an 8-year-old patient with JHF.[20]

FIBROMATOSES OF ADULT ONSET

Dupuytren Contracture (Palmar Fibromatosis)

Dupuytren contracture (palmar fibromatosis) is a fibroproliferative disease characterized by bilateral, progressive fibrosis of the palmar fascia, most commonly presenting as nodules over the fourth and fifth metacarpal head. Joint contractures and flexion deformities of the fingers soon follow. Significant risk factors for development of Dupuytren contracture include old age, male sex (three- to fourfold increase), white northern European ancestry, family history, seizures, alcohol-induced liver disease, trauma, smoking, and diabetes mellitus.[22–24] This condition rarely occurs before age 30 years and is very rare in children. Ledderhose disease is characterized by plantar fibrosis over the medial sole of the foot and is identical to Dupuytren disease histologically.[23]

Histologically, the palmar aponeurosis and adipose tissue demonstrate nodules of fibroblasts in a dense reticulin network. In older lesions, thick, acellular collagen bundles predominate.[25]

Patients may gain significant functional benefit from surgical correction of the deformity.[22] Recurrence is more common in patients with greater initial deformity, but less common if good surgical correction is achieved and postoperative rehabilitation provided.[22,29]

Peyronie Disease (Induratio Penis Plastica, Penile Fibromatosis)

Fibrosis of the fibrous septa between the corpus spongiosum and the corpora cavernosa along the dorsum of the penis is termed *Peyronie disease*. This condition is often associated with Dupuytren disease (up to 4 percent of cases), and risk factors include genetic predisposition, trauma to the penis, and systemic vascular diseases. Smoking and alcohol consumption also seem to have some role in the development.[30] The histology is very similar, if not identical, to that of Dupuytren contracture.

Over several years, many patients have spontaneous regression of their lesions.[31] However, some new surgical corrective techniques have proved safe and beneficial (e.g., corporeal plication, which consists of placing longitudinal plication sutures of braided polyester on the opposing side of curvature until it is corrected during artificially induced erection).[32]

Knuckle Pads

Knuckle pads are circumscribed, hyperkeratotic, or fibrous growths over the dorsal aspects of the interphalangeal joints.[33] In children, these tend to be reactive and primarily epidermal. The association of knuckle pads with leukonychia, sensorineural deafness, and, sometimes, palmoplantar keratoderma, is seen in Bart-Pumphrey syndrome and results from mutations in GJB2, which encodes connexin 26. Adult cases may show dermal involvement, and many patients have co-existing fibromatosis of the palmar, plantar, or penile aponeurosis or fascia.[34] Knuckle pads can sometimes be difficult to distinguish from synovitis, but ultrasound can quickly identify these su-

perficial fibrous growths.[35] Histologically, these lesions are very similar to Dupuytren disease. False knuckle pads are due to repetitive mechanical trauma or factitious injury seen in bulimic patients. Affected individuals show these characteristic, self-induced lesions as on the dorsal aspect of the second and third fingers because of chronic abrasion of the skin against the maxillary incisors during forced emesis.

Pachydermodactyly

Pachydermodactyly is a rare form of benign digital fibromatosis consisting of asymptomatic, circumscribed swelling of the fingers. Currently, there are only 62 reported cases in the literature. Clinically, it appears as a painless enlargement of the tissues surrounding the proximal interphalangeal joints of the second to fifth fingers. It primarily affects adolescent males, with a male-female ratio of 5:1.

Desmoid Tumor

Desmoid tumors, also known as *deep* or *aggressive fibromatoses*, are low-grade clonal mesenchymal neoplasms that fall within the spectrum of a variety of benign musculoaponeurotic fibromatoses. These poorly circumscribed tumors are deep-seated, characterized by an infiltrative growth pattern and locally recur, but lack the ability to metastasize. These tumors have a mutation in the adenomatous polyposis coli (APC) gene (5q21) and are associated with familial adenomatous polyposis (FAP) syndrome and Gardner syndrome.[6,7] There may be an estrogenic influence with these tumors that is noted during pregnancy.[37] Injury precedes some cases.[38]

Desmoid tumors are usually categorized as extra-abdominal or intra-abdominal tumors. The extra-abdominal tumors are often located in the area of the shoulder and pelvic girdle or chest and neck wall (Fig. 64-2). These tumors are most often sporadic.[41] Intra-abdominal desmoids have been associated in 10 percent to 15 percent of patients with FAP and Gardner syndrome, with the latter usually presenting as retroperitoneal tumors.[37,39]

Devoid of metastatic potential, they tend to form large, infiltrative masses that recur repeatedly.[40] Rarely, desmoid tumors transform into classic fibrosarcomas.[41]

Histologically, these are poorly circumscribed proliferations of mature fibrous tissue arising from a musculoaponeurosis. There is a paucity of cellularity with collagenous stroma predominating. When compared with classic fibrosarcomas, desmoid tumors are more monomorphous and less cellular.



▲ **FIGURE 64-2** Desmoid tumors involving upper chest and epigastric region. These represent recurrences after multiple surgical interventions. This patient also had intra-abdominal desmoid tumors.

Due to the aggressive and infiltrative behavior of these tumors, treatment can be very difficult. Although surgery is widely accepted as the first-line treatment for extra-abdominal and abdominal wall tumors, complete surgical excision is difficult to achieve, and recurrences occur in 25 percent to 65 percent of cases.[39]

REACTIVE AND DEGENERATIVE FIBROUS LESIONS

Hypertrophic Scars and Keloids

Hypertrophic scars and keloids result from the uncontrolled synthesis and excessive deposition of collagen at sites of prior dermal injury and wound repair. They often occur after local skin trauma (such as laceration, tattoo, burn, injection, ear piercing, vaccination, or surgery) or inflammatory skin disorders (such as acne, bites, or abscesses). A keloid extends beyond the borders of the original wound, does not regress spontaneously, grows in a pseudotumor fashion with distortion of the lesion, and tends to recur after excision (Fig. 64-3). Hypertrophic scars, in contrast, remain confined to the borders of the original wound and most of the time retain their shape. Hypertrophic scars and keloids show a predilection for areas with increased tension, such as the shoulders, sternum, mandible, and arms. They are more common in Asians and dark-skinned races.[45] Hypertrophic scars can occur at any age, whereas keloids commonly occur in the third decade. Keloidal growth can be triggered by pregnancy.

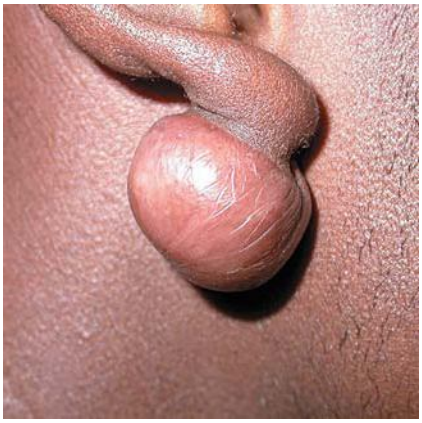

▲ **FIGURE 64-3** Keloid. Firm, non-tender erythematous nodule on the ear that developed after ear-piercing.

Keloids appear as well-circumscribed pink to purple firm nodules (see Fig. 64-3) or plaques with a smooth, but irregular border (Fig. 64-4). Compared with hypertrophic scars, these nodules are often painful and hyperesthetic. Ulceration can occur due to the thin overlying epidermis, and hyperpigmentation is common.

Although historically hypertrophic scars and keloids have been thought of as different stages of the same wound repair process, new evidence suggests that they may be two separate entities. This new perspective is based on differences observed in behavior of the lesion, morphology, cell biology, and immunohistochemically.[46] In early scars,



▲ **FIGURE 64-4** Two keloids in the presternal region, a typical location.



there is increased cellularity and an edematous, myxoid stroma that is replaced by mature collagen over time. Blood vessels are also prominent in early scar formation. With keloids, the collagen is arranged haphazardly, with the presence of large, eosinophilic, keloidal collagen bundles. The early histologic picture of hypertrophic scars resembles that of keloids, but the thickened collagen bundles flatten with time and become oriented parallel to the long axis of the scar.

Hypertrophic scars and keloids remain extremely challenging, particularly in their variable response to treatment. Hypertrophic scars tend to be more responsive than keloids and generally flatten with time. Injection of hypertrophic scars and keloids with intralesional steroids remains a mainstay of therapy, but multiple injections and higher concentrations of triamcinolone (10 to 40 mg/cc) are often required. Often, cryotherapy will be used first to aid in the ease of the injection. This combination has proved beneficial in scar reduction over time.[57] Intralesional steroids, when injected too deeply or aggressively, can cause atrophy. Other injectable treatments that have been proved to have varying success include bleomycin, 5-fluorouracil, tacrolimus, and interferon.[45,48,58]

Surgical excision of larger keloids will often result in recurrent and sometimes even larger keloids. Skin grafting, pressure garments to both the surgical site and the grafted site, and steroid or interferon-α injections to the excision site have been shown to reduce pro-α_1 type I collagen gene expression, hence reducing keloid formation.[59] Other therapies, such as topical retinoids, laser therapy, self-adherent soft silicone dressings, and radiation, have demonstrated varying success rates.[60–63] Intralesional collagenase has recently been proved ineffective.[64]

Nodular Fasciitis

Nodular fasciitis is a benign, self-limiting proliferation of fibroblasts of uncertain etiology that often follows trauma. Although it is seen most commonly in young adults, it can occur at any age, without racial or sex predilection. It presents as a rapidly growing, painful mass in the subcutis, fascia, or muscle. It is observed most frequently on the upper extremity (48 percent), followed by the trunk, head and neck, and lower extremity, in descending order.[65] Cranial fasciitis is the most common variant in children and involves the head and neck.

Histologically, nodular fasciitis presents as a poorly demarcated nodule in the subcutis, fascia, or dermis that is composed of spindled fibroblasts and myofibroblasts and ganglion cell-like fibroblasts in a loose, myxoid, highly vascular stroma that resembles granulation tissue. These lesions often have associated hemorrhage and infiltration of plasma cells, mast cells, and lymphocytes. Mitotic figures are present, but atypia and nuclear polymorphism are not seen. Immunohistochemically, this process stains positive with smooth muscle and muscle-specific actins, vimentin, and CD68. Staining shows no cytokeratin, S100 protein, or desmin.[66]

Despite the possibility of spontaneous involution, excision is the treatment of choice, with recurrences being rare. Due to the fact that this lesion mimics sarcoma clinically, biopsy and excision are necessary to eliminate sarcoma from clinical and radiologic consideration.

Elastofibroma Dorsi

Elastofibroma dorsi is a rarely diagnosed, benign, fibroproliferative, soft-tissue tumor that occurs most commonly in the periscapular region of middle-aged to elderly women. It has a male-female ratio of 1:5. Approximately 10 percent are bilateral. Besides the scapular region, other common locations include the head, as well as the abdominal and thoracic cavities. Although the exact etiology is unknown, it is suspected that chronic subclinical microtrauma may lead to reactive hyperplasia of elastic fibers, with consequently increased production of fibrous tissue. Clinically, this tumor presents as a poorly circumscribed, firm, mobile mass. More than 50 percent of patients are asymptomatic and present with a painless swelling. Magnetic resonance imaging is the best non-invasive technique to visualize the tumor.[69]

Degenerative Collagenous Plaques of the Hands (Keratoelastoidosis Marginalis, Digital Papular Calcific Elastosis)

Degenerative collagenous plaques of the hands present with keratotic, translucent papules in a linear array on the medial and lateral aspects of the fingers and thumbs. Ultraviolet light and chronic pressure or mechanical trauma seem to be the inciting factors.[71] Histologically, the epidermis is hyperkeratotic, and the reticular dermis has a band-like deposition of dense collagen. Solar elastosis is present along with calcified angular elastotic masses termed *basophilic elastotic masses*. Solar elastosis in the absence of this condition lacks basophilic elastotic masses.[71]

Pachydermoperiostosis (Primary Hypertrophic Osteoarthropathy)

Pachydermoperiostosis (primary hypertrophic osteoarthropathy) is a rare syndrome characterized by progressive enlargement of the joints due to pachydermia, periostosis, and clubbing, related to altered proteoglycan synthesis.[72] Other features include coarse facial features, palmoplantar hyperhidrosis, periostosis (fibrous covering at the ends of long bones), and acro-osteolysis. It is a self-limiting disease, but the arthralgias can be quite debilitating. Most recently, there are reports of resolution of the arthralgias when treated with tamoxifen.[73]

Acrokeratoelastoidosis of Costa

Acrochordon (Fibroepithelial Polyp, Skin Tag, Soft Fibroma)

Acrochordons are pedunculated papules or nodules that are most commonly located on the eyelids, neck, and axillae (Fig. 64-5). Larger lesions in the groin or upper thighs may be associated with diabetes mellitus. There is a familial disposition, and acrochordons are more commonly seen in obese individuals. Acrochordons are also a clinical feature of Birt-Hogg-Dubé syndrome, along with fibrofolliculomas and trichodiscomas.[76] Although usually asymptomatic, patients are often cosmetically bothered by these lesions. Furthermore, when the stalk of these pedunculated papules get strangu-



▲ **FIGURE 64-5** Soft fibromas or skin tags on the neck of a female patient who also had (endocrine) acanthosis nigricans.



lated or twisted, the lesions can undergo infarction and become irritated.

Fibrous papule of the nose is a common, solitary papule on the lower portion of the nose. It is small (2 to 5 mm), non-tender, flesh colored (sometimes pink or slightly hyperpigmented), firm, and dome shaped. It must be differentiated from an early, nodular, basal cell carcinoma and is often biopsied for that reason. Unlike a basal cell carcinoma, it rarely bleeds and stays relatively stable in its smaller size. Histologically, the dermis shows a localized area of fibrosis and vascular proliferation. There are large, triangular, and stellate cells. No treatment is necessary, but a simple shave or punch excision is usually curative.

HAMARTOMAS

Fibrous Hamartoma of Infancy

Fibrous hamartoma of infancy is a rare benign tumor that presents as a solitary, painless, rapidly growing, flesh-colored, ill-defined, subcutaneous nodule or plaque. Multiple lesions are rarely reported.[79] Approximately one-fourth are congenital, and 91 percent present during the first year of life. An approximate 2:1 male-female ratio exists. The most common locations are the axillary region, upper arm, upper trunk, inguinal region, and external genital region.[80] These lesions occasionally present with overlying skin changes such as hypertrichosis, alteration in pigmentation, and eccrine gland hyperplasia.[79,80] Some may have an overlying pink hue.

The treatment of choice is complete excision, if feasible. Simple complete excision, as opposed to radical excision, is curative. An aggressive approach should be avoided because the overall prognosis is excellent.[82]

Connective Tissue Nevus/Collagenoma

Connective tissue nevi present as asymptomatic, flesh-colored to yellow-brown papules or plaques that may be solitary or grouped, linear, or irregular in distribution (Fig. 64-6). The overlying epidermis is usually smooth.[83] These hamartomas can be divided into familial, those associated with tuberous sclerosis, eruptive, and other isolated variants. Histologically, connective tissue nevi appear with a normal epidermis overlying increased deposition of dense collagenous bundles in the lower dermis.



▲ **FIGURE 64-6** Cutaneous collagenoma, a connective tissue nevus involving almost the entire back.

Familial cutaneous collagenoma, first described by Henderson et al. in 1968,[84] is an autosomal, dominantly inherited condition of multiple connective tissue nevi usually appearing postpuberty.[85] There may be associated cardiac abnormalities such as progressive cardiomyopathy and conduction defects.[86] Familial collagenomas have a predilection for the trunk and upper extremities. Certain collagenomas may be associated with Gardner syndrome or FAP syndrome (APC gene, 5q21), and clinical, radiologic, and genetic evaluations should be conducted as appropriate.[6,7]

Smooth Muscle Hamartoma (See Chap. 127)

Basaloid Follicular Hamartoma

Angiofibroma

Angiofibromas are small, flesh-colored to brownish-red shiny papules usually distributed on the central face. Multiple facial angiofibromas are a pathognomonic feature of tuberous sclerosis (see Chap. 141).[94]

Pearly penile papules are 1- to 3-mm, pink to flesh-colored papules around the penile coronal sulcus, often in a linear distribution. They are histologically identical to other angiofibromas (see Chap. 75).[95]

Fibrofolliculoma

Fibrofolliculomas are 2- to 4-mm, dome-shaped, yellowish to skin-colored papules located on the head, neck, and upper trunk.[96] Birt-Hogg-Dubé syndrome is an autosomal dominant condition caused by a mutation in the protein folliculin and is comprised of patients with fibrofolliculomas, trichodiscomas, and acrochordons. This condition has an increased risk of renal carcinoma and pneumothoraces (see Chap. 119).[97]

Sclerotic Fibroma (Circumscribed Storiform Collagenoma, Plywood Fibroma)

Giant Cell Collagenoma

Pleomorphic Fibroma

Pleomorphic fibroma is a rare fibrous tumor characterized by nuclear atypia, yet with a benign clinical behavior. This lesion presents as a slow-growing, dome-shaped, or polypoid lesion that may resemble fibrokeratomas, nevi, neurofibromas, or fibroepithelial polyps. Pleomorphic fibromas are usually solitary and appear in middle-aged to older individuals.[102]

Desmoplastic Fibroblastoma (Collagenous Fibroma)

Desmoplastic fibroblastoma is a benign fibrous tumor that appears as a slow-growing, painless, mobile mass located in the subcutaneous tissue or just deep to skeletal muscle, often with fascial and muscle involvement. This tumor has a predilection for the arm, shoulder, posterior neck, upper back, abdominal wall, and hip joint. It usually presents in the fifth to sixth decades with a 5:1 male-female ratio.[104]

Solitary Fibrous Tumor

Solitary fibrous tumor is a tumor once thought to only involve the pleural cavity, but it is now known to be a rare soft-tissue tumor with a predilection to the head and neck region, although it may involve any anatomic site. It usually behaves as a benign tumor, although more





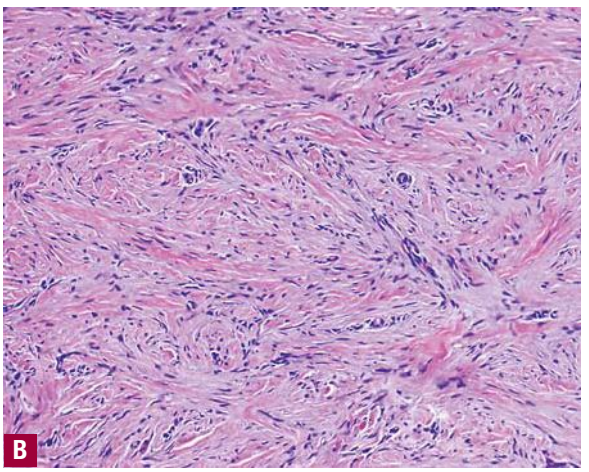

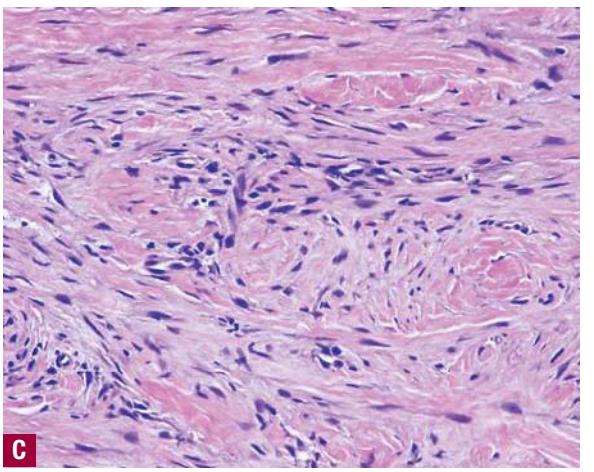

◀ **FIGURE 64-7** **A.** Dermatofibroma on the right thigh of a young man. **B and C.** Dermatofibromas may be characterized as typical, cellular, and atypical cellular. The typical dermatofibroma is composed of spindle cells in the dermis that are haphazardly arranged into fascicles and lack atypical cytologic features. The lesion edge is poorly defined, and the spindle cells often infiltrate between thickened collagen fibers (hematoxylin and eosin 100× magnification A; 200× magnification B).



aggressive variants and metastatic tumors have been reported.[105]

Dermatofibroma (Cutaneous Benign Fibrous Histiocytoma, Sclerosing Hemangioma)

Dermatofibroma is perhaps the most common mesenchymal growth of the skin. It has a predilection for the lower legs of women in their early 20s. Any age may be affected, but typically dermatofibromas appear in the 20s and 30s. Dermatofibroma is more common in women than in men. The surface may be shiny or keratotic, and the color is usually brown, sometimes with a play of colors ranging from pink to red to tan to flesh-colored (Fig. 64-7A). Characteristically, a dermatofibroma is firm, indurated, and mobile and measures from 0.5 mm to 1 cm in diameter. Lateral compression produces a dimple-like depression in the overlying skin ("buttonholing"). Dermatofibromas may be solitary or multiple, and generalized lesions have been described, as have occasional unusual tumors confined to the palms and soles. Usually asymptomatic, they occasionally are pruritic and may ulcerate after trauma. Some tumors grow very rapidly, whereas others remain static for many years. Regression may leave hypopigmentation. Dermatofibromas arising on the face are uncommon but require special mention. They are more often of cellular type, extend into the subcutaneous fat or muscle, and frequently recur; therefore, a wider initial excision is recommended.[107]

A deeper variant of dermatofibroma can be confused clinically with dermatofibrosarcoma protuberans (see Chap. 125). This dermatofibroma typically is on the trunk and extremities of younger adult patients, extending into the subcutaneous tissue, and tends to be larger in size—1 to 2 cm.

Trauma, such as insect bites, has been thought to induce some lesions. For this reason, some authors classify these as reactive/reparative lesions rather than as neoplasms. However, the recent demonstration of chromosome abnormalities in at least some cases of dermatofibroma supports a neoplastic nature.[108] Of note, the karyotypic changes identified are different from those in dermatofibrosarcoma. A viral etiology also has been considered.

Histologically, the epidermis is usually hyperplastic and hyperpigmented ("dirty fingernail" sign). The dermis has haphazardly arranged fascicles of plump spindle cells that lack atypia in most cases (see Fig. 64-7B, C). The edges of the lesion are poorly defined, with individual cells infiltrating between collagen bundles that are often thickened and hyalinized ("keloidal"). Mitotic figures may be present, but atypical forms are not a feature.

A cellular variant characterized by increased cellularity, storiform arrangement, larger size, and location in the deep dermis, often with extension into the superficial subcutaneous tissue, may be difficult to differentiate from dermatofibrosarcoma protuberans. In such circumstances, immunohistochemical expression of factor XIIIa and fascin (dendritic cell markers) rather than CD34 is often helpful.

A rare group of atypical fibrous histiocytomas[114] is characterized by pleomorphic, plump, spindle, or polyhedral cells with large, hyperchromatic, irregular, or bizarre nuclei set in a background of classic features of fibrous histiocytoma, including a storiform pattern and keloidal collagen. Some lesions attain a diameter of more than 2 cm, invade the superficial subcutis, or exhibit necrosis. Atypical mitotic figures have been noted, as have local recurrence and distant metastases. Thus, lesions with such atypical features must be excised completely and the patients followed up carefully.

Immunolabeling for factor XIIIa and fascin is usually positive in dermatofibroma,[116] but not in dermatofibrosarcoma protuberans.[117] In addition, the more cellular forms of dermatofibroma tend to express α-smooth muscle actin, whereas the lesions with more epithelioid cells and giant cells tend to express histiocytic markers.[118]

No treatment is necessary unless symptomatic. A common reason for surgical removal is due to repeated trauma to the dermatofibroma from shaving the lower legs. Because about 20 percent of cellular dermatofibromas recur after simple biopsy, a fusiform excision into the superficial subcutaneous tissue is recommended. Cryosurgery may be helpful to flatten out the dermatofibroma but usually is not curative. Excision to the deeper subcutaneous tissue is necessary to decrease the risk for recurrence of the deeper variant of dermatofibroma. Two cellular dermatofibromas have metastasized to lymph nodes and lungs.[119] Notably, both original lesions were 2 cm in diameter, an unusually large size for dermatofibroma, and had recurred locally before metastasis.

KEY REFERENCES

The full reference list for all chapters is available at www.digm7.com.

6. Hicks J, Mierau G: The spectrum of pediatric fibroblastic and myofibroblastic tumors. *Ultrastruct Pathol* **28**:265, 2004
11. Enzinger FM et al: Fibrous tumors of infancy and childhood, in *Soft Tissue Tumors*, edited by Weiss SW, Goldblum JR. St. Louis, Mosby-Year Book, 2001 p 388
39. Ferenc T et al: Aggressive fibromatosis (desmoid tumors): Definition, occurrence, pathology, diagnostic problems, clinical behavior, genetic background. *Pol J Pathol* **57**:5, 2006
57. Boutli-Kasapidou F et al: Hypertrophic and keloidal scars: An approach to polytherapy. *Int J Dermatol* **44**:324, 2005
66. Montgomery EA, Meis JM: Nodular fasciitis. Its morphologic spectrum and immunohistochemical profile. *Am J Surg Pathol* **15**:942, 1991
84. Henderson RR et al: Familial cutaneous collagenoma. Report of cases. *Arch Dermatol* **98**:23, 1968
103. Chen TM et al: Pleomorphic sclerotic fibroma: A case report and literature review. *Am J Dermatopathol* **24**:54, 2002



CHAPTER 65

Anetoderma and Other Atrophic Disorders of the Skin

Catherine Maari
Julie Powell

ANETODERMA

History

Epidemiology

The lesions in anetoderma usually occur in young adults between the age of 15 and 30 years of age and more frequently in women than men. Anetoderma is rare, but the incidence is unknown. Anetoderma has been reported in several hundred cases since the original report.

Pathogenesis

The pathogenesis of anetoderma is unknown. The key defect is damage to the dermal elastic fibers. Anetoderma might be considered to be unusual scars, because scars also have decreased elastic tissue. The loss of dermal elastin could be the result of an impaired turnover of elastin caused by either increased destruction or decreased synthesis of elastic fibers.

Clinical Findings

All types of anetoderma are characterized by a circumscribed loss of normal skin elasticity. The characteristic lesions are flaccid circumscribed areas of slack skin with the impression of loss of dermal substance forming depressions, wrinkling, or sac-like protrusions (Fig. 65-1). These atrophic, skin-colored, or blue-white lesions are 5 to 30 mm in diameter. The number varies from a few to hundreds. The skin surface can be wrinkled, thinned, and often depigmented, and a central depression may be seen. Coalescence of smaller lesions can give rise to larger herniations. The examining finger sinks without resistance into a distinct pit with sharp borders as if into a hernia ring (buttonhole sign). The protrusion reappears as soon as the pressure from the finger is removed.[4]

The most common sites for these asymptomatic lesions are the chest, back, neck, and upper extremities. They usually develop in young adults, and new lesions often continue to form for many years as the older lesions fail to resolve.

Primary anetoderma occurs when there is no underlying associated skin disease (i.e., it arises on clinically normal skin). It is historically subdivided into two types: (1) those with preceding inflammatory lesions, mainly erythema (the Jadassohn-Pellizzari type), and (2) those without preceding inflammatory lesions (the Schweninger-Buzzi type). This classification is only of historical interest, because the two types of lesions can co-exist in the same patient; the prognosis and the histopathology are also the same.[4]

True secondary anetoderma implies that the characteristic atrophic lesion has appeared in the exact same site as a previous specific pathology; the most common causes are probably acne and varicella. Numerous and heterogeneous dermatoses have been associated with secondary anetoderma, namely syphilis, Lyme disease, molluscum contagiosum, pilomatricomas, juvenile xanthogranuloma, xanthomas, granuloma annulare, leprosy, discoid lupus, sarcoidosis, and lichen planus, to mention only a few. Anetoderma has also been described in premature infants and, in some cases, it

ANETODERMA AT A GLANCE



- Circumscribed 1- to 2-cm areas of flaccid skin that may be elevated, macular, or depressed.
- Often circumscribed sac-like protrusions.
- Primary or secondary to a preceding dermatosis in the same location.
- Pathology consists of loss of elastic tissue in the dermis.





▲ **FIGURE 65-1** Anetoderma. Primary anetoderma. **A.** Multiple, sharply defined, depressed lesions that look punched out in the supraclavicular region. **B.** Soft, sac-like protrusions on the back. When depressed, there is the buttonhole phenomenon. This is the same patient as in **A**.



may have been related to the use of cutaneous monitoring leads or adhesives.[5] Both types may be associated with an underlying disease, mainly anti-phospholipid syndrome and human immunodeficiency virus. Although most cases are sporadic, rare cases of familial anetoderma have been recently described and are usually not associated with preexisting lesions.[6]

Pathology

In routinely stained sections, the collagen fibers within the dermis of affected skin appear normal. Perivascular lymphocytes are often present in all types of anetoderma and do not correlate with clinical inflammatory findings.[7]

The predominant defect as revealed by elastic tissue stains is a focal partial or complete loss of elastic tissue in the papillary and/or mid-reticular dermis. There are usually some residual abnormal, irregular, and fragmented elastic fibers (Fig. 65-2).[8] Presumably, the weakening of the elastic network leads to flaccidity and herniation. Direct immunofluorescence sometimes shows linear or granular deposits of immunoglobulins and complement along the dermal-epidermal junction or around the dermal blood vessels in affected skin.[9] Electron microscopy demonstrates that the elastic fibers are fragmented and irregular in appearance and occasionally can be engulfed by macrophages.

Differential Diagnosis

Anetoderma must be differentiated from other disorders of elastic tissue as well as atrophies of the connective tissue.

Keloids form nodules that are much firmer on palpation. A history of trauma is often elicited, and the pathology is very distinct.

Glucocorticoid-induced atrophy occurs most commonly over the triceps or buttocks at sites where injections are usually given. Clinically, the lesions resemble atrophoderma. History is obviously most helpful in making the diagnosis. Polarization may show the steroid crystals in the dermis.

Nevus lipomatosus superficialis of Hoffman and Zurhelle presents as a clustered group of soft, skin-colored to yellow nodules usually on the lower trunk and buttocks and present since birth. Histology shows ectopic mature lipocytes located in the dermis.

Papular elastorrhexis is an acquired disorder characterized by white, firm non-follicular papules measuring 1 to 3 mm, evenly scattered on the chest, abdomen, and back. It usually appears in adolescence or early adulthood. The pathology demonstrates focal degeneration of elastic fibers and normal collagen. There are no associated extra-cutaneous abnormalities. This is believed by some authors to be a variant of connective tissue nevi[10] or an abortive form of the Buschke-Ollendorff syndrome,[11] whereas others think that these represent papular acne scars.[12] They are differentiated from anetoderma by being firm non-compressible lesions.

Mid-dermal elastolysis (MDE) usually consists of larger areas with diffuse wrinkling without herniation and with elastolysis limited to the mid-dermis (Box 65-1).

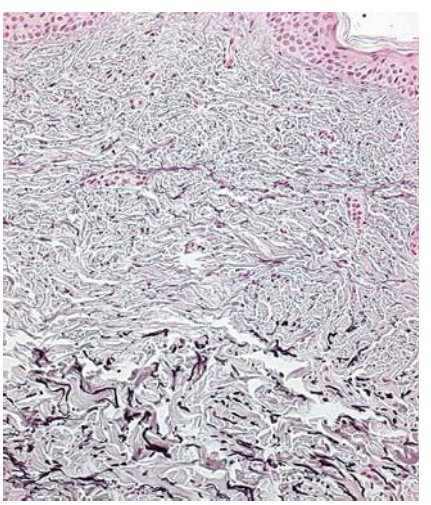

▲ **FIGURE 65-2** Anetoderma. Pathology shows decrease of elastic fibers in the papillary and reticular dermis (Weigert's stain). (Used with permission from Victor Kokta, MD.)

Box 65-1

Differential Diagnosis of Primary Anetoderma

ELEVATED	DEPRESSED
Secondary anetoderma	Secondary anetoderma
Acne scars	Glucocorticoid-induced atrophy
Keloids	Acne scars
Nevus lipomatosus superficialis	
Papular elastorrhexis	
Connective tissue nevi	

Treatment

There is no regularly effective treatment. In secondary anetoderma, appropriate treatment of the inflammatory underlying condition might prevent new lesions. In patients with limited lesions that are cosmetically objectionable, surgical excision may be useful. Various therapeutic modalities have been tried but with no improvement of existing atrophic lesions, including intralesional injections of triamcinolone and systemic administration of aspirin, dapsone, phenytoin, penicillin G (benzylpenicillin), and vitamin E. Some authors have reported improvement with hydroxychloroquine.

OTHER ATROPHIC DISORDERS OF THE SKIN

Mid-Dermal Elastolysis

MDE is a rare acquired disorder of elastic tissue. It is characterized by patches and plaques of diffuse, fine, wrinkled skin, most often located on the trunk, neck, and arms. In 1977, Shelley and Wood reported the first case of "wrinkles due to idiopathic loss of mid-dermal elastic tis-

sue."[13] Since then, fewer than 100 cases have been reported. The vast majority of patients are Caucasian women between the ages of 30 and 50 years.[14]

PATHOGENESIS The pathogenesis of this acquired elastic tissue degeneration is still unclear. Ultraviolet exposure has been postulated to be a major contributing factor in the degeneration of elastic fibers.[15] Other possible mechanisms include defects in the synthesis of elastic fibers, autoimmunity against elastic fibers, and damage to elastic fibers through the release of elastase by inflammatory cells or fibroblasts. More recent data suggest that inflammatory processes and an altered balance between matrix metalloproteinase and tissue inhibitor of metalloproteinases are possibly involved in the pathogenesis of MDE.[16]

CLINICAL FEATURES MDE is characterized by asymptomatic, well-demarcated, or diffuse areas of fine wrinkling (Fig. 65-3A). Rarely, erythematous patches and telangiectasias can be seen. Discrete perifollicular papules can be seen in some cases, leaving the hair follicle itself as an indented center. Lesions are typically found on the trunk, neck, and upper extremities. They are chronic and give the skin a prematurely aged appearance. There is usually no history of a preceding inflammatory dermatosis, but some patients report mild to moderate erythema. There is no associated systemic involvement.

HISTOPATHOLOGY The pathology shows a normal epidermis and, occasionally, a mild perivascular infiltrate in the dermis. The characteristic histology is seen on elastic tissue stains and reveals a selective band-like loss of elastic fibers in the mid-dermis (see Fig. 65-3B). There is preservation of normal elastic tissue in the superficial papillary dermis above, in the reticular dermis below, and along adjacent hair follicles. Electron microscopy studies have shown phagocytosis of normal as well as degenerated elastic fiber tissue by macrophages.[17]

DIFFERENTIAL DIAGNOSIS MDE must be differentiated from the other common disorders of elastic tissue.

Solar elastosis differs by its onset in an older age group, location in only sun-exposed areas, yellowish color, and coarser wrinkling, as well as by hyperplasia and abnormalities of elastic fibers and basophilic degeneration of the collagen in the papillary dermis.

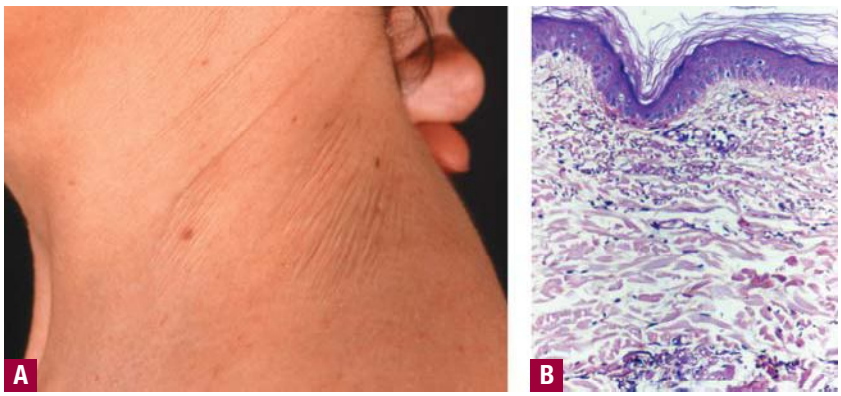

▲ **FIGURE 65-3** Mid-dermal elastolysis. **A.** Well-circumscribed area of fine wrinkling on the neck of a middle-aged woman. (Used with permission from Richard Dubuc, MD.) **B.** Histology of mid-dermal elastolysis. Note selective loss of elastic fibers in the mid-dermis. Normal elastic tissue is preserved in the superficial papillary dermis and in the reticular dermis (Weigert's stain). (Used with permission from Danielle Bouffard, MD.)

Anetoderma is characterized clinically by smaller soft macules and papules instead of diffuse wrinkling, and histologically by elastolysis that can occur in any layer of the dermis.

Perifollicular elastolysis differs by a selective and almost complete loss of elastic fibers surrounding hair follicles compared with preservation of elastic fibers around follicles in MDE. Elastase-producing *Staphylococcus epidermidis* was found in the hair follicles and is the presumed etiology of this condition.[18]

Post-inflammatory elastolysis and cutis laxa were originally described in young girls of African descent. An inflammatory phase, consisting of indurated plaques or urticaria, malaise, and fever, preceded the diffuse wrinkling, atrophy, and severe disfigurement. Insect bites may be the trigger for the initial inflammatory lesions.[19]

TREATMENT There is no known effective treatment for MDE. Sunscreens, colchicine, and topical retinoic acid have been tried without good success.[14]

Striae (See Chaps. 107 and 152)

Striae are very common and usually develop between the ages of 5 and 50 years.

They occur about twice as frequently in women as in men. They commonly develop during puberty, with an overall incidence of 25 percent to 35 percent,[20,21] or during pregnancy, with an incidence of 77 percent.[22]

The factors leading to the development of striae have not been fully elucidated. Striae distensae are the results of breaks in the connective tissue, resulting in dermal atrophy. Many factors, including hormones (particularly corticosteroids), mechanical stress, and genetic predisposition, appear to play a role.

During puberty, striae appear in areas where there is a rapid increase in size. In girls, the most common sites are the breasts, thighs, hips, and buttocks, whereas in boys, they are seen on the shoulders, lumbosacral region, and thighs. Other less common sites include the abdomen, upper arms, neck, and axillae.

Striae distensae are a common finding on the abdomen, and less so the breasts and thighs, of pregnant women, especially during the last trimester. They are more common in younger primigravidas than in older pregnant women. Striae gravidarum can be associated with a higher risk of lacerations during vaginal delivery.[23]

CLINICAL FINDINGS Striae are usually multiple, symmetric, well-defined linear atrophic lesions that follow the lines of cleavage. Initially, striae appear as red-to-violaceous elevated lines (striae rubra) (see Fig. 107-3). Over time, the color gradually fades, and the lesions become atrophic, with the skin surface exhibiting a fine, white, wrinkled appearance (striae alba).[21] The striae can measure several centimeters in length and a few millimeters to a few centimeters in width. The striae associated with systemic corticosteroid therapy and Cushing syndrome can be larger and more widely distributed.

HISTOPATHOLOGY Histologic findings show a decrease in dermal thickness and in collagen in the upper dermis. The collagen bundles are thinned and lie parallel to the epidermis, but they are also arranged transversely to the direction of the striae. Alterations in elastic fibers are variable, but dermal elastin can be fragmented, and specific elastin staining can



demonstrate a marked reduction in visible elastin content compared with adjacent normal dermis.[24] There is absence of both hair follicles and other appendages.

DIFFERENTIAL DIAGNOSIS The diagnosis of striae distensae is usually simple, but the differential diagnosis does include linear focal elastosis (elastotic striae) that was first described by Burket et al. in 1989.[25] Linear focal elastosis is characterized by rows of yellow palpable striae-like bands on the lower back. Unlike striae, the lesions are raised and yellow rather than depressed and white. Elderly men are most commonly affected, although cases in teenagers have been described. Linear focal elastosis is probably not an uncommon condition. Histologically, there is a focal increase in the number of elongated or fragmented elastic fibers and a thickened dermis. It is postulated that linear focal elastosis may represent an excessive regenerative process of elastic fibers and could be thought of as a keloidal repair of striae distensae.[26]

TREATMENT Striae distensae have no medical consequences, but they are frequently distressing to those affected. As stretch marks tend to regress spontaneously to some degree over time, the usefulness of treatments that have been tried without case controls is difficult to assess. Topical treatments that have shown some improvement of early stage striae are: tretinoin 0.1 percent cream,[27] a combination of 0.05 percent tretinoin/20 percent glycolic acid, or 10 percent L-ascorbic acid/20 percent glycolic acid.[28] Several lasers have been used in treating striae: the 585-nm pulsed-dye laser has been demonstrated to be of some efficacy in improving the appearance of striae rubra but has no effect on stria alba[29]; improvement in the leukoderma of the striae alba was noted with 308-nm excimer laser but maintenance treatment is required to sustain the cosmetic benefit.[30]

Idiopathic Atrophoderma of Pasini and Pierini

EPIDEMIOLOGY AND PATHOGENESIS Idiopathic atrophoderma of Pasini and Pierini is a form of dermal atrophy that presents as one or several sharply demarcated depressed patches with no outpouching, usually on the back of adolescents or young adults.[31] Whether atrophoderma is a nonsclerotic, primarily atrophic variant of morphea or a separate distinct entity is still debated.[32–35] Its relationship to morphea is favored by its striking clinical and histologic similarities to the atrophy seen at sites of regressing plaques of morphea. Antibodies to *Borrelia burgdorferi* have been reported.[33] Typical lesions of morphea, lichen sclerosus, and atrophoderma have been observed to occur simultaneously in the same patient but in different areas, supporting the view that these conditions are related. In a series of 139 patients, 17 percent had white induration in the central portions of their atrophic lesions, and 22 percent had superficial plaques of morphea co-existing in areas outside of their atrophic foci.[32] However, to some, the different course and outcome of atrophoderma of Pierini and Pasini as compared with morphea justifies preservation of a distinct name.

This disorder is more frequently encountered in women than in men, with a ratio of 6:1. It usually starts insidiously in young individuals in the second or third decades of life. The lesions usually occur on the trunk, especially on the back and lumbosacral region, followed in frequency by the chest, arms, and abdomen.[33] The distribution is often symmetric and bilateral.

The lesions are single or multiple and usually round or ovoid, ranging in size from a few centimeters to patches covering large areas of the trunk (Fig. 65-4). They are usually asymptomatic and lack inflammation. When lesions coalesce, they can form large, irregular, brown patches. The surface of the skin is normal in appearance, and there is no skin induration or sclerosis.

The borders or edges of these lesions are sharply defined, and they are usually described as abrupt, "cliff drop" borders ranging from 1 to 8 mm in depth, although they can have a gradual slant.[31] These depressed patches are characteristic and give the impression of inverted plateaus, or, if multiple lesions are present, they can have the appearance of Swiss cheese. They are even more apparent when present on the back because the dermis is thicker in this area. The skin surrounding the patches is normal in appearance, and there is no erythema or lilac ring as in morphea.



▲ **FIGURE 65-4** Atrophoderma of Pasini and Pierini. Brownish depressed lesions on the lower back.

COURSE The course of this benign disease is progressive, and lesions can continue to appear for decades before reaching a standstill. Transformation to generalized morphea has not been observed.

HISTOPATHOLOGY The histologic picture is generally not diagnostic. The epidermis is usually normal or slightly atrophic. Collagen bundles in the mid- and reticular dermis show varying degrees of homogenization and clumping. Dermal thickness is eventually reduced when compared with adjacent normal skin.[34] Some irregular clumping and loss of elastic fibers were described in earlier case reports,[31] but in most series, no abnormality was seen with elastic tissue stains[32,33]; therefore, this is not of diagnostic value. The appendages are usually preserved. If sclerodermatous changes appear in pre-existing patches, the histology reveals varying degrees of collagen sclerosis resembling morphea.

DIFFERENTIAL DIAGNOSIS The differential diagnosis is to be made with active lesions of morphea that usually present as indurated, often hyperpigmented plaques with a characteristic peripheral lilac rim.

THERAPY No treatment has been proved effective.

Follicular Atrophoderma

Follicular atrophoderma refers to dimple-like depressions at the follicular orifices. It can occur as an isolated defect of limited extent, in association with a variety of disorders in which hair follicles are plugged with keratin, or with rare genodermatoses.[36,37]

Distinctive ice-pick depressions around hair follicles can be seen most commonly on the back of the hands or feet and on the cheeks. These pitted scars can present at birth or early in life. A family history may be present. Follicular atrophoderma occurs in the conditions described in the following sections.

ATROPHODERMA VERMICULATUM *Atrophoderma vermiculatum* is a term that applies when the lesions are found exclusively on the cheeks. It is a condition that can





▲ **FIGURE 65-5** Atrophoderma vermiculatum. Multiple, small, pitted scars on the cheek of a young girl.



▲ **FIGURE 65-6** Ulerythema ophryogenes. Erythematous follicular papules and scarring alopecia of the eyebrow.

either occur sporadically, be inherited as an autosomal dominant disorder, be part of a group of related diseases including keratosis pilaris atrophicans, or be associated with various syndromes.

Multiple inflammatory symmetric papules on the cheeks, presumably centered around hair follicles, may precede the atrophic lesions. These papules then go on to develop pitted, atrophic, and depressed scars in a reticulated or honeycomb pattern (Fig. 65-5). These lesions can extend to the forehead and preauricular regions. This condition usually has its onset in childhood or, less often, around puberty. Men and women seem to be affected equally.[38] It usually has a slow progressive course.

Keratosis Pilaris Atrophicans. Keratosis pilaris atrophicans[39] can include atrophoderma vermiculatum but also a group of closely related disorders that includes keratosis follicularis spinulosa decalvans and ulerythema ophryogenes. These conditions are characterized by keratotic follicular papules, variable degrees of inflammation, and secondary atrophic scarring. Keratosis follicularis spinulosa decalvans begins in infancy with keratotic follicular papules over the malar area and progresses to involve the eyebrows, scalp, and extremities, with scarring alopecia. This condition is inherited in an X-linked recessive fashion in some patients. Ulerythema ophryogenes (or keratosis pilaris atrophicans faciei) differs from atrophoderma vermiculatum by affecting primarily the lateral portion of the eyebrows (ophryogenes) with erythema, follicular papules, and alopecia (Fig. 65-6).

The underlying pathologic defect in these disorders appears to be abnormal follicular hyperkeratinization of the upper third of the hair shaft leading to obstruction of the growing hair and production of chronic inflammation. The end result of this process is scarring below that level. Histopathology is usually not very helpful and shows dilated follicles, sometimes associated with plugging, inflammation, and sclerosis of dermal collagen.

Associated Syndromes. The various syndromes that include atrophoderma vermiculatum are the Rombo syndrome (milia, telangiectasias, basal cell carcinomas, hypotrichosis, acral cyanosis, and, rarely, trichoepitheliomas), Nicolau-Balus syndrome (syringomas and milia), Tuzun syndrome (scrotal tongue), and finally the Braun-Falco-Marghescu syndrome (palmoplantar hyperkeratosis and keratosis pilaris).

Therapy. These disorders are mainly a cosmetic but vexing problem. Various topical treatments, including emollients, corticosteroids, tretinoin, and keratolytics, have shown no consistent benefit. Systemic isotretinoin has been shown to stop progression and to induce remission in some cases.[39] Dermabrasion as well as carbon dioxide and 585-nm pulsed-dye lasers are other options to improve the appearance of the atrophic scars.[40]

BAZEX SYNDROME Bazex syndrome is characterized by follicular atrophoderma, multiple basal cell carcinomas, hypotrichosis, and localized hypohidrosis. The follicular atrophoderma described as multiple ice-pick marks or patulous follicles can be found most commonly on the dorsa of the hands. It is inherited in an X-linked dominant fashion, and the gene has been linked to Xq24–q27.[41] Subsequently reported findings include facial hyperpigmentation, milia, hair shaft dystrophy, and multiple genital trichoepitheliomas.

CONRADI-HÜNERMANN SYNDROME (X-LINKED DOMINANT CHONDRODYSPLASIA PUNCTATA) Conradi-Hünermann syndrome is an X-linked dominant disorder that occurs only in girls because it is usually lethal in hemizygous males. The underlying molecular defect consists of mutations in the emopamil binding protein gene at Xp11.23-p11.22.[42] The clinical manifestations include an ichthyosiform scaling erythroderma patterned along the lines of Blaschko that usually resolves during the first year of life and is replaced by bands of follicular atrophoderma.[43] Hyperpigmentation, cataracts, scarring alopecia, saddle-nose deformity, asymmetric limb reduction defects, and stippled calcifications of the epiphyses can be seen. Ichthyosis with keratotic follicular plugs containing dystrophic calcification in newborns are distinctive histopathologic features.[42]

OTHER ATROPHIES OF THE CONNECTIVE TISSUE

Many systemic conditions [scleroderma (see Chap. 158), lupus erythematosus (see Chap. 156), dermatomyositis (see Chap. 157)], and genodermatoses (poikiloderma congenitale, dyskeratosis congenita, Cockayne syndrome, Hallermann-Streiff syndrome) have skin atrophy as an associated finding and are described in other chapters.

KEY REFERENCES

The full reference list for all chapters is available at www.digm7.com.

4. Venencie PY, Winkelmann RK, Moore BA: Anetoderma: Clinical findings, associations, and long-term follow-up evaluations. *Arch Dermatol* **120**:1032, 1984
6. Thomas JE et al: Familial anetoderma. *Int J Dermatol* **42**:75, 2003
8. Venecie PY, Winkelmann RK: Histopathologic findings in anetoderma. *Arch Dermatol* **120**:1040, 1984
14. Patroi I, Annessi G, Girolomoni G: Mid-dermal elastolysis: A clinical, histologic, and immunohistochemical study of 11 patients. *J Am Acad Dermatol* **48**:846, 2003
32. Kencka D, Blaszczyk M, Jablonska S: Atrophoderma Pasini–Pierini is a primary atrophic abortive morphea. *Dermatology* **190**:203, 1995
38. Frosch P et al: Atrophoderma vermiculatum: Case reports and review. *J Am Acad Dermatol* **18**:538, 1988
39. Callaway SR, Lesher JL: Keratosis pilaris atrophicans: Case series and review. *Pediatr Dermatol* **21**:14, 2004
41. Vabres P et al: The gene for Bazex–Dupré–Christol syndrome maps to chromosome Xq. *J Invest Dermatol* **105**:87, 1995



CHAPTER 66

Constricting Bands (Ainhum and Pseudoainhum)

Robert T. Brodell
Stephen E. Helms

CONSTRICTING BANDS AT A GLANCE



- Constricting bands (ainhum and pseudoainhum) cause amputation (autoamputation) of digits.
- Ainhum is a constricting band around a digit and is most common in the tropics and sub-tropics.
- It is most common around the fifth toe of people walking barefoot.
- Pseudoainhum constrictions mimic ainhum clinically and are more common in the developed world. They are caused by the following:
  - Amniotic bands
  - Constrictions associated with keratotic disorders, infections, and trauma
  - Constriction by external materials such as hairs and threads
- Treatment is removal of the foreign strands or surgical intervention.

AINHUM AND PSEUDOAINHUM

Constricting bands are classified as ainhum and pseudoainhum. Ainhum is the development of constricting bands around toes in underdeveloped countries of Africa and may ultimately result in autoamputation. In the African Yorub language, *ainhum* means "to saw or file," and in the Brazilian patois it means "fissure."[1] In the remainder of the world, constricting bands that mimic ainhum are termed *pseudoainhum*.

EPIDEMIOLOGY

Ainhum (dactylolysis spontanea) is traditionally a disease of middle-aged African males accustomed to going barefoot. In tropic and sub-tropic climates its incidence has been reported as between 0.015 percent and 2.0 percent of the population.[2] This same condition is rarely seen throughout the rest of the world. Occasional isolated cases have been reported in North America.[3] Pseudoainhum of all types is very rare.

ETIOLOGY AND PATHOGENESIS

The pathogenesis of ainhum has not been clearly elucidated. Chronic trauma, infection, hyperkeratosis, decreased vascular supply, and impaired sensation may produce excessive fibroplasia in a susceptible host. Dent et al. described impaired blood supply to the foot proximal to the groove at the plantar digital junction. Poor perfusion was the result of attenuation of the posterior tibial artery and absence of the plantar arterial arch, which led to abnormal healing after mechanical trauma. Ainhum has also been blamed on rotational stress applied to the bare, mechanically unstable foot.[4]

There are three pathophysiologic categories of pseudoainhum: (1) congenital constricting bands caused by the umbilical cord; (2) constriction due to external forces, such as hairs or threads, which are generally factitial; and (3) constricting bands secondary to other diseases. The latter may be hereditary or nonhereditary. Hereditary causes include pachyonychia congenita, mal de Meleda, mutilating keratoderma, and psoriasis. Non-hereditary causes include vascular anomalies as seen in Raynaud disease, diabetes mellitus, linear scleroderma, and systemic sclerosis. Sensory changes associated with leprosy, tertiary syphilis, syringomyelia, and spinal cord tumors as well as trauma resulting in scar formation from burns, frostbite, and physical trauma can also cause constricting bands to form.[5,6] When pseudoainhum is associated with chronic trauma and infection of the extremities, the pathophysiology may be identical to that of true ainhum.

CLINICAL FINDINGS

Ainhum usually affects the fifth toe (Fig. 66-1). It may be unilateral, but 75 percent of cases are bilateral. In early lesions, a groove or sulcus appears at the plantar junction of the toe and the sole. As this sulcus deepens, edema develops distally, and roentgenographic examination shows resorption of the underlying bone and ultimately autoamputation.



▲ **FIGURE 66-1** Ainhum in an African male. (Used with permission from Wayne M. Meyers, MD.)

Congenital constricting bands (Streeter's bands) usually involve more than one part of the body (see eFig. 66-1.1 in on-line edition). They frequently encircle large structures such as limbs or even the trunk (Fig. 66-2). They persist throughout life and interfere with normal growth of the involved segment unless surgically treated.[7] In more than 50 percent of cases, they are associated with other congenital anomalies, usually syndactyly or clubfoot when constricting bands are found on the feet.[8]

Artifactual pseudoainhum may prove to be a most challenging diagnosis. Strands of hair, fibers, or threads may be intentionally wrapped around digits or other body parts such as a nipple or pe-



▲ **FIGURE 66-2** Pseudoainhum (congenital constricting band) of the leg in an infant. (Used with permission from Ilona Frieden, MD.)



▲ **FIGURE 66-3** Pseudoainhum on the fifth finger of a patient with severe psoriasis. (Used with permission from R. J. Crowley, MD.)

nis. This phenomenon is most commonly encountered in children but can occur in mentally ill adults.[9] Because of soft-tissue swelling, the ligating band may not be visible and the true cause of the condition may not be immediately recognized.[9]

Acquired constricting bands are associated with a variety of medical and dermatologic conditions. In general, pseudoainhum is more likely to involve any of the toes or even the hands. In children, when chronic dermatophyte infection is identified and appropriately treated, complete reversal of the constriction may occur. Severe hyperkeratosis as occurs in Vohwinkel syndrome or keratoderma hereditarium mutilans may show constricting bands due to palmar and plantar hyperkeratoses as well as starfish-like and linear keratoses (see Chap. 48). Pseudoainhum may occur in severe psoriasis of the digits (Fig. 66-3).

The pathology of ainhum and pseudoainhum is similar, with the presence of fibrotic bands resembling scar tissue. The bands in ainhum usually extend deep into the subcutaneous layers and may impinge on underlying skeletal and vascular structures. In addition, moderate inflammation and epidermal or verrucous hyperplasia may be present. In pseudoainhum the bands tend to be more superficial. Also, in pseudoainhum there may be histologic clues to the associated disorder, such as dermatophytosis, foreign bodies, or distinct patterns of keratinization.

COMPLICATIONS

The constricting bands of both ainhum and pseudoainhum ultimately produce a dangling, twisted digit, which can become gangrenous or infected. When this tenuous connection leads to necrosis, autoamputation occurs.

PROGNOSIS AND CLINICAL COURSE

Diseases caused by constricting bands proceed slowly and often painfully over many years, eventuating in autoamputation in severe cases.

TREATMENT

Surgery is the mainstay of therapy, and early intervention is important. In most cases of ainhum, prompt amputation may allow the patient to escape pain and infection. Early cases of ainhum or pseudoainhum may respond to conservative plastic repair with a Z-plasty or similar relaxing closure that prevents further disease progression and damage to underlying structures.[10]

Impending amputation in Vohwinkel syndrome can sometimes be aborted by therapy with oral etretinate (see eFig. 66-3.1 in on-line edition). When chronic fungal or bacterial infections are diagnosed in the early phase of band formation, treatment may reverse the threat to the digit. Other predisposing causes or underlying diseases should be treated aggressively in the hope of forestalling progression.

PREVENTION

Ainhum is rarely seen in people whose feet are protected by wearing shoes. Congenital pseudoainhum cannot be prevented and can lead to serious birth defects (see eFig. 66-3.2 in on-line edition). Psychological counseling may prevent recurrences of pseudoainhum in patients with factitial disease. Control of the underlying disease process may delay progression or prevent recurrence in pseudoainhum of the acquired type.

KEY REFERENCES

The full reference list for all chapters is available at www.digm7.com.

1. Carvalho N et al: Ainhum (dactylolysis spontanea): A case report. *Foot Ankle* **6**:189, 2000
2. Browne SG: True ainhum: Its distinctive and differentiating features. *J Bone Joint Surg Br* **47**:52, 1965
4. Dent DM et al: Ainhum and angiodysplasia. *Lancet* **2**:396, 1981
5. McLaurin CI: Psoriasis presenting with pseudoainhum. *J Am Acad Dermatol* **7**:132, 1982
6. Almond SL et al: Case report: Pseudoainhum in chronic psoriasis. *Br J Dermatol* **149**:1064, 2003
7. Kerhisnik W: The surgical pathology of ainhum (dactylolysis spontanea). *J Foot Surg* **25**:95, 1986
10. Pickus EJ et al: Digital constriction bands in pseudoainhum: Morphological, radiographic, and histological analysis. *Ann Plast Surg* **47**:194, 2001



CHAPTER 67

Acquired Perforating Disorders

Mark Lebwohl



ACQUIRED PERFORATING DISORDERS: AN OVERVIEW

Acquired perforating disorders consist of a group of conditions that share some clinical and histologic features. All are characterized by the transepidermal extrusion of dermal material, which clinically presents as umbilicated skin-colored papules with a central white crust. The term *perforating disorder of renal disease* has been applied to these disorders, with the exception of elastosis perforans serpiginosa (EPS), which is clinically and histologically unique.

Acquired Perforating Dermatosis

Kyrle disease, perforating folliculitis, reactive perforating collagenosis, and acquired perforating dermatosis have been reported independently of one another with differing histologies and, at times, differing clinical associations. The primary lesion in all of these conditions is an umbilicated papule with a central hyperkeratotic crust. All of the conditions have been associated with diabetes or renal failure and with the Koebner phenomenon. All have perforation of the epidermis in common, either by degenerated connective tissue that is eliminated through the epidermis (inside out) or hyperkeratotic material that penetrates into the dermis (outside in). In one study, 6 of 55 chronic dialysis patients had reactive perforating collagenosis.[1] Histologically, perforating collagen bundles are the hallmark of reactive perforating collagenosis, but these have been demonstrated in patients thought to have Kyrle disease or perforating folliculitis as well. Consequently, as long as more is learned about the pathogenesis, some authors prefer to consider them under the term *acquired perforating dermatosis* (Table 67-1).

TABLE 67-1
Acquired Perforating Dermatosis

Different entities or one reaction pattern?
Kyrle disease
Perforating folliculitis
Reactive perforating collagenosis
Acquired perforating dermatosis

HISTORY

ETIOLOGY AND PATHOGENESIS Little has been done to elucidate the mechanism by which perforating disorders occur. However, it is clear that trauma is a major trigger of perforating disorders, although the molecular basis to explain the development of lesions after trauma is unclear.

Many patients exhibit the Koebner phenomenon, and lesions can be produced experimentally by traumatizing the skin[10] and after laser hair removal.[11] Other reported triggers of perforating disorders have been elevated plasma silicon in patients on dialysis,[12] vitamin A deficiency[13,14] or excess,[15] and saltwater chemical burns.[16] Evidence supports an underlying dermal microvasculopathy in some patients[17] and aberrant epidermal migration in others.[18]

Based on light and electron microscopic examination of biopsies, an abnormal healing response after excoriation has been described, in which the regenerating epidermis forms epidermal tunnels through which the central necrotic mass and its associated collagen bundles are lifted.[19] The demonstration of type IV collagen within eliminated material suggests extrusion of basement membrane in this process.[20]

CLINICAL FINDINGS Fig. 67-1 shows the approach to the patient with perforating diseases.

Cutaneous Lesions. The acquired perforating disorders are characterized by umbilicated papules with central white, keratotic crusts (Fig. 67-2). Lesions can become quite hyperkeratotic and can resemble prurigo nodularis (Fig. 67-3). Lesions most often develop on the arms and legs, but any site on the cutaneous surface can be affected, including the trunk and scalp. Lesions have even been described on the conjunctiva and buccal mucosa of a patient with Kyrle disease.[21] Virtually all patients complain of pruritus, and scratching can lead to a Koebner phenomenon with linear umbilicated papules arising in excoriated skin.

Related Physical Findings. In the original description of reactive perforating collagenosis, renal failure and diabetes were not highlighted.[9] Nevertheless, most acquired perforating disorders are seen in association with kidney failure, diabetes, or both. However, Kyrle disease has also been described in young siblings without diabetes or kidney disease.[22] Associations with hyperparathyroidism, hypothyroidism, and liver disorders,[23] as well as human immunodeficiency virus infection,[24] pulmonary fibrosis,[25] Poland syndrome,[26] Hodgkin disease,[27] and primary sclerosing cholangitis,[28,29] have also been reported, but these may be coincidental. There have been several cases of acquired perforating disorder reported in patients with scabies.[30] This association has been attributed to koebnerization associated with scratching.

Histopathology. Histologically, the acquired perforating disorders are character-

ACQUIRED PERFORATING DISORDERS AT A GLANCE





- Acquired perforating disorders consist of a group of rare conditions characterized by transepithelial elimination of dermal material. With the exception of elastosis perforans serpiginosa (EPS), there is considerable overlap among the disorders, leading some authors to call the group *perforating disorders of diabetes and renal disease.*
- Chronic pruritic conditions triggered by trauma.
- Umbilicated papules with central white, keratotic crusts; lesions tend to be serpiginous in EPS.
- EPS is associated with inherited disorders of connective tissue and occurs in patients treated with D-penicillamine; other perforating disorders are associated with diabetes mellitus and renal failure.
- Histologically, the acquired perforating disorders are characterized by invagination of the epidermis with extrusion of dermal material through the cup-shaped epidermal depression. Follicular perforation and presence of collagen bundles or elastic fibers in the perforating material distinguishes perforating folliculitis, reactive perforating collagenosis, and EPS from one another.

	Elastosis perforans serpiginosa	Other acquired perforating diseases
History	D-penicillamine therapy	• diabetes • renal failure • hemodialysis
Physical examination	Serpiginous umbilicated papules, examine for: • Down syndrome • Marfan syndrome • Ehlers-Danlos syndrome • cutis laxa • osteogenesis imperfecta • Rothmund-Thomson syndrome • pseudoxanthoma elasticum	• Koebner phenomenon • umbilicated papules
Lab studies		Chemistry screen with serum glucose, BUN, creatinine
Treatment	First line • topical retinoids • UVB Second line • cryotherapy • laser	If patient has renal disease, stabilization of disease or transplantation may result in improvement of perforating disorders. In the absence of renal disease or if stabilization of renal disease is ineffective, topical retinoids or broadband UVB are first-line therapies. If first-line therapies are ineffective, PUVA, oral retinoids (isotretinoin, acitretin), oral antibiotics (doxycycline, clindamycin), and oral allopurinol have been effective in case reports.

▲ **FIGURE 67-1** Approach to the patient with perforating diseases. BUN = blood urea nitrogen; PUVA = psoralen and ultraviolet A light; UVB = ultraviolet B.



▶ **FIGURE 67-2** Acquired perforating dermatosis. Umbilicated, keratotic papules on the arm of a patient with diabetes and renal failure.



▶ **FIGURE 67-3** Warty and crater-like hyperkeratoses on the foot of a boy with Kyrle disease.

ized by invagination of the epidermis with extrusion of dermal material through the cup-shaped epidermal depression into the necrotic basophilic tissue within the invaginated epidermis. In the past, attempts were made to differentiate among perforating folliculitis, reactive perforating collagenosis, and Kyrle disease based on the nature of the perforating material. In reactive perforating collagenosis, collagen bundles perforate through the epidermis (Fig. 67-4), in contrast to amorphous dermal material and/or keratin that perforates through the epidermis in Kyrle disease. Perforating folliculitis is characterized histologically by follicular perforation.

In perforating folliculitis, there is a focal inflammatory infiltrate adjacent to areas of perforation of the follicular epithelium. Degenerating collagen and extracellular matrix tissues mixed with inflammatory cells and orthokeratotic and parakeratotic material fill the dilated hair follicle. Occasionally, a hair is seen. One author suggested that lesions begin as follicular pustules and develop into perforating folliculitis and, ultimately, into prurigo nodularis.[31]



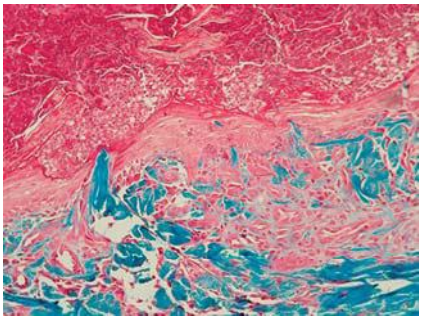

▲ **FIGURE 67-4** Reactive perforating collagenosis. Collagen bundles can be seen crossing from the reticular dermis through the epidermis into an epidermal depression containing necrotic debris. (Hematoxylin and eosin stain.)



More detailed histologic descriptions of Kyrle disease[22] report an invagination of the epidermis that is filled with a keratotic plug containing a parakeratotic column (Fig. 67-5). Within the epidermal invagination, there is a focus of vacuolated dyskeratotic cells, which extends to the basal cell layer and eventually penetrates into the dermis, leaving fragments of parakeratotic keratin in the dermis with a surrounding inflammatory and granulomatous reaction (see Fig. 67-5). Subsequent studies using Masson trichrome stains have found bundles of collagen perforating through the epidermis into the base of the invagination, suggesting an overlap with reactive perforating collagenosis.

Elastosis Perforans Serpiginosa

EPS is a unique perforating disorder characterized by transepidermal elimination of elastic fibers. The distinctive lesions are serpiginous in distribution and can be associated with specific diseases.

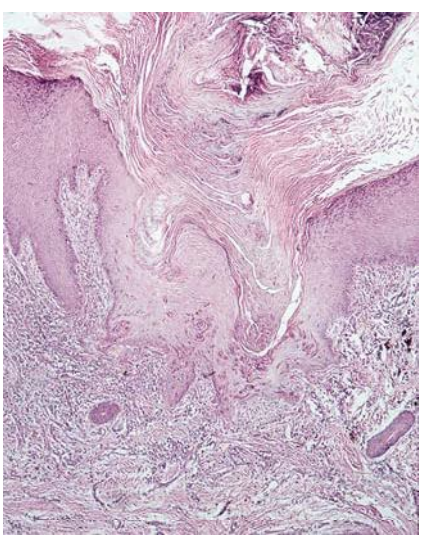

▲ **FIGURE 67-5** Kyrle disease. There is massive hyperkeratosis with a central parakeratotic column at the base of this column. Individual (apoptotic) cell keratinization can be followed down to the basal dermal epidermal junction.

HISTORY

ETIOLOGY AND PATHOGENESIS D-penicillamine appears to be a clear trigger for EPS. Alterations of elastic fibers have been described in patients with penicillamine-induced EPS, and this condition has usually occurred after long-term therapy of Wilson disease[34] or cystinuria. EPS has also been reported in a child treated with D-penicillamine for juvenile rheumatoid arthritis.[35] Abnormal elastic fibers have been found in the lungs as well as the skin of penicillamine-treated patients.[36] Abnormalities of collagen have also been described in patients with EPS.[37,38] The precise mechanism by which penicillamine induces EPS is not entirely known, but the drug chelates copper, the co-factor for lysyl oxidase, which is the enzyme that cross-links elastin.

Although most cases are sporadic, familial cases of EPS have been reported with different modes of inheritance. In at least one family, autosomal dominant inheritance with variable expression of EPS was suggested.[39] Several inherited disorders of connective tissue have also been associated with EPS (see Chap. 139), suggesting that various pathways can lead to the abnormal elastin that results in this condition.

CUTANEOUS LESIONS Skin lesions consist of hyperkeratotic papules ranging from 2 mm to 1 cm in diameter in a serpiginous distribution (Fig. 67-6). Skin within these serpiginous arcs is often atrophic. The most common site of involvement is the neck (see eFig. 67-6.1 in on-line edition), but lesions can also occur on the extremities and, more rarely, on the trunk. In rare instances, elastic tissue in the endocardium, bronchiolar walls, and arteries is involved. Rupture of the aorta has been reported.[40]

RELATED PHYSICAL FINDINGS EPS is associated with numerous inherited disorders, including osteogenesis imperfecta,[41] cutis laxa,[42] acrogeria,[43] Ehlers-Danlos syndrome, Marfan syndrome, Rothmund-Thomson syndrome,[44] and Down syndrome.[45] EPS has been reported in association with administration of D-penicillamine to treat Wilson disease (see eFig. 67-6.2 in on-line edition)[46] and with co-existing acquired cutis laxa after D-penicillamine therapy of cystinuria.[47]

HISTOPATHOLOGY Histologically, lesions are characterized by transepidermal elimination of elastic fibers. Typical changes can be identified and consist of an inflammatory response around abnormal elastic tissue in the papillary dermis. The elastic tissue penetrates through channels in the acanthotic epidermis. The channels may be straight or tortuous, and there may be multinucleated giant cells in the surrounding inflammatory infiltrate. In addition to elastic tissue, the channels contain necrobiotic material with degenerated epithelial cells and parakeratotic nuclei of inflammatory cells. The top of the epidermal channels is also filled with keratotic material.



▲ **FIGURE 67-6** Elastosis perforans serpiginosa. Erythematous, hyperkeratotic papules in a serpiginous distribution on the arm.

DIFFERENTIAL DIAGNOSIS (See Box 67-1)

The one entity easily confused with perforating diseases is prurigo nodularis. Other perforating disorders, such as perforating pseudoxanthoma elasticum (PXE) and perforating granuloma annulare, are easily distinguished from the acquired perforating disorders by skin biopsy.

Box 67-1

Differential Diagnosis of Acquired Perforating Disorders

- Perforating pseudoxanthoma elasticum
- Prurigo nodularis
- Excoriated dermal diseases (e.g., granuloma annulare, lichen planus)
- Hyperkeratosis follicularis perstans (Flegel disease)
- Acquired perforating dermatosis

Box 67-2

Treatment for Acquired Perforating Disorders

	TOPICAL	PHYSICAL	SYSTEMIC
First line	Corticosteroids	Broadband ultraviolet B Narrowband ultraviolet B	Acitretin, 30 mg daily Isotretinoin, 1 mg/kg in two divided doses daily
Second line	Retinoids	Psoralen and ultraviolet A light Surgical removal combined with oral clindamycin	Doxycycline, 100–200 mg daily in two divided doses; allopurinol, 100 mg daily

EPS is easily distinguished from other perforating disorders when characteristic serpiginous lesions are present (in contrast to individual papules in the latter) and by the finding of elastic fibers in the perforating tissue on histology. In contrast to the other perforating dermatoses, which are usually associated with diabetes or renal failure, EPS has an entirely different group of disease associations as mentioned in Elastosis Perforans Serpiginosa. There is a single case report of EPS in a patient with renal disease.[48] Histologically, however, the perforating elastic fibers of EPS usually allow differentiation, although fragments of elastic fibers may be found in the necrobiotic plug of other perforating disorders. At least one study reports the transepidermal elimination of elastic fibers in follicular occlusion disease, distinguishing that disorder from EPS.[49]

Individual lesions of perforating PXE can simulate those of the acquired perforating dermatoses, but patients with PXE have characteristic yellow papules and plaques on the neck, axillae, and other flexural sites (see Chap. 139). Moreover, on skin biopsy, von Kossa stains show calcification of elastic fibers, and Verhoeff-van Gieson stains show fragmentation and clumping of elastic tissue. There have, however, been cases of PXE with serpiginous perforating papules containing calcified elastic fibers, thus simulating EPS. The lesions of perforating granuloma annulare can also simulate acquired granuloma annulare, but on biopsy, palisading granulomas are seen (see Chap. 43). Flegel disease (hyperkeratosis follicularis perstans), a rare autosomal dominant genodermatosis, is also characterized by keratotic papules, but these are smaller and also involve the lower legs. Histologically, Flegel disease is not a perforating condition, but, occasionally, it has been confused with perforating disorders.[50]

PROGNOSIS, CLINICAL COURSE, AND TREATMENT

The perforating disorders are difficult to treat (Box 67-2). Their prognosis is tied to the underlying diseases, so treatment of the underlying cause can be effective. Although some have reported spontaneous disappearance of perforating disorders with stabilization of renal disease,[51] most of the perforating diseases continue for years unless treated. Perforating disorders frequently resolve after renal transplantation in patients with underlying kidney failure.[52] Although there are isolated reports of successful therapy using topical retinoids,[53–55] oral retinoids,[14,56,57] oral antibiotics (doxycycline[58,59] and clindamycin[60]), and allopurinol,[61–64] these are not usually effective. Phototherapy with narrowband ultraviolet B (UVB) or broadband UVB can result in substantial improvement,[40,65–68] but is not as reliably effective as phototherapy for uremic pruritus. UV light treatment, if successful, tends to require sessions two to three times per week with 10 to 15 exposures for clearance. Many of the treatments that have been applied to the other perforating disorders have also been used for EPS. Isotretinoin[69] and destructive modalities, such as cryotherapy[70] and lasers, have also been used effectively for EPS.[71,72]

KEY REFERENCES

The full reference list for all chapters is available at www.digm7.com.

1. Poliak SC et al: Reactive perforating collagenosis associated with diabetes mellitus. *N Engl J Med* **306**:81, 1982
6. Kyrle J: Über einen ungewöhnlichen fall von universeller folliculärer und parafollikulärer hyperkeratose (hyperkeratosis follicularis et parafollicularis in cutem penetrans). *Arch Dermatol Syph* (Berlin) **123**:466, 1916
8. Mehregan AH, Coskey RJ: Perforating folliculitis. *Arch Dermatol* **97**:394, 1968
19. Yanagihara M et al: The pathogenesis of the transepithelial elimination of the collagen bundles in acquired reactive perforating collagenosis. A light and electron microscopical study. *J Cutan Pathol* **23**:398, 1996
44. Mehregan AH: Elastosis perforans serpiginosa: A review of the literature and report of 11 cases. *Arch Dermatol* **97**:381, 1968
46. Becuwe C et al: Elastosis perforans serpiginosa associated with pseudo-pseudoxanthoma elasticum during treatment of Wilson's disease with penicillamine. *Dermatology* **210**:60, 2005



This page intentionally left blank

SECTION 10

DISORDERS OF SUBCUTANEOUS TISSUE

CHAPTER 68

Panniculitis

Luis Requena
Evaristo Sánchez Yus
Heinz Kutzner

The panniculitides are a group of heterogeneous inflammatory diseases involving the subcutaneous fat. Traditionally, the study of the panniculitides has several pitfalls. First, from a clinical point of view, the lesions show a disappointing, monotonous appearance because they usually consist of erythematous nodules generally located on the lower limbs. Second, superficial and inadequate biopsy specimens are often obtained for histopathologic study. A third difficulty for the specific diagnosis of panniculitides results from the evolutionary nature of the lesions because, like other inflammatory diseases of the skin, panniculitides constitute dynamic processes in which both the composition and the distribution of the inflammatory cells change within the course of a few days. Despite all these difficulties, a specific diagnosis can usually be rendered with an appropriate biopsy and an adequate clinico-pathologic correlation.

HISTOLOGY OF SUBCUTANEOUS FAT

CLASSIFICATION OF PANNICULITIDES

Histopathologic classification of panniculitides is also controversial. Classification is initially separated into mostly septal or mostly lobular panniculitis, according to the location in which the inflammatory infiltrate is more abundant. The second step for histopathologic diagnosis is to assess whether vasculitis is present. If it is, the size and the nature of the involved blood vessel should be stated. The third step should be to identify the nature of the cells present in the inflammatory infiltrate and to look for additional histopathologic features that allow a specific diagnosis of the disease involving the subcutaneous fat.[1–3] This algorithmic system is displayed in Fig. 68-1.

MOSTLY SEPTAL PANNICULITIS WITH VASCULITIS

Leukocytoclastic Vasculitis (See Chap. 164)

Superficial Thrombophlebitis (See Chap. 175)

Superficial thrombophlebitis presents with erythematous, tender subcutaneous nodules with a linear arrangement along a tender cord-like thickening of the subcutis (the involved vein) (Fig. 68-2). Usually, these cords are located on the lower limbs and are associated with venous insufficiency (see Chap. 175). The term *migratory* is applied to describe when lesions regress at the same time that new foci of thrombosis develop along the involved vein. Although a primary[4] or secondary[5] hypercoagulable state should be investigated, most of the time, venous insufficiency of the lower extremities is usually the only precipitating factor. An internal malignancy is seldom demonstrated. Patients with Behçet disease (see Chap. 167) may also have superficial migratory thrombophlebitis of the lower extremities.[6]

Histopathologically, the involved vein appears within the septa in the upper subcutis and shows luminal thrombosis and inflammatory infiltrate within its wall. In early lesions, the infiltrate is mostly composed of neutrophils, whereas in later stages, there are lymphocytes, histiocytes, and occasional multinucleated giant cells. A striking feature is that, in spite of the intense damage of the involved vein with dense

SUPERFICIAL THROMBOPHLEBITIS AT A GLANCE

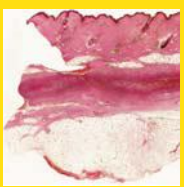

Clinical

- Erythematous, tender subcutaneous nodules with lineal arrangement along a cord-like thickening of the subcutis on the lower limbs

Histopathology

- Venous thrombosis within the septa in the upper subcutis
- Inflammatory infiltrate within the vein wall: Neutrophils in early lesions, lymphocytes in fully developed lesions, and histiocytes and multinucleated giant cells in late lesions
- Little or no involvement of the adjacent fat lobule

Treatment

- Stocking or bandage on the involved leg

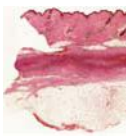

Copyright © 2008 by The McGraw-Hill Companies, Inc. Click here for terms of use.

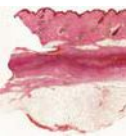

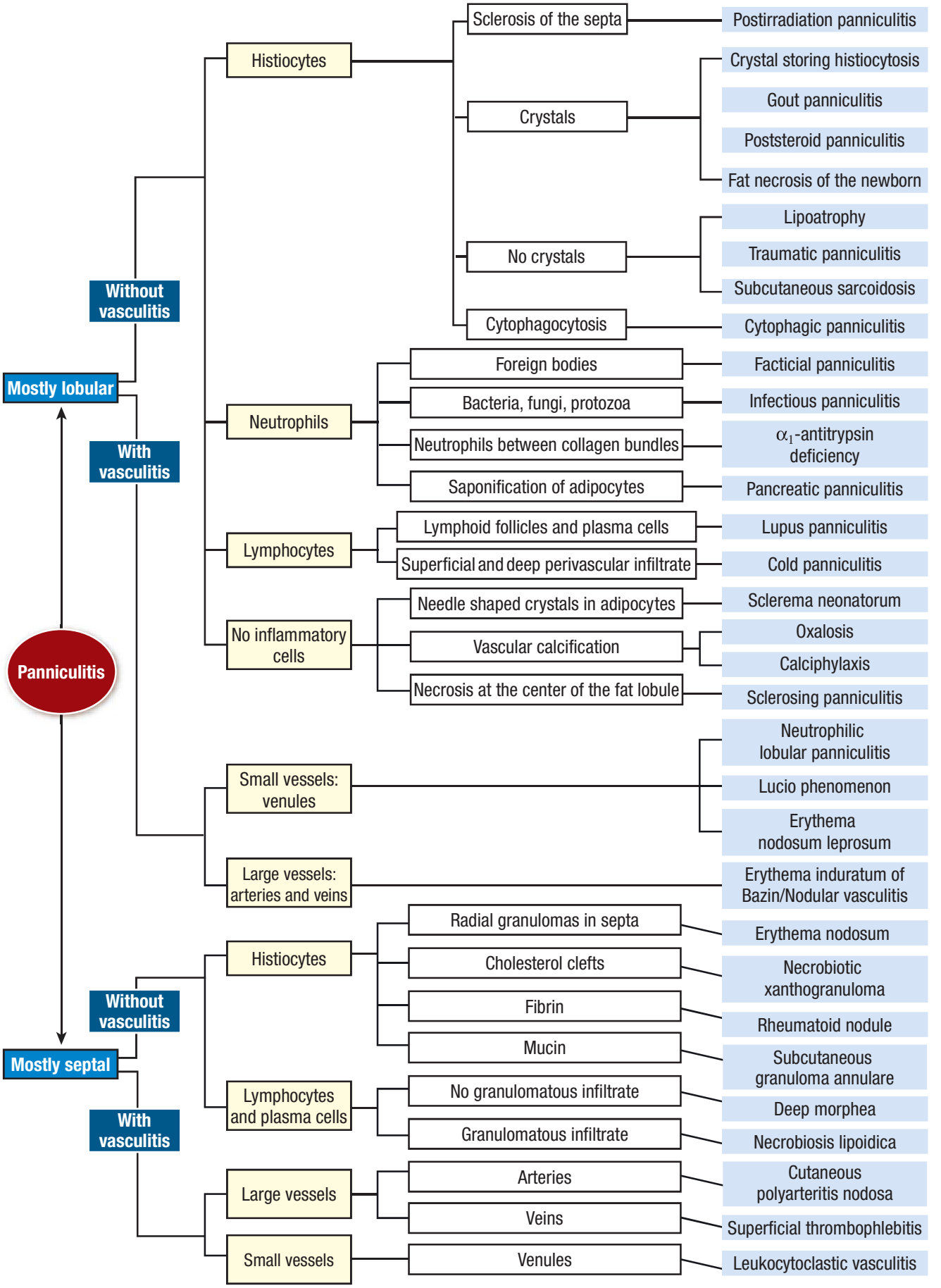

▲ **FIGURE 68-1** Approach to the patient with panniculitis.

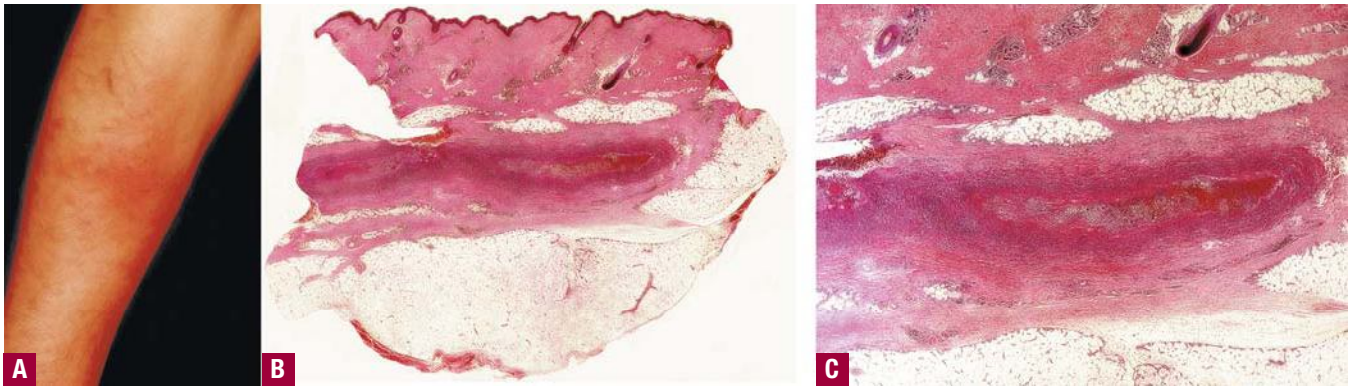

▲ **FIGURE 68-2** Superficial thrombophlebitis. **A.** Clinical appearance: Erythematous, tender, subcutaneous nodules with lineal arrangement. **B.** Histopathology: Scanning power showing the involved vein within the septa in the upper subcutis. **C.** Higher magnification showing luminal thrombosis and inflammatory infiltrate within the vein wall.

inflammatory infiltrate in its wall and marked septal thickening, the adjacent fat lobule is minimally involved.

Treatment of migratory thrombophlebitis is conservative, with application of a support stocking on the involved leg. In chronic and recurrent cases, especially those associated with malignancy, heparin and fibrinolytic drugs may be used.

CUTANEOUS POLYARTERITIS NODOSA

AT A GLANCE



Clinical

- Vasculitis involving the arteries and arterioles of the septa of the subcutaneous fat, with little or no evidence of systemic disease
- Bilateral tender erythematous nodules over a background of livedo reticularis on the lower legs

Histopathology

- Vasculitis involving medium-sized arteries and arterioles at the septa of the upper subcutis. Eosinophilic ring of fibrinoid necrosis of the intima of the involved artery, giving a target-like appearance to the vessel.
- Little or no involvement of the adjacent fat lobule.

Treatment

- Nonsteroidal anti-inflammatory drugs or low doses of prednisone

Cutaneous Polyarteritis Nodosa (See Chap. 165)

Cutaneous polyarteritis nodosa is a vasculitis involving the arteries and arterioles of the septa of the subcutaneous fat with little or no evidence of systemic disease.[7] The lower legs are usually affected. Clinically, the lesions consist of bilateral, tender erythematous nodules, which may undergo ulceration, and a background of livedo reticularis (Fig. 68-3). "Starburst" livedo is characteristic and marks a cluster of nodular lesions. Mild constitutional symptoms, including low-grade fever, arthralgias, myalgias, malaise, and fatigue, may appear simultaneously with the cutaneous lesions.[8] The absence of systemic involvement is characteristic and, although the course may be prolonged, the prognosis is good. In rare instances, patients with cutaneous polyarteritis nodosa show serologic evidence of hepatitis B infection, cryoglobulinemia, or peripheral neuropathy.[9]

Histopathologically, cutaneous lesions show vasculitis involving medium-sized arteries and arterioles at the septa and sometimes lobules of the upper subcutis. Involvement of the arterioles of the lobule may also be seen with microscopic polyangiitis. The involved vessel has a thickened wall and an inflammatory infiltrate of variable composition, depending on the stage of evolution of the lesions. Characteristically, the intima of the involved artery exhibits an eosinophilic ring of fibrinoid necrosis, giving a target-like appearance to the vessel. Although luminal thrombi may be present, they are less frequent than in lesions of superficial thrombophlebitis. Direct immunofluorescent studies of lesions of cutaneous polyarteritis nodosa have shown immunoglobulin M and complement deposition in the involved vessel walls.[10] As is the case in superficial thrombophlebitis, lesions of cutaneous polyarteritis nodosa show little or no involvement of the adjacent fat lobule, and the process is exclusively a septal arteritis.

Mild cases of cutaneous polyarteritis nodosa may be managed with nonsteroidal anti-inflammatory drugs or low doses of prednisone.[9] In patients with acute flare-ups of cutaneous polyarteritis nodosa associated with documented bacterial infections, a long course of treatment with antibiotics may be helpful.

MOSTLY SEPTAL PANNICULITIS WITHOUT VASCULITIS

Necrobiosis Lipoidica (See Chap. 152)

Deep Morphea (See Chap. 62)

Subcutaneous Granuloma Annulare (See Chap. 43)

Rheumatoid Nodule (See Chap. 161)

Necrobiotic Xanthogranuloma (See Chap. 149)

Erythema Nodosum

Erythema nodosum is the most common type of septal panniculitis. It is not a disease but a reaction pattern to a vari-

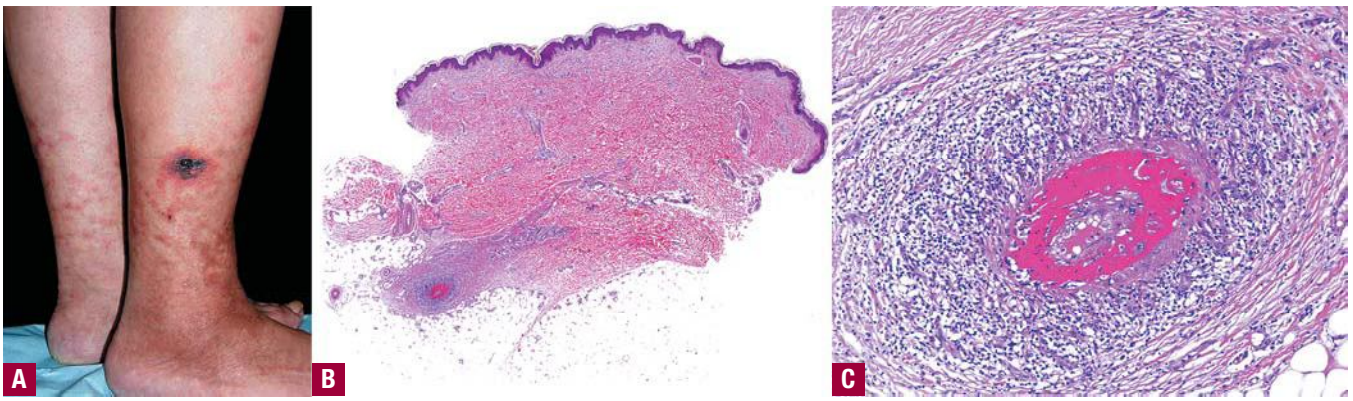

▲ **FIGURE 68-3** Cutaneous polyarteritis nodosa. **A.** Clinical appearance: Tender erythematous nodules with superficial ulceration over a background of livedo reticularis on the lower legs. **B.** Histopathology: Scanning power showing vasculitis involving a medium-sized artery at the septa of the upper subcutis. **C.** Higher magnification showing the intima of the involved artery with an eosinophilic ring of fibrinoid necrosis, giving a target-like appearance to the vessel.

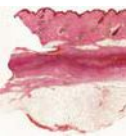

ety of etiologic agents (Table 68-1). It may occur at any age, but most cases appear between the second and fourth decades of life. It is much more common in women than in men. The erup-

ERYTHEMA NODOSUM AT A GLANCE

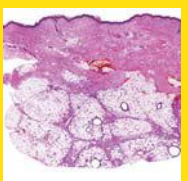

Clinical

- Symmetric, tender, erythematous, warm nodules and raised plaques on the anterior aspects of the lower extremities
- Acute onset
- No ulceration
- More common in women than in men

Histopathology

- Mostly septal panniculitis without vasculitis
- Thickened septa with inflammatory cells
- Neutrophils in early lesions and histiocytes and Miescher granulomas in late-stage lesions

Treatment

- Treatment of the associated disorder.
- Bed rest, aspirin, nonsteroidal anti-inflammatory drugs.
- Systemic corticosteroids are rarely indicated.

TABLE 68-1
Etiologic Factors in Erythema Nodosum

Infections
- Bacterial infections
  - Streptococcal infections[50]
  - Tuberculosis[51]
  - *Yersinia* infections[52]
  - *Salmonella* infections[53]
  - *Campylobacter* infections[54]
  - Brucellosis[55]
  - Tularemia[56]
  - Atypical mycobacterial infections[57]
  - Chancroid[57]
  - Meningococcemia[57]
  - *Corynebacterium diphtheriae* infections[57]
  - Cat-scratch disease[58]
  - *Propionibacterium acnes*[59]
  - *Shigella* infections[60]
  - Gonorrhea[61]
  - Syphilis[62]
  - Leptospirosis[63]
  - Q fever[64]
  - Lymphogranuloma venereum[65]
  - *Chlamydia psittaci* infections[66]
  - *Mycoplasma pneumoniae* infections[67]
- Viral infections
  - Infectious mononucleosis[68]
  - Hepatitis B[69]
  - Milker's nodules[70]
  - Orf[71]
  - Herpes simplex[57]
  - Measles[71]
  - Cytomegalovirus infections[72]
- Fungal infections
  - Dermatophytes[73]
  - Blastomycosis[74]
  - Histoplasmosis[75]
  - Coccidioidomycosis[76]
  - Sporotrichosis[57]
  - Aspergillosis[77]
- Protozoal infections
  - Toxoplasmosis[78]
  - Ancylostomiasis[57]
  - Amebiasis[79]
  - Giardiasis[79]
  - Ascariasis[80]

Drugs
- Sulfonamides[81]
- Bromides[82]
- Iodides[82]
- Oral contraceptives[83]
- Minocycline[84]
- Gold salts[85]
- Penicillin[86]
- Salicylates[86]
- Chlorothiazides[71]
- Phenytoin[71]
- Aminopyrine[57]
- Arsphenamine[57]
- Hepatitis B vaccine[86]
- Nitrofurantoin[57]
- Pyritinol[61]
- D-penicillamine[87]
- Thalidomide[88]
- Isotretinoin[89]
- Interleukin 2[90]

Malignant Diseases
- Hodgkin disease[91]
- Non-Hodgkin lymphoma[92]
- Leukemia[93]
- Sarcoma[61]
- Renal carcinoma[90]
- Post-radiotherapy for pelvic carcinoma[94]

Miscellaneous Conditions
- Sarcoidosis[95]
- Ulcerative colitis[96]
- Colon diverticulosis[61]
- Crohn disease[97]
- Behçet disease[98]
- Reiter syndrome[99]
- Sweet syndrome[100]
- Pregnancy[101]
- Takayasu arteritis[102]
- Immunoglobulin A nephropathy[103]
- Chronic active hepatitis[104]
- Granulomatous mastitis[105]
- Vogt-Koyanagi disease[106]
- Sjögren syndrome[106]



▲ **FIGURE 68-4** Classic erythema nodosum. Bilateral erythematous nodules localized over the shins.

tion consists of a sudden onset of symmetric, tender, erythematous, warm nodules and raised plaques with bilateral distribution, usually on the anterior aspect of the lower extremities (Figs. 68-4 and 68-5). Within a few days, the nodules show a vivid red or purplish color that evolves to a yellow or greenish coloration, which resembles a deep bruise, the so-called *erythema contusiforme*. Ulceration is never seen in erythema nodosum, and the lesions heal without atrophy or scarring. Acute bouts of erythema nodosum are associated with a fever, fatigue, malaise, arthralgia, headache, abdominal pain, vomiting, cough, or diarrhea. The eruption generally lasts from 3 to 6 weeks, and recurrences are frequent.

The classically described processes of erythema nodosum migrans,[43–46] subacute nodular migratory panniculitis of Vilanova and Piñol,[47,48] and chronic erythema nodosum,[49] are now just considered clinical variants of erythema nodosum.

The list of etiologic factors associated with erythema nodosum is very long, including infectious diseases, medications, malignancies, and a wide group of miscellaneous conditions (see Table 68-1).[50–106] Although there are considerable geographic variations related to endemic infections, streptococcal infections are the most frequent etiologic factor of erythema nodosum in children. In contrast, drugs, sarcoidosis, and inflammatory bowel disease are the most commonly associated disorders in adults with erythema nodosum. Erythema nodosum is considered to be a hypersensitivity response to a large number of inciting factors.

Erythema nodosum is the stereotypical histologic example of a mostly septal panniculitis with no vasculitis. The connective tissue septa of the subcutis appear thickened with inflammatory cells that extend to the periseptal areas of the fat lobules (see Fig. 68-5B). As in other panniculitides, the composition of the inflammatory infiltrate in the septa of erythema nodosum lesions varies with age of the lesion, with neutrophils being the predominant cells in early lesions, whereas histiocytes and small granulomas are seen in late-stage lesions. A characteristic histopathologic marker of erythema nodosum is the so-called *Miescher radial granuloma*, which consists of small, round, well-defined nodular aggregations of small histiocytes radially arranged around a minute slit (see Fig. 68-5C).[107–109] The nature of the central cleft is unknown, and immunohistochemical and ultrastructural studies have failed to demonstrate endothelial or other cellular lining of these clefts. In older nodules of erythema nodosum, histiocytes coalesce to form multinucleated giant cells (see eFig. 68-5.1 in online edition), many of which still keep in their cytoplasm a stellate central cleft reminiscent of those centers of Miescher radial granuloma. Another histopathologic characteristic of erythema nodosum is the absence of vasculitis.[110] In late-stage lesions of erythema nodosum, the septa are markedly widened with granulation tissue at the interface between septa and fat lobules. With time, the lesions resolve without atrophy or scarring of the involved septa.

Treatment of erythema nodosum should be directed toward the associated disorder. Usually, nodules of erythema nodosum regress spontaneously within a few weeks, and bed rest is often sufficient treatment. Aspirin, nonsteroidal anti-inflammatory drugs and 2 to 10 drops of a saturated solution of potassium iodide may be helpful to enhance analgesia and resolution.[111–116] Systemic corticosteroids are rarely indicated in erythema nodosum, and an underlying infection should be ruled out before these drugs are administered.

MOSTLY LOBULAR PANNICULITIS WITH VASCULITIS

Erythema Nodosum Leprosum (See Chap. 186)

Lucio Phenomenon

Neutrophilic Lobular Panniculitis

Neutrophilic lobular panniculitis is an uncommon, reactive inflammatory process characterized by mature polymorphonuclear leukocytes involving mostly the lobules of the subcutaneous fat. The lesions consist of erythematous subcutaneous nodules involving the lower abdomen and extremities that are clinically indistinguishable from erythema nodosum. A review of the literature reveals that this type of panniculitis has been

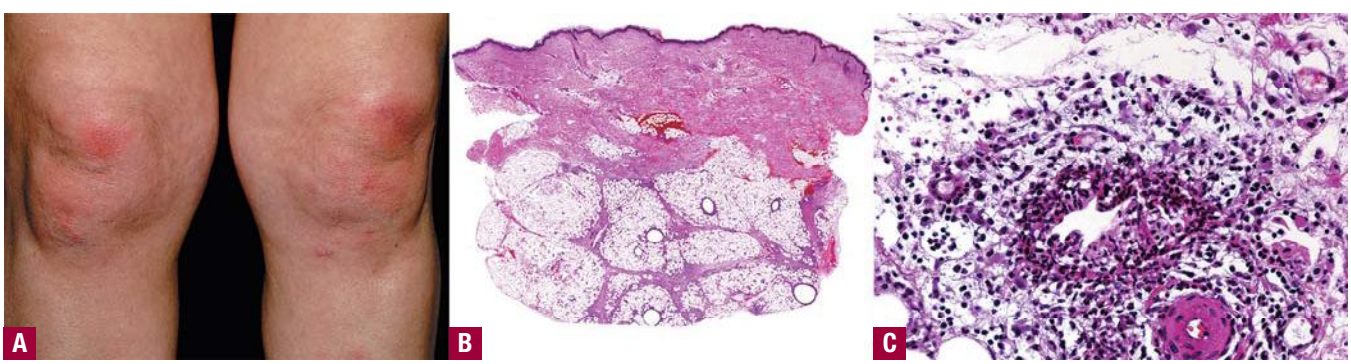

▲ **FIGURE 68-5** Erythema nodosum. **A.** Clinical appearance: Symmetric, tender, erythematous, warm nodules with bilateral distribution on the knees. **B.** Histopathology: Scanning power showing a mostly septal panniculitis. **C.** Higher magnification showing a Miescher radial granuloma, which consists of a small, round, well-defined nodular aggregation of small histiocytes radially arranged around a central slit.

described in patients with severe rheumatoid arthritis, and, in other studies, the process is significantly associated with myelodysplasia.[122–126] Some authors consider neutrophilic lobular panniculitis as subcutaneous Sweet syndrome (see Chap. 31).[127] Cultures for bacteria and fungi are negative. Serum levels of α_1-antitrypsin are normal, and the phenotype tends to be MM (see α_1-Antitrypsin-Deficiency Panniculitis). Probably, this process is more a reactive pattern than a distinctive disease.

Histopathologically, the lesions show a mostly lobular panniculitis, with severe necrosis of the adipocytes in the fat lobule and an inflammatory infiltrate composed of neutrophils, foamy histiocytes, and multinucleated giant cells. Focal features of leukocytoclastic vasculitis have been described in the lesions of patients with neutrophilic lobular panniculitis associated with rheumatoid arthritis,[125] but not in those with myelodysplasia or Sweet syndrome.[126,127]

Neutrophilic lobular panniculitis is highly responsive to oral steroid therapy.

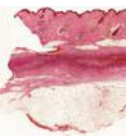

Erythema Induratum of Bazin/Nodular Vasculitis

Currently, the terms *erythema induratum of Bazin* and *nodular vasculitis* are used as synonyms by most authors to describe the most common form of lobular panniculitis with vasculitis.[128,129] Some investigators, however, prefer to retain the name *erythema induratum of Bazin* for those cases in which an etiologic relationship with tuberculosis is demonstrated and refer to the remainder of cases as *nodular vasculitis*. In some geographic areas, but not in others, polymerase chain reaction investigations have demonstrated that *Mycobacterium tuberculosis* DNA is present in most of the cutaneous biopsy specimens of patients with erythema induratum of Bazin,[130–138] supporting the notion that tuberculosis is the most important etiologic factor for this panniculitis.

Erythema induratum of Bazin/nodular vasculitis (EIB/NV) is more frequent in middle-aged women, who develop erythematous subcutaneous nodules and plaques on the posterior aspects of the lower legs. Often, the involved extremities also show erythrocyanosis, heavy column-like calves, erythema surrounding follicular pores, and cutis marmorata (Fig. 68-6). Usually, subcutaneous nodules become adherent to the skin surface, ulcerate (Fig. 68-7), and then heal with scarring. The process is more frequent in obese women with some degree of venous insufficiency of the lower extremities, and the cutaneous lesions develop mostly during the cold months of the winter. Lesions are usually tender but may be indolent or painful under pressure. The course is protracted, and recurrent episodes over years, even decades, are common.

As in other types of panniculitis, the histopathologic findings in lesions of EIB/NV vary with the evolution of the lesions.[139] In early lesions, the fat lobules are scattered by discrete collections of inflammatory cells, mostly neutrophils, and there is extensive necrosis of the adipocytes in the center of the fat lobule (see Fig. 68-7B,C). In fully developed lesions, epithelioid histiocytes and multinucleated giant cells occur that ingest lipid from necrotic adipocytes, giving a granulomatous appearance to the infiltrate. Small areas of caseating necrosis are seen at the center of some granulomas, showing all the histopathologic attributes of tuberculosis. Caseating necrosis may extend to the overlying dermis and epidermis, resulting in ulceration and discharge of liquefied necrotic fat.

The histopathologic requirement for vasculitis to establish the diagnosis of erythema induratum of Bazin is controversial. Even accepting vasculitis as a histopathologic criterion, there is no agreement about the nature of the involved vessel; some authors believe that the involved vessel is an artery,[140,141] others favor venous involvement,[142] and still others consider that both arteries and veins are involved.[143–147] In our experience, when vasculitis is present, the small veins and venules of the fat lobule are the most commonly involved vessels in lesions of EIB/NV.[148] However, we have studied cases with all the stereotypical clinico-pathologic features of this condition in which serial sections do not demonstrate findings of vasculitis. Therefore, we do not consider vasculitis as a *sine qua non* criterion to establish the diagnosis erythema induratum of Bazin when other characteristic findings are present, and the name *erythema induratum of Bazin* is, to us, more appropriate than nodular vasculitis.

ERYTHEMA INDURATUM OF BAZIN/NODULAR VASCULITIS

AT A GLANCE

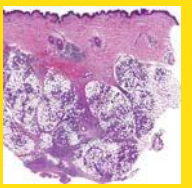

Clinical

- Erythematous subcutaneous nodules and plaques on the posterior aspects of the lower legs
- More frequent in middle-aged women
- Often, ulceration and scarring
- Chronic course

Histopathology

- Mostly lobular panniculitis with vasculitis
- Extensive necrosis of the adipocytes in the center of the fat lobule
- Variable inflammatory infiltrate in the fat lobule: Neutrophils in early lesions and epithelioid histiocytes and multinucleated giant cells in fully developed lesions
- Vasculitis of the small veins and venules of the fat lobule

Treatment

- With positive Mantoux test or when *Mycobacterium tuberculosis* DNA is demonstrated: A full course of antituberculosis triple-agent therapy
- In other cases: Potassium iodide, supporting bandages, bed rest, and nonsteroidal anti-inflammatory drugs



▲ **FIGURE 68-6** Erythema induratum of Bazin/nodular vasculitis. Column-like calves, erythrocyanosis, and erythematous, brown, and bluish nodules with ulceration on the posterior aspect of the calves.

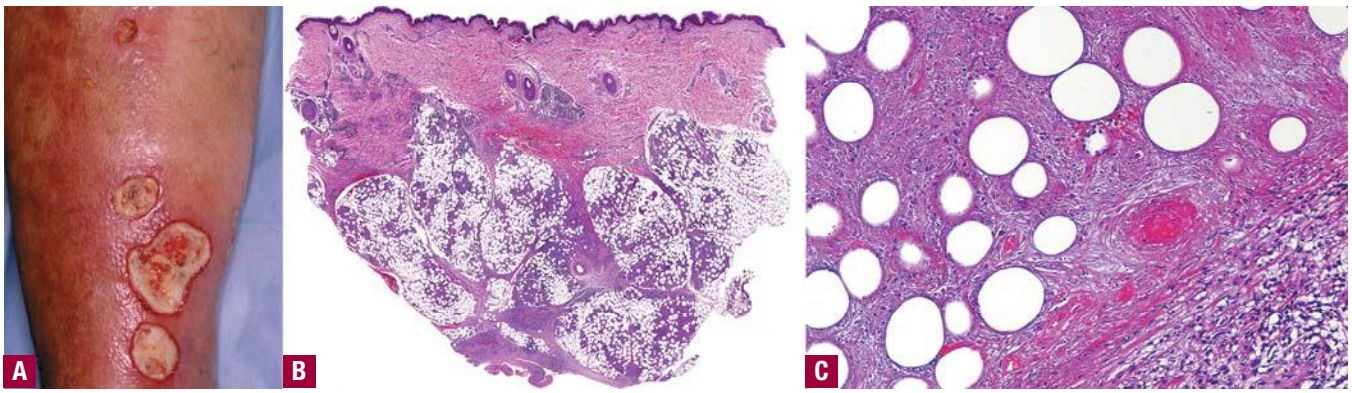

▲ **FIGURE 68-7** Erythema induratum of Bazin/nodular vasculitis. **A.** Clinical appearance: Erythematous subcutaneous nodules that ulcerate on the posterior aspects of the lower legs. **B.** Histopathology: Scanning power showing a mostly lobular panniculitis. **C.** Higher magnification showing extensive necrosis of the adipocytes and necrotizing vasculitis of the small venules of the fat lobule.

In those patients with a strongly positive Mantoux test reaction or when *M. tuberculosis* DNA is demonstrated in the cutaneous biopsy specimen by polymerase chain reaction techniques, a full course of 9 months of antituberculosis triple-agent therapy is recommended.[149–156] Potassium iodide is also an effective and rapid treatment for erythema induratum of Bazin.[113,115] Additional helpful measures include supporting stockings, bed rest, treatment of the venous insufficiency of the lower extremities, and orally administered nonsteroidal anti-inflammatory drugs.

MOSTLY LOBULAR PANNICULITIS WITHOUT VASCULITIS

Sclerosing Panniculitis (Lipodermatosclerosis)

Sclerosing panniculitis is a chronic, subcutaneous disorder characterized by indurated woody plaques with erythema, edema, telangiectasia, and hyperpigmentation. It involves the lower legs, with a stocking distribution.[157] The process is usually associated with chronic venous insufficiency, arterial ischemia, and previous episodes of thrombophlebitis (see Chap. 175). The deforming atrophy of the subcutaneous fat secondary to extensive deep fibrosis and sclerosis resembles an inverted bottle. The vascular disorder leads to sludging in the lobular capillaries, which results in ischemia and necrosis of the central portion of the fat lobule. Recent studies have demonstrated that patients with systemic sclerosis and sclerosing panniculitis frequently have pulmonary infarctions and pulmonary hypertension. In these patients, the thrombosis caused by venous hypertension of the leg is the main etiologic factor for pulmonary hypertension.[158] Lipodermatosclerosis can also manifest as an acute process that is frequently misdiagnosed as erythema nodosum.

Histopathologic findings in sclerosing panniculitis vary according to the evolution of the lesions. In the early stages, there is a sparse inflammatory infiltrate largely composed of lymphocytes between the collagen bundles of the septa. In addition, areas of ischemic necrosis characterized by pale, small, and anucleated adipocytes are found at the center of the fat lobule. Small lobular vessels appear congested, and sometimes there are numerous extravasated erythrocytes, hemosiderin, and necrosis of endothelial cells within the areas of fat necrosis. In fully developed lesions, the septa appear thickened and fibrotic, resulting in dramatic atrophy of the subcutaneous fat. In this stage, the inflammatory infiltrate is composed of lymphocytes, histiocytes, and foamy macrophages. The periphery of the fat lobule often shows lipophagic granulomas with scattered lymphocytes and plasma cells. In late-stage lesions, septal sclerosis is the main histopathologic finding. The fat lobules become small due to lipophagic fat necrosis, and there are fatty microcysts with foci of membranocystic changes. These consist of amorphous eosinophilic or amphophilic material, sometimes with a corrugated appearance, lining cystic spaces that result from fat necrosis. Lipomembranous or membranocystic fat necrosis is a frequent finding in late-stage lesions of sclerosing panniculitis but is not exclusive to any type of panniculitis.[159] It has been described in long-standing lesions of many variants of lobular panniculitis. In any stage of the process, changes of stasis dermatitis are present in the superficial dermis, with proliferation of capillaries and venules in the papillary dermis, fibrosis, and abundant hemosiderin deposition.

Treatment of sclerosing panniculitis is difficult. In some cases, standard measurements for venous insufficiency of the lower extremities, including compression stockings, have been useful but

SCLEROSING PANNICULITIS AT A GLANCE

Clinical

- Indurated plaques of wood-like consistency on the lower legs with a stocking distribution
- Chronic venous insufficiency, arterial ischemia, and episodes of thrombophlebitis
- Pulmonary hypertension in patients with systemic sclerosis and sclerosing panniculitis

Histopathology

- Mostly lobular panniculitis without vasculitis
- Ischemic necrosis at the center of the fat lobule
- Thickened and fibrotic septa and atrophy of the subcutaneous fat
- Frequent membranocystic changes

Treatment

- Compression stockings
- Successful response to stanozolol in some cases

not curative. Some authors have reported that the anabolic steroid stanozolol improves this condition rapidly and consistently.[160]

Calciphylaxis (See Chap. 151)

Calciphylaxis is an uncommon and poorly understood cutaneous process.[161–164] The process occurs almost exclusively in patients with end-stage chronic renal failure who are undergoing dialysis or have been transplanted; rarely patients with normal renal function have been reported.[165] The main feature is the calcification of the intima of the arteries and arterioles of the deeper dermis and subcutis, resulting in necrosis and ulceration (see eFig. 68-7.1A in on-line edition). Most affected patients have elevated serum calcium and phosphate levels, often in the context of the secondary hyperparathyroidism associated with renal failure. However, calcium-phosphorus metabolism is normal in some patients with calciphylaxis, supporting the idea that other factors are also involved in pathogenesis.

Oxalosis

Oxalosis is an extremely rare panniculitis seen in conjunction with renal failure. Oxalosis may be primary (inherited) or secondary (acquired).

Cutaneous involvement is more frequent in secondary than in primary oxalosis. Lesions consist of miliary deposits of calcium oxalate crystals within the dermis of the palmar aspects of the fingers.[179,181] This calcium deposition induces a granulomatous response around the crystals. In contrast, cutaneous lesions in primary oxalosis are rare, and, when present, they consist of livedo reticularis and acral gangrene.[178,182–186] Histopathologic study of the cutaneous lesions of primary oxalosis shows calcium deposition and oxalate crystals in the vessel walls, with a histopathologic picture quite similar to that of calciphylaxis.[178,182–187]

Sclerema Neonatorum (See Chap. 106)

Nowadays, sclerema neonatorum is very uncommon, probably due to the improvements in neonatal care. Most examples of this rare disorder were described in low-weight premature newborns with sepsis, congenital heart disease, and other major perinatal problems. The affected baby is generally severely ill, and cutaneous lesions appear during the first days of life. Lesions usually begin on the buttocks and thighs as diffuse, yellow-white, woody induration of the skin that rapidly extends to involve large areas of the body, resulting in immobility of the extremities. The prognosis is poor, and most infants die within a few days.[189] A higher ratio of saturated to unsaturated fatty acids in neonates, which is even higher in premature and small-for-date infants, has been postulated as predisposing to sclerema neonatorum.[190]

At low-power view, cutaneous lesions of sclerema neonatorum do not look like typical panniculitis because the inflammatory infiltrate is sparse or even absent in the subcutaneous fat, reflecting the poor immunologic response of the severely ill infant.[191] There is little evidence of fat necrosis, and the most characteristic feature is the presence of radially arranged, needle-shaped clefts in adipocytes. The same needle-shaped crystals have been identified in visceral adipocytes in autopsy studies of infants who die as consequence of sclerema neonatorum.[192,193]

Treatment of sclerema neonatorum should focus on the underlying disease. Systemic corticosteroids are ineffective but there is evidence that repeated exchange transfusions may reduce mortality.[194]

Cold Panniculitis

Cold panniculitis is also more frequent in infants following exposure to severe cold.[195–197] This variant of panniculitis has been described in the cheeks of children sucking ice cubes, ice packs, or ice lollies (popsicles),[198,199] and in the thighs and buttocks of women who ride horses wearing tight trousers during the cold months, resulting in obstruction of the blood supply to the subcutaneous fat (equestrian panniculitis).[200,201] The involved areas show indurated erythematous plaques with ill-defined margins.

The panniculitis is mostly lobular with an inflammatory infiltrate of lymphocytes and histiocytes in the fat lobules. The papillary dermis may show marked edema as well as a superficial and deep perivascular lymphocytic infiltrate, closely resembling the histopathologic picture of perniosis.[202]

If the involved area is kept warm, the plaques slowly soften and resolve in days without scarring. Looser trousers should be recommended for women who ride horses. Vasodilator drugs are not effective in preventing or treating cold panniculitis.

Lupus Panniculitis (Lupus Erythematosus Profundus) (See Chap. 156)

Lupus panniculitis is a chronic recurrent panniculitis that is more frequent in women than men. It is a mild variant of lupus erythematosus, and most patients show subcutaneous nodules as the only clinical manifestation of the disease.[203,204] The lesions exhibit a predilection for the face, shoulders, upper arms, back, and buttocks, areas infrequently involved in other forms of panniculitis (see eFig. 68-7.2 in on-line edi-

LUPUS PANNICULITIS AT A GLANCE

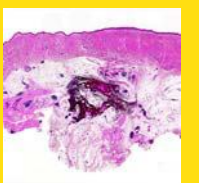

Clinical

- Erythematous nodules at the face, shoulders, upper arms, and buttocks
- Persistent areas of lipoatrophy on regressed lesions

Histopathology

- Only 20 percent to 30 percent of the patients with lupus panniculitis show features of discoid lupus erythematosus at the dermal-epidermal junction.
- Mostly lobular panniculitis without vasculitis.
- Inflammatory infiltrate predominantly composed of lymphocytes and plasma cells.
- Often, lymphoid follicles with germinal centers.
- Sclerotic collagen bundles at subcutaneous septa.
- Hyaline necrosis and atrophy of the entire fat lobule in late-stage lesions.

Treatment

- Corticosteroids under occlusion or in intralesional injections
- Short oral courses of corticosteroids or hydroxychloroquine
- Dapsone

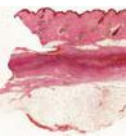

PANCRETIC PANNICULITIS AT A GLANCE

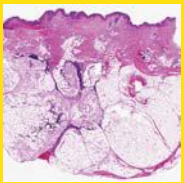

Clinical

- Erythematous subcutaneous nodules that often ulcerate spontaneously.
- The lower extremities, around the ankles and knees, are the most frequently involved sites.
- Regression of the cutaneous lesions associated with pancreatitis, but those associated with pancreatic carcinoma tend to persist.

Histopathology

- Mostly lobular panniculitis without vasculitis
- Intense necrosis of the adipocytes at the center of the fat lobule
- Ghost adipocytes with finely granular and basophilic material within their cytoplasm

Treatment

- Treatment of the underlying pancreatic disease

tion). In rare instances, lesions of lupus panniculitis have been described in the subcutaneous fat of the breast ("lupus mastitis"),[205–207] orbital fat,[208,209] and periparotid fat tissue.[210,211] An isomorphic phenomenon is frequently seen in patients with lupus panniculitis; subcutaneous erythematous nodules often develop or recur at the sites of trauma, injection, and biopsy.[212,213]

Pancreatic Panniculitis

Pancreatic panniculitis, also named *enzymatic fat necrosis*, has been associated with several pancreatic diseases, including acute and chronic pancreatitis, pancreatic carcinoma, both acinar cell and islet cell pancreatic carcinomas, pancreas divisum, pancreatic pseudocysts, vasculo-pancreatic fistulae, and drug-induced pancreatitis.[230–256] In some patients with pancreatic panniculitis, the skin lesions are the presenting feature of the pancreatic disease. In some patients, however, there is no demonstrable pancreatic disease, although high serum levels of pancreatic lipase of unknown origin have been detected.[257]

Cutaneous lesions of pancreatic panniculitis appear as erythematous, subcutaneous nodules that often ulcerate spontaneously and exude an oily brown material, which results from liquefaction necrosis of adipocytes (Fig. 68-8). The most frequently involved sites are the distal parts of the lower extremities and around the ankles and knees[257]; the nodules of enzymatic fat necrosis have less commonly been described on the thighs, buttocks, calves, arms, and abdominal skin. Cutaneous lesions of pancreatic panniculitis associated with pancreatitis usually undergo resolution when the inflammatory episode regresses, in contrast with the chronic and persistent nodules of subcutaneous fat necrosis in patients with pancreatic carcinoma.[258] Often, the onset of cutaneous lesions of pancreatic panniculitis is accompanied by acute arthritis that results from necrosis in periarticular fat tissue.[234,237,258–263] Autopsy studies of patients with pancreatic carcinoma have demonstrated that the same type of enzymatic fat necrosis also occurs in bone marrow,[246] pleural,[241,249] retroperitoneal, and mesenteric fat.[249,259]

Pancreatic enzymes, mostly lipase, that escape into the blood from the inflamed pancreas seem to be responsible for the subcutaneous fat necrosis in enzymatic panniculitis.[239,257] The finding of pancreatic lipase in the lesions of pancreatic panniculitis[257] and the immunohistochemical demonstration with anti-lipase monoclonal antibodies of that enzyme within the necrotic adipocytes,[238] support the pathogenic role of pancreatic lipase. However, some individual susceptibility may also be important because there is a contrast between the relative frequency of patients with pancreatitis with high serum levels of lipase and the rare occurrence of pancreatic panniculitis.[264] Furthermore, in vitro investigations have failed to reproduce pancreatic panniculitis when normal human subcutaneous fat is incubated with the serum of a patient with high levels of pancreatic lipase, trypsin, and amylase.[239] Well-documented examples of pancreatic panniculitis have also been described in patients with normal serum levels of all pancreatic enzymes.[265,266]

Histopathologically, pancreatic panniculitis is a mostly lobular panniculitis with intense necrosis of the adipocytes at the center of the fat lobule (see Fig. 68-8B).[267] The characteristic features consist of coagulative necrosis of the adipocytes, which leads to ghost adipocytes. Ghost adipocytes are necrotic adipocytes that have lost their nuclei and

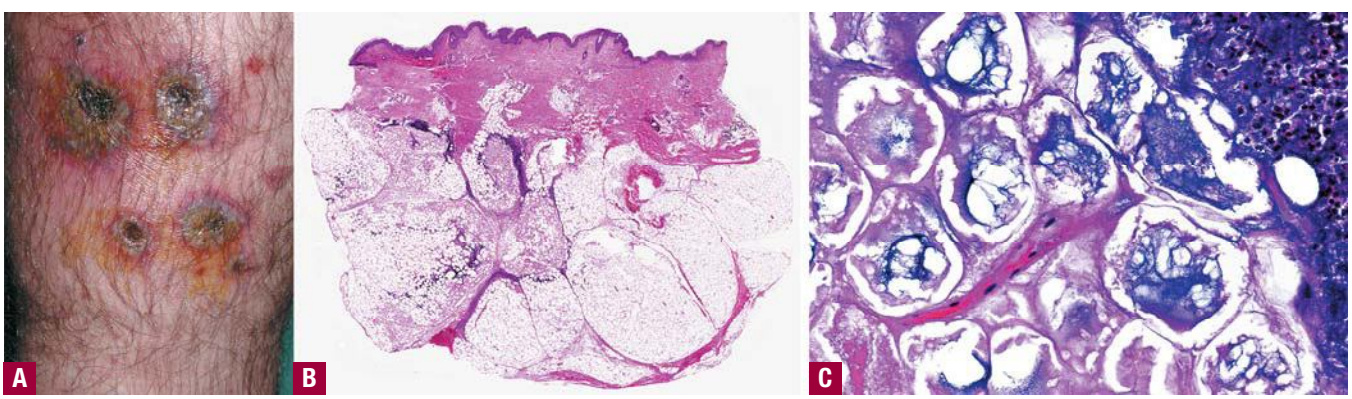

▲ **FIGURE 68-8** Pancreatic panniculitis. **A.** Clinical appearance: Erythematous subcutaneous nodules that ulcerate spontaneously and exude an oily brown material. **B.** Histopathology: Scanning power showing a mostly lobular panniculitis with intense necrosis of the adipocytes at the center of the fat lobule. **C.** Higher magnification showing ghost adipocytes, which consist of necrotic adipocytes that have lost their nuclei and show a finely granular and basophilic material within their cytoplasm due to calcification.

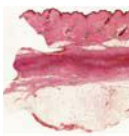

show a finely granular and basophilic material within their cytoplasm due to calcification (see Fig. 68-8C). Often, ghost adipocytes appear grouped in small clusters at the center of the fat lobule, whereas an inflammatory infiltrate of neutrophils is present at the periphery and extends into the adjacent septa. Ghost adipocytes result from the hydrolytic action of pancreatic enzymes on fat, followed by calcium deposition, a process known as *saponification*. In late-stage lesions of pancreatic panniculitis, fat necrosis and calcified ghost adipocytes are less evident, and the fat lobule is replaced by a granulomatous inflammatory infiltrate composed of foamy histiocytes and multinucleated giant cells. Ghost adipocytes are characteristic of pancreatic panniculitis, but sometimes they are sparse and are only found after serial sections.

Treatment of pancreatic panniculitis is primarily directed at the underlying pancreatic disease. When the pancreatic problem can be reversed with surgical correction, complete resolution of the cutaneous lesions occurs.[235,250]

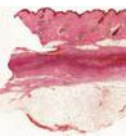

α_1-Antitrypsin-Deficiency Panniculitis

Currently, more than 90 mutant alleles of the α_1-antitrypsin gene have been recognized and are classified according to electrophoretic separation. The four major categories include: F (fast), M (medium), S (slow), and Z (very slow). In each individual, two alleles determine the specific α_1-antitrypsin phenotype. The most common allele associated with normal levels of α_1-antitrypsin is M, whereas other alleles, such as S and Z, are usually associated with low serum levels of the enzyme. Thus, a heterozygote with MS or MZ phenotype usually shows moderate deficiency of α_1-antitrypsin with few or no clinical manifestations, whereas a homozygous patient with a ZZ phenotype has severe α_1-antitrypsin deficiency with serious clinical manifestations, including emphysema, hepatitis, cirrhosis, vasculitis, and angioedema.[268–270] Occasionally, individuals with MS or MZ phenotypes show normal serum levels of α_1-antitrypsin, but clinical evidence of panniculitis as an isolated finding. Most patients with α_1-antitrypsin-deficiency–associated panniculitis have the ZZ phenotype with very low levels of α_1-antitrypsin. However, in the patients with the ZZ phenotype and very low serum levels of α_1-antitrypsin, severe pulmonary and liver diseases are almost constant, whereas panniculitis is rare. This indicates that α_1-antitrypsin-deficiency–associated panniculitis is probably a multifactorial disorder, and other etiopathogenic factors, besides α_1-antitrypsin deficiency, also play some role. Some patients with the MS variant have developed panniculitis but no liver or pulmonary disease. Some patients with this type of panniculitis show normal levels of α_1-antitrypsin, but the enzyme function may be significantly impaired.[271] In addition, α_1-antitrypsin is an acute-phase reactant, and an isolated normal serum value may not be indicative of the ability of the body to upregulate the protein in stress situations. Therefore, the serum levels of the enzyme and the α_1-antitrypsin phenotype can only be of diagnostic value in the proper clinical and histopathologic setting.

α_1-Antitrypsin is a serine protease inhibitor that mostly inhibits trypsin activity but is also a potent inhibitor of chymotrypsin, plasmin, thrombin, neutrophilic elastase, pancreatic elastase, serine proteases, collagenase, factor VIII, and kallikrein. Therefore, severe α_1-antitrypsin deficiency may be associated with disorders of blood coagulation and fibrinolysis, anomalies in the phagocytic mechanisms of the immune response, abnormalities in activation of zymogens, and the release of peptide hormones. α_1-Antitrypsin deficiency equally affects both sexes, and it may affect children, although subcutaneous fat necrosis due to α_1-antitrypsin deficiency develops most commonly during adult life.

Panniculitis associated with α_1-antitrypsin deficiency may be the first sign of the disease, although lesions of subcutaneous fat necrosis usually appear when other clinical manifestations of the disorder have already developed. These lesions consist of subcutaneous nodules mostly located on the lower abdomen, buttocks, and proximal extremities (Fig. 68-9), whereas the distal areas of the lower extremities are less frequently involved than in other forms of panniculitis.[268,271–293] Ulceration is a key clinical feature to α_1-antitrypsin-deficiency–associated panniculitis, and necrotic nodules exudate oily material that represents necrotic adipocytes. An isomorphic phenomenon is also frequent in α_1-antitrypsin-deficiency–associated panniculitis, and subcutaneous nodules often develop at sites of previous trauma, including surgery.[293]

Histopathologic studies of lesions of α_1-antitrypsin-deficiency panniculitis demonstrate a mostly lobular panniculitis with severe necrosis of the fat lobules and a dense inflammatory infiltrate of neutrophils (see Fig. 68-9B,C). Additional histopathologic features that have been described as histopathologic clues for diagnosis of α_1-antitrypsin-deficiency–associated panniculitis include splaying of neutrophils between collagen bundles of the deep reticular dermis[291] and the focality of the lesions, with large areas of normal fat adjacent to necrotic adipocytes containing many

α_1-ANTITRYPSIN-DEFICIENCY PANNICULITIS AT A GLANCE



Clinical

- Homozygous patients with ZZ phenotype and very low levels of α_1-antitrypsin have emphysema, hepatitis, cirrhosis, vasculitis, and angioedema. Uncommonly, panniculitis.
- Subcutaneous nodules mostly located on the lower abdomen, buttocks, and proximal extremities.
- Frequent ulceration and isomorphic phenomenon.

Histopathology

- Mostly lobular panniculitis without vasculitis
- Necrosis of the fat lobules with a dense inflammatory infiltrate of neutrophils
- Splaying of neutrophils between collagen bundles of the deep reticular dermis
- Large areas of normal fat adjacent to necrotic adipocytes

Treatment

- Dapsone
- Homozygous patients with severe forms of the disease: supplemental intravenous infusion of exogenous α_1-proteinase inhibitor concentrate or α_1-antitrypsin produced by genetic engineering

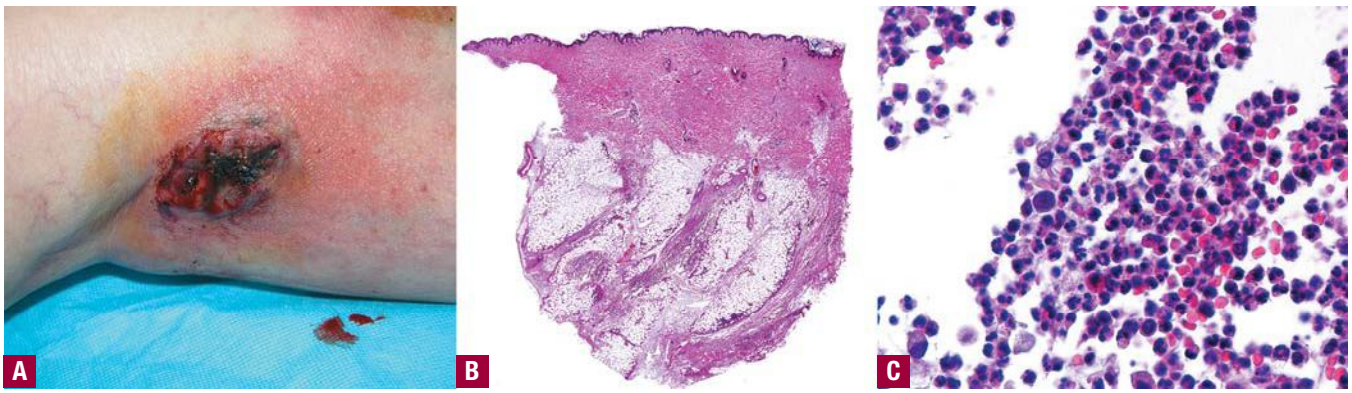

▲ **FIGURE 68-9** α_1-Antitrypsin-deficiency panniculitis. **A.** Clinical appearance showing subcutaneous necrotic nodules with ulceration and exudation of oily material, which represents necrotic adipocytes. **B.** Histopathology: Scanning power showing a mostly lobular panniculitis. **C.** A dense inflammatory infiltrate of neutrophils involving the fat lobule.

neutrophils and histiocytes.[283] Occasionally, the intense inflammatory infiltrate of neutrophils causes collagenolysis and degeneration of elastic tissue with destruction of the septa of the subcutis. The necrotic fat lobules appear to be "floating" and surrounded by neutrophils.[284] In late-stage lesions, neutrophils and necrotic adipocytes are less evident, and the fat lobules appear to be occupied by lymphocytes, foamy histiocytes, and fibrosis of variable degrees.[286]

Because trauma and surgical débridements are frequent precipitating factors of panniculitis in patients with α_1-antitrypsin deficiency, they should be avoided, if possible. Dapsone has proved to be an effective treatment in cases of panniculitis due to α_1-antitrypsin deficiency.[282,294,295] In homozygous patients with severe forms of the disease, presenting with severe emphysema and liver failure, the only therapeutic possibility is weekly intravenous infusion of α_1-proteinase inhibitor concentrate (60 mg/kg) or a liver transplantation.[296,297] The production of α_1-antitrypsin by genetic engineering is being investigated.[298,299]

Infectious Panniculitis

A wide variety of infectious agents, including several bacteria or fungi, may cause lobular panniculitis as the main clinical manifestation. Bacterial infectious panniculitides include infections of the subcutaneous fat caused by *Streptococcus pyogenes*,[300] *Staphylococcus aureus*,[300] *Pseudomonas* sp.,[300,301] *Klebsiella*,[300] *Nocardia* sp.,[300] atypical mycobacteria,[302–305] *M. tuberculosis*,[306] and *M. leprae*[121]; whereas fungi causing panniculitis include dermatophytes, *Candida* sp.,[300,307] *Fusarium* sp.,[300] *Histoplasma capsulatum*,[308,309] *Cryptococcus neoformans*,[141] *Actinomyces israelii*,[141] *Sporothrix schenckii*,[141] *Aspergillus fumigatus*,[310] and chromomycosis.[141] Many of the patients with infectious panniculitis are immunosuppressed due to an associated disease or medication intake.

The evaluation of patients with neutrophilic lobular panniculitis should include cultures of the biopsy specimen. Most infectious panniculitides show a histopathologic pattern of suppurative granulomas within the fat lobule, which consist of collections of neutrophils surrounded by epithelioid histiocytes.[305] Infectious panniculitis usually results from hematogenous dissemination, with the respiratory tract being the most common portal of entry. However, primary cutaneous infections also occur as a consequence of direct physical inoculation at the site of an occlusive dressing or an indwelling catheter. Histologic differences may be the consequence of the different routes of dissemination. In primary cutaneous infections, the epicenter of the inflammation is the superficial dermis, and thrombosed vessels do not contain intravascular organisms. In contrast, in secondary cutaneous infections, the epicenter of inflammation is more deeply seated and involves only the deep reticular dermis and subcutaneous fat. The blood vessels are thrombosed and dilated with masses of organisms expanding their lumina.[300] In immunosuppressed patients, microorganisms are numerous, and they may be identified in tissue sections with the routine hematoxylin-eosin stain or with special stains, including Gram, periodic acid-Schiff, or Ziehl-Neelsen stains. Because anti-bacille Calmette-Guérin immunostaining shows cross-reactivity with many bacteria and fungi, as well as high sensitivity and minimal background staining, it has been recently proposed as the best screening tool for detection of bacterial and fungal microorganisms in paraffin-embedded skin specimens.[311]

INFECTIOUS PANNICULITIS AT A GLANCE

Clinical

- A wide variety of infectious agents, including several bacteria or fungi, may cause infectious panniculitis.
- Often, the patients are immunosuppressed.
- Erythematous nodules with frequent ulceration and exudation of oily material.

Histopathology

- Suppurative granulomas within the fat lobule.
- In primary cutaneous infections, the epicenter of the inflammation is the superficial dermis.
- In secondary cutaneous infections, the epicenter of inflammation is the deep reticular dermis and subcutaneous fat, and the blood vessels are thrombosed and dilated with masses of organisms.
- Special stains are necessary for detection of bacterial and fungal microorganisms.
- The diagnosis must be established by a positive culture or serologic studies.

Treatment

- Appropriate antimicrobial therapy selected according to susceptibility tests

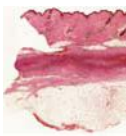

In most cases, however, the number of microorganisms in the specimen is sparse, and they cannot be identified with special stains, thus the diagnosis must be established by a positive culture or serologic studies.

Treatment of infectious panniculitis requires appropriate antimicrobial therapy, which should be selected according to susceptibility tests.

Factitial Panniculitis

Some patients with psychiatric disorders inject various substances into the subcutaneous fat, causing panniculitis. Among the injected substances are acids, alkalis, mustard, milk, microbiologically contaminated material, urine, and feces. Panniculitis may also result from the subcutaneous implantation of different materials for cosmetic or therapeutic reasons. Iatrogenic panniculitides include those due to some drugs injected into the subcutaneous fat, such as insulin, povidone,[312] meperidine,[313] pentazocine,[314,315] and vitamin K_1,[316] or substances used to augment the size of breasts or genitalia or to correct facial wrinkles or areas of lipoatrophy, such as paraffin,[317–322] silicone,[323–325] Artecoll®,[326,327] Bioplastique®,[326] Dermalive®,[327,328] or Matridex®.[329]

Histopathologically, factitial panniculitis usually shows a pattern of a mostly lobular panniculitis, with an inflammatory infiltrate predominantly composed of neutrophils at the center of the fat lobule and epithelioid histiocytes at the periphery. Given that the differential diagnosis includes infectious panniculitis, cultures are mandatory. Sometimes, polarization of the slide can identify the refractile foreign material, or additional histopathologic findings help to identify the nature of the foreign material. For example, hematoxylin-eosin stain of povidone-induced panniculitis shows blue-gray foamy deposits of povidone in the cytoplasm of large, distended macrophages within the fat lobule.[312] Povidone also stains intensely with Congo red and chlorazol-fast pink and variably with periodic acid-Schiff.[312] Panniculitis secondary to subcutaneous injections of pentazocine show marked sclerosis of the dermis and the septa of subcutaneous fat, with necrotic adipocytes, lipophagic granuloma, and thrombi in the lumina of the small blood vessels of the fat lobule.[315] Subcutaneous injections of vitamin K_1 induce sclerosis of the collagen bundles of the subcutaneous septa and an inflammatory infiltrate of lymphocytes and plasma cells, closely resembling the histopathologic features of deep morphea.[316] Paraffinoma shows a histopathologic picture of sclerosing lipogranuloma, which consists of multiple "Swiss-cheese-like" pseudocystic spaces replacing the fat lobules, surrounded by fibrosis and an inflammatory infiltrate composed of foamy histiocytes and multinucleated giant cells.[317,318] Silicone injections used for cosmetic reasons may produce lobular panniculitis histopathologically characterized by foamy histiocytes containing round vacuoles of different sizes in their cytoplasm and multinucleated giant cells replacing the fat lobule.[323–325] Some specific features have been seen in biopsy specimens of lesions from injectable agents (see Chap. 255). For example, Bioplastique® granulomas present with irregularly shaped cystic spaces of varying size containing jagged, translucent, nonbirefringent foreign bodies surrounded by multinucleated giant cells.[326] Artecoll® granulomas show numerous round vacuoles nearly identical in size and shape enclosing round and sharply circumscribed, translucent, nonbirefringent foreign bodies surrounded by sclerotic stroma.[326,327] Dermalive® granulomatous reactions exhibit translucent or slightly pink nonbirefringent polygonal foreign bodies surrounded by a dense foreign body type granulomatous reaction.[327,328] Finally, Matridex® reaction shows suppurative granuloma containing dark-blue stained spheres of dextranomers.

Treatment of these panniculitides induced by injection of soft tissue augmentation materials is a challenge. Oral or intralesional administration of corticosteroids may be helpful for isolated lesions but most of the time, the implanted material must be surgically excised.

FACTITIAL PANNICULITIS AT A GLANCE

Clinical

- Erythematous nodules with disparate location or appearance in patients with personality aberrations
- Subcutaneous implantation of cosmetic fillers

Histopathology

- Mostly lobular panniculitis without vasculitis.
- Suppurative granuloma involving the fat lobule.
- Sometimes polarization of the slide can identify the refractile foreign material.
- Different morphology or the particles in panniculitis induced by cosmetic fillers:
  - Silicone: Foamy histiocytes containing round vacuoles of different sizes.
  - Bioplastique®: Irregularly shaped cystic spaces of varying size containing jagged, translucent, nonbirefringent foreign bodies surrounded by multinucleated giant cells.
  - Artecoll®: Numerous round vacuoles nearly identical in size and shape enclosing round and sharply circumscribed, translucent, nonbirefringent foreign bodies surrounded by sclerotic stroma.
  - Dermalive®: Granulomatous reactions exhibit translucent or slightly pink nonbirefringent polygonal foreign bodies surrounded by a dense foreign body type granulomatous reaction.
  - Matridex®: Suppurative granuloma containing dark-blue stained spheres of dextranomers.

Treatment

- Oral or intralesional administration of corticosteroids.
- In panniculitis induced by cosmetic fillers, most often the implanted material must be surgically excised.

Subcutaneous Sarcoidosis (See Chap. 153)

Classic erythema nodosum is the most common panniculitis in patients with sarcoidosis. Sometimes, however, specific lesions of sarcoidosis involve the subcutaneous fat. Clinically, these lesions consist of subcutaneous nodules on the upper and lower extremities with no signs of inflammation on the skin surface.[330–333]

Traumatic Panniculitis

External injury of various types can produce panniculitis. Traumatic panniculitis may result from accidental blunt trauma in several areas of the skin and is especially frequent in women with large breasts, in which the excessive breast weight favors the trauma of the mammary subcutaneous fat. Clinically, lesions of mammary traumatic panniculi-

TRAUMATIC PANNICULITIS AT A GLANCE

Clinical

- Accidental blunt trauma or women with large breasts
- Indurated nodules deeply situated within the subcutaneous tissue of extremities or the breast covered by normal or erythematous skin
- Nodular-cystic fat necrosis or mobile encapsulated lipoma: Movable nodules surrounded by a fibrous pseudocapsule in the subcutis of lower limbs

Histopathology

- Mostly lobular panniculitis without vasculitis
- Cystic spaces of variable size and shape within fat lobules
- Variable degrees of fibrosis and hemorrhage
- Often, membranocystic or lipomembranous changes as a residual lesion

Treatment

- Not necessary. Often, spontaneous resolution.

tis consist of indurated nodules deeply situated within the breast tissue that are covered by normal or erythematous skin. Sometimes, the skin surface shows an "orange peel" appearance, raising the differential diagnosis of mammary carcinoma extending into the skin.[338,339] Lesions of traumatic panniculitis involving the breasts usually resolve, leaving areas of lipoatrophy. Other frequent locations for lesions of traumatic panniculitis are the shins, where erythematous tender subcutaneous nodules appear after minor trauma. The process, known as *lipoatrophia semicircularis*, also may be considered as a variant of traumatic panniculitis that consists of semicircular band-like areas of atrophy of the subcutaneous fat that involve half of the circumference of the anterolateral aspects of the thighs of women who repeatedly lean with their thighs against a desk or chair because of their working habits.[340] The so-called *nodular-cystic fat necrosis*, also named *mobile encapsulated lipoma* and *encapsulated fat necrosis*, is a residual stage of traumatic panniculitis in which well-demarcated and movable nodules surrounded by a fibrous pseudocapsule appear in the subcutis of lower limbs, elbows, or hips after trauma.[341–346]

As a consequence of confluent necrosis of the fat cells, and regardless of the etiology, traumatic fat necrosis shows cystic spaces of variable size and shape within lobules surrounded by variable degrees of fibrosis and hemorrhage. At the periphery of the cystic spaces, foamy histiocytes and lymphocytes are usually present.[347] In late-stage lesions, hemosiderin may be abundant both extracellularly and within the cytoplasm of the macrophages. As in other forms of residual lobular panniculitis, membranocystic or lipomembranous changes have also been described in lesions of traumatic panniculitis.[348]

Lipoatrophy

Often, *lipoatrophy* and *lipodystrophy* are used as synonymous terms, but from a pathogenic point of view, they are two different disorders that lead to loss of subcutaneous fat. *Lipoatrophy* refers specifically to a loss of subcutaneous fat due to a previous inflammatory process involving the subcutis. In contrast, lipodystrophy means an absence of subcutaneous fat with no evidence of inflammation. Lipodystrophy may be congenital or acquired, with total, partial, and localized lipodystrophy variants (see Chap. 69).[349]

Several forms of localized lipoatrophy have been described according to their clinical appearance and location, namely annular lipoatrophy,[350] abdominal lipoatrophy,[351] semicircular lipoatrophy,[352] and postinjection localized lipoatrophy.[353,354] However, the most common localized lipoatrophy appears as a sequela of panniculitis, especially lupus panniculitis.[212,355–358] Localized lipoatrophy may also appear at the sites of injection of different drugs, including corticosteroids,[354,359–362] insulin,[363–367] antibiotics,[359] vasopressin,[368] human growth hormone,[369] and glatiramer acetate treatment for multiple sclerosis.[370] Localized lipoatrophy secondary to pressure and compression by tight-fitting clothes has been also reported on the ankles,[371–373] thighs,[340,352,374] abdominal skin,[351,375–379] and over the sacrum.[380]

In contrast, fully developed lesions of lipodystrophy show total absence of subcutaneous tissue with no evidence of inflammation, although some authors have postulated an early inflammatory stage (see Chap. 69).[381–383]

From a histopathologic point of view, lipoatrophy is a residual process of several inflammatory conditions involving the subcutaneous fat lobules. In most cases, the histopathologic findings are those of lipophagic granulomas surrounding a small-sized fat lobule with perilobular fibrosis. In those cases of lipoatrophy secondary to subcutaneous injection of corticosteroids, two different histopathologic patterns have been described.[359] Both patterns are characterized by the small size of the lobules and by the atrophy of the reduced number of adipocytes. The first pattern consists of faintly acidophilic small adipocytes that are retracted from the surrounding connective tissue of the septa. These changes are more prominent at the periphery of otherwise histologically normal fat lobules, suggesting that this is an early alteration of the lipoatrophic process. The general configuration of the fat lobule and the small size of the adipocytes resemble those of embryonic fat. Inflammatory cells are sparse, and blood vessels appear prominent, congested, and dilated. The second histopathologic pattern seen in lesions of lipoatrophy secondary to subcutaneous injections of corticosteroids is characterized by small, atrophic fat cells surrounded by a prominent vasculature. The small size of the fat lobule and adipocytes, the relative absence of inflammation, and the proliferation of small blood vessels give an angiomatous appearance to the fat lobule.

In fully developed lesions of lipodystrophy, there is an absence of subcutaneous fat with deposition of new collagen, no evidence of inflammation, and the dermis and the fascia are in direct apposition. Recently, two histopathologic variants of lipodystrophy have been proposed.[384] In the first type, there are prominent involutional changes in the fat lobule, with small adipocytes and intervening hyaline or myxoid connective tissue and proliferation of small blood vessels. The second type is the inflammatory type, because lymphocytes, foamy histiocytes, and plasma cells appear within the small fat lobules with normal-appearing adipocytes and vasculature. It is uncertain, however, whether or not these two patterns represent two different stages of a single process.

Subcutaneous Fat Necrosis of the Newborn (See Chap. 106)

Subcutaneous fat necrosis of the newborn is a rare variant of localized lobular

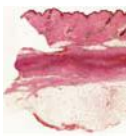

SUBCUTANEOUS FAT NECROSIS OF THE NEWBORN

AT A GLANCE

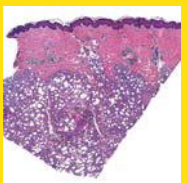

Clinical

- Circumscribed, red to violaceous, subcutaneous nodules or plaques on the buttocks, shoulders, cheeks, and thighs
- Sometimes, hypercalcemia or thrombocytopenia

Histopathology

- Mostly lobular panniculitis without vasculitis
- Dense inflammatory infiltrate composed of lymphocytes, histiocytes, lipophages, and multinucleated giant cells
- Narrow needle-shaped clefts, often in radial array within the cytoplasm of the histiocytes and multinucleated giant cells

Treatment

- Spontaneous resolution
- Etidronate in patients with hypercalcemia

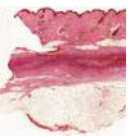

panniculitis that appears in newborns during the first days of life.[386,387] From a clinical point of view, smooth, circumscribed, red to violaceous, subcutaneous nodules or plaques develop, sometimes symmetric, involving mostly the buttocks, shoulders, cheeks, and thighs (Fig. 68-10).[388–390] Sometimes, infants affected by subcutaneous fat necrosis of the newborn have hypercalcemia or thrombocytopenia of unknown significance.[391–401] The newborn has a relatively large body surface in comparison with his or her weight and a greater ratio of saturated to unsaturated fatty acids than in adult fat, and these two factors favor the release of hydrolases that induce breakdown of unsaturated fatty acids caused by minor trauma.[386] Other etiologic factors that have been postulated in relationship with subcutaneous fat necrosis of the newborn include obstetrical trauma, induced hypothermia for cardiac surgery, gestational diabetes, hypoglycemia, Rhesus factor incompatibility, meconium aspiration, placenta previa, umbilical cord prolapse, anoxia, seizures, and preeclampsia.[386,387,402–404] Rare examples of subcutaneous fat necrosis of the newborn have been described after prostaglandin E administration,[400] in newborn infants with brown fat deficiency,[405] in newborns with serum abnormalities of lipids and lipoproteins,[406] in infants from mothers who used cocaine during pregnancy,[407] as a consequence of the intrapartum administration of calcium channel blockers,[408] and in association with thrombocytopenia.[409] Usually, cutaneous lesions of subcutaneous fat necrosis of the newborn develop during the first days of life, although cases with congenital and ulcerated lesions that were already present at delivery have also been described.[410]

The histopathologic picture of subcutaneous fat necrosis of the newborn is characteristic. It consists of a mostly lobular panniculitis, with a dense inflammatory infiltrate composed of lymphocytes, histiocytes, lipophages, multinucleated giant cells, and sometimes, eosinophils interspersed among the adipocytes of the fat lobule (see Fig. 68-10B). Many adipocytes are replaced by cells with finely eosinophilic granular cytoplasm that contain narrow, needle-shaped clefts, often in radial array (see Fig. 68-10C). These needle-shaped clefts represent crystals of triglycerides of the adipocytes; they are doubly refractile under polarized light and stain with oil red O. Some of these clefts may also be seen within the cytoplasm of multinucleated giant cells.[321,411–413] The needle-shaped crystals in radial fashion within the cytoplasm of adipocytes and histiocytes are quite characteristic of subcutaneous fat necrosis of the newborn, but are not exclusive, because identical crystals have also been described in lesions of sclerema neonatorum and poststeroid panniculitis. Histopathologic differential diagnosis of subcutaneous fat necrosis of the newborn versus sclerema neonatorum is straightforward, because lesions of the former show a dense inflammatory infiltrate of histiocytes and lymphocytes in the fat lobules; whereas in lesions of sclerema neonatorum, characteristically, the inflammatory infiltrate is lacking.[414]

In contrast to sclerema neonatorum, infants with subcutaneous fat necrosis of the newborn have an excellent prognosis, and spontaneous resolution of lesions is the rule, although a residual lesion of lipoatrophy may remain. Deaths have been reported in patients with associated hypercalcemia and, to avoid that, etidronate, a diphosphonate, has been proposed as an effective treatment.[415]

Poststeroid Panniculitis

Poststeroid panniculitis is a rare panniculitic complication that has been reported in children who were receiving high

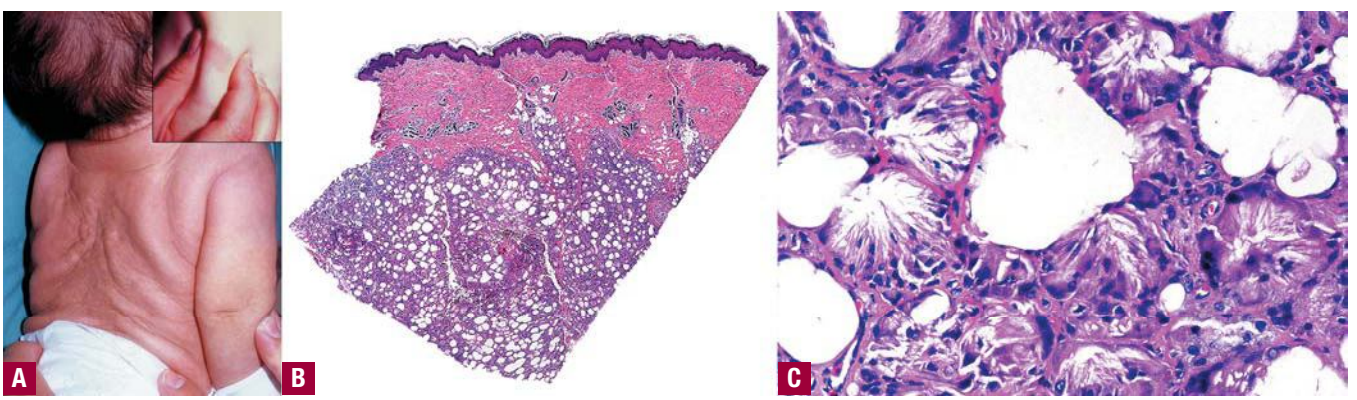

▲ **FIGURE 68-10** Subcutaneous fat necrosis of the newborn. **A.** Clinical appearance of the lesions: Circumscribed, indurate subcutaneous nodules on the back. *Inset.* A nodule with firm consistency on palpation. **B.** Histopathology: Scanning power showing a mostly lobular panniculitis. **C.** Higher magnification showing narrow needle-shaped clefts, often in radial array, within the cytoplasm of histiocytes and multinucleated giant cells.

doses of systemic corticosteroids that were tapered quickly or suddenly withdrawn. Patients who have developed this variant of panniculitis have received high doses of systemic corticosteroids for a variety of conditions, including rheumatic fever, leukemia, nephrotic syndrome, secretory diarrhea, brain stem glioma, and cerebral edema.[416–424]

Clinically, cutaneous lesions of poststeroid panniculitis consist of erythematous subcutaneous nodules and plaques that appear 1 to 10 days after stopping the high doses of systemic corticosteroids. Because the lesions develop mostly in those areas in which steroids induced the greatest accumulation of fat, subcutaneous nodules of poststeroid panniculitis appear mostly on the cheeks, posterior neck, and upper trunk.

Histopathologically, poststeroid panniculitis shows features identical to those of subcutaneous fat necrosis of the newborn. They consist of a mostly lobular panniculitis with an inflammatory infiltrate of foamy histiocytes and lymphocytes involving the fat lobules. Often, narrow strands of needle-shaped clefts are evident within the cytoplasm of some histiocytes,[424] although usually they are not as numerous as in subcutaneous fat necrosis of the newborn.

Lesions of poststeroid panniculitis gradually resolve within some weeks with no long-standing complications, except when ulceration occurs, which leaves atrophic scars on the cheeks of the infant. If the diagnosis is established at an early stage, readministration of high doses of systemic corticosteroids is indicated and then a slower and gradual tapering of the dose should be programmed.

Gout Panniculitis (See Chap. 161)

Patients with hyperuricemia may show monosodium urate crystal deposition in the fat lobule of the subcutis. These subcutaneous deposits of monosodium urate appear as subcutaneous masses or as fusiform swelling. The surface may be ulcerated, and there may be associated drainage of material. The most common locations of tophi are the skin overlying joints and the helix of the ear, but they may appear in any area of the skin.

Crystal-Storing Histiocytosis

Crystal-storing histiocytosis is a rare disease in which aggregations of histiocytes containing crystalline deposits of immunoglobulins are seen in the subcutaneous fat. Crystal-storing histiocytosis appearing as a lobular panniculitis has been described in a patient with lymphoblastic lymphoma.[427]

Histiocytic Cytophagic Panniculitis

Histiocytic cytophagic panniculitis describes a histopathologic pattern that may be seen in a variety of underlying conditions. With the advent of immunophenotyping and genetic techniques, most cases are now thought to result from involvement of subcutaneous fat by neoplastic lymphocytes in several primary or secondary T- and B-cell lymphomas (see Subcutaneous Lymphomas). However, not all cases of histiocytic cytophagic panniculitis are examples of subcutaneous lymphomas, and there are "benign" or nonneoplastic forms of histiocytic cytophagic panniculitis. Immunophenotyping and genotyping studies are helpful in the differential diagnosis of subcutaneous lymphomas with panniculitic appearance and authentic histiocytic cytophagic panniculitis,[428] although some authorities believe that most cases of histiocytic cytophagic panniculitis are actually subcutaneous lymphomas that are not detectable by current methods.

Patients with histiocytic cytophagic panniculitis develop subcutaneous erythematous plaques and nodules on the extremities and trunk (Fig. 68-11). Sometimes, the lesions are painful and appear as ill-defined hemorrhagic plaques. Spontaneous ulceration or persistent drainage after biopsy is a frequent feature. Most patients with cytophagic histiocytic panniculitis have a prolonged clinical course that lasts years and usually results in a terminal state characterized by fever, hepatosplenomegaly, and pancytopenia secondary to hemocytophagocytosis involving the bone marrow.[429–441] However, there are also well-documented examples of cytophagic histiocytic panniculitis with a benign clinical behavior, even after long follow-up.[442–456] More fulminant forms of the disease are associated with persistent fever, hepatosplenomegaly, mucosal ulcers, serosal effusions, pancytopenia, intravascular coagulation, liver failure, hemorrhagic diathesis, and death.

Histopathologically, subcutaneous nodules of histiocytic cytophagic panniculitis show a mostly lobular panniculitis with an inflammatory infiltrate in the fat lobules composed of histiocytes and mature lymphocytes. Cytophagocytosis by macrophages that contain intact or fragmented erythrocytes, leukocytes, plasma cells, or lymphocytes within their cytoplasm produces the so-called *bean-bag cells* (see Fig. 68-11C).[429–456] Often, there is considerable necrosis of the adipocytes of the fat lobule. Immunohistochemical studies demonstrate that histiocytes with cytophagic activity express histiocytic markers such as CD68, whereas most of the lymphocytes show a T-cell immunophenotype. In authentic histiocytic cytophagic panniculitis, molecular genetic studies fail to demonstrate monoclonality of the lymphoid cells, but when atypical lymphocytes are seen as a component of the infiltrate, immunophenotyping and gene rearrangement studies demonstrate the neoplastic nature of lymphocytes, most commonly a subcutaneous lymphoma, foremost, a subcutaneous T-cell lymphoma. In rapidly progressive cases of histiocytic cytophagic panniculitis, cy-

HISTIOCYTIC CYTOPHAGIC PANNICULITIS AT A GLANCE



Clinical

- Subcutaneous erythematous plaques and nodules on the extremities and trunk
- Sometimes, ill-defined hemorrhagic plaques
- Patients with long-standing disease: Fever, hepatosplenomegaly, and pancytopenia secondary to hemocytophagocytosis involving the bone marrow

Histopathology

- Mostly lobular panniculitis without vasculitis
- Histiocytes and mature lymphocytes involving the fat lobule
- "Bean-bag" cells: Cytophagocytosis by macrophages that contain intact or fragmented erythrocytes, leukocytes, plasma cells, or lymphocytes within their cytoplasm
- Necrosis of the adipocytes of the fat lobule

Treatment

- Immunosuppressive therapy with prednisone, cyclosporine, or dapsone

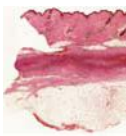

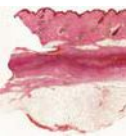





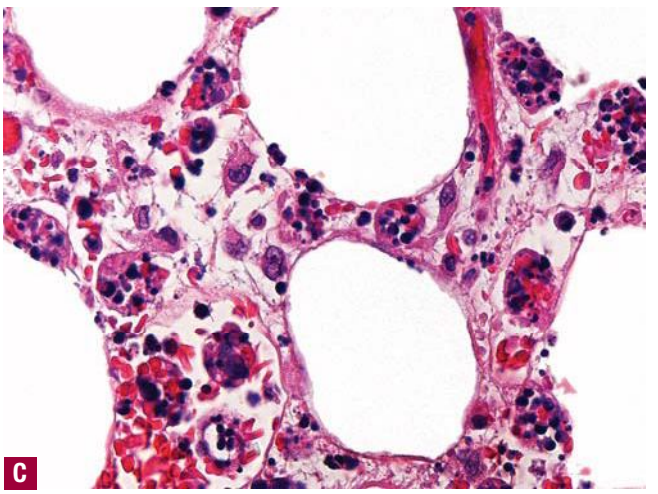

▲ **FIGURE 68-11** Cytophagic histiocytic panniculitis. **A.** Multiple erythematous nodules and plaques involving the lower extremities. **B.** Histopathologic features showing lobular pannicular inflammation. **C.** The pathognomonic feature of cytophagocytosis—"bean-bag" cells.

tophagic features are also seen in internal organs, including lymph nodes, spleen, liver, and bone marrow, resulting in pancytopenia and death.

Postirradition Sclerodermatous Panniculitis

Some women with a history of breast cancer that was treated by radical mastectomy and radiotherapy develop indurated erythematous plaques on the irradiated skin 1 to 6 months after radiotherapy (see Chap. 95).[460,461] The clinical diagnosis is usually cutaneous metastasis from the former mammary carcinoma, but histopathologic studies show hyaline collagen bundles in the dermis and subcutaneous septa and an inflammatory infiltrate of lymphocytes and plasma cells involving the fat lobules. In some areas, lipophagic granulomas are seen at the periphery of the fat lobule. This variant of radiation-induced panniculitis has been named *postirradiation sclerodermatous panniculitis*.[460,461] The main histopathologic differential diagnoses include morphea profunda and lupus panniculitis. Morphea profunda is mostly a septal panniculitis, with thickened septa composed of sclerotic collagen bundles, but the fat lobule is spared. Lupus panniculitis shows several histopathologic features similar to those of postirradiation sclerodermatous panniculitis, but the fat lobule of lupus profundus shows hyaline necrosis, and often, there are aggregates of lymphocytes and plasma cells, some of them with germinal center formation resulting in lymphoid follicles scattered in the septa and fat lobules of the subcutaneous tissue.

There is no effective treatment for postirradiation sclerodermatous panniculitis, but the indurated nodules tend to improve with time.

POSTIRRADIATION SCLERODERMATOUS PANNICULITIS AT A GLANCE

Clinical

- Women with a history of breast cancer treated by radical mastectomy and radiotherapy develop indurated erythematous plaques on the irradiated skin.

Histopathology

- Mostly lobular panniculitis without vasculitis
- Hyalin collagen bundles in the dermis and subcutaneous septa
- Inflammatory infiltrate of lymphocytes and plasma cells involving the fat lobules
- Lipophagic granuloma at the periphery of the fat lobule

Treatment

- Indurated nodules tend to improve with time.

DISORDERS ERRONEOUSLY CONSIDERED AS SPECIFIC VARIANTS OF PANNICULITIS

Subcutaneous Lymphomas (See Chap. 146)

Weber-Christian Disease

Weber-Christian disease was the term used in the past to refer to cases of mostly lobular panniculitis without vasculitis and systemic manifestations including fever and involvement of visceral fat tissue. Additional terms, such as *idiopathic nodular panniculitis*, *nodular panniculitis,* and *relapsing febrile non-suppurative nodular panniculitis,* were also used as synonyms for Weber-Christian disease.[482–491] However, many cases origi-

nally considered as examples of Weber-Christian disease were later reclassified when other variants of lobular panniculitis, including erythema induratum of Bazin, pancreatic panniculitis, and α_1-antitrypsin-deficiency panniculitis, were separated as specific diseases.[469] Therefore, most authors now consider that the term *Weber-Christian disease* should be abandoned as a diagnosis for cases of lobular panniculitis because a more specific diagnosis may be rendered in most of the cases.

Lipomembranous or Membranocystic Panniculitis

Lipomembranous panniculitis was originally described as *membranous lipodystrophy* and considered as a specific and hereditary form of lobular panniculitis associated with anomalies of the long bones and neuropsychiatric manifestations.[492] However, cases with identical histopathologic findings were described shortly afterward in late-stage lesions of several variants of lobular panniculitis. Thus, the term *lipomembranous* or *membranocystic fat necrosis* is now used to refer to a histopathologic pattern that may be seen in late-stage lesions in different types of panniculitis.[493–504] These findings consist of cystic spaces of variable size and shape in the fat lobule, which result from necrosis of the adipocytes. The cystic spaces are lined with a homogeneous eosinophilic membrane with convoluted projections into the cystic cavity. The intracystic papillary projections stain brightly with periodic acid-Schiff and Sudan black and are resistant to diastase.

Eosinophilic Panniculitis (See Chap. 35)

Eosinophilic panniculitis is the term used to refer to those cases of septal or lobular panniculitis in which eosinophils predominate in the inflammatory infiltrate. Eosinophilic panniculitis is also a histopathologic pattern rather than a distinct entity. It has been described in several types of panniculitis and other inflammatory disorders involving the skin, including erythema nodosum, deep insect bites, narcotic dependency with injection granuloma, asthma, atopic dermatitis, psychiatric diseases, thyroid diseases, parotitis, glomerulonephritis, sarcoidosis, bacterial infections, infestation with the parasites *Gnathostoma* and *Toxocara canis*, leukocytoclastic vasculitis, systemic vasculitis, Wells syndrome, lupus panniculitis, deep morphea, Sjögren syndrome, T-cell or B-cell lymphoma, leukemia, and solid neoplasms.[219,506–512] This wide spectrum of disparate disorders indicates that eosinophilic panniculitis is a non-specific reactive process, and the presence of eosinophils in the subcutaneous fat should be followed by pertinent clinical and laboratory investigations to rule out an associated systemic process.

KEY REFERENCES

The full reference list for all chapters is available at www.digm7.com.

1. Requena L, Sánchez Yus E: Panniculitis: Part I. Mostly septal panniculitis. *J Am Acad Dermatol* **45**:163, 2001
2. Requena L, Sánchez Yus E: Panniculitis. Part II. Mostly lobular panniculitis. *J Am Acad Dermatol* **45**:325, 2001
3. White WL, Wieselthier JS, Hitchcock MG: Panniculitis: Recent developments and observations. *Semin Cut Med Surg* **15**:278, 1996

109. Sanchez Yus E, Sanz Vico MD, de Diego V: Miescher's radial granuloma. A characteristic marker of erythema nodosum. *Am J Dermatopathol* **11**:434, 1989
130. Baselga E et al: Detection of *Mycobacterium tuberculosis* DNA in lobular granulomatous panniculitis (erythema induratum-nodular vasculitis). *Arch Dermatol* **133**:457, 1997
139. Schneider JW, Jordaan HF: The histopathologic spectrum of erythema induratum of Bazin. *Am J Dermatopathol* **19**:323, 1997
462. Massone C et al: Subcutaneous, blastic natural killer (NK), NK/T-cell, and other cytotoxic lymphomas of the skin. A morphologic, immunophenotypic, and molecular study of 50 patients. *Am J Surg Pathol* **28**:719, 2004
493. Snow JL, Su WPD, Gibson LE: Lipomembranous (membranocystic) changes associated with morphea: A clinicopathologic review of three cases. *J Am Acad Dermatol* **31**:246, 1994



CHAPTER 69

Lipodystrophy

Meredith P. Sheedy
Sarah A. Myers

The lipodystrophies are a heterogeneous group of diseases characterized by generalized or partial loss of subcutaneous fat. In addition to clearly exhibiting selective loss of adipose tissue, patients are also at risk for abnormalities such as insulin resistance, hyperinsulinemia, type 2 diabetes mellitus, hyperlipidemia, glomerulonephritis, and autoimmune disorders. Advances in molecular biologic techniques have allowed greater understanding of the molecular mechanisms underlying the clinical features as well as the myriad metabolic and endocrinologic abnormalities that are associated with these acquired and inherited syndromes. This chapter provides an overview of the various types of acquired and inherited lipodystrophies.

ACQUIRED LIPODYSTROPHIES

Epidemiology

The acquired lipodystrophies are more common than the inherited forms but are still quite rare. They include human immunodeficiency virus (HIV) infection–associated lipodystrophy (HIV-L), acquired partial lipodystrophy (APL), acquired generalized lipodystrophy (AGL), and localized lipodystrophy.

HIV-L has become the most common form of lipodystrophy and is rapidly increasing in prevalence as more patients receive highly active antiretroviral therapy (HAART) and survive long term with HIV infection. The incidence of this complication increases with duration of therapy and affects one-third to two-thirds of patients treated for 1 year or longer. The exact prevalence of HIV-L is unknown, but at least 100,000 patients in the United States have this form of acquired lipodystrophy.[1] APL is much less common. Approximately 250 patients of various ethnic origins (male-female ratio of 1:4) have been found to have APL since it was first described by Mitchell, Barraquer, and Simons more than 100 years ago.[1] Even more rare is AGL, which has been reported in approximately 80 patients, most of whom are Caucasian (male-female ratio of 1:3).[2]



LIPODYSTROPHY AT A GLANCE



- Rare, largely acquired but also hereditary partial or generalized loss of subcutaneous fat.
- Acquired:
  - Lipodystrophy associated with human immunodeficiency virus infection: onset after initiation of highly active antiretroviral therapy.
  - Acquired partial (Berraquer-Simons) lipodystrophy: loss of fat in cephalocaudal progression from childhood, often sparing lower extremities from mid-thigh.
  - Acquired generalized (Lawrence) lipodystrophy: generalized loss related to panniculitis or autoimmune disease, or idiopathic.
  - Localized: often due to injection of exogenous substances (i.e., insulin, steroids), pressure, or autoimmune factors.
- Inherited:
  - Familial partial [Dunnigan type, peroxisome proliferator–activated receptor-γ (PPAR-γ)–associated] lipodystrophy: autosomal dominant mutation in *LMNA* gene or *PPAR-γ*.
  - Congenital generalized (Berardinelli-Seip) lipodystrophy: autosomal recessive mutation in *AGPAT2* (type 1) or *Seipin* gene (type 2).
  - Progeria: autosomal dominant mutation in *LMNA*.
  - Leprechaunism: autosomal recessive mutation in insulin receptor.

Human Immunodeficiency Virus Infection–Associated Lipodystrophy

ETIOLOGY AND PATHOGENESIS Soon after the introduction in the mid-1990s of HAART for the treatment of patients with HIV disease, redistribution of body fat in treated patients was reported. Although the incidence of HIV-L clearly increased markedly after the introduction of protease inhibitors (PIs), there are also cases in patients treated with nucleoside reverse transcriptase inhibitors (NRTIs) as well as in patients receiving combinations of the two. Rarely, cases are seen in treatment-naive HIV-positive individuals.

The pathogenesis of HIV-L is unknown and is likely multifactorial. Risk factors consistently observed in cohort studies include increasing age, use of certain types of medication, current use of antiretroviral therapy (excluding non-NRTIs), and longer total duration of such therapy. In particular, combination therapy using two NRTIs and a PI is associated with more severe disease.[3,4] Hierarchical effects of responsible drugs have not been established because it is difficult to identify specific effects of individual drugs when patients are receiving multidrug therapy with agents from different classes.[5]

PIs may induce lipodystrophy by inhibiting several lipid and adipocyte regulatory proteins. These include sterol regulatory element–binding protein 1c and peroxisome proliferator–activated receptor-γ (PPAR-γ).[5] In vitro studies have shown PIs both to inhibit lipogenesis and adipocyte differentiation[6] and to increase lipolysis.[7] NRTI-induced lipodystrophy may be due to mitochondrial injury.[5] NRTIs inhibit adipogenesis and promote lipolysis as is observed with PIs and therefore demonstrate strong synergistic toxicity with PIs in vitro and in vivo.[8]

Other factors that may increase the risk of developing lipodystrophy have been suggested but are less clear. These include gender, diagnosis of acquired immunodeficiency syndrome, low body weight before therapy, and better therapeutic response to HAART, as measured by rapid recovery of peripheral blood $CD4^+$ lymphocytes and decreased HIV RNA levels.[5] In addition, changes in fat distribution have been reported in a limited number of HIV patients who were never treated with antiretroviral therapy, but HIV-L is far more common in treated patients, which argues against HIV infection itself as a strong factor.

CLINICAL FINDINGS As early as several months after institution of HAART, HIV-infected individuals may begin to develop loss of subcutaneous fat from the face (Fig. 69-1) and extremities. Facial lipoatrophy leads to an emaciated appearance with loss of buccal fat, triangular depression below the cheekbone, nummular depression at the temples, and a seemingly protuberant mouth due to the surrounding atrophy. Several rating scales are available to grade the severity

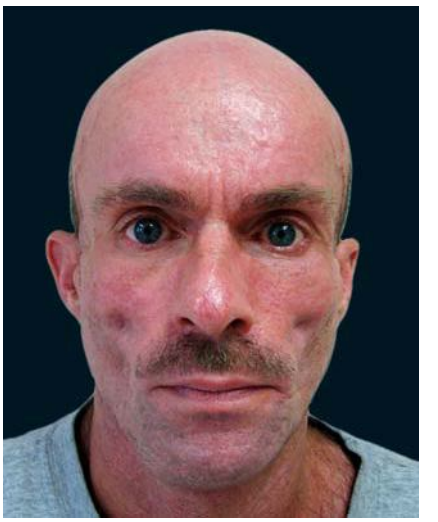

▲ **FIGURE 69-1** Human immunodeficiency virus infection–associated lipodystrophy in a patient receiving highly active antiretroviral therapy. Loss of buccal fat results in prominence of the zygomatic arch.

of facial atrophy,[9] which can be classified as mild, moderate, or severe. Fat increases at the posterior neck and upper back, which results in a "buffalo hump" similar to that seen in patients with Cushing disease. Fat may also increase in the abdomen, with increased waist-hip ratio (Fig. 69-2) and feelings of bloating and distention ("protease paunch" or "crix belly"), as well as in the breasts, sometimes with marked pain. Insulin resistance and impaired glucose tolerance often develop, progressing in some cases to frank diabe-



▲ **FIGURE 69-2** Human immunodeficiency virus infection–associated lipodystrophy with increased abdominal fat. Note loss of subcutaneous fat from lateral buttock and deposit in the trunk, which causes increased waist-hip ratio.

tes mellitus, hypertriglyceridemia, and hypercholesterolemia. This constellation of metabolic abnormalities is clearly associated with accelerated atherosclerosis in the non-HIV population, so it is expected that HIV-infected individuals may also be at increased risk for cardiovascular disease.

Acquired Partial Lipodystrophy (Barraquer-Simons, "Classic" Partial)

ETIOLOGY AND PATHOGENESIS Although the pathogenesis of APL is unclear, C3 levels are decreased in up to 90 percent of patients. Associated with this decrease is the presence of C3 nephritic factor, a circulating polyclonal immunoglobulin G that blocks degradation of the enzyme C3 convertase, which allows unopposed activation of the alternative complement pathway and increased consumption of C3.[1,10,11] Furthermore, serum containing C3 nephritic factor has been shown to be toxic to adipocytes in vitro, which suggests that this factor contributes directly to the loss of fat.[10] Factor D is another protein (identical to a serine protease, adipsin) that is produced by adipocytes and is also a key component of the alternative pathway. In the presence of C3 nephritic factor, the alternative pathway becomes dysregulated, which leads to hypocomplementemia and direct adipocyte loss, possibly of those adipocytes that express Factor D.[10]

Approximately 20 percent of patients with APL develop membranoproliferative glomerulonephritis after a median of approximately 8 years after the onset of lipodystrophy.[12] The aforementioned serologic abnormalities may also be found in patients with glomerulonephritis without APL, and currently the weight of evidence favors the hypothesis that the nephritic factor predisposes to glomerulonephritis via direct toxicity and/or hypocomplementemia.[13,14] Also, because APL often occurs after a febrile illness, it remains to be shown whether there may be a viral trigger leading to autoimmunity.

CLINICAL FINDINGS APL (Barraquer-Simons syndrome) develops in most patients before the age of 15 years, most often between 8 and 10 years of age. Patients show gradual loss of subcutaneous fat in clearly demarcated, generally symmetric areas of the body. The loss usually begins on the face and spreads downward, and may stop at any point, most often just at or above mid-thigh level. Occasionally, the lower portion of the body may be affected while the upper portion remains uninvolved. The unaffected part of the body often appears obese, partly due to the contrast with the gaunt appearance of the thin portion. Excess fat deposition over the hips and thighs frequently occurs in postpubertal women with APL.



▲ **FIGURE 69-3** Partial lipodystrophy. Emaciated facies results from a loss of buccal fat pads. (Used with permission from John Reeves, MD.)

The face appears cachectic. Buccal fat pads disappear, leaving a relative prominence of the chin and zygomas (Fig. 69-3). With loss of retro-orbital and periorbital tissue, the eyes may sink deeply into the sockets. Smiling produces many wrinkles and a prematurely aged expression. Unshielded by the usual blanket of fat, the veins and muscles of the trunk and upper extremities appear hypertrophied. The overlying skin itself is of normal color, texture, and elasticity. Visceral fat stores underlying the thin areas are also absent.

A clinically apparent inflammatory phase does not precede the fat loss, but patients often correlate the onset with an acute febrile illness. In addition to the glomerulonephritis mentioned earlier, other autoimmune diseases have been described in association with APL, including systemic lupus erythematosus and dermatomyositis.[12] In general, APL patients develop insulin resistance less frequently than patients with the generalized lipodystrophies.

Acquired Generalized Lipodystrophy (Lawrence Syndrome)

ETIOLOGY AND PATHOGENESIS The exact etiology and pathogenesis of AGL are unknown. In approximately 25 percent of patients, onset of fat loss is preceded by the development of subcutaneous inflammatory nodules.[2] Histologic evaluation of the nodules demonstrates a granulomatous reaction with a mixed lymphohistiocytic infiltrate and multinucleated giant cells, findings consistent with panniculitis.[1] These nodules heal with localized loss of the subcutaneous fat underlying them, followed by generalized loss of all subcutaneous fat.[2,15] These patients have less severe fat loss and metabolic dysfunction than is seen in the other forms of AGL. Another 25 percent of patients have associated autoimmune diseases, particularly juvenile dermatomyositis,[2,16] and it is thought that their fat loss is likely immune mediated. The remaining 50 percent of patients (with an idiopathic variety) have neither panniculitis nor associated autoimmune diseases, and other pathogenic mechanisms are likely involved.

CLINICAL FINDINGS The clinical findings of AGL are similar to those of congenital generalized lipodystrophy (CGL), but onset of fat loss is later and associated features are more mild. The patient's loss of fat may be extremely rapid and typically occurs in childhood or adolescence. Subcutaneous fat loss is severe and usually affects the face, abdomen, and extremities but has also been shown to involve the palms and soles and in some cases the intra-abdominal region.[2] Children often have a voracious appetite and acanthosis nigricans. Hepatic steatosis is commonly present, which may lead to hepatomegaly. Most AGL patients have significant metabolic derangements as well as low levels of high-density lipoprotein cholesterol and low levels of the key adipocytokines leptin and adiponectin, which are involved in adipocyte production and migration. Diabetes mellitus and hypertriglyceridemia are less prevalent in the panniculitis variety than in the idiopathic and autoimmune varieties.[2]

Localized Lipodystrophy

Localized lipodystrophy is the loss of subcutaneous fat in small areas of the body, often due to exogenous causes. Injection of drugs such as insulin, steroids, or antibiotics can cause localized lipodystrophy.[17] It can also be pressure induced or can develop in the location of resolved panniculitis. A centrifugal type of localized lipodystrophy has been described in children that spreads in a band around the abdomen. The etiology is unknown, and it was self-limited in half of the patients described.[17]



INHERITED LIPODYSTROPHIES

Epidemiology

The inherited lipodystrophies are rare entities. The familial partial lipodystrophies (FPLs) are a heterogeneous group of disorders with autosomal dominant inheritance. The most common is the Dunnigan variety, which has been identified in over 200 patients, primarily of European descent, since it was first described over 30 years ago.[18] The FPL associated with the *PPAR-γ* mutation (see next section) has been reported in 10 patients since it was first described in 2002.[19] Lipodystrophy associated with mandibuloacral dysplasia shows autosomal recessive inheritance and has been demonstrated in approximately 40 patients since its initial description in 1971.[20]



CGL has autosomal recessive inheritance and has been reported in approximately 250 patients of various ethnic origins. With allowance for incomplete reporting of cases, the estimated prevalence of CGL is 1 in 10 to 12 million people.

Familial Partial Lipodystrophies (Dunnigan Type, Peroxisome Proliferator–Activated Receptor-γ Associated)

ETIOLOGY AND PATHOGENESIS The locus for the Dunnigan variety has been mapped to chromosome band 1q21-22,[21] which led to the identification of a missense mutation in the gene encoding lamins A and C (*LMNA* gene)[22] and subsequent identification of other missense mutations within this gene. The nuclear lamins belong to the family of intermediate filament proteins that are attached to the inner surface of the nuclear envelope. Adipocyte loss in patients with *LMNA* mutations is likely due to disruption of nuclear function and loss of structural integrity of the nuclear envelope, which leads to cell death. Other mutations in the same gene can cause autosomal forms of muscular dystrophy, dilated cardiomyopathy, Charcot-Marie-Tooth neuropathy, and mandibuloacral dysplasia.[23] These individuals develop multisystem involvement in addition to the lipodystrophy, depending on the site of mutation within the gene.

For dermatologists, the most important disorder that results from mutations in lamin A is progeria (Hutchinson-Gilford progeria syndrome).[24,25] Generalized lipodystrophy in progeria is progressive and spares only the intra-abdominal fat deposits. Other features include very short stature, poor weight gain, early alopecia, scleroderma, osteolysis with decreased joint mobility, and premature aging. Lipodystrophy is the presenting sign in approximately 20 percent of patients.[24] The mean age at diagnosis is approximately 3 years, although subtle features are detectable during the first 6 months of life. Cerebral vascular accidents and coronary artery dysfunction are the most common cardiovascular problems and tend to be the cause of death at a mean age of 12.6 years. Classic progeria is an autosomal dominant disorder, although virtually all cases result from spontaneous mutation. The late-onset or non-classic form of progeria is associated with a more slowly progressive lipodystrophy, as well as less retardation of growth, longer persistence of scalp hair, and survival into adulthood. This non-classic form of progeria is distinct from Werner syndrome (see Chap. 140) and is most likely autosomal recessive.

CLINICAL FINDINGS In patients with the Dunnigan variety of FPL due to *LMNA* mutation, the fat loss of the extremities and trunk begins at puberty and is accompanied by fat deposition on the face, upper back, and intra-abdominal region as well as increased intermuscular fat in the arms and legs.[30] Affected men are often more difficult to identify than women because normal men are often quite muscular at baseline. Although some fat is maintained, the acanthosis nigricans and metabolic complications of insulin-resistant diabetes, coronary heart disease, and hyperlipidemia in these patients more closely resemble those of patients with general lipodystrophy rather than partial lipodystrophy. These metabolic abnormalities are more common in women than in men with FPL.[17,31] The 10 patients who have been described with FPL due to the *PPAR-γ* mutation showed loss of subcutaneous fat from the distal extremities that began after the second decade of life.[32]

Congenital Generalized Lipodystrophy (Berardinelli-Seip)

ETIOLOGY AND PATHOGENESIS Patients with CGL cluster in consanguineous families, most of whom have linkage evidence of abnormalities at two loci: the 1-acylglycerol-3-phosphate-O-acyltransferase 2 (*AGPAT2*) gene on chromosome band 9q34[33,34] (CGL type 1) and the Berardinelli-Seip congenital lipodystrophy 2 (*BSCL2*) or *seipin* gene on chromosome band 11q13[35] (CGL type 2).

The AGPATs are involved in the biosynthesis of glycerophospholipids and triglycerides.[36] Therefore, defective *AGPAT2* function in CGL type 1 may cause lipodystrophy either by reducing the amount of triglyceride in adipocytes or by reducing levels of glycerophospholipids, which causes defective cell signaling and membrane function. This theory is supported by the fact that metabolically active fat is affected in this syndrome but mechanical fat is normal because of the presence of other AGPAT isoforms in mechanical fat that likely counterbalance the defective *AGPAT2* product.[32]

The *seipin* gene encodes a protein with unknown function. However, *seipin's* strong expression in normal brain tissue and absent expression in normal adipose tissue supports the hypothesis that the central nervous system is involved in the pathogenesis of CGL type 2.[1] Furthermore, there is higher prevalence of mental retardation in these patients. Patients with CGL type 2 lose both metabolically active and mechanical fat.[37]

CLINICAL FINDINGS Patients with CGL have nearly absent subcutaneous fat from birth and are therefore born with a muscular appearance. The loss of fat is similar to that described for AGL, but it occurs much earlier and is more severe than in the acquired form. Because of the generalized absence of fat at birth, the muscles appear hypertrophic. However, the age at which the child sits and walks is usually normal, and muscle strength is not increased.[38] During infancy and childhood, linear growth is accelerated, and adult height may be greater than that predicted by the height of the parents. Most patients have a prominent umbilicus or umbilical hernia. Patients develop marked acanthosis nigricans in the neck, axilla, groin, and trunk, usually beginning in childhood.[1] Focal lytic lesions have been shown to develop after puberty in the appendicular bones, which may be due to loss of bone marrow adipose tissue.[39]

Daily energy consumption is increased noticeably. Children eat voraciously, perspire excessively, have an elevated basal metabolic rate, and are often heat intolerant despite normal thyroid function. Girls with CGL may develop hirsutism, clitoromegaly, and

oligomenorrhea or amenorrhea during puberty, and some may have frank virilization and polycystic ovarian disease. Some women have had sucessful pregnancies, but this is rare. Fertility is normal in men.[1] Moderate mental retardation is frequent but not universal.

Characteristically, patients have decreased glucose tolerance, and the syndrome is often termed *lipoatrophic diabetes*, which usually starts in puberty. Hyperglycemia, glycosuria, and insulin resistance are often marked, requiring high doses of insulin for glucose control. Renal, retinal, and neuropathic diabetic changes may occur. Severe hypertriglyceridemia may lead to recurrent pancreatitis. As in AGL, leptin and adiponectin levels are markedly decreased.

Nearly all patients with GL have hepatomegaly, which results initially from increased fat in the liver, although the fat around the viscera is reduced. As with fatty liver resulting from other causes, cirrhosis may develop, and the patient may die of hepatic failure. Hypertrophic cardiomyopathy has also been seen in some patients.

CGL is also a feature of leprechaunism (also called *Donohue syndrome*).[40] This rare autosomal recessive disorder results from mutations in the insulin receptor (19p13.2). In addition to the generalized decrease in subcutaneous fat, clinical features include severe intrauterine growth retardation; small, elfin facies with protuberant ears; distended abdomen; relatively large hands, feet, and genitalia; thickened skin with acanthosis nigricans; and hypertrichosis. Affected individuals die during the first decade—most during the first months of life.

TREATMENT

Treatment of the various types of lipodystrophy has proven quite difficult. The focus of treatment depends on the severity of the associated metabolic and endocrinologic abnormalities as well as the cosmetic effect of loss of subcutaneous fat in some areas and gain of fat in others in a disproportionate fashion. The major morbidity of these syndromes is due to the long-term sequelae of diabetes, dyslipidemia, and hepatic steatosis. However, the psychological side effects of facial lipodystrophy cannot be underestimated—particularly in patients with HIV, because it has often been the cause of discontinuation of critical HAART.

Aggressive glycemic control should be the focus of therapy in patients with diabetes and hyperinsulinemia associated with these syndromes. The goal of treatment is to decrease the risk of development or slow the progression of neuropathy, nephropathy, and retinopathy. Glycemic control also leads to markedly decreased triglyceride levels, which in turn prevent pancreatitis and hepatic steatosis. Adherence to a very-low-fat diet, exercise, and consumption of ω-3 fatty acids are logical to consider in all types of lipodystrophy. However, medications are often required. Metformin decreases insulin resistance and reduces appetite, and therefore may be a good oral hypoglycemic. Rosiglitazone is another oral hypoglycemic that is a PPAR-γ agonist and may be beneficial in patients with mutations in *PPAR-γ*. However, only two cases of its use have been reported (in patients with mutations in *LMNA* rather than *PPAR-γ*), and results have been equivocal.[41,42] Avandamet, a combination of rosiglitazone and metformin, may also be effective. Unfortunately, lipodystrophy patients often require high doses of insulin in addition to, or as a better alternative to, oral hypoglycemics. Fibrates (PPAR-α agonists) and statins are often used to treat hypertriglyceridemia if it persists despite glycemic control, proper diet, and exercise. Experimental use of subcutaneous recombinant leptin led to significant improvement in mouse models[43] and was shown to significantly improve glycemic control and decrease triglyceride levels in nine female patients with lipodystrophy with minimal side effects.[44]

Treatment of HIV-infected individuals with lipodystrophy is an increasingly important issue due to the number of patients receiving HAART who have developed this syndrome and the fact that facial lipodystrophy is rapidly becoming the hallmark look of HIV disease. In some patients, the cosmetic and symptomatic changes of HIV-L are so debilitating that they desire changes in their HIV drug regimens or, worse, they discontinue treatment altogether. Changes between or within classes of drugs may ameliorate the disease, and combinations that avoid the use of two PIs or a PI and an NRTI may slow the development of the complications of diabetes and dyslipidemia. Although the use of hypoglycemics, lipid-lowering medications, and other medications such as growth hormone–releasing hormone may be associated with improvement in intra-abdominal fat deposition and metabolic abnormalities, leading to reduction of risk of complications, the available options have not led to cosmetically significant re-accumulation of facial or limb fat.

Cosmetic procedures may be a useful adjunct to treatment of lipodystrophy, particularly in HIV-L. Liposuction of the upper back may reduce the cosmetic disfigurement of the buffalo hump.[45] Fillers have now become more widely used to compensate for facial fat loss. These include permanent and temporary dermal fillers, such as transferred autologous fat, bovine collagen, hyaluronic acid, calcium hydroxyapatite (CaHa), liquid injectable silicone, polymethylmethacrylate, and injectable polyalkylamide gel in addition to other injectable polymers[46] (see Chap. 255). In general, autologous fat transfer is less successful in HIV patients because there is often a dearth of fat available for transplantation at truncal donor sites, and the character and consistency of this fat may reduce its viability at the recipient site. Poly-L-lactic acid (PLA) is a longer-acting, prepackaged filler that has been approved by the U.S. Food and Drug Administration for the treatment of facial lipoatrophy in HIV patients and leads to expansion of the thickness of the dermis by stimulating fibroblasts.[47] Injectable CaHa can also provide cosmetically significant benefit for at least a year in the face. Like PLA, CaHa is completely biodegradable, and it is preferred by some patients and physicians because it does not require reconstitution or multiple treatments. Also, the cosmetic effect of CaHa begins immediately and is not delayed for several months as with PLA (see Chap. 255).

ACKNOWLEDGMENT

We acknowledge Dr. Ervin H. Epstein, Jr. for his previous contributions and expertise on this chapter subject.

KEY REFERENCES

The full reference list for all chapters is available at www.digm7.com.

1. Garg A: Acquired and inherited lipodystrophies. *N Engl J Med* **350**:1220, 2004
2. Misra A, Garg A: Clinical features and metabolic derangements in acquired generalized lipodystrophy: Case reports and review of the literature. *Medicine (Baltimore)* **82**:129, 2003
5. Grinspoon S, Carr A: Cardiovascular risk and body-fat abnormalities in HIV-infected adults. *N Engl J Med* **352**:48, 2005
12. Misra A, Peethambaram A, Garg A: Clinical features and metabolic and



autoimmune derangements in acquired partial lipodystrophy: Report of 35 cases and review of the literature. *Medicine (Baltimore)* **83**:18, 2004
17. Garg A: Lipodystrophies. *Am J Med* **108**:143, 2000
19. Agarwal AK, Garg A: A novel heterozygous mutation in peroxisome proliferator-activated receptor-gamma gene in a patient with familial partial lipodystrophy. *J Clin Endocrinol Metab* **87**:408, 2002
44. Oral EA et al: Leptin-replacement therapy for lipodystrophy. *N Engl J Med* **346**:570, 2002
46. Jones D: HIV facial lipoatrophy: Causes and treatment options. *Dermatol Surg* **31**:1519, 2005; discussion, 1529



SECTION 11

DISORDERS OF MELANOCYTES

CHAPTER 70

Biology of Melanocytes

Hee-Young Park
Marinya Pongpudpunth
Jin Lee
Mina Yaar

EMBRYONIC DEVELOPMENT

Melanocytes are pigment-producing cells that originate from the dorsal portions of the closing neural tube in vertebrate embryos (Fig. 70-1).[1] They derive from pluripotent neural crest cells that differentiate into numerous cell lineages, including neurons, glia, smooth muscle, craniofacial bone, cartilage, and melanocytes (reviewed in refs. 2 and 3). Progenitor melanoblasts migrate dorsolaterally between the mesodermal and ectodermal layers to reach their final destinations in the hair follicles and the skin as well as inner ear cochlea, choroids, ciliary body, and iris (reviewed in refs. 2 and 4). Pigment-producing cells can be found in fetal epidermis as early as the fiftieth day of gestation.

Melanoblast migration and differentiation into melanocytes is influenced by a number of signaling molecules produced by neighboring cells. These include Wnt, endothelin-3 (ET3), bone morphogenetic proteins (BMPs), steel factor [SF; stem cell factor (SCF), c-Kit ligand], and hepatocyte growth factor (HGF)/scatter factor.[5–10] By interacting with their specific cell surface receptors, these molecules induce intracellular and intranuclear signaling to influence gene transcription and protein synthesis.

Wnt

Wnt is expressed in the dorsal neural tube during neural crest cell migration and directs the maturation of pluripotent neural crest cells into melanoblasts.

The Wnt family is composed of 16 different secreted glycoproteins. They bind and activate Frizzled, a transmembrane heptahelical G protein–linked receptor,[11] and induce the accumulation of β-catenin (Fig. 70-2A). Under baseline conditions, when Wnt does not bind Frizzled, cytosolic β-catenin is complexed with the enzyme glycogen synthase kinase 3β (GSK3β) that induces rapid ubiquitin-mediated degradation of β-catenin by cellular proteosomes. Binding of Wnt to its receptor Frizzled inhibits GSK3β activity, leading to β-catenin accumulation in the cytosol followed by its translocation to the nucleus (Fig. 70-2B). In the nucleus, β-catenin binds specific transcription factors, and together the complex induces the transcription of microphthalmia-associated transcription factor (Mitf).[10] Mitf affects melanoblast differentiation by inducing the transcription of three enzymes that regulate melanin synthesis: tyrosinase, tyrosinase-related protein-1 (TRP-1), and 3,4 dihydroxyphenylalanine (DOPA)chrome tautomerase (TRP-2) (reviewed in ref. 12).

Bone Morphogenetic Proteins

BMPs are disulfide-linked dimeric proteins produced as large precursors.[13] They include more than 20 secreted proteins all sharing amino acid homology (reviewed in ref. 14). BMPs belong to the transforming growth factor-β family of secreted growth factors, and their signaling suppresses neural crest cell differentiation into melanoblasts and thus may be viewed as Wnt antagonists. Accordingly, there is a decrease in BMP expression in the dorsal neural tube at the time of melanoblast migration.[8]

Endothelins

ETs are a family of peptides, 21 amino acids long, originally identified by their

BIOLOGY OF MELANOCYTES AT A GLANCE

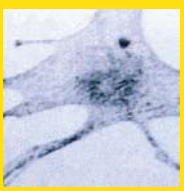

Melanoblasts

- derive from the neural crest. Their migration/survival in the epidermis is influenced by numerous factors.

Melanocytes

- populate the epidermis, hair follicle, eye, cochlea and meninges.
- synthesize melanin, an indole derivative of 3,4-dihydroxyphenylalanine that is stored in melanosomes.
- are influenced by endocrine, paracrine and autocrine factors and by ultraviolet irradiation.

Melanosomes

- display four maturation stages.
- contain structural matrix proteins, melanogenic enzymes, pH maintaining proteins and free radical scavengers.
- are transported to melanocyte dendrite tips and transferred to keratinocytes.



Copyright © 2008 by The McGraw-Hill Companies, Inc. Click here for terms of use.

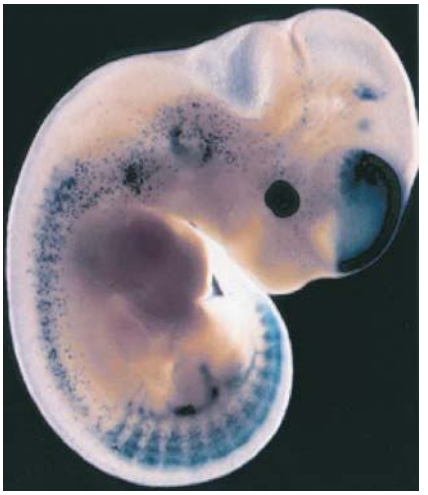

▲ **FIGURE 70-1** Migration of melanoblast precursors. Migrating melanoblasts in an E11.5 transgenic mouse embryo expressing the Lac Z reporter gene under the control of the melanocyte-specific Dct (DOPAchrome tautomerase) promoter. The melanoblasts are visualized by staining for β-galactosidase. (Used with permission from Ian Jackson and Alison Wilkie, Medical Research Council, Human Genetics Unit, Western General Hospital, Edinburgh, Scotland.)

vasoactive properties, that include three members, ET1, ET2, and ET3 (reviewed in ref. 15). They are produced via proteolysis of larger precursor molecules. Like Wnt, ETs bind and activate heptahelical transmembrane G protein–linked receptors EdnrA and B. ET3, which is synthesized by ectodermal cells, and its EdnrB receptor are particularly important during melanoblast migration along the dorso-lateral pathway (reviewed in ref. 15), and their proper expression is required for survival, proliferation, and/or migration of melanoblasts.

Defects in either ET3 or its EdnrB receptor result in prominent melanocyte loss.[16] It appears that the receptor plays a more critical role in melanocyte development as compared to its ligand, as ET3 null mice do not have as severe depigmented phenotype as EdnrB null mice. Because ETs and Ednrs also affect the development of neural crest cells other than melanoblasts, defects in ET3 or EdnrB lead to disease symptomatology beyond pigmentary disorders, such as that present in type IV Waardenburg syndrome and in Hirschsprung syndrome[16] (see also Chap. 71).

Steel Factor

Early melanoblast development requires the presence of the cytokine SF (mast/SCF, c-Kit ligand) and its tyrosine kinase transmembrane receptor c-Kit.[17] SF is expressed by epidermal keratinocytes, and, as soon as c-Kit is expressed on melanoblasts, they begin their migration to their final destination (reviewed in ref. 18).

Piebaldism is an autosomal dominant disorder that results from mutations of c-Kit or SF and leads to melanoblast failure to migrate to the skin and/or survive there[19,20] (see Chap. 71). Affected individuals display broad depigmented patches, most prominent on the central forehead and trunk. Interestingly, the ventral aspect of the body is more frequently affected than the dorsal aspect, supposedly because it is the area farthest from the dorsally located neural crest where melanoblast migration begins.[19,21] Complete absence of melanocytes as well as abnormalities of the reproductive and hematopoietic systems, whose development also depends on SF/Kit receptor, have been observed in mice with homozygous loss of SF or c-Kit.[22,23]

Hepatocyte Growth Factor

HGF (scatter factor) is the ligand for the transmembrane tyrosine kinase receptor Met. In vitro studies performed on murine neural crest cells show that HGF induces melanoblast proliferation and allows their differentiation into mature melanocytes.[24] In addition, HGF regulates cadherin expression in melanocytes, specifically downregulating E-cadherin, thus affecting melanoblast homing (see Cadherins). Interestingly, in mice, *Met* null mutations do not appear to affect melanoblast number or migration, and no decrements in Met function have been identified to date in human pigmentary disorders. Thus, the role of HGF/Met signaling during melanocyte development is still unclear.

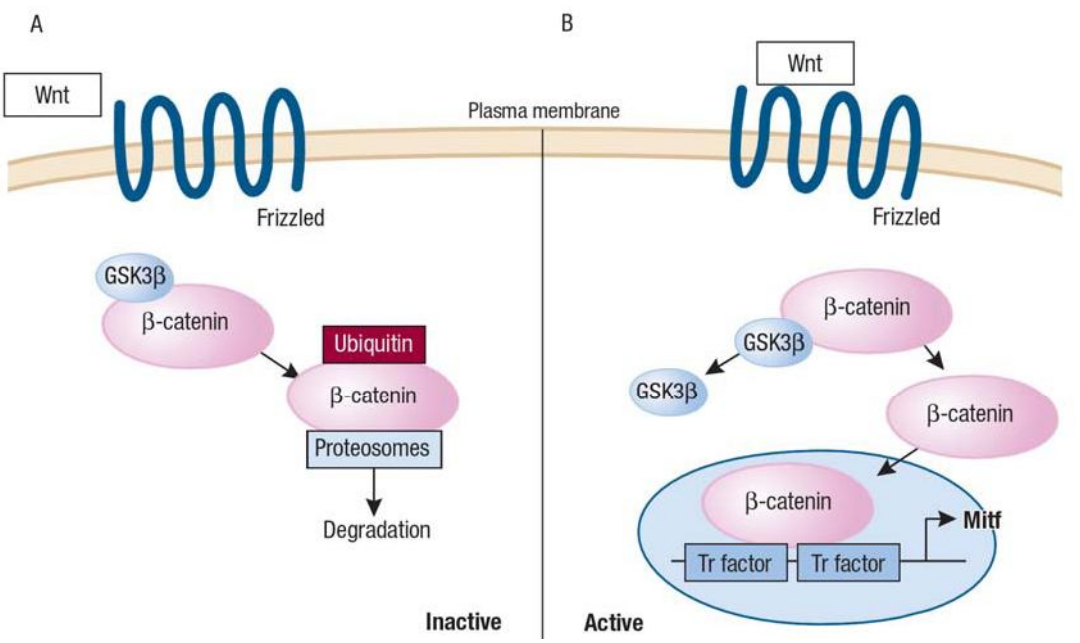

▲ **FIGURE 70-2** Regulation of microphthalmia-associated transcription factor (Mitf) transcription by Wnt signaling. **A.** When Wnt is not bound to Frizzled, a membrane-spanning domain receptor, Frizzled is inactive. Under these inactive conditions, glycogen synthase kinase 3β (GSK3β) is complexed with β-catenin, enhancing its ubiquitin-mediated degradation by cellular proteosomes. **B.** Wnt binding activates Frizzled, leading to GSK3β dissociation from β-catenin. β-Catenin then translocates to the nucleus, where it binds with specific transcription factors (Tr factor) to initiate Mitf transcription.

Cadherins

Cadherins are a family of transmembrane glycoproteins (E-, P-, and N-) that promote calcium-dependent cell-to-cell adhesion (reviewed in ref. 25). In melanoblasts, their cytoplasmic domains bind β-catenin. Murine studies show that E-cadherin is induced in melanoblasts before their entry into the epidermis. Later, when melanoblasts migrate into the hair follicle, E-cadherin expression is muted, and melanoblasts begin to express P-cadherin.[26,27] It is thought that coordinate expression of E-cadherins by epidermal keratinocytes and melanocytes plays a role in suppressing melanocyte proliferation in the epidermis. Interestingly, at times, some epidermal melanocytes switch from E-cadherin to N-cadherin, and this switch allows them to escape the keratinocyte-mediated growth suppression and proliferate/aggregate in nests to form nevocellular nevi.[28] Generally, cadherin expression by melanocytes matches cadherin expression of surrounding cells.

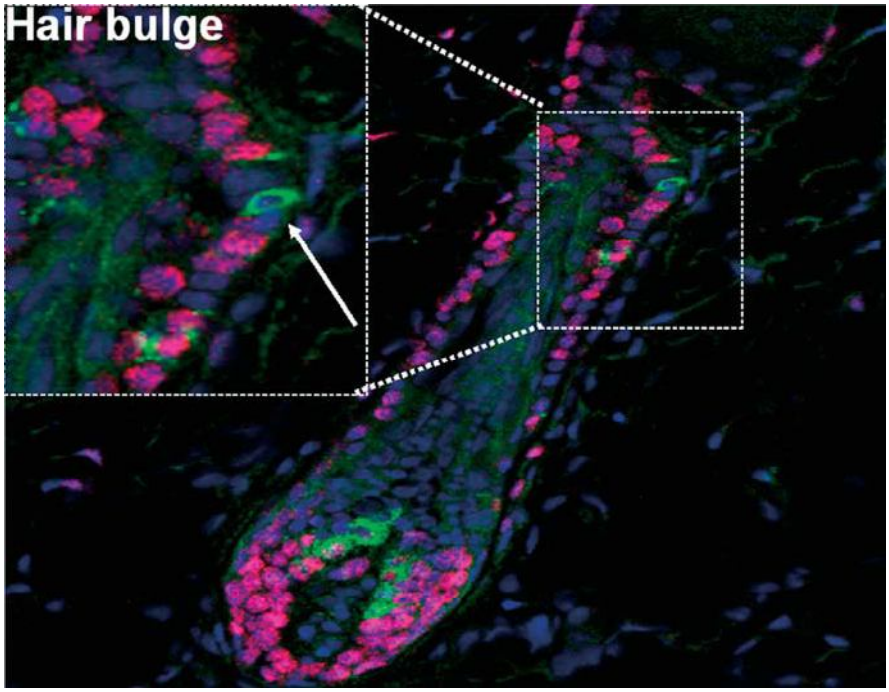

▲ **FIGURE 70-3** Melanocyte stem cells in the hair follicle bulge. A stem cell melanocyte is shown in the hair follicle bulge, indicated by an *arrow* in the high-power insert. These cells stain positive for TRP-2 (*green fluorescence*), an early marker of commitment to the melanocyte lineage, but are negative for the proliferation marker Ki-67 (*red fluorescence*) that characterizes melanocytes migrating down the follicle to the dermal papilla during the anagen phase of the hair cycle. (From Botchkareva NV et al: SCF/c-kit signaling is required for cyclic regeneration of the hair pigmentation unit. *FASEB J* **15**:645, 2001, with permission.)

SITE-SPECIFIC MELANOCYTES

Melanocyte Stem Cells

Generally, stem cells are defined by their undifferentiated state and their capacity to develop into several differentiated cell types. They are quiescent, slow-cycling cells that frequently are found in niches where they are surrounded by differentiated cells that affect their behavior through the secretion of cytokines and growth factors (reviewed in refs. 29 and 30).

Melanocyte stem cells reside in the hair follicle bulge (Fig. 70-3). They express TRP-2 as well as the neural crest stem cell intermediate filament nestin in addition to other neural crest stem cell markers, including the transcription factors Sox10 and Pax5 that participate in the regulation of Mitf and TRP-2. Melanocyte stem cells can leave the bulge region and migrate/differentiate in the epidermis or the hair follicle.

Cutaneous Melanocytes

The largest number of melanocytes is present in the skin and hair follicles. In most furred mammals, melanocytes are found only in the hair follicle, but in humans melanocytes are also present in interfollicular epidermis, specifically in the basal layer (reviewed in ref. 28). There is approximately one melanocyte per five or six basal keratinocytes. Melanocytes synthesize melanin, a pigmented polymer that is stored in cytosolic organelles called *melanosomes* that are transferred to keratinocytes through melanocyte dendritic processes (Fig. 70-4). As keratinocytes are continuously being desquamated, there is a constant need for synthesis and transfer of melanosomes from melanocytes to keratinocytes to maintain cutaneous pigmentation.

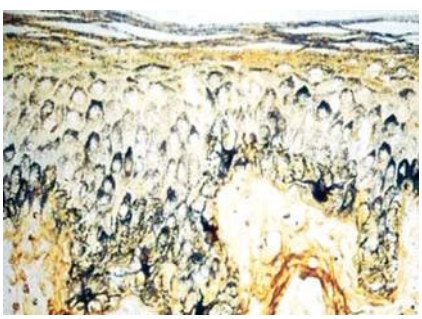

▲ **FIGURE 70-4** Melanosomes are organized into supranuclear "caps" within keratinocytes. Note melanized dendritic melanocytes and adjacent keratinocytes with the supranuclear "caps." Melanin silver stained (Fontana-Masson) section of a heavily melanized human epidermis. (Bar = 50 μM.) (From Byers HR et al: Role of cytoplasmic dynein in perinuclear aggregation of phagocytosed melanosomes and supranuclear melanin cap formation in human keratinocytes. *J Invest Dermatol* **121**:813, 2003; with permission.)

The term "epidermal melanin unit" describes a single epidermal melanocyte surrounded by several epidermal keratinocytes[31] (Fig. 70-5). Interestingly, signals from keratinocytes substantially regulate epidermal melanocyte survival, dendricity, melanogenesis, and the expression of cell surface receptors[32] (see Signaling Pathways Regulating Melanocyte Function). Most keratinocyte-derived signals are induced by ultraviolet (UV) irradiation.

Melanocyte density/mm^2 ranges from approximately 550 to > 1200, with the highest concentrations found in the genitalia and face.[33,34] Melanocyte density is the same in individuals of different ethnic backgrounds,[34] and thus cutaneous pigmentation does not depend on melanocyte number, but rather on melanogenic activity within the melanocyte, the proportion of mature melanosomes, and/or their transfer and distribution within the keratinocytes (reviewed in ref. 35). Indeed, in light-skinned individuals, melanosomes are smaller and are present in clusters within the keratinocytes, whereas in ethnic groups with darker complexion, melanosomes are larger,

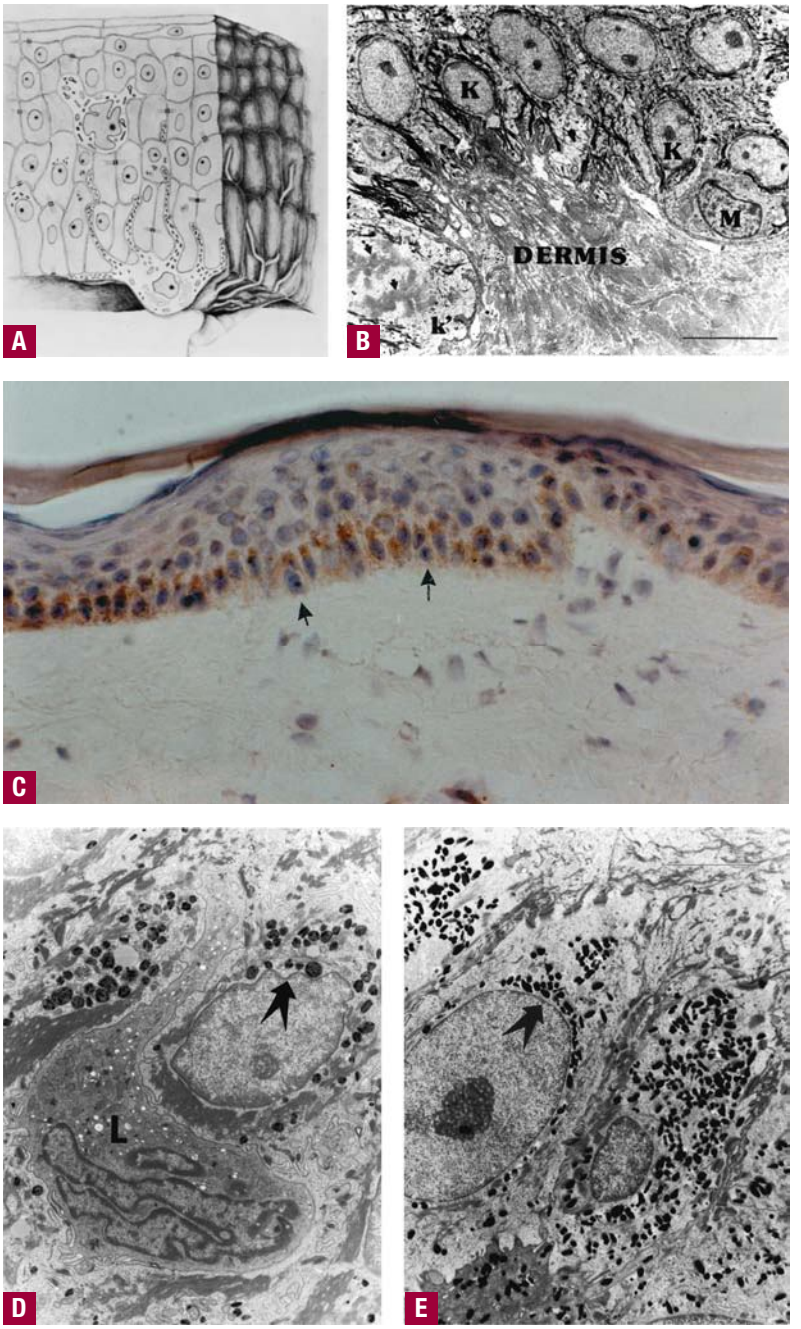

◀ **FIGURE 70-5** The epidermal melanin unit. **A.** Representation showing the relationship between basal melanocytes, keratinocytes, and Langerhans cells, shown at the upper layer of the epidermis. (From Quevedo WC Jr. The control of color in mammals. *Am Zoology* **9**:531, 1969, with permission.) **B.** Electron micrograph of the epidermal-dermal junction of human skin showing a dendritic melanocyte (M) among the basal keratinocytes (K). k′ represents a basal keratinocyte undergoing mitosis with condensed chromatin (*arrows*). (Bar = 10.0 μm.) (Illustration used with permission from Raymond E. Boissy, Department of Dermatology, University of Cincinnati, Cincinnati, Ohio.) **C.** Human epidermis immunostained for fibroblast growth factor-2 (FGF2). The figure shows basal keratinocytes with peroxidase reaction indicating the presence of immunoreactive FGF2. *Arrows* point to melanocytes. (Used with permission from Glynis Scott, M.D., Department of Dermatology, University of Rochester School of Medicine and Dentistry, Rochester, NY.) **D and E.** Distribution of melanosomes within keratinocytes in lightly pigmented Caucasian and darkly pigmented African American skin. Melanosomes in lightly pigmented Caucasian skin **(D)** are distributed in membrane-bound clusters. In contrast, in darkly pigmented African American skin **(E)** the melanosomes are individually distributed throughout the cytoplasm of epidermal keratinocytes. Melanosomes in both skin types are frequently concentrated over the apical pole of the nucleus (*arrows*). L = Langerhans cell. (Bar = 3.0 μm.) (From Minwalla L et al: Keratinocytes play a role in regulating distribution patterns of recipient melanosomes in vitro. *J Invest Dermatol* **117**:341, 2001.)

darker, and are individually dispersed within the keratinocytes.[36]

Hair Follicle Melanocytes

In contrast to interfollicular epidermal melanocytes, the follicular melanin unit undergoes cyclic modifications in coordination with the hair cycle (Fig. 70-6). Melanocytes are located in the proximal hair bulb during anagen, and there is a ratio of 1:5 between melanocytes and keratinocytes and 1:1 between melanocytes and basal layer keratinocytes.[37] Melanocytes proliferate, migrate, and undergo maturation during early to mid anagen. Melanogenesis and melanin transfer to keratinocytes occur throughout anagen. Melanocytes eventually apoptose during late catagen. In mice, melanocyte proliferation and differentiation during anagen depends on c-Kit expression by melanocytes and SF synthesis by keratinocytes.[38]

Similar to their role in the epidermis, in hair, melanocytes transfer melanin to differentiated keratinocytes that ultimately form the hair shaft. They thus determine hair color by the amount of melanin transferred, as well as by the ratio of eumelanin (black-brown) to pheomelanin (red-yellow) (see Melanin Biosynthesis) (reviewed in ref. 39).

In hair, melanin does not appear to have a protective effect, as UV irradiation does not reach the hair follicle. Still, in furry animals hair color plays an important role in camouflage, mimicry, and social communication.[40] It is also speculated that melanocytes restrain keratinocyte proliferation, affect calcium homeostasis, and protect against reactive oxygen species (ROS) during the rapid proliferation and differentiation of the hair follicle.[37]

Ocular Melanocytes

Ocular melanocytes are found in the uveal tract (reviewed in ref. 28). Unlike cutaneous melanocytes, ocular melanocytes are in contact only with each other, and they do not transfer their melanosomes (Fig. 70-7). It is proposed

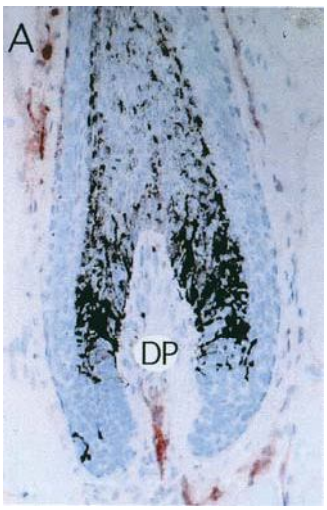

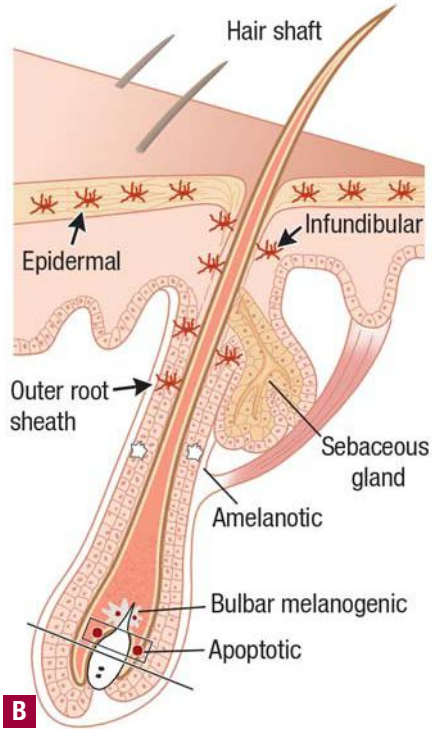

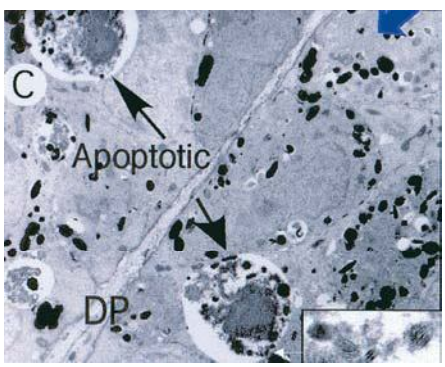

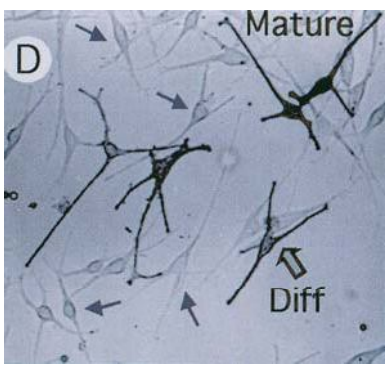

▲ **FIGURE 70-6** Melanocytes in the hair. **A.** Pigmented human scalp hair follicle in full anagen with high levels of hair bulb melanogenesis. Mature melanin granules are transferred into cortical keratinocyte. **B.** Scalp hair bulb. Representation of early catagen hair follicle showing loss of some bulbar melanotic melanocytes via apoptosis. *Arrows* point at melanocytes located in epidermal, infundibular, and outer root sheath regions. **C.** Transmission electron micrograph of section of an early catagen hair bulb showing apoptosis of melanotic melanocytes. *Inset*, high-power view of premelanosomes. **D.** Primary culture of human scalp hair follicle melanocytes. Mature, fully differentiated (Diff; *large arrow*) and less differentiated (*small arrows*) are indicated. DP = dermal papilla. (From Tobin DJ, Paus R: Graying: Gerontobiology of the hair follicle pigmentary unit. *Exp Gerontol* **36**:29, 2001, with permission.)



▲ **FIGURE 70-7** Ocular tissue demonstrating the choroid (C), the retinal pigment epithelium (R), and the photoreceptor cells of the retina (P). The connective tissue of the choroid contains numerous fibroblasts (F) and dendritic melanocytes (M) with cytoplasm filled with mature melanosomes. The retinal pigment epithelium is a single layer of polarized cuboidal melanocytes containing relatively elongated mature melanosomes both within the cell body of the retinal pigment epithelium cells and in the numerous slender apical processes (*arrows*) that interdigitate between the rod and cone photoreceptor cells. (Bar = 10.0 μm.) (Illustration used with permission from Raymond E. Boissy, Department of Dermatology, University of Cincinnati, Cincinnati, Ohio.)

that ocular melanocytes are exposed to high oxygen tension and melanin serves as protection against oxidative damage. Iris melanin may be required to protect capillaries, muscles, and motor nerves that control pupil contraction.[28]

Melanocytes appear to be essential for the development and function of the eye and optic nerve (reviewed in ref. 41). It is thought that they may play a role in the proper routing of ipsilateral and contralateral neural fibers in the optic chiasm during early development of the optic cup,[42,43] as in the absence of melanin, the path of the highly intermixed optic nerve axons is deranged, resulting in disruption of the topographic relationship of the nerve fibers.[44,45] The importance of melanin for proper ocular function is demonstrated by the visual abnormalities observed in patients with albinism.[44]

Otic Melanocytes

Melanocytes reside in the cochlea[28] and are important for hearing, as loss of otic melanocytes leads to deafness. It is thought that otic melanocytes help in the maintenance of the endolymph through the regulation of potassium transport.[46] The endolymphatic fluid in the cochlea is one of the few extracellular fluids with high concentrations of positively charged potassium, and melanocytes are believed to play a critical role in its maintenance, probably by transporting potassium from areas of high concentration to areas of low concentration through plasma membrane ionic channels.[47] In the absence of cochlear melanocytes, the endolymphatic potential is low, leading to deafness.[48]

Loss of melanocytes at any age can eventually lead to deafness, and patients with Waardenburg syndrome type 2 (see Chap. 71) are deaf because of lack of melanocytes in the inner ear.[49,50] Interestingly, the preservation of hearing in albinos indicates that melanin production within otherwise viable melanocytes is not essential for hearing. However, it appears that because albinos are more susceptible than the normal population to hearing loss from noise and/or exposure to toxic agents,[51,52] melanin must provide some protective effect.

Cephalic Melanocytes

Melanocytes are dispersed throughout the meninges and are particularly dense



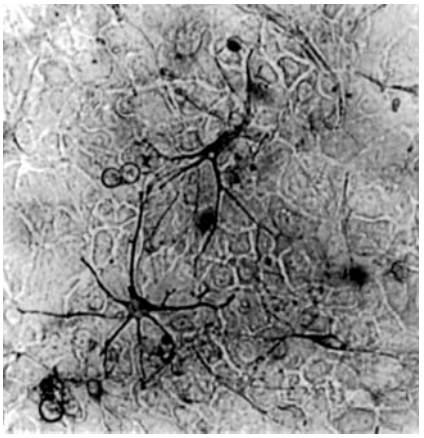

▲ **FIGURE 70-8** Melanocytes cultured on keratinocytes. Light micrograph showing dendritic melanocytes from a Black donor loaded with melanin and adjacent pigmented keratinocytes due to transfer of melanosomes. (From Halaban R et al: bFGF as an autocrine growth factor for human melanomas. *Oncogene Res* **3**:177, 1988, with permission.)

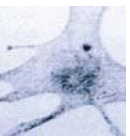

in the leptomeninges above the pons and the medulla oblongata.[53] They are thought to function as scavengers for toxic cations and ROS.[54,55]

MELANIZATION

The major differentiated function of melanocytes is to synthesize melanin in specialized organelles within the melanocytes, the melanosomes, and to transfer melanosomes to neighboring keratinocytes to provide protection from UV irradiation (Fig. 70-8). Pigmentation, the synthesis and distribution of melanin in the epidermis, involves several steps: transcription of proteins required for melanogenesis, melanosome biogenesis, sorting of melanogenic proteins into the melanosomes, transport of melanosomes to the tips of melanocyte dendrites, and transfer of melanosomes to keratinocytes. Disruption in any of these events results in hypopigmentation.

MELANOSOMES

Melanosome Biogenesis

The melanosome is a unique membrane-bound organelle in which melanin biosynthesis takes place. Because melanosomes contain enzymes and other proteins also present in lysosomes, they are thought to represent a modified version of the latter. Proteins common to both organelles include the liposomal-associated membrane proteins (LAMPs) that participate in autophagy and regulation of intra-vesicular pH (reviewed in ref. 56), as well as acid phosphatase, a marker enzyme for lysosomes.[56] Also like lysosomes, melanosomes can endocytose receptors that are targeted for degradation.[56]

Depending on the type of melanin synthesized, melanosomes can be divided into eumelanosomes and pheomelanosomes (Fig. 70-9). Eumelanosomes are large (~0.9 × 0.3 μm), elliptical in shape, and contain a highly structured fibrillar glycoprotein matrix required for eumelanin synthesis.[40] Pheomelanosomes are smaller (~0.7 μm in diameter), spherical in shape, and their glycoprotein matrix appears disorganized and loose.[40] Although both eumelanosomes and pheomelanosomes may be present within a single melanocyte,[57] once committed, they do not change.[58]

Melanosomes display four maturation stages (see Fig. 70-9). Stage I melanosomes or premelanosomes likely develop from the endoplasmic reticulum (ER).[40] They have an amorphous matrix and display internal vesicles that form as a result of membrane invagination. Premelanosomes already contain the glycoprotein Pmel17 (gp100), but it requires further processing to become a component of the final fibrillar matrix.[59] Stage II eumelanosomes have organized structured fibrillar matrix, but no active melanin synthesis, whereas in stage II pheomelanosomes, melanin synthesis already takes place. Although no active melanogenesis takes place in stage II eumelanosomes, they already contain the enzyme tyrosinase. Deposition of melanin on the fibrillar matrix is found in stage III eumelanosomes, whereas stage IV eumelanosomes are fully melanized, and their internal matrix is masked by melanin deposits (reviewed in refs. 60 and 61).

Melanogenic Proteins

The timely and organized sorting of melanogenic enzymes and structural proteins to melanosomes is an integral part of melanosomal maturation. Melanosome proteins express sorting signals at their amino terminus, and these direct them into the ER and eventually into the melanosomes (reviewed in refs. 40, 60, and 61).

ENZYMES ***Tyrosinase.*** Tyrosinase is present in plants, insects, amphibians, and mammals. It was initially identified in the early 1900s in mushroom extracts and was subsequently isolated and purified in 1949 from murine melanoma cells.[62] Mouse and human *tyrosinase* genes are 60 to 70 kb, and 50 kb long,

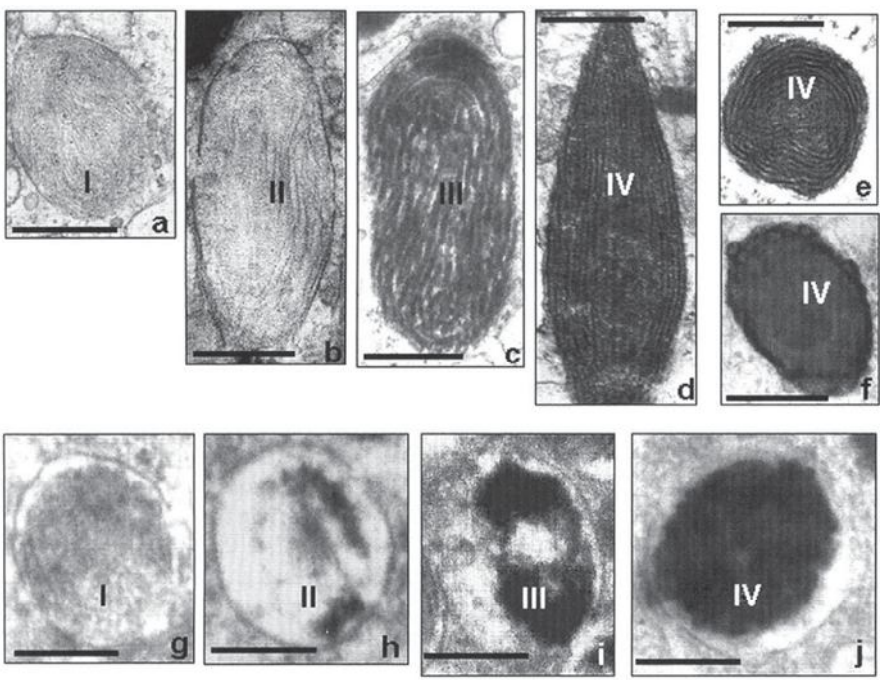

▲ **FIGURE 70-9** Melanosome biogenesis. Electron microscopy of eumelanosome **(a–f)** and of pheomelanosome **(g–j)** development. I, II, III, and IV in **a–j** represent the different maturation stages of melanosomes. [Scale bars are as follows (in μm): a = 0.20; b = 0.23; c = 0.24; d = 0.22; e = 0.20; f = 0.35; h = 0.26; i = 0.26; j = 0.30; k = 0.5.] (From Slominski A et al: Melanin pigmentation in mammalian skin and its hormonal regulation. *Physiol Rev* **84**:1155, 2004, with permission from the American Physiological Society.)

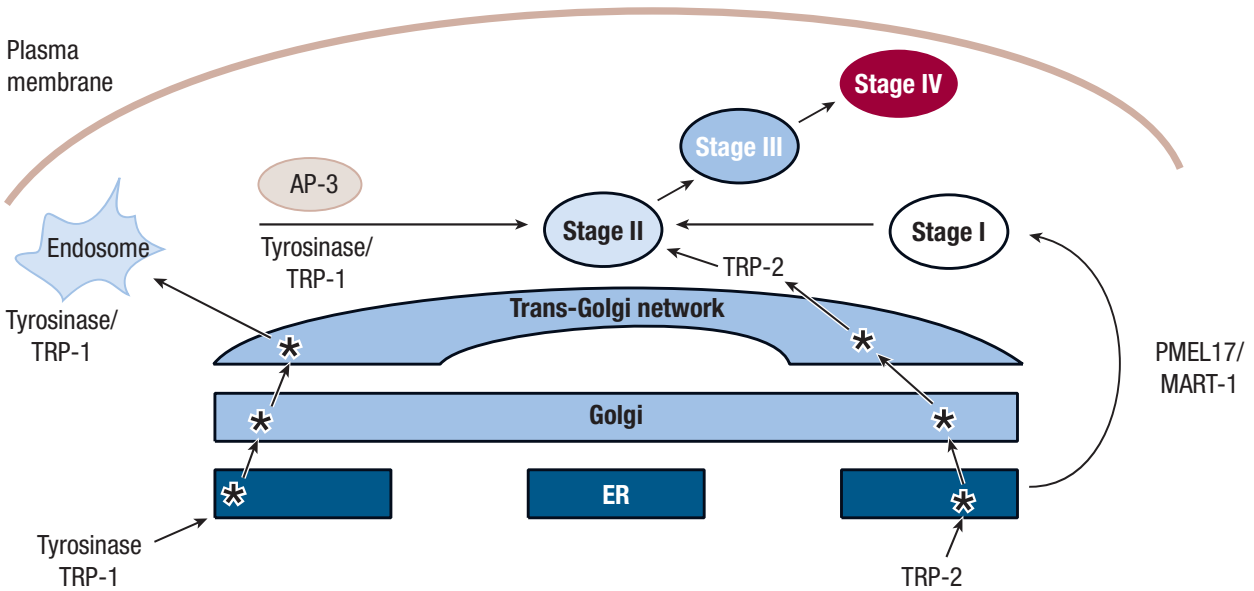

▲ **FIGURE 70-10** Sorting of melanosomal proteins into melanosomes. Tyrosinase and tyrosinase-related protein-1 (TRP-1) are initially synthesized in the endoplasmic reticulum (ER) and, after additional maturation steps (*) in the Golgi and Trans-Golgi network, are packaged in endosomes as a complex. TRP-2 follows similar maturation steps. Melanosomes originate in the ER as stage I already containing the melanosomal proteins PMEL17 and MART-1. They then mature to stage II melanosomes and fuse with tyrosinase/TRP-1 in a process directed by the adaptor protein 3 (AP-3). Melanosomes become progressively darker as melanin biosynthesis takes place.

respectively. The murine *tyrosinase* gene maps to chromosome 7, whereas human *tyrosinase* gene maps to chromosome 11. The human *tyrosinase* gene is composed of 5 exons and 4 introns,[63] and tyrosinase messenger RNA is approximately 2-kb long (gene bank access number NM_000372).

Tyrosinase is synthesized in the ER as a precursor protein whose nascent chain is processed in the Golgi complex where sialic acid and neutral sugars are added to the peptide via N- and O-glycosidic linkages through a process called *glycosylation* (reviewed in ref. 64) (Fig. 70-10). At least four forms of tyrosinase, all differing with regards to their degree of glycosylation, have been identified. The glycosylation steps have been shown to be important for proper association of tyrosinase with melanosomes, as well as for its activity.[64] After the glycosylation steps, mature tyrosinase is folded in the ER, a step required for appropriate trafficking/sorting of tyrosinase into the Golgi apparatus and ultimately into endosomes and finally into melanosomes. A strict control mechanism guarantees the elimination of defective tyrosinase.

Within the melanosome, tyrosinase spans the melanosomal outer membrane (Fig. 70-11). It has three domains: an inner melanosomal domain, a melanosomal transmembrane domain, and a cytoplasmic domain. The inner domain that contains the catalytic region is approximately 90 percent of the protein. It is followed by a short transmembrane domain and a cytoplasmic domain composed of approximately 30 amino acids (reviewed in ref. 65). Histidine residues present in the inner (catalytic) portion of tyrosinase bind copper ions, and the latter are required for tyrosinase activity.

The biologic function of the tyrosinase cytoplasmic domain was not known for a long time. In a mouse model in which the entire cytoplasmic domain is missing, tyrosinase protein is inserted into the cellular plasma membrane instead of into the melanosomal membrane, suggesting that tyrosinase cytoplasmic domain is required for proper trafficking of tyrosinase into melanosomes. Indeed, it was found that the motif EXXQPLL (glutamic acid-X-X-glutamine-proline-leucine-leucine, where "X" stands for any amino acid) in the cytoplasmic domain is responsible

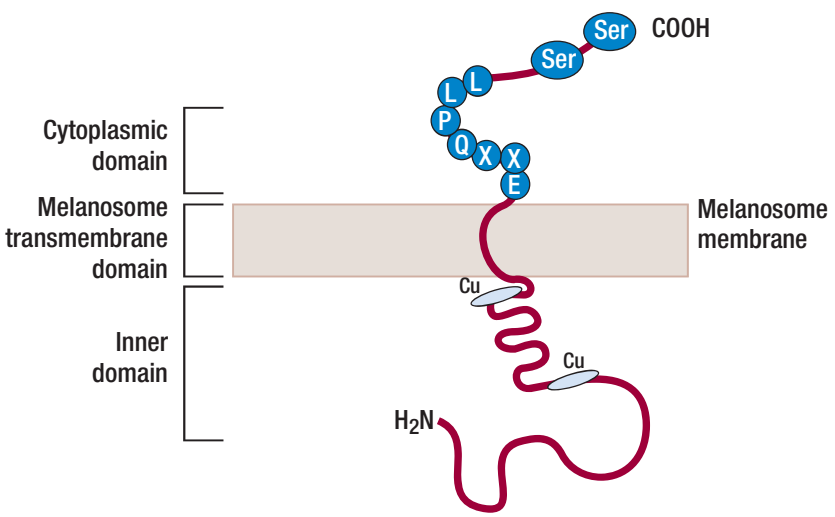

▲ **FIGURE 70-11** Schematic diagram of tyrosinase protein structure. Tyrosinase protein can be divided into three domains: the inner melanosomal domain, the transmembrane domain, and the cytoplasmic domain. The inner domain contains the catalytic activity of the enzyme and the copper (Cu) binding sites. The cytoplasmic domain contains the sequence (EXXQPLL) that participates in cellular trafficking of tyrosinase into melanosomes. The cytoplasmic domain also participates in regulating tyrosinase activity through phosphorylation of serine residues (Ser).



for tyrosinase trafficking into the melanosomes.[66] In addition, protein kinase C-β (PKC-β) (see Protein Kinase C-β) must phosphorylate two serine residues on this cytoplasmic domain to activate tyrosinase,[65] and in the absence of those phosphorylation events pigmentation does not occur.

Tyrosinase mutations, including missense, nonsense frameshift, and deletion mutations that lead to inactivation of the enzyme, are found in oculocutaneous albinism type I (see Chap. 71 and Albinism database: http://albinismdb.med.umn.edu/). Such mutations may affect tyrosinase glycosylation, interfering with enzyme maturation, or may involve copper binding sites, disrupting tyrosinase activity (reviewed in ref. 64).



Tyrosinase-Related Proteins. Two TRPs, TRP-1 and TRP-2, play important roles in melanogenesis.[67–69] They are structurally related to tyrosinase and share ~40 percent amino acid homology. Also, similar to tyrosinase, TRP-1 and TRP-2 are glycoproteins located within the melanosomes and span the melanosomal membrane.[70] The conserved nucleotide and amino acid sequences among these three melanogenic enzymes suggest that they originated from a common ancestral gene.[71,72]

TRP-1. In mice, TRP-1 maps to the brown locus on chromosome 4 and spans ~18 kb on the genomic DNA.[69,72] The human homolog of TRP-1 maps to chromosome 9 and spreads over 24 kb of the genomic DNA.[72] Like tyrosinase, TRP-1 is synthesized in the ER and undergoes several glycosylation steps (see Fig. 70-10). The exact function of TRP-1 in melanin biosynthesis, especially in human melanogenesis, is not well understood. In mice, TRP-1 displays a wide range of enzymatic activities, including DOPAchrome tautomerase,[73] tyrosine hydroxylase,[74] DOPA oxidase,[69,75] catalase,[76] and 5,6-dihydroxyindole-2-carboxylic acid (DHICA) oxidase[67,77] (see Melanin Biosynthesis). Conversely, in humans TRP-1 does not display DHICA oxidase activity, and the additional activities described above have not been reported to date for this enzyme.

Nevertheless, the presence of TRP-1 appears to be required for melanin synthesis in human melanocytes, as TRP-1 absence results in the pigmentary disorder oculocutaneous albinism type 3[78] (see Chap. 71). Because recently TRP-1 was shown to influence tyrosinase activity by forming a complex with tyrosinase, it is possible that TRP-1 plays a role in tyrosinase activation and/or stabilization.[79,80] A known TRP-1 function in both murine and human melanocytes at least in vitro is to increase the ratio of eumelanin to pheomelanin.[81,82] TRP-1 may also play a role in melanosomal biogenesis, as suppression of TRP-1 is associated with structurally abnormal melanosomes.[61]

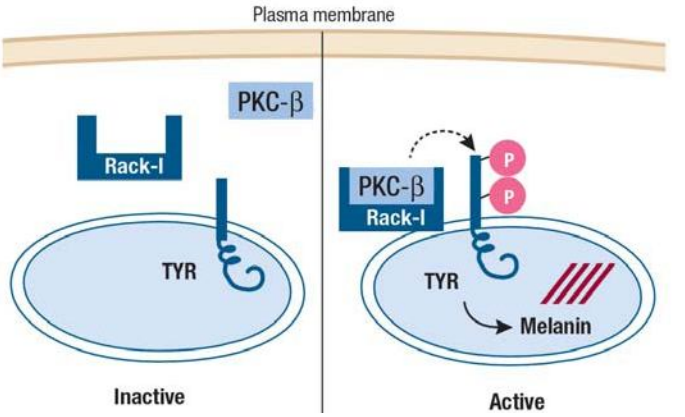

▲ **FIGURE 70-12** Activation of tyrosinase by protein kinase C-β (PKC-β). Under baseline conditions, there is no activation of PKC-β, and tyrosinase (TYR) is not phosphorylated. Activated PKC-β binds receptors for activated C-kinase-I (RACK-I), the complex translocates to the melanosome, and phosphorylates serine residues on the cytoplasmic tail of tyrosinase. Tyrosinase phosphorylation activates the enzyme to catalyze melanin biosynthesis.

TRP-2. In mice, TRP-2, also known as *DOPAchrome tautomerase*, maps to the *Slaty* locus on chromosome 14, whereas human TRP-2 maps to chromosome 13.[68] Mouse and human TRP-2 share 84 percent nucleotide homology.[83] Like tyrosinase and TRP-1, TRP-2 is a glycoprotein[84] that is synthesized in the ER and undergoes several maturation steps in the Golgi and trans-Golgi network (see Fig. 70-10). Like tyrosinase and TRP-1, it eventually localizes to melanosomes, and it spans the melanosomal membrane. Within the melanosome, TRP-2 is complexed with tyrosinase and TRP-1. During melanin synthesis, TRP-2 converts DOPAchrome to the carboxylated derivative DHICA. As is the case for tyrosinase, TRP-2 also requires metal ions for its enzymatic activity, but it is zinc rather than copper that is required for TRP-2 function.[85]

Protein Kinase C-β. PKC constitutes a family of at least 12 isoforms (reviewed in ref. 86) among which PKC-β has been shown to be involved in regulating tyrosinase activity.[87] The mechanisms through which PKC mediates a wide range of membrane-generated signals and their relevance to melanocyte biology are further discussed below (see Signaling Pathways Regulating Melanocyte Functions). PKC-β phosphorylates serine residues on the cytoplasmic domain of tyrosinase, thus activating tyrosinase.[88] Still, the means by which PKC-β–mediated phosphorylation of tyrosinase leads to the enzyme activation is not well elucidated. It has been suggested that phosphorylation of tyrosinase causes a complex to form between tyrosinase and TRP-1,[89] an event known to stabilize tyrosinase and increase its enzymatic activity.[79]

In melanocytes, activated PKC-β is associated with melanosomes, and the enzyme is found in close proximity to the melanosomal membrane.[88] Although structural differences among PKC isoforms may contribute to their associations with particular subcellular fractions, receptors for activated C-kinase (RACK), unique for each PKC isoform, primarily determine the translocation of specific PKC isoforms to specific cellular compartments to activate its target on the membrane[90–92] (Fig. 70-12). RACK-I is the PKC-β partner,[90] and in human melanocytes, the activated PKC-β/RACK-I complex translocates to the melanosome membrane to allow tyrosinase phosphorylation (see Fig. 70-12).[93]

STRUCTURAL PROTEINS Fibrillar matrix proteins within the melanosomes are required for proper deposition of melanin. Pmel17 and MART-1 are two such melanosomal structural matrix proteins.

Pmel17. Pmel17, also known as *gp100* and the *silver locus product*, is a glycoprotein recognized by the antibodies

HMB45, HMB50, and NKI-beteb (reviewed in ref. 94). It plays a critical role in fibril matrix formation within eumelanosomes.[59,95] Pmel17 transcription is induced by α-melanocyte-stimulating hormone (MSH) through Mitf, and it is synthesized as a precursor protein in the ER, and the protein undergoes glycosylation and eventual cleavage (see Fig. 70-10). After its synthesis, Pmel17 is transported to stage I melanosomes to form a fibrillar structure that is the backbone of eumelanosome matrix,[94] contributes to melanosome ellipsoid shape, and promotes melanin polymerization.[94] Melanosomes lacking Pmel17 cannot transit to stage II and have no active melanogenesis (reviewed in ref. 96). It has been suggested that loss of functional Pmel17 results in melanin cytotoxicity, perhaps through leakage of melanin intermediates from abnormal melanosomes into the cytosol.[94,97] However, there are no known hypopigmentary disorders in humans linked to mutations of *Pmel17*.

MART-1/Melan A. MART-1, also known as *Melan A*, is a membrane-associated protein[98] that is present in stage I and II melanosomes and forms a complex with Pmel17 (see Fig. 70-10). MART-1 affects the expression, stability, trafficking, and processing of Pmel17 within the melanosomes.[98] To date, no hypopigmented phenotypes associated with nonfunctional MART-1 have been identified.

ADDITIONAL MELANOGENIC PROTEINS

P Protein. The p protein (pink-eyed dilution) is a transmembrane protein with 12 membranes spanning domains whose sequence is homologous to that of other transmembrane transport proteins, including anion transporters[97,99,100] thought to function as a transport protein.[101] Studies have identified the protein as an adenosine triphosphate–associated proton pump responsible for maintaining acidic environment within the melanosomes (reviewed in ref. 102). Other proposed functions of p protein include stabilizing the tyrosinase/TRP-1/TRP-2 complex and/or transporting tyrosine into the melanosomes.[99] Individuals lacking functional p protein display oculocutaneous albinism type 2, largely due to improper melanosomal pH.[102–104] Also, Angelman and Prader-Willi syndromes display deletion mutations that include the p locus on chromosome 15.

Heterotetrameric Adaptor Protein Complexes. Sorting of membrane-associated proteins, including tyrosinase, TRP-1, TRP-2, and Pmel17, and directing them to the appropriate cytosolic organelles are facilitated by heterodimeric adaptor protein complexes (APs).[105,106] AP-3 and possibly also AP-1 facilitate tyrosinase transport from endosomes to melanosomes[107] (see Fig. 70-10). Patients with Hermansky-Pudlak syndrome, an autosomal recessive disorder of oculocutaneous albinism, platelet dysfunction, and pulmonary disease (see Chap. 71), have defects in specific subunits of the AP-3 adaptor protein complex and as a result display several anomalies associated with cellular transport of molecules.[108]

SLC24A5. SLC24A5 is a melanosomal protein whose structure and homology to cation exchange proteins suggests that it is a melanosome-associated cation exchanger.[109] Mutations in *slc24α5* in zebrafish lead to hypopigmentation of the organism.[109] The ancestral human homolog is expressed by darker complexioned individuals, including Africans and Asians, whereas lighter-complexioned Europeans tend to express a variant allele.[109]

Lysosomal-Associated Membrane Proteins. LAMPs are linked to melanosome membranes and/or matrix. They are thought to protect melanosomal integrity by acting as scavengers of free radicals that are produced during melanin biosynthesis.[110] Because LAMPs are also present in lysosomes, it is thought that melanosomes and lysosomes share a common ancestral origin.[110]

REGULATORY PROTEINS

Microphthalmia-Associated Transcription Factor. **GENE AND PROTEIN.** Mitf, a basic-helix-loop-helix and leucine zipper transcription factor, has been termed the master gene for melanocyte survival and is a key factor regulating the transcription of the major melanogenic proteins, tyrosinase, TRP-1, TRP-2,[12] PKC-β,[111] and MART-1.[112] Mitf binds to conserved consensus elements in gene promoters, specifically the M- (AGTCATGTGCT) and E- (CATGTG) boxes.[113] It can bind as a homodimer or a heterodimer with another related family member (reviewed in ref. 114). Mitf appears to be a key regulator determining cell fate, as transfection of human Mitf complementary DNA into mouse fibroblasts converts these cells into dendritic cells expressing melanocyte-specific genes.[115]

Mitf comprises a family of nine isoforms, Mitf-M, -A, -B, -H, -C, -D, -E, -J, and -Mc.[116,117] Mitf-M expression is highly specific for melanocytic cells.[118] Melanocytes express in addition other Mitf isoforms, specifically, Mitf-A, -B, and -E.[112] In melanocytes, it is the Mitf-M isoform that stimulates transcription of *tyrosinase* and *PKC-β*.[112] The biologic role of other Mitf isoforms in normal melanocytes is not known.

REGULATION OF MICROPHTHALMIA-ASSOCIATED TRANSCRIPTION FACTOR ACTIVITY AND EXPRESSION. The activity and stability of Mitf are modulated by phosphorylation of the protein. Mitf activity is increased on its phosphorylation by the mitogen-activated protein kinase-2 (MAP kinase-2), whose activity is in turn induced by binding of SF/kit/SCF to c-Kit receptor[119] (see Fig. 70-12). Phosphorylated Mitf binds to another protein, p300/CBP, that belongs to a coactivator family of proteins and acts to enhance Mitf transcriptional activity.[119,120] Another kinase that is activated by SF/c-Kit interaction is p90RSK, which also phosphorylates Mitf, but at a different site from that phosphorylated by MAP kinase-2.[121] These phosphorylation events both activate Mitf and at the same time decrease the stability of the protein, as phosphorylated Mitf is targeted for degradation by proteosomes (Fig. 70-13A).[121,122]

The expression of Mitf is under the control of several transcription factors, including Sox10 (mutated in Waardenburg syndrome type 4, see Chap. 71) and Pax3. Mitf expression is also controlled by the cyclic adenosine monophosphate (cAMP)-response element binding protein (CREB) and Lef1 transcription factor, which participates in Wnt signaling. These transcription factors bind to specific sites within MITF promoter regions to induce Mitf transcription (reviewed in ref. 114). The promoter region of the *MITF* gene contains a cAMP-response element (CRE) that interacts with CREB when the cAMP-dependent pathway is activated.[123,124] Therefore, cAMP-elevating agents such as α-MSH induce the expression of Mitf (see Fig. 70-13B).

MICROPHTHALMIA-ASSOCIATED TRANSCRIPTION FACTOR ROLE IN MELANOCYTE PROLIFERATION AND SURVIVAL. Mitf promotes melanocyte survival by upregulating the expression of a major anti-apoptotic protein, Bcl2.[125] It is frequently overexpressed or amplified in melanomas, contributing to their increased survival.[126–129] A role for Mitf in melanocyte proliferation has also been

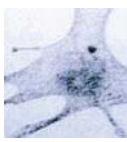

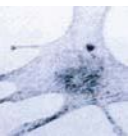

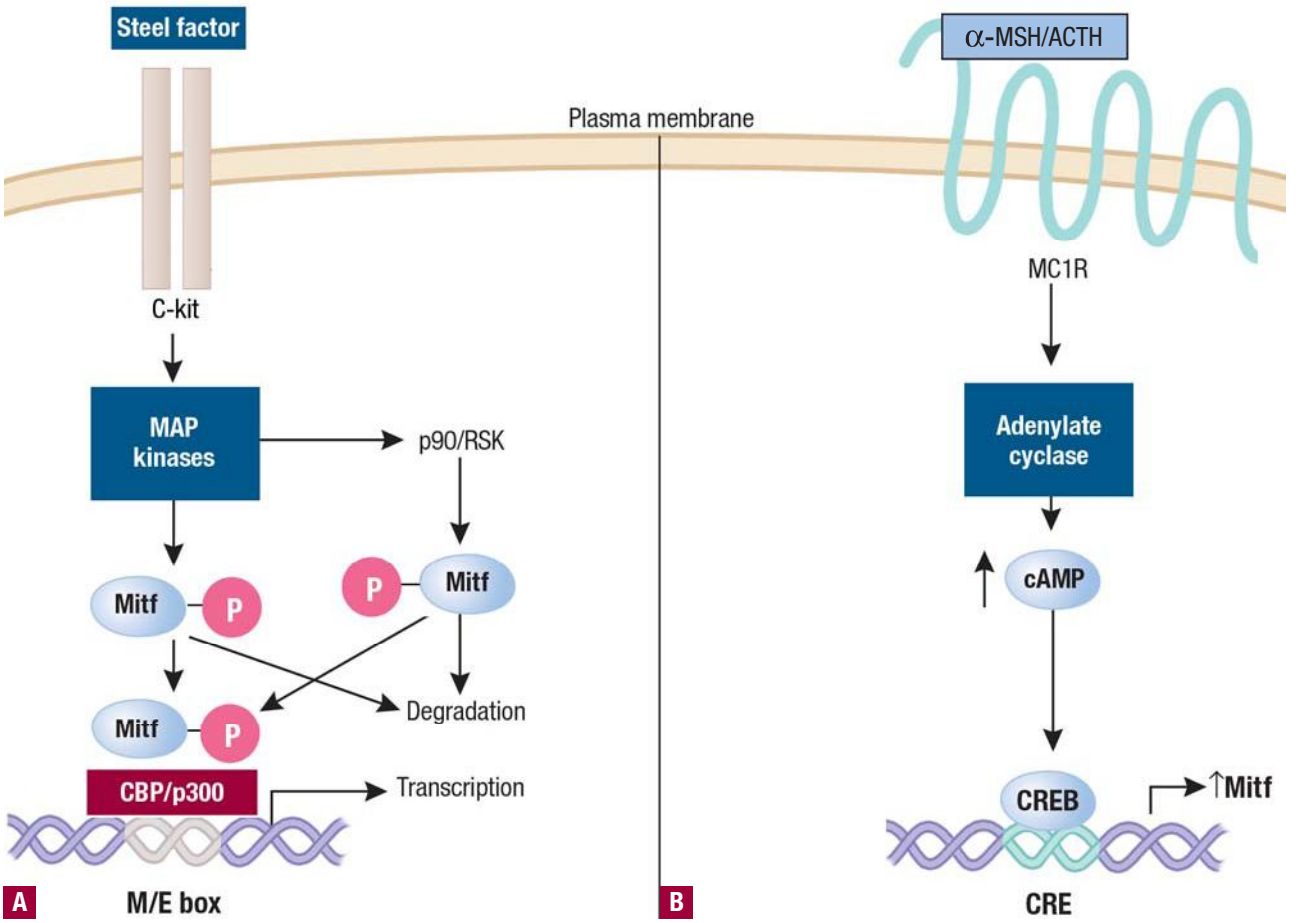

▲ **FIGURE 70-13** Microphthalmia-associated transcription factor (Mitf) regulation. **A.** Mitf is activated when steel factor (SF) binds to its cell surface receptor c-Kit. SF/c-Kit interaction activates mitogen-activated protein (MAP) kinases, which then phosphorylate Mitf. Phosphorylated Mitf then recruits the co-transcription activator CBP/p300, and the complex binds to the M- or E-boxes (M/E box) within the promoter of target genes to regulate their transcription. Mitf can also be phosphorylated at a different site by p90/RSK kinase. Both phosphorylation events lead to Mitf ubiquitination and subsequent proteosome-mediated degradation. **B.** On binding to melanocortin receptor-1 (MC1R), α-melanocyte-stimulating hormone (α-MSH)/adrenocorticotropic hormone (ACTH) activate the enzyme adenylate cyclase that upregulates the cyclic adenosine monophosphate (cAMP) level, leading to cAMP-response element binding protein (CREB) activation and binding its DNA consensus sequence CRE in the Mitf promoter to induce Mitf transcription.

proposed, as under certain conditions, Mitf induces the expression of the cell cycle–associated kinase Cdk2 that is involved in the progression of cells from G1 into S phase of the cell cycle.[130] Mitf also suppresses the expression of p21, a protein that inhibits Cdk2 activation.[130,131] Conversely, under different conditions, Mitf can induce p21 expression, and it can also stimulate the expression of $p16^{INK4a}$, a protein that inhibits the activation of kinases required for progression through the cell cycle, thus promoting cell cycle arrest.[132,133] Because Mitf cooperates with other transcription factors to induce its effects, it is to be expected that these transcription factors would influence Mitf activity, resulting in either stimulation or inhibition of melanocyte proliferation.

Mice bearing null mutations of *MITF* display loss of melanocytes, deafness, and failure of differentiation of retinal pigment epithelium.[12] Mutations in *MITF* are found in the pigmentary disorder Waardenburg syndrome type 2[134] (see Chap. 71).

Melanocortin 1 Receptor. Melanocortin receptors (MCRs) comprise a family of five related receptors (MC1R, MC2R, MC3R, MC4R, and MC5R). Each has seven transmembrane domains, and they belong to the G-protein–coupled receptor superfamily.[135] MC3R and MC4R are mainly found in the central nervous system, are absent in melanocytes,[136] and are thought to control energy intake. MC2R is expressed in the adrenal cortex, and MC5R is expressed in peripheral adipocytes.[137] MC1R is expressed in a number of cells, such as endothelial cells, fibroblasts,[138] and keratinocytes,[138] but the highest expression is found in melanocytes.[138]

α-MSH and adrenocorticotropic hormone (ACTH), a 39 amino acid proopiomelanocortin–derived peptide that contains the α-MSH sequence (Fig. 70-14A) (reviewed in refs. 139–141), activate MC1R (see Fig. 70-14B). Receptor ligand interaction leads to G-protein–dependent activation of the enzyme adenylate cyclase followed by increased intracellular cAMP level (reviewed in ref. 139), inducing Mitf transcription and upregulating the level of melanogenic proteins, including tyrosinase,[40] promoting the synthesis of brown/black eumelanin (reviewed in 139). Agouti, a protein expressed in both humans and mice, whose expression in mice leads to yellow coat color, antagonizes α-MSH by competitive binding to MC1R. It thus blocks adenylate cyclase activation[142–144] and favors pheomelanin over eumelanin synthesis (Fig. 70-15). However, the role of agouti in human pigmentation is poorly documented.

Polymorphisms within the *MC1R* gene are largely responsible for the dif-

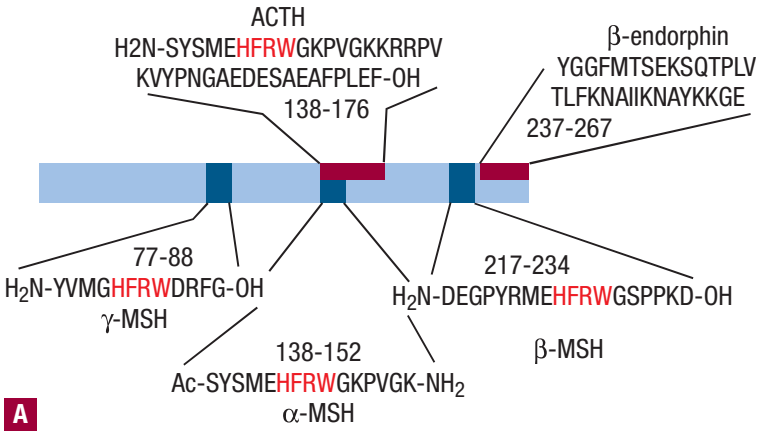

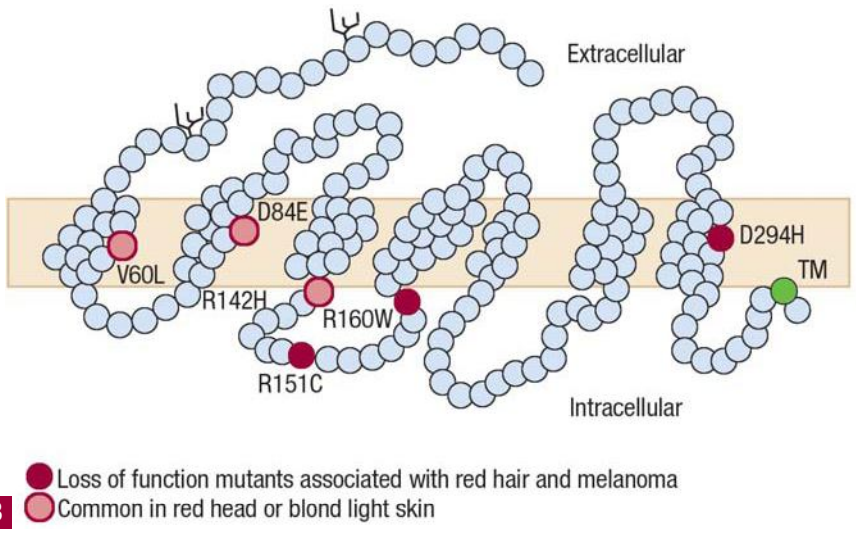

▲ **FIGURE 70-14** The melanocortin receptor (MCR) and its ligands. **A.** Structure of the proopiomelanocortin precursor. Standard abbreviations for amino acids are used. The synthetic superactive α-melanocyte-stimulating hormone (α-MSH) analogue [Nle^4 D-Phe^7]-α-MSH is modified by the exchange of methionine (M) with norleucine and L-phenylalanine (F) with D-phenylalanine. In *red* are critical amino acids required for binding to the MCR. **B.** Schematic representation of the human MC1R receptor. Each of the 318 amino acid residues in the polypeptide chain of the receptor is represented by an empty circle. Branched structures represent *N*-linked glycosylation sites. Reduced function mutants (*red circles*), variants common in red- or blond-haired and fair skinned individuals (*orange circles*), and the conserved *C*-terminal cysteine (*green circle*), the possible site for fatty acid acylation and anchoring to the plasma membrane, are indicated. Ac = acetylated; ACTH = adrenocorticotropic hormone; NH_2 = amidated; TM = transmembrane domain.

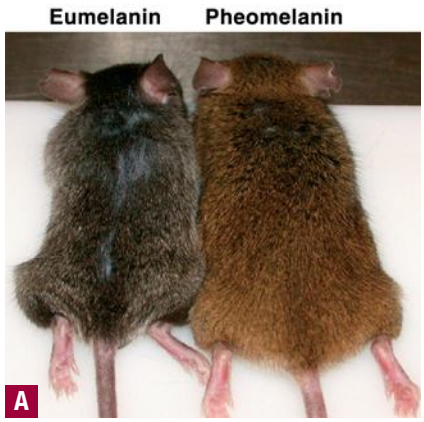



▲ **FIGURE 70-15** Eumelanin and pheomelanin presentation in mice. **A.** Two mice with different coat colors are shown. The one on the left displays brown/black coat color due to eumelanin, and the one on the right displays red/yellow coat color due to pheomelanin. **B.** Representative hair shafts of these mice. (From Sharov et al: Bone morphogenic protein (BMP) signaling controls hair pigmentation by means of cross-talk with the melanocortin receptor 1 pathway. *PNAS* **102**:93, 2004, with permission.)

ferent skin/hair color among different ethnic groups.[145] At least 30 MC1R variants have been identified, and nine of them display loss of function[146,147] (see Fig. 70-14B), not being able to induce intracellular cAMP production in response to α-MSH despite adequate receptor/ligand binding. Other MC1R variants have reduced affinity for α-MSH.[146,147] Three MC1R variants, each with only a single amino acid substitution, have been associated with red/yellow hair and fair skin[148] of Northern Europeans and Australians.[149–154] Mice expressing a loss-of-function MC1R variant receptor also fail to respond to UV irradiation with increased pigmentation despite an increased level of epidermal α-MSH,[155] but do tan if provided forskolin, a chemical enhancer of pigmentation that bypasses the receptor to directly increase cAMP, demonstrating that the intracellular melanogenic pathway is functional in such individuals.[155]

MELANIN BIOSYNTHESIS

Two types of melanins are synthesized within melanosomes: eumelanin and pheomelanin.[156] Eumelanin is dark, brown-black, and insoluble, whereas pheomelanin is light, red-yellow, sulfur-containing, and soluble.[156] Melanins are indole derivatives of DOPA, and they are formed in melanosomes through a series of oxidative steps (reviewed in ref. 157) (Fig. 70-16). Melanosomal pH affects the activity of the melanogenic enzymes and influences melanin polymerization.

The synthesis of both types of melanin involves the rate-limiting catalytic step in which the amino acid tyrosine is oxidized by the enzyme tyrosinase (also called *tyrosine oxidase*, *DOPA oxidase*, monophenol, L-*DOPA:oxygen oxidoreductase*) to L-DOPA, a reaction known as the *Raper-Mason pathway*[158] (see Fig. 70-16). Conversion of tyrosine to L-DOPA is thought to be the critical rate-limiting step in melanogenesis, as inhibition of this reaction blocks melanin synthesis.[159] In both reactions, L-DOPA acts as a co-factor and also as a substrate for tyrosinase. Although the exact interaction between tyrosinase and its substrates is not completely understood, in vitro kinetic studies suggest that distinct sites mediate tyrosinase binding to tyrosine and to L-DOPA, and that binding to L-DOPA causes a conformational change

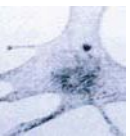

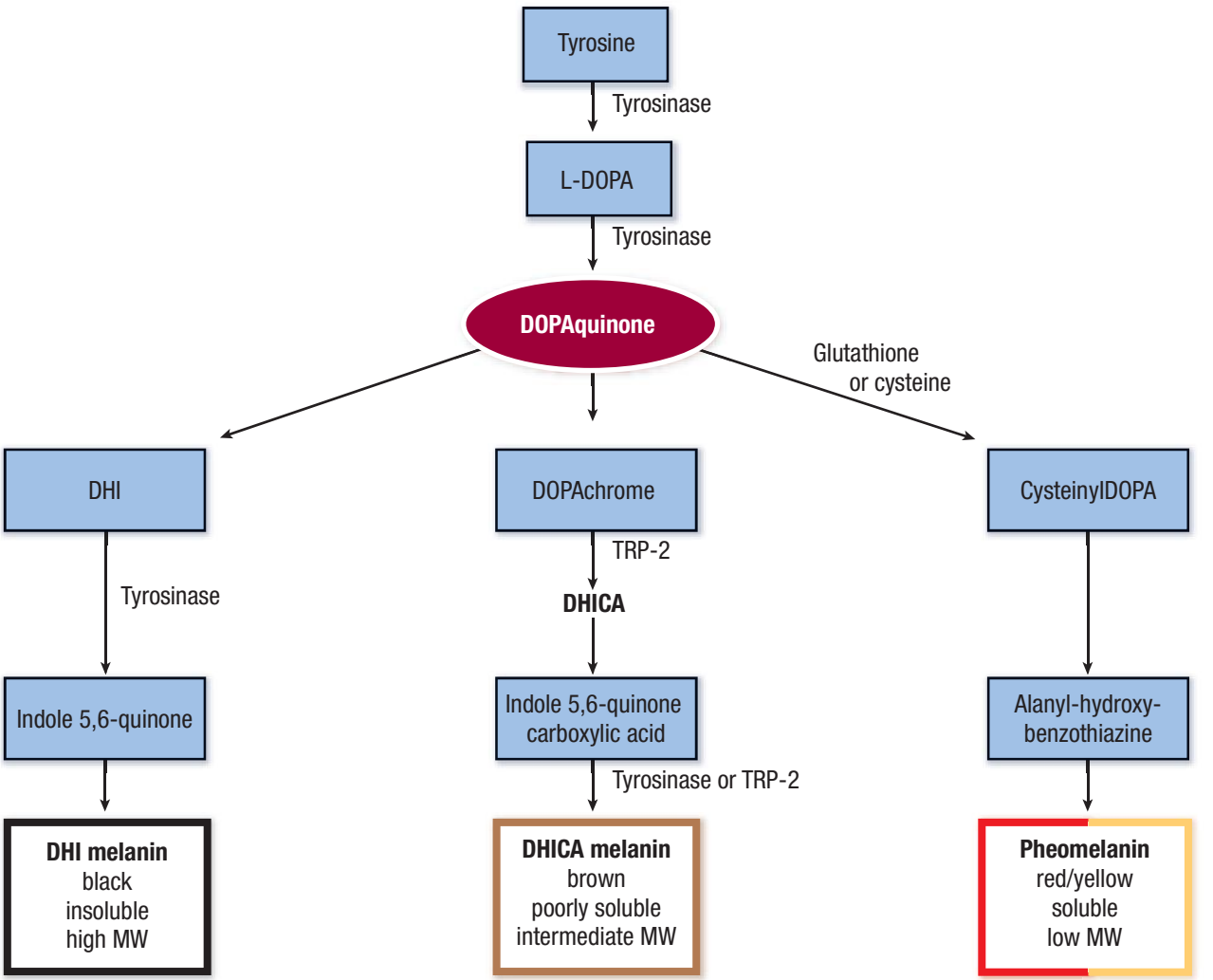

▲ **FIGURE 70-16** Melanin biosynthesis. Melanin biosynthesis begins with the amino acid tyrosine that is converted to L-DOPA (3,4 dihydroxyphenylalanine) in the rate-limiting step of melanin biosynthesis catalyzed by tyrosinase. L-DOPA is subsequently converted to DOPAquinone by the same enzyme. DHI (5,6-dihydroxyindole) and DHICA (5,6-dihydroxyindole-2-carboxylic acid) are then formed to produce either black or brown eumelanin. Alternatively, through incorporation of glutathione or cysteine, DOPAquinone can form pheomelanin. MW = molecular weight; TRP = tyrosinase-related protein.

in tyrosinase, resulting in increased affinity for both tyrosine and L-DOPA.

L-DOPA is oxidized into DOPAquinone,[160] DOPAquinone is further converted to DOPAchrome, and DOPAchrome can be converted to 5,6-dihydroxyindole (DHI) or to 5,6-dihydroxyindole-2-carboxylic acid (DHICA). The latter reaction is catalyzed by the enzyme DOPAchrome tautomeras or TRP-2. The level of brown versus black eumelanin appears to correlate with the DHI/DHICA ratio, with a higher ratio leading to the formation of black eumelanin and a lower ratio to brown eumelanin.[161] DOPAquinone can also combine with glutathione or cysteine to form cysteinylDOPA, which then becomes the yellow/red, soluble, low-molecular-weight pheomelanin.[161] Interestingly, tyrosinase also catalyzes a more distant step in melanin biosynthesis, namely DHI conversion to indole-5,6-quinone. In mice, the enzyme TRP-1 (also called *DHICA oxidase*) converts DHICA to indole-5,6-quinone carboxylic acid. However, the TRP-1 role in human melanin biosynthesis is not well established.

The main function of melanin is to provide protection against UV-induced DNA damage by absorbing and scattering UV radiation (280 to 400 nm). Accordingly, energy absorption by melanin is maximal in this portion of the electromagnetic spectrum and decreases gradually across the visible light spectrum. UV absorbed by melanin is converted into heat, a less toxic form of energy (reviewed in ref. 162). Still, in vitro studies conducted by several investigators suggest that melanin's capacity to act as a sunscreen is limited, and that melanin, when incorporated into a cream and spread over the skin, absorbs only 50 percent to 75 percent of incident sunlight. Naturally, it is possible that in vivo, by virtue of localizing above the nucleus, melanin in melanosomes achieves a higher level of protection.

Melanin intermediates as well as melanin itself can also be harmful to the cell because, depending on their molecular weight and polymerization state, they can promote UVA (320 to 400 nm)-induced DNA damage, most likely through the generation of ROS.[163] It has been suggested that the increased incidence of UV-induced melanomas in light-skinned, red-haired individuals is not only due to decreased ability of pheomelanin to protect against UV-induced DNA damage, but may also be due to mutagenic capacity of pheomelanin and possibly other melanin intermediates as a result of their pro-oxidant capacity.[164]

MELANOCYTE DENDRITES

Melanocyte dendrites are branching protoplasmic processes that interact with ke-

ratinocytes. Actin is a major structural component of melanocyte dendrites, and actin filament disruption leads to dendrite loss.[165] Co-cultures of keratinocytes and melanocytes demonstrate that keratinocyte-derived factors play a role in melanocyte dendricity (reviewed in ref. 166). These factors include ET1, nerve growth factor (NGF), α-MSH, ACTH, prostaglandins E_2 (PGE_2) and $F_{2\alpha}$ ($PGF_{2\alpha}$),[166] and β-endorphin.[167] Integrins, receptors that mediate actin-extracellular matrix contact, are likely to play a role in dendrite formation as well.[168]

Another group of proteins, the Rho family, also plays a role in melanocyte dendrite formation. Rho proteins become active when they bind guanosine triphosphate and inactive when binding guanosine diphosphate.[169,170] It appears that when Rho is activated, dendrites retract; whereas when its family member Rac is activated, dendrites form.[170] Indeed, it is currently assumed that by increasing cAMP levels, α-MSH inhibits Rho, enhancing melanocyte dendricity. Thus, the equilibrium between Rho and Rac appears to be an important factor influencing melanocyte dendricity.

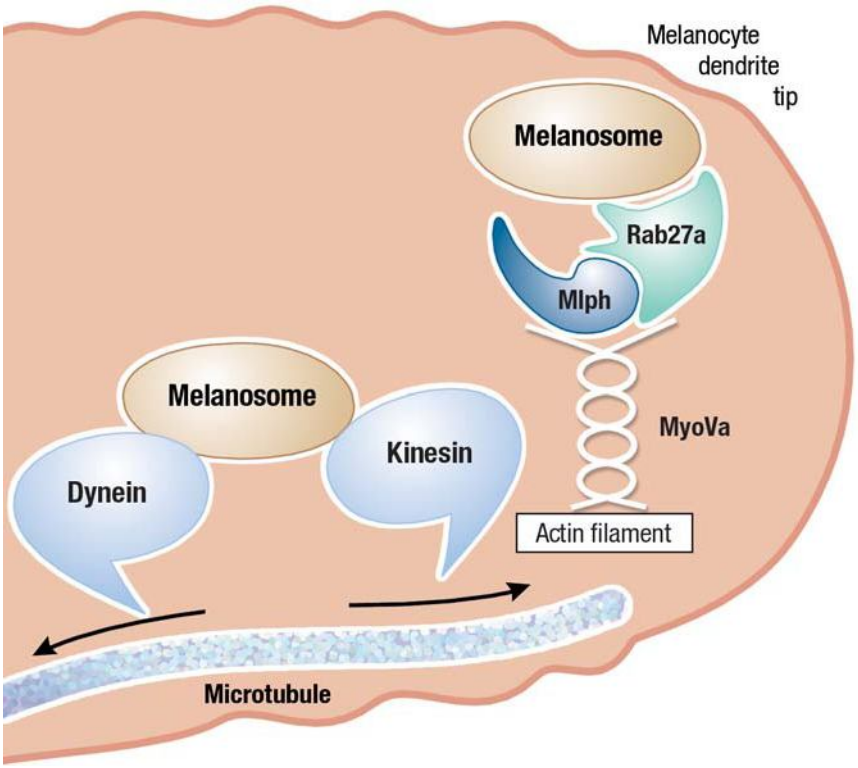

▲ **FIGURE 70-17** Schematic diagram of melanosome transport across melanocyte dendrites. Melanosomes move bidirectionally along melanocyte dendrites. They are attached to microtubules through the motor proteins kinesin (anterograde) and dynein (retrograde). At the tip of the dendrite, melanosomes are captured in the actin-rich periphery. Myosin-Va (MyoVa) mediates melanosome binding to actin through the linker proteins Rab27a and melanophilin (Mlph).

MELANOSOME TRANSPORT

Within Melanocytes

Melanosomes are transferred from their site of origin in melanocyte perikaryon to the tips of melanocyte dendrites. Melanosome transport takes place on microtubules that are arranged parallel to the long axis of the dendrite and is controlled by two classes of microtubule-associated motor proteins: kinesins[171–173] and cytoplasmic dyneins[174–178] (Fig. 70-17). Both motor proteins act as short cross-bridge structures connecting the organelle to the microtubules.

Centrifugal, anterograde organelle movement is mediated primarily by kinesin, whereas centripetal movement is controlled by cytoplasmic dynein. Studies examining melanosomal transport suggest that their microtubule-dependent movement is bidirectional,[179] consistent with a cooperative forward and backward pull of kinesin[171] and dynein,[174] respectively. For melanosomes with net centrifugal movement, the bidirectional movement appears to terminate with myosin-Va (encoded by dilute locus)–dependent melanosomal capture in the actin-rich periphery of the dendrite (see Fig. 70-17).[179]

Additional proteins that participate in melanosome transport include Rab27a (encoded by *ashen* locus), that mediates myosin-Va binding to melanosomes through another linker protein-melanophilin (encoded by *leaden* locus) (see Fig. 70-17).[180] In the absence of myosin-Va, melanosomes do not collect in dendrite tips.

Mutations in any of the above gene products results in decreased cutaneous pigmentation. Griscelli syndrome, a rare autosomal recessive disorder in which individuals display dilute skin and hair color, is the result of mutations of *myosin-Vα*, *Rab27α* or *melanophilin*[180] (see Chap. 71). *Myosin-Vα* and *Rab27α* are closely located on chromosome 15.[181–184] Because myosin-Va is also expressed in the brain, mutations of this gene may also cause neurologic abnormalities. Rab27a also plays a role in immunoregulation, and individuals with mutations of this gene display abnormalities of the immune system. Mutations of *melanophilin* result only in the distinctive hypopigmentation that characterizes the syndrome.[184]

To Keratinocytes

Transfer of melanosomes from melanocytes to neighboring keratinocytes is a critical step in normal pigmentation. Studies suggest several ways for melanosomal transfer, including exocytosis, cytophagocytosis, fusion of plasma membranes, and transfer by membrane vesicles (reviewed in ref. 185).

The exocytosis pathway of melanosomal transfer involves fusion of the melanosomal membrane with the melanocyte plasma membrane, melanosome release into the intercellular space, and phagocytosis by surrounding keratinocytes. *Cytophagocytosis* is a term indicating the phagocytosis of a live cell or a portion of it. With regard to keratinocytes, they cytophagocytose the tip of a melanocyte dendrite, which then fuses with lysosomes inside the keratinocyte, which is transported to a supranuclear location where the phagolysosome membranes break up, releasing the melanosomes. Fusion of keratinocyte and melanocyte plasma membranes creates a space through which melanosomes are transferred from the melanocyte to the keratinocyte. Indeed, high-resolution photography shows the presence of filopodia, slender, filiform, pointed, cytoplasmic projections at the tip of melanocyte dendrites.[186] These filopodia



adhere and fuse with keratinocyte plasma membrane before melanosome transfer. The fourth way of melanosomal transfer involves shedding of melanosome-filled vesicles followed by phagocytosis of these vesicles by keratinocytes or their fusion with keratinocyte plasma membrane.

The molecular and cellular mechanisms involved in melanosome phagocytosis have been partially elucidated. It appears that keratinocytes express a seven transmembrane G-protein–coupled receptor called *protease-activated receptor-2* (PAR-2). PAR-2 is activated when serine proteases cleave the extracellular portion of the receptor, exposing a new segment that acts as a tethered (attached) ligand.[187,188] Activation of PAR-2 increases keratinocyte phagocytic activity.[187,188]

Interestingly, and consistent with its role in melanosome phagocytosis, UV induces the activity and expression of PAR-2.[189] UV effect on PAR-2 activity and expression is more pronounced in individuals with skin phototypes II and III than in those with skin phototype I.[189] Keratinocyte growth factor receptor has also been implicated in enhancing phagocytosis of melanosomes by keratinocytes.[190]

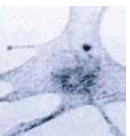

REGULATION OF MELANOCYTE FUNCTION

Melanocyte behavior in skin is largely influenced by signals from neighboring keratinocytes as well as autocrine signals and environmental factors such as UV irradiation (also see Ultraviolet Irradiation and Melanocytes). The synthesis and secretion of most keratinocyte-derived factors is increased by UV irradiation, but it is also evident that UV can directly stimulate melanocyte dendricity and melanin production.[169,191] Melanocytes receive both positive and negative paracrine signals that modulate their proliferation and differentiated function.

Melanogenic Stimulators

PROOPIOMELANOCORTIN AND DERIVED PEPTIDES It is well documented that MSH and ACTH are potent stimulators of melanogenesis. They belong to a family of peptides derived from the precursor proopiomelanocortin (POMC) that is synthesized, in addition to the pituitary gland, also by epidermal keratinocytes. Interestingly, POMC expression in keratinocytes is induced by UV, phorbol esters, and interleukins (ILs).[192,193] In rodents, α-MSH stimulates melanogenesis and favors eumelanin over pheomelanin production, but systemic administration of α-MSH, β-MSH, and ACTH to people increases skin pigmentation predominantly in sun-exposed areas.[194,195] However, in certain disease conditions characterized by abnormally high levels of ACTH, such as Addison disease[196] or Nelson syndrome[197] (ACTH-secreting pituitary adenoma), more generalized hyperpigmentation of the skin has been observed.[198]

Aside from its effect on melanogenic proteins and eumelanin synthesis, α-MSH was also reported to enhance the repair of UV-induced DNA damage in melanocytes, specifically the repair of pyrimidine dimers, and also to reduce the level of UV-induced hydrogen peroxide in the cell.[199] These data suggest a role for POMC-derived peptides beyond merely stimulating melanogenesis.

ENDOTHELIN-1 ET1 appears to play a role in mature melanocytes, inducing melanogenesis by activating tyrosinase and increasing TRP-1 levels.[200,201] ET1 also leads to melanocyte proliferation[200,201] and promotes dendrite formation.[202] Cultured keratinocytes synthesize and secrete ET1,[201–203] and UV irradiation stimulates ET1 production by keratinocytes.[201,202] ET1 can also cooperate synergistically with other growth factors/cytokines to further influence melanocyte function.

ET1 upregulates the MC1R level and increases MC1R affinity for α-MSH.[204,205] Similar to α-MSH, ET1 displays photoprotective effects on melanocytes, enhancing thymine dimer repair, decreasing the level of UV-induced hydrogen peroxide, and inducing the level of anti-apoptotic proteins.[199,206]

STEEL FACTOR Like other keratinocyte-derived factors, SF is induced by UV irradiation, and, in guinea pigs, anti-Kit antibodies block UV-induced tanning. SCF can also act synergistically with other cytokines such as IL-3, IL-6, IL-7, IL-9, and granulocyte-macrophage colony-stimulating factor to regulate UV-induced melanogenesis and melanocyte survival.[207,208]

INFLAMMATORY MEDIATORS Several inflammatory mediators can affect skin pigmentation. PGs (arachidonic acid–derived metabolites) and leukotrienes (lipid compounds related to PGs), both mediators of inflammatory responses, affect melanocyte function. Their level is elevated in sunburned skin[209] and in a variety of inflammatory dermatoses, including atopic dermatitis[210] (see Chap. 14) and psoriasis[211] (see Chap. 18).

Human melanocytes express several PG receptors, including the receptors for PGE_2 and $PGF_{2\alpha}$.[212,213] Indeed, $PGF_{2\alpha}$ stimulates melanocyte dendrite formation and activates tyrosinase,[212,213] and UV irradiation upregulates the level of PG receptors on melanocytes.[212,213] Similarly, leukotrienes B_4 and C_4 increase melanin synthesis and stimulate melanocyte proliferation and motility.[214] Interestingly, melanocytes also contribute to cutaneous inflammatory responses, as they synthesize and release IL-8 when stimulated by the pro-inflammatory cytokines IL-1 and tumor necrosis factor-α.[215]

Melanocytes also respond to histamine released by mast cells during cutaneous inflammation. Histamine binds H_1 and H_2 receptors to induce melanocyte dendricity and upregulate tyrosinase level.[216,217] These effects are decreased when melanocytes are pretreated with the H_2 receptor antagonist famotidine.[217]

NEUROTROPHINS Neurotrophins (NTs) are a family of molecules that enhance neuronal survival in the central and peripheral nervous systems. They include NGF,[218] NT3,[219–221] NT4,[222] and brain-derived neurotrophic factor.[223,224] Melanocytes express the low affinity receptor common to all NTs, $p75^{NTR}$,[225] as well as the high affinity receptors for NGF (TrkA) and NT3 (TrkC) (reviewed in ref. 226). Keratinocyte-derived NGF, whose expression is upregulated by UV irradiation, is chemotactic for melanocytes and induces their dendricity.[227] Both NGF and NT3, the latter expressed by dermal fibroblasts, increase melanocyte survival. Specifically, after UV irradiation, NGF supplementation increases the level of the anti-apoptotic Bcl2 protein, reducing melanocyte apoptotic cell death.[228,229] Thus, in addition to other keratinocyte-derived cytokines, NGF may help preserve the population of cutaneous melanocytes that would otherwise be depleted by UV damage.

BASIC FIBROBLAST GROWTH FACTOR Basic fibroblast growth factor (bFGF), named for its ability to stimulate the growth of fibroblasts, was one of the first identified melanocyte mitogens.[230,231] It is produced by keratinocytes, but lacks a

secretory signal and hence is presumed to affect melanocytes through cell-cell contact. It binds tyrosine kinase transmembrane receptors to induce its mitogenic effect in the presence of cAMP-elevating factors. Like other keratinocyte-derived cytokines, it is upregulated in response to UV irradiation.[231,232] Keratinocyte growth factor, another member of the FGF family of proteins, has been shown to promote melanosome transfer from melanocytes to keratinocytes.[190]

NITRIC OXIDE Nitric oxide (NO) is a diffusible free radical displaying pleiotropic bioregulatory effects in diverse cells and tissues.[233,234] Melanocytes and keratinocytes produce NO in response to inflammatory cytokines,[235–238] and NO production in keratinocytes is induced by UV irradiation.[239] NO increases tyrosinase activity and melanogenesis[239] and is thus an autocrine as well as paracrine molecule that affects melanocyte behavior in skin.

Melanogenic Inhibitors

Numerous reports have suggested the existence of endogenous melanogenic inhibitors,[240,241] but only few specific molecules have been identified. One group of inhibitors include sphingolipids, a class of membrane-associated lipids (reviewed in ref. 242) that act as signal transducers. Sphingolipids were shown to decrease melanogenesis, at least in part by enhancing Mitf degradation via ubiquitin-meditated pathways.[243,244] Another melanogenic inhibitor, BMP-4, downregulates tyrosinase expression in melanocytes,[245] also in part via its effects on Mitf.[246] Interestingly, physiologic doses of UV irradiation, a potent melanogenic stimulator, decrease the expression of BMP receptors on melanocytes,[245] presumably eliminating its inhibition during UV-induced tanning. Mice that transgenically overexpress the physiologic BMP antagonist noggin have a darker coat color than wild-type mice, and their hairs have a higher eumelanin-pheomelanin ratio.[247]

SIGNALING PATHWAYS REGULATING MELANOCYTE FUNCTION

Growth factors, cytokines, hormones, and other ligands for receptors expressed on melanocytes exert their biologic effect by interacting with their specific cell surface receptors, generating a signaling cascade involving activation or inhibition of protein kinases, and leading to distinct patterns of protein phosphorylation. Two types of kinases participate in cellular signaling: serine/threonine and tyrosine kinases that by definition phosphorylate serine and/or threonine residues and tyrosine residues, respectively, on their specific target proteins. This section reviews the major signaling pathways that affect melanocyte behavior in skin.

Cyclic Adenosine Monophosphate/PKA–Dependent Pathway

cAMP, one of the first identified intracellular second messengers, plays a key role in diverse biologic functions such as cellular metabolism, growth, and differentiation.[248,249] It also mediates α-MSH effect (reviewed in ref. 250) and was one of the first recognized regulators of mammalian pigmentation.[251] The intracellular level of cAMP is upregulated by a membrane-associated enzyme called *adenylate cyclase* that is activated on receptor/ligand interaction in receptors that are coupled to guanosine triphosphate–binding proteins like MC1R[252] (see Fig. 70-13; Fig. 70-18). cAMP is also elevated by reagents such as choleragen or isobutylmethyl xanthine. Providing melanocytes with dibutyryl cAMP, a cAMP analog, increases the intracellular level of cAMP and induces signaling that leads to melanogenesis.[253]

cAMP-dependent protein kinase (PKA) mediates most of the biologic actions of cAMP.[252] PKA is a serine/threonine kinase consisting of two regulatory subunits and two catalytic subunits.[252] It exists in the cytosol in an inactive form, and binding of cAMP to its regulatory subunits releases the catalytic subunits, activating the enzyme.[252] PKA phosphorylates the CREB that binds its DNA consensus sequence CRE in the Mitf promoter to induce Mitf transcription (see Fig. 70-13). cAMP elevation also affects other target genes, increasing or decreasing their transcription[254] (see Fig. 70-18). In vitro, PKA effect can be antagonized by the protein kinase inhibitor that acts as a pseudo substrate for the catalytic subunit of PKA and thus prevents it from phosphorylating its endogenous substrates.[255]

Protein Kinase C–Dependent Pathway

PKC is a serine/threonine kinase involved in diverse cellular functions, including growth, transformation, and differention.[256] PKC resides as an inactive enzyme in the cytoplasm, and it is activated by diacylglycerol (DAG), a component cleaved from the plasma membrane when cell surface receptors interact with their ligands. DAG can also be released from the membrane by UV irradiation (see Fig. 70-18). DAG induces PKC translocation to membranes where the latter is activated[256] to induce phosphorylation of serine/theonine residues on target proteins like tyrosinase. Phorbol esters mimic DAG action and initially activate PKC.[256] However, within 24 hours the entire cellular reserves of PKC are depleted, and when melanocytes are treated with phorbol esters they can no longer signal through PKC.

The critical role of PKC in melanogenesis was first suggested by the observation that addition of DAG, the endogenous activator of PKC, to cultured human melanocytes rapidly increased total melanin content,[257] and this increase was blocked by a PKC inhibitor.[257] Moreover, topical application of DAG to guinea pig skin increased epidermal melanin content.[258]

The expression of the 12 PKC isoforms varies among different tissues.[86] Each isoform is thought to carry out a distinct biologic function. Human melanocytes express PKC-α, -β, -ε, -δ, and -ζ,[259,260] and the PKC-β isoform is specifically involved in regulating tyrosinase activity (see Protein Kinase C-β). ET1 and histamine also utilize the PKC-dependent pathway (in addition to the cAMP-dependent pathway) to exert their regulatory effects on melanocyte function.[261,262]

Receptor Tyrosine Kinases

Melanocytes express several distinct tyrosine kinase receptors that bind BMP, bFGF, HGF, and c-Kit ligand. Receptor/ligand interaction activates an intracellular tyrosine kinase domain on the receptor, phosphorylating the receptor and subsequently activating a series of kinases called *MAP kinases*, or other intracellular signaling molecules (see Fig. 70-18). Through a chain reaction involving phosphorylation of proteins like Mitf, the signals are transferred to the nucleus to activate or suppress the transcription of genes that participate in melanocyte proliferation, melanogenesis, and/or survival.

Cyclic Guanosine Monophosphate Pathway

NO and histamine activate the enzyme guanylate cyclase that increases the intracellular level of cyclic guanosine mono-



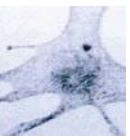

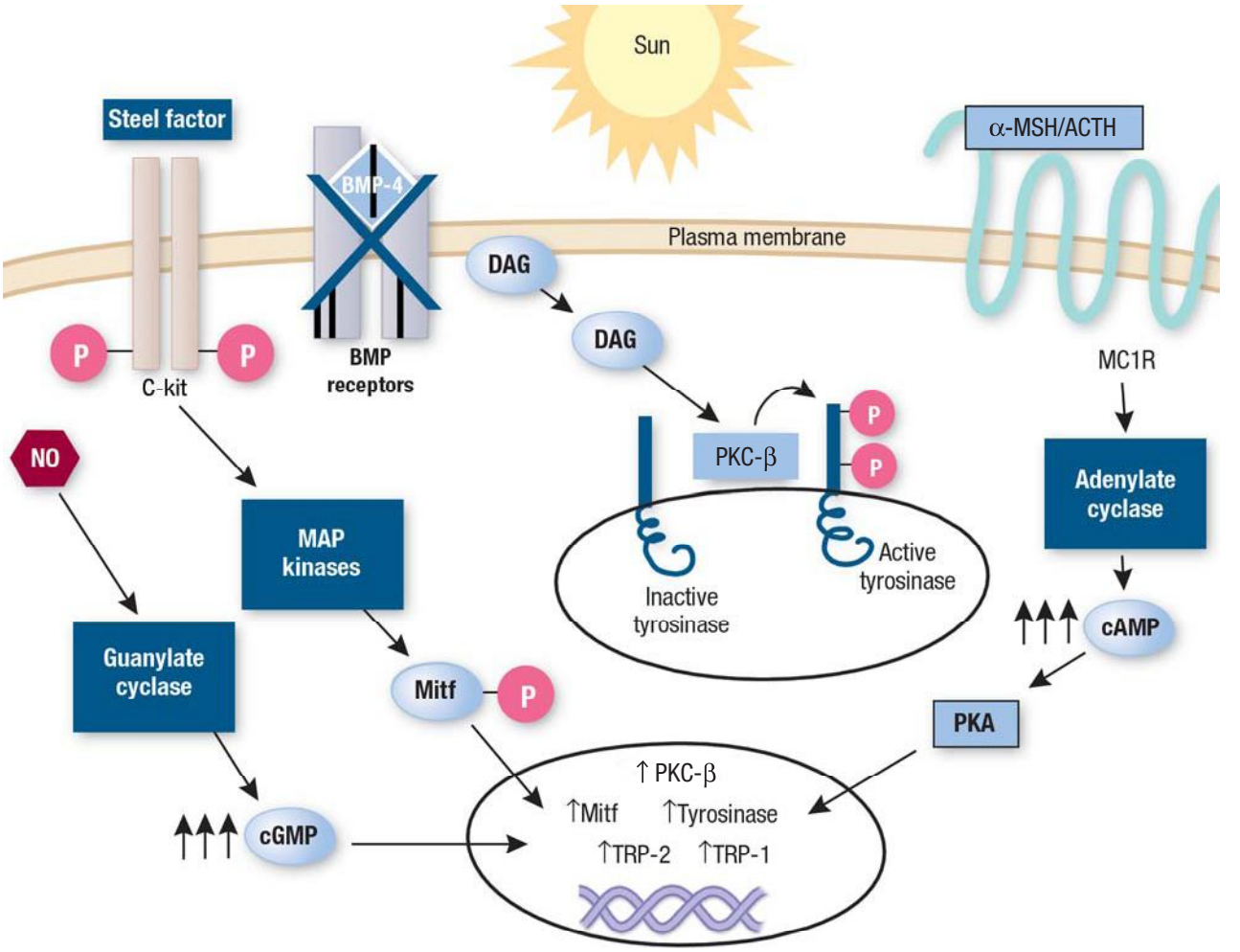

▲ **FIGURE 70-18** Signaling pathways regulating melanogenesis. Melanogenesis is stimulated through cyclic adenosine monophosphate (cAMP) or protein kinase C (PKC)–dependent pathways. α-Melanocyte-stimulating hormone (MSH)/adrenocorticotropic hormone (ACTH) binding to melanocortin receptor-1 (MC1R) activates the enzyme adenylate cyclase, increasing cAMP levels, activating the enzyme PKA, and inducing gene transcription. Ultraviolet (UV) irradiation upregulates the levels of α-MSH, ACTH, and their cognate receptor MC1R to stimulate cAMP production. Steel factor, by binding to c-Kit, leads to receptor autophosphorylation and activation of mitogen-activated protein (MAP) kinases. MAP kinases phosphorylate (activate) microphthalmia-associated transcription factor (Mitf), leading to transcription of the melanogenic enzymes tyrosinase, tyrosinase-related protein-1 (TRP-1), and TRP-2. UV irradiation (as well as cell surface receptors not shown in this figure) releases diacylglycerol (DAG) from the cell membrane. DAG activates PKC-β, which then phosphorylates serine residues on tyrosinase, activating the enzyme. Nitric oxide (NO) activates the enzyme guanylate cyclase that increases the intracellular level of cyclic guanosine monophosphate (cGMP). UV irradiation, by decreasing the level of bone morphogenetic protein (BMP) receptors, prevents BMP-4–mediated inhibition on melanogenesis. P = phosphate group.

phosphate in melanocytes[235–237,239,263] to induce melanogenesis. Inhibition of NO and cyclic guanosine monophosphate signaling impedes UV-induced tanning.[239]

ULTRAVIOLET IRRADIATION AND MELANOCYTES

Tanning Response

Melanocyte survival, proliferation, and differentiated function are influenced by environmental factors, the most important of which is UV irradiation. UV irradiation induces tanning, so-called *facultative skin color*, an increase above baseline or constitutive skin pigmentation that provides protection against future UV irradiation (reviewed in ref. 264). Tanning is divided into immediate tanning and delayed tanning.

IMMEDIATE TANNING Immediate tanning, or immediate pigment darkening, occurs within 5 to 10 minutes of exposure and fades within minutes to days depending on the UV dose and the complexion of the individual (Fig. 70-19B). As summarized in Table 70-1, immediate tanning does not provide photoprotection and does not increase epidermal melanin level.[265] It is primarily produced by UVA irradiation, although visible light can also induce immediate tanning.[266] Immediate tanning is only visible in darker individuals and is of greyish-brown color, and it is thought to represent melanosomal relocation from the perikaryon to melanocyte dendrites.[267]

DELAYED TANNING Delayed tanning, summarized in Table 70-1 and shown in Fig. 70-19A, occurs within 3 to 4 days after UV exposure.[264,265] UV is arbitrarily divided into UVC (100 to 280 nm), UVB (280 to 320 nm), and UVA (320 to 400 nm). The UVC portion of the spectrum is generally not present in terrestrial sunlight because it is absorbed by the atmospheric ozone layer. Delayed tan-

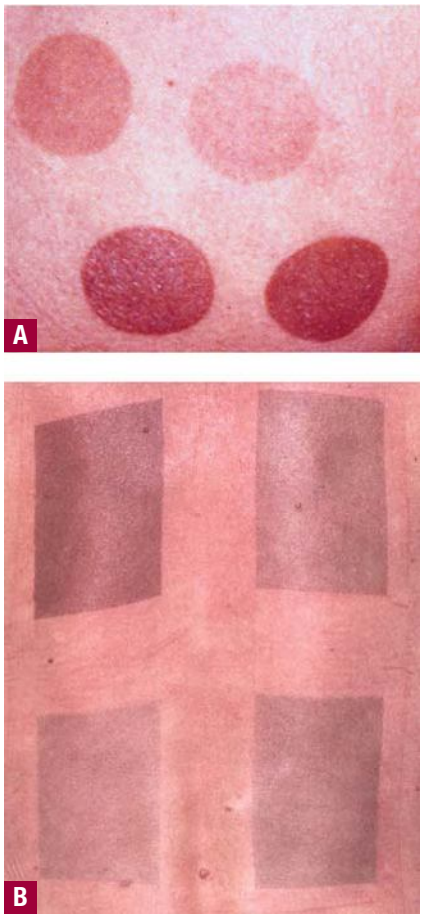

▲ **FIGURE 70-19 A.** Delayed tanning. Four template test sites in a phototype III individual were exposed to repeated erythemogenic doses of ultraviolet B (UVB) (+UVA) delivered in 24-hour intervals, and the photograph was taken 10 days after the last exposure. The tan in the more heavily pigmented test sites persisted for 2 months. **B.** Immediate tanning in a phototype III individual. Four template test sites were exposed to various doses of UVA, and the photograph was taken 2 hours after the end of exposure. After 48 hours, the tan had almost completely faded.

TABLE 70-1
Immediate Tanning vs. Delayed Tanning

	IMMEDIATE	DELAYED
Onset	Minutes[278,282]	3–4 days[278,282]
Peak intensity	Minutes to a few hours[278,282]	10–28 days[278,282]
Fading	Within 24 h[278,282]	Weeks[265,278,282]
Mechanism	Redistribution of melanosomes[278,283]	↑Keratinocyte-derived melanogenic cytokines ↑Tyrosinase level and activity ↑Melanin synthesis ↑Melanocyte dendricity ↑Melanosome number ↑Melanosome transfer ↑Melanocyte proliferation[265,278,282–284]
Photoprotection	Unchanged[278]	Increased[278,282]
Change in skin color	Undetectable in fair skin[278,283] Subtle in darker skin	Obvious in most light-skinned and all dark-skinned individuals[283]

ning is affected by both UVB and UVA. The action spectrum that produces delayed tanning is the same as for UV-induced erythema (sunburn), with UVB wavelengths far more effective than UVA.[264] Especially in darker-skinned individuals, sub-erythemogenic UV doses may be effective as well. Delayed tanning peaks between 10 days and 3 to 4 weeks, depending on the absorbed UV dose and the individual's skin type, then fades gradually over a few weeks. Histologically, there are increased epidermal melanocytes, melanocyte dendricity, and melanosome transfer to keratinocytes, with greater melanization of individual melanosomes.[265,267] Overall, total epidermal melanin is increased, providing additional photoprotection from UV irradiation.

Direct and Indirect Effects of Ultraviolet Irradiation

UV irradiation affects melanization and melanocyte proliferation and survival, both directly and indirectly, through its effect on keratinocytes, inducing the synthesis and secretion of paracrine keratinocyte factors.

DIRECT EFFECTS UV irradiation triggers several biologic reactions through its interaction with cellular chromophores that absorb photons. Photochemical reactions affect proliferation, survival, and the differentiated function of melanocytes. Most UVA effects are assumed to be the result of oxidative damage mediated through UVA absorption by cellular chromophores like melanin precursors that act as photosensitizers, leading to the generation of ROS and free radicals.[268] UVB irradiation is directly absorbed by cellular DNA, leading to the formation of DNA lesions, mainly cyclobutane dimers and pyrimidine (6-4) pyrimidone photoproducts.[269] DNA damage repair systems are activated, at least in part through the tumor suppressor p53 protein. It has been shown that plasma membrane lipids are also affected by UV irradiation to release DAG,[270] which then activates PKC-β to stimulate melanogenesis by activating tyrosinase (see Protein Kinase C-β).

INDIRECT EFFECTS Key keratinocyte paracrine factors induced by UV irradiation and their effects on melanocytes are summarized in Table 70-2. These factors can act alone and/or synergistically to modulate melanocyte function. Interestingly, UV irradiation also induces the

TABLE 70-2
Ultraviolet Irradiation-Induced Keratinocyte-Derived Paracrine Cytokines

KERATINOCYTE-DERIVED FACTOR	PROLIFERATION	DENDRICITY	MELANOGENESIS	MELANOSOMAL TRANSFER	SURVIVAL
Basic fibroblast growth factor	↑↑				
Endothelin-1	↑	↑	↑		
Interleukin-1 α/1 β	↓	↑	↓		
Adrenocorticotropic hormone	↑		↑		↑
α-Melanocyte-stimulating hormone	↑	↑	↑		↑
Prostaglandin E_2/prostaglandin $F_{2\alpha}$		↑	↑	↑	
Granulocyte-macrophage colony-stimulating factor	↑		↑		
Nitric oxide			↑		
Tumor necrosis factor-α			↓		
Nerve growth factor		↑			↑

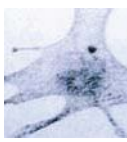

level of tumor necrosis factor-α and IL-1, cytokines that inhibit melanogenesis, suggesting a fine-tuned epidermal equilibrium between melanogenic stimulators and inhibitors after UV irradiation, with the final outcome of increased melanogenesis and melanocyte proliferation.

Role of DNA Damage in Melanogenesis

Interestingly, the action spectrum for tanning is virtually the same as that for the formation of thymine dimers,[271,272] and UV-induced melanogenesis can be augmented in pigment cells by treatment with T4 endonuclease V,[273] an enzyme that acts exclusively to enhance the repair of UV-induced DNA damage. Moreover, treatment of melanocytes with agents that act exclusively by damaging DNA, unlike UV that has multiple cellular targets, also stimulates melanogenesis.[274]

A central role for DNA damage and/or its repair in stimulating melanogenesis is further suggested by the fact that p53, a tumor suppressor protein and transcription factor termed the *Guardian of the Genome*, when activated, upregulates the level of tyrosinase messenger RNA and protein, enhancing melanogenesis.[275–278] Thus, tanning may be viewed as part of a p53-mediated DNA damage adaptive response that protects the skin during subsequent exposure to UV irradiation.

MELANOCYTE AGING AND PHOTOAGING

Epidermal melanocyte aging is affected by both genetic and environmental factors. With aging, there is a decrease in the density of epidermal melanocytes (number per unit area of skin surface), approximately 10 percent per decade.[279] However, the number of DOPA-positive melanocytes is greater in chronically sun-exposed skin than in sun-protected skin,[279] possibly due to melanocyte proliferation after sun exposure and/or UV-induced keratinocyte-derived paracrine factors. Melanocyte loss is especially notable in hair follicles with age, with total loss of melanocytes in approximately one-half of all scalp follicles by middle age.[37] Hair graying (depigmentation) occurs over the entire body but is usually first noted on the scalp, perhaps because of the long anagen (growth) cycle and resulting requirement for melanocyte proliferation and sustained high level of melanogenesis.

In vitro melanocytes derived from older individuals show decreased proliferative capacity compared to those derived from younger individuals. Also, with aging in vitro, there is a general increase in the levels of total melanin as well as in the level of differentiation-associated proteins such as Mitf, TRP-1, and TRP-2[280,281] and decrease in the level of proliferation-associated proteins such as cyclin D1 and cyclin E.[280,281]

KEY REFERENCES

The full reference list for all chapters is available at www.digm7.com.

3. Westerhof W: The discovery of the human melanocyte. *Pigment Cell Res* **19**:183, 2006
23. Mizoguchi M: Melanocyte development: With a message of encouragement to young women scientists. *Pigment Cell Res* **17**:533, 2004
39. Ito S: Biochemistry and physiology of melanin, in *Pigmentation and Pigmentary Disorders*, edited by Levine N. Boca Raton, FL, CRC Press, 1993, p 34
40. Slominski A et al: Melanin pigmentation in mammalian skin and its hormonal regulation. *Physiol Rev* **84**:1155, 2004
65. Park HY, Gilchrest BA: Signaling pathways mediating melanogenesis. *Cell Mol Biol* **45**:919, 1999
169. Scott G: Rac and rho: The story behind melanocyte dendrite formation. *Pigment Cell Res* **15**:322, 2002
180. Matesic LA, Copeland NG, Jenkins NA: A genetic approach to the study of vesicle transport in the mouse, in *Mechanisms of Suntanning*, edited by Ortonne JP, Ballotti R. Nice, Martin Dunitz, 2002, p 199
185. Van Den Bossche K, Naeyaert JM, Lambert J: The quest for the mechanism of melanin transfer. *Traffic* **7**:769, 2006
251. Lerner AB: My 60 years in pigmentation. *Pigment Cell Res* **12**:131, 1999
264. Gilchrest BA et al: The photobiology of the tanning response, in *The Pigmentary System: Physiology and Pathophysiology*, edited by Nordlund JJ et al. New York, Oxford Press, 1998, p 359

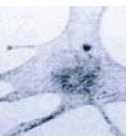

CHAPTER 71

Albinism and Other Genetic Disorders of Pigmentation

Thomas J. Hornyak

EPIDEMIOLOGY

Epidemiology of Albinism

Oculocutaneous albinism (OCA) is the most common inherited disorder of generalized hypopigmentation, with an estimated frequency of 1 in 20,000 in most populations. Four different types of OCA have been described. OCA types 1 and 2 (OCA1, OCA2) are most frequent and account for approximately 40 percent and 50 percent, respectively, of OCA cases worldwide. OCA2 occurs in approximately 1 in 30,000 to 1 in 36,000 Caucasians and 1 in 10,000 to 1 in 17,000 blacks in the United States,[1–3] but is reported at higher frequencies ranging from 1 in 1400 to 1 in 7000 in sub-Saharan Africa.[4,5] OCA3 and OCA4 are far less frequent, although the rufous OCA phenotype, described later, associated with OCA3 in southern African blacks has been reported at an incidence of approximately 1 in 8500.[6]

Hermansky-Pudlak syndrome (HPS) is rare except in the Caribbean island of Puerto Rico, particularly in the northwestern region where the majority of patients are found, and has an incidence there of 1 in 1800.[7] Chédiak-Higashi syndrome (CHS) is also quite rare.

Epidemiology of Congenital Disorders of Pigmentation

Waardenburg syndrome (WS) is probably less frequent than OCA. The highest reported incidence is 1 in 20,000 in Kenya, and most estimates of its incidence in the Netherlands, where it was originally reported, are in the range of 1 in 40,000. Incidences of WS with deafness are lower, ranging between 1 in 50,000 and 1 in 212,000. WS has been described occurring at varying frequencies in the congenitally deaf, ranging from 0.9 percent to 2.8 percent in some studies to 2 percent to 5 percent in others. The incidence of pie-

ALBINISM AND CONGENITAL DISORDERS OF PIGMENTATION

AT A GLANCE



- World-wide occurrence.
- Typically inherited with marked differences in penetrance. Albinism is usually a recessive trait, and congenital disorders of pigmentation usually show a dominant pattern of inheritance.
- Clinical features of albinism include lightly pigmented or non-pigmented skin and silvery white or lightened hair color.
- Clinical features of congenital disorders of pigmentation include patches of white hair (poliosis), variations in iris color, and depigmented patches of white skin.
- Ocular nystagmus and reduced visual acuity distinguish albinism from congenital disorders of pigmentation.
- In albinism melanocytes have reduced or absent DOPA positivity. In certain congenital disorders of pigmentation, affected areas of skin can lack melanocytes completely.

baldism is estimated to be lower than 1 in 20,000.[8,9]

ETIOLOGY, PATHOGENESIS, AND CLINICAL FEATURES

Awareness of the biologic basis of the distinction between congenital disorders of pigmentation, which are disorders of melanocyte development, and the varieties of albinism, which are disorders of melanocyte differentiation, can be important for fully understanding their clinical manifestations. Albinism results from the dysfunction of a normal complement of pigment cells, which results in complete or partial loss of cutaneous pigmentation. The forms of albinism, including the sub-types of OCA as well as albinism syndromes with systemic manifestations, result either from enzymatic defects in the biosynthesis of melanin, from melanosomal defects that interfere with melanin formation, or from problems in the intracellular transport and localization of proteins essential for melanin biosynthesis (see Chap. 70). Congenital disorders of pigmentation usually result from mutations in genes critical for melanocyte development during embryogenesis. These disorders can also be associated with other systemic problems because of the requirement for these gene products in the development of cell types other than melanocytes. More accurate descriptors of these disorders could be *congenital (or genetic) disorders of melanocyte differentiation* and *congenital (or genetic) disorders of melanocyte development*, to reflect the fact that both categories of conditions, albinism and developmental pigmentary syndromes, are generally inherited but result from different mechanisms of disease (Fig. 71-1).

Etiology, Pathogenesis, and Clinical Features of Albinism

Although the pigmentary abnormalities associated with various types of albinism can vary widely, common to all types of albinism is reduced visual acuity and ocular nystagmus, a result of misrouting of the optic nerve at the optic chiasm and foveal hypoplasia. This has been described not only in humans[10] but also in other albino mammals.[11] Experiments using the tyrosinase promoter to express both tyrosinase and tyrosine hydroxylase in albino transgenic mice suggest that the tyrosine hydroxylase activity of tyrosinase is particularly important for ensuring the proper routing of retinal projections at the optic chiasm during development.[12,13] The ocular manifestations of albinism can vary greatly, ranging from severe (legal blindness) to nearly undetectable. They also include a reduction in iris pigment, a reduction in retinal pigment, and alternating strabismus.

OCULOCUTANEOUS ALBINISM TYPE 1 OCA type 1 [OCA1; Online Mendelian Inheritance in Man (OMIM) #203100] is produced by loss of function of the melanocytic enzyme tyrosinase resulting from mutations of the *TYR* gene.[14–16] Null mutations are associated with a total loss of function and no pigment formation (OCA1A), whereas "leaky" mutations result in an enzyme that retains some function and is associated with some pigment formation (OCA1B).

Analyses of DNA from individuals with OCA1A have shown a large number of different mutations in the *TYR* gene. These mutations include missense, nonsense, frameshift, splice site, and deletion mutations. Most individuals with OCA1 are compound heterozygotes with different mutant maternal and paternal alleles.[6] Missense mutations in the *TYR* gene are distributed among distinct regions of the coding sequence, which suggests that the encoded protein has multiple functional domains. Two of the clusters are in the copper-binding regions, with a third near the amino terminus of the mature protein, in the extra-melanosomal domain of tyrosine shown to require phosphorylation for enzyme activation.[17,18] Clustering of mutations in discrete regions of the coding sequence is consistent with these regions' being important either for the melanogenic activity of tyrosinase or for functions related to its maturation or processing.[6,18] Missense mutations at the signal peptide cleavage site[19,20] implicate this cleavage event as an important step in the development of tyrosinase activity. Frameshift mutations near the C-terminus of the coding region[21,22] indicate that the cytoplasmic domain of tyrosinase is also important for full activity, possibly because of the presence of protein kinase C-β–dependent phosphorylation sites that have been identified at the extreme C-terminus of the protein.[18]

All nonsense and frameshift mutations are associated with a complete loss of tyrosinase activity, presumably because of the subsequent production of a truncated protein. With missense mutations the picture is more complicated. A set of missense mutations that were associated with the accumulation of pigment with age in either OCA1B or temperature-sensitive OCA (OCA1TS) patients[23] were shown to have residual enzymatic activity. Hence, it is likely that a subset of *TYR* missense mutations are responsible for the OCA1B and OCA1TS phenotypes because of the reduced, rather than absent, tyrosinase activity in their melanocytes.[6] However, other missense mutations leading to the OCA1A and OCA1TS phenotypes result in defective intracellular processing of tyrosinase and retention of the mutant tyrosinase proteins in the endoplasmic reticulum, which suggests that some molecular variants of OCA1 represent an endoplasmic reticulum retention disease.[24–26] Thus, the residual enzymatic activity of a missense tyrosinase mutant cannot fully predict its phenotype, because other, presum-





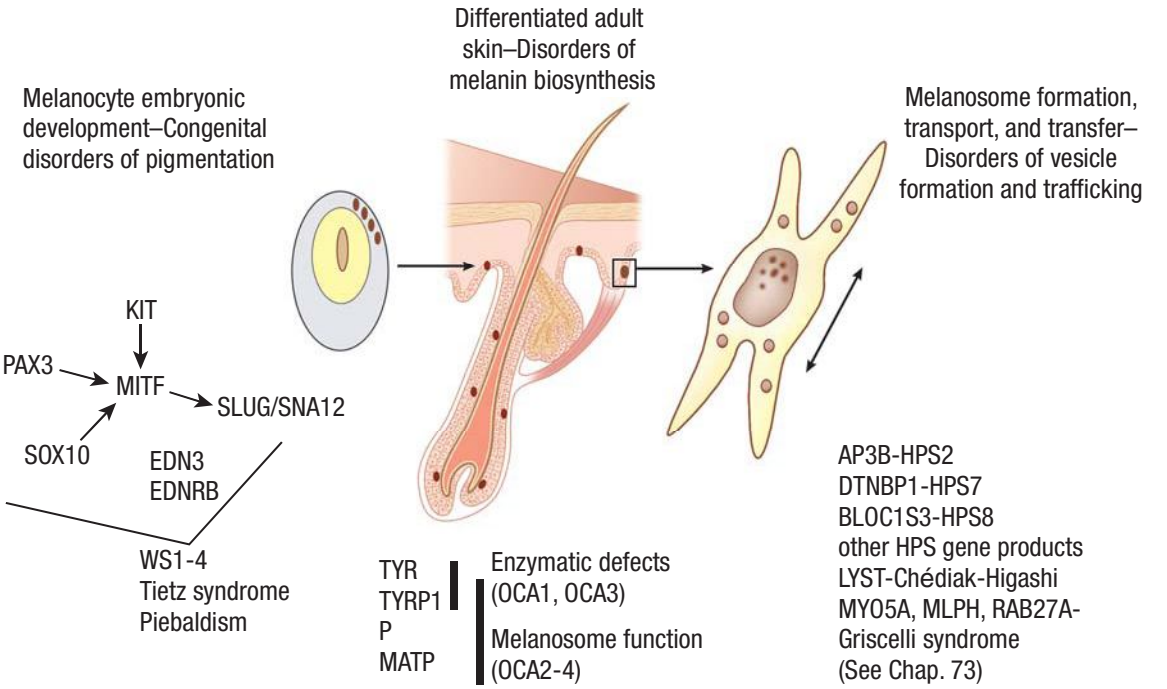

▲ **FIGURE 71-1** Schematic diagram illustrating the steps of the melanocyte life cycle, from development through differentiation, in which key genes, altered in the indicated genetic diseases, act to control the function of the melanocyte. HPS = Hermansky-Pudlak syndrome; OCA = oculocutaneous albinism; WS = Waardenburg syndrome.

ably conformational, determinants of nascent mutant proteins may lead to their retention in the endoplasmic reticulum, block transport to the melanosome, and cause a more severe pigmentary phenotype.

In OCA1A, or the classic tyrosinase-negative OCA, there is a complete inability to synthesize melanin in skin, hair, and eyes, which results in the characteristic "albino" phenotype. Affected individuals are born with white hair and skin, and there are no changes as they mature. The phenotype is the same in all ethnic groups and at all ages (Fig. 71-2). The hair may develop a slight yellow tint due to denaturing of the hair protein related to sun exposure and/or shampoo use. The irides are translucent, appear pink early in life, and often turn a gray-blue color with time. No pigmented lesions develop in the skin, although amelanotic nevi can be present. The architecture of skin and hair bulb melanocytes is normal. The melanosomes show a normal melanosomal membrane, and normal internal matrix formation is observed in stage 1 and 2 melanosomes.

The phenotype of OCA1B can range from minimal hair pigment to near-normal skin and hair pigment. Most individuals with OCA1B have very little or no pigment at birth and develop varying amounts of melanin in the hair and skin in the first or second decade of life (Fig. 71-3). In some cases the melanin develops within the first year. The hair color changes to light yellow, light blond, or golden blond first, as a result of residual pheomelanin synthesis, and eventually can turn dark blond or brown in adolescents and adults. The irides can develop light tan or brown pigment, sometimes limited to the inner third of the iris, and iris pigment can be present on globe transillumination. However, some degree of iris translucency, as demonstrated by slit-lamp examination, is usually present. Many individuals with OCA1B will tan with sun exposure, although it is more common to burn without tanning. Pigmented lesions (nevi, freckles, lentigines) develop in the skin of individuals who have developed pigmented hair and skin. In some patients, the moderate amount of residual tyrosinase activity can lead to near-normal cutaneous pigmentation, so that the clinician may overlook subtle cutaneous pigmentary abnormalities and render instead the mistaken diagnosis of ocular albinism.

One variation of OCA1B is the temperature-sensitive phenotype. In this variation, scalp and axillary hair remain white or slightly yellow, but arm and leg hair pigments. The skin remains white and does not tan. The retention of mela-



▲ **FIGURE 71-2** Patient with oculocutaneous albinism type 1A with no hair or skin pigment, demonstrating iris translucency.



▲ **FIGURE 71-3** Patient with oculocutaneous albinism type 1B with golden blond scalp hair and tan skin.

nin synthesis in the cooler areas of the body, such as the arms and legs, but not the warmer areas, such as the trunk and the scalp, is associated with a temperature-sensitive mutation in tyrosinase, which loses activity above 35°C (95°F).[23] Similar tyrosinase mutations have been described in the Himalayan mouse[27] and in the Siamese (pointed) cat.[28]

OCULOCUTANEOUS ALBINISM TYPE 2 Mutations of the *P* gene, which maps to chromosome arm 15q, are responsible for OCA2 (OMIM #203200).[29] OCA2 occurs worldwide, although somewhat more frequently in the African, African American, and certain Native American populations. Historically, affected individuals have benefitted from limiting their sun exposure, especially in desert and equatorial climates. Interesting anthropologic studies have described how various societies have differed in their treatment of members with OCA2.[30] From the standpoint of melanin synthesis, the defect in OCA2 appears to involve primarily a reduction in eumelanin synthesis, with less effect on pheomelanin synthesis. The predicted structure of the *P* gene, a melanosomal protein, contains 12 transmembrane domains.[31,32] As expected, a number of mutations of the human *P* gene are associated with human OCA2.[33,34]

In sub-Saharan Africa, a single 2.7-kb deletion allele accounts for 60 percent to 90 percent of mutant *P* alleles and is associated with a common haplotype, which suggests a common founder.[5,34–36] It has been estimated that this single mutation is associated with 25 percent to 50 percent of all mutant *P* alleles in African Americans.[5,34–40] However, other diverse mutant alleles have been described in this population and in Africans. The Brandywine, Maryland, isolate is an inbred American population, originally located in a rural area east of Washington, D.C., that has been studied extensively for its prevalence of albinism, dentinogenesis imperfecta, and osteogenesis imperfecta, with mixed Caucasian, African, and possibly Native American ancestry.[41] In this isolate, 1 in 85 individuals has OCA2[41,42] and is homozygous for the 2.7-kb deletion allele of the *P* gene.[34] Thus it is likely that this 2.7-kb deletion allele accounts for the distinct OCA2 phenotype in Africans and African Americans.[43]

OCA2 also has been reported at relatively high frequencies ranging from 1 in 28 to 1 in 6500 in specific Native American groups, including those populations in the southwest United States (Hopi population), southern Mexico, eastern Panama (Cuna population), and southwest Brazil.[30] In the Navajo population, a homozygous 122.5-kb deletion has been described in members with OCA2. This mutation results in the loss of exons 10 to 20 of the *P* gene, corresponding to a region containing seven of the transmembrane domains, and appears to be specific for OCA2 within the Navajo population.[44] Unlike the mutations in *TYR*, the missense mutations described to date in the *P* gene do not seem to cluster in any specific region.

Regarding *P* gene product function, it has been shown that melanosomes from p protein–deficient melanocytes have an abnormal pH. Melanosomes in cultured melanocytes derived from wild-type mice are typically acidic, whereas melanosomes from p protein–deficient mice are nonacidic.[45] Hence, it is likely that the p protein regulates the acidic pH of melanosomes, perhaps by functioning as an anion co-transporter in conjunction with a proton pump on the melanosomal membrane. An alternate possibility is that the acidic conditions mediated by the p protein favor the normal biogenesis of melanosomes, including the correct targeting of other melanosomal proteins such as tyrosinase.[46]

In African and African American individuals, there is a distinct OCA2 phenotype (Fig. 71-4). Hair is yellow at birth and remains so throughout life, although the color may turn darker. Hair color can turn lighter in older individuals, and this probably represents normal graying with age. The skin is creamy white at birth and changes little with time. No generalized skin pigment is present, and no tan develops with sun exposure, but pigmented nevi, lentigines, and freckles often develop. The irides are blue-gray or light tan or brown. The development of lentigines or ephelides, well-demarcated pigmented patches usually on sun-exposed areas of the skin, may be evidence of a separate genetic susceptibility, because these lesions develop only in some OCA2 families and not in others. The presence of ephelides is associated with a lower risk of skin cancer in South African individuals.[47]

The brown OCA phenotype is a distinct OCA2 phenotype that has been described in the African and African American populations. In this clinically less severe phenotype,[48] the hair and skin are light brown and the irides are gray to tan at birth (see eFig. 71-4.1 in on-line edition). With time, skin color changes little, but the hair may turn darker, and the irides may accumulate more tan pigment. The skin generally does not burn but may darken with sun exposure. Affected individuals are recognized as having albinism rather than a variation in normal pigmentation because of the ocular changes present. The iris has punctate and radial translucency, and moderate retinal pigment is present. Visual acuity ranges from 20/60 to 20/150. In brown OCA, the amount of eumelanin in the skin and hair is reduced but not absent. Studies have now shown that brown OCA is associated with heterozygosity for *P* gene alleles, one of which is null and the other partially functional.[49]



▲ **FIGURE 71-4** Oculocutaneous albinism (OCA) type 2 with yellow hair, white skin, and freckles in an African individual (classic tyrosinase-positive OCA phenotype).

In Caucasian individuals with OCA2, the amount of hair pigment present at birth or developing with time varies from minimal in northern Europeans (particularly Scandinavians) to moderate in southern European or Mediterranean individuals. The hair can be very lightly pigmented at birth, having a light yellow or blond color, or more pigmented with a definite blond, golden blond, or even red color. The normal delayed maturation of the pigment system and sparse hair early in life can make it difficult to recognize albinism early in normally pigmented northern European individuals. For all types of OCA in northern European families, the cutaneous hypopigmentation at birth or early in life is often similar to that of the parents and relatives, and concern is only raised when it appears that the child is not tracking well visually or has developed nystagmus.

The skin is creamy white and does not tan. The iris is blue-gray or lightly pigmented, and the amount of translu-



cency correlates with the development of iris pigment. With time, pigmented nevi and lentigines may develop, and pigmented freckles are seen in areas with repeated sun exposure. The hair in Caucasian individuals may slowly turn darker through the first two or more decades of life.

PRADER-WILLI AND ANGELMAN SYNDROMES Prader-Willi and Angelman syndromes often are associated with hypopigmentation.[50,51] The intragenic deletion encompassing one *P* allele in these patients[52,53] suggests that the observed pigmentary phenotype is related to OCA2 and the *P* gene, even if the details of this association are not fully understood.[54]



OCULOCUTANEOUS ALBINISM TYPE 3 Four distinct sets of mutations in the *TYRP1* gene resulting in OCA3 (OMIM #203290) have now been described. The first mutation was found in an African American newborn twin who was initially classified clinically as having brown OCA. Mutation analysis revealed a single-base deletion at codon 368 producing a frameshift and premature stop codon in exon 6 and a slightly truncated TYRP1 molecule.[57] This mutation is shared by a substantial proportion of the rufous OCA population in southern Africa.[58] Rufous OCA is a distinct OCA phenotype in which the skin color is a mahogany brown with a slight reddish hue, and the hair color varies from deep mahogany to sandy red.[2,58] The second *TYRP1* mutation, also identified in the rufous OCA population, is a single-base substitution at codon 166 resulting in the alteration of a serine to a premature stop codon in exon 3 and a truncated TYRP1 molecule.[58] In a Pakistani kindred, individuals homozygous for another premature termination mutation have been described.[59] A Caucasian male was compound heterozygous for a missense mutation, inherited from the patient's mother, in *TYRP1* located in the second copper-binding domain and a stop codon, which apparently occurred spontaneously.[60]

OCA3 has presented with both the brown OCA and the rufous OCA phenotypes in the African and African American populations. In the two examples of individuals not of African descent, the phenotype has been that of a tyrosinase-positive albinism, such as OCA1B or OCA2. As additional examples of OCA3 are characterized, a genotype-phenotype correlation may become clearer.

OCULOCUTANEOUS ALBINISM TYPE 4 OCA4 (OMIM #606574) appears rarely worldwide but is more common in East Asian populations. A variety of mutations, including a splice acceptor site mutation and missense mutations, have been found in a gene called *MATP* (membrane-associated transporter protein), located on chromosome arm 5p.[63–65] OCA4 can have a variable phenotype, ranging from absence of pigmentation to some pigmentation with brown irides. Improvement during the first decade of life has been reported.[65]

The protein product of the *MATP* gene is predicted to be a membrane protein spanning the membrane 12 times and containing a conserved sucrose transporter signature sequence, which suggests an important functional role for this motif.[64] In addition, melanosome anomalies have been observed in the medaka fish and mouse homologs of OCA4.[64,66] These data indicate that MATP/Matp plays a critical role in vertebrate pigmentation and suggest that MATP/Matp may be a component of the melanosomal membrane, presumably mediating the transport of a molecule required for melanogenesis or for another melanosome function.

HERMANSKY-PUDLAK SYNDROME Mutations in eight different genes to date have been associated with HPS.[7] Currently, our understanding of the function of their gene products varies greatly. However, a common theme is their functional involvement in trafficking cell type–specific products in cells containing lysosome-related organelles, including melanosomes in melanocytes.

HPS patients have OCA, with variable hypopigmentation of the skin, hair, and irides, and ocular abnormalities (Fig. 71-5 and see eFigs. 71-5.1, 71-5.2, and 71-5.3 in on-line edition). In addition, they lack platelet dense bodies and demonstrate prolonged bleeding time, mucous membrane bleeding, a predisposition to epistaxis, easy bruising, and metromenorrhagia.[67] Whole-mount electron microscopy is used to provide a definitive determination of the absence of platelet dense bodies.[68]

The greatest clinical experience exists with patients with HPS1 (OMIM #604982), HPS3 (OMIM #606118), and HPS4 (OMIM #606118). Pulmonary fibrosis is a common and severe manifestation of HPS1 and HPS4, generally causing death between the fourth and sixth decades of life.[7,69] Pulmonary fibrosis appears not to be associated with



▲ **FIGURE 71-5** Puerto Rican patient with Hermansky-Pudlak syndrome type 1, deceased due to pulmonary fibrosis. (Photograph used with permission from Dr. William A. Gahl, National Human Genome Research Institute, National Institutes of Health.)

HPS3, however, which also features less severe pigmentary abnormalities.[70–72] Among HPS1 and HPS4 patients, a granulomatous colitis is seen, occurring in approximately 15 percent.[73,74] Ceroid lipofuscin, a complex lipid-protein material, has been reported to accumulate in the cells of HPS patients, predominantly those with HPS1.[67]

Mutations in distinct genes, rather than clinical phenotypes, define the various types of HPS. For example, 23 distinct mutations have been found to cause *HPS1*.[7] The most common, found in over 400 Puerto Rican individuals, is a 16-base-pair frameshift duplication in exon 15.[84,85] Although the precise function of HPS1 protein is not yet known, HPS1 associates with HPS4 in the 200-kd BLOC-3 (biogenesis of lysosome-related organelles complex-3) complex[86] and has also been found in association with HPS4 in a larger, 500-kd complex in melanoma cells and fibroblasts.[87–89] In melanocytes cultured from the skin of HPS1 patients, the melanogenic enzymes TYR, TYRP1, and DCT (dopachrome tautomerase)/TYRP2 are found in large vesicular structures in the cell body and dendrites, instead of in the granular pattern typically associated with melanosomal localization,[90,91] which suggests a role in the control of protein trafficking to the melanosome. Mutations in *HPS4* have been described in 15 patients,[7] although its exact cellular role is not yet known. Functionally, the adenosine triphosphate–dependent pump MRP4 (multidrug resistance protein 4), also known

as ABCC4 (adenosine triphosphate-binding cassette, subfamily C, member 4), normally localized to platelet granules and the plasma membrane, was found to be greatly reduced in HPS4 platelets.[92]

Mutations or deficiencies in the *AP3B1* gene, encoding the β_{3A} subunit of adaptor complex 3 (AP-3), one of four known adaptor complexes, cause HPS2 disease.[78] AP-3 interacts with tyrosinase, which is not targeted properly to melanosomes in *AP3B1*-deficient melanocytes. Hence, AP-3 is required for the trafficking of tyrosinase, and possibly other melanosomal proteins, from an intracellular site to melanosomes. Interestingly, the sub-cellular distribution of TYRP1 is unchanged in HPS2 melanocytes, which suggests that transport of TYRP1, in contrast to tyrosinase, is not entirely dependent on the AP-3 mechanism.[93] The respiratory infections associated with HPS2 may be due to the abnormal movement of lytic granules in cytotoxic T lymphocytes to the immunologic synapse, impairing microbial killing.[77]

The most commonly described mutation in *HPS3* is a 3904-base-pair deletion mutation that includes the entire first exon, found in a Puerto Rican population, which is distinct from the *HPS1* Puerto Rican mutation.[70] In addition, a splice site mutation has been described in Ashkenazi Jews with HPS3 who are either homozygous for this mutation or compound heterozygous for this mutation and other, non-conserved mutations.[71] The HPS3 protein associates with the HPS5 and HPS6 proteins in the 340-kd BLOC-2 complex.[94,95] Melanocytes from HPS3 patients exhibit defective localization of tyrosinase and TYRP1 in later-stage melanosomes, whereas proteins normally incorporated into early-stage melanosomes, such as silver/Pmel17/gp100 and melan-a/MART1, are unaffected.[90,96] These melanocytes exhibited lower levels of melanin than control melanocytes, which suggests that the trafficking defect in tyrosinase, and perhaps also TYRP1, is responsible for the pigmentary dilution observed in these patients.

GRISCELLI SYNDROME Griscelli syndrome is discussed in Chap. 73.

CHÉDIAK-HIGASHI SYNDROME CHS (OMIM #214500) is a rare autosomal recessive disorder characterized by severe immunologic defects, hypopigmentation, bleeding tendency, progressive neurologic dysfunction, and the presence of giant peroxidase-positive lysosomal granules in peripheral blood granulocytes (see also Chap. 144).[105,106] Mutations in the *LYST* (lysosomal regulator trafficking) gene have been associated with CHS.[107] Although the precise role of the *LYST* product is not known, structural comparisons and inferences from the cell biology of *LYST* mutant cells suggest that it may be important for membrane fusion during vesicular transport from the trans-Golgi network to late endosomes and multivesicular structures.[106,107]

Most patients with CHS have a severe form of the disease, childhood CHS,[108] with early onset of the so-called *accelerated phase*, characterized by fever, anemia, and neutropenia, including a lymphoproliferative syndrome with hemophagocytosis and benign infiltration of most tissues by activated T lymphocytes. This form of the disease is uniformly fatal unless patients undergo allogeneic bone marrow transplantation. However, this treatment does not prevent future neurologic complications.[67] Ten percent to 15 percent of patients exhibit a much milder clinical disease, adult CHS,[108] surviving to adulthood but developing progressive and often fatal neurologic dysfunction in middle age. Very rare patients exhibit the intermediate adolescent CHS phenotype,[108] which presents with severe infections in early childhood but has a milder course by adolescence and no accelerated phase. Interestingly, mutation analysis of patients with the childhood, adolescent, and adult forms of CHS showed that patients with severe childhood CHS had only functionally null mutant *LYST* alleles, whereas patients with the adolescent and adult forms of CHS tended to exhibit missense mutant alleles that likely encode *LYST* polypeptides with partial function. Furthermore, some patients with the CHS phenotype did not have *LYST* mutations detectable with established techniques.[108]

The hypopigmentation phenotype of CHS is variable and can be quite mild. The hair is light brown to blond and commonly has a silvery or metallic sheen.[106] Iris pigment is present, and nystagmus and photophobia may be present or absent. Histologic studies of the eye in CHS have shown reduced iris pigment, a marked reduction in retinal pigment granules, and infiltration of the choroid with reticuloendothelial cells.[109] Cutaneous hypopigmentation is probably a consequence of both the giant, hypopigmented melanosomes clustered around the nucleus within CHS melanocytes and their inability to be transferred efficiently to keratinocytes.[110] Pigment granules in the hair shaft are large and have an irregular shape.[111]

The giant, peroxidase-positive lysosomal granules in neutrophils are a hallmark of the disease. These granules appear to inhibit neutrophil function, which along with the neutropenia commonly observed is a likely determinant of the recurrent bacterial infections.[106] CHS natural killer cells have defective lytic granule secretion,[112] and defective cytotoxic T lymphocyte–associated antigen 4 function has been proposed as a potential mechanism for the accelerated, lymphoproliferative stage of the disease.[113] A reduced number of irregular platelet dense granules in CHS is responsible for the bleeding diathesis component.[67,106]

Etiology, Pathogenesis, and Clinical Features of Congenital Disorders of Pigmentation

WAARDENBURG SYNDROME WS, described by the Dutch physician Petrus Waardenburg in 1951,[114] is the prototypic congenital disorder of pigmentation. Although it was originally described as a syndrome combining pigmentary defects of the hair (poliosis, or white forelock) and iris, congenital deafness, and developmental craniofacial abnormalities, it was subsequently realized that additional phenotypic manifestations could be part of the same syndrome. Four types of WS, WS1 through WS4, have been described.[115–120] The discovery of molecular mutations accounting for the different types of WS has helped to explain its wide variety of manifestations as well as to illuminate the importance of specific genes for the development of different tissues and organs. Although practically all cases of WS1 and WS3 show mutated *PAX3*,[115,116,119,120] WS4 individuals either have homozygous mutations in *EDN3* (the endothelin-3 gene)[121–123] or *EDNRB* (the endothelin B receptor gene)[124] or heterozygous mutations in *SOX10*.[125] On the other hand, WS2 appears to arise more heterogeneously, because a mutation in *MITF* has been shown in only a small fraction of WS2 patients.[117,118] In addition to *MITF*, *SLUG/SNAI2*, another transcription factor gene, was found to be mutated in two unrelated individuals with WS2.[126]

Waardenburg Syndrome Type 1. Individuals with WS1 (OMIM #193500) are usually heterozygous for mutations in *PAX3*; hence, WS1 is autosomal domi-





▲ **FIGURE 71-6** Patient with Waardenburg syndrome type 1. Note poliosis (white forelock) and dystopia canthorum (lateral displacement of the medial canthi of the eyes).



nant in inheritance. Although many different mutations in *PAX3* have been associated with WS1, these mutations are thought either to be functionally null alleles or to abrogate the interactions of PAX3 with DNA.[127]

Individuals with WS1 have pigmentation abnormalities associated with craniofacial abnormalities (Fig. 71-6). Dystopia canthorum, which is lateral displacement of the medial canthi of the eyes, is the hallmark craniofacial defect found in virtually all cases of WS1. A broadening of the nasal root, the presence of hypoplastic alae nasi, and synophrys are other craniofacial abnormalities associated with WS1. Poliosis, such as the presence of a white forelock, is the most common pigmentation abnormality associated with WS1. However, a wide variety of other pigmentary abnormalities can also be associated with WS1, albeit less frequently. These include depigmented white spots on the skin and pigmentary abnormalities of the iris. Iris pigmentary abnormalities may include complete heterochromia irides (differently colored irises), partial heterochromia irides (variations of color within an iris), or hypoplastic blue irides. Premature graying may also be associated with WS1. Congenital deafness is present in 57 percent of cases.[128]

The importance of PAX3 for the expression of MITF,[129,130] with consequent effects on melanocyte survival during development, is likely to account for the pigmentary defects of WS1. A role for PAX3 in governing the development of neural crest derivatives that contribute to bony and cartilaginous structures of the face,[131] particularly those contributing to the formation of the frontal bone, explain the craniofacial anomalies observed in WS1. Sensorineural deafness, observed with incomplete penetrance in WS1, results from the variable failure of melanoblasts to migrate to or to survive in the stria vascularis in the lateral wall of the cochlea.[132,133]

Waardenburg Syndrome Type 2 . Linkage analysis of families with WS2 (OMIM #193510, 608890, 600193, 606662) identified the *MITF* locus as a candidate locus for the disease gene. At least nine different mutations have been found in the coding region of the *MITF* gene in WS2 families.[117,134] However, *MITF* mutations account for only a minor portion (15 percent) of WS2 cases. A mutation in the transcription factor gene SLUG/SNA12 has also been associated with WS2, but mutations in other, as yet undefined genes are likely to be implicated in the future.WS2 is inherited in an autosomal dominant pattern. Because most of the known MITF mutations in WS2 compromise the HLHZip region, thereby interfering with dimerization of mutant MITF with wild-type MITF,[135] the pigmentary developmental pathology in most cases of WS2 probably occurs through haploinsufficiency (reduced gene dosage, expression, or protein activity) rather than through dominant-negative effects.[134] Tietz syndrome, described later, is likely to result from dominant-negative effects of mutant MITF.

Although all types of WS have skin, hair, and iris pigmentation anomalies and the possibility of hearing loss, WS2 is notable for featuring only these auditory-pigmentary symptoms. Diagnostic criteria for WS2 have previously been defined.[128] Individuals fulfilling two of the following four criteria, in the absence of dystopia canthorum, limb deformity, or Hirschsprung disease, should be counted as affected:

1. Congenital sensorineural hearing loss
2. Pigmentary disturbance of iris
   a. Complete heterochromia irides (two eyes of different color)
   b. Partial or segmental heterochromia (segments of blue or brown pigmentation in one or both eyes)
   c. Hypoplastic blue eyes (characteristic brilliant blue in both eyes)
3. Pigmentary disturbance of the hair
   a. White forelock from birth or in teens
   b. Premature graying before age 30 years
4. A first- or second-degree relative with two or more of criteria 1 to 3

A survey of 124 cases of WS2 and 270 cases of WS1 revealed differences of phenotypic penetrance between WS2 and WS1: congenital sensorineural hearing loss occurred in 77 percent and 57 percent, respectively; heterochromia irides in 48 percent and 27 percent, respectively; hypoplastic blue eye in 9 percent and 17 percent, respectively; white forelock in 9 percent and 17 percent, respectively; early graying in 23 percent and 26 percent, respectively; and white skin patches in 6 percent and 31 percent, respectively. The higher incidence of hearing loss in WS2 may be due to the difficulty of diagnosing WS2 in individuals without hearing loss. The hearing loss is congenital, sensorineural, and nonprogressive, showing marked variation between and within families. Among a series of 81 WS2 cases studied by these investigators, 84 percent of patients reported bilateral hearing loss; 40 percent of patients noted profound loss, whether unilateral or bilateral.[128]

Waardenburg Syndrome Type 3. WS3 (OMIM #148820), also known as *Klein-Waardenburg syndrome*, is regarded as a variant of WS1. Most affected persons are heterozygous for a mutation in *PAX3*, although a few severely affected homozygotes have been described.[119] No specific mutations in *PAX3*, with the possible exception of a missense mutation at Asp47, have been correlated with the WS3 phenotype rather than the WS1 phenotype. In addition to the features of WS1, WS3 patients have musculoskeletal abnormalities, manifested as limb contractures and hypoplasia of the limb musculature. The WS3 phenotype is consistent with the previously described role of PAX3 in the activation of transcription factors that govern muscle and limb development,[136] distinct from its role in regulating the development of neural crest derivatives.

Waardenburg Syndrome Type 4. WS4 (OMIM #277580), also known as *Shah-Waardenburg syndrome*, is caused by heterozygous mutations in the transcription factor gene *SOX10* or by homozygous mutations in the gene encoding the peptide ligand endothelin-3, *EDN3*, or its receptor, *EDNRB*.[137] In addition to governing aspects of melanocyte development, these genes are important determinants of the development of the distal aspect of enteric nervous system cells, also neural crest derived, that innervate the distal part of the colon, which explains the associated Hirschsprung disease (megacolon). WS4 is the combination of the WS1 phenotype with Hirschsprung disease, or congenital aganglionosis of the colon.

TIETZ SYNDROME Tietz syndrome[138] (OMIM #103500) is a hypopigmentation-deafness syndrome resulting, like WS2, from mutations in *MITF*. Tietz syndrome has only been described in two families to date. In each case, the mutation is found in the basic region of the *MITF* gene, the region encoding the DNA-binding domain. An in-frame deletion mutation (DelR217) was described in one family[139] that affects the DNA-binding basic domain of MITF and leaves the dimerization HLHZip domain intact and functional. In these heterozygous individuals with Tietz syndrome, it is likely that DelR217-MITF binds with wild-type MITF and interferes with the ability of the dimer to bind to DNA, a dominant-negative effect. Indeed, the identical mutation in mice,[140] causing a semi-dominant phenotype in vivo with a mild heterozygous spotting phenotype but a prominent homozygous phenotype with early embryonic loss of all melanocyte precursors,[141] was shown to have a dominant-negative effect in vitro.[135] In addition, another mutation described in the family originally reported with the syndrome is predicted to exhibit an Asn210Lys substitution in the basic region.[142] The localization of this mutation to the DNA-binding region also suggests that it has dominant-negative effects.

Although Tietz syndrome is sometimes regarded as a variant of WS2A (MITF-associated WS2),[143] individuals with the disorder exhibit generalized cutaneous hypopigmentation similar to that found in OCA2, rather than distinct depigmented patches. Affected individuals invariably exhibit profound hearing loss.

PIEBALDISM Piebaldism (OMIM #17280) is caused by mutations in the *KIT* proto-oncogene.[144] Stimulation of the KIT receptor tyrosine kinase by its ligand, stem cell factor/KIT ligand, results in the phosphorylation of MITF and potentiation of MITF activity.[145] This relationship between the KIT receptor and MITF, as a final common effector of melanocyte survival during development, is likely to explain the developmental patchy loss of melanocytes occurring in human piebaldism when KIT receptor function is compromised.

Patients with piebaldism generally have depigmented patches on the ventral or lateral trunk and/or the mid-extremities, with the hands and feet spared. Poliosis is a common feature. The depigmented patches tend to be larger than those observed in WS. Typically piebaldism is not associated with deafness, although piebaldism with deafness, otherwise referred to as Woolf syndrome, has been molecularly confirmed.[146]

Box 71-1

Differential Diagnosis of Albinism

- Oculocutaneous albinism types 1–4
- Hermansky-Pudlak syndrome
- Griscelli syndrome
- Chédiak-Higashi syndrome
- Ocular albinism
- Currently unclassified types of albinism
- Tietz syndrome
- Vitiligo (extensive)
- Ziprkowski-Margolis syndrome (X-linked albinism-deafness syndrome)
- Cross (Cross-McCusick-Breen) syndrome (oculocerebral syndrome with hypopigmentation)

Box 71-2

Differential Diagnosis of Congenital Disorders of Pigmentation

- Waardenburg syndrome types 1–4
- Tietz syndrome
- Piebaldism
- Woolf syndrome
- Generalized vitiligo
- Segmental vitiligo
- Vogt-Koyanagi-Harada syndrome
- Chemical leukoderma
- Tuberous sclerosis (hypopigmented macules and patches)
- Ziprkowski-Margolis syndrome (X-linked albinism-deafness syndrome)

DYSCHROMATOSIS SYMMETRICA HEREDITARIA Dyschromatosis symmetrica hereditaria (OMIM #127400), an autosomal dominant condition, has been shown to be caused by mutations in *DSRAD*, encoding double-stranded RNA–specific adenosine deaminase (DSRAD), an RNA-editing enzyme.[147] It is not known how reduced activity of this enzyme results in pigmentary loss at acral sites. Patients exhibit speckled hypopigmentation that is limited to the dorsa of the hands and feet.

DIFFERENTIAL DIAGNOSIS OF ALBINISM AND CONGENITAL DISORDERS OF PIGMENTATION

The differential diagnosis of albinism and congenital disorders of pigmentation is summarized in Boxes 71-1 and 71-2.

COMPLICATIONS OF ALBINISM AND CONGENITAL DISORDERS OF PIGMENTATION

Complications of Albinism

The complications of albinism revolve around the impact of reduced visual acuity and hypopigmentation. The primary medical complications are the early appearance of skin tumors in individuals with inadequate sun protection in equatorial climates. Cutaneous squamous cell carcinoma and melanoma in this setting may lead to early death.

Complications of Congenital Disorders of Pigmentation

The complications of congenital disorders of pigmentation more often relate to their associated manifestations, such as deafness or aganglionic megacolon, than to pigmentary loss.

PROGNOSIS AND CLINICAL COURSE OF ALBINISM AND CONGENITAL DISORDERS OF PIGMENTATION

Prognosis and Clinical Course of Albinism

With the exception of individuals with OCA1A, patients with OCA can gradually attain some pigmentation of the skin and hair over the course of their lives and develop melanocytic nevi.

Prognosis and Clinical Course of Congenital Disorders of Pigmentation

As long as the life-threatening aganglionic megacolon of WS4 is recognized at birth and corrected surgically, the prognosis of congenital disorders of pigmentation is favorable, with minor long-term health consequences. Spontaneous repigmentation of both the white forelock and white spots has been reported, as has contraction of the white spots.

TREATMENT

Treatment of Albinism

All individuals with albinism should be under the care of an ophthalmologist and should have annual examinations into adulthood. Most are hyperopic or myopic, and many have significant astigmatism; refractive correction aids in their visual attentiveness and performance.

Proper dermatologic care and protection from solar ultraviolet radiation are strongly advised for individuals with OCA who have little or no skin and hair pigment. Precautions include the use of sunscreens, hats, and long-sleeved garments, as well as sun avoidance.



The drug pirfenidone is currently under investigation as a treatment for the pulmonary complications of HPS. Topical control of bleeding can be achieved with thrombin and Gelfoam. In advance of dental procedures or biopsies, intravenous infusion of 1-desamino-8-D-arginine vasopressin can be used prophylactically.[67]

Treatment of Congenital Disorders of Pigmentation

No treatment has been reported for the pigmentary loss associated with congenital disorders of pigmentation. However, melanocyte grafting, either with epidermal grafts or epidermal cell suspensions as used for the treatment of stable vitiligo,[153–155] might be an option to consider. Placement of cochlear implants in the pediatric population with WS has led to positive outcomes.[156] It is important to recognize the hearing defect early so that suitable management, including promotion of social and mental development and proper schooling, can be implemented.

PREVENTION OF ALBINISM AND CONGENITAL DISORDERS OF PIGMENTATION

Genetic counseling can help affected individuals assess their chances of transmitting the disorder to their progeny.

KEY REFERENCES

The full reference list for all chapters is available at www.digm7.com.

7. Wei ML: Hermansky-Pudlak syndrome: A disease of protein trafficking and organelle function. *Pigment Cell Res* **19**:19, 2006
15. Spritz RA et al: Detection of mutations in the tyrosinase gene in a patient with type IA oculocutaneous albinism. *N Engl J Med* **322**:1724, 1990
23. King RA et al: Temperature-sensitive tyrosinase associated with peripheral pigmentation in oculocutaneous albinism. *J Clin Invest* **87**:1046, 1991
43. Brilliant MH: The mouse p (pink-eyed dilution) and human P genes, oculocutaneous albinism type 2 (OCA2), and melanosomal pH. *Pigment Cell Res* **14**:86, 2001
106. Introne W, Boissy RE, Gahl WA: Clinical, molecular, and cell biological aspects of Chédiak-Higashi syndrome. *Mol Genet Metab* **68**:283, 1999
128. Liu XZ, Newton VE, Read AP: Waardenburg syndrome type II: Phenotypic findings and diagnostic criteria. *Am J Med Genet* **55**:95, 1995
134. Tassabehji M et al: The mutational spectrum in Waardenburg syndrome. *Hum Mol Genet* **4**:2131, 1995



CHAPTER 72

Vitiligo

Rebat M. Halder
Sumayah J. Taliaferro

EPIDEMIOLOGY

Vitiligo occurs worldwide, with a prevalence of 0.1 percent to 2.0 percent. In the United States, the estimated incidence is 1 percent. Vitiligo commonly begins in childhood or young adulthood, with peak onset of 10 to 30 years, but it may occur at any age. All races are affected, and both sexes are equally afflicted. A female preponderance has been reported, but the discrepancy has been attributed to a presumed increase in reporting of cosmetic concerns by female patients. Although familial clustering of cases is commonly seen, inheritance occurs in a non-Mendelian pattern. Approximately 20 percent of patients with vitiligo have at least one first-degree relative with vitiligo, and the relative risk for first-degree relatives of vitiligo patients is increased by 7- to 10-fold.[1,2]

ETIOLOGY AND PATHOGENESIS

Vitiligo is a multifactorial polygenic disorder with a complex pathogenesis. Although several theories have been proposed to explain the loss of epidermal melanocytes in vitiligo, the precise cause remains unknown. Considerable progress has been made, however, over the last two decades. Theories include autoimmune, cytotoxic, biochemical, oxidant-antioxidant, neural, and viral mechanisms for destruction of epidermal melanocytes. Several studies also point to a significant role of genetic susceptibility to vitiligo.

Genetics of Vitiligo

Vitiligo is characterized by incomplete penetrance, multiple susceptibility loci, and genetic heterogeneity. The inheritance of vitiligo may involve genes associated with melanin biosynthesis, response to oxidative stress, and regulation of autoimmunity.

The frequent association of vitiligo with autoimmune diseases prompted investigations of possible HLA associations in vitiligo. HLA types associated with vitiligo in more than one study include A2, DR4, DR7, and Cw6.[3]

Autoimmune Hypothesis and Humoral Immune Response

The association of vitiligo with autoimmune conditions is well established. Thyroid disorders, particularly Hashimoto thyroiditis and Graves disease, are commonly associated with vitiligo, along with other endocrinopathies such as Addison disease and diabetes mellitus. Alopecia areata, pernicious anemia, systemic lupus erythematosus, inflammatory bowel disease, rheumatoid arthritis, psoriasis, and autoimmune polyglandular syndrome are other associated disorders, but the significance of some of these associations is debated.

VITILIGO AT A GLANCE



- Worldwide, roughly 1 percent of the population is affected.
- A chronic disorder with multifactorial predisposition and triggering factors such as trauma, sunburn, stress, and systemic illness.
- Characterized by depigmented macules, which may slowly enlarge with concurrent development of new lesions.
- Most common sites are periorificial, face, genitals, mucous membranes, extensor surfaces, hands, and feet.
- Associated with systemic autoimmune and/or endocrine diseases, and, rarely, malignant melanoma.
- Fully developed lesions lack melanocytes and inflammatory infiltrate. Early lesions may have some melanocytes and inflammation.

The most convincing evidence of an autoimmune pathogenesis is the demonstration of circulating autoantibodies in patients with vitiligo.

The question has been raised whether vitiligo antibodies are present as a result of pigment cell destruction, as an epiphenomenon, or if these antibodies cause destruction of pigment cells. Support for the latter possibility comes from animal studies in which pigment cell antibodies appear before the onset of pigment loss.[6,9]

Smyth Chicken Model

Aberrant processes involved in the pathogenesis of vitiligo have been studied using animal models. The mutant Smyth line chicken is a well-studied animal model for autoimmune vitiligo. The hypomelanosis that develops in the feathers and ocular tissue of the birds is similar to vitiligo in humans.[10] Murine, equine, and porcine models of vitiligo have also been described.[10,11]

Cellular Immune Mechanisms

In addition to the involvement of humoral immune mechanisms in the pathogenesis of vitiligo, there is strong evidence indicating cellular immune processes. Destruction of melanocytes may be directly mediated by autoreactive cytologic T cells. An increased number of circulating $CD8^+$ cytotoxic lymphocytes reactive to MelanA/Mart-1 (melanoma antigen recognized by T cells), glycoprotein 100, and tyrosinase has been reported in patients with vitiligo.[7] Activated $CD8^+$ T cells have been demonstrated in perilesional vitiliginous skin.[12] Interestingly, the melanocyte-specific T-cell receptors found in melanoma and vitiligo patients are structurally very similar. Given the potential therapeutic implications for melanoma, studies looking at the similarities between melanoma and vitiligo are currently areas of active investigation. Research has already led to the application of immunization strategies, such as induction of tumor-specific T cells for prevention and eradication of cancer.

Disturbance in the Oxidant-Antioxidant System in Vitiligo

Oxidant stress may also play an important pathogenic role in vitiligo. Several studies validate a possible oxidant stress theory, which suggests that accumulation of free radicals toxic to melanocytes leads to their destruction. Increased nitric oxide levels have been demonstrated in cultured melanocytes and in the serum of patients with vitiligo, suggesting that nitric oxide could lead to autodestruction of melanocytes.[16,17]

Neural Theory

Segmental vitiligo frequently occurs in a dermatomal pattern, leading to a neural hypothesis that proposes certain chemical mediators released from nerve endings cause decreased melanin production.

Viral

Convergence Theory

Together, available data suggest that vitiligo is multifactorial and may be the end result of several different pathologic pathways. Experts concur that vitiligo may be a syndrome rather than a single disease.

CLINICAL FINDINGS

Patients with vitiligo present with one to several amelanotic macules that appear chalk- or milk-white in color. The lesions are usually well-demarcated, but the margins may be scalloped. They are accentuated on Wood's lamp examination. Lesions enlarge centrifugally at an unpredictable rate and can appear on any body site, including mucous membranes. However, initial lesions occur most frequently on the hands, forearms, feet, and face. When vitiligo occurs on the face, it often favors a perioral and periocular distribution.

Classification of Vitiligo

Vitiligo is classified as segmental, acrofacial, generalized, and universal, or by pattern of involvement as focal, mixed, and mucosal types.

- Focal vitiligo (Fig. 72-1): Usually a solitary macule or a few scattered macules in one area, most commonly in the distribution of the trigeminal nerve, although the neck and trunk are also commonly involved.







▲ **FIGURE 72-1** Focal vitiligo of (**A**) buttocks and (**B**) face.



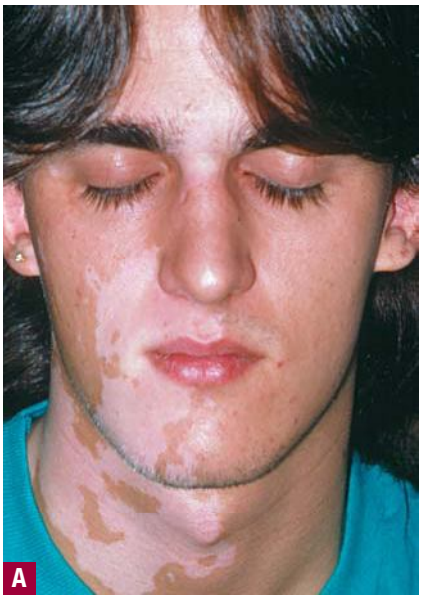



▲ **FIGURE 72-2** Segmental vitiligo (**A**) of the face and neck in a quasi-dermatomal distribution, and (**B**) causing poliosis of the eyelashes and eyebrow.



▲ **FIGURE 72-5** Vitiligo universalis.

- Segmental vitiligo (Fig. 72-2): Unilateral macules in a dermatomal or quasi-dermatomal distribution. This tends to have an early age of onset and, unlike the other types, is not associated with thyroid disease or other autoimmune diseases. This type occurs more commonly in children. Alteration of neural peptides has been implicated in the pathogenesis of this type. More than one-half of the patients with segmental vitiligo have patches of white hair, known as *poliosis*.
- Acrofacial vitiligo (Fig. 72-3): Depigmentation of the distal fingers and periorificial areas.
- Generalized vitiligo (Figs. 72-4): Also termed *vitiligo vulgaris*, the most common pattern. Depigmented patches are widely and usually symmetrically distributed.
- Universal vitiligo (Fig. 72-5): Depigmented macules and patches over most of the body, often associated with multiple endocrinopathy syndrome.
- Mucosal vitiligo: Involvement of the mucus membrane sites only.

Koebnerization commonly occurs in vitiligo. Lesions frequently develop at sites of trauma, such as mild friction from clothes, or from a cut, burn, or abrasion (Fig. 72-6).

Depending on ethnic color, vitiligo is more or less conspicuous (see eFigs. 72-6.1, 72-6.2, 72-6.3, and 72-6.4 in on-line edition).

Clinical Variants

Trichrome vitiligo is characterized by both depigmented and hypopigmented macules in addition to normally pigmented skin. The natural evolution of the hypopigmented areas is progression to full depigmentation. *Quadrichrome vitiligo* refers to the additional presence of marginal or perifollicular hyperpigmentation. This variant is recognized more frequently in darker skin types, particularly in areas of repigmentation. Cases of pentachrome vitiligo have also been reported with additionally blue-gray hyperpigmented macules, representing areas of melanin incontinence (dermal melanin). Occasionally, patients with vitiligo may present with an unusual variant called the *confetti type* or *vitiligo ponctue*. These patients have several tiny, discrete hypomelanotic macules. Inflammatory vitiligo is characterized clinically by erythema at the margins of vitiligo macules.



▲ **FIGURE 72-3** Acrofacial vitiligo.





▲ **FIGURE 72-4** Generalized vitiligo (**A**) in an adult and (**B**) in a child.



◀ **FIGURE 72-6** Koebnerization under brassiere.

DIFFERENTIAL DIAGNOSIS (Box 72-1)

RELATED PHYSICAL FINDINGS

Associated Disorders

Vitiligo is frequently associated with disorders of autoimmune origin. The most prevalent associated endocrinopathy is thyroid dysfunction, either hyperthyroidism (Graves disease) or hypothyroidism (Hashimoto thyroiditis). Vitiligo usually precedes the onset of thyroid dysfunction. Addison disease, pernicious anemia, alopecia areata, and diabetes mellitus also occur with increased frequency in patients with vitiligo. Patients with autoimmune polyendocrinopathy candidiasis-ectodermal dystrophy have an increased prevalence of vitiligo. Mutation of the AIRE (autoimmune regulator) gene (see Chap. 155) has been identified in this syndrome. Patients should be questioned about symptoms for these disorders.

Vitiligo may affect active melanocytes throughout the body, including pigment cells present in hair, the inner ear, and the retina. Poliosis (leukotrichia) occurs in many patients. Premature graying has been reported in vitiligo patients and in their close relatives. Auditory and visual disturbances are present in some patients. Aseptic meningitis may rarely result from destruction of leptomeningeal melanocytes.

Vitiligo-like depigmentation can occur in patients with malignant melanoma and is believed to result from a T-cell–mediated reaction to antigenic melanoma cells, with cross-reaction to normal melanocytes.[13] Such depigmentation has also been observed during the course of autologous T-cell–based immunotherapy of melanoma.[14] Depigmentation in this setting may portend a better prognosis. Amelanosis around primary tumors may resemble a halo nevus, but vitiligo-like depigmentation can also occur at sites remote from the melanoma.[13]

OCULAR DISEASE Although patients with vitiligo do not usually have ophthalmologic complaints, they can have several ocular findings. Pigmentary abnormalities of the iris and retina may occur. Choroidal abnormalities have been reported in up to 30 percent of patients and iritis in approximately 5 percent. Uveitis can be a frequent ocular manifestation. Exophthalmos may occur in the setting of concomitant Graves disease. Visual acuity is generally not affected.

VOGT-KOYANAGI-HARADA SYNDROME The Vogt-Koyanagi-Harada syndrome (VKH) consists of vitiligo in association with uveitis, aseptic meningitis, dysacusis, tinnitus, poliosis, and alopecia. It is a rare, systemic, T-cell–mediated autoimmune disorder. VKH syndrome is associated with other autoimmune disorders such as autoimmune polyglandular syndrome, hypothyroidism, Hashimoto thyroiditis, and diabetes mellitus. VKH syndrome classically occurs in three phases. During the first phase, the meningoencephalic phase, patients may have headache, meningismus, seizures, muscle weakness, or paralysis after a prodrome of fever, malaise, nausea and vomiting. Subsequently, the acute ophthalmic phase occurs when patients may develop photophobia, eye pain, and altered visual acuity. Patients may develop uveitis, iridocyclitis, choroiditis, and retinal detachment during this phase and can later develop complications such as cataracts and glaucoma. Vitiligo, alopecia, and poliosis[22] usually follow, but can occur before the other manifestations.

ALEZZANDRINI SYNDROME The constellation of clinical findings in Alezzandrini syndrome includes facial vitiligo, poliosis, deafness, and unilateral tapetoretinal degeneration. The etiology remains poorly understood, but as in vitiligo and VKH syndrome, autoimmune processes are thought to be involved. Only a few cases have been reported since the first description of a patient with vitiligo, poliosis, and unilateral retinitis in 1959.[23]

Laboratory Tests

The diagnosis of vitiligo is primarily based on clinical examination. However, given the association between vitiligo and other autoimmune diseases, several screening laboratory tests are helpful, including thyroid stimulating hormone level, antinuclear antibody, and complete blood count. Clinicians should also consider investigating for serum antithyroglobulin and antithyroid peroxidase antibodies, particularly when patients have signs and symptoms of thyroid disease. Antithyroid peroxidase antibodies, in particular, are regarded as a sensitive and specific marker of autoimmune thyroid disorders.

Histology

By definition, vitiligo lacks melanocytes in lesional skin. As well, a superficial dermal, perivascular and perifollicular primarily lymphocytic infiltrate may be observed at the margin of vitiliginous lesions and in early lesions, consistent with cell-mediated immune processes destroying melanocytes in vitiligo.[24]

PROGNOSIS AND CLINICAL COURSE

The prognosis and course of vitiligo are unpredictable. Initial clinical sub-type of vitiligo does not predict future anatomical sites of involvement or activity of disease.

Box 72-1

Differential Diagnosis of Vitiligo (Site Specific)

Most Likely

- Face
  - Tinea versicolor
  - Pityriasis alba
  - Post-inflammatory hypopigmentation
- Anogenital area
  - Lichen sclerosus et atrophicus

Consider

- Face
  - Chemical leukoderma
  - Sarcoidosis
- Hands
  - Chemical leukoderma



TREATMENT

There are many different treatment options available for patients with vitiligo (Box 72-2). Most therapies are intended to restore pigment to the skin. All approaches have advantages and disadvantages; and none is appropriate for every patient with vitiligo.

Box 72-2

Treatments for Vitiligo

	TOPICAL	PHYSICAL	SYSTEMIC	SURGICAL
First line	Corticosteroids Calcineurin inhibitors	Ultraviolet B (narrow band) Systemic psoralen and ultraviolet A light		
Second line	Calcipotriol	Topical psoralen and ultraviolet A light Excimer laser	Corticosteroids (pulse therapy)	Grafting Melanocyte transplant

Sunscreens

Sunscreens help prevent sunburn and thus may lessen photodamage as well as the chance that a Koebner phenomenon will occur. Sunscreens also decrease tanning of the uninvolved skin and therefore lessen the contrast with vitiliginous lesions.



Cosmetics

Many patients, especially patients with focal vitiligo, find cosmetic cover-ups to be a valuable treatment option. Areas of leukoderma, especially on the face, neck, or hands can be covered with conventional make-up, self-tanning products, or other topical dyes (see eFig. 72-6.4 in on-line edition). Cosmetics offer limited cost, minimal side effects, and the ease of application. As well, many of the cover-ups can be individualized to obtain an exact color match to the patient's normal skin.

Topical Corticosteroids

Topical corticosteroids are indicated for the treatment of limited areas of vitiligo and are often the first line of therapy for children,[25–29] although most experience is anecdotal. Lesions on the face appear to have the best response to topical corticosteroids; lesions on the neck and extremities (with the exception of the fingers and toes) also have a favorable response.[25] It is not known why lesions on the face have a better response rate. Possible explanations include a high permeability of the facial skin to the corticosteroids, a larger number of residual melanocytes in the uninvolved facial skin, greater follicular reservoirs, or melanocyte damage that is more easily reversed. Lesions on the face often re-pigment diffusely whereas a dot-like follicular pattern of repigmentation is more common elsewhere.

Localized lesions can be treated with a high-potency fluorinated corticosteroid for 1 to 2 months, after which prudence dictates that therapy is gradually tapered to a lower-potency corticosteroid. In children and patients with larger lesions, a medium potency non-fluorinated corticosteroid is often used, likely at the expense of efficacy. Caution must be used when using topical steroids on and around the eyelids, as their use can increase intraocular pressure and exacerbate glaucoma.

Wood's lamp examination can be used to monitor response to treatment. If no response is seen by 3 months, therapy should be discontinued. Maximum repigmentation may take 4 months or longer (there is a 30 percent to 40 percent response rate with 6 months of corticosteroid use). More darkly pigmented patients often have a more favorable response to topical corticosteroids than those with lighter complexions. The ease of application, high rate of compliance, and limited cost are the benefits of topical corticosteroid therapy for treating limited vitiligo. Recurrence after cessation of treatment and corticosteroid side effects (skin atrophy, telangiectases, striae, and, rarely, contact dermatitis) are the limiting factors. All patients, particularly children, should be monitored closely, for these potential side effects.

Topical Immunomodulators

Topical tacrolimus ointment 0.03 percent to 0.1 percent is effective in repigmentation of vitiligo when applied twice daily in patients with localized disease, particularly on the face and neck.[30–33,36,37] It is reported to be more effective when combined with ultraviolet B (UVB) or excimer (308 nm) laser therapy.[34,35] Tacrolimus ointment is generally considered safer for children than topical steroids.

Topical Calcipotriol

Topical calcipotriol 0.005 percent produces cosmetically acceptable repigmentation in some patients with vitiligo.[38–41] It can be combined with topical corticosteroids in adults and children to give possibly faster onset of repigmentation with better stability of achieved pigmentation.

Pseudocatalase

Catalase, an enzyme normally found in skin that decreases damage from free radicals, has been reported to be low in the skin of vitiligo patients. A replacement therapy using an analog of normal human catalase (pseudocatalase) in combination with narrowband UVB (NB-UVB) phototherapy has been reported in uncontrolled trials to re-pigment some vitiligo patients and prevent progression of disease.[42–44]

Systemic Therapies

Systemic immunosuppressive drugs have many potential side effects that are difficult to justify for a disease such as vitiligo. However, systemic corticosteroids have been used as pulse therapy with variable results and may prevent rapid depigmentation in active disease.[45–47]

Psoralen and Ultraviolet A Therapy

Topical or oral 8-methoxypsoralen combined with UVA (320 to 400 nm) irradiation (PUVA) is effective for treating vitiligo,[48–50] although frequent treatments over many months are required (see Chap. 239). After exposure to UVA, psoralens covalently bind to DNA and inhibit cell replication. How this then leads to repigmentation of vitiligo areas is not well understood. PUVA stimulates tyrosinase activity (an essential enzyme in melanin synthesis) and melanogenesis in unaffected skin. PUVA is also locally immunosuppressive, and decreased expression of vitiligo-associated melanocyte antigens has been reported.

In vitiligo, melanocytes in the bulb and infundibulum of the hair follicle are

often destroyed; but the lower and middle portions of the follicle as well as the outer root sheath are spared. PUVA stimulates follicular melanocytes to migrate into the epidermis and repopulate the surrounding depigmented skin, possibly as a result of the release of cytokines and chemotactants from the epidermal keratinocytes (see eFig. 72-6.5 in on-line edition).

Topical PUVA is sometimes used in patients whose vitiligo involves less than 20 percent of the body surface area (see Chap. 239). However, unwanted side effects are common and include cosmetically displeasing hyperpigmentation of skin surrounding vitiligo areas due to inadvertent psoralen application, severe phototoxicity reactions, and intense pruritus. Oral psoralens are used for patients with more extensive involvement or in patients who do not respond to topical PUVA (see Chap. 239).

It is important to select vitiligo patients carefully for PUVA therapy. Although 70 percent to 80 percent of patients experience some repigmentation with PUVA, fewer than 20 percent of patients totally re-pigment. In general, vitiligo on the trunk, proximal extremities, and face respond well to PUVA, but lesions on the distal extremities respond poorly. As with corticosteroids, patients with a darker complexion tend to respond better to PUVA, possibly because they tolerate higher PUVA exposures.[48–50] Potential side effects of PUVA therapy are discussed in Chap. 239.

Narrowband Ultraviolet B Radiation

NB (311 nm)-UVB irradiation is another option for patients with vitiligo and is considered by many to be the first choice for most patients. In patients with extensive generalized vitiligo, NB-UVB therapy was more effective than topical PUVA (67 percent versus 46 percent response rate, respectively; see Chap. 238). If no improvement is seen within 6 months of treatment, NB-UVB therapy should be abandoned. In one study, 53 percent of children experienced more than 75 percent repigmentation after NB-UVB therapy and 6 percent showed complete repigmentation. Again, better pigmentation was achieved on the face, trunk, and proximal extremities than with the distal extremities and groin.

Excimer Laser

Excimer (308 nm) laser has been recently studied in several trials for its efficacy in treating vitiligo. It has been found to be most effective when treatments are given three times weekly, with treatment periods of more than 12 weeks necessary to obtain satisfactory repigmentation. The initial dose is 50 to 100 mJ/cm^2. As with standard phototherapy, excimer laser produces the best treatment results on the face; the least responsive areas are the hands and feet.[57–63]

Depigmentation

Monobenzyl ether of hydroquinone (Monobenzone) is the only agent available in the United States and Europe for depigmenting residual normal skin in patients with extensive vitiligo. Monobenzone is a phenolic toxin that destroys epidermal melanocytes after protracted use. Monobenzone can therefore produce a uniform depigmented state that is cosmetically more acceptable for many patients than the contrast between normal and affected skin (see eFig. 72-6.6 in on-line edition). Monobenzone is available as a 20 percent cream and can be formulated at concentrations up to 40 percent. The individual using monobenzone should avoid direct contact with others for 1 hour after application, as contact may cause depigmentation of others' skin.[64] Monobenzone may also be irritating and allergic sensitization may occur.

Autologous Thin Thiersch Grafting

Thin split-thickness grafts in the treatment of vitiligo are obtained using scalpel or dermatome and are placed onto recipient sites prepared in a similar manner or by dermabrasion. Achromic areas ranging in size from 6 to 100 cm^2 can be treated. Recently, the technique of thin split-thickness grafts has been modified for the treatment of vitiligo with the harvesting of grafts by mechanical dermatome, which has shown excellent results. This technique has also been used to successfully treat vitiligo of the lip. The advantage of this technique is that it allows the grafting of large areas in a relatively short time. However, this must be weighed against the need for general anesthesia and the risk of hypertrophic scarring of both donor and recipient sites.[65–67]

Suction Blister Grafts

Separation of viable epidermis from dermis can be accomplished through the production of suction blisters that separate skin immediately above the dermal-epidermal junction. This is adapted to the treatment of vitiligo; pigmented epidermis is harvested by this technique and is used to cover achromic areas that have been prepared by denuding them with liquid nitrogen blisters. Melanocytes are contained within the epidermal roof of 2.0- to 2.5-cm suction blisters. The tops of these blisters are removed and are directly applied to the denuded area of achromic skin. Pigmentation usually develops in 3 to 6 months. There may be areas of achromic fissures between grafts in the recipient areas. An advantage of suction blister grafts is that scarring is minimal, as the dermis is left intact in both donor and recipient sites. However, most physicians do not have the mechanical apparatus needed for the production of the blisters at the donor site.[68,69]

Autologous Mini-Punch Grafts

The autologous mini-punch grafts technique uses 1.20- to 1.25-mm full-thickness punch grafts placed 4 to 5 mm apart onto comparably sized recipient sites (see eFig. 72-6.7 in on-line edition). This graft size was found to minimize both the "cobblestoning" (trap door) effect and the cosmetic damage to the donor site that is especially prominent with larger-sized grafts, yet it also contained enough melanocyte sources to stimulate the spotty perifollicular repigmentation (see eFig. 72-6.8 in on-line edition).[70,71]

Transplantation of Cultured Autologous Melanocytes

The technique of transplanting melanocyte-containing cultures of cells has the theoretic advantage of potentially treating large areas using cells harvested from a small piece of donor skin by expanding the melanocyte population in vitro. Its major disadvantage lies in the complexities and cost of the culture systems. As well, there is concern about what, if any, effects the additives required for culturing the cells have on the melanocytes and, subsequently, on the patient.[72,73] Melanocytes can be cultured more readily in the presence of keratinocytes, and co-cultures can be used to re-pigment areas of skin depigmented by disease or injuries.[74–76] In the United States, these techniques now require that the cultures be performed using Good Manufacturing Practices, a





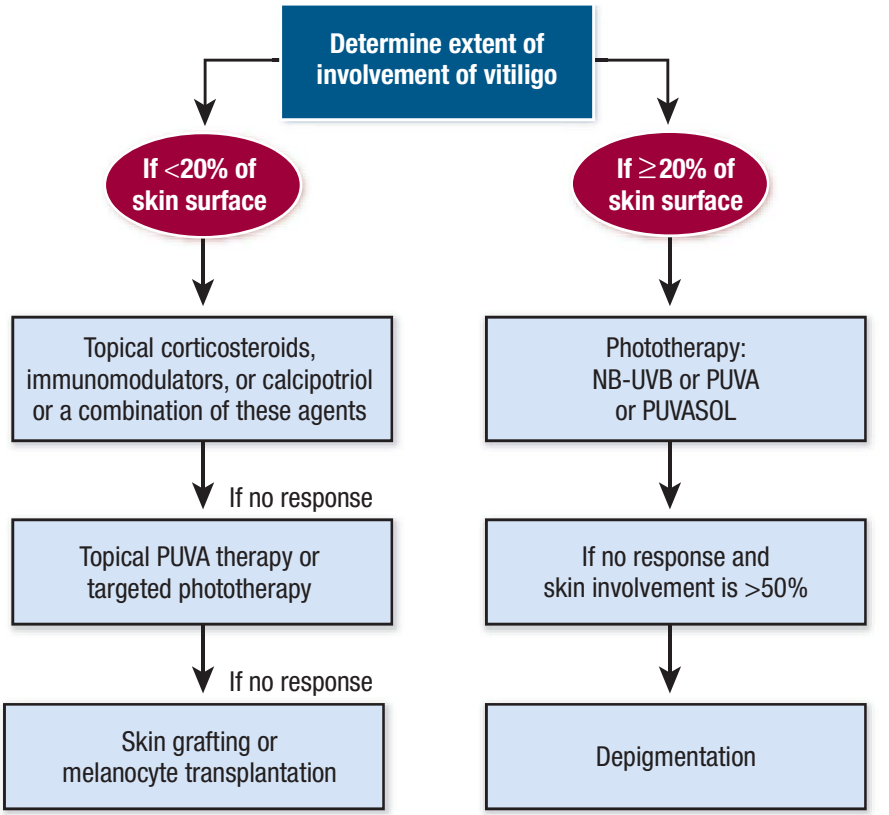

▲ **FIGURE 72-7** Treatment algorithm for vitiligo. NB-UVB = narrowband ultraviolet B; PUVA = psoralen and ultraviolet A light; PUVASOL = psoralen, ultraviolet A, and solar light.

very regulated and expensive approach available at very few academic centers (Fig. 72-7).

PREVENTION

No therapy prevents vitiligo from developing in patients. However, systemic steroids or topical pseudocatalase may slow depigmentation in some patients with active disease.

KEY REFERENCES

The full reference list for all chapters is available at www.digm7.com.

4. Spritz RA et al. Novel vitiligo susceptibility loci on chromosomes 7 (AIS2) and 8 (AIS3), confirmation of SLEV1 on chromosome 17, and their roles in an autoimmune diathesis. *Am J Hum Genet* **74**:188, 2004
10. Lamoureux L, Boissy RE: Animal models, in *Vitiligo*, edited by SK Hann, JJ Nordlund. London, Blackwell Science, 2000, p 281
27. Halder R, Brooks H: Medical therapies for vitiligo. *Dermatol Ther* **14**:1, 2001
48. Parsad D, Kanwar AJ, Kumar B: Psoralen-ultraviolet A vs. narrow-band ultraviolet B phototherapy for the treatment of vitiligo. *J Eur Acad Dermatol Venereol* **20**:175, 2006

CHAPTER 73

Hypomelanoses and Hypermelanoses

Hilde Lapeere
Barbara Boone
Sofie De Schepper
Evelien Verhaeghe
Katia Ongenae
Nanja Van Geel
Jo Lambert
Lieve Brochez
Jean-Marie Naeyaert

AN ALGORITHMIC APPROACH TO PIGMENTATION DISORDERS

Pigmentation disorders of the skin can either be hypomelanotic or hypermelanotic, or may present with a pattern of mixed hypo- and hypermelanosis. The diagnosis of these disorders can be quite challenging. An algorithmic approach based on clinical features and history of pigmentary disorders is used throughout this chapter and serves as a guide for the clinician (Figs. 73-1 and 73-2).

HYPOMELANOSIS

Congenital Hypomelanosis

Some genetic disorders with reduced skin and hair pigmentation are caused by impaired melanocyte migration/differentiation or melanosome abnormalities.[1] Piebaldism and Waardenburg syndrome, characterized by a localized absence of melanocytes resulting in "white patch" patterns, belong to the first group, whereas oculocutaneous albinism, Griscelli syndrome (GS), Elejalde syndrome (ES), Chédiak-Higashi syndrome (CHS), and Hermansky-Pudlak syndrome belong to the second group; oculocutaneous albinism, CHS, and Hermansky-Pudlak syndrome are discussed in Chap. 71, GS and ES are discussed here. They are rare, autosomal recessive disorders in which biogenesis or transport of "lysosome-related organelles" (a group of specialized cytoplasmic organelles including melanosomes, platelet dense bodies and lymphocyte lytic granules) is affected.[2] GS, ES, and CHS are termed *silvery hair syndromes* because hair of these patients has a particular silver-gray hue.[3]

GRISCELLI SYNDROME Today, three types of GS are known. The phenotype of the patients is characterized by various degrees of skin hypopigmentation and metal-colored hair (Fig. 73-3) accompanied by neurologic signs and symptoms and/or immunologic impairment with "accelerated phases" of uncontrolled lymphocyte and macrophage activation with lymphohistiocytic infiltration of the central nervous system.[4] Skin hypopigmentation and silvery-gray hair in GS patients are not caused by deficient melanosome biogenesis, but by impaired melanosome intramelanocytic transport. Murine models with autosomal recessive mutations on the dilute (d), ashen (ash), and leaden (ln) locus present a phenotype close to that of

HYPOMELANOSES AND HYPERMELANOSES AT A GLANCE




- Pigmentation disorders confront the clinician with a sometimes complex differential diagnosis, but can be approached logically as
  - Congenital or acquired,
  - Isolated or part of a syndrome,
  - Diffuse or circumscribed,
  - Epidermal or dermal,
  - With or without inflammation.
- Altered skin pigmentation may be caused by
  - Increased or decreased melanin,
  - Abnormal melanin distribution,
  - Decreased hemoglobin,
  - Deposition of exogenous pigments.

their human GS counterparts.[5] These loci respectively encode three molecules, myosin Va, rab27a, and melanophilin (Mlph), that act as a tripartite complex linking the melanosome to subcortical actin. In melanocytes, if one of the three is defective, melanosomes can no longer be tethered near the plasma membrane for transfer toward keratinocytes, which leads to a pigmentary defect.

The prognosis for patients with GS is generally bad. They usually die in the first or second decade of their life. As for therapy, bone marrow transplantation has appeared to be successful in some cases, especially when carried out at an early age.[6–8] Palliative therapy for the accelerated phases consisted of corticosteroids, etoposide, intrathecal methotrexate, and cyclosporine.

ELEJALDE SYNDROME (OMIM #256710) ES, also referred to as *neuroectodermal melanolysosomal disease,* is another autosomal recessive pigment mutation with silvery hair, pigment abnormalities, and severe central nervous system dysfunction.[17] These are the same features as GS1. ES patients do not manifest hemophagocytic syndrome or immunologic impairment, which are clinical features associated with GS2.[18,19] Currently, research groups are investigating the MYO5A locus of these patients to see whether ES is related to or allelic to GS1.

Acquired Localized Hypomelanosis

PITYRIASIS VERSICOLOR (See Chap. 189) Pityriasis versicolor is characterized by slightly scaling macules that can be hypopigmented, pink or salmon-colored, or hyperpigmented (Fig. 73-4). Recently, variants with respectively red and black macules have been described. The lesions most commonly occur in young adults and are located on the trunk, chest, back, and shoulders. Atypical sites such as axillae, penis, perineal region, and groin can also be affected. In tropical climates, lesions are also found on the face. This superficial mycosis is caused by *Malassezia* sp., of which *M. globosa* and *M. sympodialis* most frequently have been identified in scales of pityriasis versicolor lesions. The round yeast form is a saprophyte of the skin. It is hypothesized that pityriasis versicolor occurs when the yeast phase changes to a parasitical mycelial phase. It is unclear which mechanisms cause this change, but genetic, endogenous (such as the intake of oral anticoagulants or systemic steroids), and environmental factors have been suggested. Prevalences of pityriasis versicolor are very high in hot and humid climates.

Pityriasis versicolor is readily recognized by the typical clinical pattern. Direct examination of scales using a solution containing equal parts of 10 percent to 20 percent potassium hydroxide and Parker ink demonstrates the hyphae and blastospores in the typical "spaghetti and meatballs" pattern. In approximately one out of three patients, a yellow-green fluorescence is visible using Wood's light. It should be differentiated from the non-scaling depigmented lesions of vitiligo, which frequently affect hands and feet whereas pityriasis versicolor is mainly located on the trunk. The slightly scaling patches of pityriasis alba (PA) usually occur on the face and limbs and are non-fluorescent. Other differential diagnoses are tinea corporis, pityriasis rosea, erythrasma, confluent and reticulated papillomatosis of Gougerot-Carteaud, pityriasis rotunda, secondary syphilis, and pinta. Many local and systemic antifungal preparations are effective, but relapses often occur.[51,52]

PIGMENTARY DEMARCATION LINES Originally described in Japanese patients as a line present on upper and lower extremities corresponding to a border of transition between the more deeply pigmented skin of the anatomically dorsal outer surfaces and the lighter ventral surfaces, the concept of pigmentary demarcation lines was expanded to include five specific patterns, labelled A to E, with (A) upper anterolateral arms, across pectoral area (Fig. 73-5), (B) posteromedial portion of lower limb, (C) vertical hypopigmented line in pre- and parasternal area, (D) posteromedial area of spine, and (E) bilateral aspect of chest, marking from the mid third of clavicle to periareolar skin. In a population survey of black and white patients, it was determined that these lines appeared in early childhood. They are present in the majority of female black adults, with types A and B being most prevalent. Seventy-five percent of black adult males had at least one type of pigmentary demarcation line, with type C the most prevalent. Fifteen percent of white female adults had at least one line and 14 percent of black women saw type B lines appearing during pregnancy.[53]

PITYRIASIS ALBA PA is a common benign condition mainly affecting the head and neck region of preadolescent children. Although the disease is more noticeable in darker skin types, there is no sex or skin type predilection. The etiology and pathogenesis remain poorly understood. PA has been commonly characterized as a mild form of atopic dermatitis. Excessive and unprotected sun exposure as well as hygienic habits (frequent bathing and hot baths) are strongly related to the development of PA.

PA may present as a pink patch with an elevated border, fading after several weeks into a paler spot covered with powdery white scale (Fig 73-6). The lesions progress to non-scaly hypopigmented macules persisting for months or years. This hypomelanosis is due to a decreased number of melanocytes and melanosomes. The three stages may occur simultaneously. Most cases of PA are diagnosed clinically.[54–58] The histology is non-specific.

Extensive PA, more commonly seen in adults, is characterized by the features of PA, distributed in a more generalized fashion often involving the inferior torso in a symmetric pattern. The lack of preceding inflammatory phase





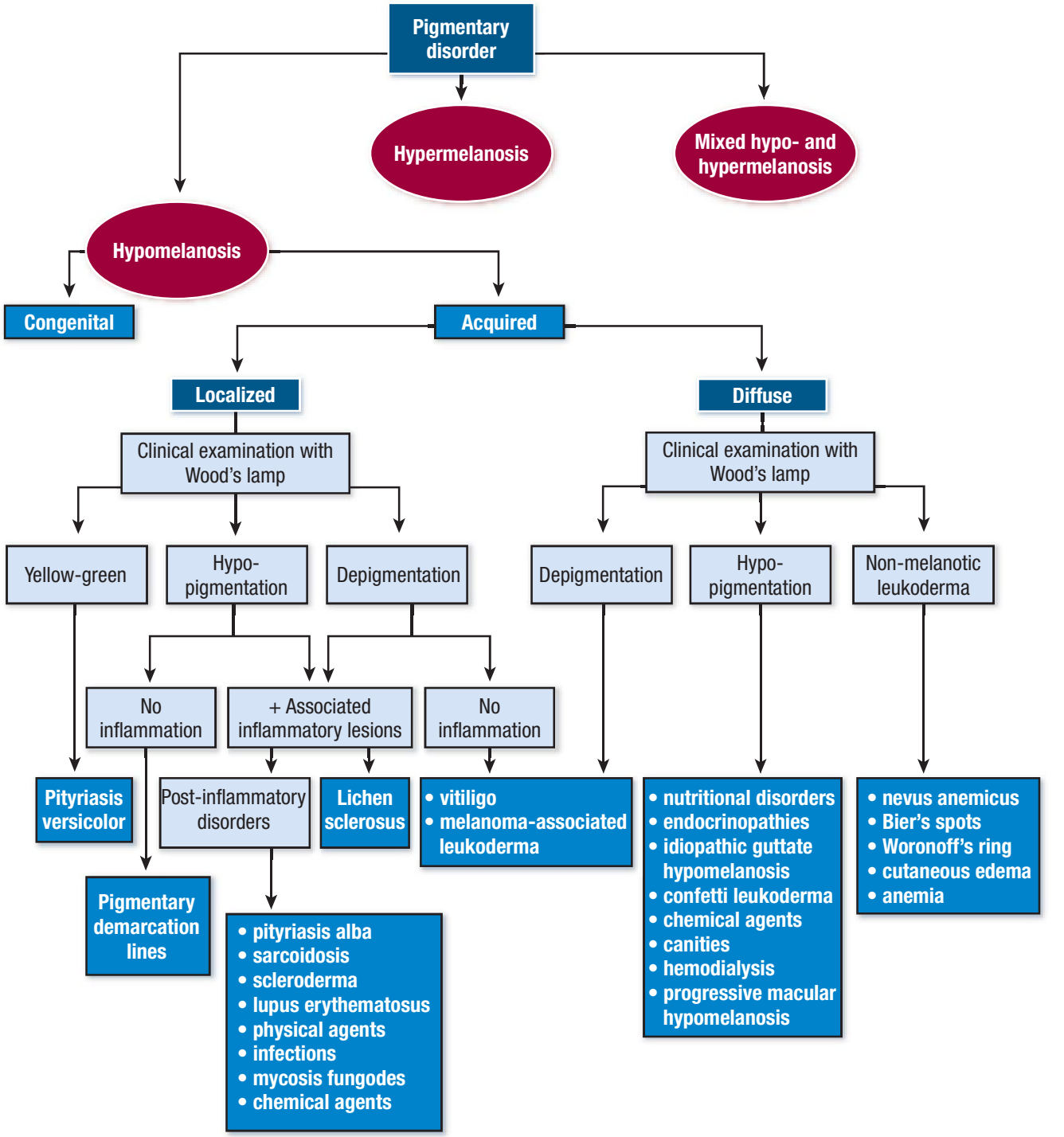

▲ **FIGURE 73-1** Algorithm for the diagnostic approach to hypomelanosis.

and the absence of spongiosis differentiate extensive PA from the classic form. A possible overlap of this particular form of PA with progressive macular hypomelanosis has been hypothesized. The latter condition, mainly described in young female adults, is characterized by relapsing, hypopigmented, non-scaling patches involving the back particularly after summer.

Pigmenting PA has been described as a variant of PA associating classic PA with a superficial dermatophyte infection almost always affecting the face. It is clinically characterized by a bluish hyperpigmentation surrounded by a hypopigmented scaly area. The pigmented area is attributed to melanin deposits in the dermis. One-third of the patients have concurrent classic PA.

Differential diagnoses include any localized forms of hypopigmentation, especially inflammatory skin conditions associated with post-inflammatory hypopigmentation, such as psoriasis but also fungal infection, nevus depigmentosus, nevus anemicus, tuberous sclerosus, mycosis fungoides (MF), or vitiligo.

The disease is self-limiting and treatment is often not completely successful. Topical steroids and emollients are helpful. Topical tretinoin has also been used with success, but may be irritating. The less common variants extensive PA and pigmenting PA have a better response to their respective treatments ultraviolet (UV) therapy and oral antifungals. Supportive measures such as decreasing sun exposure, use of sunscreens, and reduc-



Pigmentary disorder

- **Mixed hypo- and hypermelanosis**
  - **Hypermelanosis**
    - **Acquired**
      - **Circumscribed**
        - nevus of Hori
        - lentigo
        - Becker's nevus
        - ephelides
        - post-inflammatory hyperpigmentation
        - familial periorbital hyperpigmentation
        - partial unilateral lentiginosis
        - xanthoma planum
        - inherited pattern lentiginosis in blacks
        - acquired brachial cutaneous dyschromatosis
        - Riehl melanosis
        - cutaneous amyloidosis
        - Laugier-Huinziker syndrome
        - atrophoderma of Pasini-Pierini
        - fixed drug eruption
        - erythema dyschromicum perstans
        - idiopathic eruptive macular hyperpigmentation
      - **Diffuse**
        - Patterned
          - Linear
            - Pigmentary demarcation lines
            - phytophotodermatitis
            - flagellate pigmentation
          - Reticulate
            - erythema ab igne
            - prurigo pigmentosa
        - Non-figured
          - endocrinologic conditions
          - nutritional conditions
          - metabolic conditions
          - tumoral conditions
          - physical agents
          - toxin- or medication-induced hypermelanosis
          - ochronosis
          - Fanconi anemia
          - POEMS syndrome
          - Cronkhite-Canada syndrome
          - progressive systemic sclerosis
          - infectious diseases
    - **Congenital**
      - **Circumscribed**
        - Dermal melanocytes
          - nevus of Ota
          - nevus of Ito
          - Mongolian spots
          - dermal melanocyte hamartoma
        - Lentigo
          - Carney complex
          - Peutz-Jeghers syndrome
          - Bannayan-Riley-Ruvalcaba syndrome
          - LEOPARD syndrome
          - centrofacial neurodysraphic lentiginosis
        - CALM
          - neurofibromatosis type I
          - Watson syndrome
          - McCune-Albright syndrome
          - Bloom syndrome
          - Silver-Russel syndrome
      - **Diffuse**
        - Patterned
          - Linear
            - linear and whorled nevoid hypermelanosis
            - incontinentia pigmenti
          - Reticulate
            - dyskeratosis congenita
            - X-linked reticular pigmentary disorder
            - Naegeli-Franceschetti-Jadassohn syndrome
            - dermatopathia pigmentosa reticularis
            - Dowling-Degos disease
            - Kitamura reticular acropigmentation
            - dyschromatosis hereditaria universalis
        - Non-figured
          - carbon baby
          - arterial dissection with lentiginosis
          - familial progressive hyperpigmentation
  - **Hypomelanosis**

▲ **FIGURE 73-2** Algorithm for the diagnostic approach to hypermelanosis. CALM = café-au-lait macule; LEOPARD syndrome = *l*entigines; *e*lectrocardiogram conduction defects; *o*cular hypertelorism; *p*ulmonary stenosis; *a*bnormalities of genitalia; *r*etardation of growth, and sensorineural *d*eafness; POEMS = *p*olyneuropathy, *o*rganomegaly, *e*ndocrinopathy, *M* protein, and *s*kin changes.





▲ **FIGURE 73-3** A Griscelli patient with silvery gray eyebrows/eyelashes.

ing frequency and temperature of baths should be recommended.

SARCOIDOSIS (See Chap. 153) Hypopigmentation is a rare manifestation of sarcoidosis. Hypopigmented macular lesions are scattered over the trunk and extremities, but papular or nodular lesions may also be presenting. The presence of noncaseating dermal granulomas, usually most evident in biopsies of indurated lesions, reinforce the diagnosis. A reduction in melanin content of the epidermis with preservation of melanocytes has been demonstrated.

The pathogenesis of pigment loss is unclear.[59–61]





▲ **FIGURE 73-4** Pityriasis versicolor. **A.** Typical macules are round, very well circumscribed, have fine scale, and are off-white to tan colored. Typical distribution involves the upper back and upper chest. Involvement of the lower arms and legs and of the face is unusual. **B.** Confluent macules create scalloped borders. This is a characteristic pattern of macules of pityriasis versicolor.



▲ **FIGURE 73-5** Pigmentary demarcation line. These lines are often barely perceptible but common in darker-skinned phototypes.

SCLERODERMA (See Chap. 158) Hypopigmentation has been described as a pigmentary change in morphea (localized scleroderma) (Fig. 73-7) and scleroderma (progressive systemic sclerosis). Localized hypopigmentation and/or hyperpigmentation may be seen in areas of localized sclerosis. Focal depigmentation with perifollicular hyperpigmentation ("salt and pepper pigmentation") especially on upper trunk and extremities, mimicking vitiligo, is reported in up to 30 percent of patients with scleroderma. The co-existence of scleroderma and vitiligo has also been reported.[62,63]

LUPUS ERYTHEMATOSUS (See Chap. 156) Pigment alterations are frequently seen in discoid lupus erythematosus. Hypopigmented patches result from the interface dermatitis with destruction of the epidermal basal layer containing melanocytes. The healed scar tissue is atrophic and depigmented and may be surrounded by hyperpigmentation. Cutaneous depigmentation is also reported in systemic lupus erythematosus, usually secondary to inflammatory skin lesions, localized to the same sites. Biopsy specimens in depigmented skin feature degeneration of the basal layer with epidermal atrophy, a variable number of melanocytes, and pigmentary incontinence in the superficial dermis. The mechanism of hypopigmentation in lupus is not known, but could be post-inflammatory or cicatricial.

Vitiligo has also been reported in association with lupus erythematosus. A



▲ **FIGURE 73-6** Pityriasis alba.

shared genetic predisposition may explain the association of these two autoimmune disorders.[64]

MYCOSIS FUNGOIDES (See Chap. 146) MF, the most common type of cutaneous T-cell lymphoma, is clinically characterized by three cutaneous phases: the patch phase, the plaque phase, and the tumor phase. Different pigmentary changes have been described in MF.

In poikiloderma vasculare atrophicans, mottled pigmentation, atrophy, and telangiectasia of the involved skin are observed. A mix of hyper- and hypopigmentation may remain after regression of the skin lesions after treatment.

Hypopigmented MF is an uncommon variant of this lymphoma. It mainly develops before the fourth decade in dark-skinned individuals and has no sex predilection. Irregular hypopigmented patches with distinct or indistinct borders are preferentially located on trunk and extremities. Erythema, scaling, and infiltration may be present. A central area of normal pigmentation may be observed. These lesions may also be associated with the more typical lesions of the three cutaneous phases. The hypopigmentation develops without preceding skin changes and, occasionally, complete depigmentation is observed.



▲ **FIGURE 73-7** Morphea. Note the discrete hyperpigmentation in the area of localized sclerosis.

Histopathologically, hypopigmented MF is characterized by minimal dermal involvement, lack of epidermal atrophy, and marked to moderate exocytosis. Pigment incontinence and decrease or absence of epidermal melanin may be observed. Infiltrating lymphocytes often have a T-suppressor cell $CD8^+$ phenotype but $CD4^+$ phenotype has also been reported.

Electron microscopy may disclose degenerative changes in melanocytes. Melanocytes may be incompletely melanized or occasionally reduced in number. The number of melanosomes within keratinocytes is normal or decreased, and melanin-containing macrophages can be observed in the papillary dermis. T-cell receptor gene rearrangement analysis may help to confirm the diagnosis, but may be negative, as in other forms of early stage MF.

The pathogenesis of hypopigmented MF is not clear. At least in cases showing a $CD8^+$ phenotype, hypopigmentation could be due to the melanocytotoxic effect of non-neoplastic $CD8^+$ lymphocytes in a similar way as is suspected in vitiligo.

Hypopigmented MF responds well to treatment, particularly psoralen and UVA light (PUVA), and, more recently, narrowband UVB therapy, and has a relatively benign course, although recurrences are common.

Hypopigmented MF should be distinguished from other causes of diffuse hypopigmentation, especially vitiligo, tinea versicolor, PA, or post-inflammatory hypopigmentation.[65–67]

INFECTIONS ***Treponematoses.*** (See Chap. 201) Non-venereal treponematoses are currently endemic in parts of Central and South America, Africa, Asia, and the Pacific Islands and can be severely disfiguring. Depigmentation is seen in several stages of yaws, bejel, and pinta. When the primary lesion of yaws disappears, a typical depigmented and pitted scar is left behind. In the tertiary stage of bejel, gummatous nodules develop in the skin and in other organs. Most lesions regress, leaving depigmented, noncontracted scars. Pinta is the only treponematosis that only affects the skin and causes pigmentary abnormalities in the first, second, and third stages of the disease. The sentinel lesion of pinta may heal at the end of the primary stage, leaving a hypo- or gray-blue hyperpigmented macule. The secondary stage is characterized by the appearance of so-called *pintids,* which are initially red but often turn brown, slate blue, gray, or black. This stage can last several years, leading to a mix of depigmentation and hyperpigmented lesions. Generalized pigmentary abnormalities develop during the tertiary stage. A symmetric pattern of vitiligo-like lesions and brown, gray, or blue and black lesions is often seen over bony prominences (Fig. 73-8).[68]



▲ **FIGURE 73-8** Pinta. The hypomelanosis in pinta is a vitiligo-like hypomelanosis that occurs later in the disease and is associated with deep blue to slate-gray areas of hyperpigmentation.



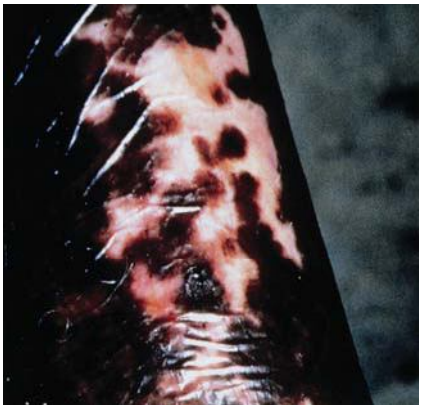

▲ **FIGURE 73-9** Onchocerciasis.



Onchocerciasis. (See Chap. 207) Several different skin manifestations can become apparent during the course of onchocerciasis. Onchocercal depigmentation or "leopard skin" is rarely associated with pruritus and is one of the most common skin manifestations of onchocerciasis. Hypopigmented patches with perifollicular spots of normally pigmented skin, typically occur symmetrically on the pretibial area of older people in endemic areas (Fig. 73-9).[69]

Post-Kala-Azar Dermal Leishmaniasis. (See Chap. 206) Post-kala-azar dermal leishmaniasis develops in insufficiently treated kala-azar or visceral leishmaniasis, a disease caused by *Leishmania donovani*. Skin manifestations of post-kala-azar dermal leishmaniasis are nodules and plaques, facial erythema. and hypopigmented macules. Nodules and plaques typically develop around the mouth and spread to the face, arms, and chest but macules may occur over the whole body. Mild disease can heal spontaneously but severe forms require systemic treatment.[70,71]

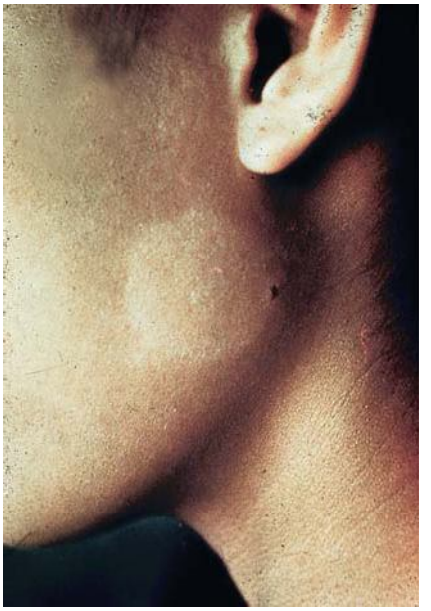

▲ **FIGURE 73-10** Leprosy. A characteristic off-white hypomelanotic and anesthetic macule.

Leprosy. (See Chap. 186) The presence of a hypopigmented lesion with reduced sensation is the hallmark of leprosy and is one of the diagnostic criteria (Fig. 73-10). Indeterminate leprosy, frequently the first manifestation of leprosy, is characterized by the presence of a few such lesions. Tuberculoid leprosy usually manifests a limited number of well-defined, depressed, hairless lesions that appear hypopigmented in black patients and erythematous in white patients.[72]

CHEMICAL AND PHARMACOLOGIC AGENTS

The potential for chemicals to induce hypopigmentation was discovered in the first half of the twentieth century. Leukoderma was noticed in rubber workers exposed to the monobenzyl ether of hydroquinone (MBEH), a frequently used antioxidant in the rubber industry. Since then, depigmenting properties have been attributed to many chemicals and new therapeutic depigmenting agents have been developed.[73]

Occupational exposure to chemicals that have a destructive effect on melanocytes can result in chemical leukoderma. Agents such as *para*-tertiary butylphenol, para-tertiary butyl catechol, MBEH, and hydroquinone can cause permanent depigmentation. The depigmentation caused by chemicals is difficult to distinguish from idiopathic vitiligo. The former usually starts at the hands and forearms, presumptive sites of contact, but depigmentation at distant sites is also possible (Fig. 73-11). Chemical leukoderma spreads by coalescence of small macules, whereas the sudden appearance of large patches with perifollicular sparing is more suggestive of vitiligo. Chemical leukoderma is very likely if several exposed workers develop depigmentation. However, not all exposed individuals develop leukoderma and it is hypothesized that the individual susceptibility is variable.[73,74]

There are three main mechanisms of action for bleaching agents. Some act before melanin is synthesized by inhibiting tyrosinase transcription and glycosylation. Other agents act during melanin synthesis by inhibiting enzymes such as tyrosinase or peroxidase or act as reducing agents or radical oxygen species scavengers. Finally, some agents act after melanin synthesis because they are responsible for tyrosinase degradation, inhibition of melanosome transfer,



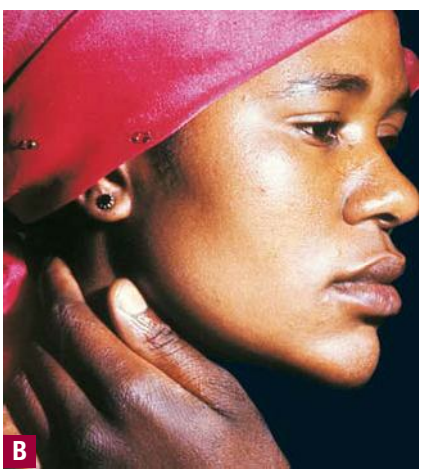



▲ **FIGURE 73-11** Chemical leukoderma. **A.** O-Syl (a phenolic disinfectant)–induced chemical leukoderma that mimics vitiligo clinically. Repeated exposure is required to depigment, but antecedent clinical inflammation is not observed. **B.** Reversible hypomelanosis of the face in a South African woman after several weeks application of topical hydroquinone. Note color contrast of face to that of (untreated) hand. **C.** African American factory worker depigmented from repeated exposure to monobenzyl ether of hydroquinone.

or acceleration of skin turnover, leading to depigmentation.[75]

MBEH was used as a lightening agent until its ability to cause total, permanent, often confetti-like depigmentation became apparent. It should only be used if total depigmentation is wanted in patients with extensive vitiligo. A formulation with 20 percent MBEH is prescribed most for that purpose. Hydroquinone is one of the most popular depigmenting substances and is frequently used for the treatment of melasma in concentrations between 2 percent and 5 percent. Concentrations higher than 5 percent incur a risk of permanent depigmentation. Adverse effects are irritation, post-inflammatory pigmentation, and exogenous ochronosis.[73,75–77]

PHYSICAL AGENTS Heat, freezing, x-ray, ionizing radiation, UV irradiation, and laser light can cause hypopigmentation or permanent depigmentation by damaging melanocytes, leading to their destruction or impaired function.[78]

LICHEN SCLEROSUS (See Chap. 63) Lichen sclerosus typically presents as a pruritic erythematous patch in the early stage, evolving to a depigmented atrophic plaque with porcelain white appearance. Several mechanisms likely play a role in the development of this leukoderma: decreased melanin production, blocked transfer of melanosomes to keratinocytes, and loss of melanocytes.

MELANOMA-ASSOCIATED LEUKODERMA (See Chap. 124) The most typical clinical sign of regression in a primary melanoma lesion is a white, depigmented, scar-like area within the lesion.

Melanoma-associated hypo- or depigmentation, also know as leukoderma acquisitum centrifugum can occur around the primary melanoma or metastases or at distant sites. The latter is often called vitiligo, although the resemblance is limited. Whereas vitiligo depigmentation is usually symmetric and spreads centripetally to the trunk, melanoma-associated hypodepigmentation tends to be extensive, patchy, and asymmetric. The lesions may be mottled (hypomelanotic) or milk white (amelanotic). In most cases, leukoderma begins simultaneously with the finding of metastases. Histologic examination shows a decrease or complete absence of melanocytes. Macromelanocytes with stubby dendrites can be observed. Melanoma with associated leukoderma may be associated with a better survival rate than comparably advanced lesions without epidermal pigment loss. Strong evidence suggests that melanoma-associated leukoderma results from an immune reaction involving humoral and cellular mechanisms. Both passive and active immunotherapeutic strategies used in the treatment of melanoma have been associated with leukoderma (Fig. 73-12).[79]

Acquired Diffuse Hypopigmentation

Nutritional disorders and endocrinopathies mainly cause hyperpigmentation. Diseases such as copper deficiency, vitamin B_{12} deficiency, kwashiorkor, Addison disease, hyperthyroidism, and diabetes can also be associated with hypopigmentation, but are discussed under Hypermelanosis because hyperpigmentation is their main feature.

HYPOTHYROIDISM (See Chap. 152) Hypothyroidism results from inadequate circulating levels of thyroid hormone and is frequently associated with cutaneous alterations. The skin is pale due to anemia and vasoconstriction. Yellowish discoloration of the palms, soles, and nasolabial folds is caused by an accumulation of carotene in the stratum corneum. The associated hypercarotenemia results from reduced hepatic conversion of β-carotene to vitamin A. Vitiligo has been associated with autoimmune hypothyroidism.[80,81]

HYPOPITUITARISM Panhypopituitarism results from a variety of conditions that compromise the anterior pituitary. As a consequence, release of pituitary-derived factors including thyroid stimulation hormone, adrenocorticotrophic hormone, luteinizing hormone, follicle-stimulating hormone, growth hormone, and vasopressin is decreased. Due to the reduction of circulating pituitary hormones, production of cortisol, thyroxine, estrogens, and testosterone in target organs is lowered.

Patients suffering from panhypopituitarism look pale due to anemia and decreased cutaneous blood flow. As well, generalized hypopigmentation results from decreased adrenocorticotrophic and melanocyte-stimulating hormones that stimulate epidermal melanogenesis.[81]

HYPOGONADISM Castrated human males are characteristically pale and their genital skin is not normally hyperpigmented. An impaired tanning response to UV radiation has been described. Administration of testosterone makes the skin turn darker and restores the tanning response.[82]

SELENIUM DEFICIENCY Loss of hair and skin pigmentation due to selenium deficiency has been described in children receiving long-term total parenteral nutrition. After selenium supplementation skin and hair darken.[83]







▲ **FIGURE 73-12** Melanoma-associated leukoderma. **A.** This hypomelanosis may resemble vitiligo clinically and be characterized by an absence of melanocytes. It may be associated with a favorable prognosis. **B.** These macules in a different patient developed after the patient developed metastases to the skin. They surround the individual metastases.





▲ **FIGURE 73-13** Idiopathic guttate hypomelanosis. Lesions on the leg of an African American individual.

COPPER DEFICIENCY Acquired copper deficiency occurs in severely malnourished infants. Hypopigmentation of the hair is attributed to copper deficiency, presumably because tyrosinase is a copper-dependent enzyme, but as multiple nutritional deficiencies tend to co-exist, pathogenesis is difficult to confirm.[84]

IDIOPATHIC GUTTATE HYPOMELANSOSIS Idiopathic guttate hypomelanosis (IGH) is an acquired leukoderma, characterized by discrete, round or oval porcelain-white macules of approximately 2- to 5-mm diameter, which increase in number with aging (Fig. 73-13). Any associated hairs often remain pigmented. Lesions are found in a photodistribution and tend to occur in chronically sun-damaged skin. They are often seen pretibially and on the forearms, although they may also arise on other sun-exposed areas including the face, neck, and shoulders. IGH has been hypothesized not to be idiopathic but UV induced, although controversy exists in literature. Another hypothesis suggests that IGH may reflect the normal aging or photoaging process.[85]

Histologically, IGH lesions are characterized by slight basket-weave hyperkeratosis with epidermal atrophy and flattening of the rete pegs. Lesions show a decrease in melanocytes and melanin content of the affected epidermis and pigment granules are irregularly distributed.

A variety of therapies with variable success are described, including cryotherapy, superficial abrasion, topical steroids, and topical retinoids.[86,87]

LEUKODERMA PUNCTATUM Leukoderma punctatum was first described by Falabella et al. in 1988.[88] They reported the development of multiple punctiform hypopigmented and achromic spots after several months of PUVA treatment. Later, similar observations were described after UVB therapy in psoriasis patients and after topical PUVA in one case of segmental vitiligo.[89]

Lesions are predominantly present on the extremities, upper back, and chest. They are round or oval, sharply demarcated, and small (0.5 to 1.5 mm) and without follicular distribution. Spontaneous reduction of the leukodermic lesions has been observed.[88]

It has been suggested that the phototoxicity damage to keratinocytes and melanocytes is the etiologic factor. Leukoderma punctatum is suggested to be distinct from IGH on the basis of its clinical and histologic features. In IGH, lesions are larger, and spontaneous resolution is not reported. Ultrastructurally, leukoderma punctatum demonstrates slight to severe damage of keratinocytes and melanocytes not reported in IGH.

CANITIES Hair graying, or canities, is a process of chronologic aging and occurs regardless of gender or race.[90] The usual age of onset is in the fourth decade and appears to be hereditary. The average age for whites is mid-30s, for Asians late 30s, and for Africans mid-40s. Premature canities (before 20s or 30s) can be associated with pernicious anemia, hyper/hypothyroidism, osteopenia, and several rare syndromes like progeria and pangeria. Graying usually appears at the temples first, then the vertex, and, finally, the occiput. Beard and body hair are affected later. Gray hairs seem to be thicker and longer than normally pigmented hairs, for a yet unknown reason. The perception of "gray hair" derives in large part from the admixture of pigmented and white hair, but individual hair follicles can indeed exhibit pigment dilution or suboptimal melanocyte-cortical keratinocyte interactions.[91–93] An acute episode of alopecia areata may result in a very sudden "overnight" graying (so-called *canities subita*) that is caused by the preferential loss of pigmented hair in this immune-mediated disorder.

HEMODIALYSIS Chronic hemodialysis patients frequently show disorders of skin pigmentation, primarily involving hyperpigmentation of sun-exposed body areas. Hypopigmentation of skin and hair is rather exceptional but occurs, possibly due to a disturbance of phenylalanine metabolism.

PROGRESSIVE MACULAR HYPOMELANOSIS Progressive macular hypomelanosis is an entity that affects the trunk with unsharp nummular, hypopigmented nonscaly macules. It affects young adults, mainly women. Although described in people of mixed racial ancestry (known as *Creole dyschromia*),[96] it is seen in all races. It can be mistaken for PA and pityriasis versicolor. Topical and systemic antifungal treatment and topical steroids are ineffective, but the disorder may resolve, sometimes temporarily, after sun exposure or phototherapy.

Acquired Diffuse Hypopigmentation with Vascular Cause

BIER'S SPOTS Bier's spots are small, irregular apparently hypopigmented macules, usually on arms and legs in young adults, resulting in a reticulated appearance. The surrounding skin is erythematous and blanches with pressure, causing the hypopigmented macules to disappear. The condition is more correctly considered a vascular anomaly with vasoconstriction in the pale areas and venodilatation in erythematous skin.[97,98]

WORONOFF'S RING (See Chap. 28) Woronoff's ring represents a blanched halo surrounding a psoriatic lesion. It is observed after UV treatment or topical steroid treatment but may also occur in untreated psoriasis. The pathogenesis is not clear. A decreased melanin content has been found in both psoriatic and halo epidermis, suggesting a true hypomelanosis. A local decreased prostaglandin synthesis with decreased vasodilatation or a diffusion of anti-inflammatory mediators from the psoriatic lesion to the halo has also been proposed.

CUTANEOUS EDEMA Cutaneous edema produces an appearance of leukoderma that is not a true hypomelanosis. Decreased absorption of light, reduced capillary blood flow and increased dermal thickness may contribute to the pale aspect of the skin.

ANEMIA The color of the skin is determined by several chromophores, usually predominantly melanin pigment, but the hemoglobin content of the skin also contributes to the skin color. The

pale skin color observed in anemia is due to decreased levels of circulating oxyhemoglobin and is proportional to the severity of the anemia.

HYPERMELANOSIS

Congenital Diffuse Hypermelanosis

CONGENITAL DIFFUSE NON-FIGURED HYPERMELANOSIS

CONGENITAL DIFFUSE LINEAR HYPERMELANOSIS

Linear and Whorled Nevoid Hypermelanosis. Linear and whorled nevoid hypermelanosis (LWNH) is characterized by hyperpigmented macules in streaky configuration along the lines of Blaschko without preceding inflammation or atrophy. In 1988, Kalter et al. described several important diagnostic criteria to differentiate LWNH from hypomelanosis of Ito, incontinentia pigmenti (IP), epidermal nevus, and chimerism/mosaicism.[102] In the past, similar cases were described in literature, all bearing different descriptive names (*zosteriform hyperpigmentation, zosteriform lentiginous nevus, zebra-like hyperpigmentation*). Lesions are typically located on the trunk and limbs and do not cross the midline. Face, palms, soles, eyes, and mucous membranes are spared. Kalter et al. described LWNH as having onset within a few weeks of age and progression during the first 1 to 2 years of age. The pigmentation can fade gradually with increasing age.

Extra-cutaneous abnormalities have been observed in a number of LWNH cases, including developmental and growth retardation, facial and body asymmetry, ventricular septal defect, and pseudohermaphroditism.

There is increasing evidence that LWNH is due to mosaicism, which has been confirmed in a few cases (mosaic trisomy 7, 14, 18, 20 and X-chromosomal mosaicism).[103] Differentiation is possible by chromosomal analysis of lymphocytes or cultured dermal fibroblasts.

Histologic examination reveals increased pigmentation of the basal layer and prominence or vacuolization of melanocytes. Pigment incontinence is usually, but not always, absent.[104a]

Incontinentia Pigmenti. IP, also known as *Bloch-Sulzberger syndrome*, was first described by Garrod et al. in 1906.[104b] It is an X-linked, dominantly inherited disorder, reported primarily in females, and believed to be embryonic lethal in the majority of males. In most cases, IP is due to a mutation in a gene called *NEMO* [nuclear factor κB (NF-κB) essential modulator] in chromosome Xq28.[105–107] It is characterized by typical skin lesions along the lines of Blaschko, which usually follow four cutaneous stages, sometimes with some overlap: (1) vesicular stage (from birth or shortly thereafter), (2) verrucous stage (between 2 and 8 weeks of age), (3) hyperpigmented stage (several months of age into adulthood), followed by (4) hypopigmentation stage (from infancy through adulthood) (Fig. 73-14). A significant percentage of IP patients have ocular, dental, skeletal, and central nervous system anomalies.[108]

The cutaneous findings in the first stage represent the population of NEMO-deficient cells. The deficiency results in disruption of the signaling pathway, which results in failure to activate NF-κB, leading to apoptosis (NF-κB normally protects against tumor necrosis factor–induced apoptosis). The number of NEMO-deficient cells decreases secondary to apoptosis and is replaced by cells expressing the normal allele. Subsequently, the inflammatory and vesicular stage ends. The hyperproliferation in the second stage is likely due to the proliferation of normal NEMO keratinocytes. Hyperpigmentation subsequently appears in the third stage because of incontinence of melanin pigment from the epidermis into the dermis.



▲ **FIGURE 73-14** Incontinentia pigmenti in a mother and her baby. **A.** Verrucous lesions in a 2-week-old baby. **B.** Hypopigmented atrophic lesions following the Blaschko's lines.

The hyperpigmentation (stage) appears in streaks and whorls along the lines of Blaschko and is usually most pronounced on the trunk, but they can also appear on the extremities. The degree of hyperpigmentation varies individually. Histologically, the areas of pigmentation show many melanin-laden melanophages, extensive deposits of melanin in the basal cell layer and dermis. There is vacuolization and degeneration in the epidermal basal cell layer. Usually, the hyperpigmentation fades gradually after several years and can become hypopigmented (stage 4), which represents post-inflammatory dermal scarring. The hypopigmentation stage is characterized by linear, atrophic, hairless scars following the Blaschko's lines.

Histologically, the number of melanocytes seems to be normal, although a reduced number of melanocytes also has been reported. The epidermis is thinner and there is an absence or reduction of skin appendages in the dermis that may contribute to the impression of hypopigmentation.[109]

CONGENITAL DIFFUSE RETICULAR HYPERMELANOSIS

Dyskeratosis Congenita. Dyskeratosis congenita (DKC) is a degenerative skin disorder, characterized by reticulate skin pigmentation, nail atrophy, leukoplakia, and bone marrow failure. It is also known as the *Zinsser-Engman-Cole syndrome* and is genetically heterogeneous. Three patterns of inheritance have been described: X-linked (males), autosomal dominant, and autosomal recessive (both sexes). The autosomal dominant form has the best prognosis.

Bone marrow failure and malignancy develop in the second and third decades. Increased levels of chromosomal breaks have been demonstrated in lymphocytes, fibroblasts, and bone marrow cells of some patients. The gene for DKC, DKC1, is located at Xq28 and its gene product dyskerin is associated with telomerase RNA. It is now thought that DKC is due to a defective telomerase maintenance, limiting the proliferative capacity of hematopoietic and epithelial cells. The finding of shortened telomeres in DKC was the first evidence of



TABLE 73-1
Differential Diagnosis and Management of Dermal Melanocytosis

	Nevus of Ota	Nevus of Ito	Mongolian Spot	Nevus of Hori	Dermal Melanocyte Hamartoma
Epidemiology	• Mostly congenital. • Sporadic (rare familial cases). • Asian and female predominance.	• Mostly congenital • Sporadic (rare familial cases) • Asian and female predominance	• Congenital • Often familial • Asian, African, and Hispanic population with slight male predominance	• Acquired • Familial or sporadic • Asian and female predominance	• Congenital
Clinical presentation	• Blue to slate-gray mottled macular hyperpigmentation.	• Blue to slate-gray mottled macular hyperpigmentation	• Uniform blue to slate-gray macular hyperpigmentation	• Brown-blue progressing to slate-gray mottled macular hyperpigmentation	• Mottled hyperpigmentation with small blue-gray macules in a diffuse pigmented patch
Distribution	• Trigeminal nerve.	• Acromioclavicular nerve	• Lower back and sacrum	• Especially malar region of the cheek (also forehead, upper eyelids, temple)	• Dermatomal distribution
Histology	• Spindle-shaped melanocytes diffusely throughout the dermal layers. Sometimes more band-like melanocytic proliferation and stromal fibrotic reaction.	• Spindle-shaped melanocytes diffusely throughout the dermal layers. Sometimes more band-like melanocytic proliferation and stromal fibrotic reaction	• Spindle-shaped melanocytes diffusely throughout the dermal layers	• Dermal melanocytes in the upper and mid-dermis	• Dermal melanocytes in the upper two-thirds of the dermis (including subpapillary layer)
Therapy	• Q-switched ruby laser. • Cryotherapy. • Surgery.	• Q-switched ruby laser • Cryotherapy • Surgery	• Usually spontaneous regression during childhood	• Q-switched ruby laser in combination with bleaching cream	• None
Associated features	• Rare malignant transformation.	• No associated features of medical concern	• Possible association with inborn errors of metabolism	• No associated features of medical concern	• None



the role of telomeres in cell biology (cellular aging).[110] In autosomal dominant DKC, the gene TERC at 3q21-28 codes for telomerase component 3.[111,112] Skin biopsy of hyperpigmented skin shows non-specific changes including epidermal atrophy, a chronic inflammatory infiltrate with numerous melanophages in the upper dermis. DKC may be confused with Fanconi syndrome, characterized by short stature, hypoplastic or aplastic thumbs, and a reduced number of carpal bones. Here, there is a patchy hyperpigmentation of the trunk, neck, groin, and axillary region that manifests itself earlier than in DKC (i.e., in the first few years of life). For Naegeli-Franceschetti-Jadassohn syndrome, dermatopathia pigmentosa reticularis, Dowling-Degos disease, Kitamura reticular acropigmentation, and Partington syndrome, see on-line version.

Congenital Circumscribed Hypermelanosis

CONGENITAL CIRCUMSCRIBED HYPERMELANOSIS WITH DERMAL MELANOCYTOSIS

Dermal melanocytoses or dermal dendritic melanocytic proliferations are characterized by the presence of melanin-producing dendritic melanocytes in the dermis. They include the nevus of Ito, nevus of Ota, and mongolian spot and dermal melanocyte hamartoma (Table 73-1). Associated vascular malformation has been described in phakomatosis pigmentovascularis (port-wine stain type, Klippel-Trenaunay, or Sturge-Weber syndrome).[118]

Nevus of Ota. Nevus of Ota (nevus fusco-caeruleus ophthalmomaxillaris) was first described by Ota in 1939.[119] It is characterized by blue-black or gray-brown dermal melanocytic pigmentation and typically occurs in areas innervated by the first and second branches of the trigeminal nerve. Mucosal pigmentation may occur, involving the conjunctiva, sclera, and tympanic membrane (oculodermal melanocytosis) (Fig. 73-15). It is most frequently seen in the Asian population, has a female predominance, and is usually congenital, although appearance in early childhood or in puberty has been described. In 1988, Ota nevus was subclassified as mild (type 1), moderate (type 2), intensive (type 3), and bilateral (type 4). Bilateral Ota nevus should be differentiated from Hori nevus (acquired bilateral nevus of Ota-like macules), which is acquired, does not have mucosal involvement, and is less pigmented (see Table 73-1).[120]

Malignant melanoma may rarely develop in a nevus of Ota. This necessitates careful follow-up of the lesion, especially if it occurs in Caucasian patients, in whom malignant degeneration seems to be more frequent. Malignant melanocytic tumors in association with nevus of Ota have been shown to arise in the chorioidea, brain, orbit, iris, ciliary body, or optic nerve.[121,122]

Nevus of Ito. Nevus of Ito is a congenital dermal melanocytosis first described by Ito in 1954 as *nevus fusco-caeruleus acromio-deltoideus*.[123] It can be considered as a variant of nevus of Ota that cutaneously involves skin of the acromioclavicular and deltoideal region. Clinical, demographic, and histologic characteristics are similar to nevus of Ota and both lesions can occur simultaneously (see Table 73-1).

Mongolian Spots. Mongolian spots are congenital, benign hyperpigmentations that occur primarily in the African,



▲ **FIGURE 73-15** Nevus of Ota in 20-year-old woman. **A.** Hyperpigmentation around the orbita. **B.** The hyperpigmentation extends into the sclera.

Asian, and Hispanic populations and only rarely in Caucasians.[124] They occur in both sexes but with a slight male predominance[125] and preferentially in the sacral area (Fig. 73-16). They can also be found in the gluteal and lumbar region and on the thorax, abdomen, arms, legs, and shoulders. In most cases, mongolian spots show spontaneous regression during childhood, but persistence into adulthood has been described.[126] Histologically, these macules consist of spindle-shaped melanocytes in the lower dermis that have failed to migrate to the dermal-epidermal junction during fetal life. Several cases are described with extensive Mongolian spots involving the trunk and extremities, associated with inborn errors of metabolism such as GM1 gangliosidosis and mucopolysaccharidosis.[127,128]



▲ **FIGURE 73-16** Classic mongolian spot in the lumbosacral region and aberrant or extrasacral mongolian spots on the back.

Dermal Melanocyte Hamartoma. Dermal melanocyte hamartoma is a distinctive form of congenital dermal melanocytosis first described by Burkhart et al. in 1981. Here the gray-blue pigmentation, caused by melanocytes residing in the dermis, occurs in a dermatomal pattern.[129]

CONGENITAL CIRCUMSCRIBED HYPERMELANOSIS WITH LENTIGINOSIS ***Familial Lentiginosis Syndromes.*** Familial lentiginosis syndromes are characterized by the presence of lentigines [small (usually smaller than 5 mm in diameter)] circumscribed brown macules which display an increased number of melanocytes in the epidermis (epidermal melanocytic hypermelanosis) and an increased incidence of cardiovascular, endocrine, or gastrointestinal neoplasias. They include Carney complex, Peutz-Jeghers syndrome (PJS), LEOPARD syndrome (*l*entigines; *e*lectrocardiogram conduction defects; *o*cular hypertelorism; *p*ulmonary stenosis; *a*bnormalities of genitalia; *r*etardation of growth; and sensorineural *d*eafness; LS), arterial dissection and lentiginosis, Laugier-Hunziker disease, familial benign lentiginosis, Bannayan-Ruvalcaba-Riley syndrome (BRRS), centrofacial lentiginosis, and segmental and agminated lentiginosis (Fig. 73-17).[130] In recent years, genetic loci and genes have been identified for Carney complex, PJS, and BRRS.

Peutz-Jeghers Syndrome. PJS is an autosomal dominant cancer predisposition syndrome first described by Peutz (1921) and Jeghers (1949).[133] Mucocutaneous pigmentation and intestinal hamartomatous polyposis are hallmarks of the disease (Fig. 73-18). The pigmentary lesions resemble those of Carney complex, with small hyperpigmented macules typically appearing in childhood (not present at birth) on the lips and buccal mucosa but they may also involve the eyelids, hands, and feet.[130]



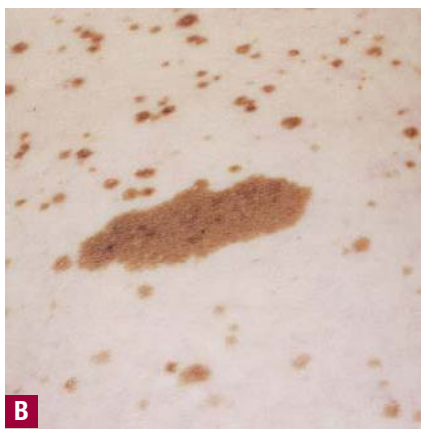

▲ **FIGURE 73-17** **A, B.** A 27-year-old woman with LEOPARD (*l*entigines; *e*lectrocardiogram conduction defects; *o*cular hypertelorism; *p*ulmonary stenosis; *a*bnormalities of genitalia; *r*etardation of growth; and sensorineural *d*eafness) syndrome. Note the characteristic widespread lentigines and several café-au-lait macules.

The most common malignancies associated with PJS are gastrointestinal (small intestine, colorectal, stomach, pancreas). In addition, nongastrointestinal neoplasms such as breast, cervix, and endocrine tumors (thyroid, testicular, ovarian) have been described. More than one-half of all cases of PJS can be attributed to a mutation in the serine/threonine kinase 11 (STK 11 or LKB 1) gene, which is therefore thought to act as a tumor suppressor gene.[134] Close surveillance of PJS patients from a young age is warranted. For Bannayan-Riley-Ruvalcaba syndrome, see online version.

LEOPARD Syndrome. LS is an autosomal dominant genodermatosis.[130] The char-







▲ **FIGURE 73-18** Peutz-Jeghers syndrome. **A.** Lentigines, which are dark brown to gray-blue, appear on the lips, around the mouth, and on the fingers. Lip macules may, over time, disappear. **B.** Macules of the buccal mucosa are blue to blue-black and are pathognomonic; unlike lip lesions, these do not tend to disappear with time.

acteristic lentigines usually develop during childhood and in the first months of life. Clinical diagnosis is primarily based on the typical facial features and the presence of hypertrophic cardiomyopathy and/or café-au-lait macules. The disorder is caused by mutations in the PTPN11 gene, coding for the protein tyrosine phosphatase SHP-2, and situated on chromosome 12. LS is allelic to Noonan syndrome and shares several clinical features (see Fig. 73-17).[137]

Centrofacial Lentiginosis

CONGENITAL CIRCUMSCRIBED HYPERMELANOSIS WITH CAFÉ-AU-LAIT MACULES Café-au-lait macules (CALMs) consist of sharply (and irregularly) bordered hyperpigmented patches of skin, varying in size from 0.5 cm to more than 20.0 cm. They are often present at birth or appear in the early months of life. Between 0.3 percent and 18 percent of all newborns display isolated CALMs.[139] Histologically, isolated CALMs show a normal number of melanocytes but increased epidermal melanin (epidermal melanotic hypermelanosis). Multiple CALMs are well-known markers for several multisystem disorders.

Neurofibromatosis Type 1. Neurofibromatosis type 1 (NF1) was first recognized by Friedrich von Recklinghausen in 1882 and is therefore also called *von Recklinghausen disease* (see Chap. 142).

NF1 is an autosomal dominant disease caused by a mutation in the NF1 gene, situated on chromosome 17q11.2 and encoding the neurofibromin protein. Neurofibromin takes part in several signaling pathways and exhibits multiple isoforms through alternative splicing mechanisms. The most important neurofibromin function involves downregulation of the Ras signal transduction pathway and it is therefore considered a tumor suppressor gene.[130]

NF1 has been considered as a neurocristopathy and is characterized by a number of cutaneous and non-cutaneous pigment cell-related manifestations such as CALMs, intertriginous freckling, and iris Lisch nodules.[140] In 1987, the U.S. National Institutes of Health Consensus Development Conference established clinical diagnostic criteria for NF1 (see Chap. 142). The presence of 6 or more CALMs greater than 5 mm in greatest diameter in prepubertal individuals or greater than 15 mm after puberty is one of the hallmarks of the disease. NF1-associated CALMs, contrary to isolated CALMs, contain a significantly increased number of melanocytes in the epidermis.[141] Intertriginous freckles, pathognomic for NF1, also display increased numbers of epidermal melanocytes, which differentiates them from ordinary freckles (ephelides) (see eFig. 73-18.1 in on-line edition).

Watson Syndrome

McCune-Albright Syndrome. McCune-Albright syndrome (MAS) was first described by McCune (1936) and Albright (1937) as a triad of poly/monostotic fibrous dysplasia, CALMs, and hyperfunctioning endocrinopathies including precocious puberty, hyperthyroidism, hypercortisolism, hypersomatotropism, and hypophosphatemic rickets.[144,145] The CALMs are fewer in number and have more irregular borders than those seen in NF1. They are classically demarcated at the midline. MAS is caused by a post-zygotic activating mutation of the α subunit of the cAMP-regulating Gs protein. Consequently, a mosaic distribution of MAS cells bear the constitutively active adenylate cyclase.[146] For Bloom syndrome and Silver-Russel syndrome, see on-line version.

Nevus Spilus. Nevus spilus or speckled lentiginous nevus is a hyperpigmented patch with smaller, darker macules and/or papules superimposed. Nevus spilus is mostly limited to one isolated lesion but generalized and dermatomal (zosteriform) variants have been described.[154] It is discussed in Chap. 122.

Acquired Diffuse Non-Figured Hypermelanosis

ENDOCRINOPATHIES ***Addison Disease.*** Addison disease is a clinical syndrome characterized by salt-wasting and skin hyperpigmentation, associated with adrenal deficiency and consequent inadequate secretion of corticosteroid and androgenic hormones. In the Western world, Addison disease is usually autoimmune in etiology.

Hyperpigmentation is the most striking cutaneous sign of patients with chronic Addison disease. The hyperpigmentation is diffuse and occurs preferentially on sun-exposed areas (face, neck, hands), on sites of trauma, scars, or chronic pressure (knees, spine, knuckles, elbows, shoulders), in the palmar creases and on nipples, areolae, axillae, perineum, and genitalia. It is discussed in Chap. 152.[161,162]

Cushing Syndrome. Cushing syndrome is characterized by clinical signs and symptoms due to chronic glucocorticoid excess (see Chap. 152).

Various degrees of hyperpigmentation can be seen, usually most severe in patients with the ectopic adrenocorticotropic hormone (ACTH) syndrome. As in Addison disease, hyperpigmentation is generalized, but most prominent in sun-exposed areas such as face, neck, and dorsal hands, as well as in areas subject to chronic mild trauma or pressure (shoulders, midriff, waist, elbows, knuckles, spine, knees) and on mucosal surfaces.

Nelson Syndrome. Nelson syndrome comprises an enlarging pituitary tumour associated with elevated fasting plasma ACTH levels, hyperpigmentation, and neuro-ophthalmologic symptoms in patients with Cushing disease after bilateral adrenalectomy and inadequate hormonal replacement.[163]

Pheochromocytoma. Pheochromocytoma is a tumor derived from chromaffin cells of the adrenal medulla with associated ex-

cessive production of catecholamines. Pallor of the face due to vasoconstriction may be observed. In contrast, addisonian-like hyperpigmentation has been reported and is probably due to ectopic ACTH and melanocyte-stimulating hormone (MSH) production by the tumor. Pigmentation rapidly fades after surgical treatment.[164]

Carcinoid Syndrome. Diffuse hyperpigmentation due to MSH-producing tumors, such as gastric or thymic carcinoid tumors have been described in carcinoid syndrome. Carcinoid syndrome can also be accompanied by a pellagra-like rash occurring on light-exposed skin (see Chap. 130). The rash is secondary to a tryptophan deficiency, as a large amount of dietary tryptophan is diverted to serotonin by the tumor.[170]

Hyperthyroidism. Thyrotoxicosis has multiple causes. The most common cause is Graves disease, characterized by circulating antibodies against thyroid-stimulating hormone receptors (see Chap. 152).

The occurrence of hyperpigmentation in thyrotoxic patients has been estimated from 2 percent to as high as 40 percent in large series. The increased cutaneous pigmentation can be localized or generalized and is more common in dark-skinned people. The distribution of hyperpigmentation is often similar to that in Addison disease with pigment deposition in the creases of the palms and soles. However, several features distinct from that of Addison disease have been noted. Involvement of the mucous membranes is uncommon and pigmentation of the nipples and genital skin is less striking. Hyperpigmentation associated with thyrotoxicosis is thought to be due to an increased release of pituitary ACTH, compensating for accelerated cortisol degradation. The response of hyperpigmentation to therapy for the hyperthyroidism is reported to be poor.[158,171,172] Autoimmune Graves disease has been reported in association with vitiligo.

Melasma. Melasma is a common hypermelanosis that typically occurs on sun-exposed areas in the face. The pathogenesis is poorly understood, but genetic and hormonal influences in combination with UV radiation are important. Specific precipitants include: birth control pills, estrogen replacement therapy, mild ovarian or thyroid dysfunction, ovarian tumors, cosmetics, nutrition, phototoxic and photoallergic medications, phototoxic drugs, and medication for epilepsy.

Melasma is rarely reported before puberty and is far more common in women, especially those of reproductive age. People with darker skin (type IV, V, or VI) are more frequently affected. The lesions are brownish macules with irregular borders and symmetric distribution in the face (Fig. 73-19), often coalescing in a reticular pattern. Sun exposure intensifies the lesions. There are three major patterns of distribution of the lesions: centrofacial (63 percent: forehead, nose, chin, and upper lip), malar (21 percent: nose and cheeks), and mandibular (16 percent: ramus mandibulae). The anterior chest and dorsal forearms may also be affected.



▲ **FIGURE 73-19** Melasma. Typical yellowish to brownish macules with irregular borders on the forehead of a young woman.

From its appearance under Wood's lamp, melasma is classically classified into epidermal, dermal, and mixed. Clinically, the epidermal type has sharp borders, whereas the mixed or dermal type has a blotchy appearance. Epidermal pigmentation is accentuated under Wood's lamp, whereas dermal pigmentation is less apparent. In most patients, the melanin distribution is in the basal layer of the epidermis and the dermis.

Sun exposure is one of the most important causative factors, and sun protection should be included in management. Epidermal pigmentation is known to be more sensitive to topical treatment than dermal pigmentation. Hypopigmenting agents as hydroquinone, tretinoin cream, azelaic acid, rucinol, and kojic acid are helpful when used for prolonged periods. The Kligman formula is a popular combination of hydroquinone, tretinoin, and a weak topical corticoid. Chemical peels and laser therapy may be helpful in the treatment of melasma, but can also result in further unwanted hyperpigmentation. Sometimes, melasma slowly disappears after discontinuation of the hormonal stimulus and/or careful sun avoidance.[173–175]

Pregnancy. During pregnancy increased pigmentation occurs in 90 percent of women and is most prominent in darker skin types. Pre-existing pigmented lesions such as nevi and ephelides become darker. Also, recent scars often darken. In normally pigmented areas such as nipples, areolae, and genitalia, the pigmentation becomes more intense. The linea alba, the median line on the anterior abdominal wall, often becomes hyperpigmented during pregnancy and is then called *linea nigra*. In a small proportion of pregnant women, hyperpigmentation occurs in the axillae or the inner upper thighs. Melasma or "mask of pregnancy" (see the section Melasma) occurs in more than 50 percent of pregnant women (see Chap. 107).

Acanthosis Nigricans. Acanthosis nigricans is associated with hyperpigmentation and is discussed in Chaps. 152 and 154.

Diabetes. (See Chap. 153) A higher vitiligo prevalence has been reported in patients with diabetes type I and II compared to the general population. Diabetic dermopathy is characterized by asymptomatic, irregular, light brown, depressed patches on the anterior lower legs,[80] but the pathogenesis is not known.

NUTRITIONAL CONDITIONS (See Chap. 130) Pigmentary changes can be secondary to nutritional conditions such as kwashiorkor, vitamin B_{12} deficiency, folic acid deficiency, or pellagra. The skin changes are reversible on correction of the nutritional deficiency.

METABOLIC CONDITIONS ***Porphyria Cutanea Tarda.*** Porphyria cutanea tarda is a metabolic disorder that has been associated with diffuse brown hypermelanosis accentuated in sun-exposed areas. In females, a melasma-like hyperpigmentation of the face can be observed (see Chap. 132).

Hemochromatosis. Hereditary hemochromatosis is an autosomal recessive disorder associated with increased intestinal absorption of iron and deposition of excessive amounts of iron in the liver, pancreas, and other organs, including the skin. In the past, hemochromatosis was usually diagnosed at an advanced stage by the classic triad of hyperpigmentation, diabetes mellitus ("bronze diabetes"), and hepatic cirrhosis. Darkening of the skin was present in 70 percent of the patients, due to two different mechanisms: hemosiderin deposition causing a diffuse, slate-gray coloring and increased



melanin production causing bronzing. Because hemochromatosis is now usually diagnosed early, hyperpigmentation is less frequently observed. The pigmentation is usually generalized, but may be more pronounced in sun-exposed areas, genitalia, and scars. Skin bronzing is reversible once phlebitic therapy is started.[189–191]

TUMORAL CONDITIONS ***Mast Cell Disorders.*** Mast cell disorders can lead to hyperpigmentation and are discussed in Chap. 150.

Melanoma. (See Chap. 124) Diffuse, generalized melanosis associated with advanced metastatic melanoma is a rare, although well-documented, event. It is characterized by a slate bluish-gray to brown discoloration of the skin (Fig. 73-20). Histology reveals melanin particles and melanin-containing histiocytes and dendritic cells in the dermis and subcutaneous fat. No melanoma cells can be detected in the skin, and there is no increase in epidermal melanin pigment or number of melanocytes. Melanosomes circulating in the blood have been detected, supporting the hypothesis that diffuse melanosis may result from tumor lysis[199] with release of their organelles into the circulation and subsequent deposition in the skin.

PHYSICAL AGENTS ***Ultraviolet Radiation.*** The major acute effects of UV radiation on normal human skin are sunburn, followed by tanning (see Chap. 89).

Ionizing Radiation. (See Chap. 95) Exposure of skin to ionizing radiation during accidents, such as in Chernobyl, or after local fractionated radiotherapy can give rise to a cutaneous radiation syndrome, characterized by fibrosis, keratosis, telangiectasias, and sharply demarcated lentiginous hyperpigmentation, resembling UV-induced lentigines. Small hypopigmented spots can be intermingled with zones of hyperpigmentation. Skin biopsy shows altered melanin content in melanocytes and basal keratinocytes, corresponding to the clinical appearance. Electron beam therapy has been reported to induce tan-like transient hyperpigmentation and transverse melanonychia.[202–207]

Thermal Radiation. In superficial thermal burn injuries, when the melanocyte-bearing basal epidermis has not been destroyed, various degrees of hyperpigmentation result, depending on the skin color and time after the injury. Thermal injury resulting from laser therapy with intense, high-dose visible light also can give rise to hyperpigmentation, especially in dark-skinned patients. Cryotherapy, tissue destruction by application of cold, commonly causes sometimes permanent hypopigmentation in combination with peripheral hyperpigmentation in treated skin due to melanocyte injury.[208–211]





▲ **FIGURE 73-20** Metastatic melanoma-associated, slate-gray, dermal pigmentation involving the entire body. There was melanogenuria and at autopsy all internal organs were found to be black.

Trauma. Friction melanosis in an acquired pigmentary disorder due to repeated rubbing of the skin. The entity is characterized by brownish pigmentation distributed over the bony prominences of the trunk and extremities.[212]

Toxin- and Medication-Induced Hyperpigmentation

Hyperpigmentation caused by toxic agents or medication accounts for 10 percent to 20 percent of all cases of acquired hyperpigmentations. Central nervous system drugs, antineoplastic agents, antiinfectious drugs, antihypertensive medications, and hormones are most commonly responsible (Table 73-2).

Various pathogenetic mechanisms are involved. Accumulation of melanin that is complexed to the drug [drug-pigment complex (e.g., hydroxychloroquine)], occurs most often without increased melanocyte number. Accumulation of melanin can occur after cutaneous inflammation (post-inflammatory) and/or DNA damage (e.g., carmustine). Some drugs (e.g., carotene) are heavy metals that are directly deposited in the skin. In other cases, non-melanin pigments are synthesized or produced under the influence of the drug (e.g., bile pigments), lipofuscin, or iron after dermal vessel damage and hemoglobin breakdown.

Clinical features vary with characteristic sites, patterns, and shades of discoloration. The forms associated with melanin accumulation are often worsened by sun exposure. Sometimes, the manifestation is more or less specific for the responsible drug, although the mechanism is often poorly understood. For example, a linear, sometimes flagellate hyperpigmentation can be observed in patients taking bleomycin or zidovudine. A diffuse hyperpigmentation on the palms and soles may be present in patients taking cyclophosphamide or doxorubicin. Bleomycin and doxorubicin may produce localized hyperpigmentation around small joints. Estrogen-related hormonal substances and phenytoin-like medication may cause melasma-like pigmentation. Nail unit involvement can be observed with some medications, most frequently chemotherapeutic agents, zidovudine, psoralens, minocycline, antimalarials, and gold. Mucosal hyperpigmentation has been reported with cyclophosphamide, doxorubicin, zidovudine, minocycline, and some heavy metals.

Amiodarone can produce blue-gray pigmentation in sun-exposed areas due to accumulation of a lipid-like substance in macrophages. Some of these patients display photosensitivity (Fig. 73-21). (Hydroxy)chloroquine may give rise to a yellow-brown to bluish-gray pigmentation on the face, the neck, the lower extremities, and the forearms after several years of intake, due to deposition of a drug-melanin complex in the dermis. The nail unit and hard palate may be involved. Exogenous ochronosis has been reported after chronic hydroquinone use (see the section Ochronosis).

Chlorpromazine and related phenothiazines can produce a bluish-gray pigmentation, especially in sun-exposed areas, and pigmentations of the conjunctivae. Minocycline can induce skin hyperpigmentation, as well as pigmentation of the nails, sclerae, oral mucosa, thyroid, bones, and teeth. Skin hyperpigmentation may present as a blue-black discoloration, especially at sites of inflammation, but also in noninflamed sites, especially the anterior legs. In some patients, there is a dull brown dis-

TABLE 73-2
Medications Reported with Hyperpigmentation

Topical treatments	Anti-infectious drugs	Central nervous system drugs	Antineoplastic agents	Miscellaneous
Aminolevulinic acid	Amphotericin B	Amitriptyline	Bevacizumab	Alitretinoin
Carmustine (BCNU)	Ceftriaxone	Carbamazepine	Bleomycin	Amiodarone
Bergamot	Chloroquine	Chlorpromazine	Busulfan	Azathioprine
Bimatoprost	Cidofovir	Citalopram	Capecitabine	Cetirizine
Carteolol	Clofazimine	Clomipramine	Carboplatin	Cevimeline
Chlorhexidine	Dapsone	Clonazepam	Carmustine	Cyclobenzaprine
Hydroquinone	Demeclocycline	Desipramine	Cisplatin	Cyclosporine
Imiquimod	Doxycycline	Diazepam	Cyclophosphamide	Deferoxamine
Latanoprost	Emtricitabine	Donepezil	Dactinomycin	Dicumarol
Nitrogen mustard	Enoxacin	Eletriptan	Daunorubicin	Dinoprostone
Tretinoin	Foscarnet	Fluoxetine	Doxorubicin	Etodolac
Verteporfin	Ganciclovir	Fluphenazine	Epirubicin	Glatiramer
Antihypertensive drugs	Grepafloxacin	Fluvoxamine	Estramustine	Heroin
Acebutolol	Griseofulvin	Haloperidol	Etoposide	Interferon
Betaxolol	Hydroxychloroquine	Imipramine	Floxuridine	Isotretinoin
Bisoprolol	Indinavir	Kava	Fluorouracil	Ketoprofen
Captopril	Ketoconazole	Loxapine	Hydroxyurea	Leflunomide
Clonidine	Linezolid	Mephenytoin	Ifosfamide	Levobupivacaine
Diltiazem	Lomefloxacin	Mesoridazine	Irinotecan	Lidocaine
Esmolol	Minocycline	Methamphetamine	Mechlorethamine	Methimazole
Indapamide	Ofloxacin	Molindole	Mercaptopurine	Methoxsalen
Labetalol	Oxytetracycline	Olanzapine	Methotrexate	Methysergide
Methyldopa	Pyrimethamine	Paroxetine	Mitomycin	Metoclopramide
Metoprolol	Quinacrine	Perphenazine	Mitotane	Niacin
Minoxidil	Quinine	Phenytoin	Mitoxantrone	Nicotine
Nisoldipine	Ribavirin	Pimozide	Paclitaxel	Orphenadrine
Propranolol	Rifabutin	Prochlorperazine	Pentostatin	Pantoprazole
Spironolactone	Rifapentine	Promazine	Procarbazine	Pentazocine
Timolol	Saquinavir	Promethazine	Thiotepa	Phenazopyridine
Heavy metals	Sertaconazole	Risperidone	Vinblastine	Phenolphthalein
Arsenic	Smallpox vaccine	Ropinirole	Vincristine	Propylthiouracil
Bismuth	Sparfloxacin	Thioridazine	Vinorelbine	Psoralens
Gold (compounds)	Sulfadiazine	Thiothixene	Hormones	Quinidine
Iron	Terbinafine	Tiagabine	Chlorotrianisene	Rabeprazole
Lead	Tetracycline	Tolcapone	Corticosteroids	Riluzole
Mercury	Voriconazole	Topiramate	Diethylstilbestrol	Sulfasalazine
Silver	Zidovudine	Trifluoperazine	Estrogens	Tacrolimus
		Venlafaxine	Insulin	Toremifene
		Zaleplon	Leuprolide	Trioxsalen
			Medroxyprogesterone	Vitamin A
			Oral contraceptives	
			Progestins	
			Stanozolol	

Adapted from Litt JZ: *Litt's Drug Eruption Reference Manual*, 11th ed. London, Taylor & Francis, 2005.

coloration, especially in sun-exposed areas. Argyria patients present with a generalized grayish-blue pigmentation; the nails and the sclerae may be involved.

Treatment of toxin- and medication-induced hyperpigmentation involves discontinuation of the responsible agent, if possible. In a small subset of patients, the hyperpigmentation persists even after discontinuation. Sun protection should be advised, especially in forms entailing melanin accumulation. Laser treatment has been reported to be successful in some cases (e.g., amiodarone).[213]

OCHRONOSIS ***Endogenous Ochronosis/Alkaptonuria.*** Endogenous ochronosis/alkaptonuria is discussed in Chap. 131.

Exogenous Ochronosis. Exogenous ochronosis results from the use of certain medications, which form an homogentistic acid polymer-like substance during their metabolism. It presents as an asymptomatic hyperpigmentation of the face, sides and back of the neck, back, and extensor sites of the extremities (Fig. 73-22). Histopathologically, there is a collection of yellowish-brown (ochronotic) globules in the papillary dermis. There is no articular, renal, or cardiovascular involvement. It has been most frequently reported in association with hydroquinone (bleaching creams), usually in skin phototype VI patients, although it has been described in other skin types. Exogenous ochronosis has also been noticed after the use of antimalarials and products containing resorcinol, phenol, mercury, and picric acid. Treatment is rarely helpful, but the offending drug should be stopped to prevent progression.[215] For POEMS syndrome and







▲ **FIGURE 73-21** Amiodarone hyperpigmentation. This patient exhibits a striking amiodarone-induced, slate-gray pigmentation of the face. The blue color (ceruloderma) is due to the deposition of a brown pigment in the dermis, contained in macrophages and endothelial cells.

Cronkhite-Canada syndrome, see on-line version.

SYSTEMIC SCLEROSIS (See Chap. 158) Different types of abnormal pigmentation have been described in systemic sclerosis. A diffuse, generalized hyperpigmentation similar to Addison disease but without increased levels of MSH can be observed in severe systemic sclerosis.

Focal depigmentation with perifollicular hyperpigmentation may occur, especially on friction sites (e.g., shins, elbows, and dorsum of the hands). There can be localized hyper- and hypopigmentation.

A streaky hyperpigmentation over blood vessels on a background of depigmentation has been reported. It is hypothesized that the thermoregulatory properties of the blood vessels could play a role in the development of this pattern. Diffuse reticulated hyperpigmentation accentuated on the trunk has been reported in one case.[63]



▲ **FIGURE 73-22** Exogenous ochronosis. Hyperpigmentation on the nose and cheeks after the use of a hydroquinone cream.

INFECTIONS (See Chap. 201) Erythematous, scaling papules termed *pintids* develop during the secondary stage of pinta. These initially red lesions can turn brown, slate blue, black, or grayish.[68]

Chronic papular onchodermatitis is one of the skin manifestations of onchocerciasis. It is characterized by a severely pruritic maculopapular rash with hyperpigmented macules, most often occurring on shoulders, buttocks, and extremities (see Chap. 207).[69]

Acquired Diffuse Patterned Linear Hypermelanosis

PHYTOPHOTODERMATITIS Contact with plants containing phototoxic agents and subsequent UV exposure may lead to phytophotodermatitis, which is followed by a patterned of hyperpigmentation (see Chap. 91).

FLAGELLATE PIGMENTATION DUE TO BLEOMYCIN (See Chap. 228)

FLAGELLATE MUSHROOM DERMATITIS Flagellate mushroom dermatitis is characterized by linear grouped, erythematous, and intensely pruritic papules, a clinical pattern very similar to bleomycin-induced flagellate dermatitis. It is caused by eating raw or insufficiently boiled shiitake mushrooms (*Lentinus edodes*) and is not elicited by topical contact or ingestion of well-boiled shiitake. The pathogenesis is not yet known, but it is hypothesized that a thermolabile polysaccharide is responsible.[219–221]

Acquired Diffuse Reticular Patterned Hypermelanosis

ERYTHEMA AB IGNE Erythema ab igne is caused by a chronic exposure to moderate heat. The reticular erythema can be accompanied by epidermal atrophy, scaling, and hyperpigmentation. It was frequently seen in the past in people who frequently sat in front of open fires for warmth, but it occurs less often since the introduction of central heating. Nevertheless, it is still seen after local application of heating pads, hot water bottles, or heating blankets. Modern appliances that have been reported to elicit erythema ab igne are furniture with built-in heaters, car heaters, and laptop computers (Fig. 73-23).[224–226]



▲ **FIGURE 73-23** Reticular hyperpigmentation (erythema ab igne) resulting from repeated applications of a heating pad over several years.

PRURIGO PIGMENTOSA Approximately 200 cases of prurigo pigmentosa have been published in the international literature since it was first described in 1971 by Nagashima. It is an intensely pruritic skin disease characterized by coalescing erythematous papules and vesicles that develop symmetrically on the back, chest, neck, and lumbosacral region. These lesions heal spontaneously, leaving a reticular hyperpigmentation (see eFig. 73-23.1 in on-line edition). The disease has a fluctuating course with exacerbations and recurrences. It is twice as frequent in females as in males. The eruption and pruritus respond well to minocycline and dapsone but the pigmentation does not. Environmental and metabolic factors have been suggested as causative agents but the pathogenesis remains unknown.[227]

Acquired Circumscribed Hypermelanosis

NEVUS OF HORI Nevus of Hori was first described by Hori in 1984 as acquired, bilateral nevus of Ota-like macules (ABNOM).[228] It consists of blue-brown to slate-gray mottled hyperpigmentation on the face with predilection for the malar regions. Similar to Ota nevus, it also typically affects the Asian population and has a female predominance. However, the lack of ocular and mucosal membrane involvement and the acquired bilateral character distinguishes the entities. Histologically, melanocytes with stage III or IV melanosomes reside in the upper and middle layers of the dermis. Sun exposure and hormonal changes during pregnancy have been described as triggering factors.[229] Hori described three possible mecha-

nisms for the pathogenesis of ABNOM: (1) "dropping" of epidermal melanocytes into the dermis, (2) migration of melanocytes from hair bulbs, and (3) reactivation of pre-existing latent or immature dermal melanocytes.[228] The latter has been suggested as being the most probable mechanism with UV-radiation and sex hormones as activating factors. In some cases, ABNOM can occur simultaneously with other pigmentary abnormalities such as melasma, freckles, solar lentigines, and Ota nevus.[120,229]

Lentigo simplex and solar lentigines are discussed in Chap. 122.

BECKER'S NEVUS (BECKER HAMARTOMA, BECKER MELANOSIS) This acquired hyperpigmented epidermal nevus was first described by Becker in 1949 (Fig. 73-24).[234] It preferentially occurs in the scapular region, although it has been described in any area of the body, and classically after an intense sun exposure. The lesion is androgen-dependent and becomes more prominent in adolescence, especially in the male population in which hypertrichosis is often associated. Associated anomalies, such as ipsilateral breast hypoplasia, musculoskeletal abnormalities (scoliosis, ipsilateral limb hypoplasia, etc.), maxillofacial abnormalities, and additional cutaneous hypoplasias, occur in the rare Becker's nevus syndrome. Microscopic examination demonstrates normal numbers of melanocytes, but increased levels of melanin in the basal epidermal layer (epidermal melanotic hypermelanosis). The epidermis is acanthotic with variable hyperkeratosis and elongation of the rete ridges. In the dermis, the number of arrector pili muscles is increased, making it difficult to differentiate from the related smooth muscle hamartoma.



▲ **FIGURE 73-24** Becker's nevus on the upper arm and shoulder of a male individual. Note the typical localization and marked hypertrichosis.

Becker's nevus is suggested to follow a paradominant inheritance pattern, which means it (almost) always occurs sporadically. The rare familial cases that have been described (especially in Becker's nevus syndrome) can be explained by a somatic mutation during embryogenesis, resulting in loss of heterozygosity and formation of a mutant cell population. Moreover, a chromosomal mosaicism has been detected in fibroblasts derived from a Becker's nevus.[235–237]

EPHELIDES Ephelides or freckles are small light brown macules appearing in sun-exposed skin of fair-skinned individuals, often with red or blond hair and Celtic ancestry. They are more pronounced during spring and summer and fade during the winter period. They appear in early childhood and often regress later in life. Histopathologic examination shows a normal number of sometimes hypertrophic melanocytes but increased melanin in the basal epidermal layer.

POST-INFLAMMATORY HYPERPIGMENTATION Post-inflammatory hyperpigmentation (PIH) is a common condition caused by numerous preceding cutaneous insults such as drug and phototoxic reactions (see elsewhere in this chapter), infections (see elsewhere), physical injury or trauma, allergic reactions, and inflammatory diseases. Clinically, PIH consists of a macular hyperpigmentation at the site of inflammation (Fig. 73-25).[190] It is far more common and persistent in darker skin types and can be characterized by epidermal as well as dermal melanotic hypermelanosis. A Wood's lamp examination can determine depth of the hyperpigmentation (see Melasma above). Histologic features include pigment incontinence with accumulation of melanophages and increased melanin in dermal or epidermal layers.[238]

FAMILIAL PERIORBITAL HYPERPIGMENTATION Increased pigmentation of the upper and lower eyelids has been described in a number of families. Histologically, characteristics of PIH with increased basal pigmentation and dermal melanophages are seen. However, inflammation does not appear to precede the hyperpigmentation.[239]



▲ **FIGURE 73-25** Post-inflammatory hyperpigmentation. May follow a drug eruption, psoriasis, or lichen planus, especially in skin phototypes V and VI as was the case in this middle-aged East Indian woman. Post-inflammatory hyperpigmentation is a major problem in young women with skin phototypes V and VI.

PARTIAL UNILATERAL LENTIGINOSIS Partial unilateral lentiginosis (PUL) is also known as *unilateral lentigines, lentiginous mosaicism, zosteriform lentiginous nevus, segmental lentiginosis*, and *agminated lentiginosis*.

INHERITED-PATTERN LENTIGINOSIS

ACQUIRED BRACHIAL CUTANEOUS DYSCHROMATOSIS

RIEHL MELANOSIS Riehl melanosis, also known as *female facial melanosis*, is mostly seen in middle-aged women, especially in darker skin types, such as Mexican and Asian women (see eFig. 73-25.1 in on-line edition).

It is characterized by a rapid onset of a reticular gray-brown to almost black hyperpigmentation.

The face (especially the forehead, zygomatic area, and temples) and the neck are principally involved but the hands, forearms, and trunk can also be affected. Inflammatory findings such as erythema and pruritus are usually absent.

The main histopathologic feature is liquefactive degeneration of the basal layer of the epidermis, resulting in pigment incontinence in the dermis. The pathogenesis is not understood.[242,243] The hyperpigmentation has been postulated to be induced by repeated contact with threshold doses of a contact sensitizer such as fragrances, some pigments, and bactericides used in cosmetics and optical whiteners, but is poorly documented in most cases.



CUTANEOUS AMYLOIDOSIS Macular amyloidosis presents as brown to gray-brown macules, mainly on the back (see Chap. 133).

LAUGIER-HUNZIKER SYNDROME

ATROPHODERMA OF PASINI-PIERINI (See Chaps. 62 and 65) The cutaneous lesions of atrophoderma of Pasini-Pierini can be described as single or multiple gray to violaceous-brown atrophic patches from 1 cm to more than 10 cm in diameter with slight depression with a characteristic "cliff drop" border.

Fixed drug eruption can cause hyperpigmentation (see Chap. 40).



ERYTHEMA DYSCHROMICUM PERSTANS Erythema dyschromicum perstans, also known as *ashy dermatosis, dermatosis cinecienta*, and *erythema chronicum figuratum melanodermicum*, was first described by Ramirez in 1957. The patients with this eruption were labeled as *los cenicientos*, the ash ones.[251] The disease is characterized by hyperpigmented macules and patches of variable shape and size with an ashen-gray to brown-blue color. They may have a thin, raised erythematous border in the early stage that later can be absent or, mainly in darker skin types, evolve into a hypopigmented border that accentuates the hyperpigmentation. The eruption can also be polymorphic, presenting simultaneously hypo- and hyperpigmented macules. Lesions occur primarily on the face, the neck, the trunk, and the proximal part of the arms. The lesions are usually asymptomatic, although slight pruritus can be reported. There is a slow progression of the lesion over several years, usually without spontaneous regression.

Erythema dyschromicum perstans is mainly observed in intermediate skin types. It is a disease of young adults, although there are small series reporting the disease in prepubertal children. There is no clear sexual predilection.[252]

Histologic examination of the inflammatory border may demonstrate lichenoid dermatitis with vacuolization of the basal cell layer, occasional colloid bodies, and increased epidermal melanin. The dermal changes are edema of the papillary dermis, a moderate or mild lymphohistiocytic infiltrate, and dermal melanophages.

In inactive lesions there is no vacuolization of the basal cell layer, a diminished dermal infiltrate, and an increased number of dermal melanophages. There is no effective treatment for the disease.[251,252]

Idiopathic Eruptive Macular Hyperpigmentation

Idiopathic eruptive macular hyperpigmentation is an uncommon disorder of pigmentation characterized by an eruption of asymptomatic, brown macules 5 mm to several cm in diameter involving the trunk, neck, and proximal extremities in children and adolescents. There is no previous drug exposure and the lesions disappear gradually over several months to years.

Histopathologically, there is hyperpigmentation of the basal layer of the epidermis and prominent dermal melanophages. The number of mast cells is normal.[253]

MIXED HYPO- AND HYPERMELANOSIS

Dyschromatosis Hereditaria Universalis

Dyschromatosis hereditaria universalis is an autosomal dominant disorder that usually presents in infancy or early childhood in Asian families and is characterized by pinpoint to pea-sized hypo- and hyperpigmented macules, distributed in a reticulated pattern over the trunk, abdomen, and limbs usually sparing the face and palmo-plantar surfaces.[254]

Reticulate Acropigmentation of Dohi

Reticulate acropigmentation of Dohi is a localized form of dyschromatosis universalis hereditaria, also called *dyschromatosis symmetrica hereditaria*. It is characterized by symmetric, small, hyper- and hypopigmented macules on the dorsa of hands and feet and is mainly seen in young children in South American and Asian families.

Westerhof Syndrome

Westerhof disorder, described in three generations of one family, displays congenital hypo- and hypermelanotic macules. There is also growth and mental retardation.[255]

Vagabond Leukoderma

Vagabond leukoderma is a condition found in persons living in poor hygienic conditions. Many abuse alcohol, live on an inadequate diet, and are infested with lice and/or scabies. Diffuse light-brown hyperpigmentation is present at the shoulder and waist girdle and the neck and back are dotted with depigmented macules. The condition improves on institutions of a healthier lifestyle and likely represents a co-existence of many of the disorders.[256]

KEY REFERENCES

The full reference list for all chapters is available at www.digm7.com.

1. Tomita Y, Suzuki T: Genetics of pigmentary disorders. *Am J Med Genet C Semin Med Genet* **131C**:75, 2004
3. Van Den Bossche K et al: The quest for the mechanism of melanin transfer. *Traffic* **7**:769, 2006
51. Crespo-Erchiga V, Florencio VD: Malassezia yeasts and pityriasis versicolor. *Curr Opin Infect Dis* **19**:139, 2006
68. Farnsworth N, Rosen T: Endemic treponematosis: Review and update. *Clin Dermatol* **24**:181, 2006
75. Briganti S et al: Chemical and instrumental approaches to treat hyperpigmentation. *Pigment Cell Res* **16**:101, 2003
76. Perez-Bernal A et al: Management of facial hyperpigmentation. *Am J Clin Dermatol* **1**:261, 2000
80. Jabbour SA: Cutaneous manifestations of endocrine disorders: A guide for dermatologists. *Am J Clin Dermatol* **4**:315, 2003
90. Tobin DJ, Paus R: Graying: Gerontobiology of the hair follicle pigmentary unit. *Exp Gerontol* **36**:29, 2001
102. Kalter DC et al: Linear and whorled nevoid hypermelanosis. *J Am Acad Dermatol* **19**:1037, 1988
106. Happle R: A fresh look at incontinentia pigmenti. *Arch Dermatol* **139**:1206, 2003
118. Zembowicz A, Mihm MC: Dermal dendritic melanocytic proliferations: An update. *Histopathology* **45**:433, 2004
130. Stratakis CA: Genetics of Carney complex and related familial lentiginoses, and other multiple tumor syndromes. *Front Biosci* **5**:D353, 2000
140. De Schepper S et al: Pigment cell-related manifestations in neurofibromatosis type 1: An overview. *Pigment Cell Res* **18**:13, 2005
173. Victor FC et al: Melasma: A review. *J Cutan Med Surg* **8**:97, 2004
180. De Schepper S, Naeyaert JM: Acanthosis nigricans, in *Encyclopédie Médico-chirurgicale (EMC)*, Paris, Elsevier SAS, 2006
190. Stulberg DL et al: Common hyperpigmentation disorders in adults: Part II. Melanoma, seborrheic keratoses, acanthosis nigricans, melasma, diabetic dermopathy, tinea versicolor, and postinflammatory hyperpigmentation. *Am Fam Physician* **68**:1963, 2003
213. Dereure O: Drug-induced skin pigmentation. Epidemiology, diagnosis and treatment. *Am J Clin Dermatol* **2**:253, 2001
218. Bowers AG: Phytophotodermatitis. *Am J Contact Derm* **10**:89, 1999
238. Lacz NL et al: Postinflammatory hyperpigmentation: A common but troubling condition. *Int J Dermatol* **43**:362, 2004
250. Lee AY: Fixed drug eruptions. Incidence, recognition, and avoidance. *Am J Clin Dermatol* **1**:277, 2000

SECTION 12

DISORDERS OF THE ORAL AND GENITAL INTEGUMENT

CHAPTER 74

Biology and Pathology of the Oral Cavity

Ginat Wintermeyer Mirowski
Eva Rawlings Parker

CLINICAL FINDINGS

Workup of the patient with oral complaints requires an organized approach consisting of obtaining complete medical, dental, dermatologic, family, social, and medication histories, and allergic reactions.

The examination includes evaluation of the musculoskeletal and soft tissues of the head and neck, including lymph nodes, thyroid and salivary glands, and a complete mucocutaneous examination. Evaluation of the teeth and periodontal status may be necessary. Directed laboratory studies, including scrapings, cytology, serum studies, culture, and biopsies, should be performed as indicated. This chapter focuses on mucocutaneous aspects of the oral cavity.

The vermillion of the lips is pink, hairless, and covered by a thin dry epithelium; the vermillion border is palpable. The labial mucosa begins at the wet dry line and extends to the sulcus of the dental arches. Minor salivary glands secrete myxoid saliva directly onto the mucosa. Yellow to white 1- to 2-mm papules (Fordyce granules) may be found on the vermillion and buccal mucosa.

Leukoedema is the opalescent appearance of the buccal and labial mucosa that diminishes with stretching of the mucosa. This normal variant has been noted in up to 90 percent of black adults. No treatment is indicated.

The tongue's appearance is distinct on the dorsal, ventral, and lateral aspects. Proper examination requires retraction of the tongue for proper visualization and a bimanual examination. Dorsally, three types of papillae are visualized—filiform, fungiform, and circumvallate papillae. Circumvallate papillae are arranged in an inverted V with the tip indicating the foramen cecum. On the ventral aspect of the tongue, the underlying prominent lingual veins are visible. Foveate papillae and tonsillar tissues are sometimes evident posterior laterally.

The dental arches vary in appearance, depending on the presence or absence of the teeth. The gingival epithelium overlies the alveolar bone.

Abnormalities or diseases of the oral cavity are either localized and confined to the oral mucosa, gingival tongue, palate, and teeth or are signs and symptoms of systemic, acquired, or inherited disorders and genodermatoses.[1–3] Table 74-1 presents an overview of the oral manifestation of systemic disorders.

Diseases of the Lips

ACTINIC CHEILITIS Actinic cheilitis, a premalignant condition due to chronic ultraviolet light exposure, typically affects the lower lip, resulting in an ill-defined, atrophic, white, scaling plaque that may obliterate the vermillion border. Microscopically, solar elastosis, hyperkeratosis, and atypical basal keratinocytes are seen. Any ulceration or induration requires a biopsy to rule out malignant transformation (see Chap. 113).

ANGULAR CHEILITIS (PERLÈCHE) Angular cheilitis (perlèche), an inflammatory reaction, presents with erythema and maceration at the angles of the mouth. Fissuring and crusting results from chronic pooling of saliva (see eFig. 74-0.1 in on-line edition). Predisposing factors include advanced age, ill-fitting dentures, and thumb-sucking in children. Oral candidiasis and secondary bacterial infections are common. Nutritional deficiencies, diabetes, and human immunodeficiency virus (HIV) or other immunosuppressive states are occasionally noted. Treatment begins with eliminating precipitating factors. Topical or systemic antifungal therapy is the mainstay of treatment. Application of petroleum jelly as a mechanical barrier before meals and at bedtime decreases irritation and maceration from food and saliva and reduces inflammation.[4]

CHEILITIS GLANDULARIS Cheilitis glandularis is a rare inflammatory, painless enlargement of the lower lip, usually in el-

BIOLOGY AND PATHOLOGY OF THE ORAL CAVITY AT A GLANCE



- The oral cavity plays an important role in mastication, digestion, speech, and immunologic defense.
- Conditions affecting the oral mucosa may be
  - Normal variants
  - Congenital abnormalities
  - Restricted to the oral mucosa
  - Infections, a reactive processes, or neoplasia



Copyright © 2008 by The McGraw-Hill Companies, Inc. Click here for terms of use.

TABLE 74-1
Oral Manifestations of Systemic or Inherited Disorders and Genodermatoses

Disorder	Oral Manifestations
• Acanthosis nigricans	Velvety, papillomatous mucosal plaques on the lips, tongue, gingiva, and palate
• Addison disease	Diffuse, cutaneous, and mucosal hyperpigmentation that may be initial sign of disease
• Amyloid	Macroglossia
• Angiokeratoma corporis diffusum universalis	Punctate angiokeratomas on labial mucosa
• Ataxia telangiectasia	Intra-oral telangiectasias
• Basal cell nevus syndrome	Odontogenic keratocysts, high arched palate, cleft lip/palate
• Behçet disease	Recurrent aphthous ulcers
• Blue rubber bleb syndrome	Oral cavernous hemangiomas
• Crohn disease	Recurrent aphthous ulcers
• Carney complex	Labial macules and mucosal lentigines
• Chronic granulomatous disease	Ulcerations, severe gingivitis
• Congenital erythropoietic porphyria	Erythrodontia
• Cowden disease	Gingival papillomas
• Darier disease	Cobblestoning of the palate, major salivary gland enlargement
• Dyskeratosis congenita	Pre-malignant leukoplakia
• Focal epithelial hyperplasia	Multiple mucosal papules
• Ectodermal dysplasias	Hypodontia/anodontia, conical shaped teeth, xerostomia
• Gardner syndrome	Osteomas of the mandible, supernumerary teeth, odontomas
• Goltz syndrome	Papillomas/fibromas, notching of alveolar ridge, anodontia, enamel defects
• Hailey-Hailey disease (familial benign pemphigus)	Painful vegetative papules and ulcerations
• Hereditary angioedema	Lip and tongue swelling
• Incontinentia pigmenti	Hypodontia, conical shaped teeth
• Laugier-Hunziger syndrome	Lentigines
• Lipoid proteinosis	Pebbly pink-yellow papules diffusely, thickened, bound-down tongue, parotitis, fissured tongue
• Melkersson-Rosenthal syndrome	Cheilitis granulomatosa
• Multiple mucosal neuromas (Sipple syndrome)	Multiple mucosal neuromas
• Neurofibromatosis	Neurofibromas
• Oral-digital-facial syndrome	Multiple hyperplastic frenula, tongue clefting, nodular hamartomas of tongue and gingiva
• Pachyonychia congenita (type I)	Leukoplakia, natal teeth (type II)
• Papillon-Lefèvre syndrome	Severe gingivitis, alveolar bone destruction, exfoliation of teeth
• Peutz-Jeghers syndrome	Labial melanotic macules
• Plummer-Vinson syndrome	Cheilitis, smooth tongue
• Polycythemia vera	Erythematous to violaceous mucosa
• Reiter syndrome	Geographic tongue
• Riley-Day (familial dysautonomia)	Absence of fungiform and circumvallate tongue papillae (smooth tongue), self-inflicted oral mutilation
• Rendu-Osler-Weber syndrome (hereditary hemorrhagic telangiectasia)	Hemorrhagic telangiectasias
• Sjögren syndrome	Xerostomia
• Systemic lupus erythematosus	Discoid lupus erythematosus and sunburst ulcers
• Tuberous sclerosis	Pitted enamel, fibromas
• Wegener granulomatosis	Large deep ulcers, strawberry gingivae; maxillary sinus
• White sponge nevus	Corrugated white plaques on buccal mucosa



derly men. It is triggered by a variety of stimuli including actinic damage, bacterial infection, tobacco exposure, and chronic irritation. With time, the minor salivary gland duct openings become dilated and inflamed, resulting in excessive mucous secretion. Ultimately, painful enlargement and eversion of the lip with



▲ **FIGURE 74-1** Granulomatous cheilitis. Severe enlargement of the lips.

erosions and recurrent bacterial infections (cheilitis glandularis apostematosa) or malignant transformation is seen. Intralesional corticosteroids early in the disease course may be helpful; however, more aggressive surgical intervention, including vermillionectomy, may be required.[5,6]

GRANULOMATOUS CHEILITIS (CHEILITIS GRANULOMATOSA) Granulomatous cheilitis is characterized by the acute onset of asymmetric swelling of the upper lip or, less commonly, the lower lip (Fig. 74-1). Erythema, scaling, fissuring, and erosions may develop. There is prolonged and recurrent course with eventual fixed swelling. Lingua plicata ("fissured" or furrowed tongue), facial paralysis/ptosis, and granulomatous cheilitis define the clinical triad of Melkersson-Rosenthal syndrome. However, granulomatous cheilitis presents as the sole manifestation of the syndrome in approximately one-third to one-half of patients. Microscopically, granulomatous inflammation is pathognomonic, although not always observed. Case reports suggest limited success with intralesional or systemic corticosteroids, clofazimine, hydroxychloroquine, tetracycline, dapsone, sulfasalazine, and thalidomide.[4,7]

Conditions of the Tongue

GLOSSODYNIA (BURNING MOUTH SYNDROME, GLOSSALGIA, STOMATODYNIA, GLOSSOPYROSIS, GLOSSITIS) Glossodynia, a spontaneous syndrome of burning, discomfort, pain, irritation, or rawness of the tongue, has no identifiable etiology. Classification is based on clinical presentation, with most patients complaining of constant pain, whereas others note either intermittent or increasing pain as the day progresses. Patients may also complain of painful lips, palate, and dysgeusia (altered taste) or xerostomia (dry mouth). Clinical suspicion and serologic findings should

TABLE 74-2
Classification and Etiology of Glossodynia

- Primary
  - Idiopathic[a]
- Secondary
  - Oral disorders
    - Infection (candidiasis, fusospirochetal, viral)
    - Allergic/contact hypersensitivity (dentures, amalgams, additives, others)
    - Mechanical trauma (abnormal tongue habit, dentures)
    - Xerostomia
    - Geographic tongue
    - Fissured tongue
    - Vesiculobullous disease
    - Temporomandibular dysfunction
    - Referred pain from teeth or tonsils
  - Drug related
    - Antibiotics, psychiatric medications, chemotherapy, etc.
    - Any medication that can cause xerostomia
  - Neurologic
    - Peripheral nerve damage
    - Diabetic neuropathy
    - Trigeminal neuralgia
    - Acoustic neuroma
  - Systemic disorders
    - Anemia (iron deficiency, pernicious)
    - Nutritional deficiency (folate, zinc, Vitamin B_{12}, B complex vitamins)
    - Diabetes mellitus
    - Gastroesophageal reflux disease
    - Sjögren syndrome
    - Hypothyroidism
    - Acquired immunodeficiency syndrome
    - Menopause (controversial)
  - Psychiatric
    - Depression
    - Anxiety
    - Cancerophobia
    - Somatoform disorder
    - Obsessive-compulsive disorder

[a]Normal appearing tongue with no other etiology found by history or by physical examination.

guide the workup (Table 74-2). Depressive or anxiety symptoms have been reported in 30 percent to 72 percent and xerostomia in 20 percent of patients with glossodynia. Treatments with sialogogues or antidepressants and selective serotonin reuptake inhibitors, pentoxyphylline, or hypnosis have been found to improve glossodynia even when a psychogenic component exists.[8–11]

GLOSSITIS Glossitis, or inflammation of the tongue, occurs in a heterogeneous group of disorders. Patients complain of pain, irritation or burning, hypogeusia, or dysgeusia. Treatment consists of correcting any underlying etiology, recommendation of a soft, bland diet, and analgesics.

Atrophic glossitis, characterized by filiform de-papillation, ranges from a mild and patchy erythema to a completely smooth, atrophic, beefy-red surface. Etiology includes pernicious anemia, protein and other nutritional deficiencies (iron, vitamin B_{12}, riboflavin, or niacin), chemical irritants, drug reactions, amyloidosis, sarcoidosis, vesiculobullous diseases, oral candidiasis and systemic infections. Moeller or Hunter glossitis of pernicious anemia affects the lateral aspects and tip of the tongue, respectively. Median rhomboid glossitis is an atrophic disorder of the tongue secondary to chronic candidiasis.[12]

Trauma from biting, hot foods, or irritation due to sucking on hard candies may cause inflammation of individual filiform papillae. This exquisitely painful condition may be missed unless careful inspection is undertaken. Elimination of the underlying trauma may be necessary for resolution.

Geographic tongue, a benign inflammatory condition, affects 2 percent of the population. Loss of filiform papillae and erythematous plaques with an annular or serpiginous well-demarcated white border are seen (Fig. 74-2). Recurrences reveal a changing geographic appearance. The increased prevalence in patients with more severe or early onset psoriasis and identical histologic findings supports the hypothesis that geographic tongue may be a form of intraoral psoriasis. Treatment with topical corticosteroids and analgesics is reserved for symptomatic patients. Geographic tongue is seen in Reiter syndrome and is associated with atopic dermatitis, diabetes mellitus, anemia, hormonal disturbances, Down syndrome, and lithium therapy.[12–14]



▲ **FIGURE 74-2** Geographic tongue. Note depapillated patches on dorsal surface of the tongue.



▲ **FIGURE 74-3** Fissured or furrowed tongue. Deep crevices are visible on the dorsal surface of the tongue.

FISSURED TONGUE (FURROWED TONGUE, LINGUA FISSURATA, LINGUA PLICATA, SCROTAL TONGUE, GROOVED TONGUE) Fissured tongue is a normal variant seen in up to 5 percent to 11 percent of individuals. Numerous small irregular fissures are oriented laterally on the dorsal tongue (Fig. 74-3). It is also a classic but nonspecific feature of Melkersson-Rosenthal syndrome [see Granulomatous Cheilitis (Cheilitis Granulomatosa)] and may be seen in psoriasis, Down syndrome, acromegaly, and Sjögren syndrome. Food particles may become trapped and bacterial overgrowth may occur. Thus, regular brushing of the tongue should be emphasized.[9,12]

HERPETIC GEOMETRIC GLOSSITIS (See Chap. 193) Herpetic geometric glossitis, a rare cause of fissuring of the tongue, presents with acute onset of pain and deep longitudinal grooves with smaller lateral fissures. A 4- to 7-day course of systemic antiviral agents results in complete resolution (Fig. 74-4).[15]

HAIRY TONGUE (WHITE OR BLACK HAIRY TONGUE) Hairy tongue, hypertrophy of filiform papillae resembling hair-like



▲ **FIGURE 74-4** Herpetic geometric glossitis. Acute onset of painful fissures on dorsal tongue. These resolved with antiviral therapy.







▲ **FIGURE 74-5** Hairy tongue. Elongated filiform papillae on dorsal tongue.

projections, is associated with heavy tobacco use, mouth breathing, antibiotic therapy, poor oral hygiene, general debilitation, radiation therapy, use of oxidizing mouthwashes containing hydrogen peroxide, chronic use of bismuth-containing antacids, and lack of dietary roughage. Overgrowth of *Candida albicans* may complicate the clinical picture (Fig. 74-5). The white, yellow, green, brown, or black color is due to chromogenic bacteria or staining from exogenous sources. Patients may complain of a gagging sensation, altered taste, or halitosis. Treatment consists of elimination of predisposing factors and initiation of a good oral hygiene regimen with gentle brushing of the tongue. Off-label use of podophyllin or tretinoin gel has been described.[12]

ORAL HAIRY LEUKOPLAKIA (See Chap. 198) Oral hairy leukoplakia (OHL), caused by Epstein-Barr virus, presents as asymptomatic, corrugated, white plaques with accentuation of the vertical folds along the lateral border of the tongue. OHL occurs predominantly in HIV-infected individuals and rarely in organ transplant recipients and patients on chemotherapy. *Candida* infection co-exists in half the cases. OHL responds to acyclovir and cidofovir (an antiviral agent used to treat cytomegalovirus), topical retinoids, and podophyllin, but recurrences are common. Administration of antifungal agents may be helpful. Since initiation of highly active antiretroviral treatment, OHL is rarely seen.[16,17]

MACROGLOSSIA (TONGUE ENLARGEMENT) Macroglossia may be a congenital or acquired process in which the tongue is disproportionately large relative to the patient's jaw size. Pressure against the teeth results in scalloping along the lateral aspects of the tongue. Difficulty with mastication and speech and accidental tongue biting are common. The differential includes Down syndrome, hypothyroidism, Beckwith-Wiedemann syndrome, neurofibromatosis, and infection by mycobacteria, filamentous bacteria, or fungus. Woody induration on palpation suggests amyloid.[9,12]

Diseases of Salivary Glands

XEROSTOMIA (DRY MOUTH) Xerostomia is a common debilitating condition that occurs when saliva production decreases or stops. Xerostomia may be due to medications, medical conditions, dehydration, radiation, and surgical therapy (Table 74-3).[18,19] Xerostomia is graded as mild, moderate, or severe. Objective findings or measurable decrease in salivary flow is found in 15 percent to 44 percent of patients. Subjective complaints may be severe. Women are twice as likely to be affected as men. Ongoing dental and oral care is mandatory because saliva normally neutralizes acids and helps remove food, debris, and plaque from the tooth surfaces. Signs and symptoms of xerostomia include diminished or altered taste and smell, halitosis, heavy plaque accumulation, difficulty in wearing dentures, recurrent yeast infections, burning sensation, difficulty swallowing, dry or cracked lips, salivary calculi, and increased thirst. The workup of patients with xerostomia includes a complete history and physical examination, serum studies, and possible biopsy. Symptomatic relief can be obtained by conservative measures and with sialogogues.[20,21] Side effects of sialogogues may include excessive sweating, nausea, diarrhea, frequent urination, and runny nose. Sialogogues should not be used by people who have uncontrolled asthma or narrow-angle glaucoma and should be used with caution in patients with cardiovascular disease, chronic bronchitis, and chronic obstructive pulmonary disease.

MUCOCELE (MUCOUS RETENTION CYSTS) Mucoceles are benign, painless, dome-shaped fluctuant papules, with a translucent bluish hue, that result from trauma or obstruction of the minor salivary gland ducts. Most mucoceles range in size from a few millimeters to more than 2 cm (Fig. 74-6). They may rupture spontaneously and heal without intervention, although surgical excision may be required to treat persistent or recurrent lesions. Multiple mucoceles, a rare finding that may be mistaken for herpes simplex virus of the hard or soft palate, are seen in graft-versus-host disease, lichen planus (LP), and cicatricial pemphigoid (see Fig. 74-6). Ranula is a large, bluish, translucent fluctuant mass in the floor of the mouth due to obstruction of the submandibular and or sublingual duct. Despite its otherwise benign nature, the ranula may plunge

TABLE 74-3
Etiology of Xerostomia

Medications	Antidepressants, antihistamines, diuretics.
Medical conditions	Parkinson disease, colds, diabetes, anemia, cystic fibrosis, rheumatoid arthritis, granulomatous inflammation: tuberculosis, sarcoid, Sjögren syndrome, human immunodeficiency virus, amyloid.
Dehydration	Fever, excessive sweating, vomiting, diarrhea, blood loss, burns, smoking, consumption of tea, coffee.
Radiation therapy of the head and neck	Radiation of the head and neck associated damage or destruction of salivary glands.
Surgical removal of the salivary glands	Surgical destruction of salivary glands.
Age	Older people may reduce their fluid intake because they are less active or because they fear bladder accidents.



▲ **FIGURE 74-6** Mucocele: A smooth-surfaced, exophytic, fluid-containing, recurrent lesion caused by a traumatic rupture of the minor salivary gland duct.

through the mylohyoid muscle, into the neck, resulting in airway obstruction—a life-threatening emergency. Treatment consists of marsupialization; surgical removal or laser destruction of the affected glands.[22] Diffuse parotid gland enlargement is noted in acute mononucleosis. In HIV infection, parotid gland enlargement due to cyst formation and infiltration with suppressor T cells is a sign of less aggressive disease.

Disease of the Gingiva, Periodontium, and Mucous Membranes

GINGIVITIS AND PERIODONTITIS (PERIODONTAL DISEASE) Gingivitis, inflammation of the gingiva, is characterized by erythema, edema, and blunting of the interdental papillae, without bone loss. Predisposing factors include poor oral hygiene, tobacco use, and diabetes. Periodontitis, chronic infection of connective tissue, periodontal ligament, and alveolar bone, is the most common cause of tooth loss in adults. Long-term periodontitis is associated with increased risk of diabetes, heart disease, stroke, and preterm birth. Clinically, accumulation of subgingival calculus (calcified plaque) and infection with *Actinobacillus actinomycetemcomitans* result in painless, soft-tissue edema, insidious alveolar bone resorption, deepening periodontal pockets, and, ultimately, tooth loss. Malocclusion, birth control pills, diabetes, and steroids may also predispose to periodontitis. Treatment is aimed at decreased inflammation and eliminating the periodontal pockets by mechanical removal of dental plaque through brushing, flossing, use of plaque removal rinses containing chlorhexidine, and regular dental visits. Professional cleaning is necessary to remove the calculus. Systemic tetracycline or metronidazole and periodontal surgery may be required in more advanced disease. Juvenile periodontitis is associated with genetic defects in leukocyte chemotaxis. Periodontal disease is associated with HIV, diabetes, Down syndrome, and Langerhans cell histiocytosis. Children with Papillon-Lefèvre syndrome also develop severe and destructive periodontal disease, with exfoliation of the deciduous and permanent teeth. Oral retinoids have been reported to significantly reduce the exfoliation of teeth seen with Papillon-Lefèvre syndrome, and external beam radiation may be necessary to treat the periodontitis of Langerhans cell histiocytosis.



▲ **FIGURE 74-7** Irregular white striae of classic oral lichen planus on the buccal mucosa.

EROSIVE GINGIVOSTOMATITIS (DESQUAMATIVE GINGIVITIS) Erosive gingivostomatitis is characterized by inflammation and erythema of the gingiva, and is a nonspecific reaction pattern which may be due to viral infection, or autoimmune, inflammatory (e.g., LP; see Chap. 26), and blistering disorders [e.g., erythema multiforme (see Chap. 38) pemphigus (see Chap. 52), and cicatricial pemphigoid (see Chap. 55)]. Gingivitis and periodontitis are specifically excluded from this entity. Other mucocutaneous sites may be affected.[23,24]

LICHENOID MUCOSITIS Lichenoid mucositis, characterized by reticulated white plaques and painful erythematous erosions of mucosal surfaces, may result from LP; multiple medications, including nonsteroidal anti-inflammatory or antihypertensive medications; contact allergy; and graft-versus-host disease. Underlying causes or triggers should be addressed. Topical steroids followed by the use of systemic corticosteroids may be necessary if there is no response to elimination of the underlying etiology.[23–26]

LICHEN PLANUS LP is a very common, chronic, inflammatory condition of the skin and mucosa that affects adult patients, predominantly women. The condition is characterized by painful or asymptomatic lacy, white patches and plaques or papules, often with erosions and ulcerations (Fig. 74-7).

ACUTE NECROTIZING ULCERATIVE GINGIVITIS (TRENCH MOUTH, VINCENT DISEASE) Necrotizing ulcerative gingivostomatitis presents with characteristic, punched-out ulcers of the interdental papillae (Fig. 74-8). Precipitating factors include stressful situations, such as during major school testing periods; poor oral hygiene; nutritional deficiency; and alcohol and tobacco use. Immunosuppressed patients, particularly those with HIV, are at increased risk. Gingival hemorrhage, severe pain, foul odor, fever, and lymphadenopathy are common. Occasionally, necrotizing ulcerative stomatitis may progress to alveolar bone destruction. *Treponema*, *Selenomonas*, *Bacteroides fusiformis*, *Prevotella intermedia*, and *Borrelia vincentii* bacterial species are etiologic agents. Treatment includes improved oral hygiene, antiseptic rinses, systemic antibiotics, and, in severe cases, surgical débridement.[27]

GINGIVAL HYPERPLASIA Gingival enlargement, characterized by hypertrophy of both the free and attached gingiva, particularly the interdental papillae, may be due to infiltration by malignant lymphocytes as in leukemic hyperplasia or glycogen storage disease type Ib or due to medications such as phenytoin, calcium channel blockers, and cyclosporine.[28–31] Management includes discontinuation of the medication if possible, attention to oral hygiene, antibiotics, and gingivectomy in moderate to severe cases.[23,32]

APHTHOUS ULCERATION (APHTHAE, CANKER SORE, RECURRENT APHTHOUS ULCERATION) Aphthous ulceration, acute, recurrent, painful ulcers on nonkeratinized mucosa, is the most common cause of oral ulcerations. Up to 30 percent of the population report having recurrent aphthous ulceration, and most develop ulcers



◀ **FIGURE 74-8** Acute necrotizing ulcerative gingivitis. Very painful gingivitis with necrosis on marginal gingival, edema, purulence, and halitosis.



TABLE 74-4
Clinical Classification of Oral Aphthous Ulcers

	Clinical Appearance	Prevalence	Clinical Course
Minor	One or more < 5-mm shallow ulcers	90%–95%	7–10 days; resolve without scarring
Major	One or more 1- to 3-cm deep ulcers	5%–10%	6 wk; may scar
Herpetiform	1–100 1- to 3-mm shallow ulcers	1%–5%	< 7 days

by age 30 years.[27,33–36] One-third of children younger than age 18 years report having oral ulcers. Aphthous ulcers have a gray or yellow pseudomembrane and an erythematous margin. Three clinical presentations are recognized: minor (90 percent to 95 percent), major (5 percent to 10 percent), and herpetiform (1 percent to 5 percent; Table 74-4). Potential triggers include heredity, food and medication allergy, decreased mucosal barrier integrity, hematologic and immunologic disorders, emotional stress, and trauma. Pregnancy is associated with clinical improvement, whereas smoking cessation and use of sodium lauryl sulfate are associated with clinical exacerbation. A cell-mediated immune response plays a role in pathogenesis. Mononuclear infiltrate of T lymphocytes, macrophages, and mast cells, as well as an increase in tumor necrosis factor, is evident. Aphthous ulcers may present as an oral manifestation of a number of systemic diseases, including acute HIV infection, Behçet disease, syndrome of reactive arthritis, and others (Table 74-5). Classification of simple versus complex aphthosis is based on the clinical course.[34] Simple aphthosis is characterized by one to three oral ulcers that recur one to three times per year. Complex aphthosis is characterized by continuous ulcers (i.e., new ulcers may persist as new lesions form) and associated with systemic disease or genital ulcers (see Table 74-5). To exclude underlying systemic disease, a workup may be undertaken (Table 74-6). A biopsy should be performed when the lesion does not heal within 3 or 4 weeks or if the history is worrisome. Histologic findings show nonspecific ulcerated mucosa with a chronic mixed inflammatory infiltrate. Topical measures are aimed at supportive care and minimizing exacerbating factors.[34,36–38] Systemic treatment includes prednisone, colchicine, and thalidomide.

Behçet disease (see Chap. 167), a rare multisystem disorder most prevalent in Japan, Turkey, and the Middle East, is characterized by oral and genital ulcers, iridocyclitis, and variable presence of synovitis, meningoencephalitis, and cutaneous pustular vasculitis with aphthae and at least two of the other findings required for diagnosis. The oral ulcerations of Behçet disease are an almost universal finding and often herald the onset of this syndrome. The lesions present as multiple aphthous-like ulcers that heal within a few weeks and recur at least three times per year (Fig. 74-9). Cyclic neutropenia, an autosomal dominant disorder characterized by cyclic decreases in the number of circulating neutrophils, presents with ulcerative gingivostomatitis that lasts a few days and recurs at intervals of 21 to 27 days.[37] Progression to periodontal disease with subsequent alveolar bone loss is seen over time.[26,39] Spontaneous improvement is seen as the neutrophil count recovers, but systemic antibiotic therapy may be required to prevent bone loss.

NON-APHTHOUS EROSIONS AND ULCERS

Shallow, painful erosions on the gingiva and buccal mucosa, which at times may be extensive and may lead to ulcerations, occur in pemphigus vulgaris (see Chap. 52; Fig. 74-10), paraneoplastic pemphigus (see Chap. 53), and, less frequently, in bullous pemphigoid (see Chap. 54).

Virtually all patients with cicatricial pemphigoid (see Chap. 55) develop mucosal lesions that consist of a desquamative gingivitis with painful erosions on the tongue, buccal and palatal mucosa, and ocular symblepharon.[40]

Oral erosions that heal without scarring are commonly seen in both epidermolysis bullosa (EB) simplex and junctional EB (see Chap. 60). Patients with dystrophic EB demonstrate the most severe oral involvement. In the recessive form, caries, diffuse oral ulceration, scarring, microstomia, vestibular obliteration, and ankyloglossia are frequent findings. The dominant form has similar features but demonstrates less severity (see Chap. 60). Minimizing trauma and optimizing nutrition are paramount and early referral to dentistry is key in maintaining oral function. EB acquisita pa-

TABLE 74-5
Systemic Conditions Associated with Recurrent Oral Ulcers

- Hematinic deficiency (up to 20%)
- Gastrointestinal malabsorption (3%)
- Celiac disease, dermatitis herpetiformis, and gluten-sensitive enteropathy (HLA DRW10 and DQW1), Crohn disease, pernicious anemia
- Systemic lupus erythematosus
- Human immunodeficiency virus
- Behçet disease
- Trisomy 8, myelodysplasia
- Cyclic neutropenia
- PFAPA (*p*eriodic *f*ever, *a*phthous stomatitis, *p*haryngitis, and cervical *a*denitis)
- MAGIC (*m*outh *a*nd *g*enital ulcers with *i*nflamed *c*artilage)

TABLE 74-6
Clinical and Laboratory Workup of Recurrent Oral Ulcers

No specific tests available,[a] so exclude other disorders

- Obtain a complete medical history and review of systems
- Comprehensive hematologic evaluation
  - Complete blood cell count
  - Erythrocyte sedimentation rate
  - Serum iron, ferritin levels, total iron binding capacity
  - Folate, vitamin B_{12}, vitamin B_1, vitamin B_2, vitamin B_6
  - Weekly complete blood cell count × 5
- Serum anti-endomysium antibody and transglutaminase assay (positive in celiac disease)
- Biopsy for hematoxylin and eosin with special stains
- Tzanck smear, viral studies, and viral cultures
- Colonoscopy, especially in the setting of gastrointestinal complaints
- Central nervous system evaluations, including examination and magnetic resonance imaging

[a]All positive findings should be addressed.





▲ **FIGURE 74-9** Behçet disease. Extensive aphthae in a child involving the lips and tongue.



▲ **FIGURE 74-10** Pemphigus vulgaris. Superficial erosions on the lips, tongue, and palate.

tients frequently have oral involvement consisting primarily of bullae and erosions on the tongue, palate, and buccal mucosa (see Chap. 58). Both discoid and systemic lupus erythematosus have oral discoid plaques, erosions, and ulcerations (see Chap. 156). Oral discoid lupus is characterized by "sunburst" erythematous plaques surrounded by white radiating striations.

Oral lesions of erythema multiforme (see Chap. 38) and Stevens-Johnson syndrome/toxic epidermonecrolysis (see Chap. 39) range from lip edema with erythematous, target-like erosions, to diffuse, painful, intraoral hemorrhagic ulcerations that are often preceded or accompanied by fever and malaise (Fig. 74-11).

Chronic ulcerative stomatitis is an autoimmune mucosal erosive disorder that may involve the skin. Clinically, erosions and ulcers of the mouth resemble erosive LP. However, direct immunofluorescence reveals immunoglobulin G bound to nuclei of keratinocytes of the basal and lower epithelial layers. Patient sera also exhibit circulating stratified anti-nuclear reactions on indirect immunofluorescence using an esophagus substrate. Chronic ulcerative stomatitis differs from other oral ulcerative conditions in that it may be refractory to standard treatments with topical corticosteroids, but it is responsive to hydroxychloroquine.[41,42]



▲ **FIGURE 74-11** Stevens-Johnson syndrome. A young man with mycoplasma pneumonia. Note the erosive lesions on the skin and mucosal surfaces.

IATROGENIC MUCOSITIS Oropharyngeal mucositis, one of the most common complications of systemic chemotherapy and head and neck radiation, occurs due to direct tissue injury of the mucosal epithelium. Early mucositis is characterized by erythema, progressive edema, and ulcerations, especially in areas of trauma and friction such as the tongue and buccal and labial mucosa. Hemorrhage, severe pain, and dysphagia are common. Radiotherapy- and chemotherapy-induced salivary gland hypofunction exacerbates the mucositis and cheilitis. Secondary fungal and herpes infections are common. No effective protocol for prevention of mucositis has been identified. Treatment is aimed at supporting the patient until the bone marrow is reconstituted and the mucosa has healed. Palliative treatment is essential and site-specific cocktails are identified with numerous hospitals. Intra-oral trauma should be minimized. Water-based lubricants, saline or baking soda rinses, ice chips, topical coating agents (kaolin-pectin, aluminum or magnesium hydroxide, sucralfate), topical anesthetics, topical steroids, and systemic analgesics are recommended.[23,27,43,44]

Diseases of the Teeth

Dental caries, a common and important entity, is beyond the scope of dermatology. However, several other noteworthy dental conditions are considered here and presented in Table 74-7.[23,45–47]

Benign Tumors

PYOGENIC GRANULOMA (PREGNANCY TUMOR) (See Chap. 126) Pyogenic granuloma (PG), an exaggerated, reactive proliferation of granulation and vascular tissue, is an oral tumor seen most often in children and young adults. PGs may be triggered by minor trauma or medication. Women classically develop gingival PGs during pregnancy. Surgical excision or other destructive methods are curative. If left untreated, fibrosis occurs, leading to the development of an oral mucosal fibroma. Pulp polyp, an uncommon exaggerated reactive proliferation of the dental pulp (neurovascular bundle), results when gross caries destroys the enamel crown. Treatment is aimed at either conserving the tooth with a root canal and a full coverage restoration or with extraction.[48–50]

VERRUCIFORM XANTHOMA Verruciform xanthoma appears as minute white or yellow verrucous papules on the gingiva, alveolar mucosa, or hard palate. Foamy, lipid-laden macrophages are seen on biopsy. There is no associated hyperlipidemia. Surgical excision is effective.[50]

OTHER TUMORS Mucosal lipomas present as asymptomatic, soft, yellow nodules

TABLE 74-7
Disorders Involving Teeth

DISORDER	FINDINGS
• Bulimia	Erosion of enamel and loss of dentin
• Congenital cytomegalovirus	Yellow dentin and hypoplastic pitted enamel
• Congenital erythropoietic porphyria	Erythrodontia of canine teeth and molars and brown discoloration of incisors
• Congenital syphilis	Hutchinson teeth, mulberry molars
• Ectodermal dysplasia	Hypodontia/anodontia/microdontia, peg-shaped teeth, supernumerary teeth, enamel defects
• Gardner syndrome	Supernumerary teeth
• Goltz syndrome	Anodontia and enamel defects
• Incontinentia pigmenti	Hypodontia, conical-shaped teeth
• Lepromatous leprosy	Reddening of upper teeth (pink spots) due to infection of dental pulp
• Primary biliary cirrhosis	Green pigment deposits
• Sjögren syndrome	Caries, increased plaque accumulation, poor oral hygiene
• Reflux	Erosion of enamel due to repeated exposure to gastric acid Seen in bulimia and chronic regurgitation.
• Tetracycline staining	Permanent gray discoloration
• Tuberous sclerosis	Pitted enamel of the permanent teeth



on the buccal or vestibular mucosa, tongue, floor of the mouth, or lips of middle-aged adults.

Traumatic neuroma may occur around the mental foramen, the alveolar ridge, the lip, or the tongue. Neurofibromas and schwannomas (neurilemmoma) may occur on the tongue or buccal mucosa may be occasionally painful. Malignant transformation is rare.[51] Conservative surgical excision is indicated for symptomatic relief. Patients with neurofibromatosis may present with macroglossia, multiple mucosal neuromas (Sipple syndrome) may be associated with pheochromocytoma, parafollicular thyroid cysts secreting calcitonin, medullary thyroid carcinoma, and opaque nerve fibers on the cornea.



Granular cell tumor (Abrikosov tumor, granular cell myoblastoma), a rare reactive process of Schwann cell origin, appears on the dorsal tongue as single or multiple asymptomatic firm, ill-defined papule(s). Extra-lingual involvement has been reported (see Chap. 127).

Disorders of Pigmentation or Pigment Cells

Physiologic hyperpigmentation is characterized by well-demarcated, symmetric pigmentation of the attached gingiva and tips of the fungiform papillae and is noted in individuals with a darker natural complexion and in women who are pregnant or on hormone replacement therapy. Lentigines, brown macules on the palate, gingiva, or lips, are common oral melanocytic lesions. Labial melanotic macules, brown, black, or blue asymptomatic macules, occur on the lips, palate, gingiva, and buccal mucosa (see Chap. 122). Microscopically, increased basal layer melanin without rete ridge elongation is observed. Both lentigines and melanotic macules tend to be solitary and are more common in women older than age 40 years. Multiple labial melanotic macules are associated with Peutz-Jeghers syndrome (see Chap. 73; see eFig. 74-11.1 in on-line edition),[52–54] Carney complex, and Laugier-Hunziker syndrome (see eFig. 74-11.2 in on-line edition).

Intra-oral nevi are uncommon acquired lesions that appear at any age as gray, brown, or blue papules. The palate is the most frequently affected site, but lesions have been noted to occur on the buccal and labial mucosa, gingiva, alveolar ridge, and vermillion. Histologically, these lesions are similar to cutaneous nevi, demonstrating junctional or intramucosal nests of nevus cells (see Chap. 122). Blue nevi also occur intra-orally, typically on the palate, and show spindle-shaped nevus cells deep in the mucosal connective tissue. Thus far, dysplastic nevi of the oral mucosa have not been reported. Although nevi are asymptomatic and benign, they can mimic oral melanoma clinically. Therefore, any uncertain lesion, or those which are ulcerated, exophytic, or atypical, should be biopsied.[53]

Intra-oral melanoacanthoma, a rapidly progressive phenomenon, arises in response to a traumatic stimulus. Melanoacanthoma arise suddenly on the buccal mucosa in black women in the third decade of life and may reach a diameter of several centimeters in just a few weeks. Melanoacanthoma are darkly pigmented, well-demarcated irregular plaques. A biopsy must be performed to exclude malignant melanoma. Dendritic melanocytes are seen throughout the mucosal epithelium accompanied by acanthosis and spongiosis. Importantly, no pleomorphism or mitoses are observed. Melanoacanthomas may spontaneously regress after eliminating local trauma.[55]

Neuroectodermal tumor of infancy, a rare, rapidly growing, darkly pigmented tumor derived from neuroectodermal tissue, presents most commonly on the anterior maxillary alveolar ridge. An ill-defined lucency with potential displacement of teeth is seen radiographically. Collections of large melanin-containing cells interspersed between the collagen are seen histologically. Patients have high serum levels of vanillylmandelic acid and α-fetoprotein. Surgical excision is indicated to prevent local tissue destruction.[56,57]

Pre-Malignant Lesions (See Chap. 113)

Pre-malignant leukoplakia, a chronic, white, verrucous plaque with histologic atypia, occurs largely in men older than the age of 40 years. The severity of leukoplakia is linked directly to the duration and quantity of tobacco and alcohol use. Lesions may occur anywhere in the oral cavity, but lip, tongue, or floor of the mouth lesions are most worrisome for progression to squamous cell carcinoma (SCC).[25,57,58] Erythroleukoplakia, or speckled leukoplakia, has the highest rate of malignant transformation. Histologically, hyperkeratosis, epithelial hyperplasia, and, uncommonly, dysplasia are seen. Cessation of tobacco use, early in the evolution, results in resolution of the leukoplakia. Despite this, leukoplakia requires a biopsy to rule out malignant transformation. Mild dysplasia may be followed clinically. Chemoprophylaxis with topical or systemic retinoids may be beneficial. Moderate to severe dysplasia should be surgically excised or ablated (see Chap. 13). Frequent clinical monitoring is indicated as recurrences are common.

Erythroplakia, a non-inflammatory erythematous plaque on the floor of the mouth, lateral and ventral tongue, or soft palate, is analagous to intra-oral erythroplasia of Queyrat or SCC in situ. In contrast to leukoplakia, most biopsies of erythroplakia demonstrate severe dysplasia and may contain areas of frank invasion.

Submucous fibrosis, a unique premalignant condition, presents as a generalized white discoloration of the oral mucosa of individuals in India and Southeast Asia who chew betel quid, a concoction of tobacco, lime, areca nut, and betel leaves. Progressive fibrosis results in the development of painful mucosal atrophy and restrictive fibrotic bands. Ultimately, trismus (defined as spasm of masticatory muscles), dysphagia, and severe xerostomia predominate. Up to 15 percent of cases demonstrate dysplasia, and approximately 5 percent to 10 percent of patients progress to SCC. Submucous fibrosis is an irreversible condition with no effective treatment. Frequent monitoring for malignant transformation is essential. Surgical interventions may be necessary in more advanced cases to release fibrotic bands and improve trismus.[59,60]

Malignant Lesions

SQUAMOUS CELL CARCINOMA Oral SCC may present as leukoplakia, erythroplakia, erythroleukoplakia, irregular endophytic masses with ulceration, or exophytic nodules (see Chap. 114). High-risk anatomic sites for development of SCC are the ventrolateral tongue, floor of the mouth, and the vermillion border of the lip. Gingival lesions are more common in women. Any persistent oral lesion should be biopsied. High risk lesions, including any persistent ulcer, in high-risk sites (floor of mouth, site of previous SCC, site of previous radiation) have a high probability of being malignant. A second primary lesion of the aerodigestive tract is found in up to one-fourth of patients with oral SCCs.[25,57]

Verrucous carcinoma, an uncommon, locally aggressive SCC occurs in older adults. Risk factors include use of smokeless tobacco products and infections with human papillomavirus (HPV) sub-types 16 and 18. Clinically, verrucous carcinoma presents as a hyperkeratotic, verrucous, exophytic white mass on the vestibules or mandibular gingiva, floor of the mouth, palate, and lip (see Chap. 114).

Proliferative verrucous leukoplakia, a rare progressive multifocal leukoplakia, presents as white, hyperkeratotic, verrucous plaques that progress to involve large areas of mucosa (Fig. 74-12). Women are affected four times as frequently as men. Early lesions may be solitary homogenous leukoplakia that shows hyperkeratosis without dysplasia. However, lesions tend to recur and spread to involve several sites. Greater than 90 percent undergo malignant transformation, largely to SCC, although some lesions may transform into verrucous carcinoma. Smoking is not associated, although HPV may be an etiologic factor. Polymerase chain reaction confirms the presence of HPV. Treatment is highly unsatisfactory, with a very high rate of recurrence after surgical excision and laser destruction.[25,58,61–63]

Intra-oral melanoma presents as an irregular pigmented macule, patch, or papule on the hard palate or maxillary gingiva in patients older than the age of 50 years. Although often asymptomatic, advanced lesions may ulcerate or bleed. As with cutaneous lesions, Breslow depth is the most important prognostic factor, but, unfortunately, these lesions often go undetected until they are advanced, resulting in an overall poor prognosis for intra-oral melanomas (see Chap. 124).

Hodgkin, non-Hodgkin, cutaneous T-cell, and Burkitt lymphoma may present as non-specific, intra-oral, indurated, painless masses that are often ulcerated.



▲ **FIGURE 74-12** Proliferative verrucous leukoplakia. Note white plaque on floor of mouth.



▲ **FIGURE 74-13** B-cell lymphoma. Red violaceous nodule on gingival margin.

Common locations include the palate, tonsillar pillar, vestibule, gingiva, and tongue. Lymphadenopathy of the cervical, submandibular, and supraclavicular nodes is frequently observed. Burkitt lymphoma is associated with alveolar bone destruction. Atypical lymphocytic infiltrates are noted histologically. Specific chemotherapy and/or radiation treatment regimens are indicated and depend on the type of lymphoma (Fig. 74-13).

In Langerhans cell histiocytosis, oral findings, such as ulcerative gingivitis and severe periodontitis, ulceration, and bony destruction, are common and may represent the initial or sole manifestation of this disease (see Chap. 148). Treatment involves curettage or excision of the affected tissue, radiation, and cytotoxic agents.[26,64,65] In multicentric reticulohistiocytosis, up to 50 percent of patients demonstrate flesh-colored to reddish-brown nodules on the oral or nasal mucosa in addition to the classic cutaneous lesions and associated arthropathy (see Chap. 149). Kaposi sarcoma (see Chap. 128) presents as single or multiple hemorrhagic patches or exophytic nodules anywhere in the mouth but most often on the gingiva (Fig. 74-14) or palate.

VARICOSITIES Varicosities appear as asymptomatic, blue, soft nodules on the lips and ventrolateral tongue and are extremely common in middle-aged and older individuals.[9,12] Occasionally, varicosities thrombose, but revascularization is rapid. Varices are not associated with any known systemic disease, and no treatment required. A biopsy is indicated if a melanoma is suspected.

Caliber-persistent labial artery, an under-recognized vascular anomaly, presents as a raised pulsatile tortuous, blue rubbery bleb that is above the mucosal surface. Appreciation of lateral pulsation is diagnostic. Histologically, there is a relatively large-caliber superficial artery is noted on a lip biopsy.[66]

Mucosal hemangiomas, benign vascular tumors of infancy, appear as erythematous or bluish vascular nodules, sometimes with associated thromboses and phleboliths. Although spontaneous regression with time is typical, very large or symptomatic lesions that interfere with feeding should be treated with intralesional or systemic steroids, vascular laser, or surgical excision.[67,68]

Petechiae, ecchymoses, hematomas, and spontaneous gingival hemorrhage may appear as red, blue, or brown macules on the soft and hard palate, the buccal mucosa, or the gingiva in patients with a bleeding diathesis. One should consider thrombocytopenia and coagulation defects resulting from hemolytic anemia, von Willebrand disease, or anticoagulant therapy as the etiology.[39,69]

Salivary Gland Tumors

Evaluation and treatment of salivary gland tumors are beyond the scope of dermatology, but affected patients may present to the dermatologist. Minor salivary gland tumors occur most commonly on the palate and on the retromolar pad, distal to the third molar. A biopsy is indicated for suspicious pap-



◀ **FIGURE 74-14** Kaposi sarcoma. Hemorrhagic nodules on the gingiva.



ules and particularly for ulcerated papules and nodules.

Medication-Related Oral Changes

A number of systemic medications may induce changes of the oral mucosa. In general, women appear more susceptible to drug-induced pigmentary change. The common offenders include minocycline, antimalarials, clofazimine, amiodarone, ketoconazole, and zidovudine. Many patients are disturbed by the cosmetic appearance. The pigment gradually fades after discontinuation of the implicated medication, or it may persist for months to years.[23,53,70]



Intra-oral fixed drug eruptions may occur alone or in conjunction with typical cutaneous lesions. The mucosal lesion appears as a bulla or eroded plaque that evolves into a hyperpigmented patch with surrounding erythema. Diagnosis is made from the history and clinical appearance of the lesion. However, a biopsy may be helpful in ruling out other etiologies, and medication challenges or patch testing may confirm the causative agent.

Amalgam tattoos (focal argyrosis), the most common source of exogenous pigmentation of oral mucosa, results from the iatrogenic introduction of the metal alloy by traumatic mucosal implantation of dental amalgam particles, transfer through chronic friction of the mucosa against the dental restoration, or introduction into gingival tissue. Amalgam may contain silver, tin, and copper alloys and is used in dentistry for tooth restoration ("fillings"). Lesions are seen more frequently in women and appear as black, blue, or gray pigmentation at sites on the gingiva, buccal mucosa, alveolar mucosa, palate, or tongue. One-fourth of lesions may be diagnosed by x-ray due to their radiopaque nature. Histologically, amalgam particles appear as dark granules deposited perivascularly and between collagen fibers. Additionally, fibrosis, chronic inflammatory infiltrates, and multinucleated foreign-body giant cells may be noted. Treatment is not necessary, but Q-switched ruby and alexandrite laser have demonstrated success in patients who desire cosmetic removal of the tattoo.[53,71]

Cultural tattooing is commonplace among many of the world's populations. For example, Ethiopian women tattoo the anterior maxillary gingiva. A similar practice is seen among male prison inmates who may tattoo vulgar written messages on the labial mucosa, a so-called "jail house tattoo."[72,73]

Ingestion or exposure to heavy metals such as lead, mercury, silver, gold, arsenic, bismuth, chrome, cadmium, or platinum may result in a gray to black pigmentation of the gingival mucosa. Hyperpigmentation of oral mucosa has been linked to smoking.[53,74,75] It is postulated that a component of tobacco smoke stimulates melanin production, a phenomenon that may be further exacerbated by both endogenous and exogenous estrogen. The anterior aspect of the labial gingiva is the most common site for cigarette-related melanosis, whereas palatal and buccal mucosal pigmentation is associated with pipe smoking. Smokeless tobacco products have not been implicated. The degree of hypermelanosis is related to duration and quantity of tobacco consumed. The discoloration may reverse slowly after smoking cessation. Although tobacco use in general is associated with mucosal dysplasia, this hyperpigmentation is felt to be benign.[76]

Endogenous causes of oral pigmentation encompass a variety of systemic diseases and primary melanocytic processes. The most noteworthy are postinflammatory hyperpigmentation and Addison disease. However several others deserve mention, including Albright disease, hemochromatosis, Wilson disease, acanthosis nigricans, nutritional deficiency, lentigines and nevi, and several genodermatoses.

Physical and Chemical Trauma

Chronic biting and manipulation of the lips and the buccal mucosa, usually as a nervous habit, produce a ragged, irregular, white plaque at the site of trauma, representing a form of reactive hyperkeratosis. The wedge-shaped lesion on the buccal mucosa that is narrower at the posterior aspect is highly suggestive of the diagnosis. Histologic examination reveals hyper- and parakeratosis, epithelial spongiosis, and many superficial bacterial colonies. This benign condition requires no treatment, but resolves gradually if the biting stops.[25,77] Frictional keratosis, a thickened white plaque that correlates with the microscopic findings of marked hyperkeratosis and acanthosis, requires a biopsy to rule out a neoplastic process. Identification and elimination of the source of friction (e.g., sharp tooth or overextended denture) should resolve the lesion. Irritation fibroma, a sessile nodule at any site of chronic mucosal irritation, also requires tissue biopsy to demonstrate a dense fibrous connective tissue tumor with overlying hyperkeratosis. Conservative surgical excision typically results in a cure. Epulis fissuratum commonly develops beneath poorly fitting dentures due to chronic trauma and friction. Patients display painless, elongated ridges of hypertrophic mucosa along the anterior labial alveolar ridge. As the tissue redundancy increases, ulceration may occur. Excess tissue can be surgically excised, and dentures should be refitted.[78] Giant cell epulis, a reactive hyperplastic proliferation, appears as a deep red papule on the interdental papillae. Many multinucleated giant cells are seen histologically in a vascular proliferation. Older lesions show collagenous or pathologic bone formation. In 10 percent of patients, giant cell granulomas are associated with hyperparathyroidism. Reactive papillary hyperplasia affects areas of the palate beneath ill-fitting dental prostheses. Mechanical mucosal injury and subsequent colonization by *C. albicans* results in erythema and short papillary projections, pain, and burning. Improved oral hygiene and refitting of dental appliances is recommended. Additionally, antifungal therapy should be initiated. If patients do not respond, a biopsy is warranted.

Smoker's palate, or nicotine stomatitis, results from thermal injury to the hard palate of pipe smokers. Erythema of the minor salivary gland orifices is initially seen. Hyperkeratosis is noted later on the surrounding palatal mucosa. This appears as a diffusely white palate studded with 2- to 5-mm erythematous umbilicated papules. The diagnosis is based on the clinical appearance and a history of chronic pipe smoking. Resolution is noted with smoking cessation.[75]

In persons who use chew tobacco, a granular or wrinkled white plaque may develop in the mucobuccal fold where the patient habitually places the tobacco. Long-standing lesions have a more opaque and corrugated appearance. Microscopically, epithelial hyperplasia and hyperkeratosis is observed. Although lesions generally resolve with cessation of the habit, use of smokeless tobacco is a risk factor for oral SCC. Therefore, any lesion that persists should undergo biopsy to rule out dysplasia or overt malignancy.

In some instances, bite trauma or laceration of the mucosa may produce an ulcer with fibrinous exudate and surrounding erythema on the buccal mucosa, tongue, or lips. On occasion, the lesion may have a hyperkeratotic white border. Patients complain of moderate pain and experience relief with topical anesthetics. Otherwise, treatment is not

necessary, as these lesions are self-limited. However, traumatic ulcers may be confused with SCC. If the diagnosis is uncertain, biopsy is warranted.[27]

CHEMICAL BURN Aspirin burns occur when a patient places an aspirin tablet inside the cheek near a painful tooth to relieve the symptoms of a toothache. As a result, the mucosa in direct contact with the pill becomes necrotic and painful, a desquamating white lesion. Over-the-counter oral pain relief medications that contain phenol can cause a lesion that is clinically identical to an aspirin burn. The diagnosis of a chemical burn is usually established from the patient's history and physical examination findings. These lesions resolve spontaneously with avoidance of the chemical trigger.[23,27]

CONTACT STOMATITIS The oral mucosa is susceptible to contact allergy. Cheilitis due to allergens in foods, dental products, or cosmetics may occur alone or in conjunction with intra-oral erythema, ulceration, or a lichenoid mucositis. Dental amalgams may produce a localized lichenoid reaction pattern on the mucosa. Cinnamate allergy is more likely to result in diffuse erythema. The large number of other substances that can result in oral contact allergy include flavorings, food additives, spices, toothpaste, mouthwash, dental epoxy resins, and cosmetic lip products. Identification and removal of the offending substance generally results in resolution. Amalgam-containing restorations may be polished or recontoured but fusion of composite, gold, or porcelain to the metal amalgam (fillings) may be necessary. In rare instances, the restoration must be completely removed.[4,23,79]

Infections

Bacteria, viruses, and fungi are important commensals and pathogens of the oral cavity. In this chapter, the oral manifestations are highlighted. The clinical findings are summarized in Table 74-8. For a complete description of the organ-



TABLE 74-8
Oral Manifestations of Viral, Bacterial, and Fungal Infections

Infection	Etiologic Agent	Oral Findings	Comment
Viral			
Herpes	HHV-1 and HHV-2	Lip edema with erythematous, grouped vesicles, target-like erosions, and intra-oral hemorrhagic ulcers. Tongue involvement in immunocompromised patients.	Primary infection—sub-clinical childhood to acute ulcerative gingivostomatitis; reactivation—herpes labialis and erythema multiforme.
Chickenpox	Varicella-zoster virus (HHV-3)	Oral ulcers on palate or buccal mucosa.	—
Herpes zoster	Varicella-zoster virus (HHV-3)	Painful, unilateral, aphthous-like ulcers in second and third trigeminal nerve branch.	Postherpetic neuralgia, Ramsay Hunt syndrome.
Infectious mononucleosis	Epstein-Barr virus (HHV-4)	Exudative tonsillitis, uvular edema, palatal petechiae, and, uncommonly, necrotizing ulcerative gingivitis.	Confirm infection with heterophil antibodies, *Candida* superinfection in 50% of oral hairy leukoplakia.
Oral hairy leukoplakia	Epstein-Barr virus (HHV-4)	White plaques with prominent vertical folds on lateral tongue > dorsal tongue > buccal mucosa and vestibule in immunocompromised individuals.	Presence is predictive of progression to acquired immunodeficiency syndrome.
Congenital cytomegalovirus	Cytomegalovirus (HHV-5)	Yellow dentin and hypoplastic pitted enamel of the teeth. Aphthous-like ulcers are seen in adults.	Seen in one-third of congenital cases. Intranuclear inclusion bodies called *owl's eye* seen on biopsy.
Roseola infantum (exanthem subitum)	HHV-6	Erythematous macules on soft palate.	Enanthem precedes exanthem.
Kaposi sarcoma	HHV-8	Erythematous to violaceous macules on the palate, gingiva, or tongue. Evolve into painful, ulcerated nodules.	Almost exclusively with HIV infection.
Herpangina	Group A coxsackievirus	Acute onset, 1- to 2-mm erythematous macules on palate and uvula. Lesions vesiculate and ulcerate, leaving painful superficial erosions.	—
Hand-foot-and-mouth disease	Coxsackie A16	Many small, painful ulcers with surrounding erythema on the tongue, buccal mucosa, palate.	Discomfort often so great patients cannot consume food.
Acute lymphonodular pharyngitis	Group A coxsackievirus	White or yellow papules with an erythematous base on uvula, tonsils, oropharynx.	—
Measles (rubeola)		Koplik spots—brightly erythematous macules with white centers on buccal mucosa adjacent to the posterior teeth.	Histology shows giant cells with cytoplasmic inclusions.
Rubella (German measles)		Forschheimer spots—small erythematous macules on palate.	Not a feature of congenital rubella.

(continued)

TABLE 74-8
Oral Manifestations of Viral, Bacterial, and Fungal Infections (Continued)

Infection	Etiologic Agent	Oral Findings	Comment
Acute seroconversion of HIV	HIV	Erythema, ulcerations, and secondary candidiasis.	High fever [38.9°C (102°F)], malaise, sore throat, gastrointestinal distress, generalized adenitis, and night sweats. An exanthema, seen in 70%, presents within 1–2 days on the trunk and face as a morbilliform eruption or hemorrhagic macules.
Squamous papilloma	HPV	Solitary, exophytic, pedunculated, mucosa-colored papule, occurs on the palate or tongue.	—
Verruca vulgaris	HPV	Solitary or clusters of verruciform papules on the buccal mucosa, lips, or perioral skin.	Verrucae often result in autoinoculation; HPV types 2 and 4.
Condyloma acuminatum	HPV	Resemble verruca vulgaris but are larger. Oral involvement of the labia, lingual frenum, soft palate, and gingiva.	Due to orogenital transmission of HPV type 6, 11, 16, or 18
Focal epithelial hyperplasia (Heck disease)	HPV	Benign, soft, painless 1- to 4-mm papules on the labial, buccal, or lingual mucosae, and, rarely, the gingiva. A cobblestone or fissured appearance disappears when the mucosa is stretched.	Prevalent in North, South, and Central American Indians. HPV types 13 and 32. An association with HLA-DR4 (DRB1*0404).
Kawasaki disease	Unknown	Beefy red oropharynx, strawberry tongue (inflammation and papillary enlargement), and severe hemorrhagic cheilitis.	—
Bacteria			
Scarlet fever	Group B streptococcus	Erythema of the hard palate and a white-coated tongue with erythematous, edematous, fungiform papillae. Later, the tongue becomes beefy red (strawberry tongue).	Mediated by bacterial toxins
Diphtheria	*Corynebacterium diphtheriae*	Thick, gray pseudomembrane with erythematous halo on tonsils, pharynx, and, occasionally, gingiva, tongue, and buccal mucosa. Pseudomembrane wipes away to reveal hemorrhagic erosions.	—
Tularemia	*Francisella tularensis*	Painful, necrotic oral ulcers or diffuse stomatitis.	Painful cervical lymphadenopathy and fevers accompany oral lesions.
Lepromatous leprae	*Mycobacterium leprae*	Firm yellow-pink ulcerative nodules (lepromas) on the palate or tongue. Macroglossia due to tongue infiltration. Reddening of upper teeth (pink spots) due to infection of dental pulp.	Lesions heal with scarring.
Granuloma inguinale	*Chlamydia granulomatis*	Painful hemorrhagic ulcers or vegetative nodules. Severe scarring is common.	Most common site for extragenital involvement.
Primary syphilis	*Treponema pallidum*	Chancre—painless ulceration with indurated borders on the lip, tongue, buccal mucosa, or oropharynx with cervical lymphadenopathy.	Labial chancre is the most common site for extragenital syphilis. Oral lesions are highly contagious through direct contact.
Secondary syphilis	*T. pallidum*	Mucous patches—oval plaques on the tongue with a white or gray pseudomembrane. Split papules—macerated, flat-topped papules at the oral commissures (condyloma lata). Occasionally, chronic oral ulcerations.	Oral lesions are highly contagious through direct contact.
Tertiary syphilis	*T. pallidum*	Interstitial glossitis with significant atrophy of the filiform and fungiform papillae and deep fissuring of the tongue. Pre-malignant leukoplakia. Rarely, gummas involve palate.	—
Congenital syphilis	*T. pallidum*	Hutchinson teeth in 50%—peg shaped with crescentic notches along incisal edge of incisors. Mulberry or Moon's molars—rounded or crenated occlusal cusps of first molars.	—
Gonorrhea	*Neisseria gonorrhoeae*	Most often, an asymptomatic pharyngitis with diffuse erythema of the tonsils. Can present with purulent tonsillitis, pseudomembranous ulcers, and lymphadenopathy.	Concomitant urogenital gonorrhea common. Asymptomatic oral infection is important reservoir for transmission and a source for disseminated gonococcemia. Oral gonorrhea often requires multidrug therapy for successful treatment.

(continued)



TABLE 74-8
Oral Manifestations of Viral, Bacterial, and Fungal Infections (Continued)

Infection	Etiologic Agent	Oral Findings	Comment
Mycobacteria			
Tuberculosis	*M. tuberculosis*	Solitary or multiple painful, irregular ulcers with surrounding erythema on tongue or gingival. Less often, vegetative nodules or plaques.	Rare complication of pulmonary tuberculosis resulting from autoinoculation with infected sputum.
Fungus			
Primary oral aspergillosis	*Aspergillus*	Necrotic, violaceous ulcerations with black eschar on the gingiva and palate. Advanced disease may involve alveolar bone and facial muscles.	Histology reveals necrosis and angioinvasive, septate hyphae with 45° branching.
Maxillary sinus aspergillosis	*Aspergillus*	Untreated maxillary infection can progress to necrotic palatal perforation with a yellow and black palatal ulcer and facial edema.	—
Zygomycosis	*Mucor* and *Rhizopus*	Rhinocerebral form displays a black, necrotic palatal ulceration.	Associated with poorly controlled insulin-dependent diabetes and ketoacidosis.
Histoplasmosis	*Histoplasma capsulatum*	Chronic verrucous or necrotic mucosal ulceration.	—
Blastomycosis	*Blastomyces dermatitidis*	Chronic verrucous or necrotic mucosal ulceration.	—
Cryptococcus	*Cryptococcus neoformans*	Chronic verrucous or necrotic mucosal ulceration.	—
Coccidioidomycosis	*Coccidioides immitis*	Chronic verrucous or necrotic mucosal ulceration.	—
Para coccidioidomycosis	*Paracoccidioides brasiliensis*	Chronic verrucous or necrotic mucosal ulceration.	—

HHV = human herpesvirus; HIV = human immunodeficiency virus; HPV = human papillomavirus.



isms, mucosal, and cutaneous manifestations and treatment, please see the individual chapters.

Parulis (gum boil, abscess), presents as an asymptomatic soft-tissue swelling and results from a chronic dental infections. These dental abscesses may extend into alveolar bone and spread along fascial planes to adjacent sites, including the skin, forming a cutaneous dental sinus. In the cutaneous dental sinus, the chin is most commonly affected; other sites include the neck and along the nasolabial groove. On the skin, these painless, erythematous nodules with superficial ulceration or suppuration may be mistaken for an inflamed epidermal cyst, a PG or a cutaneous malignancy. Intraoral examination may reveal dental decay, a fractured tooth, or periodontal disease. Dental radiographs are useful in identifying an infected tooth. Definitive treatment requires either extraction or root canal therapy. If periodontitis is the etiology, antibiotics and periodontal surgery are indicated. Rapid resolution occurs with removal of the source of infection.[80,81]

Actinomycetes (see Chap. 185) are filamentous bacteria commonly isolated from the oral cavity. *Actinomyces israelii*, a pathogenic strain, results in actinomycosis with young adults, particularly men, after oral surgery or trauma. Lumpy jaw, the most common form of actinomycosis, presents with indurated, violaceous cervical and submandibular masses due to abscesses and sinus tracts with purulent drainage that contains small yellow sulfur granules. Diagnosis is made by positive anaerobic culture, microscopic examination of the granules, and fluorescent antibody testing.[82,83]

C. albicans (see Chap. 189), a commensal yeast organism of the gastrointestinal tract, vagina, and oral cavity, occurs in a compromised oral environment (i.e., under appliances; in xerostomia, HIV, and diabetes mellitus; and with administration of systemic antibiotics, chemotherapy agents, or immunosuppressant medications therapy).[84,85] The clinical presentation, a positive potassium hydroxide examination, and a favorable response to antifungal therapy are highly suggestive of the diagnosis. When the clinical signs are questionable, cultures to identify *Candida* sp. may be required. However, cultures may be non-diagnostic because 20 percent to 60 percent of patients have *Candida* as a component of their normal oral flora.

Pseudomembranous candidiasis (thrush), by far the most commonly diagnosed form of candidiasis in infants, individuals on antibiotics or steroids, and in immunosuppressed individuals presents with curdlike white plaques that wipe off to reveal an underlying intact but erythematous mucosa. Patients complain of a burning mouth or dry, thickened tongue and lips. Erythematous candidiasis presents with localized or generalized erythema, burning, and atrophy of the filiform papilla and occurs as a complication of broad-spectrum antibiotic therapy. Chronic atrophic candidiasis (denture stomatitis) appears as asymptomatic, well-demarcated erythematous patches beneath dentures worn during sleep, especially in the setting of poor oral hygiene. Median rhomboid glossitis appears as a diamond- or oval-shaped, erythematous atrophic and depapillated plaque of the mid-line dorsal tongue and is common in acquired immunodeficiency syndrome. Angular cheilitis is discussed in the section Angular Cheilitis (Perlèche).

Hyperplastic candidiasis, an uncommon presentation of candidiasis, is a thickened, firm, fixed, white plaque affecting smokers at sites of friction, such as the anterior buccal mucosa. Chronic mucocutaneous can-

didiasis may be localized and diffuse, or associated with endocrinopathy and thymoma disorders (see Chap. 144).

OPPORTUNISTIC FUNGAL INFECTIONS A large number of viral and fungi may play a pathogenic role in immunosuppressed patients. Oral involvement can occur as a result of primary infection or from dissemination. Potential pathogens include herpes simplex virus, cytomegalovirus, HPV, *Aspergillus*, *Zygomycetes*, *Fusarium*, *Trichosporum*, *Histoplasma capsulatum*, *Blastomyces dermatitidis*, *Cryptococcus neoformans*, *Coccidioides immitis*, and *Paracoccidioides brasiliensis*. Viral involvement typically presents as erosions or ulcerations or as papillomas. Regardless of the species, fungal opportunistic infections typically present as a chronic, verrucous, or necrotic mucosal ulceration. Biopsy and culture confirm the diagnosis, and aggressive treatment with appropriate medications is essential.[27,86–90,128]

KEY REFERENCES

The full reference list for all chapters is available at www.digm7.com.

1. Tyring S: *Mucocutaneous Manifestations of Viral Diseases*. New York, Marcel Dekker, Inc, 2002
2. Eisen D, Lynch D: *The Mouth: Diagnosis and Treatment*. St. Louis, Mosby-Year Book, Inc, 1998
3. Mirowski GW, Mark L: Oral and cutaneous manifestations of gastrointestinal disease, in *Sleisenger & Fordtran's Gastrointestinal and Liver Disease—Pathophysiology/Diagnosis/Management,* 8th ed., edited by Feldman M, Scharschmidt BF, Sleisenger MH. WB Saunders, 2006
9. Rogers RS, Bruce AJ: The tongue in clinical diagnosis. *J Eur Acad Dermatol Venereol* **18**:254, 2004

12 Byrd JA, Bruce AJ, Rogers RS III: Glossitis and other tongue disorders. *Dermatol Clin* **21**:123, 2003

25. Jordan RCK: Diagnosis of periodontal manifestations of systemic diseases. *Periodontology* 2000 **34**:217, 2004



CHAPTER 75

Diseases and Disorders of the Male Genitalia

Christopher Barry Bunker

EPIDEMIOLOGY

The incidence and prevalence of male genital dermatoses are not known with accuracy, but most, like sexually transmitted diseases, are more common and more severe in the uncircumcised; these include psoriasis, seborrheic dermatitis, and lichen planus (LP).[1] The global prevalence of circumcision is estimated at 25 percent.[2] Religious and cultural practices and medical intervention account for this rate. Circumcision is a topic that evokes controversy, but the benefits are proven (Table 75-1).[1–10] Although there is little evidence of significant adverse effects on health and psychosexual function, circumcision can have side effects and complications.[3,11–14] Although views of circumcision range from prophylaxis to child abuse, the rational stance is that non-therapeutic circumcision of male infants should be left to parental discretion.[3,13–15]

TABLE 75-1
Benefits of Circumcision

- Reduced or abolished risk of penile cancer
- Decreased risk of cervical cancer in partners
- Protection from sexually transmitted infections, including human immunodeficiency virus infection
- Reduced risk of urinary tract infections (controversial)
- Reduced risk of inflammatory genital skin diseases

ETIOLOGY AND PATHOGENESIS

Etiologic and pathogenetic factors have to be understood in relationship to structure, function, and microecology.[3] Obviously the genital area differs between the sexes, but it also provides a good example of regional human variation.

Although the whole organ of the skin is concerned with sexual expression and activity, the penis is the male structure most intimately involved in sexual intercourse. It is also the conduit for urinary excretion. The scrotum is the extracorporeal sack that maintains the testes at the ideal temperature for spermatogenesis. The essential structures of the penis and its important landmarks are illustrated in Fig. 75-1.[3] As at other sites, topographical and regional anatomic nomenclature is an essential part of the vernacular for a dermatologist. The anatomic position is that of full penile erection.

The perineal area is abundant in eccrine and apocrine (some functionless) sweat glands and holocrine sebaceous glands, usually in association with hair follicles as pilosebaceous units but also occurring as free glands at some sites such as the anal rim or around the coronal sulcus (Tyson's glands). Adnexal secretions lubricate the hinge between limb and torso, lubricate hair, lubricate the mucocutaneous junctions to assist in the voiding of excreta, and protect the epithelia from irritation and lubricate the penis for the retraction of the foreskin during sexual activity. The pattern of keratinization differs throughout the male genital

DISEASES AND DISORDERS OF THE MALE GENITALIA AT A GLANCE



- Men with genital skin problems can present to physicians who are not trained or experienced in the diagnosis and management of these problems.
- Skin problems of the male genitalia may be any of the following:
  - Normal variants
  - Manifestations of sexually transmitted diseases
  - Dermatoses that may be generalized or found at extragenital sites but that have a predilection for the genitalia
  - Dermatoses that are specific to the genitalia
- Much dermatologic disease of the male organ can be linked to the causes or consequences of preputial dysfunction.
- The guiding philosophy behind diagnosis and management is to exclude sexually transmitted disease and to minimize or abolish sexual and urinary dysfunction and the risk of cancer of the penis.
- Circumcision is controversial, but it is indispensable in the management of some diseases of the penis and foreskin.

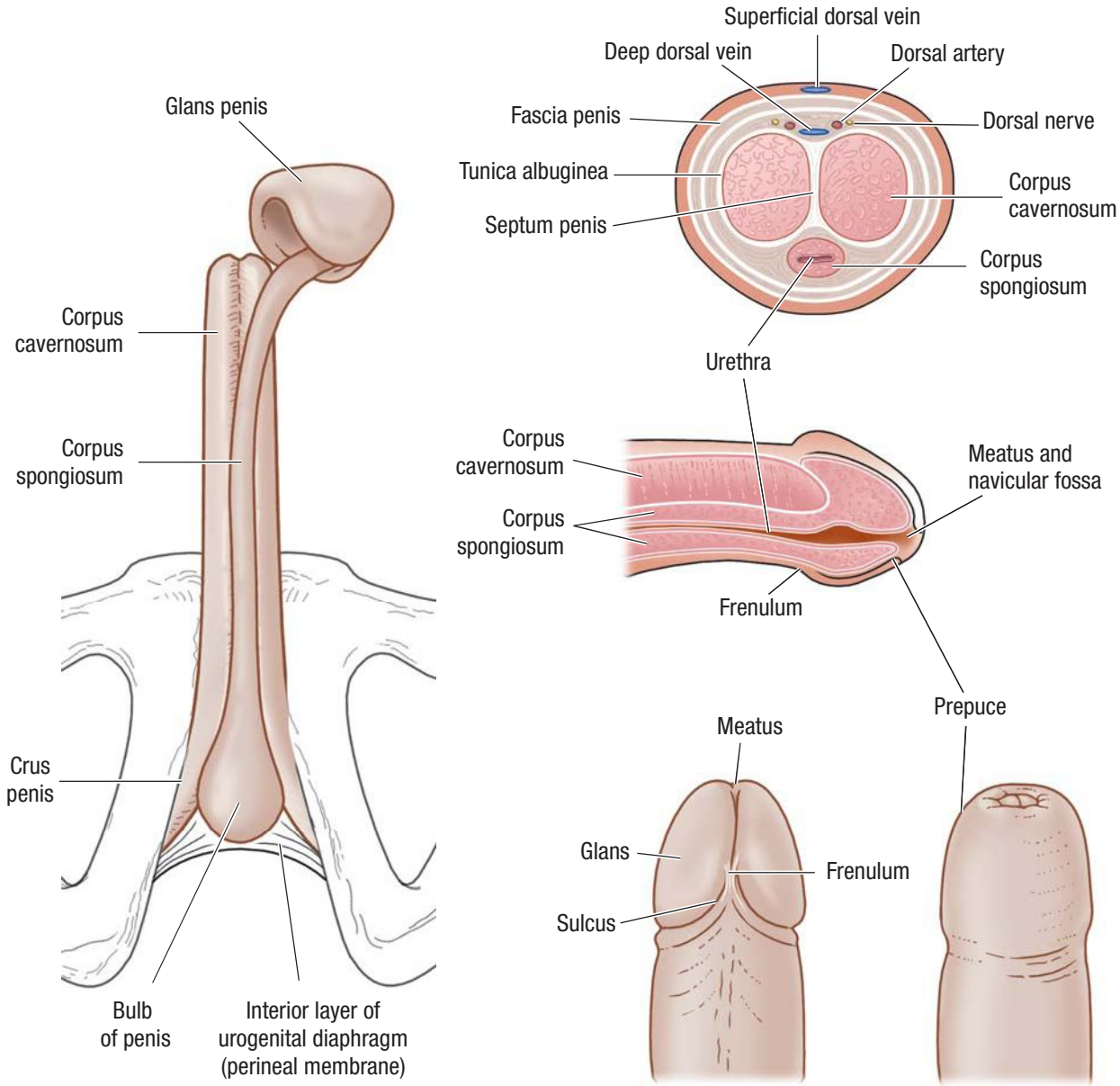

▲ **FIGURE 75-1** Anatomy and landmarks of the penis. (Adapted from Bunker CB. *Male Genital Dermatology*. London, Saunders, 2004.)

tract area, most markedly so at the mucosal junctions, the prepuce and distal penile shaft, and especially the glans in the circumcised individual. The detritus of mucosal turnover combines with adnexal secretions to produce smegma that can accumulate in the preputial sac of the uncircumcised individual, especially if hygiene is poor. There is wide normal variation in the anatomy of the penis (particularly the urethral meatus) and its relationship to the prepuce, which perhaps reflects susceptibility to minor embryologic anomalies; the embryogenesis of the anogenital structures is complex.[3] The foreskin is a delicate, busy tissue that is in close contact with urine and exposed to sexual secretions, detergents, and infectious agents, especially opportunistic organisms and those that are sexually transmitted. Of the latter, human papillomavirus (HPV) is the most important known from the point of view of precancerous dermatoses and invasive squamous carcinoma. All these congenital and acquired factors can conspire to produce a dysfunctional foreskin,[16] often clinically expressed as male sexual dysfunction in the form of male dyspareunia. The genitals may be a site of predilection or exclusive manifestation of disorders often encountered extragenitally (e.g., vitiligo, psoriasis, and LP), in part due to the Koebner phenomenon.[3]

CLINICAL FINDINGS

The algorithm shown in Box 75-1 emphasizes the need to obtain a complete history, perform an adequate examination, and construct a differential diagnosis. Initiating investigations to exclude sexually transmitted disease or performing a biopsy may be indicated. Occasionally a trial of treatment may help crystallize a diagnosis.

The responsibility for the elucidation of anogenital symptoms may need to be shared with the genitourinary physician, pediatrician, urologist, or colorectal surgeon.

History

Although classic dermatologic symptoms (itch, rash, lumps or bumps, or ulceration) may be present, the physician must be alert to symptoms of sexually transmitted disease (e.g., discharge, dysuria), urologic disease (e.g., pain, hematuria, dysuria),



Box 75-1

Approach to Male Genital Dermatosis

HISTORY

- Age
- Job
- Symptoms
  - Itchiness, soreness, pain
  - Rash
  - Lump, bump, ulcer, blister
- History of presenting complaint
- Time and space relationships, especially to sexual activity
- Personal and family history
  - Circumcision
  - Atopy
  - Psoriasis
- Drugs and allergies
  - Systemic medication
  - Topicals
  - Over-the-counter medication
- Sexual history
  - Single/married
  - Heterosexual/homosexual/bi-sexual
  - Regular partner
  - Last sexual activity
    - When
    - How (vaginal, oral, anal)
  - Contraception
  - Partner symptomatology
- Urologic history and symptomatology
- Smoking

EXAMINATION

- Complete
- Mucous membranes
- Hair, nails, and teeth
- Inguinal folds and nodes
- Scrotum and contents
- Perineum and anus
- Prepuce
  - Circumcised/uncircumcised
  - Retractibility
  - Phimosis, paraphimosis
- Penis
  - Navicular fossa
  - Glans
  - Coronal sulcus
  - Frenulum
  - Shaft
- Signs
  - Pigmentary change
  - Purpura
  - Red patches
  - Balanitis/posthitis/intertrigo
  - Scaly patches
    - Eczematous/psoriasiform/lichenoid
  - Erosions/blisters/ulcers
  - Papules/nodules
  - Swelling
  - Urinalysis

DIFFERENTIAL DIAGNOSIS

- Normal variant
- Sexually transmitted disease
- Systemic disease (e.g., diabetes)
- Genital manifestation of extragenital dermatosis
- Primary genital dermatosis
- Pre-cancer (penile carcinoma in situ)
- Cancer



and male sexual dysfunction. Symptomatic male sexual dysfunction equates with male dyspareunia—that is, painful or difficult sexual intercourse. Many men will not volunteer such information, so specific inquiry should be tactfully made. The components of normal male sexual function are libido, erection, ejaculation, and orgasm.

Cutaneous Lesions

A systematic approach to the penis and prepuce is summarized in the algorithm (see Box 75-1). The foreskin should be gently retracted (if present), the gluteal and crural folds and the meatal lips parted, and the rectum examined digitally. Site, distribution, and morphology of lesions should be conventionally noted and analyzed. Specific male genital signs include phimosis (non-retractable foreskin; Fig. 75-2), paraphimosis (foreskin fixed in retraction; Fig. 75-3), balanitis (inflammation of the glans penis), posthitis (inflammation of the prepuce), and dorsal perforation of the prepuce (glans and shaft of penis ulcerated through the prepuce, which lies ventrally as an empty sleeve). Phimosis should be regarded as a sinister situation and impedes complete inspection and palpation of the glans and coronal sulcus. The causes of phimosis are listed in Table 75-2. Paraphimosis is rarer and is caused by vigorous sexual activity, acute contact urticaria, acute allergic contact dermatitis, and lichen sclerosus (LSc). *Balanitis* and *posthitis xerotica (obliterans)* can be confusing terms, used to signify the end stage of all chronic cases of balanitis and posthitis (e.g., scarring dermatoses such as LP and cicatricial pemphigoid), but these conditions are usually due to LSc and are therefore considered synonymous by some. Dor-



▲ **FIGURE 75-2** Phimosis. Foreskin unretractable. Lichen sclerosus. (© Medical Illustration UK.)



▲ **FIGURE 75-3** Paraphimosis. Foreskin fixed in retraction. (From Bunker CB: *Male Genital Dermatology*. London, Saunders, 2004. © Medical Illustration UK.)

TABLE 75-2
Causes of Phimosis

- Lichen sclerosus
- Non-specific balanoposthitis (e.g., in diabetes)
- Lichen planus
- Hidradenitis suppurativa
- Crohn disease
- Cicatricial pemphigoid
- Chronic penile lymphoedema
- Kaposi sarcoma

sal perforation of the penis is very rare and is caused by gross penile disease such as hidradenitis suppurativa, pyoderma gangrenosum, florid condylomata, chancroid, herpes simplex, idiopathic balanoposthitis, and podophyllin misuse.[3,17,18]

Related Physical Findings

The algorithm (see Box 75-1) underlines the necessity to examine patients conventionally, systematically, and completely, because important signs will be found at non-genital sites.

LABORATORY TESTS

The most commonly required special investigational procedures are taking a swab or smear for microbiologic or virologic analysis, obtaining scrapings for fungal microscopic examination and culture, taking scrapings for mite identification, and performing a skin biopsy. Wood's light examination is helpful in the clinical diagnosis of vitiligo, erythrasma, and fungal infections. The investigations pertinent to the diagnosis of sexually transmitted disease are discussed in Section 32 (see Chaps. 200 to 205).

A genital skin biopsy is informative under selected clinical conditions. It is important to obtain the right specimen from the right site at the right time (the most floridly inflamed areas may not be the best from which to obtain a specimen and histologically often show nonspecific or zoonoid features) and to provide the pathologist with a differential diagnosis. Examination of biopsy specimens should not be regarded as a substitute for clinical diagnosis. It is safe and helpful to use small amounts of adrenaline—the region is highly vascular. Knowledge of anatomy is crucial: Ventrally, the urethra can lie very close to the surface in the coronal sulcus. It is often not necessary to suture a preputial punch biopsy site.[3,19]

Special Tests

Diagnostic imaging of the penis, scrotum, and perineum by ultrasonography or magnetic resonance can be helpful under some circumstances.[4] Patch testing is sometimes indicated.[3]

DIFFERENTIAL DIAGNOSIS

The principal presenting scenarios are tabulated in Box 75-2.

NORMAL VARIANTS

Pearly Penile Papules (Angiofibromas)

Pearly or pink penile papules, which may be found in between 15 percent and 48 percent of men, are flesh-colored, smooth, rounded papules (1 to 3 mm) occurring predominantly around the coronal margin of the glans, rarely on the glans. Often there are rows or rings of the papules. Ectopic lesions, for example on the penile shaft, have been reported. They are frequently mistaken for warts or Tyson's "ectopic" sebaceous glands and often cause anxiety in adolescents. The histologic findings are those of angiofibroma, and the lesion is analogous to other acral angiofibromas such as adenoma sebaceum, subungual and periungual fibromas, fibrous papule of the nose, acquired acral angiofibroma, and oral fibroma. Reassurance should suffice, but cryotherapy and laser treatment have been used.[3]

Sebaceous Gland Prominence

Sebaceous gland prominence, Tyson's glands, sebaceous hyperplasia, and "ectopic" sebaceous glands (Fordyce condition) are all essentially equivalent, common, normal variants of the skin of the scrotal sac and penile shaft, analogous to the situation on the vermillion of the lips. Nevoid linear lesions on the penile shaft and lesions on the glans have been reported. Reassurance is usually adequate, but patients can be inordinately distressed.[3]

Melanocytic Nevi

It is possible that nevi on the penis occur more frequently in patients with the atypical nevus syndrome.[3] A divided or "kissing" nevus is a lesion with one-half located on the glans and the other half located on the distal penile shaft separated by uninvolved skin across the coronal divide; an analogous nevus affects the eyelids.[20] Epithelioid blue nevus of the genitals is very rare.[21]

Prominent Veins

Prominent veins are common and very occasionally give rise to concern but very rarely cause complications.[3]

Angiokeratoma

Angiokeratomas are more common in white men and are common on the genitalia (where, confusingly, together with prominent sebaceous glands they have attracted the eponymous epithet of *Fordyce's spots*). Angiokeratomas are blue to purple, smooth, 2- to 5-mm papules on the scrotum, penile shaft, or glans. They generally appear and multiply during life but occasionally present as singletons. They may bleed after trauma and may be mistaken for a nevus, melanoma, or Kaposi sarcoma. The angiokeratomas of Fabry disease (see Chap. 136) are smaller than common angiokeratomas, presenting as less hyperkeratotic pinhead lesions, and are found more extensively around the lower limb girdle and upper thighs from the navel to the knees. Angiokeratoma circumscriptum very, very rarely may affect the penis (see Chap. 173).

Electrocautery or laser ablation can be offered, but the lesions may recur.

Congenital Abnormalities

The complicated embryogenesis of the anogenital region involving sexual differentiation and pubertal determination of secondary sexual characteristics means that congenital and developmental anomalies are common. Consequent anatomic and functional abnormality may increase the vulnerability of the area to dermatoses and infections.

Common abnormalities include meatal pit, hypospadias, median raphe cysts, canals and sinuses, and ambiguous genitalia. Rarer anomalies include hypospadias variants, meatal stricture, mucoid or urethral cysts, dermoid cysts, buried penis, urethral atresia, penoscrotal transposition, congenital lymphedema, giant preputial sac, megaprepuce, accessory scrotum, hemangiomas, strawberry nevus, os penis, and true aposthia. These entities may be features of congenital syndromes.[3]



Box 75-2

Differential Diagnosis of Male Genital Dermatoses

MALE GENITAL PRURITUS

Most Likely	*Consider*	*Always Rule Out*
Eczema/dermatitis	Insect bite/papular urticaria	Sexually transmitted diseases
Psoriasis	Hirsutism	Bowen disease
Lichen sclerosus	Hyperhidrosis	Erythroplasia of Queyrat
Lichen planus	Fox-Fordyce disease	Extramammary Paget disease
Herpes simplex	Urticaria and dermatographism	Langerhans cell histiocytosis
Candidosis	Dermatitis herpetiformis	
Scabies	Trichosporosis	
Pediculosis	Larva currens/cutaneous larva migrans	
Dysesthesia syndromes	Onchocerciasis	
	Drugs and foods	

MALE GENITAL HYPOPIGMENTATION/LEUKODERMA/PLAQUES

Most Likely	*Consider*	*Always Rule Out*
Scar	Bier's spots	Squamous hyperplasia
Vitiligo	Striae	Extramammary Paget disease
Post-inflammatory	Cicatricial pemphigoid	Mycosis fungoides
Lichen sclerosus	Pityriasis versicolor	
Viral warts		

MALE GENITAL HYPERPIGMENTATION

Most Likely	*Consider*	*Always Rule Out*
Hyperpigmentation of median raphe	Tattoos	Acanthosis nigricans
Post-inflammatory hyperpigmentation	Purpura	Acral lentiginous melanoma
Lentigines	Addison and Nelson syndromes	
Melanosis	Laugier-Hunziger syndrome	
	Peutz-Jeghers syndrome	
	LAMB (*l*entigines, *a*trial *m*yxoma, *b*lue nevi) syndrome	
	LEOPARD (multiple *l*entigines, *e*lectrocardiographic abnormalities, *o*cular hypertelorism, *p*ulmonary stenosis, *a*bnormalities of the genitalia, growth *r*etardation, *d*eafness) syndrome	
	Ruvalcaba-Myhre-Smith syndrome	
	Pseudo–acanthosis nigricans	
	Drugs and metals	

MALE GENITAL POST-INFLAMMATORY HYPOPIGMENTATION

Most Likely	*Consider*	*Always Rule Out*
Post-cryotherapy	Contact dermatitis	Leprosy
• Electrotherapy	• Condom leukoderma	Syphilis
• Chemocautery	Systemic sclerosis	• Leukoderma—post–secondary syphilide gumma
Lichen sclerosus	Cicatricial pemphigoid	Pseudoepitheliomatous and micaceous keratotic balanitis
Lichen planus	Gonococcal dermatitis	
	Herpes simplex	
	Pityriasis versicolor	
	Onchocercal "leopard skin"	
	Peyronie disease	

MALE GENITAL POST-INFLAMMATORY HYPERPIGMENTATION

Most Likely	*Consider*	*Always Rule Out*
Post-traumatic	Fixed drug eruption	Bowenoid papulosis
Lichen planus		
Herpes simplex		

MALE GENITAL PURPURA

Most Likely	*Consider*	*Always Rule Out*
Physical effect (e.g., from suction)	Henoch-Schönlein purpura	Amyloidosis
Zoon balanitis		
Lichen sclerosus		

(continued)

Box 75-2

Differential Diagnosis of Male Genital Dermatoses (Continued)

MALE GENITAL RED SCALY PATCHES

Most Likely	*Consider*	*Always Rule Out*
☐ Eczema/dermatitis	☐ Inflammatory linear verrucous nevus	☐ Pseudoepitheliomatous and micaceous keratotic balanitis
☐ Psoriasis	☐ Reiter syndrome	☐ Mycosis fungoides
☐ Lichen sclerosus	☐ Pityriasis rosea	☐ Extramammary Paget disease
☐ Lichen planus	☐ Acrodermatitis enteropathica	☐ Langerhans cell histiocytosis
☐ Erythrasma	☐ Hailey-Hailey disease	
☐ Candidosis	☐ Darier disease	
☐ Scabies	☐ Kawasaki syndrome	
☐ Bowen disease	☐ Primary and secondary syphilis	
	☐ Pityriasis versicolor	
	☐ Tinea	
	☐ Porokeratosis	
	☐ Fixed drug eruption	

MALE GENITAL RED PLAQUES

Most Likely	*Consider*	*Always Rule Out*
☐ Psoriasis	☐ Giant lichen simplex (of Pautrier)	☐ Extramammary Paget disease
☐ Lichen planus	☐ Inflammatory linear verrucous nevus	☐ Kaposi sarcoma
☐ Bowen disease and bowenoid papulosis	☐ Leishmaniasis	☐ Carcinoma erysipeloids
☐ Fixed drug eruption		☐ Langerhans cell histiocytosis

BALANOPOSTHITIS AND INTERTRIGO

Most Likely	*Consider*	*Always Rule Out*
☐ Eczema/dermatitis	☐ Reiter syndrome	☐ Sexually transmitted disease
• Contact, seborrheic	☐ Acrodermatitis enteropathica	• Gonorrhea
☐ Psoriasis	☐ Hailey-Hailey disease	• Syphilis
☐ Zoon balanitis	☐ Darier disease	• Chancre with balanitis
☐ Non-specific balanoposthitis	☐ Crohn disease	• Human papillomavirus infection
☐ Lichen sclerosus	☐ Streptococcal dermatitis	• Herpes simplex
☐ Candidosis	☐ Staphylococcal cellulitis	• Mycoplasma infection
	☐ Non-syphilitic spirochetal ulcerative balanoposthitis	• Trichomonas vaginalis infection
	☐ Tinea	• Lymphogranuloma venereum
	☐ Amebiasis	☐ Leprosy
	☐ Myiasis	☐ Erythroplasia of Queyrat
	☐ Scabies	☐ Squamous carcinoma
	☐ Eccrine syringofibroadenomatosis	☐ Carcinoma erysipeloides
	☐ Chronic lymphatic leukemia	☐ Extramammary Paget disease
	☐ Fixed drug eruption	☐ Kaposi sarcoma

MALE GENITAL EROSIONS

Most Likely	*Consider*	*Always Rule Out*
☐ Trauma	☐ Autoimmune bullous diseases	☐ Kaposi sarcoma
• Excoriated pruritic dermatoses (e.g., scabies)	• Pemphigus	☐ Langerhans cell histiocytosis
☐ Inverse pattern psoriasis	• Bullous pemphigoid	
☐ Zoon balanitis	• Cicatrizing pemphigoid	
☐ Lichen sclerosus	• Linear immunoglobulin A disease	
☐ Lichen planus	• Dermatitis herpetiformis	
☐ Herpes simplex	☐ Streptococcal dermatitis	
☐ Candidosis	☐ Gonorrhea	
☐ Erythroplasia of Queyrat	☐ Secondary syphilis	
	☐ Herpes zoster	
	☐ Acute primary human immunodeficiency virus (HIV) infection	
	☐ Cytomegalovirus in HIV infection	
	☐ Tinea	
	☐ Paracoccidioidomycosis	
	☐ Pediculosis	
	☐ Porokeratosis	
	☐ Topical steroids	
	☐ Fixed drug eruption	

(continued)



Box 75-2

Differential Diagnosis of Male Genital Dermatoses (Continued)

MALE GENITAL VESICLES AND BLISTERS

Most Likely

- Erythema multiforme/Stevens-Johnson syndrome
- Lichen sclerosus
- Bullous impetigo
- Herpes simplex
- Fixed drug eruption

Consider

- Acute contact dermatitis (e.g., phytophotodermatitis)
- Lichen planus
- Autoimmune bullous diseases
  - Bullous pemphigoid
  - Cicatrizing pemphigoid
  - Linear immunoglobulin A disease
  - Dermatitis herpetiformis
- Herpes zoster

PENILE NECROSIS



Most Likely

- Decubitus ulcer
- Spider bite
- Strangulation/tourniquet syndromes
- Vacuum erection device use
- Priapism
- Embolism
- Pyoderma gangrenosum
- Coagulopathy
- Warfarin

Consider

- Chronic renal failure
- Diabetes mellitus
- Thrombocytopenia
- Polycythemia
- Cryoglobulinemia
- Vasculitis
- Calciphylaxis
- Ecthyma gangrenosum
- Herpes simplex

Always Rule Out

- Fournier gangrene
- Leukemia

MALE GENITAL ULCERS

Most Likely

- Trauma
- Aphthae
- Erythema multiforme
- Ulcerative sexually transmitted disease
  - Chancre of primary syphilis
  - Chancroid
  - Donovanosis
  - Lymphogranuloma venereum
  - Syphilis
- Squamous carcinoma

Consider

- Dermatitis artefacta
- Spontaneous scrotal ulceration
- Hidradenitis suppurativa
- Crohn disease
- Sarcoid
- Behçet disease
- Autoimmune bullous diseases
  - Bullous pemphigoid
  - Cicatrizing pemphigoid
  - Linear immunoglobulin A disease
- Necrobiosis lipoidica
- Hypereosinophilic syndrome
- Gonorrhea
- Tuberculosis and tuberculids
- Leprosy
- Yaws
- Non-syphilitic spirochetal ulcerative balanoposthitis
- Herpes simplex (e.g., in HIV)
- HIV giant aphthae
- Deep fungal infections
  - Histoplasmosis
  - Blastomycosis
  - Paracoccidioidomycosis
  - Cryptococcosis
- Actinomycosis
- Leishmaniasis
- Amebiasis
- Filariasis
- Porokeratosis
- Basal cell carcinoma
- Drug reaction

Always Rule Out

- Embolization
- Penile necrosis
- Pyoderma gangrenosum
- Necrotizing vasculitis
  - Wegener granulomatosis
  - Systemic lupus erythematosus
  - Polyarteritis nodosa
  - Idiopathic systemic vasculitis
- Hereditary spherocytosis and vascular necrosis
- Degos malignant atrophic papulosis
- Calciphylaxis
- *Pseudomonas* infection
  - Ecthyma gangrenosum
  - Necrotizing anorectal ulcer in leukemia
- Fournier gangrene
- Sweat gland carcinoma
- Kaposi sarcoma
- Langerhans cell histiocytosis
- Extramammary Paget disease
- Leukemia
- Lymphoma

(continued)

Box 75-2

Differential Diagnosis of Male Genital Dermatoses (Continued)

MALE GENITAL FLESH-COLORED PAPULES AND MICROPAPULES

Most Likely	*Consider*	*Always Rule Out*
Scrotal calcinosis	Median raphe cyst	Amyloidosis
Lichen nitidus	Mucoid cyst	Squamous hyperplasia
Viral warts	Tick bite/tick in situ	Amelanotic malignant melanoma
Secondary syphilis	Sclerosing lymphangitis	Malignant schwannoma
Mollusca	Lichen nitidus and lichen planus	
Acrochordons (skin tags)	Mucinous syringometaplasia	
Angiofibroma (pearly penile papules)	Demodicidosis	
Fordyce's spots (ectopic sebaceous glands)	Syringoma	
Seborrheic keratosis	Leiomyoma	
Epidermoid cyst	Genital smooth muscle hamartoma	
	Neurofibroma	
	Lymphangioma circumscriptum	
	Lipoid proteinosis	

MALE GENITAL RED OR PIGMENTED PAPULES AND MICROPAPULES

Most Likely	*Consider*	*Always Rule Out*
Angioma/angiokeratoma	Tick bite/tick in situ	Amyloidosis
Lichen planus and nitidus	Insect bite	Angiokeratoma corporis diffusum
Inflamed viral wart	Granuloma annulare	Carcinoma erysipeloids
Secondary syphilis	Sarcoid	Kaposi sarcoma
Inflamed mollusca	Primary granuloma inguinale (donovanosis)	Malignant melanoma
Melanocytic nevus	Primary lymphogranuloma venereum	Langerhans cell histiocytosis
Seborrheic keratosis	Tuberculide (lichen scrofulosorum)	Xanthoma disseminatum
Scabies	Leprosy	Metastases
Venous varicosities	Early chancre of primary syphilis	
Bowenoid papulosis	Superficial phaeohyphomycosis	
	Schistosomiasis	
	Inflamed epidermoid cyst	
	Dermatofibroma	
	Acanthosis nigricans	
	Nevus comedonicus	
	Syringoma	
	(Juvenile) xanthogranuloma	
	Pseudo–Kaposi sarcoma	

MALE GENITAL PUSTULES

Most Likely	*Consider*	*Always Rule Out*
Penile acne	Herpes zoster	Behçet disease
Candidosis	Steroid acne	Tuberculide (acne scrofulosorum)
Folliculitis (e.g., occlusional)		
Gonorrhea		
Herpes simplex		

MALE GENITAL PLAQUES

Most Likely	*Consider*	*Always Rule Out*
Lichen sclerosus	Halogenoderma	Secondary syphilis
Confluent condylomata	Granuloma inguinale	Squamous hyperplasia
Secondary syphilis	Atypical mycobacterial infection	Squamous carcinoma
Seborrheic keratosis	Yaws	Buschke-Lowenstein carcinoma
Bowen disease and bowenoid papulosis	Leprosy	Extramammary Paget disease
	Herpes simplex (e.g., in HIV infection/immune restoration disease)	Xanthoma disseminatum
	Candidosis	
	Deep mycoses (e.g., blastocytosis)	
	Epidermal nevus	
	Verruciform xanthoma	

(continued)



Box 75-2

Differential Diagnosis of Male Genital Dermatoses (Continued)

MALE GENITAL LYMPHEDEMA

Most Likely

- Idiopathic penile edema
- Post-infectious
- Cellulitis and erysipelas
- Chancroid
- Granuloma inguinale
- Lymphogranuloma venereum
- Syphilis

Consider

- Idiopathic congenital lymphedema (Milroy disease)
- Lipogranuloma and silicone granuloma
- Iatrogenic
  - Radical abdominopelvic surgery
  - Radiotherapy
- Granulomatous lymphangitis
- Tuberculosis
- Leprosy
- Filariasis/onchocerciasis

Always Rule Out

- Strangulation of the penis
- Carcinomatosis
- Lymphatic involvement
- Lymphatic blockage
- Lymphoma

MALE GENITAL CYSTS OR NODULES



Most Likely

- Median raphe cysts
- Scrotal calcinosis
- Sclerosing lymphangitis
- Hidradenitis suppurativa
- Crohn disease
- Scabies
- Epidermoid cyst
- Pilar cyst
- Squamous cell carcinoma

Consider

- Segmental urethral hypospadias
- Urethral/mucoid cysts
- Hernias and herniation
- Foreign body
- Lipogranuloma
- Keloid
- Scrotal fat necrosis
- Sarcoid
- Amyloid
- Granuloma inguinale
- Penile acne
- Bacillary angiomatosis
- Leprosy
- Histoplasmosis
- Paracoccidioidomycosis
- Schistosomiasis
- Onchocerciasis
- Benign appendageal tumors
- Myxoma
- Dermoid cyst
- Granular cell tumor
- Giant cell fibroblastoma
- Connective tissue nevus
- Fibrous hamartoma of infancy
- Leiomyoma
- Neurofibroma
- Hemangioma
- Masson tumor (intravascular papillary endothelial hyperplasia)
- Epithelioid hemangioma
- Angiolymphoid hyperplasia with eosinophilia/ Kimura disease
- Lymphangioma circumscriptum
- Solitary reticulohistiocytic granuloma
- Penile horn
- Keratoacanthoma
- Basal cell carcinoma

Always Rule Out

- Buschke-Lowenstein tumor/giant condyloma
- Extramucosal anorectal carcinoma
- Malignant melanoma
- Merkel cell carcinoma
- Malignant eccrine poroma
- Sarcoma
- Malignant schwannoma
- Kaposi sarcoma
- Chronic lymphocytic leukemia
- Langerhans cell histiocytosis
- Metastases

(continued)

Box 75-2

Differential Diagnosis of Male Genital Dermatoses (Continued)

PENOSCROTAL SWELLING

Most Likely	*Consider*	*Always Rule Out*
☐ Paraphimosis	☐ Idiopathic congenital lymphedema	☐ Aortic aneurysm
☐ Foreign body	☐ Giant hemangioma	☐ Abscess of corpus cavernosum
☐ Strangulation of the penis	☐ Urethral diverticulum	☐ Kaposi sarcoma
☐ Iatrogenic	☐ Segmental urethral hypospadias	☐ Lymphoma
• Continuous ambulatory peritoneal dialysis	☐ Accessory scrotum	☐ Sarcoma
• Raised right heart filling pressure in intensive therapy unit	☐ Herniation of scrotal contents into penile shaft	
• Post-surgery	☐ Foreign body	
• Post-radiotherapy	☐ Lipogranuloma/silicone granuloma	
☐ Varicocele	☐ Scrotal fat necrosis	
☐ Hydrocele	☐ Henoch-Schönlein purpura	
☐ Priapism	☐ Familial Mediterranean fever	
☐ Peyronie disease	☐ Acute hemorrhagic edema of childhood	
☐ Epididymitis and orchitis	☐ Granulomatous lymphangitis	
☐ Cellulitis	☐ Sarcoid	
☐ Idiopathic penile edema	☐ Infected cyst	
☐ Testicular tumors	☐ Tuberculosis	
	☐ Paracoccidioidomycosis	
	☐ Giant scrotal tumor (e.g., neurilemoma)	
	☐ Epithelioid hemangioma	
	☐ Epithelioid hemangioendothelioma	
	☐ Drugs (e.g., angioedema due to lisinopril)	

SEXUALLY TRANSMITTED DISEASES

Venereal Diseases

The clinical manifestations on the male genitals of syphilis, chancroid, lymphogranuloma venereum, granuloma inguinale, gonorrhea, and other venereal diseases as well as their pathogenesis, diagnosis, treatment, and complications are discussed in depth in Chaps. 200 and 202 to 205. Here it may suffice to alert the physician that any inflammatory, nodular, or ulcerative lesion on the genitals requires exclusion of sexually transmitted diseases.

Pediculosis (See Chap. 208)

Pediculosis pubis, or lice infestation ("crabs"), can cause severe genital itching with few physical signs unless the hairs are examined assiduously for nits and the base of individual hairs is scrutinized with a hand lens for the crab lice (1 to 2 mm), which will be tightly adherent to the skin because their mouth parts are embedded in perifollicular blood vessels. Sometimes grey-blue macules (tache bleu, maculae caeruleae) are seen on the affected sites.

Scabies (See Chap. 208)

Scabies is a cause of intense itching that characteristically keeps patients awake at night. Usually there is a rash of diagnostic distribution and morphology. Some patients with scabies—who may have had it for a long time, have had it before, have been inadequately treated, or have been adequately treated but develop secondary eczema or nodules—may have itch in the anogenital region only.

Viral Warts (See Chap. 196)

CLINICAL FINDINGS HPV infection can usually be diagnosed with certainty on clinical grounds (Figs. 75-4, 75-5). Morphology is described in Chap. 196. Clinically inapparent penile warts may present as balanoposthitis.

DIFFERENTIAL DIAGNOSIS Disorders from which viral warts must be differentiated are listed in Box 75-3.



▲ **FIGURE 75-4** Viral warts. Condyloma acuminata. (© Medical Illustration UK.)

COMPLICATIONS HPV infection is a risk factor for anogenital cancer, particularly of the cervix and anus. HPV is associated with the clinical expressions of penile carcinoma in situ [PCIS, or Bowen disease of the penis, erythroplasia of Queyrat (EQ), or bowenoid papulosis (BP)] and approximately 50 percent of cases of squamous carcinoma of the penis.[40] Infection with human immunodeficiency virus (HIV) may alter and worsen the expression and consequences of anogenital



▲ **FIGURE 75-5** Viral warts. Confluent plaque. No histologic dysplasia. Patient with diabetes. (© Medical Illustration UK.)



Box 75-3

Differential Diagnosis of Viral Warts

Most Likely

- Pearly penile papules
- Seborrheic keratoses
- Nevi
- Mollusca

Consider

- Lichen planus
- Lichen nitidus
- Bowenoid papulosis

Always Rule Out

- Condylomata lata (secondary syphilis)
- Squamous carcinoma (and variants)



HPV infection.[3,41] High-grade dysplasia associated with high-risk HPV types have been found in genital warts from HIV-positive individuals.[42,43]

TREATMENT Patients presenting with warts, as well as their sexual partners, should be counseled and screened for HPV, other sexually transmitted diseases including HIV infection, and cervical neoplasia.

HPV infection may be very hard to treat. Sub-clinical infection is very common, difficult to detect, and virtually untreatable, so there is divergence between ambitions for treatment and achievability. The principles of management are based on diagnosing and treating relevant lesions that are causing personal genital morbidity or psychosexual stress or long-term risk to the patient or his partner. Reasonable goals include (1) inducing cure or wart-free periods, (2) relieving or improving symptoms such as dyspareunia, (3) ensuring that side effects or complications of the treatment are no worse than the symptoms or risks of the warts, (4) minimizing morbidity and mortality from cervical cancer in female partners, (5) minimizing mortality and morbidity from PCIS and frank cancer in the patient.[22]

Treatments are summarized in Box 75-4.[3,22,41,44]

Mollusca (See Chap. 195)

Mollusca may be sexually acquired, as in adult men, but genital lesions are common caused by autoinoculation are common in children. Classically small, flesh-colored, monomorphic, dome-shaped papules indented by a central dell or umbilicus are seen. Multiple lesions are usually present. Giant and polypoidal lesions may occur in the setting of HIV infection. Inflammation and purulence may be due to infection but are a common phenomenon when individual lesions spontaneously involute. Condylomata lata (secondary syphilis) and LP enter the differential diagnosis of mollusca, as do simple HPV infection and BP.

DERMATOSES WITH A PREDILECTION FOR THE MALE GENITALIA

Vitiligo (See Chap. 72)

Vitiligo commonly affects the genitalia in men and may be the only site to be affected. Perianal involvement is also common.[3] Other organ-specific autoimmune diseases should be excluded.

Seborrheic Dermatitis (see Chap. 22)

A diagnosis of seborrheic dermatitis is made when a non-specific psoriasiform or eczematous balanitis or balanoposthitis is found in conjunction with classic symptoms and extragenital manifestations of the diathesis.[3]

No treatment other than reassurance may be required. However, treatments that diminish the commensal pityrosporum load and reduce irritation and eczematization can be very successfully and safely used long term. These include topical antifungals (such as clioquinol, nystatin, and imidazoles) in the form of ointments, creams, lotions, or shampoos and mixtures of the same agents with mild and moderately potent topical corticosteroids used alongside emollients and soap substitutes. In severe cases, such as with concomitant seborrheic folliculitis or in acquired immunodeficiency syndrome (AIDS), treatment with an oral imidazole might be indicated.

Psoriasis (See Chap. 18)

Psoriasis is probably the most common dermatosis of the male anogenitalia, either in isolation or in association with frank or mild, subtle extragenital disease.[3] The Koebner phenomenon is a likely factor in site predilection. Drugs such as lithium, β blockers, antimalarials, and angiotensin-converting enzyme inhibitors may be responsible for the onset or exacerbation of psoriasis.

In circumcised men, genital psoriasis presents with variably itchy, silvery-scaled, erythematous patches or plaques (Fig. 75-6). On the glans or in the preputial sac of the uncircumcised patient, scale is absent from the patches or

Box 75-4

Treatments for Genital Warts

TREATMENT	CLEARANCE RATES (%, AT END OF TREATMENT)	CLEARANCE RATES (%, AT ≥ 3 MO)	RECURRENCE RATES (%)
Cryotherapy	63–88	63–92	0–39
Surgical/scissor excision	89–93	36	0–29
Electrocautery/electrotherapy	93–94	78–91	24
Loop electrosurgery	≤ 90	—	—
Laser surgery	27–89	39–86	< 7–45
Interferons			
Intralesional	19–62	36–62	0–33
Systemic	7–51	18–21	0–23
Topical	6–90	33	6
Podophyllin/podophyllotoxin	32–88	22–77	10–91
Trichloroacetic acid	50–81	70	36
5-Fluorouracil	10–71	37	10–13

After Beutner in Maw R: National guideline for the management of anogenital warts. Clinical Effectiveness Group (Association of Genitourinary Medicine and the Medical Society for the Study of Venereal Diseases). *Sex Transm Infect* **75 Suppl 1**:S71, 1999, by kind permission of Dr. Karl Beutner, Vallejo, CA; and Bunker CB: Male Genital Dermatology. London, Saunders, 2004.



▲ **FIGURE 75-6** Psoriasis. Circumcised glans penis. (© Medical Illustration UK.)



▲ **FIGURE 75-7** Psoriasis. Uncircumcised glans penis and prepuce. (© Medical Illustration UK.)

plaques because of the mucosal site (Fig. 75-7). The scalp, ears, umbilicus, and face (in sebopsoriasis) may be involved, and there may be variable additional anogenital involvement, especially of the sacrum, buttocks, intergluteal cleft, pubic mound and groin, perianal skin, and, less commonly, the scrotum. Psoriatic balanoposthitis can be part of the spectrum of inverse-pattern psoriasis and may be associated with intertriginous disease of the axillae, intergluteal cleft, gluteal folds, and groin.

Patients with the reactive arthritis syndrome (see Chap. 20) may sometimes have involvement of the penis with circinate balanitis or small, flat pustules. These penile lesions have the same histopathology and ultrastructure as psoriasis. Sometimes this morphology is seen clinically with no background urethritis, gastroenteritis, or arthritis (Fig. 75-8).

Usually the diagnosis of psoriasis is clinical. Soreness might indicate superinfection, especially with *Candida*. Inordinate itch would make one suspect another dermatosis such as an eczematized dermatitis or tinea. A biopsy may be necessary if there are solitary mucosal lesions in the uncircumcised to exclude Zoon balanitis (ZB), LP, EQ, and Kaposi sarcoma. Bowen disease and extramammary Paget disease may be misdiagnosed as psoriasis when there are single or several foci on the penile shaft and/or in the groin.

Topical treatment is based on the use of emollients, soap substitutes, corticosteroids combined with antibiotic and antifungal agents, or weak tar solutions. Atrophy is a risk with long-term use of potent topical steroids, and anogenital skin has a heightened tendency to absorb topical agents. Strong crude tar preparations should also therefore be avoided at this site because of the risk of genital cancer. Dithranol application may lead to burning and so is usually avoided in this region. Vitamin D analogues and calcineurin inhibitors seem safe, but with the latter, the prescriber must be certain of the absence of PCIS. Severe anogenital inverse psoriasis can be an indication for systemic treatment. Phototherapy is conventionally contraindicated because of the risk of anogenital cancer. It is possible that chronic anogenital psoriasis and its treatment may create a risk for anogenital squamous cancer.



▲ **FIGURE 75-8** Circinate balanitis. HLA-B27 positive. No background urethritis, gastroenteritis, or arthritis. (© Medical Illustration UK.)

Lichen Planus (See Chap. 26)

LP has a particular predilection for the mucosa, which is perhaps partly explained by the Koebner phenomenon. LP can present in, and remain focalized to, the pelvic girdle, the genital area including the groin, and the perianal skin. Alternatively, symptoms and morphology of the classic disease—lilac papules and plaques with white lacy scale—may be present at other sites (Fig. 75-9). However, it may affect the penis (like the mouth, vulva, and anus) in isolation as the cause or consequence of foreskin dysfunction (by "koebnerization") and so present as dyspareunia and a nonspecific dermatosis.[3]

The differential diagnosis includes eczema, psoriasis, seborrheic dermatitis, non-specific balanoposthitis, ZB, LSc, drug eruption, porokeratosis, viral warts, penile pre-cancer, and frank squamous cell carcinoma (SCC). LP can cause phimosis; the causes of phimosis are given in Table 75-2.

Just as extragenital disease, for example, on the palms and soles, may be erosive in rare cases, occasionally an erosive form of genital disease is encountered (Fig. 75-10). A male equivalent of the vulvo-vaginal syndrome of Hewitt with chronic erosive gingival and genital lesions (genito-gingival syndrome) has been described.[45]

Although LP is self-limiting, some patients experience relapses and remissions. Adhesions can form. Post-inflammatory hyperpigmentation can persist for months or years.



▲ **FIGURE 75-9** Lichen planus. Annular plaque. Circumcised glans penis. Coronal rim. (From Bunker CB: *Male Genital Dermatology*. London, Saunders, 2004. © Medical Illustration UK.)





▲ **FIGURE 75-10** Lichen planus. Erosions on glans penis and prepuce. Severe dyspareunia. (© Medical Illustration UK.)



Chronic mucosal erosive LP is associated with a risk of SCC, although most reports linking the two concern oral LP. SCC may complicate chronic hypertrophic LP of the lower leg but has also occurred in the context of hypertrophic LP of the glans penis.

A biopsy is frequently necessary for diagnostic purposes but, more importantly, is performed in following up the rare cases of chronic anogenital disease in which the appearance of ulcero-erosive or verrucous features leads to concern about the development of SCC. The classic histologic findings are discussed in Chap. 26.

Potent or very potent topical corticosteroids usually produce remission. Patients should be warned about post-inflammatory hyperpigmentation. Systemic corticosteroids are sometimes indicated for severely symptomatic disease, erosive orogenital involvement, and scarring of the scalp and nails. Topical and systemic cyclosporin has been used. Circumcision may be necessary if there is phimosis and should be seriously considered in cases of refractory disease, especially the erosive form, because the removal of "koebnerizing" influences may allow the LP to remit. The toxicity and the lack of efficacy of systemic therapy in treating this distressingly symptomatic situation are other powerful arguments in favor of circumcision.[3,46]

Lichen Nitidus (See Chap. 27)

Lichen nitidus is sometimes held simplistically and controversially to be a micropapular variant of LP. It has an affinity for the penis and can be difficult to diagnose because the signs may be subtle, even when the lesions are widespread. Also, when the lesions are very pruritic, the signs due to excoriation and eczematization may eclipse those due to the lichen nitidus.[3]

Granuloma Annulare (See Chap. 43)

Erythematous smooth, ovoid nodules of granuloma affecting the penis have been described. They are perhaps related to trauma and koebnerization, because circumcision can be curative.[47]

Necrolytic Migratory Erythema

Necrolytic migratory erythema can be focalized to the male genitalia as a sore or painful annular erythematous eruption with a central glassy appearance and serpiginous border surrounded by scaling. It is a characteristic cutaneous manifestation of the glucagonoma syndrome (see Chap. 154).[48,49]

Aphthae

The diagnosis of aphthous ulceration of the genitalia requires the exclusion of sexually transmitted diseases and other causes of genital ulceration, especially Behçet disease. This is in contradistinction to oral ulceration, in which a clinical diagnosis is acceptable practice.[3] The causes of aphthae are obscure. The histologic findings of idiopathic aphthous ulceration are non-specific. Aphthae and idiopathic orogenital ulceration are more common and are worse, symptomatically and morphologically, in HIV-infected individuals. In patients with AIDS, biopsy must be performed on all mucocutaneous ulcers and specimens must be cultured; several pathologies may co-exist. Treatment of simple aphthae is with topical corticosteroid/antibiotic/anticandidal combinations. In patients with AIDS, thalidomide may be efficacious.

Behçet Disease (See Chap. 167)

The genital ulcers in men are painful, sometimes very painful, and this distinction may be helpful. They occur anywhere on the anogenitalia, including the scrotum and perianal skin. They are said to be bigger, deeper, fewer, and less recurrent than those in the mouth.

To diagnose Behçet disease according to strict diagnostic criteria, oral ulceration must be present; then patients must also either manifest genital ulceration and ophthalmic involvement or genital ulceration and skin signs (or a positive pathergy test result). In practice, there are many patients who have an incomplete syndrome. Although their disease does not satisfy these rigid diagnostic criteria, "possible" or "probable" Behçet disease is an acceptable label for everyday practical purposes. Essentially, Behçet disease is a systemic vasculitis that may involve many organs, so that protean presentations and complications are possible. Patients with relapsing polychondritis (see Chap. 160) and Behçet disease have been reported, and the term *MAGIC* (*m*outh *a*nd *g*enital ulcers with *i*nflamed *c*artilage) *syndrome* applied.[50,51] Histologic findings are usually non-specific and do not distinguish idiopathic aphthae, although sometimes necrotizing vasculitis can be seen. Topical treatment with corticosteroid/antimicrobial combinations may suffice. However, some patients will require systemic treatment with colchicine, prednisolone, azathioprine, cyclosporin, or thalidomide (see Chap. 167).

Cicatricial Pemphigoid (See Chap. 55)

Cicatricial pemphigoid is a rare disease that must be in the differential diagnosis for blistering, erosions, ulcers, transcoronal adhesions, scarring, and phimosis.[3,52] These manifestations can occur in isolation, but ophthalmic, oropharyngeal, and cutaneous lesions are more common than genital involvement. Direct immunofluorescence usually yields positive results, but indirect immunofluorescence does not. Topical and oral steroids may be ineffective. Dapsone and sulphamethoxypyridazine may be used.

Pyoderma Gangrenosum (See Chap. 32)

Pyoderma gangrenosum is a rare event but is frequently misdiagnosed or diagnosed late while infections and cancer are pursued diagnostically (Fig. 75-11). It may represent a pathergic reaction after urologic surgery or complicate inflammatory bowel disease or leukemia. Treatment must be aggressive to avoid permanent damage to the urethra and erectile tissues.[3]

Drug Eruptions (See Chap. 40)

The penis is a classic site of predilection for fixed drug eruptions.[3] Clinically, fixed drug eruption is characterized by the acute eruption of itchy, painful, swollen plaques, sometimes with central blister formation, erosion, and ulceration. Post-inflammatory hyperpigmentation can be persistent. On first exposure to the drug the eruption can take 1 to 2 weeks to appear but subse-



▲ **FIGURE 75-11** Pyoderma gangrenosum. Most of the shaft of the penis, but not the glans, has been destroyed. (© Medical Illustration UK.)

quently appears just a few hours after administration. Recurrence is at the same site(s) each time the drug is encountered, and rechallenge/provocation can be used as a diagnostic test. For causes, see Chap. 40.

Ulceration due to papaverine has been reported when the drug is inadvertently injected subcutaneously for the treatment of erectile impotence.[53] Heparin and warfarin have induced skin necrosis of the genitalia.[3] All-*trans* retinoic acid has been reported to induce genital ulceration in patients with hematologic malignancy.[54] Foscarnet is a recognized cause of genital ulceration in HIV-infected patients due to the high urinary concentrations of the drug.[55]

Lisinopril has been reported to cause genital angioedema.[56] The cutaneous side effects of topical steroids are well known: Striae, atrophy, erythema, telangiectasia, erosion, and modification of cutaneous, bacterial, viral, and fungal infections occur commonly. Drugs can also cause pruritus and urticaria.

Streptococcal Dermatitis (See Chap. 177)

Streptococcal dermatitis causing a perianal cellulitis is a recognized syndrome in children, but a similar clinical situation occasionally occurs in adults and might affect the genitalia alone.[3] It is much more common in boys, and if the penis is involved, there may be dysuria, erythema, swelling, and balanoposthitis. Group A β-hemolytic streptococci can be isolated, and the lesions may be associated with streptococcal infection of the upper respiratory tract in other members of the family. Treatment is generally with systemic penicillin.

Herpes Zoster (Shingles) (See Chap. 194)

Sacral herpes zoster is relatively rare but can be associated with severe morbidity due to nocturia, dysuria, acute urinary retention, constipation, and fecal retention.[3] When the pain precedes the rash, the differential diagnosis of an acute surgical emergency is evoked. Painful, grouped, crusting, vesicopustular lesions may be found unilaterally on the buttock, in the perineum, on the scrotum and penis, in the groin, and on the upper thigh. Hospitalization, urologic assessment, observation, possibly catheterization and sigmoidoscopy, and possibly assisted fecal extraction are indicated. Treatment should be with intravenous acyclovir.

Tinea (See Chap. 188)

Tinea of the penis or scrotum is not common, and when it occurs it is usually associated with crural disease. Rarely encountered is tinea that occurs on the glans penis as a seat of itch or pain and produces an erythematous patch or a crop of scaly papules.[3] In India, it is associated with penile lesions due to the wearing of a langota, an occlusive T-shaped loincloth.[57]

Schistosomiasis (See Chap. 207)

Perineal granulomatous lesions are a rare manifestation of schistosomiasis (infection with *Schistosoma haematobium*).[3,58] Rarely genital skin lesions may lead to the diagnosis. They occur because of ova shed by worms that have entered the perineal vessels from the pelvic venous plexuses. Papules and nodules may be itchy; may be skin colored, pink, or brown; may be scattered or grouped; and may affect the penis and scrotum. They can spread onto the perineum and around the anus and may develop into soft, warty, vegetating lesions but remain relatively asymptomatic. Ulceration is rare and carcinoma even rarer. Diagnosis is by biopsy (see Chap. 207). Ova may be recovered from urine or stool.

Onchocerciasis (See Chap. 207)

The dermatologic genital consequences of onchocerciasis are pruritus, "leopard skin" hypopigmentation (on shins and scrotum), nodules (on ileal crests, scrotum, and ribcage), dermatitis including "lizard skin" lichenification, "hanging groin," and scrotal enlargement.[3] The differential diagnosis of the scrotal enlargement includes bancroftian filariasis. The diagnosis is made by demonstrating microfilariae in skin snips.

Porokeratosis

Genital porokeratosis of Mibelli (see Chap. 50) is rare.[3,59] Annular raised (double-rimmed) lesions have been found in the intergluteal cleft, on the scrotum, and on the penis, including the glans. Rarely lesions may be ulcerative. Porokeratosis may be misdiagnosed clinically as psoriasis, Bowen disease, granuloma annulare, or LP but histologic examination of the margin shows the characteristic cornoid lamella. Cryotherapy and topical 5-fluorouracil can be used for treatment.

Kaposi Sarcoma (See Chap. 128)

Solitary Kaposi sarcoma of the penis was recognized, if rarely, before the HIV epidemic, and cases are still occasionally seen in HIV-negative patients.[3] AIDS-related Kaposi sarcoma is usually multicentric and often involves the face, oral mucosa, palate, and penis (20 percent). A solitary lesion is not unusual. It can present as a dull red patch or plaque on the glans penis or in the preputial sac and can also affect the penile shaft, scrotum, and perianal skin in one of its more classic manifestations—namely, purple, slightly scaly patches or plaques, nodules, and ulcerative lesions. An engorged, "hypervascular" presentation has been described, as has penile lymphedema, acute phimosis, and rectourethral fistulation. Odd morphology should arouse suspicions of mixed pathology.

Lymphoma, Leukemia, Metastases

Ulceration of the penis in chronic lymphocytic leukemia and scrotal ulceration in acute myelogenous leukemia due to leukemic infiltration have been reported.[3] Pyoderma gangrenosum, *Pseudomonas* infection, and Fournier gangrene can be associated with hematologic malignancy. Although the groin is a classic site of involvement in Langerhans cell histiocytosis (see Chap. 148), involvement of the penis is very rare. Metastases to the penis and scrotum occur uncommonly. They are usually secondary to cancer of the urogenital tract or gastrointestinal system (e.g., rectum) or complicate other



common cancers such as those of the lung. They may present with pain, swelling, priapism, urinary symptoms, or hematuria. A cutaneous nodule or nodules may be seen or infiltration of the deeper penile structures palpated.

PRIMARY MALE GENITAL DERMATOSES

Penile Melanosis and Lentiginosis

Several terms have been coined to describe benign pigmented macules of the penis such as penile melanosis, penile melanotic macules, and atypical pigmented penile macules: penile melanosis, vulvovaginal melanosis, and the predominantly oral mucosal hyperpigmentation of Laugier-Hunziker syndrome (see Chap. 73) may be grouped under the umbrella of essential melanotic hyperpigmentation of the mucosa.[3,60] Some if not all cases may represent post-inflammatory hyperpigmentation from previous disease or insult [e.g., phimosis, balanoposthitis, topical treatment, LSc (Fig. 75-12), LP, circumcision]. It has been suggested that relative adjacent depigmentation is an essential element of the condition.[61] Although *penile melanosis* is a good term for lesions without lentiginous hyperplasia on histologic examination, there may be increased basal epidermal pigmentation with or without benign lentiginous melanocytic hyperplasia, including ultrastructurally. The possibility of Addison or Nelson syndrome should be entertained, as should the possibility of a lentiginosis syndrome [Peutz-Jeghers, LAMB (*l*entigines, *a*trial *m*yxoma, *b*lue nevi), LEOPARD (multiple *l*entigines, *e*lectrocardiographic abnormalities, *o*cular hypertelorism, *p*ulmonary stenosis, *a*bnormalities of the genitalia, growth *r*etardation, *d*eafness), or Bannayan-Riley-Ruvalcaba syndrome (see Chap. 73)], although idiopathic lentigines of the penis are recognized.

If lesions are large or enlarging, with irregular edges and multifocal and variegated pigmentary patterns, concern may be raised about atypical melanocytic proliferation and acral lentiginous melanoma.

Despite being benign, penile melanosis can be cosmetically disturbing. Laser treatment may be helpful.



▲ **FIGURE 75-12** Penile melanosis. Glans penis. Post lichen sclerosus. (© Medical Illustration UK.)

Zoon Balanitis

ETIOLOGY AND PATHOGENESIS The evidence indicates that ZB is a chronic, reactive, principally irritant mucositis that causes, or is due to, a dysfunctional foreskin.[3,14,16] Irritation is induced by retention of urine and squames between two tightly apposed and infrequently and inadequately separated and/or infrequently or inappropriately bathed, commensally hypercolonized, desquamative, secretory epithelial surfaces.

CLINICAL FINDINGS An asymptomatic presentation with little or no dyspareunia is classic. Conversely, the signs can be florid. Well-demarcated, glistening, moist, shiny, bright red or autumn brown patches symmetrically involve the glans and inner prepuce, sparing the keratinized penile shaft or foreskin (Fig. 75-13). Other signs include dark red stippling or "cayenne pepper spots" due to hemosiderin deposition and solitary or multiple lesions of differing sizes (guttate or nummular), characteristically "kissing." Rarely, erosive and vegetative presentations have been reported, but lesions with asymmetric, atypical, or unusual morphology should be viewed with great suspicion and the organ inspected diligently for other, less florid signs. ZB may be secondary and may thus conceal more subtle evidence of underlying preputial disease such as LSc, pre-cancer, or frank cancer that might have induced the manifest zoonoid changes. Overt cases of other dermatoses such as contact dermatitis, psoriasis, LSc, LP, penis pre-cancer, and penile cancer may appear to have zoonoid changes on clinical and histologic examination (Fig. 75-14). It is possible that some of the clinical and histologic variants that have been reported and the dubious claim that ZB per se is a pre-malignant condition are a consequence of this phenomenon.[62]



▲ **FIGURE 75-13** Zoon balanitis. Symmetric red patches. Glans penis and prepuce. (© Medical Illustration UK.)

ZOON BALANITIS AT A GLANCE



- Zoon plasma cell balanitis (ZB; properly balanoposthitis) affects the middle-aged and older uncircumcised male.
- ZB is a chronic, reactive, irritant mucositis.
- ZB is characterized by silent symptomatology and florid signs.
- Zoonoid inflammation is a common corollary of other dermatoses that cause a dysfunctional prepuce. Asymmetric, atypical, or unusual morphology should be viewed with suspicion.
- Circumcision is the definitive treatment in the majority of cases.

LABORATORY TESTS On histologic examination the epidermis is attenuated with absence of the granular and horny layers, sparse dyskeratosis and spongiosis, and diamond- or lozenge-shaped basal cell kerat-

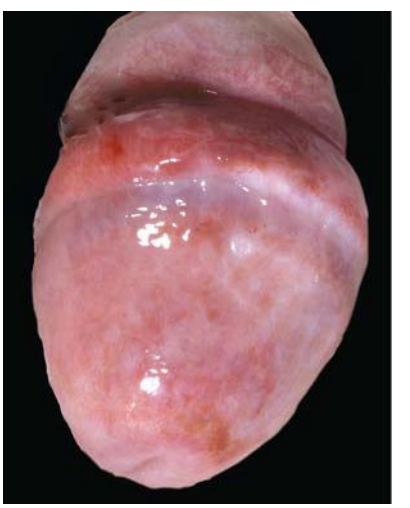

▲ **FIGURE 75-14** Zoonoid inflammation. Florid zoonoid balanoposthitis complicating lichen sclerosus. (© Medical Illustration UK.)

Box 75-5

Differential Diagnosis of Zoon Balanitis

Most Likely

- Psoriasis
- Seborrheic dermatitis
- Lichen sclerosus
- Non-specific balanoposthitis

Consider

- Contact dermatitis
- Erosive lichen planus
- Viral warts
- Herpes simplex
- Fixed drug eruption

Always Rule Out

- Erythroplasia of Queyrat
- Kaposi sarcoma

inocytes. In the dermis there are variably seen a band of plasma cells infiltration, extravasated erythrocytes, hemosiderin, fibrosis, and vascular proliferation.[14,63]

DIFFERENTIAL DIAGNOSIS Disorders from which ZB must be differentiated are listed in Box 75-5.

TREATMENT Although the condition may be ameliorated by improvement in washing habits and micturition practices and by the intermittent application of mild or potent topical corticosteroids (with or without antibiotics and anticandidals) and topical tacrolimus, ZB usually persists or relapses. Definitive curative treatment is surgical circumcision.[14]

Lichen Sclerosus[63]

EPIDEMIOLOGY Genital LSc is more common than extragenital disease, but there may very occasionally be involvement in both areas. In adults, anogenital LSc is said to be about 10 times more common in women than in men. Perianal disease is very rare in the male, if ever encountered. LSc may be much more frequent than is generally supposed in young boys. In boys, persistent primary phimosis or the secondary development of phimosis in a previously retractable foreskin should be viewed with suspicion: Some, many, or most of such cases will be due to LSc.[3,14,16]

ETIOLOGY AND PATHOGENESIS The pathogenesis of LSc, particularly the role of autoimmunity, is discussed in Chap. 63. Anti–extracellular matrix protein 1 antibodies have been found in the sera of female and male patients with genital LSc.[64,65] In male genital LSc, roles seem likely for trauma (as suggested by cases

LICHEN SCLEROSUS AT A GLANCE



- Male genital lichen sclerosus (LSc) is an idiopathic inflammatory fibrosing dermatosis.
- It is principally a disease of uncircumcised men, although it can persist or recur after circumcision.
- LSc can be the cause of significant morbidity expressed as preputial dysfunction and male dyspareunia.
- Between one-fourth and one-half of cases of squamous cell carcinoma of the penis may be preceded by LSc. Squamous cell carcinoma complicating LSc carries a high mortality.

in which the development of LSc was related to injury or surgery[66]) and contact with urine (as suggested by the association of genital LSc with anatomic abnormality, particularly hypospadias,[67] and the striking differences in the pattern of distribution between the sexes) but not for infection (men with genital LSc rarely if ever have sexual partners with LSc[14]).

CLINICAL FINDINGS LSc is discussed in detail in Chap. 63. The symptoms and signs of male genital LSc are summarized in Table 75-3 and partially illustrated in Figs. 75-15 and 75-16. The classic genital morphologic presentation of LSc is of atrophic white patches or plaques. However, lilac, slightly scaly patches with telangiectasia and sparse purpura, like those of the classic clinical manifestations of extragenital LSc, may be seen. Urethral involvement may be more common and extensive than hitherto supposed.[68]

Most cases of LSc can be diagnosed clinically. If there is clinical doubt, then a biopsy should be performed. The histologic findings are discussed in Chap. 63.

DIFFERENTIAL DIAGNOSIS Disorders from which LSc must be differentiated are listed in Box 75-6.

COMPLICATIONS SCC of the penis is the most worrying complication of LSc.[3,14,16,69–76] A rate of between 4 percent and 9.5 percent has been claimed, and the latent period may be 10 to 30 years.[3,14,16,75,76] Involvement of the glans with LSc is a significant risk.[76] Carcinoma complicating LSc constitutes approximately 25 percent to 50 percent of all cases of penile cancer.[14,72,77–80] A pseudohyperplastic preputial SCC of the penis complicating LSc has been described; this entity is an extremely well differentiated, non-verruciform, often multicentric SCC.[79]

TABLE 75-3
Symptoms and Signs in Male Genital Lichen Sclerosus

- Asymptomatic
- Spontaneous
  - Itching, burning, soreness, pain, adhesions
  - Blisters, white patches, purpura, balanoposthitis, phimosis
- Dyspareunia
  - Itching, burning, soreness, pain, bleeding, tearing, splitting, blisters, raw patches, balanoposthitis, phimosis, paraphimosis
- Effacement of normal architectural features
  - Phimosis, narrow meatus, dissolution of frenulum, short frenulum, broad frenulum, "bunched" frenulum, white papules and patches, loss of coronal definition, adhesions, telangiectasia, scarring, fibrotic band ("waisting" or "bunching")
  - Posthitis and balanitis xerotica
- Dysuria, voiding difficulties, urinary retention
- Renal failure
- Cancer

Treatment of LSc is discussed in Chap. 63 and on-line.

Non-Specific Balanoposthitis

Non-specific balanoposthitis is viewed either as a diagnosis of exclusion or as a descriptive term that indicates the limitations of diagnostic acumen.[3,14,16] Sexually transmitted disease, immunosuppression, and diabetes or an identifiable primary dermatosis such as psoriasis, seborrheic dermatitis, ZB, LSc, LP, warts, or carcinoma in situ must be sought. A biopsy is essential. When patients present with symptoms and signs of balanoposthitis, non-specific histopathologic features are found in approximately 10 percent of biopsy specimens.[87] Genitourinary physicians frequently diagnose candidosis, but dermatologists believe that *Candida* infection may complicate any inflammatory mucocutaneous dermatosis and is found as a secondary opportunistic phenomenon rather than as a primary cause of disease.[3] Preputial dysfunction is the





▲ **FIGURE 75-15** Lichen sclerosus. Posthitis and tight fibrotic band causing "waisting" or "bunching." (© Medical Illustration UK.)

cause or consequence in probably all cases of non-specific balanoposthitis, and many patients probably have LSc as the underlying morbid state. Treatment[88] can be very difficult, and the disease may fail to respond to local hygienic measures, soap substitution, topical steroids, and topical and systemic antibiotics.

The ultimate recourse is circumcision, which is curative in most instances. Histologic examination of the whole prepuce may substantiate the presence of an underlying genital dermatosis such as LSc. In a significant number of patients, however, the circumcision histologic findings will be non-specific, even after review with the pathologist for early signs of LSc and even if there had been either hard or soft signs of an underlying dermatosis such as LSc on clinical evaluation on one or more occasions. These observations imply that such patients have non-specific preputial dysfunction due to non-specific irritation, trauma, and secondary candidosis such that a genuine non-specific balanoposthitis ensues, with the pace of normal preputial repair and regeneration being exceeded by the pace of day-to-day attrition or wear and tear.[3,14,16]



▲ **FIGURE 75-16** Lichen sclerosus. Lichenoid posthitis. Effacement of frenulum. (© Medical Illustration UK.)

Dermatologic Non-Disease, Dysesthesia, and Chronic Pain Syndromes

Dermatologic non-disease[89] should be considered when florid symptomatology is accompanied by a paucity or complete absence of any primary dermatologic signs.[90] Patients with symptoms of itching, burning, redness, and pain focalized to the penis or scrotum, in some cases so severe as to prevent the patient from sitting down, are not uncommonly encountered. The chronic urogenital and rectal pain syndromes are described by the terms *penodynia, scrotodynia, orchialgia, prostatodynia, coccygodynia, proctalgia fugax, perineal pain, descending perineum syndrome,* and *vulvodynia*.[91–94]

Box 75-6

Differential Diagnosis of Lichen Sclerosus

Most Likely

- Lichen planus
- Non-specific balanoposthitis

Consider

- Cicatricial pemphigoid

Always Rule Out

- Child sexual abuse
- Squamous carcinoma

The red or burning scrotum syndrome has been defined as "persistent redness of the anterior half of the scrotum that may involve the base of the penis … usually accompanied by a persistent itching or burning sensation and hyperalgesia."[95] Accompanying the erythema there may be telangiectasia. It is a chronic condition that is resistant to treatment and its cause is unknown.[90,95]

The neuroanatomy of the pelvis is complicated, and the neuropathophysiologic basis of these syndromes is poorly understood. They seem to share features of neurogenic inflammation and neuropathic pain.[96] Although their clinical presentations are well recognized by physicians in many specialties, these diagnoses should be arrived at after comprehensive clinical assessment, contemplation of the differential diagnosis, and a process of exclusion based on suitable investigations and response to treatment.[97] Localized dermatographism should be sought by stroking the inside of the thigh. Contact urticaria, irritant and contact dermatitis, and scrotal rosacea due to topical steroid application should be considered. Tinea and candidosis must be excluded. Intercurrent herpes simplex or postherpetic neuralgia might mislead. Angiokeratoma corporis diffusum and multiple sclerosis are causes of odd sensory symptoms. Zinc deficiency and migratory necrolytic erythema could be entertained. Penile sensitivity is reduced in diabetic patients, and this may correlate with erectile dysfunction in some of these men.[98] The drug chart should be reviewed. Some men with "idiopathic" anogenital pruritus may be found to have lumbosacral radiculopathy if investigations such as plain radiography, nerve conduction studies, computerized tomography, and needle electromyography are performed, and significant improvement may be obtained by paravertebral injections of triamcinolone and lidocaine.[99]

A diagnosis of a chronic pain syndrome carries the possibility of considerable psychological morbidity. Dysmorphophobia, depression, and psychosis may be present, and attempted or completed suicide is a real risk in such patients.[14]

Scrotal rosacea (see Chap. 79) should be treated with oral tetracyclines. If anogenital dermatographism and/or urti-

caria is suspected, oral antihistamines can be prescribed. Prednisolone and antidepressants such as doxepin, amitriptyline, and paroxetine can afford some relief. Neuromodulation by sacral root stimulation might be tried.[96] Treatment is generally problematic, however, and at best only empiric. Invasive and irreversible procedures should be avoided if at all possible. Multi-disciplinary management is the ideal.[14]

Penile Acne

Penile acne is an ill-documented entity occasionally encountered in clinical practice.[3] Young men complain of penile spots or boils or blackheads and on examination have comedones, papules, pustules, and inflammatory nodules of the proximal penile shaft. An important differential diagnosis of acneiform disease presenting at any site is chloracne caused by occlusion of the skin with machine oil. Conventional treatment for acne is prescribed in a hierarchical manner: topical keratolytics, antibiotics, and retinoids; oral antibiotics; and isotretinoin (see Chap. 78).

Chronic Idiopathic Penile Edema

Chronic idiopathic penile edema is a rare, ill-understood condition.[3,100] It is the cause of significant morbidity, sexual dysfunction, and phimosis. Patients present with swelling and intercurrent attacks of cellulitis and lymphangitis of the penis, scrotum, and pelvic girdle. Recurrent sexually transmitted diseases, a chronic dermatosis, and hypoplastic lymphatics are sometimes incriminated. The antistreptolysin-O titer may be elevated, and a biopsy specimen may show granulomatous lymphangitis, and Crohn disease (Fig. 75-17) should be sought even if the patient has no gastrointestinal symptoms. Sarcoidosis should be excluded. Treatment has to be aggressive to prevent intercurrent infection and further lymphatic damage and scarring. Long-term treatment with oral antibiotics such as erythromycin, clarithromycin, clindamycin, trimethoprim, or ciprofloxacin is advocated. Occasionally, a short cause of oral prednisolone is helpful. The goal should be to reduce the preputial edema to allow circumcision.

Spontaneous Scrotal Ulceration

Rare cases of spontaneous scrotal ulceration in young, previously fit men have been described.[101] Histologic examination showed non-specific vasculitis, and spontaneous resolution occurred. A related entity may be idiopathic scrotal panniculitis and fat necrosis,[102] because trauma, extreme cold, and Fournier gangrene were excluded.



▲ **FIGURE 75-17** Chronic penile edema. Crohn disease. Histologic examination showed a granulomatous lymphangitis. (© Medical Illustration UK.)

Fournier Gangrene (See Chap. 179)

Fournier gangrene is a medical and surgical emergency.[3] Patients present with systemic upset and painful erythematous swelling of the genital, perianal, or lower abdominal skin and may be in urinary retention. An ominous black spot may appear on the scrotum. There is gross systemic toxicity (peculiarly, sometimes absent in children) and no suppuration. Necrosis of skin and deeper tissues rapidly supervenes and death ensues (the mortality may be higher than 50 percent) unless diagnosis is prompt and radical management is instituted. In its clinical picture Fournier gangrene overlaps with necrotizing fasciitis and Meleney gangrene. Risk factors are presented in Table 75-4.

TABLE 75-4
Risk Factors for Fournier Gangrene

- Debilitation
- Diabetes mellitus
- Alcoholism
- Anogenital infection
- Chemotherapy
- Acquired immunodeficiency syndrome
- Post-instrumentation
- Post-surgery (urologic and colorectal)
- Heroin addiction
- Trauma
- Unconventional sexual practices

The process probably begins with appendageal or urethral infection, and polybacterial infection develops. Most of the organisms isolated from cases prove to be resident urethral or lower gastrointestinal flora, and most patients have mixed infections. What then follows is a necrotizing cellulitis, perhaps exotoxin mediated, that affects skin, subcutis, fascia, and muscle—the human counterpart of the local Shwartzman phenomenon. In children, the most commonly isolated pathogens are staphylococci and streptococci. Radiologic studies may show soft tissue gas.

Disorders from which Fournier gangrene must be differentiated are listed in Box 75-7.

If the clinical diagnosis of Fournier gangrene is entertained, then drastic emergency management is required.

Box 75-7
Differential Diagnosis of Fournier Gangrene

Most Likely
- Trauma
- Herpes simplex
- Cellulitis
- Gonococcal balanitis and edema

Consider
- Migratory necrolytic erythema
- Allergic vasculitis
- Polyarteritis nodosa
- Ecthyma gangrenosum
- Warfarin necrosis

Always Rule Out
- Necrotizing fasciitis
- Vascular occlusion syndromes



Surgical and microbiologic expertise, often in an intensive care setting, may be required. Radical surgical débridement of all affected tissue is undertaken and broad systemic antibiotic therapy initiated. If the patient survives, then plastic surgical repair can be performed.[103] Hyperbaric oxygen treatment has been advocated, as has high-dose systemic corticosteroid treatment. Children can be treated with more conservative surgery, and the mortality rate is lower.[104]

In adults, the mortality is around 25 percent and is highest in disease of anorectal rather than urogenital origin, which likely reflects a less typical presentation and longer delay in diagnosis.[105]



Non-Syphilitic Spirochetal Ulcerative Balanoposthitis

Non-syphilitic spirochetal ulcerative balanoposthitis is recognized in the tropics and South Africa and presents as large, serpiginous, foul-smelling ulcers in uncircumcised men, associated in some with non-tender inguinal lymphadenopathy.[106] Treatment is with penicillin or metronidazole.

Scrotal Calcinosis

Scrotal calcinosis is a relatively common, benign idiopathic disorder presenting as rock-hard smooth white papules or nodules on the scrotum, multiple or solitary.[3] Occasionally the lesions may become secondarily inflamed or infected after trauma. Rarely, a lesion or lesions occur on the penis. The differential diagnosis includes epidermoid cyst. Indeed, it is debatable whether the lesions are indeed idiopathic or whether they arise from epidermoid cysts, eccrine duct milia, eccrine epithelial cysts, dystrophy of the dartos muscle, trauma, or foreign bodies (e.g., thorn or even *Onchocerca* organisms). Cold, trauma, and the thinness and specialization of scrotal skin are thought to be etiologic factors. Treatment is by surgical excision, but the lesions recur.

Sclerosing Lymphangitis

Non-venereal sclerosing lymphangitis [there are a confusing number of synonyms: *penile venereal edema, Mondor phlebitis, localized penile (venereal) lymphedema, penile lymphocele*] is increasingly recognized.[3] Patients present with a serpiginous mass in the coronal sulcus, spreading sometimes onto the dorsal penis. The lesion may appear for the first time or become tender and enlarge after prolonged or frequent sexual intercourse. In circumcised men the circumferential scar may be a predisposing factor. It has not been established whether this entity represents a post-traumatic lymphangitis or phlebitis. The problem may resolve spontaneously, or surgical excision may be required.

True thrombophlebitis of superficial penile and scrotal veins is analogous to Mondor phlebitis of the chest wall. Herpes simplex virus infection, polyarteritis nodosa, and thromboangiitis obliterans may initiate it. Penile thrombophlebitis has been seen as the initial presentation of a paraneoplastic migratory thrombophlebitis caused by pancreatic cancer.

Verruciform Xanthoma

Verruciform xanthoma is a rare entity that principally involves the mouth. Genitalia are the next most frequently affected area, where it presents as a painless, yellow-brown or red, verrucous, sessile or papillary plaque.[3] Histologically there is hyperkeratosis, focal parakeratosis, and irregular epidermal acanthosis. Rete ridges are lengthened and extend into the dermis, forming areas called *dermal papillae* and enclosing capillary vessels surrounded by foam cells that are $CD68^+$ but $S100^-$. It is thought that the lesion results from epidermal degeneration and that keratinocyte lipid is taken up by dermal macrophages or fibroblasts to form the foam cells. HPV-6 DNA has been found in one case. SCC may arise within the lesion. Treatment is by surgical excision.

Penile Carcinoma In Situ and Squamous Cell Carcinoma

EPIDEMIOLOGY SCC of the penis accounts for 0.3 percent to 0.6 percent of cases and less than 1 percent of cancer deaths in the United States.[3,14,16,40,107] One hundred deaths and 400 cases are seen per year in the United Kingdom.[108,109] It is estimated that penile SCC represents 10 percent to 20 percent of tumors seen in males in the developing world, where neonatal or infantile circumcision is not part of the culture.[110] However, in developed countries such as Japan and Denmark where circumcision is not routinely practiced, penile cancer incidence is falling and is approximating that in the United Kingdom and United States.[111] The epidemiology of PCIS is not well established; it is probably underdiagnosed and underreported.[108,112]

PENILE CARCINOMA IN SITU AND SQUAMOUS CELL CARCINOMA

AT A GLANCE



- Erythroplasia of Queyrat, Bowen disease of the penis, and bowenoid papulosis are synonymous in describing clinical situations (usually of uncircumcised men) in which histologically penile carcinoma in situ is present.
- *Penile carcinoma in situ* (PCIS) is a better term than *penile intraepithelial neoplasia* or PIN (corresponding to cervical intraepithelial neoplasia, vulval intraepithelial neoplasia, and anal intraepithelial neoplasia) because of the potential for confusion with prostatic intraepithelial neoplasia.

ETIOLOGY AND PATHOGENESIS (See Chaps. 110 and 111) Acknowledged risk factors for SCC are presented in Table 75-5.[14,40,79,80]

TABLE 75-5
Risk Factors for Penile Cancer

- Uncircumcised state
- Phimosis
- Poor hygiene
- Chronic irritation and inflammation
- Scarring
- Smoking
- Lichen sclerosus
- Lichen planus
- Squamous hyperplasia
- Bowen disease of the penis
- Erythroplasia of Queyrat
- Bowenoid papulosis
- Human papillomavirus infection
- Other sexually transmitted diseases
- Multiple sexual partners
- Human immunodeficiency virus infection
- ?Psoriasis
- Photochemotherapy
- Iatrogenic immunosuppression



▲ **FIGURE 75-18** Erythroplasia of Queyrat. Coronal sulcus. (From Bunker CB: *Male Genital Dermatology*. London, Saunders, 2004. © Medical Illustration UK.)



▲ **FIGURE 75-20** Bowenoid papulosis. Red papules, distal penile shaft. (© Medical Illustration UK.)



CLINICAL FINDINGS EQ is exemplified by bright red, shiny patches or plaques of the mucosal sites, the glans and prepuce of the uncircumcised (Fig. 75-18). Bowen disease of the penis (BDP) is characterized by red, scaly patches and plaques of the keratinized penis (Fig. 75-19). Both affect the older male. BP presents as multiple warty lesions rather than as erythematous patches or red, scaly plaques (Fig. 75-20). BP is pigmented in keratinized sites, and lesions are multiple and more inflamed in mucosal sites; lesions are more polymorphic, more coalescent, less papillomatous, and smoother topped than common genital viral warts. BP is seen in younger, sexually active men. Pseudoepitheliomatous micaceous and keratotic balanitis is probably not a separate entity but a clinical variant of PCIS, perhaps in association with LSc and with a risk of development of invasive SCC.[3,40]

In SCC irregular nodular and ulcerative morphology is encountered (Fig. 75-21). Clinically there may be evident background PCIS and/or LSc (or even LP). Inguinal lymphadenopathy may be present, although in penile cancer only 50 percent of enlarged glands will be found to contain tumor. Verrucous carcinoma, warty carcinoma, Buschke-Lowenstein tumor (BLT), and giant condyloma may be dramatic clinical lesions, often polypoid or cauliflower-like. Although locally deeply invasive, they are well demarcated from surrounding tissue.

Verrucous carcinoma, *warty carcinoma*, *Buschke-Lowenstein tumor*, and *giant condyloma* are often used synonymously to describe rare, low-grade, well-differentiated squamous carcinomas.[115–122] The potential for aggressive behavior, mortality risk, and clinical, histologic, and virologic differences may distinguish them. Giant condyloma and BLT are thought likely to have their origin in common genital warts.[14] BLT has also been associated with LSc.[123]

DIFFERENTIAL DIAGNOSIS (Box 75-8) A biopsy is indicated in most instances. The histopathology of mucosal PCIS is generally that of a bowenoid pattern of dysplasia with dysmaturation and atypical cells and increased mitoses at different levels of the epithelium. This is often accompanied by HPV-related cytopathic changes in the upper layers of the epithelium, but there is as yet no formal consensus on clinicopathologic classification and clinical utility. Increasingly encountered are the terms *squamous hyperplasia* and *squamous intraepithelial lesion* of squamous, basaloid, or warty type and low or high grade to describe the histologic findings of epithelial lesions associated with penile SCC.[124,125]

In SCC, tongues of invasive atypical keratinocytes invade the lamina propria or deeper structures and contain foci of aberrant and ectopic keratinization (squamous pearls). Penile SCC is morphologically heterogenous, and the frequency of occurrence of different types in 61 U.S. cases was 59 percent usual (squamous), 15 percent papillary (not otherwise specified), 10 percent basaloid, 10 percent warty (condylomatous), 2 percent verrucous, and 2 percent sar-



▲ **FIGURE 75-19** Bowen disease of the penis. Multifocal psoriasiform scaly plaques. (From Bunker CB: *Male Genital Dermatology*. London, Saunders, 2004. © Medical Illustration UK.)



◀ **FIGURE 75-21** Squamous carcinoma. Human immunodeficiency virus–positive patient. (© Medical Illustration UK.)

comatoid.[126] The histologic type of SCC has a bearing on prognosis, with basaloid and sarcomatoid cancers associated with a high rate of nodal dissemination and mortality.[126] The prognosis is also related to the degree of differentiation and the depth of invasion of crucial anatomic landmarks.

Suspected verrucous carcinoma demands a deep surgical biopsy. Verrucous carcinoma has different pathologic features from typical squamous carcinoma, showing well-differentiated and maturing squamous epithelium with very little atypia or pleomorphism and few mitoses. The diagnosis of verrucous carcinoma in biopsy specimens may be difficult to establish because it relies very much on the depth of invasion of the lesion in relation to surrounding epidermis, and the growth pattern is of a "pushing" margin rather than infiltration. Warty carcinoma, BLT, and giant condyloma differ further in having marked squamous proliferation with HPV-related changes; they are not associated with bowenoid dysplasia but do have more atypia and mitoses than classic verrucous carcinoma.

Box 75-8

Differential Diagnosis of Penile Carcinoma In Situ and Squamous Cell Carcinoma

BOWEN DISEASE OF THE PENIS/ERYTHROPLASIA OF QUEYRAT

Most Likely
- Psoriasis
- Zoon balanitis
- Non-specific bowenoid papulosis
- Lichen sclerosus

Consider
- Extramammary Paget disease
- Kaposi sarcoma
- Erosive lichen planus

Always Rule Out
- Squamous cell carcinoma

BOWENOID PAPULOSIS

Most Likely
- Viral warts
- Seborrheic keratosis
- Lichen planus

Consider
- Mollusca
- Nevi

Always Rule Out
- Condylomata lata

SQUAMOUS CELL CARCINOMA

Most Likely
- Ulcerative sexually transmitted disease
- Lichen sclerosus
- Erosive lichen planus

Consider
- Artifact
- Behçet disease

Always Rule Out
- Fournier gangrene
- Pyoderma gangrenosum

PROGNOSIS The prognosis of established, thick, invasive SCC remains poor, but that of early thin disease is much better. HPV status does not correlate with survival.[133] In the United States, previously or currently married men present earlier and have increased survival overall; African Americans present later and do less well.[134]

TREATMENT There are several approaches to the treatment of PCIS, summarized in Box 75-9. The guiding principle is to be conservatively ablative.[14,40,108] A rational initial step is to recommend circumcision. Patients presenting with these conditions (and their sexual partners) should be counseled and screened for HPV and other sexually transmitted diseases, including HIV infection. Smoking should be discouraged. Follow-up should be long term, and the focus should include the whole perineum, anus, and perianal skin.

Box 75-9

Treatments for Penile Carcinoma In Situ
- Circumcision
- Cryotherapy
- Salicylic acid
- Podophyllin/podophyllotoxin
- Curettage and cautery
- Simple excision
- Mohs surgery
- Laser therapy
- Photodynamic therapy
- Radiotherapy (not advised)
- 5-Fluorouracil
- Imiquimod

For SCC, adequate surgical excision is required. This may need to be radical (i.e., penile amputation), depending on location and extent, but the trend is toward tissue-conserving techniques for functional and cosmetic reasons.[40,109] Mohs micrographic surgery and laser procedures have their proponents. Local staging to inform management decisions is achieved by clinical evaluation, histologic analysis, sonography, and magnetic resonance imaging. The histologic grade predicts proximal histologic extent beyond grossly visible tumor margin. Sentinel node biopsy has been advocated, but the management of ilioinguinal lymphadenopathy is controversial. Established lymphatic or hematogenous dissemination requires individualized multidisciplinary management. Combination chemotherapy has been used for palliation and proposed for adjuvant treatment but is of uncertain value. Brachytherapy or external beam radiotherapy and chemoradiotherapy have their proponents.

PREVENTION Chronic disease and dysfunction of the foreskin confer a significant risk of PCIS or frank SCC. The "field changes" due to LSc and HPV create situations of multifocality or multicentricity and a temporal dynamic, contributing to long-term risk even if corrective treatments have been initiated. Feasible measures for penile cancer prophylaxis are treatment of chronic inflammatory conditions such as LSc, LP, and non-specific balanoposthitis; prevention of phimosis; limitation of psoralen and ultraviolet A treatment; smoking cessation; and prophylaxis for HPV infection.[137]

Melanoma (See Chap. 124)

Melanoma is a rare neoplasm of the penis, but the prognosis is poor because of late diagnosis and early lymphovascular

invasion. It should always enter the differential diagnosis of penile melanosis and lentiginosis as well as genital papules, nodules, and ulcers.[3]

Extramammary Paget Disease (See Chap. 121)

Extramammary Paget disease (EMPD)[3] presents as an irritating, itchy, burning, red scaly patch or plaque and may be multicentric. It can be found anywhere around the anogenital area, including the glans penis. An "underpants" pattern of erythema has been described in some patients. EMPD is frequently misdiagnosed as an inflammatory dermatosis, such as psoriasis, eczema, or Bowen disease. Subclinical EMPD disease occurs, in which the skin looks normal macroscopically but is involved microscopically. The disease behaves indolently, spreading by local extension and metastasis. The combination of genital and extragenital EMPD is rare but overt, and latent axillary EMPD disease may co-exist. Axillary macular lesions that changed shape and color daily have been reported in association with penile and pubic Paget disease. Very rarely, depigmented EMPD disease presents as a pale patch in the genital area, evoking a differential diagnosis of vitiligo, depigmented mycosis fungoides, and LSc.

EMPD has been treated with cryotherapy and topical 5-flurouracil, but wide excisional surgery (e.g., Mohs), with plastic repair if needed, is probably the treatment of choice. Radiotherapy is controversial. Photodynamic therapy is under evaluation. Topical imiquimod holds promise.[138]

KEY REFERENCES

The full reference list for all chapters is available at www.digm7.com.

1. Mallon E et al: Circumcision and genital dermatoses. *Arch Dermatol* **136**:350, 2000
3. Bunker CB: *Male Genital Dermatology*. London, Saunders, 2004
13. Hutcheson JC: Male neonatal circumcision: Indications, controversies and complications. *Urol Clin North Am* **31**:461, 2004
14. Bunker CB: Management of penile dermatoses. *Expert Rev Dermatol* **1**:241, 2006
16. Porter WM, Bunker CB: The dysfunctional foreskin. *Int J STD AIDS* **12**:216, 2001
40. Micali G et al: Penile cancer. *J Am Acad Dermatol* **54**:369, 2006
82. Neill SM et al: Guidelines for the management of lichen sclerosus. *Br J Dermatol* **147**:640, 2002.
87. Alessi E, Coggi A, Gianotti R: Review of 120 biopsies performed on the balanopreputial sac. From Zoon's balanitis to the concept of a wider spectrum of inflammatory non-cicatricial balanoposthitis. *Dermatology* **208**:120, 2004
110. Misra S, Chaturvedi A, Misra NC: Penile carcinoma: A challenge for the developing world. *Lancet Oncol* **5**:240, 2004
125. Cubilla AL, Velazquez EF, Young RH: Epithelial lesions associated with invasive penile squamous cell carcinoma: A pathologic study of 288 cases. *Int J Surg Pathol* **12**:351, 2004



CHAPTER 76

Diseases and Disorders of the Female Genitalia

Rochelle R. Torgerson
Libby Edwards

Diagnosis and management of vulvar skin disease require thorough history taking, complete mucocutaneous examination, modification of some common dermatologic principles, evaluation for and correction of vaginitis, and careful patient education regarding expectations and therapy.

EPIDEMIOLOGY

The incidence and prevalence of dermatoses affecting the female genitalia are generally not well established. They are most likely under-reported and underdiagnosed diseases. Approximately 20 percent of women report undiagnosed chronic vulvovaginal pain at some time in their lives.

ETIOLOGY AND PATHOGENESIS

As with epidemiology, the etiology and pathogenesis of many diseases of the female genitalia are not well understood. Those that also affect other areas of the body are better characterized. Also, the environment of the vulva strongly affects the course of disease.

CLINICAL FINDINGS

History

The approach to the patient with vulvar complaints requires directed history taking, as outlined in Box 76-1.

Cutaneous Lesions and Symptoms

The warm, moist environment of the vulva often alters disease morphology or symptomatology. For example, scaling dermatoses may lack clinically obvious scale, and in diseases that usually exhibit well-demarcated plaques the lesions may be less distinct. In addition, diseases that normally do not produce scarring of keratinized skin or oral mucosa can induce agglutination (resorption) of the labia minora, narrowing of the introitus, and scarring of the clitoral hood. Vulvar scarring can occur from any inflammatory condition.[1] Conversely, unimpressive physical findings are sometimes associated with extremely severe itching and pain of the vulva. Lichenification manifested only by a slight texture change can be associated with excruciating pruritus

Box 76-1

Elements of History Taking for Patient with Vulvovaginal Complaints

- Symptoms: Onset, initial trigger, duration, alleviating and exacerbating factors
- Previous treatments: Duration and effectiveness
- Previous evaluations
- Daily cleansing and care practices
- Contactants: Tampons, pads, lubricants, deodorants, fragrances
- Gynecologic history
  - Menstruation/menopause/estrogen replacement
  - Pap tests
  - Contraception
  - Pregnancy
  - Sexual activity
  - Sexually transmitted diseases
  - Surgeries
- Urologic history
  - Continence/incontinence
  - Surgery
- Psychiatric history
  - Previous diagnoses and treatments
  - Current symptoms

VULVOVAGINAL DISEASES AT A GLANCE



- Common problems: Approximately 20 percent of women report undiagnosed chronic vulvovaginal pain at some time.
- Normal variants of vulvar anatomy can be a source of confusion.
- In addition to common infections, a large number of other conditions may cause vulvovaginal symptoms:
  - Inflammatory dermatoses
  - Bullous and erosive diseases
  - Ulcers
  - Vulvodynia
- Challenges in the evaluation, diagnosis, and management of female genital diseases include the following:
  - Normal vulvar skin is red to varying degrees, and this does not imply disease.
  - Morphology is often non-specific.
  - Scarring is common with any inflammatory process of the vulva.
  - Causes are often multifactorial.
  - Vaginal abnormalities may contribute and must be evaluated and addressed.
  - Histologic characteristics of inflammatory dermatoses are often non-specific.
  - Patient anxiety and depression are often severe, can worsen symptoms, and must be addressed.
  - Vulvodynia and vestibulodynia are common and produce no cutaneous abnormalities.
- Careful patient education and support are crucial to the successful treatment of vulvovaginal disease.



deserving of and responsive to aggressive therapy. Finally, a complete mucocutaneous examination is crucial, because extragenital findings can assist in the diagnosis of several genital conditions.

Related Physical Findings

Skin disease affecting the vulva more often has multifactorial causes than that affecting other areas of the body. The primary skin disease is often accompanied and driven by a secondary yeast infection or bacterial colonization, even in the absence of obvious clinical findings. The infection can be purely cutaneous, purely vaginal, or both. Irritant contact dermatitis from multiple applied topical agents often exacerbates symptoms and needs to be considered.

Vulvar symptoms cannot be divorced from vaginal abnormalities. Irritating or infected vaginal secretions are a common cause of vestibular (introital) symptoms, which makes a speculum examination highly advisable in many instances.

LABORATORY TESTS

Skin biopsy specimens for hematoxylin and eosin staining and direct immunofluorescence testing may be required. Sometimes multiple biopsy samples are required to establish a specific histologic diagnosis. When previously well-controlled dermatoses flare, repeat biopsy may be needed to rule out squamous cell carcinoma or a second disease process.

Culture of cutaneous swab samples is indicated when concurrent infection is considered. Infection can complicate treatment at any point in the course of a disease.

A microscopic evaluation of vaginal smears allows inspection for yeast (see Chap. 189), *Trichomonas*, and bacterial vaginosis (see Chap. 205). Abnormalities such as an increased number of white blood cells or the presence of immature epithelial cells may be seen as well and may be markers for inflammatory skin diseases, estrogen deficiency, foreign body, or pyogenic bacterial infection. Vaginal cultures, done in addition, can identify infection caused by a non-*albicans Candida* organism, a pathogen difficult to see on microscopic smears but occasionally a cause of significant symptoms.

Patch testing is important if allergic contact dermatitis is suspected (see Chap. 13). Consultation with specialists in gynecology, urology, or urogynecology may be necessary to assist with diagnosis, management, or treatment. This is particularly true in the setting of multifactorial processes (e.g., incontinence as a confounding factor) or diseases requiring surgical intervention (e.g., posterior fourchette fissuring).

DIFFERENTIAL DIAGNOSIS

Because of the varied morphologies and frequent multifactorial presentations, the differential diagnosis for a vulvar condition can be quite broad (Box 76-2). Normal variants can be confusing as well. The diseases discussed in this chapter are grouped into the categories of inflammatory dermatoses, bullous and erosive diseases, ulcers, abscesses, and vulvodynia.

PROGNOSIS AND CLINICAL COURSE

Women with vulvovaginal symptoms assume they have a curable, infectious disease. Patients need to be counseled that many genital dermatoses are controllable but not curable. These women cannot be evaluated and treated in a 10-minute office visit; rather, they require adequate time for education and reassurance.

TREATMENT

Several factors need to be considered when treating most dermatoses of the female genitalia.

Many women are unfamiliar with their genital anatomy and do not have the vocabulary to accurately discuss their problem or follow instructions

Box 76-2

Differential Diagnosis of Vulvovaginal Disorders

INFLAMMATORY DERMATOSES
- Lichen simplex chronicus
- Irritant contact dermatitis
- Allergic contact dermatitis
- Psoriasis
- Lichen sclerosus
- Vulvar fissures

BULLOUS AND EROSIVE DISEASES
- Lichen planus
- Erythema multiforme major
- Toxic epidermal necrolysis
- Cicatricial pemphigoid
- Pemphigus vulgaris
- Fixed drug eruption
- Herpes simplex
- Extramammary Paget disease
- Vulvar carcinoma

ULCERS
- Aphthous ulcers
- Crohn disease
- Syphilis
- Chancroid
- Other in sexually transmitted diseases

ABSCESSES
- Bartholin gland abscess
- Hidradenitis suppurativa

VULVODYNIA

for applying topical medications. Diagrams and/or a use of a hand-held mirror is extremely helpful for patient education.

An ointment is generally the most comfortable vehicle for delivering medication to the modified mucous membranes of the vulva. Ointments spread easily, require very small volumes per application, and generally cause less burning.

Irritant contact dermatitis is a common complicating factor in any genital dermatosis. Aggressive washing and use of soaps, topical medications, and home remedies are the most common offenders. Because soaps, douches, disinfectants, and very hot or cold water often are not considered relevant by patients, information regarding their use is often not volunteered, and very careful questioning is warranted. Gentle cleansing of the area can be accomplished by flushing once a day with water (or mild soap and water) and patting dry. Washcloths and scrubbing are to be avoided.

High-potency glucocorticoids such as clobetasol propionate are often required to treat dermatoses of the female genitalia. Fortunately, glucocorticoid atrophy is surprisingly uncommon on the modified mucous membranes of the vulva. Nonetheless, patients should be re-evaluated monthly during periods of daily use and warned about side effects in the surrounding areas where atrophy is more likely to occur, such as the inguinal crease, proximal medial thighs, and perianal skin.

Tacrolimus or pimecrolimus can be used as steroid-sparing medications on vulvar skin. Stinging can occur with initial application, however, and these agents are often less effective than glucocorticoids (for efficacy and side effects, see Chap. 221).

Warmth and moisture of the genital area are unavoidable and promotes infection and maceration. Bacterial superinfection can be treated with oral antibiotics. Yeast infections are especially common, particularly when patients are treated with topical glucocorticoids and/or oral antibiotics. The identification of infection on red, scaling, and often exudative skin can be difficult and should be pursued actively in patients with recalcitrant symptoms.

COMMON NORMAL VARIANTS

There is great variety in normal vulvovaginal anatomy. Vulvar and vaginal erythema of varying degrees is present in most asymptomatic premenopausal women, but this redness is rarely noticed before the onset of discomfort. Architecturally, the labia minora exhibit a wide range of asymmetry and size. Normal but very small labia minora may be difficult to differentiate from agglutination produced by inflammatory skin disease.

INFLAMMATORY DERMATOSES

Clinically subtle inflammation of the vulva sometimes produces remarkable symptoms. Therefore, a very careful examination with a high index of suspicion for a dermatosis is required.

Lichen Simplex Chronicus (See Chap. 15)

The morphologic manifestations of lichen simplex chronicus when it occurs on the vulva vary from minimal hyperpigmentation and dullness of texture of the modified mucous membranes to remarkable lichenification, edema, and even elephantiasis nostra verrucosa (Fig. 76-1, see eFigs. 76-1.1 and 76-1.2 in on-line edition). Erythema can be subtle on the labia majora because hair obscures the skin. Excoriations and fissures within skinfolds are common but heal quickly and may not be seen in the office. Sometimes, hydrated, thickened lichen simplex chronicus appears white, mimicking lichen sclerosus or leukoplakia of intraepithelial neoplasia.

Although the histologic findings, differential diagnosis, and therapy are the same for lichen simplex chronicus affecting the vulva as for that involving other parts of the body, there are several notable modifications.[2] Topical glucocorticoid therapy is a mainstay, but prompt alleviation of symptoms often requires a higher-potency preparation than is standard for intertriginous skin. Those with significant lichenification do well with an ultrapotent preparation such as clobetasol propionate for the first few weeks. The potency or frequency can be decreased as the patient improves. Nighttime sedation is crucial to interrupt the itch-scratch cycle.[3] Subtle skin and vaginal infections are extremely common and often drive lichen simplex chronicus. Therefore, a vaginal culture should be performed for any patient who does not improve as expected or who requires ongoing mid- or high-potency topical glucocorticoid therapy for control. Moisturization is not needed, however, because of the occluded, naturally moist nature of this skin. Patients with lichen simplex chronicus that is not intensely inflamed, excoriated, or eroded generally prefer medications in a cream base, because an ointment can be too occlusive, which increases pruritus.



▲ **FIGURE 76-1** Lichenification, seen here most marked on the left, is the characteristic finding in lichen simplex chronicus. Moist lichenified skin is generally hypopigmented, and the mid-line fissure anteriorly is common as well.

Irritant and Allergic Contact Dermatitis (See Chaps. 46 and 13)

Irritant and allergic contact dermatitis of the vulva can be either a primary or secondary diagnosis.[4] This is true in part because the vulvar skin is thin, damp, and permeable and in part because there may be exposure to multiple allergens in the form of medications and cleansers applied to alleviate symptoms.

A patient with acute irritant contact dermatitis experiences burning on contact with the offending substance. Deep erythema is common. Vesiculation can occur on keratinized skin, whereas erosion is usual on modified mucous membranes (Fig. 76-2). Therapies such as fluorouracil, imiquimod, podophyllum resin, some topical antifungal creams, and topical gentian violet can produce a brisk reaction. Chronic irritant contact dermatitis is characterized by poorly demarcated erythema or hyperpigmentation that can be difficult to appreciate because the vulva normally is pink or dusky (see eFig. 76-2.1 in on-line edition). Lichenification and scale, when present, make diagnosis easier. Pruritus can be intense.

Although the British have found allergic contact dermatitis to be a common



▲ **FIGURE 76-2** Patchy erythema, superficial desquamation, and small erosions are often seen with an irritant contact dermatitis such as this eruption caused by benzocaine and resorcinol.

finding on the vulva, American physicians report few relevant positive results on patch tests for patients with eczematous vulvar skin.[4–7] However, women with refractory vulvar symptoms should be evaluated clinically and a thorough history taken to identify allergic contact dermatitis. In acute allergic contact dermatitis of the genital area, vesicles erode as quickly as they form, producing painful exudative plaques. Chronic allergic contact dermatitis is manifested more often by mild erythema and subtle edema. Notable scale is infrequent. More severe chronic disease can produce lichenification. Common allergens include diphenhydramine, neomycin, polymyxin, sulfonamides, some anesthetics, some antifungal creams, spermicides, glucocorticoids, some antiseptics, fragrances, and preservatives (see Chap. 13). As can occur with eyelid dermatitis, allergens can be carried inadvertently from fingertips to the vulva during the course of scratching or wiping. In addition, the habits of sexual partners can be important (consort dermatitis).

The therapy for vulvar contact dermatitis is the same as for this disease occurring in other areas and hinges most importantly on avoidance of irritants and allergens. Irritant, and to a lesser extent allergic, contact dermatitis can be a complicating factor in vulvar symptoms.[8] It can also obscure underlying disease. Women with chronic symptoms often are well served by discontinuing all topical therapies. Triamcinolone ointment 0.1 percent applied twice daily can hasten improvement. Re-evaluation 1 or 2 weeks later may reveal an underlying primary process.

Psoriasis (See Chap. 18)

Although vulvar psoriasis generally is accompanied by psoriasis in other typical locations, the vulva is a common site of initial involvement. Vulvar psoriasis usually affects only fully keratinized skin, sparing the modified mucous membrane of the inner labia majora and the labia minora. Vulvar psoriasis typically exhibits dusky red, well-demarcated plaques. Rather than thick, silver scale, the moistness of inverse psoriasis or a glazed, shiny surface texture is seen (Fig. 76-3, see eFig. 76-3.1 in on-line edition). Extension of erythema into the gluteal cleft is characteristic.

Genital psoriasis often responds well to topical therapy. First-line therapy consists of a topical glucocorticoid. A mid- or high-potency glucocorticoid generally is required for significant clinical or symptomatic improvement. Calcipotriene ointment, tacrolimus ointment, or pimecrolimus cream can be tried as well, but some patients find these too irritating. Sometimes, methotrexate, oral retinoids, cyclosporine, or the newer biologics are required.

Lichen Sclerosus (See Chap. 63)

CLINICAL FINDINGS Lichen sclerosus begins asymptomatically in most patients. Often women tolerate their disease comfortably until they develop a superimposed complicating event, such as candidiasis or atrophic vaginitis, that produces itching followed by scratching, and the process becomes self-perpetuating. At



▲ **FIGURE 76-3** Psoriasis of the vulva is often manifested by shiny, glazed skin, whereas psoriasiform scale and well-demarcated borders are absent.

LICHEN SCLEROSUS AT A GLANCE



- Inflammatory condition of the vulva occurring at any age.
- Most symptomatic in childhood and postmenopausal years (low estrogen levels).
- Cellophane paper–like texture to the plaques classically.
- Chronic, long-term disease leads to scarring and resorption.
- Active disease increases risk of squamous cell carcinoma of the vulva.
- Treatment is with clobetasol propionate ointment.
- Maintenance therapy is typically needed for long-term control.

presentation, the most common symptom of lichen sclerosus is pruritus (mild or severe). Because vulvar skin affected by lichen sclerosus is fragile, scratching often produces painful erosions. Many women, by the time they come for treatment, exhibit late signs of lichen sclerosus, including remarkable textural changes and scarring. Scarring and narrowing of the introitus may make intercourse painful, even intolerable.

Lichen sclerosus begins with white papules or plaques that often occur first on the anterior vulva and periclitorally. Although these papules and plaques are sometimes smooth and somewhat waxy, especially when they occur on moist skin, the classic presentation is one of a hypopigmented, well-demarcated plaque with a cellophane paper–like texture (Fig. 76-4, see eFigs. 76-4.1, 76-4.2, 76-4.3, and 76-4.4 in on-line edition). Generally, the skin is quite fragile and thin, with erosions and purpura being common manifestations. Some women, particularly those who experience excruciating itchiness, exhibit thickened, hyperkeratotic skin (see eFig. 76-4.5 in on-line edition). Many patients with lichen sclerosus experience progressive scarring. Resorption of the labia minora and scarring of the clitoral hood, which buries the clitoris, are common in



▲ **FIGURE 76-4** Hypopigmentation, crinkled texture, and purpura are classically seen in lichen sclerosus.



▲ **FIGURE 76-5** Occasionally, the texture of lichen sclerosus can be waxy or even thin and smooth, as seen here, rather than crinkled. The loss of labia minora and midline agglutination of the clitoral hood are also seen commonly in late lichen sclerosus.

long-standing disease (Fig. 76-5). Extragenital lichen sclerosus of keratinized skin occurs in a minority of women with vulvar lichen sclerosus and is most often located on the upper trunk and arms (see Chap. 63). Usually, extragenital lesions are asymptomatic.

An association of lichen sclerosus with circulating autoantibodies has been reported, but the only association with autoimmune disease sufficient to justify laboratory testing is with hypothyroidism.[21]

DIFFERENTIAL DIAGNOSIS Fully developed lichen sclerosus with hypopigmentation and distinctive shiny or crinkled textural changes is easily recognized. Unfortunately, lichen sclerosus is sometimes subtle or mimics other diseases (Box 76-3).

COMPLICATIONS Before the advent of topical glucocorticoid therapy, 2 percent to 3 percent of patients were reported to develop a local squamous cell carcinoma in the natural course of lichen sclerosus.[22,23] Squamous cell carcinomas occurred primarily in patients with chronic hyperkeratosis or erosions. With effective topical therapy, this risk is understood to be far lower.

TREATMENT Although midpotency topical glucocorticoids reduce symptoms, they often do not normalize the skin texture or prevent scarring. The application of an ultrapotent topical preparation such as clobetasol propionate ointment once or twice a day alleviates symptoms within a few days, but several months of therapy is required for resolution of the clinical findings.[24,25] Most patients require 3 to 5 months of once- or twice-daily application to achieve maximal improvement. Patients should be followed monthly during periods of daily treatment to monitor the skin for steroid side effects and for improvement so that the frequency of application can be decreased. As an adjunct therapy for the first week or two to control scratching and hasten healing, sedating dosages of an antihistamine or a tricyclic antidepressant are helpful.

Lichen sclerosus usually is not eliminated permanently by therapy. One survey showed an 84 percent recurrence rate when patients were off therapy.[26]

Box 76-3

Differential Diagnosis of Lichen Sclerosus of the Vulva

Most Likely
- Lichen simplex chronicus
- Lichen planus
- Vitiligo

Consider
- Immunobullous disease
- Contact dermatitis

Always Rule Out
- Squamous cell carcinoma

Despite the frequent requirement for long-term maintenance therapy, however, there is no proven optimal schedule. Most patients do well with thrice-weekly application of an ultrapotent glucocorticoid on an ongoing basis.

No other treatments for lichen sclerosus produce the striking and prompt benefit of a topical ultrapotent glucocorticoid. In addition, other medical therapies generally have shown benefit only in open-label series. Tacrolimus[27–29] and pimecrolimus[30,31] (see Chap. 235) have been reported effective. Beneficial effects have also been seen with topical testosterone, progesterone, and estrogen, but the benefit is minimal and equivalent to that of vehicle or lubrication alone.[32–34] Often, addition of hormone tends to increase irritation.[35] Topical tretinoin 0.025 percent and calcipotriol sometimes produce improvement, but their usefulness is limited because they can cause irritation.[36,37] Oral retinoids have been reported to be helpful for some.[38] The Chinese literature abounds with reports of benefit from traditional Chinese herbs and acupuncture for lichen sclerosus.[39]

Surgical therapies, including cryotherapy, vulvectomy, carbon dioxide laser vaporization, pulsed dye laser therapy, and photodynamic therapy have been advocated for the treatment of lichen sclerosus.[40–44]

Vulvar Fissures

Small, linear fissures on the vulva are common causes of itching, stinging, and dyspareunia.[45] Sometimes these fissures present clinically as painful, erythematous lines in skinfolds and at other times they present as obvious linear erosions.

Most well recognized are fissures at the posterior fourchette that split during intercourse (Fig. 76-6, see eFig. 76-6.1 in on-line edition). These produce tearing pain initially, followed by burning and stinging when alkaline semen touches the area. The skin heals quickly, but splits recur with intercourse. The cause is unknown. The condition usually occurs suddenly, after years of comfortable coitus. Adequate lubrication and positioning of the woman on top can minimize tearing. Otherwise, surgical excision (perineoplasty) is required, with the vertical fissure excised and the skin closed front to back with advancement of the vaginal mucosa to cover the area.[46]

Recurrent fissuring within skinfolds, especially in the interlabial sulci of the vulva, is a common cause of stinging and irritation of the vulva. Women typi-



▲ **FIGURE 76-6** Recurrent fissuring of the posterior fourchette with intercourse is a commonly recognized phenomenon of unknown cause that often requires perineoplasty, a type of excisional surgery.



cally complain of a sensation of "paper cuts." Intercourse and tight clothing are often precipitating events. Isolated acute fissuring is associated most often with *Candida* colonization or infection. However, skinfold fissures can result from any inflammatory dermatosis, including psoriasis, seborrhea, lichen sclerosus, and lichen simplex chronicus. When one of these factors is identified, treatment is directed toward the correction of it. When no specific underlying cause is found, a topical glucocorticoid ointment combined with an oral antibiotic and anti-candidal medication often eliminates the fissuring. However, almost immediate recurrence is common, and prolonged therapy may be required to break the cycle.

BULLOUS AND EROSIVE DISEASES

Lichen Planus (See Chap. 26)

CLINICAL FINDINGS Vulvovaginal lichen planus has a wide variety of clinical manifestations. Symptomatic vulvovaginal lichen planus is generally of the erosive form. It presents with symptoms of itching, burning, rawness, and dyspareunia. Although non-erosive lichen planus of the vulva may appear bland, significant and symptomatic accompanying erosive vaginal disease is often present. Irritating inflammatory vaginal secretions can produce symptoms of introital burning and stinging. Rectal and perianal disease is common and often produces pain.

White, lacy, reticulate striae resembling papular oral lichen planus sometimes occur on the modified mucous membranes of the vulva (Fig. 76-7, see eFig. 76-7.1 in on-line edition). Less easily recognized



▲ **FIGURE 76-7** Although these white, well demarcated linear papules are typical for papular lichen planus, they are often accompanied by nearby erosive disease.

are solid, uniformly hypopigmented, flat white plaques that mimic lichen sclerosus except for the absence of crinkled cellophane paper–like texture (see eFig. 76-7.2 in on-line edition). Finally, erosive lichen planus is sometimes manifest by red, painful erosions that are either nonspecific or surrounded by typical white epithelial changes (see eFigs. 76-7.3 and 76-7.4 in on-line edition). Erosive vulvovaginal lichen planus is often accompanied by erosive buccal and gingival oral disease.[48] Lichen planus, especially when erosive, produces remarkable scarring (see eFig. 76-7.5 in on-line edition). Resorption of the labia minora and obliteration of the clitoris under an agglutinated clitoral hood are very common. Narrowing of the introitus occurs more often and more severely than with lichen sclerosus, and vaginal adhesions can close the vagina, preventing intercourse and introduction of a speculum.

Vaginal erosions are often obvious, appearing as bright red patches, but sometimes equally painful disease can be subtle and show only mild erythema on a speculum examination. An examination of vaginal smears is a sensitive test for the presence of vaginal inflammation. Large, flat, cuboidal, mature desquamated vaginal epithelial cells are replaced by smaller, rounded basal cells shed from erosions and rapidly proliferative inflamed vaginal epithelium. Often vaginal secretions exhibit sheets of leukocytes as well.

The diagnosis of lichen planus is made either by biopsy or by the identification of classic lacy lesions in association with other typical mucous membrane lesions.

DIFFERENTIAL DIAGNOSIS When lichen planus presents classically and involves oral and genital mucosa it is easy to diagnose. Unfortunately, lichen planus on the vulva alone can be indistinguishable from other diseases (Box 76-4).

COMPLICATIONS Vulvar squamous cell carcinoma has been well described in patients with erosive genital lichen planus. The magnitude of this risk is not known, but patients should be evaluated for this condition regularly.

TREATMENT The aggressive treatment of vaginal lichen planus is crucial for patient comfort. Meticulous local care with early treatment of infection, minimization of external irritants, and attention to superimposed atrophy of estrogen deficiency are important measures. A vaginal dilator should be used daily to prevent adhesions of the vaginal walls. Emotional support and careful patient education regarding the nature of the disease, its prognosis, and its therapy are vital.

Pruritic, noneroded vulvar lichen planus is usually quite well managed simply by the application of a potent topical glucocorticoid. Severe erosive vulvovaginal lichen planus can present a difficult therapeutic problem. An ultrapotent glucocorticoid ointment applied to the vulva is standard first-line therapy. A gram of the glucocorticoid can be inserted into the vagina as well, or hydrocortisone acetate 25-mg rectal suppositories can be inserted nightly into the vagina.[49] Any patient with vulvar disease receiving an intravaginal glucocorticoid should be told of her increased risk for yeast infection. There is little tendency for erosive vulvovaginal lichen planus to remit. The severity tends to wax and wane, sometimes as a result of secondary infections,

Box 76-4

Differential Diagnosis of Vulvar Lichen Planus

Most Likely
- Lichen sclerosus
- Immunobullous disease
- Stevens-Johnson syndrome

Consider
- Fixed drug eruption
- Contact dermatitis

Always Rule Out
- Squamous cell carcinoma

exposure to irritants, or stress but more often for no identifiable cause. Bursts of oral prednisone can be helpful for flares.

Topical tacrolimus and pimecrolimus have been reported to be useful in the treatment of vulvar lichen planus, but these medications are irritating.[50,51] Although topical cyclosporine has been found effective for oral lichen planus, its usefulness in treating vulvovaginal lichen planus is limited by its cost, its tendency to burn with application, and its minimal effectiveness.[52,53] Other medications that have been reported primarily in open trials as useful for the treatment of erosive mucous membrane lichen planus include hydroxychloroquine, methotrexate, retinoids, azathioprine, cyclophosphamide, mycophenolate mofetil, and thalidomide.[54–58]

Erythema Multiforme Major, Stevens-Johnson Syndrome, and Toxic Epidermal Necrolysis (See Chaps. 38 and 39)

Erythema multiforme major, Stevens-Johnson syndrome, and toxic epidermal necrolysis all lead to erosive vulvar disease. One retrospective survey of 40 women with toxic epidermal necrolysis revealed that 28 had vulvovaginal involvement with severe erosions, of whom 5 experienced permanent scarring.[59] These patients were unable to engage in intercourse, even after corrective surgery. Local care during the serious phase of the illness can prevent long-term dysfunction due to scarring. Prompt treatment of secondary bacterial or candidal infection may be important. In addition, daily insertion of a vaginal dilator or syringe cover can help ensure patency.

Cicatricial Pemphigoid (See Chap. 55)

Cicatricial pemphigoid regularly produces multiple mucosal erosions. The non-specific, painful erosions of the vulva and surrounding epithelium can be clinically indistinguishable from lichen planus and lichen sclerosus. Vulvar erosions generally are accompanied by non-specific vaginal erosions that can result in significant vaginal scarring.

Management consists of both local glucocorticoid therapy and systemic treatments.[60] Again, local care, the use of vaginal dilators, and secondary infection control are important factors in management.

Pemphigus Vulgaris (See Chap. 52)

Pemphigus vulgaris often presents with mucosal erosions on the vulva. Although pemphigus vulgaris is usually considered to be a non-scarring disease, vulvovaginal involvement can lead to scarring, with obliteration of vulvar architecture and vaginal adhesions. As with cicatricial pemphigoid, a high index of suspicion and confirmatory biopsies are important in reaching the correct diagnosis. For treatment, see Chap. 52.

Fixed Drug Eruption (See Chap. 40)

Erosions due to fixed drug eruption sometimes occur on the vulva. Common offenders include acetaminophen, nonsteroidal anti-inflammatory medications, oral contraceptives, sulfa drugs, penicillin, tetracyclines, allopurinol, barbiturates, and furosemide.[61] Lesions are most often located in the vestibule or on the modified mucous membranes of the labia minora or medial labia majora. Unlike the classic, round, edematous plaques or blisters seen on keratinized skin, the erosions of a fixed drug eruption on the vulva are often irregular, sometimes with a slightly shaggy border. Often there are one or a few typical lesions on keratinized skin, or there are oral erosions. The deepening hyperpigmentation seen on keratinized skin affected by recurrent fixed drug eruptions is usually absent on the modified mucous membranes of the vulva.

Herpes Simplex (See Chap. 193)

Extramammary Paget Disease (See Chap. 121)

Vulvar Carcinoma (See Chaps. 113 and 114)

ULCERS

Aphthae (See Chaps. 74 and 167)

The most common non-infectious ulcers of the vulva are aphthae. These usually occur in women who have a history of oral aphthae, although oral and genital ulcers may not be present concomitantly. These recurrent ulcerations occur most often on the modified mucous membranes of the vulva and are larger, more irregular, and deeper than oral aphthae. Often, as with oral aphthae, the base of a vulvar lesion is covered with white fibrin debris (Fig. 76-8). Unlike with oral aphthae, significant scarring may occur on the vulva. Some women experience only one episode of genital ulceration, whereas others develop frequently recurrent or chronic crops of ulcerations. Aphthae exhibit a predisposition for girls between the ages of 10 and 17 years in the setting of FAPA syndrome (*f*ever, *a*phthae, *p*haryngitis, and *a*denitis). Fever, malaise, and sore throat are followed quickly by vulvar pain and ulceration.[62] These ulcerations are probably precipitated by a viral infection, and an association with Epstein-Barr virus has been documented.[63]



▲ **FIGURE 76-8** Aphthae of the vulva are characterized by large size, punched-out borders, and a white fibrin base as seen on the medial labium minus of this patient with concomitant vaginal candidiasis.





The diagnosis of vulvar aphthae is made after ruling out infectious causes of ulceration, primary syphilis (see Chap. 200) and chancroid (see Chap. 202) as well as Crohn disease and hidradenitis suppurativa.[64] The association of oral aphthae with larger genital aphthae does not constitute Behçet syndrome, which is characterized by systemic disease such as inflammatory eye disease, arthritis, and neurologic disease (see Chap. 167). In women without a typical history of recurrent aphthae or with atypical lesions, lesion biopsy should be performed. Testing for human immunodeficiency virus should be considered, especially with large aphthae (see eFig. 76-8.1 in on-line edition), and chronic ulcerative herpes simplex should be excluded.[65]

The treatment of vulvar aphthae is the same as for such ulcers occurring in the mouth. Potent topical glucocorticoid ointments can hasten the healing of mild aphthae. A burst of oral prednisone is indicated when outbreaks are occasional. Daily dapsone alone or with colchicine often suppresses or decreases the frequency and severity of aphthae, and thalidomide is beneficial although there are concerns of neurotoxicity and teratogenicity (see Chap. 236).[64,66,67]

Crohn Disease (See Chap. 151)

Crohn disease is a non-infectious disorder of granulomatous inflammation that primarily involves the bowel, but vulvar and perianal skin are sometimes affected. Draining sinus tracts and fistulas from the bowel to the overlying skin are classic manifestations (see eFig. 76-8.2 in on-line edition). However, cutaneous ulcers not extending to the bowel can occur. These are linear, resemble lacerations, and lie in skinfolds. Non-specific painless, firm edema and erythema can also represent Crohn disease (Fig. 76-9).[68]



▲ **FIGURE 76-9** Diffuse firm vulvar edema is a common presentation of Crohn disease.

The diagnosis is made on the basis of biopsy results and identification of the bowel disease. The primary disease to be differentiated from anogenital Crohn disease is hidradenitis suppurativa (see Hidradenitis Suppurativa). Treatment consists of systemic therapy for underlying intestinal Crohn disease.[69,70] Topical and intralesional glucocorticoids and local care can help to induce healing of ulcerations.

Syphilis (See Chap. 200)

Chancroid (See Chap. 202)

Other Ulcerations in Sexually Transmitted Diseases (See Chaps. 203 and 204)

ABSCESSES

Abscesses occur in Crohn disease (see Crohn Disease) and in gonorrhea (see Chap. 205) in which Bartholin gland is swollen, fluctuant, and extremely painful. Such an abscess is located on the labium minus close to the posterior fourchette (see eFig. 76-9.1 in on-line edition). Pain may be so exquisite that it interferes with walking.

Hidradenitis Suppurativa (See Chap. 83)

One manifestation of hidradenitis suppurativa is chronic ulceration as inflamed cysts break down. This can occur on keratinized, hair-bearing areas of the vulva as well as on modified mucous membranes. Ulcerations are especially likely to occur in the setting of chronic edema (Fig. 76-10).[71] Not only is the clinical presentation similar to that of Crohn disease, but these two conditions reportedly co-exist more often than predicted by chance.

The diagnosis is made based on the setting and the elimination of infectious causes. Ulcerations may heal with long-term suppressive antibiotic therapy (a combination of clindamycin and rifampicin).[72] Although oral retinoids can be useful in the short term, long-term results are poor.[73] Surgical excision is a treatment of choice, and removal of individual lesions is often practical and beneficial.[74] Cyclosporine and finasteride have been reported to be beneficial for some.[75,76] Success has been reported with the use of infliximab or etanercept (see Chap. 235).[77–80]



▲ **FIGURE 76-10** The diagnosis of hidradenitis suppurativa is made by the presence of chronic draining nodules localized to the anogenital skin and axillae.

VULVODYNIA

Vulvodynia is the symptom of chronic vulvar burning, soreness, stinging, or rawness in the absence of objective physical signs.[81–83]

Epidemiology

Vulvodynia previously was held to be a rare occurrence, but it is now known that approximately 20 percent of women experience vulvodynia at some point.

Etiology and Pathogenesis

In the past, vulvodynia was believed to be a solely psychosomatic disease. The cause of vulvodynia is now believed to be neuropathic pain, especially complex regional pain syndrome. The neuropathy may be peripheral or a central sensory processing disorder. Associated with and complicating neuropathy as a cause of vulvodynia is pelvic floor muscle dysfunction.[84] Candidiasis (or hypersensitivity to colonizing yeast) and sub-clinical human papillomavirus infection have both been thought to cause vulvodynia, but the poor response of patients to antifungal therapy and other evidence have shown these to be unlikely culprits in most patients.[85–87]

Clinical Findings

Patients with vulvodynia describe discomfort, often associated with self-

perceived redness and swelling. Although an occasional patient with vulvodynia describes itching, this is a minor aspect of the symptomatology, and the patient denies both scratching and relief with scratching. Usually, women report dyspareunia and pain with constrictive clothing. Women with vulvodynia are almost uniformly depressed, often anxious, and usually have experienced significant disruption in their lives and relationships. Patients with vulvodynia are more likely than nonsymptomatic women to report an increased frequency of headaches, interstitial cystitis, irritable bowel syndrome, chronic fatigue syndrome, fibromyalgia, poor sleeping, and low energy levels as part of a generalized central processing disorder.[88] There are no characteristic laboratory findings, and biopsy specimens reveal only non-specific chronic perivascular inflammation, sometimes with mild squamous hyperplasia. Many of these women have a presumed diagnosis of chronic yeast infection not substantiated by positive culture results.

Differential Diagnosis

The diagnosis of vulvodynia is one of exclusion. Patients with vulvodynia should be examined carefully for any underlying skin disease, infection, neoplasm, or well-defined neurologic disorder. Irritant contact dermatitis, vulvar fissures, and lichen planus are the most common skin diseases to be mistaken for vulvodynia. A significant portion of women with vulvodynia are found to have a non-infectious, inflammatory vaginitis (desquamative inflammatory vaginitis) manifested by grossly and microscopically purulent vaginal secretions and immature epithelial cells similar to those seen in lichen planus. Non-*albicans Candida* infections such as *C. glabrata*, *C. krusei*, and *Saccharomyces cerevisiae* infection and vaginal group B streptococcal infection or colonization are most commonly implicated in the chronic vulvovaginal pain. These infections are easily missed unless a culture is performed and can be resistant to therapy. When these infections are cleared, symptoms may remit. However, these infections often are coincidental rather than causative. Finally, neurologic disorders such as postherpetic neuralgia, pudendal nerve entrapment, and spinal compression need to be addressed through history and imaging studies when appropriate.

Treatment

Women with vulvodynia fall into two major groups: those who experience generalized pain and those who experience localized pain. Both of these groups can be further divided into those who experience provoked (brought on by touch), unprovoked (spontaneous), or mixed (both provoked and unprovoked) pain. The distinction between these groups is important for management. Pain evoked only by touch in the introitus is referred to as *vestibulodynia* or *vulvar vestibulitis* (see eFig. 76-10.1 in on-line edition). Women with introital, well-localized, provoked pain are the only women with vulvodynia for whom surgical excision is a reasonable option.[89]

Generally, the management of women with vulvodynia requires attention to both the physical and psychological aspects of the disease. The elimination of irritants, including overwashing and topical medications, can improve symptoms significantly. Topical lidocaine jelly 2 percent can improve day-to-day quality of life. Attention to depression and sexual dysfunction is mandatory. Most patients benefit from referral for counseling to help them cope with their debilitating symptoms. Tricyclic antidepressants such as amitriptyline or desipramine, beginning at very low dosages and increasing up to 150 mg or until the patient is comfortable, are a first-line treatment for neuropathic pain.[90] For women who do not tolerate tricyclic antidepressants or who experience suboptimal improvement, gabapentin has been used.[91] The newer antidepressants venlafaxine and duloxetine have been used effectively as well. Pregabalin provides yet another possible option. Therapies said to provide improvement in anecdotal reports include a low-oxalate diet with calcium citrate supplementation, topical estrogen, topical capsaicin, and long-term suppressive antifungal therapy. Acupuncture has been found useful in a small open study as well.[92]

Most women with vulvar pain syndrome exhibit abnormal pelvic floor muscle function that can contribute to their symptoms. These patients are more likely than symptom-free women to show abnormally high resting pelvic floor tension and irritability but poor contractile strength on surface electromyography.[84] These women benefit remarkably from pelvic floor rehabilitation (biofeedback-directed exercises to retrain the pelvic floor musculature) and subsequently are able to engage in comfortable sexual activity.[93,94] Improvement is slow, however, and trial-and-error therapy with support by the physician is required frequently.

PRURITUS VULVAE

A small proportion of women experience itching with no associated clinical findings and do not respond to treatment for lichen simplex chronicus. In addition, these patients generally do not respond to anti-yeast therapy, topical doxepin, anesthetics, or tacrolimus. Some of these patients may have pruritus resulting from neuropathy and respond to therapy directed toward this. In other women, depression and anxiety play a major role, and these must be addressed.[95]

KEY REFERENCES

The full reference list for all chapters is available at www.digm7.com.

2. Lynch PJ: Lichen simplex chronicus (atopic/neurodermatitis) of the anogenital region. *Dermatol Ther* **17**:8, 2004
4. Margesson LJ: Contact dermatitis of the vulva. *Dermatol Ther* **17**:20, 2004
10. Smith YR, Haefner HK: Vulvar lichen sclerosus: Pathophysiology and treatment. *Am J Clin Dermatol* **5**:105, 2004
45. Edwards L: Vulvar fissures: Causes and therapy. *Dermatol Ther* **17**:111, 2004
47. Rogers RS 3rd, Eisen D: Erosive oral lichen planus with genital lesions: The vulvovaginal-gingival syndrome and the peno-gingival syndrome. *Dermatol Clin* **21**:91, 2003
71. Wiseman MC: Hidradenitis suppurativa: A review. *Dermatol Ther* **17**:50, 2004
83. Haefner HK et al: The vulvodynia guideline. *J Low Genit Tract Dis* **9**:40, 2005



This page intentionally left blank

PART 3

Disorders of the Skin Appendages

Copyright © 2008 by The McGraw-Hill Companies, Inc. Click here for terms of use.





SECTION 13

DISORDERS OF THE SEBACEOUS GLANDS

CHAPTER 77

Biology of Sebaceous Glands

Amanda M. Nelson
Diane M. Thiboutot

ANATOMY OF THE SEBACEOUS GLAND

Histology

Sebaceous glands are uni-lobular or multi-lobular structures that are usually associated with a hair follicle. They consist of acini connected to a common excretory duct composed of stratified squamous epithelium. The glands are composed of lipid-producing sebocytes and of keratinocytes that line the sebaceous ducts. Just inside the basement membrane at the periphery of the sebaceous gland is a basal cell layer composed of small, cuboidal, nucleated, highly mitotic sebocytes. Cells progress toward the middle of the gland and accumulate lipid droplets as they terminally differentiate. These fully differentiated sebocytes are full of lipid and lack all other cellular organelles (Fig. 77-1). Surrounding the glands are connective tissue capsules composed of collagen fibers that provide physical support.[1]

◀ Acne vulgaris, mild to moderate. **Top.** Close-up of the lower face with comedones, papules, pustules, and scars. **Bottom.** Close-up of the cheek, showing large open comedones, and inflammatory papules and pustules that become confluent, forming an erythematous plaque.

SEBACEOUS GLANDS AT A GLANCE



- Sebaceous glands are uni-lobular or multi-lobular structures that consist of acini connected to a common excretory duct composed of stratified squamous epithelium; they are usually associated with a hair follicle.
- Sebaceous glands vary considerably in size, even in the same individual and in the same anatomic area.
- The sebaceous glands exude lipids by disintegration of entire cells, a process known as *holocrine secretion*.
- Human sebum, as it leaves the sebaceous gland, contains squalene, cholesterol, cholesterol esters, wax esters, and triglycerides.
- Sebaceous glands are regulated by androgens and retinoids, but other factors, such as melanocortins and peroxisome proliferator–activated receptors, have been postulated to play a role as well.

Location

Sebaceous glands are associated with hair follicles all over the body. A sebaceous gland and the associated hair follicle are termed a *pilosebaceous unit*. The glands may also be found in certain non-hairy sites, including the eyelids (meibomian glands), the nipples (Montgomery's glands), and around the genitals (Tyson's glands). Only the palms and soles, which have no hair follicles, are totally devoid of sebaceous glands. Sebaceous glands vary considerably in size, even in the same individual and in the same anatomic area. On the external body surface, most glands are only a fraction of a millimeter in size. The largest glands and the greatest density of glands (up to 400 to 900 glands/cm^2) are found on the face and scalp.[1–3] The hairs associated with the large glands in these areas are often tiny, and it has been suggested that the total structures be more properly termed *sebaceous follicles* rather than *hair follicles*.

In the oral epithelium, sebaceous glands known as *Fordyce's spots* are sometimes present. Fordyce's spots are visible to the unaided eye because of their large size (up to 2 to 3 mm) and the transparency of the oral epithelium. In this location, the sebaceous ducts open directly to the surface.

Embryogenesis and Morphogenesis

In the human fetus, sebaceous glands develop in the thirteenth to sixteenth week of gestation from bulges (epithelial placodes) on the developing hair follicles. The bulge region of the follicle contains the epidermal stem cells that generate multiple cell lineages, including epidermal and follicular keratinocytes as well as sebaceous glands. As daughter cells migrate

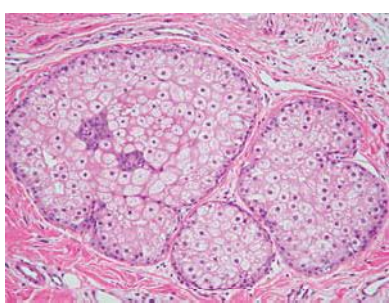

▲ **FIGURE 77-1** Hematoxylin and eosin–stained section of the human sebaceous gland showing its multi-lobular structure.

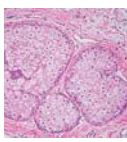

Copyright © 2008 by The McGraw-Hill Companies, Inc. Click here for terms of use.

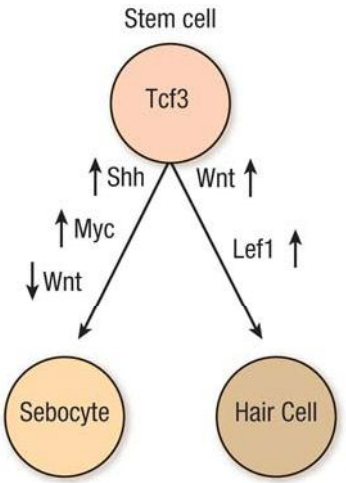

▲ **FIGURE 77-2** Signaling pathways and transcription factors involved in cell lineage determinations. As daughter cells migrate from the bulge region, changes in the expression patterns of numerous transcription factors determine their final cell lineage. Data are far from complete in this area; it is very likely that other pathways and transcription factors will be found to play a significant role in determining each cell lineage. Lef1 = lymphoid enhancer binding factor 1; Myc = myelocytomatosis oncogene; Shh = Sonic Hedgehog; Tcf3= transcription factor 3; Wnt = wingless (wg)/int.

from the bulge region, changes in the expression patterns of numerous transcription factors determine their final cell lineage. Wnt/wingless (Wnt) and Sonic Hedgehog (Shh) signaling pathways are intricately involved in embryonic patterning and cell fate decisions. Cells destined to become sebocytes have increased Shh and myelocytomatosis oncogene (Myc) signaling and decreased Wnt signaling (Fig. 77-2). In transgenic mouse models, intact Wnt signaling promotes hair follicle differentiation, whereas inhibition of Wnt signaling through the prevention of Lef1/β-catenin interaction leads to sebocyte differentiation.[4] Loss-of-function and gain-of-function transgenic mouse models show that blocking Shh signaling inhibits normal sebocyte differentiation and constitutively activating Shh signaling results in increased number and size of sebaceous glands in skin.[5] When fully formed, the glands remain attached to the hair follicles by a duct through which sebum flows into the follicular canal and eventually to the skin surface.

Physiology of the Sebaceous Gland: Holocrine Secretion

The sebaceous glands exude lipids by disintegration of entire cells, a process known as *holocrine secretion*. The life span of a sebocyte from cell division to holocrine secretion is approximately 21 to 25 days.[6] Because of the constant state of renewal and secretion of the sebaceous gland, individual cells within the same gland are engaged in different metabolic activities depending on their differentiation state.[7] The stages of this process are evident in the histology of the gland.[8] The outermost cells, basal cell layer membrane, are small, nucleated, and devoid of lipid droplets. This layer contains the dividing cells that replenish the gland as cells are lost in the process of lipid excretion. As cells are displaced into the center of the gland, they begin to produce lipid, which accumulates in droplets. Eventually the cells become greatly distended with lipid droplets, and the nuclei and other sub-cellular structures disappear. As the cells approach the sebaceous duct, they disintegrate and release their contents. Only neutral lipids reach the skin surface. Proteins, nucleic acids, and the membrane phospholipids are digested and apparently recycled during the disintegration of the cells.

Lipid Composition of Sebum

Human sebum, as it leaves the sebaceous gland, contains squalene, cholesterol, cholesterol esters, wax esters, and triglycerides (Fig. 77-3). During passage of sebum through the hair canal, bacterial enzymes hydrolyze some of the triglycerides, so that the lipid mixture reaching the skin surface contains free fatty acids and small proportions of monoglycerides and diglycerides in addition to the original components. The wax esters and squalene distinguish sebum from the lipids of human internal organs, which contain no wax esters and little squalene. Human sebaceous glands, however, appear to be unable to cyclize squalene to sterols such as cholesterol. The patterns of unsaturation of the fatty acids in the triglycerides, wax esters, and cholesterol esters also distinguish human sebum from the lipids of other organs. The "normal" mammalian pathway of desaturation involves inserting a double bond between the ninth and tenth carbons of stearic acid (18:0) to form oleic acid (18:1Δ9). However, in human sebaceous glands, the predominant pattern is the insertion of a Δ6 double bond into palmitic acid (16:0). The resulting sapienic acid (16:1Δ6) (see Fig. 77-3) is the major fatty acid of adult human sebum. Elongation of the chain by two carbons and insertion of another double bond gives sebaleic acid (18:2Δ5,8) (see Fig. 77-3), a fatty acid thought to be unique to human sebum.[9]

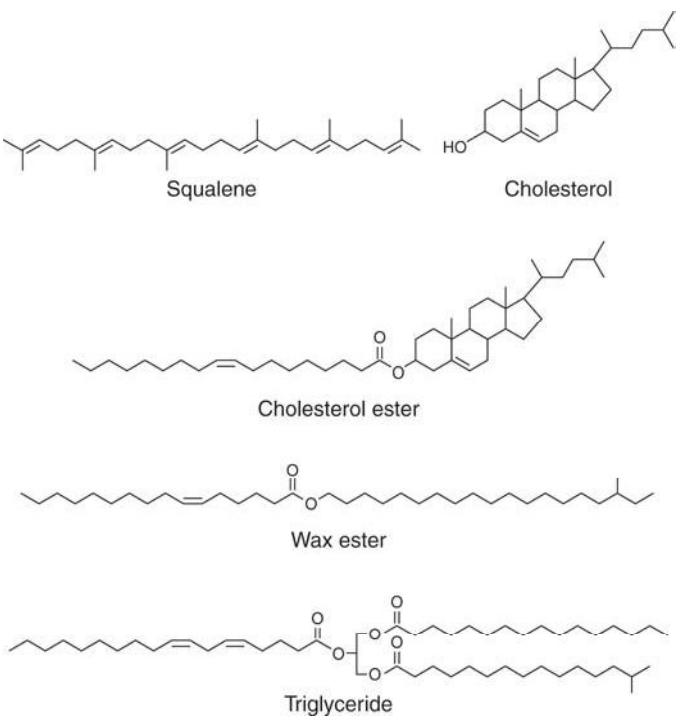

▲ **FIGURE 77-3** Human sebaceous gland lipids. The structures of the cholesterol ester, wax ester, and triglyceride are representative of the many species that are present. Two sebaceous-type unsaturated fatty acid moieties are shown: sapienic acid (16:1Δ6) (in the wax ester structure) and sebaleic acid (18:2Δ5,8) (in the triglyceride structure). Anteiso branching is shown in the alcohol moiety of the wax ester, and iso branching is shown in the triglyceride.

Sebaceous fatty acids and alcohols are also distinguished by chain branching. Methyl branches can occur on the next to last (penultimate) carbon of a fatty acid chain (iso branching), on the third from the last (antepenultimate) carbon (anteiso branching), or on any even-numbered carbon (internal branching). Examples of these unusual unsaturated and branched-chain moieties are included in the lipid structures shown in Fig. 77-3.

Function of Sebum

The precise function of sebum in humans is unknown. It has been proposed that its sole role is to cause acne.[10] The suggestion has been made that sebum reduces water loss from the skin's surface and functions to keep skin soft and smooth, although evidence for these claims in humans is minimal; however, as demonstrated in the sebaceous gland–deficient mouse (Asebia) model, glycerol derived from triglyceride hydrolysis in sebum is critical for maintaining stratum corneum hydration.[11] Sebum has been shown to protect the skin from infection by bacteria and fungi, at least in part because it contains immunoglobulin A, which is secreted from most exocrine glands.[12] Vitamin E delivery to the upper layers of the skin protects the skin and its surface lipids from oxidation. Thus, sebum flow to the surface of the skin may provide the transit mechanism necessary for vitamin E to function.[13]

FACTORS REGULATING SEBACEOUS GLAND SIZE AND SEBUM PRODUCTION

Sebum production is continuous and is not controlled by neural mechanisms. The exact mechanisms underlying the regulation of human sebum production have not been defined. Clearly, sebaceous glands are regulated by androgens and retinoids, but other factors, such as melanocortins, peroxisome proliferator–activated receptors (PPARs), and fibroblast growth factor receptors (FGFRs) have been postulated to play a role as well.

Androgens

It has long been recognized that sebaceous glands require androgenic stimulation to produce significant quantities of sebum. Individuals with a genetic deficiency of androgen receptors (complete androgen insensitivity) have no detectable sebum secretion and do not develop acne.[14] However, there is still a question as to which androgen is physiologically significant. Although the most powerful androgens are testosterone and its end-organ reduction product dihydrotestosterone, levels of testosterone do not parallel the patterns of sebaceous gland activity. For example, testosterone levels are many-fold higher in males than in females, with no overlap between the sexes, whereas average rates of sebum secretion are only slightly higher in males than in females, with considerable overlap between the groups. Also, sebum secretion starts to increase in children during adrenarche, a developmental event that precedes puberty by approximately 2 years.

The weak adrenal androgen dehydroepiandrosterone sulfate (DHEAS) might be a significant regulator of sebaceous gland activity through its conversion to testosterone and dihydrotestosterone in the sebaceous gland. Levels of DHEAS are high in newborns, are very low in 2- to 4-year-old children, and start to rise when sebum secretion starts to increase. In adulthood, DHEAS levels show considerable individual variation but are only slightly higher in men than in women on the average. There is a decline in DHEAS levels in both sexes starting in early adulthood and continuing throughout life. This decline parallels the decline of sebum secretion. DHEAS is present in the blood in high concentration. The enzymes required to convert DHEAS to more potent androgens are present in sebaceous glands.[15] These include 3β-hydroxysteroid dehydrogenase, 17β-hydroxysteroid dehydrogenase, and 5α-reductase. Each of these enzymes exists in two or more isoforms that exhibit tissue-specific differences in their expression. The predominant isozymes in the sebaceous gland include type 1 3β-hydroxysteroid dehydrogenase, type 2 17β-hydroxysteroid dehydrogenase, and type 1 5α-reductase.

Retinoids

Isotretinoin (13-*cis* retinoic acid) is the most potent pharmacologic inhibitor of sebum secretion. Significant reductions in sebum production can be observed as early as 2 weeks after use.[16] Histologically, sebaceous glands are markedly reduced in size, and individual sebocytes appear undifferentiated, lacking the characteristic cytoplasmic accumulation of sebaceous lipids.

Isotretinoin does not interact with any of the known retinoid receptors. It may serve as a prodrug for the synthesis of all-*trans* retinoic acid or 9-*cis* retinoic acid, which do interact with retinoid receptors; however, it has greater sebosuppressive action than does all-*trans* or 9-*cis* retinoic acid.[17] The mechanism by which 13-*cis* retinoic acid lowers sebum secretion is unknown, but it inhibits the 3α-hydroxysteroid activity of retinol dehydrogenase and leads to decreased androgen synthesis.[18] In addition, isotretinoin triggers cell cycle arrest in human sebocytes and immortalized cell culture models of human sebocytes (SZ95 and SEB-1) and also induces apoptosis in SEB-1 sebocytes.[19–21] Inhibition of androgen synthesis, cell cycle arrest, and apoptosis by 13-*cis* retinoic acid may explain the reduction of sebaceous gland size after treatment.

Melanocortins

Melanocortins include melanocyte-stimulating hormone and adrenocorticotropic hormone. In rodents, melanocortins increase sebum production. Transgenic mice deficient in the melanocortin-5 receptor have hypoplastic sebaceous glands and reduced sebum production.[22] The melanocortin-5 receptor has been identified in human sebaceous glands, where it may play a role in the modulation of sebum production.[23]

Peroxisome Proliferator–Activated Receptors

PPARs are orphan nuclear receptors that are similar to retinoid receptors in many ways. Each of these receptors forms heterodimers with retinoid X receptors to regulate the transcription of genes involved in a variety of processes, including lipid metabolism and cellular proliferation and differentiation. PPAR-α, PPAR-δ, and PPAR-γ receptor sub-types have been detected in basal sebocytes. PPAR-γ is also detected in differentiated sebocytes. In patients receiving fibrates (PPAR-α ligands) for hyperlipidemia or thiazolidinediones (PPAR-γ ligands) for diabetes, sebum secretion rates are increased.[24] Rat preputial cells serve as a model for human sebocytes in the laboratory.[25] In rat preputial cells, agonists of the PPAR-γ receptor, such as drugs of the thiazolidinedione class, increase lipid accumulation.[26]

Fibroblast Growth Factor Receptors

FGFR1 and FGFR2 are expressed in the epidermis and skin appendages. Expression of FGFR3 and FGFR4 is localized to dermal vessels and microvessels and is notably absent in epidermis and ap-

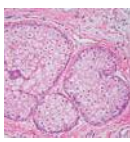

pendages.[27] FGFR2 plays an important role during embryogenesis in skin formation.[28] Germline mutations in *FGFR2* lead to Apert syndrome, which is commonly associated with acne. In addition, somatic mutations in the same gene can lead to localized acne, but how this receptor is involved in sebaceous gland development and how its mutation leads to acne is unknown.[29,30]

CONCLUSION

The regulation of human sebum production is complex. Advances are being made in this area, which may lead to alternative therapies for the reduction of sebum and improvement in acne.

KEY REFERENCES

The full reference list for all chapters is available at www.digm7.com.

1. Downie MMT, Guy R, Kealey T: Advances in sebaceous gland research: Potential new approaches to acne management. *Int J Cosmet Sci* **26**:291, 2004
4. Merrill B et al: Tcf3 and Lef1 regulate lineage differentiation of multipotent stem cells in skin. *Genes Dev* **15**:1688, 2001
5. Allen M et al: Hedgehog signaling regulates sebaceous gland development. *Am J Pathol* **163**:2173, 2003
9. Nicolaides N: Skin lipids: Their biochemical uniqueness. *Science* **186**:19, 1974
15. Chen W, Thiboutot D, Zouboulis C: Cutaneous androgen metabolism: Basic research and clinical perspectives. *J Invest Dermatol* **119**:992, 2002
16. Stewart M et al: Effect of oral 13-*cis* retinoic acid at three dose levels on sustainable rates of sebum secretion and on acne. *J Am Acad Dermatol* **8**:532, 1983
24. Trivedi NR et al: Peroxisome proliferator–activated receptors increase human sebum production. *J Invest Dermatol* **126**:2002, 2006

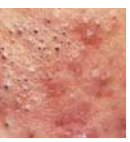

CHAPTER 78

Acne Vulgaris and Acneiform Eruptions

Andrea L. Zaenglein
Emmy M. Graber
Diane M. Thiboutot
John S. Strauss

ACNE VULGARIS

Acne vulgaris is a self-limited disorder of the pilosebaceous unit that is seen primarily in adolescents. Most cases of acne present with a pleomorphic variety of lesions, consisting of comedones, papules, pustules, and nodules. Although the course of acne may be self-limiting, the sequelae can be lifelong, with pitted or hypertrophic scar formation.

Epidemiology

Acne is sufficiently common that it often has been termed *physiologic*. Mild degrees of acne are frequently seen at birth, probably resulting from follicular stimulation by adrenal androgens, and may continue into the neonatal period. However, in the vast majority of cases it is not until puberty that acne becomes a more significant problem. Acne is often an early manifestation of puberty; in the very young patient the predominant lesions are comedones. In girls, the occurrence of acne may precede menarche by more than 1 year. The greatest numbers of cases are seen during the middle-to-late teenage period. Afterward, the incidence steadily decreases. However, particularly in women, acne may persist through the third decade or even later. Acne seems to be familial, but owing to the high prevalence of the disease this has been extremely difficult to assess. Nodulocystic acne has been reported to be more common in white males than in black males, and one group of investigators has found that acne is more severe in patients with the XYY genotype.[1,2]

Etiology and Pathogenesis

The pathogenesis of acne is multifaceted, but four basic steps have been identified. These key elements, illustrated in Fig. 78-1, are (1) follicular epidermal hyperproliferation, (2) excess sebum production, (3) inflammation, and (4) the presence and activity of *Propionibacterium acnes*.

Follicular epidermal hyperproliferation results in the formation of the primary lesion of acne, the microcomedo. The epithelium of the upper hair follicle, the infundibulum, becomes hyperkeratotic with increased cohesion of the keratinocytes. The excess cells and their tackiness result in a plug in the follicular ostium. This plug then causes downstream concretions of keratin, sebum, and bacteria to accumulate in the follicle. These packed concretions cause dilation of the upper hair follicle, producing a microcomedo (see Fig. 78-1A,B). The stimulus for keratinocyte hyperproliferation and increased adhesion is unknown. However, several proposed factors in keratinocyte hyperproliferation include: androgen stimulation, decreased linoleic acid, and increased interleukin (IL)-1α activity.

Androgenic hormones may act on the follicular keratinocytes to stimulate hyperproliferation. Dihydrotestosterone (DHT) is a potent androgen that may play a role in acne. Fig. 78-2 demonstrates the physiologic pathway for dehydroepiandrosterone sulfate (DHEAS) conversion to the androgen DHT. 17β-hydroxysteroid dehydrogenase and 5α-reductase are enzymes responsible for converting DHEAS to DHT. When compared to epidermal keratinocytes, follicular keratinocytes show increased 17β-hydroxysteroid dehydrogenase and 5α-reductase activities, thus enhancing

ACNE AT A GLANCE



- Common disorder of the pilosebaceous unit.
- Four key elements of pathogenesis: (1) follicular epidermal hyperproliferation, (2) excess sebum production, (3) inflammation, and (4) the presence and activity of *Propionibacterium acnes*.
- Comedones, papules, pustules, nodules on face, chest, and back.
- Treatment often includes combinations of oral and topical agents such as antimicrobials, retinoids, and hormonal agents. Laser and light sources are additional treatment options.
- Acne variants and acneiform eruptions also exist, many of which have an identifiable and reversible etiology.

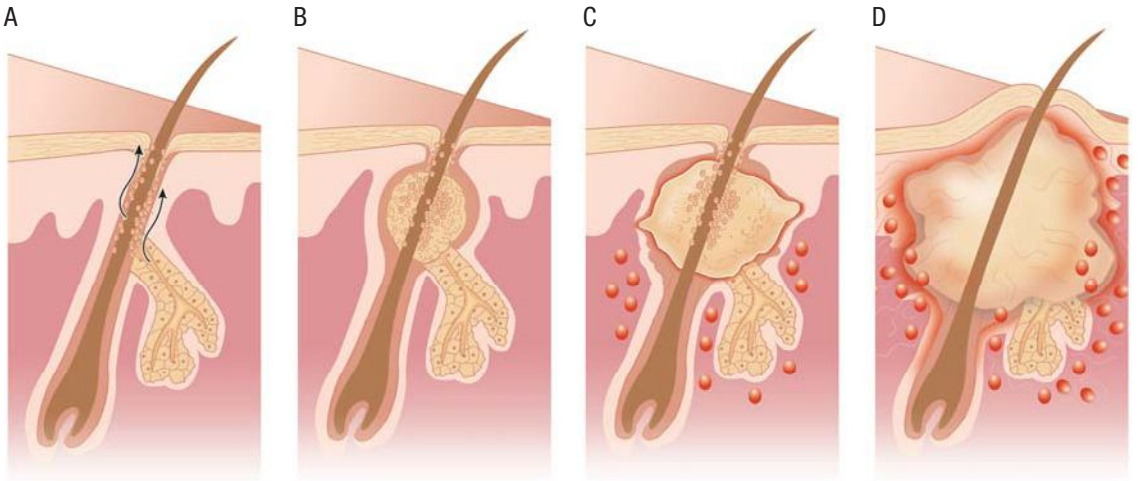

▲ **FIGURE 78-1** **A–D.** Acne pathogenesis.

DHT production.[3,4] DHT may stimulate follicular keratinocyte proliferation. Also supporting the role of androgens in acne pathogenesis is the evidence that individuals with complete androgen insensitivity do not get acne.[5]

Follicular keratinocyte proliferation may also be regulated by linoleic acid. Linoleic acid is an essential fatty acid in the skin that is decreased in subjects with acne. The quantity of linoleic acid normalizes after successful treatment

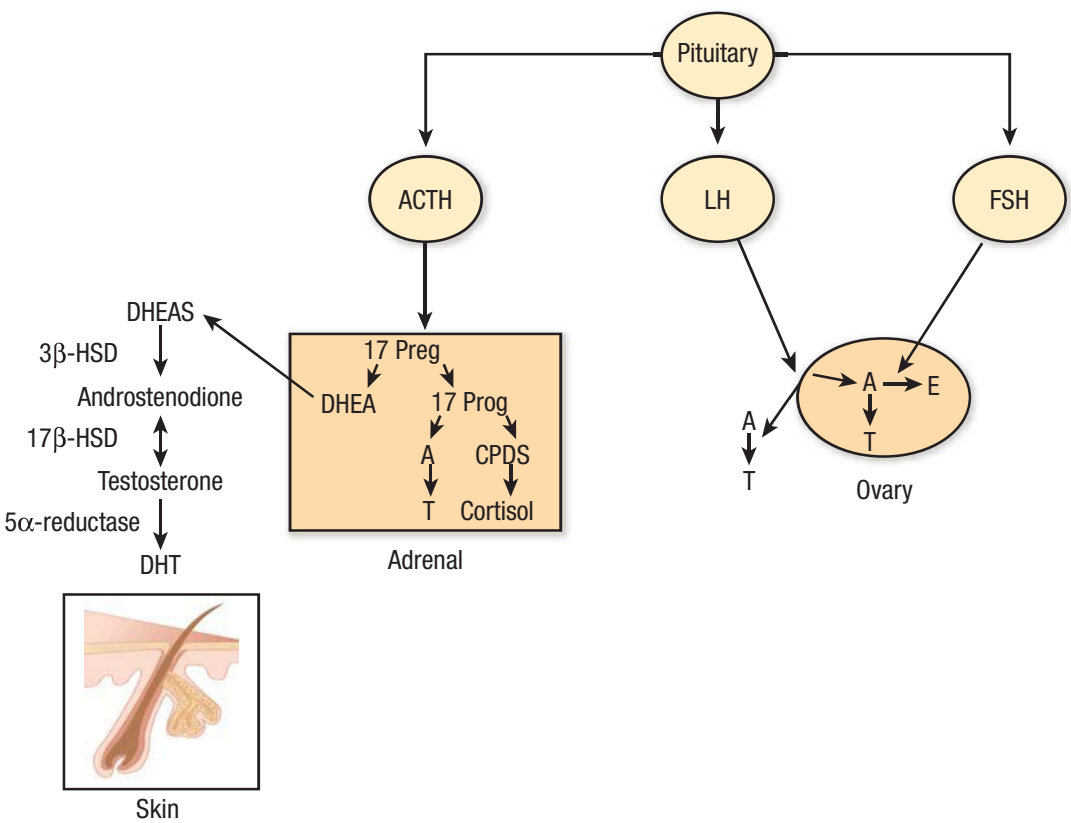

▲ **FIGURE 78-2** Pathways of steroid metabolism. Dehydroepiandrosterone (DHEA) is a weak androgen that is converted to the more potent testosterone by 3β-hydroxysteroid dehydrogenase (HSD) and 17β-HSD. 5α-reductase then converts testosterone to dihydrotestosterone (DHT), the predominant hormonal effector on the sebaceous gland. The sebaceous gland expresses each of these enzymes. A = androstenedione; ACTH = adrenocorticotropin-stimulating hormone; DHEAS = dehydroepiandrosterone sulfate; E = estrogen; FSH = follicle-stimulating hormone; LH = luteinizing hormone; T = testosterone.



with isotretinoin. Subnormal levels of linoleic acid may induce follicular keratinocyte hyperproliferation and produce pro-inflammatory cytokines. It has also been suggested that regular quantities of linoleic acid are actually produced but are simply diluted by increased sebum production.[6]

IL-1 may also contribute to keratinocyte hyperproliferation. Human follicular keratinocytes demonstrate hyperproliferation and microcomedone formation when IL-1 is added. IL-1 receptor antagonists inhibit microcomedone formation, providing additional support for the cytokine's role in acne pathogenesis.[7,8]

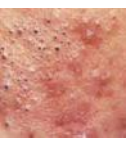

The second key feature in the pathogenesis of acne is excess sebum production from the sebaceous gland. Patients with acne produce more sebum than those without acne, although the quality of sebum is the same between the two groups.[9] One of the components of sebum, triglycerides, may play a role in acne pathogenesis. Triglycerides are broken down into free fatty acids by *P. acnes*, normal flora of the pilosebaceous unit. These free fatty acids promote further bacterial clumping and colonization of *P. acnes*, incite inflammation, and may be comedogenic.[10]

Androgenic hormones also influence sebum production. Similar to their action on the follicular infundibular keratinocytes, androgen hormones bind to and influence sebocyte activity.[11] Those with acne have higher average serum androgen levels (although still within normal range) than unaffected controls.[12,13] 5α-Reductase, the enzyme responsible for converting testosterone to the potent DHT, has greatest activity in areas of skin prone to acne, the face, chest, and back.[14]

The role of estrogen on sebum production is not well defined. The dose of estrogen required to decrease sebum production is greater than the dose required to inhibit ovulation.[15] The mechanisms by which estrogens may work include: (1) directly opposing the effects of androgens within the sebaceous gland; (2) inhibiting the production of androgens by gonadal tissue via a negative feedback loop on pituitary gonadotrophin release; and (3) regulating genes that suppress sebaceous gland growth or lipid production.[16]

The microcomedo continues to expand with densely packed keratin, sebum, and bacteria (see Fig. 78-1B). Eventually this distension causes follicular wall rupture (see Fig. 78-1C). The extrusion of the keratin, sebum, and bacteria into the dermis results in a brisk inflammatory response (see Fig. 78-1D). The predominant cell type within 24 hours of comedo rupture is the lymphocyte. $CD4^+$ lymphocytes are found around the pilosebaceous unit whereas $CD8^+$ cells are found perivascularly. One to two days after comedo rupture, the neutrophil becomes the predominant cell type surrounding the burst microcomedo.[17]

It was originally thought that inflammation follows comedo formation, but there is new evidence that dermal inflammation may actually precede comedo formation. Biopsies taken from comedo-free, acne-prone skin demonstrate increased dermal inflammation compared to normal skin. Biopsies of newly formed comedos demonstrate even greater inflammation.[18] More studies are needed to further elucidate this series of events.

The fourth key element in acne *P. acnes* also plays an active role in the process of inflammation. *P. acnes* is a Gram-positive, anaerobic, and microaerobic bacterium found in the sebaceous follicle. Adolescents with acne have higher concentrations of *P. acnes* compared to non-acne controls. However, there is no correlation between the raw number of *P. acnes* organisms present in a sebaceous follicle and the severity of the acne.[19]

The cell wall of *P. acnes* contains a carbohydrate antigen that stimulates antibody development. Those patients with the most severe acne have the highest titers of antibodies.[20] The antipropionibacterium antibody enhances the inflammatory response by activating complement, thus initiating a cascade of pro-inflammatory events.[21] *P. acnes* also facilitates inflammation by eliciting a delayed type hypersensitivity response and by producing lipases, proteases, hyaluronidases, and chemotactic factors.[22,23] Additionally, *P. acnes* has been shown to stimulate an upregulation of cytokines by binding to Toll-like receptor 2 on monocytes and polymorphonuclear cells surrounding the sebaceous follicle.[24] After binding Toll-like receptor 2, pro-inflammatory cytokines such as IL-1, IL-8, IL-12, and tumor necrosis factor-α are released.[25,26]

The four elements of acne pathogenesis—follicular keratinocyte hyperproliferation, seborrhea, inflammation, and *P. acnes*—are intertwined steps in the formation of acne. Various acne treatments target different elements in acne pathogenesis. Understanding the mechanisms of action of the multitude of therapeutic options in treating acne will help assure better therapeutic results.

Clinical Findings

HISTORY Most patients with acne vulgaris report gradual onset of lesions around puberty. In other cases, acne can be seen in the neonatal or infantile age. Neonatal acne appears at approximately 2 weeks of age (see Chap. 106) and infantile acne develops at 3 to 6 months of age. Because classic acne vulgaris is usually gradual in onset, patients describing an abrupt onset of acne should be further questioned to consider an underlying etiology.

Hyperandrogenism should be considered in the female patient whose acne is severe, sudden in its onset, or associated with hirsutism or irregular menstrual periods. The patient should be asked about the frequency and character of her menstrual periods and whether her acne flares with changes in her menstrual cycle. Hyperandrogenism can also result in deepening of the voice, an increase in libido, and hirsutism.

A complete medication history is important, as some medications can cause an abrupt onset, monomorphorous acneiform eruption. Drug-induced acne may be caused by: anabolic steroids, corticosteroids, corticotrophin, phenytoin, lithium, isoniazid, vitamin B complexes, halogenated compounds, and certain chemotherapy medications.

CUTANEOUS LESIONS The primary site of acne is the face and, to a lesser degree, the back, chest, and shoulders. On the trunk, lesions tend to be concentrated near the midline. The disease is characterized by a great variety of clinical lesions (Fig. 78-3). Although one type of lesion may be predominant, close observation usually reveals the presence of several types of lesions. The lesions may be either noninflammatory or inflammatory. The noninflammatory lesions are comedos, which may be either open (blackheads; see Fig. 78-3B) or closed (whiteheads; see Fig. 78-3A). The open comedo appears as a flat or slightly raised lesion with a central dark-colored follicular impaction of keratin and lipid (Fig. 78-4). The closed comedones, in contrast to the open comedones, may be difficult to visualize. They appear as pale, slightly elevated, small papules and do not have a clinically visible orifice (see Fig. 78-3A). Stretching of the skin is an aid in detecting the lesions.

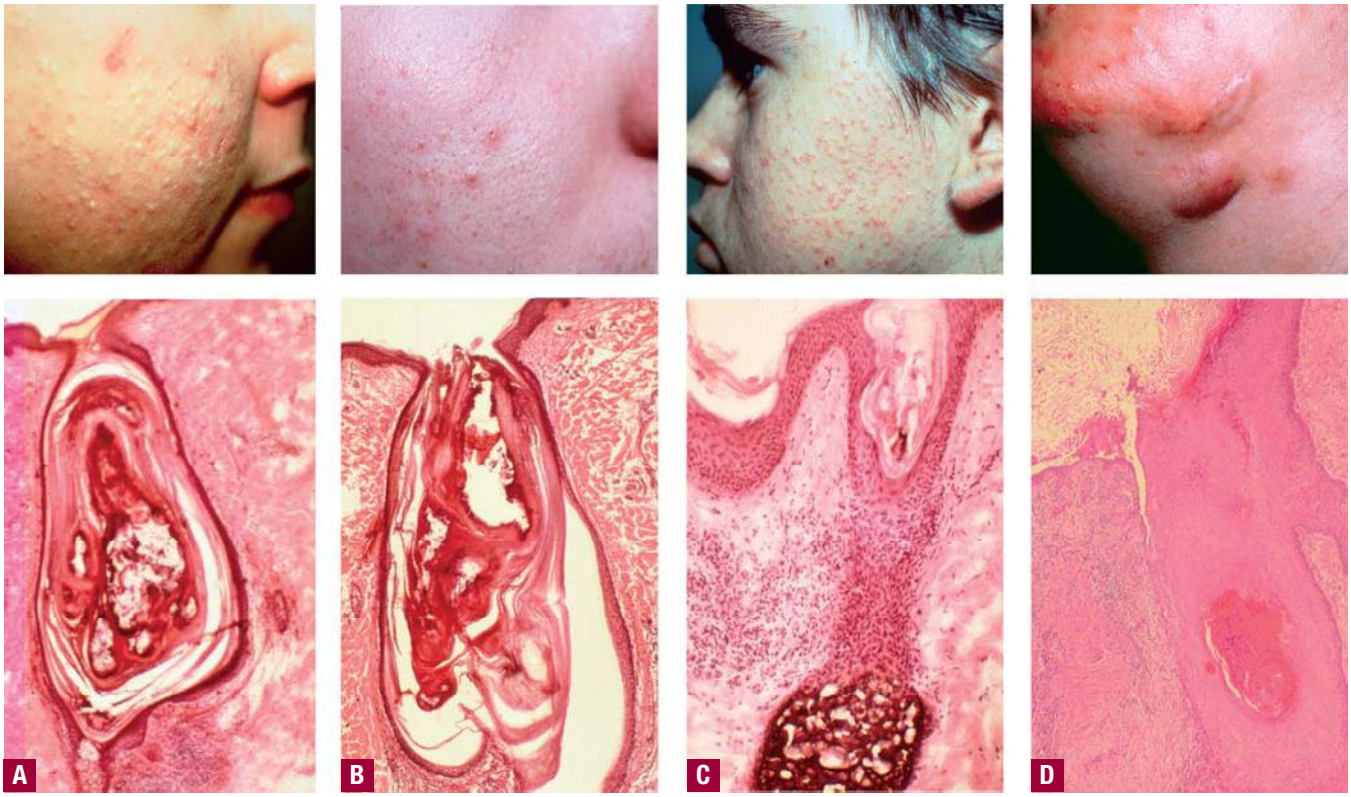

▲ **FIGURE 78-3** Clinicopathologic correlation of acne lesions. **A.** Closed comedone. The follicular infundibulum is distended, filled with keratin and sebum, and the follicular epithelium is attenuated. The follicular ostium is narrow. **B.** Open comedone. Resembles the closed comedone with the exception of a patulous follicular ostium. **C.** Inflammatory papule. Acute and chronic inflammatory cells surround and infiltrate the follicle, which shows infundibular hyperkeratosis. **D.** Nodule. The follicle is filled with acute inflammatory cells. With the rupture of the distended follicle, there is a foreign body granulomatous response.

The inflammatory lesions vary from small papules with a red border to pustules to large, tender, fluctuant nodules (see Figs. 78-3C,D and Figs. 78-4, 78-5, and 78-6). Some of the large nodules were previously called *cysts* and the term *nodulocystic* has been used to describe severe cases of inflammatory acne. True cysts are rarely found in acne, and this term should be abandoned and the term *severe nodular acne* used instead (see Figs. 78-3D and 78-6). Whether the lesion appears as a papule, pustule, or nodule depends on the extent and location of the inflammatory infiltrate in the dermis.

Scarring can be a complication of both noninflammatory and inflammatory acne. There are four general types of acne scars: ice pick, rolling, boxcar, and hypertrophic (Fig. 78-7).[27] Ice pick scars are narrow, deep scars that are widest at the surface of the skin and taper to a point in the dermis. Rolling scars are shallow, wide scars that have an undulating appearance. Boxcar scars are wide, sharply demarcated scars. Unlike ice pick scars, the width of boxcar scars is similar at the surface and base. In rare instances, especially on the trunk, the scars may be hypertrophic.

Acne vulgaris is usually an isolated cutaneous finding. As mentioned in the History section, some cases of acne are driven by hyperandrogenism. Such cases may have associated hirsutism, precocious puberty, and other signs of hyperandrogenism.

Laboratory Tests

In general, laboratory workup is not indicated for patients with acne unless hyperandrogenism is suspected. There are numerous clinical studies relating acne to elevated serum levels of androgens in

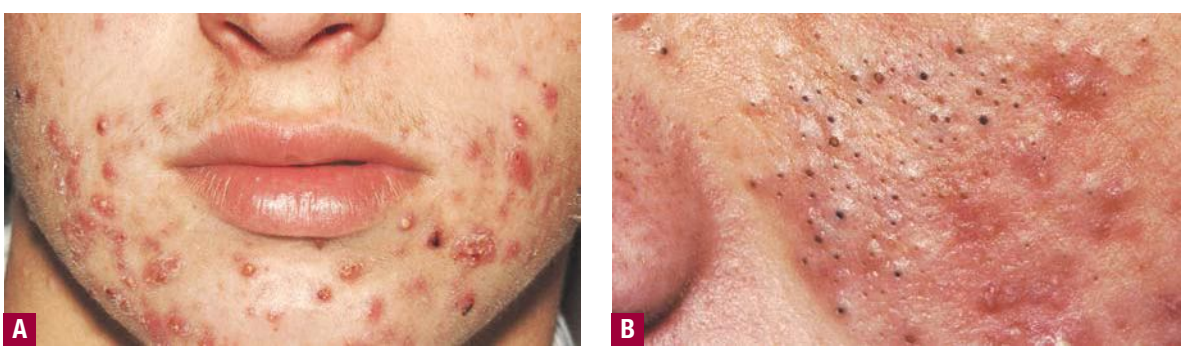

▲ **FIGURE 78-4** Acne vulgaris, mild to moderate. **A.** Close-up of the lower face with comedones, papules, pustules, and scars. **B.** Close-up of the cheek, showing large, open comedones and inflammatory papules and pustules that become confluent, forming an erythematous plaque.



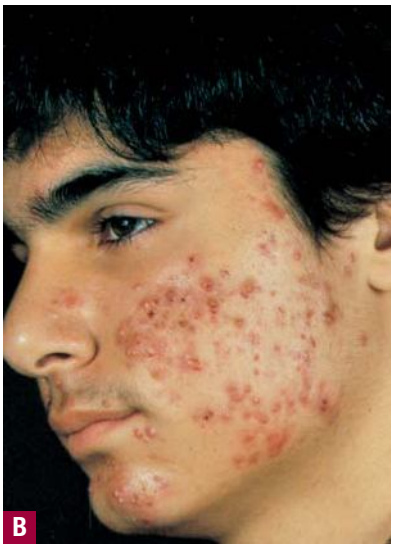



◀ **FIGURE 78-5** Acne vulgaris, nodular, moderate to severe. **A.** Many papules and nodules are seen on the forehead and cheeks with little scarring apparent at this time. **B.** Nodular acne with scars on the cheek. **C.** Larger nodules on the cheek and chin with significant scarring.

both adolescents and adults. Among 623 prepubertal girls followed over time, girls with acne had increased levels of DHEAS as compared to aged-matched controls without acne.[28] DHEAS can serve as a precursor for testosterone and DHT. Elevated serum levels of androgens have been found in cases of severe cystic acne and in acne associated with a variety of endocrine conditions, including congenital adrenal hyperplasia (CAH; 11β- and 21β-hydroxylase deficiencies), ovarian or adrenal tumors, and polycystic ovarian disease. In the majority of acne patients, however, serum androgens are within the normal range.[29,30]

Many patients report that their acne flares during periods of stress. Although objective data are limited, stress is known to increase the output of adrenal steroids, which may affect the sebaceous gland.[31] It has been shown that patients with acne have a greater increase in urinary glucocorticoid levels after corticotropin administration.[32]

Differential Diagnosis

Although one type of lesion may predominate, acne vulgaris is diagnosed by a variety of acne lesions (comedones, pustules, papules, and nodules) on the face, back, or chest (Box 78-1). Diagnosis is







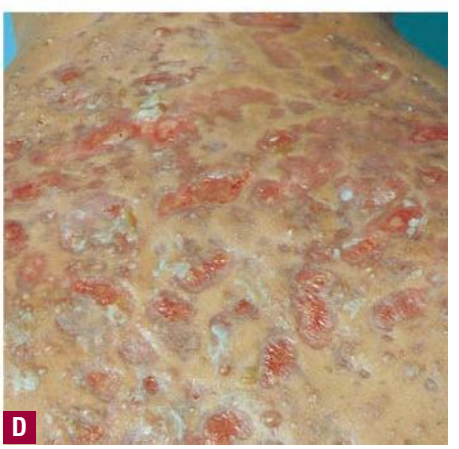

◀ **FIGURE 78-6** Acne vulgaris, nodular, severe. **A.** Large, confluent nodules formed by confluence of smaller lesions with interconnecting channels, associated with atrophic and hyperplastic scars. **B.** Extensive nodules on the chest and arms with severe scarring. **C.** Close-up of nodules, crusted ulcers, and scars on the shoulder. **D.** Severe nodular acne of the back with little residual uninvolved skin.

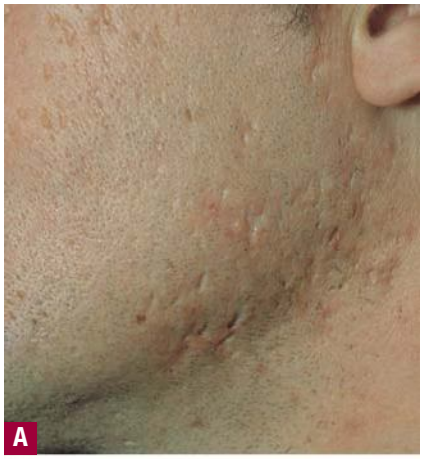





▲ **FIGURE 78-7** Acne vulgaris, scarring. **A.** Punched-out and ice pick scars are seen on the cheek as a residual of burned-out nodular acne. **B.** Extensive atrophic scarring of the back associated with recent nodular acne. **C.** Severe hypertrophic scarring of the back in a patient with history of nodular acne.

usually easy, but acne may be confused with folliculitis, rosacea, or perioral dermatitis. These do not have comedos.

Acne can also be seen in association with different endocrinologic abnormalities. Patients with hyperandrogenism may have acne plus other stigmata of increased androgen levels (i.e., hirsutism, deepened voice, irregular menses). Endocrinologic disorders, such as polycystic ovarian syndrome [including *h*yper*a*n-drogenism, *i*nsulin *r*esistance, and *a*can-thosis *n*igricans (HAIR-AN) syndrome], CAH, and adrenal and ovarian neoplasms, often have accompanying acne.

Box 78-1

Differential Diagnosis of Acne

Most Likely

- Closed comedonal acne
  - Milia
  - Sebaceous hyperplasia
- Open comedonal acne
  - Dilated pore of Winer
  - Favre-Racouchot syndrome
- Inflammatory acne
  - Rosacea
  - Perioral dermatitis
- Neonatal acne
  - Miliaria rubra

Consider

- Closed comedonal acne
  - Osteoma cutis
  - Trichoepitheliomas
  - Trichodiscomas
  - Fibrofolliculomas
  - Eruptive vellus hair cysts, steatocystoma multiplex
  - Colloid milia
- Open comedonal acne
  - Trichostasis spinulosa
  - Nevus comedonicus
- Inflammatory acne
  - Pseudofolliculitis barbae, acne keloidalis nuchae
  - Keratosis pilaris
  - Neurotic excoriations/factitial
  - Lupus miliaris disseminatus faciei
- Neonatal acne
  - Sebaceous hyperplasia
  - Milia

Always Rule Out

- Closed comedonal acne
  - Acne due to systemic agents (e.g., corticosteroids)
  - Contact acne (e.g., occupational acne)
  - Chloracne
- Open comedonal acne
  - Acne due to systemic agents
  - Contact acne
  - Chloracne
- Inflammatory acne
  - Acne due to systemic agents
  - Staphylococcal folliculitis
  - Gram-negative folliculitis
  - Eosinophilic folliculitis
  - Furuncle/carbuncle
- Neonatal acne
  - Candidal infections
  - Benign neonatal cephalic pustulosis

Variants of acne must also be differentiated from typical acne vulgaris to guide treatment. These types of acne include: neonatal acne, infantile acne, acne fulminans, acne conglobata, acne with solid facial edema, and acne excoriée des jeunes filles. These and other acneiform eruptions such as medication-induced acne, halogen acne, chloracne, acne mechanica, tropical acne, radiation acne, and other disorders are discussed in the section Acneiform Eruptions.

Complications

All types of acne lesions have the potential to resolve with sequelae. Almost all acne lesions leave a transient macular erythema after resolution. In darker skin types, post-inflammatory hyperpigmentation may persist months after resolution of acne lesions. In some individuals, acne lesions may result in permanent scarring.

Acne vulgaris may also take a psychological toll on many patients. It is estimated that 30 percent to 50 percent of adolescents with acne experience psychiatric disturbances due to acne.[33] Studies have shown that patients with acne have similar levels of social, psychological, and emotional impairment as those with asthma and epilepsy.[34] Also, unemployment rates are higher among adults with acne than those without.[35] It is important that we recognize the serious psychological consequences that may occur in patients with acne vulgaris. When appropriate, patients should be referred for psychiatric counseling.

Prognosis and Clinical Course

The age of onset of acne varies considerably. It may start as early as 6 to 8 years of age or it may not appear until the age of 20 years or later. The course is one of several years' duration followed by spontaneous remission. Although most patients clear by their early 20s, some have acne extending well into the third or fourth decades. The extent of involvement varies, and spontaneous fluctuations in the degree of involvement are the rule rather than the exception. In the northern sections of the United States, where seasonal differences are great, relative clearing occurs in the summer for reasons that are not understood.

Also, in women, there is often a fluctuation in association with menses, with a flare just before the onset of menstruation. This flare is not due to a change in sebaceous gland activity as there is no increase in sebum production in the luteal phase of the menstrual cycle. It has been shown that prepubes-



TABLE 78-1
Treatment Algorithm for Acne Vulgaris

	Mild		Moderate		Severe
	Comedonal	Papular/Pustular	Papular/Pustular	Nodular	Conglobata/Fulminans
First	Topical retinoid	Topical retinoid + topical antimicrobial	Oral antibiotic + topical retinoid ± BPO	Oral antibiotic + topical retinoid ± BPO	Oral isotretinoin ± oral corticosteroids
Second	Azelaic acid or salicylic acid	Azelaic acid or salicylic acid	Oral antibiotic + topical retinoid ± BPO	Oral isotretinoin or oral antibiotic + topical retinoid ± BPO/azelaic acid	High-dose oral antibiotic + topical retinoid + BPO
Female	—	—	+ Oral contraceptive/anti-androgen	+ Oral contraceptive/anti-androgen	+ Oral contraceptive/anti-androgen
Invasive options	Comedone extraction	—	Comedone extraction	Comedone extraction; intralesional corticosteroid	Intralesional corticosteroid
Refractory to treatment	Check compliance		Check compliance Exclude Gram-negative folliculitis Females: Exclude polycystic ovary syndrome, adrenal or ovarian tumors, congenital adrenal hyperplasia Males: Exclude congenital adrenal hyperplasia		
Maintenance	Topical retinoid ± BPO				

BPO = benzoyl peroxide.
Adapted from Gollnick H et al: Management of acne: A report from a Global Alliance to Improve Outcomes in Acne. *J Am Acad Dermatol* **49**:1, 2003.

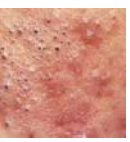

cent females with comedonal acne and those females with high DHEAS levels are predictors of severe or long-standing nodulocystic acne.[36]

Overall, the prognosis for acne is favorable. Treatment regimens should be initiated early and be sufficiently aggressive to prevent permanent sequelae. If significant scarring does occur, referral for surgical correction may be warranted.

Treatment

An understanding of the four major steps in the pathophysiology of acne in turn governs its therapeutic principles. The mechanism of action of the most common treatments for acne can be categorized in the following categories as they relate to the pathophysiology:

- Correct the altered pattern of follicular keratinization
- Decrease sebaceous gland activity
- Decrease the follicular bacterial population, particularly *P. acnes*
- Exert an anti-inflammatory effect

Tailoring a patient's acne regimen with the knowledge of the pathogenesis of acne and the mechanism of action of the available acne treatments ensures maximum therapeutic response. Often, multiple treatments are used in combination so as to combat many factors in the pathogenesis of acne (Table 78-1).

LOCAL THERAPY ***Cleansing.*** The importance of cleansing in the treatment of acne is generally intuitive. Overcleansing or using harsh alkaline soaps is likely to increase the skin's pH, disrupt the cutaneous lipid barrier, and compound the irritancy potential of many topical acne treatments. Use of a syndet (synthetic detergent) allows cleansing without disruption of the skin's normal pH. Several antibacterial soaps containing agents such as triclosan are marketed for acne as well. These have been shown to inhibit gram-positive cocci but may increase gram-negative rods, with their overall affect on acne being unclear. Medicated cleansers, containing benzoyl peroxide or salicylic acid, offer convenience of use in a wash form and are excellent for hard to reach areas such as the back. All in all, a prudent approach to cleansing should be emphasized. Twice daily washing with a gentle cleanser followed by the application of acne treatments may encourage a routine and therefore better compliance.

Topical Agents. **Sulfur/Sodium Sulfacetamide/Resorcinol and Salicylic Acid.** Sulfur/sodium sulfacetamide/resorcinol and salicylic acid, once favored treatments for acne, are still found in several over-the-counter and prescription niche formulations.

Azelaic Acid. Azelaic acid is available by prescription in a 20 percent cream or 15 percent gel. This dicarboxylic acid has both antimicrobial and comedolytic properties.[38] Additionally, it is a competitive inhibitor of tyrosinase, thus decreasing pigmentation.[39] This effect can be used to the advantage of patients with post-inflammatory hyperpigmentation. It is generally well tolerated, though transient burning can occur, and is safe in pregnancy.

Benzoyl Peroxide. Benzoyl peroxide preparations are among the most common topical medications prescribed by dermatologists and are readily available in the over-the-counter acne market as well. Benzoyl peroxide is a powerful antimicrobial agent. This effect is probably related to a decrease in the bacterial population and an accompanying decrease in the hydrolysis of triglycerides. Benzoyl peroxide preparations are available in creams, lotion, gels, washes, and pledgets. Products that are left on the skin, such as a gel, are generally considered more effective. Benzoyl peroxide can produce significant dryness and irritation. Allergic contact dermatitis has been uncommonly reported. Of significance, bacteria are unable to develop resistance to benzoyl peroxide, making it the ideal agent for combination therapy.[40]

Topical Antibiotics. (See Chap. 218) Erythromycin and clindamycin are the most commonly used topical antibiotics for the treatment of acne. These two agents have also been used in combination preparations with benzoyl peroxide. Increased levels of *P. acnes* resistance have been reported in patients who are

being treated with antibiotics. However, the development of resistance is less likely in patients who are treated with a combination of benzoyl peroxide/erythromycin or clindamycin.[41] Therefore, the combination of these two products is preferable over monotherapy with topical antibiotics.

RETINOIDS. (See Chap. 217) Retinoids are defined by their ability to bind to and activate retinoic acid receptors (RARs) and in turn activate specific gene transcription, resulting in a biologic response. Some have chemical structures similar to tretinoin (all-*trans* retinoic acid) but may be entirely dissimilar, such as adapalene or tazarotene, and still potentiate a retinoid effect.

Tretinoin is commercially available in several strengths and formulations. Having both potent comedolytic and anti-inflammatory properties, it is widely used. In general, all retinoids can be contact irritants with alcohol-based gels and solutions having the greatest irritancy potential. Some newer formulations use a microsphere delayed-delivery technology (0.04 percent or 0.10 percent gel) or are incorporated within a polyolprepolymer to decrease the irritancy potential of tretinoin while allowing greater concentration of medication. Advising patients to apply tretinoin on alternate nights during the first few weeks of treatment can help ensure greater tolerability. Patients must also be cautioned about sun exposure due to thinning of the stratum corneum, especially those patients with any irritant reaction. Regular use of a sunscreen should be advised. The comedolytic and anti-inflammatory properties of topical retinoids make them ideal for maintenance therapy of acne. Tretinoin is inactivated by concomitant use of benzoyl peroxide and is photolabile. Therefore, patients should be counseled to apply tretinoin at bedtime.

Adapalene is a synthetic retinoid widely marketed for its greater tolerability. It specifically targets the RAR-γ receptor. It is both photostable and can be used in conjunction with benzoyl peroxide without degradation. Adapalene 0.1 percent gel has been shown in clinical trials to have greater or equal efficacy to tretinoin 0.025 percent gel with greater tolerability.[44,45] It is available at a 0.1 percent concentration in both a non-alcohol gel and cream.

Tazarotene, also a synthetic retinoid, exerts action through its metabolite, tazarotenic acid, which in turn inhibits the RAR-γ receptor. It is a potent comedolytic agent and has been shown to be more effective than tretinoin 0.025 percent gel and tretinoin 0.1 percent microsphere gel.[46,47] Both the 0.1 percent cream and gel formulations are approved for the treatment of acne. The irritant properties of tazarotene can be minimized by use of short-term contact therapy. In this regimen, the medication is applied for 5 minutes then washed off with a gentle cleanser. Tazarotene has been given a pregnancy category X rating and female patients of childbearing age should be adequately counseled.

SYSTEMIC THERAPY *Antibiotics and Antibacterial Agents.* (See Chap. 231)

TETRACYCLINES. Broad-spectrum antibiotics are widely used in the treatment of inflammatory acne. The tetracyclines are the most commonly used. Although the oral administration of tetracycline does not alter sebum production, it does decrease the concentration of free fatty acids while the esterified fatty acid content increases. Decreases in free fatty acid formation also have been reported with erythromycin, demethylchlortetracycline, clindamycin, and minocycline. The free fatty acids are probably not the major irritants in sebum, but their level is an indication of the metabolic activity of the *P. acnes* bacteria and its secretion of other pro-inflammatory products. The decrease in free fatty acids may take several weeks to become evident. This, in turn, is reflected in the clinical course of the disease during antibiotic therapy, as several weeks are often required for maximal clinical benefit. The effect, then, is one of prevention; the individual lesions require their usual time to undergo resolution. However, the fact that a decrease in free fatty acids does occur strengthens the rationale for the use of tetracycline. Tetracycline may also act through direct suppression of the number of *P. acnes,* but part of its action may be due to its anti-inflammatory activity. In clinical practice, tetracycline is usually given initially in dosages of 500 mg/day to 1000 mg/day. Higher doses of up to 3500 mg/day have been used in severe cases, but prudent monitoring of liver functions is warranted. Tetracycline should be taken on an empty stomach, 1 hour before or 2 hours after meals, to promote absorption.

The tetracycline derivatives, doxycycline and minocycline, are also commonly used. They have the distinct advantage of being able to be taken with food without impaired absorption. Doxycycline is administered in dosages of 50 to 100 mg twice daily. The major disadvantage of the use of doxycycline is that it can produce photosensitivity reactions, including photo-onycholysis, and patients may need to be switched to another antibiotic during the summer months. Minocycline is given in divided dosages at a level of 100 mg/day to 200 mg/day. Patients on minocycline should be monitored carefully as the drug can cause blue-black pigmentation, especially in the acne scars, as well as the hard palate, alveolar ridge, and anterior shins. Minocycline-induced autoimmune hepatitis and a systemic lupus erythematosus–like syndrome have been reported during minocycline therapy, but to date these side effects are very rare.[48,49] Serum sickness–like reactions have also been reported with minocycline use.

MACROLIDES. Erythromycin has been used in the past in patients who have difficulty in taking tetracycline on an empty stomach, but due to the prevalence of erythromycin-resistant strains of *P. acnes* its use is generally limited to pregnant women or children. More recently, the use of azithromycin in the treatment of acne has been reported. The reported dosing for azithromycin is quite variable but typically 250 mg to 500 mg orally three times a week is used.[50] Azithromycin undergoes hepatic metabolism with gastrointestinal upset and diarrhea as the most common side effects.

TRIMETHOPRIM-SULFAMETHOXAZOLE. Trimethoprim-sulfamethoxazole combinations are also effective in acne. In general, because the potential for side effects is greater with their use, they should be used only in patients with severe acne who do not respond to other antibiotics.

CLINDAMYCIN AND DAPSONE. Less commonly used antibiotics include clindamycin and dapsone. Oral clindamycin had been used more readily in the past, but because of the fairly high risk of pseudomembranous colitis, it is now rarely used for acne. It is still commonly used topically, however, often in combination with benzoyl peroxide. Dapsone (see Chap. 226), a sulfone often used for cutaneous neutrophilic disorders, may be beneficial in severe markedly inflammatory acne and select cases of resistant acne. It is used at doses of 50 to 100 mg daily for 3 months. Glucose-6-phosphate dehydrogenase levels should be examined before initiation of therapy



and regular monitoring for hemolysis and liver function abnormalities is warranted. Although not as reliably effective as isotretinoin, it is relatively low cost and should be considered in severe cases where isotretinoin is not an option.

Antibiotics and Bacterial Resistance. Antibiotic resistance should be suspected in patients unresponsive to appropriate antibiotic therapy after 6 weeks of treatment. Over their 25 years of use, increasing propionibacterium resistance has been documented to all macrolides and tetracyclines commonly used in the treatment of acne. A prevalence rate of 65 percent was documented in one study performed in the United Kingdom.[51] Overall resistance is highest with erythromycin and lowest with the lipophilic tetracyclines, doxycycline, and minocycline.[52] The least resistance is noted with minocycline. To prevent resistance, prescribers should avoid antibiotic monotherapy, limit long-term use of antibiotics, and combine usage with benzoyl peroxide whenever possible.[40]

HORMONAL THERAPY OF ACNE The goal of hormonal therapy is to counteract the effects of androgens on the sebaceous gland. This can be accomplished with the anti-androgens, or agents designed to decrease the endogenous production of androgens by the ovary or adrenal gland, including oral contraceptives, glucocorticoids, or gonadotropin-releasing hormone (GnRH) agonists.

Oral Contraceptives. The third-generation progestins, desogestrel, norgestimate, and gestodene (not available in the United States), have the lowest intrinsic androgenic activity.[53] Two oral contraceptives are currently U.S. Food and Drug Administration (FDA) approved for the treatment of acne (Ortho Tri-Cyclen and Estrostep). Ortho Tri-Cyclen is a triphasic oral contraceptive comprised of a norgestimate-ethinyl estradiol (35 μg) combination.[54] In an effort to reduce the estrogenic side effects of oral contraceptives, preparations with lower doses of estrogen (20 μg) have been developed and are being studied for the treatment of acne. Estrostep contains a graduated dose of ethinyl estradiol (20 to 35 μg) in combination with norethindrone acetate.[55] An oral contraceptive containing a low dose of estrogen (20 μg) in combination with levonorgestrel has also demonstrated efficacy in acne.[56] Side effects from oral contraceptives include nausea, vomiting, abnormal menses, weight gain, and breast tenderness. Rare but more serious complications include thrombophlebitis, pulmonary embolism, and hypertension. With the use of estrogen-progestin–containing oral contraceptives rather than estrogen alone, side effects such as delayed menses, menorrhagia, and pre-menstrual cramps are uncommon. However, other side effects such as nausea, weight gain, spotting, breast tenderness, amenorrhea, and melasma can occur.

Glucocorticoids. Because of their anti-inflammatory activity, high-dose systemic glucocorticoids may be of benefit in the treatment of acne. In practice, their use is usually restricted to the severely involved patient often overlapping with isotretinoin to limit any potential flaring at the start of treatment. Furthermore, because of the potential side effects, these drugs are ordinarily used for limited periods of time, and recurrences post-treatment are common. Prolonged use may result in the appearance of steroid acne.

Gonadotropin-Releasing Hormone Agonists. GnRH agonists, such as leuprolide, act on the pituitary gland to disrupt its cyclic release of gonadotropins. The net effect is suppression of ovarian steroidogenesis in women. These agents are used in the treatment of ovarian hyperandrogenism. GnRH agonists have demonstrated efficacy in the treatment of acne and hirsutism in females both with and without endocrine disturbance.[58] Their use, however, is limited by their side-effect profile, which includes menopausal symptoms and bone loss.

Antiandrogens. Spironolactone functions both as an androgen receptor blocker and inhibitor of 5α-reductase. In doses of 50 to 100 mg twice a day, it has been shown to reduce sebum production and to improve acne.[59] Side effects include potential hyperkalemia, irregular menstrual periods, breast tenderness, headache, and fatigue. As an anti-androgen, there is a risk of feminization of a male fetus if a pregnant female takes this medication. Combining spironolactone treatment with an oral contraceptive can alleviate the symptoms of irregular menstrual bleeding.

Cyproterone acetate is a progestational anti-androgen that blocks the androgen receptor. It is combined with ethinyl estradiol in an oral contraceptive formulation that is widely used in Europe for the treatment of acne. Cyproterone acetate is not available in the United States.

Flutamide, an androgen receptor blocker, has been used at doses of 250 mg twice a day in combination with oral contraceptives for treatment of acne or hirsutism in females.[60] Liver function tests should be monitored as cases of fatal hepatitis have been reported.[61] Pregnancy should be avoided. Use of flutamide in the treatment of acne may be limited by its side-effect profile.

Isotretinoin. (See Chap. 217) The use of the oral retinoid, isotretinoin, has revolutionized the management of severe treatment-resistant acne.[62] It is approved for use in patients with severe, recalcitrant, nodular acne. However, it is commonly used in many other acne scenarios, including any significant acne unresponsive to treatment including oral antibiotics which results in significant physical or emotional scarring. Isotretinoin is also effective in the treatment of gram-negative folliculitis, pyoderma faciale, and acne fulminans.[63] The remarkable aspects of isotretinoin therapy are the completeness of the remission in almost all cases and the longevity of the remission, which lasts for months to years in the great majority of patients. Due to its teratogenicity, however, its use has become highly regulated in the United States with the initiation of the iPledge program in March 2006.

The mechanism of action of isotretinoin is not completely known. The drug produces profound inhibition of sebaceous gland activity, and this undoubtedly is of great importance in the initial clearing.[64,65] In some patients, sebaceous gland inhibition continues for at least 1 year, but in the majority of patients, sebum production returns to normal after 2 to 4 months.[64]

Isotretinoin therapy, due to the ubiquitous distribution of RARs, is almost always accompanied by side effects, mimicking those seen in the chronic hypervitaminosis A syndrome (see Chap. 229).[67] In general, the severity of side effects tends to be dose dependent. The most common side effects are related to the skin and mucous membranes. Cheilitis of varying degrees is found in virtually all cases. Other side effects that are likely to be seen in over 50 percent of patients are dryness of the mucous membranes, xerosis, and pruritus. An eczematous dermatitis is occasionally seen, particularly in cold, dry weather. Thinning of hair and granulomatous

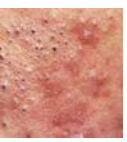

paronychial lesions are less common. Ophthalmologic findings include xerophthalmia, night blindness, conjunctivitis, keratitis, and optic neuritis. Corneal opacities and hearing loss (both transient and persistent) have also been reported with isotretinoin use.

Pseudotumor cerebri, also known as *benign intracranial hypertension*, is evidenced by severe headache, nausea, and visual changes. The risk of pseudotumor cerebri is increased with concomitant use of tetracyclines and isotretinoin; therefore, these two medications should not be used together.

The relationship between isotretinoin use and psychiatric effects is currently being examined. Risk of depression, suicide, psychosis, and aggressive and/or violent behavior are all listed as possible side effects. However, large, population-based studies have not supported causality. A cohort study comparing isotretinoin users with oral antibiotic users showed no increased risk, with the relative risk for development of depression or psychosis at approximately 1.0.[69] Careful screening of adolescents is particularly needed as the risk of depression in this population is quoted at 10 percent to 20 percent.[70]

Gastrointestinal symptoms are generally uncommon, but nausea, esophagitis, gastritis, and colitis can occur. Acute hepatitis is rare, but liver function studies should be regularly monitored, as elevation in liver enzymes can occur in 15 percent of patients. Dose adjustments should be taken. Elevated levels of serum triglycerides occur in approximately 25 percent of patients on isotretinoin. This elevation, which is dose-related, typically occurs within the first 4 weeks of treatment and is often accompanied by an overall increase in cholesterol with a decrease in the high-density lipoprotein levels.

Myalgias are the most common musculoskeletal complaint, seen in 15 percent of patients. In severe cases, creatine phosphokinase levels should be evaluated for possible rhabdomyolysis.

The greatest concern during isotretinoin therapy is the risk of the drug being administered during pregnancy and thereby inducing teratogenic effects in the fetus.[73,74] The drug is not mutagenic; its effect is on organogenesis. For this reason, it should be emphasized that isotretinoin should be given only to patients who have not responded to other therapy. Furthermore, women who are of childbearing age must be fully informed of the risk of pregnancy. The patient must use two highly effective contraception techniques such as the use of an oral contraceptive and condoms with a spermicidal jelly. Contraception must be started at least 1 month before isotretinoin therapy. Female patients must be thoroughly counseled and demonstrate an understanding of contraception techniques before starting isotretinoin. The patient must continue the two forms of contraception throughout the course of isotretinoin and for 1 month after stopping treatment. In the United States, FDA concerns regarding teratogenicity have prompted the manufacturers of isotretinoin to institute a pregnancy-prevention program for patients. This strict, computer-based risk management program, known as iPledge, ensures that pregnancy-prevention procedures are followed.

The recommended daily dosage of isotretinoin is in the range of 0.5 to 1.0 mg/kg/day. A cumulative weight-based dosing formula may also be used with a total dose of 120 to 150 mg/kg of isotretinoin during a course of therapy.[77] This dosing regimen is of particular use in patients who have variable dosages or interrupted periods of treatment, as achieving the total dose ensures the greatest chance of long-term remission. Because back and chest lesions show less of a response than facial lesions, dosages as high as 2 mg/kg/day may be necessary in those patients who have very severe truncal involvement. Patients with severe acne, particularly those with granulomatous lesions, often develop marked flares of their disease when isotretinoin is started. Therefore, the initial dosing should be low, even below 0.5 mg/kg/day. These patients often need pre-treatment for 1 to 2 weeks with prednisone (40 to 60 mg/day), which may have to be continued for the first 2 weeks of therapy. A typical course of isotretinoin is 20 weeks, but the length of the course of treatment is not absolute; in patients who have not shown an adequate response, therapy can be extended. Additional improvement may be seen for 1 to 2 months after discontinuation, so that complete clearance may not be a necessary endpoint for determining when to discontinue therapy.

Furthermore, laboratory monitoring is indicated. It is appropriate to obtain a baseline complete blood count and liver function tests, but the greatest attention should be paid to following serum triglyceride levels. Baseline values for serum triglycerides should be obtained and repeated at 3 to 4 weeks and 6 to 8 weeks of therapy. If the values are normal at 6 to 8 weeks, there is no need to repeat the test during the remaining course of therapy unless there are risk factors. If serum triglycerides increase above 500 mg/dL, the levels should be monitored frequently. Levels above 700 to 800 mg/dL are a reason for interrupting therapy or treating the patient with a lipid-lowering drug. Eruptive xanthomas or pancreatitis can occur at higher serum triglyceride levels.

DIET Several articles suggesting a role for diet in acne have been published.[78,79] Yet, overall, the implications of these studies is not clear and the role of chocolate, sweets, milk, and fatty foods in patients with acne requires further study. There is no evidence to support the value of elimination of these foods, although some patients attest to flares of their disease after ingestion of certain foods. This is especially true with chocolate. Because patients cling to their beliefs, it is best to restrict those dietary agents that they feel produce flares.

ACNE SURGERY Acne surgery, used for the removal of comedones and superficial pustules, aids in bringing about involution of individual acne lesions. Acne surgery was a mainstay of therapy in the past. However, with the advent of comedolytic agents such as topical retinoids, it is not needed as often. Its use is primarily restricted to those patients who do not respond to comedolytic agents. Even in those patients, the comedones are removed with greater ease and less trauma if the patient is treated first with topical vitamin A acid or a similar topical agent for 3 to 4 weeks. This pre-treatment should be done in all patients who are to undergo mechanical comedo removal.

Acne surgery is helpful only when properly done, and inaccurate placement of the comedo extractor may serve only to rupture the follicle and incite an inflammatory reaction. Therefore, it is inadvisable to have the patient do acne surgery at home.

INTRALESIONAL GLUCOCORTICOIDS Intralesional injection of glucocorticoids can dramatically decrease the size of deep nodular lesions. The injection of 0.05 to 0.25 mL per lesion of a triamcinolone acetate suspension (2.5 to 10 mg/mL) is recommended as the anti-inflammatory agent. This is a very useful form of ther-



apy in the patient with nodular acne, but it often has to be repeated every 2 to 3 weeks. A major advantage is that it can be done without incising or draining the lesions, thus avoiding the possibility of scar formation. Hypopigmentation, particularly in darker skinned patients, and atrophy are risks.

PHOTOTHERAPY AND LASERS Various forms of phototherapy are under investigation for their use in treating acne vulgaris. Ultraviolet (UV) light has long been thought to be beneficial in the treatment of acne. Up to 70 percent of patients report that sun exposure improves their acne.[80] This reported benefit may be due to camouflage by UV radiation–induced erythema and pigmentation, although it is likely that the sunlight has a biologic effect on the pilosebaceous unit and *P. acnes*. Although UVB can also kill *P. acnes* in vitro, it is clinically insignificant since it has low skin penetration and only high doses causing sunburn have be shown to improve acne.[81,82] UV radiation may have anti-inflammatory effects by inhibiting cytokine action.[83] Studies investigating the effect of UV radiation on acne have demonstrated a modest improvement in only inflammatory acne. There is some effect with UVB radiation alone and slightly more benefit with combined UVB and UVA radiation. UVA light alone is the least beneficial. Twice weekly phototherapy sessions are needed for any clinical improvement. The therapeutic utility of UV radiation in acne is superseded by its carcinogenic potential.[84–88]

Other types of phototherapy for acne treatment use porphyrins either endogenously produced by *P. acnes* or by applying exogenous porphyrins. Coproporphyrin III is the major endogenous porphyrin of *P. acnes*. Coproporphyrin III can absorb light at the near-UV and blue-light spectrum of 415 nm.[89] In vitro irradiation of *P. acnes* with blue light leads to photoexcitation of endogenous bacterial porphyrins, singlet oxygen production, and subsequent bacterial destruction.[90] A visible light source, either blue, red, or both, may be used to excite the endogenous porphyrins. The high intensity, enhanced, narrow band (407 to 420 nm) blue light known as *ClearLight* is currently FDA approved for the treatment of moderate inflammatory acne.[88] A multicenter study has shown that 80 percent of patients treated with the ClearLight for 4 weeks had a 60 percent reduction in acne lesions. There was a gradual return of lesions over 3 to 6 months.[91]

Photodynamic therapy involves the topical application of aminolevulinic acid 1 hour before exposure to a low-power light source (see Chap. 239). These sources include the pulsed dye laser, intense pulsed light, or a broadband red light source. Several studies using aminolevulinic acid-photodynamic therapy maintained clinical improvement for up to 20 weeks.[94,95]

Lasers are beginning to find a role in the treatment of acne. They work by emitting minimally divergent, coherent light that can be focused over a small area of tissue (see Chap. 240). The pulsed potassium-titanyl-phosphate laser (532 nm) has demonstrated a 35.9 percent decrease in acne lesions when used twice weekly for 2 weeks. The beneficial effects of a single treatment can last 12 weeks.[97] The 1450-nm diode laser has also demonstrated significant efficacy in treating acne.[98,99] This non-ablative infrared laser works by causing thermal damage to the sebaceous glands. In a pilot study, 14 out of 15 patients treated had a significant reduction in inflammatory lesions that persisted for 6 months. The 1320-nm neodymium:yttrium-aluminum-garnet and the 1540 erbium glass lasers have also been demonstrated to improve acne.[101,102] The cost of these light and laser treatments tends to be prohibitive.

ACNE VARIANTS

Neonatal Acne (See Chap. 106)

Neonatal acne can occur in up to 20 percent of healthy newborns. Lesions usually appear around 2 weeks of age and resolve spontaneously within 3 months. It is marked by small, inflamed papules across the nasal bridge and on the cheeks. Comedone formation is absent, some calling in question whether this entity is a true acne variant, but rather a variant of neonatal cephalic pustulosis. It has been shown that sebum excretion rates in newborns are transiently elevated in the perinatal period.[103] Additionally, *Malassezia sympodialis*, a normal commensal on human skin, may also play a role. Some reports have demonstrated positive cultures of the pustules with *Malassezia* and improvement with ketoconazole cream.[104] Although there appears to be a strong association between *Malassezia* and benign neonatal cephalic pustulosis, a definite causality for neonatal acne has not been proven at this time.[105]

Infantile Acne (See Chap. 106)

Infantile acne presents at 3 to 6 months of age and is usually marked by the presence of comedones. Papules, pustules, and nodules can also present on the face and scarring may occur even with relatively mild disease. Occasionally, infants only show inflammatory acne, virtually always with cystic lesions in addition to the inflammatory papules. Infantile acne is caused in part by the transient elevation of DHEA produced by the immature adrenal gland. Additionally, during the first 6 to 12 months of life boys may also have an increased level of luteinizing hormone that stimulates testosterone production. Around 1 year of age, these hormone levels begin to stabilize until they surge again during adrenarche. As a result, infantile acne usually resolves around 1 to 2 years of age. Treatment usually consists of topical retinoids and benzoyl peroxide. Oral therapy with erythromycin, trimethoprim, or isotretinoin can be used in severe or refractory cases.[105]

Acne Conglobata

Acne conglobata, a severe form of nodular acne is most common in teenage males but can occur in either sex and into adulthood. Acne conglobata (*conglobate* means shaped in a rounded mass or ball) is a mixture of comedones, papules, pustules, nodules, abscesses, and scars. It can be on the back, buttocks, chest, and, to a lesser extent, on the abdomen, shoulders, neck, face, upper arms, and thighs (see Fig. 78-6). The comedones often have multiple openings. The inflammatory lesions are large, tender, and dusky-colored. The draining lesions discharge a foul-smelling serous, purulent, or mucoid material. Subcutaneous dissection with the formation of multichanneled sinus tracts is common. Healing results in an admixture of depressed and keloidal scars. The management of these patients is very difficult and the effect of treatment is often temporary. Several medications have been used, including intensive high-dose therapy with antibiotics, intralesional glucocorticoids, systemic glucocorticoids, surgical débridement, surgical incision, and surgical excision. The use of isotretinoin has produced dramatic results in some of these patients. In severe cases, dosages as high as 2 mg/kg/day for a 20-week course may be necessary. However, because severe flares may occur when

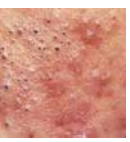

isotretinoin is started, the initial dose should be 0.5 mg/kg/day or less, and systemic glucocorticoids are often required either before initiating isotretinoin therapy or as concomitant therapy.

Acne Fulminans

Acne fulminans (also known as *acute febrile ulcerative acne*) is the most severe form of nodular acne accompanied by systemic symptoms. The sudden appearance of massive, inflammatory, tender, oozing, friable plaques with hemorrhagic crusts characterize acne fulminans. The lesions predominate on the back and chest, rapidly become ulcerative, and heal with scarring. The disease is reported to occur primarily in teenage boys. The face is often not involved. The patients are febrile, have a leukocytosis of 10,000 to 30,000/mm^3 white blood cells, and usually have polyarthralgia, myalgia, hepatosplenomegaly, and anemia. Bone pain is common, especially at the clavicle and sternum. Radiologic examination may demonstrate lytic bone lesions. Occasionally there is accompanying erythema nodosum. Although this disease is often classified with acne conglobata, there are basic differences. The onset of acne fulminans is more explosive, nodules and polymorphous comedones are less common, the face is not involved as frequently and the neck is usually spared, ulcerative and crusted lesions are unique, and systemic symptoms are more common. Systemic glucocorticoid therapy, along with oral antibiotics and intralesional glucocorticoids, is the treatment regimen required for these patients. Isotretinoin is also of benefit in these patients, but to prevent explosive flares, systemic glucocorticoids must be started before isotretinoin and continued during the first few weeks of isotretinoin therapy. The initial dosing of isotretinoin must also be lowered accordingly in the initial weeks of therapy until the inflammation is controlled. The daily dose of glucocorticoids should be slowly decreased as tolerated. Dapsone in conjunction with isotretinoin has been reportedly beneficial in the treatment of acne fulminans associated with erythema nodosum.

SAPHO Syndrome

SAPHO syndrome is manifested by synovitis, acne, pustulosis, hyperostosis, and osteitis. It is predominantly associated with hyperostosis of the anterior chest, palmoplantar pustulosis, hidradenitis suppurativa, and acne fulminans. Its etiology is unknown. Reported successful treatments for SAPHO syndrome are nonsteroidal anti-inflammatory drugs, sulfasalazine, and infliximab.[106] The bisphosphates are beneficial for treating the associated bone pain.[107]

PAPA Syndrome

PAPA syndrome, another acne variant with systemic symptoms, is marked by sterile pyogenic arthritis, pyoderma gangrenosum, and acne. Patients with PAPA syndrome may also give a history of sterile cutaneous abscesses, inflammatory bowel disease, and pancytopenia after administration of sulfa-containing medications.[108] It is an autoinflammatory disorder inherited in an autosomal dominant manner. The condition results from mutations in the CD2 binding protein-1 gene (also known as the *protein serine-threonine phosphatase interacting protein*), and IL-1β production is increased.[109] There have been reports of successful treatment with infliximab and anakinra (see Chap. 235).[108,109]

Acne *Excoriee des Jeunes Filles*

Acne *excoriée des jeunes filles* (French for *excoriated acne of young women*), as the name suggests, occurs primarily in young women who are picking at their skin, although males may be affected as well. Mild acne may be present and is accompanied by extensive excoriations. Comedones and papules are systematically and neurotically excoriated leaving crusted erosions that scar. Often, the lesions that are excoriated are minute. This condition may suggest underlying depression, anxiety, obsessive-compulsive disorder, or a personality disorder. Antidepressants and psychotherapy can be helpful in treating these patients.

Acne Mechanica

Acneiform eruptions have been observed after repetitive physical trauma to the skin such as rubbing. This can occur from clothing (belts and straps) or sports equipment (football helmets and shoulder pads). Occluding the skin with adhesive tape can also produce acne mechanica. Obstruction of the pilosebaceous gland results in comedo formation. It presents as a well-defined, lichenified, hyperpigmented papule or plaque interspersed with comedones. A classic example of acne mechanica is fiddler's neck, produced where the violin pad repetitively rubs against the player's lateral neck.

Acne with Solid Facial Edema

A rare and disfiguring variant of acne vulgaris is acne with solid facial edema, also known as Morbihan disease. There is a woody edema of the mid-third face with accompanying erythema and acne. Similar changes have been reported with rosacea and Melkersson-Rosenthal syndrome. The severity of the edema may fluctuate, but spontaneous resolution does not occur. Oral antibiotic treatment is ineffective. Treatment with low dose isotretinoin (0.2 to 0.5 mg/kg/day) alone or in combination with oral glucocorticoids, ketotifen (1 to 2 mg/day), or clofazimine for 4 to 5 months has been reported to be beneficial.[110,111]

Acne with Associated Endocrinologic Abnormalities

Although the majority of cases of acne vulgaris occur in patients without endocrinologic disturbances, there is a certain population whose acne is driven or worsened by endocrine abnormalities. As mentioned previously, it is important to screen patients for such abnormalities by taking a thorough history. In addition to the presence of acne, endocrinologic disturbances may be marked by irregular menstrual cycles, deepened voice, increased libido, and hirsutism. Laboratory work can help define an endocrinologic problem causing acne.

POLYCYSTIC OVARY SYNDROME Polycystic ovary syndrome (PCOS) occurs in roughly 3 percent to 6 percent of the general population. Patients with PCOS, also called *Stein-Leventhal syndrome*, ovulate infrequently or not at all, have multiple cysts on their ovaries, and often have irregular menses, obesity, androgenic alopecia, hirsutism, and acne. There is an increased risk of diabetes mellitus and endometrial carcinoma in patients with PCOS.[112] Serum total testosterone in the range of 150 to 200 ng/dL or an increased luteinizing hormone/follicle-stimulating hormone ratio (greater than 2.0) can be found in cases of PCOS. Patients with signs of hyperandrogenism should also be asked about insulin resistance because acne can occur with the HAIR-AN syndrome, a subset of PCOS. Hyperandrogenism, acne, insulin resistance and acanthosis nigricans are markers of this syndrome. It is important to identify these patients because they are



at increased risk for accelerated cardiovascular disease and diabetes mellitus.

CONGENITAL ADRENAL HYPERPLASIA

ACNEIFORM ERUPTIONS

Steroid Folliculitis

After administration of systemic glucocorticoids or corticotropin, a folliculitis may appear. This is very uncommon in children but may occur in adolescents and adults as early as 2 weeks after steroids are started. Similar lesions may follow the prolonged application of topical glucocorticoids to the face. For this reason, topical glucocorticoids have no place in the treatment of acne, and their use on the face, in general, should be limited. The pathology of steroid acne is that of a focal folliculitis with a neutrophilic infiltrate in and around the follicle. This type of acne clearly differs from acne vulgaris in its distribution and in the type of lesions observed. The lesions, which are usually all in the same stage of development, consist of small pustules and red papules. In contrast to acne vulgaris, they appear mainly on the trunk, shoulders, and upper arms, with lesser involvement of the face. Post-inflammatory hyperpigmentation may occur, but comedones, cysts, and scarring are unusual. Treatment consists primarily of stopping any corticosteroid use. Typical acne treatments such as topical retinoids and antibiotics may also be helpful.

Drug-Induced Acne

In addition to glucocorticoids, other medicines can also cause a monomorphic, diffuse popular eruption that mimics steroid folliculitis (Box 78-2). Halogenated compounds containing either bromides or iodides are often found in cold and asthma remedies, sedatives, radio-opaque contrast material, kelp (in many fad diet pills), and other vitamin-mineral combinations. With iodides, in particular, inflammation may be marked.[115,116] The iodine content of iodized salt is low and, therefore, it is extremely unlikely that enough iodized salt could be ingested to cause this type of acne.

Epidermal Growth Factor Receptor Inhibitor–Associated Eruption

Epidermal growth factor receptor inhibitors (EGFR inhibitors) are primarily used to treat non-small cell lung cancer, colorectal cancer, and breast cancer.

Box 78-2

Drug-Induced Acneiform Eruptions

- Glucocorticoids
- Phenytoin
- Lithium
- Isoniazid
- High-dose vitamin B complex
- Halogenated compounds
- Epidermal growth factor receptor inhibitors

Some of the EGFR inhibitors include: gefitinib, cetuximab, erlotinib, and trastuzumab. In treatment-responsive patients, the EGFR inhibitors are indefinitely administered for their long-term ability to inhibit tumor growth, progression, cell proliferation, and angiogenesis. A frequent side effect of the EGFR inhibitors is a perifollicular, papulopustular eruption distributed on the face and upper torso. The eruption occurs in up to 86 percent of patients treated with EGFR inhibitors. An associated lateral paronychia may also occur. On pathology a non-infectious perifolliculitis is seen.[117] The etiology of the acneiform eruption is not clear, but it may occur because EGFR is highly expressed in the basal cell layer of the epidermis, follicular keratinocytes, and the sebaceous epithelium. The presence and severity of the eruption correlate with a positive treatment response. If the eruption is absent, dosing may be inadequate, or the patient's tumor may be unresponsive to EGFR inhibitor therapy.[118]

Occupational Acne and Chloracne

Several different groups of industrial compounds encountered in the workplace may cause acne. These include coal tar derivatives, insoluble cutting oils, and chlorinated hydrocarbons (chlornaphthalenes, chlordiphenyls, and chlordiphenyloxides). *Chloracne* is the term that is used to describe occupational acne caused from chlorinated hydrocarbons. Occupational acne tends to be quite inflammatory and, in addition to large comedones, is characterized by papules, pustules, large nodules, and true cysts. Tar acne is often accompanied by hyperpigmentation. The lesions of occupational acne are not restricted to the face and, in fact, are more common on covered areas with intimate contact to clothing saturated with the offending compound. Because the cutting oils are so widely used, they are the most common cause of industrial acne. However, the chlorinated hydrocarbons, which cause chloracne, have posed a more difficult problem because of the severity of the disease induced with these compounds. Exposure can cause comedones, cysts, and pigmentary changes of the skin but can also affect the ophthalmic, nervous, and hepatic systems.[119] Many cases have occurred as the result of massive exposure in industrial accidents.[120] Chlorinated hydrocarbons are found in fungicides, insecticides, and wood preservatives. Chloracne classically affects the malar, retroauricular, and mandibular regions of the head and neck (see eFig. 78-7.1 in on-line edition), as well as the axillae and scrotum. Pathology demonstrates multiple tiny infundibular cysts.[121] Treatment with topical or oral retinoids and oral antibiotics may be beneficial.

Gram-Negative Folliculitis

Gram-negative folliculitis may occur in patients with pre-existing acne vulgaris treated with long-term oral antibiotics, especially the tetracyclines. Patients usually give a history of initial success with oral tetracyclines followed by a worsening of their acne. Gram-negative folliculitis may appear as either papulopustules concentrated around the nose or as deep-seated nodules. Culture of these lesions may reveal *Enterobacter*, *Klebsiella*, or *Escherichia* in the papulopustules or *Proteus* in the nodules. An appropriate antimicrobial agent with adequate Gram-negative coverage should be used. In recalcitrant cases, Gram-negative folliculitis improves with oral isotretinoin for 4 to 5 months. Gram-negative bacteria require a moist environment for survival and the drying action of isotretinoin kills the bacteria. In some cases, an oral cephalosporin may be given for 2 weeks in combination with isotretinoin.[116]

Radiation Acne

Different types of radiation, such as ionizing radiation and UV radiation may induce acneiform eruptions (see Chap. 241). Previous sites of therapeutic ionizing radiation (e.g., external beam) can develop comedo-like papules. These lesions begin to appear as the acute phase of radiation dermatitis is resolving. The ionizing rays induce epithelial metaplasia within the follicle, creating adherent hyperkeratotic plugs in the pilosebaceous unit. These keratotic plugs are resistant to extraction. Excessive exposure to UV radiation may produce a yellow, atrophic plaque studded with large,

open comedones. This condition is known as *Favre-Racouchot syndrome* but has also been called *solar comedones, senile comedones, nodular cutaneous elastosis with cysts and comedones*, and *nodular elastoidosis with cysts and comedones*. It has been estimated to occur in 6 percent of persons more than age 50 years.[122] The lesions are usually symmetrically distributed on the temporal and periorbital areas. The exact pathogenesis of Favre-Racouchot syndrome is unknown but it is suggested that extensive UV exposure as well as exposure to harsh climates and smoking may be risk factors. It can be treated with oral or topical retinoids as well as extraction.[123]

Tropical Acne

In extreme heat, a severe acneiform folliculitis may develop. This can be seen in tropical climates or in scorching occupational environments, as in furnace workers. This acneiform eruption is a major cause of dermatologic disability in military troops serving in tropical climates. Tropical acne occurs mainly on the trunk and buttocks. It has many deep, large, inflammatory nodules with multiple draining areas, resembling acne conglobata. The pathogenesis of this type of acne is unknown, although secondary infection with coagulase-positive staphylococci almost always ensues. Systemic antibiotics must be given, but often more important is removing the patient to a cooler environment.

Acne Aestivalis

Acne aestivalis, a monomorphous eruption, consists of multiple, uniform, red, papular lesions seen after sun exposure. It is referred to as *Mallorca acne* because it occurred in many Scandinavians after they had been on a sunny vacation in Mallorca in southern Europe after a long, dark winter. Almost all cases have occurred in women, mainly 20 to 30 years old. The lesions are common on the shoulders, arms, neck, and chest. Histologically, the lesions resemble steroid acne in that they show a focal follicular destruction with neutrophilic infiltrate. Comedones are not part of the clinical or histologic picture.

Pseudoacne of the Nasal Crease

The transverse nasal crease is an anatomic variant that appears as a transverse linear groove across the middle of the nose. Preadolescent patients have been described to develop acneiform red papules within the nasal crease along with milia. Histologic examination of the papules reveals keratin granulomas that may be derived from ruptured, inflamed milia. Due to its similarity in clinical appearance to acne, but deviation from acne histologically, it has been termed *pseudoacne of the nasal crease*.[124]

Apert Syndrome

Apert syndrome, also known as *acrocephalosyndactyly*, is an autosomal dominant disorder marked by synostoses of the cranium, vertebral bodies and hands and feet. It is caused by a mutation in the gene encoding fibroblast growth factor receptor 2. These patients have a diffuse acneiform eruption that often involves the arms, buttocks, and thighs. It is typically very resistant to treatment but excellent responses to isotretinoin have been reported. Patients with Apert syndrome may also present with severe seborrhea, nail dystrophy, and cutaneous and ocular hypopigmentation.

KEY REFERENCES

The full reference list for all chapters is available at www.digm7.com.

13. Lucky AW et al: Predictors of severity of acne vulgaris in young adolescent girls: Results of a five-year longitudinal study [see comments]. *J Pediatrics* **130**:30, 1997
16. Thiboutot D: Regulation of human sebaceous glands. *Dermatol Foundation* **37**:1, 2003
25. Kim J et al: Activation of toll-like receptor 2 in acne triggers inflammatory cytokine responses. *J Immunol* **169**:1535, 2002
34. Mallon E et al: The quality of life in acne: A comparison with general medical conditions using generic questionnaires. *Br J Dermatol* **140**:672, 1999
40. Gollnick H et al: Management of acne: A report from a Global Alliance to Improve Outcomes in Acne. *J Am Acad Dermatol* **49**:1, 2003
52. Ross JI et al: Antibiotic-resistant acne: Lessons from Europe.[see comment]. *Br J Dermatol* **148**:467, 2003
63. Pochi PE et al: Report of the Consensus Conference on Acne Classification. Washington, D.C., March 24 and 25, 1990. *J Am Acad Dermatol* **24**:495, 1991



CHAPTER 79

Rosacea

Michelle T. Pelle

ROSACEA

Despite universal recognition, rosacea remains a controversial topic in dermatology, largely because of its uncertain pathophysiology and clinical variation. Practitioners and the public can easily identify the prototypical red face of rosacea; however, confusion arises when photodamage, perioral dermatitis, postadolescent acne, and topical steroid overuse present in a similar guise. Recent theory has shifted conceptually from staged progression of rosacea signs and symptoms to a new classification that defines four sub-types with variable severity and potential overlap.

Rosacea is characterized by erythema of the central face that has persisted for months or more. The convex areas of the nose, cheeks, chin, and forehead are the characteristic distribution. Primary features of rosacea, which may be observed but are not required for the diagnosis, include flushing, papules, pustules, and telangiectases. Secondary features include facial burning or stinging, edema, plaques, a dry appearance, phyma, peripheral flushing, and ocular manifestations. Erythema in peripheral locations (the scalp, ears, lateral face, neck, and chest) can be observed in rosacea but is also a common feature of physiologic flushing and chronic sun damage, and therefore must be interpreted carefully.[1]

Sub-Type Classification

The sub-types of rosacea were defined provisionally by the National Rosacea Society (NRS) Expert Committee in 2002 and include erythematotelangiectatic, papulopustular, phymatous, and ocular sub-types.[1] These represent the most common groupings of rosacea signs and symptoms. The sub-types coincide with the first rosacea "staging" classification devised by Plewig and Kligman.[2] The erythematotelangiectatic sub-type is analogous to Plewig-Kligman stage I disease, the papulopustular sub-type to Plewig-Kligman stage II, and the phymatous

ROSACEA AT A GLANCE



- Rosacea affects all races, but is most common in fair-skinned individuals.
- Triggers of rosacea may include hot or cold temperature, sunlight, wind, hot drinks, exercise, spicy food, alcohol, emotions, cosmetics, topical irritants, menopausal flushing, and medications that promote flushing.
- There are four rosacea sub-types: erythematotelangiectatic, papulopustular, phymatous, and ocular.
- The primary clinical features of rosacea include flushing, inflammatory papules, pustules, and telangiectases.
- Secondary features of rosacea may include facial burning and stinging, edema, plaques, a dry appearance, phyma, peripheral flushing, and ocular manifestations.
- Sun protection and trigger avoidance are important for prevention in all types of rosacea.
- Rosacea therapy may include barrier protection practices, topical antimicrobials, oral antibiotics, retinoids, intense pulsed light, and vascular laser modalities for adequate long-term control of symptoms.



sub-type to Plewig-Kligman stage III. In contrast, the NRS classification maintains that progression of rosacea in stages (from one sub-type to another) does not occur, but that sub-types may overlap in the same individual. A provisional grading system was also incorporated by the NRS Expert Committee to standardize the clinical assessment of rosacea.[3] Rosacea severity assessments must additionally include consideration of the psychological, social, and occupational impacts of this disorder and individual responsiveness to treatment.

Epidemiology

Although the prevalence of rosacea is unknown, it is considered common in Caucasian populations. Although the vast majority of cases occur in fair-skinned individuals, persons of African and Asian descent may also develop rosacea.[2,4] The NRS has estimated that rosacea affects 14 million Americans. Rosacea occurs in both men and women, and onset typically begins after age 30.[1,5] However, children, adolescents, and young adults may develop rosacea.[6–8]

Etiology and Pathogenesis

Because of prominent clinical variation among the rosacea sub-types, it has been hypothesized that etiologic and pathophysiologic differences may exist among them. Such differences may involve facial vascular reactivity, dermal connective tissue structure or composition, matrix composition, pilosebaceous structure, microbial colonization, or a combination of factors that alter the cutaneous response to rosacea trigger factors.[9] Rosacea is unmasked or induced by chronic, repeated trigger exposure, in particular by triggers of flushing that may include hot or cold temperature, sunlight, wind, hot drinks, exercise, spicy food, alcohol, emotions, cosmetics, topical irritants, menopausal flushing, and medications that promote flushing.[10] Both neural and humoral mechanisms produce flush reactions that are visibly limited to the face. Facial prominence occurs because baseline facial blood flow is increased compared with other body sites,[11,12] and because the facial cutaneous vasculature is more superficial and comprised of larger and more numerous vessels when compared with other sites.[13]

Dermal matrix degeneration and endothelial damage have been demonstrated histologically in rosacea specimens.[14,15] Factors that contribute to matrix degeneration include inherent problems with vessel permeability and/or delayed clearance of inflammatory mediators and waste products. Alternatively, photodamaged connective tissue may alter vascular and lymphatic structure and support within the dermis.[16] In either case, chronic and persistent dermal inflammation may occur and ultimately manifest as erythema of the facial convexities in predisposed individuals.[17]

Sun damage is considered a contributing etiologic factor, but other factors must participate as well. Solar elastosis is a common background on which rosacea histologic features are superimposed. However, rosacea prevalence is not increased in outdoor workers, sun damage in non-facial locations does not progress to a rosacea phenotype, and photoprovocation studies in rosacea patients have not demonstrated increased cutaneous sensitivity to acute ultraviolet exposure.[9,15,18,19]

It has long been debated whether oral and topical antimicrobial agents for rosacea exert their effects by anti-inflammatory or antimicrobial mechanisms. The concept of microbe-induced, follicle-based inflammation in rosacea is controversial. It is unclear whether commensal organisms such as *Propionibacterium acnes* and *Demodex folliculorum*, which reside in hair follicles and sebaceous glands, trigger folliculocentric inflammatory papules in rosacea patients.[9] Alternatively, a hypersensitivity reaction may be triggered by these microbes or by mite-associated bacteria such as *Bacillus oleronius*.[20] Compelling arguments in favor of a microbe-induced mechanism for papulopustular rosacea (PPR) include the observation that nonsteroidal anti-inflammatory drugs and corticosteroids do not clear rosacea papules and pustules as effectively as oral tetracyclines. Furthermore, benzoyl peroxide is quite effective for papules and pustules in rosacea patients who tolerate this drug.[10] It remains unclear whether clinical improvement of PPR requires a quantitative reduction of *P. acnes*.

CLINICAL FEATURES

Erythematotelangiectatic rosacea (ETR) is characterized by persistent facial erythema and flushing along with telangiectases, central face edema, burning and stinging, roughness or scaling, or any combination of these signs and symptoms (Fig. 79-1). Mild, moderate, and severe sub-types are recognized. In contrast, PPR manifests as persistent, central-face erythema with papules and pustules that predominate in convex areas (Fig. 79-2).[9] Again, mild (see Fig. 79-2A), moderate, and severe (see Fig. 79-2B) are distinguished. Burning and stinging of the facial skin may occur in PPR, but occurs less commonly compared with ETR. Flushing is often less severe in PPR compared with ETR. In both sub-types, erythema spares the periorbital areas. Edema can be mild or severe. Severe edema may take on the plaque morphology of solid facial edema.[1,21] This occurs most often on the forehead and glabella (Fig. 79-3), and it less commonly affects the eyelids and upper cheeks.

Phymatous rosacea is characterized by patulous follicular orifices, thickened skin, nodularities, and irregular surface contours in convex areas (Fig. 79-4). Here also, mild, moderate, and severe sub-types are distinguished. Phyma most often occurs on the nose (rhinophyma), but may also develop on the



▲ **FIGURE 79-1** **A.** Erythematotelangiectatic sub-type. **B.** Close-up of severe sub-type showing "red skin" due to multiple telangiectases. There are also a few pustules.

chin (gnathophyma), forehead (metophyma), eyelids (blepharophyma), and ears (otophyma).[22] Women with rosacea do not develop phyma, perhaps for hormonal reasons, but they can manifest sebaceous or glandular features characterized by thickened skin and large follicular orifices.[9]



▲ **FIGURE 79-2** **A.** Papulopustular sub-type. There is persistent erythema with papules and tiny pustules. Mild sub-type. **B.** Severe form of the papulopustular sub-type.



◀ **FIGURE 79-3** Persistent edema of rosacea. The patient had papulopustular rosacea that responded to tetracyclines, but the non-pitting edema on forehead and eyelids did not respond.

Ocular rosacea may develop before cutaneous symptoms in up to 20 percent of affected individuals[23] (Fig. 79-5). In half of patients, ocular symptoms develop after skin symptoms. In a minority, skin and eye symptoms present simultaneously.[24] Ophthalmic rosacea severity does not coincide with cutaneous rosacea severity. Ocular involvement may manifest as blepharitis, conjunctivitis, iritis, scleritis, hypopyon, and keratitis, and again mild, moderate, and severe subtypes are recognized (see Fig. 79-5).[24] Blepharitis is the most common feature, characterized by eyelid margin erythema, scale, and crust, with the variable presence of chalazia and staphylococcal infections due to underlying meibomian gland dysfunction.[23] Photophobia, pain, burning, itching, and foreign body sensation may be part of the ocular symptom complex. In severe cases, rosacea keratitis may lead to vision loss.

Granulomatous rosacea is considered the only true rosacea variant.[1] Granuloma formation is a histologic feature of the condition; the clinical features of granulomatous rosacea include yellow-brown or red papules or nodules that are monomorphic and located on the cheeks and periorificial facial skin[25] (Fig. 79-6). Upon diascopy, these papules reveal apple-jelly-like change in color similar to sarcoidosis or lupus vulgaris. The background facial skin is otherwise normal. Other signs and symptoms of rosacea are not required to make a diagnosis of granulomatous rosacea.

Histopathology

Rosacea is a clinical diagnosis; histology may be helpful when the facial distribution is atypical or when granuloma for-





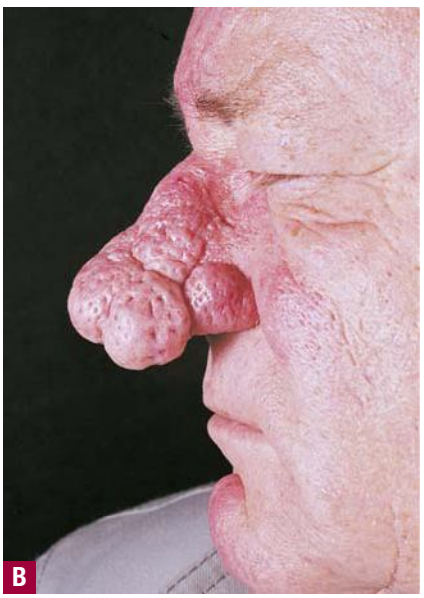

▲ **FIGURE 79-4** **A.** Phymatous sub-type. Moderate sub-type with patulous follicular orifices, thickened skin, and nodularities on nose and cheeks. **B.** Severe rhinophyma.

mation is suspected. In ETR, a sparse, perivascular lymphohistiocytic infiltrate is accompanied by dermal edema and ectatic venules and lymphatics.[14] Severe elastosis may be present. Similar features are found in the papulopustular sub-type, but the inflammatory infiltrate also surrounds hair follicles and sebaceous glands. Phymatous rosacea is characterized by prominent elastosis, fibrosis, dermal inflammation, sebaceous hyperplasia, and hypertrophy of sebaceous follicles.[14,26] Epithelialized tunnels undermine the hyperplastic tissue and are filled with inflammatory debris. *D. folliculorum* mites may be found in all types of rosacea within the follicular infundibula and sebaceous ducts.[26]



▲ **FIGURE 79-5** Ocular sub-type, severe. This patient has blepharitis, conjunctivitis, and keratitis.

Differential Diagnosis (Fig. 79-7)

Systemic diseases that must be differentiated from rosacea include polycythemia vera, connective tissue disorders (lupus erythematosus, dermatomyositis), carcinoid syndrome, mastocytosis, and neurologic causes of flushing. Neurologic causes include brain tumors, spinal cord lesions, orthostatic hypotension, migraine headaches, and Parkinson disease.[27] Unilateral auriculotemporal flushing may follow parotid gland injury or surgery.[28]

Medication-induced flushing has been associated with all vasodilators, calcium channel blockers, nicotinic acid (niacin), morphine, amyl and butyl nitrite, cholinergic drugs, bromocriptine, thyroid releasing hormone, tamoxifen, cyproterone acetate, systemic steroids, and cyclosporine.[27,29] The flush associated with nicotinic acid may be blocked with aspirin or indomethacin.[30] Disulfiram, chlorpropamide, metronidazole, phentolamine, and cephalosporins induce flushing when they are combined with alcohol.[27] Amiodarone has induced rosacea and multiple chalazia.[31] Food additives, including sulphites, sodium nitrite, nitrates, and monosodium glutamate, may also cause flushing.[27] Dumping syndrome following gastric surgery is characterized by flushing, sweats, tachycardia, and abdominal pain.

Cutaneous conditions that may mimic rosacea include topical steroid-induced acneiform eruption (formerly steroid-induced rosacea), acne vulgaris, perioral dermatitis, inflammatory keratosis pilaris, and chronic photodamage. In particular, acne vulgaris (see Chap. 78) and rosacea may co-exist, although rosacea most often begins and reaches its peak incidence in the decades after acne declines. The primary differentiating feature between acne vulgaris and rosacea is the presence of open and closed comedones in acne alone.[2]

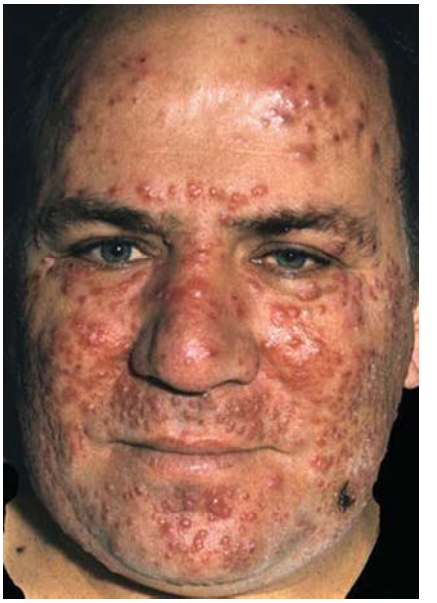

▲ **FIGURE 79-6** Granulomatous rosacea. There are multiple monomorphic red and yellow brown papules that, on diascopy, show apple-jelly-like color.

Rosacea fulminans, also known as *pyoderma faciale* and *rosacea conglobata*, occurs mainly in women in their 20s.[2,32,33] It is characterized by the sudden onset of confluent papules, pustules, nodules, and draining sinuses on the chin, cheeks, and forehead within a background of diffuse facial erythema. Rosacea fulminans has proved controversial in its classification and was not included as a rosacea sub-type or variant by the NRS Expert Committee.[1,2]

Perioral dermatitis (see Chap. 80) differs from rosacea in its facial distribution, signs, symptoms, and patient demographic. It is characterized by perioral, and sometimes periorbital, microvesicles, micropustules, scaling, and peeling. It affects younger women and also occurs in children. Central face erythema and inflammatory papules are not features of perioral dermatitis.[9] Therapy includes topical and oral antimicrobials. Perioral dermatitis is exacerbated by topical steroid use.

Steroid-induced acneiform eruption (see Chap. 78) can mimic PPR. With prolonged use of topical steroids on the face, monomorphic inflammatory papules may develop.[1] The treatment is discontinuation of the topical corticosteroid and initiation of an oral tetracycline, a topical antimicrobial, a topical calcineurin inhibitor, or a combination of these agents.[34,35] This regimen is generally continued for 1 to 3 months, and relapse does not tend to occur as long as topical steroids are not reintroduced.

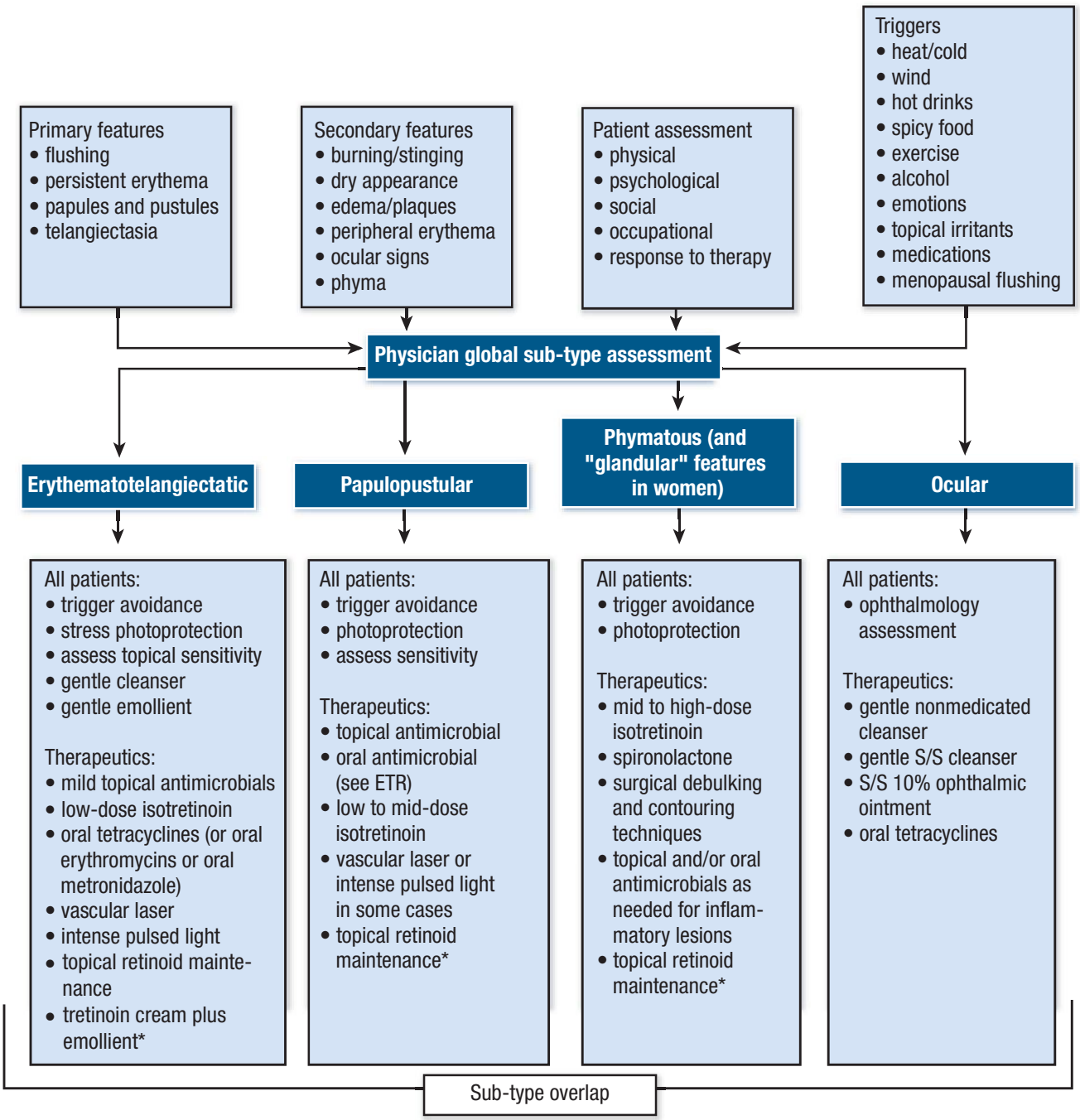

▲ **FIGURE 79-7** Approach to patient. Diagnosis and therapy of the rosacea sub-types. *Regimen recommendation based on author experience. ETR = erythematotelangiectatic; S/S = sodium sulfacetamide/sulfur.

In chronic photodamage (see Chap. 89), telangiectases and erythema are prominent features. However, unlike rosacea, actinic damage affects the periphery of the face and neck, the upper chest, and the posterior auricular skin. Hyperpigmentation and hypopigmentation are additional feature of sun damage not observed in rosacea. Chin involvement is both mental and submental in rosacea, while in chronic photodamage there is submental sparing.[9]

THERAPY

Before implementing therapy, rosacea trigger factors specific to each individual must be identified (see Fig. 79-7).[10] Patient education should stress trigger avoidance. Other key aspects of prevention include the daily application of gentle, broad spectrum ultraviolet A and ultraviolet B sunscreen, hat use, avoidance of midday sun, and seeking shade. Physical sunscreens (zinc or titanium-based) are best tolerated. Chemical sunscreens are better tolerated when barrier protective silicones (dimethicone, cyclomethicone) are included.[36]

Cosmetic intolerance and facial skin sensitivity are common features of the erythematotelangiectatic and papulopustular sub-types, perhaps due to inherent barrier dysfunction or facial vascular hyperreactivity.[37] As many as 75 percent of these individuals may experience burning, stinging, pruritus, or dry-



ness and scaling in affected areas. Avoidance of harsh products and ingredients, including astringents, toners, menthol, camphor, and sodium lauryl sulfate, is important when sensitivity is present.[38] A soap-free cleanser applied with the fingers is best tolerated. A protective, gentle emollient should be applied once or twice daily before application of other products. Light liquid foundation makeups are the best choice for patients with sensitivity. Green-tinted makeup can be applied before foundation to further mask red areas.[38]



TOPICAL THERAPY The topical agents approved by the U.S. Food and Drug Administration for rosacea include 15 percent azelaic acid gel, 0.75 percent and 1 percent metronidazole (available in cream, gel, and lotion vehicles), and 10 percent sodium sulfacetamide with 5 percent sulfur (available in cleanser, cream, suspension, and lotion vehicles). Each has proved effective for clearance of inflammatory papules and pustules and for erythema reduction when applied once daily.[39] Twice-daily application or combinations of these agents may be necessary when topical monotherapy is inadequate. Metronidazole and azelaic acid are pregnancy category B, whereas sodium sulfacetamide and sulfur is category C. Azelaic acid may be associated with initial tingling or burning that can disappear with continued use. Sodium sulfacetamide/sulfur medicated cleansers are better tolerated in sensitive patients compared with "leave-on" topical formulations that may increase burning and stinging.[40] Daily use of a barrier repair emollient is important in these patients.

Off-label topical formulations used for rosacea include benzoyl peroxide, clindamycin, erythromycin, calcineurin inhibitors, and topical retinoids.[10] Benzoyl peroxide is effective for clearance of papules and pustules but should be avoided in sensitive patients.[10] Twice-daily topical clindamycin was more effective than oral tetracycline for the eradication of pustules in one series.[41] Tacrolimus ointment and pimecrolimus cream are most beneficial for topical, steroid-induced acneiform eruptions, but they may offer a useful therapeutic alternative in some patients with rosacea.

"Manual" therapy should also be considered adjunctively in rosacea patients. Facial massage is performed in the direction of the lymphatic flow, according to Soybe's technique, beginning at a central location on the face (the glabella and nose) and pressing the fingers in a sweeping motion toward the inferolateral face (the mandibles and lateral neck).[15] This can help to mobilize edema and speeds clearance of dermal inflammation.

Tretinoin cream promotes connective tissue remodeling and minimizes dermal inflammation with long-term use.[42–44] Topical retinoids have demonstrated benefit for rosacea in small clinical series.[45,46] The clinical response to retinoids is delayed in the rosacea setting; generally 4 to 6 months of use is required to see significant effects. Because of their potential for irritation and concerns regarding promotion of angiogenesis, retinoids are often avoided for rosacea. However, their long-term use does not appear to promote the development of telangiectasia. Retinoids inhibit vascular endothelial growth factor production by cultured human skin keratinocytes via their anti-AP1 transcription factor activity.[47,48] The use of barrier emollients in conjunction with gradual introduction of topical retinoids allows them to be tolerated early on in treatment when retinoid dermatitis is a problem. Topical retinoids are especially useful for long-term maintenance in rosacea.

ORAL THERAPY Topical management of rosacea is possible and generally preferable, especially when considering issues of antimicrobial resistance and the risks associated with long-term use of oral antibiotics. Furthermore, because rosacea is photoaggravated in many affected individuals, photosensitizing oral agents must be used with caution in this population. Oral antimicrobials in particular are useful short-term tools that can achieve rapid control of symptoms, but long-term topical maintenance should be the eventual therapeutic goal. All of the oral therapies herein discussed are used off-label for rosacea.

For moderate to severe flushing or erythema, short-term oral therapy (2 to 4 months) with a tetracycline or isotretinoin may be useful for initial control. Tetracyclines achieve faster reduction of papules, pustules, and erythema when compared with isotretinoin, and since the 1950s, rosacea has been treated and maintained with both antimicrobial and sub-antimicrobial dosages of the tetracyclines.[49,50] Relapses occur in approximately one-fourth of patients after 1 month off tetracycline, and in over one-half of patients at 6 months off therapy.[50] Topical maintenance therapy is therefore advised. Oral tetracyclines should be avoided in pregnant women and in those contemplating pregnancy.

In one small series, a significant reduction of facial cutaneous blood flow, measured by laser-Doppler, was achieved in isotretinoin-treated patients (30 mg daily for 10 weeks), whereas no significant change in facial blood flow was observed in those treated with 250 mg of tetracycline twice daily for 10 weeks.[51] Low-dose isotretinoin (10 to 40 mg daily or less than 0.5 mg/kg/day) can be effective and is better tolerated in rosacea patients.[52–54] Isotretinoin is teratogenic, and its use is strictly monitored in women of child-bearing potential.

Other oral agents used for rosacea include macrolides, metronidazole, antiandrogenic agents (oral contraceptives, spironolactone, and cyproterone acetate), β blockers, clonidine, naloxone, and selective serotonin reuptake inhibitors.[10,55–61] In patients with a history of acne vulgaris or overlap of acne vulgaris with rosacea, spironolactone in low doses (25 to 50 mg daily) and/or oral contraceptive pills may prove helpful.

LASER AND LIGHT THERAPY (See Chap. 240) Vascular lasers and intense pulsed light (IPL) therapy are useful alternatives to oral rosacea therapies; they may be used adjunctively with topical and oral rosacea regimens for faster and more complete symptom resolution. These non-ablative modalities can eliminate telangiectasia, reduce or eliminate erythema, reduce papule and pustule counts, and they appear to extend the duration of remission. Their drawbacks are cost and side effects, which may include transient erythema, edema, purpura, blistering, dyschromia, burns, and, rarely, scarring.

Vascular lasers include short and long wavelength devices with a variety of pulse durations. Short wavelength lasers emit light that is selectively absorbed by oxyhemoglobin absorption peaks that occur at 541 nm and 577 nm. This allows for superficial vessel destruction without collateral tissue damage. Short wavelength lasers include the pulsed dye laser (585 nm or 595 nm), long pulsed dye laser (595 nm), the potassium–titanyl-phosphate laser (532 nm), and the diode-pumped frequency-doubled laser (532 nm).[62–64] Long wavelength vascular lasers can eradicate deeper and larger vessels by targeting the oxyhemoglobin spectral peaks at 800 nm and above 1000 nm. These lasers include the long pulsed Alexandrite (755 nm), the diode laser (810 nm), and

the neodynium:yttrium-aluminum-garnet laser (1064 nm).[10]

The success and tolerability of laser therapy for rosacea have been improved by modified pulse duration parameters and by advances in epidermal cooling mechanisms. Longer pulse durations can deliver equivalent energy at a slower rate to heat vessels uniformly and gently, minimizing tissue trauma and purpura. Epidermal cooling gels and sprays prevent epidermal damage and can help to minimize pain, erythema, and edema and help to ensure safe delivery of laser energy. Generally, two to four laser treatments are required to achieve best outcomes for rosacea; purpuric treatment settings may eradicate telangiectasia more quickly. Multiple laser passes and pulse-stacking on larger vessels may improve treatment outcomes when subpurpuric settings are utilized.[65]

Unlike laser devices that emit a single wavelength, IPL (broadband light) emits a broad wavelength spectrum, ranging from approximately 550-nm visible light to 1200-nm infrared light. Filters are used to establish the short end of the spectrum, which varies depending on the device. Fluence and pulse width also vary with the system used. IPL may cause transient erythema, transient hyperpigmentation, or hypopigmentation, and, rarely, purpura, burns, and scarring.[66] Epidermal cooling mechanisms are necessary to protect the epidermis. IPL effectively reduces facial erythema and telangiectases and is generally well tolerated.[66–68] Vascular lasers and IPL may also impact rosacea by inducing fibroblasts to increase dermal collagen production, perhaps achieving some degree of dermal remodeling and rejuvenation.[69–71]

TREATMENT OF PHYMA Oral isotretinoin monotherapy is beneficial for early to moderate phymatous change.[22] Advanced phyma is treated with surgical therapy or the combination of surgery followed by isotretinoin therapy. Surgical approaches to the reshaping of rhinophyma have included cold scalpel tangential excision, heated scalpel excision, electrocautery, dermabrasion, laser ablation, tangential excision combined with scissor sculpturing, radiofrequency electrosurgery, or a combination of these approaches.[22,72–77] Techniques that use partial thickness tangential excision and contouring with preservation of the underlying sebaceous glands allow spontaneous re-epithelialization within 2 to 3 weeks, result in minimal scarring, and give an excellent aesthetic result with a low risk of recurrence.[77]

TREATMENT OF OCULAR ROSACEA Ophthalmologic referral should be made for patients with ocular symptoms. For mild blepharitis, careful use of a gentle nonmedicated or sodium sulfacetamide/sulfur cleanser may be used once to twice daily as initial therapy. Sodium sulfacetamide 10 percent ophthalmic ointment is also effective for control of blepharitis. When topical management is inadequate, oral tetracyclines are generally effective.[7,23,24]

Summary

To effectively treat rosacea, practitioners must recognize the clinical spectrum of rosacea phenotypes and what lies outside that spectrum. Sub-typing of rosacea is a useful guide to establish a multimodality approach to therapy. Therapeutic success is achieved by inducing remission of signs and symptoms, and by minimizing and controlling relapses. Ultimately, early recognition of this disorder, some key behavioral modifications, and the combination of sunscreen and topical agents can achieve safe, effective, and long-term control of rosacea, while avoiding the risks of oral pharmaceuticals and the financial strain of laser and light therapies.

KEY REFERENCES

The full reference list for all chapters is available at www.digm7.com.

1. Wilkin J et al: Standard classification of rosacea: Report of the National Rosacea Society Expert Committee on the classification and staging of rosacea. *J Am Acad Dermatol* **46**:584, 2002
2. Plewig G, Kligman A: *Acne and Rosacea*, 3rd ed. Berlin, Springer-Verlag, 2000, p 455
3. Wilkin J et al: Standard grading system for rosacea: Report of the National Rosacea Society Expert Committee on the classification and staging of rosacea. *J Am Acad Dermatol* **50**:907, 2004
9. Crawford G, Pelle M, James W: Rosacea: I. Etiology, pathogenesis, and subtype classification. *J Am Acad Dermatol* **51**:327, 2004
10. Pelle M, Crawford G, James W: Rosacea: II. Therapy. *J Am Acad Dermatol* **51**:499, 2004
14. Marks R, Harcourt-Webster J: Histopathology of rosacea. *Arch Dermatol* **100**:683, 1969
77. Bogetti P et al: Surgical treatment of rhinophyma: A comparison of techniques. *Aesth Plast Surg* 26:57, 2002



CHAPTER 80

Perioral Dermatitis

Sarah L. Chamlin
Leslie P. Lawley

Perioral dermatitis is characterized by small discrete papules and pustules in a periorificial distribution, predominantly around the mouth. Although initially described as an eruption in young women 15 to 25 years of age, perioral dermatitis is now recognized to occur occasionally in children as well.[1] A subset of perioral dermatitis shows granulomas when lesional skin is examined histologically. Several names have been used to describe this granulomatous form of perioral dermatitis, including granulomatous perioral dermatitis, facial Afro-Caribbean childhood eruption, and granulomatous periorificial dermatitis.[2–4]

HISTORICAL ASPECTS

EPIDEMIOLOGY

Unlike adult perioral dermatitis, which affects predominantly women, pediatric perioral dermatitis is seen equally in boys and girls and among those of different races.[9] The granulomatous form of perioral dermatitis has been reported mostly in children of prepubertal age.[4] An increased prevalence in African American children has been reported, but more recent reviews do not support this finding.[2,10]

ETIOLOGY AND PATHOGENESIS

The relationship of perioral dermatitis to the misuse of potent topical corticosteroids (fluorinated or non-fluorinated) has been well established.[11] Patients often reveal a history of an acute steroid-responsive eruption around the mouth, nose, and/or eyes that worsens when the topical corticosteroid is discontinued. Depen-

PERIORAL DERMATITIS AT A GLANCE



- Inflammatory skin disorder of young women and children
- Small papules, vesicles, and pustules in perioral, periorbital, and perinasal distribution
- Treatment: Stop topical corticosteroid use; initiate 2- to 3-month course of systemic antibiotics (tetracycline family or erythromycin), topical metronidazole, and/or sulfur preparation



dency on the use of the topical corticosteroid may develop as the patient repeatedly treats the recurrent eruption. In other cases, the condition may worsen with the application of topical corticosteroids, especially in the granulomatous variant of periorificial dermatitis, which usually occurs in prepubertal children.[1] Perioral dermatitis is not always linked to topical corticosteroids, however.[8] Convincing evidence as to the exact cause of perioral dermatitis in these other cases has not been reported. Of note, the disease is predominant in young women, yet no link to hormonal causes has been found. The initial reports of photosensitivity by Frumess and Lewis[5] were not further substantiated, nor were theories of microbiologic causes such as infection with *Candida*, fusiform bacteria, or *Demodex folliculorum*.[12] Nevertheless, perioral dermatitis has been described in immunocompromised children, particularly those with leukemia, who have responded to treatment with permethrin.[13] Cases of allergenic contact with fluorides in toothpaste and dentifrices have also been reported; however, use of these agents after clearing of the perioral dermatitis without further eruption has also been described. Patch testing in a small series of patients led to few positive results, and these were not considered relevant.[8]

In the past, authors have considered the relationship of periorificial dermatitis to acne rosacea; however, the clinical features are distinct (see Differential Diagnosis). The histopathologic findings are variable. The pathology described in 26 patients showed spongiotic changes in the external root sheaths of the follicles without similarity to rosacea.[14] However, granulomatous perioral dermatitis shows the histopathologic changes of follicular hyperkeratosis, edema and vasodilation of the papillary dermis, perivascular and parafollicular infiltrates of lymphocytes, histiocytes, and polymorphonuclear leukocytes with occasional epithelioid granulomas and giant cells, similar to the histopathologic changes in acne rosacea.[4,15]

CLINICAL FINDINGS

The primary lesions of perioral dermatitis are discrete and grouped erythematous papules, vesicles, and pustules (Figs. 80-1, 80-2). The lesions are often symmetric but may be unilateral and appear in the perioral, perinasal, and periorbital regions (see eFig. 80-2.1 in on-line edition). A background of erythema and scale may occur. A distinct 5-mm clear zone at the vermilion edge is well described (see Fig. 80-2). The granulomatous variant of perioral dermatitis presents with small flesh-colored, erythematous, or yellow-brown papules, some with confluence, and shares the distribution of perioral dermatitis in adults. In addition, lesions have been reported to appear on the ears, scalp, trunk, labia majora, and extremities.[10]

Rarely an associated burning sensation or itching is reported, and intolerance to moisturizers and other topical products is described.[8] In a few cases of granulomatous perioral dermatitis an associated blepharitis or conjunctivitis has occurred.[10]



▲ **FIGURE 80-1** Typical perioral dermatitis. The eruption is confined to the nasolabial folds and the skin of the chin.



▲ **FIGURE 80-2** Perioral (granulomatous periorificial) dermatitis. This child shows the typical small papules studding the area around the mouth and eyes.

DIFFERENTIAL DIAGNOSIS (Box 80-1)

The differential diagnosis of perioral dermatitis in young adults includes acne rosacea, acne vulgaris, seborrheic dermatitis, allergic and irritant contact dermatitis, Gram-negative folliculitis, angular cheilitis, and lip-licking cheilitis.[16–18] In children, the diagnosis of irritant contact dermatitis to saliva from the use of a pacifier, sucking of the thumb or fingers, and messy eating is common and should be considered as well. Infection with *D. folliculorum* can present like perioral dermatitis but with atypical pustules and symptoms of pruritus,[19] or as a perioral dermatitis-like eruption in the immunocompromised host.[13]

Box 80-1

Differential Diagnosis of Perioral Dermatitis

Disorder	Distinguishing Clinical Features
NONGRANULOMATOUS PERIORAL DERMATITIS	
Most Likely	
Rosacea	Involves the nose, facial convexities; persistent erythema and telangiectasias
Seborrheic dermatitis	Accentuated at nasolabial folds; scale
Allergic contact dermatitis	Musical instruments, tartar-control toothpaste, latex gloves, dental appliances, and lipstick reported to be causative
Irritant contact dermatitis	Common in children (from saliva, foods)
Lip-licking cheilitis	Common in children; scale, well demarcated border
Consider	
Acne vulgaris	Involves chest and back; comedones
Gram-negative folliculitis	Predominance of pustules
Demodex folliculorum infestation	Atypical pustules, pruritus; immunocompromised host
Acrodermatitis enteropathica	Infants with acral and/or diaper dermatitis
GRANULOMATOUS PERIORAL DERMATITIS	
Most Likely	
Granulomatous rosacea	Flushing, telangiectasias, pustules, and edema; similar on histopathologic examination
Consider	
Familial juvenile systemic granulomatosis (Blau syndrome)	Synovial cysts, uveitis, granulomatous arthritis, camptodactyly, papular rash
Fungal or mycobacterial infection	
Lupus miliaris disseminatus faciei	
Benign cephalic histiocytosis	Diffuse distribution on the face
Sarcoidosis	Rare in children; reported cases may represent Blau syndrome

Granulomatous rosacea, sarcoidosis, lupus miliaris disseminatus faciei, fungal or mycobacterial infection, familial juvenile systemic granulomatosis (Blau syndrome), and benign cephalic histiocytosis should be considered in the differential diagnosis of granulomatous perioral dermatitis. Granulomatous perioral dermatitis lacks systemic symptoms. A thorough history and physical examination, review of symptoms, chest radiography, ophthalmologic examination, and histopathologic evaluation of skin biopsy specimen can differentiate these disorders when indicated.[10] Sarcoidosis in young children is rare and often accompanied by systemic signs and symptoms, particularly weight loss, fatigue, joint pains, lymphadenopathy, and uveitis.[4,20] At least some of the reported cases of sarcoidosis in young children represent Blau syndrome with underlying mutations in CARD15/NOD2 (see Chap. 134).[10,21]

COMPLICATIONS

The majority of cases of perioral dermatitis and granulomatous perioral dermatitis resolve without sequelae or relapse. However, there are rare reports of scarring.[4]

Box 80-2

Treatment for Perioral Dermatitis

	Topical	Dose	Systemic	Adult Dose
First line	Metronidazole	Apply bid	Tetracycline	250–500 mg bid
			Doxycycline	50–100 mg bid
			Minocycline	50–100 mg bid
Second line	Erythromycin or clindamycin	Apply bid	Erythromycin	400 mg tid or 30–50 mg/kg/day divided tid[a]
	Sulfur preparations	Apply bid		
	Azelaic acid	Apply bid		

[a]Pediatric dose.

PROGNOSIS AND CLINICAL COURSE

Perioral dermatitis is usually a self-limited disorder that evolves during a few weeks and resolves over months or rarely years. If treated with topical corticosteroids alone, recurrent episodes on withdrawal of therapy or with continuing therapy are typical. With appropriate treatments the condition resolves with rare recurrences.

TREATMENT (Box 80-2)

If topical corticosteroids are being used, they should be discontinued. If fluorinated corticosteroids are being applied, initial substitution with a low-potency hydrocortisone cream may minimize a flare of the dermatitis. Patients should be educated about the link between application of topical corticosteroids and exacerbation of the dermatitis.

In most cases, treatment includes oral tetracycline, doxycycline, or minocycline, for a course of 8 to 10 weeks, including a taper over the last 2 to 4 weeks. Severe cases may respond better to minocycline or doxycycline or high-dose tetracycline therapy. In children under 8 years of age, nursing mothers, or tetracycline-allergic patients, oral erythromycin is recommended. Not uncommonly, patients require continued low-dose systemic antibiotic therapy for months or sometimes years to maintain control.

Topical antibiotic therapy, most commonly with topical metronidazole, should be initiated concurrently with the systemic antibiotic. For milder cases, initial application of topical metronidazole alone may suffice.[22,23] Other options include topical clindamycin or erythromycin, topical sulfur-based preparations, and topical azelaic acid.[24] Reports of successful use of topical calcineurin inhibitors exist; however, caution is advised given the occasional reports of granulomatous eruptions after the use of these preparations.[25–28] Photodynamic therapy with topical 5-aminolevulinic acid has shown promise for treating perioral dermatitis as well.[29]

PREVENTION

The only factor widely accepted to predispose to perioral dermatitis is the use of topical corticosteroid preparations, and avoidance of these products may prevent the eruption in some cases.



KEY REFERENCES

The full reference list for all chapters is available at www.digm7.com.

1. Manders SM, Lucky AW: Perioral dermatitis in childhood. *J Am Acad Dermatol* **27**:688, 1992
4. Frieden IJ et al: Granulomatous perioral dermatitis in children. *Arch Dermatol* **125**:369, 1989
8. Wilkinson DS, Kirton V, Wilkinson JD: Perioral dermatitis: A 12-year review. *Br J Dermatol* **101**:245, 1979
11. Hafeez ZH: Perioral dermatitis: An update. *Int J Dermatol* **42**:514, 2003
18. Cheung MJ, Taher M, Lauzon GJ: Acneiform facial eruptions: A problem for young women. *Can Fam Physician* **51**:527, 2005
19. Karincaoglu Y et al: The clinical importance of Demodex folliculorum presenting with nonspecific facial signs and symptoms. *J Dermatol* **31**:618, 2004
21. Alonso D, Elgart GW, Schachner LA: Blau syndrome: A new kindred. *J Am Acad Dermatol* **49**:299, 2003



SECTION 14

DISORDERS OF THE ECCRINE AND APOCRINE GLANDS

CHAPTER 81

Biology of Eccrine, Apocrine, and Apoeccrine Sweat Glands

Theodora M. Mauro
Lowell A. Goldsmith

Generalized eccrine sweating is the physiologic response to an increased body temperature during physical exercise or thermal stress and, by enabling evaporative heat loss, is the most effective means by which humans regulate the body temperature. Failure of this mechanism can lead to heat exhaustion, heat stroke, hyperthermia, and death. Exaggerated local or systemic sweating responses (hyperhidrosis) are a nuisance that may impair social and occupational activities.

Humans have 2 to 4 million eccrine sweat glands distributed over nearly the entire body surface.[1] Although each gland weighs only 30 to 40 μg, the total mass of the eccrine sweat glands roughly equals that of one kidney (i.e., 100 g). A well-acclimatized person can perspire as much as several liters per hour and 10 L/day, a secretory rate far greater than that of other exocrine glands. The human eccrine sweat gland and duct produce sweat in two steps: (1) the secretory coil generates an ultrafiltrate of an isotonic plasma-like precursor fluid in response to acetylcholine (ACh), and (2) the duct reabsorbs sodium and chloride, producing hypotonic skin surface sweat. Under extreme conditions, in which the amount of perspiration reaches several liters a day, the ductal reabsorptive function assumes a vital role in conserving electrolytes. In addition to secreting water and electrolytes, the sweat gland excretes heavy metals, drugs and organic compounds, and macromolecules.

ANATOMY OF ECCRINE SWEAT GLANDS

In the adult, sweat glands are most numerous on the sole of the foot (620/cm^2) and least abundant on the back (64/cm^2).[2] Glands first appear in the 3.5-month-old fetus on the volar surfaces of the hands and feet (see Chap. 7).[3] Early in the fifth fetal month, anlagen of the eccrine sweat glands appear in the axillary skin, and a few weeks later they appear elsewhere on the body. The anlage of the eccrine sweat gland develops from the epidermal ridge as a cord of epithelial cells growing downward. The anlage of the eccrine sweat gland is double-layered, and the lumen is formed between the middle of the fourth and the eighth fetal months. During the eighth fetal month the lumen broadens, and the secretory cells resemble those of the adult gland. The myoepithelial cells are not recognizable until at least the ninth month and are of uncertain origin.[4]

The eccrine sweat gland consists of two segments, a secretory coil and a duct. The secretory coil is composed of three distinct cell types: clear (secretory), dark (mucoid), and myoepithelial. The clear and dark cells occur in approximately equal numbers (Fig. 81-1). The dark cells border nearly all the apical (luminal) surfaces of the secretory tubules. The clear cells rest either directly on the basement membrane or on the myoepithelial cells. Where two or more clear cells abut, intercellular canaliculi are formed. The canaliculi emerge immediately above the basement membrane or the myoepithelial cells and open directly into the lumen of the gland. The only membrane of the clear cell directly exposed to the lumen is that part of the membrane facing the intercellular canaliculus (Fig. 81-2), which is a pouch extending from the luminal space. Spindle-shaped myoepithelial cells with

SWEATING AT A GLANCE



- Humans have 2 to 24 million sweat glands.
- Up to 10 L/day of sweat is produced by acclimatized individuals.
- The three cell types are clear (secretory), dark (mucoid), and myoepithelial (contractile).
- Hypothalamic temperature is the strongest stimulus for sweating.
- Acetylcholine is the major stimulus secreted by sympathetic nerves.
- Botulinum toxin prevents acetylcholine release.
- Myoepithelial cells only contract with cholinergic drugs.
- Oxidative metabolism of glucose is a major source of eccrine gland adenosine triphosphate.
- Ductal reabsorption conserves NaCl.
- In individuals with cystic fibrosis, mutated chloride channels increase NaCl loss.
- Bacteria are necessary for apocrine odor.
- Adrenergic hormone is a major stimulus for apocrine gland secretion.

Copyright © 2008 by The McGraw-Hill Companies, Inc. Click here for terms of use.

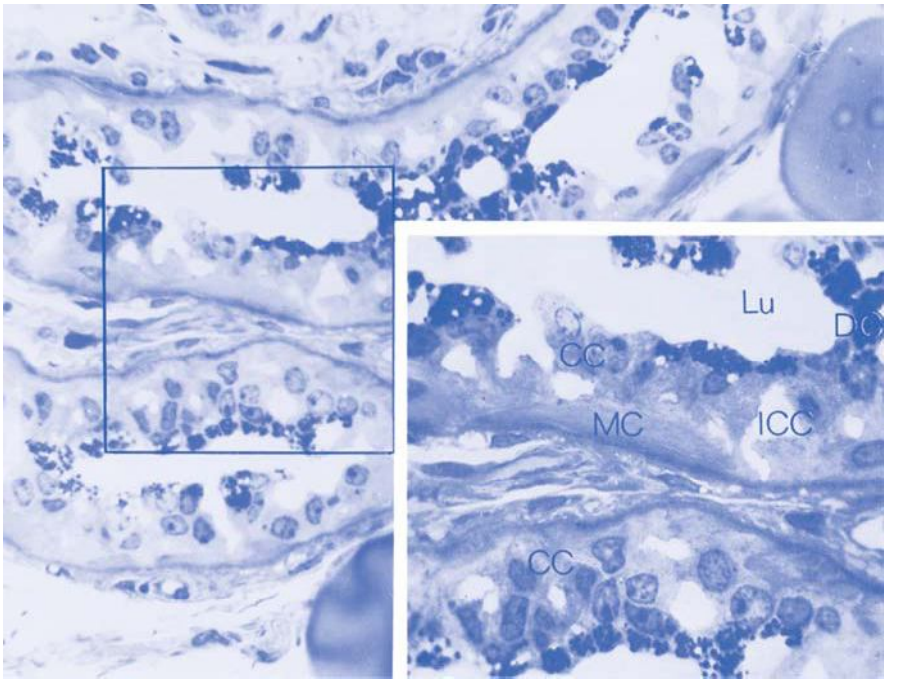

▲ **FIGURE 81-1** Light photomicrograph of the secretory coil of an acetylcholine-stimulated monkey palm eccrine sweat gland. A 1-μm thick section was cut from an Epon-embedded specimen and stained with methylene blue. *Inset:* A higher-power view of the area marked by the square. CC = clear cell; DC = dark cell; ICC = intercellular canaliculi; Lu = lumen; MC = myoepithelial cell.

masses of myofilaments lie on the basement membrane and abut the clear cells.

The eccrine sweat duct consists of an outer ring of peripheral or basal cells and an inner ring of luminal or cuticular cells. It seems that the proximal (coiled) duct is functionally more active than the distal straight portion, because Na^+,K^+-adenosine triphosphatase (ATPase) activity and the number of mitochondria are higher in the proximal portion.[3–5] The luminal cytoplasm of the ductal cells forms a cuticular border consisting of a dense layer of tonofilaments. The basal cells rest on the basement membrane, which is continued from the secretory coil. Their cytoplasmic space contains many mitochondria, which suggests an active role in ductal Na^+ reabsorption. In the epidermis, the duct spirals tightly upon itself.

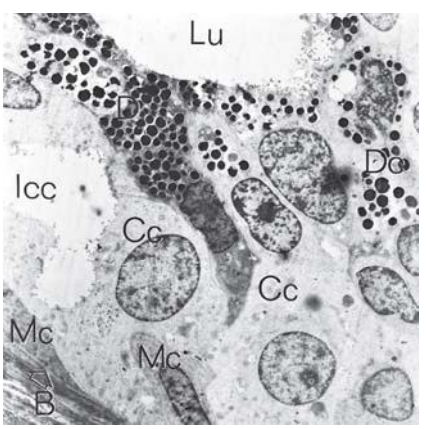

▲ **FIGURE 81-2** Electron micrograph of the secretory coil of a human eccrine sweat gland. B with *arrow* = basal lamina; other symbols are the same as in Fig. 81-1.

CELL BIOLOGY AND FUNCTION OF DIFFERENT CELL TYPES

The clear cell contains abundant mitochondria and an autofluorescent body, called a *lipofuscin granule*, in the cytoplasm. Its cell membrane is rich in villi. In contrast, the dark cell has a relatively smooth cell membrane and contains abundant dark cell granules. The clear cell is most likely responsible for secretion of water and electrolytes. This is suggested by the abundance of membrane villi, membrane infoldings, and mitochondria. Furthermore, when dissociated clear cells are stimulated in vitro by cholinergic agents, they show a dramatic cell shrinkage due to activation of K^+ and Cl^- channels in the membrane with subsequent net loss of KCl from the cell. Finally, cytoplasmic concentrations of K^+ and Cl^- in clear cells decrease during cholinergic stimulation, concomitant with an increase in intracellular Ca^{2+} concentration.[5–7]

The function of dark cells is unknown. Because the dark cells represent the only cell type that stains for periodic acid-Schiff, it was assumed that the periodic acid-Schiff–positive glycoproteins in sweat might be derived from the dark cells.

The myoepithelial cell is a contractile cell with abundant actin filaments,[8] possessing smooth muscle–like functional characteristics.[9,10] Eccrine myoepithelium responds only to cholinergic stimulation, not to α- or β-adrenergic agents. Myoepithelial cells also contain nitric oxide synthase I and choline acetyltransferase, which suggests that these cells may possess some intrinsic regulators as well.[11]

The duct is composed of two layers of cells, the basal and luminal ductal cells. The basal (or peripheral) cells are morphologically and functionally distinct from the luminal cells. The basal ductal cells are replete with mitochondria, and the circumferences of their cell membranes are rich in Na^+,K^+-ATPase (Fig. 81-3),[9] which suggests that the entire cell membrane is involved in Na^+ pumping for ductal Na^+ absorption. In contrast, the luminal ductal cells have fewer mitochondria, much less Na^+,K^+-ATPase activity, and a dense layer of tonofilaments near the luminal membrane, which is often referred to as the *cuticular border*. The cuticular border provides structural resilience to the ductal lumen, which may dilate whenever ductal flow of sweat is blocked. The entire structural organization of the duct is well designed for the most efficient Na^+ absorptive function. The luminal membrane serves as the absorptive surface by accommodating both Na^+ and Cl^- channels, and the basal ductal cells serve in Na^+ pumping by providing maximally expanded Na^+ pump sites and efficient energy metabolism. The lumen and the duct contain β-defensin, an antimicrobial, cysteine-rich, low-molecular-weight peptide.[12,13]

Neural Control of Eccrine Sweating

Regulation of internal body temperature is among the most fundamental functions of the body. The preoptic hypothalamic area plays an essential role in regulating body temperature: local heating of the preoptic hypothalamic tissue activates generalized sweating, vasodilatation, and rapid breathing, whereas local cooling of the preoptic area causes generalized vasoconstriction and shivering. The elevation of hypothalamic temperature associated with an increase in body temperature provides the strongest stimulus for thermoregulatory sweating responses. Cutaneous temper-

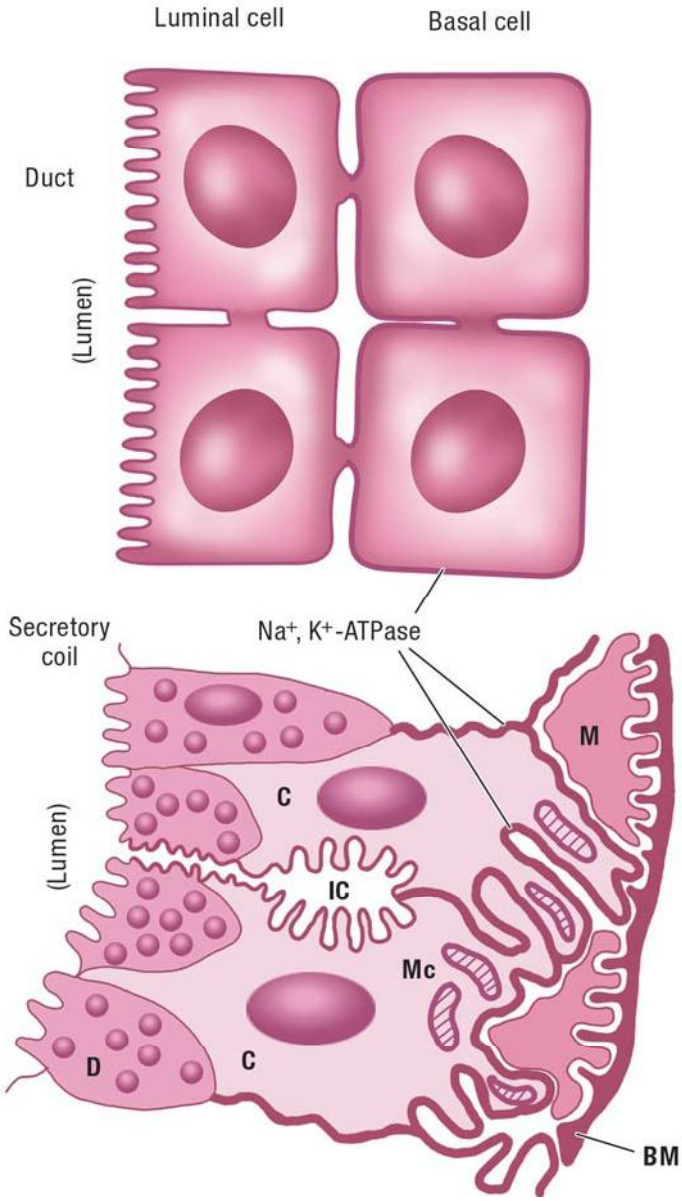

▲ **FIGURE 81-3** Drawing of the ultrastructure of the eccrine duct and secretory coil and the localization of Na^+,K^+-adenosine triphosphatase (ATPase). The *thick lines* indicate the localization of Na^+,K^+-ATPase. BM = basement membrane; C = clear cell; D = dark cells; IC = intercellular canaliculi; M = myoepithelial cell; Mc = mitochondria.

ature influences the rate of sweating. For example, an intense heat stimulus applied to one leg can elicit generalized sweating within 60 seconds before the tympanic membrane temperature (a measure of hypothalamic temperature) begins to rise, which suggests that neuronal stimuli arising from the heated leg via the cutaneous C fibers activate the hypothalamic sweat center and trigger sweating. Likewise, generalized sweating increases in correlation with an increasing mean skin temperature before core (internal) temperature begins to increase. Nadel, Bullard, and Stolwijk[14] quantified various factors involved in determining the rate of local sweating. At a given mean skin and core temperature, an increase in local skin temperature of 10°C (50°F) triples the local sweating rate until the sweat rate plateaus. On a degree-to-degree basis, an increase in internal temperature is about nine times more efficient than an increase in mean skin temperature in stimulating the sweat center. The local temperature effect is speculated to be due to increased release of periglandular neurotransmitters.

The mechanism of most sweating besides emotional sweating seems to be purely thermal, although the response of individuals to the same changes in core temperature can vary. The sweating in menopausal "hot flashes" reinforces the concept of a central hypothalamic mechanism for thermal sweating. Although hormonal factors influence sweating during menopause, the propensity to have excessive sweating does not correlate simply with hormonal levels. The proposed mechanism for hot flashes seems to be a defect in the response of the brain (particularly the hypothalamus, but perhaps the insula, anterior cingulate, amygdala, and primary somatosensory cortex as well). In asymptomatic menopausal women and premenopausal women, the core temperature can change up to 0.4°C (33°F) without eliciting a response. In symptomatic postmenopausal women, changes as small as 0.1°C (32°F) trigger peripheral vasodilation and sweating. Why the brain is hyper-responsive to small changes in core temperature is poorly understood, but increased levels of brain norepinephrine appear to influence the response to small changes in core temperature through their action on α_2-adrenergic receptors in the brain; higher levels of the norepinephrine metabolite 3-methoxy-4-hydroxyphenylglycol have also been found in symptomatic menopausal women than in asymptomatic women. Decreased norepinephrine release is postulated as the mechanism by which clonidine relieves hot flashes in symptomatic women. Decreased core temperature may be the reason that women with decreased body mass index tend to have fewer symptoms, even though their estrogen levels probably are lower than those in women with increased body mass index. Levels of estrogen, luteinizing hormone, and β-endorphins also were originally thought to influence hot flashes, but later studies have suggested no association.[15]

INNERVATION Efferent nerve fibers originating from the hypothalamic preoptic sweat center descend through the ipsilateral brainstem and medulla and synapse in the intermediolateral cell columns of the spinal cord without crossing (although sympathetic vasomotor fibers may partially cross).[16] The myelinated axons rising from the intermediolateral horn of the spinal cord (preganglionic fibers) pass out in the anterior roots to reach (through white ramus communicans) the sympathetic chain and synapse. Unmyelinated postganglionic sympathetic class C fibers arising from sympathetic ganglia join the major peripheral nerves and end around the sweat gland. The supply to the skin of the upper limb

is commonly from T2 to T8. The face and the eyelids are supplied by T1 to T4, so that resection of T2 for the treatment of palmar hyperhidrosis is likely to cause Horner syndrome. The trunk is supplied by T4 to T12 and the lower limbs by T10 to L2. Unlike the sensory innervation, a significant overlap of innervation occurs in the sympathetic dermatome because a single preganglionic fiber can synapse with several postganglionic fibers.

The major neurotransmitter released from the periglandular nerve endings is ACh, an exception to the general rule of sympathetic innervation, in which noradrenaline is the peripheral neurotransmitter. In addition to ACh, adenosine triphosphate (ATP), catecholamine, vasoactive intestinal peptide, atrial natriuretic peptide, calcitonin gene–related peptide, and galanin have been localized in the periglandular nerves. The significance of these peptides or neurotransmitters in relation to sweat gland function is not fully understood.

Botulinum toxin interferes with ACh release. Its heavy chain binds the neurotoxin selectively to the cholinergic terminal and the light chain acts within the cells to prevent ACh release. Type A toxin cleaves sensory nerve action potential-25, a 25-kd synaptosomal-associated protein; the type B light chain cleaves vesicle-associated membrane protein (also called *synaptobrevin*). Botulinum toxins are used for symptomatic relief of hyperhidrosis.[17] A more detailed description can be found in Chaps. 82 and 256.

DENERVATION Postdenervation hypersensitivity (of postganglionic fibers) of the eccrine sweat gland remains to be explained. In humans, the sweating response to intradermal injection of nicotine or ACh disappears within a few weeks after denervation of the postganglionic fibers,[18] in contrast to the sweating response to heat, which ceases immediately after resection of the nerves. For this reason, the human sweat gland was regarded as being the only exception to Cannon's law, which posits that supersensitivity develops after postganglionic denervation. In the cat and monkey, however, the eccrine sweat gland becomes hypersensitive to adrenaline, nicotine, and methacholine for several weeks after postganglionic denervation and/or the effect of these drugs lasts longer than normal. In contrast, after denervation of preganglionic fibers (due to spinal cord injuries or neuropathies), pharmacologic responsiveness of the sweat glands is maintained from several months to 2 years, even though their thermally induced sweating is no longer present.[19]

Emotional Sweating

Sweating induced by emotional stress (emotional sweating) can occur over the whole skin surface in some individuals, but it is usually confined to the palms, soles, axillae, and, in some instances, the forehead. Emotional sweating on the palms and soles ceases during sleep, whereas thermal sweating occurs even during sleep if the body temperature rises. Because both types of sweating can be inhibited by atropine, emotional sweating is cholinergic.

Pharmacology of the Eccrine Sweat Gland and Sweating Rate

Sweat glands respond to cholinergic agents, α- and β-adrenergic stimulants, and other periglandular neurotransmitters, such as vasoactive intestinal peptide and ATP. Periglandular ACh is the major stimulant of sweat secretion, and its periglandular concentration determines the sweat rate in humans. Striking individual differences exist in the degree of sweating in response to a given thermal or physical stress. In general, males perspire more profusely than females.[20,21] The sweat rate in a given area of the skin is determined by the number of active glands and the average sweat rate per gland. The maximal sweat rate per gland varies from 2 to 20 nL/min.[2,20] Sweat rate increases during acclimatization, but the morphologic and pharmacologic bases of the individual and regional differences in sweating rate during acclimatization are still poorly understood (Fig. 81-4). In thermally induced sweating, the sweat rate can be mathematically related to the body and skin temperatures in a given subject only in the low sweat rate range. Cholinergic stimulation yields a 5 to 10 times higher sweating rate than does β-adrenergic stimulation. α-Adrenergic stimulation (by phenylephrine) is no more potent than isoproterenol (ISO) (a β-adrenergic agonist) in humans in vivo.[20] Whereas cholinergic sweating begins immediately on intradermal injection, β-adrenergic sweating requires a latent period of from 1 to 2 minutes, which suggests that the intracellular mechanism of sweat induction may be different for methacholine and for ISO. Because the sweat rate in response to adrenergic agents is rather low, it may be reasonable to surmise that adrenergic stimulation in periglandular nerves may be involved in the regulation of sweat gland function but not in the induction of sweat secretion. One consequence of dual cholinergic and adrenergic innervation is to maximize tissue accumulation of cyclic adenosine monophosphate, which may be instrumental in stimulating the synthesis of sweat and glandular hypertrophy of the sweat gland. The possibility that periglandular catecholamine is directly involved in emotional sweating or sweating associated with pheochromocytoma[22] may be ruled out, because these sweating responses can be blocked by anticholinergic agents.

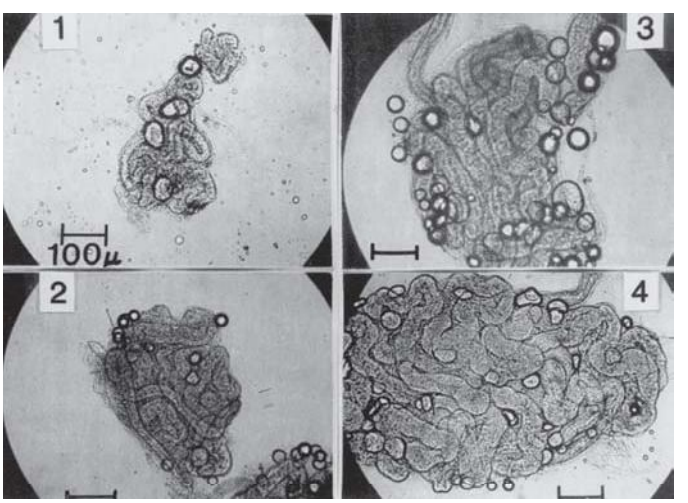

▲ **FIGURE 81-4** Individual variation in the size of the sweat gland in four male adults, aged 22 to 28 years. Sweat glands were isolated from skin biopsy specimens obtained from the upper back behind the axilla. Subject 1 is a sedentary man who does not exercise regularly, whereas subject 4 is a well-acclimatized athletic individual.

Pharmacology and Function of Eccrine Myoepithelium

The periodicity of sweat secretion in vivo is caused by the periodicity of central nerve impulse discharges, which occur synchronously with vasomotor tonus waves. Sweat secretion induced by intradermal injection of pharmacologic agents is steady and does not show such a periodicity.[23] Myoepithelial contraction occurs with cholinergic stimulation, but neither α- nor β-adrenergic agents induce tubular contraction.[24] The myoepithelial cell responds only to cholinergic stimulation: (1) myoepithelial contraction is not a prerequisite for inducing or maintaining sweat secretion by the secretory coil, and (2) the amount of so-called preformed sweat is so small before stimulation, due to the narrow lumen, that the initial myoepithelial contraction does not expel a significant amount of preformed sweat. The principal function of the myoepithelium may therefore be to provide structural support for the secretory epithelium, especially under conditions in which stagnation of sweat flow (due to ductal blockade) results in an increase in luminal hydrostatic pressure.[10]

Energy Metabolism

Sweat secretion is mediated by the energy (i.e., ATP)–dependent active transport of ions, so a continuous supply of metabolic energy is mandatory for sustained sweat secretion. Endogenous glycogen stored in the clear cells can sustain sweat secretion for less than 10 minutes; thus the sweat gland must depend exclusively on exogenous substrates for its energy metabolism. Mannose, lactate, and pyruvate are used nearly as readily as glucose; other hexoses, fatty acids, ketone bodies, intermediates of the tricarboxylic acid cycle, and amino acids are either very poorly used or not used as substrates. The physiologic significance of lactate or pyruvate utilization by the sweat gland is not yet clear. However, because the plasma level of glucose (5.5 m*M*) is much higher than that of lactate (1 to 2 m*M*) or pyruvate (less than 1 m*M*), glucose may play a major role in sweat secretion. Oxidative metabolism of glucose is favored as the major route of ATP formation for secretory activity.[24]

Composition of Human Eccrine Sweat

INORGANIC IONS Sweat is formed in two steps: (1) secretion of a primary fluid containing nearly isotonic NaCl concentrations by the secretory coil, and (2) reabsorption of NaCl from the primary fluid by the duct. Although a number of factors affect ductal NaCl absorption, the sweat rate (and thus the transit time of sweat) has the most important influence on final NaCl concentration—namely, sweat NaCl concentration is low at the low sweat rate range but increases with increasing sweat rate to plateau at around 100 m*M* (Fig. 81-5). Potassium (K^+) concentration in sweat is relatively constant. It ranges from 5 to 10 m*M*, which is slightly higher than plasma K^+ concentration. HCO_3^- concentration in the primary sweat fluid is approximately 10 m*M*, but that of final sweat is less than 1 m*M*, which indicates that HCO_3^- is reabsorbed by the duct, presumably accompanied by ductal acidification.[25] Sweat NaCl concentration is increased in individuals with cystic fibrosis.

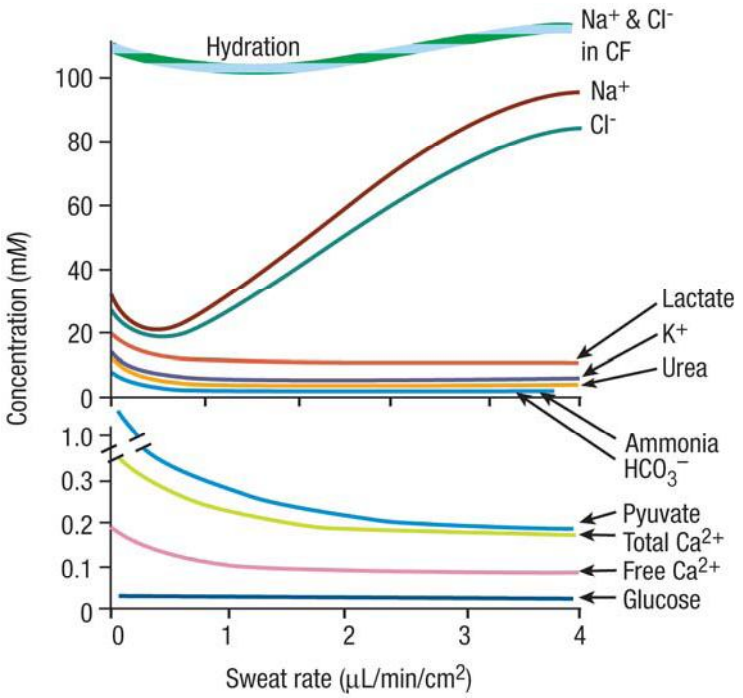

▲ **FIGURE 81-5** Relationship between the concentration of sweat ingredients and the sweat rate in thermally induced human sweat in normal individuals and in persons with cystic fibrosis (CF).

LACTATE The concentration of lactate in sweat usually depends on the sweat rate. At low sweat rates, lactate concentration is as high as 30 to 40 m*M*, but it rapidly drops to a plateau at around 10 to 15 m*M* as the sweat rate increases. Acclimatization is known to lower sweat lactate concentrations, whereas arterial occlusion rapidly raises sweat NaCl and lactate concentrations and reduces the sweat rate.[24] Because serum lactate concentration is 1 to 2 m*M* and an isolated sweat gland produces lactate in vitro,[26] sweat lactate is probably produced by glycolysis of glucose by the secretory cells.

UREA Urea in sweat is derived mostly from serum urea.[27] Sweat urea content is usually expressed as a sweat-plasma ratio (S/P urea). S/P urea is high (2 to 4) at a low sweat rate range but approaches a plateau at 1.2 to 1.5 as the sweat rate increases.

AMMONIA AND AMINO ACIDS Ammonia concentration in sweat is 0.5 to 8 m*M*,[28] which is 20 to 50 times higher than the plasma ammonia level. The concentration of sweat ammonia is inversely related to the sweat rate and sweat pH. Free amino acids are present in human sweat.[28] Because of the possibility of contamination by the large amounts of free amino acids in epidermis, most published data must be reviewed critically.

PROTEINS INCLUDING PROTEASES Proteins are present in human sweat. The concentration of sweat protein in the least contaminated, thermally induced sweat is approximately 20 mg/dL, with the major portion being low-molecular-weight proteins (i.e., MW < 10,000). Because sweat samples collected by simple scraping, and even those collected with a plastic bag, can be massively contaminated with plasma or epidermal proteins, previous reports on the presence of α- and γ-globulins, transferrin, ceruloplasmin, orosomucoid, and albumin[29,30]

and immunoglobulin E must be carefully reexamined. The sweat samples collected over an oil barrier placed on the skin (the least-contaminated sweat) contain no or trace γ-globulin and a very small amount of albumin. Yokozeki et al.[31] reported the presence of cysteine proteinases and their endogenous inhibitors in sweat and the sweat gland. Because epidermal growth factor (EGF) receptors are prominent in the human sweat duct,[32] and because EGF is also present in human eccrine sweat, it is tempting to speculate that the predominance of cysteine proteinase inhibitors in the sweat duct could be related, at least in part, to its role in the regulation of EGF receptors in the sweat duct.

Other organic compounds reported to be present in sweat include histamine,[33] prostaglandin,[34] vitamin K–like substances,[32] and amphetamine-like compounds.[35] Sweat also contains traces of pyruvate and glucose. Sweat glucose increases concurrently with a rise in plasma glucose level. Some orally ingested drugs,[24] including griseofulvin,[36] ketoconazole,[37] and possibly various chemotherapeutic agents,[38] are secreted in sweat.

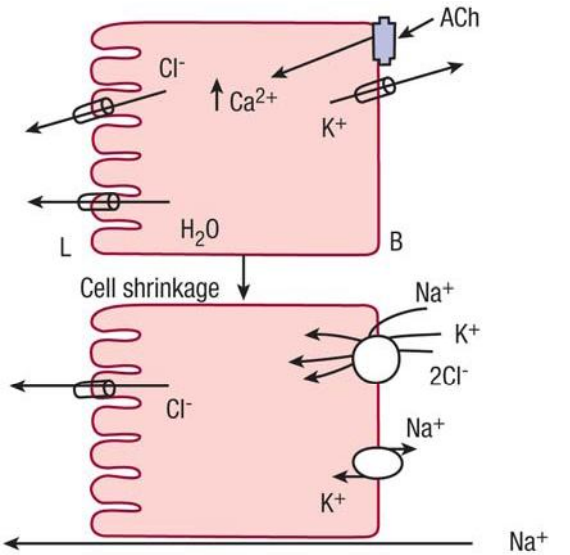

▲ **FIGURE 81-6** Modified Na/K/2Cl co-transport model for the ionic mechanism of cholinergic eccrine sweat secretion. Periglandular neurotransmitters, such as acetylcholine (ACh), bind to receptors on the basolateral membrane, which leads to increased intracellular Ca^{2+}; this in turn activates K^+ and Cl^- channels, mediating K^+, Cl^-, and H_2O efflux from the cell. The resulting cell shrinkage activates the basolateral $Na^+/K^+/2Cl$ antiporter, which leads to Na^+, K^+, and Cl^- influx. The Na^+ and K^+ fluxes are recycled across the basolateral membrane by the Na^+,K^+–adenosine triphosphatase. In contrast, Cl^- fluxes flow unopposed into the lumen, causing an electrical gradient that drives Na^+ exit from the tissue into the lumen via a paracellular pathway. Net fluxes: H_2O, Cl^-, and Na^+ (isotonic) flow into the lumen. pH of the secreted fluid is neutral. Paracellular Na^+ fluxes across the cell junction are indicated with an *arrow* at the bottom of the figure. B = basolateral membrane; L = luminal or apical membrane; *arrows* = conductive flux of ions through ionic channels.

Mechanisms of Sweat Secretion

Several distinct sequential processes lead to eccrine gland sweat production[39]: (1) stimulation of the eccrine sweat gland by ACh via increased intracellular Ca^{2+}; (2) Ca^{2+}-stimulated loss of cellular K^+, Cl^-, and H_2O, which leads to eccrine gland cell shrinkage; and (3) volume-activated transcellular plus paracellular fluxes of Na^+, Cl^-, and H_2O, which leads to net flux of largely isotonic NaCl solution into the glandular lumen. These processes are illustrated in Fig. 81-6 and discussed in more detail later. Reabsorption by eccrine ducts is discussed in the following section.

Sweating initially is stimulated when ACh is released from periglandular cholinergic nerve endings in response to thermal or emotional stimuli. ACh binds to cholinergic receptors on the clear cell plasma membrane, stimulating intracellular Ca^{2+} release and influx, and increasing cytosolic Ca^{2+} concentrations. Increased intracellular Ca^{2+}, in turn, opens Ca^{2+}-sensitive Cl^- and K^+ channels in the clear cell basolateral membrane, which allows Cl^- and K^+ to escape. Because H_2O follows K^+ and Cl^-, to maintain cell iso-osmolarity, the cell shrinks.[39]

This decrease in cell volume sets off a second cascade of cell signaling events. First, decreased cell volume stimulates the NKCC1[40] class of Na/K/2Cl co-transporters, which carry Na^+, K^+, and $2Cl^-$ into the cell in an electrically neutral fashion (i.e., two cations and two anions cancel out net charges). The resulting increase in cytosolic Na^+ activates the Na^+,K^+-ATPase, located in the basolateral membrane, which recycles Na^+ and K^+ across the basolateral membrane. The net movement of the negatively charged Cl^- ion across the apical membrane into the lumen in turn drives the positively charged Na^+ ion into the lumen as well, along a paracellular pathway. The final product of glandular secretion is therefore the net movement of Na^+, Cl^-, and H_2O into the glandular lumen to form the isotonic NaCl precursor of sweat.

ACh-induced sweating, which constitutes the bulk of sweat production, appears to be mediated by intracellular Ca^{2+}, as detailed earlier. In contrast, adrenergic-induced sweating appears to be mediated by increased intracellular cyclic adenosine monophosphate.[41,42]

Mechanism of Ductal Reabsorption

Because the production of large sweat volumes could lead to dangerous losses of NaCl, the sweat duct has evolved to reabsorb NaCl, which thus minimizes electrolyte loss, even at high sweat volumes (Fig. 81-7).

Ductal Na^+ reabsorption is accomplished through the coordinated activities of intracellular enzymes and plasma membrane ion channels, pumps, and exchangers. These mechanisms not only reabsorb electrolytes but also acidify the sweat, which results in a final sweat product that is hypotonic and acidic. Na^+ re-enters the duct cells through the apical membrane via amiloride-sensitive[43] epithelial Na^+ channels (ENaC)[42] and is transported across the basolateral membrane by ouabain-sensitive[44] Na^+,K^+-ATPase pumps. Cl^- transport appears to be both transcellular and paracellular, with the cystic fibrosis transmembrane regulator (CFTR) Cl^- channels playing an important role in transcellular fluxes.[45] In cystic fibrosis, CFTR Cl^- channels are mutated, and eccrine duct Cl^- reabsorption is defective, although not completely abolished. Na^+ is increased in the duct and the sweat at the skin surface (reviewed by Granger et al.[46]). Unlike in the lung, CFTR mutations do not lead to increased ENaC-mediated Na^+ influx, which suggests that the CFTR-ENaC interactions seen in other tissues differ from that in the eccrine duct. Sweat acid-

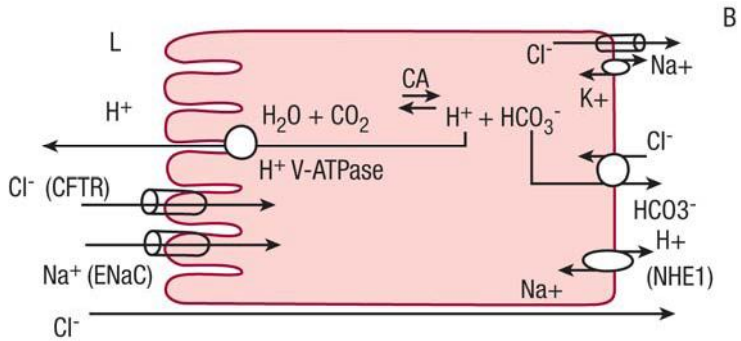

▲ **FIGURE 81-7** Illustration of ion reabsorption in the sweat duct. Na^+ enters the apical (luminal) membrane through epithelial sodium channels (ENaC) and is transported across the basolateral membrane by Na^+,K^+–adenosine triphosphatase (ATPase). Cl^- enters the cell through the cystic fibrosis transmembrane regulator Cl^- channel (CFTR) and also is transported across the lumen via a paracellular pathway. H^+ generated by the enzyme carbonic anhydrase (CA) is pumped into the lumen by a V-type H^+ ATPase (H^+ V-ATPase). Intracellular pH homeostasis is maintained by parallel HCO_3^-/H^+ and Na^+/H^+ (NHE1) exchangers. The activity of these enzymes, transporters, and channels results in H^+ secretion and Na^+ and Cl^- reabsorption, which produces a final sweat that is hypotonic and acidic. Paracellular Cl^- fluxes across the cell junction are indicated with an *arrow* at the bottom of the figure. B = basolateral membrane; L = luminal or apical membrane; *arrows* = conductive flux of ions through ionic channels.

ification appears to be mediated via the enzyme carbonic anhydrase, the HCO_3^-/Cl and Na^+/H^+ exchangers, and the V-type H^+ ATPase. The intracellular enzyme carbonic anhydrase catalyzes HCO_3^- and H^+ production. Intracellular HCO_3^- is cleared via the HCO_3^-/Cl antiporter, whereas H^+ is pumped into the luminal sweat by the V-type H^+ ATPase.[47] The Na^+/H^+ antiporter NHE1 (Na^+/H^+ exchanger isoform 1),[40,46] found in the basolateral membrane, is important in intracellular pH regulation.

Several drugs are known to modify ductal NaCl reabsorption. When aldosterone is injected systemically or locally, the Na/K ratio in sweat begins to decrease within 6 hours, reaching a nadir at 24 hours and returning to the preinjection level in 48 to 72 hours.[46] The effect of aldosterone on the sweat gland, unlike its effect on kidney tubules, is not accompanied by the so-called escape phenomenon. Na^+ deprivation stimulates both renin and aldosterone secretion, but high thermal stress per se [a single 1-hour exposure of humans to a temperature of 40°C (104°F)] is a potent stimulator of renin and aldosterone secretion in either the presence or absence of sodium deprivation. Nevertheless, direct evidence is lacking that enhancement of sweat gland function is mediated solely by aldosterone. It appears that ISO (a β-adrenergic agonist) may also enhance ductal NaCl reabsorbtion.[24] In an in vitro sweat gland preparation, neither acetazolamide (a carbonic anhydrase inhibitor) nor antidiuretic hormone changed ductal or secretory function. However, more potent carbonic anhydrase inhibitors, such as topiramate,[48] have been reported to induce oligohidrosis.

APOECCRINE SWEAT GLAND

The apoeccrine sweat gland, an additional member of the family of sweat glands, was discovered during isolation of human axillary sweat from a patient with axillary hyperhidrosis.[44,49] Although apoeccrine glands (AEGs) are readily distinguished from classic eccrine and apocrine glands, the diversity of the gross and fine anatomy of the AEGs isolated even from the same individual has puzzled investigators. The AEG develops during puberty from eccrine-like precursor glands and is consistently present in the adult axillae. Its relative frequency varies widely in different adults. In patients with axillary hyperhidrosis, however, as many as 50 percent of all the axillary glands (eccrine, apocrine, and apoeccrine) are of the apoeccrine type, whereas in some individuals with no history of axillary hyperhidrosis, the relative percentage of AEGs is much lower. Like the eccrine gland, the AEG has a long duct, which opens directly onto the skin surface (unlike that of the apocrine gland, which opens directly into hair follicles). Basically, its secretory tubule consists of a segment of small diameter (as in the eccrine secretory tubule—i.e., less than 80 μm in diameter) and a segment of uniform or irregular dilatation to as much as 500 μm in diameter. These segments are functionally connected to each other, as was shown by a micropuncture study. The fine morphology of the thick segment is very similar to that of the apocrine gland except that some of the columnar secretory cells contain a large number of mitochondria. The thin segment is indistinguishable from that of the eccrine secretory coil. Like the eccrine gland, the AEG is both cholinergic and adrenergic, and its secretory rate is as much as 10 times that of the eccrine gland, mainly because of its large glandular size,[3] which suggests that the AEG may play a role in axillary hyperhidrosis. It is interesting that the AEG responds to epinephrine as avidly as to methacholine. The AEG may be an eccrine gland that has undergone "apocrinization" due to local growth factor(s). If so, apocrinization could occur elsewhere in the body where similar local growth factors are present.

APOCRINE SWEAT GLAND

In addition to the eccrine and apoeccrine sweat glands, described earlier, apocrine sweat glands are found in humans, largely confined to the regions of the axillae and perineum.[50] They do not become functional until just before puberty; thus, it is assumed that their development is associated with the hormonal changes at puberty, although the exact hormones have not been identified. Gonadectomy of mature individuals does not affect the function of the apocrine sweat glands, so if they are to be considered among the secondary sex characteristics, it should be recognized that it is their development and not the maintenance of their functional activity that is dependent on sex hormones.

Functions

A number of functions have been attributed to the apocrine glands, including roles as odoriferous sexual attractants, territorial markers, and warning signals. These glands play a role in increasing frictional resistance and tactile sensibility as well as in increasing evaporative heat loss in some species. The production of pheromones by the apocrine glands of many species is well established.[51]

Because the apocrine glands of humans do not begin to function until puberty and are odor producing, it is attractive to speculate that they have some sexual function, which may now be vestigial. There are high levels of 15-lipoxygenase-2 in the secretory cells of the apocrine

gland. Its product, 15-hydroxyeicosatetraenoic, a ligand for the nuclear receptor peroxisome proliferator–activated receptor-gamma, may function as a signaling molecule and in secretion or differentiation.[52] For nonhuman furred primates, apocrine glands may have a purpose in thermoregulation as well.

Composition of Secretion

When it is first secreted, the apocrine sweat of humans is milky, viscid, and without odor. Subsequent bacterial action is necessary for odor production. Little is known of the chemical composition of apocrine secretion in humans, largely because of the difficulties in collecting secretion that has not been contaminated with that of eccrine glands. Furthermore, the presence of a secretory opening in common with that of the sebaceous glands means that apocrine sweat gland secretion will be mixed with sebum. This could account for the milky appearance of the secretion collected by cannulation of the sudosebaceous duct.

Mode of Secretion

Cannulation of the duct of the human apocrine sweat gland has shown that secretion is pulsatile, and it is assumed that contractions of the myoepithelial cells surrounding the secretory cells are responsible for these pulsations.

Control of Secretion

The apocrine sweat glands of humans respond to emotive stimuli only after puberty. They can be stimulated by either epinephrine or norepinephrine given locally or systemically. Denervation does not abolish the response to emotive stimuli,[53] which suggests that the glands can be stimulated humorally by circulating epinephrine or norepinephrine. Studies in other species have shown that the apocrine glands are controlled by adrenergic nerves; this is in marked contrast to the eccrine glands, which are under cholinergic control.

Denervation experiments in species other than humans have verified that an intact nerve supply is a functional requirement, but the fact that the glands are usually more sensitive to epinephrine than norepinephrine has led to speculation that elevation of circulating levels of epinephrine may supplement the neural stimulus. It is not known whether apocrine glands of all species have both neural and humoral modes of control, although studies in goats have shown that exercise does not stimulate sympathetically denervated glands.

Although an intact nerve supply is a functional requirement of apocrine sweating, the demonstration of nerve endings or varicosities in close proximity to the glands has been difficult.[50] Local capillary circulation may assist in conveying transmitter substance to the sweat gland cells, a form of neurohumoral transmission.

As would be expected, drugs that affect adrenergic systems also have an effect on apocrine sweat glands. Adrenergic neuron–blocking agents inhibit sweating, as do drugs that deplete the stores of transmitter substance in adrenergic neurons. Drugs that block specific adrenergic receptors also inhibit sweating, but the types of receptors that must be blocked differ in various species. The type of receptor that mediates the response of the apocrine glands of humans has not been elucidated.

KEY REFERENCES

The full reference list for all chapters is available at www.digm7.com.

12. Ali RS et al: Expression of the peptide antibiotics human beta defensin-1 and human beta defensin-2 in normal human skin. *J Invest Dermatol* **117**:106, 2001
13. Murakami M et al: Postsecretory processing generates multiple cathelicidins for enhanced topical antimicrobial defense. *J Immunol* **172**:3070, 2004
17. Kreyden OP, Scheidegger EP: Anatomy of the sweat glands, pharmacology of botulinum toxin, and distinctive syndromes associated with hyperhidrosis. *Clin Dermatol* **22**:40, 2004
40. Nejsum LN, Praetorius J, Nielsen S: NKCC1 and NHE1 are abundantly expressed in the basolateral plasma membrane of secretory coil cells in rat, mouse, and human sweat glands. *Am J Physiol Cell Physiol* **289**:C333, 2005
45. Reddy MM, Quinton PM: Cytosolic potassium controls CFTR deactivation in human sweat duct. *Am J Physiol Cell Physiol* **291**:C122, 2006
46. Granger D et al: Na^+/H^+ exchangers in the human eccrine sweat duct. *Am J Physiol Cell Physiol* **285**:C1047, 2003
47. Granger D et al: V-type H^+-ATPase in the human eccrine sweat duct: Immunolocalization and functional demonstration. *Am J Physiol Cell Physiol* **282**:C1454, 2002

CHAPTER 82

Disorders of the Eccrine Sweat Glands and Sweating

Robert D. Fealey
Kenzo Sato

Disorders of eccrine sweating can occur for many different reasons, including dysfunction of the thermoregulatory centers in the brain's central autonomic network, changes in the spinal sympathetic preganglionic, ganglionic, or postganglionic neurons/axons or in the muscarinic (M3) cholinergic synapse on sweat glands. Abnormalities of eccrine sweat formation by the secretory coil and sweat ductal cells may occur or ductal disruption or occlusion may develop, preventing delivery of sweat to the skin surface.

A review of the normal anatomy and physiology of eccrine sweat glands and sweating may be found in Chap. 81. This chapter focuses on neurologic and dermatologic disorders that cause focal or generalized abnormalities of sweating, highlighting an exciting interface where disorders are better understood, diagnosed, and treated based on recognition of the integrated function of nerves, skin, and the immune system (Fig. 82-1).

IN VIVO METHODS OF STUDYING SWEAT GLAND FUNCTION

Sweat is readily visualized by a topical indicator such as iodinated starch[1,2] or sodium alizarin sulfonate (alizarin Red S).[3] These techniques are used to evaluate large body surfaces (Fig. 82-2). Iodinated starch powder is prepared by adding 0.5 to 1.0 g of iodine crystals to 500 g of soluble starch in a tightly capped bottle. Sodium alizarin sulfate is mixed with an equal amount (by weight) of sodium carbonate anhydrous and twice the amount of corn starch. Both are applied

HYPERHIDROSIS AND ANHIDROSIS AT A GLANCE



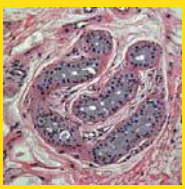

- Primary focal (essential) hyperhidrosis affects over 6 million young people worldwide. Although benign, the excessive palmar sweating interferes with many activities of daily living and induces social avoidance behaviors. Effective treatments, stratified to match the severity, include topical agents, botulinum toxin, and endoscopic thoracic sympathetic surgery.
- Localized, large areas of compensatory hyperhidrosis often provide a clinical clue to disorders producing a loss of sweating elsewhere. Thermoregulatory sweat testing combined with direct and axon reflex sweat evaluation provides a way to discern the anatomic location of the sudomotor lesion and directs further investigations of the etiology.
- Recent techniques using immunohistochemical analysis of biopsied skin stained for peptides and proteins that comprise the structure and innervation of the sweat gland hold promise to revolutionize our understanding of eccrine sweating disorders and provide new treatment strategies.
- Patterns of anhidrosis provide objective evidence of small nerve fiber and/or eccrine gland involvement in many neurologic and dermatologic disorders. Such tests can provide anatomic direction for skin biopsy sampling.
- Analysis of sweat composition continues to be diagnostic in cystic fibrosis and determination of sweat-derived antimicrobial peptides may provide evidence of impaired innate defense in skin disorders such as atopic dermatitis and neutrophilic eccrine hidradenitis.

to the skin and undergo a dramatic color change when moistened by the water (sweat) from activated sweat glands.

Sweat gland activity can be studied quantitatively by a number of techniques including: filter paper collection, weighing and analyzing of sweat composition, the quantitative sudomotor axon reflex test (QSART),[4] skin sympathetic potentials,[5] silastic mold or iodine-impregnated paper imprint after pilocarpine stimulation,[6] microcannulation of the sweat duct or coil,[7] collection into a Wescor Macroduct coil (Logan, CT),[8] humidity sensors within ventilated capsules and by determining total body surface anhidrosis to a maximal thermoregulatory stimulus during a thermoregulatory sweat test (TST).[9,10] Other, more sophisticated techniques use microdialysis membranes delivering minute quantities of transmitter substances to the dermis[11] or use confocal electron microscopy and immunohistochemical analysis of biopsied skin stained for peptides and proteins that comprise the structure and innervation of the sweat gland (Fig 82-3).



▲ **FIGURE 82-1** A patient with an acquired idiopathic anhidrosis shows anhidrotic (*yellow*) and sweating (*purple*) staining of sodium alizarin sulfonate (alizarin Red S) indicator powder. Punch skin biopsy from an anhidrotic skin site (*a* and *lower left inset*) shows marked perieccrine lymphocytic infiltration of sweat gland secretory coils, whereas sweating skin (*b* and *lower right inset*) shows normal sweat gland morphology. The presence of perieccrine inflammation prompted immunomodulatory therapy with corticosteroids and pulsed methotrexate and a trial of topical tacrolimus.

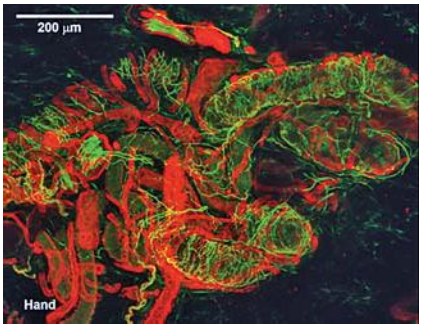

▲ **FIGURE 82-3** Secretory tubules, nerve fibers, and blood vessels in a normal human sweat gland fluorescently stained by immunohistochemical and lectin methods and visualized via laser scanning confocal microscope. Immunoreactive staining of nerves with protein gene product 9.5 antibody (*green staining*) shows axons wrapped around secretory tubules. (Photo used with permission from Dr. William Kennedy, MD, Minneapolis, MN.)

It is desirable to combine several methods for determining the integrity of the eccrine sweat response. For example, a TST can be combined with tests of the sweat gland and/or its peripheral nerve innervation to localize a sweating disorder to the peripheral or central nervous system. Or, a volumetric technique can be combined with a sweat droplet distribution imprint to estimate the sweat volume per active gland.

The composition of collected sweat can give critical information about eccrine function. For example, sweat chloride ion concentration can determine the integrity of the cystic fibrosis transmembrane conductance regulator (CFTR) Cl^- channel and provide diagnostic information for cystic fibrosis.[12]

VISUAL EXAMINATION OF THE SKIN

The physical examination continues to be important in the diagnosis of sweating disorders. For example, the skin of



◀ **FIGURE 82-2** A patient with segmental anhidrosis (*yellow*) with compensatory left-sided hemihyperhidrosis (*purple*) due to a right greater than left-sided upper thoracic spinal cord injury (sodium alizarin sulfate indicator powder).



an infant with cystic fibrosis is much saltier than infants without cystic fibrosis and when collected sweat is dried, it forms fern-like crystals. Infants with widespread sweat loss may present with "fever of unknown origin." Taking note of the beads of sweat on the palms and soles of a young adult goes a long way to making a diagnosis of primary focal (essential) hyperhidrosis. In uremia, the evaporation of sweat with high urea concentrations results in the deposition of urea on the skin, referred to as *uremic frost.* Patients with craniofacial hyperhidrosis may develop a darkened hue to their skin known as *chromhidrosis*. Focal or segmental compensatory hyperhidrosis may be apparent on examination. Dry, atrophic skin may be seen in areas affected by small-fiber neuropathy.

DISORDERS OF SWEATING

Table 82-1 organizes disorders of sweating into the six categories discussed in this chapter.

TABLE 82-1
Classification of Disorders of Eccrine Sweating

- Primary (essential) focal hyperhidrosis
  - Palmoplantar, axillary, craniofacial, generalized hyperhidrosis
- Secondary causes of localized hyperhidrosis
  - Due to cerebral infarction
    - Frontal opercular infarct
    - Brainstem stroke
  - Associated with spinal cord injury
    - Autonomic dysreflexia
    - Post-traumatic syringomyelia
    - Orthostatic hypotension triggered
  - Associated with other central nervous system disorders
    - Chiari type I and II malformation
    - Myelopathies due to infarction, syringomyelia, tumor
    - Cold-induced sweating syndrome
    - Olfactory hyperhidrosis
  - Associated with peripheral nervous system disorders
    - Peripheral motor neuropathy with autonomic dysfunction
    - Dermatomal or focal hyperhidrosis due to nerve trunk irritation
    - Compensatory segmental hyperhidrosis (post-sympathectomy, Ross syndrome, pure autonomic failure)
  - Gustatory sweating
    - Physiologic
    - Idiopathic
    - Post-herpetic
    - Post nerve injury (postsurgical, diabetic autonomic neuropathy, post-infectious, tumor invasion)
  - Lacrimal sweating
  - Harlequin syndrome
  - Idiopathic, localized hyperhidrosis
    - Idiopathic unilateral circumscribed hyperhidrosis
    - Post-menopausal localized hyperhidrosis
  - Associated with local skin disorders
    - Blue rubber bleb nevi
    - Eccrine angiomatous hamartoma—check tufted angioma
    - Glomus tumor
    - Burning feet syndrome
    - Pachydermoperiostosis
    - Granulosis rubra nasi
    - Pretibial myxedema
    - POEMS (*p*olyneuropathy, *o*rganomegaly, *e*ndocrinopathy, *M* protein, and *s*kin changes) syndrome
- Secondary causes of generalized hyperhidrosis
  - Associated with central nervous system disorders
    - Episodic hypothermia with hyperhidrosis (Hines-Bannick or Shapiro syndrome)
    - Post-traumatic or post-hemorrhagic "diencephalic epilepsy"
    - Fatal familial insomnia and Parkinson disease
  - Associated with fever and chronic infection
    - Tuberculosis, malaria, brucellosis, endocarditis
  - Associated with metabolic and systemic medical diseases
    - Hyperthyroidism, diabetes mellitus, hypoglycemia, hypercortisolism, acromegaly
  - Associated with malignancy
    - Leukemia, lymphoma, pheochromocytoma, Castleman disease, carcinoids, renal cell cancer
  - Medication-induced
    - Neuroleptic malignant syndrome
    - Serotonin syndrome, other medications
  - Toxic syndromes
    - Alcohol, opioid withdrawal, delirium tremens
  - Associated with central and peripheral nervous system disorders
    - Familial dysautonomia (Riley-Day), Morvan fibrillary chorea
- Disorders causing hypohidrosis and anhidrosis
  - Primary autonomic disorders with acquired anhidrosis
    - Progressive isolated segmental anhidrosis
    - Idiopathic pure sudomotor failure
    - Chronic idiopathic anhidrosis
    - Ross syndrome
    - Pure autonomic failure
    - Autoimmune autonomic neuropathy
- Secondary anhidrosis associated with neurologic disorders
  - Central nervous system lesions (stroke, tumor, infection, infiltration, trauma, etc.)
    - Hypothalamic lesions
    - Brainstem lesions
    - Spinal cord lesions
  - Degenerative disorders
    - Multiple system atrophy, diffuse Lewy-body disease, Parkinson disease-autonomic failure
  - Peripheral nerve lesions causing anhidrosis
    - Hereditary sensory and autonomic neuropathy types I, II, IV (congenital insensitivity to pain with anhidrosis)
    - Guillain-Barré syndrome (acute inflammatory demyelinating polyneuropathy)
    - Diabetic autonomic neuropathy
    - Amyloidosis
    - Lepromatous neuropathy
    - Lambert-Eaton myasthenic syndrome
    - Alcoholic neuropathy
    - Fabry disease
    - Idiopathic small-fiber neuropathy
    - Erythromelalgia
    - Sympathectomy and other surgical lesions
    - Harlequin syndrome
  - Anhidrosis due to toxins and pharmacologic agents
    - Botulism
    - Ganglionic blockers, anticholinergics, carbonic anhydrase inhibitors
    - Opioids
  - Heat hyperpyrexia and heat stroke
- Anhidrosis associated with disorders of skin and sweat glands
  - Anhidrosis due to physical agents damaging skin
    - Trauma, burns, pressure, scar formation, radiation therapy
  - Anhidrosis due to congenital and acquired skin diseases
    - Fabry and other congenital metabolic diseases
    - Congenital ectodermal dysplasia
    - Ichthyosis
    - Neutrophilic eccrine hidradenitis
    - Sjögren syndrome
    - Systemic sclerosis (scleroderma)
    - Incontinentia pigmenti
    - Segmental vitiligo
    - Bazex-Dupre-Christol syndrome
  - Disorders affecting the sweat duct
    - Miliaria
    - Palmoplantar pustulosis
    - Psoriasis
    - Lichen planus
    - Atopic dermatitis
  - Disorders with abnormal sweat composition
    - Atopic dermatitis (reduced dermcidin levels)
    - Cystic fibrosis (increased chloride concentration)



PRIMARY FOCAL (ESSENTIAL) HYPERHIDROSIS

Clinical Manifestations and Pathomechanism

Primary focal (essential) hyperhidrosis is one of the most common disorders of eccrine sweating.[13] Hyperhidrosis of the palms, soles, axillae, and, to a lesser extent, craniofacial and groin regions occurs during mental activity, whether stressful or not. A generalized increase in sweating may occur, and augmentation with thermal stimuli and physical exertion is common. Sweating may be continuous or phasic; when continuous, sweating is most troublesome in summer. Phasic outbursts with minor emotional activity are similar year round. Sweating does not occur during sleep. Isolated axillary or craniofacial hyperhidrosis occurs, but is uncommon.

Severe primary focal hyperhidrosis interferes with many activities of daily living. Avoiding a handshake can lead to professional embarrassment, and avoidance of touch can lead to social or interpersonal seclusion and other symptoms of social anxiety disorder. Contact dermatitis and palmoplantar keratoderma can occur. Symptoms begin in childhood or around puberty and affect either sex equally. A family history is present in approximately one-fourth of patients. The disorder persists for years with occasional spontaneous improvement after age 35 years.

The central autonomic network control of emotional sweating is distinct from the preoptic-anterior hypothalamic controller of thermoregulatory sweating. The anterior cingulate cortex, which orchestrates the sweat response from the palms and soles may modulate hypothalamic output inappropriately. These patients have less reflex bradycardia than control subjects in response to the Valsalva maneuver or facial immersion, but a higher degree of cutaneous vasoconstriction in response to finger immersion in cold, suggesting that they have increased sympathetic outflow passing through the T2–T3 ganglia.[14] Ventilated capsule recordings of palmar sweating provide further evidence of emotionally triggered, centrally derived sweat output. Such sweating is augmented at rest, bilaterally synchronous, and pulsatile (Fig. 82-4).

The severity of primary focal hyperhidrosis ranges from intermittent, slightly moist palms and soles to daily sweat drippage from hands and feet, requiring the frequent use of towels.

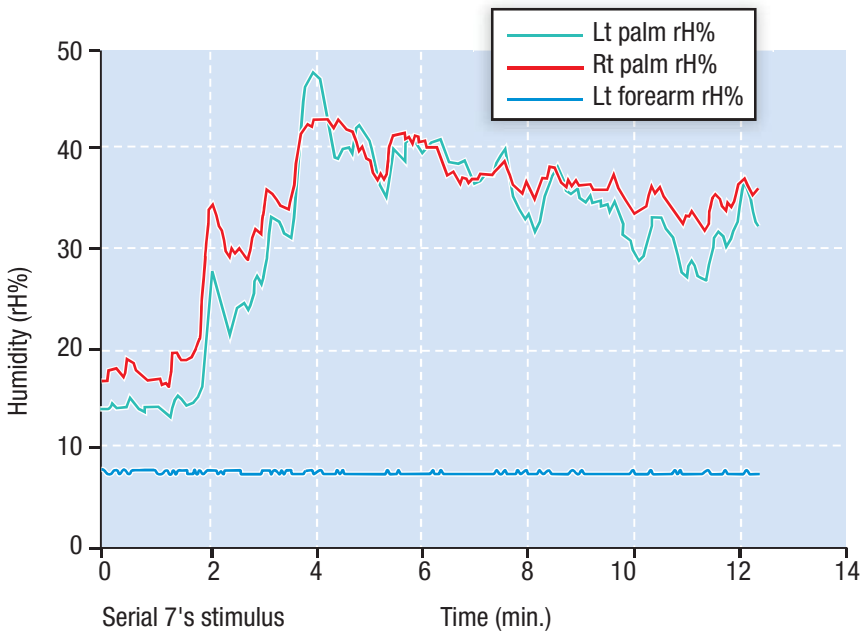

▲ **FIGURE 82-4** Ventilated capsule recording of relative humidity (rH) versus time. Bilateral palmar and left (Lt) forearm quantitative emotional sweat response from subject with primary focal hyperhidrosis. Mental arithmetic (serial subtractions from 100 by 7) triggered vigorous sweating. Note the synchrony between left and right (Rt) palm, the pulsatility of the response, and the anatomic confinement of the response to the palms, all characteristic of this disorder.

Treatment

Treatment involves determining the severity and distribution of the disorder, ruling out other causes of hyperhidrosis, and selecting a modality of therapy appropriate to severity. Some current treatment methods are shown in Box 82-1. Treatment begins with discussing the nature of the disorder and discerning patient wishes and expectations. Mild cases of axillary and palmar sweating are controlled via topical application of aluminum chloride hexahydrate or glycopyrrolate, an anticholinergic agent. Oral glycopyrrolate can be administered if topical agents alone are not helpful or are too irritating. Control of palmar-plantar sweating is sometimes possible using tap water (or a solution of glycopyrrolate) iontophoresis. Intradermal injection of botulinum toxin (BTX) type A is appropriate for treatment of focal areas, such as axillae and hands, and is effective for 2 to 8 months per treatment.[15]

More severe cases of palmar hyperhidrosis not responding to conservative treatment and having normal thermoregulatory and abnormal quantitative emotional sweat testing have recently been treated with endoscopic thoracic sympathectomy and sympathotomy.[17] These procedures are minimally invasive in the hands of experienced surgeons and produce long-lasting relief of sweating (see eFig. 82-4.1 in on-line edition) but carry the risk of creating compensatory hyperhidrosis in body segments below the treated area (see eFig. 82-4.2 in on-line edition). Recent studies using a reversible clipping technique describe selective procedures for different sympathetic sudomotor disorders and demonstrate that higher levels of sympathetic ganglion blockade are associated with an increased risk of severe compensatory hyperhidrosis.[18]

SECONDARY CAUSES OF LOCALIZED HYPERHIDROSIS

Cerebral Infarction[19]

Hemispheric strokes, especially those affecting the insular and opercular cortex, can produce contralateral hemihyperhidrosis primarily affecting the face and upper extremities. Unilateral hypothalamic, peduncular, pontine, and medullary infarcts can do the same, even in the absence of ipsilateral Horner syndrome. Bilateral pontine and cerebellar infarction can produce facial hyperhidrosis. The hyperhidrosis is acute and transient. Putative mechanisms involve interruption of inhibitory pathways controlling contralateral sweating.

Spinal Cord Injury and Autonomic Dysreflexia

Patients with spinal cord injuries experience episodes of profuse sweating



Box 82-1

Treatment Measures for Hyperhidrosis

TYPE OF HYPERHIDROSIS	TREATMENT	FORMULATION	ROUTE OF ADMINISTRATION AND DOSAGE
Craniofacial, gustatory	Glycopyrrolate	0.5–2% Vanicream base or roll-on lotion; 1- to 2-mg tablet	Topical, once to twice daily. Tablet started at 1 mg bid; increase prn up to 2 mg three to four times daily.
	Clonidine	0.1-mg tablet, 0.1–0.3 mg/day, transdermal patch	Oral incremental increases up to 0.6–1.2 mg/day in two or three divided doses; 0.1 mg/day patch first week increased weekly up to two 0.3 mg/day patches.
Craniofacial, gustatory Paroxysmal localized	Bellamine (Bellagal-S)	0.3–0.6 mg ergotamine tartrate, 0.2 mg belladonna alkaloids, 40 mg phenobarbital	One tablet orally every 12 h; may need to compound in local pharmacy as less available.
	Topiramate	25-mg tablet	Begin 25 mg twice daily; increase each dose weekly by 25 mg up to 100–200 mg daily in two divided doses.
Axillary, palmar-plantar, craniofacial	Aluminum chloride	20% aluminum chloride in anhydrous ethyl alcohol; 12% aluminum chloride in sodium carbonate-water	Topically, nightly, until desired sweat reduction achieved. Then taper to once weekly; follow *Physicians' Desk Reference* directions carefully for each body region to maximize effect and minimize skin irritation.
Palmar-plantar, axillary	Iontophoresis unit	Patient-controlled current, 15–30 mA using tap water; glycopyrrolate can be added, making a 0.1% solution	Topical, at each site for 30 min once or twice daily, or 20 min at each site every 2–3 days, or 10 min at each site three to five times weekly; anode site is most effective so switch sides after one-half of each treatment; direct current more effective, but AC current less painful and may be used part of time; glycopyrrolate solution enhances effect.
Palmar-plantar, axillary, gustatory, recalcitrant	Botulinum toxin A injection	0.1 mL of botulinum toxin appropriately diluted in 0.9% preserved saline	Given via high intradermal injections to ~1 cm^2 anesthetized skin areas; for botulinum toxin A, total of 12–20 injections (75–100 units total) given per axilla, 20 injections per palm, and 24–36 injections each foot; benefit lasts 4–8 months; reinjection is effective.
	Glycopyrrolate	1- to 2-mg tablet	Tablet started at 1 mg bid; increase prn up to 2 mg three to four times daily.
Axillary	Local incision	Liposuction and curettage of sweat glands in dermis	Define area of involvement with starch-iodide Minor test or equivalent; small incisions with sharp suction-curettage cannula; usually permanent, 40%–70% reduction in sweating achieved.
Palmar, axillary; documented severely affected cases resistant to other treatment modalities	Sympathetic surgery	Various procedures affecting the T2, T3, and/or T4 sympathetic ganglia and connections	Minimally invasive, video-assisted endoscopic thoracic procedure preferred; intraoperative monitoring of hand/finger skin blood flow/temperature suggested; sympathotomy (disconnection of sympathetic chain between T2 and stellate ganglia done to minimize compensatory hyperhidrosis; selective T3 sympathectomy may have less compensatory hyperhidrosis; T2–4 sympathectomy done for axillary hyperhidrosis has high incidence of compensatory hyperhidrosis on trunk and gustatory hyperhidrosis.



weeks, months, or years after injury. The areas of hyperhidrosis are determined by the complex interaction of exaggerated somatosympathetic reflexes, and the longitudinal and transverse extent, level, and completeness of the cord lesion. The lowest segment of cord injury is usually above T6 and the segmental hyperhidrosis involves the face, neck, and upper trunk most commonly. Associated symptoms include facial flushing and nasal congestion, headaches, piloerection, hypertension, and bradycardia. Stimuli, such as distention of the bowel or bladder, skin and visceral organ inflammation, and orthostatic hypotension, stimulate uninhibited sympathetic preganglionic neurons. Removing the stimulus is the most effective treatment, although antihypertensives (clonidine, α blockers, and calcium channel blockers) and anticholinergic agents (propantheline, glycopyrrolate) are sometimes needed.

Spontaneous syringomyelia with Chiari's I and II malformations and incomplete or asymmetric myelopathies may produce segmental hyperhidrosis not associated with other features of dysreflexia. These represent examples of compensatory or perilesional hyperhidrosis most times.

Other Central Nervous System Disorders

COLD-INDUCED SWEATING SYNDROME[28,29] Cold-induced sweating syndrome is associated with alterations of the composite cytokine CLCF1 gene. The cold-induced sweating involves the upper body segments, which paradoxically do not sweat in the heat. Cold-induced sweating is associated with limited autonomic failure and motor neuropathy.

OLFACTORY HYPERHIDROSIS SYNDROME[30–32] In olfactory hyperhidrosis syndrome, profuse facial sweating is precipitated by perfume smells, but not by gustatory or mental stimuli, and may respond to amitriptyline.

Peripheral Nervous System Disorders

INTRATHORACIC NEOPLASMS Abnormal thoracic sympathetic activity due to encroachment of mass lesions (Pancoast tumor, mesothelioma, lymphoma, osteoma, cervical rib) on the sympathetic

trunk or postganglionic fibers can cause segmental hyperhidrosis.[33] Sweating is usually spontaneous and located in the distribution of the involved sympathetic trunk or segmental spinal nerve root. An area of anhidrosis may be juxtaposed with the area of hyperhidrosis or the hyperhidrosis is contralateral to the lesion. Non-malignant causes of the same phenomenon include diabetic and idiopathic immune-mediated truncal neuropathy (see eFig. 82-4.3 in on-line edition).

COMPENSATORY SEGMENTAL HYPERHIDROSIS Segmental or localized hyperhidrosis commonly occurs post-sympathectomy and in the primary autonomic disorders such as pure autonomic failure and Ross syndrome. The latter two disorders are discussed in the section Primary Autonomic Disorders with Acquired Idiopathic Anhidrosis.

Gustatory Sweating

Localized sweating on lips, forehead, scalp, and nose while eating hot and spicy foods occurs physiologically in many people via a trigeminovascular reflex. Pathologic gustatory hyperhidrosis is asymmetric, intense, and may produce patches of sweating on the trunk and even extremities. The cause is aberrant regeneration of damaged and undamaged facial parasympathetic fibers, destined for salivary glands, to supply instead facial sweat glands that have been sympathetically denervated. Thus, gustatory stimuli that previously caused parotid, salivary gland, or gastric secretion now also cause sweating in the distribution of the damaged sympathetic nerve. The most common occurrence is in Frey syndrome, in which sweating occurs in the distribution of the auriculotemporal nerve after an injury, abscess, or surgery in the parotid region.[34] Gustatory sweating may follow upper thoracic and cervical sympathectomy,[31,35–37] facial herpes zoster, or chorda tympani injury and has been reported in cluster headache, diabetic neuropathy,[38–40] encephalitis, syringomyelia, and invasion of the cervical sympathetic trunk by a tumor.[33] The exact distribution can be delineated with indicator powder on the face, neck, and upper trunk while the subject chews and is photographed. Treatment with topical scopolamine, clonidine,[42] glycopyrrolate,[43,44] aluminum chloride, or BTX injection[45,46] can be effective; rarely, intracranial section of the glossopharyngeal nerve or tympanic neurectomy is needed.

Lacrimal Sweating

Continuous profuse sweating in the medial supraorbital region associated with Raeder syndrome (Horner syndrome plus temporal and frontal headache and paresthesia) is known as *lacrimal sweating*. Sudomotor fibers to the medial forehead traveling with the internal carotid artery presumably are damaged and parasympathetic fibers to the lacrimal gland provide aberrant regeneration to the nearby denervated sweat glands.

Harlequin Syndrome[47–49]

Harlequin syndrome (unilateral facial flushing and sweating with heat and exercise) may develop abruptly post-trauma or stroke or as an immune-mediated ganglionopathy. The flushed, sweating side attracts attention, but it is the contralateral side with anhidrosis and loss of flushing that has a sympathetic abnormality. Occasionally, tonic pupils may occur, forming an overlap with Ross syndrome[50,51]

Idiopathic, Localized Hyperhidrosis

IDIOPATHIC UNILATERAL CIRCUMSCRIBED HYPERHIDROSIS The involved area in unilateral circumscribed hyperhidrosis is usually sharply demarcated and no larger than 10×10 cm^2. It occurs mainly on the face and upper extremities of otherwise healthy individuals. Profuse sweating, which is usually precipitated by heat, lasts 15 to 60 minutes. Mental, or gustatory, stimulation also triggers sweating. There is no accompanying sensory or motor neuropathy, flushing of the face, headaches, excessive salivation, lacrimation, vasodilation, or piloerection. The pathogenesis of circumscribed hyperhidrosis is unknown. Sweating may be partially controlled by local application of 20 percent aluminum chloride in ethanol, topical anticholinergic agents, systemic clonidine (which inhibits central sympathetic outflow), or by local injections of BTX.

PAROXYSMAL LOCALIZED HYPERHIDROSIS Older women, much more so than men, are occasionally troubled by a syndrome of daytime, paroxysmal hyperhidrosis primarily affecting the head, neck, and upper trunk. Hot flashes (head and neck heat and flushing) are not commonly associated, but affected women have often experienced typical hot flashes a decade or two beforehand. Sweating before menopause is normal, distinguishing the syndrome from craniofacial essential hyperhidrosis. Normal, whole body thermoregulatory sweating rules out compensatory hyperhidrosis. Hormonal replacement therapy is usually ineffective. Alterations in hypothalamic set point temperature range for sweating are suspect in many cases. Symptomatic treatment with clonidine, glycopyrrolate (0.5 percent to 2.0 percent topical), and combination agents (ergotamine, belladonna, and phenobarbital) may be effective. Whether this syndrome is simply an "aged" version of typical hot flashes or a late onset idiopathic primary focal hyperhidrosis remains to be seen.

Localized Hyperhidrosis Associated with Skin Disorders

Localized hyperhidrosis has been reported to occur in the skin over a blue rubber bleb nevus, in the perilesional skin of a glomus tumor (presumably due to increased local temperature and/or pain), and in POEMS (*p*olyneuropathy, *o*rganomegaly, *e*ndocrinopathy, *M* protein, and *s*kin changes) syndrome, Gopalan disease (burning feet syndrome), pachydermoperiostosis, and painful pretibial myxedema. Hyperhidrosis is also often associated with eccrine angiomatous hamartoma, a nevoid proliferative condition that shows increased numbers of eccrine glands and dilated vascular channels in the deep dermis and subcutaneous tissue on histologic evaluation of lesional tissue.[52] The hamartoma is most commonly localized to an extremity, and usually presents as a solitary, sometimes painful, blue-purple, slow-growing nodule at birth or in childhood, but may first be noted in adults.

SECONDARY CAUSES OF GENERALIZED HYPERHIDROSIS

Central Autonomic Nervous System Disorders

EPISODIC HYPOTHERMIA WITH HYPERHIDROSIS Episodic hypothermia [core temperature < 35°C (95°F)] with hyperhidrosis (Shapiro syndrome) was originally described in association with agenesis of the corpus callosum,[12,53] but has more recently been reported in association with human immunodeficiency virus. However, it may occur without an identifiable brain lesion or systemic illness, and can affect both children and adults. The hypothermia may be due to periodic dysfunction of



the medial preoptic hypothalamic region with lowering of the "set-point" temperature, producing profuse sweating to lower core temperature. Treatment with anticonvulsants, oxybutynin, clonidine, and glycopyrrolate have been used with variable success.[54–56]

GENERALIZED HYPERHIDROSIS WITHOUT HYPOTHERMIA Generalized hyperhidrosis without hypothermia has been reported in patients with episodic hypertension, tachycardia, flushing, and hypothalamic-pituitary dysfunction after brain injury, infarction, or tumor in the region of the hypothalamus. These "autonomic storms" or "diencephalic epileptic" events are not true seizures but likely reflect overactivity or disinhibition of the hypothalamic areas, which control the sympathoexcitatory stress reaction. Hyperhidrosis has also been reported with fatal familial insomnia (an autosomal dominant prion disease clinically characterized by inattention, sleep loss, dysautonomia, and motor signs). Involvement of the medial thalamic nuclei and connecting "limbic" system pathways may be causative.[57] In Parkinson disease, hyperhidrosis is a frequent manifestation during dopamine drug "off" states.[58]



Fever and Chronic Infection

Malaria, tuberculosis, brucellosis, and subacute bacterial endocarditis may present with fever and generalized hyperhidrosis due to exogenous bacterial pyrogens that stimulate phagocytic leukocytes to produce endogenous pyrogen [interleukin 1 (IL-1) and IL-6, tumor necrosis factor (TNF), and γ-interferon]. These cytokines act not only as circulating hormones, but also as intrinsic modulators in the brain. Signals that stimulate IL-1 production in the brain include humoral factors, such as circulating IL-6 and activation of peripheral C fibers and vagal afferents. These effects can raise "set-point" temperature (producing fever), while simultaneously activating antipyretic mechanisms (eventually producing drenching sweats).[59]

Metabolic and Systemic Medical Problems

Increased sweating has been reported in diabetes mellitus, hypoglycemia, congestive heart failure, thyrotoxicosis, hyperpituitarism, dumping syndrome, carcinoid syndrome, and alcohol and drug withdrawal. Sweating is increased (especially in males) in acromegaly (in which the size of sweat gland acini and the density of innervation to the sweat glands is greater than in controls) and is decreased in growth hormone deficiency (GHD).

Hyperhidrosis and Malignancy

Hodgkin disease is characterized by the triad of fever, sweating, and weight loss; night sweats may be the only symptom and 31 of 100 patients present with "B"-cell symptoms (fever, weight loss, sweating).[60] The excessive production of IL-1 by activated macrophages is implicated as the cause of temperature instability.[20] IL-1 is known to induce an abrupt increase in the synthesis of prostaglandin E_2 in the preoptic anterior hypothalamic region, causing an elevation of the temperature "set point." Excessive production of IL-6 by Hodgkin lymphoma cells[61] is also implicated as cause of fever and subsequent night sweating. Advanced solid tumors may also cause sweating via immunologic mechanisms relating to TNF-α and effect of ILs on central thermoregulation.

The symptomatic triad of excessive and inappropriate paroxysmal sweating, tachycardia, and pounding headaches (associated with increased blood pressure) almost assures the diagnosis of pheochromocytoma as the cause of hyperhidrosis. Anti–α- and β-adrenergic therapy is a mainstay of this disorder, with a rare patient developing sweat gland necrosis during pre-operative therapy.

Generalized Hyperhidrosis Due to Medications/Toxins

Hyperhidrosis is frequently associated with serotonin (5-hydroxytryptamine) reuptake inhibitors, opioids, and sometimes with prostaglandin inhibitors (naproxen). The serotonin syndrome and the neuroleptic malignant syndrome include hyperthermia, labile blood pressure, hyperhidrosis, rigidity, agitation and confusion. The mechanisms may relate to 5-hydroxytryptamine (2A) and dopamine receptor antagonism. The hyperhidrosis that commonly occurs during acute and chronic administration of opioids is mainly due to stimulation of mast cell degranulation, resulting in the release of histamine.[62] Excessive sweating can occur in as much as 45 percent of patients taking methadone.[63] Hyperhidrosis is also a recognized side effect of transdermal fentanyl.[42] Sweating in combination with hypertension, nausea, and mydriasis characterizes acute opioid and alcohol withdrawal. Despite their well-recognized anticholinergic effects, tricyclic antidepressants occasionally cause hyperhidrosis due to their sympathomimetic effect. The presumed mechanism is inhibited reuptake of norepinephrine, leading to stimulation of peripheral adrenergic receptors and a generalized diaphoretic response. Cholinergic agonists such as pilocarpine and bethanechol and reversible cholinesterase inhibitors such as pyridostigmine can increase sweating by action at M3 cholinergic receptors on sweat glands.

Disorders with Central and Peripheral Nerve Abnormalities

Familial dysautonomia (FD), also known as *Riley-Day syndrome*, is the best known and most intensively studied of the hereditary sensory-autonomic neuropathies (designated as HSAN type III).

This autosomal recessive disorder is caused by mutations in the *IKAP* gene, located on chromosome 9. FD is characterized by pronounced autonomic dysregulation with episodic orthostatic hypotension, arterial hypertension, profuse sweating, skin blotching, puffy hands, and behavioral abnormalities. FD manifests only in children of Ashkenazi Jewish ancestry. Cardinal findings are diminished deep tendon reflexes, absence of overflow tears, absence of fungiform papillae of the tongue and of axon flare response after intradermal histamine injection. Thermal and vibratory testing shows pronounced impairment of temperature and pain but also of vibratory perception. Parasympathetic pupillary denervation may occur.

Morvan fibrillary chorea is characterized by neuromyotonia, pain, hyperhidrosis, weight loss, severe insomnia, and hallucinations. Voltage-gated potassium channel antibodies have been found in some cases and may be responsible for the central and peripheral nervous system manifestations. Areas of hyperhidrosis and anhidrosis may be demonstrated on testing.[65]

DISORDERS CAUSING HYPOHIDROSIS AND ANHIDROSIS

Anhidrosis is the absence of sweating in response to an appropriate stimulus and can result from poral occlusion, congenital or acquired absence of sweat glands, damage to sweat gland function by inflammation of the skin, or dysfunction at any level of thermoregulatory nerve pathways (see Table 82-1). Hypohidrosis or anhidrosis can be a component of several forms of ectodermal dysplasias

(related to developmental abnormalities of the sweat glands; see Chap. 143) and disorders with abnormal epidermal differentiation (related to poral occlusion; see Chap. 47).

Primary Autonomic Disorders with Acquired Idiopathic Anhidrosis

Widespread loss of sweating can be caused by isolated failure of sympathetic sudomotor activity, and has been termed *chronic idiopathic anhidrosis* (CIA) or acquired idiopathic generalized anhidrosis. The main clinical features include symptoms of heat intolerance: feeling hot, flushed, dyspneic, light-headed, and weak when the ambient temperature is high or when exercising. Recent accounts of acquired idiopathic anhidrosis, however, have emphasized the heterogeneous features and sub-types of this condition.[66,67] The sub-types discussed here include segmental, idiopathic pure sudomotor failure (IPSF), and CIA.

SEGMENTAL TYPE OF ACQUIRED IDIOPATHIC ANHIDROSIS Patients with the segmental type of acquired idiopathic anhidrosis develop asymmetric, slowly progressive sweat loss, conforming to sympathetic dermatomal body segments. Exercise and heat intolerance also progressively worsen (see eFig. 82-4.4 in on-line edition). The exact pathophysiology and cause are unknown, but may be a preganglionic neuronal degenerative process.

IDIOPATHIC PURE SUDOMOTOR FAILURE Isolated failure of sweating can be mediated by humoral and/or cell-mediated autoimmune responses. Clinical features of IPSF comprise sudden onset, concomitant sharp pain, or cholinergic urticaria over the entire body, lack of autonomic dysfunction other than generalized anhidrosis, elevated serum immunoglobulin E levels, and marked response to parenteral corticosteroids. Sudomotor function testing reveals complete absence of thermoregulatory sweating with well-preserved emotional sweating. Intradermal pilocarpine does not induce sweating, and microneurography may reveal preserved bursts of skin sympathetic nerve activity. Skin biopsy often shows no morphologic abnormality in the sweat glands, but may show atrophy and degeneration of the sweat glands and perieccrine infiltration by lymphocytes and mast cells.[68] The clinical findings suggest lesions on the postsynaptic side of the nerve–sweat gland junction. The lesions in IPSF may involve the muscarinic cholinergic receptors of sweat glands. Allergic mechanisms are probably responsible.

CHRONIC IDIOPATHIC ANHIDROSIS (See Fig. 82-1) Skin biopsies of lesional skin in patients with CIA may show perieccrine infiltration with small lymphocytes that presumably cause the anhidrosis (biopsies from skin retaining a sweat response show functioning sweat glands). The direct demonstration of cellular and humoral-mediated immunopathology has provided new insights into the pathophysiology and treatment of CIA. The antigenic target of the $CD3^+$ lymphocytes is unclear, but may be the M3 ACh receptor. Oral corticosteroid, parenteral methotrexate, and topical pimecrolimus cream have not improved the anhidrosis. Examining skin biopsies with electron and laser scanning confocal fluorescence microscopy[69] to discern the ultrastructural changes disrupting the neuroglandular unit and determining cell surface markers of infiltrating lymphocytes are among current and proposed methods to understand the neurobiology of these disorders and others, such as Fabry disease[70] (see Chap. 136) and small fiber neuropathies in general.[71]

Ross Syndrome

Patients with Ross syndrome present with heat intolerance, anhidrosis, and striking segmental areas of preserved sweating, the latter often their chief complaint (see eFig. 82-4.5 in on-line edition). On examination, tonic pupils and absent lower extremity deep tendon reflexes are found. Sympathetic denervation of the pupils and heart may occur. Symptomatic treatment of the hyperhidrosis (topical glycopyrrolate or BTX injections) and heat intolerance is provided.

Pure Autonomic Failure (Bradbury-Eggleston Syndrome) and Autoimmune Autonomic Neuropathy

Autoimmune Autonomic Neuropathy

SECONDARY ANHIDROSIS ASSOCIATED WITH NEUROLOGIC DISORDERS

Disorders of the Central Nervous System

Stroke, tumor, infection, infiltration, trauma at any level of the ipsilateral descending thermoregulatory sweating pathway between hypothalamus and spinal cord can cause a hemihypohidrosis or asymmetric segmental anhidrosis that is preganglionic on testing (see eFig. 82-4.6 in on-line edition). Combined TST and QSART confirm that the extensive anhidrosis is on a central or preganglionic basis.

Degenerative Disorders

Generalized anhidrosis is a common manifestation of multiple system atrophy (MSA) and sweat testing has been used to help distinguish MSA from Parkinson disease.[76] The lesion is usually preganglionic involving the intermediolateral columns. Progressive preganglionic and then postganglionic impaired sweating occurs. Diffuse Lewy body disease has an associated autonomic impairment that is more than Parkinson disease and less than in MSA. Widespread autonomic neuronal involvement with Lewy bodies in brainstem, spinal cord, and sympathetic ganglia have been described in autopsy cases.[77,78]

Peripheral Nerve Disorders Causing Anhidrosis

HEREDITARY SENSORY AND AUTONOMIC NEUROPATHY TYPES I, II, AND IV HSANs I, II, IV (also known as *congenital insensitivity to pain*), and V are associated with distal or more generalized anhidrosis and have differing genetic mutations and phenotypes distinct from HSAN III (FD, see Disorders with Central and Peripheral Nerve Abnormalities). HSAN II is characterized by distal mutilating acropathy and anhidrosis, whereas HSAN type IV features congenital or infantile onset, repeated high fevers with widespread anhidrosis, and widespread insensitivity to pain. Immunohistochemical analysis of skin biopsy specimens reveals a lack of epidermal and sweat gland innervation.[79]

GUILLAIN-BARRÉ SYNDROME Acute inflammatory demyelinating polyneuropathy (Guillain-Barré syndrome) produces regional deficits of sweating in legs in 10 percent to 20 percent of patients. Such involvement is overshadowed by the sensory and motor involvement. Rarely, acute dysautonomia without much involvement of somatic nerves occurs.

DIABETIC NEUROPATHY Diabetic neuropathy commonly involves distal sensorimotor neuropathy, painful thoracolumbar monoradiculopathy, and polyradiculopa-



thy. Of 51 patients with diabetic neuropathy, 48 presented with unequivocal abnormalities of thermoregulatory sweating.[10] Focal deficits occur with lumbar and thoracic radiculoplexus neuropathy, distal loss with length dependent neuropathy, and, rarely, global sweat loss in those with profound autonomic neuropathy. Abnormal thermoregulatory sweating in a patient with diabetes mellitus is shown in eFig. 82-4.7 in on-line edition.

AMYLOID NEUROPATHY Amyloid (familial and primary systemic) neuropathy often affects autonomic nerves, producing distal and or segmental sweating deficits, the latter commonly affecting the head and neck. Sudomotor neuropathy can progress even after liver transplantation.



LEPROSY Leprosy (see Chap. 186) is due to an infection with *Mycobacterium leprae*, which has a predilection for skin and peripheral nerves in cooler regions of the body [organisms reproduce best at 32°C (95°F)]. The tuberculoid form is associated with a few skin lesions that are both anesthetic and anhidrotic. Lepromatous leprosy is associated with little immunity to the organisms that gain access to cutaneous and intracutaneous nerve endings, destroying these elements in a highly characteristic temperature-linked pattern. Intermediate or borderline leprosy shows features between these extremes.[80] TST is one of the best ways to delineate the extent and distribution of sudomotor nerve involvement. Fig. 82-5 shows the TST result in a patient with lepromatous leprosy. There was only subtle skin changes (right inset) and only mild sensory loss in distal lower extremities. The TST (left inset), however, showed striking anhidrosis in the cooler regions of the extremities. These skin areas had reduced to absent axon reflex sweating, suggesting postganglionic axonal involvement. Skin biopsy from the right forearm showed numerous acid fast bacilli (background photo) with Fite staining, diagnostic of lepromatous leprosy.

LAMBERT-EATON MYASTHENIC SYNDROME The Lambert-Eaton myasthenic syndrome is characterized by proximal muscle weakness, decreased deep tendon reflexes and autonomic symptoms (dry mouth, constipation, erectile failure). Widespread anhidrosis occurs. The disorder is caused by a reduction in the quantal release of acetylcholine (ACh) from motor and autonomic nerve terminals, caused by autoantibodies to P/Q-type voltage-gated calcium channels. Lambert-Eaton myasthenic syndrome is associated with malignancy in 60 percent of cases.[81]



▲ **FIGURE 82-5** Thermoregulatory sweat test (*left inset*) in a patient with lepromatous leprosy. Note the well-defined anhidrotic areas of the extremities (*yellow*) with greater involvement distally in cooler body regions. The patient's skin (*right inset*) showed ill-defined, scaling, and erythematous to hyperpigmented patches. Patchy loss of pinprick sensation in the distal feet and toes was noted. Skin biopsy from the right forearm (*background photo*) shows numerous acid-fast bacilli (*red staining*) in a background of lymphohistiocytic inflammation. (Fite, ×600.) (Fite stain and skin photo used with permission from the Mayo Clinic Department of Dermatology.)

ALCOHOLIC NEUROPATHY Alcoholic neuropathy typically affects small sensory fibers. Unmyelinated, autonomic fibers are also affected and sweat loss with trophic skin changes is common in the feet. Early in the course, there may be a period of excessive acral (distal) sweating. Neuropathic ulcers, impairment of pain sensation, and the neurogenic vasodilator flare response, fissuring, and cracking of skin accompany intrinsic foot muscle atrophy with high arches and claw toes. These trophic skin changes are common in many length-dependent neuropathies (e.g., in diabetic neuropathy).

FABRY DISEASE

IDIOPATHIC SMALL-FIBER NEUROPATHY Many cases of painful, distal neuropathy are of the "small-fiber" type. Nerve conductions and electromyography are usually normal, and patient examinations only show subjective change in pain and temperature sensation. Quantitative tests of sweating and skin biopsies to determine epidermal nerve fiber density show diagnostic abnormalities in most patients. Postganglionic sympathetic sudomotor fibers show axonal degeneration and produce length-dependent loss of sweating, especially affecting the feet (see eFig. 82-5.1 in on-line edition).[83]

ERYTHROMELALGIA The occurrence of small-fiber neuropathy in association with clinically diagnosed primary erythromelalgia has been recently highlighted.[84] A relative decrease in small nerve fiber density was noted in skin biopsies from 13 of 16 patients.[85] This finding supports recent observations of deficient thermoregulatory and axon reflex sweating in primary erythromelalgia.[86]

POST-SYMPATHECTOMY As noted in the Treatment section, surgical sympathectomy has been used to treat palmar hyperhidrosis. The degree of anhidrosis resulting is related to the extent of sympathetic chain resection and varies from 35 percent to only 1 percent or 2 percent on TST postoperatively. The lower percentage is desirable as greater degrees may be associated with unwanted compensatory hyperhidrosis of the trunk just below the level of the sympathectomy.[17]

HARLEQUIN SYNDROME Patients with harlequin syndrome usually have unilateral anhidrosis (of head and neck) and pharmacologic evidence of denervation of the pupil. It is thought this precedes and is responsible for the compensatory, contralateral excessive sweating and vasodilatation characteristic of this disorder.[49,87]

Anhidrosis Due to Toxins and Pharmacologic Agents

BOTULINUM TOXIN BTX type A and B both exhibit a dose-responsive suppression of sweating when injected intra- and subcutaneously (see Chap. 256). More widespread anhidrosis can occur with BTX as well as organo-phosphate ingestion as a consequence of bioterrorism.[88]

PHARMACOLOGIC AGENTS Many pharmacologic agents can cause anhidrosis, especially those that are anticholinergic and interfere with the binding of ACh at M3 muscarinic receptor on sweat glands. Blockade at the sympathetic ganglionic

level can inhibit sweating and cause orthostatic hypotension. Recently, oligohidrosis in children has been reported in those taking the carbonic anhydrase (CAII) inhibitors zonisamide and topiramate and studies show reduction in axon reflex–mediated sweating compatible with an effect on the sweat gland.

μ-OPIOID AGONISTS μ-Opioid agonists (e.g., morphine) tend to inhibit warm-sensitive neurons in the hypothalamus. This action raises the body's set point temperature, allowing core temperature to rise substantially. This results in anhidrosis even in a hot environment. After opioid drug levels drop, set point temperature drops below the elevated core temperature, producing profuse sweating.[62] Clonidine and α_2-adrenergic agonists can suppress sweating, probably by reducing norepinephrine's effect on hypothalamic thermoregulatory neurons. The drug can be effective in Shapiro syndrome, essential hyperhidrosis, and post-menopausal sweating.

Heat Hyperpyrexia and Heat Stroke

Heat hyperpyrexia and heat stroke are states of thermoregulatory failure of sudden onset that are characterized by general anhidrosis, hyperpyrexia [rectal temperature greater than 40.5°C (105°F)], and disturbances of the central nervous system. The exact cause of this disorder is unknown. The picture is generally one of environmental stress too severe for the thermoregulatory system, which suddenly collapses. In the early stages, sweating may still be present and the patient rational, but the rectal temperature may be greater than 40.5°C (105°F). Within minutes, anhidrosis, mental confusion, coma, and/or seizures may appear. The diagnosis should be suspected from the clinical setting of activity in extreme heat and rectal temperature greater than 40.5°C (105°F); it should be accepted with the additional presence of anhidrosis, hot, dry skin, and any degree of central nervous system manifestations. If untreated, the disorder is uniformly fatal. In treated cases, the mortality is approximately 35 percent.

ANHIDROSIS ASSOCIATED WITH OTHER DISORDERS OF SKIN AND SWEAT GLANDS

Anhidrosis Due to Damage from Physical Agents

Localized anhidrosis can occur whenever sweat glands are damaged by surgery or trauma, scar formation, cutaneous neoplasms, radiation therapy, infection, inflammation of the skin, granulomatous lesions, scleroderma, or vasculitis. Delivery of sweat to the skin surface may be impaired in a variety of dermatoses and papulosquamous diseases, presumably because of poral occlusion. Blister formation with sweat gland necrosis has been reported during intoxication with barbiturates, methadone, diazepam, carbon monoxide, amitriptyline, and clorazepate. Similar changes may occur in coma induced by hypoglycemia and other neurologic events, suggesting the changes are due in part to pressure over skin areas not usually subject to pressure. Radiation-induced dermatitis can abolish eccrine function in a dose-dependent fashion. Mantle irradiation (usually in the 25- to 50-Gy range) often produces a permanent loss of eccrine gland function often discovered incidentally when previously treated patients undergo autonomic testing (see eFig. 82-5.2 in on-line edition). Keratotic changes blocking the eccrine duct with or without syringoma-like ductal proliferation have been described. Similar changes have been noted with breast cancer radiation therapy. Congenital ectodermal dysplasia (see Chap. 143), acantholytic dermatosis (Grover disease; see Chap. 49), cholinergic urticaria (see Chap. 37), and various forms of ichthyosis (see Chap. 47) may also be associated with altered sweating.

Anhidrosis Due to Congenital and Acquired Skin Diseases

STORAGE DISEASES Sweat gland cellular inclusions that can be identified on skin biopsy include membrane-bound vacuoles in secretory cells in the mucopolysaccharidoses, intracytoplasmic lipid in Niemann-Pick and Sandhoff storage diseases, inclusions in adrenoleukodystrophy, maltase deficiency, and periodic acid-Schiff (PAS)–positive granules in the outer duct cells in Lafora myoclonic epilepsy.

NEUTROPHILIC ECCRINE HIDRADENITIS Necrosis of eccrine secretory coils and associated epithelium with surrounding dense neutrophilic infiltrate characterizes neutrophilic eccrine hidradenitis (NEH) (see eFig. 82-5.3 in on-line edition). Several clinical entities produce NEH histopathology on skin biopsy. Lesions are most often painful, pruritic, erythematous plaques or papules developing on the limbs, trunk, neck, face, and ears. Most commonly reported is chemotherapy-associated NEH, typically occurring within 2 weeks of initiation of multiagent antineoplastic therapy. Fever and neutropenia may occur and the disorder is usually self-limited (lasting several weeks). A direct toxic effect of the drug on eccrine glands is suspected and recurrences with repeated chemotherapy may occur. Treatment with colchicine and dapsone has been beneficial.

Another category of NEH appears due to bacterial infection. Biopsied lesions have grown *Serratia*, *Staphylococcus*, *Enterococcus*, *Pseudomonas*, and *Nocardia*.[91] Community outbreaks due to swimming pool water contamination with *P. aeruginosa* have been described. Spontaneous resolution in weeks is common, although some patients receive antibiotics. It is not known whether susceptible individuals have deficient innate dermcidin antimicrobial peptide secretion in sweat (see Disorders Affecting the Sweat Duct) or if changes in sweat duct structural proteins produce reduced barrier protection against infection. Recurrent, palmo-plantar NEH has been increasingly reported in unaffected children between 1 and 15 years of age. Vigorous exercise with heavy sweating and damp, occlusive footwear are possible risk factors.[92] Spontaneous resolution in 3 to 4 weeks is common, but repeated bouts with subsequent exercise occur. Treatment with cool compresses and topical steroids and rest has provided symptomatic relief. NEH has been described in association with Behçet disease[93] and human immunodeficiency virus infection. A possible treatment for NEH-Behçet is an anti–TNF-α agent, such as infliximab, which has been effective for other manifestations of Behçet disease.[94,95]

SJÖGREN SYNDROME AND SCLERODERMA Variable degrees of anhidrosis can occur in Sjögren syndrome (see Chap. 162). Most often patchy areas of anhidrosis occur on proximal and/or distal limbs, compatible with a small-fiber neuropathy. Case reports of widespread anhidrosis and heat intolerance associated with dry eyes and dry mouth, positive extractable nuclear antigen panel, and lymphocytic infiltrates of minor salivary glands exist.[96,97] Skin biopsies have shown periecrine infiltrates in some patients, but not in others. The failure of the anhidrotic skin on TST to respond to ACh/pilocarpine iontophoresis in one report suggests that autoantibodies to the muscarinic (type 3, M3) cholinergic receptor interfere with eccrine gland function.[98–101] M3 cholinergic receptors predominate on salivary glands and sweat glands, which further supports an association. The stage of the immune-mediated response



may determine whether lymphocytic infiltration is present or not.[102] Atrophic sweat glands and focal anhidrosis have been noted in patients with linear scleroderma. The forehead is most commonly affected.[106]

INCONTINENTIA PIGMENTI Hypohidrosis has also been noted in the hypopigmented streaks and patches on the legs, arms, and scalp of 10 women with incontinentia pigmenti.[107] Skin biopsies reveal a lack of eccrine sweat glands and hair follicles at these sites. Hypohidrosis has also been described in segmental vitiligo, but not the generalized or acrofacial types.[108,109] Anhidrosis of the face and neck has also been reported in members of a family with "follicular atrophoderma, basal cell carcinoma, and hypotrichosis," a rare X-linked, dominantly inherited syndrome (Bazex-Dupre-Christol syndrome). Milia and sweat duct occlusions may occur, but are inconstant features of the disease.[110]



Disorders Affecting the Sweat Duct

MILIARIA Miliaria results from disruption of sweat ductal integrity[111] with consequent sweat secretion into layers of the epidermis. Ultraviolet light exposure, resident organisms on skin, and repeated sweating episodes are facilitating factors. Focal anhidrosis can occur and persist for several weeks, much longer than the miliaria in affected skin regions. Based on clinical and histopathology findings, miliaria is subdivided into four groups: (1) miliaria crystallina; (2) miliaria rubra; (3) miliaria pustulosa; and (4) miliaria profunda.

Miliaria crystallina (sudamina) consists of superficial, sub-corneal, noninflammatory vesicles that easily rupture when rubbed with a finger (Fig. 82-6). They are common in infants in warmed environments, including in intensive care units where medications employed (cholinergic and adrenergic agents) may be stimulating sweating and aggravating the problem.[112,113]

Miliaria rubra (prickly heat) results when obstructed sweat migrates into the epidermis as well as the upper dermis, causing pruritic inflammatory papules around the sweat pores (see eFig. 82-6.1 in on-line edition). This disorder is common in infants, but also occurs in children and adults after repeated episodes of sweating in a hot, humid environment. The eruption usually subsides within a day after the patient moves to a cool environment. Anhidrosis associated with miliaria, however, takes 2 weeks (the time needed to repair the affected epidermal sweat duct unit by epidermal turnover) to recover completely. Some of the eruptions of miliaria rubra become pustular, resulting in miliaria pustulosa. Miliaria profunda results when the sweat leaks into the deeper dermis. During exposure to intense heat or after local injection of cholinergic agents, the affected skin can be uniformly covered with multiple discrete, flesh-colored papules that resemble gooseflesh. Ductal blockade at various levels is the immediate cause of miliaria. However, investigators do not agree on why the sweat escapes the duct at different levels (causing different subgroups of miliaria) nor on what causes the ductal blockade and/or ductal leakage at different levels.



◀ **FIGURE 82-6** Miliaria crystallina. Note the delicate, drop-like vesicles without erythema.

OTHER DISORDERS AFFECTING THE SWEAT DUCTS Abnormalities of the epidermal portion of the spiraling sweat duct (acrosyringium) with altered sweat delivery to the skin surface are present in several disorders with immunohistologic evidence of neurogenic inflammation of skin. The presence of villinoid receptors and neuropeptide fibers containing substance P and calcitonin-gene related protein in the acrosyringium may explain the presence of mast cell and other mediators of inflammation with subsequent impairment of sweating.[116–118]

Disorders with Altered Composition of Sweat

ATOPIC DERMATITIS Dermcidin is a recently discovered antimicrobial peptide with a broad spectrum of activity. It is constitutively expressed in human eccrine sweat glands and secreted into sweat. Recent evidence suggests deficient amounts of sweat-derived antimicrobial peptides may play a role in skin inflammatory disorders characterized by increased bacterial colonization of the skin, such as atopic dermatitis.[119]

CYSTIC FIBROSIS Sweat chloride ion concentration can determine the integrity of the CFTR Cl^- channel and provide diagnostic information for cystic fibrosis.[12] This in vivo assay may prove useful in studying the effectiveness of CF gene therapy. In vitro studies of the CFTR Cl^- activity from sweat glands obtained via skin biopsy are presently under evaluation as markers of the efficiency of CF-gene delivery and expression in sweat gland epithelial cells.[120]

KEY REFERENCES

The full reference list for all chapters is available at www.digm7.com.

2. Sato K: Normal and abnormal sweat gland function, in *Clinical Autonomic Disorders*, edited by Low PA. Lippincott-Raven Publishers, Philadelphia, 1997, p 97
3. Fealey RD: Thermoregulatory sweat test, in *Clinical Autonomic Disorders*, edited by Low PA. Lippincott-Raven Publishers, Philadelphia, 1997, p 245
13. Eisenach JH, Atkinson JL, Fealey RD: Hyperhidrosis: Evolving therapies for a well-established phenomenon. *Mayo Clin Proc* **80**:657, 2005
46. Kreyden OP, Scheidegger EP: Anatomy of the sweat glands, pharmacology of botulinum toxin, and distinctive syndromes associated with hyperhidrosis. *Clin Dermatol.* **22**:40, 2004
69. Kennedy WR et al: Innervation and vasculature of human sweat glands: An immunohistochemistry-laser scanning confocal fluorescence microscopy study. *J Neurosci* **14**:6825, 1994
71. Lauria G et al: EFNS guidelines on the use of skin biopsy in the diagnosis of peripheral neuropathy. *Eur J Neurol* **12**:747, 2005
72. Nolano M et al: Ross syndrome: A rare or a misknown disorder of thermoregulation? A skin innervation study on 12 subjects. *Brain* **129**:2119, 2006
118. Jarvikallio A, Harvima IT, Naukkarinen A: Mast cells, nerves and neuropeptides in atopic dermatitis and nummular eczema. *Arch Dermatol Res* **295**:2, 2003

CHAPTER 83

Disorders of the Apocrine Sweat Glands

Marni C. Wiseman

Apocrine glands are adnexal glands that are distributed in the axillae, the anogenital region, Moll's gland of the eyelid, ceruminous glands of the external auditory meatus, and the mammary glands. Apocrine glands can also be found in a more limited distribution on the face and abdomen. Apocrine glands are quiescent until puberty. Embryologically, apocrine glands develop from the upper bulge of the hair follicle late in the fourth month of gestation, with continued development as long as hair follicles develop. Apocrine glands are composed of three components: the intraepithelial duct, the intradermal duct, and the secretory portion. Four disorders are considered in this chapter: apocrine bromhidrosis, apocrine chromhidrosis, Fox-Fordyce disease, and hidradenitis suppurativa. Fox-Fordyce disease and hidradenitis suppurativa are not considered primary disorders of apocrine glands. Rather, apocrine glands in these conditions become secondarily affected.

APOCRINE BROMHIDROSIS

Bromhidrosis refers to body odor, which is a common phenomenon in a postpubertal population. Rarely, body odor may become excessive or particularly unpleasant. *Apocrine bromhidrosis* refers to this offensive odor that arises from apocrine glands. It is most often seen in the axillae. This condition may contribute to impairment in an individual's psychosocial functioning. It is sometimes referred to as *bromhidrosis* or *osmidrosis*. Some of the terminology in the literature is confusing, using *osmidrosis* to imply offensive odor, and *bromhidrosis* to imply osmidrosis in the setting of concomitant hyperhidrosis.[1]

Epidemiology

Disease onset after puberty is common and tends to be more prevalent in African American populations. There is no geographic predilection, although summer months or warm climates may aggravate disease. Poor personal hygiene may also be a contributing factor. A family history can be elicited in some patients, particularly those from the Far East.[2]

Etiology and Pathogenesis

Apocrine glands are found in highest concentration in the axillae and genitals, but also in the breast, ear (ceruminous glands), and periorbital areas (Moll's glands). Apocrine secretions are responsible for odor production, primarily through bacterial action on its components. The axilla hosts many different bacteria, most of which are gram-positive bacteria. Apocrine secretion odor has been particularly associated with the action of aerobic *Corynebacterium* species. It is accepted that the odorous steroids, 16-androstenes, 5 α-androstenol, and 5 α-androstenone, contribute to bromhidrosis.[3,4] The biotransformation of these steroids is complex and further research is required to delineate these pathways.[3,4]

The bacterial action on apocrine secretions produces ammonia and short chain fatty acids. The best characterized short chain fatty acid is ε-3-methy-2-hexenoic acid.[5] This acid is delivered to the surface of the skin on two binding proteins, apocrine-secretion binding proteins (ASOB1 and ASOB2). ASOB2 has been identified as apolipoprotein D.[6]

5α-Reductase type I is expressed in apocrine glands. Individuals with bromhidrosis have increased levels of 5α-reductase in their apocrine glands. Because this enzyme catalyzes the conversion of testosterone to dihydrotestosterone, levels of dihydrotestosterone may be greater than testosterone in the skin of affected individuals.[7]

The effect of hyperhidrosis (excessive eccrine secretions) on bromhidrosis is unclear. Some have advocated that excessive eccrine sweat improves apocrine bromhidrosis by flushing away excessive apocrine secretions. Others have postulated that eccrine sweat augments apocrine bromhidrosis by encouraging local spread of apocrine sweat components and enhancing the moist environment in which bacteria flourish.[2]

Clinical Findings

HISTORY Patients complain of an unpleasant body odor. The axillae are the most common affected site, although the genitals or plantar feet may also be affected. The diagnosis is usually clinical. What constitutes a "normal" amount of body odor varies considerably among individuals and ethnic groups. In Asian populations, only slight odor is often considered diagnostic.[8,9]

CUTANEOUS LESIONS Physical examination of the affected individual is usually unremarkable.

LABORATORY TESTS There are no associated laboratory abnormalities.

PATHOLOGY Although some reports do not reveal any abnormalities in the apocrine glands of affected individuals, an increase in the numbers and size of apocrine glands has also been reported.[8]

Differential Diagnosis

Apocrine bromhidrosis should be distinguished from eccrine bromhidrosis, which is far less common (see Chap. 82). Eccrine secretions are distributed in a generalized fashion, are usually odorless, and serve a thermoregulatory function. Eccrine bromhidrosis may develop from the action of bacteria on keratin that has been softened by eccrine secretions. A plantar location is characteristic for eccrine bromhidrosis. Certain foods (garlic, curry, alcohol), drugs (bromides), toxins, or metabolic causes (disorders of amino acid metabolism) may result in eccrine bromhidrosis (Box 83-1).

Treatment

GENERAL MEASURES Frequent washing of the axillae, use of a deodorant or antiperspirant (aluminum chloride), per-

APOCRINE BROMHIDROSIS AT A GLANCE

- *Apocrine bromhidrosis* refers to an offensive or unpleasant body odor arising from apocrine gland secretions.
- Chronic disorder, most often developing in the axillae, but may also involve the genitals or plantar aspect of the feet.
- The best characterized short chain fatty acid causing odor is ε-3-methy-2-hexenoic acid.
- Should be distinguished from eccrine bromhidrosis.
- Surgical removal of affected glands may be effective.



Box 83-1

Differential Diagnosis of Apocrine Bromhidrosis

- Eccrine bromhidrosis
  - Fish odor syndrome (trimethylaminuria)
  - Phenylketonuria
  - Sweaty feet syndrome
  - Odor of cat syndrome
  - Isovaleric acidemia
  - Hypermethioninemia
  - Food, drug, toxin ingestion
- Liver failure (fetor hepaticus)
- Renal failure
- Nasal foreign body in children[153]
- Poor hygiene
- Olfactory hallucinations
- Body dysmorphic disorder

From Rehmus W et al: Bromhidrosis, in *emedicine*, edited by McCalmont T et al. (http://www.emedicine.com), 2005.



fumes, and changing of soiled clothing can help. Removal of axillary hair may minimize odor by preventing bacteria and sweat accumulation on the hair shafts. Antibacterial soaps or topical antibacterial agents may also be of benefit.

NON-SURGICAL THERAPY The injection of botulinum toxin A has been reported to successfully treat genital[10] and axillary bromhidrosis.[11] The frequency-doubled, Q-switched Nd:YAG laser has also been reported to be an effective non-invasive therapy for axillary bromhidrosis.[12]

SURGERY Several surgical measures have been investigated in the treatment of apocrine bromhidrosis. Patient selection is important because surgery is potentially associated with postoperative scar formation, prolonged healing times, infection, and other complications. Upper thoracic sympathectomy has been successful in treating apocrine bromhidrosis either in isolation or in association with palmar hyperhidrosis.[1] Surgical removal of the culprit apocrine glands can be achieved either by the removal of subcutaneous tissue in isolation or in combination with axillary skin.[13–15] Surgical subcutaneous tissue removal has also been used in association with CO_2 laser ablation.[16] Although surgical excision may be highly efficacious, depending on the depth of tissue removed and surgical technique used, regeneration and return of apocrine function/bromhidrosis may develop. Both superficial liposuction[17] and ultrasound-assisted liposuction[18] have efficacy in the management of apocrine bromhidrosis. In a series of 375 patients, more than 90 percent reported a satisfactory reduction in odor.[18] Another technique with reported efficacy is ultrasonic surgical aspiration of axillary apocrine glands with endoscopic confirmation.[19] This technique uses ultrasound to liquefy fat and sweat glands.

Prognosis and Clinical Course

Apocrine bromhidrosis is a chronic and nonremittive condition. Patients with apocrine bromhidrosis often feel self-conscious and embarrassed by their condition and may develop impairment with psychosocial functioning.

APOCRINE CHROMHIDROSIS

Apocrine chromhidrosis is a rare condition characterized by the secretion of colored sweat. Two variants of apocrine chromhidrosis are recognized: axillary and facial. Involvement of the mammary areola has also been described.[20,21] Yonge first recognized facial chromhidrosis in 1709. Shelley and Hurley described this entity in 1954 and associated it with an increased number of lipofuscin granules in apocrine glands.[22]

Epidemiololgy

Apocrine chromhidrosis is a rare disease. The prevalence worldwide is unknown. Onset of apocrine chromhidrosis is usually at puberty, at the time of increased apocrine gland activity. Disease persists throughout life, improving in the aged. Disease is reported most commonly in African Americans.[23] Geographic predilections have never been described. Most of the cases reported in the literature involve women; however, there is a lack of sound scientific evidence supporting a female preponderance.

Etiology and Pathogenesis

The pigment responsible for causing apocrine chromhidrosis is lipofuscins that are produced in the apocrine secretory cells and excreted to the skin surface. Lipofuscin is a golden-colored pigment that is not specific to apocrine glands. In apocrine chromhidrosis, the lipofuscin granules are in a higher state of oxidation, thereby imparting various colors of pigment, such as yellow, green, blue, or black. Higher states of oxidation produce darker colors.[20] It is uncertain why this develops in some individuals and not others.[24]

One case of facial chromhidrosis was successfully treated with capsaicin.

APOCRINE CHROMHIDROSIS AT A GLANCE

- Rare, chronic condition characterized by the secretion of colored sweat.
- Axillary and facial involvement is most common. Areola involvement has been reported.
- Caused by an increased number of lipofuscin granules in the luminal secretory cells of the apocrine glands.
- Secretions may be yellow, blue, green, brown, or black.
- Wood's light examination may demonstrate fluorescence of secretions and stained clothes.
- Adequate therapy is lacking. Reports of efficacy with manual expression, capsaicin, and botulinum toxin.

Nerve endings with receptors for substance P have been found around eccrine sweat glands, suggesting that substance P, a potent vasodilator, may play a role in sweat production and apocrine chromhidrosis. Successful treatment of facial chromhidrosis with capsaicin also implicates a role for substance P.[25]

Clinical Findings

HISTORY Individuals with apocrine chromhidrosis often describe a sensation of warmth, a prickling sensation, or tingling feeling before apocrine gland secretion. Triggers for colored sweating are usually emotional or physical stimuli.[23] The morbidity associated with apocrine chromhidrosis stems from the emotional distress experienced by affected individuals.[26] Staining of undershirts and handkerchiefs are common complaints.

CUTANEOUS LESIONS Individuals with apocrine chromhidrosis develop colored sweat in the axillae or face (Fig. 83-1). Mammary areolar involvement has also been described.[20] The pigment produced ranges in color from yellow, blue, green, brown, to even black. The quantity of pigmented sweat produced is usually quite small (approximately 0.001 mL at each follicular orifice).[27] The droplets are odorless and dry quickly. Dried secretions appear as dark flecks within affected areas. Axillary involvement causes staining of shirts and undergarments. Facial chromhidrosis commonly develops



▲ **FIGURE 83-1** Black sweat produced in a patient with facial apocrine chromhidrosis after gentle squeezing of the cheeks.

close to the lower eyelid, including the malar cheeks, and occasionally the forehead.[26,27] Colored sweat can also be manually expressed by squeezing in the affected area. Such a maneuver may also be therapeutic.[23]

SPECIAL TESTS An examination of yellow, blue, or green secretions using a Wood's light (360 nm) produces a characteristic yellow fluorescence. Black or brown pigment rarely autofluoresces.[23] Secretions can be manually expressed if not present at the time of examination. Stained clothing may also fluoresce with Wood's lamp examination.[28] Apocrine glands can be stimulated to produce colored secretions by the injection of epinephrine or oxytocin.

LABORATORY TESTS It is reasonable to check a complete blood cell count to exclude a bleeding diathesis, homogentisic levels in urine to exclude alkaptonuria, and bacterial and fungal cultures of affected areas to exclude pseudo-eccrine chromhidrosis.[24]

Pathology

Under normal circumstances, the apocrine secretory glands are located in the subcutaneous fat or deep dermis and are lined by one layer of luminal cells and one layer of myoepithelial cells. The luminal cells have an eosinophilic cytoplasm, a large nucleus, and may contain lipofuscin, iron, lipid, or periodic acid-Schiff–positive and diastase-resistant granules.[29] Under light microscopy using hematoxylin-eosin staining, an increased number of (yellow-brown) lipofuscin granules may be present in the apical portion of luminal secretory cells of the apocrine glands. The number of granules varies. Additionally, autofluorescence of paraffin-embedded non-stained sections can be demonstrated using a 360-nm wavelength.[28] The granules are positive on periodic acid-Schiff stains. Schmorl stains may also be weakly positive.[30]

Box 83-2

Differential Diagnosis of Apocrine Chromhidrosis

- Eccrine chromhidrosis
  - Quinine ingestion
- Pseudo-eccrine chromhidrosis
  - Blue sweat with copper exposure
  - Extrinsic dyes, paints
- Alkaptonuria (ochronosis)
- Hyperbilirubinemia
- Hematohidrosis (bleeding diathesis)
- Chromogenic bacteria (e.g., *Corynebacterium* species), pseudomonas

From June K et al: Chromhidrosis, in *emedicine*, edited by Burg G et al. (http://www.emedicine.com), 2005.

Differential Diagnosis

Apocrine chromhidrosis must be distinguished from eccrine chromhidrosis (Box 83-2; see Chap. 82). True eccrine chromhidrosis is very rare and occurs when water-soluble pigments are excreted from eccrine glands after the ingestion of certain drugs, such as quinines. *Pseudo-eccrine chromhidrosis* refers to the development of colored sweat when surface compounds or molecules mix with sweat to produce pigment. A classic example of this type is the formation of blue sweat in copper workers.[30] Extrinsic dyes, paints, fungi, and chromogenic bacteria (e.g., *Corynebacterium* species) are other causes of pseudochromhidrosis.[24]

Treatment

Adequate therapy for chromhidrosis is lacking. Manual expression of colored secretions may result in a temporary improvement in symptoms for the following 48 to 72 hours.[25] Botulinum toxin type A has reported to be successful in one patient with facial chromhidrosis. This patient experienced a substantial reduction in pigmented sweat and the results were sustained for 4 months.[31] Capsaicin is a topical cream that depletes and prevents re-accumulation of substance P levels in unmyelinated, slow-conducting type C sensory fibers. Case reports have demonstrated efficacy of capsaicin in the treatment of facial chromhidrosis.[25]

Prognosis and Clinical Course

Apocrine chromhidrosis is a chronic disease that improves in old age as apocrine gland activity diminishes. Disease-associated morbidity is a result of psychosocial dysfunction experienced by affected individuals.

FOX-FORDYCE DISEASE

Fox-Fordyce disease is an uncommon eruption characterized by pruritic follicular papules that localize to anatomic regions that bear apocrine glands.[32] George Henry Fox and John Addison Fordyce originally described it in 1902 in two patients with axillary involvement.[33] In 1925, Fischer hypothesized that Fox-Fordyce was a disease of the apocrine glands.[34] Shelley and Levy introduced the term *apocrine miliaria* as a synonym for this disease.[35]

Epidemiology

Approximately 90 percent of patients with Fox-Fordyce disease are female. Age of onset tends to be after puberty, with most patients between 13 and 35 years of age.[35] The incidence of this disorder is unknown. There is no reported ethnic or racial predilection.

Etiology and Pathogenesis

FOLLICULAR PLUGGING The triggers for the development of Fox-Fordyce disease

FOX-FORDYCE DISEASE AT A GLANCE

- An uncommon eruption characterized by pruritic skin-colored to pink papules localizing mainly to axillae and genitofemoral area.
- More than 90 percent of patients are female, and onset tends to be after puberty.
- Likely a result of intraluminal plugging of follicular infundibula, causing apocrine duct obstruction, rupture, and inflammation.
- The most consistent pathologic finding is hyperkeratosis and plugging of the follicular infundibula.
- Topical clindamycin, surgery, or other treatments may be of benefit.



are largely unknown. Shelley and Levy hypothesized that the clinical manifestations of this disease are a result of intraluminal keratin plugging of the follicular infundibula, causing obstruction of the apocrine duct, rupture, and inflammation.[35] Although blockage of the apocrine duct seems important in disease development, experimentally plugging the duct has not clinically reproduced disease manifestations.[36] One case report detailed the development of Fox-Fordyce disease associated with obstruction of apoeccrine sweat glands.[37]

GENETICS Genetics likely plays a role in disease development. This disease has been reported in two patients with Turner syndrome[38] and one patient with a small deletion on chromosome 21.[39] Disease has also been reported in identical male twins[40] and one set of siblings.[41]

HORMONES Hormonal influences on disease have been debated. Disease onset after puberty and improvement with pregnancy and estrogens lends support to a hormonal influence.[33,42] However, hormonal studies in one patient with Fox-Fordyce did not reveal any abnormalities.[43] Additionally, development before puberty has also been described.[44]

Clinical Findings

HISTORY Patients describe the development of pruritic papules at the time of puberty with gradual worsening. Pruritus can be triggered by emotional excitement or sweating.

CUTANEOUS LESIONS Fox-Fordyce disease manifests as numerous symmetrically distributed skin-colored to slightly yellow or red follicular, dome-shaped papules that are equidistant from one another and characteristically intensely pruritic (Fig. 83-2). These papules may resemble lichen planus, lichen nitidus, folliculitis, or syringomas (Box 83-3). Excoriations may be prominent. Apocrine-rich areas are affected, most commonly the axillae. Other areas involved include the pubic area and perineum, mammary areola,[5] presternal area, periumbilical area, and upper inner thighs. Only sparse hair growth is seen in the affected area. Apocrine sweat is not produced in affected areas.

Pathology

Although the clinical features in patients with Fox-Fordyce are quite uniform, pathologic findings can vary considerably. The most consistent pathologic finding is dilation and hyperkeratosis of the follicular infundibula. Other findings include spongiosis and solitary dyskeratotic cells throughout the infundibular epidermis, vacuolar changes at the dermal-epidermal junction in conjunction with some lymphocytes, cornoid lamella in the follicular infundibula with eosinophilic keratinocytes directly below the parakeratotic column, xanthomatous infiltrates (foamy macrophages), and few lymphocytes in the dermis surrounding the infundibula.[32]

It has been suggested that transverse histologic sectioning of the specimen is the most effective and efficient method to demonstrate the characteristic pathologic features of Fox-Fordyce disease.[45]





▲ **FIGURE 83-2** Numerous skin-colored to pink papules involving the axilla of a woman with Fox-Fordyce disease. (Used with permission from Dr. C. Hong.)

Treatment

NON-SURGICAL THERAPY Treating Fox-Fordyce disease is difficult. Avoidance of excessive sweating or heat may minimize symptoms and flares. Clindamycin with propylene glycol has demonstrated efficacy in small case series in both eliminating symptoms and resolving papules.[41,46] Topical tretinoin 0.1 percent, although potentially irritating, has also demonstrated efficacy.[47] Systemic isotretinoid led to almost complete clearance of lesions, but lesions recurred within 3 months after isotretinoin discontinuation.[39] Other reported medical therapies include oral contraceptives,[48] testosterone,[49] topical or intralesional corticosteroids,[50] ultraviolet light,[51] and x-rays.[43]

SURGERY Electrocoagulation,[52] surgical excision,[53] and liposuction-assisted curettage[54] have all demonstrated efficacy.

Box 83-3

Differential Diagnosis of Fox-Fordyce Disease

- Lichen planus
- Lichen nitidus
- Folliculitis
- Multiple syringomas

Prognosis and Clinical Course

Fox-Fordyce disease is a chronic disease characterized by intermittent flares. It rarely remits. Infection or folliculitis may develop secondary to trauma caused by scratching.

HIDRADENITIS SUPPURATIVA

Epidemiology

Hidradenitis (HS) has a point prevalence of up to 4.1 percent based on objective findings, and a 1-year prevalence of 1 percent based on patient recall.[59] This prevalence was refuted by another group of investigators, who determined a prevalence of only 1/3000.[60] It is more common in females, with reported female-male ratios ranging from 2:1 to 5:1. The reason for female preponderance is unknown. HS rarely develops before puberty or after menopause, although persistence into menopause is not uncommon.[61] The average age of onset is 23 years.[62] Although the disease may develop in any apocrine gland–bearing skin, genitofemoral lesions are more prevalent in women, whereas axillary involvement does not demonstrate a gender predilection.[59,63,64]

Etiology and Pathogenesis

Little is known about the pathogenic basis of HS. Unfortunately, only a few limited studies have attempted to clarify etiology.

ADNEXAL STRUCTURES Classically, HS was thought to represent a primary disorder of apocrine glands, and was also referred to as *apocrinitis*.[56] The anatomic location of disease in apocrine-bearing skin supported this concept. Shelley and Cahn provided additional support of this concept by hypothesizing that poral occlusion of the apocrine duct reproduced the clinical and pathologic lesions using their experimental model.[65]

HIDRADENITIS SUPPURATIVA AT A GLANCE

- Common disorder with a point-prevalence of 4.1 percent and female preponderance.
- A chronic and recurrent disorder, usually developing at puberty and most commonly involving the genitofemoral area or axillae.
- Primary pathogenic event is believed to be follicular occlusion with subsequent inflammation, secondary adnexal gland involvement, fibrosis, and scarring.
- Pathologic features may include follicular hyperkeratosis, folliculitis, abscess formation, sinus tract formation, fibrosis, and granuloma formation.
- Surgery may sometimes be curative; antibiotics, retinoids, hormonal treatments, and some immunosuppressive medications may benefit some patients.

More recent publications have refuted the concept that this primary event in HS is apocrine gland inflammation and postulate that apocrine glands become secondarily affected. HS is now generally considered to be a disorder of the follicular epithelium, with follicular occlusion giving rise to clinical findings.[66] Follicular hyperkeratosis is the initial event, leading to occlusion, occasional secondary apocrine involvement, and follicular rupture with resultant inflammation and possibly secondary infection.[66,67] Pathologic studies have supported this concept by demonstrating follicular obstruction, the absence of apocrine glands, and minimal or absent apocrine gland inflammation in specimens of HS.[68]

The concept of the follicular occlusion tetrad stems from the concept that HS, acne vulgaris, pilonidal sinus, and dissecting cellulitis all share follicular occlusion as an inciting event that eventually leads to disease expression.

GENETIC FACTORS A family history of HS may be elicited in 26 percent of patients.[69] Several studies have not demonstrated HLA associations.[70,71] Others studies have suggested an autosomal dominant mode of inheritance with single gene transmission.[72–84] No genetic locus has been identified.

ASSOCIATED DISEASE The co-existence of HS and Crohn disease, particularly with perianal involvement, has been associated with a more fulminant course.[75–78] Perianal Crohn disease may be clinically indistinguishable from perianal HS. Other reported associations include pyoderma gangrenosum,[79] nephrotic syndrome, and amyloidosis,[80] Dowling-Degos disease,[81] and arthropathy.[82–84]

HORMONES AND ANDROGENS The tendency of HS to develop at puberty or postpubertally suggests an androgen influence. Additionally, disease flares have been reported postpartum,[81,85] in association with the oral contraception pill, and in the premenstrual period (approximately 50 percent of patients).[86] Antiandrogen therapy has also demonstrated therapeutic benefit in some studies.[87–90] However, no biochemical evidence of hyperandrogenism was found in 66 women with HS.[91] Additionally, unlike the sebaceous glands, the apocrine glands are not affected by androgens. Thus, the influence of androgens on HS is unclear.

OBESITY Obesity is unlikely to be a causal factor in HS but is often regarded as an exacerbating factor by increasing shearing forces, occlusion, keratinocyte hydration, and maceration.[81,92,93] Obesity may also exacerbate disease by creating a state of androgen excess.[72] Weight reduction is recommended for overweight patients and may help to control disease.[63]

BACTERIAL INFECTION The role of bacterial infection in HS is unclear. It is believed that the pathogenic role is similar to the role of bacteria in acne. Antibacterial agents are commonly used as therapy. Bacterial involvement is thought by some authors to occur secondarily. Routine cultures are often negative, but numerous bacteria have been recovered from lesions. *Staphylococcus aureus* and coagulase-negative staphylococci are most frequently isolated.[94,95] However, other bacteria, including streptococci, gram-negative rods, and anaerobes, have also been identified. These are likely to be colonizing bacteria rather than causative bacteria.[81,96]

SMOKING The use of tobacco products is more common in HS patients than in healthy controls.[97,98] One study determined that 70 percent of their 43 patient cohort with perineal HS were smokers.[99] It is postulated that smoking affects polymorphonuclear cell chemotaxis.[61] Smoking cessation may improve the clinical course of diseases.

Box 83-4

Differential Diagnosis of Hidradenitis Suppurativa

- Abscesses (including from methicillin-resistant *Staphylococcus aureus*)
- Furuncles/carbuncles
- Actinomycosis
- Cat scratch disease
- Donovanosis
- Lymphogranuloma venereum
- Lymphadenitis
- Infected Bartholin cyst
- Crohn disease
- Ulcerative colitis
- Tuberculosis
- Tularemia
- Ruptured epidermal cyst

From Jovanovic M et al: Hidradenitis suppurativa, in *emedicine*, edited by Siegel D et al. (http://www.emedicine.com), 2006.

Clinical Findings

HS is a chronic disease with a variable clinical course. The diagnosis of HS is clinical, and a biopsy is rarely needed (Box 83-4). Clinical diagnostic criteria are wide and include recurrent disease, scarring, and multifocal location.[63]

HS involves apocrine-bearing skin with a predilection for intertriginous areas. The sites affected in order of decreasing frequency include: axillary, inguinal, perineal and perianal, mammary and inframammary, buttocks, pubic region, chest, scalp, retroauricular, and eyelid.[61]

Three stages of disease are recognized.[100] In the primary stage, abscesses develop in isolated locations. The secondary stage involves the development of sinus tracts with scars bridging individual lesions. The tertiary stage shows coalescing lesions with scarring and sinus tracts, inflammation, and chronic discharge.

The disease onset is insidious and shows variable severity. Otherwise healthy postpubertal individuals initially may experience slight discomfort or pruritus. After this, a tender papule or deep-seeded nodule (0.5 to 2.0 cm) ensues (Fig. 83-3). Pustules may also be visualized (Fig. 83-4). This nodule may slowly resolve or may expand and coalesce with surrounding nodules to form large painful inflammatory abscesses. These abscesses are rounded without central necrosis and may resolve or rupture spontaneously, producing a purulent discharge (Fig. 83-5). Eventual healing may result in scarring with fibrosis





▲ **FIGURE 83-3** A large tender boil in the genital area of a woman with hidradenitis suppurativa.

(Fig. 83-6), dermal contractures and rope-like elevation of the skin (Fig. 83-7), and double-ended comedones (Fig. 83-8). Sinus tracts may also develop (Fig. 83-9). Sinuses have been reported to involve deep tissue, including muscle and fascia, urethra, and bowel. The process then recurs in an adjacent area or different apocrine-bearing site.[63]

LABORATORY TESTS Patients with acute lesions of HS may demonstrate an increase in the erythrocyte sedimentation rate or C-reactive protein. If there is any concern over infection, then deep cultures (not skin surface) from lesions should be conducted and submitted for bacterial, tuberculosis, and fungal cultures.[101]



▲ **FIGURE 83-4** Pustules and inflammatory papules localizing to an area of hidradenitis suppurativa on the buttock of a male patient.



▲ **FIGURE 83-5** A ruptured abscess draining purulent material involving the buttock of an individual affected with hidradenitis suppurativa. (Used with permission from Dr. L. Edwards.)

SPECIAL TESTS Ultrasonography of the follicles and dermis may reveal abscess formation and abnormalities in the deep part of the follicle, but is rarely indicated.[101] Recently, magnetic resonance imaging features of the skin and subcutaneous tissue have been described. Such features included marked thickening of the skin, induration of the subcutaneous tissues, and multiple subcutaneous abscesses.[102]

Pathology

The early lesions of HS demonstrate follicular hyperkeratosis. Other dermal features include active folliculitis or abscess, sinus tract formation, fibrosis, and granuloma formation. There is evidence of an inverse relationship between fibrosis and inflammation, supporting the concept that fibrosis corresponds to areas of chronic involvement.[68] Histologic feature examination of adnexal structures reveals inflammation of the apocrine glands in only one-third of cases. Interestingly, involvement of eccrine glands (25 percent) has been reported to be more common than apocrine glands (12 percent).[103,104] Poral occlusion or cyst formation may be noted. The subcutis may demonstrate some fibrosis, fat necrosis, or inflammation.[66,67]



▲ **FIGURE 83-7** Double-ended comedone involving the axillae.

Complications

QUALITY OF LIFE Patients with HS experience a significant degree of morbidity when quality of life is measured by the Dermatology Life Quality Index. The highest scores relate to disease-associated pain. Quality of life measurements are lower than other dermatologic diseases that have been investigated using this tool.[105] Loss of workdays is a socioeconomic consequence. Women lose significantly more days of work (mean, 2.9 days) than men (mean, 1.7 days).[101]



◀ **FIGURE 83-6** Multiple areas of scarring with associated depigmentation and inflammatory nodules, involving the genitals of a woman with hidradenitis suppurativa.



▲ **FIGURE 83-8** Double-ended comedones affecting the axilla of an individual with hidradenitis suppurativa.

SYSTEMIC COMPLICATIONS Local infection may develop and lead to septicemia. A case of lumbosacral epidural abscess has been reported.[106] Anemia or leukocytosis may be detected, but does not tend to be significant clinically.[107,108]

LOCAL COMPLICATIONS Scarring may limit mobility. Anal, urethral, or rectal strictures may develop from chronic genitofemoral inflammation. Urethral fistulas have also been reported.[109] Additionally, disfiguring persistent penile, scrotal, or vulvar lymphedema may develop,[110] giving rise to significant functional impairment. This lymphedema is thought to result from fibrosis and resultant lymphatic channel obstruction. Surgical reconstruction may be necessary.[111] Squamous cell carcinoma (SCC) may rarely develop in chronically inflamed and scarred areas in individuals with long-standing disease. SCC has been reported in 3.2 percent of patients with perianal HS lasting 20 to 30 years. SCC is most common in men in the anogenital region. These carcinomas tend to be more aggressive locally and are associated with a higher incidence of metastatic disease and mortality.[112–118] One case of paraneoplastic neuropathy has been described in association with SCC complicating severe perineal HS.[119] Clinicians should have a low threshold for biopsying any non-healing lesion localizing to an area of chronic HS. One case-controlled Swedish study found that the overall incidence of malignancy, including non-melanoma skin cancer, is increased in patients with HS.[120]

Treatment

The objective of patient management is prevention of the development of primary lesions as well as resolution, amelioration, or regression of secondary disease features such as scarring or sinus tract formation. The literature reveals only three randomized controlled studies, several case series, and a plethora of case reports.

MEDICAL TREATMENT Therapy for the early stages of HS consists primarily of both topical and systemic antibiotics. Some authors advocate long-term suppressive antimicrobial therapy, although supportive evidence is lacking. Topical clindamycin has been demonstrated to be superior to placebo in a randomized clinical trial.[121] A randomized controlled study comparing topical clindamycin with systemic tetracycline did not reveal a statistical difference.[122]

Intralesional corticosteroids may be of benefit for patients with an isolated number of tender lesions.[123] Practically, such treatment may not be appropriate for individuals with extensive disease and is not appropriate for areas of chronic inflammation.

Isotretinoin as therapy for patients with HS initially held conceptual promise because both diseases share follicular occlusion in disease development. Unfortunately, isotretinoin has demonstrated only a modest therapeutic benefit. In a study of 68 patients, 23.5 percent cleared during therapy, whereas only 16.2 percent maintained improvement during a follow-up period of up to 6 months.[124] One case report described an individual with severe vulvar HS who, after treatment with prednisolone and then long-term isotretinoin (more than 1 year), remained disease free at 10 months post-treatment.[125] The other systemic retinoids, acitretin and etretinate, have also demonstrated limited efficacy in disease management.[126,127]

The analogy between acne and HS has also made hormonal therapy for HS appealing. Hormonal therapy does have some reported success. In a double-blinded study, the anti-androgen, cyproterone acetate (50 mg), in conjunction with ethinyl estradiol (50 μg), resulted in complete or partial clearance at 18 months post-treatment in 50 percent of patients.[88,89] The 5α-reductase inhibitor, finasteride (1 mg), may also have a weak limited effect on disease management.[90,128]

Infliximab, a chimeric monoclonal anti-tumor necrosis factor antibody, has demonstrated efficacy in several case reports. Efficacy has been reported in two patients with Crohn disease and HS.[77,129] Infliximab also was efficacious in achieving remission and controlling disease flares in an individual with HS and ulcerative colitis.[130] Case reports or small case series have also shown therapeutic success with other systemic therapies, including systemic corticosteroids, azathioprine, cyclosporine, dapsone, and methotrexate.[59,81,131–134]

Local therapies have also been recently examined. A single patient with aggressive perianal HS has responded favorably to wide surgical excision in conjunction with perilesional granulocyte-macrophage colony-stimulating factor injections.[135] A small case series demonstrated the efficacy of treatment of persistent painful nodules with cryotherapy. Healing time in these patients was lengthy (18 to 42 days).[136] Finally, the first case of botulinum toxin A successfully treating HS has been reported. In this case, injections into the axillae resulted in a 10-month remission.[137]

Photodynamic therapy (PDT) as treatment for HS has recently been described in two small case series. In one, four patients sustained 75 percent to 100 percent improvement over 3 months after treatment with aminolevulinic acid-PDT and blue light.[138] In the other case series, three patients receiving aminolevulinic acid-PDT with either a diode



◀ **FIGURE 83-9** Sinus tract formation developing in the vulva of a woman with hidradenitis suppurativa. (Used with permission from Dr. L. Edwards.)



laser (633 nm) or broad band red light source (570 to 670 nm) did not experience clinical improvement.[139]

SURGERY Surgical removal of all involved tissue, beyond clinically involved margins, is an effective treatment modality.[140] Postoperative recurrences may occur. Some authors have advocated the use of CO_2 laser for surgical ablation of tissue. The modality of closure has been a topic of debate. Overall, healing by secondary intent is thought to provide the best outcome. Primary closure, grafting, or flaps have been extensively used, but may be associated with poorer results.[141–147] In one series of 106 patients, there was a 70 percent recurrence rate requiring subsequent operation in the primary closure cohort and no recurrence in the split-thickness graft and flap groups.[148] A more limited surgical approach also plays a role in disease management. Deroofing or marsupializing of recurrent troublesome lesions or sinus tracts may aid with local control. Lancing an inflammatory lesion is of limited benefit and should be discouraged.[141,149,150]

RADIOTHERAPY Several authors have reported radiotherapy to be successful in the treatment of HS. Given the often young patient population with HS, long-term side effects must be considered.[151,152]



KEY REFERENCES

The full reference list for all chapters is available at www.digm7.com.

11. Heckmann M, Teichmann B, Pause BM: Amelioration of body odor after intracutaneous axillary injection of botulinum toxin A. *Arch Dermatol* **139**:57, 2003
31. Matarasso SL: Treatment of facial chromhidrosis with botulinum toxin type A. *J Am Acad Dermatol* **52**:89, 2005
37. Kamada A, Saga K, Jimbow, K: Apoeccrine sweat duct obstruction as a cause of Fox-Fordyce disease. *J Am Acad Dermatol* **48**:453, 2003
66. Yu CCW, Cook MG: Hidradenitis suppurativa: Disease of follicular epithelium, rather than apocrine glands. *Br J Dermatol* **12**:763, 1990
100. Jemec GBE: Medical treatment of hidradenitis suppurativa. *Expert Opin Pharmacother* **5**:1767, 2004
105. Von der Werth JM, Jemec GBE: Morbidity in patients with hidradenitis suppurativa. *Br J Dermatol* **144**:809, 2001
140. Kagan RJ et al: Surgical treatment of hidradenitis suppurativa: A 10-year experience. *Surgery* **138**:734, 2005

SECTION 15

DISORDERS OF THE HAIR AND NAILS

CHAPTER 84

Biology of Hair Follicles

George Cotsarelis
Vladimir Botchkarev

EVOLUTION AND FUNCTION OF HAIR

Hair is found only in mammals, where during the course of evolution its primary roles were to serve as insulation and protection from the elements. In contemporary humans, however, hair's main purpose revolves around its profound role in social interactions. Loss of hair (alopecia) and excessive hair growth in unwanted areas (hirsutism and hypertrichosis) can lead to significant psychological and emotional distress that supports a multibillion-dollar effort to reverse these conditions.

Much progress has been made in understanding hair growth, and as a result new treatments for alopecia are on the horizon.[1,2] These advances resulted from the interest of developmental biologists and other investigators in the hair follicle as a model for a wide range of biologic processes. As each hair follicle cyclically regenerates, it recapitulates its initial development. Many growth factors and receptors important during hair follicle development also regulate hair follicle cycling.[3–10] The hair follicle possesses keratinocyte and melanocyte stem cells (MSCs), nerves, and vasculature that are important in healthy and diseased skin.[11–13] To appreciate this emerging information and to properly assess a patient with hair loss or excess hair, an understanding of the anatomy and development of the hair follicle is essential.

EMBRYOLOGY

Morphologically, hair follicle development has been divided into eight consecutive stages, several of which are illustrated in Fig. 84-1. Each stage is characterized by unique expression patterns for growth factors and their receptors, growth factor antagonists, adhesion molecules, and intracellular signal transduction components.[14–16] Promising advances in understanding the molecular mechanisms behind hair follicle development arose through the discovery that mammalian counterparts (homologues) of genes important for normal *Drosophila* (fruit fly) development also affect hair follicle development. *Decapentaplegic [Dpp/bone morphogenetic protein (BMP)], Engrailed (en), Homeobox (hox), hedgehog/patched (hh/ptc), notch, wingless/armadillo (wg/wnt/catenin)* genes are all critical for hair follicle and vertebrate development in general (reviewed in refs. 17–19). These genes were all first discovered in *Drosophila*, thus, most of the names assigned to them describe the peculiar appearance (phenotype) of the flies carrying mutations in these genes.[19a]

Follicle formation begins on the head, and then moves downward to the remainder of the body in utero. The first hairs formed are lanugo hairs, which are non-pigmented, soft, and fine. Lanugo hair is typically shed between the thirty-second and thirty-sixth weeks, although approximately one-third of newborns still retain their lanugo hair for up to several weeks after birth.

Patterning genes, called *homeobox genes*, which are precisely organized in the genome so that they are expressed in strict temporal sequences and spatial patterns during development, likely are responsible for the nonrandom and symmetric distribution of hair follicles over the body.[20,21] In adult mice, homeobox gene expression reappears in hair follicles and serves to maintain normal hair shaft production.[6] *Engrailed*, a type of homeobox gene, is responsible for dorsal-ventral patterning, and mice lacking *engrailed* develop hair follicles on their footpads.[22]

Although hair follicles and hairs all share the same basic anatomy, their growth, size, shape, pigmentation, and other characteristics differ widely, based on body location and variation among

BIOLOGY OF HAIR FOLLICLES AT A GLANCE



- The primary purpose of hair in humans is to influence social interactions.
- Hair follicle development depends on interactions between epithelial and mesenchymal cells. The genes important for this interaction are slowly being elucidated.
- Genes important for hair follicle development also play a role in hair follicle cycling.
- The hair follicle bulge possesses stem cells important for the continual regeneration of the follicle during cycling.
- Hair pigmentation depends on melanocyte stem cells and differentiated cells in the follicle. Many genes important for melanocyte behavior and hair pigmentation have been defined.



Copyright © 2008 by The McGraw-Hill Companies, Inc. Click here for terms of use.

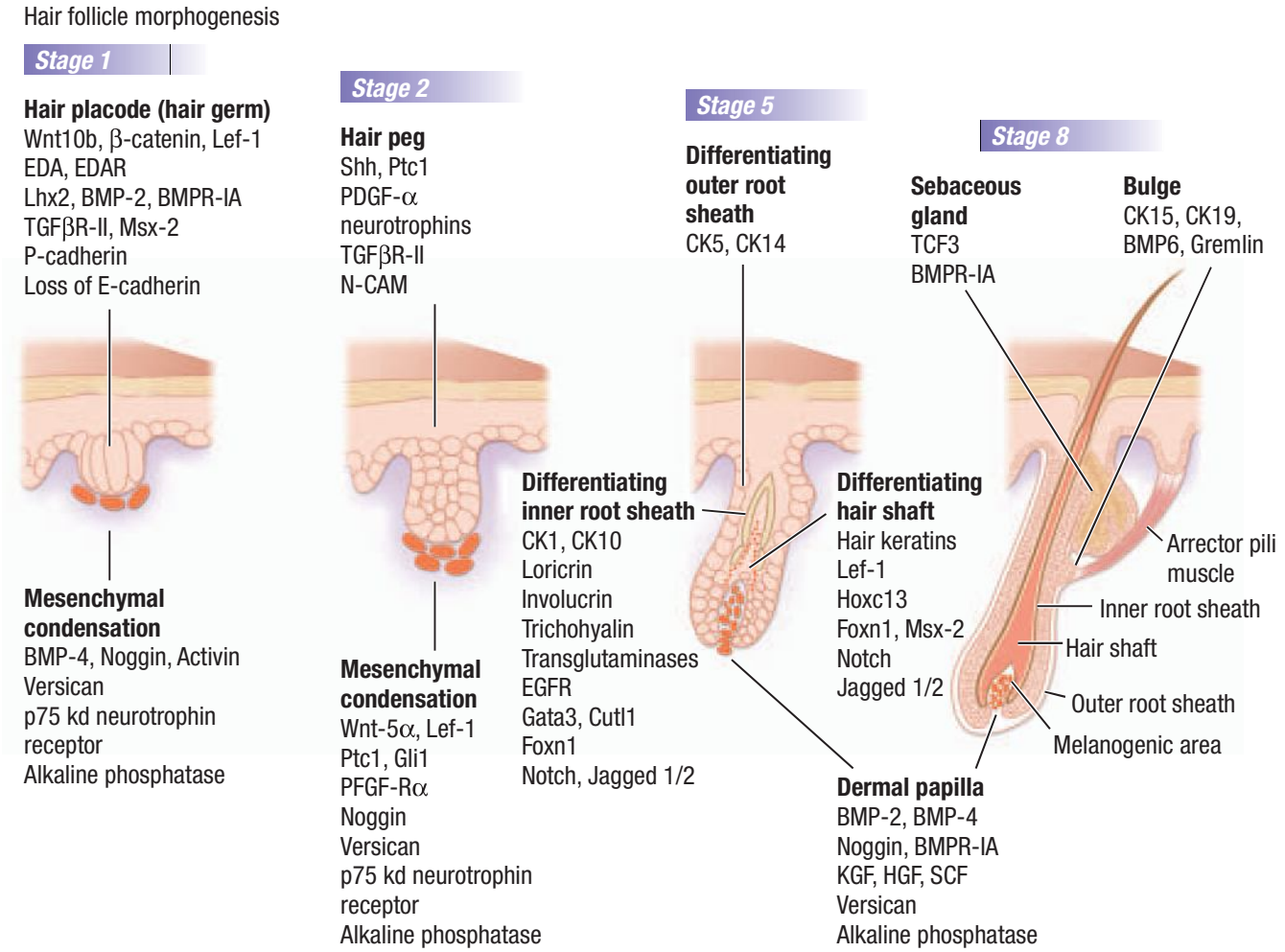

▲ **FIGURE 84-1** Molecular regulation of hair follicle morphogenesis. The scheme shows the expression of different growth factors, their receptors, adhesion, and cell matrix molecules, transcriptional regulators in hair follicle epithelium, and mesenchyme during distinct stages of hair follicle development. BMP = bone morphogenetic protein; BMPR-IA = bone morphogenetic protein receptor, type IA; CK = keratin 5; Cutl1 = cut-like 1; E-cadherin = epithelial cadherin; EDA = ectodysplasin; EDAR = ectodysplasin receptor; EGFR = epidermal growth factor receptor; Foxn1 = forkhead box N1; Gata3 = GATA binding protein 3; Gli1 = glioma-associated oncogene homolog 1; HGF = hepatocyte growth factor; Hoxc13 = homeobox C13; KGF = keratinocyte growth factor; Lef-1 = lymphoid enhancer factor 1; Lhx2 = LIM homeobox 2; N-CAM = neural cell adhesion molecule; P-cadherin = placental cadherin; PDGF-α = platelet-derived growth factor α polypeptide; PFGF-Rα = platelet-derived growth factor receptor α; Ptc1 = patched1; SCF = stem cell factor; Shh = sonic hedgehog; TCF3 = transcription factor 3; TGF-βR-II = transforming growth factor-β receptor 2.

individuals. Many of these characteristics are established during development but are then profoundly altered by hormonal influences later in life. Little is known about which genes determine hair curliness, length, volume, and appearance or which genes are responsible for conversion of one size follicle to another. Phenotypic changes in size within the same follicle occur several times throughout life. For example, lanugo hairs, which are several centimeters long, convert to vellus follicles that produce small hairs that protrude only slightly from the skin surface. Later in life, vellus follicles on the male beard enlarge into terminal follicles that generate thick, long hairs. On the scalp of genetically predisposed individuals, terminal follicles miniaturize and form effete, microscopic hairs.

Epithelial Placode or Primary Hair Germ

In the human fetus, hair follicles develop from small collections of cells, called *epithelial placodes,* which correspond to stage 1 of hair follicle development and first appear around 10 weeks' gestation (see Fig. 84-1). The epithelial placode then expands to form the "primary hair germ" whose progeny eventually generate the entire epithelial portion of the hair follicle.[23]

The cells of the hair placode and germ express placental cadherin and become oriented vertically, losing their desmosomes, hemidesmosomes, and epithelial cadherin, which decreases their adhesion to their neighbors.[24–26] Dermal cells beneath the hair placode form a cluster (or condensate), which later develops into the dermal papilla.[27]

Hair follicle formation depends on a series of mesenchymal/epithelial interactions.[27] An initial signal arises in the mesenchyme (primitive dermis) and instructs the overlying epithelium to form an appendage, indicated by the appearance of regularly spaced placodes (see Fig. 84-1). The second signal arises from the epithelial placode and causes an aggregation of cells in the underlying mesenchyme that will eventually form the dermal papilla. Finally, a signal from this primitive dermal papilla initiates prolif-

eration and differentiation of placode cells, ultimately leading to formation of a mature follicle. These reciprocal signals pass through the intervening basement membrane, which undergoes alterations in its morphology and chemical composition that may alter its ability to sequester growth factors and binding proteins, thus possibly modulating the epithelial/mesenchymal interactions.

Many of these regulatory molecules important for the formation of the hair follicle have been defined, but how they interact to generate hair follicles in an otherwise homogeneous epithelium has yet to be determined. In one model, the spacing and size of placodes are regulated by a dermal signal, which varies in character in different body regions. The dermal signal occurs uniformly within each body region and triggers the activation of promoters and repressors of follicle fate in the epithelium that then compete with one another, resulting in the establishment of a regular array of follicles.[15,28] Differences in the levels of promoter and repressor activation could account for regional differences in the size and spacing of follicles. Consistent with this model, several positive and negative regulators of hair follicle fate are initially expressed uniformly in the epidermis and subsequently become localized to placodes.

One of the earliest molecular pathways that positively regulates hair follicle initiation is the WNT/β-catenin pathway. β-Catenin is the downstream mediator of WNT signaling. WNT proteins bind to receptors on the cell membrane and, through a series of signals, inhibit the degradation of cytoplasmic β-catenin. β-Catenin then translocates to the nucleus, forming a complex with the LEF/TCF family of transcription factors and resulting in expression of downstream genes.[15,28] Activation of this β-catenin pathway appears necessary for establishing epithelial competence—a state in which the epithelial tissue has the potential to form a hair follicle. Normally, the β-catenin pathway is inactive in the adult epidermis, but by artificially activating β-catenin in epidermal basal cells of adult transgenic mice, hair follicles develop de novo.[29] This remarkable finding could eventually have therapeutic implications, although constant activation of this pathway in the hair follicle also results in pilomatricomas and trichofolliculomas, two types of relatively rare cutaneous tumors.[29,30]

Ectodysplasin (*EDA*), a molecule related to tumor necrosis factor, and its receptor (*EDAR*) also are part of another major pathway that stimulates early follicle development in both mice and humans.[31] *EDA* gene mutations cause X-linked anhidrotic ectodermal dysplasia, a syndrome associated with decreased numbers of hair follicles, and defects of the teeth and sweat glands (see Chap. 143).[32] The *EDAR* gene is mutated in autosomal recessive and dominant hypohidrotic ectodermal dysplasias, causing identical phenotypes to those resulting from *EDA* mutations. The mouse *Edar* gene is expressed ubiquitously in the epithelium before placode formation, and then becomes restricted to placodes, whereas the *Eda* gene is ubiquitously expressed even after placode formation.[33] Mice with mutations in these genes have the same phenotype as humans with similar mutations, and mice overexpressing Eda in the epidermis show formation of the "fused" follicles due to the loss of proper spacing between neighboring hair placodes.[34,35]

In contrast to EDA and EDAR, which promote hair follicle development, members of the BMP family inhibit follicle formation. *Bmp2* is expressed diffusely in the ectoderm, but then localizes to the early placode and underlying mesenchyme, while *Bmp4* is expressed in the early dermal condensate.[36,37] BMP signaling inhibits placode formation, whereas neutralization of BMP activity by its antagonist Noggin promotes placode fate, at least in part via positive regulation of lymphoid enhancer factor 1 (Lef-1) expression.[36,38–40] Mice lacking Noggin have fewer hair follicles than normal and retarded follicular development.[40] The Notch pathway also appears to play a role in determining the follicular pattern. The Notch ligand Δ-1 is normally expressed in the mesenchyme underlying the placode[41–43] and, when mis-expressed in a small part of the epithelium, promotes and accelerates placode formation while suppressing placode formation in surrounding cells.[41,44]

Another secreted protein present in the follicular placode that plays a major role in epithelial-mesenchymal signaling is sonic hedgehog (Shh).[45,46] Skin from mice lacking Shh have extremely effete hair follicles with poorly developed dermal papillae.[47–49] Patched1 (Ptc1), the receptor for Shh, is expressed in the germ cells and the underlying dermal papilla, suggesting that Shh may have both autocrine and paracrine inductive properties necessary for hair germ and dermal papilla formation.[50] Patched is the gene deficient in basal cell nevus syndrome (see Chap. 116).[19]

The Bulbous Peg or Hair Bud

In the next stage of development, the bulbous peg or hair bud (or stage 2 of hair follicle development, see Fig. 84-1) is formed by elongation of the hair germ into a cord of epithelial cells. The mesenchymal cells at the sides of the peg will develop into the fibrous sheath of the hair follicle, and those at the tip of the peg will develop into the dermal papilla. The deepest portion of the follicle peg forms a bulbous structure that surrounds the underlying mesenchymal cells destined to become the dermal papilla. These epithelial cells will become the matrix of the hair follicle, which gives rise to the hair shaft and inner root sheath. The outer root sheath forms two bulges on the side of the hair follicle forming an obtuse angle with the surface of the skin. The superficial bulge will develop into the sebaceous gland. The deeper bulge serves as the future site of epithelial stem cells that generate the new lower follicle during hair follicle cycling. The arrector pili muscle usually attaches in the bulge area, and contraction of the muscle causes a more vertical orientation of the hair shaft leading to "goose bumps." In the axillae, anogenital region, areolae, periumbilical region, eyelids (the specialized glands of Moll), and external ear canals, a third bulge develops superficial to the sebaceous gland bud and gives rise to the apocrine gland.

As the hair follicle bulb appears during the bulbous peg stage, at least eight different cell layers constituting all of the components of the mature hair follicle are formed. Understanding which genes determine specific cell lineages within the follicle is an important question. GATA-3 is important in inner root sheath differentiation.[51] Notch1, a membrane protein involved in determining cell fate through cell–cell interactions and intracellular signal transduction, and its ligands Serrate1 and Serrate2 are expressed in matrix cells destined to form the inner root sheath and hair shaft.[43,52] Notch1 appears to control the phenotype of keratinocytes as they leave the bulb matrix and differentiate into specific cell types.[53]

Mature Hair Follicle

The central lumen where the hair shaft will emerge is formed by necrosis and



cornification of epithelial cells in the infundibulum. As the hair shaft is produced, several signaling pathways are involved in the control of its differentiation. Wnt/β-catenin/Lef-1 signaling plays an important role in hair shaft formation, and ectopic expression of Wnt3 in the hair follicle outer root sheath causes hair shaft fragility.[54,55] Hair shaft keratin genes contain binding sites for Lef-1,[56] which translocates to the nucleus after activation of the WNT/β-catenin pathway. WNT signaling probably regulates expression of hair shaft keratin genes, because nearly all of these genes contain Lef-1 binding sites in their promoter regions.[57]

BMP signaling is also essential for proper differentiation of the inner root sheath and hair shaft, because conditional deletion of BMP receptor type 1A in keratinocytes results in profound alterations of the inner root sheath and hair shaft formation.[58–60] Several other putative transcription factors control hair shaft differentiation, including HOXC13,[6] a homeobox protein, and the WHN gene,[61–63] which is mutated in nude mice and rarely in humans with hair, nail, and immune defects.[64,65]

This process of hair follicle formation is repeated in several waves, with the formation of secondary follicles alongside the initial follicle. The follicles are primarily clustered into groups of three and possess an oblique orientation with a similar angle to their neighbors.

ANATOMY

Hair Types

After formation of the lanugo hair that is characteristic of the prenatal period, there are two major types of hair classified according to size (Table 84-1). Terminal hairs are typically greater than 60 μm in diameter, possess a central medulla, and can grow to well over 100 cm in length. The duration of the growing stage (anagen) determines the length of the hair. The hair bulb of terminal hairs in anagen is located in the subcutaneous fat. In contrast, vellus hairs are typically less than 30 μm in diameter, do not possess a medulla, and are less than 2 cm in length. The hair bulb of vellus hairs in anagen is located in the reticular dermis. Terminal hairs are found on the scalp, eyebrows, and eyelashes at birth. Vellus hairs are found elsewhere, and, at puberty, vellus hair follicles in the genitalia, axillae, trunk, and beard area in men transform into terminal hair follicles under the influence of sex hormones. Terminal hair follicles in the scalp convert to vellus-like or miniaturized hair follicles during androgenetic alopecia (see Chap. 86).[1,66]

TABLE 84-1
Hair Types and Characteristics

Type of Hair	Anagen Duration	Size (Diameter, Length)
Lanugo	1–3 mo	40 μm, 1–2 cm
Vellus	1–2 wk	< 30 μm, < 2 cm
Terminal	> 1 y	> 60 μm, 10– > 100 cm
Miniaturized	< 1 wk	< 30 μm, < 2 cm

The curvature of the hair varies greatly among different individuals and races, and ranges from straight to tightly curled. Curved hair shafts arise from curved hair follicles. The shape of the inner root sheath is thought to determine the shape of the hair. Curled hair in cross-section is more elliptical or flattened in comparison with straight hair, which is more round. Several genes influencing hair shape have been identified. Mutations in the epidermal growth factor receptor (EGFR) pathway and in insulin-like growth factor binding protein 5 result in curly hair in mice.[67,68]

Microscopic Anatomy

The upper follicle consists of the infundibulum and the isthmus, and the lower follicle consists of the suprabulbar and the bulbar areas (Fig. 84-2).[14,63] The upper follicle is permanent, but the lower follicle regenerates with each hair follicle cycle. The major compartments of the hair from outermost to innermost include the connective tissue sheath, the outer root sheath, the inner root sheath, the cuticle, the hair shaft cortex, and the hair shaft medulla, each characterized by distinct expression of the hair follicle–specific keratins (Table 84-2).[69,70]

OUTER ROOT SHEATH The outer root sheath is continuous with the epidermis (see Fig. 84-2) at the infundibulum and continues down to the bulb. The cells of the outer root sheath change considerably throughout the follicle. The outer root sheath in the infundibulum resembles epidermis and forms a granular layer during its keratinization. In the isthmus, the outer root sheath cells keratinize in a trichilemmal fashion, lacking a granular layer. Trichilemmal keratinization occurs where the inner root sheath begins to slough. Desmoglein expression markedly changes here as well and trichilemmal or pilar cysts retain these characteristics.[71] Keratinocytes in the outer root sheath form the bulge at the base of the isthmus (see Hair Follicle Stem Cells). These cells generally possess a higher nuclear to cytoplasmic ratio compared with other areas of the follicle. Moving downward, the outer root sheath cells become much larger and contain abundant glycogen in the suprabulbar follicle. In the bulb, the outer root sheath consists of only a single, flattened cell layer that can be traced to the base of the follicle.

INNER ROOT SHEATH The inner root sheath extends from the base of the bulb to the isthmus and contains four parts from outermost to innermost: companion layer, Henle's layer, Huxley's layer, and the inner root sheath cuticle. The companion layer (see Fig. 84-2) has been referred to as the innermost layer of the outer root sheath, but recent evidence indicates that it is more like inner root sheath than outer root sheath.[72] The companion layer attaches to Henle's layer and moves upward with the rest of the inner root sheath; thus, it provides a slippage plane between the outer root sheath, which is stationary, and the inner root sheath.[75] The companion layer is prominent in some follicles (e.g., the beard) compared with others. The cells of the companion layer are flat compared to the cuboidal outer root sheath cells and express a type II cytokeratin, K6hf.[72] Henle's layer is one-cell-layer thick and is the first to develop keratohyaline granules and the first to keratinize. Huxley's layer is two to four cell layers thick and keratinizes above Henle's layer at the region known as *Adamson's fringe*. Some cells within Huxley's layer protrude through Henle's layer and attach directly to the companion layer. These cells are called *Fluegelzellen* or *wing cells*.[73] The cells of the inner root sheath cuticle partially overlap, forming a "shingled roof" appearance, and they intertwine precisely with the cuticle cells of the hair shaft. This association between the two cuticles anchors the hair shaft tightly to the follicle. The inner root sheath, composed of hard keratins and associated proteins (see Table 84-2), is thought to

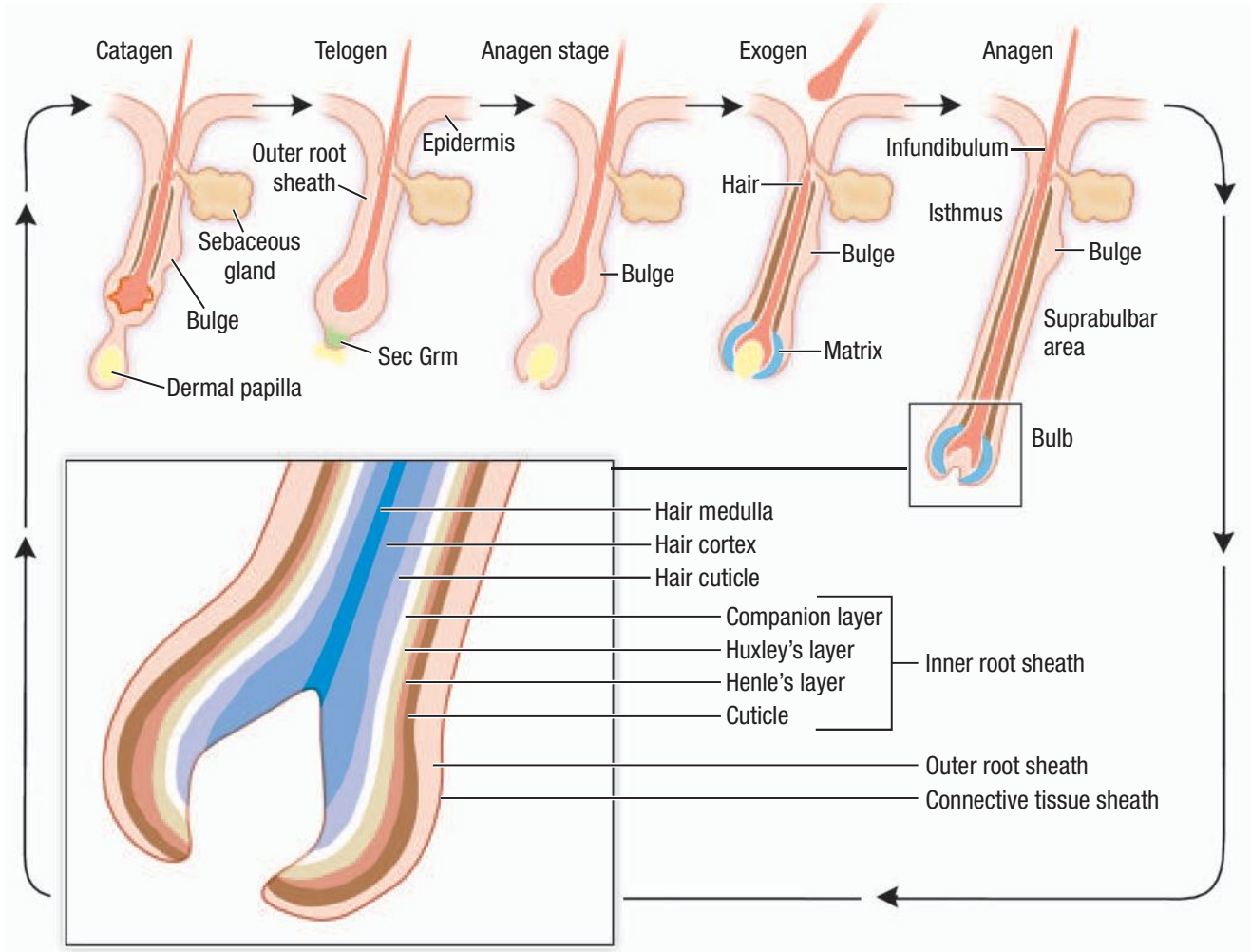

▲ **FIGURE 84-2** Hair cycle and anatomy. The hair follicle cycle consists of stages of rest (telogen), hair growth (anagen), follicle regression (catagen), and hair shedding (exogen). The entire lower epithelial structure is formed during anagen and regresses during catagen. The transient portion of the follicle consists of matrix cells in the bulb that generate seven different cell lineages, three in the hair shaft and four in the inner root sheath. B = bulge; E = epidermis; DP = dermal papilla; H = hair shaft; M = matrix; ORS = outer root sheath; S = sebaceous gland; Sec Grm = secondary germ.

TABLE 84-2
Expression of Keratin Genes in Distinct Hair Follicle (HF) Compartments

HF Compartments	Type I Keratins, New Nomenclature (Old Nomenclature)	Type II Keratins, New Nomenclature (Old Nomenclature)
Outer root sheath	K14 (K14), K15 (K15), K16 (K16), K17 (K17), K19 (K19)	K5 (K5)
Inner root sheath, companion layer	K16 (K16), K17 (K17)	K75 (K6hf), K6 (K6)
Hair matrix/precortex	K35 (Ha5)	K85 (Hb5)
Inner root sheath, Henle's layer	K25 (K25irs1), K27 (K25irs3), K28 (K25irs4)	K71 (K6irs1)
Inner root sheath, Huxley's layer	K25 (K25irs1), K27 (K25irs3), K28 (K25irs4)	K71 (K6irs1), K74 (K6irs4)
Inner root sheath, cuticle	K25 (K25irs1), K26 (K25irs2), K27 (K25irs3), K28 (K25irs4)	K71 (K6irs1), K72 (K6irs2), K73 (K6irs3)
Hair, cuticle	K32 (Ha2), K35 (Ha5)	K82 (Hb2), K85 (Hb5)
Hair, mid-/upper cortex	K31 (Ha1), K33a (Ha3-I), K33b (Ha3-II), K34 (Ha4), K35 (Ha5), K36 (Ha6), K37 (Ha7), K38 (Ha8)	K81 (Hb1),[a] K83 (Hb3), K85 (Hb5), K86 (Hb6)[a]
Hair, medulla	K16 (K16), K17 (K17), K25 (K25irs1), K27 (K25irs3), K28 (K25irs4), K33 (Ha3), K34 (Ha4), K37 (Ha7)	K5 (K5), K6 (K6), K75 (K6hf), K81 (Hb1)[a]

[a]Autosomal dominant mutations of K81 and K86 lead to monilethrix (alopecia due to increased hair fragility).

From Langbein L et al: K25 (k25irs1), K26 (k25irs2), k27 (k25irs3), and k28 (k25irs4) represent the type I inner root sheath keratins of the human hair follicle. *J Invest Dermatol* **126**:2377, 2006; and Langbein L, Schweizer J: Keratins of the human hair follicle. *Int Rev Cytol* **243**:1, 2005, with permission.

dictate hair shape by funneling the hair shaft cells as they are produced. The transcription factor, GATA-3, is critical for inner root sheath differentiation and lineage. Mice lacking this gene fail to form an inner root sheath.[51]

HAIR SHAFT The hair shaft (and inner root sheath) arises from rapidly proliferating matrix keratinocytes in the bulb, which have one of the highest rates of proliferation in the body. The cells of the future hair shaft are positioned at the apex of the dermal papilla and will form the medulla, cortex, and hair shaft cuticle (see Fig. 84-2). Immediately above the matrix cells, hair shaft cells begin to express specific hair shaft keratins in the prekeratogenous zone. The differentiation of hair shaft cells in this zone is dependent on the Lef-1 transcription factor. Lef-1 binding sites are present in most hair keratin genes. BMP receptor type 1a is also critical for matrix cell differentiation into the hair shaft, because loss of this receptor prevents hair shaft differentiation.[58–60]

The hair shaft cuticle covers the hair, and its integrity and properties greatly impact the appearance of the hair. Once the hair exits the scalp, the cuticle endures weathering, and it is often completely lost at the distal ends of long hairs. Inside the cuticle, the cortex comprises the bulk of the shaft and contains melanin. The cortex is arranged in large cable-like structures called *macrofibrils*. These, in turn, possess microfibrils that are composed of intermediate filaments. The medulla sits at the center of larger hairs, and specific keratins expressed in this layer of cells (see Table 84-2) are under the control of androgens.[74]

DERMAL PAPILLA The dermal papilla (see Fig. 84-1) is a core of mesenchymally derived tissue enveloped by the matrix epithelium. It is comprised of fibroblasts, collagen bundles, a mucopolysaccharide-rich stroma, nerve fibers, and a single capillary loop. It is continuous with the perifollicular sheath (dermal sheath) of connective tissue that envelops the lower follicle.

Tissue recombination experiments have shown that the dermal papilla has powerful inductive properties, including the ability to induce hair follicle formation when transplanted below non–hair-bearing footpad epidermis.[75,76] This shows that the tissue patterning established during the fetal period can be altered under appropriate conditions. In human follicle, the volume of the dermal papilla correlates with the number of matrix cells and the resulting size of the hair shaft.[77] In mice, sizes of the hair bulb and hair diameter strongly depend of the proliferative activity of the matrix keratinocytes.[78]

Many soluble growth factors originate from the dermal papilla that appear to act in a paracrine manner on the overlying epithelial matrix cells. Specifically, keratinocyte growth factor (KGF) is produced by the anagen dermal papilla, and its receptor, fibroblast growth factor receptor 2 (FGFR2), is found predominantly in the matrix keratinocytes. Injections of KGF into nude mice produce striking hair growth at the site of injection,[79] suggesting that KGF is perhaps necessary for hair growth and cycling. Surprisingly, however, KGF knockout mice develop morphologically normal hair follicles that produce "rough" or "greasy" hair; thus KGF's effects on hair follicle morphogenesis and cycling appear dispensable or replaceable by other growth factors with redundant functions.[80]

HAIR FOLLICLE INNERVATION Myelinated sensory nerve fibers run parallel to hair follicles, surrounding them and forming a network (reviewed in ref. 81). Smaller nerve fibers form an outer circular layer, which is concentrated around the bulge of terminal follicles and the bulb of vellus follicles. Several different types of nerve endings, including free nerve endings, lanceolate nerve endings, Merkel cells, and pilo-Ruffini corpuscles are found around hair follicles.[82] Each nerve ending detects different forces and stimuli. Free nerve endings transmit pain, lanceolate nerve endings detect acceleration, Merkel cells sense pressure, and pilo-Ruffini structures detect tension. Perifollicular nerves contain neuromediators and neuropeptides, such as substance P or calcitonin gene–related peptide, that influence follicular keratinocytes and alter hair follicle cycling.[83–87] Conversely, hair follicle keratinocytes produce neurotrophic factors that influence perifollicular nerves and stimulate their remodeling in hair cycle-dependent manner.[87,88] Merkel cells that are considered neuroendocrine cells also produce neurotrophic factors, cytokines, or other regulatory molecules. Because Merkel cells are concentrated in the bulge area, some have postulated that these secreted factors may influence the cycling of the hair follicle.[89]

PERIFOLLICULAR SHEATH The perifollicular sheath envelops the epithelial components of the hair follicle and consists of an inner basement membrane called the *hyaline* or *vitreous (glassy) membrane* and an outer connective tissue sheath. The basement membrane of the follicle is continuous with the interfollicular basement membrane. It is most prominent around the outer root sheath at the bulb in anagen hairs. During catagen, the basement membrane thickens and then disintegrates.

Surrounding the basement membrane is a connective tissue sheath comprised primarily of type III collagen. Around the upper follicle, there is a thin connective tissue sheath continuous with the surrounding papillary dermis and arranged longitudinally. Around the lower follicle, the connective tissue sheath is more prominent, with an inner layer of collagen fibers that encircle the follicle surrounded by a layer of longitudinally arranged collagen fibers.[63]

When transplanted under the skin, this perifollicular connective tissue has the remarkable ability to form a new dermal papilla and induce new hair follicle formation.[90] Even when the connective tissue sheath is transplanted to another individual, these follicles survive without evidence of immunologic rejection.

HAIR FOLLICLE CYCLE

Each individual hair follicle perpetually traverses through three stages: growth (anagen), involution (catagen), and rest (telogen).[12] The length of anagen determines the final length of the hair and thus varies according to body site; catagen and telogen duration vary to a lesser extent depending on site. Scalp hair has the longest anagen of 2 years to more than 8 years. Anagen duration in young males at other sites is shorter: legs, 5 to 7 months; arms, 1.5 to 3.0 months; eyelashes, 1 to 6 months; and fingers, 1 to 3 months. In contrast to most mammals, including mice and newborn humans, in the adult human the hairs of the scalp grow asynchronously. Approximately 90 percent to 93 percent of scalp follicles are in anagen and the rest primarily in telogen.[91] Applying these figures to the 100,000 to 150,000 hairs on the scalp indicates that approximately 10,000 scalp hairs are in telogen at any given time. However, because we lose only 50 to 100 hairs per day, this indicates that telogen is a heterogenous state. The follicles that are shedding their hair shaft are thus in "exogen," which comprises approximately 1 percent of the telogen hair follicles



(see Fig. 84-2). Hair on the scalp grows at a rate of 0.37 to 0.44 mm/day or approximately 1 cm/month.

Hair Follicle Stem Cells

Because the lower portion of the follicle cyclically regenerates, hair follicle stem cells were thought to govern this growth. Historically, hair follicle stem cells were assumed to reside exclusively in the "secondary germ" (see Fig. 84-2), which is located at the base of the telogen hair follicle. It was thought that the secondary germ moved downward to the hair bulb during anagen and provided new cells for production of the hair. At the end of anagen, the secondary germ was thought to move upward with the dermal papilla during catagen to come to rest at the base of the telogen follicle. This scenario of stem cell movement during follicle cycling was brought into question when a population of long-lived presumptive stem cells was identified in an area of the follicle surrounding the telogen club hair.[92] Subsequently, it was shown that the secondary germ is a transient structure that forms at the end of catagen from cells in the lower bulge.[93] The concept that hair follicle stem cells are permanently located in the bulge has now been confirmed using lineage analysis, which showed that the bulge cells give rise to all epithelial layers of the hair follicle.[11,94,95] In line with this, ablation of bulge cells results in destruction of the follicle.[93] These findings support the notion that loss of hair follicle stem cells in the bulge leads to permanent or cicatricial types of alopecia.

Are bulge cells the "ultimate" stem cells within the skin epithelium? For example, do they generate epidermis and sebaceous glands during homeostasis and after wounding? To answer these questions, lineage analysis and transgenic techniques were again used. As illustrated in Fig. 84-3, bulge cells do not normally move to the epidermis, but after full-thickness excision of the skin, bulge cell progeny migrate into the wound during reepithelialization.[11,93] These cells comprise approximately 30 percent of the cells in the regenerated epidermis. The role of bulge cells in sebaceous gland maintenance is still not clear, but is under investigation.

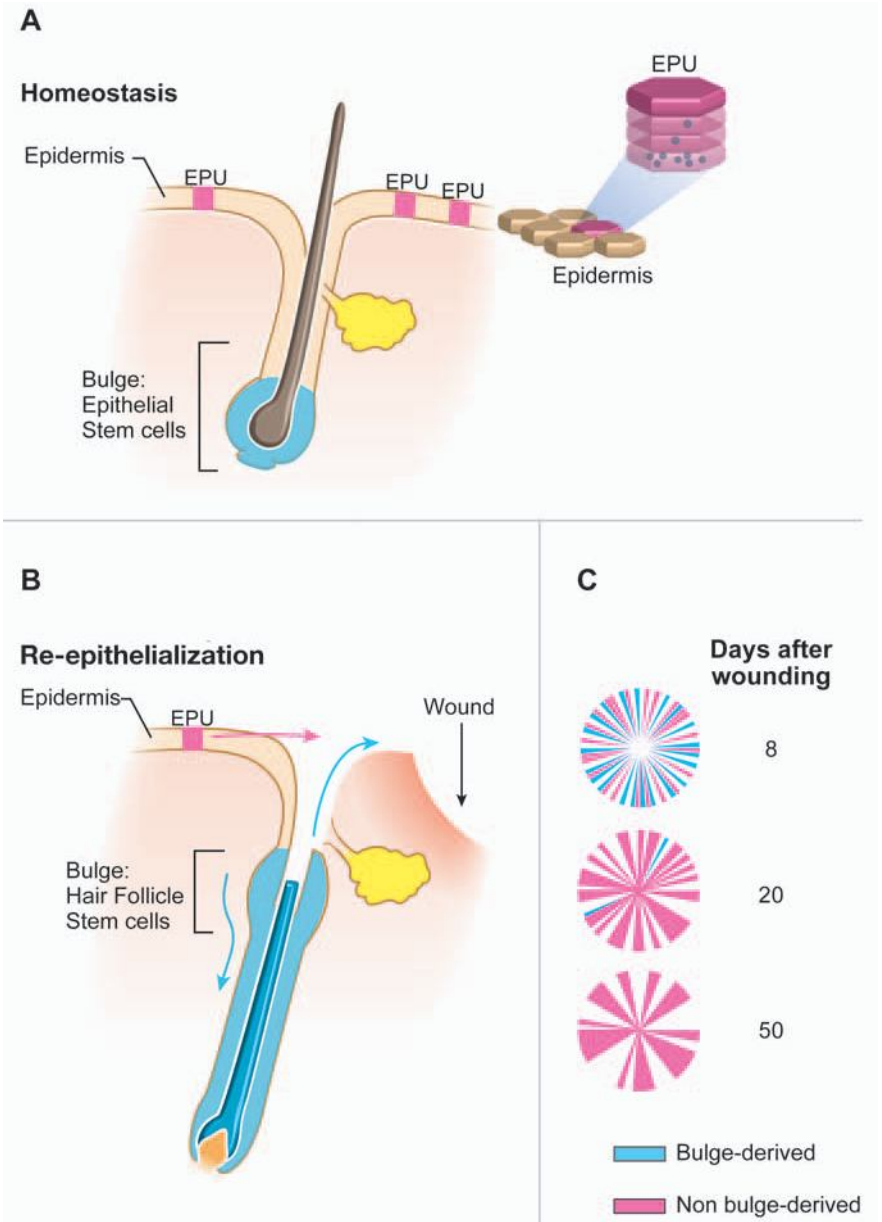

▲ **FIGURE 84-3** Relationship between epidermal and hair follicle stem cells during homeostasis and after wounding. **A.** During normal conditions, epidermal renewal is dependent on cell proliferation within epidermal proliferative units (EPUs), which are clonal populations of cells roughly arranged in hexagonally shaped columns that produce a single outer squame. Epithelial stem cells in the hair follicle bulge do not contribute to epidermal renewal. **B.** After full-thickness wounding, bulge cells contribute cells to the epidermis for immediate wound closure (*blue upward arrow*). Bulge cells also are required for hair follicle cycling (*blue downward arrow*) **C.** Over time, bulge-derived cells diminish, whereas non-bulge–derived cells (from the interfollicular epidermis and infundibulum) appear to predominate in the re-epithelialized wound.

Anagen

The formation of a new lower follicle and hair at anagen onset recapitulates folliculogenesis in the fetus. Anagen can be divided into seven stages: stage I—growth of the dermal papilla and onset of mitotic activity in the germ-like overlying epithelium; stage II—bulb matrix cells envelop the dermal papilla and begin differentiation, evolving bulb begins descent along the fibrous streamer; stage III—bulb matrix cells show differentiation into all follicular components; stage IV—matrix melanocytes reactivate; stage V—hair shaft emerges and dislodges telogen hair; stage VI—new hair shaft emerges from skin surface; and stage VI—stable growth.[96]

During proliferation and migration of keratinocytes into the dermis to reform the new lower follicle, enzymes such as proteases and collagenases appear at the leading edge of the downgrowth, and growth factors and their receptors are upregulated similar to an epithelial wound.[12] Pathways of keratinocyte differentiation that are seen in the epider-

mis during wound healing, such as expression of keratin 6, are activated. Mice lacking Stat3, a regulator of cell migration in the cutaneous epithelium, show defects in wound healing and a failure of hair follicles to enter anagen,[97] thus further illustrating the similarity between wound healing and the early events of anagen. Remarkably, the dermal papilla in the midst of this degradative milieu survives and moves downward. Neurocutaneous and vascular networks are remodeled.[88,92] Melanocytes proliferate and repopulate the new hair bulb.[98] Finally, a burst of endothelial proliferation and angiogenesis in the dermal papilla marks the time point when the lower follicle is completely restored and is actively producing the new hair shaft.[99]



Catagen

The onset of catagen is marked by cessation of the mitotic activity of the matrix cells and by well-coordinated apoptosis in the cyclic portion of the hair follicle (reviewed in refs. 12 and 100). Pigment production by melanocytes ceases before matrix cell proliferation stops, thus leading to a non-pigmented proximal end in the telogen club hair (see Fig. 84-2). Melanin is often found in the surrounding dermis and papilla where it is engulfed by macrophages. The perifollicular sheath collapses, and the vitreous or glassy membrane thickens. The lower follicle retracts upward with the dermal papilla. The perifollicular sheath forms a fibrous streamer comprised of fibroblasts, small blood vessels, and collagen.[1] Eventually, the dermal papilla becomes situated immediately below the bulge at the lower portion of the isthmus.

During catagen, the largest follicles, on the scalp for example, shorten their length from 2- to 5-mm-long structures whose deepest portion, the bulb, extends down into the subcutaneous fat to truncated 0.25- to 0.5-mm follicles in telogen. As the basement membrane around the lower follicle thickens, the dermal papilla, protected from the surrounding apoptosis and destruction (perhaps because it expresses Bcl-2, an anti-apoptotic factor[12]) condenses and begins to move upward to come to rest below the bulge during telogen. The migration of the dermal papilla from the subcutaneous fat to the dermis during catagen is necessary for continued follicle cycling. This is illustrated by the syndrome of atrichia with papules.[101,102] These patients have mutations in either their hairless gene or in their vitamin D receptor gene, in which case they also have rickets. Mice with similar mutations have the hairless phenotype. We know from these mice that folliculogenesis is normal; however, when the follicles enter catagen for the first time, the lower portion of the follicle does not involute and contract properly, and the dermal papilla remains stranded in the subcutaneous fat.[92] Although bulge cells are still present, no new anagen follicles ever form, presumably because the stem cells cannot interact with the dermal papilla.[92]

The study of mouse mutants has also resulted in several key findings that have increased our understanding of the molecular events at catagen onset. Specifically, Hebert et al.[3] discovered that mice lacking the *Fgf5* gene have hair that is 50 percent longer than their wild-type litter mates, and that mutations in this gene are responsible for the angora phenotype that was described more than 30 years ago. Although these findings were rather unexpected, careful evaluation of *Fgf5* expression throughout the normal hair cycle demonstrated that its expression was upregulated in the outer root sheath and hair matrix cells just before the onset of catagen, suggesting that *Fgf5* may trigger catagen onset. Interestingly, the follicle still eventually entered catagen, even in the absence of FGF-5, suggesting redundancy in the FGF-5 pathway or an intrinsic finite proliferative capability of the matrix cells.[92] Further studies also demonstrated that other FGF family members and their receptors are expressed during anagen, and probably also play a role in the hair follicle cycle.[103] The hair phenotype of FGF-5–deficient mice is substantially reversed by ectopic expression of the anti-apoptotic gene *bcl-xL*$_x$ in the outer root sheath, suggesting that regulation of cell survival in the outer root sheath may play a role in control of the hair growth cycle.[104]

Although it has been known for many years that exogenous EGF administered to sheep results in catagen induction,[105] only through more recent transgenic and knockout studies in mice has the importance of the EGFR system in hair cycle regulation been realized.[67,106] For example, knockout mice lacking transforming growth factor-α (TGF-α), the major ligand for EGFR, have abnormal hair follicle development and manifest the waved hair phenotype.[4,5] When EGFR is functionally downregulated in the basal layer of the epidermis and hair follicle using a dominant negative transgenic strategy, the resulting hair is not only waved, but also longer than normal.[67] The transition of the hair follicles from anagen to catagen is delayed in these mice. Hair follicles in mouse skin that completely lack EGFR also do not progress from anagen to telogen.[106] Thus, EGFR and its ligand are required for normal hair follicle development and cycling. Given the complexity of the EGFR family, which includes four receptors (ErbB1–4) and at least six ligands, future studies are needed to clarify the role of individual family members in hair follicle cycling.[107]

In addition to FGF-5 and EGF, neurotrophins and TGF-β1 induce premature catagen. Neurotrophin-3 and brain-derived neurotrophic factor transgenic mice show premature catagen development, and brain-derived neurotrophic factor overexpression leads to the shortening of hair length by 15 percent, most likely via stimulation of pro-apoptotic signaling through p75 kd neurotrophin receptor.[108,109] TGF-β1 induces premature catagen in isolated human hair follicles and in mouse skin in vivo, and TGF-β1 knockout mice display delay in catagen onset.[110–112]

Telogen and Exogen

Once the involution of catagen is complete and a club hair is formed (see Fig. 84-2), the hair follicle prepares the hair for expulsion from the scalp. About 1 percent of telogen follicles are shed each day. Milner et al.[113] have proposed distinguishing hair shedding as a separate phase called *exogen*. Exogen is a highly controlled and timed event in mammals that shed on a seasonal basis. That exogen is an active stage is supported by Headington's description of one type of telogen effluvium he termed *immediate telogen release*.[114] This type of hair loss can be seen soon after starting medications, such as minoxidil, or in response to rapid fluctuations in light/dark cycles. It consists of an increase in shedding of club hairs within weeks of the precipitating event (too soon to be caused by follicles prematurely entering telogen from anagen), suggesting that club hairs that are normally retained in the follicle can be actively shed. The heterogeneity of telogen is further supported by the work of Guarrera and Rebora,[115] who followed individual hairs in situ using macrophotographs for more than 2 years and showed that several months could transpire between hair shedding and regrowth. This "lag period" is nor-

mally not present or is very short, but often lasts several months in patients with androgenetic alopecia.

HAIR PIGMENTATION

Hair becomes pigmented as a result of a tightly coordinated program of melanin synthesis and transport from the hair bulb melanocytes to differentiating hair shaft keratinocytes.[116–118] This process is strictly coupled to anagen and ceases during catagen and telogen. Numerous signaling molecules, structural proteins, enzymes, co-factors, and transcriptional regulators control hair pigmentation (Figs. 84-4 and 84-5).[116,118,119]

Hair Melanocyte Development

Melanoblasts can be identified in the epidermis of human embryos at 50 days of estimated gestational age before the onset of hair follicle morphogenesis.[120–122] These follicular melanocytes originate in the neural crest and migrate first to the dermis and then epidermis.[123] Commitment of neural crest cells to the melanocyte lineage is regulated by Pax3 and microphthalmia transcription factors (Mitf), which stimulate the expression of dopachrome tautomerase [or tyrosinase-related protein 2 (Trp2)], an enzyme involved in melanin biosynthesis that also functions as an early melanoblast marker.[122] Subsequent steps of melanoblast development (migration into the dermis and epidermis) are controlled by signaling mechanisms activated through endothelin receptor type B and c-kit oncogene (c-kit) receptor, which are mutated in humans with Hirschprung disease and piebaldism, respectively, resulting in formation of unpigmented hairs.[123]

After entering the placode of the developing hair follicle, melanoblasts proliferate and become melanogenically active synchronously with the onset of hair fiber formation.[124] Experimental and genetic data suggest that migration of melanoblasts into the hair follicle and their development toward melanogenically active forms depend on stem cell factor (SCF)/c-kit signaling. SCF is a ligand that binds to its receptor, c-kit. Pharmacologic blockade of c-kit during embryogenesis, as well as genetic ablation of SCF or c-kit in corresponding mouse mutants results in unpigmented hairs.[125–127]

Hair Follicle Melanocyte Stem Cells and Pigment-Producing Melanocytes

MSCs located in the hair follicle bulge generate progeny that repopulate the melanocytes in the new hair bulb formed at the onset of anagen.[97,128] MSCs express Trp2, Bcl-2, Pax3, while other melanogenic enzymes (tyrosinase, Trp1) and signaling molecules (c-kit, endothelin receptor type B, SOX10, Mitf and Lef-1)[129] are expressed at low levels. MSCs can be first detected in the bulge area during late stages of hair follicle morphogenesis and similarly to epithelial stem cells they show bromodeoxyuridine-retaining capacity.[128–130] Bcl-2 plays a key role in maintenance of MSCs, and Bcl-2 knockout mice show progressive hair graying due to the depletion of MSCs.[129–132] However, Bcl-2 deficiency may be compensated by overexpression of SCF, which rescues loss of MSCs in the hair follicle bulge of Bcl-2 knockout mice.[129]

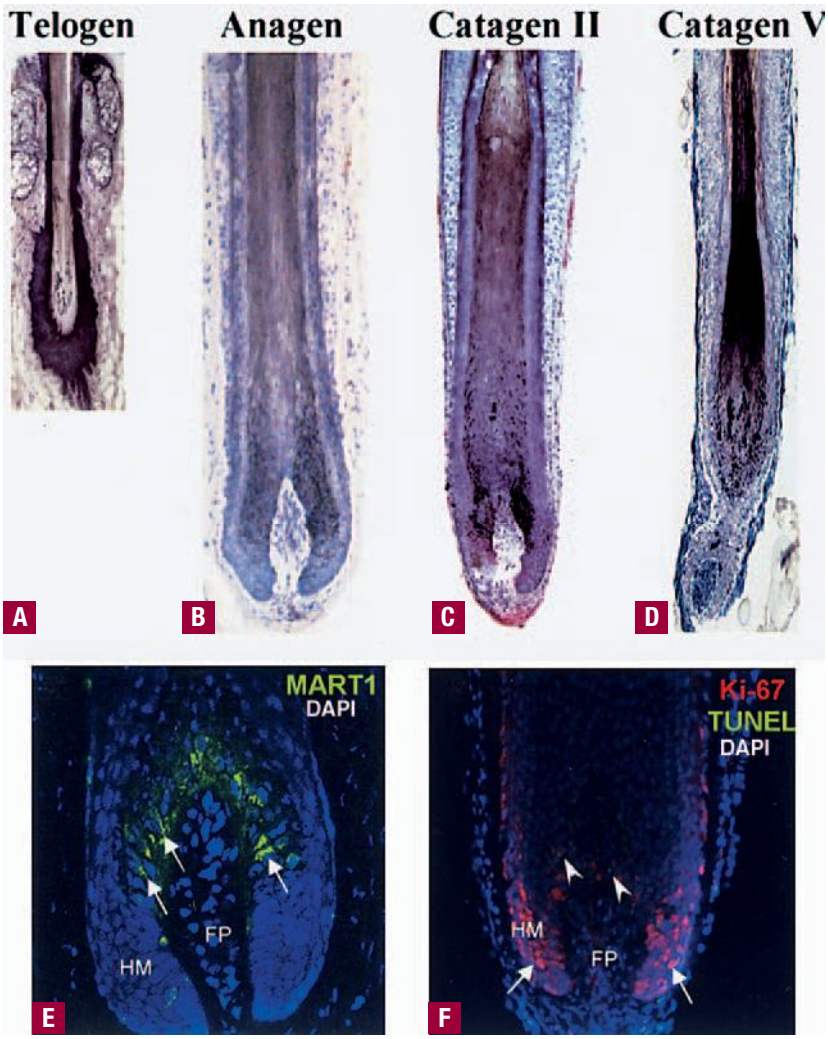

▲ **FIGURE 84-4** Morphology and fluorescent microscopy of human hair follicle at distinct hair cycle stages. **A–D**. Morphology of human hair follicle during telogen (**A**), late anagen (**B**), and early and late catagen (**C**, **D**). **E.** Immunofluorescent visualization of the melanocytes (*arrows*) in the hair bulb of late anagen hair follicle with anti–melanoma-associated antigen recognized by T cells antibody. **F.** Immunofluorescent detection of proliferative marker Ki-67 (*arrows*) and apoptotic TUNEL+ cells (*arrowheads*) in early catagen hair follicle. FP = follicular papilla; HM = hair matrix.

Melanogenically active melanocytes are located in the hair bulb above the dermal papilla.[98,118] These cells synthesize and transport melanin to hair shaft keratinocytes and express a full set of enzymes and other proteins involved in melanin biosynthesis including tyrosinase, Trp1, Trp2 (in mice), and pMel17 (in humans).[99,129]

Hair Cycle–Dependent Changes in Melanocytes

Hair follicle melanocytes undergo substantial remodeling during hair follicle cycling.[98,118] In telogen, hair follicle melanocytes are found in the bulge, secondary hair germ, and connective tissue.[98] In humans, melanocytes in the telogen hair follicle do not express Trp1 or tyrosinase



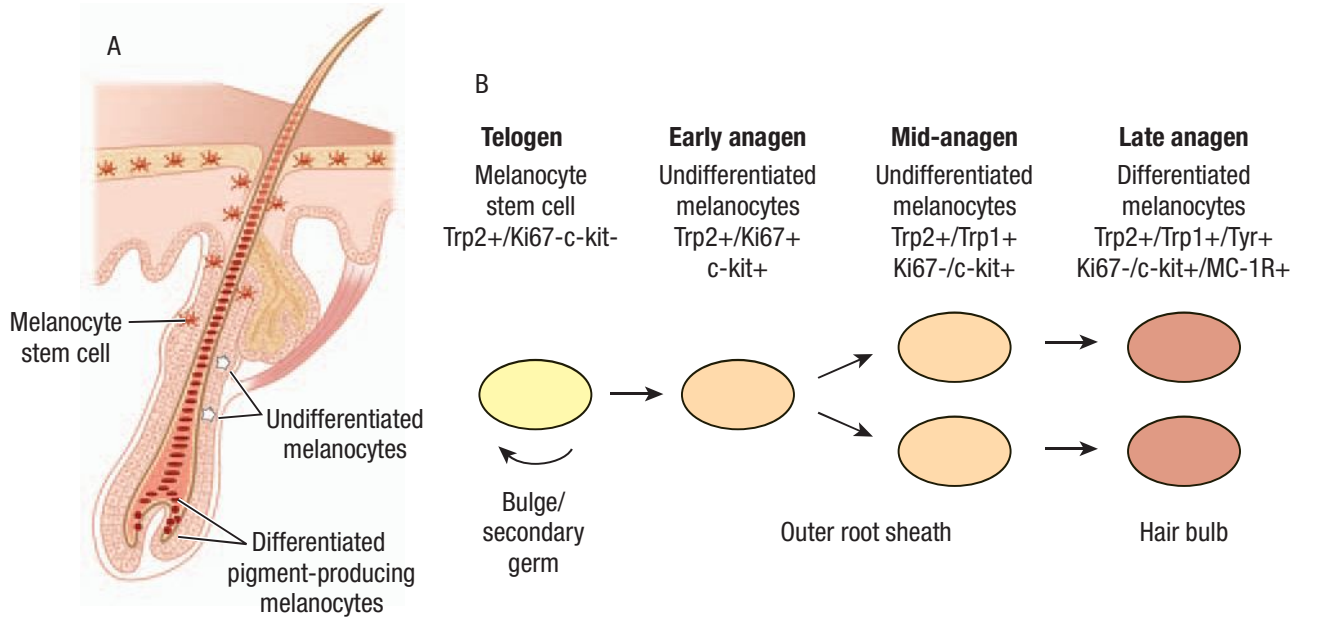

▲ **FIGURE 84-5** Hair cycle–dependent remodeling of the follicular pigmentary unit. **A.** Scheme illustrating localization of distinct sub-populations of melanocytes in anagen hair follicle. **B.** Dynamics of the follicular melanocytes during anagen. Expression of melanogenic markers and growth factor receptors indicated is based on the data obtained from murine hair follicles. Note that human follicular melanocytes do not express tyrosinase-related protein 2 (Trp2). c-kit = c-kit oncogene. (From Ando H et al: Fatty acids regulate pigmentation via proteasomal degradation of tyrosinase: A new aspect of ubiquitin-proteasome function. *J Biol Chem* **279**:15427, 2004, with permission.)

and do not proliferate. Melanocytes can be visualized by expression of pMel17.[133] Some of these cells also express c-kit receptor, whereas others remain c-kit-negative and represent MSCs.[98,128,129]

During early anagen, resting melanocytes proliferate, differentiate, and migrate within the hair follicle synchronously with regeneration of the hair follicle bulb. Hair follicle melanocytes are maximally proliferative during early and mid-anagen, and their transition to melanogenic competence is accompanied by the appearance of Trp1 and tyrosinase proteins.[98,134]

Similar to embryonic and early postnatal development, SCF/c-kit signaling plays a critical role in repopulation of the bulb with pigment-producing melanocytes. C-kit is expressed on proliferating, differentiating, and melanogenically active melanocytes, whereas overexpression of SCF in the epidermis of transgenic mice significantly increases the number of hair follicle melanocytes and their proliferative activity.[98] Similarly, administration of the ACK45 antibody blocking c-kit signaling dramatically reduces melanocyte number in anagen hair follicles, resulting in hair depigmentation.[98] However, in the next hair cycle, the previously treated animals grow fully pigmented hairs with the normal number and distribution of melanocytes, suggesting that MSCs are not dependent on SCF/c-kit.[98]

During catagen, melanogenic activity in the follicular melanocytes abruptly ceases. Immunohistochemical and electron microscopic data suggest that some pigment-producing melanocytes located above the follicular papilla undergo apoptosis, while others drop into the dermal papilla of the follicle.[135,136]

Molecular Control of Hair Color

Follicular melanocytes synthesize pigment via a cascade of enzymatic conversions of phenylalanine or tyrosine into brown-black eumelanin or yellow pheomelanin that requires melanogenic enzymes (tyrosinase, Trp1/2, γ-glutamyl transpeptidase, peroxidase) and essential co-factors, such as 6-tetrahydrobiopterin.[116,135] The balance between black and yellow pigment synthesis (eumelanin and pheomelanin, respectively) is regulated by signaling through the melanocortin type 1 receptor (MC-1R) that has long been implicated in the control of hair color.[137,138]

After binding to MC-1R, α melanocyte-stimulating hormone (α-MSH) stimulates adenylyl cyclase, resulting in elevation of intracellular cyclic adenosine monophosphate levels. This leads to increase of transcriptional activity of Mitf that stimulates synthesis of melanogenic enzymes (tyrosinase, Trp1/2) involved in eumelanin formation.[139,140] Pheomelanin synthesis in the hair follicle melanocytes of mice occurs when MC-1R signaling is inhibited by Agouti signal protein (ASP) that competes with α-MSH in binding to MC-1R.[138,139] In mice, ASP expression is positively regulated by BMP signaling, and transgenic mice overexpressing BMP antagonist Noggin show hair darkening.[141] Although ASP is expressed in human skin, its role in human pigmentation remains unclear.[140]

Recent data also demonstrate existence of fully functional proopiomelanocortin/MC-1R system in human hair follicles: MC-1R is expressed by hair follicle melanocytes, whereas its ligands α-MSH and adrenocorticotropic hormone are able to promote proliferation, dentricity, and melanogenesis.[142] Similar effects are seen with another proopiomelanocortin-derived peptide, β-endorphin that interacts with μ-opiate receptor expressed by hair follicle melanocytes.[142] However, signaling through the μ-opiate receptor may regulate hair pigmentation via modulating the activity of protein kinase C-β, a known positive regulator of melanogenesis.[143]

CONCLUSION

The hair follicle is formed as the result of a complex interplay of signals between epithelium and mesenchyme. The nature of these signals is just now being elucidated, with many molecular pathways important in development also playing roles in hair follicle formation. The product of this process is a miniature organ with distinctive vertical and concentric divisions. Both epithelial stem cells and MSCs in the follicle are important for the constant regeneration of the follicle.

KEY REFERENCES

The full reference list for all chapters is available at www.digm7.com.

1. Cotsarelis G, Millar SE: Towards a molecular understanding of hair loss and its treatment. *Trends Mol Med* **7**:293, 2001
11. Cotsarelis G: Epithelial stem cells: A folliculocentric view. *J Invest Dermatol* **126**:1459, 2006
12. Stenn KS, Paus R: Controls of hair follicle cycling. *Physiol Rev* **81**:449, 2001
15. Millar SE: Molecular mechanisms regulating hair follicle development. *J Invest Dermatol* **118**:216, 2002
16. Schmidt-Ullrich R, Paus R: Molecular principles of hair follicle induction and morphogenesis. *Bioessays* **27**:247, 2004
27. Hardy MH: The secret life of the hair follicle. *Trends Genet* **8**:55, 1992
70. Langbein L, Schweizer J: Keratins of the human hair follicle. *Int Rev Cytol* **243**:1, 2005
81. Paus R et al: Neural mechanisms of hair growth control. Review. *J Invest Dermatol Symp Proc* **2**:61, 1997
100. Botchkareva NV, Ahluwalia G, Shander D: Apoptosis in the hair follicle. *J Invest Dermatol* **126**:258, 2006

CHAPTER 85

Keratosis Pilaris and Other Inflammatory Follicular Keratotic Syndromes

Maureen Rogers

Follicular keratosis refers to orthokeratosis involving the follicular ostium and infundibulum. Horny plugs protrude from the orifices, producing a rough sensation on palpation of the skin. It may be isolated [as in standard keratosis pilaris (KP)] or associated with other pathologic processes, including follicular inflammation, atrophy, scarring, and alopecia [keratosis pilaris atrophicans (KPA)]. These are reaction patterns that occur alone or as part of a wide variety of syndromes.

KERATOSIS PILARIS

Isolated typical KP is a common condition of keratotic follicular plugging with varying degrees of surrounding erythema. Sometimes, the erythema is so striking that it is the main complaint. The clinical expression of KP varies from very subtle to very conspicuous, which, along with possible racial differences, may explain the great range of reported prevalences, from 1 percent to 42 percent.[1–4] It involves, particularly, the extensor aspects of the upper arms (Fig. 85-1) and thighs as well as the face but may rarely be more extensive, extending to the distal limbs and even the trunk. There seem to be two patterns. The more common one is commencement in early childhood, in most cases before 2 years of age, with face and arms mainly affected and gradual improvement in most cases by later childhood or adolescence. In the other pattern, the onset is in teenage years, and the extensor arms and legs are predominantly involved. It usually improves by the mid-20s. In both patterns, however, the condition may be persistent into later adult life.[5] The histopathologic pattern in skin biopsy specimens is nonspecific, simply showing the follicular orifice distended by a keratin plug.

Treatment is usually with various keratolytics, from simple urea, lactic acid, or salicylic acid preparations to topical retinoids and tazarotene.[6] These preparations may aggravate associated erythema, limiting their value.



◀ **FIGURE 85-1** Keratosis pilaris in a characteristic distribution on upper outer arm in a patient with ichthyosis vulgaris.

KERATOSIS PILARIS AT A GLANCE



- Common condition of keratotic follicular plugging with variable erythema.
- Mainly involves cheeks and extensor arms and thighs.
- Two main patterns—early childhood onset and adolescent onset.
- Usually improves gradually over years.
- Non-specific histology of follicular orifice distended by keratin plug.
- Variable response to keratolytics.
- Erythromelanosis follicularis faciei et colli is a variant with marked erythema and hyperpigmentation.

Erythromelanosis Follicularis Faciei et Colli

Erythromelanosis follicularis faciei et colli is a condition probably related to KP.[7] It is seen primarily in adolescents and young adults, most commonly in males. Well-demarcated erythema, hyperpigmentation, and follicular papules involve the preauricular and maxillary areas, usually in a symmetric distribution, with spread in some cases to the temples and sides of the neck. Atrophy is not a feature. Histopathology is nonspecific, demonstrating a variable de-

KERATOSIS PILARIS ATROPHICANS AT A GLANCE



- A group of rare follicular keratosis conditions with follicular atrophy and/or alopecia
  - Ulerythema ophryogenes—keratosis pilaris atrophicans predominantly affects eyebrow area, causing scarring alopecia; occurs in various syndromes, including Noonan and cardiofaciocutaneous syndromes
  - Keratosis pilaris rubra atrophicans faciei—possibly a form of ulerythema ophryogenes; especially involves temples and cheeks
  - Atrophoderma vermiculatum—predominantly involves cheeks and leads to a striking honeycomb-like atrophy; mosaic forms described
  - Keratosis follicularis spinulosa decalvans—predominantly involves scalp, leading to severe cicatricial alopecia; associated features include plantar keratoderma and photophobia



gree of follicular hyperkeratosis, dilation of upper dermal vessels, some perivascular inflammatory infiltrate, and hyperpigmentation of the basal layer. The frequent association with standard KP of the arms suggests that the two conditions are related.

Associations of Keratosis Pilaris

Patients with ichthyosis vulgaris (see Chap. 47) often demonstrate KP; in one series KP was found in 74.3 percent of patients (see Fig. 85-1).[1] Contrary to conventional wisdom, however, the same series found that KP was not a feature in atopic dermatitis patients who lacked the ichthyosis vulgaris phenotype.[1] Other conditions in which KP is more prevalent or more prominent are hypothyroidism, Cushing syndrome, diabetes,[8] obesity, and Down syndrome. Follicular keratosis, which may simulate KP, can occur in several nutritional deficiencies, although vitamin A deficiency is most commonly cited (see Chap. 130).[9]

KERATOSIS PILARIS ATROPHICANS

The general term *keratosis pilaris atrophicans* is used to describe a group of rare genetic follicular keratosis conditions in which follicular atrophy and/or alopecia occur. These include ulerythema ophryogenes [UO or keratosis pilaris atrophicans faciei (KPAF)], atrophoderma vermiculatum, and keratosis follicularis spinulosa decalvans (KFSD). Although the conditions show overlapping clinical features and non-diagnostic histologic findings, most authors now regard the conditions as discrete entities.[10–12]

Ulerythema Ophryogenes

UO is a form of KPA affecting particularly and initially the eyebrow areas; in some cases extending later to the cheeks and forehead.[11] Scalp and eyelash hair is normal. The onset is within months of birth, with erythema and small keratotic follicular papules involving the lateral one-third of the eyebrows. It may slowly progress through childhood to involve more of the eyebrows and sometimes beyond, leading to alopecia (Fig. 85-2). Progression usually ceases after puberty but the sequelae are permanent. The condition is frequently associated with standard KP involving the arms and legs.

Most cases have followed an autosomal dominant inheritance pattern, with incomplete penetrance.[11] Response to topical corticosteroids, topical retinoids, and keratolytics has been poor. There is one report of a good response to several months' therapy with oral isotretinoin, with lessening of the horny plugs and the erythema.[13] The improvement was maintained for some months after therapy had ceased. Some improvement in erythema was reported with the pulsed tunable dye laser at 585 nm, but the follicular plugging was unchanged.[14]

KERATOSIS PILARIS RUBRA ATROPHICANS FACIEI Sometimes, keratosis pilaris rubra atrophicans faciei is used as a synonym for UO. At other times, it has been applied to a condition almost identical to UO that initially involves the temples or cheeks, rather than the eyebrows. Like characteristic UO, it begins in early childhood, is inflammatory, results in scarring, and is associated with typical KP of the limbs.[15]

ASSOCIATIONS OF ULERYTHEMA OPHYROGENES UO has been reported in association with isolated woolly hair,[16,17] Noonan syndrome,[16,18] cardiofaciocutaneous (CFC) syndrome,[19,20] Rubenstein-Taybi syndrome,[21] Cornelia de Lange syndrome,[22] 18p deletion,[23] and one case of multiple congenital abnormalities not typical of a recognized syndrome.[24] CFC syndrome and Noonan syndrome have overlapping clinical features, and, before understanding of the underlying molecular mechanisms, there was conjecture that CFC syndrome represented a severe variant of Noonan syndrome.[20] Mutations in genes of the Ras pathways have been demonstrated in patients with both diagnoses.[25,26] In CFC, mutations have been described in BRAF, KRAS, MEK1, and MEK2 genes.[26] Primarily PTPN11, but also KRAS and SOS1 genes, have been mutated in patients with Noonan syndrome.[27,28]

Follicular keratosis in Noonan syndrome, if present, is usually limited to the face (see Fig. 85-2B) and resembles UO/KPAF with loss of eyebrow hairs.[16,18] In CFC syndrome, follicular keratosis is often much more extensive, and there may

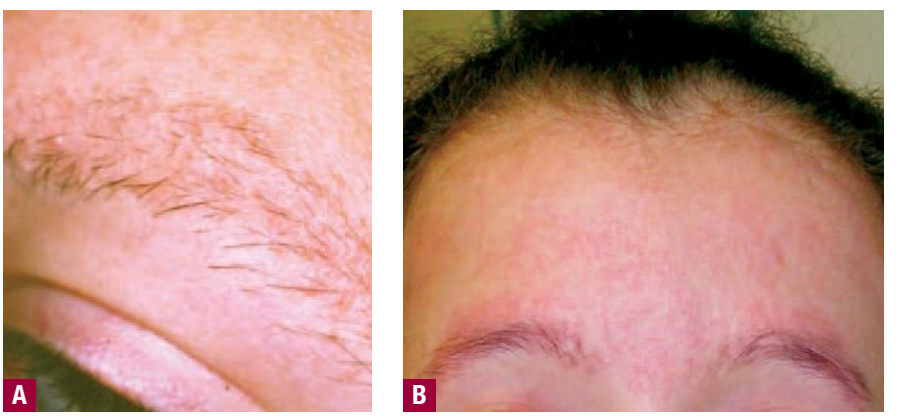

▲ **FIGURE 85-2** **A.** Ulerythema ophryogenes involving eyebrow area with scarring alopecia. **B.** Ulerythema ophryogenes involving the upper face in a patient with Noonan syndrome.

be striking alopecia involving the scalp.[20] The remaining scalp hair in CFC syndrome is brittle and curly. Patients with CFC syndrome may also show generalized thickening and psoriasiform scaling of the skin. Other cutaneous features that may be seen in Noonan syndrome are lymphedema, lymphatic malformations, prominent finger and toe pads, and pigmented nevi. The major non-cutaneous features of Noonan syndrome include short stature, hypertelorism, down-slanting palpebral fissures, low-set ears with thick helices, high nasal bridge, short webbed neck, sternal abnormalities, congenital heart defects (especially pulmonic valve anomalies), joint laxity, and hypotonia. The non-cutaneous features of CFC syndrome overlap to some extent and include short stature, macrocephaly, prominent forehead, short nose with a low nasal bridge, large posteriorly rotated ears, downward slanting palpebral fissures, cardiac malformations (especially pulmonic stenosis), and developmental delay.

Atrophoderma Vermiculatum (Folliculitis Ulerythematosa Reticulata)

Atrophoderma vermiculatum (folliculitis ulerythematosa reticulata) is a form of KPA in which the cheeks are predominantly involved, with follicular plugs and pit-like depressions up to 1.5 mm in diameter and a background of erythema. Alopecia and follicular papules are not features of the condition,[15,29] but sparse open and closed comedones and milia may be found.[30] The depressions merge into each other producing a "worm-eaten" or "honeycombed" appearance (Fig. 85-3). Involvement of the forehead, arm, and leg, as well as the typical cheek area, has been described.[31] In general, however, it is rare for the condition to involve the limbs, and eyebrow involvement does not occur. Standard KP of the extensor aspects of arms and legs is a common associated finding.[29] The onset is usually in childhood, between 5 and 12 years old, although later onset has been described; the course is usually one of inexorable worsening. The condition is often sporadic but, in some cases, appears to be inherited as an autosomal dominant trait.[32] Several more or less linear unilateral cases have been described,[33] suggesting a possible mosaic form of the condition.[34] However, it is possible that at least some of these cases may represent examples of nevus comedonicus.[34]



▲ **FIGURE 85-3** Atrophoderma vermiculatum demonstrating honeycomb atrophy on the cheek of an adolescent girl.

Histopathologic evaluation demonstrates atrophic pilosebaceous units with mild perifollicular and perivascular inflammation. The follicular orifices are dilated and filled with keratin plugs. Numerous dermal horn cysts may be found. There is perifollicular fibrosis and a decrease in elastic fibers in the dermis.[29,35]

Therapy is uniformly unsuccessful and has included topical steroids, topical retinoids, cryotherapy, and dermabrasion. There is a report of a partial response to chemical peeling with trichloroacetic acid 35 percent solution combined with topical application of 0.05 percent tretinoin cream.[36] Favorable results have also been described with carbon dioxide laser in a case in which atrophy was prominent, and pulsed dye laser in a case with a marked erythematous component.[30] Oral isotretinoin suppressed the inflammation in one patient.[37]

Keratosis Follicularis Spinulosa Decalvans

The term *keratosis follicularis spinulosa decalvans* was first used by Siemens in 1926 who described a scarring follicular condition in 20 members of a large family.[38] The condition begins in infancy with noninflammatory, flesh-colored, spiny lesions affecting hair-bearing areas, especially the scalp (Fig. 85-4) and later eyebrows, eyelashes, and the dorsal of the hands and fingers. Sometimes, more proximal limbs and even the trunk become involved.[38–40] An associated plantar keratoderma may occur, especially over the heels.[10] By puberty, many of the follicular spines have disappeared and are replaced by atrophy. Scarring alopecia of scalp (see Fig. 85-4), eyebrows, and eyelashes becomes apparent in childhood and progresses till puberty. It is often patchy and is rarely total. Facial lanugo hair is absent, and axillary and pubic hair are often thinned.

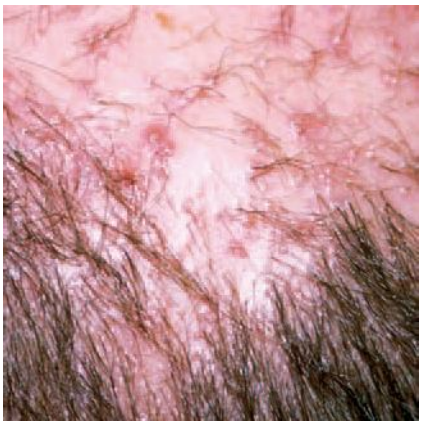

▲ **FIGURE 85-4** Keratosis follicularis spinulosa decalvans with severe scarring alopecia of scalp. (Photograph used with permission from Dr. Peter Hogan.)

Photophobia is seen in many patients, and punctate corneal epithelial defects have been seen in some.[39] It is unclear whether there is a primary epithelial defect or whether the corneal changes occur as a result of irritation from distorted remnant lashes and keratotic plugs in eyelash follicles. There are rare reports of other ophthalmologic abnormalities, including cataract and retinal detachment.[41]

Biopsy specimens show follicular-based hyperkeratosis, perifollicular and dermal inflammation, fibrosis, and distorted follicles at different stages of the condition. Family studies suggest an X-linked dominant inheritance pattern,[38,39,41,42] and the gene has now been localized to Xp22.13-p22.2.[43] In most series, men are more severely affected than women. As yet, no lesions have been described in a blaschkoid distribution in women to suggest random lyonization.

Eramo et al.[15] have pointed out the similarity of this condition to ichthyosis follicularis with alopecia and photophobia (IFAP) syndrome [see Ichthyosis Follicularis, Alopecia (Atrichia), and Photophobia Syndrome]. Features in KFSD not shared by IFAP, however, are involvement of the fingers, late atrophy and scarring of involved follicles, and the development in some patients of a red-brown telangiectatic pigmentation of cheeks and brows.

In general, treatment of KFSD is unsatisfactory; however, there are isolated reports of improvement in photophobia with oral vitamin A[39] and

remission of cutaneous inflammation and halting of the spread of alopecia with oral retinoids.[44]

Folliculitis Spinulosa Decalvans

A variant of KFSD has been called *folliculitis spinulosa decalvans* (acknowledging that this name may lead to confusion with the separate entity of folliculitis decalvans).[10] This variant is characterized by persistent pustule formation, especially on the scalp. Unlike the typical variant of KFSD, there is more severe inflammation, and it is ongoing rather than settling after puberty. In addition, the inheritance appears to be autosomal dominant rather than X-linked recessive.



OTHER SYNDROMES WITH FOLLICULAR KERATOSIS AS A SIGNIFICANT FEATURE

Apart from the conditions described in the preceding sections in association with UO, there are other conditions that have follicular keratosis as a significant feature (Table 85-1).

Monilethrix (See Chap. 86)

Monilethrix is an autosomal dominant condition producing a beaded appearance of the hair.[45] Recently, mutations in the human basic hair trichocyte keratins hHb1, hHb3, and hHb6 have been reported.[46–48] However, the failure to demonstrate these mutations in one family suggests the possibility of genetic heterogeneity.[49] A striking follicular keratosis is associated in some pedigrees and may involve the scalp (Fig. 85-5), face, and limbs. Genotype/phenotype correlation is not obvious in reported cases in which mutations have been identified.[50,51] A child of unaffected consanguineous parents has been described with severe monilethrix, widespread KP, cataracts, and facial dysmorphism with brachiocephaly.[52]

TABLE 85-1
Syndromes That May Feature Follicular Keratosis

- Monilethrix
- Keratosis pilaris and hereditary koilonychia
- Hereditary mucoepithelial dysplasia
- Ichthyosis follicularis, alopecia, and photophobia syndrome
- Keratitis, ichthyosis, and deafness syndrome
- Cardiofaciocutaneous syndrome
- Noonan syndrome
- Rubenstein-Taybi syndrome
- Cornelia de Lange syndrome
- 18p deletion



▲ **FIGURE 85-5** Striking follicular keratosis of the scalp in a patient with monilethrix.

Keratosis Pilaris and Hereditary Koilonychia

A family has been described with koilonychia and widespread KP, involving all areas of trunk and limbs. Affected family members also showed eyebrow involvement with alopecia, simulating UO/KPAF.[53] The inheritance pattern appeared to be autosomal dominant. There was no monilethrix in these cases; previously KP and koilonychia have been reported together only in cases of monilethrix.

Keratitis, Ichthyosis, and Deafness Syndrome (See Chap. 47)

Widespread follicular keratosis is a striking feature of keratitis, ichthyosis, and deafness syndrome, a connexin/gap junction disorder, which is also characterized by alopecia of scalp, body, eyebrow, and eyelash hair, vascularizing keratitis, and a profound sensorineural hearing loss.[54]

Hereditary Mucoepithelial Dysplasia

The characteristic features of hereditary mucoepithelial dysplasia (HMD) are follicular keratosis, non-scarring alopecia with some coarse abnormal hairs remaining, fiery-red palatal and gingival mucosae, photophobia with demonstrable keratitis and corneal vascularization, and psoriasiform hyperkeratotic lesions in the perineal area and often also on the extensor limbs.[55–57] The condition occurs in both sexes, and family studies suggest both autosomal dominant and autosomal recessive patterns of inheritance may be possible. Light microscopic evaluation of skin and mucosae shows dyskeratotic cells in the spinous layer, vacuolated basal cells, and lack of epithelial maturation.[55,57] Electron microscopy shows paucity of desmosomes, cytoplasmic vacuolization, and presence of multilaminar bands and wheat sheaf–like collections of filamentous fibers in the cytoplasm, resembling gap-junction material, and suggesting a disorder of desmosomal or gap junction proteins.[55] Recent studies of several characteristic cases in one pedigree found normal expression of gap junction proteins (connexins 26, 32, and 43), desmosomal proteins (desmogleins 1 and 2, plakoglobin, desmoplakins I and II, and plakophilin 1), adherens junction proteins (β-catenin and E-cadherin), and cytoskeleton proteins (keratins, β-tubulin, vimentin, and actin).[57] Genetic analysis in the studied family excluded the desmosomal cadherins in chromosome 18q12 as candidate genes and ruled out a mutation in connexin 26.[57]

Ichthyosis Follicularis, Alopecia (Atrichia), and Photophobia Syndrome

The association of ichthyosis follicularis, alopecia, and photophobia was first reported as a syndrome by McLeod in 1909,[58] and for many years additional reported cases of what came to be designated *IFAP syndrome* occurred in males. Affected individuals demonstrate widespread, flesh-colored, spiny, follicular projections with minimal, if any, inflammation, severe alopecia, often total atrichia involving eyebrows and lashes as well as scalp hair, and severe photophobia, often with demonstrable corneal vascularization.[15,59–62] The condition was postulated to be inherited as an X-linked recessive trait, which is supported by the report of the mother and sister of a male patient with classical features of IFAP syndrome having linear lesions of hyperkeratosis, hypohidrosis, and atrophy and a patchy scalp alopecia, distributed along Blaschko's lines.[63] Many patients have only cutaneous features, but neurologic and skeletal anomalies and recurrent infections have occasionally been described.[60,62,64–66]

Atypical cases have included females with generalized involvement and transmission from mother to daughter[64,67–69]; psoriasiform patches,[62,68,69] particularly involving the perineal area; and hypotrichosis rather than complete atrichia.[69] Some patients with psoriasiform plaques lack the typical spiny follicular projections[62,66] and may represent a different entity,[70] or even a variant of HMD.[69] In support of the latter is the ultrastructural finding of reduced numbers of desmo-

TABLE 85-2
Syndromes with Follicular Atrophoderma as a Feature

CONDITION	INHERITANCE	MAIN FEATURES	COMMENTS
Bazex syndrome (Bazex-Dupre-Christol syndrome)[73]	X-linked dominant	Hypotrichosis, pili torti, hypohidrosis, milia, development of basal cell carcinomas in adolescence.	—
Rombo syndrome[74]	Autosomal dominant	Hypotrichosis, especially of eyelashes, peripheral cyanosis, basal cell carcinomas, and trichoepitheliomas.	—
X-linked dominant chondrodysplasia punctata (Conradi-Hünermann syndrome)[75]	X-linked dominant, lethal in males	Congenital Blaschko-distributed red scaly lesions that resolve in months, replaced by follicular atrophoderma. Cataracts, shortening of limbs, frontal bossing, saddle nose, low-set ears.	Mutation in emopamil binding protein gene, relevant in cholesterol biosynthesis
Congenital ichthyosis, follicular atrophoderma, hypotrichosis, and hypohidrosis[76,77]	Probably autosomal recessive	Congenital, diffuse ichthyosis, hypohidrosis, hypotrichosis. Woolly hair in one pedigree.	Only described in two families so far
Hereditary perioral pigmented follicular atrophoderma associated with milia and epidermoid cysts[78]	Autosomal dominant	Epidermoid cysts and milia.	Follicular atrophoderma limited to face, especially periorally
Nevus comedonicus[79]	Somatic mutation	Blaschko-distributed comedo-like plugs in dilated follicular orifices. Cribriform atrophy follows extrusion of comedones.	Due to somatic mutation of fibroblast growth factor receptor 2, identical to that, which, if present in the germline, causes Apert syndrome

somes in one patient with IFAP and psoriatic lesions, analogous to what is seen in HMD.[68] Treatment of IFAP is usually unsatisfactory, but there is a single report of temporary flattening of the follicular keratotic papules with oral acitretin.[72]

SYNDROMES ASSOCIATED WITH FOLLICULAR ATROPHODERMA

Follicular atrophoderma occurs as a feature of several rare syndromes[73–78] and in nevus comedonicus (Table 85-2).[79] As such, these conditions may come into the differential diagnosis of atrophoderma vermiculatum.

KEY REFERENCES

The full reference list for all chapters is available at www.digm7.com.

10. Oranje AP, van Osch LD, Oosterwijk JC: Keratosis pilaris atrophicans. One heterogeneous disease or a symptom in different clinical entities? *Arch Dermatol* **130**:500, 1994
11. Callaway SR, Lesher JL: Keratosis pilaris atrophicans: Case series and review. Pediatr Dermatol **21**:14, 2004
20. Weiss G et al: Cutaneous manifestations in the cardiofaciocutaneous syndrome, a variant of the classical Noonan syndrome. Report of a case and review of the literature. *J Eur Acad Dermatol Venereol* **18**:324, 2004
29. Jansen T, Sander CA, Altmeyer P: Atrophoderma vermiculata: Case report and review of the literature. *J Eur Acad Dermatol Venereol* **17**:70, 2003
43. Oosterwijk JC et al: Molecular genetic analysis of two families with keratosis follicularis spinulosa decalvans: Refinement of gene localization and evidence for genetic heterogeneity. *Hum Genet* **100**:520, 1997
57. Boralevi F et al: Hereditary mucoepithelial dysplasia: clinical, ultrastructural and genetic study of eight patients and literature review. *Br J Dermatol* **153**:310, 2005
62. Megarbane H et al: Ichthyosis follicularis, alopecia and photophobia (IFAP) syndrome: Report of a new family with additional features and review. *Am J Med Genet* **124**:323, 2004



CHAPTER 86

Hair Growth Disorders

Ralf Paus
Elise A. Olsen
Andrew G. Messenger

Given their prominence in daily dermatologic practice, hardly any dermatologist can escape having to manage patients with hair growth disorders. These manifest as undesired hair loss (effluvium, alopecia) or as cosmetically disturbing, unwanted hair growth (hirsutism, hypertrichosis).

In this chapter, we sketch the biologic basis of hair growth disorders, explain key management principles, give definitions (Table 86-1), and provide practical advice on diagnosis and therapy. Throughout this chapter, we argue that, in order to offer our patients more effective hair therapy, it is essential to adopt a pathogenesis- and hair biology–based approach to hair growth disorders.

It is important to realize that the plight of patients with a hair growth disorder can be quite substantial, and is notoriously underestimated. The affected individual's "burden of disease" and the corresponding loss in the quality of life are easily missed (see eFig. 86-0.1 in online edition).[1,2] The clinical problem at hand is often trivialized by the consulted physician, and unrealistic patient expectations for hair restoration meet with a rather limited availability of effective medical therapy.

Despite the rather limited practical advances in the pharmacologic management of hair growth disorders during the past decade,[3–5] the cellular and molecular basis of hair growth disorders is becoming increasingly understood. However, there are now clear-cut, evidence-based

APPROACH TO THE PATIENT WITH HAIR GROWTH DISORDERS

AT A GLANCE





- Classify the hair disorder based on pathogenetic principles (see Table 86-2) and clinical pattern (see Table 86-4).
- Exclude or confirm the most common hair growth disorders based on pattern and diagnostic tools (see Table 86-3).
- Dispel misconceptions and educate the patient.
- Treat as appropriate for the confirmed or suspected diagnosis.
- Provide emotional support for patients who are adversely affected by the cosmetic effects.

guidelines for the assessment and management of patients with alopecia.[4,6,7]

PRINCIPLES OF HAIR FOLLICLE PATHOBIOLOGY

Hair growth disorders are best understood and managed if one recalls some basic concepts of hair follicle biology (for more details on hair follicle structure and function, see Chap. 84).

Clinically Relevant Hair Biology

Knowledge of the basic biology of hair enables essentially all hair growth disorders to become easily understandable as reflections of distinct pathogenetic mechanisms or combinations (Table 86-2).

Problems of the Hair Follicle Cycle

Disturbances of hair follicle cycling lie at the heart of most hair growth disorders, and have dramatic effects on visible hair growth and hair shaft shedding. If the anagen phase is prematurely terminated and catagen occurs too early, the affected skin shows largely catagen and/or telogen follicles, and loosely anchored club hairs that are eventually shed (i.e., the normal anagen/telogen ratio of approximately 4.5:1 changes in favor of telogen). Considering that our scalp skin alone has approximately 100,000 hair follicles, even relatively small shifts in the percentage of anagen versus telogen follicles have major effects on hair growth and shedding.

The resulting effluvium and alopecia is exemplified by drug- or hormonally induced telogen effluvium, or when inflammatory cells attack the anagen hair bulb in alopecia areata.[8,15] Alopecia areata offers a particularly instructive illustration of how crucial hair cycle disturbances are for hair loss: The hair-damaging inflammatory cell infiltrate almost exclusively attacks anagen hair bulbs; this immune attack then catapults anagen follicles into a dystrophic catagen, causing a major hair cycle disturbance and rapid shedding of the insufficiently anchored, improperly formed hair shafts.[22–24] As a result, the three most effective therapeutic strategies for hair loss therapy in the vast majority of patients that suffer from hair loss, in declining order of importance, are (see eFig. 86-0.2 in on-line edition):

1. To inhibit catagen development so as to prolong anagen.
2. To induce anagen in telogen follicles so as to increase the percentage of actively hair shaft-producing follicles.
3. To inhibit exogen so as to reduce hair shaft shedding.

Unfortunately, neither of the two currently available U.S. Food and Drug Administration–approved standard hair drugs (finasteride, minoxidil; see Treatment) are highly efficient and reliable catagen inhibitors or anagen inducers, and it is unknown whether they affect normal hair shedding ("exogen")[17] at all. Even 17β-estradiol, an important hair growth–modulatory hormone,[18] may inhibit catagen in human scalp hair follicles[25,26] more effectively than these standard "hair drugs." However, catagen inhibition can often simply be achieved by eliminating a catagen-inducing drug (e.g., β blockers, synthetic retinoids, anticoagulants, antithyroid drugs), by professional management of a catagen-inducing endocrine disorder (e.g., thyroid dysfunction, hyperandrogenism, hyperprolactinemia), or by adequate substitution therapy of a catagen-promoting deficiency (e.g., in iron, zinc, estradiol, or protein deficiency).[27–29]

Problems of Hair Follicle Transformation

Next to hair cycle abnormalities, the second most important cause of hair growth disorders involves the terminal-to-vellus or vellus-to-terminal transformation of hair follicles in a skin region where this does not normally occur spontaneously and/or is undesired. The former is the hallmark of patterned balding, which arises from the miniaturization of very large, well-pigmented

TABLE 86-1
Definitions

- Alopecia: Hair loss usually on the scalp
- Canities: Graying of hair
- Effluvium: Process of increased daily hair shaft shedding (normal: 25–100)
- Telogen hairs: Club hairs with depigmented rounded up proximal ends
- Anagen hairs: Hairs with pigmented malleable proximal ends
- Hair follicle cycle: Life-long cyclic transformations of the hair follicle, which begin in utero
- Catagen: Apoptosis-driven regression phase in between telogen and anagen phase
- Telogen: Period of relative quiescence, lasts variable periods of time depending on body site
- Anagen: Growth phase, lasts variable periods of time depending on body site
- Exogen: Active process of hair shaft shedding
- Hirsutism: Increased hair growth in male secondary sexual hair areas in a woman, restricted to strongly androgen-responsive hair follicles
- Hypertrichosis: Increased growth of terminal hairs in an area normally rich in vellus hairs
- Lanugo hair: Produced in utero, pigmented, in length and in form somewhere between vellus and terminal hair; occurrence in postnatal life (hypertrichosis lanuginosa) may indicate a serious problem
- Poliosis: Localized white hair
- Scarring alopecia: Cicatricial/permanent alopecia. Irreversible loss of hair follicles, with disappearance of follicular orifices, and potentially skin atrophy
- Terminal hair: Produced by large hair follicles located in the subcutis; hairs are generally > 0.03 mm in diameter
- Vellus hair: Produced by very small (but functionally fully active, cycling) hair follicles located in the dermis; thin (≤ 0.03 mm diameter), short, often depigmented, usually non-medullated hair shaft

TABLE 86-2
Pathogenesis Approach to Diagnosis

Pathogenetic Principle	Clinical Effect (Examples)
• Disturbed hair follicle cycling	Effluvium (telogen effluvium, alopecia areata, androgenetic alopecia, chemotherapy-induced alopecia)
• Unwanted hair follicle transformation	Patterned hair loss (androgenetic alopecia) Hirsutism Hypertrichosis
• Defective hair follicle regeneration	Cicatricial alopecia (lichen planopilaris, traction alopecia, radiation-induced alopecia, folliculitis decalvans, chronic discoid lupus erythematosus)
• Structural hair shaft defect	Hair shaft disorders (monilethrix, pili torti, trichothiodystrophy)
• Improper/missing hair follicle development	Aplasia cutis congenita Ectodermal dysplasias
• Combinations of the above	

Note that infectious or physical agents (e.g., staphylococci, dermatophytes, herpes–varicella zoster virus; ionizing radiation, trauma) or drugs that can lead to alopecia do so by inducing one or several of the above pathogenesis pathways (e.g., disturbed hair follicle cycling, structural hair shaft defect, defective hair follicle regeneration).

terminal hair follicles in androgen-sensitive scalp regions (i.e., vertex, temporofrontal skin) into minute, unpigmented, vellus hair follicles by dihydrotestosterone. This is usually, but not always, accompanied by telogen effluvium, due to the anagen-shortening effect of androgens (see eFig. 86-0.2 in on-line edition). The opposite transformation process underlies hirsutism, characterized by the excessive vellus-to-terminal transformation of androgen-dependent hair follicles in a male pattern, or as is seen in drug-, hormone-, or porphyrin-induced hypertrichosis.

Defects in Hair Follicle Regeneration

Permanent alopecia or cicatricial alopecia largely results from a defective capacity for hair follicle regeneration due to irreversible damage suffered by epithelial hair follicle stem cells. How exactly autoaggressive, inflammatory attacks on hair follicle stem cells are induced and regulated, how they may best be prevented, and how the recovery of these stem cells from immunologically or radiation-induced damage may be effectively promoted are all critically important, yet unanswered, questions.

Structural Hair Shaft Defects

Acquired or inherited defects in hair shaft production (e.g., from the expression of abnormal hair keratins or insufficient hair follicle supply with essential nutrients, trace elements, or vitamins) may lead to the generation of distorted, misshapen hair shafts during anagen. These structural changes may lead to hair fragility, with breakage soon after the hair penetrates the epidermal surface.

Alopecia Due to Improper or Missing Hair Follicle Development

Extremely rarely, as in aplasia cutis congenita (see Chap. 106) and in various forms of ectodermal dysplasias (see Chap. 143), hair follicles in defined regions of the integument have never developed properly. This must be distinguished from rare, inherited hair follicle abnormalities in which patients present with neonatal or early-onset alopecia, despite presumably normal intrauterine hair follicle development. This is true for the human equivalents of the well-known nude and hairless alopecia phenotypes seen in mutant mice. These conditions result from defined transcription factor defects that lead to improper hair shaft formation (nude/FOXN1)[36–38] or progressive hair follicle destruction with the onset of catagen (hairless)[39–42] after apparently normal hair follicle development.

DIAGNOSTIC TECHNIQUES

Hair loss confronts one with greater diagnostic challenges than disorders associated with excessive hair. It is optimal to follow established guidelines for considering and excluding the chief causes of effluvium and/or alopecia (Table 86-3; Fig. 86-1).[4,7] Using pattern recognition (Table 86-4) and focusing on pathogenic principles (see Table 86-2), one can use diagnostic procedures of increasing complexity (see Table 86-3) to reach a diagnosis. In general, the diagnosis is likely to be one of the four most common hair growth disorders [androgenetic alopecia (male or female pattern), telogen effluvium, alopecia areata, or hirsutism], rather than a rare diagnosis. The presence of "alarming hair signs" should be sought, and difficult differential diagnoses should be considered.

ALOPECIA: DIFFUSE (GLOBAL) HAIR LOSS

Reduced or absent hair growth in infancy may be the result of a failure of normal hair follicle development, and may be associated with other ectodermal defects (see Chap. 143). Many of these hereditary syndromes have other anomalies, most frequently bone, central nervous system, or eye. The features and mechanisms that underlie genetic disorders with hair abnormalities are discussed and regularly updated in the Online Mendelian Inheritance in Man website (http://www.ncbi.nlm.nih.gov/sites/entrez?db=OMIM).[47]

The most common of the ectodermal dysplasias, hypohidrotic ectodermal dysplasia, which is characterized by sparse hair, abnormal teeth, and reduced or absent sweating, is due to mutations in the ectodysplasin signaling pathway.[48] This pathway is involved in the early embryogenic events in formation of the hair follicle placode.[21,49,50] Ectodermal dysplasias and genetic hair disorders for which genetic loci have been identified are listed in, and are largely discussed in other chapters, particularly Chap. 143.

HAIR SHAFT ABNORMALITIES

Hair shaft abnormalities can be primary and hereditary or secondary to external factors. Some hair shaft abnormalities represent common endpoints to various forms of trauma or inherent shaft weaknesses, and some are specific to a particular constellation of findings or inherent make-up of the hair shaft. Hair shaft abnormalities can be divided into those associated with hair breakage and those associated with unruly hair.

Hair Shaft Abnormalities Associated with Hair Breakage

TRICHORRHEXIS NODOSA The most common defect of the hair shaft leading to hair breakage is trichorrhexis nodosa.[51] Mechanical or chemical damage triggers this response, which can occur in nor-



TABLE 86-3
Diagnostic Procedures

- Essential procedures
  - Hair pull test to assess scalp hair cycling
    - Manually grasp 50–100 scalp hairs and apply gentle traction from the base to the terminal ends, repeating in various areas of the scalp.
    - Shedding of more than two hairs/hair pull on multiple hair pulls is pathologic, if hair has been shampooed regularly.
    - To assess easy breakage or brittleness of hair if suspect structural hair shaft defect, hold hair shafts at both ends, and pull in opposite directions or rub hair between fingers.
  - Hair shaft microscopy
    - Align proximal portions of collected hairs on slide in a drop of cyanoacrylic glue, apply coverslip; alternative technique is to let hair shafts swell on glass slide in a drop of tap water under coverslip for 10 min before inspection.
    - Evaluate the proximal ends of pulled hairs for intact shaft and bulb, or hair breakage.
    - Assess if normal telogen club hairs (physiologic aberration; see Fig. 86-3A) versus dystrophic telogen or anagen hairs (pathologic process; see Fig. 86-3B).
  - Dermatoscope
    - Search for signs of scarring and a quick look at hair shaft details.
  - Biopsy (mandatory if scarring alopecia is suspected; insight into mechanism)
    - Take one to two 4-mm or one 6-mm punch biopsy in the direction of the follicle growth (oblique angle) and to a sufficient depth to contain the follicular bulbs in anagen located in the subcutis. The 6-mm punch should be bisected.
    - Vertical and horizontal sections have different uses: Vertical sectioning gives one a view of the epidermal/dermal interface, and horizontal sections allow quantitative assessment of the hair density.
- Additional useful tests
  - Trichogram (hair pluck test)
    - Rarely done today. Quick pull of 50–100 hairs en masse using a clamp or needle holder. Inspection of proximal hair bulbs allows determination of anagen/telogen ratio, but fraught with procedural artifacts, fails to give critical information about the type of hair being shed, and yields small sample size.
  - Phototrichogram (objective hair cycle assessment)[5]
    - To determine (1) the percentage of hairs in anagen, (2) the growth rate (with sophisticated cameras and computer software), and (3) shaft diameter requires locating the same precise target site at each time point, standardized photography, and standardized hair counting by image analysis.
    - Hairs are shaved in a demarcated target area and comparative photographs done at baseline and 2–3 days later. Only anagen hairs increase their length on follow-up (normal hair growth is ~ 1 cm/mo).
  - Global hair photography
    - Assesses the global cosmetic appearance of scalp hair in a defined area (vertex, frontotemporal, occipital) under precisely standardized conditions (constant distance, angle, and lighting) before, during, and after therapy. Optimal for independent, blinded assessments of therapeutic success or failure.
  - Hair shedding count
    - Standardized hair loss count before and 3 months after therapy.
    - Day 1: shampoo vigorously; days 2–4: no shampooing, comb only once a day. For these 3 days, have patient collect (1 envelope/day) and count only hair shafts lost during combing once daily.
  - Potassium hydroxide stain (for suspected fungal infection)
    - May reveal spores and hyphae in plucked proximal shafts. Complement with standard mycologic cultures.
    - Wood's lamp (see Chapter 5)
  - Laboratory tests
    - Most commonly performed for hair loss: complete blood cell count, ferritin or iron/total iron binding capacity, thyroid-stimulating hormone, and thyroxine
  - Additional tests as suggested by history and examination
    - Testosterone, dehydroepiandrosterone, sex hormone–binding globulin, prolactin, anti-nuclear antibody, double-stranded DNA, C-reactive protein, erythrocyte sedimentation rate, VDRL/treponemal hemagglutination.
  - Complementary techniques for hair shaft abnormalities
    - Most hair shaft abnormalities can be diagnosed by light microscopic examination, although some types require scanning electron microscopy to confirm findings suggested by light microscopy (e.g., longitudinal grooving), or to definitively rule out (e.g., monilethrix). Polariscopic examination should be performed if trichoschisis (a particular pattern of hair breakage) is seen under light microscopy to evaluate potential trichothiodystrophy (sulfur-deficient hair). The etiology of brittle hair can be further pursued by direct amino acid analysis of whole-hair hydrolysates and electrophoretic characterization of the main classes of proteins in hair (generally defined by their cysteine content, and designated ultrahigh-, high-, and low-cysteine or ultrahigh, high-, and low-sulfur proteins).

Data from Olsen EA: Current and novel methods for assessing efficacy of hair growth promoters in pattern hair loss. *J Am Acad Dermatol* **48**:253, 2003.



mal hair, but occurs much more readily in inherently weak hair. Microscopically, the affected hair develops a breach in the cuticle, with eventual separation and fraying of the exposed cortical fibers leading to a nodal swelling.[52] The fibers then fracture and the shaft breaks with the resultant appearance of a splayed paintbrush or fan-like array (Fig. 86-2). Trichorrhexis nodosa may be congenital or acquired.

Congenital trichorrhexis nodosa may be present at birth or may appear within the first few months of life. Although it might occur as an isolated defect or, rarely, with follicular hyperkeratosis or teeth/nail defects,[51] the occurrence of congenital trichorrhexis nodosa should lead to a search for an underlying metabolic disorder. Patients with argininosuccinic aciduria (see Chap. 131), primarily those with the late-onset form (occurring at more than 2 years of age),[15] have associated hair defects. In this condition, in which absence of the enzyme argininosuccinase leads to an accumulation of the nitrogenous waste precursor argininosuccinic acid, brittle lusterless hair develops along with psychomotor retardation and ataxia. The diagnosis is established by finding acidosis, hyperammonemia, and low serum arginine.[53] Citrulline (the normal precursor of argininosuccinic acid in the urea cycle) accumulates in the condition citrullinemia (see Chap. 131), which is caused by a defect in the enzyme argininosuccinic acid synthetase. In this condition, the hair is brittle and both trichorrhexis nodosa and pili torti (another common hair shaft defect) may be present.[51,54] Affected infants have an associated dermatitis that may be widespread but more pronounced in the perioral and diaper area. Patients with Menkes syndrome, caused by a defect in copper efflux,[55] and trichothiodystrophy (TTD; see Chap. 47), caused by a defect in the synthesis of the ultrahigh- and high-sulfur proteins integral to hair,[56] both have tri-

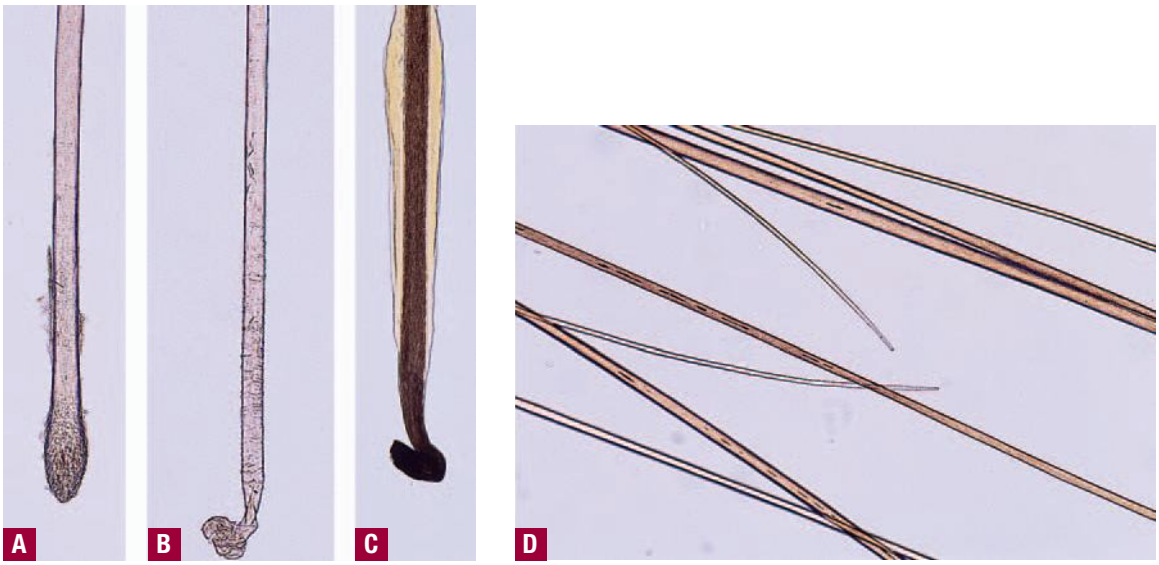

▲ **FIGURE 86-1** **A.** Telogen club hairs have a cornified, depigmented, rounded-up bulb without an attached root sheath. **B.** Loose anagen hair obtained by hair pull: Ruffled cuticle and no attached root sheath. Anagen hairs are recognized clinically by their pigmented, somewhat distorted, malleable bulb. Anagen hairs should not normally be found in a hair pull in patients with alopecia areata. **C.** Comparison with a normal anagen hair obtained by hair pluck. **D.** A newly growing anagen hair has a tapered distal tip rather than the blunt distal end of hairs that have been cut or trimmed or ends that are intrinsically broken.



chorrhexis nodosa apparent on microscopic examination of the associated brittle hair.

Acquired trichorrhexis nodosa, which is much more common than hereditary trichorrhexis nodosa, may be either distal or proximal. Proximal breakage appears most commonly in African American women, usually after repetitive chemical or hot-comb straightening.[51] Distal trichorrhexis nodosa is more commonly secondary to excessive brushing, back-combing, or sporadic use of permanent waves. Treatment of trichorrhexis nodosa, congenital or acquired, is by avoidance of chemical or physical trauma to the hair.

TRICHOSCHISIS The break in trichoschisis is a clean transverse fracture through the entire hair shaft at a location where there is a focal absence of cuticle (Fig. 86-3). Trichoschisis is usually, but not specifically, a marker for the sulfur-deficient hair of TTD, in which the hairs of the scalp, eyelashes, and brows are short and brittle.[51] The hair abnormality of TTD identifies a group of autosomal recessive disorders in which acronyms or eponyms identify particular constellations of extratrichologic neuroectodermal abnormalities (Table 86-5). In affected individuals, the hair cystine content is less than one-half normal, primarily from a major reduction and altered composition of the ultrahigh-sulfur matrix proteins.[56] Polariscopic examination of affected hairs characteristically shows alternating light and dark bands, presumably secondary to variations in sulfur content (see Fig. 86-3).[51] Various structural abnormalities can be detected by confocal and scanning electron microscopy, whereas Raman spectroscopy shows a larger contribution of energetically less favored disulfide conformers in TTD hairs. Taken together, these complex abnormalities make TTD hairs excessively prone to breakage and weathering.[57] Sulfur and/or amino acid analysis of the hair is diagnostic.

Patients with TTD, particularly the 50 percent with associated photosensitivity, may have a defect in excision repair of ultraviolet (UV) damage but without an increased risk of skin cancer.[58] Recent data support correlation of mutations in the DNA repair and transcription gene ERCC2 locus with the nucleotide excision repair characteristics of both TTD and xeroderma pigmentosum (see Chap. 140).[25] No treatment is currently available, but photosensitive patients should be tested for their cellular response to UV radiation and encouraged to practice sun protection.

PILI TORTI The short and brittle hairs in patients with pili torti, when viewed through a microscope, appear flattened and twisted through 90° to 360°.[51] The twisting must be differentiated from the normal twisting in the hair of black individuals and in the pubic/axillary hairs of other races; the hairs are distinguished by the multiple irregular intervals of twisting along an otherwise straight hair shaft (Fig. 86-4A). As with trichorrhexis nodosa, pili torti does not signify a particular abnormality but can be seen in many different syndromes and in the presence of other hair shaft abnormalities. Hereditary pili torti as an isolated finding, usually autosomal dominant, but potentially autosomal recessive or sporadic, is present at birth or develops over the first 2 years of life (see Fig. 86-4B). Clinically, the patient may have patchy alopecia with coarse stubble or longer broken hairs. The hair abnormality may improve after puberty. Pili torti, or a facsimile best characterized as "twisting hair dystrophy,"[26] may occur with other abnormalities. Particularly notable is the association of pili torti with Menkes syndrome (which results from inherited loss-of-function mutations in the gene encoding a copper-transporting adenosine triphosphatase (Atp7a) on the X chromosome[59] or trichopoliodystrophy. Infants with Menkes syndrome develop sparse, depigmented brittle hairs that show pili torti or trichorrhexis nodosa on microscopic examination.[51] The affected child characteristically has pale, lax skin, and mental and neurologic impairment secondary to degeneration of cerebral, cerebellar, and connective tissue.[60] In this X-linked recessive disorder, the defective gene, MKN or ATP7A, which maps to Xq13.3, encodes a copper-translocating membrane protein adenosine triphosphatase that prevents effective copper transport and leads to the accumulation of intracellular copper in



TABLE 86-4
Sorting Hair Growth Disorders by Clinical Pattern

- Alopecia
  - Localized, non-scarring
    - Alopecia areata
    - Trichotillomania
    - Traumatic alopecia, including traction[a]
    - Infection (tinea capitis)[a]
    - Alopecia psoriatica[a]
  - Localized, scarring
    - Lichen planopilaris
    - Frontal fibrosing alopecia (Kossard)
    - Cutaneous discoid lupus erythematosus
    - Morphea
    - Acne keloidalis nuchae
    - Infection (deep fungal infection, zoster, massive bacterial folliculitis, tinea capitis with kerion)
    - Folliculitis decalvans
    - Radiation-induced alopecia
    - Aplasia cutis congenita
    - Epidermolysis bullosa (junctional, dystrophic, or acquired)
  - Diffuse, non-scarring
    - Androgenetic alopecia
    - Telogen effluvium
    - Anagen effluvium
    - Alopecia areata
    - Androgen-induced alopecia
    - Loose anagen syndrome
    - Atrichia with papular lesions/hereditary vitamin D–resistant rickets
    - Ichthyosis follicularis, congenital atrichia and photophobia syndrome
  - Diffuse hair shaft disorders
    - Congenital papular atrichia
    - Alopecia with isolated hair shaft abnormality
    - Monilethrix
    - Trichorrhexis nodosa
    - Pili torti
    - Netherton syndrome
    - Trichothiodystrophy
    - Menkes syndrome
    - Ectodermal dysplasia syndromes
- Hypertrichosis
  - Localized: see Table 86-11
  - Generalized: see Table 86-10

[a]Can also be scarring.

some tissues.[55] The excessive intracellular copper inappropriately triggers the synthesis of metallothionein, whose normal function is to chelate copper to prevent cellular toxicity. This further deprives the copper-requiring enzymes of the copper needed for normal function.[61] A low serum level of ceruloplasmin is diagnostic. Copper replacement is ineffective in preventing the inevitable progressive and lethal neurologic decline, but



▲ **FIGURE 86-2** Trichorrhexis nodosa.

copper-histidine given immediately postpartum may prevent or ameliorate the severe neurodegeneration.[62]

TRICHORRHEXIS INVAGINATA ("BAMBOO HAIR") Bamboo hair is a distinctive hair shaft abnormality that may occur sporadically, either in normal hair or with other hair shaft abnormalities, or regularly as a marker for Netherton syndrome. The primary defect appears to be abnormal keratinization of the hair shaft in the keratogenous zone, allowing intussusception of the fully keratinized and hard distal shaft into the incompletely keratinized and soft proximal portion of the shaft.[63] This leads to the typical "ball-and-socket" deformity (Fig. 86-5) or, if fracture of the shaft occurs, a golf tee–shaped distal end of the shaft. Netherton syndrome (see Chap. 47) is an autosomal recessive–inherited disorder consisting of a triad of ichthyosis, atopic diathesis, and trichorrhexis invaginata.[51] Affected hairs are generally short and brittle and may be irregularly distributed over the scalp; this may lead to potential sampling errors on hair shaft evaluation.

MONILETHRIX The hair abnormality of monilethrix is distinctive, with extremely short, brittle hairs emerging from keratotic follicular papules (see Fig. 85-5 and Chap. 85).[67] The onset may be delayed until patients are in their teens, and the loss may be localized or diffuse. Microscopically, hairs show elliptic nodes with a regular periodicity of 0.7 to 1.0 mm (Fig. 86-6).[51] Between the nodes, the hair shaft is constricted, and it is in these areas that the hair usually fractures. Monilethrix is caused by mutations of one of three of the genes encoding type II hair cortex keratins (KHb1, KHb3, and Khb6). Rare cases that clinically resemble monilethrix are autosomal recessive; the underlying gene, desmoglein 4 (DSG4), belongs to the desmosomal cadherin superfamily and is also expressed in the cortex of the hair follicle.[68,69]

Most cases of monilethrix are of autosomal dominant inheritance, with variable expressivity. In the mildest cases, the hair defect is localized to the occiput.[15,70] The hair defect may occur alone or in association with keratosis pilaris, physical retardation, syndactyly, cataracts, and nail/teeth abnormalities. Retinoids and topical minoxidil may be useful treatments, although this condition may also improve spontaneously with age.

LOCALIZED AUTOSOMAL RECESSIVE HYPOTRICHOSIS Localized autosomal recessive hypotrichosis results from a mutation in the gene for desmoglein 4 (dsg4), a desmosomal protein.[71] Patients present in early childhood with sparse broken hair involving scalp and eyebrows, and follicular hyperkeratosis (keratosis pilaris). The clinical presentation resembles monilethrix but the hair shafts do not show beading (Fig. 86-7).



▲ **FIGURE 86-3** Trichoschisis in trichothiodystrophy. **A.** Hair shaft with trichoschisis without polarization (light micrograph ×100). **B.** Hair shaft with polarization (light micrograph ×100). (From Whiting DA: Hair shaft defects, in *Disorders of Hair Growth: Diagnosis and Treatment,* edited by Olsen EA. New York, McGraw-Hill, 2003, with permission.)

TABLE 86-5
Trichothiodystrophy

	Brittle Hair	Brittle Nails	Intellectual Impairment	Decreased Fertility	Short Stature	Ichthyosis	Photosensitivity	Neutropenia	Other Findings
Trichoschisis	+								
Trichoschisis/onychodystrophy	+	+							
Sabinas syndrome	+	+	+	+					Astigmatism, pale optic discs, retinopathy
BIDS (Amish brittle hair syndrome)	+	+	+	+	+				Quadriplegia, seizures, microcephaly, ataxia
IBIDS [Tay syndrome, Pollitt syndrome (SIBIDS)]	+	+	+	+	+	+			Abnormal teeth, tongue plaques, cataract, ventricular septal defect, osteosclerosis
PIBIDS	+	+	+	+	+	+	+		Xeroderma pigmentosum
Onychotrichodysplasia, neutropenia, mental retardation	+	+	+		+	+		+	Recurrent infections, folliculitis, conjunctivitis
Marinesco-Sjögren syndrome	+	+	+		+				Ataxia, dysarthria, cataracts, abnormal teeth (primarily neuroectodermal)

+ = present; BIDS = *b*rittle hair, *i*ntellectual impairment, *d*ecreased fertility, and *s*hort stature; IBIDS = *i*chthyosis BIDS; PIBIDS = *p*hotosensitivity, *i*chthyosis BIDS; SIBIDS = osteo*s*clerosis, *i*chthyosis BIDS.
Modified from Whiting DA: Hair shaft defects, in *Disorders of Hair Growth: Diagnosis and Treatment,* edited by Olsen EA. New York, McGraw-Hill, 2003, Table 6-3.

Hair Shaft Abnormalities Associated with Unruly Hair

UNCOMBABLE HAIR SYNDROME The distinctive hair of patients with uncombable hair syndrome may present any time from infancy to puberty. The slow-growing, silvery blonde, "spun-glass" hair is generally unmanageable and disorderly but not unduly fragile (Fig. 86-8A).[15,72] The condition may be autosomal dominant or sporadic. Under light microscopy, the hair appears normal or may have some suggestion of a longitudinal groove or ribbon-like flattening (see Fig. 86-8B). Scanning electron microscopy confirms a longitudinal groove, and the hair may, if viewed on cross-section, show a kidney bean or triangular shape, which accounts for the alternate term of pili triangulati et canaliculi. The longitudinal groove in the hair shaft



▲ **FIGURE 86-4** Pili torti. **A.** Irregularly spaced 180° twists in hair shaft. (From Whiting DA: Hair shaft defects, in *Disorders of Hair Growth: Diagnosis and Treatment,* edited by Olsen EA. New York, McGraw-Hill, 2003, with permission.) **B.** Brittle broken hair typical of congenital pili torti.



▲ **FIGURE 86-5** Trichorrhexis invaginata (light micrograph ×400). (From Whiting DA: Hair shaft defects, in *Disorders of Hair Growth: Diagnosis and Treatment,* edited by Olsen EA. New York, McGraw-Hill, 2003, with permission.)



▲ **FIGURE 86-6** Monilethrix. Typical beaded appearance of hair as seen under light microscopy (×40). (From Whiting DA: Hair shaft defects, in *Disorders of Hair Growth: Diagnosis and Treatment,* edited by Olsen EA. New York, McGraw-Hill, 2003 with permission.)







▲ **FIGURE 86-7** Localized autosomal recessive hypotrichosis.

is not specific to this syndrome but can be seen in normal hair, in other etiologies of unruly hair, and in several types of ectodermal dysplasia.[51] The defect may be secondary to an abnormal configuration of the inner root sheath, which keratinizes before the hair shaft and thus determines its shape.[72] Biotin supplementation has been advocated in one case report,[73] but generally there is no effective treatment for the syndrome.

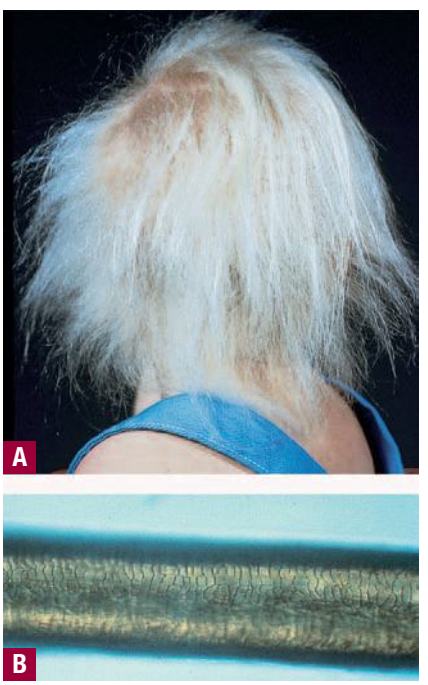

▲ **FIGURE 86-8** Uncombable hair syndrome. **A.** Typical clinical picture. (Photograph used with permission from Vera H. Price, MD.) **B.** Longitudinal groove seen in uncombable hair syndrome (light micrograph ×400). (From Whiting DA: Hair shaft defects, in *Disorders of Hair Growth: Diagnosis and Treatment*, edited by Olsen EA. New York, McGraw-Hill, 2003 with permission.)

WOOLLY HAIR Woolly hair is the presence of kinky, wavy hair on the scalp of persons of non-African or Negroid background. Microscopically, the hairs are tightly coiled. The unruly hair presents at birth or in infancy, usually as a solitary problem inherited in an autosomal dominant fashion.[74] Mutations in the genes for the desmosomal proteins plakoglobin (Naxos disease) or desmoplakin give rise to the triad of woolly hair, striate palmar-plantar keratoderma, and cardiomyopathy. Both recessive and dominant patterns of inheritance have been reported. Assessment of cardiac status should be performed in all children presenting with generalized woolly hair. A sporadic variant has been reported with fine, white-blond hair (Fig. 86-9). Diffuse partial woolly hair, a recently described autosomal dominant condition, presents in young adulthood with two distinct populations of scalp hair, one straight and the other very curly.[75] The curly hairs are thinner than normal hairs, which may contribute to the clinical appearance of a reduction in hair density. Woolly hair may also occur in a localized form (see Woolly Hair Nevus under Primary or Acquired Hair Shaft Abnormalities).

MARIA UNNA HYPOTRICHOSIS Maria Unna hypotrichosis, an autosomal dominant condition, is unusual in that the hair abnormality varies with age. The scalp hair in Maria Unna hypotrichosis is sparse or absent at birth, with variable coarse, wiry hair growth in childhood, affecting scalp and eyebrows. From late childhood, scalp hair is lost in a pattern resembling androgenetic alopecia (though both sexes are equally affected) with a scattering of coarse thickened hairs in the balding areas. Body hair is sparse to absent. Light microscopic examination of the hairs shows irregular twisting, and scanning electron microscopic examination shows longitudinal ridging and cuticle peeling. Diffuse follicular hyperkeratosis and facial milia-like lesions may be present. Marie Unna hypotrichosis maps to chromosome 8p21 close to the hairless (*hr*) gene, but the gene has not yet been identified.[76]



▲ **FIGURE 86-9** Sporadic recessive woolly hair.

Hair Shaft Abnormalities Unassociated with Breakage or Unruly Hair

The hair in pili annulati, an autosomal dominant (occasionally sporadic) condition, shows alternating light and dark bands both clinically and under light microscopy secondary to air-filled spaces in the cortex.[77] Cuticle folding and holes in the cortex are seen with electron microscopy.[51] The gene locus for pili annulati maps to chromosome 12q24.[78–80]

ABNORMALITIES OF HAIR FOLLICLE CYCLING

A wide variety of hair disorders, both genetic and acquired, relate to abnormalities or changes in the hair growth cycle. They may be associated with other changes in hair growth, particularly changes in hair follicle size as occurs in androgenetic alopecia.

Atrichia with Papular Lesions

Atrichia with papular lesions (APL), an autosomal recessive disorder, presents in infancy. Sparse hair is normally present at birth, but universal alopecia develops within the first year of life. Papular lesions, due to the formation of follicular cysts, appear later, generally 3 to 18 years after development of the alopecia.[81] The first mutation to be identified in APL was in the human homolog of the mouse hairless (*hr*) gene on chromosome 8p12.[82–84] The same clinical phenotype has been reported in some families with vitamin D–resistant rickets, in whom there is a mutation in the gene for the vitamin D receptor. Hair follicle development occurs normally in APL, but massive apoptosis in the hair bulb during the first catagen leads to separation of the dermal papilla from the base of the hair follicle and consequent failure to re-enter anagen. The follicular epithelium then undergoes a cystic change. Patients diagnosed with alopecia universalis (alopecia areata) at birth or during the first months of life may, in fact, have either APL or Vitamin D–resistant rickets particularly if the universal hair loss is persistent and/or familial.

Short Anagen Syndrome

The term *short anagen syndrome* has been applied to a poorly understood clinical presentation characterized by short fine but otherwise normal hair in children.[85] Hair density is normal, and there are no associated features. It is usually sporadic, although families showing autosomal inheritance have been described. Hair growth may improve after puberty.

Acute Telogen Effluvium

Acute telogen effluvium may occur at any age and represents a precipitous shift of a percentage of anagen hairs to telogen.[86] Telogen effluvium is a reaction pattern to a variety of physical or mental stressors[1,12,87,88]; the most common causative factors are given in Table 86-6. Although the clinical evidence that psychoemotional stress can cause telogen effluvium is still weak, the fact that defined stressors have very profound hair growth-inhibitory effects in mice[87,88] and that the central hypothalamic stress hormone, and the key stress-associated growth factor, nerve growth factor, both significantly inhibit human hair growth and prematurely induce catagen development in vitro[88,89] renders it likely that "stress" is also a negative hair growth modulator in humans. Any drug can potentially cause telogen effluvium, although some classes of drugs routinely do so.

TABLE 86-6
Causes of Telogen Effluvium

- Endocrine
  - Childbirth, miscarriage, abortion
  - Hypo- and hyperthyroidism
  - Discontinuation of estrogen-containing drugs
- "Stressful" events
  - Febrile illnesses
  - Catabolic illnesses (e.g., malignancy, "consumptive" chronic infection)
  - Major surgery
  - Major trauma
  - Acute or chronic psychological stress
- Nutritional
  - Rapid weight loss (e.g., "crash dieting")
  - Caloric or protein deprivation
  - Chronic iron deficiency
  - Excessive vitamin A ingestion
- Intoxication
  - Thallium
  - Mercury
  - Arsenic
- Drugs
  - Anticoagulants (including heparin)
  - β Blockers (propanolol)
  - Captopril
  - Cholesterol-lowering drugs
  - Colchicine
  - Cytostatic agents
  - Interferons
  - Lithium
  - Penicillamine
  - Retinoids
  - Selective serotonin reuptake inhibitors
  - Valproate
- Inflammatory scalp disease
  - Seborrheic dermatitis
  - Erythroderma

Normally, 50 to 100 hairs are shed per day. In telogen effluvium, a clinical increase in scalp hair shedding usually begins as the first group of anagen hairs that were thrown prematurely into telogen enter exogen 3 to 4 months after the inciting event. If the inciting cause is removed, the shedding resolves spontaneously over the next several months as the percentage of hairs in telogen return to normal; however, the hair density may take 6 to 12 months to return to baseline. In a significant number of patients, no obvious cause is found for telogen effluvium, and the increased shedding, and concomitantly the decreased density, of the scalp hair may become chronic.[90] Acute telogen effluvium is always potentially reversible and does not lead to total scalp hair loss, as the percentage of hairs in telogen rarely goes beyond 50 percent (Fig. 86-10). Persistent excess hair shedding after an acute episode may be an indication of other pathology, most commonly early female pattern hair loss and/or thyroid malfunction.

Chronic Telogen Effluvium

A persistent form of telogen effluvium, with loss of hair volume, lasting in excess of 6 months typically occurs in middle-aged women who may bring large amounts of shed hair for examination at a clinic visit.[91] Examination shows normal or high hair density, although there may be some rarefaction with short hairs along the frontotemporal regions. A simple method for evaluating shed hairs based on their length and the number of shed hairs per day has been proposed to help distinguish chronic telogen effluvium from androgenetic alopecia,[92] with the latter being associated with length less than 3 cm and fewer shed hairs per day. Underlying disorders, such as thyroid deficiency and systemic lupus erythematosus (SLE), should be excluded. Iron deficiency, with or without anemia, is often cited as a cause of chronic telogen effluvium,[93] although this is still controversial.[94,95] In one study, the mean ferritin level was significantly lower in patients with androgenetic alopecia than in normal controls without hair loss, but this was not seen in patients with telogen effluvium.[94]



▲ **FIGURE 86-10** Telogen effluvium.

In some women, chronic telogen effluvium is an early feature of androgenetic alopecia, and up to 60 percent of women with chronic telogen effluvium may show histologic evidence of pattern hair loss on biopsy.[96] In many women, however, no cause can be established and excess shedding may simply be the result of an age-related shortening of the hair cycle[97] that cannot reliably be distinguished from androgen-dependent anagen shortening, suggesting a relationship.[15] Retinoid-induced telogen effluvium has been the trigger for the development of androgenetic alopecia in older teenagers and young adults treated for acne.

Excessive hair shaft shedding and diffuse, non-scarring hair loss is a common feature of SLE (see Chap. 156), which occurs in 24 percent to 84 percent of SLE patients.[98–100] The degree of (telogen) effluvium is often associated with SLE activity, and patients with SLE may go on to develop cicatricial alopecia from chronic discoid lesions [see the section Cicatricial Alopecia (Destruction of the Follicle)].[101]

Anagen Effluvium

The daily loss of some telogen hairs is entirely normal, but it is always abnormal to shed anagen hairs. The term *anagen effluvium* is somewhat misleading because the abnormal anagen hairs in this condition are usually broken off rather than shed. The anagen hairs in



loose anagen syndrome and those of alopecia areata are generally shed in toto.

The classic and easily recognizable causes of anagen effluvium of the scalp are radiation therapy to the head and systemic chemotherapy, especially with alkylating agents (e.g., cyclophosphamide).[102,103] These agents can impair or totally disrupt the anagen cycle and cause varying degrees of hair follicle dystrophy.[104] The net result is either anagen hairs that break off within the follicle or at the level of the scalp (secondary to a weak point in the structurally inferior hair shaft) and are then shed without roots, or dystrophic anagen hairs that are easily dislodged from the usual follicular moorings. Replacement with a normal pelage usually occurs rapidly after discontinuation of chemotherapy, although high-dose busulfan as part of the preparatory treatment for bone marrow transplantation may lead to permanent alopecia due to irreversible damage to hair follicle stem cells.[5,105,106] Regrowth after radiation therapy depends on type, depth, and dose-fractionation, yet commonly leads to permanent follicular destruction, most likely as a result of irreversible hair follicle stem cell damage. In fact, scarring alopecia may progress long after radiation therapy has been discontinued, possibly due to persistent radiation-induced inflammatory changes that progressively damage hair follicle stem cells.[102] Lower dose cytostatic regimens or administration of less cytotoxic agents (e.g., methotrexate, dacarbazine) more often cause only telogen effluvium, because they induce premature catagen.

Cooling caps were previously advocated as a preventive measure for chemotherapy-induced alopecia,[107] but are relatively ineffective and poorly tolerated. The pharmacologic management of chemotherapy-induced alopecia has remained highly unsatisfactory.[5,103]

In the absence of obvious causes of anagen disruption such as cytostatic agents, one must consider exposure to toxic agents. Mercury intoxication, through either chronic industrial exposure, consumption of polluted water or seafood, or inadvertent exposure to mercury-containing antiseptics or fungicides, can lead to hair loss with or without other symptoms, especially neurologic ones.[111] Diagnosis is by documenting elevated mercury levels in hair, blood, or urine. Boric acid intoxication may be through exposure to household pesticides or ingestion of some common household products in which boric acid is a preservative. Patients may develop hair loss along with gastrointestinal, central nervous system, and renal symptoms; a hemorrhagic diathesis; and exfoliation or bullae.[102,112] Blood boric acid levels are elevated in affected patients.

Thallium poisoning leads to dramatic hair loss, with complete epilation occurring 2 to 3 weeks after intoxication.[113] Acutely, patients experience primarily neurologic symptoms including irritability, dysesthesia, ataxia, convulsions, and coma. Blood and urine levels are positive at the time of acute poisoning. Toxic exposure to colchicine and ingestion of certain plants can lead to anagen loss.[102] Severe protein malnutrition may also lead to anagen effluvium. Arsenic exposure does not cause hair loss; instead, arsenic is concentrated in the hair, which facilitates a diagnosis long after intoxication may have occurred.

Loose Anagen Syndrome

Loose anagen syndrome, a recently described, but not uncommon, syndrome has been primarily described in fair-haired children who have easily dislodgable hair (Fig. 86-11A).[114,115] However, loose anagen syndrome can occur in adults and may be familial. Families frequently report periods of greater scalp hair shedding or quiescence. The hair loss may be inapparent, except when traumatic pulling or extraction easily dislodges clumps of hair. Parents of affected children often show a mild form. The hair may also present with unruliness, especially at the occiput, which can be confused with uncombable hair syndrome or woolly hair (see Fig. 86-11B).[116,117] This condition can be misdiagnosed as telogen effluvium if the shed hair roots are not examined microscopically. Microscopically, the proximal shed hair shows a normal anagen bulb, with a ruffled cuticle but without the usual attached root sheath.[118] The unruly hair generally shows a longitudinal groove in the shaft as in uncombable hair syndrome. Given the disruption of the bulb structure by plucking of the hair, it is critical to gently run the fingers through the hair to collect samples, rather than plucking; obviously, hair is easier to obtain during a period of active shedding. A scalp biopsy, which is unnecessary for diagnosis, may show premature and abnormal keratinization of the inner root sheath, with clefts between the inner and outer sheath and the hair shaft. At least in some patients with loose anagen syndrome, this typical gap may result from hereditary keratin defects in the inner root sheath and/or the apposed companion layer (e.g., in families with diffuse partial woolly hair that can be associated with loose anagen hair syndrome).[119] The hair loss may improve with age, and gentle handling decreases shedding.







▲ **FIGURE 86-11** Loose anagen syndrome. **A.** Diffuse hair loss. **B.** Unruly hair. (From Olsen EA et al: The presence of loose anagen hairs obtained by hair pull in the normal population. *J Investig Dermatol Symp Proc* **4**:258, 1999, with permission.)

ALOPECIA AREATA

Epidemiology

At any given time, approximately 0.2 percent of the population has alopecia areata and approximately 1.7 percent of the population experiences an episode of alopecia areata during their lifetime.[120,121] However, there are great geographic and ethnic variations in the incidence and prevalence of the disease; this is also seen with respect to the immunogenetic background of patients with alopecia areata.[24,43,76,122–127] In most patients, the onset is within the first three decades of life although alopecia areata can start at any age. The sex incidence is probably equal.

Etiology and Pathogenesis

Alopecia areata is a chronic, organ-specific autoimmune disease, probably mediated by autoreactive T cells, which affects hair follicles and sometimes the nails.[23,128–130] There is an increased frequency of other autoimmune diseases, notably autoimmune thyroid disease in affected adults, and of organ-specific autoantibodies in patients with alopecia areata.[129,131] Hair follicle autoantibodies are also found in some patients with alopecia areata[31,132] although it is unlikely that these autoantibodies are of importance in the primary pathogenesis of alopecia areata.[128,129,133]

Studies using human hair follicles transplanted into the skin of immunodeficient mice have provided convincing evidence for a cell-mediated etiology, with a key role for $CD8^+$ T cells, which may recognize a major histocompatibility complex class I–presented autoantigen (possibly expressed during anagen and/or anagen-associated melanogenesis).[129,134,135] These experimental data are in line with the concept that a (e.g., interferon-γ–induced) collapse of the normal immune privilege of the anagen hair bulb plays a key role on the primary pathogenesis of the disease.[128,130,133,136] Evidence in support of the concept that melanogenesis-associated autoantigens, which are normally sequestered from immune recognition by a functional hair follicle immune privilege, may be a key target of autoaggressive inflammation in alopecia areata[133] is slowly accumulating.[137,138] Histologically, alopecia areata is characterized by an inflammatory infiltrate, comprised mainly of T cells, in and around the bulbs of anagen hair follicles (Fig. 86-12A). The histopathologic features of alopecia areata, however, are stage-dependent, and the classic features may be missing in subacute and chronic lesions, rendering it prudent to include alopecia areata in the differential diagnosis whenever high percentages of telogen hairs or miniaturized hairs are present, even in the absence of a peribulbar lymphocytic infiltrate.[139]

Anagen follicles attacked by this inflammatory infiltrate move prematurely into catagen, followed by telogen, and then enter a dystrophic anagen status. Most follicles may continue to cycle but, while the disease remains active, are unable to progress beyond an early stage of anagen development and thus do not produce normal hair shafts.[140] An important feature of the pathology is that hair follicles are not destroyed in alopecia areata, possibly because the disease spares the follicular stem cell compartment in the mid-outer root sheath region.

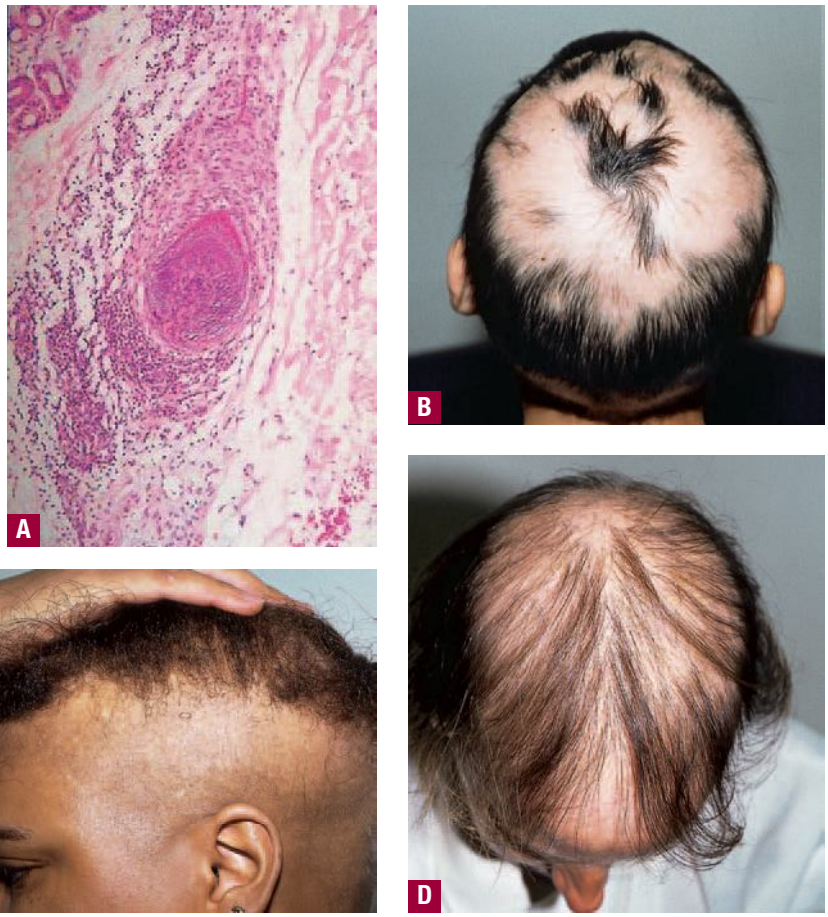

▲ **FIGURE 86-12** **A.** Peribulbar lymphocytic infiltrate in alopecia areata. **B.** Extensive patchy alopecia areata. **C.** Ophiasis pattern of alopecia areata. **D.** Diffuse pattern of loss in alopecia areata. (**B-D** are reprinted with permission from Hordinsky MK: Alopecia areata, in *Disorders of Hair Growth: Diagnosis and Treatment*, edited by Olsen EA. New York, McGraw-Hill, 1994.)

The predisposition to alopecia areata is genetically determined.[141] Between 10 percent and 20 percent of patients with alopecia areata give a family history of the disease, and the true figure is probably higher because mild cases may pass unnoticed or are concealed.[124] There are several reports of alopecia areata in twins, some with concurrent onset. One small study of alopecia areata in twins found a concordance of 55 percent in monozygotic twins but none in dizygotic twins.[142] The genetic predisposition is polygenic in nature. To date, most genes found to be associated with alopecia areata are involved in regulating immune responses, yet there are substantial geographic/ethnic differences in the immunogenetics of alopecia areata.[76,122–127,141] The strongest associations have been with genes of the HLA-D region of the major histocompatibility complex locus.[143,144] There is also an association between severe forms of alopecia areata and polymorphisms in the autoimmune regulator gene on chromosome 21.[145] Alopecia areata is common in Down syndrome,[146] and there is also a high frequency of the disease (more than 30 percent) in autoimmune polyendocrinopathy-candidiasis-ectodermal dysplasia syndrome (also called *autoimmune polyglandular syndrome-1*), a usually autosomal recessive disorder in which there are mutations in the autoimmune regulator gene (see Chap. 144).[147]

A variety of environmental factors, including infection, drugs, trauma, and stress, have been suggested as triggering alopecia areata, although most patients with alopecia areata are unaware of any obvious precipitating factor. It is possible, though hard to prove, that a diversity of insults, physical or psychological, may trigger episodes of alopecia areata[128] but there is no evidence that they influence the prognosis.





Clinical Features

Alopecia areata typically presents with round patches of hair loss. Patches may be single or multiple, and may coalesce (see Fig. 86-12B–D). Although most obvious on the scalp, any hair-bearing skin can be affected, and is frequently found to involve the beard area. The term *alopecia totalis* is used to describe complete loss of terminal hair on the scalp and *alopecia universalis* to describe total loss of all terminal hair on the scalp and body.[148] *Ophiasis* refers to a band-like pattern of hair loss at the periphery of the scalp (see Fig 86-12C). The scalp usually appears normal. The pathognomonic "exclamation mark" hairs may be present, particularly at the periphery of areas of hair loss (Fig. 86-13A). These short broken hairs, whose distal ends are broader than the proximal ends, illustrate their inherent sequence of events: follicular damage in anagen and then a rapid transformation to telogen. White or graying hairs are frequently spared and probably account, in cases of fulminant alopecia areata, for the mysterious phenomenon of "going gray overnight" (see Fig. 86-13B). Nails in patients with alopecia areata may show fine pitting or, less commonly, mottled lunula, trachyonychia, or onychomadesis (see Chap. 87).

Differential Diagnosis

Though the clinical diagnosis is usually straightforward, other conditions that typically need to be considered are:

- Tinea capitis. Obvious inflammation (e.g., scaling, pustules) in association with patchy hair loss suggests a diagnosis of tinea capitis and excludes alopecia areata.
- Trichotillomania. This can be difficult to distinguish from alopecia areata (and may, in fact, be associated with it, especially in children). However, here the hair loss is rarely complete and the broken hairs are usually firmly anchored in the scalp, unlike exclamation point hairs. A biopsy may be needed.
- Early scarring alopecia.
- Syphilis (alopecia areolaris).

Diffuse alopecia areata can be difficult to differentiate from other causes of diffuse hair loss, and may be associated with them (e.g., thyroid abnormalities, other autoimmune diseases and syphilis). Diffuse alopecia areata usually progresses rapidly and the diagnosis becomes clear with time, but a biopsy may be necessary to clarify remaining uncertainties.

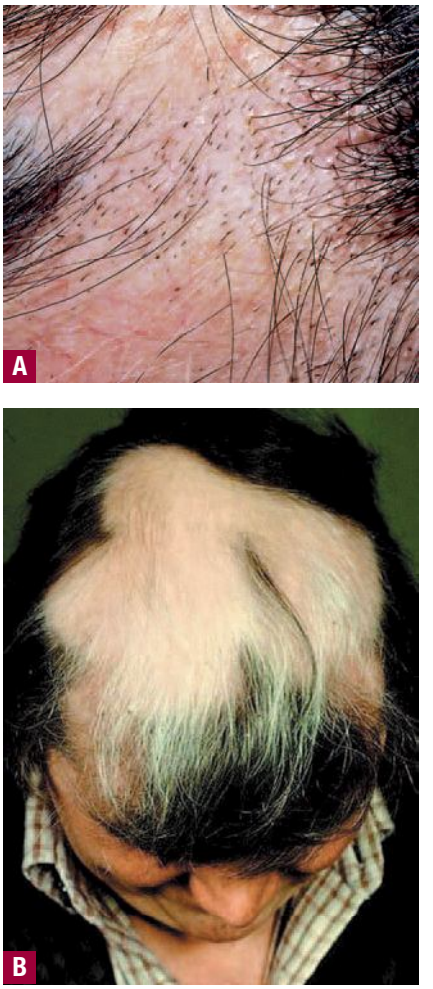

▲ **FIGURE 86-13** **A.** Exclamation mark hairs of alopecia areata. (From Olsen EA: Clinical tools for assessing hair loss, in *Disorders of Hair Growth: Diagnosis and Treatment*, edited by Olsen EA, New York, McGraw-Hill, 2003, with permission.) **B.** Sparing of white hair in alopecia areata.

Prognosis

Spontaneous remission can be expected in the majority of cases where hair loss is limited to a few small patches (possibly, up to approximately 80 percent within 1 year), although most patients experience recurrences at some stage.[149] The prognosis in extensive alopecia areata, particularly alopecia totalis and universalis, is less favorable and fewer than 10 percent of patients in the latter two groups recover spontaneously. The ophiasis pattern of alopecia also tends to be recalcitrant. Other features pointing to a poor prognosis include onset in childhood, loss of body hair, nail involvement, atopy, and a positive family history for alopecia areata.

Management

Counseling of patients on the nature of alopecia areata, its prognosis, and the treatment options is essential. For the majority of patients, alopecia areata is a cosmetic issue. Occasionally, it causes physical disability (e.g., when there is eyelash involvement or marked nail dystrophy). Nevertheless, the cosmetic importance of hair is such that alopecia areata can cause severe emotional problems, particularly in children and young women, though by no means restricted to these groups.[2] In view of the limited efficacy of current forms of treatment, the physician has an important role in helping patients adapt to their lack of hair. This is not an easy task and input from other health professionals, such as a clinical psychologist, may be needed. Many patients are helped by involvement in patient support groups. With children, it is often the parents whose reactions must be addressed for the child to adjust to the hair loss. The National Alopecia Areata Foundation (http://www.naaf.org) is an excellent source of information for patients.

Treatment

There is relatively little evidence from well-designed clinical trials, and so treatment recommendations are based mainly on case series and clinical experience (Box 86-1).[150] Helpful guidelines for managing alopecia areata have been developed.[4,6]

Box 86-1

Treatment of Alopecia Areata

- Patchy alopecia
  - Intralesional corticosteroids: Up to 2 mL injected/session and repeated at intervals.
  - Potent topical steroid 1–2×/day.
  - Topical anthralin 0.1%–2.0% once daily. Wash off after 10–20 min, steadily increase contact duration, switch to higher dose if no significant irritation.
  - Minoxidil lotion (5%) twice daily.
- Extensive or rapidly progressive alopecia.
  - Contact immunotherapy.
  - Systemic corticosteroids. Benefits are uncertain and must be weighed against risk of systemic corticosteroid therapy.
  - Wig or hairpiece.
- Alopecia totalis/universalis
  - Contact immunotherapy.
  - Topical/systemic steroids.
  - Wig or hairpiece.

CONSERVATIVE MANAGEMENT All of the currently available treatments for alopecia areata have a high failure rate and none alters the natural history of the disease. After discussion of the options patients may therefore opt not to be treated, other than to wear a wig if appropriate. 'No treatment' is a legitimate option in patients with a short history and limited disease, in view of the high rate of spontaneous remission in this group.

TOPICAL CORTICOSTEROIDS Topical corticosteroids are widely used to treat alopecia areata. There is some evidence of efficacy if potent corticosteroids are used under occlusion,[151] but less aggressive treatment regimens are probably ineffective.

INTRALESIONAL CORTICOSTEROIDS Intralesional corticosteroids are the most effective approach for treating patchy alopecia areata. Hydrocortisone acetate (25 mg/mL) and triamcinolone acetonide (5 to 10 mg/mL) are commonly used, either by subdermal injection or using a needle-less device.[152,153] Multiple injections repeated monthly are usually necessary, limited by patient discomfort. Intralesional corticosteroids are not appropriate in rapidly progressive or extensive disease. Especially with triamcinolone injections, there is a significant risk of inducing skin atrophy, which may increase exponentially with each repeated injection.

SYSTEMIC CORTICOSTEROIDS Oral corticosteroid therapy can induce short-term hair regrowth in patients with alopecia areata; however, hair regrown is usually lost after treatment is discontinued.[154] Newer regimens that involve pulsed oral corticosteroids (e.g., prednisolone 200 mg once weekly for 3 months or dexamethasone 5 mg daily for 2 consecutive days/week for 3 months) may also induce hair regrowth in some patients. No significant side effects have been reported in published series but cannot be ruled out, and long-term benefits have not been shown.[150,155,156]

TOPICAL MINOXIDIL SOLUTION There is limited clinical trial evidence that topical minoxidil solution (TMS) stimulates hair regrowth in some patients.[3,157] Minoxidil is ineffective in alopecia totalis/universalis.

ANTHRALIN Data from small case series suggest that treatment with anthralin cream is helpful in some cases, but the overall response rate is low.[158] However, especially in children where steroids or contact immunotherapy are decided against, this is a reasonable and safe treatment option.

PHOTO(CHEMO)THERAPY Phototherapy using UVB has been widely used, but there is no convincingly documented evidence of efficacy. Some case series have reported success using psoralen and UVA light (local or whole body), but there have been reports of high relapse rate when treatment is discontinued. Retrospective reviews have suggested that the response is no better than that expected from the natural history.[159–161] The deleterious long-term effects of phototherapy-induced premature skin aging and photocarcinogenesis argue against this treatment option, especially in children.

CONTACT IMMUNOTHERAPY In addition to intralesional glucocorticoid injections, this is the only form of therapy for which efficacy has been convincingly documented. This may be the most effective treatment for patients with extensive alopecia areata, although it is not widely available. Also, there is insufficient comprehensively comparative analysis with alternative treatment options. The patient is sensitized to a potent allergen [usually diphenylcycloprenone (DPCP) or squaric acid dibutylester (SADBE)] and then a solution of DPCP or SADBE is painted on the scalp once weekly. The concentration of DPCP or SADBE is adjusted to induce a mild dermatitis reaction. Published response rates vary widely (9 percent to 85 percent),[5,162] but clinical experience suggests that approximately 30 percent of patients with extensive alopecia areata achieve a cosmetically worthwhile response after 6 months of treatment. Continuous or intermittent treatment is needed to maintain the response in most patients. Alopecia totalis/universalis is less likely to respond to contact immunotherapy, and it is unclear whether patients with rapidly progressive disease profit.

Risks include severe dermatitis, urticaria, and pigmentary abnormalities including vitiligo (an important consideration in racially pigmented skin). Sensitization of health care workers and relatives handling the immunogen is also a significant hazard. Contact immunotherapy has been in use since the early 1980s, and no long-term side effects have been reported.

COSMETIC MEASURES Female patients with extensive alopecia areata often choose to wear a wig or hairpiece. Hair weaves can give good results if sufficient hair remains, although they are expensive to maintain. Locks of Love (http://www.locksoflove.org) is an organization that collects human hair and provides hairpieces to financially disadvantaged children younger than age 18 years with alopecia areata and other chronic forms of alopecia. Wigs are generally less successful in men where other hair styles, such as shaving the scalp, are often a more acceptable approach. Temporary tattooing can be helpful for loss of eyebrows.

NON-SCARRING HAIR LOSS: PRODUCTION DECLINE

Triangular (Temporal) Alopecia

Triangular alopecia may be congenital but usually appears in childhood as a focal patch of hair loss at or just behind the frontotemporal hairline. The hair loss either may be complete or fine vellus hairs may remain.[46,163] The underlying scalp is normal. The hair loss may be uni- or bilateral (Fig. 86-14). Histologically, the affected area shows a transition from terminal to vellus hair. The alopecia is usually persistent. Hair transplants are a reasonable approach. Congenital triangular alopecia may occur within families as a paradominant trait.[164]

Hypotrichosis Simplex

Hypotrichosis simplex, an autosomal dominant disorder, is characterized by progressive global loss of scalp hair



▲ **FIGURE 86-14** Triangular alopecia.





▲ **FIGURE 86-15** Hypotrichosis simplex in a 35-year-old woman.

from early/mid childhood onward. Both sexes are equally affected. The eyebrows and body hair are unaffected and there are no associated features. The pathogenesis has not been studied, but may involve a process of follicular miniaturization resembling pattern hair loss. A mutation in the gene for the adhesion protein corneodesmosin has been reported in some families with hypotrichosis simplex (Fig. 86-15).[165,166]

Pattern Hair Loss

Pattern hair loss is by far the most common type of hair loss in both sexes. Male pattern hair loss (also known as *male androgenetic alopecia, male balding*) is an androgen-dependent, genetically determined trait. Female pattern hair loss has also been termed *androgenetic alopecia*, in the belief that it is the same entity as in men, but the requirement for androgens is less clearcut than in men and the distribution of hair loss is generally different.[167,168] However, in both men and women, pattern hair loss is characterized by a progressive decline in the duration of anagen, an increase in the duration of telogen, and miniaturization of scalp hair follicles, indicating a final common pathway of follicular regression (Fig. 86-16).[169]

Pattern hair loss is a biologically normal trait. Nevertheless, the high value our societies place on maintaining a full head of hair means that loss of hair can have a significant adverse effect on quality of life. Both sexes are affected though, in general, the impairment of psychosocial well-being is more frequent and more severe in women.

EPIDEMIOLOGY ***Men.*** Almost all Caucasian men develop some recession of the hair line in the frontotemporal region following puberty. More advanced balding may start at any time after puberty and its frequency and severity in the population increase with advancing age.[170] Approximately 80 percent of men have some degree of balding by the age of 70 years, and approximately 50 percent show Norwood-Hamilton VI/VII balding (Fig. 86-17). The frequency has been reported to be lower in African American men.[171] Although it is generally thought that the prevalence of androgenetic alopecia in Asian men is much lower than in Caucasians, it is probably higher than often suspected.[172] Interestingly, in Finnish men aged 63 years androgenetic alopecia was significantly associated with insulin-linked disturbances, such as hypertension and diabetes,[173] and patients with a large prostate reportedly show a higher prevalence of androgenetic alopecia.[174,175] In a recent autopsy study, baldness (as well as hair growth in the external auditory canal) were positively associated with coronary artery disease and sudden cardiac death, which revives the long-standing controversial debate of whether and how balding and cardiovascular disease are associated.[176,177]

Women. Female pattern hair loss is less common than male balding but shows a similar age-related increase in population frequency and severity. Similar to male balding, the onset may be as early as the peripubertal period but in the great majority it is later. By the age of 30 years, 2 percent to 5 percent of Caucasian women show some thinning of their scalp hair rising to nearly 40 percent at age 70 years.[167,178] Although there is a popular view that late-onset female pattern hair loss is related in some way to post-menopausal changes, this is not apparent from the published epidemiologic data. Similar to male pattern baldness, female pattern hair loss may be associated with coronary artery disease, at least in women under the age of 55 years.[179] Female pattern hair loss is less common in Asian women.[180]

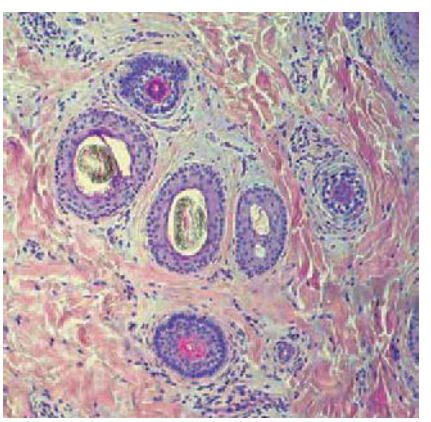

▲ **FIGURE 86-16** Histology of female pattern hair loss. There are two terminal and three vellus follicles in this field of a biopsy from female pattern hair loss.

ETIOLOGY ***Men.*** Male balding is undoubtedly an androgen-dependent trait. Men castrated before puberty do not develop balding unless subsequently treated with testosterone.[181] Balding also does not occur in XY individuals who fail to express androgen receptors due to a mutation in the androgen receptor gene (complete androgen insensitivity syndrome), despite male levels of circulating testosterone.[182] Although testosterone is the major circulating androgen in men, the balding process is driven by its metabolite dihydrotestosterone, which has greater affinity and avidity for the androgen receptor.[183]

Although testosterone is necessary for its development, it has long been recognized that male balding runs in families, and it is clear that a genetic predisposition is also required. Twin studies show a high level of concordance in monozygotic twins (80 percent to 90 percent),[187] and there is a higher frequency of balding in the fathers of bald men than in the fathers of non-bald men.[188] Osborn proposed that male balding is an autosomal dominant trait,[189] but more recent evaluation of the published data suggests that it has a polygenic basis.[190] Three studies have shown an association between male balding and variant regions in the androgen receptor gene.[191–193] However, this does not explain the paternal influence on male balding, as the locus for the androgen receptor gene is on the X chromosome and is therefore inherited exclusively from the mother.

Recent experimental evidence suggests that, in androgen-sensitive hair follicles, hair growth-inhibitory secreted factors (e.g., transforming growth factor-β) released from androgen-stimulated fibroblasts of the follicular dermal papilla may be at least one key factor in mediating hair growth inhibition and hair follicle miniaturization, at least in male pattern balding.[194–196]

Women. Scalp hair loss is a feature of hyperandrogenism in women and rapidly progressive pattern hair loss, particularly when accompanied by other signs of androgen excess such as hirsutism, amenorrhoea, and a raised circulating testosterone level, should prompt a search for an androgen-secreting tumor. Some studies,[197,198] though not all,[199] have reported that, as a group, women with slowly progressive female pattern hair loss show modest elevations of cir-

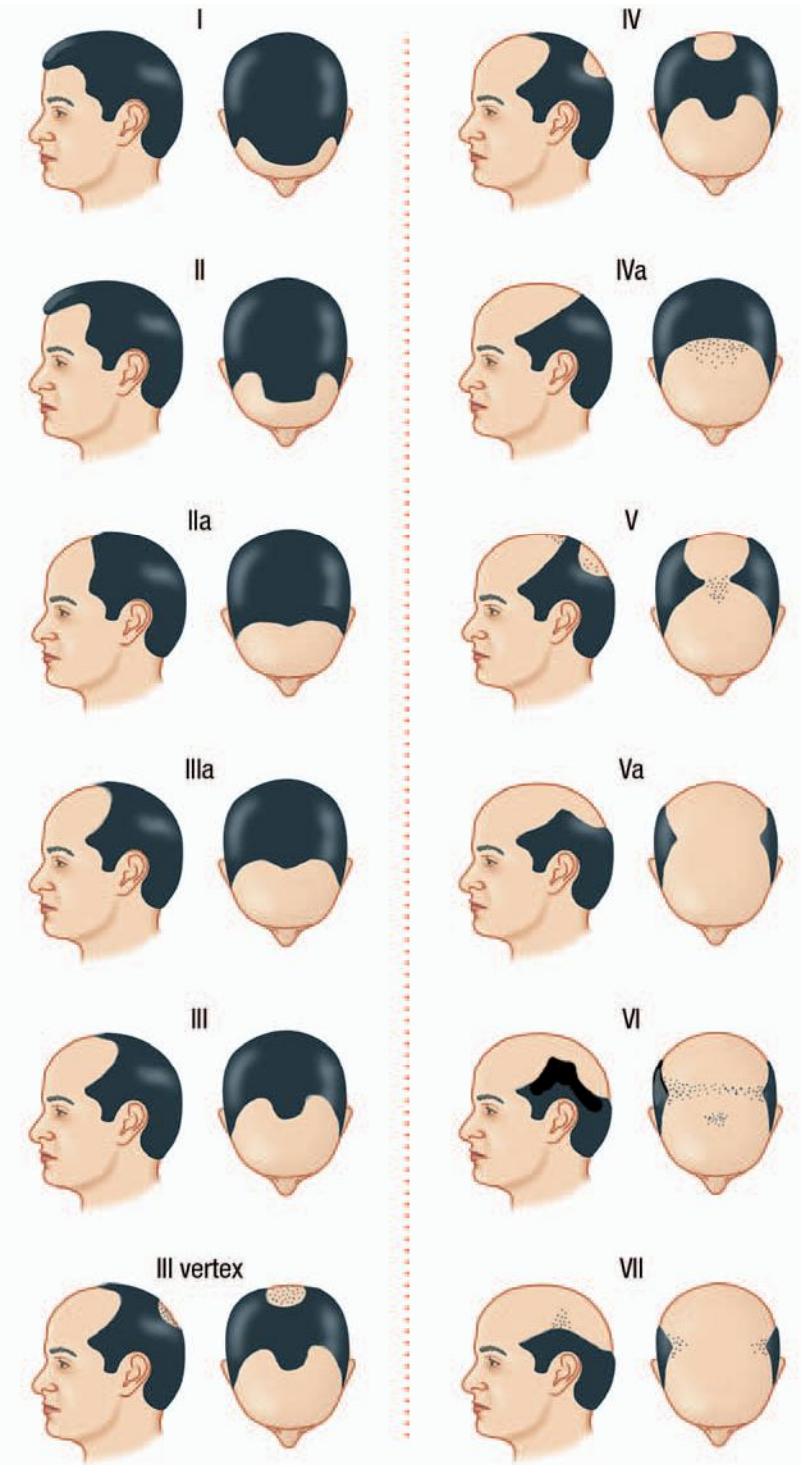

▲ **FIGURE 86-17** Hamilton-Norwood classification of pattern hair loss in men. (From Olsen EA: Female pattern hair loss. *J Am Acad Dermatol* **45**:S70, 2001.)

culating androgen levels and an increased frequency of polycystic ovaries.[200] Many women with pattern hair loss do not exhibit other biochemical or clinical signs of androgen excess, however, and do not respond to anti-androgen treatment, suggesting that androgens do not play a role.[201] No genetic loci associated with female pattern hair loss have yet been identified.

CLINICAL FEATURES Clinical diagnosis, based on male or female pattern recognition, is usually very straightforward. However, hyperprolactinemia may mimic androgenetic alopecia,[199,203,204] and androgenic alopecia due to hyperandrogenism must be distinguished from classic androgenetic alopecia.[7] In addition, a female pattern of hair loss may be seen in males, and vice versa.

Men. The two major features of male pattern hair loss are recession of the frontal hair line and balding of the scalp vertex. Eventually, hair loss may coalesce leaving a rim of normal hair growth at the sides and back of the scalp. The changes that occur during the progression of male balding were first classified by Hamilton,[205] to be later modified by Norwood.[170] Nevertheless, male balding is a continuum rather than a series of distinct stages and individual patterns can vary quite widely (see Fig. 86-17). Hairs within the balding areas may become progressively shorter and finer in caliber, eventually disappearing completely, or show a more diffuse reduction in hair density with maintenance of normal hair diameter in the remaining hairs. In a small proportion of Caucasian men (less than 5 percent), balding assumes a more diffuse distribution over the crown and frontal scalp, with retention of the frontal hair line, resembling female pattern hair loss. This pattern is more common in Asian men.[180]

Women. Female pattern hair loss is usually a more diffuse process than male balding. Typically, there is a reduction in hair density involving the crown and frontal scalp, with maintenance of the frontal hair line (Fig. 86-18).[206] There may be miniaturized hairs in the frontotemporal region but deep recession of a well-demarcated hair line is uncommon. Unlike men, the parietal regions may also be involved. Female pattern hair loss may present with excessive hair shedding and loss of hair volume, before there is an obvious reduction in hair density. Differentiation from chronic telogen effluvium can be difficult. In such cases, the diagnosis may be established by the presence of a high proportion of miniaturized follicles on biopsy. A small proportion of women display a "male" pattern of hair loss. It should be emphasized that the distribution of hair loss in women is not a reliable guide to androgen status.

Investigations are probably unnecessary in men and in most women with typical pattern hair loss. However, if the hair loss is diffuse and not localized to typical patterns, it is appropriate to check thyroid stimulating hormone and iron in men on an iron-deficient diet or in whom blood loss could be an issue. Authorities generally recommend the following tests for women with pattern hair loss:

- Serum ferritin (a measure of iron stores): The role of low iron stores in



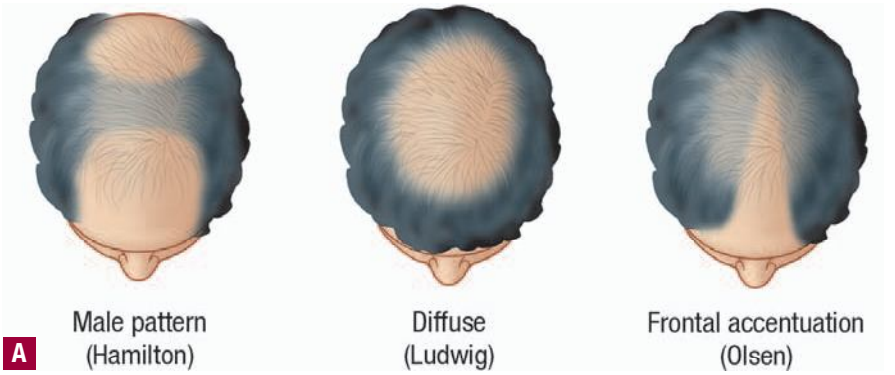



▲ **FIGURE 86-18** Pattern hair loss in women. **A.** Different phenotypic expressions. **B.** Characteristic frontal accentuation (widened hair part).



female pattern hair loss is uncertain, but there is some evidence that women with serum ferritin less than 40 μg/L respond poorly to anti-androgen treatment.[207] In women with chronic disease in whom ferritin levels may be elevated due to inflammation, iron and total iron binding capacity should be investigated. Of note, iron-containing medications (including vitamins) should be discontinued for these measurements.

- Thyroid-stimulating hormone: Hair loss is traditionally regarded as a feature of thyroid deficiency although there are few formal published data.[208]
- Serum androgens: The majority of women with female pattern hair loss have no clinical or biochemical evidence of androgen excess.[197] However, screening laboratory testing should be considered, especially in women with concomitant evidence of hirsutism, moderate to severe adult acne, acanthosis nigricans, irregular menses, and/or galactorrhea. Screening studies, at a minimum, should include free and/or total testosterone with or without dehydroepiandrosterone sulfate. Patients with raised serum testosterone levels should be referred for specialist endocrinologic evaluation[7] to consider the presence of a tumor or endocrinologic disorder, such as congenital adrenal hyperplasia.

MANAGEMENT Broadly speaking, patients presenting with pattern hair loss fall into three overlapping groups—those who wish to be reassured that their hair loss is not a manifestation of a serious underlying disease, those who are concerned by it and wish to be treated (Box 86-2), and those with a body dysmorphic disorder. The latter group is important to identify as these patients are unlikely to be satisfied with treatments aimed at restoring hair growth and involvement of other health care professionals, such as a clinical psychologist, may be needed.[1,209] Treatments for pattern hair loss are available, but patients should be counseled that none will restore hair growth to its prepubertal density and that, although some recovery of hair growth is possible, the main aim, at least for medical treatments, is to prevent further progression (see Box 86-2).

Men. Two medical treatments, TMS and oral finasteride, are licensed for the treatment of male pattern hair loss,[3,7,186] and can be used in combination. A trial of at least 6 months of therapy is needed to assess efficacy, and treatment must be continued to sustain the response.

Box 86-2

Treatment of Androgenetic Alopecia

- Caution against unrealistic expectations; primary goal is to halt progression.
- Male pattern hair loss
  - 5% topical minoxidil solution or foam twice daily.
  - Oral finasteride, 1 mg daily.
  - Combination of the above: Use for at least 6 mo to assess response, and continue treatment to maintain response.
  - Surgery (e.g., hair transplantation). Most useful for restoring frontal hair loss.
- Female pattern hair loss
  - 2%–5% topical minoxidil solution twice daily.
  - Topical 17β-estradiol (e.g., estradiol benzoate, 20–25 mg/mL isopropanol).
  - Oral anti-androgens (spironolactone, cyproterone acetate).
  - Combination of the above: Use for at least 6 mo to assess response, and continue treatment to maintain response.
  - Maintain serum ferritin > 40 μg/L.
  - Hair transplantation in selected cases.

MINOXIDIL. Clinical trials using a variety of endpoints, including hair counts, hair weight, and global photography, have shown that up to 60 percent of men show improvement in vertex balding using 5 percent TMS with a mean increase in hair density of 10 percent to 12 percent. The response rates with 2 percent TMS are lower.[211] Treatment has to be continued to maintain the response, and any hair gained is lost within 4 to 6 months of stopping treatment.[3] Minoxidil is not effective in treating frontotemporal recession. Minoxidil lotion occasionally causes scalp irritation, most commonly due to the propylene glycol in the vehicle.

FINASTERIDE. Finasteride is an inhibitor of type 2 5α-reductase. Taken orally in a dose of 1 mg daily it prevents the progression of hair loss in most men and, after 2 years of treatment, approximately two-thirds show some improvement in hair growth.[186] In an extended trial, men taking finasteride subsequently showed some loss of hair after 5 years of treatment, but hair loss progressed more rapidly in untreated men.[212] There is a marginally higher frequency of sexually related problems, such as impotence, in men taking finasteride, but otherwise it is generally well-tolerated. Any positive benefit is lost within 12 months if treatment is discontinued. It is unclear how exactly finasteride exerts its beneficial effects in those patients that respond to treatment. One recent study suggests that the reversal of apparent "hair loss" by finasteride reflects some kind of reactivation of "hypotrophic" terminal hair follicles on the basis of faster re-entry into and longer duration of anagen, but not a genuine vellus-to–terminal hair conversion.[213] Despite the absence of formal clinical studies on the efficacy of this combination, topical minoxidil and systemic finasteride are often combined

in clinical practice. A combination of 5α-reductase 1 and 2 inhibition may be beneficial in the treatment of male pattern hair loss.[214]

SURGERY. A variety of surgical techniques have been developed for treating male pattern hair loss, of which hair transplantation is the most widely used.[7,215] All involve redistributing terminal hair to the balding areas so the number of terminal hairs remains the same. In skilled hands, and with careful patient selection, good cosmetic results can be obtained. Surgery is the only treatment that can improve hair coverage on totally bald scalp, and quickly restore hair.[215] Surgery is most effective for restoring frontal hair loss (see Chap. 250).

Women. As with male pattern hair loss, a trial of at least 6 months of therapy is needed to assess efficacy, and treatment must be continued to sustain the response. Combinations of agents may be used.

MINOXIDIL. Clinical trials of topical minoxidil solution in female pattern hair loss have reported a mean increase in hair density of 10 percent to 18 percent. One large trial found no significant difference in response to the 2 percent and 5 percent formulations, although there was a trend toward superiority of the higher concentration.[216] At present, only the 2 percent formulation is licensed for women by the U.S. Food and Drug Administration. As in men, a better response is obtained when treatment is used at an early stage of hair loss. Continued treatment is necessary to maintain the response.

ANTI-ANDROGENS. Anti-androgens have been widely used to treat female pattern hair loss, but there is little clinical trial evidence to demonstrate efficacy and none is licensed for this indication. One controlled trial showed a small response to cyproterone acetate but only in those women with clinical evidence of androgen excess.[217] Uncontrolled studies of cyproterone acetate and spironolactone have reported benefit in some patients.[207,218] Generally, 100 to 200 mg/day of spironolactone is needed for response. Potentially fertile women should take contraceptive measures during antiandrogen treatment because of the risk of feminizing a male fetus.

FINASTERIDE. The final verdict on whether or not systemic finasteride may also be a treatment option in post-menopausal women with androgenetic alopecia is still out.[219] A controlled trial of finasteride in post-menopausal women did not demonstrate efficacy,[220] although small case series have reported improvement in hair growth in women with hyperandrogenism[221] and in younger women.[222] Potentially fertile women should take contraceptive measures during treatment with finasteride because of the risk of feminizing a male fetus.

TOPICAL ESTROGENS. Even though convincing clinical trials in support of topical estrogens, a long-practiced, empirical treatment regime for female androgenetic alopecia, are still lacking, topical 17β-estradiol (e.g., estradiolbenzoate, 20 to 25 mg in 70 percent isopronol) is frequently used to counteract androgenetic alopecia-related telogen effluvium in these patients.[5] Notably, estradiol prolongs the duration of anagen, at least in human scalp hair follicle organ culture.[223,224]

SURGERY. Surgical treatment of pattern hair loss is less widely used in women because of the usual diffuse nature of the condition and often poor hair quality in the donor area. However, good results can be obtained in selected cases, particularly in those women with pronounced frontal loss and good hair density in the occipital (donor) region (see Chap 257).[7]

TRAUMATIC HAIR LOSS

Exogenous trauma may cause hair loss, either temporary or permanent, by several different mechanisms, including follicular destruction, hair breakage, and changes in hair follicle cycling.

Pressure Alopecia

There are numerous reports of localized hair loss, usually affecting the occipital scalp, after prolonged surgery or ventilation. The hair loss may be permanent and is presumably due to ischemia from pressure injury.[225,226] In neonates with a history of a capus succedaneum, a "halo scalp ring" may occur, characterized by an annular alopecia that presents as a circumferential ring around the scalp from pressure necrosis; hair loss may be permanent.

Trichotillomania

Trichotillomania (Greek, hair pulling madness) manifests as a compulsive desire or habit to pull out the hair. It occurs in 0.6 percent to 3.4 percent of adults.[227] In young children, trichotillomania is usually a habit akin to thumb sucking, and most recover spontaneously. In teenagers and adults, though, trichotillomania is a more serious and often intractable psychiatric problem. Childhood trichotillomania is more common in boys, but in the adult form, women outnumber men 7:1. This cause of focal scalp hair loss is classified as an impulse control disorder,[228,230,231] and several different underlying psychopathologies can underlie this clinical sign.[229–231]



The clinical presentation is usually quite distinctive, with a confluence of very short sparse hairs within an otherwise normal area of the scalp (Fig. 86-19A,B). Microscopic examination of the ends of cut or plucked hairs generally reveals either the tapered tips of newly regrowing anagen hairs or bluntly broken hairs. (A hair pull here is usually negative because the telogen hairs have generally all been dislodged). The most difficult differential diagnosis is from alopecia areata,[234] but the absence of complete hair loss within affected sites and the firmly anchored nature of broken hairs usually permits the distinction to be made. Where doubt remains, a scalp biopsy can be diagnostic, showing the characteristic increase in the number of catagen hairs (rarely seen in biopsies of normal scalp), trichomalacia, and melanin within the follicular canal secondary to traumatic hair removal and the absence or sparsity of a perifollicular inflammatory infiltrate.[235,236] A vertically oriented hair shaft split, which contains proteinaceous material and erythrocytes ("hamburger sign") has been proposed as an additional, novel histologic pointer to trichotillomania.[237]

Treatment of these patients is difficult. In children, the habit can often be broken by mere acknowledgement of the problem or behavior modification. Adolescents and adults with this condition present a more challenging problem. In those patients who admit to pulling their hair cognitive behavioral therapy is probably the most effective form of treatment, although there is a high failure rate.[238,239] Psychotropic drugs, such as clomipramine or sertraline, may also help. The combination of behavioral therapy (habit reversal training) and medication may be more efficacious in the treatment of trichotillomania than either approach alone.[240] Patients who deny the self-inflicted nature of their



▲ **FIGURE 86-19** Trichotillomania. **A.** Bizarre pattern of localized hair loss in a boy. **B.** Extensive hair loss in a woman.



hair loss usually refuse referral to a psychiatrist or clinical psychologist.

Traction Alopecia

Traction alopecia is caused by inadvertent prolonged traction on the scalp by the physical pressure of hair styling (e.g., pony tail, tight braids, foam rollers, etc.; Fig. 86-20). There is often a cultural element, such as braiding in African American girls[241] or the "topknot" in Sikh boys.[242] The distribution of hair loss reflects that of maximal traction, but is most commonly seen at the scalp margins. Although potentially reversible in its early stages, loss of hair follicles leads to permanent hair loss if the traction is unrelenting over months to years.[243,244]

Tinea Capitis (See Chap. 188)

Tinea capitis is a very common cause of hair breakage or loss, particularly in children. It typically presents with patchy hair loss associated with inflammation of the affected scalp. The degree of inflammation varies from severe pyodermatous swellings (kerion) to barely detectable. It may also present as noninflammatory "black dot ring-worm" presentation, with broken hairs filling, but not projecting from, follicular orifices (see eFig. 86-20.1 in on-line edition).

Treatment of tinea capitis must be by the systemic route, and contacts must be sought and treated to prevent re-infection (see Chaps. 188 and 233).[247]

PRIMARY OR ACQUIRED HAIR SHAFT ABNORMALITIES

Acquired localized trichorrhexis nodosa may be seen in hair that is subject to repetitive rubbing, such as with lichen simplex chronicus or trichotillomania (see the section Trichotillomania). It may also present in focal areas secondary to trauma from chemical or heat processing of hair. Acquired pili torti may present as a focal patch of fragile hair. This is usually secondary to trauma or some underlying, potentially scarring scalp abnormality.[51] Hypervitaminosis in patients with anorexia nervosa or retinoids has also been associated with acquired pili torti.[248] Bubble hair is a recently recognized and very distinctive abnormality of the hair shaft and is characterized by rows of bubbles seen microscopically within localized areas of brittle hair.[250,251] Exposure to prolonged high temperatures from curling irons or hair dryers applied to wet or damp hair are the usual causative factors, and the defect is completely reversible.



◀ **FIGURE 86-20** Traction alopecia.

Unruly Hair

WOOLLY HAIR NEVUS Woolly hair nevus is a non-hereditary focal condition that usually appears within the first 2 years of life but can occur as late as adolescence.[252] Fifty percent of cases have an associated epidermal, verrucous, or pigmented nevus, although not necessarily immediately under the affected hair.[51] There may be associated ocular abnormalities, such as persistent papillary membrane or retinal abnormality. Spontaneous improvement in the hair may occur with age. Both woolly hair and ulerythema ophryogenes have been associated with Noonan syndrome and cardiofaciocutaneous syndrome (see Chap. 85) so that the presence of woolly hair also raises several genodermatoses as differential diagnosis.[253]

ACQUIRED PROGRESSIVE KINKING Acquired progressive kinking has been primarily reported in postpubescent males with androgenetic alopecia.[254] It presents with gradual curling and darkening of the frontal, temporal, auricular, and vertex hairs. Microscopically, affected hairs show kinks and twists, with or without longitudinal grooving.[255]

Abnormality of Cycling

ALOPECIA AREATA Alopecia areata most frequently presents as focal hair loss (see the previous section Alopecia Areata).

SYPHILIS (See Chap. 200) Hair loss may be one or the sole cutaneous manifestation of secondary syphilis.[256] This may present as a patchy "moth-eaten" alopecia (alopecia areolaris) or as generalized thin-



◀ **FIGURE 86-21** Alopecia of secondary syphilis.

ning (Fig. 86-21). If this clinical picture is seen in children, congenital syphilis is to be considered.[257] A scalp biopsy may show either a superficial and deep perivascular mixed lymphocytic/macrophage/plasma cell infiltrate, a peribulbar perifollicular lymphocytic infiltrate mimicking alopecia areata, or a noninflammatory telogen effluvium picture.[258,259] Serologic testing should be positive, and treatment with appropriate antibiotics reverses the hair loss.

Scalp Conditions Associated with Focal Hair Loss

Most eczematous conditions of the scalp do not cause hair loss, the exceptions being pityriasis amiantacea, severe scalp psoriasis or seborrheic dermatitis, scalp involvement with dermatomyositis, and malignancies such as cutaneous T-cell lymphoma or Langerhans cell histiocytosis. In pityriasis amiantacea, thick, tenaciously adherent scale infiltrates and surrounds the base of a group of scalp hairs (Fig. 86-22).[260] The condition may mimic psoriasis clinically, but, in contrast to psoriasis, the hair in involved areas is dislodged on attempts to physically remove the scale. Removal of the scale in this manner can lead to scarring alopecia. The condition usually presents in children, is best treated with the combination of keratolytics and topical corticosteroids, and usually improves with age. Pityriasis amiantacea represents a particular reaction pattern of the scalp to various inflammatory scalp diseases, most frequently seborrheic dermatitis or psoriasis. However, tinea capitis must be excluded in every case, and topical antibiotics can be a helpful adjuvant therapy if recalcitrant.[261]

CICATRICIAL ALOPECIA (DESTRUCTION OF THE FOLLICLE)

The term *cicatricial* or *scarring alopecia* implies the potential of permanent destruction of the hair follicle,[262] most likely as a result of irreversible damage to epithelial hair follicle stem cells in the region of the bulge.[263,264] Clinically, there is effacement of follicular orifices, always in a patchy or focal distribution. A biopsy is confirmative, showing replacement of follicles with fibrotic stellae and either fibrosis or hyalization of surrounding collagen.[265–268] Although some cases of cicatricial alopecia are due to physical causes (e.g., pressure or chronic traction) or to the hair follicle being secondarily involved in a destructive process (e.g., "kerion" fungal infection, necrotizing zoster, metastatic/primary neoplasm) or as the result of a developmental defect (aplasia cutis congenita), most patients seeking medical attention have a primary cicatricial alopecia. Although these conditions have a common endpoint (irreversible alopecia), they have varied clinical and histologic features and virtually no therapies (Table 86-7) are able to turn the process completely off.

A new classification system has been proposed by the North American Hair Research Society to identify and evaluate significant differences among these entities.[271] The primary cicatricial alopecias are presented in keeping with this classification system (see Table 86-7).[262] The power of routine histology to allow definitive distinctions between various types of cicatricial alopecia is disputed, but direct immunofluorescence may help to make such distinctions.[272,273]

Primary Cicatricial Alopecia

LUPUS ERYTHEMATOSUS (See Chap. 156) Chronic cutaneous lupus erythematosus may present in the scalp, usually with erythema, atrophy, and variable hypopigmentation and/or follicular plugging (see eFig. 86-22.1 in on-line edition).

LICHEN PLANOPILARIS Areas of active alopecia in lichen planopilaris are clinically distinguished by perifollicular erythema and/or a violaceous discoloration of the scalp. Keratotic follicular papules may be evident. Evidence of lichen planus may be present elsewhere, and this should be sought to help confirm the diagnosis (see Chap. 26).

Graham-Little Syndrome. Graham-Little syndrome is characterized by lichen planus–like lesions and a follicular "spines"/keratosis pilaris-like picture that develop in areas of alopecia on the scalp, eyebrows, axillary, and pubic areas (see Chap. 26).[265]

Frontal Fibrosing Alopecia. *Frontal fibrosing alopecia* is a term given to the frontotemporal hairline recession and eyebrow loss in post-menopausal women that is associated with perifollicular erythema, especially along the hairline.[277] Scalp biopsy is largely indistinguishable from lichen planopilaris, although frontal fibrosing alopecia may show more prominent apoptosis and less inflammation than lichen planopilaris, along with spared interfollicular epidermis.[276] Topi-



◀ **FIGURE 86-22** Pityriasis amiantacea. Note area of patchy alopecia after manual removal of adherent scale.



TABLE 86-7
Primary Cicatricial Alopecias: Salient Clinical Features and Treatment Regimens[a]

	Clinical			
Entity	**Epidemiology**	**Scalp**	**Non-Scalp**	**Therapy[a,b]**
Lymphocytic[c]				
Discoid lupus erythematosus	Women > men	Symptomatic, erythematous scaly plaques with follicular plugs; telangiectases, atrophy and depigmentation with time; activity in center of alopecic patch	May be present; rule out systemic lupus erythematosus	• Topical ± intralesional steroid • Hydroxychloroquine, prednisone; topical tacrolimus, tazarotene, imiquimod • Isotretinoin
LPP (classic)	Women > men	Pruritic, multifocal, or central alopecic patches with follicular hyperkeratosis and erythema at hair-bearing margin	May be present (especially as lichen ruber mucosae)	• Topical ± intralesional steroid • Oral retinoid, prednisone, hydroxychloroquine, oral cyclosporine
Frontal fibrosing alopecia	Post-menopausal women	Frontotemporal recession often with classic LPP at hair-bearing margin	May be present (eyebrows)	• Topical ± intralesional steroid • Anti-androgens, finasteride
Graham-Little syndrome	Adults	Patches with follicular hyperkeratosis	May be present (non-scarring in axillae, pubic area)	See text
Graft-versus-host disease	See Chap. 28	Usually presenting like LPP, hyperpigmentation may be present	See Chap. 28	• Prednisone • Calcineurin inhibitors • Topical steroid, psoralen and ultraviolet A light, etretinate
Pseudopelade of Brocq	Adults	Asymptomatic, noninflamed ivory-white or flesh-colored small oval-round confetti-like, reticulate, or large, irregular patches, ± atrophy	Rarely present (beard); separate entity, or end-stage variant of LPP?	• Topical ± intralesional steroid • Prednisone, hydroxychloroquine, isotretinoin
Central centrifugal cicatricial alopecia (previously also known as *follicular degeneration syndrome*, *pseudopelade* in African Americans)	Especially black women	Central scalp; noninflamed late stage; flesh-colored symmetric patch	Absent	• Cease traumatic/chemical hair-care practices • Topical steroid + oral tetracycline
Keratosis follicularis spinulosa decalvans	Onset in childhood	Patchy, follicular hyperkeratosis ± perifollicular erythema	Present; photophobia, keratosis pilaris	• Topical and intralesional steroid • Isotretinoin
Alopecia mucinosa	All ages	Polymorphous disease (e.g., erythematous plaques with patulous ostia): alopecia areata-like, diffuse, or complete alopecia	May be present; rule out malignancy, because this is a classic presenting symptom of cutaneous T-cell lymphoma (see Chap. 146)	For primary form: • Topical steroid, intralesional steroid • Minocycline, isotretinoin • Phototherapy
Neutrophilic[c]				
Folliculitis decalvans	Adults	Usually central scalp; grouped follicular pustules, miliary abscesses at hair-bearing margin	Generally absent; may represent scalp variant of hidradenitis suppurativa/acne inversa (see http://www.hs-foundation.org)	• Antibiotic ± topical steroid • Rifampin + second antibiotic • Fusidic acid + zinc • Isotretinoin
Mixed				
Acne keloidalis	Especially black men	Occipital scalp; firm red-brown papules, papulopustules, nodules and keloidal plaques	Absent	• Intralesional steroid ± antibiotics • Excision (plaque form), cryotherapy, isotretinoin
Erosive pustular dermatosis	Especially elderly women	Asymptomatic, crusted purulent plaque	Absent	• Topical steroid, calcipotriol • Zinc

LPP = lichen planopilaris.
[a]Therapy of cicatricial alopecia is severely hampered by the paucity of evidence-based medicine. Most treatment regimes are based on anecdotal reports or small study series; double-blind, randomized, placebo-controlled, prospective studies in a sufficiently large cohort of patients are virtually non-existent.
[b]The main aim of treatment is to prevent progression, and patients should be advised that significant recovery of hair growth is unlikely.
[c]Histologically, it is relatively easy to distinguish the lymphocytic and neutrophilic groups of cicatricial. However, currently it is exceedingly difficult, if not impossible, to distinguish clinically distinct primary cicatricial alopecias within these two groups.
Adapted from Ross EK, Tan E, Shapiro J: Update on primary cicatricial alopecias. *J Am Acad Dermatol* **53**:1, 2005.





▲ **FIGURE 86-23** Frontal fibrosing alopecia.

cal and intralesional steroids, topical and systemic retinoids, and hormone replacement therapy do not prevent the hair loss progression (Fig. 86-23).

PSEUDOPELADE OF BROCQ In clinical terms, pseudopelade of Brocq[278] implies flesh- to pink-colored, irregularly shaped alopecia that may begin in a "moth-eaten" or characteristic "footprints-in-the-snow" pattern with eventual coalescence into larger patches of alopecia (Fig. 86-24).[43,278] There is no follicular erythema or hyperkeratosis, yet the disease may progress inexorably. There has been considerable debate as to the specificity of this diagnosis versus an assignation of the term to describe all noninflammatory scarring alopecias, including the end-stage of a variety of initially inflammatory conditions. Histologically, the lesions are characterized by a perifollicular and perivascular lymphocytic infiltrate primarily at the level of the follicular infundibulum, loss of sebaceous epithelium, and fibrotic streams into the subcutis without interface or follicular plugging changes.[279] Elastin stains may distinguish pseudopelade (persistent elastic fibers around the midshaft of the follicle) from lichen planopilaris and lupus erythematosus (loss of elastic fibers in this location).[280] Direct immunofluorescence is negative in the majority of cases. However, in general, the histology is similar, if not identical, to that of lichen planopilaris.[273] It is unclear whether any treatment helps.

Other Forms of Scarring Alopecia

Central centrifugal cicatricial alopecia (CCCA) is a form of cicatricial alopecia that affects adults of African orgin.[43,271] This condition has also been called *hot comb alopecia* or *follicular degeneration syndrome*. This starts at the crown or midline vertex and spreads slowly in a centrifugal fashion. Inflammation has been reported more commonly in affected men than in affected women.[282] Histologically, the earliest and most distinctive change is premature desquamation of the inner root sheath with later changes through the outer root sheath (including migration of the hair shaft), a mononuclear infiltrate primarily at the isthmus, and, finally, loss of the follicular epithelium and replacement with fibrous tissue.[282] Although tight braiding, hot combs, and hair straightening agents are often invoked as causative or at least contributory factors and their use discouraged in CCCA, this has not been definitely proven. The distribution of CCCA overlaps that of pattern hair loss but the sex distribution is tremendously skewed toward women.

Alopecia mucinosa , also known as *follicular mucinosis*, generally presents as erythematous, alopecic papules, plaques, or flat patches on the scalp and face.[267] Biopsy reveals prominent follicular, epithelial, and sebaceous gland mucin, and perifollicular lymphohistiocytic infiltrate, which may be associated with follicular lymphocyte exocytosis, without concentric lamellar fibrosis.[265,267,283] In adults, alopecia mucinosa almost invariably represents follicular mycosis fungoides (see Chap. 146).[283] It is controversial whether a self-limited variant exists in children.

Keratosis follicularis spinulosa decalvans is a rare, usually X-linked disorder with the gene located at Xp22.13–p22.2 (see Chap. 85).[284,285]

Folliculitis decalvans is an inflammatory disease characterized by pustular folliculitis leading to scarring hair loss. Surviving hairs may group so that multiple hairs are seen emerging from a single follicular orifice (tufted folliculitis) (Fig. 86-25). *Staphylococcus aureus* is usually cultured from these pustules, but whether this is a primary or secondary process is unclear. Histologically, early lesions show an acute suppurative folliculitis with neutrophils and eosinophils, later mixed with lymphocytes and histiocytes.[265,266] Loss of sebaceous epithelium and perifollicular fibrosis is common.[265] Systemic antibiotics, particularly in combination with rifampin, systemic and/or topical steroids, and systemic retinoids may also be helpful.[289]

Dissecting folliculitis or perifolliculitis capitis abscedens et suffodiens is another inflammatory condition of the scalp that can lead to scarring alopecia. African Americans are particularly affected. This condition begins with deep inflammatory nodules, primarily over the occiput, that progress to coalescing regions of boggy scalp (Fig. 86-26). Sinus tracts may form and dislodge purulent material. As in folliculitis decalvans, *S. aureus* is the most common bacterial isolate. Biopsy of early lesions shows follicular plugging and suppurative follicular or perifollicular abscesses with a mixed inflammatory infiltrate of neutrophils, lymphocytes, plasma cells, or eosinophils.[265–267] Later, foreign-body giant cells, granulation tissue, and, finally, scarring with sinus tracts occur. Control is difficult to attain, but small case series have reported success with oral isotretinoin, systemic antibiotics (using similar regimens to folliculitis decalvans), systemic steroids, and dap-



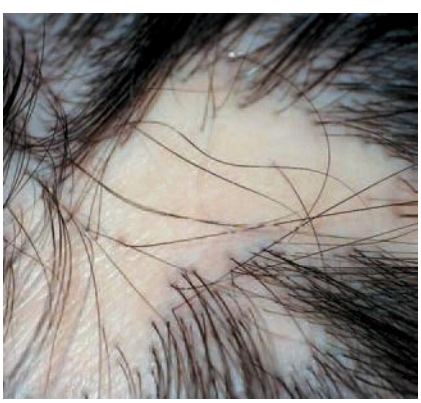

▲ **FIGURE 86-24** Pseudopelade of Brocq.



◀ **FIGURE 86-25** Folliculitis decalvans.



◀ **FIGURE 86-26** Dissecting folliculitis.



sone.[262,290] Surgical incision and drainage, excision with grafting, and/or x-ray epilation are occasionally used for refractory cases.

Acne keloidalis (nuchae) is a destructive scarring folliculitis that occurs mostly on the occipital scalp of African Americans, primarily men (Fig. 86-27). The clinically distinctive lesions begin as follicular pustules and papules and progress to persistent firm papules or coalesce into hairless keloid-like plaques.[291] On histopathologic examination of an early lesion, there is follicular dilatation and a mixed peri-infundibular infiltrate that goes into follicular rupture and foreign body granulomas, loss of sebaceous glands, and lamellar fibroplasia. Mild forms of the disease may be treated with topical or intralesional corticosteroids, or systemic antibiotics, and/or cryotherapy. Surgical excision of the affected skin the most effective treatment for severe acne keloidalis.[262]

The primary lesion in acne necrotica is a pruritic or painful erythematous follicular-based papule that develops central necrosis and crusting and heals with a varioliform scar.[292,293] The lesions are concentrated on the nose, forehead, and anterior scalp, but may spread, primarily to the trunk. The course is chronic. Histologically, acne necrotica is a lymphocytic necrotizing folliculitis.[292] Possible treatments include systemic antibiotics and oral isotretinoin.[262,292]

Erosive pustular dermatosis of the scalp is predominantly a disease of the elderly, mainly women, although pediatric cases do occur.[294] It presents as chronic boggy crusted plaque on the scalp overlying exudative erosions and pustules, eventually leading to scarring alopecia (Fig. 86-28).[295,296] A history of preceding trauma may be obtained,[294,297] and there are several reports of onset after treatment for actinic keratoses.[262] On biopsy, there is a lymphoplasmacytic infiltrate with or without foreign body giant cells and pilosebaceous atrophy. Multiple organisms, both bacterial and fungal, have been cultured, but these probably represent secondary colonization; patients do not generally respond to antibacterial or antifungal drugs. No single treatment is uniformly successful, but potent topical steroids, topical tacrolimus,[298] or isotretinoin may be helpful.[297]

Secondary Cicatricial Alopecia

Cicatricial alopecia may present as a hereditary or development problem, alone or as part of a syndrome. Examples of the latter are Conradi-Hünermann chondrodysplasia punctata; incontinentia pigmenti; ankyloblepharon, ectodermal defect, cleft lip or palate syndrome; Hallermann-Streiff syndrome; and generalized atrophic benign epidermolysis bullosa.[46]

Congenital Cicatricial Alopecia

The most common congenital cicatricial alopecia is aplasia cutis congenita, which is the congenital focal absence of epidermis with or without absence of other layers of the skin.[46] Hair follicles in the involved areas are variably affected. The condition may present at birth as an ulceration, crust, scar, or parchment-like membrane (see Chap. 106).

EXCESS HAIR

Hirsutism refers to hair growth in women in areas of the body where hair growth is under androgen control and in which normally only postpubescent males have terminal hair growth. These areas include the moustache, beard, chest, escutcheon, and inner thigh.

Hypertrichosis specifically refers to hair density or length beyond the accepted limits of normal for a particular age, race, or sex. The excess hair may be generalized or localized and may consist of lanugo, vellus, or terminal hair.

Hirsutism

EPIDEMIOLOGY What constitutes significant hirsutism is difficult to define, as it depends on a variety of cultural and racial factors, media-driven perceptions of normality, and the perceptions of the individual physician and patient.[299] Not surprisingly, therefore, estimates of the frequency of hirsutism in the female populations have varied widely. In Lon-



▲ **FIGURE 86-27** Acne keloidalis.



◀ **FIGURE 86-28** Pustular dermatosis of the scalp.

don, 1.2 percent of women were significantly hirsute.[300] Other studies have reported frequencies of up to 18 percent.[299] The frequency and distribution of female androgen-dependent hair growth also varies with age; terminal hair growth in the pubic and axillary regions declines with age, whereas facial hair growth increases. These difficulties have led to the use of the patient-determined term *unwanted hair* to influence therapeutic decision making. Nevertheless, the physician may still have to make a value judgment as to when patient concerns really represent a body dysmorphic disorder, rather than a problem solvable by hair removal.

PATHOGENESIS Terminal hair growth in a "male" pattern is undoubtedly due to the effect of androgens, and reflects the conversion of vellus to terminal hair follicles. In many women, hirsutism is associated with raised levels of circulating androgens (54 percent in one series).[301] However, in some, androgen levels are within the normal range, suggesting in these individuals that hair growth is especially sensitive to androgen stimulation. Recent evidence suggests that testosterone increases 5α-reductase gene expression in dermal papillae from lower abdominal skin of women with hirsutism; theoretically, this may raise the dihydrotestosterone-generating potency of these hair follicles.[302] Also, only certain 5α-reductase type 1 haplotypes are reportedly associated with hirsutism,[303] which further raises the question of whether inherited, constitutive abnormalities in intrafollicular dihydrotestosterone synthesis are an important element in the pathogenesis of hirsutism. Other clinical features of hyperandrogenism include oligo- or amenorrhea, sub- or infertility, acne, acanthosis nigricans, and female pattern hair loss to frank virilization with male pattern balding and clitoromegaly.[304] Table 86-8 lists causes of hyperandrogenism, of which polycystic ovary syndrome is by far the most common.[304,305]

INVESTIGATION Whether and how to investigate hirsute women depends on a number of factors, including the presence of clinical features of increased androgen production, the duration of the history, and the concerns of the patient. In fertile women with normal menses and a long history of relatively mild hirsutism, it is debatable whether investigation is necessary at all. In women with moderate to severe hirsutism, particularly when accompanied by other signs of androgen excess, further evaluation is warranted (Table 86-9). Women with hyperprolactinemia may have an increase in functional androgens through adrenal overproduction and through a decrease in sex hormone–binding globulin caused by a diminution of ovarian estrogen production.[306]

TABLE 86-8
Hirsutism

- Androgen-secreting tumors
  - Adrenal
    - Adenoma
    - Adenocarcinoma (rare)
    - Ectopic adrenocorticotropic hormone–secreting tumor (rare)
  - Ovarian
    - Gonadal stromal tumor
    - Thecoma
    - Lipoid tumor

Functional androgen excess

- Adrenal enzyme deficiencies (congenital adrenal hyperplasia)
  - Early onset 21-hydroxylase deficiency
  - Late-onset 21-hydropxylase deficiency
  - 11β-hydroxylase deficiency
  - 3β-ol dehydrogenase deficiency
- Cushing syndrome
- Polycystic ovarian disease
  - With or without adrenal contribution
  - Hyperthecosis
- "Idiopathic" hirsutism
- Medication/drug use

Hughes CL: Hirsutism, in *Disorders of Hair Growth: Diagnosis and Treatment*, edited by Olsen EA. New York, McGraw-Hill, 1994, p 344, Table 14-2.

TABLE 86-9
Recommended Investigation for Hirsutism

- Serum testosterone (if > 200 ng/mL, exclude androgen-secreting tumor)
- Serum-free testosterone and dehydroepiandrosterone (more sensitive; most women with moderately elevated androgen levels have polycystic ovarian syndrome)
- 17-hydroxyprogesterone (raised level suggests congenital adrenal hyperplasia; confirm diagnosis by repeat measurement after adrenocorticotropic hormone stimulation)
- Serum prolactin (hyperprolactinemia due to macro- or microprolactinoma or treatment with neuroleptic drugs[331]; may have associated menstrual abnormalities, infertility, and galactorrhea)

Box 86-3
Treatment of Hirsutism

Remove existing terminal hair and prevent further vellus-to-terminal transformation

- Temporary hair removal
  - Shaving, plucking, depilatory creams
  - Topical eflornithine (slows growth; does not remove hair)
- (Potentially) permanent hair removal
  - Electroepilation[332]
  - Laser hair removal[307]
- Anti-androgen measures
  - Weight loss
  - Oral anti-androgens (spironolactone, cyproterone acetate)
  - Oral contraceptives
  - Finasteride

TREATMENT The approach is two-pronged: the removal or reduction of existing unwanted terminal hair, and the reduction of the androgen drive toward further vellus-terminal transformation. The latter approach (e.g., using anti-androgens) may also help to reduce hair growth but, on its own, is unlikely to eliminate it (Box 86-3). Shaving, plucking, and use of depilatory creams are temporary means of hair removal that can be irritating and painful. The topically applied inhibitor of ornithine decarboxylase, eflornithine 13.9 percent, is approved for the reduction of unwanted facial hair in women when applied twice daily.

Laser epilation is less permanent than often suspected, is most effective when applied repetitively, and patients should be discouraged from unrealistic expectations. The mechanism of laser epilation is the selective photothermolysis of melanized hair through absorption of light energy.[307] The combination of the topically applied eflornithine with laser therapy may decrease the growth after hair removal.[308]

Weight loss may be helpful in obese patients because obesity increases free testosterone levels by reducing sex hormone–binding hormone and contributes to insulin resistance.

There are marginal differences in efficacy between systemically administered agents, but all generally take 6 to 12 months for sufficient miniaturization of terminal hairs to be clinically significant. These include oral anti-androgens (such as spironolactone, 100 to 200 mg daily) or cyproterone acetate,[309–312] oral contraceptives, and finasteride.[309,313] Oral contraceptives inhibit androgen synthesis by inhibiting the output of gonadotropins and are most effective if combined with anti-androgens. Treatment of congenital adrenal hyperplasia may also be accom-



plished through the use of low-dose dexamethasone.[314] Hyperprolactinemia may be treated directly with either medical (bromocriptine) or surgical treatment of the hyperprolactinoma, possibly combined with an anti-androgen.

Hypertrichosis

Congenital hypertrichosis lanuginosa presents as a confluent, generalized overgrowth of silvery blonde to gray lanugo hair at birth or in early infancy.[315] It is rare (1 in 1 billion) and thought to occur as an autosomal dominant trait with variable expressivity. In most cases, other than possibly anomalous dental eruptions, children are otherwise healthy. The hair may persist, increase, or decrease with age.[316–318]



There are several other congenital disorders associated with generalized hypertrichosis, but none that are so evenly distributed as congenital hypertrichosis lanuginosa (Table 86-10).[43] Patients with the autosomal dominant Ambras syndrome or hypertrichosis universalis congenita present with much longer, thicker hair, with accentuation over the entire face, ears, and shoulders.[319–321] Associated facial dysmorphism and dental anomalies are common. Members of the five-generation family described with congenital generalized hypertrichosis also have excess terminal hair on the face and upper body, more severe in men than women in keeping with the X-linked dominant inheritance.[318,322] Patients with the autosomal dominant (rarely autosomal recessive) gingival fibromatosis frequently have hypertrichosis, mostly on the face, eyebrows, limbs, and upper back, along with seizures and oligophrenia.[43,315] Hypertrichosis may be delayed until puberty, although gingival fibromatosis in this situation usually appears with the emergence of the primary, versus secondary, teeth.

ACQUIRED GENERALIZED HYPERTRICHOSIS

There are few more ominous signs in dermatology than the onset of generalized hypertrichosis without an obvious drug-related explanation. Generalized acquired hypertrichosis lanuginosa almost always signals an underlying malignancy or is a harbinger of one to develop in the near future (Fig. 86-29 and see eFig. 86-29.1 in on-line edition; see Table 86-10 and Chap. 154).[323,324] However, an association with autoimmune hepatitis has also been reported.[325] More frequently, extensive acquired hypertrichosis is a common feature of porphyria cutanea tarda, variegate porphyria, and congenital erythropoietic porphyria (see Chap. 132).

TABLE 86-10
Causes of Generalized Hypertrichosis

- Congenital/hereditary
  - Congenital hypertrichosis lanuginosa
    - Ambras syndrome
    - Congenital generalized hypertrichosis
  - With gingival fibromatosis
    Hereditary gingival fibromatosis with generalized hypertrichosis
    Zimmermann-Laband syndrome
    Ramon syndrome
  - Brachmann-de Lange syndrome
  - Wiedermann syndrome
  - Cantu generalized hypertrichosis with osteochondrodysplasia
  - Hurler syndrome
  - Reticular ichthyosiform erythroderma
  - Donahue syndrome (leprechaunism)
  - Buntinex syndrome
  - Barbar-Say syndrome
  - Pivnick syndrome
  - Jalili syndrome
  - Coffin-Siris syndrome
  - Gorlin syndrome
  - Hyperkinetic circulatory disorder
  - Schinzel-Giedion syndrome
  - Lawrence-Seip syndrome
  - Generalized smooth muscle hamartoma
    - Michelin-tire syndrome
    - Schaap syndrome
    - Parme syndrome
  - Hemihypertrophy
- Acquired
  - Acquired hypertrichosis lanuginosa (malignancy)
  - Drugs
    - Minoxidil
    - Diazoxide
    - Phenytoin sodium
    - Cyclosporine
    - Psoralen and ultraviolet A light
    - Topical steroids
    - Streptomycin
    - Acetazolamide
    - Oxadiazolopyrimidine
    - Fenoterol
  - Porphyria
    - Porphyria cutanea tarda
    - Hepatoerythropoietic porphyria
    - Variegate porphyria
    - Erythropoietic porphyria
  - POEMS (*p*olyneuropathy, *o*rganomegaly, *e*ndocrinopathy, *M* protein, and *s*kin changes) syndrome
  - Juvenile dermatomyositis
  - Hypothyroidism
  - Acrodynia
  - Malabsorption syndromes
  - Central nervous system–related problems or trauma
    - After encephalitis
    - Multiple sclerosis
    - Schizophrenia
    - Head injury
    - Hyperostosis interna
    - Anorexia nervosa

From Olsen EA: Hypertrichosis, in *Disorders of Hair Growth: Diagnosis and Treatment*, edited by Olsen EA. New York, McGraw-Hill, 2003, with permission.



▲ **FIGURE 86-29** Acquired hypertrichosis lanuginosa. (From Olsen EA: Hypertrichosis, in *Disorders of Hair Growth: Diagnosis and Treatment*, edited by Olsen EA. New York, McGraw-Hill, 2003.)

There are several drugs that routinely cause generalized hypertrichosis (see Table 86-10).[43,315] Oral minoxidil, a piperidinopyramidine derivative that is a potassium channel opener and antihypertensive agent when used systemically, causes hypertrichosis in 80 percent of patients, most prominently over the face, shoulders, and extremities.[210] Diazoxide, a benzothiadiazine used primarily in malignant hypertension or idiopathic hypoglycemia of infancy, leads to lanugo-like hypertrichosis of the face, trunk, and extremities in 1 percent to 20 percent of adults but in almost 100 percent of children. Dilantin use leads to terminal hair hypertrichosis in 5 percent to 12 percent of patients, again first over the extremities, trunk, and face. The immunosuppressive immunophilin ligand, cyclosporine A, causes terminal hair hypertrichosis in 40 percent to 95 percent of patients, with a more diffuse distribution of ex-



▲ **FIGURE 86-30** Cyclosporine-related hypertrichosis.

cess hair, but primarily over the upper body (Fig. 86-30).[326–328] Based on findings in the mouse, the underlying mechanism likely reflects premature anagen induction as well as catagen inhibition by cyclosporine A,[133,329] which may contribute to the vellus to terminal hair conversion that leads to hypertrichosis.

LOCALIZED HYPERTRICHOSIS Table 86-11 lists the conditions associated with localized hypertrichosis. These are generally inherited, developmental, or secondary to irritation or trauma.

TREATMENT Removal of the inciting cause should be the prime approach to treatment and usually leads to regression of the hypertrichosis. However, in situations in which this is not possible, one must either help the patient deal psychologically with the physical anomaly and/or use means of either temporarily or permanently removing the hair. The same methods of hair removal described for hirsutism management may be used for hypertrichosis as well, except for the anti-androgenic approaches (see Box 86-3).

TABLE 86-11
Causes of Localized Hypertrichosis

- Congenital/hereditary
  - Mid-dorsum hypertrichosis with underlying neuroectodermal abnormality
    - Spina bifida occulta
    - Traction (e.g., meningocele manqué)
    - Diastematomyelia
  - Familial cervical hypertrichosis
  - Hairy elbows
  - Anterior cervical hypertrichosis
  - Hairy pinna
  - Trichomegaly alone
  - Congenital smooth muscle hamartoma
  - Winchester syndrome
  - Nevoid hypertrichosis
  - Stiff skin syndrome
  - Congenital pigmented nevus
  - Hemimaxillofacial dysplasia
  - Becker nevus
- Acquired
  - Melorheostotic scleroderma
  - Post morphea
  - Reflex sympathetic dystrophy
  - Osteosclerotic myeloma
  - Scrotal hair in male infants
  - Drugs
    - Interferon
    - Sodium tetradecyl sulfate
    - Topical latanoprost
    - Topical minoxidil
  - Undercasts
  - Irritants (topical)
  - Repeated trauma
    - Pressure (e.g., sack bearers, costaleros)
    - Lichen simplex chronicus
    - Biting
    - Insect bites
  - Stasis/lymphedema
  - Congenital arteriovenous fistula
  - Denervated area
  - Chronic osteomyelitis
  - Site of immunizations
    - Smallpox
    - Diphtheria-tetanus
  - Chicken pox
  - Human immunodeficiency virus
  - Periphery burned area
  - Kala-azar (eyelashes)

From Olsen EA, Hypertrichosis, in *Disorders of Hair Growth: Diagnosis and Treatment*, edited by Olsen EA. New York, McGraw-Hill, 2003, with permission.

KEY REFERENCES

The full reference list for all chapters is available at www.digm7.com.

1. Hadshiew I et al: Burden of hair loss: Stress and the underestimated psychosocial impact of telogen effluvium and androgenetic alopecia. *J Invest Dermatol* **123**:455, 2004
2. Hunt N, McHale S: The psychological impact of alopecia. *BMJ* **331**:951, 2005
3. Price VH: Treatment of hair loss. *N Engl J Med* **341**:964, 1999
4. Ross EK, Shapiro J: Management of hair loss. *Dermatol Clin* **23**:227, 2005
5. Paus R: Therapeutic strategies for treating hair loss. *Drug Dis Today Ther Strat* **3**:101, 2006
6. MacDonald Hull SP et al: Guidelines for the management of alopecia areata. *Br J Dermatol* **149**:692, 2003
7. Olsen EA et al: Evaluation and treatment of male and female pattern hair loss. *J Am Acad Dermatol* **52**:301, 2005

11. Olsen EA: Methods of hair removal. *J Am Acad Dermatol* **40**:143, 1999

43. Olsen EA: *Disorders of Hair Growth: Diagnosis and Treatment*, New York, McGraw-Hill, 2003
44. Dawber RP: *Hair and Scalp Disorders: Common Presenting Signs, Differential Diagnosis and Treatment*, 2nd ed. London, Dunitz, 2004

130. Gilhar A, Paus R, Kalish R: Lymphocytes, neuropeptides, and genes involved in alopecia areata. *J Clin Invest* **111**:2019, 2007

201. Olsen EA et al: Female pattern hair loss. *J Am Acad Dermatol* **47**:795, 2002

215. Unger P: Hair transplantation: Current concepts and techniques. *J Invest Dermatol Symp Proc* **10**:225, 2005

229. Hautmann G, Hercogova J, Lotti T: Trichotillomania. *J Am Acad Dermatol* **46**:807, 2002

247. Trovato MJ, Schwartz RA, Janniger CK: Tinea capitis: Current concepts in clinical practice. *Cutis* **77**:93, 2006

262. Ross EK, Tan E, Shapiro J: Update on primary cicatricial alopecias. *J Am Acad Dermatol* **53**:1, 2005

271. Olsen EA et al: Summary of North American Hair Research Society (NAHRS)-sponsored Workshop on Cicatricial Alopecia, Duke University Medical Center, February 10 and 11, 2001. *J Am Acad Dermatol* **48**:103, 2003

304. Rosenfield RL: Hirsutism. *N Engl J Med* **353**:2578, 2005

307. Haedersdal M, Wulf HC: Evidence-based review of hair removal using lasers and light sources. *J Eur Acad Dermatol Venereol* **20**:9, 2006

315. Olsen EA: Hypertrichosis, in: *Disorders of Hair Growth: Diagnosis and Treatment*, edited by Olsen EA. McGraw-Hill: New York, 2003, p 399



CHAPTER 87

Biology of Nails and Nail Disorders

Antonella Tosti
Bianca Maria Piraccini



BIOLOGY OF NAILS

The nail apparatus consists of a horny "dead" product, the nail plate, and four specialized epithelia: the proximal nail fold, the nail matrix, the nail bed, and the hyponychium (Fig. 87-1A). The nail apparatus develops during the ninth embryonic week from the epidermis of the dorsal tip of the digit as a rectangular area, the nail fold, which is delineated by a continuous groove.[1] The proximal border of the nail fold extends downward and proximally into the dermis to form the nail matrix primordium. By the fifteenth week the nail matrix is completely developed and starts to produce the nail plate, which will continue to grow until death. The nail apparatus lies immediately above the periosteum of the distal phalanx. The intimate anatomic relationship between the nail and the bone is responsible for the common occurrence of bone alterations in nail disorders and vice versa. The shape of the distal phalangeal bone also determines the shape and the transverse curvature of the nail.

Fingernails usually present a longitudinal major axis and toenails a transverse major axis. The ratio between length and width is important for the aesthetic appearance of the nails. The size of the nails varies in the different digits. The biggest nail is that of the first toe, which covers approximately 50 percent of the dorsum of the digit.

Nails have numerous functions. Fingernails not only contribute to the pleasing appearance of the hands, but are very important in protecting the distal phalanges and enhancing tactile discrimination and the capacity to pick up small objects. They are also widely used for scratching and grooming and are an efficient natural weapon. Toenails protect the distal toes and contribute to pedal biomechanics.

Nail Plate (See Fig. 87-1A)

The nail plate is a fully keratinized structure that is continuously produced throughout life (see Fig. 87-1B). It results from maturation and keratinization of the nail matrix epithelium and is firmly attached to the nail bed, which partially contributes to its formation. Proximally and laterally the nail plate is surrounded by the nail folds, which cover its proximal third and lateral margins. At the tip of the digit, the nail plate separates from the underlying tissues at the hyponychium. The nail plate is rectangular, translucent, and transparent. It is curved in both the longitudinal and transverse axes, especially in the toes. The nail plate surface is smooth but frequently shows mild longitudinal ridges that increase with aging. The pattern of these ridges can be used for forensic identification. The bottom of the nail plate shows longitudinal ridges that correspond to the rete ridges of the nail bed. The nail plate is homogeneously pink, except for its free edge, which is white. The pink color of the nail plate is due to the nail bed blood vessels.

The proximal part of the fingernails, especially of the thumbs, shows a whitish, opaque, half-moon–shaped area, the lunula, that is the visible portion of the nail matrix. In this area the nail plate attachment to the underlying epithelium is loose. More than 90 percent of fingernails show a thin distal transverse white band, the onychocorneal band, which marks the most distal portion of firm attachment of the nail plate to the nail bed.[2] This area represents an important anatomic barrier against environmental hazards, and its disruption produces nail plate detachment with onycholysis. The onychocorneal band is separated from the nail plate white free edge by a 1.0- to 1.5-mm pink band called the *onychodermal band*.

In transverse sections, the nail plate consists of three portions: dorsal nail plate, intermediate nail plate, and ventral nail plate.[3] The dorsal and the intermediate portions of the nail plate are produced by the nail matrix, whereas its ventral portion is produced by the nail bed. Above the lunula the nail plate is thinner and consists only of the dorsal and intermediate portions. There is a natural line of cleavage between the dorsal and the intermediate nail plate.

The nail plate progressively thickens from its emergence to its distal margin. The mean toenail thickness at the distal margin is 1.65 ± 0.43 mm in men and 1.38 ± 0.20 mm in women. Fingernails are thinner; the mean thickness is 0.6 mm in men and 0.5 mm in women. There is an increase in nail thickness with age, particularly in the first two decades. Nail thickness depends on the length of the nail matrix and nail bed.[4] Thinning of the nails is usually a sign of nail matrix disorders, whereas nail thickening is most commonly a consequence of nail bed disorders.

Proximal Nail Fold (See Fig. 87-1A)

The proximal nail fold is a skinfold that consists of a dorsal and a ventral portion. The dorsal portion is anatomically similar to the skin of the dorsum of the digit but thinner and devoid of pilosebaceous units. The ventral portion, which cannot be seen from the exterior and proximally continues with the germinative matrix, covers approximately one-fourth of the nail plate. It closely adheres to the nail plate surface and keratinizes with a granular layer. The limit between the proximal nail fold and the nail matrix can be histologically established at the site of disappearance of the granular layer.

The horny layer of the proximal nail fold forms the cuticle, which is firmly attached to the superficial nail plate and prevents the separation of the plate from the nail fold. The integrity of the cuticle is essential for maintaining the homeostasis of this region.

The dermis of the proximal nail fold contains numerous capillaries that run parallel to the surface of the skin and may easily be observed in vivo by capillary microscopy (Fig. 87-2). This permits the observation of both the arterial and the venous limbs of the capillaries, which are arranged in parallel rows and appear as fine regular loops with a small space between the afferent and efferent limbs. The morphology of proximal nail fold capillaries is typically altered in connective tissue diseases.[5–8]

Nail Matrix (See Fig. 87-1A)

The nail matrix is a specialized epithelial structure that lies above the mid portion of the distal phalanx. After elevation of the proximal nail fold, the matrix appears as a distally convex crescent with its lateral horns extending proximally and laterally.

In longitudinal sections the matrix has a wedge-shaped appearance and consists of a proximal (dorsal) and a distal (ventral) portion. Nail matrix keratinocytes divide in the basal cell layer and keratinize in the absence of a granular zone. The site of keratinization (keratogenous zone) of nail matrix ony-

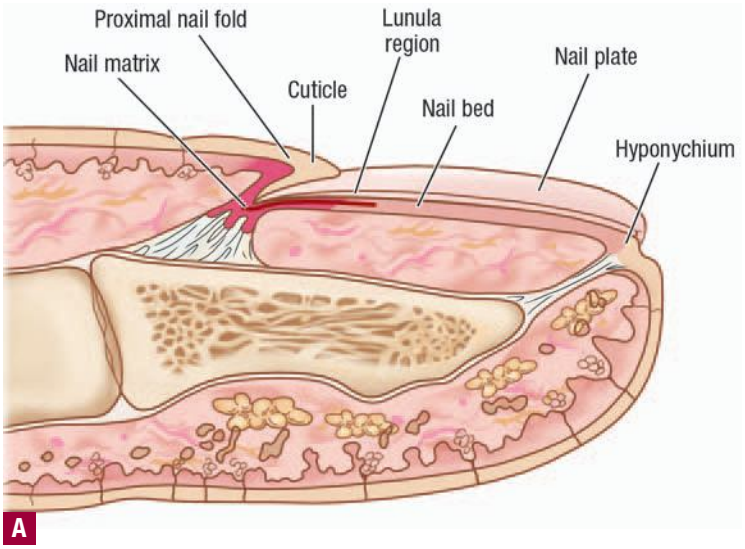

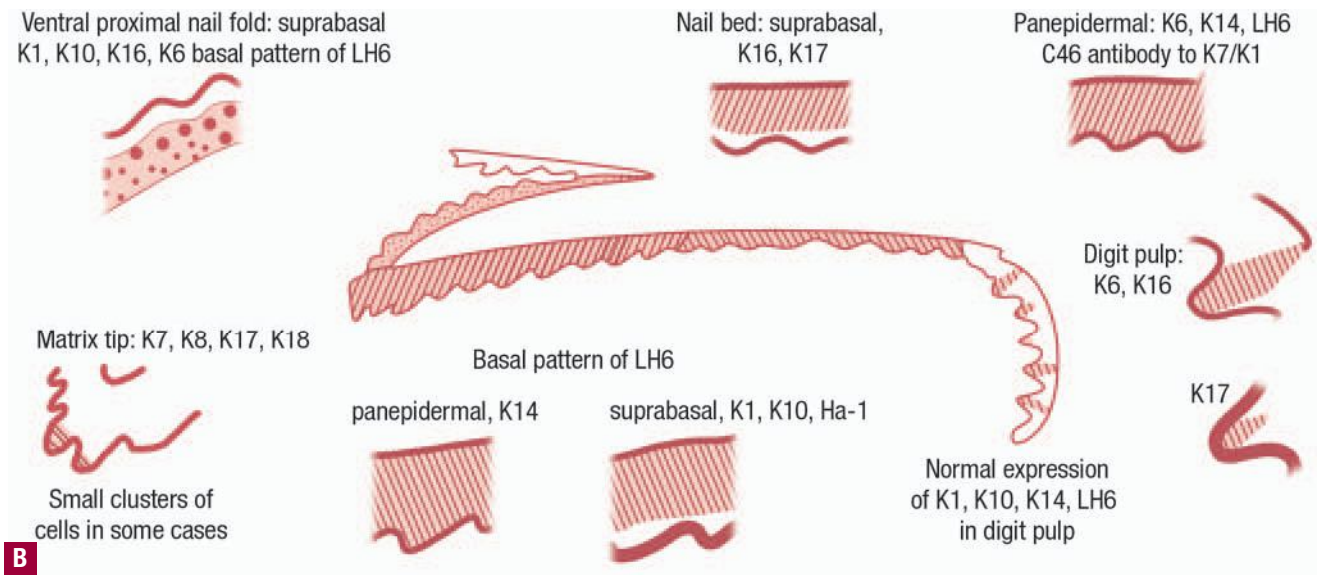

◀ **FIGURE 87-1** **A.** Diagrammatic drawing of a normal nail. **B.** Keratin gene expression at different locations within the nail. (From De Berker D et al: Keratin expression in the normal nail unit: Markers of regional differentiation. *Br J Dermatol* **142**:89, 2000, with permission.)



chocytes can be clearly distinguished in histologic sections as an eosinophilic area where cells show fragmentation of their nuclei and condensation of their cytoplasm.[1] In this area, nuclear fragments are destroyed by deoxyribonuclease and ribonuclease enzymes. In some conditions nuclear fragments may persist within the intermediate nail plate, producing leukonychial spots. These, however, frequently disappear before reaching the nail free edge, due to the persistence of active DNA and RNA lytic enzymes within the horny nail plate.

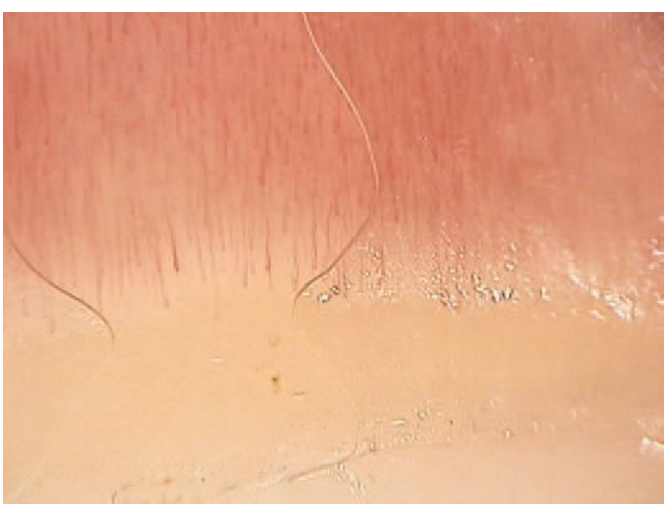

▲ **FIGURE 87-2** Capillary microscopy of the proximal nail fold showing the longitudinally oriented capillary loops.

Maturation and differentiation of nail matrix keratinocytes do not follow a vertical axis, as in the epidermis, but occur along a diagonal axis that is distally oriented. For this reason, keratinization of the proximal nail matrix cells produces the dorsal nail plate and keratinization of the distal nail matrix cells produces the intermediate nail plate.

In some fingers the distal matrix is not completely covered by the proximal nail fold but is visible through the nail plate as a white half-moon–shaped area, the lunula. The white color of the lunula results from two main anatomic factors: (1) the keratogenous zone of the distal matrix contains nuclear fragments that cause light diffraction; (2) nail matrix

capillaries are less visible than nail bed capillaries because of the relative thickness of the nail matrix epithelium.[9]

NAIL MATRIX KERATINOCYTES (See Fig. 87-1B) The nail matrix cells are able to synthesize both "soft" or skin-type and "hard" or hair-type keratins.[10–12] Evaluation of keratin expression in the different constituents of the nail apparatus showed that the nail matrix is the sole site of expression of hard keratin proteins, particularly Ha1 keratin.[13] Data indicate that fibroblasts derived from the nail matrix may induce hard keratin expression in non–nail matrix keratinocytes.[14]



MELANOCYTES (See Chap. 70) Nail matrix melanocytes are usually quiescent and therefore not detectable in pathologic sections. They possess the key enzymes that are necessary for melanin production, however, and may become activated by a large number of physiologic and pathologic conditions.[15] Nail matrix melanocyte activation produces diffuse or banded nail pigmentation and is more common in blacks and Japanese than in Caucasians. DOPA-negative (inactive) melanocytes are sparsely present in the nail matrix and in the nail bed.[16] DOPA-positive, activated melanocytes are especially seen in the distal nail matrix, where they are frequently arranged in small clusters among the suprabasal layers of the nail matrix epithelium.[17]

LANGERHANS CELLS (See Chap. 10) Langerhans cells are more numerous in the proximal than in the distal nail matrix. As in normal epidermis, Langerhans cells are predominantly found in the suprabasal layers. However, they may occasionally be seen within the basal layer of the nail matrix epithelium.

MERKEL CELLS The presence of Merkel cells in the nail matrix has been demonstrated. Their density is possibly influenced by age, with these cells being more numerous in fetus than in adult nails.[18]

Nail Bed (See Fig. 87-1A)

The nail bed extends from the distal margin of the lunula to the onychodermal band and is completely visible through the nail plate. The nail bed epithelium is so adherent to the nail plate that it remains attached to the undersurface of the nail when the latter is avulsed.

The nail bed epithelium is thin and consists of two to five cell layers. Its rete ridges, which are longitudinally oriented, interdigitate with the underlying dermal ridges in a "tongue-and-groove"–like fashion. Nail bed keratinization produces a thin horny layer that forms the ventral nail plate. Nail bed contribution to nail plate formation corresponds to approximately one-fifth of the terminal nail thickness and mass.[19] In pathologic sections, the ventral nail plate is easily distinguishable because of its light eosinophilic appearance. Nail bed keratinization is not associated with the formation of a granular layer. This may appear, however, when the nail bed becomes exposed after nail avulsion.[1]

Hyponychium

The hyponychium marks the anatomic area between the nail bed and the distal groove, where the nail plate detaches from the dorsal digit (see Fig. 87-1A). Its anatomic structure is similar to that of plantar and volar skin, and keratinization occurs through the formation of a granular layer. The horny layer of the hyponychium partially accumulates under the nail plate free margin. The hyponychium is normally covered by the distal nail plate, but it may become visible in nail biters.

Basement Membrane Zone

The antigenic structure of the basement membrane zone of the nail is identical to that of the epidermis, and there are no differences in the antigenic composition of the basement membrane zone in the different portions of the nail apparatus.[16,20] This may explain the involvement of the nails in conditions characterized by mutations of basement membrane–associated genes as well as in autoimmune skin diseases involving the basement membrane zone antigens.[21]

Dermis (See Fig. 87-1A)

The nail apparatus is devoid of subcutaneous tissue, and its dermis does not contain pilosebaceous units. The arrangement of the rete ridges varies in the different portions of the nail apparatus. The dermis beneath the proximal nail matrix consists of condensed connective tissue that forms a tendon-like structure connecting the matrix to the periosteum of the proximal phalangeal bone (posterior ligament). A small amount of subdermal fat tissue is present close to the periosteum of the base of the phalanx.[22] The close connection between the lateral horns and the periosteum is possibly responsible for the nail plate's lateral convexity. The rete ridges of the dermis underneath the nail matrix are characteristically long and root-like in shape. The dermis under the distal matrix consists of a loose network of connective tissue containing numerous blood vessels and rare glomus bodies.

The dermis of the nail bed has a unique arrangement with longitudinal grooves and ridges that run from the lunula to the hyponychium.[1] The longitudinal orientation of the capillary vessels within the nail bed grooves explains the linear pattern of nail bed hemorrhages (splinter hemorrhages). The nail bed dermis contains abundant connective tissue networks with connective tissue bundles radiating to the phalangeal periosteum. It contains numerous glomus bodies.

Blood and Nerve Supply

The nail apparatus has an abundant blood supply provided by the lateral digital arteries (see Fig. 87-2). These run along the sides of the digits and produce both branches that supply the matrix and the proximal nail fold and arches that supply the matrix and the nail bed. The nail matrix, therefore, has two different sources of blood supply. The nail bed is richly supplied (10 to 20 cm^2) by incapsulated neurovascular structures containing one to four arteriovenous anastomoses and nerve endings. These glomus bodies may be involved in the regulation of the blood supply to the digits in cold weather. The cutaneous sensory nerves, which originate from the dorsal branches of the paired digital nerves, run parallel to the digital vessels.

Chemical Properties (See Fig. 87-1B)

The nail plate, like hair, consists mainly of low-sulfur filamentous proteins (keratins) embedded in an amorphous matrix composed of high-sulfur proteins rich in cysteine. Other nail constituents include water, lipids, and trace elements. Nail keratins consist of 80 percent to 90 percent hard hair-type keratins and 10 percent to 20 percent soft skin-type keratins. Hard keratins have been identified as the acidic 44K/46K and basic 56K/60K keratins. Soft keratins have been identified as the 50K/58K and 48K/56K keratin pairs.[23] Keratin filaments have a transverse orientation that is parallel to the nail surface. This explains why the nail plate is more

susceptible to transverse fractures than to longitudinal fractures. Specific keratins are expressed only in some compartments of the nail unit; for instance, K6a and K6b, K16, and K17 are not expressed in the nail matrix.[13,24,25] Mutations of the genes encoding for these keratins are associated with nail thickening due to nail bed hyperproliferation, as is seen in pachyonychia congenita (PC).[26,27]

Under normal conditions the water content of the nail plate is 18 percent, and most of the water is in the intermediate nail plate.[28] This may vary significantly, however, because of the high porosity of the nail plate, which allows it to be rapidly hydrated and dehydrated. Dehydration is faster when the nails are kept long. When the water content decreases below 18 percent, the nail becomes brittle; when it increases above 30 percent, it becomes opaque and soft.[29]

The nail contains less than 5 percent lipids, mainly cholesterol; the nail plate lipid content is under hormonal control and decreases after menopause.[30] The nail plate also contains traces of several inorganic elements, particularly iron, zinc, and calcium. These, however, do not contribute to nail hardness.

Physical Properties

The nail plate is hard, strong, and flexible. The hardness and strength of the nail plate are due to its high content of hard keratins and cysteine-rich high-sulfur proteins, whereas its flexibility depends on its water content and increases with nail plate hydration.[31] The double curvature of the nail plate along its longitudinal and transverse axes enhances nail plate resistance to mechanical stress.[32]

The physical properties of the nail also depend on the arrangement and adhesion of onychocytes in the different portions of the nail plate, as well as on the orientation of the keratin filaments within the nail plate onychocytes.[32] At the ultrastructural level, the corneocytes of the dorsal nail plate are flat, with their shorter diameter perpendicular to the nail plate surface. The average sizes of these cells are 34 μm in length, 64 μm in width, and 2.2 μm in height.[33] Cell adhesion is strong. This portion of the nail is responsible for nail plate hardness and sharpness. The onychocytes of the intermediate nail plate show multiple interdigitations of their cell membranes. The average dimensions of these cells are 40 μm in length, 53 μm in width, and 5.5 μm in height. Cell adhesion is provided by desmosomes. This part of the nail plate is responsible for nail pliability and elasticity. The ventral nail plate is thin and consists of soft keratins. It provides adhesion to the underlying nail bed.

Nail Growth

The nail plate grows continuously throughout life. Fingernails grow faster than toenails, with a mean growth of 3 mm/month for fingernails and 1 mm/month for toenails. Complete replacement of a fingernail requires 100 to 180 days (6 months). When the nail plate is extracted, it is approximately 40 days before the new fingernail first emerges from the proximal nail fold. After a further 120 days it will reach the fingertip.[29] The total regeneration time for a toenail is 12 to 18 months. As a consequence of the slow nail growth rate, diseases of the nail matrix only become evident a considerable time after their onset and require a long time to disappear after treatment.

Nail growth rate varies among different individuals and among the different digits of the same individual. It depends on the turnover rate of the nail matrix cells and is influenced by several physiologic and pathologic conditions. Nail growth rate is slow at birth, increases slightly during childhood, and usually reaches its maximum between the second and the third decades of life. It sharply decreases after the age of 50 years.[34]

Conditions that have been associated with a slow growth rate include systemic illness, malnutrition, peripheral vascular or neurologic diseases, and treatment with antimitotic drugs. Nails affected by onychomycosis frequently exhibit a slow growth rate. An arrest of nail growth is a typical feature of yellow nail syndrome. Conditions that have been associated with accelerated nail growth include pregnancy, finger trauma, psoriasis, and treatment with oral retinoids or itraconazole. Accelerated nail growth may cause longitudinal ridging of the nail plate (nail beading).

Due to their slow growth rate, the nails may provide information on pathologic conditions that have occurred up to several months before the time of observation. Drugs, chemicals, and biologic substances accumulate in nails, where they can be detected and measured. Advantages of analyzing nail samples include the ease and non-invasiveness of their collection, the small sample size required for analysis, and the ease of storage at room temperature. The nail of the big toe is the best site for investigation because of its size and slow growth rate.[35]

NAIL SIGNS AS A FUNCTION OF THE SITE OF PATHOLOGY[1,29] (Table 87-1)

Beau's Lines and Onychomadesis (Nail Shedding)

Beau's lines result from a temporary arrest of proximal nail matrix proliferation and appear as transverse grooves, often deeper in the central nail plate, that move distally with nail growth. Onychomadesis also results from a temporary arrest in nail matrix activity, and the proximal nail plate is detached from the proximal nail fold by a whole-thickness sulcus. Causes of onychomadesis are the same as those for Beau's lines but are more severe (Table 87-2). Multiple Beau's lines or onychomadesis in the same nail indicates repetitive insults. The time of the insult leading to Beau's lines can be dated by measuring the distance of the groove from the proximal nail fold. Local trauma, such as from manicures or onychotillomania, or related to local cutaneous disease, particularly dermatitis, periungual erythema, and paronychia, are causes of Beau's

TABLE 87-1
Relation Between Resultant Clinical Manifestations and Location of Pathologic Change

Proximal matrix	Beau's lines Pitting Longitudinal striations Longitudinal fissures Longitudinal grooves Trachyonychia
Distal matrix	True leukonychia
Proximal and distal matrix	Koilonychia Onychomadesis Melanonychia
Nail bed	Longitudinal erythronychia Onycholysis Splinter hemorrhages Apparent leukonychia
Nail bed and hyponychium	Subungual hyperkeratosis
Proximal nail fold	Paronychia Periungual erythema and hemorrhage



TABLE 87-2
Causes of Beau's Lines and Onychomadesis

- Trauma
  - Manicure
  - Onychotillomania
- Dermatologic diseases
  - Eczema
  - Erythroderma
  - Paronychia
- Systemic conditions
  - Use of certain drugs
  - High fever
  - Viral illness (hand-foot-and-mouth disease; measles)
  - Kawasaki syndrome
  - Peripheral ischemia



lines (Fig. 87-3). Beau's lines at the same levels in several nails suggest a systemic cause. Most common among these are drugs (especially chemotherapy), high fever, viral illness,[36,37] surgery, and peripheral ischemia. Onychomadesis in children often relates to recent coxsackievirus infection.[36]

Pitting

Pits result from small areas of abnormal keratinization of the proximal nail matrix that produce foci of parakeratotic cells in the superficial nail plate. They appear as small punctate depressions of the superficial nail plate, which progress distally and often become more evident with nail growth (Fig. 87-4). Deep and irregularly distributed pits are seen in psoriasis and atopic dermatitis; geometric and superficial pits are typical of alopecia areata (see Chaps. 18, 14, and 86).



▲ **FIGURE 87-3** Beau's lines and toenail onychomadesis due to trauma by footwear.



▲ **FIGURE 87-4** Pitting. Note small punctate depressions of the superficial nail plate. In this patient, the presence of onycholysis surrounded by an erythematous border suggests a diagnosis of psoriasis.

Onychorrhexis (Longitudinal Striations and Fissuring)

Onychorrhexis results from diffuse defective keratinization of the proximal nail matrix. The nail plate is usually thinned and presents multiple longitudinal ridges and fissures. Onychorrhexis is typical of lichen planus (see Chap. 26).

Longitudinal Grooves

Longitudinal grooves are usually single and appear as a longitudinal depression of the nail plate (1 to 2 mm large) due to compression of the nail matrix by tumors of the proximal nail fold (Fig. 87-5).

Trachyonychia

Trachyonychia results from multiple foci of defective keratinization of the proximal nail matrix. The nails are rough due to excessive longitudinal ridging.

True Leukonychia

True leukonychia results from defective keratinization of the distal matrix with persistence of parakeratotic cells in the ventral nail plate. The superficial nail plate is structurally normal, but the nail presents opaque white patches or striae, which often disappear before reaching the distal edge of the nail. Punctate leukonychia is due to microtrauma and is typically seen in the fingernails of children. Striate leukonychia of fingernails is a consequence of aggressive manicure. Total or subtotal leukonychia is usually hereditary (Fig. 87-6).



▲ **FIGURE 87-5** Irregular longitudinal groove of the nail plate due to matrix compression by a myxoid cyst of the proximal nail fold.

Koilonychia

In koilonychia the nail plate is thin and spoon shaped. Koilonychia is physiologic in the toenails of children. In adults it can be a sign of iron deficiency or occupational factors.

Melanonychia[38]

Melanonychia is due to the presence of melanin in the nail plate. It can be caused by activation or proliferation of nail matrix melanocytes. In most cases melanonychia appears as a single or longitudinal brown to black band. Multiple bands of melanonychia are usually due to melanocyte activation, as is seen in darker-skinned individuals, pregnant women, those with inflammatory nail



▲ **FIGURE 87-6** True striate leukonychia.

TABLE 87-3
Causes of Longitudinal Melanonychia

- Race
- Acquired immunodeficiency syndrome
- Inflammatory nail disorders
- Use of certain drugs
- Addison disease
- Pregnancy
- Laugier-Huntziker syndrome
- Trauma

disorders or Laugier-Huntziker syndrome, those taking certain medications (Table 87-3), and individuals with a variety of systemic disorders, particularly human immunodeficiency virus infection and Addison syndrome. In Laugier-Huntziker syndrome, melanonychia is associated with the presence of lip and/or genital pigmented macules and usually affects several digits; it begins during adolescence[39,40] (see Chap. 73). A single band of melanonychia may be a sign of a nail matrix nevus or melanoma (see Chaps. 122 and 124). Melanonychia affecting the fourth and/or fifth toenail is usually due to trauma. Longitudinal melanonychia of a single nail often deserves biopsy.

Longitudinal Erythronychia[41]

Longitudinal erythronychia reflects a nail bed disorder. A single longitudinal red line extending from the proximal nail to the distal edge is most commonly caused by onychopapilloma or other benign subungual tumors. Multiple bands of longitudinal erythronychia are seen in Darier disease (see Chap. 49).



▲ **FIGURE 87-7** Distal splinter hemorrhages (*arrow*).



▲ **FIGURE 87-8** Schematic drawing showing pattern of exogenous pigmentation (*left*) and endogenous pigmentation (*right*).

Onycholysis

Onycholysis is detachment of the nail plate from the nail bed and can be caused by traumatic, inflammatory, infectious, or neoplastic nail bed disorders. See Onycholysis under Environmental Nail Disorders later.

Splinter Hemorrhages

Splinter hemorrhages appear as red to black small thin longitudinal lines under the nail plate. They are more commonly located in the distal nail plate and represent rupture of the longitudinally oriented nail bed capillaries (Fig. 87-7). Causes include trauma and inflammatory nail disorders, such as psoriasis.

Apparent Leukonychia

In apparent leukonychia the nails are pale white due to nail bed discoloration that fades with pressure.

Subungual Hyperkeratosis

Subungual hyperkeratosis is due to inflammatory disorders that cause an abnormal keratinization of the distal nail bed and hyponychium with accumulation of scales under the distal nail plate. The most common causes include psoriasis, onychomycosis, trauma, and atopic dermatitis (see Chaps. 18, 188, and 14).

Paronychia

Paronychia is inflammation of the proximal nail fold and presents as painful periungual erythema, sometimes with associated purulence. Acute paronychia is usually caused by infection (see Infectious Nail Disorders). Chronic paronychia is most commonly due to mechanical or chemical factors. If the periungual area is fluctuant or shows purulence, it should be drained to avoid matrix damage. Topical and/or systemic antibiotics should be administered if bacterial infection is suspected.

Nail Pigmentation

Nail pigmentation is most commonly due to exogenous staining of the nail plate. In this case the proximal margin of the pigmentation follows the shape of the proximal nail fold. Exogenous nail pigmentation is most commonly due to occupational exposures or nail cosmetics. Nail pigmentation due to endogenous causes is rare. The proximal margin of the pigmentation follows the shape of the lunula (Fig. 87-8). Possible causes include drugs, argyria, hemochromatosis, alkaptonuria, and Wilson disease.

HEREDITARY AND CONGENITAL NAIL DISORDERS[42] (Table 87-4)

Ectodermal Dysplasias (See Chap. 143)

Nail changes may be associated with hypotrichosis, hypodontia, and hypohidrosis. Most common are short, thickened, hypoplastic nails.

Epidermolysis Bullosa (See Chap. 60)

In all sub-types of epidermolysis bullosa nail changes are common and may be the first or the only symptom of the disease. Junctional and dermolytic epidermolysis bullosa may produce anonychia.

Pachyonychia Congenita (See Chap. 48)

PC is a group of autosomal dominant disorders characterized by severe nail thickening due to massive nail hyperkeratosis[42] (Table 87-5). Type 1 PC is associated with



TABLE 87-4
Hereditary and Congenital Nail Disorders

Ectodermal dysplasias	• Atrophy/thickening
Epidermolysis bullosa	• Partial or total anonychia • Pachyonychia • Subungual/periungual hemorrhagic blisters
Pachyonychia congenita	• Onychogryphosis • Severe thickening • Yellow-brown discoloration
Iso-Kikuchi syndrome	• Micronychia/anonychia • Hemionychogryphosis
Nail patella syndrome	• Hypoplasia/aplasia • Triangular lunulae
Congenital malalignment of the hallux	• Lateral deviation of the nail plate • Lateral/distal embedding of nail • Nail thickening • Yellow-brown discoloration • Transverse ridging

TABLE 87-5
Pachyonychia Congenita

- Type 1
  - Jadassohn-Lewandowsky syndrome
    - Palmo-plantar keratoderma
    - Follicular keratosis of knees and elbows
    - Oral leukokeratosis
- Type 2
  - Jackson-Lawler syndrome
    - Mild palmo-plantar keratoderma
    - Multiple pilosebaceous cysts
    - Natal teeth
    - Pili torti
    - Hoarseness



mutations of K6a and K16 genes,[43] whereas type 2 PC is caused by mutations of K6b and K17.[44,45] In PC both fingernails and toenails are thickened, yellow-gray, and transversely overcurved with marked subungual hyperkeratosis most notable at the distal portion of the nails (Fig. 87-9). Nail trimming is impossible, because the nails are extremely hard. The abnormalities usually develop during childhood, but a late-onset variety of PC has been described.[46] Focal palmo-plantar keratoderma is associated with the nail changes in 60 percent of patients or may result from mutations without detectable nail changes.[47] Up to 75 percent of patients have oral leukokeratosis; hyperhidrosis of the palms and soles, follicular keratoses, and acral bullae (especially during warmer months) are common. Patients with type 2 PC also tend to have cystic lesions (steatocystoma multiplex, vellus hair cysts), which reflects the expression of K6b and K17 in adnexal structures. The cystic lesions begin during childhood and progressively appear. Coarse or twisted hair, early primary tooth loss, and natal teeth are other occasional features of type 2 PC, reflecting expression of the affected genes in the hair follicle apparatus and teeth.

Nail Patella Syndrome

Nail abnormalities in nail patella syndrome may involve all fingernails or may be limited to the thumbs, which are always the most severely affected digits (Fig. 87-10). Nail hypoplasia is usually more marked in the medial portion of the nail. The shape of the lunula is typically triangular.[42]

Congenital Malalignment of the Hallux

Congenital malalignment of the hallux is the most common cause of ingrowing (ingrown) nails and is usually diagnosed when the child starts to walk. The great toenail shows a lateral deviation that produces embedding of the lateral side of the nail plate. The digit is painful and the toenail often shows Beau's lines and onycholysis (Fig. 87-11). Congenital malalignment may be unilateral or bilateral. Spontaneous improvement may occur, and most children do not have symptoms by the age of 2 years.[48] Inflammation due to lateral ingrowing can be managed by daily massaging of the lateral nail fold with creams containing steroids, antibiotics, and urea. Surgical treatment is invasive and usually not necessary.[49]



▲ **FIGURE 87-10** Nail patella syndrome: nail hypoplasia and triangular lunula.

INFECTIOUS NAIL DISORDERS (Table 87-6)

Acute paronychia is most commonly due to *Staphylococcus aureus* infection and typically affects a child's fingernail. Predisposing factors include nail biting or sucking and occupational traumas. The proximal nail fold is painful, erythematous, and swollen. Pus may be discharged after pressure (see Chap. 177).The differential diagnosis includes herpes simplex virus infection (see Chap.





◀ **FIGURE 87-9** Pachyonychia congenita of the fingernails in an adult (**A**) and of the toenails in a 4-year-old boy (**B**). Note the severe nail thickening and transverse hypercurvature due to compact nail bed hyperkeratosis.



▲ **FIGURE 87-11** Congenital malalignment of the big toenail. The longitudinal axis of the nail is deviated laterally. Note Beau's lines and mild lateral ingrowing.

193) and Hallopeau acrodermatitis (see Chap. 21), both of which have a typical relapsing course. Suspicion of herpes simplex virus infection should arise when the pain intensity is disproportionate to the clinical symptoms and the disease is recurrent. Most commonly, cephalosporins are initiated as therapy. However, any purulent material should be drained if possible and cultured to ensure choice of the optimal antibiotic.

Green Nails

Bacteria are not capable of attacking a healthy nail plate. The Gram-negative bacterium *Pseudomonas aeruginosa* may colonize the dorsal or ventral nail plate under propitious conditions, such as chronic paronychia or onycholysis. The presence of *Pseudomonas* is revealed by a characteristic green-black nail pigmentation due to pyocyanin staining (Fig. 87-12). Topical application of a few drops of diluted bleach or chlorhexidine solution two or three times a day clears the pigmentation in a few weeks. Administration of systemic antibiotics is unnecessary.



▲ **FIGURE 87-12** Onycholysis with green discoloration due to *Pseudomonas* colonization.

Onychomycosis[50,51]

For a detailed description of the onychomycoses see Chap. 188. Onychomycosis is a common toenail disease, and its prevalence increases with age.

Clinical features depend on type of nail invasion (Table 87-7). The possibility of mold onychomycosis should be suspected when proximal subungual onychomycosis is associated with periungual inflammation (Fig. 87-13) or when white superficial onychomycosis is severe and involves the entire nail plate (Fig. 87-14). Nondermatophytic onychomycoses are becoming more frequent worldwide and represent a clinical problem, because they usually respond poorly to systemic treatment.

TABLE 87-6
Infectious Nail Disorders

Bacterial	
Staphylococcus aureus	Acute paronychia
Streptococcus pyogenes	Acute paronychia
Pseudomonas aeruginosa	Acute paronychia
Viral	
Herpes simplex	Acute paronychia
	Onycholysis
	Periungual vesicles
Warts	Periungual/subungual papules
Fungal	
Dermatophytes	DSO
	PSO
	White superficial onychomycosis
Nondermatophytes	PSO + periungual inflammation
	Deep DSO
Candida sp.	DSO + paronychia

DSO = distal subungual onychomycosis; PSO = proximal subungual onychomycosis.

ONYCHOMYCOSIS AT A GLANCE



- Fifteen percent of the general population and 40 percent of individuals older than 60 years are affected.
- Clinical presentation reflects the route of nail invasion.
- Dermatophytes account for 85 percent of cases, nondermatophytic fungi for 15 percent.
- Infection with human immunodeficiency virus should be suspected with proximal subungual onychomycosis (PSO).
- Mold fungal infection should be suspected when PSO is associated with acute periungual inflammation or when white superficial onychomycosis involves most of the nail plate.
- *Candida* sp. are the causative agents only in immunosuppressed individuals.
- Toenails are involved in most cases; tinea pedis is usually associated.
- The cure rate for toenail onychomycosis is approximately 80 percent with the use of systemic antifungals, but recurrences are frequent (up to 20 percent). Mold infections respond poorly to systemic treatment.

ENVIRONMENTAL NAIL DISORDERS

Nail Fragility[52] (Table 87-8)

With nail fragility, the nails are brittle and show distal lamellar splitting (onychoschizia). Several nails are usually affected. The nail plate margin is irregular due to distal splitting. Idiopathic nail fragility usually affects middle-aged women who are exposed to water and chemicals that dehydrate the nail plate. Aging also is associated with increased nail fragility. The risk of nail fragility from trauma is increased by manicures, onychotillomania, and certain occupations, especially those that involve frequent exposure to water and chemicals. Fragile nails can be a feature of several



TABLE 87-7
Clinical Presentations of Onychomycosis (see Chap. 188)

Distal subungual onychomycosis[a]	*Trichophyton rubrum, Trichophyton interdigitale*	Onycholysis associated with subungual hyperkeratosis, patchy or linear yellow discoloration
Proximal subungual onychomycosis	*T. rubrum*[b]	Proximal leukonychia with normal nail plate surface
	Fusarium sp. *Aspergillus* sp. *Scopulariopsis* sp.	Associated with periungual inflammation and purulent discharge
White superficial onychomycosis	*T. interdigitale*[a]	Multiple superficial areas of friable opaque leukonychia
	Fusarium sp. *Aspergillus* sp.	Involvement more diffuse and deeper

[a]Associated with tinea pedis.
[b]Possible marker of human immunodeficiency virus infection.



dermatologic disorders, among them lichen planus, alopecia areata, psoriasis, and onychomycosis. In addition, nutritional deficiency, peripheral neuropathies, peripheral vascular disease, and use of certain medications increase the risk of nail fragility. Management includes protection of the hands by the use of cotton gloves under rubber gloves and frequent application of topical moisturizers. Oral biotin, 5 mg/day, can be helpful.[53]

Chronic Paronychia[54,55]

Chronic paronychia is an inflammatory disorder that almost exclusively involves the fingernails of adult women. Mechanical or chemical trauma damages the cuticle and permits penetration of irritant and allergenic environmental substances, which cause an inflammatory reaction of the proximal nail fold and nail matrix. Secondary colonization with *Candida* sp. and/or bacteria occurs in most cases, causing self-limited episodes of painful acute inflammation (see Chap. 189). Chronic paronychia most commonly affects the first, second, and third fingers of the dominant hand. Clinically the proximal and lateral nail folds show mild erythema and swelling, and the cuticle is absent. The nail plate may show superficial abnormalities and green discoloration due to *Pseudomonas* invasion.



▲ **FIGURE 87-13** Proximal subungual onychomycosis due to *Aspergillus niger*. Note severe periungual inflammation.

Onycholysis

Idiopathic onycholysis usually affects the fingernails of women and is a consequence of mechanical and chemical damage of the onychodermal band (Table 87-9). The detached nail plate is white due to the presence of air and frequently presents areas of green-brown discoloration due to bacterial colonization. The use of sharp tools to clean the nail plate free margin produces roller coaster onycholysis (manicure onycholysis). Traumatic onycholysis of the fingernails is usually occupational and is more commonly observed in butchers, slaughterhouse workers, chicken processing workers, and workers lifting heavy bags. Traumatic onycholysis of the toenails most frequently affects the big toe, often bilaterally. It is usually a consequence of anatomic abnormalities



▲ **FIGURE 87-14** White superficial onychomycosis due to *Aspergillus flavus* with diffuse and deep nail plate invasion.

CHRONIC PARONYCHIA AT A GLANCE



- Occurs most commonly in food handlers and housecleaners.
- Associated with mechanical or chemical cuticle damage.
- Characterized by eczematous inflammation of the proximal nail fold and matrix.
- Secondary colonization by bacteria and yeasts usually occurs.
- First, second, and third digits of the dominant hand are most often affected.
- Management includes protective measures, topical and/or systemic steroids, and topical antimicrobials.
- Systemic antifungals are not effective.

TABLE 87-8
Causes of Nail Fragility

- Idiopathic
  - Aging
  - Exposure to water and chemicals
- Traumatic
  - Occupational injury
  - Manicure
  - Onychotillomania
- Dermatologic diseases
  - Lichen planus
  - Alopecia areata
  - Psoriasis
  - Onychomycosis
- Systemic conditions
  - Use of certain drugs
  - Peripheral vascular diseases
  - Peripheral neuropathies
  - Nutritional deficiencies

IDIOPATHIC ONYCHOLYSIS AT A GLANCE



- Occurs in homemakers and those in certain occupations.
- Caused by mechanical or chemical damage.
- Follows asymptomatic and slowly progressive nail plate detachment.
- Management includes taking protective measures, trimming the onycholytic nail plate, and applying topical antiseptics.

(overlapping of the second toe on the first toe) or poorly fitting shoes. Subungual hematoma is frequently associated. Secondary onycholysis is seen in several dermatologic disorders. When only one nail is affected, it is important to explore the nail bed after cutting the onycholytic nail to rule out a nail tumor. Patients with idiopathic onycholysis should be instructed to keep the nail dry, trim the onycholytic nail plate, and wear cotton gloves under rubber gloves. Application of topical 4 percent thymol in chloroform solution on the exposed nail bed can accelerate cure.

TABLE 87-9
Onycholysis

- Primary
  - Idiopathic
    - Fingernails: women (mechanical/chemical damage)
  - Trauma
    - Fingernails: occupational injury
    - Toenails: podiatric abnormalities, improper shoes
- Secondary
  - Vesicobullous disorders
    - Contact dermatitis
    - Pompholyx
    - Herpes simplex
  - Nail bed hyperkeratosis
    - Onychomycosis
    - Psoriasis
    - Chronic contact dermatitis
  - Nail bed tumors
  - Drugs

NAIL TUMORS[56]

Tumors of the nail usually affect one digit and are often associated with nail plate furrows or grooves or localized onycholysis. In some situations nail pigmentation is altered.

Benign Tumors

FIBROMA/FIBROKERATOMA Fibroma/fibrokeratoma appears as a nodular or filiform growth that often has a keratotic surface. Most fibromas originate in the proximal nail fold and extend to the nail plate surface, where the tumor presents as a longitudinal furrow or groove (Fig. 87-15). Subungual lesions are uncommon. Tuberous sclerosis should be considered, especially if multiple lesions are present (see Chap. 141).

SUBUNGUAL EXOSTOSIS[57] Subungual exostosis appears as a subungual hard nodule that detaches and lifts the nail plate (Fig. 87-16). The toenails of young adults are usually affected, and a history of trauma is not unusual. Radiography confirms the diagnosis.

MYXOID CYST[58] Myxoid cyst appears as a nodule of the proximal nail fold associated with a longitudinal groove in the correspondent nail plate. Because the cyst often drains spontaneously, the shape of the groove is irregular (see Fig. 87-5). Myxoid cysts usually affect the fingernails of middle-aged women and are associated with osteoarthritis of the interphalangeal joints.



▲ **FIGURE 87-15** Fibrokeratoma of the proximal nail fold. Note the longitudinal groove of the nail plate due to matrix compression.



▲ **FIGURE 87-16** Subungual exostosis.

GLOMUS TUMOR Glomus tumor may hardly be seen, appearing as a small red patch under the nail plate and usually affecting the hand (Fig. 87-17). The minimal clinical appearance is disproportionate to the intense pain, which is usually accentuated by cold and radiates to the limb.

ONYCHOMATRICOMA[59] The clinical presentation of onychomatricoma is typical: the affected nail is thickened, whitish, and overcurved with longitudinal tunnels (hollows), which are evident at the frontal view (Fig. 87-18).

NAIL MATRIX NEVI[60,61] Nail matrix nevi appear as a band of longitudinal melanonychia and are usually diagnosed in childhood (Fig. 87-19). The color and width of the band are variable, and modification of the pigmentation with aging is common. Although the rate of progression of nail matrix nevi to melanoma is probably low, some advise excision of these lesions after puberty.



▲ **FIGURE 87-17** Glomus tumor of the nail bed, appearing as a violaceous subungual patch.







▲ **FIGURE 87-18** Onychomatricoma: nail overcurvature with white longitudinal striations corresponding to nail plate tunnels.

Malignant Tumors

SQUAMOUS CELL CARCINOMA (See Chap. 114) In situ squamous cell carcinoma (Bowen disease) usually manifests in fingernails with a lesion that clinically closely resembles a wart. Associated melanonychia or paronychia may be a diagnostic clue. Squamous cell carcinoma presents as a slowly growing subungual nodule that eventually ulcerates (Fig. 87-20) or a warty periungual growth. The underlying bone is commonly involved. Oncogenic human papillomavirus may be isolated in the lesion. Surgical excision with Mohs surgery is the best treatment for squamous cell carcinoma without bone involvement.

MELANOMA[62–64] (See Chap. 124) Nail melanoma most commonly affects the thumb or great toe and is usually an acral lentiginous melanoma. Most patients are middle-aged or elderly and dark skinned (one-third of nail melanoma occurs in African Americans, Asians, and Native Americans). Longitudinal melanonychia is the most common sign. The band is usually dark and has an irregular border. Periungual pigmentation (Hutchinson nail sign) indicates superficial spreading of the tumor. Amelanotic melanoma is often misdiagnosed as a pyogenic granuloma because it appears as a nail bed growth that first detaches the nail plate and then destroys the epithelium with erosion and bleeding (Fig. 87-21). The low survival rate of patients with nail melanoma is related mainly to the delay in diagnosis.

Although dermoscopy is helpful in evaluating nail pigmentation, because it distinguishes pigmentation due to hematoma from melanocytic pigmentation, dermoscopic criteria for distinguishing melanonychia due to melanocyte activation or nail matrix nevi are still not well defined and reliable. A pathologic study is recommended in all cases of longitudinal melanonychia showing suspicious features (Table 87-10).



▲ **FIGURE 87-19** Nail matrix nevus: melanonychia and periungual pigmentation.



▲ **FIGURE 87-20** Subungual squamous cell carcinoma: ulcerated nodule.



▲ **FIGURE 87-21** Amelanotic melanoma of the nail bed.

MELANOMA AT A GLANCE



- Involvement of nails is rare (0.7 percent to 3.5 percent of melanomas).
- Thumb or hallux is most often affected.
- Longitudinal melanonychia and Hutchinson sign are classic.
- Lesion is amelanotic in 25 percent of cases.
- Only 15 percent of patients survive 5 years or longer.

NAIL PSORIASIS[66] (See Chap. 18)

Psoriasis can be limited to the nails and produce nail signs that mimic those of a large number of other nail disorders. Pitting is considered by dermatologists to be the typical symptom of psoriasis. Psoriatic pits are limited to the fingernails, are large, deep, and irregular (see Fig. 87-4), and represent psoriatic involvement of the proximal nail matrix.

Onycholysis, salmon patches, and subungual hyperkeratosis are additional clinical signs of nail bed psoriasis. Onycholysis is actually the most common manifestation of nail psoriasis and may affect both fingernails and toenails. In fingernails the presence of an erythematous border along the onycholytic area is diagnostic for nail psoriasis (Fig. 87-22). In toenails onycholysis is usually combined with subungual hyperkeratosis and may closely resemble onychomycosis.

TABLE 87-10
Clinical Signs That Require Histologic Evaluation of Longitudinal Melanonychia

- Periungual pigmentation
- Adult age
- Change in color/width of the band
- Hyperpigmented lines within the band
- Proximal portion of the band wider than distal
- Thumb, index finger, or toe involvement
- Blurred margins
- History of trauma (negative prognostic factor)[65]

NAIL PSORIASIS AT A GLANCE



- Present in up to 50 percent of patients with skin psoriasis and up to 83 percent of those with psoriatic arthritis.
- Isolated nail psoriasis is not rare.
- Nail matrix and nail bed are most commonly affected.
- Most often precipitated or worsened by trauma.
- Most common signs are onycholysis, salmon patches, subungual hyperkeratosis, and irregular pitting.
- Fingernails and/or toenails may be affected. Several nails are involved in most cases.
- Treatment is often unsatisfactory.

Salmon patches (oil drop sign) are also diagnostic for nail psoriasis.[67] They are seen in fingernails and appear as yellow-red areas of discoloration in the center of the nail or bordering an onycholytic area (Fig. 87-23). Rarely, nail psoriasis may produce severe nail plate abnormalities such as trachyonychia or crumbling. Other common but rather aspecific signs include splinter hemorrhages and paronychia.

Differential Diagnosis

The differential diagnosis of nail psoriasis is summarized in Box 87-1.



▲ **FIGURE 87-22** Nail psoriasis: onycholysis surrounded by an erythematous border.



▲ **FIGURE 87-23** Nail psoriasis: salmon patches of the nail bed.

Treatment

Treatment of psoriasis affecting only the nails is often unsatisfactory and should be limited to patients who experience functional impairment or severe cosmetic problems. It is important to instruct patients to avoid trauma and to refer the patient to a rheumatologist if digital pain is described.

Systemic treatments for skin and joint psoriasis are generally effective for nail psoriasis (methotrexate, cyclosporin A, biologics). Phototherapy is not effective.

Intralesional steroids (triamcinolone acetonide 2.5 to 5.0 mg/mL in saline) are the best treatment for nail matrix psoriasis limited to a few fingernails, for which they can be injected in the proximal nail fold every 4 to 8 weeks. Acitretin at low dosages (0.3 mg/kg/day) for 4 to 6 months may also be an effective option in severe nail psoriasis. In nail bed psoriasis, topical treatment with calcipotriol or tazarotene reduces subungual hyperkeratosis.[68,69]

Box 87-1

Differential Diagnosis of Nail Psoriasis

- Onycholysis
- Onychomycosis (usually associated with subungual hyperkeratosis): up to 21% of psoriatic nails have secondary onychomycosis
- Idiopathic onycholysis (fingernails): usually seen with other nail changes
- Trauma (toenails): psoriasis usually affects several nails, not just halluces
- Pitting
- Eczema: often has periungual scaling and Beau's lines
- Alopecia areata: different morphology of pits



▲ **FIGURE 87-24** Hallopeau acrodermatitis continua.

PUSTULAR PSORIASIS (See Chaps. 18 and 21)

The diagnosis of Hallopeau acrodermatitis is suggested by a clinical history of relapsing periungual and subungual pustules with onycholysis. The patient is most commonly seen when the acute episode has subsided; at this time the affected digit shows onycholysis with nail bed and periungual erythema and scaling (Fig. 87-24). Low-dose acitretin (0.3 mg/kg/day) may be useful.

LICHEN PLANUS[66] (See Chap. 26)

Nail lichen planus is serious, because it may destroy the nails. It is therefore important to diagnose and treat the disease as soon as possible. Although lichen planus often affects both the nail matrix and the nail bed, clinical suspicion should be aroused by nail matrix signs, particularly nail thinning with longitudinal ridging and fissuring. Dorsal nail pterygium formation is not common (Fig. 87-25). It results from nail matrix destruction and appears as a V-shaped extension of the skin of the proximal nail fold that adheres to the nail bed. Idiopathic atrophy of the nails is a rare variety of nail matrix lichen planus characterized by acute and progressive nail destruction leading to diffuse nail atrophy with and without pterygium. Onycholysis is quite frequent in both fingernails and toenails. Severe toenail involvement causes features that resemble yellow nail syndrome, with thickened, yellow-brown toenails.

Differential Diagnosis (Box 87-2)

In patients with brittle nails, the nail abnormalities are milder. The nails are thin and ridged, but fissuring at multiple sites







▲ **FIGURE 87-25** Nail lichen planus: dorsal nail pterygium.

is not observed. Onychoschizia is frequently associated. Trauma that produces damage to the matrix in an area wider than 3 mm causes permanent thinning and fissuring. Only one nail is usually affected, and it may show a single fissure.

NAIL LICHEN PLANUS AT A GLANCE



- Nail lichen planus is seen in approximately 10 percent of patients with skin lichen planus.
- Nail involvement is not associated with oral, skin, or scalp lesions in most cases.
- Nail matrix lichen planus produces nail thinning, with longitudinal fissuring, dorsal pterygium, and trachyonychia. Nail bed lichen planus is frequent, especially in toenails, but clinical signs are not specific.
- Several nails are involved in most cases. Scarring of the nail matrix with nail atrophy is a possible sequela.
- Diagnosis should be confirmed by nail biopsy, and systemic treatment is necessary to avoid scarring.

Box 87-2

Differential Diagnosis of Lichen Planus

LONGITUDINAL FISSURING

- Brittle nails
- Trauma (single fissure)
- Systemic amyloidosis
- Lichen striatus
- Graft-versus-host disease

PTERYGIUM

- Trauma
- Bullous diseases
- Digital ischemia
- Dyskeratosis congenita
- Graft-versus-host disease

Nail abnormalities may be the first sign of systemic amyloidosis, with nail thinning, ridging, and fissuring closely resembling mild nail matrix lichen planus. In amyloidosis, nail bed hemorrhages are common. Diagnosis depends on nail biopsy. Lichen striatus may manifest as nail thinning and fissuring limited to one or two adjacent digits. Skin changes that course from the affected nail in a linear configuration are typical. Inherited (epidermolysis bullosa) and acquired (e.g., bullous pemphigoid) bullous diseases can produce pterygium. Skin and mucosal lesions are usually present. Digital ischemia is distinguished in that the digit is cold and shows skin signs of impaired vascular skin supply.

Treatment

Nail matrix lichen planus requires oral or intramuscular treatment with systemic steroids, which induce remission of the disease in most cases. Intralesional (vs. systemic) corticosteroid injections should be considered in patients with involvement of fewer than three digits. Dorsal pterygium is not reversible and when the sole manifestation, should not be treated. Solitary nail lichen planus presenting as trachyonychia does not lead to nail scarring and therefore does not necessarily require treatment.

PARAKERATOSIS PUSTULOSA

Parakeratosis pustulosa is a rather common condition that occurs only in children. The disease is limited to one nail in most cases (usually the thumb or index finger) with a clinical picture that closely resembles that of psoriasis (Fig. 87-26). Characteristics are distal onycholysis, fingertip desquamation, and mild subungual hyperkeratosis. Spontaneous regression usually occurs after puberty.



▲ **FIGURE 87-26** Parakeratosis pustulosa: psoriasiform nail changes limited to one digit in a child.

TRACHYONYCHIA (TWENTY-NAIL DYSTROPHY)

Trachyonychia (twenty-nail dystrophy) is a nail sign that can be caused by several inflammatory disorders that produce a mild disturbance of nail matrix keratinization. These include alopecia areata, psoriasis, lichen planus, and eczema. The nail is rough and opaque due to excessive longitudinal ridging. The disease occurs most commonly in children. Trachyonychia does not produce nail scarring, even in cases due to lichen planus.

TRACHYONYCHIA (TWENTY-NAIL DYSTROPHY) AT A GLANCE



- Idiopathic but likely reflects alopecia areata, psoriasis, dermatitis, or lichen planus of the nail. More common in children.
- Characterized by nail roughness due to excessive longitudinal ridging (sandpaper nails).
- Several nails are involved in most cases; involvement of 20 nails is not necessary for diagnosis.
- Nail changes often regress spontaneously.
- Treatment is not required.



▲ **FIGURE 87-27** Nails in Darier disease.

DARIER DISEASE[1] (See Chap. 49)

The nail abnormalities noted in Darier disease are diagnostic but are not seen in all patients (Fig. 87-27). Key features are longitudinal erythronychia, longitudinal leukonychia associated with distal nail plate nicking (V shaped), and subungual hyperkeratotic papules.

ALOPECIA AREATA (See Chap. 86)

Nail involvement is seen in approximately 20 percent of adults and 50 percent of children with alopecia areata and is most common in male patients with severe involvement. Geometric pitting is most typical (Fig. 87-28). Pits are small, superficial, and regularly distributed in a geometric pattern along longitudinal and transverse lines. Trachyonychia is quite common in children affected by alopecia totalis or universalis. Nail abnormalities may improve with systemic steroid treatment or spontaneously; they respond poorly to application of topical medications.



▲ **FIGURE 87-28** Alopecia areata: geometric pitting.

ATOPIC DERMATITIS (See Chap. 14)

Nail abnormalities associated with atopic dermatitis are non-specific in most cases. Manifestations are most commonly Beau's lines, irregular pitting, and chronic paronychia. The condition is often mistaken for candidal onychomycosis. Onycholysis and subungual hyperkeratosis are seen in severe cases, especially those triggered by occupational exposure.

YELLOW NAIL SYNDROME

Yellow nail syndrome may or may not be associated with a systemic disorder and is occasionally familial.[70,71] However, it is important to refer patients to a pneumologist to exclude respiratory tract involvement. Other conditions that may be associated with yellow nail syndrome include rheumatoid arthritis and internal malignancies. The history is the most important clue to diagnosis, because patients always claim that their nails have stopped growing.

The nail changes may benefit from treatment with high oral dosages of vitamin E. Spontaneous improvement is possible. Topical vitamin E and systemic antifungal medications (itraconazole, fluconazole) do not appear to be effective.[70–72]

YELLOW NAIL SYNDROME AT A GLANCE



- In the typical syndrome, nail changes are associated with respiratory disorders and lymphedema.
- Arrested nail growth is diagnostic.
- Nails are overcurved and thickened, the cuticle is absent, and nail color varies from pale yellow to green. Onycholysis is often associated.
- Most or all nails are usually involved.

NAIL SIGNS OF SYSTEMIC DISEASES (Table 87-11)

In systemic diseases, nail manifestations usually involve most or all nails. The diagnosis is suggested by clinical history, morphology, and distribution of the nail abnormalities.

Beau's lines located at the same level in all digits or onychomadesis occurring simultaneously in all digits is strongly diagnostic for nail matrix damage from a systemic cause. Examination and capillaroscopy of the proximal nail fold are very important for the diagnosis of connective tissue diseases (Fig. 87-29). Patients with scleroderma and dermatomyositis show enlarged capillary loops with reduced capillary density and avascular areas (see Fig. 87-29). In systemic lupus erythematous periungual erythema and telangiectasia are typical; although periungual vessels can be tortuous, the capillary density tends to be normal. Cuticular hyperkeratosis and hemorrhages are seen in systemic lupus erythematous and dermatomyositis. Pterygium inversus unguium is typical of scleroderma; in this condition the nail plate adheres to the fingertip skin, which makes nail trimming very painful. The diagnosis of systemic amyloidosis can be suggested by nail involvement, which sometimes precedes skin and mucosal changes. The nails are thinned, longitudinally fissured, and show subungual hemorrhages. Mild leukonychia is often seen in normal individuals and therefore does not represent a specific sign of systemic disorders. Clinical patterns include half-and-half nails (leukonychia affects the proximal half of the nail bed), Terry's nails (leukonychia affects the entire nail bed except for its 2-mm distal margin), and Muehrcke's lines (narrow paired transverse bands parallel to the lunula) (Fig. 87-30). Clubbing may or not be associated with cyanosis (Table 87-12). In clubbing the angle between the proximal nail fold and nail plate is greater



TABLE 87-11
Nail Signs of Systemic Disease

Beau's lines/onychomadesis	See Table 87-2
Koilonychia	Sideropenic anemia
Proximal splinter hemorrhages	Bacterial endocarditis Trichinosis Anti-phospholipid syndrome Altitude sickness
Periungual erythema	Collagen disorders Infection with human immunodeficiency virus or hepatitis C virus
Lichenoid nail changes with hemorrhages	Systemic amyloidosis
Apparent leukonychia	
Half-and-half nails	Renal disorders
Terry's nails	Hepatic disorders
Banded nails (Muehrcke's lines)	Systemic chemotherapy Hypoalbuminemia
Clubbing	See Table 87-12
Melanonychia	See Tables 87-3, 87-10



TABLE 87-12
Causes of Clubbing

- Cardiovascular disorders
  - Aortic aneurysm[a]
  - Congenital/acquired cardiovascular disease[b]
- Bronchopulmonary conditions[c]
  - Intrathoracic neoplasms
  - Chronic intrathoracic suppurative disorders
- Gastrointestinal disorders
  - Inflammatory bowel disease
  - Gastrointestinal neoplasms
  - Hepatic disorders
  - Multiple polyposis
  - Bacillary dysentery
  - Amoebic dysentery
- Chronic methemoglobinemia

[a]Unilateral.
[b]Associated with cyanosis.
[c]Associated with hypertrophic osteopathy.

than 180 degrees (Fig. 87-31). The digit has a bulbous appearance, and the nail plate is enlarged and excessively curved. Melanonychia can be associated with a variety of systemic disorders and conditions, particularly human immunodeficiency virus infection, adrenal disease, pregnancy, and certain drugs (Fig. 87-32 and Table 87-13).

DRUG-INDUCED NAIL ABNORMALITIES[73]

A few nail abnormalities are highly likely to have resulted from administration of medication (see Table 87-13). Pyogenic granulomas involving several nails are an occasional side effect of treatment with retinoids, indinavir (Fig. 87-33), and anti–epidermal growth factor receptor chemotherapeutic agents, often leading to drug discontinuation. Retinoids have also been associated with nail fragility and paronychia. Taxanes (docetaxel and paclitaxel) frequently induce painful onycholysis with subungual hemorrhage and abscess formation. The nail lesions resemble a subungual infection and are reversible after drug discontinuation. Both β blockers and bleomycin may lead to digital ischemia. Therapy with psoralen plus ultraviolet A light has been associated with photo-onycholysis and with melanonychia. Photo-onycholysis is a rare phototoxic condition observed after intake of tetracycline derivatives, psoralens, and fluoroquinolones and subsequent exposure to sunlight or ultraviolet A light. It may be associated with a photosensitivity reaction in the skin and typically affects the central part of the nail plate of one or more fingernails. Onycholysis is painful and often hemorrhagic. Thumbnails are often spared.[74]



▲ **FIGURE 87-29** Proximal nail fold capillaroscopy in dermatomyositis: avascular areas and enlarged capillary loops.



▲ **FIGURE 87-30** Muehrcke's lines.

TRAUMATIC NAIL DISORDERS

Nail Biting

Nail biting is common in children and may encourage spreading of subungual warts.

When nail biting is associated with picking and chewing of the cuticle and periungual skin, the nail plate often shows superficial abnormalities and melanonychia due to melanocyte activation.

Habit Tic Deformity (Onychodystrophia Mediana Canaliformis)

In habit tic deformity the thumb shows a central longitudinal furrow with multiple transverse parallel lines (Fig. 87-34). The nail deformity is due to the nervous tic of pushing back the cuticle and the proximal nail fold of the thumb with the index finger.



▲ **FIGURE 87-31** Clubbing.



▲ **FIGURE 87-32** Longitudinal melanonychia involving several nails in a patient undergoing polychemotherapy.

Subungual Hematoma

Subungual hematoma may be caused by a single acute trauma or by repeated microtraumas (see Chap. 98). Nail hematomas last several months because part of the blood is incorporated into the nail plate. Very dark lesions require differentiation from melanic pigmentation. Dermoscopy shows rounded red-black globules.[63,64] Acute hematomas require immediate drainage to avoid matrix compression.

Onycholysis

Traumatic onycholysis of the great toenails is frequent in athletes, in women wearing high-heeled shoes, and in individuals with podiatric abnormalities. Nail detachment is not associated with nail bed hyperkeratosis.

TABLE 87-13
Drug-Induced Nail Changes

- Chemotherapy
  - Beau's lines
  - Onychomadesis
  - Muehrcke's lines
  - Hemorrhagic onycholysis
  - Pyogenic granulomas
  - Melanonychia
- Antiretrovirals
  - Azathioprine
    - Melanonychia
  - Indinavir
    - Pyogenic granuloma
- β Blockers
  - Digital ischemia
- Bleomycin
  - Digital ischemia
- Psoralen plus ultraviolet A phototherapy
  - Photo-onycholysis
  - Melanonychia
- Retinoids
  - Nail fragility
  - Pyogenic granuloma
  - Paronychia



▲ **FIGURE 87-33** Multiple pyogenic granulomas in a patient treated with indinavir.

Onychogryphosis

Onychogryphosis is common in the elderly and neglected individuals (Fig. 87-35). The nail is thickened, distorted, opaque, and yellow-brown, and tends to have an oyster shell appearance.

Pincer Nails

Pincer nails is a painful abnormality that usually affects the toenails and may be associated with subungual exostosis. The distal nail plate is overcurved and compresses the subungual soft tissues.

Ingrowing Toenails

Ingrowing toenails most commonly affect young adults with congenital malalignment of the great toenails. Improper nail cutting may lead to embedding of a nail edge, causing inflammation and granulation tissue formation. Hyperhidrosis is frequently associated. The aim of treatment for ingrowing toenails is to extract the nail edge that is ingrowing and prevent further penetration of nail fragments into the lateral folds. To accomplish this, the lateral nail plate can be lifted by using a cotton pack or by inserting a gutter splint along the lateral nail margin.[75] The width of the nail plate can also be reduced by surgical or chemical (phenolization) removal of the lateral nail matrix.[76]



▲ **FIGURE 87-34** Longitudinal furrow of the nail plate due to habit tic.



▲ **FIGURE 87-35** Onychogryphosis. The nail plate is greatly thickened, distorted, and hard.

KEY REFERENCES

The full reference list for all chapters is available at www.digm7.com.

1. Zaias N: *The Nail in Health and Disease*, 2nd ed, edited by Zaias N. Norwalk, CT, Appleton & Lange, 1990
4. Johnson M et al: Determination of nail thickness and length. *Br J Dermatol* **130**:195, 1994
8. Bergma R et al: The handheld dermatoscope as a nail-fold capillaroscopic instrument. *Arch Dermatol* **139**:1027, 2003
13. De Berker D et al: Keratin expression in the normal nail unit: Markers of regional differentiation. *Br J Dermatol* **142**:89, 2000
15. Tosti A et al: Characterization of nail matrix melanocytes using anti-PEP1, anti-PEP8, TMH-1 and HMB-45 antibodies. *J Am Acad Dermatol* **31**:193, 1994
29. Runne U, Orfanos CE: The human nail. Structure, growth and pathological changes. *Curr Probl Dermatol* **9**:102, 1981
31. Finlay AY et al: An assessment of factors influencing flexibility of human fingernails. *Br J Dermatol* **10**:103, 1980



35. Daniel CR, Piraccini BM, Tosti A: The nail and hair in forensic science. *J Am Acad Dermatol* **50**:258, 2004
38. Baran R, Kechijian P: Longitudinal melanonychia (melanonychia striata): Diagnosis and management. *J Am Acad Dermatol* **21**:1165, 1989
42. Fistarol SK, Itin PH: Nail changes in genodermatoses. *Eur J Dermatol* **12**:119, 2002
48. Baran R, Haneke E: Etiology and treatment of nail malalignment. *Dermatol Surg* **24**:719, 1998
50. Baran R et al: A new classification of onychomycosis. *Br J Dermatol* **139**:567, 1998
52. van de Kerkhof PC et al: Brittle nail syndrome: A pathogenesis-based approach with a proposed grading system. *J Am Acad Dermatol* **53**:644, 2005
54. Tosti A, Piraccini BM: *Paronichia in Contact urticaria syndrome*, edited by Amin S, Lahti A, Maibach HI. Boca Raton, CRC Press, 1997, p.267
55. Daniel CR et al: Chronic paronychia and onycholysis: A thirteen-year experience. *Cutis* **58**:397, 1996
58. De Berker D, Goettman S, Baran R: Subungual myxoid cysts: Clinical manifestations and response to therapy. *J Am Acad Dermatol* **46**:394, 2002
59. Haneke E, Franken J: Onychomatricoma. *Dermatol Surg* **21**:984, 1995
60. Tosti A et al: Nail matrix nevi: A clinical and histopathologic study of twenty-two patients. *J Am Acad Dermatol* **34**:765, 1996
62. Levit EK et al: The ABC rule for clinical detection of subungual melanoma. *J Am Acad Dermatol* **42**:269, 2000
73. Piraccini BM et al: Drug-induced nail abnormalities. *Expert Opin Drug Saf* **3**:57, 2004



PART 4

Disorders Due to the Environment

Copyright © 2008 by The McGraw-Hill Companies, Inc. Click here for terms of use.



SECTION 16

DISORDERS DUE TO ULTRAVIOLET RADIATION

CHAPTER 88

Fundamentals of Cutaneous Photobiology and Photoimmunology

Irene E. Kochevar
Charles R. Taylor
Jean Krutmann

Knowledge of the interaction of sunlight with the skin is fundamental to understanding the pathogenesis, diagnosis, and treatment of more than 100 cutaneous disorders. Whenever ultraviolet (UV) or visible radiation is used to diagnose or treat a skin condition, important principles of photophysics involving absorption and emission of light underlie the success of the therapy. Sunscreen recommendations rely on an understanding of solar UV radiation and the ways in which the causative wavelengths can be minimized. Skin cancer is an epidemic clinical problem, whose pathophysiology necessitates comprehension of the photophysical, photochemical, and photobiologic events described in this chapter.

Almost every ancient civilization worshipped a god of the sun whose healing powers were believed to be broad reaching. Even today, sun exposure is widely felt to induce a sense of well-being. In addition, sunlight is important for the synthesis of vitamin D_3 and the setting of internal clocks. On the negative side, sunlight causes deleterious acute and chronic inflammatory skin reactions, skin cancer, and photoaging, and can elicit adverse reactions to certain drugs (see Chaps. 89, 90, 91). Although the sun is a major source of the UV and visible radiation that interacts with human skin, UV and/or visible radiation are also emitted from common sources such as fluorescent lights, incandescent bulbs, photocopy machines, and phototherapy lamps. Tanning salons are another familiar example. Dentists use UV for hardening of acrylates, as do nail salon estheticians. Thus, UV and visible radiation are a constant part of the human environment and play a role in health, disease, and therapy. Photodermatology is the study of this interaction between human skin and UV and visible radiation. To understand the responses of skin to UV and visible radiation, it is essential to be acquainted with the principles governing the interaction of these wavebands with biomolecules in the skin.

When UV and visible light photons reach the skin surface, a series of steps must occur to transform the energy of the radiation to an observable response as shown schematically in Fig. 88-1. First, the radiation must penetrate to the appropriate level in the skin where it is absorbed by molecules in the skin, termed *chromophores*. Photochemical reactions then convert the chromophores into new molecules, the photoproducts. These photoproduct molecules stimulate cellular signal transduction pathways leading to biochemical changes that culminate in cellular effects, such as the proliferation, secretion of cytokines, and apoptosis that are observed as acute skin responses. For example, in the case of the patient who has ingested tetracycline and is then sun exposed, one might see exaggerated sunburn as a classic example of a phototoxic reaction. A similar series of steps are also responsible for responses to chronic exposure to UV radiation such as actinic keratoses and wrinkles (photoaging).

◀ Chronic actinic dermatitis. Infiltrated eczematous eruption on the face.

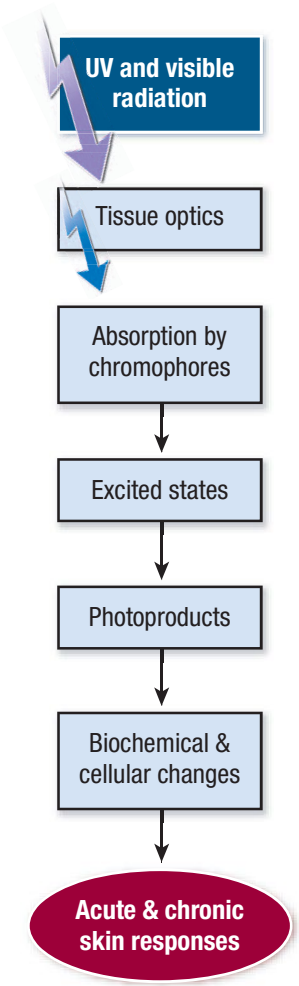

▲ **FIGURE 88-1** Generalized steps from ultraviolet (UV) and visible radiation hitting the skin to observation of clinical responses.

ULTRAVIOLET AND VISIBLE RADIATION

UV radiation and visible light are portions of the electromagnetic (EM) spectrum, which includes a wide range of wavelengths, from high-energy x-rays to low-energy microwaves and radiowaves (Table 88-1; Fig. 88-2). The short-

Copyright © 2008 by The McGraw-Hill Companies, Inc. Click here for terms of use.

FUNDAMENTALS OF CUTANEOUS PHOTOBIOLOGY AND PHOTOIMMUNOLOGY AT A GLANCE

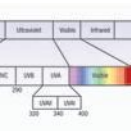

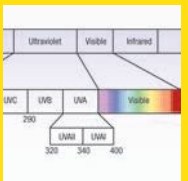

- When radiation enters the skin, it is scattered or absorbed. Only light absorbed by molecules (chromophores) in the skin can cause a photobiologic response.
- Electromagnetic radiation can be conceptualized either as a wave or as packets of energy called *photons*.
- The energy in a photon is inversely proportional to the wavelength of radiation.
- Irradiance (W/cm^2) × Time (seconds) = Exposure dose or Fluence (J/cm^2)
- The action spectrum indicates which wavelengths produce a photobiologic response most effectively and is plotted as the reciprocal of the minimum effective fluence versus wavelength.
- After absorbing energy of a photon the chromophore is in an "excited state."
- During a photochemical reaction of an excited state molecule, the chromophore is transformed into a stable "photoproduct."
- When certain drugs absorb ultraviolet (UV)/visible light, inflammation ensures. This is called *photosensitization*.
- Photosensitivity responses are usually mediated by reactive oxygen species.
- UV radiation is immunosuppressive. Local and systemic immunosuppression are recognized.
- Pyrimidine dimers, reactive oxygen species and urocanic acid are involved in UV-induced immunosuppression.
- Other molecules are interleukin 10, tumor necrosis factor-α, platelet-activating factor, and platelet-activating factor–like lipids.
- The major cellular players in UV immunosuppression are Langerhans cells, keratinocytes, macrophages, and T cells.
- UV radiation impairs T helper 1–mediated cellular immune response.

TABLE 88-1
Electromagnetic Radiation According to Wavelength

WAVEBAND	WAVELENGTH RANGE (NM)
X-ray	0.1–10
Vacuum ultraviolet	10–200
Ultraviolet C	200–290
Ultraviolet B	290–320
Ultraviolet A (UVA)	320–400
UVAI	340–400
UVAII	320–340
Visible	400–760
Violet	400
Blue	470
Green	530
Yellow	600
Red	700
Near infrared	760–1000
Far infrared	1000–100,000
Microwaves and radiowaves	$> 10^6$

est wavelengths are associated with the highest energy radiation and the longest wavelengths with the lowest energy radiation. The UV waveband is of special interest because dozens of skin disorders are aggravated by these wavelengths and many popular therapies, such as UVB phototherapy (see Chap. 238) and psoralen and ultraviolet A light (PUVA) photochemotherapy (see Chap. 239), use sources emitting UV radiation. Visible light encompasses those wavelengths perceived as color by the human eye and is also frequently used in therapies, such as blue-light aminolevulinic acid–photodynamic therapy (PDT; see Chap. 239), and is emitted by several lasers intended to target pigmented (colored) targets within the skin (e.g., pulsed dye and Q-switched ruby) (see Chap. 240).

Ultraviolet Radiation

For medical photobiology, the UV range (200 to 400 nm) is subdivided into UVA, UVB, and UVC (see Table 88-1 and Fig. 88-2). A division was made at 290 nm because wavelengths from the sun shorter than 290 nm are absorbed by ozone in the stratosphere and do not reach the earth's surface at sea level. Wavelengths in the range of 200 to 290 nm are referred to as *UVC* or *germicidal radiation*. These wavelengths are strongly absorbed by DNA and therefore can be lethal to viable cells of the epidermis or to bacteria. UVC lamps emit at 254 nm and are used for air and water purification. Care must be taken to avoid exposure of eyes and skin to UVC radiation because of the danger of UV keratitis and mutation.

The range 290 to 320 nm is known as UVB and is often referred to as *mid-UV* or *sunburn spectrum*. It includes the biologically most active wavelengths reaching the earth's surface. Also, ordinary window glass transmits only longer wavelengths. Most sunscreens efficiently reflect or absorb these wavelengths, and the sun protection factor (SPF) is based on testing against this waveband. However, it is important to note that different wavelengths within these subdivisions can elicit greatly varying biologic responses. For example, consider the response of skin to two wavelengths in the UVB range, 297 and 313 nm. Radiation at 297 nm is nearly 100 times more erythemogenic than 313-nm radiation[1] and more effectively causes DNA damage and photocarcino-

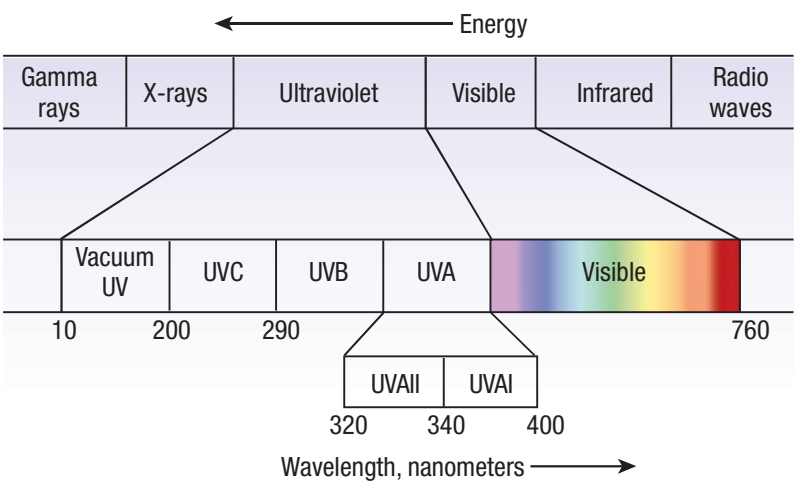

▲ **FIGURE 88-2** Electromagnetic spectrum divided into major wavelength regions. The lower band emphasizes the ultraviolet (UV) and visible bands that are important for photobiologic responses in human skin.

genesis.[2] An example relevant to phototherapy is that narrowband UVB (312 nm) and excimer laser (308 nm) are used to treat psoriasis because these wavelengths are more effective than other portions of the UVB spectrum.[3,4] UVB constitutes only approximately 5.0 percent of the UV and 0.5 percent of total radiation reaching the earth's surface; the exact amount varies markedly with the time of day, season, cloud conditions, and other factors.

Long-wave UV or UVA (320 to 400 nm) is sometimes referred to as *black light* because it is not visible to the human eye but causes certain substances to emit visible fluorescence. Approximately 95 percent of the UV radiation reaching the earth's surface is UVA. As described for UVB radiation, the response of skin to UVA is not constant across all wavelengths from 320 to 400 nm.[3] In fact, UVA has been divided into UVA I (340 to 400 nm) and UVA II (320 to 340 nm) because the latter band is more damaging to unsensitized skin than the longer wavelengths. Although most sunscreens offer their greatest protection against UVB wavelengths, those products said to be "broad-spectrum" indeed have considerable ability to protect against UVA wavelengths, although no formal measure equivalent to the SPF rating yet exists. Generally, the higher the SPF, for example, 45 or greater, the more likely one is going to find some UVA protection inherent in that preparation. Newer sunscreen agents enhance protection against damaging UVA rays (see Chap. 223). Because approximately 95 percent of the UV radiation reaching the earth's surface is UVA, protection against this waveband is quite important for minimizing adverse cutaneous effects such as photoaging and carcinogenesis.

Visible Radiation

The visible spectrum (400 and 760 nm) is defined by the wavelengths that are perceived as color by the retina. Some people can see wavelengths slightly shorter than 400 nm and others wavelengths longer than 760 nm. Specific colors are associated with different wavelengths, as shown in Fig. 88-2. Skin responses to visible light generally require photosensitization. For example, in PDT, a dye absorbing long wavelength visible light (red) is used and for aminolevulinic acid PDT, a prodrug is applied that is converted into a blue-absorbing protoporphyrin IX (see Chap. 239). Intense pulsed light sources, usually lasers, are used to treat vascular, pigmented and other lesions without application of a photosensitizing dye (see Chap. 240).

Other Wavebands of Electromagnetic Radiation

X-rays and γ rays occupy the short wavelength (high energy) end of the EM spectrum, and infrared radiation is found at longer wavelengths (lower energy) than visible radiation (see Table 88-1). X-ray and γ ray radiations ionize molecules (remove electrons) indiscriminately and are known as *ionizing radiation*, the subject of radiobiology (see Chap. 95). In radiation therapy of tumors, these wavelengths kill tumor cells by ionizing water molecules and producing free radicals that damage DNA. Infrared radiation (IR) has lower energy than visible light.[5,6] It is subdivided into IR-A (760–1440 nm), IR-B (1440–3000 nm), and IR-C (3000 nm–1 mm). In contrast to IR-B and IR-C, IR-A penetrates into the dermis and exerts biological effects. IR-B and IR-C are felt as heat. Recent studies suggest that IR-A wavelengths can damage skin, but might also be therapeutically useful although for both effects the mechanisms are still unclear.[5,6]

PROPERTIES OF ELECTROMAGNETIC RADIATION

Certain principles are better illustrated by conceptualizing EM radiation as waves, whereas others are better understood by thinking of it as packets of energy called *photons*. These two descriptions are complementary.

Waves consist of periodic motion or oscillations that travel through a medium. When the motion is perpendicular to the direction of propagation, such as waves traveling down a length of rope, the waves are called *transverse waves*. EM radiation considered as a wave consists of oscillating electric and magnetic fields at right angles to each other and to the direction of propagation. Consequently, it may be described either by its frequency (number of oscillations per second) or by its wavelength (distance traveled per oscillation). Because all EM radiation propagates at the same velocity through space, frequency and wavelength have an inverse relationship, which is expressed as: $\nu = c/\lambda$, where ν = frequency of oscillations per second, c = velocity of radiation (the speed of light, 3×10^8 m/s), and λ = wavelength in meters. When light is considered as a wave, specific colors of UV and visible radiation are associated with specific wavelengths of the EM spectrum. For example, red light is associated with wavelengths around 700 nm, whereas blue light is associated with wavelengths around 470 nm (see Table 88-1).

In addition to its wave character, EM radiation may be described as a stream of discrete packets of energy known as *quanta* or *photons*. The amount of energy in a photon (quantum) is directly proportional to the frequency of the radiation and inversely proportional to the wavelength of radiation, as expressed by Planck's law: $E = h\nu = hc/\lambda$, where E = the energy of the photon in joules (J), h = Planck's constant (6.626×10^{-34} J/s), ν = frequency of oscillations per second, c = velocity of radiation (3×10^8 m/s), and λ = wavelength in meters. This relationship shows that the energy of the photon increases when the wavelength is shorter and decreases when the wavelength is longer. In other words, radiation of shorter wavelength has greater energy per photon. For example, a 300-nm photon has twice the energy of a 600-nm photon. Because they have lower energy, photons associated with wavelengths longer than the visible range usually do not cause photochemical reactions.

SOURCES OF ULTRAVIOLET AND VISIBLE RADIATION

Sunlight

The shortest wavelength of the solar spectrum reaching the earth's surface at sea level is approximately 290 nm, although slightly shorter wavelengths have been detected at high altitudes.[7] The shorter UV wavelengths emitted by the sun are filtered out by the ozone layer and molecular oxygen of the stratosphere. Depending on the geographic location and the season, it has been estimated that sunlight produces between 2 and 6 mW/cm^2 of UV radiation between 290 and 400 nm. Filtering of wavelengths less than 290 nm by ozone is a very important process because the shorter UVC wavelengths are highly damaging to animals and plants. Ozone present in the stratosphere is constantly being generated and degraded. Because the transmission of solar UVC and UVB through the atmosphere varies exponentially with ozone concentration, small changes in the ozone layer may result in hazardous increases in UV irradiance at the earth's surface.[8] For example, calcula-

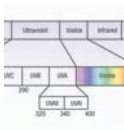

tions of the effects of ozone depletion predict a doubling of skin cancer incidence by 2100 even if the Montreal Protocol restrictions on ozone-depleting substances are followed.[9]

The UV Index developed by the National Weather Service and the U.S. Environmental Protection Agency represents an attempt to quantify the risks attendant with solar radiation at a given time and place. Among other factors, the effects of altitude, latitude, season, and clouds are considered. The scale goes up to 15, and any UV Index greater than 10 is considered a high-risk day for possible overexposure in that locale.

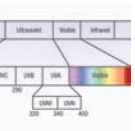

Artificial Sources of Ultraviolet and Visible Radiation

Skin is exposed to UV and visible radiation from a wide variety of sources in daily life and from a different set of light sources for therapy and diagnosis. The following is a general discussion of UV and visible light sources. Specific information should be obtained from the manufacturer before using a new light source.

INCANDESCENT SOURCES Incandescent light sources include electric lightbulbs, flood lamps, and some quartz iodide bulbs. In these lamps, an electric current passing through a metal filament heats the filament, causing it to emit EM radiation. Most of the radiation emitted is in the visible and infrared spectrum. Only the occasional patient with solar urticaria, chronic actinic dermatitis, or some porphyrias is bothered by the output of ordinary incandescent sources. Wavelengths shorter than 360 nm are usually not emitted because the hot filaments are encased in glass envelopes that transmit only UVA and visible radiation. Tungsten-halogen incandescent lamps, often used as flood lamps, emit UVA and visible radiation. Some quartz iodide incandescent lamps produce significant UVA and some UVB emission.

ARC SOURCES Arc sources include xenon lamps, medium- and high-pressure mercury (hot quartz) lamps, fluorescent lamps, and halide lamps. In arc lamps, electrons are driven through a gas by a potential difference between two electrodes. The gaseous molecules between the electrodes are ionized and subsequently release EM radiation. Radiation is emitted preferentially at specific wavelengths (emission lines) as well as in a continuum of wavelengths. The wavelengths and relative power at each wavelength depend on the gas used, the arc temperature, the pressure within the lamp, and the lamp wall material.

Xenon arc lamps emit both UV and visible radiation and are now the most common sources used in solar simulators. Photoprovocation testing for polymorphic eruption is often done with such sources. Filters are used to limit the wavelengths for phototesting with solar simulators. Xenon arcs are also used in some phototherapy and photobiologic research applications. In a xenon lamp, xenon gas under 20 to 40 atmospheres (atm) of pressure is heated to a high temperature in a rigid quartz envelope to produce intense visible and UV radiation. At these pressures, the xenon spectrum becomes a continuum—that is, all wavelengths are emitted rather than just specific wavelengths.

The wavelengths emitted by mercury arc lamps are strongly influenced by the pressure of the gas within the envelope. Low-pressure mercury germicidal lamps emit 85 percent of the radiant energy at 254 nm. Because the operating temperature is low, they are also known as *cold quartz lamps*. With increasing pressure (1 atm), the primary 254-nm emission is absorbed by other mercury atoms within the lamp and re-emitted at longer wavelengths (297, 302, 313, 334, and 365 nm, and visible wavelengths). With further pressure increases (2 to 100 atm), these spectral lines broaden and decrease relative to the intensity of the continuous spectral background. In medical practice, medium- and high-pressure mercury (hot quartz) lamps are generally used as sources of UVB, although their spectral power distribution is mainly in the UVA and visible range.

The commonly used UVB sunlamps (see Chap. 238) and UVA lamps for PUVA therapy (see Chap. 239) are fluorescent lamps. They are, in essence, modified low-pressure mercury arc lamps consisting of a glass tube containing the mercury gas with electrodes at both ends. The inner surface of the glass tube is coated with a phosphor, which absorbs the 254-nm radiation and re-emits the energy at longer wavelengths. The chemical composition of the phosphor determines which wavelengths are re-emitted. In general, fluorescent lamps have a relatively wide, bell-shaped emission spectra, with spectral emission lines of mercury superimposed, and are referred to as *broadband light sources*.

Fluorescent sunlamps (type FS) emit mainly in the UVB range (Fig. 88-3). They are often referred to as *UVB lamps*, even though they emit a portion of UVA radiation, because the therapeutically significant radiation is in the UVB range (Table 88-2). A fluorescent lamp with a major emission peak at 311 nm (Philips TL01) was developed for use in phototherapy (see Fig. 88-3).[10,11] This lamp is an efficient source for psoriasis phototherapy because, compared to a conventional UVB lamp, the energy emitted almost entirely overlaps with the action spectrum for clearance of psoriasis.[3] Interestingly, this lamp has also been successfully used for the treatment of vitiligo, atopic dermatitis, and polymorphic light eruption, all of whose action spectra are unknown and may possibly differ from that for psoriasis.

High-intensity, UVA-emitting fluorescent lamps are most often used in PUVA therapy of psoriasis, vitiligo, and other skin diseases. The most efficient UVA source for PUVA therapy would maximize the emission of 320- to 360-nm radiation for photoactivation of psoralen molecules, while minimizing the UVB emission. Table 88-2 shows the percentage of total emission that is in the 320- to 360-nm range from several UVA-emitting light sources that are used in phototherapy units.

Wood's lamps are small, low-pressure, UVA-emitting fluorescent lamps with a UVA-transmitting, visible-absorbing glass envelope. They are useful in clinical practice because, after UVA absorption, the fluorescent emission from normal and abnormal components of skin, hair, teeth, and urine may be diagnostic (e.g., in porphyria, vitiligo, and fungal infection).

Halide lamps emit a high-intensity continuum in the UVB and especially the UVA range. With appropriate filters, this lamp is used increasingly as a UVB, as well as a UVA, source for phototherapy (in particular, UVA1 therapy) and photochemotherapy. The metal halide lamp usually consists of a high-pressure mercury lamp with metal halides as additives. The continuous range of wavelengths emitted from halide lamps differentiates them from medium-pressure mercury arc lamps that emit in narrow wavelength ranges. Approximately 20 percent of the emission spectrum can be UVA radiation.

LASERS (see Chap. 240) Laser is an acronym for *l*ight *a*mplification by *s*timulated *e*mission of *r*adiation. Lasers produce intense beams of monochromatic radiation. The laser operates by exciting

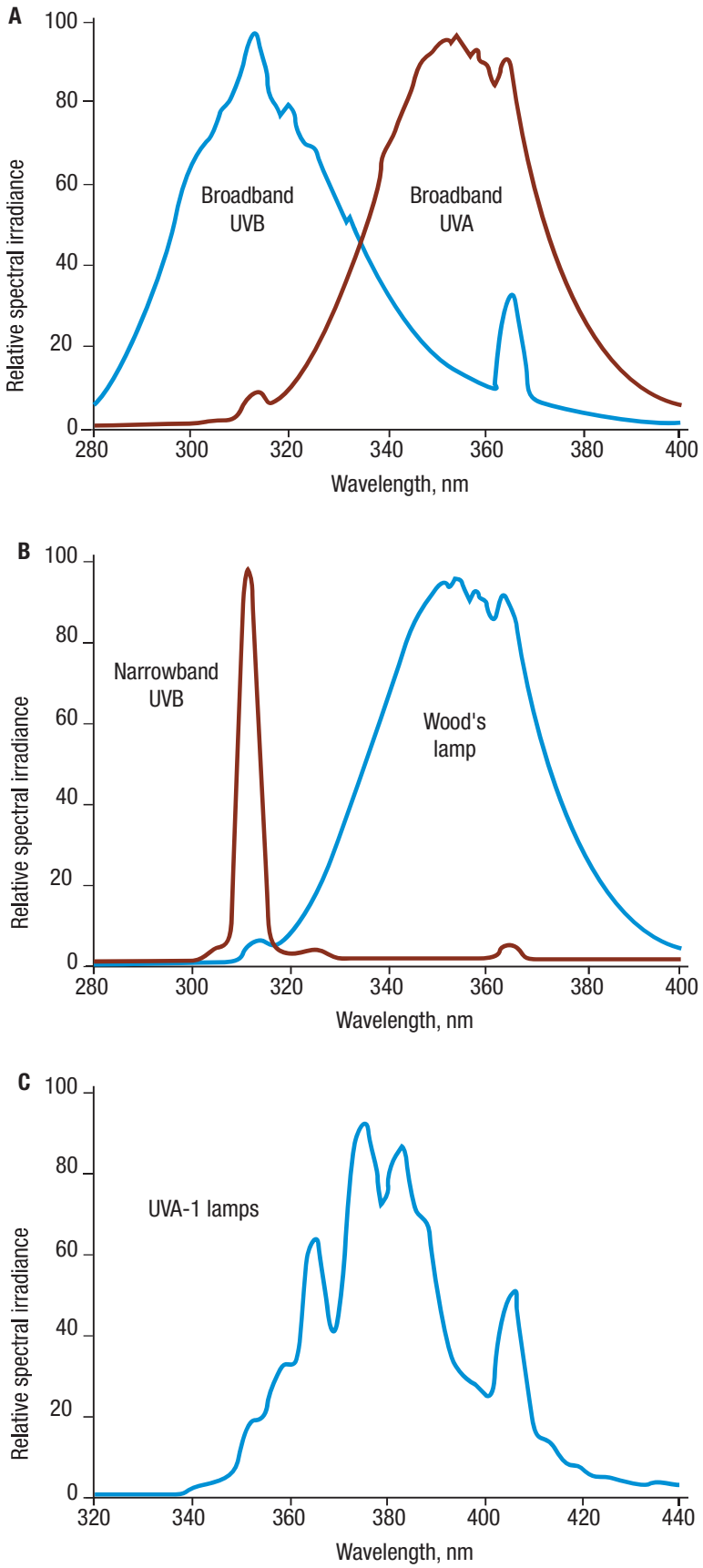

▲ **FIGURE 88-3** Emission spectra of some of the fluorescent lamps used in phototherapy. **A.** Broadband ultraviolet B (UVB) fluorescent lamps and UVA (black light) fluorescent lamps. **B.** Narrowband (Phillips TL01) fluorescent lamp with a maximum at 311 nm and a fluorescent lamp with a Wood's glass filter. **C.** UVA-1 halide lamps (Sellamed 24000 bed system). Emission spectra were measured with a Luzchem Model SPR-4001 Spectroradiometer.

TABLE 88-2
Approximate Spectral Power Distribution of Ultraviolet B (UVB) and UVA Radiation Expressed as Percentage of Total Emission in the UV Waveband in Common Phototherapy Sources

	% UVB	% UVA
Broadband UVB (Westinghouse Sunlamp)	60	40
Narrowband UVB[a] (Phillips Fluorescent UVB, TL01, 311 nm)	80	20
Broadband UVA (Houva Lite; Black Light by Sylvania, Westinghouse, and General Electric; Sylvania Puva Life Line; Dermalight Metal)	2	98
UVA-1[b] (Dermalight UltrA1, Dr. K. Hönle Medizintechnik GmbH)	0	100
Wood's light[c] (RA Fisher; Spectronics)	0	100
Halide lamps[d] (Dermalight Systems; Dr. K. Hönle Medizintechnik GmbH)	0	100

[a]Most (~95% of the UVB emission of the typical narrowband UVB source is centered around 311 nm).
[b]This UVA emission is above 340 nm.
[c]The filter used (so-called *Wood's filter*) is glass with nickel oxide phosphor. Consequently, UVB is screened. A moderate amount of visible light is produced.
[d]The actual amount depends on the model purchased and the filters used (glass vs. quartz). Some models allow the operator to change the filters readily and thus increase the amount of UVB to > 50% of the irradiance.

molecules to a metastable excited state from which photon emission is stimulated by a subsequent photon incident on the excited molecule. The emitted photon and the stimulating photon are then each capable of stimulating emission of yet other excited molecules, eventually producing an avalanche of photons of the same wavelength, phase, and direction of propagation. Lasers emit UV, visible, or infrared wavelengths and may operate as either continuous or pulsed sources. Applications of lasers in dermatology use their capacity to concentrate large amounts of energy in a small volume of tissue.

ULTRAVIOLET AND VISIBLE RADIATION DOSIMETRY

To treat patients with the appropriate amount and wavelengths of UV or visible radiation, it is important to become acquainted with how the radiation is quantified and related to the exposure

time. The basic unit of EM energy is the joule (J). Power is the rate of energy flow, joules per second (J/s). In the case of UV and visible radiation, power is the rate of radiant energy emission and is given in watts (W), with the units of J/s. The rate at which the radiant energy is delivered to a surface, such as skin, is expressed as the power delivered per unit area of surface (Power/area; W/cm^2). This quantity is called *irradiance*. The total radiant energy delivered per unit area of skin surface is called the *exposure dose* or *fluence* and is the product of irradiance and time:

$$\text{Irradiance } (W/cm^2) \times \text{Time (sec)} = \text{Exposure dose or Fluence } (J/cm^2)$$

For most responses to UV and visible radiation, it is the exposure dose at a particular wavelength that determines the magnitude of the response. The energy delivery rate of the radiation source generally does not affect the response using conventional light sources, in contrast, laser radiation effects are often influenced by the irradiance (see Chap. 240).

The irradiance delivered by a source as a function of wavelength is called the *spectral irradiance* and is expressed as units of irradiance per nanometer [(W/cm^2)/nm]. A spectroradiometer is used to measure the spectral irradiance of a light source. When measuring a light source's irradiance over a given spectral region, a detector weighted to the wavelengths of interest is most useful. For example, a broadband radiometric measurement of wavelengths less than 315 nm provides a rough indication of the erythemally effective wavelengths emitted by a source of UV radiation.

There is, however, no substitute for knowing the full spectral irradiance delivered by a source, as determined by a spectroradiometer. For example, in phototesting, only the wavelengths of interest should be used. To assess endogenous UVA sensitivity, the UVB portion of a source's emission, if present, must be filtered out so that the more erythemogenic UVB wavelengths do not lead to a falsely lower determination of erythema threshold in the UVA range. The spectroradiometer is critical in defining the full spectral output of a light source.

OPTICAL PROPERTIES OF SKIN

When UV and visible radiation strike the skin, part is remitted (reflected and scattered), part is absorbed by chromophores in various layers, and part is transmitted inward to successive layers of cells until the energy of the incident beam has been dissipated (Figs. 88-4 and 88-5). A very small fraction of the absorbed radiation is absorbed and then re-emitted at longer wavelengths as fluorescence. The two major processes limiting the penetration of UV and visible radiation into skin, absorption and scattering, vary with wavelength.[12]

UV wavelengths less than 320 nm are readily absorbed by proteins, DNA, and other components of epidermal cells. Along with scattering, this absorption accounts for the low penetration of these wavelengths into skin (see Fig. 88-4). For example, approximately 50 percent of 300-nm radiation and 10 percent of 350-nm radiation reaches the dermal–epidermal junction. Between 5 percent and 10 percent of incident light is reflected by the outer surface of the stratum corneum. This surface or so-called *specular reflectance* is relatively constant for all visible wavelengths and accounts for the surface appearance of skin, which is especially glossy if the surface is smooth, wet, or oily. In contrast, if the surface is irregular, the light is scattered and the skin appears dull or "rough." Moisturizers applied to the skin reduce this rough appearance by smoothing out the many air-surface interface irregularities, thus reducing specular reflectance and making the skin look shinier.

Scattering includes any process that deflects the path of optical radiation. For example, skin with scales, as in psoriasis, scatters more light than does normal skin. During phototherapy, application of emollients to the psoriatic plaques helps reduce the scattering of UVR and allows more of the effective wavelengths to penetrate into the viable tissue. In fair, white skin, the bulk of the visible remittance, approximately 50 percent of the incident radiation, is light that has penetrated the epidermis and has been scattered from various depths within the dermis back through the epidermis and skin surface.

Melanin, which absorbs relatively uniformly over the visible wavelengths and is normally present only in the epidermis, acts largely as a neutral density filter to diminish dermal remittance. Melanosomes in darker-skinned individuals are larger and singly dispersed as compared to those of fairer-skinned individuals. The greater overall melanin content in darker skin absorbs more visible light and therefore causes the skin to appear darker as there is less light reflected back to the observer.

Blood (hemoglobin) within the dermis absorbs the shorter (blue) visible wavelengths, diminishing these spectral regions of the dermal remittance component, and giving a reddish hue to our perception of the total remittance. Abnormal location and quantity of these or other pigments account for the appearance of the skin in pathologic conditions

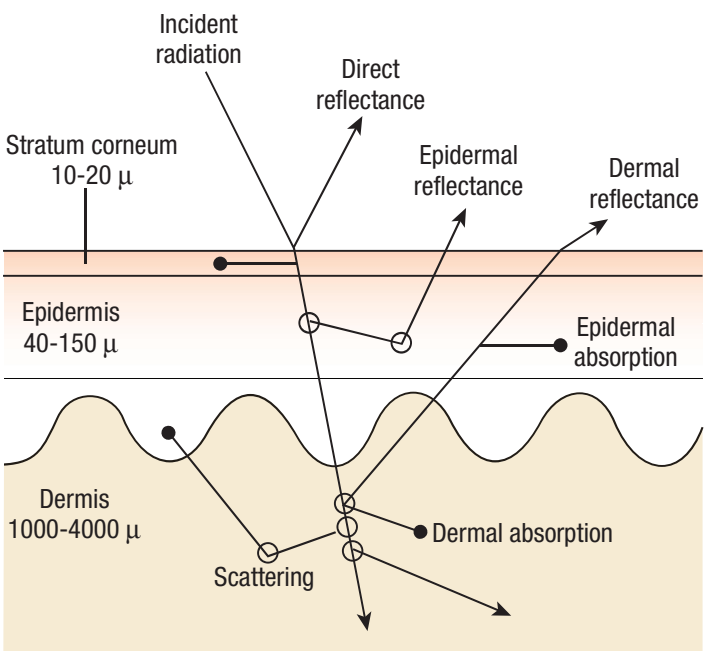

▲ **FIGURE 88-4** The interaction of ultraviolet and visible radiation with skin. The incident radiation is reflected from the surface, scattered (*circles*), and absorbed (*black dots*) as it travels through the skin.

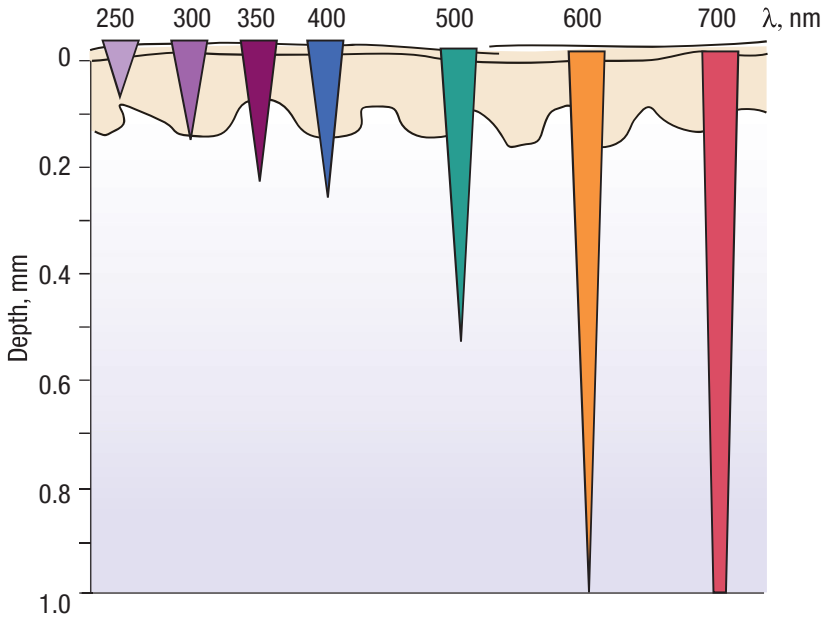

▲ **FIGURE 88-5** Illustration of the approximate penetration of ultraviolet and visible radiation into skin. λ = wavelength.

(e.g., melasma with extra pigment in the epidermis and/or dermis; vitiligo with an absence of epidermal melanin).

ABSORPTION OF ULTRAVIOLET AND VISIBLE RADIATION BY MOLECULES IN SKIN

When a photon is taken up by a chromophore, it is said that absorption has occurred. After absorption, the molecule contains extra energy and may be altered to form a new molecule called a *photoproduct*. These new molecules initiate responses in skin cells. Thus, absorption is the first step in a photobiologic response.

Skin is composed mainly of water; organic molecules, such as proteins, lipids, and nucleic acids; and inorganic ions, including Na^+, Ca^{2+}, and Cl^-. The organic molecules absorb photons in the UVA, UVB, and visible spectral regions. The specific wavelengths absorbed by each molecule (called an *absorption spectrum*) are determined by the structure of the molecule (i.e., the arrangement of the electrons). Only absorbed radiation can initiate biologic responses. The first law of photochemistry, set forth by Grotthus and Draper in 1818, states that only absorbed light can cause a photochemical change.

The absorption spectrum of a compound is a plot of the probability of absorption of photons of a specific wavelength on the Y-axis against wavelength on the X-axis (Fig. 88-6). The wavelengths that have the highest probability of absorption are called *absorption maxima*, λ_{max}, and can be used to target (e.g., DNA, λ_{max} = 260 nm; porphyrins, λ_{max} = 400 to 410 nm). Many of the biomolecules that absorb in the UVB spectrum actually have absorption maxima at shorter wavelengths in the UVC range (see Fig. 88-6). These include the purine and pyrimidine bases in DNA and RNA (λ_{max} ~ 260 nm), urocanic acid (UCA; λ_{max} = 280 nm), aromatic amino acids in proteins (λ_{max} ~ 280 nm), and 7-dehydrocholesterol (λ_{max} = 285 nm). However, within skin the absorption maxima occur at longer wavelengths because these shorter wavelengths do not penetrate sufficiently. Similarly, most photosensitizing drugs have effective action spectra in the UVA range although in solution outside the body they may have absorption maxima at shorter wavelengths. Many endogenous cutaneous chromophores absorb UVA [e.g., reduced nicotinamide adenine dinucleotide phosphate (340 nm)]. Others absorb both UVA and visible radiation, including hemoglobin (λ_{max} = 410 nm), bilirubin (λ_{max} = 450 nm), and β-carotene (λ_{max} = 460 nm). Melanin absorbs throughout the UV and visible spectrum without a distinct absorption maximum wavelength.

PHOTOCHEMICAL REACTIONS LEADING TO SKIN RESPONSES

After absorbing the energy of a photon, the chromophore is in an "excited state,"

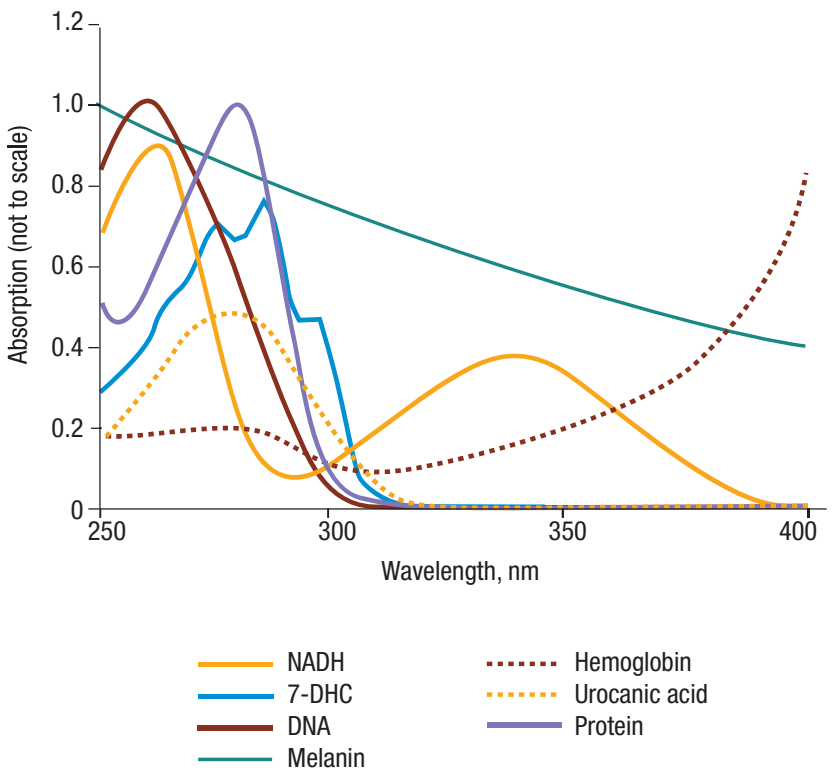

▲ **FIGURE 88-6** Absorption spectra of cutaneous chromophores absorbing ultraviolet radiation. Note that the relative amounts of ultraviolet radiation absorbed by these chromophores in skin depends on the heights of the absorption peaks as shown in this figure, the amount of each chromophore in skin, and the penetration of each wavelength into skin. 7-DHC = 7-dihydrocholesterol, NADH = reduced nicotinamide adenine dinucleotide.

which exists for only a very short time before reacting with nearby molecules. The products of these reactions initiate signal transduction processes that lead to the observed responses in skin.

Excited State Molecules

Normally, molecules are in the so-called *ground state* and have a certain distribution of electrons in space around the nuclei of their atoms. For each molecule, a series of electronic states with higher energies and different distributions of electrons also exist; these are called *excited states*. When a molecule in the ground state absorbs the energy of a UV or visible photon, the molecule is promoted to an excited electronic state (Fig. 88-7). According to quantum mechanics, only certain energy gaps are allowed to exist between electronic states. Consequently, a molecule can absorb photons only with certain energies; this results in a unique absorption spectrum for each molecule.

A molecule exists in this first excited state formed for a very brief period. It is called a *singlet excited state* and exists for a few nanoseconds. The molecule may return to the ground state by emitting light (fluorescence) or releasing the energy as heat, a process called *internal conversion* (see Fig. 88-7). Alternatively, the singlet excited state may undergo a chemical reaction to form a photoproduct, or it may convert into another excited state with lower energy, the triplet excited state, by a process called *intersystem crossing* (see Fig. 88-7). Singlet and triplet excited states differ in the spins of a pair of electrons in an orbital. If the spins are opposite, they are called *singlet states*. If the spins are the same, they are called *triplet states*. The ground state is almost always a singlet state. The triplet excited state may exist for a longer time (i.e., a few microseconds). It may emit light (phosphorescence), undergo a chemical reaction, or return to the singlet ground state by intersystem crossing (see Fig. 88-7). Formation of photoproducts by reactions of the excited states is of greatest interest to us because the photoproducts initiate photobiologic responses.

These excited state processes are responsible for the effectiveness of light for diagnosis and therapy. For example, fluorescence occurs every time a Wood's light is used. UVA emitted from this lamp causes autofluorescence of dermal collagen fibers. To the examining physician, this fluorescence is viewed through the overlying epidermis. Thus, any epidermal lesions such as lentigines tend to have their borders accentuated by contrast because the fluorescence is observed most brightly around the lesion. The heat generated by internal conversion is responsible for the denaturation of proteins and other effects of pulsed lasers (see Chap. 240). In this case, many photons are absorbed in a small volume of tissue over a very brief time, and the excited singlet state molecules release their energy to the water in the tissue, causing a rapid increase in temperature. Other phototherapies and adverse responses to UV (i.e., drug phototoxicity and photosensitivity diseases) result from the photoreactions of the excited singlet and triplet states with cellular molecules.

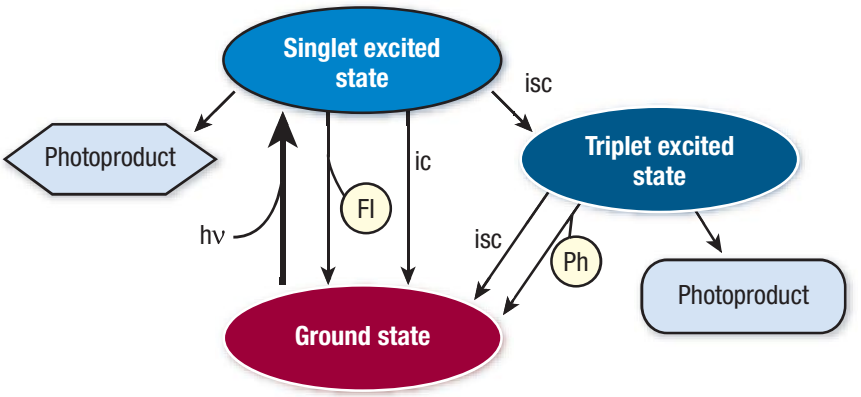

▲ **FIGURE 88-7** Absorption of ultraviolet and visible radiation (hν) by molecules and the dissipation of the absorbed energy by fluorescence (Fl), internal conversion (ic), intersystem crossing (isc), phosphorescence (Ph), and photochemistry to form photoproducts.

Photoproducts

During a photochemical reaction of an excited state molecule, the chromophore may be transformed into a new, stable molecule called the *photoproduct*. Often, the photoproduct molecule is produced when the chromophore forms covalent bonds with another molecule in the cell. These reactions are termed *bimolecular*. An important example is the formation of covalent adducts between psoralen and DNA.[13] The phototherapy of diseases such as psoriasis makes use of this photochemical reaction (see Chap. 239). The mechanism for formation of psoralen-DNA photoproducts has several steps. The psoralen molecule enters the cell nucleus and intercalates between the stacked nucleic acid bases. When the skin is exposed to UVA, the psoralen molecule absorbs a photon. If the neighboring base is a pyrimidine (cytosine or thymine), the excited state psoralen may covalently bond to the base, forming a photoadduct. The photoadduct may then absorb another UVA photon and link to a pyrimidine base on the opposite DNA strand thereby cross-linking the two DNA strands. DNA-psoralen cross-links are particularly toxic to cells and are important for the phototherapeutic effect of PUVA.

Photoproducts are also important for many UVB-induced responses in skin. When a thymine or cytosine absorbs UVB, the excited state may covalently bond to an adjacent thymine or cytosine, forming a four-membered ring structure called a *cyclobutyl pyrimidine dimer* (CPD). Additional products with somewhat different structures, but still resulting from new covalent bonds, are formed and called *6-4 photoproducts*. Both of these products lead to mutations and the sites on the DNA strands where they are formed are related to sites of mutation in nonmelanoma skin cancers.[14]

7-Dehydrocholesterol is a chromophore in skin that absorbs UVB radiation (see Fig. 88-6). The excited state molecule is converted by a bond rearrangement into previtamin D_3 without requiring another molecule, an example of a unimolecular reaction. The previtamin D_3 thermally isomerizes to vitamin D_3, enters the circulation, and is ultimately hydroxylated in the liver and the kidney to form the active hormone, 1,25-dihydroxyvitamin D. In this case, UVB-induced photochemistry in the skin is beneficial to the organism.[15]

Photochemical reactions vary in efficiency. Each chromophore molecule that absorbs a photon undergoes a photochemical reaction because, as described above, several pathways are available to molecules in excited states (e.g., fluorescence, internal conversion). The term

quantum yield is used to define the likelihood that one of these processes occurs. For example, the quantum yield for forming a certain photoproduct is:

$$\text{Photoproduct Quantum Yield} = \frac{\text{Number of photoproduct molecules formed}}{\text{Number of photons absorbed}}$$

Photosensitization

When certain drugs (tetracyclines, quinolones, psoralens) and dyes absorb UV and/or visible radiation, delayed erythema or inflammation is observed (see Chap. 91). This phenomenon is called *photosensitization*, and the dyes and drugs are called *photosensitizers*. In most cases, oxygen is required for photosensitization to occur. The exception is the phototoxicity of psoralens, which does not require oxygen in the photosensitization mechanism. Molecular level studies have shown that photosensitivity responses are mediated by reactive oxygen species (ROS), which are small molecules and free radicals that rapidly oxidize cellular molecules. Examples of ROS include singlet oxygen, hydrogen peroxide, superoxide anion, hydroxyl radical, and nitric oxide. These ROS oxidize unsaturated lipids, certain amino acids in proteins (histidine, methionine, tryptophan, cysteine), and nucleic acids. The products formed initiate signal transduction processes, leading to production of inflammatory mediators such as prostaglandin E_2 (PGE_2) and cytokines [e.g., tumor necrosis factor (TNF)-α, interleukin (IL)-1β].

When a photosensitizer absorbs a UV photon of the appropriate wavelength, changes in electron energy may create a "triplet excited state." The photosensitizer can then react with ground state oxygen (O_2). The energy transfer returns the photosensitizer to its ground state while generating highly reactive singlet oxygen ($^1O_2$). Singlet oxygen is unique among the ROS because it is an excited state molecule. It has a short lifetime in cells (< 4 microseconds) because it reacts with many cellular molecules.[16] The skin photosensitization produced by PDT drugs and by protoporphyrin IX, the porphyrin that accumulates to abnormally high levels in red blood cells of patients with erythropoietic protoporphyria (EPP), involves initial formation of singlet oxygen. Oxidation of membrane lipids is believed to initiate the signal transduction processes, leading the wheal and flare response observed in EPP photosensitivity. Singlet oxygen is also involved in the phototoxicity mechanisms for some phototoxic drugs. However, the observed skin phototoxicity responses often differ from that seen in EPP photosensitivity, possibly because of the presence of the photosensitizing agents in different tissue locations (e.g., epidermis, dermis, or vasculature). The photosensitizers may also be in different locations in the cells (i.e., nucleus, mitochondria, or cell membranes), which would influence the photoproducts formed and the subsequent cutaneous effect observed. Endogenous UVA-absorbing chromophores are believed to generate singlet oxygen in keratinocytes and fibroblasts.[17,18]

Other ROS are also produced in skin cells after photon absorption by photosensitizers and endogenous chromophores.[19] For example, hydrogen peroxide and superoxide anion are produced after photosensitized and direct photon damage to mitochondria. They are also produced by redox active enzymes in keratinocytes and fibroblasts that are stimulated in cells exposed to UVB or UVA radiation.[20,21] UVA-induced responses in normal skin and in photosensitivity conditions are generally dependent on production of ROS. Recent studies suggest that some UVB-initiated responses also involve ROS.[22] Antioxidants act by quenching (i.e., chemically reacting with and removing) ROS and other free radicals before they can damage cellular molecules.

Action Spectra

The action spectrum for a photobiologic response indicates which wavelengths produce the response most effectively. Knowing the action spectrum of a patient's photosensitivity is helpful in determining the treatment plan, as phototherapy is most efficient when the emission of the lamp matches the action spectrum for the beneficial response. In an ideal case, the action spectrum corresponds to the absorption spectrum for the chromophore. Determination of an action spectrum is, therefore, a powerful tool for identification of the putative chromophore for a given photobiologic reaction. An action spectrum is most accurately plotted as the reciprocal of the number of incident photons required to produce a given effect (Y-axis) against wavelength (X-axis). Conventionally in dermatology, the reciprocal of the minimum fluence (exposure dose) is plotted versus wavelength. Such an action spectrum for wheal formation in a patient with EPP showed a maximum at 400 nm, close to the maximum of protoporphyrin IX, which supports biochemical evidence for this porphyrin as the chromophore for the photosensitivity.[23]

Lack of correspondence between an experimentally determined action spectrum and the absorption spectrum of the actual chromophore may occur due to tissue optics. Light that impinges on a tissue is usually absorbed by other chromophores in the tissue; it is also reflected and scattered (see Fig. 88-4). These effects decrease the amount of light transmitted to a specific depth in tissue and vary with wavelength. One familiar example is that of psoralen, which has absorption maxima around 295 and 330 nm, with slight absorption extending into the longer UVA waveband in vitro. However, determinations of the psoralen photosensitization action spectrum in vivo show that maximum responses occur with wavelengths greater than 320 nm, possibly due to skin optical properties.[24,25] Whenever possible, decisions about which wavelengths to use for a treatment should be based on action spectra rather than on the in vitro absorption spectrum of the photochemotherapeutic drug.

PHOTOIMMUNOLOGY

Skin cancer is caused largely by direct damage to DNA, leading to specific gene mutations. However, for the development of clinically apparent skin cancer, a second UVB-induced mechanism is required, namely, UVB-induced immunosuppression.[26,27] The connection between sun exposure and skin cancer was realized first in the beginning of the last century when physicians observed skin tumors that grew preferentially at sites that had been extensively sun exposed. This was followed in the 1970s by a seminal study by Kripke,[28] who discovered a connection between immunosuppression and photocarcinogenesis. In a series of experiments, she demonstrated that UV-induced tumors, which had been transplanted onto syngeneic recipient mice, were rejected if the recipient mice had not been exposed to UVB. This result implies that UV-induced tumors have a highly antigenic phenotype[28] and can be rejected by a functioning immune system. Treatment with known immunosuppressive drugs, or—this was the novel finding—with low doses of UVB, led to failure of tumor rejection.[29,30] Both aspects (i.e., the strong antigenicity of UV-induced tumors and the immunosuppression by UVB) have triggered vigorous research

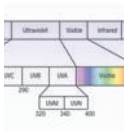

activities in the field now termed *photoimmunology*. Numerous studies tried to clarify the cellular and molecular mechanisms.[31] These have turned out to be highly complex (see Fig. 88-9). Results sometimes appear contradictory, likely due to use of various experimental approaches and model systems.

Model Systems for Ultraviolet B–Induced Immunosuppression

The standard model for studying UVB-induced immunosuppression is the delayed-type hypersensitivity (DTH) to antigens and the contact hypersensitivity reaction (CHS). The ability of UVB irradiation to block either induction or elicitation of allergic sensitization can then be quantified; typically a hapten such as dinitrofluorobenzene or oxazolone is applied to the skin as the stimulus and intensity of the subsequent immune response is measured as tissue swelling. DTH responses have become the model of choice to study the immunosuppressive effects of UVB radiation, as the tumor-associated antigens of UVB-induced tumors are only poorly characterized and testing DTH responses is less time-consuming and less laborious than examining photocarcinogenesis. UVB radiation has also been shown to affect immune responses involved in the pathogenesis of viral, parasitic, fungal, and bacterial infections. UVB-mediated immunosuppression is of two types: (1) local immunosuppression in which the immune response to antigens applied at the irradiated site is abrogated, and (2) systemic immunosuppression in which the immune response to antigens applied to unexposed sites is impaired (Fig. 88-8).[32] Of note, however, some mice are more susceptible to UVB-induced immunosuppression than others, with the genetic loci for lipopolysacharide, *Lps*, and tumor necrosis factor, *Tnf*, strongly influencing the response.[33]

Molecular Targets in Photoimmunosuppression

DNA is a chromophore for UVB radiation and can be a direct target (see Fig. 88-6). UVB radiation generates a variety of photoproducts, most commonly CPDs and (6-4) photoproducts. Pyrimidine dimer formation is a direct cause of UV-induced immunosuppression (Fig. 88-9). The cells of the opossum *Monodelphis domestica* contain endogenous photoreactivating enzymes, which are capable of repairing CPDs, and UVB does not induce immunosuppression in these animals on exposure to photoreactivating light immediately after irradiation.[34] Also in mice, a correlation between CPDs and UVB-induced systemic immunosuppression exists.[35] UVB irradiation leads to CPDs in antigen-presenting cells (APCs) and impairment of their antigen-presenting capacity. The damage persists for several days, and the damaged cells migrate from the skin to lymph nodes. Treatment at the site of UVB irradiation with liposomes containing the DNA repair enzyme T4 endonuclease V prevents the impairment in antigen presentation.[36] The role of DNA damage in UVB-induced immunosuppression was also confirmed in human skin, in which topical application of photolyase-containing liposomes to UVB-exposed sites prevents UVB-induced immunosuppression.[37]

In addition to direct DNA damage, the generation of ROS is likely to be involved in photoimmunosuppression (see Fig. 88-9). Accordingly, topical application of a polyphenolic fraction isolated from green tea before and after UVB irradiation to mouse skin protects against UV-induced immunosuppression,[38] an effect most likely mediated by the antioxidant epigallocatechin-3-gallate, the component of extract that has the ability to reduce oxidative stress, inflammatory responses, and skin cancer. It should be noted that such secondary plant metabolites affect cell signaling, however, so that protection against UVB-induced events may not exclusively be explained by antioxidant effects.

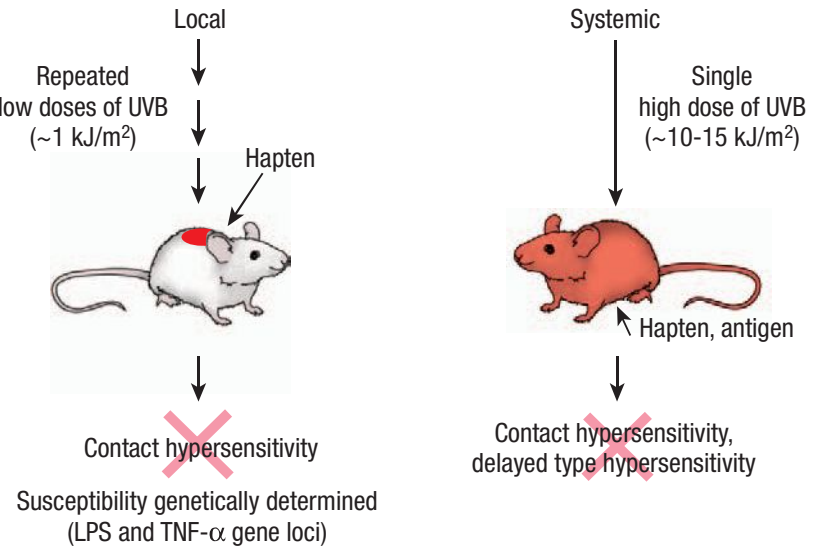

▲ **FIGURE 88-8** Ultraviolet B (UVB) radiation–induced immunosuppression: Local versus systemic. TNF = tumor necrosis factor.

The cell membrane of immunocompetent skin cells is another target for UV radiation. An important function of the cell membrane is to transfer signals from outside into the cell via membrane receptors. UVB exposure leads to clustering and internalization of cell surface receptors for epidermal growth factor, TNF, and IL-1 in the absence of the respective ligands. Clustering results in strong activation of stress-induced c-Jun NH2-terminal kinases, which are members of the mitogen-activated protein kinase family[39] (see Fig. 88-9). Conceivably, such aberrant receptor clustering may subvert signaling pathways normally used by growth factors and cytokines, eventually contributing to the immunological response.

UVB radiation can lead to lipid peroxidation, including cell membrane lipids. Phosphatidylcholine, an important membrane lipid, can be oxidized to platelet-activating factor (PAF)–like lipids that bind to PAF receptors and activate cytokine synthesis. A role of UVB-induced PAF formation in photoimmunosuppression is suggested by the observation that comparable immunosuppression can be induced in mice when they are irradiated with UVB, injected with carbamyl-PAF, or injected with phosphatidylcholine that had been exposed to UVB under atmospheric oxygen. The immunosuppressive properties of all three treatments were equally blocked by specific PAF receptor antagonists, indicating that UVB-induced PAF-like lipids can trigger the PAF receptor in a way similar to PAF. In turn, PAF receptor activation stimulates a variety of downstream effects, including the activa-

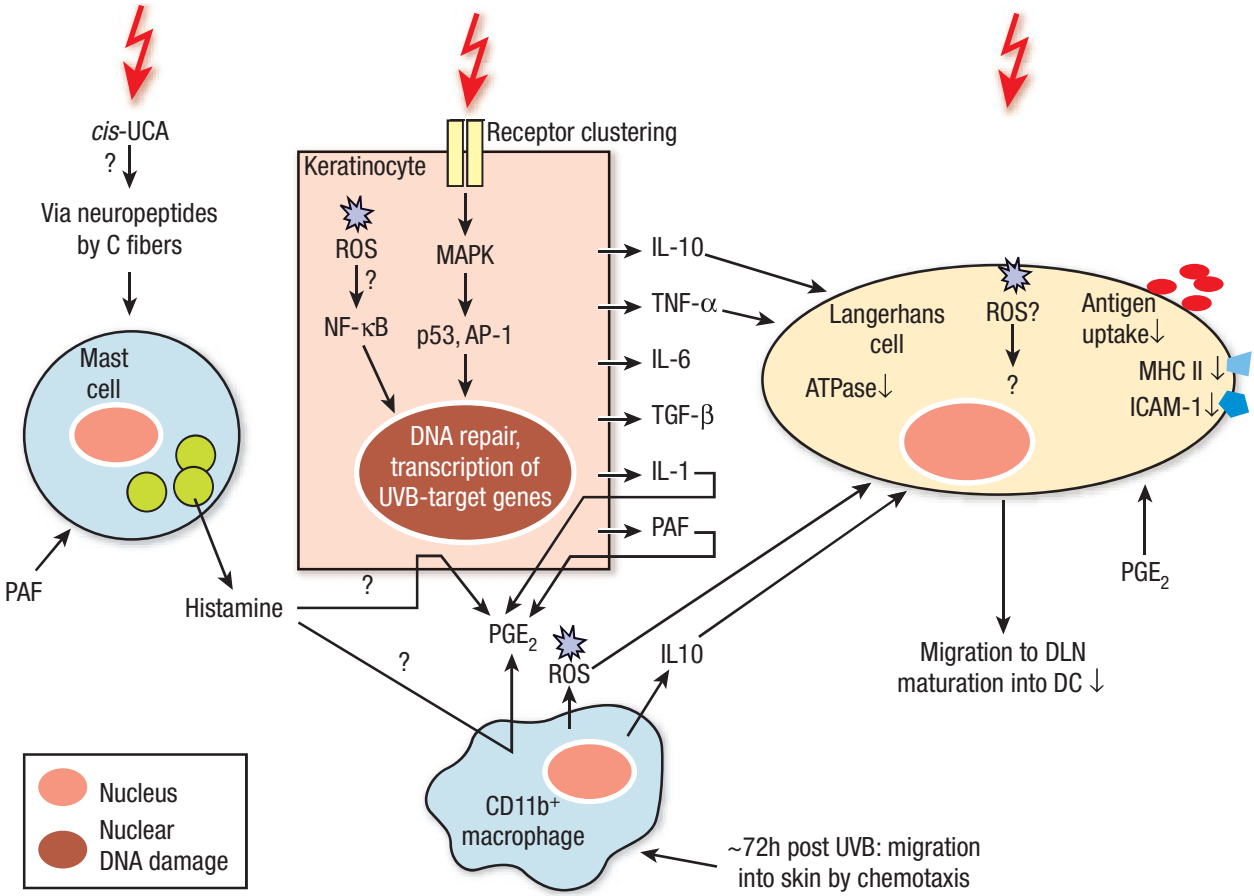

▲ **FIGURE 88-9** Ultraviolet B (UVB) radiation–induced immunosuppression: Illustration of the presumed molecular and cellular events at the irradiated skin site. ATPase = adenosine triphosphatase; DC = dendritic cell; DLN = draining lymph node; IL = interleukin; ICAM = intercellular adhesion molecule; MAPK = mitogen-activated protein kinase; MHC = major histocompatibility complex; NF-κB = nuclear factor κB; PAF = platelet-activating factor; PGE_2 = prostaglandin E_2; ROS = reactive oxygen species; TGF = transforming growth factor; TNF = tumor necrosis factor; UCA = urocanic acid.

tion of mitogen-activated protein kinase pathway and synthesis of immunosuppressive cytokines (see Fig. 88-9).[40]

An extracellular chromophore that mediates UVB-induced immunosuppression is UCA (see Fig. 88-6).[41] UV radiation isomerizes *trans*-UCA to *cis*-UCA dose-dependently until a balanced photostationary state is reached. A number of independent studies confirmed the importance for *cis*-UCA in UVB-induced immunosuppression, although the exact mechanism of action is not clear at present.

Cellular Events Involved in Photoimmunosuppression

UVB radiation of keratinocytes alters their expression of surface molecules and induces the synthesis and secretion of a whole set of immunomodulatory soluble factors, including IL-1, IL-6, IL-8, TNF-α, and PGE_2 (see Fig. 88-9).[42] Evidence for keratinocyte-derived soluble factors with immunosuppressive function came from experiments showing that either serum factors from UVB-exposed mice or supernatants from UVB-irradiated murine epidermal cells suppressed hypersensitivity reactions in mice. Subsequently, it was found that TNF-α and IL-10, two potent immunosuppressive cytokines, are produced by UVB-irradiated keratinocytes as well.[42,43] IL-10 is also released by $CD11b^+$ macrophages in human skin.[44] Injection of TNF-α mimics UVB-induced alterations on Langerhans cells (LCs). The administration of a neutralizing antibody to TNF-α before irradiation abrogates partially UVB-induced accumulation of dendritic cells (DCs) in draining lymph nodes (DLNs) and suppression of contact hypersensitivity. The release of TNF-α is of special importance for local immunosuppression, and, as mentioned above, the *Tnfa* gene locus contributes to UVB susceptibility.

IL-10 is a T-helper cell type 2 (Th2) cytokine and abrogates the production of Th1 cytokines, in particular interferon-γ (IFN-γ). UVB-induced IL-10 production by keratinocytes in murine or macrophages in human skin[47] shifts the immune response from a Th1 to a Th2 type. This can explain why Th1-mediated cellular immune reactions are impaired by UV radiation.

The interactions between the different cytokines are not fully understood, but IL-10 certainly is a major player. For instance, anti–IL-10 antibodies neutralize the suppressive effects of supernatants from UVB-irradiated keratinocytes on DTH in mice.[45] The main mechanism of IL-10 is probably inhibiting the antigen-presenting capacity of LCs. In parallel, UV-exposed keratinocytes release PAF and PAF-like lipids which trigger the PAF receptor, as described in Molecular Targets in Photoimmunosuppression.[40] Presumably, PAF and its receptor enhance the production of cyclooxygenase-2, PGE_2, IL-4, and IL-10. IL-10 production can be reversed by IL-12. Incidentally, IL-12 can restore UV-impaired CHS.[46] Injection of mice with IL-12 after UVB exposure prevented UVB-induced immunosuppression and suppressed partially UVB-induced tolerance obtained by resensitization 14 days after the UV irradiation. This IL-12 effect is most likely

linked to the capacity of this cytokine to enhance the repair of UVB radiation–induced DNA photoproducts, which form the molecular basis for IL-10 production by irradiated keratinocytes.

Cellular Mediators of Photoimmunosuppression: Langerhans Cells, Macrophages, and T Cells

LCs, 2 percent to 5 percent of epidermal cells, are a DC subset that originates from bone marrow precursors and populates the epidermis. They are the professional skin-specific antigen-presenting cells and ingest antigen locally in the skin, but lack co-stimulatory capacity. After antigen uptake, LCs migrate to the DLN, where they mature to potent stimulators for antigen-specific T cells, expressing high levels of major histocompatibility complex molecules and co-stimulatory molecules B7.1 and B7.2 and intercellular adhesion molecule-1 on their cell surface (see Chap. 10).

In the 1980s, it was demonstrated that epidermal LCs play a pivotal role in the induction and regulation of CHS reactions. LC density is an important factor for the induction of CHS responses, and UV radiation leads to the disappearance of LC from irradiated sites.[48] In these studies, mice were sensitized with the hapten dinitrofluorobenzene either on skin with typical amounts of LC or on LC-deficient skin. A significantly impaired CHS response was observed when the mice were sensitized on LC-deficient skin. The capacity to deplete LCs temporarily from the skin appears to be an important feature of UVB irradiation. Moreover, UV exposure results in reduced surface expression of co-stimulatory molecules Ia, B7.1, B7.2, and intercellular adhesion molecule-1 (see Fig. 88-9).[49,50] The depletion of these molecules might account for or contribute to immunosuppression. The loss of LCs in the skin is accompanied by an increase in DCs in the DLN.[51] Fluorescein isothiocyanate+ Ia+ CPD+ cells in the DLNs were found after painting the skin with fluorescein isothiocyanate and irradiating subsequently with UV. This demonstrates that LCs indeed leave the skin after UV exposure. UVB possibly induces LC migration in the absence of exogenous antigen, although the migratory effect is enhanced by sensitization with antigen. The ultimate fate of chronically irradiated LCs remains to be examined. UVB-induced LC migration was also observed in human skin in vivo.[52]

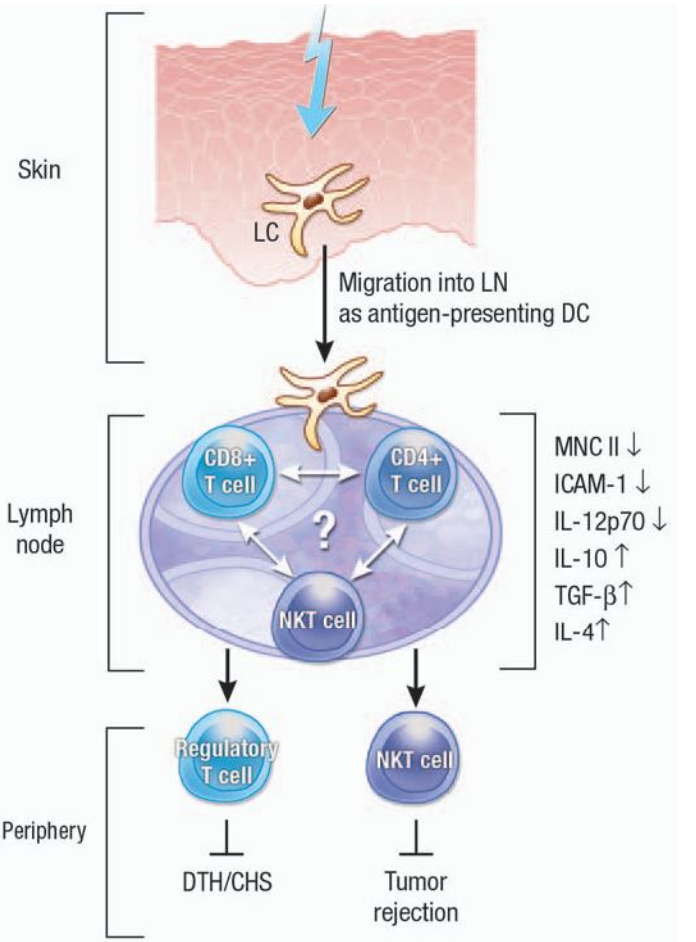

▲ **FIGURE 88-10** Ultraviolet B radiation–induced immunosuppression: Illustration of the presumed cellular interplay in skin-draining lymph nodes (LNs). CHS = contact hypersensitivity reaction; DC = dendritic cell; DTH = delayed-type hypersensitivity; ICAM = intercellular adhesion molecule; IL = interleukin; LC = Langerhans cell; MHC = major histocompatibility complex; NKT = natural killer type; TGF = transforming growth factor.

In addition to reducing the number of LCs in the skin, UVB radiation affects LC function by impairing the antigen-presenting capacity in DTH and CHS. UVB-irradiated LCs activate preferentially CD4+ Th2 cells.[53] In contrast, they do not activate CD4+ T cells of the Th1 subset, but induce clonal anergy.[54] Another cellular player in UV-induced immunosuppression is CD11b+ macrophages, which infiltrate UVB-irradiated human skin (see Fig. 88-9). These cells produce IL-10, and their deletion by antibodies makes UV-irradiated mice permissive again for CHS.[55]

In addition to immunologic unresponsiveness to haptens applied after irradiation, UVB exposure–induced hapten-specific tolerance (i.e., resensitization with the same hapten at later time points) likewise fails.[56] In adoptive transfer experiments, it was shown that UVB induces T-suppressor cells.[57] Elmets at al.[57] prepared single cell suspension of the spleen and lymph nodes from UVB-exposed and hapten-treated mice, injecting the cell suspension into naive mice. When the recipient mice were sensitized and challenged with the same hapten that was used for the donor mice, they showed significantly impaired CHS responses.

The phenotype of the regulatory T cells and their mechanism of action are not well understood (Fig. 88-10). Results obtained so far are difficult to compare. Different experimental set-ups yielded partly contradictory results. There is evidence to suggest that CD8+ T cells are important mediators of UVB-induced immunosuppression in the local immunosuppression.[58] In addition, T cells (not defined by CD4 or CD8) that express cytotoxic T lymphocyte antigen (CTLA)-4 on their surface transfer UV-induced tolerance.[59] CTLA-4 appeared to be of functional relevance, because in vivo injection of anti–CTLA-4 antibodies blocked transfer of suppression. The physiologic function of

CTLA-4 is to end immune responses by shutting down activated T cells, so CTLA-4 is an important molecule in immune regulation. On stimulation with antigen-bearing DCs, CTLA-4$^+$ T cells secrete high levels of IL-10, transforming growth factor-β, and IFN-γ, but low levels of IL-2 and no IL-4. Other studies showed that CD4$^+$ T cells from UV-exposed mice are capable to suppress CHS when injected into untreated recipient mice.[60] These CD4$^+$ T cells produce IL-10, but no IL-4 and IFN-γ on APC co-culture and inhibit IL-12 production by APCs.

Apart from CD4$^+$ regulatory T cells, natural killer T cells with regulatory capacities were found in UVB-induced systemic immunosuppression (see Fig. 88-10). In particular, CD3$^+$, CD4$^+$, and DX5$^+$ CD1-restricted natural killer T cells have been described, which secrete IL-4 and can adoptively transfer suppression of tumor rejection as well as DTH responses.[61]

Photoimmunology: Concluding Remarks

UV radiation is a permanent environmental threat, and adaptive responses against its damaging effects have been developed in all living organisms. From a theoretic point of view, it is therefore tempting to speculate that photoimmunosuppression serves a physiologic role as an adaptive response of the skin to UV-induced modifications of proteins and an immunologic response to so-called *neo-antigens* and, as a consequence, chronic inflammation. Under these conditions, the higher risk of skin cancer that appears to accompany UV-induced immunosuppression appears of less significance in evolutionary terms, as skin cancers occur principally in late life, after the reproductive period. From a practical point of view, however, photocarcinogenesis poses a serious health problem. Accordingly, modern approaches to prevent UV-induced immunopsuppression include broad-spectrum UV filters, liposomally encapsulated DNA repair enzymes, antioxidants, and osmolytes.[62]

KEY REFERENCES

The full reference list for all chapters is available at www.digm7.com.

8. de Gruijl FR et al: Health effects from stratospheric ozone depletion and interactions with climate change. *Photochem Photobiol Sci* **2**:16, 2003
12. Anderson RR, Parrish JA: The optics of human skin. *J Invest Dermatol* **77**:13, 1981
14. Daya-Grosjean L, Sarasin A: The role of UV induced lesions in skin carcinogenesis: An overview of oncogene and tumor suppressor gene modifications in xeroderma pigmentosum skin tumors. *Mutat Res* **571**:43, 2005
15. Holick MF, Smith E, Pincus S: Skin as the site of vitamin D synthesis and target tissue for 1,25-dihydroxyvitamin D_3. Use of calcitriol (1,25-dihydroxyvitamin D3) for treatment of psoriasis. *Arch Dermatol* **123**:1677, 1987
19. Pinnell SR: Cutaneous photodamage, oxidative stress, and topical antioxidant protection. *J Am Acad Dermatol* **48**:1, 2003
22. Sander CS et al: Role of oxidative stress and the antioxidant network in cutaneous carcinogenesis. *Int J Dermatol* **43**:326, 2004
26. Grabbe S, Granstein RD: Photoimmunology of UV-induced skin cancer, in *Photoimmunology*, edited by Krutmann J, Elmets CA. Boston, Blackwell Science, 1995, p 99
27. Donawho C, Kripke ML: Photoimmunology of cuteanous melanoma, in *Photoimmunology*, edited by Krutmann J, Elmets CA. Boston, Blackwell Science, 1995, p 119
43. Ullrich SE, Schmitt DA: The role of cytokines in UV-induced systemic immune suppression. *J Dermatol Sci* **23**:S10, 2000
56. Schwarz T: Ultraviolet radiation-induced tolerance. *Allergy* **54**:1252, 1999

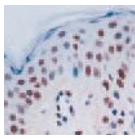

CHAPTER 89

Acute and Chronic Effects of Ultraviolet Radiation on the Skin

Antony R. Young
Susan L. Walker

THE SKIN AND ULTRAVIOLET RADIATION: AN OVERVIEW

Sunburn and tanning are the most obvious acute clinical effects of ultraviolet radiation (UVR). Photoaging and skin cancer are the consequences of chronic exposure. It has been useful to describe sun-sensitivity according to skin phototype, as shown in Table 89-1. It is widely assumed that sensitivity to UVR is primarily related to pigmentation or tanning ability. However, the relationship between skin phototype and sensitivity to sunburn still holds on vitiliginous patches,[1] indicating that other factors are important, such as differences in DNA repair capacity.

ULTRAVIOLET RADIATION

UVR represents approximately 5 percent of terrestrial solar radiation and is officially divided into UVA (315 to 400 nm), UVB (280 to 315 nm), and UVC (100 to 280 nm), though other definitions are widely used (e.g., a UVB/UVA division at 320 nm). UVA is sometimes subdivided into UVAI (340 to 400 nm) and UVAII (315/320 to 340 nm). Sea-level solar UVR is approximately 95 percent to 98 percent UVA and 2 percent to 5 percent UVB. UVC is completely absorbed by stratospheric ozone (O_3) that also attenuates UVB. A given solar UVR spectrum varies with the solar zenith angle (the angle between an imaginary perpendicular line and a line from its base to the sun), which is dependent on time of day, season, and latitude. The highest UVB content is found when the sun is directly overhead with the shortest path (e.g., noon at the equator at high altitude).

Measurement of Human Exposure to Ultraviolet Radiation

The measurement of UVR exposure is called *dosimetry* and can be done physically or biologically. Accurate physical dosimetry, in which dose rate (irradiance) is measured as W/cm^2 and exposure dose as J/cm^2 [W/cm^2 × time (seconds)], is technically demanding, and a biologic approach is more commonly used. This is based on the individual minimal erythemal dose (MED), which is the lowest dose required to produce a just perceptible erythema (sunburn) 24 hours later. In general, individuals with higher skin types have higher MEDs.[2] However, as shown in Fig. 89-1, there is considerable MED overlap between skin phototypes.

Most human UVR exposure is from sunlight, but the use of tanning devices is increasingly popular. Solar UVR exposure may be intentional or inadvertent

ACUTE AND CHRONIC EFFECTS OF ULTRAVIOLET RADIATION ON THE SKIN

AT A GLANCE

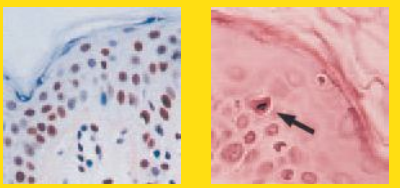

- Acute and chronic responses to ultraviolet radiation (UVR) depend on skin phototype.
- The major acute clinical effects are inflammation, tanning, and immunomodulation.
- Basal cell carcinoma, squamous cell carcinoma, malignant melanoma, and photoaging are the chronic effects of UVR.
- The majority of effects of solar UVR on the skin are the result of its small UVB content.

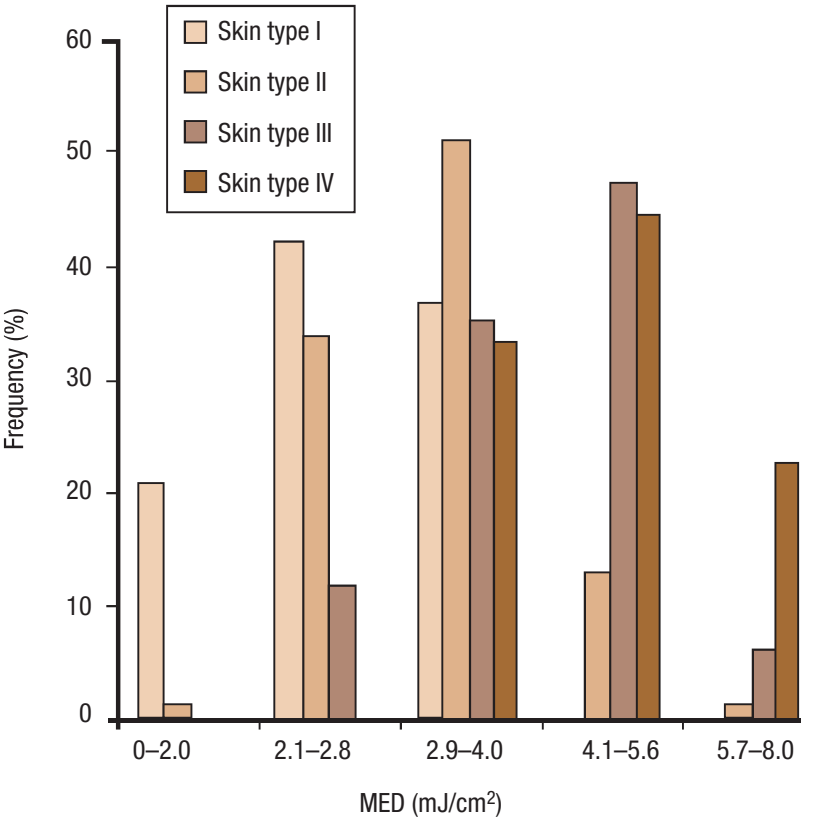

▲ **FIGURE 89-1** There is considerable overlap for solar simulating radiation [just perceptible minimal erythemal dose (MED) on previously unexposed buttock skin] in different white skin types. MED for skin types I, II, III, and IV are 2.9 [standard deviation (SD) ± 0.7], 3.5 (SD ± 1.0), 4.5 (SD ± 1.2), and 5.3 (SD ± 1.2) J/cm^2, respectively. (From Harrison GI, Young AR: Ultraviolet radiation-induced erythema in human skin. *Methods* **28**:14, 2002.)

and depends on specific behaviors and time spent outdoors, as well photoprotection strategies.

Action Spectroscopy

In any skin response to UVR, it is important to know which wavelengths are primarily responsible. This relationship is known as the *action spectrum* and is fundamentally based on the UVR absorbing properties of the molecule (chromophore) that initiates the effect (see Chap. 88). Major skin chromophores include DNA, urocanic acid (UCA), and aromatic amino acids (proteins) that absorb primarily in the UVC/UVB region; UVA chromophores are less well identified.[3]

Action spectroscopy enables another metric of UVR exposure known as the *standard erythema dose* (SED).[4] This is not based on individual UVR sensitivity and is equivalent to 100 J/m^2 after weighting the absolute emission spectrum of the UVR source with the standard erythema action spectrum as shown in Fig. 89-2. The SED is a useful approach in population exposure studies. For example, indoor workers in northern Europe have an annual exposure of approximately 200 SED (approximately 5 percent of ambient UVR exposure), mainly from weekend and vacation activities, whereas outdoor workers at comparable latitudes typically receive two to three times more.[5] The relationship between MED and SED for phototypes I through VI is shown in Table 89-1.

TABLE 89-1
A Classification of Skin Phototypes Based on Susceptibility to Sunburn in Sunlight, Tanning Ability, and Skin Cancer Risk

Skin Phototype	Sunburn Susceptibility	Tanning Ability	Skin Cancer Risk	No. Standard Erythema Dose[a] Required for Minimal Erythema
I	High	None	High	1–3
II	High	Poor	High	
III	Moderate	Good	Low	3–7
IV	Low	Very good	Low	
V	Very low	Excellent	Very low	7–> 12
VI	Very low	Excellent	Very low	

[a]A standard erythema dose is equivalent to an erythemally effective radiant exposure of 100 J/m^2.[62] Approximately three standard erythema doses are required to produce just perceptible or minimal erythema in unacclimatized skin of the most common Caucasian American and northern European skin types.[2]

ACUTE EFFECTS OF ULTRAVIOLET RADIATION

DNA Photodamage and Mutation (See Chaps. 109 and 112)

UVR absorption by epidermal DNA results in the formation of dipyrimidine lesions such as cyclobutane pyrimidine dimers (CPDs) and pyrimidine (6-4) py-

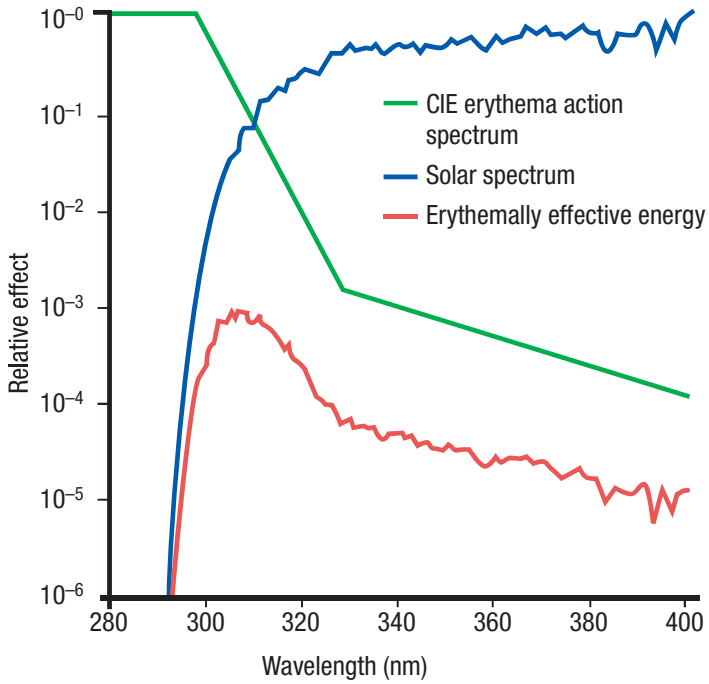

▲ **FIGURE 89-2** Standardized Commission Internationale de l'Eclairage (CIE) erythema action spectrum,[62] noontime summer spectral irradiance in London, UK (51°N 29′), and resultant erythemal effectiveness spectrum, which is the product of these two spectra. These data show that the 4.9 percent of the ultraviolet B (< 320 nm) in the solar spectrum contributes 80 percent of the erythemal effectiveness of the solar ultraviolet radiation spectrum.

rimidone photoproducts.[6] Fig. 89-3 shows an action spectrum for CPD in four different epidermal zones in skin phototypes I/II. Solar UVB causes much more damage in the basal layer than UVA per photon or unit physical dose (J/cm^2) but comparable damage is observed at comparable biologic (MED) doses. There is emerging evidence that CPDs, but not (6-4) photoproducts, can be formed by energy transfer reactions originating from UVA chromophores.[7] In vitro and in vivo studies in human skin have demonstrated UVA-induced oxidative DNA lesions such as 8-oxo-7,8-dihydro-2′-deoxyguanosine[8] and 8-hydoxy-2′-deoxyguanine.[9] The chromophores that generate the responsible reactive oxygen species after absorbing UVA are not known.

DNA REPAIR Unless repaired by nuclear excision repair (NER) dipyrimidine lesions give rise to highly characteristic so-called *UVB signature mutations*, namely C → T or CC → TT transitions.[10] NER acts in two distinct ways: (1) global genome repair (GGR) operates across the entire genome and (2) transcription coupled repair (TCR) preferentially excises lesions from actively transcribed genes. Genetic disorders provide evidence that GGR and TCR have very different biologic roles. For example, lack of GGR in xeroderma pigmentosum results in high levels of skin cancer, whereas lack of TCR in Cockayne syndrome causes acute sun sensitivity apparently without an increased skin cancer risk. Studies in transgenic mice with different GGR-TCR gene permutations confirm that these repair pathways affect different photobiological outcomes.[11]

Human studies have shown that, after a single exposure to solar simulating radiation (SSR), GGR of the (6-4) photoproduct in situ is rapid, whereas GGR of the CPD is much slower, with many lesions persisting for at least 24 hours.[6] Such slow repair means that lesions accumulate if skin is again exposed to UVR the following day, as is often the case in normal life, and this has been demonstrated with repeated sub-erythemal SSR exposure in human skin in vivo.[12] There is also limited evidence that global DNA repair in the epidermis may be inducible by repeated SSR exposure in skin types that tan well (IV) but not in skin types that tan poorly (II).[13]

SUNBURN INFLAMMATION Sunburn (erythema) shows the classic signs of inflammation (e.g., redness, warmth, pain, and swelling). Its intensity is determined by UVR exposure dose (J/cm^2) irrespective of the time over which it is delivered, at least over several hours, a relationship known as *reciprocity*. Studies with two MED SSR in skin phototypes I/II show the onset of erythema at approximately 6 hours that is maximal at 18 hours to 24 hours with persistence for at least 1 week.[6] Repeated daily sub-erythemal SSR exposures have a cumulative erythemal effect, especially in skin types I/II.

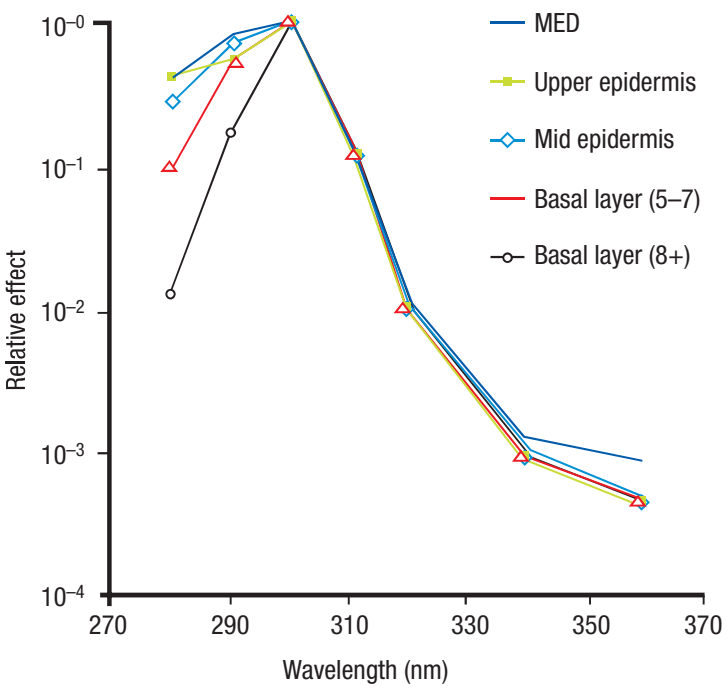

▲ **FIGURE 89-3** Comparison of action spectra for erythema and epidermal DNA photodamage (thymine dimers) in the same group of 40 skin-type I/II volunteers using same emission spectra. MED = minimal erythemal dose. (From Young AR et al: The similarity of action spectra for thymine dimers in human epidermis and erythema suggests that DNA is the chromophore for erythema. *J Invest Dermatol* **111**:982, 1998.)

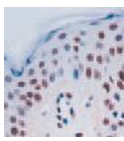

The action spectra for erythema and CPD are similar. Fig. 89-3 shows an action spectrum for erythema in skin types I/II and action spectra for CPD with the same UVR spectra in the same volunteers. The similarity of these spectra provides strong evidence that DNA is a major chromophore for erythema.[14] However, there is also evidence for a UVA-absorbing chromophore that works via an oxygen-dependent mechanism.[15,16]

PHARMACOLOGIC MEDIATORS AND NEUROPEPTIDES Mast cell preformed products, such as histamine, serotonin, and tumor necrosis factor (TNF)-α, can be detected within an hour of UVR exposure and may play a role in the initial development of erythema. In general, mediators are not stored as preformed molecules but are synthesized after the activation of their respective transcription factors in the relevant cell types. An inflammatory infiltrate, consisting largely of neutrophils and T lymphocytes, is evident in the upper dermis 3 hours after UVB exposure and increases rapidly until 48 hours. At 48 hours to 72 hours, neutrophils and macrophages are also observed in the epidermis. These infiltrating cells, as well as resident keratinocytes, contribute to the inflammatory process through the release of many putative mediators including by-products of arachidonic acid metabolism, pro-inflammatory and immunosuppressive cytokines, chemokines, adhesion molecules, angiogenesis, and growth factors.[17] The pharmacology of sunburn is incompletely understood, but there is human in vivo evidence for an important role for prostaglandins, especially prostaglandin E_2, and nitric oxide.[18] The resolution of erythema is likely to be dependent on the synthesis of T helper 2 (Th2)–type anti-inflammatory cytokines such as interleukin (IL)-10, IL-4, and transforming growth factor-β1. Macrophages, which peak in skin 72 hours after exposure, play an important role in this process.[19]

Afferent sensory nerves innervating the epidermis and dermis release a variety of neuropeptides after UVR exposure.[20] These products, such as substance P and calcitonin gene–related peptide (CGRP), may act as mediators for pain and itch as well as for inflammation and immunomodulation. In addition, a range of skin cells, including melanocytes, keratinocytes, and endothelial cells, upregulate the production of neurotrophins and hormones such as proopiomelanocortin peptides and their receptors. These mediators can then stimulate vasodilation, mast cell degranulation, and enhancement of UVR-induced cytokine production, chemokine production, and cellular adhesion molecule expression that recruit inflammatory cells into the skin. There is also evidence that the mediators, such as α melanocyte-stimulating hormone (α-MSH) and CGRP, play an important role in the resolution of UVR inflammation.

Photoimmunomodulation (See Chap. 88)

Solar UVR has immunoregulatory effects in which Th1 cytokine responses are suppressed.[21] Thus, the sensitization and elicitation arms of cutaneous cell-mediated immunity in humans, usually assessed by the contact hypersensitivity (CHS) response, are inhibited.[22] The UVR-induced depletion of epidermal Langerhans cells, the principal antigen-presenting cells, recruitment of dermal and epidermal macrophages that also act as antigen-presenting cells, and release of inflammatory mediators such as platelet-activating factor, TNF-α, IL-4, IL-10, transforming growth factor-β, α-MSH, and CGRP are important in immunomodulation. This alters the normal antigen-presentation process, leading to the generation of highly specific regulatory T cells that specifically inhibit cell-mediated immunity to newly encountered antigens.

PHOTOIMMUNOSUPPRESSION, SKIN CANCER, AND INFECTION (See Chap. 88) UVR-induced immunosuppression has a major role in mouse photocarcinogenesis, facilitating growth and emergence of tumors. Photoimmunosuppression is thought to play a role in human skin cancer as well, and the fact that organ transplant patients maintained on immunosuppressive therapy have a greatly elevated risk of all types of skin cancer is cited in support of this idea. Exposure to UVR also increases the incidence and severity of infectious diseases in animal models and suppresses the elicitation of immunity to some infectious agents in humans. To date, the best evidence for this is increased susceptibility to recurrent herpes simplex virus lesions in acutely sun-exposed skin.

Susceptibility to SSR-induced immunosuppression of the sensitization phase of CHS is skin-type dependent, which may depend on the amount of cytokine released. Individuals of skin phototypes I/II are more readily immunosuppressed than skin phototypes III/IV.[23] Fig. 89-4 shows that single sub-

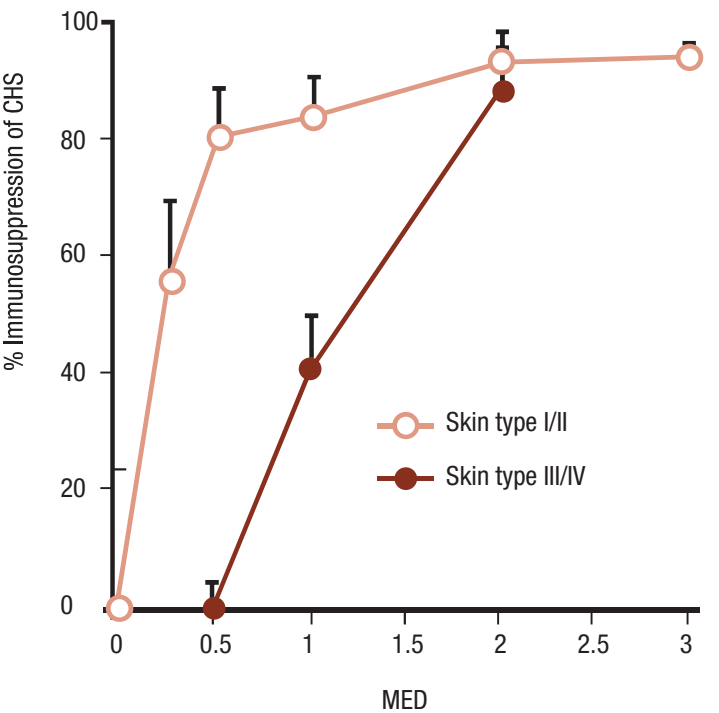

▲ **FIGURE 89-4** Erythema is a poor indicator of suppression of the induction phase of the contact hypersensitivity (CHS) response. Volunteers with skin phototypes I/II are suppressed with sub-erythemal exposure to solar-simulated radiation, whereas erythemal exposures are necessary to suppress the CHS response in skin types III/IV. MED = minimal erythemal dose. (From Kelly DA et al: Sensitivity to sunburn is associated with susceptibility to ultraviolet radiation-induced suppression of cutaneous cell-mediated immunity. *J Exp Med* **191**:561, 2000.)

erythemal exposures of either 0.25 or 0.50 MED suppresses CHS responses by 50 percent and 80 percent, respectively, in normal skin phototypes I/II, whereas a full MED may only induce 40 percent suppression in skin phototypes III/IV. Such data suggest that skin phototype–dependent sensitivity to immunosuppression may be a risk factor for skin cancer. Repeated exposure of human skin to sub-erythemal SSR does not prevent photoimmunosuppression by subsequent UVR exposure.[24]

CHROMOPHORES FOR PHOTOIMMUNOMODULATION DNA is an important chromophore for photoimmunosuppression because the enhanced repair of CPD inhibits immunosuppression in animal models and the release of immunoregulatory cytokines such as TNF-α and IL-10 in vitro. IL-12 and IL-18 inhibit photoimmunosuppression by their ability to enhance NER,[25,26] and IL-12–deficient mice are more susceptible to show a higher photocarcinogenesis than wild-type mice.[27] *Trans*-UCA, a component of stratum corneum, is also an important chromophore because its photoisomerization to *cis*-UCA provokes a wide range of immunologic responses. IL-12 has also been shown to inhibit some of the immunologic effects of *cis*-UCA.[28] Such studies show a complex interaction between DNA damage, its repair, cytokines, and immunomodulation.

ADAPTIVE RESPONSES AFTER ULTRAVIOLET RADIATION EXPOSURE

Hyperplasia

Hyperplasia of the dermis, epidermis, and stratum corneum are seen after UVR exposure. This follows a period of initial growth and cellular arrest for 24 hours to 48 hours. For example, 2 weeks of daily sub-erythemal SSR results in a 20 percent to 40 percent increase in the number of cell layers in the stratum corneum in white skin phototypes.[29] A number of studies suggest that such UVR-induced hyperplasia, particularly of the stratum corneum, plays a major role in photoprotection particularly in the fair-skinned, whereas other studies suggest a much more limited effect.[30]

Tanning (See Chap. 70)

Melanin composition is a variable mixture of lighter alkali soluble, sulphur containing pheomelanin and darker insoluble eumelanin; skin types that tan well have more eumelanin. Exposure to UVA induces a rapid but transitory grayish color known as *immediate pigment darkening* (IPD) which probably results from the photo-oxidation of existing melanins and the redistribution of melanocytic melanosomes from a perinuclear position into the peripheral dendrites. IPD progresses into persistent pigment darkening (PPD), which may remain stable for up to 2 hours post exposure. The biologic functions of IPD and PPD are not known.

Delayed tanning, also known as *melanogenesis*, is primarily a UVB response that results from increased activity and numbers of melanocytes. This becomes visible 3 to 4 days after UVR exposure and is maximal from 10 days to 3 to 4 weeks depending on complexion and UVR dose. Melanocyte tyrosinase activity also increases, melanocyte dendrites elongate and branch, and melanosomes increase in number and size. UVA tanning has distinct effects that are wavelength dependent. Thus, UVAI produces an increased melanin density localized to the basal cell layer, whereas UVAII increases the synthesis and transfer of melanized melanosomes to the keratinocytes throughout the epidermis, similar to the changes seen with UVB.

MECHANISMS OF ULTRAVIOLET RADIATION–INDUCED MELANOGENESIS (See Chap. 70) Tyrosinase, a copper-binding transmembrane glycoprotein localized to the melanosome, is the rate-limiting enzyme for melanogenesis. Its activity correlates closely with the melanin content of cultured melanocytes and increases during melanogenesis. There is evidence that DNA photodamage, and its repair, are initiators of melanogenesis. The action spectrum for human melanogenesis in vivo is similar to that for erythema,[31] which identifies DNA as the putative chromophore. Furthermore, synthetic thymidine dinucleotides (pTpT), the obligate substrate for UV-induced thymine dimers, enhance melanogenesis in vitro and in animal skin in vivo,[32] in part via p53 induction that regulates tyrosinase gene expression.[33] UVR damage also upregulates cell surface receptors for a variety of keratinocyte-derived melanogenic factors, in particular the melanocortin 1 receptor for α-MSH. In addition, there may be an increase in the production and release of factors such as basic fibroblast growth factor, nerve growth factor, endothelin-1, and proopiomelanocortin-derived products such as α-MSH, adrenocorticotrophic hormone, β-lipotropic hormone, and β-endorphin, all of which regulate the molecular and cellular aspects of melanogenesis.[34] Recent data suggest that α-MSH may enhance repair of UVR-induced DNA damage.[35] Melanogenesis may be one feature of the mammalian equivalent of the bacterial SOS response that is induced by DNA damage and reduces the impact of future exposure to DNA-damaging agents.[32] A second feature appears to be enhanced DNA repair capcity,[32,33] which may explain the strong skin cancer predisposition of phototype I/II individuals who tan poorly.

PHOTOPROTECTION AND PHOTOSENSITIZATION FROM ULTRAVIOLET RADIATION–INDUCED TANNING Several in vivo and in vitro human studies suggest that the acute photoprotection afforded by constitutive (baseline) and facultative (induced) pigmentation against DNA photodamage in keratinocytes and melanocytes and against sunburn is equivalent to a sunscreen with a sun protection factor of 2 to 4 (see Chap. 223).[36] This would result in significant reduction of biologically effective dose and such a reduction, if maintained over long periods, would theoretically be significant in terms of long-term risk of skin cancer. However, the maintenance of a facultative tan would be associated with the accumulation of epidermal DNA photodamage, negating the benefits of the protection. Furthermore, there are conflicting epidemiologic data about the role of a tan in affording protection against the development of malignant melanoma (MM).[37,38]

Although dark skin color, representing eumelanin, is clearly photoprotective, several lines of evidence suggest that pheomelanin may contribute to photosensitization and DNA damage.[39] The clinical significance of pheomelanin-mediated photodamage to skin cancer risk in blond and red-headed humans, who presumably have this pigment in their skin as well as in their hair, is not known.

Antioxidant Defenses

Various enzymatic and nonenzymatic antioxidants protect against oxidative damage in UVR-exposed skin, and are dramatically depleted after UVR exposure. Enzymes that repair oxidative injury in the skin include superoxide dismutase, catalase, and thioredoxin reductase, whereas natural antioxidants, such as vitamins A, C, and E, as well as glutathione, also act directly to prevent

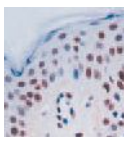

oxygen radical damage. Exogenous antioxidants have also been shown to inhibit the sunburn response, immunosuppression, and photocarcinogenesis in mice.[40–42] Genetic variation at the glutathione S-transferase locus is also linked to variable susceptibility to sunburn[43] and to nonmelanoma and melanoma skin cancer risk in humans[44,45]

Photosynthesis of Vitamin D

Vitamin D_3 (cholecalciferol) is vital for bone health and its cutaneous photosynthesis is the single well-established benefit of UVR exposure. The plasma membrane–bound chromophore 7-dehydrocholesterol (also known as *provitamin* D_3) is photoconverted to previtamin D_3 that undergoes a slow thermal isomerization to vitamin D_3. Action spectra data indicate that UVB (approximately 295 to 315 nm) is responsible for vitamin D_3 production, which is also the peak region for sunburn and non-melanoma skin cancer. Vitamin D_3 is biologically inert and requires two hydroxylation steps: the first in the liver to 25-hydroxyvitamin D_3 [25-(OH)D_3] and the second in the kidney to produce the biologically active form 1,25$(OH)_2D_3$ (calcitriol). The plasma concentration of 25-(OH)D_3 is easily measured and is the conventional indicator of vitamin D_3 status. There is no standard definition of optimal vitamin D_3 status but it is generally accepted that plasma 25-(OH)D_3 below 25 n*M* constitutes deficiency as it is strongly associated with rickets and osteomalacia. It has been suggested that a level of 50 to 80 n*M* is required to optimize bone health, particularly in the elderly, however[46]; a new and controversial category of vitamin D "insufficiency" has been defined as higher vitamin D levels than those causing rickets or elevated parathyroid hormone levels but below levels that are statistically associated with other purported vitamin D benefits in population studies.[47] Cutoff values for vitamin D insufficiency vary widely in the literature, depending on the results of the reference study, and do not depend on the presence of a disease process (e.g., rickets) but only on a statistically increased risk of disease process (e.g., cancer or hypertension) in a cohort of individuals with comparable vitamin D storage levels.

WHAT IS THE BEST WAY TO ACHIEVE OPTIMUM VITAMIN D STATUS? In temperate regions above 45° latitude there is insufficient ambient UVB during October to March to synthesize vitamin D_3. Therefore, body stores, dietary intake, supplementation and UVB (but not UVA) tanning devices are the only sources during this time. Several studies have shown substantial seasonal fluctuation of 25-(OH)D_3 with significant proportions of populations being vitamin D_3–insufficient in late winter and early spring.[48] People who habitually avoid sunlight during the summer, the elderly, and populations with high constitutive pigmentation have been shown to have relatively low levels of 25-(OH)D_3 throughout the year.[49,50] It not known how much UVB exposure in combination with dietary/supplementary vitamin D_3 is needed to maintain optimal circulating 25-(OH)D_3. Sub-erythemal UVB is highly effective at increasing plasma 25-(OH)D_3, and it has been stated that a few minutes exposure of the face, arms, and hands to noonday summer sunlight two or three times a week is "sufficient" for vitamin D_3 synthesis. However, without a precise consistent definition of vitamin D sufficiency, this cannot be formally tested.

NEW ROLES FOR VITAMIN D?

CHRONIC EFFECTS OF ULTRAVIOLET RADIATION

Skin Cancer: From DNA Photodamage to Tumors (See Chap. 112)

Basal cell carcinoma (BCC), squamous cell carcinoma (SCC), and MM are reviewed in Chaps. 114, 115, and 124, respectively. UVR, especially UVB, is a major causal factor for all types of skin cancer. Fig. 89-5 shows that the wavelength dependence for human SSC, based on animal data, is very similar to that for human erythema. Thus, the SSC effectiveness spectrum should be similar to that for erythema shown in Fig. 89-2. There are no comparable data for BCC or MM, but studies on a new transgenic mouse (HGF/SF) model for MM indicate that UVB is much more important than UVA.[53] Molecular epidemiology has also provided a direct link between non-melanoma skin cancer and dipyrimidine DNA photodamage. UVB signature mutations (C → T or CC → TT transitions) in p53 are very prevalent in SCC and in actinic keratoses, which may spontaneously regress or progress to SCC.[54] A large body of experimental data suggests that the CPD is the most important lesion. More recently, mutations compatible with UVA damage (AT → CG transversions) have been reported in p53 in actinic keratoses, BCC and SCC,[9] although mutation analysis of p53 in BCC has shown that a majority of tumors also contain UVB signature mutations.[55] BCC have also been found to harbor such mutations in the human homologue of the *Drosophila* "patched" Ptch gene,[56] shown to be critical in development of this tumor and part of the hedgehog signal transduction pathway that transmits extracellular growth and differentiation signals to the nucleus.[57]

The molecular relationship between UVR damage and MM is much less well

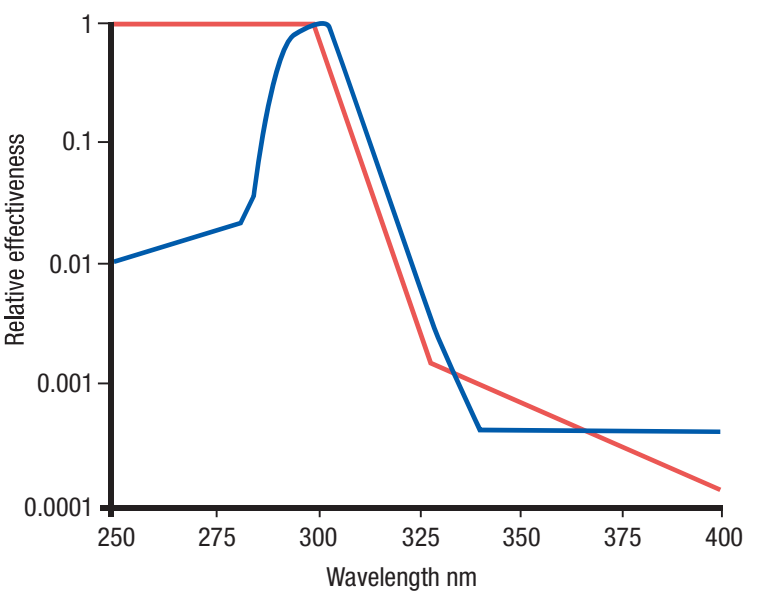

▲ **FIGURE 89-5** Commission Internationale de l'Eclairage action spectrum for human squamous cell carcinoma[63] (*blue*) in comparison with Commission Internationale de l'Eclairage erythema action spectrum[62] (*red*).

understood. Studies on familial MM have identified an important role for the CDKN2A gene that codes for two distinct tumor suppressor proteins ($p16^{INK4a}$ and $p14^{ARF}$) that affect the retinoblastoma and p53 pathways, respectively,[58] and there is emerging evidence of significant interaction between UVR and the $p16^{INK4a}$/retinoblastoma pathway, including UVR signature mutations in human MM.

Significance of Apoptosis (See Chap. 112)

The p53 protein is expressed at very low levels in normal human epidermis but is readily induced by a single dose of SSR, as shown in Fig. 89-6A. This protein monitors genomic integrity; either by responding to DNA damage (e.g., CPD) by the induction of transient cell cycle arrest at the G_1 checkpoint to facilitate DNA repair or by triggering the apoptotic death.[54] There is some evidence that UVR dose, and therefore level of DNA damage, is a factor in determining whether genomic integrity is protected by repair or apoptosis.[59] Mouse studies have confirmed that the p53 tumor suppressor gene plays an important role in apoptosis, but this can also occur via p53 independent pathways; for example, the binding of Fas ligand, TNF-α, or other cytokines to extracellular death receptors. UVB/SSR induces human epidermal apoptosis in the form of sunburn cells that are apparent within 30 minutes of exposure and maximal at 24 hours. In general, approximately two erythemal doses are required to induce sunburn cells, shown in Fig. 89-6B.

The interaction of multiple survival and apoptotic factors play a role in UVR-induced apoposis; for example, the E2F1 transcription factor that can be pro- or anti-apoptotic, depending on the circumstances.[60] Overall, keratinocyte apoptosis may have evolved to protect the skin from non-melanoma skin cancer. Much less is known about apoptosis in melanocytes, which are much more resistant to apoptotic signals in general than keratinocytes.[61] This may reflect their different roles and distribution in the skin. Numerous keratinocytes with a rapid turnover require much tighter homeostatic control than melanocytes that have a much lower density (approximately 2 percent of epidermal cells), low turnover, and are highly specialized.

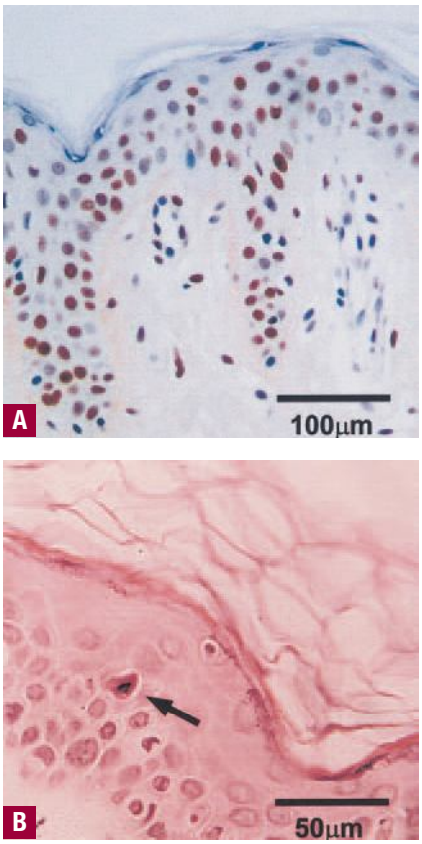

▲ **FIGURE 89-6** Epidermal responses in skin phototype II at 24 hours after two minimal erythemal doses with solar-simulated radiation. **A.** Wild-type p53 (immunostained brown with DO-7 antibody) is expressed maximally. **B.** Sunburn cell counts are maximal. Note highly characteristic shrunken eosinophilic cytoplasm and condensed pyknotic nucleus after staining with hematoxylin and eosin.

Photoaging (See Chap. 108)

Photoaging is distinct from normal chronologic aging. Clinically, photoaged skin is dry, deeply wrinkled, inelastic, leathery, and telangiectatic, often with irregular pigmentation, freckling, and lentigo formation (dermatoheliosis, Fig. 89-7). Histologically, such skin shows marked quantitative and qualitative abnormalities, particularly of the dermal connective tissue, including the accumulation of abnormal elastotic material—namely, elastosis, and proteoglycans. Furthermore, the degradation and disorganization of collagen fibrils, responsible for the strength and resilience of skin, have been observed.



▲ **FIGURE 89-7** Dermatoheliosis. Severe fine and deep wrinkling. The skin appears waxy with a yellowish hue due to actinic elastosis.

KEY REFERENCES

The full reference list for all chapters is available at www.digm7.com.

10. Melnikova VO, Ananthaswamy HN: Cellular and molecular events leading to the development of skin cancer. *Mutat Res* **571**:91, 2005
17. Clydesdale GJ, Dandie GW, Muller HK: Ultraviolet light induced injury: Immunological and inflammatory effects. *Immunol Cell Biol* **79**:547, 2001
21. Norval M. The mechanisms and consequences of ultraviolet-induced immunosuppression. *Prog Biophys Mol Biol* **92**:108, 2006
34. Gilchrest BA et al: Mechanisms of ultraviolet light-induced pigmentation. *Photochem Photobiol* **63**:1, 1996
36. Agar N, Young AR: Melanogenesis: A photoprotective response to DNA damage? *Mutat Res* **571**:121, 2005
52. Holick MF: The vitamin D epidemic and its health consequences. *J Nutr* **135**:2739S, 2005
54. Raj D, Brash DE, Grossman D: Keratinocyte apoptosis in epidermal development and disease. *J Invest Dermatol* **126**:243, 2006

CHAPTER 90

Abnormal Responses to Ultraviolet Radiation: Idiopathic, Probably Immunologic, and Photo-Exacerbated

John L. M. Hawk
James Ferguson



Abnormal responses to ultraviolet radiation (UVR) exposure can be divided into four categories (Table 90-1): acquired idiopathic, probably immunologic photodermatoses; DNA repair–defective photodermatoses; photosensitization by exogenous or endogenous drugs or chemicals, including the porphyrias; and photo-exacerbated dermatoses not directly caused by UVR. The first and last categories, and the approach to assessing the photosensitive patient, are covered in this chapter. The other categories are discussed in Chaps. 89, 91, 109, and 132 in this book.

TABLE 90-1
Abnormal Reactions to Ultraviolet Irradiation

- Acquired idiopathic, probably immunologic photodermatoses
  - Polymorphic light eruption
  - Actinic prurigo
  - Hydroa vacciniforme
  - Chronic actinic dermatitis
  - Solar urticaria
- DNA repair–defective disorders
  - Xeroderma pigmentosum
  - Cockayne syndrome
  - Trichothiodystrophy
  - Bloom syndrome
  - Rothmund-Thomson syndrome (probable)
- Chemical and drug photosensitivity
  - Exogenous
    - Systemic
    - Topical
  - Endogenous
    - The porphyrias
- Photo-exacerbated dermatoses

ACQUIRED IDIOPATHIC, PROBABLY IMMUNOLOGIC PHOTODERMATOSES

Polymorphic (Polymorphous) Light Eruption

EPIDEMIOLOGY Polymorphic light eruption (PMLE) is very common worldwide, affecting some 20 percent of southern Scandinavians,[1] 10 percent to 15 percent of North Americans[2] and southern Britons,[3] and 5 percent of southern Australians,[3] although virtually no equatorial Singaporeans.[4] Its prevalence therefore decreases steadily with decreasing latitude.

ETIOLOGY AND PATHOGENESIS A delayed-type hypersensitivity (DTH) response to sunlight-induced cutaneous photoantigen was first suggested as the cause of PMLE in 1942, based on the delay between UVR exposure and onset of the eruption as well as its lesional histologic features.[5] This has now proved almost certainly to be the case, although the considerable evidence in favor remains ultimately circumstantial.

Characterization of the inflammatory infiltrate in naturally occurring PMLE was inconclusive until biopsy specimens from lesions induced by solar-simulated irradiation eventually demonstrated the consistent appearance of a T cell–dominated perivascular infiltrate within 5 hours, peaking by 72 hours. $CD4^+$ T cells were most numerous in early lesions, whereas by 72 hours $CD8^+$ T cells predominated, perhaps abolishing the response.[6] Increased numbers of epidermal Langerhans cells and dermal macrophages were also present. These features all strongly suggested a DTH response as the basis for PMLE.

In addition, intercellular adhesion molecule-1 expression on keratinocytes overlying the perivascular infiltrate in PMLE,[7] as had been noted in DTH reactions but not irritant contact dermatitis or after the UVB irradiation of normal skin,[8,9] suggested an immunologic response. Finally, high-dose UVB and UVA irradiation of epidermal cells from a PMLE patient in one study increased their capacity to attract autologous peripheral blood monocytes,[10] again consistent with an immunologic response against a UVR-modified antigen.

More recently, the induction of allergic contact sensitization to dinitrochlorobenzene after solar-simulated irradiation of the sensitization site has been shown to occur significantly more easily in PMLE patients than in normal individuals,[11,12] which implies that patient sensitization to a putative UVR-induced cutaneous antigen may also be easier during the initial disease-inducing exposure. On the other hand, elicitation of the allergic contact response to dinitrochlorobenzene in previously sensitized PMLE patients and normal individuals was gradually and equally suppressed by irradiation,[13] which apparently also explains the frequent development of immunologic tolerance, often loosely called *hardening* or *desensitization*, in PMLE as summer progresses or during prophylactic phototherapy.

Etiologic radiation-absorbing molecules initiating PMLE have not been identified, but a variety of molecules may well be involved in the same and different patients. The altered molecule itself may hypothetically become antigenic, or else secondarily induced free radicals may interact with nearby elements to produce antigen, or both. However, any cutaneous immunologic tolerance induced by recent sunlight exposure may well inhibit the presumed DTH response.[13]

UVA radiation (315 to 400 nm) seems usually more effective than UVB (280 to 315 nm)[14,15] at initiating PMLE. In one

POLYMORPHIC LIGHT ERUPTION AT A GLANCE



- A common acquired sunlight-induced disorder, particularly at temperate latitudes, where it affects 10 percent to 20 percent of the population.
- Characterized by a pruritic, erythematous, symmetrically distributed, papulovesicular rash, on usually just some exposed areas, within hours of exposure to ultraviolet radiation (UVR), with full resolution in days to a week or two.
- Shows epidermal spongiosis with a dermal, perivascular, mainly mononuclear cell infiltrate and edema.
- Very likely a genetically determined delayed-type hypersensitivity reaction against UVR-induced cutaneous antigen(s).
- Responds to broad-spectrum sunscreen use, brief treatment with oral or topical steroids, or prophylactic low-dose immunosuppressive phototherapy in spring for frequent attacks.

wolff rev 2 lkc

study,[15] UVA irradiation successfully elicited the eruption in 56 percent of patients exposed to UVA or UVB daily for 4 to 8 days, in 17 percent of those exposed to UVB, and in 27 percent of those exposed to both. However, other reports have suggested that UVB radiation may perhaps be effective in up to 57 percent of patients.[16] Therefore, it could broadly be said that approximately 50 percent of PMLE patients seem sensitive to UVB radiation and 75 percent to UVA, including in each case approximately 25 percent who are sensitive to both, although visible light may also be responsible on very rare occasions.[17] As a result, paradoxically, patients may note that the use of sunscreens, which tend preferentially to remove UVB while transmitting UVA, may have a significant PMLE-enhancing effect.

There is very probably a genetic predisposition to PMLE,[18] but intensity of initial UVR exposure may also be important in such predisposed individuals.

CLINICAL FEATURES ***History.*** PMLE usually has onset in the first three decades of life and affects females two to three times more often than males. It occurs in all skin types and racial groups, but is more common in Caucasians. A positive family history is present in about a fifth of patients.[18]

The PMLE eruption (Fig. 90-1) typically occurs each spring or on sunny vacations after the first substantial UVR exposure after a prolonged period of no exposure. It can also occur after recreational sunbed use[19] or, very rarely, after exposure to visible radiation,[17] and often abates with continuing exposure. It is rare in winter except after exposure to UVR reflected from snow, and exposure may also occur through window glass. Individual susceptibility varies, and the period of continuing exposure needed to trigger the eruption is usually from 30 minutes to several hours, though sometimes after several days on vacations. Lesions appear in hours to days, but usually in not less than approximately 30 minutes, although itching may develop sooner. Once UVR exposure ceases, all lesions gradually resolve fully without scarring over one to several days or occasionally a week or two, rarely longer. In any given patient, PMLE outbreaks tend always to affect the same exposed sites, generally symmetrically, although perhaps gradually spreading or receding overall. Only some exposed skin is usually affected, particularly that normally covered, and large areas may be spared. An apparent extreme example of this is juvenile spring eruption,[20] which affects mainly boys in spring and is characterized by pruritic papules and vesicles of just the ear helices, although typical PMLE sometimes co-exists. Systemic symptoms in PMLE are rare, but malaise, nausea, and other sensations are possible in rare cases.

Cutaneous Lesions. PMLE has many possible morphologic forms, all probably with similar pathogenesis and prognosis. Papular, papulovesicular (Fig. 90-2), plaque (Fig. 90-3), vesiculobullous, insect bite–like, and erythema multiforme–like forms have been described, and pruritus alone may rarely occur,[21] but not, apparently, a macular variant. The papular form, characterized by large or small separate or confluent lesions that generally tend to form clusters, is most common, followed by the papulovesicular and plaque variants; the other forms are rare. An eczematous form has been claimed but almost certainly refers to mild chronic actinic dermatitis or photo-exacerbated seborrheic or atopic eczema. Differing morphologic variants may also occur at different skin sites in the same patient, with diffuse facial erythema and swelling, for example, sometimes accompanying typical papular lesions at other sites. Small papular PMLE generally sparing the face and occurring after several days of continuing exposure has been designated *benign summer light eruption* in continental Europe.[22]



▲ **FIGURE 90-3** Polymorphic light eruption. Variably sized itchy plaques on the cheek.

LABORATORY TESTS ***Histology.*** The histologic features[23] of PMLE are characteristic but not pathognomonic and vary with the clinical presentation. There is generally a moderate to dense perivascular infiltrate of the upper and mid dermis in all forms. The infiltrate consists predominantly of T cells, with neutrophils and infrequent eosinophils. Other features often seen are upper dermal and perivascular edema with endothelial cell swelling. Epidermal change, not always present, may include variable spongiosis and occasional dyskeratosis, exocytosis, and basal cell vacuolization.

Blood Tests. Assessment of the circulating anti-nuclear and extractable nuclear



▲ **FIGURE 90-1** Polymorphic light eruption. Papular lesions of exposed sites.



▲ **FIGURE 90-2** Polymorphic light eruption. Papulovesicular lesions on the arm.

antibody titers is advisable in all patients to exclude subacute cutaneous or other form of lupus erythematosus, and, if there is any uncertainty, the red blood cell protoporphyrin concentration should be measured to exclude erythropoietic protoporphyria.

Phototesting. Cutaneous phototesting with a monochromator confirms photosensitivity in up to half of cases[24] but usually does not discriminate from other photodermatoses. However, provocation testing with a solar simulator or other broadband source, sometimes repeated over 2 or 3 successive days, may often induce the eruption, for biopsy if necessary, when the history and clinical features themselves are not diagnostic.

DIFFERENTIAL DIAGNOSIS See Box 90-1.

COMPLICATIONS A very few patients with PMLE may develop lupus, and there is a higher than normal prevalence of prior PMLE in patients with lupus.[25]

PROGNOSIS AND CLINICAL COURSE Over 7 years, 57 percent of 114 patients reported steadily diminishing sun sensitivity, including 11 percent in whom the condition totally cleared.[26]

PREVENTION PMLE may often be avoided by moderation of sun exposure, the wearing of appropriately protective clothing, and regular application of broad-spectrum high-protection-factor sunscreens, particularly those against UVA, because predominantly UVB sunscreens are often ineffective. Prophylactic phototherapy each spring or before sunny vacations also tends to prevent attacks.

TREATMENT (See eFig. 90-3.1 in on-line edition) Patients who experience PMLE only infrequently, such as on vacations, usually respond well to short courses of oral steroids prescribed to be taken with them in case an eruption develops.[27] If it does, approximately 20 to 30 mg prednis(ol)one taken at the very first sign of pruritus and then each morning until the eruption clears usually provides effective relief within several days at most, and recurrence is relatively rare during the same vacation. Rare adverse effects of nausea and depression only occasionally necessitate stopping the drug. This treatment, if well tolerated, may be safely repeated every few months if required.

More severely affected individuals experiencing repeated PMLE attacks throughout the summer may require prophylactic courses of low-dose photochemotherapy (psoralen and UVA irradiation, or PUVA) in spring. This appears to be more effective than broadband UVB irradiation, controlling symptoms in up to 90 percent compared with approximately 60 percent of cases.[28] Narrowband (312-nm) UVB phototherapy (often also called *TL-01*), effective in 70 percent to 80 percent of cases, is now probably the treatment of choice, however, because it is simpler to administer.[29] Prophylactic PUVA or UVB irradiation may sometimes trigger the eruption, particularly in severely affected patients, in which case a brief course of oral steroid therapy is indicated.

Various other therapies have also been tried but appear largely ineffective. These include the traditional hydroxychloroquine,[30] which is perhaps occasionally useful; β-carotene,[31] which is probably never effective; nicotinamide,[32] which is also ineffective; and ω-3 polyunsaturated fatty acids, which are perhaps of moderate assistance in some patients.[33]

A small proportion of patients remain who are unsuitable for, unable to tolerate, or not helped by any of these measures. For these patients, if they are severely affected, oral immunosuppressive therapy, usually intermittent, with azathioprine or cyclosporine is generally helpful, if appropriate.[34,35]

Box 90-1

Differential Diagnosis of Polymorphic Light Eruption

Usual Acute Form

- Photo-exacerbated dermatoses such as atopic or seborrheic eczema or acne
- Solar urticaria
- Erythropoietic protoporphyria
- Xeroderma pigmentosum

Rare Persistent Form

- Jessner's lymphocytic infiltrate

Actinic Prurigo

EPIDEMIOLOGY Actinic prurigo (AP) appears to occur throughout much of the world. Native Americans at all latitudes are particularly affected but also, more rarely, inhabitants of the United Kingdom, the United States, Europe, Australia, and Japan.

PATHOGENESIS AP appears to be UVR induced, in that it is more severe in spring and summer and reasonably often demonstrates abnormal skin phototest responses to the UVB or UVA wavelengths, or both.[36] In addition, sunlight exposure and solar simulating irradiation may sometimes induce a rash resembling PMLE, many patients have close relatives with PMLE,[18] and a dermal, perivascular mononuclear cell infiltrate similar to that of PMLE may be seen in early lesions.

AP may therefore be a slowly evolving, excoriated form of PMLE, and thus also a DTH reaction. In addition, human leukocyte antigen (HLA) DRB1*0401 (DR4), which is present in approximately 30 percent of normal individuals, occurs in around 80 to 90 percent of those with AP, whereas HLA DRB1*0407, found in approximately 6 percent of normal individuals and not infrequently in Native Americans, occurs in around 60 percent,[37,38] so this inherited feature may well be responsible for converting PMLE into AP. In addition, some patients with the AP tissue type demonstrate clinical PMLE but also have persistent lesions, whereas in some patients clinical AP converts to clinical PMLE and in others clinical PMLE changes to clinical AP,[38] all of which further suggests a relationship between the

ACTINIC PRURIGO AT A GLANCE



- A rare, persistent, pruritic, excoriated, papular, or nodular eruption of sun-exposed and, to a lesser extent, non-exposed skin.
- Usually begins in childhood, may remit at puberty, is generally worse in summer, and normally fades in winter.
- A persistent variant of the sometimes coexistent polymorphic light eruption (PMLE).
- Similar to hereditary or familial PMLE that predominantly affects native North, Central, or South Americans but that is usually more severe and generally persists into adulthood.
- In addition to avoidance of ultraviolet irradiation, often oral thalidomide or other immunosuppressive agent is required.
- Prophylactic immunosuppressive phototherapy and topical application of calcineurin inhibitors can perhaps reduce recurrences if the eruption is cleared first.



two disorders. The cutaneous molecular UVR absorbers responsible for initiating the eruption are not known but may well be diverse, as suggested for PMLE.

CLINICAL FEATURES ***History.*** AP is more common in females and usually begins by age 10 years.[36] A positive family history of either AP or PMLE is present in about a fifth of patients,[18] but the incidence of atopy, at around 10 percent, is not increased.[39] The eruption is often present all year round, but is generally worse in summer, although very rarely it is worse in winter or both spring and fall, with immunologic tolerance presumably developing during the summer in these instances. Exacerbations tend to begin gradually during sunny weather rather than after specific sun exposure, although PMLE-like outbreaks are also possible.

Cutaneous Lesions. Lesions are typically very pruritic, usually excoriated papules or nodules (Fig. 90-4), sometimes associated with variable eczematization, lichenification, or crusting. All exposed areas are usually affected, particularly consistently uncovered sites, with a gradual fading toward habitually covered skin. The latter areas are also often mildly affected, particularly over the sacral area and buttocks. Cheilitis, particularly of the lower lip, and conjunctivitis are also possible, particularly in Native Americans.[39] Healed facial lesions may leave small pitted or linear shallow scars.

LABORATORY TESTS ***Histology.*** Early papular lesions show changes similar to those of PMLE, namely, mild acanthosis, exocytosis, and spongiosis in the epidermis and moderate lymphohistiocytic, dermal perivascular infiltration,[23] even very rarely



▲ **FIGURE 90-4** Actinic prurigo. Papules and nodules on the legs of a 15-year-old girl.

Box 90-2

Differential Diagnosis of Actinic Prurigo

Most Likely

- Polymorphic light eruption
- Atopic eczema
- Photo-exacerbated atopic or seborrheic eczema
- Insect bites
- Prurigo nodularis

Always Rule Out

- Scabies

suggesting lymphoma. In persistent lesions, however, excoriations, increasing acanthosis, variable lichenification, and dense mononuclear cell infiltration lead to a non-specific appearance.

Blood Tests. Assessment of the circulating anti-nuclear and extractable nuclear antibody titers should normally be undertaken to exclude subacute cutaneous or other form of lupus. The finding of HLA type DRB1*0401 (DR4) or DRB1*0407, particularly the latter, supports the diagnosis of AP.

Phototesting. Cutaneous phototesting with a monochromator confirms light sensitivity in up to half of cases[36] but as in PMLE does not discriminate from other photodermatoses. Provocation testing with a solar simulator or other broadband sources may occasionally induce a PMLE-like eruption.

DIFFERENTIAL DIAGNOSIS See Box 90-2.

COMPLICATIONS Permanent mild scarring, particularly on the face, and small, circular, atrophic, usually hypopigmented lesions elsewhere may arise from the chronic excoriations usual in the disease.

PROGNOSIS AND CLINICAL COURSE AP generally arises in childhood and often improves or resolves in adolescence, although persistence into adult life, sometimes in the form of PMLE, is possible. More rarely, the disorder arises in adulthood and persists indefinitely.[40] A closely related condition, which may affect North, Central, or South American patients of Native American or mixed race, appears indistinguishable from AP.

PREVENTION Annual prophylactic phototherapy in spring or the use of the topical calcineurin inhibitors tacrolimus and pimecrolimus sometimes prevents expression of the established disease. There is no known way to prevent its initial onset.

TREATMENT (See eFig. 90-4.1 in on-line edition) The restriction of sun exposure and use of broad-spectrum, high-protection-factor sunscreens may help in milder cases, assisted by intermittent use of topical or perhaps rarely oral steroids. Oral thalidomide, generally in low doses (50 to 100 mg at night) and preferably given intermittently, is almost always effective within weeks for more resistant disease in all age groups.[42] Adverse effects are generally mild and may include drowsiness, headache, constipation, and weight gain, whereas careful studies of nerve conduction performed every few months are important to minimize the risk of slowly progressive, probably dose-related peripheral neuropathy. Pregnancy must also be rigorously avoided because of the high risk of teratogenic effects. If thalidomide is unavailable or unsuitable, phototherapy with narrowband UVB or PUVA may occasionally help,[43] perhaps more reliably if the skin has been cleared first with oral steroids. Topical tacrolimus or pimecrolimus may also apparently help on occasion, again if the skin is cleared first, and oral immunosuppressive therapy with azathioprine or cyclosporine may also be useful if the other therapies are ineffective, unsuitable, or not tolerated. Treatment for hereditary AP is the same as for sporadic AP.

Hydroa Vacciniforme

EPIDEMIOLOGY Hydroa vacciniforme (HV) occurs in the United States, the United Kingdom, continental Europe, Japan, and very possibly elsewhere. However, its rarity and lack of universally acknowledged diagnostic criteria make precise evaluation difficult.

ETIOLOGY AND PATHOGENESIS The pathogenesis of HV is unknown. No chromophores have been identified, and although the UVB minimal erythemal dose reaction is normal in most patients, some have reduced UVA values.[44] Blood, urine, and stool porphyrin concentrations are normal, as are all other laboratory parameters. Nevertheless, the relationship of the eruption to sunlight exposure, its distribution, and its early clinical appearances are all very similar to those of PMLE, which strongly suggests a possible relationship to that disorder. On the other hand, the fully developed HV eruption is much more severe than that of PMLE, is always associated with permanent pock scarring, and is unresponsive to treatments effective for PMLE, apart



HYDROA VACCINIFORME AT A GLANCE



- A very rare, chronic, scarring photodermatosis of uncertain etiology.
- Characterized by recurrent sunlight-induced crops of papulovesicles and vesicles, most commonly on the face and dorsa of the hands.
- Usually begins in childhood and often remits at puberty.
- Could possibly be a scarring variant of polymorphic light eruption.
- Focal intraepidermal vesiculation, reticular keratinocyte degeneration, epidermal and upper dermal necrosis, and sometimes ulceration are virtually pathognomonic histologic changes.
- Avoidance of ultraviolet radiation, including the use of broad-spectrum high-protection-factor sunscreen, is the only established therapy.
- Prophylactic immunosuppressive phototherapy, administered with great care to avoid induction of lesions, may help.



perhaps from sunscreens and occasionally prophylactic phototherapy. Asian and Mexican reports of an HV-like disorder showing a regular association with Epstein-Barr virus infection probably represent a similar but not identical condition related to systemic disease.[45–47]

CLINICAL FINDINGS ***History.*** Most HV arises in early childhood and resolves spontaneously by puberty, although some patients suffer lifelong. There is a male predominance for severe forms, whereas milder disease is more common in females.[44,48] Familial incidence is exceptional. One estimate of the prevalence of HV is 0.34 cases per 100,000 with an approximately equal sex ratio; males had a later onset and longer duration of the disorder than females.[48]

The HV eruption (Fig. 90-5) typically occurs in summer,[36] with an often intense burning or stinging sensation followed by the appearance of individual or confluent papules and then vesicles within hours of sun exposure. This is



▲ **FIGURE 90-5** Hydroa vacciniforme. Vesicular, bullous, and crusted facial lesions, which are precursors of vacciniform scars.

followed by their umbilication, crusting, and progression to permanent pock scarring within weeks. The rash affects the cheeks and to a lesser extent other areas of the face, as well as usually the backs of the hands and outer aspects of the arms, generally symmetrically. It also rarely affects other sites.

Cutaneous Lesions. HV is characterized by initial erythema, sometimes with swelling, followed by symmetrically scattered, usually tender papules within 24 hours; vesiculation, occasionally confluent and hemorrhagic (Fig. 90-6); umbilication; then crusting and detachment of the lesions with permanent, depressed, hypopigmented scars within weeks. Oral ulcers and eye signs also rarely occur.[49,50]

LABORATORY TESTS ***Histology.*** Early histologic changes include intraepidermal vesicle formation with later focal epidermal keratinocyte necrosis and spongiosis in association with dermal perivascular neutrophil and lymphocyte infiltration.[23]



▲ **FIGURE 90-6** Typical hydroa vacciniforme lesions provoked by repeated ultraviolet A irradiation.

Older lesions show necrosis, ulceration, and scarring. Vasculitic features have been reported in rare cases.[44]

Blood Tests. Blood, urine, and stool porphyrin concentrations should be assessed to exclude cutaneous porphyria, as should the circulating anti-nuclear factor and extractable nuclear antibody titers to exclude the slight possibility of cutaneous lupus.

Phototesting. Phototesting may show reduced minimal erythema doses in short-wavelength UVA in some cases but is not usually able to discriminate from other photodermatoses. Simulated solar irradiation may also induce erythema at reduced irradiation doses or occasionally provoke the typical vesiculation of HV (see Fig. 90-6).

Other Tests. Viral studies to check for herpes infection or other viral disorders should be undertaken if photo-exacerbation or photo-induction of such a disorder seems at all possible.

DIFFERENTIAL DIAGNOSIS See Box 90-3.

COMPLICATIONS Pock scarring is an inevitable accompaniment of HV.

PROGNOSIS AND CLINICAL COURSE HV often resolves in adolescence but may occasionally persist into adult life.

PREVENTION Sun avoidance and sunscreen use, as well as prophylactic phototherapy annually in spring, tend to prevent HV in some patients.

TREATMENT (See eFig. 90-6.1 in on-line edition) The treatment of HV consists of restriction of sun exposure and use of high-protection-factor broad-spectrum sunscreens. Occasionally, antimalarials appear to have helped, but their true value is not established. Similar observations have been made for β-carotene, which in our hands was ineffective in three cases. As with PMLE, prophylactic phototherapy with narrowband UVB or

Box 90-3

Differential Diagnosis of Hydroa Vacciniforme

- Photo-exacerbated viral dermatoses such as herpes simplex
- Erythropoietic protoporphyria
- Polymorphic light eruption
- Subacute cutaneous lupus
- Xeroderma pigmentosum

CHRONIC ACTINIC DERMATITIS

AT A GLANCE



- A rare acquired persistent, eczematous, eruption of exposed skin, sometimes with pseudolymphomatous features.
- Affects mostly older men but sometimes young atopic patients and rarely patients with hydroa vacciniforme human immunodeficiency virus infection.
- The histologic features are eczematous, but pseudolymphomatous forms can be virtually indistinguishable from cutaneous T-cell lymphoma.
- Generally induced by small amounts of ultraviolet B irradiation, often also ultraviolet A, and sometimes visible as well; in rare cases induced by ultraviolet A or visible light alone.
- Persistent light reaction, actinic reticuloid, photosensitive eczema, and photosensitivity dermatitis are all considered clinical variants of the same condition (CAD).
- Very likely due to a delayed-type hypersensitivity reaction against endogenous photo-induced epidermal antigen(s).
- Therapy consists of strict avoidance of ultraviolet irradiation, along with topical and intermittent oral steroids use, topical calcineurin inhibitors use, or prolonged low-dose immunosuppressive phototherapy. Oral immunosuppression with cyclosporine or azathioprine is often required.

PUVA, particularly the latter, may be helpful but must be administered with care to avoid disease exacerbation.[44,48,51] If conservative measures are ineffective, however, as often occurs, topical or intermittent oral steroids, topical calcineurin inhibitors, or perhaps oral immunosuppressive medication might be tried if clinically appropriate, though they too are usually ineffective.

Chronic Actinic Dermatitis

HISTORICAL ASPECTS (Table 90-2)

EPIDEMIOLOGY Chronic actinic dermatitis (CAD) has regularly been diagnosed in the United Kingdom, continental Europe, United States, Australia, New Zealand, Japan, and India, and patients from Africa have also been seen. The disorder therefore appears to be of worldwide incidence and to affect all skin types, although it is perhaps more common in temperate regions.

TABLE 90-2
Original Criteria for Eczematous Photosensitivity Disorders

- Persistent light reaction[53]: Eczema of predominantly light-exposed skin sensitive to UVB ± UVA after acute photoallergic contact dermatitis
- Actinic reticuloid[57]: Infiltrated papules and plaques of mainly light-exposed skin with lymphoma-like histologic features and sensitivity to UVB + UVA ± visible light; negative results on photopatch tests
- Photosensitive eczema[58]: Morphologic and histologic eczema of mainly light-exposed skin with photosensitivity only to UVB; negative results on photopatch tests
- Photosensitivity dermatitis[59]: Morphologic and histologic eczema of mainly light-exposed skin with photosensitivity to UVB ± UVA; positive results on photopatch tests in a portion of cases
- Chronic actinic dermatitis[60]: Syndrome encompassing photosensitive eczema, photosensitivity dermatitis, and actinic reticuloid; persistent light reaction also later included

UVA = ultraviolet A radiation; UVB = ultraviolet B radiation.

ETIOLOGY AND PATHOGENESIS The likely pathogenesis of CAD has gradually been clarified, although it is not yet fully understood. Detailed studies of its clinical, histologic, and immunohistochemical features all show it precisely to resemble the DTH reaction of allergic contact dermatitis,[62–64] even in its severe pseudolymphomatous form (formerly called *actinic reticuloid*), in which the clinical and histologic features are the same as those seen in long-standing allergic contact dermatitis.[65] It is therefore highly probable that CAD is a similar reaction; however, given that it occurs after irradiation without any contact allergen in place, the reaction is presumably in this instance against photo-induced endogenous skin antigen(s).

Assessment of the action spectrum for CAD should theoretically help identify the postulated antigen, and this has been shown to resemble in shape that for sunburn in many patients.[73] However, the eruption in CAD is eczema, although much lower exposure doses than required for erythema are often needed to evoke the response. Hence, the UVR absorber in such cases may be the same as that implicated in sunburn—namely, UVR-damaged DNA[73]—but in CAD acting as an antigen. In other cases of CAD, however, the photoallergen must be different, because some patients react only to UVA[74] and perhaps a very few others just to visible light.[75]

In summary, CAD appears to be an allergic contact dermatitis–like reaction against UVR-altered DNA or a similar or associated molecule, or more rarely other molecules, perhaps as a result of enhanced immune reactivity due to concomitant airborne contact dermatitis or else reduced immunosuppressive capacity in photodamaged skin, or both, mainly in individuals with long-standing exposure to sunlight and airborne allergens.

CLINICAL FEATURES ***History.*** CAD may arise de novo in apparently normal skin or in the skin of patients with previous endogenous eczema, photoallergic or allergic contact dermatitis, perhaps occasionally oral drug photosensitivity, or rarely PMLE.[64,77] Concurrent allergic contact sensitivity to frequently encountered, often airborne, substances such as plant allergens, fragrances, or sunscreens is also common.[68] The condition usually affects middle-aged or elderly men,[64] occurrence under 50 years of age being unusual except in patients with prior atopic eczema.[69,70] The disorder is worse in summer and often also within minutes to hours of specific sun exposure, demonstrating a pruritic confluent erythematous eruption that occasionally settles over days with scaling if exposure ceases and the condition is mild. However, severely affected patients frequently do not recognize exacerbations with sun exposure, particularly if affected all year round.

Cutaneous Lesions. The lesions in CAD may be patchy or confluent and are eczematous, whether chronic, subacute, or acute (Figs. 90-7 and 90-8). In more severe cases, lichenification is common. More rarely, scattered or widespread erythematous, shiny, infiltrated pseudolymphomatous papules or plaques are present on a background of erythematous, eczematous, or normal skin.[64] Habitually exposed areas are most often affected, commonly with sharp cutoff at lines of clothing, along with sparing particularly of the depths of skin creases, the upper eyelids, the finger webs, and the skin behind the earlobes. In severe dis-



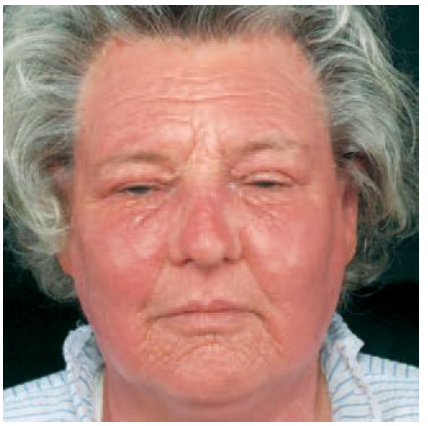

▲ **FIGURE 90-7** Chronic actinic dermatitis. Infiltrated eczematous eruption on the face.



ease, eczema of the palms and soles is also possible; eyebrow, eyelash, and scalp hair may be stubby or lost from constant rubbing and scratching, and erythroderma, usually but not always accentuated on exposed sites, may rarely supervene. Variable, sometimes geographic, sparing of exposed areas of the face or elsewhere, as well as irregular hyperpigmentation and hypopigmentation, sometimes vitiligo-like,[78] may also occasionally occur.

LABORATORY TESTS ***Histology.*** Histologic features include epidermal spongiosis, acanthosis, and sometimes hyperplasia, along with predominantly perivascular lymphocytic cellular infiltration confined to the upper dermis, with milder cases demonstrating just chronic eczema.[23] Severe CAD, however, may histologically mimic cutaneous T-cell lymphoma (CTCL), on occasion being virtually indistinguishable, with epidermal Pautrier-like microabscesses and deep, dense epidermotropic mononuclear cell infiltration, sometimes with hyperchromatic convoluted nuclei and giant cells, but no marked increase in mitoses. T-cell receptor gene rearrangement studies should be undertaken if there is any suspicion of lymphoma.

Blood Tests. Assessment of the circulating anti-nuclear and extractable nuclear antibody titers is advisable in all patients to exclude the unlikely possibility of subacute cutaneous or other form of lupus. In severe or erythrodermic CAD, there may be large numbers of circulating $CD8^+$ Sézary cells without other suggestion of malignancy.[79,80] Human immunodeficiency virus status should be checked if there is any suspicion that this infection may be a predisposing factor.[72]

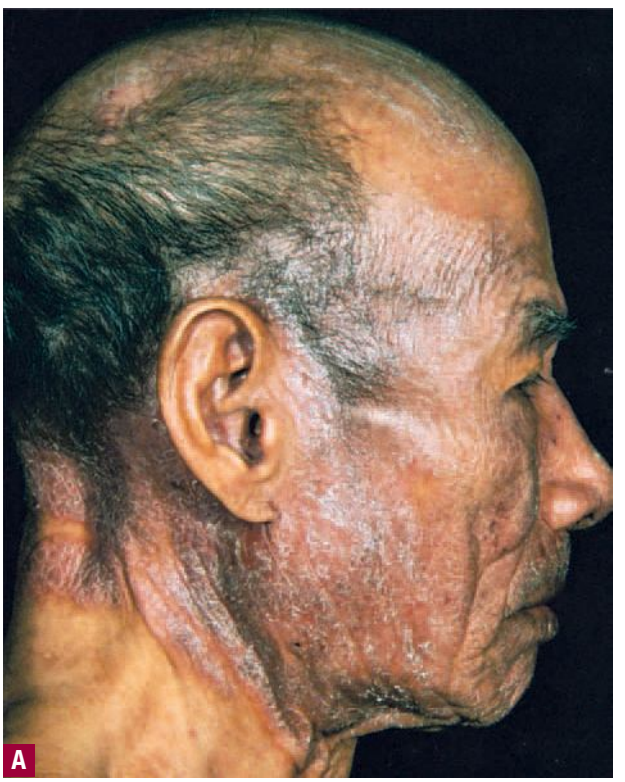







▲ **FIGURE 90-8** Chronic actinic dermatitis. **A, B.** Severe light-induced eczema of the face and neck. **C, D.** Patient in full remission after low-dose psoralen plus ultraviolet A irradiation over weeks, with initial high-dose oral steroid cover to prevent initial exacerbation.

Phototesting. Phototesting is essential if available to confirm the diagnosis of CAD. Results are virtually always characterized by low erythemal thresholds and eczematous or pseudolymphomatous responses after irradiation with UVB, usually UVA, and rarely also the visible wavelengths.[64] A very small number of patients react only to UVA,[74] and fewer still to only 600-nm visible light,[75] in which case drug photosensitivity must be carefully excluded. Testing should preferably be on uninvolved skin of the back with no topical or systemic steroid therapy for at least the preceding few days to avoid false-negative results.[81] Monochromatic and broad-spectrum sources both induce abnormal responses, with the former determining the action spectrum for disease induction and the latter tending to demonstrate acute eczema.

Patch and Photopatch Testing. Patch and photopatch testing is also essential in suspected CAD, because contact sensitivity to airborne allergens such as Compositae oleoresins, phosphorus sesquisulfide, and colophony alone may closely resemble CAD or else co-exist. In addition, occasional secondary contact or photocontact sensitivity to sunscreens or other topical therapies may further complicate the clinical picture.

DIFFERENTIAL DIAGNOSIS See Box 90-4.

COMPLICATIONS Any relationship to lymphoma seems likely to be coincidental, particularly because the results of T-cell receptor, immunoglobulin gene rearrangement, and other similar studies are negative in CAD.[79,82,83] In addition, CAD gradually resolves in many patients, there is no higher incidence of malignancy in CAD patients than expected, and life expectancy of CAD patients is normal.[84] However, it has been suggested that CTCL itself may very rarely present with severe CAD-like photosensitivity, and careful investigation to exclude CTCL is necessary if that disease is suspected.[85]

Box 90-4

Differential Diagnosis of Chronic Actinic Dermatitis

- Photo-exacerbated atopic or seborrheic eczema
- Drug or chemical photosensitivity
- Cutaneous T-cell lymphoma
- Eczematized actinic prurigo

PROGNOSIS AND CLINICAL COURSE Once established, CAD usually persists for years before not infrequent, very gradual resolution.[85]

TREATMENT (See eFig. 90-8.1 in on-line edition) The treatment of CAD is often difficult and not fully effective. Rigorous avoidance of UVR and exacerbating contact allergens is essential, along with the regular application of high protection-factor broad-spectrum topical sunscreens of low irritancy and allergenic potential. Strong topical steroids such as clobetasol propionate are also often needed and frequently produce marked symptomatic relief without adverse effects, even after long-term use, if confined to affected skin; occasional oral steroid use is often helpful too for disease flares. In more resistant disease, the topical calcineurin inhibitors tacrolimus and pimecrolimus can sometimes produce good results if tolerated.[86,87] For refractory CAD, however, oral immunosuppressive therapy is almost always necessary and generally helpful if tolerated. Azathioprine 1.5 to 2.5 mg/kg/day often produces remission in months,[88] after which it may be reduced in dosage, or perhaps discontinued in the winter. Cyclosporine 3.5 to 5.0 mg/kg/day is usually rapidly effective[89] but is more likely to produce adverse effects, which sometimes necessitate withdrawal. Mycophenolate mofetil is less often useful, whereas thioguanine has been used with good effect by one of the authors. Finally, long-term low-dose phototherapy with PUVA, usually several times weekly initially followed by maintenance exposures every 3 weeks or so, may be helpful,[90] generally accompanied initially by oral and topical steroid therapy to avoid disease flares (Fig. 90-8 C,D).

PREVENTION The risk of CAD development can probably be reduced by the moderation of outdoor pursuits, particularly those associated with plant allergen exposure such as gardening, especially for individuals who already have a tendency to eczematous eruptions in exposed areas.

Solar Urticaria

EPIDEMIOLOGY Solar urticaria (SU) has been reported in Asia, Europe, and the United States, and thus probably occurs worldwide. Perhaps 3.1 per 100,000 of the population are affected.[91]

ETIOLOGY AND PATHOGENESIS Primary SU is an immediate type I hypersensitivity response against cutaneous or circulating photoallergen generated from a precursor at the time of UVR or visible light absorption. Both circulating photoallergen and reaginic antibodies have been demonstrated. Very rarely, secondary SU may occur in association with drug photosensitivity, cutaneous porphyria, or lupus. There appears to be no genetic basis for the primary condition.

Two types of primary SU have been proposed, both involving an immunoglobulin E–mediated hypersensitivity against a photoallergen. In type 1, the photoallergen is generated only in SU patients, whereas in type 2 it is generated in both SU patients and normal individuals.[92] The wide range of responsible inducing wavelengths reported is presumably attributable to their absorption by different photoallergens. Pa-

SOLAR URTICARIA AT A GLANCE



- An uncommon sunlight-induced whealing disorder, slightly more common in females.
- Very rarely, occurs secondary to phototoxic drug use or cutaneous porphyria.
- Attacks occur within 5 to 10 minutes of sun exposure and resolve in an hour or two; they may be severely disabling and, rarely, life-threatening.
- Represents an immediate type I hypersensitivity response against cutaneous or circulating photoallergen(s).
- The histologic features are those of urticaria.
- Phototesting is useful to confirm the diagnosis and determine the action spectrum.
- Sensitivity may be to ultraviolet B, ultraviolet A, visible light, or any combination, but most commonly to ultraviolet A plus visible light.
- In addition to sun avoidance, high protection-factor broad-spectrum sunscreens may help slightly.
- Phototherapy, plasmapheresis, or oral immunosuppressive drugs rarely may help.



tients with type 1 SU appear to have photoallergens of molecular mass 25 to 34 kiloDaltons (kD) and action spectra in the visible region, whereas type 2 SU has photoallergens of 25 to 1000 kD and variable action spectra.[92] The range of eliciting wavelengths can narrow or broaden over months or years.

Mast cell degranulation and histamine release are important in SU,[95] but antihistamine therapy (H_1 or H_2) is not always effective. This suggests that other mediators such as neutrophil and eosinophil chemotactic factors accompanying histamine in the blood from irradiated skin can be important. Thus, the mast cell degranulation is accompanied by neutrophil and eosinophil recruitment and eosinophil major basic protein release, which may all amplify the whealing response.





▲ **FIGURE 90-9** Solar urticaria. Pruritic wheals with a surrounding patchy flare occurring within 15 minutes of sun exposure after irradiation of the patient's back through a template.

CLINICAL FEATURES ***History.*** Primary SU is slightly more common in females and may arise at any age, with the first attack sometimes occurring after marked sunlight or, occasionally, sunbed exposure. It also seems associated with other photosensitive skin disorders more than one might expect.[96] Typically, 5 to 10 minutes or, rarely, 20 to 30 minutes of exposure leads to itching and erythema, followed by patchy or confluent urticarial whealing, with gradual resolution over a maximum of 1 to 2 hours. Very rarely, just itching occurs, or the onset of symptoms may be delayed for up to several hours,[97] or only scattered fixed sites may be affected. In patients with mild disease, or in those who quickly recognize their SU onset and avoid further exposure, whealing may not be reported, even if it is present on phototesting. With extensive whealing, patients may also describe headache, nausea, bronchospasm, and syncope, which rarely may be life-threatening. Secondary SU should be excluded by ruling out drug photosensitivity, cutaneous porphyria, and lupus erythematosus.

Cutaneous Lesions. SU usually affects all exposed skin with an initial macular erythema, generally but not always followed rapidly by whealing and a surrounding patchy erythematous flare (Fig. 90-9), often with clear demarcation at lines of clothing. Rarely, there is sparing of the face and hands as a result of UVR-induced tolerance, or only fixed sites may be affected.

LABORATORY TESTS ***Histology.*** There is dermal vasodilation, edema, and predominantly perivascular neutrophil and eosinophil infiltration at 5 minutes and at 2, but not 24, hours.[23] Endothelial cell swelling occurs early on, with mononuclear cell infiltration later at higher irradiation doses. Extensive eosinophil granule major basic protein deposition is also present in the dermis at 2 and 24 hours, which suggests eosinophil degranulation.[98]

Blood Tests. The circulating anti-nuclear factor and extractable nuclear antibody titers should be assessed to exclude cutaneous lupus, as should the blood, urine, and stool porphyrin concentrations to exclude cutaneous porphyria, both very rare causes of SU.

Phototesting. Phototesting with a monochromator, broad-spectrum source, or sunlight allows confirmation of the diagnosis of SU and identification of the inducing wavelengths. However, negative phototest results do not necessarily exclude the disorder, because the ease of SU induction, particularly in mild cases, may vary. If no monochromator is available, appropriately filtered broadband sources can be used instead, and minimal urticarial dose estimation may help in assessing treatment efficacy.

DIFFERENTIAL DIAGNOSIS See Box 90-5.

COMPLICATIONS Severe primary SU may lead to vascular collapse and is very rarely fatal. The rare secondary SU related to drug or chemical photosensitivity, cutaneous porphyria, or cutaneous lupus may be associated with the complications of the primary conditions.

COURSE AND PROGNOSIS SU often persists indefinitely, sometimes with deterioration but also sometimes with improvement, with a probability of clinical resolution at 5 and 10 years of 12 percent and 26 percent, respectively.[91]

TREATMENT (See eFig. 90-9.1 in on-line edition) Restriction of sun exposure, use of high protection-factor broad-spectrum sunscreen, and appropriate clothing cover may be helpful for UVA-sensitive but generally not visible light–induced SU. Dark-colored clothing offers better protection than light-colored. The use of non-sedating H_1 antagonists, often in higher-than-normal dosages, which are best taken an hour or so before expected exposure and probably not helped by concurrent H_2 use, are very effective in about a third of patients and partially effective in another third. Otherwise therapy is difficult, but phototherapy may be helpful for uncer-

Box 90-5

Differential Diagnosis of Solar Urticaria (SU)

- Polymorphic light eruption (may rarely co-exist)
- Subacute cutaneous lupus (may rarely co-exist and may cause secondary SU)
- Photo-exacerbated dermatoses such as atopic or seborrheic eczema
- Erythropoietic protoporphyria (very rarely may cause secondary SU)
- Hepatic porphyrias (very rarely may cause secondary SU)
- Drug or chemical photosensitivity (very rarely may cause secondary SU)

TABLE 90-3
Selection of Diseases Sometimes Exacerbated by Ultraviolet Irradiation

- Acne
- Atopic eczema
- Carcinoid syndrome
- Cutaneous T-cell lymphoma
- Dermatomyositis
- Disseminated superficial actinic porokeratosis
- Erythema multiforme
- Familial benign chronic pemphigus (Hailey-Hailey disease)
- Keratosis follicularis (Darier disease)
- Lichen planus
- Lupus erythematosus
- Pellagra
- Pemphigus foliaceus (erythematosus)
- Pityriasis rubra pilaris
- Psoriasis
- Reticulate erythematous mucinosis syndrome
- Rosacea
- Seborrheic eczema
- Transient acantholytic dermatosis (Grover disease)
- Viral infections

tain reasons in patients who develop SU tolerance as summer advances and also sometimes in those with persistent disease, although the therapy then generally needs to be continued to maintain efficacy and consequently carries a risk of long-term adverse effects. Such phototherapy should also be undertaken with extreme care early on to avoid any risk of anaphylaxis, particularly in severely affected individuals.[98] Multiple UVA exposures with increasing doses during the same day (so-called *rush hardening*) have helped some patients.[99] Others respond to plasma exchange, or plasmapheresis, particularly if found to have a circulating SU-associated serum factor, and remissions in some cases are long-lived.[100,101] Intravenous immunoglobulin has also been helpful on occasion,[102] as has oral cyclosporine.

PHOTO-EXACERBATED DERMATOSES

Several dermatoses that are not actually induced by UVR may be worsened by it (Table 90-3). Mechanisms of this photoexacerbation have only occasionally been investigated. The initial condition may be severely worsened even if it was originally only mild or sub-clinical.[103,104] These disorders are relatively common and account for a significant proportion of all photodermatoses in some countries.[5] Such conditions, particularly the eczemas, psoriasis, and acne, improve with UVR exposure in most patients, perhaps because skin immune reactivity generally is reduced, but in a small proportion of individuals, it is instead significantly aggravated.[13] If photo-exacerbation does occur, the new eruption generally develops or worsens initially at sites typical of the basic disorder (Fig. 90-10), followed sometimes by spread to many other or all exposed areas. In photo-exacerbated seborrheic eczema, however, an unpleasant sensation at the exposed sites may be the first or only feature. Treatment consists of minimization of UVR exposure, protection by suitable clothing, application of high protection-factor broad-spectrum sunscreens, and particularly very careful treatment of the basic disorder, even if it is otherwise mild or sub-clinical. This specifically includes the daily use of an anti-eczema shampoo in seborrheic eczema. Taking these steps alone frequently, if perhaps surprisingly, totally aborts the photosensitivity.[103] If these actions are inadequate, low-dose phototherapy as for PMLE can sometimes help, for example in seborrheic or atopic eczema and psoriasis, but its use is contraindicated in cutaneous lupus or dermatomyositis,[105] in which possible aggravation of systemic disease is a significant risk. Photo-exacerbated acne generally requires oral isotretinoin.[104]

APPROACH TO THE PATIENT WITH ABNORMAL SKIN PHOTOSENSITIVITY

Clinical Features

Patients with abnormal skin photosensitivity present in one of three ways: with sporadic or persistent eruptions of habitually light-exposed areas, or, infrequently, erythroderma. In sporadic cases, patients themselves usually consider the eruption to be due to sun exposure; however, in all cases careful history taking is essential, first to confirm that light exposure is probably responsible and then to clarify the likely precise diagnosis. The patient information that is usually most important in this exercise are age at disease onset, gender, family history, any previous sunlight sensitivity, occupation, leisure pursuits, and systemic or topical drug or chemical use. Important details concerning the eruption are its seasonal behavior, exposure time required for its induction, time between exposure and



▲ **FIGURE 90-10** Photo-exacerbated seborrheic dermatitis, affecting the face only at sites of predilection for the seborrheic eruption.



lesion appearance, duration of the eruption, development after exposure through window glass or clothing, any systemic symptoms, patient-assessed morphology, and distribution of lesions. For example, mostly young women develop PMLE; women or girls develop AP; children of either gender may have HV, xeroderma pigmentosum (XP), or erythropoietic protoporphyria (EPP); and elderly males or younger individuals with atopic eczema develop CAD. A family history of sunlight sensitivity may be present in patients with PMLE, AP, XP, and the porphyrias. CAD is more common in open air enthusiasts exposed both to sunlight and airborne allergens, whereas disease worsening despite sunscreen use brings to mind a possible sunscreen allergy, although such exacerbation may also occur without allergy in PMLE. A rash appearing in minutes and settling in an hour or two strongly suggests SU or occasionally photosensitivity to drugs such as previously amiodarone. Onset within 20 minutes to several hours with resolution over days suggests PMLE, HV, EPP, XP, subacute cutaneous lupus, other photo-exacerbated dermatoses, or other drug photosensitivity, such as to thiazides. Systemic malaise rarely occurs in PMLE, HV, SU, or cutaneous lupus. Development of lesions after exposure through window glass or clothing indicates a disease induction spectrum that includes UVA, although this may occur in virtually all photodermatoses except XP.

The rash appearance described by patients with PMLE is generally of small or large, elevated, itchy, red or skin-colored, and often clumped spots or blisters, sometimes confluent, that usually involve only some exposed sites. In HV, blistering with permanent scar formation occurs, and in SU elevated itchy wheals, which are often confluent. In EPP and amiodarone drug photosensitivity, a marked burning sensation without visible change is reported, whereas lengthy exposure may lead to firm, colorless or pink, diffuse swelling, rarely with scattered blisters in EPP. In most other drug photosensitivity reactions and often XP, an exaggerated sunburn-like reaction is possible, which is often maximal in XP at 2 to 3 days. In photo-exacerbated dermatoses, the rash generally resembles that of the primary disorder, although in subacute cutaneous lupus, concomitant PMLE may also occur in rare cases.

Any photosensitive eruption is normally present on some, and occasionally all, of the forehead, nose, upper cheeks, tip of the chin, rims of the pinnae, back and sides of the neck, upper chest, backs of the hands and feet, and extensor aspects of the limbs. Covered areas may also be involved to a lesser degree. On the other hand, the forehead protected by the hair fringe, upper eyelids, finger webs, skin creases, and skin under the nose, lower lip, chin, and earlobes are frequently unaffected except occasionally by associated airborne contact dermatitis. Excoriated papules suggest AP, whereas eczema, or very rarely a light-associated erythroderma, suggests CAD or photo-exacerbated atopic or seborrheic eczema, whereas skin fragility, bulla formation, and atrophic superficial scarring suggest a hepatic porphyria or pseudoporphyria, especially if there has been drug or excessive alcohol intake or regular sunbed use.

After such a clinical appraisal, the diagnosis of any causative photodermatosis is often largely clear, but for complete certainty, at least some further investigation as outlined below is needed.

TABLE 90-4
Usual Monochromatic Phototest Responses in Idiopathic, Probably Immunologic Photodermatoses

Disease	Action Spectrum	Frequency of Abnormal Findings
Polymorphic light eruption	UVA more often than UVB	Only sometimes
Actinic prurigo	UVA more often than UVB	Only sometimes
Hydroa vacciniforme	More often UVA	Only sometimes
Chronic actinic dermatitis	UVB ± UVA ± visible light	Virtually always
Solar urticaria	UVB, UVA, or visible, or combination	Usual
Xeroderma pigmentosum	UVB	Usual
Photo-exacerbated dermatoses	UVB, UVA, or combination	Rare

UVA = ultraviolet A light; UVB = ultraviolet B light.

Laboratory Studies

Unless diagnosis is certain, important investigations for all photosensitive conditions are the assessment of circulating anti-nuclear factor and extractable nuclear antibody titers, and usually also blood, urine, and stool porphyrin concentrations. Lesional histologic features are characteristic in many photodermatoses, particularly in PMLE, HV, and CAD, but except in HV are rarely diagnostic. Direct immunofluorescence may assist diagnosis in cutaneous lupus. Phototesting of normal back skin with an irradiation monochromator in CAD and SU often produces the papules or wheals of the condition itself, frequently at low irradiation doses, and defines the eruption action spectrum. It also often helps confirm XP through the delayed development of erythema over 2 to 3 days with an abnormally low dose threshold, often with eventual blistering (Table 90-4). However, this testing is only moderately reliable in the other disorders, although solar simulating or other broadband irradiation may induce the rash to aid diagnosis. In eczematous photosensitivity, patch and photopatch testing are also essential to identify any inducing or exacerbating allergens. Finally, special techniques such as the assessment of DNA excision repair or of the RNA synthesis recovery rate in cultured patient fibroblasts after UVR exposure are essential for the diagnosis of certain genophotodermatoses.

PHOTOTESTING The use of phototesting in clinical dermatology varies greatly from country to country and center to center. Although it is the investigation of choice for photodermatoses when the diagnosis is uncertain or when details of the inducing action spectrum are required, it remains primarily a research tool restricted to a small number of clinical centers.

Essentially the skin phototesting of a patient suspected to have a photodermatosis falls into two categories. Monochromatic phototesting of the skin of the upper back at a series of wavelengths and doses is performed to elicit the eruption when possible and to identify the inducing action spectrum of the disorder, and photoprovocation testing with a broad-spectrum source is performed purely to induce the eruption for clinical diagnosis and biopsy if necessary. Table 90-4 lists the disorders for which monochromatic testing is likely to be helpful.

For precise definition of the wavelength dependency of the disorder, monochromatic testing should be conducted, preferably with a xenon arc irradiation monochromator, whereas for



photoprovocation testing, the favored device is a solar simulator, usually a xenon arc–filtered source that produces a spectrum closely resembling that of terrestrial sunlight at noon on a midsummer's day in temperate regions. Several suitable protocols have also been described for using simple broad-spectrum metal halide or fluorescent light sources with filters if necessary, and in some parts of the world, sunlight with filters has also been used, although this method is generally too unpredictable for clinical use.[105,106]

Monochromatic phototesting is preferably performed on unaffected skin of the upper back lateral to the paravertebral groove (see eFigs. 90-10.1 and 90-10.2 in on-line edition), whereas lesion induction, except when relatively easy with the monochromator as in SU and CAD, is best undertaken using broadband sources with output directed over larger areas of skin known to be susceptible to the eruption. PMLE, AP, and HV are conditions in which repeated irradiation with UVA- or UVB-emitting or combined sources is often required to produce the abnormal morphology (see eFig. 90-10.3 in on-line edition).

It is important that the use of potent topical and systemic steroids be avoided when possible for at least several days before phototesting to prevent false-negative results. It is not certain if other oral immunosuppressive agents affect testing as well, but they should also preferably be stopped. False-positive results may also occur in patients with widespread disease, and the eruption should first be well controlled whenever possible, if necessary by keeping the patient in a reduced-light setting. However, it is often difficult to fulfill these requirements if the eruption is active, and in such circumstances, testing may need to be undertaken with the knowledge that the results may possibly be unreliable.

All phototesting should be undertaken at carefully standardized sequential doses (often a geometrical series) and wavelengths, and the results read at consistent times after exposure in carefully controlled conditions of light and temperature. Furthermore, because such irradiation involves UVR exposure, potentially noxious to both skin and eyes, the patient—and particularly the repeatedly exposed investigator—should be protected throughout by appropriate clothing or other shielding and goggles.

PHOTOPATCH TESTING (See Chap. 91) Photopatch testing is a well-established investigation designed to identify photoallergic contact dermatitis, although it can also be used to help define potential phototoxic agents. It is essentially a more complex version of patch testing and is used in patients with apparent exposed-site eczema, whether or not they also have another photodermatosis, to determine if photoallergy is present.

The methodology of photopatch testing has not received the attention it deserves. Historically this has been because it has fallen between the two subspecialty areas of photodermatology and contact dermatology. In an attempt to solve this problem, therefore, earlier standardization attempts[106,107] have now been formalized in Europe with the development of a consensus methodology.[108]

In this approach, the application of test materials—usually sunscreens, topical nonsteroidal and anti-inflammatory agents, and any other possible causative agents—are applied in duplicate for 24 or 48 hours. One set of test sites is then irradiated with a broad-spectrum UVA source, usually with a 5 J/cm^2 beam from fluorescent PUVA lamps, and the results read 24 and 48 hours later. A strongly positive reaction at the sites exposed to both chemical agent and light and no reaction at the dark control sites allows a diagnosis of photoallergy (see eFig. 90-10.4 in on-line edition). Occasionally, however, an exacerbation of contact irritation or allergy occurs instead or as well, and careful interpretation is always required. Furthermore, current information concerning possible photoallergens is haphazard and based on scattered, anecdotal reports, so there is a major need for careful multicenter studies. In particular, if any new chemical is suspected of photoallergenicity, phototoxicity should first be excluded by studying it in normal volunteers.

KEY REFERENCES

The full reference list for all chapters is available at www.digm7.com.

11. van de Pas CB et al: Ultraviolet-radiation–induced erythema and suppression of contact hypersensitivity responses in patients with polymorphic light eruption. *J Invest Dermatol* **122**:295, 2004
12. Palmer RA, Friedmann PS: Ultraviolet radiation causes less immunosuppression in patients with polymorphic light eruption than in controls. *J Invest Dermatol* **122**:291, 2004
13. Palmer RA et al: The effect of solar-simulated radiation on the elicitation phase of contact hypersensitivity does not differ between controls and patients with polymorphic light eruption. *J Invest Dermatol* **124**:1308, 2005
18. McGregor JM et al: Genetic modeling of abnormal photosensitivity in families with polymorphic light eruption and actinic prurigo. *J Invest Dermatol* **115**:471, 2000
23. Hawk JLM, Calonje E: The photosensitivity disorders, in *Lever's Histopathology of the Skin*, 9th ed, edited by Elder DE et al. Philadelphia, Lippincott Williams & Wilkins, 2005, p 345
27. Patel DC et al: Efficacy of short-course oral prednisolone in polymorphic light eruption: A randomized controlled trial. *Br J Dermatol* **143**:828, 2000
29. Bilsland D et al: A comparison of narrow band phototherapy (TL-01) and photochemotherapy (PUVA) in the management of polymorphic light eruption. *Br J Dermatol* **129**:708, 1993
36. Hönigsmann H, Hojyo-Tomoka MT: Polymorphic light eruption, hydroa vacciniforme, and actinic prurigo. In *Photodermatology*, edited by Lim HW, Hönigsmann H, Hawk JLM. New York, Informa Healthcare, 2007, p 178
64. Hawk JLM, Lim HW: Chronic actinic dermatitis, in *Photodermatology*, edited by Lim HW, Hönigsmann H, Hawk JLM. New York, Informa Healthcare, 2007, p 127
91. Beattie P et al: Characteristics and prognosis of idiopathic solar urticaria: A cohort of 87 cases. *Arch Dermatol* **139**:1149, 2003
103. Palmer RA, Hawk JLM: Light-induced seborrhoeic eczema: Severe photoprovocation from subclinical disease. *Photodermatol Photoimmunol Photomed* **20**:62, 2004
133. Neumann NJ, Lehmann P: Photodiagnostic modalities, in *Dermatological Phototherapy and Photodiagnostic Methods*, edited by Krutmann J et al. Berlin, Springer, 2001, p 329
135. European Taskforce for Photopatch Testing: Photopatch testing: A consensus methodology for Europe. *J Eur Acad Derm Venereol* **18**:679, 2004



CHAPTER 91

Abnormal Responses to Ultraviolet Radiation: Photosensitivity Induced by Exogenous Agents

Henry W. Lim



Photosensitivity may be caused by exogenous or endogenous agents. It occurs when a compound, classically one with unsaturated double bonds in a six-carbon ring, absorbs radiation energy in its action spectrum, usually ultraviolet A (UVA) wavelengths. Exogenous photosensitizers can be agents administered systemically or applied topically. Well-characterized examples of photosensitivity induced by endogenous photosensitizers are the porphyrias, which are associated with enzymatic defects in heme biosynthetic pathways that result in elevated levels of porphyrins, known phototoxic agents (see Chap. 132).

Photosensitivity induced by exogenous agents can be divided into phototoxicity and photoallergy. Phototoxicity is the result of direct tissue injury caused by the phototoxic agent and radiation. It can occur in all individuals exposed to adequate doses of the agent and the activating wavelengths of radiation (Table 91-1). In contrast, photoallergy is a type IV delayed hypersensitivity response to a molecule that has been modified by absorption of light energy. It has a sensitization phase, occurs only in sensitized individuals, and requires only a minimal concentration of the photoallergen (see Table 91-1).

TABLE 91-2
Topical Phototoxic Agents

AGENT	EXPOSURE
Rose bengal	Used in ophthalmologic examinations
Furocoumarins	Occur naturally in plants (especially Compositae species), including fruits and vegetables (lime, lemon, celery, fig, parsley, and parsnip); used in topical photochemotherapy
Tar	Used as topical therapeutic agent; found in roofing materials

INCIDENCE

Almost 400 medications in the United States have been reported to cause photosensitivity. Only a small number of them, however, induce reactions frequently or have been well studied (Tables 91-2, 91-3, 91-4, and 91-5). In evaluations performed at photodermatology centers in New York City, Melbourne, Singapore, and Detroit, documented photosensitivity induced by a systemic drug occurred in from 5 percent to 15 percent of the referred patients.[1–4] In studies performed in the United States, United Kingdom, Europe, and Australia, the percentage of photopatch-tested patients who had clinically relevant reactions leading to a diagnosis of photoallergic contact dermatitis ranged from 1.4 percent to 12.0 percent, with the value in most series being around 10 percent.[5–10]

ABNORMAL RESPONSES TO ULTRAVIOLET RADIATION AT A GLANCE



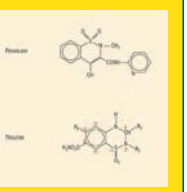

- Photosensitivity is broadly divided into phototoxicity and photoallergy, caused by topical or systemic agents that absorb ultraviolet A (UVA) energy.
- Phototoxicity occurs in anyone exposed to sufficient drug and UV radiation and usually manifests as an exaggerated sunburn reaction.
- Photoallergy is an immune reaction to a UVA-modified chemical, commonly topical sunscreen agents in the United States and the United Kingdom and topical nonsteroidal anti-inflammatory agents in Europe. It presents as eczematous eruption on photo-exposed areas.
- History taking is an important part of the evaluation; phototesting and photopatch testing are helpful.
- Differential diagnosis includes contact allergic or contact irritant dermatitis, airborne contact dermatitis, and other photodermatoses.
- Management consists of identification and avoidance of the precipitating agent, photoprotection, and symptomatic therapy.

TABLE 91-1
Characteristics of Phototoxicity and Photoallergy

	PHOTOTOXICITY	PHOTOALLERGY
Clinical presentation	Exaggerated sunburn reaction: erythema, edema, vesicles, and bullae; burning, stinging; frequently resolves with hyperpigmentation	A "rash," usually eczematous lesions and usually pruritic
Histologic features	Necrotic keratinocytes, epidermal degeneration; sparse dermal infiltrate of lymphocytes, macrophages, and neutrophils	Spongiotic dermatitis, dermal lymphohistiocytic infiltrate
Pathophysiology	Direct tissue injury	Type IV delayed hypersensitivity response
Occurrence after first exposure	Yes	No
Onset after exposure	Minutes to hours	24 to 48 h
Dose of agent needed for reaction	Large	Small
Cross-reactivity with other agents	None	Common
Diagnosis		
Topical agent	Clinical	Photopatch tests
Systemic agent	Clinical + phototests	Clinical + phototests; possibly photopatch tests

TABLE 91-3
Systemic Phototoxic Agents

Class	Generic Name (U.S. Trade Name)[a]
Antianxiety drugs	Alprazolam (Xanax)
	Chlordiazepoxide (Librax, Librium, Limbitrol)
Anticancer drugs	Dacarbazine (DTIC-Dome)
	Fluorouracil (Adrucil)
	Methotrexate (Rheumatrex)
	Vinblastine (Velban)
Antidepressants	Tricyclics
	Amitriptyline (Elavil, Limbitrol, Triavil)
	Desipramine (Norpramin)
	Imipramine (Tofranil)
Antifungal	Griseofulvin (Fulvicin, Grifulvin V, Gris-PEG)[b]
Antimalarials	Chloroquine (Aralen)
	Quinine (Formula-Q, M-KYA, Quiphile, Q-Vel)[b]
Antimicrobials	Quinolones
	Ciprofloxacin (Cipro)
	Enoxacin (Penetrex)[b]
	Gemifloxacin (Factive)
	Lomefloxacin (Maxaquin)[b,c]
	Moxifloxacin (Avelox)
	Nalidixic acid (NegGram)[b,c]
	Norfloxacin (Chibroxin, Noroxin)
	Ofloxacin (Floxin, Ocuflox)
	Sparfloxacin (Zagam)[c]
	Sulfonamides[b]
	Tetracyclines
	Demeclocycline (Declomycin)[c]
	Doxycycline (Adoxa, Doryx, Monodox, Periostat, Vibra-Tabs, Vibramycin)[c]
	Minocycline (Arestin, Dynacin, Minocin)
	Tetracycline (Helidac, Sumycin)
	Trimethoprim (Bactrim, Polytrim, Primsol, Septra)
Antipsychotic drugs	Phenothiazines
	Chlorpromazine (Thorazine)[c]
	Perphenazine (Triavil, Trilafon)
	Prochlorperazine (Compazine)[c]
	Thioridazine (Mellaril)
	Trifluoperazine (Stelazine)
Cardiac medications	Amiodarone (Cordarone, Pacerone)[c]
	Quinidine (Quinaglute, Quinidex)[b]
Diuretics	Furosemide (Lasix)[c]
	Thiazides
	Bendroflumethiazide (Corzide)
	Chlorothiazide (Aldoclor, Diuril)[c]
	Hydrochlorothiazide (Accuretic, Aldactazide, Aldoril, Atacand, Avalide, Capozide, Diovan, Dyazide, Hyzaar, Inderide, Lopressor, Lotensin, Maxzide, Micardis, Microzide, Moduretic, Prinzide, Teveten HCT, Uniretic, Vaseretic, Zestoretic, Ziac)[c]
Dye	Fluorescein (AK-Fluor, Fluor-I-Strip, Fluorescite)
	Methylene blue (Urised)
Furocoumarins	Psoralens
	5-Methoxypsoralen[c]
	8-Methoxypsoralen (Oxsoralen-Ultra)[c]
	4,5′,8-Trimethylpsoralen[c]
Hypoglycemics	Sulfonylureas
	Acetohexamide (Dymelor)
	Chlorpropamide (Diabinese)
	Glipizide (Glucotrol, Metaglip)
	Glyburide (DiaBeta, Glucovance, Glynase PresTab, Micronase)
	Tolazamide (Tolinase)
	Tolbutamide (Orinase)[c]
Nonsteroidal anti-inflammatory drugs	Acetic acid derivative
	Diclofenac (Arthrotec, Cataflam, Voltaren)
	Alkanone derivative
	Nabumetone (Relafen)[c]
	Anthranilic acid derivative
	Mefenamic acid (Ponstel)
	Cyclooxygenase 2 inhibitor
	Celecoxib (Celebrex)
	Enolic acid derivative
	Piroxicam (Feldene)[b,c]
	Propionic acid derivatives
	Ibuprofen (Advil, Motrin, Nuprin, Vicoprofen)
	Ketoprofen (Orudis, Oruvail)
	Naproxen (Aleve, Naprelan, Naprosyn)[c]
	Oxaprozin (Daypro)
	Tiaprofenic acid
	Salicylic acid derivative
	Diflunisal (Dolobid)
Photodynamic therapy agents	Porfimer (Photofrin)[c]
	Verteporfin (Visudyne)[c]
Retinoids[d]	Acitretin (Soriatane)
	Isotretinoin (Accutane)
	Etretinate
Other	Flutamide (Eulexin)
	Hypericin (St. John's wort)
	Pyridoxine (vitamin B_6)
	Ranitidine (Zantac)

[a]Although it is the policy not to use trade names in this book, exceptions are made in cases in which we consider this information essential.—*The Editors*
[b]Also reported as a systemic photoallergen.
[c]Commonly reported.
[d]Thinning of the epidermis plays a major role.

PHOTOTOXICITY

Pathophysiology

Several pathways eventuate in the development of phototoxic tissue damage, and for many phototoxic agents, more than one pathway is responsible.

PHOTODYNAMIC PROCESSES On absorption of radiation energy by the photosensitizer (P) at its ground state, formation of an excited (usually triplet) state (^3P) molecule occurs. The excited state molecule may then participate in oxygen-dependent processes (i.e., photodynamic processes) via two major pathways, type I and type II reactions,



TABLE 91-4
Topical Photoallergens

Group	Chemical Name (USAN/Trade Name[a])
Sunscreens (see Chap. 223)	Benzophenones
	Benzophenone-3 (oxybenzone)[b]
	Benzophenone-4 (sulisobenzone)
	PABA derivatives
	Amyl dimethyl PABA (padimate A)[b]
	Ethylhexyl dimethyl PABA (padimate O)[b]
	PABA[b]
	Cinnamates
	Ethylhexyl methoxycinnamate (octinoxate)
	Cinoxate (cinoxate)
	Salicylate
	Benzyl salicylate
	Others
	Butyl methoxydibenzoylmethane (avobenzone, Parsol 1789)[b]
	Menthyl anthranilate (meradimate)
	Octocrylene (octocrylene)
	Octyl triazone
	Phenylbenzimidazole sulfonic acid (ensulizole)
Fragrances	6-Methylcoumarin[b]
	Musk ambrette[b]
	Sandalwood oil
Anti-infective agents	Surface disinfectants: halogenated salicylanilides
	Dibromosalicylanilide (dibromsalan, DBS)[b]
	Tetrochlorosalicylanilide (Irgasan BS200)[b]
	Tribromosalicylanilide (tribromsalan, TBS)[b]
	Skin cleansers
	Chlorhexidine (Hibiclens)
	Hexachlorophene (pHisoHex)
	Pesticides
	Bithionol (thiobis-dichlorophenol)[b]
	Dichlorophene (G4, Korium, Teniatol)
	Dimethylol dimethyl hydantoin
	Fenticlor (bis-hydroxy-chlorophenyl sulfide)[b]
	Personal care products
	Triclosan (Irgasan DP300, Microban, Lexol 300)
	Topical antifungals
	Buclosamide (Jadit, butylchlorosalicylamide)
	Multifungin (bromochlorosalicylanilide, BCSA)
Others	Antibiotic for cattle
	Olaquindox[b]
	Nonsteroidal anti-inflammatory agents (topical)
	Etofenamate
	Fepradinol
	Flufenamic acid
	Ketoprofen[b]
	Phenothiazines
	Chlorpromazine (Thorazine)[b]
	Promethazine (Phenergan)[b]
	Miscellaneous
	Acyclovir cream (Zovirax)
	Clioquinol (Vioform, iodochlorhydroxyquin)
	Cadmium sulfide
	Cinchocaine (Dibucaine)
	Thiourea (thiocarbamide, sulfourea)

PABA = para-aminobenzoic acid; USAN = United States Adopted Name.
[a]Although it is the policy not to use trade names in this book, exceptions are made in cases in which we consider this information essential.—*The Editors*
[b]Commonly reported to be photoallergens.

both of which result in cytotoxic injury.[11]

The type I reaction involves transfer of an electron or a hydrogen atom to the excited state photosensitizer (^3P), which results in the formation of free radicals (Eq. 1). These may then participate in an oxidation-reduction reaction that results in peroxide formation and subsequent cell damage (Eqs. 2 and 3).

$$^3P + RH \rightarrow PH\cdot + R\cdot \quad (1)$$

$$PH\cdot + PH\cdot \rightarrow P + PH_2 \quad (2)$$

$$PH_2 + O_2 \rightarrow P + H_2O_2 \quad (3)$$

Alternatively, interaction of ^3P with ground state oxygen could result in the formation of superoxide anion (O_2^-), which, in turn, can be converted into highly reactive and cytotoxic hydroxyl radicals (OH·).

The type II reaction is also known as an *energy transfer process*. Transfer of energy to ground state oxygen results in the formation of singlet oxygen ($^1O_2$), which is highly reactive and has a lifetime of 50 nsec (Eq. 4):

$$^3P + O_2 \rightarrow P + {}^1O_2 \quad (4)$$

Cytotoxic injury occurs upon singlet oxygen–induced oxidation of amino acids and unsaturated fatty acids; interaction with the latter results in the formation of hydroperoxides, which initiate lipid and protein oxidation.

Phototoxicities induced by porphyrins,[11] quinolones,[12] nonsteroidal anti-inflammatory agents, tetracyclines, ami-

TABLE 91-5
Systemic Photoallergens

Property	Generic Name (U.S. Trade Name[a])
Antifungal	Griseofulvin (Fulvicin-U/F)
Antimalarial	Quinine
Antimicrobials	Quinolone
	Enoxacin (Penetrex)
	Sulfonamides
Cardiac medication	Quinidine (Quinaglute, Quinidex)
Nonsteroidal anti-inflammatory drugs	Ketoprofen (Orudis, Oruvail)
	Piroxicam (Feldene)
Vitamin	Pyridoxine hydrochloride (vitamin B_6)

[a]Although it is the policy not to use trade names in this book, exceptions are made in cases in which we consider this information essential.—*The Editors*



triptyline, imipramine, sulfonylureas, hydrochlorothiazide, furosemide, and chlorpromazine[13] are examples of photodynamic phototoxic reactions.

GENERATION OF PHOTOPRODUCTS Exposure to radiation may result in the generation of stable photoproducts that are responsible for tissue injury. Phototoxic products have been demonstrated on irradiation of phenothiazines, chlorpromazine, tetracyclines, quinolones, and nonsteroidal anti-inflammatory agents.[14]

BINDING TO SUBSTRATE Another mechanism of phototoxicity is radiation-mediated binding of the photosensitizer to its biologic substrate. A photoaddition reaction occurs when the excited state molecule covalently binds to a ground state molecule. An example is the covalent binding of 8-methoxypsoralen to pyrimidine bases of the DNA molecules, which results in the formation of a cross-link between the DNA strands.

INFLAMMATORY MEDIATORS Mediators of inflammation and inflammatory cells participate in phototoxic tissue injury. Biologically active products of complement activation, mast cell–derived mediators, eicosanoids, proteases, and polymorphonuclear leukocytes contribute to the development of phototoxicity induced by porphyrins, demeclocycline, and chlorpromazine.[15]

APOPTOSIS Photodynamic therapy (PDT) involves the use of a photosensitizer and electromagnetic radiation to treat pre-malignant and malignant skin conditions. In addition to generating reactive oxygen species, which results in cytotoxicity, PDT also is a potent inducer of apoptosis.[16]

Clinical Manifestations

ACUTE PHOTOTOXICITY (See Table 91-1) Acute phototoxicity usually occurs within hours of exposure to the phototoxic agent and UV radiation. Symptoms are drug-dose and UV-dose dependent, but at sufficient doses, the patient complains of a burning and stinging sensation on exposed areas, such as forehead, nose, V area of the neck, and dorsa of the hands. Erythema and edema may appear within hours of exposure; in severe cases, vesicles and bullae may develop. Protected areas, such as nasolabial folds, postauricular and submental areas, and areas covered by clothing, are spared (Fig. 91-1). A notable exception to these kinetics is psoralen-induced phototoxicity, in which often the acute response first appears after 24 hours, and peaks at 48 to 72 hours, which is the rationale for administering psoralen plus UVA (PUVA) photochemotherapy doses 48 to 72 hours apart. The phototoxic response usually resolves with a varying degree of hyperpigmentation, which may last for months. At lower drug/UV doses, gradual tanning only, without preceding sunburn-like reaction, can be seen.



▲ **FIGURE 91-1** Phototoxicity associated with a heterocyclic antidepressant. Note erythema and edema on sun-exposed areas and sparing of sun-protected chest and shaded upper lip and neck. (Used with permission from Dr. Adrian Tanew.)

PHOTO-ONYCHOLYSIS Separation of the distal nail from the nail bed is a manifestation of acute phototoxicity, with the nail plate serving as a lens to focus UV energy on the nail bed. It has been reported with doxycycline and other tetracyclines, fluoroquinolones, psoralens, benoxaprofen, clorazepate dipotassium, and quinine (Fig. 91-2).[17]



▲ **FIGURE 91-2** Distal onycholysis in a patient receiving psoralen plus ultraviolet A therapy.

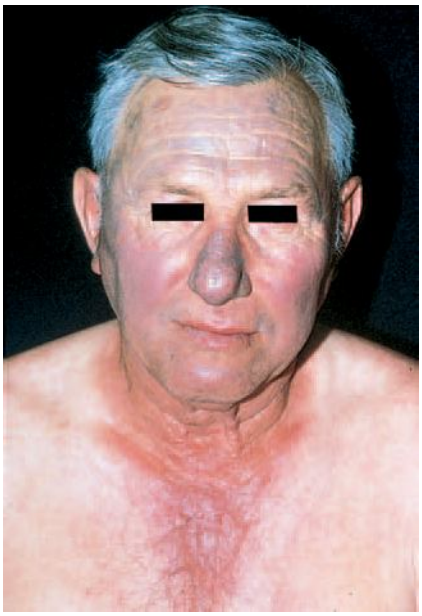

▲ **FIGURE 91-3** Amiodarone-induced phototoxicity. Note the erythema and slate-gray pigmentation (nose, forehead) on the sun-exposed area.

SLATE-GRAY PIGMENTATION Blue-gray pigmentation on sun-exposed areas has been associated with exposure to several agents.[18,19] One percent to 10 percent of patients taking amiodarone develop this side effect (Fig. 91-3). Chlorpromazine can induce a similar change. The tricyclic antidepressants imipramine and, less commonly, desipramine have also been reported to cause slate-gray pigmentation. A drug metabolite–melanin complex has been postulated to be the cause of this alteration. Chronic exposure to diltiazem, a benzothiazepine calcium channel blocker, has resulted in photodistributed, reticulated, slate-gray pigmentation (Fig. 91-4). Pigmentary incontinence and melanosome complexes are the prominent histologic and electron microscopic findings. Slate-gray pigmentation seen in argyria involves the nail lunulae, mucous membranes, and sclerae. A photochemical reaction in which silver granules are deposited in the dermis results in these pigmentary alterations.

LICHENOID ERUPTION Lichenoid eruption has been reported but is controversial.

PSEUDOPORPHYRIA The development of porphyria cutanea tarda–like cutaneous changes of skin fragility, vesicles, and sub-epidermal blisters is associated with



▲ **FIGURE 91-4** Slate-gray, reticulated patches on sun-exposed areas in a patient taking diltiazem. Note the sparing of the postauricular area and skinfolds on the neck.



several phototoxic agents (see Chaps. 132 and 151). Although histologic and immunofluorescence findings are similar to those of porphyria cutanea tarda, the porphyrin profile is normal or in the upper range of normal in these patients. Naproxen is the most commonly reported causative agent. Other drugs incriminated include amiodarone, β-lactam antibiotics, celecoxib, cyclosporine, diflunisal, etretinate, furosemide, nabumetone, nalidixic acid, oral contraceptives, oxaprozin, ketoprofen, mefenamic acid, rofecoxib (withdrawn from the U.S. market in September 2004), the tetracyclines, tiaprofenic acid, and voriconazole.[21,22]

PHOTODISTRIBUTED TELANGIECTASIA Telangiectasia on sun-exposed areas has been reported with calcium channel blockers, including nifedipine, amlodipine, felodipine, and diltiazem, and with the antibiotic cefotaxime. In some of these patients, provocation with UVA resulted in the development of telangiectasia.[23]

PERSISTENCE OF PHOTOSENSITIVITY AND EVOLUTION TO CHRONIC ACTINIC DERMATITIS Although phototoxicity usually resolves after discontinuation of the causative agent, there are reports of persistence of photosensitivity for many years after the cessation of exposure, which results in the development of chronic actinic dermatitis (see Photoallergy). This has been reported most often with dexamethahexachlorine, an ingredient previously found in some spas, but also with thiazides, quinidine, quinine, and amiodarone.[24]

CHRONIC EFFECTS Cutaneous effects of long-term, repeated phototoxic tissue injury are best exemplified by the manifestations in patients who have received long-term PUVA photochemotherapy, which is known to affect DNA. These effects include premature aging of the skin, lentigines, squamous cell and basal cell carcinomas, and melanoma. These are discussed in greater detail in Chap. 239.

Phototoxic Agents

TOPICAL AGENTS Table 91-2 lists the major topical phototoxic agents. Therapeutic or occupational exposures to these agents are the common route of contact. The action spectrum is in the UVA or visible light range.

Furocoumarins. Topical exposures to furocoumarins may occur in individuals in certain occupations (bartenders, salad chefs, gardeners) and in patients receiving topical photochemotherapy with psoralens. Such exposures were reported in the past among users of tanning preparations or perfumes containing 5-methoxypsoralen (bergapten), but these preparations have been withdrawn from the market.

Tar. Crude coal tar used in dermatologic therapy is the product of the destructive distillation of coal. It is a complex mixture of over 10,000 compounds, including many phototoxic polyaromatic hydrocarbons that produce a burning and stinging sensation on exposure to UVA ("tar smarts"). Occupational exposure to tar is associated with increased risk of non-melanoma skin cancers, in addition to phototoxicity, although the carcinogenicity of coal tar used in dermatologic therapy remains controversial.

SYSTEMIC AGENTS Table 91-3 lists the major systemic phototoxic agents.[25–53] They commonly produce an exaggerated sunburn reaction but like most phototoxins may also induce an eczematous photoallergic response in a small percentage of users, especially after topical exposure. As a rule, the action spectra are in the UVA range; exceptions include the sulfonamides and ranitidine, whose action spectra are in the UVB range, and the porphyrins, fluorescein, and other dyes, whose action spectra are in the visible light range.

Histopathology

Acute phototoxicity is characterized by individual necrotic keratinocytes and, in severe cases, epidermal necrosis (see Table 91-1). There may be epidermal spongiosis, dermal edema, and a mild infiltrate consisting of neutrophils, lymphocytes, and macrophages. Slate-gray pigmentation is associated with increased dermal melanin and dermal deposits of the drug or its metabolite.[18,19] Histologic features of lichenoid eruptions are similar to those of idiopathic lichen planus; however, there may be a greater degree of spongiosis and dermal eosinophilic and plasma cell infiltrates, and a larger number of necrotic keratinocytes and cytoid bodies. In pseudoporphyria, as in porphyria cutanea tarda, there is dermal-epidermal separation at the lamina lucida and deposits of immunoglobulins at the dermal-epidermal junction and surrounding blood vessel walls.[21,22]

Management

Identification and avoidance of the causative phototoxic agent are the most important steps in management. Beyond this, sun avoidance is essential. Because the action spectrum for most agents is in the UVA range, high sun protection factor, broad-spectrum sunscreens containing efficient UVA filters should be used (see Chap. 223). Acute phototoxicity can be managed with topical corticosteroids and compresses; systemic corticosteroids should be reserved for only the most severely affected patients. Management of patients with slate-gray pigmentation, lichenoid eruption, pseudoporphyria, and photodistributed telangiectasia is symptomatic only, and patients should be advised that it will take months after the discontinuation of the offending agent for the condition to resolve. Patients with nonsteroidal anti-inflammatory drug (NSAID)–induced pseudoporphyria who require NSAIDs should be switched to a different class of agents or to those that are less photosensitizing, such as indomethacin or sulindac.[54]

PHOTOALLERGY

Pathophysiology

Photoallergy is a type IV delayed hypersensitivity response requiring the presence of both photoallergen and the activating wavelengths of radiation, which for most agents are in the UVA range.

After the absorption of UV energy, a photoallergen may be converted to an excited state molecule, which subsequently reverts to ground state by releasing the energy. In this process, the molecule may conjugate with a carrier protein to form a complete antigen. This is thought to be the mechanism of photoallergy induced by halogenated salicylanilides, chlorpromazine, and para-aminobenzoic acid (PABA). Alternatively, a photoallergen may form a stable photoproduct on exposure to radiation, which in turn may conjugate with a carrier protein to form a complete antigen. Sulfanilamide and chlorpromazine have both been shown to participate in this reaction.

Once the complete antigen is formed, the mechanism of photoallergy is identical to that of contact allergy. The antigen is taken up and processed by Langerhans cells, which then migrate to regional lymph nodes to present the antigen to T lymphocytes. Cutaneous lesions develop when the activated T lymphocytes circulate to the exposed site to initiate an inflammatory response.

Clinical Manifestations

In sensitized individuals, exposure to the photoallergen and sunlight results in the development of a pruritic, eczematous eruption within 24 to 48 hours after exposure (see Table 91-1, Fig. 91-5). Although the morphology is clinically indistinguishable from that of allergic contact dermatitis, the distribution of the eruption in photoallergy is predominantly confined to sun-exposed areas; however, in severe cases it may spread to the covered areas, albeit at a lower intensity. Unlike the lesions in phototoxicity, those in photoallergy usually resolve without significant post-inflammatory hyperpigmentation. Lichenoid eruption has also been reported.

Currently, in the United States, United Kingdom, and France, UV filters in sunscreen products (especially benzophenone-3) are the most common cause of photoallergy, whereas NSAIDs are the leading topical photoallergens in Germany, Austria, and Switzerland.[1,8,10]

As with phototoxicity, persistence of photosensitivity and evolution to chronic actinic dermatitis (see Chap. 90) have been reported after exposure to photoallergens, including halogenated salicylanilides, musk ambrette, ketoprofen, dioxopromethazine, olaquindox, and quinidine.[55–58] The mechanism is not completely understood. One possible explanation is that UV radiation alters the carrier protein that originally binds the photoallergen; this results in the formation of a neoantigen that stimulates the immune system over the long term. This hypothesis is supported by the observation that the histidine moiety in albumin can undergo oxidation in the presence of salicylanilide, which binds to albumin.

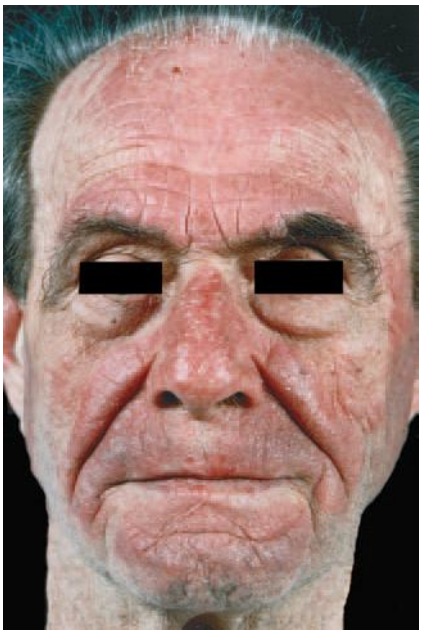

▲ **FIGURE 91-5** Photoallergic dermatitis. This eruption is clinically indistinguishable from allergic contact dermatitis, except that it is distributed predominantly in sun-exposed areas. Note the absence of dermatitis on upper eyelids, below the nose, and in the submental and neck regions.

Photoallergens

TOPICAL AGENTS Topical exposure is the most common route of sensitization to photoallergens.[59] Table 91-4 lists the common groups of photoallergens.

SYSTEMIC AGENTS Photoallergy caused by systemic agents is much less frequent than that induced by topical agents. All but one of these photoallergenic agents (pyridoxine) are also phototoxic and have been discussed previously in this chapter (see Systemic Agents under Phototoxic Agents and Table 91-3).

Histopathology

The histologic features of photoallergy are similar to those of allergic contact dermatitis. There is epidermal spongiosis associated with infiltrate of mononuclear cells in the dermis (see Table 91-1).

Management

Management is identical to that of phototoxicity: identification and avoidance of the photoallergen, sun-protective measures, and symptomatic therapy.

EVALUATION OF PATIENTS WITH PHOTOTOXICITY AND PHOTOALLERGY

The evaluation of patients with phototoxicity and photoallergy is similar to the evaluation of patients with other photosensitivity disorders and is described in greater detail in Chap. 90. A history of exposure to known photosensitizers is most important. It is also helpful to ascertain whether window glass–filtered sunlight can induce the cutaneous eruption, because UVB and UVA2 (320 to 340 nm) are filtered out by window glass. Distribution of the cutaneous eruption is a helpful clue to the type of photosensitizer responsible. Widespread eruption suggests systemic photosensitizers, whereas topical photosensitizers produce lesions only in areas that have been exposed to both sensitizers and radiation. Vesicular and bullous eruptions are most commonly associated with phototoxicity, whereas eczematous eruptions suggest photoallergy; usually, the former is associated with a burning sensation, the latter with pruritus. Skin biopsy findings may also be helpful in differentiating these two conditions: necrotic keratinocytes are commonly seen in phototoxicity, whereas spongiotic dermatitis is associated with photoallergy (see Table 91-1).

Phototests and photopatch tests are an integral part of the evaluation of photosensitivity. Approximately 10 percent of patients who undergo photopatch testing have clinically relevant positive results, which leads to the diagnosis of photoallergic contact dermatitis.[1,5–10]

The procedures for phototesting and photopatch testing are generally as follows, although there are variations in testing methods.[62] On day 1, exposure to UVB and UVA to determine minimal erythema dose (MED) is carried out, and duplicate sets of photoallergens are applied symmetrically to another site on the back and covered by an opaque tape. On day 2, the MEDs are determined. One of the duplicate set of photoallergens is exposed to 10 J/cm^2 of UVA or 50 percent of the MED to UVA, whichever is lower. After irradiation, the exposed site is covered again with an opaque tape. On day 3, both irradiated and nonirradiated test sites are uncovered, and the reactions are



graded. On day 5 or day 8, the irradiated and nonirradiated sites are evaluated for delayed reactions. Reaction at an irradiated site only indicates photoallergy. Reaction of equal intensity at both irradiated and covered sites indicates allergic contact dermatitis. Reaction at both sites, but with higher intensity at the irradiated site, signifies both photoallergy and allergic contact dermatitis. Well-defined erythema that resolves promptly indicates an irritant dermatitis.

DIFFERENTIAL DIAGNOSIS OF PHOTOTOXICITY AND PHOTOALLERGY



Airborne allergic contact dermatitis is characterized by involvement of skinfolds on exposed areas, such as the nasolabial folds, and the eyelids that receive minimal direct sunlight. It also involves exposed areas that are relatively sun protected, such as the postauricular areas and area under the chin. Allergic contact dermatitis and irritant contact dermatitis occur in both sun-exposed and in sun-protected areas.

Other photodermatoses can be differentiated from phototoxicity and photoallergy by their characteristic time course and morphology and lack of a compatible exposure history. Polymorphous light eruption manifests itself within a few hours of sun exposure as pruritic papules, plaques, and, uncommonly, vesicles on sun-exposed sites and resolves in a few days. Chronic actinic dermatitis presents as chronically lichenified plaques on sun-exposed areas. Lesions of solar urticaria appear within minutes of sun exposure as mildly pruritic urticaria and resolve within a few hours.

OTHER EXOGENOUS AGENT–INDUCED PHOTODERMATOSES AND PHOTO-EXACERBATED DERMATOSES

Porphyria Cutanea Tarda (See Chap. 132)

Ingestion of wheat treated with hexachlorobenzene (HCB) as a preservative resulted in an outbreak of a porphyria cutanea tarda–like syndrome in Turkey in the 1950s.[63] Inhibition of the enzyme uroporphyrinogen decarboxylase by HCB was thought to be responsible for the clinical manifestations. However, a study of adults highly exposed to HCB in Catalonia, Spain, did not show any increase in prevalence of porphyria cutanea tarda or increased urinary concentrations of porphyrins.[64]

Lupus Erythematosus (See Chap. 156)

Although many medications are associated with drug-induced lupus erythematosus, the association has been best established for procainamide, hydralazine, and minocycline.[65] Arthralgia and systemic symptoms are common; photosensitivity is a rare manifestation. Most patients have antibodies to histones. Individuals whose hepatic *N*-acetyltransferase system expresses a "slow acetylator" phenotype or who are positive for human leukocyte antigen DR4 are most susceptible.

Pellagra (See Chap. 130)

Skin changes of pellagra (from the Italian *pelle agra*, "rough skin") are associated with isoniazid, 6-mercaptopurine, 5-fluorouracil, chloramphenicol, sulfapyridine, anticonvulsants, and antidepressants.[66,67] The pathogenesis of drug-induced pellagra probably is related to the inhibition of conversion of niacin to nicotinamide adenine dinucleotide and nicotinamide adenine dinucleotide phosphate.

KEY REFERENCES

The full reference list for all chapters is available at www.digm7.com.

1. Fotiades J, Soter NA, Lim HW: Results of evaluation of 203 patients for photosensitivity in a 7.3-year period. *J Am Acad Dermatol* **33**:597, 1995
8. Neumann NJ et al: Photopatch testing: The 12-year experience of the German, Austrian, and Swiss photopatch test group. *J Am Acad Dermatol* **42**:183, 2000
10. Darvay A et al: Photoallergic contact dermatitis is uncommon. *Br J Dermatol* **145**:597, 2001
13. Moore DE: Drug-induced cutaneous photosensitivity: Incidence, mechanism, prevention and management. *Drug Saf* **25**:345, 2002
36. Ferguson J: Photosensitivity due to drugs. *Photodermatol Photoimmunol Photomed* **18**:262, 2002
59. Scheuer E, Warshaw E: Sunscreen allergy: A review of epidemiology, clinical characteristics, and responsible allergens. *Dermatitis* **17**:3, 2006
62. Yashar SS, Lim HW: Classification and evaluation of photodermatoses. *Dermatol Ther* **16**:1, 2003

SECTION 17

SKIN CHANGES DUE TO OTHER PHYSICAL AND CHEMICAL FACTORS

CHAPTER 92

Thermoregulation

Dean L. Kellogg, Jr.

ROLE OF SKIN IN HUMAN THERMOREGULATION: AN OVERVIEW

Human beings are homeotherms: we maintain our internal, or core, temperature of the body within a narrow range despite thermal stresses. Thermal stress can arise from variations in environmental temperature or from the human body itself, as with heat generation by skeletal muscle during dynamic exercise. When thermal stresses arise from the environment, changes in skin temperature occur before any change in core or internal temperature. When thermal stresses arise from the body itself, changes in core temperature occur before any change in skin temperature. In either case, thermal gradients are established between the skin and the body core. If skin temperature is lower than core temperature, heat will be lost from the body unless skin blood vessels constrict. If skin temperature is higher than core temperature, the body will gain heat unless skin vessels dilate and sweat glands produce perspiration. The skin is thus a crucial component of human thermoregulation.

Human thermoregulation is achieved through an integration of several physiologic processes. These integrated processes make up thermoregulatory reflexes that maintain a stable internal temperature at a "set point" of 37°C (98.6°F) despite thermal stresses. The set point is not invariant and may fluctuate as much as 0.5°C to 1.0°C (0.9°F to 1.8°F) according to circadian rhythms and during the menstrual cycle in females. The thermoregulatory reflexes designed to preserve internal temperature at the set point are coordinated by thermally sensitive neurons in the anterior hypothalamic-preoptic area and in the spinal cord that respond to changes in internal temperature and/or skin temperature. For example, when stimulated, cold-sensitive neurons in the anterior hypothalamic-preoptic area and spinal cord integrate afferent sensory inputs and activate heat-conserving mechanisms that include cutaneous vasoconstriction and increased metabolic heat production (shivering). Conversely, the stimulation of heat-sensitive neurons in the anterior hypothalamic-preoptic area and spinal cord integrate afferent sensory inputs and activate heat-dissipating mechanisms that include cutaneous vasodilation and sweat production.

HEAT TRANSFER

To maintain thermal balance, heat gained or lost by the body must equal heat dissipated from or produced by the body. This concept can be mathematically expressed as follows:

$$\Delta S = M - E \pm R \pm C \pm K - W$$

- ΔS = Change in heat storage by the body
- M = Metabolic heat production and is defined as the rate of transformation of chemical energy into heat and mechanical work.
- E = Evaporative heat loss and is defined as the rate of heat loss by evaporation of water from skin and surfaces of the respiratory tract. E is dependent on (1) the rate of sweat secretion, (2) the water vapor pressure of the environment, and (3) the area of evaporative surface.
- R = Radiant heat gain or loss and is defined as heat exchange by emission and absorption of electromagnetic (infrared) radiation. This component accounts for 50 percent to 60 percent of the heat loss in a thermally comfortable (thermoneutral) individual but can easily become a net heat

THERMO-REGULATION AT A GLANCE



- Body temperature is maintained within a narrow range.
- The skin plays a major role via the following:
  - Evaporative heat loss, modulated by sweating
  - Radiant heat loss or gain
  - Convective heat loss or gain, modulated by vasodilatation and vasoconstriction
- Papillary loops, arteriovenous anastomoses, and sweat glands are the major skin effectors.
- Cutaneous blood flow, normally approximately 5 percent of cardiac output, can vary from 0 percent to 60 percent in response to thermal stress.
- Vascular tone is subject to complex regulation by sympathetic nerves, acetylcholine, vasoactive peptides, and nitric oxide.
- Skin diseases and systemic medications may impair thermoregulation.



Copyright © 2008 by The McGraw-Hill Companies, Inc. Click here for terms of use.

gain, as when the person is in direct sunlight.

C = Convective heat gain or loss and is defined as heat exchange due to forced movement of a fluid, either liquid or gas. This component is responsible for the transfer of heat to the skin through skin blood flow and transfer from the skin to the environment by air or water movement. Within the body, the cardiovascular system is the major mediator of convective heat transfer. C is dependent on (1) body surface area, (2) temperature differences, and (3) fluid (or air) movement.

K = Conductive heat gain or loss and is defined as heat transfer by flow down a temperature gradient, as between tissues and blood, between blood and skin, and between skin and the environment. This is usually combined with convective heat transfer.

W = Useful mechanical work.

The sum of R, C, and K is determined by the temperature gradient between the skin and the environment. If ΔS is zero, the body is in heat balance. This thermoneutral condition is characterized by low skin blood flow of approximately 5 percent of cardiac output. Sweating does not occur.

If ΔS is less than zero, the body is losing heat, core temperature is falling, and thermoregulatory reflexes are evoked to conserve heat. Thermal stability is maintained through reduction of skin blood flow, which can approach zero during maximal vasoconstriction. Reduction in skin blood flow increases the thermal insulation between the body and the environment by minimizing losses through conductive (K), convective (C), and radiant (R) mechanisms. If heat loss continues despite low skin blood flow, metabolic generation of heat (M) through the shivering of skeletal muscle is initiated to restore and maintain core temperature. If, despite all these mechanisms, ΔS remains negative, core temperature will fall and potentially life-threatening hypothermia can result.

If ΔS is greater than zero, the body is gaining heat and core temperature is rising. Under this condition of heat stress, thermal stability is maintained by increases in skin blood flow to facilitate heat loss through conductive (K), convective (C), and even radiant (R) losses. If heat gain continues despite these mechanisms, sweating is evoked to increase heat loss through evaporation (E) of perspiration. If ΔS remains positive, blood flow is diverted from skeletal muscle and gastrointestinal beds, which provides for dramatic increases in skin blood flow. Sweat rate will also increase until maximal levels are achieved. If, despite maximal skin blood flow and maximal stimulation of sweating, ΔS remains positive, core temperature will rise and life-threatening hyperthermia (i.e., heatstroke) will occur.



THERMOREGULATION AND THE SKIN

Anatomic Considerations

The critical role of the skin in human thermoregulation is well understood. Thermoregulation is achieved through variations in blood flow and sweat production so as to maintain thermal stability. Without these variations, thermal stability cannot be maintained, which results in risk of hypothermia or hyperthermia (see Chaps. 93 and 94). Under normothermic conditions, skin blood flow ranges from 30 to 40 mL/minute/100 g of skin in resting humans. The cutaneous vasculature is exceedingly compliant, however, so that skin blood flow can vary from nearly zero during cold stress periods with maximal vasoconstriction to 8 L/minute over the body's surface during maximal vasodilation in heat stress.[1]

Blood vessels in the skin are arranged in several plexuses in superficial and deep layers parallel to the skin surface. Most vessels are in the superficial layer and consist of high-resistance terminal arterioles, papillary loops, and postcapillary venules. Papillary loops are true capillaries. Blood flow through the loops is controlled by highly innervated arterioles. The loops are located near the dermal-epidermal junction, a region characterized by a maximal thermal gradient because of its proximity to the skin surface. Because the papillary loops also have a large surface area, blood flow through these vessels is a major determinant of heat exchange through vasodilation during heat stress and vasoconstriction during cold stress.

Although papillary loops are found in both glabrous skin (palms, soles, and lips) and non-glabrous skin (most of the body's surface, including the limbs, head, and trunk), arteriovenous anastomoses (AVAs) are found mainly in glabrous skin. They represent direct connections between arterioles and venules that bypass the high-resistance arterioles and capillaries of the papillary loops. AVAs have thick muscular walls with rich noradrenergic innervation and lie deep to papillary loops.[2] Because of their deeper location in the dermis and smaller surface area, AVAs are less efficient in heat transfer than papillary loops. Although AVAs dilate in response to heat stress and constrict during mild to moderate cold stress, their major role is to mediate local vasodilation during prolonged cold exposure. AVA vasodilation delivers warm blood to maintain tissue temperature and thus tissue viability through cold-induced vasodilation.[3]

Sweat glands also play a major role in human thermoregulation (see Chap. 81). The critical thermoregulatory role of the eccrine sweat glands that are found over most of the body surface is well known. Clearly, the main function of eccrine sweat glands is to increase heat loss through the evaporation of sweat. The density of these glands varies from 700 glands/cm^2 in palmar and plantar skin to 64 glands/cm^2 on the back.[4] These glands may hypertrophy with repeated heat exposure.[5] Each gland is made up of a secretory coil found in the dermis with a duct that extends through the dermis and epidermis to the surface of the skin. Sweat is secreted as an isotonic fluid by the coils. NaCl is reabsorbed within the ducts, so sweat that is finally delivered to the surface is hypotonic.[6] Each liter of sweat evaporated is capable of removing 580 kcal from the body. Although apocrine sweat glands have been dismissed as "atavistic scent glands," this has now been questioned.[7] Apocrine glands are usually associated with hair follicles and are most developed on the scalp, face, upper back, and chest. It has been proposed that sweat from apocrine glands acts as a surfactant at high temperatures and thus facilitates dispersion of eccrine sweat over the skin's surface. At low temperatures, sebum may function to repel water from the skin and thus reduce heat loss.

Cutaneous Thermoregulatory Mechanisms

The cutaneous circulation is a major effector of human thermoregulation. During heat stress, elevated internal temperature and skin temperature lead to cutaneous vasodilation through neural mechanisms and the local effect of

higher temperatures on the skin vessels themselves. During periods of cold stress, reduced temperatures mediate a cutaneous vasoconstriction through neural as well as local vascular effects. Under normothermic conditions, skin blood flow averages approximately 5 percent of cardiac output; however, the absolute amount of blood in the skin can vary from nearly zero during periods of maximal vasoconstriction in severe cold stress to as much as 60 percent of cardiac output in severe heat stress.[1]

Sweating

Heat dissipation through the secretion and evaporation of eccrine sweat is critical to maintaining thermal stability in hot environments or during heat stress induced by strenuous dynamic exercise. Indeed, when environmental temperature exceeds blood temperature, the evaporation of sweat is the sole mechanism for heat dispersal. Sweat secretion is controlled by sympathetic cholinergic nerves that release acetylcholine onto muscarinic receptors on the glands. Cholinergic stimulation activates the glands to produce an isotonic fluid that becomes progressively hypotonic as the Na^+ is reabsorbed in the sweat gland duct by active ion transfer (see Chap. 81).

Neural Control Mechanisms of the Cutaneous Vasculature

In glabrous skin, cutaneous arterioles are innervated by sympathetic vasoconstrictor nerves[3,8–11] that release norepinephrine and other co-transmitters.[12–15] All thermoregulatory reflex changes in blood flow in these areas are caused by changes in noradrenergic vasoconstrictor activity and the effects of local temperatures on the skin blood vessels themselves.[3,9–11]

In non-glabrous skin, changes in skin blood flow are mediated by two branches of the sympathetic nervous system: noradrenergic vasoconstrictor nerves as found in glabrous skin, and a cholinergic active vasodilator system.[3,11,16] These dual sympathetic neural control mechanisms are the major effectors of thermoregulatory responses. Vessels in non-glabrous skin also respond to the effects of local temperature changes[3,11,16] (Fig. 92-1).

In normothermia, cutaneous arterioles are under little neural tone. During cold stress, reduction of skin temperature and/or internal temperature causes a thermoregulatory reflex-mediated reduction in skin blood flow to conserve body heat. Enhanced noradrenergic vasoconstrictor tone effects an arteriolar vasoconstriction and thus decreases skin blood flow. Conversely, during heat stress, thermoregulatory reflexes that facilitate body cooling are stimulated. As internal temperature continues to rise over a threshold value of approximately 37°C (98.6°F), a cutaneous vasodilation begins. At this threshold, active vasodilator tone to the cutaneous arterioles is enhanced. At rest, sweating also begins at the same internal temperature threshold. Vasodilator tone increases as internal temperature increases. Enhanced vasodilator activity decreases smooth muscle tone, which leads to arteriolar vasodilation and thus an increase in skin blood flow, especially through the papillary loops. High skin blood flow delivers heat to the body surface, where it is dissipated into the environment in conjunction with the evaporation of sweat. Overall, the active vasodilator system is responsible for 80 percent to 95 percent of the elevation in skin blood flow that accompanies heat stress. A small but significant portion of the vasodilation is mediated by the direct vasodilator effects of local heat on the cutaneous vessels[3,17] (see Fig. 92-1).

Dual vasoconstrictor nerves and vasodilator nerves in skin were first suggested in 1931 by Lewis and Pickering[18] and confirmed by Grant and Holling.[19] They measured skin temperature as an index of blood flow in the human forearm and found that large increases in response to heat stress could be abolished by sympathectomy or nerve blockade. They noted that although sympathectomy or nerve blockade caused only a slight cutaneous vasodilation during normothermia, heat stress elicited a much greater increase in skin blood flow. In addition, nerve blockade during established heat stress abolished any cutaneous vasodilation. These results suggested that cutaneous vessels in non-glabrous skin are innervated by sympathetic active vasodilator as well as sympathetic vasoconstrictor nerves. In the 1950s, their findings were confirmed by Edholm, Fox, and MacPherson[20] and by Roddie, Shepherd, and Whelan[21] In addition, it has been shown that bretylium tosylate (a pre-junctional noradrenergic neuronal blocking agent) abolishes the cutaneous vasoconstriction induced by cold stress but does not alter the vasodilator responses induced by heat stress.[22] This confirmed that dual efferent neural systems control the cutaneous arterioles: a noradrenergic vasoconstrictor system and a non-adrenergic active vasodilator system.

CUTANEOUS RESPONSES TO HEAT

Cutaneous Active Vasodilator Mechanisms

Despite the fact that the cutaneous active vasodilator system has been studied for many decades, the specific mechanisms by which this system functions are only partly understood.[18,19,23] Several hypotheses have been proposed for how active vasodilation in skin works, but none has been completely proven.

SUDOMOTOR ACTIVITY AND ACTIVE VASODILATION In the initial descriptions of cutaneous active vasodilation, it was noted that sweating and active vasodilation began at about the same time in a resting person subjected to heat stress.[19] This observation led to the hypothesis that the mechanism of cutaneous active vasodilation involved cholinergic sudomotor nerve activity.[19,24–26] Additional evidence that favored a close mechanistic relationship between active vasodilation and sweating came from observations of individuals with anhidrotic ectodermal dysplasia. Persons with this congenital anomaly lack sweat glands (see Chap. 82) and a cutaneous active vasodilator response to heat stress,[26] which makes such individuals extremely heat intolerant. Despite observations such as this, the precise relationship between sweat glands and active vasodilation remains poorly defined. Indeed, although it is clear that cholinergic sudomotor nerves control sweat glands, whether sudomotor and vasodilator nerves are one and the same or completely separate cholinergic nerves remains unknown.[27,28]

CO-TRANSMISSION AND CUTANEOUS ACTIVE VASODILATION One of the current areas of interest in thermoregulatory research is the nature of the co-transmitter (or co-transmitters) that effect active vasodilation (Fig. 92-2). Several studies support the involvement of vasoactive intestinal peptide (VIP) as a co-transmitter in active vasodilation.[30,35,36] This research tested whether active vasodilation is mediated, in part, by VIP co-released from cholinergic nerves with acetylcholine. The neuropeptide fragment VIP10-28 was administered by microdialysis to block the effects of VIP at VPAC1 and VPAC2 receptors. This agent was chosen





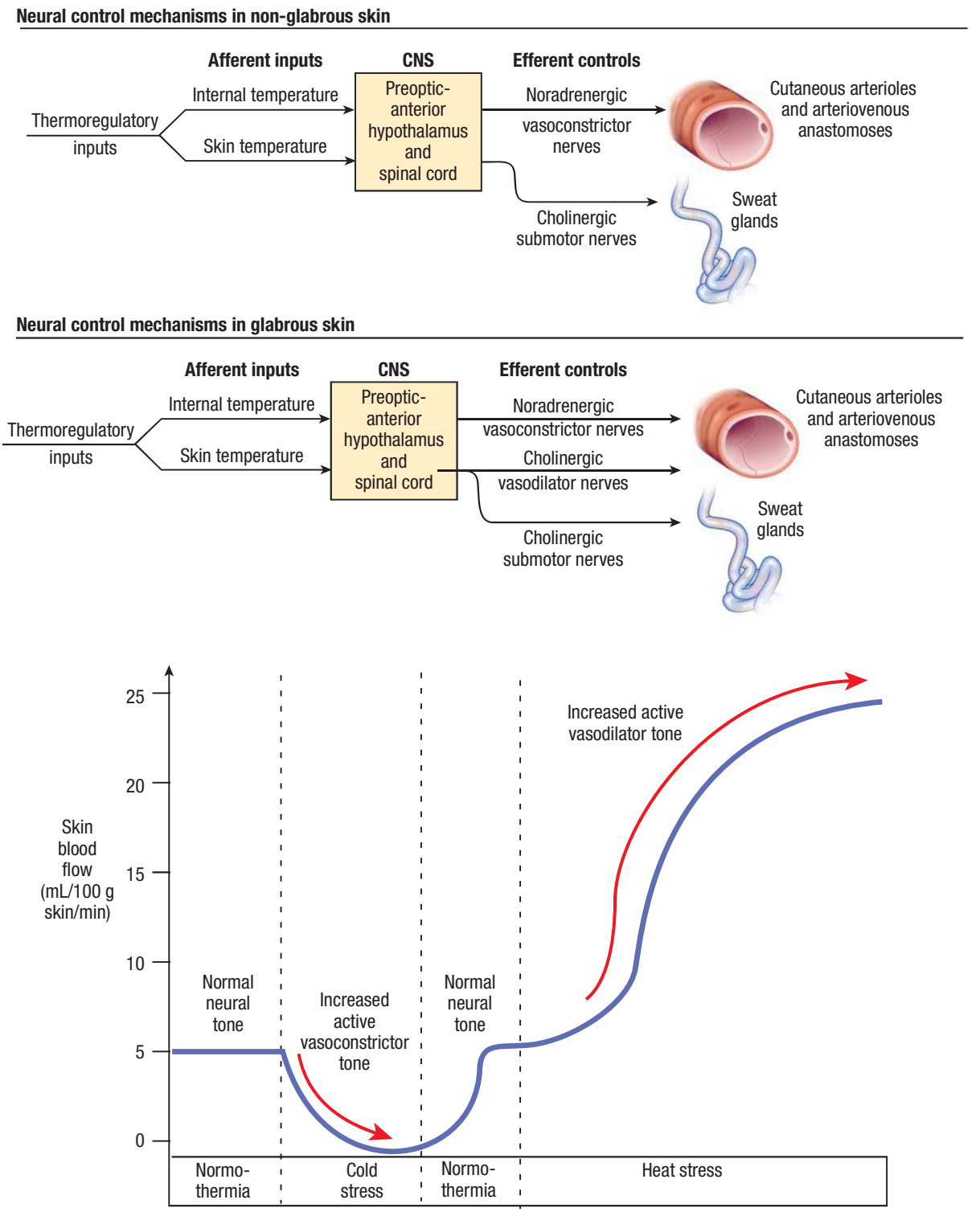

▲ **FIGURE 92-1** *Upper panels:* Summary of neural controls of thermoregulatory effectors in human skin. Thermoregulatory reflexes are mediated by the afferent inputs of internal and skin temperatures. These afferent inputs are integrated in the preoptic anterior hypothalamus and spinal cord areas of the central nervous system (CNS). Efferent control of blood vessels and sweat glands in glabrous skin is mediated by noradrenergic vasoconstrictor nerves and cholinergic sudomotor nerves, respectively. In non-glabrous skin regions, efferent control of blood vessels is effected through a system of dual sympathetic innervation: noradrenergic active vasoconstrictor nerves and cholinergic active vasodilator nerves. Sweat glands also receive cholinergic sympathetic innervation; however, whether cholinergic active vasodilator nerves and cholinergic sudomotor nerves are one and the same is not known. *Lower panel:* Skin blood flow responses to cold stress and heat stress in non-glabrous skin. Under normothermic conditions, skin blood flow is relatively low (approximately 5 percent of cardiac output) and skin vessels receive relatively minor neural inputs from active vasoconstrictor and vasodilator nerves. During cold stress, reductions of skin and internal temperatures lead to reflex increases in sympathetic noradrenergic vasoconstrictor nerve activity. Increased vasoconstrictor system tone reduces skin blood flow, thus increasing thermal insulation and conserving body heat. During heat stress, increasing skin and internal temperatures lead to reflex increases in sympathetic cholinergic active vasodilator nerve and cholinergic sudomotor activity. Increased activity of the vasodilator system leads to potentially dramatic increases in skin blood flow that can reach 60 percent of cardiac output. High skin blood flow delivers heat to the skin surface, where it is removed to the environment primarily through evaporation of sweat.

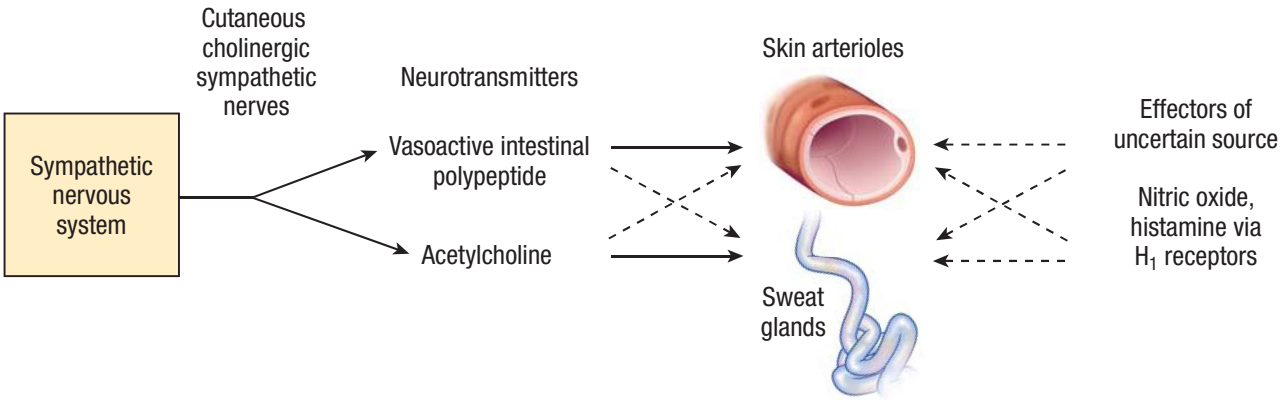

▲ **FIGURE 92-2** Summary of cholinergic active vasodilator co-transmitter system. Cutaneous active vasodilation is mediated by co-transmission. The classical neurotransmitter acetylcholine is released from cholinergic sympathetic nerves along with the neuropeptide co-transmitter vasoactive intestinal polypeptide and perhaps other co-transmitters. These neurotransmitters cause dilation of the cutaneous vasculature and activate sweating during periods of heat stress. The precise roles and interactions of acetylcholine and the co-transmitters in mediating thermoregulatory reflex responses to heat stress remain incompletely understood.



because it not only blocks the two major receptors for VIP, it also blocks the effects of peptide histidine methionine. These two neuropeptides share a close structural relationship, are formed from the same pre-propeptide, and are both reported to be present in human skin.[37] VIP10–28 attenuated (but did not abolish) the increase in skin blood flow during heat stress. Combining VIP10-28 with atropine did not enhance the degree of attenuation over that achieved with VIP10-28 alone. This finding showed a role for VIP in active vasodilation; however, because the effect of the combination of muscarinic receptor and VIP receptor blockade did not differ from the effect of VIP receptor blockade only, it was postulated that additional co-transmitters may well be involved in the process.[35,36]

NITRIC OXIDE AND ACTIVE VASODILATION

In the 1990s, a series of studies investigated the control of skin blood flow in the rabbit ear. Rabbits (and other lagomorphs) thermoregulate by actively dilating and constricting the blood vessels in their ears. Rabbits thus provided a possible animal model for study of the dual vasomotor controls of human nonglabrous skin. The studies in the rabbit ear showed a role for nitric oxide (NO) in thermoregulatory reflex-mediated active vasodilation.[38,39] This work provided the rationale to study and clarify roles for the NO system in cutaneous active vasodilation in humans.[40–42] Although initial work based on intra-arterial infusions of the NO synthetase (NOS) inhibitor NG-monomethyl-L-arginine (L-NMMA) was unable to establish such a role,[42] later work[40,43] used intradermal microdialysis to deliver NOS inhibitors NG-nitro-L-arginine-methyl ester (L-NAME) and L-NMMA into small areas of skin. These studies found that increases in skin blood flow caused by active vasodilation during heat stress were significantly attenuated but not abolished by NOS inhibition.[40,41,43] The results of these studies show that active vasodilation in skin requires functional NOS to achieve full expression.

The foregoing discussion of NO might lead one to believe that because "functional" NOS is required for active vasodilation, NO levels in skin must increase during heat stress to cause active cutaneous vasodilation. However, based on studies of how NO functions as a vasodilator in the rabbit ear during heat stress, a novel theory was proposed.[44] It had been noted that NOS antagonists abolished heat stress–induced active vasodilation in skin of the rabbit ear. Administration of low doses of the NO donor nitroprusside could restore ear skin vasodilation during heat stress despite NOS blockade; however, the same dose of nitroprusside infused into the ear circulation in normothermia did not raise ear blood flow at all. The implication was that active vasodilation in the rabbit ear required the presence of NO and activation of vasodilator nerves, but that these two elements were not arranged in series. This led to the idea that vasodilator nerve activity did not increase NO production, but rather that NO needed to be present to permit another neurotransmitter to effect increases in ear skin blood flow. It was thus proposed that NO played a "permissive" role in the active vasodilation rather than serving as an actual effector of the process; that is, NO had to be present for vasodilation to be effected by another neurotransmitter, but the absolute level of NO did not increase in heat stress.

An initial test of this proposal in human skin examined whether increased levels of NO breakdown products could be found in skin during hyperthermia, but no such increases were found.[45] This suggested that NO acted as a permissive factor rather than as an effector of cutaneous active vasodilation. However, the study of NO breakdown products is fraught with problems. Subsequent examinations of NO changes in heat stress were performed by measuring bioavailable NO by means of NO-selective amperometric electrodes in vivo.[46] This technique measures bioavailable NO directly from the tissue of interest. In contrast to the results of the initial study based on NO breakdown products, it was found that both skin blood flow and bioavailable NO concentrations increased during heat stress. This proved that NO does increase in skin during heat stress in humans, attendant to active vasodilation. This result suggests that NO has a role beyond that of a permissive factor in cutaneous active vasodilation. Rather, because NO increases in heat stress, it could well be an effector of cutaneous vasodilation during heat stress.[46–49]

Additional evidence in favor of NO as an active effector of cutaneous active vasodilation came from more recent work using an "NO-clamp" technique.[50] Intradermal microdialysis was used to deliver a combination of the NOS inhibitor L-NAME and the NO donor nitroprusside into skin. The effect of this combination was to "clamp" NO at a constant level—that is, NO was present but could not increase because of NOS blockade. When NO levels were clamped and not allowed to increase, active vasodilation during heat stress was attenuated. This finding showed

that NO did not act permissively, but rather was an active effector of vasodilation. It is thus clear that NO production increases during heat stress and that NO acts as an actual effector of cutaneous active vasodilation.

It should be noted that all of the foregoing work on NO in human skin was done in non-glabrous skin. This type of skin has a paucity of AVAs. In contrast, the skin of the rabbit ear is rich in AVAs. It may well be that NO plays a permissive role in AVA dilatation but not dilatation of the papillary loops of non-glabrous skin.

Another question about the role of NO in active vasodilation involves the factors that mediate increased production of NO during heat stress. One hypothesis was that acetylcholine from cholinergic nerves increased NO levels via muscarinic receptor stimulation.[51] This was investigated by examining the effects of combined muscarinic receptor blockade by atropine with NOS blockade by L-NAME on vasodilation during heat stress. These agents were given after activation of the active vasodilator system in prolonged heat stress, when skin blood flow had already risen significantly. Although atropine was found to have little effect on skin blood flow, L-NAME was found to significantly reduce skin blood flow during established active vasodilation in prolonged heat stress. This showed that although production of NO was required for active vasodilation, muscarinic receptor–mediated NO production was not needed to sustain active vasodilation during the late, established phase of heat stress.[51]

Subsequent work has examined whether muscarinic receptor activation leads to NO production *early* in heat stress.[52] Based on results of earlier studies showing that atropine delayed the onset of active vasodilation during heat stress, it was postulated that acetylcholine contributed to active vasodilation through muscarinic receptor–mediated NO production early in the process. To test this hypothesis, the effect of a combination of acetylcholinesterase inhibition with neostigmine (to magnify the agonist effects of acetylcholine) and NOS blockade with L-NAME (to abolish NO effects) on active vasodilation was examined. Neostigmine and L-NAME were delivered before initiation of body heating, when the active vasodilator system was quiescent, and continued throughout the early and late periods of heat stress. The results showed that early in body heating (when skin temperature was increased but internal temperature was not), skin blood flow increased sooner at sites treated with neostigmine (with presumably augmented acetylcholine levels). The augmenting effects of acetylcholinesterase inhibition was abolished by NOS inhibition. Late in heat stress, when active vasodilation was well established, the effect of neostigmine was lost, but skin blood flow at L-NAME–treated sites was attenuated. These results suggested that acetylcholine mediated the increase in NO production early in heat stress, but not after substantial cutaneous vasodilation had occurred.[52]

Evidence has been reported that H_1 receptors for histamine may play a role in the generation of NO during cutaneous active vasodilation in heat stress.[53] Administration of the first-generation antihistamine pyrilamine attenuated, but did not abolish, the rise of skin blood flow during heat stress. In addition, it was found that the NO generated during active vasodilation was mediated by H_1 receptor activation. Thus, there appear to be several pathways that may generate NO in the skin during heat stress.

Local Warming of the Skin and Vasodilation

The foregoing section outlined thermoregulatory reflex responses to heat that are mediated primarily by the sympathetic nervous system. Skin vessels themselves also respond directly to changes in local temperature. For example, in response to increases in local skin temperature, cutaneous blood vessels dilate. This dilation is accomplished by purely local temperature-dependent mechanisms, the effects of which are in addition to the previously discussed neural effects.

With local warming of skin, local skin blood flow increases in direct proportion to the temperature achieved. If heating is continued at a maximally tolerable level of 42°C to 44°C (107.6°F to 111.2°F) for 35 to 55 minutes, maximal local skin blood flow can be achieved.[54] The local vasodilation is biphasic with an initial brisk vasodilation. This initial dilation rapidly reaches a peak and is followed by a slight fall in flow. With continued heat application, a second dilation occurs that can reach maximal levels in a prolonged plateau phase. For unknown reasons, the plateau phase declines after approximately 1 hour despite continued heating[55] (Fig. 92-3).

The mediators of the local, temperature-dependent cutaneous vasodilation involve both local sensory nerve axon reflex mechanisms and the local generation of NO. These two mechanisms appear to be independent of each other.[56] The previously discussed neural cutaneous active vasodilator system does not appear to be involved in this local response, because neither botulinum toxin–induced abolition of active vasodilation nor muscarinic receptor blockade with atropine alter the skin blood flow response to local skin heating.[30,57] Prostanoids do not appear to be involved either, because cyclooxygenase inhibition has no effect on the vasodilation induced by local skin heating.[57]

The initial phase of the local warming response produces a brief peak value and is mediated by local activation of afferent cutaneous sensory nerves. This initial phase of the vasodilation can be greatly attenuated by the application of a topical anesthetic directly to the heated site. Cutaneous nerve blockade at points distant from the heated site that interrupt sensory nerve function at the heated site have no effect.[56,58] This demonstrates that the initial effects of local skin heating are mediated by a neural axon reflex mechanism. The specific neurotransmitters involved in local heating responses are uncertain; however, based on studies done with topical application of the vanilloid receptor (VR-1) activator capsaicin. It has been proposed that local increases in skin temperature stimulate heat-sensitive VR-1 receptors on afferent nerves. This activates the local axon reflex to cause the antidromic release of a vasodilatory neurotransmitter (or neurotransmitters) that mediates local vasodilation.[59]

The prolonged plateau phase of vasodilation in response to local skin heating is mediated by local generation of NO. The plateau phase can be greatly attenuated by pretreatment of the locally heated area of skin with NOS inhibitors[48,56]; thus NO generation is clearly necessary for this phase. Evidence suggests that endothelial NOS (eNOS, type III NOS) is the isoform that mediates increased NO production. Heat shock protein 90 (HSP90) has been shown to bind eNOS, enhance eNOS activation, and thus increase NO generation.[60] Treatment of skin with the HSP90 inhibitor geldanamycin attenuates the plateau phase of local skin heating by approximately 20 percent. This suggests that eNOS may be the NOS isoform that mediates the prolonged plateau phase of



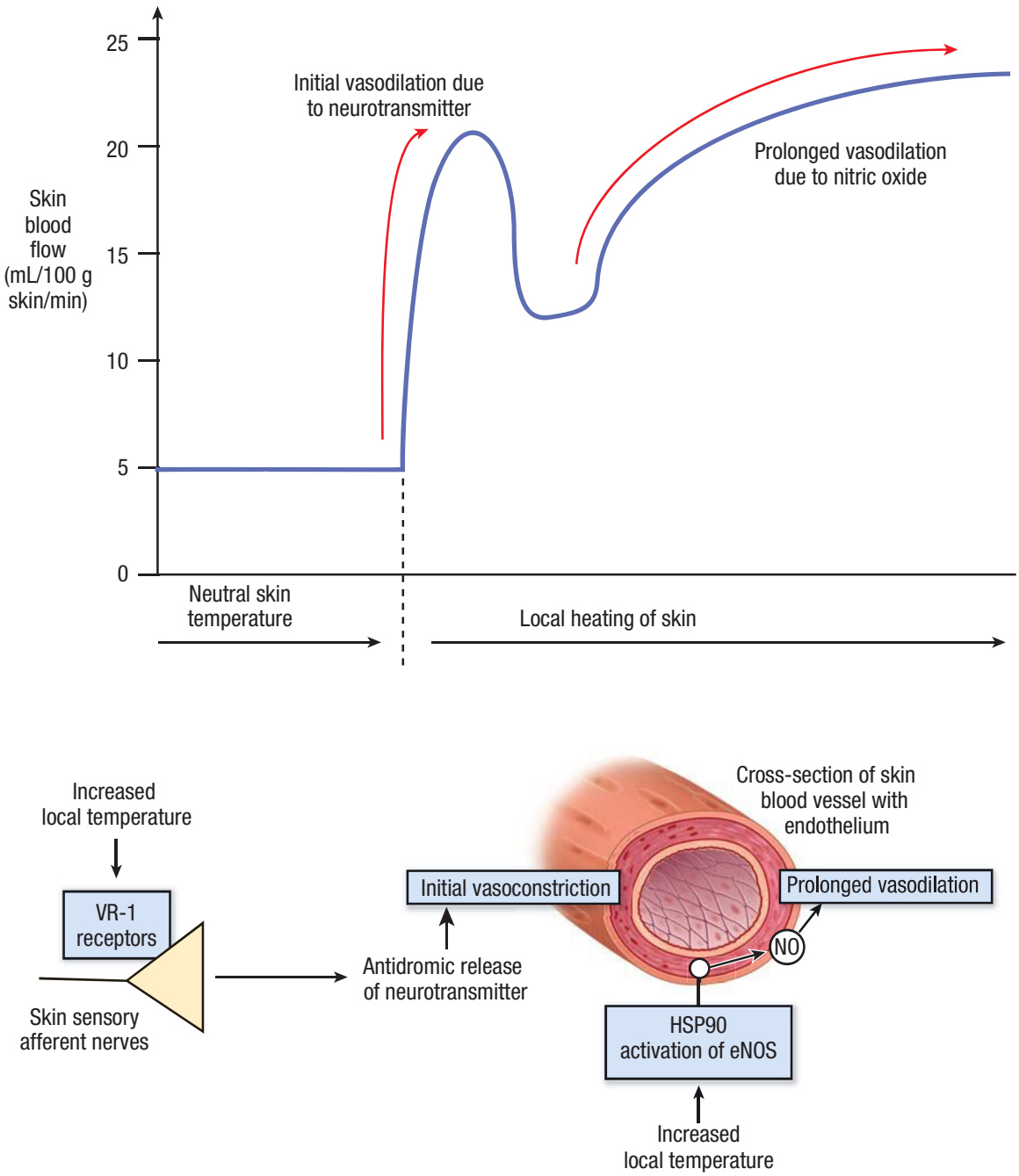

▲ **FIGURE 92-3** Local heating responses and vasodilator mechanisms in human skin. Increases in local temperature result in a biphasic vasodilation of skin blood vessels. The first phase consists of a prompt increase in skin blood flow that is mediated by temperature-sensitive vanilloid receptor 1 (VR-1) receptors. When heated, these VR-1 receptors cause antidromic release of neurotransmitter from afferent sensory nerves. The second phase consists of a skin blood flow plateau. This phase is observed with prolonged warming of the skin and is mediated by nitric oxide (NO). The generation of NO appears to involve heat shock protein 90 (HSP90) activation of endothelial nitric oxide synthase (eNOS). The effects of local temperature increases are independent of any changes in internal temperature. None of the responses to local heating of the skin depends on the presence of cutaneous active vasodilator nerves.

the cutaneous vascular response to local skin heating[61] (see Fig. 92-3).

CUTANEOUS RESPONSES TO COLD

Cutaneous Active Vasoconstrictor Mechanisms

Initial evidence for the control of skin blood vessels by sympathetic active vasoconstrictor nerves came from observations of the effects of peripheral sympathectomies in humans.[8,11,62] In these studies, the interruption of sympathetic nerve signaling by sympathectomy led to increases in skin blood flow when the intervention was done in a cool environment. This observation was consistent with the relaxation of cutaneous blood vessels and hence passive increases in blood flow after interruption of vasoconstrictor activity.

The sympathetic vasoconstrictor system in skin is well understood and causes vasoconstriction through noradrenergic stimulation of α_1- and α_2-adrenergic receptors.[8,11,19,20,63–67] This has been clearly demonstrated by studies using pre-junctional sympathetic nerve

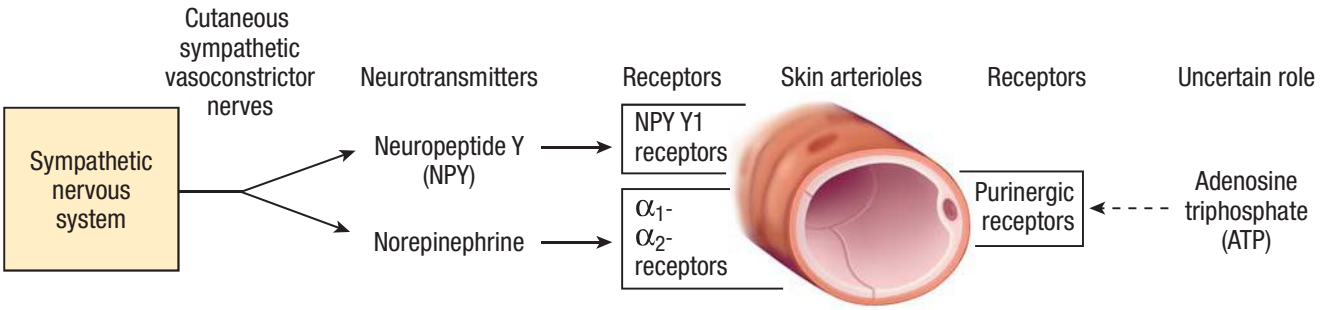

▲ **FIGURE 92-4** Summary of noradrenergic active vasoconstrictor co-transmitter system. Cutaneous active vasoconstriction is mediated by co-transmission. The classical neurotransmitter norepinephrine is released from noradrenergic sympathetic nerves along with the neuropeptide co-transmitter neuropeptide Y (NPY). Norepinephrine acts on α_1- and α_2-adrenergic receptors on the vascular smooth muscle of cutaneous arterioles to cause vasoconstriction. The neuropeptide co-transmitter NPY is also involved in active vasoconstriction of skin vessels through its action on post-junctional NPY Y1 receptors.



blockade and post-junctional blockade with α-receptor antagonists.[22,64,68,69]

Sympathetic nerves in skin have now been revealed to contain several different neurotransmitters co-localized with norepinephrine, including neuropeptide Y (NPY) and adenosine triphosphate. This suggests that the sympathetic vasoconstrictor system could be a co-transmitter system. In studies that compared the effects of differing combinations of α_1- and α_2-adrenergic agents on skin vasoconstriction during cold stress it was noted that the vasoconstriction was attenuated. These results confirmed a role for post-junctional excitation of α_1- and α_2-adrenergic receptors. It was also noted that pretreatment of skin with the β-receptor antagonist propranolol led to a more profound vasoconstriction during cold stress. This suggested that a β-receptor–mediated vasodilation modulated an α-receptor–mediated vasoconstriction during whole body cooling. It is interesting to observe, however, that simultaneous and complete blockade of α_1-, α_2-, and β-receptors fails to abolish the cutaneous vasoconstriction induced by cold stress, although blockade of all neurotransmitter release from cutaneous noradrenergic nerves with bretylium tosylate does abolish the response. These studies suggest that non-noradrenergic, co-transmitter mechanisms mediate the cutaneous vasoconstriction during cold stress.[70]

The observation that cold stress responses in skin are mediated by a co-transmitter system has led to studies designed to identify the co-transmitters of that system. It was proposed that NPY acted as a co-transmitter along with norepinephrine to mediate reductions in skin blood flow during cold stress. It was hypothesized that NPY worked through activation of NPY Y1 receptors on cutaneous arterioles. Administration of the NPY Y1 antagonist BIBP-3226 was found to significantly attenuate reductions in skin blood flow during whole body cold stress. Further, the combination of NPY Y1 receptor antagonism with complete α_1-, α_2-, and β-receptor blockade abolished reductions in skin blood flow during cold stress. These results clearly demonstrate that the cutaneous active vasoconstrictor system is a co-transmitter system that works via the release of NPY and norepinephrine. These neurotransmitters cause the post-junctional activation of NPY Y1, α_1-, α_2-, and perhaps β-receptors which in turn constricts cutaneous arterioles, reduces skin blood flow, and thus conserves body heat during cold stress[71] (Fig. 92-4).

Local Cooling of the Skin and Vasoconstriction

Decreases in skin temperature with local cooling of the skin cause a local, temperature-dependent vasoconstriction. Although the vasodilatory response to local heating of the skin is independent of the cholinergic cutaneous active vasodilator system, the vasoconstriction mediated by local skin cooling is dependent on intact noradrenergic active vasoconstrictor nerves.[58,72,73] Confirmatory studies used bretylium tosylate to block neurotransmitter release from pre-junctional noradrenergic nerve terminals in skin. When noradrenergic nerves are intact, local cooling causes a prompt and progressive reduction of skin blood flow as local temperature falls. Interruption of neurotransmitter release with bretylium changes the initial portion of the local cooling response from a prompt vasoconstriction into a prompt vasodilation. The vasodilation induced by local cooling is transient and continued local skin cooling leads to the progressive diminution of the vasodilation and eventual replacement by a progressive vasoconstriction[58,68,73] (Fig. 92-5).

Research studies have defined how the cutaneous active vasoconstrictor system participates in the vasoconstriction caused by local skin cooling and established roles for noradrenergic receptors, NPY Y1 receptors, and afferent sensory nerves.[72] It was observed that blockade of α-receptors in skin altered the local cooling vasoconstriction in the same way that bretylium did; that is, combined α- and β-receptor blockade reversed the initial phase of vasoconstriction into a vasodilation followed eventually by vasoconstriction with continued local cooling. Topical anesthesia with EMLA cream (a eutectic mixture of lidocaine and prilocaine) also reversed the initial vasoconstriction to a dilation followed again by constriction with prolonged cooling. NPY Y1 receptor blockade with BIBP-3226 had no effect on the response to local cooling. Based on this work, it is clear that local cooling of skin occurs in two phases: an initial rapid phase lasting a few minutes, and a prolonged late phase. The initial phase is caused by activation of cold-sensitive afferent neurons that mediate release of norepinephrine from sympathetic cutaneous vasoconstrictor nerves. The released norepinephrine vasoconstricts cooled skin vessels through post-junctional α-receptors. NPY Y1 receptors do not appear to be involved in either phase of the local cooling response. The mechanisms for the prolonged, late vasoconstrictor phase of cooling appear to be non-neurogenic, because no manipulations alter this portion of the response.[72]

A significant role for α_2-receptors in causing the cutaneous vasoconstriction by local skin cooling has been proposed.[74–79] For example, local skin cooling increases α_2-adrenergic receptor–mediated vasoconstriction. In contrast, local cooling does not augment constriction mediated by α_1-adrenergic receptors.[80] In mouse skin, it has been shown

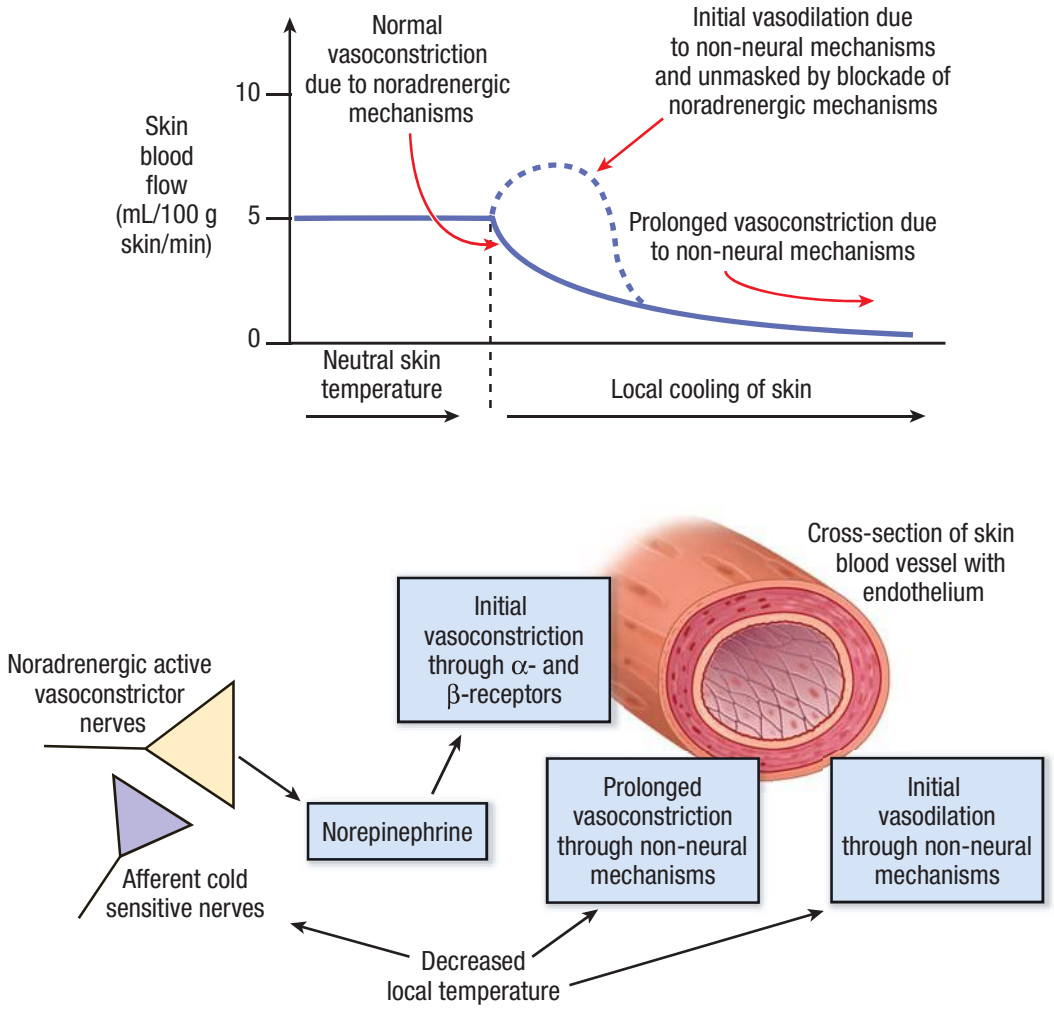

▲ **FIGURE 92-5** Local cooling responses and vasoconstrictor mechanisms in human skin. Decreases in the local temperature of skin blood vessels induce a local vasoconstriction through mechanisms that require intact sympathetic noradrenergic innervation. The effects of local temperature reductions are independent of any changes in internal temperature. Reductions in local skin temperature are sensed by cold-sensitive afferent nerves. These afferent nerves mediate the release of norepinephrine from adjacent sympathetic active vasoconstrictor nerves. Norepinephrine stimulates α- and β-receptors to cause an initial vasoconstriction. Local cooling can also mediate an initial vasodilation that competes with and buffers the extent of the initial noradrenergically mediated vasoconstriction. The competing dilation is mediated through non-neural mechanisms and is only observed when release of norepinephrine or its post-junctional effects is blocked. Protracted local cooling of the skin results in a prolonged vasoconstriction that is also mediated by non-neural mechanisms. The nature of the non-neural mechanisms is unknown.

that local cooling causes augmented noradrenergic constriction through α_{2C}-adrenergic receptors.[77] Although these receptors are not directly thermosensitive themselves, they have been found to be translocated from the trans-Golgi apparatus of vascular smooth muscle cells to the plasma membrane through the cold-induced activation of RhoA and Rho kinase.[75,76] In this way, more α_{2C}-receptors appear on the surface of vascular smooth muscle. In addition, activation of these kinases enhances the calcium sensitivity of the vascular smooth muscle contractile apparatus. These factors explain how local cooling causes the response of vasoconstriction.[75]

The generation of reactive oxygen species (ROS) from mitochondria in vascular smooth muscle appears to have a role in the vasoconstriction induced by local cooling. Cooling of mouse tail skin arteries leads to increased ROS generation in vascular smooth muscle cells. Alteration of ROS levels by application of free radical scavengers abolishes the vasoconstrictor response to α_{2C}-adrenergic receptor stimulation. Manipulation of ROS levels also abolishes the activation of RhoA in cultured human vascular smooth muscle cells. Taken together, these results suggest that the vasoconstriction caused by local cooling is due to enhanced ROS generation in mitochondria of vascular smooth muscle. Increased ROS then activates RhoA/Rho kinase, which causes a consequent movement of α_{2C}-adrenergic receptors to the cell membrane. On reaching the cell surface, α_{2C}-adrenergic receptors can be activated by norepinephrine released by sympathetic neurons and cause vasoconstriction.[76]

FACTORS THAT ALTER RESPONSES TO HEAT AND COLD

Thermoregulatory responses undergo a physiologic acclimatization after repeated thermal challenges over a prolonged (2-week) period. In general, physiologic acclimatization to hot environments is much more effective than adaptations induced by cold environments in promoting thermal stability. Indeed, after repeated exposure to a hot environment, sweat glands hypertrophy to produce more sweat. Cutaneous active vasodilation begins at lower internal and skin temperatures as well. Both of these adaptations facilitate long-term

thermal stability by favoring earlier and greater heat dissipation.[81] Humans also acclimate to cold environments after repeated exposure. These adaptations include increased metabolic heat generation and habituation to cold, but they are less effective in promoting thermal stability than adaptations to heat.[82]

Acute and chronic dermatologic disorders can impair thermoregulatory stability. For example, sunburn compromises sweat production, thus impairing evaporative cooling and reducing heat tolerance. At the same time, the inflammatory vasodilation that accompanies sunburn can compete against thermoregulatory reflex vasoconstriction during cold exposure. This will compromise the ability of thermoregulatory reflexes to reduce skin blood flow and conserve body heat, and thus reduce cold tolerance.[81]

Medications are also a major factor in altering thermal tolerance, especially during heat exposure. Numerous medications used in clinical medicine, both prescription and over-the-counter drugs, have cholinergic-antagonist properties. Given that the cutaneous active vasodilator system and sweat glands are both controlled by cholinergic sympathetic nerves, it is not surprising that anticholinergic agents have deleterious thermoregulatory consequences. Examples of commonly used medications that can compromise heat stress responses include first-generation antihistamines, H_2-receptor antagonists, tricyclic antidepressants (see Chap. 230), and most agents used to treat Alzheimer disease. These systemic agents (and many others) can reduce sweat secretion, attenuate cutaneous active vasodilation, and hence impair thermoregulation, which increases the risk of heat stroke.[83]

KEY REFERENCES

The full reference list for all chapters is available at www.digm7.com.

3. Johnson JM, Proppe DW: Cardiovascular adjustments to heat stress. in *Handbook of Physiology, Section 4: Environmental Physiology*, edited by Fregly M, Blatteis C. New York, Oxford University Press, 1996, p 215
18. Lewis T, Pickering GW: Vasodilation in the limbs in response to warming the body; with evidence for sympathetic vasodilator nerves in man. *Heart* **16**:33, 1931
19. Grant RT, Holling HE: Further observations on the vascular responses of the human limb to body warming; evidence for sympathetic vasodilator nerves in the normal subject. *Clin Sci* **3**:273, 1938
20. Edholm OG, Fox RH, MacPherson RK: Vasomotor control of the cutaneous blood vessels in the human forearm. *J Physiol Lond* **139**:455, 1957
21. Roddie IC, Shepherd JT, Whelan RF: The contribution of constrictor and dilator nerves to the skin vasodilation during body heating. *J Physiol Lond* **136**:489, 1957
30. Kellogg DL Jr et al: Cutaneous active vasodilation in humans is mediated by cholinergic nerve co-transmission. *Circ Res* **77**:1222, 1995
83. Charkoudian N: Skin blood flow in adult human thermoregulation: How it works, when it does not, and why. *Mayo Clin Proc* **78**:603, 2003



CHAPTER 93

Cold Injuries

Gérald E. Piérard
Frédérique Henry
Claudine Piérard-Franchimont

The human capacity for physiologic adaptation to cold is minimal. This deficiency may cause problems, because seasonal changes in the outdoor environment are quite prominent, even in the temperate zones of the world. In this context, skin is important in thermoregulation, and cutaneous blood flow and the resulting skin temperature may vary widely to help preserve the core body temperature.[1,2] Physiologic, behavioral, and environmental factors modulate skin responses to cold exposure.

PHYSIOLOGIC RESPONSE TO COLD

Core body temperature is maintained within a narrow range by thermoregulatory mechanisms that rely largely on control of the cutaneous blood flow. Arteriovenous anastomoses are abundant in acral areas, and they regulate the volume of blood that passes through the skin. When the skin is cooled, there is usually an immediate acute reduction in the amount of blood that flows to the surface. These events alter skin temperature, heat loss, and color. Skin reactivity and the anatomic pattern of blood supply differ in the skin of newborns, adults, and older people. For instance, a reticulate appearance of cooled skin is a common finding in young infants (Fig. 93-1).

The parallel arrangement of large arteries and veins in the limbs allows countercurrent exchange of heat. Vasoconstriction due to cold results in shunting of blood from the superficial to the deep venous system, and heat is transferred from arteries to veins. Thus the blood going to the acral part of the limbs is precooled, and less heat is lost to the environment. With such thermoregulation, the body can maintain a constant core temperature of approximately 37°C (98.6°F) over a range of external temperatures between 15°C and 54°C (59°F and 129.2°F).



▲ **FIGURE 93-1** Reticulate appearance of cooled skin in the newborn due to the anatomic pattern of the blood supply and factors influencing flow, such as arteriolar vasoconstriction and the increased viscosity of cooled blood.

Normally, the skin is to some extent adapted to a cooler environment than the 37°C (98.6°F) of internal organs. Given the presence of many cold-adapted enzymes, the skin may even function more effectively when slightly cooled. In the case of adipose tissue, mild long-term exposure to cooling may lead to progressively better insulation. Habitually cold-exposed skin also develops a more efficient system for shunting blood away from the surface. These adaptive mechanisms are most flexible during the first years of life. Tissues in the aged are less able to develop new shunts.

The effect of swimming in cold water after extreme heating—for example, after using a sauna[3]—is somewhat comparable to accidental cold water immersion. Well-being depends substantially on the degree of subcutaneous insulation, so that overweight persons, as well as those

COLD INJURIES AT A GLANCE



- Skin is important for maintaining core body temperature within a narrow physiologic range.
- Cold weather, wind, humidity, dampness, and altitude combine to inflict skin damage.
- Nonfreezing and freezing conditions can both produce cold injuries.
- Frostbite occurs after exposure to intensely cold air, liquids, or metals. Several degrees of frostbite are recognized.
- Winter xerosis and acrocyanosis are common consequences of prolonged exposure to cold.
- Erythrocyanosis tends to occur over skin areas with thick adipose tissue, whereas chilblain is more frequently seen in lean persons.
- Cold urticaria is rare and occurs at sites of localized cooling.
- Primary erythromelalgia is a rare neuropathic disorder to which there is a genetic predisposition.

who are well clothed, can survive prolonged accidental cold water exposure.[4]

Viscosity of fluids generally increases as temperature decreases. However, blood is a non-newtonian fluid that exhibits thixotropy; that is, it becomes less viscous with increasing flow velocity, independent of temperature. This effect is strongly influenced by hematocrit and by packing of erythrocytes. Macrophages also can block capillaries when they develop pseudopods as a result of reduced flow. The combination of slow flow and leukocyte conformational changes is, in part, a physiologic process that enables these cells to migrate through the endothelial lining.[5] Other factors affecting blood viscosity include increased platelet adhesiveness, changes in concentrations of proteins, and the presence of abnormal proteins. Fibrinogen level is particularly important.

THERMOREGULATION AND HUNTING REACTION

Local and systemic thermoregulation is complex. A group of neurons in the hypothalamus responds directly to temperature. When the temperature decreases, the rate of discharges decreases. From this temperature-sensitive area, signals radiate to various other portions of the hypothalamus to control either heat production or heat loss. Stimuli that influence the autonomic nervous system, such as painful stimuli, mental stress, arousal stimuli, and deep breaths, can all produce cutaneous vasoconstriction in warm subjects but vasodilation in cold subjects.[6,7]

Cold exposure produces an initial massive cutaneous vasoconstriction, which results in a fall in skin temperature. This change serves to maintain core temperature, but at the expense of the skin. Conversely, cold-induced vasodilation represents a protective mechanism to prevent skin necrosis. This physiologic reflex, known as the *hunting reaction of Lewis*, involves transient cyclic vasodilation caused by the opening of arteriovenous anastomoses.[8,9]

COLD, WIND, HUMIDITY, AND ALTITUDE

A cold environment can be a threat to the skin, leading to a subsequent fall in core body temperature. Many physiologic, behavioral, and environmental factors predispose to the global effects of cold injuries. Marked increases in convective, conductive, or radiant heat loss are responsible for the immediate effects of cold exposure. For instance, touching cold metal objects considerably increases conductive cooling. Other predisposing factors increasing heat loss and/or decreasing heat production and insulation from clothing make people especially susceptible to cold.[10]

There is ample evidence that the effect of low temperature on skin biology is, in part, a function of environmental humidity, wind speed, and altitude. In this respect, the wind chill index is indicative of the convective heat loss. Wind chill affects the gradients of temperature and water content across the stratum corneum, which result in an imbalance in condition between outer and deeper epidermal layers.[11] High altitude, which reduces the oxygen supply to tissues, also contributes to increase the skin damage induced by cold.[12]

Environmental humidity is a key factor affecting cold injuries. This parameter indicates the mass of water vapor present in a unit volume of the atmosphere. An accurate representation of the amount of moisture in the air as a function of temperature is given by the calculation of the dew point,[13] which is defined as the temperature of the air at which the gaseous moisture begins to condense, that is, the temperature at which relative humidity reaches 100 percent.

Poor clothing insulation is a common reason for cold injuries. The insulation can be insufficient when clothing is too light, wet, tight, permeable to wind, or inadequate to cover the cold sensitive body parts. Individual factors predisposing to cold injuries are physical injuries, leanness, low physical fitness level, fatigue, dehydration, previous cold injuries, sickness, trauma, poor peripheral circulation, the wearing of tight constrictive clothing, and old age.[10] Newborns, the elderly, and individuals with impaired mental faculties remain the most vulnerable. Injury is often increased by alcohol, smoking, and psychotropic drug use.

Severe cold injuries have historically influenced the outcome of battles and wars.[14–16] Peacetime military operations also impose risks.[16,17] However, cold injuries are becoming more prevalent among the general population.[18] Many cases are associated with alcohol consumption, homelessness in urban centers, and car breakdown. Frostbite also prevails among winter sport enthusiasts, such as cross-country skiers and backpackers who get lost or trapped in a snowstorm.[2,19–22]

Adaptation to cold protects one from responding inappropriately, and a moderate degree of exposure to cooling might be health promoting by stimulating a responsive and protective vasculature. In contrast, individuals who have experienced severe cold injury may have a profoundly delayed or abolished hunting reaction in the affected limbs.[23] They are rendered more susceptible to recurrent cold injury with pain, hyperesthesia, or paresthesia.[24] Some of these individuals also have coldness of the skin, which is very persistent and probably related to a functional imbalance in the sympathetic nervous system that results from increased α-adrenergic receptor density or affinity for norepinephrine.[25] In addition, altered vascular structure may reduce vasocompliance after cold exposure. There may also be impairment of normal vascular reflexes to various stimuli, including deep inspiration, venous occlusion, neck cooling, and ipsilateral skin cooling.[25]

CLASSIFICATION OF SKIN COLD INJURIES

Freezing and nonfreezing injuries can be distinguished according to the severity



and duration of chilling. However, the damage caused depends on many variables other than the actual temperature. Skin conditions caused by cold temperature are not uncommon. Recognition is generally easy at a clinical level, but awareness of potential uncommon underlying disorders is important. Treatment, both physical and pharmacologic, is aimed at keeping the body warm and maintaining vasodilation.

Frostbite is the consequence of extreme and prolonged freezing conditions. In addition, the whole body may cool down so much that life-threatening hypothermia may ensue. This is an important concern for people who enjoy cold weather sports, particularly in mountains and circumpolar regions. Prompt recognition and treatment are of paramount importance, because many hypothermia victims can recover from very low body temperatures. Treatment in an adequate medical facility can make the difference between full recovery and lifelong problems. Even if the victim appears to be dead from exposure to cold, resuscitative efforts should be started and continued until the proper core body temperature is reached.[26]

Extreme and often conductive heat loss at a given body site freezes the tissues and results in localized blistering and necrosis (Fig. 93-2). Several cutaneous disorders also occur when the tissue temperature is maintained just above freezing for long periods. These conditions include chilblains, cold urticaria, cold panniculitis, erythrocyanosis, and acrocyanosis, among others. These disorders may be a consequence of impaired blood flow, reduced sensory perception, or a change in the physical properties of the tissues, such as in adipose tissue.



▲ **FIGURE 93-2** Hemorrhagic bulla and necrosis of the skin induced by freezing a wart with liquid nitrogen.

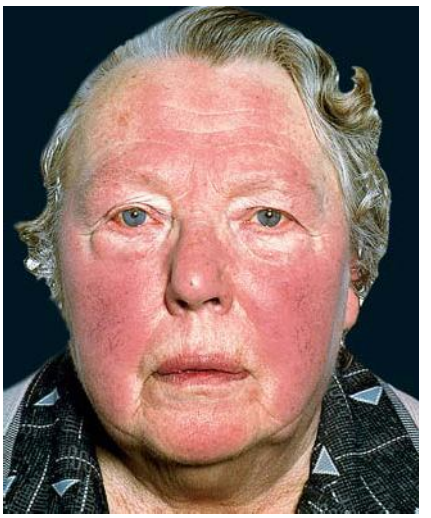

▲ **FIGURE 93-3** Facial redness in a person exposed to cold winters in a temperate climate.

Minor but long-term cold exposure combined with environmental desiccation may have profound effects on the biology of the epidermis, leading, for example, to winter xerosis.[27,28] Persistent erythema of the face and the hands is not a rare finding (Fig. 93-3).

FROSTBITE

Frostbite occurs when tissue freezes after exposure to extremely cold air, liquids, or metals. The clinical effects of accidental injury that leads to the death of tissues are similar to those caused by cryosurgery.[29] The components of tissue that may lead to damage when frozen are water, with formation of ice crystals at 0°C (32°F), and lipids such as fat globules or cell membrane constituents.

The rate of freezing determines the site of injury at the cellular level.[30] Extracellular formation of ice occurs most commonly with slow freezing, whereas fast freezing tends to produce intracellular ice. The formation of ice crystals in the extracellular space alters the osmotic properties of the tissues and disturbs the flow of water and electrolytes across the cell membranes. Thawing may be as damaging as the freezing itself, and repeated freeze and thaw cycles, as may occur in accidental injury, compound the damage, making more water available, which rapidly leads to intracellular flooding. The rewarming rate is also important. In slow rewarming, ice crystals become larger and more destructive. Cells are also exposed to a high concentration of electrolytes for a longer period than with rapid rewarming.

As the body cools, there is a reflex constriction of the arteries and veins in the extremities.[26] This results in increased venous pressure, decreased capillary perfusion, and sludging. Cooling also creates a leftward shift in the oxygen dissociation curve, and hemoglobin gives up its oxygen less readily. These two conditions result in hypoxia and damage to the capillaries and surrounding tissue. Oxygen tension is further decreased by thrombus formation in the microvasculature, which results in arteriovenous shunting. Arterial and arteriolar constriction, mediated by sympathetic outflow, initiates and probably maintains circulatory impairment. In addition, segmental vascular necrosis occurs in areas of erythrostasis, which suggests that ultimate damage may depend more on insufficient clearance of toxic substances than on initial vasoconstriction.

Cell types vary in their susceptibility to cold injury. Melanocytes are very sensitive to cold, and irreversible damage may occur at –4°C to –7°C (24.8°F to 19.4°F). This sensitivity explains the hypopigmentation that follows cryotherapy. In addition, it appears that black persons are more susceptible to frostbite than whites. Nerve axons are also easily damaged by cold, and nerve injury may occur with axonal degeneration of large myelinated fibers. Autonomic fibers are also affected, and this may account for the abnormal sweating and cold sensitivity that follow nonfreezing cold injury.[31,32] Nerve sheaths are quite resistant to cold, as are bone and cartilage.[23] Desolidification of lipids in adipose tissue and disruption of endothelial cells lining blood vessels and lymphatics, with secondary disturbances of permeability and blood flow, are other consequences of severe cold. In the overall assessment, there are marked similarities in the pathologic processes to those seen in thermal burns and in ischemia-perfusion injuries.

Three stages of cooling are recognized. The first is massive vasoconstriction, which causes a rapid fall in skin temperature. In a second step, the hunting reaction follows with a cyclic rise and fall in skin temperature. If cold exposure continues, the third stage of freezing occurs as the skin temperature falls to approach ambient temperature. The events that ensue in freezing and nonfreezing cold injuries are similar.[14,33] Consequences of cold injuries and their classification are presented in Tables 93-1 and 93-2.

Frostbite usually affects a finger, toe, ear, nose, or cheek. The clinical presentation of frostbite falls into three catego-

TABLE 93-1
Consequences of Cold Injuries

- Arterial and arteriolar vasoconstriction
- Excessive venular and capillary vasodilation
- Increased endothelial leakage
- Erythrostasis
- Arteriovenous shunting
- Segmental vascular necrosis
- Massive thrombosis

ries corresponding to mild frostbite or frostnip, superficial frostbite, and deep frostbite with tissue loss.

Frostnip involves only the skin and causes no irreversible damage. There is a sensation of severe cold progressing to numbness followed by pain. Erythema is usually present on the cheeks, ears, nose, fingers, and toes (Fig. 93-4). There is no edema or bleb formation. Frostnip is the only form of frostbite that can be treated safely in the field with first aid measures.

Superficial frostbite involves the skin and immediately subcutaneous tissues. It includes the previously described signs but with the pain subsiding to feelings of warmth. This is a sign of severe involvement. The skin has a waxy appearance, but deeper tissues remain soft and resilient. Clear blebs form, accompanied by edema and erythema within 24 to 36 hours after thawing. Lesions may become eroded (Fig. 93-5).

Deep frostbite extends to the deep subcutaneous tissue. The injured skin becomes white or bluish white with a variable degree of anesthesia. Most often the affected skin becomes deceptively pain free, and the discomfort of feeling cold vanishes. The tissue is totally numb, indurated with immobility of joints and extremities. Muscles may be paralyzed. Nerves, large blood vessels, and even bone may be damaged. Large blisters form 1 to 2 days after rewarming, and they can be classified according to depth, as in heat-induced burns (Fig. 93-6). Frostbite blister fluid contains high amounts of prostaglandins, including prostaglandin $F_{2\alpha}$ and thromboxane A_2. These mediators may contribute to increased vasoconstriction, platelet aggregation, leukocyte adhesiveness, and ultimately progressive tissue injury. The blister fluid begins to be resorbed within 5 to 10 days, which leads to the formation of hard, black gangrene. Weeks later, a line of demarcation occurs, and the tissues distal to the line undergo autoamputation (Fig. 93-7).

TABLE 93-2
Classification of Cold Injuries to the Skin

Physiologic non-damaging response to cold	• Vasoconstriction • Hunting reaction
Nonfreezing injuries	• Immersion foot • Pulling-boat hands • Acrocyanosis • Chilblains • Cold urticaria • Cold panniculitis • Erythromelalgia • Raynaud phenomenon • Sclerema neonatorum • Subcutaneous fat necrosis of the newborn • Livedo reticularis • Cryoglobulinemia • Cold agglutinins • Cryofibrinogenemia
Freezing injuries	• Frostbite



▲ **FIGURE 93-4** Frostnip.

Prevention

Prevention is key to protecting individuals from the effects of cold weather; and frostbite, frostnip, and hypothermia always should be taken seriously. Prognostic factors[22,34–37] are listed in Table 93-3. Nonmedicated ointments are traditionally used for protection against facial frostbite, but their benefit is undocumented. The thermal insulation they provide is indeed minimal. The use of protective emollients seems to cause a false sensation of safety, which leads to an increased risk of frostbite, probably through neglect of other, more efficient protective measures.[38,39] In less extreme conditions, however, some specific topical formulations bring beneficial effects.[40]



▲ **FIGURE 93-5** Superficial frostbite.



▲ **FIGURE 93-6** Deep frostbite after rewarming. Large blisters have formed. Note cyanosis of toes as a sign of developing necrosis. This cold injury occurred in a homeless person who was found on the street after heavy alcohol consumption and overnight snowfall.

Management

The first consideration in frostbite treatment is to be aware that the victim may be suffering from hypothermia.[22,26,41,42] Because of the difficulty in assessing the depth of frostbite injury, conservative waiting after the frostbite episode is often encouraged in an attempt to delineate the extent of tissue loss. Beyond this, the main principles are to avoid trauma, friction, pressure, massaging with snow, and refreezing. Slow rewarming increases tissue damage, and therefore rapid rewarming is the keystone of treatment.[17] It should be performed in a water bath no warmer than 40°C to 42°C (104°F to 107.6°F) until the most distal parts of the body are flushed. Large amounts of analgesics may be required. The damaged part should be elevated, and blisters should be left intact. Surgical debridement is often best delayed until 1 to 3 months after demarcation. However, triple-phase bone scans, magnetic resonance imaging, and magnetic resonance angiography can be used to predict ultimate tissue loss and to assess the possibility of earlier surgical intervention.[33,43,44]

There is no uniformly accepted protocol for other measures allegedly benefi-



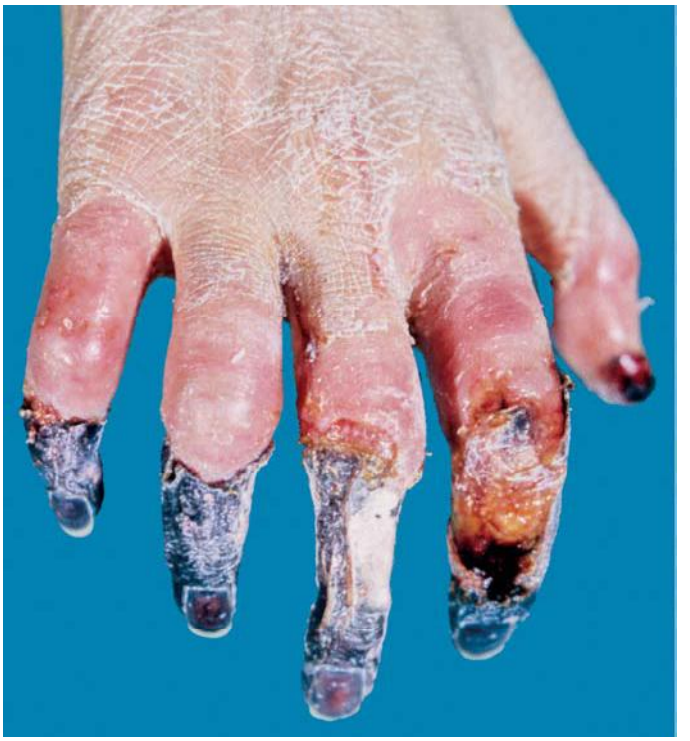

▲ **FIGURE 93-7** Dry gangrene of all fingers in a mountain climber 5 weeks after being caught in a snowstorm.



cial in the treatment of frostbite injury.[42] Intra-arterial reserpine and sympathectomy have been used to reverse vasospasm, which may contribute to tissue loss. Their role is controversial, although some patients have benefited from this therapy. To counteract vasoconstriction caused by local release of inflammatory mediators, the use of topical aloe vera, which inhibits thromboxane synthetase, and systemic ibuprofen, which inhibits cyclooxygenase, have been advocated. Oxpentifylline has been presented as an advanced therapy.[45] In addition, several adjunctive therapies, including vasodilators, thrombolysis, and hyperbaric oxygen, are sometimes useful.[46] Tetanus toxoid should be given in the case of open wounds. Surgery and amputation remain the ultimate strategies to help the victims.[47]

TABLE 93-3
Prognostic Signs of Frostbite

Good prognostic signs	• Large, clear blebs extending to the tips of the digits • Rapid return of sensation • Rapid return of normal (warm) temperature to the injured area • Rapid capillary filling time after pressure blanching • Pink skin after rewarming
Poor prognostic signs	• Hard, white, cold, insensitive skin • Cold and cyanotic skin without blebs after rewarming • Dark hemorrhagic blebs • Early evidence of mummification • Constitutional signs of tissue necrosis, such as fever and tachycardia • Cyanotic or dark red skin persisting after pressure • Freeze-thaw-refreeze injury

Sequelae

Sequelae of frostbite include permanent hypersensitivity to cold and, less often, hyperhidrosis.[31] Squamous cell carcinoma is a rare outcome, usually occurring on the heel 20 to 30 years later.[48] Epiphyseal plate damage or premature fusion may occur in children. Premature fusion can result in shortened digits, joint deviation, and dystrophic nails. In addition, frostbite arthritis, resembling osteoarthritis, may occur weeks to years later.

NONFREEZING COLD INJURY AND DAMPNESS

Nonfreezing cold injury occurs when tissues are cooled to temperatures between approximately 15°C (59°F) and their freezing point for prolonged periods. This type of injury, which is exacerbated by dampness, has claimed numerous casualties in warfare. Nonfreezing cold injury may be followed by cold sensitivity and hyperhidrosis, which may persist for years.

During World War I, trench foot was identified as a separate entity. Wet conditions at temperatures above freezing and limb dependency due to immobility and constrictive footwear were important pathogenic factors. Three stages were described. Stage I consisted of initial erythema, edema, and tenderness. Stage II followed within 24 hours with paresthesia, marked edema, numbness, and sometimes blisters. Stage III corresponded with progression to a usually superficial gangrene. Immersion foot, similar to trench foot, was described in shipwreck survivors during World War II.

Tropical immersion foot was described during the Pacific campaign in World War II. Occurring after exposure to the warm, wet conditions of jungle warfare, this condition differed from classic trench foot and immersion foot in that it caused less tissue destruction, numbness, and anesthesia and was followed by more rapid complete recovery. The role of temperature in tropical immersion foot is unclear and may not be important.[49] As with trench foot and immersion foot, prevention is most important.

Another specific condition known as *pulling-boat hands* was described, characterized by the presence of erythematous macules and plaques on the dorsum of the hands and fingers of sailors aboard rowboats.[50] Small vesicles developed later, accompanied by itching, burning, and tenderness. These individuals were exposed to long periods of high humidity, cool air, and wind, an ideal setting for the development of nonfreezing cold injury. In addition, hours of vigorous rowing daily produced repetitive hand trauma.

WINTER XEROSIS

Many individuals present with dryness of the skin, particularly on the lower extremities, during wintertime. The hands, forearms, cheeks, lips, and trunk also may be affected. Itching, a dry appearance, chapping, and cracking of the stratum corneum are more or less prominent. The condition is markedly influenced by cold environments, especially in combination with low humidity.[27,28] Predisposing factors include atopic dermatitis, ichthyosis, and increasing age. Excessive washing exacerbates winter xerosis. In-

deed, irritant dermatitis of the hands worsens in a cold and dry environment.[51] Emollients and improvement in the environmental temperature and humidity are helpful in controlling this condition.

ACROCYANOSIS

Acrocyanosis is a bilateral dusky mottled discoloration of the hands, feet, and sometimes the face. It is persistent and accentuated by cold exposure. When the temperature is very low, the skin may be bright red. Trophic changes and pain do not occur, and pulses are present. This condition must be distinguished from Raynaud phenomenon (see Chap. 171), which is clearly episodic, often segmental, and painful, as well as from obstructive arterial disease (see Chap. 174).

Acrocyanosis is genetically determined and usually starts in adolescence. Chronic vasospasm of small cutaneous arterioles or venules with a secondary dilatation of the capillaries and subpapillary venous plexus has been postulated. Stasis in the papillary loops with aneurysmal dilatation at the tips redistributes blood flow to the subpapillary venous plexus. The blood flow may be compromised by altered erythrocyte flexibility, increased platelet adhesiveness, and other plasma viscosity factors.

Tissues are less sclerotic in acrocyanosis than in Raynaud phenomenon. They contain twisted collagen fibrils and large pericytes. In cases developing for the first time late in life, an underlying myeloproliferative disorder should be excluded. Remittent necrotizing acrocyanosis is associated with enhanced susceptibility to cooling and pain, as well as ulceration and gangrene of the fingers. Arteriolar occlusion by thrombi or intima proliferation may occur.

There is no effective treatment for acrocyanosis. Supportive measures to keep the skin warm are helpful.

ERYTHROCYANOSIS

Erythrocyanosis is a dusky cyanotic discoloration, worse in winter, that occurs over areas with a thick layer of subcutaneous fat (Fig. 93-8). The condition is seen most often on the lower legs and thighs of adolescent girls and middle-aged women. Nodular lesions similar to chilblains may occur and have been described in women with severe erythrocyanosis and paraplegia. Keratosis pilaris, angiokeratomas, and telangiectases are commonly associated. Spontaneous improvement often occurs after a few years. However, the disease may persist with long-standing edema and fibrosis.



▲ **FIGURE 93-8** Erythrocyanosis of plump upper arms of a woman.

The wearing of warm clothes and weight reduction are important to decrease the insulating effect of the subcutaneous fat, which is responsible for a chronically low skin temperature. The outcome remains unpredictable.

CHILBLAINS

Chilblains, also called *pernio* or *perniosis* (Fig. 93-9), are localized inflammatory lesions caused by continued exposure to cold above the freezing point.[52,53] Dampness and wind that increase thermal conductivity and convection play a part. Absolute temperature is less important than the cooling of nonadapted tissue. The condition shows a genetic predisposition. It has been described most often in temperate regions, where winters are occasionally cold and damp. Chilblains are seen less often in very cold climates, where well-heated houses and warm clothing are available. Both acrocyanosis and chilblains appear to be more common in children, women, and persons with low body mass index. Spontaneous remission is common when spring arrives, and relapse is frequent during the following winters. However, chilblains do not always occur at the time of maximum cold.

Chilblains develop acutely as single or multiple, burning, erythematous, or purplish swellings (see Fig. 93-9A and C). Patients may complain of itching, burning, or pain. In severe cases, blisters (see Fig. 93-9B), pustules, and ulceration may occur. Characteristic locations include the proximal fingers and toes, plantar surfaces of the toes, heels, nose, and ears, but other sites like the calves and thighs can be affected[54] (see Fig. 93-9C). Lesions usually resolve in 1 to 3 weeks but may become chronic in elderly people with venous stasis. Tight garments such as gloves, stockings, and shoes are especially to be avoided in cases in which there is also peripheral vascular disease. A papular form of chilblains resembles erythema multiforme and occurs at all times of the year, usually in crops on the sides of the fingers,[55] often superimposed on a background of acrocyanosis.

A peculiar clinical presentation may occur in young women riding horses for several hours daily during winter.[56,57] Indurated red to violet tender plaques develop on the lateral calves and thighs (see Fig. 93-9C). The condition is quite similar to the nodular perniotic lesions described in adolescent girls with erythrocyanosis. For prophylaxis, experienced riders usually wear baggy breeches that provide insulation and are not tight enough to compromise the circulation.

Perniotic lesions have been described in association with myeloproliferative disorders,[58] probably as a consequence of blood flow changes, presence of cold agglutinins, and altered inflammatory response on cooling.

Idiopathic perniosis is characterized histologically by edema of the papillary dermis and by the presence of superficial and deep perivascular lymphocytic infiltrates. Necrotic keratinocytes and lym-





▲ **FIGURE 93-9** Chilblains are common at such sites as the hands and feet when they are exposed to both cooling and tight garments. **A.** Chilblains on the toes. **B.** Chilblains on the dorsum of the foot. Children and the elderly are most commonly affected, perhaps because they take less care to protect themselves from cooling. **C.** Equestrian chilblains from horse riding on a cold morning with inadequate clothing.

phocytic vasculitis also have been reported. Thickening of blood vessel walls with intimal proliferation may lead to obliteration of the vascular lumen.[59–61]

Chilblain lupus is a distinct disease and is similar to discoid lupus erythematosus.[62,63] Lupus pernio is a variant of sarcoidosis (see Chap. 153) and is unrelated to cold injuries.

The unfamiliarity of physicians with chilblains sometimes gives rise to unnecessary hospital admissions with expensive laboratory and radiologic evaluations and, at times, hazardous therapy. The most important point in management is prophylaxis through the use of adequate, loose, insulating clothing and appropriate warm housing and workplace. Maintaining the blood circulation by avoiding immobility is also helpful. A short course of ultraviolet light therapy at the beginning of winter was a recommendation but has been challenged.[64] Once chilblains occur, treatment is symptomatic with rest, warmth, and topical antipruritics. Calcium channel–inhibiting drugs may be effective in the treatment of severe recurrent perniosis,[65] although they may cause headache and flushing that are troubling to some patients. In cases of crippling severity, thyrocalcitonin and hemodilution may be helpful.

COLD URTICARIA AND POLYMORPHOUS COLD ERUPTION

Cold urticaria (Fig. 93-10) occurs at sites of localized cooling, usually when the area is rewarmed. It may be idiopathic or associated with some serologic abnormality.[66–70] It accounts for approximately 2 percent of cases of urticaria (see Chap. 37).

Most cases fall into the group of essential cold urticaria. They can be subdivided into a rare familial type and an acquired form. Immunoglobulin E and, more rarely, immunoglobulin M have been implicated in the pathogenesis. The antigen is likely a normal metabolite produced on exposure to cold. Histamine is one of the most important mediators, but leukotrienes, platelet-activating factor, and others have been incriminated. In this disease, exposure to cold causes prolonged edematous papules and plaques, often with headache, fever, arthralgia, and leukocytosis. Swelling of the oral mucosa and esophagus may occur on ingestion of cold liquids. A rather distinctive combination of cold urticaria and dermographism or cholinergic urticaria is not uncommon. Alarming signs resembling those of histamine shock may lead to loss of consciousness. Death while swimming in cold water has been reported.

Familial cold urticaria is a rare autosomal dominant condition with onset at an early age.[71,72] A CIAS1 mutation has been identified.[72] Urticaria develops when the patient is exposed to generalized cooling, particularly chilling wind, rather than local cold application. The delayed type of familial cold urticaria is characterized by localized angioedema developing 9 to 18 hours after cold exposure.

Cold urticaria may occur in 3 percent to 4 percent of patients with cryoglobulinemia, and it also may be associated with cold agglutinins, cryofibrinogens, and cold hemolysins. Cold urticaria has been reported in cases of infectious mononucleosis in association with either cryoglobulins or cold agglutinins, but such occurrences are rare. Cold urticaria may also be a sign of the Muckle-Wells syndrome.[73] *Helicobacter pylori* has been suggested as a causative agent in some cases of acquired cold urticaria.[74]



◀ **FIGURE 93-10** Cold urticaria induced by the application of ice to the skin.

Diagnosis of cold urticaria is confirmed by placing an ice cube wrapped in a plastic bag on the skin of the forearm for periods varying from 30 seconds to 10 minutes (see Fig. 93-10). Wheals form on rewarming. Sometimes water at 7°C (44.6°F) is more effective, presumably because it causes less severe vasoconstriction. Peltier effect–based temperature challenge appears to be an improved method for diagnosis.[75]

Cold erythema seems to be a related disorder with erythema and pain but without urticaria. Familial polymorphous cold eruption is a rare autosomal dominant disease characterized by childhood onset of non-pruritic, erythematous eruptions often accompanied by influenza-like symptoms after generalized exposure to cold and leukocytosis. Results of the ice cube test are negative. The pathogenesis remains unknown. The disease frequently has been referred to as *familial cold urticaria*, although the skin lesions are not urticarial.[76]

Avoiding cold wind exposure and swimming in cold water are important preventive measures. Antihistamines reduce clinical signs and symptoms. Desensitization to cold is possible by immersing one arm into water at 15°C (59°F) for 5 minutes daily.

COLD PANNICULITIS AND RELATED ENTITIES

Cold injuries may affect the subcutaneous tissue in different ways. The freezing injury in deep frostbite results in tissue gangrene. Nonfreezing injuries also can alter the hypodermis. Among them, cold panniculitis is more common in children than in adults. It affects the cheeks and legs most commonly. Tender erythematous subcutaneous nodules appear 1 to 3 days after exposure and subside spontaneously within 2 to 3 weeks. Ice cube challenge to the child's skin for 10 minutes results in the development of an erythematous plaque 12 to 18 hours later (see Chap. 68).

A perivascular mixed infiltrate with neutrophils, lymphocytes, and histiocytes is present at the dermal-subcutaneous junction after 24 hours, followed by a well-developed panniculitis at 48 to 72 hours. Some adipocytes are necrotic and they rupture to form cystic spaces. The reaction subsides completely by 2 weeks. Infants have a higher content of saturated fatty acids in adipose tissue than do adults, and this may result in solidification at higher (less cold) temperatures.[77] Cold panniculitis should be distinguished from other related disorders, including erythrocyanosis with nodules, sclerema neonatorum, and subcutaneous fat necrosis of the newborn.

SCLEREMA NEONATORUM AND SUBCUTANEOUS FAT NECROSIS OF THE NEWBORN (See Chaps. 68 and 106)

Sclerema neonatorum and subcutaneous fat necrosis of the newborn are distinct disorders involving the subcutaneous fat of the newborn. As noted in the prior paragraph, infant fat differs from adult fat in that it has a higher saturated-unsaturated fatty acid ratio, which results in solidification at a higher temperature. Prematurity and immaturity of enzyme systems may result in a relative inability to desaturate fatty acids, which alters the ratio further. Sepsis, dehydration, chilling, infection, and other stresses also may inhibit the enzyme system. Thus infants in general, and premature or otherwise compromised newborns in particular, are susceptible to such disorders.

Sclerema neonatorum is a rare disorder characterized by diffuse, rapidly spreading hardening of the skin and subcutaneous tissue in infants. It starts on the buttocks and trunk, usually in the first week of life. Palms, soles, and scrotum are spared. Fifty percent of affected infants are premature. They have difficulty feeding and are lethargic, and many are otherwise debilitated. Septicemia is frequent, and the prognosis is poor. Cold exposure does not seem to be important in the etiology of sclerema neonatorum; however, similar clinical findings have been seen in cases of primary cold injury.[78] Histologically, the subcutaneous layer is greatly thickened by enlarged fat cells and wide, fibrous bands. There is no fat necrosis, and many of the fat cells contain fine needle-like clefts.[79]

Treatment of sclerema neonatorum involves correcting dehydration and electrolyte imbalance and treating septicemia if present. The value of systemic glucocorticoids is controversial. Successful treatment with exchange transfusions has been reported.[80]

Subcutaneous fat necrosis of the newborn is characterized by discrete red to violaceous mobile plaques and nodules that usually appear within a few days of birth. The back, thighs, and cheeks are most commonly affected. Fat necrosis and crystallization are the hallmarks of the disease. There may be a granulomatous inflammatory response with foci of calcification. In most cases, the condition is benign and self-limited, although it has been associated with hypercalcemia and death.[81]

As in sclerema neonatorum, there is no clear etiologic relationship to cold, and the cause is likely multifactorial. It has been postulated that an underlying defect in fat composition, poor nutrition, and various physical stresses such as hypothermia may be important.

ERYTHROMELALGIA

Erythromelalgia or erythermalgia is a rare chronic cutaneous disorder characterized by erythema, burning discomfort, and warmth of the extremities.[82,83] Primary erythromelalgia is an autosomal dominant neuropathic disorder involving a mutation in a voltage-gated sodium channel subunit.[84–88] Vasoconstriction apparently precedes reactive hyperemia, similar to that seen in Raynaud phenomenon. An early-onset type and an adult-onset type have been recognized. When the extremity is lowered or heat is applied, the pain is intensified. The application of cold or elevation of the extremity has the opposite effect of decreasing the pain. Idiopathic erythromelalgia may involve increased thermoregulatory arteriovenous shunt flow. Secondary erythromelalgia is associated commonly with myeloproliferative syndrome–related thrombocythemia and is mostly evident in the adult-onset type.

Treatment for adults with erythromelalgia includes a single daily dose of acetylsalicylic acid, but children who have no associated underlying disorder obtain little to no relief from the drug. Other drugs including mexiletine[89] and venlafaxine[90] may also help. Pain may be decreased by topical amitriptyline combined with ketamine.[91] Lidocaine in patches[92] or administered intravenously in combination with oral mexiletine[93] may also alleviate pain. Sympathectomy in the upper extremities is another option for treating primary erythromelalgia.[94]

RAYNAUD PHENOMENON (See Chap. 171)

CRYOGLOBULINEMIA (See Chap. 170)

LIVEDO RETICULARIS (See Chap. 174)



KEY REFERENCES

The full reference list for all chapters is available at www.digm7.com.

18. Long WB 3rd et al: Cold injuries. *J Long Term Eff Med Implants* **15**:67, 2005
28. Piérard-Franchimont C, Piérard GE: Beyond a glimpse at seasonal dry skin: A review. *Exog Dermatol* **1**:3, 2002
36. Daanen HA, van der Struijs NR: Resistance index of frostbite as a predictor of cold injury in arctic operations. *Aviat Space Environ Med* **76**:1119, 2005
37. Harirchi I et al: Frostbite: Incidence and predisposing factors in mountaineers. *Br J Sports Med* **39**:898, 2005
53. Simon TD et al: Pernio in pediatrics. *Pediatrics* **116**:472, 2005
70. La Shell MS et al: Cold urticaria: A case report and review of the literature. *Cutis* **76**:257, 2005
83. Davis MD, Rooke T: Erythromelalgia. *Curr Treat Options Cardiovasc Med* **8**:153, 2006

CHAPTER 94

Thermal Injuries

Robert L. Sheridan



EPIDEMIOLOGY

The very young and very old are at increased risk of domestic burns.[1] Active young adults in industrial jobs are at modest increased risk. In developed countries, about 70 percent of pediatric burns are caused by hot liquid. Flame injuries are more common in older children and young working adults. Kitchen and bathing accidents are predominant in the elderly. As much as 20 percent of burns in younger children involve abuse or neglect.

ETIOLOGY AND PATHOGENESIS

The development of an envelope of skin was a crucial component of the adaptation of aquatic sea animals to the land environment. The vapor and fluid barrier created by the epidermal layer facilitates the maintenance of fluid and electrolyte homeostasis within very narrow limits. The dermis provides strength and flexibility, and the reactive dermal vasculature facilitates control of internal body temperature. Skin appendages provide lubrication and prevent desiccation. All of these critical functions are lost when substantial areas of the skin are burned.

There is both a local and a systemic response to the burn wound.[2] The local response consists of coagulation of tissue with progressive thrombosis of surrounding vessels in the zone of stasis over the first 12 to 48 post-injury hours. An ability to truncate this secondary microvascular injury and its associated tissue loss is a major area of ongoing investigation. In larger burns, a systemic response develops that is driven initially by release of mediators from the injured tissue, with a secondary diffuse loss of capillary integrity and accelerated transeschar fluid losses. This systemic response is subsequently fueled by by-products of bacterial overgrowth within the devitalized eschar.

Burn wounds are initially clean but are rapidly colonized by endogenous and exogenous bacteria.[3] As bacteria multiply within the eschar over the days after injury, proteases result in eschar liquefaction and separation. This leaves a bed of granulation tissue or healing burn, depending on the depth of the original injury. In patients with wounds involving 40 percent or more of the body surface, the infectious challenge generally cannot be contained by the immune system, with resulting systemic infection. This explains the rare survival of patients managed in an expectant fashion with burns of this size.

The systemic response to injury is characterized clinically by fever, a hyperdynamic circulatory state, increased metabolic rate, and muscle catabolism.[4] This stereotypical response to injury has been retained by all mammalian species. It is effected by a complex cascade of mediators, including changes in hypothalamic function resulting in increases in glucagon, cortisol, and catecholamine secretions; deficient gastrointestinal barrier function with translocation of bacteria and their by-products into the systemic circulation; bacterial contamination of the burn wound with systemic release of bacteria and bacterial by-products; and some element of enhanced heat loss via transeschar evaporation. It is likely that this response overall has significant survival value, but control of some of the adverse aspects of this response, particularly muscle catabolism, is an active area of ongoing investigation.[5]

CLINICAL FINDINGS

Burns are classified by depth:

- First-degree: Red, dry, and painful and are often deeper than they appear, sloughing the next day (Fig. 94-1A).
- Second-degree: Red, wet, and very painful with enormous variability in their depth, ability to heal, and propensity to hypertrophic scar formation (see Fig. 94-1B).
- Third-degree: Leathery, dry, insensate, and waxy (see Fig. 94-1C).
- Fourth-degree: Involve underlying subcutaneous tissue, tendon, or bone (see Fig. 94-1D).

Circumferential burns require special monitoring and possible surgical decompression. If across the torso, they will interfere with ventilation. If they involve

THERMAL INJURIES AT A GLANCE



- Burns are common injuries and will be seen by many practicing dermatologists.
- Most burns are small and are managed in the outpatient setting.
- Serious burns require inpatient care, ideally in a verified burn center.
- Large burns are managed in four general phases:
  - Initial evaluation and resuscitation
  - Wound excision and biologic closure
  - Definitive wound closure
  - Rehabilitation and reconstruction
- Styles of outpatient burn care are variable, but certain general principles are important. Proper patient selection and monitored wound healing are essential.
- Long-term outcome tends to be very good, even in large burns.



▲ **FIGURE 94-1** Burn depth is classified as first, second, third, or fourth degree. **A.** First-degree burns are red, dry, and painful and are often deeper than they appear, sloughing the next day. **B.** Second-degree burns are red, wet, and very painful. There is an enormous variability in their depth, ability to heal, and propensity to hypertrophic scar formation. **C.** Third-degree burns are leathery, dry, insensate, and waxy. **D.** Fourth-degree burns involve underlying bone and/or muscle.

an extremity, limb-threatening ischemia may occur during resuscitation.

CLINICAL COURSE: PATIENT EVALUATION AND TREATMENT PLANNING

In both outpatient and inpatient settings, a careful evaluation of the patient is essential for treatment planning.

- The burn wound should be examined for size, extent, depth, and circumferential components.
- Decisions regarding outpatient care, hospitalization, or transfer will be influenced by this information (Table 94-1).
- Burn extent is best estimated using a chart based on the Lund-Browder diagram that compensates for the changes in body proportions with age. An alternative is a "Rule of Nines" for adults and children.
- In the adult Rule of Nines, the head and neck is given 9 percent, each lower extremity is given 18 percent, each upper extremity is given 9 percent, and the anterior and posterior torso are each given 18 percent.
- In the pediatric Rule of Nines, the head and neck is given 18 percent, each lower extremity is given 15 percent, each upper extremity is given 10 percent, and the anterior and posterior torso are each given 16 percent.
- For scattered or irregular burns, the entire palmar surface of the patient's hand represents approximately 1 percent of the body surface over all ages.

Patient evaluation is organized into a primary and a secondary survey, following the guidelines of the American Col-

TABLE 94-1
American Burn Association Burn Center Transfer Criteria

- Second- and third-degree burns greater than 10% TBSA in patients younger than 10 or over 50 years of age.
- Second- and third-degree burns greater than 20% TBSA in other age groups.
- Second- and third-degree burns that involve the face, hands, feet, genitalia, perineum, and major joints.
- Third-degree burns greater than 5% TBSA in any age group.
- Electrical burns, including lightning injury.
- Chemical burns.
- Inhalation injury.
- Burn injury in patients with pre-existing medical disorders that could complicate management, prolong recovery, or affect mortality.
- Any patients with burns and concomitant trauma (such as fractures, etc.) in which the burn injury poses the greatest risk of morbidity or mortality. In such cases, if the trauma poses the greater immediate risk, the patient may be treated initially in a trauma center until stable before being transferred to a burn center. Physician judgment will be necessary in such a situation and should be in concert with the regional medical control plan and triage protocols.
- Hospitals without qualified personnel or equipment for the care of children should transfer children with burns to a burn center with these capabilities.
- Burn injury in patients who will require special social/emotional and/or long-term rehabilitative support, including cases involving suspected child abuse, substance abuse.

TBSA = total body surface area.



lege of Surgeons Committee on Trauma, and the Advanced Burn Life Support Course of the American Burn Association.

As in trauma, the primary survey begins with an assessment, and control if necessary, of the airway. Deeper burns of the face and neck can result in progressive airway edema. Occasionally, a child will aspirate hot liquids, resulting in very severe, upper airway edema mandating urgent intubation.

A burn-specific secondary survey evaluates issues uniquely associated with burn injury (Table 94-2). This may take just a few seconds if the burn is small, but will be much more time consuming in the more seriously injured.[6] In those with small injuries, essentials include a detailed determination of the mechanism of injury, a screen for associated trauma, consideration of the possibility of abuse, and a detailed assessment of the burn wound. Delayed presentation for care, confusing stories, sharply demarcated margins, immersion patterns, and contact injuries are physical findings worrisome for abuse or neglect (Fig. 94-2).[7] All such children should be admitted for evaluation.

After the patient has been evaluated, the burn wound should be examined for size, extent, depth, and circumferential components.[8] Burn extent is best estimated using a chart based on the Lund-Browder diagram that compensates for the changes in body proportions with age (Fig. 94-3). An alternative is a modified Rule of Nines, in which, for children, the head and neck is given 18 percent (instead of the adult 9 percent), each lower extremity is given 15 percent (instead of the adult 18 percent), each upper extremity is given 10 percent (instead of the adult 9 percent), and the anterior and posterior torso are each given 16 percent (instead of the adult 18 percent). For scattered or irregular burns, the entire palmar surface of the patient's hand represents approximately 1 percent of the body surface over all ages.

Burn depth can usually be assessed accurately from clinical features (see Fig. 94-1). Near or completely circumferential burns should be identified for special monitoring, as they may need to be decompressed in the hours following injury to avoid ischemia (extremities) or failure of ventilation (torso).

The majority of burns can be successfully managed in the outpatient setting. However, poorly provided outpatient burn care can be frustrating and painful for patients and providers. The key is careful patient selection and a detailed care plan. Several issues should be considered in making this decision (Table 94-3).

TABLE 94-2
Burn-Specific Secondary Survey

- History
  - Mechanism of injury
  - Closed space exposure and extrication time
  - Delay in seeking attention
  - Fluid and pain medication given during transport
  - Prior illnesses and allergies
  - Prior child protective services involvement
- Head, eyes, ear, nose, and throat
  - Early examination of the globes for corneal burns.
  - Clinical assessment for intraocular hypertension if deep facial burns.
  - Perioral and intra-oral burns and carbonaceous material.
  - Progressive hoarseness.
  - Consider hot liquid aspiration.
  - Continuously assess endotracheal tube security.
- Neck
  - Radiographic evaluation if indicated by injury mechanism
  - Rare need for neck escharotomies
- Cardiac
  - Cardiac monitoring after significant electrical injury
- Pulmonary
  - Chest escharotomies indicated if near circumferential torso burn and difficulty with ventilation
  - Inhalation injury associated with airway obstruction and bronchospasm initially
- Vascular
  - Perfusion of burned extremities should be closely monitored.
  - Escharotomy indicated for decreasing perfusion.
  - Fasciotomy indicated after electrical or deep thermal injury when flow compromised.
  - Compartment pressures can be followed in equivocal extremities.
  - Worrisome extremities should be decompressed based on serial exam.
- Abdomen
  - Nasogastric tubes often indicated especially before air transport.
  - Inappropriate volume requirement may be a sign of an occult intra-abdominal injury.
  - Torso escharotomies may be required to facilitate ventilation.
  - Ulcer prophylaxis indicated in all with serious burns.
  - Consider abdominal compartment syndrome in very large burns or delayed resuscitation.
- Genitourinary
  - Catheterization is appropriate in all who require a fluid resuscitation.
  - Ensure that the foreskin is reduced over the bladder catheter.
- Neurologic
  - Level of consciousness often reduced during the hours after injury
  - Computed tomography scanning useful to exclude head injury if mechanism appropriate
- Extremities
  - Monitor perfusion if there are near circumferential burns or electrical injury.
  - Limbs at risk should be dressed so they can be easily reexamined.
- Wound
  - Evaluate wounds for size, depth, and circumferential components.
  - Wounds often underestimated in depth and overestimated in size initially.
- Electric
  - Monitor cardiac rhythm for high (> 1000 volt) or intermediate (> 220 volt) volt exposures.
  - Neurologic and ocular examination important.
  - Extremities should be serially evaluated for intracompartmental edema.
  - Bladder catheters useful in high voltage exposures to document clearing of pigment.
- Chemical
  - Irrigate wounds with tap water for at least 30 min.
  - Irrigate eyes with isotonic crystalloid solution.
  - Blepharospasm may require ocular anesthetic.
  - Hydrofluoric acid may be complicated by life-threatening hypocalcemia.
- Tar
  - Cool with tap water irrigation and remove later with a lipophilic solvent.
- Laboratory and radiography
  - Blood gas when inhalation injury present.
  - Normal carboxyhemoglobin does not rule out significant exposure.
  - Baseline hemoglobin and electrolytes can be helpful later.
  - Urinalysis for occult blood useful in those with deep thermal or electrical injuries.
  - Radiographic evaluation as needed for mechanism of injury.

COMPLICATIONS

In the outpatient setting, patient selection should ensure that major complica-



▲ **FIGURE 94-2** Some burn patterns are very suggestive of possible abuse. This child demonstrates flexor (popliteal fossa) sparing in an immersion injury.

tions are few (Table 94-4). The most common issues that arise are wound sepsis, excessive pain and anxiety, and underestimation of burn depth.[9] The most common wound infection in this setting is streptococcal cellulitis, which presents initially with surrounding erythema that progresses to lymphangitis and systemic toxicity (Fig. 94-4). These patients often need admission for antibiotics, observation, and, sometimes, surgery. In some situations, adequate pain and anxiety management is very difficult in the outpatient setting, especially around dressing changes. This can be addressed with judicious medication and sometimes, carefully monitored membrane dressings. Some patients will require admission. It is common for burn depth to be underestimated initially, with areas of full-thickness injury not appreciated for several days. These patients may require admission for surgery.

As burns increase in size and depth, the local injury is accompanied by an increasing degree of systemic derangement. Classically, this response has two phases. An initial "ebb" phase of reduced perfusion and metabolic rate that lasts 24 to 48 hours is followed by a "flow" phase of protein catabolism and a hyperdynamic circulation.[10] This later phase lasts until well after wound closure. Management of this physiology is an essential part of inpatient burn care. Those with large burns are susceptible to a host of other complications related to sepsis and organ failures. Careful monitoring and early intervention are essential to successful outcomes (see Table 94-4).

Burn wounds and grafts typically develop some degree of hypertrophy.[11] This involves a gradual increase in vascularity and collagen deposition in the months following healing. Some wounds will demonstrate significant contracture formation, with important functional and aesthetic consequences (Fig. 94-5). Many patients will have bothersome pruritus and sometimes temporary neuropathic pain if burns are deep. A long-term, follow-up plan, consisting of scar management strategies, rehabilitation, reconstructive surgery, and emotional support, will facilitate optimal outcomes. This care is best provided in a multi-disciplinary burn clinic, ideally part of a comprehensive burn program. With such supports in place, the long-term outcome for most patients is surprisingly good. When managed in a comprehensive follow-up program, even those who have suffered devastating burns tend to become happy and productive again.[12]

TREATMENT

Outpatient Burns

Practice patterns vary widely, but certain characteristics are universal.[13] The wound should be kept generally clean and regularly inspected for infection. Desiccated exudates and topical medications should be periodically cleansed. Burns selected for outpatient management tend to be small and superficial, with a corresponding low risk of infection, so clean rather than sterile technique is reasonable. If topical agents, rather than membrane dressings, are used, wounds may be cleansed with lukewarm tap water and a bland soap. Soaking adherent dressings before removal will decrease the pain associated with daily wound care. The wound is gently cleansed with a gauze or clean washcloth, inspected for any sign of infection, patted dry with a clean towel, and redressed. It is important to instruct each patient to return promptly if they notice erythema, swelling, increased tenderness, lymphangitis, odor, or drainage so that infectious complications can be addressed early. Most small burns are adequately managed with a daily cleansing and dressing change. In some cases, a membrane dressing is applied once it is clear that early surgery is not needed, early infection is unlikely, and wounds are superficial. Pain and anxiety are issues for many, and some will benefit from an oral narcotic given 30 to 60 minutes before a planned dressing change. If dressings are occlusive, pain between dressing changes tends to be modest.

Increasing pain and anxiety associated with dressing changes, inability to keep scheduled follow-up appointments, delayed healing, signs of infection, or a wound that appears deeper than appreciated at the time of the initial examination should prompt early return and specialty evaluation. Wounds selected for outpatient management are usually fairly superficial and heal within 2 weeks; those patients with mid- and deep dermal injuries may have a deeper component with resulting scarring that may benefit from specialty evaluation. Finally, wounds of the face, ears, hands, genitalia, and feet have a functional and cosmetic importance out of proportion to their wound size. In some cases, early specialty evaluation may be prudent, as initial care can have an impact on long-term outcome.

Inpatient Burns

A system of burn center verification has evolved to ensure that patients requiring care of more serious injuries receive coordinated efforts by experienced providers. Burn center referral criteria can be found at http://www.ameriburn.org. Care of severe burns can be divided into phases: (1) initial evaluation and resuscitation, (2) initial excision and biologic closure, (3) definitive wound closure, and (4) rehabilitation and reconstruction.[14] Important objectives of each phase are listed in Table 94-5. Critical care is an important component, especially in the first three phases. Verified burn programs are required to have embedded intensive care units.

Topical Medications and Membranes

There is an increasingly confusing array of wound medications and membranes



Burn estimate and diagram
Age and area

Initial evaluation*

Signature

_____

Date of burn

_____

Date completed

_____

*To be completed by the admitting resident or LIP on admission
☐ N/A, please refer to OPD COMPlan or 1st admission burn diagram

This is a working burn estimate diagram only. It is not as accurate as photography.

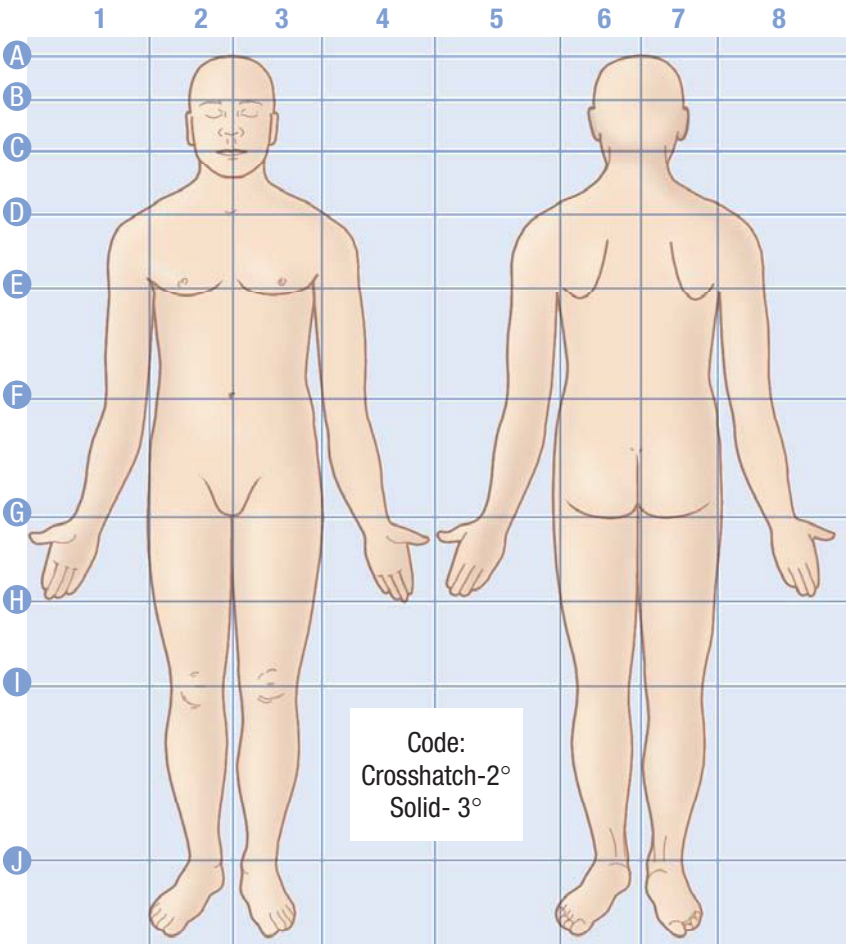

Area	Birth-1 yr	1-4 yrs	5-9 yrs	10-14 yrs	15 yrs	Adult	2°	3°	Total
Head	19	17	13	11	9	7			
Neck	2	2	2	2	2	2			
Anterior trunk	13	13	13	13	13	13			
Posterior trunk	13	13	13	13	13	13			
Right buttock	2.5	2.5	2.5	2.5	2.5	2.5			
Left buttock	2.5	2.5	2.5	2.5	2.5	2.5			
Genitalia	1	1	1	1	1	1			
Right upper arm	4	4	4	4	4	4			
Left upper arm	4	4	4	4	4	4			
Right lower arm	3	3	3	3	3	3			
Left lower arm	3	3	3	3	3	3			
Right hand	2.5	2.5	2.5	2.5	2.5	2.5			
Left hand	2.5	2.5	2.5	2.5	2.5	2.5			
Right thigh	5.5	6.5	8	8.5	9	9.5			
Left thigh	5.5	6.5	8	8.5	9	9.5			
Right lower let	5	5	5.5	6	6.5	7			
Left lower leg	5	5	5.5	6	6.5	7			
Right foot	3.5	3.5	3.5	3.5	3.5	3.5			
Left foot	3.5	3.5	3.5	3.5	3.5	3.5			

**Only 2° and 3° burns are included in the total TBSA burn percent total

▲ **FIGURE 94-3** Burn extent is best estimated using a chart based on the Lund-Browder diagram that compensates for the changes in body proportions with age.

TABLE 94-3
Issues to Consider When Making Decision Between Outpatient and Inpatient Burn Care

- No airway compromise or need for airway monitoring.
- Wound size should generally be less than 10% (fluid resuscitation not needed).
- Patient must be able to take in adequate fluid by mouth.
- No significant burns of the face, ears, hands, genitals, or feet.
- Family must have the resources to support an outpatient care plan.
- Adult caregiver should be able to stay home with child.
- Adult able to perform wound cleansing, inspection, and dressing changes.
- Child must have transportation and access to clinic follow-up.
- Family must have transportation for clinic and emergency visits.
- No suspicion of abuse or neglect.
- No clearly full-thickness areas that will require surgery.

TABLE 94-4
Frequent and Serious Burn Complications

- Common outpatient burn complications
  - Wound sepsis, usually streptococcal cellulitis
  - Excessive pain and anxiety
  - Underestimation of burn depth
- Common inpatient burn complications
  - Wound sepsis, often invasive
  - Septic shock and organ failures
  - Inadequately controlled pain and anxiety
  - Compartment syndromes
  - Ocular exposure
  - Respiratory failure
  - Gut failure
  - Pancreatitis
  - Cholecystitis
  - Urosepsis
  - Donor site infection
  - Soft-tissue contractures

available for burn wounds. Wound medications and membranes provide three benefits: (1) pain control, (2) prevention of wound desiccation, and (3) reduction of wound colonization.

Topical wound medications range from aqueous solutions through antibiotic-containing ointments and débriding enzymes. Most topical agents in outpatient use have a viscous carrier that prevents wound desiccation and a more or less broad antibacterial spectrum that reduces wound colonization. A gauze wrap minimizes soiling of clothing and protects the wound from trauma. Silver sulfadiazine is in common use because it is painless on application and has a broad spectrum of antibacterial activity. Superficial burns are commonly treated with a clear, viscous antibacterial ointment containing low concentrations of various antibiotics. Wounds around the eyes can be treated with topical ophthalmic antibiotic ointments. Significant ear burns should be treated with mafenide acetate, as it is the only agent that will penetrate the relatively avascular cartilage.

Wound membranes provide temporary physiologic wound closure while the underlying wound heals.[15] Physiologic closure implies a degree of protection from mechanical trauma, vapor transmission characteristics similar to skin, and a physical barrier to bacteria. Their major benefit is that, when successful, they minimize wound manipulations and create a moist wound environment with a low bacterial density. Occlusive synthetic membranes are intended for use on selected clean superficial wounds and skin donor sites and must otherwise be used with some caution, as sub-membrane infection can occur, deepening underlying wounds and causing systemic infection and toxicity.



◀ **FIGURE 94-4** The most common wound infection seen in outpatients is streptococcal cellulitis.



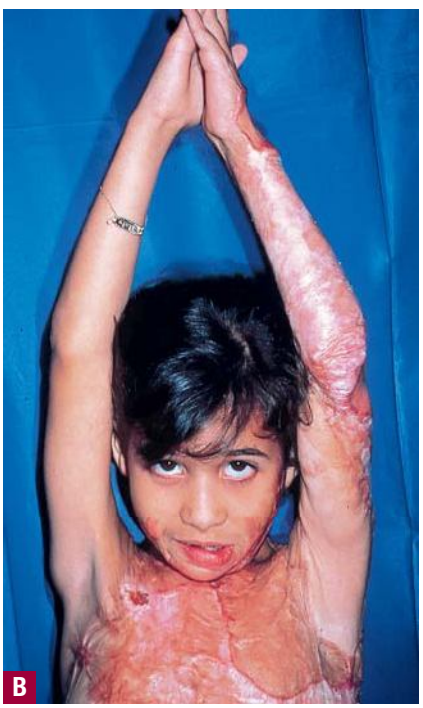

▲ **FIGURE 94-5** Hypertrophic scarring and contracture formation can become difficult problems after serious burns (**A**), but are often amenable to surgical improvement (**B**).

PREVENTION

A plethora of burn prevention efforts have met with mixed success. They can be based on (1) public education, (2) legislation, or (3) engineering.[16] Examples of public education campaigns depend for their success on an educated literate community. The "stop-drop-and roll" campaign in elementary schools is an excellent example. Legislation is often more effective. Examples include safe

TABLE 94-5
Inpatient Care of Larger Burns[a]

- Initial evaluation and resuscitation (0–72 h)
  - Clearly identify all injuries.
  - Perform an accurate individualized fluid resuscitation.
  - Ensure effective decompression of extremities and torso.
- Initial excision and biologic closure (day 1–7)
  - Accurately identify all wounds requiring surgery.
  - Excise the bulk of all full-thickness wounds.
  - Effect definitive or temporary biologic closure of wounds created by excision.
- Definitive wound closure (wk 1–6)
  - Replace temporary wound membranes with permanent coverage.
  - Close physiologically small, but functionally critical areas (e.g., hands and face).
  - Separate patient from intensive care support.
- Rehabilitation and reconstruction (day 1 through 2 yr)
  - Initiate early ranging, splinting, and anti-deformity positioning.
  - Progress to active strength and endurance training.
  - Initiate scar management program.
  - Foster reintegration with family and community.

[a]Inpatient care of larger burns has three general phases. The duration and intensity of each phase will vary with wound extent and complexity. Rough time periods and major objectives of each phase are listed here.



factory set points for home water heaters and flammability standards for children's bedclothes. Engineering solutions are perhaps the most effective. Examples are common in industry and include physical isolation of high-power lines and "child-proof" cigarette lighters. Often all three are combined, a current example being the fire-safe cigarette. A self-extinguishing cigarette has been engineered and in some places its sale mandated after public education influenced the legislative process.

KEY REFERENCES

The full reference list for all chapters is available at www.digm7.com.

1. Sheridan RL et al: Current expectations for survival in pediatric burns. *Arch Pediatr Adolesc Med* **154**:245, 2000
5. Sheridan RL, Tompkins RG: What's new in burns and metabolism. *J Am Coll Surg* **198**:243, 2004
6. Sheridan RL: Comprehensive treatment of burns. *Curr Probl Surg* **38:**657, 2001
8. Sheridan RL: Evaluating and managing burn wounds. *Dermatol Nurs* **12**:17, 2000
9. Sheridan RL: Outpatient burn care in the emergency department. *Pediatr Emerg Care* **21**:449, 2005
12. Sheridan RL et al: Long-term outcome of children surviving massive burns. *JAMA* **283**:69, 2000
14. Sheridan RL: Burn care: Results of technical and organizational progress. *JAMA* **290**:719, 2003
15. Sheridan RL, Tompkins RG: Skin substitutes in burns. *Burns* **25**:97, 1999

CHAPTER 95

Radiobiology and Radiation Effects

Frederick D. Malkinson
Renato G. Panizzon

RADIOBIOLOGY OF THE SKIN

Radiobiologic events in the skin are best interpreted from a knowledge of the general responses of cells and tissues to ionizing radiation. These responses to electromagnetic radiation (x-rays, γ rays) and to particulate radiation (electrons, neutrons, protons, α particles, etc.) may be studied in the whole organism or at the tissue, cellular, or molecular levels.

Clinical and microscopic changes in skin and its appendages were among the first reactions seen after accidental or therapeutic exposure to x-rays. In the late 1890s, Henri Becquerel and Pierre Curie both noted erythema and ulceration in their own radiation-exposed skin sites after accidental or deliberate exposure. Our current knowledge of radiation responses in skin derives from clinical observations and animal studies. The latter sources are important, because certain data for humans are only provided by accidental radiation exposure.

Mechanisms of Radiation Injury

Electromagnetic radiation with energies above 125 eV (x-rays, ^{60}Co γ rays) produce indirect ionization by ejecting orbital electrons from atoms in tissues or cells. These fast electrons ionize other atoms and break chemical bonds. The resultant free radicals (atoms or molecules carrying an unpaired electron in the outer orbital shell) have half-lives of 10^{-5} seconds, are largely formed from tissue water molecules and oxygen, and react with cell or tissue organic molecules, altering their structure and function. The activated cellular response pathways mediating cytoprotective and cytotoxic responses of cell survival or death[1] and the roles of cytokines in normal tissue radiation reactions have been reviewed.[2,3] Resulting biochemical and/or biologic changes appear within fractions of seconds, minutes, hours, days, weeks, or longer (Table 95-1).

Cellular Radiation Effects

Although functional cell loss in nonproliferating or slowly proliferating cell systems follows only large radiation doses (100 Gy*; 1 Gy = 100 rad), reproductive (mitotic) integrity is usually lost after exposure to only 3 to 4 Gy. Cell death may occur within hours but usually occurs after one to five post-radiation division cycles. Equally proliferative normal and malignant cells have similar radiation sensitivities. X-ray damage to chromosomal DNA is principally responsible for cell killing. Apoptosis, cellular necrosis, and failure to complete mitosis are the principal mechanisms of post-radiation cell death.

Loss of reproductive integrity means the loss of sustained mitotic activity of the

*Gy (gray) is the Système international d'unités unit for the absorbed dose, which replaced the former unit "rad" (radiation absorbed dose). The absorbed dose of 1 Gy is equal to the absorption of 1 J (joule) of radiation energy by 1 kg of matter. 1 Gy = 1 J/kg corresponds to 100 rad (1 rad = 100 ergs/g).

RADIOBIOLOGY AND RADIATION EFFECTS

AT A GLANCE



- Radiation reactions appear after fractions of a second, up to weeks, or longer.
- DNA is the most critical target of ionizing radiation, but the cell membranes and cytoplasm are also affected.
- Radiosensitivity varies during phases of the cell cycle.
- Among the radiation modifiers, oxygen and hyperthermia are radiation enhancers, whereas disulfides and prostaglandins are radioprotectors.
- Clinical effects of ionizing radiation include erythema, dry and moist desquamation, erosion or epilation (acute reactions), followed by fibrosis, vascular damage, ulceration hyper-/hypopigmentation, and malignancy (late reactions).

cell and consequently the possibility of the clonal growth. The loss of clonal growth is measured as the surviving fraction: The ratio of colonies in irradiated dishes to colonies in nonirradiated dishes. One also speaks of mitotic death. Mitotic death might also be provoked by spindle defects that allow aneuploid cells to develop.

Recent studies also suggest that microvascular endothelial cells may be a primary radiation target, contributing to consequent tissue or cell death.[4]

DNA and Chromosome Damage

Differences in numbers of chromosome sets (ploidy) affect radiation sensitivity.[5] Ionizing radiation impairs the synthesis of DNA, thymidine kinase, and DNA polymerase. Genetic damage from irradiation may occur in the gene at the molecular level or in the chromosome at the cellular level. Chromosome breaks may follow exposure to only 0.01 Gy (1 rad). Single-strand breaks are common and readily repaired, but infrequently erroneous repair induces mutation(s). Double-strand breaks, however, more frequently undergo error-prone repair or may be irreparable. Although more aneuploid tumors tend to be more radioresistant, there is no consistent relationship between ploidy on radiation sensitivity. When the relationship between survival and radiation-induced chromosome aberration frequency—which is a measure independent of most other modifiers of sensitivity—was determined a direct relationship between ploidy and mean lethal aberration frequency was observed. Such chromosome abnormalities may also increase genome-wide instability in future cell generations. Chromosomal translocations or inversions at sites of strand breaks may directly result in oncogene activation.

Cell Cycle Effects

Cells in the division cycle are usually more radiosensitive than non-dividing cells. In vitro and in vivo data reveal that radiosensitivity varies significantly in different phases of the cell cycle.[6] For most cell lines, G_2/M phase cells are the most radiosensitive. Late S phase and early G_1 phase cells are relatively radioresistant. Changes in DNA replication states and sulfhydryl compound content (radioprotectors) may affect cell cycle phase radiosensitivity. Overall, radiosensitivity varies by a factor of 2.5 to 3.0 among the various cell cycle phases.

Division Delay

Ionizing radiation delays cell division by 1 hour/Gy in a 2- to 10-Gy range. The delay is greatest for cells in G_2 phase.



TABLE 95-1
Late Effects Normal Tissue Scale (LENT SOMA)[a] for Skin/Subcutaneous Tissue

	GRADE 1	GRADE 2	GRADE 3	GRADE 4
Subjective				
Scaliness/roughness	Present/asymptomatic	Symptomatic	Requires constant attention	—
Sensation	Hypersensitivity, pruritus	Intermittent pain	Persistent pain	Debilitating dysfunction
Objective				
Edema	Present/asymptomatic	Symptomatic	Secondary dysfunction	Total dysfunction
Alopecia (scalp)	Thinning	Patchy, permanent	Complete, permanent	—
Pigmentation change	Transitory, slight	Permanent, marked	—	—
Ulcer/necrosis	Epidermal only	Dermal	Subcutaneous	Bone exposed
Telangiectasia	Minor	Moderate < 50%	Gross ≥ 50%	—
Fibrosis/scar	Present/asymptomatic	Symptomatic	Secondary dysfunction	Total dysfunction
Atrophy/contraction (depression)	Present/asymptomatic	Symptomatic/< 10%	Secondary dysfunction/10%–30%	Total dysfunction/> 30%
Management				
Dryness	—	—	Medical Intervention	—
Sensation	—	Intermittent medical intervention	Continuous medical intervention	—
Ulcer	—	—	Medical intervention	Surgical intervention/ amputation
Edema	—	—	Medical intervention	Surgical intervention/ amputation
Fibrosis/scar	—	—	Medical intervention	Surgical intervention/ amputation
Analytic				
Color photographs	Assessment of changes in appearance			

[a]Instructions: Score the 14 subjective, objective, and management parameters with 1–4 (score = 0 if there are no toxicities); total the scores and divide by 14.

Molecular checkpoint genes arrest cells in G_2 phase to allow chromosomes to be checked for integrity and to be repaired before mitosis occurs. Cells lacking normal checkpoint genes will likely be more sensitive to radiation killing and malignant change. Shorter division delays occur in S phase cells and are least for G_1 cells.

Radiation Modifiers

There are two principal groups of radiation modifiers, radiosensitizers and radioprotectors, both of which have been widely studied in skin and hair. For these agents, toxic effects, technological limitations, and, often, a lack of differential effects on malignant versus normal cells, limit their usefulness. Only a few of these modifiers are discussed here.

RADIOSENSITIZERS ***Oxygen.*** The addition of oxygen to low prevailing pressures of 0 to 30 mm Hg in tissues increases the effectiveness of sparsely ionizing radiation (x-rays, γ-rays), up to threefold for a dose greater than 2 Gy. A further increase in oxygen tension to an atmosphere of pure oxygen has little further effect. An oxygen concentration of 0.5 percent (or 3 mm Hg) already results in a radiosensitivity that is halfway between hypoxia and that of fully oxygenated conditions. To produce this effect, mediated by free radical and H_2O_2 formation, oxygen must be present during the irradiation time. Oxygen enhancement ratios are least for densely ionizing radiations (neutrons, α particles). Hypoxic areas in tumors are best addressed by fractionation treatment schedules and use of densely ionizing radiation, where feasible. Hyperbaric oxygen therapy is markedly compromised by sharp falls in oxygen partial pressures during tissue and tumor diffusion.

Electron-Affinic Agents. Electron-affinic agents interact with radiation-damaged DNA, blocking repair of injury produced by free radicals. The agents are cytotoxic to hypoxic cells and bind to intracellular radioprotectors such as (glutathione) (see Radioprotectors), further enhancing radiosensitivity effects. Unlike oxygen, these agents diffuse over greater distances and are metabolized more slowly. The principal compounds used are nitroimidazoles, including metronidazole and misonidazole. Cytotoxic effects (neuropathies) have limited their usefulness, but newer, less-lipophilic agents have shorter tissue half-lives and display significantly enhanced sensitization potentials. Some of these agents also potentiate chemotherapeutic drug effects. A number of compounds have been evaluated in clinical trials.[8]

Hyperthermia-Induced Radiosensitization. Heating skin before, during, or after irradiation enhances cutaneous reactions in mouse or human skin. At temperatures over 41.5°C (106.7°F) structural, chromosomal, and/or repair proteins are damaged, and RNA, DNA, and protein synthesis are impaired. At least in skin, blood flow is also increased with resulting increase in oxygen tension. Above 43°C (109.4°F), cell survival curves are similar to those for ionizing radiation. Hyperthermia also induces apoptosis in some cell lines. Overall, normal and malignant cells have similar heat sensitivities. In the clinical and experimental use of hyperthermia with radiation, heat at temperatures of 43°C (109.4°F) or higher is usually administered within 4 hours before radiation. Thermal enhancement ratios range from 2 to 4 for single doses, but are lower for fractionated therapy. Combination treatment produces more partial and complete tumor responses than radiation alone, but the sole use of hyperthermia has little effect. Cooling reduces tissue oxygen tension through vasoconstriction, decreasing radiosensitivity.

RADIOPROTECTORS With sparsely ionizing radiation, dose reduction factors of 2 to 2.5 (≥ 50 percent) have been found with thiol and disulfide compounds (cysteine, glutathione) which scavenge free radicals. If a chemical or other agent acts as if to change the dose of radiation, the dose-modifying factor indicates the ratio of dose without, to dose with the agent, for the same level of effect (e.g., 50 percent survival). A dose reduction factor of 2 implies that 50 percent of the dose is required to obtain the same level of effect in presence of the modifying agent compared to irradiation alone. Similarly, dose reduction factor 6 means one-sixth (16.6 percent) of the dose in presence of the modifying agent. The most effective of these is WR-2721 (amifostine),[9] but toxicity (hypotension) may limit its effectiveness. Leukotrienes and especially prostaglandins are effective radioprotectors in microgram amounts, yielding dose reduction factors up to 6 (84 percent) for misoprostol, although the protective mechanism is not fully understood. Given before radiation, their efficacy depends on the presence of receptors for the individual agent.[10] Prostaglandins are radioprotective after local or systemic administration, greatly reducing, for example, experimental radiation-induced alopecia.[11] They also protect against chemotherapeutic agent toxicity as well, especially for doxorubicin and cyclophosphamide.[11,12] Misoprostol holds clinical promise for the protection of normal tissues (hair, mucous membranes) lying in the path of a radiation beam, although in an experimental setting it fails to protect tumors against radiation effects.[13,14]

RADIOBIOLOGY OF THE SKIN AND HAIR

Within 2 to 3 weeks after exposure of human skin to high doses of single or fractionated radiation (Fig. 95-1), acute erythema, desquamation, erosion, and hair loss occur, followed by healing. The intensity of radiation erythema depends on age, gender, anatomic site, dose, and dose rate. These early changes reflect injury, apoptosis, and reproductive failure of germinative epidermal and hair matrix cells, reduced division rates in surviving cells, and vascular damage.[15] Epidermal cell replacement occurs from the third to the fifth week after radiation. Later chronic post-radiation changes result largely from injury to dermal structures, particularly the vasculature, and fibrosis,



▲ **FIGURE 95-1** Radiation dermatitis: Acute. Localized area of erythema and edema in the radiation portal occurring at the end of radiotherapy treatment for breast cancer.



which is actually an early (within 1 week) but progressive post-radiation event that is cytokine-mediated.[15–17]

The character and magnitude of cutaneous responses to radiation depend on total dose and dose fractionation, radiation quality and ionization density, area or volume of tissue irradiated, anatomic site, and vascular supply. The responses of irradiated skin and the effects on post-radiation skin changes of radioprotectors, radiosensitizers, and hyperthermia have been investigated.[15,18] Increased radiosensitivity and carcinogenesis in genetic disorders characterized by defective cellular and DNA repair processes are well known and discussed in Chap. 109.

Post-radiation changes in the highly proliferative anagen hair matrix cells cause hair dysplasia and reduced hair length and growth rate. In humans, 3 Gy produces complete, reversible anagen alopecia; permanent alopecia begins to occur at 5 Gy. In mice, G_0 telogen matrix cells are 2.5 times more radioresistant than anagen cells, probably due to their different proliferation rates and vascular supply. Altered matrix cell uptake of isotopically labeled amino acids, incidence of hair dysplasia, measurements of reduced hair shaft diameters, and quantitative assessments of surviving hairs or later regrown hairs have all been used as biologic end points to study general cellular radiation effects, as well as radioprotective or radiosensitizing actions of numerous pharmacologic or physical agents.[15]

Radiobiologic Effects on Melanocytes and Pigment Formation

Low-dose radiation induces cutaneous hyperpigmentation after minimal inflammation. Pigmentation is directly related to dose rate and total dose, and is characterized by increased numbers of melanocytes with increased tyrosinase activity, and by enhanced melanin transfer to epidermal cells. Higher radiation doses destroy melanocytes with resultant depigmentation. Similar radiation effects occur in mid-anagen hair follicles. At higher dose rates, hair melanocytes are far more susceptible to radiation destruction than epidermal melanocytes. In mice, telogen melanocytes are much more radiosensitive than anagen melanocytes.[19] Melanocyte survival in laboratory preparations of hair follicle and depigmentation of hair in laboratory animals have both been used to quantitate combined drug-radiation effects.

Radiobiologic Effects on Langerhans Cells

Although Langerhans cells (LCs) are relatively radioresistant,[20] in one study, single doses of 20 Gy in mice reduced LC numbers by more than 80 percent within 10 days; repopulation was complete 30 days later. Whole-body irradiation to the bone marrow delayed repopulation another 3 weeks. In mice, the effects of such radiation early in life markedly accelerated skin LC loss in aged animals, perhaps reflecting dermal fibrosis and reduced blood flow or loss stem cells at the time of irradiation. Loss of LCs and their immunologic functions may contribute to reduced ability to develop contact hypersensitivity in affected sites and to increased post-radiation tumorigenesis as a result of impaired immune surveillance.

LONG-TERM RADIATION REACTIONS

Typical changes may appear in irradiated fields months to years after radiotherapy: depigmentation often associated with atrophy, telangiectasia, hyperpigmentation, depressed scars, fibrosis, and radiation keratoses. These changes are termed *chronic radiodermatitis* (Figs. 95-2, 95-3, and 95-4). The overall appearance of chronic radiodermatitis is that of poikiloderma. After high doses, tissue eventually breaks down, and a leather-like necrosis, tightly adherent to the underlying tissue, develops (Fig. 95-5A). Such lesions are extremely tender. After many years, squamous cell carcinoma can arise in such lesions (Fig. 95-5B). The required dose for chronic radiodermatitis to develop is lower than the dose usually required for the treatment of malignant tumors, with the exception of some malignant lymphomas. The Radiation Therapy Oncology Group, in collaboration with the European Organization of Research and Treatment of Cancer, has developed the LENT (late effects normal tissue) scoring system (SOMA), which can be used to document *s*ubjective, *o*bjective, *m*anagement, and *a*nalytic information (see Table 95-1).[21] In this context, "late"



▲ **FIGURE 95-2** Chronic radiation dermatitis after x-ray radiation for cutaneous hemangioma. Two decades later: There is poikiloderma consisting of atrophy, hypopigmentation, and multiple telangiectasias.



▲ **FIGURE 95-3** Radiation dermatitis: Chronic. This poikilodermatous condition consisting of hypopigmentations and multiple telangiectasias resulted from a total body electron beam therapy for cutaneous T-cell lymphoma.



▲ **FIGURE 95-4** Radiation dermatitis: Chronic. There is poikiloderma (brown: hyperpigmentation; white: hypopigmentation; and red: telangiectasia) combined with atrophy and sclerosis. Hairs are absent. These massive skin changes are the result of (overdosed) radiation therapy the patient received as a child for fungal infection of the scalp. He is a candidate for squamous cell carcinoma in the future.





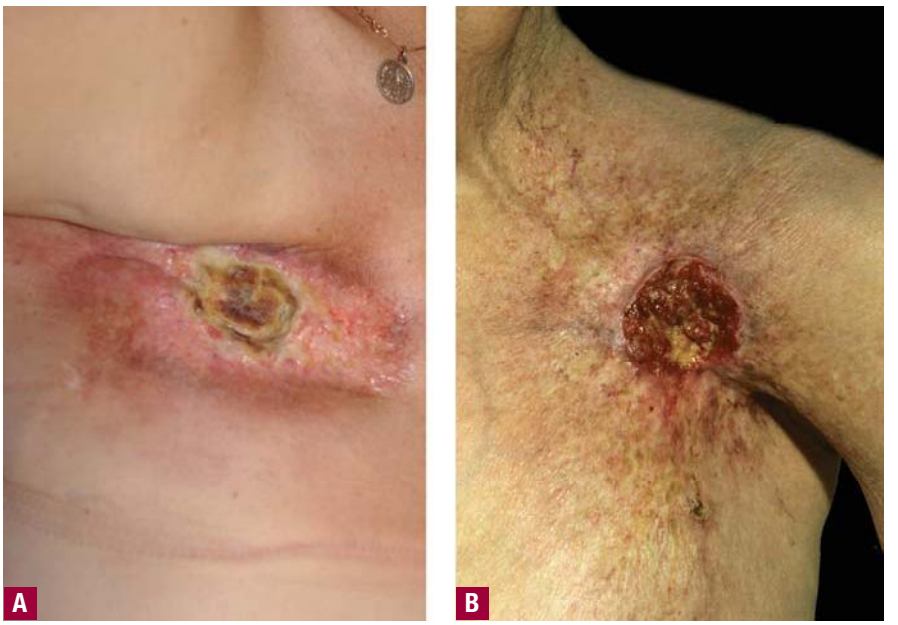

▲ **FIGURE 95-5** Radiation dermatitis: Chronic. **A.** With a central necrosis that is leathery, yellowish-brown, and tightly adherent. Surgical removal will reveal a deep ulcer. The lesion is extremely painful. **B.** A large and deep ulcer in an area of atrophy, fibrosis, poikiloderma, and telangiectasia on the chest wall. This occurred 20 years after radical mastectomy, axillary lymph node dissection, and radiotherapy. The ulceration was primarily due to radionecrosis. Now the border of the ulcer is elevated and firm and so is the granulating base: This is squamous cell carcinoma arising in this radiation dermatitis.

means more than 90 days after the onset of radiation. The four SOMA criteria are defined as follows:

Subjective: Perceptions and problems reported by the patients, such as pain or pruritus

Objective: Determined by the physician through physical examination

Management: Measures necessary to treat the side effects, either medical or surgical

Analytic: Potential deficits that can only be evaluated by sophisticated methods such as computed tomographs

KEY REFERENCES

The full reference list for all chapters is available at www.digm7.com.

1. Schmidt-Ullrich RK et al: Signal transduction and cellular radiation responses. *Radiat Res* **153**:245, 2000
3. Rosen EM et al: The molecular and cellular basis of radiosensitivity: Implications for understanding how normal tissues and tumors respond to therapeutic radiation. *Cancer Invest* **17**:56, 1999
4. Davis ST et al: Prevention of chemotherapy-induced alopecia in rats by CDK inhibitors. *Science* **291**:134, 2001
5. Schwartz JL et al: The contribution of DNA ploidy to radiation sensitivity in human tumor cell lines. *Br J Cancer* **79**:744, 1999
7. Maisin JR: Bacq and Alexander Award lecture—Chemical radioprotectors: Past, present, and future prospects. *Int J Radiat Biol* **73**:443, 1998
21. Suter L: Long term (chronic, late) radiation reactions of the skin, in *Radiation Treatment and Radiation Reactions in Dermatology*, edited by Renato G, Panizzon J. Springer Ed, Berlin, 2004, p 143

CHAPTER 96

Skin Problems in Amputees and Ostomates

Calum C. Lyon
Michael H. Beck

TECHNICAL BACKGROUND: LIMB PROSTHESES

In most centers, artificial limbs are constructed in a modular fashion.[1] The stump is placed in a thermoplastic socket that is then fitted into the main body of the limb. The bulk of the prosthesis comprises a metal frame with articulations and an outer casing of acrylic resin or carbon composite material. Before fitting the limb, many patients place their stump in a liner designed to reduce friction on the skin. This may be an expanded plastic cup, a silicon/mineral oil sleeve, or a cotton or nylon sock. The prosthetic limb, once fitted, is held in position by one of a range of suspension elements. In above-knee (Fig. 96-1) or proximal arm amputations, this is usually a fabric belt arrangement worn around the waist or shoulders, respectively. Below-knee amputees require a different system using either a butyl rubber sleeve or corset to hold the appliance firmly onto the thigh (Fig. 96-2). Many patients with above-knee amputations now use a suction socket device that provides sufficient suspension by holding the prosthesis in place through negative pressure without the need for additional belts (see Fig. 96-1).

DERMATOLOGIC PROBLEMS IN AMPUTEES

The skin of an amputation stump is not designed to withstand the physical insults it encounters within a prosthetic limb. For example, although some adaptation to friction or pressure occurs, some skin problems are inevitable. If these dermatoses cannot be prevented or rapidly resolved by prosthesis adjustment or medical intervention, they can incapacitate the patient, particularly those who have lower-limb prostheses. As a result, patients may suffer social isolation, emotional distress, or even financial deprivation if they are unable to work.

Skin problems may occur because of allergy or chemical irritation to materials in contact with the skin, as well as from trauma and occlusion. Examples of physical stresses on the skin include shearing and friction from elements in the socket and pressure on load-bearing areas, especially on the tibial tuberosity in below-knee amputations and the ischial tuberosity, adductor region, or groin in above-knee amputations. In all cases, the occlusion results in increased humidity from trapped perspiration, in-

SKIN PROBLEMS OF AMPUTEES AT A GLANCE



- Skin problems under limb prosthesis result from:
  - trauma
  - heat
  - pressure
  - occlusion and maceration
  - physical trauma, disturbances of tissue fluid dynamics may cause other distinctive skin changes
  - microclimate under prosthesis promotes bacterial and fungal infections
  - irritant and allergic contact dermatitis occurs due to materials applied to skin, worn, or used in construction of the prosthesis
- Koebner phenomenon may occur in skin under prosthesis.
- Management: most important are basic hygiene measures.
- Early medical intervention and collaboration with prosthetist are essential to address problems.

creasing the likelihood of irritation, allergy, and infection.

The common skin disorders in amputation stumps can be classified into diseases related to the reasons for the amputation, physical effects of a prosthesis, infection, contact dermatitis, and other cutaneous disorders.

Epidemiology

The great majority of artificial limb wearers are amputees, although a small proportion are people with congenital limb malformations. Lower-limb amputees are the most numerous and are also the group at greatest risk of skin problems. Modern limb prostheses allow many of today's amputees to lead an active life with good mobility. Nevertheless, as many as 62 percent of one cohort reported sores or skin irritation.[2] In a further group of 745 lower leg amputees, 40.7 percent had at least one skin problem. Further analysis identified four factors independently associated with dermatologic disorders, namely transtibial amputation, employment status, type of walking aid used, and peripheral vascular disease.[3] One-third of amputees experience a skin problem that interferes with the normal use of their artificial limb.[4]

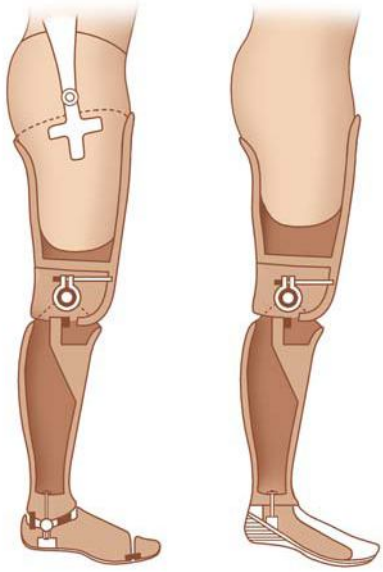

▲ **FIGURE 96-1** Above-knee prosthesis. Suction-socket prosthesis.

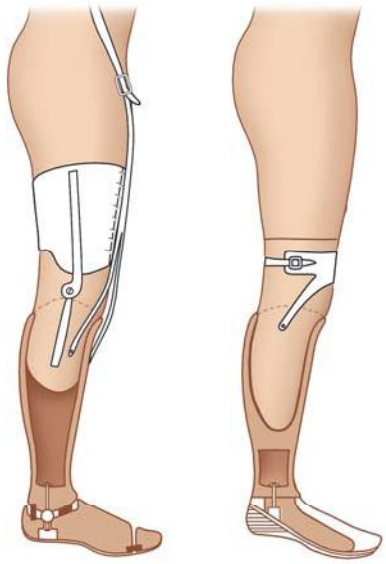

▲ **FIGURE 96-2** Below-knee prosthesis. Patellar–tendon-bearing cuff suspension.

Dermatoses Related to the Reasons for Amputation

Several disorders resulting in the need for amputation can have a significant impact on skin integrity. In general, younger patients require artificial limbs because of traumatic amputations, congenital abnormalities, or malignancy, whereas in the older age group, arterial disease and vascular complications of diabetes mellitus predominate. Amputations after trauma or severe vasculitis may be associated with scarring that makes for a suboptimal prosthesis fit (Fig. 96-3). However, it is diabetes mellitus that is particularly associated with protracted skin problems as a result of impaired wound healing, susceptibility to infection, abnormal sensory nerve function, and disruption of normal tissue fluid balance.[5] Diabetic amputees as a group require more frequent clinical review to prevent complications. Treatment of the diabetic amputee not only requires good control of the blood glucose level but possibly a change of the stump environment through adjustment or redesign of the artificial limb. The diabetic amputee highlights the need for close links with a prosthetics department, which allow rapid referral of patients for assessment.

Physical Dermatoses

The physical effects of wearing a prosthesis are the most common causes of



▲ **FIGURE 96-3** Scarring of the stump after amputation for severe postinfective vasculitis.



skin problems.[4,6] These can be divided into those resulting from repeated direct trauma and those secondary to disturbance of tissue fluid dynamics.

DIRECT PHYSICAL TRAUMA ***Ulceration.*** Ulceration and callus formation are seen where there is chronic pressure or repeated frictional forces on stump skin. Ulceration may also be caused by infection or poor cutaneous nutrition, particularly secondary to diabetes mellitus (Fig. 96-4). Stump ulcers should be treated early as malignancy may develop in long-standing ulceration. With repeated infection and ulceration, an amputation scar on the distal stump skin can erode further. In some cases, the skin may become completely adherent to bone and develop thick, callus-like hyperkeratosis (Fig. 96-5), which may necessitate revision of the distal bony surface. In every instance, the cause of the ulceration must be determined to resolve a chronic process that can become totally disabling.

Physical Dermatitis. In some patients, eczema may be caused by a poorly fitted or misaligned prosthesis or by edema and congestion of the terminal portion of the stump; only with alleviation of these problems does the condition clear.

Epidermoid Cysts and Follicular Keratoses. Epidermoid cysts and follicular keratoses are two ends of a spectrum of the same disorder. Repeated pressure and friction from the prosthesis appears to cause invagination of keratin around hair follicles, which then results in a foreign-body reaction. Follicular keratoses are therefore the earliest changes.[7] These are very common, often multiple, and distributed at sites of weight bearing such as the anterior tibial area, popliteal fossa, and the adductor or inguinal areas of the thigh (Fig. 96-6A). Fortunately, they cause little trouble in many cases,



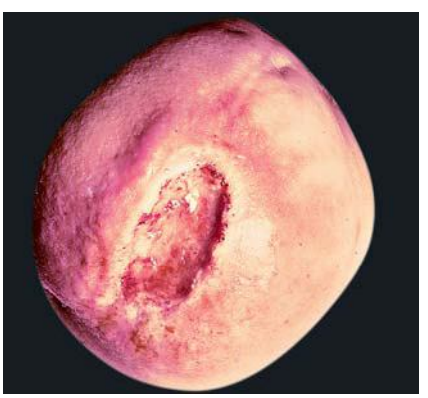

▲ **FIGURE 96-4** Chronic ulcer of stump skin.



▲ **FIGURE 96-5** Chronic ulceration resulting in thick hyperkeratosis and scab formation adherent to the underlying bone.

but they can become inflamed and painful particularly if the patient picks at them to extract the keratin plug or if they become infected. Inflamed follicular keratoses can have an acneiform appearance, leading some to suggest that they represent a form of acne mechanica. When the continued pressure and friction causes the keratin to extend deeper into the dermis, larger cystic lesions, 1 cm to 3 cm in diameter, form; these are commonly termed *post-traumatic epidermoid cysts*. Deeper cysts can be very tender when compressed by the prosthesis. Some cysts have an obvious punctum and patients may express keratinous material from them. Large cysts can be so painful that the patient can no longer wear a weight-bearing prosthesis each day (see Fig. 96-6B and C). Distention of the overlying epidermis can occur, followed by spontaneous rupture. A serous, purulent, or hemorrhagic fluid is then discharged. The resulting sinus is difficult to occlude and the discharge continues as long as the prosthesis is worn. Intercommunicating sinuses can appear and spontaneous ruptures may occur. In advanced cases, a granulomatous reaction occurs around the cyst with considerable capillary dilation, vascularization, and a heavy inflammatory infiltrate progressing to abscess formation (see Fig. 96-6B).

Management of this condition can be difficult. Clearly, prevention is the ideal but is not always possible despite regular prosthetic assessments. The fit of the prosthesis is the single most important method of preventing cyst formation. The problem can sometimes be improved or successfully eliminated by proper fitting and aligning of the prosthesis and continued adjustment by the prosthetist. Rough surfaces in areas of increased contact pressure in the socket,



▲ **FIGURE 96-6** Epidermoid cysts in different stages. **A.** Early follicular keratoses in the popliteal fossa of a man with below-knee amputation. **B.** Hemorrhagic and inflamed large epidermoid abscess in a man with an above-knee prosthesis. Note the follicular hyperkeratosis. **C.** Inflamed epidermoid cysts in the groin of a man with an above-knee prosthesis.

particularly the suction socket, tend to catch the skin, increasing the shearing forces. For this reason, the lining of the socket should be kept smooth. With the idea of inserting a buffer between the skin and the socket, protective devices such as liners and stump socks are used. Various synthetic films and adhesives, such as Teflon, have been found satisfactory as liners. They allow for a smooth, gliding action of the prosthetic socket wall or brim against the skin. Applying a vapor-permeable adhesive membrane to the skin before fitting the

appliance can also help to reduce frictional trauma. Topical glucocorticoids can be used at night to reduce inflammation and provide symptomatic relief. Intralesional injection of glucocorticoids into the cysts and their channels also results in temporary improvement.

Surgical intervention is useful in cases with a few lesions that are not infected. Lesions can be surgically incised and drained. In other instances, removal of the prosthesis is sufficient to cause the lesion to involute, provided that the cyst has not become too large. However, spontaneous rupture, incision, and drainage, and even spontaneous resorption of the lesion are of only temporary benefit. When the prosthesis is worn again, these cysts can recur so that surgical excision is not always the treatment of choice, especially in continually rubbed areas.

In selected cases, systemic retinoid therapy may be appropriate to minimize hyperkeratosis. One author found oral isotretinoin to be effective in a patient described as having acne mechanica.[8]



▲ **FIGURE 96-7** Dependent edema/early verrucous hyperplasia in a man with multiple amputations after severe peripheral vasculitis and necrosis.



DISTURBANCES OF TISSUE FLUID DYNAMICS ***Edema.*** Amputation of a lower extremity greatly disturbs the normal pattern of blood and lymph channels, as well as the relationship of pressure both inside the vessels and in the surrounding tissues of the stump. An important feature of care during convalescence after amputation is the reduction of edema and stabilization of new circulatory patterns in the stump. Swelling can be partially prevented by gradual compression of the stump tissues with an elastic bandage or "shrinker" sock before fitting the prosthesis and socket.

When an amputee begins to wear a suction-socket prosthesis, the skin must adapt to an entirely new environment. The patient can expect edema, reactive hyperemia for days or weeks, a reddish-brown pigmentation resulting from capillary hemorrhage, and, occasionally, serous exudation and crusting of the skin of the distal portion of the stump. These changes are relatively innocuous, usually short-lived, and do not usually require therapy.

The extent to which edema may persist or recur in the healed stump depends on many factors.[9] Edematous portions of the skin of the distal part of the stump may become pinched and strangulated within the socket (Fig. 96-7). Such areas may ulcerate if they catch in the spring-valve opening and become gangrenous as a result of the impaired blood supply. Therapy includes eliminating all mechanical factors contributing to the edema, such as choking by the socket, poor fitting, and misalignment. Excessive negative pressure in a suction-socket prosthesis also contributes to circulatory congestion and edema. Treatment should be directed toward better support of the distal soft tissues. Occasional use of an oral diuretic sometimes allows the edema to resolve.

Verrucous Hyperplasia. *Verrucous hyperplasia* refers to a reactive hyperplastic condition, characterized morphologically by numerous, coalescent warty papules (Fig. 96-8). It occurs when the chronic pressure effects of a poor prosthetic fit disrupt vascular and lymphatic channels, resulting in chronic tissue edema. The same appearance is seen around long-standing leg ulcers where there is an element of lymphedema (see Chap. 175). Histologic examination can show evidence of pseudoepitheliomatous hyperplasia, although the condition itself is benign and potentially reversible. However, in neglected cases, malignant change can occasionally occur (see Fig. 96-8C). Bacterial infection may play a role in the development of pseudoverrucous hyperplasia, as secondary mixed flora infections are common because of the poor superficial blood flow and the convoluted surface (Fig. 96-9). External compression is the best method of treatment, in combination with topical control of bacterial infection. In below-knee amputees, the distal part of the stump is edematous; the stump dangles freely in the socket or has



▲ **FIGURE 96-8** Verrucous hyperplasia of the distal stump skin. **A.** Before compression therapy. **B.** Total resolution after compression therapy. **C.** Malignant degeneration into squamous cell carcinoma.





▲ **FIGURE 96-9** This man developed post-infectious purpura fulminans after varicella-zoster infection as a child in the 1960s and lost both legs as a consequence. He presented with infected verrucous hyperplasia having lived a reclusive life in a cabin in the woods wearing an old-fashioned unadjusted aluminum prosthesis for many years. The infection was treated with new hygiene measures, and he was fitted with a modern modular prosthesis. The skin rapidly resolved, although some of the verrucous hyperplasia changes persisted.

no distal support or partial end-bearing. When the stump end is supported in the socket by a temporary cushion or platform, compression gradually reduces and slowly clears the verrucous condition. The greater the compression on the distal stump, the more immediate and lasting is the improvement. The use of compression bandaging, shrinker socks and other pads, and partial end-bearing all have a definite place in therapy and can be skillfully applied by the prosthetist. Short courses of oral diuretics may be indicated to reduce edema of the stump. The medication can be gradually decreased when the stump and its skin return to normal.

Acroangiodermatitis. Acroangiodermatitis occurs when the chronic pressure changes result in vessel proliferation in the upper and mid-dermis. There is also extravasation of red blood cells and these features combine to give a purplish hue to the papules and plaques that appear on a background of edematous skin. The appearance may mimic Kaposi sarcoma. Some authors suggest that acroangiodermatitis occurs in above-knee amputees who use a suction socket prosthesis that exerts negative pressure.[10] However, there are reports of acroangiodermatitis in below-knee amputees,[11] and the same condition is seen in chronic venous insufficiency and in those patients with arteriovenous shunts (acroangiodermatitis of Mali). Management of this condition is the same as for stump edema and verrucous hyperplasia.

Bacterial and Fungal Infections

The bacterial flora of amputation stumps have been examined in small groups of patients,[12,13] and the most common species encountered are *Staphylococcus epidermidis*, *S. aureus*, and *Streptococcus* sp. (see Chap. 177). The moist, occluded environment under a prosthesis is ideal for fungal and bacterial growth so that minor skin infections occur fairly frequently. In one study, *S. aureus* folliculitis or *Trichophyton rubrum* infection was identified in 3 percent of the study population.[4] Infections are more common during hot weather and in those amputees who pay insufficient attention to stump hygiene, partly because in these situations the skin becomes macerated more readily and follicular infections become more likely. Although folliculitis (Fig. 96-10) and furuncles are more common, superficial infections of the skin itself may also occur (see Chap. 177). Superficial dermatophyte and candidal infection (see Chaps. 188 and 189) are also common and may be difficult to eradicate because of the ideal environment for fungal growth within a prosthesis.

The diagnosis of infection is usually obvious when the rash extends onto skin not covered by the prosthesis. Underneath the prosthesis, any superficial infection may present as a non-specific scaling erythema indistinguishable from that caused, for example, by chronic irritation. All stump rashes should be swabbed for bacterial and fungal culture.

In the management of bacterial infections, oral antibacterial therapy should be directed by bacterial culture and sensitivity. Topical antiseptics or antibacterials can be used but some antiseptic preparations can cause irritation and there is also the potential for sensitization.

Superficial fungal infections respond to appropriate topical therapy (see Chaps. 188 and 189) but can be hard to completely eradicate because of the favorable conditions for fungal growth. In this situation, systemic antifungal therapy is useful.



▲ **FIGURE 96-10** Folliculitis of stump skin showing the typical distribution in the occluded area.

Contact Dermatitis (See Chaps. 13 and 46)

The clinical presentations of irritant and allergic contact dermatitis affecting amputation stumps are indistinguishable (Fig. 96-11), ranging from dry, scaling erythema to weeping dermatitis.[4] Indeed, the morphologic features may be the same as non-specific eczematization



▲ **FIGURE 96-11** Allergic contact dermatitis to formaldehyde-releasing biocides in a lubricating "baby oil." Note the nonspecific, dry, eczematous appearance.

where no irritant, allergic, or infectious cause is found, and where there is no history of eczema or atopy. Consequently, a careful history and examination is essential if one is to identify irritant or allergic causes (Table 96-1). This includes accurate timing of the onset of dermatitis in relation to changes in the patient's appliance routine or the composition of the prosthesis. The distribution of rash typically matches the site of the contactant. To identify a primary irritant or allergen, it is particularly important for the dermatologist to observe the patient removing and refitting their limb, making note of its construction and any medicaments or other agents such as cleansers, talcs, and creams that the patient uses. These products may contain allergens such as fragrances or preservatives. Colored stump socks may contain potentially allergenic nylon dyes.

Knowledge of the materials used in prosthesis manufacture is also necessary when considering potential sensitizers and irritants. This is best achieved by liaison with the local prosthetist, as different construction techniques may be used in different areas. In general, modern modular prostheses are fabricated with sockets, liners, and casings that may contain acrylic resins, carbon composites, and thermoplastics. Epoxy and, occasionally, polyester resins are still used by some manufacturers. Acrylate-based thread sealants are commonly used in socket bolts and metalwork. Butyl or black rubber material may be used to conceal access points to the metal frame. Rubber materials can also be found in some suction socket valves (Fig. 96-12). Suspension elements often include chrome-tanned leather and sometimes have metal fastenings, rivets, or screws containing nickel. Glues containing *para*-tertiary butylphenol formaldehyde resins are often used.

Repairs or adjustments to prostheses can introduce new irritants and allergens. For example, sockets sometimes have additional leather linings cemented to points of friction or pressure.

Irritant dermatitis (see eFig. 96-12.1 in on-line edition) can be due to occluded contact with volatile solvents in glues or resins and from fragrances and detergents in topical medicaments or lubricants. Soaps and other washing materials used to clean appliances can cause irritation if they are not removed by proper washing (see Table 96-1). Burns from a malfunctioning electrode used in a myoelectric prosthesis have been reported.[14]

Contact allergy should always be considered as a cause of inflammatory and dermatitic disorders affecting the stump, especially if there is secondary spread (see Table 96-1). In addition to standard series patch testing, the authors recommend an extra series of allergens to include components of plastics, including acrylic, epoxy, and polyester resin systems, as well as an azo dyes series. It is important to test with pieces of the prostheses and all materials applied to the stump skin, including emollients, cleansers, powders, medicaments, and cosmetics. In our experience, the most common relevant allergens are nickel, acrylates, rubber, chromate (in leather), *para*-tertiary butylphenol formaldehyde resin, and components of topical applications.[4]

TABLE 96-1
Causes of Dermatitis on Amputation Stump

- Traumatic
- Irritant
  - Soaps and washing materials
  - Topical applications, including medicaments
  - Solvents in glues and resins used to make prosthesis
- Allergic
  - Active ingredients, perfume, and excipients of topically applied materials (e.g., deodorizers, cleansers, topical medicaments, and moisturizers)
  - Acrylic, epoxy, polyester, and formaldehyde resins
  - Resin hardeners
  - Other plastic additives (e.g., *para*-tertiary butylphenol catechol)
  - Nickel
  - Rubber accelerators and antioxidants
  - Chromate (leather)
  - Nylon dyes

Other Cutaneous Disorders

Common skin diseases, for example, eczema (see eFig. 96-12.2 in on-line edition) and psoriasis (see eFig. 96-12.3 in on-line edition), may affect amputation stumps. Those diseases that exhibit the Koebner phenomenon, especially psoriasis or lichen planus, have been reported on amputation stumps with little involvement of other areas of skin. Treatment should always consider the caveat for occluded environment of a prothesis.

Benign keratoses, warts, nevi, and a variety of cutaneous papillomas may occur on stump skin and occasionally cause discomfort when a prosthesis is worn. Malignancies have also been described and squamous cell carcinoma may develop in non-healing chronic stump ulcers or verrucous hyperplasia (see Fig. 96-8C). Patients who have amputations for lymphangiomas may develop the Stewart-Treves syndrome and metastatic lymphangiosarcoma (see Chap. 128).

Treatment of these benign and malignant tumors is the same as when they occur elsewhere on the skin. Healing after tumor excision may take weeks, during which time the artificial limb may not be worn.



▲ **FIGURE 96-12** Allergic contact dermatitis to rubber materials in a suction socket from an arm prosthesis. **A.** The prosthesis fitted. **B.** The dermatitis is worst around the areas where the pressure is released on removing the limb.



General Management Considerations

Many of the more common skin problems can be prevented or controlled by adherence to an appropriate hygiene and skin-care regimen in conjunction with regular prosthetics reviews, which ensure that the prosthesis remains appropriate and correctly adjusted. To this end, it is important that good communication exists between the dermatologist and prosthetist, which permits rapid referral of patients before skin disorders become established.

As a general routine, the stump skin should be washed at night rather than in the morning, because newly washed skin is hydrated and swollen, thereby increasing the likelihood of friction and shearing trauma. Nonperfumed soap should be used to minimize contact with potential sensitizers and fully removed with tepid water and gentle rubbing with a nonabrasive towel.

Antibacterial soaps and washes can reduce the possibility of infection in addition to their cleansing action. However, these antiseptic preparations can cause irritation or allergy in a small number of cases and patients should be warned about this. If a stump sock is worn, it should be changed daily and washed and rinsed fully as soon as it is taken off, before perspiration is allowed to dry within it. Silicone liners should be washed every day.

SKIN PROBLEMS IN PATIENTS WITH ABDOMINAL STOMAS (OSTOMATES)

A stoma is a surgically created opening onto the skin of part of the gastrointestinal or urinary tract to drain the effluent from that viscus. The most frequently performed stomas are ileostomies, colostomies, and ileal conduits (urostomies). The most common indications for stoma surgery are inflammatory bowel disease, malignancy, and neurologic problems. A patient with a stoma is usually termed an *ostomist* or *ostomate*.

Epidemiology

There are estimated to be more than 1 million ostomates in the United States and 100,000 in the United Kingdom. Some stomas are temporary with surgical anastomosis delayed pending resolution of the acute disorder. Many stomas formed for malignant indications can be seen as palliative procedures.

A stoma appliance is essentially a device for collecting stoma effluent with a high degree of comfort and security until it can be disposed of. Essentially, the device is a pouch or bag held in place over the stoma by an adhesive skin barrier made solely or partly from hydrocolloid (Fig. 96-13). Many ileostomists and urostomists use two-piece appliances where the barrier remains on the skin for 2 to 4 days and is detachable; disposable bags are changed as necessary. Appliances with convexity on the surface next to the skin are available for patients with short or buried stomas.

At least two-thirds of ostomates experience skin problems that interfere with the normal use of their stoma appliance[15] and such dermatoses are the most common reasons for a visit to outpatient stoma services.[16] The majority of these problems are irritant reactions, usually dermatitis secondary to leaks from the stoma; however, there are also a number of other well-defined irritant reactions. Common coincidental dermatoses, particularly psoriasis and constitutional eczema, account for approximately 15 percent of the diseases seen.[15,17]



◀ **FIGURE 96-13** A typical drainable stoma bag.

STOMA PATIENTS AT A GLANCE



- Peristomal skin is chronically occluded and subject to:
  - pressure
  - shearing forces
  - fecal/urine soiling
- Two-thirds of ostomates develop skin problems.
- Most common: irritant reactions, common skin diseases, and infections.
- Occlusion under stoma appliance can result in unusual clinical appearances of common dermatoses.
- Swab all rashes to exclude primary or secondary infection.
- Uncommon: allergic contact dermatitis but advise patients to minimize exposure to potential allergens (fragrances and preservatives).
- Psoriasis and pyoderma gangrenosum more common around stomas than expected.

Irritant Reactions

DERMATITIS Dermatitis most frequently results from the chronic leakage of effluent onto the skin because the patient is using an inappropriately shaped appliance or one with too large a hole for their stoma. The most common cause is the remodeling of the stoma and abdominal wall that occurs in the months after surgery, whereby a stoma usually becomes a little shorter and thinner, resulting in leaks unless a correctly fitting appliance is selected (Fig. 96-14, see eFigs. 96-14.1, and 96-14.2 in on-line edition). Leaks also occur when patients gain a lot of weight after surgery and the effective length of their stoma diminishes because it becomes buried by subcutaneous fat. Irregular scarring after surgery or retraction of the stoma may also be associated with chronic leakage. Chronically irritated skin can become markedly hyperkeratotic and acanthotic (see eFig. 96-14.3 in on-line edition). These problems can be prevented and resolved by careful postsurgical follow-up by the enterostomal therapist



▲ **FIGURE 96-14** Irritant contact dermatitis circumferentially around an ileostomy because the bag aperture was cut too big, thereby allowing soiling of the skin around this short stoma.

(stoma nurse specialist) to ensure that the correct appliance is being used. Severe, acute irritant dermatitis can be effectively treated with a short course of topical corticosteroid while longer-term appliance modifications are being undertaken (Table 96-2).

Anxieties about possible leaks and odors can lead to excessively frequent bag changing, which may cause an irritant dermatitis by stripping the skin. Patients may, for the same reasons, wear waist belts too tightly thereby causing pressure damage, even ulcers (see eFig. 96-14.4 in on-line edition) and occasionally necrosis. Whatever the cause of skin inflammation, a vicious cycle can develop when the damaged skin prevents proper bag adhesion, necessitating more frequent bag changes.[20] Careful counseling is usually necessary to reassure the patient regarding leaks.

Approximately 15 percent of ostomates with skin problems suffer from a chronic or recurrent dermatitis for which no irritant, allergic, or infective cause can be found, and in whom primary skin disease is ruled out.[15] In the absence of a primary treatable cause, the use of topical corticosteroid lotions is appropriate. Most patients require only occasional short courses for a maximum of 4 weeks' duration. A small number of patients require intermittent applications longer term. Provided that the frequency of application is no more than once every 10 days, steroid atrophy of the skin appears to be unusual.

In ileostomy patients with short bowel, the output may be very high and corrosive due to the enzyme content. In this situation, some leaks are inevitable despite the use of proprietary barrier preparations or soothing lotions. Where the irritation has resulted in an eroded dermatitis, sucralfate powder applied at every stoma bag change can be very effective. In addition to forming a sticky barrier, the preparation is thought to promote healing.[21] Surgical scars and even large striae (see eFig. 96-14.5 in on-line edition) can lead to ulcerations and bag failures that may respond to topical carmellose sodium or sucralfate powders. Wound dehiscence can cause severe difficulties for bag adhesion (see eFig. 96-14.6 in on-line edition) and presents particular challenges for nursing management, in which case the dermatologist may be called on for advice as part of the multidisciplinary team.[22]

TABLE 96-2
Topical Corticosteroid Treatment of Inflammatory Peristomal Conditions

- Good adhesion between the appliance and the skin is essential. Ointments, creams, and greasy lotions cause a bag to lift so that most patients do not use them.
- One approach tolerated by some patients is to use dressings, such as thin hydrocolloid or vapor-permeable membranes, placed over the cream preparation and before applying a stoma bag.
- Another approach is to apply a cream preparation for 1 to 3 h/day before wiping off and applying a stoma bag. While the cream is in place, a nonadhesive bag can be worn, held in place with a waist belt, provided that the patient is sedentary during this time.
- A number of alternative vehicles for delivering topical corticosteroid are available, although none is ideal or designed for stoma use.
  - Adhesive tapes impregnated with fludroxycortide, 4 μg/cm^2
  - Scalp lotions (oil-free; 40 percent isopropyl alcohol): betamethasone valerate 0.1 percent, clobetasol propionate 0.05 percent. These sting on broken skin and can be applied to the bag adhesive and allowed to dry before applying to the stoma.[18]
  - Scalp gels: Fluocinolone acetonide 0.025 percent. This preparation contains propylene glycol that may impair bag adhesion a little.
  - Steroid asthma inhalers: beclomethasone dipropionate, 250 μg/metered dose. Several activations are used to the affected area.
  - Carmellose sodium oral pastes are especially useful in ulcerative conditions such as mild pyoderma gangrenosum (e.g., triamcinolone acetonide 0.1 percent in carmellose sodium paste).
- Alternative nongreasy steroid sprays are available in some regions.[19]
- With each of these preparations, the steroid is under occlusion and therefore effectively more potent. Skin atrophy and absorption, particularly in children, must be considered. The authors limit initial courses to a maximum of 4 wk and thereafter one to two times/wk if needed.

CHRONIC PAPILLOMATOUS DERMATITIS

Chronic papillomatous dermatitis (CPD) refers to clinical appearance of warty excrescences around urostomies resulting from leaks and pooling of urine on the peristomal skin (Fig. 96-15). Recurrent



▲ **FIGURE 96-15** Chronic papillomatous dermatitis affecting a urostomy in a patient who is using a bag with too large an aperture. The red area is the stoma and is becoming stenosed by the warty papules. The brown pigmentation is a typical finding in long-standing urostomies in all races. (Used with permission from Anita Eriksson, Karolinska Institute, Stockholm, Sweden.)



urinary tract infections appear to increase the likelihood of CPD, probably due to the presence of ammonia from urea-splitting bacteria. Histologically, there is massive hyperkeratosis and acanthosis. Pseudoepitheliomatous hyperplasia may also be a feature but is not universal. The histology is therefore not specific and is comparable to that of other irritant reactions. Verrucous lesions with similar appearances are occasionally seen affecting ileostomies (see eFig. 96-14.3 in on-line edition).[23] In severe cases, the lesions can encroach on the stoma and cause stenosis (see Fig. 96-15). When the leaking of urine is caused by a receding stoma, CPD resolves rapidly if a convex-backed appliance is used to increase the effective length of the urostomy and thereby stop leaks. Acetic acid soaks (10 percent domestic vinegar in water[24]) at each bag change are effective in some cases. Larger excrescences may be shaved off under local anesthetic to allow a bag with a smaller aperture to be used. In severe cases, surgical revision of the stoma may be required.



GRANULOMAS The term *granuloma* is commonly used for a range of papular lesions, which are almost all secondary to irritation. The authors have only seen the condition affecting ileostomies or colostomies and not urostomies. They may affect the stoma itself (inflammatory colonic or ileal polyps) or the mucocutaneous junction, or may be found more widely, extending onto the peristomal skin (Fig. 96-16). The latter is more frequent in patients with colostomies, and in this situation the papules may become very extensive. This occurs when the patient enlarges the stoma bag aperture to accommodate a papule, thereby exposing normal skin to fecal irritation which precipitates further lesions and prompts the patient to enlarge the aperture still further. Histologically, the lesions contain a chronic inflammatory infiltrate, granulation tissue, and sometimes metaplastic bowel mucosa where the metaplasia is probably a response to fecal irritation. Comparable lesions occur around ileostomies but are generally flatter and may even present as sheets of cherry-red granulation tissue. These lesions are sometimes caused by seeding mucosa at the time of surgery.[25]

Asymptomatic, solitary lesions can be left. When they are painful[26] or bleed easily, leading to poor stoma bag adhesion, they can be destroyed by cautery (thermal or silver nitrate) or by cryotherapy, using a liquid nitrogen spray. Larger and proliferating lesions, especially around colostomies, are best removed by shave and cautery under local anesthetic and an appliance with a correctly sized aperture fitted to prevent massive proliferation. Laser ablation is increasingly regarded as a first-line treatment being less painful and possibly more effective.[27]

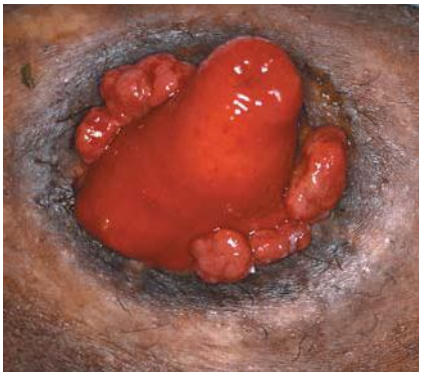

▲ **FIGURE 96-16** "Granulomas" around a colostomy. The patient has cut the bag aperture larger to accommodate the original lesion, and the area thus exposed is seen as a ring of post-inflammatory hyperpigmentation in which new lesions developed.

PSORIASIS (See Chap. 18) Psoriasis is a common cause of peristomal skin disease because it may appear in irritated or traumatized skin (Koebner phenomenon), and because it is associated with inflammatory bowel disease. Peristomal psoriasis presents as a glazed erythema similar to flexural psoriasis (see eFig. 96-16.1 in on-line edition) and can be treated in the same way with topical corticosteroids, although, at the peristomal site, a non-greasy base should be selected.

Superficial x-ray (grenz ray) therapy has been used in recalcitrant cases.

INFECTIONS The most frequent peristomal skin infection is staphylococcal folliculitis, usually, but not exclusively, in those individuals with hairy abdomens who shave regularly to help the bags to stick (see eFig. 96-16.2 in on-line edition). It responds to oral antibiotics and to a reduction in shaving frequency to no more than once per week. Although antiseptic washes can be a useful additional therapeutic measure, they can cause irritant reactions if the skin is not correctly rinsed before being occluded by the stoma bag. Localized skin infections, usually staphylococcal or streptococcal, can produce a rash indistinguishable from irritant dermatitis or primary skin disease such as psoriasis or eczema. Furthermore, pre-existing psoriasis or eczema can become secondarily infected under occlusion.

PYODERMA GANGRENOSUM Pyoderma gangrenosum (PG) is a rare, inflammatory, ulcerative neutrophilic dermatosis (see Chap. 32) and is more common in peristomal skin than in the general population.[30,31] This is partly due to its strong association with inflammatory bowel disease. There is some evidence, however, that the increased use of convex-backed appliances may contribute to the incidence via the pathergic effect of increased pressure on the skin. Although some cases of PG are associated with active inflammatory bowel disease, the association is not universal; indeed, peristomal PG occurs in ostomates who have no history of inflammatory bowel disease.[32] Peristomal PG presents as a painful papule or pustule, often hemorrhagic, which then ulcerates and is usually very painful (see eFig. 96-16.3 in on-line edition). The pain and the ulceration can have profound effects on the patient's ability to wear a bag and therefore on their quality of life. The ulcers heal with cribriform scarring that can itself impair bag adhesion: rapid, effective treatment of PG is essential (see Chap. 32).

The authors' approach to the management of PG is found in the electronic version of this text.

Contact Allergy

Modern stoma bags are made largely from food-grade materials and those with a low potential for sensitization. Nonetheless, there are case reports of sensitivities to individual ingredients, including GANTREZ (GAF Corporation, Wayne, NJ) resins and acrylate adhesive systems. Furthermore, there is a potential for contact allergy from deodorizers and topically applied preparations. These case reports of peristomal allergic contact dermatitis have recently been the subject of a literature review.[39] Despite the fact that contact allergy is a relatively uncommon cause of peristomal dermatitis, most patients and many health professionals regard contact hypersensitivity to their appliance as the likely cause of a peristomal rash. Patch testing is indicated in patients with persisting problems where infection, irritation, and constitutional skin disease has been ruled out.[40] The authors have patch tested well over 100 such patients and relevant positive allergic reactions were found in only three cases of topically applied materials, including fragrance in a deodorizer and biocides in wet wipes.

Other Conditions

In theory, almost any of the multitude of skin disorders might affect a stoma. In clinical practice, the common disorders (e.g., psoriasis) predominate, and others are more common than expected (e.g., PG). Some less common peristomal dermatoses are worthy of note either because they present practical difficulties, such as pemphigoid[41] and nicorandil ulceration (see eFig. 96-16.4 in on-line edition), or, in the case of lichen sclerosus, because they have an unusual predilection for this site.[42]

KEY REFERENCES

The full reference list for all chapters is available at www.digm7.com.

1. Marks LJ, Michael J: Artificial limbs. *BMJ* **323**:732, 2001
3. Dudek NL et al: Dermatologic conditions associated with use of a lower-extremity prosthesis. *Arch Phys Med Rehabil* **86**:659, 2005
4. Lyon CC et al: Skin disorders in amputees. *J Am Acad Dermatol* **42**:501, 2000
13. Kohler P et al: Bacteria on stumps of amputees and the effect of antiseptics. *Prosthet Orthot Int* **13**:149, 1989
15. Lyon CC et al: The spectrum of skin disorders in abdominal stoma patients. *Br J Dermatol* **143**:1248, 2000
31. Hughes AP et al: Clinical features and treatment of peristomal pyoderma gangrenosum. *JAMA* **284**:1546, 2000
39. Martin JA et al: Peristomal allergic contact dermatitis—case report and review of the literature. *Contact Dermatitis* **52**:273, 2005



CHAPTER 97

Corns and Calluses

Thomas M. DeLauro
Nicole M. DeLauro

EPIDEMIOLOGY

Every human being, with the exception of the non–weight-bearing infant, is vulnerable to the development of corns and calluses, because the skin is subjected to regular mechanical stress. The prevalence of corns and calluses can be readily appreciated by the number of nonprescription products aimed at reducing or preventing them—a billion-dollar market annually.

The earliest known discussion of these lesions can be found in the writings of Cleopatra, who authored a textbook on cosmetics.[1] Corns and calluses have plagued humankind since antiquity, affecting those at all socioeconomic levels.

Certain foot types and regions are prone to mechanically induced skin thickening, regardless of race, gender, or age.

ETIOLOGY AND PATHOGENESIS

Corns and calluses result from the prolonged application of excessive mechanical shear or friction forces to the skin. In theory, these forces induce hyperkeratinization, which leads to a thickening of the stratum corneum, although the precise mechanism by which this occurs remains unknown. If the abnormal forces are distributed over a broad area (i.e., more than 1 cm^2), a callus develops. In contrast, a corn will form if the same forces are applied to a focused location, with the lamellae of the stratum corneum becoming impacted to form a hard central core known as the *radix* or *nucleus* (Fig. 97-1).

Mechanical keratoses are not determined genetically. Heredity does play a role, however, in configuring the individual's skeletal architecture. A family history of bony abnormality or ligamentous laxity predisposes the person to the presence of sites of increased cutaneous friction or shear. The prevalence of these lesions has also proven to be significantly higher in females, certain ethnic groups, and mentally ill patients.[2,3]

CLINICAL FINDINGS

History

Corns and calluses produce painful symptoms often described as burning, especially when the affected area is weight bearing and/or shoes are worn. This discomfort is thought to result from microtearing of the thickened, inflexible skin.

Cutaneous Lesions

Corns [clavi or helomata (singular: clavus or heloma)] and calluses [tylomata (singular: tyloma)] are, respectively, keratotic papules and plaques that occur in areas that are subject to sustained excessive mechanical shear or friction forces.

Related Physical Findings

The lesions occur in predictable pedal locations, corresponding to a structural deformity or biomechanical fault. Crookedness of the lesser toes leads to prominence of the proximal and/or distal interphalangeal joints. Keratoses can therefore form either dorsal to those joints, between the toes, at the distal end of the toe, or on the lateral aspect of the fifth toe and/or toenail (lateral toenail corn, also known as *Durlacher's corn*; see eFig. 97-1.1 in on-line edition). Interdigital corns can be hard when they are adjacent to the interphalangeal joint(s) (see eFig. 97-1.2 in on-line edition) or soft when deep within the fourth interdigital space. The softness of latter last corn results from trapped perspiration, which leads to maceration of the keratotic tissue (Fig. 97-2).

In patients with bunions (hallux valgus), a callus usually forms at the medioplantar aspect of the hallux. During gait, the individual rolls off that portion of the great toe because of its incorrect position. The skin is subsequently

CORNS AND CALLUSES AT A GLANCE



- Corns and calluses result from prolonged application of forces to the skin and produce painful symptoms.
- Every weight-bearing human being is vulnerable.
- Lesions occur in predictable pedal locations.
- Corns and calluses show changes within the epidermis, dermis, and adipose layer.
- There are no associated systemic abnormalities.
- Treatments are available and vary in aggressiveness.





▲ **FIGURE 97-1** A simple corn beneath the third metatarsal head. Note the white central radix or nucleus. This radix must be pared to provide comfort.

pinched to form a "pinch callus" (see eFig. 97-2.1 in on-line edition). In addition, the first metatarsal often does not bear its fair share of the weight-bearing load. Weight is therefore transferred laterally to the second metatarsal head, which usually leads to the development of an additional corn or callus beneath that bone.

Other favored locations for lesser metatarsal head keratosis include the following:

- Beneath the first and fifth metatarsal heads in cavus foot types
- Beneath the fifth metatarsal head alone in persons with tailor's bunions (bunionette)
- Beneath the second through fourth metatarsal heads when multiple hammertoes or an equinus deformity co-exists
- Erratic locations (e.g., beneath the third and fifth metatarsal heads, isolated third or fourth metatarsal head, second and fourth metatarsal heads) in individuals with structural abnormalities such as brachymetatarsia or dislocated metatarsophalangeal joints, as in rheumatoid arthritis or neuroarthropathy (Fig. 97-3)

Another variant of corn is that referred to as *heloma miliare*, or seed corn. This title is derived from the clinical appearance of these corns: multiple guttate keratoses that are easily pared. When seamed nylon hosiery was fashionable, this garment was considered the causative factor. However, patients still present with seed corns even though they have never worn seamed stockings.

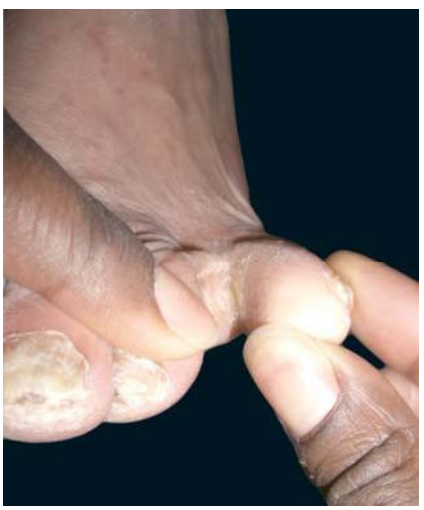

▲ **FIGURE 97-2** A soft corn (also known as a *heloma molle*) located deep within the fourth interdigital space.

HISTOPATHOLOGY

In contrast to nonmechanically induced keratoses, corns and calluses exhibit changes within the epidermis, dermis, and adipose layer. Corns demonstrate a parakeratotic plug within the stratum corneum, with a pressure-related loss of the stratum granulosum as well as atrophy of the stratum malpighii. The dermis displays significant fibrosis, dilated eccrine ducts and blood vessels, hypertrophied nerves, and scar tissue replacement of subcutaneous fat. Overall, the histologic changes in calluses are less pronounced, and include a thickened stratum corneum but intact stratum granulosum.[4]

Because corns and calluses are the result of mechanical friction and shear alone, there are no associated hematologic, chemical, serologic, or immunohistochemical abnormalities.



▲ **FIGURE 97-3** A large callus beneath the fifth metatarsal head in a post-poliomyelitis patient whose foot is now in rigid adductovarus.

DIAGNOSIS AND DIFFERENTIAL DIAGNOSIS (Box 97-1)

PROGNOSIS AND CLINICAL COURSE

If left untreated, corns and calluses result in painful ambulation and also in

Box 97-1

Differential Diagnosis of Corns and Calluses

Most Likely (Secondary to Structural Deformity)

Deformity	Corn or Callus Location
Pronation	Medioplantar heel
Pes planus foot type	Medioplantar heel
Charcot neuroarthropathy	Midsole
Cavus foot type	Submetatarsal heads 1 and 5
Tailor's bunion	Submetatarsal head 5
Hallux valgus	Submetatarsal head 2 Medioplantar hallux
Brachymetatarsia	Submetatarsal heads 3, 5
Dislocations as in rheumatoid arthritis and other structural abnormalities	Submetatarsal heads 3, 4 Submetatarsal heads 2, 4
Transmetatarsal amputation without tendo-Achilles lengthening	Stump of amputation

Consider

- Multiple guttate keratoses
  - Heloma miliare
- Painful corns
  - Intractable plantar keratoses
  - Neurofibrous or neurovascular corn
  - Porokeratosis plantaris discreta

Always Rule Out

- Lesions not associated with bony prominences
  - Verruca
  - Genokeratoses
  - Cutaneous neoplasms
  - Neuroborreliosis

subhelomal bursitis and blistering that can rupture to the surface. Because of the close proximity of some corns to joints and bone, septic arthritis and/or osteomyelitis can ensue. The mechanical forces that cause corns and calluses can also rupture portions of the subcutaneous vascular plexus, which leads to hemorrhage into keratotic tissue. In healthy patients, such findings are of minor significance, but in other cases (e.g., in diabetic patients and patients with connective tissue disease), they may herald extensive skin ulceration or vasculitis.

The need for lower-extremity amputation is a dominant fear in most diabetic patients. Such amputations are most often preceded by a history of foot ulceration (see Chap. 152). Although a number of co-morbidities contribute to the development of ulceration (e.g., peripheral vascular disease, neuropathy, and limited joint mobility), minor trauma via repetitive pressure is the pivotal precipitating event. As markers of repetitive friction and shear, corns and calluses in the diabetic foot are of special significance. Simple débridement of these hyperkeratotic lesions decreases peak plantar pressures by as much as 26 percent.[5] In a retrospective review of more than 200 diabetic foot ulcerations, patients who had their corns and calluses pared frequently experienced a statistically significant decrease in the incidence of foot ulceration, hospitalization, and surgical intervention.[6] Hemorrhage within a corn or callus is an especially ominous sign, indicating subcutaneous breakdown with a strong potential for ulceration. Therefore, ulcer care should include paring of calluses. The use of proper footwear by the diabetic as well as the non-diabetic patient may also play a role in not only preventing but also reducing the development of callosities. Shoes should be correctly sized to accommodate the width and length of the patient's foot, and the heel should be elevated minimally if at all to prevent pathology and pain.[7,8]

Box 97-2

Treatment

	PHYSICAL		TOPICAL		SURGICAL
First line	Paring Padding	Central radix of corn requires débridement	Keratolytics[a]	40% salicylic acid or 40% urea cream used as directed	
Second line	Injections[b]	4% alcohol mixed with local anesthetic	Lipid extract with garlic[c]		Osseous and/or soft-tissue procedures[d]

[a]Keratolytics are to be used with caution. Their use is contraindicated in patients with co-morbid peripheral neuropathy or arterial disease.
[b]Injections are useful for soft corns and intractable plantar keratoses. Typically up to seven injections may be required, with darkening and thrombosis of the lesion heralding a cure.[9,10]
[c]Newer modality under research. Side effects include blistering, redness, burning, and hyperpigmentation.[11]
[d]Osseous procedures are designed to redistribute weight-bearing pressures, whereas soft-tissue procedures (i.e., adipofasciocutaneous flaps[12]) are used to eliminate cicatrix (fifth digit) secondary to the use of medicated padding.

TREATMENT (Box 97-2)

PREVENTION

Corns and calluses can be prevented only by reducing or eliminating the mechanical forces that created them. Usually, this is a daunting, if not impossible, task. Repetitive occupational motions are often unavoidable, patients are commonly reluctant to alter shoe styles, and osseous architecture is predetermined through heredity.

KEY REFERENCES

The full reference list for all chapters is available at www.digm7.com.

2. Dunn JE et al: Prevalence of foot and ankle conditions in a multiethnic community sample of older adults. *Am J Epidemiol* **159**:491, 2004
4. Lemont H: Histologic differentiation of mechanical and non-mechanical keratoses of the sole. *Clin Dermatol* **1**:44, 1983
6. Sage RA, Webster JK, Fisher SG: Outpatient care and morbidity reduction in diabetic foot ulcers associated with chronic pressure callus. *J Am Podiatr Med Assoc* **91**:275, 2001
9. Costello MJ, Gibbs RC: *The Palms and Soles in Medicine.* Springfield, IL, Charles C Thomas, 1967
10. Dockery GL, Nilson RZ: Intralesional injections. *Clin Podiatr Med Surg* **3**:473, 1986



CHAPTER 98

Sports Dermatology

Dirk M. Elston

EPIDEMIOLOGY

Skin problems are common among athletes. During an 8-week survey of university athletes, 40 percent reported skin problems.[1] In a study of mountain biking injuries, skin lesions accounted for 75 percent of all injuries.[2] Skin lesions account for 35 percent of all in-line skating injuries.[3] Skin infections are more prevalent in athletes than in the general population.[4] Skin-related complaints are especially common in warm, humid climates. During the 1993 Central American and Caribbean Games, held in Puerto Rico, 1 out of every 100 athletes had a skin-related complaint severe enough to require medical care.[5] Similarly, sports that involve repeated immersion in water are associated with an increased incidence of skin injury and infection.[6]

Table 98-1 lists some unique sports-associated skin conditions that are worthy of mention but are not discussed further in this chapter (Figs. 98-1 and 98-2).

PYOGENIC SKIN INFECTIONS

Epidemiology

Cutaneous community-acquired methicillin-resistant *Staphylococcus aureus* (CA-MRSA) has emerged as the most important pathogen among athletes. Athletes at risk include weightlifters, wrestlers, and members of competitive sports teams.[7–9] During an outbreak of CA-MRSA in a college football

SPORTS DERMATOLOGY AT A GLANCE



- Forty percent of all athletes develop skin problems.
- Infections are highly prevalent.
- Community-acquired methicillin-resistant *Staphylococcus aureus* (CA-MRSA) has emerged as the most important pathogen among athletes.
- CA-MRSA typically presents as an abscess or folliculitis.
- The most important intervention for a CA-MRSA abscess is drainage.
- Control of CA-MRSA outbreaks requires treatment of fomites and skin colonization.
- Infections with *Pseudomonas*, *Vibrio*, and atypical mycobacteria are frequently associated with water sports.
- Heat and cold injury remain important problems in athletes.



team, linemen had the highest attack rate (18 percent). Having pre-existing cuts or abrasions and sharing bars of soap were important risk factors associated with infection. Nasal carriage was associated with sharing towels, living on campus, and having a locker near a teammate.[10] Cosmetic body shaving has also been identified as a risk factor for CA-MRSA infection.[11] Data from an outbreak of CA-MRSA abscesses among members of a professional football team indicate that most infections developed at turf abrasion sites. Infection was significantly associated with playing the lineman or linebacker position as well as with having a higher body mass index. MRSA was cultured from whirlpools and taping gel as well as from 35 of the 84 nasal swabs taken from players and staff.[12] In competitive male athletes, abscesses generally occur at sites of minor abrasions. In weightlifters, abscesses favor the axillae. Abscesses among female athletes favor the thighs and buttocks. Folliculitis and abscesses noted during an outbreak of CA-MRSA infection in a saturation diving facility involved the nose, external ear canal, neck, back, extremities, and buttocks.[13]

TABLE 98-1
Sports-Associated Skin Conditions

- Bikini bottom: bacterial folliculitis on the buttocks of swimmers
- Jazz ballet bottom: buttock cleft abscess
- Jogger's nipples: painful, swollen, eroded or hyperkeratotic nipples
- Karate cicatrices: linear scars on the dorsal aspects of the hands
- Mogul skier's palm: traumatic hypothenar ecchymosis
- Painful piezogenic pedal papules: transdermal fat herniations
- Ping-pong patches: traumatic ecchymotic patches
- Pool palms: smooth, shiny, tender palms secondary to rough pool surfaces
- Pulling-boat hands: pernio-like condition produced by friction and damp cold
- Rower's rump: lichenification
- Runner's nail: multiple Beau's lines or periodic shedding of the nail plate (see Fig. 98-1)
- Runner's rump: ecchymoses of the superior gluteal cleft
- Stingray hickey: bite ecchymosis
- Stretcher's scrotum: scrotal hematoma
- Swimmer's shine: facial oiliness seen in swimmers
- Swimmer's shoulder: abrasion of the shoulder by the beard during crawl stroke
- Talon noir (black heel): intradermal hemorrhage
- Tennis toe: subungual hematoma with or without subungual hyperkeratosis or nail dystrophy (jogger's toe, hiker's toe, skier's toe are similar) (see Fig. 98-2)
- Turf toe: metatarsophalangeal joint sprain

Etiology and Pathogenesis

CA-MRSA isolates usually contain the type IV staphylococcal chromosomal cassette (SCC)mec coding for methicillin resistance, as well as the Panton-Valentine leukocidin virulence factor.[14] There is a high risk of colonization in close contacts of individuals with CA-MRSA infection, and those who are colonized commonly progress to clinical infection.[15,16]

Clinical Findings

CA-MRSA infection in athletes typically presents as folliculitis or spontaneous abscess (see Chap. 177). Abscesses may begin as furuncles but rapidly evolve to fluctuance with surrounding cellulitis.



▲ **FIGURE 98-1** Runner's nail. In this case there are multiple Beau's lines with onychoschizia.

Treatment

Like other abscesses, CA-MRSA abscesses respond to drainage. Surveillance data from Baltimore, Atlanta, and Minnesota including 1647 cases of CA-MRSA infection show that therapy to which the strain was resistant was not associated with adverse patient-reported outcomes if the abscess was incised and drained.[17] Other data also suggest that many CA-MRSA abscesses respond to drainage alone.[18,19] Failure to drain CA-MRSA abscesses may have catastrophic results, even if effective antibiotic therapy is prescribed. In one report, bilateral blindness resulted.[20]

Although the SCCmec type IV gene cassette present in most CA-MRSA strains codes only for methicillin resistance, an isolate from a Japanese athlete also contained a transmissible plasmid coding for multiple-drug resistance.[21]



▲ **FIGURE 98-2** Tennis toe. Subungual hemorrhage seen in runners and basketball and tennis players that produces anxiety because of fear of melanoma. It can be easily differentiated from melanoma by dermoscopy.

Other CA-MRSA isolates have emerged that are resistant to multiple antibiotics. Some CA-MRSA isolates from Taipei carry a distinct SCCmec cassette (type VT) that codes for resistance to multiple antibiotics.[22] Although drainage will cure many CA-MRSA abscesses, some athletes require antibiotic therapy. Of the inexpensive oral agents available to treat CA-MRSA infections, sulfa drugs consistently show the best mean inhibitory concentrations. Tetracyclines are good alternative agents, although only approximately 80 percent of CA-MRSA organisms will be sensitive in many locations. Lincosamide resistance is increasing.[23–25] Inducible resistance related to the erm gene results in strains that test clindamycin susceptible in vitro but may be resistant in vivo. A D-test can be used to determine the presence of inducible resistance. In the D-test, clindamycin and erythromycin disks are placed close together on a culture plate. If inducible lincosamide resistance is present, the zone of inhibition around the clindamycin disk will be flattened on the side toward the erythromycin disk, resembling a capital letter D. Rates of inducible lincosamide resistance vary from 8 percent in Houston to 94 percent in Chicago.[26–30] In some areas in the United States, CA-MRSA strains were less likely than methicillin-sensitive strains to demonstrate inducible resistance.[31] In contrast, some locations in Asia report that 100 percent of tested CA-MRSA strains demonstrate the ermB gene.[32]

Some serious CA-MRSA infections require the use of linezolid, vancomycin, fluoroquinolones, daptomycin, quinupristin/dalfopristin, or newer-generation carbapenems. Fluoroquinolones and linezolid have the advantage of oral administration. In some groups of severely ill patients, linezolid has proved superior to vancomycin.[33–35] Daptomycin has been used effectively to treat serious MRSA infections, but resistance has been reported, and disk diffusion testing may not predict clinical outcome.[36,37] A new cephalosporin, ceftobiprole medocaril, appears to offer a good balance of efficacy and tolerability.[38]

Prevention

Because of the risk of contagion through physical contact and shared equipment, topical antiseptics such as chlorhexidine, povidone iodine, quaternary ammonium compounds, triclosan, and Dakin's solution play an important role in management. Chlorhexidine gluconate is widely used and generally has good activity against staphylococci. Some MRSA isolates are less sensitive to chlorhexidine than are methicillin-susceptible *S. aureus* (MSSA) isolates.[39,40] Some chlorhexidine-resistant isolates also exhibit resistance to quaternary ammonium compounds. Resistance can be overcome by using disinfectants containing both alcohol and chlorhexidine.[41] Seventy percent ethanol alone is an effective agent for fomite sterilization if contact can be maintained for 3 minutes.[42] Povidone iodine has shown good activity against both MRSA and MSSA isolates.[39] Triclosan-based products are readily available as "no-wash" hand sterilizers. Some triclosan resistance has been documented, and some MRSA isolates are less sensitive than MSSA isolates.[43,44] Mupirocin is commonly used to treat staphylococcal nasal carriage, but resistant strains have emerged.[45] In one double-blind, placebo-controlled trial, successful nasal eradication occurred in only 44 percent of cases.[46]

Other Pyogenic Skin Infections Among Athletes

Group A streptococcal infections may also spread rapidly among athletes.[47] Pyoderma with a nephritogenic *Streptococcus* can cause epidermic glomerulonephritis. Streptococci also produce erysipelas and lymphangitis (see Chaps. 177 and 179).

Pseudomonas infections are commonly associated with water.[48] *Pseudomonas* folliculitis, green nails, and *Pseudomonas* webspace infection are the most common (see Chap. 180 and on-line version).

VIRAL SKIN INFECTIONS

Herpes simplex virus (see Chap. 193) can be transmitted by skin-to-skin contact during any contact sport. Herpes gladiatorum is recognized as a major problem among wrestlers. Attack rates as high as 34 percent have been reported.[59] Ocular involvement is a serious complication. Wrestlers with active infections are barred from participation. The use of abrasive shirts may contribute to the spread of herpes simplex virus infection among wrestlers.[60] They should be avoided. Oral antiviral drugs such as acyclovir, valacyclovir, and famciclovir can be used to shorten the course of an outbreak. It is likely that all three of these drugs can prevent outbreaks of herpes gladiatorum when given as long-term or periodic prophylaxis.

FUNGAL INFECTIONS (See Chap. 188)

Tinea infection is particularly common among wrestlers.[61] Tinea pedis may be spread by floors around swimming pools.[62] Prevalence among runners increases with age, and asymptomatic carriers are common.[63] Periodic prophylactic treatment of carriers with topical agents to prevent clinical disease may be possible.

TRANSMISSION OF BLOOD-BORNE PATHOGENS

There is growing concern about possible transmission of blood-borne pathogens during contact sports. Minor cuts and abrasions are both a source of contamination and a portal of entry for human immunodeficiency virus and hepatitis viruses. Lacerations can be covered with self-adherent biosynthetic dressings to prevent blood transmission from minor wounds during contact sports.

HEAT AND COLD INJURY

Heat injury is a common cause of morbidity during sports participation. The skin serves as the major organ of thermal regulation. Regular exercise modifies the responsiveness of cutaneous vessels, increasing cutaneous perfusion during periods of activity.[64] The duration of exercise can be safely increased in hot environments if a volume of fluid at least equal to that lost in sweat is ingested within 60 minutes before and during exercise.[65] Uniforms promote heat retention, and adequate skin surface must be exposed during exercise to reduce the risk of heat stress injury. Evaporative cooling from forearm skin is more efficient than that from the upper trunk; therefore, the use of short-sleeved uniforms is helpful in hot climates.[66] Clothing should be lightweight and have high water permeability to facilitate evaporative cooling. At high humidity levels, evaporative cooling from skin is inefficient, and the risk of heat stress increases. Spraying water on the skin during exercise can reduce skin temperature but results in vasoconstriction and does not reduce core body temperature.[67] The use of cooling vests can improve athletic performance in hot weather.[68,69] Harlequin syndrome is a disorder of the sympathetic nervous system characterized by diminished sweating and flushing in response to exercise.[70]



Younger athletes have a greater skin surface area, which places them at greater risk for hypothermia in cold environments. Skin injuries such as frostbite and perniosis are seen in sports enthusiasts who engage in cold weather sports. Frostbite is a common problem among joggers and may involve the face, hands, feet, and penis. The decreased oxygen tension at high altitudes contributes to peripheral vasoconstriction, which decreases peripheral blood flow and increases the risk of frostbite.[71] Clothing must remain dry to retain its insulating properties. Frequent changes of socks and periodic breaks in a warm environment are important safeguards. If frostbite occurs, rapid re-warming should be accomplished as soon as the individual is in a safe environment with no risk of refreezing.



SKIN INJURIES

Skin and soft tissue injuries are common among athletes. New treatments, including hydroactive wound dressings, have advanced the treatment of superficial wounds. Application of a hydroactive dressing can provide a protective barrier that can allow an athlete to return to training. Cold gel application has been shown to provide effective symptomatic relief for sports-related soft tissue injuries.[72]

Friction Blisters

Friction blisters occur as a result of midepidermal necrosis (Fig. 98-3). Proper fitting of footwear and the use of gloves and chalk can reduce the incidence of blistering. Heat, sweating, and maceration increase the risk of blistering. Antiperspirants have been used in an attempt to reduce the incidence of blistering, but results have been mixed and they may cause irritant dermatitis. Attempts to reduce the incidence of irritant dermatitis through the addition of emollients reduces the efficacy of the antiperspirant.[73] In a study of cross-country hikers, use of a 20 percent solution of aluminum chloride hexahydrate in anhydrous alcohol reduced the rate of blister formation from 48 percent to 21 percent, but the incidence of irritant dermatitis was high and non-compliance with the treatment regimen was common.[74] The use of closed-cell neoprene insoles, acrylic socks, or thin polyester socks combined with thick wool or polypropylene socks that maintain their bulk can reduce the incidence of blisters.[75] The use of mesh-top footwear can decrease the risk of blistering by providing a cooler, dryer environment without the use of antiperspirants.

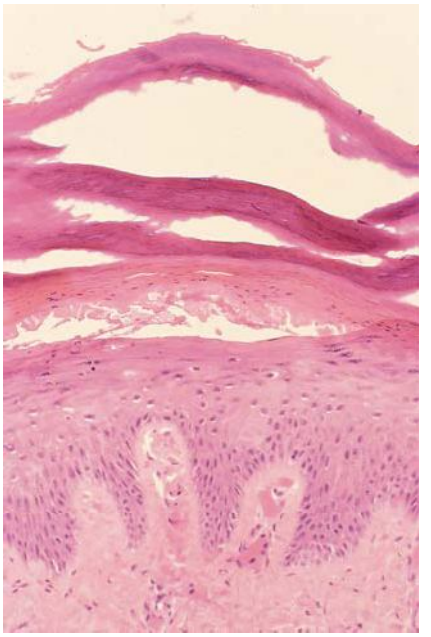

▲ **FIGURE 98-3** Friction blisters are a manifestation of intraepidermal necrosis.

Lime Burns

The use of calcium oxide (quicklime) or calcium hydroxide (slaked lime) instead of calcium carbonate (chalk) to line sports fields may result in chemical burns, especially in wet weather. Second- and third-degree burns may occur. Lime use may also result in severe inhalation and ocular injury.

ATHLETE'S NODULES

Collagenous "surfer's nodules" are a well-described complication of surf boarding. Boxers, marbles players, and football players are also prone to collagenous nodules. Surgical excision may be required.

ACTINIC DAMAGE (See Chaps. 89 and 112)

Actinic irradiation can cause burns and a risk of skin cancer in later life. Even relatively short periods of exposure during sports are associated with an increase risk of basal cell carcinoma.[76] Sweating alters hydration of the stratum corneum and lowers the minimal erythema dose of ultraviolet B light by as much as 40.9 percent after just 15 minutes of jogging.[77] Participation in water sports is an independent risk factor for melanoma.[78]

ALLERGIC CONTACT DERMATITIS (See Chap. 13)

Rubber allergens are the most common cause of sports-associated allergic contact dermatitis (Fig. 98-4). Rubber adhesives and rubber chemicals in the box toe and cushioning materials can cause dermatitis from footwear. Contact dermatitis can also result from equipment, swimming pool chemicals, athletic tape, and topical creams and sprays.

BITES AND STINGS

Unexpected bites and stings are frequent while playing sports (see Chap. 210).

SKIN PROBLEMS RELATED TO WATER SPORTS

Skin eruptions account for almost half of all illnesses related to recreational water.[79] Monitoring of water for fecal coliforms has been practiced for years and has proved to be a better predictor of the risk of skin disease than of the risk of gastrointestinal disease.[80] Contamination by storm runoff results in a predominance of organisms linked to skin infections.

Exposure to the rough surfaces of diving boards can result in a chronic plantar dermatosis. The fingers can also be affected. Some individuals with this disorder have a history of atopic dermatitis, psoriasis, or juvenile plantar dermatosis. The rough interior of swimming pools can result in "pool palms." The skin appears taught, shiny, and erythematous with loss of dermatoglyphics (Fig. 98-5). Green hair is related to the presence of copper in pool water. Copper pipes or algicides may be the source of the high copper levels. Acidic pH, fluoridation of water, and swimming pool chlorination all contribute to the release of copper into pool water. Green hair has been



▲ **FIGURE 98-4** Athletic shoe allergic contact dermatitis.



▲ **FIGURE 98-5** Finger dermatitis in this diver paralleled the intensity of her training. It resolved during breaks from training.

treated with penicillamine shampoo, hot vegetable oil, hydrogen peroxide, edetic acid, and 1-hydroxyethyl diphosphonic acid.

Swimming pool water may be treated with chlorine, bromine, or ozone ionization. All three methods are acceptable, although the use of bromine with ozone may be associated with a slightly lower risk of cutaneous reactions.

Swimmer's Itch (See Chap. 209)

Swimmer's itch is related to avian schistosome cercariae. Newly created bodies of water, such as recently abandoned quarries, are associated with a lower incidence of swimmer's itch. Administration of praziquantel to ducks inhabiting a lake can reduce the incidence of swimmer's itch.[81] Chemical control or mechanical removal of snails can also be effective. The rash heals spontaneously in 2 to 3 weeks. Topical steroids and antihistamines may be beneficial. Topical antipenetrants have been evaluated, but an ointment based on IR3535 (ethyl butylacetylaminopropionate) failed to prevent an outbreak of cercarial dermatitis during swimming races across Lake Annecy in France.[82]

Sea Bather's Eruption (See Chap. 209 and on-line version)

Other Skin Problems Related to Ocean Sports (See also Chap. 209)

Jellyfish stings result in immediate pain and may produce delayed immune-mediated reactions. *Cyanea* and *Chrysaora* sea nettles are the most common causes of jellyfish dermatitis. *Chrysaora* jellies are especially common off Atlantic beaches. *Physalia physalis*, the Portuguese man-of-war, is common in the southeastern United States and the Gulf of Mexico. *P. utriculus,* the blue bottle jellyfish, is native to the Pacific. Stings of *Chironex fleckeri*, the Pacific box jellyfish or sea wasp, may result in shock or death. Victims of any marine envenomation should immediately be removed from the water. Administration of antivenin can prevent cardiovascular collapse. Verapamil shows little effect in experimental animals and may negate some of the beneficial effect of antivenin. Unlike verapamil, $MgSO_4$ has been shown to prevent cardiovascular collapse in test animals.[84] First aid includes mechanical removal of tentacles by seawater and sand. Most northern sea nettle nematocysts are inactivated in alkaline conditions, and most man-of-war nematocysts are inactivated in acidic conditions; however, the use of either acid or alkaline solutions can be complicated by the release of venom in some species. Application of ice can provide analgesia. Most marine venoms are inactivated by heat, and hot water immersion [40°C to 41°C (104°F to 105.8°F)] generally results in better pain relief.[85] Jellyfish sting inhibitors can be added to sunscreen lotions.[86] *Haloclava producta*, the "ghost anemone," is responsible for summer outbreaks of dermatitis off the coast of Long Island, New York.[87]

Stingray injury usually occurs when a swimmer accidentally steps on a ray. Roughly 750 stingray stings are reported each year off the U.S. coast.[88] Stings are associated with severe pain, hyperhidrosis, hypotension, muscle cramps, and dysrhythmia. Tissue necrosis can be extensive, and surgical exploration is commonly required.[89,90] Hot water immersion is effective in the control of acute pain but may not prevent skin necrosis.[91] Lion fish are most common in the sub-tropical waters of the Pacific but are increasingly being reported off the coast of the United States. Stings cause pain, swelling, redness, bleeding, and mild systemic symptoms. Hot water immersion generally produces pain relief. Surgical exploration may be prudent for injuries involving the hands.

Corals, especially fire coral, can produce contact dermatitis in divers. Their stinging cells produce a powerful irritant that can produce severe local reactions, including reactions that resemble full-thickness burns. Contact with seaweed has been implicated in vesiculo-bullous reactions. Algal organisms in seaweed can cause "stinging seaweed dermatitis" and pustular folliculitis.

Mycobacterium marinum can cause epidemics of swimming pool granuloma (see Chap. 184). Mycobacterial infections are also commonly acquired in brackish coastal waters. Marine *Vibrio* infections (see Chap. 180) also occur with exposure to brackish coastal waters. Necrotizing fasciitis and sepsis may occur. Culture of specimens from wounds contaminated with seawater have a greater yield if thiosulfate-citrate-bile-sucrose agar is used, and the cultures are incubated both at room temperature and at 30°C (86°F).[92]

Decompression injury may affect the skin of divers. Livedo reticularis is commonly noted. In a porcine model of decompression injury, vascular congestion and vasculitis were common findings in skin biopsy specimens.[93]

HISTAMINE-MEDIATED REACTIONS

Exercise-associated urticarial reactions include cholinergic urticaria, solar urticaria, symptomatic dermatographism, pressure-induced urticaria, cold urticaria, aquagenic urticaria, latex-induced contact urticaria, and exercise-induced anaphylaxis. These entities are discussed in Chap. 37.

ACNEIFORM LESIONS

Acne mechanica is common among athletes, occurring under chin straps, helmets, and shoulder pads. The lesions may respond better to keratolytics than to antibacterial agents.[94] Severe acne may be a sign of anabolic steroid use. The use of these drugs is widespread among athletes of all ages.[95] Although the standard in drug testing is immunoassay screening followed by gas chromatography–mass spectrometry of urine samples to provide confirmation, newer technology may allow reliable detection of anabolic steroids in hair.[96]

DERMATOLOGIC PROBLEMS OF SPECIAL ATHLETES

Athletes with atopic eczema may experience bouts of pruritus with exercise. However, there is evidence that the sweating and vascular response improve with athletic training and that athletics may not interfere with treatment of atopic dermatitis.[97,98] Application of an emollient after showering and short periods of rest can inhibit sweat-induced itching in atopic athletes, and regular moderate exercise does not cause deterioration in the condition of their skin.[99]



The athlete treated with oral retinoids also faces special problems. Arthralgia, staphylococcal colonization, photosensitization, and fatigue may result in lost training time or lost seasons. Retinoids cause disruption of epidermal integrity and skin fragility. Greater trochanter enthesopathy (pain at the site of tendon insertion) may be a complication of short-term oral retinoid therapy in athletes.[100] When possible, retinoid treatment should be planned between seasons.

KEY REFERENCES

The full reference list for all chapters is available at www.digm7.com.

1. Strauss RH et al: Illness and absence among wrestlers, swimmers, and gymnasts at a large university. *Am J Sports Med* **16**:653, 1988
4. Brenner IK et al: Infection in athletes. *Sports Med* **17**:86, 1944
7. Cohen PR: Cutaneous community-acquired methicillin-resistant *Staphylococcus aureus* infection in participants of athletic activities. *South Med J* **98**:596, 2005
48. Zichichi L, Asta G, Noto G: *Pseudomonas aeruginosa* folliculitis after shower/bath exposure. *Int J Dermatol* **39**:270, 2000
59. Belogna EA et al: An outbreak of herpes gladiatorum at a high school wrestling camp. *N Engl J Med* **325**:906, 1991
63. Auger P et al: Epidemiology of tinea pedis in marathon runners: Prevalence of occult athlete's foot. *Mycoses* **36**:35, 1993
71. Fisher AA: Sports-related cutaneous reactions: Part 1. Dermatoses due to physical agents. *Cutis* **63**:134, 1999



CHAPTER 99

Decubitus (Pressure) Ulcers

Tania J. Phillips
Lilian M. Odo

Estimates are that between 1.5 and 3 million people in the United States have pressure ulcers and that these chronic wounds cost approximately $5 billion annually to treat. The incidence of pressure ulcers varies with the clinical setting. In acute care the incidence ranges from 0.4 to 38 percent, in long-term care from 2.2 percent to 23.9 percent, and in home care from 0 percent to 17 percent. Most pressure ulcers develop during the first few weeks of hospitalization. The prevalence of pressure ulcers in acute care settings is approximately 15 percent, in long-term care settings from 2.3 percent to 28 percent, and in home care from 0 percent to 29 percent.[1–4]

Pressure ulcers are more common in the elderly, especially those over the age of 70; in patients who have had surgery for hip fracture; and in patients with spinal cord injury.

The majority of pressure ulcers occur on the lower part of the body, 65 percent in the pelvic area and 30 percent on the lower limbs.[1–4]

ETIOLOGY AND PATHOGENESIS

The main etiologic factors contributing to pressure ulcer development include pressure, friction, shearing forces, and moisture.

Pressure or force per unit area is considered to be the most important factor in pressure ulcer formation. Normal tissue pressure is between 12 and 32 mm Hg. Pressures higher than this upper limit can compromise tissue circulation and oxygenation. When a patient lies immobile on a hospital bed, pressures as high as 150 mm Hg can be generated, especially over bony prominences. The duration as well as degree of pressure is important. If pressure is relieved regularly, tissue recovery can occur, whereas constant pressure can lead to tissue death (Fig. 99-1). Often, damage occurs deep at the bone-muscle interface, which may not be apparent at the skin surface (Fig. 99-2). Patients who are immobile should therefore be turned regularly to prevent pressure ulceration. The pathophysiology of pressure ulcer formation is summarized in Fig. 99-3, and common sites of pressure ulcers are shown in Fig. 99-4.

Shear force results from the motion of bone and subcutaneous tissues relative to the skin when the skin is fixed (e.g., when the upper body of a supine patient is raised to an angle above 30 degrees and the skin remains in contact with the bed). Shearing forces are parallel to the tissue surface, and the subsequent sliding pressure is transmitted to deeper tissues, which can become angulated and occlude the blood vessels (Fig. 99-5A).

Friction is the force that resists the relative motion between two surfaces that are in contact. This causes damage to the superficial layers of the skin (e.g., when a patient is dragged across the bedsheets) (Fig. 99-5B).

PRESSURE ULCERS[1,2] AT A GLANCE



- Commonly known as *decubitus ulcers*, *pressure sores*, and *bedsores*.
- Affect approximately 0.5 percent to 2.2 percent of the population.
- Tend to occur over bony prominences, more common from the waist down.
- Etiologic factors include pressure, shearing, frictional forces, and moisture.
- Related risk factors are prolonged immobilization, sensory deficit, impaired consciousness, circulatory disturbance, poor nutrition, and chronic diseases.
- Staged according to the degree of tissue damage observed (I to IV); pathologic findings depend on the stage of evolution.
- No specific laboratory findings. The diagnosis is made clinically.



▲ **FIGURE 99-1** Pressure ulcer, stage IV. (From Falanga V et al: *Text Atlas of Wound Management*. London, Martin Dunitz, 2000.)

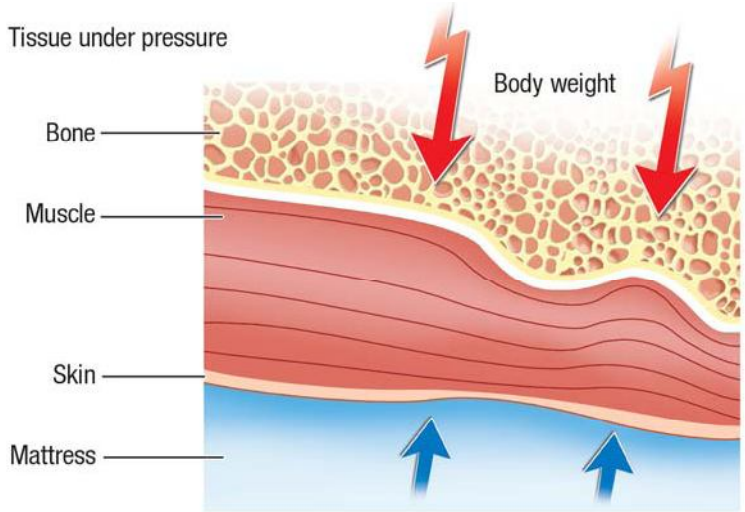

▲ **FIGURE 99-2** Tissue under pressure. (From *Preventing Pressure Ulcers: Clinical Practice Guideline.* Washington, DC, US Department of Health and Human Services, AHCPR publication 92-0047 May 1992.)

A moist environment from urinary incontinence, perspiration, or excessive wound drainage can cause maceration of the skin, which increases the risk of pressure ulcer formation fivefold. Other risk factors for pressure ulcer development include prolonged immobilization, sensory deficit, circulatory disturbances, poor nutrition, acute illness, advanced age, and a previous history of pressure ulcers as well as fecal and urinary incontinence, hip fractures, smoking, and dry skin. Concomitant use of medications such as corticosteroids, which can impair healing; sedatives and analgesics, which can impair consciousness; and drugs that can cause alterations in cutaneous blood flow, such as anti-hypertensives, can also increase pressure ulcer risk, and such drugs should be used with care (Table 99-1).

CLINICAL FINDINGS (Fig. 99-6)

History

History taking and physical examination for pressure ulcer patients should incorporate a risk assessment scale. A number of risk assessment tools have been devised in an attempt to identify persons at risk for pressure ulcers. The Braden, Waterlow, and Norton scales have been extensively tested for reliability and validity and have been recommended by the Agency for Healthcare Research and Quality for predicting the risk of developing pressure sores. Components of these scales assess the following risk factors: mobility, activity level, nutritional status, mental status, incontinence/moisture conditions, general physical condition, skin appearance, medication use, friction and shear, weight, age, predisposing diseases, and prolonged pressure (Table 99-2).

Physical Examination

All pressure ulcer patients should undergo a full physical examination to identify systemic disease contributing to wound development, such as anemia, chronic cardiac or respiratory disease, and neurologic disorders.

Ulcer Evaluation

Staging is an assessment system that classifies pressure ulcers based on anatomic depth of soft-tissue damage. Pressure ulcers often progress from lower to higher stages, and any small pressure ulcer should be considered as the possible "tip of an iceberg." Table 99-3 shows the clinical appearance of pressure lesions and ulcers and their histopathologic correlates as defined by the National Pressure Ulcer Advisory Panel. Palpation is important to assist visual evaluation, and débridement is often necessary to determine the extent of the ulceration. Ulcers that initially appear superficial can end up being classified as stage III or IV after débridement reveals their true depth. The epidermis may be hypertrophic at the ulcer margin with varying degrees of pigmentation.[5]

There are several staging systems for classifying pressure ulcers. Three of them, the National Pressure Ulcer Advisory Panel, Shea, and Yarkony and Kirk systems, are the most commonly used. Table 99-4 compares these three classification systems.[2,5–7]

Related Physical Findings

Tenderness, erythema, edema and warmth of surrounding skin, exudate, and foul odor are symptoms and signs of infection. Fever and declining mental or physical status should raise suspicion of bacteremia or osteomyelitis.

Spasticity secondary to inflammation and infection may trigger muscle contractures and joint deformity that can limit motion, which complicates positioning. Weakness and signs of anemia and dehydration can be found secondary to profound loss of fluid and protein from these open, draining wounds.

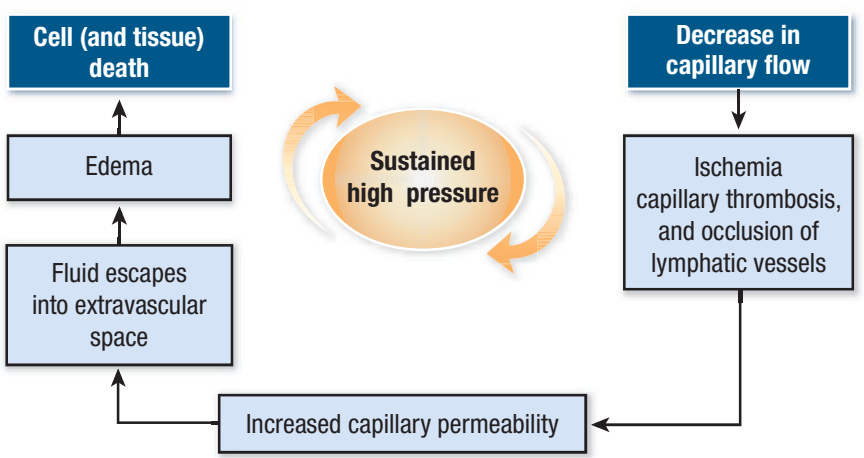

▲ **FIGURE 99-3** Pathophysiology of pressure ulceration. (From Grey JE, Harding KG, Enoch S: Pressure ulcers. *BMJ* **332**:472, 2006, with permission of Blackwell Publishing.)





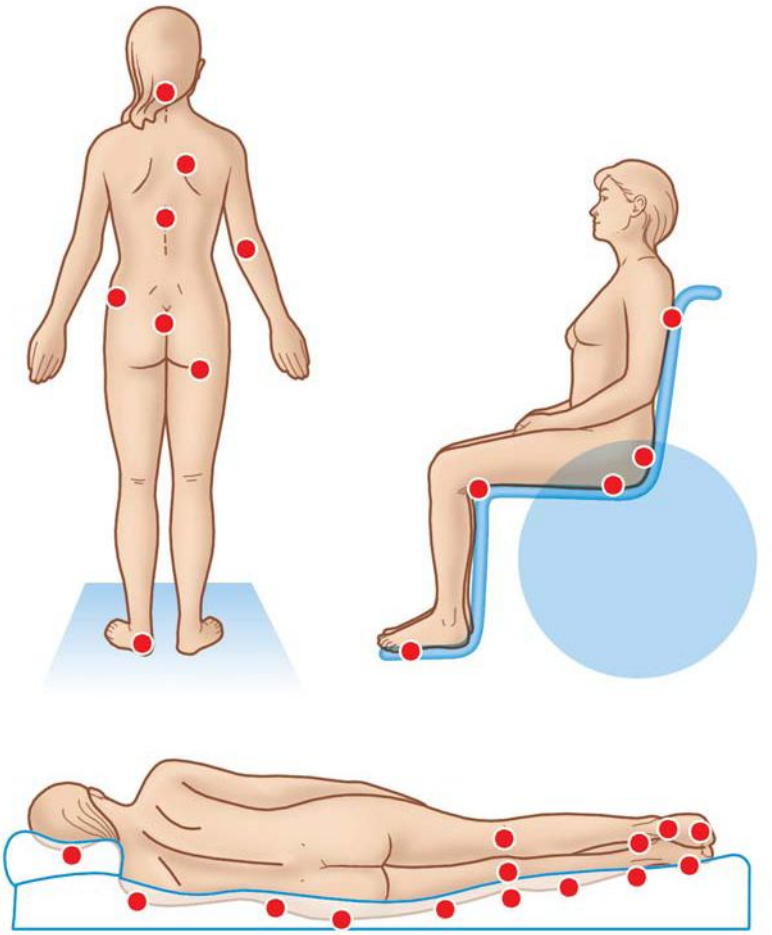

▲ **FIGURE 99-4** Common sites of pressure ulcer development. (From *Preventing Pressure Ulcers: A Patient's Guide*. Washington, DC, US Department of Health and Human Services, USGPO 617-025/68298, 1992.)

LABORATORY TESTS

The diagnosis is made clinically. However, anemia, leukocytosis, hypoproteinemia, or reduced serum iron levels may be present. It is important to exclude other diseases that can cause skin ulcers, including calciphylaxis, vasculitis, and connective tissue diseases.

Biopsy

Histologic analysis may be helpful to diagnose the pressure ulcer stage when clinical findings are insufficient to determine depth and to exclude other diseases that can present with skin ulcers. In long-standing pressure ulcers, squamous cell carcinoma can develop (Marjolin's ulcer). Histologic findings in pressure ulcers are described in Table 99-3.

Imaging Studies

Radiology is most useful to identify complications, particularly of deep pressure sores. Plain radiographs can identify ectopic bone, air in the ulcer cavity, and sclerotic or destructive changes in the underlying bony prominence. Ectopic bone can cause a pressure sore by altering the patient's posture and locally increasing pressure over soft tissue.[8] When there is clinical uncertainty about the size or extent of a pressure ulcer, sinography can be performed. Direct magnification radiography of sacral areas is useful when plain radiographs leave doubt about the condition of the bony cortex adjacent to a pressure sore. If the cortex is intact, osteomyelitis is unlikely.

Computed tomographic scanning is useful to determine the extent of a pressure ulcer and its anatomic relation to surrounding structures. It is helpful in assessing large, complicated lesions with associated sinus tracts or extensive undermined margins. Computed tomography is the only radiographic modality that can define the external margin of the lesion.

Magnetic resonance imaging (MRI) is helpful in determining the depth and extent of soft-tissue involvement underlying decubitus ulcers. It can also be a useful tool for identifying osteomyelitis, fluid collections, abscesses, and sinus tracts.[9,10] The gold standard for the diagnosis of osteomyelitis is histologic/microbiologic analysis of surgical biopsy specimens, but MRI is accurate in the diagnosis of osteomyelitis (sensitivity, 98 percent; specificity 89 percent) and associated soft-tissue abnormalities. It also can delineate the extent of infection to assist in guiding limited surgical resection and preserving viable tissue.[8]

COMPLICATIONS (Table 99-5)

Local Infection/Bacteremia

It is important to distinguish between bacterial colonization (the harmless presence of bacteria on the wound) and infection (bacterial invasion into tissue). Most chronic wounds are colonized by bacteria.[2] Common bacterial strains isolated from chronic wounds include *S. aureus* (the most prevalent), *Pseudomonas aeruginosa*, *Escherichia coli*, *Proteus mirabilis*, *Enterobacter cloacae*, *Serratia marcescens*, *Streptococcus* group G, *Staphylococcus epidermidis*, β-hemolytic *Streptococcus* group A, *Enterococcus* and *Acinetobacter* sp., and other organisms.[9] Anaerobic bacteria may also be present.

Results of superficial swab culture generally reflect colonization rather than infection, and ideally tissue samples should be obtained by needle aspiration, biopsy, or curettage.[2]

Wounds with fewer than 10^6 bacteria per gram of tissue may improve without systemic antibiotic therapy, whereas clinical signs and symptoms such as erythema, warmth, local pain or tenderness, purulent discharge, and the presence of a foul odor may indicate infection into soft tissue with more than 10^6 bacteria per gram of tissue. In patients with associated co-morbidities and advanced age, however, systemic signs of infection such as fever and leukocytosis may not be obvious, and delayed wound healing may be the only sign of infection.[9]

Pressure ulcers can cause bacteremia and may be complicated by osteomyelitis, endocarditis, sepsis, and death. Bacteremia is caused predominantly by hospital-associated organisms and occurs mainly in diabetic, malnourished, or immunosuppressed patients. This complication is associated with a mortality rate of 50 percent to 70 percent.

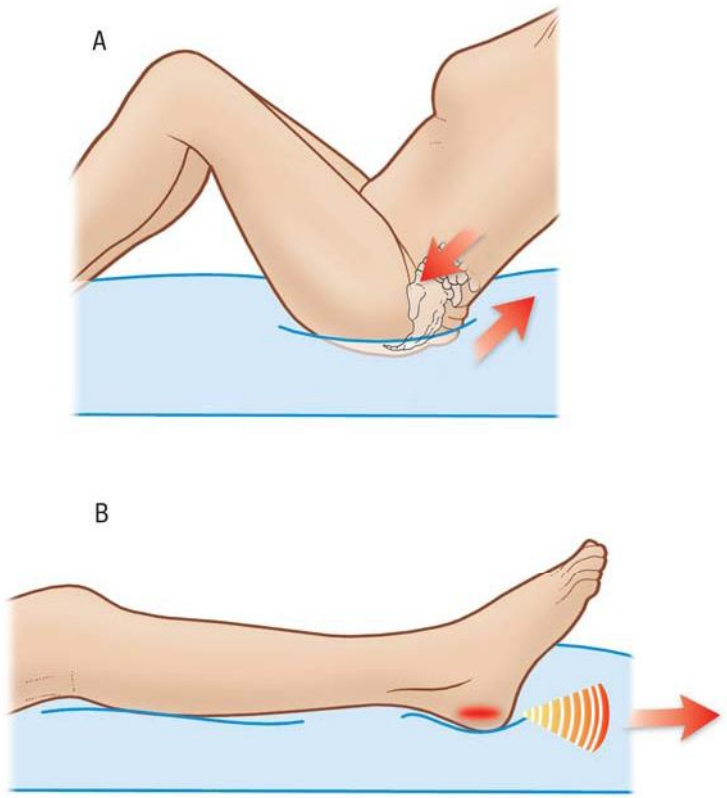

▲ **FIGURE 99-5** Shear force generated when a patient slides down a bed, for example, in the sacral region (**A**) or on the heels (**B**). (From Grey JE, Harding KG, Enoch S: Pressure ulcers. *BMJ* **332**:472, 2006, with permission of Blackwell Publishing.)

TABLE 99-1
Major Risk Factors for Developing Pressure Ulcers

Alteration in sensation or response to discomfort
• Degenerative neurologic disease
• Cerebrovascular disease
• Central nervous system injury
• Depression
• Drugs that adversely affect alertness
Alteration in mobility
• Neurologic disease or injury
• Fractures
• Pain
• Use of restraints
Significant changes in weight (≥ 5% in 30 days or ≥ 10% in previous 180 days)
• Protein-calorie undernutrition
• Edema
Incontinence
• Bowel and bladder

Excerpted from American Medical Directors Association: *Clinical Practice Guideline: Pressure Ulcers.* Columbia, MD, American Medical Directors Association, 1996. © 1996 American Medical Directors Association.

Osteomyelitis

Long-standing, deep decubitus ulcers (i.e., stage III or IV) are often complicated by osteomyelitis. This can occur through direct extension or blood dissemination. If bone is visible in a long-standing deep pressure ulcer, osteomyelitis is highly likely. Common organisms causing osteomyelitis include *S. aureus, Bacteroides fragilis*, *P. mirabilis*, *E. coli*, *Klebsiella* sp., *Pseudomonas* sp., streptococci, and enterococci.[10] Osteomyelitis should be considered whenever a pressure sore does not heal.

Fistulas/Sinus Tracts

Sinus tracts are drainage pathways from a deep focus of acute infection through tissue and/or bone to an opening on the skin surface. A sinogram is useful in determining the extent of the sinus tract or fistula. These can extend deep enough to reach the joint space or even deep viscera and cause osteomyelitis. Large sinus tracts can be demonstrated by MRI.

Malignancies (Marjolin's Ulcers)

The term *Marjolin's ulcer* is often used to describe neoplastic transformation in chronic ulcers. Squamous cell carcinoma has an estimated incidence of 0.5 percent of pressure ulcers[2] and usually behaves aggressively, with a metastatic rate of 61 percent. This makes early diagnosis and treatment imperative.[11] The possibility of malignant transformation should be considered in pressure ulcers that are unresponsive to treatment or that show morphologic changes indicative of malignancy.

Metabolic Alterations

Patients with pressure sores can demonstrate typical features seen in patients with chronic inflammatory disorders, including normocytic, normochromic anemia with reduced serum iron levels and reduced transferrin levels and transferrin saturation, but elevated ferritin levels. Hypoproteinemia with hypoalbuminemia, inverse albumin-globulin ratio, increased level of globulins, high erythrocyte sedimentation rate, and high C-reactive protein level and white cell counts may also be seen. These abnormalities return slowly to normal levels after healing of pressure sores. Bone reabsorption can lead to hypercalcemia, hypercalciuria, ectopic calcification, renal calculi, and bladder stasis.

Necrotizing Fasciitis/Myonecrosis

Necrotizing fasciitis is an aggressive soft-tissue infection that requires rapid diagnosis, early surgical intervention, frequent operative débridements, and soft-tissue reconstruction. It is rare but has a very aggressive course (see Chap. 179).

Myonecrosis and rhabdomyolysis have been described after prolonged surgery. Initially the disorder presents with an area of buttock skin breakdown, diagnosed as a simple decubitus ulcer, but it then develops into extensive myonecrosis leading to renal failure the necessitates dialysis.

Other Complications

Among elderly bedridden patients who have surgery for pressure ulcers, the mortality rate is high (68 percent in one series).[12] Other postsurgical complications include hematoma, seroma, wound dehiscence, abscess formation, sepsis, and death. Death has been reported to occur during acute hospitalization in 67 percent of patients who develop a pressure ulcer compared with 15 percent of at-risk patients without pressure ulcers. The risk does not appear to correlate with the severity of the pressure ulcer.

Other less commonly reported complications of pressure ulcers include amyloidosis, endocarditis, meningitis,





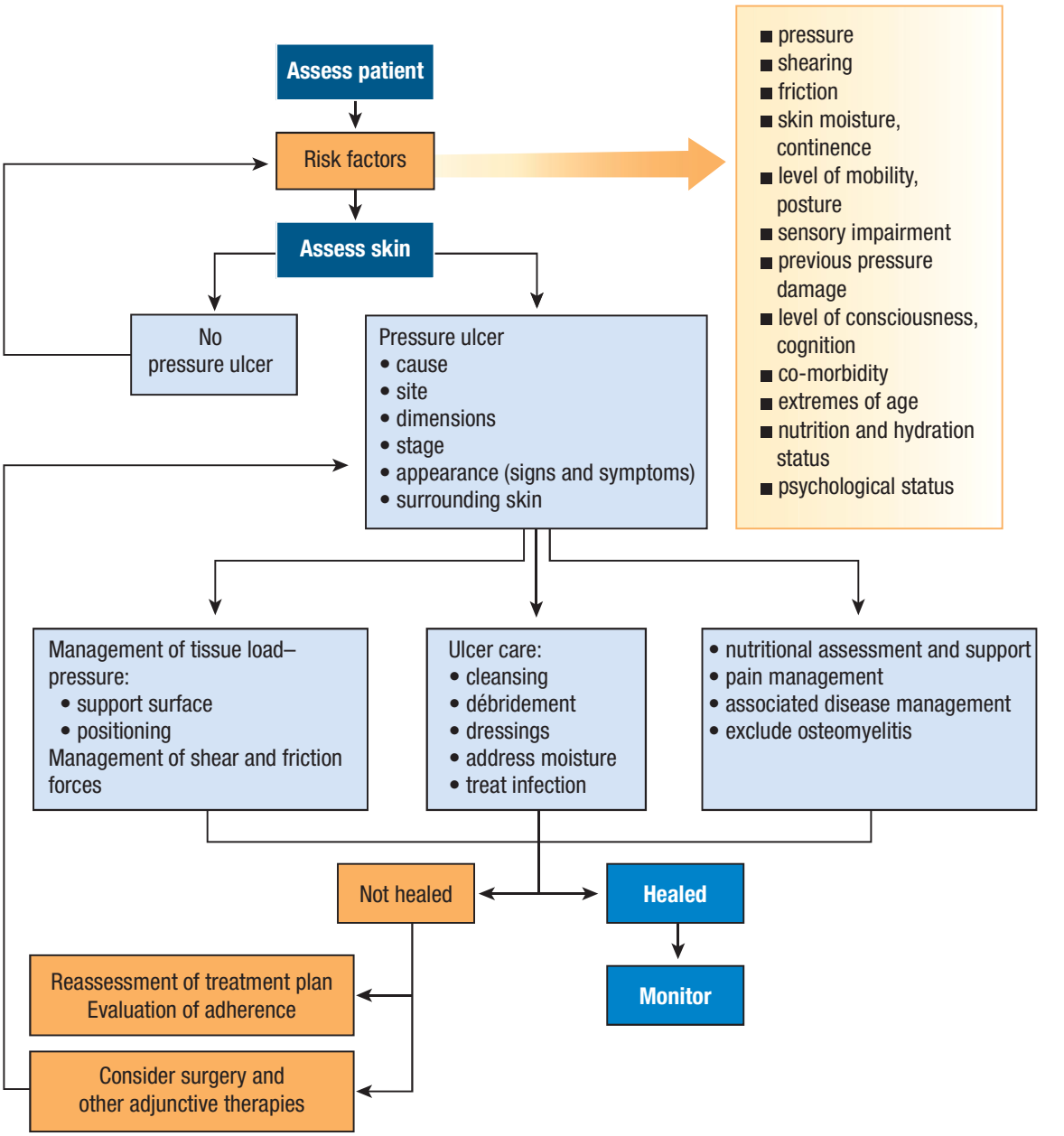

▲ **FIGURE 99-6** Algorithm for the approach to a patient with pressure ulcer.

TABLE 99-2
Components of Three Risk Assessment Scales for Pressure Ulcers

Risk Factor	Norton	Waterlow	Braden
Mobility	Yes	Yes	Yes
Activity level	Yes	No	Yes
Nutritional status	No	Yes	Yes
Mental status	Yes	No	Yes
Incontinence/moisture conditions	Yes	Yes	Yes
General physical condition	Yes	Yes	No
Skin appearance	No	Yes	No
Medication	No	Yes	No
Friction and shear	No	No	Yes
Weight	No	Yes	No
Age	No	Yes	No
Specific predisposing diseases	No	Yes	No
Prolonged pressure	No	Yes	No

Data from Grey JE, Enoch S, Harding KG: Pressure ulcers. *BMJ* **332**;472, 2006.

septic arthritis, myiasis, pseudoaneurysm formation, and gangrene.

PROGNOSIS

The prognosis of pressure ulcers depends on the cause. In paraplegic patients 50 percent to 70 percent of pressure ulcers heal with non-surgical intervention. However, in the long-term care setting in which patients may have multiple medical problems, the prognosis is worse, and complications such as sepsis, osteomyelitis, amyloidosis, anemia, and malignancy can develop.[13]

The age-adjusted mortality rate for pressure ulcers has been calculated as 3.79 deaths per 100,000 population. The majority of pressure ulcer–associated

TABLE 99-3
Comparison of Clinical and Histologic Findings by Ulcer Stage

Classification/Stage NPUAP (1989)	Clinical Findings	Histopathologic Description
Stage I 	Non-blanchable erythema of intact skin	Epidermis appears normal. Striking red blood cell engorgement of capillaries and venules, mainly in papillary dermis with platelet thrombi and hemorrhage. Degeneration of sweat glands and subcutaneous fat is often seen.
Stage II 	Partial-thickness skin loss involving epidermis, dermis, or both.	Epidermis is lost. Dermal papillae are often identifiable. Acute inflammation of papillary and reticular dermis is found. In addition to a perivascular lymphocytic infiltrate, neutrophils are seen. Necrotic changes in the appendages and fat are more pronounced.
Stage III 	Full-thickness skin loss involving damage to or necrosis of subcutaneous tissue that may extend down to, but not through, underlying fascia.	Hemorrhagic crust containing acute inflammatory cells or a thin zone of coagulation necrosis on the surface. Diffusely fibrotic dermis. Loss of appendageal structures.
Stage IV 	Full-thickness skin loss with extensive necrosis of or damage to muscle, bone, or supporting structures.	Full-thickness destruction of skin. The tissue appears basophilic with obliteration of cellular detail, although the general dermal architecture is preserved. Inflammatory infiltrate is often not seen.

NPUAP (1989) = National Pressure Ulcer Advisory Panel biennial conference since 1989 (http://www.npuap.org).
Photographs used with permission from Hollister Incorporated.

deaths occur in people at least 75 years of age. Septicemia was present in 40 percent of patients whose deaths were associated with pressure ulcers. Incapacitating chronic and neurodegenerative conditions were common co-morbidities, and mortality rates in blacks were higher than those in other racial or ethnic groups.

Interestingly, although stage II pressure sores were found to be more likely to heal than pressure ulcers of stage III or IV, the depth of the pressure ulcer did not correlate with mortality. Patients with a stage II pressure ulcer on admission to care were as likely to die as patients with a stage III or IV ulcer.[14]

TREATMENT

Therapy should be individualized for each patient and involves more than simple wound management. Pressure ulcers are frequently a clinical sign of underlying medical conditions that should be treated to facilitate healing. Few controlled trials have evaluated specific treatment modalities for pressure ulcers. The general principles of therapy for pressure ulcers are the following.

Relief of Pressure, Shear, and Frictional Forces

POSITIONING Positioning techniques are critical in the management of tissue loads.

While in bed, patients should be positioned to avoid pressure over existing ulcers or over bony prominences, specially the trochanter. Pillows or foam wedges can be used to raise a pressure ulcer off its support surface or to prevent direct contact between bony prominences, such as knees or ankles. It is important to limit the amount of time the head of the bed is elevated and to maintain the head of the bed at the lowest possible level of elevation tolerable to reduce shearing forces at sacral tissues. Immobilized patients are usually placed in a 30° oblique position to the left or right, which should be alternated every 2 hours at a minimum.

The patient and caregivers must learn appropriate transfer or mobilization techniques to avoid friction. The patient should be lifted rather than dragged across the bedsheets, using lifting devices such as a trapeze or bed linen. Repositioning should be done as frequently as warranted by the patient's condition.

Moisture from urinary or fecal incontinence, perspiration, or wound drainage should be minimized, and the skin should be kept clean. Absorbant underpads or briefs, diapers, and occasionally urinary catheters or rectal tubes may be required to help manage incontinence. Skin barrier creams can help protect the skin from maceration.

Patients who are sitting may select a pressure-relieving cushion based on specific needs. Donut-type devices should



TABLE 99-4
Staging Systems for Classifying Pressure Ulcers

Classification	Shea (1975)[5]	NPUAP (1989)	Yarkony and Kirk (1990)[7]
Stage I	Limited to epidermis, exposing dermis	Non-blanchable erythema of intact skin	Red area A. Present > 30 min but < 24 h B. Present longer than 24 h
Stage II	Full thickness of dermis to junction of subcutaneous fat	Partial-thickness skin loss involving epidermis, dermis, or both	Epidermis and/or dermis ulcerated with no subcutaneous fat observed
Stage III	Fat obliterated, limited by deep fascia undermining of skin	Full-thickness skin loss involving damage or necrosis of subcutaneous tissue that may extend to, but not through, underlying fascia	Subcutaneous fat observed, no muscles observed
Stage IV	Bone at the base of ulceration	Full-thickness skin loss with extensive necrosis of or damage to muscle, bone, or supporting structures	Muscles observed, but no bone observed
Stage V	Close large cavity through a small sinus (closed pressure ulcer)	—	Bone observed but no involvement of joint space
Stage VI	—	—	Involvement of joint spaces

NPUAP (1989) = National Pressure Ulcer Advisory Panel biennial conference since 1989 (http://wwwnpuap.org).



be avoided because they result in venous congestion and may worsen ulcers. Patients should be encouraged to reposition themselves frequently.

SUPPORT SURFACES Support surfaces can be used on top of or instead of standard mattresses. They distribute pressure over a large surface area, and the type of support surface used will depend on the patient's needs and abilities.

Static support surfaces are recommended for patients who can assume several positions without bearing weight on an ulcer. These include foams, fluid- or air-filled mattresses, and overlays.

- Foam is probably the most commonly used material for pressure reduction, because it is easy to use, lightweight, and inexpensive. An investigative study showed that the combination of turning every 4 hours and the use of a viscoelastic polyurethane foam mattress decreased the incidence of pressure ulcers (grade II to IV) in at-risk patients from 14.3 percent to 3.0 percent. [15]
- Fluid-filled products consist of small or large chambers filled with air, water, or other viscous fluid materials (silicon or polyvinyl). Most of them permit a high degree of immersion, allowing the body to sink into the surface as it conforms to the bony prominences. This increases the surface pressure distribution area and lowers the interface pressure by transferring the pressure to adjacent areas.

Patients who cannot tolerate frequent turning due to pain or severe illness, immobile patients, those with large or multiple ulcers, and patients with unresponsive ulcers may require dynamic support surfaces. These provide cyclical, alternating pressure relief, and include air-fluidized, low-air-loss, and or alternating-air beds.

- Air-fluidized beds contain microspheric silicon-coated beads encased in an air-permeable fabric (polyester or Gore-Tex). The beads are suspended by pressurized streams of warmed air, which allows patients to "float" and decreases pressure through the principle of immersion while simultaneously reducing shear. Feces and body fluids flow freely through the sheet; thus the skin is kept dry.
- Low-air-loss systems use a series of connected, air-filled cushions that are inflated to specific pressures. Some have alternating and pulsating pressure features. A prospective, randomized trial demonstrated that the use of low-air-loss beds resulted in threefold faster wound contraction than use of a foam mattress.[16] Unlike with air-fluidized beds, urine and feces do not pass through the fabric of low-air-loss beds.
- Alternating-pressure systems distribute pressure by shifting the body weight to different surface contact areas. The air is pumped into the chambers at periodic intervals to inflate and deflate them in opposite phases, which thereby changes the location of contact pressure.

TABLE 99-5
Complications of Pressure Ulcers

- Local infections
- Bacteremia
- Osteomyelitis
- Sinus tracts
- Malignancies
- Necrotizing fasciitis
- Myonecrosis
- Metabolic alterations
  - Hypercalcemia
  - Hypoproteinemia
  - Anemia
- Postsurgical complications
  - Hematoma
  - Seroma
  - Wound dehiscence
  - Abscess
- Amyloidosis and others
- Death

Wound Management

CLEANSING Cleansing should be performed gently to minimize mechanical and chemical trauma to healing tissues. Normal saline is preferred because it is most physiologic in relation to the wound. Safe and effective irrigation pressures for ulcers range from 4 to 15 psi; higher pressures than this may cause trauma and drive bacteria into the wound tissue. Certain skin cleansers and antiseptics such as povidone iodine, sodium hypochlorite solution, hydrogen peroxide, acetic acid, and liquid detergents should be avoided, because these agents are cytotoxic and may retard epithelialization.

DÉBRIDEMENT Ulcers with devitalized, necrotic tissue should be débrided, because necrotic tissue supports the growth of pathogenic organisms. Mechanical débridement techniques include application of moistened saline or wet-to-moist dressings, hydrotherapy (whirlpool), wound irrigation, and application of dextranomers. Wet-to-dry dressings changed every 4 to 6 hours are painful and are non-selective for necrotic tissue. Whirlpool devices can be considered for pressure ulcers with thick exudate, slough, or necrotic tissue. For wound irrigation, a large 35-mL syringe and 19-gauge angiocatheter can be used to provide adequate pressure.[1]

Sharp débridement involves the use of a scalpel, scissors, or other sharp instrument to remove devitalized tissue and is generally indicated in cases in which there is eschar. For smaller ulcers, local anesthesia can be used, whereas larger stage III or IV ulcers may require extensive surgical débridement under general anesthesia. Enzymatic débridement can be used in patients who cannot tolerate surgery. Topical agents such as sutilains, collagenase, papain, fibrinolysin, and deoxyribonuclease can be used. Dressings should be changed once to several times daily. Contact dermatitis can sometimes occur, and these agents should not be used if tendon is exposed.[2]

Autolytic débridement involves the use of synthetic dressings to cover the wound, which allows digestion of necrotic tissue by enzymes normally present in wound fluids.

In addition to traditional débridement methods, the use of sterile fly larvae (maggots) to clean necrotic tissue is gaining popularity and appears to be safe and effective.

DRESSING PRODUCTS Dressings can help protect the wound from the environment, reduce or prevent wound infection, stimulate autolytic débridement, reduce wound pain, and stimulate the development of granulation tissue. It has been demonstrated experimentally that wounds maintained in a moist environment heal 40 percent faster than air-exposed wounds. Control of moisture and drainage from the wound helps provide an optimum wound environment for healing. There are several types of dressings, each one of which has specific properties, advantages, and disadvantages. e Creams or gels containing metronidazole, balsam of Peru, trypsin, recombinant human platelet-derived growth factor, and papain-urea are also available. A variety of specialized dressings may be helpful for pressure ulcer management, including a bilayer matrix wound dressing, pig-derived acellular small intestine submucosa, and natural latex biomembrane.

Intact skin surrounding the ulcer should always be assessed for signs of inflammation and infection. Periwound skin must be adequately moisturized but neither macerated nor eroded.[15] Irritation of surrounding skin can be the result of epidermal skin stripping during dressing changes or maceration secondary to contact with feces, urine, or wound drainage.

Bacterial Colonization and Infection Management

Ulcer cleansing and débridement are important to control microbial burden in pressure sores. Systemic antibiotic therapy is not recommended for contamination or minor localized infections but is indicated when bacteremia, cellulitis, or osteomyelitis is present.

Topical antibiotics are used to prevent or treat wound infection, reduce bacterial load, or reduce odor and signs of inflammation. Topical antibiotics such as neomycin and bacitracin are common allergens and can cause contact dermatitis and, rarely, anaphylaxis. Topical formulations of antibiotics that are used systemically (e.g., gentamicin) should be avoided because bacterial resistance may develop. However, the Agency for Healthcare Research and Quality guideline recommends a short 2-week course of topical antibiotics for a clean ulcer that is not healing or that is producing a moderate amount of exudate despite appropriate care.[18]

Pain Management

Pain management requires a combination of conservative measures, medications, and appropriate wound care. Muscle relaxants and physical and occupational therapy may be helpful to decrease muscle spasm in the area of ulceration. Transcutaneous electrical nerve stimulation may help relieve acute and chronic pain. The use of topical anesthetics such as lidocaine-prilocaine cream on wounds 30 minutes before débridement significantly reduces pain associated with wound care procedures.

Nonopioid analgesics (aspirin, other nonsteroidal anti-inflammatory drugs) are first-line systemic therapy, followed by stronger medications such as opioids. Adjuvant medications such as tricyclic antidepressants can be used to enhance analgesia.[19] They can also improve depression in some chronic pain states and have sedative, sleep-enhancing qualities.

Nutritional Management

Screening for nutritional deficiencies is an important part of assessment and management of pressure ulcers. Adequate patient dietary intake of protein is important in healing pressure ulcers.[20] A reasonable protein amount is between 1.2 and 1.5 g/kg/day, and caloric intake should be between 30 and 35 kcal/kg/day. Vitamin C or zinc deficiency can have negative effects on wound healing, but supplementation is useful only when deficiency is confirmed or suspected. If dietary intake continues to be inadequate, oral or parenteral nutritional supplementation may be required. Markers of nutritional deficiency include a serum albumin level of less than 3.5 mg/dL and unintentional weight loss of more than 15 percent of baseline. Patients should be kept adequately hydrated.

Surgery

The long-term efficacy of surgical repair of pressure ulcers, especially in older patients, has been questioned because of high recurrence rates and mortality. The decision to undertake surgical repair should be made with full knowledge of the risks and benefits, surgical and nonsurgical alternatives, and complications associated with each procedure. Surgical techniques include skin grafting; creation of cutaneous, muscle, and fasciocutaneous flaps or pedicled flaps; microvascular free tissue transfer reconstruction; and simple direct suture, depending on the site, number, and grade of lesions, and the patient's clinical condition. In general, surgery is often required for stage IV ulcers, whereas more superficial ulcers may heal with conservative therapy.

Adjunctive Therapies

Adjunctive therapies have been used in case studies, but more data are needed to determine the effectiveness of these therapies.[21] These therapies are outlined in the electronic version of this book. e

Whenever possible, others factors that impair healing such as smoking; hypovolemia; cold; chronic diseases in-



TABLE 99-6
Preventive Measures

- Maintain personal hygiene.
- Try to assure adequate nutrition and hydration.
- Evaluate and manage urinary and fecal incontinence.
- Position to alleviate pressure over bony prominences and shearing forces over heels and elbows, base of head, and ears.
- Try to reposition every 2 h when in bed and every hour when in a chair; if alert and capable, the patient should be taught to shift his or her weight every 15 min while in a chair.
- Use appropriate positioning devices and foam padding; do not use donut-shaped devices.
- Try to avoid placing the patient on his or her trochanters or directly on the wound.
- Maintain the lowest head elevation possible.
- Use lifting devices such as draw sheets or a trapeze.
- Try to prevent contractures.
- Do not massage reddened areas over bony prominences.

Excerpted from American Medical Directors Association: *Clinical Practice Guideline: Pressure Ulcers.* Columbia, MD, American Medical Directors Association, 1996. © 1996 American Medical Directors Association.



cluding diabetes mellitus, systemic arterial hypertension, anemia, and vascular alterations; and the use of medications such as corticosteroids should be limited or controlled.

PREVENTION

Preventive actions can decrease the patient's risk of developing pressure ulcers. These steps can also keep pressure ulcers from getting worse. Preventive measures are listed in Table 99-6.

KEY REFERENCES

The full reference list for all chapters is available at www.digm7.com.

1. Gelfand JM et al: Skin changes due to mechanical and physical factors: Decubitus (pressure) ulcers and venous ulcers, in *Fitzpatrick's Dermatology in General Medicine,* edited by Freedberg IM et al. New York, McGraw-Hill Professional, 2003, p 1256
2. Kanj LF et al: Pressure ulcers. *J Am Acad Dermatol* **38**:517, 1998
3. Grey JE, Emoch S, Harding KG: Pressure ulcers. *BMJ* **332**:472, 2006
5. Shea JD: Pressure sores: Classification and management. *Clin Orthop Relat Res* **112**:89, 1975
7. Yarkony GM et al: Classification of pressure ulcers. *Arch Dermatol* **126**:1218, 1990
17. Maklebust J: Pressure ulcer assessment. *Clin Geriatr Med* **13**:455, 1997
20. Langer G et al: Nutritional interventions for preventing and treating pressure ulcers. *Cochrane Database Syst Rev* Issue 4:CD003216, 2003.

CHAPTER 100

Body Art

Anne Laumann

Body art is art made on, with, or consisting of the human body. The most common forms of body art are tattoos, body piercings, and body painting, but other types include scarification, branding, tongue splitting, and extraocular implants. *Tattooing* is the practice of producing an indelible mark or figure on the human body by inserting a pigment under the skin using needles or other sharp instruments.[1] *Body piercing* refers to the cosmetic piercing of body parts for the implantation of objects such as rings, studs, or pins.[2] *Body painting* is the application of paint onto the skin. It includes face painting, the application of mehndi, and temporary tattoos. *Scarification* is a means of permanently marking the skin by cutting alone, without the use of pigments. This includes the deliberate formation of keloids. When purposeful third-degree burns are used to induce a scar, the procedure is called *branding*.[3] *Tongue splitting* is the bisection of the tongue from the tip toward the back for about 3 to 5 cm, leading to an appearance similar to the tongue of a lizard.[4] *Extraocular implantation* is the placing of sterile non-pyrogenic platinum jewelry inside the interpalpebral conjunctiva of the eye.[5]

TATTOOING

Background

Epidemiology

Twenty-four percent of 18- to 50-year-olds in the United States have tatoos, including as many as 36 percent of those under the age of 30.[7–9] They are equally common among men and women and are seen in all ethnic groups. They are still found more commonly in those with a military association and in those of low educational and socioeconomic backgrounds. They are associated with the abuse of alcohol, the taking of illicit drugs, and having spent significant time in prison. They are inversely associated with having a religious affiliation and having never drunk alcohol.[9] Most tattoos are done in a dedicated studio, but approximately a one-fourth of people with tattoos have at least one tattoo done elsewhere.

BODY ART AT A GLANCE



- Tattoos are becoming more common: 24 percent of the U.S. 18- to 50-year-olds in 2004; equal numbers of men and women.
- Tattooing medical complications are rare: Mainly related to pigment ingredients, but include viral, bacterial, fungal, and, in particular, transfusion transmitted diseases.
- Tattoo social associations and complications are significant.
- Piercing: Soft earlobes 37 percent, and body piercing excluding the soft earlobe 14 percent of the U.S. 18- to 50-year-olds in 2004, mainly women. Body-piercing fashion started in the late 1980s.
- Piercing medical complications are common: Metal-induced contact allergic dermatitis, broken teeth, anesthetic risks, and infections of all types.
- The relationship to hepatitis is unclear.



▲ **FIGURE 100-1** Tattooing with a hand-held electric tattoo machine.

Process

A hand-held device, powered by low-voltage direct current, holds solid needles placed singly or in groups of up to 14 on an oscillating bar (Fig. 100-1). The needles are dipped into colored inks and then moved across the skin in the desired pattern, penetrating vertically 0.5 to 2.0 mm into the skin at between 50 and 3000 vibrations per minute, depositing the pigment into the dermis. A thin layer of petroleum jelly is applied to the skin before and during the procedure to minimize blood loss and prevent spatter. After the tattoo is finished, the area is cleaned with a mixture of alcohol and water, and more ointment is applied. Sometimes, the ink is spread over an area of skin, and the needles penetrate through it to carry the particles into the skin. Amateur tattooers often do it this way using hand-held needles wound round with thread to prevent too deep penetration. Other instruments used may be pencils, pens, and straight pins. Much of the pigment is extruded through the epidermis during the first 10 days (Fig.100-2). The final location of the



▲ **FIGURE 100-2** Five days after application of this tattoo. One can see extrusion of much of the inserted pigment.

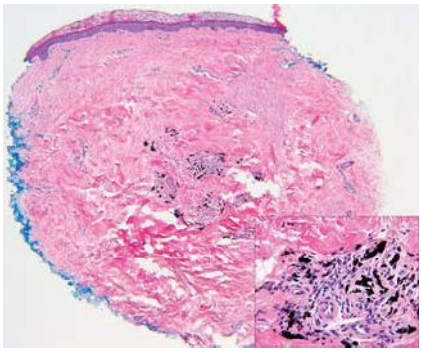

▲ **FIGURE 100-3** Tattoo pigment is seen in the reticular dermis. The particles are within fibroblasts, macrophages, and occasional mast cells around blood vessels.

pigment is in the mid to lower dermis (Fig. 100-3), but the pigment in amateur tattoos tends to be more superficially and more variably placed. The particles are membrane bound (in secondary lysosomes) within fibroblasts, macrophages, and, occasionally, mast cells around blood vessels. They may also be seen around hair follicles and sebaceous glands. Many of the pigment conglomerations are too large to traverse the vessel walls and leave the area of original deposition, but over time this may happen, leading to blurring of the visible design (Fig. 100-4) as well as the deposition of pigment in the draining lymph nodes.[10,11]

Pigments

The composition of tattoo ink as obtained from the manufacturer, and possibly further mixed by the artist, is complex, usually non-sterile, unregulated, variable, and evolving. In recent times, industrial organic pigments, including azo and polycyclic compounds, sandalwood, and brazilwood, as well as aluminum, cadmium, calcium, copper, iron, phosphorus, silica, and sulfur, have been identified.[12] In addition, titanium dioxide and barium sulfate are often used to lighten the color. The 1976 Food, Drug and Cosmetic Act limited the content of lead and mercury in cosmetics for application to the skin so that now these two elements are rarely found.[13,14] The pigment in amateur tattoos is usually black and carbon-based, often deriving from India ink, charcoal, soot, or mascara (Table 100-1).



▲ **FIGURE 100-4** This tattooed eyeliner has dispersed so that only a blur remains.

Complications

Medical complications are unusual in developed countries. Clearly, there is a real risk of contracting a contagious disease, but most recent reports are anecdotal[15–17] or from the developing world (Table 100-2).[18,19] There have been outbreaks of hepatitis B traced to tattoo parlors in the past, but currently there is a controversy as to how often hepatitis C in the United States is transmitted during the act of tattooing. During the same time that the prevalence of tattoos has increased, the absolute numbers of reported acute hepatitis B and C cases have fallen to an all-time low of 1.8/100,000 in 2005 from a high of 11.5/100,000 in 1985 for hepatitis B; and 0.2/100,000 in 2005 from a high of 2.4/100,000 in 1992 for hepatitis C.[20] Most

TABLE 100-1
Tattoo Pigments

Red	Mercuric sulfide (cinnabar); cadmium selenide; ferric hydrate (sienna); sandalwood; brazilwood; aromatic azo compounds, including naphthol-AS, quinacridone
Green	Chromium oxide, lead chromate, copper or aluminum phthalocyanine, malachite (contains copper), ferrocyanides, and ferricyanides
Purple	Manganese ammonium pyrophosphate, aluminum salts, quinacridone, dioxazine/carbazole
Blue	Cobalt aluminum oxide, chromium oxide, copper phthalocyanine
Yellow	Cadmium sulfide, curcuma (from the ginger plant family), chrome yellow (lead chromate mixed with lead sulfide)
Black	India ink, ferrous oxide, magnetite (Fe_3O_4), carbon, logwood (a heartwood extract from *Hematoxylum campechianum* found in Central America and the West Indies)
Brown	Iron oxides
White	Zinc oxide, titanium dioxide, lead carbonate, barium sulfate



TABLE 100-2
Known Infectious Complications of Tattooing

Bacterial	Viral
• Impetigo	• Warts
• Ecthyma	• Molluscum contagiosum
• Furunculosis	• Herpes simplex
• Erysipelas	• Herpes zoster
• Tuberculosis cutis	• Vaccinia
• Atypical mycobacterial infection	• Rubella
• Syphilis	• Viral hepatitis
• Leprosy	• Human immunodeficiency virus possible but no case reports
• Endocarditis (rare)	



hepatitis C infection is asymptomatic. The sources of approximately 65 percent of the cases of hepatitis C are unidentified. Cross-sectional data from a number of population groups (e.g., veterans,[21] attendees in an orthopedic practice,[22] and hospital outpatients[23]) have been inconsistent in identifying tattoos as an independent risk factor for the presence of hepatitis C. Variables such as getting the procedure in a dedicated studio or in a penitentiary[24] may be relevant, and the confusion may relate to the fact that, in some people, tattoos are a marker for other unconventional or socially disapproved behaviors.[25,26] The American Blood Bank Association recommends that blood for donation not be taken from anyone within a year of a tattoo or a body piercing unless it was done in a state-regulated facility.[27]

Many, but not all, of the pigment-based reactions are in the red areas of tattoos (Fig. 100-5). Now that cinnabar, vermillion, or other pigments containing mercuric sulfide are rarely used, other culprits have been identified. These include cadmium selenide and quinacridone.[28] Reactions may be photosensitive, and histologic evaluation of biopsied tattoo skin may show pseudolymphomatous, lichenoid,[29] or granulomatous reactions. The latter may manifest histologically as a foreign body type reaction with numerous giant cells containing pigment, or a hypersensitivity type with dense aggregates of epithelioid cells, a thin peripheral ring of lymphocytes, and few giant cells. Hypersensitivity reactions may be localized or generalized,[30] but standard epicutaneous patch testing is not often helpful, presumably related to the dermal placement of the tattoo antigen. The social implications of tattooing are protean and may alert the onlooker to other risk-taking behaviors.



▲ **FIGURE 100-5** Red tattoo reaction.

Tattoo Removal

Most people are proud of their tattoos, but approximately 17 percent desire their removal. In addition, 5 percent opt for and 8 percent are considering further tattooing to cover a disliked or faded image. Often, these people have obtained their tattoos at a young age and want them removed or changed to enhance self-esteem, or for social, domestic, and family reasons.[31,32] Many tattoo removal methods have been documented (Table 100-3), but most are only partially effective and leave scarring and pigmentary changes. In general, proximally placed and old tattoos are easier to remove than distally placed and more recent ones. With the advent of the theory of thermal relaxation, lasers with very short (nanosecond), high-energy pulses have been designed, which are less likely to heat the surrounding tissue and leave scars (Table 100-4). On the horizon are lasers (titanium:sapphire) with picosecond pulse durations, which may be even more effective. The laser energy photoacoustically explodes the pigment particles. Some of these may be allergenic or carcinogenic (Fig. 100-6). Macrophages engulf the fragments so that they are removed via the draining lymphatics, and some may be extruded through the epidermis. Lightening may take several weeks following a single treatment session, and maximum lightening may take many (often 8 to 10) sessions.

Removal of tattoos in dark-skinned individuals is difficult. A long wave-

TABLE 100-3
Methods of Tattoo Removal

Excision with primary closure or grafting	For grafting, to avoid donor site scars, techniques may be used that enzymatically separate the excised epidermis from the underlying excised pigment containing dermis and grafting this epidermis to the original tattoo site.[43]
Mechanical dermabrasion	May use a handheld mechanical unit or sterile sandpaper to abrade the skin to the reticular dermis. Rotating (up to 33,000 revolutions per minute) wire brushes, diamond fraises, or serrated wheels attached to compact electric machines are available.
Salabrasion	First described by Aetius, a Greek physician in 543 A.D., tap water dipped in salt is rubbed vigorously to abrade the skin overlying the tattoo.
Chemical extraction using a remover paste	The remover paste, made with deionized water, zinc oxide, magnesium oxide, calcium oxide, triethanolamine, isopropanol, and benzoic acid is applied.[44] A superficial microtattoo process is used to puncture the skin over the tattoo, and the paste is reapplied. Inflammation ensues and the pigment is extruded.[45]
Cryosurgery	Salt/ice –20°C (–4°F) or dimethyl ether/propane –50°C (–58°F) mixtures, solid carbon dioxide –79°C (–110°F), nitrous oxide –70°C (–94°F) or liquid nitrogen –196°C (–321°F) may be used.
Application of caustic chemicals	Phenol, trichloroacetic acid, tannic acid, or oxalic acid with silver nitrate. Nitric acid application described in Scientific American in 1891 [Todd TW, *Scientific American* **LXIV**(18):273 (May 2, 1891)]
Argon and carbon dioxide lasers	Early tattoo removal lasers but currently mainly used for the removal of tattoo granulomas, as healing times are prolonged. Significant thermal damage and hypertrophic scarring often ensue.
Q-switched lasers	Nanosecond pulses similar to the Tr of the target pigment. Each pulse has a very high peak power. Surface cooling may be used to prevent epidermal damage.

Tr = thermal relaxation time, the time it takes for the target chromophore to lose 50 percent of its incident heat without conducting heat to the surrounding tissue.

TABLE 100-4
Q-Switched Lasers for Tattoo Removal

Q-Switched Laser	Wavelength in Nanometers	Pulse Duration in Nanoseconds	Fluence Joules/cm^2	Used for This Color
Nd:YAG	1064	10	6–12	Black, blue
Frequency doubled Nd:YAG	532	10	2–12	Red, orange, purple
Ruby	694	~25	8–10	Black, blue, green
Alexandrite	755	50–100	4.5–8	Black, blue, green

Nd:YAG = neodymium yttrium:aluminum-garnet.

length laser (Q-switched Nd:YAG) may be used together with skin freezing to cause lightening of the epidermis so that the laser light not only penetrates deeply enough but also bypasses the melanin in the epidermis to avoid a permanent pigment change. Red, white, and flesh-tone tattoos, which often contain ferric and/or titanium oxides, may darken with laser treatment related to the reduction of the chemicals by the laser beam (see Chap. 240).

Temporary Tattoos

Traditional henna tattooing, practiced throughout Africa, the Middle East, and India (mehndi) for thousands of years, very rarely causes hypersensitivity reactions. Henna is made from the leaves of the plant *Lawsonia inermis*, a member of the loosestrife family, and is a reddish-brown color. Recently, the application of temporary tattoos has become popular in the developed world. Some of these are made with "black henna" found to contain up to 16 percent para-phenylenediamine, which is used as a darkening agent. Concentrations of para-phenylenediamine as high as this commonly cause sensitization and lead to contact allergic dermatitis (see Chap. 13).



▲ **FIGURE 100-6** This leg became increasingly painful after each of three attempts at laser tattoo removal.

BODY PIERCING

Background

Epidemiology

A U.S. cross-sectional study of 18- to 50-year-olds in 2004 found that 19 percent of men and 49 percent of women had soft earlobe piercings; and 8 percent of men and 21 percent of women have body piercings in other parts of the body. Thirty-six percent of the 18- to 29-year-olds have body piercings.[9] In another study of youth aged 12 to 22 years, 27 percent had had a body piercing other than the soft earlobe.[34] Women are more likely to have body piercings than men, and over 50 percent of those with body piercings have more than one. Most piercings are done in tattoo or dedicated shops, but soft earlobe piercings are often done in department or specialty stores. Important behavioral and social associations include some cultural normative attributes (e.g., being of Hispanic or South Asian heritage), but they also include the participation in a number of risk-taking behaviors such as being a drinker, having used illicit drugs, having spent time in jail, having a limited religious affiliation, and having early and multiple sex partners. It may also be a marker for depression.[35]

Process

A hollow 12- to 16-gauge needle is passed through the body part, and body jewelry is inserted in the hole. A piercing gun (Fig. 100-7) is often used for soft earlobe piercings, but these are difficult to sterilize, may lead to crush injuries, and, if used in a cartilaginous area, to loosening of the perichondrium. Swelling occurs immediately so that the jewelry inserted has to be long and fine enough to allow for this. It should be made of titanium, niobium, ≥ 14 karat yellow gold, or stainless steel to avoid the induction of nickel and/or cobalt delayed-type hypersensitivity. Postoperative healing times,



▲ **FIGURE 100-7** A plastic piercing gun with polyamide studs. The gun is hard to sterilize, but in this machine, the "carrier" and the piercing stud are disposable.

from 2 weeks for clitoris to 9 months for navel, vary with the site. There are two types of bead closures. The captive bead ring is held closed by pressure. The bead screw is similar to any other screw mechanism and is often part of hoops, barbells, and circular barbells.

Complications

Complications vary with the site on the body of the piercing, as well as with the place the procedure was done (e.g., at home or in a commercial studio). Bleeding may occur during or immediately following the procedure, and bacterial, fungal, or viral diseases may be transmitted, especially if non-sterile instruments are used (Table 100-5).[36] However, most infection comes from the subject's own flora, often related to poor hygienic practices during the healing period leading to localized infection (erythema, edema, purulent drainage). Rates of infection as high as 35 percent after ear cartilage piercings have been reported, sometimes leading to loss of ear cartilage and, rarely, endocarditis.[37] Other high-risk areas include the navel, with its propensity for movement, and any intraoral site. The treatment may not necessarily include removal of the jewelry, as this may lead to sac formation, but rather to leave it in place to facilitate drainage, as well as improving the local hygienic measures, using compresses, a topical and, if necessary, an oral antibiotic. If pseudomonas is suspected, a fluoroquinolone, which will also cover staphylococcus, is a good choice. The important viral infection that may be transmitted through the piercing needle is hepatitis, in particular hepatitis C but also hepatitis B and D, although it is not clear that this happens





TABLE 100-5
Bacterial Complications of Piercing

Complication	Reported Organisms
Loss of ear cartilage	*Staphylococcus aureus* *Pseudomonas aeruginosa*
Endocarditis: Usually superimposed on a known underlying cardiac abnormality, but occasional reports without prior cardiac abnormality	Skin piercing *S. aureus* Group A β-hemolytic streptococcus *S. epidermidis* Mucosal piercing *Streptococcus viridans* *Neisseria mucosa* *Haemophilus aphrophilus* *H. parainfluenzae*
Septic arthritis	Group A β-hemolytic streptococcus
Osteomyelitis	*S. aureus*
Toxic shock syndrome	*S. aureus*
Lymphadenitis	Lactobacillus
Cephalic tetanus	*Clostridium tetani*
Acute glomerulonephritis (may lead to acute renal failure)	Group A β-hemolytic streptococcus
Ludwig angina	Oral piercing *S. viridans* *N. mucosa* *H. aphrophilus* *H. parainfluenzae*
Fournier gangrene	Male genital piercing Group A streptococcus and mixed Gram-negative bacilli and anaerobic organisms
Brain abscess	Tongue piercing resulting in a mixed infection *S. viridans* *Peptostreptococcus micros* Actinomyces species *Eikenella corrodens*
Lupus vulgaris	*Mycobacterium tuberculosis* inoculation at time of nose piercing (India)

very often in the United States of today,[38] where disposable or sterilized piercing equipment is generally used. Transmission of human immunodeficiency virus is another potential risk that has not been proved to occur. Many non-infectious complications may also be seen (Table 100-6). In view of the high and increasing prevalence of nickel allergy,[39] some countries have restricted the amount of nickel released from the metal used in jewelry to < 0.5 μg/cm^2/week. Institution of this rule in Denmark in 1992 has lowered the incidence of new sensitization.[40]

Piercing tracts are not necessarily permanent, as they may close if the jewelry is removed. This is common with tongue piercings as the epithelium in the depths of the tract is thin and possibly missing.[41] Replacement of tongue jewelry before anesthesia can be done with a fine flexible inert catheter.



▲ **FIGURE 100-8** Magnetic jewelry avoids a piercing but still can be inhaled accidentally or become embedded in the tissue.

TABLE 100-6
Miscellaneous Complications of Piercing

- Bleeding: Usually at time of or immediately after procedure. This may lead to significant blood loss.
- Avulsion injuries
  - Earlobe tear, urethral rupture, splitting of urinary stream, rejection of jewelry near the eyebrow, navel, or nipple
- Scarring
  - May lead to phimosis or strictures
  - Keloid formation
  - Cyst related to tract closure
- Neurologic damage
  - Loss of taste, increased salivary flow, clitoral numbness
- Anesthetic risks
  - Interference with free access to the airway,[a] postoperative laryngospasm, pressure on area during surgery, electrosurgical burns, problems with catheterization
- Intra-oral
  - Aspiration of jewelry ball
  - Broken teeth and gingival recession
  - Speech impairment
  - Loss of taste
  - Increased salivary flow
  - Embedding of jewelry in tongue
- Nipples
- Galactorrhea related to hyperprolactinemia due to nipple stimulation
- Penis
  - Priapism related to entrapment of penis in a scrotal piercing hole
  - Paraphimosis related to inability to replace the prepuce over jewelry in the glans
  - Glanular hypospadias
  - Split urinary stream
- Jewelry-induced contact allergy
  - Nickel and cobalt are the most likely allergens (type IV delayed hypersensitivity)
    In the United States:
    - 12% jewelry allergy in those without piercings
    - 31% in those with piercings: 48% in those with three piercings
  - Gold and palladium rarely cause delayed reactions, which may be of granulomatous (sarcoidal) type.[45]

[a]To avoid problems, remove tongue, chin, or cheek jewelry before anesthesia and insert a nonreactive thread to preserve tract patency.

Magnetic Jewelry

This is occasionally used to avoid piercing (Fig. 100-8). Aspiration of the magnetic back of the jewelry or tissue embedment are possible complications.

KEY REFERENCES

The full reference list for all chapters is available at www.digm7.com.

1. Sperry K: Tattoos and tattooing. Part I: History and methodology. *Am J Forensic Med Pathol* **12**:313, 1991
2. Stirn A: Body piercing: Medical consequences and psychological motivations. *Lancet* **361**:1205, 2003
9. Laumann AE, Derick AJ: Tattoos and body piercings in the United States: A national data set. *J Am Acad Dermatol* **55**:413, 2006
13. Baumler W et al: Q-switch laser and tattoo pigments: First results of the chemical and photophysical analysis of 41 compounds. *Lasers Surg Med* **26**:13, 2000
20. Wasley A, Miller JT, Finelli L: Surveillance for acute viral hepatitis—United States, 2005. *MMWR Surveillance Summary* **56**(3):1 (Mar 16), 2007
35. Roberts TA et al: Body piercing and high-risk behavior in adolescents. *J Adolesc Health* **34**:224, 2004
37. Dahnert I et al: [Piercing and tattoos in patients with congenital heart disease—Is it a problem?]. *Z Kardiol* **93**:618, 2004



This page intentionally left blank

PART 5

Neurocutaneous and Psychocutaneous Aspects of Skin Disease

Copyright © 2008 by The McGraw-Hill Companies, Inc. Click here for terms of use.



SECTION 18

NEUROCUTANEOUS AND PSYCHOCUTANEOUS SKIN DISEASE

CHAPTER 101

Neurobiology of the Skin

Martin Steinhoff
Thomas A. Luger

CENTRAL NERVOUS SYSTEM AND SKIN

The nervous system is ultimately involved in cutaneous biology and disease. The central nervous system (CNS) proper is connected to skin function either directly via efferent nerves or CNS-derived mediators or indirectly via the adrenal glands or immune cells.[1] Cutaneous nerves also respond to internal stimuli from the circulation (e.g., pH changes, osmotic changes, bradykinin, cytokines) or the skin itself and to emotions (internal trigger factors).[2] Under normal circumstances, the sensory and the autonomic nervous systems modulate important biologic functions such as body temperature, blood flow, and cell growth. Mechanically induced nerve impulses transmit information such as pressure to the CNS. Chemical- or heat-responsive afferent nerve fibers are involved in recognizing dangerous signals potentially compromising body integrity. Thus, normally the innervated skin is a crucial barrier protecting the body from danger from the external environment. This is also supported by the finding that not only the dermis but also the epidermis is highly innervated up to the stratum corneum.[3]

Sensory as well as autonomic (predominantly cholinergic sympathetic) nerves influence a variety of physiologic and pathophysiologic functions of the skin such as embryogenesis, vasoconstriction, vasodilation, body temperature, barrier function, secretion, growth, differentiation, cell nutrition, nerve growth, and hair growth, and inflammation, immune defense, apoptosis, proliferation, and wound healing, respectively.

In unstimulated nerves, neuromediators are barely detectable within the skin. On direct stimulation by physical stimuli [thermal, ultraviolet (UV) light, mechanical, electrical], chemical stimuli, or chemical/biologic stimuli such as allergens, haptens, microbiologic agents, trauma, or inflammation, a significant increase of regulatory neuropeptides, neurotrophins, neurotransmitters, or oxygen products (e.g., nitric oxide) can be detected in vitro and in vivo. Thus, mediators derived from sensory or autonomic nerves may play an important regulatory role in the skin under many physiologic and pathophysiologic conditions. In addition to neuromodulation in the periphery, however, a subtle and complex communication network also exists between the spinal cord, the CNS, and the immuno-endocrine system that also modulates skin function.

The autonomic nerves exert their effects mainly by releasing classical neurotransmitters or—to a lesser extent—neuropeptides. In contrast, primary afferent (sensory) nerves release different classes of molecules such as neuropeptides, prostanoids, and nitric oxide.[1]

The skin expresses a variety of receptors for these mediators, most of them G protein–coupled receptors. This neuromediator-receptor interaction is controlled by endopeptidases [neutral endopeptidase (NEP), angiotensin-converting enzyme (ACE), endothelin-converting enzyme (ECE)], which terminate neuropeptide-induced inflammatory or immune responses.[1,2,4] A close multidirectional interaction between neuromediators, high-affinity receptors, and regulatory proteases is critically involved in maintaining tissue

◀ "Neurotic" excoriations: chin. Multiple erythematous and pigmented macules and a few crusted erosions on the chin of a 45-year-old woman with mild facial acne. No primary lesions are seen. The patient, who is moderately depressed, has mild acneiform lesions, which she compulsively picks with her fingernail.

NEUROBIOLOGY OF SKIN AT A GLANCE

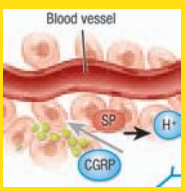

- In an interactive network, cutaneous nerves communicate with various skin cells, the endocrine system, and the immune system.
- Neurocutaneous interactions influence a variety of physiologic and pathophysiologic functions such as cell growth, inflammation, host defense, pruritus, and wound healing.
- Primary afferent as well as autonomic nerves release neuromediators and activate specific receptors on many target skin cells.
- Cutaneous cells express a variety of specific receptors tightly controlled by upregulatory or downregulatory signals.
- Many mediators (peptides, proteases, cytokines, kinins, neurotrophins, etc.) are critically involved in physiologic and pathophysiologic conditions in the skin.
- New pathways are being defined for the treatment of various skin diseases in which the neuro-immuno-endocrine axis is implicated.

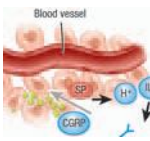

Copyright © 2008 by The McGraw-Hill Companies, Inc. Click here for terms of use.

integrity and regulating pathophysiologic conditions in the skin. From this background, it is clear that a better understanding of the complex skin nervous system opens an avenue for future therapeutic approaches to a number of skin diseases.

Taken as a whole, present information clearly indicates a crucial role for the neuronal skin network in influencing a variety of physiologic and pathophysiologic functions such as host defense, inflammation, pruritus, pain, burning, wound healing, and probably cancer (e.g., by modulating angiogenesis).

ANATOMY OF THE SKIN NERVOUS SYSTEM

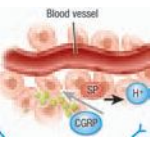

Sensory Nerves

Most nerve fibers are found in the middermis and the papillary dermis. Region-specific differences can be observed with respect to the mucocutaneous border, glabrous skin, and hairy skin.[5] In the epidermis, sensory nerves are linked to keratinocytes, melanocytes, Langerhans cells, and Merkel cells. Cutaneous nerve fibers are principally sensory, with an additional complement of autonomic nerve fibers.[6,7] In contrast to sensory nerves, autonomic nerves never innervate the epidermis in mammals. Sensory nerves innervate the epidermis and dermis as well as the subcutaneous fatty tissue[8–10] (see Fig. 102-1 in Chap. 102).

Sensory nerves are categorized into two groups: the epidermal and the dermal skin nerve organs. The epidermal skin nerve organs consist of free nerve endings or nerve organs (e.g., Merkel cells). In the dermis are found free sensory nerve endings, the hair nervous network (Pinkus discs), and the encapsulated endings [Ruffini's, Meissner's, Krause's, and Vater-Pacini (vibration) corpuscles, and mucocutaneous end organ]. These can be subdivided into four groups: A-α fibers (12 to 22 mm) are highly myelinated, show a fast conduction velocity (70 to 120 m/second), and are associated with muscular spindles and tendon organs. A-β fibers are moderately myelinated (6 to 12 μm) and innervate touch receptors. A-δ fibers have a thin myelin sheath (1 to 5 μm), show an intermediate conduction velocity (4 to 30 m/second), and are generally polymodal. The slow-conducting C fibers (0.5 to 2.0 m/second) are unmyelinated and small (0.2 to 1.5 μm). A-δ fibers constitute approximately 80 percent of primary sensory nerves sprouting from dorsal root ganglia, whereas C fibers make up approximately 20 percent of the primary afferents.[11,12]

Among human peripheral nerves, 45 percent of the cutaneous afferent nerves were found to belong to a sub-type of sensory nerves that are both mechano- and heat-responsive C fibers (C-m^+h^+).[13] However, 13 percent of these nerves were found to be only mechano-sensitive (C-m^+), 6 percent were heat sensitive (C-h^+), 24 percent were neither heat nor mechano-responsive (C-m^-h^-), and approximately 12 percent were of sympathetic origin. Fifty-eight percent of C-m^+h^+ responded to mustard oil, whereas 30 percent of C-m^+ or (C-m^-h^-) did so.[13]

A specific receptor distribution appears to be important for the various functions of the different sensory nerve sub-types. For example, mechanoreceptors exclusively express the T-type calcium channel Ca(v)3.2 in the dorsal root ganglion of D-hair receptors. Only small-diameter primary afferents express the transient receptor potential vanilloid 1 receptor.[14]

UV light, immune responses, inflammation, and trauma are able to stimulate the activation and/or sensitization of sensory nerves.[15,16]

Autonomic Nerves

Compared to sensory nerves, autonomic nerves represent only a minority of cutaneous nerve fibers. In human skin, autonomic nerve fibers derive almost completely from sympathetic (cholinergic) and rarely from parasympathetic (also cholinergic) neurons.[17] The distribution of autonomic nerves is restricted to the dermis, where they innervate blood vessels, arteriovenous anastomoses, lymphatic vessels, erector pili muscles, eccrine glands, apocrine glands, and hair follicles.[18]

Postganglionic autonomic nerves in the skin predominantly generate acetylcholine, although observations have revealed an additional role for neuropeptides in the skin autonomic nervous system. For example, neuropeptide Y (NPY) and atrial natriuretic peptide[19] are expressed solely by autonomic nerve fibers.[20]

The cutaneous autonomic nervous system adjusts sweat gland function, thereby regulating body temperature, and modulates water and electrolyte balance in various organs. Under pathophysiologic conditions, autonomic nerves are involved in hyperhidrosis or hypohidrosis, congenital sensory neuropathy type IV, progressive segmental hypohidrosis, diabetic neuropathy, syringomyelia, lepra, and dysfunction after sympathectomy.[21–24]

Autonomic nerve fibers are crucially involved in the regulation of vascular effects in the skin. Sympathetic nerve fibers release noradrenalin and/or NPY to innervate arterioles, arteriovenous anastomoses, and venous sinusoids, which results in vasoconstriction, whereas parasympathetic nerves mediate vasodilation through activation of venous sinusoids by the release of acetylcholine and vasoactive intestinal peptide (VIP)/peptide histidine methionine[25–28] (Tables 101-1 and 101-2).

TABLE 101-1
Role of Nerves in Pruritus and Pain

Pruritogenic Stimuli (in Alphabetic Order)	Receptors	Sources, Receptors by Which Expressed	Comments
Acetylcholine (ACh)	Nicotinergic (nAChR) and muscarinergic (mAChR) ACh receptors	Autonomic cholinergic nerves, keratinocytes, lymphocytes, melanocytes, dermal fibroblasts, endothelial cells	Mediates itch in atopic dermatitis; mAChR3 is probably involved in itch.
Calcitonin gene–related peptide (CGRP)	CGRP receptors	Sensory nerve fibers	Expressed on central terminals; sensitizes receptive endings. Associated with increased pain transmission, prolongation of itch latency after substance P injection (inhibitory effect on itching). Involved in itchy skin diseases.
Corticotropin-releasing hormone (CRH) and pro-opiomelanocortin (POMC)	CRH receptors (CRH-R1, CRH-R2)	CRH-R1: keratinocytes, mast cells CRH-R2: bone marrow mast cells	Induces release of histamine, cytokines, TNF-α, VEGF from mast cells. CRH-like immunoreactivity seen on sensory nerves (rat).

(continued)

TABLE 101-1
Role of Nerves in Pruritus and Pain (Continued)

Pruritogenic Stimuli (in Alphabetic Order)	Receptors	Sources, Receptors by Which Expressed	Comments
Cytokines	Cytokine receptors (e.g., IL-2, IL-31)	Leukocytes, keratinocytes, endothelial cells, nerves	T cells release IL-31 during inflammation and activate monocytes and keratinocytes via the IL-31 receptor (IL-31R). IL-31R is upregulated in atopic dermatitis and prurigo.
Endocannabinoids	Cannabinoid receptors (CB1, CB2)	Nerves, immune cells, keratinocytes, hair follicles	Antipruritic in the periphery.
Endothelins (ETs)	Endothelin receptors (ET_A, ET_B)	Endothelium, mast cells	Induces burning itch. Degraded by chymase via ET_A-receptor activation.
Endovanilloids (heat, acidosis, eicosanoids, histamine, bradykinin, extracellular ATP, prostaglandins, various neurotrophins)	Activation of transient receptor potential vanilloid 1 (TRPV1) Sensitization of TRPV1 via activation of specific receptors (see in this table)	TRPV1 is expressed on sensory neurons, mast cells, epidermal and hair follicle keratinocytes, Langerhans cells, smooth muscle, and sebocytes	Short-term TRPV1 activation: Induces pain and itch, depletes neuropeptides from sensory neurons. Long-term antipruritic effect of TRPV1 agonists (e.g., capsaicin): Suspend interplay between sensory neurons and mast cells. Affects epidermal and hair follicle proliferation, differentiation, apoptosis, and cytokine release. Increased expression in epidermal keratinocytes of prurigo nodularis patients.
Histamine	Histamine receptors (H_1R to H_4R)	Sensory fibers	In humans, histamine induces itch by stimulating specific sensory fibers, whereas H_1 (and to a lesser extent H_2) antagonists reduce itch in numerous clinical trials. In mice, H_3 antagonists induce scratching behavior, whereas H_1 and H_4 antagonists effectively suppress pruritus.
Kallikreins, proteases	Partly proteinase-activated receptors (PARs), tryptic enzymes	Keratinocytes, endothelial cells, mast cells, platelets	Massive itch behavior in mice overexpressing epidermal kallikrein-7. Potential role of other kallikreins. Chymase degrades pruritic and antipruritic peptides. Tryptase induces inflammation and itch by a neurogenic mechanism via PAR-2. Microbial proteases may induce itch and inflammation via PAR-2.
Kinins	Bradykinin receptors (B1R, B2R)	Endothelial cells, immunocytes	Bradykinin induces pain rather than pruritus. B2R antagonists reduce itch.
Leukotriene B_4	Leukotriene receptors	Sensory nerves fibers, keratinocytes	Leukotriene B_4 induces itch and is also involved in the substance P– and nociceptin-mediated induction of itch.
Neurokinin A (NKA) and substance P (SP)	Tachykinin (neurokinin) receptors (NKRs)	Sensory nerve fibers	NKA: Upregulates keratinocyte nerve growth factor expression. SP: At low (physiologically relevant) concentrations, primes mast cells. Mediates release of TNF-α, histamine, leukotriene B_4, and prostaglandins from mast cells (agents involved in pruritus and burning).
Nerve growth factor (NGF), brain-derived neurotrophic factor (BDNF), neurotrophins (NT-3, NT-4)	Specific receptors TrkA: NGF TrkB: NT-4, BDNF TrkC: NT-3	Keratinocytes, mast cells, fibroblasts, eosinophils.	NGF levels enhanced in atopic dermatitis. Induces tryptase release from mast cells. Inducible by histamine. TrkA: Enhanced in keratinocytes during inflammation. NT-4: Enhanced in atopic dermatitis and induces sprouting of sensory nerves. BDNF: Increases eosinophil chemotaxis levels in atopic dermatitis and inhibits apoptosis. Neurotrophins sensitize receptive nerve endings and upregulate neuronal neuropeptides and TRPV1.
Opioids	μ, κ, δ opioid receptors (partly receptor-independent cell activation)	Nerves, keratinocytes	Antipruritic effect of μ-opioid antagonists (central effect) and κ-opioid agonists (spinal cord level). Opioid agonists do not provoke itch on injection or intradermal application. μ-Opioid receptor upregulated in atopic dermatitis
Pituitary adenylate cyclase–activating polypeptide (PACAP) and vasoactive intestinal peptide (VIP)	VPAC receptors	Autonomic and sensory nerve fibers, lymphocytes, dermal endothelial cells, Merkel cells	PACAP: Involved in flush, vasodilation, pain, neurodegeneration, pruritus(?). Induces release of histamine from mast cells. VIP: Histamine release from mast cells, allodynia (no allodynia in atopic dermatitis) intensifies ACh-induced itch in atopic dermatitis patients (together with ACh).
Prostaglandins	Prostanoid (P) receptors	Sensory nerve fibers, keratinocytes	Prostaglandin E_2 induces itch in humans but not in mice. Prostaglandin D_2 reduces immunoglobulin E–mediated scratching in mice.

ATP = adenosine triphosphate; IL = interleukin; TNF-α = tumor necrosis factor-alpha; VEGF = vascular endothelial growth factor.

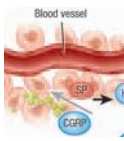

TABLE 101-2
Role of Nerves in Inflammation

Neuromediator	Receptor	Source	Target Cells/Function
Acetylcholine	Nicotinergic and muscarinergic acetylcholine receptors	Autonomic cholinergic nerves, keratinocytes, lymphocytes, melanocytes	Innervation of sweat glands and arteriovenous anastomoses; keratinocyte and lymphocyte differentiation, proliferation, adhesion, migration. α_7-Nicotinergic receptor modulates keratinocyte function, modulates skin microcirculation.
Catecholamine, noradrenaline	Adrenergic receptors	Autonomic adrenergic nerves, keratinocytes, melanocytes	Innervation of blood vessels, erector pili muscles; pain transmission; regulation of activity in natural killer cells and monocytes; induction of apoptosis in lymphocytes. β-Adrenergic–induced inhibition of keratinocyte migration
Substance P	Tachykinin (neurokinin) receptor	Sensory nerve fibers	Mediation of skin erythema, edema, pruritus; upregulation of cell adhesion molecule expression on keratinocytes and endothelial cells; induction of release of IL-8, TNF-α, histamine, leukotriene B_4, prostaglandin D_2; regulation of sebaceous glands. Released by proteinase-activated receptor 2 (PAR-2) agonists.
Neurokinin A	Tachykinin (neurokinin) receptor	Sensory nerve fibers	Upregulation of keratinocyte nerve growth factor expression.
Vasoactive intestinal peptide	VPAC receptors	Sensory nerve fibers, Merkel cells	Sweat secretion, vasodilation; proliferation, migration of keratinocytes; histamine release from mast cells. Downregulation of VPAC2 receptor in mast cells in atopic dermatitis.
Pituitary adenylate cyclase–activating polypeptide	VPAC receptors	Autonomic and sensory nerve fibers, lymphocytes, dermal endothelial cells	Vasodilatation, immunomodulation; effect on T cells and macrophages; modulation of mast cell function; inhibition of antigen-induced apoptosis of mature T lymphocytes; downregulation of pro-inflammatory cytokines and chemokines in T cells; upregulation of cytokines and cell adhesion molecules in dermal microvascular endothelial cells; nociception.
Calcitonin gene–related peptide (CGRP)	CGRP receptors	Sensory nerve fibers	Keratinocyte and endothelial cell proliferation; stimulation of cytokine production. Increased CGRP nerves in atopic dermatitis and nummular eczema; released by PAR-2 stimulation.
Pro-opiomelanocortin (POMC)	Melanocortin receptors	Melanocytes, keratinocytes, endothelial cells, Langerhans cells, mast cells, fibroblasts, monocytes, macrophages	Antagonism of effects of pro-inflammatory cytokines (IL-1α, IL-1β, IL-6, TNF-α, endotoxins); upregulation of IL-10; induction of release of histamine from mast cells; inhibition of nuclear factor κ B. Thioredoxin regulates POMC genes. MSH-induced exocytosis from melanosomes. Melanocortin 1 receptor expressed on human keratinocytes. α-MSH reduces oxidative stress.

IL = interleukin; MSH = melanocyte-stimulating hormone; TNF-α = tumor necrosis factor-α.

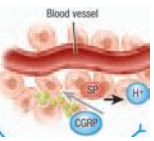

Small arteries and arterioles as well as the arteriovenous anastomoses are richly supplied with noradrenergic nerves.[29] Previous studies suggested that this system is cholinergic and involves a co-transmitter, possibly VIP.[30] Cholinergic sympathic nerves are also known to stimulate eccrine sweat glands via muscarinic receptors,[17] whereas higher concentrations of acetylcholine induce an axon-reflex flare mediated via nicotinic receptors. In the vasoconstrictor system, the transmitter appears to be norepinephrine along with one or more co-transmitters. The best-characterized sympathic co-transmitters that participate in the regulation of blood flow include adenosine triphosphate[31] and NPY.[32]

Interestingly, even without intact sensory or autonomic function the skin reveals a vasodilator response, which is replaced by non-neurogenic vasoconstriction. The mechanisms for the non-neurogenic vasodilator and vasoconstrictor components of the response to direct cooling are unknown but perhaps involve nitric oxide and sensory nerves.

BIOCHEMISTRY OF THE CUTANEOUS NERVOUS SYSTEM

Skin Neuropeptides and Neuropeptide Receptors

Classically, small peptides ranging from as few as 4 to more than 40 amino acids that are released by nerve endings and modulate various biologic functions were characterized and defined as neuropeptides. Later, these molecules were found to be generated by non-neuronal cells as well (e.g., epithelial cells and immune cells). Therefore, the designation *regulatory peptide* may be more applicable.[33] These peptides mainly activate members of the G protein–coupled receptor superfamily with seven transmembrane domains. To date more than 20 neuropeptides, including substance P (SP), neurokinin A (NKA), neurotensin, calcitonin-gene–related protein (CGRP), VIP, pituitary adenylate cyclase–activating polypeptide (PACAP), peptide histidine-isoleucinamide, NPY, somatostatin (SST), β-endorphin, enkephalin, galanin, dynorphin, cannabinoids, secretoneurin, melanocyte-stimulating hormone (MSH), and corticotropin-releasing hormone (CRH), have been detected in the skin.[1,2,34] Tables 101-1 and 101-2 list the neuropeptides and other molecules involved in pruritus, pain, and inflamma-

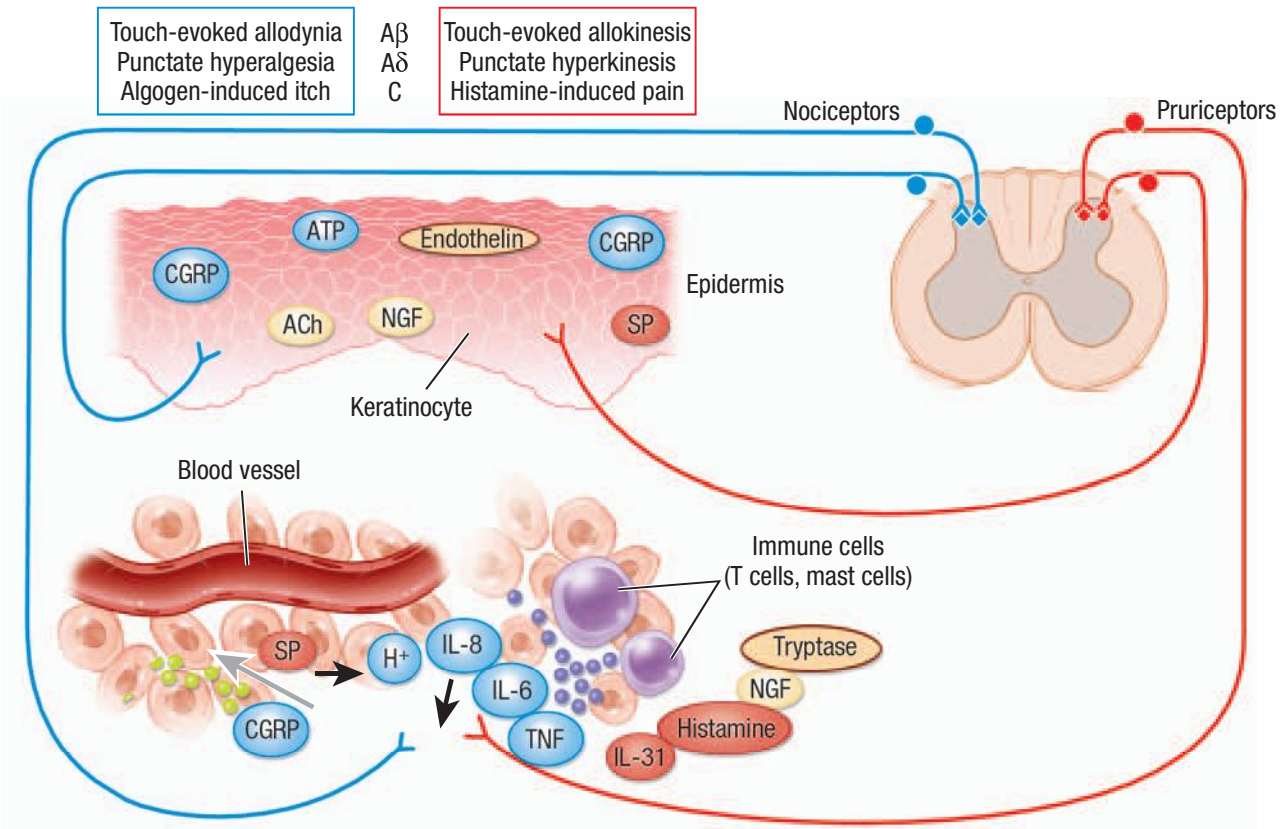

▲ **FIGURE 101-1** Mediators and the sensitization pattern of nociceptive and pruriceptive neurons. Sensitizing and activating mediators in the skin are shown for primary afferent fibers involved in itch and pain processing. Predominantly pruritic mediators are shown in *red*, algogenic mediators are shown in *blue*, and mediators equally involved in pain and itch are shown in *yellow*. Note that different classes of fibers subserve pain (mechano-sensitive polymodal nociceptors and mechano-insensitive "sleeping" nociceptors) and itch (histamine-sensitive mechano-insensitive pruriceptors,[3] and probably mechano-sensitive pruriceptors). In the spinal cord, noxious input can induce central sensitization for pain, and pruriceptive input can provoke central sensitization for itch. Of note is the corresponding pattern of central sensitization to touch by amyloid-β (A-β) fibers (allodynia vs. allokinesis), by A-δ fibers (punctate hyperalgesia vs. punctate hyperkinesis), and by C fibers (histamine-induced pain vs. algogen-induced itch). ACh = acetylcholine; ATP = adenosine triphosphate; CGRP = calcitonin gene–related protein; H^+ = hydrogen ion; IL = interleukin; NGF = nerve growth factor; SP = substance P; TNF = tumor necrosis factor.

tion, and Figs. 101-1 and 101-2 depict the basic concepts and knowledge concerning these neuropeptides. The on-line edition discusses detailed structural and physiologic functions.

Various neuropeptides are produced and released by a sub-population of unmyelinated afferent neurons (C fibers) known as *C-polymodal nociceptors*. In addition, it has been shown that cutaneous cells themselves, such as keratinocytes, microvascular endothelial cells, Merkel cells, fibroblasts, and leukocytes, are capable of releasing regulatory peptides under physiologic or pathophysiologic circumstances.

In the skin, nerves are closely linked to the vascular system. Dermal blood vessels are not only tightly associated with sensory and autonomic nerve fibers, they also synthesize certain neuropeptides after activation and express receptors for neuropeptides, which suggests that a complex autocrine and paracrine neuroendocrine system may exist in the skin. Arterial sections of arteriovenous anastomoses, precapillary sphincters of metarterioles, arteries, and capillaries appear to be the most intensely innervated regions. Although sensory nerves are important for vasodilation, neuropeptides from sympathetic neurons such as NPY mediate vasoconstriction, which supports an important role for neuropeptides in vascular regulation. Both endothelial cells and smooth muscle cells respond to neuronal modulation in inflammatory diseases such as atopic dermatitis and rosacea and during host defense, neovascularization, and wound healing.

TACHYKININS

VASOACTIVE INTESTINAL PEPTIDE

PITUITARY ADENYLATE CYCLASE–ACTIVATING POLYPEPTIDE

CALCITONIN GENE–RELATED PEPTIDE AND RECEPTORS

SOMATOSTATIN AND RECEPTORS

OPIOIDS AND PROOPIOMELANOCORTIN PEPTIDES

MELANOCYTE-STIMULATING HORMONE

CANNABINOIDS AND RECEPTORS

CORTICOTROPIN-RELEASING HORMONE

Neuropeptide-Degrading Enzymes[1]

Cytokines and Chemokines from a Neuronal Perspective[1]

Cytokines are capable of inducing pruritus, and, conversely, cytokine inhibitors have been demonstrated to reduce neurogenic inflammation, pain, and pruritus. Thus, cytokines and chemokines may communicate with sensory nerves via high-affinity receptors[194–199] (see Fig. 101-1, Table 101-1).

"Neurophilic" cytokines include interleukin 1 (IL-1), IL-6, IL-8, and IL-31 (re-

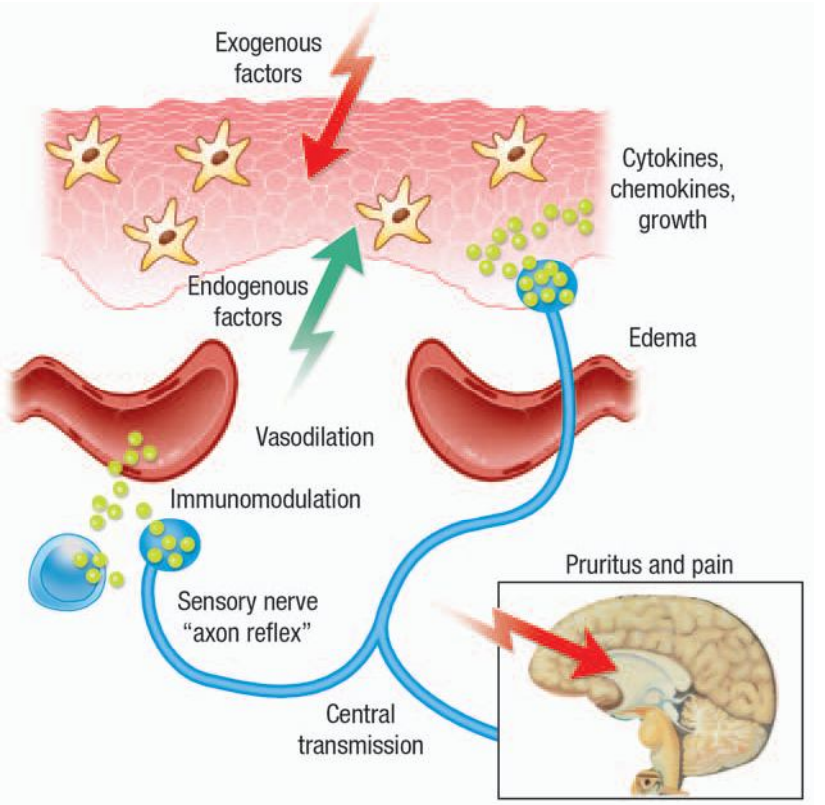

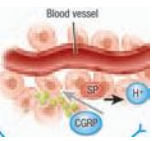

▲ FIGURE 101-2 Cutaneous neurogenic inflammation. Exogenous trigger factors (heat, scratching, irritants, allergens, ultraviolet light, microbiologic agents) or endogenous trigger factors (pH changes, cytokines, kinins, histamine, proteases, neurotransmitters, hormones, stress) may directly or indirectly stimulate nerve endings from primary afferent neurons. Signals are transmitted to the central nervous system and thereby affect regions involved in pruritus, pain, somato-sensory reactions (scratching), and probably emotional responses. In addition, peripheral nerve endings stimulate neighboring afferent nerve fibers in the dermis and epidermis in a process known as *axon reflex*. Stimulated release of neuropeptides results in vascular responses (triple response of Lewis, erythema by vasodilation, and edema by plasma extravasation), modulation of immunocyte function (e.g., mediator release from mast cells), and regulation of mediator release (cytokines, chemokines, growth factors) from keratinocytes and Langerhans cells.

viewed in refs. 33, 36). Of note, transgenic mice overexpressing IL-31 released by T cells and macrophages developed a chronic inflammatory skin disease characterized by a T-cell infiltrate and pruritus, similar to atopic dermatitis in humans. IL-31 activates the IL-31 receptor (IL-31R), a heterodimeric receptor composed of the IL-31R A subunit and the oncostatin M receptor subunit. Whether IL-31 exerts its pruritic effects via direct activation of IL-31R on sensory nerves or indirectly (e.g., via keratinocytes) is currently unknown. The finding that keratinocytes express IL-31R suggests that IL-31 may induce pruritus through the induction of a yet unknown keratinocyte-derived mediator that subsequently activates unmyelinated C fibers in the skin. Therefore, one may speculate that IL-31 is upregulated in pruritic forms of cutaneous inflammation.[200,201] These findings were confirmed in mice: The expression of cutaneous IL-31 messenger RNA was significantly higher in NC/Nga mice with scratching behavior than in NC/Nga mice without scratching behavior. Therefore, IL-31 may participate in causing an itch sensation and promoting scratching behavior.[202,203] Thus, IL-31 may serve as a link between the immune and neural systems by regulating inflammation as well as itch. For this reason, IL-31 and the IL-31R are promising targets for the treatment of inflammatory and itchy dermatoses such as atopic dermatitis.

ROLE OF THE NERVOUS SYSTEM IN SKIN PATHOPHYSIOLOGY

A number of human clinical diseases appear to have a significant neurogenic component, including atopic dermatitis, prurigo, pruritus, psoriasis, rosacea, urticaria, herpes zoster, and inflammatory arthritis[1] (see Tables 101-1, 101-2). The peripheral nervous system also modulates inflammatory responses in other organs, such as during eye inflammation, asthma, and inflammatory bowel syndrome. Moreover, neuronal mediators play a role during wound healing by regulating growth, proliferation, and angiogenesis.

The ability of neuropeptides to activate human mast cells and induce urticaria has been appreciated for a number of years.[204] For example, chronic idiopathic urticaria and, to a lesser extent, pressure urticaria showed enhanced SP- and CGRP-induced wheal-and-flare reactions (see Fig. 101-2). Certain transient receptor potential ion channels are expressed by sensory nerves as well as by mast cells.

A neurogenic component in the pathophysiology of psoriasis is suggested based on clinical observation (e.g., stress induction) and is supported by experimental studies.[205–208] Data suggest a role for nerve growth factor (NGF) as a mediator of inflammatory responses in psoriasis.[209]

In acute as well as lichenified lesions of atopic dermatitis, increased staining of cutaneous nerves or concentrations of neuropeptides has been observed.[62,116,210–216] Also, characteristics of the triple response (erythema, wheal, flare) of neurogenic inflammation as well as pruritus have been observed after injection of neuropeptides into human skin.[217,218] Furthermore, the lesions of patients with atopic dermatitis show enhanced concentrations of mast cell tryptase, a ligand for the proteinase-activated receptor 2, which is upregulated in atopic dermatitis and mediates pruritus, inflammation, and upregulation of intercellular cell adhesion molecule 1 or nuclear factor κB.[219–222] A role for pro-opiomelanocortin peptides in the pathogenesis of atopic dermatitis is supported by the in vitro observation that α-MSH modulates immunoglobulin E production and the finding of increased levels of pro-opiomelanocortin peptides in the skin of patients with atopic dermatitis.[223,224] Some studies also suggest that neurotrophins may participate in the pathophysiology of atopic dermatitis.[225]

Neuropeptides are obviously involved in the regulation of epidermal antigen presentation.[226,227] Also, pre-treatment of the skin with capsaicin enhances contact hypersensitivity (CHS) at the site of treatment. It has been suggested that capsaicin-sensitive neurons modulate this reaction via the release of neuropeptides.[93,228] Studies also indicate that SP agonists can prevent impaired CHS and tolerance after UVB irradiation.[180] CGRP significantly inhibited antigen presentation to antigen-specific T cells.[93,229] The effect of CGRP on murine Langerhans cells is probably mediated by a specific

CGRP receptor, which leads to intracellular increase in cyclic adenosine monophosphate.[230] Accordingly, IL-10 can be upregulated by CGRP.[231]

α-MSH is one of the most powerful neurohormones in terms of its ability to modify CHS reactions.[232–234] PACAP is also able to inhibit CHS reactions.[235]

The skin nervous system also plays a crucial role during wound healing and impaired wound healing processes. Released neuropeptides participate in inflammation, cell proliferation, cytokine and growth factor production, and neovascularization.[236,237] Of note, delayed wound healing occurred in animal models after surgical resection of cutaneous nerves.[238–242] For instance, decreased concentrations of SP, SST, and CGRP were observed in wounds in rats[243]; elevated levels can be observed in other wound models.[240,243] CGRP promotes proliferation and migration of human keratinocytes[244–246] and stimulates proliferation of human dermal endothelial cells.[247] VIP has both inhibitory and stimulatory effects on the proliferation of keratinocytes.[244,245,248] Angiotensin II appears to influence tissue repair via activation of the angiotensin I receptor in fibroblasts, which leads to collagen remodeling, collagen gel contraction, and upregulation of collagen-binding integrins in vitro.[249] NGF induces human skin and lung fibroblast migration but not proliferation.[250] In a mouse model, it could be observed that NGF accelerated the rate of wound healing.[251] These findings have encouraged successful treatment of leg ulcers in humans with topical NGF.[252,253] Parathyroid hormone–related protein expression is temporarily upregulated in migratory keratinocytes, myofibroblasts, and infiltrating macrophages in guinea pig skin, although topical application of a parathyroid hormone–related protein agonist did not change the healing rate or morphology in these wounds.[254,255]

NEP expression appears to be both increased and redistributed in the wound environment during wound healing, which indicates a role for neuropeptide-degrading enzymes in this process.[256] In normal skin, NEP immunoreactivity was restricted to the basal layer, whereas during wound healing, NEP was also detected in the suprabasal layer of human skin. Future studies using transgenic and knockout animals in which certain components of the neurologic system are overexpressed or deleted by homologous recombination may make it possible to examine the role of the cutaneous nervous system in normal and delayed wound healing.[257]

Pruritus is one of the most frequent symptoms of skin diseases and derives from stimulation of sensory nerve endings, spinal cord modulation, or dysfunction of certain areas in the CNS[33,258–260] (see Table 101-1). Polymodal C fibers stimulated by chemicals or heat transmit signals to the spinal cord and CNS, which results in itching. Accordingly, both the peripheral cutaneous system and the CNS coordinate the sensation of itch, which leads to the autonomic reflex of scratching. Histamine is the best-studied, albeit definitely not the only, mediator of pruritus. New histamine receptors (e.g., histamine receptor-3, histamine receptor-4) have now been cloned; their role in human itch is unknown. Another important mediator of pruritus in patients with atopic dermatitis may be IL-31[200,203,261,262] (see Table 101-1, Fig. 101-1). In notalgia paresthetica, a neuropathy characterized by pruritus, pain, and hyperalgesia, immunostaining for several neuropeptides revealed that affected areas had a significant increase in intradermal nerve fibers as well as epidermal dendritic cells, which suggests that sensory nerve fibers are involved in the pathogenesis of this disease. Agents such as capsaicin that deplete neuropeptides from sensory neurons have been shown to have a therapeutic effect in diseases associated with pruritus and pain. Other neuromediators such as opioids seem to be involved in the pathophysiology of cholestatic pruritus.[263,264] Cholestatic pruritus can be significantly reduced by application of an antagonist to 5-hydroxytryptamine.[265] Like opioids, endogenous cannabinoids appear to be implicated in itching.[33,169,260,266] Under inflammatory conditions,[267] cannabinoids are capable of activating and sensitizing the transient receptor potential vanilloid 1 receptor.[268,269] Cannabinoid receptors also induce release of analgesic β-endorphin from murine keratinocytes.[126]

SUMMARY AND PERSPECTIVES

In many ways, the nervous system modulates (and eventually "manipulates") the function of the skin, which leads to either control of skin homeostasis or disease. The interaction of the skin with the peripheral nervous system as well as the CNS plays a crucial role in skin homeostasis and disease states. Recent discoveries have increased knowledge about molecular mechanisms of neuropeptide and neuropeptide receptor functions and along with the development of modern techniques offer exciting insights into the complex network of the skin, the nerves, and the immune system during inflammation. With the use of novel technical approaches, it will be possible to define new ways to treat inflammatory skin diseases in which the neuro-immuno-endocrine axis is involved.

KEY REFERENCES

The full reference list for all chapters is available at www.digm7.com.

1. Roosterman D et al: Neuronal control of skin function: The skin as a neuroimmunoendocrine organ. *Physiol Rev* **86**:1309, 2006
14. Caterina MJ et al: The capsaicin receptor: A heat-activated ion channel in the pain pathway [see comments]. *Nature* **389**:816, 1997
16. Slominski A et al: Corticotropin releasing hormone and proopiomelanocortin involvement in the cutaneous response to stress. *Physiol Rev* **80**:979, 2000
36. Steinhoff M et al: Modern aspects of cutaneous neurogenic inflammation. *Arch Dermatol* **139**:1479, 2003
222. Buddenkotte J et al: Agonists of proteinase-activated receptor-2 stimulate upregulation of intercellular cell adhesion molecule-1 in primary human keratinocytes via activation of NF-kappa B. *J Invest Dermatol* **124**:38, 2005
260. Paus R et al: Frontiers in pruritus research: Scratching the brain for more effective itch therapy. *J Clin Invest* **116**:1174, 2006
262. Homey B et al: Cytokines and chemokines orchestrate atopic skin inflammation. *J Allergy Clin Immunol* **118**:178, 2006

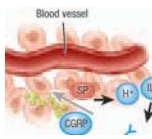

CHAPTER 102

Pathophysiology and Clinical Aspects of Pruritus

Gil Yosipovitch
Aerlyn G. Dawn
Malcolm W. Greaves



INTRODUCTION

Pruritus (itching) is the predominant symptom of skin disease and can best be defined as a sensation that leads to a desire to scratch. All human beings experience this sensation in the course of their lifetime; therefore, it is important to make a distinction between acute itch, which is of limited period of time ranging from seconds to a week such as the itch related to acute insect bite reaction, and chronic itch, which lasts for months and is the focus of this chapter. Chronic itch consists of multidimensional phenomena including sensory, emotional, and cognitive components. In most cases, chronic itch results from interaction of the brain-skin axis. Although itch and pain are separate and distinct sensations, itch has many similarities to pain.[1] Both itch and pain are unpleasant sensory experiences, follow similar neural pathways, and can severely impair patients' quality of life. However, the behavioral response patterns differ—pain elicits a reflex withdrawal, whereas itch leads to a scratch reflex.

The limited understanding of itch results from the subjective nature of itching, the absence of specific and sensitive investigational methods to study the neuropathophysiology and molecular basis of itch in humans, and from the lack of convincing animal models and incomplete knowledge of pharmacologic mediators of pruritus. Significant progress has been made in the past 10 years, partly as a result of microneurography that enables recordings to be made from individual afferent neurons after stimulation in man in vivo. The concept that itch is transmitted to the central nervous system (CNS) and processed in the brain should lead to new approaches to antipruritus therapy.[2]

TABLE 102-1
Prevalence of Itch Caused by Skin Disorders and Infectious Skin Diseases

CAUSE	ESTIMATED PREVALENCE OF PRURITUS
Skin disease	
Atopic dermatitis	17% of population
Contact dermatitis	Unknown
Poison ivy	70% of U.S. population will acquire if exposed to plant
Elderly idiopathic xerosis	30%–60% of adult population
Urticaria	15%–23% in United States
Psoriasis	80% of 40,350 psoriatics
Pityriasis rosea	Unknown
Seborrheic dermatitis	Unknown
Neurodermatitis: lichen simplex chronicus, prurigo nodularis, lichen amyloidosis	Unknown
Pityriasis rubra pilaris	Unknown
Dermatitis herpetiformis	110–588/million/yr
Linear immunoglobulin A disease	Unknown
Bullous pemphigoid	Unknown
Collagen disease	
Dermatomyositis	38%
Sjögren syndrome	Unknown
Infection	
Varicella	4 million cases of varicella occur in United States each year (equivalent to annual birth rate in United States)
HIV disease	HIV-associated folliculitis in 25%–50% of HIV patients; non-specific pruritic eruption in 11%–46% of HIV patients
Onchocerciasis	6 million have severe itching
Scabies	Unknown
Superficial fungal infections	Unknown

HIV = human immunodeficiency virus.
From Yosipovitch G: Epidemiology of itching in skin disease, in *Itch: Basic Mechanisms and Therapy*, edited by Yosipovitch G et al. New York, Marcel Dekker, 2004, with permission.

PRURITUS AT A GLANCE



- Pruritus is the predominant symptom of skin disease.
- May originate in the skin or nervous system.
- Clinical classification of itch includes:
  - itch caused by skin disorders
  - itch caused by systemic disorders
  - neuropathic itch
  - psychogenic itch
- Chronic itch consists of multidimensional phenomena including sensory, emotional, and cognitive components.
- Central and peripheral mediators include opiates, neuroadrenaline, substance P, histamine, proteinases, nerve growth factor, interleukins, and prostaglandins.
- Treatment should address the multifactorial nature of pruritus including central pathway and peripheral mediators.

EPIDEMIOLOGY

Itch is a symptom rather than a specific disease entity; therefore, epidemiologic data for itch are limited. Nevertheless, itch has been found to be the dominant skin complaint among all age groups.[3] Dalgard et al. found the prevalence of pruritus to be approximately 8 percent among Norwegian adults.[3] Itch is a primary symptom in a diverse range of skin diseases as well as in systemic diseases. The prevalence of pruritus in different dermatologic and systemic diseases is outlined in Tables 102-1 and 102-2.

ETIOLOGY AND PATHOGENESIS

Pruritus may originate in the skin or in the CNS. There is no single, definitive classification of pruritus. For the purpose of this chapter, we use the following clinical classification of itch based on Bernhard[4] and Twycross et al.[5]

TABLE 102-2
Prevalence of Pruritus in Systemic Disease

Disease	Estimated Prevalence of Pruritus
• Chronic renal failure, end stage	25%–85%
• Hepatic	
• Cholestatic jaundice	20%–25%
• Primary biliary cirrhosis	100%
• Hepatitis C	4%
• Cholestasis of pregnancy	Unknown
• Hematopoietic	
• Polycythemia vera	48%
• Iron deficiency anemia	Unknown
• Multiple myeloma	Unknown
• Mastocytosis	Unknown
• Hodgkin lymphoma	30%
• Non-Hodgkin lymphoma	Unknown
• Endocrine	
• Hyperthyroidism	60%
• Hypothyroidism	Unknown
• Carcinoid syndrome	Unknown
• Anorexia nervosa	58%

- Itch caused by skin disorders originates in the skin due to inflammation, dryness, or other skin damage and is transmitted by C nerve fibers. Examples include itch due to atopic dermatitis, scabies, urticaria, and insect bite reactions. Whether a result of specific chemical mediators or physical stimuli, such as mechanical stimulation from wool fibers, pruritus generated in the skin derives from non-specialized receptor units located within the epidermis and in the vicinity of the dermal-epidermal junction.
- Itch caused by systemic disorders may result from an imbalance in the μ- and κ-opioid systems or from changes in levels of interleukins (ILs) and neuropeptides. Examples include itch related to chronic liver disease or chronic renal failure.
- Neuropathic itch arises because of disease located at any point along the afferent pathway.[6] Post–herpes zoster neuropathy, notalgia paresthetica, and the itch occasionally associated with multiple sclerosis and brain tumors are in this category.
- Psychogenic itch is seen in the delusional state of parasitophobia, obsessive compulsive disorder, and depression.

Of course, two or more types of itch can co-exist—for example, itch of prurigo nodularis probably results from both itch of skin inflammation and neuropathic itch as well as psychogenic causes. In many cases, the etiology of itch remains elusive, particularly when it occurs in clinically normal skin.

Itch-Scratch Cycle

Itch and scratching are interwoven together in both acute and chronic itch conditions. Phylogenetically, itch is probably a mechanism for animals to remove parasites residing in the hairy skin. Scratching is also a behavioral response and studies suggest that repetitive scratching activates areas in the prefrontal cortex and orbitofrontal cortex that may involve reward systems and decision making. This may explain the hedonic and compulsive components of scratching. Furthermore, the hedonic experience may be associated with release of endogenous opioids. Repetitive scratching in chronic conditions such as atopic dermatitis and psoriasis further damages the skin and causes secretion of neuropeptides and opiates that may further augment the vicious itch-scratch cycle (Fig. 102-1).

Alloknesis: "Itchy Skin"

Alloknesis is a phenomenon in which a normally innocuous stimulus induces itch. For example, application of a fine brush to an itchy site induces itch. Alloknesis is analogous to the better known allodynia (injury to skin results in well-localized, short-lived, intense pricking pain and a surrounding diffuse area of hyperalgesia). This type of itch is mediated by mechanical mechanoreceptor units as well as an ongoing activity of afferent C nerve fibers and is considered a central neural sensitization response. Alloknesis is common in chronic atopic dermatitis; sweating or slight mechanical stimulation associated with wearing wool exacerbates itch. The exact role of central sensitization in pruritus associated with specific diseases is unknown.

Itch Transmission in the Skin

The only peripheral tissues from which itch can be evoked are skin, mucous membranes, and cornea. Interestingly the nerves in the deeper layer of the reticular dermis and subcutaneous fat do not transmit itch and inflammatory skin diseases, such as panniculitis, cause pain but not itch. Removal of the epidermis abolishes perception of pruritus, suggesting that pruritus receptor units are located predominantly within this layer.[7] We suspect that the epidermis acts as a receptor for itch, but a specific receptor has not yet been identified. Light microscope and ultrastructural studies of human skin have shown the existence of intraepidermal nerve fibers with "free" non-specialized nerve endings extending to the stratum granulosum.[8] It has not been possible to prove that these include free nerve endings that transmit pruritus; however, many of these fibers stain positively for neuropeptides.

Keratinocytes express a variety of neural mediators and receptors, all of which appear to be involved in the itch sensation.[9] These include opioids, proteases, substance P (SP), nerve growth factor (NGF), neurotrophin 4, and their respective receptors, including μ- and κ-opioid receptors, proteinase activated receptor-2 (PAR-2), vanilloid receptors, tropomyosin-related kinase A (TRKA), transient receptor potential vanilloid (TRPV) ion channels, and cannabinoid receptors 1 and 2. Keratinocytes also have voltage-gated adenosine triphosphate channels and adenosine receptors

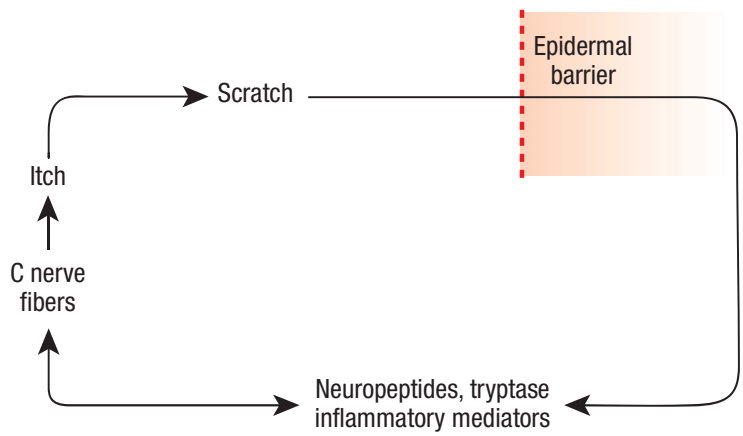

▲ **FIGURE 102-1** Basic etiologies of the itch-scratch cycle.



similar to C nerve fibers. Because these channels have a role in pain,[10] these findings suggest that keratinocytes may act as itch receptors.

Dedicated Itch-Transmitting C Nerve Fibers

Significant advances in our understanding of itch neurophysiology have been achieved in the past ten years. Microneurography has helped to disprove the historic concept that pruritus and pain are simply responses of the same neurons to mild versus intense stimuli, respectively. Studies using electric field stimulation coupled with microneurography have identified individual histamine-sensitive C nerve fibers that transmit itch.[11] The C nerve fibers have exceptionally slow conduction velocity, unusually wide innervation territories, and represent no more than 5 percent of total C fibers. These neurons are sensitive to pruritogenic and thermal stimuli, but not mechanical stimuli. The co-responsiveness of this subset of C neurons to temperature change as well as pruritic stimuli is of interest because raising the temperature of skin lowers the threshold of receptors to pruritic stimuli[12] and most pruritic patients complain of aggravation of pruritus in a warm environment. In chronic itch, spontaneous activity in these C fibers occurs.[13] In contrast, the vast majority of C fibers are sensitive to mechanical and heat stimuli and are entirely insensitive to histamine.[14]

The existence of a subset of dedicated itch-transmitting C neurons receives further support from studies of spinal cord pathways. Itch-transmitting primary afferent C neurons synapse with secondary transmission neurons that cross over to the contralateral spinothalamic tract and ascend to the thalamus. In the cat, microneurography identified lamina 1 neurons in the lateral spinothalamic tract that selectively responded to histamine, suggesting a central dedicated nerve pathway for itch.[15]

Other C nerve fibers transmit itch as well. Mechanically induced itch is commonly observed clinically; for example, itch associated with contact with wool cannot be explained by histamine-sensitive nerve fibers. Moreover, in patients with chronic pruritus, electrical or painful stimuli can also induce itch.[16,17] Oral antihistamines are ineffective in the treatment of most types of itch, suggesting that nonhistamine-mediated fibers also play an important role. In addition, the perceived sensation of pruritus can vary greatly in quality. Patients may experience sensations of burning, pricking, insects crawling on the skin, or tickle, but the neurophysiologic and psychologic correlates of these differences have not yet been elucidated. Information obtained from itch questionnaires based on previously developed pain questionnaires has enabled us to better understand the different characteristics of itch.[18–21]

Mediators of Pruritus

Both central and peripheral mediators are important in pruritus. Pro-inflammatory pharmacologic mediators cause pruritus in inflammatory skin diseases, such as urticaria. Most of such mediators also cause other signs of inflammation (pain, erythema due to vasodilation, increased vascular permeability). Several mediators cause pruritus indirectly by evoking release of histamine and other mediators from mast cells (e.g., SP and several opioid peptides) or by potentiating the actions of other mediators [e.g., prostaglandin E_1 (PGE_1)]. Potentially important peripheral mediators of pruritus include histamine, proteinases, SP, NGF, ILs, and PGs. Central mediators include opiates and neuroadrenaline.[22]

HISTAMINE Histamine is the archetypal mediator of signs and symptoms of inflammation including pruritus. Histamine is synthesized in the mast cells of the skin and stored in mast cell granules. It is released by these cells in response to a variety of injurious stimuli. Histologically, dermal mast cells and unmyelinated neurons are closely juxtaposed, raising the possibility of a pseudosynaptic relationship and implying a close functional relationship between the immune and nervous systems. Histamine acts to produce itch by way of the H_1 receptor and not via H_2 receptors.[23] Histamine also rapidly causes tachyphylaxis in human skin[24]; therefore, it is unlikely to be responsible for sustained pruritus. Nevertheless, it is an important mediator in short-lived urticarial wheal-and-flare reactions and causes pruritus after a single intradermal injection. Histamine's pruritic action can be potentiated by PGE_1. Firm evidence for histamine as the main mediator of pruritus is limited to skin diseases including acute and chronic urticaria, mastocytosis (urticaria pigmentosa), insect bite reactions, and allergic drug reactions. H_1 antihistamines are usually effective in these disorders. The role of histamine in most types of chronic itch is minimal, and antihistamines do not alleviate itch. In atopic dermatitis, histamine has no significant role, and low-sedation H_1 antihistamines are ineffective. Other histamine receptors such as H_4-receptors may also play a role in itch as demonstrated in mouse models.[25]

PROTEINASES Proteinases and their respective receptors appear to play an important role in regulation of cutaneous inflammatory and immune responses. Human dermal mast cells produce two proteases: tryptase and chymase. The proximity of dermal mast cells to afferent C neuron terminals in skin allows a functional relationship by which tryptase induces itch.[26] The activated mast cell releases tryptase (along with other mediators, including histamine), which in turn activates the PAR-2 receptor, a recently identified G protein–coupled receptor subfamily localized on C fiber terminals. The activated C fibers transmit this information to the CNS, where it may cause the sensation of itch. Additionally, activation leads to local release of neuropeptides including SP. This forms an additional pathway for itch, and represents another example of interaction between the immune and nervous systems.

PARs may play a significant role in regulation of cutaneous neurogenic inflammation. In the skin, PAR-2 expressed on sensory neurons is self-activated by peptide ligands exposed after extracellular cleavage by trypsin or mast cell tryptase. PAR-2 agonists have been demonstrated to induce release of calcitonin gene-related peptide and SP, which induce neurogenic inflammation.[27] Studies using dermal microdialysis have shown that levels of tryptase and its receptor (PAR-2) are elevated four-fold in atopic dermatitis.[28] PAR-2 is also highly expressed in the epidermis of atopic dermatitis patients. It is noteworthy that proteinase activity can also be found in common allergens[29] and staphylococcal skin infections, both of which are known to aggravate atopic dermatitis and itch.

SUBSTANCE P SP is a neuropeptide widely distributed in the periphery and CNS and is thought to intensify itch perception. SP is synthesized in the cell bodies of C neurons and causes vasodilation and increased vascular permeability. Intradermal injection of SP provokes itch as well as characteristics of neurogenic inflammation such as erythema, wheal, and flare.[30–32] SP is elevated in atopic dermatitis patients compared to con-



trols and significantly correlates with disease activity.[33]

SP is co-localized with other neurotransmitters, such as serotonin, dopamine, or calcitonin gene-related peptide, and acts as a neuromodulator. Although endogenously released SP does not degranulate mast cells in healthy human skin[34] or cause any sensation at physiological concentrations,[35] direct communication between nerve fibers and mast cells through SP has been verified.[36] High concentrations of SP are required to cause immediate mast cell degranulation; however, low concentrations can specifically activate Neurokinin 1 receptors on mast cells, leading to sensitization of these cells and increased production of tumor necrosis factor (TNF-α).[37] In turn, TNF-α sensitizes nociceptive nerve endings, which provide further evidence of the extensive cross-talk between nerve and mast cells.

OPIOIDS Opioid peptides are potent neurotransmitters and have both a central and a peripheral itch-producing action. Opioids appear to induce itch via two possible mechanisms. First, by degranulation of cutaneous mast cells[38] and second, via a direct central and peripheral pruritogenic effect by activating μ-opioid receptors.[38–41] Morphine and other endogenous and exogenous μ-opioid receptor agonists are known to cause generalized pruritus.[42–45] The concept of central sensitization in chronic pruritus and possible involvement of pruritic mediators located in the CNS is becoming increasingly recognized as important in both cutaneous and systemic diseases. The perception of pruritus is modified by endogenous opiates via central opioid receptors. Generalized pruritus may result from an imbalance between the μ- and κ-opioid systems.[43,44,46,47] Activation of μ-opioid receptors stimulates itch perception, whereas κ-opioid–receptor stimulation inhibits μ-receptor effects both centrally and peripherally.[43,44,47]

NEUROTROPHINS NGF is the prototypical neurotrophin—a factor that regulates the growth and function of nerve cells. Other members of this family include neurotrophins 3, 4, and 5 and brain-derived neurotrophic factor.[48] Increased levels of epidermal NGF correlate with the proliferation of terminal cutaneous nerves and upregulation of neuropeptides. NGF is known to induce sprouting of nerve fibers, sensitization of nerve endings, axonal transport in spinal ganglia (dorsal root ganglion cells), and increased expression of neuropeptides. NGF is required not only for survival and regeneration of sensory neurons but also controls the responsiveness of such neurons to external stimuli.[49,50] There is a significant correlation between plasma levels of NGF with disease activity in atopic dermatitis.[33] Increased cutaneous gene expression of NGF in mast cells, keratinocytes, and fibroblasts of atopic dermatitis patients was highly associated with plasma levels of NGF, thus providing further data that NGF may contribute significantly to itch in atopic dermatitis.[51] Other neurotrophins, such as neurotrophin 4, are upregulated in keratinocytes of atopic dermatitis patients.[52]

PROSTANOIDS PGs enhance histamine-induced itch in the skin.[53,54] PGs are not themselves pruritogenic when injected into skin; however, intradermal injection of PGE_1 enhances pruritus due to histamine subsequently injected into the same site.[55] Only pruritic neurons that display lasting activation after histamine are excited by PGE_2, and mechanosensitive fibers are unresponsive to both histamine and PGE_2.[14] Evidence suggests that cyclooxygenase 2 is induced in the spinal cord in response to cutaneous inflammation, and that spinal cord tissue levels of PGE_1 and PGE_2 correlate with central pruritus. PGE_2 has a direct, low-level pruritogenic effect without inducing protein extravasation in healthy and atopic dermatitis patients, suggesting that prostanoids' peripheral action is not solely via histamine and that they may potentiate pruritus via a nonspecific effect on nerve fibers. Oral administration of aspirin, a cyclooxygenase inhibitor, does not ameliorate pruritus except in polycythemia vera[56]; however, topical salicylates and topical aspirin often significantly reduces pruritus in patients with chronic localized itch.[57]

INTERLEUKINS The role and effect of ILs in inducing itch has not been thoroughly investigated. In atopic dermatitis, several cytokines induce itch, including IL-2 and IL-6. IL-2, the prototype pruritogenic cytokine, induces itch in atopic dermatitis as well as in cancer patients receiving recombinant IL-2. Inhibition of IL-2 production forms the basis for treatment of atopic dermatitis with cyclosporine and immunomodulators such as tacrolimus and pimecrolimus. IL-2 and IL-6 have receptors in nerve cells. The recent discovery of IL-31 itch induction in mice, as well as elevated IL-31 levels in atopic dermatitis and prurigo nodularis, suggests a specific role for this cytokine in pruritus.[58]

CLINICAL FINDINGS

History

It is of prime importance to determine whether the cause is related to a primary skin disease or systemic disease. Diseases such as skin dryness or scabies may exhibit few primary skin lesions; therefore, careful history and laboratory evaluation can be particularly important. It is important to differentiate between generalized pruritus and localized itch, which usually is not associated with a systemic cause. Careful history, including a full drug history, and physical examination including lymph nodes, are the starting points. The history should take into account the multidimensional nature of itching and should include details of quality, distribution, and timing. Any patient referred with generalized pruritus in the setting of other family members with pruritus should be assumed to have scabies until proved otherwise—skin signs may be clinically inapparent, perhaps confined to a few small nodules on the genitalia.

Fig. 102-2 is an algorithm showing the approach to a patient with pruritus.

Cutaneous Lesions

Secondary skin lesions characteristic of pruritus include excoriations, lichenification, and hyper- or hypopigmentation. Lichenification results from continuous rubbing or scratching and consists of well-developed, thickened plaques with marked accentuation of skin creases (see Chap. 14). Post-inflammatory hyperpigmentation or hypopigmentation is common in patients with skin phototypes skin type 4 through 6 (see Chap. 89). Lichenified plaques are most commonly distributed in areas the patient can easily scratch or rub (i.e., nape of neck, below the elbow, ankle, buttock, and genitalia). The butterfly sign consists of normal-appearing skin in the middle of the back outlined by a butterfly pattern of contrasting hyperpigmentation in areas subjected to persistent scratching, resulting from the patient's inability to reach the middle of the back. Shiny fingernails may result from prolonged rubbing. Prurigo nodules are excoriated papules that form nodules in patients with chronic pruritus (see Chap. 15). In many cases,





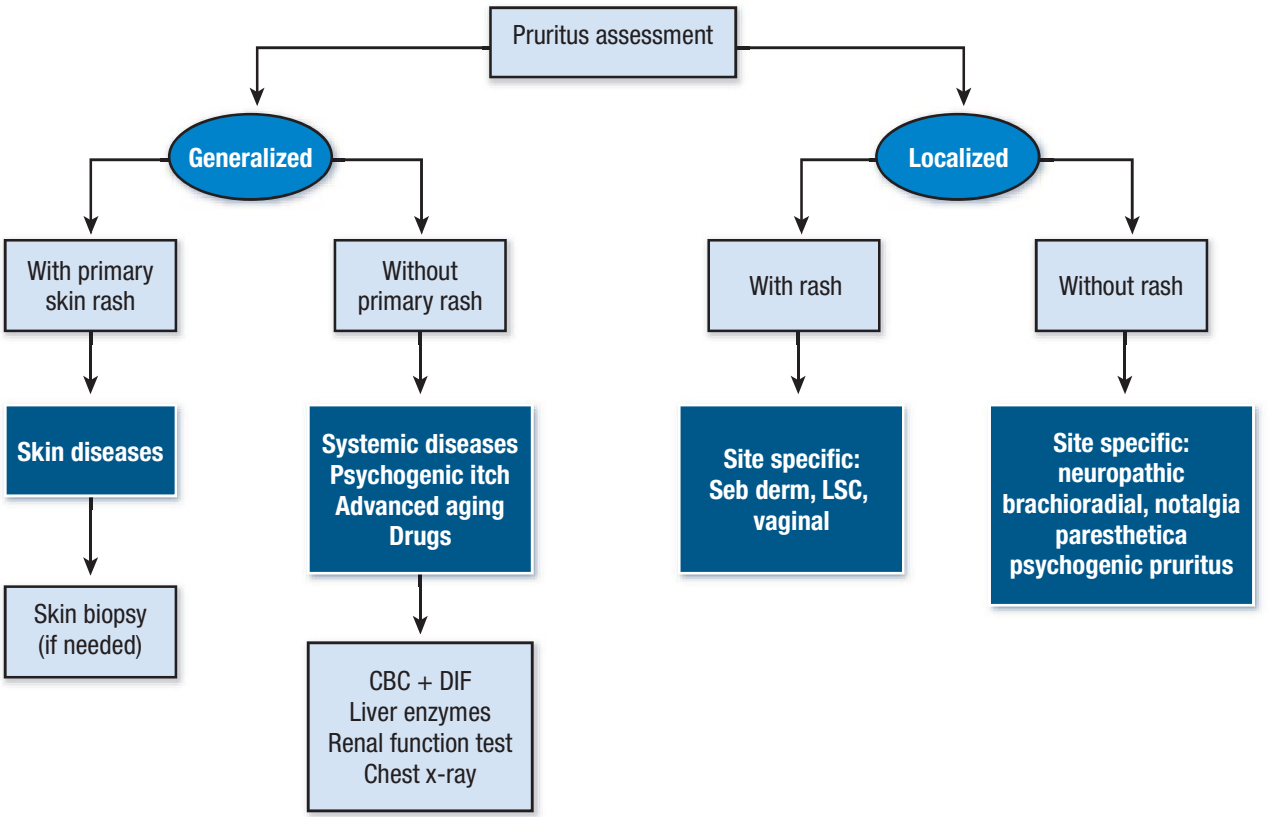

▲ **FIGURE 102-2** Approach to a patient with pruritus. CBC = complete blood cell count; DIF = differential; LSC = lichen simplex chronicus; Seb derm = seborrheic dermatitis.

this type of itch is accompanied by a painful, burning sensation suggestive of a neuropathic component. Prurigo nodules are frequently associated with emotional stress and obsessive compulsive disorder; however, they can be also be a manifestation of itch in patients with atopic dermatitis or chronic renal failure. Such nodules are usually distributed over extensor aspects of the limbs.

Some pruritic states have specific clinical patterns. Despite severe pruritus, chronic urticaria usually does not show secondary skin lesions associated with scratching. Neuropathic itch in disease entities, such as postherpetic neuralgia, brachioradial pruritus, and notalgia paresthetica, is typically associated with pain and burning sensation. Atopic dermatitis may also be associated with burning sensation after scratching.

Laboratory Tests and Special Tests

Laboratory tests to be considered in the evaluation of generalized pruritus are outlined in Table 102-3. Secondary laboratory considerations may include stool examination for ova and parasites, screening for hepatitis B or C, plasma protein electrophoresis, and immunoelectrophoresis. A computed tomography scan of the chest and abdomen may be justifiable to help rule out lymphoma. A skin biopsy is useful to exclude clinically inapparent cutaneous mastocytosis or bullous pemphigoid.

DIFFERENTIAL DIAGNOSIS (Box 102-1)

COMPLICATIONS

Pruritus can significantly impair patients' quality of life. Patients with chronic pruritus often have difficulty sleeping, difficulty concentrating, decreased sexual desire and sexual function, agitation, and depression.[18,59] In addition, eczematous lesions resulting from scratching can become secondarily infected, particularly in patients with atopic dermatitis.

TABLE 102-3
Recommended Laboratory Tests for Investigation of Patients with Generalized Pruritus

- Recommended
  - Complete blood cell count with differential
  - Chemistry profile: urea, creatinine, liver enzymes
  - Thyroid function tests
  - Chest radiograph
- Optional
  - Stool examination for parasites
  - Human immunodeficiency virus testing with other associated symptoms and signs

PROGNOSIS AND CLINICAL COURSE

Generalized pruritus can wax and wane. Changes in the clinical presentation may be associated with seasonal changes, such as exacerbation of atopic dermatitis in the winter, or changes between dry and humid environments. Pruritus associated with underlying internal disease is often multifactorial, involving both systemic and external factors, including ambient temperature and humidity. Chronic itch associated with skin disease may also include central neural sensitization.

Itch Caused by Skin Disorders

PRURITUS IN ATOPIC DERMATITIS (See Chap. 14) Pruritus in atopic dermatitis remains a controversial area and the molecular

Box 102-1

Differential Diagnosis of Generalized Pruritus without Primary Skin Disease

- Chronic renal disease
- Cholestasis
- Hyperthyroidism
- Pruritus in hematologic disease and lymphoreticular malignancy
  - Hodgkin disease
  - Polycythemia vera
  - Myeloid and lymphatic leukemia
  - Myelodysplasia
  - Mastocytosis
- Solid malignant tumors (paraneoplastic manifestation)
- Human immunodeficiency virus–associated pruritus
- Itching in senescence
- Aquagenic pruritus
- Itching as a manifestation of psychiatric disease
  - Delusions of parasitosis
  - Itch associated with obsessive compulsive disorder
  - Pruritus of anorexia nervosa
- Neuropathic itch
  - Post-cerebrovascular accident pruritus
  - Multiple sclerosis–associated pruritus
  - Pruritus of Creutzfeldt-Jakob disease ("prion pruritus")
- Drug-induced pruritus
  - Opiate-associated pruritus
  - Hydroxyethyl starch–induced pruritus

basis of pruritus in atopic dermatitis remains largely unexplained. Whether itch precedes skin lesions or vice versa is also an unresolved issue. What is certain is that a vicious itch-scratch cycle (see Fig. 102-1) exists in atopic patients, in which scratch damage enhances pruritus. Itching is particularly acute in response to punctate stimuli such as wool fibers; rubbing or scratching elicits surround inhibition. Alloknesis (see Alloknesis: "Itchy Skin") is a prominent feature of the itch of atopic dermatitis and explains the bouts of intense itching associated with sweating, sudden changes in temperature, dressing, undressing, and direct contact with wool. That there is a central (neurogenic) component to the itch of atopic dermatitis is suggested by the poor response to low sedation H_1 antihistamines.[60] The intensity of itch in atopic dermatitis has been related to mental factors,[61–63] and itch may be induced by cognitive stress, such as anxiety, as well as depression. Opioid peptides may serve as central mediators because opioid antagonists are effective in some patients. Nocturnal scratching is a major problem in atopic dermatitis, occurs during superficial sleep, and occupies 10 percent to 20 percent of the total sleeping time, leading to tiredness and irritability.

PSORIASIS Itch in psoriasis is a significant but under-recognized problem in dermatology. Several studies have demonstrated that itch is a principal symptom of psoriasis.[64–68] Among psoriasis patients, 77 percent experience pruritus on a daily basis.[59] Dermatologists emphasize observable criteria of psoriasis, such as visible lesions; however, itching frequently occurs in areas of the body where no psoriasis plaques are visible. Scalp itching, in particular, is specific to psoriasis and may require different therapies than pruritus in other areas of the body.[66]

Neuropathic Itch

POSTHERPETIC NEURALGIA Postherpetic neuralgia commonly has neuropathic pain; and often, associated neuropathic itch as well. Pruritus commonly accompanies both acute zoster and postherpetic neuralgia, particularly lesions affecting the head, face, and neck.[69]

NOTALGIA PARESTHETICA Notalgia paresthetica is a chronic localized itch, affecting mainly the interscapular area especially the T2–T6 dermatomes, but occasionally with a more widespread distribution, involving the shoulders, back, and upper chest. The sensation perceived by the patient is part itch, part paraesthesia. There are no specific cutaneous signs, apart from those attributed to scratching and rubbing. Amyloid deposition in skin biopsies is a secondary event. The current view on etiology is that it is a neuropathic itch due to entrapment of spinal nerves as they emerge through the axial muscles of the back.[70]

BRACHIORADIAL PRURITUS Brachioradial pruritus, a localized pruritus, is becoming increasingly common. Patients, usually fair skinned, affluent, and middle aged, habitually indulge in golf, tennis, sailing, or other leisure outdoor activities in sunny climates.[71,72] They develop persistent pruritus of the outer surface of the upper arm, elbow, and forearm, associated with clinical evidence of chronic sun damage and xerosis in the pruritic skin. The itch may gradually become more widespread. Results of phototesting are negative and the problem seems consequent on straightforward chronic ultraviolet (UV) overexposure (see Chap. 89).

Systemic Itch

PRURITUS OF CHRONIC RENAL DISEASE (See Chap. 151) Pruritus is one of the most distressing symptoms of chronic renal failure. It affects 50 percent of patients with chronic renal disease, especially those on dialysis, although it is becoming less prevalent, probably due to more efficient dialysis techniques.[73] Scratching is common and patients may be heavily excoriated or the skin may appear lichenified or present with prurigo nodules. The back is invariably affected, and the arm bearing the arteriovenous fistula is also a common site in dialysis patients. Patients with uremic pruritus often have dry skin, but correction of this by emollients usually provides minimal relief. Etiologic factors may include elevated calcium levels, release of pruritogenic cytokines during hemodialysis, damage to C nerve fibers, proliferation of sensory nerve endings in skin, increased numbers of dermal mast cells, elevated plasma histamine levels, secondary hyperparathyroidism and abnormal levels of divalent cations.[74,75] Secondary hyperparathyroidism, though common in patients with renal failure, is a rare cause of renal pruritus. The proliferation of nerve endings in skin is most likely a response to incessant scratching and rubbing, rather than the primary cause of pruritus. Elevation of histamine levels, with or without increased population density of dermal mast cells, is also unlikely to be important because antihistamines are rarely effective. Evidence based on response of patients to a selective κ-opioid agonist raises the possibility that opioid peptides may be involved, although this finding needs further verification.[76]

PRURITUS OF CHOLESTASIS (See Chap. 151) Pruritus of cholestasis is a highly distressing and persistent pruritus of biliary obstruction that often begins with an acral distribution, but later becomes more generalized. Both peripheral and central mechanisms are important. Cholestatic pruritus is associated with high plasma levels of bile salts; however, there is little or no evidence of a correlation between skin or serum concentrations of bile salts and itching,[77] although administration of cholestyramine, which lowers bile salt levels, does provide some relief. Patients also have elevated plasma opioid levels,[78] and pruritus has been shown to improve with treatment with opioid antagonists



including naloxone, naltrexone, and butorphanol.[79–81] In addition, animal models of cholestasis are associated with elevated levels of opioid peptides and scratching, relieved by naloxone.[82,83] Thus, combination of both bile salt–lowering and opioid antagonist strategies appear reasonable in the management of pruritus of cholestasis.

PRURITUS OF ENDOCRINE DISEASE (See Chap. 152) Generalized intractable itching is a recognized feature of thyrotoxicosis and may be a presenting symptom.[84] This may be due to increased blood flow, which raises the skin temperature, which, in turn, reduces the threshold to itching.[12] Hypothyroidism is less frequently associated with itch. Generalized itching is not a feature of diabetes mellitus.[85] However, anogenital itching is a common presenting feature, and is due to mucocutaneous candidiasis. Localized itching of the scalp and lower extremities in the form of lichen simplex chronicus can also be a manifestation of diabetic neuropathy,[86] which may respond to topical capsaicin treatment.[87]

PRURITUS IN HEMATOLOGIC DISEASE AND LYMPHORETICULAR MALIGNANCY (See Chaps. 145 and 146) Itch is common in hematologic disorders. In widespread cutaneous T-cell lymphoma, and erythrodermic forms of cutaneous T-cell lymphoma including Sézary syndrome (T-cell leukemia), intractable itch is difficult to manage. In polycythemia vera, it occurs in approximately 50 percent of patients, is often precipitated by contact with water ("bath itch"), and is associated with raised blood histamine levels.[88,89] In other lymphoproliferative diseases, itch can also be precipitated by contact with water. In Hodgkin disease, it may be a presenting symptom.[90] In cutaneous mastocytosis (see Chap. 150), itching occurs locally following rubbing the skin, although it can be widespread in severely affected patients, when it is usually associated with systemic symptoms. Itching may occur in patients with myeloid and lymphatic leukemia and myelodysplasia.

PRURITUS AS A MANIFESTATION OF SOLID MALIGNANT TUMORS (See Chap. 154) Traditionally, the onset of pruritus in a middle-aged or elderly patient with an otherwise normal-looking skin prompts a thorough investigation for underlying systemic causes, including internal neoplasia, although the latter is an uncommon cause. Although pruritus may occasionally be present years before the tumor becomes clinically detectable, even if resources are available, full investigation for a causative solid tumor is probably not worthwhile.[91,92]

PRURITUS OF HUMAN IMMUNODEFICIENCY VIRUS INFECTION (See Chap. 189) Itch is an early symptom of human immunodeficiency virus (HIV) disease and may be associated with skin disease or a result of systemic disease (e.g., hepatic, renal, adverse drug reactions, lymphoma, and systemic and skin infections including *Staphylococcus aureus* and *Pityrosporum*). However, it may occur as a primary symptom of HIV.[93] The most common example is eosinophilic folliculitis. Other common types of itch in HIV are insect bite hypersensitivity reaction, pruritic papules other than eosinophilic folliculitis, and itch associated with skin xerosis and lichenoid dermatitis, as well as exacerbation of seborrheic dermatitis and psoriasis.

Psychogenic Itch (See Chap. 103)

Delusions of parasitosis is one of the more challenging types of itch that dermatologists encounter. The patient holds a false belief that they are infested with parasites, although careful inspection reveals no supporting clinical findings. The patient often brings "evidence" in the form of collected fragments, although on examination the material proves to be non-specific debris. The patients often refuse to see a psychiatrist. Delusions of parasitosis is classically treated with typical antipsychotic agents; pimozide is most commonly used by dermatologists. Olanzapine (5 mg/day) is another new option to treat this severe type of psychogenic itch. Localized pruritus in the form of prurigo nodularis or anogenital pruritus could be a manifestation of obsessive compulsive disorders and anxiety. Patients with depression, fibromyalgia, and other somatoform disorders can suffer from severe itch that responds well to selective serotonin reuptake inhibitors (SSRIs).

Miscellaneous Types of Itch

SENESCENT SKIN AND ITCH Itch is the most common dermatologic symptom among people over 65 years of age.[96,97] At least 50 percent of persons aged 70 years or older suffer from prolonged bouts of troublesome pruritus. Idiopathic itch in the elderly, sometimes referred to inappropriately as *senile pruritus*, is common and presents a diagnostic and therapeutic challenge. Itch in senescent skin can result from a variety of causes including dry skin, inflammatory skin diseases such as low-grade eczema and scabies, as well as underlying systemic disease, especially cholestasis and renal failure. Several drugs can induce pruritus without a rash including opioids and angiotensin converting enzyme inhibitors. However, in many instances, no cause is found. Although dry skin is probably the most common associated factor, it may not be the cause of pruritus; many elderly patients have senescent skin without xerosis. Other factors may play important roles, such as age-related changes in nerve fibers and loss of input from pain fibers leading to central disinhibition of itch. Additional skin changes in elderly patients that may contribute to itch include decreased skin surface lipids, decreased clearance of transepidermally absorbed materials from the dermis, decreased sweat and sebum production, and diminished barrier repair.[98]

ITCH ASSOCIATED WITH BURNS AND SCARS (See Chaps. 64 and 94) Burn scars are common in both children and adults and are associated with significant pruritus. Fifteen percent of patients experience persistent pruritus and 44 percent occasional pruritus.[99] Compared to healthy skin, burn-graft skin displays significantly elevated SP nerve fibers as well as significantly elevated thresholds for pinprick, warming, touch, and vibration.[100] Keloids are frequently associated with itch at the periphery of the keloid lesion and less frequently pain in the center of the keloid.[101] These findings probably result from damage to small nerve fibers from traction neuropathy.

AQUAGENIC PRURITUS Originally described by Shelley[102] and subsequently characterized by Greaves et al.,[103] aquagenic pruritus is a rare, intractable pruritus of unknown etiology found mainly in the middle-aged and elderly.[104] Characteristically, local itching without visible skin signs is provoked by contact with water. Notably, aquagenic pruritus can be associated with lymphoproliferative disorders such as polycythemia vera.[89,105]

TREATMENT OF PRURITUS

Unfortunately, there are no general-purpose antipruritic drugs. Treatment of pruritus depends on identifying and removing the cause, whether systemic or



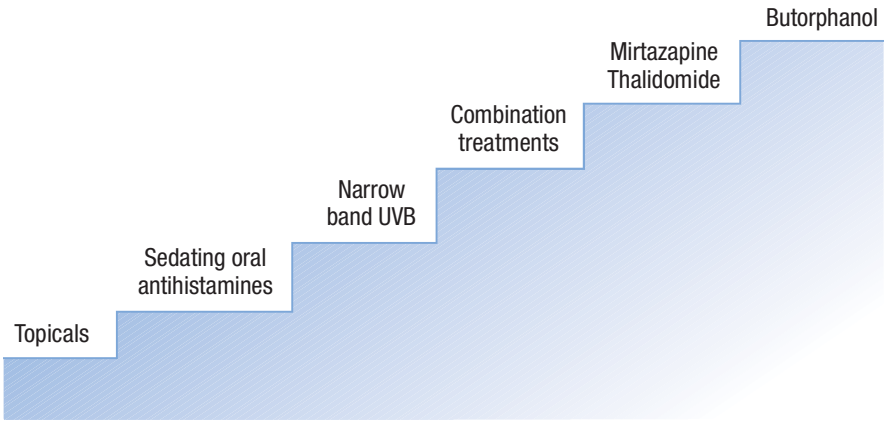

▲ **FIGURE 102-3** Therapeutic ladder for antipruritic therapies. UVB = ultraviolet B.

cutaneous. False hopes of highly effective treatment for those patients in whom no cause can be found should not be raised; there are no systemic or topical antipruritic agents that are both effective and selective with acceptable tolerability.

It is important to elicit a detailed history, including the precise quality, timing, and distribution of the itch, so that more focused therapy can be instituted. The sensation of itching is heightened if the skin is warm,[12,106] therefore measures should be taken to cool the skin down, including tepid showering, light clothes, and air conditioning where appropriate. Cooling lotions, such as calamine lotion or menthol 1%, may help. A general therapeutic ladder for generalized pruritus is presented in Fig. 102-3.

Topical Antipruritic Treatments

There is a lack of controlled studies for most topical antipruritic treatments. Many topical agents are claimed to be effective for pruritus; however, few claims are supported by more than anecdotal evidence. Although capable of relieving pruritus due to inflammatory skin disease, corticosteroids are not intrinsically antipruritic. Antihistamines are only antipruritic if the pruritus is caused by histamine, as in urticaria. However, a number of pharmacologic mechanisms offer promising avenues for treatment of itch. A summary of topical antipruritic treatments is given in Table 102-4.

BARRIER CREAMS AND COMBINATION THERAPIES Emollients and barrier repair creams often reduce pruritus through improved barrier function. They help the stratum corneum to retain water and provide an exogenous barrier to prevent transepidermal water loss. Such barrier creams are often effective treatments for itch associated with dry skin and atopic dermatitis; however, the mechanism of their antipruritic effects are not fully understood. Restoration of the barrier minimizes fissuring and reduces exposure of C nerve fibers. Atopic dermatitis patients treated with ceramide-dominant emollients demonstrate improved transepidermal water loss and overall severity of skin disease. Lipids, occlusives, and humectants also reduce damage to skin by decreasing contact between skin proteins, lipids, and surfactants. Acidifying the stratum corneum may also reduce itch. High pH solutions increase the swelling of the stratum corneum, change lipid rigidity, and increase secretion of serine proteases, suggesting that neutral or acidic pH solutions are less damaging.

TOPICAL SALICYLATES Clinical trials have shown that applying a topical salicylic acid solution to the skin relieves itch. Topical salicylic acid is a common keratolytic agent and may also increase hydration and soften the stratum corneum by decreasing its pH (see Chap. 222). Topical aspirin significantly reduced pruritus in patients with lichen simplex chronicus—a form of localized itch[57]; however, oral salicylates do not relieve pruritus except in polycythemia vera.

TOPICAL IMMUNOMODULATORS (See Chap. 221) Although topical immunomodulators, such as tacrolimus and pimecrolimus, are used primarily for atopic dermatitis, these medications are promising antipruritic treatments in other dermatologic diseases as well. Tacrolimus and pimecrolimus have both been shown to directly affect C nerve fibers.[107]

COOLANTS AND COUNTER-IRRITANTS A distinct subset of sensory neurons may directly sense changes in thermal energy via cutaneous nerve endings via receptors

TABLE 102-4
Topical Antipruritic Treatments

MEDICATION	DOSE	INDICATION	NOTES
Barrier repair creams	N/A	Atopic dermatitis, dry skin	—
Salicylic acid	2%–6%	Lichen simplex chronicus	Stinging
Tacrolimus	0.1% ointment	Atopic eczema, contact dermatitis	Stinging, burning sensation
Pimecrolimus	1% cream	Atopic eczema, contact dermatitis	Stinging, burning sensation
Menthol	1% cream	Patients who respond well to cold showers	Skin irritation
Capsaicin	0.75%–1.0% cream	Neuropathic itch (notalgia paresthetica, postherpetic itch), uremic itch, psoriasis, atopic dermatitis	Poor compliance due to transient burning sensation
Pramoxine	1.0%–2.5%	Facial eczema, atopic eczema	Particularly effective for pruritus of face
Polidocanol	5% urea + 3% polidocanol (laurylmacrogol)	Atopic dermatitis, contact dermatitis, psoriasis, uremic pruritus	—
Doxepin	5% cream	Atopic dermatitis	Drowsiness in 25% of patients; allergic contact dermatitis
Cannabinoids		Atopic dermatitis, uremic pruritus	Combine with a barrier cream



of TRP ion channels. These include vanilloid receptors, such as TRPV1, which respond to warmth and capsaicin. These receptors act synergistically with other receptors involved in itch, such as PAR-2 and SP receptor (Neurokinin 1). These receptors are targets for treatment of itch. Other receptors from the same family include cold receptors, such as TRPM8. Menthol has been used as a symptomatic topical treatment for pruritus for centuries and relieves itch in some patients by activating nerve fibers that transmit a cool sensation. Menthol may reduce itch via TRPM8 receptors in keratinocytes and nerve fibers. Menthol 1 percent cream is popular with patients who have pruritic skin; however, higher concentrations can induce skin irritation.[108] Those patients who report that cold showers and ice relieve their itch tend to respond extremely well to treatment with menthol.



CAPSAICIN Topical capsaicin, the active compound in the chili pepper, causes release of neuropeptides, including SP, from C nerve fibers. The exact mechanism is not fully understood; however, prolonged application of capsaicin to the skin depletes stores of SP, desensitizes neurons, and abolishes pruritus at the site of application. Capsaicin activates the vanilloid receptor TRPV1, which is abundant in the epidermal layer of the skin.[10] Several reports have supported capsaicin's value for localized, chronic pruritic disorders, particularly those of neuropathic origin, including notalgia paresthetica, postherpetic itch, and uremic itch. It has also been proposed for the treatment of pruritus of atopic dermatitis.[109] Unfortunately, compliance is poor because initial application causes an intense, transient burning sensation at application sites; however, this usually resolves after using the medication for a few days or with application of a topical anesthetic.

TOPICAL ANESTHETICS ***Pramoxine.*** Pramoxine is a topical anesthetic that reduces itch, especially when applied to facial areas, by blocking the transmission of nerve impulses. A double-blind study has shown that pramoxine inhibits histamine-induced itch in humans.[110]

Polidocanol. Polidocanol is a non-ionic surfactant with both local anesthetic properties and moisturizing effects. In an open-label study, a combination of 5 percent urea and 3 percent polidocanol (Larylmacrogol) was found to significantly reduce pruritus in patients with atopic dermatitis, contact dermatitis, and psoriasis.[111]

TOPICAL ANTIHISTAMINES Doxepin is a tricyclic antidepressant with potent H_1- and H_2-antihistamine properties and significant atropine-like (anticholinergic) side effects. Doxepin 5 percent cream has been shown to relieve pruritus in patients with atopic dermatitis in a large placebo-controlled, double-blind study.[112] However, percutaneous absorption of doxepin, causing drowsiness, occurs in approximately 25 percent of patients, limiting its usefulness. Allergic contact dermatitis is also a recognized adverse effect.

TOPICAL CANNABINOIDS Uncontrolled trials have shown that topical cannabinoids combined with a barrier cream have an antipruritic effect in patients with atopic dermatitis and uremic pruritus.[113]

FUTURE TOPICAL THERAPIES Although none is currently available, topical drugs that inhibit serine proteases may be an additional mechanism for future antipruritic therapies. Drugs that inhibit NGF and neurotrophin 4 may also have a potential therapeutic role in itch.

Systemic Antipruritic Treatments

ANTIHISTAMINES (See Chap. 230) Pruritus due to histamine is mediated exclusively via H_1 receptors; H_2 antihistamines are ineffective in relieving pruritus. First-generation (classic) H_1 antihistamines have marked sedative and atropine-like (anticholinergic) actions. Second generation (minimal- or low-sedation) H_1 antihistamines have lower lipophilicity and consequently are associated with less drowsiness and other unwanted side effects. Sedative (first-generation) antihistamines are useful in severe chronic urticaria with or without angioedema because they suppress pruritus and alleviate associated anxiety. Hydroxyzine is especially valuable in this context along with doxepin. Second-generation H_1 antihistamines are suitable in the daytime for relief of pruritus due to urticaria; however, the role of these non-sedating antihistamines is limited in other pruritic disorders. A summary of systemic antipruritic treatments is given in Table 102-5.

OPIATE ANTAGONISTS AND AGONIST-ANTAGONISTS As mentioned in Opioids, μ-opioid receptor agonists can cause generalized pruritus.[42,43,45,47] μ-Opioid antagonists, such as naloxone and naltrexone, have been used for the treatment of pruritus associated with cholestasis, uremia, and dermatologic diseases. The efficacy of such opioid antagonists is supported by data from controlled clinical trials.[41,79,81,114–116] Naltrexone was effective in the treatment of some cases of severe, intractable pruritus.[117] However, such μ-antagonists are associated with significant side effects including hepatotoxicity, nausea and vomiting, difficulty sleeping, and reversal of analgesia, among others. κ-Receptor agonists also inhibit μ-receptor effects. In animal models, κ-opioid receptor agonists inhibit pruritus and scratching induced by SP or histamine.[43,44] The novel κ agonist, nalfurafine (TRK-820), has been shown to be effective in treatment of severe uremic pruritus.[46,76] Thus, κ agonists are a promising treatment for severe itch;[46] however, nalfurafine is not commercially available.

Butorphanol is a commercially available opioid agonist-antagonist analgesic with both κ-agonist activity and μ-antagonist activity. Previous studies have found that epidural butorphanol was effective in relieving pruritus associated with epidural morphine.[118,119] Intranasal butorphanol is an effective treatment for many patients with chronic, severe, and intractable pruritus due to systemic diseases and inflammatory skin diseases.[120]

MIRTAZAPINE The oral antidepressant mirtazapine has been shown to relieve itch in some patients.[121,122] Unlike other SSRIs, mirtazapine is a central presynaptic α_2 noradrenergic inhibitor and specific serotonergic antidepressant. Mirtazapine is a safe medication without serious side effects and may be an effective alternative for the treatment of nocturnal pruritus.[122] It has been shown to be effective when used to treat systemic pruritus as well as pruritus of skin inflammations and in particular nocturnal itch using a low dose of 15 mg at night. A randomized, controlled study has shown that paroxetine also significantly reduces itch.[123] Other SSRIs do not appear to reduce itch.

THALIDOMIDE (See Chap. 236) Thalidomide has shown antipruritic efficacy in treatment of inflammatory skin diseases, such as prurigo nodularis, actinic prurigo, eczema, and idiopathic elderly pruritus. Thalidomide has been used for years as an immunomodulatory agent whose spectrum of activity is not fully characterized. The antipruritic activity could be related to several mechanisms, including inhibition of TNF-α synthesis. Although TNF-α does not have any di-

TABLE 102-5
Non-Classical Systemic Antipruritic Treatments

Medication	Dose	Indication	Notes
Doxepin	25–100 mg PO qd	Chronic urticaria	Drowsiness, dry mouth; abrupt withdrawal may cause confusion; should not be co-administered with other antidepressants
Naloxone	0.002 μg/kg/min increased gradually up to 0.2 μg/kg/min over 24 h	Cholestatic pruritus, uremic pruritus	Hepatotoxicity, nausea and vomiting, difficulty sleeping, reversal of analgesia
Naltrexone	12.5–250 mg PO qd	Cholestatic pruritus, uremic pruritus	Hepatotoxicity, nausea and vomiting, difficulty sleeping, reversal of analgesia; contraindicated in patients with liver dysfunction
Butorphanol (intranasal)	1–4 mg inhaled qhs	Intractable pruritus due to systemic and some inflammatory skin disease	Drowsiness, dizziness, nausea and vomiting
Mirtazapine	15 mg PO qhs	Systemic and inflammatory skin disease	Drowsiness, increased weight and appetite, dry mouth
Paroxetine	20 mg PO qd	Generalized pruritus	Insomnia, sexual dysfunction
Thalidomide	100 mg PO qd	Prurigo nodularis, actinic prurigo, postherpetic neuralgia, uremic pruritus, atopic dermatitis, idiopathic elderly pruritus	Teratogenic, peripheral neuropathy, drowsiness
Gabapentin	300–2400 mg PO qd	Neuropathic itch	Drowsiness, constipation

rect pruritogenic effect, it is elevated in many pruritic dermatoses. Thalidomide may also act directly as a peripheral and central nerve depressant. The major adverse effects of thalidomide are peripheral neuropathy and teratogenicity.

GABAPENTIN Gabapentin is a structural analog of the neurotransmitter γ-aminobutyric acid has been used as an anticonvulsant; however, its mechanism of action in the CNS is poorly understood. Studies have shown that gabapentin is effective for treatment of brachioradial pruritus, multiple sclerosis–induced itch, other types of neuropathic itch as well as uremic itch. Gabapentin appears to alter sensation and pruritus associated with itch related to nerve damage in dermatologic and systemic disease. Gabapentin may inhibit central itch pathways, as it does in pain. Pregablin is a new neuropathic pain medication that has a similar structure and function to gabapentin with fewer side effects and can reduce neuropathic itch or alter the sensation of itch in systemic diseases.

Nonpharmacologic Treatments for Itch

PHOTOTHERAPY (See Chap. 238) Phototherapy has been used for more than a decade to treat different types of itch. Recent reports have suggested that narrow band UVB may be as effective for treatment of pruritus as broad-band UVB or psoralen and UVA light. Phototherapy decreases the population density of mast cells by inducing apoptosis, causes peripheral nerve dysfunction, and reduces divalent cations in the skin. Phototherapy is an effective treatment for itch associated with atopic dermatitis, psoriasis, and chronic renal failure. Remissions may last for as long as 18 months.

CUTANEOUS FIELD STIMULATION Cutaneous field stimulation (CFS) is a new technique that electrically stimulates afferent fibers, including nociceptive C fibers. CFS has similarities to transcutaneous electrical nerve stimulation, which activates large myelinated nerve fibers; however, CFS more specifically targets unmyelinated C nerve fibers. CFS may act through endogenous central inhibitory mechanisms that are normally activated by scratching.[124] Long-term CFS appears to be an effective alternative treatment for severe localized pruritus. In patients with localized itching, CFS significantly reduces patient-reported itch and causes degeneration of epidermal nerve fibers.[125] However, CFS is only practical for localized disease.

BEHAVIORAL THERAPY TARGETING THE CENTRAL NERVOUS SYSTEM Stress and other psychogenic factors are important in itch.[126] Several studies have shown that behavioral modification therapy reduces itch intensity and perception. Other possible behavioral interventions include stress reduction and biofeedback.[126]

KEY REFERENCES

The full reference list for all chapters is available at www.digm7.com.

1. Ikoma A et al: Neurobiology of pruritus. *Nature Rev Neurosci* **7**:535, 2006
2. Summey BT Jr, Yosipovitch G: Pharmacologic advances in the systemic treatment of itch. *Dermatol Ther* **18**:328, 2005
3. Dalgard F et al: Self-reported skin morbidity among adults: Associations with quality of life and general health in a Norwegian survey. *J Investig Dermatol Symp Proc* **9**:120, 2004
4. Bernhard JD: Itch and pruritus: What are they, and how should itches be classified? *Dermatol Ther* **18**:288, 2005
5. Twycross R et al: Itch: Scratching more than the surface. *QJM* **96**:7, 2003

22. Stander S et al: Neurophysiology of pruritus: Cutaneous elicitation of itch. *Arch Dermatol* **139**:1463, 2003

42. Yosipovitch G, Greaves MW, Schmelz M: Itch. *Lancet* **361**:690, 2003

126. Gieler U et al: Psychosomatic aspects of pruritus in *Itch: Basic Mechanisms and Therapy,* edited by Yosipovitch G et al. New York: Marcel Dekker, 2004, p 343



CHAPTER 103

Psychocutaneous Diseases

Andrea Sandoz
Thomas Koenig
Daniel Kusnir
Francisco A. Tausk



Scientific advances are shedding new light on the understanding and treatment of long-recognized conditions located at the interface of dermatology and psychiatry. Both arising from ectoderm, the skin and the nervous system are connected by more than just their common origins. The skin is one of the major avenues by which we perceive the world, and, in turn, are perceived by it. When these perceptions go awry, great distress may result to the patient, as is the case in delusional parasitosis. When the skin itself is markedly affected by a primary dermatologic condition, psychological sequelae often follow, greatly impacting the patient's self-esteem, confidence, and overall quality of life.

The central nervous system (CNS) can influence the health (both actual and perceived) of other organ systems, including the skin. Psychophysiologic mechanisms for this interaction range from the stress responses mediated by neuroadrenal connections and associated changes in immunologic function, to the systemic and local action of various neuropeptides and neurohormones.[1,2]

CLASSIFICATION OF PSYCHOCUTANEOUS DISEASES

Following the original description of Koblenzer,[3] psychocutaneous diseases can be classified based on their primary etiology as:

- Primary psychiatric disorders, which can present with a variety of symptoms and behaviors, that can lead to perceived or actual dermatologic conditions, or
- Primary dermatologic disorders that can be either triggered or amplified by contextual causes (for example, life circumstances or interpersonal relationships) that may lead to demoralization, anxiety, depression, and distress through their impact on the patient's physical appearance and well-being.

The classification can guide in implementing an effective treatment approach including dermatologic, psychiatric, and contextual aspects of the disease aimed to interrupt the circular reinforcement of pathology.

Role of the Dermatologist

Between 20 percent and 40 percent of patients seeking treatment for skin complaints have some type of psychiatric or psychological problem causing or complicating the presenting symptoms.[4,5] A large number of these patients lack insight into the possible psychogenic origin of their symptoms and are often reluctant to accept any kind of psychiatric referral. Therefore, in the absence of a psychiatry liaison clinic in the dermatologic setting,[6] the dermatologist must be familiar with the most common of these diagnoses, their clinical manifestations (both psychological and dermatologic), and the basic principles of treatment.

When approaching these issues, it is important to explore psychiatric and particularly psychotic symptoms as well as compliance with medications. Collateral informants such as family members can be quite helpful if the patient grants permission. Last but not least, the consequences that the symptoms of the patient have on his or her familial and social life, or both, can be of much assistance in understanding the issues to be to addressed by the dermatologist. Nonpharmacologic therapies can be very useful in the management of these patients (Table 103-1).

PRIMARY PSYCHIATRIC DISORDERS (Table 103-2)

Delusion of Parasitosis

Dermatologic patients occasionally show evidence of monosymptomatic hypochondriacal psychosis,[7] characterized by the presence of delusions and, occasionally, hallucinations. Delusions are fixed, false beliefs that patients hold with unshakable conviction, not endorsed by the larger cultural, ethnic, or religious community. Hallucinations are sensory perceptions that occur without any external stimulus and can occur in any of the five sensory modalities. The most frequent form of this condition seen by dermatologists is delusion of parasitosis (DP),[8] a condition in which patients manifest the circumscribed false belief of being infested with parasites. Because this is frequently the only overt manifestation of the subject's psychosis, these patients most often present to dermatologists and entomologists rather than to psychiatrists.

TABLE 103-1
Nonpharmacologic Treatments

Cognitive-behavioral therapy
Insight-oriented psychotherapy
Hypnosis
Mindfulness-based cognitive therapy
Biofeedback
Family therapy
Behavioral therapy

EPIDEMIOLOGY DP predominates in middle-aged to elderly females with premorbid social isolation. In approximately 12 percent of patients the delusion of infestation is shared or at least endorsed by a family member (*folie à deux*).[9,10]

CLINICAL FINDINGS Patients with DP frequently present to the clinician in an anx-

PSYCHOCUTANEOUS DISEASES AT A GLANCE



- Primarily psychiatric
  - Body dysmorphic disorder, atypical pain/burning, trichotillomania, delusional, or factitious disorders.
  - Affecting approximately 5 percent of dermatology patients.
  - Variable degree of insight, mostly poor.
  - Mostly self-induced lesions.
  - Poor prognosis if untreated.
- Primarily dermatologic
  - Secondary emotional component (stress, depression, and other co-morbidities).
  - Affects approximately 30 percent of dermatologic patients.
  - Good insight.
  - Stress exacerbates pre-existing diseases (such as psoriasis and eczema).
  - Distress produced by pre-existing skin disease leads to psychiatric manifestations such as anxiety and depression.

TABLE 103-2
Psychocutaneous Diseases

	Disease Entity	Patient Insight (0 to ++++)	Treatment of Choice
Primary psychiatric diseases	Delusion of parasitosis	0	AAP.
	Dysesthesias/formication (illusion of parasitosis) (nondelusional dysesthesias)	++	Antidepressants, anxiolytics + NPT, eventually add AAP/G.
	Body dysmorphic disorder	0 to +	High-dose antidepressants.
	Self-induced disorders		Antidepressants + NPT.
	Dermatitis artefacta	0 to +	May need the addition of low-dose atypical antipsychotics. Doxepin and mirtazapine are useful if severe pruritus present.
	Trichotillomania	Variable: 0 to ++	
	Neurotic excoriations	+++ to ++++	
	Atypical pain/burn	++++	NPT + antidepressants.
Primary dermatologic diseases	Eczema, psoriasis, urticaria, vitiligo, seborrheic dermatitis, etc.	++++	Antidepressants, NPT, anxiolytics.

AAP/G = atypical anti-psychotics and/or gabapentin; NPT = nonpharmacologic treatment; 0 to ++++ = none to complete awareness.

ious, ruminative, overwhelmed state, with a history of visits to multiple physicians without satisfaction. In addition to proffering a long and detailed history that includes visual or tactile hallucinations of the organisms, the patient also frequently provides "evidence" of the parasitic infection in the form of clothing lint, skin crusts, or other debris that are delusionally misinterpreted as entire organisms, body parts, larvae, or ova. Skin manifestations can be quite variable, if present. Oftentimes they reflect unsuccessful attempts at treating the infestation, resulting in lesions ranging between mild excoriations to large ulcers,[11] including the damage from "topical" treatments undertaken by the patient in an attempt to free themselves of the perceived infestation.[3] Because this is a monosymptomatic delusional disorder, some patients have a well-organized train of thought and typical outward appearance, resulting in the conviction by those surrounding them that the subject has a true infestation. The delusion becomes apparent to the physician when the subject is approached.

DIFFERENTIAL DIAGNOSIS Actual infestation must be ruled out (see Section 33). Subsequently, the differential diagnosis of psychosis must be parsed through, distinguishing between the primary psychiatric conditions that manifest with delusions of infestation. True monosymptomatic hypochondriasis represents a form of delusional disorder characterized by a rather discrete, circumscribed delusional belief with possible associated hallucinations without clear syndromic changes in affect or personality.[12] On the contrary, patients with uni- or bipolar depressive psychosis describe predominantly classic changes in mood, motivations, sleep, and appetite, along with feelings of hopelessness, helplessness, and worthlessness. Schizophrenic patients may have a history of previous psychotic episodes and often show a deterioration in global functioning, impaired social relatedness, thought disorder, paranoid traits, and more bizarre delusions and hallucinations extended often to other areas of their perception beyond the skin symptoms. In arriving at the diagnosis of DP it is critical that the clinician differentiate true DP from formication, a disorder which involves the cutaneous sensation of crawling, biting, and stinging, lacking the fixed unshakable conception that the skin sensations are induced by parasites. These patients, on occasion, attribute their sensory misinterpretations to infestations, and may be considered as having illusions of parasitosis.

PROGNOSIS AND CLINICAL COURSE Although often regarded as chronic, unremitting, and difficult to treat, these patients have an improved recovery rate after appropriate pharmacologic therapy.

TREATMENT The critical tenet of treatment is to keep the patient engaged. Empathetic listening, expressing concern about how the problem is affecting his or her life and examining the material that the patient brings in helps to establish a trustful relationship.[13] Because these patients frequently reject psychiatric referrals,[14] various authors have suggested means by which patients can be retained in treatment paving the road leading to the psychiatric referral.[14,15] Targeted therapy is undertaken with antipsychotic medications. Pimozide has been used historically as the drug of choice,[11] although it is now replaced by atypical antipsychotics such as olanzapine, aripiprazole, and risperidone, which are associated with a more favorable neurologic side-effect profile.[16–19] However, the clinician needs to be aware of the need for monitoring for metabolic syndrome characterized by abdominal obesity, insulin resistance and impaired glucose tolerance, disturbance in lipid metabolism, hypertension, and very significant weight gain.[7,20]

Body Dysmorphic Disorder

Body dysmorphic disorder (BDD) is a condition characterized by an excessive preoccupation or concern with a presumed defect in physical appearance despite normal or only minimally objective anomalous findings.[21] Also known as *dysmorphophobia*,[22,23] this is a psychological experience that also results in functional impairment in various arenas of the patient's life.[12] BDD's chronicity is particularly problematic because these individuals have unusually poor functional quality of life and treatment response.

The nosologic classification of BDD revolves around the intensity with which patients hold on to their abnormal beliefs. Those with unshakable convictions are currently diagnosed as having a delusional disorder.[12] However, there appears to be a continuum of intensity and insight from preoccupations, through overvalued ideas, to clear delusions.[8,24–26] The evidence linking BDD to the obsessive-compulsive spectrum of disorders has significant potential treatment implications.[27,28] BDD patients have obsessive thoughts about their "flaws" and engage in compulsive behaviors related to how they perceive their appearance, similar to behavior seen in obsessive-compulsive disorder (OCD). BDD often causes great distress and disability and is commonly accompanied by depression and suicidality. Seventy percent of patients report a his-



tory of suicidal ideation attributed primarily to BDD, and 22 percent to 24 percent have attempted suicide.

EPIDEMIOLOGY The prevalence of BDD is estimated to be from 1 percent in the general population to 12 percent in dermatology clinic patients,[29,30] often in association with mood disorders such as major depressive disorder (37 percent), phobia (33 percent), and OCD (26 percent).[31,32] Improvement of major depressive disorder and BDD seems to be closely related, with the improvement of each disorder significantly predicting the remission of the other. Improvement of OCD significantly predicts remission of BDD, but not vice versa.



CLINICAL FINDINGS Patients present with intensely articulated distress about various body parts. Most patients also develop ideas of reference in which they think or are convinced that others notice and comment upon the presumed defect.[31,33,34] Frequently compulsive behaviors often accompany the worrisome thoughts, consuming hours each day, including repeated examination in mirrors, covering up the defect and asking others for reassurance. Consultations with other physicians are common and a history of past operations on the perceived defect is seen in a significant proportion of patients.[35] Marked restriction in social and occupational functioning is seen in up to 98 percent of individuals and 30 percent of patients were described as housebound.[31,36] Thoughts and attempts of suicide, occasionally successful, are frequent. Current or past suicidal ideation should thus be routinely assessed by the practitioner. Particular monitoring may be needed with younger patients as antidepressant action increases impulsivity and likelihood of suicidal attempts.[24,31,37–39]

TREATMENT As noted before, many patients with BDD seek dermatologic, surgical, or other nonpsychiatric treatment over the course of their illness. Evidence suggests that if patients receive such treatment they do not improve, are usually disappointed with the results,[35] and may even experience an exacerbation of their symptoms.[36] Thus, it is strongly recommended that these lines of treatment be avoided. BDD is a severe and complex disorder that often requires multimodal treatment using cognitive behavioral therapy, exposure response prevention, and medication.

Pharmacologic trials show a good response to selective serotonin reuptake inhibitors (SSRIs), decreasing distress, compulsions, and frequency and intensity of obsessions about perceived defects; they also improve insight. Interestingly, SSRIs appear equally effective for delusional as well as nondelusional patients. Relatively high dosages are usually necessary for 12 to 16 weeks for a therapeutic effect, with close monitoring of side effects. Issues of compliance require close monitoring, because they are a frequent cause of treatment failure. A significant proportion of patients who fail one adequate SSRI trial respond favorably to a trial with another one, suggesting that serial trials of similarly acting agents should be administered in initially refractory cases. Lack of clear success has been noted with other agents, such as antipsychotics (including pimozide), tricyclic antidepressants (other than clomipramine), benzodiazepines, and anticonvulsants.[24,27,28,31,34,36,40–45]

PROGNOSIS AND CLINICAL COURSE BDD is a chronic illness without clear evidence for spontaneous remission without treatment. As seen in Treatment, pharmacotherapy with appropriate medications may lead to improvement in a considerable number of patients. However, we want to reiterate that effective high doses of SSRIs required are usually beyond than those approved by the U.S. Food and Drug Administration; the data also suggest that recurrence rates are extremely high with discontinuation of treatment,[31,40] and thus patients may require long-term treatment, which should also include insight-oriented psychotherapy.

Self-Inflicted Dermatoses

TRICHOTILLOMANIA Trichotillomania is currently classified as an impulse control disorder[12] characterized by repetitive pulling of hair, resulting in alopecia. Strict criteria also include a buildup of tension before hair pulling or when resisting an urge to do so, pleasure or relief after pulling out the hair, and significant functional impairment and distress in the patient.

Epidemiology. Prevalence rates are estimated to be between 0.5 percent and 3.5 percent, with a mean age of onset between 10 and 13 years of age. Despite its current classification, there are marked similarities with OCD, which may have important treatment implications. Co-morbid psychiatric disorders are depression, anxiety, and OCD.[46–51]

Clinical Findings. (Fig. 103-1) Trichotillomania presents clinically with nonscarring alopecia, most commonly with hairs broken at different lengths; occasionally, repeated trauma may ultimately result in some scarring. Body areas involved typically include the scalp, eyelashes, eyebrows, and pubic hair, with a majority of patients pulling hair from more than one site.[46,52] Rarely, this is followed by the ingestion of the hair,[46] leading to the potentially dangerous complication of trichobezoar.[53] Awareness of the behavior is partial to complete in a vast majority of patients,[52] and frequently occurs while patients are engaged in isolated, sedentary activities.[46,54] Attempts to resist the behavior and to disguise its cosmetic sequelae are common.[46,51] Typical histo-

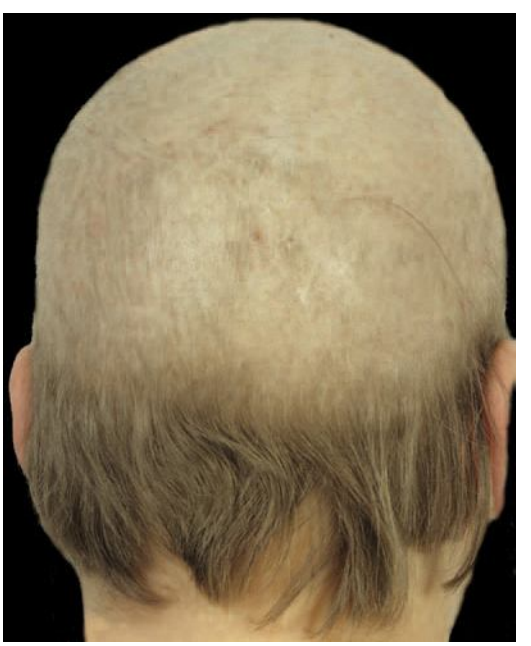

◀ **FIGURE 103-1** Trichotillomania. Hairs broken off at different lengths.

pathologic findings that may be helpful in confirming the diagnosis in questionable cases include catagen hairs, pigment casts, and traumatized hair bulbs without significant inflammation or scarring.[55,56]

Treatment. Because of trichotillomania's similarities to OCD, the use of SSRIs and clomipramine has received much attention. Successful monotherapy with paroxetine, sertraline, fluoxetine, citalopram, escitalopram, venlafaxine, olanzapine, and clomipramine have been reported, as well as the augmentation of SSRIs with the addition of olanzapine, risperidone, or pimozide. Low-dose atypical antipsychotic agents in combination with SSRIs appear to have promising results.[52,57–68] Nonpharmacologic treatment of trichotillomania relies heavily on behavioral therapies, especially habit reversal,[69,70] which entails engaging the patient in a behavior incompatible with hair pulling when the urge appears. The addition of cognitive-behavioral[71] or insight-oriented psychotherapy have good results; hypnotherapy may also be very useful, particularly in children.[72]

Prognosis and Clinical Course. Trichotillomania is a chronic disorder, and data on long-term success of pharmacologic and psychotherapeutic interventions are inconclusive. Although short-term success occurs, sustained improvement has yet to be shown convincingly.[73]

DERMATITIS ARTEFACTA Dermatitis artefacta is a form of factitious disorder in which patients intentionally feign symptoms and produce signs of disease in an attempt to assume the patient role. Unlike patients with malingering who engage in similar behavior for external or "secondary gain" (such as monetary reward or relief from occupational or other social responsibilities), the factitious patient seeks the "primary gain" of the emotional and psychological benefits that accrue to those who are "ill." Patients with borderline personality disorder also frequently exhibit self-mutilation behavior. Occasionally, a psychologically disturbed adult induces skin lesions in their children,[74,75] a form of Münchausen syndrome by proxy.

Epidemiology. Predominating in females, the age of onset varies significantly from adolescence through adulthood.[76] Comorbid depressive and personality disorders may also be seen.

Clinical Findings. (Fig. 103-2) Although it has long been observed that patients with dermatitis artefacta may present with lesions in virtually all areas of the body that can mimic most dermatoses,[77] some common elements may hint at this diagnosis. Lesions are often in areas readily accessible to the patient,[78] and may have geometric patterns or angulated borders surrounded by completely healthy skin. Morphology is often bizarre and does not conform to typical presentations of known dermatoses (Fig. 103-3). Patients are often unable to provide a clear history of the initial appearance or evolution of the process, and typically deny any role in the production of the lesions. Characteristically, the histopathology is unrevealing.



◀ **FIGURE 103-2** Dermatitis artefacta. Linear, sharply bordered ulcer.

Differential Diagnosis. As in all cases of factitious disease, the clinician must rule out possible disease entities that are consistent with the history and clinical findings. Unusual presentations of common illnesses and rare conditions must be entertained. However, exhaustive searches for primary skin pathology without supporting clinical evidence may compound the problem and actually perpetuate the patient's factitious behavior. Occlusive dressings (e.g., Unna's boot) or other means of preventing manipulation by the patient lead to healing of the lesions and are often helpful strategies in clarifying the diagnosis.

Treatment. A supportive, nonconfrontational, empathic approach to the patient is indicated initially. Immediate confrontation regarding the suspicion that the patient's lesions are self-induced can be counterproductive in that the patient often flees from treatment at that point. Frequent visits and symptomatic topical treatments are useful in the beginning.[79] However, the clinician must be careful not to collude in the patient's abnormal illness behavior and, ultimately, the recognition of the patient's role in the production of the lesions must be broached. The goal is to establish a trusting and supportive enough relationship with the patient that he or she accepts a psychiatric referral to explore the complex personality and behavioral derangements that often underlie this condition. Antidepressants and low-dose atypical anti-



◀ **FIGURE 103-3** Dermatitis artefacta. Solitary ulcer on dorsum of hand; tendons are visible at the base.



psychotics have also been reported to be useful adjunctive therapies.[80,81] In the case of Münchausen syndrome by proxy, in which the lesions are induced in children by parents or other caregivers, child protective services or equivalent agencies must be alerted immediately to safeguard the welfare of the child.

Course and Prognosis. Course and prognosis are fundamentally determined by the underlying psychopathology. In those patients with severely disturbed personalities, the recurrent self-defeating and destructive behaviors are likely to continue.[82]



NEUROTIC EXCORIATIONS Neurotic excoriation is also a condition in which patients induce skin lesions through repetitive, compulsive excoriation of their skin. However, unlike patients with dermatitis artefacta, these patients admit their role in the production of the lesions. This condition seems to be associated with underlying obsessive-compulsive personality traits and depressive disorders.[83,84]

Epidemiology. Neurotic excoriations have been reported in up to 2 percent of dermatology clinic patients,[85] with a predominance in middle-aged females, and is frequently associated with obsessive-compulsive personality and mood disorders.[86]

Clinical Findings. Patients with neurotic excoriation often describe significant itch leading to persistent scratching, which is frequently antedated by considerable psychological stressors. The development of this disorder has also been noted to be associated with the marked limitation in activity seen in illness or senescence.[87] The repeated excoriation can lead to the development of an "itch-scratch cycle," perpetuating the behavior. Patients present with multiple excoriations in various stages of evolution and healing, with postinflammatory hyperpigmentation, and frequent scarring (Fig. 103-4). The distribution of the lesions reflects their self-inflicted nature with most being on the extensor surfaces of the extremities, upper back, and face, sparing unreachable areas. Frequently, patients develop neurotic excoriations overlying pre-existing dermatosis, such as folliculitis and acne (acne excoriée). Prurigo nodularis[88] can be considered an extreme variant of this entity, characterized by severely pruritic nodules that may vary from a few millimeters to 1 to 2 cm in diameter, preferentially located on the lower extremities. Up to 58 percent of these patients have been found to have significant depressive disorder, and 45 percent co-morbid OCD.



▲ **FIGURE 103-4** Neurotic excoriations. Lesions present in all stages of evolution.

Differential Diagnosis. The clinician must evaluate the patient for causes of pruritus (see Chap. 102) and rule out possible internal diseases including neoplasms, in particular, lymphomas. The differential for the underlying psychiatric disorder, if present, must include depressive and anxiety disorders and, more rarely, excoriations secondary to DP.

Treatment. Workup for pruritus should be instituted in those patients with significant itch. In the absence of organic cause, these patients may improve with phototherapy. Additional treatment should be directed at underlying psychopathology when identifiable. Antidepressants, helpful in both depressive and anxiety disorders, including OCD, are very useful.[89] Subsequent addition of low-dose atypical antipsychotics, such as olanzapine, have been found effective. Supportive psychotherapeutic approaches are usually helpful and well tolerated,[83] and behavioral interventions similar to those used to treat self-injurious behaviors in Tourette syndrome may be useful.[90]

Course and Prognosis. Neurotic excoriation can be a chronic condition whose prognosis[83] depends on the underlying psychiatric illness. With appropriate therapy, patients with affective and anxiety disorders may have excellent outcomes, with a symptom-free, normally functioning state.

ATYPICAL CHRONIC PAIN/BURN SYNDROME Occasionally, patients present to dermatologists with complaints of burning, pain, or dysesthesias in the skin or mucus membranes for which no identifiable pathology can be found. This can be a frustrating situation for patient and clinician alike. A psychiatric approach to these patients may offer a means of understanding the complex factors underlying this syndrome, such as co-morbid affective disorders, personality vulnerabilities, behavioral problems, and life circumstances that may perpetuate the pain cycle and maintain the patient in an illness role.

There is a significantly increased rate of depression in patients with chronic pain syndromes[91] and a clear relationship between lifetime depression and the development of medically unexplained symptoms, including pain.[92] Depression not only worsens the experience of pain by psychologically magnifying negative perceptions, but may also interfere with the function of descending monoaminergic neurons that dampen nociceptive transmission.[93,94] This could explain the role for tricyclic antidepressants in analgesia. Other complicating factors include anxiety, which is also commonly seen in patients with chronic pain.[92,95] Personality disorders influence all aspects of patients' lives and may make the burden of a chronic condition more challenging to bear. At times, family or social environments may unwittingly play a role in undermining the chronic pain patient's rehabilitation by rewarding illness behaviors with well-meaning, yet oversolicitous, attention. Pain states can further be complicated if the patient develops an inappropriate pattern of using prescribed analgesics. For all of these reasons, the best course of action for patients presenting with poorly explained chronic pain is to refer them to a multidisciplinary pain center where thorough evaluation and treatment can be under-

TABLE 103-3
Antipsychotics: Typical and Atypical[a]

Drug	Dose (mg/day)	Most Common/Serious Side Effects					
		EPS	NMS	Metabolic Syndrome	Seizures (at High Doses)	Cardiac	Other[b]
Clozapine (Clozaril)[c]	25–900	±[d]	±	++	+	Myocarditis, hypotension	Severe agranulocytosis[e]
Olanzapine (Zyprexa)[c]	2.5–10.0	±[d]	±	++++	+	Hypotension	Dizziness
Risperidone (Risperdal)[c]	0.25–8.00	±[d]	±	+++	+	Hypotension	Hyperprolactinemia Dizziness
Quetiapine (Seroquel)[c]	25–400	±[d]	±	+++	+	Hypotension	Cataracts
Ziprasidone (Geodon)[c]	20–80	±[d]	±	++	+	Arrhythmia, prolonged QT, hypotension	
Aripiprazole (Abilify)[c]	2.5–30.0	±[d]	±	++	+	Hypotension	Headache
Pimozide (Orap) (typical antipsychotic)	1–10	+++	+++	–	++	++ Arrhythmia prolonged QT, ++ hypotension	

EPS = extrapyramidal symptoms (including dystonia, akathisia, rigidity, tardive dyskinesia); NMS = neuroleptic malignant syndrome; ± = very rare occurrence; – = not seen; + to ++++ = rare to very likely to occur.
[a]Important: The antipsychotics have to be titrated slowly, starting at the lowest possible dose.
[b]All antipsychotics have been associated with early death in the elderly (thromboembolism).
[c]Atypical antipsychotics.
[d]Although rare with atypical antipsychotics, can be seen in the young and elderly (particularly with risperidone).
[e]The possibility of life-threatening agranulocytosis requires close monitoring.

taken. The presence of burn syndrome may occasionally respond to the administration of gabapentin. Awaiting U.S. Food and Drug Administration approval, milnacipran is considered a serotonin/norepinephrine reuptake inhibitor (SNRI) of choice for chronic pain/burn/dysesthesia syndrome. Extreme forms of chronic dysesthesia can resolve with the administration of antipsychotic medication, suggesting that it represents a form of delusion.

PSYCHOGENIC PRURITUS Psychogenic pruritus and itch in general are discussed in Chap. 102.

PSYCHOTROPIC MEDICATIONS USED IN DERMATOLOGY

Dermatologists who elect to treat psychocutaneous disorders routinely use a number of different classes of psychotropic medications. Knowledge of the drugs and their actions, indications, side effects, therapeutic doses, and potential drug interactions is, therefore, critical.[96–102]

These drugs are classified according to their clinical utility (e.g., antidepressants or antipsychotics) and further identified by their chemical structure and/or mechanism of action. All of the drugs discussed in this section exert their clinical effects through modulation of neurotransmitter function in the CNS by altering presynaptic reuptake of the transmitters, blocking their pre- and/or postsynaptic receptor binding, stimulating those receptors, or some combination thereof. The most appropriately used in each of the following three major classes are discussed: antipsychotics, antidepressants, and anxiolytics.

Antipsychotics (Table 103-3)

Antipsychotics have a wide variety of uses in psychiatry, but their primary indication in psychocutaneous medicine is in the symptomatic treatment of disorders characterized by delusions and/or hallucinations. The most common indications in dermatology are DP and, less frequently, for the treatment of self-induced dermatoses.[80] The drugs are believed to exert their beneficial effects by the blockade of postsynaptic dopamine receptors in the CNS. Dopaminergic tracts in the mesolimbic and mesocortical systems are felt to be the most important with regard to the production of symptoms of psychotic illness. However, dopamine is found widely throughout the brain and its blockade in the nigrostriatal and tuberoinfundibular pathways can lead to significant side effects.

Antipsychotics are now classified as typical (or conventional) and atypical. The older, typical antipsychotics are potent, nonspecific blockers of postsynaptic D_2 dopamine receptors and have varying degrees of inherent anticholinergic activity. The newer atypical antipsychotics have different affinities for dopamine receptors subtypes and serotonergic blocking properties at the serotonin-2 (5-HT2) receptor. This combination allows a continued potent antipsychotic effect but with a much more preferable neurologic side-effect profile because of decreased interference with dopamine transmission in the basal ganglia. The advantages of these over typical antipsychotics include reduced risk of extrapyramidal symptoms, enhanced efficacy in treatment of cognitive and executive dysfunctions, and mood stabilizing/elevating effects. The disadvantages include significant cost and the development of metabolic syndrome.

COMPLICATIONS The most dramatic complications of the typical antipsychotics, including pimozide, are neurologic. They are divided into acute and delayed. The acute neurologic side effects (also known as *extrapyramidal symptoms*) are a result of dopaminergic blockade in the striatum causing (1) dystonias (acute increases in tone and abnormal posturing, typically involving muscles of the face, neck, tongue, and pharynx), (2) parkinsonism (with tremor, gait disturbance, stiffness, cogwheeling rigidity, marked facies, and general bradykinesia), and (3) akathisia (an experience of marked restlessness in the muscles that should be distinguished from psychic anxiety or agitation). These acute neurologic side effects are best managed by co-administration of an anticholinergic medication such as benztropine (Cogentin), 0.5 to 2.0 mg twice



daily, or diphenhydramine, 75 to 100 mg orally. In severe acute dystonia, which is most likely to occur within the first week of treatment, patients may develop muscular rigidity and cramping in the neck, tongue, face, and back, occasionally with dysphagia. Muscular cramps can cause joint dislocation and, most dangerously, laryngeal dystonia with compromise of the airway. Benztropine, 2 mg intramuscularly (IM) or intravenously (IV), or diphenhydramine, 50 mg IM or IV, often provides relief. If there is no effect, the dose can be repeated in 20 minutes. If the dystonia is still unresponsive, lorazepam, 1 mg IM/IV, may be of benefit. In laryngeal dystonia, doses may need to be IV and repeated in 10 minutes.

The most worrisome delayed side effect of antipsychotic treatment is tardive dyskinesia (TD), characterized by repetitive purposeless movements that usually involve the lips, tongue, face, and upper extremities. It is rare in patients with fewer than 6 months of treatment. Risk factors for the development of TD may include older age, female gender, and the presence of affective disorder.[83] Treatment of TD includes decrease or discontinuation of the antipsychotic if the underlying psychiatric illness allows and stopping anticholinergic medications; administration of benzodiazepines is also helpful. Quetiapine has been reported to decrease and sometimes reverse TD.

Nonneurologic side effects of antipsychotics include sedation, galactorrhea, and effects on cardiac conduction. Because of pimozide's, ziprasidone's, and aripiprazole's effect on the repolarization phase, prolongation of the QT interval is possible, which is a potential risk factor for the development of fatal ventricular tachyarrhythmias. Therefore, electrocardiograms should be obtained for all patients at baseline and after dose changes. In those patients with existing QTc prolongation or in those patients who develop it during treatment, the drug should be discontinued.

Finally, neuroleptic malignant syndrome, characterized by fever, autonomic instability, diffuse increase in muscle tone, mental status changes, rhabdomyolysis, and renal failure, is fortunately rare but potentially fatal complication of antipsychotic treatment (Table 103-4). This can occur at any time during treatment, but is more common during the first few weeks or months, or during rapid dose increases. Patients presenting with such features should be referred for emergent evaluation.

TABLE 103-4
Neuroleptic Malignant Syndrome

- Incidence of 0.2%
- Rare with atypical antipsychotics
- More frequent with high doses or rapid titration of neuroleptics
- Diagnostic criteria
  - Hyperthermia [body temperature > 38°C (100.4°F)]
  - Muscle rigidity
  - Change in mental status
  - Elevated creatine phosphokinase
  - Diaphoresis
  - Tachycardia
- Requires emergent evaluation

The more modern atypical antipsychotics have more acceptable side-effect profiles and are associated with a much smaller risk of extrapyramidal symptoms. All the drugs in this group may induce a metabolic syndrome characterized principally by abdominal obesity and insulin resistance or glucose intolerance. A thorough discussion of these risks should take place with the patient before initiating treatment. Baseline and follow-up laboratory tests should include complete blood cell count with platelet count, urinalysis, liver function tests, fasting glucose, and a lipid panel, in addition to regular measurements of weight. Incidences of cardiac, neurologic, and other side effects are summarized in Table 103-5. Finally, the following precautions should be considered in the use of antipsychotic medications:

History: Personal and family history of obesity, cardiovascular disease (particularly conduction hypertension), diabetes, and dyslipidemia.

Baseline and subsequent follow up: Weight, body mass index, waist circumference (umbilical level), blood pressure, fasting plasma glucose, lipid profile, and prolactin levels. Initially monthly and subsequently quarterly.

Consider additional interventions, referral, or change in treatment if: Significant changes in weight (>5 percent), body mass index (>25), hypertension, diabetes, lipid profile, or prolactin problems occur.

Antidepressants (See Table 103-5)

A wide array of antidepressant options currently exists, including tricyclic antidepressants, SSRIs, SNRIs (duloxetine,

TABLE 103-5
Antidepressants

Mechanism of Action/ Chemical Structure	Drug	Dose[a] (mg/day)	Side Effects
Serotonin reuptake inhibitors	Citalopram (Celexa) Escitalopram (Lexapro) Fluoxetine (Prozac) Fluvoxamine (Luvox) Paroxetine (Paxil) Sertraline (Zoloft)	10–40 10–30 10–80 100–300 20–60 50–200	Anxiety, irritability, increased suicide rates, akathisia, sexual dysfunction, hypomania/ mania, agitation, weight gain.
Norepinephrine-serotonin reuptake inhibitors	Venlafaxine (Effexor) Duloxetine (Cymbalta) Milnacipran[b]	37.5–225.0 20–60 25–100	Hypertension, tachycardia, anxiety, nausea, sexual dysfunction.
Norepinephrine-dopamine reuptake inhibitors	Bupropion (Wellbutrin)	100–450	Seizures. Avoid in patients with convulsive history, eating disorders, or alcohol withdrawal.
Blockage of presynaptic reuptake of monoamines: tricyclics	Amitriptyline (Elavil) Nortriptyline (Aventyl) Clomipramine (Anafranil) Doxepin (Sinequan)	25–150 50–150 75–250 50–300	Arrhythmias, hypertension, orthostatic hypotension, dry mouth, constipation, sexual dysfunction, sedation; avoid in glaucoma.
Presynaptic α-2, 5-HT2c/5-HT3 antagonist	Mirtazapine (Remeron)	15–45	Agranulocytosis, weight gain, dizziness.

5-HT = serotonin.
[a]These doses include minimal to maximal dose. Some of the latter may be higher than recommended by the U.S. Food and Drug Administration (FDA), but may be required for effectiveness.
[b]Milnacipran, still awaiting FDA approval, appears particularly indicated for patients with atypical pain syndrome and fibromyalgia. **All antidepressants have increased risk of suicide.**



venlafaxine, milnacipran), norepinephrine/dopamine reuptake inhibitor (bupropion), monoamine oxidase inhibitors (phenelzine, tranylcypromine, isocarboxazid, and, more recently, a safer transdermal version of selegiline), and others (presynaptic α2 blockade, 5-HT2A, 5-HT2C, and 5-HT3 antagonist: mirtazapine). In dermatology, these drugs are used to treat affective disorders such as major depression, anxiety disorders, and obsessive-compulsive spectrum disorders such as trichotillomania and BDD. This section discusses the classes most frequently used by dermatologists: tricyclics and SSRIs.

TRYCYCLIC ANTIDEPRESSANTS The tricyclic antidepressants are agents that block the presynaptic reuptake of monoamines from the synapse in the CNS. Thus, norepinephrinergic and serotonergic transmission is potentiated. Most agents in this class block this reuptake rather nonspecifically, although the drug clomipramine acts most prominently on 5-HT reuptake, which underlies its special utility in the treatment of some OCDs.

The tricyclic doxepin has found frequent use in dermatology (perhaps even more than psychiatry currently) because of its potent antihistaminergic properties in addition to its antidepressant effects. In those patients with anxious depressions in whom pruritus is a significant co-morbid dermatologic symptom, this may be the antidepressant of choice.

Dosing. In general, low initial dosing with gradual titration to therapeutic levels is advised. As most are sedating, bedtime dosing is recommended. An advantage of this class of antidepressants is that serum levels are readily obtainable and can aid in the choice of appropriate daily doses. Because individual metabolism of these compounds varies radically, objective evidence of actual blood levels is quite helpful. These levels can inform the clinician about toxicity, patient compliance, and subtherapeutic dosing, major factors that must be considered when the treatment regimen is unsuccessful.

Complications. The tricyclic antidepressants not only affect monoaminergic transmission in the CNS, but also have varying degrees of anticholinergic, antihistaminergic, and peripheral anti–α_1-adrenergic properties that can lead to significant side effects, including constipation, dry mouth, urinary retention, precipitation of an attack of narrow-angle glaucoma, sedation, and orthostatic hypotension. Orthostatic pulse and blood pressure measurements should be documented in the record for all patients receiving tricyclic antidepressants. These drugs can also lead to significant alteration in the repolarization phase of cardiac conduction, increasing the risk for ventricular tachyarrhythmias. A baseline electrocardiogram should be obtained in all patients. Tricyclics should not be used in those patients with significant prolongation of the QTc interval, left bundle-branch block, or bifascicular block. They also cause tachycardia as a result of a reflex increase secondary to orthostatic hypotension and a general decrease in vagal tone to the heart. They may also induce seizures.

Like all antidepressants, the tricyclics have the potential to precipitate an episode of mania or hypomania if used in patients with bipolar affective disorder. These patients should be screened for such a history before initiating therapy and referred to a psychiatrist who can follow the patient closely for signs of an emerging manic episode. Tricyclics are also potentially fatal in overdose; therefore, patients who express suicidal ideations are best treated by a psychiatrist.

SELECTIVE SEROTONIN REUPTAKE INHIBITORS As their name implies, SSRIs selectively block the reuptake of 5-HT into the presynpatic nerve terminal. Effective antidepressants, they are also very valuable agents in the treatment of anxiety and OCDs.

Dosing. Table 103-5 lists the usual dose ranges for SSRIs. For obsessive-compulsive spectrum disorders, higher doses of these agents may be required for clinical effect.

Complications. These are generally well-tolerated medications, even in the geriatric population. Unlike tricyclics, most of these drugs are somewhat stimulating and morning dosing is the rule. Decreased appetite, insomnia, akathisia, nausea, and diarrhea (due to 5-HT's action on gut motility) are fairly common. These are typically seen on initiation of therapy or after dose changes, and often disappear with continued treatment. Approximately 30 percent of patients experience sexual dysfunction, with decreased libido and orgasmic delay or anorgasmia being seen in both sexes. Similar to the tricyclics, SSRIs can lead to manic episodes in bipolar patients. They may actually be more likely to cause rapid cycling in which the patient experiences several depressive and manic swings in a relatively short period of time. The SSRIs are relatively safe in overdose. Because of their lack of effect on the myocardium and minimal, if any, impact on seizure threshold, they do not have the same risks as tricyclics. However, because they can be somewhat activating, patients with suicidal ideation treated with SSRIs should be followed extremely closely as energy may return before the dysphoria and suicidal wishes disappear. One rare, however life-threatening, side effect while on SSRIs includes the serotonin syndrome. This is a hypermetabolic state resulting from serotonergic excess with symptoms consisting of: disorientation, confusion, agitation, tremor, myoclonus, hyperreflexia, twitching, shivering, ataxia, hyperactivity, and hyperthermia.

These drugs also inhibit subtypes of the cytochrome P_{450} system; therefore, other drugs metabolized by this pathway are subject to significant alterations in serum levels. Dose adjustment and careful monitoring are important when coadministering such medications. When discontinuing SSRIs after prolonged use, it is important to gradually taper them to avoid withdrawal symptoms (somatic symptoms: dizziness, lethargy, nausea, vomiting, diarrhea, headache, fever, sweating, chills, malaise, incoordination, insomnia, and vivid dreams; neurologic symptoms: myalgia, paresthesia, and dyskinesias; psychological symptoms: anxiety, agitation, crying, irritability, confusion, impulsivity, disorientation, hypomania, and depersonalization).

SEROTONIN AND NOREPINEPHRINE REUPTAKE INHIBITORS SNRIs now comprise three medications: venlafaxine, duloxetine, and, more recently, milnacipran. They block the reuptake of both 5-HT and norepinephrine with differing selectivity. Whereas milnacipran blocks 5-HT and norepinephrine reuptake with equal affinity, duloxetine has a 10-fold selectivity for 5-HT, and venlafaxine has a 30-fold selectivity for 5-HT. All three SNRIs are efficacious in treating a variety of anxiety disorders, and all three seem to be helpful in relieving chronic pain associated with or independent of depression, whereas SSRIs are generally less effective. Tolerability of an SNRI at therapeutic doses varies within the class; venlafaxine seems to be the least well tolerated, combining serotonergic adverse effects (nausea, sexual dysfunction, withdrawal problems) with a dose-dependent hypertension. Duloxetine and milnacipran appear better tolerated and essen-



tially devoid of cardiovascular toxicity. The indication of milnacipran appears to be directed to the treatment of fibromyalgia and will probably prove effective for atypical pain syndrome.

Anxiolytics (Table 103-6)

Although antidepressants are effective drugs used to treat anxiety disorders, the symptomatic treatment of anxiety occasionally involves the use of other anxiolytics. Benzodiazepines are currently the most widely used class of anxiolytics, supplanting previous use of barbiturates. Buspirone, a nonbenzodiazepine anxiolytic, has also found utility in certain patients.

Benzodiazepines are CNS depressants, exerting their influence through action at the γ-aminobutyric acid (GABA) receptor. GABA is the major inhibitory neurotransmitter in the CNS. Thus, in addition to treating anxiety, other effects include sedation, loss of muscle coordination, and possible amnesia or blackouts. Buspirone is a partial 5-HT1A receptor agonist without the same liability for dependence and subsequent withdrawal phenomena common to all GABA active agents. Because of the potential for physical and psychological dependence, benzodiazepines should be used with great caution. All benzodiazepines can induce dependency, but is seen more frequently with potent, short-acting agents such as alprazolam and lorazepam. In general, the short-term symptomatic treatment of anxiety symptoms while other more definitive pharmacologic and psychotherapeutic measures are being undertaken remains the main indication for the use of these medications by the nonpsychiatrist.

Buspirone is an anxiolytic approved for the treatment of generalized anxiety disorder. It is thought to mediate its effects through serotonergic mechanisms. Unlike benzodiazepines, buspirone must be taken chronically for anxiolytic effects to be seen.

Lorazepam (between 0.5 and 2.0 mg), clonazepam (0.25 to 5.00 mg), and buspirone (between 5 and 10 mg) can be administered between one and three times a day. It is prudent to start on lower doses to evaluate tolerance.

TABLE 103-6
Anxiolytics

Drug	Dose (mg/day)	Side Effects
Lorazepam[a] (Ativan)	0.5–2.0	Fatigue, drowsiness; habit forming[b]
Clonazepam[a] (Klonopin)	0.25–4.00	Fatigue, dizziness, salivation; habit forming[b]
Buspirone (BuSpar)	5–60	Headache, dizziness, hypomania in elderly

[a]Benzodiazepines.
[b]Withdrawal syndrome with risk of seizures and delirium.

NONPHARMACOLOGIC TREATMENTS FOR PSYCHOCUTANEOUS DISORDERS (See Table 103-1)

The dermatologist should request a consultation with a psychiatrist or a liaison clinic during the treatment of patients with psychocutaneous disorders as soon as it is amenable to the patient. Although dermatologists are becoming more comfortable with the use of certain psychotropic medications, they generally do not have the time or the training to use effectively other treatment modalities such as psychotherapy and hypnosis. It is therefore sufficient that the practicing dermatologist be aware that a variety of psychotherapeutic approaches are available, including insight-oriented, cognitive-behavioral, supportive, and, to a lesser extent in current practice, psychodynamic therapy.[103] Certain types of therapies may be more effective for a given condition which underscores a fundamental point: diagnosis should drive choice of therapy and patients should not be formulated based on rigid therapeutic or theoretic biases.

PRIMARY DERMATOLOGIC DISORDERS

Role of Stress in Skin Diseases

The presence of a force that threatens to disrupt the organism's homeostatic balance is perceived as a stressor, and the ensuing reaction reflects the typical response aimed at the preservation of life.[104] Mammalian organisms respond to external (i.e., physical, environmental) or internal provocations (infections, anxiety, or anticipatory stress) by triggering a cascade of events that ultimately activate the hypothalamic-pituitary-adrenal axis,[105] allowing the organism to cope with noxious stimuli and mount a successful "fight-flight" reaction. This adaptation to challenges ("stress response"[19]) is critical for survival after an acute provocation; however, its persistence chronically can lead to exhaustion, distress, and, eventually, disease.[106,107] Whereas short-lived (acute) stressors are known to enhance immunity, chronic stress has an adverse effect on health and life expectancy, alters immunity, and favors the progression of infections as well as an increase in the development of experimentally induced neoplasms.[2] A number of studies provide clear evidence that psychosocial factors, including stress and other emotional states (such as depression), have a deleterious effect on the outcome of numerous human diseases, including those of the skin.[2,108]

Although suspected for many years, retrospective and prospective studies have provided the clinical basis to support the notion that stressful events can correlate with the onset or exacerbation of skin diseases. Additional evidence was gleaned from the results of therapeutic trials using psychotherapeutic approaches and stress-reducing interventions[21] in the treatment of dermatologic ailments such as atopic eczema, psoriasis, urticaria, herpes simplex virus (HSV) infection, alopecia areata,[109] and warts,[110] among others.

ATOPIC DERMATITIS (See Chap. 14) More than most other skin diseases, atopic eczema exemplifies the delicate balance between inherited factors, environmental influences, and psychosocial issues in the maintenance of health.[15] Up to 70 percent of atopic subjects reported preceding emotional stressors before the first episode of dermatitis,[22] whereas numerous patients with eczema suffer exacerbations of their skin symptoms after episodes of psychological stress.[113] These subjects have increased anxiety, altered coping mechanisms, and a close connection between severity of symptoms and stressful life events.[114,115] Psychodynamic approaches have emphasized the role played by an abnormal family structure[116] and altered mother-child relationships in this disease,[1] an issue that is highlighted by the improvement in the symptoms of children with atopic eczema when their mothers receive psychological treatment.[114,117,118] Other psychosocial interventions found to be effective as sole or adjuvant therapies for pediatric and adult patients[21] include behavioral therapies and biofeedback, stress reduction regimens, psychoanalysis, hypnosis, and relaxation techniques.[119–121]

PSORIASIS (See Chap. 18) Psychosocial issues appear to be closely linked to the

well-being of patients with psoriasis. Stressors often precede the initial onset of the disease or subsequent flares.[122–132] Individual or group psychotherapy, behavioral approaches, and biofeedback, among other techniques, have resulted in improvement of the psoriatic plaques, as well as enhancement of overall well-being.[133,134] A randomized controlled trial showed that highly suggestible patients treated with hypnosis significantly improved when compared to the control group,[135] and patients who used meditation tapes at the time of phototherapy cleared in half the time when compared to those who did not use them.[136]

HERPES SIMPLEX (See Chap. 193) There is strong evidence to support the role of stress in the evolution of HSV infections. Experimental restraint stress correlates with the reactivation of latent HSV infection in the dorsal root ganglion neuron of rats.[137] Human studies show that persistent, but not single, stressful events are associated with the frequency of recurrences,[138,139] which is in accordance with findings that chronic but not acute stress correlates with the development of experimental viral infections in normal volunteers.[140] Furthermore, psychosocial interventions decrease the frequency of recurrences of herpes simplex infections.[141]

URTICARIA (See Chap. 37) The relationship between stress and some forms of urticaria is supported by numerous anecdotal observations. Patients suffering from adrenergic urticaria report that their symptoms invariably follow acute stressful events.[142] Others with hereditary angioedema are known to have symptoms frequently triggered by emotional stress.[143,144] The finding that stress mediates the degranulation of mast cells via corticotropin-releasing factor[145] and neuropeptides[146] supports its putative role in the pathogenesis of urticaria.

Almost all inflammatory skin diseases have been anecdotally reported at one time or another to be associated to stressors. Up to 50 percent of females with acne suffer flares after stress,[147] and patients with seborrheic dermatitis,[148,149] lichen planus,[149,150] alopecia areata,[151] and even pemphigus vulgaris[152,153] have been reported to have symptoms triggered or exacerbated by emotional stress.

Skin Diseases and Psychosocial Distress

The physical or perceived disfigurement can become a source of significant distress, with a considerable impact on an individual's psychological, social, and physical well-being. Dermatologic conditions are responsible for a significant source of social stigmatization in many human societies and cultures, contributing to the development of co-morbid diseases such as depression and anxiety. Psoriasis, for example, impairs the social life of 40 percent of patients and 64 percent feel that their disease significantly impacts their socioeconomic functioning.[154] The presence of the frequent co-morbid associations such as depression and anxiety can be identified using available validated instruments such as the Depression Anxiety Stress Scales. The clinician should be aware of the incidence of depression and anxiety in patients with cutaneous diseases, which can be treated with the pharmacologic and nonpharmacologic approaches delineated above.

The Dermatology Life Quality Index[155] and the Skindex-16[156] are simple and practical validated instruments that can be used both in the office setting and for research purposes to quickly evaluate quality of life. Specific instruments are also available for patients with psoriasis,[155] eczema,[157] acne,[158] and urticaria[159] among others. These tests are helpful tools that can assess improvement in both the physical and the psychosocial aspects of a patient's disease. The sum of observations, studies, and therapeutic interventions suggests that stress plays a significant role in the biology and clinical expression of skin diseases, and supports the notion that therapies that address this issue may have a positive impact on the well-being of patients with dermatologic diseases. Adjuvant psychosocial interventions could also mediate an increased adherence to medical treatments, provide social support, decrease stress or alter the response to stress, ameliorate anxiety, aid patients to develop better coping mechanisms, improve depression, and help with self-image or distorted body perception.



KEY REFERENCES

The full reference list for all chapters is available at www.digm7.com.

2. Tausk FA, Nousari H: Stress and the skin. *Arch Dermatol* **137**:78, 2001
5. Gupta MA: Psychocutaneous disease. *Dermatol Clin* **4**:591, 2005
21. Grant JE, Phillips KA: Recognizing and treating body dysmorphic disorder. *Ann Clin Psychiatry* **17**:205, 2005
80. Koblenzer CS: Dermatitis artefacta. Clinical features and approaches to treatment. *Am J Clin Dermatol* **1**:47, 2000
89. Fried RG, Fried S: Picking apart the picker: A clinician's guide for management of the patient presenting with excoriations. *Cutis* **71**:291, 2003
98. Koo JY, Ng TC: Psychotropic and neurotropic agents in dermatology: Unapproved uses, dosages, or indications. *Clin Dermatol* **20**:582, 2002
103. Fried RG: Nonpharmacologic treatments in psychodermatology. *Dermatol Clin* **20**:177, 2002

CHAPTER 104

Cutaneous Manifestations of Drug Abuse

Miguel R. Sanchez

Drug abuse can be suspected or diagnosed on the basis of skin findings. The parenteral administration of drugs causes skin lesions and eruptions predominantly through local or systemic, toxic, or hypersensitivity-induced effects of the drug itself, adulterants, or infectious agents. Intravenous administration can produce a number of recognizable stigmata, which may identify an individual abusing drugs to anyone aware of illicit drug use practices.

Behavior associated with drug abuse continues to be an important factor in the spread of human immunodeficiency virus (HIV) infection. Approximately 4 of 10 acquired immunodeficiency syndrome deaths are related to drug abuse.[1] Parenteral drug users also have high risks for contracting hepatitis B and C and other blood-borne infections. About 60 percent of all new hepatitis C infections in the United States are attributed to syringe and needle sharing with an infected individual.[1] In some user populations, hepatitis C is transmitted so rapidly that within 6 months of injecting drug, one-third of users become infected, and within 2 years, 90 percent have contracted the infection.[2] Drug addicts also

CUTANEOUS MANIFESTATIONS OF DRUG ABUSE

AT A GLANCE



- The pattern and appearance of skin lesions can identify persons with former and current drug dependency.
- The most specific signs of injectable drug abuse are skin tracks, punctures, ecchymoses, or crusted papules along veins, phlebitis, scars of undetermined etiology, woody dermal induration, and cutaneous ulcerations in unusual body areas.
- Drug addicts have higher prevalences of sexually transmitted diseases, and those who inject chemicals are at higher risk of contracting blood-borne infections including human immunodeficiency virus; syphilis; hepatitis B, C, and D; and human T-lymphotropic virus 1 and 2.
- Drug-addiction-related bacterial infections predominantly involve the skin and soft-tissue. Culture-guided antibiotic therapy is essential because infection with unusual organisms, antibiotic-resistant strains, and polymicrobes is more common.



have higher incidences of sexually transmitted diseases, depression, accidental injuries, and trauma due to criminal violence or domestic abuse. Numerous sociologic problems, such as loss of work productivity and increases in crime, prison occupancy, and property damage, result from drug abuse and dependence. The Office of National Drug Control Policy reported the annual economic cost to society from drug abuse in 1998 as $143.4 billion and projected an increase to $204 billion in 2007, with health care costs accounting for 9 percent of these figures.

DEFINITIONS

COMMONLY ABUSED DRUGS

Cannabis (marijuana, Mary Jane, pot, herb, ganja, weed, boom) is a mixture of dried shredded leaves and flowers of *Cannabis sativa* that contains the chemical delta-9-tetrahydrocannabinol. Diacetylmorphine (heroin, junk, smack, horse, scag), the fastest-acting and most potent opiate, accounts for 90 percent of the opiate abuse in the United States. A "rush" develops within 7 to 8 seconds if the opiate is injected intravenously or within 10 to 15 minutes if it is snorted or smoked. Persons addicted to opiates may alternate injections of heroin and cocaine (crisscrossing) or inject highly addictive "speedballs" of the two drugs together. Cocaine (coke, blow, toot, flake, and snow) is an alkaloid stimulant and topical anesthetic that is extracted from the leaves of the coca shrub. Crack (base, rock, hubba, gravel, girl), or crystallized, freebase cocaine, is far more addictive than heroin. Crystallized methamphetamine (ice, crystal, glass, meth, tina) is usually inhaled or injected intravenously to produce a stronger rush. The typical portrait of a "speed freak" with pale, sagging sweaty complexion, body odor, cachectic appearance, discolored teeth, skin ulcers, and scars has been popularized in the media. Because withdrawal symptoms are so intense, methamphetamine addiction is more difficult than any other addiction to treat. 3,4-Methylenedioxymethamphetamine, often abbreviated as MDMA (speed, ecstasy, Adam, XTC, hug, beans, love drug) is a synthetic psychoactive drug with stimulant and mildly hallucinogenic properties. Sedatives, which are frequently misused by polydrug addicts, enhance the euphoric effects of heroin. Flunitrezepam is 10 times more potent than diazepam. Lysergic acid diethylamide (acid) continues to be a popular hallucinogen.

STATISTICS

Between 3 and 5 percent of the global population abuse drugs, and approximately 13 million of them inject them. The National Survey on Drug Use and Health estimated that 19.5 million people 12 years of age or older (8.2 percent of the population) used an illicit drug in the prior month. Injection is one of the most harmful routes of administration.

PATHOGENESIS OF DRUG ABUSE

CLINICAL MANIFESTATIONS

Most cutaneous manifestations of drug abuse are lesions that occur also in other conditions, but it is their pattern, appearance, and distribution that identify persons with drug dependency (Box 104-1).

Box 104-1

Differential Diagnosis of Cutaneous Manifestations of Drug Abuse

Most Likely

- External trauma scars (skin tracks)
- Self-induced scars (skin or pop tracks)
- Livedoid vasculitis (pop scars)
- Sporotrichosis (linear plaques)
- Atypical mycobacterial infection (nodules and ulcers)
- Ecthyma (necrotic ulcers)

Consider

- Panniculitis (woody induration)
- Mondor disease (phlebitis)
- Polyarteritis nodosa (ulcers)
- Leishmaniasis (ulcers)
- Ulcerative sarcoid (ulcers)
- Tularemia (ulcers)
- Anthrax (necrotic ulcers)
- Actinomycosis (abscess)
- Wegener granulomatosis (ulcers and nodules)
- Exposure to chromium solutions (nasal perforation)
- Nasal septum trauma from surgery, intubation, nasogastric tube (nasal perforation)
- Nasal malignancies (nasal perforation)
- Syphilis or yaws (nasal perforation)
- Rhinosporidiosis (nasal perforation)

Scars

The most specific sign of drug abuse by injection is the presence of skin tracks (Fig. 104-1). Initially, punctures, ecchymoses, and crusted lesions trail along the length of the vein (Fig. 104-2). With repeated injections of irritating drugs and adulterants, the veins become inflamed and scarred.[1] Due to their easy access, the veins of the arms and hands are injected initially by most novice addicts. However, to avoid the presence of incriminating tracks, some addicts prefer injections on the legs and feet. When these areas become scarred, drugs are injected into the vessels of the neck, abdomen, axillae, groin, sublingual area, genitals, hemorrhoids, and any visible or palpable vein or artery. When intact veins cannot be found, the skin may be cut superficially with razor blades or knifes and powdered drugs rubbed into the lacerations. Some young addicts actually prefer this technique. Subcutaneous and intradermal injections cause irregular, round, leukodermic, atrophic depressions known as *skin popping scars* (Fig. 104-3). In some



▲ **FIGURE 104-1** Skin tracks along the veins of the dorsal hand.



▲ **FIGURE 104-2** Purpuric puncture marks on several veins, suggesting intravenous drug use.

cases, indurated, linear, hypertrophic, or keloidal scars form.

Cocaine is a vasoconstrictor and can produce tissue ischemia, especially when extravasated. It does not regularly form tracks, but cutaneous fibrotic scars on the extremities resulting from intracutaneous injection have been reported.[7] Pentazocine injection can cause brawny, fibrotic skin.[8]

Ulcerations

Intradermal injections or accidental extravasation of certain drugs and adulterants can cause tissue injury. Heroin and other powder drugs are frequently "cut" with fillers such as lactose, mannitol, dextrose, baking soda, and flour.[9] Injection of sclerosing adulterants and drugs can produce tender and inflammatory plaques or nodules that ulcerate (Fig. 104-4) and heal with epidermal pigmentary changes, woody induration of the dermis and subcutaneous tissue, and retracted cicatrices. These are known as *shooter's patches*.

Even inhalation of cocaine can cause skin and muscle infarction.[10] Extensive necrosis of the nose and upper lip accompanied by a necrotizing infection of the subcutaneous soft tissue of the cheeks, forehead, and temporal regions has been caused by forced intranasal impaction of crack cocaine.[11] Injection into soft tissue of barbiturates, which are highly alkaline, results in tender, erythematous, indurated plaques that break down into deep ulcers and frequently become infected. Tripelennamine (pyribenzamine), an antihistamine usually injected in combination with pentazocine or another opioid, also induces tissue necrosis and ulceration.[12] After pentazocine injection, the skin often breaks down, resulting in irregularly shaped, deeply penetrating ulcers that extend to fat and even muscle.[8] Drug addicts have been known to sabotage medical wound healing efforts to maintain the granulation tissue for heroin injections.[13]

Granulomas

Pulmonary foreign body granulomas have been found in 30 percent of addicts on whom autopsies have been performed. Although cutaneous granulomas are not common, they can develop months and up to 50 years after the last intravenous or subcutaneous injection because granuloma formation requires conversion of silica to its colloidal form.[14] Most granulomas are caused by the injection of hydrous magnesium silicate (talc) and, less often, starch into the subcutaneous tissue, deep dermis, and walls of veins. The lesions are firm, movable cutaneous nodules. Talc granulomas also may develop in the liver, lymph nodes, spleen, and bone marrow. In addition to being a popular adulterant for powder drugs, talc is the main ingredient in some narcotic tablets that are crushed, diluted in liquid, and injected.[14]

Burns

Burns from lit matches, cigarettes, paraphernalia, and contact with fire during cooking are common during the altered state of consciousness produced by drug intoxication. Cigarette burns, most commonly on the digits and sternum, occur from lit cigarettes that addicts were smoking before falling asleep. The necklace sign is produced by cigarette ashes that fall on the neck when the smoking addict dozes off.[1] Singeing of the eyelashes and eyebrows, resulting in madarosis, may be caused by rising hot vapors during smoking of crack cocaine. Individuals who use crack also may develop linear, circular, or oval blackened, hyperkeratotic lesions caused by the heat of the glass pipe.[15] The areas affected are the thenar eminences of the thumbs (crack thumbs) and the palm (crack hands) of the dominant hand. More severe thermal burns may be incurred on the hands while lighting a crack-cocaine pipe with a butane lighter directed downward onto the pipe.

Solvent inhalation is especially popular among adolescents. Minor, superficial burns occur as a result of flash fires caused by the ignition of lighter fluid, composed of butane and isobutane, in enclosed spaces while the fumes are being inhaled. Extensive explosion burns can occur involving the face, neck, arms, and hands, as well as the trunk and/or



◀ **FIGURE 104-3** Depressed, circular scars ("pop scars") due to subcutaneous heroin injection.





▲ **FIGURE 104-4** Foreign body response and cellulitis from subcutaneous and intravenous injection of adulterated heroin.



lower extremities.[16] Severe burns also occur when other solvents, such as paint thinner or petrol, become ignited by a cigarette that the sniffer is simultaneously smoking.

Pigmentary Changes

Post-inflammatory pigmentary changes are more common in persons with darkly pigmented skin. Circumferential pigmented bands due to pressure from tourniquets are common in dark-skin intravenous drug users. Soot tattoos are black macules produced by inadvertent injection of residual carbon that remains on the needle after flaming. Persons who abuse methamphetamine develop grayish, dry, leathery skin with a strange odor.

Vascular Lesions

The most common vascular lesions in addicts are ecchymosis and hematomas from extravasated blood along injected vessels.[17] Petechiae may form distal to tourniquets. Addicts who inject drugs intra-arterially are at risk of developing vascular compromise of the hands, with discoloration, edema, and cold temperature.[17] Arterial constriction or emboli can lead to gangrene and loss of digits or a limb.[17] Repeated vascular injury and infection of the digits may cause irreversible contractures (camptodactylia) that resemble Dupuytren disease.[18] It is important to evaluate any patient with contractures, inflammation, or edema of the hand for soft tissue infection, as well as for underlying musculoskeletal complications, such as fibrous myopathy, joint restriction, muscle contractures, inflexible ankylosis, and suppurative tenosynovitis. Distal thrombosis with extensive infarctive skin lesions and associated hepatitis and glomerulonephritis may follow intravenous injection of cocaine into an arm vein.[19] Painful discoloration with resulting ulceration of the palm also can result from injection of cocaine into the radial artery.

Quinine, which is popular because of its bitter taste similar to heroin and its enhancement of the narcotic euphoria, is destructive to lymphatics, and repeated injections can lead to chronic, non-pitting hand or limb edema.[1] Injected propoxyphene produces thrombophlebitis and skin necrosis.[20]

Cocaine may produce superficial or deep venous thrombosis.[21] Mycotic aneurysms occur in 15 percent to 25 percent of patients with infective endocarditis, most frequently in the femoral artery, and require immediate surgery. Pseudoaneurysms result from infected injury to arteries during intra-arterial injection of drugs ("hitting the pinkie") and are most common in the extremities and groin.[17] The typical lesion is a tender, diffusely indurated, pulsatile mass with an associated bruit (50 percent to 60 percent of cases) and decreased peripheral pulses (25 percent). Local suppuration, petechiae, and purpura are often present.

An erythematous, tender cord is the hallmark sign of superficial septic thrombophlebitis. However, patients with deep vein thrombophlebitis present with a tender, swollen extremity, with or without erythema, that resembles cellulitis or an abscess. Indeed, infection may be simultaneously present, further complicating the diagnosis.

Cases of Henoch-Schönlein purpura, polyarteritis nodosa, and necrotizing angiitis with renal and pulmonary disease have been reported in intravenous drug abusers.

Vasculitis

Necrotizing vasculitis from injected drugs usually develops on the neck or extremity as a warm, firm, tender mass that may be misdiagnosed as an abscess. Pseudovasculitis with aggressive nasal destruction, as well as oropharyngeal and cutaneous ulcers may be misdiagnosed as Wegener granulomatosis in cocaine addicts, especially because perinuclear antineutrophil cytoplasmic antibody results may be false-negative.[22]

Vesiculobullous Lesions

Traumatic vesicles or bullae at the site of injection are observed occasionally. Comatose patients who have overdosed with barbiturates or other sedative drugs often develop pressure erythema, bullae, and ulcers.[9] Unlike bedridden patients, who typically develop pressure-induced lesions on the sacral or ischial areas, elbows, or heels, addicts may present with bullae in unusual body areas and varying configurations, depending on the body position in which they lost consciousness.

Acne and Pilosebaceous Effects

Anabolic steroid abuse can cause acne, cysts, oily hair and skin, male and female pattern alopecia, increased hair growth in women, gynecomastia in men, coarse skin, edema, testicular atrophy, and clitoral enlargement. There have been reports in habitual users of MDMA of a papulopustular, facial, acneiform eruption that may indicate a higher risk of systemic adverse effects, such as hepatic damage.[23] Hyperhidrosis is a common adverse effect of amphetamines.[23] Piloerection, paresthesias, and percutaneous flushings are manifestations of the somatic but not the perceptual phase of lysergic acid diethylamide intoxication. Together with constricted pupils and runny nose, gooseflesh skin is a sign of opiate intoxication.

Pruritus

Chronic cocaine use coupled with marijuana inhalation may cause pruritus. Prolonged use of cocaine may lead to the development of formication, tactile hallucinations during which the individual senses that insects are crawling on or under the skin (coke bugs). Foraging behavior, involving compulsive searching for pieces of crack cocaine in locations where it was once used, has been reported by some long-term users. Repetitive, stereotypical skin picking leading to excoriations and skin ulcers on the face and extremities has been observed in individuals who abuse methamphetamine. The feeling of euphoria provided by heroin may be accompa-



▲ **FIGURE 104-5** Cocaine-induced granuloma of the nasal septum.

nied by skin flushing and itching, as well as dry mouth, watery eyes, and runny nose. Heroin addicts often have dry skin that becomes easily irritated and pruritic.

Generalized or focal, especially genital, itching after drug administration has been named *"high" pruritus*. Hypoesthesia is a manifestation of low-dose exposure to phencyclidine.

Mucous Membrane Lesions

The abuse of drugs via an intranasal route is an increasingly prevalent pattern of behavior. Snorting cocaine causes erythema and erosion of the nasal turbinates, nasopharynx, and soft palate. With continued use, the erosions progress to necrosis, atrophy, and eventual perforation of the nasal septum and even the palate (Fig. 104-5).[24] The pathogenesis is vasoconstriction with resulting ischemia and occasionally infection. Chronic rhinitis, epistaxis, osteolytic sinusitis, gingival retraction, and bruxism are other complications. Halitosis and frequent lip smacking are signs of cocaine abuse. Cuts from chipped glass pipes and thermal burns may be present on the lips of some crack users. Sniffing heroin less often causes these changes. However, invasive fungal rhinosinusitis appears to be a complication unique to intranasal narcotic abuse.[24] A case of pemphigus vegetans, Neumann type, restricted to the intranasal tissue was reported to have been induced by inhalation of heroin.[25]

Xerotic cheilitis is observed commonly in methamphetamine and heroin addicts.[9] Methamphetamine users also have red, dry noses. Transient eyelid edema has been described with opiate abuse. The typical red or "bloodshot" eye frequently occurs with marijuana and sometimes with cocaine or phencyclidine use. Scleral hemorrhages in drug addicts are usually traumatic but may be caused by septic emboli due to endocarditis. There are reports of men applying cocaine powder to their glans penis to postpone ejaculation and of women rubbing cocaine on their genitals to enhance pleasure. These practices can lead to priapism, irritant dermatitis, and even ulcerations. Priapism can follow crack inhalation.[26] Penile ulcers have developed after injection of heroin into the shaft veins.

Marked dental decay and gingival disease are common in hard-core users of opiates as a result of the effects of opiates and poor hygiene. Hallucinogen-induced xerostomia also predisposes to caries. Persons addicted to methamphetamine, especially snorters, have higher tooth wear caused by teeth clenching. Habitual chewing of betel palm seeds, which contain a narcotic stimulant—a practice in some areas of Southeast Asia—stains the teeth.

Bacterial Infection

Skin and soft-tissue infections are the most common disorders for which drug addicts seek health care or are hospitalized.[27,28] In a study of 127 hospitalized intravenous drug users, the diagnoses were cellulitis (40.9 percent), abscess with cellulitis (32.3 percent), abscess alone (16.5 percent), infected skin ulcers (10.2 percent), necrotizing fasciitis (7.1 percent), and septic phlebitis with cellulitis (5.5 percent).[29] Cellulitis (see Chap. 179) is the most common (see Fig. 104-4) and lymphangitis may accompany skin infection. In any addict with soft-tissue infection, the possible presence of osteomyelitis or pyogenic arthritis should be considered. Because upper extremity vessels are used preferentially, cellulitis of the hand, arm, and forearm is very common and should be treated aggressively. Gangrene has been reported in 7 percent of drug abusers with upper extremity cellulitis.[18] About 10 percent of hand infections may require amputation of digits or of the hand, even after appropriate antibiotic and surgical treatment.[18]

In parenteral drug users, *Staphylococcus aureus* is the most frequently cultured bacterium from soft issue infections, followed by streptococcal species.[29] An attempt to obtain a culture is prudent because skin infection by Gram-negative bacteria, anaerobes, and unusual organisms is also common.[30] Notably, the flora spectrum of street heroin has no relationship to the bacteria causing infections in intravenous drug users.[18] However, tripelennamine and pentazocine may allow for the selective survival of *Pseudomonas aeruginosa*. The use of quinine to adulterate heroin appears to predispose to *Clostridium* infection. Wound botulism due to *C. botulinum* type A occurs almost exclusively in drug addicts.[31] Several cases have been reported from California and other western states during the past decade.[32] It is associated with parenteral injection, especially skin popping of black tar heroin, a form that derives its color from impurities during its manufacture and from adulterants. This form of heroin is highly hygroscopic and has a high water content that supports the growth of organisms. The spores of *C. botulinum* are not destroyed by heating the contaminated heroin and are inoculated into the subcutaneous tissue, where they germinate and produce toxin. There is pain, tenderness, and swelling, but in the early stages a cellulitis or abscess may not be prominent. In cocaine snorters, the intranasal septum or paranasal sinuses may become infected.[30] Necrotizing cellulitis of the scrotum and penis has been reported in addicts who accidentally injected drugs into the femoral artery instead of the vein.[33]

Due to the popularity of skin popping, the incidence of abscesses has been increasing. Abscesses from such subcutaneous drug injection are often multi-lobulated and deep and have extensive necrosis that requires exploration and débridement.[12] Superficial abscesses may rupture spontaneously, leaving punched-out ulcers. Abscesses may develop in any skin area of the body in which the addict injected drugs. Abscesses may be contiguous with bone when osteomyelitis of the long bones is present. Cervical abscesses usually occur in the anterior cervical triangle and may cause life-threatening complications such as mediastinitis, pneumomediastinum, airway obstruction, internal jugular vein thrombosis, and extension into the carotid sheath. Abscesses in the groin may present with only tenderness and edema. These abscesses can be deep and extensive, especially if they originate in the femoral triangle. The degree of pain usually exceeds that suspected from clinical findings. Computed tomographic scanning is needed to determine the extent of involvement of deep abscesses and abscesses in regions such as the neck and groin.

In more than one-half of the abscesses, only one pathogen is cultured, but in 33 percent to 45 percent of abscesses, more than one organism is present.[29] Fever and leukocytosis are not absolutely reliable



measures of severity and are absent in about one-half of cases. Any bacteria may be recovered from an abscess, but the more commonly cultured ones are *S. aureus* (20 percent to 60 percent), *Streptococcus* sp. (25 percent), and Gram-negative rods (up to 25 percent). Anaerobic bacteria are also common, especially in polymicrobial infections. In one study, anaerobic bacteria were recovered from two-thirds of abscesses, and in one-third of these, they were the only cultured organism.[34] *Eikenella corrodens*, an oral flora bacterium, is cultured from some abscesses caused by injections of methylphenidate. Curiously, some abscesses develop months after a patient has ceased to use drugs.



Necrotizing fasciitis with or without myositis (see Chap. 179) requires extensive subfascial débridement. In some cases, only swelling or inconspicuous cellulitis is apparent. However, severe pain, disproportionate to the clinical signs, is present in 94 percent of cases.[35,36] If the clinician disregards the patient's complaint merely as a request for narcotics, the outcome may be devastating.[35] For this reason, surgical exploration is mandatory in any addict with cellulitis and unexplainable severe pain. Multiple organisms are cultured in 59 percent to 85 percent of cases. Anaerobes are present in 12 percent of cases. The presence of gas is not pathognomic for *Clostridium* infection. The infection will progress in 75 percent of patients treated with parenteral antibiotics without débridement.[36] A decrease in the mortality rate from 27 percent to 7 percent was reported with a protocol consisting of early diagnosis, intravenous wide-coverage antimicrobial therapy, supportive care, early subfascial débridement, and repeated wound débridement every 8 to 12 hours until no necrotic tissue is formed. Between two and four débridements are needed.[35]

Sporadic cases of toxic shock syndrome related to intravenous heroin abuse have been reported. Nephrotic syndrome from amyloidosis has been reported in skin poppers and intravenous drug users with chronically draining skin lesions.[37]

Infectious endocarditis is the most common systemic bacterial infection in intravenous drug users and accounts for 5 percent to 8 percent of hospitalizations (see Chap. 181). Although in some reports, one-third of hospitalized addicts with skin and soft-tissue infection have positive blood cultures, bacteremia from skin infection is not common.[20] Intravenous drug users with advanced HIV immunosuppression are more predisposed to developing infectious endocarditis.[38]

Fungal Infection

Even in the absence of HIV infection, the incidence of dermatophytosis, including onychomycosis, tinea pedis, tinea cruris, and tinea corporis (see Chap. 188), is higher among intravenous drug addicts.[39] Injections of brown heroin have caused disseminated candidiasis due to yeast overgrowth in the lemon juice used to dissolve the heroin. For clinical signs and symptoms, see Chap. 189. Complications include ocular disease (uveitis, endophthalmitis), monarthritis, osteochondritis, and pleuritis.[40] Unlike HIV infection, intravenous drug use is a predisposing factor to zygomycosis (see Chap. 190). The characteristic cutaneous lesion is a cellulitic plaque or abscess that becomes necrotic.

DRUG-INDUCED REACTIONS

As expected, hypersensitivity reactions to drugs, especially exanthematous eruptions, urticaria, fixed drug reactions, leukocytoclastic vasculitis, erythema multiforme, and toxic epidermal necrolysis, occur more frequently in users of illicit drugs than in the general population. Dermatographism is common. Pigmented patches on the skin and mucous membranes may be extensive in addicts with fixed drug eruptions.

Narcotic abuse is a common cause of falsely reactive nontreponemal tests for syphilis (VDRL, rapid plasma reagin tests). In these cases, treponemal tests (microhemagglutinin-treponema pallidum, fluorescent treponemal antibody absorption tests) will be nonreactive. However, in addicts who have had syphilis, not only will both tests be positive but the titers of the treponemal test also may not decrease after treatment.

ASSOCIATED NON-INFECTIOUS SKIN DISEASES

Seborrheic dermatitis may be more frequent in chronic cocaine users. Eczemas, especially contact dermatitis, have been reported to occur more frequently. Drug abuse may indirectly cause skin lesions through congenital malformations in the offspring, domestic violence, or systemic disease. Pseudoacanthosis nigricans has been observed in heroin addicts.

TREATMENT

A detailed discussion of the treatment of drug abuse and dependence is beyond the scope of this chapter, but it is essential to recognize that these are chronic illnesses that require long-term strategies.[41] Potential therapies for opiate dependence include drug detoxification (office-based, inpatient, or ultrarapid under anesthesia), agonist maintenance (methadone, levomethadyl, or buprenorphine), antagonist maintenance (naltrexone), pharmacologic treatment of withdrawal symptoms (clonidine, lofexidine, or guanfacine), psychotherapy, acupuncture, counseling, and 12-step programs, which, if effective, exert benefit through peer support. Although relapses are common, successful outcomes are accomplishable, indicating the importance of candid, supportive, nonjudgmental, care-facilitating discussions in patients whose drug use has been revealed through skin examination.

KEY REFERENCES

The full reference list for all chapters is available at www.digm7.com.

1. National Institute on Drug Abuse: (2006) *HIV/AIDS*. National Institute on Drug Abuse Research Report, Series 7 (NIH Publication No. 06-5760)
7. Kircik LH et al: Scars on the legs: Cutaneous fibrosis resulting from intracutaneous injection of cocaine. *Arch Dermatol* **128**:1644, 1992
9. Burnett JW: Drug abuse. *Cutis* **49**:307, 1992
13. Williams AM et al: Conflicts in the treatment of chronic ulcers in drug addicts—Case series and discussion. *Brit J Plast Surg* **58**:997, 2005
17. Del Giudice P et al: Cutaneous complications of direct intra-arterial injections in drug addicts. *Acta Derm Venereol* **85**:451, 2005
20. Gordon RJ et al: Bacterial infections in drug users. *N Engl J Med* **353**:1945, 2005
29. Hasan SB et al: Infectious complications in IV drug abusers. *Infect Surg* **7**:218, 1988
32. Centers for Disease Control and Prevention: Wound botulism—California, 1995. *Morbid Mortal Weekly Rep* **44**:889, 1995
41. McLellan AT et al: Drug dependence, a chronic medical illness: Implications for treatment, insurance, and outcomes evaluation. *J Am Med Assoc* **284**:1689, 2000

CHAPTER 105

Skin Signs of Physical Abuse

Howard Pride

CHILD ABUSE

Child abuse is an uncomfortable topic for most practitioners and is a source of anxiety, anger, and confusion among those who care for children. True incidence statistics are difficult to determine, but each year in the United States, of the approximately three million children referred to child protective services, approximately one million are determined to be the victims of abuse and neglect and approximately 1500 die from abuse or neglect. Clearly, those whose practices involve the dermatologic care of children encounter real or suspected child abuse. Practitioners must have some basic knowledge of abuse and its evaluation to appropriately manage these cases.

Because many forms of physical abuse have external manifestations, the skin examination may serve as the first clue that abuse is taking place. Conversely, a broad knowledge of skin diseases provides a unique insight into those diagnoses that may suggest various forms of child abuse (Tables 105-1 and 105-2). The literature is rich in examples in which an astute clinician averted the disastrous results of a false claim of abuse by correctly diagnosing a dermatologic condition.

True abuse must be reported and a thorough evaluation conducted. It is essential that practitioners develop a relationship with the institution or individual in their area who is best able to manage these difficult cases. Ideally there should be an abuse team consisting of a dermatologist, pediatrician, social worker, medical photographer, and, when needed, pediatric subspecialists such as orthopedists, hematologists, psychologists, and gynecologists. It is most helpful if one's relationship is forged with the abuse team before an abuse incident and a set protocol for dealing with alleged or suspected abuse is established in the practitioner's office. Local emergency phone numbers for reporting abuse can be obtained from the Child Welfare Information Gateway or Childhelp National Headquarters (Table 105-3).

Child abuse spans all ages, races and socioeconomic classes, but typical children who suffer abuse are between the ages of 5 and 15 years, have emotional or behavioral problems, have special medical needs, have several siblings, live in single-parent households, or live at or below the poverty level. Abuse is approximately two times more common in Pacific Islanders, American Indians, Native Alaskans, and African American children compared to the average American population. Perpetrators tend to have emotional or psychological problems, have frequently been victims of abuse themselves, abuse drugs or alcohol, are perpetrators of spousal abuse or have a history of marital discord, have marginal parental skills or knowledge, and have poor self-esteem. Although these profiles are helpful, it is important to remember that any child may be the victim of abuse.

ABUSE AT A GLANCE



- Child abuse, elder abuse, and domestic violence are common.
- Abuse is a problem of all socioeconomic classes and races.
- Bruising on soft padded areas of the body and patterned bruising that are multiple and in different stages of healing are suspicious of abuse.
- Burns that are bilateral and uniform are suspicious of abuse.
- Law mandates the reporting of all suspected cases of child abuse and, in some states, elder abuse.

The Battered Child

Bruising is the result of blunt trauma, delivered either accidentally or intentionally. Active children, particularly toddlers, are prone to multiple bruises, and the identification of abusive injury is fraught with difficulty. The size, shape, color, and feel of a bruise varies based on anatomic site, the degree of force used, the firmness of the object delivering the force, and the underlying health of the injured individual. Great care and attention to detail must be exercised when evaluating these children who likely have been brought to the office for some other complaint. The history should include as much detail as

TABLE 105-1
Conditions Mistaken for Abusive Bruising

- True petechiae and purpura
  - Disorders of coagulation
  - Ehlers-Danlos syndrome
  - Infections
    - Rocky Mountain spotted fever
    - Meningococcal infections
    - Group A streptococcal infections
  - Palpable purpura of vasculitis
  - Valsalva petechiae
  - Lichen sclerosus
  - Folk remedies
    - Cao gio: rubbing vigorously with a hard object such as a coin
    - Cupping: suction mark left by the cooling of a warm metal cup
- Nodular lesions mimicking deep bruises
  - Neuroblastoma
  - Vascular malformations
  - Dermatomyositis-associated nodules
- Discolorations that look like bruises
  - Phytophotodermatitis
  - Maculae caeruleae from lice infestation
  - Mongolian spots
  - Dye from blue jeans
- Inflammatory conditions that mimic bruising
  - Urticaria/angioedema/urticarial vasculitis
  - Pernio
- Conditions that mimic whip marks
  - Incontinentia pigmenti
  - Striae
  - Phytophotodermatitis

TABLE 105-2
Conditions Mistaken for Nonaccidental Burns

- Phytophotodermatitis
- Folk remedies (Maquas, or moxibustion): burns delivered near diseased organs or therapeutic sites as in acupuncture
- Impetigo
- Epidermolysis bullosa
- Immunobullous diseases
- Sunburn/xeroderma pigmentosum
- Burns from objects heated by sun
- Electric burn from an enuresis blanket
- Chemical burn from use of undiluted acetic acid
- Chemical burn from Icy Hot balm
- Chemical burn from calcium chloride
- Diaper dermatitis
- Pernio
- Fixed drug eruption





TABLE 105-3
Helpful Agencies for Information on Abuse and Domestic Violence

- Child Welfare Information Gateway, 1250 Maryland Avenue, SW, Eighth Floor, Washington, DC 20024, Ph: (800) 394-3366 or (703) 385-7565, Fax: (703) 385-3206, email: info@childwelfare.gov, http://www.childwelfare.gov/
- Childhelp National Headquarters, 15757 N. 78th Street, Scottsdale, AZ 85260, Ph: (480) 922-8212, Fax: (480) 922-7061, http://www.childhelpusa.org
- Domestic Violence International Resources, http://www.vachss.com/help_text/domestic_violence_intl.html
- International Network for the Prevention of Elder Abuse, http://www.inpea.net
- International Society for Prevention of Child Abuse and Neglect, 245 W. Roosevelt Road, Building 6, Suite 39, West Chicago, IL 60185, Ph: (630) 876-6913, Fax: (630) 876-6917, email: ispcan@ispcan.org, http://www.ispcan.org
- National Adult Protective Services Association, 920 S. Spring Street, Suite 1200, Springfield, IL 62704, Ph: (217) 523-4431, Fax: (217) 522-6650, http://www.apsnetwork.org
- National Center on Elder Abuse, 1201 15th Street, NW, Suite 350, Washington, DC 20005, Ph: (202) 898-2586, Fax: (202) 898-2583, http://www.elderabusecenter.org
- National Committee for the Prevention of Elder Abuse, 1612 K Street, NW, Suite 400, Washington, DC 20006, Ph: (202) 682-4140, Fax: (202) 223-2099, email: ncpea@verizon.net, http://www.preventelderabuse.org
- National Coalition Against Domestic Violence, 1120 Lincoln Street, Suite 1603, Denver, CO 80203, Ph: (303) 839-1852, Fax: (303) 831-9251, email sbaca@ncadv.org, http://www.ncadv.org
- National Resource Center on Domestic Violence, Ph: (800) 537-2238, http://www.nrcdv.org

possible and inconsistencies in the parent's story clearly documented in the medical record. It is essential to perform a total body skin and mucous membrane examination. It is also important to note the child's behavior and parent-child interactions.

The color of all bruises should be noted and clearly documented. This may aid in determining the age of a bruise and may point out inconsistencies in the caretaker's history. Multiple bruises of differing colors may indicate ongoing trauma rather than one isolated incident.



▲ **FIGURE 105-1** Purpura and erosions on the soft, padded areas of the buttock and thighs, representing very obvious abuse. (Used with permission from Paul Bellino, MD.)

Caution must be exercised in dogmatically stating the time of injury based on bruise characteristics because color depends on the intensity, depth, and location of the injury. There is good evidence that a bruise with any yellow color must be older than 18 hours, but a bruise may be red, blue, or purple/black throughout its life span, from beginning to resolution. Bruises of identical age and cause on the same person may not appear as the same color and may not change at the same rate. It is most prudent to document color without alluding to a specific age of a bruise in the medical record.

Although there are no absolute differentiating features, certain aspects of an intentionally inflicted bruise may suggest abuse. Because young children tend to explore in a forward direction, accidents are more frequent on the distal arms and legs, knees, elbows, and forehead. Soft, padded, posterior, and protected areas of the body are far less likely to be accidentally injured. Bruises on the abdomen, buttocks (Fig. 105-1), thighs, genitalia, ear lobes, and cheeks are uncommon so marks in these areas should raise concern.

Inflicted bruises often leave patterned imprints of a hand, whip, or hard object.



▲ **FIGURE 105-2** Linear purpura representing the interdigital spaces from a hand slap. Note the inferior triangular shape that corresponds to the finger web space. (Used with permission from Paul Bellino, MD.)



▲ **FIGURE 105-3** Linear, circumferential hyperpigmentation at the site of previous ligature. (Used with permission from Paul Bellino, MD.)

Linear purpura with a small triangle at the base (Fig. 105-2), representing the interdigital and finger web spaces, occur after a slap injury. Grab or pinch marks can be recognized by their location on soft padded areas and their unusual patterning. Circumferential purpura or hemosiderin pigmentation (Fig. 105-3) suggest a ligature injury, which would be difficult to explain as accidental. Bite marks (Fig. 105-4) are always inflicted, although they are sometimes from siblings or other children. The shape and size of the marks can identify an adult mouth versus a bite from a child. It is helpful to include a ruled measuring scale in any photographs to help forensic identification at a later date.

The head is the most common target of physical abuse (see eFig. 105-4.1 in online edition). Black eyes are common accidental injuries but are more suspicious if they are bilateral or are unaccompanied by evidence of trauma to the nose or superior orbital ridge. Subconjunctival hemorrhages can be seen in 0.5 percent to 13.0 percent of typical newborns, but a large subconjunctival hemorrhage beyond 1 and 2 weeks of life is suspicious of abuse. Petechiae in the periorbital region have been seen in children with abuse related retinal hemorrhages. Acci-



▲ **FIGURE 105-4** Human bite marks. (Used with permission from Paul Bellino, MD.)

dental bruising or other injuries to the oral mucous membranes are unusual and should be considered as suspect (see eFig. 105-4.2 in on-line edition).

Any bruises in a young infant who is not yet pulling to a stand should raise concerns of abuse or of an unsafe environment (see eFig. 105-4.3 in on-line edition). A shaken infant may have bruising on the hands because he or she is liable to be flailing during the shaking incident (see eFig. 105-4.4 in on-line edition). Concern should be raised whenever the history of an accident is inconsistent with the developmental level of the child.

Inflicted Burns

The most common agent involved in childhood burns, both accidental and inflicted, is hot liquid. Accidents such as inadvertently stepping into a hot tub or pulling a hot liquid off a table counter or stove leave irregular or geographic burn patterns that lack symmetry. By contrast, inflicted scalds tend to be symmetric, with sharply demarcated edges and an absence or paucity of splash marks. In one study, all the children whose bathtub burns were inflicted had associated features of abuse, including bruises, fractures, or evidence of neglect. Stocking and glove burns result when the feet or hands are forcibly held under hot water. The uniformity of the burn indicates that the child was not able to reflexively withdraw from the scalding water as would happen with accidental immersion. A common pattern of inflicted immersion burn involves the buttocks, low back, and thighs. The child is flexed at the waist and dipped into the hot water, frequently as a punishment for a toilet training accident. Inflicted splash burns are much more difficult to differentiate from accidents. A careful history is needed to detect inconsistencies between the proposed injury and the physical examination. When doubt exists, it is mandatory that child protective services be contacted.

An inflicted contact burn can be recognized by the pattern that duplicates the object creating the injury (see eFig. 105-4.5 in on-line edition). Accidental contact burns tend to be smaller, less severe, less patterned, and of irregular depth. When a child is held against a hot object, the depth is more uniform, the pattern is more clearly defined, and the burn is more severe. Irons, curling irons, hot plates, and cigarettes are objects commonly used to inflict burns. Some burns may, in fact, be accidental but represent inadequate supervision and neglect. This situation is also harmful to children and needs to be reported to the appropriate agencies.

Sexual Abuse

It is estimated that more than 300,000 children suffer from sexual abuse each year in the United States. The lifetime risk of sexual abuse is approximately 25 percent to 40 percent for girls and approximately 10 percent for males. *Sexual abuse* is defined by the American Academy of Pediatrics as the engaging of a child in sexual activities that the child cannot comprehend, for which the child is developmentally unprepared, and cannot give informed consent and violate the social taboos of society. This broad definition includes inappropriate touching, genital penetration, fondling, and sexual kissing, but also includes non-contact activities such as exhibitionism, voyeurism, and the involvement of a child in verbal sexual propositions or the making of pornography. Clearly, many forms of sexual abuse leave no physical examination findings.

Girls are more likely than boys to suffer sexual abuse and the risk rises in preadolescence (Fig. 105-5). Most abuse is at the hands of someone known to the child and only 18 percent is carried out by strangers. Victims and perpetrators span all racial, religious, and socio-economic spectrums but risk factors for sexual abuse include the presence of a stepfather, single-parent families, children whose mothers are extensively out of the home, a history of parental violence, parents who have suffered abuse themselves, parental substance abuse, and low household income level.

Most victims of sexual abuse have no physical findings. Pregnancy, positive cultures for sexually transmitted diseases, presence of sperm or acid phosphatase, acute genital or anal injuries without plausible explanation, and marked hymeneal opening enlargement with associated hymeneal disruption are very definitive signs of abuse. It is very seldom that such signs are present. The American Academy of Pediatrics Committee on Child Abuse and Neglect recommends that certain findings are consistent with, but not diagnostic of, abuse. These include chafing, abrasions or bruising of the inner thighs and genitalia, scarring, tears or distortion of the hymen, a decreased amount or absent hymeneal tissue, scarring of the fossa navicularis, injury to or scarring of the posterior fourchette, scarring or tears of the labia minora, and enlargement of the hymeneal opening, even without disruption of the hymen.



▲ **FIGURE 105-5** Sexual abuse. Perianal wound in a 3-year-old girl after anal penetration. (Used with permission from Dr. Francesca Navratil, Zurich, Switzerland.)

The child's spoken word is the most valuable piece of evidence in establishing sexual abuse. All historical information must be very well documented and preserved with the same care as any piece of forensic evidence. It is immensely important to enlist the help of an experienced abuse team in obtaining the history and completing an appropriately thorough physical examination with the aid of colposcopic observations.

The skin examination's greatest contribution may be in correctly diagnosing those dermatoses that may look similar to sexual abuse but are not. Irritant dermatitis, atopic dermatitis, psoriasis, seborrheic dermatitis, pinworms, candidiasis, scabies, and other common dermatoses tend to cluster in the diaper region and should be easily diagnosed with a critical eye. Other conditions that have been reported as mimickers of sexual abuse are listed in Table 105-4.

TABLE 105-4
Conditions Mistaken for Sexual Abuse

- Lichen sclerosus
- Crohn disease
- Localized vulvar pemphigoid
- Langerhans cell histiocytosis
- Perianal streptococcal dermatitis
- Hemangiomas
- Urethral prolapse
- Entities that look like condylomata acuminata
  - Focal epithelial hyperplasia
  - Darier disease
  - Lymphangioma circumscriptum
  - Pigmented vulvar hamartomas
  - Pseudoverrucous papules
- Entities that look like herpes simplex
  - Localized varicella/zoster
  - Allergic contact dermatitis



Genital warts pose a particularly difficult problem for practitioners. They certainly can be sexually transmitted to children, and the possibility of sexual abuse needs to be discussed with parents. However, there is much evidence that genital warts can be acquired perinatally from an infected mother, through autoinoculation from warts on other parts of the body or through nonsexual contact with caretakers. Children younger than 3 years of age at the onset of warts are least likely to have acquired their warts from sexual contact, whereas children with onset at older than 5 years of age have a much greater risk of having suffered sexual abuse. The ages in between represent a gray zone. Other signs of abuse will seldom be present to aid in the diagnosis, and human papillomavirus typing is not helpful. History provides the most valuable insight into the correct diagnosis; again, it is imperative that an abuse team be involved. At the author's institution, all children with perianal or genital warts are referred, in a nonaccusatory and nonjudgmental fashion, to the hospital's abuse social worker and pediatrician as routine protocol.



ELDER ABUSE

Elder abuse is one of the fastest growing forms of abuse. Although statistics vary, the National Center on Elder Abuse in Washington, DC, estimates that 1 to 2 million Americans 65 years of age or older are victims of various forms of abuse each year. Abuse may affect a range of 2 percent to 10 percent of the elderly population. Those older than age 80 years are two to three times more likely to suffer abuse, and the American population in this age range continues to increase each year. For every case of reported elder abuse, at least another five cases go undetected. All segments of society are affected. Although there is inherent inaccuracy in these statistics, it is readily apparent that elder abuse is common enough for a busy dermatologist to encounter a few abused patients every week.

The U.S. National Academy of Sciences has defined *elder abuse* as: "(a) intentional actions that cause harm or create a serious risk of harm (whether or not harm is intended) to a vulnerable elder by a caregiver or other person who stands in a trust relationship to the elder, or (b) failure by a caregiver to satisfy the elder's basic needs or to protect the elder from harm." Acts of commission and omission are thus included in the definition. Types of abuse and their respective incidence rates are listed in Table 105-5. More than one type of abuse can occur simultaneously.

TABLE 105-5
Types of Elder Abuse

- Neglect: 55%
- Physical abuse: 15%
- Financial and material abuse: 12%
- Emotional or psychological abuse: 8%
- Sexual abuse: 1%
- Unspecified forms of abuse: 9%

Abuse most often occurs at the hands of caregivers or family members who have frequent close contact with patients and often may live with them. Historically, adult children of the abused patient have been the most common perpetrators, but most recent data show that spouses now account for the majority of abuse cases. Men are more likely to abuse than women. The abuser is often financially dependent on the victim, and they are usually in a shared living situation. Financial abuse, however, is more common among those who live alone. Risk factors for abuse are listed in Table 105-6. Note that the risk factors have far more to do with the caretaker than the abused patient. In particular, the level of debility or health status of the patient does not predict abuse.

Physical abuse is defined as the intentional application of any force that causes bodily injury, pain, or impairment to an elderly individual. It may include acts such as hitting, beating, shaking, kicking, slapping, pushing, pinching, burning, overly aggressive force-feeding, and the improper use of physical or chemical restraints. The signs discussed in Child Abuse apply to elder abuse as well and include multiple bruises or fractures in different stages of healing, bruises in normally well-protected areas such as the inner thighs, odd-shaped injuries such as from pinching or slapping, belt marks or patterned bruising (see eFig. 105-5.1 in on-line edition), unusual welts or puncture wounds, cigarette burns, rope marks that might indicate restraints, bed sores, strangely patterned alopecia, attempts to hide part of the body, and signs of malnutrition or dehydration. Because many of these signs, particularly multiple bruises, can occur normally in elderly individuals, detection of abuse can be very challenging. Unexplained repetitive injuries or explanations by caretakers that do not match the pattern of injury are concerning. Caretakers who act withdrawn, infantilize the patient, or insist on providing the medical history should alert the clinician.

TABLE 105-6
Risk Factors for Elder Abuse

- Older age
- Lack of access to resources
- Low income
- Social isolation
- Minority status
- Low level of education
- Functional impairment
- Substance abuse by elder or caregiver
- Previous history of family violence
- History of psychological problems
- Caregiver stress
- Cognitive impairment

It is important to interview by directing questions to the patient rather than the caregiver, and it is prudent to try to arrange a time to confer with and examine the patient alone. Repetitive follow-up visits help develop a rapport with the patient and allow serial observation of past and ongoing injuries. The assurance of confidentiality facilitates garnering sensitive information.

Once abuse is suspected, most states mandate that physicians contact the appropriate authorities. Information on a particular state's laws can be obtained from the National Center on Elder Abuse (see Table 105-3). The nearest medical center's social service department is well equipped to offer guidance, but the agencies listed in Table 105-3 are also helpful resources. Treatment, support, and counseling may be needed for the perpetrator as well.

DOMESTIC VIOLENCE

Domestic violence is a pattern of coercive behaviors that may include repeated battering, psychological abuse, sexual abuse, social isolation, deprivation, and intimidation perpetrated by someone who is or was involved in an intimate relationship with the victim. Conservative estimates say that approximately 1 million people suffer domestic violence each year, but the actual number likely approaches 4 million. Women comprise approximately 90 percent to 95 percent of all victims, and men 95 percent of all perpetrators. Forty percent to sixty percent of men who abuse their partner or spouse are also abusing their children. In the United States, approximately one in three women suffers a least one physical assault during her life,

and 1500 women are murdered by their husbands or boyfriends each year. Domestic violence is a devastatingly common problem.

The profiles of domestic abuse are similar to child and elder abuse. Women ages 19 to 29 years are the most common victims, with other risk factors being low income, mental health issues, alcohol or substance abuse by the victim or the perpetrator, pregnancy, large age difference between partners, separated or divorced status, and a family history or personal past history of abuse and violence. Women with educational or occupational levels above that of their partners may be at higher risk. Abusers are typically underachievers with occupational status below their educational level.

Whenever possible, the patient should be interviewed alone, without the partner's presence. A thorough examination should be done with a nurse chaperone, but not the partner, in the room. Repeat visits may be used to document new or progressing skin findings and to build trust with the patient. Statements such as "Because domestic violence is such a prevalent problem, we have begun to ask about it routinely" may open the door to more discussion regarding difficulties at home. Literature and posters in the clinic setting with information and hotline numbers for abuse victims indicate the reality of abuse and may facilitate disclosures.

For various reasons, a victim may not want to reveal abuse. Implausible explanations for an injury or a delay in seeking medical attention may be clues of abuse. Signs of depression, excessive use of sedatives, chronic pain disorders, or vague stress-related symptoms may be subtle signs of abuse.

Physical examination findings are the same as outlined for child and elder abuse. The distribution of injuries tends to be central, and the perpetrator may choose to injure hidden areas, such as the breast or genitals, to deter detection. Unlike infants or debilitated adults, blows to a young adult may be to areas suggesting a defensive posture and might include purpura, sprains, dislocations, and fractures to the wrist or forearms, palms, and soles.

The social service department at the local medical center is a good resource for information and help on domestic violence. The National Domestic Violence hotline (800-799-7233) is a 24-hour resource for women who need to find a local shelter. Other helpful organizations can be contacted (see Table 105-3).

SUGGESTED READINGS

The full reference list for all chapters is available at www.digm7.com.

Director TD, Linden JA: Domestic violence: An approach to identification and intervention. *Emerg Med Clin North Am* **22**:1117, 2004

Gorbein MJ, Eisenstein MA: Elder abuse and neglect: An overview. *Clin Geriatr Med* **21**:279, 2005

Lachs MS, Pillemer K: Elder abuse. *Lancet* 364:1263, 2004

Levine JM: Elder neglect and abuse: A primer for primary care physicians. *Geriatrics* **58**:37, 2003

Pressel DM: Evaluation of physical abuse in children. *Am Fam Physician* **61**:3057, 2000

Pride HB: Child abuse and mimickers of child abuse. *Adv Dermatol* **14**:417, 1999

Reece RM: *Child Abuse—Medical Diagnosis and Management*. Philadelphia, Lea and Febiger, 1994

Sapp MV, Vandeven AM: Update on childhood sexual abuse. *Curr Opin Pediatr* **17**:258, 2005



This page intentionally left blank

PART 6

Skin Changes Across the Span of Life

Copyright © 2008 by The McGraw-Hill Companies, Inc. Click here for terms of use.



SECTION 19

FROM BIRTH TO OLD AGE

CHAPTER 106

Neonatal, Pediatric, and Adolescent Dermatology

Mary Wu Chang
Seth J. Orlow

Many, if not all, dermatologic diseases exhibit different manifestations in infants and children. As it is impossible to discuss all of pediatric dermatology in one chapter, we focus instead on certain methods, diseases, and issues pertinent to the practice of pediatric dermatology. Within this chapter, three age divisions are used: neonates and infants, children, and adolescents. Topics of special importance to pediatric dermatology, such as pediatric medication use and biopsy pitfalls, are discussed, and a selected drug formulary is provided.

NEONATES AND INFANTS

The neonatal period is defined as the first 30 days of life. Neonatal skin diseases evolve much more rapidly than adult skin diseases, and some conditions that initially appear to be serious turn out to be trivial, whereas in others, the opposite is true. Infancy is defined as beginning after the first 30 days of life.

Neonatal Skin

After birth, the neonate's skin undergoes a series of changes in adaptation to the extrauterine environment. In utero, the skin of the fetus is protected by the vernix caseosa and is surrounded by amniotic fluid. After birth, the vernix is wiped off, and the skin is exposed and adapts to the dry ambient air. For example, desquamation of the upper layers of the stratum corneum occurs normally in all infants and is believed to be a normal adaptive process.

Research regarding the maturation of the neonatal stratum corneum in neonates has produced varying results, and the question of when full barrier function is achieved is not fully answered. Barrier stabilization appears to be a dynamic process, one dependent upon a balance between different biologic and environmental parameters. Postnatal life is believed to accelerate stratum corneum maturation in premature and term infants. Parameters such as skin thickness, skin pH, and stratum corneum hydration indicate that neonatal skin is continuously adjusting to the extrauterine environment, in contrast to the adult skin, which remains in a steady state.[1]

Although the term infant seems to possess stratum corneum function with adult barrier properties, the term infant has an increased risk for systemic toxicity from topically applied substances. This is due in large part to the great surface area–body mass ratio in the infant. In addition, the infant's metabolism, excretion, distribution, and protein binding of substances can be significantly different from those of an adult and add to increased risk of toxicity.[2]

The postmature infant (> 40 weeks' gestation) usually has dry and cracked or peeling skin noted soon after birth (Fig. 106-1). Shedding of the dry peeling skin of postdates infants occurs spontaneously in the first month of life, leaving normal, healthy skin. Topical care should include moisturizers and avoidance of overbathing.

◀ Neonatal acne. Tiny papulopustules on the cheeks of a 3-week-old infant.

NEONATAL, PEDIATRIC, AND ADOLESCENT DERMATOLOGY AT A GLANCE



- Many dermatologic diseases exhibit different manifestations in newborns, infants, children, and adolescents.
- Some dermatoses are encountered only in neonates and infants and therefore require special attention.
- Obtaining a history and methods of clinical examination in infants and children differ from the approaches chosen for adults. In adolescents, different interviewing skills are required to enhance compliance.
- The infant has increased risk for systemic toxicity from topically applied substances, and this is even more so in premature infants.
- Drug labeling for pediatric patients is different from that in adults, causing anxiety. Also, dosimetry has to take growth and increase of body weight into account. A selective pediatric dermatology formulary is presented.

Premature infants, particularly those born before 34 weeks of gestation, have markedly decreased epidermal barrier function and an even greater surface area–body mass ratio than term infants.



Copyright © 2008 by The McGraw-Hill Companies, Inc. Click here for terms of use.



▲ **FIGURE 106-1** The feet of a postdates newborn. The dry, hyperlinear, and scaly skin is typical of a postdates baby. There are also pustules of transient neonatal pustular melanosis.



In addition, the immature organs of the premature infant may affect the metabolism, excretion, distribution, and protein binding of chemical agents. Local or systemic toxicity can occur in the premature infant not only from topical medications, but also soaps, lotions, or other cleansing solutions.[2,3]

Increased skin fragility is a hallmark of prematurity. Epidermal and dermal injury may lead to significant cutaneous pain accentuated by routine handling and nursing care. The premature infant is at risk for infection and sepsis from skin-associated organisms entering through breaks in the thin and fragile skin and via iatrogenic portals of entry. Sweating in the premature infant is functionally reduced and contributes to poor thermal regulation. Heat regulation is dysfunctional due to a thin subcutaneous fat layer for insulation, poor autonomic control of cutaneous vessels, and a large surface–body ratio. In the nursery, the premature infant is usually placed in a temperature and humidity-controlled isolette until the infant matures and temperature and fluid regulation stabilizes.

The application of preservative-free, petrolatum-based ointments decreases trans-epidermal water loss of neonatal skin.[4] However, a threefold increase in the incidence of systemic candidiasis was reported after emollient therapy was implemented in extremely low birthweight (≤ 1000 g) premature infants in a neonatal intensive care unit.[5] Another outbreak of systemic candidiasis occurred in very low birthweight neonates (≤ 1500 g) in a different neonatal intensive care unit.[6] Until prospective, controlled trials are performed, neonates receiving petrolatum-based emollient therapy should be carefully monitored for systemic candidiasis, particularly those infants with birth weights less than 1500 g.

Once at home, bathing once or twice a week in plain water is sufficient for most infants; if bathing is more frequent, moisturization with unscented, simple emollients is recommended. The face, hands, and diaper area may be cleansed daily using a small amount of a mild, unscented, pH-neutral cleanser. Well-meaning parents often bathe their infants too frequently and use a multitude of products on their infant's skin. In addition to irritation and asteatosis, these practices may increase the risk of allergic contact dermatitis in infants. It has been estimated that the average newborn is exposed to approximately 10 skin care products in the first month of life, leading to exposure to more than 50 different chemicals ranging from mildly toxic to toxic.[7] Parents should be taught that "less is best."[8]

Examination Techniques

A complete history includes gestational and birth history as well as family history. Exposures during pregnancy, including medications, illicit drugs, and infectious diseases such as varicella and sexually transmitted diseases, should be reviewed. Obstetric data, including placental appearance and cultures, can be invaluable. The most important element in the examination of an infant is thoroughness. Whether the infant is examined in the lap of the parent or on the examination table, all surfaces, including the creases and valleys of body folds and the diaper region (including the genitalia), deserve close examination. A vascular stain, vasoconstricted macule, or erosion can be the presenting sign of a hemangioma.[9] A stray hair may later strangulate an appendage and should be removed. Infants with digital tourniquet (pseudoainhum) and clitoral tourniquet have been described.[10,11] Congenital lesions of all classifications (e.g., pigmented, vascular, aplasias) warrant closer inspection to rule out associated findings. Midline lesions on the face, scalp, or spine may have central nervous system (CNS) connections and should not be biopsied without proper evaluation. The diaper area has its own unique set of problems and deserves examination at every visit.

The infant is vulnerable and completely dependent on the caretakers. The social support system and family structure must be considered when implementing a medical plan.

Medical and surgical decision making for the infant is based primarily on function rather than cosmesis. For example, extraction of a natal tooth is indicated if breast-feeding is impaired; whether or not the tooth is a component of a genetic syndrome is a separate issue. There are times when the parents' desire for treatment may not be in the best interest of the patient.

Diseases of Neonates and Infants

TRANSIENT DERMATOSES OF THE NEONATE

Skin conditions encountered in newborns that tend to resolve by 30 days of age are considered to be transient. They are very common, and many are expected in newborns.

Caput Succedaneum and Cephalohematoma. Caput succedaneum is subcutaneous edema over the presenting part of the head and is a common occurrence in newborns. Cephalohematoma is a subperiosteal collection of blood and is less common. Both lesions are due to shearing forces on the scalp skin and skull during labor.

Caput succedaneum is soft to palpation, and borders are ill defined. Cephalohematoma is bounded by the suture lines of the skull and often feels fluctuant. If purpura is extensive, it can lead to hyperbilirubinemia. Congenital lymphedema or lymphatic malformations (such as in Turner syndrome) can mimic caput succedaneum. Both caput succedaneum and cephalohematoma resolve spontaneously; however, caput usually fades in 7 to 10 days, whereas cephalohematoma slowly resolves over several weeks.

Milia. Milia are multiple pinpoint- to 1-mm papules representing benign, superficial keratin cysts. They are seen most commonly on the nose of infants and may be present in the oral cavity as well, where they are called *Epstein's pearls*. They are expected findings in the newborn and resolve spontaneously within a few weeks of life.

Sebaceous Gland Hyperplasia. At least 50 percent of normal newborns have sebaceous gland hyperplasia (Fig. 106-2). Tiny (< 1-mm) yellow macules or papules are seen at the opening of each pilosebaceous follicle over the nose and cheeks of term newborns. It is a benign condition that clears spontaneously by 4 to 6 months of age.



▲ **FIGURE 106-2** Sebaceous hyperplasia on the nose of a 1-day-old infant.

Erythema Toxicum Neonatorum. Erythema toxicum neonatorum (ETN) is an idiopathic, common condition seen in up to 75 percent of term newborns. It is rarely seen in premature infants. Blotchy erythematous macules 1 to 3 cm in diameter with a 1- to 4-mm central vesicle or pustule are seen in ETN (Fig. 106-3). They usually begin at 24 to 48 hours of age, but delayed eruption as late as 10 days of age has been documented.[12] These follicular-based lesions can be located anywhere but tend to spare the palms and soles. A smear of the central vesicle or pustule contents will reveal numerous eosinophils on Wright-stained preparations. A peripheral blood eosinophilia of up to 20 percent may be associated, particularly in infants, with numerous lesions. Transient neonatal pustular melanosis (TNPM) mimics ETN, except that neutrophils rather than eosinophils are found within the pinpoint vesicles, and individual lesions heal with residual pigmentation, which is not seen in ETN. Bacterial infections, *Pityrosporum* folliculitis, and congenital candidiasis also may mimic ETN. Bacterial and fungal culture of lesions and Gram staining will help differentiate among these entities. ETN is benign and clears spontaneously by 2 to 3 weeks of age without residua.

Transient Neonatal Pustular Melanosis. TNPM is an idiopathic pustular eruption of the newborn that heals with tiny brown pigmented macules (Fig. 106-4). It is less common than ETN and is more prevalent among newborns with darkly pigmented skin. Lesions are present at birth or shortly thereafter as superficial vesicles and pustules, with ruptured lesions evident as collarettes of scale. Pigmented macules are also often present at birth or develop at the sites of resolving pustules or vesicles within hours or



▲ **FIGURE 106-3** Erythema toxicum neonatorum. Erythematous macules, some with a tiny central papulopustule, on the arm of a 1-day-old newborn.

during the first day of life. Lesions can occur anywhere but are common on the forehead and mandibular area. The palms and soles may be involved. Smear of the vesicle or pustule contents will reveal a predominance of neutrophils with occasional eosinophils on Wright-stained preparations.[13]

Miliaria rubra is frequently confused with ETN and TNPM. The erythema around miliaria rubra is small in area (1 to 2 mm vs. 20 to 30 mm in ETN). The central pustule of TNPM may mimic congenital candidiasis, *Pityrosporum* folliculitis, or bacterial folliculitis lesions. Herpes simplex should be considered if lesions are vesicular. A Gram-stained slide of the pustules of ETN or TNPM will not show organisms. A Wright-stained slide usually will show a predominance of neutrophils.

TNPM is a harmless condition that requires no treatment. The pustules usually disappear by 5 days of age, leaving residual pigmented macules that resolve over 3 weeks to 3 months.

Mottling. Mottling is a blotchy or lace-like pattern of dusky erythema over the extremities and trunk of neonates that occurs with exposure to cold air. Virtually all babies demonstrate mottling at some time during the newborn period due to immaturity of the autonomic control of the skin vascular plexus. This physiologic mottling disappears on re-warming, differentiating it from cutis marmorata telangiectatica congenita and livedo reticularis. Normal mottling resolves spontaneously by 6 months of age.

Harlequin Color Change. Harlequin color change is a rare vascular phenomenon occurring in low-birth-weight infants. When the infant is placed on one side, an erythematous flush with a sharp demarcation at the midline develops on the dependent side, and the upper half of the body becomes pale. The color change usually subsides within a few seconds of placing the baby in the supine position but may persist for as long as 20 minutes. The exact mechanism of this unusual phenomenon is not known, but it may be due to immaturity of autonomic vasomotor control. Harlequin color change is seldom seen after 10 days of age.





▲ **FIGURE 106-4** Transient neonatal pustular melanosis. **A.** A newborn with congenital, thin-walled pustules that rupture easily. **B.** Hyperpigmented macules appeared by 10 hours of age.



Sucking Blisters. Sucking blisters are uncommonly apparent at birth as the result of intrauterine sucking. Sucking blisters, however, are more commonly seen during the first weeks of life. Sucking blisters are usually solitary, intact oval or linear blisters, erosions, or drying crusts, arising on noninflamed skin of the dorsal aspect of forearms, wrists, or fingers or on the upper lip. They resolve within a few days. If the affected extremity is brought up to the infant's mouth, the infant will often commence sucking at the site, confirming the diagnosis. Herpesvirus infection is often considered when sucking blisters are encountered, but lesions of herpes simplex are grouped vesicles occurring on an erythematous base or punched out, hemorrhagic erosions.



Neonatal Acne. Neonatal acneiform facial lesions usually develop within the first 30 days of life and are estimated to occur in 50 percent of newborns (Fig. 106-5). This benign eruption appears to be hormonally mediated (see Chap. 78). Neonatal acne may be hard to distinguish from benign neonatal cephalic pustulosis, which has been attributed to overgrowth of *Malassezia* sp.[14] Most cases resolve spontaneously, but severe cases can be treated topically with ketoconazole, benzoyl peroxide, or erythromycin.

HAIR LOSS IN THE INFANT[15] ***Telogen Effluvium.*** Telogen effluvium occurs frequently in newborns and is often overlooked. The hair loss may be gradual or sudden, and may occur as soon as the first few days of life, with the telogen hairs shed by 3 to 4 months of age. No treatment is indicated as spontaneous resolution is the rule.

A transient circumscribed patch of non-scarring alopecia develops at the occiput in many infants. This is believed to be due to a combination of physiologic telogen effluvium and possibly localized pressure from laying in the supine position. This spontaneously resolves.

Triangular Temporal Alopecia. Triangular temporal alopecia is a form of non-scarring hair loss noted at 2 to 5 years of age as a triangular-, oval-, or lancet-shaped area of alopecia at the frontotemporal scalp. Often, a thin row of hair separates the affected area from the forehead. The terminal hairs are replaced by vellus hair. The condition is often mistaken for alopecia areata; however, distinguishing features include the typical location and shape, the presence of vellus hairs, and the absence of exclamation point hairs and the histologic findings of alopecia areata. There is no known treatment, and the condition persists unchanged. However, triangular temporal alopecia is benign and will not expand.



◀ **FIGURE 106-5** Neonatal acne. Tiny papulopustules on the cheeks of a 3-week-old infant.

Alopecia Areata. Alopecia areata occurs in all ages (see Chap. 86). All forms of alopecia areata occur in infants and children (patchy, universalis, etc.), with the same disease presentation and treatment challenges as in adults. Onset at younger than 2 years of age is estimated to occur in 1 percent to 2 percent of alopecia areata patients; however, it may be more common than this due to under-recognition. Several cases of congenital alopecia areata have been documented. Early onset is considered to be a marker of severe disease. Total alopecia during the first year of life after having hair at birth should be distinguished from genetic disorders, such as congenital atrichia and the alopecia associated with vitamin D–resistant rickets.

Tinea Capitis. Tinea capitis can occur at any age, including infancy (see Chap. 188). Hair loss associated with scaling, broken hairs, pustules, or black dots should prompt a potassium hydroxide scraping and fungal culture to confirm the diagnosis. Just as in older children, *Trichophyton tonsurans* is the most common dermatophyte, and oral griseofulvin is the treatment of choice. Tinea capitis and fungal infections are discussed in Chap. 188.

BIRTHMARKS Birthmarks represent an excess of one or more of the normal components of skin per unit area: blood vessels, lymph vessels, pigment cells, hair follicles, sebaceous glands, epidermis, smooth muscle, collagen, or elastin. Although most birthmarks are of little medical or psychosocial consequence, the social and cultural impact of a disfiguring birthmark should not be underestimated, from both the patient's and the parents' perspectives.[16] The age-old theory of maternal imprinting is still widely accepted in many countries, including the United States, and the mother may be subtly or actively blamed for congenital conditions in the newborn. With selective photothermolysis offered by lasers and advances in surgical and topical therapies, therapeutic options are increasing.

The two most common birthmarks are the salmon patch (see Chap. 173) and Mongolian spots (see Chap. 122). Salmon patches occur most commonly on the glabella and nuchal area and are observed with high frequency in all races, occurring in 70 percent of white infants and 59 percent of black infants. Mongolian spots, which represent collections of dermal melanocytes, are seen in 80 percent to 90 percent of infants of color but in only 5 percent of white infants.[17,18] Solitary café-au-lait macules are extremely common and benign, however the appearance of multiple café-au-lait macules raises the possibility of neurofibromatosis type 1 (see Chap. 142). Other common birthmarks are listed in Table 106-1.

TABLE 106-1
Common Birthmarks in the Newborn

- Mongolian spots
- Salmon patch ("stork bite," "angel's kiss") (see Chap. 173)
- Port-wine stain (nevus flammeus) (see Chap. 173)
- Hemangioma (see Chap. 126)
- Epidermal nevus, including nevus sebaceus (see Chap. 118)
- Congenital nevocellular nevi (see Chap. 122)
- Congenital melanocytic nevi (see Chap. 122)
- Nevus depigmentosus (see Chap. 73)
- Café-au-lait spots (see Chap. 73)

HEMANGIOMAS Infantile hemangiomas are the most common tumors of infancy. They must be differentiated from vascular malformations and other vascular anomalies. Hemangiomas are discussed in detail in Chap. 126.

LYMPHANGIOMAS Both types of lymphatic malformations, microcystic (lymphangiomas) and macrocystic (cystic hygromas), are discussed in Chap. 173.

UNCOMMON DERMATOSES OF THE NEONATE Selected dermatoses of the neonate are discussed in the following sections. Box 106-1 lists differential diagnoses for selected cutaneous conditions encountered in neonates and infants.

Cutis Marmorata Telangiectatica Congenita. Cutis marmorata telangiectatica congenita is characterized by persistent cutis marmorata, telangiectasia, and sometimes associated underlying cutaneous atrophy (Fig. 106-6). Its incidence is sporadic, and its etiology is obscure. Theories of vascular malformation are currently favored. Diagnosis is usually evident on clinical examination. Usually a lower extremity is involved, but location on the trunk or upper extremity is not uncommon. A multitude of associated anomalies can occur, including limb asymmetry, hemangiomas, and other vascular birthmarks, pigmented nevi, and aplasia cutis congenita (ACC). However, the majority of patients have a good prognosis, with half demonstrating improvement of the mottled appearance over the first two years.[19]

Subcutaneous Fat Necrosis of the Newborn. Subcutaneous fat necrosis of the newborn is characterized by firm, circumscribed, reddish or purple subcutaneous nodules or plaques that appear over the back, cheeks, buttocks, arms, and thighs (Fig. 106-7; see Chap. 68). The lesions usually begin within the first 2 weeks of life and resolve spontaneously over several weeks.[20]

Sclerema Neonatorum. Sclerema is diffuse hardening of the skin in a sick premature newborn and is becoming rare as neonatal care improves worldwide. The onset is characteristically after 24 hours of age. The skin feels hard and immobile and looks yellow and shiny. The trunk is always involved. Severely ill premature newborns that have suffered sepsis, hypoglycemia, metabolic acidosis, or other severe metabolic abnormalities are at risk. Histologically, edema of fibrous septa surrounding fat lobules is found. There is no necrosis of fat, differentiating it from subcutaneous fat necrosis of the newborn. The etiology of this rare condition is unclear, and infant mortality is high.

Box 106-1

Selected Differential Diagnosis of Neonates and Infants

- Pustules in the neonate
  - Erythema toxicum neonatorum
  - Transient neonatal pustular melanosis
  - Congenital candidiasis
  - Letterer-Siwe disease (pustular psoriasis, Langerhans cell histiocytosis) (see Chap. 148)
  - Neonatal cephalic pustulosis
  - Bacterial sepsis
  - Herpes simplex infection (see Chap. 193)
- Blistering in the neonate
  - Sucking blisters
  - Herpes simplex virus (see Chap. 193)
  - Aplasia cutis congenita
  - Cutaneous mastocytosis (see Chap. 150)
  - Epidermolysis bullosa
  - Neonatal pemphigus
  - Varicella (see Chap. 194)
  - Impetigo
  - Incontinentia pigmenti
  - Epidermolytic hyperkeratosis (see Chap. 47)
- The red scaly baby
  - Physiologic scaling and redness (postdates) infant
  - Psoriasis
  - Atopic dermatitis
  - Scabies
  - Seborrheic dermatitis
  - Immunodeficiency (see Chap. 144)
  - Hypohidrotic ectodermal dysplasia (see Chap. 143)
  - Netherton syndrome (see Chap. 47)
  - Acrodermatitis enteropathica (see Chap. 130)
- The collodion baby (see Chap. 47)
  - Lamellar ichthyosis (see Chap. 47)
  - Congenital ichthyosiform erythroderma
  - Gaucher syndrome
  - X-linked ichthyosis (see Chap. 47)
  - Epidermolytic hyperkeratosis (see Chap. 47)
- The "blueberry muffin" baby
  - TORCH infections
  - Congenital leukemia
  - Congenital self-healing reticulohistiocytosis (see Chap. 149)
  - Blue rubber bleb nevus syndrome
  - Twin-twin transfusion

TORCH = *t*oxoplasmosis, *o*ther agents, especially syphilis, but also hepatitis B, coxsackie virus, Epstein-Barr virus, varicella-zoster virus, and human parvovirus, *r*ubella, *c*ytomegalovirus, *h*erpes simplex virus.



▲ **FIGURE 106-6** Cutis marmorata telangiectatica congenita. Note the atrophic, dusky, stellate patches with overlying telangiectasias.

Aplasia Cutis Congenita. ACC represents a developmental failure of the skin usually occurring on the scalp, but any location on the body surface can be affected (Fig. 106-8). It is often an isolated finding, but a multitude of associated conditions have been described.

ACC has no single underlying cause.[21] Some cases may represent a forme fruste of a neural tube defect.[22] In the most common form of ACC, oval, sharply marginated atrophic macules are seen on the midline of the posterior scalp. They are usually solitary, but may be multiple. Aplasia cutis is always hairless, and may appear vesicular, ulcerated, or covered by a thin epithelial



▲ **FIGURE 106-7** Subcutaneous fat necrosis of the newborn. This infant developed an erythematous firm mass on the back by 2 weeks of age. She later developed hypercalcemia.



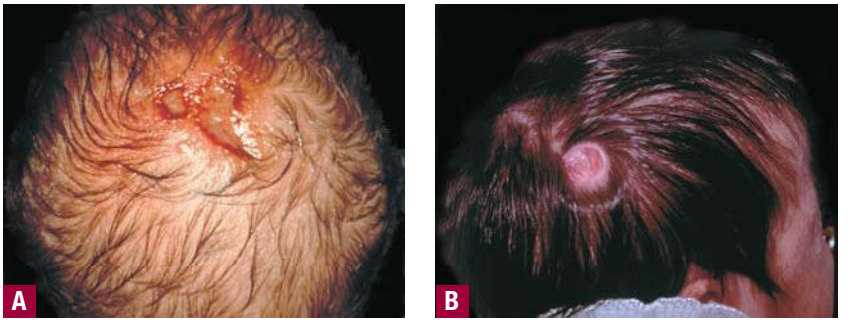

▲ **FIGURE 106-8** Two infants with aplasia cutis congenita. **A.** Scalp erosions grouped at the vertex scalp. Scraping or biopsy is contraindicated. **B.** An atrophic, well-circumscribed round patch with visible capillaries on the scalp of an infant. (**A** used with permission from 1991 Yale Resident Photograph Collection.)



membrane. When healed, lesions are usually atrophic, but sometimes develop a keloidal scar. Epidermis, dermis, and fat all may be missing, or single layers may be absent. Lesions may range from a few millimeters to many centimeters in diameter. Epidermolysis bullosa (see Chap. 60) may present as ACC, especially on one or both legs.

Scalp ulcers at birth of aplasia cutis may be mistaken for obstetric trauma. Other forms of congenital circumscribed hair loss should be considered. Midline blisters or erosions should not be biopsied, scraped for herpes cultures, or otherwise traumatized. After a careful examination to rule out associated malformations, ACC is treated conservatively to allow healing. Surgical revision of the scar later in childhood or adolescence can be done electively to improve cosmesis.

Hair Collar Sign. The "hair collar sign" is a ring of darker and/or coarser terminal hairs on the scalp, typically surrounding ACC, dermoid cyst, encephalocele, meningocele, or heterotopic brain tissue.[22] The hair collar sign itself is a marker of cranial dysraphism and its presence, like aplasia cutis, mandates careful examination of the infant, particularly of midline structures and fusion planes.

Anetoderma of Prematurity. A specific form of anetoderma has been described in premature infants. Most were extremely premature infants (born at 24 to 29 weeks' gestation); however, one was born at 32 weeks' gestation. The development of localized anetoderma appears to be triggered by the placement of monitoring leads on the skin of low-birthweight, growth-restricted infants; the majority were very ill premature infants.[23] However, anetoderma of prematurity is not well understood, and it remains a rare dermatosis despite the widespread use of monitoring leads in the neonatal intensive care unit. Anetoderma is discussed in Chap. 65.

Infections of the Neonate

Infants younger than the age of 2 months are less able to localize infection due to immature immunologic function, and life-threatening sepsis can develop insidiously. Subtle clues such as a decrease in body temperature, poor feeding, or other non-specific signs are taken seriously by the pediatrician, and a "rule out sepsis" admission is implemented when suspicions are high. At a minimum, blood, cerebrospinal fluid, and urine cultures are obtained, and intravenous antibiotic therapy begun pending cultures.

CONGENITAL VIRAL INFECTION Petechiae, purpura, jaundice, hepatomegaly, splenomegaly, microcephaly, encephalopathy, ocular abnormalities, anemia, thrombocytopenia, conjugated hyperbilirubinemia, or elevated serum hepatic transaminases should prompt the consideration of congenital viral infection, particularly if these signs arise in combination. Cutaneous infections of the neonate are listed in Table 106-2. Bacterial infections, such as staphylococcal scalded skin syndrome, and viral infections, such as varicella, are discussed in Chaps. 177, 178, and 194, respectively.

NEONATAL HERPES SIMPLEX VIRUS INFECTION (See Chap. 193) It is estimated that untreated neonatal herpes simplex virus (HSV) has a 50 percent mortality rate, with three-fourths of survivors suffering neurologic sequelae.[20] The greatest risk of neonatal herpes occurs when the delivery is vaginal and the mother has primary genital herpes (as opposed to recurrent herpes, in which the mother has antibodies protective to the neonate), the herpes infection involves the cervix, and the infant is premature and delivered with instrumentation (e.g., scalp electrodes).

The vast majority of cases are due to HSV type 2 (see Chap. 193). The typical lesions of herpes are present in the skin, eye, or mouth in a large majority of infected neonates, but some patients with CNS or disseminated disease never have skin lesions[24,25] (Fig. 106-9). Vesicles present during the first 24 hours of life suggest in utero acquisition of HSV, but onset during the first week to 10 days of life is more common, representing infection during birth.[25]

A high index of suspicion should be maintained even in the absence of maternal infection or history of genital herpes. Specimens for Tzanck smear, direct fluorescent antibody assays, and/or viral cultures for HSV should be obtained. Cultures require 12 to 120 hours to grow, and in all infected or suspected neonates, cultures of skin lesions, urine, nasopharynx, eyes, and cerebrospinal fluid are indicated. If available, a polymerase chain reaction test can be helpful in rapid diagnosis. Intravenous acyclovir should be instituted as soon as possible after specimens are collected to minimize the chance of replication of virus in the CNS and systemic dissemination of HSV. Prompt recognition and early therapeutic intervention lead to an improved outcome in the HSV-infected infant.[25]

TABLE 106-2
Selected Cutaneous Infections in the Neonate

- Staphylococcal infections (see Chap. 177)
- Impetigo
- Staphylococcal scalded-skin syndrome (see Chap. 178)
- Omphalitis
- Breast abscess (usually due to *Staphylococcus aureus* and Gram-negative organisms)
- Viral infections (see Chap. 192)
- Varicella (see Chap. 194)
- Herpes simplex virus (see Chap. 193)
- Fungal/candidal infections (see Chaps. 188, 189)
- Scabies (see Chap. 208)

Congenital Malformations of the Skin

MINOR ANOMALIES Congenital malformations are developmental defects and are frequently observed in newborns. Single minor anomalies occur in approximately 15 percent of all newborns and are, by definition, of no functional sig-



◀ **FIGURE 106-9** Herpes simplex infection. Grouped vesicles on an erythematous base. Pustules and erosions are also present. (Used with permission from Alvin H. Jacobs, MD.)

nificance. The supernumerary nipple and the accessory tragus are common examples of minor malformations. The occurrence of two is less common, however, and the presence of three or more is unusual; a complete thorough physical examination is indicated to rule out other congenital abnormalities.[26,27]

CUTANEOUS MARKERS OF DYSRAPHISM

The skin and the nervous system are both derived from the ectoderm. The neural ectoderm separates from the epithelial ectoderm during the third to fifth week of gestation, occurring simultaneously with the formation and closure of the neural tube. Hence, errors in neural tube development [i.e., dysraphism (incomplete fusion)] can be associated with cutaneous lesions. Midline facial lesions, such as dermoid cysts, nasal gliomas, and ACC, can be markers of cranial dysraphism, whereas cutaneous lesions seen on the lumbosacral midline can signify underlying spinal dysraphism. Imaging studies should be considered for midline nasal lesions before biopsy to rule out intracranial connections.[28]

A retrospective review of 54 cases of congenital lumbosacral skin lesions (including deviated gluteal cleft)[29] demonstrated that the highest risk of occult spinal dysraphism occurs with the presence of two or more congenital midline lumbosacral skin lesions, or if spinal cord dysfunction exists in the presence of one lumbar skin lesion. In addition, lumbosacral lipoma, human tail, or dermal sinus (as isolated findings) were highly associated with occult spinal dysraphism. Lumbosacral magnetic resonance imaging is indicated when these high-risk congenital lesions are present. An intermediate risk of occult spinal dysraphism was associated with atypical sacral dimple (≥ 5-mm diameter, or location ≥ 2.5 cm away from the anus), ACC, overlying hamartoma, or deviated gluteal cleft. In the presence of any of these lesions, ultrasound can be used to screen for occult spinal dysraphism if the infant is less than 4 months of age. If the infant is older, magnetic resonance imaging is needed to rule out dysraphism. Low-risk lesions that do not require imaging include isolated lumbosacral hemangioma, port-wine stain, hypertrichosis, pigmented nevus, Mongolian spot, or simple sacral dimple (≤ 5-mm diameter and location 2.5 cm or closer to the anus).[29] These findings are summarized in Table 106-3.

TABLE 106-3
Congenital Lumbosacral Midline Skin Lesions and Risk of Occult Spinal Dysraphism

Risk of Occult Spinal Dysraphism	Congenital Lumbosacral Midline Lesion
High	Group 1: MRI indicated • Two or more lesions of any kind • One lesion + spinal cord dysfunction • Lipoma • Tail • Dermal sinus
Intermediate	Group 2: Ultrasound if younger than age 4 mo (then MRI if ultrasound is abnormal), MRI indicated for age > 4 mo • Atypical sacral dimple (deep, farther than 2.5 cm from the anus, size ≥ 5 mm) • Unclassified hamartoma • Aplasia cutis congenita • Deviation of gluteal crease
Low	Group 3: No imaging needed • Hemangioma • Port-wine stain • Hypertrichosis • Pigmented nevus • Simple sacral dimple (< 5-mm diameter, 2.5 cm or closer to the anus) • Mongolian spot

MRI = magnetic resonance imaging.
Adapted from Guggisberg D et al: Skin markers of occult spinal dysraphism in children: A review of 54 cases. *Arch Derm* **140**:1109, 2004, with permission.

INFANCY AND CHILDHOOD

Evaluation Techniques

When entering the room, prolonged or intense eye contact with the young child should be avoided because this can be threatening to the child. Observing the play of a child allows for a quick assessment of his or her neurologic development.

If a language barrier exists between the parents and physician, one should resist the urge to have the bilingual patient serve as interpreter for the parents. This practice places an inappropriate burden of responsibility on the child and may increase fear and anxiety in the child. In addition, inaccurate transmission of information may occur.

Examination of young children may be performed with the child on the parent's lap or while playing with toys on the examination table. Examination of the perineum and genitalia is best accomplished with the child in the knee-chest position on the examination table (Fig. 106-10) or the parent's lap. Alternatively, the child may sit on the parent's lap with legs held apart by the parent. Fig. 106-11 illustrates anatomic terminology of the young female genitalia for accurate documentation. Caution must be used in interpreting the genital exam-







▲ **FIGURE 106-10** The knee-chest position allows visualization of the perineum and genitalia. (From Finkel MA, DeJong AR: Medical findings in child abuse, in *Child Abuse: Medical Diagnosis and Management*, edited by Reece EM. Philadelphia, Lea & Febiger, 1994, p 185, with permission.)

ination in the young female so as not to underdiagnose or overdiagnose disease or abuse. For example, the presence of labia minora adhesions is not diagnostic of trauma or abuse because they occur in as many as one-third of girls who are not abused.[30] The diastasis ani is a normal structure that can be mistaken for perianal scarring.[31] The infantile perianal pyramidal protrusion may be mistaken for condyloma acuminata but is a harmless normal finding (discussed later in this chapter in Infantile Perineal Protrusion).[32,33] Child abuse is discussed in Chap. 105.

Performing Procedures on the Young Child

Historically, there has been a widespread reluctance to biopsy skin lesions in children. In addition, children may be fearful of procedures because of their experience with immunizations and an age-appropriate fear of bodily mutilation. However, with proper preparation of the parent and child, skin biopsies and other outpatient procedures are easily performed. There are certain situations in which a biopsy can be detrimental; examples of these "biopsy pitfalls" are outlined in Table 106-4.

Eutectic mixtures of lidocaine and prilocaine (EMLA cream) or lidocaine alone (LMX cream) are useful in minimizing the pain of intralesional injections or local anesthetic injections for biopsies. As EMLA use has become widespread, reports of toxicity in children have appeared, including methemoglobinemia and seizures. The maximum dose, body surface area exposed to drug, and application time should not be exceeded; these parameters are age dependent and are listed in Chap. 243. The application of ice or anesthetic cryospray is another option to numb the skin before injections.

Before and during procedures, young infants can be soothed with a pacifier dipped in a sucrose solution. A randomized, controlled, double-blinded study of 201 newborns found that orally administered glucose solution was superior to topical EMLA cream in reducing pain with venipuncture.[34] Infants may be swaddled with a blanket for comfort and immobilization. The young child can be effectively immobilized and comforted with a restraining "hug," by a parent or assistant. Distraction techniques are invaluable as well. For example, instructing the child to blow a colorful toy windmill, blow soap bubbles, or "wiggle" his or her toes during an injection or procedure helps to decrease pain. Older children may be effectively soothed by listening to music with headphones or by watching a movie during procedures.

Alkalinizing local anesthetics to a pH of 7.0 (0.1 mEq/mL sodium bicarbonate or a 1:10 bicarbonate–anesthetic ratio by volume) minimizes the pain of cutaneous infiltration without limiting anesthetic effects.[35] Alkalinization decreases the solution's shelf life to approximately 1 week[36] due to more rapid oxidation of epinephrine. Warming lidocaine also lessens the pain of injection.[35]

Instruments and materials should be laid out ahead of time to ensure rapid performance of the procedure. Needles, instruments, and blood-stained gauze should be kept out of view and out of reach of the patient.

The use of general anesthesia for dermatologic procedures in pediatric patients is very safe when properly performed. Fears of general anesthesia should not be a barrier to delivering necessary surgical or laser procedures to healthy children.[37]

Diseases of Infancy and Childhood

INFANTILE PERINEAL PROTRUSION Also known as *infantile pyramidal protrusion*, infantile perineal protrusion (IPP) is a benign condition that occurs almost exclusively in female prepubertal girls. It appears as a pyramidal, soft-tissue, "tongue-like," smooth, or velvety pink protrusion. It is usually located in the midline just anterior to the anus. IPP is usually asymptomatic, but painful defecation has been reported. It occurs in three settings: constitutional, functional (after constipation, diarrhea, or other irritant exposure), or associated with lichen sclerosus et atrophicus. Often, IPP is misdiagnosed as condyloma acuminatum, hemorrhoids, or as a sign of trauma. Conservative management is indicated. Spontaneous resolution as well as resolution following high-fiber diet to relieve constipation has been noted.[32,33]

DIAPER DERMATITIS Diaper dermatitis, like hand dermatitis, denotes a group of region-specific dermatoses. Diaper dermatitis is one of the most common dermatologic conditions in infants and children, noted in approximately 1 million pediatric outpatient visits each year.[38] With the advent of superabsorbent disposable diapers in the last decade, severe forms of diaper dermatitis have diminished in incidence. Irritant and candidal diaper dermatitis comprise the vast majority of diaper dermatitides in diaper-wearing individuals of all ages.

The etiology of diaper dermatitis is multifactorial. The initiating factor is prolonged and increased wetness to the skin. This leads to increased frictional damage, decreased barrier function, and increased reactivity to irritants. Other interrelated etiologic factors include contact with urine and feces, fecal proteolytic and lipolytic digestive enzymes, increased skin pH, and superinfection with *Candida* and, less commonly, bacteria.[39]

Irritant Diaper Dermatitis. By far the most common type of diaper dermatitis is irritant diaper dermatitis or generic diaper

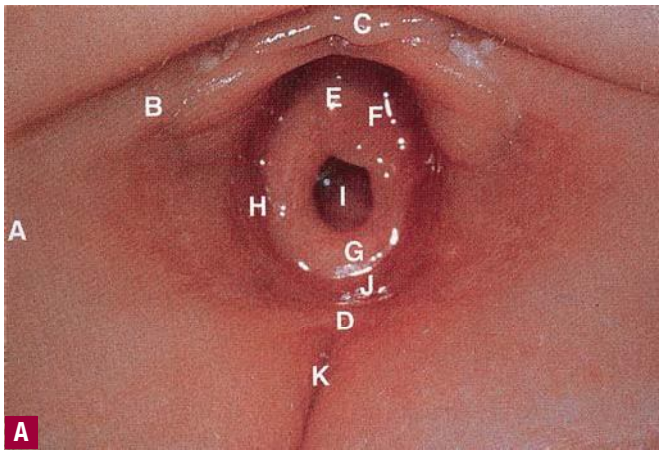

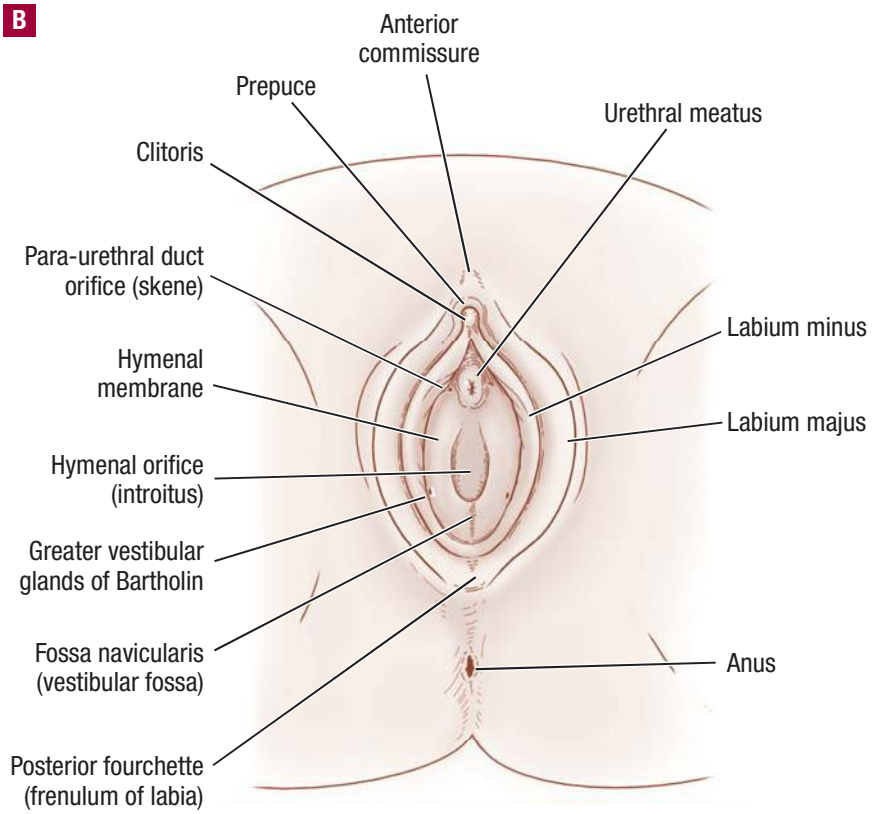

▲ **FIGURE 106-11** **A.** Magnified view of a normal female child's genital anatomy. The following structures are labeled: A, labia majora; B, labia minora; C, clitoris; D, posterior fourchette; E, urethra; F, periurethral tissue; G, hymen; H, perihymenal sulcus; I, vagina; J, posterior navicular fossa (fossa navicularis); K, perineum. (From Siegfried EC, Frasier LD: The spectrum of anogenital diseases in children. *Curr Probl Dermatol* **9**:33, 1997, with permission.) **B.** Genital anatomy of an older female child. (From Finkel MA, DeJong AR: Medical findings in child abuse, in *Child Abuse: Medical Diagnosis and Management*, edited by Reece EM. Philadelphia, Lea & Febiger, 1994, p 185, with permission.)

dermatitis. This dermatitis occurs in any person who wears diapers, regardless of age. Irritant diaper dermatitis appears as erythematous, moist, and sometimes scaly patches on the convexities of the genitalia and buttocks, beginning in areas in closest contact with the diaper. Shallow erosions are sometimes present on the convex surfaces. It can be asymptomatic or tender. Irritant dermatitis of the buttocks is often seen in toddlers who transition to pull-up diapers at night, which are poorly absorbant.

Candida *Diaper Dermatitis.* (See Chap. 189) *Candida* diaper dermatitis is the second most common type of diaper dermatitis and presents with bright red erythematous, moist papules, patches, and plaques that tend to involve body folds as well as convex surfaces. Satellite lesions are very characteristic. Oral thrush can be associated. *Candida* from intestinal flora frequently contaminates any type of diaper dermatitis present for greater than 3 days, and *Candida* levels increase with the clinical severity of the dermatitis.[40]

Miliaria Rubra ("Heat Rash"). (See Chap. 82) Miliaria rubra tends to occur at sites where plastic components of the diaper cause occlusion of eccrine ducts of the skin. It is also seen in the folds of the neck and upper torso, and is particularly common when there is a rapid shift to warm weather, and the child is overdressed.

Pseudoverrucous Papules and Nodules. Pseudoverrucous papules and nodules occur in the diaper and perianal areas in patients of any age with a predisposition to prolonged wetness. Children who wear diapers due to chronic urinary incontinence are prone to this type of dermatitis.

Infantile Granular Parakeratosis. Infantile granular parakeratosis represents an idiopathic form of retention keratosis in diaper-wearing infants. There are two clinical patterns: bilateral linear plaques in the inguinal folds and erythematous geometric plaques underlying pressure points from the diaper. A thick, flake-like scale is present in both forms and is characteristic. Therapeutic responsiveness to topical agents is ambiguous; however, spontaneous clearance after months to 1 year appears to be the rule.[41]

Jacquet Erosive Dermatitis. Jacquet erosive dermatitis is an uncommon, severe diaper dermatitis that can occur at any age. It is characterized by well-demarcated, punched-out ulcers or erosions with elevated borders. Prolonged contact with urine and feces under occlusion leads to this condition.[42] It is seen less commonly since the advent of superabsorbent diapers.

Granuloma Gluteale Infantum. Granuloma gluteale infantum is an uncommon condition characterized by reddish purplish nodules of different sizes (0.5 to 3.0 cm) occurring on the convexities of the diaper area in 2- to 9-month-old infants. It arises within pre-existing diaper dermatitis. Biopsy shows dense dermal infiltrates of lymphocytes, plasma cells, neutrophils, and eosinophils, but no true granulomas. It appears to be an unusual reaction to the usual irritant factors, candidal infection, and, in some cases, topical steroid use in the diaper region.[42] Treatment consists of



TABLE 106-4
Biopsy Pitfalls in Pediatric Dermatology

Age Group	Lesion and Site	Diagnosis	Danger	Proper Management
Newborn	Erosion or vesicle on the scalp	Aplasia cutis congenita Differential diagnosis: herpes, fetal scalp electrode trauma	Possible intracranial connection, risk of meningitis with biopsy or scraping	Protect site; do not scrape lesion or biopsy, consider ultrasound or MRI of head
Infant	"Hair collar" sign surrounding lesion on scalp or midline lesion	Encephalocele, spina bifida occulta, meningomyelocele	Possible intracranial connection; risk of meningitis	Preoperative imaging; consider neurosurgical consultation
Infant	Tuft of hair over midline spine	Spina bifida occulta, meningomyelocele	Possible intracranial connection; risk of meningitis	Preoperative imaging; consider neurosurgical consultation
Infant	Preauricular "tag"	Accessory tragus	Risk of chondritis if removed by shave or snip excision or if ligated with suture[58]	Appropriate closure when excised, if cartilaginous component present[57]
Infant or child	Mass along midline scalp, glabella, side of forehead, or other embryonic fusion plane	Dermoid cyst	Intracranial connection in up to 25 percent for midline dermoids; risk is higher if sinus present[59]; dermoids near the lateral eyebrows rarely have intracranial connections[60]	Consider MRI and neurosurgical consultation
Infant, young child	Nasal midline mass	Nasal glioma, encephalocele, or other dysraphic state Differential diagnosis: "hypertelorism," hemangioma	Intracranial connection in 100 percent of encephaloceles; gliomas may extend into oropharynx or have intranasal connections[59]	Consider MRI and neurosurgical consultation
Infant, young child	Vascular mass with greatly increased warmth, often with pulsation or bruit	Arteriovenous malformation Differential diagnosis: hemangioma	Uncontrolled bleeding, problematic bony or soft tissue hypertrophy	Consider Doppler studies, MRI, and surgical consultation

MRI = magnetic resonance imaging.



avoidance of irritants, use of barrier pastes, and avoidance of topical steroids. Resolution occurs over several months.

Dermatoses Not Etiologically Related to Diaper Wearing. Seborrheic dermatitis, atopic dermatitis, psoriasis (Fig. 106-12), bullous impetigo, acrodermatitis enteropathica, scabies, hand-foot-and-mouth disease, herpes simplex infections, and Langerhans cell histiocytosis (Letterer-Siwe disease) are conditions that occur in the diaper region but are not primarily due to the wearing of diapers and should be considered in the differential diagnosis. Skin biopsy is indicated to rule out Langerhans cell histiocytosis (see Chap. 148) if non-healing erosions or petechiae are seen in the diaper area (Fig. 106-13).

Treatment of Diaper Dermatitis. The treatment of diaper dermatitis is outlined in Box 106-2.[43] Irritant diaper dermatitis and *Candida* diaper dermatitis (or a combination of both) comprise the vast majority of diaper rashes. *Candida* is more likely to complicate diaper rash if present for more than 3 days. Although many antifungal creams are effective in this region, a new and convenient (though more costly) combination prescription cream containing both miconazole and zinc oxide is now approved for diaper dermatitis.

Education of parents and primary care physicians should include instructions regarding the use of topical steroids in the diaper area. Because of greatly increased percutaneous absorption of steroids from moisture and occlusion from diapers, topical steroid use in this anatomic region should be limited to a short course (3 to 7 days) of hydrocortisone (1 percent or 2.5 percent) ointment. This is effective in nearly all cases



▲ **FIGURE 106-12** Infantile psoriasis with involvement in the diaper region.





▲ **FIGURE 106-13** **A, B.** Langerhans cell histiocytosis. Note hepatosplenomegaly, and petechiae and erosions of the skin.

Box 106-2

ABCs in the Treatment of Diaper Dermatitis

A = Air. The diaper should be left open as much as possible when the infant sleeps to allow drying of the skin.

B = Barrier ointments. Zinc oxide pastes, petrolatum, and other bland, unmedicated barrier preparations are mainstays of therapy. A continuous layer of barrier paste or ointment should be maintained, reapplying with every diaper change, if necessary. Baby powder on the diaper area offers no antimicrobial benefit to the infant and adds a risk of aspiration.

C = Cleansing and anti-candidal treatment. Gentle cleansing with plain water, mineral oil, or unscented gentle cleanser is recommended. Avoidance of friction or rubbing is important. A topical anti-candidal agent should be added for any signs of candidiasis. Oral nystatin is indicated if oral thrush is present.

D = Diapers. Diapers should be changed as frequently and as soon after soiling as possible, especially if cloth diapers are used.

E = Education of parents and caregivers.

Modified from Boiko S: Making rash decisions in the diaper area. *Pediatr Ann* **29**:50, 2000.

when a topical steroid is needed. Similarly, use of the combination products containing halogenated steroids, such as nystatin and triamcinolone and clotrimazole and betamethasone dipropionate, should be avoided due to increased risks of steroid atrophy and hypothalamic-pituitary axis suppression when these middle- and high-potency topical steroids are used in the diaper area.

Last, parents will be reassured by the fact that even the most problematic diaper dermatitis will resolve when toilet training is achieved, and diapers are not worn.

TINEA CAPITIS (See Chap. 188) Scrapings for potassium hydroxide examination and fungal culture should be obtained before administration of systemic antifungal therapy. In children, collection of specimens for tinea capitis may be accomplished by the use of a toothbrush, ring curette, moistened cotton swab, a scalpel, or by collection of infected hairs. Alternatively, a media plate with nonslanted agar may be applied directly to the infected areas of the scalp to collect material.

ADOLESCENT DERMATOLOGY

Dermatologic diagnoses of adolescents overlap with those of general adult dermatology; however, caring effectively for the adolescent patient requires different interviewing skills and strategies to enhance compliance.

Evaluation Techniques

Greeting the adolescent first and the parents second, and interviewing the adolescent patient alone at the beginning of the visit help to earn the patient's trust.[44] The confidentiality laws of each state should be considered and the patient's right to privacy respected. Many states protect the adolescent's right to confidential medical care for problems such as drug abuse, sexually transmitted diseases, contraception, pregnancy, and abortion.

The open-ended questioning style used for adults frequently fails with adolescents. Phrasings using the third person and giving choices when asking questions are more effective techniques to obtain information. For example, "Many women on oral contraceptives forget to take their pill once in a while. How often do you forget to take your birth control pills: often, sometimes, or almost never?" will yield a more accurate reply than, "Do you take your birth control pills every day?"

Adolescents lack a well-developed sense of future time, and long-term consequences are less valued than immediate outcomes. Goals should be concrete, short term, and relevant to the present. Rather than using goals related to more distant benefits, such as the reduction of potentially serious disease complications (e.g., smoking causes increased risk of lung cancer), emphasis should be placed on immediate and concrete effects (e.g., smoking causes your clothes, hair, and breath to smell bad and your teeth to turn yellow). Body image is a more powerful motivator (e.g., tanning salons cause premature wrinkles and ugly skin) than future health concerns (e.g., tanning salons increase your risk of skin cancer). Any treatment that is disfiguring or has visible side effects will meet with resistance.[44]

Physical and psychosocial development may not be congruent. An adolescent should not be expected to shoulder all medical responsibilities for himself or herself or for younger siblings. The physician's role is not to befriend, nor is it to parent the adolescent patient, but rather it is to be a trusted, valuable authority.

Acne and the Adolescent (See Chap. 78)

Acne vulgaris is an extremely common and variable disorder that can have far-reaching detrimental effects on self-image and self-esteem. Increased unemployment has been documented among patients with a history of severe acne.[45] For adolescents, a single- or two-drug regimen will optimize compliance and cost-effectiveness.

The U.S. Food and Drug Administration (FDA) has received some reports of depression and suicide in patients using isotretinoin. The question of isotretinoin-induced depression is complicated by the high baseline incidence of depression and suicide in the adolescent population and by the depression and stress associated with severe acne.[46,47] A cohort study of 132 teenage patients with moderate to severe acne demonstrated that isotretinoin therapy did not increase symptoms of depression. On the contrary, treatment of acne with either conservative therapy or with isotretinoin was associated with a decrease in depressive symptoms.[48] Though causation is still unproven, the black box warning must be discussed with patients.

SPECIAL TOPICS IN PEDIATRIC DERMATOLOGY

Drug Labeling for Pediatric Patients

The lack of FDA approval for pediatric use does not imply that a drug is contraindicated or disapproved; it simply means that insufficient data are available to grant approval status. Although attempts have been made to equate off-label prescribing with recklessness in the medical malpractice arena, the American Academy of Pediatrics has stated that failure to prescribe medications for off-label uses when the medication is appropriate under standard of care may constitute malpractice.

The thalidomide tragedy (see Chap. 236) led to more stringent regulation of drugs in the early 1960s, and manufacturers began omitting drug studies in infants and children. In the 1970s, pediatric dosage information in package inserts tended to exclude children from therapeutic benefit. Performing research in healthy children is problematic because of ethical and logistic questions, medicolegal risk, and cost. According to the American Academy of Pediatrics, only a small fraction of all drugs marketed in the United States today have had clinical trials performed in pediatric patients, and a majority of marketed drugs are not labeled or are insufficiently labeled for use in pediatric patients.[49] Safety and effectiveness information for drug use in children under 2



years of age is particularly lacking. The absence of pediatric testing and labeling poses significant safety risks for children. Additionally, children may be denied the benefits from therapeutic advances because physicians choose to prescribe existing, less effective medications in the face of insufficient pediatric information about a new medication. In 1997, as part of the FDA Modernization Act, Congress enacted a new law known as the *Pediatric Exclusivity Provision* that provides marketing incentives (i.e., extension of patent protection) to manufacturers who conduct studies of drugs in children. This law has been effective in generating pediatric studies on many drugs. Hopefully, in the near future, physicians caring for children will no longer need to prescribe drugs "off label," and children will no longer be "therapeutic orphans."



Topical Medications

Children are at increased risk for toxicity from topically applied agents because of increased surface area–body mass ratio and alterations in metabolism of drugs. Patients with disorders of cornification (e.g., lamellar ichthyosis, Netherton syndrome) and infants, are at much higher risk of toxicity. Examples of cases of percutaneous poisoning from topical agents are listed in Table 106-5.

TABLE 106-5
Topical Medications Reported to Cause Systemic Toxicity in Children

Topical Medication	Complication	Reference
Benzocaine, 3% (Lanacane)	Methemoglobinemia in a 2-yr-old child	61
Iodoquinol, clioquinol (Vioform)	Neurotoxicity when used as treatment for diaper dermatitis	62, 63
Lindane	Neurologic toxicity in children with disrupted epidermal barrier and/or excessive topical application or ingestion	64, 65
N, N–diethyl-*m*-toluamide (DEET)	Slurred speech, tremors, seizures, and death in children after repeated and extensive application of high concentrations of DEET	66
Povidone-iodine (Betadine)	Hypothyroidism in infants with spina bifida	67
Povidone-iodine (Betadine)	Decreased free thyroxine and elevated iodine levels in infants treated with diluted povidone-iodine during *Staphylococcus aureus* epidemic	68
Salicylic acid	In a 7-yr-old boy treated for ichthyosis vulgaris, life-threatening salicylism occurred with neurologic sequelae lasting 6 mo	69
Saline, sodium chloride	Fatalities in infants and children following ancient Turkish custom of "salting"	70
Viscous lidocaine, 2%	Lidocaine overdose following frequent application to oral lesions	71

Systemic Medications

DRUG DOSAGES Pediatric doses of systemic medications are calculated according to body weight (mg/kg) or body surface area to account for size variations between patients of the same age and to account for weight gain due to growth. Prescriptions for syrups or suspensions must indicate concentration (e.g., milligrams per teaspoon) to avoid serious error. A selected pediatric dermatology formulary of systemic drugs is presented in Table 106-6. The reader is also directed to references including *Red Book*[50] and *The Harriet Lane Handbook*.[51]

SYSTEMIC GLUCOCORTICOIDS Hypothalamic-pituitary axis suppression, osteonecrosis, and other adverse effects of systemic glucocorticoid therapy affect patients of all ages and are reviewed in Chap. 225. The potential risk of growth suppression is unique to childhood. Exogenous glucocorticoids disrupt the secretion of growth hormone (GH), causing abnormal spontaneous GH secretion with reduced pulse amplitude of GH release and reduced response to provocative stimuli.[52,53] There is also decreased local production of insulin-like growth factor 1. These and other effects of glucocorticoids act to cause delayed growth at the bony epiphyses, with the most noticeable reduction in growth velocity occurring during early childhood and adolescent growth spurts. There is a linear relation between the daily dose and growth suppression. Alternate-day dosing, with single morning doses, decreases the risk of glucocorticoid growth suppression. Most children will have adequate catch-up growth eventually with reduction of doses, alternate-day therapy, or cessation of therapy.[54] For the pediatric patient on long-term systemic steroid therapy, charting height and weight on a standardized growth curve is the best method to screen for decreasing growth velocity.

Children taking immunosuppressive doses of systemic glucocorticoids should not be vaccinated with live-virus vaccines (e.g., measles, oral polio, varicella). A dosage equivalent to 2 mg/kg/day or greater of prednisone or a total of 20 mg/day or greater for children weighing more than 10 kg, when given for more than 14 days, is sufficient to warrant withholding immunization with live-virus vaccines.[55] Systemic steroids should not be given to a healthy child if he or she has had recent varicella exposure and is not varicella-immune because varicella infection can be fatal in this situation. In addition, children with ocular herpes simplex and untreated tuberculosis should not be given systemic steroids, and patients with underlying diabetes, hypertension, peptic ulcer disease, renal insufficiency, or psychosis should be treated with great caution or with an alternative agent.[50]

ANTIMICROBIALS Use of tetracycline family medications is contraindicated in children younger than 8 years of age because it causes brown discoloration of developing teeth and decreased bone growth.[50] Ciprofloxacin and quinolone use in children younger than 18 years of age is restricted because the fluoroquinolones have been shown to cause cartilage damage in every juvenile animal model tested at therapeutic doses.[50] The mechanism is unknown. To date, ciprofloxacin is the fluoroquinolone that has been used most extensively in children. It appears to be well tolerated, does not appear to cause arthropathy, and is an effective oral agent for a number of diseases that otherwise would require parenteral therapy. It is recommended that its use be restricted to relatively serious infections for which no other oral agent is available or intravenous antibiotics would be impractical

TABLE 106-6
Pediatric Dermatology Formulary of Selected Systemic Drugs

Generic Name (Trade Name)	Dosage Forms	Dose	Comment
Antiviral Agents			
Acyclovir (Zovirax)	Caps: 200 mg Tabs: 400, 800 mg Susp: 200 mg/5 mL	Note: Max. dose of oral acyclovir in children: 80 mg/kg/day. Immunocompetent patient with mucocutaneous HSV: • Initial infection: 1200 mg/day in three divided doses PO × 7–10 days. • Recurrence: 1200 mg/day in three divided doses PO × 5 days, or 1600 mg/day in two divided doses × 5 days. • Chronic suppressive therapy: 800–1000 mg/day in two to three divided doses PO for up to 1 yr; then reassess. Zoster: 4000 mg/day ÷ 5 times/day PO × 5–7 days for patients ≥ 12 yr. Varicella: 80 mg/kg per day in four divided doses × 5 days. Max. dose: 3200 mg/day.	Start therapy within the first 24–48 h of signs/symptoms. Oral absorption unpredictable. Use ideal body weight for calculating dosage for obese patients. Dose alteration necessary in patients with impaired renal function. Infrequent repots of headache, vertigo, insomnia, GI irritation, urticaria, fever. See *Red Book*[72] for neonatal, immunocompromised, and parenteral indications and dosing.[73] Resistant strains of HSV and varicella-zoster virus reported in immunocompromised patients (e.g., advanced human immunodeficiency virus infection). See Chap. 232 for treatment of viral infections.
Famciclovir (Famvir)	Tabs: 125, 250, 500 mg	Adolescents: Genital HSV: • Initial outbreak: 250 PO tid × 5 days. • Recurrences: 125 mg PO bid × 5 days. • Suppressive therapy: 125–250 mg PO bid × 1 yr; then reassess. Adults: • Herpes zoster: 500 mg q8h PO × 7 days. • Recurrent herpes labialis (cold sores): 1500 mg PO × 1 dose. • Genital herpes simplex: 125 mg PO q12h × 5 days. • Single day dosing for recurrent genital herpes: 1000 mg at first sign of onset, then 1000 mg 12 hours later. • Suppression of recurrent genital herpes: 250 mg PO bid for up to 1 yr; then reassess.	Not FDA approved for use in children. Start therapy within the first 24–48 h of signs/symptoms. Drug is converted to active form (penciclovir). Better absorption than PO acyclovir. May cause headache, diarrhea, nausea, and abdominal pain. Concomitant use of probenecid and other drugs eliminated by active tubular secretion may result in decreased penciclovir clearance. Adjust dose in renal failure. See Chap. 232 for treatment of viral infections.
Valacyclovir (Valtrex)	Tabs: 500, 1000 mg	For immunocompetent adolescents/adults.[70] Genital HSV: • Initial outbreak: 1 g PO bid × 10 days. • Recurrences: 500 mg PO bid × 3–5 days. • Suppressive therapy: 500–1000 mg PO per day × 1 yr; then reassess. For immunocompetent adults: • Zoster: 1 g PO tid × 7 days within 48–72 h of onset of rash. • Recurrent herpes labialis (cold sores): 2 g PO q12 h × 1 day.	Not FDA approved for use in children. Drug is converted to acyclovir. Better oral absorption than acyclovir, cannot be substituted for acyclovir on a 1:1 basis. Start therapy within the first 24–48 h of signs/symptoms. Adjust dose in renal failure. Use with caution in hepatic and renal insufficiency.
Antibiotics			
Amoxicillin (Amoxil, Trimox, and others)	Drops: 50 mg/mL Susp: 125, 200, 250, 400 mg/5 mL Caps: 250, 500 mg Chewable tabs: 125, 200, 250, 400 mg	Infants ≤ 3 mo: 20–30 mg/kg/day ÷ bid. Children: • Standard dose: 25–50 mg/kg/day PO ÷ bid–tid. • High dose: 80–90 mg/kg/day PO ÷ bid. Adults: 250–500 mg/dose PO tid. Max. dose: 2–3 g/day.	Rash and diarrhea may occur. Renal elimination. Serum levels about twice those achieved with equal dose of ampicillin. Chewable tabs contain phenylalanine.

(continued)



TABLE 106-6
Pediatric Dermatology Formulary of Selected Systemic Drugs (Continued)

Generic Name (Trade Name)	Dosage Forms	Dose	Comment
Amoxicillin-clavulanate (Augmentin)	Tabs: • For tid dosing: 250, 500 mg amoxicillin (with 125 mg clavulanate) • For bid dosing: 875 mg amoxicillin (with 125 mg clavulanate); Augmentin XR 1 g amoxicillin (with 62.5 mg clavulanate) Chewable tabs: • For tid dosing: 125, 250 mg amoxicillin (31.25 and 62.5 mg clavulanate, respectively) • For bid dosing: 200, 400 mg amoxicillin (28.5 and 57 mg clavulanate) • Susp: For tid dosing, 125, 250 mg amoxicillin/5 mL (31.25 and 62.5 mg clavulanate/5 mL) For bid dosing: 200, 400 mg amoxicillin/5 mL (28.5 and 57 mg clavulanate/5 mL) Augmentin ES-600: 600 mg amoxicillin/5 mL (42.9 mg clavulanate/5 mL)	Dosage based on amoxicillin component. Children < 3 mo: 30 mg/kg/day PO ÷ bid (recommended dosage form is 125 mg/5 mL suspension). Children ≥ 3 mo: • For tid dosing: 20–40 mg/kg/day PO ÷ tid. • For bid dosing: 25–45 mg/kg/day PO ÷ bid. Augmentin ES-600: ≥ 3 mo and < 40 kg: 90 mg/kg/day ÷ bid PO × 10 days. Adults: 250–500 mg/dose tid PO or 875 mg/dose bid PO for more severe and respiratory infections. Augmentin XR: > 16 yr and adults: 2 g bid PO × 10 days for acute bacterial sinusitis or × 7–10 days for community-acquired pneumonia. Max. dose: 2 g/day	Clavulanate extends coverage of amoxicillin to include β-lactamase-producing strains of *Haemophilus influenzae*, *Moraxella catarrhalis*, *Neisseria gonorrhoeae*, and some *Staphylococcus aureus*. The bid dosing schedule is associated with less diarrhea. For bid dosing, the 875-mg tab, the 200- and 400-mg chewable tab, or the 200 and 400 mg/5 mL susp should be used. Phenylketonurics should not use the bid dosage forms because they contain phenylalanine. Adjust dose in renal failure. The 250 mg or 500 mg tab cannot be substituted for Augmentin XR.
Azithromycin (Zithromax)	Tabs: 250, 500, 600 mg Susp: 100 mg/5 mL, 200 mg/5 mL Oral powder (sachet): 1 g	Children ≥ 6 mo: Otitis media or community-acquired pneumonia: 10 mg/kg PO on day 1 (not to exceed 500 mg), followed by 5 mg/kg/day PO every day (not to exceed 250 mg/day) for days 2–5 Pharyngitis/tonsillitis (≥ 2 yr old):12 mg/kg/day PO every day × 5 days (not to exceed 500 mg/day). Adolescents/adults: • Respiratory tract, skin, and soft tissue infection: 500 mg PO day 1, then 250 mg/day PO on days 2–5.	Dosages vary depending on patient's age and indication; see *Red Book*[72] and *Harriet Lane Handbook*[51] for more details. Contraindicated in patients allergic to erythromycin. Aluminum- and magnesium-containing antacids decrease absorption. Can cause cholestatic jaundice, GI discomfort. Less risk for drug interactions compared with other macrolides. central nervous system penetration poor.
Cefadroxil (Duricef and others)	Susp: 125, 250, 500 mg/5 cc Tabs: 1 g Caps: 500 mg	Infants and children: 30 mg/kg/day PO ÷ bid. Adults: 500 mg PO bid. Max. dose: 2 g/day.	First-generation cephalosporin. See Cephalexin.
Cephalexin (Keflex and others)	Susp: 125 mg/5 cc, 250 mg/5 cc Drops: 100 mg/mL Tabs: 250, 500 mg Caps: 250, 500 mg	Children: 25–100 mg/kg/day PO ÷ qid. Adults: 1 g/day PO ÷ qid. Max dose: 4 g/day.	Use with caution in renal insufficiency. Some cross-reactivity with penicillin. For uncomplicated infections, less frequent dosing (bid or tid) can be used. Give on empty stomach. Adjust dose in renal failure.
Cephradine (Velosef and others)	Susp: 125, 250 mg/5 cc Caps: 250, 500 mg	Infants ≥ 9 mo and children: 25–50 mg/kg/day PO ÷ qid or bid. Adults: 1–4 g/day PO ÷ qid or bid. Max. dose: 4 g/day.	First-generation cephalosporin. See Cephalexin.

(continued)



TABLE 106-6
Pediatric Dermatology Formulary of Selected Systemic Drugs (Continued)

Generic Name (Trade Name)	Dosage Forms	Dose	Comment
Clarithromycin (Biaxin)	Film tabs: 250, 500 mg Extended release tabs: 500 mg Granules for suspension: 125, 250 mg/5 mL	Children: Acute otitis media, pharyngitis, tonsillitis, pneumonia, uncomplicated skin infections: 15 mg/kg/day PO ÷ bid. Max. dose: 1 g/day. Adults: Pharyngitis, tonsillitis, bronchitis, pneumonia, uncomplicated skin infections: 250–500 mg/dose PO bid. Extended release: 1000 mg PO qd.	Contraindicated in patients allergic to erythromycin. Cardiac arrhythymias can occur in patients receiving terfenadine, astemizole, and cisapride. Side effects include diarrhea, nausea, abnormal taste, dyspepsia, abdominal discomfort (less than with erythromycin but more common than with azithromycin), and headache. May increase carbamazepine, theophylline, cyclosporine, and tacrolimus levels. Inhibits CYP450 3A4. Adjust dose in renal failure. All dosage forms may be administered with food.
Clindamycin	Caps: 75, 150, 300 mg Oral solution: 75 mg/5 mL	Children: 10–30 mg/kg/day ÷ PO q6–8h. Adults: 150–450 mg/dose q6–8 h. Max. dose: 1.8 g/day.	Pseudomembranous colitis may occur up to several weeks after completion of therapy. May cause diarrhea, granulocytopenia, thrombocytopenia, Stevens-Johnson syndrome.
Co-trimoxazole (trimethoprim, sulfamethoxazole, TMP-SMX, Bactrim, Septra, and others)	Tabs: 80 mg TMP/400 mg SMX Tabs (double strength): 160 mg TMP/800 mg SMX Susp: 40 mg TMP/200 mg SMX per 5 mL	Doses based on TMP component: Children: 8–10 mg/kg/day ÷ bid. Adults (> 40 kg): 160 mg/dose bid.	Not recommended for use in infants < 2 mo. Contraindicated in patients with megaloblastic anemia due to folate deficiency. May cause kernicterus in newborns; may cause blood dyscrasias, glossitis, renal or hepatic injury, GI irritation, Stevens-Johnson syndrome, hemolysis in patients with G6PD deficiency. Do not use at term pregnancy. Use with caution in renal and hepatic impairment.
Dicloxacillin (Dynapen and others)	Caps: 250, 500 mg Oral susp: 62.5 mg/5 mL	Children (< 40 kg): • Mild/moderate infections: 12.5–25 mg/kg/day PO ÷ qid. • Severe infections: 50–100 mg/kg/day PO ÷ qid. Adults (≥ 40 kg): 125–500 mg/dose PO ÷ q6h. Max. dose: 4 g/day.	Same side effects as other penicillins. Give on empty stomach. Use of oral suspension may be limited due to its taste and because dose can be a large volume due to 62.5 mg/5 mL concentration.
Doxycycline (Vibramycin and others)	Caps and tabs: 20 (Periostat), 50, 75, 100 mg Syrup: 50 mg/5 cc Susp: 25 mg/5 cc	Initial (≤ 45 kg): 5 mg/kg per day ÷ bid PO × 1 day to max. dose of 200 mg/day (> 45 kg): 100 mg bid PO × 1 day. Maintenance (≤ 45 kg): 2.5–5 mg/kg/day PO ÷ qd–bid; (> 45 kg): 100–200 mg/day PO ÷ qd–bid. Max. adult dose: 300 mg/day.	For treatment of acne, see Chap. 78. Use under age 8 yr may cause discoloration of teeth and dental enamel hypoplasia. Use with caution in hepatic or renal disease. May cause increased intracranial pressure. GI symptoms. and photosensitivity. See also Tetracycline. For periodontitis, adult dose is 20 mg bid PO for ≤ 9 mo.
Erythromycin preparations (Erythrocin, Pediamycin, E-Mycin, Ery-Ped, and others)	Erythromycin base Tabs: 250, 333, 500 mg Delayed-release tabs: 250, 333, 500 mg Delayed-release caps: 250 mg Erythromycin ethyl succinate Susp: 200, 400 mg/5 cc Oral drops: 100 mg/2.5 mL Chewable tabs: 200 mg Tabs: 400 mg Erythromycin estolate Susp: 125, 250 mg/5 cc	Children: 30–50 mg/kg/day ÷ tid. Max. dose: 2 g/day. Adults: 1–4 g/day ÷ qid. Max. dose: 4 g/day.	GI side effects common. Give doses after meals. Use with caution in liver disease. Adjust dose in renal failure. May produce elevated digoxin, theophylline, carbamazepine, cyclosporine, and methylprednisolone levels. Inhibits CYP450 1A2 and 3A3/4 isoenzymes. Contraindicated with concomitant use of cisapride, astemizole, and terfenadine. Because of different absorption characteristics, higher oral doses of erythromycin ethyl succinate are needed to achieve therapeutic effects.

(continued)



TABLE 106-6
Pediatric Dermatology Formulary of Selected Systemic Drugs (Continued)

Generic Name (Trade Name)	Dosage Forms	Dose	Comment
Erythromycin preparations *(continued)*	Tabs: 500 mg Caps: 125, 250 mg Oral drops: 100 mg/mL Chewable tabs: 125, 250 mg Erythromycin stearate Tabs: 250, 500 mg		
Minocycline (Minocin and others)	Tabs and caps: 50, 75, 100 mg Pellet-filled caps: 50, 100 mg Oral susp: 50 mg/5 mL	Children (8–12 yr): 4 mg/kg per dose × 1 PO; then 2 mg/kg per dose bid PO. Max. dose: 200 mg/day. Adolescents and adults: 200 mg/dose × 1 PO; then 100 mg bid PO.	High incidence of vestibular dysfunction. Nausea, vomiting, allergy, photophobia, injury to developing teeth, and hyperpigmentation may occur. Do not take with milk or dairy products. Hepatitis and liver failure rarely reported. See Chap. 78 for treatment of acne.
Penicillin V potassium (Pen-Vee K, V-Cillin K, and others)	Tabs: 250, 500 mg Oral solution: 125 mg/5 mL, 250 mg/5 mL	Children: 25–50 mg/kg/day PO ÷ tid–qid. Max. dose: 3 g/day. Adults: 250–500 mg/dose PO tid–qid.	Give 1 h before or 2 h after meals. Adjust dose in renal failure.
Tetracycline (Sumycin and others)	Susp: 125 mg/5 cc Caps: 250, 500 mg	Children (8 yr and older): 25–50 mg/kg/day PO ÷ qid. Max. dose: 2 g/day. Adults: 1–2 g/day ÷ qid–bid PO. Max. dose: 2 g/day.	Discoloration of teeth in children less than 8 yr of age. May cause photosensitivity, GI upset, and hepatotoxicity. Do not give with dairy products or with divalent cations (Fe^{2+}, Ca^{2+}, Mg^{2+}). Give 1 h before or 2 h after meals. Do not use outdated tetracyclines. For treatment of acne, see Chap. 78.
Antifungal/Anti-Yeast Agents[a]			
Clotrimazole troche (Lotrimin, Mycelex, and others)	Oral troche: 10 mg	Children 3 yr and older and adults: For oral thrush: Dissolve slowly (15–30 min) 1 troche in mouth 5 × per day for 14 days.	Liver enzyme elevation may occur, GI symptoms.
Fluconazole (Diflucan)	Tabs: 50, 100, 150, 200 mg Susp: 10, 40 mg/mL	Oropharyngeal and esophageal candidiasis: • Children (3–13 yr): Loading dose: 6–12 mg/kg PO; then maintenance (begin 24 h after loading dose): 3–6 mg/kg/day PO qd. • Adults: Loading dose of 200 mg PO followed by 100 mg qd 24 h after; doses up to max. dose of 400 mg/day may be used for esophageal candidiasis. Vaginal candidiasis: 150 mg PO × 1.	Not FDA approved for tinea capitis in children. Superiority to griseofulvin in the treatment of tinea capitis has not been demonstrated. May cause nausea, headache, rash, vomiting, abdominal pain, hepatitis, cholestasis, and diarrhea. Periodic monitoring of liver function tests recommended. Decrease dose in renal failure. Inhibits CYP450 2C9/10 and 3A3/4. May increase effects or levels of cyclosporine, phenytoin, theophylline, warfarin, oral hypoglycemics, and zidovudine. Rifampin increases fluconazole metabolism. Cardiac arrhythmias may occur when used with cisapride, terfenadine, and astemizole. Concomitant administration of fluconazole with any of these drugs is contraindicated. See references for other drug interactions.[73]
Griseofulvin (Grifulvin V, Grisactin, Fulvicin)	Microsize: Susp: 125 mg/5 mL Tabs: 250, 500 mg Ultramicrosize: Tabs: 125, 165, 250, 330 mg (250-mg ultramicrosize is about equivalent to 500-mg microsize)	Microsize: • Children (> 2 yr): 20–30 mg/kg/day PO ÷ qd–bid. • Adults: 500–1000 mg/day PO ÷ qd–bid. Max. dose: 1 g/24 h. Ultramicrosize: • Children (> 2 yr): 10–15 mg/kg/day PO qd. • Adults: 330–750 mg/day PO ÷ qd. Max. dose: 750 mg/day.	Give with milk or fatty food to enhance absorption. For tinea capitis, 6- to 8-week course recommended. Contraindicated in porphyria, hepatic disease. Penicillin allergy is not a contraindication. Not recommended in pregnancy due to possible teratogenicity. Reversible elevation of liver enzymes. Photosensitivity may occur. May reduce effectiveness or decrease level of oral contraceptives, warfarin, and cyclosporine. Phenobarbital may enhance clearance of griseofulvin. Not effective against *Candida* or other yeasts. See Chap. 233 for treatment of fungal infections.

(continued)



TABLE 106-6
Pediatric Dermatology Formulary of Selected Systemic Drugs (Continued)

Generic Name (Trade Name)	Dosage Forms	Dose	Comment
Itraconazole (Sporanox)	Caps: 100 mg Solution: 10 mg/mL	All dosages given in capsules. Experimental dosages for tinea capitis in children (limited data)[73–75]: 3–5 mg/kg/day × 4–6 wk. or 10–20 kg: 100 mg every other day; 20–30 kg: 100 mg/day; 30–50 kg: alternate 100 mg/day with 200 mg/day. Pulse dosing is promising, but current data are limited.	Not FDA approved for use in pediatric patients. Periodic monitoring of liver function tests recommended. Solution is approved for treatment of oral pharyngeal and esophageal candidiasis in adults. Solution should not be used interchangeably with capsules; solution has greater bioavailability, and cyclodextrin vehicle produced pancreatic adenocarcinoma in rats at normal human doses. Reversible elevation of liver enzymes, GI symptoms, headache, and dizziness may occur. Do not use with terfenadine or other non-sedating antihistamines. See Chap. 233 for treatment of fungal infections. See references for other drug interactions.[74]
Ketoconazole (Nizoral)	Tabs: 200 mg	Children (≥ 2 yr): 3.3–6.6 mg/kg/day PO qd. There are very limited data for the use of this agent in the treatment of tinea capitis in children.[73–75] Adults: 200–400 mg/day PO. Max. dose: 800 mg/day.	Give with acidic meal or drink to enhance absorption. Drugs that decrease gastric acidity will decrease absorption. Monitor liver function in long-term use. May cause nausea, vomiting, rash, headache, pruritus, and fever. Cardiac arrhythmias may occur when used with cisapride, terfenadine, or astemizole. Concomitant administration of ketoconazole with any of these drugs is contraindicated. Inhibits CYP450 3A4 isoenzyme. See references for other drug interactions.[74] Not FDA approved for the treatment of tinea capitis in children; periodic monitoring of liver function tests recommended if used for tinea capitis. See Chap. 233 for treatment of fungal infections.
Nystatin (Mycostatin, Nilstat, and others)	Susp: 100,000 U/mL Tabs: 500,000 U Troches/pastilles: 200,000 U	Infants: 1 mL (100,000 U) to each side of mouth qid. Children/adults: Susp: 4–6 mL (400,000–600,000 U) swish and swallow qid. Troche: 200,000–400,000 U 4–5 × per day.	May produce diarrhea and GI side effects. Treat until 48–72 h after resolution of symptoms. Drug poorly absorbed through the GI tract. Do not swallow troches whole. Allow troche to dissolve as slowly as possible, and oral suspension should be retained in mouth as long as possible before swallowing.
Terbinafine (Lamisil)	Tabs: 250 mg	Experimental dosage for tinea capitis in children (limited data): 3.125–6.25 mg/kg/day × 4 wk. or < 20 kg: give 62.5 mg PO every day; 20–40 kg: give 125 mg PO every day; > 40 kg: give 250 mg PO every day.[73]	Less effective for *Microsporum canis* than *Trichophyton tonsurans* infection. Inhibitor of CYP450 2D6. Rifampin increases clearance of drug. Cimetidine decreases clearance of drug. See references for other drug interactions.[74] Side effects include diarrhea, dyspepsia, abdominal pain, nausea, flatulence, and taste disturbance. Periodic monitoring of liver function tests recommended.
Corticosteroids, Nonsteroidal Anti-Inflammatory Drugs, and Analgesics			
Acetaminophen (Tylenol, Tempra, Panadol, and others)	Tabs: 325, 500, 650 mg Chewable tabs: 80, 160 mg Infant drops/solution/susp: 80 mg/0.8 mL Child solution/susp: 160 mg/5 mL Elixir: 80, 120, 130, 160, 325 mg/5 mL Caplets: 160, 325, 500 mg	10–15 mg/kg per dose PO/PR q4–6h. Or dosing by age: • 0–3 mo: 40 mg/dose. • 4–11 mo: 80 mg/dose. • 1–2 yr: 120 mg/dose. • 2–3 yr: 160 mg/dose. • 4–5 yr: 240 mg/dose. • 6–8 yr: 320 mg/dose. • 9–10 yr: 400 mg/dose.	Metabolized in the liver. Adjust dose in renal failure. Some preparations contain alcohol (7%–10%) and/or phenylalanine. Contraindicated in patients with known G6PD deficiency. Shake suspensions before use. Antipyretic, analgesic, but not anti-inflammatory.

(continued)



TABLE 106-6
Pediatric Dermatology Formulary of Selected Systemic Drugs (Continued)

Generic Name (Trade Name)	Dosage Forms	Dose	Comment
Acetaminophen *(continued)*	Suppository: 80, 120, 125, 325, 650 mg Sprinkle capsule: 80, 160 mg	11–12 yr: 480 mg/dose. Adults: 325–650 mg/dose. Max. dose: 4 g/day, 5 doses/day.	
Ibuprofen (Motrin, Advil, Nuprin, and others)	Susp: 100 mg/5 cc Oral drops: 40 mg/mL Chewable tabs: 50, 100 mg Caplets: 100 mg Tabs: 200, 300, 400, 600, 800 mg	Children: • Analgesic/antipyretic: 5–10 mg/kg dose q6–8h PO. Max. dose: 40 mg/kg/day PO. Adolescents/adults: • Pain/fever/dysmenorrhea: 200–400 mg per dose PO q4–6h. • Inflammatory disease: 400–800 mg per dose PO q6–8h. Max. dose: 3.2 g/day.	GI distress (lessened with milk), ocular problems, granulocytopenia, anemia may occur. Inhibits platelet aggregation. Use caution with aspirin hypersensitivity, hepatic or renal insufficiency, or dehydration. Contraindicated with ulcer disease.
Prednisone (many brand names)	Tabs: 1, 2.5, 5, 10, 20, 50 mg Syrup/solution: 1 mg/mL (5% alcohol) Concentrated solution: 5 mg/mL (30% alcohol)	Anti-inflammatory, immunosuppressive: 0.5–2 mg/kg/day PO ÷ qd–qid.	Alternate daily dosing or single morning dosing lessens side effects. See Chap. 225 for relative steroid potencies, side effects, and monitoring.
Prednisolone (Prelone, Orapred, Pediapred, and others)	Tabs: 5 mg Syrup: 5 mg/mL (Pediapred) or 15 mg/5 mL (Prelone)	See Prednisone.	Syrup more palatable than prednisone syrup. See Prednisone.
Antihistamines/Sedatives			
Cetirizine (Zyrtec)	Tabs and chewable tabs: 5, 10 mg Syrup: 5 mg/5 mL	6 mo to < 2 yr: 2.5 mg PO qd; dose may be increased for child 12–23 mo to a max. dose of 2.5 mg PO q12h. 2–5 yr: 2.5–5 mg PO qd. ≥ 6 yr/adult: 5–10 mg PO qd.	Mild, dose-related sedation may occur. Dry mouth and other side effects common to antihistamines may occur. Decrease dose in patients with renal or hepatic insufficiency.
Chloral hydrate (Aquachloral and others)	Caps: 500 mg Syrup: 250, 500 mg/5 mL Suppositories: 324, 500, 648 mg	Children: • Sedative: 25–50 mg/kg/day PO/PR ÷ q6–8h. Max. dose: 500 mg/dose. • Sedation for procedures: 25–100 mg/kg per dose PO/PR. Max dose: 1 g (infant); 2 g (child). Adults: • Sedative: 250 mg per dose tid PO/PR. • Hypnotic: 500–1000 mg per dose PO/PR. Max. dose: 2 g/day.	Not analgesic. Peak effects occur in 30–60 min. Do not exceed 2 wk of chronic use. Sudden withdrawal may cause delirium tremens. May cause GI irritation, paradoxical excitement, hypotension, and myocardial/respiratory depression. Requires appropriate monitoring. Contraindicated in patients with hepatic or renal disease.
Chlorpheniramine maleate (Chlor-Trimeton and others)	Tabs: 4 mg Sustained release caps and tabs: 8, 12 mg Chewable tabs: 2 mg Syrup: 2 mg/5 mL Combined immediate and sustained-release tabs (Efidac 24): 16 mg (4 mg immediate and 12 mg sustained)	Children: 0.35 mg/kg/day ÷ q4–6h PO. or 2–6 yr: 1 mg per dose PO q4–6h. Max dose: 6 mg/day. 6–11 yr: 2 mg per dose PO q4–6h. Max. dose: 12 mg/day. Sustained release (6–12 yr): 8 mg per dose PO bid. ≥ 12 yr/adults: 4 mg per dose q4–6h PO. Max. dose: 24 mg/day. Sustained release: 8–12 mg PO bid. Efidac 24: 16 mg PO qd. Max. dose: 16 mg/day.	May cause sedation, dry mouth, urinary retention, polyuria, disturbed coordination. Young children may be paradoxically excited. Sustained-release forms not recommended in children less than 6 yr old; and should not be crushed, chewed, or dissolved. Give with food.
Cyproheptadine (Periactin)	Tabs: 4 mg Syrup: 2 mg/5 mL (5% alcohol)	Children: 0.25–0.5 mg/kg/day PO ÷ bid–tid. Or dosing by age: • 2–6 yr: 2 mg q8–12h PO. Max. dose: 12 mg/day. • 7–14 yr; 4 mg q8–12h PO. Max. dose: 16 mg/day. • Adults: 12–32 mg/day PO ÷ tid. Max. dose: 0.5 mg/kg/day.	Contraindicated in neonates, patients on monoamine oxidase inhibitors, patients with glaucoma, asthma, or GI/genitourinary obstruction. May produce anticholinergic side effects, including appetite stimulation. Consider reduced dose with hepatic insufficiency.

(continued)



TABLE 106-6
Pediatric Dermatology Formulary of Selected Systemic Drugs (Continued)

Generic Name (Trade Name)	Dosage Forms	Dose	Comment
Diphenhydramine (Benadryl and others)	Elixir (may contain alcohol): 12.5 mg/5 mL Liquid, syrup: 12.5 mg/5 mL Caps/tabs: 25, 50 mg Chewable tabs: 12.5 mg	Children: 5 mg/kg/day PO ÷ qid. Max. dose: 300 mg/day. Adults: 10–50 mg per dose PO tid–qid. Max. dose: 400 mg/day.	Dry mouth, sedation, and other side effects common to antihistamines. Central nervous system side effects more common than GI disturbances. May cause paradoxical excitement. Contraindicated in neonates or with concurrent monoamine oxidase inhibitor use. Adjust dose in renal failure.
Fexofenadine (Allegra)	Tabs: 30, 60, 180 mg Caps: 60 mg	6–11 yr: 30 mg bid PO. 12 yr–adult: 60 mg bid PO; 180 mg may be used in seasonal rhinitis.	Do not administer antacids within 2 h of dose. May cause drowsiness, fatigue, dyspepsia, nausea, and dysmenorrhea. Reduce dose if renal function impaired.
Hydroxyzine (Atarax, Vistaril)	Tabs: 10, 25, 50, 100 mg Caps: 25, 50, 100 mg Syrup: 10 mg/5 mL Suspension: 25 mg/5 mL	Children: 2 mg/kg/day ÷ tid–qid. May use up to 5 mg/kg/day in mast cell diseases. Adults: 25–100 mg per dose ÷ tid–qid. Max. adult dose: 600 mg/day.	May potentiate barbiturates, meperidine, and other depressants. Dry mouth, drowsiness, tremor, convulsions, blurred vision, hypotension, and paradoxical excitement may occur.
Loratadine (Claritin)	Tabs: 10 mg Rapidly disintegrating tabs: 10 mg Syrup: 1 mg/mL	2–5 yr: 5 mg PO every day. ≥ 6 yr/adults: 10 mg PO every day.	Reduce dose in hepatic or renal insufficiency. Low incidence of drowsiness. May cause dry mouth, dizziness, and other side effects common to antihistamines.
Miscellaneous			
Isotretinoin (Accutane, Claravis, Sotret, Amnesteem)	Caps: 10, 20, 30, 40 mg	Cystic acne: 0.5 mg/kg/day PO bid × 20 wk.	Known teratogen, contraindicated in pregnancy. Conjunctivitis, xerosis, pruritus, epistaxis, anemia, hyperlipidemia, pseudotumor cerebri, bone pain, muscle aches, skeletal changes, and other toxicities. Vitamin A or tetracyclines should not be given concomitantly. Monitor complete blood cell count, liver function tests, triglycerides, and monthly pregnancy tests. Severe forms (acne fulminans) may require higher doses and longer treatment course. See Chap. 78 for treatment of acne.
Ivermectin (Stromectol)	Tabs: 3, 6 mg	Scabies: 0.2 mg/kg per dose PO × 1 per day. Cutaneous larva migrans or strongyloidiasis: 0.2 mg/kg PO per day × 1–2 days. Or dosing by body weight: Weight (kg) single oral dose: 15–24: 3 mg 25–35: 6 mg 36–50: 9 mg 51–65: 12 mg 66–79: 15 mg ≥ 80: 0.2 mg/kg	Adverse reactions in strongyloidiasis include diarrhea, nausea, vomiting, pruritus, rash, dizziness, and drowsiness. See Chap. 207 for more information on parasitic infections.
Mebendazole (Vermox)	Chewable tabs: 100 mg	Children/adults: • Pinworms: 100 mg PO × 1; repeat in 2 wk if not cured.	May be swallowed whole or chewed. Experience in children < 2 yr old is limited. Family may need to be treated concurrently. Therapeutic effect may be decreased if receiving carbamazepine or phenytoin. Give with food. See Chap. 207 for more information on parasitic infections.
Thiabendazole (Mintezol)	Suspension: 500 mg/5 mL Chewable tabs: 500 mg	Cutaneous larva migrans: Children and adults: 50 mg/kg/day ÷ bid × 2–5 days. Max. dose: 3 g/day. Suspension may be applied topically and may preclude need for oral therapy.	Use with caution in renal or hepatic impairment. Nausea, vomiting, and vertigo are frequent side effects. May increase levels of theophylline. Limited data in children < 30 lb. See Chap. 207 for more information on parasitic infections.

(continued)



TABLE 106-6
Pediatric Dermatology Formulary of Selected Systemic Drugs (Continued)

Generic Name (Trade Name)	Dosage Forms	Dose	Comment
Iron preparations (Fergon, Fer-In-Sol, Feosol, and others)	Ferrous sulfate (20% elemental Fe) • Drops (Fer-In-Sol): 75 mg (15 mg Fe)/0.6 mL, 125 mg (25 mg Fe)/1 mL • Syrup (Fer-In-Sol): 90 mg (18 mg Fe)/5 mL (5% alcohol) • Elixir (Feosol): 220 mg (44 mg Fe)/5 mL • Caps: 250 mg (50 mg Fe) • Tabs: 195 mg (39 mg Fe), 300 mg (60 mg Fe), 324 mg (65 mg Fe) Ferrous gluconate: (12% elemental Fe) • Tabs: 240 mg (27 mg Fe), 300 mg (34 mg Fe), 320 mg (37 mg Fe), 325 mg (38 mg Fe) Many other preparations available.	Iron deficiency anemia: • Children: 3–6 mg elemental Fe/kg/day ÷ PO qd–tid. • Adults: 60 mg elemental Fe PO bid–qid. Prophylaxis: • Children: 1–2 mg elemental Fe/kg/day ÷ qd–tid. Max dose 15 mg elemental Fe per day. • Adults: 60 mg elemental Fe per day PO ÷ qd–bid.	Iron preparations are variably absorbed. Less GI irritation when given with meals. Vitamin C, 200 mg per 30 mg Fe, may enhance absorption. Liquid iron preparations may stain teeth. Give with dropper or drink with straw. Side effects include constipation, dark stools, nausea, and epigastric pain. False-positive stool guaiac test is controversial. Iron and tetracycline inhibit each other's absorption. Antacids may decrease iron absorption.
Zinc salts	Tabs as sulfate, 23% elemental zinc: 66, 110, 200 mg. Caps as sulfate, 23% elemental zinc: 220 mg. Tabs as gluconate, 14.3% elemental zinc: 10, 15, 50 mg. Liquid as acetate: 5, 10 mg elemental zinc/mL (requires compounding by pharmacist.)	Zinc deficiency: • Infants and children: 0.5–1 mg elemental zinc/kg/day PO ÷ qd–tid. • Adults: 25–50 mg elemental zinc per dose PO tid.	Approximately 20%–30% of oral dose is absorbed. May give with food if GI upset occurs. Shake liquid before administering. Nausea, vomiting, GI disturbances, leukopenia, and diaphoresis may occur. Patients with excessive losses (burns) or impaired absorption may require higher doses.

Caps = capsules; FDA = U.S. Food and Drug Administration; Fe = iron; G6PD = glucose-6-phosphate dehydrogenase; GI = gastrointestinal; HSV = herpes simplex virus; max. = maximum; Susp = suspension; Tabs = tablets.
[a]Griseofulvin is currently the only FDA-approved drug for the treatment of tinea capitis in children. The use of fluconazole, terbinafine, and itraconazole for tinea capitis in children, while promising, is still experimental, and the reader should consult the primary literature before use.
Note: 5 mL = 1 teaspoon.
The drug information and doses listed herein are given as guidelines only and are not intended to be comprehensive. Drug selection and dosage should be chosen according to the individual situation. Drug information may have changed since publication of this textbook. Parenteral and neonatal indications and dosages are not listed.



and for certain pathogenic infections or situations such as multidrug resistance.[50]

Griseofulvin doses of 20 mg/kg/day of the liquid and 15 mg/kg/day of the ultramicrosized tablets for 6 to 8 weeks remain first-line therapy for tinea capitis. This drug remains the only FDA-approved drug for tinea capitis in children at this time. Although further studies are needed, itraconazole and terbinafine appear to be effective with a good safety profile. These drugs remain second-line agents for pediatric tinea capitis, and monitoring should be considered during this off-label indication. Fluconazole was not very effective in pediatric tinea capitis in a large multicenter, double-blinded randomized trial of 880 children.[56]

Child Abuse

In the United States in 2003, 906,000 children were determined to be victims of child abuse and neglect by child protective agencies, and an estimated 1500 children died of child abuse. Ninety percent of all abused children are said to have suggestive or confirmative dermatologic findings.[57] Child abuse is discussed in Chap. 105.

KEY REFERENCES

The full reference list for all chapters is available at www.digm7.com.

1. Chiou YB et al: Stratum corneum maturation. A review of neonatal skin function. *Skin Pharmacol Physiol* **17**:57, 2004
4. Nopper AJ et al: Topical ointment therapy benefits premature infants. *J Pediatr* **128**:660, 1996
5. Campbell JR et al: Systemic candidiasis in extremely low birth weight infants receiving topical petrolatum ointment for skin care: a case-control study. *Pediatrics* **105**:1041, 2000
13. Van Praag MC et al: Diagnosis and treatment of pustular disorders in the neonate. *Pediatr Dermatol* **14**:131, 1997
14. Niamba P et al: Is common neonatal cephalic pustulosis (neonatal acne) triggered by Malassezia sympodialis? *Arch Dermatol* **134**:995, 1998
15. Lenane P et al: Congenital alopecia areata. *J Am Acad Dermatol* **52**:S8, 2005
19. Amitai DB et al: Cutis marmorata telangiectatica congenita: Clinical findings in 85 patients. *Pediatr Dermatol* **17**:100, 2000
20. Burden AD, Krafchik BR: Subcutaneous fat necrosis of the newborn: A review of 11 cases. *Pediatr Dermatol* **16**:384, 1999
21. Frieden IJ: Aplasia cutis congenita: A clinical review and proposal for classification. *J Am Acad Dermatol* **14**:646, 1986
22. Drolet B et al: "Membranous aplasia cutis" with hair collars: Congenital absence of skin or neuroectodermal defect? *Arch Dermatol* **131**:1427, 1995
23. Prizant TL et al. Spontaneous atrophic patches in extremely premature infants. Anetoderma of prematurity. *Arch Dermatol* **132**:671, 1996

25. Kimberlin DW et al: Natural history of neonatal herpes simplex virus infections in the acyclovir era. *Pediatrics* **108**:223, 2001
29. Guggisberg D et al: Skin markers of occult spinal dysraphism in children: A review of 54 cases. *Arch Derm* **140**:1109, 2004
33. Khachemoune A et al: Infantile perineal protrusion. *J Am Acad Dermatol* **54**:1046, 2006
34. Gradin M et al: Pain reduction at venipuncture in newborns: Oral glucose compared with local anesthetic cream. *Pediatrics* **110**:1053, 2002
35. Mader TJ et al: Reducing the pain of local anesthetic infiltration: Warming and buffering have a synergistic effect. *Ann Emerg Med* **23**:550, 1994
36. Proudfoot J: Analgesia, anesthesia, and conscious sedation. *Emerg Med Clin North Am* **13**:357, 1995
41. Chang MW et al: Infantile granular parakeratosis: Recognition of two clinical patterns. *J Am Acad Dermatol* **50**:S93, 2004
43. Boiko S: Making rash decisions in the diaper area. *Pediatr Ann* **29**:50, 2000
46. Wysowski DK et al: Depression and suicide in patients treated with isotretinoin. *N Engl J Med* **344**:460, 2001
48. Chia CY et al: Isotretinoin therapy and mood changes in adolescents with moderate to severe acne: a cohort study. *Arch Dermatol* **141**:557, 2005

CHAPTER 107

Skin Changes and Diseases in Pregnancy

Julie K. Karen
Miriam Keltz Pomeranz

CUTANEOUS CHANGES COMMONLY ASSOCIATED WITH PREGNANCY

Pregnancy is characterized by altered endocrine, metabolic, and immunologic milieus. These dramatic alterations result in multiple cutaneous changes, both physiologic and pathologic. A comprehensive list of physiologic alterations within the skin and appendages is provided in Table 107-1.[1–3]

Pigmentary disturbances are the most common of these physiologic changes (see Table 107-1). Hyperpigmentation of the areola, axillae, and genitalia is well documented in pregnancy. *Linea nigra* refers to the typically reversible darkening of the linea alba, a hypopigmented linear patch extending from the pubis symphysis to the xiphoid process of the sternum (Fig. 107-1). Melasma or chloasma is a related finding comprising irregular, blotchy, facial hyperpigmentation that occurs in up to 70 percent of pregnant women (Fig. 107-2). This tendency is aggravated by sun exposure and by oral contraceptive intake by nonpregnant women. Melasma may regress postpartum, but oftentimes persists, posing a therapeutic challenge.[1]

Changes in melanocytic nevi were historically deemed "normal" during pregnancy. However, few studies have objectively studied whether and how nevi evolve during pregnancy. Pennoyer et al.[4] photographically monitored 129 melanocytic nevi throughout the pregnancies of 22 healthy Caucasian women. Only eight nevi (6.2 percent) changed in diameter from the first to third trimester, with a mean change in size of zero. The authors concluded that significant change in nevus size (excluding nevi on the pregnant abdomen) does not appear to be a feature of most pregnancies.[4] Until further controlled studies are performed, any pigmented lesion in a pregnant woman that undergoes change in morphology (size, color, or shape) or symptomatology (begins to itch, bleed, or scale) should be considered for histopathologic review.

The most common structural change during pregnancy is striae distensae, also known as *striae gravidarum* or *stretch marks* (Fig.107-3). Sites of predilection for striae include those areas most prone to stretch, including the abdomen, hips, buttocks, and breasts. Genetic factors as family history, personal history, and race are the strongest predictors of an individual's risk of developing striae distensae, surpassing pregnancy weight gain or changes in body mass index.[5] These findings strongly support a genetic predisposition to this condition.

Pruritus, a common complaint during pregnancy, may be physiologic, but may herald a flare of a pre-existing dermatosis or onset of a specific dermatosis of pregnancy. The majority of patients with pruritic skin disease during pregnancy have conditions unrelated to pregnancy (i.e., atopic dermatitis).[6] The remainder of this chapter outlines the relatively rare conditions that may be specific to pregnancy. An overview of these conditions is provided in Table 107-2.

DERMATOSES ASSOCIATED WITH FETAL RISK IN PREGNANCY

Pemphigoid (Herpes) Gestationis

Pemphigoid (herpes) gestationis (PG; see Chap. 57) is an intensely pruritic, vesiculobullous eruption of mid to late pregnancy and the immediate postpartum period. PG classically begins during the second or third trimester, and is manifest by the abrupt appearance of severely pruritic urticarial lesions on a background of normal or erythematous skin. PG is associated with an increased incidence of small-for-gestational age

CUTANEOUS CHANGES COMMONLY ASSOCIATED WITH PREGNANCY AT A GLANCE



- Cutaneous changes result from the altered endocrine, metabolic, and immunologic milieus that characterize pregnancy.
- Pigmentary disturbances, including hyperpigmentation, darkening of the linea alba, and melasma are the changes most commonly observed.
- Significant change in nevi size is not a feature of most pregnancies.
- Structural changes known to occur during pregnancy include, most commonly, striae distensae.
- Pruritus is a common complaint during pregnancy and may be related to flare of a pre-existing dermatosis or onset of a specific dermatosis of pregnancy.





TABLE 107-1
Physiologic Skin Changes during Pregnancy

Pigmentary
- Diffuse hyperpigmentation
- Selective hyperpigmentation (genitalia, axillae, recent scars)
- Secondary areolae
- Linea nigra
- Melasma (chloasma, mask of pregnancy)
- Darkening of ephelides and melanocytic nevi

Hair
- Hirsutism
- Thickening of scalp hair
- Postpartum telogen effluvium
- Postpartum androgenetic alopecia

Nail
- Subungual hyperkeratosis
- Distal onycholysis
- Transverse grooving
- Brittleness
- Accelerated growth

Glandular
- Increased eccrine function (except palms) (miliaria, dyshidrotic eczema, hyperhidrosis)
- Elevated thyroid activity with resultant relative iodine deficiency
- Increased sebaceous function (growth in Montgomery's tubercles) (see eFig. 107-0.1 in on-line edition)
- Decreased apocrine function

Structural changes
- Striae distensae (striae gravidarum)
- Molluscum fibrosum gravidarum (acrochorons)

Vascular
- Spider angiomas (spider nevi, nevi aranei)
- Palmar erythema (see eFig. 107-0.2 in on-line edition)
- Carpal tunnel syndrome
- Non-pitting edema (hands, ankles, feet, face)
- Varicosities
- Cutis marmorata
- Vasomotor instability
- Dermographism/pruritus
- Purpura
- Gingival hyperemia or hyperplasia
- Pyogenic granuloma (granuloma gravidarum, pregnancy epulis)
- Hemorrhoids
- Hemangiomas, hemangioendotheliomas, glomangiomas
- Unilateral nevoid telangiectasia (unilateral dermatomal superficial telangiectasia)

Mucosa
- Gingivitis (marginal gingivitis, papillomatous hypertrophy of the gums)
- Jacquemier-Chadwick sign (bluish discoloration of vagina and cervix)
- Goodell's sign (cervical softening)

Adapted from Elling SV, Powell FC: Physiological changes in the skin during pregnancy. *Clin Dermatol* **15**:35, 1997; Kroumpouzos G, Cohen LM: Dermatoses of pregnancy. *J Am Acad Dermatol* **45**:1, 2001; and Muzaffar F, Hussain I, Haroon TS: Physiologic skin changes during pregnancy: A study of 140 cases. *Int J Dermatol* **77**:429, 1998.

births and premature delivery. PG is immunologically mediated.[7]

Cholestasis of Pregnancy

NOMENCLATURE AND EPIDEMIOLOGY The terms *obstetric cholestasis*, *intrahepatic cholestasis of pregnancy*, *recurrent jaundice of pregnancy*, *cholestatic jaundice of pregnancy*, *idiopathic jaundice of pregnancy*, *prurigo gravidarum*, and *icterus gravidarum* all refer to the same clinical entity, cholestasis of pregnancy (CP), characterized by a reversible form of cholestasis in late pregnancy. Svanborg and Ohlsson first recognized CP as a distinct entity, separate from other causes of jaundice during pregnancy in 1939.[8] Jaundice develops in approximately 1 in 1500 pregnant women. With an estimated incidence of 70 cases per 10,000 pregnancies in the United States, CP ranks second only to viral hepatitis in terms of etiology of jaundice in pregnant women.[9] Mild cases of CP, in which pruritus is not accompanied by jaundice, were previously referred to as *prurigo gravidarum*.

CP is most common in Scandinavia and South America. The highest reported incidence rates are in Chile (14 percent to 16 percent), whereas much lower rates are seen among pregnant women in the United States (less than 0.1 percent to 0.7 percent), Canada (0.1 percent), Australia (0.2 percent to 1.5 percent), and Europe (0.1 percent to 1.5 percent).

Etiology

Although the precise pathogenesis remains unclear, the interplay of hormonal, genetic, environmental, and alimentary factors is thought to induce a

DERMATOSES ASSOCIATED WITH FETAL RISK IN PREGNANCY AT A GLANCE



- Pemphigoid gestationis is an immunologically mediated, intensely pruritic, vesiculobullous eruption of mid to late pregnancy that is associated with fetal risk.
- Cholestasis of pregnancy represents a reversible form of cholestasis in late pregnancy associated with biochemical abnormalities and a risk of fetal complications, but invariably lacking primary cutaneous lesions. Symptoms remit within 2 to 4 weeks of delivery, but recurrences in subsequent pregnancies are common.
- Pustular psoriasis of pregnancy is a rare, acute, pustular eruption often accompanied by fever, leukocytosis, and an elevated erythrocyte sedimentation rate. This is generally regarded as a variant of psoriasis.



▲ **FIGURE 107-1** Linea nigra. A hyperpigmented line extends from the pubis symphysis to the xiphoid process of the sternum. Hyperpigmentation is often more pronounced inferior to the umbilicus.

biochemical cholestasis in susceptible individuals. A prominent role for hormonal alterations is suggested by the following observations: (1) CP is a disease of late pregnancy (corresponding to the period of highest placental hormone levels); (2) CP spontaneously remits at delivery when hormone concentrations normalize; (3) twin and triplet pregnancies, characterized by greater rises in hormone concentrations, have been linked to CP; and, (4) CP recurs during subsequent pregnancies in an estimated 45 percent to 70 percent of patients.[9,10]

Geographic variation and familial clustering indicate a genetic predisposition. CP appears to be a polygenetic condition. Candidate genes include those mutated in a variety of other forms of inherited cholestasis: ABCB4 (multidrug resistance gene3), ABCB11 (Bsep), and ATP8B1 (FIC1). A recent decline in prevalence rates in Chile, reports of higher incidence rates during the winter months, and reports of relative reductions of selenium levels in CP patients all point towards etiologic roles for environmental and alimentary factors.[9,11] At least one study confirmed a higher risk of hepatitis C virus infection among women with CP.[12]



▲ **FIGURE 107-2** Melasma. Blotchy, mottled hyperpigmentation is evident on the malar cheek and upper cutaneous lip.

CLINICAL FEATURES Patients classically present during the third trimester with moderate to severe pruritus, which may be either localized to the palms and soles or generalized. Pruritus begins during the first and second trimester in 10 percent and 25 percent of cases, respectively. Intense pruritus is oftentimes associated with secondary excoriations, although primary cutaneous lesions are invariably absent. Initially, patients may complain of nocturnal pruritus only, and symptoms generally are more severe at night throughout the course of illness. CP is sometimes preceded by a urinary tract infection. Constitutional symptoms such as fatigue, nausea, vomiting, or anorexia may accompany the pruritus. Progression to clinical jaundice, dark urine, or lightly colored stools occurs in approximately one in five patients. Pruritus generally precedes the onset of these symptoms by 1 to 4 weeks.[9]

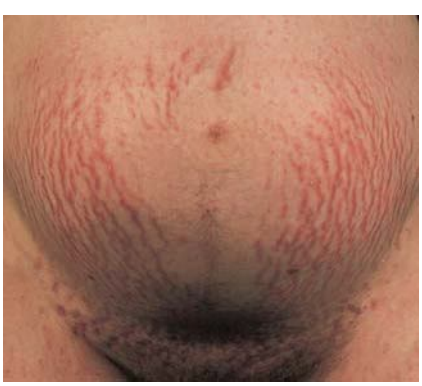

▲ **FIGURE 107-3** Striae distensae.

COURSE A hallmark of CP is that symptoms and associated biochemical abnormalities typically resolve within 2 to 4 weeks of delivery. Recurrences during subsequent pregnancies occur in an estimated 45 percent to 70 percent of patients. Some women experience recurrent CP after exposure to oral contraceptives or to contraceptive aids, such as synthetic estrogens and progestational agents.

Maternal outcomes are generally favorable, although women with severe cases are predisposed to postpartum hemorrhage secondary to vitamin K depletion. Additionally, affected women have a tendency towards the later development of cholelithiasis or gallbladder disease. Fetal risks in CP include increased rates of prematurity, intrapartal fetal distress, and fetal death. These complications are thought attributable to acute placental anoxia and an increased incidence of meconium-stained amniotic fluid. Such fetal complications may be reduced with treatment and induction of labor after fetal pulmonary maturation has been documented.[9]

LABORATORY STUDIES Elevation in serum bile acids is the single most sensitive indicator of CP. In healthy pregnant women, total bile acids (TBAs) are slightly elevated above baseline and levels as high as 11.0 μ*M* are accepted as normal in late pregnancy. Clearly defined biochemical indices of CP have not yet been established. However, Brites et al.[13] identified the following common features of CP: (1) serum TBA concentrations greater than 11.0 μ*M* (normal range, 4.6 to 8.7 μ*M*); (2) cholic acid–chenodeoxycholic acid ratio greater than 1.5 (normal range, 0.7 to 1.5) or cholic acid proportion of TBAs greater



TABLE 107-2
Summary of Dermatoses of Pregnancy

	Morphology	Distribution	Usual Onset	Fetal Risk	Synonym(s)
Pemphigoid (herpes) gestationis	Urticarial papules and plaques progress to vesicles and bullae	Begins on trunk, then progresses to generalized eruption Spares face, mucus membranes, palms, soles	Second or third trimester, or immediately postpartum	Small-for-gestational-age births Preterm delivery Neonatal pemphigoid gestationis	Herpes gestationis
Cholestasis of pregnancy	Excoriations and excoriated papules ± jaundice	Localized to palms and soles or generalized	Third trimester	Preterm delivery Fetal distress Fetal death	Intrahepatic cholestasis of pregnancy Obstetric cholestasis Recurrent jaundice of pregnancy Cholestatic jaundice of pregnancy Idiopathic jaundice of pregnancy Prurigo gravidarum Icterus gravidarum
Pustular psoriasis of pregnancy	Erythematous patches with subcorneal pustules at their margins	Begins in flexures Generalizes demonstrating centrifugal spread	Third trimester	Placental insufficiency may lead to stillbirth or neonatal death	Impetigo herpetiformis
Pruritic urticarial papules and plaques of pregnancy	"Polymorphous" including urticarial papules and plaques ± vesicles	Begins within abdominal striae Spreads to remainder of trunk and then extremities Spares umbilicus	Third trimester or immediately postpartum	None	Polymorphic eruption of pregnancy Bourne's toxemic rash of pregnancy Nurse's late onset prurigo of pregnancy Toxemic erythema of pregnancy (Holmes)
Prurigo of pregnancy	Excoriated or crusted papules	Extremities, occasionally trunk	Second or third trimester	None	Besnier's prurigo gestationis Nurse's early onset prurigo of pregnancy Papular dermatitis of Spangler Atopic eruption of pregnancy[a]
Pruritic folliculitis of pregnancy	Follicular papules and pustules	Trunk, sometimes generalized	Second or third trimester	None	NA Atopic eruption of pregnancy[a]

NA = not applicable.
[a]A newly proposed classification by Ambros-Rudolph et al.[34] combines the previously distinct entities prurigo of pregnancy and pruritic folliculitis of pregnancy into a single entity, atopic eruption of pregnancy. Atopic eruption of pregnancy also includes eczema in pregnancy, which is characterized by a pruritic eruption with a flexural predilection occurring in patients with a personal and/or family history of atopy. Atopic eruption of pregnancy may be eczematous or prurigo-like in morphology, equally affects the trunk and extremities, generally begins before the third trimester, and is not associated with any fetal risk.



than 42 percent; (3) glycine conjugates–taurine conjugates of bile acids ratio less than 1.0 (normal range, 0.9 to 2.0) or glycocholic acid concentration greater than 2.0 μ*M* (normal range, 0.6 to 1.5 μ*M*).[13] Degree of pruritus and disease severity generally correlate with bile acid concentrations.

Mild perturbations in liver function tests, including elevated transaminases, alkaline phosphatase, 5′-nucleotidase, cholesterol, triglycerides, phospholipids, and lipoprotein X are commonly found. Among these parameters, alanine transaminase is particularly sensitive, as an elevation in this enzyme is not a feature of healthy pregnancies, but is commonly seen in CP. γ-Glutamyl transferase, which is generally low in late gestation, is typically normal or slightly elevated in CP. Direct (or conjugated) fractions of bilirubin are most commonly elevated in CP. Albumin may be slightly reduced, whereas α_2-globulins and β-globulins are appreciably elevated. Routine liver tests alone, however, are not a sufficient basis for the diagnosis of CP.[13]

Cutaneous biopsy does not aid in the diagnosis of CP. Although generally unnecessary, hepatic biopsy reveals intrahepatic cholestasis with dilated, plugged bile canaliculi and deposits of bile pigment in centrilobular hepatocytes.[9]

DIFFERENTIAL DIAGNOSIS Distinction from prurigo of pregnancy (PP) can be challenging and the two conditions may be etiologically linked. The presence of erythematous, excoriated papules points away from a diagnosis of CP, which lacks primary lesions. Other causes of liver derangement and jaundice, such as viral and nonviral hepatitis, medications, hepatobiliary obstruction, and other intrahepatic diseases (i.e., primary biliary cirrhosis) must be ruled out. Finally, it must be remembered that hyperthyroidism, allergic

reactions, polycythemia vera, lymphoma, pediculosis, and scabies may each manifest as generalized pruritus in pregnant as in nonpregnant women.

TREATMENT Given the increased risk for adverse fetal outcomes, intense fetal surveillance is essential to the management of CP. Although obstetric management varies, the need for weekly fetal monitoring beginning in the thirty-fourth week of gestation is widely accepted. Additionally, most authors recommend early induction of labor, commonly at 37 to 38 weeks' gestation, but as soon as there is evidence of fetal pulmonary maturity in severe cases.[9]

In mild cases, adequate relief of symptoms can be achieved with bland emollients and topical antipruritic agents. Patients rarely respond to antihistamines. Ultraviolet B phototherapy has been variably effective. Dexamethasone suppression of fetoplacental estrogen was reported effective in an uncontrolled trial of 10 pregnant women with CP.[7,9,14] However, the literature contains one report of CP worsening after dexamethasone administration.[15]

Cholestyramine and other anion exchange resins bind bile acids, thereby decreasing their enterohepatic circulation. Several uncontrolled trials have suggested cholestyramine may effectively reduce symptoms in up to 70 percent of patients with mild CP. However, the lack of randomized, placebo-controlled cholestyramine trials precludes definite conclusions about the efficacy of this agent. Furthermore, cholestyramine must be administered for several days before taking effect, its efficacy in treating severe cases has been disappointing, and, importantly, it may precipitate vitamin K and thereby trigger a coagulopathy.[16,17]

Ursodeoxycholic acid (UDCA), a naturally occurring hydrophilic bile acid, exerts a hepatoprotective effect through augmentation of the excretion of hydrophobic bile acids, sulfated progesterone metabolites, and other hepatotoxic compounds. UDCA decreases bile acid levels in colostrum, cord blood, and amniotic fluid. The results of several small, randomized, placebo-controlled UDCA trials demonstrate that when administered at doses between 450 mg and 1200 mg daily, UDCA is well tolerated and highly effective in controlling the clinical and liver function abnormalities that define CP.[17] The effect of UDCA is more rapid and lasts longer than that of cholestyramine. Enhanced efficacy may be achieved by co-administration with *S*-adenosylmethionine.[18] UDCA is a safe and well-tolerated treatment and may decrease fetal mortality associated with CP. Randomized, controlled trials comparing UDCA head-to-head with either dexamethasone[19] or cholestyramine[20] demonstrated UDCA's superior efficacy.

Successful treatment of a case of severe and refractory CP has been reported using plasmapheresis beginning at 32 weeks' gestation. The treatment was well tolerated and led to marked and instantaneous relief of symptoms. However, the treatment did not reverse the associated biochemical abnormalities.[21]



▲ **FIGURE 107-4** Pustular psoriasis of pregnancy. Erythematous patches are studded with subcorneal pustules.

Pustular Psoriasis of Pregnancy (Impetigo Herpetiformis)

NOMENCLATURE Von Hebra first used the designation *impetigo herpetiformis* in 1872 to describe an acute pustular eruption with usual onset during the third trimester of pregnancy. It is now generally regarded as a variant of pustular psoriasis attributable to hormonal alterations during pregnancy; however, some authors maintain that it is a distinct clinical entity.[22]

CLINICAL FEATURES Pustular psoriasis of pregnancy is characterized by an acute eruption occurring as early as the first, but generally during the third, trimester of an otherwise uneventful pregnancy. The condition manifests as erythematous patches whose margins are studded with subcorneal pustules (Fig. 107-4). The eruption typically originates in flexural areas but spreads centrifugally and sometimes generalizes. Subungual lesions may result in onycholysis. Rarely, mucous membrane involvement may lead to painful erosions. The face, palms, and soles are commonly spared. The rash may be pruritic or painful. Onset of the eruption is accompanied by such constitutional symptoms as fever, chills, malaise, diarrhea, nausea, and arthralgias. Rarely, tetany, delirium, and convulsions occur if hypocalcemia is severe.[1]

Although generally regarded as a form of pustular psoriasis (see Chap. 18), absence of a positive family history, abrupt resolution of symptoms at delivery, and a tendency to only recur during subsequent pregnancies distinguish this entity from generalized pustular psoriasis. Moreover, factors known to trigger pustular psoriatic flares, such as infection, exposure to culprit drugs, or abrupt discontinuation of systemic corticosteroids are lacking in virtually all patients with pustular psoriasis of pregnancy.[1,23]

LABORATORY STUDIES Histopathologic examination reveals classic features of pustular psoriasis (see Chap. 18).

The most common laboratory derangements include leukocytosis, neutrophilia, an elevated erythrocyte sedimentation rate, hypoferric anemia, and hypoalbuminemia. Less commonly, calcium, phosphate, and vitamin D levels are decreased. Serum parathormone levels are rarely decreased. Cultures of pustule contents and peripheral blood are negative unless secondarily infected.[1]

COURSE Pustular psoriasis of pregnancy classically presents during the last trimester, but there are reports of cases occurring as early as the first trimester, during the puerperium, in nonpregnant women taking oral contraceptives, and in postmenopausal women. Symptoms are invariably progressive throughout pregnancy. A cardinal feature of this disorder is the rapid resolution of symptoms after delivery. Recurrences in subsequent pregnancies are common and characteristically are more severe with onset earlier in



Box 107-1

Differential Diagnosis of Pustular Psoriasis of Pregnancy

Most Likely

- Pustular drug eruption
- Pemphigoid gestationis

Consider

- Pemphigus vulgaris
- Dermatitis herpetiformis
- Subcorneal pustular dermatosis
- Pustular eruption in inflammatory bowel disease

Always Rule Out

- Infectious causes of pustular eruptions



gestation.[1] Several reports of subsequent menstrual exacerbation occurring either during or immediately preceding menses exist in the literature.[24]

More widespread disease generally portends a worse prognosis. Life-threatening maternal complications are infrequent today, but may result from profound hypocalcemia and bacterial sepsis. The most feared complications are placental insufficiency and consequent stillbirth or neonatal death. For these reasons, early induction of labor is often contemplated.[22]

DIFFERENTIAL DIAGNOSIS Box 107-1 outlines the differential diagnosis of pustular psoriasis of pregnancy.

TREATMENT Resolution after delivery is the norm. However, given its consistently progressive course, treatment is indicated to reduce the risk of fetal and maternal complications during pregnancy. Topical treatments include wet dressings and topical corticosteroids, but are rarely effective as monotherapy. Systemic corticosteroids (60 to 80 mg/day) are the mainstay of therapy during pregnancy. Cyclosporine, which is categorized as pregnancy category "C," has been successfully used at doses between 5 and 10 mg/kg daily to treat cases refractory to high-dose systemic corticosteroids.[13,25]

Fluid status and electrolytes should be monitored with rapid correction of imbalances. Fetal monitoring is essential as decelerations in fetal heart rate may be the earliest sign of fetal hypoxemia. Maternal cardiac and renal functions may be compromised with disease progression and therefore should be monitored as well. Induction of labor is an option when symptoms do not remit despite supportive and pharmacologic therapy. The therapeutic armamentarium available after pregnancy termination or after delivery in a non-nursing mother is much broader, and includes: phototherapy with or without oral retinoids, clofazimine, methotrexate, and sulfapyridine and sulfones.[13,26]

DERMATOSES NOT ASSOCIATED WITH FETAL RISK IN PREGNANCY

Pruritic Urticarial Papules and Plaques of Pregnancy (Polymorphic Eruption of Pregnancy)

NOMENCLATURE AND EPIDEMIOLOGY Pruritic urticarial papules and plaques of pregnancy (PUPPP) is a common benign intensely pruritic dermatosis that occurs almost exclusively in primigravidas during late pregnancy. The term *PUPPP*, introduced by Lawley et al. in 1979,[27] is synonymous with Bourne's toxemic rash of pregnancy, Nurse's late onset PP, toxic erythema of pregnancy, and polymorphic eruption of pregnancy.[28] *Polymorphic eruption of pregnancy*, a more recent term, best describes the clinical spectrum of this entity, and is favored throughout Europe.[29] The incidence of PUPPP ranges between 1 in 300 pregnancies and 1 in 130 pregnancies.[6]

ETIOLOGY The pathogenesis remains unknown. An association between PUPPP and multiple gestations is suggested by the higher than expected rates of twin and triplet pregnancies in most published series.[6,15,30] Reports linking PUPPP to increased maternal–fetal weight gain[6,31] are contested. Some postulate that increased abdominal cutaneous distension leads to altered collagen and/or elastic tissue, thereby triggering maternal immune-reactivity to previously non-antigenic stimuli.[6] Additionally, fetal DNA has been detected in involved maternal skin and is hypothesized to be etiologically linked to this condition.[32]

CLINICAL FEATURES PUPPP typically occurs in primigravidas during the last trimester of pregnancy (mean onset, 35 weeks); however, cases of otherwise classic PUPPP have occurred earlier in pregnancy and in the immediate postpartum period. Polymorphous in nature, lesions may be urticarial (most commonly), vesicular, purpuric, polycyclic, or targetoid in appearance (Fig. 107-5). Within an individual patient, lesions are generally morphologically uniform.[1]

Typical lesions are 1- to 2-mm erythematous urticarial papules surrounded by a narrow pale halo. The eruption begins on the abdomen, classically within the striae gravidarum, and demonstrates periumbilical sparing. Pruritus generally parallels with the eruption and is localized to the involved skin. Rapid spread to the thighs, buttocks, breasts, and arms is the norm. Involvement of the palms, soles, or skin above the breast is exceptional.[1] Severe pruritus contributes to disturbed sleep in many; however, no other systemic symptoms are reported by patients.

LABORATORY STUDIES Laboratory investigations reveal no abnormalities. Histopathologic findings, although nonspecific, generally include parakeratosis, spongiosis, and occasional exocytosis of eosinophils (eosinophilic spongiosis). The adjacent dermis may be edematous and contains a perivascular infiltrate of lymphocytes admixed with variable numbers of eosinophils and neutrophils. Direct immunofluorescence (DIF) studies reveal no

DERMATOSES NOT ASSOCIATED WITH FETAL RISK IN PREGNANCY AT A GLANCE



- Pruritic urticarial papules and plaques of pregnancy is a common, self-limited, intensely pruritic dermatosis that occurs almost exclusively in primigravidas during late pregnancy. The term *polymorphic eruption of pregnancy* appropriately encompasses the wide spectrum of clinical presentations.
- Pruritic folliculitis of pregnancy is a benign, pruritic, follicular papular, and/or sterile pustular eruption with classic onset between the fourth and ninth months of pregnancy.
- Prurigo of pregnancy (PP) manifests with discrete pruritic excoriated papules commonly on extensor surfaces. PP is not associated with any specific laboratory or histopathologic abnormalities; maternal and fetal outcomes are unaltered.
- Atopic eruption of pregnancy represents a newly introduced complex comprising pruritic folliculitis of pregnancy, PP, and eczema flares occurring during pregnancy.



▲ **FIGURE 107-5** Pruritic urticarial papules and plaques of pregnancy. **A.** The earliest lesions are 1- to 2-mm, erythematous, urticarial papules localized within and around the striae distensae and sparing the umbilicus. **B.** The papules coalesce to form erythematous plaques that spread to involve the buttocks and thighs.

specific immunoreactants and indirect immunofluorescence studies are negative.[1]

COURSE PUPPP mostly affects primigravidas in the last trimester, although it may occur as early as the first trimester. There are several reports of cases occurring in the immediate postpartum period as well. Duration of symptoms is typically brief, averaging 6 weeks. Severe symptoms, however, rarely persist for more than 1 week. Spontaneous remission within days of delivery is the rule. Recurrences in subsequent pregnancies or with exposure to oral contraceptives are the exception. Fetal and maternal prognoses are unaltered.[1] A single report of involvement of a newborn exists in the literature.[33] In one series, an unusually high sex ratio (male-female of 29:14) has been reported.[6]

DIFFERENTIAL DIAGNOSIS Box 107-2 outlines the differential diagnosis of PUPPP.

TREATMENT Although harmless to the mother and fetus, pruritus is often intense and unremitting. Symptomatic relief of pruritus can usually be achieved with topical antipruritics, antihistamines, and topical corticosteroids. A brief course of oral corticosteroids is rarely required, but effectively controls symptoms in most cases refractory to topical treatment. Early induction of labor has been rarely considered in instances in which severe pruritus is unrelenting, but is generally considered unnecessary.[1,34] Patient reassurance regarding the self-limited nature of PUPPP can help to assuage unnecessary anxiety.

Box 107-2

Differential Diagnosis of Pruritic Urticarial Papules and Plaques of Pregnancy

Most Likely
- Pemphigoid gestationis
- Pruritic folliculitis of pregnancy
- Prurigo of pregnancy
- Contact dermatitis

Consider
- Drug eruption
- Viral exanthema
- Pityriasis rosea
- Exfoliative or eczematous dermatitis

Always Rule Out
- Scabies

Prurigo of Pregnancy (Prurigo Gestationis)

NOMENCLATURE AND EPIDEMIOLOGY *Prurigo of pregnancy* refers to an ill-defined group of disorders comprising Besnier's prurigo gestationis, Nurse's early onset PP, and papular dermatitis of Spangler. This relatively common pruritic dermatosis of pregnancy is thought to occur in approximately 1 in 450 pregnancies.[7] In 2006, Ambros-Rudolph et al. proposed reclassifying PP as part of a newly defined disease complex, atopic eruption of pregnancy (AEP; see Atopic Eruption of Pregnancy).[35]

CLINICAL FEATURES PP presents with discrete, pruritic, excoriated papules with classic onset during the second trimester. Lesions measure 5 to 10 mm and have a predilection for extensor surfaces (Fig. 107-6). Pustules may be evident, but vesicles are never seen. Occasionally, lesions appear crusted or eczematous.[1] Some posit an etiologic role for atopy, as this condition appears to be more common among women with an atopic background, and elevated serum immunoglobulin E has been detected in several individuals.[6] Other studies, however, did not demonstrate an association between PP and an atopic diathesis.[7]



▲ **FIGURE 107-6** Prurigo of pregnancy. Multiple discrete, excoriated papules demonstrate a predilection for extensor surfaces.



LABORATORY STUDIES Serologic tests reveal no abnormalities. Histopathologic features are non-specific, revealing a superficial chronic inflammatory cell infiltrate with occasional epidermal involvement. Direct and indirect immunofluorescence studies are negative.[1]

COURSE Onset is typically during the second or third trimester, with a peak incidence during the second trimester. Lesions commonly resolve with delivery, but may persist for up to 3 months postpartum. Recurrence with subsequent pregnancies is variable. Maternal and fetal prognoses are excellent.[1]



DIFFERENTIAL DIAGNOSIS PP may resemble atopic dermatitis, and distinguishing between the two conditions can be difficult. CP, pruritic folliculitis of pregnancy (PFP), microbial folliculitis occurring in a pregnant woman, and, rarely, PUPPP may also be considered in the differential diagnosis.

TREATMENT Treatment seeks to ameliorate pruritus and includes mid-potency topical corticosteroids and antihistamines.[1]

Pruritic Folliculitis of Pregnancy

EPIDEMIOLOGY The incidence of PFP has been estimated to be 1 in 3000 pregnancies.[37] However, underreporting due to misdiagnosis as acne or microbial folliculitis is likely common, and thus the true incidence is probably higher.

CLINICAL FEATURES PFP is characterized by a pruritic, follicular, monomorphous, papular eruption with onset during the second or third trimester. Individual lesions are small, erythematous papules and pustules with a predilection for the trunk, although the eruption can be generalized.[1]

LABORATORY FINDINGS Histopathologic examination reveals a sterile folliculitis with intraluminal pustule formation containing neutrophils, lymphocytes, macrophages, and variable eosinophils. Focal perifollicular granulomatous inflammation is sometimes seen. Mild superficial dermal edema associated with a perivascular infiltrate of lymphohistiocytes and occasional eosinophils is commonly seen in the adjacent dermis. Special stains for organisms (i.e., Gram, periodic acid-Schiff, and Fite) are invariably negative. DIF studies are negative for deposition of immunoglobulins and complement.[38]

COURSE Classically, onset is during the second or third trimester, and spontaneous resolution occurs within 2 to 3 weeks postpartum. Recurrences in subsequent pregnancies are uncommon.[1] Maternal and fetal prognoses are unaltered by the condition. However, one prospective study of 14 patients indicated a predominance of male fetuses (2:1) and decreased fetal birth weight among women with PFP.[6]

DIFFERENTIAL DIAGNOSIS Other papulopustular eruptions, such as acne, microbial folliculitis, and pruritic dermatoses of pregnancy (i.e., PUPPP, PP, and PG), must be entertained in the differential diagnosis. The absence of comedones, lack of facial involvement, and the presence of pruritus can be helpful in distinguishing PFP from acne. Infectious folliculitis can be ruled out with special stains and culture. Unlike PUPPP, PFP has neither a predilection for the striae nor an urticarial component. Routine histology can further help distinguish these two conditions but is rarely necessary. Lesions of PP are non-follicular and favor the extremities. Finally, the absence of bullous lesions, together with histologic and DIF findings, are helpful in excluding PG.

TREATMENT Symptomatic relief can often be achieved with topical agents containing 10 percent benzoyl peroxide, low-potency topical steroids, or both.[1,39] Topical antifungals, as well as topical and systemic antibiotics have not proven beneficial.[38] One case of successful treatment of PFP with narrow band ultraviolet B phototherapy after 20 treatments has been reported.[40]

Atopic Eruption of Pregnancy

Ambros-Rudolph et al.[35] have proposed the term *atopic eruption of pregnancy* to denote a new disease complex comprising the previously distinct entities PP and PFP, as well as *eczema in pregnancy* (EP), which has not previously been considered a specific dermatosis of pregnancy.[35] The authors retrospectively reviewed data from 505 pregnant women who presented with a generalized, pruritic skin condition that first developed during pregnancy. Among these patients, EP was the most frequently observed skin disorder, occurring in 49.7 percent of patients. Distinguishing features of EP included onset early in pregnancy, a predilection for flexural skin, and a personal and/or family history of atopy. Total serum immunoglobulin E levels were elevated in 71 percent of EP patients whose serum was tested. Considerable clinical and histopathologic overlap was noted among patients with EP and those with PP and PFP. The authors therefore introduced the term *AEP* to encompass all patients formerly diagnosed with PP, PFP, and EP.[35]

Relative to other specific dermatoses of pregnancy, symptoms of AEP occurred significantly earlier during gestation and there was equal involvement of the trunk and extremities. No specific association with parity or gestation was observed. Whereas 20 percent of AEP patients presented with a flare of pre-existing atopic dermatitis, the remaining patients were without prior atopic dermatitis and manifested with either eczematous features (E-type AEP) or prurigo-type lesions (P-type AEP). The authors posited that shifts in cytokine profile expression leading to preferential expression of T helper 2 cytokines may favor the exacerbation of atopic dermatitis during pregnancy. Insofar as eczema is so common in pregnant as in nonpregnant women, it is unclear whether AEP warrants consideration as a distinct dermatosis of pregnancy. Eczematous eruptions, however, are the most common reason for a pregnant woman to present with a generalized pruritic skin condition, and must always be considered in the clinical differential.[35]

KEY REFERENCES

The full reference list for all chapters is available at www.digm7.com.

4. Pennoyer JW et al: Changes in size of melanocytic nevi during pregnancy. *J Am Acad Dermatol* **36**:378, 1997
5. Chang AL, Agredanon YZ, Kimball AB: Risk factors associated with striae gravidarum. *J Am Acad Dermatol* **51**:881, 2004
7. Kroumpouzos G, Cohen LM: Specific dermatoses of pregnancy: An evidence-based systematic review. *Am J Obstet Gynecol* **188**:1083, 2003
9. Lammert F et al: Intrahepatic cholestasis of pregnancy: Molecular pathogenesis, diagnosis and management. *J Hepatol* **33**:1012, 2000
13. Brites D et al: Relevance of serum bile acid profile in the diagnosis of intrahepatic cholestasis of pregnancy in an high incidence area: Portugal. *Eur J Obstet Gynecol Reprod Biol* **80**:31, 1998
22. Heymann WR: Dermatoses of pregnancy update. *J Am Acad Dermatol* **52**:888, 2005
35. Ambros-Rudolph CM et al: The specific dermatoses of pregnancy revisited and reclassified: Results of a retrospective two-center study on 505 pregnant patients. *J Am Acad Dermatol* **54**:395, 2006

CHAPTER 108

Aging of Skin

Mina Yaar
Barbara A. Gilchrest

EFFECTS OF AGING

In both developed and developing nations, the number and proportion of older people are increasing. Thirty-one percent of the U.S. population is expected to be 55 years of age or older by the year 2030.[1] This demographic shift compels health care providers and government officials to confront the pathophysiology of aging and associated health issues.

Aging is a process of progressive decreases in the maximal functioning and reserve capacity of all organs in the body, including the skin. This naturally occurring functional decline in the skin is often compounded and accelerated by chronic environmental insults, such as ultraviolet (UV) irradiation.

Aging occurs at the cellular level and reflects both a genetic program and cumulative environmentally imposed damage. Mammalian cells can undergo only a limited number of cell divisions and then arrest irreversibly[2–4] in a state known as *replicative senescence*, after which they are refractory to mitogenic stimuli. This fact has led to the perception that aging evolved in multicellular organisms as a cancer prevention mechanism[5] because it prevents the unlimited and possibly unregulated growth of cells whose DNA has been progressively damaged over their life span. Of note, in general the more proficient the DNA repair mechanisms of the organism, the longer its life span.[6] Furthermore, there is an inverse correlation between the organism's life span and metabolic rate[7] consistent with the understood role of cumulative oxidative DNA damage, due to aerobic metabolism, in the aging process.[6]

AGING MECHANISMS

Telomeres and Aging[8]

Telomeres, the terminal portions of eukaryotic chromosomes, consist of up to many hundreds of tandem short sequence repeats (TTAGGG in all mammals). During mitosis of somatic cells, DNA polymerase cannot replicate the final base pairs of each chromosome, resulting in progressive shortening with each round of cell division. A special reverse transcriptase, telomerase, can replicate these chromosomal ends, but, with the exception of stem cells and germline cells, the enzyme is normally expressed at extremely low levels, insufficient to maintain telomere length. Human telomeres shorten more than 30 percent during adulthood even in relatively quiescent skin fibroblasts, and telomeres of patients with premature aging syndromes, such as Werner syndrome,[9] progeria,[10] and dyskeratosis congenita,[11] are shorter than those of age-matched controls. Critically short telomeres signal for proliferative senescence or apoptosis, depending on cell type, and appear to compromise DNA stability and transcription of subtelomeric genes,[12] presumably contributing to the aged phenotype. Thus, telomeres appear to serve as a biologic clock that determines proliferative life span of the cell.

SKIN AGING AT A GLANCE



- Intrinsic (chronologic) aging occurs throughout the skin and causes primarily functional losses.
  - Caused by oxidative damage, cell senescence, amino acid racemization, nonenzymatic glycosylation of proteins.
  - Displays flattening of the dermal epidermal junction, decreased cellularity, decreased dermal thickness, loss of vascular and lymphatic beds.
- Photoaging is the superposition of chronic ultraviolet-induced damage on intrinsic aging and accounts for most age-associated changes in skin appearance.
  - Triggered by receptor signaling, mitochondrial damage, protein oxidation.
  - Displays variable epidermal thickness, dermal elastosis, decreased/fragmented collagen, increased matrix degrading metalloproteinases, inflammatory infiltrate, vessel ectasia.
- Dermatologic problems with increased incidence in the elderly include skin cancer, xerosis, pruritus, varicella-zoster infection, ulcers, bullous pemphigoid and drug eruptions.

DNA Damage and Aging[13]

In humans, the only genes implicated in the rate of aging are those in which mutations are responsible for premature aging syndromes. For example, Cockayne syndrome patients display mutations in DNA helicases, enzymes that participate in the repair of DNA damage[14]; ataxia telangiectasia is caused by a mutation in the *ATM* gene,[15] encoding a kinase that senses DNA damage; and Werner syndrome is caused by mutation in a protein with DNA helicase and exonuclease domains.[16] Progeria, a disease that leads to death from atherosclerotic heart disease often in the first decade of life, is caused by mutations in lamin A, a protein important in maintaining chromatin organization in the nucleus for transcriptional control and for DNA damage repair.[17,18] These human premature aging diseases suggest that decreased DNA repair capacity is associated with accelerated aging and that cumulative DNA damage plays a major role in the aging process. Still, the role of these genes in normal aging is not established, as patients with so-called *premature aging syndromes* display some manifestations of aging at an accelerated rate but lack other features of normal aging and have characteristic findings that differ greatly from those of normal aging.

Aging and the Immune System[19]

The immune system has two major roles: defense against external insults and internal immunologic surveillance. The function of antigen-presenting cells, antigen-specific B and T cells, and lymphocyte cytokine secretion declines with age.[20] Conversely, the level of proinflammatory cytokines increases with age. These changes have been attributed to oxidative stress and contribute to the increased incidence of infections and malignancies in the elderly.

SKIN AGING

Cutaneous aging includes two distinct phenomena: Intrinsic aging is a universal, presumably inevitable change attributable to the passage of time alone; photoaging is the superposition on intrinsic aging of changes attributable to chronic sun exposure, which are neither universal nor inevitable. The former is

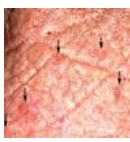

TABLE 108-1
Histologic Features of Aging Human Skin

EPIDERMIS	DERMIS	APPENDAGES
Flattened dermal-epidermal junction	Atrophy (loss of dermal volume)	Depigmented hair
Variable/decreased thickness	Fewer fibroblasts	Loss of hair
Variable cell size and shape	Fewer mast cells	Conversion of terminal to vellus hair
Occasional nuclear atypia	Fewer blood vessels	Abnormal nail plates
Fewer melanocytes	Shortened capillary loops	Fewer glands
Fewer Langerhans cells	Abnormal nerve endings	

manifested primarily by physiologic alterations with subtle but undoubtedly important consequences for both healthy and diseased skin. The latter has major morphologic as well as physiologic manifestations and corresponds more closely to the popular notion of old skin.



Intrinsic Skin Aging

The skin changes that occur with aging (Table 108-1) lead to a gradual physiologic decline (Table 108-2).[21] Major age-related changes in the skin's appearance include dryness (roughness), wrinkling, laxity, and a variety of benign neoplasms. Aged skin is inelastic and recovers more slowly after injury.

MECHANISMS OF INTRINSIC SKIN AGING A major aging theory[22] suggests that cumulative damage to biomolecules, including DNA as a result of continuous generation of free radicals, results in increased cellular vulnerability and eventually terminates in senescence or apoptosis. The skin, like other bodily systems, is continuously exposed to reactive oxygen species (ROS) generated during aerobic metabolism (Fig. 108-1A). Although the skin contains a network of antioxidant enzymes (superoxide dismutases, catalase and glutathione peroxidase) and nonenzymatic anti-oxidant molecules (vitamin E, coenzyme Q10, ascorbate, and carotenoids), this system is less than completely effective and tends to deteriorate with aging.[23]

TABLE 108-2
Functions of Human Skin That Decline with Age

Barrier function
Cell replacement
Chemical clearance
DNA repair
Epidermal hydration
Immune responsiveness
Mechanical protection
Sebum production
Sensory perception
Sweat production
Thermoregulation
Vitamin D production
Wound healing

Oxidative stress upregulates the level of stress regulatory proteins, one of which is nuclear factor κB, a transcription factor that induces the expression of pro-inflammatory cytokines like interleukin (IL)-1 and IL-6, vascular endothelial growth factor (VEGF), and tumor necrosis factor (TNF)-α. These proteins are involved in immunoregulation and cell survival,[24] stimulate the expression of matrix-degrading metalloproteins,[25] and are believed to play a central role in the aging process.

Oxidative damage also affects telomeres. A recent hypothesis suggests a common cellular signaling pathway[26,27] activated by DNA damage and involving the terminal portion of the telomeres. The terminal portion of the 3′ telomeric strand extends beyond the complementary 5′ strand (Fig. 108-1B), leaving a single stranded G-rich overhang. It is suggested that during both telomere shortening and repair of telomere damage, such as that encountered by oxidative stress, the normal loop structure at the end of telomeres is disrupted, exposing the 3′ overhang that under baseline conditions is "buried" in the loop structure.[26,27] Exposure of the TTAGGG tandem repeat sequence then appears to activate p53[28] and to stimulate[29] p53-dependent responses known to include proliferative senescence and apoptosis.[29] Thus, the intrinsic component of skin aging involves progressive oxidative stress and telomere signaling as telomeres shorten during serial cell division and in response to oxidative DNA damage[26] (see also Chap. 109).

EPIDERMIS The most striking and consistent histologic change is flattening of the dermal-epidermal junction with effacement of both the dermal papillae and epidermal rete pegs.[35] This results in a considerably smaller surface between the epidermis and dermis and presumably less communication and nutrient transfer. Dermal-epidermal separation has been demonstrated to occur more readily in old skin, undoubtedly explaining the propensity of the elderly to torn skin and superficial abrasions after minor trauma.

There is an age-associated epidermal thinning of 10 percent to 50 percent between the ages of 30 and 80 years.[36] Variability in epidermal thickness and individual keratinocyte size increases, including those of the basal layer. Evidence suggests that epidermal keratinocytes senesce, and senescent cells are more resistant to apoptosis. Such keratinocytes are therefore more likely to accumulate mutations, increasing their risk for malignant transformation. Studies also show loss of epidermal stem cell population in aged skin as determined by the loss of cells expressing CD71 (transferrin receptor) and α_6 integrin, accepted markers for keratinocyte stem cells.[37] At the electron microscopic level, sun-protected old skin is characterized by some widening of inter-keratinocyte spaces, by reduplication of the lamina densa and anchoring fibril complex in the basement membrane zone, and by loss of the numerous microvillous projections of basal cell cytoplasm into the dermis.[36]

Average thickness and degree of compaction of the stratum corneum appear constant with increasing age, although individual corneocytes become larger. The skin surface pattern, a patchwork of fine lines possibly determined by papillary dermal architecture, reveals slight age-associated loss of regularity. Age effects on percutaneous absorption depend in part on drug structure, with hydrophilic substances such as hydrocortisone and benzoic acid being less well absorbed through the skin of old versus young individuals but with hydrophobic substances such as testosterone and estradiol being equally well absorbed.[38] Of perhaps greater clinical importance, aging markedly delays the recovery of barrier function in damaged stratum corneum, apparently because of slow replacement of neutral lipids, leading to decreased amount of lipids in the newly formed lamellar bodies.[39] Lipid synthesis and activities of enzymes required to generate stratum corneum lipids decrease with age possibly because

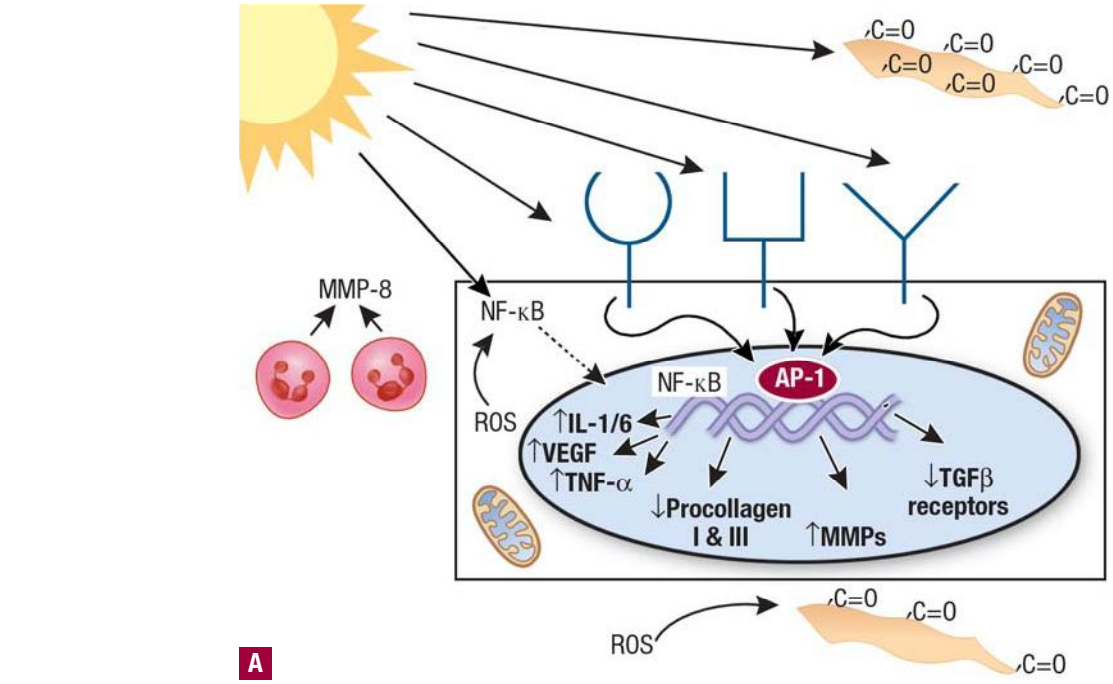

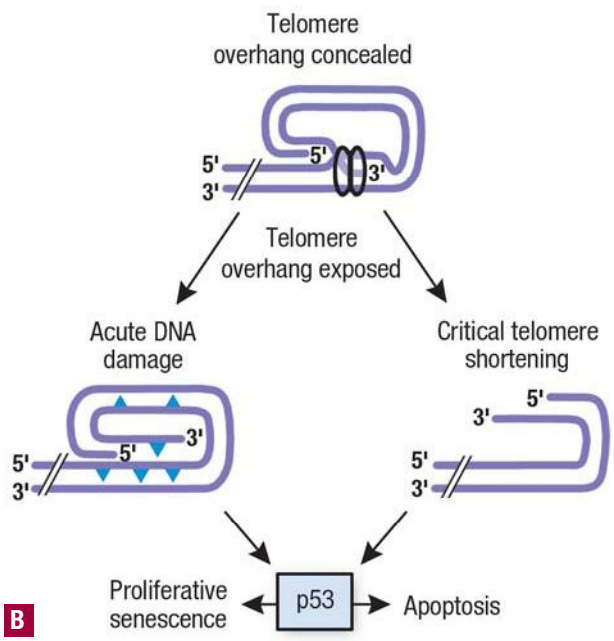

▲ **FIGURE 108-1** Mechanisms of skin aging. **A.** Reactive oxygen species (ROS) generated during aerobic metabolism activate the transcription factor nuclear factor κB (NF-κB) that induces the expression of the pro-inflammatory cytokines, vascular endothelial growth factor (VEGF), and tumor necrosis factor (TNF)-α. ROS also lead to the formation of carbonyl groups (C=O) in proteins, leading to the accumulation of damaged proteins. Ultraviolet (UV) irradiation directly activates cell surface receptors (indicated by symbols on the cell membrane), initiating intracellular signaling that eventually activates the nuclear transcription complex AP-1. AP-1 increases transcription of matrix metalloproteinases (MMPs) and decreases expression of the procollagen I and III genes and transforming growth factor (TGF)-β receptors, with a final consequence of reduced dermal matrix formation. UV also activates the NF-κB transcription factor that induces the expression of multiple proteins and aggravates the degradation of dermal matrix by increasing MMP levels. Matrix degradation is further exacerbated by MMP-8 (collagenase) of neutrophil origin, following neutrophil infiltration into UV-irradiated skin. Mitochondria display large DNA deletions and compromised function. Damaged proteins containing carbonyl groups accumulate in the upper portions of the dermis. [From Halachmi S, Yaar M, Gilchrest BA: Advances in skin aging/photoaging: Theoretic and practical implications (Part I). *Ann Dermatol Venereol* **132**:362, 2005, with permission.] **B.** Telomeres normally exist in a loop configuration, held in place by the final 150 to 200 bases (TTAGGG repeats) on the 3′ strand that forms a single-stranded overhang. When the loop is disrupted when telomeres become critically short (e.g., after repeated cell divisions or when telomeres are damaged as a result of UV irradiation or oxidative damage), the overhang becomes exposed, activating the tumor suppressor protein p53 to induce proliferative senescence or apoptosis, depending on the cell type. IL = interleukin. (From Yaar M: Clinical and histological features of intrinsic versus extrinsic skin aging, in *Skin Aging*, Springer, 2006, p 9, with permission.)

of aberrations in elements that regulate enzyme transcription, or abnormal autocrine/paracrine signaling.[40]

In the elderly, the skin often appears dry and flaky, especially over the lower extremities, an area in which a remarkable age-associated decrease in the content of epidermal filaggrin has been reported.[41] Filaggrin, required for binding of keratin filaments into macrofibrils, is also decreased in the skin of patients with ichthyosis vulgaris, and its lack has been postulated to cause the increased scaliness in both conditions.[41] Barrier function also may be affected by this structural change.

Epidermal turnover rate and thymidine-labeling index decrease approximately 30 percent to 50 percent between the third and eighth decades, with a corresponding prolongation in stratum corneum replacement rate. Linear growth rates also decrease for hair and nails. Epidermal repair rate after wounding likewise declines with age.

A decrease in the number of enzymatically active melanocytes per unit surface area of the skin, approximately 10 percent to 20 percent of the remaining cell population each decade, has



been documented repeatedly, presumably reducing the body's protective barrier against UV radiation. The number of melanocytic nevi also decreases progressively with age, from a peak of 15 to 40 in the third and fourth decades to an average of four per person after age 50 years; such nevi are rarely observed in persons beyond age 80.

Between early and late adulthood there is a 20 percent to 50 percent reduction in the number of morphologically identifiable epidermal Langerhans cells, the skin's immune effector cells responsible for antigen presentation. The remaining cells display morphologic abnormalities, including less and shorter dendrites, and they display reduced antigen-presenting capacity.[42] These changes, compounded by decreases in cytokine production by keratinocytes and lymphocytes and failure of migration through the lymphatic system, presumably contribute to the observed age-associated decrease in cutaneous immune responsiveness.



An endocrine function of human epidermis that declines with age is vitamin D production.[43] Vitamin D, by binding its nuclear receptor, induces the transcription of numerous genes.[44] Vitamin D deficiency leads to osteoporosis and recently has been implicated also in diabetes, hypertension, and prevalent tumors.[45] Elderly individuals frequently have reduced serum levels of vitamin D, leading to osteomalacia,[46] the decreased mineralization of bone classically associated with vitamin D deficiency. Although avoidance of dairy products (the principal dietary source of vitamin D), insufficient sun exposure, and sunscreen use undoubtedly contribute to vitamin D deficiency in the elderly, the level of epidermal 7-dehydrocholesterol per unit skin surface area also appears to decrease linearly by approximately 75 percent between early and late adulthood,[43] suggesting that lack of its immediate biosynthetic precursor also may limit vitamin D production. Together these observations argue for use of vitamin D dietary supplements in the elderly.[47]

With regard to susceptibility to oxidative damage, there is progressive accumulation of damaged cellular proteins and lipids with aging.[36,48] Furthermore, antioxidant defense systems decline with age, and, in addition, there is a decrease in DNA damage repair capacity.[36] These changes in combination increase cellular mutability or their tendency to become senescent, or both.

DERMIS Loss of dermal thickness approaches 20 percent in elderly individuals, although in sun-protected sites significant thinning occurs only after the eighth decade.[49] Old skin is relatively acellular and avascular, and there is age-related loss of normal elastic fibers and dermal collagen.[50,51]

Decreased inflammatory responses in the elderly are the result of decreased synthesis and secretion of keratinocyte-derived cytokines and inflammatory mediators in addition to decreased endothelial response. The dermal microvasculature in middle-aged or elderly subjects also may show mild vascular wall thickening, especially in the lower legs as a result of gravitational forces[52]; vascular wall thinning to less than one-half the normal young adult measurement, associated with absent or reduced perivascular veil cells, has been reported in skin of very elderly subjects and probably contributes to vascular fragility. Loss of elastin contributes to vascular rigidity. Electron microscopic studies show focal degeneration of the elastic component of dermal arterioles. The striking age-associated loss of vascular bed, especially of the vertical capillary loops that occupy the dermal papillae in young skin, and increased distance from the epidermis of existing loops, is thought to underlie many of the physiologic alterations in old skin, including pallor, decreased skin temperature, and the approximately 60 percent reductions in basal and peak induced cutaneous blood flow.[53]

VEGF of epidermal origin appears to play a major role in maintaining dermal vasculature, inducing the expression of anti-apoptotic proteins in endothelial cells,[52] and decreased VEGF level in aged skin probably contributes to endothelial cells apoptosis. Also, recent evidence suggests that there is an age-associated decline of both angiogenic and anti-angiogenic factors, disrupting cutaneous angiogenic homeostasis.[54] Decreased endothelial cell permeability response and decreased capacity to induce white cell adhesion[55] contribute to the compromised immune response. When exposed to intense heat or cold, aging vessels demonstrate reduced ability to constrict, dilate, or shunt.[52] Compromised thermoregulation, which predisposes the elderly to sometimes fatal heat stroke or hypothermia, may be due in part to reduced vasoactivity of dermal arterioles and, in the latter instance, to loss of subcutaneous fat as well. Reduction in the vascular network surrounding hair bulbs and eccrine, apocrine, and sebaceous glands may contribute to their gradual atrophy and fibrosis with age.

Age-associated decreases in wheal resorption and dermal clearance of transepidermally absorbed materials have been reported,[56] probably due to alterations in both the vascular bed and the extracellular matrix. Conversely, the time required for development of a tense blister after topical ammonium hydroxide application is nearly twice as long in older individuals, suggesting a decreased transudation rate with age in injured skin. Impaired transfer of cells as well as solutes between the extravascular and intravascular dermal compartments is suggested by several studies; multiple factors undoubtedly contribute.

With aging there is a decrease in the density and lumen size of lymphatic vessels accompanied by increased rigidity and decrements in lymphatic drainage, affected no doubt by decreased surrounding elastic fibers.[52] Biochemical changes in collagen, elastin, and dermal ground substance lead to increased skin rigidity primarily due to modifications in collagen. Collagen content per unit area of skin surface decreases approximately 1 percent per year throughout adult life,[57] and the remaining collagen fibrils appear disorganized, more compact, and granular, and they display increased collagen cross-links.[58–60] The latter is the result of decreased collagen I and III synthesis; decrements in enzymatic processing of collagen as well as nonenzymatic glycosylation, a process that leads to molecular damage of proteins with a long half-life such as collagen[36]; and increased collagenase levels. Such changes almost certainly contribute to impaired wound healing in the elderly.[59]

Beginning in early adulthood, elastic fibers decrease in number and diameter; by old age, they often appear fragmented, with small cysts and lacunae, especially in the dermal-epidermal junction[61] most likely due to enzymatic degradation of elastin. Elastic fibers also show progressive cross-linkage and calcification with age. At the biochemical level, there is an age-associated decrease in numerous elastic fiber components, including elastin, fibrillin, and fibulin-2. With aging, the level of fibulin-5, an extracellular matrix protein that functions as a scaffold for elastic fibers, appears to decrease before other changes are observed, suggesting that loss of fibulin-5 is a marker for skin aging.[62]

The ground substance mucopolysaccharides, glycosaminoglycans (GAGs), and proteoglycans are decreased relative

to dry weight or collagen content of the skin, especially hyaluronic acid,[63] possibly due to decreased hyaluronan secretion or due to decreased hyaluronic acid extractability.[64] Aging also affects GAG composition and binding to elastin, impeding the drainage of molecules into lymphatic vessels.[52] These changes may adversely influence skin turgor because proteoglycans bind 1000 times their own weight in water and also impact collagen fiber deposition, orientation, and size.[65]

Changes with age in the mechanical properties of the skin during adulthood include progressive loss of elastic recovery, consistent with gradual destruction of the dermal elastic network, and marked prolongation of the time required for excised skin to return to its original thickness. In vivo ultrasound studies also show age-associated differences in water distribution in the dermis,[66] no doubt affecting dermal pliability, resilience, and elasticity. Overall, a picture emerges of aging dermis as an increasingly rigid, inelastic, and unresponsive tissue that is less capable of undergoing modifications in response to injury or stress.

SUBCUTANEOUS TISSUE, MUSCLES, AND BONE Like other striated muscles, facial muscles show accumulation of the "age pigment" lipofuscin, a marker of cellular damage. Compounded by diminished neuromuscular control, this deterioration contributes to wrinkle formation.[67] In addition, subcutaneous fat is depleted from distinct facial regions, including the forehead, preorbital, buccal, temporal, and perioral regions. In contrast, there is a prominent increase in fatty tissue in other areas, including the submental regions, the jowls, the nasolabial folds, and the lateral malar areas. In contrast to the young face in which fat is diffusely dispersed, fat in the aged face, subject to the force of gravity, contributes to sagging and drooping of the skin.[68]

Finally, like other parts of the skeleton, facial bones display reduced mass with age. Bone resorption affects particularly the mandible, maxilla, and frontal bones. Bone loss in these areas enhances facial skin droopiness and contributes to the obliteration of the demarcation between the contour of the jaw and the neck that is so distinct in young adults.[69]

HAIR By the end of the fifth decade, approximately one-half the population has at least 50 percent gray (white) scalp hair, and virtually everyone has some degree of graying due to progressive and eventually total loss of melanocytes from the hair bulb.[70] Loss of melanocytes is believed to occur more rapidly in hair than in skin because the cells proliferate and manufacture melanin at maximal rates during the anagen phase of the hair cycle, whereas epidermal melanocytes are comparatively inactive throughout their life span. More specifically, hair graying reflects loss of the melanocyte stem cell population in hair follicle bulge due, at least in part, to compromised interaction between two transcription factors, microphthalmia-associated transcription factor (Mitf) and Pax3[71] (see Chap. 70).

Scalp hair may gray more rapidly than other body hair because its anagen to telogen ratio (see Chap. 84) is considerably greater than that of other body hair. Advancing age is also accompanied by a modest decrease in number of hair follicles, due in part to atrophy and fibrosis. In addition, with aging there is an increase in the proportion of telogen hair follicles. Remaining hairs may be smaller in diameter and grow more slowly. One hypothesis suggests that melanocyte loss and lack of melanosomal transfer may increase oxidative stress level in highly metabolic hair follicle keratinocytes, affecting their function and viability.[72]

The process termed *balding* results primarily from the androgen-dependent conversion of the relatively dark, thick, terminal scalp hairs to lightly pigmented short, fine, villous hairs similar to those on the ventral forearm. Women are affected less often and far less severely than men. However, in post-menopausal women, hair loss is also the result of decreased estrogen levels and estrogen-androgen ratio.[73,74] Besides hair loss, almost 50 percent of women older than age 60 years display mild facial hirsutism, presumably attributable to the same hormonal changes as scalp hair loss. In susceptible women, testosterone and/or progestin derivatives that are present in some hormone replacement regimens may exacerbate these changes.

CUTANEOUS GLANDS AND NERVES Eccrine glands decrease by approximately 15 percent in average number during adulthood in most body sites. Spontaneous sweating is further reduced by more than 70 percent in healthy older subjects as compared with younger controls, attributable primarily to a decreased output per gland, predisposing the elderly to heat stroke. Apocrine gland size and function also decrease with aging. Sebaceous gland size and number appear not to change with age, but there is an exponential decrease in sebum production in both men and women most likely due to a decrease in production of gonadal or adrenal androgens.[75]

Pacinian and Meissner's corpuscles, the cutaneous end organs responsible for pressure perception and light touch, progressively decrease to approximately one-third their initial average density between the second and ninth decades of life and display greater size variation and structural irregularities.

Decreased sensory perception in old skin encompasses optimal stimulus for light touch, vibratory sensation, and corneal sensation; ability to discriminate two points; and spatial acuity.[76,77] Cutaneous pain threshold increases up to 20 percent with advancing adult age, and compromised arteriolar constriction on changing position from supine to standing is reflective of decreased responsiveness of the sympathetic nervous system.

EFFECTS OF MENOPAUSE Estrogens play a critical role in female development and reproduction and also influence skin and hair. Not surprisingly, their influence decreases dramatically after menopause. Menopause typically occurs in a woman's early 50s, so that, with life expectancy in the developed world approaching 80 years,[78] women are post-menopausal for approximately one-third of their lives. In pre-menopausal women, the predominant estrogen is estradiol, which is produced by the ovaries,[79] and after menopause levels decrease by more than 90 percent,[80] with estron, a less active estrogen, becoming the predominant form.[81] Progestin and androgen levels also fall markedly after menopause.[81] The reduced levels of estrogen underlie many physiologic effects, including hot flashes, atrophy of reproductive tissue, and changes in non-reproductive tissues that are estrogen sensitive.[81] Age-associated decrements in keratinocyte barrier function, immune-regulation, and wound healing appear to be compounded by decreased estrogen levels and/or decreased responsiveness of cells to existing estrogens. Because both estrogen and androgen receptors are expressed by skin-derived cells, both hormones are likely to play a role in skin structure and function.

Structural and Functional Changes in Post-Menopausal Skin. Decreased circulatory levels of estrogens are associated with reduced dermal collagen content,[82–84] increased cutaneous extensibility,[85,86] and

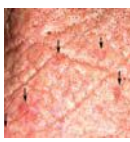

TABLE 108-3
Features of Photoaged Skin[a]

CLINICAL	HISTOLOGIC
Dryness (roughness)	Increased compaction of stratum corneum, increased thickness of granular cell layer, reduced epidermal thickness, reduced epidermal mucin content
Actinic keratoses (see Chap. 113)	Nuclear atypia, loss of orderly, progressive keratinocyte maturation; irregular epidermal hyperplasia and/or hypoplasia; occasional dermal inflammation
Irregular pigmentation	
Freckling	Reduced or increased number of hypertrophic, strongly DOPA-positive melanocytes
Lentigines (see eFig. 108-4.1 in on-line edition)	Elongation of epidermal rete ridges; increases in number and melanization of melanocytes
Guttate hypomelanosis	Reduced number of atypical melanocytes
Diffuse irreversible hyperpigmentation (bronzing) (see eFig. 108-4.2 in on-line edition)	Increased number of DOPA-positive melanocytes and increased melanin content per unit area and increased number of dermal melanophages
Wrinkling	
Fine surface lines	None detected
Deep furrows (see Figs. 108-2 and 108-4)	Contraction of septae in the subcutaneous fat
Stellate pseudoscars (see eFig. 108-4.3 in on-line edition)	Absence of epidermal pigmentation, altered fragmented dermal collagen
Elastosis (fine nodularity and/or coarseness) (see Fig. 108-4)	Nodular aggregations of fibrous to amorphous material in the papillary dermis
Inelasticity	Elastotic dermis
Telangiectasia	Ectatic vessels often with atrophic walls
Venous lakes	Ectatic vessels often with atrophic walls
Purpura (easy bruising)	Extravasated erythrocytes and increased perivascular inflammation
Comedones (maladie de Favre et Racouchot) (see eFig. 108-4.4 in on-line edition)	Ectasia of the pilosebaceous follicular orifice
Sebaceous hyperplasia	Concentric hyperplasia of sebaceous glands

[a]Basal cell carcinoma and squamous cell carcinoma also occur in photoaged skin but, unlike the table entries, affect only a minority of individuals.



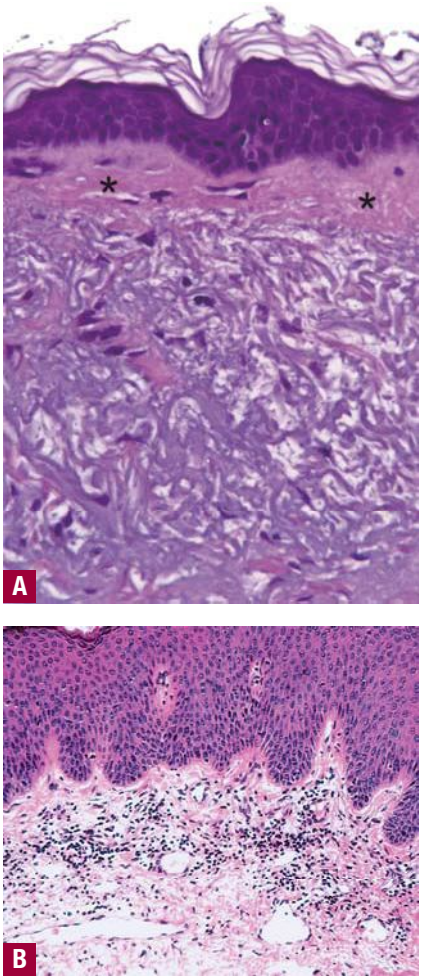

▲ **FIGURE 108-3** Photodamaged facial skin. **A.** Large masses of deranged elastic fibers characterize solar elastosis. A thin sub-epidermal Grenz zone (*asterisks*) is present, and the epidermis is acanthotic. (Used with permission from Jag Bhawan.) **B.** Marked dermal inflammatory infiltrate associated with the heliodermatitis (dermatoheliosis) that is characteristic of ongoing and chronic actinic exposure. (Used with permission from Lorraine H. Kligman.)

decreased elasticity.[87] Also, decreased water-holding capacity, increased dryness, and increased fine wrinkling are reported after menopause,[88] as are decreased sebum levels.[89] These changes are related more to menopause than to chronologic age alone,[90] and wrinkling is reported to be more pronounced in postmenopausal women who are not taking hormone replacement therapy than in treated women.[91]

After menopause, the decreased rate of wound healing is associated with reduced levels of collagen I.[92] Estrogen and progesterone are also reported to modulate cutaneous inflammation, enhance keratinocyte proliferation and collagen synthesis, decrease the activity of matrix metalloproteinases (MMPs), and increase the synthesis of dermal mucopolysaccharides and hyaluronic acid.[74,93]

Photoaging

Clinical and histologic features of actinically damaged skin are listed in Table 108-3. A prominent feature of photoaged skin is elastosis, a process characterized clinically by yellow discoloration and pebbly surface (Fig. 108-2) and histologically by tangled masses of degraded elastic fibers that further deteriorate to form an amorphous mass composed of disorganized tropoelastin and fibrillin (Fig. 108-3A). Although fibrillin is abundant in the elastotic material deeper in the dermis, in the upper portions of the dermis at the dermal-epidermal junction, fibrillin is reduced.[94] In addition, the amount of ground substance, largely composed of GAGs and proteoglycans, increases in photodamaged skin, whereas the amount of collagen decreases, in part because of increased metalloproteinase activity. In contrast with aged sun-protected skin that demonstrates hypocellularity, photodamaged skin frequently displays an increased number of hyperplastic fibroblasts as well as increased inflammatory



▲ **FIGURE 108-2** Photoaged versus intrinsically aged skin of an elderly man. Habitually sun-exposed skin above the collar line is prominently wrinkled and lax, in contrast with the equally chronologically aged but sun-protected skin of the lower neck and shoulder. Despite the striking difference in appearance, both areas manifest age-associated functional decrements.



▲ **FIGURE 108-4** Photoaging: heliodermatitis. Pronounced furrowing, yellow discoloration, and pebbly surface (solar elastosis) with plugged follicles on the neck. *Arrows* denote small actinic keratoses.

cells (Fig. 108-3B), including mast cells, histiocytes, and other mononuclear cells, giving rise to the term *heliodermatitis* (literally, "cutaneous inflammation due to sun"; Fig. 108-4). Immunohistologic studies show increased $CD4^+$ T cells in the dermis. Dermal vasculature in mildly photodamaged skin displays venule wall thickening; in severely photodamaged skin, thin vessel walls with compromised perivascular veil cells display dilations (telangiectases).

In contrast with chronologically aged skin, photodamaged epidermis is frequently acanthotic, although severe atrophy also can be seen in addition to loss of polarity and cellular atypia. Also, there is a more profound decrease in the number and function of Langerhans cells. Additional changes are described in Table 108-3.

The relative severity of sun-induced cutaneous changes varies considerably among individuals, undoubtedly reflecting inherent differences in vulnerability and repair capacity for the solar insult. Photoaging occurs not only in fair-skinned individuals (skin phototypes I and II) but also in individuals with darker skin phototypes III and IV with a history of ample past sun exposure. It usually involves the face, neck, or extensor surfaces of the upper extremities most severely. Interestingly, the gross appearance of photodamaged skin of individuals with skin phototypes I and II differs from that of individuals with darker skin types. The former generally show atrophic and dysplastic skin changes with actinic keratoses and epidermal malignancies, whereas the latter manifest hypertrophic responses such as furrowing, lentigines, and coarseness (Fig. 108-5). One study noted that patients presenting with basal cell carcinoma (BCC) are less wrinkled than peers of similar complexion and degree of photodamage,[95] suggesting that certain phenotypes of photoaging correlate with a predisposition to mutation and carcinogenesis.

Photoaging occurs not only in whites but also in Asians, Hispanics, and Africans. The differences in clinical appearance of photoaged skin between whites and other ethnic groups is primarily due to differences in their UV defense systems. In the latter three groups, melanin is a major form of protection, whereas in whites, melanin plays a lesser role, and stratum corneum thickening is relatively more important.[96] One study reported a sun protection factor for black epidermis of 13.4, compared to 3.4 for white epidermis.[97] Black epidermis transmitted approximately 6 percent of UVB to the dermis, compared to almost 30 percent transmission through white epidermis.[97] Similarly, only ~18 percent of UVA was transmitted into black dermis, compared to more than 55 percent to white dermis.[97]

Major clinical features of photoaging in Asian skin are solar lentigines and mottled pigmentation.[98] Also, melasma is common in Asians and is considered a clinical sign of photodamage in this ethnic group. Moderate to severe wrinkling occurs in Asians but only in the sixth decade and only in individuals who regularly spent ample time in the sun.[99]

There are no specific studies addressing photoaging in Hispanics, and studies on photoaging of black skin have been published only in African Americans. As expected, fairer-skinned Hispanics and Africans display clinical photoaging signs earlier and more prominently than those with very dark skin.[98] Changes include fine wrinkling and mottled pigmentation.[94,98]

MECHANISMS OF PHOTOAGING Mechanisms involved in intrinsic aging also play a role in photoaging.[100] Additional mechanisms are discussed below.

Membrane and Nuclear Signaling. UV irradiation, in part through ROS generation that inhibit phosphatases whose function is to maintain receptors in their inactive state,[101] activates (phosphorylates) cell surface receptors, including receptors for epidermal growth factor, IL-1, and TNF-α, to induce intracellular sig-

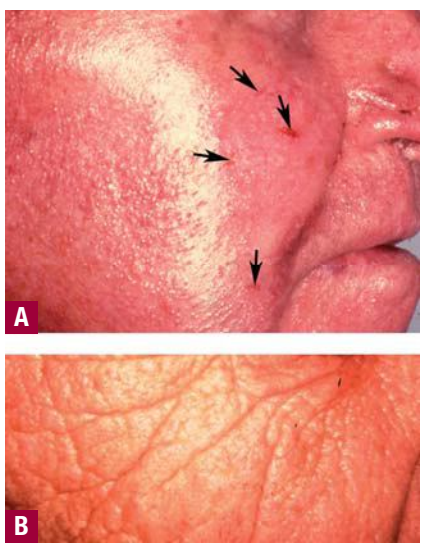

▲ **FIGURE 108-5** Photoaging. **A.** An individual with skin type I displaying atrophic skin photodamage response with relatively few wrinkles but with several actinic keratoses (*arrows*) and a site of previous basal cell carcinoma over the lateral aspect of the nose. **B.** An individual with skin phototype IV displaying hypertrophic skin photodamage response with deep wrinkles and leather-like coarse skin. (From Yaar M: The chronic effects of ultraviolet radiation on the skin: Photoaging, in *Principles and Practice of Photodermatology*, edited by Lim H. New York, Taylor & Francis LLC, 2007, p 91–106, with permission.)

naling culminating in activation of the nuclear transcription complex AP-1, composed of the proteins c-Jun and c-Fos.[102] In intact human skin, even suberythemogenic doses of UVB [~0.1 minimal erythema dose (MED)] transcriptionally upregulate and activate AP-1.[103] Increased AP-1 activity interferes with synthesis of the major dermal collagens I and III by blocking the effect of transforming growth factor (TGF)-β , a cytokine that enhances collagen gene transcription.[102,103] AP-1 also decreases the level of TGF-β receptors, further inhibiting collagen transcription,[104] and also antagonizes intrinsic retinoid effects in skin, leading to a functional retinoid deficiency and reducing collagen synthesis normally promoted by retinoic acid bound to its nuclear receptors. Additionally, UV induces the synthesis and secretion of a cysteine-rich growth regulatory factor (CYR61) that reduces type I procollagen synthesis, increases MMP-1 levels, decreases TGF-β receptor level, and induces AP-1 activation.[105] Hence, in habitually UV-irradiated photodamaged skin there is an overall reduction in collagen synthesis.[106] Increased AP-1 activity also increases the levels and activity of several enzymes that degrade extracellular matrix components, notably the MMP-1 (collagenase), MMP-3 (stromelysin-1), and MMP-9 (92-kd gelatinase).[102,57] UV also activates the nuclear factor κB transcription factor that induces the expression of multiple proteins as discussed in the section Mechanisms of Intrinsic Skin Aging (reviewed in ref. 24) and aggravates the degradation of dermal matrix by increasing the levels of MMP-1 and MMP-9.[103] Matrix degradation is further exacerbated by MMP-8 (collagenase) of neutrophil origin after neutrophil infiltration into UV-irradiated skin.[107] Although there is also a concomitant upregulation of tissue inhibitors of metalloproteinases (TIMPs) that limit matrix degradation, TIMPs presumably are not completely effective in blocking cumulative damage to dermal collagen.[108]

UV-induced collagen degradation is generally incomplete, leading to accumulation of partially degraded collagen fragments in the dermis, thus reducing the structural integrity of the skin.[102] In addition, the large collagen degradation products inhibit new collagen synthesis,[109] and, thus, collagen degradation itself negatively regulates new collagen synthesis. Interestingly, increased stress-associated AP-1 activity, increased CYR61 and MMP levels, and reduced collagen production have been documented in intrinsically aged skin,[105,110] suggesting that similar mechanisms may contribute to chronologic aging, perhaps again through the generation of ROS, as discussed in the section Mechanisms of Intrinsic Skin Aging.

Mitochondrial Damage. Mitochondria are cellular organelles that produce energy (adenosine triphosphate) by consuming oxygen. Although equipped with antioxidant defense systems, continuous generation of ROS damages mitochondrial DNA (mtDNA). To date, machinery to remove bulky DNA lesions has not been identified in mitochondria, although they display capacity for base excision repair relevant to repair of oxidative damage. Still, mtDNA mutation frequency is approximately 50-fold higher than that of nuclear DNA, and photodamaged skin has higher mtDNA mutation frequency than sun-protected skin, displaying large DNA deletions[111–114] and resulting in decreased mitochondrial function, leading to further accumulation of ROS and compromising the cell's ability to generate energy. Also, a correlation was noted between decreased mitochondrial function and increased MMP-1 levels without concomitant increase of MMP-1–specific TIMP,[111] exacerbating collagen degradation[111–114] and aggravating skin photoaging.

Protein Oxidation. Proteins are affected by oxidative damage, and photodamaged skin shows accumulation of oxidized, damaged proteins in the upper portions of the dermis.[115] In vitro studies suggest that UVA is a major contributor and the accumulation of such proteins further inhibits proteasomal function and the ability of the cell to successfully degrade additional damaged proteins.[116]

ACTION SPECTRUM The action spectrum for human photoaging has not been determined, but many studies have explored the relative contribution of the various spectral bands within sunlight, using animal models. In rodent skin, an elastosis-like condition can be produced by prolonged intense irradiation with either a predominantly UVB or UVA source.[117,118] UVB photons are on average 1000 times more energetic than UVA photons and are overwhelmingly responsible for sunburn, suntanning, and photocarcinogenesis after sun exposure.[119] UVB is the major cause of direct DNA damage and induces inflammation and immunosuppression, as well as synthesis and release of prostaglandins (PGs), particularly PGE_2, through induction of the enzyme cyclooxygenase-2. UVB also induces ornithine decarboxylase, the rate-limiting enzyme in the biosynthesis of polyamines that stimulates cellular proliferation (contributing to cancer formation[120]) and contributes to cutaneous angiogenesis by decreasing the expression of the angiogenic inhibitor thrombospondin-1 and inducing the expression of VEGF and platelet-derived endothelial cell growth factor, two angiogenic factors.[121,122] UVB also triggers the penetration of elastase-producing leukocytes into the skin, aggravating elastin degradation.

Despite the well-documented affects of UVB, UVA is suspected of playing a proportionately larger role in photoaging because of its minimally 10-fold greater abundance in terrestrial sunlight, far greater year-round and day-long average irradiance, and greater average depth of penetration into the dermis compared to UVB. Moreover, human skin exposed daily for only 1 month to sub-erythemogenic doses of UVA alone demonstrates epidermal hyperplasia, stratum corneum thickening, Langerhans cell depletion, and dermal inflammatory infiltrates with deposition of lysozyme on the elastic fibers.[123] UVA also induces the synthesis and release of cytokines and MMPs, particularly collagenase (MMP-1) and elastase, and triggers mtDNA mutations.[124–127] Both UVA and UVB lead to the generation of ROS that damage cellular lipids, proteins, and DNA.[128,129] Studies using laser-capture microdissection of human skin show that p53-mutant keratinocytes of the basal layer, in addition to UVB signature mutations, have more mutations associated with UVA (and primarily 8-OXO-dG photolesions), suggesting that UVA is an important etiologic factor in the generation of BCC.[30] UVA is more effective than UVB in inducing oxidative damage. Indeed, the degree of solar elastosis and cutaneous photoaging appear to correlate with the level of accumulated dermal protein oxidation[115] but not epidermal oxidation, suggesting a superior antioxidant network and/or better repair capacity in the epidermis.

Sun light also transmits infrared irradiation (IR) (760 nm to 1 mm).[130] Wavelengths of 760 to 1400 nm can penetrate the skin to reach the subcutaneous tissue without inducing a significant increase in



skin temperature. In contrast, wavelengths of 1400 nm to 1 mm are primarily absorbed in the epidermis and considerably increase skin temperature.[131] IR is particularly important in regions of high insulation and aggravates UVA-induced dermal changes, producing severe elastosis. Even when delivered without UV, IR affects dermal elastic fibers and increases the amount of dermal ground substance.[131] In the hairless mouse model, IR contributes to UV-induced thickening of the epidermis and dermis and alone induces the expression of MMP-3 and the mouse equivalent of MMP-1.[130] Furthermore, in human skin, the expression of tropoelastin, a major component of elastic fiber that associates with microfibrils, is increased as a result of IR, and IR induces the expression of fibrillin-1, a component of the microfibrils.[132] In addition, the level of MMP-12, the enzyme that degrades elastin, is increased.[132] Thus, IR appears to contribute to UV-induced photoaging.

Many of the age-associated physiologic decrements, such as slowed wound healing and loss of immunoresponsiveness, also appear to be accelerated in sun-exposed skin. Furthermore, cells cultured from chronically sun-exposed skin sites differ from cells cultured from sun-protected sites of the same donors in having shortened culture life spans, slower growth rates, lower saturation densities, and altered responsiveness to retinoic acid,[133] all changes also observed as a function of advanced chronologic donor age. Several of the mechanisms known to be involved in UV-mediated cellular damage are also postulated to underlie chronologic aging,[134,135] although the changes only appear after the seventh decade.[110] These include DNA injury and/or decreased DNA repair, oxidative damage, lysosomal disruption, elevated MMPs, reduced collagen production, and connective tissue damage.

Smoking and Skin Aging

Cigarette smoking exacerbates photoaging, particularly in women, with a direct correlation between the number of pack-years smoked and the severity of wrinkling and grayish discoloration.[136,137] Histologic analysis of "smoker's skin" reveals elastic fiber thickening and fragmentation, similar to that found in sun-damaged skin.[138] However, whereas solar elastosis is restricted in the papillary dermis, elastic fiber changes in smoker's skin also occur in the reticular dermis. This dermal elastosis has been suggested to result from increased elastase activity in neutrophils,[139] chronic dermal ischemia, and the pro-oxidant effects of cigarette smoke compounded by decreased levels of vitamin A, which reduce the capacity to quench free oxygen radicals and increase DNA damage.[136,137] Smoking also has been associated with decreased stratum corneum water content[136,137] and accelerated hydroxylation of estradiol, leading to decreased estrogens in the skin that may in turn contribute to dryness and atrophy.[136] Smokers display poor wound healing capacity[140] and increased incidence of skin cancers as well as increased severity of photoaging-like changes compared with nonsmokers with otherwise similar risk factors,[141] consistent with the possibility that mutagens present in cigarette smoke directly affect cells in the dermis and epidermis.

Relevance to Skin Disease in the Elderly

Closely associated with aging is increased vulnerability to disease and injury. Disorders of the skin are known to be common and bothersome in the elderly, and some occur predominantly in this age group.[1] Such disorders often appear to be the consequence of age-associated intrinsic losses of cutaneous cellular function. However, many dermatoses observed more commonly in the elderly reflect the higher prevalence of systemic diseases, such as diabetes, vascular insufficiency, and various neurologic syndromes, that compound physiologic changes in the skin itself. The increased prevalence of some disorders also may reflect reduced local skin care due to immobility or neurologic impairment rather than changes in the skin itself. As well, subtle age-associated changes in immune status may contribute, in analogy to the increased prevalence and severity of skin disease in patients with acquired immunodeficiency syndrome.

Reduced tolerance to systemically administered drugs is well documented in the elderly[142] due to decrements in lean body mass and metabolism and renal excretion of the active ingredients. Comparable data for topically applied medications do not exist, but it is tempting to postulate that retarded dermal clearance of absorbed material, reduced dermal mass and cellularity, and, possibly, altered metabolic capacity may render old skin more susceptible to both beneficial and adverse effects of topical medications or may at least alter the optimal therapeutic schedule. In the case of glucocorticoid preparations, relative vascular unresponsiveness may render blanching of erythema an unreliable indicator of other effects in old skin.

Selected common cutaneous disorders in the elderly are discussed briefly in the following sections, with special emphasis on their pathogenesis and clinical presentation in this population (Table 108-4). Most of these entities are covered more comprehensively in other chapters.

TUMORS

Skin Cancer (See Chaps. 113 to 115)

The age-specific incidence of skin cancer, including melanoma, increases exponentially with age,[148] presumably due in part to cumulative exposure to carcinogens over a lifetime interspersed with cell division, with the attendant risk of mutation. There are also well-documented age-associated decreases in DNA repair capacity[48,149] and immunosurveillance,[150] as well as subtle loss of proliferative homeostasis.

The major etiologic factor for skin cancer is UV irradiation. Habitual sun exposure of fair-skinned individuals induces squamous cell carcinoma as well as actinic keratoses, a premalignant lesion that may evolve into squamous cell carcinoma in a direct dose-response relationship.[151] In contrast, the risk of BCCs and particularly malignant melanoma is related not only to total sun exposure but also to intense intermittent sun exposure.[152] The mechanism underlying these different epidemiologic patterns is unknown, although inducible protective responses and relative resistance of the responsible cell types to apoptosis may contribute.[153]

The elderly, particularly men, present with melanomas (see Chap. 124) that are thicker than those of young adults, presumably in part because of failure to properly examine their skin, poor vision, and other medical problems; and their melanomas arise on a background of multiple benign cutaneous lesions. Presumably because of delayed diagnosis, men older than age 50 years have an increased mortality risk from melanoma compared with women or younger men. Although all types of melanoma have increased age-specific incidences,[148] lentigo maligna melanoma overwhelmingly develops in the 60s or later in habitually sun-exposed skin.[154]

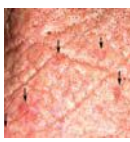

TABLE 108-4
Presumptive Pathophysiology of Common Cutaneous Disorders in the Elderly

DISORDER	PATHOPHYSIOLOGY
Benign neoplasia	
Seborrheic keratosis	Focal epidermal homeostatic loss leading to increased endothelin-1
Malignant neoplasia	
Squamous cell carcinoma and actinic keratosis	Ultraviolet-induced DNA damage
Basal cell carcinoma	Decreased DNA damage repair capacity
Malignant melanoma	Cumulative age-associated DNA damage
Merkel cell carcinoma	Decreased DNA damage repair capacity
Angiosarcoma	
Papulosquamous disorders	
Psoriasis	Changes in patient's environment leading to Koebnerization Systemic medications
Xerosis/asteatotic dermatitis	Disturbance of epidermal maturation (decreased filaggrin production and/or altered lipid profile) Decreased water content in outer layers of stratum corneum Slower corneocyte transit
Pruritus	Penetration of irritants through damaged stratum corneum (?) Altered sensory threshold (neuropathy) (?) Metabolic disorder Endocrine disorder Malignant neoplasm Adverse drug reaction Parasitic infestation
Infections	Compromised local cutaneous health predisposing to growth of infective organism Age-associated decreased immune function Underlying systemic disorder associated with decreased immune function
Ulcers	Impaired wound healing capacity (decreased levels of growth factors, decreased cellular proliferative capacity, increased perivascular fibrin deposition) Decreased mobility Underlying systemic disorder Compromised local cutaneous health (venous stasis, arteriosclerosis, hypertension)
Bullous pemphigoid	Flattening of the dermal-epidermal junction Increased circulating autoantibodies
Photosensitivity reactions	Medications with unsaturated ring structures



Merkel cell carcinoma (trabecular carcinoma) (see Chap. 120) is a rare cutaneous tumor thought to arise from a pluripotential cell that displays neuroendocrine differentiation.[155,156] It is seen most often in sun-exposed areas of the head, neck, or extremities and presents as a rapidly growing nodule. More than 90 percent of patients diagnosed with this tumor are older than age 50, with the mean age of onset being 68 years.

The most common form of angiosarcoma (see Chap. 128) occurs overwhelmingly on the head and neck of the elderly. Its rapid growth, associated with early metastasis, usually results in death within 2 years of diagnosis.[157]

PAPULOSQUAMOUS DISORDERS

Psoriasis[158] (See Chap. 18)

Xerosis and Asteatotic Dermatitis

Xerosis is a dry, rough quality of skin that is almost universal in the elderly and may be attributed to a subtle disturbance of epidermal maturation, such as inadequate filaggrin production[41] or altered lipid profile.[39,160] Histologic studies reveal little alteration of either the viable epidermis or the stratum corneum with age. Available data fail to demonstrate an overall decrease in stratum corneum lipids[39,40] or altered amino acid composition as etiologic factors.[161] Water content of the viable epidermis is normal, but there is some reduction in the outermost layers of the stratum corneum.[40] The surface irregularity may be attributed simply to slower transit of corneocytes through the stratum corneum, allowing accumulation of damage in situ. There is no explanation for the pruritus that often accompanies xerosis.[162] Speculations include frequent penetration of irritants through an abnormal stratum corneum and an altered sensory threshold due to subtle neuropathy.

Asteatotic eczema, a condition frequently found in the elderly during the wintertime, is a dermatitis superimposed on xerosis. It is often caused by low humidity in a heated environment. It manifests by dry, fissured skin with fine scale and is usually located to the pretibial region. This condition, which may be extremely pruritic, responds to application of medium-potency topical steroid ointments and/or liberal application of emollients.

Pruritus[162] (See Chap. 102)

Pruritus is perhaps the most common skin-related complaint of the elderly. In a majority of cases, pruritus is attributable only to xerosis, often exacerbated by low humidity, frequent bathing, or application of irritants to the skin. However, in up to 10 percent to 50 percent of patients in some series, pruritus may have other etiologies. These include metabolic or endocrine disorders, such as diabetes mellitus, renal failure, thyroid disease, or hepatic disease, in particular the obstructive type. Pruritus can be a manifestation of a malignant neoplasm, in particular lymphoma or leukemia, or the result of a hematologic disease such as polycythemia vera. Adverse drug reactions can manifest predominantly or exclusively as pruritus and always should be considered in this segment of the population. Finally, infestations such as scabies lead to intense pruritus, and associated primary skin lesions may be overlooked.

INFECTIOUS PROCESSES

Bacterial[163]

Impetigo and folliculitis in the elderly are caused by staphylococci, in contrast to

impetigo in the pediatric population, which usually is caused by streptococci (see Chap. 177). Hence, in the older age group, impetigo should be treated with penicillinase-resistant semisynthetic penicillin or erythromycin until culture confirms the identity of the organism.

Distinct forms of cellulitis (see Chap. 179) preferentially affect older individuals. These include orbital cellulitis that is caused by *Streptococcus viridans* alone or in combination with gram-negative bacteria. Another form of cellulitis that is relatively rare in the younger population is *Pseudomonas* cellulitis of the ear, an infectious process that affects elderly diabetic individuals. Erysipelas, a β-hemolytic streptococcal infection of the skin, is more common in the elderly and tends to spread more readily in this age group, creating a life-threatening situation.

Necrotizing fasciitis (see Chap. 179), caused by a strain of *Streptococcus*, is a rare cutaneous infection, but it is more frequent in the elderly and is associated with increased morbidity and mortality in this age group.

Methicillin-resistant *Staphylococcus aureus* (MRSA) has become an increasingly important pathogen in hospital and community acquired infections, and age > 80 years is significantly associated with MRSA carriage.[164] Because community-associated MRSA infection most often presents as skin and soft tissue infections, dermatologists should be aware of this possibility when managing infections in the elderly.

Parasitic[165] (See Chap. 208)

Scabies can occur in any age group, but nursing homes provide a fertile ground for rapid spread of the infestation. In the elderly, in part because of their decreased immunity, lesions may be atypical and display less inflammation and pruritus. In addition, frequently the elderly have xerosis, and their pruritus at times may be attributed to this etiology.

Dermatophytes and Yeasts[166] (See Chaps. 188 and 189)

Onychomycosis is present in approximately 40 percent of patients after age 60 years, and tinea pedis is present in approximately 80 percent of this patient population. Although usually present for decades, tinea pedis may exacerbate with age. Indeed, in elderly diabetic patients, interdigital tinea pedis may ulcerate and predispose to bacterial cellulitis, a presentation that is relatively rare in the young adult immunocompetent patient.

Cutaneous infections due to *Candida albicans* are common in the elderly. When recurrent or difficult to control, candidiasis may be a sign of poorly controlled diabetes, an endocrinopathy, malnutrition, or malignancy.

Viral (Varicella-Zoster Virus)[163] (See Chap. 194)

The incidence of herpes zoster peaks at approximately 1500 cases per 100,000 persons annually at age 75 years. Postherpetic neuralgia, uncommon in patients younger than 40 years old, occurs in more than 40 percent of patients aged 60 to 69 years and 50 percent of patients 70 years of age or older.[78] A number of patients older than 60 years also experience paresthesias and muscle weakness. Decreased cellular immunity and impaired wound healing in the elderly may account for slower resolution of the acute eruption, but the pathogenesis of their postherpetic neuralgia is unclear.

Ulcers[167]

Chronic ulcers of all etiologies are more common in the elderly than in younger individuals, presumably due to a combination of impaired wound healing and higher prevalence of underlying diseases. The most common are leg ulcers, usually in the setting of chronic venous insufficiency leading to venous hypertension (see Chap. 175). Exudation of macromolecules such as fibrinogen into the dermis may block the passage of oxygen and nutrients and sequester cytokines and growth factors required for tissue homeostasis, maintenance, and repair. The sclerotic indurated quality of affected skin, termed *lipodermatosclerosis*, is postulated to further impair healing. In addition, diseases such as diabetes mellitus and atherosclerotic peripheral vascular disease may contribute to ulcer evolution.

Decubitus ulcers (see Chap. 99) are proportionately far more common in elderly hospitalized patients than in younger patients, as the former tend to be less mobile, needing help turning in bed, and have additional aggravating disorders such as dry skin over bony prominences, incontinence, and/or poor nutritional state.[168]

Bullous Pemphigoid (See Chap. 54)

Bullous pemphigoid is far more common after age 60 years than in younger persons, a predilection that may be explained in part by the age-associated increases in circulating autoantibodies and ease of dermal-epidermal separation,[169] although many other autoimmune and blistering dermatoses are not more common in old age. Possibly, age-associated changes in the basement membrane itself render it specifically vulnerable to this disease process. Bullous pemphigoid is a self-limited condition that frequently resolves within 6 to 12 months, but elderly patients may experience increased morbidity and mortality because of debilitated general health or as a side effect of treatment.

DRUG ERUPTIONS

Adverse drug reactions of all kinds increase with age, in part because the elderly consume more medications than younger age groups and in part because of medical conditions, including impaired renal, cardiac, or hepatic function, that compromise drug metabolism or excretion. The most frequently observed adverse cutaneous drug reactions are pruritus, exanthems, and urticaria, but drug-induced autoimmune reactions, including pemphigus, bullous pemphigoid, and lupus erythematosus, also occur in the elderly. A careful history to elicit all prescription medications as well as over-the-counter preparations is critical to diagnosis and optimal patient care.

KEY REFERENCES

The full reference list for all chapters is available at www.digm7.com.

5. Campisi J: Replicative senescence: An old lives' tale? *Cell* **84**:497, 1996
19. Weng NP: Aging of the immune system: How much can the adaptive immune system adapt? *Immunity* **24**:495, 2006
22. Harman D: Free radical theory of aging: an update: Increasing the functional life span. *Ann N Y Acad Sci* **1067**:10, 2006
26. Kosmadaki MG, Gilchrest BA: The role of telomeres in skin aging/photoaging. *Micron* **35**:155, 2004
47. Wolpowitz D, Gilchrest BA: The vitamin D questions: How much do you need and how should you get it? *J Am Acad Dermatol* **54**:301, 2006
72. Van Neste D, Tobin DJ: Hair cycle and hair pigmentation: Dynamic interactions and changes associated with aging. *Micron* **35**:193, 2004
74. Verdier-Sevrain S, Bonte F, Gilchrest B: Biology of estrogens in skin: Implications for skin aging. *Exp Dermatol* **15**:83, 2006
102. Fisher GJ et al: Mechanisms of photoaging and chronological skin aging. *Arch Dermatol* **138**:1462, 2002
140. Freiman A et al: Cutaneous effects of smoking. *J Cutan Med Surg* **8**:415, 2004

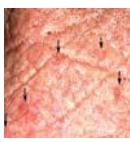

This page intentionally left blank

PART 7

Neoplasia

Copyright © 2008 by The McGraw-Hill Companies, Inc. Click here for terms of use.



SECTION 20

CARCINOGENESIS

CHAPTER 109

Genome Instability, DNA Repair, and Cancer

Kenneth H. Kraemer
Thomas M. Rünger

INTRODUCTION

The integrity of the genome of all living organisms is constantly threatened by exogenous and endogenous DNA-damaging agents. Exogenous DNA-damaging agents include physical agents, such as ultraviolet (UV) or ionizing radiation, and a wide variety of chemical agents, such as components of cigarette smoke. Endogenous DNA damage arises from regular metabolic processes within the cell, mediated, for example, by reactive oxygen species. Maintaining the stability of the genome is of utmost importance to all living organisms. Therefore, since early evolution, all organisms ranging from prokaryotes to eukaryotes have been equipped with mechanisms that react to and repair DNA damage and thereby maintain genomic stability. The types of damage produced include alterations in the structure of nucleotides, DNA strand breaks, DNA cross-links, and DNA adducts. Different types of DNA-damaging agents induce different types of DNA damage (Table 109-1), which in turn require different responses and repair pathways for processing (Table 109-2).[1]

If DNA damage is not repaired adequately, it may lead to altered cell function, cell death, or the formation of mutations (alterations of the DNA sequence) in the damaged cells. These DNA damage–induced mutations will persist as long as the affected cell survives. At a cellular level, mutations in vital genes can lead to alterations of cell functions or malignant transformation. Accumulation of mutations may lead to organ dysfunction, aging, and cancer. Although most DNA damage is adequately repaired, none of the cellular responses is 100 percent effective in repairing all DNA damage under all circumstances.

A hereditary or acquired impairment in the way cells respond to DNA damage may result in genome instability with an increased rate of mutation formation. Numerous hereditary disorders are characterized by such genome instability (reviewed in Chap. 140). Many, but not all, of those are associated with an increased cancer risk and/or accelerated aging.

Exposure of the skin to UV light has multiple cellular and clinical effects, including an increase in skin cancer risk. The photocarcinogenesis cascade of events (Fig. 109-1) exemplifies the link between genome instability, DNA repair, and cancer. UV light produces a type of DNA damage involving the generation of photoproducts, which are alterations in the structure of nucleotides. The major DNA photoproducts are cyclobutane pyrimidine dimers (CPDs; Fig. 109-2) and 6,4-pyrimidine–pyrimidone dimers. Unrepaired CPDs or 6,4-pyrimidine–pyrimidone dimers may result in characteristic mutations: C to T single base and CC to TT tandem base substitution mutations.[2–4] Such mutations are typical for UV light exposures and only rarely are induced by other mutagens. They have therefore been termed *UV-signature mutations* (see Fig. 109-2).

◀ Lentigo maligna melanoma. A large lentigo maligna on the left cheek with the typical variegation in color. The lesion is flat and macular and represents in situ melanoma. In the center of the irregular lesion there is a pitch-black nodule that indicates a switch from the radial to the vertical growth phase and thus invasiveness: The lesion is now called lentigo maligna melanoma.

GENOME INSTABILITY, DNA REPAIR, AND CANCER AT A GLANCE

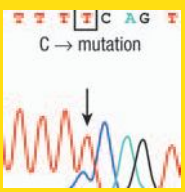

- DNA can be damaged by physical agents (ultraviolet or ionizing radiation) or chemical agents in the environment.
- DNA damage may lead to mutations (changes in DNA sequence).
- The ability of cells to repair DNA damage and to maintain genome stability is of utmost importance to prevent malignant transformation.
- Different agents induce different types of DNA damage, which in turn require different responses and repair pathways.
- A number of hereditary disorders are characterized by genome instability due to defects in genes involved in DNA repair or DNA damage signaling.
- Many different laboratory tests can be used to diagnose genome instability and/or DNA repair defects.
- Inherited or acquired genome instability is associated with an increased cancer risk.



Copyright © 2008 by The McGraw-Hill Companies, Inc. Click here for terms of use.

TABLE 109-1
Cellular Damage Induced by Physical and Chemical Agents

AGENT	DAMAGE
Ultraviolet radiation	Dipyrimidine cyclobutane dimers (TT, TC, CT, or CC), pyrimidine-pyrimidone (6-4) photoproducts (mostly TC), DNA-protein cross-links
X-irradiation	DNA single- and double-strand breaks, oxidative base damage (see below)
Psoralens plus ultraviolet A	DNA-psoralen monoadducts, DNA interstrand cross-links (binds to T at TA sequences)
Mitomycin C	DNA interstrand cross-links
Benzo-[a]-pyrene	Bulky adducts
Reactive oxygen species	Oxidative base damage (8-oxo-deoxyguanine, thymine glycol), cyclopurines (A or G) making bulky lesions

TABLE 109-2
Types of DNA Damage and Associated DNA Repair Pathways

TYPE OF DNA DAMAGE	DNA REPAIR PATHWAY
DNA photoproducts (CPDs, 6,4-PP)	Nucleotide excision repair
Oxidative base modifications (e.g., 8-oxoG)	Base excision repair
Incorrect DNA base pairing	Mismatch repair
DNA double-strand breaks	Non-homologous end joining, homologous recombination (i.e., recombination repair)
DNA adducts	Nucleotide excision repair
DNA cross-links (interstrand and intrastrand)	Recombination repair
Persistent DNA lesions	Translesion (bypass) DNA synthesis

CPDs = cyclobutane pyrimidine dimers; 6,4-PP = 6,4-pyrimidine–pyrimidone photoproducts; 8-oxoG = 8-oxo-deoxyguanine.

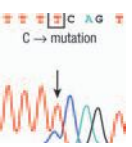

DNA repair is an important cellular defense mechanism that prevents mutation formation at sites of DNA damage after UV exposure. However, it is not the only defense mechanism (see Fig. 109-1). Most mutations are generated during replication of damaged DNA. Therefore, a damage-induced arrest in cell cycling, which allows more time for repair, is another important cellular damage response that prevents mutation formation.[5,6] Furthermore, programmed cell death (apoptosis) prevents the survival of cells with overwhelming DNA damage, and through that mechanism the frequency of cells with UV-induced mutations is also reduced.[7] Other inherent defense mechanisms against the ultimately carcinogenic properties of UV light include increased melanogenesis and thickening of the epidermis and stratum corneum, which protect from future DNA damage, as well as removal of mutated cells through host immune responses (see Fig. 109-1).

DNA DAMAGE AND REPAIR

More than 100 DNA repair genes have been identified (http://www.cgal.icnet.uk/DNA_Repair_Genes.html#NER). The nucleotide excision repair (NER) pathway acts on DNA damaged by UV radiation, repairing CPDs and other photoproducts, as well as on DNA damaged by certain carcinogens (such as benzo-[a]-pyrene) (see Table 109-2). In NER, the damaged nucleotide is removed and replaced with undamaged DNA. Multiple proteins act in concert to repair UV-induced DNA damage (Fig. 109-3). Defects in these repair genes can cause human diseases (Table 109-3), including xeroderma pigmentosum (XP), Cockayne syndrome, and trichothiodystrophy (for details on these disorders, see Chap. 140). For instance, XP can be caused by a defect in any one of several genes involved in NER. Based on cell fusion experiments, cells/patients with defects in the same gene are considered to be in the same complementation group, and in different complementation groups if different genes are affected. If DNA repair in the fused cell is normalized, with the wild-type gene from each cell giving rise to a functional protein that is absent in the other cell, the cells "complement" each other and are in different complementation groups. Seven such complementation groups have been identified (XPA to XPG), which implies that mutations in any of seven distinct genes can cause XP.

Transcribed genes are repaired faster than the rest of the genome. In the NER pathway, the first steps involving DNA damage recognition are different in non-transcribed and transcribed genes (global genome NER and transcription-coupled NER). In non-transcribed genes and noncoding areas, which represent most of the genome, the *XPE* and *XPC* gene products bind to UV-damaged DNA, marking it for further processing. In contrast, DNA damage in transcribed genes is probably sensed by a stalled

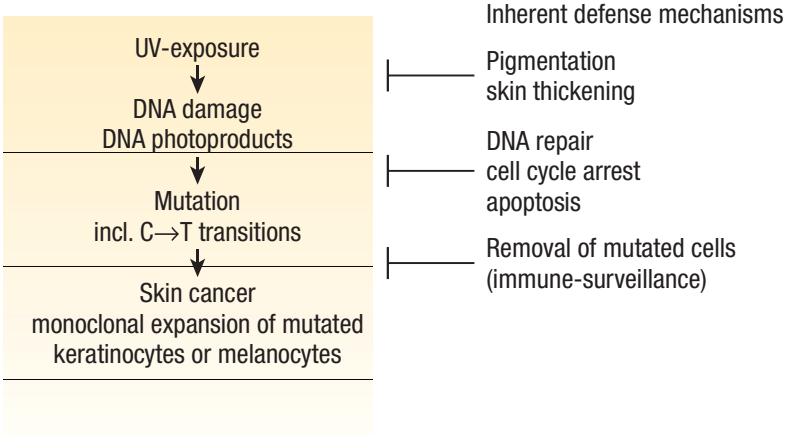

▲ **FIGURE 109-1** Photocarcinogenesis cascade of events. Exposure to ultraviolet (UV) light induces typical types of DNA damage, namely, cyclobutane pyrimidine and 6,4-pyrimidine–pyrimidone photoproducts. These often generate single and tandem base substitution mutations (C→T and CC→TT) that are typical for UV light exposure and are therefore termed *UV-signature mutations*. With sufficient numbers of inactivating mutations in crucial genes (tumor suppressor genes), individual cells may undergo malignant transformation, clonally expand, and form skin cancers. Several inherent defense mechanisms counteract this chain of events (see text).

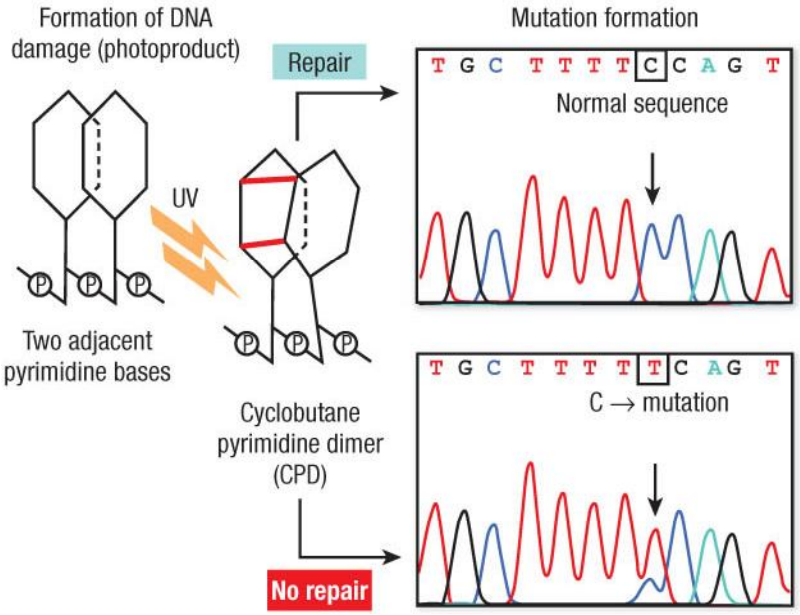

◀ **FIGURE 109-2** Example of ultraviolet (UV) light–induced generation of DNA damage and a subsequent mutation. On direct excitation of the DNA molecule by UV light, adjacent pyrimidine bases (cytosine or thymine) may form covalent bonds between them, which leads to creation of pyrimidine dimers. The illustration shows an example in which two covalent bindings generate a tri-cyclic cyclobutane ring between two pyrimidines. Hence, this type of UV light–induced DNA damage is called a *cyclobutane pyrimidine dimer*, a common type of DNA photoproduct. The nucleotide excision repair DNA repair system functions to remove this damage, which results in the normal DNA sequence (*upper box*). If the damage is not repaired, this type of DNA photoproduct can lead to formation of a typical C⟶T single base substitution mutation (*lower box*). This is most likely to occur on replication of damaged DNA and misincorporation of adenine opposite the cytosine-containing photoproduct. An example of such a UV-signature mutation is shown on the right.[4] Note that the mutation is located within a run of seven pyrimidines, a common location for UV-signature mutations.

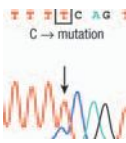

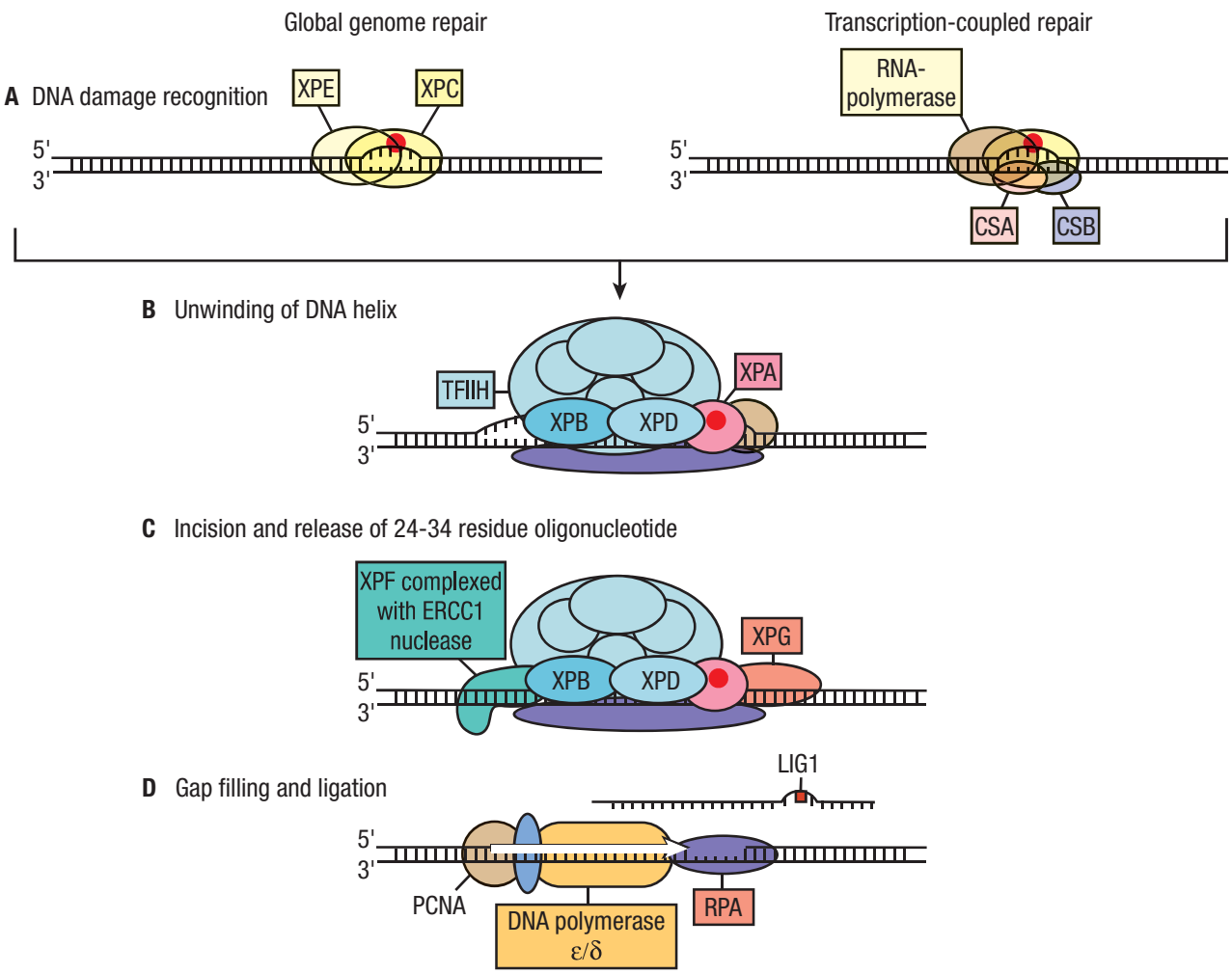

▲ **FIGURE 109-3** DNA nucleotide excision repair scheme. **A.** *Right:* Damaged DNA in actively transcribed genes results in stalling of the RNA polymerase in a process that involves the CSA and CSB proteins. This serves as a signal to initiate transcription-coupled DNA repair. *Left:* Damaged DNA in the remainder of the genome is bound by the XPE and XPC gene products. This serves as a signal to initiate global genome repair. **B.** A portion of the DNA, including the damage, is unwound by a complex of proteins including the XPB and XPD gene products. These proteins are also part of the 10-subunit basal transcription factor IIH (TFIIH). The XPA protein may stabilize the unwound DNA. **C.** The XPF and XPG nucleases make single-strand cuts on either side of the damage, releasing a 24- to 34-residue segment of DNA. **D.** The resulting gap is filled by DNA polymerase in a process that includes the proteins proliferating cell nuclear antigen (PCNA) and replication protein A (RPA). CSA, CSB = Cockayne syndrome complementation groups A and B; ERCC1 = excision repair cross-complementing gene 1; LIG1 = ligase 1; XPA, XPC, etc. = xeroderma pigmentosum complementation groups A, C, etc.

TABLE 109-3
DNA Repair Genes Associated with Human Diseases

Gene[a]	Chromosome Location	Repair Pathway	Function
XPA	9q22.3	NER	Binding of damaged DNA
XPB (ERCC3)	2q21	NER	DNA helicase, part of TFIIH
XPC	3p25	NER	Binding of damaged DNA, global genome repair
XPD (ERCC2)	19q13.3	NER	DNA helicase, part of TFIIH
XPE (DDB2)	11p12-p11	NER	Binding of damaged DNA, global genome repair
XPF (ERCC4)	16p13.3-p13.11	NER	DNA endonuclease
XPG (ERCC5)	13q22	NER	DNA endonuclease
TTDA (GTF2H5)	6p25.3	NER	Part of TFIIH
CSA (ERCC8)	5q12	NER	Transcription-coupled repair
CSB (ERCC6)	10q11	NER	Transcription-coupled repair
XPV (polymerase eta)	6p21.1-p12	Bypass	DNA damage bypass polymerase
MSH2	2p22-p21	MMR	Mismatch repair (Muir-Torre syndrome, HNPCC)
MLH1	3p21.3	MMR	Mismatch repair (Muir-Torre syndrome, HNPCC)
PMS1	2q31-q33	MMR	Mismatch repair (HNPCC)
PMS2	7p22	MMR	Mismatch repair (HNPCC)
MSH6	2p16	MMR	Mismatch repair (HNPCC)
TFGBR	23p22	MMR	Mismatch repair (HNPCC)
MLH3	14q24.3	MMR	Mismatch repair (HNPCC)

ERCC = human excision repair cross-complementing genes that correct defects in cultured hamster cells; HNPCC = hereditary non-polyposis colon cancer; NER = nucleotide excision repair; MMR = mismatch repair; TFIIH = transcription factor IIH.
[a]The genes designated XP are defective in the corresponding xeroderma pigmentosum complementation group, and those designated CS are defective in the corresponding Cockayne syndrome complementation group.

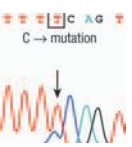

RNA polymerase acting in conjunction with the CSA and CSB (Cockayne syndrome complementation groups A and B) gene products. After the DNA damage recognition steps, global genome NER and transcription-coupled NER follow the same pathway. The *XPA* gene product probably functions in conjunction with replication protein A, the transcription factor IIH (TFIIH), XPF, and excision repair cross-complementing gene 1 (ERCC1). The following steps occur in both non-transcribed and transcribed gene repair:

- The *XPB* and *XPD* gene products partially unwind the DNA in the region of the damage, thereby exposing the lesion for further processing. These proteins are part of the TFIIH basal transcription factor (see Fig. 109-3B).
- The *XPF* gene product, in a complex with ERCC1, makes a single-strand nick at the 5′ side of the lesion, whereas the *XPG* gene product makes a similar nick on the 3′ side, which results in the release of a region of approximately 30 nucleotides containing the damage (see Fig. 109-3C).
- The resulting gap is filled by DNA polymerase using the other (undamaged) strand as a template in a process involving proliferating cell nuclear antigen. DNA ligase 1 seals the region, restoring the original undamaged sequence (see Fig. 109-3D).

Other DNA repair pathways include base excision repair, recombination repair, and mismatch repair. Defects in mismatch repair are also associated with human diseases—Muir-Torre syndrome and human non-polyposis colon cancer. More extensive descriptions of these pathways may be found in refs. 1, 8, 9, and 10.

REGULATION OF CELLULAR RESPONSES TO DNA DAMAGE

As outlined in the introduction, several cellular responses to DNA damage contribute to the maintenance of genome integrity. These include cell cycle arrest, apoptosis (programmed cell death), and DNA repair.[5,11–18] Because these responses need to be carefully orchestrated, there are many proteins involved in the signaling of DNA damage and the regulation of DNA damage responses (Fig. 109-4). Different types of DNA-damaging agents and different types of DNA damage require different DNA damage responses. Fig. 109-4 presents some of the major players in signaling DNA damage and regulating DNA damage responses. As with defects in DNA repair genes (see Table 109-3), defects in many of these DNA damage–signaling genes (boxed in Fig. 109-4) are also implicated in hereditary disorders of genome instability (Table 109-4; for further details see Chap. 140).

The tumor suppressor gene p53, termed the *guardian of the genome*,[19] plays a pivotal role in regulating and orchestrating these responses and is mutated in many cancers, including cutaneous squamous cell carcinomas. Upstream regulators of p53 in the cellular DNA damage response pathway are ATM (ataxia telangiectasia mutated) and ATR (ataxia telangiectasia- and Rad3-related) genes. One of p53's several functions is the regulation of the cell cycle in response to DNA damage. After cell division (mitosis), cells have 23 pairs of chromosomes and are in the G_1 phase of the cell cycle. The chromosomes then replicate during DNA synthesis, or S phase, and as a result have twice the number of chromosomes (G_2 phase) just before mitosis (M phase). The cell stops cycling (arrests) in specific cell cycle phases called *cell cycle checkpoints*. An important downstream effector in preventing cells from entering S phase (G_1/S checkpoint) is p21.[5,11] p53 also induces NER by transcriptionally inducing XPC, XPE/p48, and GADD45.[20,21]

If cells enter S phase with unrepaired DNA damage, or if cells are UV exposed during S phase, regular DNA polymerases stall at DNA photoproducts and fall off the DNA strand. For these instances, cells are equipped with several specialized DNA polymerases for translesional DNA synthesis.[22] DNA polymerase eta is one of these; it is specialized to bypass DNA photoproducts but may introduce mutations while doing so.[23] It is mutated in XP variant, which is clinically indistinguishable from XP (see Table 109-3, Chap. 140).[24,25] This demonstrates the importance of this second line of defense against the mutagenic and carcinogenic consequences of DNA photoproducts. It was reported that p53 and

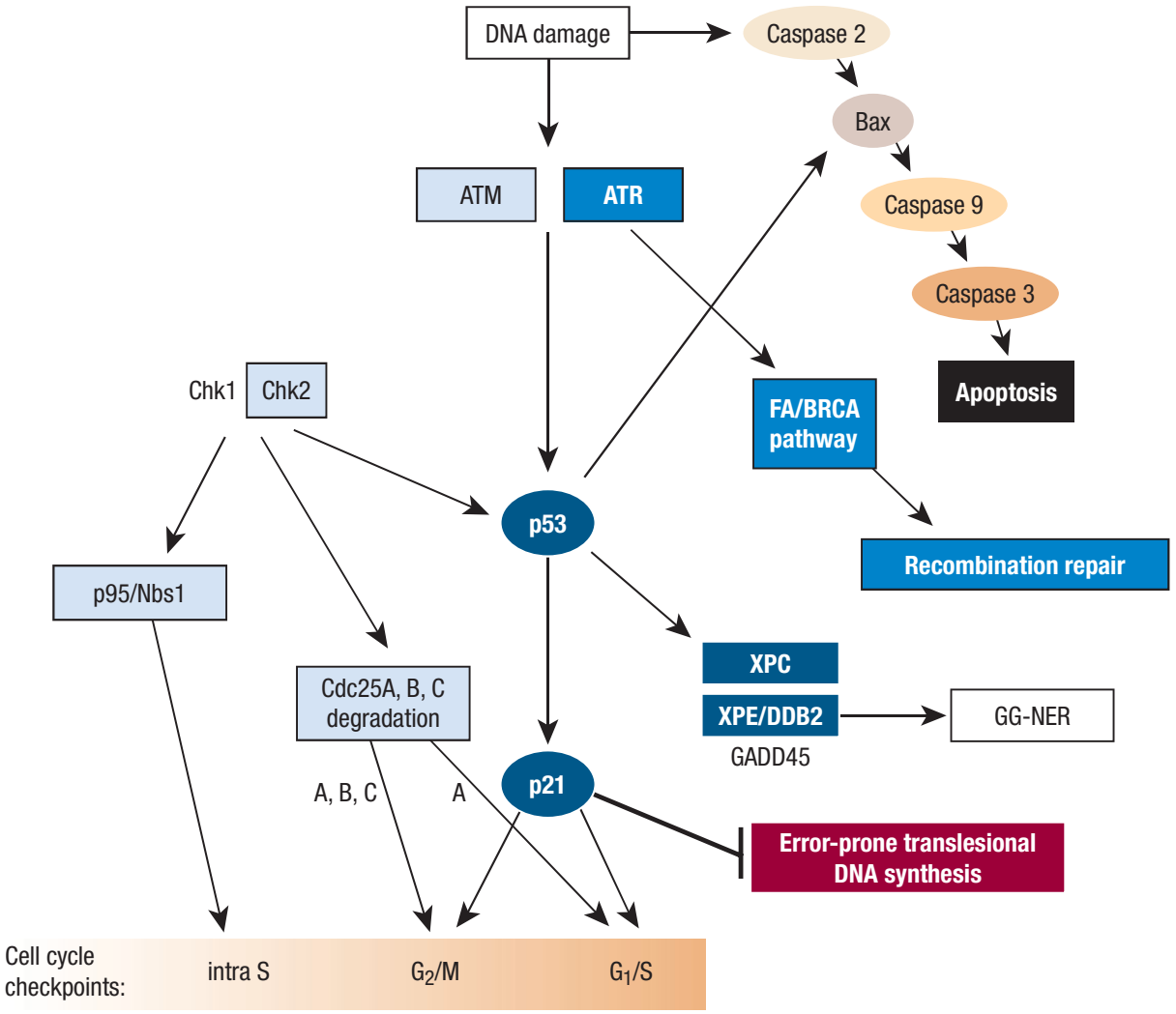

▲ FIGURE 109-4 Signaling cascades that regulate apoptosis, DNA repair, translesional DNA synthesis, and activation of cell cycle checkpoints in response to DNA damage. This is a highly simplified diagram that depicts only the most important players in the intricate and interwoven DNA damage–signaling networks. The traditional thinking was that ATM (ataxia telangiectasia mutated gene) is activated (phosphorylated) in response to ionizing radiation (IR) and ATR (ataxia telangiectasia- and Rad3-related gene) is activated in response to ultraviolet (UV) radiation, but newer data indicate that both are activated by IR and UV. ATM/ATR can activate (i.e., phosphorylate) p53 either directly or indirectly through activation (phosphorylation) of Chk2 (an ATM target) or Chk1 (an ATR target). Through transcriptional activation of p21 and subsequent inhibition of cyclin-dependent kinases, which usually drive cells from the G_1 into the S phase of the cell cycle, activated p53 activates the G_1/S checkpoint (i.e., arrests cells in G_1). The G_1/S checkpoint is also activated by Chk1/Chk2-induced phosphorylation and then degradation of Cdc25A and subsequent failure to activate cyclin-dependent kinases. Phosphorylation and subsequent degradation of Cdc25A, Cdc25B, and Cdc25C also mediate the G_2/M arrest, as does p21. Intra–S phase arrest is mediated through activation (phosphorylation) of p95/Nbs1. p53 also induces global genome nucleotide excision repair (GG-NER) through transcriptional activation of XPC, XPE/p48, and GADD45. Translesional DNA synthesis has been shown to be downregulated by p53 via p21. Recombination repair is mediated through the Fanconi anemia (FA)/BRCA pathway, which in turn is dependent on ATR activation. The mitochondrial pathway of apoptosis is activated through activation of Bax by caspase 2 and p53, the initiator caspase 9, and the effector caspases 3, 6, and 7 (for references, see text). Gene products that are defective in hereditary human diseases are boxed. DDB2 = DNA damage binding protein 2; XPC, XPE = xeroderma pigmentosum complementation groups C and E.

p21 also downregulate the activity of this translesional DNA synthesis to maintain a low mutagenic activity at the price of reduced damage bypass.[26]

If this translesional DNA synthesis fails, cells can use recombination repair to resolve stalled replication forks.[27] When invoked in response to damage from UV light, this third line of defense is mediated by activation of the Fanconi anemia/BRCA DNA damage response pathway.[28] The exact mechanisms that initiate these DNA damage response signaling cascades is under investigation. Telomeres, which are repeats of TTAGGG that cap the ends of chromosomes and whose ends form a loop structure, are suggested to be important players in sensing DNA damage, for example, through opening of the telomere loop.[29] Other sensors may be stalled DNA or RNA polymerases, or proteins that detect bending of the DNA helix at sites of DNA damage.

Apoptosis is a regulated physiologic process leading to cell death characterized by cell shrinkage, membrane blebbing, and DNA fragmentation. A group of cysteine proteases called *caspases* are central regulators of apoptosis. Triggers may be extrinsic or intrinsic to the cell (e.g., DNA damage) and involve separate initiator caspases (e.g., caspase 2 in response to



TABLE 109-4
DNA Damage–Signaling Genes Associated with Human Diseases

GENE	CHROMOSOME LOCATION	HEREDITARY DISORDER
ATM	11q22.3	Ataxia telangiectasia
ATR	3q22-24	Seckle syndrome
FANCA	16q24.3	Fanconi anemia
FANCB	Xp22.31	Fanconi anemia
FANCC	9q22.3	Fanconi anemia
FANCD1/BRCA2	13q12.3	Fanconi anemia, familial breast cancer
FANCD2	3p25.3	Fanconi anemia
FANCE	6p21-p22	Fanconi anemia
FANCF	11p15	Fanconi anemia
FANCG	9p13	Fanconi anemia
FANCI	Unknown	Fanconi anemia
FANCJ	17q22	Fanconi anemia
FANCL	2p16.1	Fanconi anemia
BRCA1	17q21	Familial breast cancer
p53	17p13.1	Li-Fraumeni syndrome
Chk2	22q12.1	Li-Fraumeni syndrome
CDKN2A (p^{16INK4})	9p21	Familial malignant melanoma
CDK4	12q14	Familial malignant melanoma
Nbs1 (p95)	8q21	Nijmegen breakage syndrome
Rb	13q14.1-14.2	Bilateral retinoblastoma

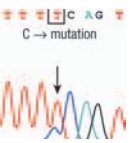

DNA damage) but share the same downstream effector caspases.[7]

APPROACHES TO DIAGNOSIS OF GENOME INSTABILITY AND/OR DNA REPAIR DEFECTS

When a disorder of genome instability is suspected, the clinician is challenged with choosing the appropriate laboratory tests to secure a diagnosis and to provide guidance for affected patients and families. Table 109-5 lists some hallmark clinical features that may indicate the presence of such disorders and should prompt clinicians to initiate testing. Various laboratory tests for genome stability, DNA repair, and response to physical and chemical agents are listed in Table 109-6.

Use of Cultured Cells

Cells obtained directly from patients and grown in culture medium are termed *primary cultures*. Dermal fibroblasts generally grow easily in culture and can generally be established from a 2- to 4-mm sterile skin punch biopsy specimen. The inner surface of the upper arm has proven to be a suitable biopsy site because this area heals easily, the resulting scar is not readily visible, the site is shielded from UV radiation, and attempts to establish cultures from specimens are generally successful. The tissue is placed in sterile culture medium (or sterile saline) with antibiotics and transported to a cell culture laboratory at room temperature.

Human cell cultures are made available for research by the National Institutes of Health–funded Human Genetic Mutant Cell Repository (401 Haddon Ave, Camden, NJ 08103; telephone: 856-966-7377; http://ccr.coriell.org/Sections/Collections/NIGMS/SsId=8).

Diagnostic Tests of Genome Instability and DNA Repair

Tests to assess genome instability and/or DNA repair capacity may be divided into tests of intact cellular function and tests of chromosome integrity and breakage in response to DNA-damaging agents. Other tests measure the mechanism of impairment of a cell function such as DNA repair or characterize or determine the expression of defective genes (see Table 109-6).

TESTS OF INTACT CELL FUNCTION Tests of cellular function measure the capacity of the intact cell to recover from DNA damage. These tests do not provide information regarding the specific type of damage resulting in cellular injury or the mechanism of cellular recovery, but they do form

TABLE 109-5
Hallmark Clinical Features That May Indicate a Disorder of Genome Instability or DNA Repair and Prompt Clinicians to Initiate Testing[a]

DISORDER	CLINICAL FEATURES
Xeroderma pigmentosum	Congenital photosensitivity, childhood freckling, early or multiple skin cancers
Cockayne syndrome	Congenital photosensitivity, postnatal growth failure, sensorineuronal deafness
Trichothiodystrophy	Brittle hair, photosensitivity, ichthyosis
Ataxia telangiectasia	Telangiectasias, ataxia, leukemias, and lymphomas
Bloom syndrome	Photosensitivity, malar erythema, growth retardation
Fanconi anemia	Aplastic anemia, growth retardation, café-au-lait spots, thumb abnormalities
Muir-Torre syndrome	Sebaceous tumors, keratoacanthomas, personal or family history of colon cancer

[a]Refer to Chap. 140 and Table 140-1 for more information.

TABLE 109-6
Diagnostic Tests of Genome Stability, DNA Repair, and Response to Physical or Chemical Agents[a]

- Intact cell function (proliferation or cell death)
  - Cell counts (growth in mass culture)
  - Thymidine incorporation
  - Colony-forming ability
- Chromosome integrity and breakage
  - Giemsa-stained metaphase karyotype analysis
  - G_2 chromosome breakage
  - Sister chromatid exchanges
  - Fluorescent in situ hybridization
  - Microsatellite instability testing
- DNA repair
  - Unscheduled DNA synthesis
  - RNA synthesis inhibition
  - Host cell reactivation
  - Comet assay
  - Immunological analysis of DNA damage and removal (enzyme-linked immunosorbent assay, slot blot)
  - Microsatellite instability testing
- Characterization and expression of defective genes
  - Real-time polymerase chain reaction
  - Western blotting
  - DNA sequencing

[a]Agents are listed in Table 109-1.

TABLE 109-7
Suggested Sequence of Diagnostic Testing for Diseases of Genome Instability or DNA Repair[a]

Disease	Step 1	Step 2	Step 3	Step 4	Testing Available[b]
Xeroderma pigmentosum	Post-UV hypersensitivity	Post-UV DNA repair	DNA sequencing	—	CLIA/R
Xeroderma pigmentosum variant	Post-UV hypersensitivity (with caffeine)	Post-UV DNA repair (normal)	DNA sequencing	—	R
Cockayne syndrome	Post-UV hypersensitivity	Post-UV inhibition of RNA synthesis	DNA sequencing	—	CLIA
Trichothiodystrophy[c]	Post-UV hypersensitivity	Post-UV DNA repair	DNA sequencing	—	CLIA/R
Ataxia telangiectasia	Chromosome breakage	X-ray hypersensitivity	Western blotting for level of protein	DNA sequencing	CLIA/R
Bloom syndrome	Chromosome breakage	Sister chromatid exchange	DNA sequencing	—	CLIA
Fanconi anemia	Chromosome breakage	Hypersensitivity to DNA cross-linking agents	Western blotting for FANCD2	DNA sequencing	CLIA/R
Muir-Torre syndrome	Microsatellite instability	Western blotting for level of protein	DNA sequencing	—	CLIA

CLIA = testing available by laboratories certified under the Clinical Laboratory Improvement Act; R = research testing available; UV = ultraviolet radiation.
[a]These are suggestions only and may change based on availability of different assays or new scientific information.
[b]Testing laboratories are listed on the National Institutes of Health–funded website http://genetests.org.
[c]Screen by polarizing microscopic examination of hair followed by measurement of sulfur-containing amino acids in the hair (see Chap. 140).

the basis for identifying cells as hypersensitive to DNA-damaging agents and are often used as simple screening tests.

Cell Counts or Thymidine Incorporation. One of simplest tests after exposure to UV radiation or x-rays is the assessment of the growth rate in mass culture by using a microscope or an automated cell counter to count the number of cells or by measuring incorporation of radioactive thymidine into newly synthesized DNA (see Tables 109-6 and 109-7).

Colony-Forming Ability. A test of colony-forming ability assesses the capacity of a single cell to proliferate enough to form a visible colony (Fig. 109-5).

TESTS OF CHROMOSOME INTEGRITY AND BREAKAGE ***Chromosome Breakage.*** Chromosome breakage is usually assessed in primary cultures of mitogen-stimulated peripheral blood leukocytes or in long-

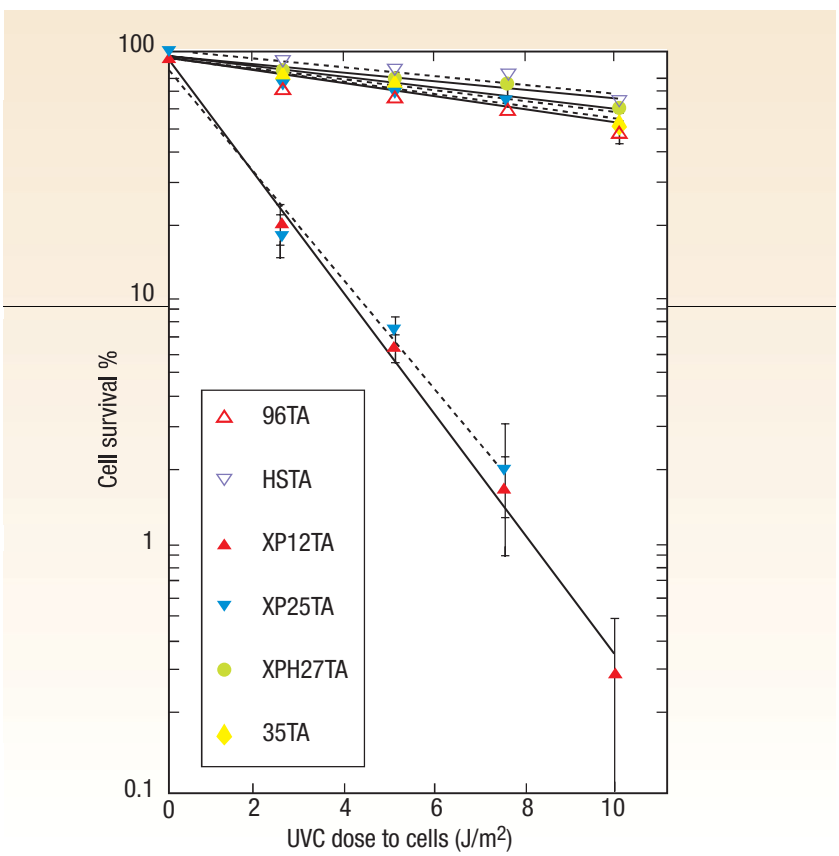

◀ **FIGURE 109-5** Colony-forming ability assay of cell sensitivity. Xeroderma pigmentosum (XP) fibroblasts from two affected siblings (XP12TA and XP25TA), their father (XPH27TA), and an unaffected brother (35TA) as well as normal fibroblasts (96TA and HSTA) were treated with 254-nm ultraviolet C (UVC) radiation and colony-forming ability was determined. The XPC (XP complementation group C) fibroblast strains from the affected siblings were much more sensitive than the normal strains and showed similar post-UVC hypersensitivity. Cells from the unaffected brother and the clinically normal father, a heterozygous carrier of the XPC defect, had normal post-UVC survival. (Modified from Slor H et al: Clinical, cellular, and molecular features of an Israeli xeroderma pigmentosum family with a frameshift mutation in the XPC Gene: Sun protection prolongs life. *J Invest Dermatol* **115**:974, 2000.)



term cultures of fibroblasts or lymphoblastoid cell lines. Cell cycle progression is stopped at metaphase by treatment of the cells with an inhibitor of mitosis such as colchicine. In this procedure, the 23 pairs of metaphase chromosomes from a single cell are spread over a discrete area of the slide and stained (usually with Giemsa stain). Preparations may be analyzed for the number of chromosomes per metaphase, the morphology of the individual chromosomes, and the attachments or rearrangements of chromosomes in relation to each other.

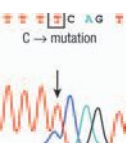

Sister Chromatid Exchange. During DNA replication, chromatids occasionally exchange positions along the arms of a chromosome. This sister chromatid exchange may be detected by permitting the cells to grow through two cycles of replication in medium containing the nucleic acid analog bromodeoxyuridine (Fig.109-6). Sister chromatid exchanges are thought to be related to DNA recombination repair, although their precise significance is not understood.

TESTS OF DNA REPAIR ***Unscheduled DNA Synthesis.*** One of the most commonly used tests of NER is unscheduled DNA synthesis. This test has been used to measure DNA repair in intact human skin, in cultured epidermal or dermal cells, and in blood cells, and for prenatal diagnosis using amniotic fluid cells. Unscheduled DNA synthesis testing measures the repair-associated DNA synthesis in G_1 or G_2 cells (which usually do not synthesize DNA). Cells are treated with UV radiation or another DNA-damaging agent and then incubated in medium containing radioactive thymidine. During the process of NER, the damage is removed and the radioactive thymidine is incorporated into the repaired region. The cells are treated with fixative, coated with autoradiographic (photographic) emulsion, and kept in the dark for an appropriate interval, and then the emulsion is developed. UV radiation of normal fibroblasts results in a large increase in the number of grains seen over all the nuclei. In marked contrast, irradiation of the XP fibroblasts that cannot repair DNA damage results in very few grains over the nuclei.

RNA Synthesis Inhibition. After exposure to UV radiation, normal cells temporarily reduce RNA synthesis from active genes. Synthesis resumes when the damage is repaired. This resumption of RNA synthesis is delayed in cells from patients with Cockayne syndrome and some forms of XP.

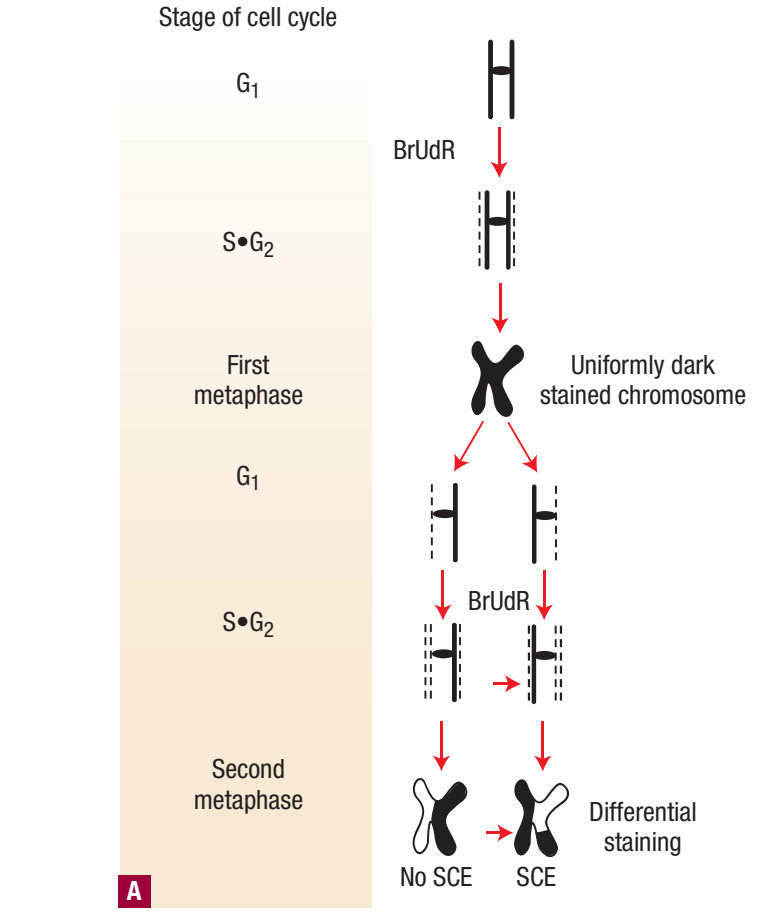





▲ **FIGURE 109-6** **A.** Sister chromatid exchange (SCE) assay of chromosome integrity. After the first cycle of replication, the DNA of the newly synthesized strand is labeled with bromodeoxyuridine (BrUdR), whereas the older strand is unlabeled. Such chromosomes appear uniformly dark with Giemsa stain. After a second cycle of replication in BrUdR-containing medium, one arm of a chromosome will contain two labeled chromatids, whereas the other will contain one labeled and one unlabeled chromatid. The doubly substituted arm will stain lightly, whereas the singly substituted arm will stain darkly. If an SCE occurred during replication, a portion of each chromosome arm will be doubly substituted and the remainder singly substituted with BrUdR. **B.** Undamaged normal cultured peripheral blood lymphocytes have approximately 10 SCEs per metaphase. **C.** Cultured peripheral blood lymphocytes from a patient with Bloom syndrome have a manifold increase in SCEs. (From Chaganti RS, Schonberg S, German J: A manyfold increase in sister chromatid exchanges in Bloom's syndrome lymphocytes. *Proc Natl Acad Sci U S A* **71**:4508, 1974, with permission.)

Host Cell Reactivation. The host cell reactivation assay relies on the fact that plasmids do not have the ability to repair

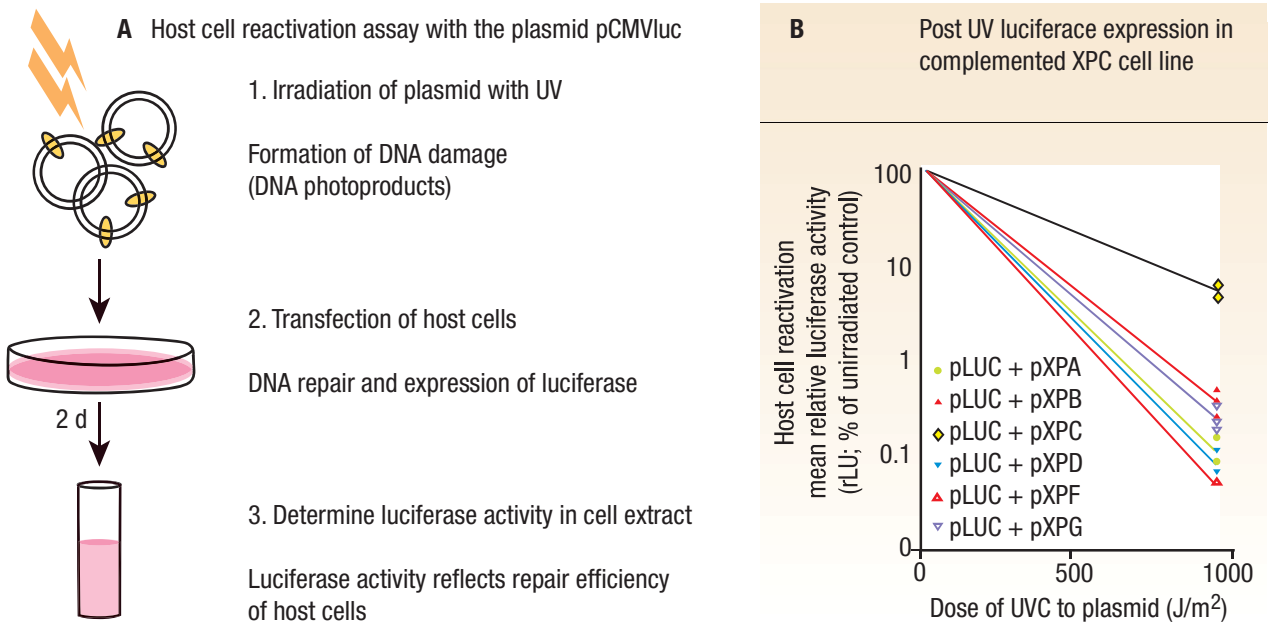



▲ FIGURE 109-7 Plasmid host cell reactivation assay with assignment to xeroderma pigmentosum (XP) complementation group. **A.** The plasmid is damaged by ultraviolet (UV) radiation and introduced into cultured human cells by a transfection technique. The cells' DNA repair enzymes repair the damage in a manner similar to the repair of cellular DNA. Repaired DNA will then function to transcribe the plasmid-encoded luciferase gene in the human cell. The amount of luciferase activity within the host cells therefore reflects the efficiency of the cellular DNA repair system. This assay can also be used to determine the complementation group by co-transfecting UV-treated plasmid plus plasmids expressing wild-type XP complementary DNA (cDNA). **B.** The results of plasmid host cell reactivation experiments and complementation group assignment with DNA excision repair–deficient XP46DC cells. UV-treated plasmid showed low expression in the XP65BE cells that was increased only by co-transfection with a plasmid expressing the wild-type XPC cDNA. This result indicates that XP65BE cells are in XP complementation group C (XPC). rLU = relative light units; pCMVluc and pLUC = plasmids containing gene for luciferase; pXPA–pXPG = plasmids expressing xeroderma pigmentosum complementation groups A–G.

damage to their DNA but depend on cellular repair systems. Thus, damaged plasmids would be expected to be expressed at a higher level in cells with normal repair capacity. A non-replicating plasmid that contains the gene for the firefly enzyme luciferase, constructed to permit expression in human cells,[30] is widely used; generation of light provides a quantitative endpoint for its repair (Fig. 109-7).

Comet Assay. The comet assay is a single cell–based technique that allows detection and quantitation of DNA damage. Damaged nuclei are embedded in agarose, lysed, and exposed to an electric field. The DNA migrates out of the nucleus forming a "comet" when stained. The length of the comet is proportional to the fragmentation of the DNA. This assay can be modified for detection of single-strand or double-strand DNA breaks, UV damage, or oxidative DNA damage. Cells from patients with XP have defective repair in the post-UV comet assay.

Microsatellite Instability. Normal DNA has tens of thousands of regions with repeats of the dinucleotide CA or other short motifs up to five nucleotides long. In normal individuals each of these microsatellites (also called *simple sequence repeats* or *short tandem repeats*) has a uniform size. However, these sizes are highly variable among different individuals and are often used for DNA "fingerprinting." The appearance of abnormally longer or shorter simple sequence repeats in different tissues or tumors from a patient is called *microsatellite instability*. This can be associated with a defect in mismatch repair genes.

CHARACTERIZATION AND EXPRESSION OF DEFECTIVE GENES ***Real-Time Polymerase Chain Reaction.*** In some genome instability genes, mutations create premature stop codons for protein synthesis. These mutations result in low levels of messenger RNA (mRNA) for the gene product through a process called *nonsense-mediated message decay*. The mRNA levels can be accurately measured by use of quantitative reverse transcriptase real-time polymerase chain reaction. For example, low XPC mRNA levels have been found in cells from most XP patients with defects in this gene.[31]

Western Blotting. Some mutations result in reduced levels or size of encoded proteins, often through creation of premature stop codons.[31] Reduced protein levels are most commonly detected by Western blotting. Cells are lysed and the proteins are extracted and separated by gel electrophoresis. The separated proteins are transferred to a membrane and probed with an antibody that is specific for the protein of interest. The intensity of the antibody staining reflects the amount of protein in the cells, and its location on the membrane is an indication of the size of the protein molecules.

DNA Sequencing. Direct sequencing of defective genes is the gold standard for determination of the presence of a mutation. The final step in confirmation of a diagnosis may be DNA sequencing to determine the disease-causing mutation. By definition, disease-causing mutations alter the function of genes. Of note, however, not every alteration in the sequence of a gene alters the function of the encoded protein. In the human genome there are millions of single nucleotide polymorphisms, or changes in one nucleotide, that are not associated with disease and may not even change the amino acid composition of

the encoded protein. In recessive disorders, each clinically unaffected parent has one normal allele and one potentially disease-causing mutation in the other allele. The affected child receives an allele with a disease-causing mutation from each parent. The two mutations must be in the same gene, although they need not necessarily be identical to each other.

Considerations in Diagnostic Testing

Diagnosis of disorders of genome instability or DNA repair is often a multistep process. A suggested sequence of steps is listed in Table 109-7. As new tests are developed and new information is obtained about these disorders, testing procedures may change accordingly. In addition, decisions regarding the extent of testing performed may be made with consideration of how much the tests cost and whether additional information would alter treatment. For example, DNA sequencing is rarely required for establishment of a diagnosis of XP in a child with classical clinical features and cells that are hypersensitive to killing by UV and have defective DNA repair. But if a family has one child affected with XP and is considering having additional children, DNA sequencing might offer them the possibility of prenatal diagnosis through DNA sequencing of a trophoblast biopsy specimen.

Genetic counseling is an important component of patient management for these genetic diseases. This function may be performed by the treating physician or by a trained genetic counselor.

In the United States, only laboratories certified in accordance with the Clinical Laboratory Improvement Act (CLIA) are allowed to perform these specialized tests in the context of patient care. Tests performed in research laboratories generally have limited use in clinical practice. However, a research laboratory may identify a disease mutation in cells from a patient that could then be confirmed in a CLIA-certified laboratory and used in clinical practice. A listing of laboratory testing facilities for these diseases may be found at the website http://genetests.org, funded by the National Institutes of Health.

KEY REFERENCES

The full reference list for all chapters is available at www.digm7.com.

1. Friedberg EC et al: *DNA Repair and Mutagenesis*. Washington, DC, ASM Press, 2006
2. Wikondahl NM, Brash DE: Ultraviolet radiation induced signature mutations in photocarcinogenesis. *J Invest Dermatol Symp Proc* **4**:6, 1999
8. Bootsma D et al: Nucleotide excision repair syndromes: Xeroderma pigmentosum, Cockayne syndrome, and trichothiodystrophy, in *The Genetic Basis of Human Cancer*, 2nd ed, edited by Vogelstein B, Kinzler KW. New York, McGraw-Hill, 2002, p 211
21. Hanawalt PC: Subpathways of nucleotide excision repair and their regulation. *Oncogene* **21**:8949, 2002
22. Lehmann AR: Replication of damaged DNA by translesion synthesis in human cells. *FEBS Lett* **579**:873, 2005
31. Khan SG et al: Reduced XPC DNA repair gene mRNA levels in clinically normal parents of xeroderma pigmentosum patients. *Carcinogenesis* **27**:84, 2006

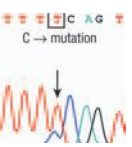

CHAPTER 110

Carcinogenesis: Chemical

Andrzej A. Dlugosz
Stuart H. Yuspa

CUTANEOUS CANCER AND PUBLIC HEALTH

Cutaneous cancers account for more than one-half of all malignancies diagnosed in the United States, totaling more than 1 million non-melanoma skin cancers (NMSCs) [800,000 to 900,000 basal cell carcinomas (BCCs) and 200,000 to 300,000 squamous cell carcinomas (SCCs)] and over 62,000 melanomas, according to estimates for 2006 by the American Cancer Society. The precise number of NMSCs is unknown, because unlike other malignancies, they are not routinely reported to registries. Although only a small fraction of patients with NMSC will die from their disease, which is nearly always SCC, the frequency of these cancers nonetheless results in an estimated death rate between 1000 and 2000 per year. In contrast, although much less common than NMSC, melanoma has a death rate estimated at nearly 8000 per year,[1] and a staggering 1 in 59 individuals born today is predicted to develop melanoma during his or her lifetime, based on 2001–2003 data compiled by the National Cancer Institute's Surveillance Epidemiology and End Results program (http://www.seer.cancer.gov). Because they are so common, cutaneous cancers have a major impact on health care costs: in addition to the mortality burden, treatment is associated with considerable morbidity and cosmetic defects. For these reasons, understanding the etiology and pathogenesis of these malignancies is a significant public health goal, and development of rational, non-deforming therapies to reduce morbidity and mortality is urgently needed. The high prevalence of skin cancer, the external location of the tumors, and well-defined pre-neoplastic lesions all provide an excellent opportunity for studying the factors regulating cutaneous cancer induction in humans. Those qualities that facilitate the study of cutaneous neoplasms in human populations have also been useful in establishing relevant animal models. Advances in molecular genetics, keratinocyte cell culture, and development of genetically altered mice and reconstructed human skin models have greatly facilitated the analysis of basic mechanisms of cutaneous carcinogenesis. The main focus of this chapter is on NMSC: the reader is referred to Chap. 124 for further discussion of melanoma.

CHEMICALS ASSOCIATED WITH SKIN CANCER INDUCTION IN HUMANS

The ultraviolet radiation (UVR) in sunlight is the primary etiologic agent for all skin cancers, and, thus, UVR is the major carcinogen in the human environment. The powerful carcinogenic activity of UVR is attributable to its ability to damage DNA and cause mutations, its capacity to clonally expand incipient neoplastic cells whose altered signaling pathways provide a survival advantage in the face of ultraviolet-induced cytotoxicity, its ability to induce reactive oxygen species, and its activity as an immune suppressant (see Chap. 112). The association of UVR with skin cancer is so strongly supported by clinical, epidemio-

CHEMICAL CARCINOGENESIS AT A GLANCE



- More than 200 chemicals have been linked to human cancer development.
- Chemicals implicated in human skin cancer development include polycyclic aromatic hydrocarbons and arsenic.
- Chemical carcinogenesis studies in mouse skin have defined operational stages of epithelial carcinogenesis, which include initiation, promotion, and malignant progression. Based on their activity in this assay, chemicals linked to human cancer can be classified as tumor initiators, promoters, or "complete" carcinogens.
- Tumor initiation is irreversible, because it is associated with gene mutations that permanently alter the biologic responsiveness of the initiated cell; tumor promotion is a non-mutagenic process that provides a selective growth advantage to initiated cells and is reversible at early stages; agents that facilitate malignant progression are generally genotoxic.
- Most carcinogens must undergo metabolic activation that involves several enzymes involved in xenobiotic metabolism, including cytochrome p450 enzymes and glutathione S-transferase.
- An individual's likelihood of developing chemically induced skin cancer is a function of exposure history, presence of additional risk factors, and genetic background, including gene polymorphisms that influence susceptibility to chemical carcinogens.

logic, and experimental data that it represents the most clear-cut etiologic factor in human malignancy. Also implicated in the development of human skin cancer are various chemicals as a result of environmental, occupational, or medicinal exposures (Table 110-1). In 1775, Sir Percivall Pott[2] attributed the increased incidence of scrotal cancer in chimney sweeps to repeated exposure to soot. This report provided the first link between occupational exposure and the development of cancer as well as the first example of chemical carcinogenesis. According to the National Toxicology Program's 11th Report on Carcinogens, published in 2005, (http://ntp.niehs.nih.gov/ntp/roc/toc11.html), 246 agents are listed as known or likely human carcinogens, and the great majority of these are chemicals. In the last 35 years, the mechanisms by which chemicals cause cancer have been unraveled and reveal striking similarities to the properties responsible for UVR carcinogenicity, namely DNA damage, selective cytotoxicity, and immune suppression. The carcinogenic potential of coal and petroleum derivatives is now firmly established as a result of experimental animal studies and epidemiologic reports. Petroleum products and grease, as well as insecticides, herbicides, and fungicides, are particularly pathogenic for SCC, while fiberglass and dry-cleaning agents increase the incidence of BCC.[3] Cigarette and pipe smokers have an overall twofold increased risk for cutaneous SCC, and the risk increases with the intensity of the tobacco use.[4]

Arsenic exposure is associated with the development of pre-malignant keratoses, Bowen disease, SCC, and BCC, as well as a number of internal malignancies.[5] Although Fowler's solution (1 percent potassium arsenite) is no longer used in medical practice, certain herbal medicines are still a source of arsenic exposure. Occupational exposures to arsenic as a component of agricultural pesticides, sheep and cattle dip, mining and smelting, glass manufacturing, and other industries are well documented. A more insidious source of environmental arsenic exposure is contaminated drinking water or shellfish, and analysis of affected populations shows a dose-dependent increase in skin cancer.[6] Mouse models have provided evidence for an interaction of ingested arsenic acting as a co-carcinogen with solar radiation to increase the frequency and size of cutaneous carcinomas and reduce the latency period.[7,8]

A variety of medications have been associated with the development of skin cancer. Systemic treatment with immunosuppressive agents results in an increased incidence of both benign and malignant skin lesions,[9] which is generally attributed to reduced immune surveillance of nascent tumor cells. However, a more specific mechanism predisposing to skin cancer has been proposed for azathioprine, which may sensitize DNA to ultraviolet A radiation via its metabolite, 6-thioguanine, leading to the production of mutagenic reactive oxygen species.[10] Topical nitrogen mustard also increases the risk of developing skin cancer. Despite the clear-cut association between occupational exposure to tars and skin cancer, the use of crude coal tar in the treatment of psoriasis appears to pose a relatively low risk for the development of skin tumors. In contrast, the use of ionizing radiation to treat a variety of skin diseases increases the risk of BCC in all treated patients and SCC in individuals with sun-sensitive skin.[11]

Systemic administration of psoralen and ultraviolet A light (PUVA) is associ-

TABLE 110-1
Environmental Agents Associated with the Development of Human Skin Cancer

AGENT	INDIVIDUAL AT RISK	ROUTE OF EXPOSURE	TUMOR TYPES
Ultraviolet radiation	General population	T	BCC, BD, SCC, M
Cigarette smoke	Smokers	T or S	SCC
Soot	Chimney sweep	T	SCC
Coal tar, pitch	Coker of coal, steelworker	T	SCC
Petroleum oils	Machinist, textile worker	T and S	SCC
Arsenic	Agriculture worker, etc.	S and/or T	BD, SCC, BCC
4,4′-Bipridyl	Pesticide manufacturer	T	SCC, BD
Polychlorinated biphenyl	Petrochemical worker	T or S	M
Dry-cleaning reagents	Dry cleaners	T or S	BCC
Fiberglass	Insulators	T	BCC
Psoralen (PUVA)	Psoriasis patient	T and S	SCC, BCC, M
Nitrogen mustard	Cutaneous T-cell lymphoma patient	T	SCC
Immunosuppressants	Transplant recipients, etc.	S	SCC, BCC
Ionizing radiation	Various skin disorders	T	BCC, SCC

BD = Bowen disease; BCC = basal cell carcinoma; M = melanoma; PUVA = psoralen and ultraviolet A; S = systemic; SCC = squamous cell carcinoma; T = topical.
Modified from Dlugosz A, Merlino G, Yuspa SH: Progress in cutaneous cancer research. *J Investig Dermatol Symp Proc* **7**:17, 2002, with permission of Nature Publishing Group, London, U.K.



ated with a dose-dependent increase in the risk of developing cutaneous SCC that persists after discontinuation of therapy.[12]

THE NATURE OF CHEMICAL CARCINOGENS: CHEMISTRY AND METABOLISM

How can such a diverse group of chemical and physical agents contribute to cutaneous cancer when the great majority of environmental agents to which humans are exposed are not carcinogenic? We now know that carcinogens can be genotoxic, non-genotoxic, or both.[16] Genotoxic carcinogens have high chemical reactivity (such as alkylating agents like nitrogen mustard) or can be metabolized to reactive intermediates by the host (such as petroleum products). They form covalent adducts with macromolecules and target DNA in the nucleus and mitochondria.[17] Because there is a good correlation between the ability to form covalent DNA adducts and the potency to induce tumors in laboratory animals, DNA is considered the ultimate target for most genotoxic carcinogens. The interaction with DNA is not random, and each class of agents reacts selectively with purine and pyrimidine targets.[17] Furthermore, targeting of carcinogens to particular sites in DNA is determined by nucleotide sequence, by host cell, and by selective DNA repair processes making some genetic material at risk over others. As expected from this chemistry, genotoxic carcinogens are potent mutagens, particularly adept at causing base mispairing or small deletions, leading to missense or nonsense mutations. Others may cause macrogenetic damage such as chromosome breaks and large deletions. In all cases, mutations detected in tumors represent a combination of the effect of the mutagenic change on the function of the protein product and the effect of the functional alteration on the behavior of the specific host cell type.

A number of chemicals that cause cancers in laboratory rodents and contribute to human skin cancer incidence are not demonstrably genotoxic.[18] Synthetic pesticides and herbicides, dry-cleaning reagents, and arsenic may fall within this group. The mechanism of action by non-genotoxic carcinogens is controversial and may be related in some cases to toxic cell death and regenerative hyperplasia. Induction of endogenous mutagenic mechanisms such as DNA oxyradical damage,[19] depurination of DNA, and deamination of 5-methylcytosine may contribute to carcinogenicity of these agents. Non-genotoxic carcinogens may interfere with host protective mechanisms as has been suggested for the action of arsenic in suppressing DNA repair or inhibiting the activity of tumor suppressor genes.[7] Thus, non-genotoxic carcinogens may serve as modifiers in concert with genotoxic agents such as UVR.

A number of metabolic pathways activate or detoxify carcinogens and procarcinogens (chemicals that can be transformed into active carcinogens).[20] These pathways are complex and interactive,[21] and genetic polymorphisms both in animal models and humans contribute to cancer susceptibility.[22] In general, metabolic activation of carcinogens involves oxidation at carbon–carbon double bonds or saturated carbon atoms, or oxidation or reduction at nitrogen moieties, yielding reactive intermediates that bind to DNA. Conjugations are also frequent intermediates of metabolism of many carcinogens and can be both activating and detoxifying pathways.[21] Metabolic activation of carcinogens and the polymorphic nature of metabolic activity among individuals provide an approach to estimate individual risk profiles for particular exposures. Furthermore, a number of metabolic pathways are inducible and modified by diet, hormones, and additional exposures, adding further complexity to the process of carcinogenesis.

HEREDITARY CANCER SYNDROMES

If DNA is the target for carcinogens, and mutagenesis is the underlying mechanism of cancer pathogenesis, how do we determine the genetic targets that contribute to the phenotype of cutaneous neoplasms? Considerable insight into the genetic basis of sporadic skin cancers has come from the elucidation of specific genes or genetic loci that define hereditary skin tumor syndromes (Table 110-2).[23] In particular, the importance of DNA as a target for carcinogenesis was strongly supported by the discovery of defects in DNA repair genes that comprise the complementation groups of skin-cancer-prone xeroderma pigmentosum (XP) families.[24,25] (see Chaps. 109 and 140). At least six independent genes on distinct chromosomal loci define proteins involved in nucleotide excision repair, a process critical for the protection of DNA against both UVR and chemical carcinogen-induced damage.[26] Among these are proteins that recognize and bind to sites of DNA damage (XPA, XPC, XPE), helicases (XPB, XPD), and endonuclease components (XPG, XPF), defects in any of which give a skin-cancer-prone phenotype. Potential polymorphisms with functional consequences in these and other DNA repair genes may contribute to susceptibility states in the general population as well.[27–29] Examination of SCCs and BCCs from XP patients has also revealed potential target genes for cancer induction because signature mutations in patched homolog 1 (*PTCH1*), *RAS*, *p53*, and *INK4a-ARF* (alternative reading frame) have been found with high frequency.[30] Chromosomal mapping studies in the basal cell nevus syndrome (see Chap. 116), coupled with genetic and functional studies in *Drosophila* and mice, implicated mutations in the *PTCH1* gene and other defects in the Hedgehog (Hh) signaling pathway in the development of hereditary and sporadic BCCs,[31] and a variety of internal malignancies.[32] All of these tumors are characterized by heightened levels of Hh signaling activity. The *INK4a-ARF* locus, specifically mutations in the *INK4A* gene, was identified in the etiology of melanoma[33] through mapping of the inheritance pattern of familial melanoma. Detection of specific mutations in Cowden syndrome [phosphatase and tensin homolog (*PTEN*)],[34,35] Muir-Torre syndrome [mutS homolog 2 (*MSH2*), mutL homolog 1 (*MLH1*)],[35,36] multiple cylindroma [cylindromatosis (*CYLD1*)],[37] multiple trichoepithelioma [cylindromatosis (*CYLD1*)],[38] Birt-Hogg-Dubé syndrome [folliculin (*FLCN*)],[39] sporadic pilomatricomas [β-catenin (*CTNNB*)],[40] and sebaceous tumors [lymphoid enhancer-binding factor 1 (*LEF1*)][41] have illuminated genetic defects associated with the development of adnexal tumors. The delineation of the specific genes mutated in other syndromes where locus mapping is confirmed (see Table 110-2) should provide even more insight into the molecular pathogenesis of a broader spectrum of skin neoplasms.

ANIMAL MODELS VERIFY THE GENETIC BASIS FOR CUTANEOUS NEOPLASMS

Using human hereditary cancer syndromes as a guide, genetically based animal models have been developed that validate the contribution of individual genes to human cancer susceptibility by prospective experimental analysis.[42] These models have also contributed to the un-

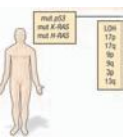

TABLE 110-2
Gene Targets for Mutations in Hereditary and Sporadic Cutaneous Cancers

GENE	FUNCTION	LOCUS	TUMOR TYPE	SYNDROME	SPONTANEOUS
P53	DNA repair, apoptosis, cell cycle regulation	17p13.1	BCC, SCC	Li-Fraumeni (but no increase in skin cancers)	Yes
XPA, XPB	DNA repair	9q22.3, 2q21	BCC, SCC, melanoma	Xeroderma pigmentosum	Possible
XPC, XPD	DNA repair	3p25, 19q13.2-q13.33	BCC, SCC, melanoma	Xeroderma pigmentosum	Possible
XPF, XPG	DNA repair	16p13.3-p13.13, 13q33	BCC, SCC, melanoma	Xeroderma pigmentosum	Possible
PTCH1	Hedgehog receptor	9q22.3	BCC, trichoepithelioma	Nevoid basal cell carcinoma	Yes
SMO	Hedgehog effector	7q31-q32	BCC	?	Yes
$p^{16INK4A}$	Cyclin-dependent kinase inhibitor	9p21	Melanoma, SCC	Familial melanoma	Yes
CTNNB (*β-catenin*)	Cell–cell adhesion, transcription factor	3p22-p21.3	Pilomatricoma	?	Yes
LEF1	Transcription factor	4q23-q25	Sebaceous tumors	?	Yes
CYLD1	Nuclear factor kappa B inhibitor	16q12-q13	Cylindroma	Multiple cylindroma, multiple trichoepithelioma	Yes
PTEN	Phosphatase	10q23.3	Trichilemmoma	Cowden	Unknown
MSH2	Mismatch repair	2p22-p21	Sebaceous gland carcinoma	Muir-Torre	Unknown
MLH1	Mismatch repair	3p21.3	Sebaceous gland carcinoma	Muir-Torre	Unknown
FLCN (*folliculin*)	?	17p11.2	Fibrofolliculoma	Birt-Hogg-Dubé	Unknown
?	?	9p21	Trichoepithelioma	Multiple trichoepithelioma	Unknown
?	?	Xq24-q27	BCC	Bazex	Unknown
?	?	9q31	Keratoacanthoma	Ferguson-Smith	Unknown

Modified from Dlugosz A, Merlino G, Yuspa SH: Progress in cutaneous cancer research. *J Investig Dermatol Symp Proc* **7**:17, 2002, with permission of Nature Publishing Group, London, U.K.

derstanding of gene–environment interactions by testing the influence of chemical and physical carcinogens on tumor development in the setting of an altered genetic makeup. The discovery of inactivating *PTCH1* mutations and activating smoothened homolog (*SMO*) mutations in BCCs led to the development of several mouse models exploring the role of deregulated Hh signaling in BCC tumorigenesis.[31] Keratinocyte-targeted overexpression of sonic hedgehog (SHH)[43,44] or an activated form of the Hh pathway signaling molecule SMO (M2SMO)[45,46] resulted in the development of basal cell–like proliferations or follicular hamartomas in mouse skin. Overexpression of SHH in human keratinocytes grafted onto severe combined immunodeficiency mice also resulted in BCC-like lesions.[47] Mice with heterozygous disruption of the *PTCH1* gene have features in common with basal cell nevus syndrome patients,[48,49] including microscopic hair follicle–derived tumors and various macroscopic skin tumors, including BCCs, after treatment with UVR or ionizing radiation.[50,51] When GLI1 or Gli2 transcription factors, which are nuclear effectors of Hh signaling, are targeted to mouse keratinocytes, multiple skin tumors develop. GLI1 mice display a variety of follicle-derived tumors with relatively few BCCs,[52] whereas Gli2 mice develop BCCs exclusively.[53] Interestingly, when Gli2 expression was extinguished in gene-switch mice, BCCs regressed but left behind a subset of residual tumor cells, at least some of which may be able to form growing tumors when the Hh pathway is re-activated.[54] Collectively, these findings provide strong evidence supporting the notion that constitutive Hh signaling plays a key role in, and may be sufficient for, BCC development.

The multistage induction of cutaneous SCC (Fig. 110-1)[55] and the absence of a hereditary syndrome that specifically imparts uniquely high susceptibility to this lesion have made the delineation of specific genetic loci involved in SCC induction more complex. Nevertheless, the analysis of genetic defects in human SCCs has focused attention on specific targets such as DNA repair genes, *RAS*, *p53*, *p16*(*INK4A*), and the epidermal growth factor receptor (EGFR) pathway. Significant progress has been made in defining pathways capable of driving NMSC development using reconstructed human skin, comprising genetically altered primary human keratinocytes on architecturally intact dermis, grafted onto immunedeficient mice.[56] Using this powerful system for modeling human skin cancer in mice, it has been shown that co-



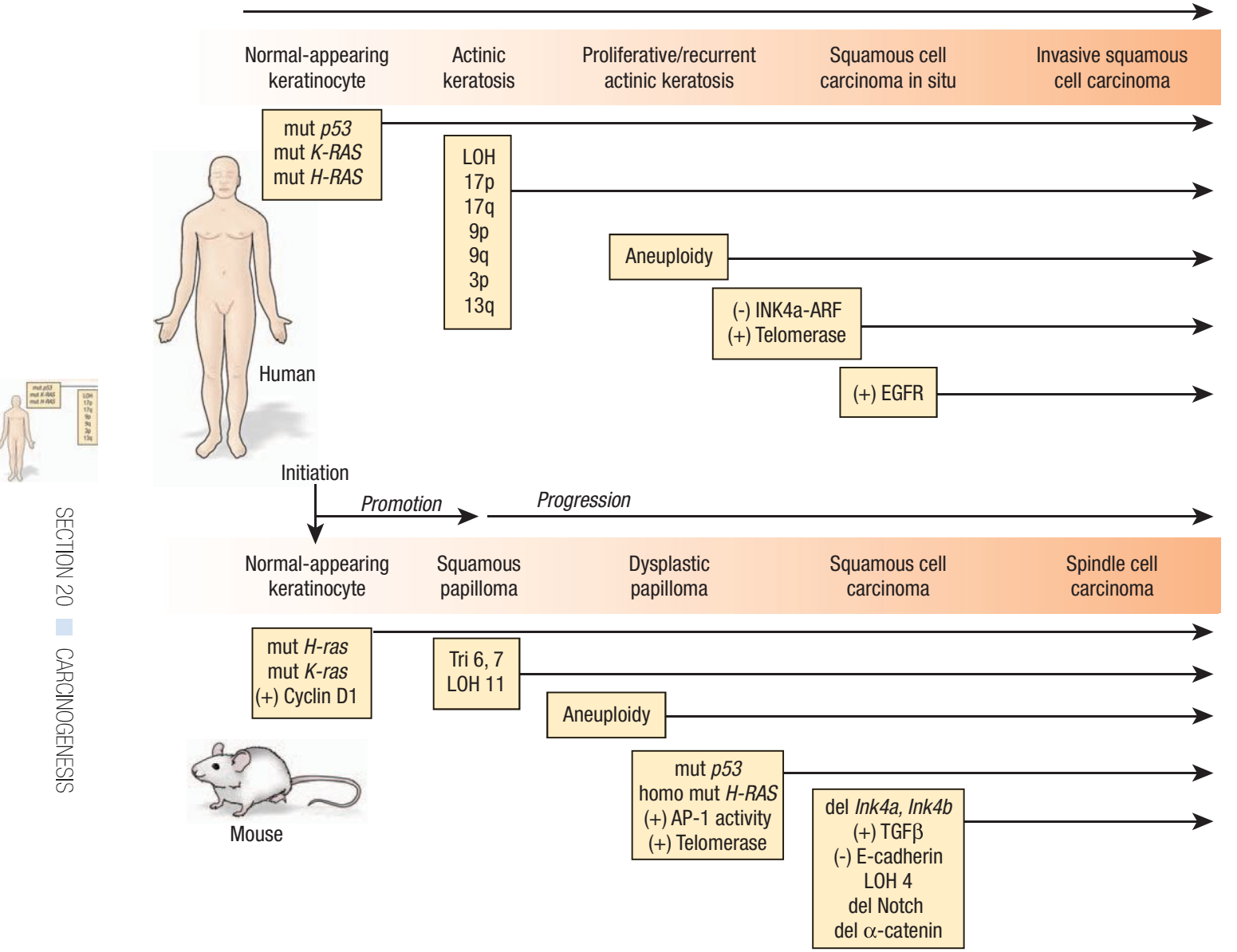

▲ **FIGURE 110-1** Genetic changes associated with development of cutaneous squamous cell carcinomas (SCCs) in humans and mice. The multistage evolution of invasive SCC in humans is depicted schematically with frequently associated genetic changes. Single base mutations in early lesions frequently are characteristic of ultraviolet light–induced damage, whereas later changes are associated with genomic instability. Increased activity of telomerase (deletion of inhibitor) or epidermal growth factor receptor (EGFR) tyrosine kinase (gene amplification) may also result from epigenetic changes. In chemically induced mouse cutaneous SCC, the multistage evolution to spindle cell tumors in this model is highly ordered both temporally and genetically. Operationally defined stages include initiation, promotion, and progression. *Ras* mutations are characteristic of chemical mutagens used to initiate tumor formation. Early upregulation of cyclin D1 and later upregulation of transforming growth factor-β1 (TGF-β1) occur through epigenetic mechanisms and appear to be important components of carcinogenesis. Note that though *p53* alterations are seen at early stages of human SCC development and ultraviolet radiation–induced mouse SCC development (not shown), *p53* mutations occur at later stages during mouse chemical carcinogenesis. AP-1 = activator protein 1; LOH = loss of heterozygosity; mut = mutant. (Modified from Dlugosz A, Merlino G, Yuspa SH: Progress in cutaneous cancer research. *J Investig Dermatol Symp Proc* **7**:17, 2002, with permission of Nature Publishing Group, London, U.K.)

expression of oncogenic Ras and either cyclin-dependent kinase 4 (Cdk4) or the nuclear factor κB inhibitor, I-κB, in human keratinocytes rapidly leads to invasive SCC development in reconstructed skin grafts.[57,58]

Mouse models for XPA, XPC, and XPE deficiency have been constructed, and all show sensitivity to UVR and enhanced development of SCC after either UVR or chemical carcinogen exposure.[25] A number of other DNA repair–deficient mutant mice are also being tested for cancer susceptibility and may reveal the mechanistic basis for new clinical syndromes by reverse genetics.[59] Mouse mutants targeting the *Ras* gene have revealed important information concerning the contribution of the Ras pathway to particular stages of SCC development. Heterozygous activating *Ras* gene mutations are sufficient to induce a benign squamous papilloma, the precursor to SCC, and the yield of chemically induced tumors in mice genetically deleted in the *H-ras* allele is markedly reduced.[60] Homozygosity of a mutant *ras*

gene is associated with progression to SCC,[61] suggesting that high penetrance of the Ras pathway can recruit additional changes required for progression. Transgenic targeting of oncogenic *Ras* to suprabasal epidermis produces terminally benign tumors while mosaic targeting to basal cells or hair follicle outer root sheath cells encourages progression to SCC,[62] indicating the target cell for early mutations may also determine the tumor phenotype.[63] Although heterozygous p53 inactivation is detected early in human SCC, p53 deletion in mice enhances malignant progression but does not increase benign tumor formation.[64] This may be analogous to the common loss of heterozygosity seen at the *p53* locus later in human SCC development.[65] Of particular interest for human tumor development is the frequent observation that double heterozygotes for p53 deletion and other cancer prone phenotypes (such as DNA repair deficiency) further sensitize mouse skin to tumor induction by UVR or chemical carcinogens. Mice with genetically defined defects in the $p^{16Ink4a}$ locus or its downstream target Cdk4 are sensitive to both squamous tumor and melanoma induction after treatment with carcinogenic chemicals, consistent with defects in this pathway detected in both melanoma and non-melanoma human skin cancers.[66,67]

TABLE 110-3
Examples of Agents Capable of Inducing Skin Cancer in Rodents

Initiating Agents	Promoting Agents
Polycyclic aromatic hydrocarbons	Phorbol esters
• Benzo(a)pyrene[a]	• 12-*O*-Tetradecanoylphorbol 13-acetate
• 7,12-Dimethylbenz(a)anthracene	• Croton oil[a]
• 3-Methylcholanthrene	Aromatics
• Tobacco tar[a]	• Phenol[a]
• Dibenz(a,h)anthracene[a]	• Anthralin[a]
Aromatic amines	• 7-Bromomethylbenz[a]anthracene
• 2-Acetylaminofluorene	Other
Alkylating agents	• Dihydroteliocidin (fungal product)[a]
• β-Propriolactone[a]	• Wounding[a]
• 4-Nitroquinoline-*N*-oxide	• Abrasion[a]
• Bis(chloromethyl)ether[a]	• Cigarette smoke condensate[a]
• Nitrogen mustard[a]	• Benzoyl peroxide[a]
• Cisplatin[a]	• 2,3,7,8-Tetrachlorodibenzo-*p*-dioxin[a]
Nitrosamines and nitrosamides	• Diacylglycerols
• *N,N′*-Dimethylnitrosourea[a]	• Ultraviolet radiation[a]
• *N*-Methyl-*N′*-nitro-*N*-nitrosoguanidine[a]	• Dodecane
Other	• Retinoic acid[a]
• Urethane[a]	
• Dinitropyrene[a]	
• Ionizing radiation[a]	
• Ultraviolet radiation[a]	

[a]Known human exposure.
Documented activity of these agents in rodent carcinogenesis models does not necessarily indicate that they also contribute to skin cancer development in humans.

TUMOR BIOLOGY AND BIOCHEMISTRY

General Principles

Malignant tumors exhibit fundamental alterations in behavior that distinguish them from the normal tissues in which they arise. These differences include a reduced requirement for growth stimuli, impaired response to growth inhibitory/differentiation signals, alterations in apoptosis, delayed or blocked senescence, prolonged angiogenesis, and the capacity for invasion and metastasis.[68] Although one or more of these abnormalities can be detected at different stages of tumor progression and may thus be seen in pre-malignant lesions, all are present in advanced cancers. The driving force behind many of these changes is genomic instability, which facilitates the accumulation of mutations in both oncogenes and tumor suppressor genes that contribute to the observed aberrations in cell function.[69] Although some of these changes are cell-autonomous and can be studied in purified populations of tumor cells, others depend on various additional cell types recruited to participate in the development and progression of cancer in intact organisms. Both the intrinsic alterations in neoplastic keratinocytes and the influence of collaborating cell types in skin tumor biology are being elucidated through the use of powerful experimental models.

From analyses of both human SCC pathogenesis and experimental skin tumor induction by chemical carcinogens, specific pre-malignant and malignant stages have been identified that have typical phenotypic, genetic, and biochemical characteristics (see Fig. 110-1).[70,71] Note that in contrast to SCCs and most other cancers, BCCs do not appear to have precursor lesions or give rise to more aggressive cancers. This is likely related to the observation that the genomic instability that fuels neoplastic progression in other tumor types is largely missing in BCCs, even though a substantial proportion of these tumors harbor p53 mutations that would be expected to facilitate the accumulation of additional genetic defects. SCC starts as a single or small number of specific mutations in a cell that has the capacity to cycle, a change understood as the "initiation" of carcinogenesis. On clonal expansion, initiated cells form a pre-malignant lesion, such as a squamous papilloma in the mouse and an actinic keratosis in the human. Agents that enhance clonal expansion of initiated cells are called *tumor promoters*. Tumor promotion may occur as a consequence of exogenous exposures such as UVR, topical chemicals, medications, infections, or wound healing. Promotion may be an endogenous process influenced by diet, smoking, or immune suppression. The acquisition of additional mutations that provide a growth advantage to the incipient cancer cell may also serve as an autonomous promoting stimulus. Pre-malignant lesions undergo further phenotypic changes, often in a predictable sequence and commonly multifocal within a single lesion.[72] Some foci or lesions progress at a faster rate than others, and these are at highest risk for malignant conversion.[73] Pre-malignant progression encompasses the majority of the tumor latency period before malignant conversion, when the lesion shows invasive properties.

Initiation is usually a low-frequency genetic event and is directly dependent on carcinogen dose. A large variety of carcinogen classes can initiate skin tumors in rodents (Table 110-3). The phenotype of initiated epidermal cells as defined from in vitro analysis includes a defect in maturation, escape from senescence, and an enhanced growth poten-



tial, but initiated cells are still responsive to negative regulation, for example by transforming growth factor-β (TGF-β). At the molecular level, initiation involves an alteration in signal transduction pathways that regulate cellular responses to extracellular signals, and these are internally regulated by proto-oncogenes and tumor suppressor genes.[68,74] Tumor promotion is generally a non-genotoxic stimulus that results in a disturbance of tissue homeostasis.[72] Multiple classes of agents have promoting properties in experimental skin carcinogenesis (see Table 110-3). The mechanisms of tumor promotion include activation of cell surface receptors, activation or inhibition of cytosolic enzymes and nuclear transcription factors, stimulation of proliferation, inhibition of apoptotic cell death, and direct cytotoxicity. Genotoxic carcinogens also can have promoting properties, and repeated exposures to low concentrations of genotoxic carcinogens can induce tumors more effectively than fewer exposures to the same total dose in experimental carcinogenesis.[75] Exogenous tumor promoters can determine the target site for tumor formation, and the promoting action of UVR may in part contribute to skin targeting for tumors when germline mutations produce an initiated state in multiple cell types. In general, initiated cells respond differently to promoters than normal cells, allowing for clonal selection of an initiated population.[76] Pre-malignant progression in an initiated cell clone occurs spontaneously but is accelerated by additional exposures to genotoxic agents, including some cancer chemotherapeutic drugs.[77] Pre-malignant progression in chemically induced mouse skin carcinogenesis is associated with nonrandom, sequential chromosomal aberrations, including amplifications, duplications, deletions, and loss of heterozygosity,[78] suggesting repeated episodes of cell selection, producing specific chromosomal aberrations that become modally dominant within the progressing focus. Thus, at least one function of the relevant genetic events in pre-malignant progression must result in a growth advantage for the affected cell. Epigenetic changes are also associated with malignant conversion, and upregulation of activator protein 1 (AP-1) transcriptional activity, alterations in cell cycle regulatory genes and secreted proteases, changes in gene splicing, and expression of modified cell surface molecules have all been reported. Together, these changes could facilitate migration and invasion that characterize the malignant phenotypes.

TABLE 110-4
Animal Models of Cutaneous Cancer Induction by Exogenous Agents

AGENT	SPECIES	COMMENTS
Basal Cell Carcinoma		
3-Methylcholanthrene	Rat	Other skin tumors
DMBA	Rat	SCC > BCC; lower DMBA doses may increase BCC incidence
Ionizing radiation	Rat	Other skin tumors
Dehydroretronecine	Mouse	BCC > SCC, also internal tumors
Squamous Cell Tumors		
(PAH, NA, AA) + promoter	Mouse, rat	Predominantly papilloma
(PAH, NA, AA) repeated	Mouse, rat	Predominantly SCC
Ultraviolet B	Mouse	*p53* mutations, immune suppression, SCC
Ultraviolet A	Mouse	Papillomas and SCC

AA = aromatic amines; BCC = basal cell carcinoma; DMBA = 7,12-dimethylbenz[a]anthracene; NA = nitrosamines; PAH = polycyclic aromatic hydrocarbons; SCC = squamous cell carcinoma.

Alterations in methylation of DNA in tumor cells could also contribute to this stage of carcinogenesis.[79]

Pathogenesis of Basal Cell Carcinomas

Animal models for induction of skin tumors by chemical and physical agents have been extremely valuable for exploring mechanisms of carcinogenesis in an experimental setting (Table 110-4). Rats exposed to chemical carcinogens (methylcholanthrene, dimethyl benzanthracene) or ionizing radiation preferentially develop BCCs[80] that are phenotypically similar to human BCCs. In contrast, mice are resistant to BCC induction in the absence of genetic modification, although one study described mouse BCC development following either subcutaneous or topical exposure to dehydroretronecine,[81] an observation that has not been explored mechanistically.

As noted in General Principles, BCCs represent an intriguing exception to the rule of multistage cancer development. Individual tumors typically consist of homogeneous, slowly growing cells that very rarely metastasize, although they can cause extensive local damage (see Chap. 115). Even those rare BCCs exhibiting cellular atypia generally have a benign course,[82] suggesting that the full complement of factors driving malignant progression in SCCs and other neoplasms is not operating in these tumors. BCC cells exhibit abnormalities in growth control and terminal differentiation, induce clinically apparent angiogenesis, and invade their immediate surroundings. However, transplantation studies using human BCCs or transgenic mouse skin with BCC-like lesions[43] suggest that the tumor cells are critically dependent on adjacent stroma for survival. This property may help explain both the lack of BCC metastases and the difficulty in establishing BCC cell lines. Interestingly, in a recent study in which global gene expression profiling was performed on stromal cells derived from tumors versus normal tissue, the bone morphogenetic protein (BMP) antagonist, GREMLIN 1, was found to be highly expressed in BCC stroma but not normal skin.[83] BCCs express BMP 2 and 4, and GREMLIN 1 stimulates growth of cultured BCC cells in vitro, suggesting that GREMLIN 1 may be a key stromal factor needed to support BCC proliferation in vivo, by antagonizing growth-inhibitory effects of BMPs.

Studies performed using human and rodent BCCs have identified additional candidate molecules that may be important in the biology of these tumors. Upregulation of various matrix metalloproteases (MMPs), both in tumor cells and stroma, is likely to be important in the local invasion of BCC and may impact on growth control and other cellular functions given the emerging role of MMPs in regulating signaling at multiple levels.[84] Expression of several adhesion molecules is downregulated in BCCs, and this may account for the characteristic appearance of artifactual clefts between tumor cells and stroma in histologic sections, but the functional significance of this finding in BCC biology has not been established. The anti-apoptotic molecule BCL2 is consistently upregulated in BCCs probably because *BCL2* is an Hh target gene, but this does not appear sufficient to block apoptosis in these tumors as it does in other set-

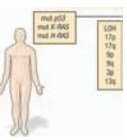

tings. Indeed, the remarkably slow growth rate of BCCs has been attributed in part to baseline apoptotic cell loss. Expression studies in human BCCs and experimental models suggest the involvement of growth factor signaling pathways such as platelet-derived growth factor[85,86] and EGFR.[87] Several lines of evidence point to components of the cell cycle machinery as potentially critical targets in mitogenic responses to Hh signaling. Keratinocytes overexpressing Shh have enhanced proliferative potential and fail to undergo growth arrest in response to the cell cycle inhibitor p21[88]; in the absence of Shh, Ptch1 interacts with and may sequester cyclin B1, which is required for mitosis and cell cycle progression[89]; and Shh can drive proliferation of immature cerebellar cells by causing prolonged induction of cyclins D1, D2, and E.[90] In skin, Hh-driven proliferation of hair follicle epithelium is likely to be mediated by cyclin D2 and N-Myc.[91] As additional Hh target molecules are uncovered, their potential involvement in keratinocyte tumor biology can be tested using mouse models of BCC that are currently available.

Pathogenesis of Squamous Cell Carcinomas

In addition to deregulated growth control, there is a progressive loss in the capacity for terminal differentiation during SCC progression (see Fig. 110-1), culminating in a tumor with a spindle cell morphology that is indistinguishable from malignancies originating in mesenchymal tissues. Although the mechanisms responsible for defective differentiation at different stages of human skin cancer are not known, there is evidence that deregulation of the protein kinase C (PKC) family of enzymes plays a role in aberrant differentiation of mouse skin keratinocytes expressing the Ras oncogene.[72] PKCδ, which has been implicated in terminal differentiation of normal epidermal keratinocytes, is rendered inactive as a result of tyrosine-phosphorylation in ras-transformed keratinocytes. Restoring PKCδ to its native, non-tyrosine phosphorylated state reversed the block to terminal differentiation in ras-transformed keratinocytes. In addition, overexpression of PKCδ in the skin of transgenic mice inhibits the development of squamous papillomas and carcinomas.[102] In contrast, skin-targeted overexpression of PKCε resulted in less differentiated SCCs that rapidly metastasized to regional lymph nodes.[103] Additional work is needed to better understand the mechanism by which SCC tumor cells evade signals that trigger differentiation of normal keratinocytes.

Prostaglandin metabolism is activated by UVR and is constitutively induced in human SCCs, probably due to overexpression of the enzyme cyclooxygenase 2 (COX-2). Although the mechanism by which changes in prostaglandins influence skin cancer is not clear, they appear to operate at the tumor promotion stage. Telomerase activity is detected in a substantial proportion of human skin cancers, suggesting that these tumor cells are capable of evading cellular senescence, and telomerase-deficient mice are resistant to chemical carcinogenesis.[104] Additional contributors that are likely to be involved in SCC development and progression include mediators of angiogenesis, MMPs, and integrins, as well as other molecules involved in cellular adhesion and migration.

Spontaneous or carcinogen-induced tumor formation on genetically modified mice has revealed genes and pathways that appear to be important in skin cancer induction but would not have been apparent from hereditary cancer syndromes or analysis of human skin cancers. Suprabasal targeting of C-myc in transgenic mice permits suprabasal cells to cycle and produces the papilloma/actinic keratosis phenotype while basal cell targeting of C-myc is not oncogenic.[105,106] Deletion of the cyclin/CDK inhibitor $p21^{waf1}$, a downstream effector of p53, increases the number of benign tumors but not the rate of pre-malignant progression.[107,108] TGF-β suppresses pre-malignant progression but is required for progression from SCC to a spindle cell phenotype.[109–112] Two AP-1 transcription factors influence distinct stages of skin tumor development, where c-Jun is essential for papilloma and c-Fos is essential for SCC development.[113,114] Inhibition of AP-1 activity in benign papillomas prevents progression to carcinomas, but instead converts these lesions into benign sebaceous adenomas,[115] supporting the concept that squamous tumors are derived from progenitor cells with multilineage potential. Additional molecules now implicated in SCC development are ornithine decarboxylase, $p16^{Ink4a}$, $p15^{Ink4b}$, E-cadherin, STAT3, C-myc, Notch, α-catenin, nuclear factor kappa B, and Smad3.[116–124]

Constitutional Modifiers of Carcinogenesis

Inbred mouse strains differ in susceptibility to particular carcinogenic exposures by several orders of magnitude, and transplantation studies indicate sensitivity resides in the target tissue rather than systemically. Genomic scans of backcrossed mice among sensitive and resistant mouse strains indicate that constitutional determinants are multigenic and distinct for benign tumor formation or progression.[125,126] Similar studies indicate genetic loci determine the survival potential for tumor bearing animals.[127] Although the classical genetic approaches are frequently difficult and complex because multiple interacting loci are likely to be involved,[128] use of these methods to identify genes involved in susceptibility and resistance in animal models is likely to reveal determinants important for human skin cancer risk. For example, the identification of a susceptibility gene for mouse skin cancer, Aurora2 (*Stk6*), led to the discovery of a variant of the homologous human gene (*STK15*) that is likely to contribute to cancer development in the colon[129] and other organs.[130] These reports underscore the power of this experimental approach and the concept that studies in skin may be highly relevant to understanding tumorigenesis at other sites, because common mechanisms underlie cancer development in different organs.

Analysis of genetically modified mouse models has also revealed pathways associated with skin tumor susceptibility. Alterations in p53,[64] drug metabolizing enzymes,[131] T-cell function,[132] and DNA repair[59] modify risk for experimental skin cancer induction. Remarkably, polymorphisms in drug metabolizing enzymes and DNA repair pathways,[133,134] and variable responses in the p53 tumor suppressor pathway or in T-cell immunity after exposure to skin carcinogens[135,136] modify the human risk for skin cancer.

Exogenous Modifiers of Carcinogenesis

In experimental models, antioxidants and agents that alter microsomal metabolism of carcinogens can reduce or prevent tumor initiation by inhibiting the formation of ultimate carcinogens or accelerating their detoxification (Table 110-5). Similar mechanisms may influence ultraviolet light or ionizing radiation mutagenesis through inhibition of mutagenic oxyradicals produced endogenously following exposure. Scavengers prevent reactive mutagens from reaching critical targets. Cell cycle in-



TABLE 110-5
Modifiers of Carcinogenesis

Inhibitor Class	Examples
Inhibitors of initiation	
Antioxidants, scavengers	Butylated hydroxyanisole; butylated hydroxytoluene; selenium; vitamin C; vitamin E; ellagic acid
Inducers of mixed function of oxidase	Polycyclic aromatic hydrocarbons; TCDD; PCB
Inhibitors of mixed function oxidase	α-Napthoflavone; glucocorticoids
Cytotoxic agent	Sulfur mustard
Suppressor of tumor development	Retinoids
Inhibitors of promotion	
Antiproliferative	Anti-inflammatory steroids: dexamethasone, fluocinolone acetonide; inhibitors of arachidonic acid metabolism: indomethacin, celecoxib; inhibitors of polyamine metabolism: α-difluoromethylornithine
Antioxidant	Antioxidants: tert-butylhydroxyanisole, selenium; protease inhibitors: leupeptin, tosyl lysine chloromethylketone; superoxide dismutase; copper (II) 3,5-diisopropylsalicyclic acid
Natural products and dietary factors	Retinoic acid; vitamin D; green tea; silymarin; resveratrol; ursolic acid; caffeic acid phenethyl ester; curcumin; 1,25-dihydroxyvitamin D_3

PCB = polychlorinated biphenyl; TCDD, 2,3,7,8-tetrachlorodibenzo-*p*-dioxin.

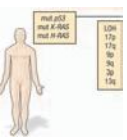

hibitors prevent fixation of mutations, allowing for DNA repair while cytotoxic agents kill initiated cells before their expansion into a tumor mass.

A number of agents are effective in the post-initiation phase of experimental tumor development, and some are being clinically evaluated.[137] Inhibitors of COX-2 (celecoxib, indomethacin) and ornithine decarboxylase (difluoromethylornithine) prevent both UVR and chemically induced tumors.[138,139] Although the mechanism of action of retinoids as modifiers of tumor development is not clear, retinoids are effective inhibitors of benign tumor formation in mouse skin carcinogenesis studies and show promise as inhibitors of actinic keratoses and cutaneous tumors in human studies. Predictable and parallel alterations in retinoid receptors in mouse and human cutaneous SCC indicate that the retinoid pathway must be central to cancer development in epidermis.[140,141] Considerable interest has developed in dietary factors that modify skin carcinogenesis. Restricted fat/energy diets reduce papilloma incidence in mouse models[142] and decrease the frequency of actinic keratoses in human populations.[143] Diverse dietary or natural factors, such as green tea, caffeic acid phenethyl ester from honey bee hives, resveratrol from grapes, silymarin from milk thistle, ginger extract, crocetin, and ursolic acid from the rosemary plant, are among natural products shown to be effective inhibitors of skin tumor formation by topical application or systemic exposure.[144] Several of these agents are believed to be antioxidants, but the precise mechanism of inhibition and their effectiveness as chemopreventive agents for human skin cancer remain to be established. Finally, immune response modifiers, such as imiquimod, may be effective for treating some types of skin cancer by modulating cytokine expression.[145]

NOVEL MOLECULAR TARGETS BASED ON NEW MECHANISTIC DATA

The substantial progress in our understanding of factors involved in skin tumor pathogenesis holds the promise of new approaches to treatment and prevention. In addition to the identification of new therapeutic targets, improved strategies are being developed for altering gene and protein function in skin with great selectivity. The abundance and unrivaled accessibility of skin cancers and pre-cancers makes them prime targets for rigorous translational studies and clinical trials. Based on the basic research studies outlined in this chapter, potential therapeutic targets include p53; COX-2; telomerase; EGFR or other receptor tyrosine kinases, and intracellular signaling elements such as SOS; Ras; ornithine decarboxylase; the DNA repair machinery; MMPs; PKC; molecules involved in cell cycle progression, such as cyclins D1 and D2, CDK4, $p^{16INK4a}$, and E2F1; retinoid receptors; and c-Fos. In all cases, the potential efficacy of the proposed treatments would need to be carefully evaluated in animal models or human tissues grown in immune-deficient mice. Because the great majority of cutaneous SCCs are effectively treated using surgery or radiation therapy, perhaps the greatest utility of these studies for dermatology patients would be in the identification of agents capable of preventing the appearance of pre-malignant lesions or blocking neoplastic progression to SCC in predisposed individuals. Along these lines, a double-blind study reported a significant reduction in the development of actinic keratoses and BCCs in XP patients treated topically with the DNA repair enzyme T4 endonuclease V, administered over a 1-year period.[146]

In contrast to the multiple genetic and biochemical changes associated with SCC development, the majority of BCCs have mutations in *PTCH1* or *SMO*, and essentially all of these tumors exhibit uncontrolled activation of the Hh pathway. Because several experimental models suggest that deregulated Hh signaling plays a central role in BCC development and maintenance, this pathway is a prime target for mechanism-based drug development. Cyclopamine and related molecules block Hh signaling by inhibiting SMO function,[147] and have been shown to inhibit growth of BCC-like tumors[148,149] and other "Hh-activated" tumors in pre-clinical studies.[150,151] However, Hh is a crucial embryonic signaling pathway[152] whose inhibition causes profound developmental defects, so attempts to treat or prevent human BCCs by modulating this pathway will need to be approached with care. Given the recent advances in our understanding of NMSC, it seems likely that new, rationally designed medical approaches for intervention will soon be available for these common neoplasms.

KEY REFERENCES

The full reference list for all chapters is available at www.digm7.com.

5. Tapio S and Grosche B: Arsenic in the aetiology of cancer. *Mutat Res* **612**:215, 2006
16. Luch A: Nature and nurture—lessons from chemical carcinogenesis. *Nat Rev Cancer* **5**:113, 2005
20. Nebert DW, Dalton TP: The role of cytochrome P450 enzymes in endoge-

nous signalling pathways and environmental carcinogenesis. *Nat Rev Cancer* **6**:947, 2006
23. Somoano B, Niendorf KB, Tsao H: Hereditary cancer syndromes of the skin. *Clin Dermatol* **23**:85, 2005
25. Cleaver JE: Cancer in xeroderma pigmentosum and related disorders of DNA repair. *Nat Rev Cancer* **5**:564, 2005
31. Daya-Grosjean L, Couve-Privat S: Sonic hedgehog signaling in basal cell carcinomas. *Cancer Lett* **225**:181, 2005
42. Dlugosz A, Merlino G, Yuspa SH: Progress in cutaneous cancer research. *J Investig Dermatol Symp Proc* **7**:17, 2002
71. Kemp CJ: Multistep skin cancer in mice as a model to study the evolution of cancer cells. *Semin Cancer Biol* **15**:460, 2005
128. Balmain A: Cancer as a complex genetic trait. Tumor susceptibility in humans and mouse models. *Cell* **108**:145, 2002
137. Wright TI, Spencer JM, Flowers FP: Chemoprevention of nonmelanoma skin cancer. *J Am Acad Dermatol* **54**:933, 2006
151. Rubin LL, de Sauvage FJ: Targeting the Hedgehog pathway in cancer. *Nat Rev Drug Discov* **5**:1026, 2006

CHAPTER 111

Oncogenes, Tumor Suppressor Genes, and Viral Carcinogenesis

Nicole Basset-Séguin
Celeste Lebbé
Charlotte Proby
Alan Storey

This chapter discusses major viruses implicated in skin cancer (Table 111-1), the evidence of their role, what is known about their mechanism of action, and how they can be controlled by preventive and/or therapeutic approaches.

INTRODUCTION TO ONCOGENES AND TUMOR SUPPRESSOR GENES

Studies looking at the mechanisms by which viruses induce tumors discovered oncogenes critical for cell transformation. Oncogenes derive from normal cellular genes referred to as *pro-oncogenes* that encode for various proteins involved in positive control of cell proliferation, such as growth factors, growth factor receptors, signal transduction proteins, and transcription factors.[1] These genes were first identified by studying retroviruses in animal models.[2] Retroviruses belong to the class of RNA viruses and convert their genetic information into DNA after infection of the host cell. Later, the human counterparts of retroviral oncogenes were recognized. Other retroviruses lack their own viral oncogene but integrate their viral DNA near a proto-oncogene, leading to its deregulated expression. It has been recognized for some time that retroviruses acquired their viral oncogenes by their capacity to integrate into and then be excised from the DNA of the host cell, allowing the virus to pick up and modify cellular genes through amplification, mutation, and deletion, thus converting them into transforming genes when reintroduced back into a host cell. The oncogenes of retroviruses derive from genes that are highly conserved in evolution. Deregulation of one or more proto-oncogenes, rendering them constitutively active, occurs in a wide variety of human and animal tumors, regardless of etiology.

In contrast to retroviruses, DNA viruses contain oncogenes that are not derived from cellular proteins. Examples include the epidermal growth factor homolog of pox viruses or the middle T antigen of polyomavirus that can activate proteins encoded by cellular proto-oncogenes. Large DNA tumor viruses have genes with cellular homologues, but small DNA tumor viruses have instead small multifunctional proteins with no cellular homolog.

Other genes identified initially from genetically susceptible cancer-prone patients or family cancer syndromes, such as retinoblastoma (Rb)[3] or Li-Fraumeni syndrome (p53), have been characterized and are called *tumor suppressor genes*. The physiologic role of these genes is to negatively control cell growth. Studying the relationship of

TABLE 111-1
Virus-Associated Cancer in Humans

Virus Group	Virus	Cancer
Hepadnavirus	Hepatitis B	Hepatocellular carcinoma
Hepadnavirus	Hepatitis C	Hepatocellular carcinoma
Herpesvirus	Herpesvirus type 4 (Epstein-Barr virus)	Burkitt lymphoma, nasopharyngeal carcinoma
Herpesvirus	Herpesvirus type 8	Kaposi sarcoma lymphoma
Papillomavirus	Oncogenic types, especially 5, 8, 16, 18, 31, 33, 35, 58	Cervical, vulval, vaginal, penile, and anal carcinoma; cutaneous squamous skin carcinoma in epidermodysplasia verruciformis, and perhaps other non-melanoma skin carcinomas
Retroviruses	Human T-cell lymphotropic virus type 1, human immunodeficiency virus	T-cell lymphoma and leukemia
Simian virus	SV40	Ependymoma, plexus choroid tumors, mesothelioma, bone tumors

VIRUSES AND CANCER AT A GLANCE

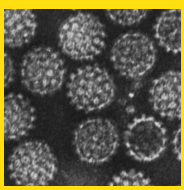

- At least 10 percent to 15 percent of human cancers are induced by viruses. Viruses may directly induce malignancy via introduction of a viral oncogene or inactivation of a host tumor suppressor gene.
- Iatrogenic immunosuppression, solar irradiation, or other factors may cooperate with viral infection to cause malignancy.
- Viral vaccines may reduce the incidence of specific cancers.

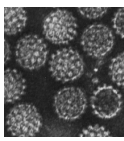

specific tumor suppressor genes with certain viral proteins increased greatly the knowledge of how viruses can be implicated in cancer in general and more particularly in skin cancer. For example, the large T antigen of SV40 virus or the E1A and E1B proteins of adenoviruses and, of more importance in dermatology, the E6 protein of oncogenic human papillomaviruses (HPVs), bind to and functionally inactivate cellular tumor suppressor genes, turning off the physiologic negative control of cell growth, thus promoting cell transformation.

VIRUSES IN DERMATOLOGIC TUMORS

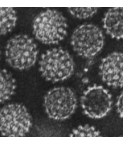

Human Papillomaviruses (See Chap. 196)

HUMAN PAPILLOMAVIRUS: STRUCTURE AND MECHANISMS OF ACTION IN TRANSFORMATION HPV can be categorized according to sequence variations in E1, L1, E6, and E7 viral genes.[4] To date, more than 120 HPV types have been characterized and classified into five subgroups—A, B, C, D, and E—with differing host specificity, tissue tropism, and oncogenic potential. A and B families include mucosal and cutaneous HPV types. A and B families include mucosal and cutaneous HPV types. These two families contain both high-risk HPV, such as mucosal HPV-16, -18, -31, -33, -35, and -58, as well as HPV-5 and -8 associated with epidermodysplasia verruciformis (EV), and low-risk HPV found in benign condyloma (HPV-6, -11) or common cutaneous viral warts (such as HPV-1 and -2).

In vitro studies have allowed the demonstration of the transforming role of E6 and E7 proteins of high-risk HPVs, particularly those of mucosal viruses. In anogenital lesions, HPV DNA is often found in an episomal state in benign lesions and is frequently integrated in invasive lesions. This integration may play a role in transformation, as it frequently disrupts the coding sequences of E1 and E2 genes. Because the E2 transcriptional regulator binds to cognate recognition sequences in HPV promoters to regulate expression of the E6 and E7 genes, its disruption can lead to dysregulated E6 and E7 expression.

The transforming property of the E7 protein of high-risk HPV was the first to be demonstrated. E7 binds a member of the Rb family, p105Rb, which dissociates p105Rb-E2F complexes by inducing proteosomal degradation of p105Rb and liberates transcription factors involved in the beginning of the cell cycle.[5] Interestingly, it has been shown that substitution of a single amino acid in the E7 protein, affecting its ability to bind and degrade Rb protein family members, could explain the difference in transforming capacity of E7 between high- and low-risk HPV.[6,7]

The E6 protein of high-risk HPV is also implicated in transformation. It was first demonstrated that cooperation between the E6 and E7 protein was more efficient in inducing cell transformation than either protein alone.[8]

The first target of the E6 protein that was identified was the p53 tumor suppressor gene protein, a key regulator of the cell cycle often referred to as the "guardian of the genome." It was demonstrated that the E6 protein of high-risk mucosal HPV is able to induce p53 degradation through its association with an E3 ubiquitin ligase of the HECT (homologous to E6-AP carboxyl terminus) domain family known as *E6-AP*.[9,10] The degradation of p53 abolishes the p53-dependent induction of cell cycle arrest or apoptosis. Thus, elimination of p53 allows HPV-infected cells to escape apoptosis, thus providing a background in which normal growth restraints are absent. Similar to the E7 protein, it has been shown that only the E6 protein of high-risk HPV but not that of low-risk HPV was able to degrade p53. Moreover, it has been shown that E6 can sequester the p53 protein in the cytoplasm, inactivating it without inducing its degradation.[11]

Additionally, HPV E6 proteins of cutaneous HPV types that, in marked contrast to anogenital viruses, do not promote p53 proteolysis are nevertheless able to inhibit p53-induced apoptosis. An additional anti-apoptotic activity of the E6 protein is its inhibition of the Bak protein, a key regulator of the mitochondrial apoptotic pathway (reviewed in ref. 12).

A cross-talk between the Rb and p53 pathways and the interaction of E6 and E7 proteins in both pathways add to the synergic role for E6 and E7 in cell transformation. Cooperation between E6 and E7 proteins and the ras family of oncogenes has also been shown. Other cellular targets are probably involved in the transforming capacity of E6 and E7 proteins.

Besides their role in the control of cell cycle key regulators, E6 proteins of high-risk HPV have been shown to play an important role in genomic stability and, more precisely, DNA repair. Skin cells expressing the high-risk HPV-5 E6 protein are defective in ultraviolet (UV) B–induced DNA damage repair.[13]

Transgenic animal models for HPV have also been generated. The first one was developed by Tinsley et al.[14] in 1992 by expressing the early gene region of HPV-1, inducing plantar warts under the K6 promoter. The transgenic murine skin showed epidermal hyperproliferation and abnormal keratinocyte differentiation. More recently, a transgenic mouse model was generated expressing the complete early region of EV-associated HPV-8 in basal keratinocytes under the control of the K14 promoter. Over 90 percent of the transgenic mice spontaneously developed benign skin tumors with significant conversion to squamous cell carcinomas (SCCs),[15] which is remarkable compared to many other HPV-transgenic mice previously developed.

HPV-associated skin diseases are frequent[4] and are discussed in more detail in Human Papillomavirus and Skin Cancers and Human Papillomavirus and Epidermodysplasia Verruciformis.[16]

HUMAN PAPILLOMAVIRUS AND CERVICAL CANCER The close relationship between infection with certain HPV types and the risk of developing cervical cancer was noted initially by zur Hausen in 1977[17] and later confirmed by many fundamental molecular and epidemiologic lines of evidence. It is now thought that 99.7 percent of invasive SCC of the cervix contain high-risk HPV types.[18] Cervical cancer is therefore the first tumor recognized to be almost exclusively virus-induced.[19]

Epidermoid cervical cancers are the major form of cervical cancer (80 percent to 95 percent) and represent a major public health problem, especially in developing countries.

The importance of oncogenic HPV in cervical cancer renders HPV typing an important clinical tool for the treatment and follow up of patients with HPV-associated cervical morphologic abnormalities.[20]

However, it is more the persistence of oncogenic HPV rather than its simple detection that is a major carcinogenic factor.[21,22] Viral load also seems to be important to consider, as the level of high-risk HPV-16 detected by quantitative polymerase chain reaction (PCR) is higher in severe dysplasia when compared to moderate or low dysplasia and even more when compared to normal tissue. However, the importance of the viral load remains controversial and awaits further clarification.

Numerous vaccine strategies have been developed and are currently under clinical application, particularly in countries and populations with high oncogenic HPV prevalence.[23] Prophylactic HPV subunit vaccines based on the ability of the viral L capsid protein to form virus-like particles inducing high levels of neutralizing antibodies have recently been approved by the U.S. Food and Drug Administration. The vaccines target both HPV-16 and HPV-18, between them accounting for approximately 70 percent of cervical cancers. The vaccines have an excellent safety profile, are highly immunogenic, and have conferred complete type-specific protection against persistent infection and associated lesions in fully vaccinated women. The key issues are the definition of the ideal target population and the cost of the vaccines, which need to be sufficiently low for widespread implementation in the developing world where 80 percent of cervical cancer occurs. Other considerations include the length of protection afforded by the current vaccines and whether observed cross-reactivity with other HPV types can be sufficiently protective to prove beneficial.

HUMAN PAPILLOMAVIRUS AND OTHER GENITAL CANCER In external anogenital cancers (e.g., vulvar or penile cancer), the role of oncogenic mucosal HPV is also well established, and the same mechanisms of action in transformation as identified in cervical cancer are implicated. However, unlike cervical cancer, HPV is not the only carcinogenic factor involved in external anogenital cancers: the inflammatory dermatosis, lichen sclerosus (see Chap. 63), is also implicated. In HPV-derived external anogenital cancer, little or no mutation of cell cycle regulator genes, such as p53 and the $p^{16ink4\text{-}ARF}$ locus, is observed, whereas in lichen sclerosus–derived tumors, mutations of both pathways are common and may relate to the aggressive nature of such tumors.[24]

HUMAN PAPILLOMAVIRUS AND SKIN CANCERS As with cervical cancers, HPV DNA is detected frequently in skin carcinomas of immunocompetent (30 percent to 35 percent) and immunocompromised (75 percent) individuals. However, many different HPV types have been found in these tumors, and no pattern of high-risk or low-risk HPV types has yet emerged for skin cancer. Furthermore, although HPV DNA is frequently detected in swab samples collected from the superficial layers of skin tumors, significantly less HPV DNA is found in incisional biopsies of the same tumors (reviewed in ref. 25), advising cautious interpretation. A possible explanation is that tape stripping would remove the outer epidermal layers that contain the productive viral infection and so might be expected to reduce the viral DNA present. Perhaps of more significance are in situ hybridization studies[26] and viral load studies, both of which find that detection of active viral infection in skin tumors is patchy and suggest that DNA detection studies may be overly sensitive and not necessarily a reliable reflection of active HPV infection. EV-associated HPV types (now termed *β-HPVs*) are also frequently reported in normal skin, in hair follicles, or even in benign dermatoses such as psoriasis. In both immunocompetent and immunosuppressed patients, the role of HPV in skin cancer remains controversial, but evidence for a viral role promoting the mutagenic effects of UV damage is increasing. The presence of β-HPVs may be considered a risk factor together with the pattern and amount of sun exposure, sun sensitivity (skin color), country of residence, and number of sunburning episodes. In immunosuppressed patients, the duration and type of immunosuppressive drugs used are important additional factors. Most recent studies confirm a prevalence of β-HPVs of 70 percent to 80 percent in organ transplant–associated SCC and approximately 30 percent of immunocompetent SCC (reviewed in ref. 27). In skin cancer, the typical high-risk mucosal HPV (HPV-16) is found only in in situ or invasive epidermoid periungual carcinoma (see Chap. 114). In that situation, the presence of high-risk HPV-16 is thought to be by contact with the genital area and is equivalent to a sexually transmitted disease state.

HPV-38 has been detected significantly more often in skin tumors (50 percent) than in normal skin (10 percent). Additionally, HPV-38 has been found in vitro to actively support immortalization of cultured human keratinocytes.[28] However, the importance of HPV-38 in skin tumor development awaits further elucidation.

Overall, the role of HPV in skin cancer is still unclear, although a role in combination with UV radiation seems likely in the early stages of tumor development.

HUMAN PAPILLOMAVIRUS AND EPIDERMODYSPLASIA VERRUCIFORMIS (See Chap. 196) EV is a rare autosomal recessive disease characterized by an early onset and lifelong occurrence of multiple flat warts, pityriasis-like macular lesions, and occurrence of skin cancer, mostly on sun-exposed skin. EV-type HPV integration is rare in skin cancer except in metastases. Additionally, the E6 protein of EV HPV does not degrade p53, and its E7 protein has little transforming potential in vitro,[29] although the E7 gene of HPV-5, another β-HPV type, was shown to induce the invasion of keratinocytes into the dermis in a skin-equivalent model. The invasion was accompanied by the destruction of basement membrane components, most likely through the induction of specific matrix metalloproteinases.[30] The E6 protein of β-HPV may interact with the pro-apoptotic Bak protein to promote cell transformation, but this needs to be further understood.[12,16]

The first breakthrough in functional studies was the demonstration that a number of different HPV E6 proteins can effectively block the epidermal apoptotic response to UVR,[31] suggesting a mechanism whereby a diverse group of HPV types might promote tumor development in cooperation with the mutagenic effects of UVR. Corresponding in vivo studies have shown that the balance between proliferation and apoptosis is altered by HPV status: HPV-positive tumors have significantly reduced apoptotic rates compared to HPV-negative lesions,[32] apparently related to degradation of Bak.[33] Bak is located in the outer mitochondrial membrane and assembles into multimeric complexes during apoptosis, acting as a "gateway" to allow transit of apoptotic effector molecules, such as cytochrome c, thereby controlling initiation of the apoptotic cascade.[12]

Additional type-specific viral activities that interfere with the cellular response to UVR can be postulated. For example, keratinocytes expressing high-risk HPV-5 E6 protein, but not the E6 protein of benign cutaneous HPV types -10 and -77, take longer to repair UV-induced thymine dimers and therefore enter the cell cycle harboring such DNA damage, specifically bypassing the G1/S checkpoint[13] (see Chap. 112). Of the HPV types tested, only the cancer-associated HPV-5 E6 and not the E6 proteins of non–cancer-associated EV HPVs, such as types -23, -24, and -49, displayed this phenotype. Similarly, E6 proteins of HPV-1 and HPV-8 have been shown to interact with the XRCC1 protein that is involved in the repair of DNA single strand breaks.[34] Perhaps E6 can help cells overcome cell cycle checkpoints, allowing the propagation of UV-induced DNA damage that, in

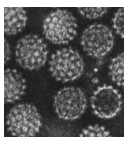

turn, increases the likelihood of accumulating errors in key genes and the acquisition of genetic instability, both driving skin tumorigenesis in the context of continuing UV exposure.[16]

Two susceptibility loci have been identified in EV patients, on chromosomes 17q and 2. In the EV1 locus, Ramoz et al. identified two new genes, EVER1 and EVER2, in which mutation seems to segregate with the disease.[35] In unaffected individuals in whom EV HPV type can be found in normal skin, no mutation in EVER1 or EVER2 is found, and therefore no EV lesion is seen, whereas in EV patients bearing EVER1 or EVER2 mutations, EV lesions develop. The long splice isoforms of EVER1 and EVER2 are identical in sequence and genomic localization to the transmembrane channel–like (TMC) proteins TMC6 and TMC8.[36] Additionally, it has been shown that EV patients have a deficiency in cellular immunity against EV HPV, which adds another carcinogenic immunologic factor to explain transformation in such patients.[37]

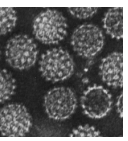

Herpesvirus in Skin Tumors

HUMAN HERPESVIRUS 8 AND KAPOSI SARCOMA AND LYMPHOMA Kaposi sarcoma herpesvirus 8 (KSHV) or human herpesvirus 8 (HHV-8) is, together with Epstein-Barr virus, a member of the herpesvirus family known for its ability to induce neoplasia in natural or experimental hosts. Strong epidemiologic studies favored the role of a sexually transmissible agent involved in KS pathogenesis (see Chap. 128). It was only in 1994 that Chang et al.,[38] using representational difference analysis, identified two fragments of an unknown herpesvirus in a biopsy from an acquired immunodeficiency syndrome–related KS, soon to be classified as the first human 2-herpesvirus or rhadinovirus.

HHV-8 has evolved into five variants (A through E) that probably emerged after population migrations over the last 40,000 years. Such variants may have functional implications, although no association between variants and pathologies have been identified so far.[39,40] HHV-8 has a long unique region of approximately 145 kilobases, with at least 87 genes and a variable number of terminal repeats. Apart from genes involved in structure, virion maturation, DNA replication, nucleotide metabolism, and gene regulation, HHV-8 encodes for human gene homologues probably acquired from human cellular complementary DNA. Due to structural modifications, some of these pirated genes have become constitutively active and are oncogenes. After infection, HHV-8 remains in a latent state in the host cell (circular episomes), with minimal gene expression (latent genes). Lytic infection can occur in vivo and can be reproduced in vitro using pharmacologic agents such as histone deacetylase inhibitors.[41]

HHV-8 cellular homolog genes can be classified according to their biologic function as cell cycle regulators; stimulators of mitosis; anti-apoptotic, pro-angiogenic, immune-response inhibitors; and stimulators of transdifferentiation.[42]

HUMAN HERPESVIRUS 6, HUMAN HERPESVIRUS 8, AND LANGERHANS CELL HISTIOCYTOSIS Langerhans cell histiocytosis (see Chap. 148) is a disease characterized by Langerhans cell infiltration of skin and bone, with sometimes severe and multifocal infiltration of many organs, in which case it is best considered a malignant disease. The role of HHV-6 has recently been proposed but remains unproved.[49,50] A recent study searching for an association of HHV-8 with Langerhans cell histiocytosis has failed to demonstrate a causal role of that virus.[51]

HUMAN HERPESVIRUS 1 AND SKIN CANCER One study of the presence of HHV-6 and HHV-1 in DNA samples from 120 nonmelanoma skin cancers and 41 normal skin tissues showed that the risk for individuals with HHV-1 to have basal cell carcinoma and SCC was increased eight and six times, respectively. However, the small number of samples studied as well as the very high prevalence of HHV-1 infection in the normal population precludes firm interpretation of this correlation.[52]

VIRUS-DERIVED FUTURE STRATEGIC THERAPIES

Besides in vaccines such as those developed for "high-risk" HPV infections, the use of viral vectors has now expanded from relatively safe, non-replicating viruses to the use of viruses that replicate preferentially in cancer cells versus normal cells and belong to the so-called *oncolytic viruses*. As these viruses replicate, they lyse their host cells. Cancer cells are ideal hosts for many viruses because they have inactivated the anti-viral interferon pathway or have mutated tumor suppressor genes, enabling viral replication. Adenovirus and herpesvirus simplex specifically mutated to replicate faster in cancer cells are the main replicating human pathogenic viruses used in the clinic. It is hoped that the use of selective replicating viruses that could avoid immune clearance and allow systemic administration will be available in the future for antitumoral treatment strategies. However, specific guidelines are urgently needed for clinical use of such oncolytic viruses.[53]

KEY REFERENCES

The full reference list for all chapters is available at www.digm7.com.

4. De Villiers EM et al: Classification of papillomavirus. *Virology* **324**:17, 2004
12. Storey A: Papillomaviruses: Death-defying acts in skin cancer. *Trends Mol Med* **8**:417, 2002
13. Giampieri S, Storey A: Repair of UV-induced thymine dimers is compromised in cells expressing the E6 protein from human papillomaviruses types 5 and 18. *Br J Cancer* **90**:2203, 2004
16. Akgûl B, Cooke JC, Storey A: HPV-associated skin disease. *J Pathol* **208**:165, 2006
23. Lowy DR, Schiller JT: Prophylactic human papillomavirus vaccines. *J Clin Invest* **116**:1167, 2006
38. Chang Y et al: Identification of herpesvirus-like DNA sequences in AIDS-associated Kaposi's sarcoma. *Science* **266**:1865, 1994
53. Chernajovsky Y: Fighting cancer with oncolytic viruses. *BMJ* **332**:170, 2006

CHAPTER 112

Carcinogenesis: Ultraviolet Radiation

Douglas E. Brash
Timothy Heffernan
Paul Nghiem

ULTRAVIOLET RADIATION AS A CARCINOGEN

Skin cancer offers our clearest picture of how a carcinogen causes human neoplasia. The basic principles of carcinogen exposure and slow development were discovered when Sir Percivall Pott traced scrotal cancers in adults to childhood employment as a chimney sweep[1] and they also apply to sunlight-induced cancers.[2,3] The process begins with carcinogen exposure, DNA damage, and failure to repair DNA or to apoptotically eliminate a damaged cell.[4–7] A mutant gene arises in a single cell which then expands into a mutant clone.[8] Rare cells of the clone repeat this carcinogenesis cycle to generate mutations in additional genes. Sunlight acts at each of these steps.

Epidemiologic Observations

The lifetime expectation of skin cancer in Australia is ~60 percent.[9] In the southern United States and Hawaii, non-melanoma skin cancers exceed all other cancers combined.[10–12] Basal and squamous cell carcinomas (BCCs and SCCs), and an SCC precursor, actinic keratosis (AK), are most frequent on sun-exposed skin, in outdoor workers, and at lower latitudes.[13–16] SCCs increase more quickly with dose or nearness to the equator than BCCs, and occur later in life, implying that SCC requires more sun-related steps.[16–20] In contrast, one-third of BCCs occur on body sites having only intermittent sun exposure, such as the trunk and legs.[16,21]

Melanoma also depends on sunlight. The relation to latitude is clear,[22–25] yet it is often stated that the predilection for the back and lower legs makes the relation to sunlight uncertain. This predilection reflects the large surface area of back and legs. When expressed as lesions per unit area, melanomas are 10- to 20-fold more frequent on the face and male ears than on intermittently exposed sites such as the lower legs in women, shoulders, back, or neck.[25,26] Melanomas are rare on the buttocks and soles. Melanoma appears to have two distinct origins:

1. A chronic sun damage (CSD) etiology affects the head and neck and is associated with chronic elastosis—a classic indicator of CSD—as well gene amplification of the cell cycle genes *CDK4* and *CCND1*.[27] The slow-growing lentigo maligna melanoma and its precursor, lentigo maligna occur on habitually exposed body sites of light-skinned individuals.[28]
2. A non-CSD route involves intermittent sun exposure of sites such as the trunk. Non-CSD melanomas carry mutations in the *BRAF* or *NRAS* oncogene—upstream regulators of cell cycle genes—and the patients have variant alleles of the melanocortin 1 receptor.[27,29,30] Intermittently exposed body sites are the location of the melanoma increase in recent decades, melanomas in patients younger than age 50 years, and the additional melanomas seen near the equator.[23,25,31] Recreational sunburn may explain these and the twofold higher melanoma incidence in office workers compared to outdoor workers.[32,33]

Sunlight is also implicated by the susceptible population: both classes of skin cancer are more frequent in light-skinned individuals with blonde or red hair who burn rather than tan.[13,34] Compared to black-skinned individuals, non-melanoma skin cancer risk rises ~10-fold in Asians and ~100-fold in Caucasians, with a further 2- to 12-fold risk for blonde or, especially, red hair.[13,34–37] The divergence is less for melanoma, about 1:1:15.[38] In black skin, BCC is rare even in patients with the hereditary nevoid BCC syndrome (NBCCS or Gorlin syndrome).[39] Skin tumors in black patients are often scar-related, but these may be associated with sunlight as well.[36] Melanin-related effects result from less melanin in light skin,[40] less shielding by pheomelanin than eumelanin, and greater production of photosensitized reactive oxygen from pheomelanin.[41–43]

Molecular epidemiology has provided the most direct evidence for ultraviolet radiation (UVR) as the active component of sunlight: UVB signature mutations are present in human BCC, SCC, and AK (see Ultraviolet Radiation Signature Mutations). Mutant cells are associated with elastotic dermis, indicating chronic sun exposure.[44] UVB's effectiveness is due to its ability to partially penetrate the ozone layer and stratum corneum and then be absorbed by DNA.[45] The ozone layer absorbs all but 1 part per million of UVC (used in germicidal bulbs), which otherwise would be lethal; UVA penetrates well but is poorly absorbed by DNA.[45,46] Nevertheless, chronic UVA can induce tumors in mice[47] and malignantly transforms predisposed human cells.[48] The cumulative dose of sunlight required to cause BCC or SCC in adults is fairly large, approximately 10,000 and 70,000 hours of exposure, respectively.[16] Psoriasis patients receiving < 100 UVB treatments [and who had low psoralen and UVA light (PUVA) exposure] had a risk of SCC or BCC on sun-shielded sites slightly above background, and risk was threefold higher with > 300 UVB treatments.[49]

ULTRAVIOLET RADIATION CARCINOGENESIS AT A GLANCE



- Ultraviolet radiation (UVR) from the sun is the most prevalent carcinogen in humans, particularly among Caucasians.
- Annual increases continue in the incidence of all types of skin cancer.
- The importance of exposure timing, dose rate, and total UVR exposure differ between the types of skin cancer.
- Sunlight leaves characteristic mutations that identify key molecular and cellular steps in skin tumor development.
- DNA repair, apoptosis, and cell signaling pathways are critical to preventing skin cancer, and UVR affects each of these processes.
- Genetic polymorphisms in genes for DNA repair, melanin, and free radical scavenging affect skin cancer risk.
- Novel, pathway-based approaches to prevent or treat skin cancer are being developed.
- Educational and behavioral approaches are key to minimizing skin cancer rates in the future.



Some melanomas appear to be independent of sunlight: tumors of the mucosa, palms, soles, and nail beds are equally frequent in whites and blacks, have remained constant while melanomas of the skin have become epidemic, and are not associated with precursor nevi.[50] Ocular melanomas are more frequent in whites than blacks, but do not depend on latitude and have not increased in the last few decades.[51]

The Skin Cancer Epidemic

The incidence of melanoma and non-melanoma skin cancers has doubled each decade since the 1930s.[10,23,25] AK, lentigo maligna, and lentigo maligna melanoma—typically lesions of the middle-aged and elderly—are now seen in young adults. But because cancer requires several events, it is not guaranteed that this increase in skin cancer is caused by an increase in one of the sun-related events. The best evidence for sun exposure is that increases have been greatest for intermittently sun-exposed sites, such as the trunk and limbs, with little change in melanomas of the head and neck.[23,25] Increased recreational exposure is usually blamed. Another suspect has been ozone depletion; because of a steep absorption curve in the UVB region, small changes in ozone concentration greatly affect UVB penetration. (UVC is fortunately still blocked). The Antarctic ozone hole caused a 50 percent ozone reduction over southern Chile and Argentina in the last two decades, with UVB increasing up to 40-fold. Yet skin cancers in these areas are increasing at the same rate as elsewhere.[52,53] The Arctic ozone hole has been offset by screening from air pollutants, yet skin cancers in Scandinavia are rising.[54]

An iatrogenic source of increased skin cancer incidence is PUVA therapy for psoriasis, which increases the risk of SCC eightfold; in some but not all patient cohorts it raises melanoma > 14-fold[55] (see Chap. 239). BCC is not affected. Cancer is now increasing as a result of tanning beds. Individuals whose first sunbed exposure occurred as a young adult, or who had long durations or high frequencies of tanning bed exposure, already have a 70 percent higher risk of melanoma.[56]

CHARACTERISTICS OF ULTRAVIOLET RADIATION–INDUCED CANCERS AND PRECANCERS

In the United States, ~1,000,000 BCCs are diagnosed annually, as well as 100,000 SCCs and 60,000 melanomas.[11,12] Survival differs strikingly. Fewer than 1 in 10,000 BCCs will metastasize and threaten the patient (see Chap. 115). This number increases to 1 in 40 for SCC, with clinical experience indicating that SCCs on sun-exposed skin are less likely to metastasize than those arising in scars.[57] One in seven invasive melanomas is lethal (see Chap. 124). Merkel cell carcinoma (see Chap. 120) is a sun-induced cutaneous neuroendocrine cancer that will kill one in three patients diagnosed with it. Its incidence has tripled in the past 15 years to approximately 1000 per year in the United States.[57a]

The type of exposure preferentially leading to each malignancy differs. Cumulative lifetime sun exposure is strongly associated with SCC incidence.[16,20] BCC and AK instead seem to depend on reaching a certain threshold of UV exposure, often attained in youth, such that sensitive individuals develop BCC at a relatively early age, and the incidence does not increase with further exposure.[16,20,58] Case-control studies link melanoma with intense exposure early in life, with one or two blistering sunburns doubling the melanoma risk (see Chap. 124 and ref. 59). This effect may be an underestimate if, as mentioned in Epidemiologic Observations, melanoma has two origins, one depending on CSD and one on intermittent exposure and sunburns.

Children are particularly sensitive to sunlight: moving from England to Australia before age 20 years confers the higher Australian incidence of AK, SCC, BCC, and melanoma, but the risk is much less when adults immigrate.[60,61] This is not simply due to children spending more time outdoors, as < 25 percent of lifetime exposure occurs before age 18 years.[62] One explanation may be that mutant cells created in youth have more years in which to acquire the additional genetic requirements for cancer.

Precursor lesions for SCC (AK) and melanoma (nevi) are also usually related to sun exposure.[14,15,63–65] Accounting for roughly 3 million physician visits each year in the United States, AKs (see Chap. 113) are the fourth leading cause for a visit to a dermatologist.[66] They typically manifest as 1- to 3-mm scaly papules that involve erythema but often are easier felt than seen. They proceed to SCC in ~1 percent of cases if left untreated.[67] Actinic cheilitis is an analogous precancerous state on the sun-exposed lip. The importance of ongoing sun exposure is made apparent by clinical studies indicating that reducing sun exposure can reduce the number of AKs over a span of months. In randomized sunscreen studies, statistically significant decreases in AKs were seen in the sunscreen group over brief periods.[68,69] Common nevi and especially clinically atypical nevi can be precursors of malignant melanoma, with abundant nevi conferring a 10-fold risk for cancer.[22,70] Acquired melanocytic nevi begin to appear at age 1 to 5 years in proportion to sunlight exposure and are most frequent in individuals with freckles and red hair.[63,64,71] Acquired nevi carry the *BRAF* mutations seen in non-CSD melanomas, but congential nevi instead have *NRAS* mutations.[72]

ULTRAVIOLET RADIATION–INDUCED GENETIC ALTERATIONS

Ultraviolet Radiation–Induced DNA Damage and Repair

DNA PHOTOPRODUCTS The first molecular step in sunlight-induced carcinogenesis occurs when UVB photons induce DNA photoproducts. UVB and UVC tend to be absorbed at the 5-6 double bond of pyrimidines (thymine and cytosine), allowing the bond to open.[73] If two adjacent pyrimidines are activated, their open bonds cross-react. Creating two single bonds (5-5 and 6-6) results in a cyclobutane pyrimidine dimer (Fig. 112-1). The most frequent is TT, but TC and CC cyclobutane dimers are also made. A single bond between the 6 position of one pyrimidine and the exocyclic group of the other instead creates a pyrimidine-pyrimidone (6-4) photoproduct.[74] Both photoproducts distort the DNA helix and are recognized by DNA repair enzymes.

UVA is 20-fold more frequent in sunlight but requires 1000-fold greater doses for its biologic effects.[45–47,75,76] UVA induces T-containing cyclobutane dimers and lesser numbers of oxidized purines and pyrimidines and single-strand breaks.[77] UVA generates these lesions indirectly by photosensitization (see Chap. 88). UVA also efficiently photoisomerizes UVB-induced (6-4) photoproducts to their poorly repaired and highly mutagenic Dewar isomers.[77]

Ultraviolet Radiation Signature Mutations

UVR leaves a characteristic signature when it interacts with DNA, and this

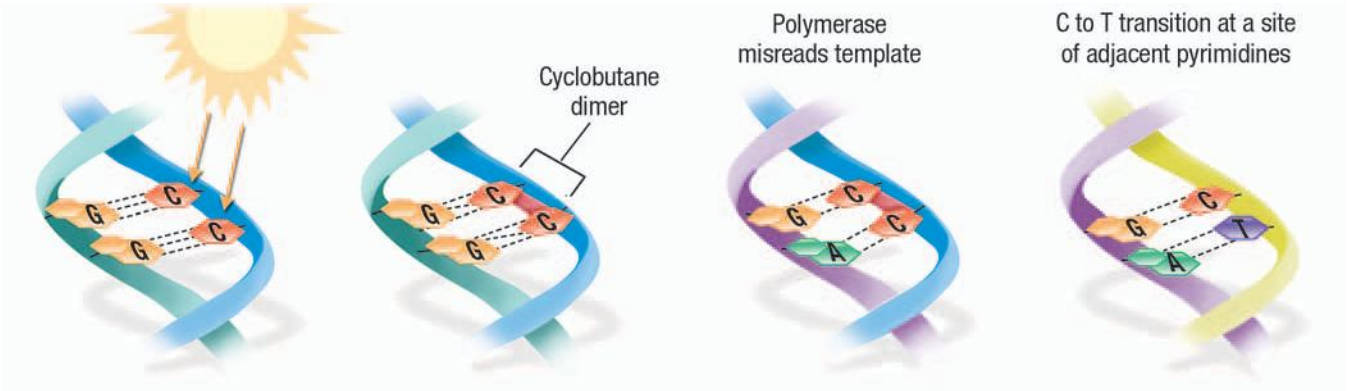

▲ **FIGURE 112-1** Ultraviolet radiation (UVR)–induced C to T "signature mutation." UVR causes adjacent pyrimidines on the same strand to form a cyclobutane dimer. If not repaired, the C in the dimer can be misread by the DNA polymerase or can degrade to uracil such that it erroneously pairs with adenine. The net change is that a cytosine in the sequence is converted to thymine. If both cytosines mutate, the result is CC to TT. (Modified from a Scientific American article by Brash & Leffell, 1996.)

signature remains in the tumor decades later. It has been used to answer many questions about the origin of cancer. A cyclobutane dimer or (6-4) photoproduct can lead to a mutation in two ways (see Fig. 112-1). When the lesion is copied during DNA replication, the DNA polymerase may read a damaged cytosine as a thymine and insert an adenine opposite it. At the next round of replication, the polymerase correctly inserts thymine across from adenine, with the result being a C→T substitution. Although the TT cyclobutane pyrimidine dimer is the best known and most frequent photoproduct, the thymines are not mutagenic because the *XPV* gene encodes a specialized polymerase (Pol eta) that adds adenines across from a T-containing cyclobutane dimer.[83] Alternatively, a mutation can arise because cyclobutane dimers accelerate deamination of their cytosines to uracil (or 5-methylcytosine to thymine), leading to a C→T substitution; no polymerase error is involved.[84] In either case, C→T mutations occur only where a cytosine lies next to a thymine or another cytosine, because the major UV photoproducts join adjacent pyrimidines. If two adjacent cytosines mutate, the result is CC→TT. This distinctive pattern of mutation, C→T where the C lies next to another pyrimidine, including CC→TT, is unique to UVR and is called the *UV signature*.[85]

UV signature mutations provide a tool for deducing backward from mutations found in tumors to the original carcinogen. Nearly all experimentally created UVB or UVC mutations are located at adjacent pyrimidines, and about two-thirds are signature mutations.[85] The remaining third, typically C→A and T→C substitutions or one to two base insertions or deletions, are still caused by UV but probably arise by photosensitized production of reactive oxygen. Because this oxidative class is caused by many carcinogens, these mutations cannot identify whether their source was UVB, UVA, tobacco smoke, or intracellular oxidative phosphorylation. A set of tumors carrying the classic UV signature mutations must, however, also have some tumors with these UV-induced oxidative mutations. UVA, in contrast, only weakly induces UVB signature mutations by photosensitization but also generates oxidation-like mutations and T→G changes. The latter are rare with UVB or other carcinogens and have been proposed to be a UVA fingerprint.[86]

p53 UV signature mutations identified *p53* as critical for preventing SCC and BCC but not melanoma.[85,87] The p53 protein is a transcription factor that controls genes involved in the cell cycle, apoptosis, and DNA repair; it also acts directly on apoptosis proteins.[7] The *p53* gene is mutated in about one-half of all human cancers and is termed a *tumor suppressor gene* because cancer arises from losing its normal function rather than gaining an abnormal function as oncogenes do. Over 90 percent of SCC in U.S. patients contain these mutations, as well as three-fourths of AK. Although nearly all BCCs overexpress p53 protein, only half carry *p53* mutations. Each mutation changes the amino acid, indicating that the mutation was selected for and contributed to tumor development, rather than being simply an indicator of sun exposure. These *p53* mutations are most frequent at nine mutation hotspots in important functional regions of the protein. Compared to internal cancers, some skin cancer hotspots are displaced several nucleotides to lie at a site of adjacent pyrimidines.[87] Some sites may be hotspots because repair is slower there.[88] Other skin hotspots, like internal cancer hotspots, lie at 5-methylCG sites where body temperature slowly deaminates 5-methylcytosine to thymine; UVR accelerates this process.

The *p53* mutations in AK indicate that these dysplasias are clonal; patients with multiple AKs have different mutations in each lesion.[89–91] The similarity of AK and SCC mutations supports the idea that AKs can progress to SCC. Aggressive skin tumors from patients exposed to both sun and chemicals contain multiple unrelated *p53* mutations, as if multiple tumors arose in an abnormal field and merged.[92] XP tumors contain very frequent CC→ TT mutations, perhaps because slow repair allows more time for cytosine deamination.[93,94] Double-base mutations are also seen in conjunctival SCC, a tumor associated with human immunodeficiency virus (HIV) in sunny areas.[95] Sunscreens reduce the level of UV signature mutations.[96] In contrast, arsenic-induced BCC and SCC have non-UV *p53* mutations; *p53* mutations in BCCs from sun-shielded body sites resemble those seen with oxidative damage.[97,98]

Sunlight mutates *p53* early.[89,99] Normal sun-exposed skin carries ~60,000 clones of p53-mutant keratinocytes, three to 3000 cells in size.[100] By hematoxylin and eosin staining, the cells in these mutant clones appear completely normal.[44] The early appearance of *p53* mutations makes it possible to trace lineages in tumor development. Microdissecting lesions containing AK, carcinoma in situ, and SCC reveals that each stage contains the same *p53* mutation.[101] Although this result shows that



each stage arose from the same founder lesion, it does not show that the stages derived from each other. To show a lineage, it is necessary to find additional mutations that appear in succession. In microdissected BCCs, one *p53* mutation is present throughout the tumor, with various second mutations in different regions of the tumor.[102] Once both *p53* alleles are mutated, the cell is prone to aneuploidy,[103,104] increasing the likelihood of a mutator phenotype.

HEDGEHOG PATHWAY Nearly all sporadic BCCs have inactivating mutations in the *PTCH* tumor suppressor gene, a part of the hedgehog pathway (see Chap. 116); the remainder have activating mutations in its target, *SMO*. The hedgehog pathway appears to be a "gatekeeper" for basal cell carcinogenesis, needing to be mutated early in BCC: minute BCCs have *PTCH* mutations, as do all histologic subtypes; no BCCs have loss on other chromosomes without involvement of *PTCH*; and a congenital lesion that can progress to BCC, the sebaceous nevus, has *PTCH* allelic loss in 40 percent of cases.[105–107]

In sporadic BCCs, about three-fourths of *PTCH* mutations are UVR-like (either UV signature mutations or the expected UVR-induced oxidative mutations) and a further 15 percent are one or two base insertions or deletions, often adjacent to a C→ T at a dipyrimidine site.[108] BCCs from XP patients contain UVR-like *PTCH* and *SMO* mutations, with CC→ TT mutations overrepresented.[109,110] About 20 percent of the mutations in sporadic BCCs are not UVR-like and resemble germline mutations seen in basal cell nevus syndrome patients—deletions or insertions larger than two base pairs. This finding may relate to the clinical observation that one-third of BCCs occur on parts of the body that are not chronically sun-exposed, as well as the correlation between truncal BCC and defects in the glutathione radical-scavenging system (see Genetic Risk Factors). *PTCH* mutations tend to code for stop codons or frameshifts that completely inactivate the protein. In hereditary BCCs, nearly all tumors arose after losing the normal allele. This allelic loss appears related to sunlight, as NBCCS tumors are most frequent on sun-exposed skin and are rare in blacks.[39] UVB rarely causes this type of large genetic rearrangement so, in analogy to the x-ray sensitivity of NBCCS patients, UVA-photosensitized reactive oxygen may be important.

PSORALEN AND ULTRAVIOLET A LIGHT TUMORS (See Chap. 239) In psoralen-treated cells, UVA forms adducts at TA, TG, or TT sequences, as well as cross-links between the two DNA strands at these sites. In human PUVA-induced keratoses, SCCs, and BCCs, about one-fourth of mutations in *p53* or *HRAS* are psoralen-like mutations at the T of TA, TG, or TT; this proportion increases as the PUVA dose increases.[111,112] The majority of mutations, however, are UV signature mutations. The UVR-like mutations could have arisen from the UVA in PUVP, UVB treatment for psoriasis, or environmental UVB.

Melanoma Mutations (See Chap. 124)

Despite the correlation between melanoma and sunlight, genes with UV signature mutations are not prevalent. The *CDKN2A* locus is frequently mutated or deleted in familial and sporadic melanoma (see Chap. 124). Its two distinct tumor suppressor proteins, INK4A (also known as P16) and ARF, inhibit cell cycle progression via RB and p53, respectively. INK4A inhibits CDK4/6's inactivation of the retinoblastoma protein, RB. ARF inhibits MDM2-mediated degradation of p53. Germline mutations in *CDKN2A* are observed in ~25 percent to 40 percent of familial melanomas.[113,114] In sporadic melanoma, allelic loss of *CDKN2A* is more common than the rare *INK4A* inactivating mutations[115–117] or inactivation of *INK4A* by promoter methylation.[118] The role of sunlight in these genetic events is unknown.

Oncogene mutations are found in the RAS-BRAF-MEK-ERK mitogen-activated protein kinase (MAPK) signaling pathway. This signaling cascade is normally activated on growth factor stimulation, and its sequential phosphorylation regulates cell proliferation and differentiation. Activating mutations in MAPK signaling remove the growth factor requirement. *RAS* mutations are present in 10 percent to 20 percent of melanomas and have been correlated with UVR exposure.[119–121] The most prevalent *RAF* mutation in melanomas, the *BRAF* V600E point mutation, renders the kinase constitutively active and enhances ERK activation.[119] This mutation is present in nearly ~80 percent of acquired melanocytic nevi, suggesting a potential early role of BRAF in melanoma development.[121] The V600E mutation is not UVR-like and is associated with intermittent sunlight exposure.[27,29]

ULTRAVIOLET RADIATION–INDUCED STEPS IN CANCER AND CANCER PREVENTION

Skin tumors arise on a background of sun-damaged skin. To prevent sun damage, the skin reacts to acute and chronic UVR exposure by multiple stress responses.

DNA Damage Signaling (See Chap. 89)

A cell with damaged DNA upregulates normal p53 protein.[121a,121b] UV signaling is initiated by cyclobutane dimers and (6-4) photoproducts specifically in the small minority of actively transcribed genes, with stalled RNA polymerase both recruiting excision repair proteins and initiating signaling.[6,7] In an unknown way, this activates ATR and CHK1 kinases, which phosphorylate p53 at sites that make it resistant to proteasomal degradation mediated by HDM2. p53 then transcriptionally activates a large repertoire of genes, including the repair proteins P48, which is required for GGR and is defective in XP group E, and GADD45. Additionally, p53 functions as a chromatin accessibility factor, modifying the structure of damaged DNA and making it more accessible to repair factors. p53 also transactivates the cell cycle arrest protein P21, although in keratinocytes UVR induces P21 even without p53.[122] UVR primarily slows down S phase ("S phase delay") and induces a modest G_2 arrest, unlike ionizing radiation, which uses p53 to induce G_1 arrest. It is often said that cell cycle arrest facilitates DNA repair and survival, but there is little evidence supporting this concept; deleting the P21 cell cycle arrest protein has no effect on repair after UVR exposure.[123] These "guardian of the genome" roles of p53 are complemented by a "cellular proofreading" role in which p53 erases aberrant cells by apoptosis rather than repairing them: it transcriptionally activates the death receptor Fas and pro-apoptotic effectors Bax (Bcl-2–associated X protein), Bak, Bid, and PUMA; it directly activates Bax protein at the mitochondrion; and it inactivates E2F1, which otherwise inhibits anti-apoptotic Bcl-2.[8] This suite of UV responses is lost when p53 is mutated by sunlight. DNA damage also activates the cytoplasmically sequestered transcription factor nuclear factor κB, which then activates pro-inflammatory cytokines such as interleukin 10, growth signals, and

anti-apoptotic signals.[124,125] Finally, DNA photoproducts trigger UVR-induced systemic immunosuppression and suppression of dendritic cell antigen-presenting activity, but not inflammatory edema.[126,127]

Cytoplasmic Signaling

"The UV response" initially referred to the p53-independent activation of JNK, its target c-JUN, and, via the FOS-JUN transcription factor AP-1, induction of genes for collagenase, metallothionein, and c-JUN and c-FOS themselves.[128] The signal begins when reactive oxygen species generated by UVB or UVA photosensitization inactivate phosphatases by converting a highly sensitive cysteine residue in the catalytic site to sulfenic acid.[129,130] Dephosphorylation of growth factor receptor dimers and death receptor trimers is slowed, leading within minutes to more phosphorylated active receptors. Activated death receptors (involved in apoptosis) such as Fas and tumor necrosis factor-α (TNF-α) receptor then cluster even without a ligand, recruiting the adapter proteins DAXX and FADD and activating cytoplasmic kinases and scaffold proteins.[131–136] These activate ASK1 and MEKK 4,7 kinases and their target, JNK.[137] Phosphatase inhibition can activate JNK directly. In parallel, AP-1 also induces genes for the death receptor ligands, FasL and TNF-α.[138–140] These ligands, together with UV upregulation of FAS receptor via p53,[141] create a delayed feedback loop that, as with ionizing radiation,[142] appears to prolong the rapid but transient response triggered by UVR's inactivation of phosphatases. Without this prolongation, UVR-activated nuclear factor kappa B quickly terminates the JNK response.[143,144] This loop is important because transient JNK activation leads to cell proliferation, but constitutive JNK activation induces apoptosis.[145,146] AP-1 also induces immunomodulatory cytokines, such as interleukin 12, which facilitates NER[147]; the AP-1–induced metalloproteinases degrade dermal extracellular matrix molecules, such as collagen, and may contribute to photoaging.[148] UVR also blocks initiation of protein translation, via kinases that inactivate elongation factor eIF2α.[149]

Cellular Responses

APOPTOSIS UV signaling generates sunburn cells—basal and suprabasal keratinocytes with dense, pyknotic nuclei and intensely eosinophilic cytoplasm (see Chap. 89). This apoptotic morphology is accompanied by pathognomic DNA double-strand breaks and cleaved caspase 3. UVR-induced apoptosis requires signals from both DNA damage and the cytoplasm: DNA photoproducts in active genes trigger p53 and its regulator Mdm-2,[89,150] but apoptosis also requires JNK and is partially blocked by antioxidants.[151,152] Although TNF-α is required, injecting TNF-α does not lead to sunburn cells, so UV-induced cytoplasmic signaling is not sufficient.[153,154] In fibroblasts, keratinocytes, or melanocytes with normal p53 and irradiated with physiologic UVB or UVC doses, apoptosis proceeds through the intrinsic mitochondrial pathway rather than the death-receptor/caspase 8 pathway.[152,155]

Apoptosis then prevents cancer by removing UVR-damaged cells, termed "cellular proofreading."[156] Mice accumulate mutations at a rapid rate if they are defective in apoptosis due to a defect in *p53* or Fas ligand, or due to overexpressing the anti-apoptotic protein Survivin.[140,157,158] In Survivin's case, this increases SCC. The epidermal hyperplasia that occurs several days after UVR exposure may replace cells lost by apoptosis or may remove additional damaged or mutant cells by desquamation. The signal for hyperplasia involves both DNA photoproducts and the epidermal growth factor receptor.[159]

STEM CELL POPULATIONS In chronically UVB-exposed human skin, *p53*-mutant clones are found at both sites of epidermal stem cells (see Chap. 44): the hair follicle, whose bulge region contributes to follicle development and transiently to wound repair, and the interfollicular epidermis, which maintains epidermal homeostasis and can also generate follicles.[100,160,161] SCCs are thought to originate in interfollicular epidermis, whereas histologic evidence and the expression pattern of PTCH indicate that BCCs originate in the follicles.[162,163] Hedgehog signaling through PTCH is crucial for maintaining skin stem cell populations and for regulating hair follicle and sebaceous gland development.[164] Chronically UV-irradiated human or mouse skin contains scattered basal cells with unusually high levels of DNA photoproducts.[165] The tumor promoter TPA (12-*O*-tetradecanoylphorbol 13-acetate), which induces skin stem cells to proliferate,[166] causes these cells to disappear and be replaced by clusters of *p53*-mutant keratinocytes. This behavior resembles that of stem cells that are quiescent and poorly repaired, at least on the parental DNA strand, until triggered to divide.[167] The immortalization-promoting enzyme telomerase is normally present only in the epidermal basal layer but is elevated in sun-exposed skin, skin precancers, and cancers.[168,169]

CLONAL EXPANSION OF MUTANT CELLS A single mutant cell must clonally expand to reach a clinical size. Less obviously, clonal expansion facilitates the multiple genetic hit mechanism of cancer. Physiologic UVR doses create mutations at a frequency of ~10^{-4}/gene per cell division[170] (Fig. 112-2). The specific mutations needed to activate an oncogene would be rarer. Spontaneous mutations, which reflect errors by the replication machinery or DNA damage due to body temperature, are also rare, on the order of 10^{-5}.[170] The probability of mutating five genes, such as an oncogene and both alleles of two particular tumor suppressor genes, is then at best 10^{-20}. With 10^6 proliferating keratinocytes per cm^2 in human skin,[171] and ~1 m^2 exposed, fewer than 1 person in 10^{10} would have a tumor. Accounting for the 60 percent lifetime expectation of skin cancer in Australia solely in terms of genetic hits in one cell is impossible. In contrast, clonal expansion increases by 1000-fold the number of targets for the next mutation.

A stem cell's clonal expansion is normally limited to its stem cell compartment.[172] Sunlight is a key driver of clonal expansion beyond this point. The *p53*-mutant clones in human skin are larger in chronically sun-exposed skin.[100] In mice, clones stop growing and regress when UVB treatment ends, indicating that clone expansion is due to a UVR-induced physiologic event rather than an irreversible mutation.[172,173] One of these physiologic events is UVR-induced apoptosis.[158] Once a *p53* mutation arises, the cellular proofreading mechanism backfires: subsequent UVR exposures eliminate damaged normal cells but spare apoptosis-resistant mutants. A mutant normally restrained within its stem cell compartment then escapes to colonize the newly vacated compartment. Repeating this process results in quantized clonal expansion. Apoptosis retards or accelerates skin cancer depending on the stage: it prevents new *p53* mutations, accelerates the expansion of *p53*-mutant clones and papillo-



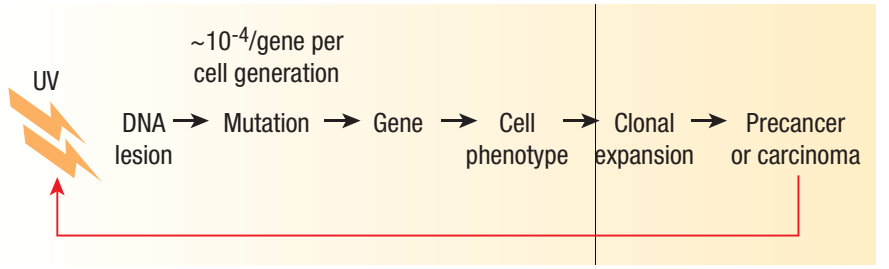

▲ **FIGURE 112-2** The carcinogenesis cycle. Ultraviolet radiation (UVR) makes chemical changes in DNA that create mutations when DNA is copied. Some mutations alter the function of the gene in which they occur and lead to a new cell phenotype. The abnormal cell expands into a clone that becomes the target of further DNA damage.



mas, and prevents the mutations that convert a papilloma to SCC.[140,158]

Cell–Cell Communication

Cell–cell interactions prevent abnormal cells from proliferating inappropriately. In human autotransplant experiments, BCCs transferred from their original site regressed—suggesting that an abnormal underlying dermis is required for the tumor to persist.[174] Dermal fibroblasts suppress transformed keratinocytes by secreting transforming growth factor-β that induces squamous differentiation.[175] Normal keratinocytes also suppress their transformed neighbors, and UVR interferes with these signals. Normal human keratinocytes eliminate adjacent transformed keratinocytes (mutated in *p53* and *HRAS*) by inducing cell cycle arrest and differentiation.[176] Physiologic doses of UVB cause apoptosis and differentiation in the normal cells, but not in the transformed keratinocytes, allowing the latter to clonally expand.[177] Other intercellular signals are mediated by integrins—membrane receptors for extracellular matrix proteins such as collagen ($\alpha_2\beta_1$ integrin), laminin ($\alpha_3\beta_1$), and fibronectin ($\alpha_5\beta_1$). In keratinocytes, integrins bound to such ligand provide a "do not differentiate" signal through MAPK pathways, suppressing keratinocyte apoptosis and allowing a stem cell pool to be maintained.[178,179] Integrin receptors are often dysregulated in tumors. UVB irradiation downregulates the β_1 integrin subunit. UVA downregulates the gap junction communication protein connexin 43, resembling the action of the tumor promoter TPA.[180,181]

Melanocyte proliferation is normally regulated by keratinocytes via cell–cell adhesion receptors such as E-cadherin, P-cadherin, and desmogleins; these receptors are lost in vertical growth phase melanomas.[182] UVR stimulates keratinocytes to secrete endothelin-1, which then downregulates melanocyte E-cadherin and upregulates their N-cadherin.[183] This E- to N-cadherin switch diverts melanocyte interactions away from keratinocytes and toward fibroblasts and melanocytes.[182] Endothelin also downregulates the α_6 integrin subunit,[184] upregulates the $\alpha_v\beta_3$ and $\alpha_2\beta_1$ integrins that anchor melanocytes to dermal collagen and are associated with vertical growth–stage melanoma, inhibits gap junction communication by phosphorylating connexin 43, and activates metalloproteinases associated with basement membrane invasion.

Immune Surveillance

In humans, the primary evidence cited for immune surveillance in preventing UVR-induced skin cancer is the 10- to 20-fold increase in AK and SCC on previously sun-exposed skin in transplant patients receiving chronic immune suppression to prevent organ rejection. In one Australian study, 27 percent of deaths in a heart transplant cohort were due to skin cancer.[185] The increase begins months to a few years after immune suppression is initiated, and both the AKs and SCCs are unusually aggressive.[186–190] Melanomas are also increased.[191] Several lines of evidence mar the interpretation as immune surveillance: Cyclophosphamide is a well-known mutagen. Cyclosporine promotes tumor growth in vitro and in immune-deficient mice in which there is no immune system to be suppressed.[192] Azathioprine is a mutagen when followed by UVA irradiation.[193] HIV patients do have a modestly increased incidence of SCC, but these tumors at sun-shielded sites are associated with human papillomavirus (HPV).[194] Skin cancers are often said to develop in patients who are immunodeficient due to leukemia or lymphoma. Most published reports lack controls or patient data, but an eightfold elevation in chronic lymphocytic leukemia seems valid.[195,196] Most of these patients had received immunosuppressive drugs, or radiation, so the mutagenicity caveat applies.

In contrast, Merkel cell carcinoma may be truly sensitive to immune function because its incidence increases 10- to 20-fold not only in solid-organ transplant recipients but also in HIV patients (~13-fold) and in chronic lymphocytic leukemia (see Chap. 120). The chance of metastasis and mortality also increases in all types of immunosuppressed patients. Regardless of why immune-suppressed patients are at increased risk of skin cancer, it is critical that they be monitored closely because, when caught early, even tumors in immunosuppressed patients are curable.

ANIMAL MODELS OF SKIN CANCER: CLINICAL IMPLICATIONS

GENETIC RISK FACTORS FOR ULTRAVIOLET RADIATION CARCINOGENESIS

Pigmentation and Initial Damage

Melanin has a large role in resistance to skin cancer. The Fitzpatrick skin phototypes (see Chap. 89) are determined not only by baseline pigmentation but also by a person's response to UVR (always burns, tans easily, or rarely burns). This simple UVR skin response scale can account for up to a 100-fold difference in susceptibility to skin cancers.[233] Similarly, the many molecular etiologies of oculocutaneous albinism, which result in a deficiency of normal melanin, markedly increase the risk of skin cancer (see Chap. 71). Increased skin cancer among albinos is mostly non-melanoma skin cancer, but melanomas seem elevated as well.[234] Another hereditary risk factor, red or blonde hair, is now understood at a molecular level as commonly caused by polymorphisms in the melanocortin 1 receptor[235] (see Chap. 70). This receptor is a G-protein coupled receptor that binds melanocyte-stimulating hormone and lies at a key point in melanogenesis. Certain mutations in this receptor render it insensitive to normal pigmentation signals, resulting in pheomelanin instead of eumelanin. This is an important distinction in terms of skin cancer prevention. Red or yellow pheomelanin is a markedly less effective free radical scavenger;

indeed, UVR-exposed pheomelanin is degraded with a net formation of superoxide.[42,236] Therefore, pheomelanin can act as a photosensitizer, even inducing apoptosis in nearby cells.[43] Decreased protection and increased damage from pheomelanin in the epidermis may partly underlie the markedly increased risk of skin cancer associated with red-haired individuals.

Reactive oxygen species are largely absorbed by radical scavengers, such as glutathione, before they cause significant membrane or DNA damage. Specific polymorphisms in the genes for glutathione *S*-transferase confer a twofold risk for truncal AK, SCC, and BCC.[237] This genetic risk increases to sixfold in patients with high sun exposure and 12-fold in sun-exposed transplant patients.

DNA Repair and Apoptosis

XP (see Chap. 109) highlights the association between DNA repair capacity and skin cancer. Although defects in any of the XP genes result in some defect in NER, the severity of the XP disorder—number of skin tumors and life expectancy—correlates with DNA repair capacity.[82,238] The correlation between repair capacity and cancer incidence is also present in the general population. Patients with AK have a 30 percent to 50 percent reduced excision repair in their normal fibroblasts or lymphocytes.[239–241] Cells from BCC patients have reduced excision repair compared to cells from control individuals.[242] These data suggest that relatively subtle variability in DNA repair capacity contributes to an individual's risk of developing skin cancer.

Viral Sensitivity

In the rare inherited sensitivity to HPV infection termed *epidermodysplasia verruciformis* (see Chaps. 111 and 196), roughly one-half of patients will develop SCC. These SCCs are typically on sun-exposed body sites and occur decades earlier than in the general population.[243] HPV may be important in UV carcinogenesis in immunosuppressed transplant patients, as it is detected twice as frequently in SCCs from these patients as in immunocompetent controls.[244]

PREVENTION

The potential of education and sunscreen to control skin cancer remains largely unproven due to the long latency between sun exposure and skin cancer appearance. Adult sunscreen use can reduce AK by twofold.[68,69] Randomized studies of school children who aggressively applied sunscreen indicate that common nevi can be reduced.[245] A regimen of sun protection longer than the typical 2- to 4-year study would likely decrease nevi and subsequent melanoma risk more impressively. Encouraging data are emerging from Australia where education campaigns, covered sidewalks, and covered playgrounds at schools have led to a stabilization of the incidence of non-melanoma skin cancers.[9] Clearly, an effective campaign to reduce skin cancer needs to begin with school-age children. This is due to the combined factors that children younger than the age of 18 years spend a significant portion of their time in outdoor recreation, and sun damage sustained early in life has more time to contribute to UV carcinogenesis.

One could ask "how much sun is too much?" The answer will vary immensely depending on many factors such as pigmentation, whether sun exposure occurs in modest doses or large exposures, the immune status of the individual, and subtle differences in DNA repair capacity. Although highly controversial, there may be some benefit to sun exposure. Several studies have suggested twofold better survival after a diagnosis of invasive melanoma among patients with extensive sun exposure as compared to those with less exposure.[246] A potential explanation is greater vitamin D synthesis induced by UVR.

NOVEL THERAPEUTIC APPROACHES

Despite the use of sunscreens and public awareness of the effects of long-term exposure to UVR, the incidence of both melanoma and non-melanoma skin cancers continues to increase. This has led to investigation of novel chemopreventive agents that interfere with the development of cancer through diverse mechanisms. Perhaps the most important recent advance in this area is the use of imiquimod (see Chap. 221), an activator of the innate immune system through the TLR7 receptor. Imiquimod has recently been approved for treating AKs and superficial BCCs, and reports of imiquimod effects also exist for atypical melanocytic proliferations such as lentigo maligna.[247]

In terms of foods, tea appears to have chemopreventive activity. Orally administered green or black tea reduces UVR-induced skin cancers in mice to less than one-half of control levels.[248] Polyphenols and caffeine appear to be the major chemopreventive components. Topical application of caffeine was similarly effective in mice.[249] The protective effect of caffeine is attributed to its ability to induce apoptosis after UV irradiation.

Low-fat diets have been well studied as an approach to preventing skin cancer. Animal studies have shown that high-fat diets shorten the time between UVR exposure and tumor formation and markedly increase the number of tumors per animal.[250] In human trials of patients with non-melanoma skin cancer, restricting calories from fat reduced the appearance of AKs by two-thirds and the development of new non-melanoma skin cancers by one-half.[251]

Chronic UVB exposure induces inflammatory responses that have been linked to tumor formation. Inflammation induces cyclooxygenase enzymes and prostaglandins. Because prostaglandins promote keratinocyte proliferation and block differentiation, inhibiting prostaglandin formation is expected to be chemoprotective. Topical application of a nonsteroidal anti-inflammatory drug (Diclofenac) is effective in treating AKs, with 50 percent of target lesions resolving after Diclofenac treatment versus 20 percent in placebo.[252] Celecoxib, a systemic inhibitor of cyclooxygenase 2, inhibits the development of UVR-induced skin tumors in mice by twofold.[253,254] Given the side-effect profile of systemic cyclooxygenase 2 inhibitors, it appears unlikely that they will be developed for this indication.

An inducible repair process has been observed using DNA oligonucleotides that share sequence with the telomere.[255] In animal models and cell culture, these oligonucleotides can initiate multiple cellular responses, including melanin production and p53 activation, apparently in the absence of DNA damage. Topical application of these oligonucleotides to UV-irradiated mice diminished UVR-induced mutations and malignant lesions by fourfold.[256] If a therapeutically appropriate mechanism can be devised to activate this pathway, it may have utility in reversing DNA damage and preventing malignancies.

A recent development in the area of chemoprevention is the ability to augment normal DNA repair pathways. If one could increase DNA repair capacity, the mutations, chromosomal aberrations, and cell death known to be causal



for skin tumors should be reduced. The most direct application of this concept is the use of a viral enzyme (T4 endonuclease V) capable of recognizing cyclobutane dimers and accelerating the initial incision step of the NER pathway. This enzyme has been formulated into a liposomal preparation, allowing penetration into the relevant layers of skin. Indeed, studies in XP patients have shown efficacy in decreasing the residual DNA damage as well as the number of actinic keratoses.[257] There are thus diverse emerging approaches by which chemopreventive therapies may increasingly serve as an adjunct to classical UVR protection with sunscreens and avoidance of UVR exposure to skin.

KEY REFERENCES

The full reference list for all chapters is available at www.digm7.com.

2. Leigh I, Newton-Bishop JA, Kripke ML: *Skin Cancer, Cancer Surveys,* vol 26. Plainview, New York, Cold Spring Harbor Laboratory Press, 1996
3. Brash DE, Pontén J: Skin precancer, in *Precancer: Biology, Importance, and Possible Prevention, Cancer Surveys*, vol 32, edited by Pontén J. Cold Spring Harbor, Cold Spring Harbor Press, 1998, p 69
4. Leffell DJ, Brash DE: Sunlight and skin cancer. *Sci Am* **275**:52, 1996
5. de Gruijl FR, Ananthaswamy HN: Biological effects of ultraviolet radiation. *Mut Res* **571**(special issue), 2005
6. Hussein MR: Ultraviolet radiation and skin cancer: Molecular mechanisms. *J Cutan Pathol* **32**:191, 2005
7. Latonen L, Laiho M: Cellular UV damage responses—Functions of tumor suppressor p53. *Biochim Biophys Acta* **1755**:71, 2005
8. Raj D, Brash DE, Grossman D: Keratinocyte apoptosis in epidermal development and disease. *J Invest Dermatol* **126**:243, 2006



SECTION 21

EPIDERMAL AND APPENDAGEAL TUMORS

CHAPTER 113

Epithelial Precancerous Lesions

Karynne O. Duncan
John K. Geisse
David J. Leffell

A precancerous or pre-malignant lesion is one that has a strong likelihood of transforming into a malignancy. There is much debate about the validity of the concept of precancerous lesions.[1–4] Lesions discussed in this chapter are those that have a clinically demonstrated potential to become invasive carcinomas and demonstrate histologic atypia confined to the epidermis. The focus is only on the precancerous keratinocyte lesions and not on those of other epithelial cells such as the melanocyte, Merkel, and appendageal cells. Discussion of malignancies and pre-malignancies associated with these cells can be found in Chaps. 124, 120, 119, and 121, respectively.

TABLE 113-1
Precancerous Keratinocytic Lesions

- Actinic keratoses
- Arsenical keratoses
- Thermal keratoses
- Hydrocarbon keratoses
- Chronic radiation keratoses
- Reactional keratoses
- PUVA keratoses
- Viral keratoses
  - Bowenoid papulosis
  - Epidermodysplasia verruciformis
- Bowen disease or squamous cell carcinoma in situ
- Erythroplasia of Queyrat
- Leukoplakia
- Erythroplakia

PUVA = psoralen plus ultraviolet A radiation therapy.

A common feature of all pre-malignant epithelial tumors (Table 113-1) is that they have the potential to become invasive squamous cell carcinoma (SCC). These precancerous lesions and SCC are considered by many to represent a continuum of disease with dysplasia at one end of the spectrum and invasive carcinoma at the other.

ACTINIC KERATOSES

Actinic keratoses (AKs) are cutaneous neoplasms consisting of proliferations of cytologically aberrant epidermal keratinocytes that develop in response to prolonged exposure to ultraviolet (UV) radiation. AKs have historically been considered precancerous or pre-malignant lesions with a potential for developing into SCCs. In recent years, however, there has been an effort to redefine AKs as malignant neoplasms, because these lesions are essentially intraepithelial SCCs in evolution. Although not all AKs become SCCs, AKs are the initial lesion in a disease continuum that may progress to SCC. This concept of a progression along a spectrum is analogous to that of cervical carcinoma, for which cervical intraepithelial neoplasia is the initial, "precancerous" lesion.[8]

AKs are clinically important lesions, not only because of their potential to develop into SCC, but because they are one of the strongest predictors that an individual may subsequently develop melanoma or non-melanoma skin cancer (NMSC).[9–11] With the increasing incidence and prevalence of melanomas and NMSCs (discussed in Chaps. 124 and 115), persons with AKs are the perfect candidates for close longitudinal observation for prevention and early treatment.

ACTINIC KERATOSES AT A GLANCE


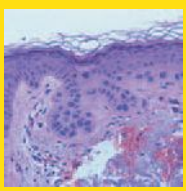

- Precancerous lesions on a spectrum from photodamaged skin to squamous cell carcinoma (SCC).
- Strongest predictors of subsequent development not only of non-melanoma skin cancer but also melanoma.
- Risk factors include individual susceptibility, cumulative ultraviolet (UV) radiation exposure, immunosuppression, prior history of skin cancers, genetic syndromes.
- Long-term and cumulative UV radiation exposure is the most important contributing factor for development of actinic keratoses (AKs).
- Risk of progression of AK to SCC varies from less than 1 percent to 20 percent.
- AKs should be treated because their course is unpredictable, they are often symptomatic, and they can progress to SCC if untreated.
- Treatment methods include cryotherapy, topical agents, electrodesiccation and curettage, and photodynamic therapy.

Epidemiology

AKs are second to acne vulgaris as the most common reason for patients to see a dermatologist. The National Am-



Copyright © 2008 by The McGraw-Hill Companies, Inc. Click here for terms of use.

bulatory Medical Care Survey data for 1990 to 1999 indicate that AKs were diagnosed in more than 47 million physician visits over that 10-year period and were found to occur in 14 percent of patients visiting a dermatologist.[12] In the northern hemisphere, 11 percent to 25 percent of adults are thought to have one or more AKs.[12] In Australia 40 percent to 60 percent of adults are thought to have one or more AKs.[13]

Various risk factors have been identified for the expression of AKs. The two major ones are individual susceptibility and cumulative UV radiation exposure (Table 113-2). One of the most important susceptibility risk factors is age, because all the epidemiologic studies indicate that AKs increase in prevalence with increasing age, with rates ranging from less than 10 percent in white adults aged 20 to 29 years to 80 percent in white adults aged 60 to 69 years. Males appear to have more AKs than females in most epidemiologic studies, which presumably reflects greater cumulative sun exposure in males than in females.[14] This gender differential is more pronounced at younger ages. Other individual susceptibility risk factors include a phenotype of fair skin that easily burns and freckles, and rarely tans; blue or light-colored eyes; and red or blond hair.[14] Another individual risk factor is immunosuppression, because it is well known that organ transplant recipients are at increased risk of developing AKs and SCCs. Last, individuals with certain genetic syndromes, namely, albinism and xeroderma pigmentosum, and possibly Rothmund-Thomson and Bloom syndromes, are at greater risk of developing AK.

TABLE 113-2
Risk Factors for Development of Actinic Keratoses

- Individual susceptibility
  - Older age
  - Male gender
  - Fair skin that easily burns and freckles
  - Blond or red hair
  - Light-colored eyes
- Cumulative ultraviolet radiation exposure
- Immunosuppression
- Prior history of actinic keratoses or other skin cancers
- Genetic syndromes
  - Xeroderma pigmentosum
  - Bloom syndrome
  - Rothmund-Thomson syndrome

Cumulative exposure to UV radiation, including tanning beds, is the other major risk factor for developing AKs. Evidence that sun exposure plays a role in the development of AKs is the fact that over 80 percent of all AKs are distributed on habitually sun-exposed areas of the body, such as the scalp, head, neck, forearms, and dorsal hands.[14] Variables that affect a person's cumulative UV radiation exposure include age, gender, occupation, recreational activities, and place of residence. As previously stated, the older the individual, the greater the prevalence of AKs and, intuitively, the greater the cumulative exposure to UV radiation. The age at which a person received the greatest amount and intensity of exposure to UV radiation appears to be significant, with such exposure in childhood apparently posing the greatest risk. In migration studies in Australia, British immigrants who moved to Australia before the age of 20 had fewer AKs than the native white Australians early in life, but they had the same rate of AKs as the native Australians in later years. British immigrants who moved to Australia after the age of 20 years never showed the same rate of AKs as the native Australians or the British immigrants who arrived at a young age.[15]

Etiology and Pathogenesis

Although genetic and environmental factors may play a role in the development of AKs and SCC, it has long been recognized that the most important contributing factor is habitual exposure to UV radiation, namely, sunlight exposure. UV radiation is responsible for the development of AK, and eventually SCC, in two ways: first, it causes mutations in cellular DNA that, when unrepaired, lead to unrestrained growth and tumor formation; and second, it acts as an immunosuppressant to prevent tumor rejection[16] (see Chaps. 109, 110, 111, and 112).

UV radiation–induced mutations in the tumor suppressor gene p53 play a pivotal role in the initiation of AKs and their development into SCC (Fig. 113-1; see Chap. 112). Multiple UV radiation–induced cellular insults to the skin result in a pathway to SCC that begins with photodamaged skin, progresses to the development of AKs, and eventually leads to some SCCs. AKs on photodamaged skin clinically represent expanded clones of genetically mutated cells that have escaped apoptosis and immune surveillance and have gone on to proliferate into clinically evident pre-malignant lesions.

Clinical Findings

The typical patient with AKs is an older, fair-skinned, light-eyed individual who has a history of significant sun exposure, who burns and freckles rather than tans, and who has significant solar elastosis on examination (Fig. 113-2). AKs can be seen in younger individuals if these individuals have sustained sufficient sun exposure over their lives. Eighty percent of AKs are found on habitually sun-exposed sites of the body, such as the head, neck, forearms, and dorsal hands. Common signs and symptoms include pruritus, burning or stinging pain, bleeding, and crusting. The typical AK lesion, sometimes called the *erythematous AK*, presents most commonly as a 2- to 6-mm erythematous, flat, rough, or scaly papule. It is usually more easily felt than seen. AKs can vary in size and sometimes reach to several centimeters in diameter. They are most often found against a background of photodamaged skin or dermatoheliosis, with solar elastosis, dyspigmentation, yellow discoloration, ephelides, telangiectases, and sagging skin notably prominent. At times the number and confluence of AKs are so great that the patient appears to have a rash.

In addition to the typical erythematous AK, there are several other clinical sub-types (Table 113-3). The hypertrophic AK (HAK) presents as a thicker, scaly, rough papule or plaque that is skin colored, gray, or erythematous (Fig. 113-3A). It can be found on any habitually sun-exposed site on the body but has a propensity for the dorsal hands, arms, and scalp. A typical erythematous AK can progress into an HAK. At times, it is difficult to distinguish an HAK from an SCC clinically, and a biopsy is necessary. Induration or thickness, pain, and ulceration are the main clues to the transition of AK to SCC.

Cutaneous horn, also known as *cornu cutaneum*, refers to a reaction pattern and not a particular lesion (Fig. 113-4). In reference to AKs, a cutaneous horn is a type of HAK that presents with a conical hypertrophic protuberance emanating from a skin-colored to erythematous papular base. In classic definitions of a cutaneous horn, the height is at least one-half of the largest diameter. Thirty-eight percent to 40 percent of all cutaneous horns represent AKs.[17] In fact, on examination of biopsy specimens, the

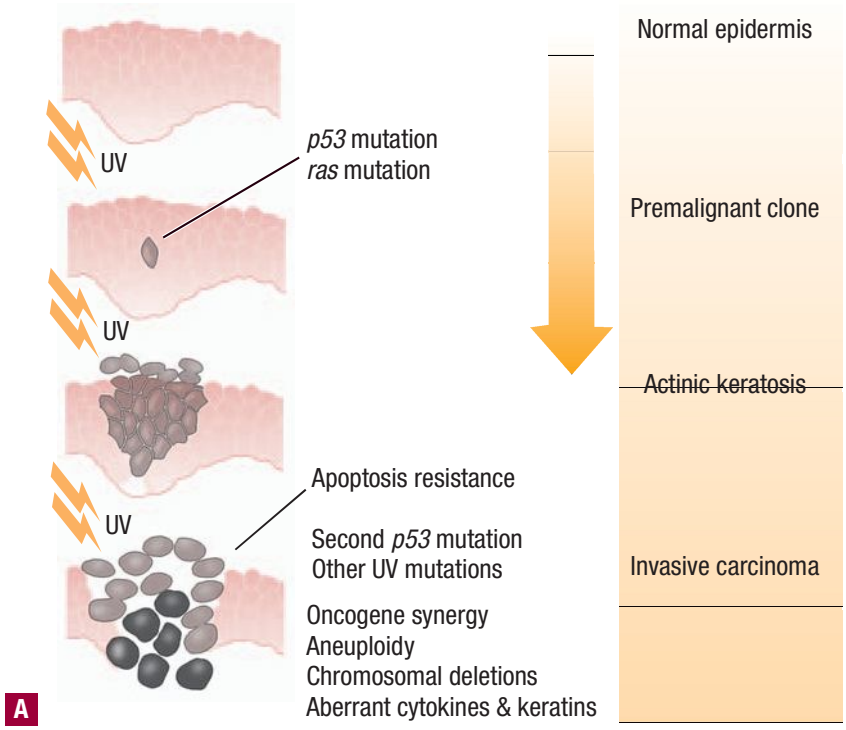

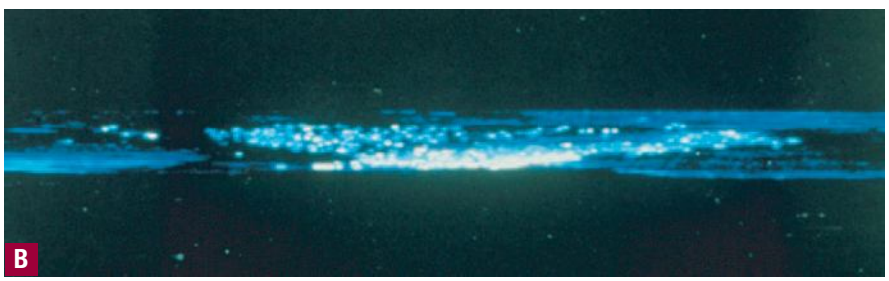

▲ **FIGURE 113-1** **A.** Development of clonal expansion of ultraviolet (UV) radiation–mutated p53 gene in epithelium. In the multistage model of carcinogenesis, UV radiation–induced mutations provide selective growth advantage to neighboring cells, which leads to clonal expansion. (Adapted from Grossman D, Leffell DJ: The molecular basis of nonmelanoma skin cancer. *Arch Dermatol* **133**:1263, 1997.) **B.** Confocal microscopy revealing expansion of UV radiation–induced clone of abnormal keratinocytes in sun-damaged skin. (From Jonason et al: Frequent clones of p53-mutated keratinocytes in normal human skin. *Proc Natl Acad Sci U S A* **93**:1402, 1996, with permission.)



▲ **FIGURE 113-2** Severe solar damage of the face revealing telangiectasias as well as actinic keratoses at different stages of development, including the flat, pink macules and hyperkeratotic papules.

base of a cutaneous horn can be a number of different lesions, such as AK, SCC, seborrheic keratosis, filiform verruca vulgaris, trichilemmoma, or keratoacanthoma. The most common underlying lesion in elderly, fair-skinned persons is an HAK.

Actinic cheilitis represents confluent AKs on the lips, most often the lower lip (Fig. 113-5). Persons with this condition have red, scaly, chapped lips, and at times erosions or fissures may be present. The vermillion border of the lip is often indistinct, focal hyperkeratosis and leukoplakia may also be seen. Individuals with this condition often complain of persistent dryness and cracking of the lips, and the diagnosis of actinic cheilitis should always be suspected in elderly patients with such complaints.

TABLE 113-3
Clinical and Histopathologic Variants of Actinic Keratoses

Clinical Variants of Actinic Keratoses
- Erythematous actinic keratosis
- Inflamed actinic keratosis
- Hypertrophic actinic keratosis
- Cutaneous horn
- Actinic cheilitis
- Pigmented actinic keratosis
- Spreading pigmented actinic keratosis
- Proliferative actinic keratosis
- Conjunctival actinic keratosis

Histopathologic Variants of Actinic Keratoses
- Inflamed actinic keratosis
- Hypertrophic actinic keratosis
- Cutaneous horn
- Atrophic actinic keratosis
- Bowenoid actinic keratosis
- Pigmented actinic keratosis
- Proliferative actinic keratosis
- Lichenoid actinic keratosis
- Acantholytic actinic keratosis
- Clear cell actinic keratosis

Persistent ulcerations or indurated areas on the lip require biopsy to ensure that SCC is not present.

Unusual variants of AK include pigmented AK, spreading pigmented AK, proliferative AK, and conjunctival AK. The pigmented AK presents as a flat, tan to brown, scaly papule. Clinically, and many times dermatoscopically, it can be difficult to distinguish from a solar lentigo or lentigo maligna.[18] Spreading pigmented AK is a particular lesion that is often found on the face or scalp. It is typically a large lesion, often reaching more than 1 cm in diameter, and presents as a scaly, verrucous, or smooth plaque with variable colors. Proliferative AK is seen as an expanding, red, oval, scaly plaque that reaches up to 4 cm in diameter. It has poorly defined borders. Conjunctival AK is classified as a type of pinguecula or pterygium. It appears as a wedge-shaped, opaque thickening near the limbus, and it may extend onto the cornea from the scleral conjunctiva.

Histopathology

The typical erythematous AK has characteristic architectural and cytologic histopathologic features. All of the abnormalities are confined to the epidermis, although dermal solar elastosis is usually present and an inflammatory dermal infiltrate may also be seen. The classic histopathologic findings include foci of atypical, pleomorphic keratino-



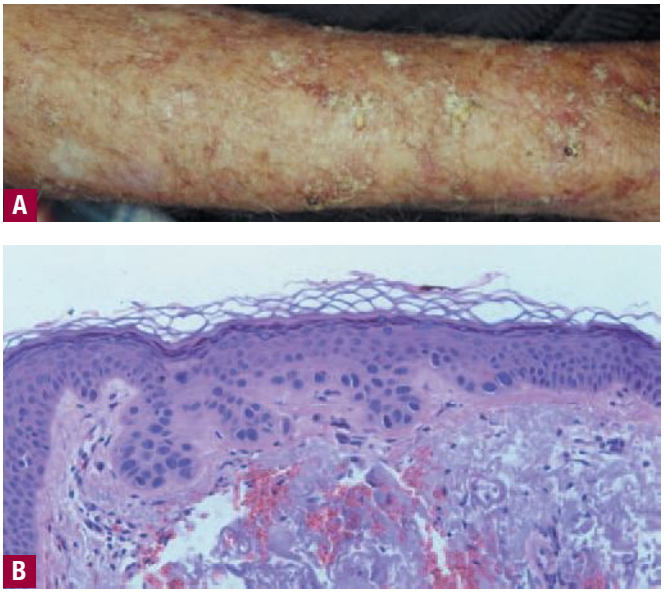

▲ **FIGURE 113-3** **A.** Severe solar damage of the dorsal arm demonstrating hypertrophic actinic keratoses and actinic keratoses. **B.** Histopathologic preparation of actinic keratosis demonstrates atypical cells along the basal layer with sparing of adnexal epithelium.



▲ **FIGURE 113-4** **A.** Cutaneous horn of the ear. Only biopsy will confirm whether this is an actinic keratosis or a squamous cell carcinoma. **B.** Cutaneous horn of the cheek.

cytes along the basal cell layer and protruding as buds into the papillary dermis. The basal cell layer appears more basophilic because of crowding of the atypical keratinocytes. Overlying these foci of abnormal cells, one often sees irregular acanthosis, hyperkeratosis, and parakeratosis. There is notable sparing of the adnexal epithelium, with orthokeratosis overlying these structures, which gives rise to the characteristic pattern of alternating orthokeratosis and parakeratosis (see Fig. 113-3B). Cytologically, there is an increased nucleus-cytoplasm ratio in the atypical keratinocytes in addition to nuclear pleomorphism and mitoses.

An important point to remember about making the diagnosis of AK histopathologically is that if the physician has a strong clinical suspicion of SCC or basal cell carcinoma (BCC) and the initial cuts reveal AK, it is prudent to section more deeply into the block of tissue to ensure that an SCC or BCC is not missed. In one study additional diagnostic findings were present on step sections in 23 of 69 specimens (33 percent) initially diagnosed histopathologically as AK. Of these additional findings, 13 percent were indicative of Bowen disease (BD), 4 percent of BCC, and 3 percent of invasive SCC. Three variables that correlated with the discovery of malignancy on step sections were ulceration on the first level, a clinical diagnosis of skin cancer, and a history of skin cancer confirmed previously by biopsy examination.[21]

Diagnosis and Differential Diagnosis

The diagnosis of AK is accurately made by clinical examination in most instances when the examiner is familiar with AK and skilled in making such diagnoses. Some investigators, however, have commented on the difficulty of accurate and consistent counting of AK lesions by experts involved in AK research studies.[22] In practice, very few AKs are histopathologically confirmed, and thus few data exist on the accuracy of clinical diagnosis. The accuracy of clinical diagnosis is higher in a clinical referral setting than in the general community setting. One study involving a referral setting revealed a diagnostic accuracy of 94 percent, based on the correct histopathologic diagnosis of 34 of 36 clinically suspect, typical AKs.[23] Another study in a community-based setting reported a diagnostic accuracy of approximately 80 percent when random clinically diagnosed AKs were subject to histopathologic confirmation.[24]

The clinical features of typical erythematous AKs are not unique to these lesions. The differential diagnosis includes other common lesions as noted in Box 113-1. Of the clinical AK variants, pigmented AK is difficult to distinguish from solar lentigo and sometimes lentigo maligna; spreading pigmented AK, from lentigo maligna or a large seborrheic keratosis; HAK, from



◀ **FIGURE 113-5** Actinic cheilitis of the lower lip in a young man with a marine occupation. The patient is at risk for developing squamous cell carcinoma of the lip. Preventative treatment of the actinic cheilitis can include laser, cryosurgery, and topical treatment.

Box 113-1

Clinical Differential Diagnosis of Actinic Keratosis

Most Likely

- Erythematous actinic keratosis
  - Benign lichenoid keratosis
  - Irritated seborrheic keratosis
  - Psoriasis
  - Seborrheic dermatitis
- Hypertrophic actinic keratosis
  - Verruca vulgaris
  - Squamous cell carcinoma
  - Discoid lupus erythematosus
  - Keratoacanthoma
  - Porokeratosis
- Cutaneous horn
  - Seborrheic keratosis
  - Verruca vulgaris
  - Squamous cell carcinoma
- Pigmented actinic keratosis
  - Solar lentigo
  - Flat seborrheic keratosis
  - Lentigo maligna
- Spreading pigmented actinic keratosis
  - Large seborrheic keratosis
  - Lentigo maligna
- Actinic cheilitis
  - Dry, chapped lips
  - Lichen planus
  - Other variants of cheilitis

Always Rule Out

- Inflamed actinic keratosis
  - Bowen disease
  - Squamous cell carcinoma
  - Basal cell carcinoma
- Hypertrophic actinic keratosis or cutaneous horn
  - Squamous cell carcinoma
  - Keratoacanthoma
- Pigmented or spreading pigmented actinic keratosis
  - Lentigo maligna

SCC; and cutaneous horn, from the many entities it may represent.

Clinically, the greatest challenge is to distinguish an AK from an SCC, because the latter portends a more serious prognosis and requires different treatment. There are no reliable clinical criteria for distinguishing between these two entities, but findings of induration, pain, larger size, marked hyperkeratosis, ulceration, bleeding, rapid growth, and recurrence or persistence after treatment make the diagnosis of SCC more likely.

Prognosis and Clinical Course

The prognosis of AK includes three possible outcomes. It can persist, regress, or undergo malignant transformation into invasive SCC. It is impossible to predict which path any given AK may take. The relative risk of progression to SCC depends on factors related to the AK itself, such as the length of time an AK has been present and the number of baseline AKs that are on the skin. In addition, the risk for SCC increases with increased UV radiation exposure and with certain individual patient characteristics, such as suppressed immune status.

Several studies have attempted to determine the risk for the progression of AK to SCC, but most of them are inadequate in one respect or another. The risk for progression of AK to SCC reported in the literature varies from less than 1 percent[25] to 20 percent.[26] In a review of five clinical research studies carried out between 1988 and 1998, Glogau found that the published risk of progression of AK to SCC for individual lesions ranged from 0.025 percent to 16 percent per year.[27] Extrapolation from these clinical studies suggests a rate of risk of progression of AK to SCC of approximately 8 percent, computed as an average of the cited statistical rates.[27] Berhane et al. observed that before an AK progresses to SCC it may become clinically tender and inflamed. Histopathologic examination of such clinically inflamed AKs revealed the actual presence of overt SCC in 50 percent.[28] Thus, pain and inflammation in an AK may be a marker of progression to SCC.

The risk of malignant transformation can also be assessed by evaluating the percentage of SCCs that arise from preexisting AKs. Several studies have approached this issue by histopathologically examining invasive SCC specimens and determining the percentage of cases in which an associated or contiguous AK could be identified. An associated AK was identified at the periphery or within the SCC in 60 percent,[25] 82.4 percent,[29] 97 percent,[30] 97.2 percent,[31] and 100 percent[32] of reviewed cases in various studies. There has been one prospective study in which all SCCs treated by the authors in one calendar year were evaluated histopathologically to see if an AK was present in the specimen. They found a contiguous AK within a histopathologically confirmed SCC in 72 percent of cases.[33]

Spontaneous regression of an AK is impossible to predict for any particular lesion. One study reported that up to 25 percent of AKs remitted over a 1-year period, especially if sun exposure was limited during that time.[34] Another study found that more AKs regressed in individuals who routinely wore sunscreen.[24]

Not only do these three basic outcomes exist for individual lesions, but AKs are also sensitive clinical markers for predicting the future development of NMSC. The presence of AKs indicates long-term sun damage and identifies a group of people who are at high risk for developing SCC, BCC, and, to a lesser extent, melanoma.[9,10,11]

The estimated rates of metastases arising from actinically derived SCC have ranged from 1 percent to 2 percent to 20 percent depending primarily on depth of invasion, with the lip, ear, and scalp representing the sites of highest risk.[35]

Treatment

The inability to predict which AKs will persist, regress, or become SCCs makes treatment of these lesions equally confusing. Although some clinicians have argued that because of the low malignant transformation risk, treatment of AKs is unnecessary, most dermatologists advocate the treatment of AKs to avoid any chance of progression to invasive SCC.[36,37] Treatment of this disease is also warranted to minimize symptoms in affected patients with painful and pruritic AKs.

In selection of the proper treatment, there are no absolute guidelines or algorithms because published studies vary considerably in their design, measured outcomes, and follow-up time (Fig. 113-6). The clinical diagnosis of AK even by expert dermatologists can be inconsistent.[22]

The ideal treatment for AK lesions would be 100 percent effective and durable, resulting in complete clearance of clinical and sub-clinical AKs. It would also be affordable, easy to administer by the clinician and/or use by the patient, convenient and free of discomfort or downtime for the patient, and have a great cosmetic outcome. No one such therapy exists. Which treatment a physician chooses depends on personal skill level and individual patient characteristics as well as the size, location, and number of AKs present.

Treatment modalities for AKs can be broadly divided into lesion-targeted therapies and field therapies (Box 113-2).

LESION-TARGETED TREATMENTS FOR ACTINIC KERATOSIS The majority of the lesion-targeted therapies for the treatment of AKs are destructive—that is, they work by physically removing the AK. Such





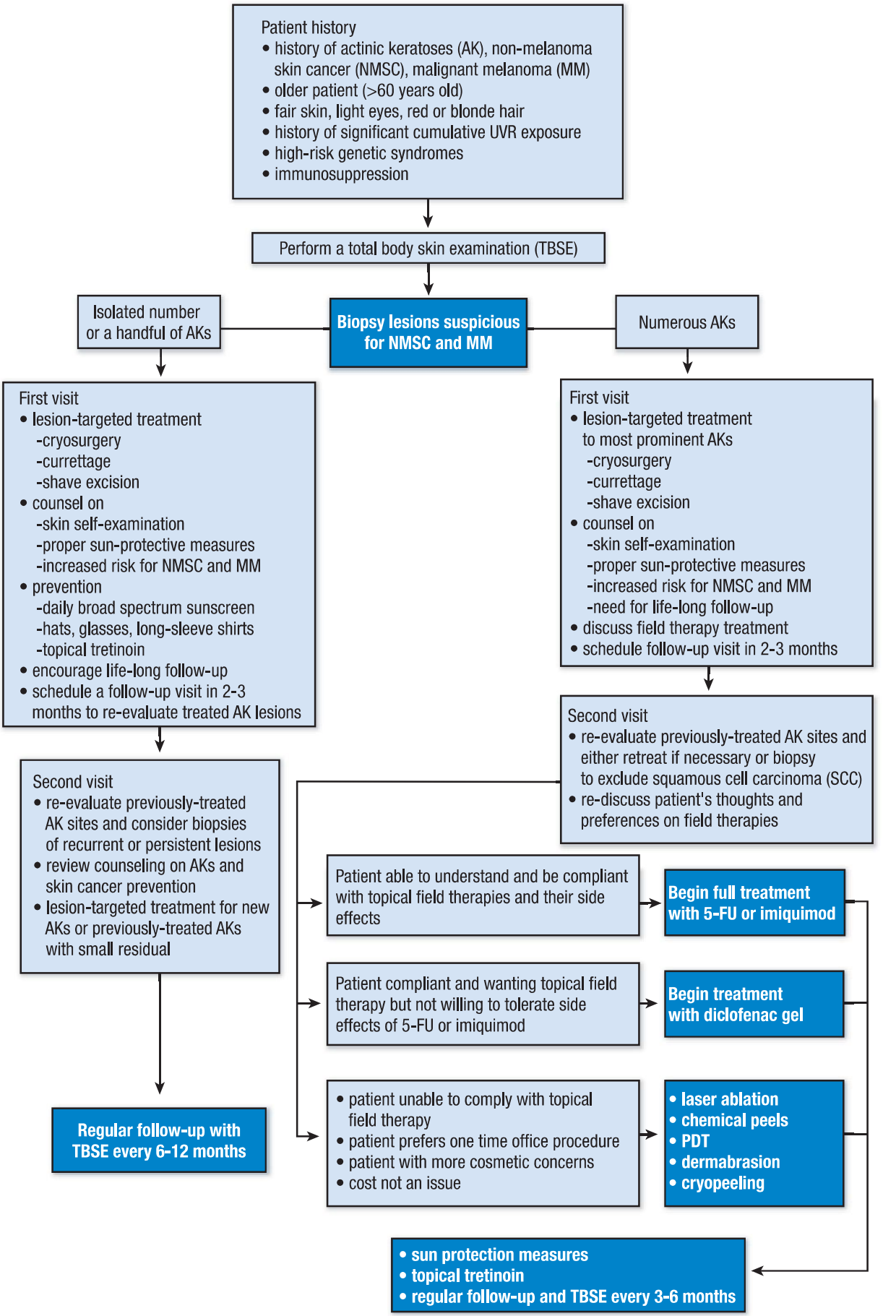

▲ **FIGURE 113-6** Approach to the management of actinic keratoses. 5-FU = 5-fluorouracil; PDT = photodynamic therapy; UVR = ultraviolet radiation.

Box 113-2

Treatment of Actinic Keratoses

LESION-TARGETED THERAPIES

- Liquid nitrogen cryotherapy
- Curettage with or without electrocautery
- Shave excision

FIELD THERAPIES

- Topical
  - 5-fluorouracil cream and solution
  - 5% imiquimod cream
  - 3% diclofenac gel
- Procedural
  - Cryopeeling
  - Dermabrasion
  - Medium-depth chemical peel
  - Deep chemical peel
  - Laser resurfacing
  - Photodynamic therapy

destructive treatments are the most common methods used to treat AKs.[38]

Liquid Nitrogen Cryosurgery. Liquid nitrogen cryosurgery is the most common destructive procedure and is typically administered with a spray device or a cotton-tipped applicator (see Chap. 247).

The benefits of cryosurgery are its ease of administration in trained hands, the lack of need for anesthetic, and the lack of reliance on patient compliance other than in post-treatment care of lesions. Potential disadvantages of the use of cryosurgery include pain or discomfort for the patient, the presence of unsightly blisters and crusted wounds for a week or longer, hypopigmentation, scarring, and possible alopecia in treated areas.[40] In rare cases serious injury to underlying tendons and nerves may occur with deep or prolonged liquid nitrogen application to the hands. Most important, cryosurgery is best used to treat a limited number of clinically perceptible or symptomatic lesions.

Curettage. Curettage, with or without electrocautery, is another destructive treatment for AKs. This procedure and cryosurgery together constitute approximately 80 percent of all treatments for AKs in the United States.[38] A curette is used to mechanically scrape away the atypical keratinocytes of the AK. Electrocautery may or may not be used to further destroy atypical cells and to provide hemostasis. If cautery is employed, minimal use is advised to enhance the final cosmetic result. A local anesthetic is needed for this procedure, and hemostatic agents such as aluminum chloride can be used to stop the bleeding if electrocautery is not to be used.

Shave Excision. The third lesion-targeted destructive therapy for AKs is shave excision. This technique involves injection of a local anesthetic followed by tangential excision of the lesion with a surgical blade (see Chap. 243). Hemostatic agents must also be used to stop the bleeding. No data exist on the cure rate with the use of this technique, but as with curettage, anecdotal experience says it is effective. Healing time may be 1 to 2 weeks, and potential complications include infection, scarring, and dyspigmentation. Use of this technique is most indicated when a clinically apparent AK is suspicious for SCC and histopathologic examination is needed.

FIELD THERAPIES FOR ACTINIC KERATOSIS

Field therapies treat larger areas of photodamaged skin that have both clinical and subclinical AK lesions. Field therapies can be categorized further into topical or medical, and procedural field therapies. Such treatments are best used in patients with moderate to severely photodamaged skin and numerous AKs that would be too burdensome and painful to treat with the lesion-targeted therapies. Many patients with AKs, on close inspection, are found to be extensively affected with early disease in sun-exposed areas, which may make field therapy the more rational approach to this difficult problem.

Topical Field Therapy. Several topical agents are available and approved by the U.S. Food and Drug Administration (FDA) for the generalized treatment of AKs, including 5-fluorouracil (5-FU), 5 percent imiquimod cream, and 3 percent diclofenac gel (Box 113-3).

5-FU therapy has been a mainstay of topical treatment for AKs since the 1960s (see Chap. 220). 5-FU acts selectively to cause cellular destruction in actinically damaged cells but not in normal skin. 5-FU treatment of sun-damaged skin usually causes a brisk inflammatory reaction, which is felt to contribute to its overall efficacy.

Although many different treatment regimens have been proposed and used with topical 5-FU, the historical standard FDA-approved method consists of twice-daily application of 5-FU cream or solution to the entire affected region, typically for 2 to 4 weeks.

Anecdotally, topical 5-FU has been thought to be 75 percent effective—that is, 7 or 8 out of 10 treated AKs will resolve with appropriate therapy.[42] The long-term remission rates after 5-FU treatment vary, but the condition frequently recrudesces in a few years and severely affected patients return to baseline.

Patients should expect discomfort, pruritus, and burning at the sites of application, as well as erythema, erosion, crusting, and ulceration beginning at around 1 week into treatment (Fig. 113-7). These and other adverse reactions to 5-FU are further discussed in Chap. 220. Areas of the skin that seemingly have no visible evidence of AKs may also become quite inflamed during treatment, because the 5-FU is uncovering incipient AKs in these treated areas. Such outcomes portend a good prognosis for resolution of AK lesions. Much lower cure rates are seen when patient compliance is poor and the expected endpoints are not reached.

The second agent available for topical field treatment of multiple AKs is 5 percent imiquimod cream (see Chap. 221). First approved in 1997 by the FDA for the treatment of genital and perianal warts, it was approved in 2004 for the treatment of non-hypertrophic AKs on the face and scalp in immunocompetent adults. It is also approved for treatment of superficial BCC (see Chap. 115).

The ideal frequency and duration of imiquimod treatment for AKs have not been determined. Currently, the FDA-approved regimen calls for twice-weekly (e.g., Monday and Thursday) night-time application of a thin layer of

Box 113-3

Topical Field Therapies of Actinic Keratoses

MEDICATION	TOPICAL PREPARATION	DOSAGE
5-Fluorouracil	1% solution	Twice daily for up to 4 wk
	2% solution	
	5% solution	
	1% cream	
	5% cream	
	0.5% micronized cream	Once daily for 4 wk
Imiquimod	5% cream	Twice per week for 16 wk
Diclofenac	3% gel	Twice daily for 90 days



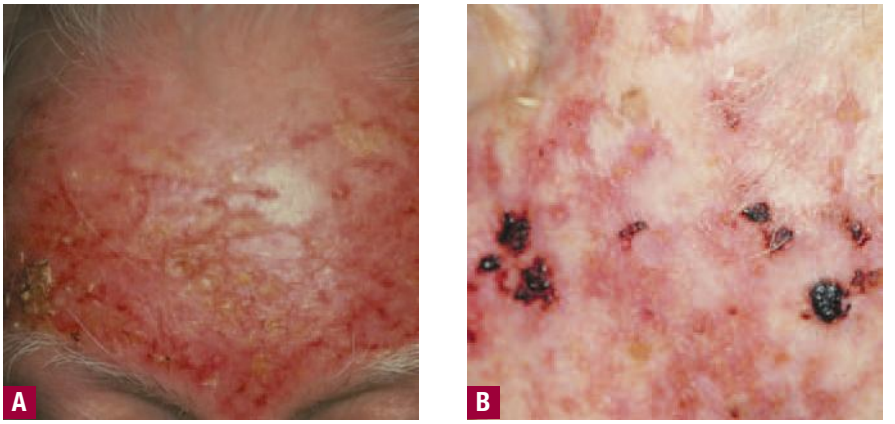

▲ **FIGURE 113-7** **A.** Erythema and crusting secondary to treatment with 5-fluorouracil (5-FU). **B.** Superficial hemorrhage in a patient taking warfarin (Coumadin) who was treated with 5-FU.

imiquimod cream to the affected area, which is the regimen used in clinical trials. After 1 to 2 weeks of therapy patients should begin to see an eruption of erythematous, crusty, eroded papules and plaques in the treated areas. If the reaction is too severe or uncomfortable, patients can take a 1- or 2-week break from the application of imiquimod and then restart therapy. Treatment should be continued for 16 weeks.

Treatment with imiquimod cream is associated with adverse reactions, most notably local skin reactions such as erythema, scabbing, flaking, erosion, weeping, and vesicle formation. Such reactions are actually a foreshadowing of better clearance of the AKs. In fact, the greatest resolution of the AKs has been seen in patients with the most severe reactions.[45–47] Systemic absorption is minimal, and overall excellent safety margins have been demonstrated with the topical administration of imiquimod cream.[48] Systemic adverse effects, including interferon-like side effects such as flu-like symptoms, headaches, and myalgia, have been infrequently reported.

No long-term safety issues have been discovered.

The third FDA-approved topical field therapy for treating AKs is 3 percent diclofenac gel. Diclofenac is a nonsteroidal anti-inflammatory drug whose mechanism of action is not completely understood but is thought to involve inhibition of cyclooxygenase (COX), a rate-limiting enzyme in the synthesis of prostaglandins. Diclofenac appears to have greater affinity for the COX-2 enzyme than for the COX-1 isoform. One theory regarding its role in eradicating AKs relates to the finding that the production of prostaglandins from arachidonic acid may contribute to UV radiation–induced NMSC. Thus, inhibition of this cascade by diclofenac may also explain its efficacy in treating AKs.[54]

The FDA-approved regimen for diclofenac in the treatment of AKs is twice-daily application for 90 days. Compared with imiquimod and 5-FU, diclofenac does not cause as much inflammation, irritation, or downtime for the patient. Adverse effects include mild local site reactions, such as erythema, pruritus, flaking, and possible contact dermatitis. In a study involving 96 patients, at 30 days after the conclusion of therapy complete clearance of AKs was observed in 50 percent of the diclofenac-treated group and in 20 percent of the vehicle-treated group.[55]

The best general approach to managing widespread AKs likely involves a combination or sequential strategy. For example, at the first visit with the patient, a handful of the largest, most notable AKs may be selected for biopsy to rule out SCC or treated with cryosurgery, and the clinician can discuss AKs and present topical field therapy options to the patient. At a subsequent visit for follow-up examination of the AKs that have been treated, another discussion can address which topical therapy is best suited to this particular patient. The next phase of treatment, involving a topical therapy, can be pursued.

Procedural Field Therapy. The second category of field therapies for treating diffuse AKs is the procedural field therapies. These include cryopeeling (see Chap. 247), dermabrasion, medium and deep chemical peels (see Chap. 252), laser resurfacing (see Chap. 240), and photodynamic therapy (PDT) (see Chap. 239).

Cryopeeling consists of extensive liquid nitrogen cryosurgery to the areas of discrete AKs as well as to the surrounding normal-appearing skin.

Dermabrasion is an older technique that is quite effective in the treatment and prophylaxis of AKs but is rarely used for this purpose. It causes physical destruction of the AKs with abrasion using either drywall sanding sheets or an electric dermabrasion device (see Chap. 252).

Medium-depth chemical peels using Jessner's solution and 35 percent trichloroacetic acid (TCA) are moderately effective in treating diffuse AKs, especially when a series of such peels are administered over time (see Chap. 252).[56,57] A combined peel in which 35 percent TCA is used after Jessner's solution has been shown to be equivalent in efficacy to 5-FU therapy.[58]

Deep chemical peeling using phenol or high concentrations of TCA is more effective in treating appendageal epithelial atypia but is rarely used because of the potential cardiac and renal toxicity of phenol, the greater risk of scarring and infection, and the dramatic hypopigmentation that can be seen after treatment.

Laser resurfacing for the treatment and prophylaxis of AK is another procedural field therapy that has been explored. The carbon dioxide (CO_2) laser and the erbium:yttrium-aluminum-garnet (er:YAG) laser are the two laser systems that have primarily been investigated for these purposes (see Chap. 240).

PDT using topical 5-aminolevulinic acid (ALA) is another procedural therapy that has been gaining popularity in the treatment of multiple and diffuse AKs. Topical PDT was approved by the FDA in 1999 for the treatment of non-hypertrophic AK lesions on the face and scalp (see Chap. 239). With PDT the topically applied ALA accumulates preferentially in the more rapidly dividing atypical cells and is converted to protoporphyrin IX, a heme precursor and a photosensitizer. When the ALA-treated skin is then exposed to a light source of the appropriate wavelength several hours later, the accumulated protoporphyrin IX generates a phototoxic reaction that destroys the treated cells.[63–67]

Patients can expect some discomfort with PDT, including erythema, edema, and burning or stinging during exposure to the light source. In a subgroup of patients with severe sun damage ALA-PDT can create intolerable pain that requires premature discontinuation of treatment. Allergic reactions to ALA have also been reported. Severe phototoxic reactions can occur if patients do not follow the protocol and practice strict sun avoidance for the prescribed

period after ALA application. Ultimate cosmetic outcomes have been good to excellent.

Prevention

Avoidance of UV radiation is the single most effective means of decreasing the risk of AK. A strategy designed to limit the amount and intensity of sun exposure, starting in childhood and continuing throughout the person's life, will likely decrease the number of AKs an individual will develop. Because complete avoidance of the sun is impractical, the next best preventive measures are to avoid exposure to intense midday sun; consistently apply and reapply broad-spectrum sunscreens; wear UV-protective clothing, hats, and sunglasses; and install UV-protective windows where indicated.

Application of SPF (sun protection factor) 15 sunscreen to mouse skin before UV irradiation has been shown to reduce the frequency of p53 mutations by 88 percent to 92 percent.[69] Sunscreens also reduce the number of tumors induced experimentally in animals exposed to UV irradiation and reduce the development of AKs in humans.[24]

There is limited evidence that adhering to a diet low in fat may decrease the incidence of AKs[70] and NMSC.[71,72] Topical retinoids have been shown to reduce the number of AKs after long-term consistent use.[73,74] More recently, long-term treatment with topical retinoic acid was shown to reduce keratinocyte and melanocyte atypia in photoaged skin.[75] Thus, topical retinoids may play a role in chemoprevention of AKs or maintenance of skin after more effective treatment of existing AKs. Oral retinoids are effective in preventing NMSC and AKs, especially in high-risk patients such as organ transplant recipients and patients with xeroderma pigmentosum, but they are effective only as long as the patient is taking the medication. The combination of low-dose 13-*cis*-retinoic acid (10 mg every other day) and topical tretinoin has been advocated for prophylaxis of both AKs and NMSC in renal transplant recipients.[76] Topical imiquimod is increasingly being used to prevent SCC in the transplant population.[77]

ARSENICAL KERATOSES

Arsenical keratoses (ArKs) are precancerous lesions found in association with chronic arsenicism. These lesions have the potential to develop into invasive SCC. Arsenic is a ubiquitous element that has no color, taste, or odor. It has the potential to cause characteristic acute and chronic syndromes in persons exposed to it, and such exposures are typically obscure because medicinal, occupational, and environmental sources exist. Detection of acute and chronic arsenicism is important, because the acute form can be fatal and the chronic form is associated with a variety of cutaneous and internal malignancies. ArKs are associated with chronic arsenicism.

Epidemiology

Knowledge of the medicinal benefits and poisoning potential of arsenic dates back to ancient times. Arsenic was introduced into the *United States Pharmacopoeia* in 1850, and before its use was discontinued around 1965, it was employed medicinally in the United States and Europe in the form of Fowler's solution, Donovan's solution, and Asiatic pills for treatment of various illnesses such as psoriasis, asthma, and syphilis. Medicinal exposure is now basically limited to treatment of tropical diseases, such as African trypanosomiasis, and more recently to treatment of various hematologic malignancies.[67] Arsenic in opium has been and is still used for medicinal and recreational purposes in India, and inorganic arsenic is still found in some traditional Chinese herbal preparations.[78] Unfortunately, these substances can be easily purchased and are increasingly being used again as homeopathic remedies, which results in modern day cases of what once was primarily a disease of historical interest.

Arsenic exposure can occur in a variety of occupations, either by direct exposure to arsenic or through indirect exposure from contaminated water and landfills. In 1973, it was estimated that more than 1.5 million workers in the United States were potentially exposed to arsenic in the workplace.[79] Occupations that carry risk of exposure include jobs in the mining, smelting, agricultural, computer microchip, forestry, electroplating, semiconductor, and glassmaking industries. Environmental exposure is often obscure and insidious, because there may be latent periods of up to 50 years before manifestations of chronic arsenicism appear. Arsenic is routinely found in soil, and it is found in much higher levels in the well water of certain regions where smelting and mining activities predominate, such as Taiwan, Sweden, and Argentina.[78] Other routes of environmental exposure include some illegally produced alcoholic beverages and the burning of pressure-treated lumber that has been pretreated with chromated copper arsenate. In all forms of medicinal, occupational, and environmental exposures, longer duration of exposure and higher cumulative dose are associated with a higher risk for the development of ArKs.

ARSENICAL KERATOSES AT A GLANCE



- Arsenical keratoses (ArKs) are precancerous lesions associated with chronic arsenicism.
- ArKs have the potential to become squamous cell carcinomas (SCCs).
- Chronic arsenicism has resulted from medicinal, occupational, and environmental exposures.
- Clinical appearance is of punctuate, keratotic, yellow papules overlying pressure points on palms and soles.
- Chronic arsenicism is associated with ArKs, Bowen disease, basal cell carcinoma, SCC, and internal malignancies, with latency periods of up to 40 years.
- No standard recommendations for treatment; most lesions are followed clinically or treated symptomatically.

History

Etiology and Pathogenesis

Arsenic is present as either organic or inorganic compounds as well as in three potential oxidative states: metalloid, trivalent, and tetravalent. Trivalent arsenicals are the most common and hazardous to humans. The toxicity of these compounds depends on the accumulation of arsenic in target tissues and its metabolism and elimination. Organic arsenicals are excreted rapidly. Trivalent inorganic arsenicals are the most acutely and chemically toxic compounds. Because arsenic is metabolized and detoxified in the liver via methylation, pa-



tients with pre-existing liver disease may be at greater risk for arsenic-related toxicity.

The mechanisms of arsenic-induced keratoses and malignancy are not fully understood. Arsenic reacts with the sulfhydryl groups in certain tissue proteins and subsequently affects many different enzymes that are essential to cellular metabolism. Arsenic has been found to cause chromosomal mutations, chromosomal breaks, sister chromatid exchanges, and mutations in p53.[83,84]

Clinical Findings

ArKs typically begin as pinpoint papules that are more easily felt than seen. They develop into small, 2- to 10-mm, punctate, yellow, keratotic papules most commonly seen on the palms and soles in areas of constant pressure or repeated trauma (Fig. 113-8A). They preferentially arise on the thenar and lateral borders of the hands, the sides of the fingers, and sometimes on the dorsal aspects of the fingers, overlying the joints. Although it is unusual, ArKs can be found on more widespread body areas such as the trunk, extremities, eyelids, and genitalia. ArKs may also present as slightly elevated, erythematous, scaly or pigmented plaques. ArKs on the palms and soles are more likely to be seen in individuals with chronic arsenicism caused by medicinal exposure than in those with arsenicism due to occupational exposure. Also, individuals with arsenical-related cancer are more likely to have palmar and plantar ArKs. The mean latency period for the development of ArKs varies considerably from 9 to 30 years.[85]



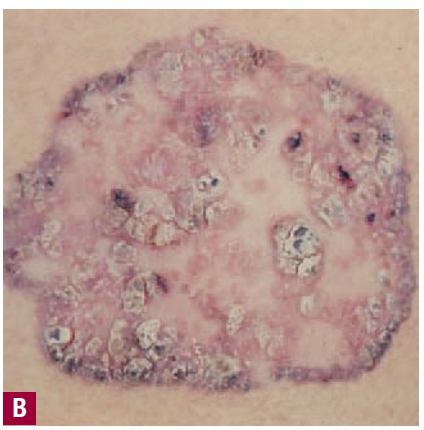

▲ **FIGURE 113-8** **A.** Arsenical keratoses of the palm. (Used with permission from James E. Fitzpatrick, MD, University of Colorado, Department of Dermatology.) **B.** Arsenical-induced in situ squamous cell carcinoma.

Other cutaneous neoplasms associated with chronic arsenicism include BD or SCC in situ, SCC (see Chap. 114), and BCC (see Chap. 115). Mean latency periods for the development of BD and SCC can also be as long as 40 years.[85] With arsenic as the carcinogen rather than UV radiation, these neoplasms, like ArKs, are distributed in more widespread, random, and nonphotodamaged areas. Arsenical BD often begins as a small flesh-colored to pink papule with a thick horny layer or crust. When this crust is removed, the underlying skin appears erythematous and oozing. Over time, unlike the relatively stable ArKs, these lesions increase in size, forming nodular and plaque-like lesions (see Fig. 113-8B) that often group together. Approximately one-third of patients have multiple lesions of BD.[78]

Arsenic-induced BCCs are also usually multiple, and the majority are of the superficial type, although small nodular BCCs are sometimes seen. These BCCs are found in a random, scattered distribution, primarily on the trunk and in hair-bearing regions. Clinically, the superficial BCCs are often indistinguishable from BD. Arsenic-related SCC can arise de novo or from malignant transformation of ArKs and BD lesions. In one study, 55 percent of SCCs arose from pre-existing ArKs or BD lesions.[85] Patients with SCC are more likely to have been exposed to arsenic earlier in life than are those without SCC.[85] They also are more likely to have multiple lesions of BD and more numerous palmar and plantar ArKs. The majority of SCCs have been found on the distal extremities of the hands and feet, and it has been hypothesized that irritation and trauma in these areas may increase the risk of malignant transformation. Clinically, ArKs that show progression to SCC often present with pain, bleeding, fissuring, and later ulceration. They tend to gradually expand in diameter, forming a large erosion or ulceration, and they sometimes reach sizes of up to 20 cm.

Other signs of chronic arsenicism include hyperpigmentation primarily affecting the nipples, axillae, groin, and other pressure points. Within these hyperpigmented patches are often seen small areas of hypopigmentation, resembling "raindrops in the dust." Diffuse alopecia of the scalp may be present. Longer term, patients may develop "blackfoot disease," which is a peripheral vascular disorder affecting the lower extremities that eventually results in gangrene. Hepatic cirrhosis can also occur. A variety of internal malignancies have been associated with chronic arsenicism, with long lag periods of 20 to 50 years reported. The internal malignancies linked with chronic arsenicism include lung, urinary tract, and hepatic tumors, hepatic angiosarcoma, leukemia, and lymphoma.

Histopathology

The histopathologic features of ArKs are essentially the same as those of AKs. No reliable histopathologic criteria can distinguish between the two. Some cases of ArKs are characterized by marked vacuolation of the epithelial cells and keratin horn formation. Also, solar elastosis is usually absent, and a chronic dermal lymphocytic infiltrate is commonly seen. Likewise, arsenic-related BD, BCC, and SCC are histopathologically indistinguishable from their non–arsenic-induced counterparts.

Diagnosis and Differential Diagnosis

ArKs may be mistaken for other types of punctate keratoses, such as disseminated punctate keratoderma, Darier disease, corns, and verruca vulgaris. Disseminated punctate keratoderma usually appears earlier in life. It has also been reported that on removal of the keratinous plugs in punctate keratoderma, small crater-like pits are left behind, whereas no pits are seen on removal of the keratin plugs in ArKs. Darier disease presents with characteristic lesions elsewhere. Corns are usually not so numerous and not so common on the hands. Warts often demonstrate evidence of thrombosed capillaries on removal of the surface keratin.

A diagnosis of ArKs and chronic arsenicism should be considered when numerous characteristic keratoses are seen on the palms and soles or when multiple lesions of BD, SCC, or BCC are found on an individual, especially when these lesions are in non–sun-exposed regions of the body. In most patients with

such neoplasms, palmar and plantar keratoses will also be present. Such patients should be questioned about previous occupations, living conditions, and environmental and medicinal exposures to elicit a history of potential arsenic exposure anywhere from 10 to 40 years previously. Biopsy of any changing ArK or erythematous nodule or plaque on the body should be performed to ensure that BD, BCC, or progression to SCC is not present.

Prognosis and Clinical Course

ArKs and arsenical-induced BD tend to persist for many years, and progression to invasive SCC is believed to be relatively rare. Invasive SCCs that arise in ArKs, however, are more locally aggressive and have a greater chance of metastasis than SCCs arising in AKs.[78] In lesions of arsenical-induced BD, locally invasive SCC has been seen histopathologically in up to 20 percent of cases. Once invasive SCC has occurred in BD, it is said that at least one-third will demonstrate evidence of metastasis unless adequate treatment is provided.[86]

Treatment

Management of patients with chronic arsenicism and ArKs should include regularly scheduled total-body skin examinations and general physical examinations, possibly every 6 months.[85] The exact incidence of internal malignancies associated with chronic arsenicism is unknown, so there is no standard protocol for the evaluation of potential internal malignancies. Exhaustive evaluations to detect such malignancies have not been recommended. Biannual detailed history taking and physical examination, yearly chest radiography, and selective testing when clinically indicated are probably reasonable recommendations.

Treatment of ArKs likewise is not standard and not mandatory, although treatment of these lesions is sometimes initiated to relieve the associated discomfort that some patients experience. Available localized treatment options include surgical excision, cryosurgery, curettage with or without electrocautery, CO_2 laser treatment, and topical chemotherapy with 5-FU, although 5-FU therapy is less successful in treating ArKs than in treating AKs.[78] PDT with ALA has also been used to treat these lesions. Oral retinoids may be useful in reducing the hyperkeratosis associated with ArKs. One can assume that imiquimod may be effective, but there are no studies of its use to date.

THERMAL KERATOSES

Etiology and Pathogenesis

Thermal keratoses (TKs) are keratotic lesions produced in the skin by exposure to infrared radiation. They have the potential to develop into SCC. Various sources of heat are implicated in causing these lesions, and several classic syndromes have been reported. Most notable are the kangri basket cancers in Kashmir, the kang cancers in China, the railway cancers in Britain, and the peat fire cancers in Ireland. The kangri is a pot that contains some type of fuel, such as charcoal, which is held against the thigh or lower abdomen as a source of warmth. In Kashmir, the malignancies would arise in the skin over the lower abdomen and thighs, where the baskets were in contact with the body. Kang are brick beds used primarily in the northeastern part of China that are usually heated by pipes connected to coal-burning stoves. The skin overlying the greater trochanter is where the cancers were most likely to develop. Heat was reported to be responsible for cancer of the skin overlying the shins of railway engine drivers in England. In Ireland, more than 150 women were reported to have lesions of erythema ab igne and SCC on the lower legs. These women all reported many years of sitting close to an open fire of burning peat to stay warm. Because peat is a less efficient fuel than coal, these women had to sit closer to the source to attain adequate warmth. The men did not experience the same cutaneous effects because they primarily wore thick, long trousers. In the United States, TKs, BD, and the development of SCCs have been noted in persons after long-term exposure to coal- and wood-burning stoves used as sources for heat and cooking.[87] The incidence and prevalence of TKs are not known. Likewise, the pathogenesis of these lesions is not fully understood, and the percentage of TKs that will progress to invasive SCC is also unknown. Erythema ab igne, the precursor lesion, has been reported as a result of long-term exposure to laptop computers and electric heating pads.[88]

Clinical Findings

Prolonged exposure to infrared radiation and to sources of heat can clinically produce the characteristic lesion of erythema ab igne, which manifests as an erythematous to brownish, fixed, thick, reticulated patch on the skin overlying the area that has been habitually exposed to heat (see Fig. 73-23 in Chap. 73). It differs from livedo reticularis in that it is more brownish, usually non-blanchable, and fixed. The sites of predilection are the back and abdomen from exposure to hot water bottles and heating pads or blankets, and the lower legs from exposure to fires or heating units as sources of warmth. After many years of such exposure, TKs may appear within these patches of erythema ab igne. SCC in situ within such patches has also been reported, and as with solar-induced AKs, progression to invasive SCC from TKs can occur. Clinically, TKs present as hyperkeratotic papules and plaques.

THERMAL KERATOSES AT A GLANCE

- Precancerous lesions that result from long-term exposure to infrared radiation; can progress to squamous cell carcinoma (SCC).
- Sources of infrared radiation include open fires, railway engines, wood-burning stoves, heating pads and blankets, and laptop computers.
- Precursor lesion is erythema ab igne; biopsy should be performed on any hyperkeratotic papule or plaque within such a patch.
- Risk of progression of thermal keratosis to SCC is unknown.

Histopathology

The histopathologic features of TKs are similar to those of AKs, including alternating hyperkeratosis and parakeratosis, keratinocyte atypia, sparing of the appendageal units, and, interestingly, even dermal elastosis and vascular ectasia. In one study, biopsy specimens from erythema ab igne patches without apparent TKs showed evidence of keratinocyte atypia.[89] Merkel cell carcinoma has also been reported to arise alongside SCC within a patch of erythema ab igne.[90]

Diagnosis and Differential Diagnosis

Biopsy should be performed on hyperkeratotic papules or plaques that de-



velop within a long-standing patch of erythema ab igne to confirm the diagnosis and to rule out progression to SCC.

Prognosis and Treatment

There is a paucity of information in the literature regarding the risk of progression of TK to invasive SCC and the general prognosis of thermal SCC. Similarly, little has been written about the treatment of these lesions. Surgical excision, curettage with or without electrocautery, cryosurgery, and possibly laser therapy appear to be reasonable therapeutic options. Patients with erythema ab igne should be counseled about the need to discontinue exposure to whatever heat source they have been in contact with, and they should be followed long term with physical examinations to identify early changes suggestive of TK or SCC.



HYDROCARBON KERATOSES

Etiology and Pathogenesis

Hydrocarbon keratoses (HKs), also known as *tar keratoses*, *pitch keratoses*, and *tar warts*, are precancerous keratotic skin lesions that occur primarily in persons who are exposed occupationally to polycyclic aromatic hydrocarbons (PAHs). SCC and keratoacanthoma have also been linked to such exposures. PAHs are produced by the incomplete combustion and distillation of coal, natural gas, and oil shale. They are found in tar, fuel oils, lubricating oils, oil shale, and bitumen.[80] Workers at risk for exposure to such compounds include workers in tar distillation and shale extraction, and workers exposed to creosotes, which are one of the main distillate fractions of coal tars and coal tar pitches.[91] Creosotes are used extensively as wood preservatives. Roofers, asphalt workers, road pavers, and highway maintenance workers are exposed to PAHs from fumes formed during the heating of bitumen.[91] Other groups of workers at risk for exposure to coal tar products include railway workers, brick masons, and diesel engineers.[80] Finally, persons exposed to mineral oils, cutting oils, and coolants also are at risk for the development of HKs and SCC.[91]

Clinical Findings

HKs present as small, oval to round, gray, flat papules that are easily removed without residual bleeding. These papules can then become larger and more verrucous in appearance, and eventually may develop into invasive SCC. Sites of predilection include the face, nostril rims, upper lip, forearms, volar wrists, dorsal feet, lower legs, vulva, and scrotum.[93] Of note, the lesions on the nostril rims, upper lip, genitalia, and forearms are not in the typical sun-exposed sites of the body. Thus, keratoses or malignancies in these regions should prompt the physician to inquire about potential occupational hazardous exposures. Other cutaneous findings related to PAH skin exposure include patchy hyperpigmentation, acne, and telangiectases at sites of exposure. The presence of acneiform lesions on the forearms and thighs should alert one to the possibility of PAH exposure. Facial features associated with long-term tar exposure include periocular fibromas, brownish or slate-gray discoloration, comedones, and hair follicle plugs.[93]

PAHs have also been reported to cause internal malignancies, such as lung and bladder cancers.[91]

Histopathology

Histopathologically, HKs appear similar to AKs and ArKs, as previously described. Often, HKs show more of a progression to full-thickness atypia or a bowenoid appearance. In early HKs, it has been said that distinction between benign and malignant epidermal changes can be difficult.

Diagnosis and Differential Diagnosis

HKs, with their grayish keratotic appearance, may be mistaken for verruca vulgaris, stucco keratoses, or even ArKs. A high index of suspicion is needed to make the diagnosis of HKs, because histopathologically they are difficult to distinguish from AKs and ArKs. The distribution of the lesions and other cutaneous findings of tar-exposed skin can aid in the diagnosis and lead to further, pointed questioning of the patient.

Prognosis and Treatment

The exact risk that an HK will progress to SCC is unknown. Most recommendations in the literature call for biopsy and surgical removal of HKs, especially in the vulvar and scrotal regions and on mucosal surfaces, where the risk of early metastasis from SCC is greater. Cryosurgery and curettage with or without electrocautery are probably reasonable treatment options for HKs at other cutaneous sites. Prevention is the key for workers exposed to PAHs in their occupations. Long-term follow-up of individuals with previous known PAH exposures is essential for early diagnosis and treatment of lesions and for early detection of internal malignancy in those at risk.

HYDROCARBON KERATOSES AT A GLANCE

- Hydrocarbon keratoses (HKs) are also known as *pitch keratoses*, *tar keratoses*, and *tar warts*.
- They occur in persons who are occupationally exposed to polycyclic aromatic hydrocarbons (PAHs).
- Occupations at risk include tar distiller, shale extractor, roofer, asphalt worker, road paver, highway maintenance worker, brick mason, diesel engineer, and chimney sweep.
- HK can progress to SCC, but the rate of progression and risk is unknown.
- Latency periods between PAH exposure and development of HK or SCC range from 2.5 to 45 years.
- Presence of atypical keratoses on the nostril rims, upper lip, and genitalia should prompt a search for occupational exposures to PAHs.
- Other skin findings include patchy hyperpigmentation, acne, and telangiectases.

CHRONIC RADIATION KERATOSES

Chronic radiation keratoses (CRKs) are precancerous keratotic lesions that may arise on the skin many years after exposure to ionizing radiation. They have been described in persons exposed to x-ray therapy, including grenz ray therapy for benign skin disorders such as acne vulgaris and tinea capitis; in medical personnel, dentists, and physicians who have administered x-rays over many years[80]; in other professionals who handle radioactive materials in their workplaces; on the fingers of persons who unknowingly wore gold rings contaminated by radioactivity (Fig. 113-9)[95]; in survivors of the atomic bomb in Japan[96]; and in the victims of nuclear accidents such as the one in Chernobyl, Ukraine.[97] For the purpose of the following discussion, *radiation* refers to

CHRONIC RADIATION KERATOSES AT A GLANCE



- Chronic radiation keratoses (CRKs) are precancerous lesions that may arise at irradiated sites years after such exposure and may progress to squamous cell carcinoma (SCC).
- Ionizing radiation sources include x-rays, grenz rays, and contaminated gold rings.
- Common sites are the palms, soles, and mucosal surfaces.
- Clinically present as hyperkeratotic papules or plaques within areas of chronic radiation dermatitis.
- Latency for the development of CRKs can be up to 56 years after exposure.
- Ionizing radiation–induced SCC can be extremely aggressive.
- Patients with ionizing radiation exposure and CRKs are also at risk for internal malignancies.

ionizing radiation; thus, the UV and infrared spectra of radiation are excluded.

Clinical Findings

The primary neoplasms resulting in the skin from exposure to ionizing radiation are CRKs, BCCs, and SCCs. Cutaneous sarcomas rarely occur. CRKs and BCCs are seen more commonly than SCCs, but any given CRK can potentially evolve into invasive SCC. The site and penetration of the ionizing radiation determine which type of tumor develops; palms, soles, and mucosal surfaces are said to be favored locations for CRK. The neoplasms that develop are often multiple, heal poorly, and recur frequently.[80] CRKs usually develop within areas of chronic radiation dermatitis or in persistent ulcerations arising in such chronically damaged areas of the skin. They appear as hyperkeratotic papules or plaques (see Fig. 113-9). The latency period from the time of exposure to the development of CRKs and radiation-induced skin cancers is typically long, having been reported to range up to 56 years. The latency period for the development of these tumors is inversely proportional to the radiation dose. Patients exposed to ionizing radiation are also at risk for the development of internal malignancies, such as those of the breast, bone, soft tissue, uterus, larynx, pharynx, thyroid, and maxillary sinus.[80]



▲ **FIGURE 113-9** Chronic radiation keratoses and squamous cell carcinoma on the thumb of an elderly radiologist who had not used gloves when doing fluoroscopic work.

Histopathology

Histopathologically, CRKs display keratinocyte dyskeratosis with hyperchromatic nuclei and abnormal mitoses. The dermis often demonstrates findings consistent with long-term radiation-induced changes, such as hyalinization of the collagen bundles, thickening and occlusion of deep dermal blood vessels, endothelial cell atypia, and destruction of the pilosebaceous units.

Prognosis and Treatment

Surgical excision is often the treatment of choice, because radiation-induced SCCs have a higher potential for metastases. Persons with ionizing radiation exposure should be followed with skin examinations at regular intervals for the rest of their lives, because the latency period for the development of cutaneous neoplasms is quite long, and the number of skin cancers in such patients tends to increase with time after irradiation. Evaluation for the development of internal malignancies, for which this exposure carries high risk, should also be considered in the long-term follow-up of these patients. Finally, these patients should be counseled to avoid other potential carcinogens, such as UV radiation.

CHRONIC SCAR KERATOSES

Chronic scar keratoses (CSKs), also known as *chronic cicatrix keratoses*, are precancerous keratotic lesions that arise in long-standing scars. CSKs can arise in association with a number of different chronic scarring processes, such as chronic ulcers, burn scars, pilonidal sinuses, draining sinuses, chronic osteomyelitis, vaccination scars, chronic hidradenitis suppurativa, old frostbite scars, and scarring acne vulgaris.

History

Etiology and Pathogenesis

The pathogenesis of a pre-malignant keratosis or a carcinoma arising in a

CHRONIC SCAR KERATOSES AT A GLANCE

- Chronic scar keratoses (CSKs), or cicatrix keratoses, are precancerous lesions that arise in long-standing scars from various causes.
- *Marjolin's ulcer* describes malignant changes within a burn scar but can also refer to such changes in chronic ulcers or sinus tracts.
- Approximately 2 percent of burn scars will undergo malignant changes.
- Most burn scar carcinomas are squamous cell carcinomas, but basal cell carcinomas, melanomas, sarcomas, and malignant fibrous histiocytomas have also been described.
- Acute Marjolin's ulcer develops within 1 year of the time of injury; chronic Marjolin's ulcer develops more than 1 year after an injury, with an average latency period of 36 years.
- Sites of predilection are the extremities and overlying joints.
- Any persistent lesion, erosion, or ulceration within a scar requires biopsy.
- Prevention includes excellent wound care, early skin grafting, avoidance of contractures, and early excision of any tissue showing degenerative changes.



chronic scar is not known. Proposed mechanisms for malignant degeneration within a burn scar include production of a carcinogenic toxin with the burn injury; immunologic privilege within scarred tissue that allows unchecked tumor growth; chronic irritation leading to malignancy; multi-step carcinogenesis involving initiation, promotion, and progression; and burn-induced DNA damage leading to malignant transformation. Characteristics of the burn scar that predispose to malignant transformation include a prolonged healing phase, repetitive trauma, and graft rejection.

Clinical Findings



CSKs present as hyperkeratotic papules, plaques, or erosions within the scarred skin. In terms of burn scars, two clinical types of carcinoma have been described. The more common presentation is of a flat, ulcerative, indurated lesion with elevated borders and surrounding induration. The less common type is an exophytic, papillomatous lesion resembling granulation tissue.[100] Bleeding, pain, and a foul odor may also be present. Typically, chronic and recurrent ulcerations have been present in the burn scar before malignant degeneration, and the malignancy often develops at an ulcer margin. One important fact about burn scar carcinomas is that usually only a portion of the ulcer undergoes malignant transformation. The remaining ulcer persists as a nonhealing wound, and thus the rate of false-negative results from biopsies of the ulcer is quite high.[99] Sites of predilection for burn scar carcinomas are the extremities and areas overlying joints, presumably because of repeated trauma in these areas.

Histopathology

Histopathologically, most scar keratoses range in pattern from several atypical keratinocytes to full-thickness epidermal atypia or in situ SCC. The majority of burn scar carcinomas are of the well-differentiated squamous cell type. When the diagnosis is based on histopathologic features, scar keratoses may be confused with pseudoepitheliomatous hyperplasia, a benign reactionary process.

Diagnosis

Biopsy should be performed on any persistent lesion, erosion, or ulceration within a scar. In addition, for burn scar carcinomas, because only a portion of the ulcer may be malignant, multiple biopsies or excisional biopsies are recommended if the suspicion of carcinoma is high, so the diagnosis will not be missed.

Prognosis and Clinical Course

CSKs may show a gradual progression to in situ carcinoma and frank SCC. Prompt diagnosis of these lesions is important, because once invasive SCC develops in a scar, it can quickly become aggressive, and the risk for metastasis is high. For burn scar carcinoma, the metastatic rate is estimated at approximately 35 percent, much higher than for actinically induced SCC.[100] Lesions occurring on the lower extremities have the highest rates of metastases, averaging 50 percent,[102] whereas those on the head, neck, and upper extremities fare better. Lymph node metastasis on presentation is the single most important indicator of poor prognosis.

Treatment and Prevention

Burn scar carcinoma may be prevented by meticulous burn wound care, early skin grafting, prompt treatment of infections, avoidance of contractures, and early excision of any degenerative changes within the scarred area, with step sections through the specimen to ensure that a malignancy has not been missed. Excision with wide margins (at least 2 cm) is the treatment of choice for burn scar carcinoma.[100,102] Radiation therapy and topical chemotherapy have not been beneficial in the treatment of these lesions.[100,102]

REACTIONAL KERATOSES

Reactional keratoses (RKs) are pre-malignant keratotic lesions that may arise in a variety of long-standing, non-scarring, inflammatory processes such as cutaneous lupus erythematosus, necrobiosis lipoidica, porokeratosis, erythema elevatum diutinum, granuloma inguinale, epidermolysis bullosa variants, pemphigus vulgaris, lichen sclerosis, lichen planus, and chronic deep fungal infections. Clinically, RKs present as hyperkeratotic papules or plaques. As with other precancerous keratotic lesions, a continuum from RK to SCC in situ to invasive SCC may be seen. Once invasive SCC has appeared, there is a significant risk that metastatic disease will develop, similar to that with scar keratoses. The main diagnosis to consider in the clinical and histologic differential is pseudoepitheliomatous hyperplasia.

PUVA KERATOSES

Psoralen plus ultraviolet A (PUVA) keratoses are precancerous keratotic lesions that arise in individuals exposed to PUVA for the treatment of a variety of cutaneous conditions. UVA light alone is thought to play a role in skin cancer formation, but the combination of UVA with psoralen is associated with a dose-dependent increased risk of pre-malignant keratoses and other cutaneous malignancies, such as SCC, melanoma, and, possibly, Merkel cell carcinoma (see Chaps. 112 and 239).

VIRAL KERATOSES

Viral keratoses, otherwise known as *warts*, are some of the most common keratotic lesions in humans. These lesions are caused by infection with the human papillomavirus (HPV). The role of HPV as an etiologic agent in the development of pre-malignant and malignant neoplasms is discussed further in Chaps. 111 and 196.

Bowenoid Papulosis

Bowenoid papulosis (BP) is characterized clinically by the presence of pigmented verrucous papules and plaques primarily on the genitalia of predisposed individuals, and histopathologically by the presence of SCC in situ–like changes (Fig. 113-10) (see also Chap. 75).

BP is caused by infection with HPV, and numerous HPV types have been linked to BP, including types 16, 18, 31 to 35, 39, 42, 48, and 51 to 54 (see Chap. 196). Lesions are pink, reddish brown, or violaceous (see Fig. 113-10). Differential diagnosis includes early condylomata acuminata (see Chaps. 75 and 76).

Histopathologically, the epidermis is usually hyperplastic with atypia, disordered maturation, scattered mitotic figures, and dyskeratotic keratinocytes.

The course of BP is variable, ranging from spontaneous regression to persistence of lesions to transformation into BD and invasive SCC. Patients with BP and their sexual partners should be followed and examined periodically, because of the risk of developing SCC, cervical, and vulvar neoplasia.[106] Patients with persistent disease should probably undergo testing for altered immune status. Treatment of BP is recommended, and it typically responds well to local therapy, although recurrences are common. Therapeutic options include local destructive measures such as curettage

VIRAL KERATOSES AT A GLANCE



- Two viral keratoses with the potential for malignant transformation are bowenoid papulosis (BP) and epidermodysplasia verruciformis (EV).
- BP is a precancerous condition of the genitalia caused by infection with human papillomavirus (HPV); oncogenic types 16, 18, and 33 are most commonly involved.
- BP may regress spontaneously, persist, or transform into Bowen disease or squamous cell carcinoma (SCC).
- Treatment options include topical imiquimod, curettage, excision, and laser vaporization.
- Sexual partners of patients must be examined and followed closely for development of cervical, vulvar, or penile carcinoma.
- EV is a rare autosomal recessive disease associated with mutations in the EVER1 and EVER2 genes.
- Affected individuals show a propensity toward infection with certain strains of HPV-5 and HPV-8.
- Clinical presentation is widespread flat wart-like papules and plaques in childhood; risk of developing SCC later in life is high.
- Sun avoidance, sun-protective measures, regular dermatologic follow-up, and screening of family members for the disease is important.

with or without electrocautery, CO_2 laser, neodymium:YAG laser, cryosurgery, and excision. Topical tretinoin, topical 5-FU, and topical cidofovir have been used in anecdotally reported cases with mixed results.[107] More recently, topical 5 percent imiquimod cream has shown promising results in a few case reports and would be the logical choice given its efficacy against HPV.[108–111]

Epidermodysplasia Verruciformis (See Chap. 196)

Epidermodysplasia verruciformis (EV) is a rare autosomal recessive genetic disease that manifests in childhood with disseminated flat, wart-like papules and plaques. These individuals are at high risk for the development of SCC in these wart-like lesions, which result from an abnormal propensity to infection with certain HPV sub-types, most notably HPV-5 and HPV-8 (see Chaps. 111 and 196). A susceptibility locus for EV was localized to chromosome band 17q25 in 1999,[112] and mutations in two novel genes from this same region (EVER1 and EVER2) were identified and associated with EV more recently.[113]

These patients present with numerous thin, pink, flat papules and plaques that resemble verruca plana. They also may have widespread scaly, erythematous, or hypopigmented macules and flat papules that appear similar to tinea versicolor.



◀ **FIGURE 113-10** Bowenoid papulosis of the penis. (Used with permission from James E. Fitzpatrick, MD.)

SQUAMOUS CELL CARCINOMA IN SITU (BOWEN DISEASE)

BD is SCC in situ, originally described in 1912 by John T. Bowen, a Boston dermatologist.[114] It affects both skin and mucous membranes and has the potential to progress to invasive SCC.

Epidemiology

BD may occur at any age in adults, but it is rarely seen in individuals younger than 30 years. The typical patient with BD is older than 60 years. The disease is said to occur with an equal incidence in men and women, although most studies report a slight preponderance in women.[115] BD can be found on any body site, including both sun-exposed and non–sun-exposed regions of the body, although it appears to have a predilection for sun-exposed surfaces such as the head and neck and for the lower legs of women, in particular. The exact incidence of BD in the United States is unknown, but in one population study in Hawaii, the incidence was estimated at 142 per 100,000 persons.[116] Lesions of BD are usually solitary but are multiple in up to 10 percent to 20 percent of individuals.

Etiology and Pathogenesis

A number of different factors have been implicated in the development of BD, including a history of significant sun exposure, arsenic exposure, ionizing radiation, immunosuppression, and certain types of HPV infection. Up to 30 percent of extragenital BD lesions have been found to harbor HPV DNA.[117,118] The age group and sites of predilection of BD suggest a strong association with sun exposure. BD is also rare in more heavily pigmented individuals, and it has been described with increased frequency in patients undergoing PUVA therapy. The association with arsenic exposure has already been discussed. SCC in situ is seen commonly in organ transplant recipients after years of immunosuppressive drug therapy. Infection with HPV has been implicated in causing certain sub-types of BD. In particular, HPV-16 has been detected in many cases of anogenital BD and in some cases of finger and periungual BD.[119]

Clinical Findings

BD typically presents as a discrete, slowly enlarging, pink to erythematous thin plaque with well-demarcated, irregular borders and overlying scale or crust (Fig. 113-11A) resembling a psoriatic plaque. Hyperkeratotic and verrucous surface changes may be seen, and a pigmented variant of BD has been reported in fewer than 2 percent of cases.[120] Indi-



SQUAMOUS CELL CARCINOMA IN SITU (BOWEN DISEASE)

AT A GLANCE



- Bowen disease (BD) is squamous cell carcinoma (SCC) in situ, with the potential to progress to SCC.
- Etiologic factors include ultraviolet radiation exposure, chronic arsenicism, previous therapy with psoralen and ultraviolet A radiation, immunosuppression, exposure to ionizing radiation, and infection with human papillomavirus.
- Clinical variants are pigmented, intertriginous, periungual, and subungual BD.
- Histopathologic features include full-thickness epidermal atypia with adnexal involvement.
- Lesions progress to invasive carcinoma in 3 percent to 5 percent of cases.
- Treatment methods include excision and Mohs micrographic surgery, which permit histopathologic evaluation to exclude invasive SCC.
- Curettage treatment of BD may miss appendageal involvement.
- Topical therapy may be used in areas that are difficult to treat with other methods.



vidual lesions may measure up to several centimeters in diameter, and multiple lesions are not uncommon. As previously mentioned, sites of predilection include sun-exposed areas such as the head and neck and lower legs, although any body site may be affected.

A few clinical variants of BD deserve special mention. Intertriginous BD can present as an oozing, erythematous, dermatitic plaque or as a pigmented patch or plaque. BD involving the periungual region may appear as an erythematous, scaly, thin plaque around the cuticular margin, a crusted erosion, nail discoloration or onycholysis, a verrucous plaque, or destruction of the nail plate. BD of the mucosal surfaces can present as verrucous or polypoid papules and plaques, erythroplakia, or a velvety erythematous plaque. These last two entities are discussed separately in the sections Erythroplakia (Erythroplasia) and Erythroplasia of Queyrat.



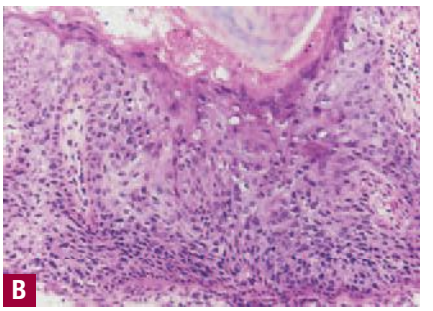

▲ **FIGURE 113-11** **A.** Large plaque of Bowen disease of the leg. **B.** Bowen disease showing full-thickness atypia of epithelium.

Histopathology

The epidermis displays full-thickness atypia, including in the intraepidermal portions of the adnexal structures (see Fig. 113-11B). Involvement reaches from the stratum corneum down through the basal cell layer, although the basement membrane remains intact. Characteristically, parakeratosis and hyperkeratosis are present, as is acanthosis, with complete disorganization of the epidermal architecture. At times the hyperkeratosis and parakeratosis are so pronounced that a cutaneous horn is present. Throughout the epidermis are numerous atypical, pleomorphic, hyperchromatic keratinocytes. These cells are sometimes vacuolated and have a prominent pale-staining cytoplasm, reminiscent of the cells in Paget disease. These cells show loss of maturation and polarity, in addition to numerous mitotic figures. Individually keratinized cells with large, rounded, eosinophilic cytoplasm and hyperchromatic nuclei can be found in the epidermis, as can multinucleated cells. These atypical cells also are seen throughout the pilosebaceous units, within the acrotrichia, follicular infundibula, and sebaceous glands. The upper dermis is typically infiltrated by numerous cells associated with chronic inflammation, including lymphocytes, plasma cells, and histiocytes.

Diagnosis and Differential Diagnosis

Clinically, BD is most often mistaken for superficial BCC; patches of dermatitis, psoriasis, or lichen planus; AK; benign lichenoid keratosis or lichen planus–like keratosis; irritated seborrheic keratosis; or amelanotic melanoma (Box 113-4). More hyperkeratotic or verrucous lesions of BD may be difficult to distinguish clinically from viral warts, seborrheic keratoses, and SCC, and pigmented BD lesions can be mistaken for melanoma. Superficial BCC can sometimes be distinguished by its raised, subtle, translucent border.

Prognosis and Clinical Course

The risk that untreated BD will progress to invasive carcinoma has been estimated in one older study at approximately 3 percent to 5 percent.[117] Estimates are that once invasive carcinoma occurs in BD [see thumbnail image in Squamous Cell Carcinoma In Situ (Bowen Disease) At a Glance box], approximately 13 percent of these carcinomas will metastasize, and, of these cases, 10 percent will end in death from widespread dissemination.[122]

The presence of BD in any given individual is a marker for a high risk of developing a subsequent NMSC.[123] In studies addressing the association between the presence of BD and the risk of other NMSCs, approximately 30 percent to 50 percent of BD patients had either previous or subsequent NMSC. Another study estimated the incidence ratio for subsequent NMSC to be 4.3.[123] Previous studies also claimed that the presence of BD is a marker for internal malignancy, although a significant number of other investigations have been unable to substantiate this association. Critical analysis and meta-analysis of these past studies do not support the need for routine investigation for internal malignancy in persons with BD. The one exception to this position is in cases of BD related to previous arsenic exposure, in which the possibility of internal malignancy is real, as previously discussed. Also, BD involving the vulvar region in females has been associated

Box 113-4

Clinical and Histopathologic Differential Diagnosis of Bowen Disease

CLINICAL DIFFERENTIAL DIAGNOSIS OF BOWEN DISEASE

- Erythematous Bowen disease
  - Superficial basal cell carcinoma
  - Dermatitis, eczema
  - Psoriasis
  - Seborrheic dermatitis
  - Lichen planus
  - Benign lichenoid keratosis
  - Irritated or inflamed seborrheic keratosis
  - Actinic keratosis
  - Squamous cell carcinoma
  - Amelanotic melanoma
- Hyperkeratotic Bowen disease
  - Verruca vulgaris
  - Seborrheic keratosis
  - Discoid lupus erythematosus
  - Hypertrophic lichen planus
  - Squamous cell carcinoma
- Pigmented Bowen disease
  - Melanoma
  - Bowenoid papulosis
- Intertriginous Bowen disease
  - Inverse psoriasis
  - Seborrheic dermatitis
  - Candidiasis
  - Paget disease
  - Hailey-Hailey disease
- Subungual or periungual Bowen disease
  - Nail dystrophy
  - Onychomycosis
  - Squamous cell carcinoma
  - Amelanotic melanoma

HISTOPATHOLOGIC DIFFERENTIAL DIAGNOSIS OF BOWEN DISEASE

- Paget disease
- Pagetoid melanoma in situ
- Eccrine carcinoma
- Merkel cell carcinoma
- Sebaceous carcinoma
- Bowenoid papulosis
- Podophyllin-induced changes in a wart

with an increased risk of uterine, cervical, and vaginal cancer, possibly due to HPV infection, as discussed.[86,124]

Treatment

A number of different modalities are available for the treatment of BD. Such treatments can be divided into three main categories: surgical and destructive therapies, topical therapies, and non-surgical ablative therapies (Box 113-5). Surgical and destructive therapies include excision, Mohs micrographic surgery, curettage with or without electrocautery, chemoablation with TCA, and cryosurgery. Topical therapies include 5-FU and 5 percent imiquimod cream (see Chap. 221). Non-surgical ablative therapies are laser ablation, radiotherapy, and PDT (see Chap. 239). Although some of these modalities have reported cure rates that are better than others, no one treatment is right for all forms of BD. Therapy must be guided by the size and location of the BD, in addition to individual patient characteristics, such as age and healing capability.

Box 113-5

Treatment of Bowen Disease

SURGICAL AND DESTRUCTIVE THERAPIES

- Excision
- Mohs micrographic surgery
- Curettage with or without electrocautery
- Liquid nitrogen cryosurgery

TOPICAL THERAPIES

- 5-Fluorouracil (5% cream bid for 6–16 wk)
- 5% imiquimod (daily for 16 wk)

NON-SURGICAL ABLATIVE THERAPIES

- Laser ablation
- Radiotherapy
- Photodynamic therapy

ERYTHROPLASIA OF QUEYRAT

ERYTHROPLASIA OF QUEYRAT AT A GLANCE



- Erythroplasia of Queyrat (EQ) is an in situ squamous cell carcinoma (SCC) involving the mucosal surfaces of the penis in uncircumcised males.
- EQ is clinically distinct from Bowen disease.
- Human papillomavirus types 8 and 16 are identified in most cases.
- EQ progresses to invasive SCC in approximately 10 percent of cases.
- Preventive measures include circumcision and excellent hygiene.
- Recommended treatment is Mohs micrographic surgery. Excision, CO_2 laser vaporization, and topical 5-fluorouracil are secondary alternatives.

Etiology and Pathogenesis

Erythroplasia of Queyrat (EQ) is an in situ SCC affecting the mucosal surfaces of the penis in uncircumcised males. This condition was described by Queyrat in 1911 as "erythroplasie du gland."[125] The term *erythroplasia of Queyrat*, rather than simply SCC in situ or BD, is preferred for this condition because it is clinically distinct, presenting as a well-demarcated, shiny, velvety, bright red plaque. EQ occurs in uncircumcised men between the ages of 20 and 80 years, although the majority of cases are seen between the third and sixth decades. Risk factors for the development of this condition in uncircumcised males include poor hygiene, accumulation of smegma, heat, friction, trauma, and genital herpes simplex virus infection.[126] Co-infection with HPV subtypes 8 and 16 was identified in almost all EQ lesions that were investigated in one study.[126] Additional co-infection with HPV sub-types 39 and/or 51 was seen in several of these lesions. This study proposed that EQ differs from BD and other genital neoplasias in that co-infection with HPV-8 and other carcinogenic genital HPV types occurs in EQ.

Clinical Findings

EQ presents as a glistening, red, velvety plaque on the glans penis, the prepuce, or the urethra (Fig. 113-12). It begins as a solitary plaque in approximately 50 percent of cases, and as multiple plaques in the remainder.[86] Affected males complain of localized pain, pruritus, difficulty retracting the foreskin over the glans, bleeding, and crusting (see Chap. 75).



▲ **FIGURE 113-12** Erythroplasia of Queyrat. (Used with permission from James E. Fitzpatrick, MD.)



Histopathology

Histopathologically, EQ is similar to BD as previously described. In addition, there may also be epidermal hypoplasia and many more plasma cells in the dermal infiltrate, as is often seen in other processes affecting mucosal surfaces.

Diagnosis and Differential Diagnosis

The differential diagnosis includes other benign inflammatory conditions such as psoriasis, seborrheic dermatitis, lichen planus, lichen sclerosus, candidiasis, plasma cell balanitis (Zoon balanitis), lymphogranuloma venereum, granuloma inguinale, syphilis, and drug eruptions. If the diagnosis of EQ is under consideration, a biopsy should be performed.



Prognosis and Clinical Course

Lesions of EQ persist and enlarge slowly, and they typically have been present for several years (an average of 3.4 years in one study)[127] before a biopsy is taken. Progression of EQ to invasive SCC is more common than for the lesions of BD and is said to occur in approximately 10 percent of cases.[126,128] Once invasive SCC has occurred, approximately 20 percent of patients will display evidence of regional lymph node involvement or more distant metastases.[86]

Treatment and Prevention

Prevention of EQ in uncircumcised males may be maximized by adherence to good personal hygiene regimens, and early circumcision may also reduce the incidence of this disease. Several treatment options are available, including excision, Mohs micrographic surgery, CO_2 laser ablation, topical 5-FU, and topical imiquimod. Because of the strong association of EQ with HPV infection, topical imiquimod would intuitively seem a likely treatment choice for EQ. Several case reports have demonstrated its efficacy in treating EQ,[117] but no large, well-designed studies have been published to date to confirm its efficacy in treating this disease. Review of current data indicates that PDT does not yet seem to be as effective as a lone treatment modality for EQ.[129]

LEUKOPLAKIA

Leukoplakia is a clinical term that refers to a predominantly white lesion of the oral mucosa that cannot be rubbed off or characterized by any other definable lesion or known disease.[130] Leukoplakia is the most common precancerous lesion of the oral mucosa, with the potential to become oral SCC (OSCC).[131] Oral leukoplakia (OL) is in the same clinical spectrum of disease as oral erythroplakia (OE), but unlike OE it is a much more frequently diagnosed lesion with a much lower rate of malignant transformation.

Epidemiology

The reported prevalence of OL varies from 0.2 percent to 5 percent, although such rates vary significantly among different geographical areas and demographic groups.[132] In a worldwide systematic review of OL that included multiple studies involving more than 1000 subjects, prevalence rates varied between 0.50 percent and 3.46 percent.[133] The pooled prevalence estimate of OL in this study was between 1.49 percent and 4.27 percent.[133]

In addition to potentially becoming a malignant growth, OL, and for that matter OE, have come to be viewed as risk factors or markers for other epithelial cancers of the oral cavity and upper aerodigestive tract. The concept of field cancerization applied to the oral mucosa implies that its entire surface can be affected by carcinogens. Indeed, approximately 20 percent of patients with SCC of the head and neck will develop another malignancy or precancerous lesion within 5 years of the first diagnosis.[134]

Etiology and Pathogenesis

Given the current definition of leukoplakia, identification of an etiologic factor for a given white lesion would exclude this diagnosis. Two factors in this setting are tobacco use and candidiasis. Tobacco use is believed to be a strong risk factor for the development of OL. Tobacco-related white lesions of the oral mucosa have been identified and then subsequently found to disappear once the habit of tobacco use has been discontinued. By current definitions and standards, such tobacco-related white lesions are thought to be different entities than true OL, which would not disappear with cessation of tobacco use.

Likewise, there has been much debate as to whether or not *Candida* infection is a cause of leukoplakia or a superimposed infection within a pre-existing OL lesion. If one adheres to the strict and accepted definition of leukoplakia, a white lesion that disappears upon treatment of *Candida* infection is not leukoplakia. Thus, it is probably best to make a preliminary diagnosis of leukoplakia and then treat any underlying candidal infection and have the patient discontinue use of any tobacco products to see if the white lesion resolves. If such a lesion then resolves, it is not true leukoplakia.

LEUKOPLAKIA AT A GLANCE

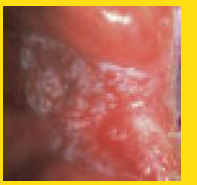

- Leukoplakia is a clinical diagnosis of exclusion for a fixed white lesion in the oral cavity that does not resolve spontaneously.
- Oral leukoplakia (OL) is the most common precancerous lesion of the oral mucosa, with the potential to become oral squamous cell carcinoma (OSCC).
- Prevalence is 0.2 percent to 5.0 percent.
- Approximately 50 percent of OSCCs are associated with precancerous lesions.
- OL and oral erythroplakia are markers for increased risk for additional oral or upper aerodigestive tract malignancies.
- Risk factors for OL are the use of any tobacco product, concomitant alcohol use, history of previous OSCC or premalignant lesions, and infection with certain human papillomavirus sub-types.
- No consensus exists on how best to treat OL.

Clinical Findings

OL is clinically divided into two subtypes: homogeneous OL and non-homogeneous OL. Homogeneous OL has been defined as a mostly white, flat, uniform lesion that may have shallow cracks and a smooth, wrinkled, or corrugated surface that is consistent throughout.[137] Non-homogeneous OL has been defined as a mostly white or white and red lesion (erythroleukoplakia) that may be either irregular and flat, nodular (speckled), ulcerative, or verrucous. Non-homogeneous OL purportedly has a risk of malignant transformation that is four to five times higher than that of homogeneous OL. Another clinical sub-type of OL is proliferative verrucous leukoplakia, which

is most often found in patients who do not use tobacco products. This sub-type has a high rate of transformation to malignancy.[138]

Histopathology

If the provisional diagnosis of OL is at all in doubt and/or a waiting period to assess for possible regression or disappearance of a white lesion after eliminating possible causative factors has not resulted in resolution of the lesion, the next advisable step in evaluating the oral white lesion is to obtain a biopsy specimen for histopathologic diagnosis. This is where the concepts of epithelial dysplasia and carcinoma in situ enter the picture.

In relation to the oral mucosa, epithelial dysplasia has been defined as a "precancerous lesion of stratified squamous epithelium characterized by cellular atypia and loss of normal maturation and stratification short of carcinoma in situ."[143] Carcinoma in situ of the oral cavity has been described as "a lesion in which the full thickness, or almost the full thickness, of squamous epithelium shows the cellular features of carcinoma without stromal invasion."[143] Criteria have been put forth for diagnosing these changes, and the more prominent and numerous the designated features are, the more severe the grade of dysplasia.[131,137]

Diagnosis and Differential Diagnosis

A diagnosis of leukoplakia is made when a fixed white lesion of the oral mucosa is detected and cannot be identified as any other definable lesion or condition. Some suggest distinguishing between a provisional clinical diagnosis of OL and a definitive diagnosis of OL.[130] A provisional diagnosis of OL is made at the time of the initial examination when no other diagnosis for the white lesion is obvious. At this point, other possibilities to consider in the differential diagnosis are tobacco-associated lesions, *Candida*-associated lesions, lichen planus, leukoedema, lupus erythematosus, Epstein-Barr virus–associated oral hairy leukoplakia, oral white sponge nevus, mechanical or frictional irritation, contact lesions, cheek/lip/tongue biting, linea alba, aspirin burn, OSCC, and verrucous carcinoma (Box 113-6). If causative factors for the white lesion are suspected, it is recommended that these factors be eliminated for a period of 2 to 6 weeks to observe for regression of the white lesion. If on re-evaluation the white lesion persists, biopsy should be performed. If the lesion is a clinically high-risk one, biopsy should be performed before such a waiting period.

Box 113-6

Clinical Differential Diagnosis of Oral Leukoplakia and Oral Erythroplakia

CLINICAL DIFFERENTIAL DIAGNOSIS OF ORAL LEUKOPLAKIA

- Tobacco-associated lesion
- *Candida*-associated lesion
- Leukoedema
- Lichen planus
- Lupus erythematosus
- Linea alba
- Habitual cheek biting
- Frictional lesion
- Aspirin burn
- Oral white sponge nevus
- Oral hairy leukoplakia
- Verrucous carcinoma
- Squamous cell carcinoma

CLINICAL DIFFERENTIAL DIAGNOSIS OF ORAL ERYTHROPLAKIA

- Erythematous candidiasis
- Atrophic lichen planus
- Lupus erythematosus
- Pemphigus
- Cicatricial pemphigoid
- Kaposi sarcoma
- Chronic contact or allergic contact dermatitis
- Chronic mechanical trauma
- Thermal or mechanical injury
- Squamous cell carcinoma
- Amelanotic melanoma

Prognosis and Clinical Course

Once a definitive diagnosis of OL has been made, the risk of transformation to OSCC needs to be evaluated. The rate of malignant transformation of OL into OSCC has been found to vary from almost 0 percent to 20 percent in 1 to 30 years.[144] A study based on European epidemiologic data investigated the natural limit of malignant transformation of OL to OSCC. This study concluded that the upper limit of the annual malignant transformation rate of OL is unlikely to exceed 1 percent.[132]

DNA aneuploidy has shown the most promise as a prognostic indicator. DNA content (DNA ploidy) of a cell roughly estimates the amount of genetic instability and aberrant DNA. In malignancies the genetically stable diploid and tetraploid cells are replaced by genetically unstable aneuploid cells. In some studies DNA aneuploidy was a powerful predictor of the development of OSCC in OL lesions, whereas normal DNA content indicated a low risk.[145] A more recent study showed that additional oral malignancies consistently arose in patients whose dysplastic OL was marked by aneuploidy and that these individuals also had worse survival rates.[146] In addition, these investigators found that surgical removal of these dysplastic OL lesions with histologically clear margins did not result in better outcomes. They proposed that it is aneuploidy that best predicts poor survival in dysplastic OL.

Treatment and Prevention

There is no consensus on the most appropriate treatment for OL. Some recommend the following approach: if no or mild epithelial dysplasia exists histopathologically, pursue treatment if the OL is in a high-risk location or is large; if moderate or severe dysplasia exists histopathologically, then active treatment to remove the entire lesion is recommended.[137]

Because the recurrence of OL after treatment is common, because the risk of OSCC is present with or without treatment, and because patients with OL are at increased risk for additional head and neck malignancies, these patients need to be followed at regular intervals with thorough examinations and potentially with additional sampling biopsies. Follow-up intervals may vary from every 3 months in individuals at high risk to every 6 months in those at lower risk, for the rest of the patients' lives.

Despite all the controversies and inconsistencies surrounding OL, standard historical, clinical, and histopathologic findings are still the most important factors for predicting the possibility of malignant transformation of precancerous oral lesions. Evaluation for DNA aneuploidy in dysplastic OL may represent a useful tool in the near future for predicting potential aggressiveness and poor outcomes, but it is not yet available in mainstream clinical practice.

Treatment plans are guided mostly by findings from careful clinical and oral examinations, especially in individuals at high risk, and by histopathologic evaluation for the presence and degree of epithelial dysplasia (Fig. 113-13).

ERYTHROPLAKIA (ERYTHROPLASIA)

Erythroplakia, or *erythroplasia*, is a clinical term used to describe a red macule or





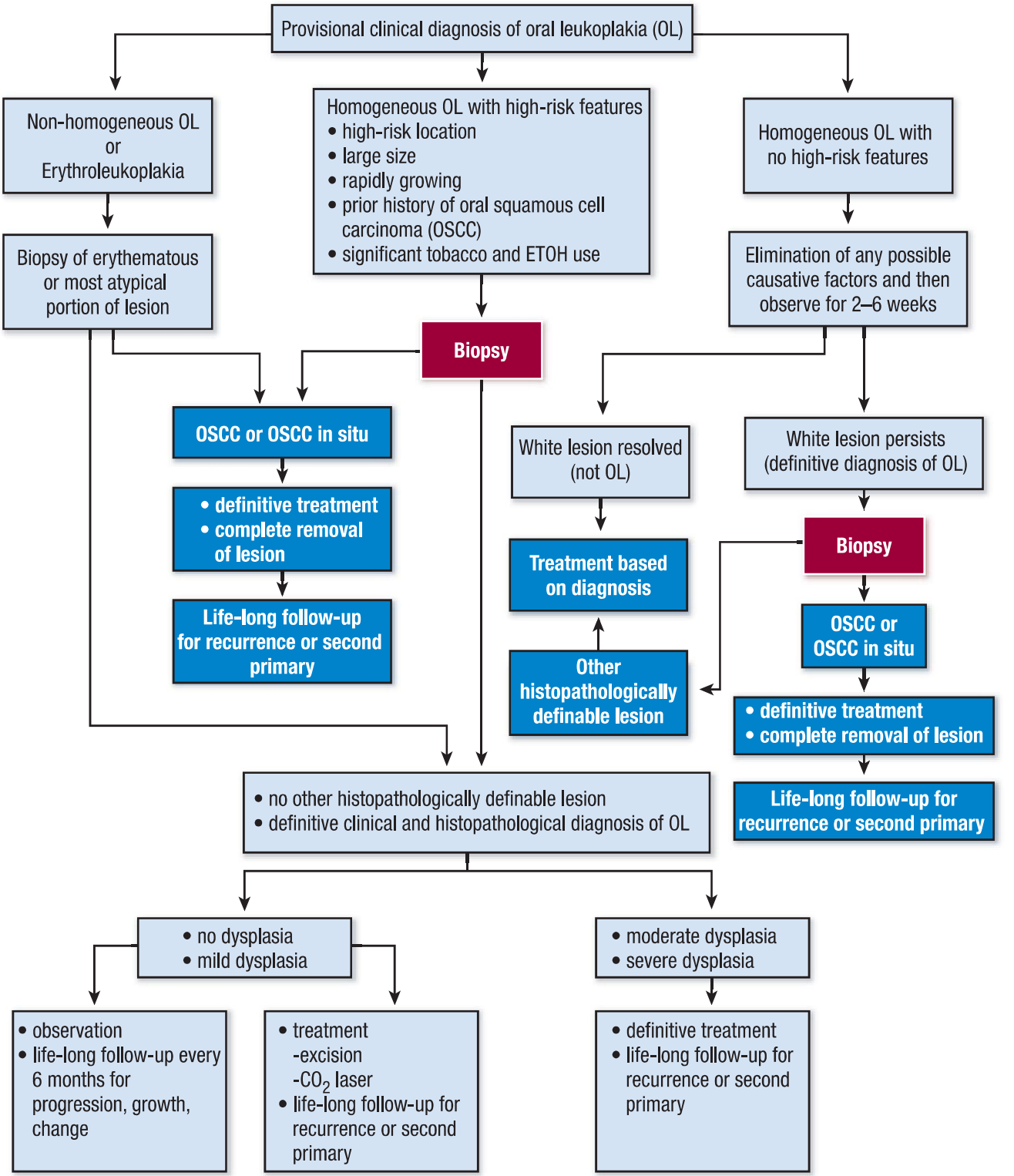

▲ **FIGURE 113-13** Approach to the management of oral leukoplakia. ETOH = ethanol.

patch on a mucosal surface that cannot be categorized as any other known disease entity caused by inflammatory, vascular, or traumatic factors. Histopathologically, it almost always displays either findings of SCC in situ or focal areas of invasive SCC, and thus is considered at least a precancerous lesion in most instances. Erythroplakia can involve any mucosal surface, but most commonly, in more than half of all cases, the lesions are on the oral mucosa. Of all oral precancerous lesions, it is considered to be the most dangerous and carries the greatest risk of progressing to or harboring invasive carcinoma.

Epidemiology

Erythroplakia is an uncommon lesion in the oral cavity, and it is said to be one of the least commonly diagnosed lesions among the group of oral lesions that may or may not become malignant.[148] The prevalence, based on a small num-

ERYTHROPLAKIA (ERYTHROPLASIA)

AT A GLANCE

- Erythroplakia is a clinical diagnosis of exclusion for a persistent fixed red patch in the oral cavity.
- It is the least common of all oral precancerous lesions but has the greatest potential to harbor or become oral squamous cell carcinoma.
- Risk factors are use of tobacco products and alcohol use.
- Histopathologic features include dysplasia, in situ carcinoma, or invasive carcinoma, seen in 40 percent to 50 percent of oral erythroplakia lesions.
- Early and effective treatment is important.
- Treatment for severely dysplastic lesions or in situ carcinoma is complete excision or Mohs micrographic surgery.

ber of worldwide studies, is between 0.02 percent and 0.83 percent.[149]

Etiology and Pathogenesis

Clinical Findings (See Chap. 74)

OE is found either intra-orally or on the vermillion surface of the lower lip. The most common areas in the oral cavity in which OE has been described are the soft palate, the floor of the mouth, and the buccal mucosa. OE presents as a subtle, asymptomatic, erythematous macule or patch. Most often it is less than 1.5 cm in its widest diameter, but lesions up to 4 cm in diameter have been described.[149] Characteristically it is sharply demarcated from the surrounding pink mucosa, and its surface is most often smooth and homogeneous in color. On occasion lesions of erythroplakia demonstrate a pebbled or stippled surface change and on palpation may have a soft and velvety feel. Induration indicates the presence of invasive carcinoma in many instances. Erythroplakia is commonly seen in association with leukoplakia, a condition termed *erythroleukoplakia*. Overwhelmingly, it is the red patches of erythroleukoplakia that are most likely to contain or develop into a malignancy.

Histopathology

Diagnosis and Differential Diagnosis

OE is a diagnosis of exclusion. The onus is on the clinician to rule out all other erythematous oral lesions before the term *oral erythroplakia* can be applied. Other entities that should be considered in the differential diagnosis include acute and chronic mechanical trauma, thermal or chemical injury, erythematous candidiasis, atrophic lichen planus, lupus erythematosus, pemphigus, cicatricial pemphigoid, Kaposi sarcoma, amelanotic melanoma, chronic contact or allergic dermatitis, submucosal hemorrhage, and various forms of glossitis (see Box 113-6). Of all of these possibilities, erythematous candidiasis and atrophic lichen planus are the most important considerations. In general, biopsy of any OE lesion should be performed if the cause is not obvious, if the lesion is in a high-risk location in the oral cavity, or if the lesion does not resolve over a period of several weeks.

Prognosis and Clinical Course

OE has the greatest risk for malignant transformation of all pre-malignant oral lesions. This elevated risk for malignant transformation is mostly based on the fact that histopathologic evaluation of OE usually reveals invasive SCC, SCC in situ, or severe dysplasia, as previously discussed. The rate at which in situ carcinoma of the oral cavity progresses to invasive SCC is not known exactly. The transformation rate for OSCC in situ or lesions with severe dysplasia has ranged from 14 percent to 50 percent, with an average of 26 percent.[148] In individuals at high risk, such as heavy smokers or drinkers, up to 80 percent of OE lesions on biopsy may contain focal areas of invasive carcinoma.[154]

Treatment and Prevention

Because OE has been shown to have the highest risk for malignant transformation, early and effective treatment of these lesions is thought to be important. The definitive treatment is controversial, and studies of the treatment of OE lesions by themselves are lacking. Recurrence rates after treatment of OE lesions are even less clear.

For severely dysplastic or in situ carcinoma lesions of erythroplakia, surgical excision or Mohs micrographic surgery is generally recommended, because the entire lesion can be removed with histopathologic confirmation of the diagnosis and adequate margins. The proper management of mildly or moderately dysplastic OE lesions is less clear, with some advocating excision and others promoting a more conservative, observational approach.

KEY REFERENCES

The full reference list for all chapters is available at www.digm7.com.

14. Salasche SJ: Epidemiology of actinic keratoses and squamous cell carcinoma. *J Am Acad Dermatol* **42**:S4, 2000
16. Grossman D, Leffell DJ: The molecular basis of nonmelanoma skin cancer. *Arch Dermatol* **133**:1263, 1997
24. Thompson SC et al: Reduction of solar keratoses by regular sunscreen use. *N Engl J Med* **329**:1147, 1993
36. Drake LA et al: Guidelines for the care of actinic keratoses. *J Am Acad Dermatol* **32**:95, 1995
47. Korman N et al: Dosing with 5% imiquimod cream three times per week for the treatment of actinic keratosis: Results of two phase 3, randomized, double-blind, parallel-group, vehicle-controlled trials. *Arch Dermatol* **141**:467, 2005
56. Lawrence N et al: A comparison of the efficacy and safety of Jessner's solution and 35% trichloroacetic acid vs 5% fluorouracil in the treatment of widespread facial actinic keratoses. *Arch Dermatol* **131**:176, 1995
66. Piacquadio DJ et al: Photodynamic therapy with ALA topical solution and visible blue light in the treatment of multiple actinic keratoses of the face and scalp: Investigator-blinded, phase 3, multicenter trials. *Arch Dermatol* **140**:41, 2004
78. Schwartz RA: Arsenic and the skin. *Int J Dermatol* **36**:241, 1997
102. Novick M et al: Burn scar carcinoma: A review and analysis of 46 cases. *J Trauma* **17**:809, 1977
118. Meyer T et al: Importance of human papillomaviruses for the development of skin cancer. *Cancer Detect Prev* **25**:533, 2001
131. Reibel J: Prognosis of oral premalignant lesions: Significance of clinical, histopathological and molecular biological characteristics. *Crit Rev Oral Biol Med* **14**:47, 2003





CHAPTER 114

Squamous Cell Carcinoma

Douglas Grossman
David J. Leffell

Cutaneous squamous cell carcinomas (SCCs) are malignant neoplasms derived from suprabasal epidermal keratinocytes. These and basal cell cancers are the non-melanoma skin cancers that represent the most common malignancies in humans. Whereas basal cell carcinoma (BCC) (see Chap. 115) is thought to arise de novo, SCC probably evolves in most cases from precursor lesions of actinic keratosis (AK) and Bowen disease (SCC in situ) (see Chap. 113). This chapter focuses on clinical aspects of invasive SCC. Cutaneous SCC represents a broad spectrum of disease ranging from easily managed, superficially invasive cancers to highly infiltrative, metastasizing tumors that can result in death. The clinical presentation can be variable despite the existence of easily identified typical lesions. The cellular and molecular aspects of SCC carcinogenesis are discussed elsewhere (see Chap. 112).

HISTORICAL ASPECTS

EPIDEMIOLOGY

Incidence

The precise incidence of BCC and SCC is unknown, because these cutaneous malignancies are not generally documented by the National Cancer Institute or most state cancer registries. It is generally accepted, however, that well over 1 million cases are diagnosed in the United States each year, with approximately 200,000 representing SCC.[10] Although less common than BCC, SCC carries a risk of metastasis and thus accounts for the majority of the several thousand deaths attributable to non-melanoma skin cancer each year. By comparison, cutaneous melanoma accounts for only 60,000 cases, but approximately 9000 deaths, annually.[11] Similar trends for SCC have been noted in Australia[12] and the Caribbean.[13]

SCC is strongly associated with advanced age, and a sharp increase in incidence is seen after age 40 years.[14] Today, the lifetime risk of SCC among whites is approximately 15 percent, almost double that of two decades ago. Increased exposures to ultraviolet (UV) radiation (through greater use of tanning salons, increased time spent outdoors, changes in clothing styles, and ozone depletion) and greater longevity have been suggested as possible causes for the increase in disease. It is likely that this trend will continue as a result of further depletion of the ozone layer and the aging of the U.S. population. The rising incidence of SCC over the past several decades has been paralleled by a 20 percent decrease in mortality, attributed largely to increased public awareness and aggressive treatment of high-risk lesions.[15] After a diagnosis of SCC, patients have a 44 percent to 50 percent cumulative risk of developing another non-melanoma skin cancer (18 percent to 30 percent risk of SCC) in the subsequent 3 to 5 years.[16] In addition, these patients are at increased risk for extra-cutaneous cancers.[17]

Demographics

Squamous cell cancer is twice as common in men as in women, probably as a result of greater lifetime UV exposure in men. Similarly, longer hairstyles and use of lipstick may account for the lower frequency of SCC on the ears and lips of women. There is an inverse relationship between skin pigmentation and SCC incidence, largely because of the protective effect of eumelanin. Thus, persons with white skin, blue eyes, fair complexion, red hair, and Celtic ancestry who tan poorly are at greatest risk. Increased pigmentation is associated not only with a lower incidence of SCC, but also with an inversion in the BCC/SCC ratio. In comparison with whites, the incidence of SCC is decreased by 30-fold in American blacks and the BCC/SCC ratio falls to 0.8:1.[14] Tanzanian albinos all develop SCC by young adulthood, and the ratio of BCC to SCC is only 0.2:1. Asians and Polynesians, with intermediate skin pigmentation, have correspondingly intermediate levels of SCC. A gene (MC1R) involved in melanogenesis that encodes the melanocortin 1 receptor is a major determinant of skin pigmentation and hair color. The MC1R gene is highly polymorphic, with more than 20 variants described.[18] Several variant MC1R alleles are associated with increased risk of SCC that is independent of skin type and hair color.

SQUAMOUS CELL CARCINOMA AT A GLANCE



- With basal cell carcinoma, most common human malignancy.
- Diagnosis is by biopsy.
- Caused by ultraviolet radiation in most cases.
- Precursor lesion is actinic keratosis.
- Treatment options are excision, Mohs microscopically controlled surgery, and radiation.

ETIOLOGY AND PATHOGENESIS

Predisposing Factors

There are a number of factors, including both acquired and genetic skin conditions, that may predispose to SCC (Table 114-1). Patients often demonstrate a multiplicity of factors that together are sufficient to induce SCC development. For example, a given skin site may be exposed to both UV radiation and another environmental carcinogen.

PRECURSOR LESIONS Most SCCs develop from precursor lesions such as AKs or Bowen disease (see Chap. 113).

ULTRAVIOLET RADIATION EXPOSURE UV radiation is considered the predomi-

TABLE 114-1
Predisposing Factors for Squamous Cell Carcinoma

- Precursor lesions (actinic keratosis, Bowen disease)
- Ultraviolet radiation exposure
- Ionizing radiation exposure
- Exposure to environmental carcinogens
- Immunosuppression
- Scars
- Burns or long-term heat exposure
- Chronic scarring or inflammatory dermatoses
- Human papillomavirus infection
- Genodermatoses (albinism, xeroderma pigmentosum, porokeratosis, epidermolysis bullosa)

nant risk factor for SCC. Importantly, there is a linear correlation between the incidence of SCC and exposure to UV radiation. The incidence of SCC has been reported to double with each 8- to 10-degree decline in geographic latitude and is highest at the equator.[19] World War II veterans stationed in the Pacific developed much higher rates of SCC than did their colleagues who served in Europe.[20] Similarly, SCC is more prevalent in Japanese people who emigrated to Hawaii than in those who remained in Japan.[21] Excessive UV radiation appears to be related more to the development of SCC than to the development of BCC. Rates of SCC rise more rapidly than those of BCC with increasing UV exposure,[22] and UV radiation–induced skin cancers in mice are almost exclusively SCCs rather than BCCs.[23] Moreover, in patients receiving long-term therapy with psoralen plus ultraviolet A (UVA) radiation for treatment of psoriasis there is an associated 30-fold increase in non-melanoma skin cancers, most of which are SCCs.[24]

IONIZING RADIATION There is a strong association between SCC and exposure to ionizing radiation. In one survey of SCC patients, an association with radiation therapy was observed only in those whose skin was likely to sunburn (see Chap. 113).

ENVIRONMENTAL CARCINOGENS Numerous occupational and environmental carcinogens, such as arsenic and aromatic hydrocarbons, predispose to the development of SCCs. With the exception of 3-methylcholanthrene and anthramine, chemical carcinogens generally produce SCCs rather than BCCs.[25] Exposures to insecticides and herbicides have also been associated with SCCs. In addition, smoking and alcohol use are strongly associated with SCCs of the oral cavity.

IMMUNOSUPPRESSION Chronic immunosuppression may lead to an increase in SCCs, primarily on sun-exposed sites.[26] An 18-fold increase in SCC has been reported in renal transplant patients[27]; these tend to appear 3 to 7 years after the onset of long-term immunosuppressive therapy, with corticosteroids, azathioprine, and cyclosporine most frequently implicated. With the increase in the total number of organ transplant patients, management of SCCs in this population is becoming more important. In patients with leukemia and lymphoma, SCCs are both increased and more aggressive.[28] Although multiple SCCs have been described in patients infected with human immunodeficiency virus, advanced human immunodeficiency virus infection has generally not been associated with an increased incidence of SCC, possibly because many patients do not live long enough to develop them.

SCARS AND UNDERLYING DISEASES Historically, SCC was associated with both burn scars and chronic ulcers as noted earlier, but such associations are seldom seen today. Also rare but reported is the development of SCCs in the context of chronic infections, particularly those associated with draining sinuses and scarring, such as perianal pyoderma, osteomyelitis, chromomycosis, hyalohyphomycosis, granuloma inguinale, lupus vulgaris, and leprosy. Chronic inflammatory processes, particularly those associated with scarring, such as venous ulcer, snakebite ulcer, discoid lupus erythematosus, oral lichen planus, morphea, lichen sclerosus, pilonidal cyst, acne conglobata, hidradenitis suppurativa, Hailey-Hailey disease, dissecting folliculitis of the scalp, and necrobiosis lipoidica, all can give rise to SCCs. An exception is vaccination scars, which are associated with BCCs rather than SCCs. SCCs have also been observed in transplanted skin, epidermal cyst, dental cyst, and dermoid cyst.

THERMAL FACTORS Long-term heat exposure can lead to SCCs. The role of thermal radiation in the development of skin cancer has long been recognized in many cultures, where common practices include placing hot ashes under the clothes to keep warm in winter or smoking opium while lying on heated beds. The incidence of SCCs is increased in persons who habitually sit in front of heating stoves and at sites of erythema ab igne (see Chap. 113).

HUMAN PAPILLOMAVIRUS INFECTION There is a role for human papillomavirus (HPV) infection in some types of SCCs. Verrucous carcinoma appears to be associated with several HPV types, as noted later. Head and neck and periungual SCCs are frequently associated with HPV-16. Patients with epidermodysplasia verruciformis are chronically infected with HPV, most commonly type 5, and one-third of these patients ultimately develop SCCs (see Chaps. 113 and 196).

GENODERMATOSES A variety of heritable diseases predispose to SCC development. Patients with oculocutaneous albinism develop predominantly SCCs (rather than BCCs) at an early age (see Chap. 71). Xeroderma pigmentosum (see Chaps. 109 and 140), a disorder of DNA repair, is also characterized by early development of SCCs. SCCs have been reported to develop in the Mibelli, disseminated superficial actinic, and palmaris et plantaris disseminata forms of porokeratosis (see Chap. 50), and in oral lesions of dyskeratosis congenita. As noted in Human Papillomavirus Infection, lesions of epidermodysplasia verruciformis can degenerate into SCCs (see Chap. 196). Finally, patients with the dystrophic form of epidermolysis bullosa are at increased risk for SCC (see Chap. 60).

Molecular Aspects

As in most cancers, the development of SCC from normal keratinocytes begins with mutations in the cellular DNA and genomic instability. Alterations in gene expression lead to loss of growth controls, penetration of the basement membrane, and ultimately invasion into surrounding tissue. Along the pathway to SCC, keratinocytes become resistant to apoptosis (programmed cell death) and immune attack.

GENETIC ALTERATIONS Most analyses of genetic alterations in SCCs have been performed in cases of oral or head and neck SCCs. Chromosomal deletions (loss of heterozygosity) commonly involve chromosomes 3, 9, 11, and 17; the regions most commonly identified include 9p21 and 17p13 where the INK4A (p16/Arf) and p53 tumor suppressors, respectively, are located.[29] Similar genetic lesions were found in a study of young patients (younger than 40 years of age).[30] It is unclear whether these genetic markers will serve as useful prognostic indicators.

P53 IN THE DEFENSE AGAINST SKIN CANCER A role for p53, cyclin D1, human telomerase reverse transcriptase, p16, and thrombospondin 1 has been identified in the multi-step process of human skin carcinogenesis.[31]

Apoptosis of keratinocytes that have sustained UV radiation–induced DNA damage, termed *sunburn cells*, requires the p53 tumor suppressor and represents a key protective mechanism against skin cancer by removing premalignant cells that have acquired mutations. In keratinocytes, UV radiation up-



regulates p53,[32] which delays cell cycle progression until DNA damage can be repaired or facilitates cell elimination by apoptosis.[33] Compromise of p53 function could undermine this apoptosis-based defense mechanism, giving UV-damaged cells a selective advantage to survive additional cycles of UV exposure.[34] Further impairment of p53 and other genes through additional UV radiation–induced mutations may then lead to even greater resistance to apoptosis, increased proliferation, and ultimately development of SCC. The increased susceptibility of p53-deficient mice to UV radiation–induced SCC[35] highlights this protective role of p53.



P53 MUTATIONS IN SQUAMOUS CELL CARCINOMA Consistent with the scenario described in p53 in the Defense Against Skin Cancer, mutations in the p53 gene are a common finding in SCC.[36] In most cases, these are C→T single base and CC→TT tandem transition mutations at dipyrimidine sequences—that is, "UVB-signature" mutations.[37] Most SCCs exhibit loss of heterozygosity with respect to p53 and isolated mutations on the remaining allele. In one study, the p53-apoptosis pathway was disrupted in 50 percent of oral SCCs. With respect to SCC precursors, p53 mutations were found in up to 75 percent of AK and SCC in situ lesions.[38] Interestingly, although different p53 mutations were found in separate AKs, all cells within a single precursor lesion had the same mutation.[31] Mutations in p53 can also be detected in keratinocytes from clinically normal sun-exposed skin.[39] Keratinocytes with p53 mutations occur in clonal patches that are larger and more frequently in sun-exposed skin.[40] These findings substantiate a clonal basis for UV radiation–induced SCC and suggest that p53 mutation is an early event in the development of SCC.

In addition to undergoing mutation, p53 can be compromised in keratinocytes infected with HPV. The E6 protein encoded by oncogenic HPV types binds p53 and targets it for rapid degradation, which disables the p53-apoptosis pathway. This is a primary mechanism by which HPV infection predisposes to SCC (see Chap. 196).

OTHER APOPTOTIC REGULATORS IN SQUAMOUS CELL CARCINOMA In addition to dysregulation of p53, dysregulation of other apoptotic regulatory proteins has been described in SCC. In a study of vulvar SCC, expression of the apoptotic inhibitor Bcl-2 correlated with metastasis.[41] Similarly, in esophageal SCC, expression of the apoptotic inhibitor Bcl-XL correlated with tumor invasion and metastasis.[42] In SCC of the tongue, low apoptotic index and decreased expression of the pro-apoptotic Bcl-2–associated X protein (Bax) correlated significantly with poor prognosis, whereas low Bcl-2 expression was associated with a favorable clinical outcome.[43] Expression of the anti-apoptotic Bcl-2–associated athanogene 1 (BAG-1) was associated with nodal metastasis in oral SCC.[44] Consistent with these observations, transgenic mice expressing Bcl-2 and Bcl-XL in the skin exhibit increased susceptibility to chemical-induced tumorigenesis. In addition to these Bcl-2 family members, the inhibitor of apoptosis protein survivin is expressed in both SCC and precursor lesions,[45] and in one study its expression correlated with aggressive tumor phenotype.[46] Interestingly, survivin may be negatively regulated by the binding of p53 to its promoter.[47] More recent studies in transgenic mice have yielded paradoxical results, which suggests that apoptosis may be required in the initial phase of UV radiation–induced clonal expansion.[48]

IMMUNE EVASION Working with UV radiation–induced SCCs in mice, Kripke and colleagues first demonstrated the importance of immunosuppression in UV radiation–induced SCC in the 1970s (see Chap. 88). They found that although UV radiation–induced SCC was promptly rejected when transplanted into genetically identical recipient mice, the transplanted tumors grew rapidly, and rejection did not occur if recipient mice were first treated with a subcarcinogenic dose of UV radiation. These experiments suggested that UV radiation not only induced SCC but also impaired the ability of host animals to mount protective immune responses against foreign tumor antigens.

CLINICAL FINDINGS

In white men and women, the majority of SCCs arise on sun-exposed areas such as the head, neck, and dorsal hands. SCC of the legs is more common in women.[49] In blacks, on the other hand, SCCs tend to be distributed equally on sun-protected and sun-exposed areas.[50] SCC typically presents in solitary fashion, arising from precursor lesions as noted earlier. An exception is in immunosuppressed patients, who may manifest eruptive SCCs.

Development from Precursor Lesions (See Chap. 113)

AKs often occur as a multiplicity of lesions, ranging in size from pinpoint to over 2 cm, and the borders are usually ill defined. A dry adherent scale gives them a rough, gritty texture. By contrast, lesions of Bowen disease are usually solitary, sharply demarcated, scaling papules or plaques, often initially mistaken for eczema, psoriasis, or lichen simplex. The latter disorders are often pruritic, whereas Bowen disease is usually not. In sun-protected sites, Bowen disease may have a noneczematous appearance. For example, it may appear verrucous in the anogenital area, nail bed, and eyelid, and as a dark patch or oozing erythematous plaque in intertriginous areas. These precursor lesions are usually asymptomatic, and the development of tenderness, induration, erosion, increased scale, or enlarging diameter may herald evolution into SCC. Typically a patient with multiple AKs may present with a single lesion that gradually becomes more prominent than the rest (Fig. 114-1), or with a solitary, persistent, non-pruritic, scaling patch that is unresponsive to treatment with topical steroids.

Squamous Cell Carcinoma Morphologies

A firm, flesh-colored or erythematous, keratotic papule or plaque is most com-



▲ **FIGURE 114-1** Papular squamous cell carcinoma (SCC) of the ear. The differential diagnosis includes chondrodermatitis nodularis helicis, which, unlike SCC, is associated with pain.

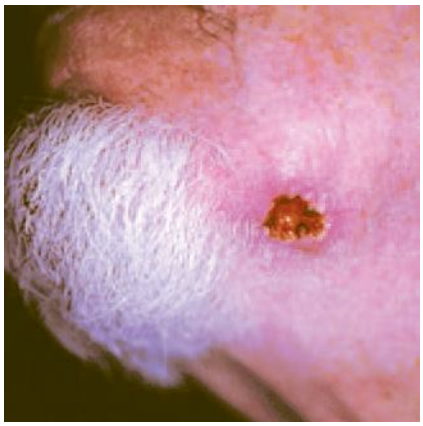

▲ **FIGURE 114-2** Ulcerative squamous cell carcinoma of the jaw. In this region, extension of the cancer can invade the marginal mandibular nerve.

mon (see Fig. 114-1), but SCCs may also be pigmented. Other presentations include as an ulcer (Fig. 114-2), a smooth nodule (Fig. 114-3), or a thick cutaneous horn. SCC may also be verrucous or present as an abscess, particularly if in a periungual location (see Fig. 113-9 in Chap. 113). The margins may be indistinct. With enlargement, there is usually increased firmness and elevation. Progressive tumor invasion ultimately results in fixation to underlying tissues. Especially in the head and neck region, an enlarged lymph node nearby that is firm and non-tender may indicate tumor metastasis (Fig. 114-4).

Oral Squamous Cell Carcinoma

SCC of the oral cavity usually occurs in patients with a long history of cigarette smoking, tobacco chewing, or alcohol use, but it has now been documented in younger adults without these traditional risk factors. There is a male predominance, and the palate and tongue are the most common sites. Oral SCC most commonly evolves from lesions of erythroplakia and is usually asymptomatic (see Chap. 113). Distinct patterns include a persistent rough red patch or granular velvety red plaque that ultimately becomes firm and nodular. Surprisingly, the risk of transformation to SCC does not appear to correlate with the degree of epithelial dysplasia.[51] The floor of the mouth, ventrolateral tongue, and soft palate are considered high-risk sites. It may also present as a peritonsillar abscess.



▲ **FIGURE 114-4** Preauricular mass resulting from metastasis of cutaneous squamous cell carcinoma (SCC). Involvement of the parotid gland can result from metastasis of SCC in the temple and ear region.

Lower Lip Squamous Cell Carcinoma

SCC of the lower lip begins as a roughened papule of actinic cheilitis or scaly leukoplakia, with slow progression to a tumor nodule (Fig. 114-5). Clinical clues associated with evolving SCC include persistent lip chapping with localized scale or crust, red and white blotchy atrophic vermilion zone of the lip, indistinct or "wandering" vermilion border, and small fissuring or ulceration within an area of indurated actinic cheilitis. Symptoms of underlying pain or altered sensation should be investigated as a potential sign of perineural invasion.

Genital Squamous Cell Carcinoma

SCC of the vulva most commonly occurs on the anterior labia majora, beginning as a small warty nodule or an erosive erythematosus plaque. These lesions may be asymptomatic but more often are associated with pruritus or bleeding. Lesions of lichen sclerosus are another common precursor of SCC of the vulva. SCC of the cervix is associated with HPV infection, most commonly with type 16. SCC of the scrotum begins as a small pruritic verrucous lesion that becomes friable with increasing size. SCC of the penis usually occurs in uncircumcised males (see eFig. 114-5.1 in on-line edition) and, although very uncommon in Western countries, may account for 10 percent of cancers in places where genital hygiene is poor. A distinct precursor of penile SCC is erythroplasia of Queyrat (see Chap. 113), characterized by a velvety red plaque. In addition to lack of circumcision, penile SCC has been associated with a history of condyloma and phimosis and lichen sclerosus et atrophicus (see Chaps. 63 and 75). The genitalia were once thought to be a common location for SCC after long-term therapy with psoralen and UVA radiation, but this complication can be avoided by shielding the genitalia during treatment, and such an association is rarely seen today. Perianal SCC may also occur (Fig. 114-6).

Scar Squamous Cell Carcinoma

SCCs arising in scars typically begin decades after injury, with skin breakdown and persistent erosion. Most commonly this occurs on the lower extremities at sites of chronic pyogenic or venous sta-



▲ **FIGURE 114-3** Nodular squamous cell carcinoma of the forehead. This lesion is recurrent and can be seen arising in the previous surgical scar. It should be considered high risk.



◀ **FIGURE 114-5** Squamous cell carcinoma of the lower lip that developed in the setting of habitual sun exposure and actinic cheilitis. There is a large but subtle nodule, better felt than seen, on the lower lip. There are areas of hyperkeratosis and ulceration. Metastasis to draining lymph nodes can occur.







▲ **FIGURE 114-6** Perianal squamous cell carcinoma (SCC) in situ. Identification of these lesions requires thorough proctoscopic examination and monitoring for invasive SCC.

sis ulcers. Gradually nodularity develops, although detection is often delayed because of concealment by surrounding indurated scar tissue. When SCC arises in chronic sinuses, however, nodularity may not be present. The development of increased pain, drainage, or bleeding alone should raise concern and warrants further investigation.

Keratoacanthoma (For full discussion, see Chap. 117)

The hallmark of keratoacanthoma is rapid growth, up to several centimeters in weeks, and then gradual involution over a period of months in most cases (see Chap. 117). The typical presentation is in an elderly patient on a sun-exposed site, particularly an extremity. Morphologically, keratoacanthoma is usually a large, smooth, dome-shaped, verrucous nodule with a central keratotic crater. Although historically viewed as a benign neoplasm because of its tendency toward spontaneous resolution, keratoacanthoma can be locally destructive and aggressive and must be viewed as a clinical sub-type of SCC. This tumor may occur in association with sebaceous neoplasms and gastrointestinal malignancies in Muir-Torre syndrome.

Verrucous Carcinoma

Verrucous carcinoma is a form of SCC that encompasses several clinical entities, all characterized by slow-growing exophytic tumors with a cauliflower-like appearance that develop at sites of chronic irritation.[52] They may be clinically mistaken for giant warts. Four subtypes are recognized based on site of occurrence. Type I consists of oral tumors on the buccal mucosa of elderly male tobacco chewers and has been referred to as *oral florid papillomatosis* (Fig. 114-7). Representing 2 percent to 12 percent of all oral cancers, these tumors are most commonly found on the buccal mucosa, tongue, gingiva, and floor of the mouth. Type II is the anogenital type, as described by Buschke and Loewenstein. It occurs on the glans penis of young uncircumcised males, on the scrotum, on the perianal region in both sexes, and, less commonly, on the female genitalia. Type III, also known as *epithelioma cuniculatum*, is a malodorous tumor often found on the plantar area in elderly men (Fig. 114-8). It usually involves the skin underlying the first metatarsal head and tends to form draining sinuses that are caniculated (like rabbit burrows) in appearance. Finally, type IV occurs at other sites, including the scalp, trunk, and extremities. Detection of sequences from HPV types 6, 11, 16, and 18 in epithelioma cuniculatum and type 11 sequences in oral verrucous carcinoma raises the possibility that these tumors evolve from verruca vulgaris.

Metastatic Squamous Cell Carcinoma

Metastatic SCC in the skin can have a variety of presentations. It may be signaled by a palpable lymph node near the site of treatment of a previous SCC.



▲ **FIGURE 114-7** Verrucous carcinoma presenting as a thick plaque arising on the buccal mucosa. This type of tumor was formerly called *oral florid papillomatosis*.



▲ **FIGURE 114-8** Epithelioma cuniculatum, verrucous carcinoma of the foot.

On the other hand, it may present as large keratotic papules or nodules resembling the primary lesion (Fig. 114-9). Metastatic SCC on the skin may be the first sign of internal malignancy, initially presenting in the skin as clusters of firm pink or red papules that may be keratotic centrally.

HISTOPATHOLOGY

General Considerations

The hallmark of invasive SCC is the extension of atypical keratinocytes beyond the basement membrane and into the dermis (Fig. 114-10). The absence of a connection between tumor cells and the epidermis should raise concern for metastatic SCC, although this may simply reflect undermining from adjacent tumor. In every case, it is important to note clues that may indicate a precursor lesion or particular etiology. For example, the presence of solar elastosis and keratinocyte atypia at the margins would suggest that the SCC is actinically derived. On the other hand, the presence of scar

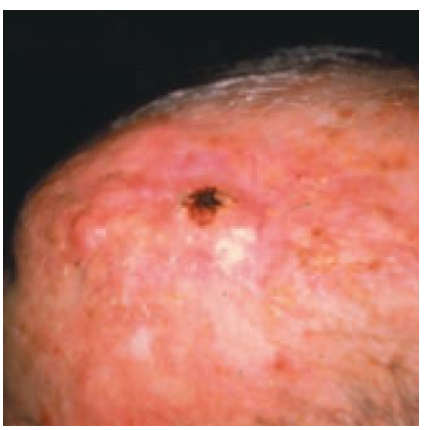

▲ **FIGURE 114-9** Squamous cell carcinoma metastatic to skin.

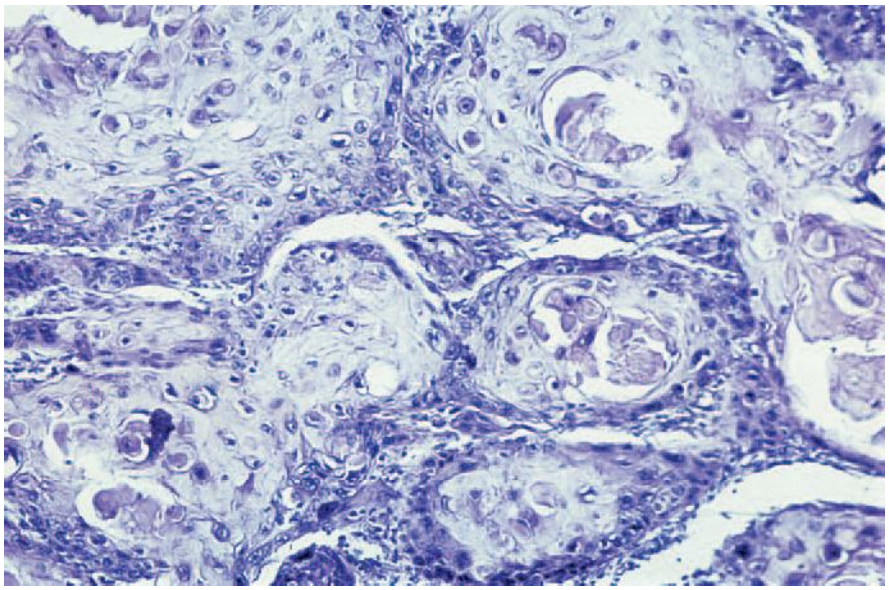

▲ **FIGURE 114-10** Squamous cell carcinoma demonstrating invasive cancer with atypical keratinocytes and foci of keratinization.

tissue may indicate recurrent disease or a sinister scar-associated SCC. These considerations have important implications for treatment and prognosis, as discussed in Treatment.

Basic Features

The tumor may appear as single cells, small groups or nests of cells, or a single mass. The inferior border may broadly impose on the dermis or be represented by individual foci of microinvasion. Invasive tumor is usually confined to the dermis, and subcutaneous involvement is unusual. There are typically varying proportions of normal-appearing and atypical squamous cells, the latter characterized by increased mitoses, aberrant mitotic figures, nuclear hyperchromasia, and loss of intercellular bridges. Squamous differentiation is seen as foci of keratinization in concentric rings of squamous cells called *horn pearls*. Loss of differentiation is associated with decreased keratin production.

Grading

Histologic grading of SCC is based on the degree of cellular differentiation. Low-grade tumors are comprised of uniform cells, resembling mature keratinocytes, with intracellular bridges and keratin production. High-grade SCCs, by contrast, are characterized by atypical cells, loss of intracellular bridges, and minimal or absent keratin production. Another feature of higher-grade tumors is a less distinct demarcation between malignant cells and adjacent normal stroma. In 1932, Broders[53] introduced a formal grading system based on keratinocyte differentiation that is still used today. Tumors are graded on a scale of 1 to 4 based on increasing percentages of undifferentiated cells (Table 114-2). In addition to grade, the depth of penetration, tumor thickness, and hair follicle involvement should also be reported.

Histologic Sub-Types

There are many histologic sub-types of SCC.[54] In the adenoid (or pseudoglandular) SCC, there is a tubular microscopic pattern and keratinocyte acantholysis. In clear cell SCC, the keratinocytes appear clear as a result of hydropic cytoplasmic swelling and accumulation of lipid vacuoles. Spindle cell SCC reveals spindle-shaped atypical cells. Signet-ring cell SCC is a rare variant characterized by concentric rings composed of keratin and large vacuoles corresponding to markedly dilated endoplasmic reticulum. In addition, a basaloid variant has been described. In verrucous carcinoma, the superficial component resembles verruca vulgaris with prominent acanthosis and papillomatosis, whereas the deeper component extends downward, displacing collagen bundles. Finally, keratoacanthoma reveals a symmetric keratin-filled crater, with the epidermis on each side extending over to form a distinct lip.

TABLE 114-2
Broders' Grading System for Squamous Cell Carcinoma

Grade	% Undifferentiated Cells	Other Features
1	< 25	Keratinization
2	< 50	
3	< 75	
4	> 75	Atypia, loss of intracellular bridges

DIAGNOSIS AND DIFFERENTIAL DIAGNOSIS

Determination of the Diagnosis

The diagnosis of SCC is always made by skin biopsy. Any persistent, enlarging, or nonhealing lesion, particularly if on a sun-exposed site, warrants biopsy evaluation. It is important that the biopsy be of sufficient depth so that invasive SCC can be distinguished from in situ disease. If a lesion is flat or minimally elevated (less than 1 mm), the superficial shaving technique can be used to minimize wound size and scarring and is usually adequate. For elevated lesions, the punch technique or a deep shave excision should be used to ensure that a specimen of adequate depth is taken. Because the diagnosis of keratoacanthoma depends largely on overall architecture, performing excisional biopsy or taking an incisional ellipse through the entire lesion is recommended. A tangential excision through the deep dermis also usually suffices.

Differential Diagnosis

Clinically, the differential diagnosis of SCC is long, but it can be narrowed based on lesion morphology. For verrucous or scaly lesions, benign conditions to consider include wart, seborrheic keratosis, AK, melanocytic nevus, pyogenic granuloma, eccrine poroma, and deep fungal infections such as chromomycosis. The entity "erosive pustular dermatosis of the scalp" is a benign condition that is often initially mistaken for SCC but responds to potent topical steroids.[55] Other malignant verrucous lesions include atypical fibroxanthoma, BCC, Bowen disease, verrucous melanoma, Merkel cell carcinoma, and, of course, metastatic SCC. Pigmented SCC in particular may mimic melanoma. For ulcerative lesions, additional diagnoses include trauma, BCC, and herpes virus infection (with either herpes simplex virus or varicella-zoster virus).

Histologically, the differential diagnosis of well-differentiated SCC includes



verruca vulgaris and inverted follicular keratosis. In addition, reactive epidermal hyperplasia (pseudoepitheliomatous hyperplasia) secondary to mycosis, eruptions in response to halogenated drugs (bromoderma and iododerma), and even mechanical trauma can mimic SCC. In these hyperplasias, however, the keratinocytes usually remain well differentiated; the margins of the proliferating epidermis are often pointed or irregular, rather than bulbous; there is leukocyte invasion with occasional keratinocyte disintegration; and granulomas or intraepidermal abscesses may be present.[56] Some adenoid SCCs may demonstrate a pseudovascular pattern, with erythrocytes in pseudovascular spaces, and may be confused with angiosarcoma; these tumors do not express factor VIII antigens or bind ulex agglutinin. Clear cell SCC may simulate adnexal tumors with sebaceous differentiation or sebaceous carcinoma. Distinguishing spindle cell SCC from atypical fibroxanthoma is difficult. The differential diagnosis of poorly differentiated SCC also includes fibrosarcoma, Merkel cell carcinoma, and melanoma. In most cases, SCC can be distinguished from these others by special stains for various cytokeratins, but in difficult cases electron microscopy may be needed to establish the diagnosis. In general, SCC does not stain for melanocyte (S100 protein, homatropine methylbromide) or smooth muscle (vimentin, actin) markers.



RECURRENCE AND METASTASIS

SCC, like BCC, may cause local tissue destruction, but it also has significant potential for metastasis. Metastases, when they occur, are generally to regional lymph nodes and are detected 1 to 3 years after initial diagnosis and treatment.[19] In many cases, metastasis is preceded by local recurrence at the site of the primary lesion. Historically, the reported rate of metastasis for SCC has ranged from 0.5 percent to 6 percent,[57] and metastasis tends to occur with tumors that are large, recurrent, and involve deep structures or cutaneous nerves (Fig. 114-11).

High-Risk Lesions

In a classic study, Rowe et al.[58] reviewed all major series of SCC dating back to 1940 to determine risk factors associated with recurrence and metastasis. Table 114-3 summarizes the characteristics of "high-risk" lesions. With respect to size, tumors smaller than 2 cm in diameter are low risk, with an overall metastatic rate of roughly 1 percent. In one study,[59] the metastatic rate increased to 9.2 percent and 14.3 percent for tumors of 2 to 5 cm and larger than 5 cm, respectively. With respect to depth and invasion, tumors less than 4 mm deep and rated as Clark levels I to III have limited metastatic potential, whereas close to half of those deeper than 4 mm and at Clark levels IV or V were metastatic in some series. Tumor involvement of bone, nerve, or muscle tissue is strongly associated with metastasis. With respect to anatomic site, SCC of the ear has the highest rate of recurrence (18.7 percent), whereas lip SCC has the highest rate of metastasis (13.7 percent), with half of lip metastases present at the time of initial diagnosis. All SCCs arising in scars are high risk, with metastatic rates approaching 40 percent in some series.[60] By contrast, SCCs arising in actinically damaged skin are of considerably lower risk, with an average metastatic rate of 5.2 percent. Poorly differentiated SCCs (Broders grade 3 or 4) demonstrate a recurrence rate of 28.6 percent and a metastatic rate of 32.8 percent, compared with 13.6 percent and 9.2 percent, respectively, for well-differentiated tumors.

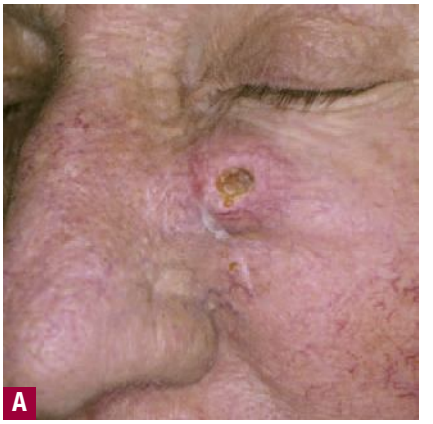

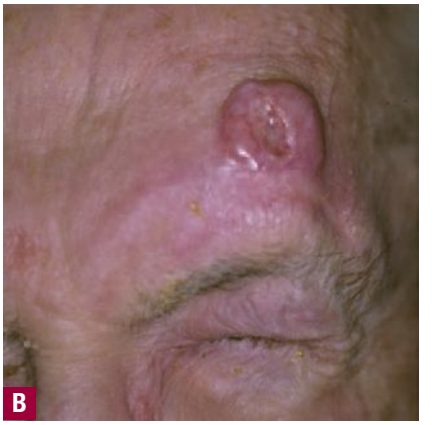

▲ **FIGURE 114-11** **A.** Infiltrative squamous cell carcinoma (SCC) demonstrating retraction of underlying tissue of the left cheek, where extension might involve infraorbital nerve. **B.** SCC of left side of forehead, where extension to bone with invasion or along the supraoptic nerves might lead to death.

TABLE 114-3
High-Risk Squamous Cell Carcinoma

- Diameter > 2 cm
- Depth > 4 mm and Clark level IV or V
- Tumor involvement of bone, muscle, nerve
- Location on ear, lip
- Tumor arising in scar
- Broders grade 3 or 4
- Patient immunosuppression
- Absence of inflammatory infiltrate

The prognosis is particularly poor for spindle cell SCCs.[61] Immune status is another important consideration. One study[62] found that 23 percent of patients with metastatic SCC were immunosuppressed. A heavy inflammatory response appears to be a favorable prognostic sign, because absence of infiltrate has been correlated with higher rates of recurrence and metastasis.

TREATMENT

Box 114-1 summarizes the various modalities available for treatment of SCCs. Treatment selection is directed largely by assessment of tumor risk for recurrence and metastasis, as discussed in the previous section. Ablative techniques such as electrodesiccation and curettage, liquid nitrogen cryotherapy, carbon dioxide laser, intralesional chemotherapy, and photodynamic therapy are superficial, do not allow histologic margin control, and thus are generally inappropriate for treatment of invasive SCCs. An exception may be the use of topical 5-fluorouracil for treatment of conjunctival SCCs.[63]

Surgical Excision

Conventional surgical excision is viewed by many as the treatment of choice for small primary SCCs. Recommended margins are 4 mm for low-risk lesions or

Box 114-1
Treatment of Squamous Cell Carcinoma

- Non-excisional ablative techniques (in situ disease only, or in special circumstances)
- Mohs surgery
- Conventional surgical excision
- Radiation therapy

TABLE 114-4
Indications for Mohs Surgery

- Infiltrative squamous cell carcinoma (SCC)
- Poorly defined clinical margins
- Location on lip, ear, nail bed, nasal tip, eyelid, genitalia
- History of radiation at site
- Involvement of nerve, bone, muscle
- Immunosuppressed patient
- Recurrence of large SCC
- Verrucous carcinoma
- SCC arising from chronic scarring conditions

SCCs with a depth of less than 2 mm; for lesions with a depth of more than 6 mm or a diameter larger than 1 cm, Mohs microscopically controlled surgery (MMCS) is recommended.[64] MMCS is also recommended in specific circumstances when the highest cure rate and minimal tissue destruction are desired (Table 114-4). Specifically, tumors involving the periocular or periauricular areas; recurrent or large tumors; lesions with poorly defined clinical margins; tumors at sites where tissue preservation is important (nasal tip, lip, eyelid, ear, genitalia); deeply infiltrative tumors; lesions at sites that were previously irradiated; tumors with involvement of underlying structures (nerve, bone, muscle); tumors in immunosuppressed patients; and lesions at sites associated with high recurrence rates should strongly be considered for MMCS.[65] Additional indications include verrucous carcinomas and high-risk SCCs such as those arising from chronic scarring conditions.

Radiation

Radiation can be used to treat superficially invasive to moderate-risk lesions and serves as an important adjuvant to excisional surgery in treating residual microscopic disease and providing prophylaxis against metastatic disease. It has been shown to be particularly useful for SCCs of the external auditory canal,[66] although radiation therapy may lead to hearing loss.[67] Radiation therapy is not advised for verrucous carcinoma, in which there is an associated low rate of anaplastic transformation. Radiation may also be used as adjuvant therapy in cases in which perineural SCC was identified in surgical pathologic specimens but treatment failures occurred.

Recurrence Rates

Many risk factors for recurrence and metastasis have been identified.[68] In their review noted in High-Risk Lesions, Rowe et al.[58] also assessed responses to treatment. They reported increasing combined rates of recurrence for each of the following treatment modalities (for primary cancers): MMCS (3.1 percent), electrodesiccation and curettage (3.7 percent), excisional surgery (8.1 percent), and radiation (10 percent). A review of the use of MMCS to treat SCC with 4-year follow-up reported a cure rate of 92 percent.[69] The surprisingly low rate of recurrence for electrodesiccation and curettage likely reflects its judicious use for treatment of low-risk lesions. Similarly, the recurrence rates for both MMCS and excisional surgery may be somewhat skewed by their use in treating high-risk lesions. For lip SCC, the overall recurrence rate was 2.3 percent with MMCS compared with 10.5 percent with other treatment modalities; for ear SCC, the recurrence rates were 5.3 percent and 18.7 percent, respectively. For all recurrent tumors, cure rates were 76.7 percent with excision, compared with 90 percent with MMCS. For low-risk SCCs, overall recurrence rates were 1.9 percent with MMCS versus 16.5 percent with all other modalities. Overall 5-year survival rate for patients with metastatic SCCs was 26.8 percent, with poorer outcomes among patients with lip lesions[70] and those treated with surgery alone (and no radiation).

Treatment of High-Risk Lesions

Management of high-risk lesions is reviewed elsewhere.[71] Oral 5-fluorouracil has been used to treat aggressive lesions refractory to conventional therapies. Additional treatments, including β-carotene, interferon, and retinoids, have been employed with variable results. High-risk lesions may require formal staging. Computed tomography or magnetic resonance imaging may be useful in the detection of advanced perineural involvement of head and neck SCC.[72] Sentinel lymphadenectomy has been combined with MMCS.[73] Involvement of lymph nodes may warrant radical lymph node dissection and radiation therapy. Elective cervical lymphadenectomy may be indicated for high-risk lesions of the lip.[74] When a clinical lymph node examination yields negative results, further intervention may still be indicated if the tumor is considered sufficiently high risk.

Patient Follow-Up

After a diagnosis of SCC, all patients should be considered at high risk for developing additional lesions of SCC as well as BCC. They should be seen at regular intervals, ranging from 3 and 12 months, depending on the degree of risk of prior lesions, status of precursor lesions, and individual patient compliance. A complete skin examination should be performed at each visit, including examination of the oral mucosa. In addition, sites of previous lesions and treatments should be assessed for signs of recurrence. Finally, a lymph node examination is indicated to monitor for metastatic disease.

PREVENTION

Those at risk for SCC—namely, persons with a prior history of non-melanoma skin cancer or any of the predisposing conditions discussed earlier—should be monitored closely. They should receive complete skin examinations on a regular basis.

Sun Protection

The most effective preventive measure is protection from sun exposure. It is likely that adequate sun protection beginning in early childhood could prevent most SCCs.[75] This requires establishing patterns of behavior at an early age, such as applying sunscreen repeatedly, wearing hats and protective clothing, and avoiding the sun during the hours of peak intensity. However, the importance of sun exposure prevention in childhood should not be construed to mean that sun protection later in life will be of no benefit. There is evidence that aggressive sun protection throughout life can prevent the development of SCC precursor lesions and cancers themselves.

Treatment of Precursor Lesions

Treatment of precursor lesions is expected to reduce the incidence of SCC. Several options are available for treatment of AK (see Chap. 113). Isolated lesions can often be effectively removed by liquid nitrogen cryotherapy. For patients with many AKs or areas of skin with a multitude or confluence of lesions, topical chemotherapy using 5-fluorouracil is an option. Topical diclofenac and imiquimod have now been introduced as therapies for widespread AK.

Other Preventive Measures

A number of additional preventive measures can be taken that may reduce the



incidence of SCC in individual patients. For example, the use of condoms can prevent transmission of HPV and may thereby reduce the risk of genital SCC. Decreased alcohol consumption and smoking cessation is likely to reduce the risk of oral SCC. Several years ago there was great interest in the use of both retinoids and interferons as systemic chemopreventive agents. Low-dose etretinate (10 mg/day) has been used successfully in renal transplant patients.[76] A more recent recommendation is isotretinoin (Accutane; 10 mg every day or every other day) in addition to topically applied tretinoin.[77] Topical application of a DNA repair enzyme in liposomes was shown in one experimental trial to reduce the incidence of new AK in xeroderma pigmentosum patients, but further clinical studies have not been published and the potential clinical role of the repair enzyme is unknown.[78] Finally, the introduction of a vaccine for the prevention of infection with HPVs and of precancerous lesions of the cervix may one day translate into the prevention of all HPV-induced precancerous lesions of the skin.[79]



KEY REFERENCES

The full reference list for all chapters is available at www.digm7.com.

9. Alam M, Ratner D: Cutaneous squamous-cell carcinoma. *N Engl J Med* **344**:975, 2001
14. Miller DL, Weinstock MA: Nonmelanoma skin cancer in the United States: Incidence. *J Am Acad Dermatol* **30**:774, 1994
15. Weinstock MA: Nonmelanoma skin cancer mortality in the United States, 1969 through 1988. *Arch Dermatol* **129**:1286, 1993
19. Johnson TM et al: Squamous cell carcinoma of the skin (excluding lip and oral mucosa). *J Am Acad Dermatol* **26**:467, 1992
31. Burnworth B et al: The multi-step process of human skin carcinogenesis: A role for p53, cyclin D1, hTERT, p16, and TSP-1. *Eur J Cell Biol* Jan. 2, 2007 [Epub ahead of print]
34. Leffell DJ, Brash DE: Sunlight and skin cancer. *Sci Am* **275**:52, 1996
36. Brash DE: Roles of the transcription factor p53 in keratinocyte carcinomas. *Br J Dermatol* **154 Suppl 1**:8, 2006
58. Rowe DE et al: Prognostic factors for local recurrence, metastasis, and survival rates in squamous cell carcinoma of the skin, ear, and lip. Implications for treatment modality selection. *J Am Acad Dermatol* **26**:976, 1992
64. Brodland DG, Zitelli JA: Surgical margins for excision of primary cutaneous squamous cell carcinoma. *J Am Acad Dermatol* **27**:241, 1992
68 Alam M, Ratner D: Cutaneous squamous-cell carcinoma. *N Engl J Med* **344**:975, 2001
79. Griffiths P: Anticipating full benefits from the new papillomavirus vaccines. *Rev Med Virol* **17**:1, 2007

CHAPTER 115

Basal Cell Carcinoma

John A. Carucci
David J. Leffell

Basal cell carcinoma (BCC) is a malignant neoplasm derived from nonkeratinizing cells that originate in the basal layer of the epidermis. If left untreated, BCC will continue to invade locally and may result in substantial tissue damage that compromises function and cosmesis. Metastasis is an extremely rare event.

EPIDEMIOLOGY

BCC is the most common cancer in humans. It is estimated that over 1 million new cases occur each year in the United States.[1] BCC is more common in elderly individuals but is becoming increasingly frequent in people younger than 50 years of age. Christenson et al. noted a disproportionate increase in BCC in women under age 40.[2] The malignancy accounts for approximately 75 percent of all non-melanoma skin cancers and almost 25 percent of all cancers diagnosed in the United States.[1] The tumor characteristically develops on sun-exposed skin of lighter-skinned individuals, with 20 percent occurring on the nose. Men are affected slightly more often than are women. Levi et al. reported that the incidence of BCC rose steadily in the Swiss Canton of Vaud between 1976 and 1998 to levels of 75.1 in 100,000 in males and 66.1 in 100,000 in females.[3,4] A study of non-melanoma skin cancers in Aruba supported these findings.[5] In that study, BCC was the most common type of skin cancer diagnosed between 1980 and 1995. Tumors were more frequent in patients older than 60 years of age, and 57 percent were in men. The highest percentage of lesions occurred on the nose (20.9 percent), followed by other sites on the face (17.7 percent).

Risk factors for BCC have been well characterized and include ultraviolet light (UVL) exposure, light hair and eye color, northern European ancestry, and inability to tan.[1] Patients with BCC are at increased risk for melanoma but not for other internal malignancies. Bower et al. reported that individuals with BCC had a threefold increased risk for melanoma but no increased risk for any other type of cancer.[6]

ETIOLOGY AND PATHOGENESIS

The pathogenesis of BCC involves exposure to UVL, particularly the ultraviolet B spectrum (290 to 320 nm) that induces mutations in tumor suppressor genes.[7,8] Some studies indicate that intermittent brief holiday exposures may place patients at higher risk than occupational exposure.[9] Ramani and Bennett reported a significantly higher incidence of BCCs in World War II servicemen stationed in the Pacific theater than in those stationed in Europe.[10] This suggests that several months or years of intense exposure to UVL may have deleterious long-term effects. Other factors that appear to be involved in the pathogenesis include mutations in regulatory genes,[11] exposure to

BASAL CELL CARCINOMA AT A GLANCE



- Most common cancer in humans.
- Caused by exposure to ultraviolet light; associated with PTCH gene mutation in many cases.
- Incidence increasing in younger populations.
- Locally destructive.
- Treated by surgical excision, electrodesiccation and curettage, Mohs surgery, and occasionally irradiation.

ionizing radiation,[12] and alterations in immunosurveillance.[13]

The propensity to develop multiple BCCs may be inherited. Included among heritable conditions predisposing to the development of this epithelial cancer are nevoid basal call carcinoma syndrome or basal cell nevus syndrome (BCNS),[14] Bazex syndrome,[15] and Rombo syndrome.[16] Patients with BCNS may develop hundreds of BCCs and may exhibit a broad nasal root, borderline intelligence, jaw cysts, palmar pits, and multiple skeletal abnormalities. BCNS occurs due to mutations in the tumor suppressor PTCH gene (see Chap. 116).[17,18]

Bazex syndrome is transmitted in an X-linked dominant fashion.[15] Patients have multiple BCCs, follicular atrophoderma, dilated follicular ostia with ice-pick scars, hypotrichosis, and hypohidrosis. In contrast, Rombo syndrome is transmitted in an autosomal dominant fashion.[16] Patients have vermiculate atrophoderma, milia, hypertrichosis, trichoepitheliomas, BCCs, and peripheral vasodilation. Hypohidrosis is not a feature of Rombo syndrome (see Chap. 65).

The role of the immune system in the pathogenesis of skin cancer is not completely understood. Immunosuppressed patients with lymphoma or leukemia[19] and patients who have received an organ transplant[13] have a marked increase in the incidence of squamous cell carcinoma but only a slight increase in the incidence of BCC. Bastiaens et al. found that transplant recipients developed more BCCs on the trunk and arms than did nonimmunosuppressed patients.[20] Patients with human immunodeficiency virus infection develop BCCs at the same rate as immunocompetent individuals, based on similar risk factors.[21] Immunosuppressed long-term alcoholics tend to develop infiltrative BCCs with increased frequency.[22]

A potential link between UVL and decreased immunity has been suggested by Gutierrez-Steil et al., who demonstrated that UVL-induced BCCs express Fas ligand (CD95L).[23] They further showed that these cells were associated with CD95-bearing T cells undergoing apoptosis. This represents a potential mechanism by which UVL might help tumor cells avoid being killed by cytotoxic T lymphocytes.

CLINICAL MANIFESTATIONS

Presentation

The presence of any friable, non-healing lesion should raise the suspicion of skin cancer. Frequently, BCC is diagnosed in patients who state that the lesion bled briefly then healed completely, only to recur. BCC usually develops on sun-exposed areas of the head and neck but can occur anywhere on the body. Features include translucency, ulceration, telangiectasias, and the presence of a rolled border. Characteristics may vary for different clinical sub-types, which include nodular, superficial, morpheaform, and pigmented BCCs and fibroepithelioma of Pinkus (FEP).



▲ **FIGURE 115-1** Nodular basal cell carcinoma presenting with a translucent ulcerated nodule.



▲ **FIGURE 115-3** Pigmented basal cell carcinoma (BCC), a variant of nodular BCC.

Basal Cell Carcinoma Sub-Types

NODULAR BASAL CELL CARCINOMA Nodular BCC is the most common clinical sub-type of BCC (Fig. 115-1).[24] It occurs most commonly on the sun-exposed areas of the head and neck and appears as a translucent papule or nodule depending on duration. There are usually telangiectasias and often a rolled border. Larger lesions with central necrosis are referred to by the historical term *rodent ulcer* (Fig. 115-2). The differential diagnosis of nodular BCC includes traumatized dermal nevus and amelanotic melanoma.

PIGMENTED BASAL CELL CARCINOMA Pigmented BCC is a sub-type of nodular BCC that exhibits increased melanization. Pigmented BCC appears as a hyperpigmented, translucent papule, which may also be eroded (Fig. 115-3). The differential diagnosis includes nodular melanoma.

SUPERFICIAL BASAL CELL CARCINOMA Superficial BCC occurs most commonly on the trunk and appears as an erythematous patch (often well demarcated) that resembles eczema (Fig. 115-4).[24] An isolated patch of "eczema" that does not respond to treatment should raise suspicion for superficial BCC.

MORPHEAFORM (SCLEROSING) BASAL CELL CARCINOMA Morpheaform BCC is an aggressive growth variant of BCC with a distinct clinical and histologic appearance. Lesions of morpheaform BCC may have an ivory-white appearance and may resemble a scar or a small le-



▲ **FIGURE 115-2** Rodent ulcer with central necrosis.



▲ **FIGURE 115-4** Superficial basal cell carcinoma, which can mimic the appearance of an isolated inflammatory lesion.





▲ **FIGURE 115-5** Morpheaform basal cell carcinoma, which may resemble a scar.



sion of morphea (see Chap. 62) (Fig. 115-5). Thus, the appearance of scar tissue in the absence of trauma or previous surgical procedure or the appearance of atypical-appearing scar tissue at the site of a previously treated skin lesion should alert the clinician to the possibility of morpheaform BCC and the need for biopsy.

FIBROEPITHELIOMA OF PINKUS FEP classically presents as a pink papule, usually on the lower back.[25] It may be difficult to distinguish from an acrochordon or skin tag.

BIOLOGIC BEHAVIOR

Local Invasion

The greatest danger of BCC results from local invasion (Fig. 115-6). In general, BCC is a slow-growing tumor that invades locally rather than metastasizes.[26,27] The doubling time is estimated to be between 6 months and 1 year. If left untreated, the tumor will progress to invade subcutaneous tissue, muscle, and even bone. Anatomic fusion planes appear to provide a low-resistance path for tumor progression. Tumors along the nasofacial or retroauricular sulcus may be extensive. In one informative case, a patient documented the progression of his own tumor with photographs over a 27-year period.[28] The lesion, which encompassed an entire side of the face, including the maxillary sinus, apparently doubled over a 10-year period and grew rapidly in the 2 years before hospital admission. This scenario occurs in the context of physical or psychiatric disability that interferes with judgment or access to health care. In another case, a 35-cm BCC on the back of a 65-year-old man recurred after wide local excision and x-ray therapy (XRT), resulting in spinal cord compression.[29] Lethal extension to the central nervous system from aggressive scalp BCC has been reported.[30]



▲ **FIGURE 115-6** Massive local tissue damage from multiply recurrent basal cell carcinoma.



▲ **FIGURE 115-7** Orbital invasion by basal cell carcinoma, which requires extensive surgery.

Perineural Invasion

Perineural invasion is uncommon in BCC and occurs most often in histologically aggressive or recurrent lesions. In one series, Niazi and Lamberty identified perineural invasion in fewer than 0.2 percent of cases.[31] In that series, perineural BCC was seen most often with recurrent tumors located in the preauricular and malar areas. Ratner et al. found a higher incidence in their study (3.8 percent).[32] Leibovitch et al. reported perineural spread in more than 50 percent of periocular BCCs eventuating in orbital invasion. These tumors required extensive surgery and in some cases exenteration (Fig. 115-7).[33] Perineural spread may manifest as pain, paresthesias, weakness, or paralysis. The presence of focal neurologic symptoms at the site of a previously treated skin cancer should raise concern about nerve involvement.

Metastasis

Metastasis of BCC occurs only rarely, with rates varying from 0.0028 percent to 0.55 percent.[34–36] Involvement of lymph nodes and lungs is most common. Von Domarus et al. reported five cases of metastatic BCC in which perineural or intravascular invasion had been noted in three.[37] Squamous differentiation was not observed in the primary tumors in the cases they presented but was noted in two of five cases of metastatic cancer. Overall, squamous differentiation was present in 15 percent of the primary or metastatic tumors from the 170 cases reviewed. Aggressive histologic characteristics, including morpheaform features, squamous metaplasia, and perineural invasion, have been identified as risk factors for metastasis.[36]

DIAGNOSIS

Diagnosis of BCC is accomplished by accurate interpretation of the skin biopsy results. The preferred biopsy methods are shave biopsy, which is often sufficient, and punch biopsy. A sterilized razor blade, which can be precisely manipulated by the operator to adjust the depth of the biopsy specimen, is often superior to a No. 15 scalpel for shave biopsies. A punch biopsy may be useful for flat lesions of morpheaform BCC or for recurrent BCC occurring in a scar.

HISTOPATHOLOGY

Histopathologic features vary somewhat with sub-type, but most BCCs share some common histologic characteris-

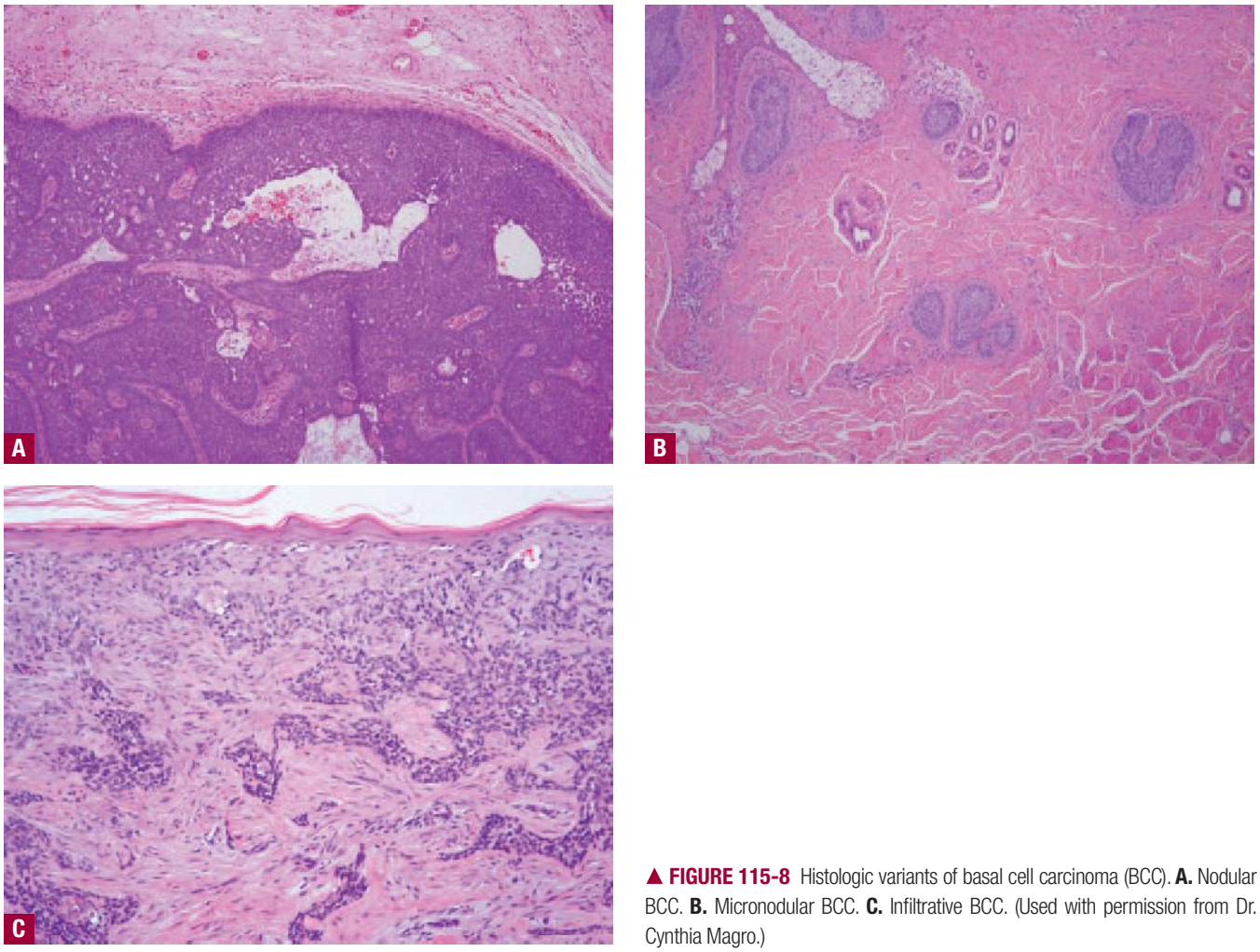

▲ **FIGURE 115-8** Histologic variants of basal cell carcinoma (BCC). **A.** Nodular BCC. **B.** Micronodular BCC. **C.** Infiltrative BCC. (Used with permission from Dr. Cynthia Magro.)



tics.[38] The malignant basal cells have large nuclei and relatively little cytoplasm. Although the nuclei are large, they may not appear atypical. Usually, mitotic figures are absent. Frequently, retraction of stroma from tumor islands is present, creating peritumoral lacunae that are helpful in histopathologic diagnosis.

Nodular Basal Cell Carcinoma

Nodular BCCs account for half of all BCCs and are characterized by nodules of large basophilic cells and stromal retraction (Fig. 115-8A). The term *micronodular BCC* is used to describe tumors with multiple microscopic nodules smaller than 15 μm (see Fig. 115-8B).

Pigmented Basal Cell Carcinoma

Pigmented BCC shows histologic features similar to those of nodular BCC but with the addition of melanin.[38] Approximately 75 percent of BCCs contain melanocytes, but only 25 percent contain large amounts of melanin. The melanocytes are interspersed between tumor cells and contain numerous melanin granules in their cytoplasm and dendrites. Although the tumor cells contain little melanin, numerous melanophages populate the stroma surrounding the tumor.

Superficial Basal Cell Carcinoma

Superficial BCC is characterized microscopically by buds of malignant cells extending into the dermis from the basal layer of the epidermis.[38] The peripheral cell layer shows palisading. There may be epidermal atrophy, and dermal invasion is usually minimal. This histologic sub-type is encountered most often on the trunk and extremities but may also appear on the head and neck. There may be a chronic inflammatory infiltrate in the upper dermis.

Morpheaform Basal Cell Carcinoma

Morpheaform or infiltrative BCC consists of strands of tumor cells embedded within a dense fibrous stroma (see Fig. 115-8C).[38] Tumor cells are closely packed and, in some cases, only one cell thick. Strands of tumor extend deeply into the dermis. The cancer is often larger than the clinical appearance indicates. Recurrent BCC may also demonstrate infiltrating bands and nests of cancer cells embedded within the fibrous stroma of scar.

Fibroepithelioma of Pinkus

In FEP, long strands of interwoven basiloma cells are embedded in fibrous stroma.[38] Histologically, FEP shows features of reticulated seborrheic keratoses and superficial BCC.

DIFFERENTIAL DIAGNOSIS

The differential diagnosis for BCC is summarized in Box 115-1.

TREATMENT

Management of BCC is guided by anatomic location and histologic features. Approaches include Mohs micrographic surgery (MMS), standard surgical excision, destruction by various modalities, and topical chemotherapy.[38] The best



Box 115-1

Differential Diagnosis of Basal Cell Carcinoma (BCC)

- Nodular BCC
  - Dermal nevus
  - Squamous cell carcinoma
  - Appendageal tumor
  - Dermatofibroma
  - Scar
  - Seborrheic keratosis
- Pigmented BCC
  - Nodular melanoma
  - Superficial spreading melanoma
  - Lentigo maligna melanoma
  - Appendageal tumor
  - Compound nevus
  - Blue nevus
- Superficial BCC
  - Bowen disease
  - Mammary or extramammary Paget disease
  - Superficial spreading melanoma
  - Single plaque of psoriasis
  - Single plaque of eczema
- Morpheaform BCC
  - Scar
  - Morphea
  - Trichoepithelioma
- Fibroepithelioma of Pinkus
  - Skin tag
  - Papillomatous dermal nevus
  - Fibroma

chance to achieve cure is through adequate treatment of primary BCC, because recurrent tumors are more likely to recur and to cause further local destruction. An algorithmic approach to management is summarized in Fig. 115-9.

Mohs Micrographic Surgery (See Chap. 245)

MMS offers superior histologic analysis of tumor margins while permitting maximal conservation of tissue compared with standard excisional surgery.[39] Rowe, Carroll, and Day report a recurrence rate of 1 percent for primary BCCs treated by MMS.[40] This was superior to the rate for other modalities, including standard excision (10 percent), curettage and desiccation (C&D) (7.7 percent), XRT (8.7 percent), and cryotherapy (7.5 percent). Recurrent BCCs treated by MMS reappeared at a rate of 5.6 percent, which was again superior to the rate for other modalities, including excision (17.6 percent), XRT (9.8 percent), and C&D (40 percent).[41] MMS is the treatment of choice for morpheaform, poorly delineated, incompletely removed, and otherwise high-risk primary BCCs. It is the preferred treatment for recurrent BCC and for any BCC that occurs at a site where tissue conservation is desired. MMS is particularly useful in treating BBCs at high-risk anatomic sites, including the embryonic fusion planes represented by the nasofacial junction and retroauricular sulcus (Table 115-1).

Standard Excision (See Chap. 244)

Compared with non-excisional techniques, standard surgical excision offers the advantage of histologic evaluation of the removed specimen. Although standard excision is appropriate for many BCCs, cure rates for standard excisional surgery are inferior to those for MMS in cases of primary morpheaform BCCs, recurrent BCCs, and tumors located in high-risk anatomic sites.[40,41] Wolf and Zitelli demonstrated that margins of 4 mm were adequate for 95 percent of nonmorpheaform BCCs smaller than 2 cm in diameter when treated by standard excision.[42] Johnson, Tromovitch, and Swanson reported a 96.7 percent cure rate when the excision included a 2-mm margin beyond the area defined by curettage.[43] Tumor was present in 64 of 403 curette margins and in 12 of 403 excision

TABLE 115-1

Indications for Mohs Surgery for Basal Cell Carcinoma

- Location on a high-risk anatomic site including mask area of face, scalp, anatomic fusion planes, periorbital area/eyelid
- Tumor > 2 cm
- Aggressive histologic sub-type
- Recurrent tumor
- Incompletely excised basal cell carcinoma
- Location on previously irradiated skin
- Immunosuppression of patient after solid organ transplantation
- Indistinct clinical border
- Situation requiring conservation of normal tissue to preserve function and cosmesis
- Situation requiring highest achievable probability of cure to preserve function and cosmesis

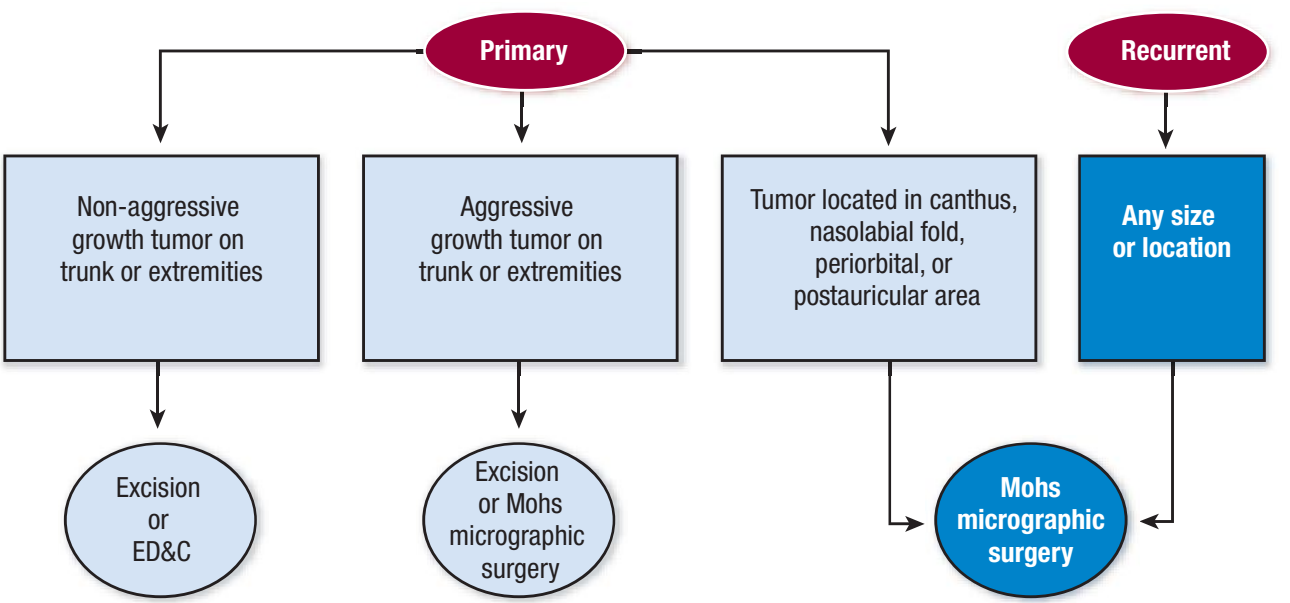

▲ **FIGURE 115-9** Management of basal cell carcinoma is guided largely by anatomic site and histologic sub-type of the lesion. ED&C = electrodesiccation and curettage.

margins. The histologic sub-type was aggressive in 11 of 12 cases with positive excision margins. Margins of 5 mm are necessary for primary morpheaform BCC or recurrent BCC. Excision of primary BCC should extend to fat to ensure adequate tumor removal.

Curettage and Desiccation (See Chap. 247)

C&D is one of the most frequently used treatment modalities for BCC.[44] That C&D is operator dependent was shown by Kopf et al., who identified a significant difference in cure rate between patients treated by private practitioners (94.3 percent) and those treated by residents (81.2 percent).[45] Spiller and Spiller reported a cure rate of 97 percent in 233 patients.[46] Cure rate decreased as a function of primary lesion size: for lesions smaller than 1.0 cm, the cure rate was 98.8 percent; for lesions between 1.0 and 2.0 cm, 95.5 percent; and for lesions larger than 2.0 cm, 84 percent. Recurrences were noted most often on the forehead, temple, ears, nose, and shoulders. C&D is not recommended for large primary BCC, morpheaform BCC, or recurrent BCC.

Cryosurgery (See Chap. 247)

Cryosurgery is another destructive modality that has been used in the treatment of BCC.[47] Two freeze-thaw cycles with a tissue temperature of –50°C (–58°F) are required to destroy BCC. In addition, a margin of clinically normal tissue must be destroyed to eradicate sub-clinical extension. Cryosurgery lacks the benefit of histologic confirmation of tumor removal. Kuflik and Gage reported 99 percent cure rates in 628 patients followed for 5 years.[48] Possible complications of cryosurgery include hypertrophic scarring and post-inflammatory pigmentary changes. Another serious potential adverse outcome is the obscuring of tumor recurrence by fibrous scar tissue. Any recent change in a cryosurgery scar after normal healing is completed should raise the suspicion of recurrent BCC.

Topical Treatment

IMIQUIMOD Imiquimod (5 percent cream) (see Chap. 221) has been used in the treatment of skin cancers.[49] Imiquimod is a Toll-like receptor 7 agonist and is believed to induce interferon-α and other cytokines to boost T helper 1 type immunity. In two double-blind, randomized, vehicle-controlled trials, clinical and histologic clearance rates for dosing five and seven times per week were 75 percent and 73 percent, respectively, for superficial BCC.[50,51] In another study, 10 of 19 nodular BCCs (approximately 53 percent) cleared after treatment with imiquimod.[52] In general, adverse side effects are limited to local skin reactions. Follow-up in case series has generally been shorter than that in retrospective studies of recurrence rates after definitive surgical management.

5-FLUOROURACIL (See Chap. 220) 5-Fluorouracil (5-FU), a topically applied chemotherapeutic agent used in the treatment of actinic keratoses, has also been used to treat BCCs. In one series, Epstein showed a 5-year recurrence rate of 21 percent after 5-FU treatment, which was reduced to 6 percent when curettage was performed initially.[53] 5-FU is metabolized by dihydropyrimidine dehydrogenase, and its use is contraindicated in patients deficient in that enzyme.[54,55] The use of 5-FU to treat BCC should be considered carefully and should include an evaluation of the risk of recurrence and treatment failure.

Photodynamic Therapy (See Chap. 239)

Photodynamic therapy involves the activation of a photosensitizing drug by visible light to produce activated oxygen species that destroy the constituent cancer cells.[56] Exogenous δ-aminolevulinic acid increases intracellular production of the endogenous photosensitizer protoporphyrin type IX, which preferentially accumulates in tumor cells. Morrison et al.[59] reported an 88 percent initial clearance of 40 large (> 2 cm) BCCs after one to three treatments. The time of follow-up was between 12 and 60 months. Reports of higher recurrence rates by others suggest that this method may be best reserved for select situations in which better established methods are not feasible.[57] Marmur et al. reviewed photodynamic therapy for non-melanoma skin cancer and reported recurrence rates ranging from 0 percent to 31 percent for BCC.[57]

Radiation Therapy (See Chap. 241)

XRT may be useful in cases of primary BCC or in cases in which postsurgical margins are positive for cancer. Advantages include minimal patient discomfort and avoidance of an invasive procedure for a patient unwilling or unable to undergo surgery. Potential disadvantages include lack of histologic verification of tumor removal, prolonged treatment course, cosmetic result that may worsen over time, and predisposition to aggressive and extensive recurrences. Local control rates of 93 percent to 97 percent have been reported[58,59]; however, cosmesis has been rated inferior to results achieved surgically.

Special Management Issues

INCOMPLETELY EXCISED BASAL CELL CARCINOMA Based on data from the 1960s suggesting that 50 percent to 70 percent of incompletely excised BCCs do not recur, some physicians adopted a "wait and see" approach.[60] In some cases, flap and graft repair may have been performed before confirmation of negative margins, so that the anatomy was distorted. This confounds identification of positive margins for definitive treatment. Incomplete resection was addressed by Robinson and Fisher,[61] who reported on 994 patients consecutively referred for treatment of incompletely excised BCCs with subsequent clinical recurrence. Of these, only 32 were referred for MMS for complete tumor removal at the time the original operating surgeon received the pathologic confirmation of positive excision margins. For the remaining 962 recurrent BCCs, the nose was the most common anatomic site (43 percent), and flap repair was the most common form of reconstruction (52 percent). The authors recommend MMS for the treatment of incompletely excised BCC. Ideally, patients should receive treatment at the time of diagnosis, because delay will likely result in increased local tissue damage (Fig. 115-10). Patients unable to undergo re-excision to achieve clear margins should be evaluated for XRT.

NEUROTROPIC BASAL CELL CARCINOMA Perineural invasion by BCC is a rare event (< 0.2 percent of cases).[32,33] When perineural invasion is detected, every effort should be made to clear the tumor, preferably by MMS. Patients with gross perineural invasion manifested by neurologic symptoms would benefit from preoperative magnetic resonance imaging to assess extent of tumor spread. Classic examples include brow paralysis due to involvement of the temporal branch of the facial nerve and mid-face paresthesias secondary to involvement of the trigeminal nerve.





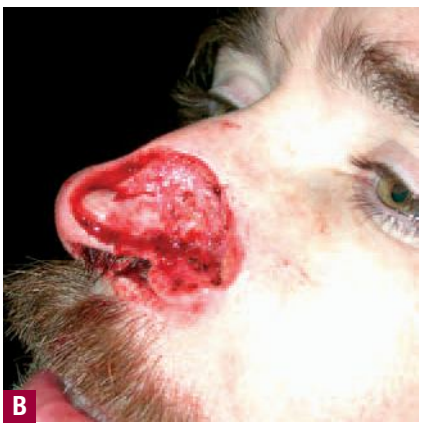

▲ **FIGURE 115-10** Incompletely excised basal cell carcinoma (BCC) resulting in extensive spread after observation rather than immediate definitive management. **A.** Recurrent BCC after skin graft placement over tumor-bearing area. **B.** Intraoperative view during Mohs surgery to achieve a tumor-free plane before reconstruction.

METASTATIC BASAL CELL CARCINOMA Although it is exceedingly rare, the possibility of metastatic disease exists and may need to be addressed.[36] If nodal disease is suspected on surgical examination, lymph node biopsy and imaging studies, as well as evaluation by medical and surgical oncologists, are indicated. Platinum-based chemotherapy has been used with modest results in treatment of metastatic BCC; however, rapid clinical response was reported using a combination of cisplatin and paclitaxel.[62]

COURSE AND PROGNOSIS

With appropriate treatment, the prognosis for most patients with BCC is excellent. Control rates as high as 99 percent have been achieved by MMS. Although tumor control rates for primary tumors are high, patients must be monitored for recurrence and development of new primary BCCs. The risk for development of a second primary BCC ranges from 36 percent to 50 percent.[63] Periodic full-body skin examinations and counseling about sun protection are recommended for any patient with a history of BCC. This is especially important because patients with a history of BCC are at increased risk for melanoma.

The prognosis for patients with recurrent BCC is favorable, although recurrent tumors are more likely to appear again and to behave aggressively. Patients with a history of recurrent disease must be monitored more frequently for the development of further recurrences and new primary tumors. For the rare patient with metastatic disease, prognosis is poor, with a mean survival of 8 to 10 months from the time of diagnosis.

KEY REFERENCES

The full reference list for all chapters is available at www.digm7.com.

1. Crowson AN: Basal cell carcinoma: Biology, morphology and clinical implications. *Mod Pathol* **19 Suppl 2**:S127, 2006
8. van Dam et al: Risk factors for basal cell carcinoma of the skin in men: Results from the health professionals follow-up study. *Am J Epidemiol* **150**:459, 1999
17. Bale AE, Gailani MR, Leffell DJ: Nevoid basal cell carcinoma syndrome. *J Invest Dermatol* **103**:126S, 1994
24. McCormack CJ, Kelly JW, Dorevitch AP: Differences in age and body site distribution of the histological subtypes of basal cell carcinoma. A possible indicator of differing causes. *Arch Dermatol* **133**:593, 1997
31. Niazi ZB, Lamberty BG: Perineural infiltration in basal cell carcinomas. *Br J Plast Surg* **46**:156, 1993
41. Rowe DE, Carroll RJ, Day CL Jr: Mohs surgery is the treatment of choice for recurrent (previously treated) basal cell carcinoma. *J Dermatol Surg Oncol* **15**:424, 1989
50. Geisse J et al: Imiquimod 5% cream for the treatment of superficial basal cell carcinoma: Results from two phase III, randomized, vehicle-controlled studies. *J Am Acad Dermatol* **50**:722, 2004

CHAPTER 116

Basal Cell Nevus Syndrome

Anthony E. Oro

Basal cell nevus syndrome (BCNS), also known as *nevoid basal cell carcinoma syndrome* and *Gorlin syndrome* [Online Mendelian Inheritance in Man (OMIM) #109400], is a rare autosomal dominant disorder associated with a panoply of phenotypic abnormalities that can be divided into developmental anomalies and postnatal tumors, especially basal cell carcinomas (BCCs).[1] Although individual aspects had been reported previously, their syndromic association was first appreciated widely in the late 1950s.[2,3]

EPIDEMIOLOGY

The prevalence of BCNS is variously estimated to be 1 in 60,000 and 1 in 120,000 persons.[4,5] The syndrome affects both sexes and occurs in a wide variety of cultural groups, and therefore does not have a predilection for a particular skin type. The condition appears to have complete penetrance and variable expressivity of traits, which makes clinical presentation among families variable. Further, as with many dominantly inherited conditions, new mutations are common. As a result, in many cases, patients may have no apparent affected ancestors or siblings.

ETIOLOGY AND PATHOGENESIS

Genetic Abnormality

All known BCNS patients thus far carry mutations in the *PATCHED1* (*PTCH1*, UniGene Hs.494538) gene residing on the long arm of chromosome 9.[6,7] PTCH1 plays a central role in the hedgehog signaling pathway that is essential for the establishment of normal body and limb patterning in metazoan organisms.[8] The PTCH1 locus behaves like a classic tumor suppressor gene (Fig. 116-1). The appearance of BCCs in small numbers at an older age in sporadic cases and in larger numbers at a younger age in patients with BCNS is reminiscent of differences in sporadic and hereditary cases of retinoblastoma.[9] BCNS, like other tumor susceptibility syndromes, is inherited in an autosomal dominant manner, with inheritance of a loss-of-function allele followed by somatic loss of the remaining copy before tumor formation.

Identification of the gene mutation responsible for BCNS facilitated a molecular verification of the tumor suppressor prediction.[6,7] In BCNS, patients inherit

BASAL CELL NEVUS SYNDROME AT A GLANCE



- A rare autosomal dominant disorder with phenotypic abnormalities that include developmental anomalies and postnatal tumors, especially basal cell carcinomas (BCCs).
- The three most characteristic abnormalities are tumors such as medulloblastomas or BCCs, pits of the palms and soles, and odontogenic cysts of the jaw.
- Related findings include calcification of the falx cerebri, enlarged body habitus, and skeletal abnormalities of the ribs and skull.
- Diagnosis is suggested to the dermatologist in a patient with multiple BCCs arising at an unexpectedly early age on non–sun-exposed skin, with an average age of onset of 21 years.
- Histologic features are similar to those of sporadic infundibulocystic BCCs or medulloblastomas.

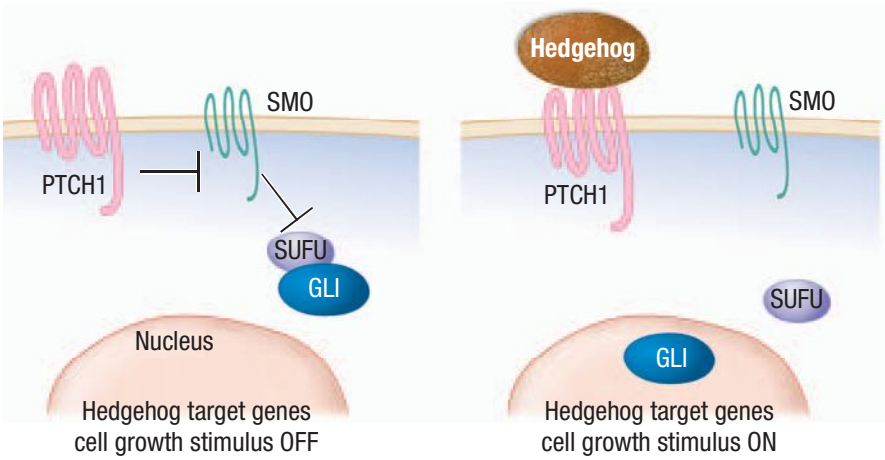

▲ **FIGURE 116-1** The mammalian hedgehog signaling pathway. PTCH1 is the receptor for the growth factor hedgehog and inhibits the function of smoothened (SMO). SMO inhibits Suppressor of Fused (SUFU), which in turn inhibits the GLI transcription factors.

one defective PTCH1 allele, but their tumors contain an additional somatic mutation. As with other tumor suppressor genes, PTCH1 mutations have also been found in older adults with sporadic BCCs and other sporadic tumors known to be over-represented in BCNS patients (e.g., medulloblastomas and meningiomas), which supports the idea that two somatic "hits" are required in sporadic tumors.

Are PTCH1 mutations the only cause of BCNS? Despite direct sequencing of *PTCH1* exons in patients, somatic mutations are found in fewer than half of BCCs and constitutional mutations in fewer than 100 percent of BCNS patients.[13,14] On the one hand, this suggests that mutations in other unidentified genes may underlie the disease. On the other hand, early linkage studies found strong association with the PTCH1 locus. Moreover, although mutations are not found in PTCH1 exons in some patients, hedgehog signaling pathway abnormalities are still present in these tumors. This indicates that either mutations in another PTCH1-like gene or insensitivity or incompleteness of the screening methods explain the discrepancy.

PTCH1 Function[15]

PTCH1 protein plays a critical role in the hedgehog signaling pathway. Genetic and biochemical studies in *Drosophila* and mammals indicate that PTCH1 protein inhibits this signaling pathway by inhibiting the function of the central G protein–coupled receptor smoothened (SMO), and that the extracellular ligand hedgehog reduces this inhibition. Signaling by SMO results in the activation of the GLI family of zinc finger proteins that mediate all the transcriptional effects of hedgehog signaling. Three GLI proteins mediate activation and suppression of hedgehog target genes, with GLI1 and GLI2 acting as activators and GLI2 and GLI3 as suppressors. SMO signaling tips the balance towards activation and away from target gene suppression. In mammals, GLI activity is controlled by the novel cytoplasmic protein Suppressor of Fused (SUFU), which promotes the transcriptional repression and inhibits activation.[16] SMO functions to inhibit SUFU activity, thus releasing GLI proteins to become transcriptional activators. When hedgehog binds to PTCH1, PTCH1 inhibition of SMO is relieved and the pathway is activated. The loss of PTCH1 function that allows unregulated SMO activity forms the basis of the tumor induction.

How PTCH1 functions as a tumor suppressor is still under investigation. A significant aspect of PTCH1 function is inhibition of SMO, although how PTCH1 accomplishes this is unknown. PTCH1 acts in an enzymatic manner, with only a few molecules able to inhibit several-fold times more SMO.[17] Moreover, PTCH1 and SMO are thought not to physically interact and exist in distinct endosomes in the cell. One clue is that SMO activity appears to be linked to its sub-cellular location, because loss of PTCH1 or mutations that trap SMO at the membrane result in SMO phosphorylation and increased activity.[18] Another clue is that PTCH1 shares homology with sterol-sensing domain–containing proteins such as the cleavage activation protein SREBP (sterol regulatory element–binding protein) and β-hydroxy-β-methylglutaryl–coenzyme A reductase.[19] It also shares significant structural identity with the resistance-nodulation-division (RND) permease family of small-molecule transporters, which suggests that it acts like a molecular pump. This evokes the tantalizing hypothesis that PTCH1 regulates SMO localization by regulating the production or distribution of small-molecule second messengers in the cell.

Mutations in Sonic Hedgehog Pathway in BCCs

Supporting the central role of Sonic Hedgehog (Shh) target gene induction in BCC pathogenesis is the finding of mutations in members of the Shh pathway in both BCNS patients and in sporadic BCCs. Identified mutations involving PTCH1 are by far the most common and are found in approximately 40 percent of tumors.[23] Epidemiologic evidence implicates ultraviolet light in the



pathogenesis of sporadic BCCs. The particular type of mutation found in PTCH is consistent with mutation caused by ultraviolet light, which provides additional evidence for PTCH and sunlight in cancer development.[24]

Mutations of SMO protein have been identified in approximately 10 percent of BCCs, and these mutations appear to render SMO protein resistant to PTCH1 inhibition.[25] Indeed, experimental transfection of cells with mutant SMO sequences can transform them to a malignant phenotype. This finding that BCCs may have upregulation of hedgehog target gene expression due to mutations in either PTCH1 or SMO argues that it is the upregulation of hedgehog signaling rather than the specific mutation that is crucial to BCC formation. Consistent with this is the finding that mutations in the gene encoding SUFU have been reported to underlie formation of medulloblastomas.[26]

The identification of these molecular abnormalities in BCCs for the first time has permitted the development of mouse models of this tumor. Previously, insults to mouse skin—ultraviolet or ionizing radiation or carcinogenic chemicals—have produced papillomas and carcinomas of the squamous, but not the basal cell, lineage. Mouse models that show spontaneous development of BCC-like tumors include those with epidermal overexpression of hedgehog,[27] of mutant SMO,[25] or of GLI1[28,29] or GLI2.[30] In addition, *ptc1*$^{+/-}$ mice, which, like BCNS patients, have one instead of two functioning alleles of *PTCH1*, not only develop BCCs and related tumors but also develop plantar pits, medulloblastomas, and rhabdomyosarcomas, as do BCNS patients. The mouse BCCs (mimicking BCCs in BCNS patients) occur spontaneously in low numbers and in small sizes, but in much higher numbers and of larger size in mice exposed to ultraviolet or ionizing radiation.[11,30,31]



CLINICAL FINDINGS

Cutaneous Lesions

Hedgehog signaling plays a critical role in the expansion of progenitor cells in a wide variety of tissues in both invertebrate and vertebrate organisms. PTCH1 normally is expressed both during development and in the adult, which suggests an ongoing role postnatally. Studies involving experimental models inappropriately expressing components of the hedgehog signaling pathway have revealed significant developmental anomalies.[31] The resemblance of these anomalies to those characteristic of BCNS implies that aberrant activation of the hedgehog signaling pathway is a sufficient explanation for the developmental and tumorigenic anomalies of BCNS, even if the precise pathogenic mechanisms have yet to be elucidated.

Patients with BCNS show multiple abnormalities, none of which is unique to this syndrome[5,13,14] (Table 116-1). The three abnormalities considered to be most characteristic of the syndrome are tumors such as medulloblastomas or BCCs, pits of the palms and soles, and odontogenic cysts of the jaw.

BCCs in patients with BCNS cannot be distinguished individually from those in sporadic cases (see Chap. 115), which is not surprising in view of the similar pathogenesis in familial and sporadic cases. What is distinguishing is their appearance in large numbers starting at an early age. They may be banal appearing and confused grossly with nevocytic nevi—hence the name *basal cell nevus*. They may also have a translucent, papulonodular appearance more characteristic of sporadic basal cell carcinomas and may invade locally. In rare cases, they may even metastasize, causing the patient's death. Although the ratio of sun-protected to sun-exposed BCCs may be higher in BCNS than in sporadic cases, sunlight and ionizing radiation clearly accelerate BCC formation in BCNS patients, and darkly pigmented BCNS patients may have few to no BCCs (Figs. 116-2, 116-3, and 116-4).

TABLE 116-1
Frequency of Anomalies in Basal Cell Nevus Syndrome

	IGR[14] (France)	Evans et al.[36] (United Kingdom)	Shanley et al.[5] (Australia)	Kimonis et al.[13] (USA)
Number of cases	22	84	118	105
Number of families	5	29	64	26
Average age (yr)	44.9		35	34.5
Sex ratio (Male:Female)	1:1.75	1:1.3	1:1.3	1:1.2
BCC (%)	100	47	76	80
Average age at first BCC (yr)	24.2		20.3	21.4
Palmar pits (%)	45	71	80	8
Dental cysts (%)	62	66	75	74
Falx calcification (%)	66		92	65
Epidermal cysts (%)	41		51	
Craniofacial Anomalies				
Macrocephaly (%)	27		80	49
Skull protrusion (%)	18		66	26
Cleft palate (%)	?	5	4	3
Ophthalmologic Anomalies				
Hypertelorism (%)	18		6	42
Strabismus (%)	4.5			19
Skeletal Anomalies				
Pectus excavatum (%)	23		23	12
Scoliosis (%)	18			31
Kyphosis (%)	9			
Cervical ribs (%)	5			16
Bifid ribs (%)	16			26
Spina bifida (%)	9			19
Vertebral fusion (%)	4.5			10
Neurologic Anomalies				
Anosmia (%)	4.5		9	
Deafness (%)	4.5			
Corpus collosum tumor (%)	9			10
Tumors				
Medulloblastoma (%)	13	4	1	4
Meningioma (%)	18	1		5
Ovarian fibroma (%)	13	24	14	17

BCC = basal cell carcinoma; IGR = intrauterine growth retardation.
From Pruvost-Balland C et al: Etude clinique et recherche de mutations germinales du gene PTCH1 dans le syndrome des harmartomaes basocellulaires. *Ann Dermatol Venereol* **113**:117, 2006, with permission.



▲ **FIGURE 116-2** Face of a man with severe scarring from growth and treatment of multiple basal cell carcinomas (BCCs). Note multiple outlined new BCCs despite extensive and frequent surgery.

Palmo-plantar pits are small defects in the stratum corneum and may be pink or, if dirt has accumulated, dark in color (Fig. 116-5). They appear early in life and can be a valuable aid in diagnosis in addition to jaw cysts or medulloblastoma. Their basis is poorly understood, but they are thought to be due to aborted attempts to generate hair follicles in the palms. They are also seen in mouse PTCH1 heterozygotes.[31]

Related Physical Findings

Tissue overgrowth, which is also a feature of hedgehog signaling pathway activation in *Drosophila*, often is manifested by an overall body size larger than that of other family members. Limbs may be particularly long, giving a marfanoid appearance (Fig. 116-6), and a large head circumference (at least in probands) and frontal bossing are often described.

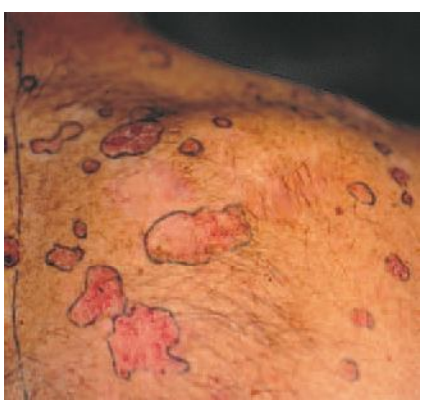

▲ **FIGURE 116-3** Upper back of man with basal cell nevus syndrome with innumerable basal cell carcinomas, some of which are nodular and most of which are flat, erythematous patches.



▲ **FIGURE 116-4** Basal cell carcinoma (BCC) on the toe of a patient with basal cell nevus syndrome (BCNS), which illustrates that the whole skin surface of BCNS patients is susceptible to BCC formation.

Jaw cysts often are the first detectable abnormality[5,13,14] (Fig. 116-7). They may be asymptomatic and therefore diagnosed only radiologically. However, they also may erode enough bone to cause pain, swelling, and loss of teeth. They occur more often in the mandibular jaw than in the maxillary jaw.[32] They presumably form from inappropriate Shh induction of dental epithelium, can recur often, and can be the most debilitating aspect of the syndrome.[33]

Table 116-1 lists the phenotypic abnormalities that have been reported often enough that they probably are true components of the syndrome. These include tissue overgrowth seen in other epithelial organs such as the meninges or ovary that give rise to meningiomas or ovarian fibromas. Variation in clinical severity is typical even within a single kindred, and this heterogeneity is likely due to both environmental differences (e.g., exposure to ultraviolet and ionizing radiation) and genetic background differences.

Of interest is the finding that Shh signaling plays a key role in up to 25 percent of all human cancers, including small cell lung cancer, pancreatic cancer, and prostate cancer.[34] This finding suggests a wider role for hedgehog signaling than that seen in BCNS patients. Although BCNS is a rare syndrome and exhaustive controlled studies have not been performed, no excess of these associated cancers has been documented in BCNS patients. This might reflect a distinct mechanism of action, because these other tumors demonstrate hedgehog ligand overexpression rather than the loss of PTCH1. Alternatively, pathway induction in older adults may have different consequences than pathway activation in younger individuals.

DIAGNOSIS

Because the individual abnormalities are not unique to BCNS patients, it is possible to diagnose BCNS clinically only when multiple typical defects are present (Table 116-2). The severity of abnormalities may differ markedly among members of a single kindred, and diagnostic certainty may be difficult for specific individuals even if they be-



▲ **FIGURE 116-5** **A.** Unusually florid palmar pits in a patient with basal cell nevus syndrome (BCNS). **B.** Larger magnification showing that these lesions in BCNS are really punched-out pits.





▲ **FIGURE 116-6** Skeletal and radiographic findings in basal cell nevus syndrome. **A.** Unusually large body habitus and extremities. **B.** Syndactyly in digits. **C.** Calcification of the falx cerebri. **D.** Rib development abnormalities, including rib fusion (*arrow*).

long to a kindred with known BCNS.[35] Generally, the diagnosis is suggested to the dermatologist when multiple BCCs arise in a patient at an unexpectedly early age and in unexpectedly large numbers, with the average age of onset in the early 20s.

Further evaluation should include (1) questions about whether other family members have had abnormalities consistent with BCNS (although perhaps 25 percent to 30 percent of patients with BCNS have no affected ancestors) and whether the patient is taller and heavier than his or her relatives; (2) examination for palmo-plantar pits and skin cysts and assessment of body and head size; and (3) radiologic evaluation for jaw cysts (which often appear around the start of the second decade and frequently recur after surgery), calcification of the falx (which occurs in nearly all adults with BCNS and may be present in early childhood in BCNS patients, thus suggesting the diagnosis of BCNS in patients with early-onset medulloblastomas), and abnormalities of the ribs, spine, and phalanges (flame-shaped lucencies), each of which is present in one-third to one-half of BCNS patients.[5,13,14,36] Kimonis and colleagues proposed a set of major and minor criteria for presumptive diagnosis of BCNS, which has since been modified (see Table 116-2).[13] For cases in which the diagnosis is in doubt, or for genotyping of other family members, identification of *PTCH1* gene mutations is now available commercially through GeneDX (Gaithersburg, MD).

DIFFERENTIAL DIAGNOSIS

Other syndromes exist that are characterized by the development of multiple BCCs. These include Bazex syndrome (OMIM 301845),[37] Rombo syndrome (OMIM 180730),[38] and a syndrome observed in a family with BCCs, milia, and coarse, sparse hair.[39] Hair abnormalities are present in all three syndromes, which is a finding of interest in view of the often-repeated suggestion that BCCs arise from hair follicles rather than from interfollicular epidermis. The exact nosologic relationships among these three syndromes are uncertain, but patients with BCNS have normal hair, and all three syndromes seem quite different from BCNS.

Two other syndromes that have been described include multiple hereditary infundibulocystic basal cell carcinoma[40] and generalized basaloid follicular hamartoma.[41] Both demonstrate histologic variants of BCCs, with more hamartomatous lesions, and are characterized by palmar pits and milia. The latter syndrome is acquired and associated with autoimmune disease, which suggests an immunologic stimulation of the hedgehog pathway. The former appears to be linked to the PTCH1 locus and thus may be due to a PTCH1 allele.

Patients with long-term arsenic ingestion may have multiple BCCs. Their dyschromia and lack of other phenotypic abnormalities differentiate them from BCNS patients (see Chap. 113). Patients with xeroderma pigmentosum develop multiple BCCs but are readily differentiated from BCNS patients by their severe photosensitivity and other phenotypic abnormalities (see Chap. 140).

The most challenging patients are those who have a marked propensity to develop multiple BCCs early in life, sometimes sporadically or in rare cases after therapeutic irradiation (e.g., for Hodgkin disease) without showing any of the other signs of BCNS. These cases occasionally produce diagnostic confusion because, due to the variable expressivity of individual PTCH1 alleles, it is not known whether their defect is related to the hedgehog pathway, to DNA repair, to an unknown toxin, and/or to undescribed mechanisms. One insightful study argues against constitutional PTCH1 mutations as the cause of multiple BCCs, because PTCH1 mutations have not been found in individuals who do not have at least one other key manifestation of BCNS.[42]

COMPLICATIONS, PROGNOSIS, AND CLINICAL COURSE

Although disease pathogenesis involves abnormalities in Shh signaling, the wide variability in clinical course among fam-

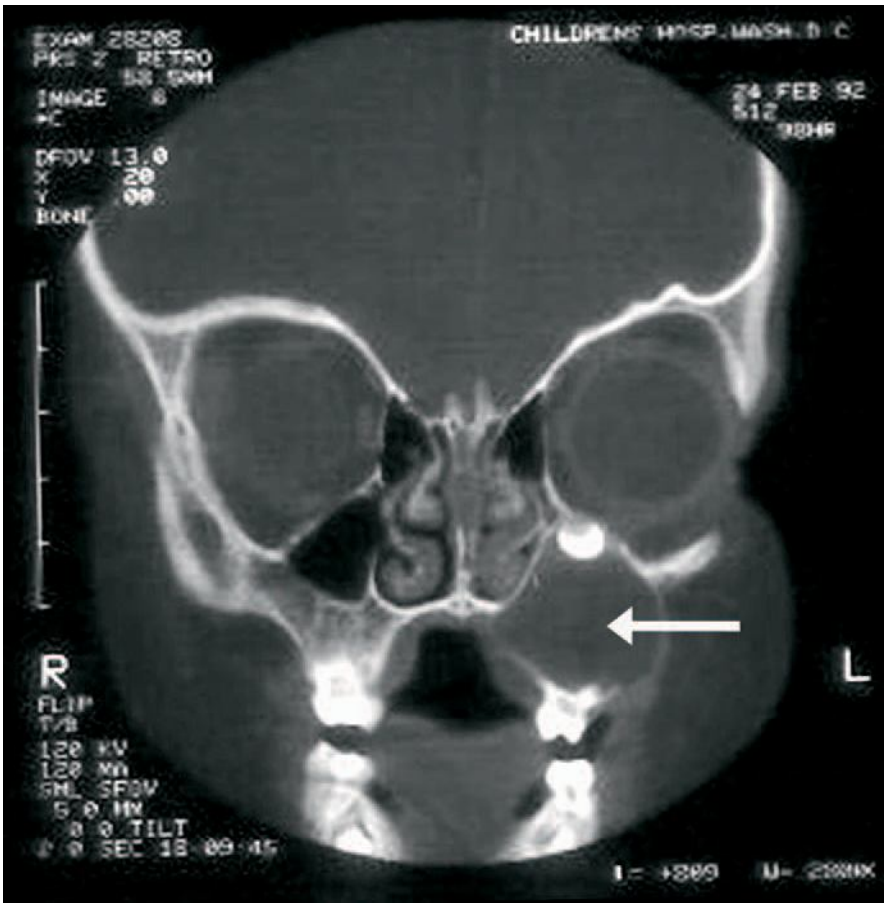

▲ **FIGURE 116-7** Radiographic findings of odontogenic keratocyst (*arrow*).

TABLE 116-2
Diagnostic Criteria for Basal Cell Nevus Syndrome (BCNS)

Major Criteria
1. Basal cell carcinoma before age 20 yr
2. Odontogenic keratocysts before age 15 yr
3. Three or more palmar and/or plantar pits
4. Bilamellar calcification of the falx cerebri (if younger than 20 yr)
5. Fused, bifid, or markedly splayed ribs
6. First-degree relative with BCNS
7. *PTC* gene mutation in normal tissue

Minor Criteria
1. Macrocephaly determined after adjustment for height
2. Congenital malformations: cleft lip or palate, frontal bossing, "coarse face," moderate or severe hypertelorism
3. Skeletal abnormalities: Sprengel deformity, marked pectus deformity, or marked syndactyly of the digits
4. Radiologic abnormalities: bridging of the sella turcica; rib anomalies such as bifid or splayed ribs; vertebral anomalies such as hemivertebrae, fusion, or elongation of the vertebral bodies; modeling defects of the hands and feet; or flame-shaped lucencies of the hands or feet
5. Ovarian fibroma
6. Medulloblastoma

Data from Kimonis VE et al: Clinical manifestations in 105 persons with nevoid basal cell carcinoma syndrome. *Am J Med Genet* **69**:299, 1997; and First BCCNS Colloquium, St. Louis, May 2005.

ilies, and even between generations of the same family, make prediction of clinical course difficult. If BCNS is suspected or confirmed, physicians should also screen for the most frequent sequelae of the disease during childhood or adolescence. (Fig. 116-8). No large-scale survival studies have been performed to determine whether BCNS patients die earlier because of their disease.[13,43] The major complications are associated with developmental abnormalities that result in developmental delay or physical impairment in children and the childhood tumors that arise, such as medulloblastoma. The latter often occur within the first 5 years of life and are frequently the initial sign of BCNS. Complications arising from medulloblastoma treatment (radiation, shunt placement) are relatively common, and multidisciplinary teams of physicians are required to optimally treat these patients.

In the skin, BCCs that arise are locally aggressive but very rarely metastasize.[44] No reports document an increased risk for metastatic BCCs, which suggests that the basic character of the tumor is similar to that seen in sporadic BCC cases. However, because of the high numbers and wide distribution of the tumor, even in the absence of sun exposure, involvement of key epithelial surfaces or membranes is likely and can be disfiguring for the patient.

TREATMENT

Therapy must be directed at the individual lesions as they arise, and the most important aspect of management is frequent examination, enthusiastic counseling about avoidance of sun exposure, and early treatment of small tumors. In animal models of BCNS, small clinically undetectable tumors arise throughout the skin. This suggests that many more tumors form than are detectable visibly by the clinician.[29] This has several therapeutic ramifications. One is that clinicians caring for BCNS patients should become confident in their clinical acumen so that they can diagnose and treat tiny BCCs without histopathologic confirmation. This would eliminate multiple scar-inducing biopsies in addition to potentially disfiguring treatments. Another is that invasive treatments should be focused on those lesions that are potentially most harmful, such as those invading mucous membrane or adjacent structures. Repetitive surgical treatments run the risk of severe disfigurement for the patient. Finally, clear surgical margins may be difficult to achieve when using Mohs surgery, so aggressive pursuit of a clear margin needs to be balanced against other factors in treating these patients.

Non-surgical approaches to BCC treatment should be used aggressively in BCNS patients when possible. Because the key is to convince the patient to accept frequent treatments, minimization of discomfort and scarring is a major goal. Approaches that may be of benefit are topical treatment with 5-fluorouracil (with or without occlusion, depending on the degree of inflammation produced),[45] the Toll-like receptor agonist imiquimod,[46] and photodynamic therapy.[47] Oral therapy with retinoids also may be of value, but often only at a dosage that causes severe side effects.

Studies have now identified a natural antagonist of the hedgehog pathway derived from the *Veratrum californicum*



Approach to a patient with known or suspected BCNS

Pediatric patients

- baseline MRI of brain, repeat yearly (if asymptomatic) until age 8
- baseline dermatologic exam, repeat yearly until first BCC develops, then every 6 months or more frequently as needed) throughout life
- digital panorex of jaw at age 3 or 4 years (or as soon as tolerated), then yearly until first jaw cyst develops. Repeat yearly (or more frequently as needed), until age 21
- pelvic u/s in girls at menarche (or earlier if symptomatic)
- molecular diagnosis, (if desired) for patients with family history and known mutation
- baseline scoliosis assessment at 1 year of age and then annually for progression if present
- routine developmental screening and referral for all children who do not meet developmental milestones

Adult patients

- baseline MRI of brain (if not done at age 8 or later)
- dermatologic exam at 4 months (or more frequently if new lesions present at each exam)
- digital panorex of jaw twice yearly until cyst free for two years, then yearly or less frequently (depending on patient's concern about radiation)
- prenatal or preconception counseling if desired

▲ **FIGURE 116-8** Approach to the patient with known or suspected basal cell nevus syndrome (BCNS). BCC = basal cell carcinoma; MRI = magnetic resonance imaging; u/s = ultrasonography. (Data from Kimonis VE et al: Clinical manifestations in 105 persons with nevoid basal cell carcinoma syndrome. *Am J Med Genet* **69**:299, 1997; and First BCCNS Colloquium, St. Louis, May 2005.)

plant called *cyclopamine*.[12] This substance binds and antagonizes SMO activity and has been shown to be effective in animal models of BCCs. Other small-molecule hedgehog pathway antagonists with similar properties have been identified and are currently being tested for their clinical efficacy.[48] These bring the promise of a specific therapy for BCCs and other hedgehog signaling–dependent tumors.

The x-irradiation of BCCs has been advocated in otherwise normal patients who are not surgical candidates. However, excessive radiation should be avoided if possible, because enhanced radiation-induced carcinogenesis (e.g., in the skin of the portals of irradiation for childhood medulloblastomas) is characteristic of BCNS. Patients with BCNS who receive radiation have developed an unusually large number of basal cell tumors in the irradiated area a short time after exposure (Fig. 116-9). Radiosensitivity in PTCH heterozygotes has also been detected at the cellular level, although the mechanism is poorly understood.[49]

Genetic counseling is appropriate. With the availability of direct sequencing of the PTCH1 locus, genotyping for prenatal diagnosis is potentially achievable for interested families. Because PTCH1 is transmitted with complete penetrance, half of the children of affected individuals are expected to develop BCNS.

ACKNOWLEDGMENTS

I would like to thank Drs. Sheri Bale and Thierry Magnaldo for patient information and Ray Herrman for administrative help.



▲ **FIGURE 116-9** Basal cell nevus syndrome. Multiple large, fungating basal cell carcinomas (BCCs) arising in a portion of the lower back treated years earlier with superficial x-irradiation for BCCs.

KEY REFERENCES

The full reference list for all chapters is available at www.digm7.com.

1. Gorlin RJ: Nevoid basal-cell carcinoma syndrome. *Medicine (Baltimore)* **66**:98, 1987
7. Johnson RL et al: Human homolog of *patched*, a candidate gene for the basal cell nevus syndrome. *Science* **272**:1668, 1996
13. Kimonis VE et al: Clinical manifestations in 105 persons with nevoid basal cell carcinoma syndrome. *Am J Med Genet* **69**:299, 1997
15. Taipale J, Beachy PA: The Hedgehog and Wnt signalling pathways in cancer. *Nature* **411**:349, 2001
31. Aszterbaum M et al: Ultraviolet and ionizing radiation enhance the growth of BCCs and trichoblastomas in patched heterozygous knockout mice. *Nat Med* **5**:1285, 1999
46. Stockfleth E et al: Successful treatment of basal cell carcinomas in a nevoid basal cell carcinoma syndrome with topical 5% imiquimod. *Eur J Dermatol* **12**:569, 2002
48. Williams JA et al: Identification of a small molecule inhibitor of the hedgehog signaling pathway: Effects on basal cell carcinoma-like lesions. *Proc Natl Acad Sci U S A* **100**:4616, 2003

CHAPTER 117

Keratoacanthoma

Lorenzo Cerroni
Helmut Kerl

Keratoacanthoma is a common epithelial tumor of the skin characterized by rapid growth, histopathologic features similar to those of cutaneous squamous cell carcinoma, and a certain tendency toward spontaneous regression. The exact nosology and classification of keratoacanthoma are a matter of debate. Some authors regard keratoacanthoma as a benign cutaneous tumor that is the prototype of a "pseudomalignant" tumor of the skin, whereas others maintain that it is a malignant neoplasm and should be regarded as a variant of cutaneous squamous cell carcinoma.

The authors of this chapter believe that keratoacanthoma represents a peculiar variant of squamous cell carcinoma, based on the rare but well-known potential for distant metastases, and the capability for local destruction of important structures.

EPIDEMIOLOGY

The exact incidence of keratoacanthoma is unknown. The tumor is more frequent in light-skinned persons, and rarer in dark-skinned and Japanese persons. The relative frequency in comparison with squamous cell carcinoma of the skin is controversial, but most studies show a lower incidence of keratoacanthoma than of squamous cell carcinoma. Discordant results may be explained, at least in part, by differences in classification of these lesions.

Studies on gender distribution reveal that both sexes are affected equally, possibly with a slight predilection for men. Keratoacanthoma occurs mostly in adult life, with a peak between the ages of 55 and 65 years; it has been observed rarely in younger patients. The familial type of keratoacanthoma occurs often during adolescence, and a neonatal case has been reported.[8] Although the incidence was thought to remain stable after a peak in the sixth decade, a study conducted in a defined population in Hawaii revealed that keratoacanthoma increases with age, in a fashion similar to that observed for cutaneous basal and squamous cell carcinomas.[9]

Relationship to Squamous Cell Carcinoma

The authors of earlier reports considered keratoacanthoma to be a form of epithelial cancer of the skin, and named it accordingly. However, since the introduction of the concept of keratoacanthoma as a benign, self-healing neoplasm distinct from squamous cell carcinoma, the relationship between these two epithelial tumors has been the subject of debate. In their paper published in 1950, Rook and Whimster wrote, "This disease is evidently not cancerous or precancerous."[2] On the other hand, Kwittken, in 1975, stated, "I have come to the firm conclusion that all of these lesions are malignancies and that the formerly accepted concept of a self-healing squamous cell carcinoma of the skin is a correct one,"[10] and in 1979, even Rook amended his initial concept by writing, "…transformation from keratoacanthoma to squamous cell carcinoma occurs frequently."[11] Cases of typical keratoacanthoma with metastases have been observed,[12] and four possible explanations for this phenomenon have been suggested: an initial misdiagnosis of keratoacanthoma; the presence of both keratoacanthoma and squamous cell carcinoma in the same lesion; the malignant transformation of keratoacanthoma into squamous cell carcinoma; and, finally, the possibility that keratoacanthoma may be a peculiar variant of squamous cell carcinoma.[13] The debate is not settled yet, and some authors still maintain that keratoacanthoma represents a benign epithelial tumor, distinct from squamous cell carcinoma,[14] whereas others hold that it is a variant of squamous cell carcinoma with tendency to spontaneous regression, but with the potential for giving rise to lethal distant metastases.[15] Two studies of large numbers of cases highlighted the impossibility of reliably differentiating keratoacanthoma from squamous cell carcinoma using histopathologic criteria alone.[16,17] Recently, a patient under infliximab therapy developed multiple squamous cell carcinomas as well as keratoacanthomas, suggesting a common pathogenetic pathway on immunosuppression.[18] In addition, multiple keratoacanthomas and multiple squamous cell carcinomas may be observed at the same skin site ("field cancerization") (Fig. 117-1). Keratoacanthomas have a higher proliferation rate than squamous cell carcinomas.[19] Other investigations pointed at similarities among squamous cell carcinoma and keratoacanthoma in the expression of oncogenetic and cell-cycle–regulating proteins as well as regarding the presence of trisomy 7 in a subset of tumors in both groups, thus suggesting a close relationship between these two entities.[20–25] On the other hand, studies on loss of heterozygosity, on expression of angiotensin type 1 receptor and of desmogleins 1 and 2, on adhesion molecules vascular cellular adhesion molecule and intercellular adhesion molecule, on telomerase activity, on apoptotic and cell adhesion markers, and on chromosomal aberrations assessed by comparative genomic hybridization showed differences among keratoacanthomas and squamous cell carcinomas.[26–32] Using different molecular techniques, both similarities and differences between keratoacanthoma and squamous cell carcinoma have been recently demonstrated.[33] In short, at present, and in spite of the great amount of clinical and experimental data collected over the decades, the exact nosology of keratoacanthoma is not clear, and the term *abortive malignancy* has been proposed.[34]

KERATOACANTHOMA AT A GLANCE


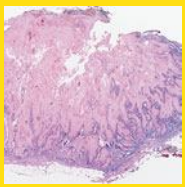

- A common, rapidly growing epithelial tumor with histopathologic features similar to squamous cell carcinoma and a tendency to spontaneous regression.
- Considered a variant of squamous cell carcinoma because of potential of metastases and local tissue destruction if untreated. Considered by others a *pseudocancer*, but this issue is unresolved.
- Clinically, keratoacanthoma is a hyperkeratotic solitary tumor. Multiple keratoacanthomas occur.
- Predilection for sun-exposed areas.
- May be associated with Muir-Torre syndrome.
- Pathology reveals a central keratotic plug surrounded by an epithelial proliferation with atypical keratinocytes and mitoses; neurotropism may be observed.







▲ **FIGURE 117-1** Multiple keratoacanthomas and invasive squamous cell carcinomas on the upper chest of a 90-year-old man.

ETIOLOGY AND PATHOGENESIS

Different etiologic factors are probably involved in the development of keratoacanthomas in different patients, and it seems likely that these different factors act synergistically to induce the onset of a lesion in a given patient. The role of chronic ultraviolet (UV) light exposure in the etiology of keratoacanthoma is well documented by the frequent occurrence on sun-exposed areas, as well as by the presence of keratoacanthomas in patients with xeroderma pigmentosum and after prolonged psoralen and UVA light (PUVA) treatment. In patients with multiple keratoacanthomas, PUVA treatment accelerates the development of the tumors,[35] but the risk for keratoacanthoma after therapy with PUVA seems lower than that for squamous or basal cell carcinoma.[36] An etiologic link to UV light has been confirmed also by experimental studies in mice.

The relationship of keratoacanthoma to chemical carcinogens has been well documented in humans and in several animals.[37] In fact, the incidence of keratoacanthoma is higher in industrial towns, and among industrial workers coming in contact with pitch, mineral oils, and tar. Chemical carcinogens may act in conjunction with UV rays to induce the onset of keratoacanthomas. Smokers seem also to be more affected than nonsmokers.[37]

Keratoacanthomas have been reported at the site of injury. The association with trauma is also documented by the report of cases occurring after skin grafting, at both the donor and the recipient sites, and at the site of arterial puncture and vaccination.[38–40] The role of human papillomavirus (HPV) remains controversial. Recently, evidence of HPV infection was documented by the highly sensitive polymerase chain reaction technique,[41,42] but other studies failed to detect viral material within lesions of keratoacanthoma.[43] Some studies found an association with HPV-25, and HPV-19 and HPV-48 have been isolated in a lesion arising in a human immunodeficiency virus (HIV) patient.[44,45] Several other types of HPV have been linked to keratoacanthoma, including types 6, 9, 14, 16, 19, 35, 37, 58, and 61.

Genetic factors probably play a major role in the familial type of keratoacanthoma. In the other variants of keratoacanthoma, it seems likely that genetic aspects interplay with other etiologic factors (i.e., UV rays, trauma, infections) by providing the genetic predisposition for the development of the tumor. Keratoacanthomas are commonly observed in patients with Muir-Torre syndrome, suggesting that the genetic defect(s) of this syndrome also plays a role in the development of keratoacanthoma.[46–49] In addition, keratoacanthomas have been observed in patients affected by a variety of skin diseases including psoriasis, lupus erythematosus, lichen planus, atopic dermatitis, herpes zoster, acne conglobata, and pemphigus foliaceus, among others.[38]

Keratoacanthomas also have been observed in patients under immunosuppression as a result of bone marrow transplantation, cyclosporine treatment, or infection with HIV, thus suggesting that immunosuppression may play an etiologic role in some cases. In these patients, most lesions of keratoacanthoma tested for presence of HPV proved positive, suggesting that immunosuppression may contribute by decreasing the immune response against possible causative agents.[50] Similarly, UV light may act not only by direct carcinogenesis, but also by virtue of the local immunosuppression caused by sun exposure (see Chap. 89).

Little is known about the pathogenesis of keratoacanthoma, and about the exact mechanisms of regression in the absence of any treatment. Studies on p53 oncoprotein expression and p53 gene mutations revealed expression of p53 oncoprotein in the great majority of tested cases, and association with a point mutation in the p53 gene in slightly more than 10 percent of these cases, suggesting a possible role of p53 gene in the development of some keratoacanthomas.[21,25]

Multiple keratoacanthomas of the Ferguson-Smith type show a familial distribution and are transmitted in an autosomal dominant fashion. The gene responsible for this syndrome is localized to chromosome 9q. The majority of the cases have been described in some Scottish families, and in these patients, the syndrome is thought to be caused by a single genetic mutation that occurred before 1790.[57]

CLINICAL FINDINGS

Keratoacanthomas occur mostly on sun-exposed skin of the face, forearms, and dorsal aspects of the hands (see eFig. 117-1.1 in on-line edition and Fig. 117-2). Actinic damage is commonly found in the surrounding skin. In most instances, they are located on hairy skin, but lesions with similar clinicopathologic aspects have been described in the oral cavity, the subungual region, the genital mucosa, and the conjunctiva.

The stereotypic example of keratoacanthoma is represented by a solitary lesion growing rapidly within a few weeks, and subsequently showing a slow involution over a period of a few months. Three clinical stages have been described: proliferative, mature, and resolving.[38] Lesions in the proliferative stage are rapidly enlarging erythematous papules that grow up to a dimension of 1 to 2 cm or more. In this stage, the lesions are symmetric and firm and show a smooth surface. In the mature stage there are symmetric, firm, erythematous or skin-colored nodules with a central keratotic core (see Fig. 117-2). The central part can appear crateriform if the keratotic core is removed. Ghadially divided mature keratoacanthomas into three main morphologic types: type 1, or bud-shaped; type 2, or dome-



▲ **FIGURE 117-2** Mature keratoacanthoma on the temple of a 93-year-old woman. Note central keratotic core giving a white-yellowish appearance to the superficial part of the lesion.

shaped; and type 3, or berry-shaped.[39] Regressing lesions are characterized by a keratotic, partly necrotic nodule that becomes progressively flat upon elimination of the keratotic plug, eventually leaving a hypopigmented scar (Fig. 117-3; Box 117-1).

Systemic Associations

Keratoacanthomas may be associated with multiple internal cancers in patients with Muir-Torre syndrome and the related hereditary nonpolyposis colorectal cancer syndrome. Patients with multiple keratoacanthomas should always be evaluated for the presence of typical traits of Muir-Torre syndrome, where cutaneous sebaceous tumors and low-grade visceral malignancies can be observed (most commonly carcinomas of the gastrointestinal tract, but also carcinomas of the lung and genitourinary system, and, occasionally, colonic polyps). It has been suggested that at least some of the patients with multiple keratoacanthomas of the Ferguson-Smith type may have an incomplete form of the Muir-Torre syndrome.

Keratoacanthomas may also occur in patients with xeroderma pigmentosum (see Chap. 140) and, rarely, in patients with lymphomatoid papulosis (see Chap. 146).



▲ **FIGURE 117-3** Regressing keratoacanthoma on the lower leg of a 59-year-old man. There is a whitish flattened plaque with superficial ulceration in the center.

Box 117-1

Clinical Differential Diagnosis of Keratoacanthoma

Most Likely

- Squamous cell carcinoma

Consider

- Well-developed tumors
  - Common warts
  - Molluscum contagiosum
  - Prurigo nodularis
  - Metastatic carcinoma
- Regressing tumors
  - Regressing lesions of lymphomatoid papulosis
  - Regressing lesions of anaplastic large cell lymphoma
  - Amelanotic melanoma

Variants

Several variants of keratoacanthoma have been described, and different morphologic types of keratoacanthoma have been observed in a single patient.[58]

Giant Keratoacanthoma

In some instances, keratoacanthomas may reach dimensions of several centimeters (see eFig. 117-3.1 in on-line edition), and even a tumor reaching 15 cm in its diameter has been observed. Giant keratoacanthomas show a predilection for the nose and the dorsum of the hands. In some cases, the growth of the tumor may be associated with destruction of underlying tissues (Fig. 117-4).

Keratoacanthoma Centrifugum Marginatum

Keratoacanthoma centrifugum marginatum is characterized by multiple tumors growing on a localized area, usually on the face, trunk, or extremities (Fig. 117-5).[59] Tumors are annular, polycyclic, or circular in morphology. The area affected may reach 20 cm in diameter, and resolution may be slower than in solitary keratoacanthoma.



▲ **FIGURE 117-4** Giant keratoacanthoma on the tip of the nose of a 52-year-old man. Note the destructive appearance of the tumor.



▲ **FIGURE 117-5** Multiple keratoacanthomas with an annular arrangement and central, keratin-filled craters on the back of the hand (keratoacanthoma centrifugum marginatum). This 42-year-old male patient also had lupus erythematosus.

Multiple Keratoacanthomas of the Ferguson-Smith Type

The Ferguson-Smith type is a familial form of keratoacanthoma that affects both sexes with approximately equal severity, which is characterized by the appearance of multiple, sometimes hundreds of keratoacanthomas, each with the clinicopathologic aspects of a solitary keratoacanthoma. The disorder is inherited in an autosomal-dominant manner, and the majority of the cases have been described in a few Scottish families. Patients develop keratoacanthomas during adolescence and early adulthood, but onset during childhood is not infrequent. It has been suggested that at least some of these patients may have an incomplete form of the Muir-Torre syndrome.

Generalized Eruptive Keratoacanthomas of Grzybowski

Keratoacanthomas of Grzybowski is a variant characterized by the presence of hundreds to thousands of tiny follicular keratotic papules disseminated all over the body, with predominance on sun-exposed areas. Facial involvement is usually severe, and coalescence of lesions around the eyes may cause ectropion. The mucosal regions (oral, genital) may be affected, whereas palms and soles are usually not involved. The age of onset is similar to that of solitary keratoacanthoma, and clustering in families has not been observed.



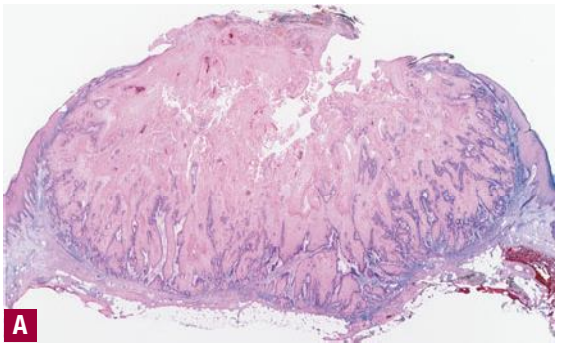

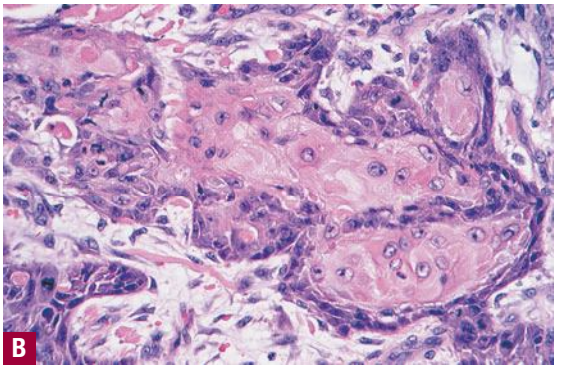

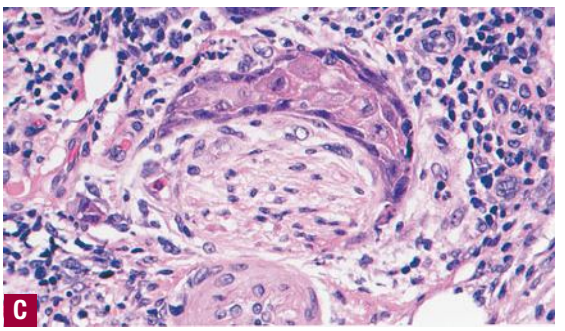



◀ **FIGURE 117-6** Mature keratoacanthoma. **A.** Low-power magnification revealing a symmetric lesion with a central keratotic core. **B.** Tumor complexes with large eosinophilic cells admixed with atypical cells and a few mitoses. **C.** Perineural growth of tumor cells (neurotropism).

Subungual Keratoacanthoma

Subungual keratoacanthoma (see eFig. 117-5.1 in on-line edition) differs from the other types of keratoacanthoma by being persistent and often causing destruction of the underlying bone. The tumor originates in the distal nail bed, separating the nail plate from the nail bed, and can grow rapidly causing destruction of the entire phalanx.

Keratoacanthoma of the Mucosal Regions

Keratoacanthomas have been described in the oral mucosa, the conjunctiva, the nasal mucosa, and the genital mucosa. In fact, involvement of the oral and genital mucosa is common in the generalized eruptive keratoacanthomas of the Grzybowski type. Keratoacanthomas arising on mucosal regions, especially on the oral mucosa, present clinically as slowly growing crateriform lesions that tend to persist for many months or years.

PATHOLOGY

The histopathologic diagnosis of keratoacanthoma rests mainly on the silhouette of the tumor as assessed at scanning magnification; inadequate specimens (i.e., punch biopsies, shave biopsies, curettage) do not allow a diagnosis and differentiation from squamous cell carcinoma. Two large studies on the histopathologic criteria for diagnosis of keratoacanthoma emphasized the overlapping features between this tumor and squamous cell carcinoma, which render differentiation very difficult or even impossible in given cases.[16,17]

The histopathologic features of keratoacanthoma depend on the stage of evolution of the tumor. In early, proliferative lesions, the epithelium is markedly hyperplastic, and the central keratotic plug is not as pronounced as in fully developed lesions. The lesion has an overall symmetric aspect (see eFig. 117-5.2 in on-line edition). Although atypical cells do not represent the majority of the cells in typical keratoacanthoma, there may be atypical keratinocytes and mitoses, especially at the lower margin of the tumor. Nests of epithelial cells may detach from the main tumor mass and be found in the superficial reticular dermis. Fully developed, mature lesions are characterized by a large central core of keratin surrounded by a well-differentiated proliferation of squamous epithelium that in some cases may resemble squamous cell carcinoma (Fig. 117-6A). The epidermis at both sides of the central core extends over the keratotic area in a fashion that has been described as "lipping" or "buttressing," giving a distinct crateriform appearance to the lesion. Nests and strands of keratinocytes may be found apart from the main bulk of the tumor but usually do not extend lower than the level of sweat glands (Box 117-2).

Cytomorphologically, large keratinocytes with eosinophilic cytoplasm are commonly observed, together with atypical cells and mitoses (see Figure 117-6B). An inflammatory infiltrate containing lymphocytes, plasma cells, histiocytes, eosinophils, and neutrophils is a common feature, and in some instances may be conspicuous. Neurotropism and even vascular invasion can be observed in otherwise typical keratoacanthomas, but the prognosis does not seem to be affected by these histopathologically worrisome features (see Fig. 117-6C).[14]

PROGNOSIS

Solitary keratoacanthoma behaves as a benign tumor in the majority of the cases, but lymph node and visceral metastases have been observed in a small number of patients. Central facial keratoacanthoma may behave aggressively. There are no clear-cut features to predict the biologic behavior of a given tumor, but persistent and recurrent lesions should be managed by complete surgical excision. Histopathologic features that are associated with a poor prognosis in common squamous cell carcinoma, such as neurotropism and vascular invasion,

Box 117-2

Histopathologic Differential Diagnosis of Keratoacanthoma

Most Likely

- Squamous cell carcinoma

Regressing Tumors: Consider

- Other regressing epithelial tumors
- Regressing lesions of lymphomatoid papulosis
- Regressing lesions of anaplastic large cell lymphoma

do not seem to have prognostic implications in keratoacanthomas.[14] Ungual keratoacanthomas do not show a tendency to spontaneous regression and often are the cause of massive bone destruction.[60] In spite of aggressive local behavior, however, distant metastases have not been observed in ungual and mucosal types of keratoacanthoma.

TREATMENT (Box 117-3)

Keratoacanthomas show a tendency to spontaneous regression, and, in typical cases, an acceptable therapeutic option may be to adopt the so-called watchful waiting strategy. However, because of the uncertainty regarding the exact nosology of this tumor, as well as the difficulty to differentiate it clinically from squamous cell carcinoma, complete conservative excision is advised in most cases, especially in those of solitary keratoacanthoma and in keratoacanthoma of the face. Removal by shave excision below the base to preserve architecture for diagnostic purposes followed by electrodesiccation and curettage are being increasingly performed for keratoacanthoma.[62] Punch biopsies never allow differentiation of keratoacanthoma from well-differentiated squamous cell carcinoma and should be avoided. For diagnostic purposes, a longitudinal biopsy that includes normal skin at both margins of the lesion as well as the underlying fat tissues is acceptable. Mohs micrographic surgery has been adopted for difficult cases such as recurrent lesions, lesions in the central facial area, giant lesions, or lesions of keratoacanthoma centrifugum marginatum that may cover a large area of the body.[61] Therapy by laser vaporization, electrodesiccation, and cryosurgery with liquid nitrogen does not allow the histopathologic verification of the clinical diagnosis.

Keratoacanthomas have been treated by radiotherapy (electron beam, or the voltage radiation, superficial x-ray) with excellent results.[63] This type of treatment is particularly indicated for lesions that can be difficult to manage surgically. Intralesional instillation of chemotherapeutic agent (methotrexate, bleomycin, and 5-fluorouracil) has also proved therapeutically successful,[38,64] and 5-fluorouracil has been applied also topically.[65] Some keratoacanthomas have been treated by intralesional injection of interferon-α 2a,[66,67] and others have been successfully treated with intralesional application of triamcinolone. Successful topical treatment has been performed with podophyllin, either alone or in combination with other treatment modalities. However, podophyllin is also capable of inducing keratoacanthomas. Multiple keratoacanthomas have been treated successfully with oral retinoids in several cases, but larger studies have not been performed.[68] Systemic treatments include chemotherapy with methotrexate, cyclophosphamide, or 5-fluorouracil.

A further treatment option for keratoacanthoma of both solitary and multiple types is represented by photodynamic therapy with δ-aminolevulinic acid (see Chap. 239). The treatment is simple and has been shown to achieve good therapeutic and cosmetic results.[69,70] Topical imiquimod has been reported to induce regression of keratoacanthoma.[71]

Box 117-3

Treatment for Keratoacanthoma

FIRST LINE

- Complete surgical excision

SECOND LINE

- Curettage followed by electrodesiccation
- Radiotherapy
- Intralesional chemotherapeutic agents, intralesional interferon
- Oral retinoids
- Photodynamic therapy

Specific types of keratoacanthomas may require other treatment modalities (e.g., generalized eruptive keratoacanthomas of Grzybowski)

PREVENTION

Preventive measures against the development of keratoacanthomas are similar to those applied for basal and squamous cell carcinoma of the skin. In predisposed subjects (i.e., fair skin, history of multiple actinic keratoses, basal and/or squamous cell carcinomas, Muir-Torre syndrome), avoidance of direct sun exposure should be achieved, and skin protection creams applied.

KEY REFERENCES

The full reference list for all chapters is available at www.digm7.com.

11. Rook A, Whimster I: Keratoacanthoma: A thirty-year retrospect. *Br J Dermatol* **100**:41, 1979
17. Cribier B et al: Differentiating squamous cell carcinoma from keratoacanthoma using histopathological criteria. Is it possible? A study of 296 cases. *Dermatology* **199**:208, 1999
29. Clausen OP et al: Keratoacanthomas frequently show chromosomal aberrations as assessed by comparative genomic hybridization. *J Invest Dermatol* **119**:1367, 2002
34. Schwartz RA: Keratoacanthoma: A clinico-pathologic enigma. *Dermatol Surg* **30**:326, 2004
38. Schwartz RA: Keratoacanthoma. *J Am Acad Dermatol* **30**:1, 1994
48. Ponti G et al: Identification of Muir-Torre syndrome among patients with sebaceous tumors and keratoacanthomas: Role of clinical features, microsatellite instability, and immunohistochemistry. *Cancer* **103**:1018, 2005
62. Kingman J, Callen JP: Keratoacanthoma: A clinical study. *Arch Dermatol* **120**:736, 1984



CHAPTER 118

Benign Epithelial Tumors, Hamartomas, and Hyperplasias

Valencia D. Thomas
Neil A. Swanson
Ken K. Lee

Benign epithelial tumors comprise a large and disparate group of tumors commonly seen by dermatologists and primary care physicians. No single classification system unifies these lesions under one theme, as their cells of origin and clinical presentation can vary substantially. In this chapter, the clinical entities are grouped by clinical or histologic features to better understand them from a practical diagnostic and treatment point of view (Table 118-1).

SEBORRHEIC KERATOSIS

Etiology

The precise etiology of seborrheic keratoses (SKs) is unknown. Genetics, sun exposure, and infection have all been implicated as possible factors. Many individuals with SKs have a positive family history for the condition. SKs demonstrate irregularities in the expression of the apoptosis markers p53 and Bcl-2, though no genetic locus or chromosomal imbalance has been detected to date.[1,2] The higher prevalence of SKs on sun-exposed skin implies a possible causative role.[3]

Viral infection has also been considered a possible cause of SKs based on occasional clinical similarities to warts. Although no human papillomavirus (HPV) DNA was detected in a study of 40 genital SK biopsies, non-genital skin yielded different results. Epidermodysplasia verruciformis-associated HPV DNA has been demonstrated in 42 of 55 (76 percent) non-genital SK biopsies compared to only 13 of 48 (27 percent) healthy controls ($p < 0.005$).[4] These findings indicate the possible role of viral infection in the development of SKs in non-genital skin.

Although the etiology of SKs remains unknown, the monoclonal nature of these neoplasms has been established in 2001.[5] By tracking polymorphisms in a human androgen receptor, researchers found that more than half of the 38 SKs sampled, regardless of subtype, were clonal in nature.[5] The development of SKs has also been associated with circulating epidermal growth factors and melanocyte-derived growth factors in addition to the local increased expression of tumor necrosis factor-α and endothelin-converting enzyme.[6] The latter two are associated with an increased expression of the keratinocyte melanogen, endothelin-1, resulting in hyperpigmentation within SKs.

Epidemiology and Clinical Features

SKs are the most common benign epidermal tumor of the skin and a frequent focus of patient concern because of their variable appearance. These lesions are common in middle-aged individuals and can arise as early as adolescence.[7] Although there are many clinical variants of the lesions, these lesions usually begin as well-circumscribed, dull, flat, tan, or brown patches. As they grow, they become more papular, taking on a waxy, verrucous, or "stuck-on" appearance (Figs. 118-1 and 118-2). Many lesions display distinctive pseudohorn cysts that represent plugged follicular orifices. SKs may arise on any non-mucosal surface, and multiple lesions may be distributed in a "Christmas tree" pattern along skin folds or in Blaschko's lines.[8] The color of these lesions ranges from pale white to black. At times, distinguishing these lesions from a nevus or melanoma can be clinically challenging. Because melanoma, basal cell carcinoma, and other cutaneous malignancies have been reported to arise in SKs, care must be taken to critically evaluate

SEBORRHEIC KERATOSES AT A GLANCE

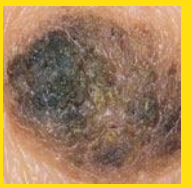
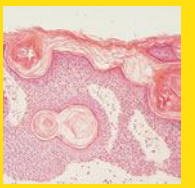

- Seborrheic keratosis is the most common benign epidermal tumor.
- Usually begin as well-circumscribed, dull, flat, tan, or brown patches with pseudohorn cysts.
- Rapidly-growing, symptomatic, or atypical lesions should be biopsied to rule out malignancy such as basal cell carcinoma, squamous cell carcinoma, or melanoma.
- Clinical and histopathologic variants include the common seborrheic keratosis, reticulated seborrheic keratosis, stucco keratosis, clonal seborrheic keratosis, irritated seborrheic keratosis, seborrheic keratosis with squamous atypia, melanoacanthoma, and dermatosis papulosa nigra.
- Hallmark histopathologic findings: Acanthosis, papillomatosis, pseudohorn cysts, hyperkeratosis.
- Internal malignancy: Individuals can develop multiple, eruptive seborrheic keratoses (Leser-Trélat sign). Adenocarcinoma of the stomach is most common associated malignancy.

TABLE 118-1
Overview

- Seborrheic keratosis
  - Common seborrheic keratosis
  - Skin tags
  - Reticulated seborrheic keratosis
  - Stucco keratosis
  - Clonal seborrheic keratosis
  - Irritated seborrheic keratosis
  - Seborrheic keratosis with squamous atypia
  - Melanoacanthoma (pigmented seborrheic keratosis)
  - Dermatosis papulosa nigra
  - Leser-Trélat sign
- Epidermal nevi
  - Linear verrucous epidermal nevus-localized, systematized
  - Nevus unius lateris
  - Ichthyosis hystrix
  - Inflammatory linear verrucous epidermal nevus
  - Nevus sebaceous of Jadassohn
  - Nevus comedonicus
  - Eccrine nevus
  - Apocrine nevus
  - Becker's nevus
  - White sponge nevus
  - Epidermal nevus syndrome
- Lichen striatus
- Clear cell acanthoma
- Warty dyskeratoma
- Acanthoma fissuratum
- Cysts of epithelial origin
  - Epidermal cyst
  - Trichilemmal cyst
  - Milium
  - Steatocystoma multiplex
  - Dermoid cyst
  - Branchial cyst
  - Preauricular cyst and sinus
  - Chondrodermatitis nodular helicis

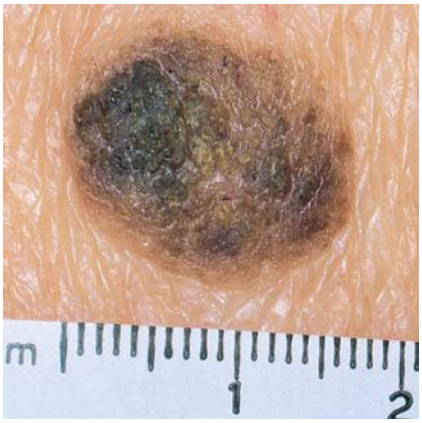

▲ **FIGURE 118-1** Seborrheic keratosis (basal cell papilloma) showing lackluster surface and "stuck-on" appearance.



▲ **FIGURE 118-3** Seborrheic keratosis (basal cell papilloma) showing a papillomatous acanthotic epidermis consisting of basaloid cells.



rapidly-growing, symptomatic, or unusual lesions.[9,10]

Clinicopathologic Variants

COMMON SEBORRHEIC KERATOSIS Common SK is classically a stuck-on, verrucous papule (see Figs. 118-1 and 118-2) with pseudohorn cysts (Fig. 118-3). Hyperkeratosis, acanthosis, and papillomatosis are hallmark pathologic findings. An increased number of melanocytes may also be present, giving lesions a tan or dark brown color. SKs are usually asymptomatic but may itch. Common SKs spare the palms, soles, and mucosa.

SKIN TAGS These rough, 1- to 2-mm, pedunculated papules are commonly located in areas of friction. The axilla, inframammary area, and neck are common locations where these papules commonly appear. Spontaneous regression can occur.

RETICULATED SEBORRHEIC KERATOSIS Reticulated SKs are also known as *adenoid SKs*. A solar lentigo usually precedes this often pigmented patch or papule. Histologically, there are small horn cysts suspended among interwoven strands of basophilic cells (Fig.118-4).[11]

STUCCO KERATOSIS Stucco keratoses are also described as *verrucous, serrated, hyperkeratotic,* and *digitate.* These lesions are commonly 1- to 3-mm, flat-topped, white to tan papules that adhere tightly to the skin on the lower legs (see eFig. 118-4.1 in on-line edition). No keratinocytic vacuolar changes or viral cytopathic changes are observed, thus distinguishing them from verruca plana.

CLONAL SEBORRHEIC KERATOSES Intraepithelial nests of basophilic keratinocytes of varying sizes with admixed melanocytes is the common histopathologic finding in clonal SKs (Fig. 118-5).

IRRITATED SEBORRHEIC KERATOSIS Irritated SKs represent SKs that have been mechanically or chemically irritated or are involved in immunologic responses. Although inciting trauma is occasionally associated with irritated SKs, spontaneous inflammation is common (Fig. 118-6). Histologically, the dermis underlying these lesions is filled with a dense inflammatory infiltrate predominantly of lymphocytes. This inflammation is occasionally lichenoid or neutrophil-rich. Swirled collections of eosinophilic keratinocytes can be seen in the epidermis.[12] Eczematous changes in or around the lesion, also known as *Meyerson phenomenon*, can also be seen.[13]

SEBORRHEIC KERATOSIS WITH SQUAMOUS ATYPIA Varying degrees of squamous atypia can be seen in SKs. Bowenoid transformation of benign SKs into squamous cell carcinoma in situ has also been documented. The development of basal or squamous cell carcinoma in a SK is rare.[14]

MELANOACANTHOMA Melanoacanthoma is also known as *pigmented SK*. This benign, slow-growing SK resembles melanoma and is located on the trunk, head, or neck of older individuals. The term *mel-*



▲ **FIGURE 118-2** Multiple small seborrheic keratoses.

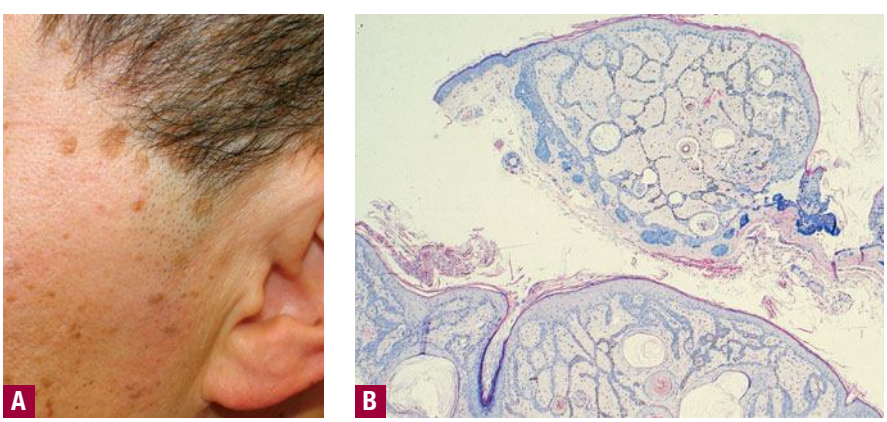

▲ **FIGURE 118-4** **A.** Multiple reticulated seborrheic keratoses. **B.** Reticulated seborrheic keratosis showing reticulated cords of basaloid cells descending from the base of the epidermis.

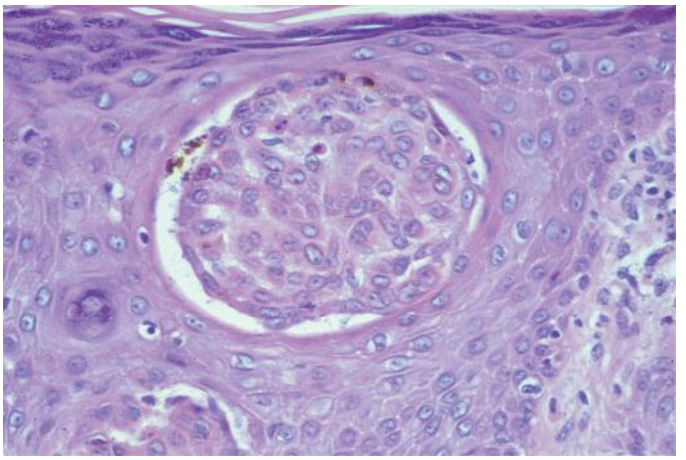

▲ **FIGURE 118-5** Clonal seborrheic keratosis showing round nests of keratinocytes and some melanocytes.



anoacanthoma was introduced in 1960 to describe a pigmented lesion composed of nested melanocytes and keratinocytes.[15]

Dermatosis Papulosa Nigra. Dermatosis papulosa nigra are small dark brown to black papules that are commonly found on the face of individuals of Fitzpatrick skin phototype IV or greater. They are histologically identical to SKs, though clinically, these lesions resemble melanoacanthomas (Fig. 118-7).

Association with Skin Cancers. Lesions demonstrating the histology of both SKs and malignancies have been reported.[16,17] Although it is likely that most of these lesions represent collision tumors, malignant transformation of SKs into basal cell carcinomas, squamous cell carcinomas, and melanomas can occur. In a retrospective study of 813 lesions histologically diagnosed as SKs, 5.3 percent were associated with non-melanoma skin cancer. In this study, the most common malignancy was squamous cell carcinoma in situ, followed by basal cell carcinomas and invasive squamous cell carcinomas; no melanomas were observed.[17] Clinically atypical or rapidly growing SKs should be biopsied to rule out the possibility of malignancy.

LESER-TRÉLAT SIGN In the context of internal malignancy, individuals can develop multiple, eruptive SKs also known as the *Leser-Trélat sign*. Adenocarcinoma of the stomach is the most commonly associated malignancy,[18,19] though adenocarcinoma of the lung and colon have also been linked (see Chap. 154). Other diseases reported to occur with eruptive SKs are leukemia, lymphoma, lepromatous leprosy, human immunodeficiency virus infection, erythrodermic eczema, and melanoma.[20–23] Inflammation of eruptive SKs during chemotherapy, especially cytarabine, is known to occur (see Fig. 118-6).[24] The common presentation of eruptive SKs with acanthosis nigricans led many to speculate a common reactive mechanism.[25] Abnormal immune responses may also play a role in the development of this clinical sign.



▲ **FIGURE 118-6** Inflamed, irritated seborrheic keratoses occurring during cytarabine therapy. This is in the submammary region, and there are also pustules of *Candida* infection.



▲ **FIGURE 118-7** Dermatosis papulosa nigra.

Treatment

Symptomatic SKs or cosmetically undesirable lesions may require treatment. Destruction with cryotherapy, electrodesiccation followed by curettage, curettage followed by desiccation, or laser ablation have all been shown to be very effective. Reports of giant SKs measuring many centimeters have been treated successfully with either dermabrasion or topical fluorouracil.[26,27] Recurrence of the lesions may occur if destruction of the perimeter is not fully achieved. Common complications of these destructive measures include scarring, pigmentary alteration, incomplete removal, or recurrence. It is not uncommon to require multiple treatments to ensure the complete destruction of the initial lesion. Surgical excision of the lesion is also an accepted treatment modality, especially if the lesion is pedunculated and can be transected at its base. It is preferable to ensure that the method of removal of these benign lesions minimizes the risk of scarring.

The concern for malignant lesions appearing as SKs or possible collision lesions between a SK and a malignant lesion necessitates histopathologic examination before destruction or removal. Thus, for any lesion with a possibility of malignancy, removal must be done in a fashion to yield tissue for evaluation. Rapid growth, atypical morphologic features, unusual lesion location, or symptomatology should all be considered when evaluating SKs, and care should be taken not to destroy a lesion that begs further pathologic examination.

EPIDERMAL NEVUS

Epidermal nevus is a generalized term for hamartomatous proliferations of epithelium. Sub-types of this tumor differ according to the distribution of the lesions or the predominant histologic cell type: keratinocyte (verrucous epidermal nevus), sebaceous gland (nevus sebaceous), pilosebaceous unit (nevus comedonicus), eccrine gland (eccrine nevus), or apocrine gland (apocrine nevus). Table 118-2 provides a classification of one framework to discuss this large and diverse entity. Currently, there are six different epidermal nevus syndromes described: Proteus, congenital hemidysplasia with ichthyosiform nevus and limb defect syndrome, phakomatosis pigmentokera-

EPIDERMAL NEVUS AT A GLANCE



- Epidermal nevi are hamartomatous proliferations of the epithelium, including keratinocytes, sebocytes, pilosebaceous units, eccrine glands, or apocrine glands.
- Six different epidermal nevus syndromes: Epidermal nevi present with developmental abnormalities of the nervous, cardiovascular, urogenital, or skeletal systems.
- Linear configurations common on limbs following Blaschko's lines or in relaxed skin tension lines. Tend to appear between birth and adolescence.
- Epidermal nevus presenting with pruritus, erythema, scaling is likely a variant known as *inflammatory linear verrucous epidermal nevus*.
- Differential diagnosis: Lichen striatus, linear Darier disease, linear porokeratosis, linear lichen planus, linear psoriasis, verrucous stage of incontinentia pigmenti.



▲ **FIGURE 118-8** Verrucous epidermal nevus.

totica, sebaceous nevus, Becker's nevus, and nevus comedonicus.[28]

Epidemiology

Epidermal nevi occur in 1 in 1000 live births.[29] Eighty percent of lesions appear within the first year of life, with the majority of lesions appearing by age 14 years. There are rare reports of adult onset of epidermal nevi, with the oldest patient being a 60-year-old woman.[30] Such late-developing epidermal nevi probably represent lesions that have always been present sub-clinically, but recent growth resulted in clinical recognition.[31] There is an equal male–female prevalence, and most cases are sporadic. However, some familial cases have been documented.[32]

TABLE 118-2
Classification of Epidermal Nevi

Epidermal Nevus Variant	Predominant Structure	Morphology	Extent
Verrucous epidermal nevus	Surface epidermis	Verrucous	
Localized			Localized
Systematized			Widespread
Nevus unius lateris			Widespread unilateral
Ichthyosis hystrix			Widespread bilateral
Inflammatory linear verrucous epidermal nevus		Inflamed	Localized
Nevus sebaceous	Sebaceous glands	Yellow verrucous	Localized, rarely diffuse
Nevus comedonicus	Hair follicles	Grouped comedones	Localized, rarely diffuse
Eccrine nevus	Eccrine sweat glands	Nondescript papule	Localized
Apocrine nevus	Apocrine sweat glands	Nondescript papule	Localized
Becker's nevus	Surface epidermis Hair follicles, + smooth muscles, melanization	Pigmented, hairy	Localized
White sponge nevus	Mucosal epithelium	Gray-white plaque	Localized or diffuse



▲ **FIGURE 118-9** Verrucous epidermal nevus showing linear configuration.

Verrucous Epidermal Nevus

Verrucous epidermal nevus is also known as linear verrucous epidermal nevus or *linear epidermal nevus*.

CLINICAL FEATURES Verrucous epidermal nevi are characterized by localized or diffuse, closely set, skin-colored, brown, or gray-brown verrucous papules, which may coalesce to form well-demarcated papillomatous plaques (Fig. 118-8). Linear configurations are common on the limbs as is distribution in Blaschko's lines or in relaxed skin tension lines (Fig. 118-9).

Extensive distribution of a verrucous epidermal nevus is termed *systemized epidermal nevus*. Variants of this type of nevus include nevus unius lateris (Fig. 118-10), epidermal nevi distributed on one-half of the body; and ichthyosis hystrix, epidermal nevi distributed bilaterally. Commonly, systematized nevi take on a transverse configuration on the trunk and linear configuration on the limbs.

An epidermal nevus presenting with pruritus, erythema, and scaling is likely a variant of the epidermal nevus termed an *inflammatory linear verrucous epidermal nevus* (ILVEN) (Fig. 118-11). These lesions are found most commonly on the buttocks and lower extremities and may resemble linear psoriasis.

COURSE AND COMPLICATIONS Linear epidermal nevi tend to appear between birth and adolescence. Although congenital lesions tend not to expand significantly, lesions that present after birth







▲ **FIGURE 118-10** Nevus unius lateris. Epidermal nevus affecting one-half of body.

may expand during childhood, stabilizing in size at or around puberty.[33] Although intertriginous lesions may become macerated and secondarily infected, the majority of epidermal nevi remain quiescent after adolescence. Rare cases of basal cell carcinoma and squamous cell carcinoma arising within epidermal nevi has been reported. This malignant transformation is most common in middle-aged or elderly individuals, though the youngest reported case occurred in a 17-year-old woman.[34]

Epidermal nevi may present in conjunction with other epidermal lesions such as café-au-lait macules, congenital hypopigmented macules, and congenital nevocellular nevi.[33] Extensive lesions may be associated with abnormalities in other systems (see Epidermal Nevus Syndrome).

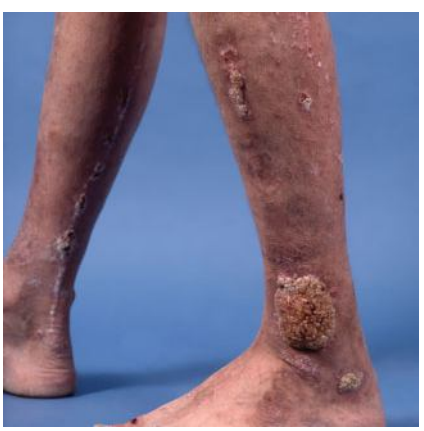

▲ **FIGURE 118-11** Inflammatory linear verrucous epidermal nevus showing psoriasiform erythema, scaling, and hyperkeratosis. The nodule on the left leg was a giant wart.

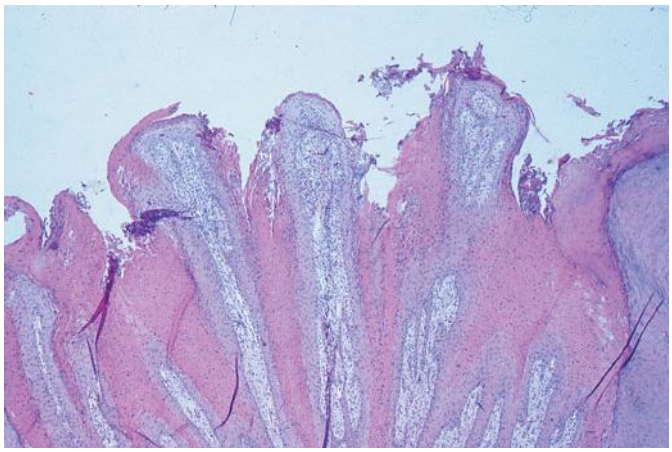

▲ **FIGURE 118-12** Epidermal nevus showing hyperkeratosis, acanthosis, papillomatosis, and elongation of rete ridges.

Rarely, patients with epidermal nevi have offspring with epidermolytic hyperkeratosis (EHK), a condition resulting from a mutation in keratin 10 (K10). Paller et al.[35] investigated three families with this occurrence. The analysis of skin samples of parents and offspring with EHK demonstrated a parental mutation in one of the two K10 alleles within the epidermal nevus; non-lesional skin showed no mutation. Offspring showed the same K10 mutation as their parents.[35] The presence of two genetically distinct cell lines in the parents, also known as *mosaicism*, is a result of postzygotic mutation during embryogenesis.[35a] If histopathologic evaluation of an epidermal nevus reveals findings consistent with EHK, the patient is at risk of having a child with EHK. Prenatal counseling may be very important for these patients.

PATHOLOGY There are 10 histologic variants of the epidermal nevus, with over 60 percent of lesions displaying acanthosis, papillomatosis, and hyperkeratosis (Fig. 118-12).[36] Rare variants may have features similar to SKs, with thin, elongated rete ridges; or EHK, with compact orthokeratosis, vacuolization of the granular layer of the epidermis, and large keratohyaline granules within or outside cells.[37] Epidermal hyperkeratosis may be a more common finding in ichthyosis hystrix. ILVEN is a histologically distinct variant of the epidermal nevus that displays a chronic dermal inflammatory infiltrate, psoriasiform epidermal hyperplasia, and alternating bands of ortho- and parakeratosis. In this variant, the granular layer is absent underlying the areas of parakeratosis.[38]

DIFFERENTIAL DIAGNOSIS (Box 118-1) Lichen striatus, linear Darier disease, linear porokeratosis, linear lichen planus, linear psoriasis, and the verrucous stage of incontinentia pigmenti may all have similar clinical presentations as the linear verrucous epidermal nevus. Lichen striatus may mimic ILVEN clinically, but is self-limited and pruritic as compared with epidermal nevi. Histology may be useful in differentiating these entities. Linear Darier disease and linear porokeratosis can be differentiated pathologically with linear Darier disease having the distinct pathologic findings of acantholytic dyskeratosis, and linear porokeratosis having coronoid lamellae. Although some consider linear lichen planus and linear psoriasis to be variants of the ILVEN, the genetics and the immunology has yet to be fully characterized.[39–41] Incontinentia pigmenti can be distinguished clinically based on the transient nature of this phase and the preceding verrucous phase. Histologically, this entity can be distinguished by its dyskeratosis, pigment incontinence, eosinophilic exocytosis, and basal layer vacuolization.

TREATMENT Complete excision of an epidermal nevus to the level of the deep dermis is necessary to prevent recurrences. Based on the size and distribution of the

Box 118-1

Differential Diagnosis of Linear Epidermal Nevus

- Lichen striatus
- Linear Darier disease
- Linear porokeratosis
- Linear lichen planus
- Linear psoriasis
- Incontinentia pigmenti

NEVUS SEBACEOUS AT A GLANCE



- Linear, hairless, yellow, waxy, and verrucous plaque presenting from birth to adolescence.
- Benign tumor of sebaceous gland: Immature sebaceous glands located high in the dermis and malformed pilosebaceous units are key features.
- Most common benign tumors arising within a nevus sebaceous: Syringocystadenoma papilliferum, trichoblastoma.
- Differential diagnosis: Epidermal nevi, aplasia cutis, congenital triangular alopecia.
- Rapidly growing papules or nodules: Require pathologic evaluation to rule out malignancy but excision should be considered on a case-by-case basis.

lesion, however, excision may not be an appropriate treatment option. Multiple other surgical and medical treatments are available to treat or destroy these lesions. Laser ablation, electrofulguration, cryotherapy, and medium to full-depth chemical peels may offer partial or full destruction of lesions. Although topical retinoids and calcipotriene offer little relief, these medications can be used as an adjunctive therapy to increase the efficacy of the surgical intervention. Systemic retinoids and anti-psoriatic agents may offer some clinical improvement. There are reports of successful treatment of ILVEN with etanercept.[42] If malignant transformation is confirmed within an epidermal nevus, the lesion should be completely excised.

Nevus Sebaceous

Nevus sebaceous is also known as *nevus sebaceous of Jadassohn* and *organoid nevus*.

CLINICAL FEATURES Nevus sebaceous presents as a linear, hairless, yellow, waxy, and verrucous plaque (Fig. 118-13). It can be flat at birth, becoming plaque-like under the hormonal influences of puberty. These nevi are common in the scalp, but there are reports of lesions on the face, chest, and in oral mucosa. Tumors can arise within nevus sebaceous. The most common benign tumors are syringocystadenoma papilliferum and trichoblastoma.[43] Other benign tumors reported to arise in a nevus sebaceous are the leiomyoma, syringoma, spiradenoma, hidradenoma, and keratoacanthoma.[44] It was once believed that individuals with this tumor were at increased risk of basal cell carcinomas, but a retrospective review of 596 cases by Cribier et al. revealed that most lesions initially diagnosed as basal cell carcinoma were actually trichoblastomas.[45] A second retrospective study of 757 tumors confirmed this finding.[46] This does not exclude the possibility of the development of basal cell carcinoma in these lesions. Rarely, malignant tumors such as apocrine carcinoma, squamous cell carcinoma, and malignant eccrine poromas may arise within nevus sebaceous.[47]



▲ **FIGURE 118-13** Nevus sebaceous.

Nevus sebaceous syndrome is the very rare association of an extensive, congenital nevus sebaceous with ocular abnormalities and cerebral defects such as mental retardation or seizures. This syndrome is also known as *Schimmelpenning-Feuerstein-Mims syndrome* or *organoid nevus syndrome*.[48,49]

PATHOLOGY Immature sebaceous glands located high in the dermis and malformed pilosebaceous units are features of nevus sebaceous (Fig. 118-14). Vellus hairs are more common than terminal hairs in these lesions. Epidermal acanthosis, hyperkeratosis, and pseudoepitheliomatous hyperplasia can also be seen.

DIFFERENTIAL DIAGNOSIS Epidermal nevi, aplasia cutis, and congenital triangular alopecia may be clinically similar to nevus sebaceous but biopsy can easily distinguish between these entities.

TREATMENT Excision of nevus sebaceous was common when these lesions were thought to carry an increased risk of basal cell carcinoma. Rapidly growing papules or nodules demand pathologic evaluation to evaluate for rare malignancies, but excision should be considered on a case-by-case manner.[47]

Nevus Comedonicus

Nevus comedonicus is also known as *comedo nevus*, *nevus follicularis keratosis*, *nevus acneiformis unilateralis*, and *nevus zoniforme*.[50] Nevus comedonicus is a rare hamartoma of the pilosebaceous unit.[51,52] Clinically, comedo-like dilated pores with keratinaceous plugs present in a linear, nevoid, bilateral, or zosteriform pattern (Fig. 118-15).[51] An inflammatory variant also exists, with suppurative cysts and acne-like lesions. These lesions appear on the face, chest, or upper arms at birth or during childhood.[28] Nevus comedonicus syndrome is the association of nevus comedonicus with non-cutaneous findings such as

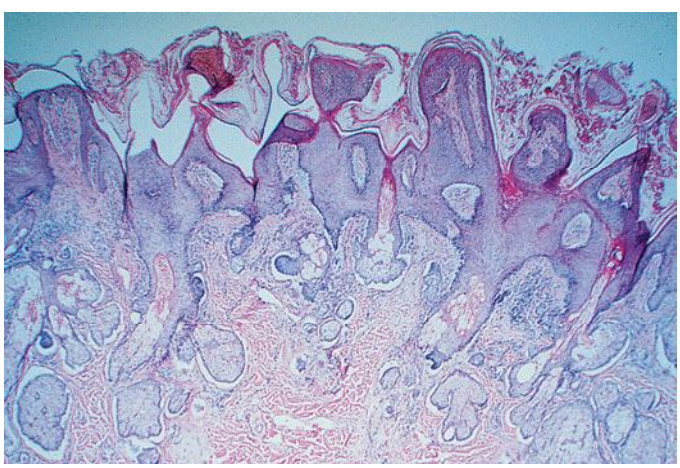

▲ **FIGURE 118-14** Nevus sebaceous showing epidermal hyperplasia and increased numbers of sebaceous glands and apocrine glands in the dermis.





NEVUS COMEDONICUS AT A GLANCE



- Presents as comedo-like dilated pores with keratinaceous plugs; linear, nevoid, bilateral, or zosteriform pattern.
- Nevus comedonicus syndrome: Association of nevus comedonicus with non-cutaneous findings such as skeletal defects, cerebral abnormalities, and cataracts.
- Hallmark findings: Keratin-filled epidermal invaginations associated with atrophic sebaceous glands or follicles.
- Differential diagnosis: Acne vulgaris, acne neonatorum, milia nevus sebaceous, linear Darier disease.
- Inflammatory variant can result in significant suppuration and pain, requiring medical or surgical intervention.

skeletal defects, cerebral abnormalities, and cataracts.[53]

COURSE AND COMPLICATIONS Nevus comedonicus lesions follow a noninflammatory or inflammatory course and do not resolve spontaneously. The inflammatory course may result in scarring. Nevus comedonicus syndrome results in developmental, cerebral, skeletal, or ocular defects that present by the age 15 years.[54]

PATHOLOGY The hallmark findings in nevus comedonicus are keratin-filled epidermal invaginations associated with atrophic sebaceous glands or follicles. EHK may be seen.[55]



▲ **FIGURE 118-15** Nevus comedonicus consisting of linear closely set comedones.

DIFFERENTIAL DIAGNOSIS The differential diagnosis of this lesion includes acne vulgaris, milia, acne neonatorum, nevus sebaceous, and linear Darier disease.

TREATMENT The noninflammatory variant of nevus comedonicus is usually asymptomatic, with treatment based on the cosmetic concerns of the patient. The inflammatory variant can result in significant suppuration and pain, requiring medical or surgical intervention. Inflammation may be controlled with tazarotene cream or other retinoids, tacrolimus ointment, calcipotriene cream, and intralesional steroids.[56] Keratolytics may be of some help. Systemic antibiotics may help to control infection or inflammation. Surgical interventions, such as extraction, excision, dermabrasion, or laser resurfacing, may result in good clinical results.[57,58]

Eccrine Nevus

An eccrine nevus, the simplest form of eccrine hamartoma, is characterized by an increase in the number or size of eccrine coils.[59–62] These lesions do not always display hyperhidrosis, however. Fewer than 20 cases of eccrine nevi have been described in the literature. Commonly distributed on the trunk, arms, or legs, these lesions occur equally in men and women. Although there seems to be a childhood predominance, the onset ranges from birth to the eighth decade.[63] The morphology of eccrine nevi may vary, appearing clinically as tan papules or normal skin.[64,65] Treatment is targeted at the control of hyperhidrosis. Agents such as aluminum chloride solution, anticholinergics, antidepressants with anticholinergic activity, botulinum toxin, iontophoresis, or sympathectomy have been reported to help control the hyperhidrosis. Surgical excision of the lesion is also an acceptable treatment.[66,67]

Apocrine Nevus

Apocrine nevi are hamartomatous proliferations of mature apocrine glands often found within a nevus sebaceous. Clinical presentation varies, but they can be found as soft nodules or papules in the axilla or on the upper chest. Histologically, the apocrine glands extend from the epidermis to the fat. These lesions can be surgically excised if desired.[68]

EPIDERMAL NEVUS SYNDROME AT A GLANCE



- Epidermal nevus syndrome is the association of any type of epidermal nevus with various cutaneous, ocular, neurologic, skeletal, cardiovascular, or urogenital developmental abnormalities.
- Historically, six epidermal nevus syndromes described: Proteus syndrome, congenital hemidysplasia with ichthyosiform nevus and limb defects, phakomatosis pigmentokeratotica, sebaceous nevus, Becker's nevus, and nevus comedonicus.
- Affects men and women equally, and presents within the first 40 years of life.
- Patients with extensive epidermal nevi or those with epidermal nevi and systemic abnormalities should be suspected of having the epidermal nevus syndrome.
- Evaluation and management: Require multidisciplinary team approach involving the dermatologist, pediatrician, ophthalmologist, neurologist, plastic surgeon, and orthopedic services.

Epidermal Nevus Syndrome*

Epidermal nevus syndrome is also known as *Schimmelpenning syndrome*, *Feuerstein-Mims syndrome*, and *Solomon syndrome*. Epidermal nevus syndrome is the association of any type of epidermal nevus with various cutaneous, ocular, neurologic, skeletal, cardiovascular, or urogenital developmental abnormalities. Historically, there have been six epidermal nevus syndromes described: Proteus syndrome, congenital hemidysplasia with ichthyosiform nevus and limb defects, phakomatosis pigmentokeratotica, sebaceous nevus, Becker's nevus and nevus comedonicus. Some authors argue that epidermal nevus syndrome is a collection of many different distinct clinical syndromes.

*This follows the discussion of this syndrome by SG Silver and V Ho in *Dermatology in General Medicine* (6th edition).[58]

Happle[69] proposed that the epidermal nevus syndrome is not a single entity but consists of at least six distinct diseases that differ in genetic origin and share the common feature of mosaicism. The entities include Schimmelpenning syndrome; nevus comedonicus syndrome; pigmented hairy epidermal nevus syndrome; Proteus syndrome; congenital hemidysplasia, ichthyosiform dermatitis, and limb defects syndrome; and phacomatosis pigmentokeratotica.

EPIDEMIOLOGY Epidermal nevus syndrome affects men and women equally and presents within the first 40 years of life. Inheritance is sporadic, although anecdotal reports of familial transmission has been reported.[69] Although the exact incidence of epidermal nevus syndrome is unknown, a study of 119 cases of epidermal nevi showed that 33 percent of patients showed one or more extra-cutaneous abnormalities, 16 percent showed two or more abnormalities, 10 percent showed three or more abnormalities, and 5 percent showed five or more abnormalities.

CLINICAL FEATURES Solomon and Esterly provided a detailed account of the spectrum of epidermal nevi seen in the epidermal nevus syndrome.[29] They described seven types of lesions. The majority of patients had nevus unius lateris; 20 percent of patients had ichthyosis hystrix; and another 20 percent had what the authors termed the *acanthotic form* of epidermal nevus. These lesions presented as large, unilateral, brown, slightly scaly patches. About 10 percent of patients had linear nevus sebaceous involving the scalp and face. Localized linear verrucous nevus and a velvety epidermal nevus in the axilla similar to acanthosis nigricans were seen in a minority of cases. Some patients had a mixture of several types of lesions.

Table 118-3 lists the mucocutaneous changes other than epidermal nevus that may be seen in patients with epidermal nevus syndrome.[70] Hemangiomas and pigmentary changes are found in 10 percent to 20 percent of patients. Less common findings are hair abnormalities, dental abnormalities in association with mucosal epidermal nevi, and dermatomegaly. This last condition involves an increase in skin thickness, warmth, and hairiness. As discussed earlier, various cutaneous tumors may develop within the epidermal nevus.

A wide range of skeletal abnormalities has been reported (Table 118-4).[69–71] The incidence of skeletal changes has ranged from 15 percent to 70 percent.

Neurologic abnormalities occur in 15 percent to 50 percent of cases (Table 118-5).

From 9 percent to 30 percent of patients with epidermal nevus syndrome have ocular abnormalities (Table 118-6).[72]

As in isolated epidermal nevi, malignant transformation may occur within the epidermal nevi in patients with epidermal nevus syndrome. This occurrence is most common in those with nevus sebaceous. Perhaps less well known is the association of visceral malignancies with the epidermal nevus syndrome. The following tumors are reported to occur at a higher frequency and at an earlier age in patients with epidermal nevus syndrome: tumors of the genitourinary system (Wilms' tumor, nephroblastoma, metastatic transitional cell carcinoma of the bladder, and rhabdomyosarcoma of the bladder); tumors of the gastrointestinal tract (hepatic adenoma, salivary gland adenocarcinoma, and carcinoma of the esophagus and stomach); and tumors of the central nervous system (astrocytoma, mixed glioma, and meningioma). Breast carcinoma, mandibular ameloblastoma, chondroma, odontoma, and endometrioma are other tumors associated with epidermal nevus syndrome.[40] However, these associations have not been confirmed by case-controlled studies.

MANAGEMENT Patients with extensive epidermal nevi or those with epidermal nevi and systemic abnormalities should be suspected of having the epidermal nevus syndrome. Evaluation and management of patients with epidermal nevus syndrome requires a multi-disciplinary team approach involving the dermatologist, pediatrician, ophthalmologist, neurologist, plastic surgeon, and orthopedic services. These patients require a careful history with particular attention given to developmental history, attainment of

TABLE 118-3
Cutaneous Findings in Epidermal Nevus Syndrome

- Epidermal nevus
- Hemangioma
- Pigmentary changes
  - Café-au-lait spots
  - Hypopigmentation
  - Melanocytic nevi
- Dermatomegaly
- Cutaneous malignancies
  - Keratoacanthoma
  - Basal cell carcinoma
  - Squamous cell carcinoma
  - Syringocystadenoma papilliferum
  - Other adnexal tumors

TABLE 118-4
Skeletal Findings in Epidermal Nevus Syndrome

- Bone cysts
- Bone hyperplasia or hypertrophy
- Chondroblastoma
- Asymmetry of skull
- Short stature
- Brachydactylia
- Kyphosis
- Scoliosis
- Spina bifida
- Syndactyly, polydactyly, clinodactyly
- Vitamin D–resistant rickets

TABLE 118-5
Neurologic Findings in Epidermal Nevus Syndrome

- Cerebrovascular accidents
- Cerebrovascular malformations and neoplasias
- Cortical atrophy
- Cortical blindness
- Cranial nerve palsies
- Delayed milestones
- Macrocephaly
- Encephalocele
- Hemiparesis
- Hydrocephalus
- Mental retardation
- Seizures (generalized focal infantile spasms)
- Spinal cord stenosis

TABLE 118-6
Ocular Findings in Epidermal Nevus Syndrome

- Astigmatism
- Lipodermoid
- Bilateral cataracts
- Blocked tear duct
- Choristomas
- Colobomas of lid, iris, choroid retina
- Corneal opacity and pannus formation
- Cortical blindness
- Ectopic lacrimal glands
- Extension of epidermal nevus to eyelid, conjunctiva, or sclera
- Micro- or macrophthalmia
- Nystagmus
- Oculomotor dysfunction
- Optic nerve hypoplasia
- Ptosis
- Strabismus



milestones, history of seizures, and abnormalities of the bones, eyes, and urinary tract. Thorough mucocutaneous, neurologic, ophthalmologic, and orthopedic examinations are necessary. Depending on the findings on history and physical examination, further investigations may be indicated. These may include biopsy of the epidermal nevus, electroencephalography, computed tomography, magnetic resonance imaging, intravenous pyelography, and radiographic evaluation of bones. A regular follow-up program should be planned for the patient.



LICHEN STRIATUS

Lichen striatus is a rare, idiopathic, linear, papular eruption that usually resolves in 1 to 2 years.

Etiology and Epidemiology

Lichen striatus, which is also known as *Blaschko linear acquired inflammatory skin eruption*, most commonly affects individuals from 4 months to 15 years of age.[73] The etiology is unknown. This self-limited dermatosis occurs most commonly on the limbs in females. Distribution on the face and trunk has been reported, however.[74] Nail changes are uncommon.[75] Most cases are distributed in Blaschko's lines, though axial distributions have been reported. A retrospective analysis of 155 cases of children with lichen striatus revealed an association with atopic dermatitis in 70 of the cases.[76]

Clinical Features[77]

Lichen striatus is an eruption characterized by the sudden onset of flat-topped, 1 to 3 mm, pink, tan, or hypopigmented papules in a linear configuration or Blaschkoid distribution (Fig. 118-16). Bilateral eruptions have been reported, though unilateral lesions are the norm. These flat-topped papules may have an associated scale. Longitudinal ridging and nail plate thinning can be seen. This eruption is usually self-limited, lasting from a few months to two years before spontaneously regressing.

Pathology

Lichen striatus is characterized by a lichenoid, lymphocytic infiltrate involving three to four adjacent dermal papillae with overlying epidermal acanthosis, dyskeratosis, hyperkeratosis, and occasional parakeratosis.[77,78] Intraepidermal vesicles containing Langerhans cells can be seen in half of the cases.[79]

LICHEN STRIATUS AT A GLANCE



- Lichen striatus is a rare, idiopathic, linear, papular eruption that usually resolves in 1 to 2 years.
- Occurs most commonly on the limbs of females.
- Eruption is characterized by the sudden onset of flat-topped, 1 to 3 mm, pink, tan, or hypopigmented papules in a linear configuration or Blaschkoid distribution.
- Differential diagnosis: Lichen planus, psoriasis, linear porokeratosis, lichen nitidus, Darier disease, inflammatory linear verrucous epidermal nevus.

Differential Diagnosis

Lichen planus, psoriasis, linear porokeratosis, lichen nitidus, Darier disease and ILVEN can have similar morphology and distribution to lichen striatus. These clinical entities can usually be separated based on histopathology. ILVEN can be distinguished clinically because of its earlier onset and lack of spontaneous regression.[79]

Treatment

Symptomatic control of pruritus with topical steroids may be necessary. Otherwise, treatment is generally not necessary for this self-limited condition.



▲ **FIGURE 118-16** Lichen striatus. Linear configuration of slightly scaling papules in Blaschkoid distribution on the leg.

CLEAR CELL ACANTHOMA

Epidemiology

Clear cell acanthoma is most commonly found equally in men and women ages in the sixth to eighth decade.

Etiology and Pathogenesis

The etiology of clear cell acanthoma, also known as *Degos acanthoma* and *pale cell acanthoma*, is unknown. When initially described by Degos et al. in 1962, the lesion was thought to be benign tumor of epithelial origin.[80] Although initially thought to be of follicular or sweat-gland origin, the expression of involucrin and epithelial membrane antigen by clear cell acanthomas indicates an epithelial origin.[81–83] The cytokeratin staining patterns, interestingly, reveal staining patterns commonly found in inflammatory dermatoses such as lichen planus, psoriasis, and discoid lupus.[84] The presence of clear cell acanthomas on psoriatic plaques has led many to question the role of inflammation in the development of these lesions.[85]

Clinical Features

Clear cell acanthoma is commonly a solitary, shiny, erythematous to brown, well-demarcated papule or nodule that blanches almost fully with pressure (Fig.

CLEAR CELL ACANTHOMA AT A GLANCE



- Clear cell acanthoma is a tumor of epidermal origin.
- Solitary, shiny, erythematous or orange to brown, blanching, well-demarcated papule or nodule with collarette of scale.
- Composed of distinctive, glycogen-rich keratinocytes.
- Differential diagnosis: Lichenoid keratosis, basal cell carcinoma.

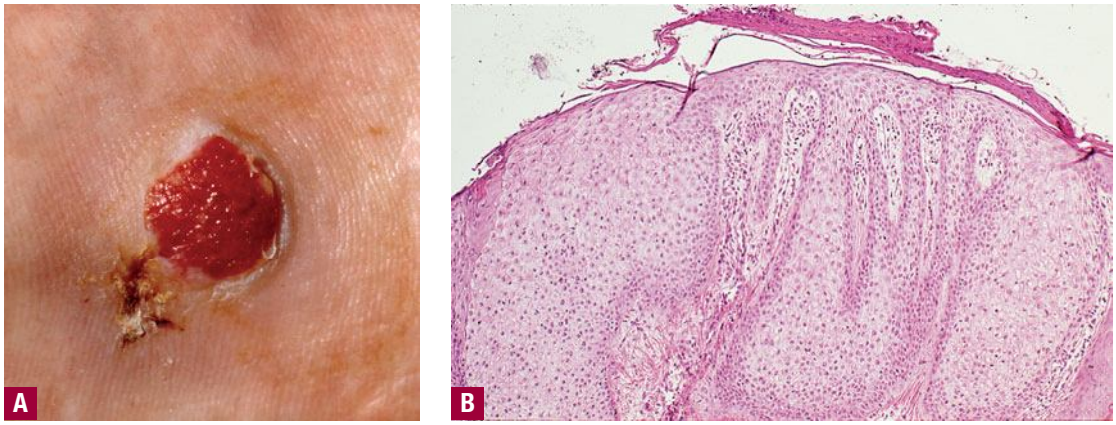

▲ **FIGURE 118-17** **A.** Clear cell acanthoma presenting as a flat orange nodule on the sole. **B.** Histologically, it is a well-circumscribed epidermal tumor composed of clear (glycogen-rich) cells.

118-17A). Surrounding the lesion is a collarette of scale. These lesions range from 5 mm to 2 cm, although the giant clear cell acanthoma can measure greater than 5 cm.[86] The lesions are usually found on the legs but can be located on the trunk and face. Although commonly solitary, multiple lesions have been reported. The dermatoscopic findings of the clear cell acanthoma is similar to that seen in psoriasis, with vascular puncta prominent in the lesion.[87] These lesions bleed with trauma.

Pathology

Pale-staining keratinocytes within a background of epidermal psoriasiform hyperplasia is characteristic in clear cell acanthoma (see Fig. 118-17B). Other epidermal findings include suprapapillary plate thinning, neutrophils, and sparing of adnexal epidermis. A mixed inflammatory infiltrate, papillary dermal edema, and enlarged vessels can be seen in the dermis. The glycogen-rich keratinocytes in the epidermis stain distinctively with periodic acid-Schiff and periodic acid-Schiff with diastase.[88]

Treatment

Cryotherapy, curettage and electrodesiccation, laser ablation, or surgical excision have been used to successfully treat this lesion.[89]

WARTY DYSKERATOMA AT A GLANCE

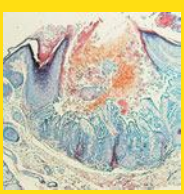

- Solitary focus of acantholytic dyskeratosis
- Lesions: Solitary, skin-colored, umbilicated papules located on the head or neck
- Histology: Cup-shaped epidermal invagination with acantholysis and dyskeratosis filled with keratinaceous material
- Differential diagnosis: Actinic keratosis, squamous cell carcinoma
- Treatment: Excision

WARTY DYSKERATOMA (ISOLATED DYSKERATOSIS FOLLICULARIS)[90]

ACANTHOMA FISSURATUM

CYSTS OF EPIDERMAL ORIGIN

Epidermoid Cyst

An epidermoid cyst, also known as a *keratin cyst, epidermal cyst, epidermal inclusion cyst, sebaceous cyst,* or an *epithelial cyst,* is a keratin-filled epithelial-lined cyst.

EPIDEMIOLOGY Epidermoid cysts are found most commonly in adult men and women. Genetic disorders, such as Gorlin syndrome (nevoid basal cell carcinoma syndrome), pachonychia congenita type 2 (Jackson-Lawler type), and Gardner syndrome, may predispose individuals to having this type of cyst.

ETIOLOGY AND PATHOGENESIS Epidermal cysts are most commonly the result of plugged pilosebaceous units. These cysts express the same cytokeratin profile as the follicular infundibulum.[96] Epidermal cysts can also be caused by the traumatic implantation of epidermal cells into deeper tissues or by the proliferation of viable epidermal remnants along embryonic fusion planes.[97,98] Epidermoid cysts can be located anywhere on the body and are characterized by their distinctive pathology. Recently, HPV type 57 and 60 DNA has been detected in palmoplantar epidermoid cysts.[99,100]

CLINICAL PRESENTATION Epidermoid cysts are classically dermal or subcutaneous mobile nodules with a central punctum (Fig. 118-18). Lesions not associated with trauma are commonly located on the upper chest, upper back, neck, or head. Traumatic lesions are more common on the palms, soles, or buttocks. The punctum, when present, represents the plugged pilosebaceous unit from which cheesy debris may be expressed. These lesions can be skin-colored, yellow, or

ACANTHOMA FISSURATUM AT A GLANCE



- Fissured or ulcerated, usually retroauricular nodule that appears in areas of friction, as with ill-fitting eyeglasses
- Differential diagnosis: Basal cell carcinoma, squamous cell carcinoma, chondrodermatitis nodularis helicis
- Usually resolve after correction of ill-fitting appliance



CYSTS OF EPIDERMAL ORIGIN

AT A GLANCE




- Epidermoid cysts are a keratin-filled epithelial-lined cysts.
- Result most commonly from a plugged pilosebaceous unit.
- Classically dermal or subcutaneous mobile nodules with a central punctum.
- Brisk, foreign-body giant cell reaction is possible if epidermoid cysts rupture into surrounding tissue.
- Trichilemmal cysts are keratin-filled, epithelial-lined cysts usually on the scalp arising from outer root sheath of the hair follicle. These pilar cysts are mobile, firm, well-circumscribed nodules. Pathology: Cyst wall without a granular layer.
- Milia: Thought to be the result of pilosebaceous or eccrine sweat duct plugging.
- Pathology similar to epidermal cyst that is smaller in scale.
- Steatocystoma multiplex: Numerous, epithelial-lined, sebum-filled dermal cysts with characteristic sebaceous glands in the cyst walls.
- Dermoid cysts: Collections of epidermis located along embryologic fusion planes most commonly on the forehead, lateral eye, or neck.
- Branchial cysts: Asymptomatic cysts caused by the occlusion of branchial cleft sinuses that are located along the angle of the mandible if arising from the first branchial cleft and the middle to lower third of the anterior border of the sternocleidomastoid in cases arising from the second branchial cleft.
- Preauricular cysts or sinuses: Epithelial invaginations located in the preauricular area that arise from the incomplete fusion of the first and second branchial arches in the preauricular area.
- Rupture or secondary infection are the most common complications of epidermal cysts.
- Removal of the entire cyst wall is required to prevent cyst recurrence.



▲ **FIGURE 118-18** Epidermoid cyst presenting as a dome-shaped protuberance of the cheek.

white. Cysts are usually slow-growing and asymptomatic, though rupture is common.

COMPLICATIONS A brisk, foreign-body giant cell reaction is possible if epidermoid cysts rupture into surrounding tissue. This foreign-body reaction may mimic that of secondary bacterial infection. However, polymicrobial infection of a cyst with aerobic or anaerobic organisms may occur. Common aerobes include *Staphylococcus aureus*, group A *Streptococcus*, and *Escherichia coli*, while common aerobes include *Peptostreptococcus* species and *Bacteroides* species. Polymicrobial infection is most common. Although the clinical course of epidermoid cysts is benign, basal cell carcinoma, squamous cell carcinoma, epithelioid carcinoma, and other malignancies have been reported to occur in conjunction with these cysts, though malignant transformation is rare.[101–103]

PATHOLOGY An epidermoid cyst has a stratified, squamous lining with an intact granular layer (Fig. 118-19). These cysts contain central, eosinophilic, keratinaceous debris that can incite a foreign-body reaction of multinucleated giant cells and histiocytes when released into the dermis and surrounding tissue.

DIFFERENTIAL DIAGNOSIS Steatocystoma multiplex, pilar cysts, and lipomas can all mimic epidermoid cysts. Clinically, however, steatocystoma multiplex usually express a liquid rather than a cheesy material, pilar cysts are most commonly on the scalp, and lipomas are softer, deeper, and without a punctum. Pathology also distinguishes between these lesions.

TREATMENT Removal of the entire cyst wall is required to prevent cyst recurrence. Intralesional steroids at a concentration of 5 mg/mL can be used to control small, inflamed, symptomatic lesions. If the cyst becomes inflamed, painful, or purulent, infection must be considered. Incision and drainage with oral antibiotic therapy to treat *S. aureus* should be initiated. Wound cultures with directed therapy may be indicated, based on the clinical presentation of the lesion. Complete excision or destruction of the cyst lining is the definitive treatment. If the cyst has ruptured or has become infected, excision of the lesion should be deferred until the inflammation has decreased. This will decrease the likelihood of wound dehiscence.

Trichilemmal Cyst (Pilar Cyst)

Trichilemmal cysts are keratin-filled, epithelial-lined cysts usually on the scalp that arise from the outer root sheath of the hair follicle.

EPIDEMIOLOGY Trichilemmal cysts can be found in 5 percent to 10 percent of the population, most commonly in middle-aged women.

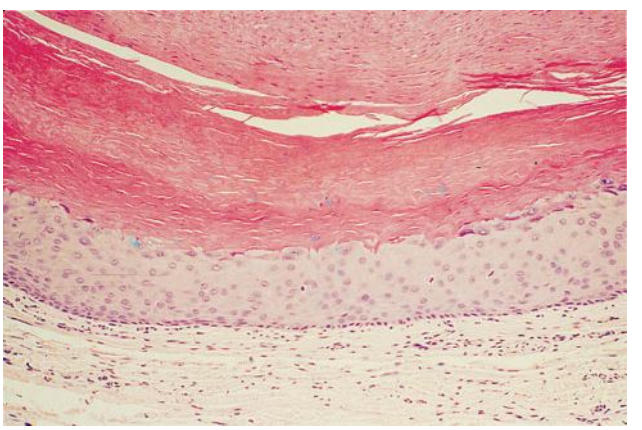

▲ **FIGURE 118-19** Epidermoid cyst lined by stratified epithelium with a granular layer. Within the cyst, the keratinous material is arranged in laminated layers.

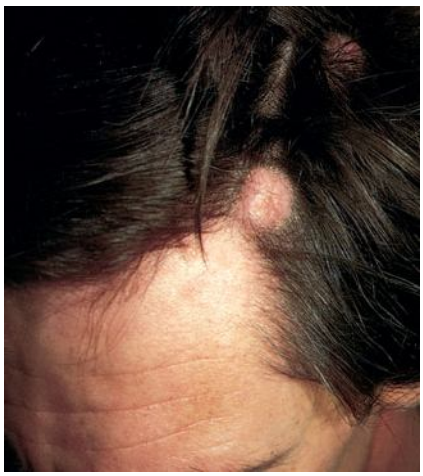

▲ **FIGURE 118-20** A trichilemmal (pilar) cyst on the scalp.

ETIOLOGY AND PATHOGENESIS Pilar cysts arise from the epithelium located between the orifice of the sebaceous gland and the arrector pili muscle. This squamous epithelium undergoes rapid keratinization resulting in a cyst wall without a granular layer.

CLINICAL FEATURES Pilar cysts are mobile, firm, well-circumscribed nodules located overwhelmingly in the scalp (Fig. 118-20). These lesions can also be found on the face, head, and neck. Most patients have more than one lesion, with 10 percent of people having more than 10 lesions. Rapid growth is abnormal and can be a sign of infection or malignant transformation.[104]

COMPLICATIONS Although these lesions largely remain asymptomatic, rupture and infection can occur. Proliferating trichilemmal tumors are a variant of this benign lesion and are commonly found on the scalp of elderly women. This lesion can destroy adjacent lesions and ulcerate, mimicking skin cancer. Malignant degeneration of pilar cysts into malignant proliferating trichilemmal cysts can occasionally occur.

PATHOLOGY The hallmark finding of these cysts is the absence of a granular layer within the cyst wall (Fig. 118-21). The cyst content is usually eosinophilic keratin, but basophilic areas of calcification may occur in the lumen of these lesions. If lobules of squamous epithelium are seen in the walls of the lesion, it is most likely a proliferating trichilemmal cyst. Invasion of the cyst lining into the surrounding tumor indicates malignancy.

DIFFERENTIAL DIAGNOSIS See Differential Diagnosis under Epidermoid Cyst.

TREATMENT The treatment is the same as with epidermoid cysts. Because the cyst wall of these tumors is clinically more firm than that of epidermoid cysts, it is possible to extract the lesion through a small incision made with a dermal punch trephine.

Milium

Milia are minute epidermoid cysts, lined with epidermis and filled with keratin.

Epidemiology. Milia are common congenital and acquired lesions in both infants and adults. Men and women are affected equally.

ETIOLOGY AND PATHOGENESIS Milia are thought to result from pilosebaceous or eccrine sweat duct plugging. These superficial lesions can be primary or secondary, with the latter resulting from injury to the skin. Secondary lesions are common in sub-epidermal blistering diseases such as epidermolysis bullosa and porphyria cutanea tarda, burns, after dermabrasion or ablative laser resurfacing, or in conjunction with topical therapy such as glucocorticoid therapy or 5-fluorouracil treatment.[105–108]

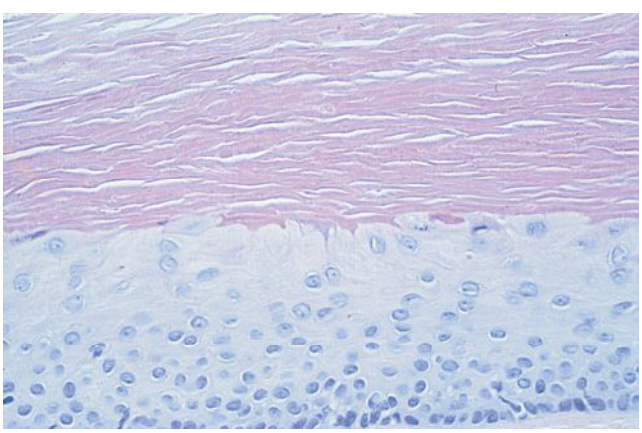

▲ **FIGURE 118-21** Trichilemmal cysts showing an epithelial lining that lacks a granular layer.



▲ **FIGURE 118-22** Primary milium. A 3-mm, hard, seed-like white papule.

CLINICAL FEATURES Milia are 1- to 2-mm, white, domed papules commonly located on the cheeks and eyelids of adults (Fig. 118-22). In infants, milia are common on the face and the mucosa. Epstein's pearls are milia on the palate. Eruptive milia have been reported, though this is a rare occurrence.[108] *Milia en plaque* is a plaque-type, inflammatory variant of milia that is commonly located on the ear.[109] Acquired milia (see eFig. 118-22.1 in on-line edition) can be located anywhere the predisposing trauma or other factors have occurred.

PATHOLOGY The pathology of a milium is similar to that of an epidermoid cyst, but the small size and occasional connection to eccrine ducts or vellus hair follicles distinguish these two entities. Bacteria are not usually seen in milia.

TREATMENT Congenital milia tend to spontaneously resolve. Acquired milia can resolve spontaneously as well, but can also be removed by disrupting the overlying epidermis with light electrodesiccation or an 11-blade and expressing the keratin contents.

Steatocystoma Multiplex

Steatocystoma multiplex are numerous, epithelial-lined, sebum-filled dermal cysts with characteristic sebaceous glands in the cyst walls.

ETIOLOGY AND PATHOGENESIS Steatocystoma multiplex, (sebocystomatosis, epidermal polycystic disease) can be a sporadic or autosomal-dominant disorder. These lesions can also be found in syn-





▲ **FIGURE 118-23** Steatocystoma multiplex. Multiple skin-colored cystic lesions on the trunk.

dromes such as Alagille syndrome and pachyonychia congenita type II (see Chap. 48). In the latter, lesions are associated with mutations in K17. Sporadic solitary lesions are termed *steatocystoma simplex*.

CLINICAL FEATURES These lesions present as asymptomatic, yellow or skin-colored dermal papules or cysts located most commonly on the trunk, upper arms, scrotum, or chest (Fig. 118-23). Oily material can be expressed from these lesions when incised. These lesions can become infected and suppurate, resulting in sinus formation and scarring.

PATHOLOGY The cyst walls of steatocystoma multiplex are composed of stratified, squamous epithelium with an absent granular layer. Sebaceous glands are located in the cyst wall (see eFig. 118-23.1 in on-line edition). There is an eosinophilic cuticle on the luminal side of this wall with keratin, oil, and hairs in the lumen.

DIFFERENTIAL DIAGNOSIS Eruptive vellus hair cysts can mimic steatocystoma multiplex clinically. They may have a tuft of hairs protruding from the cyst centrally, with findings of vellus hairs in the lumen with follicles in the wall. Epidermal inclusion cysts also have to be excluded. The pathogenesis of steatocystoma, epidermal inclusion cysts, and eruptive vellus hair cysts may be similar.[110]

TREATMENT Removal of these lesions can be successfully achieved with simple excision or drainage of the cyst with manual removal of the cyst wall which, at times, results in the clinical resolution of lesions.[111,112] Inflamed lesions have been reported to respond to intralesional steroids, carbon dioxide laser, oral retinoids, or cryotherapy.[113]

Dermoid Cyst

Dermoid cysts are epithelial-lined cysts containing various appendageal structures resulting from retained epithelium along embryonic fusion planes. These cysts are either congenital or develop in childhood. The prevalence is equal in men and women.

CLINICAL FEATURES Dermoid cysts are smooth, occur in the midline, and commonly possess a deep sinus tract that connects to the epidermis. They can measure between 1 cm and 4 cm, and are most commonly located on the forehead, lateral eye, or neck.[114,115] A superficial dermoid cyst located on the dorsal nose is referred to as *fistula of the dorsum of the nose* and is characterized by a central tuft of hair or communication intracranially. Dermoid cysts can be located deep in the subcutaneous tissue, intracranially, or intraorbitally.[116]

COMPLICATIONS Infections, rupture, and abscess formation from the manipulation of these cysts are possible serious complications.

PATHOLOGY Stratified squamous epithelium with a variety of adnexal structures may be present in the walls of dermoid cysts. Smooth muscle, pilosebaceous units, apocrine or eccrine glands, or goblet cells may also be present in the cyst walls. These cysts contain keratin and hairs.

DIFFERENTIAL DIAGNOSIS The differential diagnosis of dermoid cysts includes gliomas, encephaloceles, hemangiomas, soft tissue sarcomas, and other epidermal cysts such as branchial cleft cysts and thyroglossal duct cysts.

TREATMENT Imaging studies that help to characterize the extent of the tumor are necessary before excision is undertaken. Consultation with neurosurgery, otolaryngology, or plastic surgery may be indicated.

Branchial Cyst (Branchial Cleft Cyst)

Sequestration of first or second branchial cleft membranes results in these cysts, sinuses, or tags.

EPIDEMIOLOGY Branchial cleft cysts are largely sporadic, but autosomal dominant cases have been reported. There is no gender predominance. Ten percent of lesions are bilateral.

ETIOLOGY AND PATHOGENESIS These cysts result from the occlusion of branchial cleft sinuses.

CLINICAL FEATURES These asymptomatic lesions are located along the angle of the mandible if arising from the first branchial cleft and the middle to lower third of the anterior border of the sternocleidomastoid in cases arising from the second branchial cleft. They may present after an upper respiratory infection as a painful mass. These lesions tend to drain internally, but communication with the epidermis can occur. Branchial cysts may become complicated by infection.

PATHOLOGY Branchial cleft cysts are lined with epithelium containing lymphoid follicles, mucous glands, or smooth muscle. A dense lymphocytic infiltrate may also be seen. The cyst contents contain mucin.

TREATMENT Excision is the treatment of choice. Infected cysts may require incision and drainage or antibiotic therapy.

Preauricular Cyst and Sinus (Congenital Auricular Fistula, Ear Pits)

Preauricular cysts or sinuses are epithelial invaginations located in the preauricular area.

CHONDRODERMATITIS NODULARIS HELICIS

Clavus helicis CNH is a chronic, solitary, tender, ulcerated nodule on the helix of the ear, first described in 1915.[124]

Etiology and Pathogenesis

Many etiologic factors have been suggested for CNH. It is thought to be a disease of degenerated collagen that undergoes trans-epithelial elimination.[125] Vascular insufficiency, pressure, injury to the cartilage, sun-exposure, and low temperature have all been implicated in inciting cartilage damage. Recently, Magro et al. described 24 patients with early-onset CNH who had concomitant microvascular disease, strengthening the argument for the role of ischemia in the development of this process.[126] Re-

CHONDRODERMATITIS NODULARIS HELICIS

AT A GLANCE



- Chondrodermatitis nodularis helicis is a chronic, solitary, tender, nodule on the helix of the ear. Sometimes ulcerated.
- Thought to be a disease of degenerated collagen that undergoes transepithelial elimination.
- Often: History of a suddenly-appearing, skin-colored to pink papule or nodule on the ear that grew rapidly and subsequently remained quiescent.
- Differential diagnosis: Basal cell carcinoma, keratoacanthoma, wart, rheumatoid nodules, squamous cell carcinoma, clavus, tophus.
- Treatment: Conservative, includes pressure-relieving pillows with a "doughnut," steroid injection. If needed: Excision.

ports of CNH in association with the pressure from cell phone use has also been documented.[127] The finding of solar elastosis histologically at the periphery of many lesions along with the prevalence of CNH in lightly-pigmented populations raise the possible link between sun-exposure and CNH.[128]

CLINICAL FEATURES This disorder is found overwhelmingly in adult men over the age of 50, with the male-female prevalence being greater than 2:1.[129] Two cases of CNH in children have been reported.[130,131] Patients present with a history of a suddenly appearing, skin-colored to pink papule or nodule on the ear that grew rapidly and subsequently remained quiescent. These lesions tend

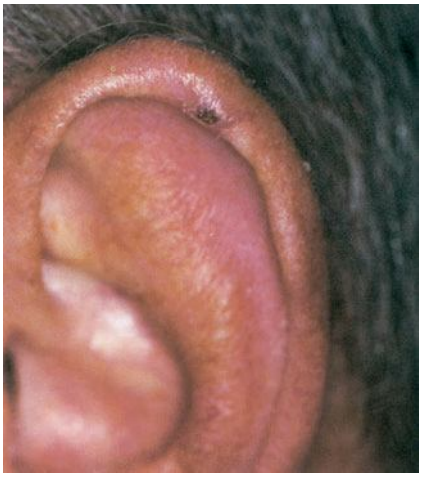

▲ **FIGURE 118-24** Painful nodule of the ear: a typical lesion of chondrodermatitis nodularis helicis.

to be on the right helix, measure less than 1 cm, and are associated with pain (Fig. 118-24). The pain can be paroxysmal or associated with changes in ambient temperature. The lesion may have a central ulceration with an adherent hemorrhagic or scale crust. Spontaneous resolution of CNH is unlikely. A possible subset of CNH may be seen in elderly women who have a history of prior trauma. For these women, spontaneous regression is not uncommon.

Differential Diagnosis

Basal cell carcinoma, keratoacanthoma, warts, rheumatoid nodules, squamous cell carcinoma, clavus, and tophus are all within the differential of CNH.

Pathology[132]

In the epidermis, there is commonly hyperkeratosis and parakeratosis; ulceration may be present. Occasionally, degenerated collagen is seen in the epidermis, indicating a trans-epidermal elimination process. A brisk, predominantly lymphocytic infiltrate is noted in the dermis with admixed histiocytes and few neutrophils. Telangiectasias and solar elastosis are often noted in the adjacent dermis. The perichondrium shows inflammation and fibrous thickening. The cartilage may show hyalinization, necrosis, and, at times, ossification.

Treatment

Conservative treatment includes pressure-relieving pillows with a "doughnut" shape that are commercially available. In a recent study examining the role of such pressure-relieving devices, 13 of 15 patients (87 percent) were healed at follow-up after 1 month of conservative treatment.[133] High-potency steroids, intralesional steroids, and laser ablation may also be used to induce symptom control or regression of the lesion.[134] Excision of CNH nodules using a shave or excisional technique through and around the affected cartilage is also an accepted treatment option, though recurrences may occur at the edge of the lesion.[135]

KEY REFERENCES

The full reference list for all chapters is available at www.digm7.com.

3. Yeatman JM, Kilkenny M, Marks R: The prevalence of seborrhoeic keratoses in an Australian population: Does exposure to sunlight play a part in their frequency? *Br J Dermatol* **137**:411, 1997
18. Schwartz RA: Sign of Leser-Trélat. *J Am Acad Dermatol* **35**:88, 1996
29. Solomon LM, Esterly NB: Epidermal and other congenital organoid nevi. *Curr Probl Pediatr* **6**:1, 1975
33. Rogers M et al: Epidermal nevi and the epidermal nevus syndrome. A review of 131 cases. *J Acad Dermatol* **20**:476, 1989
36. Weedon D: Tumors of the epidermis, in *Skin Pathology*, edited by Weedon D. New York, Churchill Livingstone, 2002, p 754
42. Bogle MA: Successful treatment of a widespread inflammatory verrucous epidermal nevus with etanercept. *Arch Dermatol* **142**:401, 2006
45. Cribier B, Scrivener Y, Grosshans E: Tumors arising in nevus sebaceus: A study of 596 cases. *J Am Acad Dermatol* **42**:263, 2000
61. Vazquez MR et al: Eccrine naevus: Case report and literature review. *Acta Derm Venereol* **82**:154, 2002
69. Happle R: Epidermal nevus syndromes. *Semin Dermatol* **14**:111, 1995
114. Pryor SG et al: Pediatric dermoid cysts of the head and neck. *Otolaryngol Head Neck Surg* **132**:938, 2005
133. Moncrieff M, Sassoon EM: Effective treatment of chondrodermatitis nodularis chronica helicis using a conservative approach. *Br J Dermatol* **150**:892, 2004



CHAPTER 119

Appendage Tumors and Hamartomas of the Skin

R. Stan Taylor
Jennifer B. Perone
Steven Kaddu
Helmut Kerl



GENERAL CONSIDERATIONS

Appendage tumors of the skin differentiate from epithelial components of normal (embryonal or mature) adnexal structures. During embryologic development, eccrine differentiation is independent of development of the hair follicle, apocrine system, and sebaceous glands (pilosebaceous units; Table 119-1).[1–6] Therefore, when considering appendageal tumors, differentiation from these adnexal units is used to classify the lesion.

Adnexal neoplasms may occur singly or multiply. Solitary lesions generally reveal no distinctive clinical features; however, site can be used as an aid in diagnosis. The anatomic distribution corresponds with the normal distribution of the adnexal structure from which the neoplasm differentiates. Appendage tumors arising as multiple lesions frequently display a characteristic distribution. They are often inherited in an autosomal dominant fashion and may be associated with other cutaneous and extra-cutaneous pathology.

Histopathology is the most important tool for diagnosis and classification of appendage skin tumors given the nondescript clinical appearance of many of these neoplasms. Assessment of architectural and cytomorphologic characteristics as well as determination of which normal adnexal structures the differentiation of the tumor most closely resembles are the cornerstones of microscopic evaluation.[1–6] On routine hematoxylin and eosin–stained sections, diagnostic criteria are apparent in the vast majority of cases, although the degree of involvement may vary greatly within the same tumor. A careful and adequate sampling of the specimen is therefore essential.

Immunohistologic analyses are occasionally necessary for interpretation of the tumors (Table 119-2). Interestingly, there is a significant overlap of immunohistologic features among tumors with ductal differentiation (apocrine and eccrine tumors) and certain visceral malignancies. Ultrastructural studies are of limited value in routine diagnosis of these tumors.

Cytogenetic and molecular studies have shed some light on the pathogenesis of several cutaneous appendage tumors. For instance, *p53* mutations have been detected in a number of neoplasms, suggesting an etiologic role for ultraviolet light exposure.[7] Mutation of the human homolog of *Drosophila patched* (*PTC*) gene has been shown to be the molecular defect in follicular appendage tumors arising in patients with nevoid basal cell carcinoma syndrome (Gorlin syndrome; see Chap. 116).[8] Germline mutations have consistently been reported in other familial syndromes, suggesting a role for these aberrations in pathogenesis. For example, mutations of *PTEN*, a tumor-suppressor gene, have been identified in tumors from patients with Cowden (multiple hamartoma) syndrome[9] (see Chap. 154). Microsatellite instability as well as mutations of the *hMSH2* and *hMLH1* mismatch repair genes have also been detected in neoplasms from patients with Muir-Torre syndrome[10] (see Chaps. 109 and 154).

DIFFERENTIAL DIAGNOSIS

Differential diagnosis largely depends on the histologic findings. Ductal differentiation characterizes apocrine and eccrine tumors. Features of apocrine secretion (i.e., decapitation secretion) are seen in ductal structures of apocrine neoplasms, whereas ductal structures in eccrine tumors are lined by a flattened epithelium.[1] Follicular tumors show a range of morphologic features that recapitulate specific portions of normal hair and hair follicle[3] such as the infundibulum, isthmus, stem, and bulb (see Chap. 84). The finding of matrical cells reflects differentiation toward follicular bulbs. Trichohyalin granules and blue-gray corneocytes indicate differentiation toward the inner root sheath. Differentiation toward the outer root sheath is manifested by the presence of either clear columnar cells aligned in a palisade (outer root sheath differentiation at the bulb), subtly cornified cells with pink cytoplasm (outer root sheath differentiation at the stem), or fully cornified cells with red cytoplasm ("trichilemmal keratinization"), which corresponds to outer root sheath differentiation at the level of the isthmus.

Sebaceous tumors reveal areas with sebocytes (cells with vacuolated cytoplasm and scalloped nuclei) and tubular structures.[2] Some tumors may display one or more lines of differentiation, making even histopathologic diagnosis challenging at times.

Determination of whether an appendage neoplasm is benign or malignant requires assessment of architectural and cytomorphologic characteristics. Great care is necessary when applying traditional morphologic criteria of malignancy such as asymmetry, poor circumscription, and presence of epithelial aggregations with prominent atypia and mitotic activity. Some malignant and aggressive adnexal neoplasms [e.g., microcystic adnexal carcinoma (MAC)] show deceptively bland appearances. Furthermore, there are certain neoplasms whose malignant potential is not always predictable on morphologic grounds alone.

APPENDAGE TUMORS AT A GLANCE



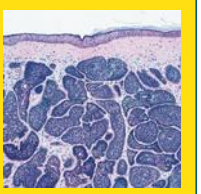

- Differentiate from cutaneous adnexal structures into eccrine, apocrine, hair follicle unit, or sebaceous tumors.
- Clinical diagnosis is difficult, as most present as nodules. Anatomic location, presence of single or multiple lesions, knowledge of distribution of adnexal structures should be considered in development of a differential diagnosis.
- Risk of malignant degeneration varies with individual lesions.

CLASSIFICATION AND PATHOGENESIS

The number of current classifications of appendage tumors of the skin indicates how little consensus exists about their grouping and their etiology and pathogenesis.[1–6] There is also no unanimity among authors as to whether particular tumors are truly neoplasms, hyperplasias, or hamartomas. In this chapter, we categorize appendage tumors of the skin as cysts, hamartomas, hyperplasias, and benign or malignant neoplasms, and arrange them alphabetically (see Table

TABLE 119-1
Classification of Appendage Tumors of the Skin

Tumors with Apocrine Differentiation	Tumors with Eccrine Differentiation	Tumors with Follicular Differentiation	Tumors with Sebaceous Differentiation
Cysts	*Cysts*	*Cysts*	*Cysts*
• Hydrocystoma	• Hydrocystoma	• Epidermal cyst	• Steatocystoma
• Moll's gland cyst		• Hybrid follicular cyst	
		• Keratocyst	
		• Pigmented follicular cyst	
		• Trichilemmal cyst	
		• Vellus hair cyst	
Hamartomas	*Hamartomas*	*Hamartomas*	*Hamartomas*
• Apocrine nevus	• Eccrine hamartoma	• Basaloid follicular hamartoma	• Folliculo-sebaceous cystic hamartoma
		• Hair follicle nevus	• Fordyce's spots and Montgomery's tubercles
		• Linear unilateral basal cell nevus	• Nevus sebaceus
		• Neurofollicular hamartoma	
		• Nevus comedonicus	
		• Nevus sebaceus	
Hyperplasias	*Hyperplasias*	*Hyperplasias*	*Hyperplasias*
• Fibroadenoma of the breast	• Mucinous syringometaplasia	—	• Sebaceous hyperplasia and rhinophyma
	• Syringolymphoid hyperplasia		
Benign Neoplasms	*Benign Neoplasms*	*Benign Neoplasms*	*Benign Neoplasms*
• Adenoma of the nipple	• Cylindroma	• Desmoplastic trichoepithelioma	• Mantleoma
• Hidradenoma papilliferum	• Eccrine syringofibroadenoma	• Dilated pore (Winer)	• Reticulated acanthoma
• Mixed tumor	• Hidradenoma	• Fibrofolliculoma	• Sebaceoma
• Reticulated acanthoma	• Poroma	• Fibrous papule	
• Syringocystadenoma papilliferum	• Spiradenoma	• Inverted follicular keratosis	
	• Syringoma	• Lymphadenoma (cutaneous)	
	• Tubular adenoma	• Panfolliculoma	
		• Pilar sheath acanthoma	
		• Pilomatricoma	
		• Proliferating pilar tumor	
		• Trichoadenoma	
		• Trichoblastoma	
		• Trichodiscoma	
		• Trichoepithelioma	
		• Trichofolliculoma	
		• Tricholemmoma	
		• Tumor of follicular infundibulum	
Malignant Neoplasms	*Malignant Neoplasms*	*Malignant Neoplasms*	*Malignant Neoplasms*
• Adenoid cystic carcinoma	• Aggressive digital papillary adenoma and adenocarcinoma	• Basal cell carcinoma with follicular (and sebaceous) differentiation	• Sebaceous carcinoma (and neoplasms in Muir-Torre syndrome
• Apocrine adenocarcinoma	• Cylindrocarcinoma	• Pilomatrical carcinoma	
• Ductal carcinoma	• Eccrine carcinoma	• Trichilemmal carcinoma	
• Extramammary Paget disease	• Hidradenocarcinoma		
• Hidradenocarcinoma papilliferum	• Microcystic adnexal carcinoma		
• Malignant mixed tumor	• Polymorphous sweat gland carcinoma		
• Mucinous carcinoma	• Porocarcinoma		
• Signet-ring cell carcinoma	• Spiradenocarcinoma		
• Syringocystadenocarcinoma papilliferum			

119-1). A cutaneous cyst is defined as an epithelium-lined, round, or oval sac-like lesion. The term *cutaneous hamartoma* refers to an embryologic malformation characterized by an abnormal arrangement of "normal" cutaneous tissues. Cutaneous hyperplasia represents an increase in the number of normal cells but with relatively normal arrangement. A benign neoplasm has no potential to metastasize. A malignant neoplasm possesses the potential for local destruction and metastasis.

TREATMENT

A diagnostic biopsy of a suspicious lesion yielding a correct diagnosis is usually the first step in appropriate management of patients with appendageal skin tumors. A number of tumor-related and patient-related factors influence the choice of treatment. Tumor-related factors include the type, size, and anatomic location. Patient-related factors include life expectancy, comorbid conditions, and cosmetic concerns.

Specific treatment of benign appendage tumors is sometimes unnecessary. In some cases, removal of the tumor is indicated for cosmetic reasons only. Treatment of choice for the majority of benign appendage tumors and relatively



TABLE 119-2
Immunohistochemical Findings in Appendage Tumors of the Skin

Tumors	Carcinoembryonic Antigen	Cytokeratin 5/6	Epithelial Membrane Antigen	Gross Cystic Disease Fluid Protein	Pancytokeratin	S-100	Vimentin
Tumors with apocrine differentiation	±	+	+	+	+	–	–
Tumors with eccrine differentiation	±	+	+	±	+	±	±
Tumors with follicular differentiation	–	+	±	–	+	–	–
Tumors with sebaceous differentiation	–	+	+	–	+	–	–

– = no reaction; ± = weak reaction; + = strong reaction.



non-aggressive, malignant appendage neoplasms is excisional surgery. A variety of superficial ablative techniques (electrodesiccation and curettage and cryotherapy) have proved to be effective in selected patients. A number of other alternative treatment options, including the use of systemic retinoids, lasers, and photodynamic therapy, have also been advocated for use in some cases; however, most do not have sufficient data for universal application.

Treatment of malignant appendage tumors aims mainly at eradication of the cancer, preservation or restoration of normal function, and cosmesis. High-risk patients with tumors known to have a high rate of recurrence or metastasis most frequently require wide excisional surgery, Mohs micrographic surgery, and/or radiotherapy. Notably, sentinel node biopsy is sometimes valuable in staging of patients with eccrine and apocrine carcinomas.[11]

APPENDAGE TUMORS WITH APOCRINE DIFFERENTIATION

Appendage tumors with ductal differentiation (sweat gland tumors) have traditionally been divided into apocrine and eccrine. However, over the years, it has become increasingly recognized that distinction between apocrine and eccrine is not always possible, as classic features of apocrine differentiation are sometimes observed in tumors traditionally categorized as eccrine.

Generally, the anatomic distribution of apocrine tumors reflects that of normal glands manufacturing apocrine secretion, which are confined to the head and neck, axillae, and genital or perianal skin. The vast majority of apocrine tumors are benign.[1] Malignant neoplasms show varied and diverse morphologic features and biologic potential.

Cysts: Hidrocystoma

EPIDEMIOLOGY Hidrocystoma (cystadenoma) is a relatively common cystic lesion presenting mostly in middle-aged or elderly individuals.

ETIOLOGY Hidrocystoma shows features of either apocrine (apocrine type) or eccrine (eccrine type) differentiation.

CLINICAL FINDINGS Hidrocystoma is a solitary, small- to medium-sized, skin-colored, reddish or bluish cystic nodule situated on the head or neck, especially in the periorbital region[1,4–6,12] (Fig. 119-1A). Unusual presentations include multiple lesions, giant tumors (up to 7 cm), and lesions occurring in childhood. Hidrocystoma occasionally develops within a nevus sebaceus (see Chap. 118). Multiple apocrine hidrocystomas on the upper and lower eyelid margins bilaterally may be a feature of a rare variant of ectodermal dysplasia (Schopf-Schulz-Passarge syndrome).[13]

HISTOPATHOLOGY On histologic examination, there is a unilocular or occasionally a multilocular cyst located in the dermis. The epithelial lining displays either features of apocrine (decapitation secretion) or eccrine (single or double layered, cuboid often flattened epithelium) differentiation.[1] Prominent papillations protruding into the lumen are noted in a subset of cases (see Fig. 119-1B). Secretory products contain lipofuscin, melanin, and/or hemosiderin.

TREATMENT Treatment of choice in solitary lesions is simple surgical excision. Multiple lesions may be removed using a carbon dioxide or nonablative diode laser,[14] electrodesiccation, local infiltration of trichloroacetic acid,[15] or surgery with blepharoplasty.

Hamartomas

APOCRINE NEVUS ***Epidemiology.*** Apocrine nevus is a rare hamartoma that consists of proliferation of normal-appearing apocrine glands in the dermis.

Clinical Findings. Pure apocrine nevus presents as a unilateral or bilateral, soft, lobulated, dermal mass in the axilla or as a circumscribed area on the scalp.[1,4–6,12] Two variants are recognized: (1) a type occurring as a part of nevus sebaceus



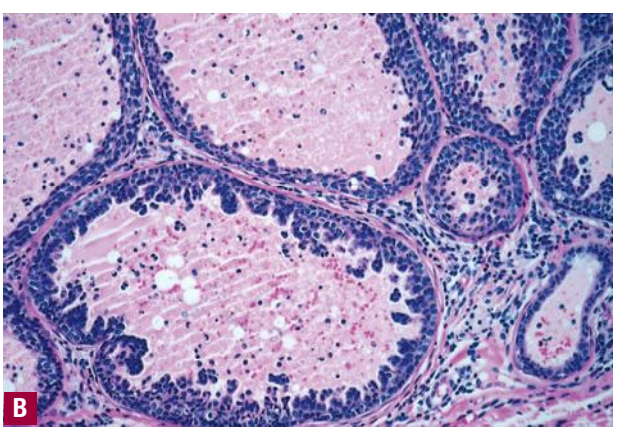

◀ **FIGURE 119-1** Apocrine hidrocystoma. **A.** Reddish-brown to bluish cystic nodule. **B.** Multilocular tumor with papillary projections ("apocrine secretion").

and (2) an extremely rare type arising independently (pure apocrine nevus). Cases of apocrine nevus occurring as multiple, firm papules on the chest have been reported.[16]

Histopathology. Histologically, there are numerous, discrete, closely spaced tubular structures in the dermis and/or the subcutaneous fat. The tubules are lined by typical apocrine glandular epithelium and contain a homogeneous or vacuolated pink material (apocrine secretion). An apocrine nevus developing within a pre-existing nevus sebaceus usually arises in the deeper portion, sometimes in association with a syringocystadenoma papilliferum or trichoblastoma.[17]

SUPERNUMERARY NIPPLE ***Epidemiology.*** Lesions present mainly in young individuals.[1] Males and females are equally affected.

Etiology. Most cases are sporadic, but some lesions show a genetic transmission.

Clinical Findings. Supernumerary nipple is characterized by the presence of solitary or multiple rudimentary nipples developing along the embryonal milk line. They occur commonly as solitary, asymptomatic, soft, brown papules with a dimple, resembling dermatofibromas, fibromas, or melanocytic nevi. Less frequently, patients show supernumerary nipples with an appearance of an areola (polythelia areolaris), a patch of hair (polythelia pilosa), or a subcutaneous mass with or without areola. Rare cases present as a pedunculated or dermal mass in the axilla or vulva. Supernumerary nipples have also been reported in association with adenoma of the nipple (erosive adenomatosis)[1,18]; with renal abnormalities, including renal cell carcinoma; and with cardiovascular disorders, including congenital heart abnormalities.[19]

Histopathology. A dome-shaped lesion consisting of variable components of a normal nipple, including sebaceous lobules and ducts (Montgomery's tubercles). A rudimentary vellus follicle, various lactiferous ducts, dilated venules, and fascicles of smooth muscle can be observed.

Treatment. Treatment is by simple surgical excision if desired.

Hyperplasia: Fibroadenoma

EPIDEMIOLOGY Fibroadenoma is the most common cause of a breast mass in women younger than 25 years of age.

ETIOLOGY AND PATHOGENESIS The etiology is unknown, but the condition probably results from a proliferation of breast tissue in response to excessive circulating estradiol over progesterone.

CLINICAL FINDINGS Rarely, the tumor arises along the embryonic milk line or in other locations.[1,20] Lesions commonly present as single or multiple firm, rubbery, smooth, mobile, painless infiltrates ranging up to 2 cm in diameter that can be bilateral. A distinct juvenile type that arises in teenage females presents with large tumors measuring 15 to 20 cm that can grow rapidly, often leading to extensive stretching of the skin and distortion of the nipple.

HISTOPATHOLOGY Histopathologic examination reveals a variably hyalinized or mucinous, fibrous stroma surrounding a proliferation of ductal structures with apocrine secretion.

SPECIAL TESTS Routine mammography may reveal smaller lesions.

TREATMENT Treatment is complete local surgical excision. Conservative management has also been proposed.[20]

Benign Neoplasms: Adenoma of the Nipple

EPIDEMIOLOGY Peak incidence is in the fifth decade in women; however, the lesion may present at any age. Men are occasionally affected.

ETIOLOGY AND PATHOGENESIS Adenoma of the nipple (florid papillomatosis, erosive adenomatosis, papillary adenoma) is a rare, benign neoplasm currently thought to originate from terminal lactiferous ducts and subareolar breast tissue.

CLINICAL FINDINGS Patients sometimes complain of pain or an itchy, burning sensation within the lesion. Clinically, there is usually a unilateral enlargement and/or induration of the nipple that contains a palpable, firm, subareolar nodule.[1,5,6,12] The surface is occasionally erythematous, ulcerated, or crusted, and may ooze a serous, serosanguineous, or bloody discharge. Importantly, the overall clinical appearance is often indistinguishable from that of mammary Paget disease (see Chap. 121). Bilateral tumors have been reported. The lesion has also been observed to develop in association with a supernumerary nipple.[18]

HISTOPATHOLOGY An endophytic proliferation of tubular structures in the dermis with a verrucous or ulcerated surface is usually found. Some of the tubular structures exhibit cystic dilatations with discrete papillations. They are lined by an inner apocrine secretory epithelium and an outer myoepithelial layer and are separated by a fibrous stroma.

TREATMENT The treatment of choice is complete surgical excision. Persistence or recurrences are common. Mohs micrographic surgery may be beneficial for conservation of the nipple.[21] Cryosurgery may be useful in the treatment of some patients.

Hidradenoma Papilliferum

EPIDEMIOLOGY Hidradenoma papilliferum (papillary hidradenoma) is a relatively uncommon benign neoplasm in adult women.

CLINICAL FINDINGS This lesion usually occurs as a unilateral, small (up to 1 cm in diameter), asymptomatic, skin-colored nodule on anogenital skin.[1,4–6,12] There are, however, a few reports of similar neoplasms arising on the eyelid[22] and external auditory canal.

PROGNOSIS AND CLINICAL COURSE Malignant transformation has been reported. A fatal metastasizing squamous carcinoma arising in a hidradenoma papilliferum has also been reported.[23]

HISTOPATHOLOGY Histopathologic examination reveals a partly solid or solid-cystic lesion, usually without an epidermal connection. The tumor shows a complex pattern, with anastomosing papillary structures and tubules as well as some glandular areas (Fig. 119-2). The papillary structures are interconnected in a trabecular pattern. The epithelial lining consists of an inner layer of tall and columnar cells with eosinophilic cytoplasm and features of decapitation secretion. A thin, outer myoepithelial layer is frequently present, with a surrounding lymphoplasmacytic infiltrate.

TREATMENT Treatment is by simple surgical excision. In perianal tumors, consultation with a colorectal surgeon is advised to assure preservation of normal sphincter function.

Mixed Tumor of the Skin

EPIDEMIOLOGY Lesions are seen in middle-aged and elderly men.





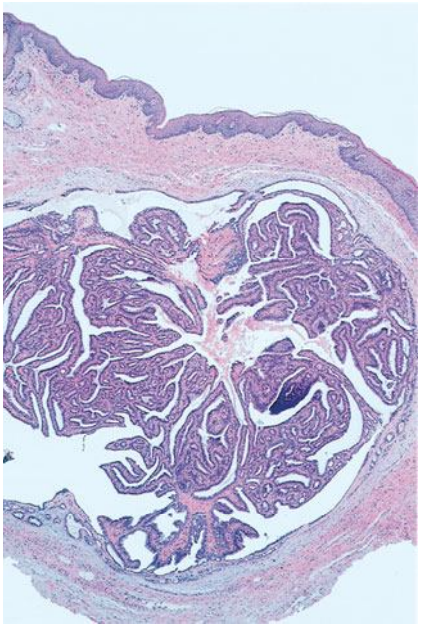

▲ **FIGURE 119-2** Hidradenoma papilliferum. Cystic tumor with papillary and glandular areas.

ETIOLOGY AND PATHOGENESIS Mixed tumor of the skin (chondroid syringoma) is a group of adnexal neoplasms with ductal differentiation and a fibromyxochondroid stroma.[1,4–6,12] Apocrine or eccrine features predominate in individual cases.

CLINICAL FINDINGS Skin lesions present usually as solitary, firm, non-ulcerated, shiny, or waxy nodules measuring from 2 mm to several centimeters in diameter, situated on the head and neck[24] (Fig. 119-3A). Mixed tumors may occasionally develop on a variety of other anatomic sites, including genitalia.

HISTOPATHOLOGY There is a well-circumscribed dermal and/or subcutaneous lesion composed of elongated, partly ramifying tubular structures and/or complex solid nests as well as cords (see Fig. 119-3B). The epithelial component is typically embedded in an abundant stroma of spindled and stellate cells, mucin, and chondroid material. The apocrine type reveals, at least focally, small tubular lumina and cystic structures with apocrine secretion. A homogenous material is sometimes noted within the cystic cavities. Foci of polygonal, plasmacytoid, pale, and clear cells may be observed. Occasional cases display follicular and sebaceous differentiation, fat metaplasia, and/or collagenous spherulosis.[1,25] The eccrine type is characterized by tubulocystic spaces with cuboidal cell linings attached to solid elements, resembling the tadpole configuration seen in syringomas.

Notably, some mixed tumors reveal atypical histologic features, including an infiltrative margin, satellite tumor nodules, and tumor necrosis. These atypical histologic appearances do not generally correspond with aggressive potential.

PROGNOSIS AND CLINICAL COURSE To date, there are no convincing reports of malignant transformation of benign mixed tumor in the literature.[1,5]

TREATMENT Complete surgical excision is the treatment. Chondroid syringoma of salivary origin requires complete surgical excision.

Syringocystadenoma Papilliferum

EPIDEMIOLOGY Syringocystadenoma papilliferum occurs in adults.

ETIOLOGY AND PATHOGENESIS Most authors consider syringocystadenoma papilliferum to be a benign tumor,[5,6] whereas others categorize it as a hamartoma.[1] The lesion develops either independently or arises in association with a nevus sebaceus.[17] Syringocystadenocarcinoma papilliferum may develop from long-standing syringocystadenoma (see Syringocystadenocarcinoma Papilliferum).

CLINICAL FINDINGS Solitary syringocystadenoma papilliferum occurs as a single, papillomatous, verrucous, sometimes erosive plaque or nodule measuring 1 to 3 cm in diameter, situated on the head and neck of adults[1,4–6,12] (Fig. 119-4A). A small fistula discharging a clear, bloody, or malodorous exudate may be noted. Less common presentations include childhood tumors, lesions located on unusual anatomic sites (e.g., trunk, upper arms, vulva, and thighs), and lesions arising as multiple or linearly arranged cutaneous nodules.

HISTOPATHOLOGY There is a crateriform epidermal invagination, with the upper portion lined by squamous epithelium and the lower portion lined by apocrine epithelium (see Fig. 119-4B). The surrounding epidermis usually reveals papillomatosis, hypergranulosis, and hyperkeratosis. Foci with variously sized papillations covered by a squamous epithelium are frequently observed within the epidermal invagination. In the dermis, cystic structures with villous projections exhibiting apocrine secretion may be present. The lesion is often surrounded by a variable lymphoplasmacytic infiltrate. Syringocystadenoma papilliferum arising in nevus sebaceus (see Chap. 118) sometimes co-exists with trichoblastomas or basal cell carcinoma and has been reported with verrucous carcinoma.[17,26]

TREATMENT Treatment of choice is surgical excision. Carbon dioxide laser may be effective in removing tumors on anatomic sites unfavorable to surgical excision.

Malignant Neoplasms

APOCRINE ADENOCARCINOMA ***Epidemiology.*** Apocrine adenocarcinoma (apocrine carcinoma) is a rare, poorly documented, aggressive adnexal neoplasm. Lesions present predominantly in adults.



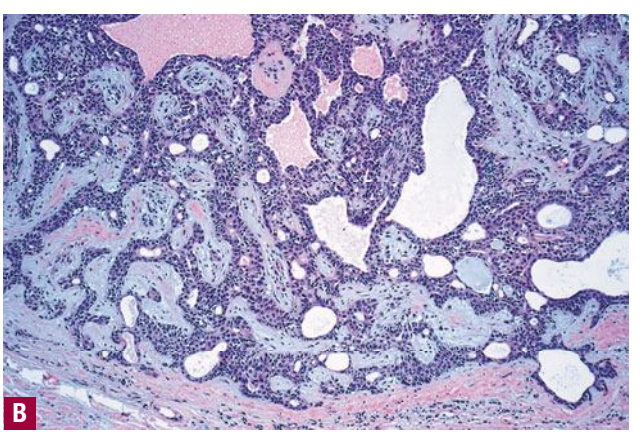

◀ **FIGURE 119-3** Mixed tumor. **A.** Mixed tumor on the nose. **B.** Solid cords and tubular structures in a background of a fibromyxoid stroma.

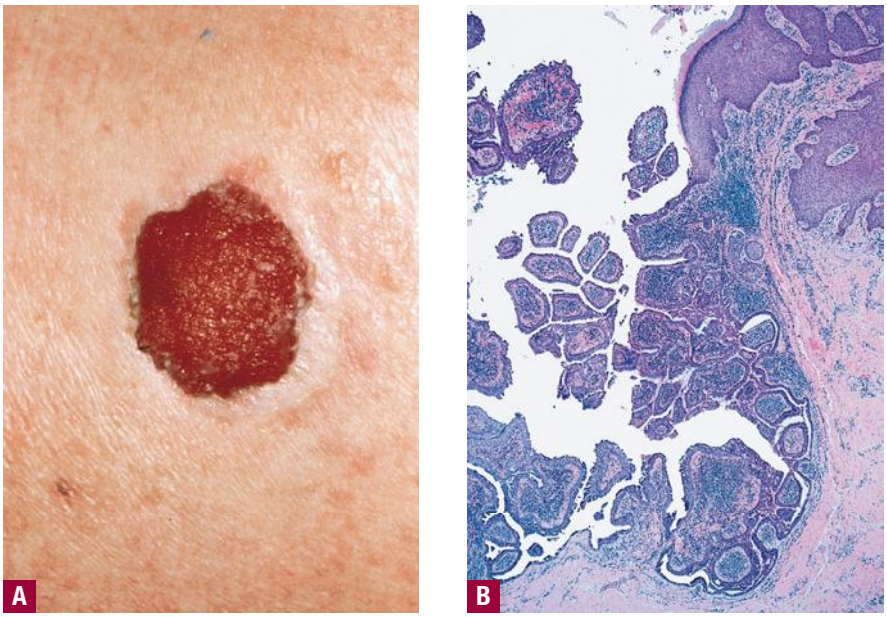

▲ **FIGURE 119-4** Syringocystadenoma papilliferum. **A.** Erosive nodule on the forehead. **B.** Epidermal invagination with papilliferous projections.

Clinical Findings. Apocrine adenocarcinoma presents as either solitary or multiple nodules and plaques measuring 2 to 8 cm in diameter situated in the axilla or anogenital area.[1,4,12] Occasional cases may involve the fingers, nipples, eyelid, or chest. Lesions occasionally develop in association with nevus sebaceous (see Chap. 118), apocrine hamartoma, or extramammary Paget disease (see Chap. 121).[1,27] Eyelid apocrine adenocarcinoma tumors are considered to be derived from Moll's gland.[28]

Histopathology. Histopathologic examination reveals a dermal/subcutaneous non-encapsulated tumor with infiltrative margins. The epithelial component shows variable papillary, solid, or mixed patterns. Foci of partly anastomosing tubular structures exhibiting apocrine (decapitation) secretion and infiltrating cords of neoplastic cells can be observed, but not ubiquitously. Neoplastic cells display variable pleomorphism and mitotic activity, as well as abundant, sometimes granular or vacuolated, eosinophilic cytoplasm. Myoblastomatoid adenocarcinoma of the breast is a variant of apocrine adenocarcinoma with neoplastic cells with foamy, granular cytoplasm.[29] It is particularly important to differentiate apocrine adenocarcinoma from cutaneous metastases from other organs, especially from the breast.

Prognosis and Clinical Course. Apocrine adenocarcinoma (apocrine carcinoma) is aggressive. Regional lymph node metastases and fatal visceral metastases have been recorded.[30]

Treatment. Surgical excision with adequate margins should be performed.

DUCTAL CARCINOMA ***Epidemiology.*** Ductal carcinoma occurs in elderly patients, preferentially in men.[31]

Etiology and Pathogenesis. The term *ductal carcinoma* has been suggested to denote a rare type of malignant sweat gland carcinoma characterized by prominent, closely packed tubular structures with either apocrine or eccrine features.[1,31]

Clinical Findings. Tumors present usually as solitary, asymptomatic nodules in the axilla.[31] Occasional cases arise as multiple lesions or are situated on unusual sites, including face, scalp, sternal region, and nipple. Clinical presentation can mimic Paget disease.[32] Tumors developing within a pre-existing nevus sebaceus have been reported.[27]

Histopathology. There is a deep dermal and/or subcutaneous proliferation composed of numerous closely packed, tubular structures, sometimes with cystic and solid aggregations of neoplastic cells. The tubular and solid elements are composed of atypical neoplastic cells with abundant eosinophilic cytoplasm, hyperchromatic nuclei, and frequent mitotic figures. Features of apocrine or eccrine differentiation can be observed in individual cases.[1,31]

Prognosis and Clinical Course. Metastases, especially to regional lymph nodes, lungs, and to other organs, can develop. Recurrences are common.

Treatment. Treatment is by surgical excision with adequate margins.

EXTRAMAMMARY PAGET DISEASE See Chap. 121.

HIDRADENOCARCINOMA PAPILLIFERUM ***Epidemiology.*** Hidradenocarcinoma papilliferum is a rare appendage tumor presenting mainly in middle-aged women.

Etiology and Pathogenesis. This tumor most often arises from a pre-existing, usually long-standing, benign hidradenoma papilliferum.[1,33] It presents as a solitary, small, often ulcerated nodule in the anogenital region and, rarely, in the axilla. Most lesions are asymptomatic, but a few patients complain of slight pain or a brownish, watery discharge. Lesions have occasionally been observed in association with extramammary Paget disease.[34]

Histopathology. Histopathologically, unlike hidradenoma papilliferum, this malignant tumor often shows asymmetry and high cellularity. It consists of tubules and cystic cavities with features of apocrine differentiation surrounded by compressed fibrous stroma. Papillations with a central fibrovascular tissue core are noted projecting in the cyst cavities.

Prognosis and Clinical Course. Fatal metastases, often initially involving lymph nodes, have been recorded. Sentinel node biopsy may be valuable in staging of these patients.

Treatment. Local surgical excision is the treatment of choice.

MALIGNANT MIXED TUMOR ***Epidemiology.*** Malignant mixed tumor presents in middle-aged adults, most commonly in women.

Etiology. This malignant counterpart of benign mixed tumor appears mainly to develop de novo.[1,5,35]

Clinical Findings. Malignant mixed tumor shows predilection for the trunk and extremities,[1,5,36] anatomic sites not usually involved by benign mixed tumors. It appears as a solitary, occasionally painful, firm or cystic, non-ulcerated cutaneous or subcutaneous nodule measuring 2 to 10 cm in diameter.[1,4–6,12,36]



Histopathology. The tumor shows lobulated epithelial aggregations with tubular structures, cords, and solid elements. The epithelial component is surrounded by a fibrous stroma with myxomatous and cartilaginous areas. Neoplastic cells display polygonal, plasmacytoid, or cuboidal appearances with variable pleomorphism and scattered mitotic figures. Tubular structures show either apocrine or eccrine differentiation.

Treatment. Treatment of choice is total surgical excision. Local and distant metastases, especially to lymph nodes, are common. Prophylactic removal of regional lymph node chains and/or adjuvant radiotherapy may facilitate long-term survival.[5]



MUCINOUS CARCINOMA ***Epidemiology.*** Primary mucinous carcinoma of the skin (colloid, gelatinous, or adenocystic carcinoma) is a rare, low-grade carcinoma.

Etiology. This lesion bears close morphologic resemblance to mucinous carcinoma of the breast.

Clinical Findings. It presents as a solitary, slowly growing, soft to firm, grayish, reddish, or bluish smooth-surfaced nodule measuring up to 3 cm in diameter.[1,4–6,12,37] Lesions tend to occur in older adults (particularly men) on the head and, particularly, around the eyelids.[37] Scalp tumors may occur as a patch of alopecia.

Laboratory Tests. There are solid and cystic aggregations of neoplastic cells within the dermis, often with extension to the subcutis, embedded in large pools of mucin. Mucinous areas are typically separated by fibrous septae.

Prognosis and Clinical Course. Recurrences have been reported in about 28 percent of cases.[37] Metastases are rare and involve mostly regional lymph nodes.

Treatment. Treatment is by wide surgical excision.

SYRINGOCYSTADENOCARCINOMA PAPILLIFERUM ***Etiology.*** Syringocystadenocarcinoma papilliferum is a rare neoplasm that usually arises in a long-standing syringocystadenoma papilliferum and occasionally in a nevus sebaceus.[1,12,38,39]

Clinical Findings. The tumor preferentially involves the scalp of adult women. A few cases have been reported on the chest.

History. Patients may give a history of sudden enlargement of long-standing clusters of skin-colored or yellowish, sometimes ulcerated, papules or nodules.[39]

Histopathology. Syringocystadenocarcinoma papilliferum superficially resembles syringocystadenoma papilliferum on scanning magnification. However, the malignant tumor is characteristically asymmetric and poorly circumscribed, with extension deep into the subcutis. It consists mainly of papillations that project above the skin surface into cystic cavities. Cells are crowded and atypical, with numerous mitotic figures. Tubular structures with apocrine secretion are noted in some sections.

Prognosis and Clinical Course. The neoplasm occasionally gives rise to regional lymph node metastases.[39]

Treatment. Treatment of choice is surgical excision, but Mohs micrographic surgery has been used.[40]

APPENDAGE TUMORS WITH ECCRINE DIFFERENTIATION

Eccrine tumors show a wider anatomic distribution than do apocrine tumors.[41] This is due to the broader distribution of normal eccrine glands in virtually all topographic sites, in contrast to normal apocrine glands, which are confined to the head and neck, axillae, genital, and perineal skin.

Histopathologically, eccrine tumors comprise a large spectrum of lesions with differentiation to various portions of normal eccrine apparatus, including intraepidermal (acrosyringium), dermal, and secretory ducts.[41] There are no uniform criteria for diagnosis. The most important feature is the tendency to form lumina with a flattened epithelium. Distinction from apocrine tumors is not always straightforward, as the ducts of each gland type are similar and "decapitation" can be observed in certain tumors traditionally classified as "eccrine."

Cyst: Hidrocystoma

CLINICAL FINDINGS Eccrine hidrocystomas can be either solitary (Smith type) or multiple (Robinson type).[42] Clinically, they have a generic appearance as domed, skin colored, or translucent papules most commonly on periorbital skin. Multiple eccrine hidrocystomas have been associated with warm climates, hyperhidrosis, and Graves disease.[43]

HISTOPATHOLOGY The cyst lining is a double layer of cuboidal epithelium lacking decapitation secretion. Eosinophilic contents may be seen.

TREATMENT Treatment is similar to apocrine hidrocystoma. Use of topical atropine,[44] botulinum toxin,[45] and pulsed dye laser[46] has also been reported.

Hamartoma: Eccrine Hamartoma

EPIDEMIOLOGY Eccrine hamartoma occurs in children.

ETIOLOGY AND PATHOGENESIS The term *eccrine hamartoma* is employed for a number of conditions characterized by an increase in size and/or number of normal intradermal eccrine ducts and coils, including eccrine nevus, eccrine angiomatous hamartoma, and porokeratotic eccrine ostial and dermal duct nevus.[12,41] It may be congenital.

CLINICAL FINDINGS Eccrine nevus usually presents as a solitary, well-circumscribed area of hyperhidrosis on the extremities of children. A few cases occurring as linear papules and multiple plaques have been reported. Eccrine angiomatous hamartoma commonly shows a solitary, flesh-colored, hyperhidrotic, painful papule or plaque appearing at birth or during childhood.[47,48] A few cases arising as multiple, symmetrically located lesions have been reported. Porokeratotic eccrine ostial and dermal duct nevus typically presents as congenital keratotic papules and plaques located on the distal extremities. Lesions may show a linear arrangement.

HISTOPATHOLOGY There is an increase in size and/or number of normal eccrine ducts and coils in the dermis.

TREATMENT Most patients require no specific treatment. Surgical excision is indicated for painful eccrine angiomatous hamartomas. Successful treatment of eccrine nevus with botulinum toxin has been reported.[49] Carbon dioxide laser therapy has been employed in some cases of porokeratotic eccrine ostial and dermal duct nevus.[47]

Hyperplasias: Syringolymphoid Hyperplasia

EPIDEMIOLOGY Males are preferentially affected.

ETIOLOGY AND PATHOGENESIS Syringolymphoid hyperplasia is a chronic skin condi-

tion that may present either as an isolated lesion or in association with cutaneous T-cell lymphoma.[50]

CLINICAL FINDINGS Patients usually show patches of hairless, anhidrotic, reddish-brown papules with pseudofollicular hyperkeratosis.

HISTOPATHOLOGY Hyperplastic eccrine structures are surrounded by a dense lymphocytic infiltrate with "syringotropism." Lesions associated with mycosis fungoides occasionally reveal a perifollicular lymphocytic infiltrate and follicular mucinosis (see Chap. 146).

PROGNOSIS AND CLINICAL COURSE Careful follow-up with biopsy of persistent lesions is recommended in apparently idiopathic cases to exclude lymphoma.

Benign Neoplasms

CYLINDROMA ***Epidemiology.*** Women are more commonly affected than men.

Etiology. Multiple cylindromas are often familial and inherited as an autosomal dominant trait, mainly in the setting of Brooke-Spiegler syndrome (familial autosomal dominant cylindromatosis).

Clinical Findings. Two main clinical forms of cylindroma are recognized; namely, a common, solitary type and a less-frequent form showing multiple lesions. Solitary cylindromas occur as slowly growing, asymptomatic, or painful, skin-colored, reddish, or bluish papules, nodules, or tumors on the head and neck region of adults.[4–6,12,41]

Multiple cylindromas occur as numerous papules, nodules, or variously sized tumors distributed mostly on the scalp and sometimes on the face or trunk. They show a tendency to confluence and may cover the entire scalp (so-called *turban tumors*; Fig. 119-5A) or display a linear arrangement. Rarely, patients reveal widespread nodules, a clinical picture that mimics neurofibromatosis. Patients with Brooke-Spiegler syndrome show multiple cylindromas and trichoepitheliomas, occasionally in association with multiple basal cell adenomas of the parotid glands, milia, organoid nevi, basal cell carcinomas, and spiradenomas (see Spiradenoma). The susceptibility gene has been mapped to chromosome 16q12-q13 and has features of a recessive oncogene/tumor-suppressor gene.[51]

Histopathology. There is usually a well-circumscribed dermal and/or subcutaneous lesion composed of irregularly shaped tumor islands and cords of basaloid cells arranged in a jigsaw puzzle–like pattern (see Fig. 119-5B). Islands of basaloid cells are surrounded by a prominent rim of uniformly thickened periodic acid-Schiff (PAS)–positive basement membranes. They consist of two types of basaloid cells, namely, a central population with large nuclei and abundant cytoplasm and a peripheral population with smaller nuclei, arranged in a palisade at the periphery.



▲ **FIGURE 119-5** **A.** Cylindroma or turban tumor. **B.** Cylindroma with irregularly shaped aggregations of basaloid cells arranged in a "jigsaw puzzle" pattern.

Treatment. Cylindromas may recur if incompletely excised. Local aggressive behavior and malignant transformation has occasionally been observed, especially in long-standing turban tumors of the scalp.[52]

HIDRADENOMA ***Epidemiology.*** Hidradenoma (eccrine acrospiroma) presents mainly in adults, primarily in women.

Clinical Findings. Hidradenoma presents as a slowly growing, firm, solitary, smooth-surfaced, usually bluish-red, movable dermal and/or subcutaneous papule or nodule.[4–6,12,41] Lesions are located mostly on the scalp, face, trunk, and abdomen, and, occasionally, on the extremities (Fig. 119-6A). Unusual presentations include childhood neoplasms, large or rapidly growing lesions,[53] painful and/or ulcerated lesions, as well as pedunculated tumors.

Histopathology. A nodular, solid, or solid-cystic lesion in the dermis, sometimes with extension to the subcutis (see Fig. 119-6B). The epithelial component consists of closely packed aggregations of round, fusiform, or polygonal cells with either eosinophilic or clear cytoplasm. Individual lesions show a variable cellular composition. Clear cells predominate in about one-third of cases. Mitotic figures are sometimes noted within the epithelial component, a feature that does not generally indicate malignancy. The cystic spaces are often filled with mucin.

Prognosis and Clinical Course. Hidradenoma shows a high rate of local recurrence and may rarely undergo malignant transformation.[54]

Treatment. Treatment is complete surgical excision.

POROMA ***Etiology.*** The term *poroma* refers to a group of rare cutaneous appendage tumors composed of cells (cuticular and poroid cells) similar to those of the acrosyringium. Poromas are traditionally subcategorized histopathologically based on their location in relation to the epidermis into three main variants; namely, hidroacanthoma simplex, eccrine poroma, and dermal duct tumor.[4–6,41] Some authors add poroid hidradenoma to this group.[41] There are also reports of "poromas" with differentiation toward the follicolosebaceous–apocrine unit.

Clinical Findings. Clinically, hidroacanthoma simplex presents mostly in middle-aged and elderly individuals, preferentially in women as a solitary, hyperkeratotic plaque, with predilection for the extremities. Eccrine poroma occurs commonly as a solitary, slowly growing, skin-colored, or pigmented sometimes bright red, itchy, or painful pedunculated, sessile papule or nodule, situated mostly on the soles and palms of adults (see eFig. 119-6.1 in on-line edition).







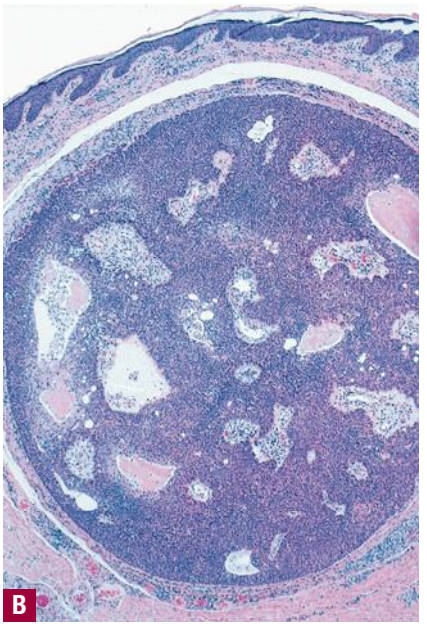

▲ **FIGURE 119-6** Hidradenoma. **A.** Dome-shaped nodule on the leg. **B.** Well-circumscribed, dermal nodule composed of two cell types.

Histopathology. Hidroacanthoma simplex shows sharply demarcated aggregations of cuboid to ovoid cells confined to the epidermis. Eccrine poroma reveals aggregations of uniform basaloid cells that radiate from the basal layer of the epidermis into the dermis (Fig. 119-7). Dermal duct tumor consists of several sharply circumscribed, mainly dermal nodules composed of poroid and cuticular cells. Ductal structures are frequently observed. Poroid hidradenoma is characterized by intradermal, solid, and cystic aggregations of poroid cells.

Prognosis and Clinical Course. Eccrine poroma is rarely observed to precede the development of porocarcinoma.

Treatment. Treatment of choice is total surgical excision.

SPIRADENOMA ***Epidemiology.*** Spiradenoma occurs in young and middle-aged adults.

Clinical Findings. Spiradenoma usually presents as a solitary, slowly growing, sometimes painful, reddish-brown, intradermal, or deeply subcutaneous nodule[4–6,12,41,55] (Fig. 119-8A). Eccrine spiradenomas may be seen in Brooke-Spiegler syndrome (an autosomal dominant condition) in association with multiple cylindromas and trichoepitheliomas.

Histopathology. There are one or several well-circumscribed, basophilic nodules in the dermis, sometimes with extension to the subcutis. Nodules show epithelial cell aggregates arranged in sheets and cords or in a trabecular pattern (see Fig. 119-8B). They consist of two types of cells; namely, small, dark-staining basaloid cells located at the periphery, and larger cells with a pale nucleus situated mostly in the center. Tubular or cystic structures are occasionally noted within the epithelial aggregations. Some areas of the tumor contain a PAS-positive hyaline material.

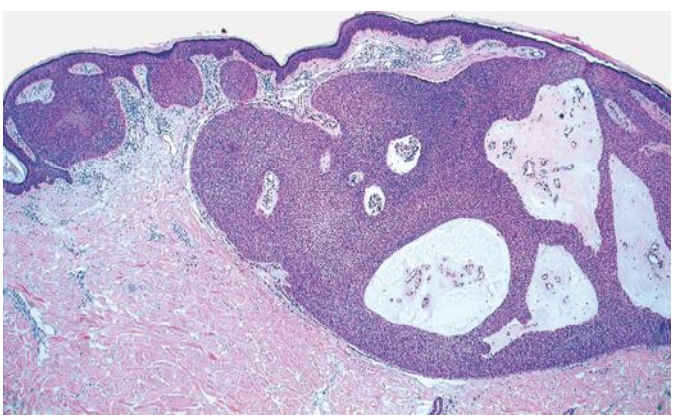

▲ **FIGURE 119-7** Eccrine poroma. Nodular aggregations of basaloid cells extend from the epidermis into the superficial dermis.

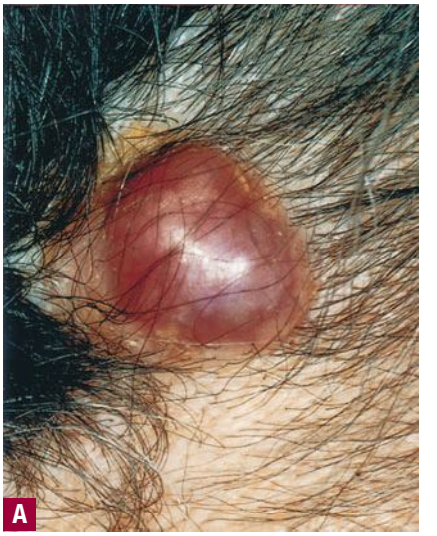

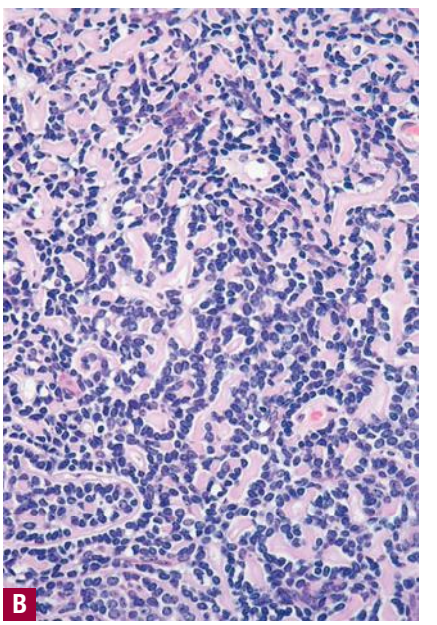

▲ **FIGURE 119-8** Spiradenoma. **A.** Reddish-brown tumor on the scalp. **B.** Tumor cells arranged in a trabecular pattern. Note hyaline material in the background.

Prognosis and Clinical Course. Malignant transformation is infrequent and presents with ulceration.[52]

Treatment. Complete surgical excision is the treatment of choice.

SYRINGOMA ***Epidemiology.*** Common. Adult women are most commonly affected, but these can occur in all adults.



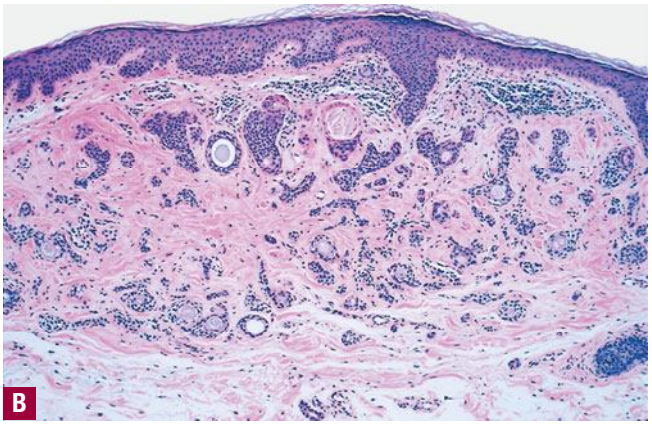

▲ **FIGURE 119-9** Syringoma. **A.** Multiple, small papules on the periorbital skin of a young woman. **B.** Solid, tubular, and cystic structures in the upper dermis. Note "tadpole"-like morphology of tumor lobules.

Etiology. Syringoma is a benign neoplasm with differentiation toward eccrine acrosyringium.

Clinical Findings. Syringomas present as numerous, small, firm, smooth, skin-colored, or slightly yellowish papules situated on the face, particularly around the lower eyelids of adults, but can develop in other anatomic sites[4–6,12,41] (Fig. 119-9A). Women are more commonly affected. Scalp lesions often present as non-scarring alopecia. Syringomas occasionally show a unilateral, linear, or bathing trunk–type distribution. Familial cases have been recorded. There appears to be an increased frequency of syringomas in patients with Down syndrome. Eruptive syringomas represent a distinctive, occasionally familial form presenting mainly in pubescent or adolescent girls as successive crops of numerous, disseminated, sometimes confluent papules. These lesions tend to involve the upper half of the body, particularly the anterior aspect of the neck, chest, trunk, axillae, inner aspects of the upper arms, and umbilical area.

Histopathology. Numerous epithelial aggregations of small, tadpole-shaped solid nests, cords, and tubular structures in the upper half of the dermis (see Fig. 119-9B). The epithelial areas are commonly surrounded by thickened, closely packed, collagen bundles.

Treatment. Some patients seek removal of the lesions because of cosmetic concerns. Surgical excision generally produces less than satisfactory cosmetic results. Alternative therapeutic approaches may include dermabrasion, electrodesiccation with curettage, and laser resurfacing.[56]

TUBULAR ADENOMA ***Epidemiology.*** Tubular adenomas are found in middle-aged adults as solitary, slowly growing, well-circumscribed nodules, situated mostly on the extremities. Black women appear to be preferentially affected.

Etiology. The term *tubular adenoma* defines a group of benign appendage tumors histopathologically characterized mainly by numerous cystic, dilated, and branching tubular structures in the dermis surrounded by a compressed fibrous stroma.[12,41,57] Lesions show either eccrine (tubular eccrine adenoma) or apocrine (tubular apocrine adenoma) differentiation.

Clinical Findings. Unusual presentations include their occurrence during childhood, large tumors, and lesions with verrucous or eroded surfaces. Some cases arise in association with a preexisting nevus sebaceus or syringocystadenoma papilliferum.

Histopathology. This lesion demonstrates a relatively well-circumscribed dermal nodule consisting of numerous cystic, dilated, and branching tubules, surrounded by compressed or focally hyalinized fibrous tissue.

Prognosis and Clinical Course. Tubular adenomas sometimes recur after surgical excision, but malignant transformation has not been observed.

Treatment. Treatment is by simple surgical excision.

Malignant Neoplasms

AGGRESSIVE DIGITAL PAPILLARY ADENOMA AND ADENOCARCINOMA ***Epidemiology.*** Aggressive digital papillary adenoma and adenocarcinoma are rare neoplasms presenting mainly in middle-aged adults, primarily in white males.

Clinical Findings. These tumors are characterized mainly by an acral localization and a tendency to recur.[1,4,12,58] *Aggressive digital papillary adenoma* has been the term used to represent the less-aggressive end of the spectrum, whereas *aggressive digital papillary adenocarcinoma* has been reserved for more aggressive tumors with metastatic potential. The neoplasms present as single, flat, or slightly elevated, often ulcerated, crusted, or bleeding nodules measuring up to 2 cm in diameter. The volar surface of the fingers and toes and the adjacent parts of the palms and soles are predominantly involved. Adherence to underlying deeper tissues is often apparent.

Histopathology. There is usually a dermal and/or subcutaneous lobular proliferation of ductal and glandular structures with focal solid and cribriform zones.[58] Epithelial components are separated by a fibrocollagenous stroma. Ductal structures show variable dilatations forming cystic spaces in which several intraluminal papillary projections are present. Solid and ductal structures are composed mainly of polygonal cells. Squamous metaplasia and spindle cells as well as apocrine or sebaceous differentiation can be found. An inflammatory infiltrate consisting predominantly of lymphocytes and plasma cells is sometimes noted.

Prognosis and Clinical Course. Approximately 50 percent of aggressive digital papillary adenomas recur locally. Metastases, when they occur, involve mainly the lungs, but have occasionally been observed in other tissues such as lymph nodes, brain, skin, bone, and kidney.

Treatment. Standard treatment is surgical excision.



CYLINDROCARCINOMA ***Epidemiology.*** Cylindrocarcinoma is a very rare appendage tumor that presents in middle-aged and elderly individuals (mean age, 66 years). Women are more commonly affected than men.

Clinical Findings. Cylindrocarcinoma is a rapidly growing ulcerated or bleeding nodule on the scalp.[36,41,60]

Histopathology. The vast majority of cylindrocarcinomas show a remnant of a benign cylindroma (see Cylindroma). The cylindrocarcinomatous areas consist of irregularly shaped, poorly circumscribed, focally confluent nests and cords of atypical basaloid cells.

Prognosis and Clinical Course. There is a tendency for local destructive growth and the potential for metastasis to lymph nodes in particular but also to liver, lung, and bone. This aggressive tumor develops most commonly in patients with multiple cylindromas.

Treatment. Treatment is surgical excision.

ECCRINE CARCINOMA ***Etiology.*** *Eccrine carcinoma* is a term used for a group of rare, malignant, eccrine neoplasms with a great diversity in histomorphologic features and wide differences in biologic behavior.[5,12,31,41] The common histopathologic denominator is the presence of variable areas of basaloid cells with tubular structures. These tumors have previously been described under different names, including basal cell tumor with eccrine differentiation (eccrine epithelioma), syringoid carcinoma, and eccrine syringomatous carcinoma.

Clinical Findings. Lesions show no distinctive clinical features. They present as slowly growing, solitary, nodules, plaques, and tumors on the scalp, extremities, or trunk of older adults.

Histopathology. There is a wide spectrum of histopathologic features. Some tumors show confinement to the dermis, whereas others reveal involvement of the subcutis and deeper soft tissues. Lesions may display relatively well-differentiated features with areas of clear-cut ductal differentiation. A subset of lesions exhibits anaplastic features, with only subtle signs of ductal differentiation. Relatively well-differentiated tumors are characterized by basaloid aggregations arranged in strands, solid nests, and dilated or branching tubular structures (Fig. 119-10). Foci with syringomatous features may be present. Perineural invasion is a common finding.

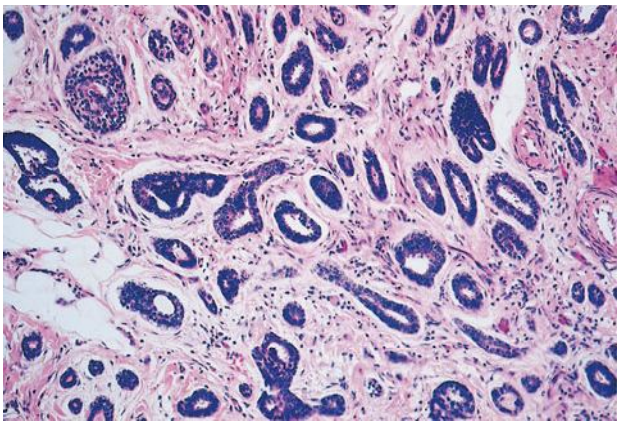

▲ **FIGURE 119-10** Eccrine carcinoma with nests and tubular structures. Note focal syringomatous features.

Prognosis and Clinical Course. Eccrine carcinoma can be invasive and destructive, with frequent recurrences. Local recurrences are common. Lymph node and distant metastases are observed in some patients.

Treatment. Treatment is by wide surgical excision. Sentinel node biopsy may be valuable in diagnosis of lymph node metastases.

HIDRADENOCARCINOMA ***Epidemiology.*** Hidradenocarcinoma (clear cell hidradenocarcinoma, malignant clear cell hidradenoma, solid-cystic hidradenocarcinoma, malignant acrospiroma, malignant clear cell myoepithelioma, clear cell eccrine carcinoma) occurs in middle-aged or elderly individuals.

Clinical Findings. This tumor presents as a solitary, ulcerated nodule on the head/neck, trunk, and extremities of middle-aged or elderly individuals[1,12,41,54] (Fig. 119-11).

Histopathology. A non-encapsulated, dermal/subcutaneous nodule consisting of irregularly shaped lobules of predominantly large, atypical, polygonal cells with eosinophilic cytoplasm and foci of clear cells (due to glycogen) are frequently observed. Cords and nests of tumor cells may infiltrate surrounding tissues. Mitotic figures are frequent. Ductal structures with either eccrine (usual) or apocrine differentiation are seen. Areas with basaloid or squamoid features are may be noted.

Prognosis and Clinical Course. Hidradenocarcinoma is a rare aggressive tumor. Local recurrence is common despite treatment. Distant metastases via lymphatic spread are not uncommon.

Treatment. Wide surgical excision is the treatment of choice.

MICROCYSTIC ADNEXAL CARCINOMA ***Etiology.*** MAC is also known as *syringomatous carcinoma* and *sclerosing sweat duct carcinoma*.

Epidemiology. MAC is a rare, locally aggressive tumor with a high potential for local recurrence.



◀ **FIGURE 119-11** Hidradenocarcinoma. Large ulcerated tumor.

Clinical Findings. MAC usually presents in elderly individuals as a solitary, slowly growing, firm, indurated plaque on the face, particularly around the upper lip or orbit.[1,4,5,12] For unclear reasons, the tumor tends to occur on the left side of the face. Lesions may occasionally be found on extra-facial locations, including the nipple, axilla, and lower extremities.

Prognosis and Clinical Course. Local recurrences are common (about 50 percent of cases) and may develop several years after initial diagnosis and therapy. Prolonged follow-up is therefore usually necessary.

Treatment. Treatment of choice is surgical. A more favorable cure rate (up to 89 percent) has been achieved with Mohs micrographic surgery. Regional and distant metastases are rare.[61]

POROCARCINOMA ***Epidemiology.*** Porocarcinoma is a rare, potentially aggressive neoplasm presenting in elderly individuals.

Etiology. It has been suggested that porocarcinoma is a malignant transformation of an eccrine poroma or hidroacanthoma simplex due to the frequent history of a long-standing nodule at the site where the cancer develops.

Clinical Findings. Porocarcinoma is the malignant counterpart of eccrine poroma (or malignant eccrine poroma). It presents as a partially ulcerated, verrucous plaque or polypoid tumor on the lower extremities.[4–6,12,41,62,63] Other common anatomic sites are the head and neck,[62] trunk, and, less frequently, the upper extremities, and genitalia.

Histopathology. Histopathologically, primary porocarcinoma can appear alone or as a component of benign eccrine poroma or a hidroacanthoma simplex component.

Prognosis and Clinical Course. A generally poor response to treatment is seen, with frequent local recurrences (up to 20 percent of cases), lymph node metastases, and, occasionally, distant metastases. Distant metastases can develop in the lung, breast, mediastinum, peritoneum, spine, and liver.

Treatment. Wide local surgical excision or Mohs micrographic surgery is the treatment of choice. Metastatic porocarcinoma is very resistant to adjunctive chemotherapy or radiation, and such patients have a high mortality rate.[62] Despite previous disease patterns, mounting evidence indicates that porocarcinoma may not be as aggressive as previously thought.[63]

SPIRADENOCARCINOMA ***Epidemiology.*** Spiradenocarcinoma presents mainly in middle-aged and elderly individuals and is very rare.

Etiology. Spiradenocarcinoma is a malignant, sometimes aggressive, appendage tumor that usually arises from a benign spiradenoma.[12,41,64]

Clinical Findings. Typically, patients report a single, large nodule on the extremities, trunk, or abdomen with slow growth for many years and recent rapid size increase, color change, pain, or possible ulceration.

Histopathology. The tumor usually shows a carcinomatous area, representing spiradenocarcinoma, in association with a typical, benign spiradenoma.

Prognosis and Clinical Course. Local recurrences and/or lymph node involvement are frequent, and fatal metastases have been reported in about 20 percent of cases.[36]

Treatment. Wide surgical excision is the preferred treatment.

APPENDAGE TUMORS WITH FOLLICULAR DIFFERENTIATION

The follicular cysts, hamartomas, and neoplasms reviewed in this section show predominantly histopathologic features that resemble different portions of a normal hair follicle, hair shaft, and/or perifollicular fibrous sheath. They exhibit a wide range of morphologic features and may display variable degrees of differentiation. Consequently, uniform diagnostic criteria do not exist for a number of entities.[3–6,12]

Cysts

EPIDERMAL CYST (See Chap. 118) Multiple epidermal cysts may be a feature of Gardner syndrome.[4,5,66] Gardner syndrome, caused by mutations in the *adenomatous polyposis coli* (*APC*) gene, is a rare, inherited, autosomal dominant trait characterized by multiple epidermal cysts and pilomatricomas, soft-tissue proliferations (fibromatosis, lipomas, leiomyomas), multiple craniofacial osteomas, bilateral pigmented ocular fundus lesions (congenital hypertrophy of the retinal epithelium), and intestinal (colorectal) polyposis. If intestinal polyposis is undetected or untreated, virtually all patients develop colonic carcinoma at a young age. The cutaneous cysts frequently predate the intestinal polyps.

HYBRID CYST Hybrid cysts occur in all age groups. Follicular hybrid cyst has been reported to occur within a nevus sebaceous.[67] They present usually as solitary, cystic nodules situated on the head and neck.[4,68]

Histologically, there is a cystic lesion displaying a mixed type of epithelial lining with a stratified squamous epithelium in its upper portion and outer sheath differentiation with trichilemmal cornification in its lower portion.



KERATOCYST Cutaneous keratocysts present typically in patients with basal cell nevus syndrome[66,69] (see Chap. 116).

They have been observed on the trunk and extremities independent of basal cell nevus syndrome[70] and show similar histopathologic features to the jaw keratocysts of patients with this syndrome.

There is a cystic structure with a corrugated or festooned configuration. The epithelial lining reveals several layers of squamous epithelium without a granular zone. A lanugo hair is observed within the cyst cavity of some lesions.

PIGMENTED FOLLICULAR CYST Pigmented follicular cyst shows differentiation toward the infundibular portion of the hair follicle. This cyst usually presents as a solitary, relatively small (0.4- to 1.5-cm), pigmented papule or nodule situated on the head and neck region of adult males.[4,66,71] Vulvar lesions have also been reported. Histopathologically, there is a cystic structure filled with numerous, heavily pigmented hair shafts. The cyst is lined by a stratified squamous epithelium.

TRICHILEMMAL CYST (See Chap. 118)

VELLUS HAIR CYST Lesions are either sporadic or inherited in an autosomal dominant fashion. The cysts show differentiation toward the infundibular portion of the hair follicle and typically contain numerous vellus hairs. Multiple, small (1- to 3-mm), asymptomatic, pigmented, reddish, or grayish papules are distributed on the chest, abdomen, and

axilla (eruptive vellus hair cysts) and, occasionally, on the face, neck, and extremities.[5,6,66] Familial cases present most commonly at birth or in early infancy. Sporadic lesions tend to develop in the first or second decades of life. Eruptive vellus hair cysts may be associated with steatocystoma multiplex, trichostasis spinulosa, anhidrotic ectodermal dysplasia,[72] and pachyonychia congenita, as well as some neurologic disorders. Histopathologic examination reveals a cystic structure located in the middle or upper dermis. It is lined by a stratified squamous epithelium with focal features of outer root sheath differentiation at the level of the follicular isthmus and trichilemmal cornification. Several vellus hair shafts and keratin material are present within the cystic lumen. Eruptive vellus hair cysts are difficult to treat surgically. Patients may benefit from therapy with isotretinoin, pulsed carbon dioxide, and erbium: YAG-laser ablation.[73] Spontaneous regression has occasionally been observed.



Hamartomas

BASALOID FOLLICULAR HAMARTOMA Basaloid follicular hamartoma occurs either as a solitary, sporadic tumor or as multiple, hereditary lesions.[74,75] Familial, multiple, basaloid follicular hamartomas manifest as numerous, small (1 to 2 mm in diameter), flesh-colored papules located predominantly over the central face, and occasionally elsewhere on the head and neck. Lesions have been reported in association with myasthenia gravis, alopecia, hypohidrosis, facial sclerosis, systemic lupus erythematosus, or cystic fibrosis.[74,75] Solitary forms of basaloid follicular hamartoma are commonly found on the face and scalp. Localized linear and unilateral variants have also been documented. Histopathologically, there are anastomosing strands of basaloid cells with numerous epidermal connections. Central areas of epithelial aggregations occasionally reveal cells with a squamoid appearance. Features of follicular differentiation, including horn cysts, rudimentary germs, and follicular papillae, are variably present.

HAIR FOLLICLE NEVUS Hair follicle nevi have been reported in all age groups.[3,12,76] There is currently disagreement as to whether "hair follicle nevus" ("congenital vellus hamartoma") represents a distinct entity or a variant of trichofolliculoma.[3] Hair follicle nevi occur as slightly dome-shaped, skin-colored papules and nodules on hair-bearing skin, particularly on the face.[76] Cases with a linear arrangement have been documented. A number of specific conditions have been included as variants of hair follicle nevus by different authors; namely, the so-called *faun-tail* (a cutaneous lesion characterized by the presence of a patch of hairs arising over the lower sacral area), hair follicles arising on the palms and soles, and Becker's pigmented hairy nevus.[12,77]

Histologically, the upper dermis reveals a well-circumscribed area with numerous closely packed mature vellus follicles. Hair follicles are surrounded by prominent sheaths of perifollicular connective tissue. Clefts are usually observed bordering the perifollicular connective tissue. Some lesions display sebaceous lobules. Treatment of choice is surgical excision.

LINEAR UNILATERAL BASAL CELL NEVUS Linear unilateral basal cell nevus presents at birth or in infancy as numerous, cutaneous papules or nodules distributed unilaterally, sometimes in a zosteriform fashion. Lesions often show comedone plugs and closely resemble nevus comedonicus. One patient with diffuse osteoma cutis, unilateral anodontia, and abnormal bone mineralization has been reported.[78] Histopathologic features simulate those of basal cell carcinoma. Lesions are characterized by a lattice-like pattern of basaloid cells attached to the undersurface of the epidermis. Hints of follicular differentiation are usually present.

NEVUS COMEDONICUS (See Chap. 118)

NEVUS SEBACEUS (See Chap. 118)

Benign Neoplasms

DESMOPLASTIC TRICHOEPITHELIOMA ***Epidemiology.*** Desmoplastic trichoepithelioma (sclerosing epithelial hamartoma) is a relatively uncommon tumor. The tumor shows a predilection for young and middle-aged adults, more commonly in women.

Clinical Findings. Desmoplastic trichoepithelioma presents as a small (up to 1 cm in diameter), asymptomatic, firm, oval, oblong, or annular papule or plaque on the face (Fig. 119-12), particularly around the angle of the lip.[3–6,12] Plaques often reveal a raised border and depressed center. Familial cases have been reported.

Histopathology. Histopathologic examination reveals a relatively well-circumscribed lesion in the upper two-thirds of the dermis with a focal epidermal connection. It is composed of basaloid aggregations arranged predominantly in columns and cords and admixed with infundibulocystic structures, surrounded by a dense, hypocellular desmoplastic stroma. It may occasionally be difficult to distinguish this entity histologically from malignant desmoplastic lesions such as aggressive growth basal cell carcinoma or MAC.



▲ **FIGURE 119-12** Desmoplastic trichoepithelioma located on the infraorbital region.

Treatment. Local surgical excision is the preferred treatment.

DILATED PORE OF WINER Although classified as a neoplasm in this section, there is currently some debate as to whether dilated pore represents a type of follicular (infundibular) cyst or a neoplastic process.[3,5,6,79]

The lesion presents usually as a solitary, comedo-like, keratin-filled structure on the head and neck of elderly individuals.[79] In some cases, lesions arise in the setting of cystic acne or actinic damage. Histologically, a single or several contiguous, markedly dilated infundibula are observed in the upper dermis, sometimes with extension to the lower dermis. The epithelial lining reveals focal acanthosis and finger-like projections radiating into the surrounding dermis. Dilated infundibula contain cornified cells arranged in basket-weave and laminated patterns. Heavy pigmentation of the epithelium can be observed in some cases.

If desired, local surgical excision can be performed to remove the lesion.

FIBROFOLLICULOMA Fibrofolliculoma is a rare tumor that presents in middle age. Fibrofolliculoma presents with multiple, small papules measuring 2 to 4 mm in diameter, situated on the head and neck, upper trunk, and arms.[3,5,6] Multiple, fa-

milial fibrofolliculomas occurring in association with trichodiscomas, perifollicular fibromas, and skin tags are a feature of Birt-Hogg-Dubé syndrome.[80] Patients with this autosomal dominant syndrome show a tendency to develop colonic polyposis, spontaneous pneumothorax, and a range of internal neoplasms (e.g., renal carcinoma).

Fibrofolliculoma is histologically characterized by a dome-shaped lesion with a central, relatively well-formed hair follicle displaying a single or several contiguous, dilated, keratin-filled infundibula. The infundibula are connected to several thin, focally anastomosing epithelial strands that extend in a radial fashion into the connective tissue. The lesion is often surrounded by a well-circumscribed fibrillary collagenous or mucinous stroma with scant or no elastic tissue. Surgical excision may be useful in the treatment of solitary lesions. Carbon dioxide laser or other destructive modalities may be practical in removal of multiple lesions. Patients should be screened for other features of Birt-Hogg-Dubé syndrome.

FIBROUS PAPULE Currently, there is some disagreement as to whether fibrous papule represents a neoplastic process or a hamartoma.[3] Fibrous papule (perifollicular fibroma) presents mainly as a solitary papule or as several dome-shaped, skin-colored, pigmented, or reddish lesions situated on the face, particularly around the nose of adults.[3,5,6,12] Multiple fibrous papules can be seen in patients with tuberous sclerosis. Multiple fibrous papules occurring in association with fibrofolliculomas and trichodiscomas are a feature of Birt-Hogg-Dubé syndrome.[80] Histologically, a dome-shaped or polypoid lesion consists of one or more poorly formed hair follicles surrounded by cellular fibrous stroma in the upper dermis. The epidermis sometimes reveals an increased number of large, single melanocytes located along the dermal–epidermal junction. There is usually a proliferation of small vessels within the dermis. Spindle- and stellate-shaped, sometimes multinucleated fibroblasts can be found within the stroma. Several histologic variants have been described, including classic, hypercellular, clear cell, pigmented, pleomorphic, and inflammatory.[81] Treatment of choice is surgical excision. Carbon dioxide laser is useful in removing multiple lesions.

INVERTED FOLLICULAR KERATOSIS Inverted follicular keratosis occurs most often in middle-aged and older men. Because of the wart-like morphology, it has been suggested that inverted follicular keratosis may represent a manifestation of human papillomavirus infection rather than a true follicular neoplasm.[3] Inverted follicular keratosis presents as an asymptomatic, small (3 to 10 mm in diameter), solitary papule or nodule, most often on the face.[4–6,12] Most lesions are located around the cheek and upper lip, but may occur on the eyelid. Histopathologic examination reveals an endophytic or exophytic–endophytic lesion consisting of several large epithelial lobules extending into the dermis. Four distinctive histopathologic patterns are recognized; namely, papillomatous, keratoacanthoma-like, solid, and cystic. The center of the epithelial lobules is composed of squamous cells focally arranged in a whorled pattern (squamous eddies). The periphery is sometimes occupied by basaloid cells. Additional features in some lesions include foci of trichilemmal differentiation, mucinous areas with spongiosis, and melanin pigmentation. A mild lymphohistiocytic inflammatory infiltrate often surrounds the lesion. Treatment is by surgical excision.

PANFOLLICULOMA Panfolliculoma is a recently described benign neoplasm that shows differentiation toward portions of both the upper and lower segments of a normal hair follicle.[3] The tumor reveals several morphologic similarities to trichoblastoma. Clinically, cystic, skin-colored or reddish, dome-shaped papules, situated on the head, trunk, and lower limbs of adults, can be found. Histologically, the tumor is characterized by several closely packed, solid, solid-cystic, or cystic aggregations of epithelial cells in the dermis, sometimes extending into the subcutis. They are surrounded by a fibrous stroma with focal clefts between the stroma and adjacent "normal" dermis or subcutaneous fat. Neoplastic cells reveal a spectrum of morphologic features reflecting bulbar, stem, isthmic, and infundibular differentiation. These include the presence of germinative and matrical cells (bulb), cells with trichohyalin granules and blue-gray corneocytes (inner root sheath), and cells with abundant pale and clear cytoplasm (outer root sheath). Cystic structures are lined by infundibular epithelium with a granular zone and filled with blue-gray corneocytes arranged in basket-weave, laminated, and compact patterns. Treatment is surgical excision.

PILAR SHEATH ACANTHOMA Middle-aged and elderly individuals are commonly affected. Pilar sheath acanthoma is characterized by a small (5 to 10 mm in diameter), solitary, skin-colored papule situated on the head and neck, particularly around the upper lip.[3–6,82] A central, occasionally keratin plugged pore is often present. Histologically, there is a crateriform depression in the epidermis representing a widely dilated, keratin-filled infundibulum or closely set infundibula contiguous at the base with numerous epithelial lobules of pink keratinocytes. The epithelial lobules radiate into the dermis, sometimes with involvement of the subcutis. They are surrounded by a narrow rim of fibrous tissue. The epithelium shows similar features to those of the isthmus of a normal hair follicle. Small infundibulocystic structures, tubular structures, and foci of sebaceous differentiation (ducts or sebaceous lobules) are variably observed in individual cases. Treatment is surgical excision.



PILOMATRICOMA ***Epidemiology.*** Pilomatricoma most commonly occurs in children and young persons.[3–6,12] Some tumors arise in older adults. Mutation of the β-catenin gene, a mediator in the Wnt signal transduction pathway, is common in pilomatricomas.

Etiology. Pilomatricoma (calcifying epithelioma of Malherbe) is a relatively common appendage tumor that predominantly shows differentiation toward the matrical portion of a normal hair follicle at the level of the bulb.

Clinical Findings. Lesions present as solitary, skin-colored, or pigmented cystic or firm nodules on the head and neck (Fig. 119-13A) and upper extremities. Unusual clinical features include rapidly growing tumors, lesions associated with overlying striae or anetodermic changes, and tumor arising in a nevus sebaceus. Several variants, including multiple pilomatricomas, bullous or giant tumors, and lymphangiectatic variants, have been reported.[83,84] Multiple pilomatricomas have also been reported in patients with Gardner syndrome.[4,66]

Histopathology. Pilomatricoma shows a spectrum of morphologic features that mainly reflect different evolutionary stages.[85] Early and well-developed pilomatricomas reveal variably sized, round to oval cystic lesions lined by a basaloid epithelium at the periphery and filled in the center with masses of eosinophilic, faulty hair matrix material containing "shadow" ("ghost") cells (see Fig. 119-13B).

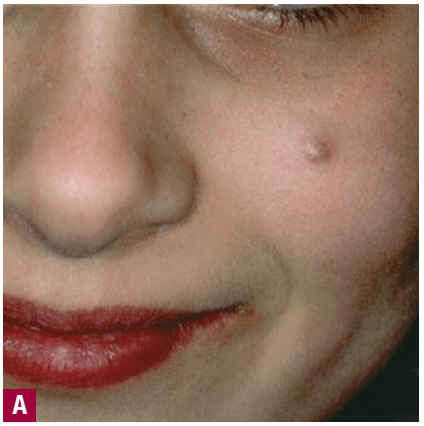

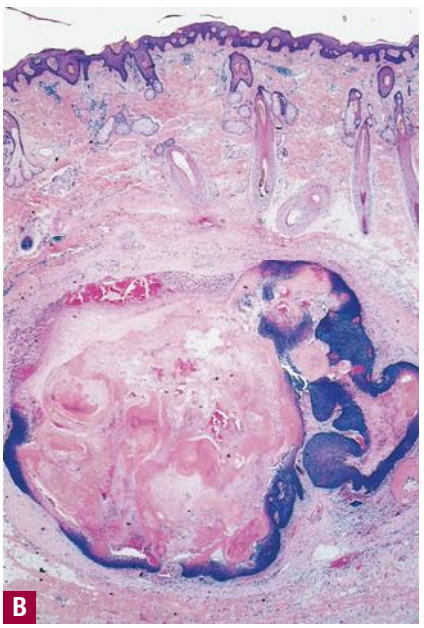

▲ **FIGURE 119-13** Pilomatricoma. **A.** A tumor in a young girl. **B.** Cystic lesion lined focally at the periphery by basaloid epithelium and filled with masses of eosinophilic, cornified material with shadow cells.

Basaloid (matrical) cells show monomorphous round nuclei with one or more distinctive nucleoli and variable numbers of mitotic figures. Foci of squamoid epithelium are sometimes noted within the epithelial lining. Regressing pilomatricomas display haphazardly arranged foci of basaloid cells and shadow cells as well as an inflammatory infiltrate with multinucleated histiocytic giant cells. Granulation tissue is sometimes noted. Old pilomatricomas reveal no basaloid component but show irregularly shaped, partially confluent masses of shadow cells with foci of calcification or ossification. Melanin deposition, trans-epidermal elimination, and extramedullary hematopoiesis have been described in some pilomatricomas. A peculiar variant with relatively large areas of basaloid cells and small foci of shadow cells ("proliferating pilomatricoma") is occasionally observed in older adults.

Treatment. Surgical excision is the most common treatment. Some lesions show spontaneous regression. Local recurrences may occasionally develop after surgical excision. Malignant transformation has been rarely described.[86]

PROLIFERATING PILAR TUMOR (See Chap. 118) ***Epidemiology.*** Women are approximately two times more commonly affected than men.

Etiology. Rarely, the neoplasm has been reported in association with nevus sebaceus or basaloid follicular hamartoma.

The exact nature of proliferating pilar tumor is still debatable. Traditionally, the tumor has been regarded as a benign follicular neoplasm. There are, however, several well-documented reports demonstrating that proliferating pilar tumor is capable of undergoing frank carcinomatous transformation, even with development of distant metastases. This has prompted some authors to advance the view that proliferating pilar tumor represents a low-grade type of squamous cell carcinoma ("proliferating trichilemmal cystic squamous carcinoma").[3]

Clinical Findings. Clinically, lesions present as solitary, slowly growing, cystic, or lobulated nodules and tumors on the scalp and trunk, as well as on the extremities of older adults.[3,5,12] A few patients show multiple, sometimes familial, lesions. Occasional tumors may be ulcerated or occur as relatively large extracranial masses (up to 25 cm in diameter; Fig. 119-14).



▲ **FIGURE 119-14** Proliferating pilar tumor. Ulcerated giant nodule on the scalp.

Histopathology. Histopathologic examination usually reveals a sharply circumscribed, round or oval, cystic neoplasm occupying the lower dermis and subcutis. There is an epithelial component lining nearly the whole lesion and extending within it in a radial fashion. The epithelium forms several partially interconnecting solid and cystic lobules. A zone of fibrous stroma with clefts between the stroma and surrounding normal tissue encompasses the tumor. Tumor nests are composed mainly of squamous cells with some areas of clear cells containing glycogen. A characteristic feature is the presence, in the center of lobules, of trichilemmal cornification—that is, abrupt formation of compact eosinophilic keratin without granular layer interposition. Foci with keratohyaline granules, small horn pearls and squamous eddies, calcification, stromal calcium deposition, ossification, and shadow cells, as well as a palisading arrangement of the nuclei at the periphery of the lobules, are observed in individual tumors.

Prognosis and Clinical Course. Local recurrences and metastatic spread have been observed even in histopathologically typical cases.

Treatment. Treatment is by complete excision. Accurate follow-up is recommended in all patients.

TRICHOADENOMA Trichoadenoma (of Nikolowski) is a rare follicular tumor that some authors consider a neoplastic process, whereas other authors consider it a malformation.[3–6,12] These lesions occur most commonly in adults. Clinically, trichoadenoma presents as solitary, slowly growing, grayish nodules measuring up to 1.5 cm in diameter. They are mainly situated on the face and trunk. Histopathologically, a dome-shaped, sharply defined nodule composed of numerous, round to oval, infundibulocystic structures is observed in the dermis. Involvement of the subcutis may be noted in some cases. Infundibulocystic structures are lined by a squamous epithelium with a clear-cut basal layer, spinous zone, and granular layer. They contain corneocytes arranged in a laminated pattern. A conspicuous collagenous stroma often surrounds the tumor cell nests. A subset of cases shows prominent verrucous hyperplasia of the epidermis. Treatment is surgical excision.

TRICHOBLASTOMA Trichoblastomas are best subdivided according to the pre-

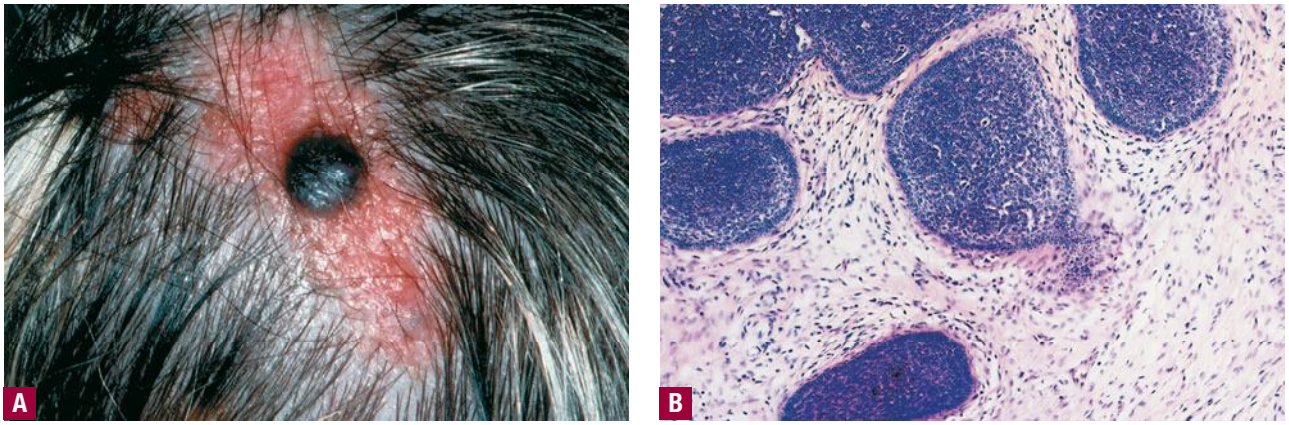

▲ **FIGURE 119-15** Trichoblastoma. **A.** Pigmented type arising in a nevus sebaceous. **B.** Nodular aggregations of basaloid cells surrounded by abundant fibrous stroma. Note prominent peripheral palisading of nuclei and a focus with a follicular germ and papilla.

dominant morphologic pattern into large nodular (including pigmented), small nodular (including adamantinoid or lymphadenoma), retiform (giant solitary trichoepithelioma), cribriform (classic trichoepithelioma), racemiform (nonclassic trichoepithelioma), and columnar (desmoplastic trichoepithelioma) variants.[3] Exact subclassification is difficult in some lesions because of the presence of more than one predominant morphologic pattern. Here we focus mainly on "conventional" trichoblastomas.

Clinical Findings. Clinically, trichoblastomas present as solitary, non-ulcerated, skin-colored to brown or bluish-black papules/nodules situated mostly on the head and neck, particularly on the scalp and face of adults. Trichoblastomas are also commonly observed in association within a pre-existing nevus sebaceus[17,88] (Fig. 119-15A) or may occasionally coexist with a basal cell carcinoma.[3] Cutaneous lymphadenoma (adamantinoid trichoblastoma) is a rare appendage tumor classified as a variant of trichoblastoma.[3] It presents mainly in adults in the fourth to fifth decades as a solitary, skin-colored nodule situated on the head and neck.[3,4,12,89]

Histopathology. Lesions are characterized by several dermal/subcutaneous, smooth-bordered aggregations of basaloid (germinative) cells arranged in different morphologic patterns, including cribriform, nodular, racemiform, and retiform. Epithelial aggregations are surrounded by a variable sclerotic or partly hyalinized stroma. They typically reveal peripheral palisading and several foci with rudimentary follicular papillae and germs (see Fig. 119-15B). The basaloid cells are relatively monomorphous and exhibit dark-staining nuclei with large prominent nucleoli and scanty, pale, or eosinophilic cytoplasm. A few mitotic figures and single necrotic cells are sometimes noted. Additional findings in some cases include heavy melanin pigmentation, horn cysts, and amyloid deposits.

Treatment. Treatment is by complete excision.[3]

TRICHODISCOMA Multiple trichodiscomas may be inherited in an autosomal dominant fashion in the setting of Birt-Hogg-Dubé syndrome.[80] Trichodiscoma is a rare tumor that presents as multiple, asymptomatic, small, skin-colored papules situated on the face, arms, trunk, and, sometimes, the legs.[3,5,6,12] Recently, the cutaneous lesions in Birt-Hogg-Dubé syndrome (fibrofolliculomas and trichodiscomas) have been interpreted as different developmental stages of one single tumor with sebaceous differentiation, called "mantleoma." Histopathologic examination reveals a well-circumscribed, non-encapsulated, dome-shaped nodule in the dermis consisting of a zone of loose, finely fibrillar connective tissue with bundles of collagen, fibrocytes, and venules. The lesion is encircled by collarettes of infundibular epithelium that are focally continuous, with epithelial cords radiating into the stroma. The epithelial cords sometimes contain sebaceous cells. A hair follicle or nerve fibers may be noted at the edge. Treatment of choice in solitary lesions is surgical excision. Carbon dioxide laser is useful in removal of multiple lesions. Patients should be screened for other features of Birt-Hogg-Dubé syndrome.

TRICHOEPITHELIOMA ***Etiology.*** Trichoepithelioma shows a spectrum of histopathologic features reflecting mainly differentiation toward hair and hair follicle, particularly follicular germs.[3–6,30] This neoplasm is therefore best regarded as a distinct variant of trichoblastoma (described in the section Trichoblastoma).

Clinical Findings. Three distinctive forms of trichoepitheliomas are recognized; namely, solitary, multiple, and desmoplastic.[3]

Solitary trichoepithelioma occurs mainly as a small (5 to 8 mm in diameter), skin-colored papule situated on the face, especially around the nose, upper lip, and cheeks of adults.[4–6,12] Occasional lesions develop on the trunk, neck, scalp, and lower extremities.

Multiple trichoepitheliomas present usually in adolescents as numerous, small papules distributed on the face, with predilection for the area around the nasolabial folds, forehead, chin, and preauricular area (Fig. 119-16A). A few patients reveal plaques, nodules, or tumors due to coalescing of several lesions. Multiple trichoepitheliomas are mostly transmitted as an autosomal dominant trait in patients with Brooke-Spiegler (epithelioma adenoides cysticum) syndrome. In this syndrome, patients show predisposition for developing multifocal cylindromas, spiradenomas, and milia.[90] Multiple trichoepitheliomas have also rarely been associated with a number of other systemic conditions, including Rombo syndrome (atrophoderma, milia, hypotrichosis, basal cell carcinomas, and peripheral vasodilatation),[91] systemic lupus erythematosus, and myasthenia gravis.

Histopathology. This is a dome-shaped, sharply circumscribed lesion composed of aggregations of relatively monomorphic basaloid (germinative) cells in the upper dermis surrounded by abundant fibrous stroma with intrastromal clefts (see



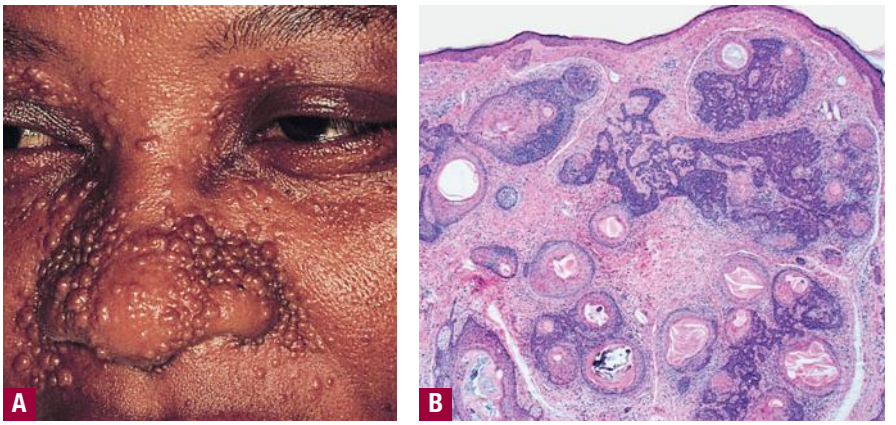

▲ **FIGURE 119-16** Trichoepithelioma. **A.** Multiple familial type. **B.** Well-circumscribed, multi-lobular dermal tumor consisting of solid and branching basaloid aggregations admixed with horn cysts surrounded by abundant fibrous stroma. Note a focal cribriform pattern.



Fig. 119-16B). The basaloid aggregations are mainly arranged in a cribriform pattern but may show other architectural patterns, including nodular, racemiform, and retiform. They typically reveal peripheral palisading and several foci with rudimentary follicular papillae and germs. In some lesions, other findings include infundibulocystic structures, shadow cells, sebaceous glands, amyloid, calcification, melanin pigmentation, and mucin deposition. A lymphohistiocytic infiltrate with small foreign-body granulomas is sometimes present.

Treatment. Surgery is usually effective in removing solitary lesions. However, surgical treatment of multiple trichoepitheliomas is generally disappointing. Alternative therapies have included cryotherapy, electrodesiccation, and carbon dioxide laser.

TRICHOFOLLICULOMA Trichofolliculoma is a rare tumor that presents mainly in adults. It presents as a small, solitary, dome-shaped papule or nodule situated on the face, particularly around the nose.[3–6,12] A central, dilated keratin plugged ostium with vellus hair(s) is often present (Fig. 119-17). Histologically, the lesion is basically centered on one or, less frequently, on several contiguous, variably dilated, primary follicles lined by infundibular and isthmus type epithelium and opening to the skin surface. Numerous, smaller, secondary (vellus) follicles bud from the wall of the central follicle in a radial fashion. The central follicle is commonly filled with cornified cells and sometimes contains vellus hairs. The secondary follicles often reveal differentiation toward germinative epithelium or formation of hair. They are surrounded by a prominent fibrous stroma. Surgical excision is the treatment of choice.

TRICHOLEMMOMA Tricholemmoma lesions usually present in adulthood. A tumor-suppressor gene (designated *PTEN/MMAC1*) has been demonstrated to play a causative role.[9] Recently, some authors have proposed tricholemmoma to represent an old viral wart.[3] Tricholemmoma (trichilemmoma) shows differentiation toward the outer root (trichilemmal) sheath of a normal hair follicle at the level of the bulb. Clinically, tricholemmomas are solitary, small (3 to 8 mm in diameter), asymptomatic, keratotic, or smooth-surfaced papules on the face, particularly around the nose and upper lip.[3–6,12] Some cases arise in association with nevus sebaceus.[88] Multiple facial tricholemmomas represent an important cutaneous marker for Cowden syndrome, which is discussed in Chap. 154. Patients with Cowden syndrome show a tendency to develop particular internal malignancies, especially involving the breast, colon, and thyroid.



▲ **FIGURE 119-17** Trichofolliculoma. Papule on the forehead with a hair emanating from its central pore.

Histologically, lesions show a lobular, folliculocentric, exo-endophytic proliferation of polygonal, pale-staining, glycogen-containing squamoid cells. The epidermal surface often reveals parakeratosis with scale crusts and sometimes a cutaneous horn (trichilemmal horn). The periphery of the lobules is bordered by columnar cells arranged in a palisade. Foci with small squamous eddies are occasionally observed within the center of tumor lobules. A conspicuous basement membrane usually surrounds the lesions. Desmoplastic tricholemmoma represents a special variant with prominently hyalinized or desmoplastic stroma.[92] Treatment is by surgical excision.

TUMOR OF THE FOLLICULAR INFUNDIBULUM Middle-aged and elderly individuals are most commonly affected by tumor of follicular infundibulum. Despite its name, tumor of the follicular infundibulum shows mainly differentiation toward the isthmus of a normal hair follicle rather than the infundibulum. Lesions present as solitary, small (5 to 10 mm in diameter), asymptomatic, smooth, or keratotic papules on the head and neck.[3,5,12] A small subset of cases occur as multiple lesions (infundibulomatosis, eruptive infundibulomas). Tumors developing in association with Cowden syndrome or with a pre-existing nevus sebaceus have been reported.

Histologically, there is a horizontally oriented, plate-like tumor in the upper dermis with an epithelial component showing multifocal connections to the epidermis or hair follicles. The epithelium typically reveals a fenestrated pattern with interconnecting cords and columns. Infundibulocystic structures are focally present. Cells display small, monomorphic nuclei and abundant pale to pink-staining cytoplasm. The tumors are sometimes surrounded by a collagenous stroma with a network of elastic fibers. Variable areas with single necrotic cells, clear cells, rudimentary papillae and germs, ductal structures, and features of sebaceous differentiation are observed in some cases. Surgical excision may be used to remove the lesions.

Malignant Neoplasms

BASAL CELL CARCINOMA WITH FOLLICULAR DIFFERENTIATION (See Chap. 115)

PILOMATRICAL CARCINOMA Pilomatrical carcinoma (matrical carcinoma) is a rare tumor found on the head and neck of

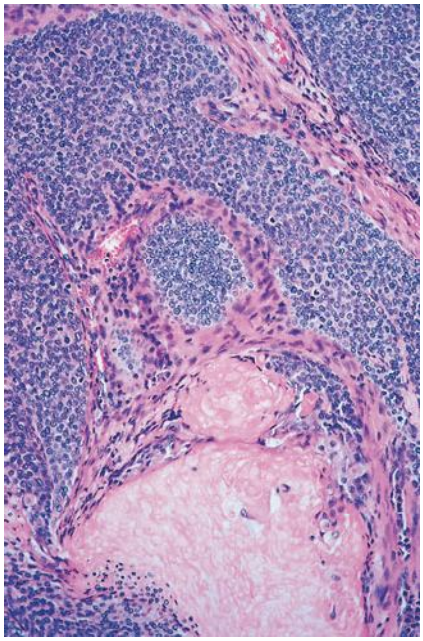

▲ **FIGURE 119-18** Pilomatrical carcinoma. Irregular aggregations of atypical basaloid cells continuous with an area of cornified material containing shadow cells.

older adults.[3–6,12] Clinical appearances are generally not distinctive. Most cases probably develop de novo, but malignant transformation from a benign pilomatricoma has been reported.[86] Histopathologic examination shows irregularly sized and variously shaped cutaneous/subcutaneous epithelial islands of basaloid (matrical and supramatrical) cells with conspicuous foci of shadow cells (Fig. 119-18). The basaloid cells reveal nuclear atypia and mitoses, as well as areas of geographic necrosis.

Pilomatrical carcinoma is primarily locally aggressive, but distant metastases, especially to lungs, bones, and lymphatics, have rarely been reported. Treatment of choice is surgical excision with adequate margins.[86]

APPENDAGE TUMORS WITH SEBACEOUS DIFFERENTIATION

Apart from sebaceus hyperplasia, sebaceous tumors appear to be less common and to show less morphologic diversity than other types of appendage tumors. Terminology is still controversial. Benign sebaceous neoplasms were conventionally divided into sebaceous hyperplasia, sebaceous adenoma, and sebaceous epithelioma, and malignant sebaceous neoplasms into basal cell carcinoma with sebaceous differentiation and sebaceous carcinoma.[5,6] Recently, the existence of sebaceous epithelioma as a distinctive neoplasm was challenged.[2] The term *sebaceoma* has been recommended for the most common benign neoplasm with sebaceous differentiation, whose malignant counterpart is sebaceous carcinoma. Furthermore, it has been proposed that sebaceous adenoma represents a superficial sebaceous carcinoma rather than a benign neoplasm. This section adopts this classification.

Cyst: Steatocystoma (See Chap. 118)

Hamartomas

FOLLICULOSEBACEOUS CYSTIC HAMARTOMA Folliculosebaceous cystic hamartoma is a cutaneous hamartoma that is comprised of follicular, sebaceous, and mesenchymal elements. Lesions present as solitary, long-standing, asymptomatic papules or nodules measuring 0.5 to 2.0 cm or more in diameter situated on the head and neck.[12,93] The face, especially the region around the nose, is mainly involved. Some lesions show a slightly depressed area with a centrally located crateriform pore.

Histologically, a dome-shaped nodule with a mature infundibular structure to which numerous rudimentary hair follicles and/or sebaceous units are attached is observed. The follicular structure is typically surrounded by abundant fibrous and elastic tissue. Adipocytes, nerves, and blood vessels are frequently found within the stroma. Treatment is by simple surgical excision.

FORDYCE'S SPOTS (FORDYCE DISEASE) AND MONTGOMERY'S TUBERCLES Fordyce's spots are found on adult women. Fordyce's spots and Montgomery's tubercles represent the occurrence of sebaceous glands on the lips and buccal mucosa, and on breast areola, respectively.[2] Despite the ectopic locations, both conditions reveal sebaceous glands with a "normal" histopathologic appearance and are therefore best regarded as hamartomas. Clinically, Fordyce's spots present as tiny, white or yellowish, focally grouped papules on the lip near the vermilion or on a buccal mucosa of adults. Rare lesions develop on the genital mucosa. Montgomery's tubercles arise as tiny papules distributed in a circle near the periphery of the breast areola.

Fordyce's spots show similar features to those in Montgomery's tubercles. They consist of a single sebaceous gland or lobule located in the upper submucosa or dermis, respectively. Some lesions reveal no accompanying sebaceous duct.

NEVUS SEBACEUS (See Chap. 118)

Hyperplasia: Sebaceous Hyperplasia

Males are more commonly affected than females by sebaceous hyperplasia, a common tumor. Rare cases show a familial pattern. Sebaceous hyperplasia presents commonly as solitary or multiple, small (less than 3 mm in diameter), yellowish papules on the face, particularly on the forehead of middle-aged individuals.[2,4–6,12] Lesions often reveal a central dell (Fig. 119-19). Clinically, lesions are often suspected to be basal cell carcinomas. Unusual presentations of sebaceous hyperplasia include linear and zosteriform lesions, giant and diffuse tumors, and lesions confined to the areola or genital (vulva) region. Rhinophyma (see Chap. 79) is currently widely considered to represent a special form of sebaceous hyperplasia.[2]

Histologically, sebaceous hyperplasia reveals large mature sebaceous lobules clustered around discrete, often dilated, infundibula located mainly in the upper dermis. The infundibulum is sometimes filled with debris and bacteria, and may contain a vellus hair.

A variety of treatment options exist including electrodesiccation, CO_2 laser surgery, cryosurgery, and shave excision with curettage.

Benign Neoplasms

MANTLEOMA Mantleoma (see also Fibrofolliculoma) is a recently described benign tumor that shows differentiation toward the sebaceous mantle.[3]

Mantleomas occur either as solitary or as multiple tumors.[3,12] Solitary mantleomas appear to be sporadic. They present as small papules on the face, frequently mimicking basal cell carcinomas or dermal nevi. As far as multiple mantleomas are concerned, it was proposed that both fibrofolliculomas and trichodiscomas arising in patients with Birt-Hogg-Dubé syndrome actually represent different developmental stages of mantleoma. Multiple mantleomas in these patients occur as numerous, small papules located mainly on the head and neck, as well as the trunk.

Mantleomas show various histopathologic features. Some lesions consist only of cords and columns of undifferentiated epithelial cells that radiate



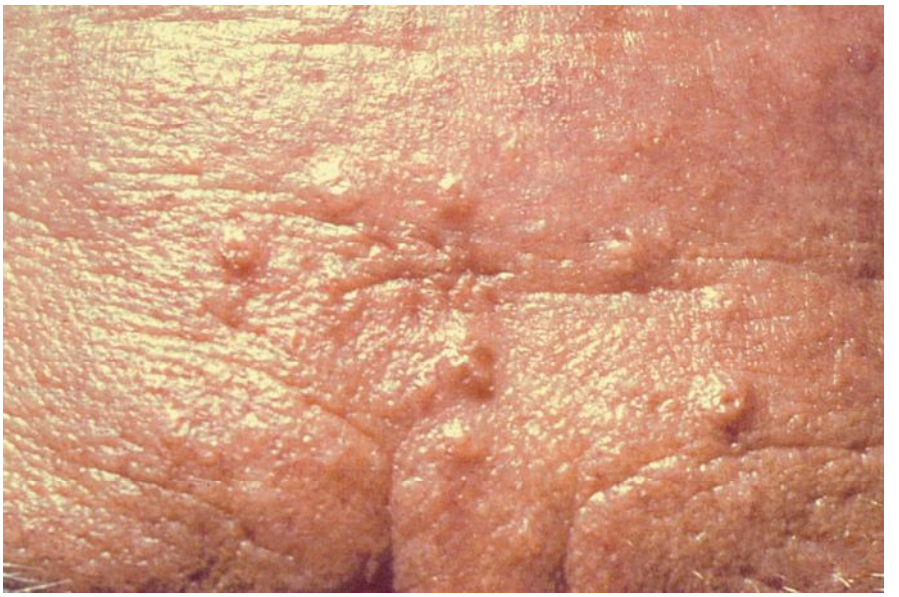

▲ **FIGURE 119-19** Sebaceous hyperplasia. One- to 3-mm smooth papules with central umbilication on the forehead.

from an infundibulum. Other lesions reveal interconnected cords with sebocytes and sebaceous ductal structures.

Solitary lesions may be excised. Management of multiple mantleomas is that of multiple fibrofolliculomas and trichodiscomas.

RETICULATED ACANTHOMA See the earlier section Appendage Tumors with Apocrine Differentiation.

SEBACEOMA ***Epidemiology.*** Sebaceoma usually occurs in older individuals and in the Muir-Torre syndrome (see Malignant Neoplasms: Sebaceous Carcinoma and Neoplasms in the Muir-Torre Syndrome).

Etiology. Sebaceoma represents the most common benign neoplasm with sebaceous differentiation.

Clinical Findings. Sebaceoma usually presents as a solitary, slowly growing, asymptomatic, yellowish papule or small nodule on the face or scalp[2,90] (Fig. 119-20A). Women appear to be more commonly affected than men. Occasional tumors arise in association with nevus sebaceus or seborrheic keratosis.

Histopathology. Lesions are centered in the dermis and consist of relatively symmetric, well-circumscribed, and smoothly bordered lobular aggregations of epithelial cells with focal connections to preexisting infundibula.[2,94] Involvement of the subcutis is observed in some cases. Epithelial aggregations are composed of basaloid cells with relatively monomorphous nuclei admixed with variable foci of discernible sebocytes and sebaceous ductal structures (see Fig. 119-20B). Some cases reveal entirely immature sebocytes—that is, cells with small monomorphous nuclei and scant cytoplasm but without vacuoles. Other cases display a variable mixture of immature and mature sebocytes with highly vacuolated abundant cytoplasm and nuclei exhibiting scalloped borders. Scattered mitoses are observed in some cases. Additional features may include a "ripple-like" pattern and cystic as well as ductlike structures containing sebaceous secretion.

Treatment. Treatment of choice is simple surgical excision. Electrodesiccation, curettage, and cryotherapy are effective in some cases.

Malignant Neoplasms: Sebaceous Carcinoma and Neoplasms in the Muir-Torre Syndrome

EPIDEMIOLOGY Sebaceous carcinoma occurs more commonly in women than in men, and there may be a history of radiation. Rare cases have been observed in young individuals infected with human immunodeficiency virus.

ETIOLOGY Sebaceous carcinoma represents a spectrum of rare malignant appendage tumors with sebaceous differentiation that have a potential for aggressive behavior.[2,4–6,12,94] They have traditionally been divided into ocular and extraocular types. Of these, the ocular type is the most common.

CLINICAL FINDINGS The ocular type of sebaceous carcinoma usually presents in older adults as a small, solitary papule or nodule on the eyelid, particularly around the meibomian glands and glands of Zeiss of the upper eyelid.[2] Lesions are often suspected to be chalazions.

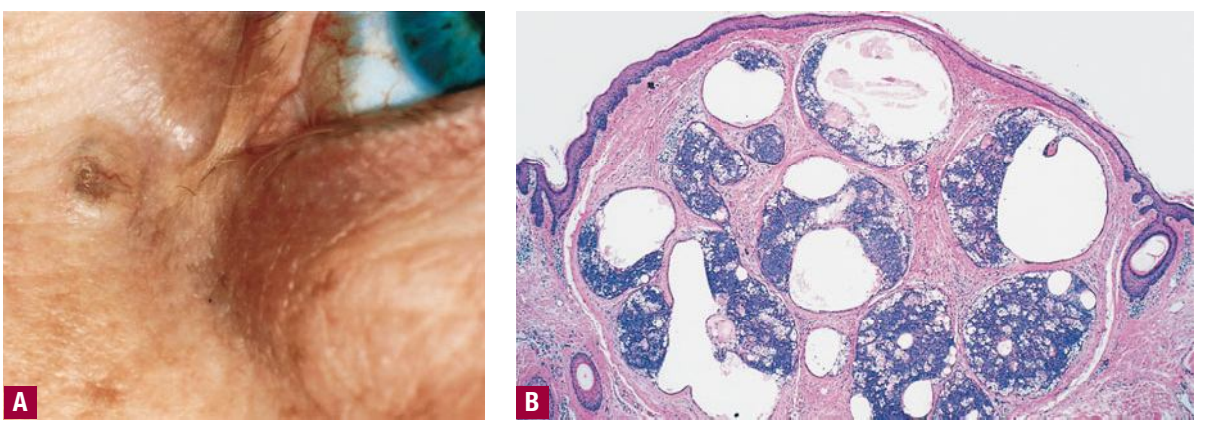

▲ **FIGURE 119-20** Sebaceoma. **A.** Yellowish nodule near the inner canthus of the eye. **B.** Well-circumscribed tumor composed of basaloid aggregations admixed with sebocytes and ductal as well as cystic structures.

Extraocular sebaceous carcinoma occurs mostly as a yellowish, firm, often ulcerated nodule on the head and neck of elderly individuals. Other anatomic sites, such as the foot and genital regions (labia and penis), may occasionally be involved. Lesions often mimic pyogenic granuloma, hemangioma, or squamous cell carcinoma.

Sebaceous carcinoma represents an important cutaneous marker of Muir-Torre syndrome[95] (see Chap. 154). In this syndrome, the tumors occur as single or multiple, skin-colored, yellowish or reddish-brown, sometimes ulcerated papules with the appearance of sebaceus hyperplasia and nodules, situated commonly on the face. They may coexist with keratoacanthomas and/or epidermal cysts. There is still controversy regarding the nature of sebaceous tumors arising in patients with Muir-Torre syndrome. Previous examples have mostly been considered as benign neoplasms ("sebaceous adenomas" or sebaceomas) and less commonly as sebaceous carcinomas. Based mainly on morphology, some authors recently proposed that the vast majority of sebaceous tumors arising in these patients are, in fact, sebaceous carcinomas.[94]

HISTOPATHOLOGY Sebaceous carcinoma is characterized by an asymmetric lesion centered in the dermis and consisting of variously sized and irregularly shaped aggregations of neoplastic cells.[2,94] Involvement of the subcutaneous tissue and/or underlying muscle is observed in some cases. Neoplasms may be relatively well-differentiated, with prominent sebaceous lobules and/or sebaceous ductal structures, or show undifferentiated features, with neither readily discernible cytoplasmic vacuoles nor ductal differentiation. The nuclei of the neoplastic cells, especially along the periphery of the tumor nests, tend to be crowded and pleomorphic and may exhibit marked atypia, as well as increased mitotic figures. Sections often reveal areas with geographic necrosis. A peculiar variant with cystic features may be difficult to differentiate from sebaceoma.

Treatment of choice is surgical excision with adequate margins. Radiation therapy may be effective in some patients with eyelid neoplasms. Up to one-third of patients with the ocular type of sebaceous carcinoma show lymph node metastases, particularly to the preauricular and cervical nodes, and the 5-year mortality rate is about 20 percent. Histopathologic features suggestive of a poor prognosis include the presence of vascular and lymphatic invasion, orbital extension, poor differentiation, an infiltrative growth pattern, and large tumor size. In contrast to ocular tumors, extraocular sebaceous carcinoma very rarely reveals nodal or visceral metastases. Sebaceous carcinomas arising in Muir-Torre syndrome, like visceral malignancies in these patients, also seem to be less aggressive than their ocular counterpart, which is unassociated with the syndrome.[95]

KEY REFERENCES

The full reference list for all chapters is available at www.digm7.com.

1. Requena L et al: *Neoplasms with Apocrine Differentiation*. Philadelphia, Lippincott-Raven, Ardor Scribendi, 1997
2. Steffen C, Ackerman AB: *Neoplasms with Sebaceous Differentiation*. Philadelphia, Lea & Febiger, 1994
3. Ackerman AB et al: *Neoplasms with Follicular Differentiation*. New York, Ardor Scribendi, 2001
4. Hurt MA, Santa Cruz DJ: Adnexal tumors, in *Diagnostic Histopathology of Tumors*, 2nd ed, edited by Fletcher CDM. Edinburgh, Churchill Livingstone, 2000, p 1378
8. Aszterbaum M et al: Ultraviolet and ionizing radiation enhance the growth of BCCs and trichoblastomas in patched heterozygous knockout mice. *Nat Med* **5**:1285, 1999
27. Domingo J, Helwig EB: Malignant neoplasms associated with nevus sebaceus of Jadassohn. *J Am Acad Dermatol* **1**:545, 1979
31. Urso C et al: Histologic spectrum of carcinomas with eccrine ductal differentiation (sweat-gland ductal carcinomas). *Am J Dermatopathol* **15**:435, 1993
36. Santa Cruz DJ: Sweat gland carcinomas: A comprehensive review. *Semin Diagn Pathol* **4**:38, 1987
39. Numata M et al: Syringadenocarcinoma papilliferum. *J Cutan Pathol* **12**:3, 1985
41. Abenoza P, Ackerman AB: *Neoplasms with Eccrine Differentiation*. Philadelphia, Lea & Febiger, 1990
52. Galadari E et al: Malignant transformation of eccrine tumors. *J Cutan Pathol* **14**:15, 1987
61. Carroll P et al: Metastatic microcystic adnexal carcinoma in an immunocompromised patient. *Dermatol Surg* **26**:531, 2000
64. Fernandez-Acenero MJ et al: Malignant spiradenoma: Report of two cases and literature review. *J Am Acad Dermatol* **44**:395, 2001
70. Cassarino DS, Linden KG, Barr RJ: Cutaneous keratocyst arising independently of the nevoid basal cell nevus syndrome. *Am J Dermatopathol* **27**:177, 2005
75. Brownstein MH: Basaloid follicular hamartoma: Solitary and multiple types. *J Am Acad Dermatol* **27**:237, 1992
77. Headington JT: Tumors of the hair follicle. A review. *Am J Pathol* **85**:479, 1976
80. Toro JR et al: Birt-Hogg-Dubé syndrome: A novel marker of kidney neoplasia. *Arch Dermatol* **135**:1195, 1999
81. Bansal C et al: Histologic variants of fibrous papule. *J Cutan Pathol* **32**:424, 2005
95. Schwartz RA, Torre DP: The Muir-Torre syndrome: A 25-year retrospect. *J Am Acad Dermatol* **33**:90, 1995



CHAPTER 120

Merkel Cell Carcinoma

Paul Nghiem
Natalia Jaimes

Merkel cell carcinoma (MCC) is a neuroendocrine carcinoma of the skin. Although it is 40 times less common than malignant melanoma, it has a higher mortality (33 percent) than melanoma (15 percent). From 1986 to 2001 there was a rapidly increasing incidence in reported cases of MCC, with a tripling in the rate over this 15-year period. Management of MCC is challenging and optimal therapy is controversial, at least in part due to a lack of quality data on which to base treatment decisions.

MCC is a relatively recently described entity, although the Merkel cell was described more than 100 years ago. In 1875, human Merkel cells were first described by Friedrich S. Merkel (1845–1919). He named these cells *Tastzellen* (touch cells) assuming that they had a sensory touch function within the skin due to their association with nerves. In 1972, Toker described five cases of "trabecular cell carcinoma of the skin." In 1978, Tang and Toker found dense core granules on electron microscopy that were typical of Merkel cells and other neuroendocrine cells. In 1980, the name *MCC* was first applied to this tumor. In 1992, antibodies to cytoker-

MERKEL CELL CARCINOMA AT A GLANCE



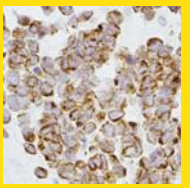

- Higher mortality (33 percent) than melanoma (15 percent).
- Incidence tripled from 1986 to 2001.
- Affects elderly/whites/immunosuppressed.
- Consider in differential diagnosis of any rapidly growing, nontender nodule on sun-exposed area.
- Sentinel lymph node biopsy, surgery, and radiation are indicated in most cases.
- Imaging (computed tomography/magnetic resonance/positron emission tomography): poor sensitivity and specificity at time of diagnosis and in early stages.
- Management: challenging; therapy is unique and controversial.
- Avoid over-aggressive surgery: adjuvant radiation therapy highly effective.
- Adjuvant chemotherapy: high morbidity, no proven benefits.
- Optimum care: multidisciplinary coordination between dermatologists, surgeons, radiation, and medical oncologists.



atin-20 allowed for the first time specific and relatively easy diagnosis of MCC to be made through immunohistochemistry. Since that time, electron microscopy is essentially no longer used to make the diagnosis. Most recently, in 2004, an elegant transgenic mouse model was used to isolate normal Merkel cells from mouse skin and find that they possessed excitable calcium channels and were capable of neurotransmitter release, suggesting that they do indeed play a role in touch sensation within the skin.[1]

EPIDEMIOLOGY

Over the 15-year period between 1986 and 2001, the incidence of MCC tripled from 0.15 per 100,000 to 0.44 per 100,000.[2] There are likely two factors that contribute to this increase in incidence that is more rapid than that of any other type of skin cancer. One factor is an increase in the accurate diagnosis of this malignancy through the routine use of cytokeratin-20 immunohistochemistry and the improved recognition of this malignancy by dermatopathologists. In the past, many MCCs were no doubt mischaracterized as lymphoma, melanoma, or undifferentiated carcinoma in the era before immunohistochemistry. A second likely reason is an increase in the number of people over age 65 years with extensive sun exposure history and prolonged immune suppression. Each of these factors is a known risk factor for MCC and several will be discussed in the section Etiology and Pathogenesis.

Recent studies have indicated that the number of MCC cases within the United States is between 600 and 1000 cases per year depending on the particular tumor registry analyzed.[3,4] This cancer is far more common in whites than in blacks, consistent with a known role for ultraviolet radiation in the pathogenesis. Specifically, the rates in whites have been reported as 0.23 per 100,000 as compared to 0.01 per 100,000 for blacks.[5] Although not specifically reported, rates in Hispanics and Asians are likely intermediate between those in blacks and whites. MCC tends to be more common in men than in women (2:1 in ratio).[3]

ETIOLOGY AND PATHOGENESIS

There are several known risk factors for MCC that will likely continue to lead to an increase in the incidence of this disease.

Age Greater Than 65 Years

The median age for diagnosis of MCC is 70 years, and there is a 5- to 10-fold increase in incidence after age 70 as compared with age less than 60 years, as shown in Fig. 120-1. Indeed, only about 5 percent of MCC cases present in patients under age 50 and it is extremely rare in childhood.[6]

Sun Exposure

Sunlight, prolonged ultraviolet exposure, and photochemotherapy are all associated with an increased risk of MCC. The vast majority of MCC present on sun-exposed skin. It is clear, however, that sun is not required for MCC to develop. MCC cases can occur on sun-protected skin, including buttocks and vulva as well as portions of the scalp that are covered by hair.

Immune Suppression

The role of the immune system in preventing and fighting MCC is apparent within several different populations of immune-suppressed patients. Solid organ transplant recipients make up approximately 8 percent of all MCC cases.[7] There is thus approximately a 10-fold increase in MCC in the solid organ transplant population as compared to a control population.[5] In organ transplant recipients, the median age of presentation of MCC is far younger with almost half of patients presenting at less

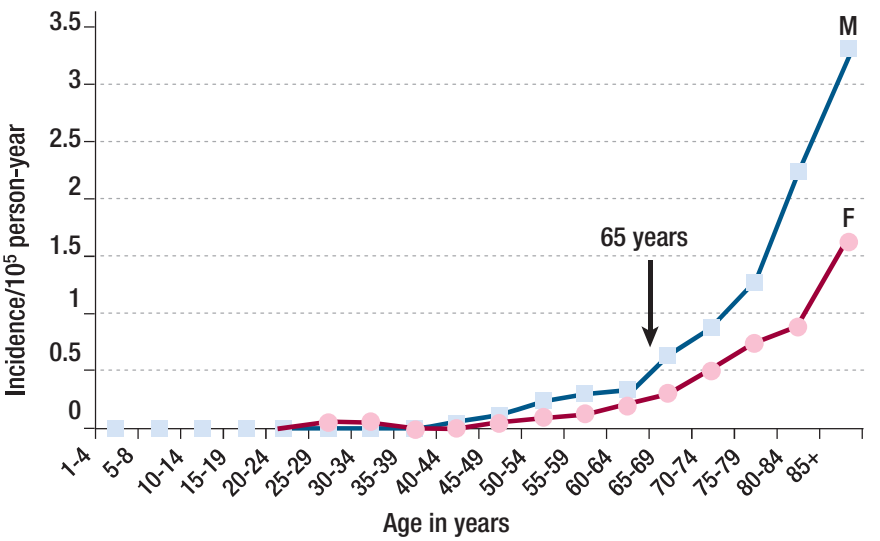

▲ **FIGURE 120-1** Frequency of Merkel cell carcinoma by age and sex. The most significant risk factor for Merkel cell carcinoma is age. M, male (■); F, female (●). (Reprinted from Agelli M, Clegg LX: Epidemiology of primary Merkel cell carcinoma in the United States. *J Am Acad Dermatol* **49**:832, 2003, with permission.)

than 50 years of age as compared to only 5 percent in the typical population.[6] In transplant recipients, MCC is more aggressive than melanoma with 68 percent of these patients developing lymph node metastases as compared to 20 percent for melanoma.[6] The death rate due to MCC in this population is 60 percent as compared to 29 percent for melanoma.[6,7] The ratio of post-transplant melanoma to MCC is 6:1 as compared to 65:1 in the general population,[5] indicating the relative importance of the immune system in suppressing MCC as compared to melanoma.

Several of the drugs used to suppress the immune system in transplant recipients, including cyclosporine, have previously been shown to act directly on certain tumor cells to augment their growth and aggressive behavior. Data from several other populations suggest, however, it is likely the immune suppression itself that is most important for MCC and not the direct effects of drugs such as cyclosporine acting on the tumor. Specifically, among human immunodeficiency virus–positive patients, there is a relative risk of 13-fold for the development of MCC as compared to the general population.[8] Similar to solid organ transplant recipients, in human immunodeficiency virus–positive patients, this disease also behaves more aggressively and presents at a younger age than in the general population. An increased incidence has also been noted in patients with chronic lymphocytic leukemia which is well known to cause profound and prolonged immune suppression, particularly in the T lymphocyte arm of the immune system.

Molecular Genetics

At the molecular level, virtually nothing is known about MCC. It shares histologic features with another neuroendocrine carcinoma, small cell lung cancer, but it is unclear if these similarities at the histologic level extend to the genetic level as well. Thus far there is no clear tumor suppressor gene or oncogene that has been conclusively implicated in MCC. Diverse chromosomal abnormalities have been reported, including in chromosomes 1, 6, 7, 11, 12, and 18, but these are low-resolution genetic abnormalities and the specific tumor suppressors, or oncogenes, associated with these have not been identified. The p53 gene has been studied in MCC and no significant elevation in p53 mutations has been noted, suggesting that p53 mutation does not play an important role in the development or progression of MCC.[9]

TABLE 120-1
Clinical Features of Merkel Cell Carcinoma

Firm; red, purple, or skin-colored, nontender papule or nodule (see Figs. 120-2A and B)
Most lesions are < 20 mm in diameter at diagnosis
Rapid growth within 1–3 mo
Usually on a sun-exposed location (but not always)
Ulceration is rare
Locally aggressive, with local discontinuous and distant lymphatic spread (see Fig. 120-2B)

CLINICAL PRESENTATION OF MERKEL CELL CARCINOMA

Although there have been no large studies to describe the clinical presentation of MCC, based on our observations among over 100 cases,[13] we have generated a list as shown in Table 120-1. In distinction to melanoma, there are no clear "ABCD" features that alert a clinician to whether they are looking at an MCC or not. However, if several of the features shown in Table 120-1 are present, it is clearly appropriate to carry out a biopsy to evaluate for MCC or a separate malignant process. In our population,[13] we have analyzed the biopsy reports of more than 70 patients in which the clinician had submitted a presumed diagnosis at the time of biopsy. Strikingly, the clinician listed as clinical impression a benign diagnosis in over one half of cases. In particular, a cyst or acneiform lesion was the single most common of these (Box 120-1 and Figs. 120-2A and B) and -melanoma skin cancer was also relatively frequent as a presumptive diagnosis (Fig. 120-2C).

Box 120-1
Differential Diagnosis of Merkel Cell Carcinoma

Most Likely
- Cyst
- Basal cell carcinoma
- Squamous cell carcinoma (see Fig. 120-2C)
- Amelanotic melanoma
- Cutaneous lymphoma
- Adnexal tumor

Consider
- Metastasis
- Dermatofibromasarcoma protuberans
- Keratoacanthoma
- Neuroblastoma

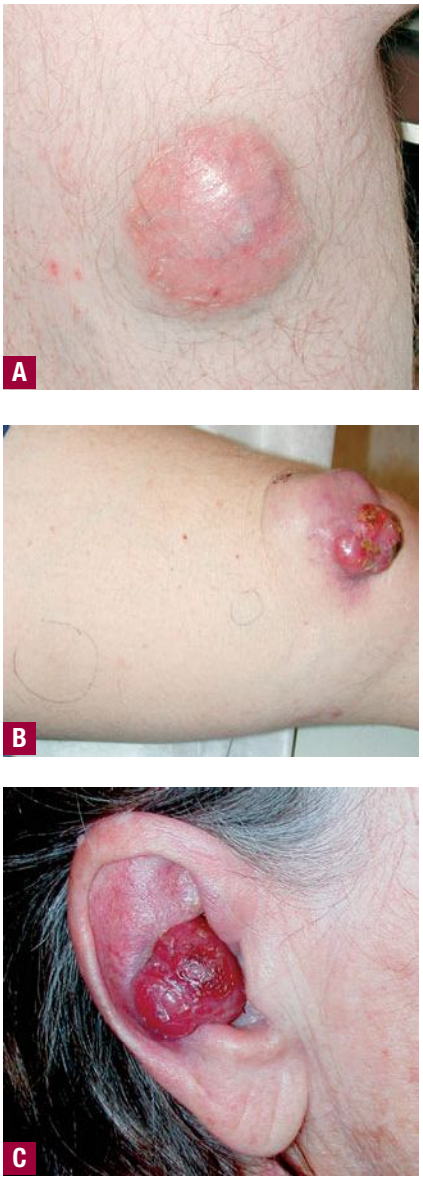

▲ **FIGURE 120-2** Clinical appearance of Merkel cell carcinoma (MCC). **A.** MCC frequently has a "cyst-like" appearance. This is reflected in the differential diagnoses given by clinicians at the time of the biopsy, with cyst/acneiform lesion being the most common clinical impression. **B.** MCC on the knee of a 70-year-old woman with chronic lymphocytic leukemia. For 6 months this lesion was thought to be a "cyst"; consequently, diagnosis and treatment were delayed. Pen marks indicate palpable satellite metastases that developed several months after the primary lesion, presumably tracking via lymphatics. **C.** MCC on the ear of an 87-year-old woman. The lesion grew rapidly and was non-tender. After approximately 3 months, it was biopsied by a clinician who listed squamous cell carcinoma as the presumptive diagnosis.

PATHOLOGY

Merkel cells are thought to be mechanoreceptors involved in fine touch lo-



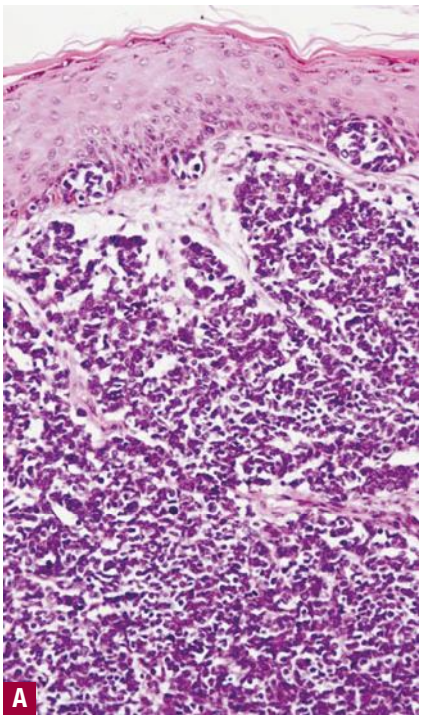

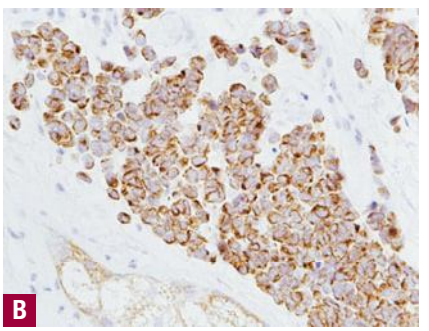

▲ **FIGURE 120-3** Merkel cell carcinoma pathology. **A.** Hematoxylin and eosin. There is diffuse dermal as well as intraepidermal involvement with Merkel cell carcinoma. This case was seen in consultation, with an initial diagnosis of cutaneous T-cell lymphoma. **B.** Cytokeratin-20. Showing the pathognomonic "perinuclear pattern" of cytokeratins (CAM5.2). (Reprinted from Nghiem P, Mckee P, Haynes H: Merkel cell (cutaneous neuroendocrine) carcinoma, in *Skin Cancer, Atlas of Clinical Oncology*, edited by A Sober, F Haluska, American Cancer Society, 2001, with permission.)

cated within the basal epidermis. This is based on their close association with cutaneous nerves as well as recent data that show Merkel cells are excitable cells with calcium channels and capable of release of neurotransmitters.[1] Although it has not been formally shown, it is widely agreed that Merkel cells in the skin are the precursor cells to MCC. As shown in Fig. 120-3A, the classic histologic features of MCC include sheets of small basophilic cells with scant cytoplasm, fine chromatin, and no nucleoli. There are numerous mitotic figures and occasional individual necrotic cells. Lymphovascular invasion is a very common feature and often can be found when it is specifically searched for even in a "negative" margin. This helps to explain the high local recurrence rate in MCC for narrow or even relatively wide margin excision when adjuvant radiation therapy is not given.

TABLE 120-2
Immunohistochemistry Panel

	Cytokeratin-20	Cytokeratin-7 and thyroid transcription factor-1	Leukocyte common antigen	S-100
Merkel cell carcinoma	+	–	–	–
Small cell lung carcinoma	–	+	–	–
Lymphoma	–	–	+	–
Melanoma	–	–	–	+

Hematoxylin and Eosin Stain

Three histologic patterns have been described up to now and none is clearly associated with a better or worse prognosis. The most common type is the "intermediate type." This has uniform small cells with minimal cytoplasm, pale nuclei, and a dispersed chromatin appearance. On hematoxylin and eosin staining, the differential diagnosis for this presentation is that of the small, blue-cell tumors including melanoma and lymphoma. The second most common pattern is the "small cell type." This takes its name from small cell lung carcinoma, which is the principal differential diagnosis for this pattern. It shows irregular, hyperchromatic cells with scant cytoplasm and malignant cells that are arranged in linear patterns infiltrating stromal structures. The least common but perhaps most histologically distinctive type is the "trabecular" type. This is the pattern originally described by Toker in 1972. It has a lattice-like, or network appearance, and the differential diagnosis includes metastatic carcinoid tumor.

Immunohistochemical Stains

The use of antibody-based stains has greatly facilitated the ease and specificity of MCC diagnosis (Table 120-2). The single most useful of these stains to rule in MCC is cytokeratin-20.

Cytokeratin-20

Intermediate filament protein is expressed in MCC as well as in adenocarcinomas of the colon, stomach, and pancreas. Within the skin, however, the expression of cytokeratin-20 is limited to Merkel cells. A "perinuclear dot" pattern of cytokeratin is essentially pathognomonic for MCC (see Fig. 120-3B).

Antibodies to CAM5.2

CAM5.2, a cocktail of antibodies that detects multiple human cytokeratin epitopes, typically reacts with both MCC and small cell lung carcinoma. Although it is useful as an initial screening tool to detect tumors of squamous origin, its lack of selectivity relative to cytokeratin-20 means that it cannot be used to definitively diagnose MCC.

Thyroid Transcription Factor-1

Thyroid transcription factor-1 is negative in MCC and positive in small cell lung cancer and thus useful for the differential diagnosis between these two tumors that can look identical by routine histology.

Cytokeratin-7

Cytokeratin-7 has the same staining pattern as thyroid transcription factor-1, that is, negative in MCC and positive in small cell lung carcinoma; it is also expressed in epithelial cells of the lung, ovary, and breast.

Neuron-Specific Enolase

Neuron-specific enolase is positive in MCC and other neoplasms derived from neural or neuroendocrine tissue. In some cases, neuron-specific enolase is released by neuroendocrine carcinomas including MCC and can be detectable in the blood.

Leukocyte Common Antigen

Leukocyte common antigen is useful to differentiate between lymphomas and carcinomas, as it is positive in lympho-

mas and negative in carcinomas including MCC.

S-100

S-100 is positive in most melanomas and glial cell tumors and negative in MCC.

Before cytokeratin-20 and cytokeratin-7, many MCC cases were misdiagnosed as lymphoma, small cell lung carcinoma metastases, or undifferentiated carcinoma. Currently, if immunohistochemistry is carried out properly, MCC diagnosis is typically definitive.

STAGING AND PROGNOSIS

According to the American Joint Committee on Cancer, there are four clinical stages for MCC based on features at time of presentation. Localized disease is either Stage I (primary lesion ≤ 2 cm) or Stage II (primary lesion > 2 cm). Nodal spread of MCC is stage III, whereas patients presenting with metastatic disease beyond the local node bed have Stage IV disease. Survival after a diagnosis of MCC is highly dependent on the stage at presentation. Patients with truly local only disease have a greater than 90 percent chance of survival, which decreases to approximately 60 percent with nodal involvement, and below 10 percent among those presenting with metastatic disease. Unlike malignant melanoma, if MCC recurs it tends to do so rapidly with 90 percent of recurrences occurring within 3 years of diagnosis (Fig. 120-4A).[10]

Sentinel Lymph Node Biopsy and Staging of Merkel Cell Carcinoma

Over the past 20 years, sentinel lymph node biopsy (SLNB) has become quite common in staging malignant melanoma presenting with a depth of greater than 1 millimeter. More recently, several studies have indicated that SLNB is also a sensitive test for detecting MCC spread to the lymph nodes.[11–13] SLNB clearly has less morbidity than an elective lymph node dissection. Interestingly, MCC has a much higher rate of involving the lymph nodes (approximately 30 percent of all cases) than melanoma (approximately 5 percent of all cases). If an SLNB is to be carried out properly, it needs to be performed at the time of the wide resection as opposed to after the wide excision when local lymphatics have been disturbed. The importance of SLNB in determining prognosis in MCC can be seen by comparing Figs. 120-4B and 120-4C. The essential difference is that one-third of patients with local only disease as determined by clinical palpation of lymph nodes, in fact, have microscopic disease in the lymph nodes that very much affects their subsequent survival.[13] The 5-year survival rate of pathologically staged node-negative patients was 97 percent compared with 5-year survival of node-positive patients of 52 percent.[10]

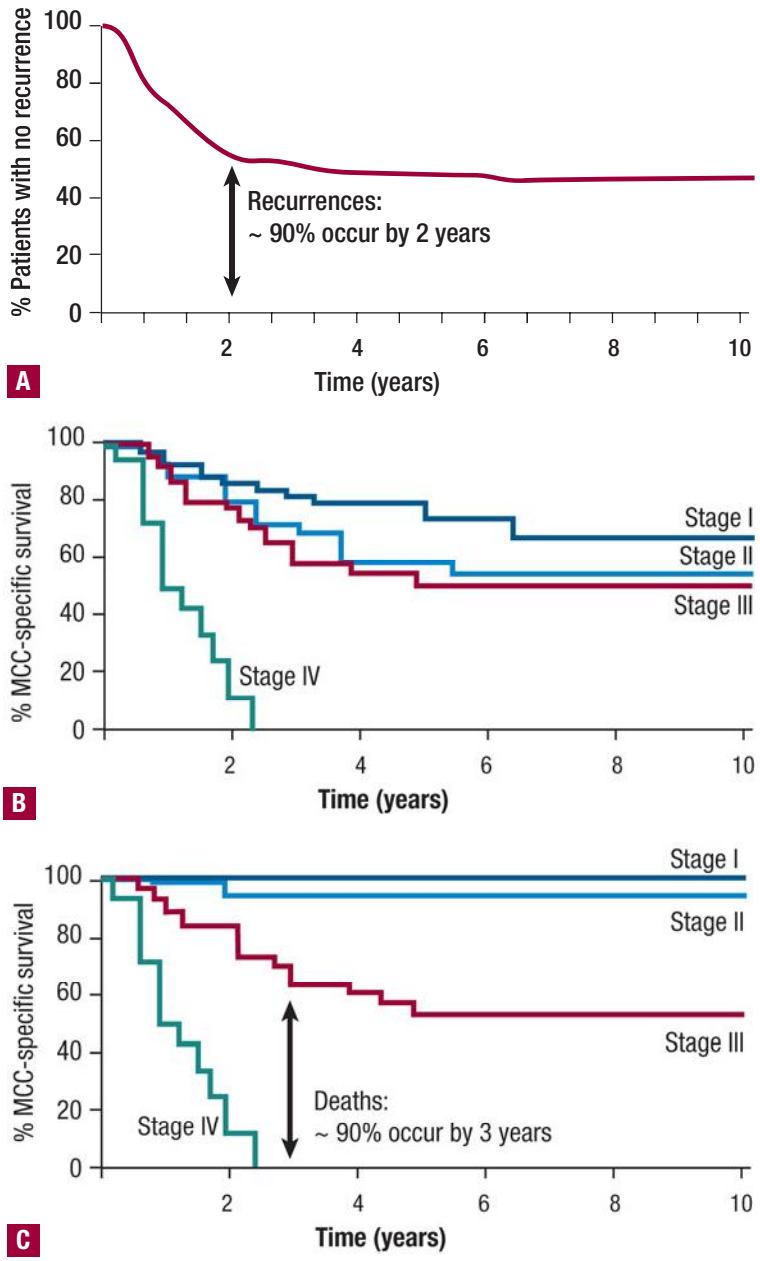

▲ **FIGURE 120-4** Prognosis of Merkel cell carcinoma depends on stage at presentation. **A.** Fraction of patients with Stage I, II, or III disease with no recurrence. Approximately 90 percent of patients who experienced a recurrence did so within 2 years of diagnosis (n, 237 patients). **B.** Disease-specific survival for patients who underwent clinical staging only. Clinical node staging does not provide optimal information for prognosis and treatment (n, 180 patients). MCC = Merkel cell carcinoma. **C.** Disease-specific survival for patients who underwent pathologic staging. Pathologic staging can be done by sentinel lymph node biopsy or other lymph node surgery. At 5 years, patients with no lymph node disease (Stage I or II) had a 97 percent survival rate. Those with lymph node disease (Stage III) had a 52 percent survival at 5 years (n, 145 patients). (Adapted from Allen PJ et al: Merkel cell carcinoma: prognosis and treatment of patients from a single institution. *J Clin Oncol* **23**:2300, 2005, with permission.)

Radiologic Imaging Studies

Although most patients who present for management of MCC have not had an



SLNB, the majority have had computed tomographic (CT) scans. We studied our own series of patients to determine the sensitivity and specificity of CT scans in patients presenting with MCC.[13] We found that scans were not sensitive at all (missing 90 percent of positive cases) in terms of detecting nodal involvement of MCC as compared with SLNB. Among patients who had low-risk disease (negative sentinel lymph nodes or very small primary tumors) all of the "positive" scan results were, in fact, false positives.[13] We therefore reserve CT scans for patients presenting with more advanced disease, such as positive nodal involvement or clinical evidence of metastatic disease.



TREATMENT

Optimal therapy for MCC is controversial and there is no broad consensus on how to manage this disease. One summary of multi-institution management is available through the National Comprehensive Cancer Network (http://www.nccn.org). The National Comprehensive Cancer Network generates a treatment algorithm for MCC with annual updates. The best outcome for MCC is clearly obtained when multidisciplinary management is carried out by an experienced team. Each major treatment modality is summarized below.

Surgery at Primary Site

The initial management in almost all cases of MCC is surgical excision of the tumor. When carried out without subsequent adjuvant radiation, surgery has a relatively high recurrence rate depending on the margins chosen. Surgery alone with 0.5 centimeter margins resulted in a 100 percent recurrence rate in 38 patients.[14] When wide local excision was carried out with 2.5 centimeter margins, the recurrence rate fell to 49 percent.[15] For Mohs surgical excision, the local recurrence rate was 16 percent, which was reduced further to 0 percent in patients who had adjuvant radiation therapy as well.[16] There are no data to suggest that extremely wide excision margins improve overall survival. Depending on the location of the tumor, significant morbidity can result when 2 to 3 centimeter margins are taken. Numerous studies show that if surgery is the sole treatment, recurrence rates are significantly higher than if radiation therapy is added to the regimen. Excision with narrow but clear margins (carried out at the time of SLNB) followed by adjuvant radiation therapy is a reasonable approach to management. Overly aggressive surgery, including amputation, or very wide margins in cosmetically sensitive areas, decreases quality of life, increases morbidity, delays time to initiation of adjuvant radiation, and does not appear to improve survival or local cure rates.

Surgery at the Draining Node Bed

The role of completion lymphadenectomy is controversial. It is typically carried out if there is gross involvement of the draining node bed clinically or if the SLNB is positive. One study showed a benefit of elective lymph node dissection in decreasing nodal recurrences but this was not associated with overall improved survival and clearly has significant morbidity associated with it.[17,18] The relatively greater morbidity of completion lymphadenectomy in combination with relatively frequent nodal recurrences after complete nodal dissection has led us to favor radiation therapy to the lymph node bed rather than surgical therapy.

Radiation Therapy

MCC is an unusually radiosensitive tumor.[14,19] Recently, there have been reports of successful treatment of MCC with radiation as monotherapy. With a 3-year median follow up, there was 0 percent disease recurrence in 9 patients treated with radiation monotherapy.[19] One case treated with radiation monotherapy is shown in Fig. 120-5. In most of these cases, the lesion was felt to be inoperable and radiation was given for palliation, but resulted in at least local cure in almost all cases. Data to support radiation as monotherapy remain very scant at this time.

The much more common use of radiation is as an adjuvant to surgery. Adjuvant radiation clearly is critical if surgical margins are positive or if margins are relatively narrow. Adjuvant radiation therapy to the draining node bed is an excellent means of treating sentinel lymph node–positive patients. Numerous studies, although mostly retrospective case studies, indicate a statistically significant improved local and nodal rate of control in this cancer if radiation is added.[20] The typical doses of radiation for MCC are shown in the legend of Fig. 120-6. Acute side effects from radiation therapy include erythema at the site and mild-to-moderate fatigue that peaks towards the end of radiation and usually resolves within 1 to 2 months of completing a 5-week course. Chronic radiation skin changes include temporary or permanent alopecia within the irradiated field, epidermal atrophy, loss of adnexal structures leading to skin or mucosal dryness, and risk of subsequent secondary skin cancers in the irradiated region in patients with a life expectancy of greater than 20 years after the radiation treatment. Perhaps the most significant potential side effect is lymphedema. This is more commonly an issue in lower extremities, when radiation therapy is given to the inguinal lymph nodes, especially after surgery has also been carried out in that region.

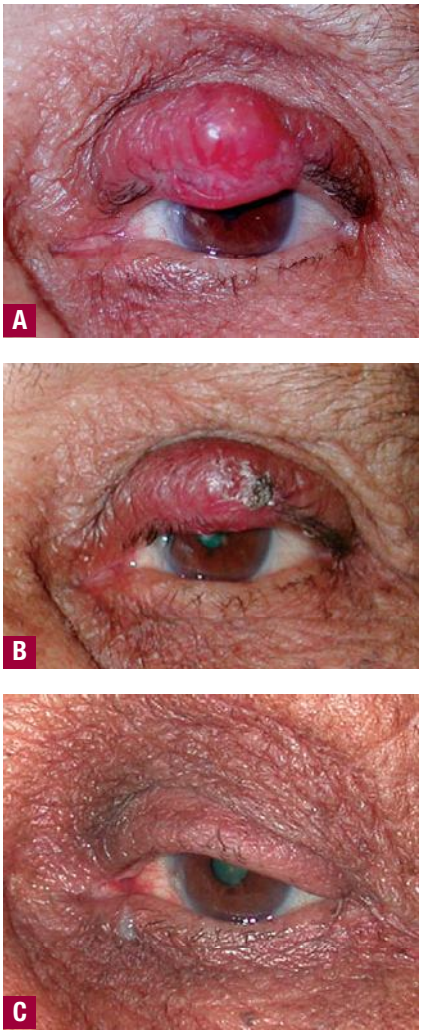

▲ **FIGURE 120-5** **A.** Merkel cell carcinoma on the eyelid arising 3 months before biopsy. The lesion was initially presumed to be a chalazion or cyst. **B.** Using a thin lead shield to protect the globe, the eyelid, the surrounding tissues, and draining lymph node bed were treated with radiation monotherapy. **C.** The patient remains recurrence-free at 2.5 years after diagnosis, and thus has a greater than 95 percent chance of cure at this point.

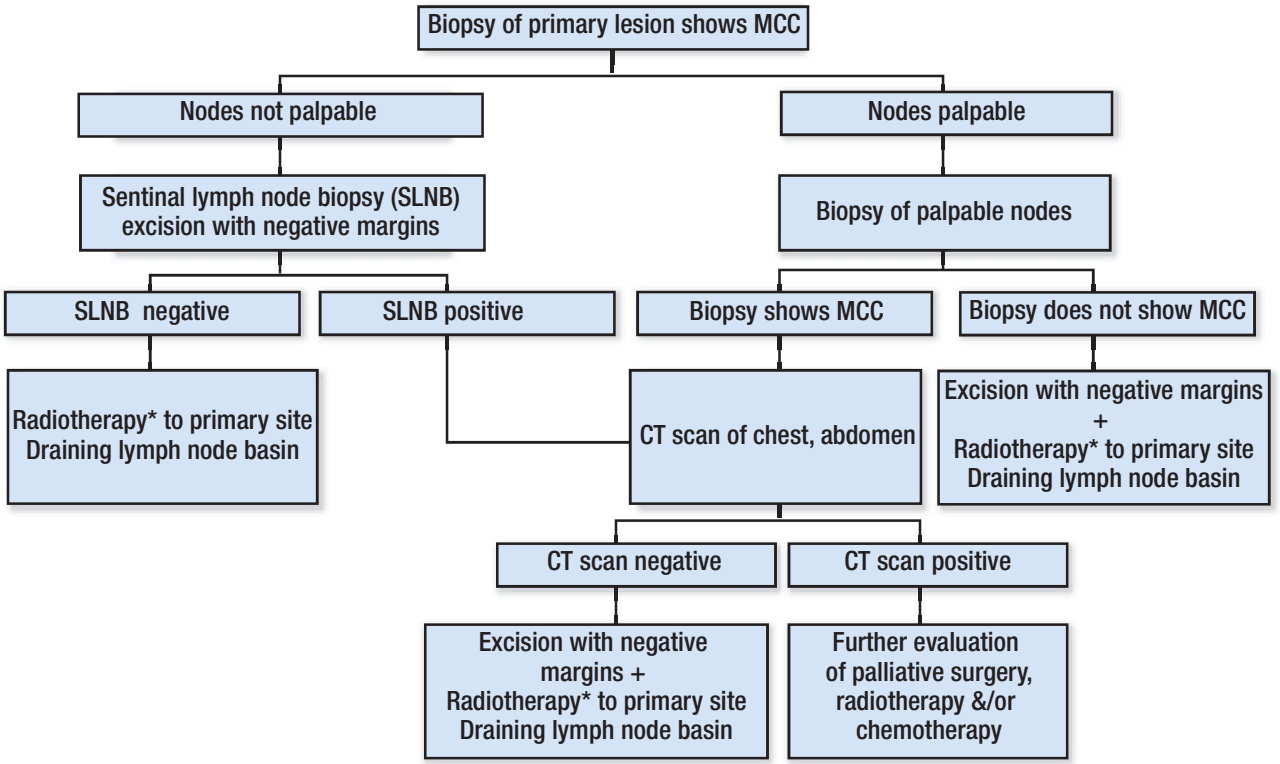

▲ **FIGURE 120-6** Approach to the patient with Merkel cell carcinoma (MCC). *Recommended radiation therapy dose (National Comprehensive Cancer Center Guidelines for MCC, 2006): 45–50 Gy for primary site with negative excision margins and node bed with no palpable disease. 55–60 Gy for primary site with positive excision margins and node bed with palpable disease. Radiation therapy given in 2-Gy fractions, 5 times/week over 4–6 weeks. CT = computed tomography.



Chemotherapy

The most commonly used regimen in MCC is the combination of carboplatin and etoposide. Chemotherapy is without a doubt useful in palliation for symptomatic disease that is otherwise inoperable. Most patients who have not received chemotherapy yet have a significant response with shrinkage of the tumor. Unfortunately, in almost all cases, the tumor grows back and is resistant to chemotherapy even if entirely different agents are used on a subsequent round of chemotherapy. After careful analysis of the literature, we currently do not recommend adjuvant chemotherapy for patients whose MCC has been treated with surgery, radiation therapy, or both. There are six reasons why we currently do not recommend adjuvant chemotherapy.

1. Mortality: there is a 4 to 7 percent acute death rate due to adjuvant chemotherapy in MCC partly due to the fact that these patients are often elderly.[21,22]
2. Morbidity: Neutropenia occurs in 60 percent of patients with fever, and sepsis in 40 percent.[23]
3. Decreased quality of life: this is quite severe in this older population, including fatigue, hair loss, nausea, and vomiting.
4. Resistance to chemotherapy: MCC that recurs after chemotherapy is less responsive to later palliative chemotherapy.
5. Immunity: Chemotherapy suppresses immune function, and this is known in general to be very important in preventing and controlling MCC.
6. Apparent poorer outcomes: Among patients with nodal disease, there was a 60 percent survival if chemotherapy was not given among 53 patients. In contrast, survival was only 40 percent among node positive MCC patients who did receive adjuvant chemotherapy.[10] Although this is not a randomized trial and was not statistically significant, it certainly does not suggest a survival benefit for administrating adjuvant chemotherapy.

Optimal Treatment for Merkel Cell Carcinoma

In general, optimal treatment for MCC should involve obtaining pathologically clear margins by surgery, typically with 1- to 2-centimeter margins as possible, depending on the site. More narrow margins or even positive margins can often be effectively treated by local radiation, typically extending 3 to 5 centimeters beyond the tumor bed. We also recommend treating the draining lymph node bed, likely with radiation therapy, for patients with high-risk disease including a positive SLNB, immune suppression, or a tumor greater than 2 centimeters in diameter. Fig. 120-6 summarizes a treatment plan for patients with MCC.

CLINICAL COURSE AND COMPLICATIONS

In more than 90 percent of cases, MCC is an unanticipated diagnosis at the time the pathology results become known. Most commonly, the lesion in question was thought to be a cyst or acneiform lesion. Although most patients and physicians are not familiar with this disease or its specific management, this disease can be lethal and there is a need to initiate therapy rapidly. Because of the rarity of this cancer, patients and physicians increasingly resort to the internet for medical information. One website, http://www.merkelcell.org, is devoted to aiding patients and physicians by presenting current data and referral center availability.

Among patients who experience a recurrence of their MCC, 90 percent of these happen within 2 years of diagnosis. The most common site of recurrence is

the draining nodal basin or adjacent skin.[10] The chance of developing metastasis and subsequent death is highly associated with the stage of disease at presentation, varying from greater than 95 percent chance of cure to less than 10 percent chance of cure. For those who have recurrences, the locations and frequencies are skin (28 percent), lymph nodes (27 percent), liver (13 percent), lung (10 percent), bone (10 percent), brain (6 percent), bone marrow (2 percent), pleura (2 percent), and other sites (4 percent).[22] Once MCC has spread to viscera, it is essentially incurable.

Fortunately, for more than 50 percent of patients, a good outcome can be anticipated. Those who have had no recurrences for 3 to 5 years, unlike melanoma, are considered cured. The complications for those who do not experience a metastasis depend very much on the therapy they received. We believe that treatment with surgical excision and radiation therapy as outlined in this chapter has relatively minimal complication rates and the best possible chance of cure based on current literature. However, for those who receive very aggressive surgical excision, amputation or chemotherapy for low-risk disease, complication rates tend to be higher without improved outcomes.

KEY REFERENCES

The full reference list for all chapters is available at www.digm7.com.

2. Hodgson NC: Merkel cell carcinoma: changing incidence trends. *J Surg Oncol* **89**:1, 2005
3. Agelli M, Clegg LX: Epidemiology of primary Merkel cell carcinoma in the United States. *J Am Acad Dermatol* **49**:832, 2003
6. Penn I, First MR: Merkel's cell carcinoma in organ recipients: report of 41 cases. *Transplantation* **68**:1717, 1999
10. Allen PJ et al: Merkel cell carcinoma: prognosis and treatment of patients from a single institution. *J Clin Oncol* **23**:2300, 2005
13. Gupta S et al: Sentinel lymph node biopsy for evaluation and treatment of patients with Merkel cell carcinoma: The Dana-Farber experience and meta-analysis of the literature. *Arch Dermatol* **142**:685, 2006
19. Mortier L et al: Radiotherapy alone for primary Merkel cell carcinoma. *Arch Dermatol* **139**:1587, 2003
20. Longo MI, Nghiem P: Merkel cell carcinoma treatment with radiation: A good case despite no prospective studies. *Arch Dermatol* **139**:1641, 2003

CHAPTER 121

Mammary and Extramammary Paget Disease

Isaac M. Neuhaus
Roy C. Grekin

EPIDEMIOLOGY

Mammary Paget disease (MPD) represents approximately 1 percent to 3 percent of breast neoplasms.[1] The peak incidence is between 50 and 60 years of age. MPD in males is extremely rare; almost all reported cases occur in women.

Extramammary Paget disease (EMPD) is a rare neoplasm that affects apocrine gland–bearing skin, such as the vulva, perianal region, scrotum, and penis. The majority of patients are women in the sixth through eighth decades of life.[2,3] The vulva is the most commonly affected area, and EMPD represents 2 percent of all vulval malignancies.[3]

ETIOLOGY AND PATHOGENESIS

MPD is almost always associated with underlying in situ or invasive intraductal adenocarcinoma of the breast (up to 98 percent of cases in some studies).[4,5] Malignant cells directly extend from the underlying tumor into the epidermis via the lactiferous ducts. Rare cases are reported to have originated primarily in the epidermis of the nipple.[6]

Unlike MPD, in which almost all cases have a documented underlying neoplasm, EMPD does not have a uniform histogenesis, and several different forms have been described. Primary EMPD is the most common type and accounts for the majority of all patients with this disease. Underlying carcinoma is not present, and these cases represent a primary intraepithelial neoplasm. The malignant cells are thought to originate from intraepidermal apocrine glands or from pluripotential cells of the epidermis. The neoplasm can then invade the dermis and metastasize via lymphatic spread. In contrast, a smaller proportion of EMPD cases are associated with an underlying apocrine carcinoma or internal malignancy (secondary EMPD). These cases are due to epidermotropic spread of malignant cells from the underlying tumor. Approximately 15 percent of cases are associated with an underlying internal carcinoma. The most common visceral malignancies associated with EMPD are carcinomas of the rectum, bladder, urethra, cervix, and prostate.

CLINICAL FINDINGS

History

Both MPD and EMPD often present with a long-standing history of pruritic, erythematous, scaly patches on the breast and in the groin, perineum, and axilla, respectively. Frequently there is a delay in diagnosis of many months to years as treatment with topical steroids and antifungal agents for presumed inflammatory or infectious dermatitis are initiated. After continued failure to respond to these medications, a diagnostic biopsy is ultimately performed.

MAMMARY AND EXTRAMAMMARY PAGET DISEASE AT A GLANCE



- Rare intraepithelial adenocarcinoma occurring primarily in women.
- Erythematous, scaly, eczematous plaque frequently misdiagnosed as inflammatory or infectious dermatitis.
- Most commonly affected sites: Unilateral nipple/areola complex [mammary Paget disease (MPD)], vulva, perianal skin, scrotum, and penis [extramammary PD (EMPD)].
- Most cases are associated with underlying breast carcinoma (MPD); EMPD not usually associated with underlying neoplasm but may be present in minority of cases.



▲ **FIGURE 121-1** Paget disease of the nipple. Sharply circumscribed erythematous and scaly plaque involving the nipple and areola.



▲ **FIGURE 121-2** Extramammary Paget disease. Moist, well-demarcated, eroded, oozing plaque on the scrotum and inguinal fold in an older man.

Cutaneous Lesions

MPD frequently presents as a unilateral, erythematous, scaly plaque or patch involving the nipple and occasionally the areola (Fig. 121-1). Ulceration and weeping with an eczematous appearance is frequently present. Nipple erosion and discharge may occur. Retraction of the nipple can be seen. Pain, burning, and pruritus are frequently reported by patients. See Box 121-1 for differential diagnosis of MPD and EMPD.

Lesions of EMPD are clinically similar to MPD and often present as a well-defined, moist, erythematous, scaly, eczematous patch. Hypo- and hyperpigmentation can occur. Burning and intense pruritus are commonly reported. Lesions typically involve apocrine gland–bearing skin (i.e., groin and axilla); the most frequent site is the vulva, but perineal, scrotal (Fig. 121-2), perianal (Fig. 121-3), and penile skin are also common areas. Rarely, ectopic EMPD has been reported in areas that are relatively free of apocrine glands, such as the chest, abdomen, thigh, eyelids, face, and external auditory canal.[7–11] Given the unclear association with underlying carcinoma in EMPD as compared to MPD, a palpable mass is much less frequently found on examination.

Related Physical Findings

Up to one-half of all patients with MPD have a palpable underlying breast mass.[4,5,12,13] Of those patients with a palpable underlying tumor, half have axillary adenopathy due to lymph node metastasis.[4,5] Palpable lymph nodes are much less frequently present in EMPD. Complete physical examination is required in all cases of MPD and EMPD for indications of metastases and underlying malignancy. Patients may present with symptoms and physical findings associated with any underlying carcinoma.

Laboratory Tests

PATHOLOGY The intraepidermal adenocarcinoma of EMPD and MPD has a similar histologic appearance. There are groups, clusters, or single cells within the epidermis that show nuclear enlargement with atypia, prominent nucleoli, and well-defined ample cytoplasms (Fig. 121-4).[12] Intercellular bridges are absent. The cells can be within all levels of the epidermis and can compress but preserve the basal layer without junctional nest formation. The cells can extend into the contiguous epithelium of hair follicles and sweat gland ducts. Acanthosis, hyperkeratosis, and parakeratosis are often present. These cells have a "pagetoid" appearance and simulate other intraepidermal malignancies, including melanoma, pagetoid squamous cell carcinoma in situ, mycosis fungoides, cutaneous adnexal carcinomas (sebaceous carcinoma, porocarcinoma, and others), Merkel cell carcinoma, Langerhans cell histiocytosis, and other epidermotropic cutaneous metastases. The cells of MPD and EMPD can be pigmented, which should not necessarily indicate they are melanocytic.

Paget's cells have intracellular mucopolysaccharides, with EMPD having a greater amount of mucin as compared

Box 121-1

Differential Diagnosis of Mammary (MPD) and Extramammary Paget Disease (EMPD)

	Most Likely	*Consider*	*Always Rule Out*
MPD	Nipple eczema	Hailey-Hailey disease	Bowen disease
	Erosive adenomatosis	Pemphigus	Basal cell carcinoma
	Psoriasis		Malignant melanoma
	Dermatophyte infection		
EMPD	Candidiasis	Lichen sclerosus et atrophicus	Bowen disease
	Tinea cruris	Pemphigus	Erythroplasia of Queyrat
	Psoriasis	Lichen simplex chronicus	Malignant melanoma
	Seborrheic dermatitis	Lichen planus	
	Nummular dermatitis	Drug eruption	



▲ **FIGURE 121-3** Perianal Paget disease presenting as moist, superficially eroded patch. (Used with permission from Robert Spencer, MD.)



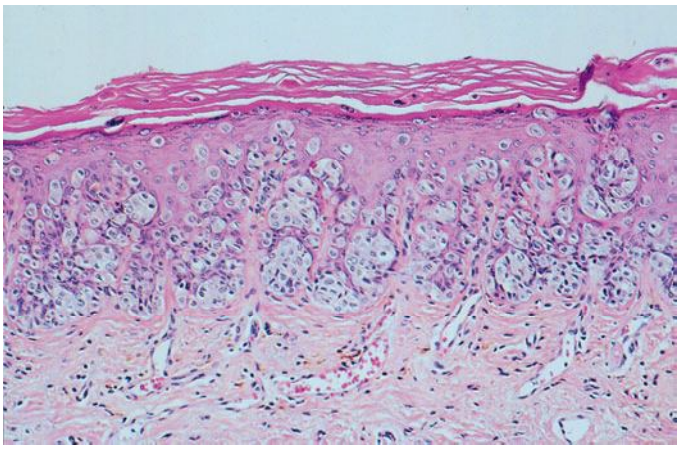

▲ **FIGURE 121-4** Paget disease, hematoxylin and eosin stain. Paget's cells have distinctive pale-staining cytoplasm and are usually randomly dispersed throughout the epidermis.



to MPD. As a result, cells frequently show positive staining for periodic acid-Schiff and diastase resistance, mucicarmine, Alcian blue at pH 2.5, and colloidal iron (see eFig. 121-4.1 in online edition). However, there are can be focal "skip areas" that are devoid of mucin, resulting in negative stains.

Immunohistochemistry is a useful adjunct in making the correct diagnosis. Low-molecular-weight cytokeratin stains cytokeratin 7 (CK7) and anti-cytokeratin (CAM 5.2) are sensitive markers for both MPD and EMPD (see eFig. 121-4.2 in online edition). They are not completely specific, however, with both Toker and Merkel cells showing CK7 positivity. The cells of MPD and EMPD may stain with carcinoembryonic antigen and epithelial membrane antigen. The most useful keratin markers for Paget disease are CAM 5.2 and CK7, as they stain more than 90 percent of Paget's cells but do not react with epidermal or mucosal keratinocytes.[13,14] The cells of pagetoid squamous cell carcinoma in situ typically do not stain with CK7 and CAM 5.2. S100 and HMB-45 are useful markers to exclude melanoma, as both are typically negative in MPD and EMPD.

CK20 positivity has been found more frequently in cases of secondary EMPD with underlying carcinoma as compared to those cases of primary intraepithelial EMPD ($CK7^+/CK20^-$).[15]

Gross cystic disease fluid protein-15 (GCDFP-15) is a marker for apocrine epithelium and is typically positive in primary EMPD not associated with underlying neoplasm. In contrast, GCDFP-15 is frequently negative in those cases of secondary EMPD with an associated malignancy.[16]

Mucin core protein (MUC) expression is useful in the diagnosis of MPD and EMPD.[17] MUC1 positivity is noted in both MPD and EMPD. MUC2 expression is generally negative in primary EMPD, but may be expressed in those cases of secondary EMPD with an associated underlying gastrointestinal adenocarcinoma. MUC5AC is frequently positive in primary EMPD and less commonly noted in secondary EMPD or those cases of primary intraepithelial EMPD that becomes invasive.

SPECIAL TESTS Diagnosis of MPD and EMPD should be accompanied by a thorough search for underlying malignancy. Mammography is indicated in all cases of MPD, with biopsy of any underlying breast mass.

In cases of EMPD, workup is directed toward the possibility of an underlying gastrointestinal or genitourinary neoplasm. Imaging of the abdomen and pelvis, colonoscopy, barium enema, cystoscopy, intravenous pyelogram, chest x-ray and mammogram (for the rare association of EMPD and MPD), and blood work are appropriate tests. Some reports have suggested that positron emission tomography scans may be useful for cases of invasive EMPD to evaluate for lymph node involvement and metastases.[18,19]

COMPLICATIONS

Failure to identify and adequately treat cases of MPD can lead to metastatic disease with a poor prognosis. EMPD, if left untreated, can become invasive with a less favorable outcome.

PROGNOSIS AND CLINICAL COURSE

Overall survival in patients with MPD is affected by lymph node status and the presence of an underlying breast mass. Patients with negative lymph nodes have been shown to have a 10-year survival rate of 75 percent to 95 percent, whereas those with positive lymph nodes have a survival rate of 20 percent to 45 percent.[4] Patients with a palpable breast mass have a 5-year survival probability of 35 percent to 51 percent, as compared to 75 percent to 82 percent in patients without a palpable mass.[5]

The prognosis for primary EMPD confined to the epidermis is excellent with appropriate treatment. Careful monitoring for early detection of local recurrence is critical given the multifocal pattern often present in EMPD. In contrast, invasive EMPD has a high rate of metastasis and carries a poor prognosis. The depth of invasion appears to be an important prognostic factor, with microscopic invasive disease (less than 1 mm) having a more favorable prognosis as compared to those with deeper invasion.[20,21] Lymphovascular invasion and regional lymph node metastases markedly reduces overall survival rate and indicates a very poor prognosis. Clitoral EMPD has been shown to have a higher incidence of death from the disease as compared to other vulvar EMPD locations.[20] In cases of secondary EMPD, the prognosis is related to the underlying carcinoma.

TREATMENT

Mammary Paget Disease (Fig. 121-5)

Treatment of MPD is surgical. However, optimal surgical management of MPD remains to be defined, and treatment choice is frequently based on the presence or absence of an underlying breast mass. Mastectomy remains the standard definitive treatment. However, evidence suggests that MPD treated with breast-conserving surgery results in local control and survival rates similar to those achieved with mastectomy.[22,23] Proper preoperative imaging is required to rule out multi-focal disease that would make breast-conserving therapy less effective and favor mastectomy.[24] Lymph node evaluation via axillary dissection or sentinel lymph node biopsy must be considered in MPD. Adjuvant therapy with radiation, chemotherapy, or hormonal therapy is recommended based on lymph node status and specific features of the primary tumor.[4] All diagnoses of MPD require referral to a physician with expertise in the management of breast cancer.

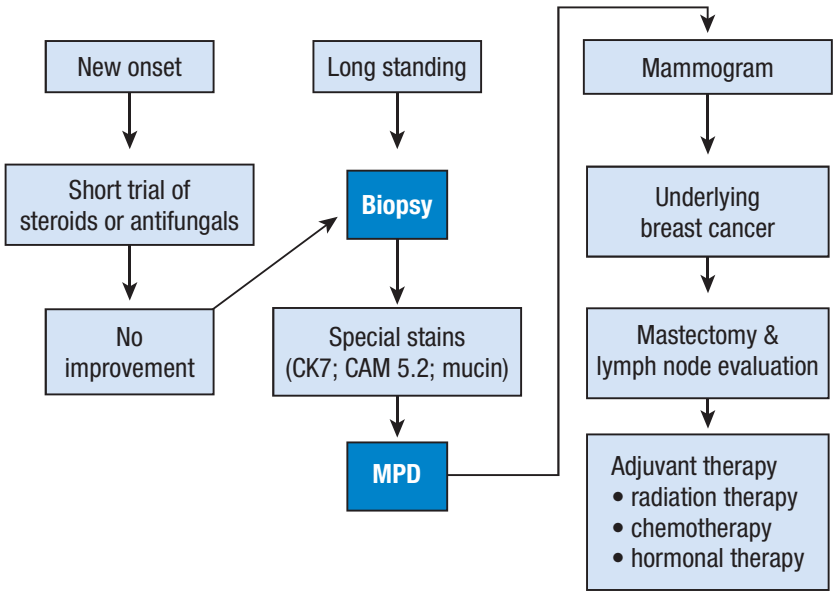

▲ **FIGURE 121-5** Approach to the patient with mammary Paget disease (MPD). CAM 5.2 = anti-cytokeratin stain; CK7 = cytokeratin 7 stain.

Extramammary Paget Disease (Fig. 121-6)

EMPD has been treated with a variety of different modalities. Although surgical management of the disease is the most frequently used method, various other treatments have a role for non-surgical candidates and as adjuvant therapy.

SURGERY Surgery remains the treatment of choice for EMPD when tolerated by the patient. However, high local recurrence rates are seen after standard surgical excision, even with wide margins. This is most likely due to the irregular margins, multi-focal nature of the condition, and subclinical involvement of apparently unaffected skin.

Several reviews have shown an overall recurrence rate of up to 44 percent with wide local excision,[2,25] The local recurrence rates are higher in cases of invasive disease as compared to those limited to intraepithelial involvement. In addition, more radical and extensive surgeries are associated with lower rates of local recurrence. Patients with primary vulvar EMPD treated with radical vulvectomy, radical hemivulvectomy, and wide local excision have reported recurrence rates of 15 percent, 20 percent, and 43 percent, respectively.[25]

Multiple scouting biopsies to help delineate the extent of the disease before surgery can be a useful adjuvant technique.[26] Intraoperative staining with CK7 is the preferred immunostain for intraoperative tissue evaluation.[27] Sentinel lymph node biopsy has been described in the treatment of EMPD.[28] Although this technique has been limited to a small number of reported patients and most cases of EMPD have in situ disease, sentinel lymph node biopsy may prove beneficial for those patients with increased risk of lymph node involvement and metastasis (i.e., dermal invasion of Paget's cells).[29]

MOHS MICROGRAPHIC SURGICAL EXCISION Given the high rates of local recurrence and the significant morbidity associated with radical and repeated surgeries, Mohs micrographic surgical excision (MMS) has been used to improve cure rates and for tissue sparing of critical genitourinary anatomic structures as compared to wide local excision.[2,27,30,31] The recurrence rate after treatment with MMS has been reported as 16 percent for primary EMPD and 50 percent for recurrent EMPD. Ninety-seven percent of the cases treated with MMS required margins of 5 cm from the clinical tumor margin. However, if surgical margins of only 2 cm were used, as may be the case because wider margins may not be feasible when operating on the genitalia, only 59 percent of

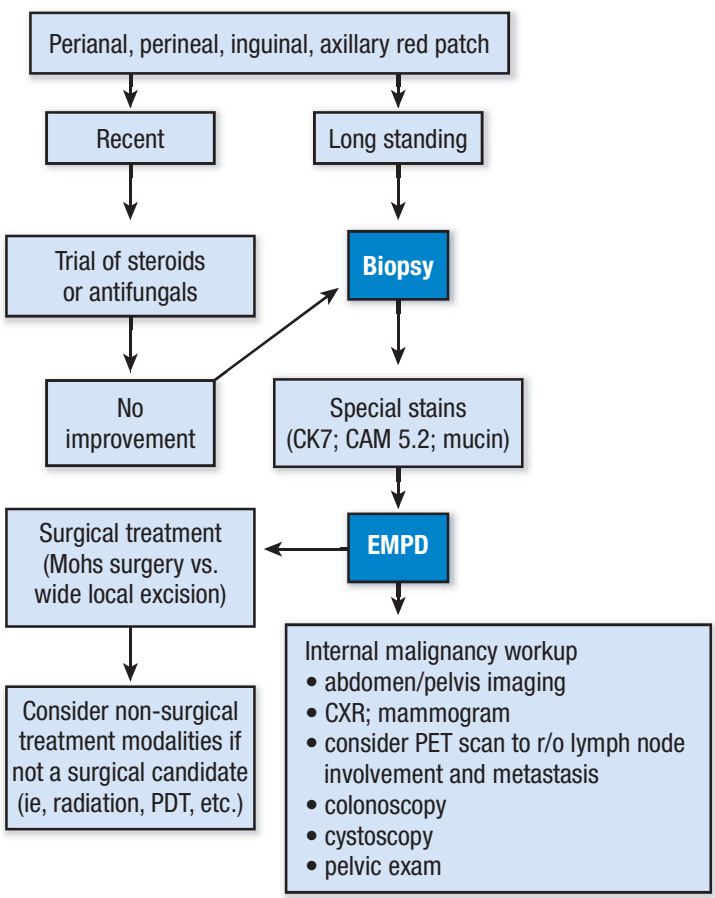

▲ **FIGURE 121-6** Approach to a patient with extramammary Paget disease (EMPD). CAM 5.2 = anti-cytokeratin stain; CK7 = cytokeratin 7 stain; CXR = chest x-ray; PDT = photodynamic therapy; PET = positron emission tomography; r/o = rule out.



the tumors would have been cleared. The 40 percent expected recurrence rate with 2-cm margins is consistent with what is seen in various reports of EMPD treated with standard wide excision. This further validates a potential benefit of frozen horizontal sectioning to evaluate 100 percent of the surgical margin and reduces the possibility of residual tumor, which may result from narrow margins in standard excision.

RADIOTHERAPY Although surgery remains the traditional treatment for EMPD, radiotherapy may be indicated in those patients who are poor surgical candidates or are concerned with the morbidity of genitourinary function due to extensive surgery that is often required for curative treatment.[32–34] In addition, radiotherapy has been described as useful for local recurrence after surgery or as an adjuvant therapy in those patients with a high risk of recurrence.[34,35] No randomized controlled studies comparing surgery to radiotherapy have been performed to date.

TOPICAL CHEMOTHERAPY AND IMMUNOMODULATORS Topical agents, including 5-fluorouracil (5-FU) and imiquimod, have been used to treat EMPD with varying degrees of success.

5-FU may be useful as a preoperative adjunctive treatment to highlight the subclinical extent of disease before MMS or for early postoperative detection of recurrence.[36] However, topical 5-FU has not proven to be a reliably curative agent in the treatment of EMPD.[37] This is likely due to the limited penetration of the drug and the inability to reach the deeper epidermal layers and adnexal structures that are frequently involved in EMPD.

Imiquimod has been reported to result in clinical and histologic cure in several case reports.[38–42] Given the limited number of patients treated with this medication, further studies and long-term follow-up in a larger cohort is necessary.

SYSTEMIC CHEMOTHERAPY Systemic chemotherapy has been used to treat patients with invasive and metastatic disease and may be considered in rare cases in which surgery and radiotherapy are contraindicated. Limited reports of systemic chemotherapy for the treatment of EMPD have been described, including a combination of low-dose 5-fluorouracil and cisplatin[43]; a combination of 5-FU, cisplatin, mitomycin C, epirubicin, and vincristine[44,45]; and docetaxel.[46,47]

PHOTODYNAMIC THERAPY Given the patchy nature of EMPD and extension beyond clinically visible tumor, photodynamic therapy (PDT) is a potentially useful treatment modality. Although the limited number of studies and reports makes further investigation necessary, PDT may be considered in patients who are poor surgical candidates, are at risk for significant functional morbidity due to the anatomic location of the disease, or have recurrent postsurgical disease.[48–51] Limiting treatment to intraepithelial disease is prudent given the limitations of current PDT technology. PDT has been described as an adjuvant to surgical treatment to better define clinical margins and improve recurrence rates.[27]

PREVENTION

Both EMPD and MPD are not preventable diseases. Rather, early diagnosis is the key to a favorable prognosis, and any unilateral eczematous rash on the breast or in the groin that does not respond to an appropriate course of topical treatment warrants a biopsy. Routine mammography may allow early detection of underlying breast carcinoma in women of appropriate screening age.

KEY REFERENCES

The full reference list for all chapters is available at www.digm7.com.

2. Zollo JD, Zeitouni NC: The Roswell Park Cancer Institute experience with extramammary Paget's disease. *Br J Dermatol* **142**:59, 2000
3. Shepherd V, Davidson EJ, Davies-Humphreys J: Extramammary Paget's disease. *BJOG* **112**:273, 2005
4. Fu W, Mittel VK, Young SC: Paget disease of the breast: Analysis of 41 patients. *Am J Clin Oncol* **24**:397, 2001
5. Kollmorgen DR et al: Paget's disease of the breast: A 33-year experience. *J Am Coll Surg* **187**:171, 1998
20. Parker LP et al: Paget's disease of the vulva: Pathology, pattern of involvement, and prognosis. *Gynecol Oncol* **77**:183, 2000
25. Fanning J et al: Paget's disease of the vulva: Prevalence of associated vulvar adenocarcinoma, invasive Paget's disease, and recurrence after surgical excision. *Am J Obstet Gynecol* **180**:24, 1999
27. O'Connor WJ et al: Comparison of Mohs micrographic surgery and wide excision for extramammary Paget's disease. *Dermatol Surg* **29**:723, 2003
34. Luk NM et al: Extramammary Paget's disease: Outcome of radiotherapy with curative intent. *Clin Exp Dermatol* **28**:360, 2003



SECTION 22

MELANOCYTIC TUMORS

CHAPTER 122

Benign Neoplasias and Hyperplasias of Melanocytes

James M. Grichnik
Arthur R. Rhodes
Arthur J. Sober

Benign melanocytic proliferative lesions form a spectrum of disorders ranging from a massive accumulation of cells in multiple tissue elements to epidermal foci with a simple increase in epidermal melanocyte number. Here these lesions are separated into *melanocytic neoplasias* and *melanocytic hyperplasias.* The term *melanocytic neoplasia* is used to describe the presence of melanocytic cells in epidermal nests (defined as three or more melanocytic cells in direct contact (also known as *thèque*), within the dermis, or in other tissues. The melanocytic neoplasms are referred to as nevi (singular: nevus) and the melanocytic cells forming these nevi are referred to as *nevomelanocytes*. The term *melanocytic hyperplasia* is used to indicate increased melanocytes confined to the basal layer of the epidermis.

The specific molecular events causing melanocytic neoplasias and hyperplasias are still largely unknown. Given the identification of specific mutations (such as B-RAF)[1] and the clonal nature of nevi,[2–4] it is likely that these lesions are derived from a single progenitor cell and are the result of the dysregulation of specific cellular pathways. Given the presence of immature (less melanized) cells in many melanocytic neoplasias, it seems likely that specific underlying mutations disrupt normal melanocytic development and result in accumulation of the nevomelanocytic cells that do not complete typical migration and differentiation. The melanocytic hyperplasias are comprised of epidermal melanocytes at an increased concentration and thus alterations of normal melanocytic homeostatic mechanisms appear to be operative. These alterations could be due to a primary melanocytic defect (such as an ultraviolet-induced mutation) or homeostatic signaling changes in the local environment (possibly driven by mutations within the local keratinocytes, fibroblasts, or other resident cells).

Until discrete molecular markers are better defined, definitive subclassification of these melanocytic lesions is not possible. This heterogeneous group of disorders is currently loosely subcategorized based on clinical features and microscopic characteristics. The neoplasias described include congenital nevomelanocytic nevi (CNNs), nevus spilus, common acquired nevomelanocytic nevi (excluding atypical/dysplastic nevi covered in Chap. 123), blue nevi, pigmented spindle cell nevi (PSCN), Spitz nevi, and nodal nevi. Cutaneous melanoma is covered separately in Chap. 124. The benign melanocytic hyperplasias described in this chapter include lentigo simplex (including agminated lentigines) and solar lentigines.

CONGENITAL NEVOMELANOCYTIC NEVI

Epidemiology

The vast majority of CNNs noted at birth are small and singular, and no gender predilection has been demonstrated. The most reliable prevalence rate for CNN in a homogeneous ethnic group was obtained by biopsying all pigmented lesions in 841 white infants examined within 72 hours of birth: Of 21 infants with pigmented lesions, 7 babies (0.83 percent of 841) had a biopsy-confirmed nevomelanocytic nevus.[5] Many other series have yielded equivalent results. CNNs of 99 mm or more in diameter occur in only 1 of every 20,000

CONGENITAL NEVOMELANOCYTIC NEVUS AT A GLANCE



- Melanocytic neoplasm often exhibiting extensive nevomelanocytic infiltration of the dermis with potential involvement of the underlying adipose and muscular tissue.
- The lesions may be small or cover a substantial portion of the body surface. They are generally darker than the surrounding skin, have a rugated or smooth elevated surface, and may demonstrate long, darker, thicker hairs.
- Present at birth (or shortly thereafter—tardive congenital nevomelanocytic nevus).
- Large lesions have a significant risk of melanoma development. Cranial or midline lesions and large congenital nevomelanocytic nevus lesions with satellite lesions have an increased risk of leptomeningeal involvement.
- Synonyms: garment nevus, nevus pigmentosus et pilosus, giant nevus, verrucous nevus, and giant pigmented nevus.



Copyright © 2008 by The McGraw-Hill Companies, Inc. Click here for terms of use.



▲ **FIGURE 122-1** Familial aggregation of small congenital nevomelanocytic nevi. Note small congenital nevus on the thigh of a 3-year-old white boy and on the back of his 5-year-old male sibling.



newborns, and CNNs with a garment distribution occur in only 1 of every 500,000 newborns.[6] Familial aggregation has been demonstrated for both large and small varieties of CNN (Fig. 122-1). Discordance for giant CNNs has been demonstrated for identical twins in at least three cases and for non-identical twins in two cases.

Etiology and Pathogenesis

CNNs represent a developmental abnormality of normal melanocytic development. This is presumably due to mutation (potentially NRAS)[7] that occurs in a progenitor cell that results in the abnormal extensive accumulation of melanocytic cells along migration pathways during normal development. The events leading to the nevomelanocyte accumulation may also have effects on the surrounding tissue (i.e., increased length/darker hair) possibly due to changes in the local cytokine environment of the nevomelanocytic cells. Clinical findings such as a congenital divided nevus of the eyelid (Fig. 122-2) can give us insight into when these events occur.[8] The eyelids form at between 5 and 6 weeks in utero, begin to fuse at about 8 to 9 weeks, and reopen during the sixth uterine month.[9] Because of the contiguous nature of this lesion on the upper and lower eyelids, it may be presumed that the nevomelanocytes migrated into this location sometime during or after eyelid fusion but before the eyelids split.

Clinical Findings (Fig. 122-3)

HISTORY Most CNNs are present at birth; however, there are also rare varieties of relatively large nevomelanocytic nevi (> 1.5 cm) that appear for the first time between 1 month and 2 years of life, according to parental observations and corroborated by photographs (tardive congenital nevi).



▲ **FIGURE 122-2** Congenital divided nevomelanocytic nevus of the eyelid. The nevus is contiguous when the eyelids are closed, suggesting that the lesion was formed in the developing fetus before the eyelids split (i.e., before 24 weeks).

As a child grows, the CNN should grow relatively proportionally[10] and continue to "mature." History of disproportionate growth, especially after 6 months, or change in a non-uniform manner is of concern for possible melanoma.

Both small and large varieties of CNNs have been associated with loss of pigmentation, halo depigmentation, and even regression.

CUTANEOUS LESIONS Although CNNs are on average larger than acquired nevi, for lesions less than 1.5 cm in diameter there is no specific size limitation that can be used to predict reliably whether a given nevus is congenital or acquired. Lesions attaining a diameter of 1.5 cm or more are likely to be congenital, atypical melanocytic nevi, or melanoma.

There is no completely satisfactory way to categorize CNNs as small or large. Definitions have been based on ease of removal and termed *small* if they can be excised and the wound defect closed primarily without significant deformity. Arbitrary size criteria have also considered small (< 1.5 cm; see eFig. 122-3.1 in on-line edition), medium (1.5 to 19.9 cm), and large (≥ 20 cm). Size, of course, is all relative to the location and the patient. *Giant* has been variously defined as a lesion as large as the patient's palm if it occurs on the head and neck (and twice that area for other anatomic sites), 30 percent of the body surface, or 900 cm^2 in adults (or smaller if it involves a major anatomic area) (see Congenital Nevomelanocytic Nevus At a Glance figure). Depending on the definition used, lesions that are regarded as small or medium in the newborn period may be designated medium or large, respectively, by late childhood or adulthood, given that CNNs appear to grow in proportion to the affected anatomic site.[10]

Pigmented lesion present at birth, macular or papular, may be extensive.
If diagnosis is not clear a small biopsy may be indicated.
Differential diagnosis includes café au lait macule (CALM), dermal melanocytosis (Mongolian spot), and epidermal nevus

↓

Cranial or midline large CNN and large CNN with satellite lesions, have an increased risk of neurocutaneous/leptomeningeal involvement.
MRI may be indicated

↓

When deciding whether lesion is to be excised or observed, one must weigh risk of melanoma, cosmetic and functional issues against anesthesia, surgical and scarring risks.

↓

Any lesion that is non-uniform in appearance on a single examination or demonstrates a non-uniform change over time must be considered for excision to rule out melanoma

▲ **FIGURE 122-3** Approach to the patient with congenital nevomelanocytic nevus (CNN). MRI = magnetic resonance imaging.

The contour of CNNs is usually smooth, regular, and sharply demarcated, and skin markings distort the skin surface at least slightly when assessed by oblique lighting. Some CNNs are relatively hairless. However, coarse, long, darkly pigmented hair may be present at birth, appear within the first year or two of life, or be delayed for several years. Lesions may have a smooth, pebbly, rugose, verrucous, cerebriform, or grossly lobular surface. CNNs with a cerebriform appearance may present as cutis verticis gyrata.

Dermoscopy may reveal a reticular pattern or globular/cobblestone pattern and may be useful in the identification of small foci of melanoma. In large congenital nevi, there can be significant variability in pigmentation and structure, and melanomas may develop in the deep components potentially reducing the utility of dermoscopy in these lesions.

Unique varieties of CNNs may have an atypical appearance and be striking for their haphazard, very dark-brown, black, or blue-black pigmentation or discontinuous pigmentation and poorly demarcated and/or irregular outlines, often associated with atypical histopathologic features. Very darkly pigmented CNNs are distinctly uncommon in whites and should suggest the possibility of atypical histopathologic features. In darkly pigmented infants, CNNs are usually darkly pigmented.

RELATED PHYSICAL FINDINGS CNNs of the head, neck, or posterior midline, and/or the presence of multiple satellite lesions associated with large CNN may be complicated by underlying cranial and/or spinal leptomeningeal melanocytosis. This phenomenon may be asymptomatic or may give rise to communicating or noncommunicating hydrocephalus, seizures, focal neurologic deficits, mental retardation, or even melanoma. CNNs need not be giant to be associated with this underlying disorder.

There is a significant association between neurofibromatosis and giant CNNs. In a study by Crowe et al.,[11] 3 of 223 patients with neurofibromatosis had extensive CNNs. In his monograph on neurofibromatosis, von Recklinghausen described 1 of 28 patients as having a giant CNN.[12] Tumors indistinguishable from neurofibroma in the absence of von Recklinghausen neurofibromatosis may develop in association with giant varieties of CNN.

Malignant degeneration of large CNNs may be associated with the relatively sudden appearance of a dermal or subcutaneous nodule, very dark pigmentation, itching, pain, bleeding, or ulceration. Often, CNN-associated melanomas appear to have evolved in nonepidermal locations.[13] Therefore, early detection of melanoma in association with a giant CNN may be difficult and not recognized until a dermal nodule or metastatic disease appears. The prognosis for patients who develop melanoma in association with giant CNNs is usually grave.[13] Unlike melanoma in general, there is no ethnic predilection for melanoma developing in giant CNN. There have been multiple cases of lethal melanoma developing in association with giant CNNs in black children.

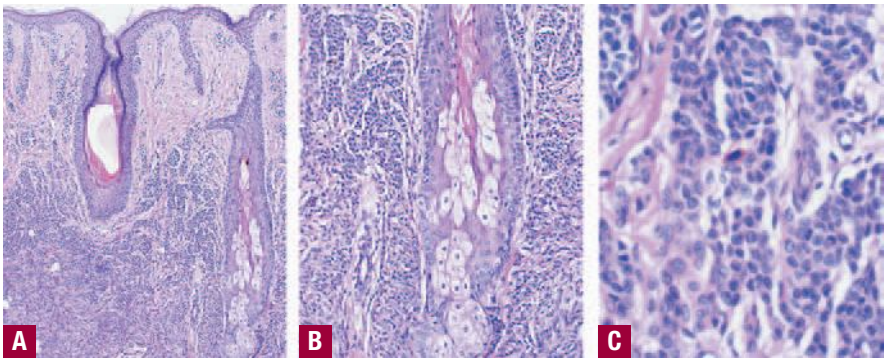

▲ **FIGURE 122-4** Histopathologic features of congenital nevomelanocytic nevus. Nevomelanocytes in the low-magnification image (**A**) reveal dense accumulation in the lower two-thirds of the dermis; at medium magnification (**B**), these cells encroach on dermal adnexal structures (follicular and eccrine); and higher magnification (**C**) reveals dense collections of small nevomelanocytic cells.

Laboratory Tests

HISTOPATHOLOGY CNNs are characterized by the presence of nevomelanocytes in the epidermis as well-ordered thèques and/or nevomelanocytes in the dermis which are present as sheets, nests, cords, and/or single cells. Although histopathologic features are cited as being useful in distinguishing nevi as congenital or acquired, there are no known features with absolute specificity and sensitivity. The histopathologic features of very large CNNs may be divided into nevomelanocytic, neuroid, epithelioid cell and/or spindle cell, blue, and mixed types.

In the nevomelanocytic type of large CNN, the histopathologic appearance may be identical to typical acquired nevi, with nevomelanocytes in the epidermis as well-defined thèques and/or nevomelanocytes in the papillary dermis as sheets, cords, or nests. CNNs are more likely than acquired nevi to have nevomelanocytes in the lower two-thirds of the reticular dermis and to be associated with appendageal and neurovascular structures (Fig. 122-4). There may be preferential involvement of one or more epithelial structures in CNN, such as eccrine ducts, and these structures may be abundant and malformed. Veins may be preferentially involved, with an "inflammatory" appearance showing nevomelanocytes within and around blood vessel walls. Subendothelial protrusion by nevomelanocytes in lymphatic vessels may be prominent. Arrector pili may be malformed, large, and infiltrated by nevomelanocytes. Hair follicles are often quite large and frequently associated with abundant melanin in the hair bulb. Nevomelanocytes in the deep reticular dermis may be distributed as single cells or as a single-file array insinuating among collagen bundles, sheets of cells, or combinations of patterns.

Unique to the very large CNN is the occasional presence of nevomelanocytes within the substance of muscle, bone, placenta, umbilical cord, cranium, and dura mater. Very extensive CNN may be intermixed with elements of vascular malformation, hemangiomas, increased numbers of mast cells, cartilage, calcification, and even bone. There may be sparse mononuclear cell infiltrates associated with some giant CNNs. In addition to melanoma, associated tumors developing in CNN include schwannoma, neuroid tumor, lipoma, rhabdomyosarcoma, neurofibroma, sebaceous nevus, hemangioma, lymphangioma, and mastocytoma. A possible explanation for these mixed neoplasms containing melanocytic, neuronal, and other elements is that the CNN precursor cell, at least in some cases, is a pluripotent stem cell that has the capacity to give rise to multiple cell types.

In giant CNNs, nevomelanocytes have been found in regional lymph nodes



without further evidence of progressive metastatic disease. Whether this deposition occurred during the migration of the cells through the dermis or was secondary to migration from the skin after the neoplasm developed is unknown. The presence of nevomelanocytes in the nodal tissue from these lesions does not imply malignancy (see nodal nevi).

CNNs may also give rise to proliferative nodules that may be difficult to differentiate from melanoma.[14]

SPECIAL TESTS For patients with concern of possible leptomeningeal involvement, magnetic resonance imaging should be considered. For patients with concern of melanoma, positron emission tomography scan may be considered.



Differential Diagnosis (Box 122-1)

Complications

The relationship between melanoma and large CNNs is well documented. The risk of melanoma development appears to be proportional to the size of the congenital nevus. The cumulative 5-year risk has been calculated to be 2.3 percent[15] and 5.7 percent[16] in patients with congenital nevi that involve over 5 percent of the body surface. The lifetime risk of melanoma for patients with very large CNNs has been estimated to be at least 6.3 percent, based on a questionnaire follow-up study of 151 persons with CNNs examined between 1915 and 1973 in Denmark.[17] Melanoma may develop in large CNNs at any time, but the diagnosis of melanoma was established in the first 3 to 5 years of life in approximately one-half of published cases in which patients ultimately developed melanoma in association with giant CNN.

A causal association between small CNNs and melanoma is more difficult to establish than for large CNNs. When histopathologic features were studied, 6 percent to 8 percent of primary melanomas were found to be in contiguity with nevi that had microscopic features characteristic of CNN.[18,19] These findings support the concept of melanoma risk even with small congenital nevi, given the expected chance association based on body-surface-area considerations.[20]

For cranial, midline, or CNN with multiple satellite lesions, there is a risk of leptomeningeal involvement. Symptomatic leptomeningeal melanocytosis carries a poor prognosis, even in the absence of malignant degeneration.

Box 122-1

Differential Diagnosis of Congenital Nevomelanocytic Nevus

- Café-au-lait macule
- Nevus spilus
- Lentigo simplex
- Nevus of Ota/Ito
- Dermal melanocytosis (mongolian spot)
- Becker's melanosis
- Arrector pili (smooth muscle) hamartoma
- Epidermal nevus
- Nevus sebaceous
- Solitary mastocytoma

Prognosis and Clinical Course

CNNs have a dynamic evolution during body growth. CNNs at birth usually distort the skin surface at least slightly when assessed by oblique lighting and may become more elevated over time. Surface pigmentation also may change. Lightly pigmented CNNs may become more darkly pigmented, and darkly pigmented CNNs eventually may become less pigmented. CNNs also may develop a halo of depigmentation, potentially heralding spontaneous regression. Loss of pigmentation has been associated with regression of underlying nevomelanocytes and the replacement with sclerosis in some cases. Relatively hairless CNNs at birth may develop long, dark, coarse hair or may maintain a relatively normal hair density. With few exceptions, CNNs generally expand in direct proportion to growth of a given anatomic zone, although disproportionately rapid area expansion of some congenital nevi may occur during early infancy.[10] Lesions in fully grown individuals should remain stable.

Treatment

The treatment of CNNs, large and small, depends on the perceived risk of melanoma plus cosmetic and functional considerations.

Melanoma may arise in very large CNNs even in the first several years of life. Therefore, excision of very large CNNs should be considered as early as possible, but it is probably prudent to wait until after the first 6 months of life to reduce surgical and anesthetic risks. Management of patients with very large CNNs must be individualized. Extensive involvement of the body surface, with little or no normal skin available for graft sites, may necessitate abandoning efforts at prophylactic excision and accepting lifelong surveillance to detect the earliest signs of malignant change. It may be impossible to remove every nevomelanocyte in very large CNNs, particularly when there is involvement of vital structures or deep anatomic zones. The treatment goal is to remove as much of the nevus as possible while preserving function and improving cosmetic appearance. Tissue expansion and artificial skin replacement are invaluable in repairing large wound defects. Other indications for surgical excision of very large CNNs include chronic pruritus, ulceration, and infection. Unlike surgical excision, dermabrasion and other modes of destructive therapy do not address the malignant potential of CNN; nevomelanocytes may still be left behind in the dermis, and the cosmetic results associated with destructive therapy are unpredictable. Melanoma has been reported after dermabrasion of large CNNs.[21] "Pseudomelanoma" has been described after laser treatment of a giant CNN.[22]

The approach to small CNNs needs to be considered carefully. It appears that the risk of melanoma development depends on CNN size, and therefore, smaller lesions appear to have less risk. However, due to the smaller size, complete excision of small congenital nevi may be relatively straightforward, resulting in excellent cosmetic results. Although atypical-appearing CNNs should be considered for immediate excision, careful surveillance without excision may be an option for clinically benign lesions depending on gross appearance, size, location, cosmetic and functional deficits (or improvement) resulting from excision, and general health issues. Given the risk of general anesthesia, for lesions perceived to be at low risk during the first decade of life it is appropriate to consider waiting until the child is old enough to tolerate local anesthesia. All CNNs should be documented at birth, preferably in the form of high-quality photographs that can be used to aid follow-up by parents and physicians. Follow-up is complicated by the natural evolutionary changes that take place in a nevus during body growth (i.e., surface, size, color, and hair), and periodic updates of photographs may be warranted. Suspicious changes in color, surface, or size require urgent evaluation.

Prevention

There is no known preventive approach to avoid the development of congenital nevi. Ultraviolet radiation (UVR)–induced mutations clearly play no role

NEVUS SPILUS AT A GLANCE

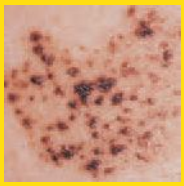

- Localized collection of melanocytic neoplasias forming in the background of a melanocytic hyperplasia. The neoplastic elements within the lesion tend to be histologically similar in appearance. In some lesions, the darker elements may only demonstrate increased hyperplasia compared to the background lesion.
- Clinically, the lesion appears as a hyperpigmented patch with scattered darker elements clinically similar in appearance.
- Background lesion may be present at birth but generally develops during infancy or early childhood. The neoplastic or hyperplastic elements may continue to develop within the lesion over time.
- Overall, risk is low but melanoma has been noted to develop in nevus spilus.
- Nevus spilus (derived from Greek *spilos*, meaning *spot*)—spotted nevus. Synonyms: speckled lentiginous nevus and zosteriform lentiginous nevus.
- Related variants with localized collection of nevomelanocytic neoplasias without the background of melanocytic hyperplasia are referred to as agminated nevomelanocytic nevi.
- Related variants with localized collection of melanocytic hyperplasias without the background of melanocytic hyperplasia are referred to as *agminated lentigines* (see Lentigo Simplex).

in the initial development of the lesions already present at birth. There is no current data on parental exposure that may give rise to congenital nevus formation in their offspring. The role of subsequent UVR exposure for secondary development of melanoma is unclear. However, it seems prudent to protect lesions from unnecessary UVR exposure.

NEVUS SPILUS

Epidemiology

Nevus spilus occurs in less than 0.2 percent of newborns, 1 percent to 2 percent of white school children, and 2 percent of white adults.[23] There are no prevalence data in darkly pigmented persons. There does not appear to be a gender predilection.[23] When viewed as a risk marker for melanoma, nevus spilus shows a trend for being more common in melanoma cases than in controls. Kopf et al.[23] detected nevus spilus in 5 (4.8 percent) of 105 white adults with melanoma compared with 14 (2.3 percent) of 601 dermatology outpatients.

Etiology and Pathogenesis

Nevus spilus may be postulated to develop along similar pathways as a congenital nevus, but instead of the underlying mutation creating a massive accumulation of nevomelanocytic cells in the dermis, the genetic defect creates a field of cells that are susceptible to a secondary event leading to the development of focal individual melanocytic neoplasms within the localized melanocytic hyperplasia. The specific mutations, chromosomal aberrations (mosaicism), and/or dysregulated pathways involved in this process are unknown.

Clinical Findings (Fig. 122-5)

HISTORY Rarely, nevus spilus may be present at birth. More commonly, the lesion becomes evident during infancy or early childhood. More darkly pigmented, flat, or raised elements are usually present when the lesion is first recognized, but new pigmented elements may appear over time.

CUTANEOUS LESIONS Clinically the lesion presents as a circumscribed macule/patch of tan pigmentation with features consistent with lentigo or café-au-lait macule including scattered, more darkly pigmented nevomelanocytic (or more hyperplastic) macular and/or papular elements (see figure in At a Glance box). The tan macular background pigmentation ranges from less than 1 cm to greater than 10 cm in diameter (Fig. 122-6). Although nevus spilus may occur anywhere, lesions have been noted primarily on the torso and extremities. A divided nevus spilus of the eyelid has been reported.[24] Lesions may be localized or have a segmental distribution. Giant varieties of nevus spilus may occur.

RELATED PHYSICAL FINDINGS Nevus spilus has been associated with other anomalies of vascular, central nervous system, or connective tissue origin. Multiple granular tumors and nevus flammeus have been associated with a giant nevus spilus.

Laboratory Tests

HISTOPATHOLOGY The tan background pigmentation usually consists of increased numbers of melanocytes in a lentiginous epidermal pattern. Routine and electron microscopic studies of nevus spilus may demonstrate melanin macroglobules in some cases. The flat, dark elements of nevus spilus may demonstrate foci of increased melanocytic hyperplasia or melanocytic dysplasia (architectural disorder and variable cellular atypia), whereas the raised elements usually contain collections of nevomelanocytes in the epidermis and/or dermis. The neoplastic elements of nevus spilus also may consist of epithelioid and/or spindle cell nevi, nevi with dysplastic features, or blue nevi.

SPECIAL TESTS There are no identified molecular tests of value, at least currently.

Differential Diagnosis (Box 122-2)

Complications

There are insufficient data to be certain of the natural history of nevus spilus or to comment specifically about its malignant



Background evenly hyperpigmented patch but also including scattered hyperpigmented foci. Wood's light may be required to visualize background hyperpigmention.

↓

New hyperpigmented foci may develop over time.
If one of the foci is unusual compared to the others, is non-uniform, and/or changing, it should be excised to exclude the possibility of melanoma.

▲ **FIGURE 122-5** Approach to the patient with nevus spilus.







▲ **FIGURE 122-6** Nevus spilus. **A.** Nevus spilus appearing first at age 3 years on the ankle and foot of a 25-year-old white woman. **B.** Congenital nevus spilus on the arm of a 10-year-old white male.

potential; however, caution must be exercised in affected individuals. Melanoma has been noted to develop in contiguity with nevus spilus, with some cases ending in metastatic disease and death.

Prognosis and Clinical Course

In general, nevus spilus is a benign lesion that may develop more spotted elements over time. Once developed, nevus spilus lesions are presumed to persist throughout life, although it is possible that some elements within the nevus spilus or even the entire nevus spilus itself could regress with time. There are no long-term follow-up studies of nevus spilus.

Treatment

No standard guidelines exist for the management of patients with nevus spilus. Clinical appearance (typical or atypical), history of stability or instability of pigmented elements, congenital or noncongenital onset, perceived risk of developing melanoma, and cosmetic concerns are considerations when determining whether to excise or recommend periodic clinical evaluation for life. Atypical-appearing new and/or unstable elements in nevus spilus should be evaluated by histopathologic examination to exclude melanoma. A nevus spilus with dysplastic or congenital features may have a greater risk of developing melanoma.[25,26]

Box 122-2

Differential Diagnosis of Nevus Spilus

- Agminated nevomelanocytic nevi
- Agminated lentigines
- Becker melanosis
- Congenital nevomelanocytic nevus
- Café-au-lait macule

Prevention

It is theoretically possible that increased UVR exposure results in the development of new nevomelanocytic proliferations or increased malignant potential of nevus spilus.

COMMON ACQUIRED NEVOMELANOCYTIC NEVUS

Epidemiology

Common (also called *typical*) acquired nevomelanocytic nevi develop after birth, slowly enlarge symmetrically, stabilize, and after a period of time may regress. The majority of common acquired nevi appear to develop during the second and third decades of life, although some lesions may appear in the first 6 to 12 months of life.

A number of studies have quantified the number of typical acquired nevi in different age groups. In 432 European whites between the ages of 4 days and 96 years, nevi that were 3 mm in diameter or larger were detected in females and males, respectively, at median numbers of 0 and 2 in the first decade, 10 and 16 in the second decade, 16 and 24 in the third decade, 10 and 19 in the fourth decade, 12 and 15 in the fifth decade, 4 and 12 in the sixth decade, and 2.0 and 3.5 in the seventh through the ninth decades.[27] In a series of Australian whites, the average number of nevi per person peaked at 43 for males and 27 for females during the second and third decades, respectively, and decreased to very few in the sixth and seventh decades.[28] A similar age-related prevalence rate for nevi has been documented in other countries. A difference in frequency distribution of nevi according to gender is not clear, although most series show a close to equal prevalence in males and females.

The prevalence of acquired nevi varies according to ethnicity. In African blacks, the overall prevalence of nevi (regardless

COMMON ACQUIRED NEVOMELANOCYTIC NEVUS AT A GLANCE





- A spectrum of nevomelanocytic neoplasias often subcategorized based on location of cells: cells in the epidermis (junctional), dermis (intradermal), or both areas (compound). Pathologically, the cells in the deeper dermis tend to be smaller in size and express melanocytic antigens at reduced levels.
- Clinically, the lesions tend to be uniform in appearance and relatively small in size.
- Primarily develop during childhood/young adulthood.
- Increased numbers of acquired nevi suggest an increased risk for melanoma development (see Chap. 124).
- Synonyms: nevus cell nevus, nevocellular nevus, nevocytic nevus, soft nevus, neuronevus, pigmented nevus, pigmented mole, common mole, melanocytic nevus, hairy nevus, cellular nevus, and benign melanocytoma.

of size) tends to be higher in those with lighter skin versus those with darker skin.[29] When prepubertal whites were examined for nevi, a significant association for excess nevi was documented for pale skin, blue or green eyes, blond or light-brown hair, and a tendency to sunburn, but not a tendency to freckle.[30] Other studies show variable relationships to these same parameters.

Environmental exposure to UVR appears to be a critical permissive or inciting factor for the development of nevomelanocytic nevi. In an Australian study, nevus density has been shown to increase with increasing sun intensity in the northern parts of the continent.[31] Furthermore, the use of UVR-blocking sunscreens has been shown to decrease the number of new nevi in children.[32]

Genetic factors appear to play a role in the development of nevomelanocytic nevi. The size, frequency, and distribution patterns of acquired nevi tend to aggregate in families. This observation is well documented for atypical nevi in the setting of familial cutaneous melanoma (see Chap. 124) and CNN.

Acquired nevi may be attacked by the patient's immune system, resulting in the development of a halo nevus (see History). Of 8298 whites aged 12 to 16 years, there were 51 males (1.2 percent) and 22 females (0.5 percent) who had one or more halo nevi, for an overall prevalence rate of 0.9 percent.[33] In one large series of halo nevus,[34] individuals ranged in age from 3 to 42 years (mean age, 15 years), with the vast majority of cases occurring before age 20 years.

Etiology and Pathogenesis

There has been an ongoing debate as to the origin of nevi. Although many theories have been proposed, and some supporting data are available, the critical events leading to nevus development remain a mystery. Current data suggest that nevomelanocytic nevi are clonal,[2–4] and a specific B-RAF[1] mutation has been identified and is likely to play a role in the majority of common acquired (including atypical) and congenital nevi. However, the B-RAF mutation does not seem to play a major role in blue nevi or Spitz nevi. H-RAS may play a role in some Spitz nevi, but it is clear that many more mutations are yet to be identified and correlated with the different nevus phenotypes.

Melanocytic "precursor" cells have been shown to be present in adult human skin,[39] and melanocytic stem cells have been identified in the epidermis in murine system.[40] It is assumed that these melanocytic stem cells accumulate mutations, and when needed to replenish melanocytes, they produce nevomelanocytes instead. Presumably, these nevomelanocytes then attempt to migrate along normal developmental pathways from the dermis into the epidermis. Dependent on the underlying mutation, some cells might also migrate aberrantly. The defect, timing, and local tissue influences could allow for the creation of a variety of different melanocytic neoplasias.

The clinical phenomenon of eruptive nevi also further confounds the location of the cell of origin issue. In these patients, there is the abrupt appearance of numerous similar appearing nevi often in the setting of immunosuppression or chemotherapy. Although it is generally assumed that these lesions all directly originate in the skin, drawing a comparison with epidermotropic metastatic melanoma leaves open the possibility of a circulating nevomelanocytic precursor.

Clinical Findings (Fig. 122-7)

HISTORY Acquired nevi primarily develop during childhood and early adulthood. Although nevi can clearly persist in a stable state for decades, many eventually regress. In a study following patients with dysplastic/atypical nevi, the highest rate of nevus development and nevus regression was present in patients younger than 30 years of age.[42] In later adult years, nevus counts are significantly less than those in young adulthood, and new nevi are rare, but melanoma is more prevalent. Thus, a growing lesion in an adult has a greater risk of being melanoma.

Spontaneous and concurrent development of scattered nevomelanocytic nevi often similar in appearance has been termed *eruptive nevi*. Often, these patients have experienced a blistering skin disease, immunosuppression, or chemotherapy. Eruptive nevi may have a pattern consistent with common acquired nevi, but Spitz nevi and blue nevi have also been described.

Patients may also present with the history of spontaneous development of a zone of depigmentation around a preexisting nevus. This phenomenon has been called a *halo nevus*. The halo phenomenon may be associated with acquired and CNN as well as with melanoma and non-melanocytic tumors. This phenomenon often, but not always, indicates the onset of involution and subsequent regression of the melanocytic nevus. Other names for this phenomenon include *leukoderma acquisitum centrifugum, Sutton's nevus, leukopigmentary nevus, perinevoid vitiligo,* and *perinevoid leukoderma*. Time for full evolution to depigmentation of the halo is not known, but patients report the phenomenon occurring over days to weeks, with little change occurring in the halo thereafter. The central nevus may persist or eventually disappear. Disappearance may take months to years. Areas of depigmentation that remain after the central nevus disappears may remain stationary for many years or re-pigment after months to years. There are lesions in which the nevus does not involute, and repigmentation of the depigmented halo may occur.



CUTANEOUS LESIONS Common acquired nevi vary considerably in their gross appearance. In general, appearance to the naked eye is orderly: The lesions have a homogeneous surface and coloration pattern, round or oval shape, regular outlines, and relatively sharp borders (Fig. 122-8). Common acquired nevi may be papillomatous, dome-shaped, pedunculated, or flat-topped and usually are flesh-colored, pink, or brown. More elevated acquired nevi tend to be more lightly pigmented, and flatter acquired nevi tend to be more darkly pigmented. More elevated and less pigmented lesions tend to have a prominent intradermal nevus component, whereas flatter and darker lesions have a more prominent junctional melanocytic or nevomelanocytic component and a less prominent dermal component. Very dark brown and black are unusual colors for common acquired nevi in lightly pigmented people. In contrast, dark pigmentation is usual for common acquired nevi in people who have darkly pigmented skin. Blue, gray, red, and white areas in a nevus are not typical features and ought to be viewed with suspicion. The surfaces of nevi may reveal hair that is less than, equal to, or greater than that of surrounding skin. Hair in nevi may be coarser, longer, and darker than that in surrounding skin (often these lesions reveal congenital features). Lesions on palms and soles are usually hairless. Size, shape, skin markings, and hair quality of nevi in darkly pigmented races are similar to those in whites.

Dermoscopy reveals a number of diagnostic patterns in common acquired nevi. In general, these lesions reveal a reticular or globular pattern. On the palms or soles, a parallel-furrow, lattice, or fibrillar pattern may be present. Non-



Acquired nevi are prevalent and benign. Melanoma is infrequent but deadly. One of the best tools for the differential diagnosis of an acquired lesion is dermoscopy.

↓

Dermoscopy

Step 1: establish whether a lesion is melanocytic or non-melanocytic

Classic melanocytic patterns
reticular, parallel, globular, homogenous, and starburst.

Classic non-melanocytic patterns
fingerprint, fissures, comedo-like and milia-like structures (as in seborrheic keratoses), red lacunas or sacular structures (as in hemangiomas), and spoke wheel, leaf, and ovoid structures (as in basal cell carcinaomas).

↓

Step 2: further evaluate lesions that are melanocytic or not clearly non-melanocytic for findings that may suggest melanoma. These findings may include a multi-component pattern, asymmetric dots, radial streaming, blue white veil, and irregular vascular structures. Lesions suggesting the possibility of melanoma should be excised.

↓

Dermoscopy will not be able to discriminate some of the early melanomas from acquired nevi. In order to identify these early melanomas, an additional three-step approach is recommended.

1. Is the lesion unusual? Unusual lesions would be those identified by patient as concerning, not matching the patient's average type of mole, and/or not displaying a clearly benign dermoscopic pattern.
2. Is the lesion growing? Patient history or photographic documentation may help. Baseline total skin photographs of patients at high risk for melanoma are invaluable for detecting new or changing lesions. Keep in mind that all acquired nevi are new and grow at some point, so growth alone is not a sufficient reason for excision.
3. Does the lesion have non-uniform features? As melanomas develop, they become more non-uniform. A lesion that is unusual and changing should be excised. In addition, if non-uniform features are also present, the concern for melanoma is further increased.

▲ **FIGURE 122-7** Approach to the patient with acquired nevomelanocytic nevus.

uniform patterns and parallel-ridge patterns are worrisome for melanoma.

Pigmented nevi of the nail apparatus may be a dark or light brown, extending from the nail matrix to the distal edge of the nail plate (see eFig. 122-8.1 in online edition; see Fig. 87-19 in Chap. 87); extension of the pigmentation onto the skin of the nail fold or beyond the distal nail groove should be considered suspicious for melanoma. Nevi on palms and soles, even compound nevi, may not distort the skin surface, perhaps because of a thickened stratum corneum in these sites.

The typical halo nevus has a pink or brown central nevomelanocytic nevus surrounded by a symmetric round or oval halo of depigmented skin. The central nevus may be small in typical acquired nevi, or large in acquired atypical or congenital nevi (Fig. 122-9). The halo of depigmentation is variable in size, usually a radial zone 0.5 to 5.0 cm around the central lesion. White hairs may be seen in hair-bearing depigmented areas. Alopecia areata surrounding a halo nevus has been reported. The number of halo nevi per person may be one or many, multiple lesions occurring in 25 percent to 50 percent of patients. For patients who have multiple lesions, only a few nevi are usually affected, but as many as 90 halo nevi have been reported in a single person. Any nevus in any anatomic site may be involved, but the posterior torso is involved most commonly. Lesions are usually asymptomatic. UVR may cause redness and even blistering in the perinevic halo. An atypical gross appearance of the central nevus or an asymmetric halo of depigmentation around a suspicious nevus, particularly in adults, should raise suspicion for melanocytic dysplasia or melanoma. The depigmented halo associated

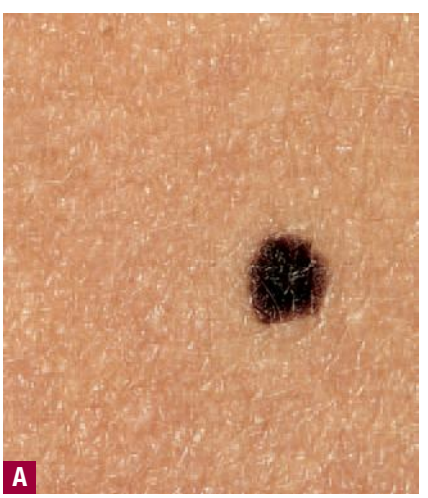



◀ **FIGURE 122-8** Typical acquired nevomelanocytic nevi. **A.** Junctional nevus. A uniformly dark brown macule, round in shape, with smooth, regular border. **B.** Two compound nevi. A uniformly pigmented papule and domed nodule. The upper lesion is flatter and tan with slight central elevation. The lower lesion is older and is uniformly elevated due to an increased intradermal component.



▲ **FIGURE 122-9** Halo nevomelanocytic nevus. **A.** Acquired halo nevus on the chest of a 16-year-old white boy whose maternal grandmother had melanoma. **B.** Acquired halo nevi on the back of a 6-year-old white boy who has dysplastic nevi in the hairy scalp and a history of melanoma in his maternal grandmother. Scale in millimeters. **C.** Halo congenital nevomelanocytic nevus on the neck of a 4-year-old female of a black African-American mother and white father. This child also had scattered areas of vitiligo-like depigmentation in other sites. A 3-year follow-up after excision of the nevus revealed almost total repigmentation of the widely scattered previously depigmented areas.



with melanoma tends to be irregular and surrounds the tumor asymmetrically, and the central lesion usually has an atypical appearance.

A second process that may provide some insight into factors involved in melanocytic interactions with the immune system is a process that results in the development of an eczematous dermatitis presenting as a red halo around nevi (halo dermatitis). Unlike halo nevi, regression of the nevus does not usually occur, and the eczematous changes clear over the course of several months.

RELATED PHYSICAL FINDINGS For patients with multiple nevi, there is an increased risk for cutaneous melanoma (see Chap. 124). This risk is further increased in the setting of atypical nevi and/or a personal or family history of melanoma. For patients with eruptive nevi, there may be findings suggestive of a blistering disease or immunosuppression. For patients with halo nevi, the most common associated condition is vitiligo, occurring in 18 percent to 26 percent of patients. Halo nevus may be associated with poliosis, Vogt-Koyanagi-Harada syndrome (see Chap. 72), pernicious anemia, and a personal or family history of melanoma (including ocular melanoma). Relatively large and numerous nevi are common in Turner syndrome and Noonan syndrome.

Laboratory Tests

HISTOPATHOLOGY Nevomelanocytes in the epidermis have a nuclear size similar to or larger than nuclei of epidermal melanocytes. Nevomelanocytes are arranged in nests surrounded by a smooth perimeter of epidermis and separated from nevomelanocytes by a retraction artifact (Fig. 122-10). Nevomelanocytes have abundant pale-staining eosinophilic cytoplasm and may have pseudopodic or dendritic extensions that are more evident when enzymatic or immunohistochemical techniques are used for visualization. Nuclei of nevomelanocytes are pale-staining, characterized as vacuolated or reticulated; a nucleolus is usually visible.[43] Epidermal melanocytes between junctional thèques of nevomelanocytes in typical nevomelanocytic nevi are disposed as single typical cells, with overall numbers equal to or slightly greater than that in adjacent sun-exposed skin (see Fig. 122-10).[44] The overlying epidermis is often normal in appearance but may be thickened in a lentiginous pattern (elongated and club-shaped rete ridges), with an appearance similar to seborrheic keratosis complete with horn cysts or epidermal verrucous hyperplasia similar to epidermal nevus.

The dermal component of nevi has an orderly progression from top to bottom, with larger epithelioid cells above (epi-

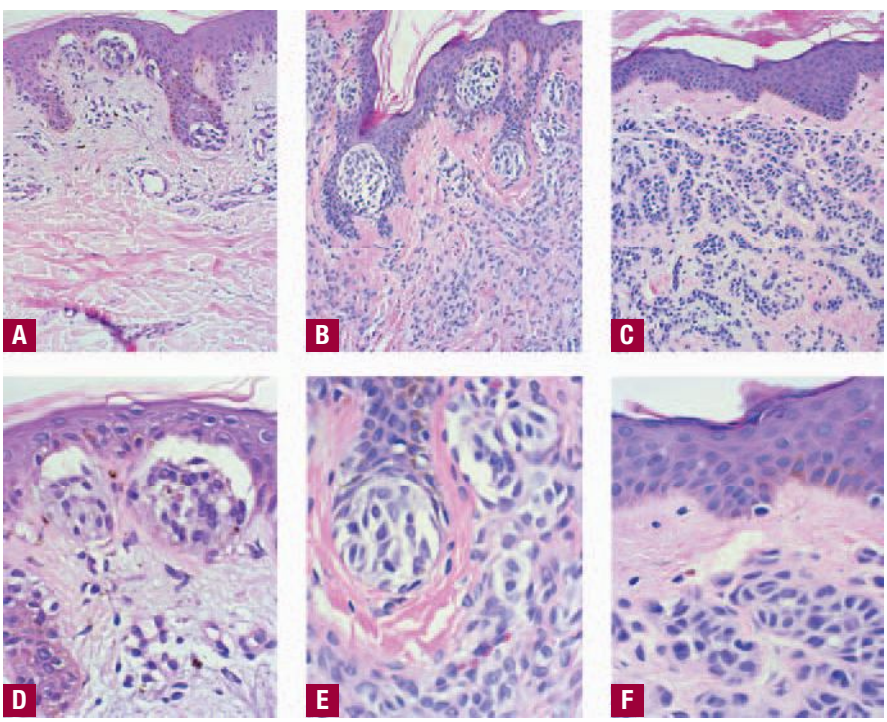

▲ **FIGURE 122-10** Histopathologic features of acquired nevi. Junctional nevus (**A**) and higher magnification (**D**). Compound nevus (**B**) and higher magnification (**E**). Intradermal nevus (**C**) and higher magnification (**F**). Well-formed nests of nevomelanocytes are present in the junctional and compound nevi. Sheets and cords of nevocytes are present in the dermis of the compound and intradermal nevi. A grenz zone free of nevomelanocytes is present just below the epidermis in the intradermal nevus (**C** and **F**).

dermis and superficial papillary dermis) blending into a pattern of smaller cells in the deeper dermis.

Some acquired lesions are found to have congenital features (reviewed earlier in Congenital Nevomelanocytic Nevi) suggesting that though these features may be present in congenital nevi, they are not limited to those present at birth. Others may be found to have atypical features (see Chap. 123).

Inflammatory cellular infiltrates in typical, stable acquired nevi are usually scanty[43] or absent. Melanin-laden macrophages are usually apparent in the superficial papillary dermis of nevi, their number usually proportional to degree of melanin production.[43] Blood vessel proliferation, eosinophilic fibrosis, and lamellar fibroplasia (features frequently seen in atypical melanocytic nevi) are usually not prominent in typical acquired nevi. Langerhans cell density overlying typical acquired nevi and atypical nevi is increased compared with adjacent skin.[46]

Intradermal nevi that have few or no junctional nests frequently have a grenz zone relatively free of nevomelanocytes just below the epidermis (see Fig. 122-10).

The *balloon cell nevus* is composed of peculiar foam cells comprising a portion or all of a given lesion. In addition to clear cells with single basophilic nuclei, multinucleated balloon cells and multinucleated giant cells are seen frequently. Electron microscopic studies suggest that the vacuolization of the nevomelanocytes is due to enlargement and destruction of melanosomes. There appears to be no distinguishing gross features of balloon cell nevi.

The *combined nevus* refers to the in-contiguity association of different types of melanocytic nevi. Most combined blue nevi are found in association with a benign compound nevus (acquired or congenital).

Recurrent melanocytic nevus (pseudomelanoma) is the name given to recurrent lesions after incomplete removal of a benign nevomelanocytic nevus.[47] Recurrent nevi are relatively common after superficial destructive procedures (i.e., shave biopsy or dermabrasion). A markedly atypical clinical and histopathologic appearance may accompany this recurrence, making these lesions worrisome for possible melanoma. Clinically, the recurrent nevus is confined to the scar but may be markedly irregular. Histopathologically, the recurrent lesions often demonstrate the presence of melanocytic hyperplasia in a lentiginous or junctional pattern (often to a greater extent than the original nevus). Moderate nuclear atypia may be present in 12 percent of recurrent nevi, mitotic figures in 8 percent, and pagetoid upward migration in 3 percent, raising concern about the potential biologic behavior of some recurrent lesions.[48] It is important to review the original histopathologic specimen when making re-excision and margin decisions.

No definitive pattern has been described for eruptive nevi beyond that for the nevus type.

For halo nevi, the usual histopathologic findings are a central nevomelanocytic nevus associated with a dermal band-like lymphohistiocytic infiltrate and a depigmented zone totally or almost totally devoid of epidermal melanocytes. Immunohistochemical staining [melanoma antigen recognized by T cells (Mart-1), S100 protein, or other melanocytic markers] may help to identify the residual epidermal melanocytes or the nevomelanocytes in the inflammatory infiltrate. The lymphocytes appear to be antigenically stimulated, and 80 percent are T lymphocytes, whereas B lymphocytes are scarce or absent. The T cells appear to belong to the $CD8^+$ population.[49]

The state of the nevus at the time of excision may also influence the histologic appearance. Nevi recently sunburned or traumatized may acutely have features worrisome for melanoma, and these changes resolve as the lesion heals.[52] It is also possible that nevi in their early growth phase also have more concerning features such as epithelioid cell appearance and pagetoid upward migration, but this has not yet been substantiated.

SPECIAL TESTS Special tests are not generally required. However, for patients who have eruptive nevi, given the association with immunosuppression, immunologic tests may be in order. Immunohistochemical profiles may be of value for difficult to diagnose lesions. Low Ki67 activity and loss of HMB45 in dermal (deeper) cells may help confirm a benign diagnosis. Compared to melanoma, common acquired nevi are genomically stable.[53] Gene chip analysis may be a useful way to discriminate these lesions in the future.

Differential Diagnosis (Box 122-3)

Complications

Multiple studies demonstrate that prominent numbers of nevi indicate an increased melanoma risk. Tucker et al.[54] noted a 3.4 (95 percent confidence interval: 2.0 to 5.7) adjusted relative risk for patients with 100 nevi or more (> 2 mm and < 5 mm) compared with those with fewer than 25 nevi. The relative risk was increased to 12 (95 percent confidence interval: 4.4 to 31.0) for patients with 10 or more atypical nevi compared with patients without atypical nevi. Absence of direct site specificity of nevi

Box 122-3

Differential Diagnosis of Common Acquired Nevomelanocytic Nevus

- Pigmented lesions
  - Solar lentigo
  - Lentigo simplex
  - Café-au-lait macule
  - Blue nevus
  - Pigmented fibrous histiocytoma (dermatofibroma)
  - Kaposi sarcoma
  - Pigmented basal cell carcinoma
  - Pigmented actinic keratoses
  - Mastocytoma
  - Seborrheic keratoses
  - Epidermal nevus
  - Subungual hematoma
  - Supernumerary nipple
  - Pigmented spindle cell nevus
  - Spitz nevus
  - Sclerosing hemangioma
  - Pyogenic granuloma
  - Atypical (dysplastic) melanocytic nevus
  - Cutaneous melanoma
- Nonpigmented/pink lesion
  - Basal cell carcinoma
  - Fibrous papule
  - Wart
  - Molluscum contagiosum
  - Dermal mucinosis
  - Spitz nevus (epithelioid cell nevus)
  - Appendageal tumors
  - Clear cell acanthoma
- Other lesions with halo phenomenon
  - Congenital nevomelanocytic nevus
  - Atypical melanocytic nevus
  - Melanoma
  - Spitz nevus
  - Histiocytoma
  - Molluscum contagiosum
  - Flat wart
  - Seborrheic keratoses
  - Basal cell epithelioma
  - Neurofibroma
  - Congenital dermal melanocytosis (mongolian spot)
  - Blue nevus
  - Lichen planus
  - Sarcoidosis
  - Psoriasis
  - Angioma



and melanoma suggests that nevus proneness per se indicates a general melanoma risk,[55] largely independent of hair and eye color and overall sun exposure.[56] Other traits, including skin color and freckles, may be multiplicative to the number of nevi in increasing melanoma risk.[57] The annual risk of a melanoma developing in a mole has been calculated to be approximately 1 in 200,000.[58] Furthermore, it has been reported that only 26 percent of melanomas are found in association with nevus elements.[59] Thus, it is possible that the majority of melanomas develop directly from normal skin (see Chap. 124). In patients with numerous nevi (and/or atypical nevi) these nevi are best viewed as risk markers, not precursors (or precancers) of melanoma.

Prognosis and Clinical Course

It is likely that acquired nevi evolve through a life cycle, first becoming apparent after infancy in the vast majority of cases, peaking in number during the second and third decades of life, and then disappearing by the seventh to ninth decades.[27,28,50] Regression of nevi is believed to occur by neuroid, fibrous, mucinous, or fatty degeneration.[49] Transepidermal elimination of nevomelanocytes has also been noted.[51,60] Nevi also may involute during the course of inflammatory halo depigmentation (halo nevi). The pathogenesis of the halo phenomenon is poorly understood. Available evidence suggests that both humoral and cellular factors may be responsible for nevus destruction. Atypical nevi, melanoma, and vitiligo may occur more frequently in individuals with halo nevus.

Eruptive nevi may occur as a spontaneous development of multiple nevi. These nevi are often similar in appearance to each other clinically and histopathologically. Reports generally link the initiating event to a blistering skin disease, systemic immunosuppression, chemotherapy, or treatment with "biologics."[61] The setting allowing for the eruptive nevi may also allow for melanoma development, as reported for some transplant patients, so such patients may need to be monitored carefully.

There may be relatively sudden changes in nevi that are unrelated to malignant transformation. Any single nevus that is noted to suddenly change independently should be cause for concern. Causes of sudden changes in a nevus (color, surface, or size, with or without pain, itching, ulceration, or bleeding) over days or weeks include cystic dilatation of a hair follicle, epidermal cyst formation, folliculitis, abscess formation, trauma, hemorrhage, and, in the case of a pedunculated nevus, strangulation and thrombosis. These benign causes of sudden change may require close observation for 1 to 2 weeks until resolution occurs, or excision for histopathologic examination.

The vast majority of acquired nevi are harmless. New nevi may continue to appear and disappear throughout life, but most develop during childhood and early adulthood. New or growing nevi in older individuals are more worrisome. Melanoma risk appears to be related to the number and size of nevi; patients with numerous nevi, atypical nevi, and a personal or family history of melanoma should be considered for periodic surveillance examinations for life.

Treatment

The vast majority of acquired nevomelanocytic nevi require no treatment. Indications for removal of benign-appearing lesions may include cosmetic concerns or continual irritation. Lesions with worrisome clinical features need to be excised for histopathologic examination. These features are further addressed in Chaps. 123 and 124. Dermoscopy may be used to differentiate benign and potentially malignant features. A photographic medical record can play a critical role in identifying change, or lack of change, in making risk assessments of particular nevi. All acquired nevi have an initial growth phase; other factors such as unusual features and/or non-uniformity must be considered when making a decision as to whether a particular lesion needs to be removed.[41,62]

Although a benign-appearing nevus associated with halo depigmentation need not be removed, it is reasonable to recommend periodic examination of affected individuals for atypical melanocytic nevi, vitiligo, and melanoma. Atypical-appearing central nevi, presence of an asymmetric halo, eccentric placement of a melanocytic lesion in the halo, or the setting of atypical melanocytic nevi and/or melanoma (personal or family) should suggest the need for histopathologic examination for melanoma. Cover-ups or sunscreens should be recommended for sun-exposed areas of depigmentation to prevent acute burn, chronic actinic damage, and carcinogenesis.

Complete removal of nevi is best accomplished by excision. Leaving a partially excised nevus, regardless of the initial pathology, is fraught with potentially concerning consequences of repigmentation and/or regrowth (pseudomelanoma).[47] Incisional biopsy, even for melanoma, is necessary at times, particularly for lesions that cannot be excised easily but require histopathologic diagnosis. Destructive modes of therapy (electrodesiccation, cryotherapy, dermabrasion, and laser) should be avoided and considered very carefully if used in the management of melanocytic and nevomelanocytic nevi. They have the disadvantage of not providing tissue for histopathology. Although dermabrasion has been used to eliminate pigmentation of nevomelanocytic nevi, residual nevomelanocytes in the dermis are to be expected, cosmetic outcome is often unpredictable, and recurrence with worrisome clinical features may complicate future management. Laser treatment of melanocytic and nevomelanocytic lesions has the theoretic risk of malignant transformation, but there is no proof for this.

Prevention

There appears to be a direct relationship between the number of acquired nevi and sun exposure, and a decrease with sunscreen use. Patients at increased risk should be reminded to minimize UVR overexposure. This can be done in a manner that should not impede day-to-day activities but will help reduce melanoma risk. This is best accomplished by first rearranging outdoor activities to the early morning or late afternoon/evening. This avoids the most intense UVR which hits the earth 2 hours either side of high noon. Second, cover-up clothing that blocks light transmission should be worn. Clothing is often easier to put on than sunscreen and does not rapidly wear off with sun exposure or sweating. Finally, sunscreens should be used as part of a comprehensive sun protection program.

BLUE NEVUS

Epidemiology

Blue nevi are present in fewer than 1 of 3000 newborns, in approximately 1 of 1000 aged 5 years or less, in 1 percent to 2 percent of white school children, in 3 percent of Japanese adults, and in 0.5 percent to 4.0 percent of healthy white adults. The vast majority of blue nevi are single, small, deep-blue macules or papules approximately 1 to 2 mm in diameter.



BLUE NEVUS AT A GLANCE



- Melanocytic neoplasia comprised of pigmented melanocytic cells in the mid-dermis. Includes common blue, cellular blue, combined blue, atypical, and large patch/plaque lesions.
- Lesions appear as blue, blue-gray, or blue-black papule, nodule, or plaques.
- Lesions are generally acquired but may be congenital.
- Cellular blue nevi may have an elevated risk for development of melanoma.
- Synonyms: benign mesenchymal melanoma, blue neuronevus, chromatophoroma, melanofibroma, Jadassohn-Tièche nevus, and dermal melanocytoma.
- Related lesions include nevus of Ota/Ito and mongolian spot.



Multiple blue nevi may be associated with lentigines, cardiac myxoma, and mucocutaneous myxomas [lentigines, atrial myxomas, mucocutaneous myxomas, and blue (LAMB) nevi, Carney complex]. Blue nevi have been associated with nodular mastocytosis, and a histogenic relationship has been claimed for melanocytes and mast cells.[63] Blue nevi have been reported to occur in oral mucosa, uterine cervix, vagina, spermatic cord, prostate, and lymph nodes.[64]

Etiology and Pathogenesis

The origin of common blue nevi and cellular blue nevi is unknown, but they may be derived from a mutant precursor cell resulting in the accumulation and differentiation of the melanocytic cells in the dermis instead of their normal location in the epidermis. Differentiation towards hair follicular melanocytes is possible. Some varieties of cellular blue nevi stain for CD34,[65] suggesting a potential "stem cell" origin. Bednar's tumors (dermatofibrosarcoma protuberans including cells with melanocytic marker expression) also express $CD34^+$ suggesting a similar stem cell origin for these tumors with different differentiation pathways.[66] Nevus of Ito/Ota is related to common blue nevi but represents an extensive localized acquired proliferation. The extension of these neoplasms along specific neural pathways may provide insight into the etiology of these dermal proliferations, including the possible role of certain neural factors. Although no specific mutations have been attributed to blue nevi, in the murine system a number of genes have been identified that result in the accumulation of dermal melanocytic cells,[67] and it is possible that some of these mutations may be involved in human dermal melanocytoses.

Clinical Findings (Fig. 122-11)

HISTORY Common blue nevi are usually acquired, and once developed should remain stable. Nevus of Ota and Ito may share similar underlying defects to blue nevi and are also often acquired (in early childhood, often before age 1 year or around puberty) but are far more extensive encompassing a portion of trigeminal (ophthalmic and maxillary) and brachial (posterior supraclavicular and lateral cutaneous) nerve distributions respectively. Dermal melanocytosis (mongolian spot) may also be related to blue nevi, but is usually present at birth or within the first few weeks of life and centered over the lumbosacral area. These lesions usually regress in early childhood but may persist in approximately 10 percent of cases.

CUTANEOUS LESIONS Common blue nevi are usually solitary, asymptomatic blue, blue-gray, or blue-black papules, usually less than 10 mm in diameter (Fig. 122-12). The blue-gray color of blue nevi is an optical effect of blue light backscatter from the skin over the dermal melanin (Tyndall effect). Hypopigmented, target or targetoid, and combined blue nevi (compound nevomelanocytic nevus and a blue nevus) also exist. Common blue nevi occur anywhere, but about half the reported cases present on the dorsa of hands and feet. Usually, the common blue nevus is singular, but rarely, lesions may be multiple and agminated or arranged in large plaques consisting of multiple solitary papules or nodules with intervening areas of blue discoloration. Common blue nevi also occasionally may have satellite lesions that may be mistaken for melanoma metastasis.[68] Rare giant varieties of congenital blue nevus occur, often with multiple satellite lesions.[13] The large plaque blue nevus (pilar neurocristic hamartoma) may occasionally be associated with a background of lentigo simplex.

The deep penetrating nevus may be considered a unique form of blue nevus, but some would include this lesion in the category of Spitz nevus. Deep penetrating nevi are darkly pigmented, blue-black papules or nodules, mostly on the head and neck or upper extremities, 2 to 9 mm in diameter, and occurring predominantly in the first four decades of life, including childhood.[69]

Cellular blue nevi are blue-gray or blue-brown nodules or plaques 1 to 3 cm in diameter, occasionally larger (see Fig. 122-12C). Their surface is usually smooth but may be irregular. Approximately one-half the cases are located on the buttocks or sacrum. Cellular blue nevi may develop in association with CNN, occasionally with target appearance. Cellular blue nevus differs from the common blue nevus in that it is usually larger, more ele-

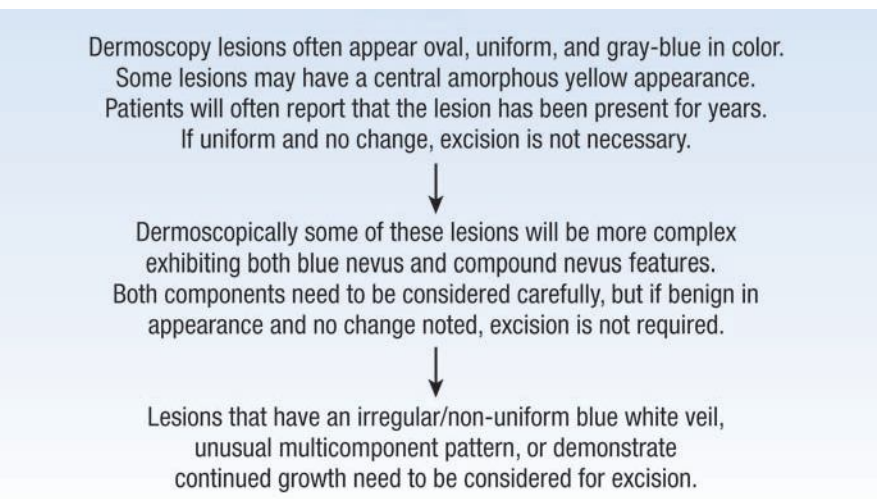

▲ **FIGURE 122-11** Approach to the patient with blue nevus.

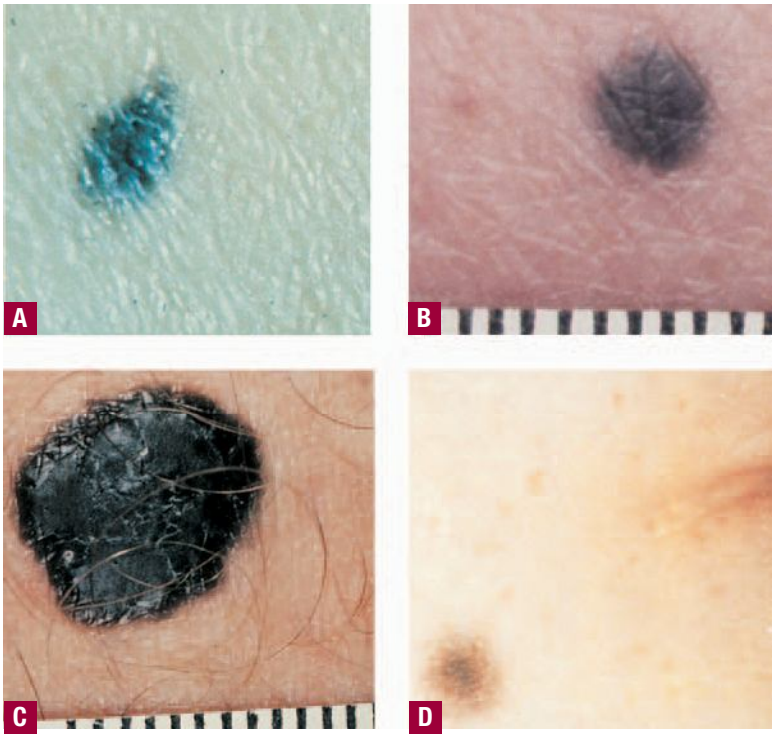

▲ **FIGURE 122-12** Blue nevus. **A.** Common blue nevus appearing as an acquired blue-gray papule on the shoulder of an 18-year-old white woman. **B.** Common blue nevus appearing as an acquired blue-gray papule on the buttock of a 62-year-old white man. **C.** Cellular blue nevus appearing as a congenital blue papule on the low back of a 30-year-old white man. **D.** Combined common blue nevus–nevomelanocytic nevus appearing as a brown papule with a blue-gray center on the cheek of a 12-year-old white boy, beginning as a pinpoint dot at age 1 year and enlarging slowly over time. Scale in millimeters.

vated, more aggressive locally, and occasionally associated with lymph node "benign metastasis." Complicating the picture is the fact that melanoma may develop in a cellular blue nevus.

Malignant blue nevus (melanoma) may develop in contiguity with a cellular blue nevus, nevus of Ota, combined congenital blue nevus, or de novo. Malignant blue nevus presents as an expanding dermal nodule with or without ulceration. There is some dispute as to whether malignant blue nevus should be considered a separate entity from melanoma or simply referred to as a *melanoma developing in a blue nevus*.

RELATED PHYSICAL FINDINGS The presence of epithelioid blue nevi may warrant consideration of Carney complex/myxoma syndrome/LAMB syndrome, with evaluation for related findings, including atrial myxomas and endocrine tumors.

Laboratory Tests

HISTOPATHOLOGY In common blue nevi, dermal melanocytes appear as melanin-containing fibroblast-like cells grouped in irregular bundles admixed with melanin-containing macrophages, associated with excessive fibrous tissue in the middle or upper reticular dermis, occasionally extending downward to subcutaneous fat or upward to papillary dermis (Fig. 122-13). Elongated melanin-producing dermal melanocytes in common blue nevi usually lie with their long axis parallel to the epidermis. Except in the case of combined blue nevus (with a compound nevomelanocytic nevus component), the epidermis in common blue nevi appears normal. Combined blue nevi have been noted in 1 percent of melanocytic nevi excised for histopathologic examination.[70]

In cellular blue nevi, there is usually a component of a common blue nevus plus fascicles of spindle-shaped cells with ovoid nuclei and abundant pale cytoplasm with little or no melanin, and often epithelioid cells, present in the dermis and often in subcutaneous fat in nests, bundles, and neuroid forms with little or no intervening stroma (see Fig. 122-13C and D). Epithelioid cell and amelanotic varieties of the cellular blue nevus have been described. Epithelioid blue nevi have been reported in association with cardiac myxoma[73] or in isolation.[74] Histopathologic diagnosis may be difficult when the common blue nevus component and melanin production are sparse or inapparent. Differentiation of some cellular blue nevi from melanoma can be difficult. Occasionally, small groups of well-differentiated melanocytes are present in the marginal sinus or parenchyma of lymph nodes draining the anatomic site of the cellular blue nevus, making it difficult to differentiate true metastasis from pseudometastasis. It is likely that "inert" deposits of melanocytes in the capsules and peripheral sinuses of lymph nodes draining some varieties of cellular blue nevus are transported passively (see Nodal Nevi).

The malignant blue nevus is a variant of melanoma, distinguished from cellular blue nevus by invasiveness, cellular atypia, pleomorphism, atypical mitoses, and areas of necrosis.

SPECIAL TESTS Imaging tests of the heart may be required if there is concern for Carney complex/myxoma syndrome/LAMB syndrome.

Differential Diagnosis (Box 122-4)

Complications

A major complication of blue nevi is the potential risk of melanoma. This risk appears to be highest for cellular blue nevi. Melanoma has been noted to evolve in large blue nevus patches or plaques and in associated with nevus of Ota and Ito.

Prognosis and Clinical Course

The natural evolution has not been studied for common blue nevi or cellular blue nevi. It is likely that once established, blue nevi remain unchanged or possibly regress over time. "Change" is worrisome for melanoma development.

Treatment

A common blue nevus that is stable for many years in an adult usually requires no therapy. Sudden appearance of a blue nodule, expansion of a pre-existing blue nodule, a congenital blue nodule, or a relatively large blue nodule or plaque greater than 10 mm in diameter should be considered for histopathologic examination. Excision should include subcutaneous fat to ensure complete removal of deep dermal melanocytes, which are frequently present in the subcutaneous tissue of cellular blue nevus. The large plaque blue nevus (pilar





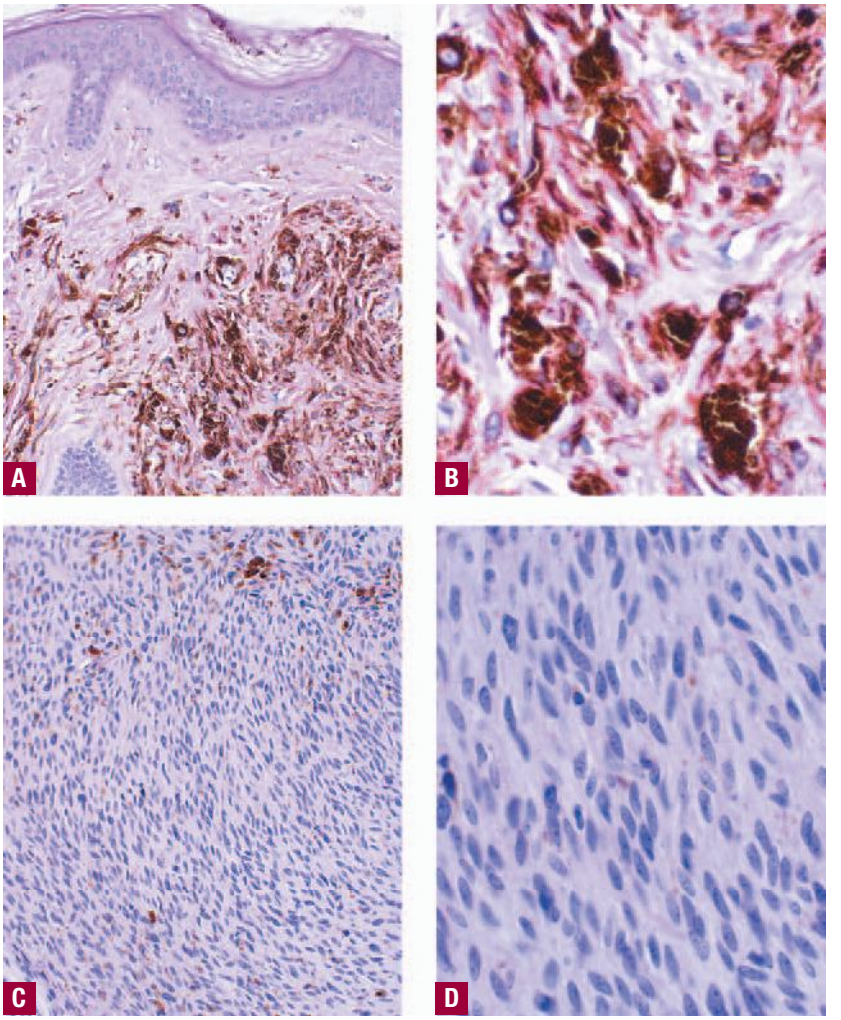

▲ **FIGURE 122-13** Histopathologic features of common and cellular blue nevi. Common blue nevus (**A**) and higher magnification of the dermal component (**B**) revealing heavily pigmented, elongated melanocytes. Cellular blue nevus (**C**) and higher magnification (**D**) revealing sheets of melanocytes with ovoid nuclei.

neurocristic hamartoma) requires consideration for excision or periodic evaluation for suspicious change. Cellular blue nevus should be evaluated for excision because of its malignant potential.

Prevention

The causative factor in eruptive blue nevi has been attributed to sun exposure.[75] Thus, as with other nevi, it is reasonable to minimize excessive UVR exposure.

Box 122-4

Differential Diagnosis of Blue Nevus

- Pigmented spindle cell nevus
- Tattoo (traumatic, radiation port marker)
- Primary or metastatic melanoma
- Glomus tumor
- Pyogenic granuloma
- Sclerosing hemangioma
- Dermatofibroma
- Ochronosis

PIGMENTED SPINDLE CELL NEVUS

Epidemiology

The mean age of presentation has been reported as 25.3 years, ranging from 2.5 to 56.0 years of age.[76] Similar age ranges have been reported in other studies.[77] The majority of cases occur in the third decade of life. Female patients outnumber male patients with reported ratios of 2:1,[76] 1.4:1.0,[77] and 1.3:1.0.[78] The majority of these lesions are found on the extremities with reported frequencies of 67.0 percent,[76] 69.6 percent,[78] and 75.0 percent.[77] There is a preference for the lower extremity, especially the thigh, with the back being the next most common site.[77]

Etiology and Pathogenesis

It may be presumed that PSCN are derived from the same progenitor cells giving rise to epidermal melanocytes and nevomelanocytes. No known specific mutation has been identified.

PIGMENTED SPINDLE CELL NEVUS AT A GLANCE



- Acquired, benign melanocytic tumors comprised of heavily pigmented spindle-shaped melanocytic cells confined primarily to the epidermis.
- The pigmented spindle cell presents as a jet black lesion often with "starburst" appearance.
- These nevi are thought to develop quickly and then stabilize.
- Malignant degeneration is thought to be rare.
- Synonyms: Reed nevus, pigmented Spitz nevus.

Clinical Findings (Fig. 122-14)

HISTORY PSCN was first described by Reed in 1975.[79] These lesions are generally detected as acquired lesions, often during the third decade of life. At presentation, patients often note that the lesion has increased in size.[77,78] It is not known how quickly these lesions grow, but growth may be relatively rapid as one case report of a lesion on a 3-year-old child documented significant growth over a 3- and 6-month period.[80] Once fully developed, it is assumed that these lesions will remain stable, but the full natural history of these lesions is not well characterized.

CUTANEOUS LESIONS The PSCN is usually a sharply circumscribed, uniformly darkly pigmented papule[76–78] (Fig. 122-15). Dermoscopically, most of the lesions are jet black but may be blue-gray or brown. In the initial growth phase, the lesions may have a globular appearance[80] but the vast majority of these lesions are uniformly dark centrally, with a sharp interface with surrounding skin often exhibiting streaks/pseudopods and giving the lesion a starburst appearance.

Dermoscopically, this lesion is often diffusely jet black with a sharp well defined border. The border should interface with the skin in a similar (uniform) manner for the full circumference of the lesion. The pattern is often "starburst" in appearance.

↓

Non-uniform edge, active growth, and/or atypical features warrant excision

▲ **FIGURE 122-14** Approach to the patient with pigmented spindle cell nevus.

RELATED PHYSICAL FINDINGS No known association.

Laboratory Tests

HISTOPATHOLOGY PSCN consists of vertically oriented fascicles of spindle-shaped, pigment-producing melanocytes (Fig. 122-16); some pagetoid upward migration may be present, but the lesion can be distinguished from melanoma by uniform nuclei, uniform cellular detail, and distinctive pattern of growth. Almost all cases of pigmented spindle cell nevus have a lymphohistiocytic host response. Spindle cells extend down eccrine ducts in 40 percent and involve hair follicles in 22 percent of lesions.[76] There is an overlap of these lesions with Spitz nevi. In a review of 91 PSCN by Sagebiel et al.,[76] cells were predominantly spindle in 74 percent and mixed spindle cell and epithelioid cell in 26 percent of patients. There are atypical variants of PSCN in which there are architectural alterations and striking cellular atypia.[78]

SPECIAL TESTS No known specific mutation or genetic markers.

Differential Diagnosis (Box 122-5)

Complications

There are no reported complications, but misinterpretation of benign or malignant behavior of the lesion could result in unnecessary or insufficient treatment, respectively.

Prognosis and Clinical Course

The PSCN are thought to be benign. No local recurrence or distant spread was noted for 38 patients followed for an average of 14 months.[76] In another study, 57 patients were followed for an average of 6 years and again no local recurrence or metastasis was noted.[77]

Treatment

If there is clinical concern, these lesions should be excised with a narrow margin of normal skin.

Box 122-5

Differential Diagnosis of Pigmented Spindle Cell Nevus

- Spitz nevus
- Blue nevi
- Hematoma
- Atypical nevomelanocyte
- Melanoma

Prevention

The role of UVR exposure in the development of PSCN is unknown. Generally, it is best to avoid UVR overexposure.

SPITZ NEVUS



Epidemiology

An annual incidence rate of 1.4 cases of Spitz nevus per 100,000 individuals has been estimated in Australia, compared with 25.4 per 100,000 individuals for cutaneous melanoma during the same time interval.[81] Among melanocytic nevi excised in children, 1 percent to 8 percent of cases are interpreted as Spitz nevus.[82] In a case series of 308 patients with Spitz nevi reported by Allen,[83] 15 percent of lesions occurred in adolescents and adults, the oldest patient being 56 years of age. There appears to be no gender predilection for Spitz nevus. Published cases have been described primarily in whites.

Etiology and Pathogenesis

It may be presumed that Spitz nevi are derived from the same progenitor cells that give rise to epidermal melanocytes and nevomelanocytes. Unlike common

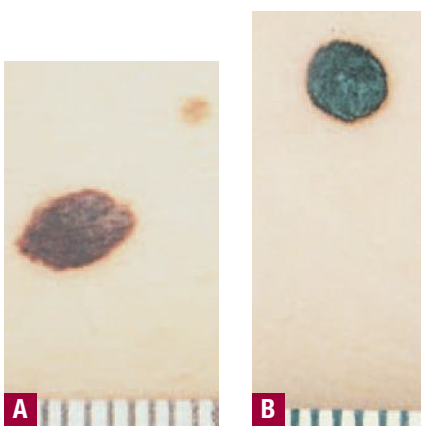

▲ **FIGURE 122-15** Pigmented spindle cell nevus. **A.** Very dark brown plaque appearing over several weeks on the posterior thigh of a 22-year-old white woman. **B.** Very dark-bluish plaque appearing de novo 3 months previously on the back of an 8-month-old white (Hispanic) boy. Scale in millimeters.

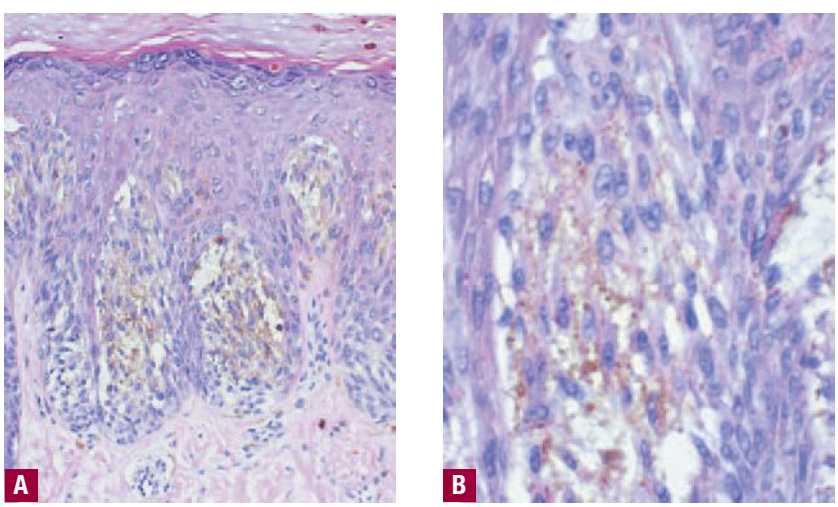

▲ **FIGURE 122-16** Histopathologic features of pigmented spindle cell nevus (**A**) and higher magnification of the intraepidermal component (**B**) revealing pigmented spindle-shaped cells.

SPITZ NEVUS AT A GLANCE



- Spitz nevi represent a spectrum of unique, usually acquired lesions, exhibiting epithelioid and often spindle-shaped melanocytic cells with abundant eosinophilic cytoplasm and large nuclei. Often develop in the dermis with some involvement of the overlying epidermis. Atypical variants exist.
- Clinically, the lesion is often a pink, dome-shaped papule.
- Thought to develop quickly and then stabilize. Their clinical presentation and histopathology can cause diagnostic concern for melanoma.
- Synonyms: Spitz tumor, nevus prominens et pigmentosus, pseudomelanoma, spindle and epithelioid cell nevus, nevus of large spindle and/or epithelioid cells, and compound melanocytoma. The previously used terms *Spitz's juvenile melanoma*, *benign juvenile melanoma*, and *prepubertal melanoma* should not be used.



acquired nevi and congenital nevi, the B-RAF mutation does not appear to be involved. Amplifications of chromosome 11p and H-RAS and activating mutations of H-RAS have been noted in a subset of Spitz nevi.[84] Heritable genetic factors have not been investigated systematically, but there is a single report of multiple tumors in identical twin boys.[82] The role of trauma in the histogenesis of Spitz nevi is speculative. One case has been reported at the site of bacille Calmette-Guérin vaccination.[85]

Clinical Findings (Fig. 122-17)

HISTORY The rate of growth, period of stabilization, and rate of regression of Spitz nevi are not known. The duration of solitary Spitz nevus before presentation is usually less than 9 months. Lesions usually show an increase in radial size over time, some gradual and others rapid.[86] Based on patients with eruptive Spitz nevi, regression has been reported to occur and may even occur in some lesions while new lesions are appearing.[87]

CUTANEOUS LESIONS The most common variety of Spitz nevus is solitary, asymptomatic, pink or red, hairless, firm, and dome-shaped (Fig. 122-18). Some Spitz nevi may resemble a keloid. The surface is commonly smooth, and the borders may fade into surrounding skin. Verrucous, scaly, stippled, crusted, or (rarely) eroded lesions have been noted. Spitz nevi are usually asymptomatic, but pruritus, tenderness, and/or bleeding may occur.[82] A halo of depigmentation has been associated with several cases of Spitz nevus.[33,88] Spitz nevi are part of a spectrum in which some also include PSCN and deep penetrating nevi.

Spitz nevi can also present as widespread eruptive lesions or in a grouped manner as multiple agminated lesions consisting of red, red-brown, brown, or dark-brown papules or nodules, with a fine stippled surface (see Fig. 122-18C). Agminated Spitz nevi often occur in the early years of life within a background of congenital (sometimes acquired) macular pigmentation (nevus spilus) or occasionally within a hypopigmented plaque. Spitz nevi may also develop as single or multiple lesions in a large CNN.

The diameter of Spitz nevi ranges from several millimeters to several centimeters, the average being 8 mm in one series.[82] In 73 percent of patients in one series,[81] the tumor diameter was 6 mm or less, and in 94 percent of patients, the tumor diameter was less than 10 mm. Most cases are described as superficial papules or nodules, although subcutaneous involvement may occur.[87] In one series of 43 patients,[82] the anatomic location included the head or neck in 18, upper extremities in 9, torso in 9, and lower extremities in 7. Spitz nevi tend to spare palms, soles, and mucous membranes.

RELATED PHYSICAL FINDINGS There is no known association with other somatic abnormalities.

Laboratory Tests

HISTOPATHOLOGY Unlike ordinary nevi and melanomas, melanocytic cells in Spitz nevi are large—often twice the size of epidermal basal keratinocytes,[86] with prominent mononuclear or multinucleated giant cells in the epidermis and/or dermis (Fig. 122-19). Mitoses, usually few in number, are detected in one-half the cases,[88] whereas atypical mitoses are uncommon in Spitz nevi. In contrast to melanoma, the melanocytic cells in Spitz nevi show progressive maturation with increasing depth, becoming smaller and more similar to ordinary nevomelanocytes,[86,88] with the overall distribution of cells in the dermis being wedge-shaped, with narrowing of the wedge toward the subcutaneous fat.

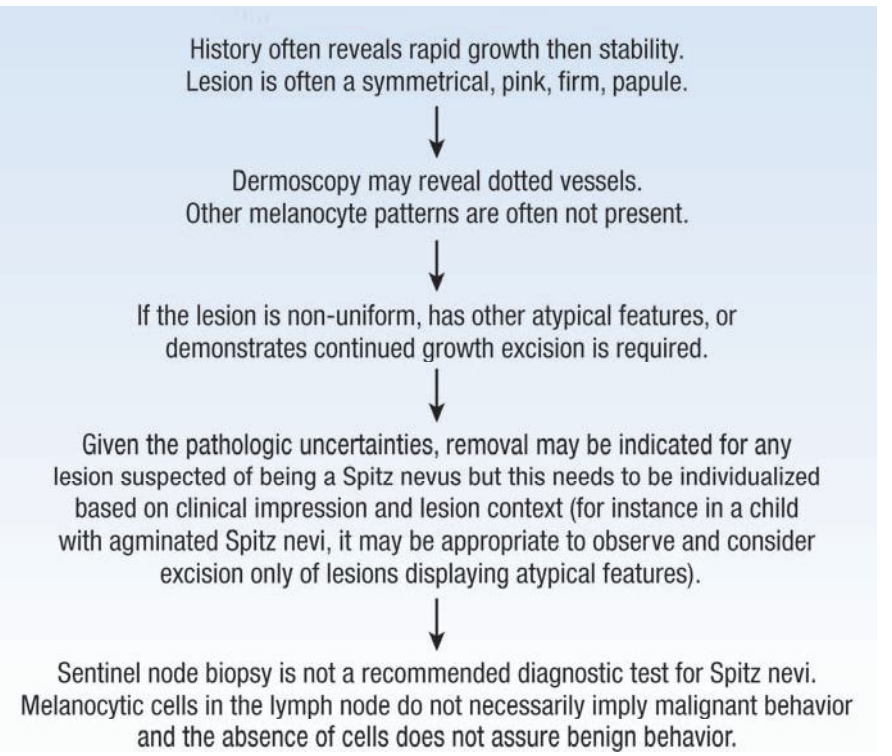

▲ **FIGURE 122-17** Approach to the patient with Spitz nevus.



▲ **FIGURE 122-18** Spitz nevi. **A.** Pink plaque, which appeared de novo over an 8-week period, becoming more elevated with time, in the preauricular area of a 4-year-old white boy. **B.** Dome-shaped pink papule, which appeared de novo over a 2-week interval 4 months before, on the forehead of a 5-year-old white boy. **C.** Agminated Spitz nevi. Numerous grouped pink papules and plaques, appearing at age 6 months, on the face of a 4-year-old white boy.

Coalescent eosinophilic globules (Kamino bodies), periodic acid-Schiff–positive and diastase-resistant (resembling colloid bodies), have been reported in 60 percent of Spitz nevi[89] (see Fig. 122-19). Similar globules may be detected in 2 percent of melanomas and 0.9 percent of typical acquired nevi, but the globules are smaller in size, more difficult to find, single rather than coalescent, and commonly periodic acid-Schiff–negative.[89]

Melanocytic elements are usually arranged in well-circumscribed nests, although there may be permeation of the epidermis by single cells or small groups of cells. In those cases with epidermal nests, artifactual clefts are usually seen above the nests in half the cases, a finding rarely observed in melanoma.[81] The epidermis is usually hyperplastic, with elongated and bulbous pegs and knobs extending into the dermis, although thinning and even ulceration may occur rarely. The dermal inflammatory cell infiltrate may be slight or marked, band-like, and mainly at the base or patchy around blood vessels and/or intermixing with tumor cells. Although melanin was observed in all 13 patients originally described by Spitz,[86] more recent studies have determined that melanin was moderate in 10 percent of cases and heavy in 5 percent.[88]

Although the bizarre histopathologic features and frequent occurrence of dermal inflammation may cause diagnostic confusion, Spitz nevus usually can be differentiated from melanoma. The histologic features of Spitz nevus in children and adults are similar.

SPECIAL TESTS A subgroup of Spitz nevi have a gain of chromosome 11p and amplification or activation of H-RAS.[84] These markers are not routinely used in the clinical setting but may be helpful in the future for discriminating these nevi from other melanocytic neoplasias.

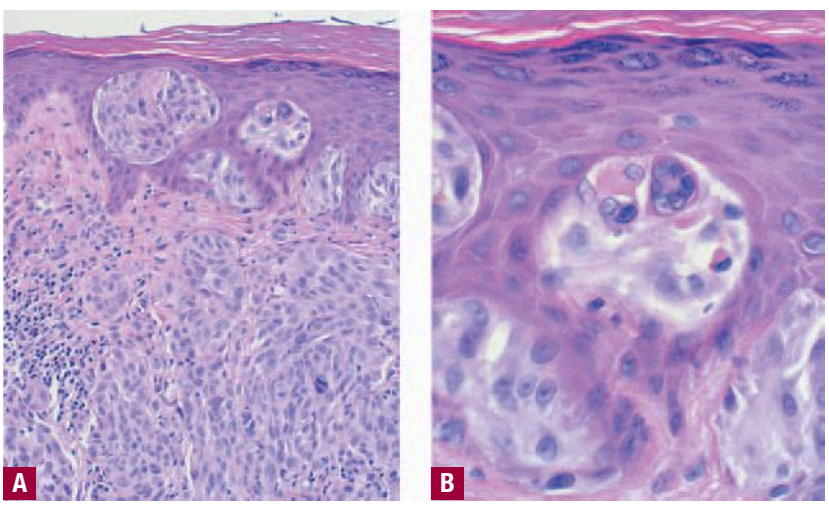

▲ **FIGURE 122-19** Histopathologic features of Spitz nevus (**A**) and higher magnification of the intraepidermal component revealing eosinophilic cytoplasmic changes (Kamino bodies) in several cells (**B**).

Differential Diagnosis (Box 122-6)

Complications

Misinterpretation of benign or malignant behavior of the lesion could result in unnecessary or insufficient treatment, respectively.

Prognosis and Clinical Course

The natural history of the Spitz nevus is largely unknown. Based on patients with eruptive Spitz nevi, it is clear that spontaneous regression can occur.[87] A

Box 122-6

Differential Diagnosis of Spitz Nevi

- Nonpigmented/pink
  - Amelanotic melanoma
  - Juvenile xanthogranuloma
  - Hemangioma
  - Pyogenic granuloma
  - Molluscum contagiosum
  - Intradermal nevus
  - Solitary mastocytoma
  - Granuloma
  - Clear cell acanthoma
  - Insect bite reaction
  - Dermatofibroma
  - Appendageal tumor
  - Keloid
- Pigmented
  - Blue nevus
  - Deep penetrating nevus
  - Pigmented intradermal nevus
  - Melanoma
  - Hematoma
- Warty variants
  - Verruca vulgaris
  - Seborrheic keratoses
  - Epidermal nevus
  - Epidermolytic acanthoma



concern is that some lesions diagnosed as Spitz nevi may progress to melanoma or represent melanoma at the outset.[90]

Treatment

Complete excision with a clear margin of normal skin is generally sufficient treatment for Spitz nevi. Given the difficulty of confidently excluding the possibility of melanoma in certain cases, a wider margin of normal skin may be prudent for histopathologically worrisome lesions.[90] Incompletely excised lesions may recur in as many as 7 percent to 16 percent of patients.[82,91–93] Although some authors have advocated sentinel node biopsies in these lesions, this may only add to the confusion because Spitz nevus cells may be present in the regional lymph nodes but not necessarily indicate malignancy.[94] Management of patients who have numerous Spitz nevi requires individual judgment and periodic examination for new or unstable lesions.

Prevention

The role of UVR exposure in the development or progression of Spitz nevi is unknown.

NODAL NEVI

Epidemiology

Nevomelanocytes can be identified in lymph nodes with a frequency ranging from 0.3 percent to 7.3 percent in lymphadenectomies not related to melanoma and up to 22 percent in regional nodes removed because of melanoma.[95] When nevomelanocytes are evident in lymphadenectomies due to melanoma, it has been reported that 75 percent of the primary cutaneous melanomas had an associated nevomelanocytic nevus, often with congenital features.[96] A significant association has also been noted for the presence of cutaneous nevomelanocytic nevi in the zones of skin drained by lymph nodes that were found to include nevomelanocytes.[97] In most cases, the nevomelanocytes appear to be derived from common acquired nevi, but congenital nevi, blue nevi, cellular blue, and Spitz nevi have all also been reported to involve regional lymph nodes.[64]

Etiology and Pathogenesis

There are two prevailing theories as to the mechanism by which nevomelanocytes appear in regional lymph nodes.

NODAL NEVI AT A GLANCE

- A benign melanocytic neoplasia present in a lymph node. Nevomelanocytes are often located in the capsule but they may also be present in the parenchyma of the nodal tissue.
- Generally asymptomatic and found as a result of lymph node removal.
- Cells may be deposited passively into the node from a cutaneous melanocytic lesion. It is also possible that abnormal migration pathways result in the nevomelanocytes taking up residence in the nodes during embryonic development.
- The presence of these cells in nodal tissue creates difficulties for pathologists evaluating sentinel node biopsies.

The first theory is that during development, nevomelanocytes get trapped in the developing nodal tissues. Some support for this theory could be based on the fact that nodal nevi can be found in association with congenital nevi. This observation suggests that there is an opportunity for nevomelanocytes to be deposited during development. Further, blue nevus cells can be found in tissues such as prostate, cervix, vagina, spermatic cord, and seminal vesicles.[64] Thus, aberrant migration and differentiation of melanocytic cells do occur.

The second theory suggests that there may be passive transfer from the cutaneous lesion to the lymph node. Substances such as carbon, tattoo ink, and radioactive colloid are readily transferred to the draining lymph node. It is reasonable to assume that loosely adherent nevomelanocytes could also traverse the same path. In fact, nevomelanocytes have been noted in lymph channels.[64] Once in the lymph node, nevomelanocytes are generally identified in the capsule, but they can also be found in the parenchyma.[95] It is not known how nevomelanocytes get into the capsule, but it is reasonable to assume that these cells migrate from the parenchyma into the capsule. It is important to note that melanoma cells can also be found in the capsule,[98] so it is rational to assume that entry into the capsule is not limited to a developmental event. The fact that nevomelanocytes in regional lymph nodes are highly correlated with the presence of nevomelanocytic nevi in the skin, supports the concept that these cells arrive in the lymph nodes via dissemination from the benign cutaneous lesion.

Clinical Findings (Fig. 122-20)

HISTORY Generally, nodal nevi are identified in lymph nodes that are removed because of melanoma, but these benign cells are also identified in nodes removed for other reasons. Generally, the patient does not note symptoms related to the nodal nevus.

CUTANEOUS LESIONS Common acquired nevomelanocytic nevi, congenital nevomelanocytic nevi, blue nevi, and Spitz nevi have been noted to give rise to nodal nevi.[64]

RELATED PHYSICAL FINDINGS Due to concern for melanoma, patients should be

Lymph node often removed due to concern for melanoma, but could also have been removed for other reasons.

↓

Histopathologic evaluation is required. It is best to review the lesion in the skin draining to the node along with the node. Location of the nevomelanocytes and cellular appearance may be sufficient for diagnosis.

↓

Immunohistochemistry revealing a lack of proliferative component or high p16 level may help substantiate the benign diagnosis. Molecular PCR based tests do not generally differentiate between benign and malignant melanocytic cells.

▲ **FIGURE 122-20** Approach to the patient with nodal nevus. PCR = polymerase chain reaction.

Box 122-7

Differential Diagnosis of Nodal Nevi

- Melanoma
- Cells from other neoplastic source
- Foreign body deposit (tattoo ink, carbon)

evaluated for findings that might be worrisome for metastatic melanoma.

Laboratory Tests

HISTOPATHOLOGY Pathology often reveals nevomelanocytes largely confined to the nodal capsule. However, cells may also be noted in the parenchyma. These cells should bear resemblance to the cells in the cutaneous lesion. Lack of proliferative markers (Ki67) and possibly high levels of p16 immunohistochemistry markers support the benign diagnosis.[99]

SPECIAL TESTS The use of standard immunohistochemical tests may help identify the location and cellular features of the nevomelanocytes in the lymph node tissue sections. Reverse transcriptase–polymerase chain reaction tests do not discriminate benign from malignant melanocytic nodal disease.

Differential Diagnosis (Box 122-7)

Complications

Complications, such as scarring or lymphedema, may exist for the surgical procedure. A misinterpretation of benign nodal deposits as malignant could result in unnecessary regional lymph node dissection and treatment with systemic agents. An interpretation of malignant nodal cells as benign would not flag the patient as having a worse prognosis and may delay other treatments.

Prognosis and Clinical Course

If the lymph node deposits are determined to be benign, no further treatment is warranted.

Treatment

None required for benign nodal nevi.

LENTIGO SIMPLEX

Epidemiology

The frequency of lentigo simplex in children and adults has not been determined. There does not appear to be a racial or gender predilection. Lentigo simplex is the most common histopathologic pattern of darkly pigmented lesions excised from acral sites of darkly pigmented races.[28] Pigmented nail bands, noted in up to 20 percent of Japanese, may have histopathologic features of lentigo simplex.[100] For agminated lentigines, the population prevalence is unknown, but it is believed to be rare.

Etiology and Pathogenesis

The increased density of melanocytes in lentigines is presumably due to an underlying developmental or intrinsic defect in melanocyte homeostasis. In some lentigines, the presence of melanin macroglobules in melanocytes and keratinocytes suggests that defects affecting melanization pathways are also involved. The presence of lentigo simplex in association with somatic abnormalities in such diverse conditions as Peutz-Jeghers syndrome, LEPOARD syndrome (*l*entigines; *e*lectrocardiogram conduction defects; *o*cular hypertelorism; *p*ulmonary stenosis; *a*bnormalities of genitalia; *r*etardation of growth, and sensorineural *d*eafness), and LAMB/myxoma syndrome suggests that lentigo development may be influenced by a number of different genetic factors. For agminated lentigines, it is possible that chromosomal mosaicism plays a role in the development of the localized collection of lentigines.

Clinical Findings (Fig. 122-21)

HISTORY Unlike solar lentigines, lentigo simplex is thought to be largely UVR independent. Lentigo simplex may appear as early as the first decade and may occur anywhere on skin or mucous membranes.

Generalized lentigines may occur as an isolated phenomenon without known familial aggregation and first appear at birth, during infancy, or during adulthood. Familial clustering in an autosomal pattern also has been noted. A number of syndromes are recognized (see Chap. 73).

In Moynahan (LEOPARD) syndrome, lentigines are present at birth or shortly thereafter and may increase in number during childhood. In Peutz-Jeghers syndrome, numerous lentigines may be present at birth or appear during early childhood. Oral pigmentation usually persists in Peutz-Jeghers syndrome, whereas cutaneous lentigines usually fade after puberty. In LAMB syndrome, the lentigines on the lips and genital sites appear in early childhood and tend to persist.

Agminated lentigines first become manifest at birth or early childhood.

CUTANEOUS LESIONS Lentigo simplex usually is a sharply circumscribed, light-brown or dark-brown macule.

In Moynahan (LEOPARD) syndrome, lentigines occur on both sun-exposed and sun-protected sites, including genitalia, conjunctiva, oral mucosa, palms, and soles. In Peutz-Jeghers syndrome, lentigines are almost always present on the oral mucosa. Other common sites of involvement include lips, nose, eyelids, anus, nail bed, and dorsal and ventral surfaces of hands and feet.

LENTIGO SIMPLEX AT A GLANCE





- Includes a spectrum of melanocytic hyperplasias consisting of intraepidermal melanocytic hyperplasia and increased melanin formation. The extent of melanocytic hyperplasia can be quite variable, ranging from lesions in which the increased melanin content is notable but the increase in melanocyte number is marginal, to lesions in which accumulation of melanocytes is marked.
- Lesions consist of hyperpigmented macules and may be isolated, agminated (focal cluster), or multiple and present on skin, nails, and mucous membranes.
- May be congenital or acquired.
- Multiple lentigines may be associated with somatic abnormalities.
- Synonyms: simple lentigo, melanotic macule, lentiginosis. Other names for agminated lentigines include unilateral lentigines, partial unilateral lentiginosis, lentiginous mosaicism, and segmental lentiginosis.
- Other lesions in which epidermal melanocytic hyperplasia may be noted, and some overlap may exist with simple lentigines, include café-au-lait macules, melasma, and inflammatory/cytokine-induced proliferation.





Dermoscopy tends to reveal a simple well defined regular pigment network without any other dermoscopic findings, such as dots or globules, that might suggest junctional or dermal collections of nevomelanocytes.

↓

If lesions are multiple and in one focal location, agminated lentigines should be considered. Wood's light will help to exclude background hyperpigmentation that might indicate nevus spilus.

↓

If lesions are multiple and dispersed, consider possible associated syndromes and evaluate for associated abnormalities.

↓

If lesions are in an adult and in sun exposed (or tanning/UV box exposed) area, consider the possibility that the lesions are solar lentigines.

↓

A lesion not displaying uniform features, particularly if changing, needs to be considered for biopsy to exclude melanoma.

▲ **FIGURE 122-21** Approach to the patient with lentigo simplex. UV = ultraviolet.

Lentigines in the myxoma syndrome (LAMB) occur mainly on the face and genitalia as tan to black macules (Fig. 122-22). In centrofacial lentiginosis, the presence of pigmented macules is restricted to a horizontal band across the central face.

Agminated lentigines first become manifest at birth or early childhood as small, circumscribed, light-brown macules, 2 to 10 mm in diameter, confined to a localized area of the skin, often in a segmental distribution (Fig. 122-23) and frequently in a curvilinear or swirled pattern. Wood's lamp examination may be required to differentiate agminated lentigines from nevus spilus, because the macular background pigmentation is evident in the latter and absent in the former.

RELATED PHYSICAL FINDINGS If there is concern that the lentigines are part of a syndrome, further evaluation is appropriate, and should be guided by the physical findings and syndrome under consideration.

Laboratory Tests

HISTOPATHOLOGY Lentigo simplex consists of intraepidermal melanocytic hyperplasia in the basal layer of elongated epidermal rete ridges, without nest formation. At one end of the lentigo spectrum, lesions are more similar to café-au-lait lesions, in which the melanocyte number may only be minimally increased but pigmentary differences are marked; at the other end of the spectrum, the number of melanocytes is sufficiently increased to begin forming nests, appearing similar to a junctional nevus. Depending on the degree of keratinocytic hyperplasia, distinct separation from solar lentigo may not be possible based on histopathologic interpretation alone. Giant pigment granules (melanin macroglobules) may occur in lentigo simplex in isolation, and in association with multiple-lentigines (LEOPARD) syndrome.

In agminated lentigines, histopathologic studies reveal increased numbers of melanocytes in elongated epidermal rete ridges, similar to lentigo simplex, without nests of nevomelanocytes or cellular inflammation.

SPECIAL TESTS Mart-1, Mel-5, and DOPA histochemistry may be useful to demonstrate increased number of melanocytes confined to the basal layer and lacking junctional nest formation. If a syndrome is under consideration, imaging studies may be required.

Differential Diagnosis (Box 122-8)

Complications

There are no known complications from lentigo simplex. Complications arise from the associated syndromes. Atypical varieties of lentigo simplex (in any anatomic site) may be potential precursors or masqueraders of melanoma.

Prognosis and Clinical Course

The natural history of isolated lentigo simplex is not known. Once developed, the lesions are presumed to be relatively stable. There is no convincing evidence that lentigo simplex evolves to a nevomelanocytic nevus. As with any process in which melanocytes are present (including normal skin), it is possible for melanoma to arise in a lentigo, but an elevated risk has not been demonstrated conclusively for lentigo simplex.

The long-term course and malignant potential of agminated lentigines are unknown.

Treatment

There is no need to treat benign-appearing lentigo simplex. Cosmetic removal may be achieved with cryotherapy or





▲ **FIGURE 122-22** Lentigo simplex. **A.** Acquired darkly pigmented lentigines on the vulva of a 13-year-old white girl who has *l*entigines, *a*trial myxomas, *m*ucocutaneous myxomas, and *b*lue nevi (LAMB, myxoma) syndrome. **B.** Multiple lentigines on the lips of the same patient. This patient died in her mid-20s of a malignant schwannoma.



▲ **FIGURE 122-23** Agminated lentigines. **A.** Grouping of small light brown macules, present since age 14 years, on the right side of the shaft and glans penis of a 17-year-old healthy white male. **B.** Grouping of small, light brown macules, present for at least 6 years, on the right cheek of a healthy 10-year-old African-American male. **C.** Grouping of small, light-brown macules, present since age 2 years, on the right neck and supraclavicular area of a 13-year-old healthy white female.

other destructive approaches such as Q-switched laser. However, caution must be taken to ensure the lesion being treated is benign. Lesions that are significantly unusual, irregular, asymmetric, or changing in shape should be examined histopathologically to exclude melanoma. Wood's lamp examination is useful in defining margins of lentigo simplex.

Until the long-term course of agminated lentigines is known, it may be prudent to recommend periodic examinations to detect the earliest signs of possible malignant evolution.

Box 122-8

Differential Diagnosis of Lentigo Simplex

- Solitary
  - Solar lentigo/ephelids
  - Junctional nevomelanocytic nevus
  - Atypical (dysplastic) melanocytic nevus
  - Café-au-lait macule
  - Melanoma (lentigo maligna)
- Grouped
  - Agminated nevi
  - Nevus spilus

Prevention

UVR is clearly associated with the development of solar lentigines, but its role in the different types of simple lentigines is not known. However, it is rational to limit UVR overexposure.

SOLAR LENTIGO

Epidemiology

The prevalence of solar lentigines is correlated directly with increasing age, and they are present in 90 percent of white people over 60 years of age.[101] Solar lentigines are common in individuals who sunburn easily and do not tan, whereas they are uncommon among people who have darkly pigmented skin.[102]

Lentigines may be induced by photochemotherapy [psoralen and ultraviolet A light (PUVA) lentigo], occurring in 40 percent to 50 percent of patients an average of 5.7 years after starting therapy, their frequency and severity directly attributable to the total number of treatments (Fig. 122-24; see Chap. 239).[102] Darkly pigmented skin is associated with the lowest risk for PUVA-induced or solar-induced lentigines.[102] Lentigines have been associated with UVA tanning bed use.[103]

Lesions similar in gross and microscopic appearance to solar lentigo, freckle (ephelis), may occur in children and young adults.[104] They may appear within the first 5 years of life, tend to aggregate in families, and are significantly associated with red hair; their location and density correlate with sun sensitivity and sun exposure. The presence of freckles has been associated with a 2.5-fold increase in the rate of sunburn susceptibility and poor tanning

SOLAR LENTIGO AT A GLANCE



- Solar lentigo is distinguished from lentigo simplex histopathologically on the basis of shape and extent of epidermal hyperplasia. The epidermal hyperplasia is often more prominent in solar lentigines and may include "bud-like" structures at the base of rete ridges.
- Solar lentigines appear as circumscribed pigmented macules occurring singly or as multiple lesions and present on the skin surface exposed to natural or artificial sources of ultraviolet radiation. Distinct subtypes exist and include the ink spot lentigo.
- Most solar lentigines occur in adults.
- Solar lentigines are benign but caution must be taken to discriminate benign lesions from lentigo maligna.
- Outdated synonyms: sun-induced freckle, liver spot, lentigo senilis, and senile lentigo.



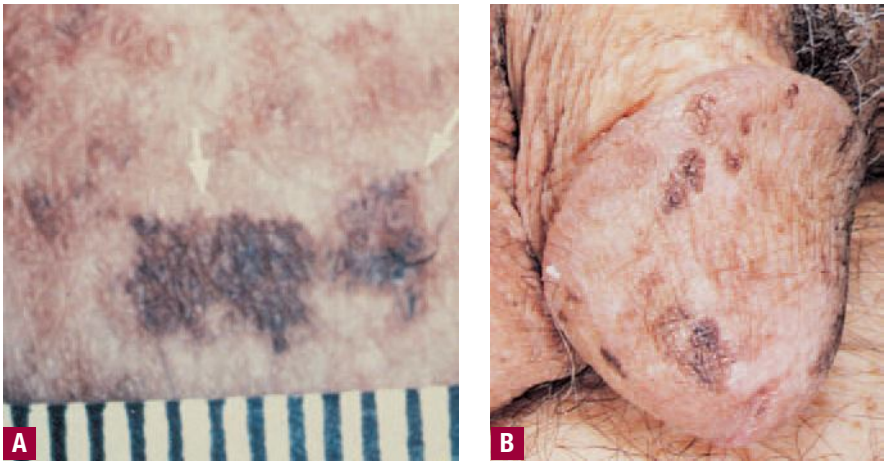



▲ **FIGURE 122-24** Photochemotherapy [psoralen and ultraviolet A light (PUVA)]-induced lentigines on the buttock (**A**) and penis (**B**) of a 57-year-old white man who had received PUVA for psoriasis several times per week for 5 years. The PUVA lentigines appeared between 1 to 2 years after PUVA therapy was begun. The current recommendation is to shield the male genitalia during PUVA therapy to prevent epithelial tumors of the penis and scrotum.

response and a three-fold greater likelihood of a lower minimal erythema dose in people who mostly burn and tan minimally or not at all.[105] The presence of dense sun-induced freckling increases the estimated risk for melanoma by three- to fourfold.[106]

Etiology and Pathogenesis

Solar lentigines are thought to represent a marker of intermittent high-intensity UVR, cumulative UVR, and/or a unique susceptibility to the proliferative, stimulatory, and/or mutagenic effects of UVR. Given the hyperplasia of both the keratinocytes and melanocytes, the primary defect in solar lentigines could be in either cell type eliciting a secondary proliferative response in the other.

There is a pronounced link between UVR exposure and the development of lentigines. Single exposures of experimental UVB radiation (320 mm) that is 6 to 10 times the minimal erythema dose induces "freckling" in susceptible individuals.[107] Phototoxic doses of PUVA may lead to the development of lentigines 6 to 8 months later.[108] In addition to the total dose of UVR received during photochemotherapy, individual susceptibility factors to lentigo development include race, age, and burning/tanning response to sunlight.[102]

Supportive of the underlying mutation being present in the melanocytes is the finding that epidermal melanocytic cellular atypia persists in lentigines developing in patients receiving chronic photochemotherapy for 1 to 2 years or longer after therapy is discontinued.[102]

In xeroderma pigmentosum (XP), in which patients have an increased sensitivity to UVR, hyperpigmented macules develop on light-exposed skin within the first 5 years of life (see Chap. 109), and these lesions demonstrate hyperplasia of variably atypical epidermal melanocytes (i.e., atypical lentigines). In one series of XP patients from Japan,[109] lentigo maligna melanoma was the predominant melanoma type, suggesting an association between this tumor subtype, sensitivity to UVR, and the presence of UVR-induced atypical solar lentigines, and supportive of the underlying mutation being in the melanocytic lineage.

Clinical Findings (Fig. 122-25)

HISTORY Solar lentigines appear as acquired lesions, generally in fair-skinned individuals, on sun-exposed skin surfaces. For the majority of solar lentigines, it is assumed that once present, they remain stable.

CUTANEOUS LESIONS Solar lentigo occurs as a pigmented macule on skin exposed to natural sunlight or artificial sources of UVR, usually in the presence of similar lesions in the same location (Fig. 122-26). Lesions may be tiny (< 1 mm in diameter) or large (up to a few centimeters in diameter), with a tendency to confluence in severely sun-damaged skin and with smooth or irregular outlines. Lesions are usually light brown, but varieties of solar lentigo are jet black, similar to an India ink stain (ink spot lentigo). Although solar lentigo usually occurs on sun-exposed skin, identical-appearing lesions may occur on sun-protected sites (including the penis and buttocks) that have been exposed to photochemotherapy (see Fig.

Dermoscopically these lesions are of uniform color and may have a prominent network pattern or a diffuse uniform very light brown pigmentation. The borders may have a jagged shape, but the interface between lesion and normal skin is generally visible. These lesions may occasionally be difficult to differentiate from a junctional nevus or a flat seborrheic keratoses.

↓

Solar lentigines are more likely to be found on fair skinned individuals with advancing age.

↓

The lesions should be found in areas of significant UVR exposure. Important to keep in mind, these lesions may even be present on genital skin in the setting of PUVA or other intense UVR exposures.

↓

Lesions appearing different than the others and changing, especially if non-uniform, need to be considered for biopsy to exclude melanoma (particularly the lentigo maligna subtype). On the face, dermoscopic structures that increase concern for melanoma include asymmetric follicular pigmentation, gray pigment network, and annular/granular and rhomboidal structures.

▲ **FIGURE 122-25** Approach to the patient with solar lentigo. PUVA = psoralen and ultraviolet A light; UVR = ultraviolet radiation.

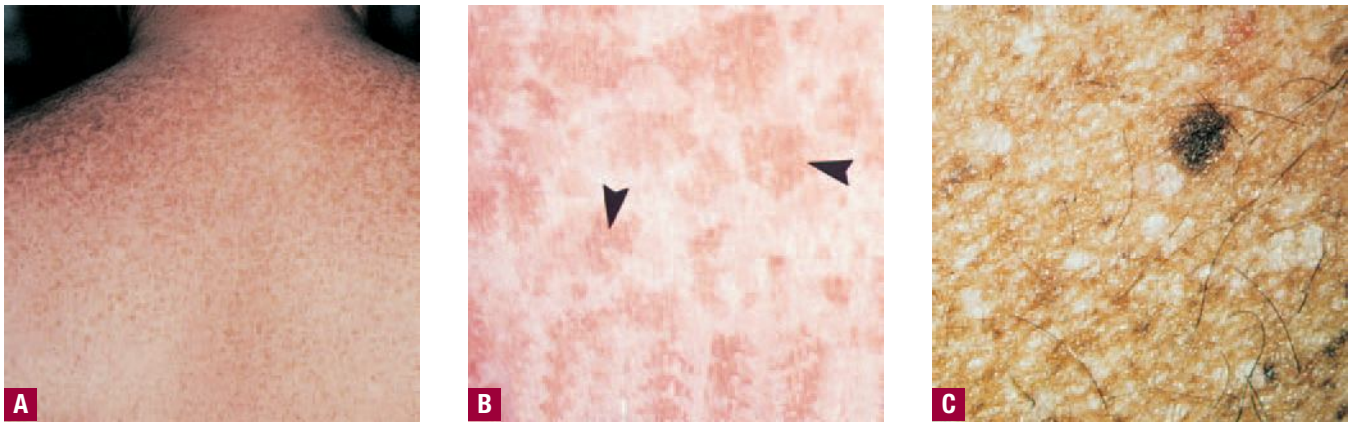

▲ **FIGURE 122-26** Solar lentigo. **A.** Uncountable solar lentigines on the back of a 30-year-old white man, appearing initially during early childhood after multiple sunburns. **B.** High magnification of lentigines in (**A**) showing light-brown macules with markedly irregular outlines. **C.** Solar lentigines on sun-damaged dorsal hand skin (hypopigmentation, wrinkling, and telangiectasia) of an elderly white man.

122-24). When examined by dermoscopy, solar lentigines reveal a uniform reticular network.[110] Lentigines in patients receiving PUVA and in individuals who have XP are often darkly and/or irregularly pigmented.

Solar lentigines not apparent in visible light may be visualized using Wood's lamp illumination.

The oral-labial melanotic macule has gross morphologic characteristics similar to solar lentigo (Fig. 122-27), but its relation to a sun-sensitive phenotype or excessive sun exposure has not been well documented.

A clinical distinction is made between a freckle (ephelis) and a solar lentigo. Freckles are common on the central face and often first noted in early childhood, presumably developing after significant sun exposure and are said to fade or even disappear when sun exposure is discontinued. Unfortunately, there are no longitudinal studies of ephelides or solar lentigines that document gross morphologic or time-course differences that would reliably allow a clinical distinction between ephelides and solar lentigines. According to L-3, 4-dihydroxyphenylalanine (DOPA) studies on epidermal sheets, ephelides have been reported to show increased melanogenesis but decreased melanocyte number, which implies a different pathologic basis.[107,111] However, counting melanocytes in DOPA-incubated epidermal sheets is unreliable for pigmented lesions, and these early studies must be questioned. Studies in DOPA-incubated tissue vertical sections demonstrate that melanocytes are increased in "ephelides" in children and young adults, similar to solar lentigines.[44,110]

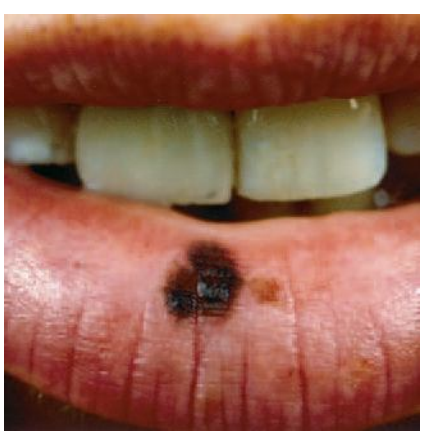

▲ **FIGURE 122-27** Labial melanotic macule, appearing 5 years earlier, on the lower lip of a 26-year-old white woman.

RELATED PHYSICAL FINDINGS Patients with solar lentigines are more likely to be fair skinned, particularly those with red hair and or lighter eye color. Along with the lentigines, increased solar damage may be noted and other lesions such as idiopathic guttate hypomelanosis, actinic keratoses, and seborrheic keratoses may be present. The presence of solar lentigines is a risk factor for melanoma, basal cell cancer, and squamous cell cancer.

Laboratory Tests

HISTOPATHOLOGY Solar lentigines reveal elongated epidermal rete ridges with club-shaped or bud-like extensions, frequent branching and fusing of rete ridges, a thinned or atrophic epidermis between rete ridges, and increased numbers of epidermal melanocytes without nesting. The microscopic appearance suggests a concurrent proliferation of keratinocytes and melanocytes.[112] There is a scant to moderate perivascular mononuclear cell infiltrate in the dermis, usually associated with scattered melanin-laden macrophages.

Histopathologic characteristics of the labial melanotic macule (labial lentigo) are similar to those of solar lentigo, showing melanocytic hyperplasia but without cellular atypia. The presence of melanocytic hyperplasia in labial melanotic macule is not a uniform finding in all studies.

SPECIAL TESTS Mart-1 and DOPA histochemical studies may be useful to demonstrate increased number of melanocytes confined to the basal layer and a lack of junctional nest formation.

Differential Diagnosis (Box 122-9)

Complications

A potential complication is the discovery that an atypical solar lentigo is actually melanoma (often of the lentigo maligna variety).

Prognosis and Clinical Course

Solar lentigines may appear at any time of life. A solar lentigo may enlarge, darken, and become stable over time, but longitudinal studies of solar lentigines are lacking. It is possible that once formed, solar lentigines may persist indefinitely

Box 122-9

Differential Diagnosis of Solar Lentigo

- "Reticulated" seborrheic keratoses
- Lentigo simplex
- Ephelis
- Junctional nevomelanocytic nevus
- Pigmented actinic keratoses
- Lentigo maligna



or fade slightly with time. Solar lentigines may be a heterogeneous population that includes lesions that fade and lesions that do not fade after UVR avoidance. The presence of these lesions suggests an increased risk for melanoma and nonmelanoma skin cancers.

It has been proposed that some varieties of lichenoid keratosis (see Chap. 113) may be due to an acute inflammatory reaction targeting the solar lentigo, and that resolution of lichenoid keratosis may cause regression of the associated lentigo.[114]

The long-term course of atypical varieties of PUVA lentigo is unknown, but it is clear that PUVA lentigines (see Fig. 122-24) may persist 1 to 2 years or longer after therapy is discontinued[102] and that cellular atypia of epidermal melanocytes in these lesions may persist as well. It is also clear that these patients may be at increased risk for melanoma[115] and should be followed periodically for life.

Lentigo maligna (see Chap. 124) may masquerade as a solar lentigo early in its development or, alternatively, may evolve from a pre-existing solar lentigo. A solar lentigo not matching the patient's other lentigines and/or enlarging/darkening out of step should be examined histopathologically or followed closely.



Treatment

Solar lentigo usually requires no therapy, but importantly, its presence indicates sensitivity and/or excessive exposure to UVR. Bleaching creams containing hydroquinone are usually not effective. Cryotherapy or other superficial destructive techniques (such as Q-switched laser) may be an option if the lesion is clearly benign, but lesions may recur after therapy.

Prevention

It may be possible to prevent further solar lentigines by reducing sun exposure. This may be accomplished through avoidance, protective clothing, and sunscreens. Optimally, these measures should be initiated during early childhood and continued throughout life.

KEY REFERENCES

The full reference list for all chapters is available at www.digm7.com.

1. Gill MG, Celebi JT: B-RAF and melanocytic neoplasia. *J Am Acad Dermatol* **53**:108, 2005
23. Kopf AW et al: Congenital nevus-like nevi, nevi spili, and cafe-au-lait spots in patients with malignant melanoma. *J Dermatol Surg Oncol* **11**:275, 1985
31. Kelly JW et al: Sunlight: A major factor associated with the development of melanocytic nevi in Australian schoolchildren. *J Am Acad Dermatol* **30**:40, 1994
35. Zalaudek I et al: Age-related prevalence of dermoscopy patterns in acquired melanocytic nevi. *Br J Dermatol* **154**:299, 2006
37. Chudnovsky Y et al: Use of human tissue to assess the oncogenic activity of melanoma-associated mutations. *Nat Genet* **37**:745, 2005
38. Grichnik JM et al: Melanoma a tumor based on a mutant stem cell? *J Invest Dermatol* **126**:142, 2006
40. Nishimura EK et al: Dominant role of the niche in melanocyte stem-cell fate determination. *Nature* **414**:105, 2002
41. Cramer SF: The histogenesis of acquired melanocytic nevi: Based on a new concept of melanocytic differentiation. *Am J Dermatopathol* **6**:289, 1984
42. Banky JP et al: Incidence of new and changed nevi and melanomas detected using baseline images and dermoscopy in patients at high risk for melanoma. *Arch Dermatol* **141**:998, 2005
52. Pharis DB, Zitelli JA: Sunburn, trauma, and the timing of biopsies of melanocytic nevi. *Dermatol Surg* **27**:835, 2001
58. Tsao H et al: The transformation rate of moles (melanocytic nevi) into cutaneous melanoma: A population-based estimate. *Arch Dermatol* **139**:282, 2003
59. Bevona C et al: Cutaneous melanomas associated with nevi. *Arch Dermatol* **139**:1620, 2003
62. Lucas CR et al: Early melanoma detection: nonuniform dermoscopic features and growth. *J Am Acad Dermatol* **48**:663, 2003
64. Patterson JW: Nevus cell aggregates in lymph nodes. *Am J Clin Pathol* **121**:13, 2004
84. Bastian BC et al: Mutations and copy number increase of HRAS in Spitz nevi with distinctive histopathological features. *Am J Pathol* **157**:967, 2000
94. Wick MR: Melanocytic lesions with features of Spitz nevus. *Human Pathol* **37**:779, 2006
95. Biddle et al: Intraparenchymal nevus cell aggregates in lymph nodes a possible diagnostic pitfall with malignant melanoma and carcinoma. *Am J Surg Pathol* **27**:673, 2003
99. Mihic-Probst D et al: Immunostaining for the tumor suppressor gene p16 product is a useful marker to differentiate melanoma metastasis from lymph-node nevus. *Virchows Arch* **443**:745, 2003
102. Rhodes AR et al: The PUVA lentigo: An analysis of predisposing factors. *J Invest Dermatol* **81**:459, 1983
115. Stern RS: The risk of melanoma in association with long-term exposure to PUVA. *J Am Acad Dermatol* **44**:755, 2001

CHAPTER 123

Atypical Melanocytic Nevi

Margaret A. Tucker

EPIDEMIOLOGY

The term *atypical melanocytic nevi* includes several clinical entities, including the common atypical dysplastic nevi, and rare atypical Spitz or spitzoid nevi, atypical genital nevi, and other unusual melanocytic nevi.[1] This chapter will focus on the common atypical/dysplastic nevi, which are relatively frequent melanocytic neoplasms.

Atypical nevi were first recognized as distinct pigmented lesions during the clinical assessment of melanoma-prone families.[2] The nomenclature associated with these lesions also includes B-K moles (recognizing the first two families described whose surnames began with B and K),[2] familial atypical multiple mole and melanoma syndrome,[3] atypical mole syndrome,[4] Clark's nevus,[5] atypical moles, and nevus with architectural disorder (with varying degrees of melanocytic atypia).[6] The nomenclature has been contentious in the past. The term *dysplastic nevus* (DN) is more frequently used at present, both for clinical and histologic diagnoses,[7,8] and it is the personal preference of the author. Therefore, the term will be used throughout this chapter.

The usual clinical criteria for the diagnosis of a DN are two obligate features: Diameter in one dimension at least 5 mm and a prominent flat component, and two of three other features: Irregular, asymmetric outline, indistinct borders, and variable pigmentation (Fig. 123-1).[9] The histologic features include the presence of an immature or disordered growth pattern with a lymphocytic host response and random cytologic atypia in melanocytes (Fig. 123-2).[10] Multiple studies have demonstrated that the clinical

ATYPICAL/ DYSPLASTIC NEVI AT A GLANCE



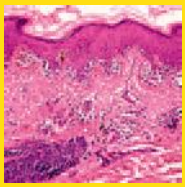

- Prevalence among Caucasian young adults roughly 10 percent; varies by population
- Flat (totally or partially), large (> 5 mm) lesions with irregular shape, indistinct borders, and variable pigmentation
- Risk markers for melanoma and precursors of melanoma
- Most frequent on sun-exposed areas, especially intermittently exposed, such as back
- Associated with large numbers of common acquired nevi
- Majority of lesions will involute and disappear over time
- Histologic features include presence of immature, disordered growth pattern with a lymphocytic host response and random cytologic atypia in melanocytes

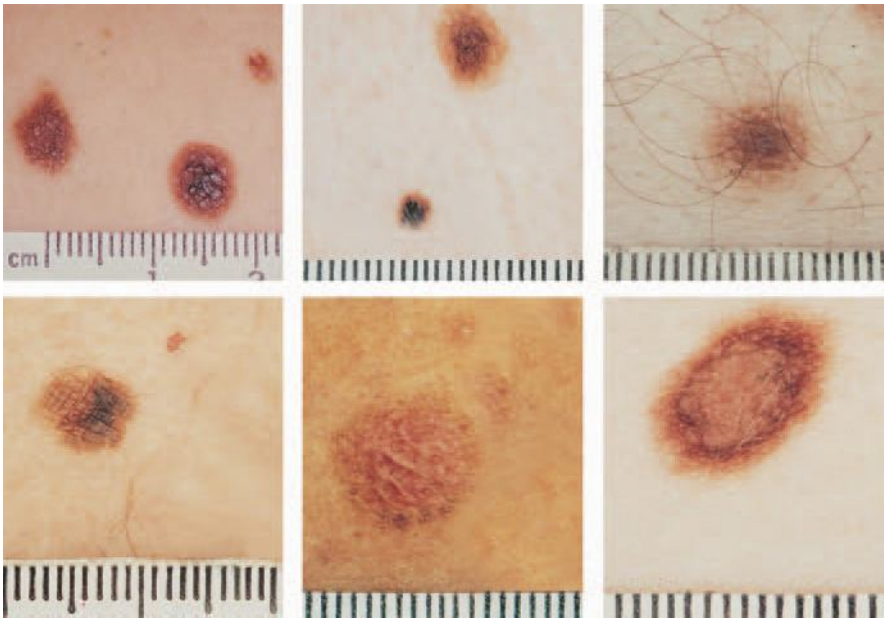

▲ **FIGURE 123-1** Atypical nevi have two obligate features: diameter in one dimension at least 5 mm and a prominent flat component, and two of three other features: irregular asymmetric outline, indistinct borders, and variable pigmentation.

and histologic criteria are each reproducible across observers.[11–14]

Most of the information on the epidemiology of DN has been obtained from studies of melanoma etiology. In virtually every study that has assessed risk of melanoma associated with DN, these nevi are associated with increased risk of melanoma.[15] Most of the epidemiologic studies have used the clinical diagnosis of DN as the risk factor analyzed. DN occur in approximately 10 percent of the adult populations of northern European descent based on the results of multiple case-control studies evaluating risk of melanoma associated with these lesions.[15] Among studies, the prevalence of DN in control populations has ranged from 7 percent to 24 percent. The studies occurred in different geographic regions, with varied control selection, and somewhat different criteria for the clinical diagnosis of DN. Given the differences in exposures and selection criteria for both study participants and nevi, the studies are remarkably consistent.

Limited data on the population prevalence of these lesions exist, and geographic and racial differences are likely. One early cross-sectional study in a New Zealand cohort (independent of melanoma) revealed DN in 9 percent of European descent adults.[16] A joint case-control study of nevi and melanoma in Australia and the United Kingdom demonstrated that DN were three times more frequent in the Australian controls (6 percent) than in the British controls (2 percent).[17] There are a few case reports of DN in Japanese, primarily in melanoma-prone families.[18]

DN are frequently found in melanoma-prone families in North America, Europe, and Australia.[19–27] They appear in the majority of Northern European families (from England, France, Holland, North America, Scotland, Sweden) and, to a somewhat lesser extent, in Spanish and Italian families. One of the differences in the Mediterranean families is that the nevi tend to be somewhat smaller than the 5-mm diameter criterion and may not be counted as dysplastic.

ETIOLOGY AND PATHOGENESIS

The etiology of DN is largely unknown, but there appears to be a genetic component of risk. DN occur in a familial pattern; limited segregation analyses suggest an autosomal dominant transition of the trait.[28] To date, no germline susceptibility genes have been identified for these lesions. Early on, it was hypothesized that melanoma and DN represented pleiotropic effects of a single gene.[29] After the first major melanoma susceptibility gene, cyclin-dependent kinase inhibitor 2A (*CDKN2A*), was identified, this hypothesis could be directly tested. Within melanoma-prone families with identified mutations in *CDKN2A*, DN do not consistently co-segregate with the mutation in the family.[30,31] This observation implies that the alteration in *CDKN2A* associated with risk of melanoma is not causal for DN. Within families having *CDKN2A* germline mutations, DN also appear to be an independent risk factor for melanoma.[22,31] Germline mutation testing of several other candidate genes for melanoma (e.g., *PTEN*, *BRAF*, *CDK4*) in individuals with DN, but not necessarily melanoma, has also not found mutations in the candidates selected.[32] Germline polymorphisms in *BRAF* were also not related to nevi or freckles in another study.[33] Although two groups have found evidence for linkage of a gene for increased number of nevi in the region around *CDKN2A* in twin studies,[34,35] a specific gene that is mutated has not yet been identified. One group also evaluated "atypical mole count" and found some areas of modest interest on chromosomes 1, 6, and X.[35] It is likely that DN, like melanoma, is a complex, heterogeneous trait.

One author has hypothesized that a single mutation in melanocyte precursors would be sufficient to explain the pathogenesis of nevi (not specifically DN).[36] Detecting novel characteristic somatic mutations in the atypical melanocytes within DN has been difficult,



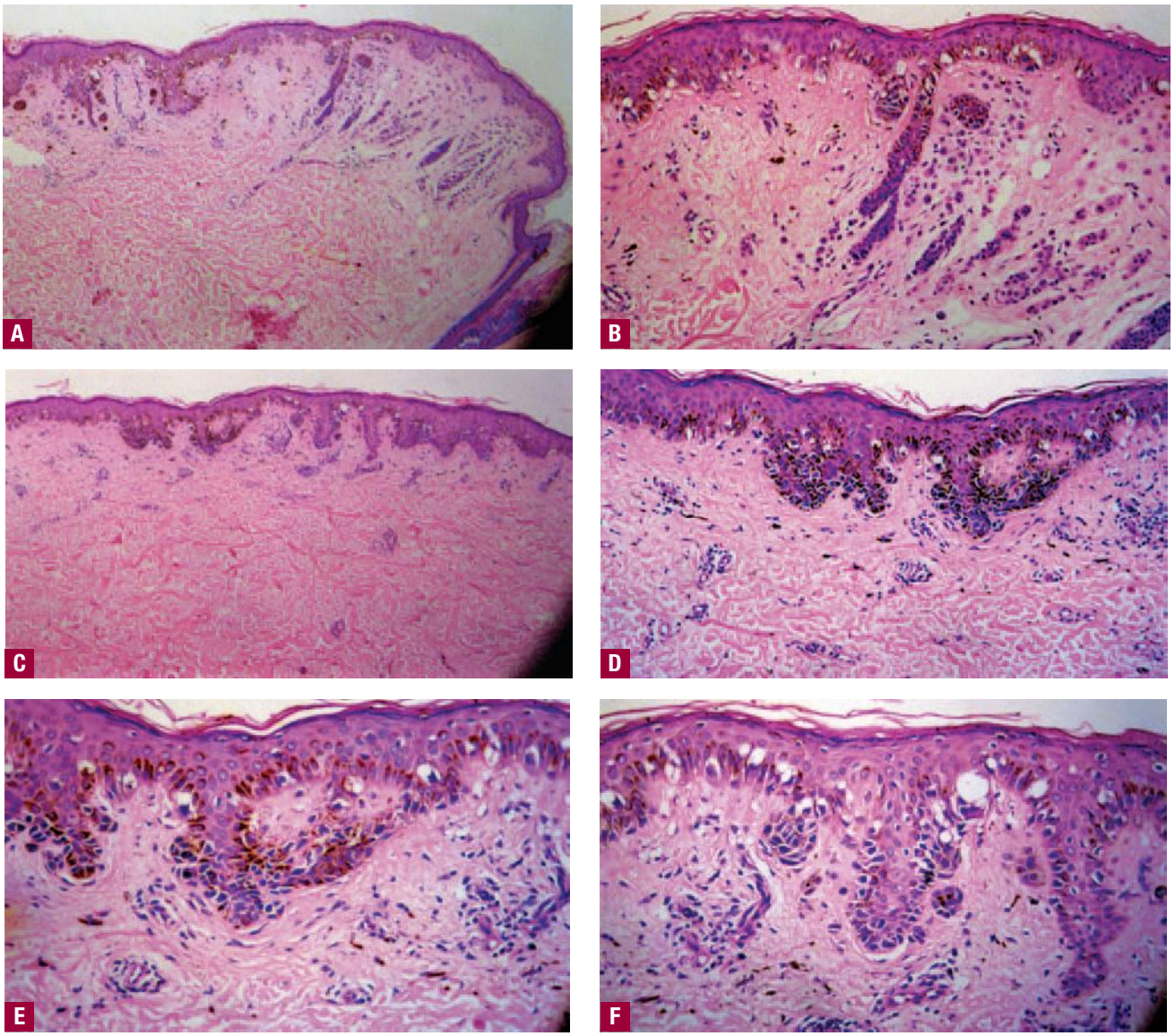

▲ **FIGURE 123-2** The histopathology of the lesion shown in Figure 123-10. **A.** The low-power view shows a dermal nevus with dysplasia. **B.** A closer view of the dysplasia at the shoulder of the dermal nevus. **C.** Another area of dysplasia. **D.** On closer view, there is an increased number of melanocytes without an apparent increase in keratinocytes, with the melanocytes clustered on the sides and the ends of the retia. The nuclei of the melanocytes are quite atypical. **E.** At higher power, the nuclei of the melanocytes are atypical and enlarged, characteristic of epithelioid melanocytic dysplasia. **F.** Another area of the lesion with melanocytes in linear array, characteristic of lentiginous melanocytic dysplasia. The melanocytes are not as enlarged as in the area of epithelioid dysplasia. With > 30 atypical melanocytes and the level of disorganization of the architecture, the lesion is classified as severely dysplastic. (Photomicrographs used with permission from Wallace H. Clark, Jr.)

even with microdissection, because of the small clusters of atypical melanocytes. On account of this technical difficulty, data are available for relatively sparse numbers of lesions. For instance, in a report assessing *BRAF* V600E (formerly V599E) mutations in 77 nevi, mutations were found in 82 percent of all nevi, but only five DN were included.[37] Among these, four (80 percent) had the mutation. Another method for evaluating V600E, the ligase detection reaction, does not require microdissection and can be performed on paraffin sections of formalin fixed tissue.[38] This method has been used to evaluate the presence of mutations within 6 DN, half of which had the V600E mutation in *BRAF*. Based on limited data, although the V600E mutation occurs early in melanocyte tumor progression (in benign nevi), the mutation is not distinctively associated with DN, nor does it appear to be more frequent than in common nevi.

Somatic mutations in *NRAS* have also been described in melanomas and in nevi.[39,40] These mutations are found in lesions that do not have *BRAF* mutations. There is a specific activating mutation in codon 61 of *NRAS* that was evaluated in Swedish individuals with germline *CDKN2A* mutations. Seven DN, 21 melanomas, and two common acquired nevi were studied. All but one of the melanomas and five of the seven DN had the *NRAS* mutation; neither of the common acquired nevi did.[39] An earlier study using microdissection in 13 common nevi and nine DN showed hemizygous deletion in the region of p16 in seven of nine DN and in none of the common nevi.[41] In a similar manner, three of seven of the DN had hemizygous loss in the region of p53; all three also had deletions in the region of p16. None of the common nevi had hemizygous loss in the p53 region.

Senescence is usually driven by telomere shortening and is associated with increased expression of p16, among other tumor suppressors. One group re-

cently explored whether *BRAF* mutations, particularly V600E, in nevi were associated with senescence.[42] They measured activity of senescence-associated acidic β-galactosidase, a common senescence marker, and p16 in congenital (not dysplastic) nevi and in melanocytes transduced with lentivirus expressing V600E. They found that senescence-associated acidic β-galactosidase was always expressed in the nevi (n = 23) and in 80 percent of the cultured melanocytes. All of the nevi had some melanocytes expressing p16, but none showed upregulation of p21 and p53. Eight of the congenital nevi had V600E mutations; the pattern of p16 expression was heterogeneous and similar in lesions with and without V600E mutations. These findings suggest that other mechanisms in addition to p16 are important in the growth arrest of congenital nevi.

Several lines of evidence suggest that sun or ultraviolet light (UV) exposure is important in the etiology of DN. First, the lesions occur most frequently in sun-exposed areas, particularly in those intermittently exposed, but DN may also occur in unexposed areas.[19,44–47] The most common area for DN is on the trunk, primarily the back (Fig. 123-3; see eFig. 123-10.1 in on-line edition). There is relative sparing of the more sun-protected lateral thoracic regions and the inner aspect of the arms. Fewer DN occur in doubly covered areas such as on the buttocks. In a comparison of Australian and British controls from a joint case-control study, the prevalence of DN was three times higher overall in the Australians, but the prevalence of nevi on non–sun-exposed areas was the same.[17] Second, several studies have also demonstrated, to varying degrees, that individuals with DN report more frequent sun exposure and sunburns, especially before age 20, than individuals without DN.[48–50] Individuals who tan well appear to develop fewer DN. Third, based on longitudinal studies of melanoma-prone families, individuals with DN who use sun protective measures consistently develop fewer new nevi, and the dysplastic and common nevi they have are more likely to involute and disappear.[47] Sun-protected children in these high-risk families also develop fewer nevi. None of the existing data, however, prove causality between UV exposure and DN. Over time, some of the cohort studies of nevi in children from the general population may yield important information about the etiology of DN.



▲ **FIGURE 123-3** **A.** A back view showing the distribution of dysplastic nevus and lesion to lesion variability, with an increased number of common acquired nevi also. **B.** A closer view of a cluster of lesions marked as #2 on the back. The lesions are different sizes, colors, shapes, with differing amounts of asymmetry, and indistinct borders. Only the largest lesion meets all of the criteria for a clinical dysplastic nevus.

Clinical Findings (Fig. 123-4)

History

Many individuals with DN come to the attention of a clinician because they are worried about a changing mole. These individuals should be asked about their sun exposure patterns, their personal and family history of melanoma, other skin cancers, and other nevi. Most individuals with multiple DN consider themselves "moley" and often have "moley" family members. They will often report they have been "very moley all of their life." It is useful to ask if their moles changed during adolescence (puberty) or pregnancy.

Knowing the individual's sun exposure is important to understand both their nevus pattern and also, associated melanoma risk. Sun exposure patterns have several components. Although sun exposure at an early age is clearly a risk factor for nevi and melanoma, adult exposure is also important.[51] The practitioner should elicit residential history (e.g., ever lived in the southern half of the United States or in very sunny areas); recreational history (e.g., place and types of exposure); occupational exposure; sunburn (bad blistering) history; and tanning bed/solarium use. Individuals who burn easily may alter their exposure patterns as they age to minimize burning as they age. Time of day of exposure is also clearly important, as is shade-seeking behavior. Understanding current and past sun exposure patterns or sun-seeking behavior also helps personalize sun protection education.

Past history of melanoma or other skin cancer identifies individuals who have already had the exposure to make cancers and are at increased risk of developing another. Individuals who have had one melanoma are at substantially increased risk of developing another primary melanoma, especially within the first 5 years.[52] During this time period, individuals in the general population with melanoma have a 10-fold increased risk of melanoma. Having multiple nevi, especially DN, is one of the risk factors identifying those most likely to develop another primary melanoma.[53] A previous history of nonmelanoma skin cancer approximately doubles the risk for melanoma, especially in older men.[54] Members of melanoma-prone families with DN are at quite high risk of developing melanoma.[47] The risk of melanoma in individuals with multiple DN without a personal or family history of melanoma is also elevated,[9] but probably not as high as that of someone with such a history. It is important to know whether the patient has had multiple excisions of nevi in the past; if so, the current exam will not reflect their original nevus pattern. It is likely that their most atypical or largest nevi may have been removed; the pathology reports from these lesions are often quite useful. Despite the concern about melanoma in individuals with DN, most of these people will never develop melanoma.

For a specific lesion of concern, it is helpful to obtain information about the time period over which it has changed, what brought it to their attention, and whether there are sensations associated with it. It is also important to know if other lesions are also changing, because DN can have "bursts of activity" when





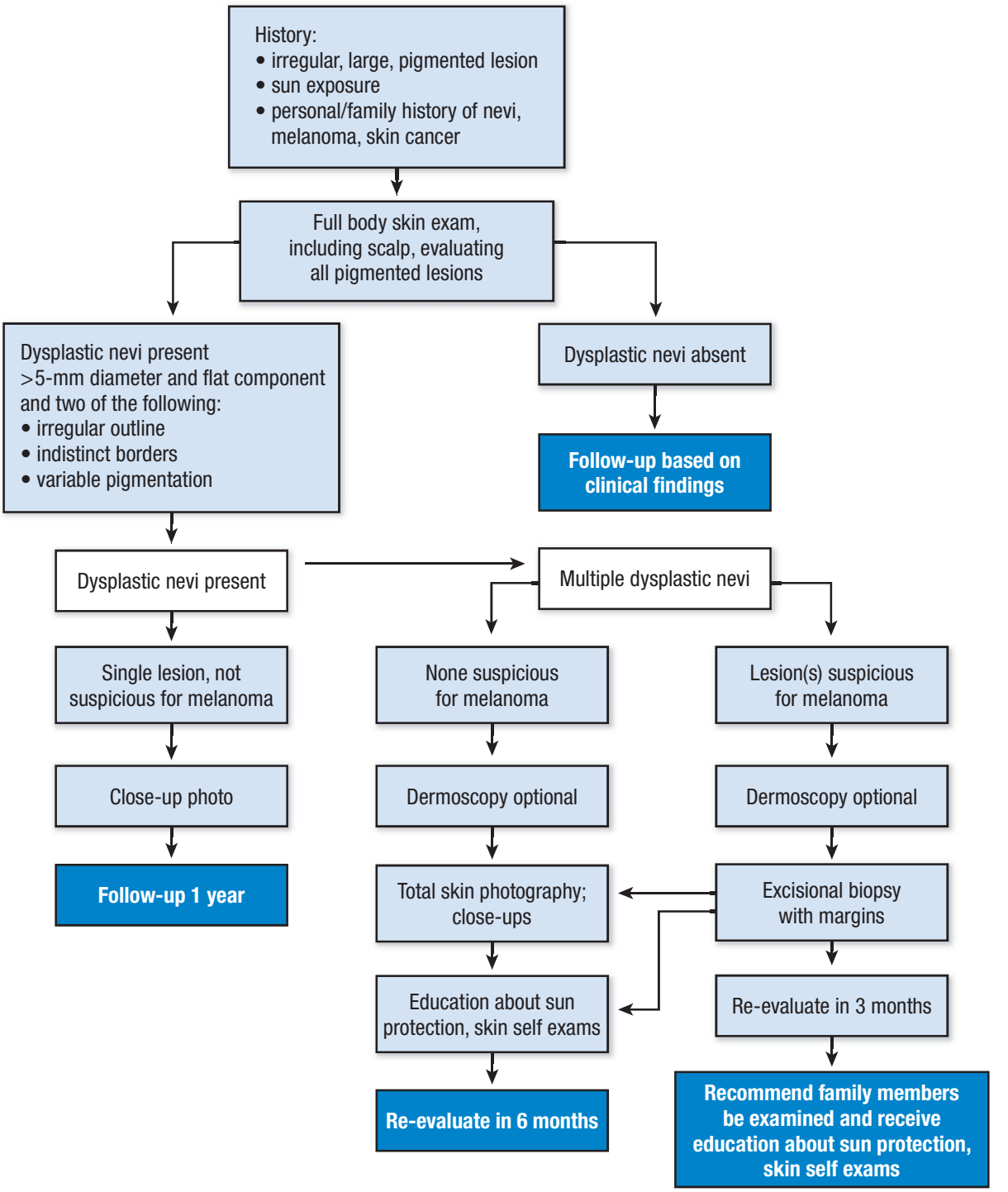

▲ **FIGURE 123-4** Approach to the patient with dysplastic nevi.

multiple lesions are changing. The reasons for the increased rate of change are not understood. Anecdotally, the changes can occur after increased sun or UV exposure (see Figs. 123-9 and 123-10), or in times of hormonal/growth changes such as puberty and pregnancy.[47]

Cutaneous Lesions

DN are large, flat, asymmetric lesions with irregular outline and variable coloration (see Fig. 123-1). Within an individual, there is lesion-to-lesion variability, but there tends to be some consistency in the appearance (see Fig. 123-3B). Between individuals, even within the same family, there can be very broad differences in appearance of DN.[47] Any specific lesion needs to be assessed in the context of where it is in its natural life history. By usual clinical criteria, to be a DN, the lesion must be at least 5 mm in one dimension. Some groups have used other sizes, such as 5 mm in all directions, 7 mm in diameter, or 8 mm in diameter. The most commonly accepted size now is 5 mm in at least one diameter. The requirement of 5 mm in all directions forces a relative symmetry which is not frequent in these lesions. DN tend not to be circular or smoothly ovoid. A DN must also have a flat component, which may be the dominant part of the lesion or might only be a remaining shoulder of the lesion (Fig. 123-5; see Fig. 123-1). Often, DN develop a somewhat "pebbly" surface, with several small papules (Fig. 123-6;

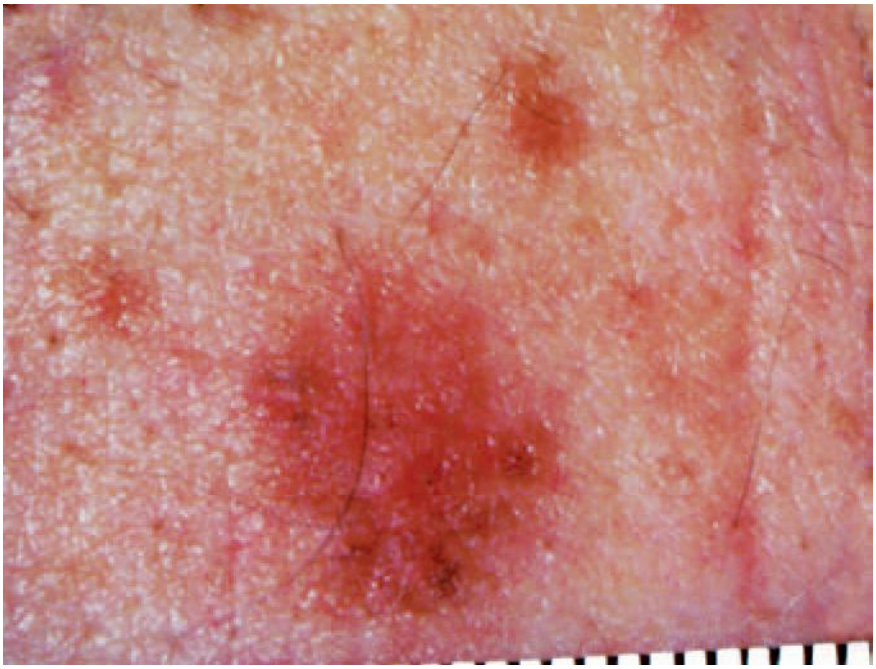

▲ **FIGURE 123-5** The largest diameter of this lesion is approximately 11 mm (from 12 to 6 o'clock); it is mostly flat with a plaque-like low papule off center to the lower right. All of the borders are indistinct; the outline is quite irregular; the lesion is asymmetric; the colors vary from pink to light tan. The lesion is from an individual with quite fair skin and hair who does not make dark pigment. There are also two small other nevi in the photo with the same range of pigmentation.

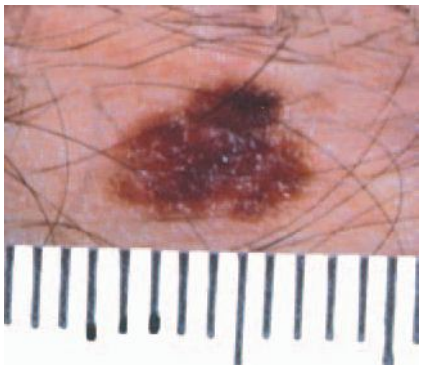

▲ **FIGURE 123-8** This lesion is 7 mm in greatest diameter and predominantly flat. It is quite irregular in outline and asymmetric. The borders are somewhat smudged in some areas; there is clear pigment variation. This person makes very dark nevi; this lesion was typical of many of the patient's nevi.

see Fig. 123-1). If a lesion is completely raised or papular, it is not a DN. Many DN, in the process of involution, become fully papular, and are no longer considered dysplastic. The surface of a DN usually retains fairly normal skin markings (Fig. 123-7A). If there is a papule without skin markings, one needs to think about an expansive process that distorts the architecture, such as a growing tumor. The lesions are asymmetric with an irregular outline. Often the outline is "geographic" and quite irregular. Lesions are frequently rhomboidal or polygonal; others may be almost ovoid or round, but have irregular projections into the surrounding skin (Fig. 123-8). The borders of the lesions are often smudged, with the pigment fading into the adjacent skin. Some of the border may be definitive; other areas may be indistinct. Color variation usually ranges from pink to very dark brown, but this needs to be evaluated in comparison with other pigmented lesions an individual has (see Fig. 123-3B). A very dark brown area in someone with a fair complexion may be suspicious for melanoma. Conversely, someone who is quite dark may make very dark nevi. A prominent erythematous component may correspond to an inflammatory infiltrate in the lesion. A disproportionate erythema in lesion in comparison with other lesions may also be suspicious for melanoma. Similarly, an area of central inflammation and pigment clearing in a DN may be suspicious for regressing melanoma.

Most DN start as ordinary appearing small, symmetric nevi (Fig 123-9A).[47] Unlike other nevi, they continue to enlarge in diameter over varying periods of time. Often, one of the first atypical



▲ **FIGURE 123-6** This lesion is 11 mm in diameter, with a "pebbly" central papular area and a several mm "shoulder" around the papular area. The borders are irregular and quite indistinct around the whole lesion. There is color variation from pinkish tan to medium brown.

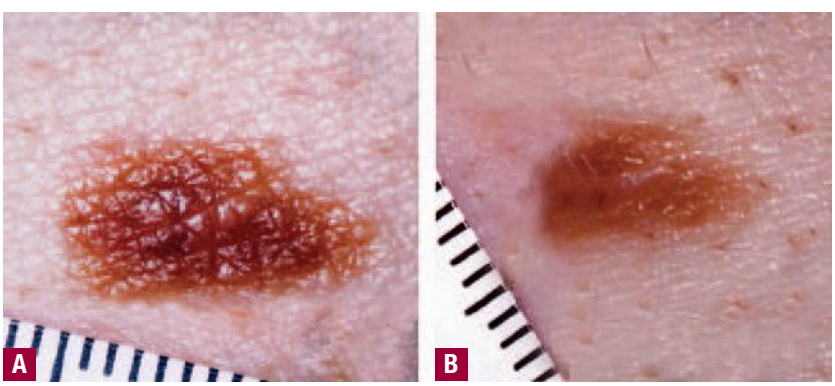

▲ **FIGURE 123-7** **A.** This is a lesion with largest diameter 8 mm, primarily flat with a central low papule, irregular outline, somewhat indistinct border at the upper left corner and far right protrusion, and variable pigmentation. The normal skin markings are well seen. **B.** The same lesion 4 years later after initiation of rigorous sun protection. The entire lesion is flatter. On the right side of the lesion in the area of the "shoulder," there is clear involution of the promontory and invagination of the shoulder area just above it. On the left, the outline has also invaginated toward the center. The entire lesion is also substantially lighter. This is an involuting dysplastic nevus.



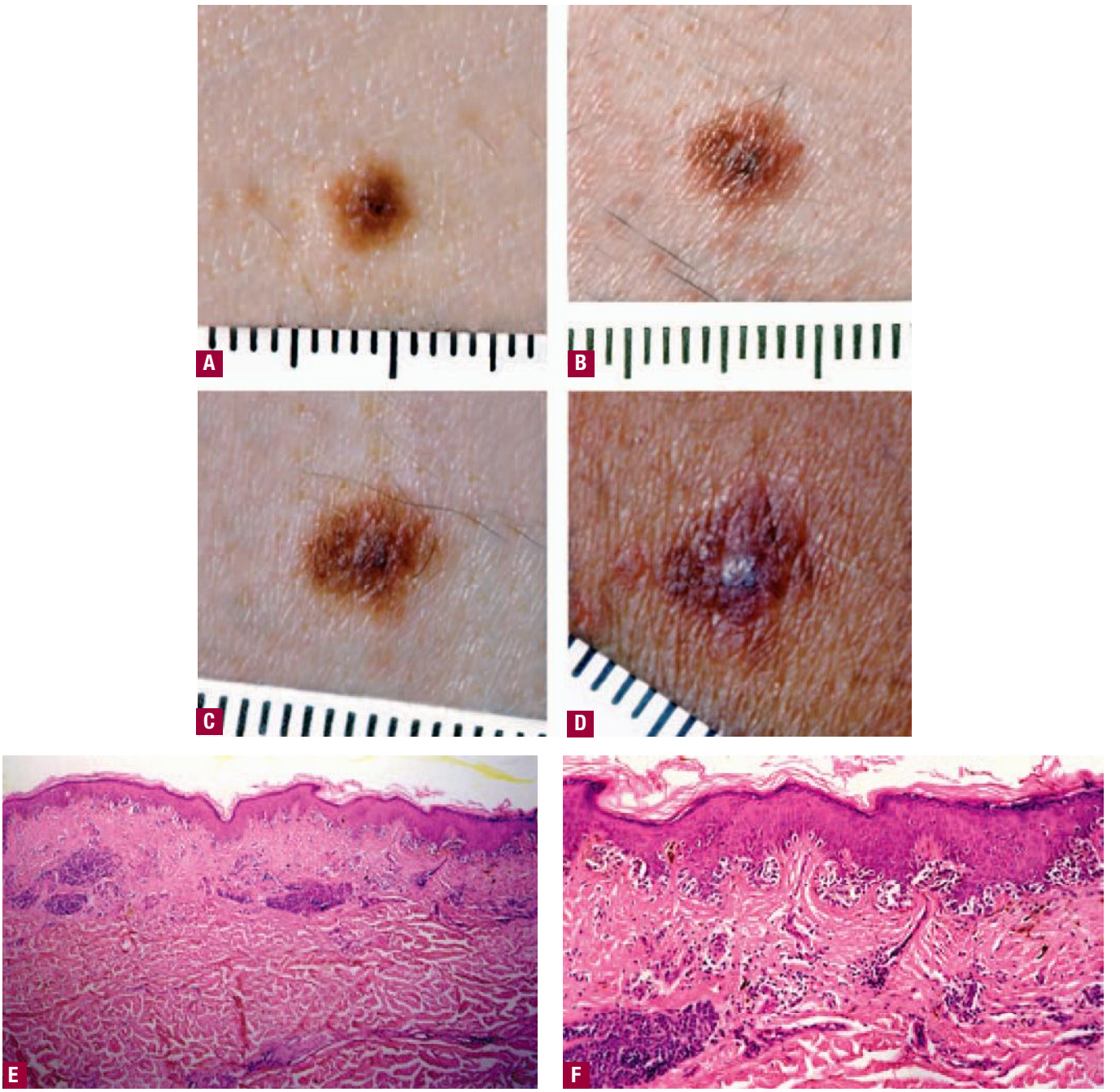

▲ **FIGURE 123-9** **A.** A close-up was taken of this lesion because of increasing prominence in comparison with previous overview photographs. The lesion does not meet criteria for a clinical dysplastic nevus (DN). The largest diameter is not over 5 mm, but it is somewhat irregular in outline with indistinct borders and variable pigmentation. **B.** The same lesion 2 years later has increased in size to 6 mm; become more irregular with an indistinct border from approximately 4 to 6 o'clock and from 11 to 1 o'clock. The central hyperpigmentation has increased, and there is the beginning of central elevation. The lesion now meets criteria for a DN, but is not suspicious for melanoma. **C.** A year and a half later, the lesion now measures 7 mm and has become more irregular and asymmetric. The central papule is dark, but consistent with many other nevi. **D.** A year later, the patient had been using a sunbed for several months and was deeply tanned. The borders of the lesion are difficult to appreciate; the surface of the central papule is exfoliative and has lost the skin markings. The lesion was removed because of the continued changes. **E.**, **F.** There is a plaque of nevus cells at the base of the photomicrograph. Above this, there is an increased amount of connective tissue. Along the dermal-epidermal interface, there is proliferation of moderately atypical melanocytes. Below them is concentric eosinophilic fibroplasia. (Photomicrographs used with permission from Wallace H. Clark, Jr.)

features is a smudging of the border of the lesion, followed by increasing irregularity of outline, and increasing asymmetry (see Fig. 123-9 B,C). Color variation may appear early. Some lesions will have growth arrest before reaching a diameter of 5 mm. Often the nevi will remain as relatively flat lesions over extended periods of time. Some will develop a central papule and evolve to a more typical compound or dermal nevus. As this occurs, the flat component generally recedes toward the papular component (see Fig. 123-7 A,B). Over time, most lesions involute and disappear, leaving no obvious trace.[47]

The most important clinical question in following each specific nevus is the determination of whether or not it is a melanoma (see Chap. 124). When using the "ABCDE" criteria in assessing a DN, each

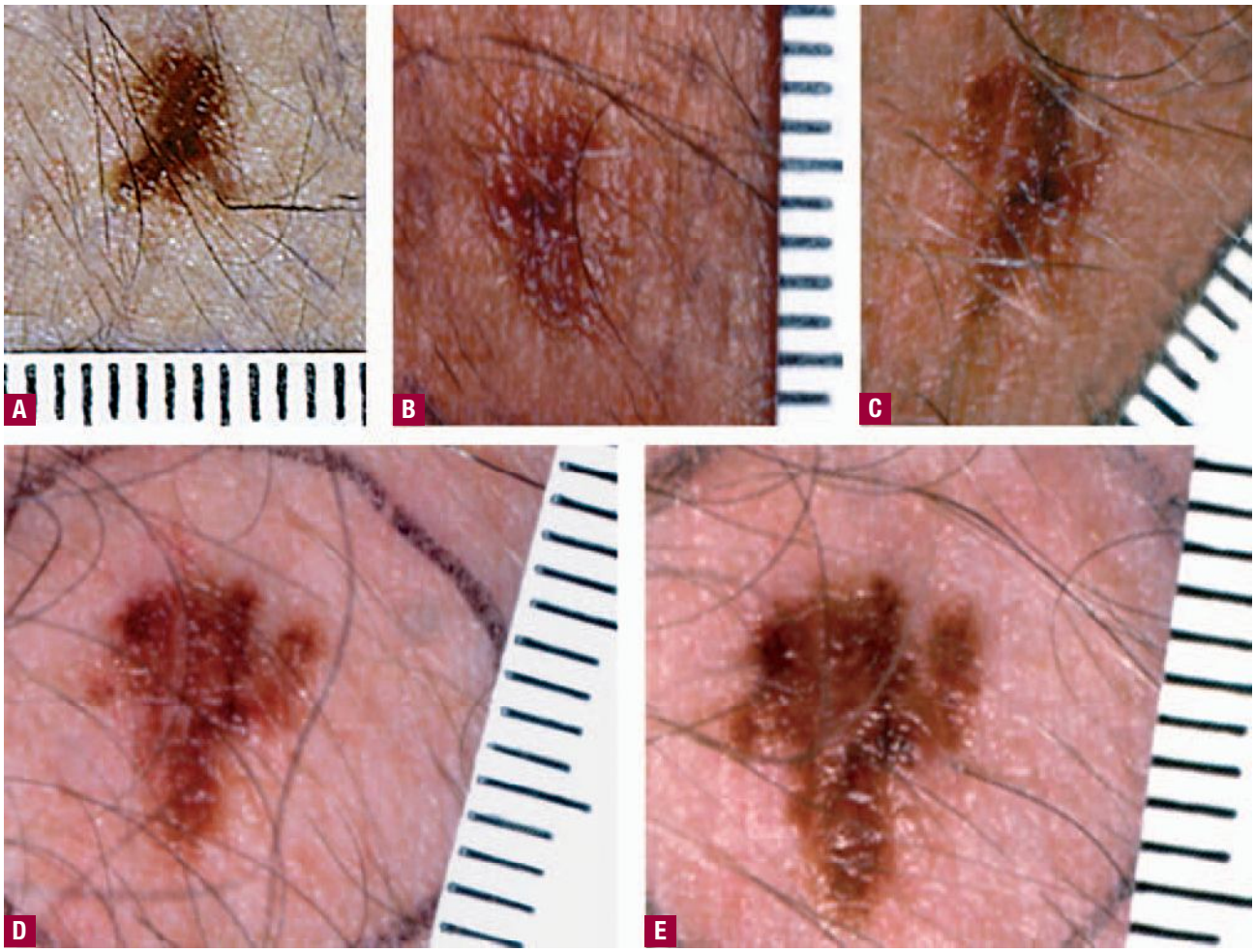

▲ **FIGURE 123-10** The lesion's histopathology is demonstrated in Figure 123-2. **A.** The lesion was photographed because of increasing prominence on overview photographs. It meets all the clinical criteria for dysplastic nevus: It is larger in diameter than 5 mm; is asymmetric with irregular, indistinct borders; and has variable pigmentation. **B.** Four months later, after a couple months of sunbed use,[119] the lesion is somewhat darker, but it is difficult to see distinct boarders because of the deep tan. The outline generally looks similar to the previous photo. **C.** A year later, after continued sunbed use, the lesion is larger, darker, and more asymmetric. It had changed less than other lesions, and other, higher risk lesions were removed. **D.** Six months later, after stopping tanning, the lesion is much lighter. The darkest areas have lightened considerably. The upper pole of the lesion is expanding, and the whole lesion is asymmetric with some indistinct borders. **E.** Three months later, the darker areas were even darker and larger, and the lesion was excised. (Photomicrographs used with permission from Wallace H. Clark, Jr.)

characteristic will be a matter of degree, because DN share these characteristics with early melanoma (Asymmetry, Border irregularity, Color variegation, Diameter greater than 6 mm, and Evolving over time).[55–57] When assessing the evolution, change towards senescence or involution is not worrisome, but change towards morphology closer to melanoma is. Continuing change over several examinations out of proportion to changes in other lesions is also of concern for melanoma (Fig. 123-10).[47] Each lesion should be assessed within the context of the other lesions an individual has. For instance, a lesion on someone with red hair that has a quite dark brown area may be more suspicious for melanoma (because that individual doesn't usually make dark brown pigment) than a lesion with almost black pigmentation in a darker skinned individual. Some individuals have multiple lesions with severely atypical morphology, but the lesions have not changed over years.[47] These lesions usually do not need to be biopsied. If most lesions, including other DN, are in the process of involution, but a DN remains stably atypical or progresses and becomes even slightly more abnormal appearing, then it is reasonable to biopsy the lesion. Obviously, a new dark area in a previously relatively stable lesion is suspicious for melanoma. One becomes most suspicious of a lesion if it is disproportionately more atypical appearing than all of the other lesions. A recent survey of dermatologists[58] in Europe suggests that most dermatologists already use such a process. The recognition of melanoma is more of an overall pattern recognition and a differential recognition process, also known as the "ugly duckling sign," than an analytic criteria recognition (systematically going through all of the ABCDE criteria). The best predictors of melanoma were overall irregularity, the ugly duckling sign, and history of recent change.

Earlier recommendations suggested biopsy of a suspected DN at the time of initial examination to verify histologically that an individual has DN.[60] Over time, with the validation of epidemiologic studies identifying the clinically diagnosed DN as risk markers of melanoma and with the established reproducibility of the clinical diagnosis, it has become clear that the clinical diagnosis can generally be used for patient management. Many individuals with multiple DN will likely have excisional biopsy of lesions at some time in their clinical course; histologic information can be obtained at that time. This approach is also consistent with the rec-

ommendation that the only reason to biopsy a DN is to rule out melanoma.

Related Physical Findings

The major related physical findings in an individual with DN are the cutaneous phenotype and extent of solar injury, both of which are independent risk factors for melanoma.[54] Individuals who are heavily freckled and have DN are at higher risk of developing melanoma than those with DN who are not freckled.[9] In the nonfamilial setting, these effects appear additive. Recent melanoma studies have evaluated the variations in *MC1R*, the melanocortin 1 receptor gene, as a risk factor for melanoma.[61–65] Some variations in the gene are related to the freckling phenotype, fair skin, and red hair, the "red hair variants." Other, more common variants do not have a recognizable phenotype, but do increase melanoma risk. In melanoma-prone families, many individuals have information not only on the cutaneous phenotype, but on genetic variations in *MC1R* as well as the major melanoma susceptibility genes.[66–69] All the family studies showed an increase in risk of melanoma in *CDKN2A* mutation carriers associated with *MC1R* polymorphisms. Multiple alleles raised the risk higher. Only one study also evaluated DN. Within these families, DN and variations in *MC1R* both increase the risk of melanoma in *CDKN2A* mutation carriers.[69]

Evidence of chronic solar injury is also associated with an increased risk of melanoma in men with DN, especially in older men.[54]

Laboratory Tests

HISTOPATHOLOGY The major relevant diagnostic laboratory tests are the careful histologic examination of excised lesions. It is helpful to alert the pathologist to the particular area of concern that led to the biopsy. Sectioning through the area of most interest is essential to ensure that melanoma is not missed. The pathologist should also comment on the adequacy of the excision margins.

Histopathologic features are an immature growth pattern and random cytologic atypical of melanocytes (see Fig. 123-2) and a lymphocytic host response.

DN occupy a middle ground between common acquired nevi and early melanoma. As with virtually any biologic phenomenon, there is a continuum in melanocytic lesions between completely banal and malignancy. The difficulties in clinical and histologic diagnoses of DN lie in the border between common acquired nevi and nevi that barely meet criteria for DN (see Fig. 123-9E); and between severely DN and early melanoma (see eFig. 123-10.1 in on-line edition; see Figs. 123-2, 123-10F). The newly described *de novo intraepidermal epithelioid melanocytic dysplasia* is a variant that may lie within the severely DN-melanoma in situ continuum.[70]

The histologic diagnosis of DN can be considered in two components: architectural and cytologic.[71] The lesions are usually larger than common nevi; interpreting small lesions may be problematic. There is usually a junctional component which may be most of the lesion, or an edge or shoulder to a compound papule. The junctional component extends several retia beyond the dermal component. In the lesion, particularly in the junctional component, melanocytes are frequent, either singly or usually in small nests. Rete ridges are elongated, with the nests of melanocytes along the side or at the tips. Occasionally, the nests bridge between retia. There is fibroplasia in the dermis, often concentric eosinophilic fibroplasia or lamellar fibroplasia. Lymphocytes tend to be patchy and perivascular. Scattered melanocytes along the dermal-epidermal junction (at least 5 to 10) are atypical (random cytologic atypia). The atypical melanocytes are one-third to one-half larger than the melanocytes in the normal surrounding skin and have more abundant cytoplasm.[72] The nuclei of the normal melanocytes tend to be 4 to 6 μm, but those of the atypical melanocytes are 8 to 24 μm. The nuclei may be slightly irregular or folded with hyperchromasia and clumping of chromatin. Some may have prominent nucleoli. The melanocytes in DN are intermediate between ordinary nevus cells and early melanoma with regard to histologic characteristics, cell surface markers, and (often) somatic mutation detection. Several groups have proposed criteria for grading histologic dysplasia to help place a specific DN within the spectrum from almost normal nevus to melanoma.[13,73–75] Most of these systems, when evaluated, have good intraobserver reproducibility, but less interobserver reliability. It is often helpful for the clinician, however, for the pathology report to include an assessment whether the lesion is close to melanoma, because those lesions may need re-excision.

SPECIAL TESTS For clinical care of individuals with DN, full body photography is an essential tool.[47] Both overview photographs and close-up photographs of the most atypical nevi are extremely useful. These may be difficult to obtain in a practice with limited access to photography. The quality of the photography often reflects the frequency with which patients having pigmented lesions are seen and photographed, not just the quality of the photography equipment. Several algorithms for "covering" full skin surface areas have emerged, each with some advantages. In evaluating the different algorithms, it is useful to note how well each displays the anatomic regions with sufficient magnification and illumination to evaluate patterns, relative sizes, and pigmentary characteristics of nevi. Another important consideration is how reproducible the system is within one's practice. The usual system chosen may have to be altered for individuals with profuse dark body hair because the pattern and size of nevi with standard overviews may not be visible. The important uses of overviews in future examinations include (1) recognition of new lesions; (2) change in specific lesions in relation to others (see eFig. 123-10.2 in on-line edition); and (3) involution of lesions over time. There are commercially available photography management tools to aid in organizing the images for each patient. Each practitioner should evaluate what system works best in their practice and use this consistently.

Close-up photographs of the most atypical appearing nevi should be at 1:1 or 2:1 magnification with a ruler in the photograph (see Fig. 123-10). This allows careful comparison of the size, outline, color patterns, surface patterns, and skin markings at the time of the photograph with examinations in the future. In addition, photography of scalp nevi is also useful when they are not visible on overview photos. The location of each close-up photograph should be recorded to aid in identifying the specific nevus at future examinations. Again, commercially available management tools may be helpful. Many studies have demonstrated that the comparison of previous photography with the current skin examination aids in the recognition of changing lesions. Melanomas occurring in patients who are regularly followed using clinical photographs appear to be predominantly in situ or very thin invasive melanomas.[47,76–82]

In experienced hands, dermoscopy, or epiluminescence microscopy, is also a useful adjunct for examining specific lesions. Dermoscopy is a skill acquired through formal training, and it requires proficient pattern recognition and analy-



sis. It is more widely used and taught in Europe than in the United States. It is often impractical to examine every DN with dermoscopy during a routine evaluation, especially of someone with many DN. Most practitioners use dermoscopy only to examine select lesions.[82] Recent atlases have illustrated dermoscopy of DN and melanoma.[83,84] Several sets of criteria for differentiating nevi, including DN from melanoma, have been developed, including pattern analysis, ABCD (Asymmetry, Border, Color, Dermascopic structures) rule, Menzies method, and 7-point check list. These algorithms were compared among expert examiners.[85] Pattern analysis was the preferred method among most participants. It is not surprising, therefore, that the interobserver agreement was good for this method and that this method performed best, with highest sensitivity and specificity. There was substantial interobserver variation among the different variables in sets of criteria, but very high intraobserver consistency. This implies that the observers may interpret the components of the criteria differently but were very consistent in their interpretations. This analysis, however, did not focus specifically on DN.

Digital epiluminescence microscopy (digital dermoscopy) is also available, in which the digital dermoscopy images of specific pigmented lesions are stored and compared. Dermoscopic imaging in follow-up surveillance can thus be captured, similar to sequential photography of pigmented lesions. Sequential digital dermoscopy in compliant patients by experienced examiners increased the specificity of diagnoses.[90] Multiple different systems are available[86,90–92]; there are sparse data on direct comparisons between the systems. Some of the systems also include image analysis for automating diagnoses. Evaluation of the diagnostic precision of both dermoscopy by clinicians and digital dermoscopy with image analysis suggests that some systems may perform as well as or better than clinicians.[93] There is some evidence that these more quantitative comparisons may lead to higher specificity in the recognition of early melanoma. There is still major overlap, however, between DN and early melanoma.[94] Use of digital dermoscopy may also enhance confidence in care provided and an enhancement of self skin exams.[95] Use of digital epiluminescence microscopy is time consuming for the patients and the staff. The costs of the equipment at this time would likely limit the use of the modality to clinics having a high number of patients with pigmented lesions being followed.

New imaging techniques, such as confocal scanning laser microscopy, also hold much promise for identifying very early melanomas.[96,97] Confocal microscopy can visualize tissue architecture down to the papillary dermis at the individual cell level. Criteria for the diagnosis of melanoma are being developed. Specific criteria for DN should follow. Again, the technology is expensive, and the imaging is time consuming.

Box 123-1

Differential Diagnosis

Most Likely

- Common acquired nevus
- Congenital or congenital-type nevus
- Dermatofibroma
- Seborrheic keratosis

Consider

- Combined nevus
- Spitz nevus/Spitz variant
- Pigmented spindle cell nevus
- Blue nevus
- Pigmented actinic keratosis

Always Rule Out

- Melanoma in situ
- Superficial spreading melanoma
- Pigmented basal cell carcinoma

Differential Diagnosis (Box 123-1)

COMPLICATIONS

The major complication of DN is melanoma, but melanoma is a relatively uncommon event. These lesions are both risk markers for melanoma and precursor lesions for melanoma. Numerous studies have documented that DN are dynamic lesions, but only a small percentage progress toward or develop into melanoma.[79,82,89]

In most of the case-control studies evaluating risk of melanoma, the risk increases with more DN.[9,15,98,99] These risks are estimated based on the clinical recognition of DN. At this time, there are few data to address the risk of melanoma associated with only histologic evidence of DN. The correlation between the clinical and histologic diagnoses is not perfect; the optimal evaluation of this has not yet been done. It is likely that some of the discrepancies between histology and clinical diagnoses are in the border between normal and minimally dysplastic and between severely dysplastic and melanoma.

A continuum of risk of melanoma from the border of common acquired nevi to mild dysplasia to severe dysplasia is likely. In one large study, there was no risk associated with clinically very mild lesions that were at the borderline between normal and dysplastic where experienced observers disagreed about the diagnosis.[15] One unequivocal DN, however, increased risk of melanoma twofold. More than 10 increased the risk 12-fold [95 percent confidence interval (CI): 4.4–31]. A meta-analysis of 47 studies revealed the risk of melanoma associated with any atypical nevus was 10-fold increased (95 percent CI: 5.0–20.3).[99] The different studies used various criteria for the classification of a nevus as atypical or dysplastic. There was evidence of heterogeneity of the risks associated with DN according to the type of study (case-control vs. cohort), source of controls (hospital, population, or other), and exposure measure (dichotomous or not). Some of the heterogeneity in the combined data likely reflects the different diagnostic criteria for DN in the studies. When the analysis was limited to case-control studies, the risk of melanoma associated with five or more DN was sixfold increased (95 percent CI 3.8–10.3). Individuals with DN and melanoma are more likely to develop multiple primary melanomas than individuals who have melanoma, but not DN.[53] Individuals who are immunosuppressed, such as those with transplants[100,101] or those who have had lymphoma,[102] are at two- to eightfold more likely to develop melanoma. Where it has been investigated, the melanomas occur in individuals with DN.

Removal of all DN is not recommended for several reasons. Complete removal of all DN is not only unnecessary surgery; it also does not alter the need for continued surveillance of these individuals. Individuals with DN continue to develop new nevi until late middle age, and can develop melanoma de novo not associated with a nevus.[47] Some have hundreds of nevi, tens of which are dysplastic. Most nevi will undergo physiologic involution. Removal of all of the nevi does not change the need for careful sun protection, regular skin self exams, or routine professional examinations. Nevi need only be removed when clinically suspicious for melanoma.

PROGNOSIS AND CLINICAL COURSE

Much of the natural history information about DN derives from longitudinal studies of melanoma-prone families.[47] In



these families, DN may start to appear early in childhood. For some reason, atypical lesions may first appear on the scalp of young children, not usually in infancy or in toddlers.[103] For most children in melanoma-prone families who go on to develop DN, the first finding is an increased number of small typical nevi, most often in sun-exposed areas (see Fig. 123-10A).[104] Over time, some of these lesions grow in diameter, become more asymmetric with irregular, indistinct borders and variable pigmentation (see Fig. 123-10 B,C). Often by the time of puberty, characteristic DN exist. During puberty, individuals often develop more nevi and more atypical nevi. Children who have been carefully sun-protected tend to develop many fewer nevi. These findings are consistent with the epidemiologic studies which have shown that sun protection decreases the number of nevi that develop in children from the general population.[105]



Typically, DN are most frequent on intermittently exposed skin surfaces.[44–47] Epidemiologic studies have demonstrated that the most frequent site is the back; often the large irregular nevi are prominent on the lower back (see Fig. 123-3A), with relative sparing of the heavily sun-exposed upper back and shoulders. DN can, however, occur in minimally sun-exposed areas such as the doubly covered buttocks, breasts, scalp, and pubic regions. Individuals with DN may also develop nevi, not necessarily atypical, on palmar and plantar surfaces and in webspaces of hands and feet. It is uncommon for individuals with DN to have nevi on mucosal surfaces, but they do occur.

Individuals with DN continue to develop new nevi late into adulthood.[79,82,89] The majority of nevi in individuals with DN are ordinary common acquired nevi. In a longitudinal study (at least 5 years of follow-up) of individuals with DN in a pigmented lesion clinic, nevi were dynamic lesions.[79] One-third of individuals developed new nevi; most new nevi occurred in individuals under age 30. About one-half of the lesions with close-up photographs changed over time; 15 percent of lesions developed more atypical features; 35 percent became less atypical. Among these nevi, 2.4 percent disappeared. During the study period, 11 of 153 individuals developed new melanomas 0.25 to 0.85 mm thick. In a prospective study from Australia, nevi were also dynamic, but the study did not give specific information on DN, and the rates of change were highest in the individuals with over 20 DN at the first visit.[89]

Relatively few of an individual's total nevi are dysplastic (see Figs. 123-3A, 123-10C). Even in individuals from melanoma-prone families, the majority of DN involute and disappear over time.[47] Nevi and DN tend to have periods of relative stability and periods of increased activity, when several new nevi appear and existing nevi change in color, size, or appearance. The triggers for this activity are not well studied; anecdotally, sun exposure seems to stimulate nevus activity (see Figs. 123-9, 123-10, see eFig. 123-10.1 in on-line edition). After sun or UV exposure, new nevi may appear and existing nevi may enlarge, become more irregular, or darken. Pregnancy also seems to increase the number, size, and sometimes, pigmentation in DN. Long-term prospective studies documenting total changes in all nevi over decades (appearance, development, changes, involution) have not been done. The relationship of activity of nevi to molecular markers of senescence also has not been explored. Changes in tissue microenvironment or signaling may also be important in nevus changes.

Nevus counts and counts of DN in general decrease with age. In a longitudinal study of Australian individuals at increased risk of melanoma,[89] those over age 50 had fewer nevi develop or change. If lesions changed, however, they were more likely to be melanoma. Over age 50, most individuals do not have clinical DN.[15] Those who have remaining DN are at highly increased risk of melanoma. The lack of normal involution of these lesions may be a powerful risk marker for melanoma. About 20 percent of individuals who have had DN in their forties, though, continue to develop new nevi beyond age 50,[79] again indicating that they may have an "activated melanocyte system."[106]

The risk of melanoma has also been estimated among individuals with DN who have been followed in pigmented lesion clinics for a number of years.[79,82,89,107] In general, these patients were followed at least yearly. Overview and close-up photographs were used, and dermoscopy of suspicious lesions was also often used. Although the measures of level of risk of melanoma vary between studies, in general, the risk associated with the presence of DN was substantially elevated overall and increased with more DN. The risks tend to be highest in individuals with a personal and family history of melanoma; followed by those with a family history of melanoma, but no personal history; then those with a personal but no family history of melanoma; and lowest in those with neither personal nor family history of melanoma.

Although the familiarity of DN is not fully understood, it is reasonable to examine the first-degree relatives of individuals with multiple DN. If they are found to have DN, the same approach should be followed for their care.

The recommended frequency of regular health care provider examinations has not been systematically evaluated. Empiric recommendations have been suggested for individuals in melanoma-prone families,[47,108] but these have not been rigorously evaluated in a prospective study. The risk in these individuals is also likely to be higher than in individuals with DN without a family history of melanoma. For individuals having a large number of severe DN, it is reasonable to begin following them at 3-month intervals. If their nevi are relatively stable, this time can be extended to every 6 months, then to yearly. If an individual has few mild DN, yearly exams are reasonable. Whenever the activity of the nevi increases, new nevi are developing, and/or nevi are becoming darker and more irregular; it is important to increase the frequency of exams. The frequency of exams is also an interplay between what the individual patient will tolerate (with work absences, care expenses, etc.) and their reliability in performing skin self exams. If they are consistent in performing exams, and call for appointments when nevi are changing, the frequency of prescheduled exams can be more flexible.

Patients should receive copies of their overview and close-up clinical photographs for their use at home. A diagram of the close-up photos is helpful, especially for individuals with a large number of photographs. Patients should also undergo detailed instruction in skin self-examination using their photographs. The best methods for teaching the components of skin self-examination have not been systematically evaluated. Recent work has demonstrated that nurse instruction in skin self-examination using the patient's own photographs resulted in much better adherence to a program of regular self-exams.[109] There is also recent evidence that having patients map their moles on a body diagram may help improve self-exam accuracy.[110] The instruction about self-exams is also a good opportunity for reinforcing sun protective measures and the early recognition of melanoma. The determinants of continuing self-exams are not fully understood; women, highly educated individuals, people who have had skin cancers, and those who are confident about doing self-exams are more likely to do the exams.[111]

Education about sun protection is another component of the patient management. Although randomized clinical trial data are not available, a growing body of evidence supports the assumption that minimizing sun and UV exposure is prudent in individuals with multiple DN (see eFig. 123-10.1 in on-line edition). DN are both precursor lesions and risk markers for melanoma.[59] Minimizing exposure to the major environmental risk factor for melanoma, UV exposure, is warranted in this group. The suggestions for sun protection should be the same as those for the prevention of melanoma: avoidance of midday sun exposure, shade-seeking when out of doors, scheduling outdoor activity for early morning or late afternoon, use of protective clothing, and use of sunscreens. One of the important cohort studies that clearly established a risk of melanoma associated with use of UV tanning devices also demonstrated a high risk of melanoma in the women with large irregular nevi on their legs (14 percent of the cohort overall; 27 percent of cases).[112] Unfortunately, the authors did not report whether those with irregular nevi had a higher risk associated with using the tanning devices than those without the irregular nevi. Nonetheless, it seems sensible to advise that individuals with DN not use tanning devices.

Although there have been some reports of individuals with ocular melanoma being more likely to have DN, it is likely to be an extremely rare event. In a survey of usual practices among dermatologists, only 2.9 percent always recommended an exam for ocular melanocytic neoplasms.[113] Another 11.5 percent said they usually did. Most said that they recommended such an exam infrequently or never. It is reasonable to suggest that at the patient's next routine eye exam, they inform the ophthalmologist that they have DN. The ophthalmologist can, at that time, be alert for ocular pigmented lesions.

TREATMENT

Treatment of a DN that is suspicious for early melanoma is excisional biopsy of the entire lesion with visibly clear margins. Shave biopsies of these lesions are discouraged. Not infrequently, a shave biopsy does not fully excise the elongated rete, and the abnormal nests at the base of the rete are not removed. Repigmentation and re-growth can occur (see eFig. 123-10.1 in on-line edition). In melanoma-prone families, recurrences after shaves have sometimes been melanoma. The atypia in the melanocytes and nests is not uniform across the lesions. Because the major reason for removal of an DN is to rule out melanoma, it is important to completely remove the lesion to allow adequate histologic assessment of the lesion and the margins. One of the reasons commonly given for a shave biopsy is that the scarring will be less noticeable. If the shave is sufficiently deep to ensure removal of the entire lesion and to preserve the architecture for adequate histologic review, the scar will likely not be less noticeable. Because individuals with multiple DN may have a number of lesions removed over their lifetime, excisional biopsy with sutures may yield a much better cosmetic result for them. If the histology reveals severe dysplasia, reexcision to obtain adequate margins (usually 5 mm for severe dysplasia) may be required. In a survey of management of DN among dermatologists in practice that was conducted a number of years ago, 23 percent usually shaved a DN to fully remove it; 32 percent used saucerization, 12 percent used a punch, and 30 percent excised the lesion.[113]

Over the years, a number of different topical and systemic treatments have been tried to induce DN to differentiate or to remove them. One of the first agents was topical 5-fluorouracil (5 percent). Use of this agent on selected DN-induced inflammation, ulceration, and disappearance of the DN.[114] Parallel evaluations of topical and systemic antioxidants were then initiated. In a pilot study, topical retinoic acid–induced inflammation and clinical and histologic reversion toward common nevi.[115] Use of this agent, however, was limited by poor compliance due to skin irritation and inflammation. Another variation was adding cortisone to the treatment and using occlusive dressings.[116] A small randomized trial of oral β-carotene versus placebo for 3 years was conducted in 62 patients with numerous DN.[117] The endpoint was the number of new nevi that developed. At the time of analysis, there was no difference in the number of new nevi in the two groups. More recently, topical imiquimod cream (5 percent) was used three times a week for 20 weeks.[118] The endpoint was clinical response assessed by sequential confocal microscopy. There were difficulties in the comparison of the imaging techniques, but there were no obvious clinical changes in the treated lesions. The treated lesions showed a relative reduction of junctional and intraepidermal nevocytes with papillary fibrosis and some inflammation. The authors concluded that topical immune modulators may have some promise in chemoprevention of melanoma, but imiquimod did not warrant further investigation. In summary, although several promising topical agents have been tried, none have been efficacious and acceptable. These trials are difficult to design and conduct; there is a parallel large effect of removing UV exposure that affects the nevi and drives them toward regression/senescence. Documenting additional involution of nevi related to a medication can be problematic.

PREVENTION

The major preventive intervention for the development of dysplastic, as well as common acquired nevi, is likely decreased UV exposure, although this is not proven. With the growing body of evidence that childhood sun exposure is important in the number of nevi that develop,[105] it is important to initiate sun-protective behaviors early.

KEY REFERENCES

The full reference list for all chapters is available at www.digm7.com.

2. Clark WH Jr et al: Origin of familial malignant melanoma from heritable melanocytic lesions. 'The B-K mole syndrome.' *Arch Dermatol* **114**:732, 1978
7. Naeyaert JM, Brochez L: Dysplastic nevi. *N Engl J Med* **349**:23, 2003
37. Pollack PM et al: High frequency of BRAF mutations in nevi. *Nat Genet* **33**:19, 2003
47. Tucker MA et al: A natural history of melanomas and dysplastic nevi: An atlas of lesions in melanoma-prone families. *Cancer* **94**:3192, 2002
50. Garbe C et al: Associated factors in the prevalence of more than 50 common nevi, atypical melanocytic nevi, and actinic lentigines: Multicenter case-control study of the Central Malignant Melanoma Registry of the German Dermatological Society. *J Invest Dermatol* **102**:700, 1994
72. Clark WH Jr et al: Atypical melanocytic nevi of the genital type with a discussion of reciprocal parenchymal-stromal interactions in the biology of neoplasia. *Hum Pathol* **29**:S1, 1998
76. Kopf AW et al: Photographs are useful for detection of malignant melanomas in patients who have dysplastic nevi. *J Am Acad Dermatol* **19**:1132, 1988
85. Argenziano G et al: Dermoscopy of pigmented skin lesions: Results of a consensus meeting via the internet. *J Am Acad Dermatol* **48**:679, 2003
99. Gandini S et al: Meta-analysis of risk factors for cutaneous melanoma: I. Common and atypical naevi. *Eur J Cancer* **41**:28, 2005
113. Tripp JM et al: Management of dysplastic nevi: A survey of fellows of the American Academy of Dermatology. *J Am Acad Dermatol* **46**:674, 2002



CHAPTER 124

Cutaneous Melanoma

Sandra C. Paek
Arthur J. Sober
Hensin Tsao
Martin C. Mihm, Jr.
Timothy M. Johnson



EPIDEMIOLOGY

The incidence of melanoma has increased significantly worldwide over the last several decades. In the United States, the lifetime risk of developing invasive melanoma was 1 in 1500 for persons born in 1935, 1 in 600 persons for those born in 1960, 1 in 150 persons for those born in 1980, and is estimated to be 1 in 62 persons for persons born in 2006 (1 in 34 including in situ melanoma). The American Cancer Society estimates that in 2006, 111,900 new cases of melanoma were diagnosed, including 49,710 in situ and 62,190 invasive cases (34,260 men and 27,930 women).[1] Melanoma had the greatest annual percent change in cancer incidence rate among the top 10 cancer sites by gender, all ages, and all races, between 1990 and 1997.[2] Invasive melanoma of the skin is the fifth most frequent site for cancer to occur in men and the sixth most frequent site in women, representing approximately 5 percent of all newly diagnosed cancers. Melanoma represents the most common cancer type in Caucasian women 25 to 29 years, second to thyroid cancer in women 15 to 24 years of age, and second to breast cancer in women 25 to 44.[3]

Mortality rates have also risen over the last several decades but not as quickly as incidence rates. The American Cancer Society estimates that in 2006, there were 7910 deaths (5020 men and 2890 women) due to melanoma.[4] Melanoma accounts for 79 percent of all skin cancer deaths. One American dies from melanoma approximately every hour. Melanoma is one of the leading cancers in terms of average years of life lost per death from disease. Although mortality rates have increased, survival for those diagnosed with melanoma have also increased. Based on U.S. Surveillance, Epidemiology, and End Results Program (SEER) data, the overall survival rates for melanoma were estimated at 60 percent in 1960 to 1963, 80 percent in 1974 to 1976, and 89 percent in 1992 to 1997.[5]

The mean age of diagnosis is relatively young at 52 years, which is 10 to 15 years earlier than the mean age of diagnosis in the more common tumors of the breast, lung, colon, and prostate. More than 25 percent of melanomas occur in persons less than 45 years of age. Incidence rises with age, especially in men. In the United States, women have a slightly higher incidence of melanoma before the age of 40 years. After age 40, men have a higher incidence, and the difference becomes remarkably large with increasing age. Mortality data parallel incidence data, with older men having the highest mortality rates. Although mortality rates in older persons, especially men, are rising, rates in younger persons and females have been steady or actually declined.[6] Lightly pigmented Caucasians have the highest incidence rates, much more than Hispanics, Asians, and African Americans.

ETIOLOGY AND PATHOGENESIS

Risk Factors (Table 124-1)

SUN EXPOSURE Both genetic and environmental factors are related to melanoma pathogenesis and certainly not all melanomas are sun related. There is, however, clear convincing evidence that sun exposure, and more specifically ultraviolet (UV) exposure, is a major environmental cause of melanoma, especially in high-risk populations. Epidemiologic studies suggest that periodic, intense sun exposure (particularly during the critical time period of childhood and adolescence) rather than long, continued, heavy sun exposure is most important in melanoma causation, termed the *intermittent exposure* hypothesis. Sunburn history, notably blistering and peeling burns, serves as a surrogate measure of intermittent intense sun exposure. In one review of published literature, there was a significant positive association between sunburns during childhood and risk of melanoma development.[7] One blistering sunburn in childhood more than doubles a person's chances of developing melanoma later in life. Sunburns in adulthood have also been shown to contribute to melanoma risk.[8] Data from the behavior risk factor surveillance system of the Centers for Disease Control and Prevention show that nearly 32 percent of all adults aged ≥ 18 years, 58 percent between 18 and 29 years of age, and more than 40 percent of children report having had at least one annual sunburn defined as red skin for more than 12 hours.[9] Crude sunburn prevalence rates in white adults by state demonstrated higher sunburn rates among Caucasian adults living in the Midwest, possibly a reflection of a population that is more sun sensitive or less likely to practice sun-safe behaviors.

Migration studies generally indicate an increased melanoma risk in individuals who spent childhood in sunny geographic areas or emigrated to sunnier areas.[10] Younger migrants to sunny areas have an increased risk for melanoma as compared with adult immigrants. Lastly, there is an increased melanoma risk with longer duration of residence in the sunny locale.

Melanoma incidence and mortality among Caucasians correlate inversely with latitude of residence and dose of UV radiation, termed the *latitude gradient*.

MELANOMA AT A GLANCE



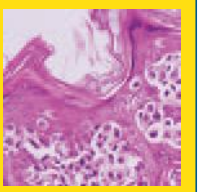

- Rising incidence worldwide; U.S. estimated lifetime risk of invasive melanoma is 1 in 1500 if born in 1935, 1 in 600 if born in 1960, 1 in 62 if born in 2006 (1 in 34 with inclusion of in situ melanoma).
- Risk factors: history of sunburns and/or heavy sun exposure, blue or green eyes, blonde or red hair, fair complexion, > 100 typical nevi, any atypical nevi, prior personal or family history of melanoma, *p16* mutation.
- Mean age of diagnosis: 52 years, 10 to 15 years younger than other more common cancers, (e.g., breast, lung, colon, and prostate).
- Most common location: back in men, lower extremities, then trunk in women.
- Features used for melanoma recognition: A (asymmetry), B (irregular borders), C (color variegation), D (diameter > 6 mm is most common use but others have changed D to difference-"ugly duckling" sign or different with respect to change in size, shape, color, or persistent lesional pruritus), E (evolving over time).
- Follows highly variable course and represents a heterogeneous disorder.
- Surgically curable if diagnosed and treated in early phase, but potentially lethal with increased risk when diagnosed and treated late.

TABLE 124-1
Risk Factors for Cutaneous Melanoma

- Ultraviolet radiation exposure
  - Blistering sunburns at any time in life; intermittent or sporadic high levels of exposure
  - Excessive chronic exposure to sunlight
- Phenotypic characteristics
  - Fair skin, inability to tan, tendency to sunburn or freckle (SPT I and II)
  - Blue or green eyes
  - Red or blond hair
  - Numerous typical nevi and/or more than one atypical nevus
  - Large congenital nevus
- History of prior melanoma
- Family history of melanoma
- Mutation in p16, BRAF, or MC1R
- Xeroderma pigmentosum
- Immune suppression (debatable)

The highest rates are nearest the equator. In areas as geographically diverse as the United States, New Zealand, and Australia, the incidence of melanoma is greater in regions closer to the equator. However, this gradient may be confounded by other risk factors for melanoma. In Italy, for example, more darkly pigmented persons reside in the South whereas more lightly pigmented persons live in the North, so that the latitude gradient is actually reversed.[3] Even in the United States, SEER data from 1992 to 2001 demonstrate that the latitude gradient applies only to non-Hispanic whites; melanoma incidence was not associated with latitude and UV index in African Americans, Hispanics, Asians, and Native Americans.[11]

The anatomic distribution of melanoma by body site demonstrates that intermittently exposed skin areas have the highest rates of developing melanoma. In men, the trunk, particularly the upper back, is the most common site for melanoma. In women, the lower legs, followed by the trunk, are the most common sites.[12] These intermittently exposed areas are the most common areas to develop melanoma in younger persons. In older persons, there is a greater incidence of melanomas located on chronically exposed areas with maximal cumulative sun exposure. The face is the most common location for melanoma in older persons, with the addition of the neck, scalp, and ears as well, in older men.[13,14]

Several forms of artificial light have been associated with the development of melanoma, particularly psoralen and ultraviolet A light (PUVA) and UVB, and tanning booths. The so-called *PUVA Follow-up Study* demonstrated increased rates of melanoma after PUVA exposure, with an incidence rate ratio of 9.3 approximately 20 years after PUVA therapy; these rates increased over time and were higher in patients exposed to high doses of PUVA.[15] However, the role of PUVA in the development of melanoma has been disputed (see Chap. 239). There is also rising concern over tanning beds and melanoma risk, especially as exposure to the artificial UV radiation is intermittent in nature. Any exposure to artificial tanning devices modestly, but significantly, increases the risk of cutaneous melanoma (odds ratio, 1.25), and longer duration of bed use, younger age at first exposure, and higher frequency of use are associated with a significantly elevated risk (odds ratio, 1.69).[16]

SKIN PHENOTYPE Light skin pigmentation, blond or red hair, blue or green eyes, prominent freckling tendency, and tendency to sunburn with Fitzpatrick skin phototype I–II are phenotypic features associated with an increased risk of melanoma. Melanoma occurs infrequently in type V–VI skin, suggesting that skin pigment plays a protective role.

MELANOCYTIC NEVI There is an increased risk of melanoma associated with nevi, both in a quantitative (i.e., number of nevi) and qualitative (i.e., typical vs. atypical nevi) manner. Adults with more than 100 clinically typical-appearing nevi, children with more than 50 typical-appearing nevi, and any patient with atypical nevi (see Chap. 123) are at risk. Tucker et al. found that the presence of a solitary dysplastic nevus doubled the risk of melanoma, while having 10 or more atypical nevi was associated with a 12-fold elevation of risk.[17] Nevi more often serve as a genetic marker of increased risk rather than a pre-malignant lesion, as most melanomas arise de novo. In a study of 1606 patients with melanoma, only 26 percent of the melanomas were histologically associated with nevi (43 percent of these atypical nevi, 57 percent other nevi).[18]

On the other hand, large congenital nevi are recognized potential precursors of melanoma, although the degree of risk varies depending on the size of the lesion (see Chap. 122).[19] Many series define large congenital nevi as greater than 20 cm in diameter in adulthood, and lifetime risks for developing melanoma are generally accepted to be in the 5 percent to 10 percent range. It is estimated that 70 percent of melanomas in large congenital nevi develop before the age of 10 years old and may occur deep within the nevus or even in the central nervous system, making detection of a thin lesion difficult. Patients with large congenital nevi located on the posterior axis (paraspinal, head, and neck regions) or in conjunction with multiple satellite lesions are at risk for neurocutaneous melanosis, with an increased risk of developing melanoma in the central nervous system. For small- to medium-sized congenital nevi, the melanoma risk is similar to any other area of skin; in this case, melanoma usually occurs later in life (after puberty), and arises at the dermal-epidermal junction, making early detection possible.[19] Thus, prophylactic excision of small- and medium-sized congenital nevi is usually unwarranted.

FAMILY HISTORY Patients with familial melanoma are estimated to account for 10 percent to 15 percent of all patients with melanoma. Having one first-degree relative with melanoma doubles the risk of melanoma, whereas having three or more first-degree relatives with melanoma increases the risk 35- to 70-fold.[20] Some of this risk may be attributed to shared risk factors such as skin phenotype, multiple nevi, and excessive sun exposure. The association between familial melanoma and multiple atypical nevi has historically been given various names, including *B-K mole syndrome*, *familial atypical multiple mole-melanoma syndrome*, and *dysplastic nevus syndrome* (see Chap. 123). Patients with familial melanoma typically have earlier onset melanoma and multiple primaries as well as atypical nevi. The molecular basis for some familial atypical multiple mole-melanoma syndrome kindreds will be discussed in Genetics.

PERSONAL HISTORY A previous history of melanoma increases the risk for another primary melanoma, with 5 percent to 15 percent of individuals developing multiple primary melanomas.[21,22] In patients with multiple primary melanomas, roughly one-half develop a second primary tumor in the same region of the body (i.e., trunk, extremity, head, and neck) and roughly one-half develop a second primary melanoma within the first year of initial diagnosis. However, subsequent primary melanomas may develop decades after diagnosis of the

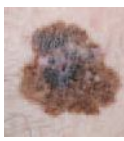

initial lesion, stressing the need for long-term surveillance. Subsequent melanomas are thinner compared with the first melanoma in roughly 70 percent to 75 percent of cases.[21]

Immunosuppression has also been described as a risk factor for melanoma with a two- to fivefold increased incidence reported post-transplantation in a few studies.[3] The increased incidence of melanoma with immunosuppression, however, remains debatable. Finally, a history of actinic keratosis or non-melanoma skin cancer also confers a small increased risk of developing melanoma.



GENETICS ***CDKN2A-CDK4-TP53 Pathway.*** Germline mutations in the chromosome 9p21 tumor suppressor gene, cyclin-dependent kinase inhibitor 2A (*CDKN2A*), account for approximately 40 percent of hereditary melanoma cases (≥ 3 melanomas in one lineage) and confer a 76 percent chance of developing melanoma in the United States[23]; concordant with ambient rates, this risk is somewhat higher in Australia and lower in Europe. Individuals with germline *CDKN2A* mutations also exhibit a higher risk of pancreatic cancer; an estimated 15 percent of individuals with a mutant allele will develop pancreatic cancer in their lifetime.[24] Bona fide deleterious point mutations in *CDKN2A* are relatively uncommon in primary melanoma tumors although homozygous deletions of this gene may obscure the true rate of somatic loss in melanoma. *CDKN2A*, encodes two gene products: p16 (also known as *INK4a*, inhibitor of kinase 4a) and p^{14ARF} (alternative reading frame). p16 is a cell cycle regulator that binds and inhibits cyclin-dependent kinases CDK4 or CDK6, thereby inhibiting progression of cells through the G1 phase of the cell cycle. If p16 function is absent or inactivated by mutation, unrestrained CDK4 activity phosphorylates the retinoblastoma protein thereby releasing the transcription factor E2-F and inducing S-phase entry. This sequence culminates in enhanced cellular proliferation which, in the absence of checkpoint regulation, results in unrestrained growth and neoplasia.

The binding partner of the p16 protein is CDK4. Only a handful of families worldwide thus far have been reported to carry hereditary mutations in CDK4 while somatic mutations in this gene have also been detected in some melanoma cell lines. Functional studies suggest that mutations in CDK4 render the cyclin-dependent protein kinase resistant to p16 inhibition, resulting in a phenotype identical to that from p16 loss.

The p^{14ARF} protein from CDKN2A inhibits a cellular oncogene MDM2, which in turn accelerates the destruction of the p53 tumor suppressor gene.[25] Thus, complete loss of CDKN2A also leads to abrogation of p^{14ARF} and loss of p53 function. Thus, this single locus can impact both the retinoblastoma protein and p53 pathways and probably explains the low rate of direct *TP53* mutagenesis in melanoma.

RAS Signaling Pathway. Davies et al. first reported in 2002 a somatic mutation in the *BRAF* gene in 66 percent of melanomas.[26] B-raf is a serine/threonine kinase, which is a major player in the Ras-Raf-Mek-Erk mitogen-activated protein kinase (MAPK) signaling transduction pathway that regulates cell growth, proliferation, and differentiation in response to various growth factors, cytokines, and hormones. The stimuli activate the G-protein Ras by inducing the exchange of guanosine 5′-diphosphate for guanosine 5′-triphosphate, which then binds and activates Raf. Raf phosphorylates and activates Mek, which in turn phosphorylates MAPK (i.e., Erks). This signaling cascade serves to intracellularly amplify the extracellular signals mediated by growth factors. There are three functional Raf proteins in humans, A-raf, B-raf, and C-raf. B-raf has a much higher basal kinase activity than either A-raf or C-raf, and somatic mutations in B-raf occur with moderate to higher frequency in melanoma and colorectal, ovarian, and papillary thyroid carcinomas, implicating activating oncogenic mutations of B-raf as critical promoters of malignancy.[27]

BRAF mutations are significantly more common in melanomas occurring on skin subject to intermittent sun exposure, with 81 percent of melanomas on skin without chronic sun damage having *BRAF* or *NRAS* mutations.[28] On the other hand, the majority of melanomas from acral sites (palms, soles, subungual skin), mucosa, or chronically sun-damaged skin do not carry a mutation in either gene. There are also significant differences in the number of copies of genomic DNA in melanomas located in the various regions. Melanomas with wild-type *BRAF* or *RAS* frequently had increases in the number of copies of the genes for *CDK4* and *CCND1* (cyclin D1), two critical G1 cell cycle proteins and two genes that are transcriptionally induced by activated MAPK signaling.[28]

Mutations in *PTEN/MMAC1* tumor suppressor gene also lead to enhanced Ras pathway signaling.[29] This protein/lipid phosphatase downregulates signaling through the Akt arm of the Ras circuitry. When PTEN is inactivated, there is dysregulated Akt activity along with increased cellular survival.

Other Genes. **MICROPHTHALMIA.** Recently, somatic amplifications of the microphthalmia (*MITF*) gene in a subset of melanoma tumors were identified, and it was demonstrated that overexpression of *MITF*, in conjunction with ectopic expression of *BRAF*, resulted in melanocyte transformation.[30] The Mitf protein is a transcription factor that appears to be a master regulator of melanocyte differentiation, and amplification of this gene appears to contribute to a novel carcinogenic mechanism known as *lineage addiction*.

MELANOCORTIN-1-RECEPTOR. As mentioned above, red hair and sun sensitivity represent epidemiologically demonstrated risk factors for cutaneous melanoma. Recently, mutations in the melanocortin-1-receptor (*MC1R*) were shown to strongly contribute to the red hair/fair skin phenotype.[31] As such, germline mutations in the *MC1R* gene have also been shown to increase melanoma risk by approximately two- to fourfold in the general population[32]; it also confers risk for non-melanoma skin cancer. Because the prevalence of *MC1R* mutations is quite high in the white population, its attributable risk to melanoma is higher than the rarer high-risk *CDKN2A* mutations.

XERODERMA PIGMENTOSUM GENES. Xeroderma pigmentosum (XP) is a rare autosomal recessive genodermatosis comprised of at least seven complementation groups each defined by a separate gene. The XP genes are involved in excising DNA photoproducts in a reparative program termed *nucleotide excision repair*. Thus, heritable defects in these genes lead to increased mutagenesis and early carcinogenesis. Patients with XP harbor a 600- to 1000-fold increased risk for skin cancer, including cutaneous melanoma.

BREAST CANCER SUSCEPTIBILITY GENE. Carriers of the breast cancer susceptibility gene, *BRCA2*, appear to harbor an increased risk for melanoma (2.58-fold).[33] Although an interaction between breast cancer and melanoma risk has been suggested on epidemiologic

grounds, the genetic interaction between BRCA2 and melanoma risk remains to be fully determined.

Tumorigenesis and Tumor Progression

Five stages of malignant transformation and tumor progression in melanocytes have been suggested, based on clinical, histopathologic, immunopathologic, cytogenetic, and in vitro properties: (1) benign melanocytic nevi; (2) atypical nevi; (3) primary malignant melanoma, radial growth phase; (4) primary malignant melanoma, vertical growth phase; and (5) metastatic malignant melanoma. It is believed that with each successive step of tumorigenesis, a new clone of cells emerges with growth advantages over the surrounding tissue, resulting in "clonal expansion." It has been postulated that a critical step in tumor progression of melanoma may be the transition from radial to vertical growth phases. The radial growth phase consists of primarily intraepidermal proliferation of melanoma cells, but also invasion of the papillary dermis by small numbers of cells that have gained a growth advantage. These cells are thought to have the capacity for autonomous proliferation in this location, but not for aggregative growth. Radial growth phase cells are characterized by the presence of E-cadherin, an adhesion molecule that interacts with keratinocytes and impedes migration of the cells from their intraepidermal location[34] Melanomas in this phase are probably incapable of metastasis. The vertical growth phase is signaled by the property of aggregative growth, resulting in the formation of expansile nests or nodules of cells. Because the metastatic cascade comprises a complex range of numerous biochemical events, the vertical growth phase is likely an oversimplified correlate for the metastatic phenotype. Among other characteristics, vertical growth phase cells lose E-cadherin and express N-cadherin, a molecule that interacts with fibroblasts, macrophages and endothelial cells. This latter interaction may facilitate intravasation of the malignant cells.[34]

A discussion of tumorigenesis of melanoma must take into account several important clinical observations: (1) the association between precursor nevi and melanoma in approximately 30 percent of cases (an apparent absence of precursor nevi in 70 percent of melanoma); (2) the role of UV light in the pathogenesis of melanoma; (3) pigmentary phenotype of patients in whom melanoma develops; and (4) family history of melanoma and other genetic factors. When the above observations are considered in light of the multistep process of tumor progression of melanoma, at least two major pathways of tumorigenesis can be envisioned.

In the first pathway, melanomas, particularly superficial spreading melanomas (SSMs), at least in some cases, develop in association with melanocytic nevi. Nevi may represent the first stage of tumor progression of melanoma or an initiated clonal proliferation. The most likely initiating agent would be UV exposure, perhaps at an early age. There is epidemiologic evidence that sun exposure earlier in life may result in larger numbers of nevi. The number of precursor nevi may be important as greater numbers of initiated cells would increase the target population for another mutational event. As UV is believed to be a complete carcinogen, sunlight exposure, perhaps of intermittent nature, could lead to this second mutational event, resulting in tumor progression. A second pathway of melanoma development is exemplified by lentigo maligna melanoma (LMM). This form of melanoma results from cumulative sun exposure and a corresponding cumulative insult to the DNA of melanocytes on sun-exposed skin. The age-incidence rates show a steady increase with age, consistent with continuous exposure (initiation) to a carcinogenic agent such as UV light.

Curtin et al. compared genome-wide alterations in the number of copies of DNA and mutational status of *BRAF* and *NRAS* in melanomas from variable groups in which the degree of exposure to UV light differed.[28] The genetic alterations identified in melanomas at different sites with different levels of sun exposure indicated that there are distinct genetic pathways in the development of melanoma. This supports the hypothesis that the clinical heterogeneity notable for melanoma may be explained by genetically distinct types of melanoma with different susceptibility to UV light.[28] Certainly, other as yet unknown pathways may exist that are independent of UV light.

CLINICAL FINDINGS

Sub-Types of Melanoma

SUPERFICIAL SPREADING MELANOMA SSM is the most common sub-type, accounting for approximately 70 percent of all cutaneous melanomas. It is diagnosed most commonly in the fourth and fifth decades on intermittently sun-exposed areas, most frequently the lower extremity of women, and the upper back of men. Its classic clinical appearance best fits into the ABCD criteria (see Making a Diagnosis), with irregular borders and irregular pigmentation, but it may present subtly as a discrete focal area of darkening within a pre-existing nevus. The range of appearance of SSM is broad (Figs. 124-1 and 124-2). Although varying shades of brown typify most melanocytic lesions, striking aspects of dark brown to black, blue-grey, pink, red, and grey-white (which may represent regression) may be found in melanoma. SSM is the sub-type of melanoma most commonly associated with pre-existing nevi. The history of SSM is often of a lesion slowly changing over months to years. It may be mistaken for an atypical nevus or seborrheic keratosis.

DIFFERENTIAL DIAGNOSIS (Box 124-1)

NODULAR MELANOMA Nodular melanoma (NM) is the second most common melanoma sub-type and accounts for approximately 15 percent to 30 percent of all melanomas. The median age of onset is 53 years, and the trunk is the most common site. NM is remarkable for rapid evolution, often arising over several weeks to months. NM clinically lacks an apparent radial growth phase. It is more common for NM to begin de novo than to arise in a pre-existing nevus. NM typically appears as a uniformly dark blue-black or bluish-red raised lesion, but 5 percent are amelanotic (Fig. 124-3). A substantial proportion of thick melanomas are of the nodular type.[35] Early lesions often lack asymmetry, have irregular borders, and are a size > 6 mm. Amelanotic lesions may be mistaken for basal cell carcinoma, pyogenic granuloma, or hemangioma, whereas pigmented lesions may be mistaken for blue nevi or pigmented basal cell carcinomas.

DIFFERENTIAL DIAGNOSIS (Box 124-2)

LENTIGO MALIGNA AND LENTIGO MALIGNA MELANOMA LM is a sub-type of melanoma in situ with a prolonged radial growth phase that may progress to invasive LMM with time. Invasive LMM constitutes 10 percent to 15 percent of cutaneous melanomas. LM and LMM are diagnosed most commonly in the seventh to eighth decades in an older population than other types of melanoma; they are uncommon before the

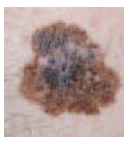





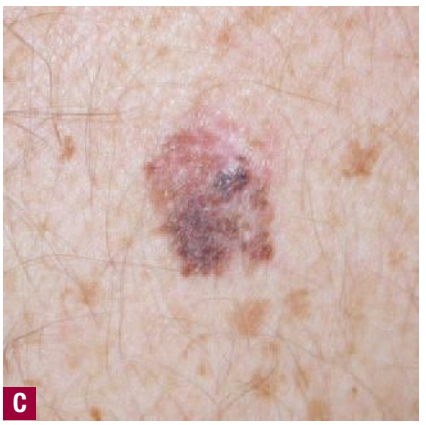



◀ **FIGURE 124-1** Superficial spreading melanoma (SSM). **A.** Classic clinical appearance with cardinal features of SSM: asymmetry, irregular scalloped borders, mottled variegate color, large diameter, and central elevation with surface distortion in a 45-year-old man, left chest, Breslow depth 1.25 mm. **B.** Another SSM with similar features but with pronounced areas of pink, shades of blue and white, with peripheral areas of black and brown in a 54-year-old woman, right lower abdomen, Breslow depth 3.5 mm, 26 mitoses/mm^2, ulceration focally present. **C.** Earlier detection in a 55-year-old man with many atypical nevi, patient unaware of the lesion, lesion noted by primary care physician during a routine physical examination, "different" than other nevi, right upper back, Breslow depth 0.50 mm. The pink/tan upper portion is an atypical nevus, the lower portion SSM arising in an atypical nevus. **D.** Still earlier detection with more subtle ABCDs (asymmetry, border, color, diameter/difference, elevation/evolving), forearm, Breslow depth 0.14 mm. The lesion was 0.8 cm in diameter with a history of a "brown spot," which grew in size, changed shape, and changed to a darker color over several months.

age of 40 years. The most common location is on the chronically sun-exposed face, on the cheeks and nose in particular; the neck, scalp, and ears are also involved in men. Its pathogenesis is thought to be related to cumulative sun exposure rather than intermittent exposure. LM is a flat, slowly enlarging, brown, freckle-like macule with irregular shape and differing shades of brown and tan, usually arising in a background of photodamage (Fig. 124-4). The life-







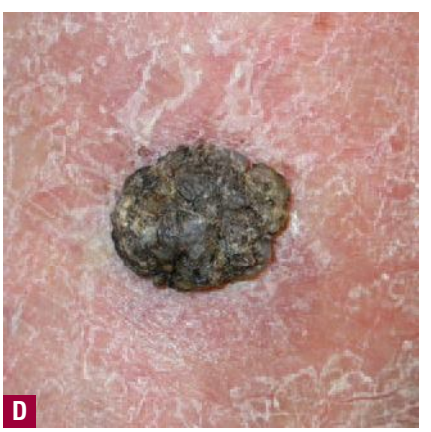

◀ **FIGURE 124-2** Superficial spreading melanoma (SSM) showing a broad range of appearance. **A.** Breslow depth 0.51 mm, central back within a "sea" of seborrheic keratosis but "different" than the surrounding seborrheic keratoses. **B.** Amelanotic SSM, upper back, Breslow depth 0.38 mm. **C.** Unusual presentation, left posterior shoulder, 60-year-old man, 11 cm × 9 cm SSM, slowly growing peripherally for over a decade, large areas of regression, pink amelanotic areas, and a small black component in the superior pole, Breslow depth 1.60 mm, 3 mitoses/mm^2. **D.** Unusual presentation of SSM with papillomatous features, right ankle, Breslow depth 6.3 mm, 3 mitoses/mm^2, vertical growth phase.

Box 124-1

Differential Diagnosis of Superficial Spreading Melanoma

- Atypical nevus
- Common nevus
- Seborrheic keratosis
- Basal cell carcinoma

Box 124-2

Differential Diagnosis of Nodular Melanoma

PIGMENTED
- Common nevus
- Blue nevus
- Pigmented Spitz nevus
- Pigmented basal cell carcinoma

AMELANOTIC
- Basal cell carcinoma
- Hemangioma
- Pyogenic granuloma
- Merkel cell carcinoma

time risk of LMM developing from LM is estimated to be low but the invasive component is potentially lethal.[36] LMM is frequently larger than LM and may continue to be macular in early lesions, although a nodular portion is often seen within the patch later. Both LM and LMM often have clinically ill-defined borders, which may be obscured by background actinic damage consisting of lentigines, pigmented actinic keratoses, or ephelides. LM and LMM are associated with significantly higher rates of extensive sub-clinical lateral growth, resulting in higher recurrence rates with standard recommended margins and failure to completely excise the lesion. LM and LMM have the least common association with nevi, at 3 percent of cases, but the highest rate of association with desmoplastic melanoma (DM).

DIFFERENTIAL DIAGNOSIS (Box 124-3)

ACRAL LENTIGINOUS MELANOMA Acral lentiginous melanoma (ALM) is a sub-type of melanoma with distinct differences in frequencies seen between ethnic groups. ALM constitutes only 2 percent to 8 percent of melanomas in Caucasians but represents the most common form in darker-pigmented individuals (60 percent to 72 percent in blacks, 29 percent to 46 percent in Asians). Although the proportion of ALM seen in darker-pigmented individuals is higher, the incidence of ALM is similar for Caucasians and other ethnicities. ALM is diagnosed in an older population, with the median age of onset being 65 years old. The most common site for ALM is the sole, with the palm and subungual locations following (Fig. 124-5). Not all palmar or plantar melanomas are ALMs; a minority are SSMs or NMs. The clinical appearance of ALM can be brown, black, tan, or red with variegations in color and irregular borders; however, the most common color is brown-black. There is often a delay in the diagnosis of ALM, often misdiagnosed as a plantar wart or hematoma, leading to a more advanced lesion upon diagnosis associated with poorer outcomes.[37] ALM is not thought to be associated with sun exposure.

Subungual melanoma, considered a variant of ALM, generally arises from the nail matrix, most commonly on the great toe or thumb (Fig. 124-6). It appears as a brown to black discoloration or growth in the nail bed. A widening, dark, or irregularly pigmented longitudinal nail streak (melanonychia striata) with or without nail dystrophy and nail plate elevation may be seen. Hutchinson sign, the finding of pigmentation of the posterior nail fold, has been considered an ominous finding associated with advanced subungual melanoma. Benign lesions that can mimic subungual melanoma include

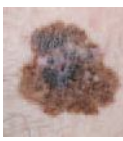





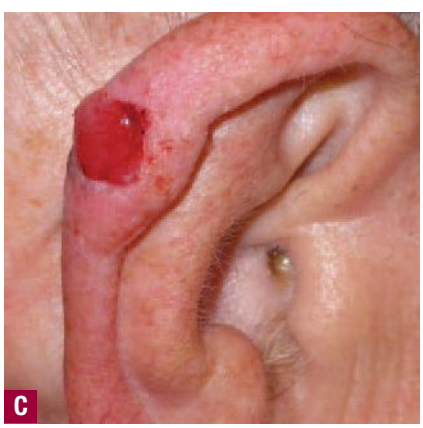



◀ **FIGURE 124-3** Nodular melanoma. **A.** Classic nodular melanoma, left lower back, Breslow depth 4.3 mm, angiolymphatic spread present. (Used with permission from Walter Barkey, MD.) **B.** Nodular polypoid melanoma, left flank, Breslow depth 16.0 mm, 38 mitoses/mm^2, ulceration and angiolymphatic spread present. **C.** Amelanotic nodular melanoma, Breslow depth 2.37 mm, 32 mitoses/mm^2, vertical growth phase, ulceration present. **D.** Amelanotic nodular melanoma with spindle cell features, noted approximately 1 to 2 months with elevation and bleeding, right posterior shoulder, Breslow depth 3.95 mm, 6 mitoses/mm^2.



▲ **FIGURE 124-4** Lentigo maligna and lentigo maligna melanoma (LMM). **A.** Lentigo maligna (in situ) displays prominent asymmetry, poorly defined irregular borders, and pigment variegation. **B.** Extensive LMM with large nodules. **C.** Amelanotic LMM with nodular component initially suspected to be a basal cell carcinoma, nose, Breslow depth 2.2 mm, 5 mitoses/mm^2, ulceration present. **D.** A pigmented patch of hair was noted after discontinuing practice of hair coloring. Over 6 weeks the area became pruritic and bled once. **E.** Inspection of the skin in the area of pigmented hair revealed the melanoma. Breslow depth 3.4 mm, ulceration present, 6 mitoses/mm^2, two foci of dermal melanoma satellite metastases.

longitudinal melanonychia, subungual hematoma, or pyogenic granuloma or even onychomycosis with pigmentation or hemorrhage.

DIFFERENTIAL DIAGNOSIS (Box 124-4)

Other Variants

DESMOPLASTIC MELANOMA DM is an uncommon type of melanoma that is locally aggressive with high rates of local recurrence. It most commonly develops in older persons, usually in the sixth or seventh decade, and has a male predominance 2:1. The sun-exposed head and neck regions are the most common sites. The lesions typically have a firm, sclerotic, or indurated quality, and one-half are amelanotic (see eFig. 124-6.1 in on-line edition). Approximately one-half of the lesions arise in association with the LM histologic sub-type. Many DMs are deeply invasive at diagnosis and have a propensity to infiltrate perineurally, otherwise called *neurotropic melanoma*. Neurotropism enhances the likelihood of local recurrence. Occasionally, there are some lesions with prominent perineural invasion and no evidence of an intraepidermal component. These lesions are designated *neurotropic melanoma*. Although deeply invasive, DM is associated with lower metastatic rates than other sub-types of melanoma when matched for depth of invasion. A recent study has shown that lesions with fusiform and/or epithelioid melanoma cells had a higher metastatic rate than those with pure DM with only fibrosing component.[38] Results from a small study that involved 10 samples that investigated gene expression profiling demonstrated a molecular distinction between DM and nondesmoplastic melanoma.[39]

Box 124-3

Differential Diagnosis of Lentigo Maligna Melanoma

- Solar lentigo
- Pigmented actinic keratosis
- Flat seborrheic keratosis
- Superficial pigmented basal cell carcinoma

MUCOSAL MELANOMA Melanoma infrequently can arise on mucosal surfaces. The most common sites are the head and neck (conjunctival, intranasal, sinus, and oral cavities), vulva, anorectal, or even urethral melanoma (Fig. 124-7). With the exception of the conjunctiva, patients present most often with delayed detection and a deeply pigmented, irregular lesion, but due to its location, may also present with bleeding or a mass lesion.[40] As most of these lesions present with a radial growth phase manifesting a macular pigmentation, any suspicious area in these sites should be biopsied. Lesions of the conjunctiva are easily visible and appear increased in patients with atypical nevus.[41,42]

NEVOID MELANOMA Nevoid melanoma describes a heterogeneous group of rare lesions that histologically resemble benign nevi by their symmetry and apparent maturation with descent in the dermis, thus with greater potential for misdiagnosis. Clues to their histologic diagnosis include marked hyperchromasia of the nuclei of the tumor cells, the presence of mitoses, and an expansile



▲ **FIGURE 124-5** Acral lentiginous melanoma (ALM). **A.** Classic ALM demonstrating ABCDs (asymmetry, border, color, diameter/difference, elevation/evolving), left foot, Breslow depth 1.72 mm, ulceration present. **B.** Early detection of lesion followed by the patient, present for many decades, over several months began growing with irregular border and shape, changed in color from brown to black, in situ ALM arising in a dysplastic nevus. **C.** Amelanotic ALM, fourth toe of left foot, Breslow depth 5.0 mm.

growth of the dermal cells with effacement of the adventitia in affected areas. Clinically this may correspond to a tan papule or nodule, more often > 1 cm in diameter on a young adult.[43]

SPITZOID MELANOMA Spitzoid melanoma is a sub-type of melanoma that clinically and histologically resembles a Spitz nevus (see Chap. 122), but tends to be larger and have asymmetry and irregular coloration. Distinction between the two is sometimes extremely difficult, especially in the younger patient with mitoses favoring melanoma. In this tumor, the size of the lesion, greater than 1 cm in diameter; thickness of the invasive component, well over 2 mm; and quite numerous mitoses, many atypical; are helpful in identifying these lesions. The role of *BRAF* or *NRAS* is less clear in the pathogenesis of Spitzoid melanoma.[44]

OTHER RARE TYPES Several other rare and unusual types of melanoma are beyond the scope of this chapter, but previously reported in a comprehensive review, which include metaplastic melanoma, balloon cell melanoma, signet-ring cell melanoma, myxoid melanoma, rhabdoid melanoma, minimal-deviation melanoma, animal-type melanoma, malignant blue nevus.[43]



▲ **FIGURE 124-6** Subungual acral lentiginous melanoma (ALM). **A.** Extensive involvement of periungual skin (Hutchinson sign) with dystrophy and loss of the nail plate secondary to the tumor. **B.** ALM great toe, without notable Hutchinson sign, Breslow depth 3.4 mm, 6 mitoses/mm^2, two positive sentinel nodes identified, disease free at 2 years. **C.** Advanced subungual ALM with proximal periungual macular component and subungual and distal ulcerated nodular component. **D.** Subungual ALM, thumb nail bed streak, Breslow depth 0.5 mm. This was her fourth primary melanoma, other three located on the shoulder, cheek, and neck, the first 14 years prior.

Melanoma and Pregnancy

Melanoma is the second most common cancer in women of child-bearing age, and so it also constitutes one of the more common types of cancers diagnosed in pregnancy.[3,45] There has been much controversy regarding the effect of pregnancy on the clinical course of melanoma. The biologic basis of potential hormonal ef-

Box 124-4

Differential Diagnosis of Acral Lentiginous Melanoma and Subungual Acral Lentiginous Melanoma

- Plantar wart
- Hematoma
- Palmoplantar nevus
- Longitudinal melanonychia
- Onychomycosis
- Pyogenic granuloma



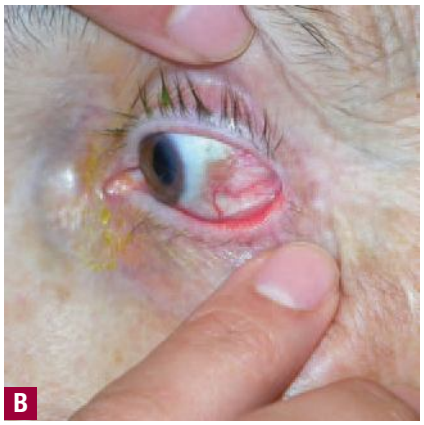



▲ **FIGURE 124-7** **A.** Irregularly deeply pigmented melanoma arising on the left upper wet lip extending onto the mucosa. **B.** Conjunctival melanoma. **C.** Ulcerated deeply invasive anal melanoma presented with rectal bleeding initially thought to be due to internal hemorrhoids.



fects on melanoma includes the well-known hyperpigmentation associated with pregnancy, and the elevation of many endogenous hormones, including estrogens and melanocyte-stimulating hormone. However, the literature demonstrates that pregnancy before, during, or after a woman is diagnosed with melanoma does not appear to influence overall survival.[46] Overall survival in pregnant women is similar to nonpregnant women diagnosed with melanoma when corrected for prognostic factors; in addition, pregnancy subsequent to the diagnosis of primary melanoma is not associated with an increased risk of death.[47] There is no difference in the distribution of disease stage of melanoma, tumor thickness, lymph node positivity or assessment, and survival for pregnancy-associated melanoma (i.e., melanoma diagnosed during or within 1 year).[48] Pregnant women with melanoma should be offered the same surgical treatments, including sentinel lymph node (SLN) biopsy (usually with omission of blue dye), as nonpregnant counterparts; however, certain chemotherapeutic and immunologic regimens used in advanced melanoma may be contraindicated in pregnancy. After the initial diagnosis and treatment of melanoma, there are no standard, defined guidelines for patients who desire to become pregnant. Counseling recommendations should be comprehensive and individualized on a case-by-case basis, depending primarily on the risk of recurrence (related to the stage at diagnosis) and degree of personal desire to become pregnant relative to risk. Waiting for a period of up to 5 years is generally advised, depending on these factors.

Pediatric Melanoma

Melanoma in childhood and adolescence is rare. Of all newly diagnosed melanomas, 1 percent to 4 percent occur in patients younger than 20 years of age, and only 0.3 percent to 0.4 percent occur in prepubertal children.[49] However, melanoma is being increasingly diagnosed in this age group and being reported to occur more commonly without the classic predisposing risk factors of familial melanoma, congenital nevi, dysplastic nevi, and xeroderma pigmentosum.[50] Based on SEER data of 1255 melanoma patients less than 20 years of age, a 2.9 percent increase in the incidence of pediatric melanoma per year from 1973 to 2001 has been noted; the rate of increase was lower (1.4 percent) in young children less than 10 years.[51] Factors conferring risk of adult melanoma, including increasing age, UV exposure, and Caucasian background, were also found to be important in pediatric melanoma. The classic predisposing factors for adult melanoma are likely to be applicable to some proportion of children. In general, pediatric melanomas tend to have a greater proportion of thicker primaries, possibly related to delayed diagnosis compared with adults.

Making a Diagnosis

Early detection is the key to improving prognosis in melanoma. Although melanoma may have a characteristic appearance, there is no single clinical feature that ensures or excludes a diagnosis of melanoma. Even among expert dermatologists, the clinical diagnosis of melanoma can be made in only about 80 percent to 90 percent of cases. The well-known ABCD acronym for melanoma detection was developed in 1985 and continues to be a useful tool for the lay public and physicians.[52] A stands for asymmetry (one half is not identical to the other half); B for border (irregular, notched, scalloped, ragged, or poorly defined borders as opposed to smooth and straight edges); C for color (having varying shades from one area to another); and D for diameter (i.e., greater than 6 mm, approximately the size of a pencil eraser). Lesions having these characteristics may potentially represent melanoma. Studies have found the sensitivity of the ABCD checklist (Box 124-5) to be in the 90 percent to 100 percent range, but the specificity much lower.[53] NM is notable for the frequency it is overlooked using the ABCD rule; it tends to have smooth borders, be evenly colored, and may be small (less than 6 mm) especially in the early stage. Another diagnostic aid that is useful in detecting melanoma is the "ugly duckling" sign.[54] A pigmented lesion that is different from other pigmented lesions on a particular individual should be approached with a high index of suspicion. This is based on the premise that within an individual, nevi should globally share a common appearance or family resemblance. Even in an individual with multiple atypical nevi, the nevi should be morphologically similar.

History is very important in the evaluation of a lesion. The ABCD rule is relatively static and does not account for a critical element of change. For this reason, some have added an E to the ABCD

Box 124-5

ABCD Checklist[a]

- A = Asymmetry
- B = Border
- C = Color
- D = Diameter/Difference
- E = Elevation/Evolving

[a]Does not apply to nodular melanoma.

rule, where E stands for evolving.[55] Others have advocated for the D to stand for "difference" (i.e., a change in appearance or symptomatology over time or difference from the other lesions, similar to the "ugly duckling" sign). Change in color and increase in size (or a new lesion) are the two most common early characteristics noticed by patients that may be useful in discriminating between melanoma and other benign lesions.[56] In addition to change in color, size, or shape/elevation, persistent lesional itching is also an earlier (albeit non-specific) symptom; ulceration, bleeding, and tenderness generally signify a more advanced primary lesion.[57] Therefore, it is important to ask patients if lesions have changed over time, and to pay particular attention to changing or symptomatic lesions. The development of a new pigmented lesion, especially in an individual beyond the age of 40 to 50 years old and on an anatomic site without similar lesions, is also worthy of suspicion.

Physical Examination

The skin examination should be conducted under optimal lighting and encompass the entire skin integument, including the scalp, external ocular/conjunctivae, oral mucosa, genitalia, buttocks, and palms/soles/web spaces. Melanomas in hidden anatomic sites are associated with thicker tumors at diagnosis, often due to later detection.[58] A global assessment of an individual's skin, including number of nevi, both typical- and atypical-appearing, and distribution of nevi should be noted. Other risk factors, such as a family or personal history of melanoma or previously biopsied atypical nevi, should also be noted. Total body and lesional photography may be useful, especially in high-risk patients with numerous nevi.[59] The use of photography to document the appearance of skin lesions (or the absence of a skin lesion) can allow for better and earlier detection of a changing or new lesion. In high-risk patients, a proportion of melanomas are diagnosed with the aid of photographic surveillance rather than being noted by the patient or even the physician.[60] If a lesion suspicious for melanoma is found on skin examination, palpation of the regional lymph nodes should be performed to evaluate for lymphadenopathy.

Dermoscopy

Dermoscopy (also known as *epiluminescence microscopy*, *dermatoscopy*, *incident light microscopy*, and *surface microscopy*) is a simple, non-invasive technique in which a liquid, usually immersion oil, is applied to the lesion, which is then examined with a hand-held lens (magnification usually 10×) or a commercially available device. In experienced hands, it improves both the sensitivity and specificity for the clinical diagnosis of melanoma and other pigmented and non-pigmented lesions, although those without experience and the appropriate training do not realize this benefit. Morphologic features that are otherwise not visible to the naked eye are observed using this technique. Approximately 23 percent of dermatologists in a 2002 report the clinical use of dermoscopy.[61] Its use and popularity as an adjunct to the clinical examination are increasing for both dermatologists and non-dermatologists. Many enthusiastic investigators continue to advance the field of dermoscopy with efforts to improve, refine, and standardize terminology; and simplify the diagnostic categories of pigmented skin lesions.

A new terminology and set of criteria have subsequently been developed for dermoscopy. The *pigment network*, seen as a series of pigmented lines, identifies a pigmented lesion as being melanocytic; it correlates to pigment along rete ridges, both in the basal layer and nests along the dermal-epidermal junction. A typical pigment network pattern has regular delicate lines with gradual thinning at the periphery; whereas an atypical pigment network pattern has irregular, variable, and widened lines that end abruptly at the periphery. *Brown globules* correlate with pigmented nests of melanocytes in the papillary dermis; *black dots* are focal collections of melanocytes and clumps of melanin in the stratum corneum. A *blue-grey veil* represents regression in melanoma. Different diagnostic algorithms using dermoscopic findings have been developed for melanoma, including the ABCD rule, and the 7-point checklist.[62] Pattern analysis, which provides an overall impression of multiple dermoscopic patterns without rigid rules, based primarily on a subjective, simultaneous evaluation of a number of different criteria, is probably the most widely used among experienced experts of dermoscopy. Lists of the important dermoscopy features with clinical pathologic correlations and significance have been widely published and are relatively easily obtainable through courses, societies, and the Internet. Fig. 124-8 summarizes several of these features.

Digital dermoscopy, or digital epiluminescent microscopy, is an advance in non-invasive technology; it permits computerized digital dermoscopic images to be retrieved and examined at a later date so that comparisons can be made and changes detected over time (Fig. 124-9). There are also a number of commercially available automated computer image analysis programs, devices that incorporate image analysis algorithms to digital dermoscopic images, providing objective measurement of changes over time. The use of automated instruments for the diagnosis of melanoma is in an evolving phase. The use of body or lesional photography, professionally obtained or taken by the patient, is also very useful to aid physicians and patients for following lesions, particularly in patients with many nevi.

Histopathology

The gold standard for diagnosing melanoma is based on histopathologic evalua-

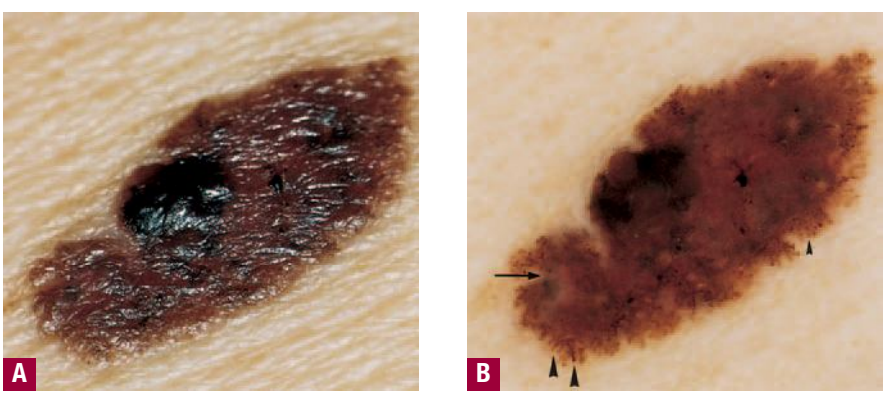

▲ **FIGURE 124-8** **A.** Superficial spreading melanoma as viewed by close inspection with a hand-held lens or a dermoscope without oil immersion. **B.** With oil immersion, new features become apparent, such as the pigment network, brown globules (*small arrowhead*), pseudopods (*large arrowheads*), and depigmentation, extending irregularly to the periphery of the lesion (*arrow*). (Used with permission from Michael Binder, MD.)

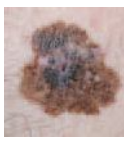



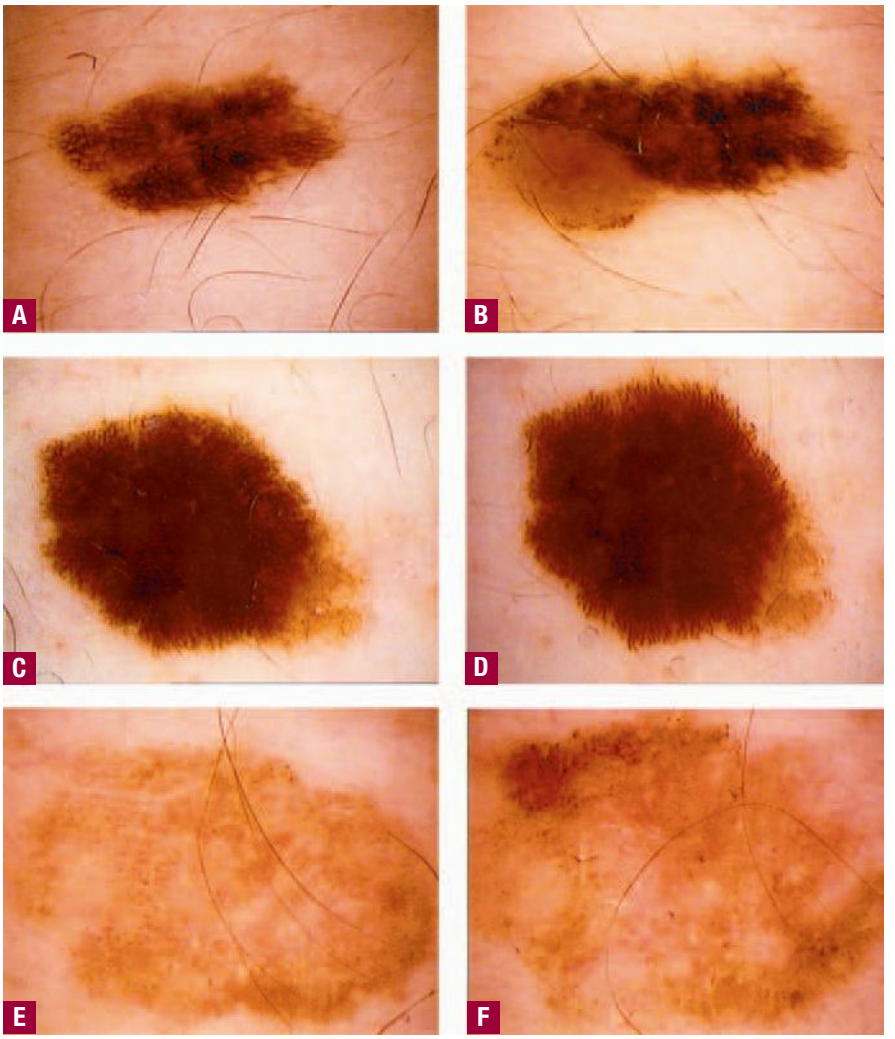

▲ **FIGURE 124-9** Monitoring of atypical nevi (AN) by digital epiluminescence microscopy. All lesions are from patients with multiple atypical nevus syndrome. **A.** Image of AN at time of presentation. The lesion shows features of an AN and, because the patient has multiple such lesions, clinical monitoring at 6-month intervals was scheduled. **B.** Follow-up of the same lesion after 8 months. The lesion has changed. There is asymmetric increase in size and the appearance of a new hypopigmented structure at the periphery on the left. The lesion was excised and histology revealed AN in the right portion of the lesion and superficial spreading melanoma (SSM) < 0.75 mm on the left. **C.** This AN is more difficult to evaluate. Typical AN at baseline (**C**) but after 6 months, (**D**) subtle changes have occurred. There is an increase in size, albeit symmetric, of the lesion, but the pigment network at the upper and lower margin has transformed into a fringe of fine pseudopods suggesting SSM. Histology confirmed SSM < 0.75 mm. **E.** Another AN at baseline. **F.** Follow-up image of the same lesion at 6 months. The most prominent changes are asymmetric increase in size, appearance of a new irregular pigment network, dots, and globules at the upper left margin of the lesion. Histology revealed SSM < 0.75 mm. (Used with permission from Harald Kittler, MD.)

tion of the biopsy specimen, preferably by a dermatopathologist or a pathologist experienced with pigmented lesions. There is some histologic diagnostic discordance in the diagnosis of melanomas and melanocytic lesions, especially with early melanomas, even among experts, but the percentage of cases in which the diagnosis changes from benign to malignant or vice versa, or would result in a major modification in therapy or prognosis, is small.[63–65] The histologic diagnosis of melanoma is based on the assessment of a constellation of findings, including both architectural and cytologic features. No single feature is diagnostic. Cytologic atypia, referring to cellular enlargement, nuclear enlargement, nuclear pleomorphism, hyperchromasia of nuclei, nucleolar variability, and the presence of mitoses especially deep in the dermis, is considered necessary for a diagnosis of melanoma. The major architectural features of melanoma include asymmetry, poor circumscription (i.e., cells at the edge of the lesion tend to be small, single, and scattered), and large size (> 5 to 6 mm). Nests of melanocytes in the lower epidermis and dermis tend to vary a good deal in size and shape, and to become confluent. There is a lack of maturation of nests with descent into the dermis. Pagetoid spread of large solitary epidermal melanocytes, usually considered diagnostic of melanoma, should be assessed cautiously in the context of other findings, as pagetoid spread may be seen in benign lesions including Spitz nevi, spindle cell nevi, vulvar nevi, and acral nevi.

The different sub-types of melanoma have histopathologic differences as well. SSM is characterized by a population of melanocytes appearing uniformly atypical (Figs. 124-10 and 124-11). LM and LMM are characterized by atypical melanocytes singly and in nests, predominantly confined to the basal layer of the epidermis, which become confluent without pagetoid spread, occurring in the background of photodamage (Figs. 124-12, 124-13, and 124-14). The cells may extend down hair follicles and appendageal structures. The epidermis is thin and atrophic, with loss of rete ridges. There is variable cytologic atypia. The "lentiginous" in ALM is derived from the characteristic lentiginous pattern of most cells being single and located near the dermal-epidermal junction (Fig. 124-15). ALM differs from LM in that there is irregular acanthosis, and the melanoma cells are uniformly malignant and often dendritic. In LM, the cells are highly pleomorphic in an atrophic epidermis. NM demonstrates little tendency for intraepidermal growth; instead, there is a dermal mass of atypical melanocytes (Figs. 124-16 and 124-17). DM is composed of strands of elongated, spindle-shaped cells that often infiltrate deeply. Neurotropic melanoma describes a subset of DMs in which the cells invade perineurally and form patterns resembling nerves.

The typical pathology report useful for management includes creation of a 14-point melanoma profile shown in Box 124-6.

Immunohistochemistry

Immunohistochemistry may be useful for the diagnosis of melanoma, especially in poorly differentiated neoplasms with little or no pigment (i.e., amelanotic melanomas), spindle cell tumors, or tumors with pagetoid spread that are not obviously melanoma. S100 protein is ex-

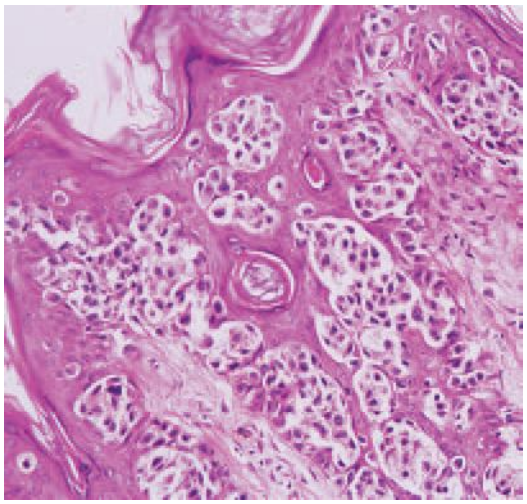

◀ **FIGURE 124-10** Superficial spreading melanoma. This tumor shows intraepidermal growth. In this photomicrograph, the pagetoid distribution is evident in the epidermis. The cells are relatively uniform and have an abundance of dusty, fine pigment. These relatively large melanoma cells are frequently referred to as epithelioid cell type.

pressed by virtually all melanomas, but also by melanocytic nevi, Langerhans cells, and cutaneous neural tumors. HMB-45 is a monoclonal antibody with high specificity for melanoma cells, although it is frequently negative in DM; DMs commonly exhibit vimentin and S100 positivity. Melan-A and MART-1 (melanoma antigen recognized by T cells) are the names given independently to the same gene encoding a melanocytic differentiation antigen expressed in skin and retina but not other normal tissues. Melan-A is broadly expressed in benign and malignant melanocytic lesions but not in most DMs. It is more sensitive than HMB-45 and more specific than S-100 for melanoma. Search for the microphthalmia-associated transcription factor (Mitf) may be extremely useful, especially in amelanotic melanomas, as it is a marker in the nucleus, whereas all other markers are intracytoplasmic.[66] It stains most melanomas except for DM where staining is usually negative but variable.

PROGNOSIS AND CLINICAL COURSE

Staging and Prognostic Factors

Accurate staging of melanoma is essential for determining optimal treatment and for assessing prognosis. Accurate staging forms the basis for prognosis and treatment, which is invaluable for the majority of patients in their informed decision-making process. The American Joint Committee on Cancer (AJCC) revised the staging system for melanoma in 2002 with several fundamental changes,[67] which incorporates the most

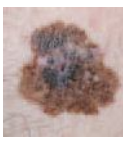

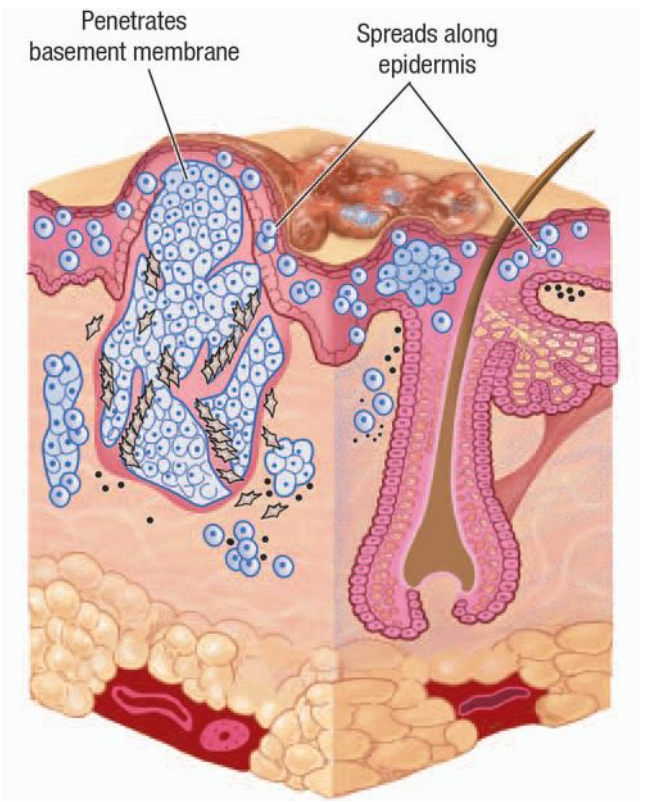

▲ **FIGURE 124-11** Superficial spreading melanoma. The border is irregular, and the lesion is elevated throughout its entirety. Biopsy of the area surrounding the large nodule shows a "pagetoid" distribution of large melanocytes that are occurring singly or in nests, and uniformly atypical. On the left is a large nodule, and scattered throughout the surrounding portion of the nodule are smaller popular and nodular areas. The nodule on the left shows malignant melanocytes that are very large, have an abundance of cytoplasm, and often have regularly dispersed fine particles of melanin. The nodules may also show spindle cells or small malignant melanocytes as in lentigo maligna melanoma and nodular melanoma.

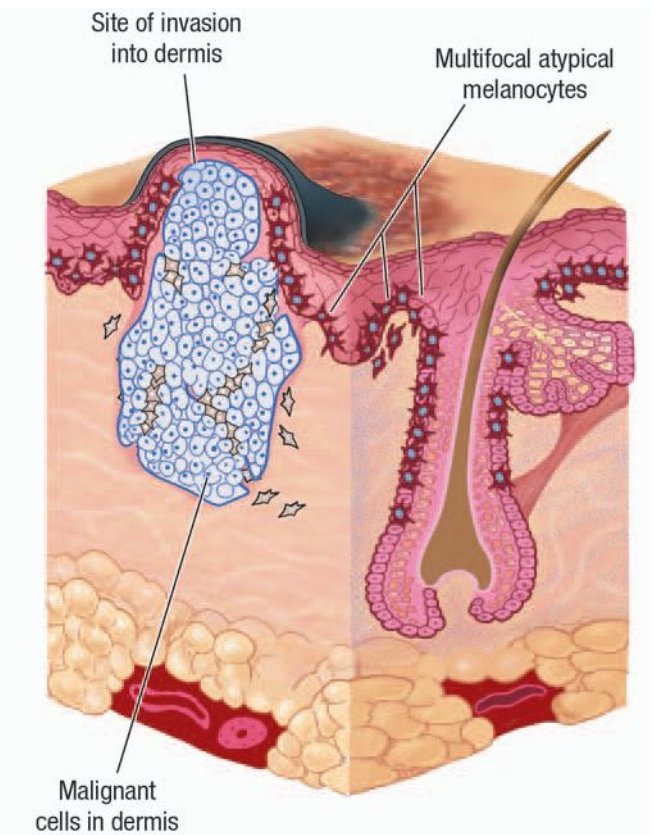

▲ **FIGURE 124-12** Lentigo maligna melanoma. Illustrated on the right is a large, variegated, freckle-like macule (not elevated above the plane of skin) with irregular borders; the tan areas show increased numbers of melanocytes, usually atypical and bizarre, and are distributed single file along the basal layer; at certain places in the dermis, malignant melanocytes have invaded and formed prominent nests. At the left is a large nodule that is composed of epithelioid cells in this illustration; the nodules of all four main subtypes of melanoma are indistinguishable from each other.

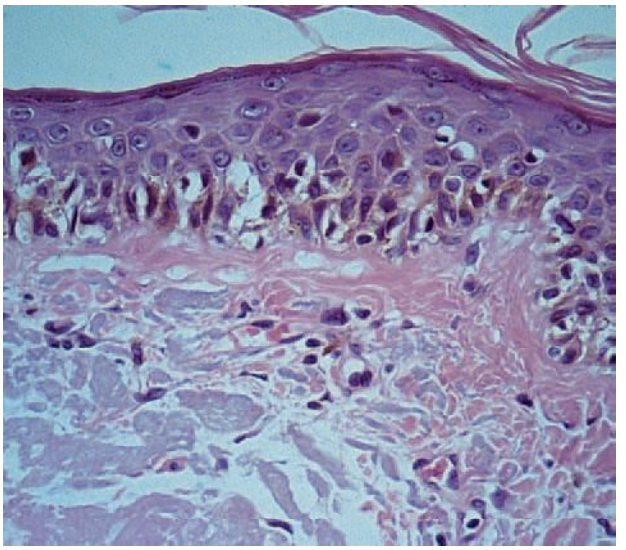

▲ **FIGURE 124-13** Lentigo maligna. This is a proliferation of pleomorphic melanocytes in the basal layer of an atrophic epidermis in sun-damaged skin.

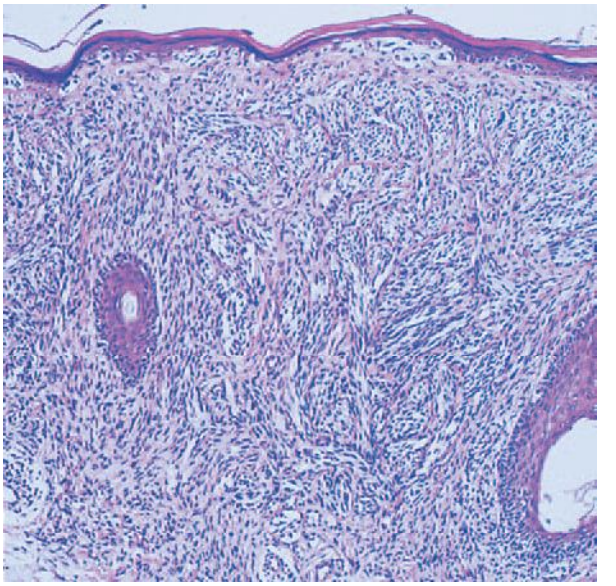

▲ **FIGURE 124-14** Lentigo maligna melanoma. Extending from the epidermis into the dermis are numerous elongated melanocytes. In lentigo maligna melanoma, these cells are frequently spindle-shaped.



important prognostic factors, such as microstaging and nodal status, and translates them into reported survival rates. It is well recognized that the current staging classification system is not perfect, and plans for the next revision are anticipated in 2009. In spite of some drawbacks, the current staging system is clinically valuable and should be used, particularly in clinical trials, reports, and studies to make data comparable. Multicenter retrospective data from 17,600 patients with melanoma were used to determine the significant prognostic variables in the current AJCC classification system.[68] T describes the extent or thickness of the primary tumor, N the extent of lymph node metastases, and M the extent of distant metastases. Table 124-2 presents the TNM categories (*t*umor size, *n*ode status, *m*etasasis classification), and Table 124-3 lists the stage groupings. There are five stages based on prognosis: stage 0 (in situ disease), stages I and II (localized disease), stage III (regional disease), and stage IV (distant metastatic disease). In general, prognosis and survival rates worsen with increasing stage (Table 124-4). At initial presentation, approximately 85 percent of patients have localized disease (stages I and II), 10 percent have regional metastatic disease, and 5 percent have distant metastatic disease.[67]

Prognostic Factors in Microstaging (See Table 124-4)

TUMOR THICKNESS The single most important prognostic factor for survival and clinical management in localized stage I and II cutaneous melanoma is tumor thickness.[68] As originally described by Breslow, thickness is measured from the top of the granular layer of the epidermis to the greatest depth of tumor invasion using an ocular micrometer and measured in millimeters (see eFig. 124-17.1 in online edition). Survival decreases with increasing Breslow depth. Clark level is an alternate, less accurate method of depicting tumor thickness by the anatomic level of invasion and is less important in current microstaging. Historically described by Clark, melanoma is confined to the epidermis in level I, extends into the papillary dermis in level II, accumulates in and expands in the papillary dermis in level III, extends into the reticular dermis in level IV, and invades the subcutaneous fat in level V (see eFig. 124-17.1 in on-line edition). Clark level of invasion may have an impact on survival for thin melanomas < 1 mm, when a Clark level of IV or V upstages a melanoma from T1a to T1b. However, other data suggest that, compared to Breslow depth, Clark level is a weaker prognostic indicator for survival.[69]

ULCERATION Ulceration also currently represents an independent prognostic

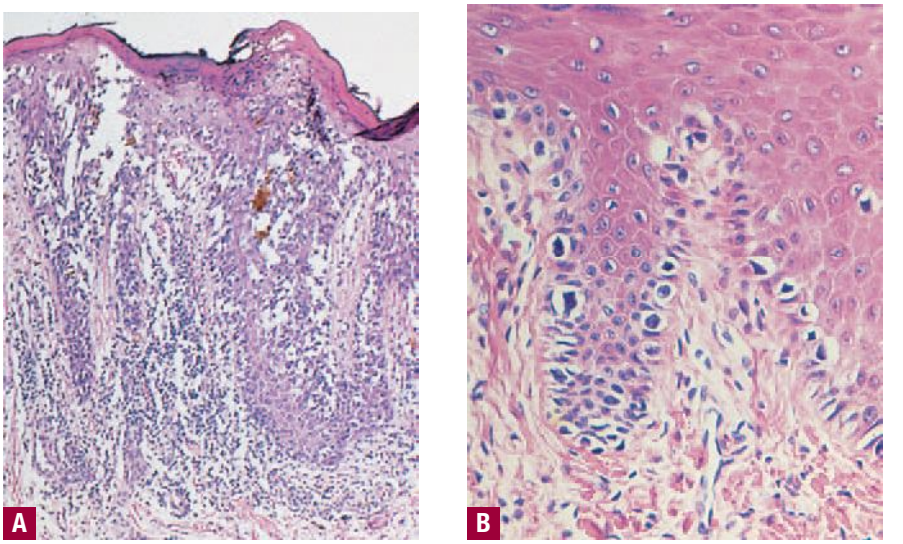

▲ **FIGURE 124-15** Acral lentiginous melanoma. **A.** Photomicrograph showing hyperkeratosis associated with plantar location of this melanoma. Fibrosis and patchy host response are noted in the dermis. **B.** High-powered photomicrograph showing lentiginous proliferation of abnormal melanocytes along the dermal-epidermal junction.

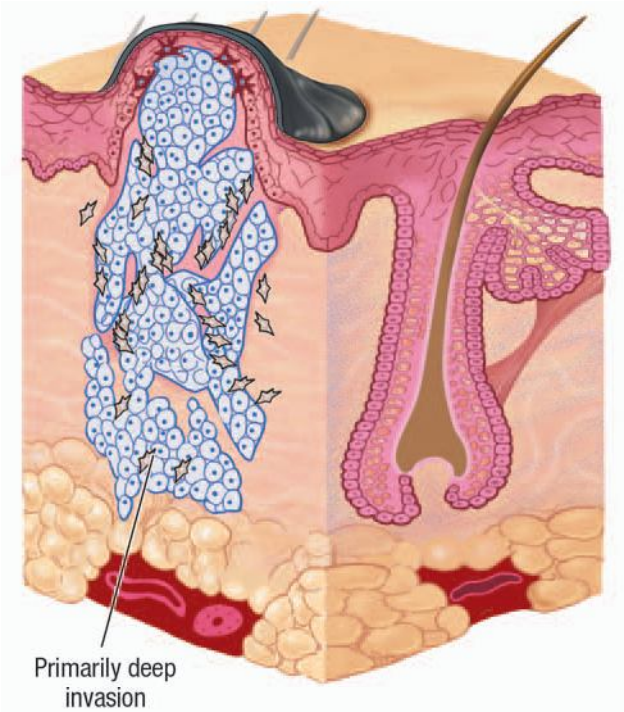

▲ **FIGURE 124-16** Nodular melanoma. This tumor arises at the dermal-epidermal junction and extends vertically into the dermis; intraepidermal growth is present only in a small group of tumor cells that conjointly are also invading the underlying dermis. The epidermis lateral to the areas of this invasion does not demonstrate atypical melanocytes. As with lentigo maligna melanoma and superficial spreading melanoma, the tumor may show large epithelioid cells, spindle cells, small malignant melanocytes, or mixtures of all three.

factor for localized melanoma in the AJCC study and was highly correlated with survival.[68] The presence of ulceration in the primary confers a higher risk of developing advanced disease and lower survival rate. The presence of ulceration upstages all patients with localized as well as regional disease [i.e., stages I to III (see Table 124-2)]. Ulceration correlates with tumor thickness; it occurs infrequently in thin melanomas (6 percent for melanomas < 1 mm) and frequently in thick melanomas (63 percent for melanomas > 4 mm). Conversely, multivariate analysis of data from the German Central Malignant Melanoma Registry demonstrated ulceration to have a significant negative impact on the prognosis for patients with T2 and T3 lesions, but not for T1 and T4. For stage III regional disease, the impact of ulceration on overall survival was significant in bivariate but not multivariate analysis. In spite of these drawbacks, the new staging classification should be used, particularly in clinical trials, to make data internationally comparable.[70] One potential shortcoming of ulceration as a variable is that ulceration is not always a homogeneous phenomenon and may result from trauma, which is prognostically insignificant. For this reason, ulceration should only be reported when there is evidence of host response at the site, including fibrin and nuclear debris. Their presence indicates a preoperative event not possibly associated with artifactual causes due to surgery or processing.

Box 124-6

Melanoma Pathology Checklist

- Body site
- Histologic pattern sub-type
- Breslow depth
- Clark level
- Mitotic rate
- Vertical vs. radial growth phase
- Ulceration
- Regression
- Satellitosis
- Angiolymphoid spread
- Neurotropism
- Tumor-infiltrating lymphocytes
- Co-existing nevus
- Margins

MITOTIC RATE There is a growing body of literature and studies to strongly support a significant independent relationship between tumor mitotic rate and prognosis in melanoma. Mitotic rate, measured as the number of mitoses per square millimeter, is usually counted as

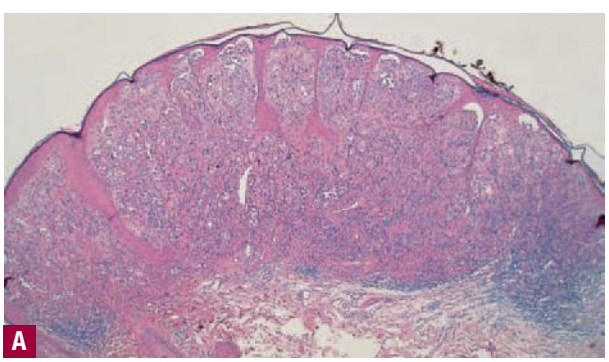

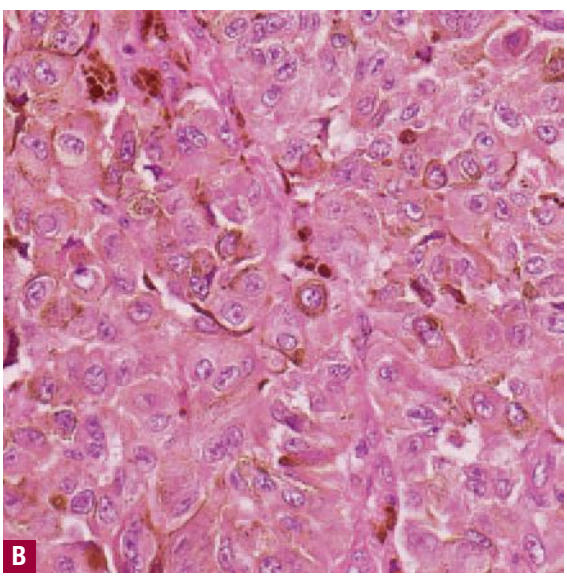

▲ **FIGURE 124-17** Nodular melanoma. **A.** Low-powered photomicrograph demonstrating a dome-shaped expansile tumor located in the upper dermis. **B.** High-powered photomicrograph reveals nests of anaplastic epithelioid cells in the tumor.

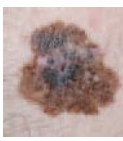

TABLE 124-2
Melanoma TNM Classifications[a]

T Classification	Thickness (mm)	Ulceration Status
T1	≤ 1.0	a: without ulceration and level II/III b: with ulceration or level IV/V T2
T2	1.01–2.0	a: without ulceration b: with ulceration
T3	2.01–4.0	a: without ulceration b: with ulceration
T4	> 4.0	a: without ulceration b: with ulceration
N Classification	**Number of Metastatic Nodes**	**Nodal Metastatic Mass**
N1	1	a: micrometastasis[b] b: macrometastasis[c]
N2	2–3	a: micrometastasis[b] b: macrometastasis[c] c: in-transit met(s)/satellite(s) without metastatic nodes
N3	4 or more nodes, or matted nodes, or in-transit met(s)/satellite(s) with metastatic node(s)	
M Classification	**Site**	**Serum Lactate Dehydrogenase**
M1a	Distant skin, subcutaneous, or nodal metastases	Normal
M1b	Lung metastases	Normal
M1c	All other visceral metastases	Normal
	Any distant metastasis	Elevated

TNM = tumor size, node status, metastasis classification.
[a]Six major changes are included in the 2002 version of American Joint Committee on Cancer melanoma staging system:
1. Anatomic level is used only in the staging of thin tumors. Thickness and ulceration are primarily used in the T category. The anatomic level of invasion (Clark levels) is currently understood to be an independent prognostic feature only for thin melanomas. As a result, Clark levels are incorporated only into staging of thin melanomas (< 1.0 mm or category T1).
2. Ulceration of the tumor has been added to the staging system. Ulceration is an independent risk factor and portends a higher risk of developing advanced disease. The presence of ulceration "upstages" all patients with stages I to III disease. In a given T grouping, the new system subclassifies patients as "a" for tumors without ulceration, and "b" for tumors with ulceration.
3. The number of metastatic nodes, rather than the size of nodes, is used as a primary criterion in the N staging.
4. The system incorporates a new convention for categorizing patients both clinically and pathologically. This system incorporates date from lymphatic mapping and sentinel node biopsy.
5. In-transit and satellite metastases have been grouped in the same subclassification (N2c). Patients with intralymphatic metastases but no nodal metastases are recognized as having a similar prognosis and are thus grouped together.
6. Distant metastatic melanoma is classified by site(s) of metastases and levels of lactic dehydrogenase detected in serum.

[b]Micrometastases are diagnosed after sentinel or elective lymphadenectomy.
[c]Macrometastases are defined as clinically detectable nodal metastases confirmed by therapeutic lymphadenectomy or when nodal metastasis exhibits gross extracapsular extension.
From Balch CM et al: Final version of the American Joint Committee on Cancer staging system for cutaneous melanoma. *J Clin Oncol* **19**:3635, 2001, with permission.

the number of mitoses seen in five high-power (×40) microscope fields (the equivalent of a 1-mm^2 area), starting in the fields with the most mitoses. Several large studies have reported mitotic rate to be an independent prognostic risk factor in melanoma survival, which will be closely examined in the future revised AJCC staging system.[71,72] Patients with a mitotic rate of 0 mitoses/mm^2 have a significantly better survival than those with ≥ 1 mitosis/mm^2. There may be some variability in the reproducibility of mitotic rate, as it is subject to sampling error in the high-power fields used.

ANGIOLYMPHATIC INVASION Vascular involvement denotes the invasion of tumor cells into the microvasculature in the dermis. Several reports note that vascular invasion significantly increases the risk of relapse, lymph node involvement, distant metastases, and death.[73,74]

OTHER HISTOLOGIC FACTORS Other factors have been variably reported as predictive of prognosis in melanoma including the presence of microsatellitosis, tumor-infiltrating lymphocytes, regression, tumor lymphangiogenesis (i.e., formation of new vessels), and radial versus vertical growth phase. The presence of microscopic satellitosis in particular has been consistently reported with a correlation with poorer outcome and is incorporated into the current AJCC staging system.

Clinical Prognostic Factors

AGE Many studies have reported that increasing patient age portends a worse prognosis with respect to overall survival rates. Males more than 60 years of age have the highest mortality rates from melanoma. Older patients have thicker primaries and a higher proportion of ulcerated melanomas, but even after adjusting for these factors, age appears to be an independent prognostic factor.[3,6,57,74] It has been postulated that age may serve as a surrogate for declining host immune defense mechanisms.

GENDER A large number of studies have reported that women have better survival rates than men, even after adjustment for tumor thickness and anatomic site.

ANATOMIC SITE The anatomic location of primary cutaneous melanomas has been variably reported to affect survival. In the AJCC study, melanomas located on the trunk and head and neck were correlated with worse prognosis than melanomas on the extremities, but the recorded locations were only (1) extremities, or (2) trunk, head, or neck.[68] In another large study of 5093 patients, melanomas on the *ba*ck and thorax, upper *n*eck, and *s*calp (BANS regions) were associated with significantly lower survival rates than melanomas on the lower trunk, thigh, lower leg, feet, lower arms, hands, and face.[75] Nonetheless, anatomic site has not been confirmed as an independent factor in many studies.

Prognostic Factors in Regional Metastasis

The status of the regional lymph nodes is the most powerful prognostic factor for survival in melanoma. The presence of regional lymph node metastasis portends a worse prognosis. The number of lymph nodes involved, independent of size, is the most significant risk factor in

TABLE 124-3
Proposed Stage Groupings for Cutaneous Melanoma

	Clinical Staging[a]			Pathologic Staging[b]		
	T	N	M	T	N	M
0	Tis	N0	M0	Tis	N0	M0
IA	T1a	N0	M0	T1a	N0	M0
IB	T1b	N0	M0	T1b	N0	M0
	T2a	N0	M0	T2a	N0	M0
IIA	T2b	N0	M0	T2b	N0	M0
	T3a	N0	M0	T3a	N0	M0
IIB	T3b	N0	M0	T3b	N0	M0
	T4a	N0	M0	T4a	N0	M0
IIC	T4b	N0	M0	T4b	N0	M0
III[c]	Any T	N1	M0			
		N2				
		N3				
IIIA				T1-4a	N1a	M0
				T1-4a	N2a	M0
IIIB				T1-4b	N1a	M0
				T1-4b	N2a	M0
				T1-4a	N1b	M0
				T1-4a	N2b	M0
				T1-4a/b	N2c	M0
IIIC				T1-4b	N1b	M0
				T1-4b	N2b	M0
				Any T	N3	M0
IV	Any T	Any N	Any M1	Any T	Any N	Any M1

T = tumor size; N = node status; M = metastasis classification.
[a]Clinical staging includes microstaging of the primary melanoma and clinical/radiologic evaluation for metastases. By convention, it should be used after complete excision of the primary melanoma with clinical assessment for regional and distant metastases.
[b]Pathologic staging includes microstaging of the primary melanoma and pathologic information about the regional lymph nodes after partial or complete lymphadenectomy. Pathologic stage 0 or stage 1A patients are the exception; they do not require pathologic evaluation of their lymph nodes.
[c]There are no stage III subgroups for clinical staging.
From Balch CM et al: Final version of the American Joint Committee on Cancer staging system for cutaneous melanoma. *J Clin Oncol* **19**:3635, 2001, with permission.

patients with stage III melanoma.[68] The second most important risk factor is tumor burden, stratified into micrometastatic disease as determined by SLN biopsy or imaging scans, and macrometastatic disease (i.e., clinically palpable nodes). In clinically node-negative stage I or II patients, SLN status was the most significant prognostic factor with respect to disease-free and disease-specific survival.[76] As such, SLN biopsy to search for micrometastatic disease has become widely used to obtain prognostic information and is incorporated into the current AJCC staging classification system for melanoma.[67] As mentioned earlier, ulceration of the primary lesion is still a prognostic factor in regional disease, and the presence of ulceration signifies a worse prognosis in stage III disease. Satellite, both clinical and microscopic, metastases around a primary melanoma and in-transit metastases between the primary and its nodal basin represent intralymphatic metastases (N2c or N3) and portend the worst prognosis for regional metastases.

Prognostic Factors in Distant Metastasis

The presence of distant metastases portends the worst prognosis, with mean survival rates measured in months rather than years. Site of metastasis was the most important prognostic factor in the AJCC melanoma study; visceral metastases had a relatively poorer prognosis than non-visceral (skin, subcutaneous tissue, and distant lymph nodes) sites.[68] Other variables of prognostic significance are the number of metastatic sites and surgical resectability. Solitary metastases resected after radiologic demonstration of stability over 3 to 6 months have been associated with prolonged survival in some, but no strong evidence exists that asymptomatic detection is associated with significant overall survival to date.[77] Elevated serum lactate dehydrogenase (LDH) levels are associated with a poorer prognosis.

Clinical Course

STAGES I AND II MELANOMA In general, the prognosis of patients with thin primary melanoma < 1 mm in Breslow depth and localized disease is excellent, with long-term survival achieved in more than 90 percent of patients. However, approximately 15 percent to 36 percent of patients with stages I and II melanoma will have some form of local, regional, or distant recurrence or metastasis during their clinical course. Melanoma typically recurs in a predictable fashion, first in a local and regional distribution, then to distant sites. It is also recognized that melanoma may bypass the regional nodes with direct hematogenous dissemination. The vast majority of recurrences manifest in the first 1 to 5 years after diagnosis and treatment, depending on tumor thickness and other prognostic features of the primary lesion (see Prognostic Factors in Microstaging). However, melanoma can recur at any time, and the incidence of late recurrence 10 or more years after initial diagnosis is approximately 1 percent to 5 percent. Most tumors with late recurrences are of intermediate thickness (mean, 1.6 mm; most in the 0.70 to 3.0 mm range) and occur at a mean of 14.3 years.[78] "Ultra late" recurrences more than 15 years after diagnosis are extremely rare but do occur.[79]

STAGE III MELANOMA Data from the Sunbelt Melanoma Trial with over 1100 melanoma patients indicate that recurrence rates are significantly higher with early stage III melanoma (i.e., micrometastatic nodal disease found on SLN biopsy) than with SLN-negative melanoma (15.5 percent vs. 6.0 percent, respectively).[80] Patients with SLN-positive melanoma were also significantly more likely to have distant metastases (as opposed to locoregional recurrence) versus those with SLN negative (67 percent vs. 46 percent, respectively). Pooled analysis reveals estimated 5-year overall survival rates between 93 percent and 88 percent for patients with a negative SLN, versus between 51 percent and 67 percent for a positive SLN.[81] Stage III melanoma encompasses a heterogeneous population of patients with a marked diversity in clinical course (Fig. 124-18). This is reflected by 5-year survival rates ranging from 70 percent for patients with non-

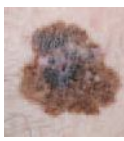

TABLE 124-4
Survival Rates for Melanoma TNM and Staging Categories

Stage	TNM	Thickness	Ulceration	Number of Positive Nodes	Nodal Size	Distant Metastases	Number of Patients	Survival (%)			
								1-yr	2-yr	5-yr	10-yr
IA	T1a	≤ 1	No	0	—	—	4510	99.7	99.0	95.3	87.9
IB	T1b	≤ 1	Yes or level IV, V	0	—	—	1380	99.8	98.7	90.9	83.1
	T2a	1.01–2.0	No	0	—	—	3285	99.5	97.3	89.0	79.2
IIA	T2b	1.10–2.0	Yes	0	—	—	958	98.2	92.9	77.4	64.4
	T3a	2.01–4.0	No	0	—	—	1717	98.7	94.3	78.7	63.8
IIB	T3b	2.01–4.0	Yes	0	—	—	1523	95.1	84.8	63.0	50.8
	T4a	> 4.0	No	0	—	—	563	94.8	88.6	67.4	53.9
IIC	T4b	> 4.0	Yes	0	—	—	978	89.9	70.7	45.1	32.3
IIIA	N1a	Any	No	1	Micro	—	252	95.9	88.0	69.5	63.0
	N2a	Any	No	2–3	Micro	—	130	93.0	82.7	63.3	59.6
IIIB	N1a	Any	Yes	1	Micro	—	217	93.3	75.0	52.8	37.8
	N2a	Any	Yes	2–3	Micro	—	111	92.0	81.0	49.6	35.9
	N1b	Any	No	1	Macro	—	122	88.5	78.5	59.0	47.7
	N2b	Any	No	2–3	Macro	—	93	76.8	65.6	46.3	39.2
IIIC	N1b	Any	Yes	1	Macro	—	98	77.9	54.2	29.0	24.4
	N2b	Any	Yes	2–3	Macro	—	109	74.3	44.1	24.0	15.0
	N3	Any	Any	4	Micro/ macro	—	396	71.0	49.8	26.7	18.4
IV	M1a	Any	Any	Any	Any	Skin, SQ	179	59.3	36.7	18.8	15.7
	M1b	Any	Any	Any	Any	Lung	186	57.0	23.1	6.7	2.5
	M1c	Any	Any	Any	Any	Other viscera	793	40.6	23.6	9.5	6.0
Total							17,600				

SQ = subcutaneous; TNM = tumor size, node status, metastasis classification.
From Balch CM et al: Final version of the American Joint Committee on Cancer staging system for cutaneous melanoma. *J Clin Oncol* **19**:3635, 2001, with permission.



ulcerated primaries and micrometastatic disease in one lymph node, to 25 percent for patients with multiple, matted lymph nodes or in-transit/satellite metastases. The presence of greater tumor burden in the regional lymph nodes is highly predictive of visceral metastases.

STAGE IV MELANOMA Melanoma is well known for its propensity to metastasize to virtually any organ and also for its highly variable clinical course. Melanoma metastasizes to non-visceral sites: distant skin/subcutaneous tissue and distant lymph nodes in approximately one-half of the stage IV cases (42 percent to 57 percent) (Fig. 124-19). The most common visceral sites are the lungs (18 percent to 36 percent), liver (14 percent to 20 percent), brain (12 percent to 20 percent), bone (11 percent to 17 percent) and gastrointestinal tract (1 percent to 7 percent). Once metastases to distant sites have been detected, median survival is approximately 6 to 8 months, and a minority live beyond 1 year.[68]



◀ **FIGURE 124-18** Uncontrollable bulky metastatic melanoma to the regional lymph nodes.

METASTATIC MELANOMA OF UNKNOWN PRIMARY Metastatic melanoma of unknown primary is defined as the presence of histologically confirmed melanoma in a lymph node, visceral site, or distant skin/subcutaneous tissues without a history or evidence of a primary cutaneous, mucosal, or ocular melanoma. This situation occurs in approximately 2 percent to 5 percent of all cases of melanoma. Approximately 60 percent of such metastases involve the lymph nodes, most commonly in the axilla, and the rest involve distant sites, typically the skin/subcutaneous tissue, and less commonly lung, brain, or gastrointestinal tract.[82] Melanoma of unknown primary has similar survival rates compared to equivalently staged melanomas of known primary origin. In the largest study to date, melanoma of unknown primary metastatic to lymph nodes had 5- and 10-year survival rates of 46 percent and 41 percent, which is comparable to the equivalent stage III melanoma of known primary.[83] Melanoma of unknown primary metastatic to viscera had a median survival of 6 months.[84]

Although rare, a handful of cases have been reported in which a solitary melanoma of the skin confined to the dermis or subcutaneous tissue presumed to be metastatic melanoma of unknown pri-

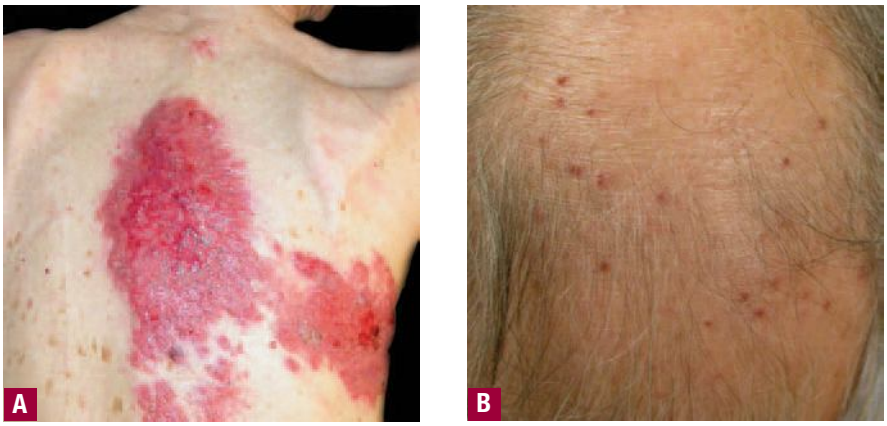

▲ **FIGURE 124-19** **A.** Zosteriform pattern metastases on the back. The primary melanoma was also on the back, Breslow depth 3.9 mm with ulceration and satellitosis. **B.** Epidermotropic and dermal metastatic melanoma on the scalp (also present on the face and neck) occurring 1 year following diagnosis of nodular primary mid-back melanoma, Breslow depth 3.75 mm, sentinel lymph node biopsy positive left and right axilla.

mary has unexpectedly high survival rates.[85,86] *Primary dermal melanoma* is the term used to describe these solitary lesions with 5-year survival rates reported in the 80 percent range. It may represent a distinct sub-type of melanoma actually originating in the dermal and/or subcutaneous tissue.

Evaluation of melanoma of unknown primary or dermal melanoma should involve a complete skin examination looking for a primary site. Wood's lamp may be used to identify sub-clinical hypopigmented areas, which may suggest a regressed primary lesion. In melanoma of unknown primary metastatic to a lymph node, particular attention should be focused on the skin areas that drain to the nodal basin involved. A complete history of previously excised skin lesions should be reviewed. The patient should be referred for proctoscopic, gynecologic, ocular, and nasal mucosal examinations, when warranted. Staging workup and treatment should be performed as for the equivalent clinical stage of known primary.

TREATMENT (Fig. 124-20)

Staging Workup

BIOPSY Patients with lesions clinically suspicious for melanoma should, whenever possible, undergo prompt excisional biopsy with narrow margins. A wider margin should be avoided to permit the most accurate subsequent SLN biopsy, if indicated. Most melanomas undergo initial biopsy in their clinical entirety, but if the lesion is large and/or located on certain sensitive anatomic areas such as the palm/sole, digit, face, or ear, an incisional full-thickness to adipose skin biopsy may be performed. An incisional biopsy should be obtained in the most elevated or darkest area of the lesion, with an appreciation that the clinically most suspicious area may not always correlate with the thickest portion of the lesion. There is no evidence that biopsy or incision of a primary melanoma leads to "seeding" of tissue and adversely affects survival. If subtotal incisional biopsy confirms melanoma, and there is significant residual clinical lesion, a narrow margin excisional biopsy should be performed first for accurate microstaging if the patient is a candidate for SLN biopsy. Excisional biopsy performed after incisional biopsy of melanoma with ≥ 50 percent of the lesion remaining resulted in significant upstaging in 21 percent of patients, and change in SLNB consideration in 10 percent of patients, who then became candidates for SLN biopsy.[88]

Evaluation for Regional Metastasis

MACROSCOPIC METASTASES The foundation of the initial workup following diagnosis of primary cutaneous melanoma is thorough history taking and physical examination. The findings on a good history and physical examination will, to a great extent, drive any further workup. Patients should be evaluated for regional spread by careful palpation of lymph nodes, particularly the primary echelon nodal basin(s). The concepts of aberrant lymphatic drainage pathways to unexpected nodal basins and interval nodes located between the primary site and the expected regional nodal basin have taught physicians to search for clinically detectable nodal disease in unexpected locations.[89,90] If a palpable lymph node or a dermal/subcutaneous nodule in the regional area of the primary is found, fine needle aspiration may be utilized to make a histological diagnosis supported by the current 2006 National Comprehensive Cancer Network (NCCN) guidelines. An excisional biopsy of the lymph node should be performed if fine needle aspiration is inconclusive or not feasible.[91] Non-invasive imaging, most commonly with ultrasound or computerized or positron emission tomography (PET), is perhaps the most sensitive noninvasive method to detect small nodal metastases. However, the sensitivity and specificity of these tests are inferior to tissue diagnosis obtained with SLN biopsy.[92–94]

MICROSCOPIC METASTASES ***Sentinel Lymph Node Biopsy.*** One of the most significant advances in melanoma management over the last decade is SLN biopsy. It is currently one of the most powerful staging and prognostic tools for a subset of patients with melanoma.[87] SLN biopsy is a staging technique used to detect occult nonpalpable micrometastases in regional lymph nodes. SLN biopsy represents the best baseline staging test for detection of occult nodal metastasis in a relatively small subset where it may be indicated, and the only staging test with both relatively high sensitivity and specificity. There is a small likelihood of identifiable distant disease if the SLN is negative.[95]

In the early 1990s, Morton et al. initially reported the technique to selectively sample the first draining regional lymph node(s), or SLN(s) for melanoma[97]; this SLN is most likely to contain any tumor cells that may have metastasized from the primary.[97] Blue dye injected intradermally at the primary site was identified in the SLNs 90 percent of the time, and 15 percent of the SLNs contained melanoma; subsequent lymphadenectomy found melanoma in only 1 percent of non-SLNs. In current practice, both blue dye and technetium-99-labeled radiocolloid solution are used together; this allows for detection of the SLN > 95 percent of the time in skilled hands. Ideally, the procedure should be performed at the same time as wide local excision (WLE) of the primary melanoma for greatest accuracy. SLN biopsy may not be accurate if performed after WLE in areas of ambiguous lymphatic drainage or following a local skin flap due to radiocolloid and dye injection location away from the true primary site. Once removed, the SLN(s)

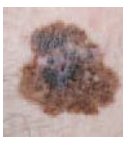



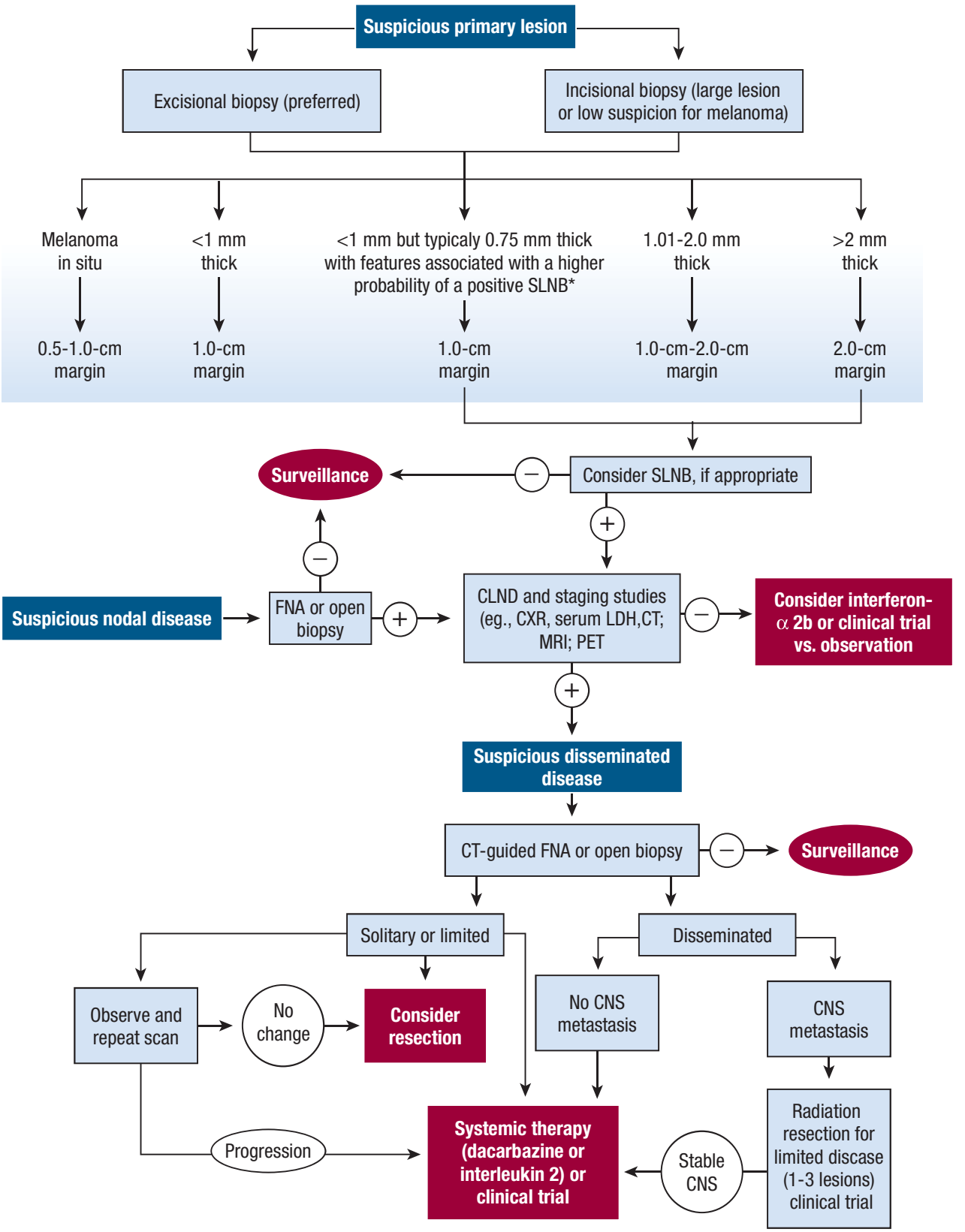

▲ **FIGURE 124-20** General guideline algorithm for the treatment of cutaneous melanoma. *Ulceration, extensive vertical regression to at least 1 mm thick, young patient age, high mitotic rate, especially in younger persons, shave biopsy with positive deep margin, presence of angiolymphatic invasion, and Clark level IV. CLND = completion lymph-node dissection; CNS = central nervous system; CT = computed tomography; CXR = chest x-ray; FNA = fine-needle aspiration; LDH = serum lactate dehydrogenase; MRI = magnetic resonance imaging; PET = positron emission tomography; SLNB = sentinel-lymph-node biopsy. A minus sign indicates no evidence of disease, and a plus sign evidence of metastasis. Patients who are candidates for sentinel-lymph-node biopsy should be referred to a surgeon experienced in performing the procedure so that the benefits and complications can be fully discussed. (From Tsao H, Atkins MB, Sober AJ: Management of cutaneous melanoma. *N Engl J Med* **351**:998, 2004; with permission.)

must be assessed with serial sectioning, using standard hematoxylin and eosin (H&E) techniques combined with immunohistochemical stains such as S100, HMB-45 and/or Melan-A if H&E is negative or inconclusive. This increases sensitivity for melanoma and has resulted in the upstaging of up to 20 percent of patients.[98] The SLN biopsy procedure requires the expertise and experience of three disciplines: surgery, nuclear medicine, and pathology.

Current 2006 guidelines call for consideration of SLN biopsy for relatively healthy patients with primary localized melanoma ≥ 1 mm in Breslow depth (see Fig. 124-20).[67] The most important and consistently reported predictor of SLN positivity is Breslow depth. The likelihood of regional nodal involvement rises with increasing tumor thickness. For melanomas < 1 mm, the likelihood of a positive SLN has been reported to be 5 percent to 10 percent; for melanomas 1 to 2 mm, 15 percent to 20 percent; for melanomas 2 to 4 mm, 25 percent to 35 percent; and for melanomas > 4 mm, 40 percent to 50 percent.[76,87,99,–102] The incidence of SLN positivity has increased compared with initial reports, mainly due modifications, experience, and the routine use of immunostains in current practice. As melanomas < 1 mm uncommonly metastasize to lymph nodes, SLN biopsy is not routinely performed. However, SLN biopsy may be considered for thinner lesions 0.75 to 0.99 mm in Breslow depth in the presence of certain adverse features that have been found to increase SLN positivity in thin lesions: ulceration, extensive vertical regression to at least 1 mm, young patient age, high mitotic rate especially in younger persons, shave biopsy with positive deep margin, and the presence of angiolymphatic invasion.[73,100,101,103,104] Clark level IV is still used as an indication for consideration of SLNB by some centers but not by many others.[69]

Evaluation for Distant Metastasis

A thorough melanoma-focused review of systems constitutes the foundation of the evaluation for distant metastases with particular attention to the general/constitutional, neurologic, psychiatric, gastrointestinal, musculoskeletal, skin, lymphatic, endocrine, cardiovascular, and respiratory systems.[104] Routine imaging and hematologic tests in asymptomatic patients rarely identifies occult systemic disease that is associated with improved survival based on asymptomatic detection.[95] The presently available imaging modalities including computed tomography (CT), magnetic resonance imaging (MRI), PET, chest x-ray (CXR), and hematologic tests such as LDH lack both high sensitivity and specificity to make them routinely indicated. The reported true-positive rate of routine baseline CXR in asymptomatic patients ranges from 0 percent to 0.5 percent[105]; CT of the chest, abdomen, and pelvis 0.07 percent, and brain CT or MRI 0 percent.[95] Specificity is also low, and false-positive rates with these modalities range from 8 percent to 15 percent[104]; this leads to additional costly studies and possibly invasive procedures, as well as increased patient anxiety. Unfortunately, there are no data demonstrating improved survival rates if metastases are detected when clinically asymptomatic versus early symptomatic stage IV disease.[67,77,104] Current 2006 NCCN guidelines call for no additional workup in Stage 0 and 1A, optional CXR in stage 1B and II, optional CXR and LDH for stage III, and CXR and/or chest CT plus LDH for stage IV. Even for stage III and IV, further imaging with CT, MRI, or PET is recommended to be performed as clinically indicated, which emphasizes the importance of a thorough melanoma-focused review of systems and physical examination. In patients with a newly diagnosed stage III disease, a battery of tests may be indicated to obviate the need for surgery in the event that the patient has widespread asymptomatic metastatic disease.

Treatment of Primary Melanoma

SURGERY A general guideline algorithm for the management of cutaneous melanoma in 2006 is noted in Fig. 124-20. The standard of therapy for primary cutaneous melanoma is WLE. The purpose of the wider excision is to prevent local recurrence due to persistent disease by complete excision with histopathologically confirmed tumor-free margins. True local recurrence from inadequate excision is clinically significant in a small subset with the potential lethal consequence of preventable recurrence (Fig. 124-21). Current recommended clinical margins around the residual lesion or biopsy scar for melanoma in situ, non-LM pattern, is 0.5 to 1 cm; for melanoma < 1 mm Breslow depth a 1-cm margin; for melanoma 1 to 2 mm a 1- to 2-cm margin as anatomically possible; for melanoma > 2 mm a 2-cm margin (with pathologic confirmation of clear peripheral margins for all). Historically, surgical margins of 3 to 5 cm were taken, but several large, randomized controlled trials have failed to demonstrate a difference in survival rates or local recurrence rates between narrow (1 to 2 cm) versus wide (3 to 5 cm) margins.[106–112] Ultimately, each patient should be evaluated individually, taking into account current surgical guidelines as well as anatomic site (i.e., location near a vital structure), the possibility of primary closure versus need for skin graft, and the presence or lack of adverse prognostic factors from microstaging. Melanoma excision at special sites, such as the digits, soles, ears, vagina, or anus, also requires separate surgical and functional considerations. Still, the fundamental oncologic principle should be followed: tumor clearance first and most important, reconstruction second. A partial or complete amputation of the digit is still the preferred surgical treatment for subungual melanoma.



▲ **FIGURE 124-21** Potentially preventable deep local recurrence at both poles of previous local excision scar with satellite lesions, occurring approximately 4 years after narrow excision of a thin melanoma with 0.5-cm margins.

LENTIGO MALIGNA AND LENTIGO MALIGNA MELANOMA Histologic confirmation of negative margins is especially important for LM and LMM, sub-types of melanoma well known for their propensity for sub-clinical peripheral extension, as clinical margins are often poorly defined and obscured by background photodamage. The risk of a macular invasive desmoplastic component in the setting of the LMM pattern sub-type is also increased. Standard surgical recommendations of 0.5 cm margins for LM and 1 cm margin for LMM < 1 mm thick are often insufficient, and clear only about 50 percent of lesions. One study found that the average margin required to clear LM was 0.8 cm, and 1.5 cm to

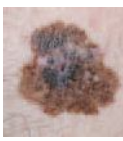

clear 96 percent of LM lesions; the mean margin to clear LMM was 1.1 cm, 2.6 cm to clear 95 percent of LMM lesions.[113] Another reported that 97 percent of melanomas < 1.5 cm in diameter required 1.5-cm margin for complete excision whereas 95 percent of melanomas > 3 cm in diameter required 2.5-cm margin for complete excision.[114]

Recurrence rates for standard excision of LM range from 8 percent to 20 percent.[115] A variety of surgical techniques and methods of histologic evaluation have been advocated: standard excision with standard vertical sectioning (i.e., "bread loafing"); mapped staged excision with vertical sectioning cut at narrow intervals; Mohs micrographic surgery with frozen horizontal sectioning with or without immunostains; Mohs micrographic surgery with permanent horizontal sectioning; and mapped (i.e., "slow Mohs"), staged, geometric perimeter excisions with vertical sectioning of perimeter specimens (i.e., "square" technique).[116] The Mohs technique is desirable from a tissue-sparing perspective, but frozen section slides are extremely difficult to accurately interpret, even with the use of immunostains. Formalin fixed permanent section histology is the "gold standard" for histologic evaluation of surgical margin assessment of melanocytic lesions and are, in general, far superior to frozen sections.[117] Even with "slow Mohs," permanent processing and interpretation of horizontal sections is problematic in laboratories and for pathologists unaccustomed to this technique. The "square" technique provides high-quality material for complete margin evaluation in a format familiar to both the laboratory and the pathologist. Histologic margins require significant experience to evaluate, as there is a spectrum ranging from background benign junctional melanocytic hyperplasia to lesional trailing edge atypical junctional melanocytic hyperplasia.[118] One of the most frequently overdiagnosed proliferations are ones in which there are activated melanocytes. These cells are present very frequently in sun-damaged skin and exhibit a uniformity of appearance with either small round nuclei surrounded by a pale cytoplasm lying in the center of the "clear space" of a semilunar-shaped hyperchromatic nucleus with minimal cytoplasm lying along the basement membrane zone. This type of change can be found overlying most dermal nevi and angiofibromas in sun-exposed areas. An experienced pathologist is crucial.

Treatment of Regional Metastasis

MACROMETASTATIC NODAL DISEASE ***Complete Lymph Node Dissection.*** The current standard of therapy for microscopic or macroscopic melanoma in lymph nodes is complete lymph node dissection (CLND) of the involved regional basin. Uncontrolled nodal disease is a cause of melanoma-related morbidity with a significant negative impact on quality of life (see Fig. 124-18). The NCCN guidelines define an adequate lymphadenectomy as at least 10 lymph nodes in the groin, at least 15 lymph nodes in the axilla (levels I–II as clinically indicated), and at least 15 lymph nodes in the neck (levels I–V as clinically indicated). CLND is associated with significant morbidity, including wound infection, delayed wound healing, seroma, lymphedema, and nerve damage.[119]

CLND for regional metastatic melanoma is associated with long-term survival in a clinically significant proportion of patients. The best available evidence, although retrospective, reports overall melanoma-specific survival ranges at approximately 18 percent to 63 percent, and long-term (> 15 to 25 years) survival at approximately 35 percent, depending primarily on the number of nodes involved, palpable versus non-palpable nodes, ulceration status of the primary lesion, age, gender, and status of extracapsular spread.[120]

MICROMETASTATIC NODAL DISEASE ***Elective Lymph Node Dissection Versus Sentinel Lymph Node Biopsy.*** Elective lymph node dissection (ELND) is the removal of regional lymph nodes draining the site of a primary cutaneous melanoma in the absence of any palpable or clinically evident metastatic disease. Historically, before the advent of SLN biopsy, ELND was advocated for melanomas at higher risk of regional spread to eradicate subclinical micrometastases in a timely and potentially curative manner. Over the decades, multiple prospective randomized-controlled trials have all failed to demonstrate a significant improvement in survival from ELND versus clinical observation for melanoma as a whole.[121,122] Thus, there is no role for elective node lymph node dissection today, especially in light of its significant morbidity and the availability of SLN biopsy, which carries minimal morbidity.[123]

As mentioned previously (see Microscopic Metastases), the SLN biopsy procedure is a powerful staging tool that identifies micrometastatic nodal disease.[124] However, SLN cannot be classified as therapeutic yet. After positive SLN biopsy, 15 percent to 21 percent of patients have evidence of other non-SLN metastases found during CLND.[125] A positive SLN biopsy should be followed by a CLND. In addition, there is not yet definitive, high-level evidence that a positive SLN biopsy followed by immediate CLND improves overall survival in melanoma, compared to delayed CLND for clinically evident disease. Two large, prospective randomized trials designed to answer this question have been implemented and are ongoing. The Multicenter Selective Lymphadenectomy Trial enrolled 2001 patients with melanoma at least 1 mm Breslow depth or Clark level IV to receive WLE alone or WLE with SLN biopsy. Positive SLN biopsies led to immediate CLND; otherwise a delayed CLND was performed after development of clinical nodal metastases. Interim results indicate that 5-year survival was significantly higher for SLN-positive patients with immediate CLND than delayed CLND for clinical nodal recurrence (71 percent vs. 55 percent). For the WLE/SLN biopsy arm, 5-year survival was significantly higher for SLN-negative than SLN-positive patients (88 percent vs. 71 percent).[126] These interim results are promising and may be validated with maturation and complete reporting of full trial data.

The large, prospective, randomized, multi-institutional Sunbelt Melanoma Trial evaluated the role of reverse transcriptase-polymerase chain reaction (RT-PCR) for molecular staging with histologically negative SLNs. RT-PCR analysis was performed using four markers: tyrosinase, MART-1, MAGE3, and glycoprotein 100 and also was performed on peripheral-blood mononuclear cells. RT-PCR analysis on SLNs and peripheral-blood mononuclear cells provided no additional prognostic information beyond standard histopathologic (H&E plus immunohistochemical) analysis of SLNs, and there was no difference in disease-free, distant disease–free, or overall survival.[127] Thus, at present, RT-PCR for molecular staging of melanoma should not be used to direct therapy. Ongoing and future modifications and approaches in molecular staging of melanoma may hold promise.

ADJUVANT THERAPY ***Interferon-α 2b.*** Adjuvant therapy is additional treatment for patients surgically resected of clinical disease but at high risk for relapse (i.e., thick primaries > 4 mm or nodal



disease). High-dose interferon-α 2b (IFN-α 2b) is the only adjuvant therapy approved by the U.S. Food and Drug Administration (FDA) that has been shown to improve disease-free survival for stage IIB–III melanoma and improved overall survival in two multicenter cooperative group or intergroup trials, but not in pooled analysis. The high-dose regimen consists of 20 million units per square meter of body surface area per day, given intravenously 5 days a week for 4 weeks (induction phase), followed by 10 million units per square meter per day, given subcutaneously three times a week for 48 weeks (maintenance phase). Three large randomized controlled trials sponsored by the Eastern Cooperative Oncology Group (ECOG) have demonstrated higher disease-free survival (3 of 3 studies), and overall survival (2 of 3 studies) in stage IIB–III melanoma. ECOG 1684 demonstrated a significant increase in median disease-free survival (1 to 1.7 years) and overall survival (2.8 to 3.8 years) in the high-dose IFN arm compared to observation.[128] ECOG 1690 enrolled patients to either a high-dose IFN regimen, a low-dose regimen of 3 million units per day given subcutaneously three times a week for 2 years, or observation; there was a significant increase in disease-free survival but not overall survival for the high-dose regimen only.[129] ECOG 1694 enrolled patients to receive high-dose IFN or GMK vaccine (directed against a well-defined melanoma cell surface antigen GM2), and demonstrated a significant increase in both disease-free and overall survival. Interestingly, the appearance of autoantibodies or clinical manifestations of autoimmunity during treatment with IFN was assessed in a substudy of a larger, ongoing IFN randomized trial. Autoantibodies (antithyroid, anti-nuclear, anti-DNA, and anticardiolipin autoantibodies) and clinical manifestations of autoimmunity (vitiligo) were detected in 26 percent and were associated with statistically significant improvements in relapse-free survival and overall survival in these patients with melanoma undergoing adjuvant IFN.[130]

There are significant toxicities associated with the high-dose IFN regimen, the most frequent being flu-like symptoms in almost all patients (i.e., fatigue, anorexia, weight loss, myalgias, fever, nausea, headache). Other side effects include depression, hepatotoxicity (elevated transaminases), and myelosuppression. The toxicities require dose modification of IFN in most patients, but the majority are able to complete at least 80 percent of scheduled dosing, and are able to finish treatment if they make it through the first 3 months of therapy.[128] In addition, quality-of-life is improved, and patients seem to prefer IFN therapy to no treatment.[131,132] Consideration of potential benefits and risks of toxicities should be done on an individual basis.

Several studies have been conducted on low-dose IFN regimens to minimize toxicities associated with the high-dose regimen. Most have not been able to demonstrate significant increases in disease-free or overall survival. Two studies have shown improved disease-free but not overall survival in patients with medium-risk melanomas > 1.5 mm without nodal involvement.[133,134] It is possible to consider adjuvant therapy for melanoma with an intermediate risk of recurrence, but it is not generally done in current practice and should not be routinely done unless more studies demonstrate better overall survival.

Melanoma Vaccines. A number of autologous, allogeneic, and peptide vaccines have been studied widely in the management of melanoma but unfortunately without significant progress, as none is currently available as approved therapy. Vaccines are attractive, given elegant antigen-directed approaches and low toxicities. Vaccines attempt to stimulate a specific immune response against melanoma-associated antigens using autologous tumor cells or allogeneic melanoma cell lines, to which non-specific immunologic adjuvants such as bacille Calmette-Guérin or DETOX may be added. Newer strategies include the use of more specific targets such as heat shock proteins and T-cell defined tumor-associated antigens MART-1, glycoprotein 100, and tyrosinase, and the use of antigen-pulsed dendritic cells, antigen presenting cells, to activate T cells to these antigens.[135] None of the trials has reported a significant improvement in overall survival for patients who received vaccines.[136] However, one study's (Southwest Oncology Group 9035) subset analysis of patients who were positive for HLA-A2 and/or HLA-C3 demonstrated a significant 5-year overall survival benefit of 93 percent for patients in the vaccine group compared with 74 percent for patients in the observation group ($p = 0.009$).[137] A trial of autologous melanoma cells engineered to secrete granulocyte-macrophage colony-stimulating factor resulted in potent antitumor immune responses in patients with metastatic melanoma. Seventeen of 25 patients developed delayed-type hypersensitivity reactions to irradiated, dissociated, autologous, nontransduced tumor cells. There was one complete response, one partial, and one mixed response. Ten patients were reported as surviving in follow-up of 36 months.[138]

SATELLITE OR IN-TRANSIT METASTASES

Isolated Limb Perfusion. In general, regional in-transit or satellite disease should be surgically excised with clear margins whenever possible. However, if multiple lesions make surgery unreasonable, isolated limb perfusion (ILP) may be considered for locoregional disease limited to an extremity. ILP is a form of regional chemotherapy that delivers higher doses of chemotherapeutic agents with much less systemic toxicities. The complex, invasive technique involves perfusing an isolated extremity under hyperthermic conditions with cytotoxic agents, conventionally melphalan. In use for at least four decades, ILP with melphalan is an effective form of therapy, producing 80 percent overall responses rates and 50 percent complete responses (i.e., complete disappearance of all lesions).[139] ILP with tumor necrosis factor-α (TNF-α) in combination with melphalan has also garnered interest. However, the American College of Surgeons Oncology Group randomized phase III trial of ILP with melphalan, with or without TNF-α, was recently prematurely closed due to interim analysis showing comparable response rates for melphalan plus TNF-α and melphalan alone.[140]

The ILP procedure is associated with serious local morbidities, including significant tissue damage or compartment syndrome. Elderly age and serious medical co-morbidities are generally considered exclusion criteria. Isolated limb infusion (ILI) is a newer, simpler, less invasive technique. Early studies of ILI with melphalan and actinomycin D demonstrate comparable efficacy to ILP with melphalan.[141] ILI may be considered for patients ineligible for ILP. Both ILP and ILI are available only at a few specialized centers.

Treatment of Distant and/or Disseminated Metastasis

The treatment of stage IV melanoma must take into account that the average survival is 6 to 8 months and that no systemic therapies have been shown to significantly increase survival in randomized

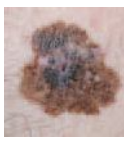

controlled trials.[87] Goals of treatment should be increasing length of survival and palliation of symptoms. The option of observation and conservative treatment is reasonable, especially in the asymptomatic, elderly, or those with serious comorbidities. Surgical excision of isolated visceral metastases (i.e., metastasectomy) demonstrated to be stable over a 3- to 6-month period before excision may be performed but long-term survival is the exception. Surgical excision of skin/subcutis or distant lymph node metastases may result in better locoregional control and decreased morbidity.[142] Surgery may also be palliative—for example, to relieve obstruction from gastrointestinal metastases. Melanoma is not known to be very radiosensitive, but radiotherapy is used for brain metastases. Palliative radiation may be indicated for spinal cord compression and painful bone metastases.



SYSTEMIC THERAPIES ***Chemotherapy.*** The alkylating agent dacarbazine (DTIC) is the only FDA-approved chemotherapy (for > 25 years) for metastatic melanoma and is considered to have the greatest efficacy as a single agent. Response rates are in the 10 percent to 20 percent range, with median response duration 4 to 6 months.[143] There is no difference in terms of response rates and duration of response between the various dosing schedules used. The major side effects are nausea and vomiting. Temozolomide (TMZ) is an alkylating agent with the same active metabolite as DTIC, but it is able to cross the blood-brain barrier and can be absorbed orally. TMZ has been shown in a randomized phase III study to have efficacy equal to DTIC.[144] There has been interest for TMZ as a treatment of melanoma metastatic to the brain. An oral regimen of TMZ and thalidomide for brain metastases in conjunction with radiation is under investigation.[145] Still, TMZ has not received FDA approval. Higher response rates are seen with combination therapies, typically of dacarbazine along with other cytotoxic agents such as cisplatin, vinblastine (CVD regimen), carmustine, or tamoxifen. Still, no randomized controlled trial has shown any combination to be superior to DTIC alone.[87]

Immunotherapy. High-dose bolus interleukin 2 (IL-2) is the only FDA-approved (recently in 1998) immunologic treatment of metastatic melanoma that may produce durable complete responses. It has been shown as a single agent to produce a 16 percent overall response rate but with a durable response in up to 5 percent to 8 percent of patients. The median response duration of 9 months; 28 percent of the responders have remained progression-free at a median follow-up of 62 months.[146] Furthermore, no patient responding longer than 30 months has relapsed, suggesting the possibility of a "cure." However, high-dose IL-2 is associated with significant toxicity, including hypotension [most common (64 percent)], capillary leak syndrome, arrhythmia (particularly supraventricular tachycardia), respiratory distress, transient renal insufficiency, and infections/sepsis. Its use is limited to specialized programs with experienced clinicians.

Combining IL-2 with immunologically active cells (i.e., adoptive immunotherapy) is also being studied. The adoptive transfer of stimulated immune effector cells to generate an antitumor effect has been tried with lymphokine activated killer cells and tumor-infiltrating lymphocytes. Results of clinical trials with lymphokine activated killer cells have been uniformly disappointing, but IL-2 with tumor-infiltrating lymphocytes has shown potential promise in small clinical trials.[147]

Biochemotherapy. Ongoing therapeutic investigations have focused on immunotherapies, especially vaccine-based therapies, in combination with other available systemic agents. Various biochemotherapy regimens of dacarbazine, other chemotherapeutic agents, and IFN, vaccines, or IL-2 are being tested in numerous trials, but again, have not shown survival benefit compared to chemotherapy or immunotherapy alone.[87]As might be expected, these combination regimens are more toxic than the individual components alone.

Novel Therapies. Impairment of apoptosis, or programmed cell death, contributes to tumorigenesis and tumor resistance to chemotherapy. The anti-apoptotic protein B-cell lymphoma 2 (Bcl-2) has been implicated in the intrinsic resistance of melanoma to chemotherapy. Oblimersen sodium (Genasense) is a novel antisense Bcl-2 oligonucleotide that selectively targets Bcl-2 messenger RNA, leading to its degradation and decreased Bcl-2 levels. Oblimersen sodium enhances apoptosis by itself and in conjunction with other cytotoxic agents. In a large randomized phase III trial, oblimersen plus dacarbazine has shown potential promise.[148]

B-raf mutations have been found in two-thirds of melanomas.[26] Sorafenib is a novel RAF inhibitor that inhibits B-raf and C-raf, and is orally available. Early studies have demonstrated clinical response in metastatic melanoma to Sorafenib monotherapy, and it was well tolerated. A phase III trial is in the process of being coordinated by ECOG; 800 patients will be randomized to receive carboplatin and paclitaxel with or without Sorafenib.

Prognostic modeling with molecular profiling represents a future tool to assist in improved selection of surgical and systemic therapies. Unfortunately, no satisfactory curative adjuvant or systemic therapy exists today for patients with stage IV metastatic disease.

Follow-Up

Patients with melanoma are at risk for local, regional, and distant recurrence, with the level of risk dependent on the stage at initial diagnosis and workup. Follow-up visits are an opportunity to review how to perform monthly self-skin and lymph node examinations, address any psychosocial emotional distress issues, obtain a melanoma-focused review of systems, and provide continuing patient education regarding early detection signs and symptoms and sun protection/prevention strategies. Regular follow-up is indicated for all patients with melanoma. Current NCCN and national melanoma center guidelines call for at least annual follow-up visits for life, with follow-up intervals generally ranging from every 3 to 6 months for 1 to 3 years after diagnosis and annually thereafter, depending primarily on stage of disease. Patients with other risk factors, such as a positive family history of melanoma, numerous nevi, a mutation in p16 or BRAF, or difficulty with self-examination, may require more frequent follow-up. A referral to a genetics counselor is warranted if there is a strong family history of melanoma.

The follow-up visit should consist of a thorough complete skin examination for additional primary lesions and cutaneous/subcutaneous metastases, particularly in the regional distribution of the primary, palpation of lymph nodes with particular attention to the regional nodal basin, and thorough history-taking. The review of systems is the foundation for detecting symptomatology possibly attributable to melanoma, and directs additional testing or imaging. The yield and value of routine imaging to re-stage asymptomatic patients as part of standard melanoma follow-up are low and, thus, imaging and hematologic tests are

based on any suspicious findings from a good history and physical examination.

PREVENTION

Public awareness and knowledge of melanoma and UV exposure is improving, but still a substantial gap exists between knowledge and behavior. Primary prevention strategy should focus on safe sun exposure, including limited UV exposure and sunburn prevention, especially in childhood and adolescence when the risk is greatest. Avoidance of peak sunlight hours and use of wide-brimmed hats, clothing, and sunscreen are recommended. In addition, early detection by regular self-skin examinations, skin awareness, and knowledge of the early signs and symptoms of melanomas should also be emphasized. The goal of secondary prevention is early diagnosis, which greatly reduces melanoma-related morbidity and mortality.

KEY REFERENCES

The full reference list for all chapters is available at www.digm7.com.

1. Jemal A et al: Cancer statistics, 2006. *CA Cancer J Clin* **56**:106, 2006
3. Berwick M, Wiggins C: The current epidemiology of cutaneous malignant melanoma. *Front Biosci* **11**:1244, 2006
6. Geller AC et al: Melanoma incidence and mortality among US whites, 1969–1999. *JAMA* **288**:1719, 2002
11. Eide MJ, Weinstock MA: Association of UV index, latitude, and melanoma incidence in nonwhite populations—US Surveillance, Epidemiology, and End Results (SEER) Program, 1992 to 2001. *Arch Dermatol* **141**:477, 2005
23. Bishop DT et al: Geographical variation in the penetrance of CDKN2A mutations for melanoma. *J Natl Cancer Inst* **94**:894, 2002
28. Curtin JA et al: Distinct sets of genetic alterations in melanoma. *N Engl J Med* **353**:2135, 2005
34. Miller AJ, Mihm MC Jr: Melanoma. *N Engl J Med* **355**:51, 2006
43. Magro CM, Crowson AN, Mihm MC: Unusual variants of malignant melanoma. *Mod Pathol* **19**:S41, 2006
54. Gachon J et al: First prospective study of the recognition process of melanoma in dermatological practice. *Arch Dermatol* **141**:434, 2005
67. Balch CM et al: Final version of the American Joint Committee on Cancer staging system for cutaneous melanoma. *J Clin Oncol* **19**:3635, 2001
68. Balch CM et al: Prognostic factors analysis of 17,600 melanoma patients: Validation of the American Joint Committee on Cancer melanoma staging system. *J Clin Oncol* **19**:3622, 2001
72. Azzola MF et al: Tumor mitotic rate is a more powerful prognostic indicator than ulceration in patients with primary cutaneous melanoma: An analysis of 3661 patients from a single center. *Cancer* **97**:1488, 2003
87. Tsao H, Atkins MB, Sober AJ: Management of cutaneous melanoma. *N Engl J Med* **351**:998, 2004
96. Morton DL et al: Intraoperative lymphatic mapping and selective cervical lymphadenectomy for early-stage melanomas of the head and neck. *J Clin Oncol* **11**:1751, 1993
100. Sondak VK et al: Mitotic rate and younger age are predictors of sentinel lymph node positivity: lessons learned from the generation of a probabilistic model. *Ann Surg Oncol* **11**:247, 2004
102. Morton DL, Cochran AJ: The case for lymphatic mapping and sentinel lymphadenectomy in the management of primary melanoma. *Br J Dermatol* **151**:308, 2004
104. Johnson TM et al: Staging workup, sentinel node biopsy, and follow-up tests for melanoma: update of current concepts. *Arch Dermatol* **140**:107, 2004
117. Prieto VG et al: Are en face frozen sections accurate for diagnosing margin status in melanocytic lesions? *Am J Clin Pathol* **120**:203, 2003
124. Morton DL et al: Sentinel node biopsy for early-stage melanoma: Accuracy and morbidity in MSLT-I, an international multicenter trial. *Ann Surg* **242**:302, 2005

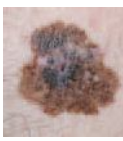

This page intentionally left blank

SECTION 23

TUMORS AND HYPERPLASIAS OF THE DERMIS AND SUBCUTANEOUS FAT

CHAPTER 125

Malignant Fibrous Tumors of the Dermis

Jennifer Z. Cooper
Marc D. Brown

Malignant fibrous tumors of the dermis represent one end of a spectrum[1] that begins with benign fibrous tumors and fibroplasias. Fibrous lesions are often composed predominantly of stroma and only in certain high-grade sarcomas is the neoplastic nature of the lesion obvious.[2] Identification of defined chromosomal abnormalities suggests a neoplastic status for some fibrous lesions traditionally regarded as reactive. This chapter focuses on malignant lesions and Chap. 64 discusses benign fibroplasias and tumors.

DERMATOFIBROSARCOMA PROTUBERANS

Epidemiology

Dermatofibrosarcoma protuberans (DFSP) is a rare, locally aggressive dermal and subcutaneous mesenchymal neoplasm that typically occurs during the third and fourth decades of life, although it has been reported in patients from infancy to the ninth decade. DFSP accounts for less than 0.1 percent of all malignant neoplasms and represents 2 percent to 6 percent of all soft-tissue sarcomas. There does not seem to be a racial predilection for the tumor, however, the pigmented variant (Bednar's tumor) is more common in black patients. There seems to be a fairly equal distribution between male and female patients.[3]

Etiology and Pathogenesis

The histogenesis of DFSP is uncertain: fibrohistiocytic, purely fibroblastic, and neural-related differentiation have all been hypothesized. A very sensitive, although non-specific, marker for DFSP is CD34. A distinctive cell population within normal nerves has been shown to express CD34, consistent with a possible neural-related histogenesis of DFSP. CD34 can help distinguish between DFSP and scar tissue in re-excision specimens.

At the molecular level, DFSP exhibits the reciprocal translocation t(17;22)(q22;q13), producing a fusion of the collagen type I α 1 gene and the platelet-derived growth factor B-chain gene. Current techniques permit sensitive and specific detection of these fusion transcripts in paraffin-embedded DFSP tumor specimens by reverse transcription polymerase chain reaction. Both fibrosarcomatous transformation of DFSP and some cases of superficial fibrosarcoma have been shown to harbor these fusion transcripts, suggesting a close affinity between DFSP and fibrosarcoma.

Clinical Findings

HISTORY DFSP is a slow-growing lesion that often presents on the trunk and proximal extremities of patients. Due to its indolent onset, the patient may present for evaluation when the tumor is several centimeters in size (Fig. 125-1). The tumor is often misdiagnosed as a simple scar or cyst. It often grows to several centimeters in diameter and may form large, infiltrative tumors. In a small portion of patients, previous trauma at the site has been reported. DFSP has also been described as arising in scars, including surgical, burn, and vaccination sites.

CUTANEOUS LESIONS The clinical morphology of DFSP is variable. The most common presentation is a firm, indurated plaque, often skin-colored with red-brown exophytic nodules (see Fig. 125-1A). It also can present as a nonprotuberant, atrophic, violaceous lesion resembling morphea, sclerosing basal cell carcinoma, anetoderma, or scar (Fig.

MALIGNANT FIBROUS DERMAL TUMORS AT A GLANCE



- A group of uncommon and rare cutaneous tumors with varying degrees of malignant potential.
- Includes dermatofibrosarcoma protuberans, atypical fibroxanthoma, malignant fibrous histiocytoma, fibrosarcoma, and epithelioid sarcoma.
- Diagnosis is made by biopsy.
- Dermatofibrosarcoma protuberans is a locally aggressive tumor with a high rate of local recurrence with rare metastases.
- Atypical fibroxanthoma is an intermediate-grade neoplasm that usually arises on sun-damaged skin in the eighth decade.
- Malignant fibrous histiocytoma represents a morphologic pattern that a large number of poorly differentiated neoplasms share.
- Epithelioid sarcoma is a rare tumor that classically presents on the hands and fingers of young males, which can mimic nonneoplastic inflammatory lesions.



Copyright © 2008 by The McGraw-Hill Companies, Inc. Click here for terms of use.

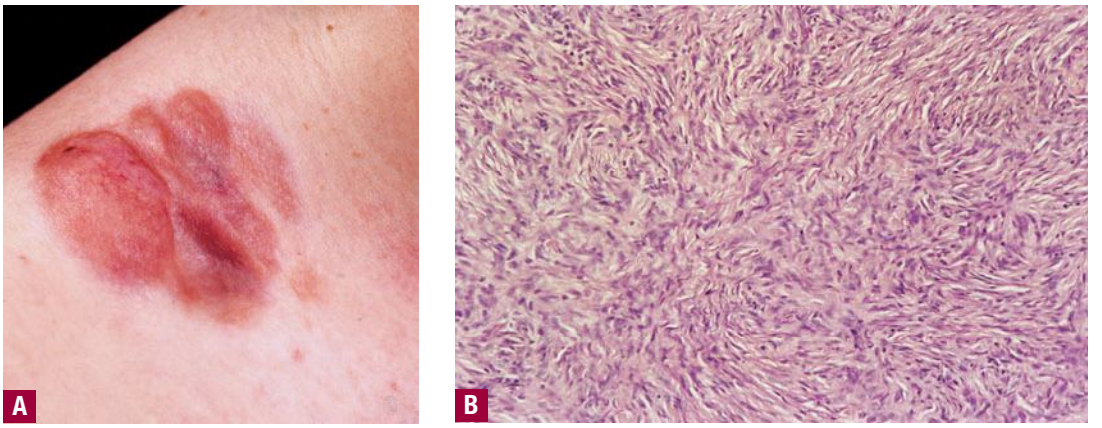

▲ **FIGURE 125-1** **A.** Dermatofibrosarcoma protuberans presenting as reddish brown confluent flat nodules. **B.** Dermatofibrosarcoma protuberans showing fibroblastic spindle cells that are arranged in interlacing fascicles. These intersect and bend at acute angles, producing a starburst (storiform) pattern.



125-2). Large nodular tumors may occur. The epidermis may be atrophic and focal ulceration may occur. The most common site of DFSP is the trunk, followed by the extremities. Approximately 15 percent of DFSP occurs on the head and neck.

LABORATORY TESTS ***Histopathology.*** DFSP is diagnosed with a skin biopsy. A deeper wedge biopsy may be required to diagnose the atrophic variant. Histologically, DFSP is a poorly circumscribed dermal proliferation of monomorphous, slender or slightly plump spindle cells with little pleomorphism arranged in a storiform pattern (see Fig. 125-1B). The proliferation commonly infiltrates the subcutaneous fat, isolating adipocytes to form lucencies ("honeycomb" or "Swiss cheese" pattern). In contrast to dermatofibroma, the tumor is much more cellular and usually does not have mature collagen interspersed between fascicles of spindle cells.

Variable histologic patterns described include myxoid, neuroid, fibrosarcomatous, myxoid, and granular cell types. The tumor may be relatively monomorphous or show combinations of various patterns within the original tumor or in the recurrences. Some lesions show overlap between giant cell fibroblastoma and DFSP. The fibrosarcomatous variant has basic features of DFSP but focal areas in which the cells exhibit a high grade of atypia and are arranged in long fascicles in a herringbone (fibrosarcoma-like) pattern. This transformation appears to be related to mutations in the p53 pathway. Several series indicate an increased biologic aggressiveness of this type compared with ordinary DFSP In a series from Memorial Sloan-Kettering Cancer Center, patients with this histologic variant had a 28 percent 5-year recurrence-free survival, as compared to 81 percent of those with classic DFSP. However, in a series from the Cleveland Clinic, patients with sarcomas arising in DFSP did not have an increased risk of distant metastasis within a 5-year follow-up period, providing that adequate surgical excision with wide margins was performed. It is estimated that there is a 5 percent transformation rate from DFSP to conventional fibrosarcoma. The true impact of fibrosarcomatous changes seen within a DFSP remains uncertain.



▲ **FIGURE 125-2** Atrophic variant of dermatofibrosarcoma protuberans.

Special Tests. Immunohistochemical staining with CD34 is useful to distinguish DFSP from dermatofibroma, which stains positively for factor XIIIa. Other markers, such as CD44, a membrane glycoprotein, and hyaluronate, a component of the extra-cellular matrix, may serve as markers to better distinguish DFSP from dermatofibroma as well. Apolipoprotein D also may have future application as a marker for DFSP.

Differential Diagnosis (Box 125-1)

Complications

DFSP is a low-grade malignant tumor, often infiltrating diffusely through the dermis and into the subcutaneous fat but seldom metastasizing. Increased age, high mitotic index, and increased cellularity are predictors of poor clinical outcome. Approximately 30 percent to 50 percent of DFSPs recur locally after simple excision, so it is generally recommended that a wide excision with 1- to 3-cm margins to the fascia or periosteum be performed (see Treatment).

Prognosis and Clinical Course

Local recurrences even after wide excision are common, although, much

Box 125-1

Differential Diagnoses of Malignant Dermal Tumors

Dermatofibrosarcoma protuberans

- Classic presentation
  - Keloid/hypertrophic scar
  - Dermatofibroma
  - Fibrous histiocytoma
  - Nodular melanoma (Bednar variant)
- Atrophic presentation
  - Morphea
  - Lichen sclerosis
  - Morpheaform basal cell carcinoma

Atypical fibroxanthoma/superficial malignant fibrous histiocytoma

- Squamous cell carcinoma
- Basal cell carcinoma
- Amelanotic malignant melanoma

Epithelioid sarcoma

- Granuloma annulare
- Rheumatoid nodule
- Gouty tophi
- Dupuytren contracture
- Infectious ulcer

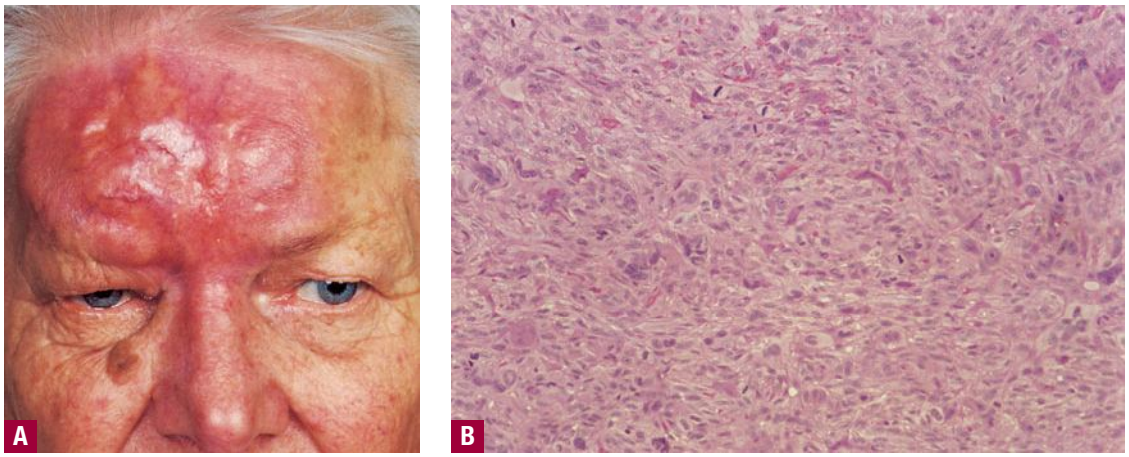

▲ **FIGURE 125-3** **A.** Atypical fibroxanthoma presenting as a flat, bosselated tumor on the forehead of an elderly woman. Note the yellowish to reddish color. **B.** Atypical fibroxanthoma showing atypical plump spindle cells and multinucleated giant cells.

greater success seems to be had with using the Mohs technique for tumor extirpation. Metastases of DFSP are extremely rare, usually occurring in the setting of multiply recurrent tumors. Metastases to the lung are most common, with nodal disease the next most common site of spread. Metastatic disease portends a poor prognosis. It has been suggested that tumors with fibrosarcomatous change may have a higher chance of recurrence or metastases.

Treatment

Surgical removal with clear margins is the goal with DFSP. With standard excision, margins of 1 to 3 cm may be necessary to achieve clear margins. Risk of local recurrence decreases with increasing surgical margins. Pathologic examination of margins during surgery is helpful in delineating the extent of the tumor. Multiple case series have shown Mohs surgery to be an extremely effective method of resection of DFSP, with an extremely low rate of local recurrence.[4,5] As a result, Mohs micrographic surgery represents the preferred surgical approach of many practitioners. Adjuvant radiation therapy may help decrease the local recurrence rate. The use of imatinib, a chemotherapeutic agent that targets the molecular translocation distinctive to this tumor, has shown promise in the setting of localized advanced disease (i.e., unresectable tumors) or metastatic disease.[6] Imatinib may also emerge in the future as an adjunct to surgery.

GIANT CELL FIBROBLASTOMA

Giant cell fibroblastoma, a rare neoplasm, now known to be a juvenile variant of DFSP,[7] typically presents as a dermal or subcutaneous mass, which most frequently involves the trunk, thigh, or inguinal region. It presents much earlier in life, often within the first decade, although occurrences in adults have been reported. Histologically, this tumor has dense connective tissue with a paucity of fibroblasts and occasional wreath-like giant cells. There are also scattered mast cells present. These tumors resemble DFSP with their pattern of tumor infiltration. The tumor cells infiltrate the subcutis and surround adnexal structures. Most characteristically, the stroma displays prominent cracking artifact, with the formation of pseudovascular spaces lined by a discontinuous layer of enlarged, multinucleated tumor giant cells with coarse nuclear chromatin and scalloped nuclear borders. Immunohistochemically, these tumors stain positive for CD34 and occasionally α1 antichymotrypsin. They stain negative for factor VIII, von Willebrand's factor, CD31, actin, desmin, epithelial membrane antigen, and S100. As noted previously, this tumor shares the identical translocation with DFSP—(t17;22), collagen type I α 1 gene–platelet-derived growth factor B-chain gene.

The clinical behavior of giant cell fibroblastoma is much like that of DFSP. It shows local aggressive behavior, frequent local recurrences (up to 50 percent), and rare metastasis. Treatment is the same as for DFSP.

ATYPICAL FIBROXANTHOMA

Epidemiology

Atypical fibroxanthoma (AFX) is a relatively common rapidly growing neoplasm of intermediate malignant potential. It occurs mainly on sun-exposed skin (face, neck, and hands) of elderly individuals. The male-to-female ratio is essentially equal. AFX has been reported in the second to tenth decade, with a mean age of approximately 69 years.

Etiology and Pathogenesis

The anatomic distribution and the presence of cyclobutane pyrimidine dimers support a pathogenic role for ultraviolet radiation in the development of AFX. Tumors may occur 10 to 15 years after local ionizing irradiation.

Clinical Findings

HISTORY The patient may report a lesion on sun-damaged skin of relatively rapid onset. The lesion usually presents as a solitary, often dome-shaped nodule, which may be eroded or ulcerated. The size of presentation is usually less than 3 cm in diameter.

CUTANEOUS LESIONS AFX appears as an asymptomatic, solitary papule or nodule (Fig. 125-3) often resembling a squamous cell carcinoma, basal cell carcinoma, or even a necrotic pyogenic granuloma. It is often friable, eroded, or ulcerated. The AFX is typically less than 2 cm in size and is most commonly seen on the actinically damaged skin of older patients, especially ears, cheeks, nose, and scalp. The background skin is often sun damaged. AFX may be found in the setting of other non-melanoma cutaneous malignancy.

LABORATORY TESTS ***Histopathology.*** Diagnosis is by skin biopsy. Specimens often show partially exophytic tumors with ulceration of the overlying epidermis. A grenz zone may be present, but usually the tumor abuts onto the dermal-epider-

mal junction. A poorly circumscribed hypercellular tumor may extend deeply into the reticular dermis or subcutis. It consists of spindle cells in a collagenous or occasionally myxoid stroma admixed with multinucleated giant cells and epithelioid cells (see Fig. 125-3B). The neoplastic cells display pronounced atypia, with bizarre, large, round or ovoid hyperchromatic nuclei with numerous mitotic figures (some of them atypical); large, prominent eosinophilic nucleoli; and abundant, occasionally vacuolated cytoplasm. Some cells may contain fine droplets of lipid, demonstrable by oil red O stains on frozen tissue. The spindle cell sub-type of AFX occurs in the same clinical setting as an ulcerated tumor and is characterized by a monomorphous proliferation of spindle cells with very little pleomorphism.



Special Tests. Immunohistochemically, AFX has variable profiles, but cells usually express vimentin and histiocytic markers such as α_1-antitrypsin, α_1-antichymotrypsin, HAM-56 antigen, and CD68. A few express factor XIIIa. CD99 has been proposed to be a relatively sensitive marker (73 percent of cases) and, in context, a specific marker for these tumors. Expression of S100A6 also appears to be a sensitive marker for AFX. MIB1 (Ki-67) may be another useful marker in this highly proliferative tumor. LN2 (CD74) has been suggested to represent a marker of more aggressive behavior in this tumor.

Differential Diagnosis

See Box 125-1.

Prognosis and Clinical Course

AFX has long been regarded as a neoplasm with extremely low metastatic potential. There have been several reports of metastatic disease, some resulting in death.[7] Many consider AFX to be a superficial variant of malignant fibrous histiocytoma (MFH), which has much more ominous behavior. Overlap between these two tumors may account for the AFX cases with reported metastases. AFX is often found in the setting of diffuse actinic damage and other non-melanoma skin cancer, so close follow-up after complete tumor extirpation is prudent.

Treatment

Treatment for AFX is surgical. Studies have suggested that Mohs micrographic surgery provides a lower rate of recurrence than wide local excision. Excision should be to the level of the deep subcutaneous tissue. Adjuvant treatment with radiation may be considered for tumors with particularly aggressive onset. It also may be considered in the setting of positive LN2 (CD74) staining of the tumor.

Prevention

Protection from ultraviolet damage may serve as one measure of prevention of this tumor.

MALIGNANT FIBROUS HISTIOCYTOMA

Epidemiology

In the recent past, MFH has been considered to be the most common malignant soft tissue tumor. Reclassification of soft tissue sarcomas by the World Health Organization in 2002 has mandated identification of cell line origin in the classification of tumors.[8] Thus, MFH as previously considered, is merely a morphologic pattern rather than a defined pathologic entity. In most cases, careful immunohistochemical and ultrastructural examination permits probable or definite classification into defined histogenetic sub-types of sarcoma. Currently, MFH remains in the soft-tissue sarcoma nomenclature as a synonym for undifferentiated pleomorphic sarcoma, not otherwise specified. In future reclassification schema, the term *MFH* may become obsolete.

Keeping the more current classification system in mind, two tumors are more likely to have a cutaneous presentation. The undifferentiated pleomorphic sarcoma, (former pleomorphic and storiform MFH) and the myxofibrosarcoma (former myxoid MFH). Both of these tumors tend to occur on the limbs of elderly patients. Myxofibrosarcoma now represents one of the most common soft tissue sarcoma of the elderly.

Etiology and Pathogenesis

The pathogenesis of soft-tissue sarcomas has not been well defined. Depending on the cell of origin, various genetic, physical, chemical, and viral etiologies have been suggested.

Clinical Findings

HISTORY Both the undifferentiated pleomorphic sarcoma and the myxofibrosarcoma may present as a subcutaneous mass, most commonly on the limb (or limb girdle in the case of myxofibrosarcoma). Both can be progressively enlarging.

CUTANEOUS LESIONS When presenting as cutaneous lesions, these tumors are usually skin-colored subcutaneous nodules, varying from elastic to firm in texture. At times, growth of the tumor may be rapid. It is usually solitary but can be multinodular and may be 5 to 10 cm at the time of initial diagnosis. The more superficial MFH tumors are usually smaller. The extremities are the most common site of involvement, with the lower extremities affected more commonly than the upper extremities. Any area of the body may be involved, and approximately 10 percent to 15 percent of MFH tumors are on the head and neck region.

Laboratory Tests

HISTOPATHOLOGY The most common appearance is of spindle cells in a storiform pattern. The stroma may be finely fibrillary, myxoid, or densely collagenous. Bizarre epithelioid and giant cells may be present and may contain small amounts of lipid. Many mitotic figures, bizarre giant cells, and necrosis are common. Ultrastructurally, the neoplastic cells have features consistent with fibroblastic, myofibroblastic, and histiocytic differentiation.

SPECIAL TESTS Immunohistochemistry using a broad antibody panel is required to rule out metastatic carcinoma, lymphoma, leiomyosarcoma, melanoma, and similar lesions.

Differential Diagnosis

See Box 125-1.

Prognosis and Clinical Course

Up to 50 percent of patients presenting with an undifferentiated pleomorphic sarcoma may have distant metastases (lung most likely). Recurrence is common, and may result in up to a 30 percent to 35 percent metastatic rate. Low-grade variants, including superficial cutaneous tumors are much less likely to metastasize.

Treatment

Complete surgical resection at presentation offers the best chance for survival. Radiation therapy plays an important role

in combination with surgery for better local control, particularly in high-grade lesions and in patients with positive surgical margins after wide complete gross excision. Special note should be made of angiomatoid fibrous histiocytoma (AFH) that occurs primarily in children and young adults. AFH was mistakenly classified as a sub-type of MFH/AFH. Based on AFH's benign behavior and rare ability to metastasize, it is now considered to be a benign tumor of uncertain differentiation. This tumor has four key morphologic features: (1) multinodular proliferation of eosinophilic, histiocytoid, or myoid cells; (2) pseudoangiomatoid spaces; (3) thick fibrous pseudocapsule; and (4) pericapsular lymphoplasmacytic infiltrate. Immunohistochemical studies demonstrate scattered desmin, variable epithelial membrane antigen, and variable $CD68^+$ cells. Laminin and collagen IV are expressed in this tumor. Ultrastructure demonstrates a pericytic differentiation. The use of reverse transcriptase-polymerase chain reaction for the detection of fusion transcripts (FUS-ATF1 and EWSR1-ATF1) may be helpful in the distinction between AFH and other soft tissue tumors. Some AFH tumors have 11q24 deletions. These tumors require local excision and have an indolent behavior. Recurrence occurs in 2 percent to 10 percent of cases and rarely have metastases been reported (less than 1 percent of cases).

EPITHELIOID SARCOMA

Epidemiology

Epithelioid sarcoma (ES), an extremely rare, aggressive sarcoma, occurs most often on the hands and fingers of young males.[9] Proximally located tumors (e.g., groin, thigh, vulva, and axilla) have a much worse prognosis.

Etiology and Pathogenesis

The etiology is obscure; possibly trauma plays some role. Inactivation of the SMARCB1/INI1 tumor suppressor gene was identified in a series of 6 of 11 ES, which may in part explain its pathogenesis or propensity for progression.

Clinical Findings

HISTORY The patient may present with subcutaneous nodules on the hand or fingers. Often, there is a delay in diagnosis due to the rare nature of this tumor and the resemblance to more common inflammatory skin lesions, such as granuloma annulare.



▲ **FIGURE 125-4** Epithelioid sarcoma typically occurring over the wrist. Note ulceration and granuloma-like border.

CUTANEOUS LESIONS ES usually presents as a firm dermal or subcutaneous nodule, sometimes with ulceration or sinus formation (Fig. 125-4). Linear subcutaneous nodules due to progressive multifocal spread along tendons, nerves, and fascia may give a sporotrichoid appearance.

LABORATORY TESTS Diagnosis is by biopsy, dermal lesions may be biopsied by punch or wedge biopsy. Most lesions occur in fascia, tendon, or subcutaneous septa; approximately 25 percent arise in the dermis. The tumor usually presents as a multinodular mass composed of epithelioid cells with abundant eosinophilic, often vacuolated, cytoplasm admixed with spindle cells in a collagenous and myxoid stroma. Characteristically, there is central necrosis with a surrounding palisade of tumor cells.

SPECIAL TESTS Tumor cells express vimentin and epithelial markers. In a large series, epithelial membrane antigen was present in 96 percent of patients, and muscle-specific actin and CD34 were noted in 41 percent and 52 percent of the patients, respectively.

Differential Diagnosis

See Box 125-1.

Prognosis and Clinical Course

The tumor has local recurrence rates of up to 50 percent and nodal or hematogenous metastasis in 40 percent of patients. The lung and pleura are the most common sites of metastatic disease.

Because the classic location on distal extremities often discourages early deep biopsy, and because epithelioid sarcoma may closely mimic various non-neoplastic lesions histologically such as granuloma annulare, it often evades diagnosis at an early, localized stage.

Treatment

Radical excision traditionally has been the treatment of choice, but recurrences occur even with amputation. Conservative (limb-sparing) surgery combined with preoperative or postoperative radiation therapy has been tried, with results comparable with those reported with radical amputation. Chemotherapeutic regimens have not been successful. A high mitotic rate, large areas of necrosis, vascular invasion, and size greater than 5 cm are associated with worse prognosis.

REFERENCES

1. Bowne WB, Antonescu CR, Leung DH: Dermatofibrosarcoma protuberans: A clinicopathologic analysis of patients treated and followed at a single institution. *Cancer* **88**:2711, 2000
2. Stadler F, Scott GA, Brown MD: Malignant fibrous tumors. *Semin Cutan Med Surg* **17**:141, 1998
3. Cooper JZ et al: Metastasizing atypical fibroxanthoma (cutaneous malignant histiocytoma): Report of five cases. *Dermatol Surg* **31**:221, 2005
4. Dei Tos AP: Classification of pleomorphic sarcomas: Where are we now? *Histopathology* **48**:51, 2006
5. Gloster HM, Harris KR, Roenigk RR: A comparison between Mohs micrographic surgery and wide surgical excision for the treatment of dermatofibrosarcoma protuberans. *J Am Acad Dermatol* **35**:82, 1996
6. McArthur G et al: Molecular and clinical analysis of locally advanced dermatofibrosarcoma protuberans treated with Imatinib: Imatinib Target Exploration Consortium Study B2225. *J Clin Oncol* **23**:866, 2005
7. Shmookler BM et al: Giant cell fibroblastoma: A juvenile form of dermatofibrosarcoma protuberans. *Cancer* **64**:2154, 1989
8. Snow SN et al: Dermatofibrosarcoma protuberans: A report on 29 patients treated by Mohs micrographic surgery with long-term follow-up and review of the literature. *Cancer* **101**:28, 2004
9. Spillane A, Thomas M, Fisher C: Epithelioid sarcoma: The clinicopathological complexities of this rare soft tissue sarcoma. *Ann Surg Oncol* **7**:218, 2000





CHAPTER 126

Vascular Tumors

Tara Miller
Ilona J. Frieden

Vascular anomalies are common birthmarks.[1] Their classification has often been problematic, with contradictory and confusing descriptive nomenclature. A classification system first proposed by Mulliken and Glowacki was revised in 1996 by the International Society for the Study of Vascular Anomalies based on clinical, radiologic, and hemodynamic characteristics, into vascular malformations and vascular tumors.[2] Vascular malformations (see Chap. 173) are errors of morphogenesis whereas hemangiomas and other vascular tumors grow by cellular proliferation.

There are several types of vascular tumors, most of which occur in childhood. These tumors have also had confusing nosology,[3] with descriptive but imprecise terminology such as *strawberry*, *capillary*, and *cavernous*. Several types of hemangiomas have been described (infantile, rapidly involuting congenital, lobular capillary, etc.), so whenever possible, *hemangioma* should not be used as a stand-alone noun but rather qualified by an adjective based on the specific condition.

INFANTILE HEMANGIOMAS

Epidemiology

Infantile hemangiomas (IH) are the most common benign tumors of childhood, occurring in up to 10 percent of children by 1 year of age.[4] In contrast to other types of hemangiomas and vascular malformations, IH have a characteristic proliferative phase followed by a slower involution phase. They are more common in females (2–3:1 ratio) and in premature infants, especially those weighing less than 1500 grams.[5] Other risk factors are Caucasian race and multiple gestation pregnancy.

Etiology and Pathogenesis

IH are primarily composed of endothelial cells but also contain fibroblasts, pericytes, interstitial cells, and mast cells. Although the precise pathophysiologic mechanisms of the growth and involution of endothelial cells remains unknown, several recent discoveries have advanced the understanding of IH.[6] Glucose-transporter-1 (GLUT-1) has been identified as an immunohistochemical marker expressed in IH, regardless of stage, and in the microvasculature of the placenta.[7,8] GLUT-1 is not expressed in other vascular tumors and malformations, thus making it a specific and useful marker for IH. IH and the placenta share other vascular antigens such as FcγRII, Lewis Y antigen, and Merosin; the two also have similar gene expression profiles based on DNA-based microarrays.[9] Both "intrinsic" and "extrinsic" hypotheses exist to explain these findings: A somatic mutation may cause fetal vascular precursor cells (angioblasts) to improperly differentiate toward a placental microvascular phenotype or, alternatively, hemangiomas may originate from the placental vasculature. IH lack placental trophoblastic markers, suggesting that embolization of the placenta itself (as distinct from placental microvasculature) is not the source of IH.[10]

Proliferating IH express CD31 and CD34, known markers for endothelial cells, in addition to CD133, expressed in primitive cell populations.[11] This coexpression suggests that endothelial progenitor cells are involved in the pathogenesis of IH. However, IH also express myeloid markers CD14, CD15, CD32, and CD83 suggesting that these endothelial cells are distinct from those of normal vasculature.[12] While most IH are negative for lymphatic markers such as Prox-1, podoplanin, and D2-40, some IH express the lymphatic marker LYVE-1.[13] This immunophenotype is similar to the immature endothelial cells in the cardinal vein, which can differentiate into either lymphatic or blood vessels.[14] Expression of CD31, CD34, CD133, and LYVE-1 is markedly reduced or absent in other vascular tumors and malformations and during the involuting phase of IH. The concept of hemangioma cells being immature and incompletely differentiated could help explain their rapid growth during the first few months of life, followed by their eventual self-destruction via apoptosis.

Clinical Findings

HISTORY The clinical history is one of the most important keys to diagnosing an IH (Table 126-1).[21] Absence at birth or presence as a premonitory mark, usually an area of pallor, telangiectasias, or duskiness is characteristic, whereas a fully formed soft-tissue mass at the time of birth is most likely not an IH, but another vascular anomaly or other disease process.

CUTANEOUS LESIONS ***Growth Characteristics.*** Though IH are not present at birth as fully formed tumors, they almost al-

INFANTILE HEMANGIOMAS AT A GLANCE



- Infantile hemangiomas are the most common tumor of infancy.
- Hemangiomas in high-risk anatomic sites are likely to require further work-up and, often, intervention.
- Segmental hemangiomas have a greater risk for morbidity than localized hemangiomas.
- Kasabach-Merritt syndrome is not due to infantile hemangioma.

TABLE 126-1
History

- Birth history
  - Was the child premature?
  - Part of a multiple gestational birth?
  - Complications during the pregnancy or delivery?
- Overall health and past medical history
  - Is the child feeding well and gaining weight appropriately?
  - Have there been any hospitalizations or major illnesses?
- History of "birthmark"
  - Was it visible at the time of birth?
  - Has it changed since birth?
  - Growth: Is it growing proportionately or disproportionately with child's somatic growth? Is it still growing, stable, or shrinking in size? (Serial photographs are often helpful.)
  - Any complications such as pain, bleeding, or ulceration?
  - Any prior treatments?
- Family history
  - Is there a family history of hemangiomas or other vascular birthmarks?

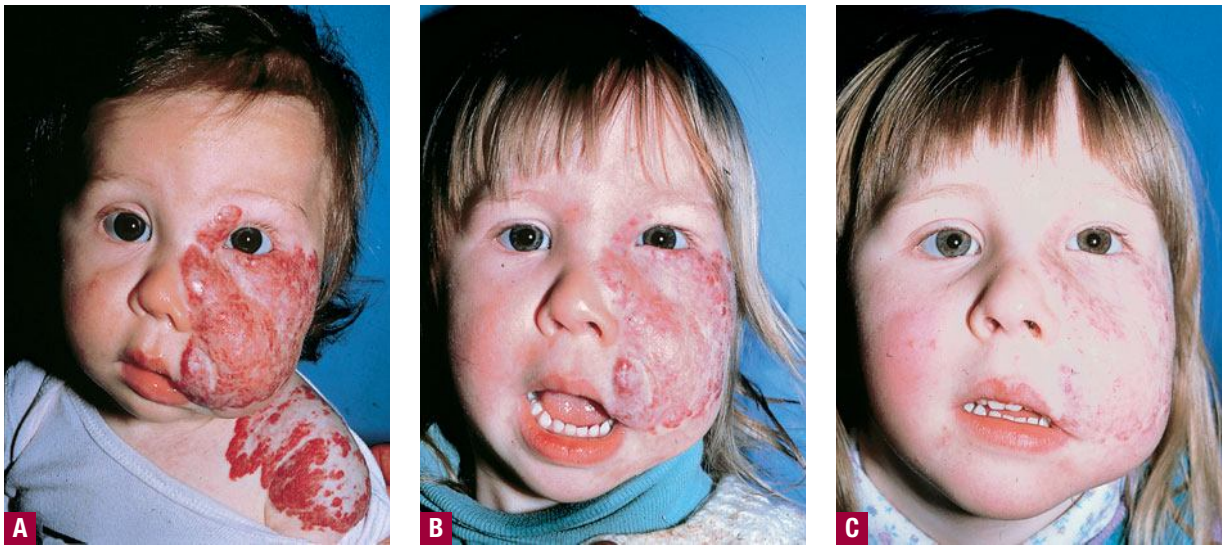

▲ **FIGURE 126-1** Natural history of segmental infantile hemangioma. Note the plaque-like, geographic configuration. **A.** Age 11 months, peak of proliferating phase. **B.** Age 2 years, involuting phase, apoptosis is maximal. **C.** Age 4 years, some further involution expected.



ways become apparent within the first month of life. The exception is deep hemangiomas, which are noted on average 1 month later than more superficial ones. The period of most rapid growth typically occurs within the first 5 months of life but can continue up to 1 year of age and in very large hemangiomas up to 18 months. This is followed by a slower involution phase which is more variable in length, lasting for months to years (Fig. 126-1).[22] Smaller hemangiomas typically involute sooner than very large ones, but there are exceptions. Most IH complete their course by the age of 7 to 10 years. Some children have normal skin after involution whereas the remainder has telangiectasias, atrophy, fibrofatty residuum, or scarring.

***Classification*[23].** Hemangiomas which involve the upper dermis (so-called *superficial hemangiomas*) have a bright red color; whereas those with deep dermal and subcutaneous location are skin color to blue in color. Those involving both superficial and deeper skin structures, so-called *mixed* hemangiomas, have both features. In addition to this clinical appearance, infantile hemangiomas can be classified as localized, segmental, or indeterminate.[24,25] Localized hemangiomas exhibit clear spatial containment as if arising from one central focus (Fig. 126-2). Segmental hemangiomas (similar to other segmental dermatologic disease such as vitiligo and neurofibromatosis) correspond to a portion of a developmental segment or broad anatomic territory (Fig. 126-3). They are often plaque-like in nature with a linear or geographic configuration. Those hemangiomas not clearly identifiable as localized or segmental are termed *indeterminate* (see Fig. 126-3). The patterns of facial segmental IH have been found to correspond to neural-crest derived facial prominences, and a new map for them has recently been proposed.[23] Multifocal hemangiomas are usually multiple localized hemangiomas. Though the exact number is somewhat arbitrary, more than five hemangiomas confers a risk of extra-cutaneous hemangiomas.

Classification of hemangiomas by subtype not only facilitates communication but also helps predict risk of complications and need for treatment. A prospective study of 1058 children with IH showed that segmental hemangiomas are 11 times more likely to experience complications and eight times more likely to receive treatment than localized hemangiomas even when controlled for size.[26]

Atypical Presentations. Atypical presentations of IH include deep hemangiomas and telangiectatic hemangiomas. Deep IH proliferate in the lower dermis and subcutaneous tissue without penetration of the papillary dermis (Fig. 126-4). They present as a localized, firm, rubbery subcutaneous mass that can be slightly raised with a bluish color or with telangiectasias involving the overlying skin, or they may be deep enough that the overlying skin is completely flat and of normal hue. If there is involvement of the papillary dermis, the cutaneous surface is often bright red and thus classified as a superficial and deep IH. Telangiectatic hemangiomas are flat or slightly elevated and deep red with an array of superficial dilated capillaries radiating over the surface (Fig. 126-5). These are virtually identical to premonitory marks, but for unknown reasons, have not proliferated.



▲ **FIGURE 126-2** Localized infantile hemangioma, cheek of an infant.



▲ **FIGURE 126-3** Indeterminate infantile hemangioma, cheek, age 14 months.



▲ **FIGURE 126-4** Natural history of a deep infantile hemangioma, right cheek/parotid. **A.** Age 1 year, peak of proliferation. **B.** Age 3 years, involuting phase.



Medical and Extracutaneous Risks. Certain hemangiomas have known associated risks. Anatomic location is one of the most important clues to these risks. Sites such as the periocular, lumbosacral, or mandibular areas should lead to closer scrutiny. In addition, the presence of multiple or segmental hemangiomas is associated with greater risk of extracutaneous disease.[21]

PHACES. Facial segmental IH are associated with PHACES (Online Mendelian Inheritance in Man #606519), a neurocutaneous syndrome that consists of the following features: *p*osterior fossa brain malformations, segmental cervicofacial *h*emangioma, *a*rterial anomalies, cardiac defects or *c*oarctation of the aorta, *e*ye anomalies, and *s*ternal defects, such as sternal clefting or supraumbilical raphe.[27] Only one extracutaneous anomaly is required for diagnosis, thus the clinical spectrum varies considerably.[28] Posterior fossa malformations, particularly the Dandy-Walker malformation, are the most commonly reported feature of PHACE syndrome, and intracranial arterial defects can lead to a Moyamoya phenomenon, ischemia, and stroke.[29,30] Thus, brain imaging [magnetic resonance imaging (MRI) and magnetic resonance angiography] should be considered in all infants with a large segmental hemangioma of the face.[31] In addition, formal ophthalmologic examination and echocardiogram may be performed, given the relative frequency of anomalies in these sites.

Periocular Hemangiomas. Infants with periocular hemangiomas are at risk for anisometropia and amblyopia, which if untreated, can lead to permanent visual loss (Fig. 126-6).[32] Direct pressure on the cornea can produce astigmatism or myopia, and the mass effect of the tumor itself can cause ptosis, proptosis, visual axis occlusion, or strabismus. Any patient with a hemangioma in the periocular area should have a prompt formal ophthalmologic evaluation with repeat visits during the proliferative phase (typically the first 3 to 4 months of life). Imaging studies may be needed to assess whether retrobulbar involvement is present.

"Beard Area" Hemangiomas. Segmental hemangiomas involving the preauricular, mandibular, chin, and neck skin (or so-called *beard area*) have a 60 percent risk of having symptomatic airway disease.[33] They usually present with the insidious onset of biphasic stridor between weeks 4 and 12 of life and are often mistakenly diagnosed as tracheomalacia, upper respiratory infection, or croup. If the hemangioma continues to enlarge, respiratory distress can ensue and become life-threatening. Prompt evaluation by a pediatric otolaryngologist and treatment is essential.[34] Hemangiomas can also involve the parotid gland, and often require treatment due to deformity of adjacent structures, and, in rare cases, high-output congestive heart failure.[35,36]

Lumbosacral and Perineal Hemangiomas. Segmental hemangiomas overlying the lumbosacral area can have associated spinal, bony, and genitourinary anomalies. Most frequently, posterior midline IH have a particularly high risk of spinal dysraphism and tethered cord, and MRI is strongly recommended.[37] Segmental perineal hemangiomas may be associated with urogenital and anorectal anomalies such as anterior or vestibular anus, hemiclitoris, atrophy or absence of the labia minora, and hypospadias.

Multifocal Hemangiomas. Multifocal IH are multiple, small (1 to 20 mm), noncontiguous lesions that can be confined to the skin but can also involve the viscera, termed *diffuse neonatal hemangiomatosis* (Fig. 126-7). Visceral hemangiomas are most commonly found in the liver (see hepatic IH) but have been reported in the lymph nodes, spleen, brain/meninges, iris, retina, salivary glands, thymus, gastrointestinal tract, lung, bladder, kidney, gallbladder, pancreas, and adrenal gland. Although most often described with multiple cutaneous hemangiomas, visceral hemangiomas have also been reported with solitary seg-



▲ **FIGURE 126-5** Telangiectatic infantile hemangioma, left foot. This lesion could be confused with a port-wine stain. **A.** Reticulated stain and minor soft-tissue hypertrophy. **B.** Age 11 years, only fine telangiectasias remain (involuted phase).

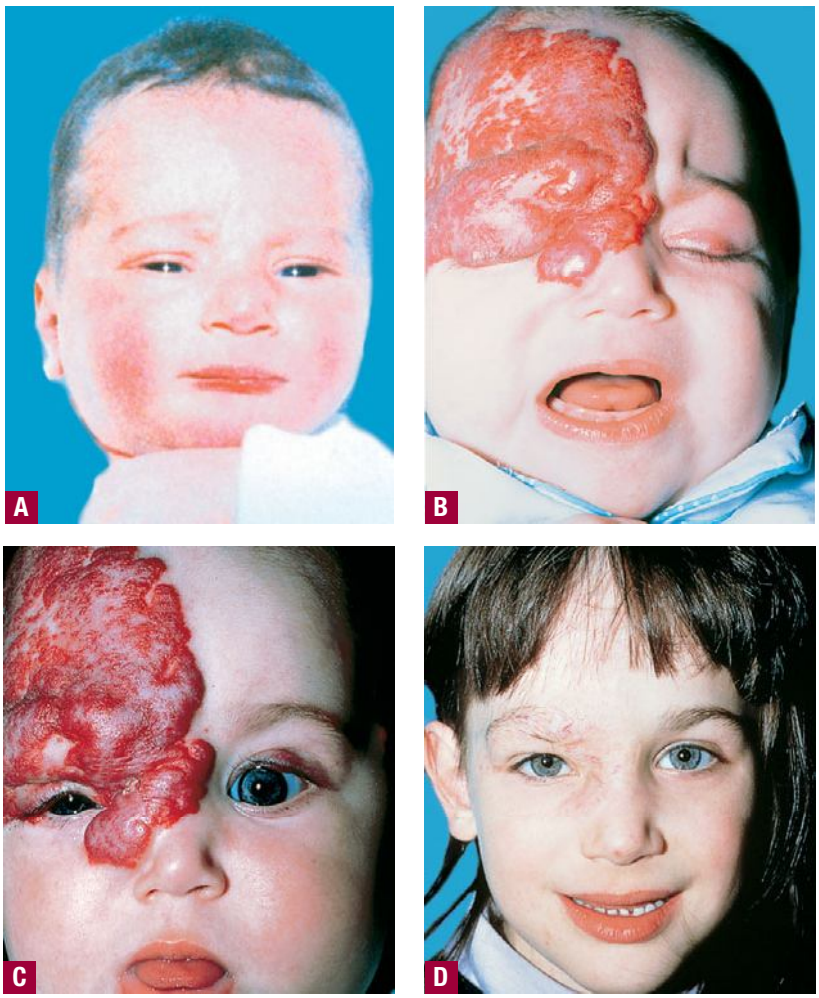

▲ **FIGURE 126-6** Vision-endangering segmental infantile hemangioma treated with systemic glucocorticoids. **A.** No premonitory signs of tumor seen on infant's photograph. **B.** By age 3 months, extensive infantile hemangioma infiltrating the upper lid and surrounding tissue, causing blocked vision. **C.** Eyelid opened within 2 weeks of glucocorticoid therapy. **D.** Involuted tumor, age 6 years.

mental hemangiomas.[38] The associated IH is most often located on the face but can be seen anywhere on the body. A combined prospective and retrospective study of 750 infants revealed 45 percent of infants with numerous small "miliary" hemangiomas have hepatic hemangiomas whereas 12 percent to 14 percent of those with three to five small lesions, six or more cutaneous hemangiomas, or one large (> 5 cm) lesion have involvement.[39]



▲ **FIGURE 126-7** Multifocal infantile hemangiomas in a 6-month-old infant. There are multiple, dome-shaped, erythematous papules on the left arm, flank, and back.

Hepatic Hemangiomas. The liver is the second most common site for IH and can be associated with hypothyroidism (see the section Laboratory Tests). Many hepatic hemangiomas are small, focal, low-flow lesions which are asymptomatic and unlikely to need treatment. However, those with high-flow or shunting (either arteriovenous or portovenous) are more likely to present with high-output cardiac failure, liver dysfunction, or abdominal compartment syndrome often requiring embolization or surgical intervention.[40,41] Infants with multiple hepatic tumors or left-to-right shunting typically present within the first 16 weeks of life with a clinical triad of hepatomegaly, congestive heart failure, and anemia. GLUT-1 immunohistochemical staining has revealed two distinct groups: GLUT-1–positive tumors, which are small, multifocal, histologically similar to IH, more common in females, and only symptomatic when numerous lesions were present; and GLUT-1–negative tumors, which have no gender predilection, are symptomatic at birth or shortly thereafter, and require aggressive medical and surgical intervention.[42] In most instances, ultrasound may be initially used as a screening technique followed by computed tomography or MRI if multiple, unusually large, or symptomatic hepatic hemangiomas are found.

LABORATORY TESTS ***Thyroid Function Tests.*** Hypothyroidism is a rare complication in infants with massive hemangiomas of the liver.[43,44] First reported by Huang et al., hemangioma tissue demonstrates high levels of type 3 iodothyronine deiodinase activity, which accelerates the degradation of thyroid hormone.[45,46] Infants with significant hepatic hemangiomas should have thyroid function evaluated, including T3 (the hormone consumed) and thyroid-stimulating hormone, because T4 levels may initially remain normal. Conversely, screening liver ultrasound looking for hemangiomas should be performed in infants with hypothyroidism of unknown etiology even in the absence of cutaneous hemangiomas.

Platelet Studies. Platelet studies are not indicated as the Kasabach-Merritt phenomenon (KMP) is not associated with IH but rather with kaposiform hemangioendothelioma (KHE) and tufted angioma (TA) (see the section Pharmacologic Therapy).

Recommended tests and imaging studies are included in the section Cutaneous Lesions with discussion of specific IH and their related physical findings.

Complications

Ulceration is the most common complication of IH, occurring in approximately 15 percent of patients usually during the proliferative phase. It occurs most frequently with segmental IH and at sites that are constantly exposed to moisture and friction such as the perioral, perianal, and other intertriginous sites.[47,48] Secondary infection can occur but its frequency is debatable. Cultures usually show polymicrobial growth and are



likely the result of colonization.[49] However, if infection is suspected, systemic antibiotics should be prescribed.

Local wound care, barrier protection, and pain control are essential for treatment. Bio-occlusive dressings may be helpful but those intended to stick to the skin may be limited by location because they do not adhere well near orifices.[50] In these areas, thick applications of petrolatum-based ointments can be helpful. Pain can be a major issue in management. It can be minimized with an occlusive dressing, oral acetaminophen with or without codeine, and the use of very small amounts of topical lidocaine ointment no more than a few times a day. Ulcerations generally heal with scarring within 2 to 3 weeks with topical care. For refractory cases, other treatment modalities including pulsed dye laser or Becaplermin 0.01% gel, a synthetic platelet-derived growth factor, have anecdotally been reported to be effective.[51,52] Therapies aimed at halting hemangioma growth, such as intralesional and systemic steroids or excision, may be useful in some cases.

Other serious complications such as hypothyroidism, internal organ involvement, or vital structure compromise due to the location of IH in certain anatomic sites have been discussed in the section Cutaneous Lesions.



Prognosis and Clinical Course

The prognosis of most IH is excellent, with spontaneous involution and little to no sequelae, but a significant minority can result in permanent disfigurement or medical sequelae. Certain characteristics are associated with an increased risk of complications and need for treatment (Table 126-2).[53] Consideration of early treatment should be given to hemangiomas with these characteristics, depending on the specific clinical setting.

Treatment

The decision to initiate treatment is based on many factors, including size and location, psychosocial implications, and risks and benefits of the proposed therapy. For the majority of small hemangiomas, "active nonintervention" is the most appropriate approach. This does not mean doing nothing. The infant should be seen frequently, especially during the first few months (corresponding to the proliferative phase). During these visits, education about the natural course of IH and discussions about the psychosocial impact on the child and/or the family should occur.[54] Photographs of the likely outcome for a similar lesion are often helpful. Many parents experience anxiety and may find themselves subject to comments from complete strangers about their child's hemangioma.[55] Most parents of young children do not think their child is deeply affected by these reactions, but facial hemangiomas in particular can cause psychological suffering once the child reaches school age.[56,57] Potential treatment options should be discussed well ahead of entrance to elementary school.

If it is decided that treatment is necessary, options include pharmacologic, laser, or surgical interventions. However, management remains controversial with few double-blind controlled studies and no Food and Drug Administration-approved labeled indications for medical treatments.

PHARMACOLOGIC THERAPY ***Corticosteroids.*** Systemic corticosteroids are the first-line treatment for deforming, endangering, or life-threatening IH (see Fig. 126-6).[58] They work best during the growth phase, causing slowing or cessation of growth in up to 90 percent of cases, with actual shrinkage in approximately one-third. Although the mechanism of action is not well understood, recent studies suggest the upregulation of mitochondrial cytochrome b, clusterin/ApoJ (possible apoptotic markers), and/or interleukin-6 as markers of corticosteroid-induced cessation of hemangioma growth.[59–61] Prednisone or prednisolone is given at a dose of 2 to 3 mg/kg/day, typically for 4 to 8 weeks followed by a tapering of varying length, depending on the age of the child and indication for treatment. A recent large meta-analysis showed an 84 percent response rate with an average dose of 2.9 mg/kg for a mean of 1.8 months before tapering. Although 3 mg/kg/day is more effective (94 percent response) than 2 mg/kg/day (75 percent response), greater adverse events are found with the higher dose.[62]

Short-term complications of systemic corticosteroids include: cushingoid facies (71 percent), personality changes (29 percent), gastric irritation (21 percent), fungal infection (oral or perineal, 6 percent), and diminished gain of height (35 percent) and weight (42 percent) during treatment. More than 90 percent of children with diminished gain of height return to their pre-treatment growth curve by 24 months of age (Table 126-3).[63] Other complications include hypertension, steroid-induced myopathy, and immunosuppression. Blood pressure should be monitored with each visit to the dermatologist or pediatrician.[64] Children taking more than 2 mg/kg/day of prednisone for longer than 14 days are considered to have a deficit in cell-mediated immunity. Live-viral vaccinations should be deferred in infants receiving high-dose corticosteroids. Rare cases of *Pneumocystis carinii* pneumonia have been reported in this setting, leading some physicians to use trimethoprim-sulfamethoxazole prophylaxis during treatment.[65]

Intralesional corticosteroids can be an effective treatment for relatively small localized hemangiomas located in high-risk sites such as the lip, nasal tip, cheek, and ear. Injections for periocular hemangiomas are usually performed by oph-

TABLE 126-2
High-Risk Infantile Hemangioma Sites and Sub-Types

Sub-types	Segmental, multifocal
Sites	Face—periorbital, perioral, any large facial; "beard" area; lumbosacral; genital

TABLE 126-3
Major Side Effects of Common Infantile Hemangioma Treatments

TREATMENT	MAJOR SIDE EFFECTS
Systemic corticosteroids	Diminished gain of height and weight, cushingoid facies, personality changes, gastric irritation, hypertension, immunosuppression
Intralesional corticosteroids	Arterial embolization/injection, atrophy, systemic absorption
Topical corticosteroids	Local atrophy, systemic absorption
Interferon-α	Spastic diplegia (neurotoxicity), fever, hepatotoxicity, neutropenia, anemia
Vincristine	Central line placement, neuropathy, abdominal pain, constipation
Laser	Pain, scarring, hypopigmentation, textural change, ulceration
Surgery	General anesthesia, scarring

thalmologists, but reports of retinal artery embolization and blindness have resulted in a reduced use of this modality.[66–68] The largest published case series of intralesional steroids found that the majority showed greater than 50 percent reduction in volume with the best results occurring in relatively superficial hemangiomas. Adverse events occurred in 6.4 percent of patients and included cushingoid appearance, cutaneous atrophy, and anaphylactic shock (see Table 126-3).[69]

A few case series have reported on the efficacy of class 1 topical corticosteroids, especially for small, superficial hemangiomas.[70–72]

Interferon-α. Interferon-α therapy is reserved for hemangiomas causing morbidity that are unresponsive to oral corticosteroids, or where such therapy is contraindicated. It is quite effective, but a severe neurotoxicity, spastic diplegia, has been reported in up to 20 percent of infants treated (see Table 126-3). A recent meta-analysis of 441 patients showed 11 developed irreversible spastic diplegia and 16 developed motor disturbances that were reversible on discontinuation of the drug.[73] All affected patients were younger than 1 year of age at initiation of therapy, suggesting that the drug may be safer after 1 year of age. Neurologic evaluations should also be performed monthly in treated children.

Chemotherapy. Vincristine is often used in the treatment of the KMP and its associated tumors, KHE and TA.[74–76] Given the potential neurotoxicity of interferon (see the section Interfon-α), vincristine is considered by some to be a second-line treatment for aggressive, complicated IH that do not respond to corticosteroids. However, further evaluation through prospective clinical trials is needed (see Table 126-3).

Cyclophosphamide has been reported in the pediatric hematology-oncology literature to be effective in the treatment of life-threatening diffuse neonatal hemangiomatosis.[77,78]

Imiquimod. Imiquimod 5% cream has anecdotally been reported to be effective in treating small superficial hemangiomas, but crusting and ulceration are potential side effects.[79–81]

LASER THERAPY The pulsed dye laser (PDL), originally designed to treat port-wine stains, has been used to treat IH with varying results.[82] Several reports have shown improvement in treating hemangioma ulceration,[83,84] and its use in diminishing residual telangiectasias and erythema after involution is well accepted. Its use in the treatment of proliferating hemangiomas is controversial.[85] Batta et al. performed the only prospective, randomized, controlled study to date regarding the treatment of IH in 121 patients aged 1 to 14 weeks, using 585-nm PDL without cooling compared to observation alone.[82] Their results showed no difference between complete and nearly complete clearance with laser compared to observation alone at age 1 year, with a trend toward increased hypopigmentation and textural change in the laser-treated group. Other studies have shown good results with either the 585-nm PDL or 595-nm PDL, with varying fluences, but several have emphasized that treatments work best for more superficial hemangiomas and are unable to halt growth of deeper components.[86–88] Severe ulceration and scarring, particularly in treating segmental hemangiomas during the proliferative phase, have been reported (see Table 126-3).[89] A conservative approach is to reserve PDL primarily for treating ulceration and for hastening resolution of erythema in IH that have stopped proliferating or have already undergone involution.[90]

SURGICAL THERAPY Surgical excision may be indicated at any time during the life cycle of an IH (Fig. 126-8).[1] In most instances, it is best to wait until regression is well under way and a more accurate assessment can be made regarding whether scarring and textural changes have occurred. Decisions regarding this can often be made at age 3 to 5 years, even if involution is not complete.[91] Certain anatomic locations such as the nasal tip and lip often require surgery.[92–97] Even earlier excision may be indicated in cases where clinical characteristics, such as pedunculated, very ulcerated, or extremely thick dermal involvement dictate that scarring will inevitably occur. A standard elliptical excision is often performed; however, circular excision followed by a purse-string closure may leave a smaller scar.[98]



▲ **FIGURE 126-8** Surgical correction of involuting-phase infantile hemangioma. **A.** Age 3 years, infantile hemangioma on upper eyelid. **B.** Age 9 years, after staged surgical resection, including vertical shortening of eyelid, repair of blepharoptosis, and formation of tarsal crease.

OTHER VASCULAR TUMORS

Many other benign vascular neoplasms occur in both children and adults.[99] This chapter highlights many of the important ones. More comprehensive reviews of this subject can be found elsewhere.[99–101]

Congenital Hemangiomas

Hemangiomas that are fully formed tumors at the time of birth and do not proliferate in postnatal life are referred to as *congenital hemangioma* or *congenital nonprogressive hemangioma*. There are two major sub-types recognized on the basis of their natural history: the rapidly involuting congenital hemangioma (RICH) and non-involuting congenital hemangioma (NICH).[102] Collectively, both are sometimes referred to as *congenital nonprogressive hemangioma*. The distinguishing pathologic features of these tumors are lobules of capillaries set within densely fibrotic stroma containing hemosiderin deposits, focal lobular thrombosis, and sclerosis.[103] They are GLUT-1 negative.[104] Both have similar anatomic sites of predilection, such as the extremities or postauricular skin, but they can occur elsewhere. RICH often appears as a raised, violaceous tu-



OTHER VASCULAR TUMORS AT A GLANCE



- Congenital hemangiomas are fully formed at birth. Rapidly involuting congenital hemangiomas and non-involuting congenital hemangiomas are recognized sub-types.
- Tufted angiomas represent subtle pink or dusky-red patches and may evolve into plaques or nodules and have a characteristic histology.
- Kaposiform hemangioma is morphologically similar to but etiologically distinct from Kaposi sarcoma and can be associated with Kasabach-Merritt phenomenon.
- Multifocal lymphangiomatosis with thrombocytopenia consists of cutaneous vascular papules and plaques associated with intermittent thrombocytopenia, often with gastrointestinal bleeding.
- Spindle cell hemangioendothelioma usually occurs in the extremities most often associated with Maffucci syndrome.
- Congenital eccrine angiomatous hamartoma is a rare ill-defined plaque associated with increased lanugo hair and sweating.
- Pyogenic granuloma is very common; a rapidly growing papule or nodule with a collarette of scale or eroded surface. Treatment is excision or electrocautery.



mor with large, radiating veins or with overlying telangiectasia and a halo of pallor (Fig. 126-9). Central ulceration may be present. Most RICH involute spontaneously by age 14 months, often sooner, and usually leave residual atrophic inelastic skin in their wake.[105]

NICH are also present at birth, but usually flatter than RICH, presenting as a well-circumscribed round to oval, slightly indurated or raised soft-tissue mass with overlying telangiectasias and a rim of pallor (Fig. 126-10).

Both NICH and RICH are high-flow vascular anomalies, often showing arteriovenous micro-fistulas on Doppler interrogation. Some cases of RICH involute only partially, and the residual tumor resembles NICH, supporting the concept that RICH and NICH may be variants of each other.

Indications for treatment of NICH or RICH are similar to those for IH, including impairment of visual function and congestive heart failure. Excision should definitely be considered for ulceration, which in this setting can lead to severe hemorrhage, and for post-involutional skin changes if disfiguring. NICH do not go away but are often asymptomatic; decisions regarding their removal must weigh risks and benefits of the proposed treatment.



▲ **FIGURE 126-10** Non-involuting congenital hemangioma on right mandible. Note the overlying telangiectasias and rim of pallor.

Tufted Angioma

ETIOLOGY TA is a benign vascular tumor that has also been called *angioblastoma of Nakagawa*. Its etiology and pathogenesis are uncertain. Unlike IH, there are no known gender or gestational age correlates.

CLINICAL FINDINGS Most cases are acquired early in childhood and have a protracted course. Rare congenital forms also exist. TAs display various clinical patterns. They may present as a subtle stain-like area that later thickens, as a large, plaque-like, infiltrated, red or dusky blue-purple lesion, or as an exophytic, firm, violaceous, cutaneous nodule (Fig. 126-11). TA must be differentiated from infantile hemangiomas as well as other vascular tumors. They are often somewhat firmer and may be tender. Histologically, both acquired and congenital TAs demonstrate vascular tufts of tightly packed capillaries, randomly dispersed throughout the dermis in a typical "cannonball distribution" with crescentic spaces surrounding the vascular tufts, and lymphatic-like spaces within the tumor stroma.[106,107]

COMPLICATIONS KMP may develop in TA but this is more common with KHE (see the section Kaposiform Hemangioendothelioma).

PROGNOSIS AND CLINICAL COURSE TA may persist unchanged or regress completely within a few years.

TREATMENT No single treatment is effective. Interferon-α and PDL have anecdotally been reported to be effective.

Kaposiform Hemangioendothelioma

KHE is a rare vascular tumor that has usually been reported in association with

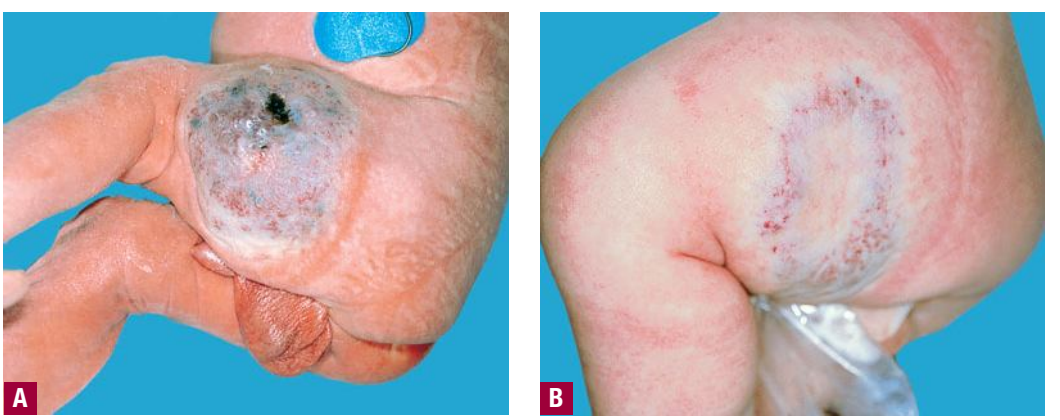

◀ **FIGURE 126-9** Rapidly involuting congenital hemangioma on left thigh. **A.** Note central ulceration, violaceous color, and pale periphery. Fast-flow vessels were detected on Doppler examination. **B.** Rapid regression at age 2 months.



▲ **FIGURE 126-11** Age 18 months. Tufted angioma (confirmed by biopsy) of the left leg, buttocks, lower abdomen. Laboratory evaluation revealed elevated D-dimers.

KMP. It may be present at birth or develop in early childhood. Rare adult cases have been reported. It may present as a brown-red stain at birth which begins to thicken and become purpuric, or as a plaque or nodule similar to tufted angioma. Regional lymph node involvement may occur, but not distant metastases. Spontaneous involution is rare. Most reported cases have had associated KMP, but the KHE can occur in the absence of a coagulopathy.[108,109]

The histology of KHE is characterized by spindled cells with minimal atypia and infrequent mitoses lining slit-like or crescentic vessels containing hemosiderin. The tumor is GLUT-1 negative. The overlap of both clinical and histologic features has led some to suggest that TA and KHE are part of a spectrum of disease. Increased lymphatic spaces have suggested a lymphatic origin, similar to that of Kaposi sarcoma.

Kasabach-Merritt Phenomenon

KMP has been used to describe infants with vascular tumors and thrombocytopenia with an associated coagulopathy (Fig. 126-12). It was long considered to be a complication of "hemangioma," but it is now recognized to be a complication of TA and KHE, not IH.[110,111]

KMP must be differentiated from a coagulopathy which can arise in association with venous and mixed venous-lymphatic malformations (sometimes erroneously called *KMP*) due to chronic clotting and consumption of clotting factors, but not primarily by platelet trapping.[112] The hallmark of KMP is severe thrombocytopenia. Consumption of fibrinogen, elevated D-dimers, and decreased coagulation factors occurs to



▲ **FIGURE 126-12** Kasabach-Merritt phenomenon secondary to kaposiform hemangioendothelioma. An indurated, purpuric tumor appeared at age 3 months and is seen here at age 8 months. Kaposiform hemangioendothelioma confirmed by magnetic resonance imaging and biopsy. Platelet count < 5000/mm^3.

varying degrees. Most cases involve the skin and musculature, but deeper viscera including cervicothoracic, abdominal, and pelvic regions can be affected. Although the tumors causing KMP can persist, the coagulopathy usually abates by 1 year of age or sooner with treatment. KMP may resolve with atrophic or stain-like areas, infiltrated plaques and papules, or nodules. Residual fibrosis is not rare and can result in considerable morbidity.[113]

No one treatment is uniformly effective. Options include corticosteroids, vincristine, cyclophosphamide, actinomycin-D, methotrexate, interferon-α, ticlopidine plus aspirin, surgical excision, arterial embolization, and radiotherapy. Platelet transfusions should be avoided unless active bleeding occurs or before surgical procedures.[114,115]

Multifocal Lymphangioendotheliomatosis with Thrombocytopenia

Multifocal lymphangioendotheliomatosis with thrombocytopenia (also known as *cutaneovisceral angiomatosis with thrombocytopenia*), a rare condition, is characterized by multiple cutaneous vascular papules and plaques that are usually present at birth with more developing over time. Affected infants have intermittent thrombocytopenia and lesions in the gastrointestinal tract, leading to gastrointestinal bleeding. Other reported sites of involvement include bones, synovium, lungs, liver, and spleen. Skin biopsy specimens demonstrate thin-walled vessels, some hobnailed endothelial cells, and intraluminal papillary projections similar to Dabska tumor.[116,117]

Spindle Cell Hemangioendothelioma

Spindle cell hemangioendothelioma is a rare vascular tumor most often seen with Maffucci syndrome. It can occur at any age and site but the extremities are the most commonly affected. The histology is of a nodular, dense, spindle cell proliferation in association with dilated dysplastic veins. Lesions can be locally aggressive and may recur even after excision.[118]

Congenital Eccrine Angiomatous Hamartoma (Sudoriparous Angioma)

Congenital eccrine angiomatous hamartoma is a rare condition characterized by ill-defined plaques with increased lanugo hair and sweating at the site of the lesion. They are usually located on the extremities or abdomen. Diagnosis is established on the basis of characteristic histologic findings: closely packed eccrine sweat glands associated with dilated capillaries, a few dysplastic venous channels, and a dense collagenous matrix.[119]

Pyogenic Granuloma (Lobular Capillary Hemangioma)

Pyogenic granuloma (PG) is also known by its correct histopathologic description *lobular capillary hemangioma.* It is one of the most common vascular tumors of infants and children and can also occur in adults, particularly in pregnant women. PG usually presents as a solitary, red, rapidly growing papule or nodule, often with a subtle collarette of scale (Fig. 126-13). Typical locations include the cheek or forehead but virtually any body site may be affected. They often develop an



▲ **FIGURE 126-13** Large pyogenic granuloma on chest, age 2 years.



eroded surface, with subsequent bleeding which can be profuse, resulting in the moniker *the band-aid disease*. In very young infants, PG is often mistaken for an infantile hemangioma.[120]

PG does not involute spontaneously, but simple curettage with electrocautery is usually curative. Other options include excision, laser surgery (carbon dioxide or pulsed dye), and cryotherapy. Recurrence and even satellite lesions surrounding the original PG have been reported.[121,122]

Other Vascular Tumors

Targetoid hemosiderotic hemangioma is a benign lesion presenting as a violaceous papule, often surrounded by a pale rim and peripheral ecchymotic halo, which fades with time. Lesions usually present on the trunk or extremities and histologically consist of dilated vascular channels within intraluminal papillary projections dissecting into collagen bundles in the subcutis. Extravasated erythrocytes and hemosiderin are present, hence the designation.

Endovascular papillary angioendothelioma (Dabska tumor) is a dermal nodule or a diffuse swelling on the head, neck, or extremities. Dabska tumor is a low-grade angiosarcoma. Epithelioid hemangioendothelioma and retiform hemangioendothelioma are other examples of low-grade angiosarcomas. These tumors, Kaposi sarcoma, and angiosarcoma are discussed in Chap. 128. Vascular malformations are discussed in Chap. 173.

KEY REFERENCES

The full reference list for all chapters is available at www.digm7.com.

1. Mulliken JB, Fishman SJ, Burrows PE: Vascular anomalies. *Curr Probl Surg* **37**:517, 2000
4. Frieden IJ et al: Infantile hemangiomas: Current knowledge, future directions. Proceedings of a research workshop on infantile hemangiomas, April 7–9, 2005, Bethesda, Maryland, USA. *Pediatr Dermatol* **22**:383, 2005
6. Bauland CG et al: The pathogenesis of hemangiomas: A review. *Plast Reconstr Surg* **117**:29e, 2006
21. Bruckner AL, Frieden IJ: Hemangiomas of infancy. *J Am Acad Dermatol* **48**:477, 2003
23. Haggstrom AN et al: Patterns of infantile hemangiomas: New clues to hemangioma pathogenesis and embryonic facial development. *Pediatrics* **117**:698, 2006
26. Haggstrom AN et al: Prospective study of infantile hamangiomas: Clinical characteristics predicting complications and treatment. *Pediatrics* **118**:882, 2006
83. Batta K et al: Randomized controlled study of early pulsed dye laser treatment of uncomplicated childhood haemangiomas: Results of a 1-year analysis. *Lancet* **320**:521, 2002
100. Weiss SW, Goldblum JR: Benign tumors and tumor-like lesions of blood vessels, in Enzinger and Weiss's *Soft Tissue Tumors,* 4th edition. St Louis, Mosby Inc, 2001 p.837 and 891

CHAPTER 127

Neoplasias and Hyperplasias of Muscular and Neural Origin

Lucile E. White
Ross M. Levy
Murad Alam

TUMORS OF SMOOTH MUSCLE

The dermis contains smooth muscle fibers in the arrector pili muscles, in the walls of dermal blood vessels, and in the dartos muscle of the scrotum, vulva, nipple, and areola. There are three types of cutaneous smooth muscle lesions: leiomyomas, leiomyosarcomas, and hamartomas. Smooth muscle is recognized histologically by spindle cell shape, eosinophilic, fibrillary cytoplasm, and blunt-ended, oval, "cigar-shaped" nuclei. On immunohistochemical staining, cells express smooth muscle actin and the muscle-specific intermediate filament desmin, but are negative for S100 protein and epithelial membrane antigen (EMA).

Leiomyoma

EPIDEMIOLOGY The exact incidence of leiomyomas is unknown. In one study, the 10-year incidence was 0.04 percent with the majority of lesions occurring in women.[1] Although leiomyomas are thought to be relatively uncommon neoplasms, the actual incidence may be higher than previously believed due to failure to recognize and biopsy the lesion.

ETIOLOGY AND PATHOGENESIS Cutaneous leiomyomas are divided into three subsets: (1) solitary or multiple piloleiomyomas originating from the arrector pili muscles; (2) genital leiomyomas originating from the mammillary, dartoic, or labial/vulvar muscles; and (3) angioleiomyomas, originating from vascular smooth muscle. Most leiomyomas are acquired; however, familial inheritance patterns have been described. Especially noteworthy are patients with multiple piloleiomyomas. Starting in early adulthood, these patients present with increasing numbers of tumors, developing as many as 100 to 1000 lesions. Transmission appears to be autosomal dominant with variable penetrance.[2] Women with multiple piloleiomyomas may also develop uterine leiomyomas, an entity termed *multiple cutaneous and uterine leiomyomatosis* (also known as *familial leiomyomatosis cutis et uteri* or *Reed syndrome*).[2] In addition, some families with multiple cutaneous and uterine leiomyomatosis have been shown to cluster renal cell cancer, and this has been termed *hereditary leiomyomatosis and renal cell cancer*. Recently, a loss of function mutation in the gene encoding fumarate hydratase on chromosome 1q42.3-43 has been shown to predispose individuals to these conditions. Fumarate hydratase catalyses the conversion of fumarate to malate in the Krebs cycle but is also considered to be to be a tumor suppressor gene.[3]

LEIOMYOMA AT A GLANCE



- Benign cutaneous neoplasm derived from arrector pili muscle (piloleiomyoma), mammillary, dartoic or labial/vulvar muscle (genital leiomyoma), or the walls of blood vessels (angioleiomyoma).
- Present as solitary or multiple flesh-colored, occasionally painful papules; rarely associated with uterine leiomyomas and renal cell cancer.
- Treatment: Surgical; recurrence is common.



▲ **FIGURE 127-1** Clinical photograph showing multiple leiomyomas involving the back.

CLINICAL FINDINGS The most common presentation is that of multiple pilole iomyomas.[4] Individual lesions range in size from several millimeters to 1 cm and are usually reddish-brown firm papulonodules that are fixed to the skin but freely moveable over underling deeper structures (Fig. 127-1). They can coalesce to form plaques or linear, grouped, or dermatomal patterns.[4] The extensor extremities, trunk, and sides of the face and neck are the most common locations. Patients with piloleiomyomas often have pain that may be spontaneous or secondary to cold, pressure, or emotion.[2,4–6] Possible explanations for this phenomenon include pressure of the tumor on local nerve fibers and contraction of the smooth muscle fibers.[4] Genital leiomyomas are clinically similar to piloleiomyomas except that they are usually asymptomatic.[4] They commonly present as solitary, deep papulonodules or occasionally, pedunculated papules on the scrotum, vulva, penis, or areolar region. Angioleiomyomas present most commonly as solitary, painful subcutaneous nodules on the legs in women that can grow to several centimeters in diameter.[7]

HISTOPATHOLOGY Pilar leiomyomas are composed of a poorly circumscribed proliferation of haphazardly arranged, bland-appearing smooth muscle cells with characteristic eosinophilic cytoplasm, blunt-ended nuclei and perinuclear halos in cross-section. They are located in the dermis and can infiltrate the surrounding tissue with extension into the subcutis (see eFig. 127-1.1 in on-line edition). Genital leiomyomas usually resemble pilar leiomyomas. Angioleiomyomas are well-circumscribed, richly vascularized dermal or subcutaneous nodules composed of well-differentiated smooth muscle fibers (Fig. 127-2).

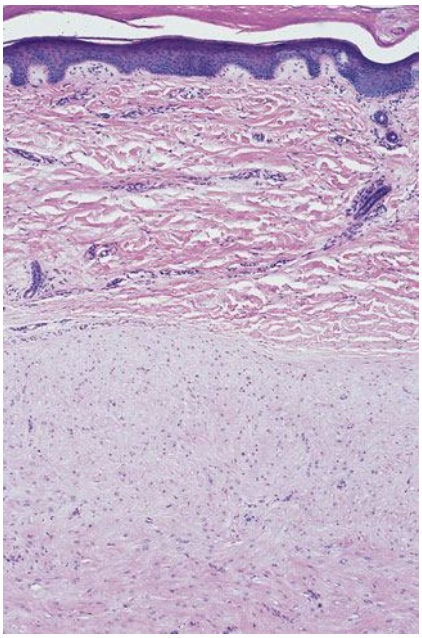

▲ **FIGURE 127-2** Histologic appearance of an angioleiomyoma. Compared with the pilar leiomyoma, this tumor is more sharply circumscribed (but not encapsulated). Furthermore, the smooth muscle fibers form a solid nodule with little, if any, intervening collagen. (Hematoxylin and eosin, ×40.)

Occasionally, the vessel of origin can be identified. Leiomyomas stain positive with smooth-muscle actin and desmin.

DIFFERENTIAL DIAGNOSIS Differential diagnosis of leiomyoma includes any flesh-colored or reddish-brown superficial or deep-seated papule or nodule: angiolipoma, glomus tumor, eccrine spiradenoma, neurofibroma, nevus, or lipoma.

PROGNOSIS AND CLINICAL COURSE Cutaneous leiomyomas do not regress spontaneously, and there does not appear to be risk of malignant degeneration into leiomyosarcoma. A minority of patients may also develop uterine leiomyomas and, in some families, association with renal cell carcinoma has been described. Occasionally, leiomyomas are associated with polycythemia. This may be due to erythropoietin-like activity of leiomyomas, which has been demonstrated in tumor extracts.[8]

TREATMENT Excision is the treatment of choice for leiomyomas that cause pain or cosmetic concern; however, recurrence is common. In patients with numerous lesions, this method is impractical. Carbon dioxide laser ablation was reported as an effective modality[9] whereas cryotherapy and electrosurgery have been used with disappointing results.[10] Pain may be a significant source of morbidity and, when surgical intervention is not possible, potential treatment options include nitroglycerin, phenoxybenzamine, nifedipine, gabapentin, or topical analgesics.[2,11–13]

LEIOMYOSARCOMA AT A GLANCE

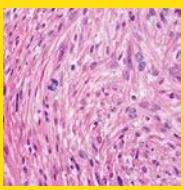

- Rare malignant tumor of smooth muscle: Cutaneous and subcutaneous types based on location of origin.
- Presentation: Enlarging cutaneous or subcutaneous tumor most commonly on hair-bearing areas of the lower extremities.
- Recurrence rate: High, with significant risk of metastases in case of subcutaneous leiomyosarcoma.

Leiomyosarcoma

EPIDEMIOLOGY Exact incidence is unknown, but older studies suggest that leiomyosarcomas comprise approximately 3 percent of soft-tissue sarcomas.[14] Superficial leiomyosarcoma occurs in all age groups, and there appears to be no gender predilection.

ETIOLOGY AND PATHOGENESIS Leiomyosarcoma is a rare, malignant mesenchymal tumor of smooth muscle origin usually found in the uterus, the retroperitoneum, gastrointestinal tract, or deep soft tissue. The term *superficial leiomyosarcomas* refers to those tumors whose primary site of origin is the skin. Those derived from arrector pili or genital smooth muscles are termed *cutaneous leiomyosarcomas*, and those derived from blood vessel smooth muscle are termed *subcutaneous leiomyosarcomas*. In some cases, tumors have arisen in sites of earlier radiotherapy or trauma.[4] Leiomyosarcomas typically arise de novo rather than from pre-existing leiomyomas.

CLINICAL FINDINGS Leiomyosarcomas present as solitary, enlarging lesions most commonly on the hair-bearing ar-



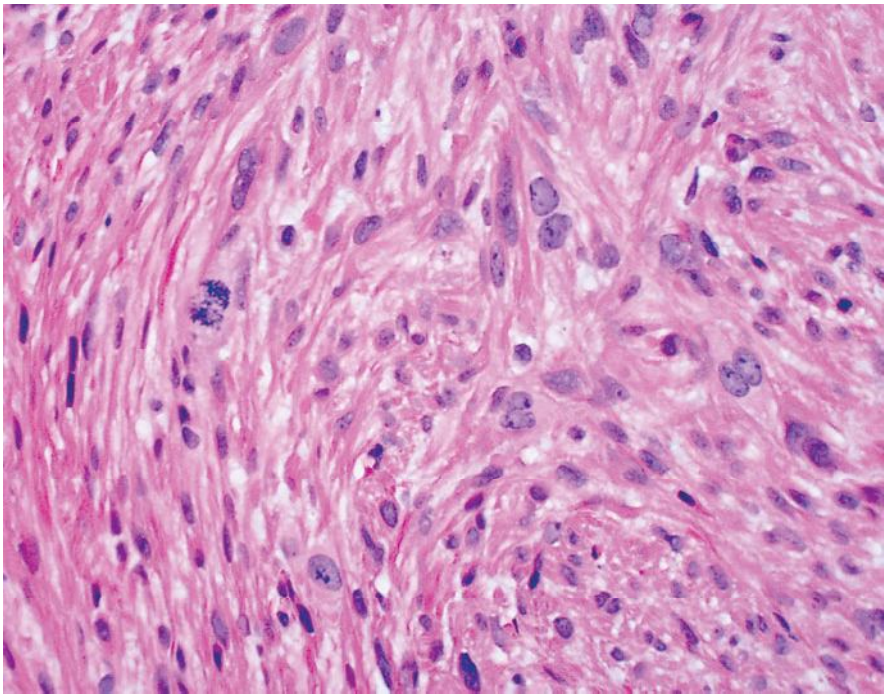

▲ **FIGURE 127-3** Histologic examination of a leiomyosarcoma. This tumor exhibits smooth muscle differentiation with atypical cytologic features such as nuclear hyperchromasia, prominent nucleoli, and mitoses. (Hematoxylin and eosin, ×400.)

eas of lower extremities.[19] They can exhibit a variety of colors and may be painful, pruritic, or paresthetic. Cutaneous leiomyosarcoma usually presents as small (< 2 cm), sometimes ulcerated nodules that are fixed to the epidermis. Subcutaneous leiomyosarcomas tend to be larger and are usually not associated with epidermal change. Some patients have multiple grouped lesions; in one series, four of seven such patients had a previous retroperitoneal leiomyosarcoma,[15] highlighting the importance of ruling out metastases in patients with numerous superficial leiomyosarcomas.

HISTOPATHOLOGY Leiomyosarcomas are large tumors consisting of smooth muscle fibers arranged in irregular, intersecting bundles and fascicles in the dermis and subcutis, often with infiltrating borders. Tumor cells exhibit smooth muscle differentiation with atypical cytologic features such as nuclear hyperchromasia, prominent nucleoli, mitosis, and necrosis (Fig. 127-3). In less well-differentiated areas, highly pleomorphic and multinucleated cells may be found.[4] Granular cell, epithelioid cell, myxoid, and sclerosing (or desmoplastic) variants have been described.[16] Leiomyosarcomas must be histopathologically distinguished from other malignant cutaneous spindle cell tumors, such as spindle cell melanoma, spindle cell squamous cell carcinoma, or atypical fibroxanthoma. Leiomyosarcomas stain positive with smooth-muscle actin, desmin, and vimentin and occasionally with S100 and cytokeratin, which makes distinguishing them from melanoma and squamous cell carcinoma difficult in certain cases.[4,17,18]

DIFFERENTIAL DIAGNOSIS Differential diagnosis of leiomyosarcoma includes any solitary, enlarging dermal or subcutaneous nodule: lipoma, dermatofibroma, dermatofibrosarcoma, neurofibroma, spindle cell melanoma, spindle cell squamous cell carcinoma, and atypical fibroxanthoma.

PROGNOSIS AND CLINICAL COURSE The most important prognostic factor depends on whether the leiomyosarcoma is of cutaneous or subcutaneous origin. Although both cutaneous and subcutaneous lesions may recur locally in up to one-third to one-half of cases, the risk of metastasis is 5 percent to 10 percent for cutaneous leiomyosarcomas compared with 30 percent to 60 percent for subcutaneous leiomyosarcomas.[4,8,14,19–23] The lung is the most common location of metastasis.

TREATMENT Therapy for superficial leiomyosarcoma is wide local excision with 3- to 5-cm margins and re-excision for recurrent lesions.[19] On acral locations, complete excision may require amputation.[19] Patients with subcutaneous leiomyosarcomas should undergo a chest x-ray for metastases. Adjuvant radiation and/or chemotherapy has unclear benefit. Alternative local treatment modalities in selected patients include Mohs micrographic surgery, cryosurgery, and isolated limb perfusion with chemotherapeutic agents.[19,24]

SMOOTH MUSCLE HAMARTOMA

AT A GLANCE

- Benign hamartomatous proliferation of smooth muscle.
- Presenting as a solitary patch or plaque on the trunk.
- Associated with variable pigmentation, hypertrichosis, and follicular prominence.
- Clinical and histologic features similar to Becker's nevus.

Smooth Muscle Hamartoma

EPIDEMIOLOGY First described by Stokes in 1923,[25] smooth muscle hamartoma has become increasingly recognized during the last two decades. Most cases are congenital but some are acquired,[26,27] and prevalence estimates of up to 0.2 percent in children have been reported.[27]

ETIOLOGY AND PATHOGENESIS Smooth muscle hamartoma is a benign proliferation of mature smooth muscle. The cause is unknown, and the majority of cases are present from birth.

CLINICAL FINDINGS Smooth muscle hamartoma is usually found on the trunk or extremity (Fig. 127-4) and may take one of several forms: a single patch or plaque with or without follicular prominence, grouped solitary lesions (rarely with a linear distribution), and diffuse skin involvement as seen in the Michelin tire baby syndrome.[28,29] Lesions can exhibit variable hyperpigmentation and hypertrichosis. Vellus hairs may be prominent. Some can produce worm-like movements ("vermiculation"), and stroking may induce transient induration with piloerection ("pseudo-Darier sign"). Smooth muscle hamartoma shares some clinical and histologic features with Becker's nevus. Some authors consider these lesions a

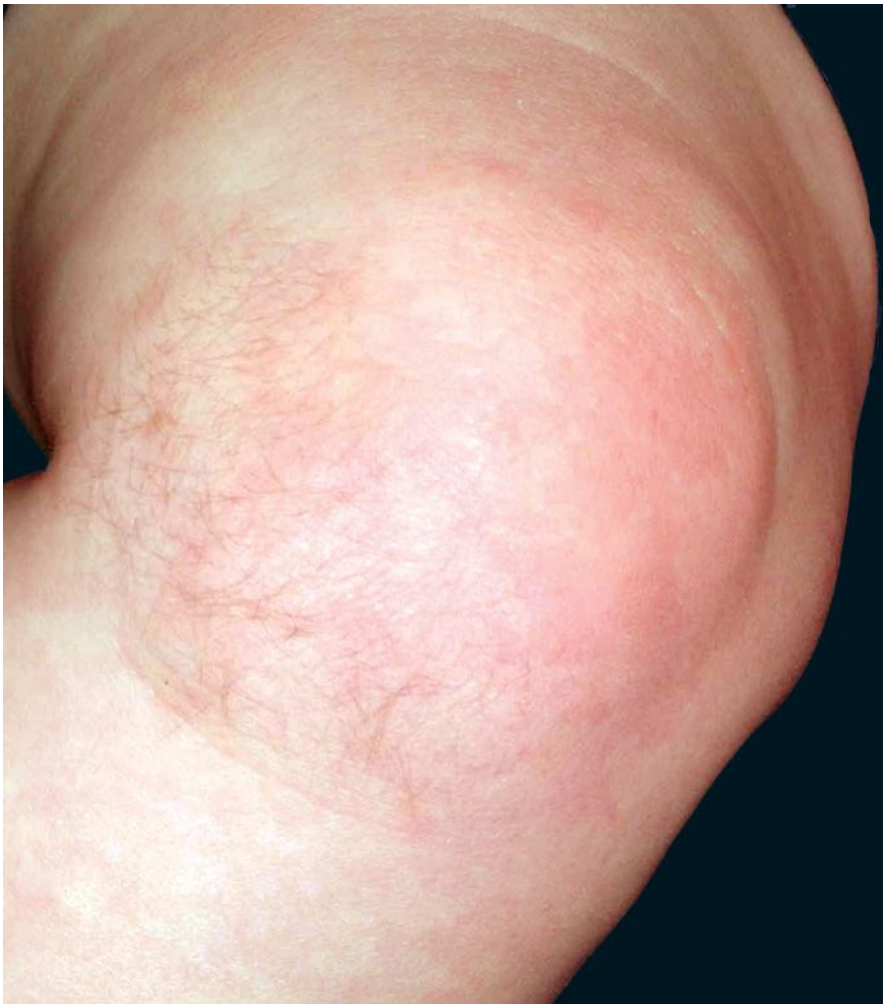

▲ **FIGURE 127-4** Smooth muscle hamartoma. This tumor presented with a focal area of hypertrichosis on the leg. (Photo from the collection of Dr. Amy Paller, MD, Children's Memorial Hospital, Chicago, IL.)

spectrum,[27] whereas others prefer to keep them separate.[26,30]

HISTOPATHOLOGY There is a marked increase of sharply circumscribed bundles of smooth muscle fibers that are haphazardly arranged in the reticular dermis. These fibers are sometimes associated with follicular units. There may be basal layer hyperpigmentation, as well as acanthosis and papillomatosis of the overlying epidermis. Factors that help to distinguish smooth muscle hamartomas from pilar leiomyomas include the grouping of smooth muscle fibers into discrete bundles and the lack of intermingling of these bundles with dermal collagen fibers.

DIFFERENTIAL DIAGNOSIS Differential diagnosis of hamartoma includes congenital nevus, Becker's nevus, café-au-lait macule, leiomyoma, neurofibroma, and solitary mastocytoma.

PROGNOSIS AND CLINICAL COURSE Malignant degeneration has not been reported. Although the localized form is usually not associated with other congenital anomalies,[27] patients with the generalized form have been reported to have multiple associated congenital malformations[31] and psychomotor retardation.[31,32]

TREATMENT No specific treatment is indicated. Surgical excision can be performed if the lesions are of cosmetic concern.

TUMORS OF STRIATED MUSCLE

Tumors of striated muscle include true neoplasms of striated muscle differentiation (rhabdomyomas and rhabdomyosarcomas) as well as non-neoplastic neuromuscular and rhabdomyomatous mesenchymal hamartomas (RMHs).

Rhabdomyoma

EPIDEMIOLOGY Extracardiac rhabdomyomas are extremely rare and comprise fewer than 2 percent of striated muscle neoplasms.[33] The adult and fetal types of rhabdomyomas occur predominantly in male patients. Cardiac rhabdomyomas occur in approximately 30 percent to 50 percent of patients with tuberous sclerosis (TS; see Chap. 141).[34]

ETIOLOGY AND PATHOGENESIS Rhabdomyomas are benign tumors of striated muscle. Extracardiac rhabdomyomas are not associated with TS, whereas a significant portion of patients with cardiac rhabdomyomas are ultimately diagnosed with TS.

CLINICAL FINDINGS Extracardiac rhabdomyomas are subdivided into three types: adult, fetal, and genital.[33,35] The designation as *adult* or *fetal* refers to the tumor's resemblance to adult or fetal skeletal muscle, not to the age of the patient.[35] Adult and fetal types usually arise in the soft tissues or mucosal surfaces of the head and neck region soon after birth. They are usually asymptomatic. The fetal type has been repeatedly associated with basal cell nevus syndrome.[35] Genital rhabdomyomas usually occur as small polypoid vaginal or vulvar lesions in middle-aged women.[35]

HISTOPATHOLOGY Rhabdomyomas are composed of fascicles of oval and polygonal-shaped cells with eosinophilic, often vacuolar cytoplasm and eccentrically placed nuclei.[33] Atypia, mitosis, and pleomorphism are absent.

DIFFERENTIAL DIAGNOSIS Differential diagnosis of rhabdomyomas includes granular cell tumor (GCT), hibernoma, and reticulohistiocytoma.

PROGNOSIS AND CLINICAL COURSE Extracardiac and cardiac rhabdomyomas have a very low risk of malignant degeneration. Many cardiac rhabdomyomas regress spontaneously with age.

TREATMENT The treatment of choice for symptomatic extracardiac rhabdomyomas is surgical excision.

RHABDOMYOMA AT A GLANCE

- Benign neoplasms of striated muscle.
- Most common on the head and neck of young males.
- Non-cardiac rhabdomyomas usually asymptomatic.
- Surgical excision is treatment of choice.





RHABDOMYOSARCOMA AT A GLANCE

- Malignant neoplasm of striated muscle.
- Most common soft-tissue sarcoma in children.
- Presentation: Subcutaneous or ulcerated tumor on extremities or head and neck; rare cause of "blueberry muffin baby."
- Treatment: Surgical excision, chemotherapy, and/or radiotherapy.
- Prognosis: Poor.

Rhabdomyosarcoma

EPIDEMIOLOGY Rhabdomyosarcoma is the most frequent soft-tissue sarcoma of childhood with annual incidence of 4.3/million, accounting for approximately 50 percent of soft-tissue sarcomas in children younger than age 15 years and 5 percent to 8 percent of all childhood cancers.[36–38] Only approximately 0.7 percent occur as primary skin lesions.[38] Males are more commonly affected than females.[36]

ETIOLOGY AND PATHOGENESIS Rhabdomyosarcomas are malignant neoplasms derived from skeletal muscle precursors. Primary cutaneous disease is rare, and skin involvement is more commonly a result of either direct extension from underlying soft tissues or metastases.[39] Four sub-types have been described based on histologic appearance: embryonal, alveolar, botryoid, and pleomorphic. The embryonal type is most common, followed by alveolar. Alveolar rhabdomyosarcoma is characterized at the molecular level by novel fusion genes combining the forkhead (*FKHR*) gene with either the *PAX3* or the *PAX7* gene, producing a t(2;13)(q35;q14) or t(1;13)(p36;q14), respectively.[36]

CLINICAL FINDINGS Cutaneous rhabdomyosarcoma typically presents as an enlarging subcutaneous or ulcerated tumor involving the head and neck, the genitourinary tract, or the extremities. A deep soft-tissue rhabdomyosarcoma can also extend into the overlying skin and present as a cutaneous nodule.[38] In neonates, congenital alveolar rhabdomyosarcoma is a very rare cause of "blueberry muffin baby" in which multiple cutaneous and subcutaneous metastases present as scattered blue nodules.

HISTOPATHOLOGY Rhabdomyosarcoma is composed of sheets of pleomorphic, small blue cells infiltrating the dermis and subcutaneous tissue. High mitotic index is present, and focal areas of necrosis can often be identified.[39] The embryonic type is composed of interlocking bands of spindle cells and sheets of small round cells whereas the alveolar type exhibits loss of cellular cohesion leading to spaces resembling alveoli. Immunohistochemistry can be helpful in differentiating rhabdomyosarcoma from other "small blue cell tumors." Rhabdomyosarcomas express positivity for muscle-specific actin, desmin, myoD1, and myogenin. Reverse transcription polymerase chain reaction and fluorescence in situ hybridization analysis can used to detect the t(2;13)(q35;q14) and t(1;13)(p36;q14) chromosomal translocations.[36,39]

DIFFERENTIAL DIAGNOSIS Differential diagnosis of rhabdomyosarcoma includes hemangioma, hematoma, neuroblastoma, and other soft-tissue sarcomas.

PROGNOSIS AND CLINICAL COURSE Prognosis is poor, with many patients succumbing to their disease. Even with appropriate treatment, rhabdomyosarcomas can recur and metastasize to regional lymph nodes, lung, bone, and heart. Congenital alveolar rhabdomyosarcoma has an especially poor prognosis: There are no reports in the literature of survivors.[36]

TREATMENT Treatment of rhabdomyosarcoma consists of a combination of surgical excision, chemotherapy, and radiotherapy.

Neuromuscular Hamartoma

Rhabdomyomatous Mesenchymal Hamartoma

BENIGN PROLIFERATIONS OF NERVES: NEUROMAS

Traumatic (Amputation) Neuroma

EPIDEMIOLOGY The exact incidence of traumatic neuromas is not known. Several small studies suggest that up to 30 percent of amputations result in neuromas.[42,43]

ETIOLOGY AND PATHOGENESIS When a nerve is partially or completely severed, axons and Schwann cells can proliferate from the proximal stump and form a disorganized tangle of nerves and fibroblasts, called a *traumatic neuroma*. Within the bundle of nerves and fibroblasts, the axons can begin to synapse and send pain signals. These signals occur spontaneously or after mechanical thresholds lower than in normal nerves. The nerve proliferation typical of accessory digits may also represent an example of traumatic neuroma.

NEUROMAS AT A GLANCE

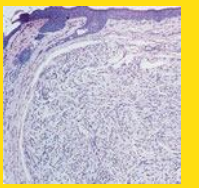

- Nonneoplastic overgrowths of nerves; benign
- Consist of both Schwann cells and axons
- Presentation: Flesh-colored papules or nodules
- Treatment: Excision

CLINICAL FINDINGS Traumatic neuromas are flesh-colored papules or nodules occurring at the sites of previous trauma or surgery. They often occur within suture lines and can be very painful.

HISTOPATHOLOGY Histologically, a neuroma appears as a collection of nerve fascicles that are haphazardly arranged. A fibrous or collagen sheath may surround neuromas, but these neuromas are not encapsulated by perineurium. The neuromas stain for EMA. Staining of the neural lesions is reviewed in Table 127-1.

DIFFERENTIAL DIAGNOSIS Differential diagnosis of neuromas includes hypertrophic scar, dermatofibroma, digital fibrokeratoma, and verruca vulgaris.

TREATMENT Temporary pain relief can be achieved with a local anesthetic nerve block. For more permanent pain relief, surgical treatment aims either at isolating the nerve from injury or excising the neuroma.[44]

TABLE 127-1
Staining of Neural Hyperplasias and Neoplasms

Neural Proliferation	S100	Neurofilament	Epithelial Membrane Antigen (EMA)	Other
Traumatic neuroma	+	+	+	Neuron-specific enolase positive
Palisaded encapsulated neuroma	+	+	+ for the capsule	
Schwannoma	+	–	+ for the capsule only	Vimentin positive
Neurofibroma	+	Variable	–	
Plexiform neurofibroma	+	+		
Neurothekeoma	+	–	Variable	Vimentin variable; usually EMA negative
Cellular neurothekeoma	–		–	CD57 positive; Ki-Mip positive
Perineurioma	–	–	+	Vimentin positive; neuron-specific enolase negative
Malignant peripheral nerve sheath tumor	+	+	Variable	Vimentin variable; cytokeratin negative; neuron-specific enolase positive
Primitive neuroectodermal tumor	+ if differentiated			Neuron-specific enolase positive; CD99 positive
Granular cell tumor	+			Neuron-specific enolase positive

+ = positive; – = negative.

Palisaded Encapsulated Neuroma

EPIDEMIOLOGY Palisaded encapsulated neuromas (PENs) present in adults, mostly in their third to fifth decade. There appears to be no gender predilection. PENs makes up approximately one-fourth of benign cutaneous neural lesions.[45]

ETIOLOGY AND PATHOGENESIS PENs consist of a hamartomatous overgrowth of Schwann cells.[46] The etiology is unknown.

CLINICAL FINDINGS PENs often present as asymptomatic, flesh-colored papules or nodules that are smaller than 1 cm in diameter. PENs are located on the face in approximately 80 percent of cases.[45] PEN is almost never diagnosed clinically; the most common misdiagnoses are dermal melanocytic nevus, basal cell carcinoma, and adnexal tumor.

HISTOPATHOLOGY PENs are well-demarcated dermal nodules composed of fascicles of Schwann cells (Fig. 127-5). Contrary to what the name implies, the capsule is rarely complete and the palisading typical of schwannomas is often indistinct. Special stains demonstrate variable numbers of axons within the lesion. The capsule often stains with EMA, suggesting a perineural origin, and the tumor body stains for S100, suggesting a Schwann cell origin (see Table 127-1).[47,48] Some PENs may actually be small dermal schwannomas that contain a few residual entrapped axons.[49]

DIFFERENTIAL DIAGNOSIS Differential diagnosis of PEN includes dermal melanocytic nevus, basal cell carcinoma, adnexal tumor, and neurofibroma.

TREATMENT Excision is the treatment of choice. There is no evidence of an association between PEN and neurofibromatosis (NF; see Chap. 142) or multiple endocrine neoplasia syndrome type 2B (MEN2B; see Mucosal Neuromas and Multiple Endocrine Neoplasia Syndrome Type 2B).

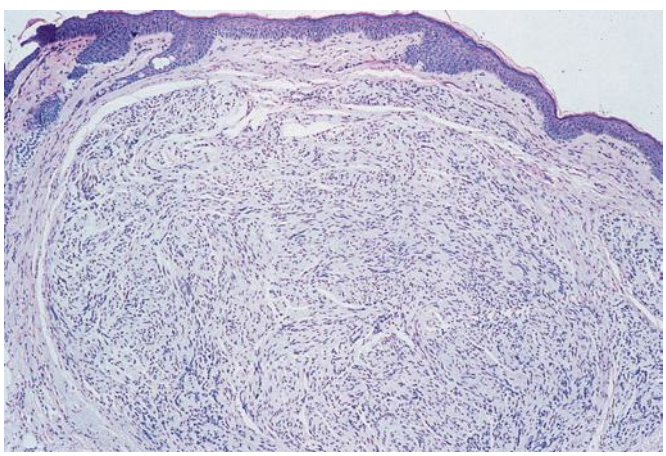

▲ **FIGURE 127-5** Histologic appearance of a typical palisaded encapsulated neuroma. The tumor is composed of fascicles of Schwann cells and surrounded by a delicate capsule best seen on the left. There is a suggestion of nuclear palisading, but this is not as pronounced as that seen in a schwannoma. (The axons that are normally also present cannot be seen on this stain; hematoxylin and eosin, ×40.)

Mucosal Neuromas and Multiple Endocrine Neoplasia Syndrome Type 2B

EPIDEMIOLOGY Due to inconsistent nomenclature, the incidence of mucosal neuromas is not known.[50]

ETIOLOGY AND PATHOGENESIS MEN2B is an autosomal dominant condition. MEN2B is caused by germline mutations of the *RET* proto-oncogene located on chromosome 10q11.2.[51] The mutation is a result of substituting a threonine for a methionine in the tyrosine kinase domain of the RET protein.[49]





CLINICAL FINDINGS MEN2A is characterized by the triad of medullary carcinoma of the thyroid gland, pheochromocytoma, and parathyroid hyperplasia. The neoplastic spectrum of MEN2B is similar, but in addition, these patients have malformations (marfanoid habitus, facial dysmorphism) and overgrowth of mucosal nerves leading to the mucosal neuromas.[53]

The neuromas appear by 2 years of age and thus serve as an important clinical marker for identifying affected individuals in MEN2B families.[51] The neuromas involve all mucosal surfaces (oral mucosa, lips, tongue, conjunctivae) and appear as pink, pedunculated papules or nodules. The lips become enlarged and bulging, and the eyelids may be everted. Other cutaneous lesions include café-au-lait spots, facial lentigines, and hyperpigmentation of the hands and feet.

HISTOPATHOLOGY Histologically, there is hypertrophy of the mucosal nerves; some lesions may resemble PENs.

DIFFERENTIAL DIAGNOSIS Differential diagnosis of mucosal neuromas and MEN2B includes PEN and mucocele.

TREATMENT The main threat to these patients is the development of related cancers. Virtually all patients have a medullary carcinoma of the thyroid by early adulthood, and approximately one-half develop pheochromocytomas. The thyroid carcinoma is highly aggressive. Early detection and prophylactic thyroidectomy by 5 years of age are essential.[51]

OTHER NEUROMAS

Morton Neuroma

Hyperplastic/Hypertrophic Pacinian Corpuscle

BENIGN NERVE SHEATH NEOPLASMS

Schwannoma

EPIDEMIOLOGY The peak incidence of schwannomas is in the third to sixth decades. Men and women are affected similarly. Schwannomas occur sporadically or in association with neurofibromatosis type 2 (NF2), which is discussed in greater detail in Chap. 142.

ETIOLOGY AND PATHOGENESIS Schwannomas are also called *neurinomas*, *neurolem(m)omas*, or *neurilem(m)omas*. Mutations in the NF2 gene are the underlying cause of the schwannomas of both the sporadic type and NF2. They usually arise in cranial nerves, especially the vestibular nerve (the so-called *acoustic neuromas* are actually schwannomas of the vestibular division of the eighth cranial nerve); they also occur in other peripheral nerves and spinal roots.

BENIGN NERVE SHEATH NEOPLASMS AT A GLANCE

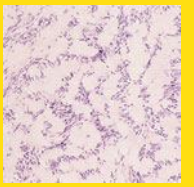

- Schwann cells and the endo- and perineurial fibroblasts make up the nerve sheath.
- Schwannomas: Benign encapsulated tumors originating from the Schwann cells.
- Neurofibromas: Benign nerve sheath tumors that are proliferations of all the nerve's elements. Presentation: Usually isolated lesions, but multiple neurofibromas found in neurofibromatosis type 1 and bilateral vestibular schwannomas found in neurofibromatosis type 2.
- Treatment: If solitary, excision. Schwannomas can often be resected without sacrificing the nerve of origin, whereas resection of a neurofibroma usually requires transection of the nerve.

CLINICAL FINDINGS ***Cutaneous Lesions.*** The classic schwannomas often involve the head and neck. Most schwannomas are either intracranial, intraspinal, or deep soft-tissue lesions. In the skin, schwannomas present as soft, asymptomatic, dermal, or subcutaneous papules or nodules. They are usually solitary.

Multiple Schwannomas. Neurilemmomatosis or schwannomatosis presents with multiple cutaneous, soft-tissue, or spinal schwannomas, but without vestibular schwannomas or other central nervous system tumors typical of NF2 (such as meningiomas or ependymomas). This entity is usually sporadic but can rarely be familial. Some of these patients may have unrecognized NF2, either because they have had insufficient cranial imaging or because they are still too young to exclude the eventual growth of the tumors.[56] Among those in whom vestibular schwannomas have been definitively excluded, a minority carry germline mutations of the NF2 gene.[56,57] Some patients are in fact somatic mosaics, which could explain the limited extent of their disease.[58] However, the majority of schwannomatosis patients (including those with the familial form) do not have germline mutations of NF2, even though their schwannomas do harbor the typical somatic mutations seen in NF2-associated schwannomas. It has been surmised that this type of schwannomatosis is due to an inheritable predisposition to somatic NF2 mutations.[58] Finally, a last group of patients has neither germline nor somatic NF2 mutations; in these individuals, an as yet unknown gene may be involved.[55]

HISTOPATHOLOGY Because a schwannoma is a neoplastic proliferation composed only of Schwann cells and devoid of axons, it grows as an eccentric nodule, displacing its nerve of origin. This growth pattern and its cellular composition distinguish schwannoma from neurofibroma (Fig. 127-6).

Schwannomas are well encapsulated. The capsule is derived from the epineurium of the schwannoma's nerve of origin. The tumor cells are typically slender, spindled, elongated, and "wavy" in appearance. Areas of high cellularity (called *Antoni A*) alternate with areas of hypocellularity (*Antoni B*), which can have a myxoid quality. In the cellular Antoni A areas, adjacent cells have a tendency to align, creating stacks of nuclei known as *palisades*. These palisades are separated by an anuclear area made up of stacked cytoplasmic extensions; these stacks of nuclei and cell processes form the so-called *Verocay bodies* (see Fig. 127-6). Tumor blood vessels are characteristically thick and hyalinized.

By immunohistochemistry, schwannomas are strongly positive for S100 protein and negative for EMA and smooth muscle markers (desmin, α-actin), which distinguishes them from perineuromas (S100 negative, EMA positive, desmin and α-actin negative) and leiomyomas (S100 and EMA negative,

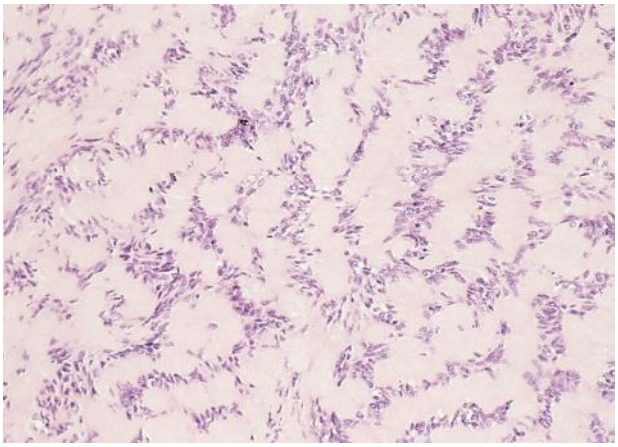

▲ **FIGURE 127-6** Photomicrograph of a schwannoma showing orderly arrangement of tumor cells into palisades and Verocay bodies. (Hematoxylin and eosin, ×100.)

desmin and α-actin positive) (see Table 127-1).

Several histologic variants of schwannoma are recognized.[59] Some tumors have extensive degeneration with cyst formation, old hemorrhage, and marked hyalinization (ancient schwannoma). This may be accompanied by bizarre nuclear morphology that does not imply malignancy. Other schwannomas are cellular with few hypocellular areas and few palisades or Verocay bodies. These tumors have been called *cellular schwannomas*.[60] They may have significant mitotic activity but behave in a benign fashion. A rare and unusual variant is the melanotic schwannoma and contains concentrically lamellated microcalcifications called *psammoma bodies*. Although this psammomatous melanotic schwannoma only rarely involves the skin, it is noteworthy that roughly one-half the affected patients have Carney syndrome (myxomas, spotty hyperpigmentation, endocrine overactivities, schwannomas)[50] and approximately 10 percent of cases metastasize.[61]

The plexiform schwannoma is a tumor that grows within a nerve, forming an agglomeration of small nodules and interconnected cords. Plexiform schwannomas have a distinct predilection for the dermis and subcutaneous tissue. The relationship between plexiform schwannoma and NF is somewhat ill-defined, because of confusing nomenclature and because some authors do not distinguish between NF1 and NF2. Some solitary, and, especially, multiple plexiform schwannomas can be associated with NF2.[62,63]

DIFFERENTIAL DIAGNOSIS Differential diagnosis of schwannomas includes lipoma, cyst, leiomyoma, and malignant peripheral nerve sheath tumor (MPNST).

TREATMENT Malignant transformation of classic schwannomas is exceedingly rare but has been reported. Excision is the treatment of choice. Plexiform schwannomas may recur, but this probably reflects incomplete excision due to their multifocal nature rather than true recurrence. Pregnancy does not alter the natural history of schwannomas.[64]

Neurofibroma

EPIDEMIOLOGY Neurofibromas often occur as solitary lesions and are common in the general population. NF1 has a prevalence of 1 in 4000.[65]

ETIOLOGY AND PATHOGENESIS Neurofibromas are hyperplasias of all the nerves elements.[66] Neurofibromas can be seen as sporadic lesions or in the context of NF1, which is covered in detail in Chap. 142. The gene for NF1 is located on the long arm of chromosome 17 (17q11.2). At least one of the functions of the NF1 protein, neurofibromin, is regulation of the *ras* oncogene.[67–69] Although it has been shown that ablating NF1 in mice can lead to the development of neurofibromas,[70] the effects on the levels of *ras* are not consistent and, thus, other stromal or genetic effects must contribute to the development of neurofibromas.

CLINICAL FINDINGS Cutaneous neurofibromas present as protuberant to pedunculated, flesh-colored, soft papules or nodules. They are usually asymptomatic, but they can be pruritic. Subcutaneous neurofibromas are usually larger than dermal lesions and consist of a fusiform swelling involving a larger nerve. In patients with NF1, the tumors start appearing in early childhood and may be quite variable in size. NF1 has a highly variable expressivity, even among patients from the same kindred who have identical germline mutations.[71] Another type of neurofibroma is the plexiform variant (Fig. 127-7), which involves an entire large nerve and its branches (see eFig. 127-7.1 in on-line edition), forming a mass of tangled, rope-like structures that feel similar to a "bag of worms" on palpation and can be associated with massive soft-tissue overgrowth, leading to functional impairment.

HISTOPATHOLOGY Histologically, a neurofibroma is composed of Schwann cells, fibroblasts, endothelial cells, perineurial fibroblasts, mast cells, and axons, all arranged haphazardly in a matrix that contains collagen and myxoid ground substance in various proportions (see eFig. 127-7.2 in on-line edition). Dermal neurofibromas are circumscribed but unencapsulated nodules. A rare sub-type of neurofibroma is the diffuse variant that involves the skin and subcutaneous tissue in a plaque-like fashion, surrounding rather than displacing pre-existing structures such as skin appendages. Plexiform neurofibromas have the same histologic appearance as ordinary neurofibromas but involve an entire nerve and its branches; they also infiltrate the surrounding soft tissue. A variant with a very unusual histologic appearance has been described as *dendritic cell neurofibroma with pseudorosettes*.[72] Finally, some neurofibromas are melanotic.

DIFFERENTIAL DIAGNOSIS Differential diagnosis of neurofibroma includes fibrolipoma, lipoma, and MPNST.

TREATMENT Solitary dermal neurofibromas can be excised. Management of patients with NF1[73] and is discussed in Chap. 142. Resection is currently the best treatment option for plexiform neurofibromas; however, the lesions frequently recur after resection. Recurrence is more commonly associated with a young patient age, incomplete tumor resection, or non-extremity tumor location.[74]

Neurothekeoma/Nerve Sheath Myxoma

EPIDEMIOLOGY The classic nerve sheath myxoma occurs in middle-aged adults with a female-male ratio of 2:1. Cellular





▲ **FIGURE 127-7** Plexiform neurofibroma on the arm. The excoriations show the pruritus associated with these lesions. (Photo from the collection of Dr. Amy Paller, MD, Children's Memorial Hospital, Chicago, IL.)

neurothekeoma most commonly occurs in younger adults.[75–77] This lesion has also been reported in children.[78]

ETIOLOGY AND PATHOGENESIS Neurothekeoma can be found in the literature under several different names such as *nerve sheath myxoma, benign myxoid tumor of nerve sheath, perineurial myxoma, bizarre cutaneous neurofibroma,* and *pacinian neurofibroma*. The last two names are actually misnomers. Two large series established it as an entity.[79] Nerve sheath myxomas consist of Schwann cells and perineural cells in a myxoid stroma. Variants of nerve sheath myxoma that are more cellular and lack the myxoid matrix have been reported as *cellular neurothekeoma*, but these tumors often lack evidence of nerve sheath differentiation and may be more closely related to fibrohistiocytic tumors.[79,80]

CLINICAL FINDINGS ***Cutaneous Lesions.*** These tumors arise in the dermis of the head, neck, shoulder, or arm where they present as nondescript, asymptomatic papules or nodules. The most common locations are the upper extremity (33.6 percent), the head and neck (29.4 percent), and the trunk (17.2 percent).[78]

HISTOPATHOLOGY The "classical" nerve sheath myxoma is hypocellular, very myxoid, and has a distinctly lobulated growth pattern. These tumors are S100 positive with immunohistochemical evidence of nerve sheath derivation (see Table 127-1).[79] They usually stain negatively for EMA. The tumor expands the dermis, leaving a grenz zone. Several cases of neurothekeomas have been reported that stain negatively for S100, and these tumors have been called *myxoid cellular neurothekeomas*.

Typical cellular neurothekeomas do not express the Schwann cell marker, S100, or the perineural marker EMA but they stain positively for CD57 and the monocyte marker Ki-M1p (see Table 127-1).

DIFFERENTIAL DIAGNOSIS Differential diagnosis of neurothekeomas includes cyst, fibrolipoma, dermatofibroma, dermal nevus, neurofibroma, neuroblastoma, and leiomyoma.

TREATMENT Neurothekeomas are clinically benign, and there is no recurrence after complete excision, but incomplete excision may result in recurrence.

Perineuroma

EPIDEMIOLOGY These are uncommon benign tumors and, due to the limited reports, epidemiologic data are scarce. Cutaneous and soft-tissue perineuriomas have a female-male ratio of 2:1.

ETIOLOGY AND PATHOGENESIS Perineurial cells form a sheath for peripheral nerves. A perineurioma is a benign peripheral nerve sheath tumor composed of cells that stain positive for EMA and negative for S100 and neurofilament (see Table 127-1).

Neither intra- nor extraneural perineuriomas appear to be associated with NF1 or NF2, but chromosome 22 deletions have been seen.[82,85,87]

CLINICAL FINDINGS There are two forms of perineurioma. One is intraneural and presents as a fusiform swelling of a major nerve, often with signs of mononeuropathy. The other form of perineurioma is extraneural. It usually arises in soft tissue, but, recently, cutaneous examples are increasingly being reported. Cutaneous perineuriomas present as flesh-colored, superficial nodules ranging in size from 4 to 14 mm. Soft-tissue perineuriomas tend to be larger and have been reported up to 58 mm in

size.[81] Perineuriomas are most commonly reported on the leg or trunk; however, sclerosing perineuriomas most commonly present on the hand.

HISTOPATHOLOGY Histologically, the intraneural perineurioma is confined to the nerve and composed of very delicate, elongated spindle cells that grow around axons, forming whorls composed of multiple concentric layers.[82] These whorls are similar to the "onion bulbs" seen in certain types of hypertrophic neuropathy. In the older literature, intraneural perineurioma is often called *localized hypertrophic neuropathy*. The cells in perineurioma clearly differentiate along perineurial lines, as shown by ultrastructure and immunohistochemistry,[82] whereas the "onion bulbs" of hypertrophic neuropathy are composed of Schwann cells. Cytogenetic evidence indicates that intraneural perineurioma is a true neoplasm. Immunohistochemistry[81,83–86] indicates perineurial differentiation (see Table 127-1).

DIFFERENTIAL DIAGNOSIS Differential diagnosis of perineurioma includes dermal nevus, dermatofibroma, and infundibular cyst.

TREATMENT Excision is curative.

MALIGNANT TUMORS OF NERVE

Malignant Nerve Sheath Tumors

EPIDEMIOLOGY Only 2 percent of nerve sheath tumors are MPNSTs.[88] Depending on the series, approximately 20 percent to 70 percent of MPNSTs occur in patients with NF1.[69] Young and middle-aged adults are most commonly affected.

ETIOLOGY AND PATHOGENESIS MPNST is also known as *neurofibrosarcoma*, *neurogenic sarcoma*, *neurosarcoma*, and *malignant schwannoma*, but because its histogenesis is uncertain, the noncommittal term *MPNST* is preferred. Plexiform neurofibromas and neurofibromas involving medium-sized to large nerves can undergo malignant degeneration into MPNSTs. Benign schwannomas and cutaneous neurofibromas, on the other hand, almost never undergo malignant transformation. There have been very few cases reported.[89]

CLINICAL FINDINGS These neoplasms arise mostly in the deep, soft tissues as nodules. Primary cutaneous MPNSTs are rare.[90,91]

HISTOPATHOLOGY MPNSTs often have a relatively non-specific presentation of interlacing bundles of spindle cells. Most tumors consist of perineural or endoneural fibroblasts.[92] Often, the major reason for calling such a tumor MPNST is that it arises within a nerve or a neurofibroma and shows some immunoreactivity for S100 protein.[93] In addition to S100 staining, MPNSTs can also stain for neuron-specific enolase, neurofilament protein, and myelin basic protein, although staining can be very weak (see Table 127-1). Cytokeratin stains are negative. MPNSTs can contain heterologous components such as bone, cartilage, glandular or squamous epithelium, and skeletal muscle. An MPNST with a rhabdomyosarcomatous component is called a *malignant triton tumor* and stain positive for myoglobin. In some MPNSTs, the tumor cells have an epithelioid appearance, and this variant must be distinguished from melanoma.[94]

DIFFERENTIAL DIAGNOSIS Differential diagnosis of MPNSTs includes neurofibroma, lipoma, and cyst.

TREATMENT MPNSTs in patients with NF are aggressive tumors with a tendency to recur and metastasize. Treatment is surgical. Outcome is guarded with reported 5-year survival rates of no more than 50 percent in spite of aggressive therapy.[69] Primary cutaneous MPNSTs may have a better prognosis.[90,91]

MALIGNANT NERVE SHEATH TUMORS AT A GLANCE

- Malignant nerve sheath tumors are also known as *neurofibrosarcoma*, *neurogenic sarcoma*, *neurosarcoma* or *malignant schwannoma*.
- Two percent of nerve sheath tumors are malignant peripheral nerve sheath tumors.
- Twenty percent to seventy percent of malignant peripheral nerve sheath tumors occur in neurofibromatosis type 1.
- Clinical presentation: Nodules in the deep soft tissues.
- Treatment: Surgical.
- Outcome: Guarded, with 5-year survival rates of not more than 50 percent.

Primitive Neuroectodermal Tumor

MISCELLANEOUS TUMORS

Granular Cell Tumor

EPIDEMIOLOGY GCTs are rare. The age range at presentation is usually from the second through the sixth decades.[100]

ETIOLOGY AND PATHOGENESIS GCTs may also be referred to as *Abrikossoff tumors*. GCTs are neoplasms of uncertain histogenesis, but due to the S100 staining, current opinion favors neural crest origin.[101] The etiology is unknown, but they have been attributed to chronic trauma.[100]

CLINICAL FINDINGS GCTs have been reported in many anatomic sites but are most often seen in the tongue and skin. The tongue is the most common single anatomic site reported; however, 44 percent of GCTs occurred in skin or subcutaneous tissue. GCTs have also been reported in the breast, genitalia, esophagus, and larynx.[100] Multiple GCTs are seen in approximately 10 percent to 25 percent of affected patients.[101] Most cutaneous GCTs are asymptomatic papules or nodules smaller than 3 cm in diameter.

HISTOPATHOLOGY The classical histologic picture is that of an ill-defined, dermal, non-encapsulated nodule composed of large, polyhedral cells that grow in a sheet-like fashion. The cells have distinct cell borders, small, round, central nuclei,

GRANULAR CELL TUMOR AT A GLANCE

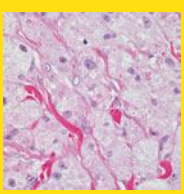

- S100 positive; suspected to be of neural crest origin.
- Most common single anatomic site: Tongue.
- Forty-four percent occur in skin.
- Treatment: Excision.



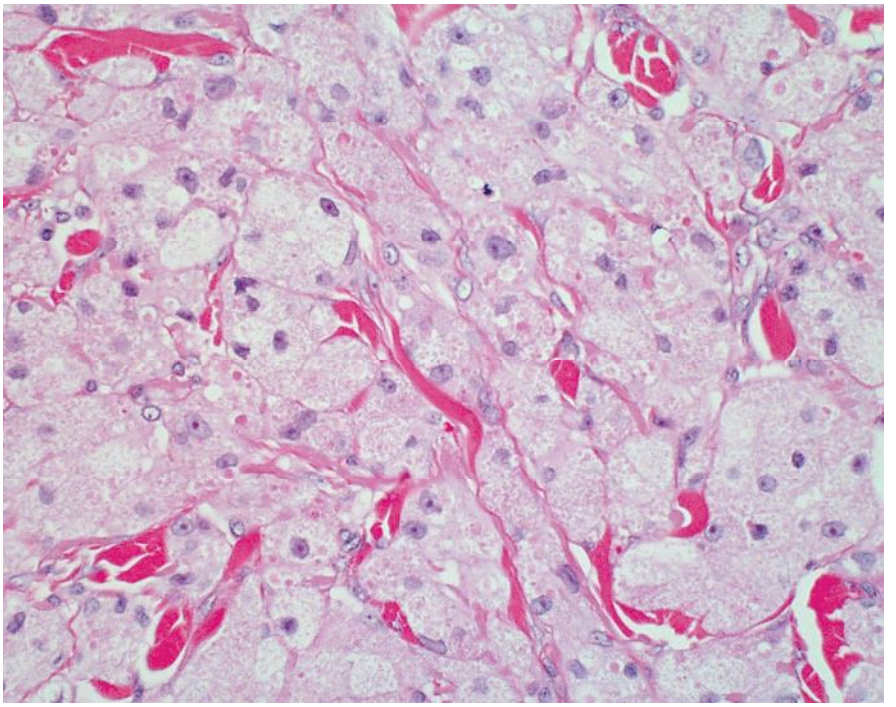

▲ **FIGURE 127-8** Histologic examination of granular cell tumor. The cells have distinct cell borders; small, round, central nuclei; and abundant granular cytoplasm. (Hematoxylin and eosin, ×400.)

and abundant granular cytoplasm (Fig. 127-8). The cytoplasmic granules stain strongly with the periodic acid-Schiff stain and retain this characteristic after diastase digestion. By immunohistochemistry, the granular cells are strongly positive for S100 protein (see Table 127-1; see eFig. 127-8.1 in on-line edition). Ultrastructurally, the granules consist of phagolysosomes containing granular and membranous debris.[101] An unusual plexiform variant has been described.[101] Cutaneous and mucosal lesions typically have pseudoepitheliomatous hyperplasia of the overlying epithelium.

Only 1 percent to 2 percent of GCTs are malignant.[101] Clinical findings that should raise concern are a size larger than 4 to 5 cm, location in deep soft tissue, and recurrence. Histologic warning signs are the presence of increased cellularity, cytologic atypia, and especially mitotic figures and necrosis. However, some clinically malignant GCTs were small and/or histologically innocuous.[101] Therefore, the only definite proof of malignancy is metastasis. Other malignant cutaneous tumors that can contain a subpopulation of cells with granular cytoplasm, such as leiomyosarcoma, melanoma, or angiosarcoma have to be excluded pathologically.

DIFFERENTIAL DIAGNOSIS Differential diagnosis of GCTs includes squamous cell carcinoma of the tongue, leiomyosarcoma, melanoma, and angiosarcoma.

TREATMENT Excision is the treatment of choice.

Central Nervous System Heterotopia

Central nervous system heterotopias are composed of ectopic neural tissue and are divided into neuroglial heterotopia ("nasal glioma") and meningeal heterotopia (MH).

NEUROGLIAL HETEROTOPIA ***Epidemiology.*** Heterotopic neuroglial tissue or nasal gliomas are rare congenital lesions.[103]

Etiology and Pathogenesis. Neuroglial heterotopias represent displaced mature neuroglial tissue that is entrapped in dural diverticula. This occurs during craniofacial development and sometimes does not regress. These lesions are now considered malformations[104] rather than neoplasms, as the designation *nasal glioma* implies.

Clinical Findings. Heterotopic neuroglial tissue occurs as a solitary, firm, papule, often vascular appearing, most commonly in or on the nose but can also be present on the face, scalp, lip, tongue, oro- and nasopharynx, or orbit.

Histopathology. There are various admixtures of neurons, astrocytes, oligodendrocytes, ependyma, and choroid plexus. There may be significant fibrosis, which can obscure the neuroglial component.[104,105]

NEUROGLIAL HETEROTOPIA AT A GLANCE

- Rare congenital lesion commonly referred to as *nasal glioma*.
- Developmental anomaly consists of mature displaced neuroglial tissue; not a true neoplasm.
- Presentation: Most commonly as round, firm papule on the nose.
- Rarely connected to intracranial cavity.

Differential Diagnosis. Differential diagnosis of neuroglial heterotopia includes encephalocele, dermoid cyst, hemangioma, intracranial astrocytoma or meningioma with nasal extension, lymphatic malformation, lymphoma/plasmacytoma, and carcinoid tumor.

Prognosis and Clinical Course. Neuroglial heterotopias can be connected to the intracranial cavity, and therefore computed tomography and/or magnetic resonance imaging of the head is imperative before biopsy or excision. In one small series, three of 10 patients had lesions that extended into the intracranial cavity.[106]

Treatment. Surgical excision is the treatment of choice.

MENINGEAL HETEROTOPIA ***Epidemiology.*** Heterotopic meningeal tissue is a rare condition that presents most commonly in the neonatal period but can also be seen in adults. Rare familial cases have been reported.[107,108]

MENINGEAL HETEROTOPIA AT A GLANCE

- Rare lesion characterized by meningothelial elements in skin.
- Occurs in children secondary to developmental defect; occurs in adults secondary to extension of intracranial meningioma.
- Can be connected to intracranial cavity.

Etiology and Pathogenesis. MH is characterized by meningothelial elements present in the skin.[107] This condition is also known as *cutaneous meningioma, rudimentary meningocele, acroleic meningocele,* and *meningeal hamartoma*. In adults, these lesions usually represent cutaneous or subcutaneous extension of an aggressive intracranial meningioma and are commonly referred to as *cutaneous meningiomas*. In children, they are often referred to as *rudimentary meningoceles* and most likely represent a developmental defect related to abnormal attachment and closure of the neural tube during embryogenesis. There is evidence to suggest that rudimentary meningoceles represent an atretic form of a meningocele.[107] Some lesions may contain a central lumen and be connected to the dura by a fibrous band running through a skull or vertebral defect.

Clinical Findings. MH typically presents as a skin-colored nodule on the scalp over the midline or along the spine. In children, they can be associated with the "hair collar" sign, in which a ring of long, dark, coarse hair surrounds a midline scalp nodule. In adults with cutaneous meningiomas, the intracranial component itself may surprisingly cause few neurologic symptoms, and patients may actually present because of an enlarging nodule on their scalp.

Histopathology. Microscopic examination reveals a mass composed of meningothelial elements in the superficial and deep dermis surrounded by dense collagen bundles.[107] The meningothelial cells contain round nuclei with stippled chromatin and clear cytoplasm.[108] Occasionally, a whorled pattern can be observed. Psammoma bodies, collagen bodies, and calcification are variably present.[107,108]

Differential Diagnosis. Differential diagnosis of MH includes meningocele, encephalocele, aplasia cutis, and epidermal/pilar cyst.

Prognosis and Clinical Course. These lesions can be connected to the intracranial cavity, and, therefore, radiographic imaging is necessary before any invasive procedure such as biopsy or excision.

Treatment. The treatment of choice is surgical excision.

Myxopapillary Ependymoma

Cutaneous Ganglioneuroma and Ganglion Cell Tumor

KEY REFERENCES

The full reference list for all chapters is available at www.digm7.com.

3. Alam NA et al: Fumarate hydratase mutations and predisposition to cutaneous leiomyomas, uterine leiomyomas and renal cancer. *Br J Dermatol* **153**:11, 2005
4. Holst VA et al: Cutaneous smooth muscle neoplasms: Clinical features, histologic findings, and treatment options. *J Am Acad Dermatol* **46**:477, 2002
12. Batchelor RJ et al: Successful treatment of pain in two patients with cutaneous leiomyomata with the oral alpha-1 adrenoceptor antagonist, doxazosin. *Br J Dermatol* **150**:775, 2004
13. Alam M et al: Gabapentin treatment of multiple piloleiomyoma-related pain. *J Am Acad Dermatol* **46**:S27, 2002
52. Marx SJ: Molecular genetics of multiple endocrine neoplasia types 1 and 2. *Nat Rev Cancer* **5**:367, 2005
53. Tsao H: Update on familial cancer syndromes and the skin. *J Am Acad Dermatol* **42**:939, 2000
101. Ordonez NG: Granular cell tumor: A review and update. *Adv Anat Pathol* **6**:186, 1999



CHAPTER 128

Kaposi Sarcoma

Erwin Tschachler

In 1872, the Austro-Hungarian dermatologist Moriz Kaposi described five patients with multicentric cutaneous and extra-cutaneous neoplasm that primarily affected older individuals.[1] This disease, originally described as *idiopathic multiple pigment sarcoma*, was later eponymously designated Kaposi sarcoma (KS). Since then, different variants of this tumor have been described, which have distinct epidemiologic features and run distinct clinical courses but show comparable histopathologies.

ETIOLOGY AND PATHOGENESIS

Human Herpesvirus-8 and Kaposi Sarcoma

Several decades of epidemiologic data and electron microscopic studies have suggested the involvement of an infectious agent in the etiology of KS.[2,3] This suspicion was substantiated in 1994 when Chang and colleague discovered DNA of an unknown virus in KS lesions.[4] This discovery led to cloning, isolation, and characterization of a novel human herpesvirus now referred to as *Kaposi sarcoma-associated herpesvirus* (KSHV) or alternatively, human herpesvirus (HHV)-8.[5,6]

HHV-8 is a member of the γ-herpesviridae subfamily, genus rhadinovirus.[5–9] Its 165-kb DNA genome has been entirely sequenced and shown to contain approximately 90 open reading frames.[6–8] Many of the HHV-8 regulatory genes are homologous to genes of other rhadinoviruses, and several are homologous to human genes involved in regulation of apoptosis, cell proliferation, and angiogenesis.[6,9,10] As in other herpesviruses, HHV-8 gene expression is tightly controlled and either associated with viral latency such as LANA-1, V cyclin and vFLIP or lytic viral replication such as vGPCR, vIL 6, and v-bcl-2.[6,10] Several HHV-8 gene products, both of the lytic and the latent viral life cycles, have been shown to transform cells in vitro as well as in animal models in vivo.[6,10–13] It is therefore generally accepted that HHV-8 is a transforming herpesvirus[7] and that this capacity plays a direct role in the development of KS.

The host range of HHV-8 in vivo and in vitro comprises vascular and lymphatic endothelial cells as well as different types of hemopoietic cells.[5] The widely expressed 12-transmembrane light chain of the human cystine/glutamate exchange transporter system xc– has recently been put forward as fusion entry receptor of HHV-8.[14] Other surface molecules such as $\alpha_3\beta_1$ integrin and heparan sulphate proposed earlier to allow for HHV-8 infection appear to play only a secondary role.[15] However, because peripheral blood $CD19^+$ B cells, which are permissive for infection in vitro, appear not to express the cystine transporter xCT[14] other receptor molecules are likely to be identified in the future.

The routes of HHV-8 transmission are not completely known. The high number of KS in homosexual and bisexual men and the association of tumor development with certain sexual practices early on suggested the sexual transmis-

KAPOSI SARCOMA AT A GLANCE



- Multifocal, systemic tumor of endothelial cell origin with stage-dependent characteristic histopathology.
- Four clinical variants:
  - Classic Kaposi sarcoma (KS)—in old men, starts as localized form, progresses slowly.
  - Endemic African KS—most frequent neoplasm in some central African countries; includes a rapidly progressive lymphadenopathic variant.
  - KS associated with immunosuppressive therapy—most frequently in organ transplant recipients.
  - Acquired immunodeficiency syndrome (AIDS)-related KS—rapidly progressive form with early systemic involvement, predominantly in bisexual and homosexual AIDS patients.
- Invariably linked with human herpesvirus-8 infection.
- Responds well to chemo- and radiation therapy.



sion of the virus.[3] In later epidemiologic studies sexual activities were confirmed as a route for HHV-8 transmission and it was demonstrated that the transmission risk increases with the increase of numbers of sexual partners[16] and participation in certain forms of oral/genital and oral/anal sex.[16,17] By contrast, in areas where the virus is widespread, such as in Mediterranean countries and in Africa, strong evidence exists that nonsexual transmission among family members[16] plays a major role. The oropharynx is the site of strongest viral replication and high HHV-8 copy numbers are present in saliva.[18] Based on these findings, the nonsexual transmission via saliva is widely assumed to play the most important role in childhood transmission in endemic areas.[19] Vertical transmission from mother to child during pregnancy or birth seems not to play an important role for the spread of the virus.[16] For the medical profession, it is important to remember that HHV-8 may also be transmitted by blood and blood products as well as from donor organs in the course of transplantations.[16,20]

HHV-8 is present in all KS variants[21,22] and the evidence for a causal relationship between HHV-8 infection and KS tumor development is overwhelming. Among the most important arguments for a role of HHV-8 in KS pathogenesis are the findings that (1) the HHV-8 viral genome is detectable in KS lesions of all stages regardless of the clinical variant;[5,6,21,22] (2) within KS lesions HHV-8 is present in latent form in virtually all tumor cells;[23,24] and (3) KS tumor cells show monoclonal integration of viral DNA.[5,6] Furthermore, the prevalence of HHV-8 infection is largely congruent with that of KS: In areas of low incidence of KS, such as the United States and Northern Europe, HHV-8 infection is very rare (below 0.1 percent).[16,25] By contrast, in areas where high incidence of KS has been reported, such as in Southern Italy, HHV-8 prevalence is much higher and approaches 20 percent.[16,26] As expected, the highest HHV-8 prevalence has been found in central Africa in the regions known to be hotspots of African endemic KS. In this region, the seroprevalence in adults ranges from 22 percent to 71 percent.[16] Similarly, in human immunodeficiency virus (HIV)-1–infected patients in developed countries, HHV-8 prevalence is highest in homosexual and bisexual men and reflects the incidence of KS in this risk group.[16,27]

The time span from infection with HHV-8 to development of KS depends on the clinical type. Immunosuppression/dysregulation plays an important aggravating role and leads to disease manifestation in organ transplant recipients within 1 to 2 years and in HIV-1 infected patients 5 to 10 years after infection.[16] For classic KS this time span is far longer and the contributions of either host or environmental factors are not yet established.[16]

In addition to KS, HHV-8 has been implicated in the pathogenesis of pleural effusion lymphoma, a rare B cell neoplasm seen primarily in acquired immunodeficiency syndrome (AIDS) patients, and multicentric Castleman disease (MCD).[5,6,10,16] In the former, HHV-8 is invariably present and diagnostic, in the latter it is found in the majority (> 95 percent) of HIV-infected patients with MCD but only in approximately 40 percent of HIV-negative MCD patients.[10] MCD has been associated in the past also with classic KS.[28]

Histogenesis

The histogenetic derivation of the KS tumor cells (i.e., the cells lining the irregular vascular-like spaces of early and angiomatous lesions and the cells composing the bundles and interlacing fascicles of solid tumors) has been the subject of intense research over the past two decades. The immunophenotype of these cells (i.e., vWF$^{+/-}$, PAL-E^{-}, CD31^{+}, CD34^{-}, VEGFR3^{+}) characterizes them as part of the lymphatic endothelial differentiation lineage.[29,30] The recent demonstration that HHV-8 replicates better in lymphatic than in blood vascular endothelial cells is a further argument for this assumption.[31] However, the finding that infection of blood vascular endothelial cells with HHV-8 leads to a phenotypic switch towards lymphatic endothelial cells[31,32] leaves the possibility that an immature angioblast either resident in the skin or circulating and able to differentiate into both endothelial cell lineages is the initial precursor of KS tumor cells.[33,34]

Some controversy also surrounds the question of whether KS is a reversible proliferative disorder or a true malignant neoplasm. Analyses of the methylation pattern of the human androgen receptor gene have shown that lesions with both clonal and polyclonal proliferations can be identified.[5,35,36] Moreover, multiple lesions that arise in an individual patient may develop independently from distinct transformed cells and later acquire clonal characteristics.[5] Studies of HHV-8 terminal repeat sequences which show monoclonality in nodular KS lesions support these findings[37] and indicate that KS starts as a polyclonal disease with subsequent evolution to a monoclonal process.[5]

Classic Kaposi Sarcoma

EPIDEMIOLOGY The annual incidence rates for classic KS vary greatly in different geographic regions and ranges from 0.14 per million inhabitants (for both women and men) in Great Britain to 10.5 per million in men and 2.7 per million in women in Italy.[38] A preponderance of male patients has existed since the original description and a male-female ratio of approximately 3:1 is found in large surveys of most regions.[38,39] The higher KS incidence in countries surrounding the Mediterranean has led some authors to speak of a Mediterranean KS variant as a distinct entity.[40] However, because the clinical course is comparable to that of classic KS, Mediterranean KS is not treated separately here.



▲ **FIGURE 128-1** Classic variant. Plaques and papules localized on the dorsum of the foot, a site of predilection of classic Kaposi sarcoma.

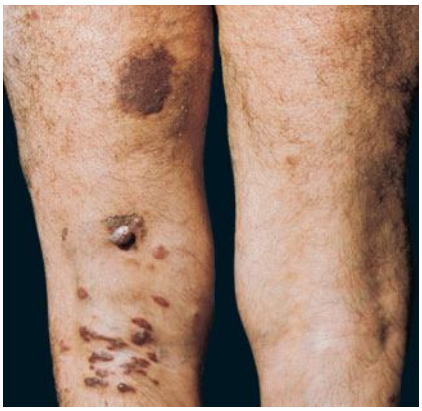

▲ **FIGURE 128-2** Tumor nodules of more advanced classic Kaposi sarcoma (Mediterranean variant) with severe involvement of extremities.

CLINICAL MANIFESTATIONS The typical patient with classic KS is a Caucasian male in his sixties with a Mediterranean or Jewish background. The tumors usually start on the skin of the distal portions of the lower extremities as unilateral or bilateral bluish-red (hematoma-like) macules. These lesions tend to progress slowly both horizontally and vertically and develop into firm plaques (Fig. 128-1) and, eventually, into nodules. During tumor progression the color changes to brownish and the skin overlying the tumor becomes hyperkeratotic and, in particular on the lower extremities, may ulcerate. Surrounding the tumor there is frequently a pitting edema which may evolve into fibrosis. Classic KS usually runs a rather benign course slowly extending proximally and patients may sometimes live with slowly progressive disease for decades.[38,39,41] After several years of progression (Fig. 128-2), dissemination to other body sites is frequently seen, and tumors may become manifest in lymph nodes, on mucous membranes, and in internal organs such as the gastrointestinal tract where it is rarely symptomatic.[41,38] Because classic KS affects mostly elderly patients, death from other causes may precede its full spread.

African Endemic Kaposi Sarcoma

EPIDEMIOLOGY An increased frequency of KS in black Africans in Central Africa was noted several decades before the outbreak of the AIDS pandemic.[42–44] In some countries of this region, KS accounts for up to 10 percent of all malignancies in men.[5,16,42,43] A prevalence of male patients, with male-female ratios ranging from 3:1 in children and up to 18:1 in adults is seen with endemic African KS.[38] The age at onset is lower than that in classic KS at 35 to 39 years for males and 25 to 39 years for females.[38]

CLINICAL MANIFESTATIONS African-endemic KS occurs as nodular, florid, infiltrative, and lymphadenopathic types.[45,46] The florid/vegetating and infiltrative variants are characterized by a more aggressive biologic behavior and lesions extend deeply into the dermis, subcutis, muscle, and bone. Lymphadenopathic African KS predominantly affects children and young adults and may follow a fulminant course with rapid progression.[47] Skin and mucosa are affected to a lesser degree. The reasons for the different courses observed in African KS are not clear and potential co-factors have not been unequivocally identified.

Kaposi Sarcoma in Therapeutically Immunosuppressed Patients

EPIDEMIOLOGY During the 1970s, a high incidence of KS was described in organ-transplant recipients receiving immunosuppressive therapy (up to 500-fold increased as compared to the control population).[48,49] Transplantation-associated KS is observed predominantly in kidney allograft recipients, whereas it occurs rarely in recipients of other solid organs and bone marrow allografts.[48–50] In addition to post-transplantation, KS has been reported in patients receiving immunosuppressive therapy for other reasons, most notably the treatment of autoimmune diseases.[51–53]

The clinical appearance and the course of KS in therapeutically immunosuppressed patients may be slowly progressive as with the classical variant but can also be rapidly disseminating like in AIDS KS (see the section Clinical Manifestations). KS can occur from 1 month to more than 10 years after transplantation.[54] The dose and type of the immunosuppressive drug are very important risk factors for developing KS and determining its clinical course.[40,50] For example the risk of KS associated with cyclosporin A is higher than with other drugs, such as glucocorticoids and azathioprine, and the disease onset is earlier.[49,50] Regression of KS can be achieved by reduction or withdrawal of the immunosuppression (see the section Clinical Manifestations). Conversely, rapid tumor progression can occur after dosage increase.[49,50] In transplantation-associated KS, a preponderance of male patients, with a ratio of approximately 3:1 is observed[50] and in geographic regions with a high incidence of classic KS as well as in ethnic groups with a higher risk KS development, the risk for transplantation associated KS is increased.[50]

CLINICAL MANIFESTATIONS Skin lesions of KS in this group of patients are identical to those of classic and HIV-associated KS. In a large series, skin involvement was found in more than 85 percent of patients with transplantation-associated KS whereas less than 15 percent had visceral disease (gastrointestinal, lungs, lymph nodes) without skin involvement.[50]

AIDS-Associated Kaposi Sarcoma

EPIDEMIOLOGY A major harbinger of the AIDS pandemic were clusters of young homosexual men suffering from KS in large U.S. cities in 1981.[55] During the first decade of the AIDS pandemic, KS had been diagnosed as the AIDS-defining disease in more than 20 percent of HIV-1–infected patients in Europe.[56] Despite a decline in recent years, KS is still the most frequent AIDS-associated tumor in men who have sex with men. Other patient groups at risk for AIDS, including intravenous drug users, hemophiliacs, blood transfusion recipients, and children born to HIV-positive mothers in industrialized countries, are far less affected.[3,57] The situation is different in Africa, where KS is the most frequent tumor arising in HIV-1–infected patients independent of risk groups, including children suffering from AIDS.[58,59]

AIDS KS differs from classic KS by its more rapid course and its rapid multifocal dissemination: early AIDS-KS lesions appear as small oval violaceous macules that develop rapidly into plaques and small nodules. They are frequently present at multiple locations at





▲ **FIGURE 128-3** Acquired immunodeficiency syndrome–associated Kaposi sarcoma. Multiple lesions at all stages of development (macules, papules, nodules) are present on the trunk. Note that the lesions follow the skin's relaxed tension lines.

disease onset and have a tendency for rapid progression. In contrast to other variants of KS, the initial lesions in AIDS patients frequently develop on the face, especially on the nose, eyelids, and ears, and on the trunk, where the lesions follow the relaxed skin tension lines (Fig. 128-3). If untreated, disseminated AIDS-KS lesions may coalesce to form large plaques involving large areas of the face, the trunk, or extremities and lead to functional impairments. The oral mucosa is frequently involved and represents the presenting site in 10 percent to 15 percent of AIDS KS (Fig. 128-4). Involvement of the pharynx is not uncommon and may result in difficulty eating, speaking, and breathing.[60]

Involvement of extra-cutaneous sites occurs more rapidly and more dramatically in patients with AIDS KS than in those with classic KS. In addition to the oral mucosa, KS lesions are most frequently found in lymph nodes, the gastrointestinal tract, and the lungs.[61–63] Although gastrointestinal KS is usually found when cutaneous lesions are present, exclusive gastrointestinal involvement is possible. The stomach and duodenum represent predilection sites and KS lesions there can cause clinical symptoms such as bleeding and ileus. Although visible on gastroscopy, such lesions are underdiagnosed histologically because they are located in the submucosa and may escape the biopsy forceps. Pulmonary KS can cause respiratory symptoms such as bronchospasm, coughing, and progressive respiratory insufficiency.[62] Bronchoscopy with transbronchial biopsy is most appropriate for the diagnosis of pulmonary KS.



▲ **FIGURE 128-4** Kaposi sarcoma lesions on the hard palate are typical manifestations of acquired immunodeficiency syndrome–associated Kaposi sarcoma.

DIFFERENTIAL DIAGNOSIS Differential diagnoses for cutaneous KS depend on the clinical stages and are shown in Box 128-1.

Box 128-1

Clinical Differential Diagnoses of Cutaneous and Mucosal Kaposi Sarcoma

Most Likely

- Localized early disease
  - Hematoma
  - Stasis dermatitis
  - Bacillary angiomatosis
  - Pyogenic granuloma
  - Well-differentiated angiosarcoma
- Advanced disease
  - Acroangiodermatitis (pseudo Kaposi)
  - Bacillary angiomatosis
- Oropharyngeal lesions
  - Non-Hodgkin lymphoma
  - Squamous cell carcinoma
  - Bacillary angiomatosis

Consider

- Localized disease
  - Dermatofibroma
  - Melanoma
  - Dermatofibrosarcoma protuberans
  - Leiomyosarcoma
  - Kaposiform hemangioendothelioma (in children)
  - Blue rubber bleb nevus syndrome
- Advanced disease
  - Metastasizing melanoma
  - Cutaneous metastasis of internal malignancies and leukemias
  - Erythema elevatum et diutinum
  - Angiosarcoma

Always Rule Out

- HIV-1 infection
- Non-HIV-1–related causes of immunosuppression
- Melanoma

HIV = human immunodeficiency virus.

HISTOPATHOLOGY

The histopathology of KS is dependent on the stage of KS development.[64–66] Early patch-like lesions exhibit rather discrete histopathologic changes, consisting mainly of an increase in the number of dermal vessels, outlined by slightly irregular endothelial cells (Fig. 128-5). These vessels, located mainly in the superficial dermis are parallel to the skin surface, are frequently slightly irregular, and may form bizarre slits and clefts. In the surrounding skin focal hemosiderin, deposits and extravasated erythrocytes can be found as well as a moderate inflammatory infiltrate. Important differential diagnoses of this stage include lymphangioma and granulation tissue.

The pathology of KS plaques is more characteristic and reveals extensive vascular proliferation at all levels of the dermis with multiple dilated and angulated vascular spaces dissecting the collagen leaving a spongy network of collagen tissue. A characteristic sign of KS papules is the presence of solid cords and fascicles of spindle cells arranged between the jagged vascular channels. This biphasic angiomatous and solid tumor morphology changes to a clear-cut sarcomatous morphology with progression of the disease.

Nodular lesions consist predominantly of spindle cells arranged in bundles and interlacing fascicles and interspersed, irregular, slit-like vascular spaces without endothelial linings. Advanced lesions may display pronounced pleomorphism, nuclear atypia, and mitotic figures. At the periphery of solid tumors, (lymph) angiomatous-like portions of KS with bizarre vascular lumina and intravascular and extravasated erythrocytes, as well as siderophages, may be preserved. Erythrocytes, which appear as eosinophilic globules, are trapped within the slits and clefts formed by the spindle cells and erythrophagocytosis are occasionally observed. As in all other stages of KS, a moderate inflammatory infiltrate consisting of lymphocytes, histiocytes, plasma cells, and, sporadically, neutrophils is regularly present.

TREATMENT

The treatment modalities for KS depend on the clinical type, the extent of the le-

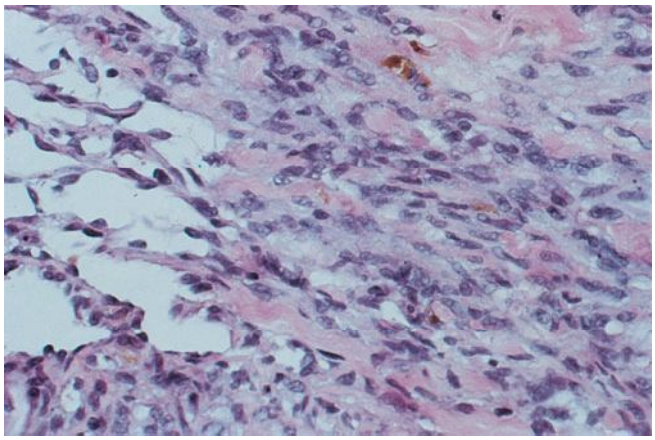

▲ **FIGURE 128-5** Histopathology of Kaposi sarcoma (biopsy taken from a nodular Kaposi sarcoma lesion). Angiomatous portions, reminiscent of a lymphangioma, as well as solid, sarcomatous fascicles are present.

sions, and on the organ system involved (Box 128-2). Despite the overwhelming evidence that infection with an oncogenic herpesvirus, i.e., HHV-8 plays a central role in KS pathogenesis; antiherpetic drugs have so far been only of experimental value.[67] Because AIDS KS incidence has been much higher than that of the other clinical variants in the past decades and due to the fact that KS in AIDS patients quickly progress into a life-threatening disease, studies on AIDS KS have brought about many of the recent insights and advances in the treatment of KS.[68,69]

Localized Cutaneous Disease

Regardless of the clinical variant, if a patient presents with only limited disease confined to the skin, local therapies aimed at eliminating individual lesions are frequently used as initial treatment.[68,69] Although recurrence rates are high, local therapies may satisfactorily slow progression of classic KS for several years. By contrast, in the other clinical variants it is imperative that local therapy is supported by additional measures such as change of the immune suppressive therapy in transplantation-associated KS and initiation of highly active antiretroviral therapy (HAART) in patients with AIDS KS.

Local therapies include surgical excision,[70] local destruction with liquid nitrogen, laser or photodynamic therapy,[71] and topical therapy with 9-*cis* retinoic acid.[72] Radiation therapy[73] is useful in localized disease at sites that are difficult to reach by other local approaches such as the nose and oral mucosa. It should also be considered in more advanced KS, in particular in resource poor settings.

PROGRESSIVE CUTANEOUS DISEASES AND INVOLVEMENT OF OTHER ORGANS ***Classic Kaposi Sarcoma.*** Chemotherapy, including doxorubicin, bleomycin, vincristine, etoposide and dacarbazine, alone or in combination has been given to patients with rapidly progressive or widespread classic KS especially if internal organs are involved.[74] However, due to the low incidence of classic KS, large comparative prospective studies are not available. As in AIDS KS, liposomal anthracyclines are effective[75] and in one recent retrospective study were demonstrated superior to low dose interferon-α.[76]

Kaposi Sarcoma in Patients with Therapeutic Immunosuppression. KS in transplant patients responds well to a reduction of immunosuppressive therapy.[49,50] Recently, replacement of calcineurin inhibitors by rapamycin has led to dramatic therapeutic improvement with complete remission of advanced KS lesions.[77,78] This effect seems to be due to the modulation of the immune response by the change of therapy and to direct antitumor effects of the drug.[78] Rapamycin may therefore also be of potential benefit for treating KS in patients not receiving immunosuppressive therapy.

AIDS-Associated Kaposi Sarcoma. Until the advent of HAART, treatment of advanced AIDS KS had been mostly palliative with either combination chemotherapies or radiation therapy.[79] During the mid 1990s HAART became available and it became possible for the first time to achieve sustained suppression of HIV-1 replication and immune recovery. Subsequent to the introduction of HAART a decrease in AIDS KS incidence and frequent remission of early KS lesions were observed during therapy.[80] Besides their effects on HIV-1 replication, protease inhibitors (one drug of the combination antiretroviral therapy) have been suggested to have a direct antitumor effect and trials evaluating these drugs in HIV-negative patients with KS are currently under way.[81] However, HAART alone is not sufficient to control KS that has already advanced. Therefore, if despite successful HAART and the control of HIV-1 replication, widespread lesions and/or the involvement of organs other than the skin occurs, addition of chemotherapy is required.[82] Of the chemotherapeutic regimens used in the past, liposomal anthracyclines have been shown to be more efficient and better tolerated than combination therapies such as bleomycin and vincristine or both combined with doxorubicin (see Box 128-2).[83–85] A typical drug regimen consists of 20 mg/m^2 liposomal anthracyclines given intra-

Box 128-2

Treatment Options for Kaposi Sarcoma

Localized disease

- Local therapy
  - Surgical excision
  - Cryotherapy
  - Topical 9-*cis* retinoic acid
- Radiation therapy

Disseminated disease/internal organ involvement

- Systemic therapy
  - For patients with AIDS—initiate highly active antiretroviral therapy
  - For patients on immunosuppressive therapy—re-evaluate drug regimen
  - For AIDS patients not responding to highly active antiretroviral therapy alone—systemic cytotoxic chemotherapy
    - Liposomal anthracyclines (e.g., liposomal doxorubicin 20–40 mg/m^2 every 2–4 wk)
    - Paclitaxel (100 mg/m^2 given every 2 wk)
  - For patients with classic Kaposi sarcoma
    - Liposomal anthracyclines (e.g., liposomal doxorubicin 20–40 mg/m^2 every 2–4 wk)
    - Vinblastine (6 mg IV once a week)
    - Doxorubicin//bleomycin//vincristine (20–30 mg/m^2//10 mg/m^2//1–2 mg// every 2–4 wk)
    - Interferon-α (3 million–30 million units daily to 3×/wk)
- Investigational treatments
  - Thalidomide
  - Vascular endothelial growth factor-antisense
  - COL-3 (matrix metalloproteinase inhibitor)

AIDS = acquired immunodeficiency syndrome.



ANGIOSARCOMA AT A GLANCE



- Malignant tumor of endothelial cell origin.
- Occurs in 3 clinical variants:
  - Primary angiosarcoma (mostly affects elderly with a predilection for head, neck, and face).
  - Angiosarcoma in areas of chronic lymphedema [most frequently in patients after lymph-node dissection due to mammary carcinoma—(Stewart-Treves syndrome)].
  - Postirradiation angiosarcoma.
- Despite complete surgical excision and/or chemotherapy, prognosis of angiosarcoma is poor.
- Several very rare low-grade angiosarcomas exist:
  - Endovascular papillary angioendothelioma
  - Epithelioid hemangioendothelioma
  - Retiform hemangioendothelioma

venously every 2 to 4 weeks.[86] An advantage of the use of liposomal anthracyclines is their continued therapeutic efficacy in patients who have been previously treated by other forms of chemotherapy. For patients with anthracycline-refractory AIDS KS, paclitaxel has recently been added as potential rescue therapy.[87] Interferon-α which has been a mainstay therapeutic approach for AIDS KS during the 1980s and early 1990s still holds some promise for AIDS patients with early disseminated KS who simultaneously receive HAART.[67]

In addition to the therapies mentioned above there are several experimental therapies ranging from vascular endothelial growth factor antisense to anti-herpetic drugs currently being evaluated in clinical trials.[68]

ANGIOSARCOMA

Epidemiology and Pathogenesis

Angiosarcomas are highly malignant vascular tumors with an incidence of approximately 0.01/100,000 affecting primarily adult patients.[88] They may occur in different organs but in more than 50 percent localize to the skin of the head and neck regions.[89,90] Besides primary tumors, which appear in previously normal skin, angiosarcomas show an increased incidence in skin with chronic lymphedema, most frequently, but not exclusively, after mastectomy with lymph node dissection. This variant is also referred to as *Stewart-Treves syndrome*[91] and was formerly classified as lymphangiosarcoma. A rare variant is postirradiation angiosarcoma, which may develop after radiation therapy for mammary carcinoma.[92]

Tumor cells of angiosarcoma express to varying degrees differentiation markers of both the lymphatic and vascular endothelial cell lineage.[93] Whether common precursor cells (i.e., angioblasts) give rise to the tumor cells remains to be seen. Therefore, the designation angiosarcoma instead of either lymphangiosarcoma or hemangiosarcoma seems appropriate at the moment. In contrast to KS, angiosarcoma is usually negative for HHV-8.

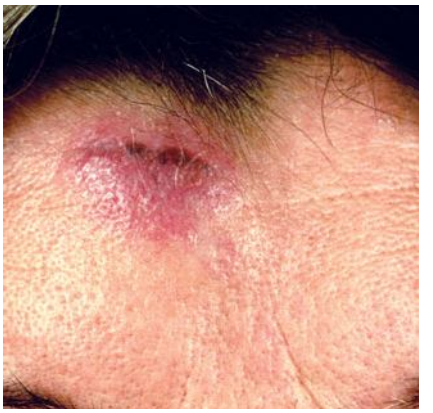

▲ **FIGURE 128-6** Cutaneous angiosarcoma of the face. Early bruise-like lesions on the forehead.



▲ **FIGURE 128-7** Cutaneous angiosarcoma of the head. Advanced lesion presenting as violaceous patch extending over the right forehead, ear, and scalp and crusted nodules in the parietal and temporoparietal regions.

Clinical Manifestations

Initially, primary angiosarcoma of the skin presents as singular or multifocal "bruise"-like patches on the skin, most frequently on the face (Fig. 128-6), scalp, or neck regions. In the "head-tilt" maneuver, where the patient lowers the head below the level of the heart, the involved skin becomes deeper red and violaceous and painful throbbing may be felt.[94] On progression, the lesions become violaceous and ill-defined spongy nodular tumors appear, which bleed easily. Horizontal spread can lead to the involvement of large skin portions (Fig. 128-7). The tu-



▲ **FIGURE 128-8** Stewart-Treves syndrome on the right forearm and hand.



▲ **FIGURE 128-9** Postirradiation angiosarcoma of the breast.

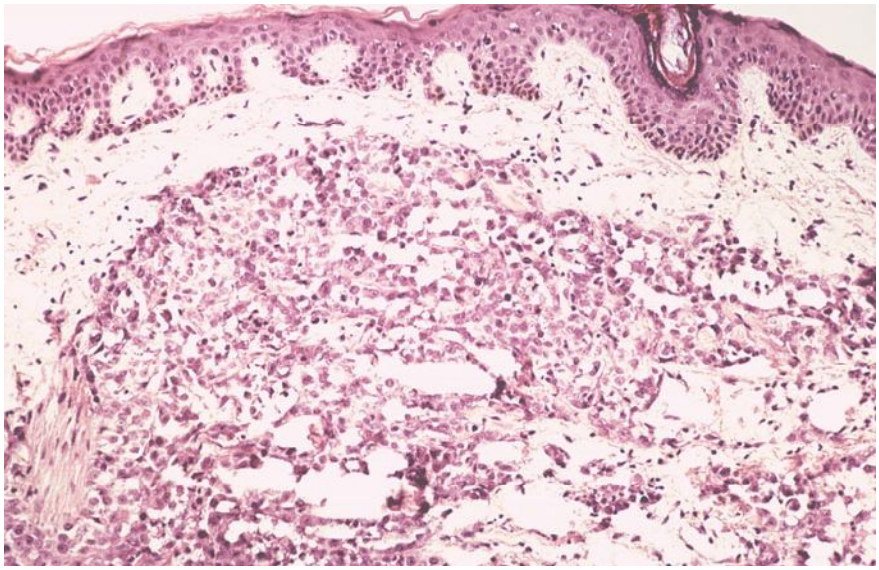

▲ **FIGURE 128-10** Histopathology of cutaneous angiosarcoma.

mor usually progresses along the vascular structures of the neck (see eFig. 128-7.1 in on-line edition) to the mediastinum but distant metastases also occur. Prognosis is poor. Angiosarcoma developing in chronic lymphedema [i.e., Stewart-Treves syndrome (Fig. 128-8) as well as post-irradiation angiosarcoma (Fig. 128-9)] arises as infiltrating hemorrhagic plaques or violaceous nodules accompanied by edema. They are also high-grade malignancies with a poor prognosis.

Differential Diagnoses

Early lesions can be confused with various skin pathologies with vascular involvement including ecchymoses, port-wine stain, rosacea, and early KS. For advanced tumors, pyogenic granuloma, lymphoma, and amelanotic melanoma, cutaneous metastasis of internal malignancies have to be considered.

HIstopathology

The different clinical variants are indistinguishable histologically and great variability with regard to differentiation of vascular elements can be seen even within individual lesions. Irregular, anastomosing vascular channels lined by endothelial cells with different degrees of atypia and mitotic activity may alternate with areas of closely packed cells with a high mitotic index and sometimes spindle-like morphology (Fig. 128-10). In the latter, less well-differentiated areas and little or no luminal differentiation is present. In particular, in these instances immunostaining for vascular markers such as CD31 and CD34 is helpful for the establishment of the diagnosis.

Treatment

Current treatment is not highly effective with an overall estimated 5-year survival of 15 percent.[90,95] Due to the rarity of angiosarcomas, comparative therapeutic trials are not available. Treatment of choice for small tumors is excision with wide margins.[95] When surgery is not an option, palliative radiotherapy or chemotherapy should be considered.[95–97] Both liposomal doxorubicin and paclitaxel were recently demonstrated to be of benefit for patients with widespread disease.[96–98] Interferon-α, although not effective by itself, holds some promise in combination with either doxorubicin or 13-*cis* retinoic acid.[99]

Rare Low-Grade Angiosarcomas

KEY REFERENCES

The full reference list for all chapters is available at www.digm7.com.

1. Kaposi M: Idiopathisches multiples Pigmentsarkom der Haut. *Arch Dermatol Syphil* **4**:265, 1872
4. Chang Y et al: Identification of herpesvirus-like DNA sequences in AIDS-associated Kaposi's sarcoma. *Science* **266**:1865, 1994
5. Boshoff C, Weiss RA: Epidemiology and pathogenesis of Kaposi's sarcoma-associated herpesvirus. *Phil Trans R Soc Lond B* **356**:517, 2001
6. Dourmishev LA et al: Molecular genetics of Kaposi's sarcoma-associated herpesvirus (human herpesvirus-8) epidemiology and pathogenesis. *Microbiol Mol Biol Rev* **67**:175, 2003
16. Dukers NH, Rezza G: Human herpesvirus 8 epidemiology: What we do and do not know. *AIDS* **17**:1717, 2003
29. Weninger W et al: Expression of vascular endothelial growth factor receptor-3 and podoplanin suggests a lymphatic endothelial cell origin of Kaposi's sarcoma tumor cells. *Lab Invest* **79**:243, 1999
38. Iscovich J et al: Classic Kaposi's sarcoma: Epidemiology and risk factors. *Cancer* **88**:500, 2000
44. Cook-Mozaffari P et al: The geographical distribution of Kaposi's sarcoma and of lymphomas in Africa before the AIDS epidemic. *Br J Cancer* **78**:1521, 1998
50. Penn I: Kaposi's sarcoma in organ transplant recipients. *Transplantation* **64**:669, 1997
66. Chor PJ, Santa Cruz DJ: Kaposi's sarcoma. A clinicopathologic review and differential diagnosis. *J Cutan Pathol* **19**:6, 1992
68. Aoki Y, Tosato G: Therapeutic options for human herpesvirus-8/Kaposi's sarcoma-associated herpesvirus-related disorders. *Expert Rev Anti Infect Ther* **2**:213, 2004d
72. Walmsley S et al: Treatment of AIDS-related cutaneous Kaposi's sarcoma with topical alitretinoin (9-cis-retinoic acid) gel. Panretin Gel North American Study Group. *J Acquir Immune Defic Syndr* **22**:235, 1999
73. Kirova YM et al: Radiotherapy in the management of epidemic Kaposi's sarcoma: A retrospective study of 643 cases. *Radiother Oncol* **46**:19, 1998
86. Hengge UR et al: Long-term chemotherapy of HIV-associated Kaposi's sarcoma with liposomal doxorubicin. *Eur J Cancer* **37**:878, 2001
88. Beyeler M et al: The spectrum of mesenchymal skin neoplasms reflected by the new WHO classification. *Onkologie* **27**:401, 2004
90. Holden CA, Spittle MF, Jones EW: Angiosarcoma of the face and scalp, prognosis and treatment. *Cancer* **59**:1046, 1987
95. Budd GT: Management of angiosarcoma. *Curr Oncol Rep* **4**:515, 2002
98. Skubitz KM, Haddad PA: Paclitaxel and pegylated-liposomal doxorubicin are both active in angiosarcoma. *Cancer* **104**:361, 2005



CHAPTER 129

Neoplasms of Subcutaneous Fat

Thomas Brenn

LIPOMA

- Lipoma is the most common soft-tissue tumor.
- It is benign and presents in adulthood as a small circumscribed mass. The anatomic distribution is wide with relative sparing of the head, hands, and feet.
- Histologically, the tumors are circumscribed, encapsulated, and composed of mature white adipose tissue.

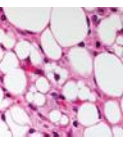

Epidemiology

Lipomas are the most common soft-tissue neoplasms. Although they affect individuals in a wide age range, they occur predominantly in adults between the ages of 40 and 60 years; presentation in childhood is rare. There is no gender predilection. Lipomas are multiple in approximately 5 percent of cases.[1]

Etiology and Pathogenesis

The majority of lipomas (approximately 75 percent) show karyotypic abnormalities. The cytogenetic findings are heterogeneous, but rearrangements of 12q13-15 are most common.[2–4] Other affected loci are on chromosomes 6 and 13.[2–4] Numerical abnormalities are scarce, and most tumors are diploid.

Clinical Findings

The most common presentation is as a painless, slowly enlarging mass involving the subcutaneous tissue of the trunk, neck, or proximal extremities. Involvement of the head, hands, and feet is uncommon. These superficial lipomas are typically small, measuring less than 5 cm.[1] Lipomas may be multiple and familial and show a predilection for the arms and thighs in familial multiple lipomatosis (Fig. 129-1).[5] The constellation of multiple lipomas, macrocephaly, lymphangiomas, and hemangiomas is known as *Bannayan (Bannayan-Zonana)* syndrome.[6,7] This autosomal dominant disease shares features with other independently described entities and is currently also referred to as *Bannayan-Riley-Ruvalcaba syndrome*.[8,9] Further clinical findings include intestinal polyposis, genital pigmented macules, and other hamartomas. The syndrome is caused by mutations in the PTEN gene and belongs to the larger family of PTEN hamartoma-tumor syndromes, including Cowden disease.[10–15] Lipomas may also be seen as a manifestation of Gardner syndrome. Gardner syndrome is part of the spectrum of familial adenomatous polyposis and includes extracolonic manifestations such as desmoid fibromatosis, osteomas, cysts, and lipomas.

Less frequently, lipomas may be deep-seated and grow to sizes larger than 5 cm. They can affect a variety of anatomic locations, including the surface of bone (parosteal lipoma) and skeletal muscle (intramuscular and intermuscular lipoma). Intramuscular lipoma arises within skeletal muscle and may be circumscribed or infiltrative. It presents in adulthood and only rarely affects children. The range of anatomic sites is wide, but there appears to be a predilection for the trunk.[16,17] In contrast, intermuscular lipoma develops between individual muscles and does not infiltrate skeletal muscle bundles. It is a rare lipomatous tumor with a predilection for the anterior abdominal wall.[16,17] Lipomas of the forehead are frequently deep-seated, presenting in a submuscular or subgaleal location. They show a predilection for male adults.[18,19]

NEOPLASMS OF SUBCUTANEOUS FAT AT A GLANCE

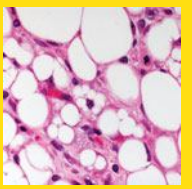

- Adipocytic tumors are the most frequently encountered group of mesenchymal neoplasms. This is due to the high prevalence of lipoma and angiolipoma.
- Tumors range from entirely benign neoplasms (e.g., lipomas) to those of intermediate malignant potential with risk for local recurrence (e.g., atypical lipomatous tumor) to high-grade pleomorphic sarcomas (e.g., pleomorphic liposarcoma).
- Although liposarcoma is the single most frequently encountered sarcoma, the large majority of adipocytic tumors are benign.
- The clinical presentation of adipocytic tumors is generally non-specific.
- Most adipocytic tumors show distinctive cytogenetic abnormalities that may be of diagnostic value.
- Treatment is surgical excision. Adjuvant radiation therapy and/or chemotherapy may be of benefit for treatment of malignant tumors that are not amenable to complete excision or in cases of advanced disease.



▲ **FIGURE 129-1** Familial multiple lipomatosis. Multiple lipomas of variable size show a symmetric distribution involving the forearms of this middle-aged man.

Histologic Features

Conventional lipomas are circumscribed masses surrounded by a thin fibrous capsule. They are composed of lobules of mature white adipose tissue divided by delicate and inconspicuous fibrous septa containing thin-walled capillary sized vessels (Fig. 129-2). The adipocytes are univacuolated and mature with eccentrically placed, compressed nuclei.

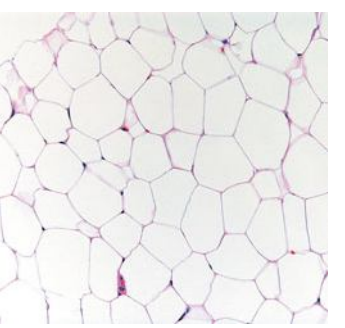

▲ **FIGURE 129-2** Lipoma. Mature univacuolated adipocytes show only mild variation in size, and cytologic atypia is not a feature. Delicate intervening capillaries are present.

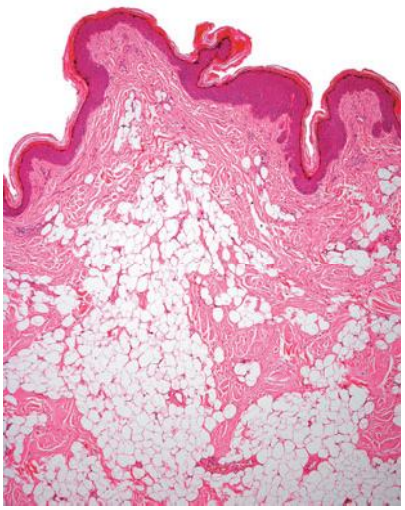

▲ **FIGURE 129-3** Intradermal lipoma. Mature adipocytes diffusely infiltrate pre-existing dermal collagen bundles. Note the sparing of the papillary dermis.

There is only slight variation in adipocyte size, and nuclear atypia is not a feature. Morphologically, lipomas are indistinguishable from the surrounding adipose tissue and the identification of a distinct mass is necessary for the diagnosis. Lipomas may show changes of trauma with varying amounts of fat necrosis and inflammation. Extensive involvement of the dermis is known as *dermal lipoma*. These tumors are not encapsulated and are frequently less circumscribed than other forms of superficial lipoma (Fig. 129-3). Lipomas with increased fibrous tissue are referred to as *fibrolipomas* (Fig. 129-4). In contrast to atypical lipomatous tumors, cellularity is low within the fibrous strands, and no nuclear atypia is present. *Myxolipomas* are characterized by the presence of conspicuous myxoid stroma. *Angiomyxolipoma* or vascular myxolipoma is characterized by a myxoid stromal background in addition to a proliferation of vessels of variable sizes. A lipoma containing

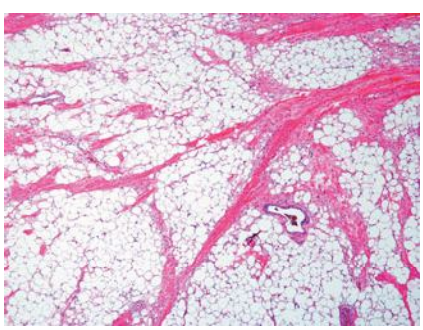

▲ **FIGURE 129-4** Fibrolipoma. This variant is characterized by the presence of increased fibrous tissue within a lipoma.

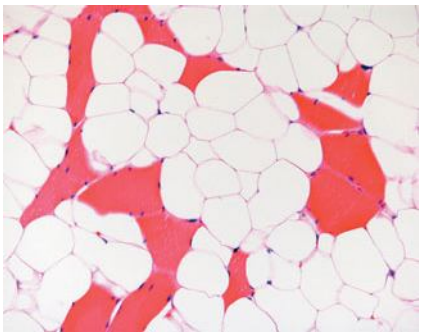

▲ **FIGURE 129-5** Intramuscular lipoma. Mature adipocytes show an infiltrative growth pattern within skeletal muscle, splaying apart individual muscle fibers. (Used with permission from Dr. J. Hornick, Brigham and Women's Hospital and Harvard Medical School, Boston, MA.)

metaplastic bone or cartilage within the tumor is referred to as an *osteolipoma* or *chondrolipoma*, respectively.

Intramuscular lipoma can either present as a circumscribed intramuscular mass or show an infiltrative growth of adipocytes in between skeletal muscle fibers (Fig. 129-5).

Clinical Course, Prognosis, and Treatment

Lipomas are entirely benign tumors and, with the exception of intramuscular lipomas, local recurrence is rare. The infiltrative variant of intramuscular lipoma is associated with an approximately 19 percent chance of local recurrence, but metastasis does not occur.[16]

LIPOMATOSIS

- Lipomatosis is characterized by diffuse overgrowth of adipose tissue infiltrating through pre-existing structures.
- Different clinical presentations are recognized.

Epidemiology and Clinical Findings

Diffuse lipomatosis[20,21] is characterized by overgrowth of adipose tissue involving subcutaneous tissue and skeletal muscle of the trunk and extremities. Osseous involvement may also be a feature. Young children are predominantly affected, but presentation may become apparent in adulthood. Tumors can grow to a large size, causing disfigurement and loss of function of the affected limb. Due to the diffuse growth of these tumors, complete excision may not be possible and recurrences are frequent.



▲ **FIGURE 129-6** Symmetric lipomatosis. There is diffuse and symmetric overgrowth of adipose tissue affecting predominantly the upper trunk, neck, and proximal arms.

Benign symmetric lipomatosis (Madelung disease, multiple symmetric lipomatosis)[22–29] is characterized by multiple symmetric masses composed of nonencapsulated adipose tissue with a predilection for the subcutaneous tissue and skeletal muscle of the neck, shoulder, and proximal upper limbs (Fig. 129-6). Presentation is in adulthood with a marked male predominance of 15:1. The estimated overall incidence is 1 in 25,000, with increased frequency in the Mediterranean region. The disease is associated with increased alcohol intake in the majority of cases. Two clinical variants are currently recognized. Type 1 disease is characterized by a symmetric distribution of adipose tissue, giving rise to a "pseudoathletic" appearance, whereas type 2 disease shows a more diffuse distribution, giving rise to a picture of more generalized obesity. An associated polyneuropathy affecting sensory, motor, and autonomic function is frequently present. The disease course is slowly progressive, and treatment is difficult due to infiltration of deep-seated structures and major nerves and vessels. There is significant disease-related mortality due to compression of vital structures as well as autonomic neuropathy with sudden cardiac death. Etiologically, the disease has been speculated to be a result of hypertrophy of brown fat due to a defect in adrenergic lipolysis.

Pelvic lipomatosis[30–33] is an unusual proliferation of adipose tissue involving the pelvis and retroperitoneal space. The disorder is most common among men in the third and fourth decades, and blacks account for about two-thirds of cases. Urinary symptoms are frequent presenting signs, and the disease is associated with cystitis in 75 percent of cases. Ob-

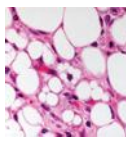

structive uropathy and renal failure may be complications of the disease.

Adiposis dolorosa (Dercum disease)[34–41] is rare and typically affects middle-aged women, although men may occasionally also be affected. The disease is typically sporadic, and familial cases are exceptional. There is an increased incidence with obesity. Patients present with multiple painful subcutaneous lipomatous lesions frequently associated with other symptoms such as weakness, depression, confusion, lethargy, or dementia. The disease predominantly involves the arms and trunk but may be progressive to involve large parts of the body. Treatment modalities include pain relief as well as surgical control with excision or liposuction. Weight reduction can be beneficial.

Human immunodeficiency virus lipodystrophy[42–46] occurs in the setting of protease inhibitor treatment or other forms of antiretroviral therapy in patients with acquired immunodeficiency syndrome (see Chap. 198). There is a predilection for cervical fat pads, the breast, and visceral fat. Other associations include hyperlipidemia, insulin resistance, type 2 diabetes, and fat wasting affecting the face and limbs.

Histologic Features

The histologic features of all forms of lipomatosis are similar and show unencapsulated adipose tissue diffusely infiltrating pre-existing structures such as skeletal muscle.

LIPOMATOSIS OF NERVE (FIBROLIPOMATOUS HAMARTOMA OF NERVE)

- Lipomatosis of nerve is a rare tumor that affects infants and children and presents as a growing mass with a predilection for the hand.
- Pathology shows a proliferation of adipose and fibrous tissue within the epineurium and perineurium. The median nerve is predominantly affected.

Epidemiology

Lipomatosis of nerve is rare and affects predominantly infants and young children. Presentation at birth is not uncommon.[47] It is only rarely seen in young adults.

Clinical Findings

Clinical presentation is as a slowly growing mass that may be associated with pain and paresthesia due to compression of the affected nerve. There is a strong predilection for the hand, including the wrist, palm, and fingers, and, less frequently, the foot. The median nerve and its branches followed by the ulnar nerve are most commonly affected.[47] Involvement of cranial nerves and the brachial plexus has been reported but is exceptional.[48,49] In a subset of patients there may be accompanying overgrowth of bone resulting in macrodactyly.

Histologic Features

The lesions are characterized by a proliferation of adipose and fibrous tissue within the epineurium infiltrating along and in between nerve bundles. There is marked concentric fibrosis affecting both epineurium and perineurium.[47] Metaplastic bone formation may rarely occur.[50]

Clinical Course, Prognosis, and Treatment

The clinical behavior is entirely benign, but adequate treatment is difficult because of the anatomic location and involvement of major nerves.[47]

NEVUS LIPOMATOSUS SUPERFICIALIS

- Nevus lipomatosus superficialis is a rare entity that affects children and young adults.
- Papules and plaques show a predilection for the buttocks, lumbar back, and posterior thighs.
- Bands of mature adipose tissue infiltrate dermal collagen.

Epidemiology

Nevus lipomatosus superficialis is a rare form of connective tissue–type nevus that affects children and young adults in the first two decades of life. There is an equal gender distribution.[51–55]

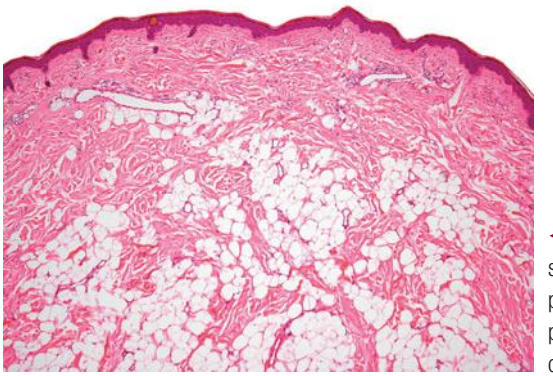

◀ **FIGURE 129-7** Nevus lipomatosus superficialis. Infiltration of adipose tissue into the dermis with penetration of dermal collagen is a characteristic finding.

Clinical Findings

The classic presentation is as multiple papules and nodules that may coalesce to form larger plaques. There is a predilection for the buttocks, upper posterior thighs, and lumbar back. Occasionally, involvement may be extensive, and the lesions may form confluent linear plaques along the skinfolds. This phenomenon has been reported as the "Michelin tire man" appearance.[56,57] Solitary lesions occur predominantly in adults and are more likely to represent a fibroepithelial polyp containing adipose tissue.

Histologic Features

The histologic features show mature adipose tissue in varying amounts within the superficial dermis (Fig. 129-7).

ANGIOLIPOMA

- Angiolipoma is a relatively common lesion that presents as a small nodule with a predilection for the forearm.
- Young adults are affected, and lesions are frequently multiple and painful.
- Histologically, this circumscribed lesion shows an admixture of mature adipose tissue and a proliferation of capillary-sized vessels.

Epidemiology

Subcutaneous angiolipomas are relatively frequent and typically occur in young adults in their teens and 20s, with a strong male predilection.[58–60] They are rare in children and in the elderly.

Etiology and Pathogenesis

Angiolipomas have traditionally been classified as adipocytic tumors. In con-

trast to most lipomas, however, they appear to have a consistently normal karyotype, and it has been suggested that they may be reactive or hamartomatous rather than neoplastic.[60] The fact that angiolipomas can occasionally be almost exclusively composed of blood vessels (cellular angiolipoma) has led to the speculation that they may in fact be hemangiomas rather than lipomas.[60] There is an increased familial incidence, but no inheritance pattern has been elucidated as yet.[61]

Clinical Findings

A wide range of sites can be affected, but there is a predilection for the forearm followed by the trunk, upper arm, and legs.[58–60] Angiolipomas are often multiple and present as subcutaneous nodules characteristically smaller than 2 cm. Tenderness and pain are frequently associated symptoms.

Histologic Features

Angiolipomas are circumscribed and encapsulated. They show an admixture of mature fat and capillary-sized small branching vessels in varying proportions (Fig. 129-8; see eFig. 129-8.1 in on-line edition). The vascular density is often increased at the periphery in a subcapsular distribution. Fibrin thrombi are typically encountered. The term *cellular angiolipoma* is applied to those lesions that are almost exclusively composed of vascular elements (see eFig. 129-8.2 in on-line edition).[62–64]

Differential Diagnosis

The appearances of angiolipoma are quite characteristic. The differential diagnosis of cellular angiolipoma includes vascular tumors such as Kaposi sarcoma, spindle cell hemangioma, and angiosarcoma.

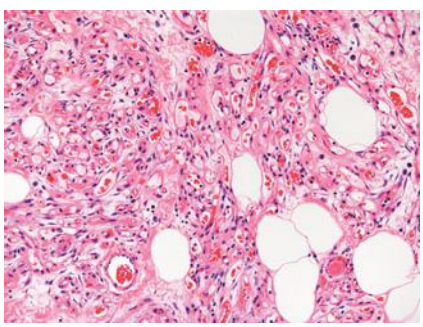

▲ **FIGURE 129-8** Angiolipoma. A proliferation of capillary-sized vessels is admixed with mature adipose tissue.

Clinical Course, Prognosis, and Treatment

The clinical behavior of angiolipomas is entirely benign. The tumors are frequently multiple as well as painful, however, and clinical management can be a challenge.

SPINDLE CELL LIPOMA AND PLEOMORPHIC LIPOMA

- Spindle cell lipoma and pleomorphic lipoma are currently considered to represent a morphologic continuum.
- They typically occur on the posterior neck, upper back, and shoulder of middle-aged men.
- Morphologically characteristic is the admixture of mature fat with bland and uniform spindle cells in a myxoid stroma containing ropey collagen bundles and mast cells. Multinucleate (floret-type) giant cells are present in pleomorphic lipoma.

Epidemiology

Spindle cell lipoma and pleomorphic lipoma are believed to constitute a morphologic continuum. This view is based on the finding that there is significant clinical, histologic, and cytogenetic overlap and the fact that features of both can be present in a single lesion.[65–73] These lipomas are rare; they represent only approximately 1.5 percent of all fatty tumors and are 60 times less frequent than conventional lipomas.[66] They show a predilection for middle-aged to elderly adults (median age, 55 years) and a strong male predominance.[65–73]

Clinical Findings

Spindle cell and pleomorphic lipoma present as circumscribed, mobile masses, often with a long-standing history. They are small, measuring around 5 cm, and almost exclusively present on the posterior neck, shoulder, and upper back.[65–73] Other anatomic sites in the head and neck region can occasionally be affected. Rarely, these tumors are multiple and familial.[78,79]

Histologic Features

Both tumors are circumscribed and are typically located within the subcutis.

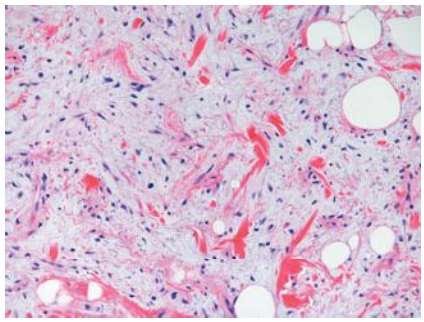

▲ **FIGURE 129-9** Myxoid spindle cell lipoma. Extensive myxoid stromal change is seen in this tumor.

Spindle cell lipoma is characterized histologically by the presence of mature adipocytes admixed with bland-appearing and uniform, stubby spindle cells in a collagenous and myxoid stroma containing ropey collagen fibers and conspicuous mast cells (see eFigs. 129-8.3, 129-8.4, and 129-8.5 in on-line edition). Myxoid change can be prominent (Fig. 129-9), and occasionally slit-like spaces resembling vascular channels may be present (pseudoangiomatous variant).[80] Mitotic activity is virtually absent. The characteristic feature of pleomorphic lipoma is the presence of bizarre multinucleate giant cells, termed *floret cells*. These cells show eosinophilic cytoplasm and multiple crowded and overlapping hyperchromatic nuclei arranged in a circle or semicircle resembling the petals of a flower (Fig. 129-10).

Differential Diagnosis

The differential diagnosis for spindle cell and pleomorphic lipomas includes the following:

- Atypical lipomatous tumor
- Solitary fibrous tumor
- Cellular angiofibroma

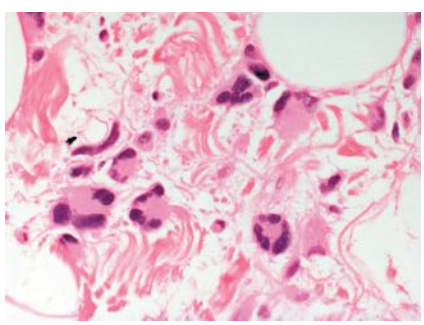

▲ **FIGURE 129-10** Pleomorphic lipoma. The characteristic floret-type giant cells contain overlapping hyperchromatic nuclei in a circular or semicircular arrangement. (Used with permission from Dr. S. Banerjee, Christie Hospital, Manchester, UK.)

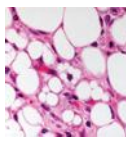

Clinical Course, Prognosis, and Treatment

Spindle cell and pleomorphic lipomas are entirely benign adipocytic neoplasms and local recurrences are rare.

CHONDROID LIPOMA

- Chondroid lipoma is a rare and benign tumor that affects adults and shows a female predominance.
- The anatomic distribution is wide, but there is a predilection for the proximal extremities and limb girdle.
- The unique histologic features include the presence of mature adipose tissue, lipoblasts, and a chondroid matrix.

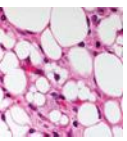

Epidemiology

Chondroid lipoma is a relatively recently recognized and exceedingly rare benign lipomatous tumor.[82] It shows a predilection for adults and a wide age distribution with a median of 36 years. There appears to be a significant female predominance (estimated at 1:4).[82]

Clinical Findings

Chondroid lipoma is a relatively small tumor measuring approximately 5 cm. Larger examples of over 10 cm have also been reported. It presents as a painless circumscribed mass of variable duration and often comes to clinical attention because of a history of recent growth. The proximal extremities and limb girdles are the most frequently affected anatomic sites,[82] but the trunk as well as the head and neck region, including intraoral sites, may also be affected.[82,86–88] Tumors are typically deep-seated, involving deep subcutaneous tissue, fascia and skeletal muscle.[82] Imaging studies are rather non-specific and show a multilobular and circumscribed mass containing fatty elements.[88–90]

Histologic Features

The characteristic feature of chondroid lipoma is the admixture of a mature adipocytic component and a chondroid matrix containing lipoblasts.[82] This well-circumscribed tumor is frequently encapsulated and multi-lobulated. It is composed of univacuolated and multivacuolated cells, occasionally with eosinophilic cytoplasm, showing cytologic features reminiscent of those of lipoblasts or

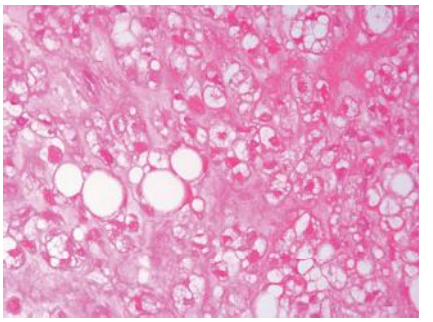

▲ **FIGURE 129-11** Chondroid lipoma. Univacuolated and multivacuolated cells reminiscent of lipoblasts or chondroblasts are present adjacent to mature adipocytes. (Used with permission from Dr. S. Banerjee, Christie Hospital, Manchester, UK.)

chondroblasts (Fig. 129-11).[82] These cells contain small lipid droplets as well as periodic acid-Schiff–positive glycogen.[82] They are arranged in cords, nests, and strands as well as more solid areas set in a background of a chondroid matrix typically containing chondroitin sulfates (see eFig. 129-11.1 in on-line edition).[91] Intricately admixed are variable amounts of mature adipose tissue. Tumors can be highly vascularized and show areas of hemorrhage, fibrosis, and calcifications.

Differential Diagnosis

Differential diagnosis for chondroid lipoma includes the following:

- Myxoid liposarcoma
- Extraskeletal myxoid chondrosarcoma

Clinical Course, Prognosis, and Treatment

Chondroid lipoma is a benign lipomatous neoplasm, and neither recurrences nor metastases have been demonstrated so far. Excision is the treatment of choice.

MYOLIPOMA OF SOFT TISSUE

Epidemiology

Myolipoma of soft tissue is also known as *extrauterine lipoleiomyoma* and is characterized by its admixture of mature adipocytic and smooth muscular components. It is an exceedingly rare tumor occurring in adulthood, with a female predominance of 2:1.[92]

Clinical Findings

Myolipomas can grow to a significant size and average 15 cm. They occur in deep soft tissue of the retroperitoneum, abdominal cavity, and inguinal area but can also arise within subcutaneous tissue of the trunk and extremities. Involvement of deep structures such as skeletal muscle and fascia is frequent. Myolipomas present as palpable masses but may be incidental findings when located at visceral sites.

Differential Diagnosis

The differential diagnosis for myolipoma of soft tissue includes the following:

- Liposarcoma
- Angiomyolipoma

Clinical Course, Prognosis, and Treatment

Myolipoma of soft tissue is a benign neoplasm, and recurrences have not been reported. Complete excision is curative.

HIBERNOMA

- Hibernoma is a benign neoplasm that resembles brown fat and typically presents in adulthood.
- A wide range of anatomic locations may be affected.

Epidemiology

Hibernoma is a well-recognized but rare benign adipocytic tumor that shows a wide age distribution. Young adults (mean age, 38 years) are predominantly affected, but presentation in the pediatric population as well as in the elderly is possible. Males appear to be affected only slightly more frequently than females.[93]

Etiology and Pathogenesis

The etiology of this rare tumor is unclear. Karyotypes can be slightly more complex than those observed in other benign lipomatous tumors, but structural rearrangements involving chromosome band 11q13 appear to be reproducible.[94–97]

Clinical Findings

Hibernoma is a painless, slowly enlarging tumor affecting a wide range of anatomic sites. There appears to be a predilection for areas in which brown fat can be found physiologically, and presentation on the trunk, especially the scapular area, the shoulder, and the head and neck is common. Curiously, however, the thigh appears to be the single most fre-

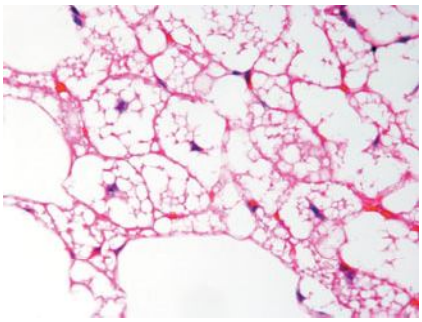

▲ **FIGURE 129-12** Hibernoma. The characteristic feature is the presence of multivacuolated adipocytes with centrally placed nuclei and clear to eosinophilic granular cytoplasm.

quently affected site.[93] Hibernomas are typically located in subcutaneous tissue or skeletal muscle but may occasionally affect the abdominal cavity, retroperitoneum, or intrathoracic location.[98]

Histologic Features

Hibernoma is a well-demarcated and lobulated neoplasm. The hallmark feature is its morphologic resemblance to brown fat. The tumors are composed of variable numbers of multivacuolated adipocytes with small, centrally placed nuclei and pale to eosinophilic and granular cytoplasm (Fig. 129-12). Based on the appearance of these brown fat cells, the quality of intervening stroma, and the presence of a spindle cell component, six histologic variants are recognized.[93]

The typical variant is the most frequently encountered form and is characterized by large numbers of brown fat cells admixed with mature white fat (see eFig. 129-12.1 in on-line edition). Those tumors composed almost exclusively of brown fat cells with palely staining cytoplasm are further subclassified as the *pale cell subtype*. Tumors are labeled *eosinophilic subtype* when at least 50 percent of brown fat cells contain a deeply eosinophilic and granular cytoplasm. The *mixed subtype* is intermediate between the two and shows a roughly equal distribution of eosinophilic and pale-staining brown fat cells. Myxoid, lipoma-like, and spindle cell variants exist.

Differential Diagnosis

The differential diagnosis of hibernoma includes the following:

- Granular cell tumor
- Spindle cell lipoma
- Atypical lipomatous tumor/well-differentiated liposarcoma

Clinical Course, Prognosis, and Treatment

- The behavior of hibernoma is entirely benign without recurrence after local excision.

LIPOBLASTOMA/ LIPOBLASTOMATOSIS

- Morphologically, the benign adipocytic neoplasm lipoblastoma resembles fetal adipose tissue. It is most frequently found in individuals younger than 5 years of age.
- Lipoblastoma has a multilobular and circumscribed appearance, whereas lipoblastomatosis shows an infiltrative growth.

Epidemiology

Lipoblastoma/lipoblastomatosis is an uncommon neoplasm affecting infants and young children. Its incidence decreases significantly in those older than 5 years of age, and presentation in adolescents is rare.[104–109] Infrequently, tumors may be congenital.[110–112] There is a male predominance, with a male-female ratio of approximately 2:1.[104–109]

Clinical Findings

Most tumors present as painless, slowly growing, solitary soft-tissue masses. Lipoblastomas are well circumscribed and located in subcutaneous tissue. In contrast, tumors with an infiltrative growth often extend into deeper structures such as skeletal muscle and are termed *lipoblastomatosis*.[109] The extremities, trunk, and head and neck are predominantly affected sites. Visceral involvement of retroperitoneum, mediastinum, peritoneal cavity, or solid organs is rarely seen.[104–109] Tumors are relatively small, measuring around 5 cm. However, larger tumors of more than 20 cm have been reported. In certain locations, tumors can become symptomatic due to compression of adjacent structures and organs.

Histologic Features

Lipoblastomas are well-circumscribed, lobulated tumors with fibrous septa (Fig. 129-13) composed of an admixture of mature and immature adipocytes in varying proportions (see eFig. 129-13.1 in on-line edition). Lipoblasts are present in different stages of development ranging from univacuolated forms

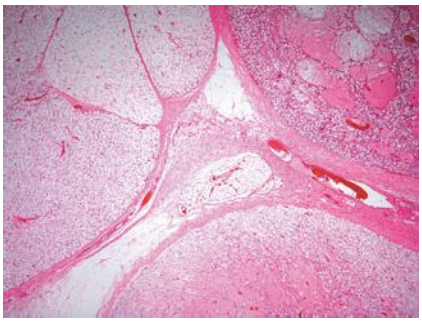

▲ **FIGURE 129-13** Lipoblastoma/lipoblastomatosis. Lipoblastoma is a circumscribed tumor showing prominent multilobulation with dividing fibrous septa. (Used with permission from Dr. S. Banerjee, Christie Hospital, Manchester, UK.)

with eccentrically placed and compressed nuclei to bivacuolated and multivacuolated forms (see eFigs. 129-13.2 and 129-13.3 in on-line edition).

Differential Diagnosis

The differential diagnosis of lipoblastoma/lipoblastomatosis includes the following:

- Myxoid liposarcoma
- Atypical lipomatous tumor
- Hibernoma
- Lipofibromatosis

Clinical Course, Prognosis, and Treatment

Lipoblastoma/lipoblastomatosis is a benign tumor with a tendency to recurrence if inadequately excised. Complete surgical excision is curative and is the treatment of choice.

HEMOSIDEROTIC FIBROHISTIOCYTIC LIPOMATOUS LESION/TUMOR

Epidemiology

The exceedingly rare hemosiderotic fibrohistiocytic lipomatous lesion or tumor was first described by Marshall-Taylor and Fanburg-Smith[120] in 2000. Only 25 cases have been reported in the literature so far.[120–122] Although the age range of occurrence is wide, the lesion typically presents in adulthood (median age, 50 years) and affects women more frequently than men.[120,121]

LIPOFIBROMATOSIS

Lipofibromatosis is an uncommon pediatric neoplasm that predominantly af-

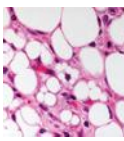

fects infants at a median age of 1 year.[124–127] It can be congenital, but children and adolescents may also be affected. There appears to be a significant male predominance.

ATYPICAL LIPOMATOUS TUMOR/WELL-DIFFERENTIATED LIPOSARCOMA

Epidemiology

Atypical lipomatous tumor/well-differentiated liposarcoma is a neoplasm of adulthood with a peak incidence in the sixth decade.[128–136] It represents the largest subgroup of liposarcomas. There is no gender predilection.

Clinical Findings

Tumors typically present in deep soft tissue. The subcutaneous tissue may occasionally also be involved. The predominantly affected site is the musculature of extremities with a predilection for the thigh, followed by the retroperitoneum, groin, and paratesticular area as well as the mediastinum.[128–136] A wide range of other anatomic sites including the larynx, orbit, oral cavity, and vulva may be affected.[144–147] An enlarging painless mass is the typical presenting sign, and especially in a retroperitoneal location, tumors can grow to a very large size before becoming symptomatic.

Histologic Features

Atypical lipomatous tumors are large, multilobulated, and most often circumscribed. The most frequently observed adipocytic (lipoma-like) morphologic variant closely resembles a lipoma. It is composed of relatively mature-appearing adipocytes with marked variation in cell size (see eFig. 129-13.4 in on-line edition). Additional findings include focal adipocytic atypia (see eFig. 129-13.5 in on-line edition) and the presence of hyperchromatic and often multinucleate bizarre stromal cells in cellular fibrous septa (see eFigs. 129-13.6 and 129-13.7 in on-line edition). Floret-type giant cells may also be a feature (see eFig. 129-13.8 in on-line edition). Lipoblasts may be monovacuolated or multivacuolated and vary in number (see eFig. 129-13.9 in on-line edition). They may be entirely absent and are not a prerequisite for the diagnosis. Sclerosing, inflammatory, and spindle cell variants exist.

Differential Diagnosis

The differential diagnosis of atypical lipomatous tumor/well-differentiated liposarcoma includes the following:

- Lipoma
- Spindle cell/pleomorphic lipoma
- Dedifferentiated liposarcoma
- Angiomyolipoma
- Massive localized lymphedema

Clinical Course, Prognosis, and Treatment

The clinical behavior and prognosis are largely dependent on the anatomic site. Surgery is curative at anatomic locations where complete surgical excision with clear margins can be achieved (e.g., somatic soft tissue such as the limbs). The estimated rate of progressing to dedifferentiated liposarcoma is less than 2 percent with a mortality rate of virtually zero at these anatomic locations. In contrast, tumors arising at deep locations such as the retroperitoneum, mediastinum, or spermatic cord, where complete surgical clearance is not possible, are characterized by repeated local recurrence and ultimately may result in death from uncontrolled local disease or dedifferentiation with metastasis. The overall risk of development of dedifferentiated liposarcoma is estimated to be higher than 20 percent with an overall mortality rate of around 80 percent for tumors occurring in the retroperitoneum. The disease has a protracted course, and the median survival time ranges from 6 to 11 years.[132,135,150] The primary approach to treatment is surgical excision. Adjunct chemotherapy and radiation treatment are reserved for advanced disease.

DEDIFFERENTIATED LIPOSARCOMA

- Tumors typically present as large masses in the retroperitoneum of adults.
- The disease course is protracted, with a high rate of local recurrence and a significant risk for metastasis and associated mortality.
- The morphologic characteristic is the presence of non-lipogenic areas adjacent to well-differentiated liposarcoma.

Epidemiology

The epidemiologic features of dedifferentiated liposarcoma are similar to those of well-differentiated liposarcoma, and it typically affects adults in the sixth decade.[151–153] There is no gender predilection. De novo presentation is most commonly seen, occurring in approximately 90 percent of cases. Only around 10 percent of cases represent dedifferentiation of a previously well-differentiated liposarcoma.[151,152]

Clinical Findings

Tumors present as large painless masses with a predilection for the retroperitoneum followed by the limbs and paratesticular area and spermatic cord.[151–153]

ATYPICAL LIPOMATOUS TUMOR/WELL-DIFFERENTIATED LIPOSARCOMA AT A GLANCE

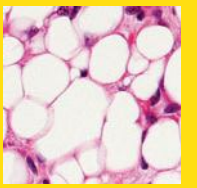

- Atypical lipomatous tumor/well-differentiated liposarcoma is a tumor of adulthood that presents as an enlarging mass with a predilection for the extremities, retroperitoneum, and paratesticular tissue.
- The most important prognostic predictor is anatomic location:
  - The rate of recurrence, risk of dedifferentiation, and associated mortality is negligible at sites amenable to surgical excision (i.e., extremities).
  - In contrast, tumors at anatomic sites such as the retroperitoneum and paratesticular region, where complete excision with tumor-free margins cannot be achieved, show a disease course characterized by multiple recurrences and a high risk of dedifferentiation and metastasis. Long-term mortality is high.
- Tumors at surgically amenable sites for which excision is curative are referred to as *atypical lipomatous tumors*, whereas those tumors arising in the retroperitoneum or other areas where clear margins cannot be achieved should be regarded as *well-differentiated liposarcoma*.

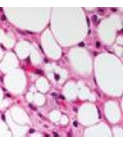

Other sites, including the head, neck, and trunk, are rarely affected. Presentation in the subcutis is unusual.[155]

Histologic Features

The tumors are multilobulated and consist of yellow, fatty areas as well as discrete more solid areas representing dedifferentiation. The characteristic histologic finding is the presence of both atypical lipomatous tumor/well-differentiated liposarcoma and non-lipogenic sarcoma. The proportions may vary, and careful gross examination and adequate sampling may be necessary to identify the lipogenic areas. There is usually a very sharp demarcation between lipogenic and non-lipogenic areas (see eFig. 129-13.13 in on-line edition), but a more gradual transition or co-mingling may also be seen. The non-lipogenic component is most frequently morphologically high grade, showing a pleomorphic sarcoma–like (pleomorphic and storiform malignant fibrous histiocytoma–like) (Figs. 129-14 and 129-15) or a myxofibrosarcoma-like appearance.[151–153,156]

Differential Diagnosis

The differential diagnosis of dedifferentiated liposarcoma includes the following:

- Spindle cell liposarcoma
- Pleomorphic liposarcoma
- Other pleomorphic sarcomas

Clinical Course, Prognosis, and Treatment

Dedifferentiated liposarcoma is characterized by a protracted course with a high risk of local recurrence. Retroperitoneal tumors almost invariably recur if followed over a long period of time. The overall risk of distant spread is estimated at around 20 percent, with a disease-related

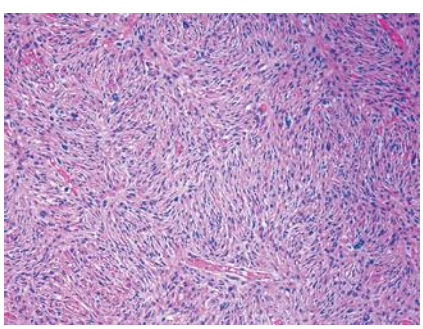

▲ **FIGURE 129-14** Dedifferentiated liposarcoma. Tumor cells are arranged in short fascicles and give rise to a storiform appearance.

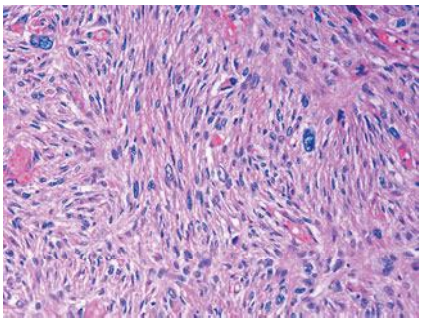

▲ **FIGURE 129-15** Dedifferentiated liposarcoma. There is an admixture of spindle cells and large pleomorphic cells.

mortality rate of approximately 30 percent.[152] Although these rates are likely to be higher with long-term follow-up, the prognosis appears to be more favorable than that for other high-grade pleomorphic sarcomas, which are associated with a high mortality rate and shorter time to death. Anatomic location is the most important prognostic factor, and retroperitoneal tumors are associated with a poor prognosis. In contrast, neither the extent of dedifferentiation nor the morphologic features appear to be prognostically predictive. The mainstay of treatment is surgical removal with adjuvant chemotherapy and radiation in advanced disease.

MYXOID/ROUND CELL LIPOSARCOMA

Epidemiology

Myxoid liposarcomas represent approximately 10 percent of all soft-tissue sarcomas. They comprise more than one-third of all liposarcomas and are the second most frequent variant of liposarcoma.[159] The tumor presents in young to middle-aged adults with a peak in the fourth to fifth decade and a slight male predominance.[159–161]

Clinical Findings

Presentation as a large, painless mass with a predilection for the extremities is characteristic. Tumors are located in deep soft tissue and involve the thigh in over two-thirds of cases.[159–161] Presentation in subcutis or retroperitoneum is rare. Not infrequently, patients are found to have multifocal disease at initial presentation, which is generally regarded to represent metastases.[169]

Histologic Features

Tumors are large, well circumscribed, and multinodular with a gelatinous cut surface on gross examination. The appearance becomes fleshier in areas with increased cellularity, but large areas of tumor necrosis are not typically seen.

Microscopically, myxoid liposarcoma is a lobulated tumor composed of a mixture of bland-appearing oval mesenchymal cells without evidence of adipocytic differentiation and small univacuolated or bivacuolated lipoblasts, often with a signet-ring cell appearance (see eFigs. 129-15.1 and 129-15.2 in on-line edition). The cellularity is low but increased toward the periphery of the tumor lobules (see eFig. 129-15.1 in on-line edition). The cells are placed in a myxoid matrix showing a characteristic pattern of delicate, branching capillary-sized vessels often referred to as *chicken wire* or *crow's feet* (see eFig. 129-15.3 in on-line edition). In the central areas the extracellular mucin may become confluent to form mucin pools, giving rise to a pulmonary edema–like appearance (see eFig. 129-15.4 in on-line edition). In the well-differentiated areas, the tumors lack significant cytologic atypia, mitotic activity, or tumor necrosis. Poorly differentiated, high-grade tumors are characterized by increased cellularity with the formation of solid sheets of small to medium-sized round cells showing scant acidophilic cyto-

MYXOID/ROUND CELL LIPOSARCOMA AT A GLANCE

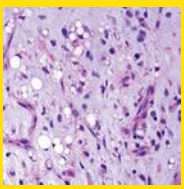

- Presentation is as a large mass involving the extremities and in particular the thigh of middle-aged adults.
- There is a significant rate of local recurrence as well as metastasis.
- Tumors are lobulated and circumscribed and are composed of a myxoid matrix containing primitive mesenchymal cells and lipoblasts in varying stages of differentiation. A prominent vascular pattern is a characteristic feature.
- Round cell liposarcoma is currently regarded to represent the high-grade end of the morphologic spectrum.

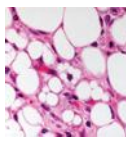

plasm (see eFig. 129-15.5 in on-line edition). Mitotic figures are more easily identified, but nuclear pleomorphism is not a feature.

Differential Diagnosis

The differential diagnosis of myxoid liposarcoma includes the following:

- Lipoblastoma
- Myxofibrosarcoma
- Low-grade fibromyxoid sarcoma
- Chondroid lipoma
- Myxoid melanoma

Clinical Course, Prognosis, and Treatment

The clinical course of myxoid liposarcoma is characterized by local recurrence with a rate of distant metastasis of 30 percent to 40 percent.[159–161] There is an unusually high incidence of soft-tissue and bone metastases in addition to metastases to the lung. Patients with multifocal disease at presentation have a poor prognosis, and adverse histologic features include the presence of round cell differentiation in more than 5 percent of the tumor, tumor necrosis, and p53 overexpression.[160,161,170]

PLEOMORPHIC LIPOSARCOMA

- Pleomorphic liposarcoma is an aggressive sarcoma that shows a predilection for the extremities of adults and is associated with a high rate of metastasis and mortality.
- Histologic examination shows a pleomorphic high-grade sarcoma containing variable numbers of lipoblasts.

Epidemiology

Pleomorphic liposarcoma is a rare tumor representing only approximately 5 percent of all liposarcomas and up to 20 percent of pleomorphic sarcomas.[171,172] It shows a slight male predominance and presents in adulthood (median age, 50 to 60 years). The age range, however, is wide.[173–175]

Clinical Findings

Tumors present as enlarging firm masses, frequently with a short history. They are typically large, deep-seated, and subfascial sarcomas measuring 8 to 10 cm in median. Presentation in subcutaneous tissue is less frequent, and dermal location is unusual.[173–176] The extremities are the most frequently affected sites, and there is a predilection for the lower limbs. The trunk, retroperitoneum, head and neck, abdomen, and pelvis may also be involved.

Histologic Features

Tumors can be well circumscribed but unencapsulated. More frequently, however, they have infiltrative margins. In its classic appearance pleomorphic liposarcoma shows features of a high-grade pleomorphic (malignant fibrous histiocytoma–like) sarcoma containing pleomorphic spindle cells and multinucleate giant cells (see eFig. 129-15.6 in on-line edition). Admixed are lipoblasts in varying numbers. They may be scarce in areas or arranged in larger sheets (see eFig. 129-15.7 in on-line edition). Mitotic figures are frequent, including atypical forms, and areas of necrosis are often present. An additional finding is the presence of intracellular as well as extracellular eosinophilic hyaline droplets.

Two morphologic variants, a high-grade myxofibrosarcoma-like and an epithelioid variant, are recognized.

Differential Diagnosis

The differential diagnosis of pleomorphic liposarcoma includes the following:

- Dedifferentiated liposarcoma
- Leiomyosarcoma
- Pleomorphic rhabdomyosarcoma
- Myxofibrosarcoma
- Melanoma
- Carcinoma

Clinical Course, Prognosis, and Treatment

Pleomorphic liposarcoma is characterized by a relatively aggressive clinical course with a more than 30 percent rate of local recurrence, a 30 percent to 50 percent metastatic rate, and an estimated overall 5-year survival rate of 50 percent to 60 percent. The lung is the preferred metastatic site. The treatment is surgical with adjuvant radiation and chemotherapy for advanced disease.

KEY REFERENCES

The full reference list for all chapters is available at www.digm7.com.

3. Willen H et al: Comparison of chromosomal patterns with clinical features in 165 lipomas: A report of the CHAMP study group. *Cancer Genet Cytogenet* **102**:46, 1998
60. Sciot R et al: Cytogenetic analysis of subcutaneous angiolipoma: Further evidence supporting its difference from ordinary pure lipomas: A report of the CHAMP Study Group. *Am J Surg Pathol* **21**:441, 1997
93. Furlong MA, Fanburg-Smith JC, Miettinen M: The morphologic spectrum of hibernoma: A clinicopathologic study of 170 cases. *Am J Surg Pathol* **25**:809, 2001
136. Rosai J et al: Combined morphologic and karyotypic study of 59 atypical lipomatous tumors. Evaluation of their relationship and differential diagnosis with other adipose tissue tumors (a report of the CHAMP Study Group). *Am J Surg Pathol* **20**:1182, 1996
151. Nascimento AG: Dedifferentiated liposarcoma. *Semin Diagn Pathol* **18**:263, 2001
159. Tallini G et al: Combined morphologic and karyotypic study of 28 myxoid liposarcomas. Implications for a revised morphologic typing (a report from the CHAMP Group). *Am J Surg Pathol* **20**:1047, 1996
173. Hornick JL et al: Pleomorphic liposarcoma: Clinicopathologic analysis of 57 cases. *Am J Surg Pathol* **28**:1257, 2004



The Skin in Systemic Disease

Copyright © 2008 by The McGraw-Hill Companies, Inc. Click here for terms of use.



SECTION 24

SKIN IN NUTRITIONAL, METABOLIC, AND HERITABLE DISEASE

CHAPTER 130

Cutaneous Changes in Nutritional Disease

Melinda Jen
Kara N. Shah
Albert C. Yan

Nutrition is the complex series of events by which living organisms consume and assimilate foods and other nutrients to live, grow, and maintain homeostasis. Proper nutrition involves the consumption of key macronutrients in balanced tandem with essential micronutrients. Consisting of carbohydrates, proteins, and lipids, macronutrients are those that are needed in large quantities by an organism to both fuel metabolic processes and provide the substrate for building and maintaining cellular structure. By contrast, micronutrients signify vitamins and minerals, which, though required in relatively minute quantities, are essential to good health. Clinical disease results when disturbances occur in that equilibrium—most commonly from nutrient deficiencies, but also from an unbalanced ratio of consumed nutrients, or, less commonly, from nutrient excesses.

With an improved understanding of the role of diet in health and the advent of nutritional supplements, longstanding scourges such as scurvy, beriberi, and pellagra have largely become diseases of historical interest. Even so, nutritional diseases remain problematic in developing countries and in settings of war, famine, and poverty. In industrialized countries, nutritional diseases may still arise among the disenfranchised: the homeless and those suffering from alcoholism or other forms of substance abuse. Individuals at risk also include those with derangements in their normal diets such as might be encountered with eating disorders, unusual dietary habits, or with parenteral nutrition. Hypercatabolic states, exemplified by cancer, acquired immunodeficiency syndrome, hepatic or renal disease, and certain disease states such as carcinoid syndrome, may develop nutrient deficiencies even in the face of normal intake due to increased metabolic requirements. Excessive nutrient losses may occur from decreased absorption arising from gastrointestinal diseases such as cystic fibrosis, inflammatory bowel disease, celiac disease, or after gastrointestinal surgery. Those receiving chronic medications, such as anticonvulsants or antibiotics, may experience impaired utilization of their nutrients when their medications interfere with gastrointestinal absorption and normal metabolism. Underlying genetic metabolic defects, enzyme deficiencies, hepatic disease, or drug-nutrient interactions may also impair utilization of nutrients. By contrast, syndromes of nutrient excess generally stem from dietary surplus or iatrogenic therapeutic intake.

Patients at risk for one nutrient deficiency may be suffering from other concomitant deficiencies as well. Appropriate evaluation of the patient with suspected nutritional disease should commence with a detailed history of dietary and medication intake, a review of past medical and family history, and a complete physical examination with careful inspection of the skin, with special attention paid to the status of hair, nails, and mucous membranes. Although some skin findings may be pathognomonic for certain nutritional disorders, individual physical findings are more oftentimes non-diagnostic. Clinical improvement after replacement therapy may represent the best or only means to confirm the clinical diagnosis of some nutritional deficiencies. This chapter reviews the important clinical features observed in nutritional disease states.



◀ Scleroderma: CREST syndrome. Numerous macular or matlike telangiectases without other findings of scleroderma on the face. Complete features include calcinosis cutis, Raynaud phenomenon, esophageal dysmotility, sclerosis, and telangiectasia.

MACRONUTRIENTS

Protein-Energy Malnutrition

EPIDEMIOLOGY Protein-energy malnutrition (PEM) is a medical concern of global significance. The United Nations estimates that 852 million individuals, including approximately 170 million or a quarter of the world's children, suffer from PEM,[1] and up to 5 million deaths each year can be attributed to PEM alone.[2]

In developing countries, malnutrition most commonly arises as a result of inadequate dietary intake, often compounded by disease. War, famine, and poverty states often aggravate the inadequate access to food, which may arise from political unrest, natural disasters, infectious diseases, seasonal and climatic factors, insufficient food production, lack of education, poor sanitation, regional and religious practices, and the limited availability of health care.[3] In Western industrialized countries such as the United States, less than 1 percent of children nationally suffer from PEM. When it is encountered, chronic illness, malabsorption, presumed food allergies, nutritional ignorance, and fad diets are more typical etiologies.

ETIOLOGY AND PATHOGENESIS *Protein-energy malnutrition* refers to a spectrum of disorders describing varying degrees of protein and calorie deficiency. Several

Copyright © 2008 by The McGraw-Hill Companies, Inc. Click here for terms of use.



sub-types of PEM have been defined on the basis of relative deficiencies in protein and total calorie intake.

Children with marasmus suffer from severe wasting and stunting and are at less than 60 percent expected body weight for age. The term *marasmus* derives from the Greek *marasmos* meaning "wasting." These changes are the result of chronic and global nutrient deficiencies, often because of a lack of available food. Children with kwashiorkor have body weights less than 60 percent to 80 percent expected for age, generally arising from a diet of grain-derived foods without adequate accompanying protein or fat. This might occur in geographic areas where grains are more plentiful, but where more expensive proteins and fats are not. In fact, the term *kwashiorkor* derives from the Ghanese term for "the one who is deposed," referring to the child who is weaned off of breast milk onto a carbohydrate-rich but often protein-poor diet when the next sibling is born. The exclusive use of rice beverages, so-called "rice milk" products, as a substitute for baby formulas—either because of their lower cost or because of their perceived hypoallergenicity—has been linked to the development of kwashiorkor among infants in the United States and other western countries.[4–6] A hybrid form of malnutrition in which stunting of growth is associated with edema has been termed *marasmic kwashiorkor*.

The pathophysiology of these disorders can also be conceptualized as adapted and nonadapted forms of starvation. In adapted starvation (marasmus), decreased intake of all macronutrients, particularly carbohydrates, suppresses insulin production. Catabolic hormones thereby act unopposed to stimulate the conversion of glycogen into glucose. In the early stages of adapted starvation, muscle breakdown occurs during the first 24 hours, permitting gluconeogenesis to release glucose into the systemic circulation. Fat breakdown creates ketone bodies that can also be utilized by the brain and central nervous system. This reduces the need for further muscle breakdown and therefore ammonia synthesis so that lean body mass and some protein synthesis can be spared. In prolonged states of adapted starvation, wasting occurs and lean body mass is eventually utilized when all other sources are expended; in the absence of additional nutrient intake, the organism dies. In nonadapted starvation states (kwashiorkor), an imbalance results when intake of carbohydrate is increased relative to decreased intake of protein and fat. Without concomitant fat and protein intake, insulin continues unabated, which suppresses protein production. Hypoproteinemia, edema, and diarrhea develop, and affected individuals are unable to manufacture lipoproteins, so fats accumulate in the liver; more important, necessary immune proteins are not produced, so patients become susceptible to opportunistic infection and septicemia, which represent the major causes of mortality in these patients.

Although the concepts of adapted and nonadapted starvation provide convenient explanations for why some children develop PEM, exactly why some children develop marasmus and others develop kwashiorkor in the face of starvation remains controversial.

CLINICAL FINDINGS Childhood is marked by periods of significant and rapid growth and development, and nutritional deprivation often manifests as alterations in these patterns of normal growth and development. Failure to thrive, a key finding in patients with PEM, may appear first as wasting (poor weight gain or weight loss), and eventually, as decreased rates of linear growth (stunting). Various measurements have been recommended as markers for malnutrition, and include: body weight and length/height relative to age, body mass index, triceps or middle upper arm circumference, as well as skin and hair characteristics.[7,8] Suboptimal neurodevelopmental outcomes, heightened susceptibility to infection, and increased mortality may also be observed in chronically malnourished children.

Marasmus typically affects infants younger than 1 year of age. The physical findings of marasmus include dry, thin, loose, wrinkled skin resulting from loss of subcutaneous fat with an emaciated appearance[9] (Fig. 130-1). Hair growth slows and examination may reveal easy hair loss, leading to thin, fine, brittle, hair and alopecia. Increased lanugo hair may also be present. Nails may show signs of fissuring, with impaired growth.[10] As the body mobilizes all endogenous energy stores to survive, both subcutaneous fat and muscle mass are lost. The loss of buccal fat pads creates the aged or wizened appearance attributed to children with marasmus that has been referred to disparagingly as "monkey facies" (Fig. 130-2). Perianal fat loss can lead to rectal prolapse, and abdominal muscle hypotonia may result in abdominal distention.[11] Constipation may alternate with periods of diarrhea, which may or may not be associated with concomitant gastrointestinal infection. Angular cheilitis and mucous membrane changes have also been observed in patients with marasmus.[12] Patients often show both decreased resting body temperature and bradycardia.



▲ **FIGURE 130-1** Marasmus. General appearance with advanced disease.

The hallmark features of kwashiorkor—also known as *edematous* or "wet" *PEM*—include failure to thrive in association with edema and is primarily noted in children between 6 months and 5 years of age. Children are often initially irritable, but may become lethargic and apathetic. In contrast to marasmus, skin findings are common in kwashiorkor. The generalized dermatitis seen in edematous PEM has been likened to flaking enamel paint, with the pattern of skin fissuring suggesting cracked or



▲ **FIGURE 130-2** Marasmus. "Monkey facies" in an Arab infant, with wrinkled skin and loss of subcutaneous fat.



◀ **FIGURE 130-3** The "flaky paint" or "crazy pavement" dermatitis of kwashiorkor.

"crazy" pavement (Fig. 130-3). Increased pigmentation of skin may be observed on extensor surfaces of the arms and legs. Hair often changes from its natural color, typically developing a red tint (Fig. 130-4A) before further pigment dilution results in light, gray-white hair (see Fig. 130-4B). If a child experiences intermittent periods of kwashiorkor and improved nutrition, alternating bands of light and dark color within the hair shaft may be observed and has been referred to as the "flag sign" (see Fig. 130-4A). Increased lanugo hair can also be noted in kwashiorkor. In addition to the peripheral edema, a direct consequence of hypoproteinemia, distention of the abdomen is noted as a result of fatty infiltration of the liver.

Adults may also be at risk for PEM, particularly those suffering from chronic illnesses, eating disorders such as anorexia nervosa, and the elderly. The prevalence of PEM in adult dialysis patients has been estimated at 25 percent to 50 percent and is posited to occur as a result of semistarvation with inadequate caloric and protein intake, possibly complicated by the presence of a chronic systemic inflammatory response to dialysis.[13] Cases of macronutrient PEM have been reported as a complication of bariatric surgery.[14] The manifestations of PEM in adults may be less prominent, manifesting more as xerosis or acquired ichthyosis and may be the result of decreased sebaceous gland secretions or concurrent micronutrient deficiency.[15]

Hyperpigmentation at characteristic sites may also be present, including the perioral, periocular, and malar areas. Diffuse telogen effluvium; lanugo; and thin, dry, dull hair has also been reported in adult PEM.[16]

LABORATORY TESTING Initial laboratory testing in PEM recommended by the World Health Organization (WHO)[17] includes screening for hypoglycemia, anemia, and an investigation into potential comorbid infectious diseases. Because patients with PEM are at significantly increased risk of serious infection, examination of urinalysis for urinary tract bacterial infection and, in the appropriate geographic areas, blood smear for malaria parasites and feces for blood, ova, and parasites is essential. Skin testing for tuberculosis should be performed. Chest radiography may demonstrate concomitant signs of bacterial pneumonia, tuberculosis, heart failure, rickets, and fractures. Patients with kwashiorkor will also demonstrate hypoproteinemia, which may help guide treatment and prognosis. Evaluation of electrolyte levels before treatment should be interpreted with caution, as refeeding will likely alter mineral balances.

Histologic evaluation is generally unnecessary as the clinical features in association with an appropriate history is diagnostic. Histologic evaluation of the skin, however, reveals increased thickness of the stratum corneum, atrophy of the granular layer, increased basal layer pigmentation, reduction of collagen fibers, and crowding of elastic fibers. Atrophy of the hair appendages with sparing of the sweat gland apparatus can also be noted.[18]

TREATMENT Patients with severe PEM often require hospitalization due to the concurrent risks of hypoglycemia, hypothermia, dehydration, and sepsis. Individuals who are not awake and responsive may require intravenous hyperalimentation during the initial stages of therapy; care must be taken to avoid excessively rapid rehydration due to the risks of congestive heart failure. Oral refeeding using oral rehydration salts containing a mixture of essential electrolytes is generally preferred at least until diarrhea subsides or using fortified formulas as soon as these can be tolerated. Because severely malnourished children are relatively immunocompromised, empiric antibiotic therapy may be considered on admission for suspected sepsis, and any identified infections should be appropriately addressed.[17]

DIFFERENTIAL DIAGNOSIS Differential diagnoses include acrodermatitis enteropathica (AE), atopic dermatitis, seborrheic dermatitis, and Langerhans cell histiocytosis.

Essential Fatty Acids

EPIDEMIOLOGY Naturally occurring essential fatty acid (EFA) deficiency states are uncommon in humans. Cases of deficiency arise instead from inadequate intake, malabsorption, or excessive loss. In the past, prolonged parenteral nutrition was a common cause of EFA deficiency, but, with the introduction of lipid supplementation during parenteral nutrition in 1975, the incidence of EFA deficiency has decreased substantially. Patients at risk for EFA deficiency include those with poor dietary intake, including alcoholics and patients with anorexia nervosa, or those with malabsorptive conditions such as biliary disease, inflammatory bowel disease, and



▲ **FIGURE 130-4** **A.** Flag sign in a Salvadoran child. **B.** Hypomelanization of the hair and skin.



post-gastrointestinal surgery (e.g., bariatric surgery), and may represent one of the primary etiologies for the characteristic rash observed in cystic fibrosis patients.[19] Premature, low-birthweight infants are born with inadequate EFA stores and are at special risk.

ETIOLOGY AND PATHOGENESIS EFAs represent a group of 18-, 20-, or 22-carbon polyunsaturated fatty acids that cannot be synthesized de novo by the human body. The ω-3 series of fatty acids is found in fish oils and is derived from α-linoleic acid. The ω-6 series is found in vegetable oils and is derived from linoleic acid.[9] Linoleic acid and α-linoleic acid are the two EFAs that serve as precursors for other EFAs and therefore must be obtained from dietary intake. In cell membranes, EFAs increase lipoprotein unsaturation to modulate cell membrane fluidity. Arachidonic acid, a derivative of linoleic acid, is converted into prostaglandins, eicosanoids, and leukotrienes, which are important mediators of inflammation. In the epidermis, linoleic acid contributes to lamellar granule formation in the stratum corneum. EFAs, therefore, play a number of key roles in maintaining homeostasis.

CLINICAL FINDINGS Skin manifestations of EFA deficiency include xerosis; scaly, diffuse erythema; and associated intertriginous erosions. Poor wound healing, traumatic purpura secondary to capillary fragility, brittle nails, and alopecia may be observed. Affected individuals may also demonstrate hyperpigmentation or hypopigmentation of the hair. Fatty liver infiltration, increased susceptibility to infection, a blunted immune response, anemia, thrombocytopenia, and growth retardation can also be observed.

LABORATORY TESTING In EFA deficiency states, linoleic acid levels are low, and the enzymes that normally convert linoleic acid to arachidonic acid use oleic acid to create the abnormal byproduct 5,8,11-eicosatrienoic acid. Laboratory evaluation would therefore demonstrate decreased levels of linoleic and arachidonic acids, and elevated plasma levels of 5,8,11-eicosatrienoic acid. Measurements documenting an increased ratio (≥ 0.2) of this abnormal intermediary relative to arachidonic acid is diagnostic for EFA deficiency.

TREATMENT Although topical application of sunflower seed and safflower oils, which contain linoleic acid, may improve the clinical cutaneous findings of EFA deficiency,[20] topical absorption is unpredictable[21] and optimal treatment typically consists of oral or intravenous supplementation of EFA. To prevent EFA deficiency, EFA should represent 1 percent to 2 percent of total daily calories.[22]

MICRONUTRIENTS

Fat-Soluble Vitamins

VITAMIN A (RETINOL) ***Etiology and Pathogenesis.*** Vitamin A is a fat-soluble vitamin involved in retinal photoreceptor function, epithelial proliferation, and keratinization. The two most clinically important metabolites of vitamin A are retinal, which is a key component of rhodopsin generation, and retinoic acid, which regulates cell differentiation.[23] Dietary intake of vitamin A derives from both plant and animal sources. Plant sources include dark, green, leafy vegetables; red palm oil; and brightly colored fruits such as papaya, mango, carrots, tomatoes, apricots, and cantaloupe. In plants, the vitamin A precursor β-carotene can be found as a two-molecule complex of the carotenoid known as *retinal*. Retinal is reduced to retinol in the intestinal villous cells. Animal sources of vitamin A include egg yolk, liver, fish, fortified milk, and other dairy products. In animal sources, vitamin A exists as retinyl esters, which are then hydrolyzed to retinol in the intestinal lumen and then absorbed into intestinal mucosal cells. All retinol vitamin A alcohol is esterified to retinyl esters within the intestinal mucosa, released into the bloodstream bound to chylomicrons, and then transported to the liver for storage. Here, vitamin A can be stored as retinyl esters in the liver; when needed, this storage form may be converted to retinol and transported with retinol-binding protein and transthyretin and circulated throughout the body.

Vitamin A Deficiency. **EPIDEMIOLOGY.** Vitamin A deficiency (VAD) can result in cutaneous as well as ocular complications. It is, in fact, the most common cause of preventable blindness in children, according to the WHO.[24] VAD has also been associated with defects in immune regulation.

ETIOLOGY AND PATHOGENESIS. The primary causes of VAD continue to be inadequate intake, fat malabsorption states, and liver disease. In the United States, inadequate intake can be seen in individuals with eating disorders, restrictive diets, and chronic illness. Because vitamin A is fat-soluble, conditions associated with malabsorption of fat, such as pancreatic or biliary tract disease, celiac disease, Crohn disease, Shwachman-Diamond syndrome, cystic fibrosis, cholestatic liver disease, and gastric bypass surgery, can predispose to VAD.

CLINICAL FINDINGS. The earliest manifestations of VAD are ocular changes. Impaired dark adaptation (nyctalopia) is followed by xerophthalmia, and as corneal keratin desquamates and overgrowth of *Xerosis bacillus* on the sclera occurs, white patches known as *Bitot spots* develop. Severe deficiency may lead to corneal xerosis, ulceration, and keratomalacia, which may result in corneal perforation, prolapse of the iris, and blindness (Fig. 130-5).

The cutaneous findings of VAD are the result of abnormal keratinization. Mild deficiency may manifest as xerosis and scaling, whereas more severe deficiency may result in deep skin fissuring referred to as *dermomalacia*. Squamous metaplasia of the salivary glands as well as the nasal and oral mucosa may occur, leading to xerostomia, hyposmia, and hypogeusia. Laryngeal, bronchial, and vaginal mucosa can also become involved. Phrynoderma, meaning "toad skin," is typically associated with VAD. These keratotic follicular papules often first develop on the anterolateral thighs and posterolateral upper arms, which then spread to extensory surfaces of the



▲ **FIGURE 130-5** Vitamin A deficiency, advanced keratomalacia, in a 5-month-old Arab child. Note hyperkeratosis of facial skin. Serum vitamin A level was 2 μg/dL (normal, 20 to 50 μg/dL).





▲ **FIGURE 130-6** Vitamin A deficiency. Typical perifollicular hyperkeratosis of the chest in a Tanzanian adult male.

extremities, shoulders, abdomen, back, buttocks, face, and posterior neck (Fig. 130-6). Although originally reported in association with VAD, phrynoderma is a non-specific finding that can be observed with deficiencies in B-complex vitamins and vitamins C and E, as well as EFA deficiency, PEM, and general malnutrition states.[25]

LABORATORY TESTING. Vitamin A levels can be measured from serum. Normal serum levels are typically between 20 and 50 μg/dL.

TREATMENT. The recommended daily allowance (RDA) of vitamin A is between 1000 and 5000 IU, with younger individuals requiring a lower intake of vitamin A. Recommended treatment for VAD is 100,000 to 300,000 IU of oral vitamin A daily until symptoms resolve and serum levels normalize.

Vitamin A Toxicity. **EPIDEMIOLOGY.** Vitamin A toxicity is the result of excess intake of vitamin A and can occur on an acute or chronic basis. Acute toxicity occurs when excessive amounts of vitamin A are ingested over a period of several hours or days. Toxicity typically results when intake exceeds 20 times the RDA in a child or 100 times the RDA in an adult. Chronic toxicity results from daily ingestion of greater than 25,000 IU for more than 6 years or greater than 100,000 IU for more than 6 months of pre-formed vitamin A. Children appear to be more sensitive to excess vitamin A intake than adults. Individuals most at risk for toxicity include patients taking systemic vitamin A derivatives for the treatment of dermatologic conditions such as acne, psoriasis, and ichthyosis. The other populations at risk include vitamin food faddists who consume large quantities of nonprescription vitamin A supplements.[26] Two notable episodes of vitamin A toxicity occurred in the 1950s when very high levels of vitamin A supplementation were added to infant formulas and the 1970s when high doses of vitamin A were used to treat a variety of dermatologic diseases.[27]

CLINICAL FINDINGS. Individuals with acute vitamin A toxicity have dry, scaly skin, with large areas of desquamation and fissuring of the lips and angles of the mouth. Other signs and symptoms include headache, fatigue, anorexia, nausea, vomiting, blurred vision, pseudotumor cerebri, myalgias, and arthralgias. An early cutaneous sign of chronic vitamin A toxicity in adults is dryness of the lips, which may progress to diffuse, dry, pruritic, scaly skin with peeling of palms and soles, alopecia, follicular hyperkeratosis, and hyperpigmentation of the face and neck. Anorexia, fatigue, and weight loss may also occur. It is interesting to note that follicular hyperkeratosis may occur in the settings of both VAD and toxicity.

In children, chronic toxicity presents as coarse hair with diffuse alopecia, coarse skin with generalized exfoliation, hyperpigmentation, and exfoliative cheilitis. Pseudotumor cerebri may cause headaches and papilledema, whereas infants may have a bulging fontanelle. Skeletal changes are common with vitamin A toxicity, and may present with growth retardation secondary to premature closure of the epiphyses and spontaneous bone fractures. Proposed mechanisms for the pathologic bone findings seen in vitamin A toxicity involve antagonism between vitamin A– and vitamin D–mediated intracellular signaling pathways and interactions with calcium-regulating hormones.[16,26] Deposition of excess vitamin A in adipose tissue and perisinusoidal fibrosis of the liver leading to cirrhosis are the most significant effects of long-term vitamin A toxicity.

LABORATORY TESTING. Laboratory findings in patients with hypervitaminosis A include elevated levels of vitamin A, serum calcium, and alkaline phosphatase (AP). This alteration in calcium homeostasis can lead to calcification of tendons, ligaments, and soft tissues. Deposition of excess vitamin A in adipose tissue and perisinusoidal fibrosis of the liver, which can lead to cirrhosis, are the most significant effects of long-term vitamin A toxicity.

TREATMENT. Almost all of the symptoms of vitamin A toxicity subside after the excess vitamin intake is discontinued, with the exception of liver cirrhosis and consequences of pseudotumor cerebri.

Carotenemia and Carotenoderma. **EPIDEMIOLOGY.** Although hypervitaminosis A is a disease that causes a broad spectrum of clinical findings, excessive intake of carotene results in a benign disorder characterized by yellow-orange skin pigmentation. The condition was described as "carotenemia" in 1919 by Hess and Meyers, who reported a connection between yellow skin pigmentation and increased serum carotene levels.[28] During World War I and World War II, carotenemia was more commonly seen because of the dietary shift from a meat-based diet to a more plant-based diet due to food shortages.



ETIOLOGY AND PATHOGENESIS. Carotenes are not synthesized endogenously and are obtained through intake of carotene-rich foods. Plant carotenes are converted to vitamin A in the gastrointestinal tract, but approximately one-third of carotene is directly absorbed. Several factors can affect carotene absorption, including thyroid hormone, pancreatic lipase and bile acid concentrations, processing of foods, and dietary fat and fiber content. Hypothyroid patients notice an elevation of carotene levels as a result of decreased conversion to retinol. Pancreatic lipase and bile acids digest carotene so that a deficiency of these enzymes due to pancreatic or biliary or hepatic dysfunction could result in elevated carotene levels. Mashing, cooking, and pureeing fruits and vegetables increase the availability of carotene because cell membranes are ruptured in the process, whereas dietary fiber decreases absorption. Because carotene is fat-soluble, a high-fat meal increases absorption. Patients with conditions that lead to hyperlipidemia, such as diabetes mellitus, nephrotic syndrome, and hypothyroidism, also are predisposed to carotenemia because of a linear relationship between the amount of β-lipoprotein and carotene. Impaired conversion of carotene to vitamin A in patients with hypothyroidism and liver disease further contributes to carotenemia. Some patients with anorexia nervosa can present with carotenemia because of increased intake of vegetables. Other groups at risk for carotenemia are food faddists; those with excessive intake of nutritional supplements, dried seaweed (nori), carrots, and papayas;

and infants ingesting a large amount of pureed vegetables.[29–31]

Clinical Findings. Excessive ingestion of carotenes does not result in hypervitaminosis A because the slow conversion of carotene to vitamin A in the intestinal mucosa is not rapid enough to produce toxic amounts of vitamin A.

Excess carotene deposits in the stratum corneum due to its high lipid content. The yellow discoloration of skin secondary to carotenemia is called *carotenoderma*. The carotene is excreted by sebaceous glands and in sweat, so the yellow pigmentation appears first on the face, predominantly in the nasolabial folds and forehead, and then becomes diffusely distributed, with accentuation on the palms and soles. The pigmentation is particularly noticeable in artificial light. Of note, carotenoderma, in contrast to jaundice, spares mucous membranes, including the sclera.



Laboratory Testing. Carotenemia does not occur until serum carotene levels reach three to four times normal levels or greater than 250 μg/dL and is detectable approximately 4 to 7 weeks after initiation of a carotenoid-rich diet.

Treatment. Treatment involves discontinuation of excessive carotene intake, and carotenoderma typically fades as the intake of carotene decreases.

VITAMIN D (CALCITRIOL)

Etiology and Pathogenesis. Vitamin D is essential for regulation of calcium and phosphorus metabolism. Vitamin D acts on the gastrointestinal tract to increase dietary calcium and phosphate absorption, stimulates increased bone resorption of calcium and phosphate, and stimulates the renal tubules to increase reabsorption of calcium and phosphate.

Humans obtain vitamin D from two sources: (1) dietary intake, and (2) synthesis in the skin from exposure to ultraviolet light. Common dietary sources of vitamin D include fortified milk, fish oil, and fishes such as salmon, sardines, herring, tuna, cod, and shrimp. Vitamin D can also be synthesized in the epidermis from the precursor molecule 7-dehydrocholesterol (provitamin D_3) by ultraviolet light in the 290- to 320-nm range. Previtamin D_3 then undergoes a spontaneous, temperature-dependent isomerization to vitamin D_3 (cholecalciferol), which enters the dermal capillaries. At this point, endogenous vitamin D_3 and exogenous dietary D_2 (ergocalciferol) undergo hydroxylation in the liver to 25-hydroxyvitamin D. This molecule travels to the kidney where it is again hydroxylated to make mature vitamin D (1,25-hydroxyvitamin D, also known as *calcitriol*).

The most common disorder of vitamin D metabolism is vitamin D–deficient rickets, which results from decreased dietary intake of vitamin D. Two types of vitamin D–dependent rickets have been described. Type I is an autosomal recessive disorder caused by a deficiency in renal vitamin D-1α-hydroxylase. Type II, also referred to as *hereditary vitamin-D–resistant rickets*, is a rare autosomal recessive disorder caused by mutations in the vitamin D receptor gene or, less commonly, by the production of a nuclear ribonucleoprotein that interferes with the ability of the vitamin D receptor to bind to DNA. Both types of vitamin D–dependent rickets result in end-organ resistance to physiologic levels of 1,25-hydroxyvitamin D.

Epidemiology. Although the earliest classic accounts of the clinical symptoms of rickets were published in 1645 by Daniel Whistler and in 1650 by Francis Glisson, it was not until 1861 that Trousseau of France hypothesized that rickets was caused by inadequate diet and sun exposure. During the Industrial Revolution, a combination of poor diet, smog and tall buildings that obscured the sun, and inadequate time outdoors all contributed to the persistence of rickets in the United States and Europe. By 1918, John Howland, Edward Park, and Paul Shipley had used rat models of rickets to identify the anti-rachitic molecule in cod liver oil as vitamin D.[26]

Vitamin D–deficient rickets continues to occur in modern times. A recent resurgence in vitamin D–deficient rickets has prompted further evaluation of those at risk.[27–29] Groups at risk for vitamin D deficiency include those with inadequate diet, malabsorption, and decreased exposure to sunlight. This includes the elderly or debilitated who have decreased sun exposure or decreased vitamin intake; patients on anticonvulsant therapy; those with malabsorption from gastrointestinal surgery, celiac disease, or pancreatic or biliary disease; and dark-skinned individuals living in areas with poor sun exposure. Rickets also occurs with greater frequency during puberty, when physical and behavioral changes modulate vitamin D availability and the demand for calcium, phosphorus, and vitamin D intake increases. In societies in which women are expected to cover their skin in public for cultural reasons, the scant opportunities for sun exposure increases the risk for vitamin D deficiency if dietary intake is insufficient to meet daily requirements.

Exclusively breast-fed infants, especially those with dark skin tones, may require vitamin D supplementation.[29] In the past, preterm infants were at risk for rickets because of an inadequate supply of calcium and phosphorus at the time of birth. Since the introduction of breast milk fortifiers and preterm formulas, the incidence of rickets of prematurity has decreased dramatically. In response to the continued increase in cases of vitamin D–deficient rickets, the American Academy of Pediatrics in 2003 outlined three populations who should be given supplemental vitamin D (200 IU): (1) all breast-fed infants unless they take in 500 mL/day of fortified formula or milk; (2) all non–breast-fed infants taking in less than 500 mL/day of fortified formula or milk; and (3) children and adolescents who do not obtain regular sun exposure, do not ingest at least 500 mL of fortified milk a day, or do not take a multivitamin with at least 200 IU vitamin D.[32] It appears that only limited sunlight exposure is necessary to produce adequate amounts of vitamin D_3. For patients with Fitzpatrick skin type II, it has been calculated that only 5 minutes of summertime noon sun two to three times weekly provides adequate vitamin D production to satisfy physiologic requirements.[33,34] Given the movement to encourage sunscreen use, there has been concern regarding secondary vitamin D deficiency. Chronic sunscreen use does decrease 25-hydroxyvitamin D, but with intermittent lapses in sunscreen application, there seems to be no significant impact on the incidence of vitamin D deficiency.

Clinical Findings. The classic clinical manifestations of vitamin D–deficient rickets are skeletal in nature. Calcium and phosphorus deficiency leads to poor calcification of new bones, resulting in fraying and widening of the metaphyses. This can be best appreciated at costochondral junctions of the anterior ribs, creating the well-known "rachitic rosary." Poor calcification of the skull bones results in craniotabes, a softening of the skull bones that gives them a ping-pong ball feel on palpation. As the bones become weaker, they cannot support the weight of the

child, and progressive lateral bowing of the lower extremities occurs. Other findings can include frontal bossing, widening of the wrists, scoliosis, hypotonia, fractures, dental defects, and, rarely, hypocalcemic seizures or tetany. Early radiographic signs of rickets include widening of the epiphyseal plate and blurring of the epiphyseal and metaphyseal junction. If the disease progresses, deformities at the growth plate develop, including cupping, splaying, formation of cortical spurs, and stippling. The bone cortices appear thinner, and generalized osteopenia is noted.

Vitamin D–dependent rickets type II has also been associated with cutaneous features that are clinically indistinguishable from the syndrome of generalized atrichia associated with mutations in the hairless gene.[35,36] In both conditions, affected patients are born with hair. However, within a few months after birth, scalp and body hair are lost, with the exception of eyebrows and eyelashes. Small papules and cysts representing abnormal, rudimentary hair structures characteristically develop on the face and scalp. These cysts typically show disintegration of the lower two-thirds of the follicular unit. Although the cutaneous features—notably the alopecia and cysts—are phenotypically and histologically identical, these are distinct clinical entities (Table 130-1).

Laboratory Testing. In addition to the clinical and radiologic signs of rickets, laboratory examination may be helpful. Elevated serum AP levels and low serum 25-hydroxyvitamin D levels are often useful laboratory indicators of vitamin D deficiency. In the early stages of rickets, parathyroid hormone levels increase to compensate for declining serum calcium levels, but this compensatory mechanism becomes inadequate if the deficiency continues.

Treatment. The recommended daily value of vitamin D is 5 to 10 μg. Treatment includes oral vitamin D repletion with dihydroxyvitamin D in addition to a calcium-rich diet. Supplementation with 200 to 400 μg vitamin D per day until resolution of symptoms, about 2 to 3 months, is usually adequate. Additional therapy can include judicious sun exposure.

TABLE 130-1
Physical Signs of Nutritional Disease

- Hair findings
  - Alopecia
    - Adult starvation
    - Anorexia
    - Biotin deficiency
    - Bulimia
    - Essential fatty acid deficiency
    - Iron deficiency
    - Marasmus
    - Selenium intoxication
    - Vitamin A intoxication
    - Vitamin D–resistant rickets, type II
  - Hair shaft changes
    - Copper deficiency
    - Vitamin C deficiency
  - Hair color
    - Kwashiorkor
    - Manganese deficiency
    - Selenium deficiency
    - Selenium intoxication
    - Vitamin B_{12} deficiency
  - Follicular hyperkeratosis
    - Essential fatty acid deficiency
    - Starvation
    - Vitamin A deficiency
    - Vitamin B complex deficiency
    - Vitamin C deficiency
    - Vitamin E deficiency
- Nail findings
  - Anorexia
  - Kwashiorkor
  - Selenium deficiency
  - Selenium intoxication
  - Vitamin A intoxication
- Skin findings
  - Biotin deficiency
  - Kwashiorkor
  - Marasmus
  - Vitamin A deficiency
  - Vitamin A intoxication
  - Xerosis
  - Hypopigmentation
    - Biotin deficiency
    - Copper deficiency
    - Kwashiorkor
  - Hyperpigmentation
    - Carotenemia
    - Iron overload
    - Kwashiorkor
    - Lycopenemia
    - Vitamin B_{12} deficiency
  - Dermatitis
    - Seborrheic dermatitis
      - ~ Pyridoxine deficiency
      - ~ Riboflavin deficiency
    - Periorificial dermatitis
      - ~ Biotin deficiency
      - ~ Essential fatty acid deficiency
      - ~ Zinc deficiency
    - Acral dermatitis
      - ~ Zinc deficiency
    - Photodistributed dermatitis
      - ~ Niacin deficiency
    - Other dermatitis
      - ~ Folate deficiency
      - ~ Manganese deficiency
  - Purpura
    - Vitamin C deficiency
    - Vitamin K deficiency
- Oral and perioral findings
  - Bulimia nervosa
  - Kwashiorkor
  - Riboflavin deficiency
  - Selenium intoxication
  - Thiamine deficiency
  - Vitamin A intoxication
  - Vitamin B_{12} deficiency
  - Vitamin C deficiency
  - Zinc deficiency
- Ocular findings
  - Biotin deficiency
  - Vitamin A deficiency
  - Vitamin C deficiency

VITAMIN E (TOCOPHEROL) Vitamin E is rarely associated with deficiency or excess states of disease. Vitamin E is found in oils and shortenings, as well as various fortified grains, dark green leafy vegetables, legumes, nuts, avocado, and small fishes such as herring and sardines.[37] Because it is a fat-soluble vitamin, excessive intake may augment the effects of anticoagulant medications, leading to purpura and propensity for hemorrhage.[38] Deficiency states are rare. However, ataxia with isolated vitamin E deficiency is a rare and severe spinocerebellar neurodegenerative disorder with autosomal recessive inheritance. Patients with mutations in the α-tocopherol transfer protein are unable to properly transfer vitamin E (α-tocopherol) from lysosomes into lipoproteins, which results in a predisposition to oxidative stress in affected cells and leads to neurologic degeneration.[39–41]

VITAMIN K (PHYTONADIONE) ***Etiology and Pathogenesis.*** Vitamin K is a necessary co-factor in the carboxylation of glutamate residues on coagulation factors II, VII, IX, X, and proteins C and S. Dietary vitamin K, phylloquinone, is found in green, leafy vegetables, certain legumes, soybeans, cereals, and beef liver. Phylloquinone is actively transported in the distal small bowel. Approximately one-half of the body's vitamin K is obtained though these dietary sources, and the other half is synthesized by gastrointes-



tinal flora as menaquinones, which are passively absorbed in the distal small bowel and colon.

Epidemiology. Vitamin K is so named after the Danish word "koagulationsvitamin," which literally translates to mean "clotting vitamin." Vitamin K deficiency beyond the newborn period is rare, but may result from malabsorption, liver disease, inadequate dietary intake, or medications. Fat malabsorption occurs in conditions such as regional ileitis, topical sprue, celiac disease, cystic fibrosis, pancreatic insufficiency, and biliary obstruction. Antibiotic use can result in vitamin K deficiency by altering the populations of normal bowel flora. Coumarin interferes with vitamin K epoxide reductase, an enzyme important in the recycling of inactive vitamin K into its active form. Other medications that can interfere with vitamin K metabolism include anticonvulsants (phenytoin), rifampin, isoniazid, high-dose salicylates, cholestyramine, and cephalosporins.[9,42]



Clinical Findings. Vitamin K deficiency leads to impaired coagulation and hemorrhage and can present in the neonatal period, when it is referred to as *hemorrhagic disease of the newborn* (HDN). Neonates are particularly prone to vitamin K deficiency because of poor transplacental transfer, low dietary intake, and a sterile bowel. HDN is divided into early presentation and late presentation. The incidence of early HDN is 0.25 percent to 1.7 percent and causes unexpected bleeding in the first week of life in an otherwise healthy neonate. It can present as ecchymoses, cephalohematomas, or nasal, subgaleal, umbilical, intestinal, or intracranial hemorrhages. Late HDN is defined by the American Academy of Pediatrics as unexpected bleeding from severe vitamin K deficiency in 2- to 12-week-old infants who are primarily breast-fed and who received no or inadequate neonatal vitamin K prophylaxis.[43] Vitamin K deficiency in older children and adults can present as purpura, ecchymoses, gingival bleeding, and gastrointestinal, genitourinary, and retroperitoneal hemorrhage.

Laboratory Testing. Because vitamin K is a key co-factor in the coagulation pathway, deficiency of vitamin K typically manifests as elevations in both prothrombin time and activated partial thromboplastin time. Serum levels of vitamin K can also be measured.

Treatment. Neonatal prophylaxis is traditionally administered as a single intramuscular dose of 0.5 to 1.0 mg of vitamin K. Several studies have evaluated the use of oral vitamin K prophylaxis, but there are no definitive data on efficacy, safety, or bioavailability.[43]

Acute treatment of vitamin K deficiency with hemorrhage is with fresh frozen plasma to replace deficient coagulation factors. Vitamin deficiency can also be treated with parenteral or intramuscular 5 to 10 mg vitamin K per day to correct severe deficiency.

Water-Soluble Vitamins

VITAMIN B_1 (THIAMINE) ***Etiology and Pathogenesis.*** Disorders of thiamine may have broad-ranging clinical implications because thiamine is an essential coenzyme for several enzymes involved in nicotinamide adenine dinucleotide phosphate (NADPH) synthesis, carbohydrate metabolism, and deoxyribose and ribose synthesis. Thiamine is used as a coenzyme for transketolase in the pentose phosphate pathway to produce NADPH. Thiamine pyrophosphate acts as a coenzyme in pyruvate dehydrogenase and α-ketoglutarate dehydrogenase, which are involved in oxidative decarboxylation reactions in the metabolism of carbohydrates and branched-chain amino acids.

Epidemiology. Thiamine is obtained from whole grains, enriched bread products, dried peas and beans, potatoes, and fish. Polished rice eliminates the thiamine-containing husk and predisposes to thiamine deficiency.

Disorders of thiamine excess are extremely rare. Most arise as a result of intravenous administration for suspected thiamine deficiency in the context of chronic alcoholism. Local irritation at the site of intravenous administration, generalized pruritus, and anaphylactic or anaphylactoid reactions have been described.[44] Neurotoxicity can occur in experimental settings when thiamine is administered directly into the central nervous system.[45] In general, thiamine excess states are extremely rare in humans.

Historically, the term *beriberi,* derived from Sinhalese meaning "extreme weakness," has been used to refer to thiamine deficiency. The symptoms of beriberi have been recognized in East Asian countries for thousands of years because polished white rice is a dietary staple.

Clinical Findings. Thiamine deficiency in the United States is now rare. Predisposing factors for pediatric thiamine deficiency include unsupplemented parenteral nutrition, breast-fed infants of thiamine-deficient mothers, congestive heart failure,[46] and severe malnutrition. Early signs include irritability, apathy, restlessness, and vomiting. As the disease progresses, neurologic signs of Wernicke encephalopathy may develop, such as ophthalmoplegia, ataxia, nystagmus, and characteristic laryngeal nerve paralysis resulting in aphonia, which is a classic manifestation of infantile beriberi. Other symptoms include congestive heart failure, tachycardia, dyspnea, and cyanosis. In 2003, a series of infants presenting with ophthalmoplegia as a manifestation of Wernicke encephalopathy was reported in Israel as a result of a thiamine-deficient infant soy formula. In all these cases, a prodromal illness was observed. Early symptoms included vomiting, anorexia, diarrhea, lethargy, irritability, and developmental delay. Upbeat nystagmus and ophthalmoplegia were the primary neurologic signs. After treatment, those with early disease had complete recovery, but those with severe disease had residual neurologic complications.[47]

Adult beriberi has been categorized into dry and wet forms. Dry beriberi describes a symmetric distal peripheral neuropathy involving both sensory and motor systems. Wet beriberi includes neuropathy and signs of cardiac involvement, including cardiomegaly, cardiomyopathy, congestive heart failure, peripheral edema, and tachycardia. A red, burning tongue and peripheral edema have also been observed with wet beriberi.

Laboratory Testing. Diagnosis of thiamine deficiency is made by measurement of erythrocyte thiamine transketolase or blood thiamine concentration. The more reliable measure is erythrocyte thiamine transketolase activity before and after thiamine pyrophosphate stimulation, represented as a percentage of thiamine pyrophosphate effect. Normal values are up to 15 percent.

Treatment. Because thiamine is a co-factor in a variety of metabolic pathways, daily thiamine requirements are calculated from an individual's ideal total caloric intake, with current recommendations of 0.5 mg per 1000 kcal.

Treatment of thiamine deficiency can be via intravenous, intramuscular, or oral routes of administration. Usually, treatment for beriberi is initiated with

intravenous or intramuscular thiamine of 50 to 100 mg per day for 7 to 14 days, then oral supplementation is provided until full recovery is documented.

VITAMIN B_2 (RIBOFLAVIN) ***Etiology and Pathogenesis.*** Riboflavin was discovered in 1879 as a fluorescent yellow-green substance found in milk. Riboflavin is used in two coenzymes, flavin mononucleotide (FMN) and flavin-adenine dinucleotide (FAD), both of which are involved in oxidation-reduction reactions in cellular respiration and oxidative phosphorylation. These two enzymes are also involved in pyridoxine (vitamin B_6) metabolism. Recent studies have suggested that riboflavin deficiency may contribute to increased plasma homocysteine levels, impaired handling of iron, and night blindness.[48]

Riboflavin is typically obtained through dairy products, nuts, meat, eggs, whole grain and enriched bread products, fatty fish, and green leafy vegetables. A small amount of dietary riboflavin is present as free riboflavin; most are found as FAD or FMN. Dietary FAD and FMN are hydrolyzed to riboflavin in the small intestines by brush border enzymes. Free riboflavin in the intestinal lumen is then taken up by active transport in the proximal small bowel.

Deficiency states can be caused by decreased intake, inadequate absorption, and phototherapy. Alcoholics, the elderly, and adolescents are groups at risk for riboflavin deficiency secondary to poor nutritional intake. In areas of India, China, and Iran, riboflavin deficiency is endemic as a result of their dependence on an unenriched cereal diet. Infants of riboflavin-deficient mothers are also at risk of deficiency because breast milk concentrations of the vitamin are proportional to maternal concentrations. Once weaned from the breast, these infants are at additional risk if they are not transitioned to milk. When confounded by PEM, riboflavin deficiency may be worsened because the usual renal compensatory mechanism of increased riboflavin absorption is impaired in this setting. Visible light phototherapy for jaundiced neonates causes photodecomposition of riboflavin.[49] Certain drugs also affect riboflavin levels through effects on absorption or metabolic inhibition. Chlorpromazine and other tricyclic drugs inhibit transport of riboflavin in the gastrointestinal tract, predisposing to deficiency states.[50] Borate displaces riboflavin from binding sites, increases urinary riboflavin excretion, and inhibits riboflavin-dependent enzymes, contributing to riboflavin deficiency.[51]

Clinical Findings. Signs of acute riboflavin deficiency include a deep red erythema, epidermal necrolysis, and mucositis. The severity of symptoms depends on the severity of deficiency.[52]

Clinical signs of chronic riboflavin deficiency or ariboflavinosis begin 3 to 5 months after initiation of an inadequate diet. Skin and mucous membrane findings predominate. Initially, angular stomatitis manifests as small papules at the corners of the mouth that enlarge and ulcerate before developing into macerated fissures that extend laterally and often bleed (Fig. 130-7). Pronounced cheilosis with erythema, xerosis, and vertical fissuring of lips can occur. Early glossitis appears as prominent lingual papillae, but after these papillae are lost, the tongue becomes smooth, swollen, and magenta in color. The dermatitis of riboflavin deficiency resembles seborrheic dermatitis in that it involves the nasolabial folds, nostrils, nasal bridge, forehead, cheeks, and posterior auricular regions. Flexural areas of the limbs may also be affected. Plugging of the sebaceous glands (dyssebacia) may be observed around the nose. The dermatitis can affect the genitalia, more often to a greater extent in males than in females. A red, confluent, crusty, or lichenified dermatitis of the scrotum often spreads to involve the inner thighs. In general, the dermatitis is worse in areas of chafing or trauma. Infants frequently manifest the dermatitis in the inguinal areas. In older individuals, the dermatitis is often more pronounced in facial creases and wrinkles, and, if incontinent, can involve the perianal and buttock areas. Cutaneous findings are not aggravated by light exposure, but are exacerbated by heavy physical activity. Ocular findings, in particular photophobia and conjunctivitis, are also a prominent feature of this. *Oculo-orogenital syndrome* is the term used to describe this constellation of symptoms.



▲ **FIGURE 130-7** Riboflavin deficiency. Angular stomatitis with maceration in an Arab child. Riboflavin excretion in the urine was diminished.

Laboratory Testing. A normochromic, normocytic anemia may be observed. Measurement of erythrocyte glutathione reductase activity can be used as a screening test, but a trial of riboflavin supplementation is often the most optimal method to confirm a riboflavin deficiency.

Treatment. The recommended daily intake of riboflavin is 0.6 mg per 1000 kcal. Treatment for deficient infants and children is 1 to 3 mg per day, and for adults, 10 to 20 mg.

VITAMIN B_3 (NIACIN) ***Etiology and Pathogenesis.*** Niacin (vitamin B_3) is a vitamin co-factor that can be obtained in the diet or synthesized endogenously from the essential amino acid tryptophan. Niacin is found in whole grains and enriched bread products, nuts, dairy products, liver, animal meat, mushrooms, and dried beans. Dietary niacin exists primarily in the form of nicotinamide adenine dinucleotide (NAD) and NADPH. NAD and NADPH are hydrolyzed in the intestinal lumen to form nicotinamide. Nicotinamide can be converted to nicotinic acid by intestinal bacteria or be absorbed into the bloodstream. Nicotinamide and nicotinic acid then travel to the liver, kidney, and intestines, where they are converted back to NAD and NADPH. These two agents act as hydrogen donors and acceptors in oxidation-reduction reactions involved in the synthesis and metabolism of carbohydrates, fatty acids, and proteins.

Epidemiology. Deficiency of niacin or vitamin B_3 results in pellagra. In 1735, Gasper Casal described a group of poor peasants in northern Spain who were particularly affected by a skin disorder referred to then as "mal de la rosa," so named because of the reddish, glossy rash on the dorsum of the hands and feet. He noted that these peasants were all poor, ate mainly maize, and rarely ate fresh meat.

Pellagra was endemic in the southern United States in the early 1900s because of a common diet consisting principally of cornbread, molasses, and pork fat. Pellagra remains endemic in parts of the world, including South Africa, China,



and India, where corn and maize continue to be a dietary mainstay. Corn and maize contain bound niacin, so without alkaline hydrolysis to release the niacin, it is unavailable for absorption. Jowar, a type of millet found in parts of India, contains adequate levels of niacin, but large quantities of leucine interfere with the conversion of tryptophan to niacin.[53] Although Mexicans have a predominantly maize-based diet, pellagra is relatively uncommon because preparation of the maize includes washing it in lime water, which releases the complexed niacin.

Because niacin is absorbed from the gastrointestinal tract, gastrointestinal disorders can predispose to pellagra. Impaired absorption of tryptophan and niacin occurs in patients with jejunoileitis, gastroenterostomy, prolonged diarrhea, anorexia nervosa, chronic colitis, ulcerative colitis, cirrhosis, Crohn disease, and subtotal gastrectomy.[54] Patients with Hartnup disease, a rare autosomal recessive disorder caused by a defective renal and intestinal transport of neutral amino acids such as tryptophan, develop pellagra-like symptoms in childhood. This is caused by a defect in the neutral brush border system, resulting in malabsorption of amino acids, including tryptophan.[55] Alcoholics develop pellagra from a combination of poor diet and malabsorption. Overly restrictive diets seen in patients with eating disorders, such as anorexia nervosa, presumed food allergies, or food faddism can also cause pellagra.

Patients with carcinoid syndrome are at risk for pellagra. Normally, about 1 percent of tryptophan is metabolized to serotonin, but in carcinoid syndrome, an excessive amount, about 60 percent, is converted to serotonin. Because of this diversion of tryptophan to serotonin production, less tryptophan is available to make niacin.

Medications can also induce symptoms of pellagra. Isoniazid is a competitive inhibitor of NAD because of their similar structures and also impairs pyridoxine functioning, which is essential for niacin synthesis from tryptophan. 5-Fluorouracil inhibits conversion of tryptophan to niacin, and 6-mercaptopurine inhibits NAD phosphorylase, which inhibits NAD production. Other implicated medications include phenytoin, chloramphenicol, azathioprine, sulfonamides, and antidepressants.[56]

Clinical Findings. Pellagra is classically described with the four Ds of dermatitis, diarrhea, dementia, and death. The characteristic photosensitive dermatitis begins as erythematous, painful, or pruritic patches. The skin becomes progressively more edematous, and several days later may develop vesicles and bullae that can rupture, leaving crusted erosions, or develop into brown scales (Fig. 130-8). Over time, the skin thickens into sharply demarcated, keratotic, hyperpigmented plaques. Painful fissures can develop in the palms and soles, resembling goose skin. The dorsum of the hands is the most commonly affected site, and when the rash extends proximally, more on the radial than ulnar side, it forms the "gauntlet" of pellagra. A butterfly distribution may be apparent on the face when it extends from the nose to the cheeks, chin, and lips. When the dermatitis affects the upper central portion of the chest and neck, it is referred to as "Casal's necklace." It can sometimes extend down over the sternum to create a "cravat." Mucous membrane involvement may manifest as cheilitis, angular stomatitis, glossitis, and ulceration of the buccal mucosa and vulva.

Gastrointestinal symptoms may represent the earliest signs of pellagra. Diarrhea, nausea, vomiting, abdominal pain, and anorexia have been reported. Neurologic symptoms, such as insomnia, fatigue, nervousness, apathy, impaired memory, and depression, can progress to psychosis and dementia in later stages. Without treatment, pellagra leads to death from multiorgan failure.

Laboratory Testing. Diagnosis is primarily made on clinical grounds and through a rapid response to vitamin supplementation. However, measurement of the urinary metabolites of niacin N-methylnicotinamide and pyridone may be used to aid in the diagnosis.

Treatment. The recommended daily value of niacin is 15 to 20 mg of niacin, or about 60 mg of exogenous tryptophan. Treatment with 500 mg per day of nicotinamide or nicotinic acid is given over





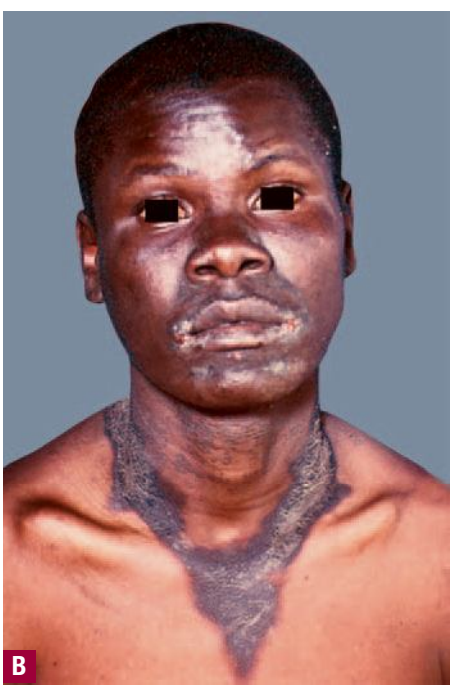

▲ **FIGURE 130-8** Pellagra. Acute dermatosis. **A.** "Glove" or "gauntlet" exudative and crusted lesions on the hands. **B.** "Casal's necklace" on the neck with facial involvement.

several weeks. Nicotinamide is preferred over nicotinic acid because nicotinic acid is frequently associated with headache and flushing. Neuropsychiatric symptoms may remit after 24 to 48 hours of treatment, but skin lesions often take 3 to 4 weeks to clear.[57]

VITAMIN B_6 (PYRIDOXINE) ***Etiology and Pathogenesis.*** Vitamin B_6 describes three interchangeable molecules: pyridoxine, pyridoxamine, and pyridoxal. Humans are unable to synthesize any of these molecules, but fortunately they are widely available in both plant and animal products. Meats, whole grains, vegetables, and nuts are the best sources for vitamin B_6. Processing of these foods can decrease the amount of available vitamin B_6 that is absorbed through passive diffusion in the jejunum. The most common form of vitamin B_6 is pyridoxal-5-phosphate. Vitamin B_6 is employed in multiple pathways, including the decarboxylation and transamination of amino acids, gluconeogenesis, conversion of tryptophan to niacin, sphingolipid synthesis, prostaglandin synthesis, and neurotransmitter synthesis. As such, clinical features of pyridoxine deficiency may overlap with those of niacin deficiency.

Epidemiology. Due to the availability of dietary vitamin B_6, deficiency is seldom caused by inadequate intake, but can occur in alcoholics due to poor diet. More commonly, causes are malabsorption and medication-induced deficiency. Small bowel disorders, such as Crohn disease and celiac disease, can interfere with vitamin B_6 absorption. Medications that have been implicated in causing deficiency include isoniazid, hydralazine, penicillamine, and oral contraceptives. Isoniazid, hydralazine, and penicillamine bind to pyridoxal-5-phosphate and increase excretion and/or decrease activity of the coenzyme.

Clinical Findings. Vitamin B_6 deficiency presents as a seborrheic-like dermatitis of the face, scalp, neck, shoulders, buttocks, and perineum. Clinical features resemble niacin deficiency, including photodermatitis, glossitis, and cheilitis. Glossitis appears as redness, burning, and ulceration of the tongue, leading to flattening of the filiform papillae. Other manifestations include angular stomatitis, cheilosis, and conjunctivitis. This condition produces an oculo-orogenital syndrome quite similar to that seen with riboflavin deficiency.[58] Somnolence, peripheral neuropathy, paresthesias, weakness, and confusion can occur. Other signs and symptoms are nonspecific, and include nausea, vomiting, depression, anorexia, and anemia. Vitamin B_6 deficiency often resembles pellagra because vitamin B_6 is needed for the conversion of tryptophan to niacin.

Vitamin B_6 toxicity from excessive intake does not typically produce skin findings, although it can be associated with peripheral neuropathy.

Laboratory Testing. Vitamin B_6 can be evaluated by mean measurement of plasma pyridoxal-5-phosphate. Low levels of plasma pyridoxal-5-phosphate indicate deficiency.

Treatment. Recommended daily values of pyridoxine depend on age and gender. Adult males require at least 2 mg per day; adult females require at least 1.6 mg per day; and infants require about 0.3 mg per day. Treatment involves discontinuation of inciting medication where relevant and initiating replacement therapy with 100 mg of pyridoxine per day. Oral lesions resolve in days, skin and hematologic changes resolve in weeks, and neurologic symptoms over several months.[9]

VITAMIN B_9 (FOLATE) ***Etiology and Pathogenesis.*** Folate can be found in almost all foods, particularly in liver, wheat bran and other grains, leafy green vegetables, and dried beans. Tetrahydrofolate, the coenzyme form of folate, is used for single-carbon transfers in amino acid, purine, and pyrimidine metabolism. Malabsorptive states (such as celiac disease, chronic diarrhea, status-post total gastrectomy) and antifolate medications (such as methotrexate, trimethoprim, oral contraceptives, and pyrimethamine) have been implicated in producing folate deficiency. The antiepileptics phenobarbital and phenytoin can also lead to folate deficiency states through induction of microsomal hepatic enzymes by anti-epileptics, which deplete folate stores.[59] The poor diets of alcoholics can produce folate deficiency. In children, folate deficiency can be also be associated with excessive boiling of milk or a goat's milk diet because of its low bioavailability of folate when compared with human or cow's milk.[60,61]

Clinical Findings. The primary manifestation is hematologic: hypersegmented neutrophils, macrocytosis, and megaloblastic anemia. Neutropenia, thrombocytopenia, diarrhea, and irritability may also be observed. In contradistinction to vitamin B_{12} deficiency, folate deficiency is not associated with neurologic symptomatology.

Mucocutaneous findings include glossitis with atrophy of the filiform papillae, angular cheilitis, mucosal ulceration, perirectal ulcerations, perineal seborrheic dermatitis, and diffuse brown hyperpigmentation concentrated in the palmar creases and flexures.[62,63]

Laboratory Testing. Macrocytic and megaloblastic anemia with hypersegmentation of neutrophils is suggestive. Diagnostic confirmation can be accomplished through measurement of serum folic acid levels.



Treatment. Folic acid supplementation is typically curative. Discontinuation of antifolate agents if implicated is recommended if involved. Ruling out concurrent vitamin B_{12} deficiency is crucial before initiating treatment for folate deficiency. If vitamin B_{12} deficiency is present but not treated, the hematologic symptoms may respond to folate, but the neurologic symptoms will progress. Treatment involves 1 to 5 mg of folic acid per day.

VITAMIN B_{12} (COBALAMIN) ***Etiology and Pathogenesis.*** Vitamin B_{12} is an important coenzyme for two biochemical pathways in humans. Methylcobalamin is a coenzyme for methyltransferase that converts methylate homocysteine to methionine, which is used in DNA, protein, and lipid metabolism. 5′-Adenosylcobalamin is required to catalyze the reaction by methylmalonyl coenzyme A (CoA) mutase to convert methylmalonic acid to succinyl-CoA, which is used in fat and carbohydrate metabolism.

Vitamin B_{12} is found primarily in animal products, with liver, eggs, milk, beef, and organ meats being excellent sources. Gastric acid separates vitamin B_{12} from food proteins so it can bind to intrinsic factor in the duodenum. This complex is taken up by specific ileal receptors in the terminal ileum. In the enterocyte, vitamin B_{12} dissociates from intrinsic factor and enters the portal circulation bound to transcobalamin II for transport to tissues. Between 1 percent to 5 percent of free cobalamin is absorbed along the intestinal wall by passive diffusion. The body is able to store large amounts of vitamin B_{12}, so symptoms of deficiency often take 3 to 6 years to develop.

Epidemiology. Causes of vitamin B_{12} deficiency can be divided into three groups: inadequate intake, malabsorption, and other. Elderly individuals and psychiatric patients with poor diets, and strict vegetarians and their breast-fed infants are most likely to become deficient from inadequate intake. Cases related to malabsorption can be further divided into four groups: decreased gastric acid states (chronic proton pump inhibitors and histamine H_2 receptor blockers), decreased intrinsic factor (pernicious anemia, atrophic gastritis, postgastrectomy), microbial competition in the gut (bacterial overgrowth, *Diphyllobothrium latum* infection), and impaired absorption (Crohn disease, Whipple disease, Zollinger-Ellison syndrome, celiac disease). The other causes of cobalamin deficiency relate to inborn errors of transport or metabolism.[64]



Clinical Findings. Vitamin B_{12} deficiency manifests primarily in four systems. As with cases of folate deficiency, mucocutaneous manifestations of vitamin B_{12} deficiency include glossitis, angular cheilitis, hair depigmentation, and cutaneous hyperpigmentation. Glossitis is characterized by an atrophic, red, and painful tongue with atrophy of the filiform papillae, which is referred to as *Hunter glossitis*. Hair depigmentation may be localized or diffuse. Hyperpigmentation can be diffuse and symmetric or involve a few scattered macules. The greatest concentration is usually observed on the hands, nails, and face, with the most commonly affected areas being the palmar creases, flexural regions, and pressure points. This hyperpigmentation often resembles Addison disease, but patients show no evidence of adrenal insufficiency.[65–68]

Three proposed hypotheses exist regarding the pathophysiology of the hyperpigmentation. Vitamin B_{12} maintains glutathione in reduced form, which is used to regulate tyrosinase, an enzyme necessary in melanogenesis. The first hypothesis is that, in vitamin B_{12} deficiency, increased tyrosinase activity results in hypermelanosis. Another proposed hypothesis involves defective melanin transport between melanocytes and keratinocytes. Finally, megaloblastic changes in keratinocytes from B_{12} deficiency may affect melanin distribution.[9,16,67,68]

Cobalamin deficiency can cause the neurologic manifestations of subacute combined degeneration of the dorsal and lateral spinal column. Generalized weakness with paresthesias progresses to ataxia and symmetric loss of vibration and proprioception, worse in the lower extremities, eventuating in severe weakness, spasticity, paraplegia, and incontinence. Other neurologic findings include apathy, somnolence, irritability, memory loss, dementia, and psychosis. Early neurologic findings may present before hematologic signs.

Laboratory Testing. The hematologic findings are similar to those found in folate deficiency, namely macrocytic anemia and hypersegmented neutrophils. Bone marrow biopsy reveals a hypercellular marrow secondary to disordered maturation.

Deficiency is diagnosed by measuring serum cobalamin levels, with levels less than 200 pg/mL indicating definite B_{12} deficiency and 200 to 300 pg/mL being borderline low.

Treatment. Treatment depends on treating the cause of deficiency and supplementing with vitamin B_{12}. Oral supplementation is not recommended due to poor absorption. For vitamin B_{12} deficiency in adults, supplementation with 30 μg administered via the intramuscular or subcutaneous route for 5 to 10 days, followed by 100 to 200 μg per month is recommended. In children, a dose of 100 μg/day for 10 to 15 days followed by 100 μg per week for several months may be required. For pernicious anemia, supplementation with cyanocobalamin at a dose of 1000 μg per week for 1 month administered via the intramuscular or subcutaneous route is usually sufficient. If symptoms persist, continued supplementation with 1000 μg of parenteral cyanocobalamin every month may be required.

VITAMIN C (ASCORBIC ACID) ***Etiology and Pathogenesis.*** Vitamin C is an antioxidant and essential co-factor in several biologic reactions, including collagen biosynthesis, prostaglandin metabolism, fatty acid transport, and norepinephrine synthesis. Humans are unable to synthesize ascorbic acid because they lack gulonolactone oxidase, an enzyme most other animals use to convert glucose to ascorbic acid.

The majority of dietary vitamin C is obtained from fruits and vegetables, like potatoes, tomatoes, berries, citrus fruits, and green vegetables. Vitamin C is absorbed in the distal small bowel. Most dietary vitamin C is completely absorbed, but absorption decreases as dietary intake increases. Depletion of body stores occurs after 1 to 3 months of a deficient diet.

As a water-soluble vitamin, ascorbic acid excess states are not typically associated with significant clinical disease. However, vitamin C deficiency is a disease of both great clinical importance and one of great historical significance.

Epidemiology and Pathogenesis. Scurvy, the disease of vitamin C deficiency, has been documented since antiquity. Ancient Greek, Roman, and Egyptian texts make reference to scurvy. Scurvy plagued sailors for hundreds of years before its cause was fully understood. George Anson's famous pursuit of Spanish ships in 1740 to 1744 began with more than 1400 crew members. By the end of the 4-year journey, he returned with only 145 of his original crew members, with 4 killed in enemy action and over 1300 having died from scurvy.[69]

In 1747, James Lind devised one of the earliest clinical trials to investigate crew members from the HMS Salisbury afflicted with scurvy and discovered that oranges and lemons were the most effective treatment for scurvy.[70] Although these findings were published in 1753, it was not until 1793 that lemon juice became a required daily provision on long sea voyages.[71]

As the incidence of scurvy decreased at sea, several epidemics on land occurred. The Great Potato Famine of 1845 to 1848 and World War I and II were times of nutritional impoverishment. The armies of the Crimean War and American Civil War, Arctic explorers, and California gold rush communities suffered from scurvy in large numbers. In the late nineteenth and early twentieth centuries, an explosion in cases of infantile scurvy occurred in the United States because of the trend toward heated milk and proprietary foods.[72] Heating or pasteurization of milk decreases its available vitamin C content.[73]

Causes of scurvy include insufficient vitamin C intake, increased vitamin requirement, and increased loss. Inadequate intake is the most common cause. Elderly individuals living alone may have limited diets as a result of poverty, immobility, poor dentition, poor access to groceries, or dementia.[74,75] Alcoholics, food faddists, individuals with presumed food allergies, and cancer patients may have decreased overall dietary intake or may simply avoid fruit and vegetables.[76] Iatrogenic scurvy occurs when physicians recommend dietary restrictions for certain conditions, such as in ulcerative colitis,

Whipple disease, peptic ulcers, and gastroesophageal reflux, or with inadequate vitamin supplementation with parenteral nutrition. Increased vitamin C requirements are encountered with certain drugs, including aspirin, indomethacin, tetracycline, oral contraceptives, corticosteroids, and tobacco smoking. Peritoneal dialysis and hemodialysis can induce scurvy because the water-soluble vitamin is removed during the dialyzing process[77] Scurvy has also been reported among patients receiving liver transplants.[78]



◀ **FIGURE 130-9** Vitamin C deficiency in an 18-year-old girl after gastrointestinal surgery. Note the "corkscrew" or "swan-neck" hairs associated with perifollicular purpura.

Clinical Findings. Ascorbic acid is required for the hydroxylation of proline residues on procollagen, allowing the formation of hydrogen–hydrogen bonding in the triple helix of mature collagen. Without ascorbic acid, the polypeptides are unstable and unable to form stable triple helices. This results in decreased collagen secretion from fibroblasts, increased collagen solubility, and unstable collage fibrils. This abnormal collagen creates pathology in skin, mucous membranes, blood vessels, and bone, leading to the four Hs of scurvy: *h*emorrhagic signs, *h*yperkeratosis of hair follicles, *h*ypochondriasis, and *h*ematologic abnormalities.

The earliest cutaneous sign of scurvy is phrynoderma—enlargement and keratosis of hair follicles, especially on the posterolateral aspect of the arms, resembling keratosis pilaris. The keratotic plugging generalizes, extending to the back, buttocks, posterior thighs, calves, and shins. The hairs within these plugged follicles become curled, resulting in corkscrew hairs (Fig. 130-9). The corkscrew hair results from impaired keratin cross-links by disulfide bonds. As the disease progresses, the follicles, red from congestion and proliferation of surrounding blood vessels, then turn purple, and finally red and hemorrhagic. This palpable perifollicular purpura is characteristically found on the legs. "Woody edema" of the lower extremities is associated with pain and ecchymosis. Other non-specific cutaneous findings include xerosis and acne. Poor wound healing and even dehiscence of old wounds in skin and bone can occur because vitamin C is necessary for wound healing and maintenance of healed wounds. Splinter hemorrhages in the nail bed can also occur.

Oral manifestations are common. Gingival disease manifests as swelling, ecchymoses, bleeding, and loosening of teeth. Interdental and marginal gingivae become red, smooth, swollen, and shiny before becoming purple, black, and necrotic. Existing gingivitis and poor dentition predispose to more severe disease, but those without teeth do not develop hemorrhagic gingivitis.

Hemorrhage can occur in areas other than the skin, mouth, and nails. Bone disease is a frequent manifestation in children. Hemorrhage can be intra-articular, intramuscular, and subperiosteal. This can lead to pain and disruption of the growth plates. Bowing of the long bones and a depressed sternum with an outward projection of the end of the ribs are noted on musculoskeletal examination. Metaphyseal spurs with marginal fractures (Pelkan sign), a ring of increased density surrounding the epiphysis (Wimberger sign), widening of the zone of provisional calcification (white line of Frankl), and a transverse band of radiolucency in the metaphysis (scurvy line or Trummerfeld zone) are seen on radiographs of extremities. Periosteal bleeding may occur. Epistaxis, hematuria, intracerebral hemorrhage, subconjunctival hemorrhage, and gastrointestinal hemorrhage have been reported. Weakness, fatigue, emotional lability, hypochondriasis, weight loss, arthralgias, hypotension, anorexia, and diarrhea are non-specific findings associated with vitamin C deficiency.

The causes of a normochromic, normocytic anemia are multifactorial, including blood loss from hemorrhage, intravascular hemolysis, intracellular iron depletion, and decreased folate levels.

Laboratory Testing. Scurvy is a clinical diagnosis, but when uncertain of the diagnosis, measurement of leukocyte ascorbate level can be helpful.

Treatment. Recommended daily intake of vitamin C is 40 to 60 mg of ascorbic acid. With vitamin C supplementation, clinical symptoms rapidly improve within several days after initiation of supplementation. Therapeutic doses of 100 to 300 mg of ascorbic acid are administered daily until symptoms completely resolve.

BIOTIN ***Etiology and Pathogenesis.*** Biotin is an essential co-factor for several carboxylating enzymes: acetyl-CoA carboxylase in fatty acid synthesis and lipogenesis; pyruvate carboxylase in gluconeogenesis; and propionyl-CoA and 3-methylcrotonyl-CoA carboxylases, both involved in amino acid catabolism.

Eggs, liver, milk, peanuts, mushrooms, chocolates, and hazelnuts are common sources of biotin. Release of protein-bound dietary biotin depends on pancreatic biotinidase. Free biotin diffuses across the gut to bind to plasma proteins. Because biotin is found in many dietary sources and can be synthesized by enteric bacteria, deficiency is uncommon. In 1941, Paul Gyorgy described that avidin in egg white bound and inactivated biotin, and, indeed, biotin deficiency can be induced by feeding normal volunteers raw egg white–rich diets. Individuals following fad diets high in raw egg whites can be at risk for deficiency.[79] Biotin deficiency may arise from long-term parenteral nutrition without biotin supplementation.[80] Individuals on unsupplemented parenteral nutrition and on long-term antibiotics are particularly at risk because the antibiotics eradicate biotin-producing enteric flora.[81] A series of biotin deficiency cases were reported in Japan secondary to an elemental infant formula without supplemental biotin.[57]

Clinical Findings. Symptoms can develop 3 to 6 months after initiation of unsupplemented parenteral nutrition or a raw egg white–rich diet, but appear earlier in infants because of the greater biotin re-



quirement for growth. The cutaneous manifestations are similar to those of AE and EFA deficiency. An erythematous, scaling, and crusting dermatitis usually begins around the eyes, nose, and mouth and continues to involve multiple periorificial areas, including the perianal region. Alopecia, conjunctivitis, and glossitis have also been associated. Neurologic findings include irritability, lethargy, paresthesias, hypotonia, developmental delay, and myalgias. Nausea and anorexia have also been described.

Two inborn errors of metabolism, both autosomal recessive multiple carboxylase deficiencies, also alter normal biotin metabolism and may manifest with features of biotin deficiency as well as other systemic findings.



Laboratory Testing. If dietary history does not adequately explain findings suggestive of biotin deficiency, consultation to evaluate for inborn errors of metabolism is recommended. Biotinidase levels, serum amino acids, urine organic acids, carnitine studies, and ammonia may be helpful in differentiating this disorder from other metabolic diseases.

Treatment. The recommended daily value increases from 30 μg in neonates to 100 to 200 μg in adults. Acquired deficiency is treated with 150 μg of biotin per day until resolution of symptoms.

Minerals

IRON Iron is used in several biologic pathways, including heme synthesis, oxidation-reduction reactions, collagen synthesis, and as a co-factor for enzymes such as succinic dehydrogenase, monoamine oxidase, and glycerophosphate oxidase. Iron is found in red meats, egg yolks, dried beans, nuts, dried fruits, green leafy vegetables, and enriched grain products.

Iron deficiency remains an international problem that crosses socioeconomic and ethnic divides. Deficiency states result from inadequate intake or chronic blood loss. Groups at high risk include infants, menstruating females, and individuals with chronic gastrointestinal bleeds. Infants on an iron-fortified formula are at risk for deficiency 3 to 6 months after transitioning to cow's formula because of the lower iron content of cow's milk.[82]

Changes seen in iron deficiency involve the skin, mucous membranes, hair, and nails. Moderate iron deficiency causes fragile, longitudinally ridged, lamellated, or brittle nails. As deficiency progresses, the nail plate shows thinning, flattening, and a spoon-shaped convexity known as *koilonychia*. The index and third fingernails are usually the most severely involved. Even after iron replacement therapy begins, koilonychia resolves slowly. Hair changes include lusterless, brittle, dry, and focally narrow or split hair shafts, likely caused by impaired keratin production. Heterochromia of black scalp hair with alternating segments of dark brown, white, and silver bands has been described. Hair loss has been associated with iron deficiency.[83,84] However, the role of iron deficiency in hair loss continues to be a controversial topic.[85,86]

Mucous membrane manifestations include aphthous stomatitis, angular stomatitis, glossodynia, and absent or atrophied tongue papillae. Blue sclerae that persist after iron replacement are likely secondary to impaired collagen synthesis. Generalized pruritus of variable severity has been reported in some individuals with iron deficiency and is sometimes associated with dermatitis herpetiformis. Plummer-Vinson syndrome is an iron deficiency–associated syndrome encountered predominantly in middle-aged women with microcytic anemia, dysphagia, glossitis, koilonychia, and angular stomatitis. This is considered to be a pre-cancerous phenomenon, associated with carcinoma of the mouth or upper respiratory tract.

Iron deficiency in a microcytic anemia is diagnosed by measurement of serum iron levels, ferritin, total iron binding capacity, and transferrin saturation as well as free or zinc protoporphyrin levels. Treatment involves appropriate iron supplementation.

Chronic iron overload, hemosiderosis, can be associated with tissue injury, which is called *hemochromatosis*. Hyperpigmentation and ichthyosis-like changes of the skin are seen. Associated findings are cirrhosis of the liver, diabetes mellitus, and cardiomyopathy.

ZINC Zinc is an important micronutrient that is an essential component of many metalloenzymes involved in a variety of metabolic pathways and cellular functions, and is particularly important in protein and nucleic acid synthesis. Adequate zinc levels are also important for wound healing and for T-cell, neutrophil, and natural killer cell function. Zinc homeostasis depends on adequate zinc absorption and maintenance of appropriate intracellular and extracellular zinc levels. Dietary sources of zinc include meat, fish, shellfish, eggs, dairy products, and legumes, with the highest and most bioavailable forms of zinc found in meats, fish, and shellfish. Other vegetables, fruits, and refined carbohydrates contain very little zinc. Phytates (found in cereal grains, legumes, and nuts) and fiber interfere with intestinal zinc absorption. Human breast milk contains very high levels of zinc during the first 1 to 2 months of lactation, averaging 3 mg/L; subsequently, zinc levels decrease. Human breast milk also contains a zinc-binding ligand that increases the bioavailability of breast milk zinc. Although cow's milk formula contains higher levels of zinc, the bioavailability is significantly less than that in human breast milk.

Enteral zinc absorption occurs in the small intestine. Zinc excretion occurs primarily via the gastrointestinal tract via pancreatic and intestinal secretions, with lesser amounts excreted in the urine complexed to free amino acids. Two important families of zinc transporter proteins, including 9 ZnT (zinc transporter) genes and 15 Zip (Zrt- and Irt-like proteins) transporters, have been identified in humans.

Although total body zinc is stored primarily in the bones, muscles, prostate, and skin, there is no free exchange of stored zinc, and metabolic needs must be met by a continued supply of dietary zinc. In plasma, approximately 50 percent of the total zinc is complexed with albumin, while the remainder is bound to other serum proteins, including transferrin and α_2-macroglobulin, or bound to free amino acids. Plasma levels may decrease transiently in response to intercurrent illness, surgery, or other stressors. Excess plasma zinc levels inhibit copper absorption, possibly through competitive inhibition of a common divalent cationic transporter. Zinc deficiency also results in impaired mobilization of hepatic retinol stores and is associated with impaired night vision (nyctalopia). Conversely, excessive calcium intake can interfere with normal zinc absorption, likely also a result of competitive inhibition.

Zinc Deficiency. **EPIDEMIOLOGY.** Zinc deficiency occurs worldwide. Populations at special risk include patients with intestinal malabsorption syndromes, liver disease, anorexia nervosa or food faddism, extensive cutaneous

burns, and nephrotic syndrome. Iatrogenic zinc deficiency may result from prolonged parenteral or enteral nutrition that contains inadequate zinc levels to meet metabolic demands. Certain rural populations with diets high in phytates, as have been reported in certain parts of Iran, Turkey, and Yugoslavia, are also at risk for acquired zinc deficiency.



▲ **FIGURE 130-10** **A.** Patient with acrodermatitis enteropathica. These clinical findings resolved within 2 weeks of initiating zinc supplementation. **B.** This crusted and scaly, erosive, and sharply demarcated eruption appeared shortly after weaning. The child was highly irritable, whining and crying, and had diarrhea.

ETIOLOGY AND PATHOGENESIS. Zinc deficiency may be either inherited or acquired. The inherited form of zinc deficiency, AE, classically presents during infancy on weaning from breast milk to formula or cereal, which have lower zinc bioavailability than breast milk. These infants have a defect in an intestinal zinc transporter, the human ZIP4 protein, which prevents appropriate enteral zinc absorption.[87–89] There is a form of acquired zinc deficiency that may also present during infancy but, in contrast to AE, these infants become symptomatic while breast-feeding and improve after weaning to formula or table foods. Many of these reported infants have been premature, but cases have also been reported in full-term infants. The mothers of these infants have a presumed defect in mammary excretion of zinc into their breast milk, resulting in inadequate zinc intake in their infants.[90–92] Measurement of breast milk zinc levels is diagnostic when less than 70 μg/dL.

Acquired zinc deficiency may result from states associated with inadequate intake, impaired absorption, or increased excretion, including pregnancy, lactation, extensive cutaneous burns, generalized exfoliative dermatoses, food faddism, parenteral nutrition, anorexia nervosa, and even excessive sweating. Intestinal malabsorption syndromes, such as inflammatory bowel disease and cystic fibrosis, result in impaired intestinal absorption of zinc, whereas alcoholism and nephrotic syndrome result in increased renal zinc losses. Penicillamine has been reported to cause zinc deficiency in a patient with Wilson disease. Ornithine transcarbamylase deficiency has also been associated with zinc deficiency.

CLINICAL FINDINGS. AE presents soon after weaning in affected infants or during the fourth to tenth week of life in infants who are not breast-fed. The classic features of AE include alopecia, diarrhea, lethargy, and an acute eczematous and erosive dermatitis favoring acral areas—perioral, periocular, anogenital, hands, and feet (Fig. 130-10). The cutaneous findings are highly characteristic and often present initially as a nonspecific, acrally distributed, symmetric, eczematous dermatitis. Over time, bullae and erosions with a characteristic peripheral crusted border develop. Patients also appear to be predisposed to systemic infections as a result of impaired cell-mediated immunity, and superinfection with *Candida albicans* and bacteria, usually *Staphylococcus aureus*, is common. Delayed wound healing, acute paronychia, conjunctivitis, blepharitis, and photophobia may also be observed. Diarrhea may be prominent but is not seen in all cases. If untreated, the disease is fatal. Acute zinc deficiency secondary to impaired absorption of zinc, inadequate intake, or excessive renal or intestinal losses may result in a clinical picture that resembles AE and occurs also in adults (Fig. 130-11).

A chronic or subacute form of zinc deficiency is also recognized. These patients often have zinc levels in the mildly deficient range (40 to 60 μg/dL). Clinical manifestations include growth retardation in children and adolescents, hypogonadism in males, dysgeusia, poor appetite, poor wound healing, abnormal dark adaptation, and impaired



▲ **FIGURE 130-11** Zinc deficiency. **A.** There are plaques of dry, scaly, eczematous skin around the buttocks. The lesions often become secondarily infected with *Candida albicans*. **B.** Hands. The fingers are enlarged, and there are paronychia and bright erythema on the terminal phalanges.

mentation. Cutaneous manifestations, when present, are usually less striking and present predominantly as a psoriasiform dermatitis involving the hands and feet and, occasionally, the knees.

Laboratory Testing. A low plasma zinc level is the gold standard for diagnosing zinc deficiency. Use of contaminated needles, catheters, and sample tubes may lead to erroneously high measured zinc levels. Contact with collection tubes with rubber stoppers should be avoided as they may contain high levels of zinc. Hemolyzed samples are also inaccurate, as red blood cells contain very high zinc levels and cell lysis releases zinc. Normal plasma zinc levels range from 70 to 250 μg/dL. Measurement of serum AP—a zinc-dependent enzyme—is another useful indicator of zinc status, as AP may be low even when plasma zinc levels are low-normal; serum AP will increase with zinc supplementation, thus confirming the diagnosis.

In cases in which the plasma zinc level is equivocal and the diagnosis is uncertain, skin biopsy for routine histology may be helpful. The characteristic features are variable psoriasiform hyperplasia with confluent parakeratosis, spongiosis and pallor of the upper epidermis, focal dyskeratosis, and variable epidermal atrophy, These findings, however, are not specific; any may be seen in a number of other nutritional deficiencies.

Treatment. Zinc supplementation with either an enteral or parenteral formulation is appropriate. Clinical response is usually rapid, with initial improvement noted within several days. Although several zinc formulations are available, the most commonly used enteral formulation is zinc sulfate. Zinc chloride is recommended for parenteral supplementation.

In children, 0.5 to 1.0 mg/kg of elemental zinc given as one to two daily doses is recommended for mild to moderate zinc deficiency. Higher doses may be required in cases of acquired zinc deficiency due to intestinal malabsorption. In adults, 15 to 30 mg of elemental zinc per day is usually sufficient in cases of acquired zinc deficiency. Serum zinc levels should be monitored during therapy. Patients with AE require lifelong treatment. Patients with acquired zinc deficiency may need variable levels of supplementation, depending on their underlying disease. Of note, excess zinc levels may interfere with copper metabolism.

Zinc Toxicity. Zinc toxicity has been reported with exposure to zinc-containing fumes, intravenous poisoning, and ingestion of large amounts of zinc. There are no cutaneous manifestations. Severe vomiting, nausea, lethargy, dizziness, neuropathy, and dehydration. Hypocupremia may result.

COPPER

Copper is an essential component of several metalloenzymes, including tyrosinase and lysyl oxidase. Tyrosinase is involved in melanin biosynthesis, and lysyl oxidase deaminates lysine and hydroxylysine in the first step in collagen cross-linking. Other copper enzymes are involved in catecholamine production, free radical detoxification, and oxidation-reduction reactions.

Copper is found in fish, oysters, whole grains, beef and pork liver, chocolate, eggs, and raisins.

Copper Deficiency. Copper deficiency is uncommon, but can result from malnutrition, malabsorptive states, chronic unsupplemented parenteral nutrition, infants with a strictly cow's milk diet, and excessive intake of antacids, zinc, iron, or vitamin C, which can interfere with absorption. Celiac disease, cystic fibrosis, and short bowel syndrome lead to malabsorption of dietary copper.

Clinical manifestations in these cases include hypopigmentation of hair and skin and bony abnormalities (osteoporosis, fractures, periosteal reaction, and flaring of anterior ribs).

Microcytic anemia, neutropenia, hypocupremia, and hypoceruloplasminemia can be observed. Neutropenia is the earliest and most common sign of copper deficiency and is a sensitive measure of treatment adequacy. Treatment is with supplemental copper in the diet.

Copper and Menkes Disease. Menkes disease, also known as *kinky hair disease*, was described by John Menkes in 1962 as a multifocal degenerative disease of gray matter. Menkes originally described five male infants born into an English-Irish family who all showed an X-linked syndrome of neurologic degeneration, particular hair, and failure to thrive. The incidence of Menkes disease ranges from 1 in 100,000 to 1 in 250,000 live births. The Menkes gene, MNK, has been identified on chromosome Xq13. The protein product is a copper-transporting P-type adenosine triphosphatase, which is expressed in almost all tissues, except the liver. Mutations in MNK lead to decreased concentrations of copper because of impaired intestinal absorption and consequent decreased activity of cuproenzymes.[59,60]

Classically, signs of Menkes disease begin at 2 to 3 months of age, although neonatal indicators include preterm labor, large cephalohematomas, hypothermia, hypoglycemia, and jaundice. The characteristic facies of Menkes disease is a cherubic appearance with a depressed nasal bridge, ptosis, and reduced facial movements. By 2 to 3 months of age, there is loss of developmental milestones, hypotonia, seizures, and failure to thrive. Structural changes in the hair are seen (see Chap. 86), with the general appearance of short, sparse, lusterless, tangled, and depigmented hair. The eyebrows have the same steel wool appearance as scalp hair. On light microscopy, pili torti is classically seen. Monilethrix, segmental shaft narrowing, and trichorrhexis nodosa, small beaded swelling of the hair shaft with fractures at regular intervals, may also be observed. Other cutaneous findings include follicular hyperkeratosis and soft, inelastic, depigmented skin, especially at the nape of the neck, axillae, and trunk. A high arched palate and delayed tooth eruption may be noted on oral examination.

Neurologic deficits represent the major morbidity in this disorder. Profound truncal hypotonia with poor head control is typical, and appendicular tone may be increased. Deep tendon reflexes are hyperactive. Suck and cry remain strong. Optic disks are pale with impaired visual fixation and tracking. Hearing remains normal. Developmental arrest occurs at occasional smiling and babbling. Bony changes most often involve the extremities and the skull, and, less often, the thorax, vertebrae, and pelvis. They include osteoporosis, metaphyseal widening and lateral spur formation, ossification of sutures, a diaphyseal periosteal reaction, scalloping of the posterior aspects of the vertebral bodies, and subperiosteal new bone formation. Renal involvement as hydronephrosis, hydroureter, and diverticula of the bladder can occur.

Elongation and tortuosity of many large vessels lead to severe arterial disease, a frequent cause of death by the age of 3 or 4 years.

The condition is identified by clinical history, physical examination, and reduced levels of serum ceruloplasmin and copper. Early treatment with copper histidinate has resulted in good outcomes, including normal neurodevelopmental



milestones, in some patients. Initiation of therapy in older patients may be helpful in the alleviation of symptoms such as irritability and insomnia.[93,94]

SELENIUM Selenium is an essential component of glutathione peroxidase, an antioxidant. Selenium is found in seafood, red meat, egg yolks, grain products, and chicken. The amount of selenium available in cereal grains depends on the selenium content of the soil where it was grown. Selenium deficiency in humans is endemic in the Keshan region of China where low selenium levels are present in soil.[95,96] Selenium deficiency can also occur in the context of restricted protein diets, unsupplemented parenteral nutrition, malabsorption states, and increased losses.[97,98] Two disorders have been attributed to selenium deficiency: Keshan disease and Kaschin-Beck disease. These diseases have only been reported in endemic areas of Asia.

Keshan disease is a multifocal myocarditis leading to fatal cardiomyopathy that is seen primarily in women and young children in endemic areas. Acute or chronic insufficiency of cardiac function, cardiomegaly, arrhythmias, and electrocardiographic abnormalities have been noted. Muscle pain and weakness with hepatic congestion, mesenteric lymphadenosis, erythrocyte macrocytosis without anemia, and pancreatic exocrine dysfunction have also been seen. Cutaneous findings in these patients have included white nail beds, similar to those of Terry's nails in hepatic cirrhosis, and hypopigmentation of skin and hair (pseudoalbinism). These findings resolve with selenium supplementation. Kaschin-Beck disease is an osteoarthropathy that affects the epiphyseal and articular cartilage and the epiphyseal growth plates, resulting in enlarged joints and shortened fingers and toes. Diagnosis of selenium deficiency is through measurement of plasma selenium levels and glutathione peroxidase activity. Selenium supplementation is used for both acute correction and long-term maintenance.

Selenium toxicity can be acutely fatal. Cases of toxicity have been associated with increased soil selenium and overdose through supplements. In the 1960s, reports of selenium toxicity came out of Enshi County in Hubei, China. The cause of this endemic toxicity arose from selenium-contaminated fertilizer products.[99] Sporadic cases of selenium intoxication secondary to excess supplement ingestion have been reported.[100] Hair becomes dry and brittle in association with an exfoliative dermatitis on the scalp, often resulting in broken hairs and alopecia. Nails also become brittle, with white horizontal streaking on the surface. Breaks in the wall of the nail eventually lead to nail loss. The new nail is fragile and thickened with a rough surface. Nails, hair, and teeth can all develop a reddish hue. Skin on the extremities and neck can become red, swollen, blistered, and, occasionally, ulcerate, which heals slowly. Neurologic complaints of peripheral anesthesia, hyperreflexia, numbness, convulsions, and paralysis have been reported. Nausea, vomiting, diarrhea, garlic or sour-milk breath odor, and hypersalivation can occur. Screening of plasma can be used to document elevated selenium levels. Treatment involves removal of the source of excess selenium.

MANGANESE Manganese activates glycosyltransferases used in the synthesis of glycosaminoglycans and glycoproteins and is used in two metalloenzymes (pyruvate carboxylase and superoxide dismutase). Manganese is also found in high concentrations in melanocytes. Reported cases of manganese deficiency are rare. Manganese deficiency was reported during a study of vitamin K requirements, when a study subject was accidentally placed on a manganese-deficient diet. He developed a mild dermatitis, reddening of his black hair, slowed hair and nail growth, and occasional nausea and vomiting with moderate weight loss. A subsequent study of manganese-deficient states showed no hair changes, but miliaria crystallina developed in half the subjects and disappeared after repletion. Long-term parenteral nutrition without adequate supplementation can induce manganese-deficient states.[101] Likewise, in cases in which manganese is supplemented in parenteral nutrition, hypermagnesemia can occur and has been associated with neurologic sequelae.[102]

NOMA (CANCRUM ORIS)

Noma (necrotizing ulcerative stomatitis, stomatitis gangrenosa, or cancrum oris), first described in 1848 by Tourdes,[103] is a devastating gangrenous condition that destroys soft and hard tissue of the face that predominantly affects young children between the ages of 1 and 4 years. "Noma" originates from the Greek word *nome*, which means to graze or to devour, which reflects the rapid progression of this condition. As public health initiatives improved sanitation in developed countries, the global epidemiology of noma likewise improved. Noma has become a rare occurrence in developed countries and is predominantly encountered now only in parts of Africa, Latin America, and Asia, although intermittent epidemics of noma have been reported.[104] In response to reports from humanitarian organizations, the WHO declared noma a health priority in 1994. The WHO estimates the worldwide incidence of noma to be 500,000 cases per year, with a 79 percent mortality rate. Unfortunately, the data on the incidence of noma are likely an underestimation of the true incidence, as less than 10 percent of affected individuals actually seek medical care.[105]



An increase in noma has been observed in developed countries over the last two decades, mostly in association with immunosuppressive therapy, human immunodeficiency virus/acquired immunodeficiency syndrome, and severe combined immunodeficiency.[106]

Malnutrition and deficiencies in vitamins A, B_6, C, and E; trace elements iron and zinc; and amino acids cysteine, methionine, serine, and glycine have been identified as possible contributing factors to immune dysfunction. Adrenal hyperfunction in PEM has also been implicated in depression of cell-mediated immunity and a decrease in mucosal resilience. Early malnutrition and chronic infections due to early weaning from breast milk may also represent predisposing factors.[107]

Noma appears to be a polymicrobial infection, with *Prevotella intermedia* and *Fusobacterium necrophorum* being the two most frequently isolated organisms.[108] Other frequently identified organisms are *Tannerella forsynthesis*, *Peptostreptococcus micros*, *Campylobacter*, streptococci, and enteric gram-negative rods. Although organisms are isolated from noma lesions, there is a low likelihood of transmissibility. There are no reports of outbreaks in families or villages after one child develops noma. Groupings of noma seem to be more associated with common risk factors rather than true transmission.

Parents often describe initial fever and apathy. Early acute noma often presents with soreness of the mouth, halitosis, tenderness of the lip or cheek, cervical lymphadenopathy, and purulent oral discharge. The intraoral lesion is a necrotizing stomatitis generally starting on the alveolar margin and extending to the mucosal surface of the cheek. This evolution is rapid, taking 24 to 48 hours.



▲ **FIGURE 130-12** Cancrum oris (noma). Massive destruction of the face in a Tanzanian child.



Swelling and blue-black discoloration of the skin overlying the intraoral lesion develops and rapidly becomes necrotic with well-defined borders. As it becomes black, this necrotic zone expands and forms a classic cone shape, cone gangreneux, with internal destruction greater than external involvement (Fig. 130-12). Laboratory investigation often shows severe anemia, a high white blood cell count, and hypoalbuminemia.

Acute necrotizing gingivitis, a painful inflammation and necrosis of the interdental papillae, was the precursor to noma. Progression to necrotic stomatitis and noma can occur if appropriate dental hygiene and antibiotics are not initiated. Acute necrotizing gingivitis is associated with poor oral hygiene, stress, and malnutrition. However, any oral mucosal ulceration or trauma, including tooth eruption and viral ulcers, can develop into noma.[109]

Noma neonatorum is thought to be a related but separate entity from noma. Gangrenous lesions appear on patients' noses, eyelids, oral cavities, anal regions, and genitalia in apparent response to *Pseudomonas aeruginosa* isolated from skin lesions and many of their blood cultures. This condition is almost uniformly fatal. Clinical experience indicates that preterm and low-birth-weight newborns, especially those with severe intrauterine growth retardation, are at greatest risk. The causative organism is usually *Pseudomonas*, but *Escherichia coli*, klebsiella, and staphylococci have occasionally been isolated. Because most cases of noma neonatorum are caused by *Pseudomonas*, it is possible that this represents a severe form of ecthyma gangrenosum.[110] Almost all reported cases have been from India, China, Lebanon, or Israel, but there was one reported case in the United States in 2002, and the vast majority (98 percent) of affected children were impoverished, living in very poor homes with an average of seven children per family.[111]

Healing lesions of noma are also difficult to manage because of extensive fibrous scars. These scars can lead to strictures of the mouth, severe dental malposition, defective speech, and even complete closure of the mouth from contractures. Management of acute noma is geared toward minimizing damage, but invasive intraoral procedures are contraindicated. Key goals of acute management are:

1. Correction of dehydration and electrolyte imbalances.
2. Treatment of predisposing disease (i.e., malaria, measles, human immunodeficiency virus, tuberculosis).
3. Antibiotics: some researchers recommend broad-spectrum antibiotics, whereas others believe that metronidazole is adequate as anaerobic organisms predominate.
4. Oral hygiene with chlorhexidine digluconate rinses.
5. Nutritional rehabilitation: oral, enteral, or parenteral.
6. Local wound care.
7. Physiotherapy: to reduce strictures from fibrous scarring.

Surgical intervention should not occur until the acute phase has ended, and is aimed at restoring function and improving appearance to allow patients to reintegrate into society.

CONCLUSION

Nutritional disorders arise most commonly as a result of nutrient deficiencies, but may also derive from imbalances in nutrients or at times from nutrient excess. Because macronutrients and micronutrients play roles in multiple biochemical pathways, these disorders often present with clinical features in a variety of organ systems. The key to diagnosis is in having a familiarity with the range of clinical presentations associated with these disorders and maintaining an appropriate index of suspicion for these disorders when evaluating dermatologic patients with skin findings or a history that might suggest a nutritional etiology.

KEY REFERENCES

The full reference list for all chapters is available at www.digm7.com.

8. Barness LA: Nutrition and nutritional disorders, in *Nelson Textbook of Pediatrics*, 14th ed, edited by Behrman RE. Philadelphia, WB Saunders, 1992, p 105
9. Miller SJ: Nutritional deficiency and the skin. *J Am Acad Dermatol* **21**:1, 1989
10. Prendiville JS, Manfredi LN: Skin signs of nutritional disorders. *Semin Dermatol* **11**:88, 2001
15. Strumia R: Dermatologic signs in patients with eating disorders. *Am J Clin Dermatol* **6**:165, 2005
16. Ryan AS, Goldsmith LA: Nutrition and the skin. *Clin Dermatol* **14**:389, 1996
27. Brooke P: Diseases of nutrition and metabolism. *Adv Dermatol* **8**:155, 1993
34. Lim HW et al: Sunlight, tanning booths, and vitamin D. *J Am Acad Dermatol* **52**:868, 2005
42. Goskowicz M, Eichenfield LF: Cutaneous findings of nutritional deficiencies in children. *Curr Opin Pediatr* **5**:441, 1993
43. Committee on Fetus and Newborn: Controversies concerning vitamin K and the newborn. *Pediatrics* **112**:191, 2003
74. Pimentel L: Scurvy: Historical review and current diagnostic approach. *Am J Emerg Med* **21**:328, 2003
76. Weinstein M, Babyn P, Zlotkin S: An orange a day keeps the doctor away: Scurvy in the year 2000. *Pediatrics* **108**:55, 2001
89. Wang K et al: A novel member of a zinc transporter family is defective in acrodermatitis enteropathica. *Am J Hum Genet* **71**:66, 2002

CHAPTER 131

Cutaneous Changes in Errors of Amino Acid Metabolism

Peter H. Itin
Lowell A. Goldsmith

Inborn errors of amino acid metabolism are inherited defects of enzymes that result in important disturbance in amino acid biology.[1] Most of them are autosomal recessive disorders. Amino acids are the molecular units that make up proteins, and all proteins are various combinations of 20 specific naturally occurring amino acids.

Diseases of amino acid metabolism may lead to multiorgan disorders with signs and symptoms of mental retardation and dysfunction in numerous additional organs, including skin and hair.[2] With more sophisticated diagnostic techniques, metabolic diseases have gained increasing importance, and numerous rare entities have been identified, including hyperphenylalaninemias, hypertyrosinemias, disorders of histidine metabolism, disorders of proline and hydroxyproline metabolism, hyperornithinemias, dysfunctions of urea cycle enzymes, disorders of lysine metabolism, disorders of branched-chain amino acid and keto acid metabolism, disorders of transsulfuration with homocystinuria and homocystinemia, sarcosinemia, and non-ketotic hyperglycinemia.

Several diseases have important cutaneous manifestations that might be a clue to diagnosis (Table 131-1). An example of such a key manifestation representing errors of amino acid metabolism is acrodermatitis acidemica. These patients have characteristic cutaneous lesions that are similar to those in acrodermatitis enteropathica (see Chap. 130). Psoriasiform dermatitis on the trunk and extremities may occur together with diffuse alopecia and brittle hair.[4] In general, acral dermatitis with perioral erythema and desquamation is associated with poor feeding, lethargy, hypotonia, vomiting, and dehydration. Patients often have progressive neurologic symptoms. Patients with branched-chain aminoacidopathies may have methylmalonic acidemia, propionic acidemia, glutaric acidemia, biotinidase deficiency, multiple carboxylase deficiency, or maple syrup urine disease, all

TABLE 131-1
Inherited Disorders of Amino Acid and Organic Acid Metabolism with Skin Manifestations

Disease	Skin Manifestations	Deficient Enzyme/Pathophysiology (Mode of Inheritance)
Alkaptonuria	Ochronosis Black cerumen, eccrine, and apocrine secretions	Homogentisic acid oxidase (AR)
Argininosuccinic aciduria	Trichorrhexis nodosa Rough skin	Argininosuccinase (AR)
Aspartylglycosaminuria	Thick skin Coarsening of face Sagging skinfolds Increased acne Photosensitivity	Aspartylglycosamidase (AR)
Biotinidase deficiency	Erythematous rash Alopecia Oral candidiasis Seborrheic dermatitis Glossitis	Biotinidase (AR)
Citrullinemia	Light, short hair with interrupted cuticle	Argininosuccinate synthetase (AR)
Hartnup disease	Pellagra-like lesions Photosensitivity	Defect of neutral amino acid transport in renal and intestinal brush border (AR); increases excretion of tryptophan metabolites
Histidinemia	Light-colored hair and eyes	Histidase (AR)
Holocarboxylase synthetase deficiency	Seborrheic dermatitis Alopecia	Holocarboxylase synthetase (AR)
Homocystinuria	Fine, sparse, friable hair Thin skin Livedo reticularis Malar flush Vascular occlusions Marfanoid habitus	Cystathionine β-synthetase (AR)
Hydroxykynureninuria	Chronic stomatitis Ulcerated gums, gingivitis Photosensitivity	Kynureninase (AR)
Hyperprolinemia	Ichthyosis	Proline oxidase (AR)
Iminodipeptiduria (prolidase deficiency)	Chronic skin ulcers Recurrent infections	Prolidase (AR)
Isovaleric acidemia	Odor of sweaty feet, alopecia	Isovaleryl–coenzyme A dehydrogenase (AR)
Methionine malabsorption syndrome	White hair Dried celery or oasthouse odor Edema	Defective methionine transport
Phenylketonuria	Hypopigmentation Atopic dermatitis Scleroderma	Phenylalanine hydroxylase (AR) Dihydropterine reductase Defective dihydropterine synthesis
Tyrosinemia II	Painful, acral erosions Hyperkeratosis Corneal/conjunctival plaques and erosions	Tyrosine aminotransferase (AR)
Xanthurenic aciduria	Urticaria	Kynureninase (AD)

AD = autosomal dominant; AR = autosomal recessive.



of which are sometimes accompanied by cutaneous problems.

In general, all patients with acrodermatitis acidemica have absolute missing enzyme activity of their autosomal recessive mutated gene. Diagnosis is confirmed by documentation of increased amounts of amino acids in the urine. Exact diagnosis is the first step for adequate treatment of these diseases.

Hartnup disease results from a deficiency of neutral amino acid transport within the kidneys and small intestine and leads to pellagra-like features in a photodistribution (see Chap. 130). Neurologic deficiencies and reduced mental skills are often associated. The treatment of choice is nicotinamide.



TYROSINEMIAS

The genetic tyrosinemias are characterized by the accumulation of tyrosine in body fluids and tissue.[5,6] Tyrosine is a semi-essential amino acid, derived from the liberation of tyrosine from hydrolysis of dietary or tissue protein, or from the hydroxylation of the essential amino acid phenylalanine, and is the starting point for the synthesis of catecholamines, thyroid hormones, and melanogenesis. There are three types of tyrosinemia. The skin is not involved in tyrosinemia types I and III, but it is involved in tyrosinemia II, which is also called the *oculocutaneous tyrosinemia* and *Richner-Hanhart syndrome* [Online Mendelian Inheritance in Man (OMIM) #276600]. Tyrosinemia II is a rare distinctive clinical symptom complex involving the eyes, skin, and central nervous system and is potentially treatable. Tyrosine levels are elevated because of a deficiency of hepatic tyrosine aminotransferase (TAT).

Clinical Features

Approximately 100 patients with this clinical syndrome have been reported. Goldsmith and Reed were the first to correlate the oculocutaneous syndrome with an underlying tyrosinemia.[7] All patients had tyrosinemia, phenolic aciduria, and inflammatory skin and eye lesions. The sexes are affected equally, and the disease is worldwide in distribution. Transmission of tyrosinemia II is autosomal recessive. Consanguinity has been documented, and occurrence in several siblings within a family is well known (pseudodominant pattern). Heterozygotes are unaffected clinically and demonstrate no biochemical alterations of tyrosine or its metabolites in blood or urine.

TYROSINEMIA AT A GLANCE



- Approximately 100 cases are reported worldwide.
- Tyrosinemia is an autosomal recessive disease induced by a deficiency of cytoplasmic tyrosine aminotransferase related to a defect on chromosome bands 16q22.1-22.3 (Online Mendelian Inheritance in Man #276600).
- Dermatologic manifestations include focal/diffuse palmoplantar keratosis with erosions, bullae or erythema, hyperhidrosis, and painful corneal erosions with photophobia; 50 percent of patients have mental retardation.
- Diet restriction of phenylalanine and tyrosine leads to amelioration of cutaneous symptoms and eye lesions.
- Differential diagnosis includes other forms of palmoplantar keratodermas and herpetic keratitis.
- Prenatal diagnosis is possible by amniocentesis with tyrosine aminotransferase assay and DNA analysis.

DERMATOLOGIC FEATURES Patients have hyperkeratotic yellowish skin lesions limited to the palms and soles, which in 80 percent of cases occur on the peripheral pressure-bearing areas.[5,7] Lesions usually begin during the first year of life. The skin lesions are painful, nonpruritic, and frequently associated with hyperhidrosis (Fig. 131-1). Diffuse plantar keratoderma and self-mutilation have been observed in individuals with tyrosinemia II.[8] Leukokeratosis of the tongue has been reported. Bullous lesions may occur and progress rapidly to erosions; these then become crusted and hyperkeratotic.[9] The fingertips and hypothenar eminences are commonly involved. Rare patients have hyperpigmentation and/or hyperkeratotic subungual lesions, and in older persons hyperkeratosis in the elbows, knees, and ankles may appear.[2]

OPHTHALMOLOGIC FEATURES The most important manifestations of oculocutaneous tyrosinemia are those involving the eye, because they can lead to permanent visual impairment.[10] Eye lesions occur weeks to months before the skin lesions. Ophthalmologic symptoms start as early as the first day of life and as late as 38 years of age. Tearing, redness, pain, and photophobia are early signs and symptoms; late findings include corneal clouding and central or paracentral opacities, which are initially intraepithelial and can progress to superficial or deep pseudodendritic keratitis (Fig. 131-2). Slit-lamp examination may reveal some degree of corneal ulceration, and occasionally birefringent crystals of tyrosine may be observed. Neovascularization is prominent. The eye disease occurs in 75 percent of affected patients and may lead to scarring, nystagmus, and exodeviation. Ocular symptoms may show spontaneous remission and recurrences and may occur independently of other manifestations. Topical therapy is ineffective, and herpes simplex virus and bacterial cultures consistently yield negative results.

NEUROLOGIC FEATURES Mental retardation of varying degrees is reported in half the cases, as is normal mental development. Hyperactivity has been observed in several affected children, as



▲ **FIGURE 131-1** Hyperkeratotic (**A**) and erosive (**B**) lesions in a patient with tyrosinemia II.

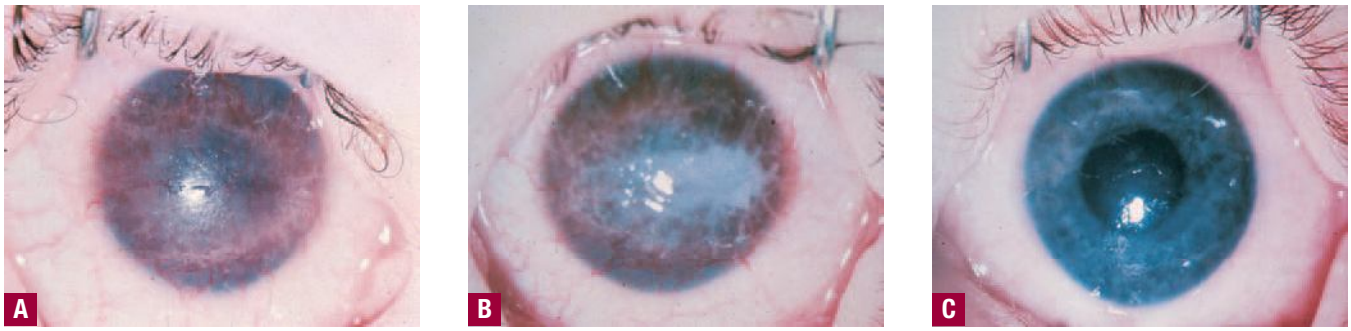

▲ **FIGURE 131-2** Corneal changes in tyrosinemia II. **A.** Cornea before treatment (left eye); corneal opacity and neovascularization are prominent. **B.** The right eye has even more extensive involvement. **C.** After 6 weeks of therapy, there is marked clearing of the lesions.

has abnormal language development. Untreated tyrosinemia II during pregnancy may be associated with mental retardation or seizures in the children resulting from that pregnancy.[11]

Laboratory Findings

AMINO ACID ABNORMALITIES In establishing the diagnosis in a child with tyrosinemia II, laboratory verification of plasma amino acid and urine organic acid levels is mandatory. The blood and urine tyrosine levels of affected patients are markedly elevated. Levels of other amino acids are not increased. Urinary tyrosine metabolite levels are elevated; these include *p*-hydroxyphenylpyruvic acid, *p*-hydroxyphenyllactic acid, *p*-hydroxyphenylacetic acid, and *N*-acetyltyrosine (Fig. 131-3). All these metabolic effects are consequences of the deficiency of hepatic TAT. A fluorometric procedure exists as well as a tandem mass spectrometry, which is used for neonatal screening.

TAT is a pyridoxal phosphate–dependent cytoplasmic enzyme that transaminates tyrosine, forming *p*-hydroxyphenylpyruvate (PHPPA). The human *TAT* gene contains 12 exons and transcribes a 2.75-kb messenger RNA (mRNA) that codes for a 454–amino acid protein.[5] The liver is the richest source of TAT; this specific TAT is not present in skin. In tyrosinemia II, the liver biopsy specimen shows little or no soluble TAT, although there is normal or slightly increased mitochondrial tyrosine (aspartate) transami-



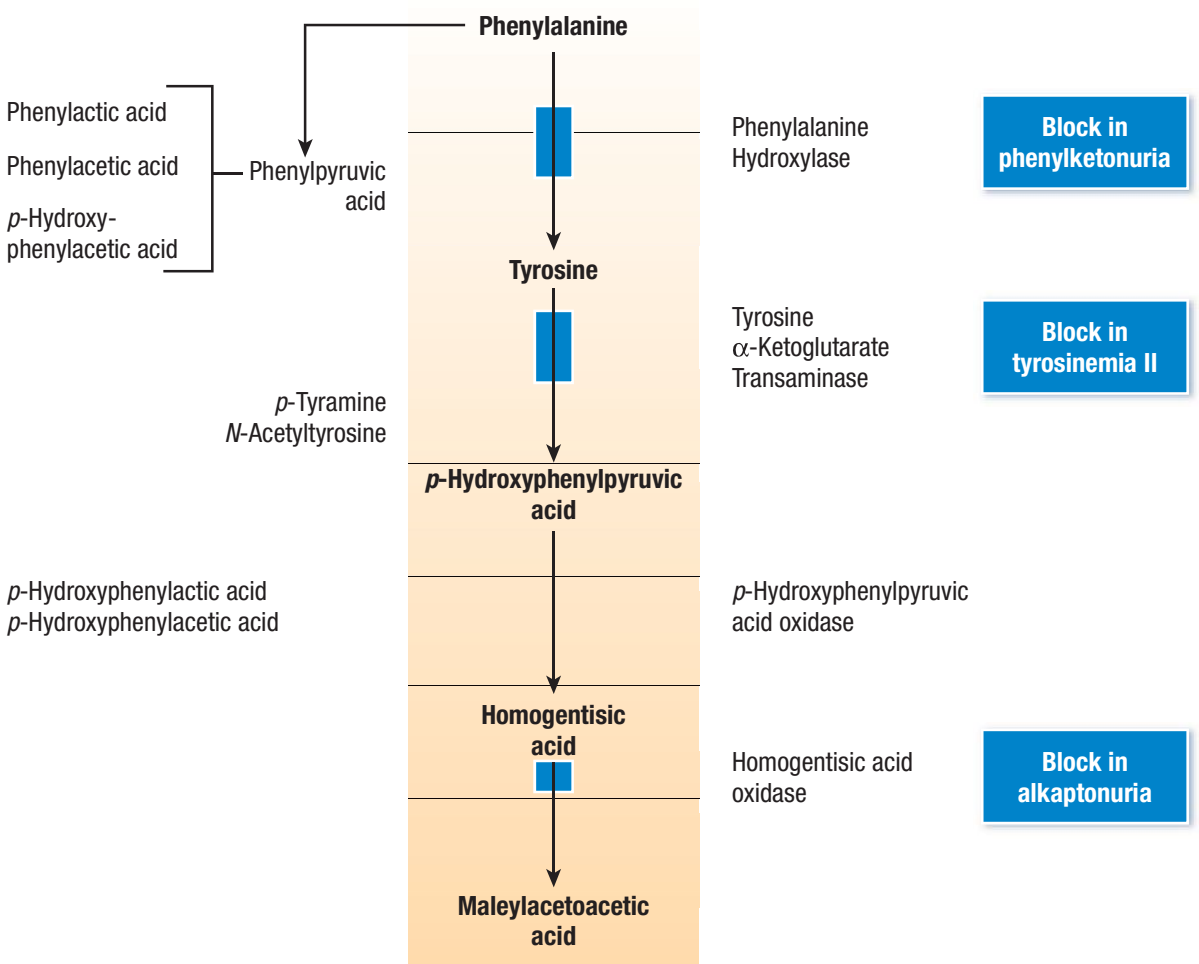

▲ **FIGURE 131-3** Metabolic pathway of phenylalanine, tyrosine, and their derivatives.

nase activity.[12,13] Mitochondrial aspartate aminotransferase using tyrosine as a substrate produces increased amounts of PHPPA from the increased amounts of tyrosine available in tyrosinemia II. Because mitochondria do not have PHPPA oxidase activity, PHPPA and its metabolic products increase and appear in the urine, which creates the unusual situation in which metabolites are increased both proximally and distally to the defective enzyme.

HISTOPATHOLOGY Routine histopathologic analysis of the skin is not diagnostic; it shows hyperkeratosis, parakeratosis, and acanthosis.[9] In some cases, electron microscopy studies have shown lipid droplets in the cornified layer, increases in tonofibrils and keratohyalin, very tightly packed microtubular and microfibrillar masses, and minute tyrosine crystals in keratinocytes and Merkel cells.[14]

GENETICS Mutations occur in the human *TAT* gene, which results in high levels of tyrosine. *TAT* maps to the q22-q24 region of chromosome 16 and has been sequenced.[5] Multiple point mutations scattered throughout the *TAT* gene have been associated with tyrosinemia II.[15]

PATHOPHYSIOLOGY OF THE SKIN AND EYE LESIONS IN TYROSINEMIA II

Differential Diagnosis (Box 131-1)

Corneodermatoosseous syndrome (OMIM #122440), an autosomal dominant symptom complex of volar keratosis and keratitis that is clinically similar to tyrosinemia II, has been described in one family.[20] The lesions were more extensive than those in the classic Richner-Hanhart syndrome. In addition, brachydactyly with short distal phalanges, short stature, and soft teeth may occur.

Box 131-1

Differential Diagnosis of Tyrosinemia

Main Features

- Eyes
  - Herpetiform corneal ulcers
- Skin
  - Punctate, painful palmoplantar keratoderma on weight-bearing areas
- Neurologic features
  - Mental retardation
  - Hyperactivity

Consider

- Palmoplantar keratoderma with associated features
  - Corneodermatoosseous syndrome

Always Rule Out

- Eyes
  - Viral and bacterial infection
- Skin
  - Other forms of keratodermas, acquired or genetic

Treatment

With consumption of a low-tyrosine, low-phenylalanine diet (Mead Johnson, Tyromex-Ross), there is a rapid decrease in tyrosine to normal levels (30 to 90 μ*M*). Skin and eye lesions cleared within days and weeks in all individuals treated with the diet[7,12] (see Fig. 131-2C; Fig. 131-4; Box 131-2).

Some patients have responded objectively to etretinate, although plasma tyrosine levels remained unchanged.[21] In none of the patients studied has there been a response to cortisone acetate, ascorbic acid, pyridoxine, or folic acid, which are co-factors or known inducers of TAT and PHPPA oxidase. Surgical treatment is recommended for palmar lesions but not for the plantar form.

Box 131-2

Treatment of Tyrosinemia

- Low-tyrosine, low-phenylalanine diet
- Etretinate systemically

Because the consequences of tyrosinemia II are serious and a safe treatment is available, a patient presenting with any atypical bullous or hyperkeratotic disease on the palms and soles in the first months of life should be screened for tyrosine and its metabolites; screening tests are available in most hospital laboratories.[22] Amino acid analysis is necessary to confirm the diagnosis and follow the response to diet therapy. Dietary control in pregnancy should be recommended. A patient with tyrosinemia II was reported who had undergone two untreated pregnancies. During the pregnancies, plasma tyrosine level was raised, and the infants were retarded. On the other hand, several normal children of mothers with the disease have been observed.[23]

PHENYLKETONURIA

Phenylketonuria (phenylpyruvic oligophrenia, PKU) is an autosomal recessive disorder of aromatic amino acid metabolism (OMIM #261600) in which phenylalanine cannot be converted to tyrosine. PKU is caused by a deficiency of hepatic phenylalanine hydroxylase or co-factors for phenylalanine hydroxylase. There are additional causes that may lead to hyperphenylalaninemias, and eight subtypes have been described. Maternal PKU may lead to hyperphenylalaninemia. Unless the mother follows a special diet, the child is at risk to develop the typical signs and symptoms of PKU. Defects of biopterin metabolism, prematurity, liver disease, use of medications such as methotrexate, and high-protein diets may produce findings similar to those in PKU. Genotype-based prediction and







▲ **FIGURE 131-4** **A.** Diffuse plantar hyperkeratosis in an adult with tyrosinemia. **B.** The hyperkeratosis cleared on a low-tyrosine, low-phenylalanine diet without topical treatment.

PHENYLKETONURIA AT A GLANCE

- Autosomal recessive disorder induced by phenylalanine hydroxylase deficiency (Online Mendelian Inheritance in Man #261600). Gene on chromosome bands 12q22-24.1; incidence of 1 in 10,000 live births among Europeans.
- Clinical features include mental retardation, generalized hypopigmentation, blond hair, blue eyes, eczematous rash, vomiting in infancy, hyperactivity and seizures, mousy odor.
- Diagnosis is confirmed by a positive result on urinary ferric chloride test.
- Treatment consists of restricting phenylalanine in the diet.
- Differential diagnosis includes albinism, Chédiak-Higashi syndrome, and scleroderma.
- Prenatal diagnosis is possible by chorionic villus sampling/amniocentesis, measurement of metabolite levels, and DNA analysis.

classification of the biochemical phenotype is now possible in the majority of newborns with hyperphenylalaninemia.[24]

Epidemiology

The prevalence of PKU varies markedly in various countries. The highest incidence of PKU is found in Ireland and Scotland (1 in 4000), whereas in Finland only 1 in 40,000 births are affected. The overall frequency among northern Europeans was calculated to be approximately 1 in 10,000 and in the United States classic PKU was estimated to occur in approximately 1 in 11,000 births in the white population. Among blacks the frequency was estimated to be only approximately 1 in 50,000.

Clinical Features

The clinical hallmarks of PKU are mental retardation, diffuse hypopigmentation, seizures, eczematous dermatitis, and photosensitivity.[26] Newborns appear to be normal and develop manifestations of psychomotor alterations between 4 and 24 months of age. Early symptoms include heavy vomiting. The most important defects are marked mental retardation with irritability, hyperactivity, self-destructive behavior, hypertonicity, and seizures. Peculiar gait and increased deep tendon reflexes are noted. Microcephaly, brain calcification, and cataracts are observed quite commonly. Typically a mousy odor induced by phenylacetic acid is noted in urine and sweat.

Early infantile eczema, indistinguishable from atopic dermatitis, may be one of the first signs of PKU and occurs in 20 percent to 50 percent of affected infants during the first year of life. Later on, the incidence may be even higher. Dramatic clearing of eczema and seborrheic dermatitis with a low-phenylalanine diet has been reported in some patients, and a potential role for altered biotin recycling is suggested.[27] A further skin clue in PKU is pigment dilution, with impressive pale pigmentation, blond hair, and blue eyes seen in 90 percent of patients. The pigment dilution is reversible with phenylalanine restriction. The color changes may be especially striking in the rare black or Japanese patient with PKU, whose eye or hair color may be very different from that of other members of the ethnic group. The increased levels of phenylalanine and its oxidation products (phenylpyruvic acid, *o*-hydroxyphenylacetic acid, phenylacetic acid) inhibit the enzyme tyrosinase and therefore reduce melanization.[28]

Patients develop moderate photosensitivity. Edematous scleroderma of the extremities, which spares the hands and feet, is characteristic.[29] Plaque, guttate or generalized morphea, and atrophoderma of Pasini and Pierini (see Chap. 62) as well as lichen sclerosus et atrophicus (see Chap. 63) have been observed in PKU.[30]

Diagnosis

Diagnosis of PKU is made by documenting elevated levels of phenylalanine in the serum (20 mg/dL or higher, 10 to 50 times the normal level). Plasma tyrosine levels may be normal or elevated. In addition, elevated urinary phenylpyruvic acid levels can be documented. Additional laboratory abnormalities include phenylalanine hydroxylase deficiency, phenylpyruvic acidemia, and increased urinary levels of *o*-hydroxyphenylacetic acid and phenylacetylglutamine. Increased urinary levels of phenylpyruvic acid can be detected by a typical green coloration of urine after addition of 10 percent ferric chloride. In numerous countries PKU screening is performed in the neonatal screening program either by the semi-quantitative bacterial inhibition assay method in which several drops of capillary blood may show an elevated level of phenylalanine in a microbiologic procedure (Guthrie test) or by a quantitative chemical reaction method (Quantase test).[31] In affected babies, serum phenylalanine levels begin to rise on the third or fourth day of life. Prenatal diagnosis is possible by performing amniocentesis or chorionic villus sampling with identification of the gene. In addition, preimplantation genetic diagnosis for PKU made possible the birth of PKU-free children.[32]

Pathophysiology and Histology

The classic type of PKU is induced by a deficiency of phenylalanine hydroxylase or its co-factor tetrahydrobiopterin and a consequent accumulation of the precursor phenylalanine. The normal phenylalanine-tyrosine ratio is 1:1, whereas in PKU it is more than 3:1. It is widely believed that the pigment dilution is a result of the inhibitory effect of phenylalanine on tyrosinase. Biopsy specimens show increased fibroblasts and histiocytes and atrophy of skin appendages. The elastic fibers are scanty and fragmented and are thus different from those found in true scleroderma. Histologic examination shows a normal number of melanocytes but a decrease in mature melanosomes.

Differential Diagnosis

Atopic dermatitis and scleroderma as primary disorders must be distinguished from PKU (Box 131-3). Premature infants and individuals with liver disease

Box 131-3

Differential Diagnosis of Phenylketonuria

Main Features

- Skin
  - Pale pigmentation, dry skin and eczema, scleroderma-like lesions, fair hair
- Eyes
  - Blue eyes
- Neurologic features
  - Mental retardation
  - Seizures
  - Irritability and increased deep tendon reflexes

Consider

- Other disorders of amino acid metabolism with neurocutaneous features

Always Rule Out

- Atopic dermatitis
- Scleroderma



Box 131-4

Treatment of Phenylketonuria

- Low-phenylalanine diet
- Fish oil supplementation, which seems to improve visual evoked potentials
- Tyrosine supplementation (?)
- New phenylalanine-free formulas
- Reduction of phenylalanine uptake with purified phenylalanine ammonia-lyase
- Recombinant or pegylated phenylalanine ammonia-lyase
- Tetrahydrobiopterin supplementation to increase phenylalanine hydroxylase activity
- Large neutral amino acids supplementation to compete for blood-brain barrier carriers



may also show elevated plasma levels of phenylalanine.

Treatment

With a low-phenylalanine diet, which should probably be followed for life, the skin color, photosensitivity, odor, and eczema are reversible. In addition, early diet can dramatically reduce mental retardation, and if the blood phenylalanine levels are maintained at reasonable levels in early childhood, normal to low-normal intelligence can be expected[33] (Box 131-4). However, rigorous control of diet can lead to protein deficiency and an eczematous dermatitis.

ARGININOSUCCINIC ACIDURIA

Definition and Clinical Features

Argininosuccinic aciduria (ASA; OMIM #207900) is an autosomal recessive disorder of the urea cycle. Its incidence is estimated to be 1 in 70,000. ASA is characterized by hepatomegaly, mental retardation, seizures, episodic lethargy and ataxia, and friable, brittle hair with the morphology of trichorrhexis nodosa (see Chap. 86). The deficiency of an essential cytosolic enzyme in the urea cycle, argininosuccinase (argininosuccinate lyase), causes citrullinemia and an increase in blood ammonia. Argininosuccinate is increased in the blood and spinal fluid and is excreted in large amounts (2 to 9 g/day) in the urine.

The detailed clinical and biochemical features of the disease and the principles of therapy are reviewed by Nyhan, Barshop, and Ozand.[2] The hair abnormality is more characteristic of the late-onset disease, but in the early cases this peculiar type of alopecia brought the first patients to clinical attention.[38] Weaning and a change to a diet with a higher protein content can be precipitating factors in clinical disease. Essential to current therapeutic regimens are diets providing adequate energy, protein, and arginine.

The molecular pathology of the nucleic acids in this disease has been clarified, but the detailed pathophysiology of the hair defect remains to be determined.

Hair Defects

CLINICAL AND MORPHOLOGIC FEATURES[42]

About half the reported patients have had abnormally friable hair with visible trichorrhexis nodosa (see Chap. 86); the other half have had grossly normal hair. Brushing and combing accentuate breaking (i.e., brittle hair). No definite correlation can be made between liver argininosuccinase level, argininosuccinic acid levels, arginine levels, and the degree of hair abnormalities; some patients with severe ASA have had seemingly normal hair. Some patients' hair has improved with diet or without specific therapy. Hair shafts may show pseudo-trichothiodystrophy under polarizing microscopy with the typical dark and light banding.[43] Diet reverses grooving and abnormal polarization of hair shafts in argininosuccinase deficiency.[44] Eyelashes, eyebrows, and general body hair, as well as the nails, may be involved.

MOLECULAR NATURE OF HAIR DEFECTS

The basic nature of the hair defects is not known.

Increasing arginine in the diet aids hair growth and structure in this disease, which suggests that the decrease in arginine may be related to the defective hair. Because the urea cycle is depressed in ASA, the arginine required for protein synthesis would come predominantly from dietary sources. Hair protein is rich in arginine (up to 10 percent of the amino acid residues are arginine); furthermore, the citrulline present in certain specialized proteins in the medulla and internal root sheath is derived from arginine.

Other Disorders of the Urea Cycle[30]

In citrullinemia (OMIM #215700), a rare recessive disease caused by the absence of argininosuccinic acid synthetase, there is somatic and mental retardation and increased levels of citrulline in blood, urine, and cerebral spinal fluid; low to normal values of plasma arginine; and increased blood ammonia levels. Hair in such patients may be brittle, breaking easily. Microscopically, plucked hairs may be flattened, may be twisted through 180 degrees on their own axes, and may show breakage at the point of twisting.[47] Irregular areas of dystrophy and interruption of the cuticle were observed.

Deficiency of the cytosolic enzyme argininosuccinic acid synthetase is associated with trichorrhexis nodosa. Its overall clinical presentation is almost identical to that of ASA, although the plasma citrulline levels are usually higher (more than 1 m*M*) in the former disease. Enzymatic and genetic analyses confirm the diagnosis.

Diagnosis

Retardation, ammonia intolerance, and abnormal hair will suggest these syndromes. The diagnosis is confirmed by high-voltage electrophoresis or ion-exchange chromatography of the urine, blood, or spinal fluid. Only a tiny percentage of the cases of trichorrhexis nodosa and brittle hair are due to ASA. Prenatal diagnosis is possible after chorionic villus sampling or amniocentesis to ensure the birth of unaffected infants.[40]

ALKAPTONURIA

Alkaptonuria (OMIM #203500), or homogentisic acid oxidase (HGO) deficiency, is a rare metabolic disorder. Excessive homogentisic acid (HGA) is excreted in the urine, which often turns dark, and HGA accumulates in connective tissues, including the dermis[49] (ochronosis).

Epidemiology

Alkaptonuria is inherited as an autosomal recessive trait. Pedigrees suggestive of a dominant mode of transmission contain a high degree of consanguinity and, when subjected to careful scrutiny, are actually found to show pseudodominance. In general populations, alkaptonuria is rare (1 in 250,000), but clusters of high incidence are found in certain groups with inbreeding (e.g., in Slovakia and Santo Domingo). Among Slovakian newborns the incidence is 1 in 19,000. Disease distribution is worldwide, and there is an approximately equal incidence in both sexes.[50]

Etiology and Pathogenesis

The *HGO* gene maps to the q21-q23.60 region of chromosome 3. Multiple mutations have been found.[51–53] The muta-

ALKAPTONURIA AT A GLANCE



- Autosomal recessive metabolic disease in which homogentisic acid, an intermediate product in the metabolism of phenylalanine and tyrosine, cannot be further metabolized (Online Mendelian Inheritance in Man #203500). The cause is a mutation in the homogentisate 1,2-dioxygenase acid oxidase gene on chromosome bands 3q21-q23.
- Clinical features are blue-black or gray discoloration of sclerae, face, pinnae, cartilage, and nails; dark sweat; arthritis; and homogentisic aciduria. Urine is dark after standing in alkaline pH.
- It is suggested that high tissue concentrations of ascorbic acid might delay and possibly reduce the degree of pathologic changes in the connective tissue.
- Differential diagnosis includes argyria, chrysiasis, and pigmentation after treatment with amiodarone and other medications.
- Prenatal diagnosis is possible through DNA analysis.

tions change residues, which are conserved evolutionarily between *Aspergillus* HGO and human HGO, which suggests that they are fundamental to the activity of HGO. Both compound heterozygotes and homozygotes have been detected.[54]

The biochemical pathway by which phenylalanine and tyrosine normally undergo oxidative degradation to acetoacetic acid is shown in Fig. 131-3. HGA (2,5-dihydroxyphenylacetic acid), the last molecule in the sequence to contain an intact aromatic ring, is cleaved to maleylacetoacetic acid (Fig. 131-5). The enzyme catalyzing ring cleavage, HGO, is normally present in the soluble fraction of liver and kidney cells. It is highly specific for HGA. HGO mRNA is found in liver, kidney, and prostate.[54] Atmospheric oxygen, ferrous ion, and sulfhydryl groups are required for enzymatic function. Quinones inhibit the enzyme. HGO activity is totally absent in both liver and kidney tissue from alkaptonuric subjects. In patients with alkaptonuria, HGA undergoes renal excretion or is transformed to

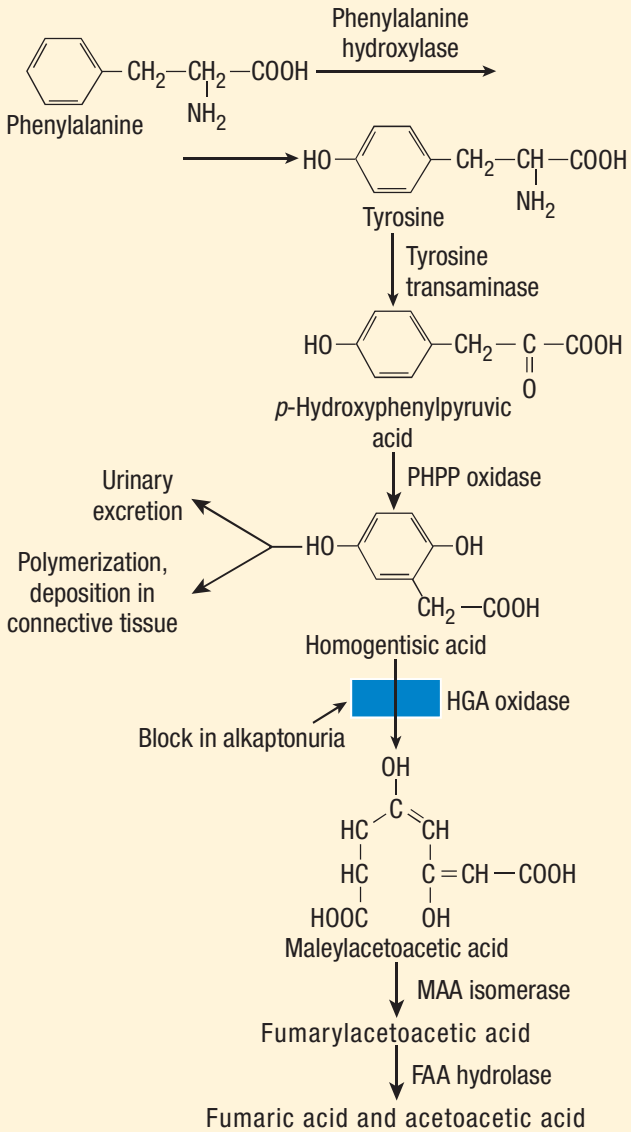

▲ **FIGURE 131-5** Metabolic pathway of phenylalanine and tyrosine degradation with homogentisic acid metabolites. FAA = fumarylacetoacetic acid; HGA = homogentisic acid; MAA = maleylacetoacetic acid; PHPP = *p*-hydroxyphenylpyruvic.

ochronotic pigment within connective tissue. HGA may not be present in the first days of life due to the absence of enzymatic activity of other enzymes in the pathway of tyrosine catabolism.

The renal clearance of HGA is extremely high (up to 400 to 500 mL/minute) in both normal and alkaptonuric subjects, which indicates active tubular secretion of HGA. This explains how with relatively low fasting plasma concentrations of HGA (in the range of 3 mg/dL) excretion may be up to 4 to 8 g/day in HGO deficiency. Compounds inhibiting this secretion may be an important factor in ochronosis. Once excreted, HGA (which is itself colorless in solution) gradually oxidizes to dark products. Oxidation occurs by degrees when the urine is exposed to air, but it can be hastened markedly by alkalinization. Urinary pH is the major variable causing the darkening of the urine, and some patients with acidic urine may never have spontaneously black urine. A diet high in protein or tyrosine increases the amount of HGA excreted in disease.

The precise manner by which HGA accumulation in tissues leads to ochronosis is only partially understood. A presumed HGA polymer has never been characterized.

Alkaptonuric mice (*aku*) do not have black urine or deposition of pigment, which is possibly related to the mouse's ability to synthesize ascorbic acid.[56]

Experimental ochronosis induced by prolonged feeding of high-tyrosine diets



to rats may delineate the precise interaction between HGA and its products and connective tissue.[57] HGO also has been produced in experimental animals by L-phenylalanine feeding and diets deficient in sulfur amino acids or tryptophan and the iron chelator α,α′-dipyridyl.

HGA inhibits lysyl hydroxylase, an enzyme crucial for collagen cross-linking, in chick embryo calvaria, which suggests that a reduction in the structural integrity of collagen consequent to deficient hydroxylysine-derived cross-linkages may be responsible for cartilaginous degeneration in alkaptonuria.[58]



Clinical Features

Dark urine is not always the initial manifestation of HGO deficiency. The urine is most apt to discolor rapidly when pH is above 7.0 and when reducing substances such as ascorbic acid, which normally protect HGA from oxidation, are not present in sufficient quantity. An early diagnosis of HGO deficiency is frequently made when (1) it is specifically sought because of family history, (2) discoloration of diapers occurs after cleansing in (alkaline) soap, (3) the urinary pH favors the oxidation of HGA, or (4) testing for urinary glucose with Benedict's solution yields an orange precipitate (which indicates a reducing substance) accompanied by a dark supernatant. A positive finding for Benedict's reaction and a negative result on glucose analysis with a glucose oxidase test reagent strongly suggest the diagnosis.

Although the diagnosis of alkaptonuria may be made during childhood, in rare cases the disorder is not detected until the individual develops pathologically significant changes in connective tissue in the third or fourth decade.[59] If coincidental renal disease prevents effective HGA excretion, the development of ochronosis may be accelerated, and diffuse hyperpigmentation may result.

Dark brown or black cerumen may be present in the first decade, even in those younger than 5 years of age. Axillary skin pigmentation (greenish blue, blue, greenish yellow, or brown) in the pattern of glandular orifices may be present late in the first decade. This may be accompanied by staining of underwear ("sweat that stains"). A patient with pigmentary changes confined to sun-exposed areas has been described.[60]

A grayish blue tinge overlying ear cartilage is common in adulthood but is rarely seen before 20 years of age.[61] Ochronotic discoloration is rarely seen

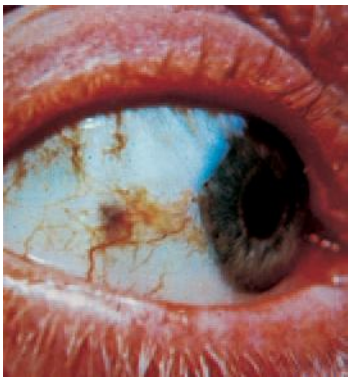

▲ **FIGURE 131-6** Ochronosis (alkaptonuria) has pathognomonic ocular signs. The first to appear is grayish black scleral pigmentation anterior to the tendon insertions of the horizontal recti muscles. At times, pigmentation of the elastic tissue in pinguecula may stain a dark brown or black, and it usually has the configuration of small, dark rings. In advanced cases of ochronosis, Bowman's membrane, adjacent to the limbus, may have areas of black pigmentation.

in childhood but is common in adulthood and can affect the sclera, cornea, conjunctiva, tarsus, and eyelid skin. Scleral involvement is noted in most patients[62,63] (Fig. 131-6). Scleral discoloration generally is restricted to that portion of the globe exposed by the palpebral fissure. The scleral pigmentation is usually triangular, with the base of the triangle facing the cornea. Tiny "oil droplets" of ochronotic pigment appear at the inner and outer poles of the corneas in advanced ochronosis. Later in the disease, structural changes result in loss of transillumination, stiffening, irregular contours, and eventually, in the third decade, calcification of the pinnae. The tympanic membrane may be blue. Tinnitus and variable degrees of deafness have been ascribed to ochronotic degeneration of the tympanic membrane and underlying ossicles. Laryngeal and tracheal cartilage becomes heavily pigmented but is asymptomatic.

The visible changes that occur with the passage of time are primarily due to the formation of ochronotic pigment granules in the dermis and sweat follicles and, most important, to the transmission of ochronotic discoloration through thin areas of skin overlying pigmented cartilage and tendon. The latter pigmentation, which is fairly uniform in ochronosis, is most apparent at the nose tip, ear (Fig. 131-7), costochondral junctions, and extensor tendons of the hands. Pigmented colloid milium on the dorsa of the hands have been reported.[64] Pigmentation of the skin is less



▲ **FIGURE 131-7** Ochronotic discoloration seen through the thin area of skin overlying the pigmented cartilage of the ear.

prominent but may occur in a butterfly pattern on the nose and cheeks and even the palms as a presenting sign.[65] Rarely, bluish gray fingernails and intensely dark nevi have been reported. Exogenous ochronosis and striae atrophicae may follow the use of bleaching creams.[66]

Insidious progression of ochronotic arthropathy, which generally begins in the third and fourth decades in men and approximately 10 years later in women, is the most disabling manifestation of alkaptonuria.[67] The disease is more severe in males. Bouts of acute inflammation may occur. Hip, knee, and shoulder limitation is an early sign. Lumbar pain, lordosis, kyphosis, and sciatica are common. Radiographs show a characteristic appearance of early calcification of the intervertebral disk and later narrowing of the intervertebral spaces, with eventual disk collapse and progressive loss of height (Fig. 131-8). The hands and feet generally are spared. Pseudogout may coexist with ochronosis.

There is some suggestion of an increased incidence of cardiovascular disease in patients with ochronosis, but accelerated arteriosclerosis has not been clearly documented. At postmortem examination, pigmentation is commonly observed in the heart valves and annuli and in arteriosclerotic plaques.[68] Prostatic symptoms in older men frequently are due to the formation of soft pigmented calculi in the alkaline secretions of the ducts and sinuses of that gland. Porous black renal stones containing calcium, phosphate, and oxalate also have been reported. The prostate has high levels of HGO mRNA, which may ex-

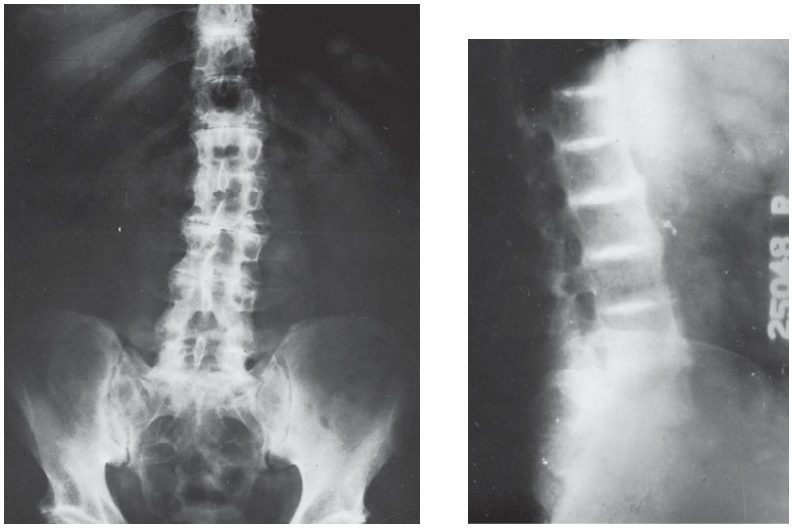

▲ **FIGURE 131-8** Roentgenographic findings in ochronosis. Marked intervertebral disk calcification is present.

plain the black prostate calculi that are occasionally present in the disease.[41]

Laboratory Findings

Aside from the excretion of HGA, alkaptonuric patients show no abnormalities on routine clinical laboratory tests. Normal individuals do not excrete HGA; therefore, darkening of the urine on the addition of sodium hydroxide is presumptive evidence of alkaptonuria.

Other tests based on the reducing properties of HGA include the black reaction after treatment with $FeCl_3$ and blackening of photographic emulsion paper on application of a drop of alkaptonuric urine followed by a drop of sodium hydroxide. Specific identification and quantification of urinary (as well as blood) HGA can be achieved by the use of a direct spectrophotometric method using HGO or with high-performance liquid chromatography or stable isotopes.[54]

With the development of ochronotic arthropathy, radiographs of the spine show characteristic disk calcification, which occurs rarely in other forms of spondylitis (see Fig. 131-8). Periostitis, ligament calcification, and sacroiliac sclerosis are not features of ochronotic spondylitis.

PATHOLOGY Yellow to light-brown (ochre) pigment granules, which led to the original designation of *ochronosis*, are present as free bodies and in dermal macrophages.[69] Irregular masses may be over 100 μm in diameter. The pigment, in contrast to melanin, is not bleached by 10 percent H_2O_2 after 72 hours.[69] Routine special stains for melanin react with the ochronotic pigment.

Electron microscopic studies show smaller-sized homogeneous bodies fusing to form larger non–membrane-bound structures.[69] Although the original pigment is brown, Tyndall scattering of light makes involved skin appear blue.

The tendency of connective tissue, cartilage in particular, to darken gradually over the years constitutes the cardinal pathologic finding in alkaptonuria. Intervertebral disks are pigmented (jet black) and darken when examined. Articular cartilage, when heavily pigmented, displays the degenerative changes of fibrillation, fissuring, fragmentation, and erosion to bare bone. Phagocytosis of collagen fibrils is found in synovial macrophages.[70]

Diagnosis and Differential Diagnosis

The diagnosis of alkaptonuria may be made on the basis of typical urinary discoloration or may await the onset of ochronosis in adulthood. Inasmuch as the disease behaves in a quite stereotypical manner with few confusing variants in its mode of presentation, it has been concluded that the diagnosis need only be thought of to be made. Other causes of dark urine—melaninuria, porphyria, myoglobinuria, bilirubinuria, and hematuria—should not to be confused with alkaptonuria. An ochronosis-like pigmentation of skin and cartilage has been produced iatrogenically by quinacrine administration over a period of months and at the site of quinine injections.[69] Pigmentation due to antimalarial treatment is usually much more pronounced on mucosal surfaces and will fluoresce with a Wood's lamp. A slate gray to blue pigmentation in sun-exposed sites occurs after amiodarone treatment, and similar discoloration also involving the mucous membranes is seen in argyria and chrysiasis (Box 131-5).

Box 131-5

Differential Diagnosis of Alkaptonuria

Main Features

- Skin
  - Black-gray skin on ear cartilage.
- Eyes
  - Brown to black pigmentation of the sclera
- Rheumatologic features
  - Skeletal pathologies, including spinal degeneration with kyphosis
  - Ochronotic arthritis and arthropathy
  - Thickened Achilles tendon
- Miscellaneous
  - Urolithiasis
  - Ochronotic prostate stones
  - Aortic and mitral valve calcification

Consider

- Exogenous ochronosis
- Argyria
- Chrysiasis
- Treatment-induced pigmentation (amiodarone, quinacrine, quinine)

It is possible that the reversible ochronotic pigmentation caused by prolonged carbolic acid treatment is due to polymerization of the carbolic acid by HGA polyphenol oxidase to an HGA polymer–like substance that differs from the polymer found in the genetic disease by the reversibility of the polymerization.

Exogenous ochronosis and pigmented colloid milia have been reported in a number of South Africans who used hydroquinone bleaching creams at strengths greater than 2 percent for a prolonged period.[66,71,72] Forty-two percent of women and 15 percent of men who used hydroquinones developed exogenous ochronosis.[72] A similar condition has been seen in American blacks.[73]

Treatment

The course of alkaptonuria is generally slow but irreversible. Treatment is primarily supportive, with close observation for the development of arthropathy, cardiac disease, and urinary tract disease (Box 131-6). Appropriate management includes genetic counseling, pain management with nonsteroidal anti-inflammatory agents, physical therapy to increase range of motion, and



Box 131-6

Treatment of Alkaptonuria

- Avoidance of high-protein diet
- Avoidance of high-phenylalanine diet
- Avoidance of high-tyrosine diet
- Large amounts of dietary vitamin C
- 2(-2-nitro-4-trifluoromethylbenzoyl)-1,3-cyclohexanedione

regular follow-up visits.[20] Avoidance of high-protein, high-phenylalanine, and high-tyrosine diets has been reported to be important. A well-balanced normal diet seems the best approach during childhood. It has been postulated that large amounts of dietary vitamin C may be helpful, because vitamin C protects HGA against oxidation and thus may prevent the deposition of ochronotic pigment; however, no long-term clinical studies have been undertaken to verify the effectiveness of this approach.

It is disappointing that despite advances in our biochemical understanding of alkaptonuria and the disposition of accumulated HGA to form ochronotic pigment in connective tissue, this information has yet to be translated into a successful therapeutic program for managing the disease. Exogenous cutaneous ochronosis induced by hydroquinone has been treated with the carbon dioxide laser.[79]

Course and Prognosis

The ultimate course in adults with alkaptonuria is that of increasing pigmentation and skeletal incapacity. Little can be done to interrupt this progression; however, the disease is not incompatible with a normal life span, and the oldest patient on record lived to 99 years of age.

OTHER ABNORMALITIES OF AMINO ACID METABOLISM

Table 131-1 lists some of the abnormalities of amino and organic acid metabolism and their associated skin manifestations.

KEY REFERENCES

The full reference list for all chapters is available at www.digm7.com.

2. Nyhan WL, Barshop BA, Ozand PT: *Atlas of Metabolic Diseases*, 2nd ed, London, Hodder Arnold, 2005
5. Scott CR: The genetic tyrosinemias. *Am J Med Genet C Semin Med Genet* **142**:121, 2006
7. Goldsmith LA, Reed J: Tyrosine-induced eye and skin lesions: A treatable genetic disease. *JAMA* **236**:382, 1976
8. Madan V, Gupta U: Tyrosinaemia type II with diffuse plantar keratoderma and self-mutilation. *Clin Exp Dermatol* **31**:54, 2006
9. Viglizzo GM et al: Richner-Hanhart syndrome (tyrosinemia II): Early diagnosis of an incomplete presentation with unusual findings. *Pediatr Dermatol* **23**:259, 2006
10. Macsai MS et al: Tyrosinemia type II: Nine cases of ocular signs and symptoms. *Am J Ophthalmol* **132**:522, 2001
14. Minami-Hori M et al: Richner-Hanhart syndrome: Report of a case with a novel mutation of tyrosine aminotransferase. *J Dermatol Sci* **41**:82, 2006
15. Charfeddine C et al: Clinical and mutational investigations of tyrosinemia type II in Northern Tunisia: Identification and structural characterization of two novel TAT mutations. *Mol Genet Metabol* **88**:184, 2006
16. Leib SR, McGuire TC, Prieur DJ: Comparison of the tyrosine aminotransferase cDNA and genomic DNA sequences of normal mink and mink affected with tyrosinemia type II. *J Hered* **96**:302, 2005
19. Jackson JK et al: The involvement of phosphatidylinositol 3-kinase in crystal induced human neutrophil activation. *J Rheumatol* **24**:341, 1997
23. Cerone R et al: Pregnancy and tyrosinaemia type II. *J Inherit Metab Dis* **25**:317, 2002
24. National Institutes of Health Consensus Development Panel: National Institutes of Health consensus conference statement: Phenylketonuria: Screening and management. *Pediatrics* **108**:972, 2001
25. Hanley WB: Adult phenylketonuria. *Am J Med* **117**:590, 2004
27. Schulpis KH et al: Biotin recycling impairment in phenylketonuric children with seborrheic dermatitis. *Int J Dermatol* **37**:918, 1998
30. Belloso LM, Lowitt MH: Cutaneous findings in a 51-year-old man with phenylketonuria. *J Am Acad Dermatol* **49**:S190, 2003
31. Abadie V et al: Neonatal screening and long-term follow-up of phenylketonuria: The French database. *Early Hum Dev* **65**:149, 2002
40. Kleijer WJ et al: Prenatal diagnosis of citrullinemia and argininosuccinic aciduria: Evidence for a transmission ratio distortion in citrullinemia. *Prenat Diagn* **26**:242, 2006
41. Reid Sutton V et al: A mouse model of argininosuccinic aciduria: Biochemical characterization. *Mol Genet Metabol* **78**:11, 2006
49. Phornphutkul C et al: Natural history of alkaptonuria. *N Engl J Med* **347**:2111, 2002
50. Itin P et al: Hereditary metabolic disorders, in *Pediatric Dermatology*, 3rd ed, edited by Schachner LA, Hansen RC. Edinburgh, Mosby, 2003, p 350
66. Bongiorno MR, Arico M: Exogenous ochronosis and striae atrophicae following the use of bleaching creams. *Int J Dermatol* **44**:112, 2005
68. Butany JW et al: Ochronosis and aortic valve stenosis. *J Card Surg* **21**:182, 2006



CHAPTER 132

The Porphyrias

David R. Bickers
Jorge Frank

The porphyrias are among the most intriguing diseases of humans. Widely variable, almost bizarre in their clinical manifestations, these disorders of porphyrin or porphyrin-precursor metabolism result from aberrations in the control of the heme biosynthetic pathway. Heme is essential for oxygen binding and transport (as in hemoglobin and myoglobin), for electron transport (as in cytochromes), and for the activity of mixed-function oxidases such as cytochrome P_{450}. Chlorophyll, a magnesium-chelated porphyrin, is another important tetrapyrrole that is critical for photosynthesis, the specialized energy-storing system found in plants in which the conversion of light energy into stabilized chemical energy is achieved with a sequence of oxidation-reduction reactions. The corrin ring, a cobalt-chelated tetrapyrrole, is a major constituent of vitamin B_{12}, the lack of which results in pernicious anemia. Porphyrins, therefore, are ubiquitous and essential biochemical constituents of living beings. The biologic importance of the porphyrins and their iron complexes in metabolism lies in their capacity to act as mediators of oxidation reactions, either as oxidative components in the metabolism of steroids, drugs, and environmental chemicals or as a means of exchanging gases, such as oxygen and carbon dioxide, between the environment and the tissues of the body.

Daily synthesis of porphyrins and heme in humans occurs in amounts suffi-

TABLE 132-1
Normal Values of Porphyrins and Porphyrin Precursors in Humans

Porphyrins or Precursors	Urine (μg/24 h)	Red Blood Cells (μg/100 mL Packed Cells)	Plasma (μg/100 mL)	Feces (μg/g Dry Weight)
δ-Aminolevulinic acid (ALA)	< 4000	—	15–23	—
Porphobilinogen (PBG)	< 1500	—	—	—
Uroporphyrin (URO)	< 40	0–2.0	0–2	10–50
Coproporphyrin (COPRO)	< 280	0–2.0	0–1	10–50
Protoporphyrin (PROTO)	Absent	< 90	0–2	0–20
X-porphyrin	Absent	Absent	Absent	Trace
Isocoproporphyrin (ISOCOPRO)	Absent	Absent	Absent	—
	(nmol/day)	(nmol/dL)	(nmol/dL)	(nmol/g Dry Weight)
ALA	8.8×10^3	—	$1.1–1.8 \times 10^2$	—
PBG	4.6×10^4	—	—	—
URO	< 40	—	24	—
COPRO	< 280	—	46	—
PROTO	0	285	0.5	134

cient to provide for the body's metabolic requirements. The control of heme synthesis is so precise that, under normal circumstances, only microgram quantities or less of pathway intermediates are present in plasma, red blood cells (RBCs), urine, and stool (Table 132-1).

The porphyrias are a clinically and genetically heterogeneous group of metabolic diseases that result from either an inherited or an acquired dysfunction of enzymes crucial for heme biosynthesis (Fig. 132-1). Heme synthesis is controlled by eight enzymes along the heme biosynthetic pathway. The human porphyrias arise from deficient activity of the second to eighth enzymes in this pathway (see Fig. 132-1).[1–3] Each of these enzymes is discussed separately later in the context of the corresponding type of porphyria.

Biochemically, the different porphyrias are characterized by particular pat-

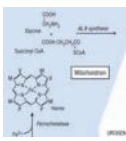

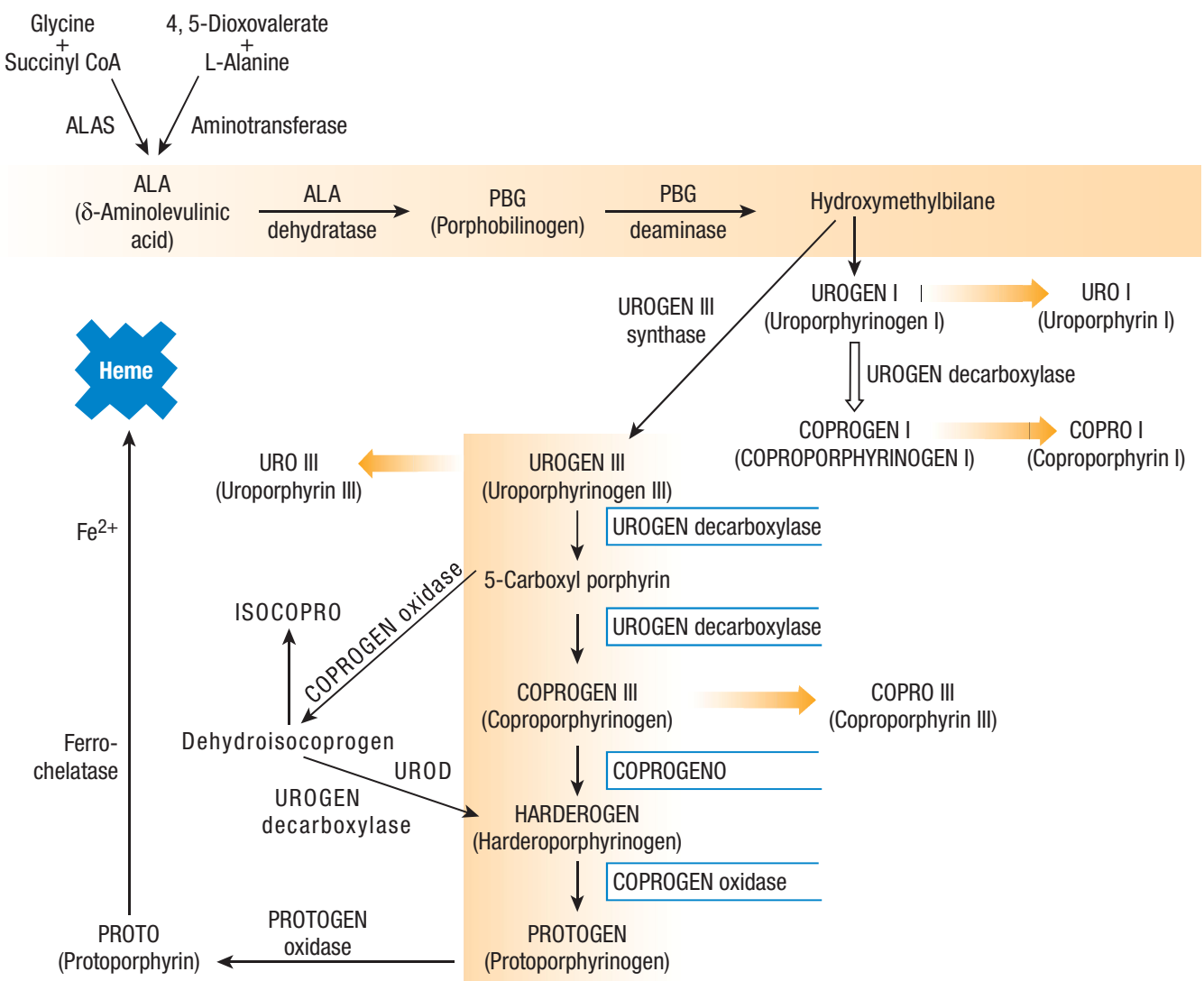

▲ **FIGURE 132-1** The porphyrin-heme biosynthetic pathway (see also legend for Fig. 132-2). ALAS = δ-aminolevulinic acid synthase; CoA = coenzyme A; COPROGENO = coproporphyrinogen oxidase; ISOCOPRO = isocoproporphyrin; UROD = uroporphyrin decarboxylase.

terns of accumulation and excretion of porphyrins and/or their precursors. In general, the porphyrins excreted in a specific type of porphyria are the irreversibly oxidized substrate(s) of the deficient enzyme (Table 132-2). These intermediates, when present in excess amounts, exert toxic effects that are responsible for the cutaneous and neurologic signs and symptoms of clinically overt porphyria. The porphyrias are of particular dermatologic interest because several types exhibit cutaneous manifestations that may permit diagnosis from clinical signs alone.

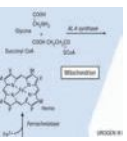

PORPHYRIN-HEME BIOSYNTHESIS

The major sites of heme synthesis in the body are the bone marrow and the liver. Heme is the prosthetic group for a number of proteins, including among others hemoglobin, myoglobin, mitochondrial cytochromes, microsomal cytochromes (including cytochrome P_{450}), catalase, peroxidase, tryptophan pyrrolase, prostaglandin endoperoxide synthase, and the soluble form of guanylate cyclase. Approximately 85 percent of heme synthesis occurs in the bone marrow, where heme is used for the production of hemoglobin; the majority of the rest occurs in the liver for production of cytochrome P_{450}, catalase, and various mitochondrial cytochromes. Heme is a critical cellular constituent essential for a variety of metabolic processes, primarily because of its unique ability to take up and release oxygen and to facilitate electron transport. Heme synthesis is regulated by the interplay of a number of factors and is directly dependent on its concentration within cells and on the requirements of the cell for production of the various hemoproteins listed at the beginning of the paragraph. Many of these have rapid turnover times (minutes to hours), which necessitates continuously high rates of hepatic heme synthesis (e.g., cytochrome P_{450}, an important membrane-bound enzyme in the liver involved in the detoxification and metabolism of drugs, has a half-life of 90 to 180 minutes).

Regulation of Heme Biosynthesis

The regulation of heme biosynthesis (and indeed the ability to synthesize heme at all) is dependent on the serial interaction of eight intracellular enzymes (see Fig. 132-1). The first, δ-aminolevulinic acid (ALA) synthase, and the last three enzymes involved, coproporphyrinogen (COPROGEN) oxidase, protoporphyrinogen (PROTOGEN) oxidase, and ferrochelatase, are mitochondrial, whereas the remaining enzymes, ALA dehydratase, porphobilinogen (PBG) deaminase, uroporphyrinogen III (UROGEN III) synthase, and UROGEN decarboxylase, are localized in the cytosol. Once heme is formed, heme cleavage is catalyzed by the microsomal enzymes nicotinamide adenine dinucleotide phosphate (reduced form)–cytochrome C reductase, heme oxygenase, and biliverdin reductase, which convert the cyclic tetrapyrrole to linear bile pigments. Complementary DNAs (cDNAs) for each of the eight enzymes involved in heme biosynthesis as well as the enzymes along the heme catabolic pathway have been cloned in mammalian cells.[2,3] Abnormal control of heme synthesis may result from defects in enzymes of the synthetic pathway, and this may occur as the result of inherited and/or environmental factors that lead to the accumulation in the body of one or more heme pathway intermediates, such as the porphyrins or their precursors. Although a diagnosis of porphyria can often be made from a careful medical history (including the familial history) and physical examination, the definitive diagnosis requires (1) measurement of porphyrins and/or porphyrin precursors in urine, stool, plasma, or erythrocytes (RBCs); or (2) measurement of the residual activity of specific enzymes in the heme pathway; or (3) the identification of mutations in the genes encoding these enzymes (see Fig. 132-1). Modern molecular biologic techniques have helped to clarify the mechanistic basis of the porphyrias.[3–8] The steps involved in the biosynthesis of porphyrins and heme and their regulatory control are summarized in Figs. 132-1, 132-2, 132-3, and 132-4.

TABLE 132-2
Enzyme Activities in Various Porphyrias

ENZYME	TISSUE	DISEASE-DISPLAYING ENZYMATIC DEFECT
δ-Aminolevulinic acid (ALA) synthase	Liver, kidney, fibroblasts, and lymphocytes	Increased activity in AIP, HCP, VP
ALA dehydratase	Erythrocytes, liver, and kidney	Decreased in lead intoxication, decreased in ALA dehydratase deficiency porphyria
Porphobilinogen deaminase	Erythrocytes, liver, fibroblasts, lymphocytes, and amnion cells	Decreased in AIP
Uroporphyrinogen III synthase	Erythrocytes and fibroblasts	Decreased in CEP
Uroporphyrinogen decarboxylase	Erythrocytes and liver	Decreased in PCT (sporadic and familial) and HEP
Coproporphyrinogen oxidase	Fibroblasts, lymphocytes, and liver	Decreased in HCP
Protoporphyrinogen oxidase	Liver and fibroblasts	Decreased in VP
Ferrochelatase	Bone marrow and fibroblasts	Decreased in EPP and lead poisoning

AIP = acute intermittent porphyria; CEP = congenital erythropoietic porphyria; EPP = erythropoietic protoporphyria; HCP = hereditary coproporphyria; HEP = hepatoerythropoietic porphyria; PCT = porphyria cutanea tarda; VP = variegate porphyria.

δ-Aminolevulinic Acid Synthase (See Figs. 132-1 and 132-2)

Heme synthesis begins in the mitochondrion of the cell where succinate and glycine (single molecules of glycine and succinyl coenzyme A) are conjugated to form a five-carbon aminoketone, ALA. The reaction requires pyridoxal 5′-phosphate as a co-factor. ALA synthase is the mitochondrial enzyme that catalyzes the formation of ALA and is a homodimer of two identical catalytically active subunits of molecular mass 55 kd, linked to catalytically inactive substrates of higher molecular mass.[3,8,9]

The major significance of this enzyme is that it plays a regulatory role in controlling the rate of heme synthesis in the liver via a negative feedback mechanism. Heme acts at multiple sites to regulate hepatic ALA synthase. Currently, two differentially expressed isoforms of ALA synthase are known, one with ubiquitous expression, including in the

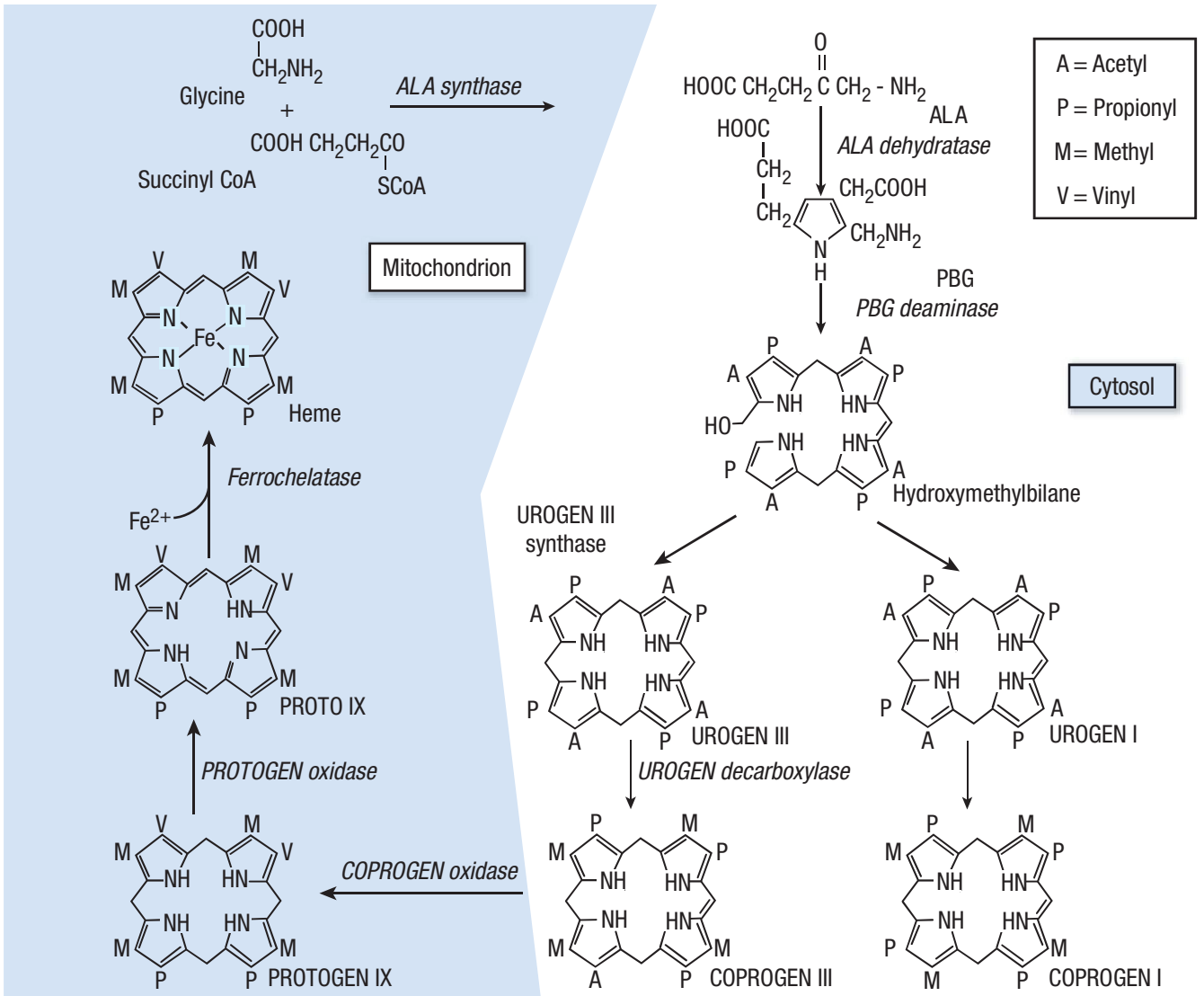

▲ **FIGURE 132-2** Major steps in the porphyrin-heme biosynthetic pathway. (1) δ-Aminolevulinic acid (ALA) synthase can be formed from glycine and succinyl coenzyme A (SCoA), which is the primary source in mammalian systems and is catalyzed by the mitochondrial enzyme ALA synthase. Two molecules of ALA form the monopyrrole porphobilinogen (PBG). (2) Four molecules of PBG are converted by PBG deaminase to a linear tetrapyrrole, hydroxymethylbilane, which can cyclize spontaneously to form uroporphyrinogen (UROGEN) I. (3) The four acetyl groups of UROGEN I are sequentially decarboxylated by UROGEN decarboxylase to form coproporphyrinogen (COPROGEN) I. (4) Hydroxymethylbilane can also be converted to UROGEN III by the enzyme UROGEN III synthase. In this reaction, one of the monopyrrole rings is "flipped over," which alters the sequence of the side chains. (5) The acetyl groups of UROGEN III are sequentially decarboxylated by UROGEN decarboxylase to form COPROGEN III. (6) COPROGEN III is converted to protoporphyrinogen (PROTOGEN) IX by the enzyme COPROGEN oxidase, which oxidatively decarboxylates each of the propionyl groups. (7) PROTOGEN IX is converted to protoporphyrin (PROTO) IX by PROTOGEN oxidase. PROTO IX is converted to heme by ferrochelatase, which catalyzes the insertion of ferrous iron into the molecule.

liver, and the other with exclusive expression in erythroid tissues. It is thought that two pools, one cytosolic and one nuclear, regulate the respective isozymes. Two genes encoding different tissue-specific ALA synthase messenger RNAs (mRNAs) have been found. The human housekeeping gene is located on chromosome 3p21, and the erythroid gene has been assigned to a distal subregion of chromosome Xp21-Xq21. The erythroid pre-protein reveals more than 75 percent homology with the hepatic protein. Immunochemical differences exist between the hepatic and erythroid enzyme in various animal species.[9,10] In contrast to deficiencies of the second to eighth enzymes in the heme biosynthetic pathway, a reduction in residual ALA synthase activity is not associated with a specific type of porphyria.

CLASSIFICATION OF THE PORPHYRIAS

Traditionally, most classifications of the porphyrias are based on the primary site of expression of the specific enzymatic defect, so that erythropoietic and hepatic forms are distinguished. From a dermatologic perspective, the porphyrias might also be classified into cutaneous and non-cutaneous forms. From a general clinical perspective, however, it seems reasonable to classify the porphyrias into two categories, non-acute and acute, so that patients in whom dermatologic findings predominate are differentiated from those who are susceptible to potentially life-threatening acute neurovisceral attacks. This latter classification is used throughout this chapter. It should be pointed out that variegate porphyria (VP) and hereditary coproporphyria (HCP) are often referred to as *neurocu-*

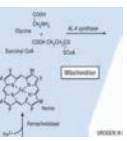

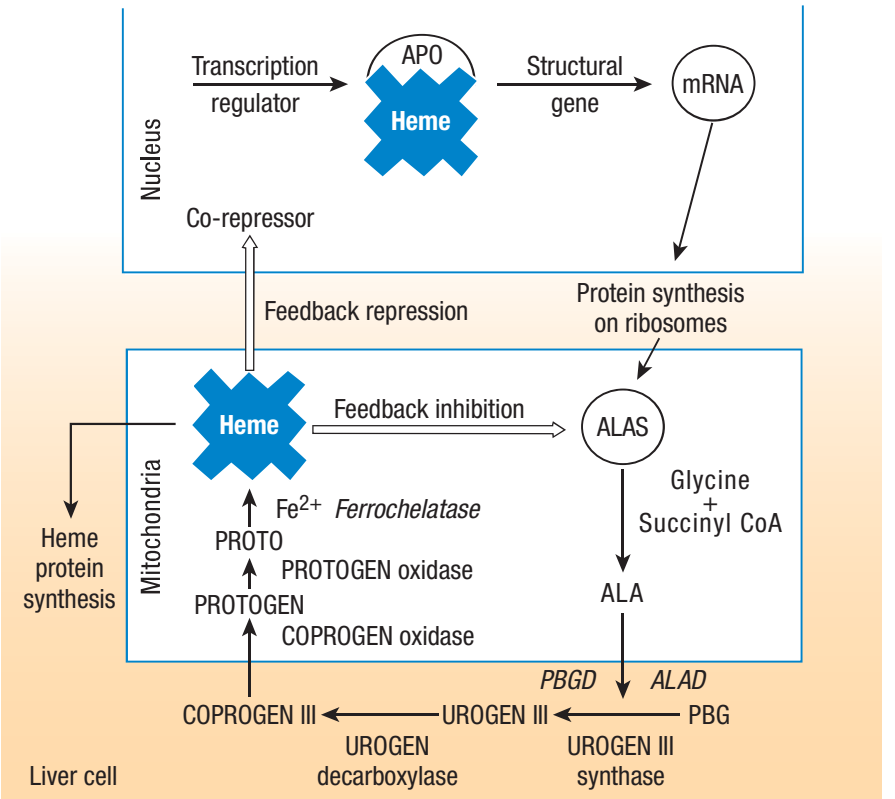

▲ **FIGURE 132-3** Heme is capable of regulating its synthesis by either directly inhibiting or repressing the synthesis of its rate-limiting enzyme, δ-aminolevulinic acid synthase (ALAS). The repression may result from the binding of heme, as a co-repressor, to an aporepressor protein (APO), which, when combined with heme, becomes a functional unit that blocks transcription of ALAS messenger RNA (mRNA). Heme may also block transport of the holoenzyme into the mitochondrion. ALA = δ-aminolevulinic acid; ALAD = δ-aminolevulinic acid dehydratase; CoA = coenzyme A; COPROGEN = coproporphyrinogen; PBGD = porphobilinogen deaminase; PROTO = protoporphyrin; PROTOGEN = protoporphyrinogen; UROGEN = uroporphyrinogen.

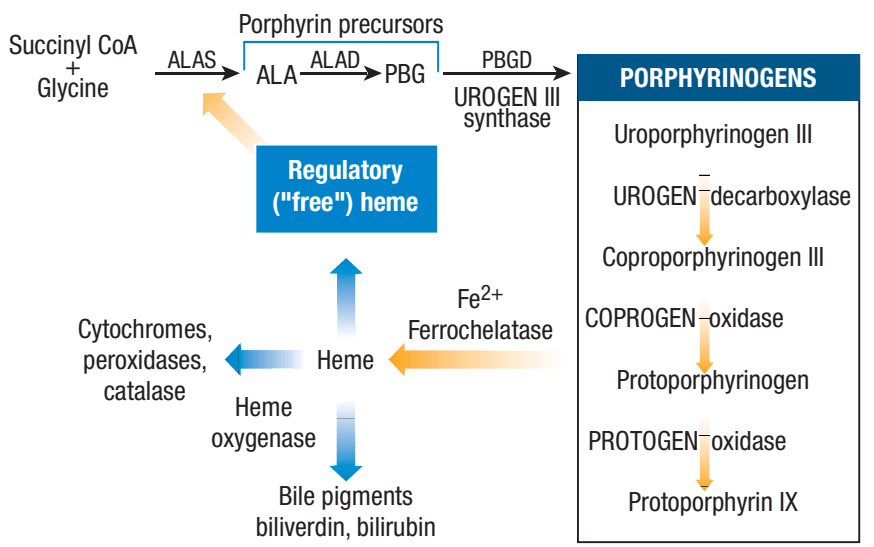

▲ **FIGURE 132-4** A regulatory pool of "free" heme unbound to apoproteins may be the critical determinant for regulation of synthesis of δ-aminolevulinic acid synthase (ALAS) activity. ALA = δ-aminolevulinic acid; ALAD = δ-aminolevulinic acid dehydratase; CoA = coenzyme A; PBG = porphobilinogen; PBGD = porphobilinogen deaminase; COPROGEN = coproporphyrinogen; PROTOGEN = protoporphyrinogen; UROGEN = uroporphyrinogen.

THE PORPHYRIAS AT A GLANCE

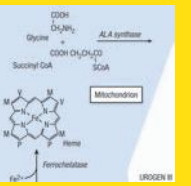

- The porphyrias result from a dysfunction of specific enzymes involved in heme biosynthesis.
- At least eight different types of porphyria are known and can be classified as nonacute and acute.
- Cutaneous features manifest exclusively on sun-exposed body areas.
- Life-threatening acute neurologic attacks can occur.
- Diagnosis is often difficult due to overlapping clinical and biochemical findings.
- All genes encoding the enzymes involved in heme synthesis are well characterized, which allows for accurate molecular diagnosis and genetic counseling.

taneous porphyrias because patients with these diseases may have both neurovisceral and cutaneous manifestations.

An acute porphyric attack can present a constellation of symptoms and signs, among them intense abdominal pain, vomiting, electrolyte dysregulation (hyponatremia), constipation, tachycardia, hypertension, muscle pain and weakness, seizures, paresis of the upper and lower extremities, paralysis, and a variety of other neurologic and psychiatric symptoms.[11] These myriad clinical manifestations inevitably mimic those of other diseases, which challenges the diagnostic acumen of even the most experienced clinicians, particularly because the porphyrias are rare disorders.[12] It is known that acute porphyric attacks can be precipitated by a variety of external factors, in particular porphyrinogenic drugs, ethanol, hormonal fluctuations, and diminished caloric intake from dieting or fasting.[11,13] Yet in practice it is often impossible to identify the immediate cause of an acute crisis in an individual patient. Timely diagnosis of an acute porphyric attack can be lifesaving, because several complications may have fatal consequences if not recognized and treated. As an example, in a patient with episodic abdominal pain, treatment with analgesics may prolong or aggravate the

attack. Diffuse abdominal pain can mimic acute appendicitis, diverticulitis, or other painful gastroenterologic disorders that may necessitate surgical intervention.[14,15] After administration of certain drugs (e.g., barbiturates) or during general anesthesia, acute attacks may ensue.[1] A particularly problematic complication is muscle weakness. This can range from mild paralysis of small muscle groups to flaccid paralysis of multiple muscle groups resulting in paraplegia and respiratory compromise. These findings may be accompanied by severe sensory loss and amyotrophy.[16] In some cases, paralysis may progress rapidly and can affect cranial nerves or develop into a Guillain-Barré–like syndrome.[17]

NON-ACUTE AND ACUTE PORPHYRIAS

Patients with all forms of non-acute porphyria manifest cutaneous findings predominantly on sun-exposed body areas. The non-acute porphyrias include porphyria cutanea tarda (PCT), the most prevalent type of porphyria overall; erythropoietic protoporphyria (EPP); congenital erythropoietic porphyria (CEP); and hepatoerythropoietic porphyria (HEP), the homozygous variant of PCT. The non-acute porphyrias can present with variable cutaneous features, including mild to severe photosensitivity, increased skin fragility, vesicles and bullae, burning and stinging, edema, pruritus, hypertrichosis, scarring, hyperpigmentation, and mild to severe scleroderma-like changes.[4]

The acute porphyrias include acute intermittent porphyria (AIP), VP, HCP, and ALA dehydratase deficiency porphyria or plumboporphyria. Although AIP is the most prevalent form of acute porphyria worldwide, in some countries other acute forms may predominate, as is the case for VP in Chile and South Africa.[18,19] Besides neurovisceral symptoms, individuals with VP or HCP can also present with cutaneous findings, including increased photosensitivity, abnormal skin fragility, and bullous skin lesions on sun-exposed areas, erosions, chronic scarring, and post-inflammatory pigmentary change. Thus, VP and HCP are also referred to as *neurocutaneous porphyrias*, to distinguish them from AIP and ALA dehydratase deficiency porphyria, which are not associated with any cutaneous abnormalities.[4,20]

It is of interest that ethanol and estrogens, which can trigger acute porphyric attacks in AIP, VP, and HCP, can also exacerbate PCT, although acute attacks do not occur in this disease and the mechanisms likely differ.[21]

Pathophysiology of Cutaneous Signs and Symptoms in the Non-Acute Porphyrias

The most common cutaneous manifestation of the non-acute porphyrias is photosensitivity. It is observed in patients with several of these disorders (PCT, EPP, CEP, HEP) as well as in patients with VP and HCP, who have both cutaneous and neurovisceral findings. The sine qua non of photosensitivity in porphyria is increased levels of plasma and tissue porphyrins. Patients with AIP, in whom only non-photosensitizing porphyrin precursors (ALA, PBG) are formed in substantially increased amounts, do not experience photosensitivity, nor do any of the handful of patients reported with ALA dehydratase deficiency porphyria.

Patients with the erythropoietic types of porphyria frequently complain of a painful and intense burning sensation and pruritus during or after sun exposure. A "priming" effect of sun exposure on cutaneous photosensitivity in EPP has been described in which a threshold exposure on one day that evokes virtually no reaction seems to augment the response to subsequent exposure on the following day.[22] The cause of this is unknown, but the phenomenon suggests that repair of damage to skin by photosensitized porphyrins may be prolonged. These subjective symptoms are notably absent in patients with the chronic hepatic porphyrias such as PCT and VP. Although there is some information about the pathophysiology of photosensitivity and sclerodermoid skin changes in the chronic hepatic porphyrias, the causes of the pigmentary alterations and hypertrichosis seen in these patients remain to be elucidated.

Porphyrins have certain unique photobiologic and spectroscopic properties that make them efficient photosensitizers. It is important to note that metal-chelated porphyrins [e.g., heme or ferrous protoporphyrin (PROTO)] show no fluorescence and are not photosensitizers. Porphyrins that are chelated to other paramagnetic metals, such as Mn^{2+}, Co^{2+}, or Zn^{2+} (e.g., chlorophyll, zinc PROTO), also do not fluoresce. For this reason, patients with lead intoxication, in which zinc PROTO level is elevated, do not have photosensitivity.[23,24] However, metal-free porphyrins [e.g., uroporphyrin (URO), coproporphyrin (COPRO), PROTO] in acidic solutions show a major absorption peak in the 400- to 410-nm region (Soret band); they also exhibit four additional absorption bands with decreasing intensity between 500 and 700 nm. Exposure of porphyrins to the Soret band spectra results in fluorescence emission peaks between 550 and 680 nm (Table 132-3). Although there is no single clearly defined pathway that can currently explain the photosensitization evoked by porphyrins and light, there are a number of potential cellular and soluble factors that likely are involved. Among them are reactive oxygen species (ROS) and their effect on certain cells (erythrocytes, mast cells, polymorphonuclear cells, and fibroblasts), and soluble mediators (the complement system and matrix metalloproteinases), which are discussed later in the section Cellular and Soluble Factors Contributing to Photosensitivity (Table 132-4). It is likely that a combination of these factors will prove to be responsible for the pathogenesis of the cutaneous lesions in the porphyrias.

Of note, porphyrin abnormalities can also occur in lead poisoning; sideroblas-

TABLE 132-3
Fluorescence Characteristics of Porphyrin-Containing Plasma Diluted with 1:10 Phosphate Buffered Solution

TYPE	EXCITATION (NM)	EMISSION (NM)	FLUORESCENT PORPHYRINS
Congenital erythropoietic porphyria	398	619	URO I, COPRO I
Erythropoietic protoporphyria	409	634	PROTO
Porphyria cutanea tarda	398	619	URO I, III; COPRO III
Variegate porphyria	405	626	COPRO III, PROTO
Acute intermittent porphyria	398	619	URO III
Hereditary coproporphyria	398	619	COPRO III
Hepatoerythropoietic porphyria	398	619	URO I

COPRO = coproporphyrin; PROTO = protoporphyrin; URO = uroporphyrin.
Modified from Poh-Fitzpatrick MB, Lamola AA. Direct spectrofluorometry of diluted erythrocytes and plasma: A rapid diagnostic method in primary and secondary pophyrinemias. *J Lab Clin Med* **87(2)**:362, 1976.

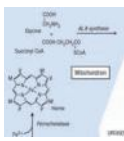

TABLE 132-4
Factors Contributing to the Development of Cutaneous Lesions in Porphyrias

- Sunlight, especially blue and red light (380–760 nm)
- Reactive oxygen species ($^1O_2$, $O_2^{\cdot-}$, H_2O_2, ·OH).
- Cells
  - Erythrocytes
  - Mast cells
  - Polymorphonuclear leukocytes
  - Fibroblasts
- Soluble mediators
  - The complement system
  - Factor XIII–dependent pathways
  - The eicosanoids
  - Matrix metalloproteinases

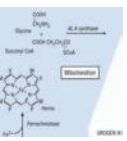

tic, hemolytic, and iron deficiency anemia; renal failure; cholestasis; liver disease; and gastrointestinal hemorrhage. Of these conditions, however, cutaneous photosensitivity has been documented only in rare cases of sideroblastic anemia.

Pathophysiology of Neurovisceral Signs and Symptoms in the Acute Porphyrias

Two porphyria variants, AIP and ALA dehydratase deficiency porphyria, do not manifest cutaneous symptoms. In these diseases, the dysfunctional enzymes act early in heme biosynthesis, and their substrates are non-phototoxic porphyrin precursors. However, patients with both AIP and ALA dehydratase deficiency porphyria as well as VP and HCP can manifest life-threatening acute neurovisceral attacks. Although the exact pathogenesis of these attacks is not well understood, it seems that the porphyrin precursors ALA and PBG that are massively excreted from the liver during an acute attack are particularly neurotoxic. Furthermore, as a result of porphyria-related enzyme defects, there may be heme deficiency in nerve tissue. Thus, the autonomic and peripheral nervous systems are particularly susceptible to porphyrin- and porphyrin precursor–induced neuropathy.[25]

Cellular and Soluble Factors Contributing to Photosensitivity (See Table 132-4)

REACTIVE OXYGEN SPECIES Porphyrins such as URO, COPRO, and PROTO absorb light intensely around 400 nm and in the longer visible spectrum between 580 and 650 nm. Absorption results in the generation of excited state porphyrin molecules (Fig. 132-5). The initial excited state porphyrin generated has an extremely short half-life of less than 0.01 μs. Singlet excited state porphyrins may spontaneously convert to a triplet, another excited state that has a lower energy level but a longer half-life (on the order of microseconds to milliseconds). Because of their long half-life, triplet state porphyrins are more likely to react with biologic substrates and are likely candidates to mediate most porphyrin-associated photobiologic reactions. Excited state porphyrin molecules ultimately must return to their normal ground states by releasing their absorbed energy in the form of light (fluorescence is emitted by singlet state molecules and phosphorescence by triplet state molecules) or heat, or by transferring energy to cell constituents (cell membranes, organelles, proteins, DNA) (see Figs. 132-5 and 132-6).

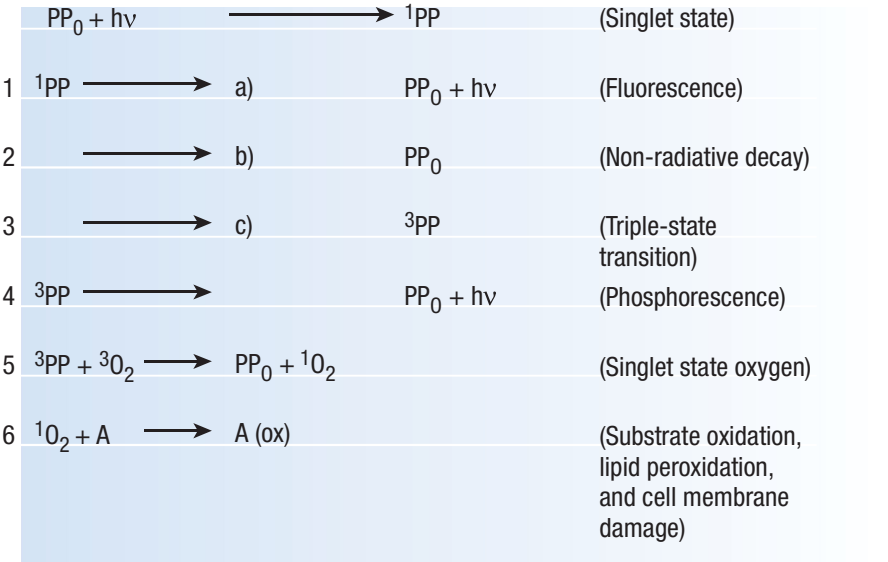

▲ **FIGURE 132-5** Photoexcited porphyrins release energy in a variety of ways when returning to their ground state, and these may contribute to damaging reactions in biologic systems. A = acceptor; A (ox) = oxidized acceptor; hν = radiant energy; PP = photoexcited porphyrin.

Excited porphyrins in their singlet and triplet states can also transfer their absorbed energy to oxygen molecules, thereby creating reactive excited oxygen states.[26] Cellular and tissue damage induced by photoactivated porphyrins is believed to occur primarily as a result of the formation of reactive singlet oxygen ($^1O_2$), as illustrated in Figs. 132-5 and 132-7.[27,28] In some cases, the sensitized porphyrin may further react with oxygen to yield hydrogen peroxide (H_2O_2) or with water to form hydroxyl radicals

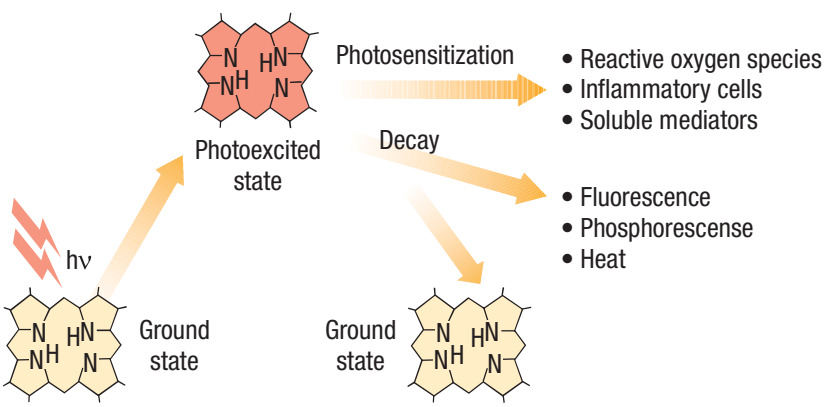

▲ **FIGURE 132-6** Porphyrins in a ground state, on absorption of radiant energy (hν), undergo transition to photoexcited states. The photoexcited porphyrins generate reactive oxygen species, which damage cells by release of pro-inflammatory mediators; in turn, these may contribute to damaging reactions in biologic systems such as skin.

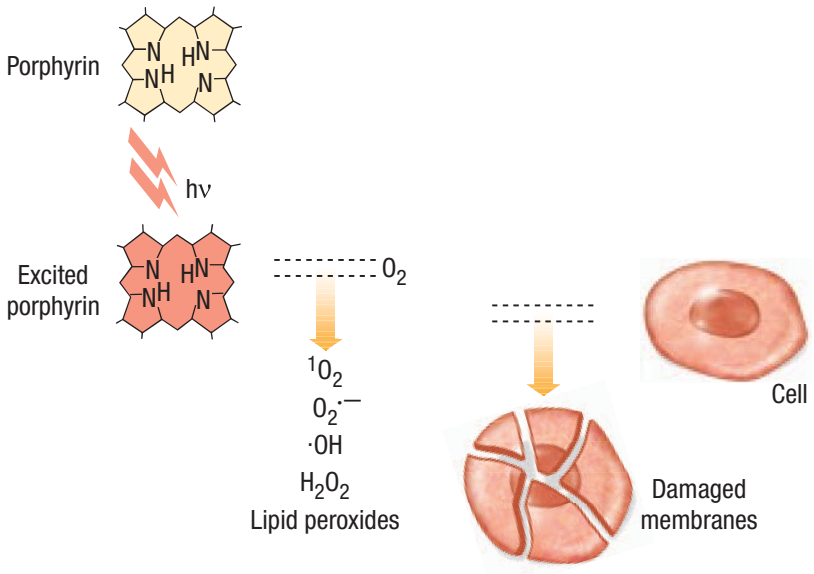

▲ **FIGURE 132-7** Photoexcited porphyrins in their triplet state transfer the absorbed energy to oxygen (O_2) molecules, thereby producing reactive oxygen species ($^1O_2$, $O_2^{\cdot-}$, ·OH, and lipid peroxides). These reactive oxygen species interact with cell membranes to cause tissue damage. hν = radiant energy.

(OH). Those processes in which activated oxygen species play a role in photosensitization are referred to as *photodynamic reactions*.[29] Most of the porphyrin-mediated cutaneous photosensitization reactions are essentially photodynamic and can be minimized or prevented if reactive oxygen is eliminated by inactivation processes known as *quenching* or *scavenging*.

Although these concepts regarding excited porphyrins and ROS are valid in simple systems and several hypotheses based on them have been advanced to explain the mechanism of porphyrin-induced photosensitivity, their applicability to complex tissues such as the skin remains to be established.

COMPLEMENT SYSTEM Cutaneous phototoxicity in the porphyrias is directly related to the interaction of porphyrins with light of the Soret and other bands in the solar spectrum, which results in the generation of ROS. This in turn can induce lipid peroxidation and cell membrane alterations. Release of mediators and enzymes from cells such as mast cells and polymorphonuclear leukocytes contributes to the inflammatory response. Variations in solubility influenced by the lipid-water partitioning of porphyrins may account for the striking patterns of the skin findings observed in various types of porphyria. It is important to emphasize that porphyrinogens (reduced porphyrins) are the true intermediates in heme synthesis. The irreversibly oxidized porphyrins, with the exception of PROTO, do not function as substrates for the enzymes of the pathway. Thus, porphyrins are actually heme pathway by-products, which are of special interest to dermatologists because of their unique photosensitizing properties.

THE NON-ACUTE PORPHYRIAS (Table 132-5)

Porphyria Cutanea Tarda

EPIDEMIOLOGY PCT occurs throughout the world[46] and is the most common of all the porphyrias. The prevalence is estimated at 1 in 10,000.[47] The disease most often begins in middle-aged individuals but can develop earlier. Before the widespread use of oral contraceptives, PCT developed predominantly in males.[48,49] Others, however, have emphasized that the sex incidence is now approximately equal.[50] The rising incidence of PCT in females is probably due to the widespread ingestion of estrogens in oral contraceptives or in hormone supplements. It should be noted that males treated with estrogens, for example as adjunctive therapy for carcinoma of the prostate, have also developed PCT.

ETIOLOGY AND PATHOGENESIS PCT is due to either an inherited or an acquired de-

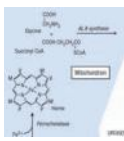

TABLE 132-5
Overview and Summary of the Features of the Non-Acute Porphyrias

	Porphyria Cutanea Tarda	Erythropoietic Protoporphyria	Congenital Erythropoietic Porphyria	Hepatoerythropoietic Porphyria
Synonym(s)	Symptomatic porphyria, acquired hepatic porphyria, chemical porphyria	Erythropoietic porphyria, protoporphyria	Günther disease, congenital hematoporphyria, erythropoietic uroporphyria	Hepatoerythrocytic porphyria
Inheritance	Autosomal dominant in approximately 20% of patients; otherwise acquired	Autosomal dominant	Autosomal recessive	Autosomal recessive
Age of onset	Usually in third or fourth decade; rare before puberty	Early childhood (1–4 yr); late onset extremely rare	Usually infancy or first decade	Early infancy, before age 2 yr
Incidence	Most common porphyria worldwide	Second most common of the cutaneous porphyrias	Very rare (fewer than 200 cases)	Extremely rare (fewer than 20 cases)
Photosensitivity	Moderate to severe with high interindividual variation; indistinguishable from variegate porphyria	Mild to severe; onset immediate (in minutes); interindividual variation	Severe to very severe	Severe
Skin reactions (on sun-exposed areas)	Vesicles and bullae, erosions, crusts, milia, scarring, hypertrichosis; indistinguishable from variegate porphyria	Edema, erythema, urticarial plaques; very rarely bullae, skin thickening, waxy scars	Vesicles and bullae, erosions, hypertrichosis, hypermelanosis, mutilation	Vesicles and bullae, erosions, crusts, milia, scarring, hypertrichosis, mutilation

PORPHYRIA CUTANEA TARDA AT A GLANCE



- Most frequently occurring type of porphyria worldwide.
- Sporadic and inherited (autosomal dominant) forms of the disease arise due to deficiency of uroporphyrinogen decarboxylase.
- Age of onset is usually in the third to fourth decade of life; the disorder is unusual before puberty.
- Characterized by moderate to severe photosensitivity; cutaneous signs include vesicles and bullae, erosions, crusts, milia, scarring, hyperpigmentation, and hypertrichosis.
- Cutaneous features overlap with those of variegate porphyria and hereditary coproporphyria.

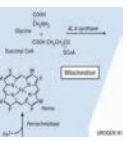

ficiency of UROGEN decarboxylase, the fifth enzyme in the heme pathway (see Figs. 132-1 and 132-2), which has a molecular mass of approximately 42 kd.[51] UROGEN I and III each contain eight carboxyl groups as side chains, four of which are acetate ($-CH_2COOH$) and four of which are propionate ($-CH_2-CH_2-COOH$) moieties (see Fig. 132-2). The soluble cytosolic enzyme UROGEN decarboxylase catalyzes the sequential oxidative decarboxylation of the four carboxyl groups of the acetate side chains to methyl groups to form COPROGEN (see Fig. 132-2). Decarboxylation first occurs on ring D, after which the enzyme turns around to decarboxylate rings A, B, and C in a clockwise fashion. This converts the original 8-carboxyl porphyrinogen (UROGEN I or III) first to 7-carboxyl, then to 6-carboxyl and to 5-carboxyl porphyrinogen. The 5-carboxyl porphyrinogen can then undergo decarboxylation of its last acetyl group to form the 4-carboxyl porphyrinogen that is known as *COPROGEN I* or *III* (see Fig. 132-2). These intermediates are also referred to as *hepta-*, *hexa-*, *penta-*, and *tetracarboxylate porphyrinogens*. COPROGEN I cannot be further metabolized to heme.

Human UROGEN decarboxylase is encoded by a single-copy gene of the same name, *UROGEN decarboxylase*, that is located on chromosome 1p34, spreads over a genomic distance of 3 kilobases (kb), and contains 10 exons.[51] The human UROGEN decarboxylase cDNA has been isolated, and the deduced sequence was found to be equivalent to 367 amino acids, consistent with the molecular mass and the amino acid composition of the purified protein.

Most classifications of PCT separate the disorder into at least two broad categories, both associated with decreased UROGEN decarboxylase activity: (1) acquired PCT, also referred to as *sporadic* or *type I PCT*; and (2) hereditary PCT, also referred to as *familial* or *type II PCT*.

In acquired (type I) PCT, the enzyme is deficient only in the liver, which could be explained either by the presence of a different gene defect restricted to the liver or by exposure to chemicals that selectively inhibit the hepatic but not the RBC enzyme.[52] Some of these substances (e.g., alcohol and estrogen) may provoke PCT only in selected individuals and others (e.g., hexachlorobenzene or HCB) in practically all exposed individuals.

Hereditary (type II) PCT is an autosomal dominant disorder, and the residual UROGEN decarboxylase activity is decreased approximately 50 percent in all tissues, including RBCs and cultured skin fibroblasts.[53–56] Decreased enzyme concentration appears to follow a bimodal distribution, which suggests two overlapping groups of patients: A large group (more than 80 percent) with normal UROGEN decarboxylase concentration and a small group (fewer than 20 percent) in whom the amount of detectable enzyme is about half the normal level. Some patients with type II PCT were found to have UROGEN decarboxylase activity at the lower end of the normal range. The clinical penetrance of type II PCT is relatively low (approximately 20 percent), so that the majority of individuals with the inherited enzyme defect do not manifest the disease. This suggests that additional genetic or non-genetic factors are needed for disease expression. To date, more than 100 different mutations in the *UROGEN decarboxylase* gene have been identified that either decrease the stability of the enzyme or produce defective pre-mRNA splicing.[3,47,51,56–59]

It is important to emphasize that not every patient with a positive family history of PCT will have type II disease. In support of this notion, several patients have been described who have one or more relatives with PCT but have normal RBC UROGEN decarboxylase activity.[60] This latter category of PCT has been designated as type III by some investigators.[54] Either these patients could have inherited some form of UROGEN decarboxylase that is immunochemically indistinguishable from the normal enzyme but that is uniquely susceptible to inhibition in the liver, or they could have a second inherited enzyme deficiency unrelated to UROGEN decarboxylase. These possibilities require further investigation.

It is likely that some patients who were initially reported as having hereditary PCT actually had VP, another dominantly inherited porphyria. PCT and VP may occur in different members of the same family in the so-called *dual porphyrias*.[61–63] Another form of dual porphyria in which PCT and AIP co-exist has also been described.[64]

Numerous agents and conditions are known to contribute to the development of PCT (type I, acquired, or sporadic), including alcohol; estrogens; iron; viral infections [hepatitis C and human immunodeficiency virus (HIV) infection]; polychlorinated hydrocarbons, particularly HCB and 2,3,7,8-tetrachlorodibenzo-*p*-dioxin (TCDD); and hemodialysis in patients with renal failure (Table 132-6). Each of these precipitating factors is discussed briefly in the following sections.

Alcohol. Alcohol ingestion has long been recognized to exacerbate PCT. Ethanol has been shown to induce hepatic ALA synthase in patients with PCT.[65] Erythrocyte UROGEN decarboxylase activity is diminished in healthy individuals after acute ethanol ingestion and in those with chronic alcoholism.[66] Ethanol can also inhibit the activity of other enzymes in the heme pathway, including ferrochelatase and

TABLE 132-6
Drugs and Chemicals Associated with the Clinical Expression of Porphyria Cutanea Tarda

- Ethyl alcohol
- Estrogenic hormones
- Hexachlorobenzene (HCB)
- Chlorinated phenols
- Iron
- 2,3,7,8-Tetrachlorodibenzo-*p*-dioxin (TCDD)
- Polychlorinated biphenyls (PCB)
- Herbicides 2,4-dichloro- and trichlorophenoxyacetic acid

ALA dehydratase. Chronic alcoholism leads to suppression of erythropoiesis[67] and increased absorption of dietary iron, which are perhaps linked to inherited mutations associated with hemochromatosis (see Iron). The fact that ALA synthase is increased in patients with hepatic cirrhosis without porphyria raises questions concerning the relevance of alcohol effects on ALA synthase in the clinical expression of PCT.[68]

Estrogens. The widespread use of estrogens as contraceptive agents or as hormone supplements for post-menopausal hormone replacement therapy in females and as adjunctive hormonal therapy in males with prostatic carcinoma has been associated with the development of PCT.[50] The mechanism of the estrogen effect on the expression of PCT has not been elucidated. Although diethylstilbestrol, an estrogen, induces hepatic ALA synthase,[69] this would not explain the distinctive porphyrin excretion pattern found in PCT. The vast majority of patients receiving estrogens do not manifest the biochemical abnormalities associated with PCT.

Hexachlorobenzene. The fungicide HCB caused an "epidemic" of a PCT-like syndrome in southeastern Turkey in the 1950s.[70] It was added as a preservative to wheat intended for planting, but because of a famine, several thousand individuals of diverse ethnic origin, mostly children, ingested the seed wheat and subsequently developed typical PCT. Over 4000 cases of this syndrome were reported between 1956 and 1961. The porphyrin excretion pattern and the cutaneous findings in these patients were quite similar to those seen in PCT evoked by ethanol or estrogens. The outbreak of PCT in Turkey caused by ingestion of HCB indicated that the disease could occur in non–genetically predisposed individuals.

Twenty-five years later, the most common clinical findings in these HCB-poisoned individuals were those of chronic porphyria, including sclerodermoid scarring (84 percent), hyperpigmentation (78 percent), hirsutism (49 percent), thyromegaly, and increased skin fragility (38 percent).[71] A painless arthritis was seen in two-thirds of affected individuals, and a variety of neurologic signs and symptoms occurred in the majority. Stool and urine porphyrin levels remained elevated in many patients.

Studies have shown that the long-term administration of HCB to experimental animals produces excessive porphyrin accumulation in the liver in a pattern quite similar to that seen in PCT in humans.[72] These data are consistent with the hypothesis that chlorinated hydrocarbons such as HCB, or their metabolites, inhibit hepatic UROGEN decarboxylase, which leads to excessive hepatic storage of URO and other acetate-substituted porphyrins.[73,74] Experimental studies have also shown that HCB can inactivate UROGEN decarboxylase and thereby abolish catalytic activity without changing the amount of immunoreactive enzyme protein.[75] Chemical porphyria similar to PCT is caused by other chlorinated hydrocarbons such as the polychlorinated biphenyls and TCDD, a by-product in the synthesis of the herbicide 2,4,5-trichlorophenoxyacetic acid.[76] Additional studies on the porphyrinogenic effects of chlorinated hydrocarbons suggest that metabolic activation of the compounds mediated by cytochrome P_{450} 1A2 and involving iron-generated ROS is associated with an attack on the catalytic site of UROGEN decarboxylase.[56,77]

Tetrachlorodibenzo-p-Dioxin. TCDD is a toxic environmental pollutant. Among its numerous effects are chloracne, liver damage, and hepatic porphyria in experimental animals and perhaps also in humans.[78] It has been shown that the hepatic porphyrinogenic effect of TCDD can be abolished in mice by first depleting them of iron.[79] Furthermore, it is known that highly inbred mouse strains vary in their susceptibility to induction of hepatic porphyria by TCDD, which indicates that the porphyrogenic effect of this hydrocarbon is modulated by as yet undefined genetic factors.[80]

Iron. Serum iron and ferritin concentrations are elevated or in the upper range of normal in individuals with PCT, which confirms the important role of iron in the pathogenesis of the disease.[81] Hepatic iron overload accompanies clinical PCT in practically all cases, and elevation of plasma iron level is found in one-third to one-half of patients.[50] In PCT, the quantity of iron that can be mobilized by phlebotomy indicates that total iron stores are approximately twice the normal level. Ferrokinetic studies in patients with PCT are said to yield normal results. The long remissions that follow repeated phlebotomy and the apparent ineffectiveness of this treatment if supplemental iron is administered concomitantly suggest that iron plays a role in the excessive hepatic porphyrin production in PCT.[82] PCT is particularly common when alcoholism and iron overload occur together.

The role of iron in the pathogenesis of PCT is complex, and several hypotheses have been proposed to explain it. Iron may directly inhibit UROGEN decarboxylase. However, studies using purified UROGEN decarboxylase prepared from human erythrocytes show that the purified enzyme is not inhibited by Fe^{2+} or Fe^{3+} ions.[83] Chronic iron overload can produce peroxidative damage to lipid-rich mitochondrial and microsomal membranes in the liver of experimental animals, but the relationship of this toxic effect to changes in hepatic heme synthesis has not been clearly defined.[84] An increased frequency of the hemochromatosis C282Y mutation in a gene encoding for a human leukocyte antigen class I–like protein, *HFE*, has been found in British patients with sporadic PCT.[85,86] This mutation is responsible for much of the iron overload in populations of European descent. A second mutation in the *HFE* gene, H63D, may also be associated with PCT in some populations.[87] PCT is rare in heterozygotes for each of these mutations, but 20 percent of British patients with PCT are C282Y homozygotes. C282Y homozygosity is an important susceptibility factor for both type I and type II PCT.[57]

Iron may have a permissive effect on the inhibition of UROGEN decarboxylase by halogenated hydrocarbons, and it can also enhance the induction response of hepatic ALA synthase to drugs.[88,89] Although such an iron-augmented increase in ALA synthase activity could lead to enhanced porphyrinogenesis, this alone would not explain the porphyrin excretion pattern seen in PCT. Kushner, Lee, and Nacht have shown that the addition of ferrous iron to liver in vitro causes a marked increase in porphyrin synthesis and inhibits UROGEN III synthase activity, which provides an explanation for the URO isomer I excess that is characteristic of PCT.[90] More recently, a mouse model of type II PCT was developed in which one allele of UROGEN decarboxylase is disrupted, and these animals were then bred to mice homozygous for HFE disruption.[91] These animals developed a PCT-like phenotype.

Viral Infections. There is an association between PCT and hepatitis C virus (HCV) infections and combined HCV and HIV infections.[92,93] The role of these viruses in the pathogenesis of PCT

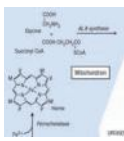

is unclear, although some connection with the *HFE* gene mutation H63D has been suggested.[56] It is also possible that the connection is fortuitous and secondary to non-specific hepatotoxic effects of these viruses.

From these known effects of alcohol, estrogens, chlorinated hydrocarbons, iron, and viral infections on the heme pathway, it is clear that each of these could contribute to the excessive hepatic porphyrinogenesis characteristic of PCT. There is growing evidence that hepatic siderosis is the critical pathologic endpoint in PCT and that the other agents somehow intensify the ability of iron to attack the catalytic site of UROGEN decarboxylase. The clinical expression of PCT is therefore dependent on the interaction of a number of factors, both genetic and environmental. However, it is important to note that the ingestion of drugs that have been associated with the induction of acute neurovisceral attacks in the acute porphyrias is not known to exacerbate similar neurologic crises in PCT.

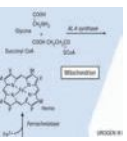

CLINICAL MANIFESTATIONS Vesicles and bullae followed by erosions and crusting occur predominantly in areas subject to repeated trauma (Fig. 132-8). There is increased skin fragility, usually on the dorsa of the hands. The traumatized skin becomes crusted, and as the lesions resolve, areas of scarring may ensue. Numerous small milia can develop, particularly on the fingers and hands. These are pearly white to yellow in each of the hepatic porphyrias associated with cutaneous photosensitivity (PCT, VP, and HCP) (see Fig. 132-8). Although the cutaneous lesions are seen primarily on the light-exposed areas, patients are often unaware that sunlight plays a role in producing their lesions, because the acute painful and burning photosensitivity so characteristic of the erythropoietic porphyrias is rare in PCT. However, most patients do recognize that their skin condition worsens in the spring and summer and seems to improve in the fall and winter. Porphyrin excretion in PCT appears to increase in the summer months and decrease in the winter months.

Other skin changes seen in PCT include hyperpigmentation and hypopigmentation that may be mottled, resembling chloasma. There may be an associated purplish red ("heliotrope") suffusion of the central part of the face, particularly involving the periorbital areas, which may bear a striking resemblance to the plethora seen in polycythemia rubra vera (Fig. 132-9). This is not seen in the porphyrias of bone marrow origin.



▲ **FIGURE 132-8** A case of porphyria cutanea tarda showing bullae filled with clear fluid. Elsewhere are remnants of blisters and on the second metacarpophalangeal joint are small milia.

Hypertrichosis (non-virilizing) is a useful diagnostic sign that often brings the female patient to the dermatologist (Fig. 132-10). Facial hypertrichosis develops gradually and is more apparent in females. The hair may vary in texture from fine to coarse and in color from light to dark. These hairs are particularly prominent along the temples and the cheeks but may occasionally involve the trunk and extremities in severe cases. Such hair may continue to grow, darken, and thicken, particularly on the cheeks, the forehead between the eyes, and at the hairline of the scalp. Males may complain that shaving is more difficult and that the growth pattern of their beard has changed. Hypertrichosis may be the presenting symptom in women, and a particularly severe form of hypertrichosis may occur in younger children with PCT and HEP. In the reports of HCB poisoning in Turkey, some of the children were described as "monkey-like" because of marked hypertrichosis.[94] The mechanism of this phenomenon is unknown; androgen levels are reported to be normal. It is possible that surface receptors or growth factors for hair bulb keratinocytes are activated by the dual action of light and porphyrins. The hypertrichosis of PCT usually improves slowly after depletion of excessive hepatic iron stores.

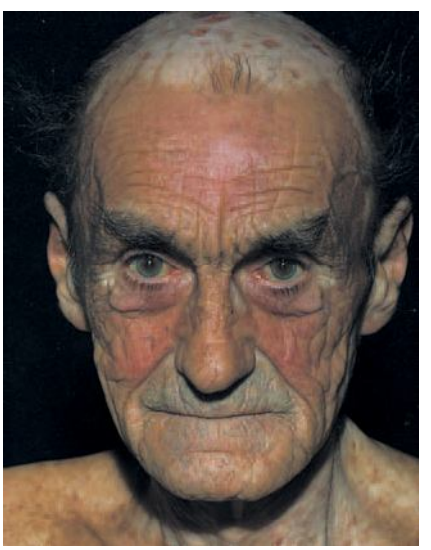

▲ **FIGURE 132-9** Porphyria cutanea tarda. Purple-red suffusion ("heliotrope") of central facial skin is most pronounced in the periorbital and frontal areas. Note also sclerodermoid plaque on scalp.

Sclerodermoid plaques can occur in PCT and in HEP and typically develop on both light-exposed and light-protected body areas (see Fig. 132-9; Fig. 132-11).

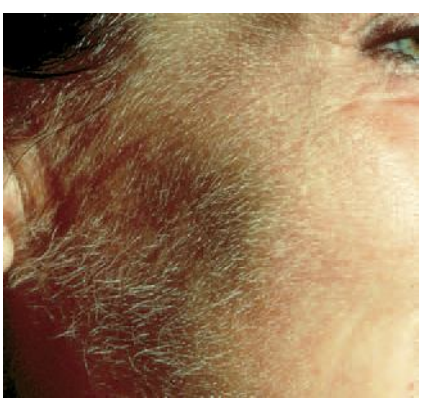

▲ **FIGURE 132-10** Hypertrichosis in a female with porphyria cutanea tarda; mostly pronounced on the zygomatic and malar skin.



▲ **FIGURE 132-11** Shiny sclerodermoid plaques on the chest of a patient with porphyria cutanea tarda.

These are usually scattered, waxy yellow to white, indurated plaques that closely resemble morphea or scleroderma both clinically and histopathologically. There is some evidence to indicate that PCT may occur concomitantly with true scleroderma, but this seems to be quite rare. URO I stimulates collagen synthesis in human skin fibroblasts.[37] In some patients, calcification has developed in these sclerodermoid plaques, which necessitates excision and grafting.

PCT-like syndromes are occasionally seen in association with hepatic tumors and lupus erythematosus.[95,96] Sub-epidermal bullous dermatoses mimicking PCT clinically and histologically have been described (see Pseudoporphyria). A number of cases of true PCT have occurred in patients with renal failure undergoing hemodialysis.[97] Confirmation of the diagnosis rests on detection of markedly elevated plasma levels of porphyrins (usually 5- to 100-fold) and increased levels of isocoproporphyrin (ISOCOPRO) in the feces (Table 132-7).

LABORATORY FINDINGS Patients with PCT excrete increased amounts of porphyrins in the urine, which rarely may exhibit characteristic pink-red fluorescence when examined with a Wood's lamp. The porphyrin excretion pattern of PCT has three main features: (1) increased urinary excretion of URO and of other acetate-substituted porphyrins; (2) a distinctive pattern of excretion of isomer series I and III porphyrins; and (3) increased excretion of fecal ISOCOPRO.[56,98,99] PCT patients excrete greatly increased amounts of urinary 8-carboxyl URO and also porphyrins with 7, 6-, and 5-carboxyl groups; the level of 4-carboxyl porphyrin (COPRO) is also increased but to a lesser extent than that of URO and rarely surpasses 600 μg per 24 hours (see Table 132-7). In PCT, the hepatic UROGEN decarboxylase deficiency results in the accumulation of 5-carboxyl porphyrinogen III (see Figs. 132-1 and 132-2). This can be used as a substrate by the enzyme COPROGEN oxidase, thereby forming dehydroisocoproporphyrinogen, which in turn is oxidized to ISOCOPRO. This results in the characteristic elevation of this compound in the feces of these patients.

The 8-carboxyl URO and 7-carboxyl porphyrins are the predominant urinary porphyrins in patients with PCT (more than 90 percent of total porphyrins). The urinary porphyrin excretion pattern is a mixture of type I and type III isomers. URO is approximately 60 percent type I isomer and 40 percent type III; the 7- and 6-carboxyl porphyrins are more than 90 percent type III and less than 10 percent type I isomer; the 5- and 4-carboxyl porphyrins are approximately 50 percent each isomer. This distinctive isomer pattern is found consistently in patients with PCT.

In general, only trace amounts of URO are present in the stool of individuals without porphyria. The porphyrin content of stool is increased in patients with PCT and consists primarily of ISOCOPRO (type III), 7-carboxyl porphyrin, and lesser amounts of URO and COPRO. The total daily 24-hour fecal porphyrin excretion may exceed total urinary porphyrin excretion.

The ratio of URO to COPRO in the urine is often helpful in differentiating PCT and VP. In PCT, the URO-COPRO ratio is usually greater than 3:1, whereas in VP the ratio is usually less than 1:1. Occasionally, 24-hour urine porphyrin levels will be normal or only slightly increased in a patient with the cutaneous findings of PCT. This should alert the physician to evaluate stool porphyrins, because these are elevated in patients with VP (see Variegate Porphyria).

It should be emphasized that patients with clinical signs of PCT may have negative results on a urine fluorescent screening test for porphyrins. In such patients, it is absolutely essential to obtain plasma porphyrin levels and perform quantitative 24-hour urine URO and COPRO determinations and stool PROTO and COPRO determinations, preferably using high-performance liquid chromatography, which often permit differentiation of PCT from VP. Rarely, some patients with VP will have normal fecal porphyrin excretion, and bile porphyrin measurements may be helpful in evaluating such patients.[100]

Virtually all patients with PCT have excessive total body iron stores manifested as increased serum iron, ferritin, and/or hepatocellular iron levels. Occasionally, there is mild erythrocytosis. An abnormal glucose tolerance test result is seen in a minority of patients.

Biochemical tests for liver function may be performed to identify liver disease. Elevated serum transaminase and γ-glutamyltranspeptidase levels may be found. Serum iron and ferritin concentrations may be elevated. The measurement of erythrocyte UROGEN decarboxylase is useful for the detection of patients with type II PCT. Mutational analysis is an essential part of evaluating these patients (see Molecular Genetic Research Strategies for the Porphyrias).

HISTOPATHOLOGY The characteristic histopathologic finding in PCT is a sub-epidermal blister (Fig. 132-12). Bullae typically show a corrugated, undulating base that has been termed *festooned*.[101] There is little or no inflammatory infiltrate. Periodic acid-Schiff (PAS) stain reveals a mild degree of thickening of the papillary vessel wall, not nearly as marked as that seen in patients with EPP. Reticulin staining demonstrates slight proliferation of fibers along the basement membrane. Direct immunofluorescence studies reveal deposition of C3 and immunoglobulin G in a granular pattern at the dermal-epidermal junction and in and around vessel walls in affected individuals.[102] These changes are most apparent in sun-exposed areas in patients with active disease and high urinary porphyrin excretion, and they decrease substantially in patients after appropriate treatment. It is also possible that the deposition of immunoglobulins and complement is a non-specific result of injury to the cutaneous tissue. The injury seen to the upper dermal vessels and at the dermal-epidermal junction suggests that damage to these areas induced by porphyrin photosensitivity may be responsible for the unique skin fragility seen in PCT.

Regardless of these findings, it should be emphasized that histopathologic examination does not substantially contribute to confirming the diagnosis of PCT. This is also true for the other cuta-

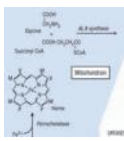



TABLE 132-7
Biochemical Features of the Porphyrias

	Blood				Stool			Urine				
Type of Porphyria	RBC URO	RBC COPRO	RBC PROTO	Plasma	URO	COPRO	PROTO	Color	ALA	PBG	URO	COPRO
Erythropoietic												
Congenital erythropoietic porphyria	++++	++++	+++	↑URO & COPRO	+	+++	+	Pink to red	N	N	++++[a]	++[a]
Erythropoietic protoporphyria	N	N to +	++++	↑PROTO	N	++	++ to ++++	N	N	N	N	N
Hepatic												
Acute intermittent porphyria												
Latent	N	N	N	N	N to +	N to +	N to +	Red to purple	+ to +++	+ to +++	N	N to +
Acute	N	N	N	N	N to +	N to +	N to +	Red to purple	++ to ++++	++ to ++++	++++	++
Variegate porphyria												
Latent	N	N	N	?N	N	+++	++++	N	N	N	N	N
Acute	N	N	N	?N	++	++	+++	Pink to red	++ to +++	++ to +++	+++	+++
Porphyria cutanea tarda	N	N	N	↑URO	++	+ ISOCOPRO	+++	Pink to red	N	N	++++	++
Hereditary coproporphyria												
Latent	N	N	N	?N	++	++++	N to +	N	N to +	N to +	N	N
Acute	N	N	N	?N	+	+++	N to +	Red	++ to N	++ to N	++	++++
Hepatoerythropoietic porphyria	N	±	++++	↑URO	N	ISOCOPRO	N	Pink to red			+++	ISOCOPRO
ALA dehydratase	N	N	++	↑ALA ↑ COPRO ↑ PROTO	N	+	+	?	+++	N	+	++

+ = above normal; ++ = moderately increased; +++ and ++++ = greatly increased; ↑ = increased; ALA = δ-aminolevulinic acid; COPRO = coproporphyrin; ISOCOPRO = isocoproporphyrin; N = normal; PBG = porphobilinogen; PROTO = protoporphyrin; RBC = red blood cell; URO = uroporphyrin.
[a]Type I isomers.
Findings of major diagnostic importance are boxed.

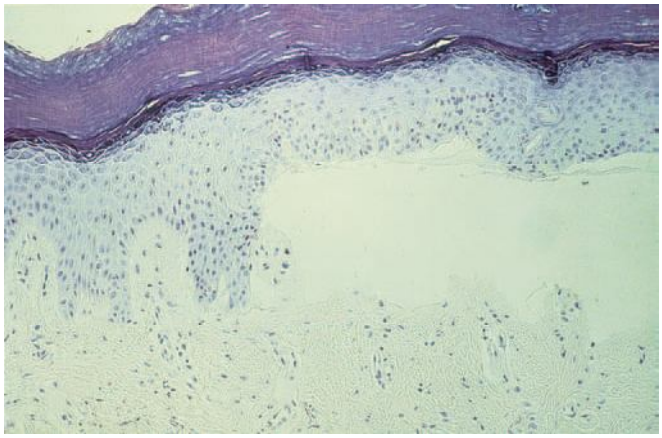

▲ **FIGURE 132-12** Porphyria cutanea tarda. Sub-epidermal blistering in a late lesion. There is virtually no inflammatory response, but the form of the dermal papillae is partially preserved.

neous porphyrias. Consequently, it is not essential to perform a skin biopsy if one of the cutaneous porphyrias is suspected, mainly for two reasons: First, simple non-invasive biochemical laboratory techniques (see Laboratory Tests earlier) can usually permit presumptive diagnosis of porphyria, and second, external trauma (such as a biopsy or excision) inevitably constitutes an avoidable risk for delayed and/or dysfunctional wound healing, which is a characteristic feature of all cutaneous porphyrias.

DIFFERENTIAL DIAGNOSIS Other dermatoses that can be confused with PCT include VP, HCP, mild forms of HEP and/or CEP, pseudoporphyria, scleroderma, and epidermolysis bullosa acquisita. Each of these can be differentiated by appropriate porphyrin studies. Careful evaluation of urine, stool, and plasma porphyrins will almost always permit confirmation of the diagnosis of PCT. Nonsteroidal anti-inflammatory drugs, such as naproxen, and antibiotics, such as the tetracyclines and nalidixic acid, as well as a variety of other agents, may rarely produce bullous lesions closely resembling PCT but in contrast to it show no evidence of abnormal porphyrins (see Pseudoporphyria).

TREATMENT (Box 132-1) Initially, a careful history should be taken in an effort to identify an environmental toxin (e.g., alcohol, estrogen, or chlorinated hydrocarbon) that may have triggered the disease. If HCV or HIV infection is present, these should be managed appropriately. Elimination of toxin exposure alone may result in gradual improvement. In most patients with PCT, however, more aggressive treatment is usually appropriate to accelerate therapeutic benefit, and this currently consists of either repeated phlebotomy[56,103,104] or orally administered antimalarials (either chloroquine or hydroxychloroquine),[105,106] or a combination of both.[107] Other forms of treatment that have been described include administration of iron chelators[108,109] and the oral administration of cholestyramine.[110]

Phlebotomy. Phlebotomy is still the treatment of choice for PCT. Numerous reports have emphasized the safety and efficacy of this form of therapy,[111] which was introduced by Ippen.[103] Phlebotomy is effective because it depletes the excessive hepatic iron stores characteristic of PCT. Biochemical remission of PCT has occurred in patients treated with phlebotomy with iron overload as well as in patients with quantitatively normal iron stores. Replenishment of iron after phlebotomy-induced remission of PCT has resulted in biochemical and clinical exacerbation of the disease. Abstinence from the environmental triggers alone, especially alcohol, may induce a clinical and biochemical remission, although this may take months to years.[111]

The efficacy of phlebotomy may relate to several effects:

1. *Iron effects on ALA synthase.* Iron can enhance the induction response of ALA synthase to drugs and the hepatic porphyrinogenic response to HCB in experimental animals, and its depletion could render ALA synthase less inducible and thereby diminish hepatic porphyrinogenesis.
2. *Iron depletion effects on other heme pathway enzymes.* Ferrous iron inhibits UROGEN decarboxylase and increases the rate of hepatic porphyrin synthesis from ALA or PBG, which suggests that removal of iron can allow UROGEN decarboxylase activity to return to normal and/or reduce excessive porphyrinogenesis.[81,90] This concept has been verified by the creation of genetically engineered mice

Box 132-1

Treatment of the Non-Acute Porphyrias

TYPE	MANAGEMENT
Porphyria cutanea tarda	☐ Photoprotection (e.g., with broad-band sunscreens and/or protective clothing) ☐ Avoidance of sun exposure and trauma ☐ Discontinuation of alcohol ingestion and estrogen therapy ☐ Phlebotomy (venesection): 400–500 mL every 2 wk over 3–6 mo ☐ Low-dose chloroquine treatment: 125 mg twice weekly for 6–12 mo until porphyrin excretion is within normal range ☐ Measurement of urinary porphyrin excretion and plasma porphyrins quarterly to monitor progress
Erythropoietic protoporphyria	☐ Photoprotection (e.g., with broad-band sunscreens and/or protective clothing) ☐ Avoidance of sunlight exposure (common window glass does not provide protection) ☐ Oral β-carotene: 30–90 mg/day in children; 60–180 mg/day in adults; desirable maximum plasma level is 600–800 μg/dL
Congenital erythropoietic porphyria	☐ Photoprotection (e.g., with broad-band sunscreens and/or protective clothing) ☐ Strict avoidance of sunlight exposure ☐ Change of day-night rhythm ☐ Splenectomy if hemolytic anemia is severe ☐ Bone marrow transplantation
Hepatoerythropoietic porphyria	☐ Photoprotection (e.g., with broad-band sunscreens and/or protective clothing) ☐ Strict avoidance of sunlight exposure and trauma ☐ Change in day-night rhythm ☐ *Caution:* Therapeutic approaches used in porphyria cutanea tarda (phlebotomy, antimalarials) are ineffective.

in which iron overload inhibits the enzyme.

3. *Iron effects on hepatic lipid peroxidation secondary to ROS.* Iron depletion could reverse this response of the liver to iron overload.[84]
4. *Iron effects on oxidation of URO.* Removal of iron could result in a diminished capacity of the ferrous metal to irreversibly oxidize the UROGEN substrate to non-metabolizable porphyrins.[112]

Phlebotomy is carried out as an ambulatory procedure. The total amount of blood removed varies widely, usually ranging from 1500 to 12,000 mL. It is most convenient to use plastic blood-drawing bags available in any blood bank. Approximately 500 mL of blood is removed at weekly or biweekly intervals until the hemoglobin level decreases to approximately 10 g/dL or until the serum iron level drops to 50 to 60 µg/dL. Some believe that phlebotomies should be continued until serum ferritin level falls to the lower range of normal. Patients are strongly encouraged to discontinue or decrease exposure to porphyrinogenic agents, because this usually hastens clinical and biochemical remission.

It is particularly important to reassure the patient that clinical improvement may not become apparent for variable intervals after the phlebotomies are begun. Porphyrin excretion continues to fall long after phlebotomies are discontinued. It has been shown that in more than 90 percent of patients treated with regular phlebotomy, urinary URO excretion reaches normal levels (less than 100 µg/24 hour) after 5 to 12 months.[111] Blistering is the first sign to disappear; this is followed by improvement in skin fragility and in hypertrichosis over a period of 3 to 18 months. Even sclerodermoid changes can resolve slowly, although this may take several years. There are few published data on long-term follow-up of treatment, but most patients who experience relapse have again responded to repeated courses of phlebotomy.[104] The length of remission induced by phlebotomy varies widely and ranges from 6 months to more than 10 years. At least 10 percent to 20 percent of patients will experience relapse within 1 year.

Phlebotomy is a safe, effective, and relatively simple form of therapy with minimum associated morbidity. A few patients may complain of mild to moderate fatigue and weakness during the treatment period, but this usually resolves as the hemoglobin level returns to normal.

Antimalarials. In some patients, phlebotomy is not recommended or is contraindicated because of the presence of anemia, cardiopulmonary disorders, or HIV infection. In such cases low-dose antimalarial therapy is a useful alternative. The antimalarial aminoquinolines chloroquine and hydroxychloroquine are used.[105,106] In 1957, it was first suggested that chloroquine was useful in treating PCT.[113] The cutaneous signs of the disease cleared within 1 year in one patient who received 500 mg daily for several months. Such dosages may trigger severe hepatotoxicity in many PCT patients, however, and this is no longer considered an acceptable approach.

Instead, low-dose chloroquine therapy at a dosage of 125 mg twice weekly is effective in treating PCT and avoids the hepatotoxic effects of high-dose therapy.[114] In addition to producing a successful therapeutic outcome in single patients and small cohorts,[115] low-dose chloroquine (125 mg twice weekly for 8 to 18 months) has been used successfully to treat more than 100 patients with PCT.[116] Liver function test results and urinary porphyrin levels are monitored quarterly, and the medication is continued until urinary URO level is less than 100 µg/24 hours. This usually requires 6 to 12 months of treatment. Studies comparing the therapeutic efficacy of phlebotomy with that of low-dose chloroquine suggest that they are equally efficacious, and, likewise, the clinical and biochemical remission of PCT obtained with chloroquine appears to be identical in all respects to that induced by phlebotomy. However, it has been reported that rapid relapse occurred in several patients treated with hydroxychloroquine,[117] and therefore chloroquine may be preferable. The mechanism of action of chloroquine may relate to the formation of water-soluble drug-porphyrin complexes that are then excreted from the liver.[118] Taljaard et al., however, believe that chloroquine chelates iron in the hepatocyte and that the bound iron is then eliminated.[115]

The combination of phlebotomy and chloroquine treatment may reduce the severity of the hepatotoxic response to chloroquine and also accelerate remission of the disease.[107] Patients are treated with a series of one to four phlebotomies before starting chloroquine therapy (250 mg daily for 7 days). The procedure is repeated when signs of biochemical or clinical relapse develop, which may occur in 1 to 2 years. It should be emphasized that despite the tendency of the antimalarials to evoke hepatotoxic responses in patients with PCT, there is no evidence to suggest that the changes in hepatocellular pathology characteristic of PCT worsen as a result of treatment with these drugs.[119] The antimalarials may cause retinopathy, and the low-dose regimen helps to minimize the risk of this complication. Pre-treatment and semi-annual ophthalmologic examinations should be performed in patients treated with these drugs. In patients with PCT and chronic renal failure, standard phlebotomy and antimalarial therapy are not feasible. The combination of high-dose recombinant erythropoietin and small-volume phlebotomy has been successful in selected patients.[120]

HEPATO-ERYTHROPOIETIC PORPHYRIA AT A GLANCE



- Extremely rare (approximately 25 cases reported).
- Autosomal recessive disorder due to homozygous deficiency of uroporphyrinogen decarboxylase.
- Patients have been reported in the United States and Europe.
- Age of onset is early infancy (1 to 4 years).
- Characterized by severe photosensitivity, including vesicles and bullae, erosions, excoriations, crusts, and milia; mutilating scarring; and hypertrichosis.

Hepatoerythropoietic Porphyria

HEP is the homozygous/compound heterozygous variant of PCT and results from a profound deficiency of UROGEN decarboxylase.[51] Measurement of the enzyme in hemolyzed whole blood or skin fibroblasts from three unrelated patients with the disease showed that levels were reduced to 7 percent to 8 percent of normal. There is no evidence

as yet to show that clinical expression of HEP is related to exposure to environmental drugs or chemicals, as is true for PCT. Clinical, biochemical, and enzymatic studies of three generations of one family in which a second-generation 31-year-old man was shown to have HEP revealed that both of the proband's parents and each of his three children had a moderate deficiency of UROGEN decarboxylase.[121]

EPIDEMIOLOGY Patients with HEP have been reported in Europe (predominantly in Spain), America, and Japan.

CLINICAL MANIFESTATIONS The disease typically manifests in early childhood, and dark red urine is often the first sign. Severe cutaneous photosensitivity with blistering and pruritus then ensues. The photosensitivity may diminish with age and is followed by hypertrichosis, hyperpigmentation, and scleroderma-like scarring similar to that seen in CEP (Günther disease) (Fig. 132-13). Ocular manifestations include ectropion associated with cutaneous sclerosis and scleromalacia perforans. Splenomegaly has occurred in a small percentage of affected individuals, particularly after the age of 10, and hemolytic anemia has been documented as well. In some patients, liver function test results have been abnormal, but serum iron and iron binding are normal. In summary, the clinical manifestations of HEP resemble a combination of those of PCT and CEP.

LABORATORY FINDINGS The urinary porphyrin pattern is similar to that found in PCT (see Table 132-7). However, elevated RBC PROTO levels in HEP helps to distinguish it from PCT. Elevated levels of urinary URO I and III (URO-COPRO ratio of more than 5:1) and 7-carboxyl porphyrins (more than 90 percent isomer III), elevated levels of fecal COPRO and ISOCOPRO, and elevated levels of RBC PROTO (zinc-chelated) have been observed in all patients. These findings suggest that there is abnormal porphyrin synthesis in both the liver and the bone marrow. Unlike in PCT patients, serum iron concentrations are usually normal in those with HEP.



▲ **FIGURE 132-13** Sclerodermoid thickening and shrinkage of facial and scalp skin with ulcerations and scars in a patient with hepatoerythropoietic porphyria in whom these sclerodermoid changes are particularly pronounced.

HISTOPATHOLOGY Skin biopsy specimens of blistering lesions show sub-epidermal bullae resembling those of PCT, and PAS-positive material is seen in and around dermal capillaries. However, skin biopsy is not essential for making the diagnosis of HEP.

DIFFERENTIAL DIAGNOSIS The differential diagnosis includes childhood porphyrias (e.g., the rare homozygous or compound heterozygous variants of VP and HCP), clinically severe forms of PCT, and CEP. In contrast to patients with HEP, those with CEP show erythrodontia and mutilating scarring.

TREATMENT There is no known treatment aside from careful photoprotection.

Pseudoporphyria

The term *pseudoporphyria* is used to describe patients who clinically exhibit cutaneous manifestations resembling those of PCT without the characteristic abnormal porphyrin profile. This disorder may develop in association with ingestion of certain drugs such as furosemide,[122] nalidixic acid,[123] tetracycline,[124] naproxen,[125] pyridoxine,[126] and isotretinoin[127] (see Chap. 91).

In the drug-induced type of pseudoporphyria, the blistering process is subepidermal with little or no dermal inflammation. Staining with PAS reveals little or no deposition around upper dermal blood vessels and capillary walls. Indirect immunofluorescence studies conducted on split skin reveal no dermal deposition of fluorescent material in pseudoporphyria. Direct immunofluorescence studies have shown patchy granular deposition of immunoglobulin G and C3 at the basement membrane zone in pseudoporphyria, PCT, and epidermolysis bullosa acquisita.

A bullous dermatosis that is morphologically and histologically indistinguishable from PCT has also been observed in patients with chronic renal failure treated with long-term hemodialysis (see Chap. 151). Some of these patients have moderately elevated plasma porphyrin levels (twofold to fourfold) secondary to impaired renal clearance as well as diminished clearance through dialysis filters.

ERYTHROPOIETIC PROTOPORPHYRIA

AT A GLANCE



- Second most common of the cutaneous porphyrias.
- Autosomal dominant disorder involving a deficiency of ferrochelatase.
- Age of onset in early childhood (1 to 4 years); rarely late onset can occur.
- Cutaneous findings include erythema, edema, purpura, skin thickening, and waxy scars; blistering is rare.
- Symptoms include acute burning and stinging of the skin that may be severe.
- In approximately 5 percent of patients potentially fatal hepatic failure develops.

Erythropoietic Protoporphyria

EPIDEMIOLOGY Although the exact incidence of EPP is unknown, it has been reported with increasing frequency since its initial recognition in 1961, and it is likely the second most common type of cutaneous porphyria. Studies from one laboratory performing diagnostic tests for RBC porphyrins in patients with suspected cutaneous photosensitivity indicated that 8 percent of such samples demonstrate elevated RBC PROTO levels diagnostic of EPP. The disease occurs globally, and it is likely that no ethnic group is spared.[128]

ETIOLOGY The specific defective enzyme in EPP is ferrochelatase, which is decreased in various tissues of affected patients, including RBCs, mitogen-stimulated lymphocytes, and cultured skin





◀ **FIGURE 132-14** **A.** One hour after exposure to sunlight, the face of this 35-year-old woman with erythropoietic protoporphyria is edematous and erythematous, and there is purpura on the forehead, cheeks, and nose. The patient experiences severe burning sensations. **B.** A case of erythropoietic protoporphyria showing swelling and purpura on the dorsa of the hands resulting from exposure to solar radiation.

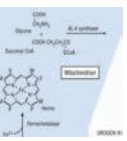

fibroblasts of patients with the disorder and unaffected carriers.[129–132] Ferrochelatase is located at the matrix face of the inner mitochondrial membrane and catalyzes the final step in the formation of heme, the incorporation of ferrous iron (Fe^{2+}) into PROTO (see Figs. 132-1 and 132-2). This lysine-rich enzyme has a molecular mass of 63 kd and an optimal pH of 7.8, and is also referred to as *heme synthase* or *proto-heme-ferro-lyase*. Unlike other enzymes in the heme biosynthesis pathway, which require reduced forms of the porphyrins (porphyrinogens) as substrates, ferrochelatase uses PROTO, the oxidized isomer of PROTOGEN. The end product of the pathway, ferrous PROTO or heme, diffuses out of the mitochondrion into the cytoplasm where it is available to function as a prosthetic group by combining with appropriate apoproteins (see Figs. 132-1, 132-3, and 132-4). Heme thus controls its own synthesis based on the needs of the cell.

The cDNA for human ferrochelatase has been cloned, sequenced, and shown to have 88 percent homology to the mouse enzyme. Human ferrochelatase mRNA is encoded by a single nuclear gene of the same name, *ferrochelatase*, that is located on chromosome 18q21.3 and spans approximately 45 kb of genomic DNA.[132] The gene consists of 11 exons and 10 introns. Molecular genetic studies have been conducted in patients with EPP and revealed more than 60 different mutations of various types, with deletions and insertions being the most common. It is of interest that expression of these mutations in bacteria identified a common loss of the iron-sulfur metal center essential for catalytic activity.[133]

Because the activity of ferrochelatase in cultured skin fibroblasts of EPP patients was found to be only 10 percent to 25 percent of normal, questions have been raised about the dominant inheritance of the disease. Studies have now shown that the penetrance of EPP is modulated by expression of wild-type ferrochelatase that contains an intronic single nucleotide polymorphism that results in aberrantly spliced mRNA. Thus, slight variations in expression of the wild-type allele may be decisive in determining clinical expression of EPP. This variable expression of the wild-type ferrochelatase allele is directly associated with the presence or absence of cutaneous symptoms, and it is clear now that EPP occurs only in individuals heterozygous for a *ferrochelatase* gene mutation on one parental allele with a specific intronic *ferrochelatase* polymorphism, IVS3-48T/C, on the other parental allele. On the genetic level this additional nucleotide alteration *in trans* leads to modulation of splicing and the use of a constitutively aberrant acceptor splice site. The aberrantly spliced mRNA is degraded by a nonsense-mediated decay mechanism, which produces a decreased steady-state level of mRNA. On the enzymatic level, this leads to an additional in vivo decrease in residual ferrochelatase activity of 15 percent to 40 percent that diminishes catalytic activity to the point where the EPP phenotype is expressed.[134]

CLINICAL MANIFESTATIONS ***Skin.*** Typically the disease begins early in life and is characterized by acute episodes of cutaneous photosensitivity, including burning, stinging (smarting), and pruritus affecting light-exposed skin, particularly the nose, cheeks, and dorsal aspects of the hands. These symptoms are followed by erythema, edema (Fig. 132-14A), urticarial lesions, and, less commonly, purpura (see Fig. 132-14B). Symptoms may occur within minutes of sun exposure. Manifestations are often seasonal, starting early in the spring, continuing through the summer, and diminishing in the winter. The skin lesions often resolve slowly, leaving small, atrophic, waxy or pitted scars (Fig. 132-15). There may be some pursing of perioral skin (pseudorhagades). The skin of the knuckles and fingers, particularly over the metacarpophalangeal and interphalangeal joints, often appears thickened, wrinkled, and waxy, suggesting a premature aging (so-called *old knuckles*, in a child). This subtle change is pathognomonic. Superficial scarring over the bridge of the nose and small annular shallow scars occur on the face. Vesicular or bullous lesions are rare in temperate climates, although they have been reported in patients exposed to tropical sunlight. In most affected individuals cutaneous involvement persists throughout life, although some patients seem to become less symptomatic over time.



▲ **FIGURE 132-15** A 15-year-old patient with erythropoietic protoporphyria with severe sensitivity to light. The nose, lower lip, and chin show erythematous, in part erosive, and crusted lesions. Nose and cheeks show erythematous lesions, a few small slightly depressed scars, and peculiar waxy thickening of skin. Linear scars are seen between the nose and mouth and on cheeks and face.

Liver. Severe life-threatening hepatotoxicity occurs in a small percentage of patients with EPP. This is thought to relate to the hepatic clearance of the excessive burden of PROTO, which ultimately compromises liver function. This may be aggravated by hemolysis of PROTO-laden RBCs, which creates a vicious cycle of increased erythropoiesis and increased PROTO loading of the liver. The net result of these alterations is terminal hepatic failure in approximately 5 percent of EPP patients.[135] Affected individuals become severely jaundiced, develop hepatic cirrhosis, and may go into hepatic coma and die. Some EPP patients with end-stage liver disease may develop axonal neuropathy resembling that in the acute hepatic porphyrias despite having normal serum ALA and PBG levels.[136] Risk factors for EPP-associated hepatic failure remain unknown, but parenchymal crystallization of incompletely cleared hepatic PROTO is a likely explanation. Experimental studies have shown that perfusion of rat liver with PROTO induces a dose-dependent cholestasis that could contribute to the hepatotoxicity of PROTO.[137] Liver failure has also occurred in two siblings who inherited EPP in an autosomal recessive pattern as compound heterozygotes, which suggests that the presence of this genotype may somehow augment the risk of this complication.[138] This is debatable, however, because some compound heterozygotes maintain normal liver function, whereas others develop liver failure.[139]

The cutaneous and hepatic symptoms are the major findings in EPP. There is no hypertrichosis, milia, sclerodermoid change, or hyperpigmentation as in PCT, and no erythrodontia as in CEP. Hemolytic anemia is decidedly uncommon, although approximately 11 percent of patients with EPP have a mild anemia of unknown cause.[128] Gallstones have been reported in some patients with EPP at a relatively early age; in one series, 12 percent of patients had cholelithiasis, of whom three underwent cholecystectomy.[140]

LABORATORY FINDINGS The diagnosis of EPP is based on the detection of elevated levels of free PROTO in the RBCs and/or feces (see Tables 132-2 and 132-7). Controversy exists concerning the tissue origin of the excessive PROTO. Some have shown that RBC PROTO levels alone are sufficient to explain the increased levels of PROTO,[24,141] whereas others have suggested that hepatic PROTO production contributes to the excessively high levels of circulating PROTO.[142] In addition, there may be increased plasma PROTO levels, increased fecal COPRO levels, and occasionally slightly increased levels of RBC COPRO. In patients with deteriorating hepatic function the fecal excretion of PROTO may decrease as plasma levels and cutaneous photosensitivity increase.[143]

Examination of a blood smear under a fluorescent microscope reveals red-fluorescing RBCs (5 percent to 30 percent) (Fig. 132-16). Because the fluorescence is often transient and quite light sensitive, the procedure should be carried out in subdued light or preferably in the dark. However, this is not a reliable diagnostic test, because RBCs from patients with chronic lead intoxication also show fluorescence.

A rapid quantitative microfluorometric assay for free erythrocyte and plasma PROTO may be used to screen for suspected EPP.[144] In one series of 32 patients with EPP, the RBC PROTO levels ranged from 131 to 1617 μg/dL of RBC (normal is less than 90 μg/dL of RBC).[145]

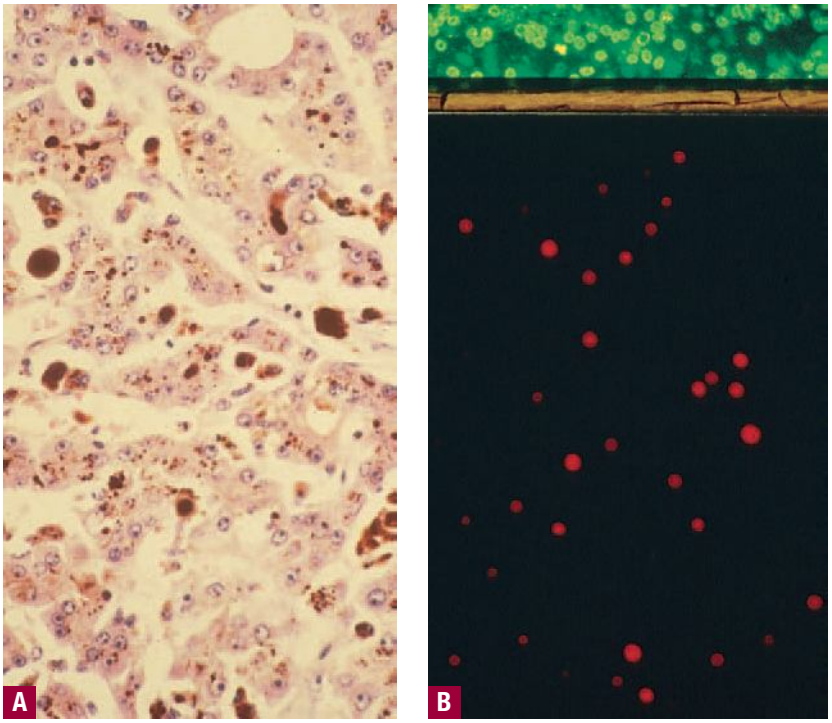

▲ **FIGURE 132-16** **A.** Brown pigment deposits in the liver tissue found in bile canaliculi, hepatocytes, and Kupffer cells. **B.** Bright red fluorescence in red blood cells (RBCs) of a fresh smear from a patient with erythropoietic protoporphyria. Whereas almost all RBCs contained in this smear are revealed by green fluorescence only (*top*), a few RBCs contain increased amounts of protoporphyrins and thus fluorescence in red (*bottom*).

HISTOPATHOLOGY ***Skin.*** Immediately after irradiation, endothelial cell damage, mast cell degranulation, and polymorphonuclear cells are seen in the dermis.[33] In sun-exposed areas, there is often marked eosinophilic homogenization and thickening of vessels in the papillary dermis due to the accumulation of an amorphous, homogeneous, slightly basophilic (hyaline-like) substance in and around the vessel walls.[128] The perivascular deposits of concentric eosinophilic layers of hyaline-like material stain strongly positive with PAS and are diastase positive (Fig. 132-17). Histochemical studies suggest that this material may be a neutral glycoprotein with smaller amounts of acid mucopolysaccharide and lipids.[146] The histologic findings are similar to those of lipoid proteinosis (hyalinosis cutis et mucosae).[147] Electron microscopic studies in EPP show that the amorphous material consists of a multi-layered, partially fragmented basement membrane and finely fibrillar material of moderate density that permeates and surrounds the vessel walls (see Fig. 132-17).[148] Other studies have shown that type IV collagen and laminin as well as amyloid P and fibronectin are deposited in the walls of dermal blood vessels.[149]

Liver. Light microscopy of liver biopsy specimens has revealed slight portal and periportal fibrosis and deposition of brown pigment, which may occlude bile

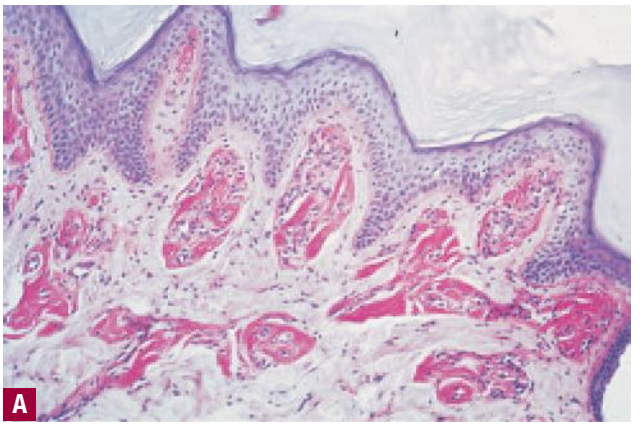

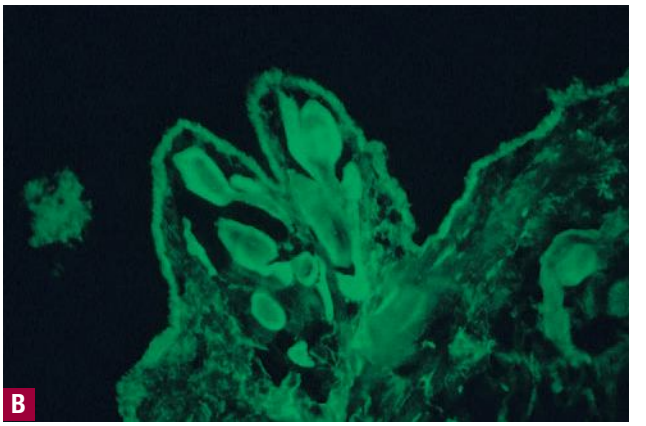

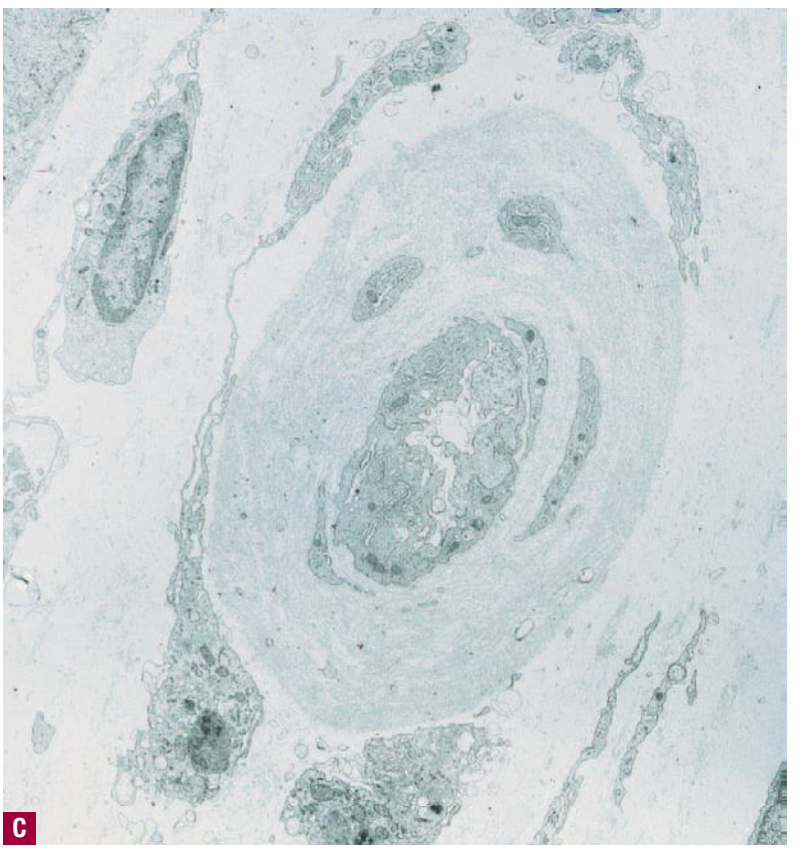

◀ **FIGURE 132-17** **A.** A biopsy specimen of light-exposed skin from a patient with erythropoietic protoporphyria. There is marked thickening of the blood vessel walls of the upper dermis, which are surrounded by hyaline-like materials that stains brightly red with the periodic acid-Schiff (PAS) stain. **B.** Direct immunofluorescence testing reveals that the PAS-positive material around papillary vessels contains immunoglobulins of different classes. Immunoglobulins are also deposited along the dermal-epidermal junction. **C.** Electron micrograph of biopsy specimen of habitually exposed skin from a patient with erythropoietic protoporphyria. Multiple concentric basal laminae surrounding dermal blood vessels and finely fibrillar material admixed with amorphous masses within perivascular tissue are shown.

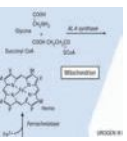

canaliculi and ducts; it is also present in hepatocytes, in Kupffer cells, and in periportal macrophages. The pigment is birefringent on polarization microscopy.[150] Hepatocytes may also contain cytoplasmic or mitochondrial inclusions, which at the ultrastructural level appear as needle-like crystals (Maltese crosses), probably due to precipitated PROTO (see Fig. 132-16).[151] Biliary excretion of PROTO is coupled to secretion of phospholipid translocated from the inner to outer canalicular membrane leaflet by the mdr2P glycoprotein.[133] PROTO excretion from the liver requires bile acids, and excessive amounts of the porphyrin inhibit its transport out of the hepatocyte.

DIFFERENTIAL DIAGNOSIS EPP must be differentiated from other photosensitivity diseases, primarily polymorphic light eruption (PMLE), actinic prurigo, hydroa vacciniforme, idiopathic solar urticaria, and other types of porphyria. Photoallergic and phototoxic contact dermatitis and angioedema should also be considered.

In PMLE, the lesions are characteristically papules, plaques, and papulovesicles. A family history of photosensitivity is less common. Burning and smarting of the skin during or soon after sun exposure is unusual in PMLE, whereas it is common in EPP. If doubts persist, RBC PROTO measurement or plasma porphyrin determination will differentiate the two. The same is true for idiopathic solar urticaria. Airborne contact dermatitis may involve non–light-exposed areas such as the skinfolds and the submental areas. Results of patch testing with suspected allergens and normal porphyrin values help to differentiate this condition. The lesions of angioedema may occur anywhere on the body, including the mucous membranes. Because the discomfort described by patients with EPP is often disproportionate to visible lesions, the disease can be confused with psychoneurosis or even malingering. Porphyrin determinations will clarify this issue.

TREATMENT (See Box 132-1)

Skin Manifestations. Topical sunscreens, such as products containing ecamsule (Mexoryl), titanium, or zinc oxides, are at best only marginally helpful. Other sub-

stances (e.g., antimalarial drugs, cholestyramine, and vitamins E and C) have been suggested but are of unproven benefit.

Although its efficacy has not been confirmed by double-blind placebo-controlled trials, tolerance to sunlight in some patients with EPP may improve with the use of orally administered β-carotene.[152,153] Many patients claimed to triple their tolerance to sunlight after an adequate course of β-carotene exceeding 2 months. These results, however, are based on limited controlled laboratory testing and uncontrolled clinical impressions; the one controlled clinical trial failed to confirm the therapeutic effectiveness of β-carotene although the adequacy of the dosage used has been questioned.[154] To achieve optimal photoprotection, serum carotene levels should be maintained at a minimum of 600 μg/dL. In adult patients, this can usually be achieved by oral administration of two to six capsules of 30 mg each per day, which will produce serum carotene levels of 600 to 800 μg/dL after 4 to 6 weeks of therapy. Children under 12 years of age may receive 30 to 90 mg daily. Maximum effectiveness may not occur until 1 to 2 months after initiation of therapy; hence patients should be treated throughout periods of greatest sun exposure. The drug is remarkably well tolerated at these dosages, and there are no known toxic systemic effects of β-carotene. Diarrhea occurs in a small number of patients. Orange or rusty discoloration of the stools is common and is not an indication for discontinuing treatment. The only other side effect of note is the visible yellowing of the skin that occurs as a result of carotenoderma, and this is more noticeable on the palms and soles. The mechanism of the photoprotective effect of β-carotene is not precisely known. One study involving cultured keratinocytes showed that β-carotene can suppress induction of matrix metalloproteinases (MMPs), including MMP-1, MMP-3, and MMP-10, and that these effects are mediated by quenching of singlet oxygen–mediated induction of MMPs.[155] A further study using microarrays showed that β-carotene inhibited ultraviolet A–induced extracellular matrix degradation.[156]

The amino acid cysteine has been shown to reduce photosensitivity.[157] Hematin infusions may decrease the production of heme temporarily and are associated with a decrease in fecal and plasma PROTO levels in some patients.[141] The use of RBC exchange with autologous washed cells has also been explored for its ability to induce clinical and biochemical remission of EPP. In one patient with EPP, such therapy resulted in a marked decrease in photosensitivity associated with a decline in free erythrocyte PROTO levels.[158]

In summary, the currently available treatments for EPP are not optimal and do not address the underlying molecular pathogenesis of the disease.

Liver Disease. Management of EPP-associated hepatic failure is particularly challenging. Orally administered bile salts may diminish the enterohepatic re-circulation of the excessive PROTO and thereby enhance the clearance capacity of the liver.[159] Oral administration of iron was tried in one patient who manifested incipient hepatic failure as well as elevated erythrocyte and plasma PROTO levels with concomitant iron deficiency anemia, but this therapy proved ineffective.[160] In another patient, oral iron therapy exacerbated the disease.[161] Liver transplantation has also been used, and the 5-year patient survival rate is good, but recurrence of EPP liver disease appears to diminish long-term graft and patient survival.[162,163] Future therapy could include recombinant enzyme replacement of defective ferrochelatase.[164] The feasibility of obtaining detectable levels of the enzyme in fibroblasts from EPP patients by adding the cDNA for normal ferrochelatase using a retroviral vector has been demonstrated.[164] Gene replacement has been achieved in a mouse model of EPP in which ex vivo pre-selection of hematopoietic stem cells transduced with a polycistronic retrovirus expressing human ferrochelatase resulted in complete correction of skin photosensitivity.[165]

Congenital Erythropoietic Porphyria

EPIDEMIOLOGY CEP occurs globally. Fewer than 500 cases have been reported. The disease nearly always begins in childhood, although adult onset can occur.[166] CEP is also seen in animals, including swine, cattle, and cats, and studies in these animal models have greatly aided research into this disease.

ETIOLOGY CEP is a disorder with an autosomal recessive pattern of inheritance that results from a variable but profound deficiency of UROGEN III synthase, the fourth enzyme in the heme synthetic pathway, which catalyzes the formation of UROGEN III from hydroxymethylbilane or from PBG if PBG deaminase is also present. The only difference between porphyrinogen isomers I and III is the reversal of the side chains on the D ring of this tetrapyrrole. By simple inversion of one PBG molecule during synthesis of UROGEN I, the III isomer is formed (see Fig. 132-2). This apparently minor structural alteration is of considerable biologic importance, because only III isomers can form heme. The formation of UROGEN III is catalyzed by the cytoplasmic enzyme UROGEN III synthase, closely linked to PBG deaminase. This enzyme has been purified from human erythrocytes, is monomeric, and has a molecular mass of approximately 29.5 kd; it is thermolabile and exhibits maximum catalytic activity at pH 7.4.[167] In most tissues, UROGEN III synthase is present in considerable excess compared with PBG deaminase, which assures efficient conversion to the III isomer. The hepatic and erythroid forms of the enzyme are identical.

The human gene for UROGEN III synthase is encoded by a single-copy gene of the same name, *UROGEN III synthase*, that consists of 10 exons and is located on chromosome 10q25.3-26.3. Human UROGEN III synthase cDNA has been cloned and sequenced and encodes a protein of 265 amino acids.[168] To date, approximately 30 mutations in the *UROGEN III synthase* gene have

CONGENITAL ERYTHROPOIETIC PORPHYRIA AT A GLANCE



- Very rare (approximately 200 patients reported).
- Autosomal recessive disorder involving a deficiency of uroporphyrinogen III synthase.
- Age of onset in infancy or first decade of life.
- Cutaneous manifestations include vesicles and bullae, erosions, crusting, milia, mutilating scarring, hyperpigmentation, and hypertrichosis.
- Systemic findings include hemolytic anemia and hepatosplenomegaly.
- Porphyrin deposition occurs in bones and teeth (erythrodontia).

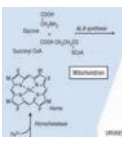

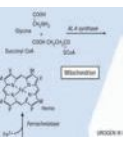







▲ **FIGURE 132-18** Two cases of congenital erythropoietic porphyria (Günther disease). **A, B.** Severe scarring damage of the ear and nose cartilage, hair loss, and discolored teeth. (Used with permission from A. Wiskemann, MD, and J. Kimmig, MD.) **C.** Skin fragility, blisters, erosions, and contractures due to severe scarring on the hands.

been identified, including several in the erythroid-specific promoter.[169]

CLINICAL MANIFESTATIONS The disease usually develops during the first few months of life with moderate to severe cutaneous photosensitivity associated with pinkish red urine.[170] Patients have excessive URO I and COPRO I in RBCs, plasma, and skin.

CEP is the most mutilating of the cutaneous porphyrias. Cutaneous manifestations include skin fragility and vesicles and bullae, which may contain pink fluorescent fluid. Secondary infection, delayed healing, and scarring is common. This may lead to loss of acral tissue, such as the tips of the ears, the nose, and the fingers (Fig. 132-18), and facial mutilation. Hirsutism with long, dark, lanugo-like hair may occur and is particularly evident in light-exposed areas such as the face, neck, and extremities. The scalp may develop a cicatrizing alopecia. Other findings over the disease course include eye changes (photophobia, keratoconjunctivitis, ectropion, symblepharon, and even loss of vision) and irregular hyperpigmentation and hypopigmentation of the skin. Erythrodontia (red-stained teeth) is a common finding in both deciduous and permanent teeth and is virtually pathognomonic of CEP. The urine may also fluoresce reddish pink.

Associated non-cutaneous findings include splenomegaly, porphyrin-rich cholelithiasis, and fluorescent bone marrow normoblasts. Hemolytic anemia associated with shortened erythrocyte life span (36 vs. 120 days) and hypersplenism occurs. Whether the hemolytic anemia is due to "photohemolysis" of circulating porphyrin-laden erythrocytes or to an associated intracorpuscular red cell defect is unresolved.[171]

LABORATORY FINDINGS The primary defect in CEP is decreased UROGEN III synthase activity, which results in accumulation of predominantly type I porphyrins in the tissues. The pink to burgundy red color of the urine from excess URO I is often visible on inspection. Marrow normoblasts exhibit relatively stable fluorescence and contain markedly elevated levels of URO I, COPRO I, and PROTO. Urinary excretion of ALA and PBG is normal. COPRO I may be present in large amounts in the feces. The typical biochemical findings of CEP are summarized in Table 132-7.

HISTOPATHOLOGY The bullous lesion of CEP is sub-epidermal with minimal degrees of inflammation. Thickening of collagen bundles may be seen in areas of scarring. Perivascular deposits of porphyrin can be found when the unstained sections of skin or liver are viewed with a fluorescence microscope.

DIFFERENTIAL DIAGNOSIS The diagnosis of CEP can usually be made from the early onset of severe cutaneous photosensitivity associated with reddish pink fluorescent urine and erythrodontia. Distinguishing CEP from other congenital photodermatoses is important. Cutaneous findings in patients with xeroderma pigmentosum, epidermolysis bullosa, hydroa vacciniforme, and bullous pemphigoid may mimic those of patients with CEP, but porphyrin analysis will distinguish them.

Patients with chronic hepatic porphyrias such as PCT and VP have normal RBC PROTO levels. The cutaneous manifestations of HEP may be strikingly similar to those of CEP, and measurement of levels of RBC UROGEN III synthase (decreased in CEP) and UROGEN decarboxylase (decreased in HEP) will distinguish the two. The dual occurrence of HCP and CEP in a single patient who inherited the HCP trait from her mother and the CEP trait from both of her parents has been reported.[172]

TABLE 132-8
Overview and Summary of the Features of the Acute Porphyrias

	Acute Intermittent Porphyria	Variegate Porphyria	Hereditary Coproporphyria	ALA Dehydratase Deficiency Porphyria
Synonym(s)	Swedish porphyria	Mixed porphyria, South African genetic porphyria, protocoproporphyria hereditaria, PCT hereditaria	Idiopathic coproporphyria	Plumboporphyria.
Inheritance	Autosomal dominant	Autosomal dominant	Autosomal dominant	Autosomal recessive.
Age of onset	10–40 yr; extremely rare before puberty	Usually between ages 15 and 30 yr	Any age	Early and late clinical onset has been described.
Incidence	1.5 in 100,000; more common in Scandinavia and Lapland	Common in South Africa (3 in 1000); relatively rare elsewhere	Rare (fewer than 50 cases reported)	None.
Photosensitivity	Absent	Moderate to severe with high interindividual variation; similar to that in PCT	Very rare	Absent.
Skin reactions (on sun-exposed areas)	None	Vesicles and bullae, erosions, crusts, milia, scarring, hypertrichosis; similar to those in PCT	Usually blistering	None.

ALA = δ-aminolevulinic acid; PCT = porphyria cutanea tarda.

TREATMENT (See Box 132-1) The treatment of CEP is essentially preventive and symptomatic and includes avoidance of sun exposure, surveillance of the anemia, and treatment of recurrent skin infections. Absolute protection from sunlight using photoprotective clothing may be of substantial benefit. Topical sunscreens have no proven efficacy. Oral β-carotene (120 to 180 mg daily) is not effective. Splenectomy performed to relieve intractable hemolytic anemia has occasionally resulted in marked improvement of both the anemia and cutaneous photosensitivity. Suppression of erythropoiesis by transfusion of packed erythrocytes can diminish porphyrin production and excretion,[173] but secondary iron overload is of concern. Oral administration of activated charcoal to a single patient (60 g three times a day) for 9 months decreased porphyrin levels in plasma and skin and resulted in complete remission of photosensitivity during the treatment period.[174] Charcoal is thought to interfere with the enterohepatic recirculation of the porphyrin. This beneficial effect has been disputed, however.[175] Allogeneic bone marrow transplantation has been curative for a small number of patients and thus seems to be the current first-line treatment.[176,177]

THE ACUTE PORPHYRIAS (Table 132-8)

Acute Intermittent Porphyria

EPIDEMIOLOGY AIP occurs globally. The incidence in the human population is approximately 1 to 2 in 100,000, although it is much higher in Scandinavia, particularly Lapland (1 in 1000).[178] AIP rarely, if ever, manifests before puberty. Most published series emphasize the female predominance of affected patients, ranging from 1.5:1.0 to 2:1.[7]

ETIOLOGY AIP is due to a deficiency of PBG deaminase, the third enzyme in the heme biosynthetic pathway (see Figs. 132-1 and 132-2). This enzyme combines four molecules of the monopyrrole PBG to form the linear tetrapyrrole hydroxymethylbilane, which cyclizes spontaneously to form the initial porphyrinogen, or tetrapyrrole, known as UROGEN I (see Fig. 132-2). Depending on the manner in which the PBG molecules are arranged, several different isomers of the tetrapyrroles are possible. The sole difference between type I and type III porphyrinogens is that one of the four pyrrole rings is "flipped over." Only two of them (designated I and III) are known to occur in the mammalian heme synthetic pathway. PBG deaminase has been purified from human RBCs and shown to have a molecular mass of approximately 37 kd and a pH optimum of 8.2.[179] In AIP patients, PBG deaminase activity is approximately 50 percent of that in unaffected normal individuals, consistent with an autosomal dominant mode of inheritance. Diminution of PBG deaminase levels partially blocks heme synthesis, which in turn decreases the regulatory heme pool and leads to de-repression of ALA synthase mRNA synthesis.

The *PBG deaminase* gene has been cloned and characterized.[180] Two isoforms, one ubiquitous and one erythroid specific, are encoded by a single gene localized to 11q23→11qter.[3] It comprises 15 exons spread over 10 kb of DNA. The two isoforms of the enzyme are encoded by two distinct mRNAs that arise from two overlapping transcription units. The first (upstream) is active in all tissues and its promoter has some features of a housekeeping promoter, whereas the second, located 3 kb downstream, is active only in erythroid cells and displays structural homology with β-globin gene promoters. Differential splicing gives rise to two isozymes of slightly different molecular sizes.[8] To date, more than 200 mutations have been reported at the PBG

ACUTE INTERMITTENT PORPHYRIA AT A GLANCE

- Most common of the acute porphyrias
- Autosomal dominant disorder involving deficiency of porphobilinogen deaminase
- Frequency as high as 1 to 2 in 100,000
- Age of onset in second to fourth decade of life; rare before puberty
- Acute neurologic attacks but no photosensitivity or cutaneous findings

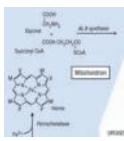

deaminase locus, including deletions, insertions, and missense, nonsense, and splicing mutations.[181]

PBG deaminase is present in the second lowest concentration of any enzyme in the heme pathway; ALA synthase is in the lowest. This suggests that additional factors (genetic or acquired) that influence PBG deaminase activity may have important regulatory influences on the rate of heme synthesis. Consequently, if excessive PBG is formed because of increased ALA synthase activity, as is often seen in the acute hepatic porphyrias, there may be only partial conversion of this monopyrrole to UROGEN I. These factors account for the elevated urinary PBG levels characteristic of attacks of the acute hepatic porphyrias. PBG deaminase activity is known to be reduced by approximately 50 percent in the tissues of patients with AIP and is currently thought to be the primary enzymatic abnormality in this autosomal dominant disorder. There is a variant form of AIP (occurring in perhaps 10 percent of cases) in which the PBG deaminase defect is restricted to non-erythropoietic tissues due to mutations in exon 1 that are absent from erythroid mRNA.

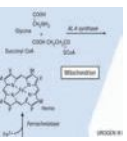

CLINICAL MANIFESTATIONS (See Table 132-8) Fewer than 10 percent of latent carriers of the PBG deaminase defect ever express the clinical phenotype. Hence, the gene defect alone seems to be inconsequential unless the individual is exposed to additional triggering factors, among which certain drugs that induce hepatic cytochrome P_{450} enzymes are particularly important (Table 132-9).[182,183] The clinical signs and symptoms of AIP may also relate to the effects of excessive porphyrin precursors or to heme depletion in the autonomic nervous system.[5]

An acute porphyric attack is characterized by abdominal pain (in 80 percent to 90 percent of AIP patients) and neurologic and psychiatric symptoms that can mimic those of numerous disorders. The pain may be diffuse or localized and is often intermittent and spastic. Vomiting and constipation are frequently associated. Mild fever and leukocytosis may occur, which makes differential diagnosis extremely difficult. This is one reason many patients with AIP have undergone multiple exploratory laparotomies before the correct diagnosis is established. Between attacks patients are often remarkably symptom free. Attacks are often precipitated by ingestion of drugs such as those listed in Table 132-9. Acute attacks of AIP may be accompanied by seizures, especially in patients with hyponatremia resulting from vomiting and inappropriate fluid therapy. Peripheral neuropathy is a major part of the clinical syndrome in many patients, varying from sensory (localized pain) to motor (weakness progressing to generalized flaccid paralysis).[12,184] Patients may succumb to the disease, usually due to respiratory failure, or may improve slowly, although residual muscle weakness frequently persists for extended periods.

TABLE 132-9
Examples of Drugs Potentially Hazardous in Patients with the Acute Hepatic Porphyrias

Amidopyrine	Isopropylmeprobamate
Aminoglutethimide	Mephenytoin
Aminopyrine	Meprobamate
Amphetamines	Methyldopa
Antipyrine	Methyprylon
Barbiturates	*N*-butylscopolammonium bromide
Bemegride	Nalidixic acid
Carbamazepine	Nikethamide
Carbromal	Nitrazepam
Chloromethazone	Nortriptyline
Chlorpropamide	Novobiocin
Chloroquine	Pargyline
Danazol	Pentazocine
Dapsone	Pentylenetetrazole
Diclofenac	Phenoxybenzamine
Diethylpropion	Phenylbutazone
Diphenylhydantoin	Primidone
Dramamine	Pyrazinamide
Enflurane	Rifampin
Ergot preparation	Sedormid
Erythromycin	Succinimides
Ethchlorvynol	Sulfonamides
Ethinamate	Sulfonethylmethane
Ethosuximide	Sulfonylureas
Ethyl alcohol	Synthetic estrogens, progestins
Fentanyl	Theophylline
Furosemide	Tolazamide
Furoxone	Tolbutamide
Glutethimide	Trimethadione
Griseofulvin	Valproic acid
Halothane	
Heavy metals	
Hydralazine	

Cutaneous photosensitivity does not occur in AIP. This is logical, because the abnormal excretion pattern of the disease consists mostly of the non-photosensitizing porphyrin precursors ALA and PBG.

LABORATORY FINDINGS The primary gene defect in AIP results in PBG deaminase deficiency, which causes excessive urinary excretion of ALA and PBG. Urinary porphyrin levels may also be slightly elevated (see Table 132-3). Urinary excretion of ALA and PBG may be as high as 100 mg/24 hours in an acute attack. During remission urinary excretion of ALA and PBG decreases but usually remains above normal values. This is in contrast to VP and HCP, in which urinary excretion of ALA and PBG is often normal between acute attacks.

Two rapid screening tests are available to test freshly voided urine for increased PBG level. The first is simply to expose the urine to bright sunlight for several hours. Darkening to a deep red color suggests but does not prove that excessive PBG is present, because porphobilin, another dark pigment, can also be photocatalytically formed in urine. The second rapid screening test, known as the *Hoesch test*, is more definitive and involves a simple procedure for detecting excessive urinary PBG.[185] Two drops of fresh urine are added to 2 mL of Ehrlich's reagent (3 g of *p*-dimethylaminobenzaldehyde dissolved in 125 mL of acetic acid and 24 mL of perchloric acid). A uniform cherry-red color of the sample indicates a positive reaction. This test is based on the formation of a chromogen by PBG and Ehrlich's aldehyde reagent that produces a red pigment with strong absorption at 552 nm. The classic Watson-Schwartz test is based on this same principle. The results of these qualitative tests, although potentially useful for screening, must be confirmed by quantitative 24-hour measurement of urinary ALA and PBG using ion-exchange chromatography or high-performance liquid chromatography.[186]

HISTOPATHOLOGY AIP does not manifest cutaneous symptoms.

DIFFERENTIAL DIAGNOSIS The clinical manifestations of AIP are protean and resemble so many different diseases that Waldenström has used the term *little imitator* to describe it.[12,178] Several excellent reviews have summarized the differential diagnosis of AIP,[3,181,187] and because this disorder has no cutaneous findings, it is not discussed further here.

TREATMENT There is no cure for AIP. Management of the acute attack uses multiple approaches, including glucose loading (2 L of 20 percent glucose over 24 hours in divided doses of 500 mL through a central venous line).[119,187,188] Administration of a gonadotropin-releasing hormone analog has also been recom-

TABLE 132-10
Drugs Considered to Be Safe (or Probably Safe) in Patients with the Acute Hepatic Porphyrias

Acetaminophen	Insulin
Adrenaline	Labetalol
Amitriptyline	Lithium
Aspirin	Mandelate
Atropine	Methenamine
Bromide	Naproxen
Cephalosporins	Narcotic analgesics
Chloral hydrates	Neostigmine
Chloramphenicol	Nitrofurantoin
Chlordiazepoxide	Nitrous oxide
Colchicine	Oxazepam
Digoxin	Penicillin and derivatives
Diphenhydramine	Phenothiazines
Ethylenediaminetetraacetic acid (EDTA)	Propranolol
Ether	Prostigmin
Glucocorticoids	Rauwolfia alkaloids
Guanethidine	Streptomycin
Heparin	Succinylcholine
Hyocine	Tetracycline
Hypocine	Thiouracil
Ibuprofen	Thyroxine
Indomethacin	

Box 132-2
Treatment of the Acute Porphyrias

TYPE	MANAGEMENT
Acute intermittent porphyria, variegate porphyria, hereditary coproporphyria, δ-aminolevulinic acid dehydratase deficiency porphyria	Acute attacks • Identification and elimination of precipitating factors (porphyrinogenic drugs, alcohol, hormones) • Monitoring in intensive care unit and/or contacting of specialized porphyria center (centers are available worldwide) • Provision of appropriate analgesia (e.g., with pethidine or other opiate derivatives) • Management of nausea and vomiting (e.g., with promazine, chlorpromazine, or triflupromazine) • Intravenous administration of either heme arginate (Normosang, Europe) in a dose of 3 mg/kg body weight once daily over 4 consecutive days or hematin (Panhematin, USA; see http://www.blooddiagnostics.com/Product%20Inserts/Ovation/panhematin_pi.pdf) • If necessary, intravenous glucose loading • Measurement of excretion of urinary porphyrin precursors (δ-aminolevulinic acid and porphobilinogen) during the acute attack (daily, if possible)
Variegate porphyria, hereditary coproporphyria	Cutaneous manifestations • Photoprotection (e.g., with broadband sunscreens and/or protective clothing) • Avoidance of sunlight exposure and trauma

mended.[189] Intravenous infusion of hematin in the form of heme arginate is effective in shortening attacks.[187] Precipitating factors such as drugs (see Table 132-9), sex steroid hormones, starvation, and so on, should be avoided. AIP patients should wear medical warning bracelets and should be given lists of drugs to avoid. Drugs thought to be safe for AIP patients are listed in Table 132-10.

Currently recommended therapeutic regimens for the treatment of an acute porphyric attack and associated prophylactic measures are described in the following sections. These procedures are applicable for all patients with acute porphyrias presenting with neurovisceral manifestations.

Treatment of Neurovisceral Attacks in the Acute Porphyrias. (Box 132-2) Most patients with acute porphyria experiencing an attack can now be treated successfully, and life-threatening complications such as muscle paralysis, respiratory failure, and coma can be avoided if appropriate aggressive treatment is implemented immediately. Untreated or inappropriately treated patients experiencing an acute porphyric attack may have a 10 percent to 15 percent risk of mortality.[11] Today, with mechanism-based therapeutic intervention, the mortality rate of the acute attack has decreased to approximately 2 percent. There are four major steps in treating an acute porphyria attack.

First, all potentially porphyrinogenic drugs should be stopped immediately, and the patient should be monitored carefully and admitted to an intensive care unit if possible. Several sources are available that categorize drugs as relatively safe or unsafe for patients with acute porphyria.[13] Additional information is available on the Internet at the website of the European Porphyria Initiative (EPI) at http://www.porphyria-europe.com.

Second, symptomatic treatment of neurovisceral manifestations like abdominal pain, vomiting, tachycardia, and seizures should be initiated promptly. The following recommendations originate from different sources, including guidelines published by the EPI and a consortium of Northern American porphyria specialists:

SYMPTOM/SIGN	TREATMENT
Abdominal pain	Acetylsalicylic acid; morphine
Vomiting	Chlorpromazine; promethazine
Hypertension and tachycardia	Propranolol
Hyponatremia	Electrolyte balance; saline infusions
Convulsions	Gabapentin
Constipation	Neostigmine

Third, high doses of carbohydrates should be infused intravenously, preferably 400 to 500 g of glucose per 24 hours using 5 percent or 10 percent glucose solutions. Simultaneously, diuresis should be induced by administration of furosemide with careful monitoring of serum electrolyte levels. Patients experiencing an acute attack are often unable to eat or drink because of severe nausea and recurrent vomiting. The rationale for high doses of glucose is based on experimental evidence showing that carbohydrates suppress the induction of ALA synthase, the first and rate-limiting enzyme of the heme biosynthetic pathway. Studies have now shown that ALA synthase is regulated by the peroxisome proliferator–activated receptor-γ coactivator 1α (PGC-1α).[190] Elevation of PGC-1α levels in mice increases the levels of heme precursors in vivo as observed in patients during acute porphyric attacks, whereas the induction of ALA synthase by fasting is lost in liver-specific PGC-1α knockout animals, as is the ability of porphyrogenic drugs to dysregulate heme biosynthesis. These data show that PGC-1α links nutritional status to heme biosynthesis and acute hepatic porphyria and provides a rationale for high-dose glucose infusions. Unfortunately, in many patients this regimen is only partially helpful, and thus glucose infusions are considered to be adjuvant therapy until hematin preparations are available.

Fourth, intravenous administration of heme arginate, currently not approved by the U.S. Food and Drug Administration, is the most efficient method to sup-

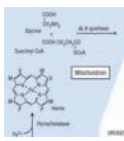

press heme synthesis. The rationale for this approach is that intravenous administration of high doses of the end product heme repress the synthesis of ALA synthase.[191] Initially the available hematin preparations were quite unstable and frequently caused thrombophlebitis.[119,192] A newer derivative, heme arginate, consists of human hemin and L-arginine as an additive to increase the solubility and stability of the product. This preparation does not affect coagulation and fibrinolysis, and the frequency of thrombophlebitis as well as the overall rate of side effects is markedly reduced.[193] Heme arginate exerts its specific action by correcting the underlying heme deficiency and restoring the negative feedback control of heme on ALA synthase, thereby decreasing the excessive hepatic production of porphyrins and porphyrin precursors. Heme arginate should be administered intravenously as a short infusion at a dosage of 3 mg/kg body weight per day over a period of 4 days. Administration can be continued cautiously if the attack is not aborted; however, use of heme arginate for more than 7 days is not recommended. In the United States, an alternate form of heme known as *hemin* can be administered for the treatment of an acute porphyric attack. It is currently recommended that hemin administration be considered only after an appropriate period of alternate therapy (i.e., 400 g glucose/day for 1 to 2 days).

Prevention of Attacks. Patients should be advised to avoid fasting or dieting, to abstain from alcohol use, and to be aware of porphyrinogenic drugs, such as barbiturates, sulfonamides, and estrogens, to name several.[13,186] Lists of safe and unsafe drugs are available on the website of the American Porphyria Foundation at http://www.porphyriafoundation.com/about_por/drugs/drugs02.html and, in 10 different languages, on the website of the EPI (see Treatment of Neurovisceral Attacks in the Acute Porphyrias).

Using appropriate screening procedures, asymptomatic family members of individuals with known acute porphyria should be screened for enzymatic deficiency and mutations to help define inheritance patterns and to identify individuals at risk.

Variegate Porphyria (See Table 132-8)

EPIDEMIOLOGY VP occurs worldwide but is most prevalent in South Africa and Chile, mainly due to founder effects in both countries.[5,18,194–196] In South Africa, this form of porphyria is quite common among the Caucasian and so-called *Cape-coloured* South Africans. A high proportion of the present Caucasian population is descended from a pair of early Dutch settlers who emigrated from the Netherlands to South Africa in 1688. The incidence of VP in South Africa is the highest in the world, with the disorder affecting approximately 1 in 300 individuals in the white population.

VARIEGATE PORPHYRIA AT A GLANCE



- Incidence of approximately 1 in 300 in South Africa; relatively rare elsewhere, with the exception of Chile.
- Autosomal dominant disorder involving deficiency of protoporphyrinogen oxidase.
- Age of onset in second to third decade of life; rare before puberty.
- Skin manifestations are indistinguishable from those of porphyria cutanea tarda; acute attacks similar to those in acute intermittent porphyria can occur (neurocutaneous porphyria).
- Founder mutations have been identified in South Africa and Chile.

ETIOLOGY VP results from decreased PROTOGEN oxidase activity and is an autosomal dominant disorder.[197–199] PROTOGEN oxidase is an integral protein of the inner mitochondrial membrane and catalyzes the oxidation of PROTOGEN IX to PROTO, removing six hydrogens from PROTOGEN IX (see Figs. 132-1 and 132-2). This reaction can also occur nonenzymatically, but the enzyme appears to be necessary for normal heme synthesis. The enzyme acts specifically on PROTOGEN IX, the penultimate step in heme synthesis. COPROGEN I or III and UROGEN I or III are not substrates for this enzyme. PROTOGEN oxidase isolated from rat liver mitochondria has been shown to have a molecular mass of 51 kd and requires molecular oxygen to catalyze the oxidation of PROTOGEN to PROTO.

Human PROTOGEN oxidase is encoded by a single-copy gene of the same name, *PROTOGEN oxidase*, that has been mapped to chromosome 1q22-23, spans 8 kb, and consists of 13 exons. Northern blot analyses of specimens from a variety of tissues indicate that there is a single transcript of 1.8 kb encoding a protein of 477 amino acids.[200] Multiple mutations have been identified, including founder mutations in South Africa (R59W) and Chile (1239delTACAC).[19,201]

CLINICAL MANIFESTATIONS The clinical manifestations of VP encompass those of both PCT and AIP, which can occur simultaneously or separately in the same individual. The major difference between VP and PCT is that skin signs and symptoms usually develop at an earlier age in VP (second and third decades) than in PCT (fourth and fifth decades). The major difference between VP and AIP is that acute attacks are much less common in VP. In South Africa, excessive intake of home-brewed spirits (Kaffir beer) and dietary iron overload from cooking vessels are considered important factors in the development of clinically overt disease. Thus, VP occurring in the descendants of the Dutch immigrants of South Africa is quite distinct from the PCT seen in the native black population. As pointed out by Dean for a group he designated as *Cape-coloured*, (descendants of white European and Indian immigrants who intermarried with black natives), VP and PCT may co-segregate in the same family.[202]

Skin Lesions. The cutaneous lesions of VP are indistinguishable from those of PCT and HCP. These include bullae and erosions on light-exposed skin (Fig. 132-19). Hyperpigmentation, milia, hypertrichosis, and increased skin fragility are also seen. They appear to be more common in the hot climate of South Africa and are less frequently seen in affected individuals in colder climates. Blisters are often blood tinged, heal slowly, and heal with scarring and milia formation. Occasionally the patient gives a history of acute sun sensitivity that occurs during or soon after a period of exposure; this may include burning, erythema, and edema. In the chronic state, the skin changes may include thickening and scarring (Fig. 132-20). Some believe that melanin pigmentation may reduce the severity of the photocutaneous findings. The skin manifestations do not correlate with the acute attacks in most patients, and in general,



▲ **FIGURE 132-19** Large bullae on the dorsum of foot and toes of a patient with variegate porphyria. Note that these patients also develop pigmentary changes and milia just as in porphyria cutanea tarda.

males are more likely to have the PCT-like skin findings, whereas females are more prone to AIP-like acute attacks.

Neurovisceral Symptoms. Neurovisceral symptoms are identical to those occurring in AIP and consist of attacks of abdominal pain, constipation, vomiting, muscle weakness, and neuropsychiatric manifestations of stupor and coma. Factors that trigger attacks of AIP also appear to induce VP (various drugs, starvation, etc.). All patients with the skin findings of PCT should be screened for VP because of its life-threatening potential.

These clinical features rarely develop before puberty, except in the rare homozygous patients who may develop cutaneous signs and symptoms at or shortly after birth. In addition to the early onset of skin symptoms, for unknown reasons these patients frequently manifest short stature and small hands with shortening of the digits.[203–205]



▲ **FIGURE 132-20** South African patient with variegate porphyria showing photodamage as in porphyria cutanea tarda but changes that are less severe than in Caucasians.

LABORATORY FINDINGS Urinary ALA and PBG levels are elevated during acute attacks of VP (when results of the Watson-Schwartz test may be positive) but characteristically fall to normal levels between attacks (see Table 132-3), whereas in AIP patients, urinary ALA and PBG levels are elevated both during and between attacks. Another feature distinguishing the two disorders is stool porphyrin excretion. Asymptomatic patients with VP usually, but not always, have marked elevations of stool PROTO and COPRO levels between attacks.[206] These may fluctuate somewhat during acute attacks, and PROTO typically exceeds COPRO. In AIP, fecal levels of porphyrins are not elevated between attacks and usually increase only slightly during attacks. Certain patterns of fecal and urinary porphyrin excretion may help in distinguishing VP from PCT.[207] URO in the urine is only moderately elevated in VP, and urinary COPRO level typically exceeds URO level. This is in marked contrast to active PCT, in which the reverse is seen (i.e., urinary URO level is usually several-fold higher than COPRO level). Again in VP, fecal porphyrins usually exceed 500 μg/g dry weight in more than 90 percent of patients, whereas in PCT this amount of stool porphyrin is excreted by only 1 percent of patients. Furthermore, the ratio of stool PROTO to COPRO in VP usually exceeds 1.5:1.0, whereas in PCT the ratio is almost always less than 1:1 due to the increased ISOCOPRO content characteristic of the latter disease. However, stool porphyrin excretion patterns consistent with both VP and PCT have been found in different members of single families.[61,62] These types of findings have led to the suggestion that measurement of bile porphyrins may be decisive in confirming a diagnosis of VP when excretory porphyrin patterns are ambiguous.[100] Saline-diluted plasma specimens from patients with VP have characteristic fluorescence emission spectra (626 nm emission peak) that can be used to differentiate this disease from other forms of acute porphyria, PCT, EPP, and lead poisoning (see Table 132-4).[208]

HISTOPATHOLOGY The histopathologic alterations in VP are indistinguishable from those in PCT.

DIFFERENTIAL DIAGNOSIS The differential diagnosis of VP should be considered from two perspectives. The skin lesions of VP are identical to those of PCT, and because of this, the differential diagnosis includes the bullous diseases as well as other photosensitivity disorders. HEP must also be considered, but the latter usually begins in early childhood and is characterized by markedly deficient erythrocyte UROGEN decarboxylase activity and elevated erythrocyte PROTO levels as well as increased stool ISOCOPRO levels. The presence of skin lesions rules out AIP. The determination of urinary ALA and PBG concentrations may help to rule out PCT and HEP. Screening of family members by measuring fecal porphyrins may also be helpful in differentiating VP and PCT.

Acute attacks of abdominal pain and neurologic signs and symptoms are identical to those described for AIP (see Box 132-2). Fecal and biliary PROTO and COPRO measurements and determination of plasma fluorescence spectra are decisive in making the diagnosis. In HCP there may be identical acute attacks, but markedly elevated fecal COPRO III levels are diagnostic for this disease.

TREATMENT Preventive and symptomatic treatment of the acute attacks in VP is identical to that described for AIP, including avoidance of inducing drugs (see Table 132-9) and glucose loading as well as hematin infusions. Unlike in PCT, there is no evidence of iron overload in VP, and therefore phlebotomy and antimalarial drugs are ineffective.[209]

Hereditary Coproporphyria (See Table 132-8)

EPIDEMIOLOGY Although apparently rare, HCP occurs worldwide and, like AIP, affects females more than males. To date, fewer than 50 patients have been reported. In addition to classic HCP, an extremely rare form of porphyria, designated *harderoporphyria*, has been described. This disease is a homozygous variant of HCP in which COPROGEN oxidase activity is very low (10 percent of control values).[210–212]

ETIOLOGY HCP is an autosomal dominant disorder resulting from a decrease in the residual catalytic activity of COPROGEN oxidase (see Figs. 132-1 and 132-2).[213,214] The enzyme is localized in the intermembrane space of the mitochondrion, has a molecular mass of 74 kd, and catalyzes the conversion

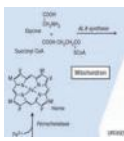

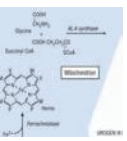

HEREDITARY COPROPORPHYRIA

AT A GLANCE

- Very rare (fewer than 50 cases reported).
- Autosomal dominant disorder involving a deficiency of coproporphyrinogen oxidase.
- Age of onset in second to third decade of life; rare before puberty.
- Skin findings that are indistinguishable from those of porphyria cutanea tarda occur in fewer than 10 percent of patients; acute attacks similar to those of acute intermittent porphyria are the most common feature (neurocutaneous porphyria).

of COPROGEN III to PROTOGEN. COPROGEN III has four carboxyl groups, each of which is part of a propionate side chain. COPROGEN oxidase catalyzes the sequential oxidative removal of the carboxyl group from two of the propionate groups, forming first the 3-carboxyl porphyrinogen known as *harderoporphyrinogen (HARDEROGEN)* and next the 2-carboxylporphyrinogen known as *PROTOGEN* (see Fig. 132-2).

COPROGEN oxidase is encoded by a single-copy gene of the same name, *COPROGEN oxidase*, as suggested by Southern blot analysis of human restriction fragments. The *COPROGEN oxidase* gene is located on chromosome 3q12, spans a genomic distance of 14 kb, and consists of 7 exons and 6 introns.[215] Multiple mutations have been found in patients with heterozygous and homozygous HCP. These include point mutations resulting in base substitutions or exon skipping. This leads to increased excretion of COPRO in the urine and stool.[215]

CLINICAL MANIFESTATIONS As in VP, the spectrum of clinical symptoms includes both cutaneous manifestations and potentially life-threatening acute neurologic attacks. Cutaneous symptoms apparently occur in fewer than 10 percent of patients, and when they occur they are clinically indistinguishable from those seen in PCT and VP.[186]

The acute attacks are similar to those of AIP, and neurovisceral symptomatology predominates in HCP. This includes abdominal pain, vomiting, constipation, neuropathies, and psychiatric symptoms. The oral hypoglycemic agent glipizide has been reported to exacerbate a coproporphyria-like syndrome that was reversed after discontinuation of the drug.[216]

LABORATORY FINDINGS HCP is characterized by increased excretion of COPRO III in urine and feces. Markedly increased levels (usually 10- to 100-fold) of fecal COPRO, more than 90 percent of which is the III isomer, is present at all times in these patients. The feces may also contain increased amounts of hepta-, hexa-, and pentacarboxylic porphyrins. Urinary COPRO III level is also elevated during attacks, as are levels of the precursors ALA and PBG. The latter may be normal between attacks (see Table 132-3).

HISTOPATHOLOGY Skin lesions usually do not occur. When they are present, histopathologic features are similar to those in PCT.

DIFFERENTIAL DIAGNOSIS In HCP, cutaneous signs are uncommon and, if they do occur, are most often seen in homozygous patients with disease onset in childhood. The skin manifestations resemble those seen in PCT and VP. Fecal predominance of COPRO III is more suggestive of HCP than of VP, in which PROTO and COPRO levels are usually increased.

Acute attacks are similar to those seen in AIP. The differential diagnosis rests on stool porphyrin determinations and measurement of COPROGEN oxidase in fibroblasts or leukocytes. DNA analysis for mutations in the *COPROGEN oxidase* gene can also be performed.

TREATMENT Treatment is the same as for AIP and VP and is described in Box 132-2.

δ-Aminolevulinic Acid Dehydratase Deficiency Porphyria (See Table 132-8)

ALA dehydratase deficiency porphyria is a very rare type of acute hepatic porphyria with an autosomal recessive inheritance pattern; no more than 10 patients with the disorder have been reported.[217–220] Clinically, these patients have symptoms similar to those of AIP. Stress and ethanol ingestion have been reported to precipitate attacks.

The disease results from a profound deficiency of ALA dehydratase, the second enzyme in heme biosynthesis, levels of which are less than 5 percent of normal. ALA dehydratase is a cytosolic enzyme and catalyzes the formation of PBG from two molecules of ALA.

δ-AMINOLEVULINIC ACID DEHYDRATASE DEFICIENCY PORPHYRIA

AT A GLANCE

- Extremely rare (fewer than 10 cases reported).
- Early and late clinical onset has been described.
- Neurologic symptoms similar to those in other acute hepatic porphyrias can occur; no photosensitivity or cutaneous symptoms.

The enzyme is encoded by the ALA dehydratase gene, which is located on chromosome 9q34, and the mutations described to date are very heterogeneous. Although it has been suggested that ALA dehydratase deficiency porphyria may represent a homozygous ALA dehydratase defect, cloning of a mutant ALA dehydratase cDNA in a patient showed that the patient was compound heterozygous for two independent mutant alleles of the enzyme.[218]

In the few patients studied, the urinary porphyrin excretion shows elevated levels of ALA, COPRO, and, to a lesser extent, URO. Analysis of fecal porphyrins revealed mildly elevated levels of COPRO and PROTO in one patient, elevated COPRO levels in another, and a normal profile in two others. Erythrocyte PROTO level was elevated in all patients. Increases in plasma ALA, COPRO, and PROTO have been reported.[221] The porphyrin excretion pattern in these patients is unexplained.

CONFIRMATION OF A SUSPECTED DIAGNOSIS OF PORPHYRIA

Diagnostic procedures traditionally consist of a combination of thorough medical history taking (including, in particular, a complete family history), clinical examination, and biochemical determi-

nation of levels of porphyrins and porphyrin precursors in urine, feces, and blood (Fig. 132-21). In specialized laboratories, these diagnostic procedures can be extended to the measurement of specific enzymatic activities in erythrocytes, lymphocytes, or fibroblasts of affected patients and family members. Molecular techniques now provide the most precise diagnostic information based on isolation of DNA from peripheral blood followed by polymerase chain reaction amplification and automated DNA sequencing. Furthermore, these methodologies permit detailed analyses of genes and their function and allow genetic counseling of affected individuals and their family members.

Even with the use of these sophisticated diagnostic tools, however, there are times when the results may remain inconclusive. This is particularly true for the dual porphyrias.

DUAL PORPHYRIAS

In the dual porphyrias, laboratory test results may point to the simultaneous deficiency of two enzymes in the heme biosynthetic pathway, either in one individual or within one family. To date, approximately 15 patients and families with this constellation of findings have been reported, which indicates that these porphyria variants are very rare.

The majority of the dual porphyrias involve a deficiency of UROGEN decarboxylase combined with a deficiency of PBG deaminase, COPROGEN oxidase, or PROTOGEN oxidase. This is not surprising, because the prevalence of PCT exceeds that of any other type of human porphyria. In three families, the simultaneous deficiency of COPROGEN oxidase and either PBG deaminase, UROGEN III synthase, or ALA dehydratase was detected. In one patient with CEP, the UROGEN III synthase defect was accompanied by a deficiency of UROGEN decarboxylase.

Until recently, the diagnosis of dual porphyria in all patients and families was established based on biochemical measurement of porphyrins and/or porphyrin precursors in urine and feces and enzymatic assays.

Two groups have now independently reported on the first porphyria patients in whom DNA analysis unequivocally confirmed the presence of mutations in two different genes encoding distinct enzymes in the heme synthetic pathway. Harraway et al. described a young female patient who developed skin symptoms on the sun-exposed areas of her body and showed increased urinary PBG excretion.[222] The initial diagnosis of VP could not be confirmed, however, and biochemical analysis of her urine, feces, and plasma suggested a combined deficiency of PBG deaminase and UROGEN decarboxylase. Subsequent automated sequencing of the *PBG deaminase* and *UROGEN decarboxylase* genes revealed mutations in both genes, which confirmed the diagnosis of dual porphyria. Akagi et al. studied a patient who experienced acute porphyric attacks accompanied by increased urinary excretion of ALA, PBG, and COPRO.[223] Although these findings were suggestive of HCP, the authors observed marked elevation of ALA levels and increased erythrocyte zinc PROTO levels, which suggested ALA dehydratase deficiency. Subsequent automated sequencing of both the *COPROGEN oxidase* and *ALA dehydratase* genes led to the detection of disease-causing mutations in each gene. Both genetic defects were confirmed by in vitro expression experiments, which established the molecular basis of dual porphyria in a single individual consisting of simultaneous COPROGEN oxidase and ALA dehydratase deficiencies.

These reports emphasize that for patients for whom biochemical and enzymatic studies indicate co-existent deficiency of two enzymes in the heme biosynthetic pathway, molecular genetic analysis of the corresponding genes should be carried out to identify the disease-causing mutations underlying a particular variant of dual porphyria.

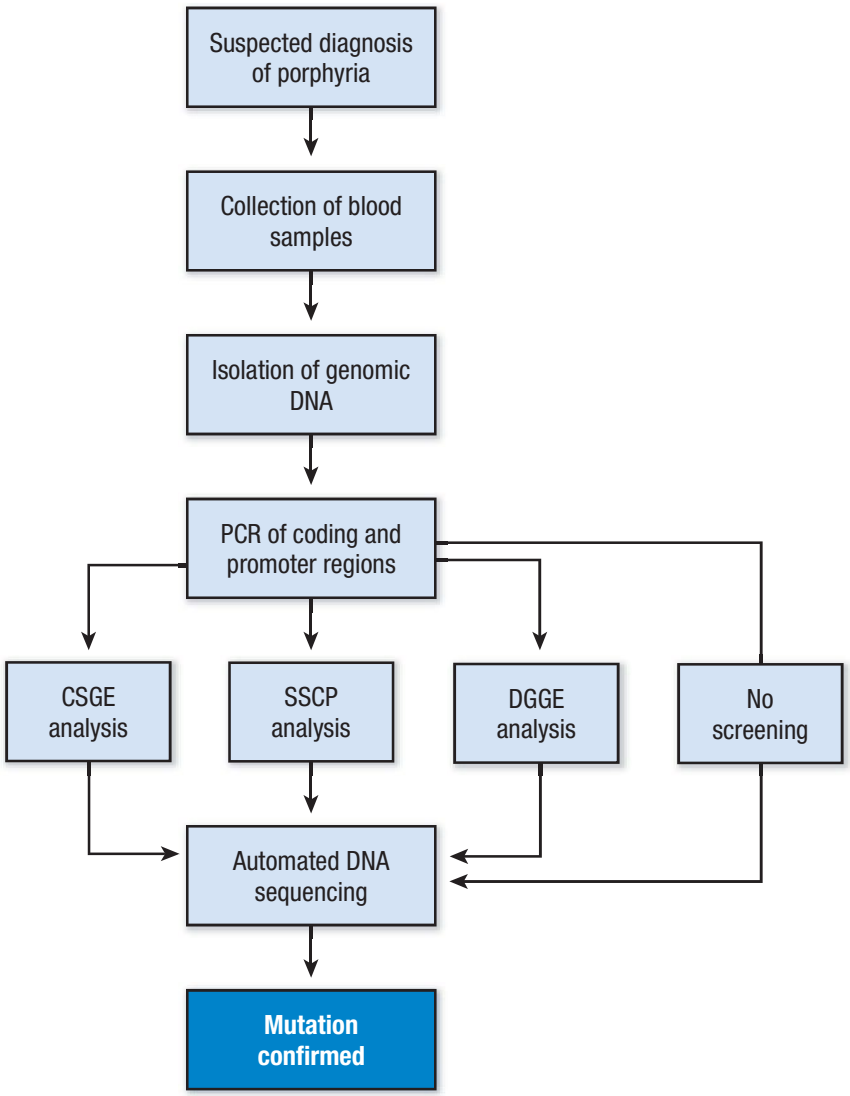

▲ **FIGURE 132-21** Algorithm for assessing the molecular genetics of human porphyria. CSGE = conformation sensitive gel electrophoresis; DGGE = denaturing gradient gel electrophoresis; PCR = polymerase chain reaction; SSCP = single strand conformational polymorphism.

ABNORMAL PORPHYRIN PROFILE AND SIDEROBLASTIC ANEMIA

Some cases of sideroblastic anemia may be associated with abnormal porphyrin profiles.[224–226] These patients may have cutaneous photosensitivity closely resembling that of EPP, and they subsequently develop sideroblastic anemia. In some cases, the two conditions may develop within a few months of each other. All patients have elevated levels of PROTO in RBCs and/or plasma; many also have elevated stool PROTO levels. Urinary COPRO and URO levels are also elevated. The activities of ferrochelatase and, less frequently, of ALA synthase may be decreased. Chromosomal abnormalities, which include deletions in chromosomes 18 and 20, have been described.

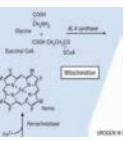

MOLECULAR GENETIC RESEARCH STRATEGIES FOR THE PORPHYRIAS

In the various types of porphyrias, discrepancies between clinical findings and the results of biochemical tests or enzyme essays often lead to doubtful or incorrect diagnoses. In the case of the acute porphyrias, this can have fatal consequences for the patient if an accurate diagnosis is not established in a timely manner.

Once a mutation is identified in a patient with porphyria, the detection of asymptomatic gene carriers within the patient's family is easily accomplished using standard molecular biologic techniques. In the acute porphyrias, the identification of these "silent" carriers is the first and most important step in the prevention of life-threatening acute attacks. Genetic analysis provides an effective way to make an early diagnosis and thereby enhance the likelihood of providing patients and asymptomatic gene carriers in their families with advice regarding the avoidance of precipitating factors.

ANIMAL MODELS AND FUTURE OPTIONS FOR GENE THERAPY

Animal models for EPP and PCT have been described.[91,165,227] These models afford unique opportunities to explore the pathogenesis of these types of porphyria using in vivo models and to study the feasibility of achieving phenotypic reversion by gene therapy. Retrovirus-mediated gene transfer of human ferrochelatase cDNA into deficient fibroblasts from an EPP patient has been achieved.[164] In transduced cells, ferrochelatase catalytic activity increased from 7 percent to 550 percent of the normal value, and partial metabolic correction of the phenotype was demonstrated. In CEP, correction of the underlying enzymatic defect in cultured cells was also accomplished by retrovirus-mediated gene transfer, which led to partial normalization.[228] Excessive porphyrin levels in the transduced cells were reduced to normal. These investigations demonstrate the potential usefulness of somatic stem cell gene therapy for the treatment of different types of human porphyria.

CONCLUSIONS AND FUTURE PROSPECTS

The various human porphyrias often present with overlapping clinical and laboratory findings, which makes precise diagnosis a challenging proposition, especially in the acute porphyrias. The clinical signs and symptoms are highly variable in different patients and even in the same patient at different times. Biochemical analyses of urinary and/or fecal porphyrins and precursors often display overlapping values. These methods, as well as the measurement of enzymatic activity in fibroblasts or lymphocytes, are somewhat imprecise, and it is not uncommon to find values that do not distinguish between clinically unaffected gene carriers (so called *silent carriers*) and normal controls. The identification of silent carriers within families affected by the acute porphyrias is the first and foremost step toward the prevention of life-threatening acute attacks. Once a DNA-based diagnosis is made, patients and their families can be provided with genetic counseling and with advice regarding how to avoid precipitating factors. In case of a life-threatening acute attack, a prior genetic diagnosis permits the attending physician to begin appropriate treatment immediately.[186]

KEY REFERENCES

The full reference list for all chapters is available at www.digm7.com.

25. Kauppinen R: Porphyrias. *Lancet* **365**:241, 2005
45. Pawliuk R et al: Prevention of murine erythropoietic protoporphyria–associated skin photosensitivity and liver disease by dermal and hepatic ferrochelatase. *J Invest Dermatol* **124**:256, 2005
52. Elder GH, Lee GB, Tovey JA: Decreased activity of hepatic uroporphyrinogen decarboxylase in sporadic porphyria cutanea tarda. *N Engl J Med* **299**:274, 1978
57. Brady JJ et al: Co-inheritance of mutations in the uroporphyrinogen decarboxylase and hemochromatosis genes accelerates the onset of porphyria cutanea tarda. *J Invest Dermatol* **115**:868, 2000
85. Roberts AG et al: Increased frequency of the haemochromatosis Cys282Tyr mutation in sporadic porphyria cutanea tarda. *Lancet* **349**:321, 1997
105. Kordac V, Papezova R, Semradova M: Chloroquine in the treatment of porphyria cutanea tarda. *N Engl J Med* **296**:949, 1977
107. Swanbeck G, Wennersten G: Treatment of porphyria cutanea tarda with chloroquine and phlebotomy. *Br J Dermatol* **97**:77, 1977
119. Mustajoki P et al: Heme in the treatment of porphyrias and hematological disorders. *Semin Hematol* **26**:1, 1989
134. Gouya L et al: The penetrance of dominant erythropoietic protoporphyria is modulated by expression of wildtype FECH. *Nat Genet* **30**:27, 2002
153. Mathews-Roth MM et al: Beta-carotene as an oral photoprotective agent in erythropoietic protoporphyria. *JAMA* **228**:1004, 1974
164. Mathews-Roth MM, Michel JL, Wise RJ: Amelioration of the metabolic defect in erythropoietic protoporphyria by expression of human ferrochelatase in cultured cells. *J Invest Dermatol* **104**:497, 1995
165. Pawliuk R et al: Long-term cure of the photosensitivity of murine erythropoietic protoporphyria by preselective gene therapy. *Nat Med* **5**:768, 1999
177. Thomas C et al: Correction of congenital erythropoietic porphyria by bone marrow transplantation. *J Pediatr* **129**:453, 1996
183. McColl KE, Moore R: The porphyrias: An example of pharmacogenetic disease. *Scott Med J* **26**:32, 1981
188. Mustajoki P, Nordmann Y: Early administration of heme arginate for acute porphyric attacks. *Arch Intern Med* **153**:2004, 1993
195. Meissner PN et al: A R59W mutation in human protoporphyrinogen oxidase results in decreased enzyme activity and is prevalent in South Africans with variegate porphyria. *Nat Genet* **13**:95, 1996
210. Lamoril J et al: A molecular defect in coproporphyrinogen oxidase gene causing harderoporphyria, a variant form of hereditary coproporphyria. *Hum Mol Genet* **4**:275, 1995
217. Doss M et al: New type of hepatic porphyria with porphobilinogen synthase defect and intermittent acute clinical manifestation. *Klin Wochenschr* **57**:1123, 1979
222. Harraway JR et al: Dual porphyria with mutations in both the UROD and HMBS genes. *Ann Clin Biochem* **43**:80, 2006
227. Fontanellas A et al: Successful therapeutic effect in a mouse model of erythropoietic protoporphyria by partial genetic correction and fluorescence-based selection of hematopoietic cells. *Gene Ther* **8**:618, 2001

CHAPTER 133

Amyloidosis and the Skin

Helen J. Lachmann
Philip N. Hawkins

Amyloidosis is classified according to which protein is deposited (Table 133-1) as well as whether the amyloid deposits are localized, distributed in only one tissue or organ, or deposited more widely.

EPIDEMIOLOGY

Amyloidosis is a rare condition, and the exact incidence remains unclear. The overall sex- and age-adjusted rate per million person-years was reported as 6.1 from 1950 to 1969 and 10.5 from 1970 to 1989 in the United States. Systemic AL amyloidosis is the most common type of systemic amyloidosis, accounting for more than 60 percent of cases. Biopsy and postmortem series suggest that the prevalence of AA amyloidosis deposition in patients with chronic inflammatory diseases is between 3.6 percent and 5.8 percent, although a smaller proportion of patients have clinically significant amyloidosis. Localized amyloidosis accounts for fewer than 10 percent of all diagnoses. Hereditary forms are quite rare, and most are inherited in an autosomal dominant pattern. The most common cause of hereditary amyloidosis is mutations in the gene for transthyretin (TTR), which affects approximately 10,000 individuals worldwide and leads to familial amyloid polyneuropathy. The formerly used term *X-linked cutaneous amyloidosis*, or *Partington syndrome*, has been abandoned for the designation *X-linked reticulate pigmentary disorder*, given the lack of amyloid deposits in the skin.[1] Both localized and systemic forms of amyloidosis become more frequent with increased age, and presentation before the age of 30 years is extremely unusual. No known racial, occupational, geographic, or other environmental factors have been implicated in the genesis of systemic amyloidosis, although there is evidence for a slight male preponderance.

ETIOLOGY AND PATHOGENESIS

Amyloidosis is caused by extracellular deposition of insoluble abnormal fibrils, derived from the aggregation of misfolded plasma protein. More than 20 unrelated proteins are known to form human amyloid fibrils in vivo.[2] The ultrastructural morphology and histochemical properties of all amyloid fibrils, regardless of the precursor protein type, are remarkably similar,[3] and fibril diffraction studies have confirmed that they all share a common core structure consisting of a cross β core and polypeptide chains lying perpendicular to the long axis of the fibril.[4,5] This extremely abnormal highly ordered conformation underlies the distinctive physicochemical properties of amyloid fibrils, including their relative stability and resistance to proteolysis. Amyloid deposits universally contain the normal plasma glycoprotein serum amyloid P component (SAP), heparan sulfate and dermatan sulfate proteoglycans, and glycosaminoglycan chains as non-fibrillar constituents. Other plasma proteins, such as apolipoprotein E, are sometimes detectable in amyloid deposits, but without the universality and abundance of SAP.

Amyloid formation in vivo occurs with both normal wild-type proteins and with genetically variant proteins. The fibrils may contain the intact amyloidogenic protein or proteolytic cleavage fragments. There is always a lag period, often of many years, between the first appearance of the potentially amyloidogenic protein and the deposition of clinically significant amyloid.

Systemic AL Amyloidosis

AL fibrils are derived from monoclonal immunoglobulin light chains and consist of the whole or part of the variable (V_L) domain.[6] AL amyloidosis may occur in association with any monoclonal B cell dyscrasia.[7,8] A degree of amyloid deposition is seen in up to 15 percent of patients with myeloma, but the vast majority (more than 80 percent) of patients who present with clinically significant AL amyloidosis have very low grade and otherwise "benign" monoclonal gammopathies.[9]

Systemic AA Amyloidosis

Reactive systemic AA amyloidosis is a potential complication of any disorder associated with a sustained acute-phase response, and the list of chronic inflammatory, infective, and neoplastic disorders that can underlie it is almost without limit. Although 60 percent of patients have inflammatory arthritis, some of the underlying diseases may require dermatologic input, including psoriatic arthritis, epidermolysis bullosa, basal cell carcinoma, chronic cutaneous ulcers, and hereditary periodic fever syndromes, particularly Muckle-Wells syndrome.[10] The amyloid fibrils are derived from cleavage fragments of the circulating acute-phase reactant serum amyloid A protein (SAA).[11] SAA is an apolipoprotein of high-density lipoprotein[12] that, like C-reactive protein, is synthesized by hepatocytes under the transcriptional regulation of cytokines. A sustained high plasma level of SAA is a prerequisite for the development of AA amyloidosis, but why amyloidosis develops in only a small proportion of cases remains unclear.

Hereditary Amyloidosis

In addition to familial amyloid polyneuropathy, which is caused by mutations in the TTR gene, there are other hereditary systemic amyloidoses associated with mutations in apolipoproteins A1 and A2, fibrinogen A α chain, gelsolin, and lysozyme.[13]

Localized Amyloidosis

Localized amyloid deposition is not uncommon, although it is often undiag-

AMYLOIDOSIS AT A GLANCE



- In amyloidosis, normally soluble plasma proteins are deposited in the extracellular space in an abnormal insoluble fibrillar form.
- Amyloid deposition is remarkably diverse and can be localized or systemic, rapidly lethal or incidental.
- Diagnosis of amyloidosis relies on the demonstration of pathognomic red-green birefringence when biopsy specimens stained with Congo red are viewed under cross-polarized light.
- Management relies on determining the type (defined by the precursor protein) and discriminating systemic from localized forms. Treatment of systemic disease centers on reducing the production of the fibril precursor protein; management of localized disease is usually surgical or symptomatic.



TABLE 133-1
Classification of Systemic Amyloidosis

Type	Fibril Protein Precursor	Clinical Syndrome
AA	Serum amyloid A protein	Reactive systemic amyloidosis associated with chronic inflammatory diseases
AL	Monoclonal immunoglobulin light chains	Systemic amyloidosis associated with monoclonal plasma cell dyscrasias
Aβ_2M	β_2-Microglobulin	Periarticular and, occasionally, systemic amyloidosis associated with long-term dialysis
ATTR	Normal plasma transthyretin	Senile systemic amyloidosis with prominent cardiac involvement
ATTR	Genetically variant transthyretin	Autosomal dominant systemic amyloidosis Familial amyloid polyneuropathy
ACys	Genetically variant cystatin C	Hereditary cerebral hemorrhage with cerebral and systemic amyloidosis
AGel	Genetically variant gelsolin	Autosomal dominant systemic amyloidosis Predominantly cranial nerve involvement with lattice corneal dystrophy
ALys	Genetically variant lysozyme	Autosomal dominant systemic amyloidosis Non-neuropathic with prominent liver and renal involvement
AApoA1	Genetically variant apolipoprotein-A1	Autosomal dominant systemic amyloidosis May be neuropathic or with prominent liver and renal involvement
AApoA2	Genetically variant apolipoprotein-A2	Autosomal dominant systemic amyloidosis Non-neuropathic with prominent renal involvement
AFib	Genetically variant fibrinogen A α chain	Autosomal dominant systemic amyloidosis Non-neuropathic with prominent renal involvement



nosed, and accounts for 9.3 percent of all amyloidoses.[14] It results either from local production of fibril precursors or from properties inherent to the particular microenvironment that favor fibril formation in a widely distributed precursor protein. The vast majority of deposits are AL in type, and symptomatic deposits occur most frequently in the eye, skin, and respiratory and urogenital tracts.[15] They are often associated with extremely subtle focal monoclonal B-cell proliferation confined to the affected site, and surgical resection of these localized "amyloidomas" can sometimes be curative. Symptomatic apparently localized amyloid deposits can in rare cases be manifestations of systemic disease, and a full investigation should always be made to exclude more generalized amyloid deposition.[16] Progression from localized to systemic amyloidosis is very rare. In lichen and macular amyloidosis the fibrils are derived from keratin released from apoptotic keratinocytes. The etiology is not entirely clear, but the association with other pruritic conditions suggests that mechanical factors associated with chronic scratching and skin friction are probably crucial.[17]

CLINICAL FINDINGS

Most important in approaching amyloidosis is to determine whether the patient has systemic in addition to cutaneous involvement (Fig. 133-1).

History

In the majority of patients with systemic amyloidosis the presentation is non-specific, and as a result, amyloid is often an unexpected finding on biopsy of an affected organ.

AL AMYLOIDOSIS AL amyloidosis usually occurs in patients over the age of 50 years, although it can appear in very young adults.[9] In the majority of cases the underlying plasma cell clone is not detected until the patient presents with amyloid-related organ dysfunction. Clinical manifestations are extremely variable, because almost any organ other than the brain can be directly involved.[18] Although certain clinical features such as macroglossia and periorbital ecchymoses are very strongly suggestive of AL amyloidosis (Table 133-2) and multiple vital organ dysfunction is common, many patients have non-specific symptoms such as malaise and weight loss.

SYSTEMIC AA AMYLOIDOSIS AA amyloidosis can present anytime between childhood and old age, with a median age at presentation of 48 years in the United Kingdom. Almost 95 percent of patients have a previously diagnosed chronic inflammatory disease such as rheumatoid arthritis or one of the other inflammatory arthritides; chronic sepsis, usually with bronchiectasis; complications of paraplegic conditions; or drug abuse. The disorder is slightly more common in men, and although disease can develop very rapidly, the median latency between presentation with a chronic inflammatory disorder and clinically significant amyloidosis is almost two decades. Amyloidosis usually presents with proteinuria followed by progressive renal dysfunction, often accompanied by nephrotic syndrome.

SYSTEMIC HEREDITARY AMYLOIDOSIS The presentation of hereditary amyloidosis varies depending on the variant protein and mutation, and even differs within kindreds. Severe progressive peripheral and/or autonomic neuropathy is the major feature of hereditary TTR amyloidosis (familial amyloid polyneuropathy), but cardiac involvement is also common. Apolipoprotein-A1 amyloidosis sometimes causes neuropathy, but this is not a feature of the other hereditary types, which typically involve the viscera. All the amyloidogenic mutations are dominant, but they are variably penetrant and there may be no family history of the disorder.

Cutaneous Lesions

SYSTEMIC AL AMYLOIDOSIS Cutaneous manifestations are common in systemic amyloidosis, particularly the AL type, and are reported in up to 40 percent of patients.[9] The lesions usually reflect capillary infiltration and fragility, and manifest as petechiae and purpura, particularly affecting the eyelids, beard area, and upper chest (Fig. 133-2A). Xanthomatous papules or plaques are also frequently observed, and amyloidotic hyperpigmented keratotic lesions have been reported occasionally. *Pinch purpura* describes a phenomenon

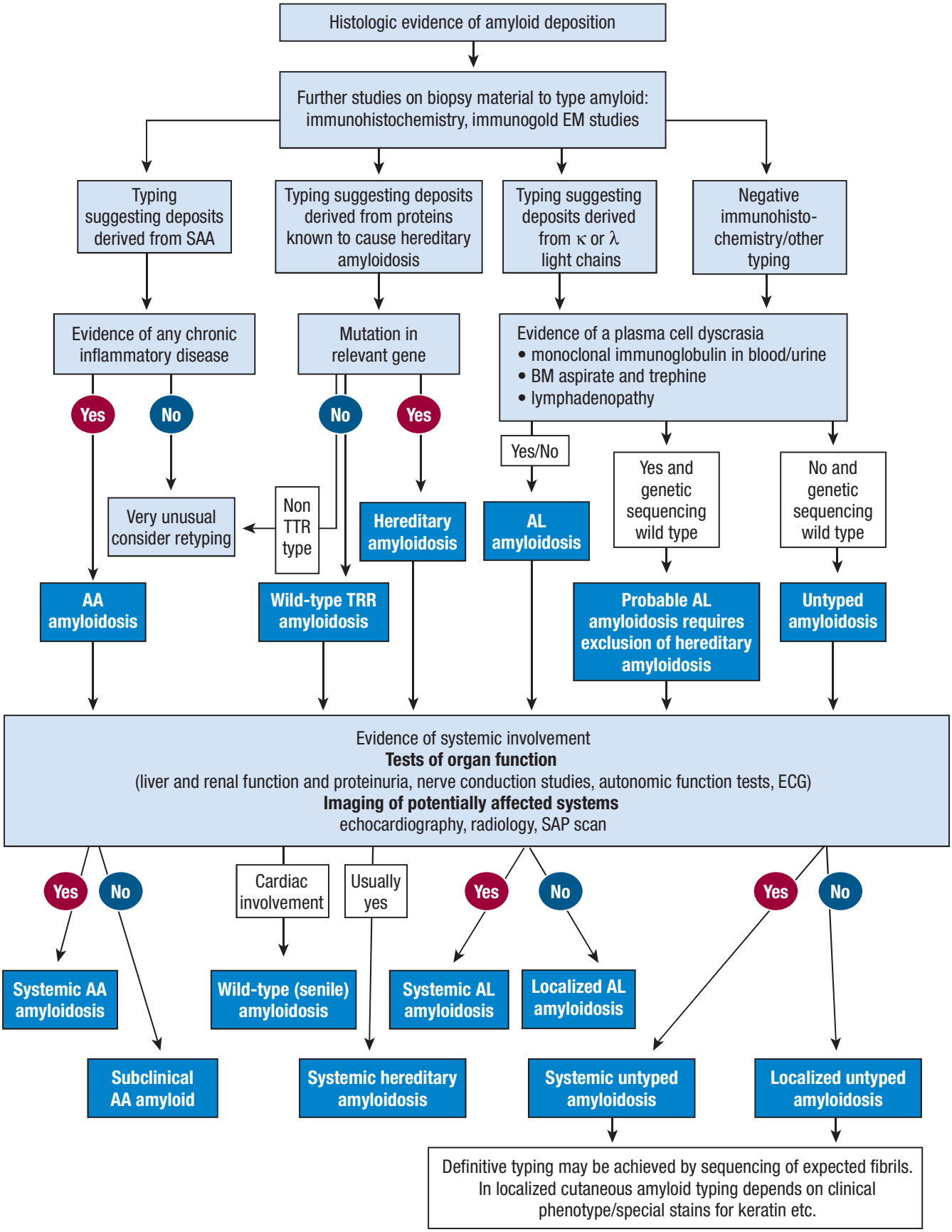

▲ **FIGURE 133-1** Approach to the patient with amyloidosis. Management of amyloidosis depends entirely on correct typing. This is both highly specialized and complex. Definitive typing requires a number of special tests and is best carried out in experienced centers. BM = bone marrow; ECG = electrocardiography; EM = electron microscopy; SAA = serum amyloid A protein; SAP = serum amyloid P component; TTR = transthyretin.





TABLE 133-2
Clinical Features That May Be Seen in Association with Systemic AL Amyloidosis

Visible tissue infiltration	Bruising (particularly periorbital) Macroglossia Muscle or joint pseudohypertrophy
Kidneys	Proteinuria Hypertension Chronic renal failure
Heart	Restrictive cardiomyopathy Arrhythmias Congestive cardiac failure
Liver	Hepatomegaly Liver failure (very rare)
Peripheral nervous system	Carpal tunnel syndrome Symmetric sensorimotor neuropathy
Autonomic nervous system	Orthostatic hypotension Impotence Disturbed bowel motility Impaired bladder emptying
Gastrointestinal system	Weight loss Gastrointestinal blood loss Disturbed bowel motility
Lymphoreticular system	Splenomegaly Lymphadenopathy
Adrenal axis	Hypoadrenalism

that appears when an amyloid papule or plaque is pinched or rubbed and hemorrhage into the tissue occurs (see eFig. 133-2.1 in on-line edition). Other rare cutaneous lesions include scleroderma-like changes (see Fig. 133-2B), alopecia, and nail dystrophy (see Fig. 133-2C). Bullous amyloidosis has been described in a few individuals. The bullae of the skin and mucosae can be intradermal or sub-epidermal and present as tense, often hemorrhagic blisters. Generalized infiltration of cutaneous tissues can frequently cause the appearance of skin thickening with loss of facial wrinkles and can be sufficient to limit mouth opening.

HEREDITARY AMYLOIDOSIS Lysozyme amyloidosis frequently causes petechial rashes (see eFig. 133-2.2 in on-line edition), and apolipoprotein-A1 amyloidosis can also manifest as yellowish infiltrated plaques and acanthosis nigricans–type lesions.[19] Cutaneous lesions in familial amyloid polyneuropathy seem to be largely due to the peripheral neuropathy and included xerosis in 82 percent, seborrheic dermatitis in 22 percent, trauma or burn lesions in 20 percent, neuropathic ulcers in 14 percent, and onychomycosis in 10.5 percent of 142 Portuguese patients.[20]



▲ **FIGURE 133-2** Cutaneous manifestations of systemic AL amyloidosis. **A.** Purpura caused by capillary fragility. **B.** Scleroderma-like skin changes affecting the hands. **C.** Nail dystrophy.

LOCALIZED CUTANEOUS AL AMYLOIDOSIS As in systemic AL amyloidosis, the fibrils in localized AL amyloidosis are derived from N-terminal cleavage fragments of monoclonal immunoglobulin light chains. The lesions are those seen in systemic AL amyloidosis and present as single or, more frequently, multiple lesions anywhere on the skin. In a series of 20 patients; 35 percent had indolent







▲ **FIGURE 133-3** **A–C.** Localized AL amyloidosis resulting in slowly progressive papular to plaque lesions.

papular, nodular, or xanthomatous lesions (Fig. 133-3); 20 percent had purpuric rash; 20 percent had pruritus; 15 percent had local bleeding; and 10 percent had localized swelling. In only 15 percent of cases were the lesions painful.[21]

MACULAR AMYLOIDOSIS AND LICHEN AMYLOIDOSIS Macular and lichen amyloidosis are variants of a single pathology in which the amyloid fibrils are derived from keratin after epidermal damage and keratinocyte apoptosis. They are usually idiopathic or friction related but have been reported in association with connective tissue diseases (primary biliary cirrhosis and systemic lupus erythematosus)[22] and in a few kindreds with pachyonychia congenita[23] and multiple endocrine neoplasia type 2a.[24]

Macular amyloidosis usually affects the upper back and limbs and can persist for many years (Fig. 133-4). The rash is pruritic in the great majority of cases and consists of small brownish macules distributed in a rippled pattern. There may be a female preponderance,[25] and the disorder is more common among Central and South Americans, Middle Easterners, and non-Chinese Asians. Amyloid deposits usually are confined to the papillary dermis and do not involve blood vessels or adnexal structures. Early lesions contain small, multifaceted, amorphous globules within the papillae, and these are missed easily without the use of special stains. Later lesions show globules that coalesce, expand the papillae, and displace the rete ridges laterally.

Lichen amyloidosis is the most common type of cutaneous amyloidosis in Chinese individuals and usually affects adults. It is clinically characterized by an intensely pruritic eruption of multiple discrete hyperkeratotic papules that may coalesce to form gray-brown plaques (Fig. 133-5). They are usually distributed on the extensor surfaces of the lower extremities, although lesions may also involve the extensor aspects of the arms and the trunk. Histologically the deposits are very similar to those in macular amyloidosis but slightly larger and are accompanied by irregular acanthosis and hyperkeratosis of the overlying epidermis.



▲ **FIGURE 133-4** Macular amyloidosis of the back in a patient of Arab extraction.

ANOSACRAL CUTANEOUS AMYLOIDOSIS Anosacral cutaneous amyloidosis is a rare syndrome described in Japanese and Chinese males in which pigmented macules and glossy hyperkeratotic lesions radiate out from the anus.[24]

OTHER TYPES OF LOCALIZED CUTANEOUS AMYLOIDOSIS Deposition of insignificant microscopic amounts of amyloid in association with a variety of cutaneous lesions is well recognized. Reported predisposing conditions include intradermal nevi, sweat gland tumors, pilomatrixoma, dermatofibroma, seborrheic keratosis, solar elastosis, photosensitive annular elastolytic giant cell granuloma, actinic keratosis, porokeratosis of Mibelli, Bowen disease, basal cell carcinoma, and treatment with psoralen plus ultraviolet A radiation.

Related Physical Findings

SYSTEMIC AL AMYLOIDOSIS Systemic AL amyloidosis is protean in its manifestations (see Table 133-2), it can present with visible lymphadenopathy, macroglossia, muscle pseudohypertrophy, and periorbital purpura (Fig. 133-6) and can cause signs in any organ system except the brain.

SYSTEMIC AA AMYLOIDODOSIS Systemic AA amyloidosis presents with nephrotic



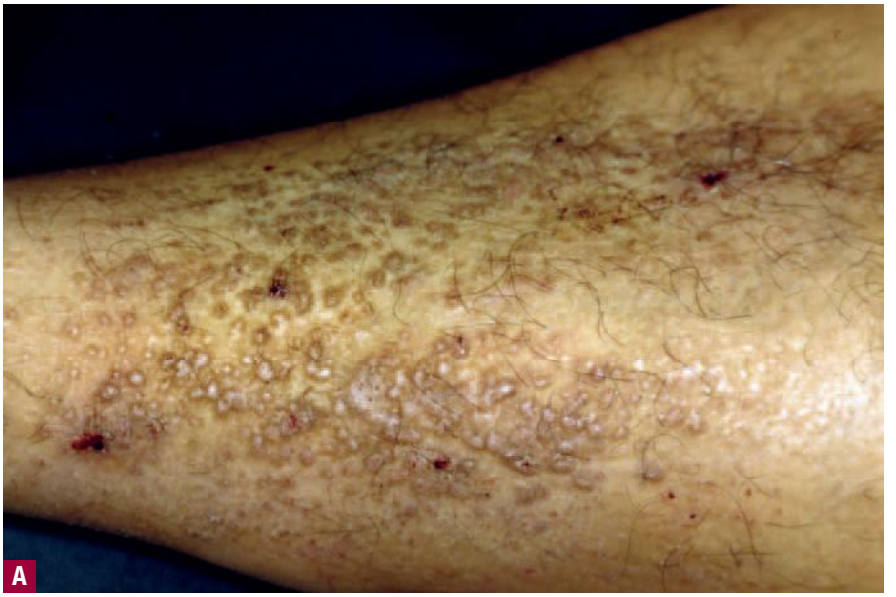

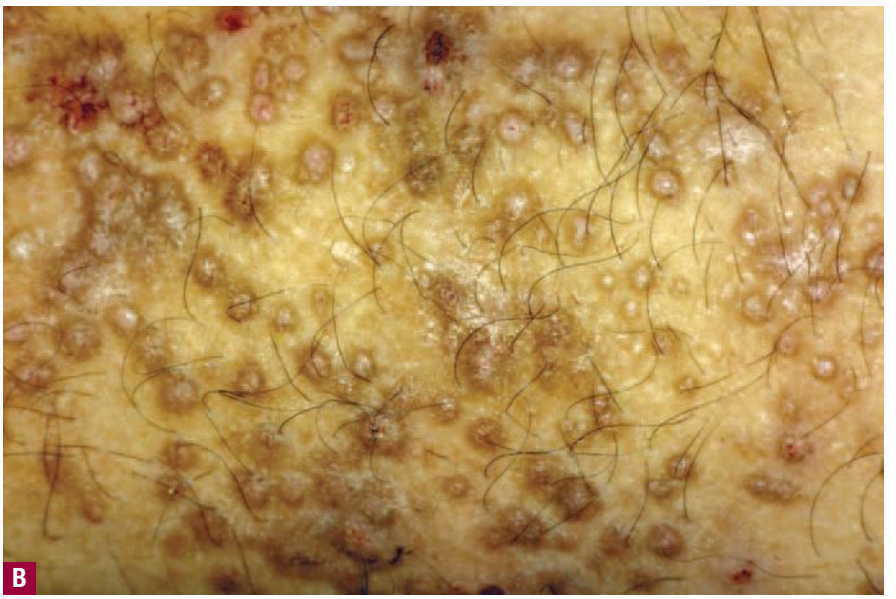

▲ **FIGURE 133-5** Lichen amyloidosis. **A.** Multiple extremely pruritic hyperkeratotic papules. **B.** Larger magnification to show the hyperkeratotic appearance of the lesions.

syndrome in just under half of patients. Clinically, splenomegaly is frequent and hepatomegaly is detected in 10 percent of cases. Cardiac involvement and peripheral or autonomic neuropathy are very rare.

HEREDITARY AMYLOIDOSIS The physical findings in hereditary amyloidosis depend on the variant protein and specific mutations and may differ even within individual families.

LABORATORY TESTS

All patients should undergo comprehensive assessment of renal and liver function, including blood tests and quantification of creatinine clearance and proteinuria.[27] A search should be made for evidence of an underlying plasma cell dyscrasia by serum and urine electrophoresis and immunofixation.[28] In suspected amyloidosis of the AL type, bone marrow aspiration and trephine sampling are usually mandatory. Where available, serum assays of potential fibril precursor proteins, free immunoglobulin light chains in AL type, and SAA in AA amyloidosis are very valuable.[29]

SPECIAL TESTS

Histopathology

The identification of amyloid depends on the pathognomonic red-green dichroism observed when tissue stained with the aniline dye Congo red is viewed under cross-polarized light[30] (Fig. 133-7). This optical effect is produced by alignment of the dye molecules along the fibrils. Binding of thioflavin T usually corresponds to Congo red birefringence but is less specific. Congo red staining for amyloid is not a very sensitive test and requires the presence



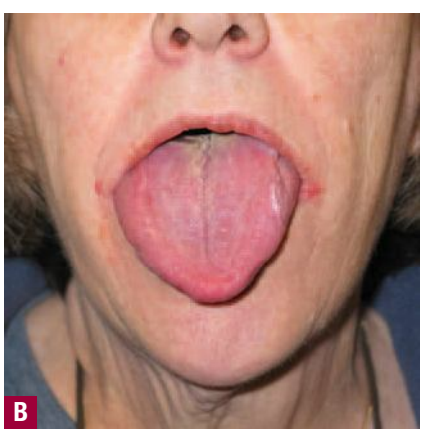



▲ **FIGURE 133-6** Visible tissue infiltration in systemic AL amyloidosis, causing lymphadenopathy (**A**), macroglossia (**B**), and periorbital purpura (**C**).

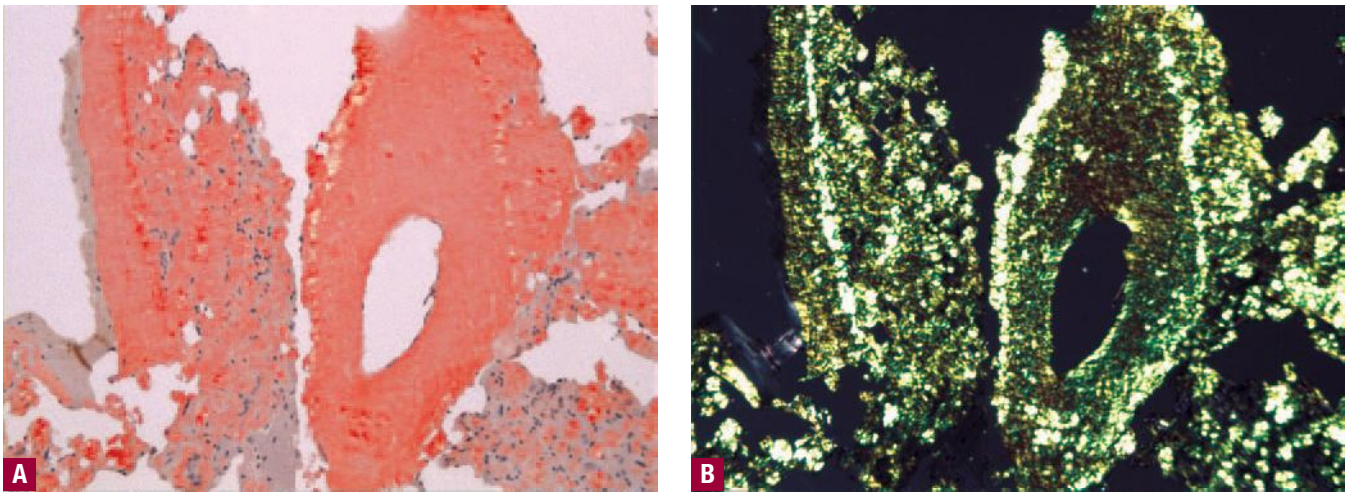

▲ **FIGURE 133-7** Typical appearances of amyloid deposits. **A.** Congo red staining. **B.** Same section viewed under cross-polarized light with red-green birefringence.

of an adequate amount of amyloid, the use of sufficiently thick tissue sections, technically correct staining and visualization procedures, and adequate observer experience. In negatively stained electron microscopic specimens, amyloid fibrils are usually approximately 10 nm in diameter, straight, rigid, nonbranching, of indeterminate length, and composed of twisted protofibrils.

Positive results for amyloid on histologic analysis must be followed up by immunohistochemical testing to determine the fibril protein type.[16] Suitable antibodies are widely available, but although immunohistochemical analysis usually yields definitive results in AA amyloidosis, it is frequently not diagnostic for AL deposits.[31] Expertise in the immunohistochemical typing of amyloid in hereditary disease is limited, and definitive immunohistochemical typing of amyloid deposits cannot always be achieved.[32] Direct sequencing of extracted fibrils permits identification of the amyloid type, but the required techniques are generally available only in a research setting.

Genetic Sequencing

Amyloidogenic mutations should be sought in all patients in whom the amyloid type remains undetermined, because hereditary amyloidosis accounts for a substantial number of these cases.[32]

Imaging of Amyloid In Vivo

SERUM AMYLOID P COMPONENT SCINTIGRAPHY SAP is a highly conserved, invariant plasma glycoprotein of the pentraxin family that becomes specifically and highly concentrated in amyloid deposits of all types as a result of its calcium-dependent binding to amyloid fibrils. Radiolabeled SAP scintigraphy can be used for diagnosis and quantitative monitoring of amyloid deposits.[33] This safe and non-invasive method provides information on the presence, distribution, and extent of visceral amyloid deposits (except in the heart), and serial scans allow monitoring of progress and response to therapy (see eFig. 133-7.1 in on-line edition).

CARDIAC IMAGING Cardiac amyloidosis is best evaluated by a combination of echocardiography and electrocardiography.[34] Two-dimensional Doppler echocardiography classically reveals concentric biventricular wall thickening with a restrictive filling pattern. Amyloid causes diastolic dysfunction with well-preserved contractility until a very late stage. The electrocardiogram may be normal in patients with substantial cardiac amyloidosis, but in advanced disease commonly shows small voltages, pathologic Q waves (pseudo-infarct pattern).[35] Newer magnetic resonance imaging techniques can also contribute to assessment of the severity of cardiac amyloidosis,[36] as can serum assays of the cardiac biomarkers N-terminal pro-brain natriuretic peptide[37] and troponin T.[38]

DIFFERENTIAL DIAGNOSIS

See Box 133-1.

COMPLICATIONS

Systemic AL Amyloidosis

Restrictive cardiomyopathy is the presenting feature in up to one-third of patients and ultimately the cause of death in one-half.[39] Renal involvement is frequent and presents with proteinuria and progressive renal impairment.[40] Gut involvement can cause motility disturbances (often secondary to autonomic neuropathy), malabsorption, perforation, hemorrhage, or obstruction.[41] Peripheral neuropathy occurs in one-fifth of cases and typically manifests as a painful sensory polyneuropathy followed later by motor deficits.[9] Autonomic neuropathy causing orthostatic hypotension, impotence, and gastrointestinal disturbances may occur in isolation or with a peripheral neuropathy.[18]

Systemic AA Amyloidosis

Progressive renal failure and nephrotic syndrome are the usual complications in AA amyloidosis. Although splenic amyloid deposits are almost universally

Box 133-1

Differential Diagnosis of Cutaneous Amyloidosis

Most Likely

- Atopic dermatitis
- Lichen sclerosus
- Prurigo nodularis
- Poikiloderma of Civatte
- Post-inflammatory hyperpigmentation
- Sebaceous hyperplasia
- Xanthoma

Consider

- Dermatomyositis
- Scleroderma
- Mastocytosis
- Pseudoxanthoma elasticum
- Colloid milium
- Pretibial myxedema
- Nodular pseudolymphoma

Always Rule Out

- Systemic amyloidosis



present in the AA type, they are usually asymptomatic. Hepatic involvement and autonomic neuropathy are well recognized but usually occur very late in the disease. Cardiac amyloidosis occurs in fewer than 2 percent of cases.

Hereditary Amyloidosis

Familial polyneuropathy causes progressive peripheral and/or autonomic neuropathy and cardiomyopathy and in some cases visual loss due to vitreous amyloid deposits. Apolipoprotein-A1 amyloidosis can cause peripheral neuropathy, but as with apolipoprotein-A2, lysozyme, and fibrinogen A α chain types, renal or hepatic amyloidosis is typical. Gelsolin-related amyloidosis causes a characteristic clinical picture of corneal lattice dystrophy and cranial neuropathy.



Localized Cutaneous Amyloidosis

Localized cutaneous amyloidosis produces only local complications, usually in the form of pruritus or bleeding, and is rarely painful.

PROGNOSIS AND CLINICAL COURSE

Although recent advances have greatly extended median survival time, the prognosis for systemic amyloidosis remains grave.

Systemic AL Amyloidosis

Prognosis is particularly poor in AL disease, because the diagnosis is often made late when patients already have substantial visceral and/or neural involvement. A 5-year survival rate of approximately 10 percent and a 10-year survival rate of less than 5 percent have been reported for the AL type.[9] Most affected individuals eventually die of heart failure, uremia, or autonomic failure.

Systemic AA Amyloidosis

The prognosis of AA amyloidosis depends on how much renal dysfunction is present at diagnosis and whether the underlying chronic inflammatory disease can be effectively suppressed, so that the plasma SAA level is maintained within the normal healthy range.[42] In a cohort of 374 patients, median survival was just over 11 years, and a third of patients developed end-stage renal failure, which was the major cause of death.

Hereditary Amyloidosis

In familial amyloid polyneuropathy, median survival time is 10 to 15 years without liver transplantation.[43] Death is from progressive neuropathy and/or cardiomyopathy. In the other hereditary amyloidoses, either renal or hepatic failure is the major cause of mortality, but the time to reach end-stage organ failure is very variable.

Localized Cutaneous Amyloidosis

The localized cutaneous amyloidoses are skin-limited conditions that are not usually associated with any increase in mortality.

TREATMENT

Treatment of all types of amyloidosis centers on measures that can reduce the supply of the respective amyloid fibril precursor protein, while supporting or replacing compromised organ function.[29,42] Under favorable circumstances, this results in regression of existing amyloid deposits, preservation or recovery of the function of amyloidotic organs, and much improved patient survival. Such treatment requires precise identification of the amyloid fibril type, for which specialist diagnostic expertise and immunohistochemical testing, DNA sequencing, and direct fibril sequencing may be required. Monitoring of therapeutic efficacy and rational decision making about further treatment options are enhanced by the current availability of routine assays for circulating free immunoglobulin light chains in AL amyloidosis[44] and SAA in AA amyloidosis.[45]

Systemic AL Amyloidosis

Treatment in AL amyloidosis aims to suppress proliferation of the underlying B-cell clone and, therefore, production of the amyloidogenic monoclonal immunoglobulin. This approach is not without problems.[46] Chemotherapy regimens are based on those used in the treatment of multiple myeloma, but the majority of plasma cell dyscrasias in AL patients are low grade and may be less chemosensitive. Diagnosis can be delayed, and many patients have advanced multisystem disease,[47] which limits their options for chemotherapy. Regression of amyloid is a gradual process that may not lead to measurable clinical improvement or recovery of organ function for many months, or even years, after successful suppression of the causative plasma cell dyscrasia.[48,49] Mobilization of amyloid from the heart is much slower than mobilization from the liver or kidneys, and many patients with cardiac or multisystem dysfunction do not live long enough to benefit from chemotherapy, even when it has suppressed their clonal disease. Nonetheless, many patients with AL amyloidosis do benefit substantially from chemotherapy. Prolonged low-intensity cytotoxic regimens such as oral melphalan and prednisolone are beneficial in approximately 20 percent of patients, and this is the only treatment to have been proven helpful in placebo-controlled trials.[50,51] Although there have been no comparative clinical trials, dose-intensive infusional chemotherapy regimens such as vincristine, doxorubicin (Adriamycin), and dexamethasone (VAD)[52] and autologous peripheral blood stem cell transplantation are almost certainly much more effective.[53,54] Very rigorous patient selection for high-dose chemotherapy is essential, because the procedure-related mortality is extremely high in individuals with multiple-organ involvement.[55]

Systemic AA Amyloidosis

Significant reduction of SAA values by treatment of the primary inflammatory conditions responsible for AA amyloidosis dramatically improves survival and is associated with arrest of amyloid deposition and frequently regression of deposits.[56] The new biologic drugs targeting key cytokine mediators of inflammation potently suppress the acute-phase response in many patients with inflammatory arthritis, Crohn disease, and some hereditary periodic fevers. Treatment with colchicine is mandatory to prevent AA amyloidosis in familial Mediterranean fever.

Hereditary Amyloidosis

At present, apart from transplantation to replace failed organs and liver transplantation to reduce production of amyloidogenic proteins that are synthesized by the liver, only symptomatic treatment is available for hereditary systemic amyloidosis. The liver is the source of plasma TTR, and almost 1000 liver transplants have been performed for treatment of hereditary TTR amyloidosis since this "surgical gene therapy" approach was introduced in 1991.[43] In younger patients carrying the common Val30Met mutation the outcome is gen-

erally good, with arrest of neuropathy and regression of visceral amyloid, but the outcome in patients with other mutations has been less positive.[57]

Systemic Amyloidosis: Novel Treatments

Better understanding of the mechanisms underlying amyloid formation[58] has led to the development of novel treatment strategies aimed at inhibiting fibrillogenesis or destabilizing existing amyloid deposits.[59,60]

Localized Cutaneous AL Amyloidosis

Small localized amyloid deposits can be removed surgically or by laser if they are cosmetically disfiguring or bleeding, but there is a very high rate of local recurrence. The possibility that systemic chemotherapy may be of any benefit in localized AL amyloidosis has not been systematically tested.

Macular and Lichen Amyloidosis

Persistent friction is a major etiologic factor in the macular and lichen forms of localized amyloidosis. Treatment modalities should be directed toward minimizing trauma and relief of pruritus in these conditions.[61] Sedating antihistamines have been found to be moderately effective, and intralesional steroids are beneficial if combined with other modalities. Topical dimethylsulfoxide has been used with moderate success but is often unacceptable to patients due to the smell. Treatment with ultraviolet B light can provide symptomatic relief.[62] There is one report of improvement after treatment with 0.1 percent topical tacrolimus ointment.[63] Administration of acitretin may also be beneficial.[64]

KEY REFERENCES

The full reference list for all chapters is available at www.digm7.com.

29. Lachmann HJ et al: Outcome in systemic AL amyloidosis in relation to changes in concentration of circulating free immunoglobulin light chains following chemotherapy. *Br J Haematol* **122**:78, 2003
32. Lachmann HJ et al: Misdiagnosis of hereditary amyloidosis as AL (primary) amyloidosis. *N Engl J Med* **346**:1786, 2002
58. Merlini G, Bellotti V: Molecular mechanisms of amyloidosis. *N Engl J Med* **349**:583, 2003
60. Dember LM: Emerging treatment approaches for the systemic amyloidoses. *Kidney Int* **68**:1377, 2005



CHAPTER 134

Systemic Autoinflammatory Diseases

John G. Ryan
Daniel L. Kastner

ABNORMAL INFLAMMATORY RESPONSE

The autoinflammatory diseases are a group of disorders that are characterized by seemingly unprovoked inflammation. Unlike autoimmune diseases, these conditions are notable for the general absence of high titers of autoantibodies or autoreactive T-cell populations.[1] Advances in our knowledge of these diseases suggest that abnormalities in proteins involved in activation of the innate immune system may result in abnormal triggering of the body's proinflammatory cytokine network. The number of conditions falling under the rubric of autoinflammatory continues to expand. It now encompasses a broad range of seemingly disparate disorders, including vasculitic syndromes (Behçet disease), granulomatous diseases (Blau and Crohn diseases), metabolic disorders (gout and pseudogout), and fibrosing disorders (idiopathic pulmonary fibrosis) as well as the group of hereditary recurrent fevers that established the autoinflammatory disease grouping. The focus of this chapter is the Mendelian autoinflammatory diseases, which include all of the hereditary recurrent fever syndromes and the syndrome of pyogenic arthritis with pyoderma gangrenosum and acne. The hereditary recurrent fever syndromes are characterized by self-limiting episodes of fevers with localized inflammatory manifestations, including skin rashes, serositis, and arthritis. Based on clinical features and inheritance patterns, distinct groups of conditions can be identified among these hereditary recurrent fever syndromes (Table 134-1). Two of these conditions, familial Mediterranean fever and hyperimmunoglobulinemia D with periodic fever syndrome, are inherited in an autosomal recessive manner. The other diseases are dominantly inherited. Specific gene mutations have been identified in each of these conditions.

FAMILIAL MEDITERRANEAN FEVER

Epidemiology, Etiology, and Pathogenesis

Familial Mediterranean fever (FMF) is the prototype autoinflammatory disease. FMF [Online Mendelian Inheritance in Man (OMIM) #249100][2] is a rare, recessively inherited disease most frequently observed in those of Jewish, Arabic, Armenian, Turkish, or Italian ancestry.[3] A male predominance has been reported.[4] FMF is caused by mutations in *MEFV* (MEditerranean FeVer), a 10-exon gene encoded on the short arm of chromosome 16. To date, over 70 disease-associated mutations have been described, with many clustered on exon 10.[5,6] In high-risk populations, the carrier frequency for *MEFV* mutations may reach one in three. An on-line database of periodic fever mutations, INFEVERS,[7] has been established that provides an updated list of *MEFV* mutations and polymorphisms. *MEFV* codes for a 781–amino acid protein called *pyrin*, which may act as a regulatory molecule in the innate immune system. Abnormal pyrin may lead to an excess of interleukin 1β (IL-1β) secretion.[8]

Clinical Findings

A typical FMF attack is characterized by a prodromal period of a few hours, during which some patients experience chills, followed by episodes of fever that usually last 1 to 3 days, associated with serositis, synovitis, or skin rash.[9] The first clinical episode usually occurs in childhood or adolescence.[10] The time between attacks may vary from days to years. At some point during their illness up to 95 percent of patients experience FMF-associated episodes of abdominal

SYSTEMIC AUTOINFLAMMATORY DISEASES AT A GLANCE



- Seemingly unprovoked inflammation without high titers of autoantibodies or antigen-specific T cells.
- Disorders of innate immunity.
- Mendelian autoinflammatory diseases include hereditary recurrent fever syndromes and the syndrome of pyogenic arthritis with pyoderma gangrenosum and acne (PAPA).
- Hereditary recurrent fevers are characterized by episodes of fever with localized inflammation. Skin, joints, and serosal membranes are commonly affected. Symptom onset usually occurs in childhood.
- Two recessively inherited recurrent fever syndromes: Familial Mediterranean fever (FMF) and hyperimmunoglobulinemia D with periodic fever syndrome (HIDS).
- Four dominantly inherited syndromes: Tumor necrosis factor receptor–associated periodic syndrome (TRAPS) and three cryopyrinopathies—familial cold autoinflammatory syndrome (FCAS), Muckle-Wells syndrome (MWS), and neonatal-onset multisystem inflammatory disease (NOMID).
- FMF, MWS, FCAS, and NOMID are caused by mutations in the pyrin family of proteins, which play a key role in the innate immune system.
- Characteristic skin rashes are noted in each of the recurrent fever syndromes.
- Colchicine prevents the attacks and amyloidosis in FMF.
- Targeted anti-cytokine therapy appears promising in the treatment of TRAPS, HIDS, the cryopyrinopathies, and resistant cases of FMF.
- PAPA syndrome is a dominantly inherited disorder caused by mutations in a pyrin-binding protein. Anecdotal reports of therapeutic responses to targeted anti-cytokine therapy are encouraging.



pain, which may range from a dull ache to full-blown peritonitis. Pleuritic episodes may occur without fever. Scrotal pain may occur in 5 percent of prepubertal boys. Acute monoarticular arthritis is most characteristic of FMF and may affect the hip, knee, or ankle. Febrile myalgia may occur, notable for excruciating muscle pain lasting as long as several weeks.[11] Attacks may vary both in intensity and clinical features. Very young children may have fever alone.[12] Strenuous physical activity or emotional stress may precipitate attacks.

Erysipeloid erythema is the most characteristic rash of FMF.[13] It consists of warm, tender, swollen erythematous plaques, 10 to 15 cm in diameter, with well-defined borders. Lesions are located on the lower limbs, usually below the knee, and may in particular affect the dorsum of the foot, ankle, or lower leg. The lesions may be bilateral, may be initiated by prolonged walking, and subside within 24 to 48 hours. On palpation the lesion is hot, tender, and swollen. Other cutaneous manifestations of FMF have been described, including localized edema affecting the upper or lower limbs, face, or neck, and subcutaneous nodules.[14] Vasculitic purpura, including Henoch-Schönlein purpura, has also been described in up to 5 percent of FMF patients. Episodic scattered non-specific purpuric papular lesions affecting the face, trunk, or extremities are more frequently observed in children.[15]

Laboratory Tests and Special Tests

During attacks, complete blood counts demonstrate leukocytosis, with elevated erythrocyte sedimentation rate and elevated levels of acute-phase reactants, including C-reactive protein, fibrinogen, haptoglobin, and serum amyloid A (SAA) (see Chap. 133). Transient albuminuria and microscopic hematuria may be noted during attacks. In ethnicities with a high incidence of FMF, typical symptoms and a therapeutic response to colchicine may suffice to establish the diagnosis of FMF. Genetic testing for mutations in *MEFV* may be used as an adjunct in the diagnosis of FMF in atypical cases and in ethnicities with a low prevalence of FMF. The interpretation of genetic testing is complicated by the observation that a significant fraction of patients with typical clinical symptoms may have only one *MEFV* mutation, rather than two as would be expected in an autosomal recessive condition.

Histopathology

Biopsy specimens of patients with erysipeloid erythema demonstrate slight edema of the superficial dermis with sparse perivascular infiltrates of lymphocytes, polymorphonuclear leukocytes, histiocytes, and nuclear dust. Immunofluorescence demonstrates C3 deposits in the capillary walls in the papillary and, occasionally, the upper reticular dermis.[13]

Differential Diagnosis

The differential diagnosis in a particular patient is specific to the type of attack (Box 134-1). In patients with peritonitis, acute appendicitis may be suspected; however, spontaneous resolution of fever is a clue to the diagnosis of FMF. Hereditary angioedema may present with abdominal pain but usually does not cause fever. Hypertension and a pattern of dominant inheritance help to differentiate porphyria from FMF in patients with abdominal pain and fever. In children, systemic-onset juvenile idiopathic arthritis (SOJIA) is a consideration. Evanescent rash, quotidian fever pattern, lymphadenopathy, and polyarthritis are highly suggestive of SOJIA.

Complications

The most serious complication of FMF is the development of systemic amyloidosis due to deposition of the acute-phase reactant SAA (see Chap. 133). SAA may be deposited in the kidneys, gastrointestinal tract, spleen, testes, thyroid, adrenal glands, and lung. Amyloid deposits in the kidney may result in nephrotic syndrome and subsequent renal failure. Amyloidosis is associated with significant morbidity and mortality. Before the use of colchicine, renal failure secondary to amyloidosis was the most common cause of death in patients with FMF.

Prognosis and Clinical Course

Daily use of colchicine results in near complete remission in three-fourths of patients, with 95 percent noting a marked improvement. Widespread use of colchicine has reduced the incidence of amyloidosis and resultant complications. Rarely, patients may develop polyarteritis nodosa, an arteritis of small- and medium-sized vessels affecting multiple sites, especially the intestine,

TABLE 134-1
Characteristics of the Mendelian Autoinflammatory Diseases

	Familial Mediterranean Fever (FMF)	Hyperimmunoglobulinemia D Syndrome (HIDS)	TNF Receptor–Associated Periodic Syndrome (TRAPS)	Familial Cold Autoinflammatory Syndrome (FCAS)	Muckle-Wells Syndrome (MWS)	Neonatal-Onset Multisystem Inflammatory Disorder (NOMID)	Pyogenic Arthritis with Pyoderma Gangrenosum and Acne (PAPA)
Inheritance	AR	AR	AD	AD	AD	AD, de novo	AD
Underlying gene	*MEFV*, encoding pyrin	*MVK*, encoding mevalonate kinase	*TNFRS1A*, encoding p55 TNF receptor	*CIAS1*, encoding cryopyrin	*CIAS1*, encoding cryopyrin	*CIAS1*, encoding cryopyrin	*PSTPIP1*
Ethnic groups usually affected	Turkish, Armenian, Arab, Jewish, Italian	Dutch, other northern European	Any ethnicity	Mostly European	Mostly European	Any ethnicity	Any ethnicity
Duration of attacks	12–72 h	3–7 days	Days to weeks	12–24 h	24–48 h	Continuous, with flares	Episodic, lasting weeks to months
Cutaneous lesions	Erysipeloid erythema on lower leg, ankle, foot	Diffuse maculopapular rash, urticaria	Migratory rash with underlying myalgia	Cold-induced urticarial rash	Urticaria-like rash	Urticaria-like rash	Severe cystic acne, pyoderma gangrenosum
Abdominal findings	Sterile peritonitis, constipation	Severe pain, vomiting, diarrhea	Peritonitis, diarrhea or constipation	Nausea	Abdominal pain	Not common	Not seen
Arthropathy	Monoarthritis-arthritis in knee or hip	Arthralgia, symmetric polyarthritis	Arthritis in large joints, arthralgia	Polyarthralgia	Polyarthralgia, oligoarthritis, clubbing	Epiphyseal overgrowth, contractures, clubbing	Destructive arthritis; purulent, sterile joint fluid.
Ocular findings	Rare	Uncommon	Periorbital edema, conjunctivitis, rarely uveitis	Conjunctivitis	Conjunctivitis, episcleritis	Vision loss, uveitis	Not seen
Neurologic findings	Rarely aseptic meningitis	Headache	Controversial	Headache	Sensorineural deafness	Deafness, meningitis, retardation	Not seen
Systemic amyloidosis	Depends on *MEFV* genotype, geographical factors, and colchicine use	Rare	Occurs in ~10%	Rare	Occurs in ~25%	May develop in some patients	Not described
Treatment	Daily colchicine, anti-TNF, IL-1 investigational	Anti-TNF, IL-1 receptor antagonist, or montelukast investigational	Corticosteroids, anti-TNF	IL-1 receptor antagonist	IL-1 receptor antagonist	IL-1 receptor antagonist	Corticosteroids, IL-1 receptor antagonist, or anti-TNF

AD = autosomal dominant; AR = autosomal recessive; IL-1 = interleukin 1; TNF = tumor necrosis factor.

kidney, and peripheral nerves[16] (see Chap. 165).

Treatment and Prevention

Daily oral colchicine is the mainstay of treatment. Adults and children over 5 years may require 1.2 to 1.8 mg for clinical effect.[17] Lower dosages may suffice for younger children. A common side effect of colchicine is diarrhea, which can be minimized by commencing treatment at a low dosage and gradually titrating upward. Lactose intolerance may develop in some patients treated with colchicine and should be appropriately addressed. Elderly patients or those with renal impairment treated with colchicine may develop myopathy or neuropathy.[18] In patients with amyloidosis, the aim of therapy is to reduce SAA levels below 10 mg/L. Patients with incomplete response to colchicine may benefit from biologic therapies targeted at IL-1β or tumor necrosis factor (TNF), or administration of subcutaneous interferon-α, although these therapies remain investigational for this condition. Those who develop vasculitis may require corticosteroids alone for Henoch-Schönlein purpura or corticosteroids and cyclophosphamide for manifestations of polyarteritis nodosa.

HYPERIMMUNOGLOBULINEMIA D WITH PERIODIC FEVER SYNDROME

Epidemiology, Etiology, and Pathogenesis

Hyperimmunoglobulinemia D with periodic fever syndrome (HIDS) is a rare condition (OMIM #260920) that occurs most commonly in persons of northern European ancestry,[19] although cases



Box 134-1

Differential Diagnosis of the Hereditary Recurrent Fever Syndromes

All Recurrent Fever Syndromes

- Systemic-onset juvenile idiopathic arthritis
- Adult-onset Still disease
- Behçet disease

Familial Mediterranean Fever and TNF Receptor–Associated Periodic Fever Syndrome

- Acute abdominal pain
  - Acute surgical abdomen
  - Appendicitis/pancreatitis or cholecystitis
  - Porphyria
  - Hereditary angioedema
  - Pelvic inflammatory disease
  - Crohn disease

Familial Cold Autoinflammatory Syndrome

- Acquired cold urticaria

Hyperimmunoglobulinemia D with Periodic Fever Syndrome

- Periodic fever with aphthous stomatitis, pharyngitis and cervical lymphadenopathy

TNF Receptor–Associated Periodic Fever Syndrome

- Adult-onset Still disease
- Systemic-onset juvenile idiopathic arthritis

Pyogenic Arthritis with Pyoderma Gangrenosum and Acne

- Synovitis, acne, pustulosis, hyperostosis, and osteitis syndrome

TNF = tumor necrosis factor.



have now been reported in many other ethnic groups.[20] HIDS is inherited as a monogenic autosomal recessive trait. In 1999, the genetic basis for HIDS was discovered[19,21] with the demonstration of mutations in the gene encoding mevalonate kinase, an enzyme involved in cholesterol and nonsterol isoprene biosynthesis.[21] HIDS-associated mutations result in low levels of residual enzyme function, which lead to increased levels of the substrate, mevalonic acid, in the urine, particularly during febrile episodes. Mutations producing complete loss of enzyme activity result in mevalonicaciduria, a condition associated with mental retardation, cataracts, and failure to thrive, in addition to those features seen in HIDS. Elevation of serum immunoglobulin D (IgD) levels is not considered to cause the clinical syndrome, because IgD levels do not correlate with disease activity, either in any given patient or across patients. It has been postulated that an excess of mevalonic acid or deficiency of isoprenoid may result in perturbation of the innate immune system.

Clinical Findings

Attacks are characterized by recurrent episodes of fever, frequently preceded by chills and accompanied by severe headache, abdominal pain, and diarrhea. Bilateral painful cervical lymphadenopathy is considered a characteristic finding in HIDS. Splenomegaly is common during attacks. Median age of onset is 6 months of age, and attacks sometimes follow childhood immunizations. Other triggers may include trauma, surgery, and menses. Episodes may occur once or twice a month from childhood to adolescence, but may become less frequent when the patient reaches adulthood.[22]

CUTANEOUS LESIONS Most patients develop skin manifestations with febrile episodes. Erythematous macules 0.5 to 2.0 cm in diameter are the most common skin lesions and may be confluent or solitary in distribution (Fig. 134-1).[23] Large macules may show an annular formation with normal skin centrally and slight irregularity of the margin. Lesions may be widespread but occur predominantly on the extremities and, unlike in FMF, show no predilection for the lower limbs. Other less common lesions include erythematous papules and nodules and a morbilliform rash. HSP and erythema elevatum et diutinum (see Chap. 166) have been described.



▲ **FIGURE 134-1** Erythematous macular and papular rash distributed over the lower and upper extremities and trunk during an attack of hyperimmunoglobulinemia D with periodic fever syndrome. (From Takada K et al: Favorable preliminary experience with etanercept in two patients with the hyperimmunoglobulinemia D and periodic fever syndrome. *Arthritis Rheum* **48**:2645, 2003. Copyright © 2003 by the American College of Rheumatology. Reprinted with permission of Wiley-Liss, Inc., a subsidiary of John Wiley & Sons, Inc.)

Laboratory Tests and Special Tests

During attacks, leukocytosis and elevated levels of acute-phase reactants are notable. The diagnosis of HIDS can be established in patients with a compatible history and clinical findings by measuring elevated urinary mevalonate levels during attacks or by demonstrating two mutations in *MVK* on genetic analysis. A small percentage of mutation-positive patients with recurrent fevers have normal IgD levels. Serum IgD levels do not correlate with the frequency or severity of attacks. Elevated serum IgA levels have been noted in up to 80 percent of patients during attacks.[23]

Histopathology

Biopsy specimens from affected skin may demonstrate varying degrees of cutaneous vasculitis, with endothelial swelling and perivascular inflammatory infiltrates composed of varying numbers of lymphocytes and polymorphonuclear cells. Sweet syndrome–like changes have been noted in some biopsy specimens.[24]

Differential Diagnosis

An important consideration is the syndrome of periodic fever with aphthous stomatitis, pharyngitis, and cervical adenopathy, a relatively common disorder in children (see Box 134-1). The presence of a rash and the triggering of attacks by childhood vaccinations are suggestive of HIDS.

Complications

There have been reports of systemic amyloidosis in rare instances.[25]

Prognosis and Clinical Course

Symptoms appear to improve with age, rarely persisting into adulthood. In the absence of amyloidosis, HIDS does not appear to have any significant effect on longevity.

Treatment and Prevention

There is no satisfactory treatment for HIDS. Colchicine therapy does not result in clinical improvement. Cyclosporine, intravenous immunoglobulin, and corticosteroids are not generally effective. A modest benefit from the use of hydroxymethylglutaryl–coenzyme A reductase inhibitors, a group of medications commonly known as *statins*, has

been described.[26] A pilot study involving two patients treated with etanercept, the p75 TNF receptor fusion protein, demonstrated dramatic clinical improvement.[27] Anecdotal reports suggest that some patients benefit from the use of the oral leukotriene receptor antagonist montelukast or treatment with anakinra, an IL-1 receptor antagonist.

TUMOR NECROSIS FACTOR RECEPTOR–ASSOCIATED PERIODIC SYNDROME

Epidemiology, Etiology, and Pathogenesis

TNF receptor–associated periodic syndrome (TRAPS) is a rare, dominantly inherited condition (OMIM #191190) caused by mutations in *TNFRSF1A*, which is found on the short arm of chromosome 12 and encodes the p55 receptor for TNF.[28] Before the recognition of the genetic defect, this condition was known by a number of clinical names, including *familial Hibernian fever*. To date, over 50 mutations in *TNFRSF1A* have been identified. The p55 receptor has four highly conserved extracellular cysteine-rich domains, a transmembrane domain, and an intracellular death domain. Roughly one-half of the currently known mutations result in amino acid substitutions at the cysteine residues. These cysteines participate in disulfide bonds that are required to maintain the receptor's three-dimensional conformation. Other mutations have been shown to interfere with hydrogen bonding or to result in the addition or deletions of amino acids in the receptor's extracellular domains. As yet, no patients with TRAPS have been identified with mutations affecting the intracellular or transmembrane domains. Reports have emphasized the finding that two variants of *TNFRSF1A*, P46L and R92Q, are seen at high frequency in the African American and Caucasian populations, respectively.[29] These variants may be associated with a wide spectrum of clinical symptoms.

Initial studies suggested that mutations in *TNFRSF1A* may result in an inability to shed TNF receptors from the cell surface, leading to excess TNF signaling.[28] Under normal circumstances the p55 TNF receptor is cleaved by metalloproteinases from the cell membrane after activation. This prevents further activation and, in addition, creates a pool of soluble receptors that may compete with membrane-bound receptors for TNF. Consistent with this, serum assays in patients with TRAPS demonstrated low levels of soluble p55 receptors when patients were not experiencing an attack, and initial in vitro studies confirmed impaired cleavage of the extracellular domains after activation. A number of other functional abnormalities have been identified, including impaired trafficking of receptor to the cell surface,[30] a finding which suggests that cellular activation may occur through multiple pathways and independently from ligand (TNF) binding.

Clinical Findings

Attacks usually begin in early childhood. Episodes typically last longer than in the other periodic fever syndromes, often continuing for more than 1 week, and there are reports of individual attacks lasting longer than 1 month. Ocular involvement is common, with periorbital edema seen in up to 90 percent of patients, and conjunctivitis or uveitis may occur. Serositis that may result in pleuritic chest pain or abdominal pain is frequently described; however, frank peritonitis is less common. Arthralgia rather than frank arthritis is common. Local trauma or stressful episodes may trigger an attack.[31]

CUTANEOUS LESIONS The cutaneous lesions may be quite distinctive. Migratory macular erythematous areas ranging in size from 1 cm to 30 cm can occur on the torso or limbs (Fig. 134-2). The rash, when present on the limbs, typically migrates distally. Migratory erythematous lesions on the limbs may be associated with severe myalgia in the underlying muscle groups. These lesions are tender and warm and blanch on palpation. Other less characteristic lesions include



▲ **FIGURE 134-2** Migratory erythematous rash on the right lower extremity of a patient with tumor necrosis factor receptor–associated periodic syndrome.



▲ **FIGURE 134-3** Annular lesion in the inguinal region of a patient with tumor necrosis factor receptor–associated periodic syndrome.

annular patches (Fig. 134-3) and serpiginous patches and plaques (see eFig. 134-3.1 in on-line edition).[31]

Laboratory Tests and Special Tests

Acute attacks are notable for a brisk acute-phase response and leukocytosis. Thrombocytosis is a prominent finding in children. In patients with symptoms suggestive of TRAPS, the detection of a mutation in *TNFRSF1A* is considered the gold standard.

Histopathology

Biopsy specimens usually demonstrate superficial and deep perivascular and interstitial mononuclear infiltrates. A low-grade lymphocytic vasculitis is less commonly seen.

Granulomata, mast cells, and eosinophils have not been described in typical lesions.[32]

Differential Diagnosis

In patients with prolonged episodes, TRAPS may be confused with SOJIA or adult-onset Still disease, but a characteristic migratory erythematous rash with underlying myalgia and periorbital edema is seen in TRAPS, and a quotidian fever pattern is observed in SOJIA (see Box 134-1).

Complications, Prognosis, and Clinical Course

Systemic amyloid A (AA) amyloidosis may occur in approximately 10 percent of patients, with associated high morbidity and mortality. The risk of amyloidosis may be elevated in those with a family

history of amyloidosis and those with mutations causing substitutions in cysteine residues (see eFigs. 134-3.2 and 134-3.3 in on-line edition).[29] In the absence of amyloidosis, however, prognosis is good.

Treatment and Prevention

Use of nonsteroidal anti-inflammatory drugs may suffice for mild attacks, with corticosteroids reserved for more severe cases. However, patients in need of corticosteroids frequently require increasing dosages with time. Colchicine neither reduces the frequency of clinical attacks nor prevents the development of amyloidosis. Studies of etanercept, the p75 TNF receptor fusion protein (see Chap. 235), suggest a favorable clinical response.[31,33] In patients at risk of amyloidosis, tailoring the dose of anti-TNF therapy in response to SAA levels may prevent development of amyloidosis. There are anecdotal reports indicating that patients who are unable to tolerate etanercept therapy may respond to the use of anakinra, an IL-1 inhibitor (see Chap. 235), a finding that supports the hypothesis of a ligand-independent pathogenesis in TRAPS.



CRYOPYRINOPATHIES

Epidemiology, Etiology, and Pathogenesis

The cryopyrinopathies include familial cold autoinflammatory syndrome (FCAS; OMIM #120100),[34] Muckle-Wells syndrome (MWS; OMIM #191900),[35] and neonatal-onset multisystem inflammatory disease (NOMID; OMIM #607115).[36] These represent three clinical disorders that are caused by dominantly inherited mutations in *CIAS1*.[37–39] This gene encodes the cryopyrin protein, which forms part of a macromolecular complex called the *inflammasome*. The inflammasome complex activates caspase 1, which cleaves IL-1β from its precursor protein; this produces a biologically active 17-kd fragment.[40] Mice deficient in cryopyrin are unable to produce IL-1β in response to certain bacteria. Leukocytes from patients with the cryopyrinopathies exhibit accentuated IL-1β production both at baseline and in response to various stimuli.

Clinical Findings

The cardinal presenting signs are an urticaria-like skin rash in infancy with fevers. The severity of joint and neurologic involvement serves in part to differentiate among the syndromes. However, there is considerable overlap among them. FCAS,[34] previously known as *familial cold urticaria*, is the mildest, with episodic cold-induced episodes of fever, skin rash, and polyarthralgia.[41] NOMID, also known as *chronic infantile neurologic, cutaneous, and articular syndrome* (CINCA), has a more severe phenotype with nearly continuous inflammation that results in a deforming arthropathy, chronic aseptic meningitis, sensorineural hearing loss, and loss of vision. Lymphadenopathy and splenomegaly are notable on clinical examination.



▲ **FIGURE 134-4** Urticaria-like skin rash in a patient with Muckle-Wells syndrome.

MWS patients demonstrate an intermediate phenotype with fever, skin rash, and joint pains with sensorineural hearing loss.

In FCAS, generalized cold exposure results in the development of urticaria-like skin lesions. The rash may present as petechiae or erythematous plaques. Symptoms begin early in childhood, within the first 6 months of life, with the characteristic rash initially affecting the extremities or face and then becoming generalized. The rash usually begins 1 hour after cold exposure and may last for 12 to 24 hours. Localized exposure to cold objects does not induce attacks.[42] In MWS, similar urticarial lesions are noted (Fig. 134-4). These may begin in infancy. Attacks are associated with both hot and cold temperatures. Emotional stress may provoke episodes.[43] In NOMID, urticarial lesions are present constantly but may wax and wane in severity. Rash onset occurs days after birth. The rash is migratory and usually non-pruritic; however, exposure to sunlight and fever may result in itch.

Laboratory Tests and Special Tests

Leukocytosis and elevated levels of acute-phase reactants are noted in each of these diseases. In addition, NOMID is associated with anemia of chronic inflammation (previously called *anemia of chronic disease*), thrombocytosis, and eosinophilia. The diagnosis of these conditions usually involves a combination of clinical and genetic analysis. Among patients suspected to have NOMID by experienced clinicians, genetic analysis reveals mutations in only 50 percent of patients.

Histopathology

Affected skin typically demonstrates perivascular and interstitial infiltration of neutrophils and lymphocytes in the papillary dermis, with no evidence of vasculitis, and the epidermis is normal.[36,44] Mast cells are not seen in increased numbers, and serum histamine levels are normal. These features serve to differentiate these lesions from true urticaria (see Chap. 37).[4]

Differential Diagnosis

In FCAS, a consideration is acquired cold urticaria (ACU) (see Chap. 37), which usually presents in adulthood. Spontaneous remission, the presence of mast cells in biopsy specimens, and increased serum histamine levels are notable in ACU. In contrast to patients with FCAS, those with ACU develop symptoms in response to localized cold exposure. Angioedema, wheezing, and hypotension may also be seen in patients with ACU. (See Box 134-1.)

Prognosis and Clinical Course

NOMID, the most severe phenotype, is associated with 20 percent mortality by age 20.[45] Mental retardation and painful arthropathy result in significant morbid-

ity. Persistent inflammation leads to the development of systemic AA amyloidosis with resultant high mortality. MWS is less severe but is associated with sensorineural deafness and the development of AA amyloidosis. FCAS rarely results in amyloidosis.

Treatment and Prevention

For all three of the cryopyrinopathies, promising reports of dramatic clinical responses to the IL-1 receptor antagonist anakinra have been reported (see Chap. 235). Patients with FCAS and MWS experience almost complete remission of the disease. One trial involving 18 patients with NOMID who were treated with anakinra demonstrated disappearance of rash and conjunctivitis within 3 days.[46] Before enrollment all patients had failed to respond to either corticosteroids or TNF blockers. Clinical improvement in hearing and neurologic symptoms was demonstrated, and in eight patients headache resolved completely. Vision remained stable in all patients. Complete remission of inflammatory symptoms occurred in 10 of the 18 patients after 6 months of treatment. Magnetic resonance imaging demonstrated a marked reduction in cochlear and leptomeningeal enhancement. These findings suggest that the manifestations of NOMID are mediated by an excess of IL-1β, and that these symptoms can be ameliorated by the administration of anakinra. Longer follow-up will be required to determine if anakinra can prevent the intellectual impairment caused by NOMID. Continuous treatment with anakinra was required to maintain clinical response. A significant reduction in acute-phase response was noted, including a decrease in SAA levels. This raises the possibility that anakinra may prevent the development of amyloidosis in these patients.

PYOGENIC ARTHRITIS WITH PYODERMA GANGRENOSUM AND ACNE

Epidemiology, Etiology, and Pathogenesis

Pyogenic arthritis with pyoderma gangrenosum and acne (PAPA) is a dominantly inherited condition (OMIM #606347) caused by mutations in the gene encoding PSTPIP1, a protein that interacts with pyrin and is involved in cytoskeletal organization.[47,48]



▲ **FIGURE 134-5** Forearm of a patient with the syndrome of pyogenic arthritis with pyoderma gangrenosum and acne demonstrating a large ulcerated lesion with irregular borders that are slightly elevated and erythematous. A hemorrhagic purulent exudate is evident. Features are typical of pyoderma gangrenosum. (From Shoham NG et al: Pyrin binds the PSTPIP1/CD2BP1 protein, defining familial Mediterranean fever and PAPA syndrome as disorders in the same pathway. *Proc Natl Acad Sci U S A* **100**:3501, 2003, with permission. © 2003 by The National Academy of Sciences of the USA.)

Clinical Findings

Pyogenic arthritis may be a sequela of minor trauma and may result in the development of destructive arthropathy. Synovial fluid is purulent but sterile on culture.

Pyoderma gangrenosum (PG) lesions evolve from a small erythematous pustules to necrotic ulcers in days (see Chap. 32). Minor trauma may be sufficient to provoke the development of large PG lesions, which may cover large areas on the arm, leg, or trunk (Fig. 134-5). Severe cystic acne develops, affecting the face, chest, and back.[49] Pathergy is notable, and patients may develop large sterile abscesses at sites of injections.

Laboratory Tests and Special Tests

During acute episodes, levels of acute-phase reactants are elevated, and leukocytosis and anemia of chronic disease are present. As with the other autoinflammatory diseases, results of serologic testing are usually negative.

Histopathology

Affected skin demonstrates intense infiltrates of polymorphonuclear cells with no evidence of vasculitis.

Differential Diagnosis

PG may be associated with a wide range of systemic diseases, as described in Chap. 32. Genetic testing may facilitate the correct diagnosis of PAPA in ambiguous cases. (See Box 134-1.)

Complications, Prognosis, and Clinical Course

The psychological consequences of widespread scarring from both acne and PG cannot be minimized. Destructive arthropathy has been described.[49,50]

Treatment and Prevention

Early institution of high-dose corticosteroids is the most effective treatment. Affected joints may require aspiration and drainage. Chap. 32 outlines the management of PG in detail. Local wound care and pain management are extremely important. Case reports suggest that the use of biologic therapies targeted at IL-1 or TNF may have clinical benefit.[51]

KEY REFERENCES

The full reference list for all chapters is available at www.digm7.com.

3. Tunca M et al: Familial Mediterranean fever (FMF) in Turkey: Results of a nationwide multicenter study. *Medicine (Baltimore)* **84**:1, 2005
4. Kastner DL, Aksentijevich I: Intermittent and periodic arthritis syndromes, in *Arthritis and Allied Conditions: A Textbook of Rheumatology*, 15th ed, edited by Koopman W. Philadelphia, Lippincott Williams & Wilkins, 2005, p 1411
23. Drenth JP, Haagsma CJ, van der Meer JW: Hyperimmunoglobulinemia D and periodic fever syndrome. The clinical spectrum in a series of 50 patients. International Hyper-IgD Study Group. *Medicine (Baltimore)* **73**:133, 1994
31. Hull KM et al: The TNF receptor-associated periodic syndrome (TRAPS): Emerging concepts of an autoinflammatory disorder. *Medicine (Baltimore)* **81**:349, 2002

34. Wanderer AA, Hoffman HM: The spectrum of acquired and familial cold-induced urticaria/urticaria-like syndromes. *Immunol Allergy Clin North Am* **24**:259, 2004

46. Goldbach-Mansky R et al: Neonatal-onset multisystem inflammatory disease responsive to interleukin-1β inhibition. *N Engl J Med* **355**:581, 2006

49. Lindor NM et al: A new autosomal dominant disorder of pyogenic sterile arthritis, pyoderma gangrenosum, and acne: PAPA syndrome. *Mayo Clin Proc* **72**:611, 1997

CHAPTER 135

Xanthomatoses and Lipoprotein Disorders

Lucile E. White



XANTHOMAS

Xanthomas are plaques or nodules consisting of abnormal lipid deposition and foam cells. They do not represent a disease but rather are symptoms of different lipoprotein disorders or arise without an underlying metabolic effect. Xanthomas develop through several mechanisms. Through scavenger receptors for enhanced low-density lipoprotein (LDL) uptake, macrophages incorporate lipid that has been transported through the capillary walls, thus becoming foam cells. Foam cells can also develop as a result of in situ lipid synthesis by the macrophage. Further, lipid that has been extravasated by the capillaries can also recruit additional foam cells into an already established xanthoma. Extravasated and oxidized LDL recruits foam cells by inducing vascular cellular adhesion molecule and E-selectin.[1,2] Local factors such as heat, movement, and friction may increase LDL capillary leakage, and, hence, result in the development of xanthomata.[3] These local factors help explain the location of tuberous xanthomas, tendinous xanthomas, and xanthelasmata.

Clinical Findings

CUTANEOUS LESIONS Clinically, xanthomas can be classified as eruptive, tuberoeruptive or tuberous, tendinous, or planar.[4] Planar xanthomas include xanthelasma palpebrarum/xanthelasma, xanthoma striatum palmare, and intertriginous xanthomas. There are characteristic clinical phenotypes associated with specific metabolic defects (Table 135-1).

Eruptive xanthomata are multiple, reddish-yellow papules that appear suddenly and are arranged in crops on the extensor surface of the extremities and the buttocks (Figs. 135-1 and 135-2). Tuberous xanthomata are nodules that are frequently localized to the extensor surfaces of the elbows, knees, knuckles, and buttocks (Fig. 135-3). Tendinous xanthomata are firm subcutaneous nodules found in fascia, ligaments, Achilles tendons, or extensor tendons of the hands, knees, and elbows (Fig. 135-4). Planar xanthomata are yellow macules, soft papules, or plaques found commonly on the upper eyelids (xanthelasma palpebrarum), the palms (xanthoma striatum palmare) (Fig. 135-5), and in intertriginous areas.

HISTOPATHOLOGY Foam cells are macrophages that contain lipid. These cells characterize xanthomata. Along with foam cells, eruptive xanthomata often consist of lymphoid cells, histiocytes, neutrophils, and, frequently, free lipid in the dermis. Tuberous xanthomata reveal foam cells and cholesterol clefts (Fig. 135-6). Cholesterol is doubly refractile whereas other types of lipid are not. Tendon xanthomata are histopathologically similar to tuberous xanthomata; however, xanthelasmata can be differentiated by their superficial location. Along with the foam cells, xanthelasmata may reveal striated muscle, vellus hair, and/or a thinned epidermis, indicative of the superficial location.[5]

Differential Diagnosis

See Box 135-1.

TABLE 135-1
Clinical Presentations of Xanthomas

Type of Xanthoma	Genetic Disorders	Secondary Disorders
Eruptive	Familial lipoprotein lipase deficiency (type I) Apo-C2 deficiency (type I) Familial hypertriglyceridemia (type IV) Familial hypertriglyceridemia with chylomicronemia (type V)	Obesity Cholestasis Diabetes Medications: Retinoids, estrogen therapy, protease inhibitors
Tuberous	Familial hypercholesterolemia (type II) Familial dysbetalipoproteinemia (type III) Phytosterolemia	Monoclonal gammopathies
Tendinous	Familial hypercholesterolemia (type II) Familial defective apo-B Familial dysbetalipoproteinemia (type III) Phytosterolemia Cerebrotendinous xanthomatosis	
Planar		
Palmar	Familial dysbetalipoproteinemia (type III)	
Intertriginous	Familial homozygous hypercholesterolemia (type II)	Cholestasis
Diffuse		Monoclonal gammopathies, cholestasis
Xanthelasma	Familial hypercholesterolemia (type II) Familial dysbetalipoproteinemia (type III)	Monoclonal gammopathies
Other		
Corneal arcus	Familial hypercholesterolemia (type II)	
Tonsillar	Tangier disease	

apo = apolipoprotein.



▲ **FIGURE 135-1** Eruptive skin xanthomata characteristic of severe chylomicronemia.

Treatment

The treatment for xanthomas depends on the underlying etiology.[6]

LIPOPROTEINS AND THEIR METABOLISM[7,8]

Chylomicrons

Most dietary lipid is triglyceride. In the intestine, triglycerides are hydrolyzed by pancreatic lipase into fatty acids and monoglycerides, which are solubilized by the bile and taken up by the intestinal mucosa (Fig. 135-7). In the enterocyte, fatty acids and monoglycerides are resynthesized into triglycerides and are incorporated into lipoproteins called chylomicrons. Chylomicron particles have an inner core of triglycerides plus small amounts of cholesterol ester and a surface coat composed of unesterified cholesterol, phospholipids, and proteins (apolipoproteins). The major apolipoprotein of the chylomicron is apolipoprotein-B48 (apo-B48); other apolipoproteins that affect the metabolism of chylomicrons are apo-C, apo-E, apo-A1, and apo-A4.

Chylomicrons are secreted into the intestinal lymph and enter the systemic circulation through the thoracic duct, passing into the capillary bed of the peripheral circulation where they come into contact with lipoprotein lipase (LPL) in the capillary walls. This enzyme, located on the endothelial surfaces of capillaries, hydrolyzes the triglycerides of chylomicrons into fatty acids. Several other surface components of chylomicrons are lost to the circulation during triglyceride lipolysis. When most of the triglycerides in chylomicrons have been hydrolyzed by LPL, a residual particle (chylomicron remnant) returns to the circulation. These chylomicron remnants disappear quickly from the circulation in the liver, facilitated by the presence of apo-E.

Very-Low-Density Lipoproteins

Very-low-density lipoproteins (VLDLs) are triglyceride-rich lipoproteins that are derived from the liver. VLDL particles contain less triglyceride than chylomicrons but relatively more cholesterol. Their synthesis in hepatocytes is analogous to chylomicron synthesis in enterocytes. In contrast to chylomicrons, however, VLDL particles contain apo-B100 as their major apolipoprotein; they also have apo-Cs and apo-Es. The total amount of triglyceride secreted daily associated with VLDL is only approximately one-fourth that entering through chylomicrons from the typical American diet. Like chylomicrons, circulating VLDLs pass into the peripheral circulation, where they interact with LPL, which hydrolyzes most of the VLDL tri-



▲ **FIGURE 135-4** Tendon xanthomata typical of heterozygous familial hypercholesterolemia. Similar xanthomata occur in patients with familial defective apolipoprotein B-100, cerebrotendinous xanthomatosis, and sitosterolemia.



▲ **FIGURE 135-2** Eruptive skin xanthomata in an African American woman characteristic of severe chylomicronemia.

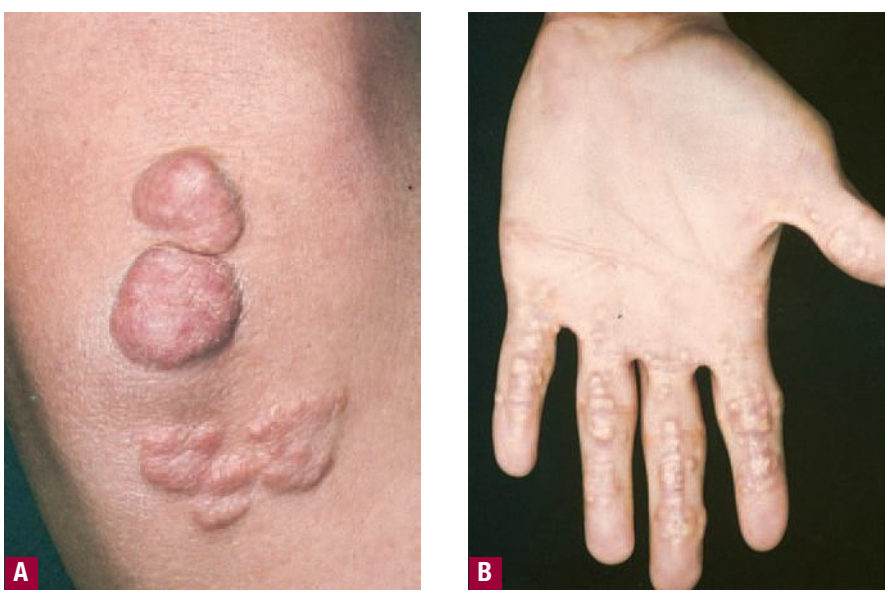

▲ **FIGURE 135-3** Tuberoeruptive and tuberous xanthomata typical of familial dysbetalipoproteinemia. **A.** Knee **B.** Palm.



▲ **FIGURE 135-5** Xanthoma striatum palmare characteristic of familial dysbetalipoproteinemia.



glycerides. After much of the triglyceride is removed, a residual particle, called a *VLDL remnant,* returns to the circulation. Approximately one-half of VLDL remnants are removed directly by hepatic uptake, facilitated by apo-E. A portion of VLDL remnant uptake occurs via receptors for LDLs located on the surface of hepatocytes, where they bind both to apo-E and apo-B100. When VLDL remnants attach to liver cells, many are internalized and degraded. A portion of these particles interacts with hepatic lipase, which removes residual triglycerides and converts them into LDL. Newly formed LDL particles are released from hepatocytes and returned to the circulation.

Low-Density Lipoproteins

LDL particles carry most of the cholesterol present in the fasting serum. LDLs are smaller than VLDLs and contain mostly cholesterol esters in their lipid cores. The only apolipoprotein associated with LDL is apo-B100. Approximately three-fourths of circulating LDL is removed through LDL receptors on liver cells. Lesser amounts of LDL are cleared via nonreceptor pathways or by extra-hepatic tissues. When LDL particles bind to LDL receptors, they are internalized and pass into lysosomes, where they are degraded.

High-Density Lipoproteins

High-density lipoproteins (HDLs) perform a "clean-up" function. Excess unesterified (free) cholesterol in the membranes of peripheral tissue cells may be taken up by HDL. This uptake is the first step of a process called *reverse cholesterol transport*; the process is so named because cholesterol synthesized in peripheral tissues is eventually returned to the liver for its disposal from the body. HDLs have many surface proteins. Apo-A1 and apo-A2 proteins on HDL are derived by direct secretion from the liver.

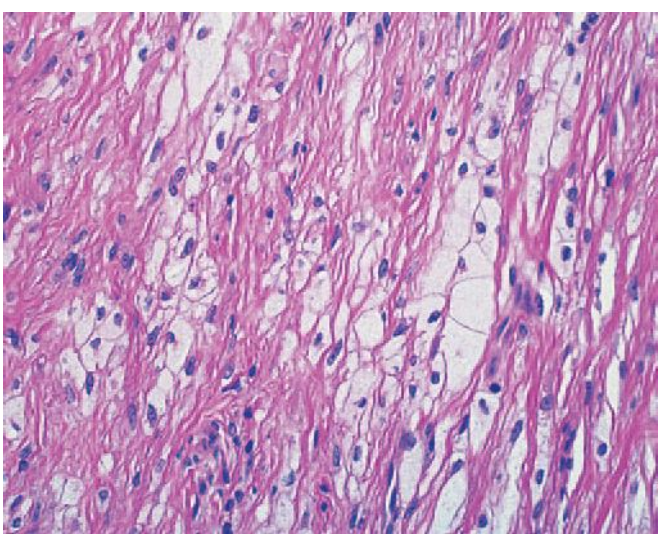

▲ **FIGURE 135-6** The histopathology of a tuberous xanthoma reveals foam cells.

Box 135-1

Differential Diagnosis of Xanthomas

- Eruptive xanthomas
  - Sarcoid
  - Interstitial granuloma annulare
  - Xanthoma disseminatum (non-Langerhans cell histiocytosis)
- Tuberous or tendinous xanthomas
  - Cyst
  - Lipoma
  - Neurofibroma
- Plane xanthomas
  - Pseudoxanthoma elasticum
  - Amyloidosis
  - Sarcoidosis
- Xanthelasma
  - Syringoma
  - Sebaceous hyperplasia
  - Adnexal neoplasms

FAMILIAL CHYLOMICRONEMIA SYNDROME (FREDERICKSON TYPE I HYPERLIPIDEMIA)

Lipoprotein Lipase Deficiency

EPIDEMIOLOGY LPL deficiency is a rare condition with 1 per 1 million patients homozygous for genetic defects in LPL function.[4]

ETIOLOGY AND PATHOGENESIS A large series of mutations in the LPL gene prevent the normal function of LPL. Patients who are homozygous for LPL defects typically manifest severe chylomicronemia.

When triglyceride levels are below 500 mg/dL, most of the triglycerides are carried in VLDLs. At higher concentrations, chylomicrons consisting of triglycerides begin to accumulate in the serum. Some patients manifest severe chylomicronemia, with triglyceride levels ranging from 1000 to 10,000 mg/dL. These marked elevations result from genetic defects in triglyceride metabolism or genetic defects combined with aggravating acquired factors.

CLINICAL FINDINGS ***Cutaneous Lesions.*** In LPL deficiency, only eruptive xanthomata occur (see Fig. 135-1). Typical locations are over the buttocks, shoulders, and extensor surfaces of the extremities (see Fig. 135-2). Their rapid appearance usually signifies a striking rise of triglyceride concentrations. Eruptive xantho-

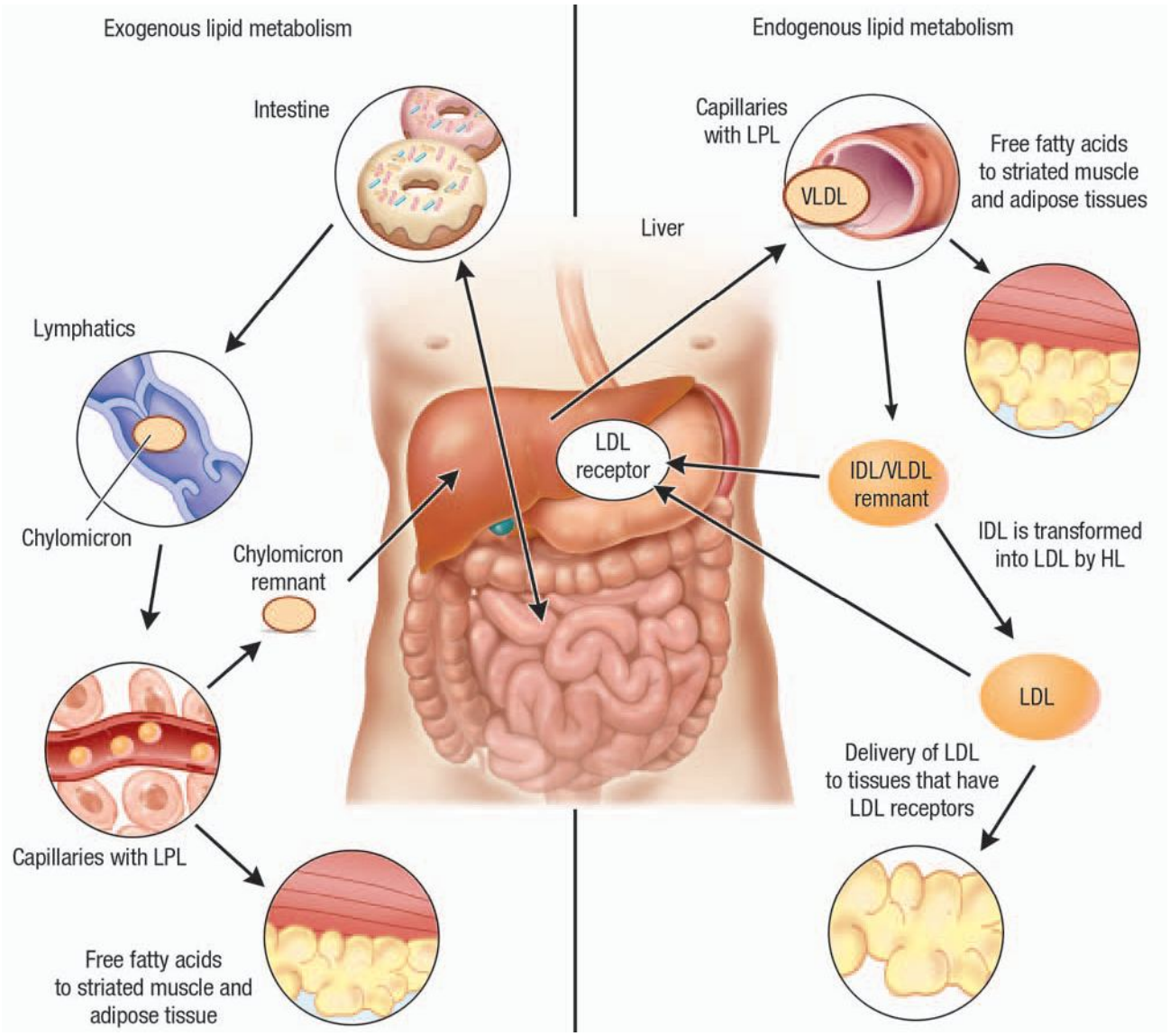

▲ **FIGURE 135-7** Lipid metabolism. The exogenous pathway of lipid metabolism involves eating foods that contain fat and delivering the fatty acids to tissues. The triglycerides in the intestines are packaged into chylomicrons in the intestinal enterocytes. Capillary lipoprotein lipase (LPL), which requires apolipoprotein-C (apo-C) as a co-factor, hydrolyzes the triglycerides and releases fatty acids to the peripheral tissues. The remaining chylomicron particle is called a *chylomicron remnant* and is recycled by the liver. The endogenous pathway of lipid metabolism involves the hepatic production of very-low-density lipoprotein (VLDL) and the delivery of free fatty acids to peripheral tissues. VLDL particles have apo-B100 instead of apo-B48. LPL, which requires apo-C as a co-factor, hydrolyzes the triglycerides and releases fatty acids to the peripheral tissues. This remnant is called an *intermediate-density lipoprotein* (IDL). The LDL receptor of the liver removes these remnants by binding to apo-E on the remnant. IDL can also be transformed into LDL by hepatic lipase (HL) in the liver. The new particles of LDL can bind to the LDL receptor through apo-B100.

mata are often associated with lipemia retinalis and pancreatitis.

Laboratory Tests. Triglyceride levels can be severely elevated from birth. Patients who are heterozygous for LPL deficiency either have normal serum triglycerides or have mild hypertriglyceridemia.

PROGNOSIS AND CLINICAL COURSE When serum triglyceride concentrations exceed 2000 mg/dL, patients are at high risk for developing acute pancreatitis.

Patients with LPL deficiency generally are not at increased risk for coronary heart disease (CHD). Although a few patients with LPL deficiency have manifested some atherosclerosis, premature CHD is rare.

TREATMENT There are no available drugs that can effectively treat the severe chylomicronemia of LPL deficiency. The most effective management is through dietary modification. The formation of chylomicrons can be curtailed by reducing the fat content of the diet to less than 10 percent of total calories. Medium-chain triglycerides (MCTs) can be used as a substitute for dietary fat. The fatty acids of MCT are not incorporated into chylomicrons; thus, 10 percent to 15 percent of total calories can be safely consumed as MCTs. The goal of therapy is to keep total triglyceride levels below 1500 mg/dL, which greatly reduces the risk for pancreatitis.

Eruptive xanthomas can also be a result of secondary causes, and it is important to rule out obesity, excessive alcohol intake, diabetes (type 2), and drugs as a cause of these lesions. Drugs that can cause eruptive xanthomas include retinoids, estrogen therapy, and protease inhibitors.



FAMILIAL CHYLOMICRONEMIA SYNDROME (FREDERICKSON TYPE I HYPERLIPIDEMIA)

AT A GLANCE





- Chylomicronemia often presents with eruptive xanthomas.
- Chylomicronemia is due to lipoprotein lipase deficiency or apolipoprotein-C2 deficiency.
- Secondary causes of elevated chylomicrons include obesity, diabetes, alcohol abuse, or medications.
- Medications that can cause elevated triglycerides, and thus eruptive xanthomas, include oral retinoids, estrogen therapy, and protease inhibitors.
- There is very little risk of coronary atherosclerosis.
- Eruptive xanthomas can also be seen in Frederickson type IV and V hyperlipidemia.
- Treatment is most commonly through dietary modification.

Apolipoprotein-C2 Deficiency

EPIDEMIOLOGY Apo-C2 deficiency is a rare condition.

ETIOLOGY AND PATHOGENESIS Apo-C2 is carried on triglyceride-rich lipoproteins and activates LPL. Without LPL, chylomicrons are not degraded.

CLINICAL FINDINGS: CUTANEOUS LESIONS These patients develop severe chylomicronemia and eruptive xanthomata resembling those developed in LPL deficiency.

TREATMENT Treatment of chylomicronemia associated with apo-C2 deficiency is the same as in patients with LPL deficiency.

HYPERCHOLESTEROLEMIA (FREDERICKSON TYPE II HYPERLIPIDEMIA)

Familial Homozygous Hypercholesterolemia

EPIDEMIOLOGY Approximately 1 per 1 million persons in the general population are affected with familial hypercholesterolemia (FH).[4]

ETIOLOGY AND PATHOGENESIS The primary defect in FH is a genetic deficiency of the LDL receptors, which remove LDL from the circulation. Homozygous FH is a condition with defects in both alleles, and these patients have either no LDL receptor activity or very low activity.

CLINICAL FINDINGS ***Cutaneous Lesions.*** Patients with homozygous FH usually have severe xanthomatosis. Multiple types of xanthomata are found (Fig. 135-8). These include tuberous xanthomata (especially over the elbows), subperiosteal xanthomata (below the knees and over the olecranon process), tendon xanthomata (especially in the Achilles tendon and in the extensor tendon of the hand), and elevated xanthomatous plaques (over the extremities, buttocks, and hands). Intertriginous xanthomas are rare but usually associated with this condition. The rate of xanthoma deposition and growth is associated with the duration and severity of the LDL elevation.

Laboratory Tests. In homozygous FH, serum LDL-cholesterol levels are markedly elevated, often in the range of 800 to 1000 mg/dL.

PROGNOSIS AND CLINICAL COURSE These patients commonly develop CHD or other forms of atherosclerotic disease before their teenage years.

TREATMENT Because LDL receptor function is largely absent, drugs that act by enhancing LDL receptor activity, such as bile acid sequestrants and HMG-coenzyme A (HMG-CoA) reductase inhibitors (statins), produce little benefit. High doses of statins, however, may cause moderate reductions in LDL-cholesterol levels in homozygous FH patients, probably by partial inhibition of VLDL secretion. A more radical approach to treatment of homozygous FH is liver transplantation. This procedure supplies normal LDL receptors from the donor liver. A more practical approach is to remove LDL periodically from the circulation by plasmapheresis or LDL-apheresis.[9]

HYPERCHOLESTEROLEMIA (FREDERICKSON TYPE II HYPERLIPIDEMIA)

AT A GLANCE



- Homozygous familial hypercholesterolemia, heterozygous familial hypercholesterolemia, or defective apoliprotein-B100 cause this type of hyperlipidemia.
- Severe hypercholesterolemia can present with tendinous or tuberous xanthomas.
- These conditions are usually treated by HMG-coenzyme A reductase inhibitors.
- There is a significant risk of coronary atherosclerosis.

Familial Heterozygous Hypercholesterolemia

EPIDEMIOLOGY The more common form of FH is heterozygous FH. The prevalence of heterozygous FH is approximately 1 in 500 people.[4]

ETIOLOGY AND PATHOGENESIS Heterozygous FH occurs from the inheritance of a single abnormal allele for the LDL receptor.

CLINICAL FINDINGS ***Cutaneous Lesions.*** In contrast to patients with homozygous FH, heterozygotes only rarely show tuberous xanthomata; tendon xanthomata, however, are common (see Fig. 135-4). In fact, the majority of patients with tendon xanthomata have heterozygous FH.

Laboratory Tests. Heterozygous hypercholesterolemia usually presents on routine adult screening with serum LDL-cholesterol levels approximately twice the normal value.







◀ **FIGURE 135-8 A–C.** Xanthomata typical of homozygous familial hypercholesterolemia.

PROGNOSIS AND CLINICAL COURSE Men with heterozygous FH commonly develop CHD in their 30s and 40s; affected women typically manifest CHD in their 50s and 60s.

TREATMENT Statins have proven to be effective drugs for the treatment of heterozygous FH.[10] These agents inhibit HMG-CoA reductase, the rate-limiting enzyme in cholesterol synthesis.[11] A reduction in cellular cholesterol content sends a signal to the nucleus of the cell to stimulate the synthesis of LDL receptors. In patients with heterozygous FH, the one functional allele for the LDL receptor is "upregulated" by statin therapy; this supplies more LDL receptors and reduces serum LDL levels.

The major side effects of statins are myopathy and hepatotoxicity. These side effects are relatively rare but increase in frequency with increasing doses. The risk for myopathy is increased substantially when the statin is given with either a fibric acid (e.g., gemfibrozil) or cyclosporine. In patients with heterozygous FH, the lowering of LDL cholesterol levels can be enhanced substantially by combining a statin with a bile acid sequestrant (e.g., cholestyramine or colestipol).

In patients with type II hyperlipidemia that were treated with a low cholesterol diet and colestipol, tendinous xanthomas subsided in 2 of 11 patients and improved in 9 of 11 patients. Xanthelasma subsided in two of four patients and improved in two of four patients.[12] Probucol, diet, statins, and LDL apheresis have also been effective in decreasing the size of Achilles tendon xanthomas in patients with FH.[13,14]

Familial Defective Apolipoprotein-B100

Familial defective apo-B100 (FDB) is another cause of moderately severe hypercholesterolemia.[15,16] In this condition, the primary structure of apo-B100 is defective, and LDL does not bind the hepatic LDL receptor effectively. As a result, serum LDL levels are elevated. Patients with FDB frequently resemble those with heterozygous FH except that they typically have somewhat lower LDL cholesterol levels. Most patients with FDB are heterozygotes, and only one-half their LDL particles are defective in binding to LDL receptors. Rare patients are homozygous and have more severe hypercholesterolemia, although usually not to the degree seen in patients with homozygous FH. Some patients with heterozygous FDB develop tendon xanthomata that are identical in appearance to those associated with heterozygous FH. Patients with FDB are prone to premature CHD,[17] and their hypercholesterolemia usually responds well to statin therapy.

DEFECTIVE METABOLISM OF LIPOPROTEIN REMNANTS

Dysbetalipoproteinemia (Frederickson Type III Hyperlipidemia)

ETIOLOGY AND PATHOGENESIS Dysbetalipoproteinemia (type III hyperlipoproteinemia) denotes a category of lipid disorders defined by accumulation of remnant lipoproteins (i.e., chylomicron remnants and VLDL remnants). The usual abnormality is the presence of an



DYSBETALIPOPROTEINEMIA (FREDERICKSON TYPE III HYPERLIPIDEMIA)

AT A GLANCE



- Dysbetalipoproteinemia is defined by accumulation of chylomicron remnants and very-low-density lipoprotein remnants.
- Xanthoma striatum palmare is the characteristic cutaneous feature of this condition.
- Tuberous xanthomas can also be seen with this condition.
- Treatment consists of fibric acids, nicotinic acid, or statin therapy.

abnormal isoform of apo-E, named *apo-E2*. Normal isoforms are apo-E3 and apo-E4; these isoforms promote remnant uptake by the liver. When apo-E2 is present, especially in the homozygous form of the disease, remnant uptake is impaired; as a result, remnant lipoproteins are removed slowly and accumulate in the serum. Isolated homozygous apo-E2 typically produces mild remnant accumulation but not categoric hyperlipidemia. However, hyperlipidemia of the dysbetalipoproteinemic type can develop when lipoprotein metabolism is otherwise disturbed (i.e., in patients with obesity, diabetes mellitus, or endogenous hypertriglyceridemia).

CLINICAL FINDINGS ***Cutaneous Lesions.*** Approximately two-thirds of these patients have tuberoeruptive and tuberous xanthomata (see Fig. 135-3). They also have a characteristic lipid deposition in the creases of the palms of the hands (xanthoma striatum palmare) (see Fig. 135-5). Occasionally, patients manifest tendon xanthomata and xanthelasma. Some patients with dysbetalipoproteinemia exhibit tuberous xanthomata in the absence of raised serum levels of total cholesterol and triglyceride; in these patients, tissue susceptibility combined with increased remnant lipoproteins appears to be responsible for tuberous xanthomata. Tuberous xanthomata of the hands have been observed in two normolipidemic patients who were homozygous for apo-E2. In one patient, xanthomata apparently developed in the fingers because of heavy manual labor.[18]

Laboratory Tests. Typically, in hyperlipidemic patients with dysbetalipoproteinemia, serum concentrations of cholesterol and triglycerides are approximately equally raised. The cholesterol to triglyceride ratio in the VLDL fraction usually exceeds 0.30. A definite diagnosis of dysbetalipoproteinemia is made by identifying the apo-E2 isoform.

PROGNOSIS AND CLINICAL COURSE Hyperlipidemic patients with dysbetalipoproteinemia are at increased risk for CHD and often have peripheral arterial disease.

TREATMENT The hyperlipidemia in patients with dysbetalipoproteinemia is responsive to fibric acids or nicotinic acid; however, if total cholesterol levels are markedly raised, statin therapy is more effective. Reducing serum lipids with drug therapy often causes xanthomata to regress.

MULTIFACTORIAL HYPERLIPIDEMIAS

Familial Hypertriglyceridemia (Frederickson Type IV Hyperlipidemia)

In familial hypertriglyceridemia, the liver overproduces VLDL. Xanthomas are rarely seen. This condition is usually detected only because of routine adult lipid screening, and treatment consists of a low fat diet and fibric acids.

Familial Hypertriglyceridemia: Chylomicronemia Combined with Endogenous Hypertriglyceridemia (Frederickson Type V Hyperlipidemia)

ETIOLOGY AND PATHOGENESIS Chylomicronemia combined with endogenous hypertriglyceridemia is defined by combined elevations in levels of chylomicrons and VLDL. Most cases appear to result from a dual defect in triglyceride metabolism, namely, overproduction of VLDL and defective lipolysis of triglyceride-rich lipoproteins.[19] Both abnormalities can have multiple causes, including the heterozygous state for LPL mutations, a functional reduction of LPL activity, obesity, insulin resistance, and non-insulin–dependent diabetes mellitus.[19]

OVERPRODUCTION OF VERY-LOW-DENSITY-LIPOPROTEIN (FREDERICKSON TYPE IV HYPERLIPIDEMIA)

AT A GLANCE

- Usually detected only because of routine lipid screening.
- Underlying defect unknown.
- Xanthomas as unusual; eruptive xanthomas have been described but are rare.
- Laboratory testing shows elevated very-low-density lipoprotein with normal or only mildly elevated cholesterol levels (> 250 mg/dL).
- Treatment consists of dietary modification, fibrates, and niacin.

CLINICAL FINDINGS ***Cutaneous Lesions.*** Eruptive xanthomas can be a feature of chylomicronemia combined with endogenous hypertriglyceridemia. The cutaneous findings for the familial hyperlipidemias are reviewed in Table 135-2.

Laboratory Tests. Chylomicronemia combined with endogenous hypertriglyceridemia is defined by elevations of chylomicrons and VLDL.

PROGNOSIS AND CLINICAL COURSE Patients with type 5 hyperlipoproteinemia appear to be at increased risk for CHD, and they commonly manifest peripheral arterial disease. The risk for acute pancreatitis rises sharply when triglyceride levels exceed 2000 mg/dL.

TREATMENT Treatment of type 5 hyperlipoproteinemia consists of a low-fat diet (less than 10 percent of total calories as fat) and fibric acids (e.g., gemfibrozil). In addition, weight reduction in obese patients reduces triglyceride levels and may improve glucose control in diabetic patients.

FAMILIAL HYPERTRIGLYCERIDEMIA: CHYLOMICRONEMIA COMBINED WITH ENDOGENOUS HYPERTRIGLYCERIDEMIA (FREDERICKSON TYPE V HYPERLIPIDEMIA)

AT A GLANCE

- Chylomicronemia combined with endogenous hypertriglyceridemia is defined by elevations of chylomicrons and very-low-density lipoprotein.
- Eruptive xanthomas can be seen with this condition.
- Treatment consists of a low-fat diet and fibric acids.

TABLE 135-2
Frederickson Classification of Familial Hyperlipidemias

Frederickson Classification	Condition	Type of Xanthoma
Type I	Familial chylomicronemia	Eruptive xanthomata
Type IIa	Familial hypercholesterolemia	Tendon, tuberous, plane xanthomas (xanthelasma and intertriginous)
	Heterozygous	15% with xanthoma by second decade
	Homozygous	Xanthomata by age 6 yr
Type IIb	Familial combined hypercholesterolemia	Usually absent, but can have xanthomas as in type IIa
Type III	Familial dysbetalipoproteinemia	Palmar, tuberous, tuberoeruptive xanthoma, xanthelasma
Type IV	Familial hypertriglyceridemia	Rare eruptive xanthomas
Type V	Mixed hyperlipidemia	Eruptive xanthomas



XANTHOMATOSES WITHOUT ELEVATED SERUM LIPIDS

A suggested classification of normocholesterolemic xanthomatoses has been proposed.[20] Type I normocholesterolemic xanthomatoses are conditions that result in xanthomas due to altered lipoproteins. Type II normocholesterolemic xanthomatoses are caused by lymphoproliferative diseases, and type III conditions are xanthomatoses associated with local tissue alterations.

Sitosterolemia (Phytosterolemia)

EPIDEMIOLOGY Sitosterolemia is rare condition for which the prevalence is unknown.

ETIOLOGY AND PATHOGENESIS Sitosterolemia, a rare, autosomal-recessive disorder results from accumulation of plant sterols such as β-sitosterol in the serum.[21] The molecular defect in sitosterolemia is in the adenosine triphosphate-binding cassette (ABC) transmembrane transporters encoded by ABCG5 and ABCG8.[22] These defects cause cellular retention of both cholesterol and plant sterols.

CLINICAL FINDINGS ***Cutaneous Lesions.*** Tendon and tuberous xanthomata are common in sitosterolemia; they resemble those of patients with heterozygous FH (see Fig. 135-4).[23]

Laboratory Findings. Early in life, serum cholesterol levels are extremely elevated, similar to those of homozygous FH. Hence, sitosterolemia has been called *pseudohomozygous FH*. Later in life, cholesterol levels decline, but serum sitosterol levels remain elevated. Elevated serum sitosterol concentrations of a few milligrams per deciliter promote xanthoma formation, even without significant hypercholesterolemia.

PROGNOSIS AND CLINICAL COURSE Patients with sitosterolemia are at high risk of atherosclerosis and CHD.

TREATMENT Treatment of sitosterolemia consists of a reduced intake of cholesterol and plant sterols. In addition, bile acid sequestrants and ezetimibe are often used to treat this condition. Ezetimibe is a newer medication that has been shown to block the intestinal absorption of cholesterol and plant sterols.[24,25]

Cerebrotendinous Xanthomatosis

EPIDEMIOLOGY The prevalence of cerebrotendinous xanthomatosis (CTX) is approximately 1 per 50,000.[26]

ETIOLOGY AND PATHOGENESIS The genetic abnormality results in incomplete oxidation of cholesterol into bile acids in the liver due to mutations in mitochondrial C27-steroid 26-hydroxylase (CYP27A1).[27] A by-product of this defect is increased synthesis of the sterol cholestanol.

CLINICAL FINDINGS In CTX, xanthomata develop in the tendons and brain. CTX causes severe neurologic manifestations. Patients with juvenile cataracts should undergo testing for CTX, which can be diagnosed by elevated plasma cholestanol.

PROGNOSIS AND CLINICAL COURSE Patients with CTX are at increased risk for CHD.

TREATMENT Treatment consists of replacement of the bile acid pool with oral chenodeoxycholic acid. This therapy reduces cholestanol synthesis and has been reported to alleviate neurologic symptoms. HMG-CoA reductase inhibitor and LDL apheresis are also reported as possible treatments.[28,29] A combination of LDL apheresis, chenodeoxycholic acid, and a HMG-CoA reductase inhibitor more effectively reduce serum cholestanol than LDL apheresis alone.[30]

Tangier Disease

ETIOLOGY AND PATHOGENESIS Tangier disease is a rare, autosomal-recessive condition caused by defects in the gene ABCA1.[31] This protein is responsible for transporting cellular cholesterol to the cell surface where it is delivered to circulating HDL. A defect in the transmembrane transporter causes an accumulation of cholesterol in peripheral tissues due to the inability to perform "reverse transport" via the HDL particles.

CLINICAL FINDINGS ***Cutaneous Lesions.*** Tangier homozygotes accumulate cholesterol esters in tonsils, spleen, lymph nodes, bone narrow, thymus, and intestinal mucosa. These accumulations most commonly produce yellow/orange hyperplastic tonsils, mild lymphadenopathy, and splenomegaly.

Laboratory Findings. Patients with Tangier disease have low plasma HDL cholesterol and apo-A1 levels.

PROGNOSIS AND CLINICAL COURSE Older patients with Tangier disease often develop CHD.



High-Density Lipoprotein Metabolic Defects: Apolipoprotein A1 Deficiency

ETIOLOGY AND PATHOGENESIS Apo-A1 is the major lipoprotein in HDL. Mutations in apo-A1 can reduce HDL synthesis and produce HDL deficiency.[32]

CLINICAL FINDINGS Patients with defects limited to synthesis of apo-A1 may manifest plane xanthomata.[32]

PROGNOSIS AND CLINICAL COURSE It is uncertain whether these patients are prone to premature CHD; however, they do not appear to develop fulminant atherosclerosis. In some cases, there is a concomitant defect in synthesis of apo-C3 and apo-A4. When the latter defects are present, complex abnormalities are present in lipoprotein metabolism, and affected patients are prone to premature CHD.

Dysproteinemias

ETIOLOGY AND PATHOGENESIS Diffuse plane xanthomata have been reported in multiple myeloma, monoclonal gammopathy, cryoglobulinemia, leukemia, lymphoma, eosinophilic granulomatosis, and rheumatoid arthritis.[33] When diffuse xanthomas are found in monoclonal gammopathies, the M protein is usually immunoglobulin G.[33] Xanthomas are produced as a result of a complex between the paraprotein and a lipoprotein. Cellular uptake of these complexes by macrophages produces plane xanthomata.

CLINICAL FINDINGS: CUTANEOUS LESIONS A number of forms of dysglobulinemia or paraproteinemias are accompanied by diffuse plane xanthomata that typically manifest as yellow-orange macules or slightly raised plaques over the eyelids, neck (Fig. 135-9), and trunk.[34]



◀ **FIGURE 135-9** Diffuse plane xanthoma in a patient with lymphoma.

PROGNOSIS AND CLINICAL COURSE All patients with negative laboratory studies should have routine follow-up for the future development of dysproteinemias.

TREATMENT Treatment is dependent on the underlying condition.

SPECIAL CONSIDERATIONS

Biliary Obstruction or Hypoplasia

ETIOLOGY AND PATHOGENESIS Prolonged obstruction of the biliary tree leads to accumulation of cholesterol in the serum. Causes include primary biliary cirrhosis and secondary biliary obstruction. Serum cholesterol is high in unesterified cholesterol, which leads to the formation of an abnormal lipoprotein called *lipoprotein X*.

In children, Alagille syndrome is an inherited syndrome of biliary hypoplasia leading to elevated serum cholesterol.

CLINICAL FINDINGS: CUTANEOUS LESIONS Prolonged hypercholesterolemia leads to plane xanthomata (beige-orange plaques on hands, feet, and trunk), xanthelasma, and occasionally, tuberous xanthomata. Patients with prolonged biliary obstruction can also manifest jaundice, pruritus, and hyperpigmentation of the skin.

Children with Alagille syndrome have a characteristic facies with a prominent forehead, hypertelorism, pointed chin, and nasal dystrophy.

PROGNOSIS AND CLINICAL COURSE In Alagille syndrome, serum cholesterol is elevated when patients are young but can decrease over time. Cirrhosis develops in approximately 12 percent of patients with Alagille syndrome.

TREATMENT Treatment involves relieving the underlying cause of obstruction. Treatment for Alagille syndrome is medical management or, if cirrhosis develops, liver transplantation. Xanthomas have been found to resolve after liver transplantation.[35]

Xanthomas in Children

Xanthomas in children are uncommon and must always be investigated. The differential for xanthomas in children includes homozygous FH, sitosterolemia, CTX, and Alagille syndrome. If laboratory investigation reveals a childhood hyperlipidemia, treatment algorithms are available.[36]

Normolipemic Xanthelasma

Although the presence of xanthelasma warrants and investigation to rule out hyperlipidemia,[37] more than 50 percent of patients with xanthelasma may have normal serum lipids.[38,39] In these cases, the removal of xanthelasma is often a cosmetic concern. Treatment options include surgical excision, ablative laser therapy, trichloroacetic acid, or cryotherapy.[40]

Verruciform Xanthoma

Verruciform xanthoma commonly occurs in the oral cavity and are discussed in Chap. 74. Histologically it shows foamy histiocytes within elongated dermal papillae. Verruciform xanthoma is the characteristic lesion in *c*ongenital *h*emidysplasia with *i*chthyosiform erythroderma and *l*imb *d*efects (CHILD) syn-

drome (see Chap. 47), and mutations in the 3β-hydroxysteroid dehydrogenase gene (the gene that is mutated in CHILD syndrome), has been shown to underlie two cases of sporadic verruciform xanthoma.

Xanthoma Disseminatum

Xanthoma disseminatum is a histiocytic condition associated with diabetes insipidus and is discussed in Chap. 149.

Xanthogranuloma

Xanthogranulomas are also histiocytic conditions and are discussed in Chap. 149.

ACKNOWLEDGMENT

This is an adaptation of the chapters by Scott M. Grundy and Lowell A. Goldsmith in the previous editions of *Fitzpatrick's Dermatology in General Medicine*.

KEY REFERENCES

The full reference list for all chapters is available at www.digm7.com.

4. Cruz PD, East C, Bergstresser PR: Dermal, subcutaneous, and tendon xanthomas: Diagnostic markers for specific lipoprotein disorders. *J Am Acad Dermatol* **19**:95, 1988
5. Burgdorf B: The histiocytoses, in *Lever's Histopathology of the Skin*, edited by Lever WF, Elder DE. Lippincott Williams & Wilkins: Philadelphia, 2005, p 682
8. Rader HH: Disorders of lipoprotein metabolism, in *Harrison's Principles of Internal Medicine*, edited by Kasper DL, Harrison TR. McGraw-Hill, Medical Pub. Division: New York, 2005, p 2
26. Lorincz MT et al: Cerebrotendinous xanthomatosis: Possible higher prevalence than previously recognized. *Arch Neurol* **62**:1459, 2005
31. Maxfield FR, Tabas I: Role of cholesterol and lipid organization in disease. *Nature* **438**:612, 2005
36. Kanani PM, Sperling MA: Hyperlipidemia in adolescents. *Adolesc Med* **13**:37, 2002
40. White L, Shea CR, Horenstein M: Xanthomas, in *Treatment of Skin Disease: Comprehensive Therapeutic Strategies*, edited by Lebwohl M. Mosby/Elsevier, New York, 2006, p 691

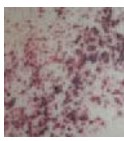

CHAPTER 136

Fabry Disease

Margarita M. Larralde
Paula C. Luna

EPIDEMIOLOGY

Fabry disease is the second most prevalent lysosomal storage disorder, after Gaucher disease,[1] with an estimated incidence ranging between 1:40,000 to 1:170,000 persons. Some authors consider this incidence to be underestimated given the existence of milder variants (renal and cardiac), postmortem diagnoses, and diagnoses in the setting of affected relatives.[2] The majority of patients are Caucasians, but it has been reported in other ethnicities.[1]

ETIOLOGY AND PATHOGENESIS

Fabry disease (Online Mendelian Inheritance in Man #301500) is a rare X-linked metabolic disorder caused by the partial or complete deficiency of a lysosomal enzyme, α-galactosidase A (Fig. 136-1). As a result of this enzyme deficiency, neutral sphingolipids with terminal α-galactosyl residues [predominantly globotriaosylceramide (Gb3)] accumulate in the lysosomes of different tissues and fluids (epithelial cell of glomeruli and tubules of the kidneys; cardiac myocytes; ganglion cells of the autonomic system; cornea; endothelial, perithelial, and smooth muscle cells of blood vessels; and histiocytic and reticular cells of connective tissue) (Fig. 136-2).[3] It manifests primarily in affected hemizygous men and, to some extent, in heterozygous females. Clinical onset is variable (Fig. 136-3); the disease usually appears during childhood, but may not appear until the second or third decade.

The gene GAL for α-galactosidase A is located at the Xq22.1 region. The entire 12Kb seven exon gene has been completely sequenced,[4] and mutations have been found in all seven exons.[1] More than 300 mutations of the gene have been detected, showing a wide variety of molecular lesions that have been demonstrated to be responsible for Fabry disease. Approximately 57 percent of alleles are missense mutations, 11 percent nonsense mutations, 18 percent partial gene deletions, 6 percent insertion, and 6 percent RNA processing defects due to aberrant splicing. Most families have "private" mutations, that is, mutations found only in that particular family.[3] No clear genotype-phenotype correlation has been demonstrated. Different mutations may cause similar phenotypes and, even within families, the same mutation may cause different phenotypes.

The Fabry gene is highly penetrant in males. Female heterozygotes (previously known as *carriers*) have variable expressivity ranging from completely asymptomatic to complete clinical and biochemical expression similar to hemizygous patients.[5–7] This variable expression is attributed to the Lyon hypothesis (where one X chromosome is inactivated on a random basis in the female, while the other provides the genetic information).[8]

FABRY DISEASE AT A GLANCE



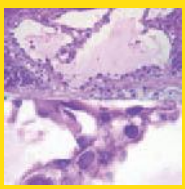

- Incidence estimated at 1:40,000 to 1:170,000 in all ethnicities.
- X-linked lysosomal storage disorder.
- Highly penetrant in males; female heterozygotes have variable expressivity.
- Partial or complete deficiency of α-galactosidase A with deposition of glycosphingolipids (mostly globotriaosylceramide).
- Typical variants affect predominantly skin, kidneys, heart, eyes, and brain.
- Life expectancy shortened by 20 years in males and 15 years in females.
- Atypical variants: Renal and cardiac.
- Dermatologic manifestations: Angiokeratomas and hypohidrosis.
- Light microscopy: Thinned epidermis over dilated or vacuolated blood vessels.
- Electron microscope: Zebra-like inclusion bodies.
- Treatment: Palliative, enzyme replacement.

HISTORICAL ASPECTS

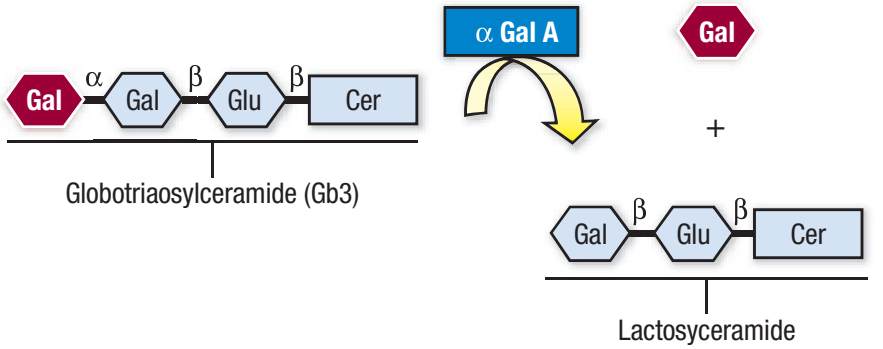

▲ **FIGURE 136-1** Metabolic pathway of globotriaosylceramide into galactose (Gal) and lactosylceramide secondary to the activity of α-galactosidase A (α Gal A). Cer = ceramide; Glu = glucose.

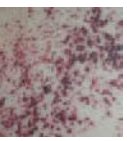

CUTANEOUS FINDINGS

Angiokeratomas

Angiokeratomas (AKs) are the most obvious and one of the most frequent clinical features of Fabry disease.[3,11] These lesions usually become evident between the age of 5 and adolescence, but significantly later in heterozygous females.[12] AKs usually present as clustered red to black papules that measure up to 1 cm in diameter, do not blanch with pressure, and often show a verrucous surface (Figs. 136-4 and 136-5).[4,13] They typically localize symmetrically in the bathing trunk area (buttocks, lower abdomen, groin, umbilicus, upper thighs) (Figs. 136-6 and 136-7, see eFigs. 136-6.1 and 136-6.2 in on-line edition; see Fig. 136-5), elbows, waist, and extensor surfaces of arms, as well as along the spine, suggesting a role for trauma in their occurrence (Koebner phenomenon). AKs are occasionally found on the hands (see eFig. 136-7.1 in on-line edition), feet, ears, and axillae, and rarely on the face, upper chest or back.[12,14] The number of lesions and their extent increases progressively with time.[3] The presence or extent of cutaneous involvement does not always correlate with systemic morbidity.[15]

Female patients usually show scattered, single AKs, often in an atypical distribution (upper chest or patches in a dermatomal distribution on the upper

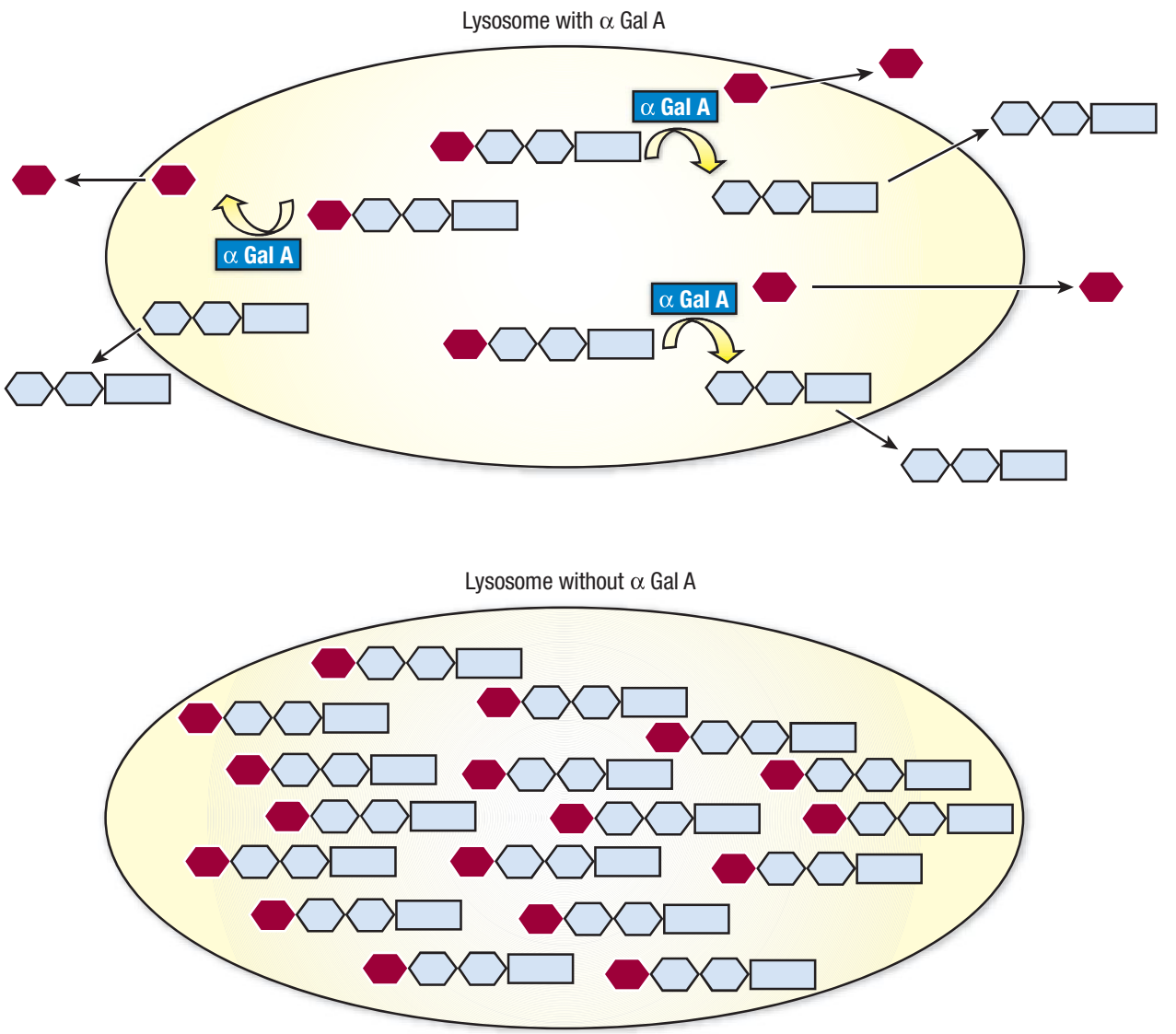

▲ **FIGURE 136-2** Deficit of α-galactosidase A (α Gal A) results in the accumulation of the substrate inside the lysosome.

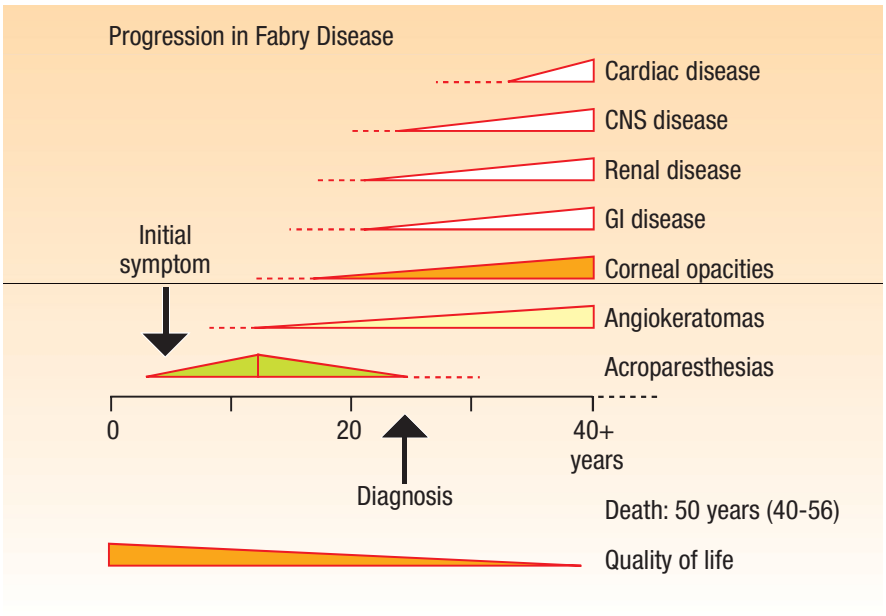

▲ **FIGURE 136-3** Natural history of Fabry disease: Acroparesthesias, angiokeratomas, corneal opacities, and gastrointestinal symptoms are often the first manifestations. Diagnosis is usually delayed and occurs around the second decade. CNS = central nervous system; GI = gastrointestinal.

or lower limbs).[16] In one series, 83 percent of hemizygous males had generalized AKs, but 80 percent of heterozygous females had isolated AKs.[3]

Hypohidrosis

Hypohidrosis is usually present by childhood or adolescence, leading to dry skin, intolerance to heat and exercise, and fever of unknown origin. It has been linked to peripheral nerve damage and/or lipid deposits in the small blood vessels surrounding eccrine glands and in the eccrine cells, as well as to abnormal nerve function due to an ischemic process.[17] By electron microscopy, marked degeneration of the secretory and myoepithelial cells of the sweat glands is demonstrable. The ability to sweat is not affected by the extent of the deficiency of α-galactosidase A.[18] Hyperhidrosis has also been reported in some patients.[19]



▲ **FIGURE 136-4** Multiple red pinpoint papules (angiokeratomas).

Oral Mucosal Lesions

AKs are found both periorally and intraorally, are mostly present in the anterior buccal mucosa, and can occasionally be present elsewhere (soft palate, tonsillar pillars, retromolar pads, and gingiva). They may appear telangiectatic (see eFig. 136-7.2 in on-line edition). Fissures and erythematous fungiform papillae have been described on the dorsal surface of the tongue.[20] Other mucosal findings include a cobbled tongue, glossitis, cheilitis granulomatosa, punctate

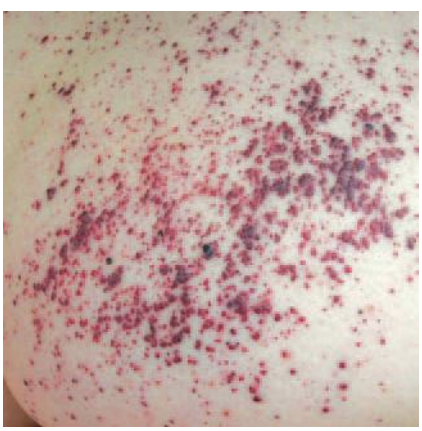

▲ **FIGURE 136-5** Larger magnification of multiple red to black angiokeratomas with a verrucous surface.



▲ **FIGURE 136-6** Angiokeratomas over the lower abdomen of a male patient with complete phenotypic expression.

angiectasis, and a twofold increase in the prevalence of cysts/pseudocysts of the maxillary sinuses.[20] There may be increased vascular tortuosity of the conjunctival vessels (see eFig. 136-7.3 in on-line edition). Although many patients complain of xerostomia, the salivary glands appear to be normal.

Other Mucocutaneous Features

Lymphedema of the legs has been frequently described and is thought to be due to the deposition of Gb3 in lymphatics (see eFig. 136-7.4 in on-line edition).[21] Although not as striking as in

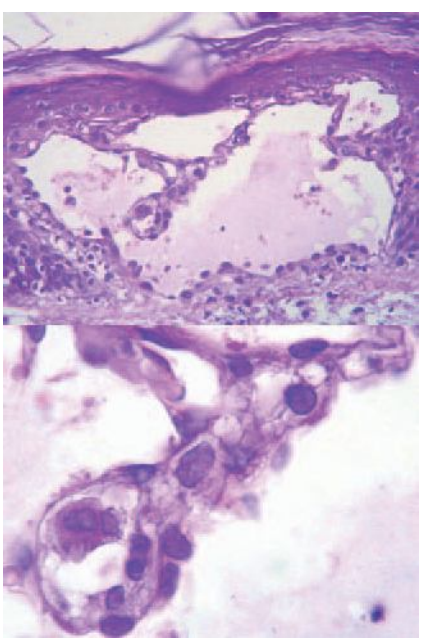

▲ **FIGURE 136-7** Light microscopy: Very dilated capillaries surrounded by an acanthotic epidermis. Larger magnification reveals cytoplasmic vacuoles inside endothelial and perithelial cells. (Used with permission from Dr. Gabriel Casas.)

other lysosomal diseases, some male patients have subtle dysmorphic facial features.[22] It is likely that these features become more pronounced over time together with the storage material, as patients with residual enzyme have less pronounced features. They tend to show periorbital fullness, prominent lobules of the ears, bushy eyebrows, recessed forehead, pronounced nasal angle, generous nose, prominent supraorbital bridge, broad alar base, and coarse features.[1,12,23] Alterations of the density of body hair have also been described.[19]

Histopathology

By light microscopy, AKs are characterized by a thin epidermis overlying a dermis with dilated blood vessels. Older, fully developed AKs may show hyperkeratosis (see Fig. 136-7). Endothelial, perithelial, eccrine, and smooth muscle cells are filled with cytoplasmic vacuoles containing glycosphingolipid that can be seen with toluidine stains. To preserve vacuolar contents (which are cleared by routine fixation), fixed tissue can be frozen or fixed with 1 percent calcium formol.

Characteristic electron-dense concentric or lamellar (zebra-like) inclusion bodies with a pattern of alternating (every 4 to 6 nm) light- and dark-staining bands are evident ultrastructurally under the electron microscopy (Fig. 136-8), in the endothelium, smooth muscle cells of the blood vessels, erector pilorum muscle cells, and dermal macrophages. These inclusion bodies can also be recognized in clinically normal skin.[24,25] The electron-dense lamellar (zebra-like) inclusions are strikingly prominent in the eccrine sweat glands.[17]

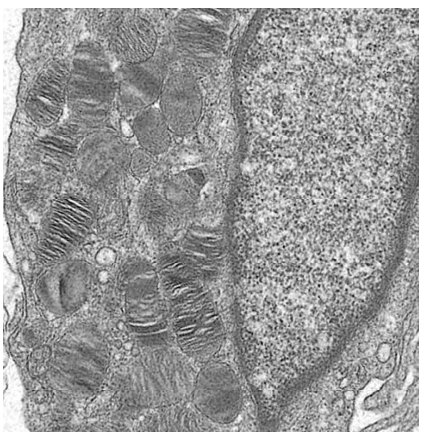

▲ **FIGURE 136-8** Electron microscopy. Osmiophilic lamellar bodies in a larger magnification reveals zebra bodies in a cutaneous endothelial cell. (Used with permission from Dagmar Foedinger, MD.)

Electron microscopy and immunoelectron microscopy using anti-Gb3 antibodies are useful tools when other diagnostic tests are not conclusive.[26]

NON-CUTANEOUS FINDINGS (Table 136-1, see Fig. 136-3)

Neurologic Findings (See Table 136-1)

ACROPARESTHESIAS Burning pain and tingling of the extremities is the most constant (80 percent to 90 percent) and early (in the first decade) clinical feature of Fabry disease in male patients. Female carriers report numbness or increased sensitivity of the extremities later in life.[12] Pain is described as feeling like pins and needles on the hands and feet, radiating proximally. It is constant or can be intermittent, triggered by changes of environmental or body temperature, exercise, or emotional stress.[18] Lipid accumulation within intradermal nerve fibers with degeneration of small unmyelinated nerve fibers and reduction of intraepidermal innervation can be seen ultrastructurally.[13,27,28] With time, patients often note a reduction in the intensity and frequency of acroparesthesias due to the complete destruction of the nerve fibers.

CEREBROVASCULAR DISEASE (See Table 136-1) Ischemic or hemorrhagic strokes occur early in life (average onset of 34 years in hemizygotes and 40 years in heterozygotes) and are, after renal failure, the most devastating and life-limiting event. Fabry disease should be considered as a differential diagnosis in young patients with cryptogenic stroke, for it has shown to affect nearly 1.5 percent of these patients.[29] Strokes lead to death in 55 percent of male and 40 percent of female patients.[13] A higher incidence of venous and arterial intravascular thrombosis, as well as increased levels of soluble intercellular adhesion molecule 1, P-selectin, and plasminogen activator inhibitor, and decreased thrombomodulin levels, have been detected.

OTHERS (See Table 136-1) Depression and dementia often occur in patients as they grow older. Some authors also report an increased frequency of suicidal ideation and suicide.[30,31] Sexual activity is often affected by the presence of AKs of the genital region or genital pain, leading to decreased self-esteem and libido. Autonomic dysfunction may include abnormalities in tears and saliva formation, cerebrovascular reactivity, cardiac rhythm, gastrointestinal motility, pain perception, and peripheral edema.[31] In contrast to other lysosomal storage diseases, mental retardation is not an early problem; however, older patients complain of dizziness, cephalalgia, and abnormal muscle reflexes.

TABLE 136-1
Non-Cutaneous Findings

- Renal
  - Chronic renal failure
- Cardiovascular
  - Hypertension
  - Coronary vascular disease
  - Left ventricle hypertrophy
  - Valve disease
  - Arrhythmias
  - Elevated high-density lipoprotein
- Neurologic/psychiatric
  - Acroparesthesias
  - Cerebrovascular disease
  - Dementia
  - Depression
  - Increased suicide ideation
- Ocular
  - Cornea verticillata
  - Conjunctival vessel aneurysms
  - Increased tortuosity of retinal vessels
  - Fabry cataract
- Gastrointestinal
  - Diarrhea
  - Nausea
  - Vomiting
  - Postprandial flank pain
  - Malabsorption
- Others
  - Hearing loss and tinnitus
  - Hypothyroidism
  - Obstructive airway disease
  - Osteopenia and osteoporosis
  - Anemia

Renal Manifestations (See Table 136-1)

Proteinuria develops around adolescence with gradual deterioration of renal function and the development of end-stage renal disease by around the third to fifth decade.[4] Characteristic maltese cross-shaped birefringent lipid globules can be found in the urine or the urinary sediment under polarizing microscopy (see eFig. 136-8.1 in on-line edition). A renal variant of Fabry disease has been described.[32,33] Patients have decreased, but not absent, α-galactosidase A activity and develop end-stage renal disease at ages similar to that of classically affected patients, but lack other characteristic manifestations.[34]

Cardiac Manifestations (See Table 136-1)

Cardiac involvement is a constant feature.[35] It is thought to be due to the deposition of Gb3 in myocardium, valves, and the conduction system,[27] although other mechanisms might contribute.[35,36] Deposition may manifest as left ventricular hypertrophy, mitral valve collapse, and arrhythmias, as well as coronary artery disease (angina, myocardial infarction, and electrocardiogram abnormalities).[27,37] An interesting finding in Fabry disease is their unusual lipoprotein phenotype, showing elevated high-density lipoprotein cholesterol, normal low-density lipoprotein cholesterol and triglycerides, and a borderline increase in total cholesterol.[38] Some patients with low residual α-galactosidase A levels and cardiac manifestations have a milder and later-onset phenotype than typical affected patients (cardiac variant).[34,39]

Ocular Findings (See Table 136-1)

The most characteristic and common ocular finding is cornea verticillata (opacities characterized by one or more lines radiating from near the center of the cornea), which occurs in 94 percent of male and 70 percent of female patients.[40] Conjunctival vessel aneurysms, increased tortuosity of retinal vessels (especially of the posterior pole) (see eFig. 136-7.3 in on-line edition), papilledema, optic atrophy, anterior cataracts, and lenticular changes can also be found.

Gastrointestinal Manifestations (See Table 136-1)

Episodic diarrhea, nausea, vomiting, postprandial flank pain, and malabsorption are the most common gastrointestinal complaints. Other gastrointestinal signs (pancreatic insufficiency, achalasia, and jejunal diverticulosis) have also been described. All these symptoms may relate to the deposition of glycosphingolipid in intestinal small vessels and in autonomic ganglia. Many patients consider gastrointestinal symptoms to be the most debilitating features of the disease, especially during childhood.[13]

Other Non-Cutaneous Manifestations (See Table 136-1)

Tinnitus and high-frequency sensorineural hearing loss are also common manifestations of Fabry disease, with a prevalence of around 50 percent. The severity of the hearing loss is thought to be closely related to the renal function impairment.[41]

Although Gb3 deposits in many endocrine glands, the function of most endocrine organs seems to be intact, with normal production of gonadotropins and sex hormones, as well as normal fertility rates.[42] The exception is a much higher incidence of sub-clinical hypothyroidism in both male and female patients.[43]

Some patients can develop severe obstructive airway disease. Spirometry studies show a reduced forced residual volume and increased mean residual capacity. Older patients may also show reduced Vmax25 (25 percent of vital capacity) and diffusing capacity. Osteopenia and osteoporosis are complications that likely result from malabsorption of vitamin D, reduction of physical activity because of pain, chronic renal failure, and, possibly, decreased osteoblastic activity because of endothelial glycosphingolipid accumulation.[44] Anemia often occurs, largely related to the impaired renal function, heart failure, and chronic inflammation.[45]

Quality of Life (See Fig. 136-3)

The severe clinical manifestations (affecting kidney, gastrointestinal system, heart, and brain), the presence of sometimes visible AKs, as well as the debilitating pain and hypohidrosis, affect patient well-being, physical and social functioning, work, and the ability to carry out daily activities.[46]

DIAGNOSIS

The definitive diagnosis of Fabry disease is usually delayed, with a mean time between the onset of symptoms and diagnosis of 15 years.[47] Although clinical and histopathologic findings might lead to suspicion of Fabry disease,[48] the diagnosis must be confirmed by the demonstration of deficient α-galactosidase A activity in tears, plasma, serum, or leukocytes and in dried blood spots on filter paper,[3]

Box 136-1

Differential Diagnosis of Angiokeratomas

- Hemangiomas
- Papular spider angiomas
- Pyogenic granulomas
- Eruptive angiomas
- Hereditary hemorrhagic telangiectasia (Osler-Weber-Rendu syndrome)
- Melanoma
- Molluscum contagiosum
- Warts
- Condylomas

Box 136-2

Differential Diagnosis Among Types of Angiokeratomas

- Angiokeratoma of Fordyce
- Angiokeratoma of Mibelli
- Solitary papular angiokeratoma
- Angiokeratoma circumscriptum

as well as the presence of Gb3 in urinary sediment, plasma, and cultures of fibroblasts in hemizygous and some heterozygous patients. Female patients have variable, and, occasionally, even normal levels of enzyme activity. Thus, identification of a pathogenic mutation is required to confirm diagnosis.[18]

Biopsy of tissues, such as skin and kidney, demonstrates the presence of lipid deposition and multilamellated myelin bodies in electron micrographs (see Fig. 136-8).[13] As Gb3 deposition starts in utero,[49] prenatal diagnosis can be performed from chorionic villi or culture of amniotic cells, where low α–galactosidase A activity can be demonstrated.[50]

DIFFERENTIAL DIAGNOSIS (Boxes 136-1, 136-2, and 136-3)

The discomfort is often mistaken for rheumatoid arthritis, rheumatic fever, erythromelalgia, Raynaud disease, or simply as "growing pains."[13,51]

The clinical diagnosis of AKs may be difficult. They may resemble petechiae, pyogenic granulomas, or eruptive angiomas; older lesions with a verrucous surface may be misdiagnosed as warts, condylomas, or even melanoma.[52] The AKs from Fabry disease should also be differentiated from other AKs,[53] particularly angiokeratoma of Fordyce, angiokeratoma of Mibelli, the solitary papular angiokeratoma, and angiokeratoma circumscriptum (Table 136-2).

AKs have also been described in several other lysosomal storage disorders (Table 136-3).[54] In addition to the distinct enzyme deficiency in each of these storage diseases and other clinical features, AKs from Fabry disease can be

Box 136-3

Differential Diagnosis Among Disorders with Angiokeratomas Corporis Diffusum

- Fucosidosis
- Aspartylglycosaminuria
- Galactosialidosis
- Schindler/Kanzaki disease
- β-Mannosidosis
- β-Galactosidosis
- Idiopathic

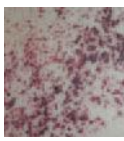

TABLE 136-2
Clinical Manifestations of Different Types of Angiokeratomas

Type	Age (Yr)	Sex	Clinical Aspect	Body Site	Trigger	Inherited	Association
Fabry	5–12	Both, predominantly in males	Multiple, clustered red to black papules, do not blanch with pressure. Older lesions become warty.	Any part of the body, especially bathing trunk area	No	Yes, X-linked	Acroparesthesias, heart and renal failure, stroke, cornea verticillata, etc.
Mibelli	10–15	Both, more frequent in female	Few warty, dark red papules (1–5 mm).	Lateral aspect and dorsa of fingers and toes, hands, and feet	Cold	Yes, autosomal dominant	History of acrocyanosis and chilblains
Fordyce	> 60	Male	Multiple warty, vascular lesions.	Genitals	No	No	Local venous hypertension[71]
Solitary papular	Second to fourth decade	Both	Few dark-red warty papules (2–10 mm).	Any part of the body, especially in lower extremities	Trauma	No	—
Circumscriptum	Congenital (rarely may appear later in life)[72]	Both	Single dusky purple plaque. Tends to the zosteriform configuration.[53]	Lower legs or foot	No	No	Bleed easy when traumatized Vascular malformations[73] Cobb syndrome[52]

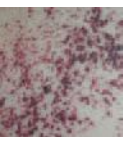

TABLE 136-3
Differential Diagnosis of Angiokeratoma Corporis Diffusum

Group	Name	Enzyme Deficiency	Gene	Electron Microscopy Findings[55]	Clinical Findings	Dermatologic Findings
Sphingolipidoses	Fabry (OMIM #301500)	α-Galactosidase A	Xq22	Electron-dense lysosomal deposits	Acroparesthesias, heart and renal failure, stroke, cornea verticillata	Angiokeratoma corporis diffusum, telangiectasias, hypo/anhidrosis, lymphedema
	GM1 gangliosidosis (OMIM #230500)	β-Galactosidase	3p21-3pter	Electron-lucent lysosomal dilation	Facial dysmorphism, hematologic signs, mental retardation, organomegaly	Angiokeratoma corporis diffusum
Glycoproteinoses	Aspartylglucosaminuria (OMIM #208400)	Aspartylglycosaminidase	4q32-33	Electron-lucent lysosomal dilation	Coarse facies, macroglossia, organomegaly, ocular findings, cardiac valve involvement	Angiokeratoma corporis diffusum, facial angiofibromas, oral fibromatosis and leukokeratosis[74]
	Fucosidosis (OMIM #230000)	α-Fucosidase	1p34	Electron-lucent lysosomal dilation	Mental retardation, coarse facies, growth retardation, recurrent respiratory infections, dysostosis multiplex, visceromegaly	Angiokeratoma corporis diffusum, widespread telangiectasias, acrocyanosis, purple transverse distal nail bands, increased vasculature in hands and feet, sweating abnormalities[55,75]
	β-Mannosidosis (OMIM #248510)	β-Mannosidase	4q22-q25	Electron-lucent lysosomal dilation	Mental retardation, neuropathy, hearing loss, recurrent infections	Angiokeratoma corporis diffusum in bathing trunk area[76]
	Sialidosis II (OMIM #256550)	Neuraminidase	6p21.3	Electron-lucent lysosomal dilation	Mental retardation, dysostosis multiplex, vacuolated lymphocytes, subtle coarse facial features	Angiokeratoma corporis diffusum
Multiple enzyme deficiency	Galactosialidosis (OMIM #256540)	β-Galactosidase and neuraminidase	20q13.1	Electron-lucent lysosomal dilation	Dwarfism, gargoyle facies, mental retardation, seizures, corneal clouding, dysostosis multiplex, and hearing loss	Angiokeratoma corporis diffusum scattered along entire body, especially knees, elbows, and bathing trunk area[77]

(continued)

TABLE 136-3
Differential Diagnosis of Angiokeratoma Corporis Diffusum (Continued)

Group	Name	Enzyme Deficiency	Gene	Electron Microscopy Findings[55]	Clinical Findings	Dermatologic Findings
	Kanzaki (OMIM #104170)	α-N-acetyl-galactosamini-dase (α-N-acetylgalac-tosaminidase)	22q11	Electron-lucent lyso-somal dilation	Mental retardation, coarse facial features, ocular signs, hearing loss, neu-ropathy	Angiokeratoma corporis diffusum of entire body, more dense on the bath-ing trunk area, axillae, and breasts Telangiectasias on lips and oral mucosa[78,79]

OMIM = Online Mendelian Inheritance in Man.

differentiated by electron microscopic examination by the characteristic electron-dense, lamellar (zebra-like) inclusions within endothelial and other cell types.[55] Widespread AKs have been also described in a 29-year-old patient with tuberous sclerosis,[56] a 12-year-old patient suffering from juvenile dermatomyositis,[57] two infants with neonatal lupus erythematosus, and co-existing with a familial cerebral cavernous angioma syndrome. Generalized AKs without an associated metabolic disorder have been also described (see eFig. 136-8.2 in on-line edition).

PROGNOSIS AND CLINICAL COURSE

Life-span reduction in patients with Fabry disease has been calculated to be 20 years for male patients and 15 years for female heterozygotes. Unless the patient undergoes hemodialysis or renal transplantation, death most often is due to uremia (see Fig. 136-3).

TREATMENT (Box 136-4)

The many different debilitating symptoms of Fabry disease demand a multidisciplinary approach that involves the primary caregiver, as well as experienced nephrologists, cardiologists, dermatologists, and neurologists.

Palliative Therapies

AKs can be treated with cryotherapy, electrocoagulation, or excisional surgery. However, the treatment of choice is laser therapy (neodymium YAG, pulsed dye, KTP 532nm, copper, argon, candela V, or beam laser).[19,58] Pain is the most disturbing and early symptom, and can sometimes be partially managed with diphenylhydantoin, carbamazepine, or gabapentin. Nonsteroidal anti-inflammatory drugs are not only ineffective, but also contraindicated because they can affect renal function. Narcotics are also best avoided, given the chronic nature of the disease and the high risk of addiction. Patients should be encouraged to identify and try to avoid their personal precipitating stimuli if possible.

For the primary or secondary prevention of stroke and other vascular pathologies, such as retinal artery occlusion, anti-platelet and anticoagulant therapy might be needed.[59]

Metoclopramide and pancrelipase are used to reduce gastrointestinal symptoms. Hypertension must be controlled, as it significantly affects three of the most affected organs, the kidney, brain, and heart. Special attention should also be paid to renal function, because renal dysfunction is the most frequent and serious late complication. For maintaining a good cardiac functioning, antiarrhythmics, artificial pacemakers, and even cardiac transplant might be required.

If an engrafted kidney has normal α-galactosidase A activity, it will metabolize the glycosphingolipids and remain free of Gb3 deposition through life.[4] Allograft kidneys from Fabry carriers, however, should be avoided because they may function correctly initially, but over time may become less effective; furthermore, the carrier female donor is at risk for the development of renal disease and may suffer for having only one kidney.

Specific Therapeutics: Enzyme Replacement Therapy

One enzyme preparation, agalsidase β (Fabrazyme), has been approved and is available in the United States and Europe; another, agalsidase alfa (Replagal), is available only in Europe. Several clinical trials have shown enzyme replacement therapy (ERT) to be effective in reducing the amount of stored tissue glycolipids.[60–62] Additionally, the therapy

Box 136-4

Treatment: A Multi-Disciplinary Approach Is Always Advisable

PALLIATIVE

Angiokeratomas
- Liquid nitrogen
- Electrocoagulation
- Excisional surgery
- Laser (neodynium YAG, dye laser, KTP 532nm, copper, argon, candela V or beam laser)

Pain
- Diphenylhydantoin
- Carbamazepine
- Gabapentin
- Avoid triggers
- Nonsteroidal anti-inflammatory drugs
- Narcotics

Stroke
- Anti-platelet
- Anticoagulant

Hearing
- Hearing aid devices
- Avoid noise trauma

Lungs
- Bronchodilators
- Avoid smoking

Gastrointestinal
- Pancrelipase
- Metoclopramide

Cardiovascular
- Antihypertensive drugs
- Antiarrhythmia drugs
- Artificial pacemakers
- Coronary bypass

Chronic renal failure
- Hemodialysis
- Allograft transplant

SPECIFIC
- Enzyme replacement
  - α-Galactosidase B (Fabrazyme)
  - α-Galactosidase A (Replagal)

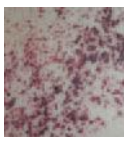

reduces pain episodes, stabilizes or improves renal function in patients with a mild renal disease, and reduces excess cardiac mass, gastrointestinal symptoms, and hypohidrosis. Gb3 deposition in the skin has also been reduced by the ERT, suggesting that periodic ultrastructural examination of skin might be useful to monitor response to therapy.[24,63] Whether or not ERT will positively impact on mortality is still unknown.[64] When to start ERT is still controversial,[65] especially among female and patients with milder variants.[66] Experts recommend that ERT should be provided in the second decade in male patients or as soon as symptoms are observed.[39,67] Adverse events to date have only been infusion related (hives, pruritus, fever, and rigors) and respond to premedication and a decrease in infusion rate.

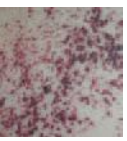

New Treatments

A new strategy for treating this disease is chaperone-based enzyme enhancement therapy (phase II clinical trial by Amicus Therapeutics). This novel therapy consists of small molecules that rescue misfolded/mistrafficked enzymes from the lysosomes and transport them to the endoplasmic reticulum. The principal benefit of this therapy is that it can be administered orally and can cross the blood-brain barrier.[68] Chaperone-based ERT is useful only for patients with some residual enzyme.

Substrate deprivation (inhibition of an early step in the synthesis of glycosphingolipids)[14] and the infusion of galactose are other therapeutic options that are still in the research state.

Gene therapy and hematopoietic cell transplantation are still being developed.[69]

Genetic Counseling

All families that have a member with Fabry disease should have an opportunity to receive genetic counseling. Given the X-linked nature of Fabry disease, female patients have a 50 percent chance of transmitting the gene both to their sons and daughters while male patients will have no affected sons and 100 percent of daughters are affected. The genotype-phenotype variability should also be stressed especially among patients with subtle manifestations.[70]

KEY REFERENCES

The full reference list for all chapters is available at www.digm7.com.

1. Mehta A: New developments in the management of Anderson-Fabry disease. *QJM* **95**:647, 2002
3. Larralde M et al: Fabry disease: A study of 6 hemizygous men and 5 heterozygous women with emphasis on dermatologic manifestations. *Arch Dermatol* **140**:1440, 2004
4. Desnick RJ, Ioannou YA, Eng CM: α-galactosidase A deficiency: Fabry disease, in *The Metabolic and Molecular Bases of Inherited Diseases*, edited by Scriver CR, Sly WS: New York, McGraw-Hill, 2001, p 3733
12. Galanos J et al: Clinical features of Fabry's disease in Australian patients. *Intern Med J* **32**:575, 2002
13. Hauser AC, Loenz M, Sunder-Plassmann G: The expanding clinical spectrum of Anderson–Fabry disease: A challenge to diagnosis in the novel era of enzyme replacement therapy. *J Intern Med* **255**:629, 2004
18. Ries M et al: Pediatric Fabry disease. *Pediatrics* **115**:344, 2005
19. Möhrenschlager M et al: Fabry disease: Recognition and management of cutaneous manifestations. *Am J Clin Dermatol* **4**:189, 2003
20. Baccaglini L et al: Oral and craniofacial findings in Fabry's disease: A report of 13 patients. *Oral Surg Oral Med Oral Pathol Oral Radiol Endod* **92**:415, 2001
22. MacDermot KD, Holmes A, Miners AH: Anderson-Fabry disease: Clinical manifestations and impact of disease in a cohort of 98 hemizygous males. *J Med Genet* **38**:750, 2001
39. Desnick RJ et al: Fabry disease, an under-recognized multisystemic disorder: Expert recommendations for diagnosis, management, and enzyme replacement therapy. *Ann Intern Med* **138**:338, 2003

CHAPTER 137

Lipoid Proteinosis

Jonathan A. Dyer

EPIDEMIOLOGY

Lipoid proteinosis (LP) is also known as *hyalinosis cutis et mucosae* (Online Mendelian Inheritance in Man #247100) and is a very rare genodermatosis. Only about 300 cases have been reported in the literature. However, it is relatively common in the Namaqualand area of Northern Cape Province in South Africa (frequency of 1 in 300 population). To date, all South African LP patients studied have carried the same mutation (Q276X), likely contributed by a German settler who arrived in 1652 (founder effect).[1]

ETIOLOGY AND PATHOGENESIS

LP is inherited in an autosomal recessive fashion and is caused by mutations in the gene encoding extracellular matrix protein-1 (ECM-1). Although it was given this name because of its discovery among various connective tissue proteins in a murine stromal cell line, ECM-1 likely has broader functions. ECM-1 is known to inhibit bone mineralization, contribute to epidermal differentiation, and stimulate angiogenesis.[2]

ECM-1 is present both in the epidermis and as a secreted protein in the dermis. There are three splice variants, with ECM-1a encoded by the full gene, ECM-1b lacking exon 7, and ECM-1c containing an additional exon 5a. ECM-1a is widely expressed, whereas ECM-1b is expressed only in tonsils, keratinocytes, and the upper respiratory tract. ECM-1c is also expressed in the skin. The function of ECM-1 is unknown, although it has been shown to interact with perlecan, a heparin sulfate proteoglycan present in basement membranes. The ECM1 gene is located next to the epidermal differentiation complex on chromosome band 1q21. This localization, along with expression of ECM-1a in basal keratinocytes but ECM-1b in terminally differentiated keratinocytes, suggests a role in keratinocyte differentiation. Both ECM-1a and ECM-1b may stimulate blood vessel endothelial cell proliferation and promote angiogenesis in chicken embryo.[3] Abnormalities of the cutaneous vasculature are described in LP.[4]

Mutations in ECM1 in LP lead to loss of function of ECM-1. The majority of mutations occur in exon 7, with frameshift mutations leading to ablation of the ECM-1a transcript but not that of ECM-1b, which typically lacks exon 7. The majority of mutations outside of exon 7 occur in exon 6 and are nonsense or

LIPOID PROTEINOSIS AT A GLANCE





- Rare worldwide occurrence, with the greatest incidence (1 in 300) in the Namaqualand region of South Africa.
- Autosomal recessive disorder with variable phenotype, even within families.
- Caused by defects in extracellular matrix protein-1.
- Hoarseness is the most frequent finding.
- Skin fragility and blistering occur in some affected children; blisters heal as infiltrated lesions with scar-like appearance.
- Progressive development of infiltrated papules and plaques is seen, especially on the elbows and extensor aspects of the arms and lower legs.
- Beaded papules on the eyelid margin (moniliform blepharosis) are a classic finding but are not always present.
- Calcification of the temporal lobes and amygdala may lead to neurologic and/or psychiatric symptoms.
- Some patients have airway compromise from upper airway infiltration.
- Periodic acid-Schiff–positive, diastase-resistant thickening is seen at the dermal-epidermal junction, perivascularly, and along adnexal epithelia with hyaline material in the dermis.
- Electron microscopy reveals deposited dermal material and excess basement membrane material around blood vessels with irregular duplication of the lamina densa at the dermal-epidermal junction.
- No effective treatment exists. Laser ablation/dermabrasion of papules is helpful in some cases.

frameshift mutations. Patients with exon 7 mutations may have a slightly milder phenotype than those with non–exon 7 mutations with regard to respiratory and skin (but not neurologic) manifestations.

The second tandem repeat of ECM1, encoded by exon 7, binds fibulin-1, an extracellular component of most basement membranes. Thus, ECM-1a binds to fibulin, whereas ECM-1b, lacking exon 7, does not bind fibulin.[5] Given the differential expression of ECM-1 isoforms in skin, the ability to bind fibulin-1 may be important in keratinocyte differentiation. Antibodies to ECM-1 have now been detected in patients with lichen sclerosus et atrophicus (see Chap. 63), which suggests that this disorder represents an acquired form caused by antibody-induced ECM-1 loss.[6]

CLINICAL FINDINGS

The most reliable clinical signs for diagnosing LP are a hoarse voice and thickened sublingual frenulum, which prevents patients from protruding the tongue—thus the clinical admonition, "Listen to them talk and have them stick out their tongues." Secondary features include beaded eyelid papules, infiltration and warty papules of the skin around the elbows and extensor forearms, and mild alopecia. Increased scarring and photoaging of sun-exposed skin may be seen. Scars or scar-like lesions are present in areas of minor trauma but are not increased at sites of surgery or vaccination.[1] An algorithm outlining an approach to the patient with suspected LP is shown in Fig. 137-1.

History

Cutaneous Lesions

The phenotypic features of LP are quite variable, even within families. This is well demonstrated in studies of South African patients, all of whom share the same mutation yet exhibit highly variable phenotypes. The variable expressivity can lead to difficulty in diagnosis of affected patients. The earliest finding in LP is hoarseness from vocal cord infiltration, which occurs at birth or in the first few years of life. Initially, this may be noted as a faint or weak cry and is one of the most striking and consistent features. Hoarseness may progress during the lifetime of a patient. Dysphagia may occur from involvement of the upper aerodigestive tract and esophagus.[1,8,9]

Skin lesions usually develop in the first years of life, although the timing of their onset is variable. Importantly, two stages of skin lesions may be noted. A long-neglected and underappreciated clinical feature of LP is the erosions that can develop during childhood. Blistering can be extensive enough to mimic epidermolysis bullosa. The associated vesicles (and rarely bullae) are typically noninflammatory and heal slowly with hemorrhagic crusting and resultant scarring (Fig. 137-2). Scars may be linear and resemble pseudoporphyria on the face. In some patients, blistering is worse during warmer weather. Skin fragility and easy wounding with minor trauma or friction are noted. Spontaneous development of extra-facial pustular lesions has also been noted. Shedding of sheets of skin, which leaves red oozing areas, has also been described.

The skin lesions of the second stage are better recognized. Although beaded papules along the eyelid margins (moniliform blepharosis) (Fig. 137-3) are considered a classic clinical finding, they are variable and may be subtle. Other cutaneous stigmata include generalized skin thickening with a waxy, yellow appearance as well as areas of distinct papules and nodules. Areas subject to repeated friction or trauma, such as the elbows, halluces, and extensor aspects of the arms and lower legs, may develop overlying hyperkeratosis, which may be quite striking and verrucous (Fig. 137-4). The scarring usually begins during childhood and is often worst on the face. It may follow trauma or occur spontaneously, yet no tendency to excessive scarring is noted after surgery or vaccination. Pock-like or acneiform scarring is well described in LP, especially on the face and extremities.[10] Some areas may resemble solar elastosis (see Fig. 137-3). Flexural lichenification may also be seen, and patients with LP have been misdiagnosed as having atopic dermatitis.[8] Some patients report increased photosensitivity, and, in some patients, sun-exposed areas exhibit the greatest amount of scarring. Significant pruritus, alterations in the ability to sweat, and an abnormal pain sensation have been noted. Alopecia may occur, although it is variable in severity. Nails are normal.[9]

Related Physical Findings

The mucosa of patients with LP exhibits infiltration and thickening. Early in life, oral erosions may be noted. Thickening of the lingual frenulum leads to inability to protrude the tongue (Fig. 137-5). The pharynx, tongue, soft palate, tonsils, and lips are typically involved. Laryn-





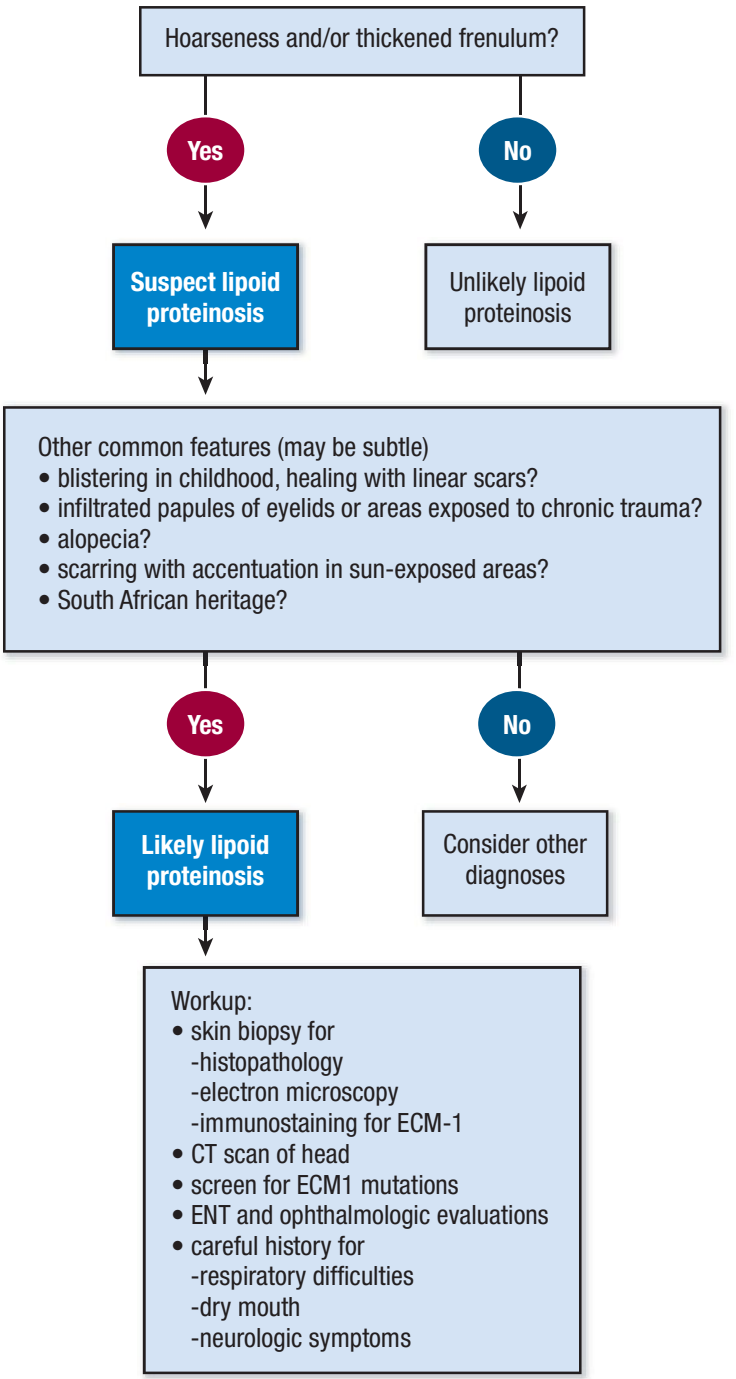

▲ **FIGURE 137-1** Approach to the patient with possible lipoid proteinosis. CT = computed tomography; ECM-1 = extracellular matrix protein-1; ENT = ear, nose, and throat.



▲ **FIGURE 137-2** Lipoid proteinosis. Early bullous lesion with typical hemorrhagic crust healing with scarring. (From Dyer JA, Yu QC, Paller AS: "Free-floating" desmosomes in lipoid proteinosis: An inherent defect in keratinocyte adhesion? *Pediatr Dermatol* **23**:1, 2006, with permission.)

geal and pharyngeal involvement may be severe enough to trigger respiratory difficulty, and tracheostomy has been required in rare cases. Shortness of breath or worsening of respiratory difficulties as well as swelling of the salivary glands (submandibular and parotid) may be triggered by upper respiratory tract infections. Xerostomia and dental caries may be seen.[9,11] Dental abnormalities (absent permanent upper lateral incisors) have also been described. Parotitis from infiltration of Stenson's duct and subsequent blockage can occur.

Central nervous system involvement is a well-recognized, but variable, feature of LP. Amygdala dysfunction has been described, which leads to abnormal perception and appraisal of fear. More recent studies have demonstrated subtle differences between LP patients and normal controls in the judgment of facial expression and emotion, in memory for negative and positive pictures, and in odor-figure association tests. Because of the frequent bilateral amygdala damage, LP has been used as a model disorder for the investigation of the function of the amygdala.[12] Neurologic and psychiatric findings include seizures, memory deficits, social and behavioral changes, paranoid symptoms, mental retardation, and aggressiveness. Severe generalized dystonia has also been reported.

The ocular examination may reveal drusen-like fundal lesions.[13] Eyelid infiltration may induce corneal ulcers due to abnormal eyelash positioning, and alopecia of the eyebrows and eyelashes can occur. The abnormal deposition of hyaline material has been detected histopathologically in many internal organs, although this is typically asymptomatic.[14]



▲ **FIGURE 137-3** Lipoid proteinosis. Beaded papules along margin of the eyelids (moniliform blepharosis). Note increased severity of yellowish, waxy lesions in sun-exposed areas. (Used with permission from O. Braun-Falco, Munich.)

LABORATORY TESTS

Light microscopic evaluation of lesional sections reveals deposition of amorphous eosinophilic material at the dermal-epidermal junction, perivascularly, and along adnexal epithelia. There is deposition of hyaline material in the dermis, often perpendicular to the basement membrane (Fig. 137-6). The hyaline material is periodic acid-Schiff positive and diastase resistant, with a composition similar to that of basement membrane. Often arranged in concentric, "onion-skin" layers around vessels, these layers include type III and type IV collagen as well as laminin. Electron microscopy reveals irregular duplication of the lamina densa at the dermal-epidermal junction. Cytoplasmic vacuoles are noted in dermal fibroblasts.[15] The presence of lipids varies and is considered a secondary phenomenon due to lipid adherence to glycoproteins present in the hyaline material rather than a primary defect of LP.

The histologic features of the early bullous lesions of LP have only recently been described. Acantholysis of keratinocytes apparently is the cause.[16] Electron microscopy suggests an abnormality of desmosomal attachment, with "free-floating" desmosomes noted in bullous lesions. These preliminary findings require confirmation; however, given the pattern of expression of ECM-1 in the epidermis, a role in keratinocyte cell–cell adhesion appears plausible.[17]

Three-dimensional analysis of the cutaneous vasculature in LP shows enlarged vessels in the mid- and deep dermis with an orientation parallel to the dermal-epidermal junction. The dermal papillary plexus also lacks capillary loops. As in lichen sclerosus et atrophicus, the subcutaneous plexus and transverse connecting vessels are atretic or poorly formed.[4] Such vascular abnormalities may reflect a disturbance of ECM-1 function during angiogenesis.

SPECIAL TESTS

Computed tomographic scans of the brain reveal bilateral anterior medial temporal lobe calcifications, often bean-shaped, and especially within the amygdala, in 50 percent to 75 percent of LP patients.[12]

Histopathologic evaluation of these lesions shows amorphous masses of calcium and bone along with multiple haphazardly arranged small blood vessels with wall calcification and gliotic adjacent tissue. The cortex and white matter show isolated blood vessels occluded by fibrin, parietal calcification, small perivascular infarctions, and demyelination.[18] Immunohistochemical staining of skin biopsy specimens may show absence or attenuation of ECM-1. This may prove to be a valid diagnostic test, not only to aid in diagnosis in mild cases but also potentially to direct molecular investigations.[19]

DIFFERENTIAL DIAGNOSIS

See Box 137-1.

PROGNOSIS AND CLINICAL COURSE

The prognosis of LP is variable. Often, there is progressive worsening of cutaneous features, with clearance during childhood of blistering lesions and progressive development of infiltrative lesions. The hoarseness and mucosal lesions also may



▲ **FIGURE 137-4** Hyperkeratotic papular lesions on the dorsal hands (**A**) and interdigital web and sides of the fingers (**B**), and verrucous nodular lesions on the knee (**C**).





▲ **FIGURE 137-5** Restricted mobility of the tongue due to infiltration of the frenulum is seen in most patients with lipoid proteinosis. Note discoloration of the lips as well. (Used with permission from O. Braun-Falco, Munich.)



progress with time. Although some patients have experienced respiratory complications from upper respiratory tract infiltration that have, in rare cases, led to early mortality, most patients have a normal life span. It is important to recognize the impact of LP on the quality of life of affected patients. The disfiguring nature of the skin lesions, along with the abnormal voice, significantly impact the interactions of LP patients with others. Patients have increased difficulty holding jobs.[1]



▲ **FIGURE 137-6** Extensive deposition of periodic acid-Schiff–positive, diastase-resistant hyaline material in the dermis of a scar-like lesion of lipoid proteinosis.

TREATMENT

Many agents, including topical and systemic corticosteroids, oral dimethyl sulfoxide,[20] and intralesional heparin, have been investigated and used in the treatment of LP. None of these agents has demonstrated any sustained benefits. Given the apparent photo-exacerbation of lesions in a subset of LP patients, photoprotection seems reasonable, although there are no data confirming any benefit. Early intervention for developmental problems is important, and management of other stigmata by the appropriate specialists is warranted. Various surgical modalities such as dermabrasion and CO_2 laser procedures have been used to treat cutaneous lesions. CO_2 laser surgery for vocal cord lesions and eyelid papules has been helpful.[21,22]

PREVENTION

Prenatal genetic testing in families at risk is theoretically possible using DNA-based analysis.

Box 137-1

Differential Diagnosis of Lipoid Proteinosis

CLINICAL

Most Likely

- Erythropoietic protoporphyria (EPP) or pseudoporphyria (clinically and histologically)—in EPP most changes are in sun-exposed areas, whereas in lipoid proteinosis they are present in non–sun-exposed sites as well; EPP has no beading of the eyelids.
- Variegate porphyria—especially in South Africa
- Epidermolysis bullosa—hoarseness with blistering (infancy)
- Impetigo—childhood blisters and erosions

Consider

- Scarring from acne
- Scleromyxedema
- Amyloidosis
- Residual lichenification from atopic dermatitis

HISTOPATHOLOGIC

- Erythropoietic protoporphyria
- Diabetic microangiopathy
- Amyloidosis
- Lichen sclerosus

KEY REFERENCES

The full reference list for all chapters is available at www.digm7.com.

1. Van Hougenhouck-Tulleken W et al: Clinical and molecular characterization of lipoid proteinosis in Namaqualand, South Africa. *Br J Dermatol* **151**:413, 2004
2. Hamada T et al: Extracellular matrix protein 1 gene (ECM1) mutations in lipoid proteinosis and genotype-phenotype correlation. *J Invest Dermatol* **120**:345, 2003
3. Chan I: The role of extracellular matrix protein 1 in human skin. *Clin Exp Dermatol* **29**:52, 2003
6. Oyama N et al: Autoantibodies to extracellular matrix protein 1 in lichen sclerosus. *Lancet* **362**:118, 2003
9. Hamada T: Lipoid proteinosis. *Clin Exp Dermatol* **27**:624, 2002

CHAPTER 138

Cutaneous Mineralization and Ossification

John S. Walsh
Janet A. Fairley

CALCIUM

Calcium is involved in many physiologic processes. It is key to skeletal muscle and myocardial contraction, neurotransmission, and blood coagulation. In addition, it is the primary mineral in the bony skeleton. On the cellular level, its diverse functions include transmission of information into and between cells, regulation of plasma membrane potential, and exocytosis. Only over the last 20 years has its effect on skin been fully appreciated. Calcium regulates major functions in the epidermal keratinocytes including proliferation, differentiation, and cell-cell adhesion.[1–6]

REGULATORY HORMONES

At least three regulatory hormones control the ionic calcium concentration in serum: parathyroid hormone (PTH), calcitonin, and 1,25 dihydroxyvitamin D_3 [$1,25(OH)_2D_3$].

PTH is an 84-amino acid, single-chain polypeptide that is synthesized in the parathyroid glands. Under normal conditions, a decrease in the serum concentration of ionized calcium results in an increase in PTH production, whereas an increase in the serum concentration of ionized calcium results in a decrease in PTH production. In the kidney, PTH increases renal tubular reabsorption of calcium and increases renal clearance of phosphate. PTH also acts directly on the bone to increase the plasma calcium concentration. It does this acutely by mobilizing calcium from bone into the extracellular fluid. Osteocytes and osteoblasts are the presumed target cells for this effect. PTH also stimulates osteoclastic bone resorption, possibly by stimulating osteoblasts to release factors that activate osteoclasts. PTH together with a decreased plasma phosphate concentration stimulates 1α-hydroxylase activity in the kidney, causing an increase in the plasma concentration of $1,25(OH)_2D_3$. $1,25(OH)_2D_3$ increases intestinal absorption of calcium.

Calcitonin is a 32-amino acid polypeptide that is produced by parafollicular or C cells of the thyroid gland. Calcium is the primary stimulant for calcitonin secretion. Calcitonin lowers the serum calcium concentration, primarily through osteoclast inhibition, but whether it plays a major role in serum calcium metabolism outside of the neonatal period in vivo is unclear.

Vitamin D_3, or cholecalciferol, is a secosteroid formed by the opening of the β ring of 7-dehydrocholesterol. In humans, this formation occurs in the basal layer of the epidermis. First there is an ultraviolet B–mediated conversion of 7-dehydrocholesterol to previtamin D_3. Previtamin D_3 then undergoes thermal isomerization to form vitamin D_3. To become biologically active, vitamin D_3 must first be hydroxylated at carbon position 25 in the liver and then at carbon position 1α by the enzyme 1α-hydroxylase in the kidney. 1α-hydroxylase is tightly regulated. PTH and calcitonin increase its activity, whereas calcium, phosphate, and $1,25(OH)_2D_3$ inhibit it.[7]

$1,25(OH)_2D_3$, similar to PTH, increases the concentration of plasma calcium. Its primary action is to stimulate the active transport of calcium across the intestine. $1,25(OH)_2D_3$ also increases the plasma calcium concentration by mobilizing calcium from bone.[8] The simultaneous presence of PTH appears to be necessary for this effect.

$1,25(OH)_2D_3$ also plays a major role in the growth and differentiation of tissues, including skin.[9] Receptors for $1,25(OH)_2D_3$ are present on epidermal keratinocytes, pilosebaceous structures, and in the dermis.[10–13] In human keratinocyte cultures, $1,25(OH)_2D_3$ causes a dose-dependent decrease in proliferation, an increase in morphologic differentiation, and an increase in terminal differentiation markers.[14] Cultured human keratinocytes can also convert $25(OH)D_3$ to $1,25(OH)_2D_3$, suggesting that the epidermis may regulate its own growth and differentiation by endogenously produced $1,25(OH)_2D_3$.[14] The mechanism by which $1,25(OH)_2D_3$ may induce differentiation of epidermal cells may be through calcium, because calcium is required for terminal differentiation of keratinocytes. $1,25(OH)_2D_3$ may facilitate calcium entry into cells and, through induction of calcium-binding proteins, facilitate the ability of calcium to regulate various cellular processes.

ABERRANT CALCIFICATION AND OSSIFICATION

Despite the careful regulation of serum calcium, calcification and ossification of cutaneous and subcutaneous tissues may occur.[15] Calcification is the deposition of insoluble calcium salts; when it occurs in cutaneous tissues it is known as *calcinosis cutis*. Ossification is the formation of true bony tissue by the deposition of calcium and phosphorus in a proteinaceous matrix as hydroxyapatite crystals. Cutaneous calcification may be divided into four major categories: dystrophic, metastatic, idiopathic, and iatrogenic. Dystrophic calcification is the most common type of calcinosis cutis and occurs as a result of local tissue injury. Although calcium and phosphate metabolism and serum levels are normal, local tissue abnormalities, such as alterations in collagen, elastin, or subcutaneous fat may trigger calcification. The internal organs usually remain unaffected. Metastatic calcification is the precipitation of calcium salts in normal tissue secondary to an underlying defect in calcium and/or phosphate metabolism. The calcification may be widespread and, in addition to the skin, affects predominantly blood vessels, kidneys, lungs, and gastric mucosa. All patients presenting with signs of metastatic calcification should receive a calcium and phosphate metabolic evaluation. Idiopathic calcification occurs without identifiable underlying tissue abnormalities, abnormal calcium, and/or phosphate metabolism. Cutaneous calcification also may be iatrogenic. Cutaneous ossification most commonly occurs secondary to local tissue alteration

CUTANEOUS MINERALIZATION AT A GLANCE



- Results from the deposition of calcium salts in the dermis, subcutaneous tissue, or vascular endothelium when the local calcium concentration exceeds its solubility in the tissue.
- Clinically, may be categorized as dystrophic, metastatic, idiopathic, or iatrogenic.
- Pathology shows aggregates of calcium that stain with Alizarin red S or von Kossa stains.



or pre-existing calcification. Any calcifying disorder of the skin may ossify secondarily. On rare occasions, primary cutaneous ossification may occur without underlying tissue abnormalities or pre-existing calcification.

DYSTROPHIC CALCIFICATION

Connective Tissue Diseases

Dystrophic calcification frequently occurs in connective tissue diseases.[16] Scleroderma and CREST syndrome (calcinosis cutis, *R*aynaud phenomenon, *e*sophageal dysfunction, *s*clerodactyly, *t*elangiectasia) are notable examples that are frequently associated with calcinosis cutis (Fig. 138-1; see Chap. 158). In these disorders, nodules and plaques of calcium deposits may occur in the skin, subcutaneous tissue, muscle, or tendons. The calcium deposits most commonly occur on the upper extremities, especially on the fingers and wrists, but may occur in any area subject to trauma or motion. As the calcifications enlarge, they may ulcerate and exude a chalky material.

Dystrophic calcification also occurs in dermatomyositis (see Chap. 157). It is more commonly associated with juvenile rather than adult-onset dermatomyositis, occurring in 44 percent to 70 percent of children as opposed to 20 percent of adults.[17] The calcification tends to occur 2 to 3 years after disease onset and most frequently appears on the elbows, knees, shoulders, and buttocks.[18] The calcium deposits may be painful and can ulcerate. They also may exude a chalky material, form sinuses, and become chronically infected. Calcium salt deposition may become quite extensive, progressing along fascial planes of skin and muscle, forming an "exoskeleton," and leading to significant morbidity and mortality. Calcinosis cutis in dermatomyositis is difficult to treat; however, if the patient survives long enough, the calcified nodules may improve spontaneously.

Although uncommon, calcinosis cutis has been described in all clinical subsets of lupus erythematosus.[19–22]

There is no standard treatment for dystrophic calcification. A diet low in calcium and phosphate along with aluminum hydroxide has been reported to arrest or facilitate regression of the calcified nodules.[23] Disodium etidronate has also been used with some success.[24] Several series report long-term treatment with diltiazem improves the calcinosis in some patients.[25,26] Other reported treatments include warfarin, colchicine, probenecid, and bisphosponates.[16,27] Occasionally, calcium deposits must be removed surgically to clear sinus tracts, ulcers, or chronic infections.





▲ **FIGURE 138-1** Dystrophic calcification in CREST syndrome (*c*alcinosis cutis, *R*aynaud phenomenon, *e*sophageal dysfunction, *s*clerodactyly, *t*elangiectasia).

Panniculitis

Pancreatic enzyme panniculitis (see Chap. 68) is a lobular panniculitis that commonly demonstrates dystrophic calcification. It occurs in patients with pancreatitis or pancreatic adenocarcinoma and is presumably caused by the action of liberated pancreatic enzymes on subcutaneous fat. The fatty acids formed by lipolysis may combine with calcium and form calcium soap.

In subcutaneous fat necrosis of the newborn, erythematous, well-defined nodules and plaques occur during the first few weeks of life over the cheeks, back, buttocks, and extremities.[28,29] The affected infants are generally otherwise healthy, and the nodules and plaques usually clear spontaneously. Occasionally, the lesions calcify, and in a small subset of patients symptomatic hypercalcemia may develop, sometimes several months after birth.

Inherited Disorders

Dystrophic calcification occurs in patients with pseudoxanthoma elasticum (PXE; see Chap. 139). PXE is a hereditary disorder of elastic tissue characterized by progressive calcification of elastin fibers, primarily within the skin, Bruch's membrane of the retina, and the cardiovascular system. The cause of PXE was recently identified as a mutation in the ABC-C6 gene.[30] This gene is thought to play a critical role in transmembrane transport. Most patients with PXE have normal calcium-phosphate metabolism, but a few have been identified who have abnormal calcium, phosphate, and/or vitamin D metabolism. Patients in this subset may develop metastatic calcification in the form of calcified or ossified tumors, calcification of the falx cerebri, and arterial calcification.[31–33]

Ehlers-Danlos syndrome (EDS; see Chap. 139) is a group of inherited disorders of fibrillar collagen metabolism. Mutations in the collagen genes or enzymes that regulate collagen biosynthesis have been determined to underlie a number of EDS sub-types.[34–36] The skin characteristically shows hyperelasticity and fragility with formation of pseudotumors and large gaping scars. Subcutaneous calcified nodules, termed *spheroids* may appear, and are thought to represent calcified ischemic fat lobules.[37,38] Calcification of healing surgical incisions has also been reported in patients with EDS.[39]

Dystrophic calcification has been observed in patients with porphyria cutanea tarda (see Chap. 132).[40,41] Sclerodermoid plaques with dystrophic calcification have occurred on the preauricular area, scalp, neck, and dorsa of the hands. Ulceration with trans-epidermal elimination of sheets of calcium is also rarely reported.

Other genetic disorders in which calcification may occur include Werner syndrome and Rothmund-Thomson syndrome (see Chap. 140).[42,43]

Cutaneous Neoplasms

Dystrophic calcification occurs in association with a variety of benign and malignant cutaneous neoplasms. Often the neoplasms also show ossification in the surrounding stroma.

Pilomatricomas (see Chap. 119) are the most common cutaneous neoplasms that manifest calcification and ossification. Approximately 75 percent of pilomatricomas show calcification and 15 percent to 20 percent show ossification.[44,45] Ossification usually occurs within the connective tissue adjacent to the shadow cells, probably through metaplasia of fibroblasts into osteoblasts. Activating mutations in the adherens junction protein β-catenin have been identified in some pilomatricomas.[46]

A large number of other neoplasms may be associated with calcification and ossification, including: pilar cyst, basal cell carcinoma, intradermal nevi (probably as a result of inflammation or folliculitis), desmoplastic malignant melanoma, atypical fibroxanthoma, pyogenic granuloma, hemangioma, neurilemmoma, trichoepithelioma, and seborrheic keratoses.[47–51] Mixed tumors (chondroid syringomas) may also show calcification and ossification. However, unlike other neoplasms, the ossification occurs within the tumor via ossification of the chondroid cells, much like endochondral bone formation occurring in the epiphyses of bones.

Infections

Infectious agents may produce enough cutaneous damage to cause dystrophic calcification. Parasitic infections that may result in calcinosis cutis include onchocerciasis (*Onchocerca volvulus*) and cysticercosis (*Taenia solium*).[52,53] Calcinosis cutis has also been reported as a complication of intrauterine herpes simplex infection.[54]

Other

Dystrophic calcification has been reported in a variety of settings where local tissue injury occurs, such as in scarring caused by burns, trauma, neonatal heel sticks (sub-epidermal calcified nodule), surgery, and keloids.[55–59]

METASTATIC CALCIFICATION

Chronic Renal Failure

Metastatic calcification most commonly occurs in chronic renal failure and takes the form of either benign nodular calcification or calciphylaxis. In chronic renal failure, decreased clearance of phosphate results in hyperphosphatemia. In addition, the impaired production of $1,25(OH)_2D_3$ results in a decrease in calcium absorption from the intestine and decreased serum calcium levels. The hypocalcemia results in increased PTH production and secondary hyperparathyroidism. Elevated levels of PTH cause bone resorption and mobilization of calcium and phosphate into the serum, leading to normalization of the serum calcium concentration but marked hyperphosphatemia. If the solubility product of calcium and phosphate is exceeded, metastatic calcification may occur. In benign nodular calcification, the calcifications typically occur at periarticular sites, and their size and number tend to correlate with the degree of hyperphosphatemia. The lesions disappear with normalization of calcium and phosphate levels.

Calciphylaxis is a life-threatening disorder characterized by progressive vascular calcification, soft tissue necrosis, and ischemic necrosis of the skin (see Chap. 151).[60] Clinically, it presents as firm, extremely painful, well-demarcated, violaceous plaques associated with soft tissue necrosis and ulceration (Fig. 138-2). The lesions may occur anywhere, but the lower extremities are most frequently involved. The mortality rate is estimated to be approximately 80 percent. Histopathologically, there is medial calcification of small and medium-sized arteries with intimal hyperplasia, primarily in dermal and subcutaneous tissues. Calciphylaxis occurs almost exclusively in patients with a history of chronic renal failure and prolonged secondary hyperparathyroidism. However, there exist rare reports of the occurrence of calciphylaxis in the absence of renal failure.[61] Most of the patients reported are female, and there may be an association with obesity and poor nutritional status.[62,63]

The pathogenesis of calciphylaxis is unknown. Experiments in a rat model have suggested that calciphylaxis may be triggered by exposure to a sensitizing agent (PTH, dihydrotachysterol, or vitamin D) followed by a challenging agent (metal salts, albumin, or corticosteroids).[64] However, the clinical description and histopathology of the animal lesions differ from the human disease. Protein C dysfunction has also been described in a subset of patients with calciphylaxis, but this more likely is a mark for a coagulation defect that predisposes this group to calciphylaxis.[65] More recently, it has been proposed that glycoproteins that regulate vascular fibrosis and calcification are involved in the pathogenesis of this disorder.

The current therapy of calciphylaxis involves attempts to normalize the calcium-phosphate product and meticulous wound care. Normalizing methods include low calcium dialysis, use of phosphate binders that combine calcium acetate and magnesium carbonate, sodium thiosulfate, and parathyroidectomy.[60] Parathyroidectomy may increase survival.[66] Aggressive management of wound infections and judicious use of débridement may help lower the incidence of sepsis and death in these patients.

Hypervitaminosis D

Chronic ingestion of vitamin D in supraphysiologic doses (50,000 to 100,000 units/day) may produce hypervitaminosis D.[67] The initial signs and symptoms of hypervitaminosis D are attributable to hypercalcemia and hypercalcuria, and include weakness, lethargy, head-



▲ **FIGURE 138-2** Calciphylaxis. The lesions develop as violaceous plaques that may progress to necrotic ulcers, as shown in this patient.



ache, nausea, and polyuria. Metastatic calcification may also occur.

Milk-Alkali Syndrome

Milk-alkali syndrome is characterized by excessive ingestion of calcium-containing foods or antacids, leading to hypercalcemia.[68] Complications other than the acute manifestations of hypercalcemia include irreversible renal failure, nephrocalcinosis, and subcutaneous calcification, occurring predominantly in periarticular tissues.

Tumoral Calcinosis



Tumoral calcinosis (TC) is a disorder characterized by the deposition of calcific masses around major joints, such as hips, shoulders, elbows, and knees. The masses are intramuscular or subcutaneous and may enlarge to sizes causing significant impairment of joint function. Usually the overlying skin is normal, but associated ulceration and calcinosis cutis may occur. It generally occurs in otherwise healthy adolescents. Tumoral calcinosis may be either sporadic or familial. The familial type may be associated with hyperphosphatemia or normophosphatemia. Inactivating mutations in either the GALNT3 or FGF23 genes may lead to hyperphosphatemic TC.[69–71] GALNT3 encodes a glycosyltransferase (N-acetylgalactosaminyltransferase 3 or ppGalNAc-T3) that initiates mucin-type O-glycosylation. It is hypothesized that FGF23, an important regulator of phosphate homeostasis, must be glycosylated by ppGalNAc-T3 to function properly. The defect in normophosphatemic TC is unknown. Surgical excision is the treatment of choice, but phosphate deprivation has met with some success.

Other Disorders

Other systemic disorders associated with hypercalcemia and/or hyperphosphatemia are reported to cause metastatic calcification. These include neoplasms associated with bony destruction, such as lymphoma, leukemia, multiple myeloma, and metastatic carcinoma.[72–74] Sarcoidosis may also be associated with metastatic calcification.[75]

IDIOPATHIC CALCIFICATION

Calcified nodules characterize idiopathic calcification of the scrotum. The lesions usually appear in otherwise healthy males and tend to increase in size and number with time.[76] Eventually, they may break down and exude a chalky material. Controversy exists over the etiology of this disorder. Many believe idiopathic calcification of the scrotum is truly idiopathic; others maintain that calcified scrotal nodules are inflamed or ruptured epidermoid cysts that undergo dystrophic calcification.[77–79] Excision of the lesions is the treatment of choice, although patients may continue to develop nodules at other sites. Idiopathic calcification of the penis, vulva, and breast has also been reported.[80,81]

Sub-epidermal calcified nodules appear on the exposed areas of the head and the extremities.[82] They may be congenital or acquired and typically appear as hard, 3- to 10-mm solitary lesions, although multiple lesions may occur. Some investigators believe the lesions represent calcified sweat gland hamartomas.[83]

Reports have described the appearance of milia-like idiopathic calcinosis cutis on the dorsa of hands and forearms of patients with Down syndrome.[84–86] Some of the calcifications are associated with syringomas.

IATROGENIC CALCIFICATION

Cutaneous calcification may be iatrogenic. Calcinosis cutis is a complication of intravenous calcium chloride and calcium gluconate therapy.[85] Calcified nodules may appear at sites of extravasation, probably as a result of an elevated tissue concentration of calcium and tissue damage. Minor trauma and prolonged contact with calcium salts can lead to calcinosis cutis in a variety of settings.[86,87] It has occurred in patients undergoing electroencephalography with saturated calcium chloride electrode paste.[88] Cutaneous calcification of skin graft donor sites after the application of calcium alginate dressings has also been reported.[89] Transient deposits of calcium in the skin and other soft tissues have also been reported after liver transplantation.[90] It is hypothesized that these transient deposits are caused by the large amounts of calcium- and citrate-containing blood products used during surgery, combined with metabolic abnormalities in the perioperative period.

PRIMARY OSSIFICATION

Primary ossification of cutaneous and subcutaneous tissues rarely occurs without any underlying tissue abnormality or pre-existing calcification. In addition to miliary osteoma of the face, there are four well-described ossifying syndromes[93]: fibrodysplasia ossificans progressiva (FOP), Albright hereditary osteodystrophy (AHO), progressive osseous heteroplasia (POH), and plate-like osteoma cutis. Other primary ossification disorders reported in the literature, such as isolated osteoma or widespread osteoma, probably are variants of the described ossifying syndromes or represent a group of poorly described primary ossification disorders.

Fibrodysplasia Ossificans Progressiva

FOP is an autosomal-dominant syndrome characterized by the progressive ossification of deep connective tissues leading to significant morbidity and mortality.[94] Ossification is of the endochondral type, and involvement of the skin occurs as a result of direct extension from underlying tissues. Dysmorphic great toes are a characteristic feature of FOP. Other features include abnormal phalanges of the hands, deafness, baldness, and mental retardation. Although the genetic defect remains unknown, linkage analysis studies have identified potential loci at 4q27–31.[95] Genes involved in the bone morphogenesis protein-signaling pathways are located in these regions.

Albright Hereditary Osteodystrophy, Progressive Osseous Heteroplasia, and Plate-Like Osteoma Cutis

AHO, POH, and plate-like osteoma cutis are three closely related syndromes that are characterized by intramembranous bone formation in skin. Mutations in the gene encoding for the α-subunit of the stimulatory G protein of adenyl cyclase (GNAS1), a negative regulator of bone formation, have been identified in all three of these disorders.[93,96–99] In addition, families have been described in which some members have plate-like osteoma cutis whereas other members have POH.[100] Several families have demonstrated an "imprinting" effect; inheritance of an inactivating mutation in GNAS1 from the father results in POH, whereas inheritance from the mother leads to AHO.[102] In addition, different splice variants are expressed solely by maternal or paternal alleles.

AHO is an autosomal-dominantly inherited syndrome characterized by the



▲ **FIGURE 138-3** Progressive osseous heteroplasia. The appearance of the skin in progressive osseous heteroplasia can be subtle, but the lesions have a distinctive textural change that feels like rice grains in the skin.

ossification of cutaneous and subcutaneous tissues in childhood. AHO generally follows a limited course, and significant deformity and physical impairment are rare. Patients typically have brachydactyly, dimpling over the metacarpophalangeal joints (Albright's sign), obesity, round or moon facies, short stature, and mental retardation. Most patients have a deficient end-organ response to PTH or "pseudohypoparathyroidism" with hypocalcemia, hyperphosphatemia, and elevated levels of PTH. Other patients have "pseudo-pseudohypoparathyroidism" with normal serum levels of calcium and phosphorus.[93]

POH is characterized by progressive ossification of skin and deep tissues during infancy or childhood.[102,103] Most reported patients are female, although a small number of male patients have also been described. Ossification usually begins in the dermis and progresses to involve deeper tissues, such as muscle, as well as overlying skin. Skin involvement has been described as a papular eruption resembling "rice grains" and having a "gritty" consistency (Fig. 138-3). Unlike AHO or FOP, there are no associated dysmorphic features. Secondary orthopedic problems, such as limb-length discrepancy or ankylosis of the joint, arise if the cutaneous ossification is severe enough to limit motion.

Plate-like osteoma cutis is currently used to describe patients with a more limited, nonprogressive form of cutaneous ossification.

Miliary osteoma cutis of the face most commonly occurs as multiple small, firm nodules on the faces of young women with a history of acne vulgaris. There are, however, reports of multiple miliary osteoma cutis in older patients without acne vulgaris or other underlying skin disease.[104]

KEY REFERENCES

The full reference list for all chapters is available at www.digm7.com.

9. Bikle DD: Vitamin D regulated keratinocyte differentiation. *J Cellular Biochem* **92**:436, 2004
15. Walsh JS, Fairley JA: Calcifying disorders of the skin. *J Am Acad Dermatol* **33**:693, 1995
16. Boulman N et al: Calcinosis in rheumatic diseases. *Semin Arthritis Rheum* **34**:805, 2005.
60. Arseculeratne G, Evans AT, Mroley SM: Calciphylaxis—A topical overview. *J Eur Acad Derm Venereol* **20**:493, 2006
71. Kato K et al: Polypeptide GalNAc-transferase T3 and familial tumoral calcinosis. Secretion of fibroblast growth factor 23 requires O-glycosylation. *J Biol Chem* **281**:18370, 2006
93. Kaplan FS et al: Heterotopic ossification. *J Am Acad Ortho Surg* **12**:116, 2004.



CHAPTER 139

Heritable Disorders of Connective Tissue with Skin Changes

Mario E. Lacouture
Amy S. Paller

Inherited disorders of connective tissue comprise a clinically and genetically diverse group of conditions affecting primarily the skin, joints, and, often, the cardiovascular system. The severity of the skin phenotype depends on the type of mutation and the role of the affected protein on dermal structure and function (see Chap. 61). Although genetic testing for most patients is not available commercially at this time, a listing of research laboratories that conduct testing can be found at http://www.genetests.com. Some inherited connective tissue disorders are characterized by hyperextensible skin, whereas others show cutaneous laxity. Yet other disorders have specific cutaneous changes that reflect the alternations in the dermis, such as the striae in Marfan syndrome and the cutaneous papules of pseudoxanthoma elasticum.

EHLERS-DANLOS SYNDROMES

The Ehlers-Danlos syndromes (EDSs) are a heterogeneous group of disorders characterized by hypermobile joints, hyperextensible skin, and fragile tissues that are extremely susceptible to trauma.[1–3] As many as 1 in 5000 individuals may be affected by some form of the disease.[4] The seven sub-types of EDS have been categorized based on clinical[5] and corresponding molecular pathogenetic findings in collagen types I, III, and V, or processing enzymes[6] (Table 139-1). These collagen types are all fibrillar types of collagen with cross-banding that are expressed in different locations in the skin and in other tissues (see Chap. 61 for distribution). Pathogenic alterations of fibrillar collagens in EDS result from deficient collagen-processing enzymes, haploinsufficiency, or mutations in collagen α chains.[7] A uniform finding in all types of EDS is generalized joint hypermobility, which can be assessed clinically according to the Beighton scale (Table 139-2).[8]

Classical Type

EPIDEMIOLOGY The classical form of EDS is one of the most common, occurring in 1 in 10,000 to 20,000 infants.[9]

ETIOLOGY AND PATHOGENESIS The classical type of EDS is characterized by an alteration in type V fibrillary collagen and is inherited in an autosomal dominant (AD) fashion. Mutations in *COL5A1* and *COL5A2* have been shown to cause this variant[10,11] in up to 50 percent of cases.[12–15] The abnormal allele leads to dominant-negative effects or haploinsufficiency, depending on the mutation.[16,17] At least one other locus is involved, because several families are discordant for linkage to both *COL5A1* and *COL5A2*.[13,18] A few patients have shown mutations in *COL1A1*, a gene more commonly mutated in osteogenesis imperfecta (OI; see Osteogenesis Im-

EHLERS-DANLOS SYNDROMES AT A GLANCE



- Combined incidence of almost 1 in 5000 persons.
- Seven sub-types.
- Most commonly autosomal dominant (classical and hypermobile types).
- The gene encoding collagen V is most often affected.
- Cutaneous features include soft, velvety skin that bruises easily and wounds that heal as thin, atrophic, gaping scars.
- Extracutaneous manifestations include hypermobile joints with frequent dislocations, problems with pregnancy and delivery, and, less commonly, cardiovascular manifestations, particularly aortic root dilatation.
- Information for patients and professionals at http://www.ehlers-danlos.org and http://www.ednf.org.



perfecta).[19,20] Whereas *COL5A1* is located on the long arm of chromosome 2q31, the *COL5A2* gene resides on the long arm of chromosome 9q34.2-34.3. Although collagen V is not abundant in skin, tendons, or ligaments, the clinical phenotype attests to its important structural role.

Ultrastructural findings show thickened collagen fibrils in skin,[21] with an approximate 25 percent increase in diameter, underscoring the function of collagen V in limiting fibril diameter, as shown in vitro.[22] This effect is thought to be due to the negative charge of the amino terminus of α1(V), conferred by abundant tyrosine residues, which inhibits fibril growth.[7] Another hallmark of classical EDS is the presence of rare composite fibrils also known as "collagen cauliflowers."[23] These abnormalities are present in less than 5 percent of fibrils, suggesting that other factors may be responsible for the severe clinical phenotype, such as the arrangement of collagen fibrils in tissue. This disorganized arrangement of collagen fibrils and their interaction with other extracellular matrix (ECM) proteins is thought to cause the altered biomechanical properties of EDS skin.[24]

CLINICAL FINDINGS Classical EDS is characterized by joint laxity, hyperextensibility of skin, and poor wound healing. The skin manifestations can vary in severity from mild to severe; milder forms were previously termed the "mitis" type, or type II, EDS. The skin is soft, velvety, and can be stretched easily (Fig. 139-1). It is not lax, except in late stages. Skin hyperextensibility should be determined at the volar surface of the forearm or some other site that is not subjected to mechanical forces or scarring. Approximately 50 percent of patients with Ehlers-Danlos of the classic and hypermobile types can touch the tip of their nose with their tongue (Gorlin's sign), in contrast to 10 percent of individuals who do not have EDS (Fig. 139-2).

The dermis is fragile and easily bruised. The shins show persistent discoloration, often beginning in early childhood (Fig. 139-3). When the skin splits from trauma, it is relatively painless and does not bleed excessively, but the wounds tend to gape. The wound margins tend to retract, heal slowly, and often become infected. Dehiscence is common, and complete wound breakdown

TABLE 139-2
Beighton Criteria for Joint Hypermobility

1. Passive dorsiflexion of the fifth finger > 90 degrees
2. Passive apposition of the thumbs to the flexor aspect of the forearm (Beighton sign)
3. Hyperextension of the elbow > 10 degrees
4. Hyperextension of the knees > 10 degrees
5. Ability of the palms to completely touch the floor during forward flexion of the trunk with knees fully extended

Numbers 1–4 are scored for each side, so that a maximal score of two is possible if both left and right sides show criteria; number 5 is scored as 1. A score of ≥ 5/9 is hypermobile.

TABLE 139-1
The Ehlers-Danlos Syndromes: Clinical Sub-Types and Associated Defects

VILLEFRANCHE TYPE/(OMIM)	CLINICAL FEATURES	INHERITANCE	PROTEIN/(GENE DEFECT)
Classical/(130000 and 130010)	Hyperextensible skin; easy bruising; wide, atrophic scars; hypermobile joints	AD	Collagen type V/(*COL5A1*, *COL5A2*)
Hypermobility/(130020)	Smooth, velvety skin; joint hypermobility	AD/AR	Unclear for most; collagen type III; tenascin XB/(*COL3A1*; *TNXB*)[a]
Vascular/(130050)	Thin, translucent skin with easy bruising; arterial and visceral rupture; typical facies	AD	Collagen type III/(*COL3A1*)
Kyphoscoliosis/(225400 and 229200)	Atrophic scars, easy bruising; neonatal hypotonia; scoliosis; ocular rupture; marfanoid habitus	AR	Lysyl hydroxylase/(*PLOD1*)
Arthrochalasia/(130060)	Hyperextensible and fragile skin; severe joint hypermobility; congenital hip dislocation	AD	Collagen type I/(*COL1A1*; *COL1A2*)
Dermatosparaxis/(225410)	Severely fragile, sagging, redundant skin; hernias and premature rupture of fetal membranes	AR	Procollagen I N-peptidase/(*ADAMTS2*)
Other types[a]			
Progeroid variant[190]/(130070)	Wrinkled, loose facial skin, curly fine hair, scanty eyebrows and eyelashes	AR	Due to mutations in galactosyltransferase

AD = autosomal dominant; AR = autosomal recessive; OMIM = Online Mendelian Inheritance in Man.
[a]Few reported cases.



▲ **FIGURE 139-1** Classical Ehlers-Danlos syndrome. Dermal elasticity is demonstrated. Unlike cutis laxa, the skin returns to original shape after stretching.

may require repeated suturing or healing by secondary intention (Fig. 139-4). Alternatively, the skin may appear to hold the stitches well initially, but the wound may fall apart after sutures are removed. Scars after trauma or surgical procedures are thin, papyraceous (having the consistency of paper), and may stretch considerably after healing (see Figs. 139-3 and 139-4). The more severely affected individuals have scars with a characteristic "fish mouth" or "cigarette paper" appearance. Thin, atrophic, darkly pigmented scars form as a consequence of intradermal or subdermal hematomatas, and occur mainly at pressure points. Molluscoid pseudotumors, fleshy lesions associated with scars, are present at the extensor surfaces of joints, in the foot, and on the shins. Spheroids are well-defined, mobile, subcutaneous indurated nodules that occur at sites of recurrent trauma and can be confused with subcutaneous granuloma annulare. Affected persons



▲ **FIGURE 139-2** Classical Ehlers-Danlos syndrome (EDS). Gorlin's sign is the ability to touch the tip of the nose with the tongue and is described in approximately 50 percent of patients with Ehlers-Danlos, in contrast to 10 percent of individuals who do not have EDS.



▲ **FIGURE 139-3** Classical Ehlers-Danlos syndrome. Chronic discolored scars on the shin and ankle after repeated trauma. This is often associated with firm subcutaneous nodules that can be confused with subcutaneous granuloma annulare. Note the widened scar at the knee area.

may have pressure-induced herniation of subcutaneous fat on the wrists or on the medial or lateral aspect of the heels, evident when the patient is standing (piezogenic pedal papules). Hiatal hernia, postoperative hernias, and anal prolapse have been noted as manifestations of the tissue hyperextensibility and fragility.[25]

Musculoskeletal features seen in classical EDS include joint hyperextensibility in all patients and a fairly high frequency of scoliosis and pes planus.[26] Patients tend to have "double-jointed" fingers and frequent sprains or subluxation of larger joints (Fig. 139-5), either spontaneously or after slight trauma. Affected individuals complain of chronic joint and limb pain despite normal skeletal radiographs.[27] The joint hypermobility can lead to the onset of osteoarthritis in the third or fourth decade. Muscle hypotonia and delayed gross motor development have been described.

Dyspareunia and sexual dysfunction have been reported,[28] and the signs of classical EDS may be aggravated by pregnancy. Forty percent of affected individuals and 21 percent of babies of affected mothers are born prematurely, typically between 32 and 37 weeks, owing to premature rupture of fetal membranes or infection of the chorioamnionic membrane.[29,30] Fetuses with classical EDS may exhibit retarded growth, hernias, and joint dislocations. A significant number of individuals with EDS have abnormal cardiac echocardiographic parameters, showing aberrant vessels and incompetent valves.[31] Aortic root dilatation has been described in 29 percent of patients with the classical and hypermobile forms of EDS,[27,32] especially in the former, and may lead to rupture. The most commonly affected site is the sinus of Valsalva. Initial screening of all EDS patients by echocardiography is recommended.[32] Aortic valve incompetence, aortic rupture, and dissection occur far less commonly than in Marfan syndrome. β Blocker therapy with agents such as atenolol has been attempted in individual cases, but too few data exist to determine whether therapy is indicated or effective. Mitral valve prolapse (MVP) occurs no more frequently than in the general population.[31]



▲ **FIGURE 139-4** Classical Ehlers-Danlos syndrome. After suturing for a laceration, the wound dehisced with secondary infection and marked widening. Note the evidence of former sutures at the lower border, now 3 weeks after the injury and treatment with antibiotics. Scars tend to stretch further in the 6 months after closure.



▲ **FIGURE 139-5** Classical Ehlers-Danlos syndrome. Hyperextensibility of digits is demonstrated.



The diagnosis is confirmed by clinical examination, family history, and the identification of mutations in *COL5A1* or *COL5A2*, a test not commercially available.

Hypermobile Type

EPIDEMIOLOGY Hypermobile EDS, as the classical type, is a relatively common type of EDS, affecting 1 in 10,000 to 1 in 15,000 individuals.[9]

ETIOLOGY AND PATHOGENESIS The underlying molecular abnormality for this form of EDS has not been clearly defined. However, mutations in two genes have been found in a few cases: *COL3A1* (responsible for type III collagen)[33] and *tenascin-XB* (which encodes tenascin-X [TNX])[34] (see Chap. 61). TNX is a glycoprotein with a structure comprised of a cysteine-rich N-terminal domain and epidermal growth factor (EGF)–like repeats, followed by a number of fibronectin type III–like domains and a carboxy-terminal fibrinogen–like domain. Most cases are AD, although patients with *tenascin-XB* mutations show autosomal recessive inheritance.[6] EDS of the hypermobile type has been associated with congenital adrenal hyperplasia, owing to recombinational events in the gene encoding TNX. This aberration leads to deletions in *CYP21*, which results in congenital adrenal hyperplasia and decreased TNX messenger RNA (mRNA) and protein in fibroblasts and skin of affected individuals, causing EDS.[7]

CLINICAL FINDINGS The diagnosis of hypermobile EDS is made on the basis of clinical criteria and family history. Predominant features include generalized joint hypermobility, with recurrent dislocations and arthralgias. Hyperextensibility of both large and small joints is present, although predominantly the shoulders, hips, patellae, temporomandibular joints, and digits are affected.[3] As in the classical form of EDS, scoliosis and pes planus are common. Musculoskeletal pain is a prominent, debilitating feature in many patients; temporo-mandibular joint disorder is seen with increased prevalence,[35] and complex regional pain syndrome has been described, likely due to stretch injury to nerves traversing hypermobile joints and increased fragility of nerve connective tissue.[36] Chronic pain is frequently compounded by secondary depression.[37] Individuals with hypermobile EDS have mildly hyperextensible or soft, velvety skin, but near-normal scarring and no molluscoid pseudotumors. Patients with TNX deficiency tend to be intermediate in severity between the classical and more common hypermobile forms. Electron microscopic evaluation of skin biopsies show increased degeneration of elastic fibers when compared with controls.[38] A significant number of individuals with both the classical form and the hypermobile form have dilatation or rupture of the ascending aorta, or both.[31]

Vascular Type

EPIDEMIOLOGY Vascular type EDS is the most clinically significant due to arterial or major organ rupture. It affects approximately 1 in 100,000 to 200,000 individuals.[9]

ETIOLOGY AND PATHOGENESIS The vascular form of EDS is an AD disorder[39] caused by dominant-negative mutations in the gene for *COL3A1*,[40] which is located on chromosome 2q24.3-q31.[41] More than 320 mutations of this gene have been identified, most of which are either exon-skipping or missense, and disrupt the triple-helical structure.[25] Genotype-phenotype correlations have not been demonstrated.[25] Collagen III is a homotrimer, so the mutant pro α1(III) chain will be incorporated into almost all fibrils, leading to abnormalities of secretion and intracellular accumulation.[42] Collagen III is an important component of vascular walls and the upper dermis. Decreased collagen III leads to dermal atrophy and weakening of vessels.[43] Testing for this form of EDS can be reliably accomplished by analysis of type III procollagen and collagen chains harvested from cultured dermal fibroblasts or genetic testing.

CLINICAL FINDINGS The four major hallmarks of vascular-type EDS are distinctive facial features; thin, translucent skin; bruising/hematomas; and rupture of vessels or viscera, or both.[25,39] Patients with this condition often have short stature and a characteristic thin nose; thin upper lip; small earlobes; and a sunken, pigmented appearance around the eyes. The skin is thin and easily bruised; unlike in the classical or hypermobile types, hyperextensibility is minimal to absent. Individuals are prone to forming large and frequent hematomas with minimal to no trauma, including after inflation of a blood pressure cuff. Papyraceous scars are present over bony prominences. In fair-skinned individuals, subcutaneous vasculature is easily visible beneath the skin (Fig. 139-6).



▲ **FIGURE 139-6** Vascular Ehlers-Danlos syndrome. The venous pattern is apparent in a fair-skinned individual. (In order to enhance visibility of the venous network, the image was colorized.)

Affected individuals are at high risk for life-threatening rupture of the medium-sized arteries, particularly of the mesenchymal arteries in the abdomen, the splenic and renal arteries, and the descending aorta.[43] The aortic disease in this form is more prevalent than that found in the other forms of EDS and is different in its location. Rupture or dissection of the aorta, or both, when it occurs, is usually at or distal to the mid-aortic arch and extends distally. Arterial rupture generally occurs in the third, fourth, and fifth decades, and is the major cause of reduced life span in patients with this disorder. Dissection and rupture of aorta or arteries is usually not preceded by dilatation, in contrast to the rupture in Marfan syndrome and other forms of EDS.[32]

Patients are also at increased risk for stroke. Pregnancies are high risk, as arterial or uterine rupture in the peripartum period may lead to maternal death in 12 percent to 25 percent of cases[43,44]; vaginal or perineal tears can occur, and wounds after cesarean section frequently dehisce.[9]

Kyphoscoliotic Type

EPIDEMIOLOGY Characteristics of the kyphoscoliotic type of EDS have been described in fewer than 60 reported cases worldwide and are evident at birth.[9]

ETIOLOGY AND PATHOGENESIS The kyphoscoliotic type is the only type of EDS that is always inherited in an autosomal recessive fashion. It is caused by a deficiency of procollagen-lysine, 2-oxoglutarate 5-dioxygenase (PLOD1 or lysyl hydroxylase),[45] an enzyme that adds hydroxyl groups to lysines in collagen in an X-lys-gly se-

quence. The gene coding for this enzyme is located on chromosome 1p36.3-36.2. All patients with the kyphoscoliosis form of EDS have decreased hydroxylysine content in dermal tissues.[46] Many of the cross-links that normally occur between adjacent collagen monomers within a fibril begin as chemical modifications of hydroxy lysyl residues. Therefore, although hydroxylysine-deficient collagen is efficiently secreted from cells, it is not capable of normal cross-linking.[47] The deficiency is highly tissue- and collagen type–specific, apparently affecting only type I and III collagens.[48] Hautula and co-workers[49] reported homozygosity for an intragenic duplication of exons 9 to 15 in two patients, which appears to be the only common mutant allele, with an allele frequency of 19.1 percent in families with kyphoscoliotic EDS.[50] There appears to be a rare subtype that is clinically indistinguishable but has normal lysyl hydroxylase activity and normal hydroxy lysyl content in skin.[51]

CLINICAL FINDINGS Patients show joint laxity, kyphoscoliosis, and hypotonia.[52] Ocular fragility with microcornea, which was observed in the original reports, is found in only a minority of patients. Skin fragility, easy bruisability, and dermal hyperextensibility occur to some extent in most patients, although they are much less prominent features than in patients with the classical form of EDS. Individuals with the kyphoscoliosis form of EDS, like those with the vascular form, are at risk of having a potentially catastrophic arterial rupture. Most patients have radiologically detectable osteopenia, but pathologic fractures are rare. They can also exhibit a marfanoid habitus.

Although enzymatic testing for lysyl hydroxylase activity in cultured fibroblasts is available as a diagnostic test, measurement of the ratio of urinary excretion of total urinary hydroxy lysyl pyridinoline and lysyl pyridinoline has become widely used to screen for this disorder. Affected individuals demonstrate a narrow range of deoxypyridinoline-pyridinoline ratios that are at least one order of magnitude greater than age-matched controls.[53,54] This method shows great promise in providing a rapid, inexpensive diagnostic test for this type of EDS.

Arthrochalasia Type

EPIDEMIOLOGY Arthrochalasia-type EDS is rare; approximately 30 cases have been reported.[9]

ETIOLOGY AND PATHOGENESIS This rare form of EDS is caused by mutations in the type I collagen (*COL1A1* or *COL1A2*) genes that result in the loss of exon 6 sequences from the mature mRNA.[55–57] The molecular mechanism is almost always a mutation that disrupts the splice acceptor or splice donor sequences 5′ or 3′ to exon 6, causing removal of that exon (also known as *exon skipping*) during processing of mRNA. This alteration leads to failure of cleavage of the amino-terminal propeptides and subsequent lack of intermolecular cross linking of type I collagen. Thus, type I collagen is the major structural protein affected in connective tissues in EDS VII. This rare AD form is the combination of what was formerly called *types VIIA* and *VIIB*; the former type VIIC is now the dermatosparaxis type (see Dermatosparaxis Type) based on differences in the clinical phenotype and molecular pathogenesis.

CLINICAL FINDINGS Patients present with bilateral congenital hip dislocations, extreme multiple joint laxity, and recurrent subluxations of both large and small joints that are difficult to repair surgically.[58] Thoracolumbar scoliosis, short stature, and muscle hypotonia are common features. Congenital dislocation of the hip is a hallmark of the arthrochalasia form, although it also occurs in the classical and the vascular forms. Cutaneous features include tissue fragility and widened scars; these findings are less prominent than in the classical form of EDS.[59]

Electron micrographs of collagen fibrils from skin of a patient with this disorder show abnormal collagen fibrils that are irregular in outline and vary widely in diameter. Confirmation of the diagnosis is accomplished by electrophoretic demonstration of pNα1(I) or pNα2(I) chains extracted from dermal collagen or harvested from cultured skin fibroblasts. Direct demonstration of exon 6 skipping in complementary DNAs of *COL1A1* or *COL1A2* can be performed, followed by mutation analysis.[57]

Dermatosparaxis Type

EPIDEMIOLOGY The dermatosparaxis type of EDS is well defined in cattle[60] and is the rarest form of EDS, with fewer than 10 reported cases.[9]

ETIOLOGY AND PATHOGENESIS The biochemical defect that results in this autosomal recessive form of EDS is the failure to cleave the amino-terminal propeptide of type I collagen due to deficiency of type I procollagen N-peptidase.[60,61] Homozygosity or compound heterozygosity of mutant alleles in the *ADAMTS-2* gene lead to this alteration.[62] In skin, procollagen metabolites that contain the N-propeptides are present, and cultured dermal fibroblasts secrete procollagens in which the N-propeptide, but not the C-propeptide, is retained.

CLINICAL FINDINGS Dermatosparactic EDS is characterized by extreme skin fragility, easy bruising, large fontanels, blue sclerae, puffy eyelids, micrognathia, umbilical hernia, and short fingers.[63] Orofacial features include micrognathia, malocclusion, and hyperkeratotic gingival hyperplasia.[64] The deciduous teeth show abnormal molars and severe enamel attrition. There may also be agenesis, microdontia, discoloration, dysplastic roots, and tooth pulp obliteration in permanent teeth. The striking dermal fragility and sagging, redundant skin are the cutaneous hallmarks; although the skin is lax, it is not extensible. Large umbilical/inguinal hernias, internal organ rupture, and premature rupture of membranes have been described. Diagnosis can be made by electrophoresis, demonstrating procollagen α1(I) and α2(I) chains from collagen type I extracted from dermis in the presence of protease inhibitors or from fibroblasts.[6]

Other Types of Ehlers-Danlos Syndromes

Treatment and Prevention

The most productive avenue of therapy for EDS involves a triad of anticipatory guidance, pain management, and physical therapy. Regular evaluation by a physician familiar with EDS is strongly recommended. Early intervention is key, along with appropriate education.[72–74]

Avoidance of injury is critical, including making homes safe to prevent falls and avoiding contact sports. Gentle skin care should be encouraged, using mild soaps and non-adherent bandages. Sun protection is critical to prevent the skin thinning and loss of dermis associated with ultraviolet radiation–induced damage. When injuries occur that disrupt skin integrity, sutures should be placed. In addition to supplemental absorbable sutures within the wound, retention sutures tied at a distance from the incision may help. Adhesive strips may be used to support the skin during scar formation, but must be



retained for long periods. Given the problems with skin infection, prophylactic anti-staphylococcal antibiotics should be considered. Scar revision is often requested at the knees and elbows but may require grafting. Early adolescence is often the optimal time for this surgery, because subsequent traumatic events are less likely. Pseudotumors are more easily removed from the elbows and knees than those over the heels.

With the exception of congenital dislocation of the hip, joint dislocations in EDS either spontaneously resolve or can usually be corrected by closed reduction. Orthopedic procedures designed to reduce ligamentous laxity and therefore prevent recurrent dislocations include bracing or fusion of joints.

Avoidance of standing or working on hardened floors for long periods and the wearing of supportive, cushioned shoes reduces foot, knee, hip, and back pain. Nonsteroidal anti-inflammatory drugs (NSAIDs) may bring temporary relief; none are demonstrably superior. The relevant issue is the best-tolerated drug at the least cost. Other medications that may be used include fixed combination products (NSAID/opioid) or single-entity opioids and tricyclic antidepressants. There is some evidence that a subset of patients with the kyphoscoliotic type of EDS may respond to hydralazine and ascorbic acid.[75] Hydrotherapy and behavioral or cognitive coping strategies, or both, may also be tried to improve pain. Physical therapy, particularly directed at strengthening the shoulder girdle, has lowered the frequency of shoulder dislocations in individuals with chronic or recurrent dislocation. A regular exercise program may be helpful for strengthening muscles, helping to stabilize the joints, and relieve stress. Swimming and lifting weights are noncontact sports that have been tolerated well by many patients. Some patients use orthopedic devices such as orthotics and braces.

Pregnant women with EDS should be referred to high-risk obstetric practices when possible because of increased pregnancy risks. The extremely friable arteries of vascular-type EDS are very difficult to repair.[76]

MARFAN SYNDROME

Epidemiology

Marfan syndrome is a generalized connective tissue disease affecting approximately 1 in 5000 to 10,000 individuals,[77,78] with no racial, gender, or geographic predilection. Whereas most affected individuals will have a family history of the disease, approximately 25 percent will not, suggesting de novo mutations.[79]

Etiology and Pathogenesis

Routine histopathologic examination of biopsies do not show significant changes. However, ultrastructurally the dermis of Marfan patients demonstrates abnormal collagen fibrils with varied thickness, whirl- and wave-formed disarray, and twisted fibrils with flower-like shapes with zigzagged margins, similar to EDS.[38] In addition, the ratio of collagen I–collagen III content is decreased.[38]

Marfan syndrome is typically an AD disorder caused by heterozygous mutations in the gene for fibrillin 1 (FBN1),[80] localized to 15q21.1. More than 500 mutations in the *FBN1* gene have been reported that span the entire coding region of the gene (65 exons). Some, but not all, mutations result in the classical features of Marfan syndrome, and a few genotype-phenotype correlations are possible. Most missense mutations in the EGF domains result in the classic form of the disease. Patients with dramatic structural rearrangements, such as exon skipping (approximately 10 percent of the total), have comparatively severe forms of the disease.[81] Patients with mutations that lead to premature stop codons and reduced mRNA transcripts from the mutant allele have a surprisingly wide range of clinical severity, which is unlike the clear differences seen between OI patients with dominant-negative mutations and loss-of-function mutations (null alleles). The only established genotype-phenotype correlation is that of severe neonatal onset with mutations clustered in the middle of the *FBN1* gene.[82]

FBN1 is a major constitutive element of ECM microfibrils throughout the body. It is abundant in tissues affected in Marfan syndrome—the ascending aorta, suspensory ligament of the lens, periosteum, and the skin. Fibrillin plays a major role in the normal functioning of microfibrils, which are critical structural components of many tissues. The fibrillin molecule is spanned by cysteine-rich repeats interspersed with latent transforming growth factor-β (TGF-β)–binding protein-like and EGF-like motifs.[82]

Genetic alterations in *FBN1* produce a spectrum of clinical abnormalities well beyond the classic Marfan phenotype, the so-called *fibrillopathies*.[83] The spectrum includes the severe neonatal Marfan phenotype at one end, extending to isolated aortic root dilatation or marfanoid skeletal features lacking cardiovascular involvement or ectopia lentis at the other. Other phenotypes that can result from mutations in *FBN1* include: the mitral, aortic, skin, and skeletal manifestations (MASS) phenotype; bicommissural aortic valve with ascending aortic aneurysm; Shprintzen-Goldberg syndrome; MVP syndrome; familial ectopia lentis; isolated marfanoid habitus, and Weill-Marchesani syndrome.[78]

Mutations in the *FBN2* gene on chromosome 5q23[84] can result in an AD disorder that resembles neonatal Marfan syndrome, especially in its skeletal manifestations—congenital contractural arachnodactyly (Beals syndrome).[85] It is characterized by multiple flexion contractures (especially elbow, knee, and finger joints), arachnodactyly, severe kyphoscoliosis, crumpled pinnae, and muscular hypoplasia. Aortic root dilatation and the ocular manifestations of Marfan syndrome do not tend to be associated.

Heterozygous mutations in the TGF-β receptor 2 on chromosome 3p24.2-25 have also been described in a subset of patients[86] with prominent aortic dilatation but without ocular abnormalities.[87]

MARFAN SYNDROME AT A GLANCE



- Incidence: 1 in 5000 to 10,000 (Online Mendelian Inheritance in Man #154700).
- Autosomal dominant inheritance with mutations in fibrillin 1 (*FBN1*; chromosome 15q21.1).
- Cutaneous features include striae distensae (two-thirds of patients), inguinal or incisional hernias, and, rarely, elastosis perforans serpiginosa.
- Extracutaneous manifestations include hyperextensible joints, upward lens displacement, skeletal abnormalities, and cardiac aberrations, such as aortic aneurysm and rupture.
- Information for patients and professionals at http://www.marfan.org.



Clinical Findings

Marfan syndrome is a generalized disorder of connective tissue that has primary manifestations in the skeletal, ocular, and cardiovascular systems.[79] Patients with Marfan syndrome may have major abnormalities primarily in three organ systems: in the eye—most characteristically dislocation of the lenses; in the skeletal system—excessive length of extremities, loose-jointedness, kyphoscoliosis, and anterior chest deformity; and in the cardiovascular system—most characteristically aortic aneurysm and mitral valve redundancy.[83] Skin manifestations consist of striae distensae, a common finding, and elastosis perforans serpiginosa (see Chap. 67), a rare finding.

Virtually all patients with Marfan syndrome have myopia as the result of an abnormally long anterior-posterior axis of the orbit and relatively flat corneas.[88] In addition, approximately 70 percent of affected patients have ectopia lentis, with the lens usually displaced upward. In an examination after the dilation of the pupil, the margin of the lens is usually visible in the lower part of the pupil. Dislocation of the lens into the anterior chamber or trapping of the lens in the pupil sometimes occurs, and acute glaucoma may result. Detection of mild ectopia lentis requires full dilation of the pupils and slit-lamp examination for redundancy of the suspensory ligament of the lens. Therefore, clinical exclusion of ectopia lentis in an individual suspected of having Marfan syndrome must include a slit-lamp examination after dilation of the pupils. Strabismus and cataracts may also develop.

The skeletal features, particularly the long, narrow extremities, figured prominently in Marfan's initial description in 1896 of the syndrome that now bears his name. Patients with Marfan syndrome are usually taller than their same-sex siblings. There is skeletal disproportion, with the most consistent and reliable measure being an abnormally low ratio of the upper segment (height minus lower segment) to the lower segment (measured from the pubic symphysis to the floor) (Fig. 139-7). The arm span (fingertip to fingertip when expanded) is usually longer than the height by several centimeters. These discrepancies may be magnified by associated kyphoscoliosis. The ribs appear to undergo the same excessive longitudinal growth, as do the bones of the extremities. Depression of the sternum (pectus excavatum) or projection (pectus carinatum) or an asymmetric deformity of the anterior chest results.



▲ **FIGURE 139-7** Marfan syndrome. Frontal view of teenage girl with Marfan syndrome. Note the tall stature, arachnodactyly, abnormally low ratio of the upper segment to lower segment, and long arms.

Joint hyperextensibility is present in some, but not all, patients with Marfan syndrome. Flat-footedness, hyperextensibility at the knees (genu recurvatum) and elbows, and occasional dislocation of joints are manifestations of the loose-jointedness. Because of joint hyperextensibility and long, narrow extremities, the patient is often able to touch his or her umbilicus with the right hand passed around the back and approaching the umbilicus from the left. A relatively narrow palm of the hand with a long thumb and hyperextensibility is the basis of Steinberg's sign, in which the thumb propped across the palm extends well beyond the ulnar margin of the hand.

The cardiovascular manifestations of Marfan syndrome are by far the most clinically significant and account for the overwhelming majority of morbidity and mortality associated with this disorder. The two major cardiovascular manifestations are MVP and aortic root dilatation. MVP is a consequence of the redundancy of the valve leaflets, the stretching of the chordae tendineae, and dilatation of the valve annulus. The prevalence of MVP in Marfan syndrome increases with age and is present in approximately 75 percent of individuals.[79] MVP can occasionally be associated with abnormal electrocardiograms, regurgitation, and cardiac arrhythmias that can lead to sudden death.[89]

Dilatation of the proximal aorta is progressive and, in some cases, may even occur in utero. Dilatation is often first seen in the sinuses of Valsalva, but is often discontinuous and unpredictable.[90] Patients with Marfan syndrome should be monitored on a yearly basis, as aortic complications of Marfan syndrome do not occur in aortas that are normal for age or in adults in aortas less than 40 mm in diameter. The aortic pathology of Marfan syndrome is almost always in the proximal (ascending) aorta; distal pathology is usually a result of forward progression of a dissecting lesion. Premature death in Marfan syndrome is a result of its cardiovascular complications: proximal aortic dilatation associated with aortic valve incompetence, aortic rupture, or aortic dissection.[89] Other manifestations of this syndrome include a high-arched palate and crowding of the anterior teeth, emphysema, spontaneous pneumothorax, and dural ectasia.

Cutaneous lesions develop in approximately two-thirds of patients with Marfan syndrome and represent minor diagnostic signs in the revised 1996 Ghent criteria.[91] These include striae distensae (more prominent during adolescence and on the buttocks, thighs, breasts, abdomen, and thighs) and inguinal or incisional hernias.[89,92] Histology reveals abnormal elastic fibers with a moth-eaten appearance and collapsed, distorted adipocytes.[93]

The large size of the gene, along with the absence of mutational hot spots and the heterogeneity of these mutations preclude sensitive testing for *FBN1* mutations.[94,95] Clinical assessment remains the current diagnostic method, but in individuals with a familial phenotype, mutational or linkage analysis may yield positive results.[76]

Treatment

Management of patients with Marfan disease should be multi-disciplinary, targeting each affected organ system.

Prevention

Patients with aortic dilatation are encouraged to avoid caffeine, stressful circumstances, and vigorous exercise. Contact sports or heavy lifting should be avoided.[88] Early use of either a valve-

saving aortic repair or composite graft placement is now prudent because of significant improvements in the success of these procedures and the well-known difficulties in managing an acute aortic dissection in Marfan patients. To prevent pneumothorax, patients should avoid smoking and activities that involve rapid changes in pressure such as flying or scuba diving.[98]

HOMOCYSTINURIA

Epidemiology

The incidence of homocystinuria varies from 1 in 344,000 worldwide[101] to a much greater incidence of 1 in 65,000 in Ireland.[102] It is the second most common treatable aminoaciduria after phenylketonuria.



Etiology and Pathogenesis

Patients with homocystinuria have primary hepatic deficiency of cystathionine β-synthase (CBS), a pyridoxine-dependent enzyme in the methionine transsulfuration pathway,[103,104] resulting in high plasma levels of the toxic amino acid L-homocysteine.[105] A minority of patients have an acquired (dietary) deficiency of cobalamin or heritable disorders that prevent conversion of dietary cobalamin to its biologically active forms; rarely, some have defects that cause decreased availability of 5-methyltetra-hydrofolate, which is also required in the metabolism of methionine.

By definition, homocystinuria is a biochemical abnormality, not a specific disease entity. By far the most common cause of this condition is a deficiency of the enzyme CBS because of recessive mutations in its gene. The *CBS* gene is located at chromosome 21q22.3.[106] More than 92 disease-causing mutations have been described.[105] Molecular analysis of the *CBS* locus has identified several mutant alleles in patients with homocystinuria. Substitution of serine for glycine at amino acid position 370 (G370S) is the most common mutation in northern European populations, and the T191M point mutation is found frequently in Spanish and South American patients.[107] Another common mutation in Europe (I278T) has prognostic significance, as it indicates responsiveness to pyridoxine,[108,109] in contrast to the lack of response in most patients with G370S or T191M mutations. Most patients are compound heterozygotes for rare mutant alleles.[110]

HOMOCYSTINURIA AT A GLANCE

- Incidence: 1 in 65,000 to 344,000 (Online Mendelian Inheritance in Man #236200).
- Autosomal recessive inheritance, mutations in cystathionine β-synthase, chromosome 21q22.3.
- Cutaneous features include malar flush, fair and thin skin and hair, and livedo reticularis.
- Extracutaneous manifestations include downward lens displacement, osteoporosis, mental retardation, thromboembolism, and severe hyperhomocysteinemia.
- Information for patients and professionals at http://www.pku-allieddisorders.org and http://www.hcusupport.com.

The pathogenesis of the connective tissue abnormalities, including ectopia lentis, osteoporosis, and the vertebral and thoracic abnormalities, may be related to elevated homocystine levels, which inhibit cross-linking of collagen. The mechanism for decreased cross-linking in vivo is unknown. It might be in the earliest step in cross-linking, which is catalyzed by lysyl oxidase, or in later steps, which serve to mature the cross-links. Ultrastructurally, elastic fibers from affected patients show an elastic matrix with lucent and dense stripes and numerous abnormal elastic microfibrils.[38] The biologic basis for mental retardation and psychiatric disturbance in patients with homocystinuria is also unknown.

Patients with combined methylmalonic aciduria and homocystinuria [cblC; Online Mendelian Inheritance in Man (OMIM) #277400] are also at risk for the same neurologic, ophthalmologic, and cardiac abnormalities as in CBS, presumably related to the high levels of homocysteine.[112,113] The most frequent hereditary abnormality of vitamin B_{12} (cobalamin, cbl) metabolism, cblC results from mutations in *MMACHC*. Features often manifest during infancy, but late-onset disease occasionally occurs and is primarily characterized by neurologic deterioration.

Clinical Findings

The major clinical manifestations of CBS deficiency include ocular, skeletal, vascular, and central nervous system abnormalities.[114] These include ectopia lentis, osteoporosis, mental retardation, and thromboembolism. By the age of 10 years, 82 percent of patients develop ectopia lentis, and by 15 years, 50 percent have radiographic signs of osteoporosis.[115]

The cutaneous manifestations include malar flush, thin hair and skin, and cutis reticulata. A prominent malar flush has been reported in many patients, which is most easily seen after vigorous exercise or after cold exposure. This malar flush was also found to be more frequent in pyridoxine responders, although the difference was not significant, likely due to the small sample of patients.[114] The dermis is usually fair and thin, and livedo reticularis is commonly seen on the extremities. In patients with deep venous thromboses, collateral venous channels are visible through the skin. Hair is often thinned and fair. Treatment may cause hair to darken.

Treatment

Therapeutic modalities include pyridoxine, in combination with folic acid and vitamin B_{12}; methionine-restricted, cystine-supplemented diet; and betaine. Approximately one-half of patients with clinical CBS deficiency respond to very high doses of pyridoxine (250 to 500 mg/day) with decreases of methionine in plasma and virtual elimination of homocysteine from urine.[103,117] In these patients, pyridoxine treatment, if initiated in infancy, significantly reduces the risk of thrombosis, grand mal seizures, and mental retardation. Increases in responsiveness are likely caused by increased production of pyridoxal-5′-phosphate, the active form of vitamin B_6 that is the cofactor for CBS. Sensitivity to pyridoxine may be predicted by the specific CBS mutation,[103] is constant in affected siblings, and only occurs in the presence of residual CBS activity. Betaine is a methyl donor agent that lowers homocysteine through remethylation of methionine.[118] Increase in methionine levels is a potential risk of betaine therapy and led to cerebral progressive cerebral edema in a child with CBS deficiency[119]; betaine should be used as an adjunct to other therapies, particularly to dietary restriction of methionine.

PSEUDOXANTHOMA ELASTICUM

Epidemiology

The disease prevalence is estimated at 1 in 25,000 to 100,000 persons and occurs

PSEUDOXANTHOMA ELASTICUM

AT A GLANCE



- Incidence: 1 in 25,000 to 100,000 (Online Mendelian Inheritance in Man #177850 and #264800).
- Autosomal recessive inheritance, occasional pseudo-dominant.
- Mutations in multidrug resistance associated protein (MRP6), encoded by (*ABCC6*) on chromosome 16q13.1.
- Cutaneous features include yellow, flat papules in the neck, flexures, and periumbilical areas. Less frequent skin lesions include acneiform lesions, elastosis perforans serpiginosa, reticulate pigmentation, and granulomatous nodules.
- Extracutaneous manifestations include angioid streaks, visual impairment, *peau d'orange* retinal hyperpigmentation, cardiovascular disease, and bleeding.
- Histopathology shows swollen, clumped, fragmented elastic fibers and calcium deposits in the mid and deep reticular dermis. Alterations easily visualized with calcium (i.e., von Kossa) and elastic (i.e., Verhoeff-van Gieson or orcein) stains.
- Information for patients and professionals at http://www.pxe.org and http://www.napxe.org.

twice as frequently in females.[120] Pseudoxanthoma elasticum (PXE) has been reported in all ethnic groups, with an average age of initial manifestation of 13.5 years.

Etiology and Pathogenesis

PXE, also known as *Grönblad-Strandberg syndrome*, is characterized by progressive calcification and fragmentation of elastic fibers in various tissues, including skin (particularly flexural sites), eye (angioid streaks and retinal defects), and cardiovascular system (hypertension, gastrointestinal bleeding, and vascular disease).

At the histologic level, PXE is known to be caused by progressive calcification and fragmentation of elastic fibers. Elastic fibers in the deep and reticular dermis show a swollen, clumped, and fragmented appearance with calcium deposits (Fig. 139-8). Interspersed are more normal-appearing elastic fibers, which may also stain blue because of their high calcium content. These changes are also present in fibers of other organs, including blood vessels, Bruch's membrane of the eye, and the heart. Dermatopathologic findings are more easily seen with the use of calcium (von Kossa's) or elastic (Verhoeff-van Gieson) stains. As evidenced with electron microscopy, calcification occurs in a centripetal fashion within the fiber.[121] Affected skin also reveals deposits of other ECM components associated with elastic fibers such as fibronectin, vitronectin, and proteoglycans.[122] Some patients also show increased levels of urinary and skin glycosaminoglycans.[123]

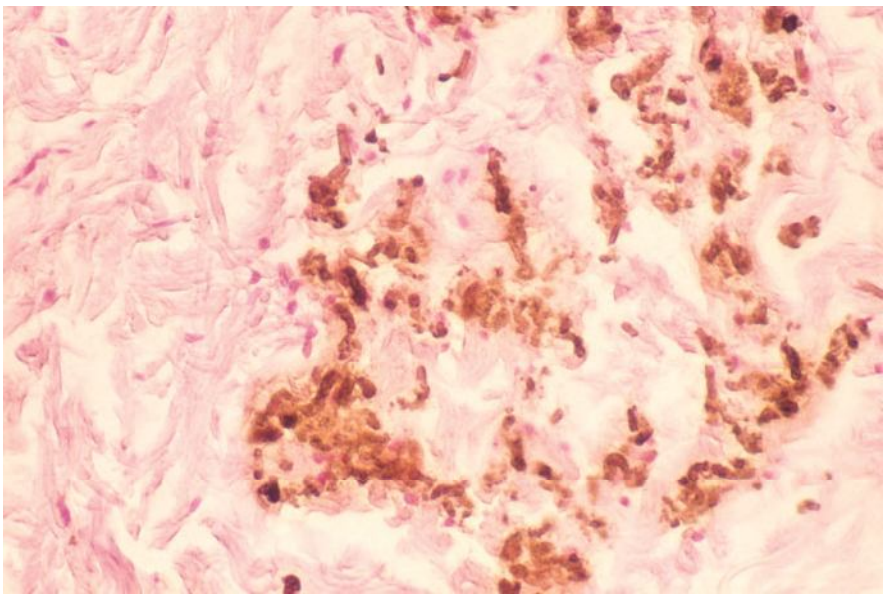

▲ **FIGURE 139-8** Pseudoxanthoma elasticum, elastic tissue stain. The elastic fibers show marked degeneration: They are swollen, tortuous, and irregularly clumped.

The gene responsible for PXE has been localized to chromosome 16p13.1, and it encodes an adenosine triphosphate–binding cassette (ABC) subfamily C member 6 (*ABCC6*) transporter.[124–127] The *ABCC6* gene is a member of a family of 48 genes, some of which have also been associated with other dermatologic conditions (for example, *ABCA12* with lamellar ichthyosis and harlequin ichthyosis)[128] (see Chap. 47). The gene consists of 31 exons spanning 75 kb and encodes the 165-kd transmembrane multidrug resistance–associated protein 6 (MRP6), which is a transporter protein. MRP6 expression in liver and kidneys is low in PXE, suggesting a metabolic origin with secondary tissue involvement in this disease.[129]

More than 60 mutations have been detected in *ABCC6*, of which more than 90 percent result in recessive inheritance and less than 10 percent in dominant fashion (likely pseudo-dominant forms of PXE with milder manifestations),[126,129–131] most of which are inactivating mutations. Although most mutations appear to be unique variants, two disease-causing alleles occur frequently in apparently unrelated individuals. *R1141X* has been found predominantly in Europe at a frequency of 28.4 percent (overall, 18.8 percent). *ABCC6del23–29* occurs at an overall frequency of 12.9 percent and is most prevalent in patients from the United States (28.4 percent). These results suggest that *R1141X* and *ABCC6del23–29* might be derived regionally from founder alleles.[125] Molecular studies can be performed to confirm the clinical diagnosis and to help recognize asymptomatic patients with a positive family history.

The precise function of the ABCC6 transporter is unknown, and the genotype-phenotype relationship between *ABCC6* mutation and pathologic changes in PXE tissues remains to be elucidated. Abnormalities in the attachment and proliferation of cultured fibroblasts from the dermis of affected patients suggest a functional role for ABCC6.[132] However, recent studies support the concept that a circulating factor in the serum of affected individuals interferes with the normal assembly



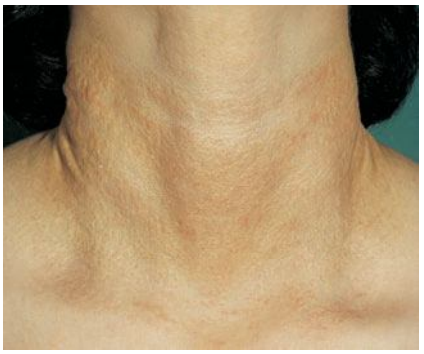

▲ **FIGURE 139-9** Pseudoxanthoma elasticum. Papules on the neck. There is a distinct yellowish hue. Loose, thickened skin with a pebbled appearance on the neck.



of elastic fibers. PXE fibroblasts cultured with normal human serum deposit structurally normal elastic fibers, but normal and PXE fibroblasts deposit abnormal aggregates of elastic fibers when maintained in the presence of serum from PXE patients.[133]

Clinical Findings

PXE usually involves the skin, Bruch's membrane of the eye, and vascular tissues.[134] Cases with involvement of other systems have occasionally been reported, including urinary tract and pulmonary tissues. The mortality and morbidity of PXE is dependent on the extent of extracutaneous involvement, especially the extent of vascular disease.

Typically, yellowish papules giving a "plucked chicken" or "cobblestone" appearance in flexural skin begin in childhood[120] (Fig. 139-9). These 1- to 5-mm symmetric papules may form a reticulated pattern but often coalesce to form plaques that have also been compared with "Moroccan leather." However, their presence is usually not noted until adolescence or even later adulthood because of their asymptomatic nature. These papules are generally first seen on the lateral areas of the neck. Additional commonly involved areas include the antecubital, popliteal, inguinal, neck, axillae, and periumbilical regions, as well as oral, vaginal, and rectal mucosae. Involvement may be progressive, and the disease may ultimately involve the entire skin, although severe involvement is rare. In time, the skin may become soft, lax, wrinkled, and hang in folds, particularly in the neck, axillae, and groin. Prominent horizontal and oblique mental creases (separating the lower lip from the chin) before 30 years of age are highly specific. Patients usually present to their physicians with these lesions because of cosmetic concern. Careful complete physical examination is warranted, and a skin biopsy of scars or flexural skin should be performed, as abnormal histologic findings may be present in the absence of visible cutaneous lesions.[135] The differential diagnosis of the skin lesions of PXE is listed in Box 139-1.

Once they appear, the skin defects of PXE usually remain unchanged throughout life. Elastosis perforans serpiginosa

Box 139-1

Differential Diagnosis of the Skin Lesions of Pseudoxanthoma Elasticum (PXE)

DISORDER	MORPHOLOGY	DISTRIBUTION	ASSOCIATIONS	DIFFERENTIATION
Dermatofibroma lenticularis[191]	Asymptomatic, flat-topped yellowish papules and nodules, which, when grouped, form large plaques several centimeters in diameter	Often proximal extremities, truncal; symmetric; may be more widespread	Osteopoikilosis, fractures in Buschke-Ollendorff syndrome [due to LEMD3 (MAN1) mutations][191]	Clinical; biopsy shows increased elastic tissue
Localized acquired cutaneous PXE[192]	Asymptomatic, coalescing yellow macules and papules, occasional reticulate or checkered pattern; lax, redundant areas	Neck, axillae, groin, flexural surfaces, areas exposed to saltpeter fertilizer (calcium-ammonium-nitrate)	Older age, exposure to saltpeter fertilizer in Norwegian farmers, uremia	Histology shows fragmented, thickened, mineralized elastic fibers in mid and deep reticular dermis
Perforating periumbilical PXE[193]	Asymptomatic or pruritic, erythematous lesions that progress to hyperpigmented plaques, with central atrophy, a red, scaly border, and peripheral hyperkeratotic papules, sometimes expressing elastotic debris	Periumbilical or breast area	Multiparity, ascites, abdominal surgery; uremia and hyperphosphatemia in chronic renal failure	Histopathology shows elimination of basophilic, elastotic debris through channels in addition to thickened and mineralized elastic fibers in mid and deep reticular dermis
Long-term penicillamine therapy[194]	Varied presentations; may resemble pseudoxanthoma elasticum, elastosis perforans serpiginosa, cutis laxa, and anetoderma	Similar to those seen in idiopathic forms of disease (i.e., neck and flexures for PXE, flexures in elastosis perforans serpiginosa)	Use of D-penicillamine	Histopathology shows thickened elastic bundles with prominent lateral protrusions ("bramble-bush"), granulomatous dermal inflammation, infrequent calcification, and trans-epidermal elimination of elastic fibers
Actinic damage to neck[154]	Numerous small, asymptomatic, discrete, white papules	Neck	Middle aged to elderly individuals	Histology shows elastolysis and fibrosis in papillary and mid-reticular dermis
Papular elastorrhexis[154]	Asymptomatic, firm, non-follicular 1- to 5-mm whitish papules on trunk and upper extremities	Chest, abdomen, shoulders, back, proximal extremities	Rarely familial occurrence	Loss of elastic tissue in reticular dermis (relative increase in fibrillar component) and fragmentation, with occasional perivascular mixed infiltrate

may co-exist with PXE, and perforating disease may occur, with transdermal elimination of calcium (see Chap. 67).[136] Hyperpigmented, reticulated macules, telangiectasias of the lips, and acneiform and granulomatous lesions may also occur.[136,137]

The characteristic ocular defects of PXE are angioid streaks of the retina, characterized by reddish-brown curvilinear bands that radiate from the optic disk. Angioid streaks result from calcification of the elastic fibers in Bruch's membrane of the retina, with cracking and fissuring in its outer portion, the lamina elastica. Approximately 85 percent of the patients with PXE may have those lesions identified on routine ophthalmologic examination.[121,134] The angioid streak is usually present bilaterally and is often first noted between the ages of 20 and 40 years, typically many years after the onset of cutaneous lesions. The streaks may progress slowly or remain stationary for years. Angioid streaks are often mistaken for blood vessels, though they are irregular and generally wider. They are not unique to PXE and may be present in EDS, Marfan syndrome, lead poisoning, sickle cell anemia, thalassemia,[138] Paget disease of bone, acromegaly and other pituitary disorders, and familial hyperphosphatemia.[134] The most common retinal feature associated with angioid streaks is the presence of "*peau d'orange*," a mottled fundus appearance that usually precedes the appearance of the streaks. These are small, relatively symmetric, drusen-like, flat, yellow, and, occasionally, confluent lesions in the retinal pigment epithelium. Leopard spotting of the posterior pole of the retina is another early sign. Fibrovascular ingrowth in the retina may result in retinal hemorrhages and lead to a risk of retinal detachment and vision loss that increases with each hemorrhage.[139] Other retinal changes include salmon patches (typically a healing subretinal hemorrhage), black dots (pigmentation after focal hemorrhage), and "pearls" (tiny white foci after subretinal or pigment epithelial hemorrhage, or a focal scar). The most visually devastating complication is disciform degeneration of the central visual area. Peripheral vision is generally spared.

Cardiovascular complications occur primarily in affected adults, but occasionally occur in children.[140,141] Calcification of the elastic media of blood vessels with subsequent intimal proliferation leads to a variety of physical findings and to serious complications of PXE. Intermittent claudication is the most common cardiovascular manifestation and the one that presents the earliest. In adults, peripheral pulses are often severely diminished. Angina pectoris or abdominal angina may become incapacitating. Hypertension, caused by renal artery involvement, is three times more common in patients with PXE than in the general population. Severe coronary artery disease may cause early myocardial infarction. MVP has a higher prevalence in PXE than the general population and is almost always accompanied by a murmur.[142] Cerebral artery involvement has also been reported. Seizures occur more frequently than in the general population because of the cerebral involvement.[143] Subarachnoid hemorrhage has been a major cause of death.

Gastrointestinal hemorrhage, apparently caused by the fragility of calcified submucosal vessels, is the most significant vascular complication of PXE, and it is usually gastric in origin. Hemorrhage may occur early in the disease progression and is often the presenting sign, beginning without warning in the second to fourth decade of life. Approximately 10 percent to 15 percent of patients with PXE have a gastrointestinal hemorrhage at some point in their lives. Lung involvement has been seen, but rarely. Bleeding may occur in the urinary tract, and the patient presents with hematuria.[144] Pregnancy is uncomplicated and thus not contraindicated in these patients, but there is an increased risk of miscarriage in the first trimester, and multiple pregnancies may aggravate the disease course.[145]

TABLE 139-3
Monitoring Studies for Patients with Pseudoxanthoma Elasticum

STUDY	REASON
Complete blood cell count	Occult blood loss; iron-deficiency anemia
Calcium, phosphate	Rare reports of hypercalcemia and hyperphosphatemia
Fasting lipids	Hyperlipidemia aggravates risk of cardiovascular disease
Urinalysis	Hemorrhage from urinary tract
Fecal test for blood	Occult blood loss from GI hemorrhage
Eye examination	To detect angioid streaks, retinal hemorrhage, early retinopathy
Endoscopy	If evidence of GI bleeding
Echocardiography	If murmur, angina, or personal or family history of coronary artery disease
Doppler blood pressure (ankle, brachial)	To investigate claudication or if decreases peripheral pulses
Computed tomography of head	If focal neurologic problems or evidence of cerebral hemorrhage
Radiographs	If seeking calcifications

GI = gastrointestinal.

Treatment

Tissue alterations in PXE patients are irreversible, so most efforts are directed toward minimizing complications. Early diagnosis of this disease allows early recognition of ocular and cardiovascular manifestations, thus reducing potential major complications. Surgical excision of the sagging skin seen late in the disease can be corrected by surgical excision if desired.[146] Fillers or autologous fat injections may improve the appearance of the mental creases.

Prevention

Prevention or minimization of complications in patients with PXE through education is of critical importance. Providing information on support groups is extremely important (PXE International, Inc., at http://www.pxe.org and National Association for Pseudoxanthoma Elasticum, or NAPE, at http://www.napxe.org). Recommended testing for patients with PXE is reviewed in Table 139-3. A healthy diet and exercise regimen are key components to minimizing the extent of the cardiovascular disease. Diet should be low in calcium (60 to 1200 mg/day)[147] and lipids, and medications to control these should be introduced if diet and exercise alone are not sufficient. Medications that decrease coagulation, such as NSAIDs and aspirin, should be avoided.

Patients and family members should be monitored by an ophthalmologist regularly for funduscopy, as early eye changes often precede skin changes.[148] Patients should be instructed to self-test with an Amsler grid, which can find early evidence of retinal hemorrhage. Changes can be confirmed by intravenous fluorescein angiography. Patients should avoid heavy lifting, straining, and head trauma, as in weight lifting or head-contact sports, to decrease the risk



of retinal hemorrhage. This early detection allows for the use of laser photocoagulation to minimize vision loss. Although early attempts to treat with laser photocoagulation were disappointing, more recent studies show Verteporfin photodynamic therapy every 3 months for the choroidal neovascularization to be promising.[149]

Regular cardiologic monitoring is also important. Prophylactic antibiotics should be prescribed before any dental procedure or surgical procedures if mitral valve insufficiency is present to prevent bacterial endocarditis. Intermittent claudication can be treated by weight reduction and exercises that stimulate collateral blood vessel development, and tobacco use should be prohibited. Patients should be monitored carefully for gastrointestinal bleeding. Depending on its severity, hospitalization, blood transfusion, endoscopic treatment, and surgery with partial gastrectomy may be necessary to manage bleeding. Appropriate referrals for urologic, pulmonary, and neurologic consultation should be made based on concerns and physical findings.



CUTIS LAXA (GENERALIZED ELASTOLYSIS)

Epidemiology

Few cases reported.

Etiology and Pathogenesis

Cutis laxa (CL) describes a group of disorders that share loose, redundant skin as a feature. Most cases are inherited in an AD, autosomal recessive, or X-linked manner,[150–153] but acquired cases have also been described.[154]

Because of histologic abnormalities in elastin quantity or structure in virtually all forms of CL, investigations into the molecular pathogenesis have focused on genetic mutations that result in alterations in the structure or processing of elastin in the ECM. The genetic heterogeneity of CL reflects the fact that several genes are required for normal elastin biosynthesis and function.[155] Decreased synthetic activity of skin fibroblasts and qualitative and quantitative abnormalities of elastic fibers been reported.[156,157]

Elastin gene mutations that result in abnormal tropoelastin and abnormal elastic fibers result in AD CL (OMIM #123700).[150,158] Elastin is one of several matrix components responsible for the properties of reversible deformability in many tissues, including the skin, lungs, and large blood vessels. The human elastin gene (*ELN*) is 45 kb in length and has been mapped to 7q11.2.[159] Elastin initially is synthesized as individual tropoelastin molecules that are aligned on a network of elastic fibers. This alignment is stabilized by the formation of intermolecular cross-links that are mediated by the copper-dependent enzyme lysyl oxidase.

Type I autosomal recessive CL (OMIM #219100) is frequently fatal and is caused by mutations in the fibulin-5 gene (*FBLN5*, also known as *EVEC* or *DANCE*),[160] which is critical for elastic fiber development.[161] Mutations in FBLN5 can rarely lead to AD disease. The molecular basis for type II CL, (also known as *CL with joint laxity and developmental delay*; OMIM #219200),[152] remains elusive, but lysyl oxidase deficiency is also found in these patients.[158,162,163] A girl with CL in association with severe aortic dilatation and arachnodactyly has recently been described and found to have a mutation in the fibulin-4 (*FBLN4*) gene[164] (Fig. 139-10).

Mutations in the gene encoding ATP7A, a member of the P-type adenosine triphosphatase family responsible for copper transport, have been described in the X-linked type of CL, which is allelic to Menkes syndrome.[158] ATP7A mediates copper transport from the gastrointestinal tract, efflux of excess copper from cells, and delivery of intracellular stores of copper to cuproenzymes.

Acquired forms of this disease are present after skin inflammation and structural damage of elastic fibers. Increased neutrophil elastase is found in affected skin and is presumed to disrupt elastic fiber integrity.[165] A recent report described heterozygous mutations in *FBLN5* and *ELN* in an adult with "acquired" CL and aortic root aneurysm after a toxocara infection; predisposition to inflammatory damage by the missense mutations is theorized.[166]

Clinical Manifestations

The clinical presentation of CL shows considerable heterogeneity.[167,168] Congenital onset is generally indicative of an autosomal recessive or X-linked form of CL; later onset is consistent with either a heritable or acquired form. In both inherited and acquired forms, internal organs can be involved. As a rule, the AD form

CONGENITAL CUTIS LAXA AT A GLANCE



- Inheritance may be autosomal dominant [Online Mendelian Inheritance in Man (OMIM) #123700), autosomal recessive (OMIM #219100 or #219200), or X-linked recessive (also known as *occipital horn syndrome* (OMIM #304150).
- Mutations in elastin (*ELN*) or fibulin-5 (*FBLN5*) in autosomal dominant; in fibulin-5 (*FBLN5*, *EVEC*, *DANCE*) or fibulin-4 (*FBLN4*) in autosomal recessive; a copper transport adenosine triphosphatase (*ATP7A*) in the X-linked type.
- Cutaneous features include pendulous, inelastic skin, with an aged facies.
- Extracutaneous manifestations may include pulmonary emphysema, aortic aneurysm, pulmonary artery and valve stenosis, hernias, gastrointestinal diverticula, joint laxity, low serum ceruloplasmin, and bilateral exostoses of the occiput (or occipital horn syndrome).
- Histopathology shows sparse and fragmented elastic fibers, better visualized with stains (i.e., Verhoeff-van Gieson or orcein).
- Information for patients and professionals at http://www.orpha.net/nestasso/cutislax/.

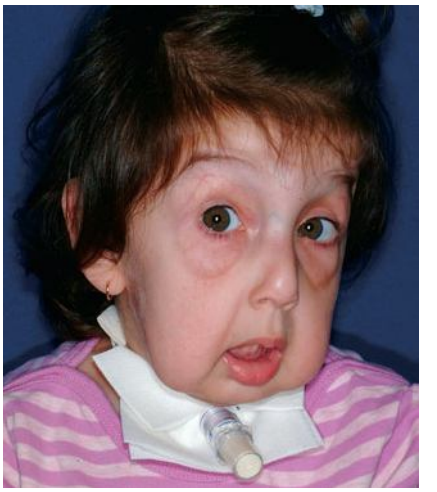

▲ **FIGURE 139-10** Cutis laxa due to fibulin-4 mutation. The facial skin hangs in loose folds, giving the appearance of premature aging. Note the prominent periorbital vessels. The tracheostomy was placed for diaphragmatic eventration and respiratory difficulty.

of CL has primarily skin involvement, and is thus largely a cosmetic problem with a good prognosis.

The autosomal recessive and X-linked forms are often associated with more severe multisystem complications that include emphysema, diaphragmatic hernia, and gastrointestinal and genitourinary diverticula. Type I autosomal recessive CL is associated with severe cardiorespiratory complications and early death from cor pulmonale. Type II is a less severe recessive form, characterized by growth retardation, developmental delay, and ligamentous laxity. X-linked CL is characterized by mild joint laxity, bladder diverticula, hernias, and cranial occipital exostoses or horns. Many cases of acquired CL have developed after a febrile illness and/or inflammatory skin diseases such as lupus erythematous, urticaria, eczema, erythema multiforme, vesicular eruption, amyloidosis, and angioedema, as well as reactions to penicillin and D-penicillamine.[154,169] CL may also be associated with amyloidosis and plasma cell dyscrasias.

CUTANEOUS FEATURES In all forms of CL, the skin gives the appearance of being too large for the rest of the body (see eFig. 139-10.1 in on-line edition). CL may affect any portion of the body, but it often causes attention when it is present with loose appearance around the face, neck, shoulders, and thighs. At birth, the skin may be noticeably soft, loose, and hyperextensible. It tends to sag in the areas where the skin is normally loose, for example, around the face and eyes (see Fig. 139-10). In contrast to the skin of EDS, it returns very slowly to its normal position after being stretched; skin fragility, easy bruisability, joint hypermobility, and poor wound healing are not usually associated with CL. The skin may be excessively wrinkled and appears prematurely aged. Children with severe CL may have characteristic facial features known as the "bloodhound" look—an aged appearance with sagging jowls (see Fig. 139-10).

Biopsy sections of clinically affected skin show a reduced number of elastic fibers in the dermis, with the remaining fibers being fragmented, shortened, clumped, or granular. Calcifications are not present. CL can also be an acquired condition and present diffusely or localized, giving individuals the characteristic "bloodhound-like" facies.[170] It is more common in adults, although children may also be affected. In more than one-half of cases, the disorder is preceded by a urticarial eruption, which may respond to dapsone, but progression will be unaffected.[171] Common associated findings include hiatal hernias, aortic aneurysm and rupture, intestinal and genitourinary diverticula, and emphysema. Some cases with cardiovascular or pulmonary involvement may be fatal.[172] Moreover, associated systemic conditions include multiple myeloma, lymphoma, sarcoidosis, amyloidosis, and α_1-antitrypsin deficiency.[154] Histology shows initial inflammation with concurrent loss of elastic fibers.

EXTRACUTANEOUS FEATURES The X-linked form of CL is known as *occipital horn syndrome* because of occipital exostoses. Characteristic facial features include inverted lower eyelids, a hooked nose, inverted nostrils, a short columella, and a long upper lip. The cry of an affected infant may be hoarse, and a low-pitched voice is often associated redundancy of the vocal cords. Diagnostic skeletal features of this condition can be identified radiologically and include short flat clavicles, fused carpal bones, and the occipital horns, which may not be present until a few years of age. This is the only form of CL with joint laxity.

The autosomal recessive forms of CL are often associated with severe internal complications, such as genitourinary and gastrointestinal diverticula. Chronic diarrhea is a widely reported complication, and secondary kidney damage may result from diverticula causing urinary tract obstruction. The most serious complications are diaphragmatic hernia and emphysema, which may lead to cor pulmonale and death in the first few years of life, especially in patients with *FBLN5* mutations. Rare cardiovascular features include aortic dilatation with secondary cardiomegaly and congestive heart failure. Rectal prolapse, diaphragmatic atony, pneumothorax, peripheral pulmonary stenosis, and aortic dilatation have also been reported. Facial features include down-slanting palpebral fissures, broad/flat nose, and large ears.

Several multisystemic disorders have features that have been called "cutis laxa," and must be considered in the differential diagnosis listed in Box 139-2.

Box 139-2

Differential Diagnosis of Cutis Laxa

SYNDROMES	FEATURES
DeBarsy syndrome[195]	Cutis laxa, mental retardation, cloudy corneas, athetoid posturing, dislocations, aged appearance
Lens-Majewski hyperostotic dwarfism (OMIM #151050)[196]	Skin hyperplasia, joint laxity, progeroid features, skeletal abnormalities, generalized osteosclerosis
SCARF syndrome (OMIM #312830)[197]	Skeletal abnormalities, cutis laxa, craniostenosis, ambiguous genitalia, retardation, facial abnormalities
Congenital hemolytic anemia and pulmonary emphysema (OMIM #235360)[198]	Hemolytic anemia, pulmonary emphysema, cutis laxa
Costello syndrome (faciocutaneoskeletal syndrome (OMIM #217040), mutations in the HRAS oncogene[199,200] (Fig. 139-11)	Wrinkly skin, redundant skin of palms, soles and fingers and neck. Deep palmar creases with mildly hyperkeratotic palms and soles. Postnatal growth retardation, early feeding difficulties, mental retardation, coarse facies, thick lips and ear lobes, macroglossia, aged appearance, hyperextensible fingers and papillomas not infrequent: acanthosis nigricans, sleep apnea, cardiac abnormalities, increased risk of tumors, especially rhabdomyosarcoma, neuroblastoma[199]
Wrinkly skin syndrome (may be a variant of cutis laxa with growth and developmental delay) (OMIM #219200) linked to 2q32[201]	Wrinkling of skin (hands, feet, abdomen), hyperextendibility of joints (hands), dysmorphism, failure to thrive, developmental delay

OMIM = Online Mendelian Inheritance in Man; SCARF = skeletal abnormalities, cutis laxa, craniostenosis, psychomotor.

Treatment

Surgical correction of redundant skin folds, rectal prolapse, or any hernias is temporarily beneficial and can be undertaken without major complication. Botulinum toxin has also been used to improve facial cosmesis.[173] There is no known medical treatment to prevent disease progression in the inherited





▲ **FIGURE 139-11** Costello syndrome. Note the coarse facial features, hypertrophic lower gingival, and papillomatosis of the right cheek, eyelids, and lips.



forms. Regular evaluation of internal organ involvement is important in prevention and management of major complications. Dapsone has been used to control the acute swelling of affected skin that precedes acquired CL, consistent with the suspected role of neutrophil elastase.[174]

OSTEOGENESIS IMPERFECTA

Epidemiology

The incidence of OI varies depending on type: I (1 in 20,000 to 30,000); II (1 in 60,000); III (1 in 70,000); IV (rare); V, VI, and VII (very rare).[175]

Etiology and Pathogenesis

Primary osteopenia and fractures are the hallmarks of OI.[176] Decreased bone mass is a consequence of mutations in either *COL1A1* or *COL1A2*, both of which encode the polypeptide chains forming the collagen type I molecule.[177–179] Type I collagen is the most abundant protein in skin and bone. It provides tensile strength and interacts with other matrix proteins. As a result, OI osteoblasts show abnormal expression of thrombospondin, proteoglycans, hyaluronan, decorin, and fibronectin.[180] The mineral phase is also affected, and bones from OI patients have higher average mineralization density than controls. Although the severe forms of OI were once assumed to be autosomal recessive, almost all cases of OI are now known to result from mutations in a single allele. Germline mosaicism has been shown to explain the lack of parental involvement in some cases of OI with affected siblings, and uniparental disomy has also been described. Glycine residues, which are normally present at every third position, are critical for triple helical conformation of type I collagen. Thus, point mutations in glycine have profound effects on molecular structure. Frameshift and null mutations lead to early termination and nonsense-mediated mRNA decay; as a result, only normal collagen is produced, but at a decreased rate, and a mild phenotype results.

OSTEOGENESIS IMPERFECTA AT A GLANCE



- Combined incidence of 1 in 12,000 people (Online Mendelian Inheritance in Man #166200 and #166240 type I; #166210 type II; #259420 type III; #166220 type IV; #166220 type V).
- Seven sub-types (ranging from mild, nondeforming (type I) to severe perinatal lethal (type II).
- Most commonly autosomal dominant inheritance.
- The gene encoding procollagen I is most often affected.
- Cutaneous features include hyperextensible skin and blue sclerae.
- Extracutaneous manifestations include increased fractures, dentinogenesis imperfecta, ligament laxity, triangular facies, short stature, hearing impairment, and wormian bones.
- Information for patients and professionals at http://www.oif.org.

Clinical Findings

The most notable finding in OI patients is the development of multiple fractures throughout life.[181] Whereas type I tends to be mild, type II tends to be lethal in the perinatal period, with fractures in utero. Type III individuals survive birth but have severely deforming fractures, with a short triangular face and severe scoliosis. Types IV to VII are moderately deforming and rare.[180] Individuals with OI type I (relatively milder type) have very blue sclerae (Fig. 139-12) that stays



▲ **FIGURE 139-12** Osteogenesis imperfecta (OI). Blue sclerae are the most characteristic mucocutaneous feature of patients with mild OI.

intensely blue throughout life, in contrast to the sclerae in OI type III and OI type IV, which may also be blue at birth and during infancy, but tends to fade by later childhood or adolescence. Other abnormalities include limb deformities, dentinogenesis imperfecta, short stature, triangular face, scoliosis, and hearing loss (> 50 percent of individuals).[182,183] Just as in the bone, the cutaneous findings in the skin of OI patients reflect the decreased type I collagen,[184,185] and cultured skin fibroblasts from affected individuals show decreased or abnormal type I procollagen molecules, a finding often used as a diagnostic tool. The skin is stiffer and less elastic than normal, as documented using the suction cup technique.[186] Histologic analysis shows a relative increase of argyrophil and elastic fibers when compared to collagen.

Treatment

Therapy for OI involves a multi-disciplinary approach. Orthopedic surgeons, physical therapists, and rehabilitation personnel are the primary providers of care. Careful mobility is encouraged, and surgical repairs and support are frequently employed, giving patients a more active lifestyle.[187] More recently, remarkable success has been attributed to the use of potent antiresorptive bisphosphonates. Intravenous and oral administration of these agents has been shown to decrease bone pain, increase muscle strength, enhance well-being, and increase bone mineral density. However, these preliminary results are currently being further investigated in randomized clinical trials.[188] Transplantation of adult mesenchymal stem cells is currently under investigation as a means to correct bone fragility, and HLA-mismatched mesenchymal stem cells have led to

clinical improvement when transplanted into an affected fetus at 32 weeks gestational age.[189]

KEY REFERENCES

The full reference list for all chapters is available at www.digm7.com.

7. Mao JR, Bristow J: The Ehlers-Danlos syndrome: On beyond collagens. *J Clin Invest* **107**:1063, 2001
9. Lawrence EJ: The clinical presentation of Ehlers-Danlos syndrome. *Adv Neonatal Care* **5**:301, 2005
82. Ramirez F: Fibrillin mutations in Marfan syndrome and related phenotypes. *Curr Opin Genet Dev* **6**:309, 1996
112. Lerner-Ellis JP et al: Identification of the gene responsible for methylmalonic aciduria and homocystinuria, cblC type. *Nat Genet* **38**:93, 2006
118. Lawson-Yuen A, Levy HL: The use of betaine in the treatment of elevated homocysteine. *Mol Genet Metab* **88**:201, 2006
126. Miksch S et al: Molecular genetics of pseudoxanthoma elasticum: Type and frequency of mutations in ABCC6. *Hum Mutat* **26**:235, 2005
132. Quaglino D et al: Abnormal phenotype of in vitro dermal fibroblasts from patients with pseudoxanthoma elasticum (PXE). *Biochim Biophys Acta* **1501**:51, 2000
166. Hu Q et al: Inflammatory destruction of elastic fibers in acquired cutis laxa is associated with missense alleles in the elastin and fibulin-5 genes. *J Invest Dermatol* **126**:283, 2006
178. Kadler KE et al: Collagen fibril formation. *Biochem J* **316**:1, 1996
198. Anderson CE et al: Association of hemolytic anemia and early-onset pulmonary emphysema in three siblings. *J Pediatr* **105**:247, 1984



CHAPTER 140

Hereditary Disorders of Genome Instability and DNA Repair

Thomas M. Rünger
John J. DiGiovanna
Kenneth H. Kraemer

Because the genome is the basic control for cellular function, maintaining genome stability is important for the continued function of cells, tissues, and organisms. DNA is the carrier of genetic information. Its structure is regularly threatened by damaging agents that include oxidative stress, ultraviolet (UV) and x-radiation, and chemical agents. Although much damage is repaired, failure to maintain genomic integrity may lead to abnormal cell function or cell death. If the cell divides, progeny may accumulate additional damage and this progressive accumulation of damage can lead to malignancy (see Chap. 109).

This chapter describes the relevant skin disorders with genome instability and the underlying defective mechanisms of DNA repair or DNA maintenance (Table 140-1). All of these exhibit prominent cutaneous abnormalities that involve dermatologists in their diagnosis and management. Most, but not all, are also characterized by an increased risk of malignancies. This demonstrates that the maintenance of genome integrity is of utmost importance for the prevention of malignant transformation. As malignant transformation requires the accumulation of several mutations in specific genes of a single cell, a mutator phenotype is often regarded a prerequisite for carcinogenesis, because without genome instability it would be exceedingly unlikely that all of those mutations occur in a single cell.[1–4] The same genes that are affected in the hereditary genome instability disorders can also confer genome instability to individual cells when impaired through acquired mutations, thereby playing an important role early in spontaneous carcinogenesis.

In addition, although these heritable diseases are rare (on the order of 10^{-5} or 10^{-6}), carriers of the affected genes may comprise several percent of the general population. These individuals are usually free of clinical symptoms, as most of these disorders are characterized by autosomal recessive inheritance. However, epidemiologic studies suggest that heterozygote carriers may have an increased risk of neoplasia as well.

Spontaneous genome instability is present in Bloom syndrome (BS), ataxia telangiectasia, and Fanconi anemia (FA) as manifested by increased chromosome breakage in primary blood or skin cells. On the other hand, genome instability is present in cells from patients with xeroderma pigmentosum (XP) only after exposure to DNA-damaging agents such as UV radiation or other carcinogens such as benzo[*a*]pyrene, which is present in cigarette smoke. In XP, many of the severe disease manifestations such as cancer and corneal scarring leading to blindness are the result of the interplay between genetic risk and environmental exposure. For example, XP patients who avoid UV radiation dramatically reduce or eliminate the probability of developing skin cancer and blindness.

HEREDITARY DISORDERS OF GENOME INSTABILITY AND DNA REPAIR AT A GLANCE



- Genome instability characterizes a large group of inherited disorders with prominent cutaneous abnormalities; many have an increased cancer risk.
- Genome instability is caused by impaired repair and/or maintenance of DNA.
- Xeroderma pigmentosum is a prototype with impaired repair of environmentally induced DNA damage and a greatly increased frequency of sunlight-induced cancers.
- Although these disorders are rare, heterozygote carriers of affected genes, which may comprise several percent of the general population, may carry an increased cancer risk as well.

In some of the disorders discussed here, genome instability is caused by an impaired ability to repair damage to DNA introduced by certain physical or chemical agents. Cells are equipped with different DNA repair pathways



TABLE 140-1
Hereditary Disorders of Genome Instability and DNA Repair

	Clinical Features				Mechanisms		
Disorder	Cutaneous	Neoplasia	Other	Inheritance	Cellular Abnormalities	Affected Gene(s)	Impaired Function
Disorders of genome instability with defective DNA repair							
XP	Photosensitivity, poikiloderma (hyper- and hypo-pigmentation, atrophy, telangiectasia), skin cancers	BCC, SCC, melanoma, central nervous system tumors	Sensorineural deafness, progressive neurologic degeneration, primary loss of neurons (some patients)	Autosomal recessive	Increased UV-induced cell killing and mutagenesis	*XPA, XPB, XPC, XPD, XPE, XPF, XPG*, or DNA polymerase eta	Nucleotide excision repair: global genome and transcription-coupled DNA repair; translesional DNA synthesis (XP-variant)
Cockayne syndrome (CS)	Photosensitivity	No increased incidence	Typical facial features (deep-set eyes, loss of subcutaneous fat), pigmentary retinal degeneration, postnatal growth failure, sensorineural deafness, progressive neurologic degeneration, primary dysmyelination, brain calcifications	Autosomal recessive		*CSA* or *CSB*	Nucleotide excision repair: transcription-coupled DNA repair only
XP-CS	Same as XP	BCC, SCC	Neurologic changes of CS	Autosomal recessive	Same as XP	*XPB, XPD,* or *XPG*	Nucleotide excision repair: global genome and transcription-coupled DNA repair
TTD	Brittle hair, photosensitivity, ichthyosis, collodion membrane	No increased incidence	Congenital cataracts, developmental delay, primary dysmyelination, recurrent infections	Autosomal recessive	Increased UV-induced cell killing	*XPB, XPD, TTD-A,* or *TTDN1*	Nucleotide excision repair: transcription-coupled pathway of nucleotide excision repair
HNPCC/MTS	Sebaceous tumors (benign and malignant), keratoacanthomas	Low-grade cancers of the colon, endometrium, stomach, small intestine, hepatobiliary system, upper urethral tract, larynx and ovary; sebaceous carcinoma, BCC with sebaceous differentiation	—	Autosomal dominant	High level of microsatellite instability in tumors	*hMSH2* (MTS, HNPCC1), *hMLH1* (MTS, HNPCC2), *PMS1* (HNPCC3), *hPMS2* (HNPCC4), *hMSH6* (HNPCC5), *TGFBR2* (HNPCC6), or *hMLH3* (HNPCC7)	Mismatch repair
Other Disorders of Genome Instability							
Bloom syndrome	Photosensitivity, malar erythema, café-au-lait macules	Most cancer types; in particular leukemias, lymphomas, carcinomas of the breast and gastrointestinal tract	Immune deficiency, growth retardation, unusual facies, male infertility and female subfertility, type 2 diabetes	Autosomal recessive	Spontaneous chromosome breakage and rearrangements, increased sister chromatid exchanges, quadriradial chromosomes	*BLM*	A RecQ DNA helicase, recombination, replication

Werner syndrome	Graying of hair, skin atrophy, leg ulcers, melanomas	Sarcomas, thyroid cancers, meningiomas, melanomas (acral lentiginous, and mucous membrane melanomas)	Premature aging (atherosclerosis, diabetes mellitus, osteoporosis, cataracts)	Autosomal recessive	Chromosomal instability, accelerated telomere shortening	*WRN*	A RecQ DNA helicase, transcription, DNA repair (DSBR, SSBR, recombination), DNA replication, telomere maintenance
Rothmund-Thomson syndrome	Photosensitivity, poikiloderma, alopecia	Osteosarcomas, cutaneous SCC, and others	Skeletal abnormalities, growth deficiency, juvenile cataracts, osteoporosis	Autosomal recessive	Chromosomal instability in response to ionizing radiation	RECQL4 (some patients)	A RecQ DNA helicase
Fanconi anemia	Café-au-lait macules	Myeloid leukemias, SCC of head and neck	Aplastic anemia, pancytopenia, growth retardation, thumb and other bone abnormalities	Autosomal recessive	Increased sensitivity to DNA cross-linking agents	*FANCA, FANCB, FANCC, FANCD1/BRCA2, FANCD2, FANCE, FANCF, FANCG, FANCI, FANCJ, FANCL*	DNA damage signaling, recombination repair
AT	Telangiectasias	T-cell leukemias, lymphomas	Progressive cerebellar ataxia, immune defects, hypogonadism, increased acute toxicity of therapeutic x-ray	Autosomal recessive	Increased spontaneous and x-ray–induced chromosome breakage, increased sensitivity to killing by ionizing radiation, impaired cell cycle arrest and/or apoptosis in response to DNA damage	*ATM*	DNA damage signaling (control of cell cycle, apoptosis), repair of DNA double strand breaks
AT-like disorder	Similar to AT	Similar to AT	Similar to AT, but no ocular telangiectasias	Autosomal recessive	Increased spontaneous and x-ray–induced chromosome breakage, increased sensitivity to killing by ionizing radiation, impaired DNA strand break repair	*LIG4*	DNA ligase 4, strand break repair
Nijmegen breakage syndrome	Café-au-lait macule, vitiligo	B- and T-cell lymphomas, rhabdomyosarcoma, neuroblastoma	Immune defects, growth retardation, microcephaly, mental retardation, characteristic facies	Autosomal recessive	Increased spontaneous and x-ray–induced chromosome breakage, increased sensitivity to killing by ionizing radiation	*NBS1*	Nibrin (p95), which is part of the MRE11-RAD50-NBS1 complex, DNA damage signaling, recombination, DNA double-strand break repair, cell cycle checkpoint

(continued)



TABLE 140-1
Hereditary Disorders of Genome Instability and DNA Repair (Continued)

	Clinical Features				Mechanisms		
Disorder	**Cutaneous**	**Neoplasia**	**Other**	**Inheritance**	**Cellular Abnormalities**	**Affected Gene(s)**	**Impaired Function**
Seckel syndrome	Café-au lait macules	Leukemia	Proportionate dwarfism, microcephaly, mental retardation, characteristic facies (receding forehead, narrow face, large beaked nose, micrognathia), immune deficiency, pancytopenia	Autosomal recessive	Spontaneous and mitomycin C–induced chromosome instability, sensitivity to killing by UV and DNA cross-linking agents	*ATR*	Ataxia telangiectasia– and RAD3-related protein, DNA damage response, cell cycle checkpoints
Dyskeratosis congenita	Poikiloderma, nail dystrophy, skin cancer	Mucosal leukoplakia leading to cancer of anus or mouth, Hodgkin disease, pancreatic adenocarcinoma	Stenosis of lacrimal duct, anemia, pancytopenia, learning difficulties, deafness, brain calcifications, testicular atrophy, growth retardation	X-linked recessive, autosomal dominant	Increased frequency of chromatid breaks after x-radiation during G_2 phase of cell cycle	*DKC1* X-linked; *TERC* autosomal dominant form	Dyskeratin, involved in cell cycle and nucleolar function, impaired internal ribosome entry site–dependent translation; TERC (associated with telomerase RNA)

AT = ataxia telangiectasia; BCC = basal cell carcinoma; CS = Cockayne syndrome; HNPCC = hereditary non-polyposis colon cancer; MTS = Muir-Torre syndrome; SCC = squamous cell carcinoma; TTD = trichothiodystrophy; UV = ultraviolet; XP = xeroderma pigmentosum.

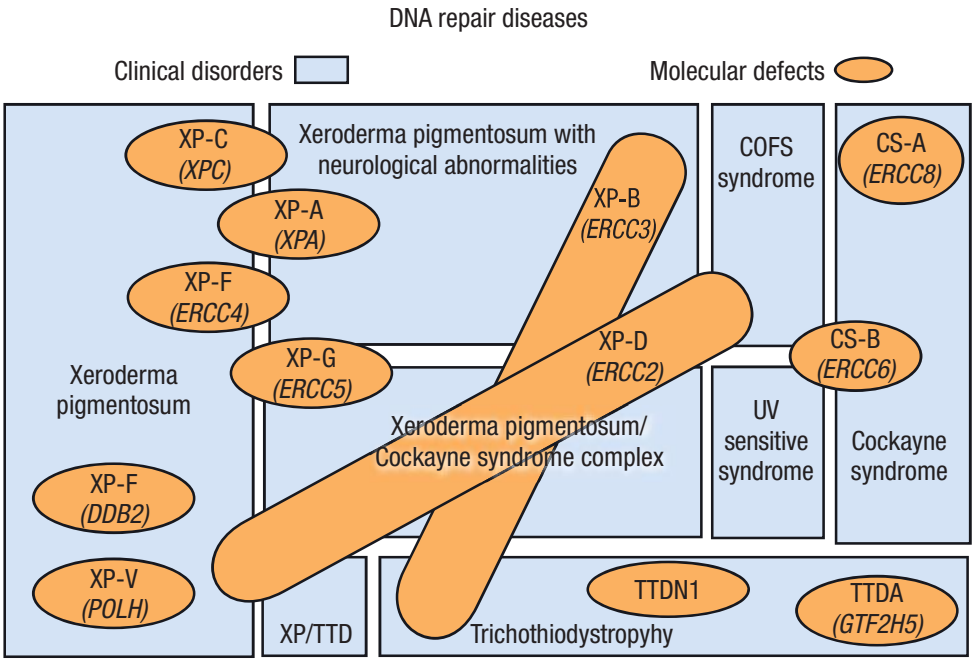

▲ **FIGURE 140-1** Relationship of clinical disorders and molecular defects in DNA repair diseases. Eight clinical phenotypes of DNA repair diseases have been recognized (*blue rectangles*). Defects in 12 genes have been associated with these clinical phenotypes (*orange ovals*). Mutations in different DNA repair genes can be associated with the same clinical phenotype. On the other hand, different mutations in one DNA repair gene can be associated with different clinical phenotypes. For example, mutations in the XPD (ERCC2) gene have been associated with xeroderma pigmentosum (XP), with XP with neurologic abnormalities, with the XP-Cockayne syndrome complex, with trichothiodystrophy, with XP-trichothiodystrophy, or with COFS (cerebro-oculo-facio-skeletal syndrome). The official names of the genes are in parentheses, whereas the names of the corresponding complementation groups are in caps.



(reviewed in Chap. 109) that repair different types of DNA damage. The nucleotide excision repair (NER) pathway, which processes bulky DNA lesions, including UV-induced DNA photoproducts, is impaired in XP, Cockayne syndrome (CS), and trichothiodystrophy (TTD). Cells from patients with these conditions are characterized by increased killing and mutation formation following exposure to UV light. However, only XP patients have increased cancer risk. The reason for this difference in cancer risk is not known.

Proteins encoded by some of the affected genes in these three disorders are not only involved in DNA repair, but also in transcription and cellular DNA damage responses. Thus, mutations affecting different functions of the same gene appear to play a role in various phenotypes that are not directly linked to DNA repair functions and underlie several overlap syndromes between those three conditions (Fig. 140-1).

XP variant, which is clinically indistinguishable from XP, is a disorder of DNA damage tolerance. Although normal cells can bypass DNA damage during replication (translesional DNA synthesis), cells from XP-variant patients have a defect in this process. The DNA mismatch repair pathway (see Chap. 109) is affected in hereditary nonpolyposis colon cancer (Lynch syndrome) and its subform, Muir-Torre syndrome which has cutaneous features including sebaceous gland tumors. Those are reviewed in Chap. 154.

Helicases are proteins that unwind DNA and are required for a multitude of metabolic processes involving DNA, such as transcription, replication, repair, and more. Two genes involved in NER are helicases that are also part of the basal transcription factor, TFIIH. The XPB (ERCC3) gene product unwinds DNA in the 3′ to 5′ direction whereas the XPD (ERCC2) gene product unwinds DNA in the opposite direction. The RecQ family of DNA helicases is highly conserved in evolution from bacteria to humans.[8,9] Of the five known human RecQ family members, three [BLM, WRN, and RECQL4, which cause BS, Werner syndrome (WS), and Rothmund-Thomson syndrome (RTS) respectively] are mutated in distinct clinical disorders associated with chromosomal instability, cancer predisposition, and/or premature aging.[10]

BASC (*B*RCA1-*a*ssociated genome *s*urveillance *c*omplex) is a multi-enzyme complex centered around the BRCA1 protein in the nucleus.[11] It contains important DNA damage response proteins including ATM, ATR, the MRE11-RAD50-NBS1 complex, BRCA1, BLM, FANCD2, and MLH1. These proteins physically interact with each other. Genome instability may result from a defect in any of those and cause the genome instability disorders ataxia telangiectasia (reviewed in Chap. 144), Seckel syndrome, Nijmegen breakage syndrome, hereditary breast cancer, BS, FA, or hereditary colon cancer. BS and FA are reviewed here.

DISORDERS OF DNA REPAIR

Xeroderma Pigmentosum

XP serves as the prototype heritable disease with increased sensitivity to cellular injury.[11–13] XP is an autosomal recessive disease with sun sensitivity, photophobia, early onset of freckling, and subsequent neoplastic changes on sun-exposed surfaces. There is cellular hypersensitivity to UV radiation and to certain chemicals in association with abnormal DNA repair. Some of the patients have progressive neurologic degeneration.

FREQUENCY XP occurs with an estimated frequency of 1 in 1 million persons in the United States[12] and 1 per 100,000 thousand people in Japan.[15] It is relatively more common in areas such as the Middle East where marriage of close relatives is practiced. Patients have been reported worldwide in all races, including whites, Asians, blacks, and Native Americans.



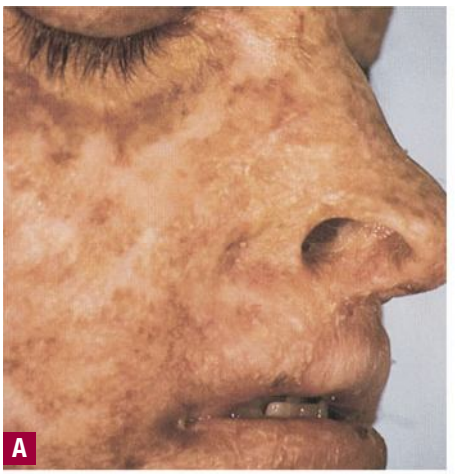

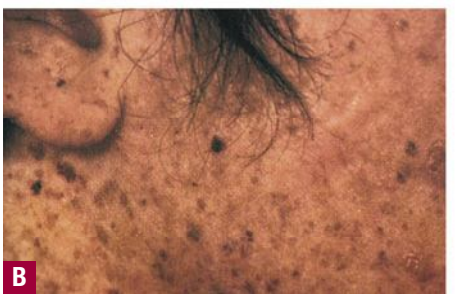



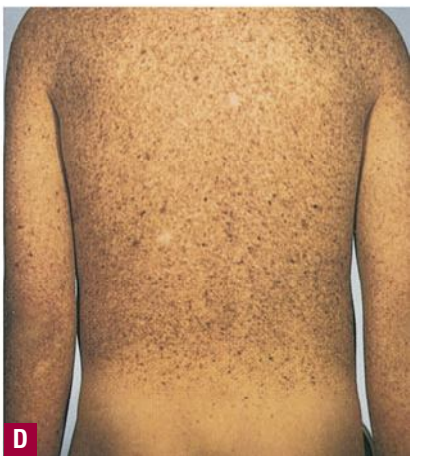

▲ **FIGURE 140-2** Xeroderma pigmentosum. **A.** Pigmentary changes, atrophy, dryness, and cheilitis in a 16-year-old patient. **B.** Cheek of a 14-year-old patient with pigmented macules of varying size and intensity, actinic keratosis, basal cell carcinoma, and a surgical scar. **C.** Corneal clouding, prominent conjunctival blood vasculature, and loss of lashes. **D.** Myriads of pigmented macules of varying size and intensity and scattered achromic areas on the back, with marked sparing of sun-protected buttocks of a 14-year-old patient.

CLINICAL FEATURES ***Skin.*** Approximately one-half the patients with XP have a history of acute sunburn reaction on minimal UV exposure. The other patients tan normally without excessive burning. In all patients, numerous freckle-like hyperpigmented macules appear predominately on sun-exposed skin (Fig. 140-2). The median age of onset of the cutaneous symptoms in XP is between 1 and 2 years (Fig. 140-3).[13] These generally spare sun-protected sites such as the buttocks (see Fig. 140-2D). However, some severely sun-exposed patients may show pigmentary abnormalities in the axillae. Continued sun exposure causes the patient's skin to become dry and parchment-like, with increased pigmentation, hence the name *xeroderma pigmentosum* ("dry pigmented skin"; see Fig. 140-2A). Pre-malignant actinic keratoses develop at an early age (see Fig. 140-2B). The appearance of sun-exposed skin in children with XP is similar to that occurring in farmers and sailors after many years of extreme sun exposure.

Cancer. Patients with XP younger than 20 years of age have a greater than 1000-fold increased risk of cutaneous basal cell carcinoma, squamous cell carcinoma, or melanoma.[11,12,15] The median age of onset of non-melanoma skin cancer reported in patients with XP is 8 years. This 50-year reduction in comparison with the general population is an indication of the importance of DNA repair in protection from skin cancer in unaffected individuals (see Fig. 140-3). Multiple primary cutaneous neoplasms, including melanomas, occur commonly in XP patients.

Review of the world's literature on XP has revealed a substantial number of cases of oral cavity neoplasms, particularly squamous cell carcinoma of the tip of the tongue, a presumed sun-exposed location. Brain (sarcoma and medulloblastoma), central nervous system (astrocytoma of the spinal cord), lung, uterine, breast, pancreatic, gastric, renal, and testicular tumors and leukemia have been reported in a few patients with XP.[11,12,15,16] Overall, these reports suggest an approximate 10- to 20-fold increase in internal neoplasms in XP.

Eyes. Ocular abnormalities are almost as common as the cutaneous abnormalities and are an important feature of XP (see Fig. 140-2C).[13,16] The posterior portion of the eye (retina) is shielded from UV radiation by the anterior portion (lids, cornea, and conjunctiva). Clinical findings are strikingly limited to these anterior, UV-exposed structures. Photophobia is often

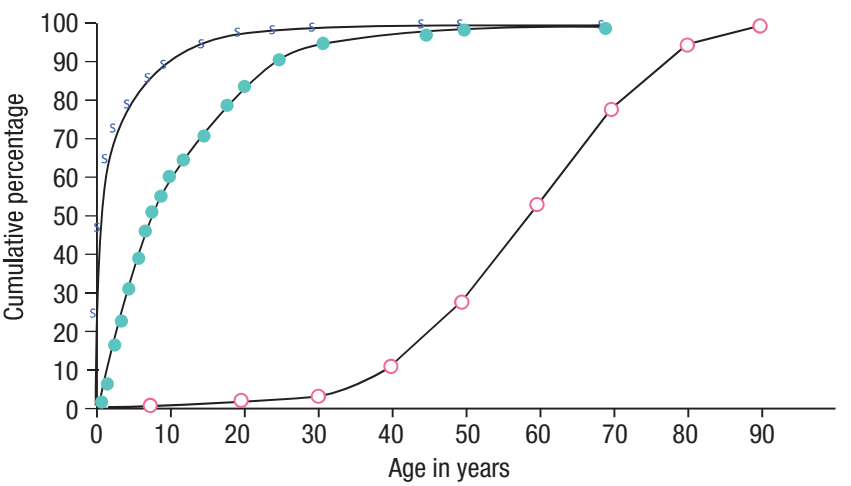

▲ **FIGURE 140-3** Xeroderma pigmentosum. Age at onset of clinical symptoms and skin cancers. Age at onset of cutaneous symptoms (generally sun sensitivity or pigmentation) was reported for 430 patients. Age at first skin cancer was reported for 186 patients and is compared with the age distribution for 29,757 patients with basal cell carcinoma or squamous cell carcinoma in the U.S. general population. There is a 50-year reduction in age of onset of skin cancer in the XP patients compared with the U.S. general population. (From Kraemer KH, Lee MM, Scotto J: Xeroderma pigmentosum. Cutaneous, ocular, and neurologic abnormalities in 830 published cases. *Arch Dermatol* **123**:241, 1987, with permission.)

present and may be associated with prominent conjunctival injection. Schirmer's testing frequently reveals reduced tearing leading to dry eyes. Continued UV exposure of the eye may result in severe keratitis, leading to corneal opacification and vascularization. The lids develop increased pigmentation and loss of lashes. Atrophy of the skin of the lids results in ectropion, entropion, or, in severe cases, complete loss of the lids. Benign conjunctival inflammatory masses or papillomas of the lids may be present. Epithelioma, squamous cell carcinoma, and melanoma of UV-exposed portions of the eye are common. The ocular manifestations may be more severe in black patients.[19]

Neurologic System. Neurologic abnormalities have been reported in approximately 30 percent of the patients.[12,15,18] The onset may be early in infancy or, in some patients, delayed until the second decade. The neurologic abnormalities may be mild (e.g., isolated hyporeflexia) or severe, with progressive mental retardation, sensorineural deafness (beginning with high-frequency hearing loss), spasticity, or seizures. The most severe form, known as the *De Sanctis-Cacchione syndrome,* involves the cutaneous and ocular manifestations of classic XP plus additional neurologic and somatic abnormalities, including microcephaly, progressive mental deterioration, low intelligence, hyporeflexia or areflexia, choreoathetosis, ataxia, spasticity, Achilles tendon shortening leading to eventual quadriparesis, dwarfism, and immature sexual development. The complete De Sanctis-Cacchione syndrome has been recognized in very few patients; however, many patients with XP have one or more of its neurologic features. In clinical practice, deep tendon reflex testing and routine audiometry usually can serve as a screen for the presence of XP-associated neurologic abnormalities. In cases where there is clinical evidence of early neurologic abnormalities, a brain magnetic resonance imaging (MRI) may show enlarged ventricles.

The predominant neuropathologic abnormality found at autopsy in patients with neurologic symptoms was loss (or absence) of neurons, particularly in the cerebrum and cerebellum. There is evidence for a primary axonal degeneration in these patients.[19]

LABORATORY ABNORMALITIES ***Cellular Hypersensitivity.*** Cultured cells from patients with XP generally grow normally when not exposed to damaging agents. The population growth rate or single-cell colony-forming ability is reduced to a greater extent than normal, however, after exposure to UV radiation. A range of post-UV colony-forming abilities has been found with fibroblasts from patients, some having extremely low post-UV colony-forming ability and others having nearly normal survival (see Chap. 109).[11,13]

XP fibroblasts are deficient in their ability to repair some UV-damaged viruses or plasmids to a functionally active state.[11,13,19] These host cell reactivation assays have detected an abnormality in every form of XP tested.

UV-irradiated XP fibroblasts are hypermutable compared to normal fibroblasts. This post-UV hypermutability is believed to be the basis of the increased frequency of sunlight-induced somatic mutations that lead to cancer in XP patients.[21]

Chromosome Abnormalities. XP cells generally are found to have a normal karyotype without excessive chromosome breakage or increased sister chromatid exchanges (as seen in Bloom syndrome). After exposure to UV radiation, however, abnormally large increases in chromosome breakage and in sister chromatid exchanges have been observed.[22] The extent of this induced abnormality varies in different patients.

DNA Repair. In 1968, hypersensitivity of cultured XP cells to UV damage was reported by Cleaver[23] to be the result of defective DNA repair. He found defective UV-induced repair replication, indicating a defect in the NER pathway. Most XP cells have a normal response to treatment with x-rays, indicating the specificity of the DNA repair defect. The defective genes for the seven NER-defective forms of XP and the XP variant have been cloned[24] and their functions are being investigated (see Chap. 109).

Complementation Groups. Genetic heterogeneity among the XP DNA repair defects was found by fusing cultured fibroblasts from different patients and defining complementation groups (see Chap. 109). Up to 2006, seven such DNA excision repair–deficient complementation groups have been identified (named *XP-A* to *XP-G*) and the corresponding genes have been identified (see Fig. 140-1).[24] Additional patients with clinical XP but normal NER have been called *XP variants*. Studies of cellular hypersensitivity revealed a slightly increased sensitivity to UV-induced inhibition of cell growth that was potentiated by caffeine. Cells from XP-variant patients have a defect in an error-prone DNA polymerase (pol eta) that bypasses unrepaired DNA damage.[25,26]

Prenatal Diagnosis. Prenatal diagnosis has been reported by measuring UV-induced unscheduled DNA synthesis in cultured amniotic fluid cells[27] and by use of DNA diagnosis of trophoblast cells obtained early in pregnancy.[28]

Drug and Chemical Hypersensitivity. A number of DNA-damaging agents other than UV radiation have been found to yield hypersensitive responses with XP cells. These agents include drugs (psoralens, chlorpromazine), cancer chemotherapeutic agents (cisplatin,[29] carmustine), and chemical carcinogens (benzo[*a*]pyrene derivatives). Presumably, these agents induce DNA damage whose repair involves portions of the DNA repair pathways that are defective in XP.[29]

TREATMENT Management of patients with XP is based on early diagnosis, lifelong protection from UV radiation exposure, and early detection and treatment of neoplasms. Diagnosis rests on recognition of the characteristic clinical features and is confirmed by laboratory tests of cellular hypersensitivity to UV and defective DNA repair (see Chap. 109). Molecular determination of disease-causing mutations may soon move from only being performed in research laboratories to being certified for clinical testing.

Sun Protection. Patients should be educated to protect all body surfaces from UV radiation by wearing protective clothing and UV-absorbing glasses and long hair styles. They should adopt a lifestyle to minimize UV exposure and use sunscreens with high sun protective factor (SPF) ratings (minimum SPF 15) daily. Patients should be examined frequently by a family member who has been instructed in recognition of cutaneous neoplasms. A set of color photographs of the entire skin surface with close-ups of lesions (including a ruler) is often extremely useful to both the patient and the physician in detecting new lesions. A physician should examine patients at frequent intervals (approximately every 3 to 6 months depending on severity of skin disease). Pre-malignant lesions such as actinic keratoses may be treated by freezing with liquid nitrogen, or with topical 5-fluorouracil or imiquimod. Photodynamic therapy, using, for example,



the topical photosensitizer 5-aminolevulinic acid followed by exposure to blue light, is an effective treatment modality for normal patients with multiple actinic keratoses. There are no data on the safety or efficacy of this treatment in XP patients. *Caution is recommended because an abnormal response to photodynamic therapy or other light- or laser-based therapies cannot be excluded in XP cells.* Larger areas have been treated with therapeutic dermatome shaving or dermabrasion to remove the more damaged superficial epidermal layers.[30–33] This procedure permits repopulation by relatively UV-shielded cells from the follicles and glands.



Because cells from patients with XP are also hypersensitive to environmental mutagens such as benzo[*a*]pyrene found in cigarette smoke, prudence dictates that patients should be protected against these agents. One of our patients who smoked cigarettes for more than 10 years died of bronchogenic carcinoma of the lungs at age 35 years and another patient who smoked has developed a lung cancer at age 48 years.[34] Thus, we recommend that XP patients refrain from smoking cigarettes and that parents should protect children with XP from being exposed to second-hand smoke.

Cancers. Cutaneous neoplasms are treated in the same manner as in patients who do not have XP. This involves electrodesiccation and curettage, surgical excision, or Mohs micrographic surgery (see Chaps. 113 and 114). Because multiple surgical procedures are often necessary, removal of undamaged skin should be minimized. Extremely severe cases have been treated by excision of large portions of the facial surface and grafting with uninvolved skin.[31]

Most patients with XP are not abnormally sensitive to therapeutic x-rays, and XP patients have responded normally to full doses of therapeutic x-radiation for treatment of inoperable neoplasms such as an astrocytoma of the spinal cord,[17] a frontal lobe astrocytoma, or recurrent squamous cell carcinoma in the orbit. However, cultured cells from two XP patients were found to be hypersensitive to x-rays,[35,36] so when x-ray therapy is indicated, an initial small dose is advisable to test for clinical hypersensitivity.

Oral isotretinoin has been shown in a controlled study to be effective in preventing new neoplasms in patients with multiple skin cancers.[37] Because of its toxicity (hepatic, hyperlipidemic, teratogenic, calcification of ligaments and tendons, premature closure of the epiphyses), oral isotretinoin should be reserved for patients with XP who are actively developing large numbers of new skin cancers. We found that the effective dose varies among patients and some patients may respond to doses of oral isotretinoin as low as 0.5 mg/kg/day.

A bacterial DNA repair enzyme, den V T4 endonuclease, in a topical liposome-containing preparation, has been reported to reduce the frequency of new actinic keratoses and basal cell carcinomas in XP patients in one research study.[38] As of 2007, this treatment has not yet been approved by the U.S. Food and Drug Administration.

A study treating multiple melanoma in situ lesions with intralesional interferon-α in one XP patient showed localized clearing only of lesions injected with the intralesional interferon-α but not with the control diluent.[39] There are several case reports of XP patients responding to topical treatment with the immune modulator imiquimod (see Chap. 221).[40–43] However, none of these reports long-term follow-up.

Eyes. The eyes should be protected by wearing UV-absorbing glasses with side shields. Methyl cellulose eyedrops can be used to keep the cornea moist. Corneal transplantation has restored vision in patients with corneal opacity from severe keratitis. However, some of these suffered graft rejection due to neovascularization. Neoplasms of the lids, conjunctiva, and cornea are usually treated surgically.[44–46] We are examining the possibility of using a swab to obtain cytologic specimens from the surface of the eye to determine if early neoplasms can be detected or excluded without the need for performing biopsies.

CLINICAL-LABORATORY CORRELATIONS Patients with XP are hypersensitive to UV radiation, as are their cultured cells. Cutaneous and ocular abnormalities are strikingly limited to UV-exposed areas and usually spare such UV-shielded locations as the axillae, buttocks, and retina. The fact that black patients with XP have an increased frequency of skin cancer indicates that a normally functioning DNA repair system provides greater protection against skin cancer than does the natural pigmentation of black skin.

Complementation Groups. At least eight different molecular defects are associated with the clinical abnormalities recognized as XP, as indicated by the existence of seven DNA excision repair–deficient complementation groups (A to G) and the variant form. A discussion of the cloned XP genes and their function can be found in Chapter 109. There is a complex relationship among the DNA repair genes and clinical disease (see Fig. 140-1). Eleven NER genes are associated with at least seven different clinical phenotypes. A clinical phenotype can be associated with defects in each of several genes. Conversely, mutations in one gene can be associated with several different clinical phenotypes. These complex relationships and the roles of DNA repair genes in regulation of transcription and in immune functions are under intense investigation.

COMPLEMENTATION GROUP A. Complementation group A (see Fig. 140-2) contains patients with the most severe neurologic and somatic abnormalities (the De Sanctis-Cacchione syndrome) as well as patients with minimal or no neurologic abnormalities.[12] Long-term follow-up of these patients has revealed a relationship between the genotype and the phenotype. Patients with the most severe disease appear to have truncating mutations in both alleles of the XPA gene leading to no detectible normal protein. In contrast, patients with minimal neurologic abnormalities have splice-site mutations that permit a small amount of normal messenger RNA (mRNA) to be made. This form is seen in the United States, Europe, and the Middle East. It is the most common form of XP in Japan. Approximately 90 percent of Japanese XP-A patients have the same single-base-substitution founder mutation.[47] This finding has served as the basis for development of a rapid diagnostic assay for Japanese XP-A patients (including prenatal diagnosis) using polymerase chain reaction analysis of a small sample of DNA.[33] Heterozygous carriers of this disease-causing mutation who have one mutated allele and one normal allele have been estimated to comprise approximately 1 percent of the Japanese population.[15]

COMPLEMENTATION GROUP B. Complementation group B (Fig. 140-4) is composed of five patients in four kindreds who had the cutaneous abnormalities characteristic of XP (including neoplasms) in conjunction with neurologic and ocular abnormalities typical of CS.[12,48] Another family had two adult sisters with XP without CS who had ocular melanomas and were parents of normal children. Surprisingly, a patient with TTD also was found to have a defect in the *XPB* gene.





▲ **FIGURE 140-4** Xeroderma pigmentosum XP/CS complex. **A.** 28-year-old patient (XP11BE) in XP complementation group B with cutaneous changes of xeroderma pigmentosum, including pigmentary changes and atrophy. She has a beak-like nose and loss of subcutaneous tissue typical of Cockayne syndrome. **B.** The patient is of short stature (less than 4 ft. tall). Her mother, an obligate heterozygote, is clinically normal.

COMPLEMENTATION GROUP C. Patients in complementation group C (see Fig. 140-2), with rare exceptions, have XP with skin and ocular involvement but without neurologic abnormalities.[12,49–54] This is the most common group in the United States, Europe, and Egypt, but has been found rarely in Japan. Most patients have truncating mutations in both alleles leading to undetectable levels of *XPC* mRNA (due to nonsense-mediated message decay). However, a splice lariat branchpoint mutation resulting in as little as 3 percent to 5 percent of normal mRNA resulted in milder clinical symptoms in one family in Turkey.[52] XP-C patients typically do not give a history of severe burning on minimal sun exposure and at times are first diagnosed with the appearance of skin cancer in a child. One XP-C patient was reported to be hypersensitive to ionizing radiation;[36] however, correction of the *XPC* gene defect did not correct the cellular ionizing radiation hypersensitivity, suggesting that more than one gene was defective in this patient.

COMPLEMENTATION GROUP D. Patients in complementation group D have been described with six different clinical phenotypes (see Fig. 140-1). They may have cutaneous XP with late onset of neurologic abnormalities in their second decade of life or XP with no neurologic abnormalities.[12,55] Two XP-D patients have been reported with clinical symptoms of both XP and CS. Cells from patients with a photosensitive form of TTD (without XP) also were assigned to the XP complementation group D. Two patients were reported with combined symptoms of both TTD and XP (one patient had a skin cancer) and mutations in the *XPD* gene.[56] Finally, a patient with cerebro-oculo-facio-skeletal (COFS) syndrome had a mutation in the *XPD* gene.[57]

COMPLEMENTATION GROUP E. Complementation group E was found in one kindred in Europe and several in Japan (see Fig. 140-1).[12,58] These patients had relatively mild cutaneous abnormalities without neurologic involvement.

COMPLEMENTATION GROUP F. Complementation group F patients have been found mainly in Japan.[59,60] Most of these patients have mild clinical symptoms without neurologic abnormalities or skin cancer. However, we recently found two families with adult onset of severe neurodegeneration with mutations in the XPF gene. The residual rate of DNA repair, however, is very low (only 10 percent to 20 percent of normal).

COMPLEMENTATION GROUP G. Thirteen patients in XP complementation group G have been identified in the United States, Europe, and Japan (Fig. 140-5).[61] There is a large variation in clinical features among these patients. Several patients with mutations in the *XPG* gene had clinical features of both XP and severe CS with cachexia and death in the first decade (see Fig. 140-4). Other patients with different mutations in the same gene had no neurologic abnormalities.

XERODERMA PIGMENTOSUM VARIANT. XP-variant cells have normal DNA NER and thus do not fall into any of the complementation groups of cells with defective DNA excision repair (see Fig. 140-2).[13] There is, however, a defect in an error-prone, translesional DNA damage bypass polymerase, pol eta (see Chap. 109).[23,24,62] Most XP-variant patients have clinical XP with no neurologic abnormalities. The cutaneous and ocular abnormalities have been severe in some patients and mild in others.

Heterozygotes. XP heterozygotes (parents and some other relatives) are carriers of the gene for XP but are clinically normal. There is limited epidemiologic evidence to indicate that such persons have an increased risk of developing skin cancer.[7] Most tests of cell function or DNA repair yield normal responses with cells from XP heterozygotes.

PATIENT SUPPORT GROUPS The Xeroderma Pigmentosum Society is an educational, advocacy, and support organization for XP patients and their families: Xeroderma Pigmentosum Society, Inc., Box 4759, Poughkeepsie, NY 12602-4759; website: http://www.xps.org; e-mail: xps@xps.org; telephone: toll-free (877) XPS-CURE (877-977-2873). Another support group is the XP Family Support Group, 8375 Folsom Blvd Suite 201, Sacramento Ca, 95826. Their website is http://www.xpfamilysupport.org/.

A website listing disease-causing mutations in XP and CS genes has been established at http://xpmutations.org/.

Cockayne Syndrome (Including Xeroderma Pigmentosum–Cockayne Syndrome Overlap)

CS is a very rare, autosomal recessive degenerative disease with cutaneous,





▲ **FIGURE 140-5** Severe and mild xeroderma pigmentosum XP-G patients. **A,B.** XP82DC. **C–F.** XP65BE. **A.** Patient XP82DC at 3 years of age has deep-set eyes characteristic of Cockayne syndrome (CS) and irregular lentiginous pigmentation on her face characteristic of XP, indicating XP-CS complex. **B.** Patient XP82DC at 3 years of age has characteristic XP pigmented lesions on her forearms and dorsa of hands along with thin, translucent skin with readily visible veins. The small size of her hands is apparent in comparison with the hands of her mother. **C.** Patient XP65BE at age 6 months experienced severe sunburn on her face with minimal sun exposure. Erythema and swelling are seen on skin of forehead, cheeks, and periorbital area. **D.** Patient XP65BE at age 9 months shows erythema and peeling of skin of malar area of face after sun exposure. **E.** Patient XP65BE at age 4.5 years shows pigmentary changes on her nose, malar area, and other portions of her face. **F.** Patient XP65BE at 4.5 years shows blistering sunburn on her upper thigh. Note spared area above knee where sunscreen was applied. **G.** Patient XP65BE shows minimal pigmentary changes on face and sparing of neck and hand. She used measures to protect her skin from sun exposure. (From Emmert S et al: Relationship of neurologic degeneration to genotype in three xeroderma pigmentosum group G patients. *J Invest Dermatol* **118**:972, 2002, with permission.)



ocular, neurologic, and somatic abnormalities (see Table 140-1).[64,65] A review published in 1992 described 140 cases reported in the literature.[66]

CLINICAL FEATURES In 1936, E.A. Cockayne described a syndrome characterized by cachectic dwarfism, deafness, and pigmentary retinal degeneration with a characteristic "salt and pepper" appearance of the retina.[67] The skin had photosensitivity without the excessive pigmentary abnormalities seen in XP. There was marked loss of subcutaneous fat, resulting in a "wizened" appearance with typical "bird-headed" facies and prominent "Mickey Mouse" ears. Other ocular findings included cataracts and optic atrophy.[68] Neurologic abnormalities, in addition to deafness, include peripheral neuropathy, normal pressure hydrocephalus, and microcephaly. Birth weight and early development are usually normal. The disease onset is usually in the second year of life with slowly progressive neurologic degeneration. Intellectual deterioration may be non-uniform, with some functions preserved better than others. A severe infantile form has been described[69,70] as well as a milder form with late onset. COFS syndrome[57,71,72] with microcephaly and severe mental retardation and CAMFAK syndrome of congenital *ca*taracts, *m*icrocephaly, *fa*ilure to thrive, and *k*yphoscoliosis[73] have some similar features. CS is not associated with an increased incidence of neoplasia.

LABORATORY ABNORMALITIES Clinical laboratory testing often shows sensorineural deafness, neuropathic electromyogram, and slow motor nerve conduction velocity.[12,19,64,66,69,74] The electroencephalogram may be abnormal, and x-ray examination may show thickened skull and microcephaly. Computed tomography may be diagnostically useful in the detection of normal-pressure hydrocephalus and showing calcification of the basal ganglia and other structures (see eFig. 140-5.1 in on-line edition). MRI of the brain shows atrophy and dysmyelination of the cerebrum and cerebellum. Bone age is usually normal. Height and weight are usually well below the third percentile for the age.

Cellular Hypersensitivity. As with XP, cultured cells (fibroblasts or lymphocytes) from patients with CS are hypersensitive to UV-induced inhibition of growth and colony-forming ability.[12,75] Host cell reactivation of UV-damaged adenovirus or plasmids is reduced, although generally to a lesser extent than in XP. There are two complementation groups (A and B) in CS (see Fig. 140-1). Patients with defects in CSA or CSB have similar features.[66] A patient with COFS syndrome was reported with a defect in CSB[73] and another with a defect in XPD.[51]

Prenatal Diagnosis. Prenatal diagnosis of CS has been performed[77] based on the delay in recovery of post-UV RNA synthesis and the increased cell killing by UV radiation.

CLINICAL-LABORATORY CORRELATION

PATIENT SUPPORT GROUP

There is an educational, advocacy, and support organization for helping patients with CS and their families: The Share and Care Cockayne Syndrome Network, Inc., Box 570618, Dallas, TX 75357; website: http://www.cockayne-syndrome.org.

Xeroderma Pigmentosum–Cockayne Syndrome Complex

Approximately one dozen patients with CS have been found to have, in addition, clinical features of XP.[19,48,61] These features include freckling on sun-exposed skin and cutaneous neoplasms (see Fig. 140-5). Cells from these XP-CS patients have reduced DNA excision repair characteristic of XP. Clinically, these patients may be distinguished from XP patients with neurologic abnormalities by the presence of the CS features of pigmentary retinal degeneration, calcification of the basal ganglia, normal-pressure hydrocephalus, and hyperreflexia. Cells from patients with this complex have been found to have mutations in three different XP genes: *XPB, XPD,* and *XPG,*[48,61,75] demonstrating that several different genes are implicated in this disorder (see Fig. 140-1).

Trichothiodystrophy

TTD is an autosomal recessive disorder that is characterized by sulfur deficient, brittle hair and includes a spectrum of clinical phenotypes that may include photosensitivity, ichthyosis, intellectual impairment, short stature, microcephaly, characteristic facial features (protruding ears, micrognathia), and decreased fertility (Fig. 140-6).[78–83] Some patients have immunodeficiency, dystrophic nails, and cataracts. Developmental delay may be associated with dysmyelination,[84] a feature similar to CS; however, patients do not have retinal changes of CS. The spectrum of clinical involvement is broad ranging from only hair to severe multisystem abnormalities (see Fig. 140-6). TTD encompasses patients who have been described as *Amish brittle hair syndrome, Sabinas brittle hair syndrome,* or *Pollitt syndrome*.

In 1980, Price proposed the term *trichothiodystrophy* [derived from Greek tricho (hair) thio (sulfur) *dys* (faulty) *trophe* (nourishment)] recognizing the hair shaft sulfur deficiency as a marker for this symptom complex.[81] Under light microscopy with polarization, TTD hair shafts have a characteristic dark and light banding pattern which gives a "tiger tail" appearance (see Fig. 140-6E). In addition, they usually have hair shaft abnormalities including trichoschisis (a clean transverse break through the hair) (see Fig. 140-6G), trichorrhexis nodosa-like defects, and ribboning (see Fig. 140-6H).[79,80] Hair shafts are brittle because of a reduction of high-sulfur matrix proteins, and amino acid analysis of the hair demonstrates reduced levels of cysteine and cystine in hair shaft proteins. This is associated with a decrease in the ratio of strong to weak disulfide bonds within the hair shafts.[82]

Approximately 50 percent of TTD patients have clinical photosensitivity that ranges from subtle to severe. However, in contrast to the typical clinical features of XP, patients with TTD do not develop poikilodermatous changes (hyper- and hypo-pigmentation, telangiectasias, and atrophy) or skin cancers. Rarely, patients may have features of both TTD and XP, with typical hair features of TTD and the pigmentary and skin cancers characteristic of XP (see Fig. 140-1).[56]

The majority of TTD patients have a defect in *XPD (ERCC2)*. A few have mutations in *XPB (ERCC3)* or *TTDA (TFB5)*, genes which are components of the transcription factor TFIIH that regulates both DNA repair and transcription. Some TTD patients have mutations in *TTDN1*, a gene of unknown function.[85] It is believed that mutations that affect the repair function of the NER genes are associated with features of XP, whereas mutations affecting the transcription-related function results in features of TTD.[86]

The diagnosis of TTD is based on examination of hair shafts (see Fig. 140-6E–H). TTD hair shafts display tiger tail banding under polarizing microscopy. In addition, they show a spectrum of typical hair shaft abnormalities, including trichoschisis, trichorrhexis nodosa–like fractures, surface irregularities, and ribboning.[79,80] Amino acid analysis of hair shafts can confirm reduced levels of cysteine and cystine (see Chap. 86).

Management includes sun protection and varies with the individual clinical features. Patients with developmental delay and intellectual impairment may have dysmyelination as seen on MRI of the brain and may benefit from neurologic and developmental assessment. Ophthalmologic involvement can include cataracts (which may be congenital), nystagmus, and errors of refraction. Some patients have recurrent infections that have been managed with prophylactic antibiotics or intravenous immunoglobulin G. Patients with skeletal abnormalities may benefit from rehabilitation medicine evaluation and support.

DISORDERS OF GENOME INSTABILITY

Bloom Syndrome

BS is a rare, autosomal recessive disorder characterized by growth deficiency, unusual facies, sun-sensitive telangiectatic erythema, immunodeficiency, and predisposition to a variety of different cancers.[8,87] It is most frequent among





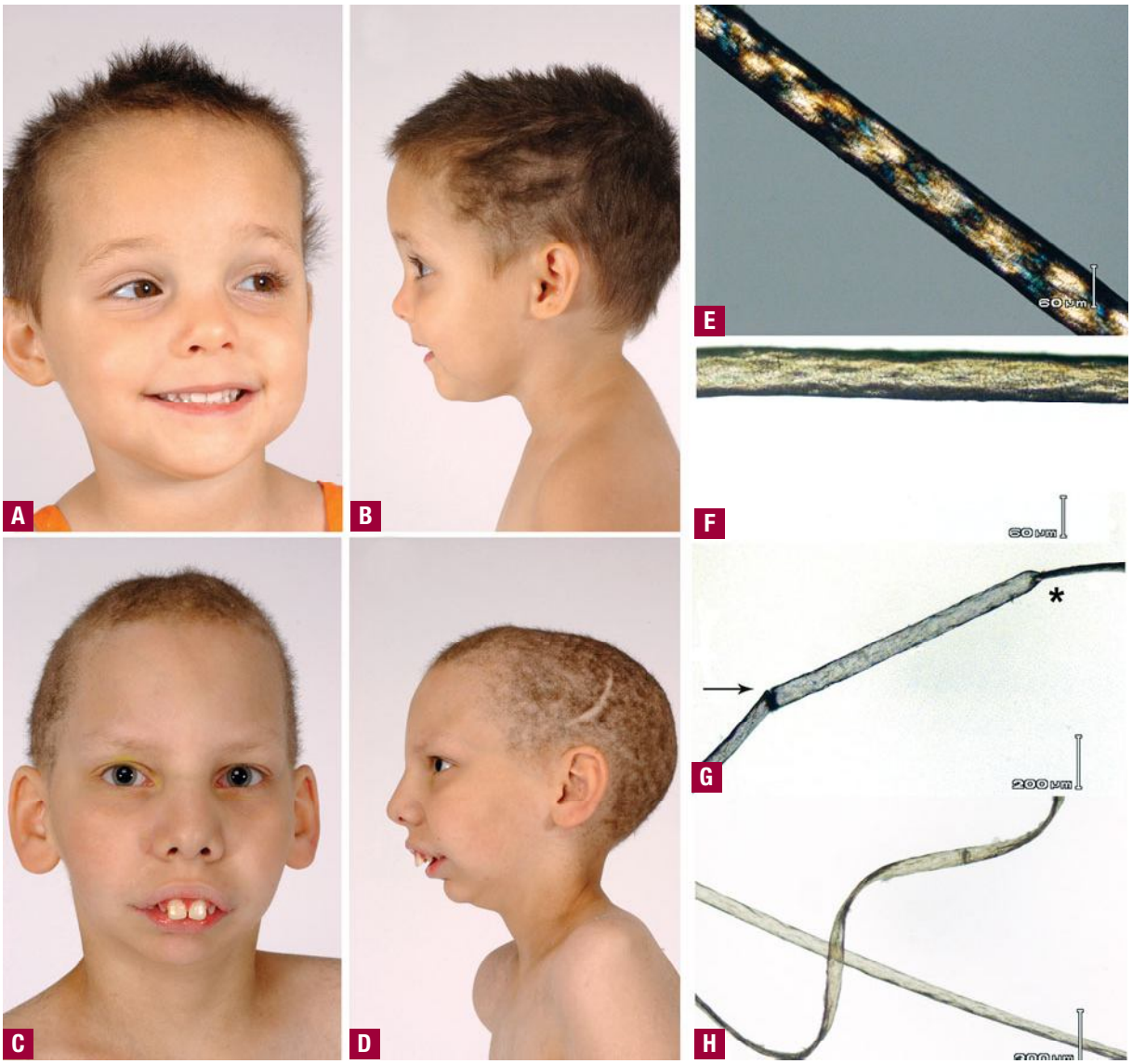

▲ **FIGURE 140-6** Trichothiodystrophy (TTD): Clinical and microscopic hair findings. **A,B.** Mild clinical phenotype: Three-year-old girl with TTD having short, brittle hair that is sparse and broken off at different lengths. She rarely has haircuts except to trim uneven hairs. She has no other abnormal findings. **C,D.** Severe clinical phenotype: 14-year-old boy with short brittle hair and dysmorphic facies with protruding ears, micrognathia, deep set eyes, head elongation in frontooccipital plane. He also has ichthyosis, intellectual impairment, short stature, photosensitivity, osteosclerosis, neurologic abnormalities, and recurrent infections. Light microscopy findings: **E.** TTD hairs displaying alternating light and dark "tiger tail" bands using polarizing microscopy. **F.** Irregular, undulating hair shaft with light microscopy **G.** Trichoschisis (*arrow*): Clean, transverse cleavage fracture; marked narrowing of shaft diameter (*asterisk*). **H.** Ribboning. (Modified from Liang C et al: Characterization of tiger tail banding and hair shaft abnormalities in trichothiodystrophy. *J Am Acad Dermatol* **52**:224, 2005.)

Ashkenazi Jews.[88] Approximately 250 patients have been recognized.

CLINICAL FEATURES Facial erythema and telangiectasia superficially resembling lupus erythematosus (Fig. 140-7) are often present within the first few weeks after birth in the malar area, on the nose, and around the ears.[87] Sun exposure accentuates these abnormalities and may induce bullae, bleeding, and crusting of the lips and eyelids. Café-au-lait spots are common, at times accompanied by adjacent depigmented areas. Patients are well proportioned but small. Adult height is usually under 150 cm. Patients have a long, narrow head with a characteristic facies consisting of a narrow, prominent nose, relatively hypoplastic malar areas, and a receding chin.

Patients with BS are predisposed to multiple infections, as there is immune dysfunction. Fertility is decreased and diabetes mellitus is common.

Approximately 20 percent of patients with BS develop malignancies, comprising a normal spectrum of cancer types, of which one-half occur before age 20 years.[87] Patients usually die before the age of 30 years from either cancer or infection.

GENE DEFECT, PATHOGENESIS, AND LABORATORY ABNORMALITIES BS is caused by mutations in *BLM*, which encodes a RecQ helicase.[8,10,89] BS cells are characterized by an increase in the frequency of spontaneous sister chromatid exchanges (see Chap. 109) and in exchanges between homologous chromosomes. The latter is often visualized by quadriradial chromosomes. These are four-armed chromosomes most likely formed by recombination between two chromosomes (and almost never found in unaffected individuals). These observations demonstrate that BS cells are characterized by hyper-recombination.

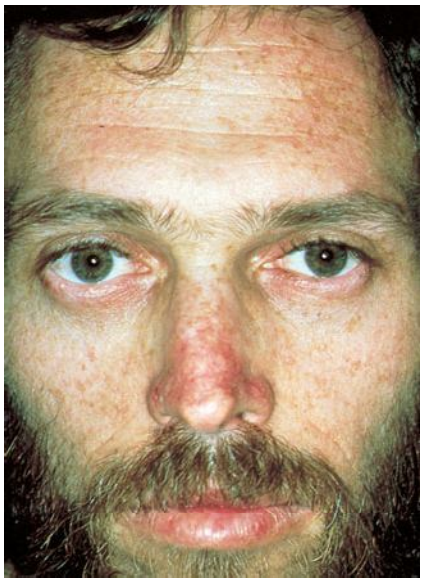

▲ **FIGURE 140-7** Bloom syndrome. Prominent telangiectasia in malar distribution.

Although the exact mechanisms of how mutations in the BLM helicase lead to hyper-recombination are still not completely understood, it has been suggested that they are related to defective DNA replication or defective resolution of stalled replication forks. Hyper-recombination may result in an increased frequency of loss of heterozygosity and through that mechanism, in conjunction with increased spontaneous mutation frequency, an increased frequency of malignant transformation. The immune deficiency, characterized by diminished immunoglobulin levels, reduced cellular proliferative response to mitogens, and decreased proliferation in the mixed leukocyte reaction, probably further contributes to the increased cancer risk.

TESTING The observation of quadriradial chromosomes (observed in 0.5 percent to 14 percent of lymphocytes of BS patients) and the approximately 10-fold increased frequency of spontaneous sister chromatid exchanges are used to diagnose BS.[90] A founder deletion/insertion mutation in the *BLM* gene was identified in Ashkenazi Jews at a frequency of approximately 1 percent (BLM^{Ash})[88,91] and can be used for DNA diagnosis of BS patients and carriers among Ashkenazi Jews.

Werner Syndrome (Adult Progeria)

WS is a rare, autosomal recessive disorder, characterized by several features of premature aging and an increased cancer risk. More than 800 patients have been reported.[92] Most of the WS patients are Japanese.

CLINICAL FEATURES Patients with WS are clinically normal until adolescence, when they do not show the usual growth spurt and start to prematurely develop features and disease of aging, including graying and thinning of hair, loss of subcutaneous fat, wrinkling of skin, type 2 diabetes, osteoporosis, and cardiovascular disease secondary to atherosclerosis.[93] Often, ophthalmologists are first to make the diagnosis of WS, as cataracts develop early.[94] Other features that are not part of the normal aging process are scleroderma-like changes with subcutaneous atrophy, leg ulcers, soft tissue calcifications, and a bird-like facies. Although an increased incidence and early onset of cancer is related to aging, the 10:1 ratio between epithelial to mesenchymal cancers seen in a normal aging population is shifted to 1:1 in WS patients, with, for example, sarcomas and melanomas being more frequent.[95] As in the Japanese general population, most of the melanomas are of the acral-lentiginous type or arise from mucous membranes and are therefore not considered to be related to UV-exposure. Thyroid cancer occurs at a younger age in WS patients than in the Japanese general population. Death usually occurs before the age of 50 years due to either myocardial infarction or cancer.

GENE DEFECT, PATHOGENESIS, AND LABORATORY ABNORMALITIES WS is caused by a mutation in *WRN*, which encodes a RecQ helicase.[8,96,97] Most mutations of *WRN* result in truncation of the protein, sometimes by only a small amount, with loss of the nuclear targeting sequence. WRN is involved in many metabolic processes of DNA metabolism and *WRN* mutations cause various defects in DNA replication, recombination, base excision repair of oxidative DNA damage, repair of DNA strand breaks, recombination, DNA damage signaling and transcription. Cells from WS patients have a reduced replicative lifespan in culture[98] and show altered telomere structure and length. Genome instability in WS cells is shown by an increased frequency of non-homologous chromosome exchanges and of large chromosomal deletions.

Rothmund-Thomson Syndrome

CLINICAL FEATURES The hallmark of RTS, a rare, autosomal recessive disorder, is poikiloderma with variegated cutaneous pigmentation, atrophy, and telangiectasias beginning in infancy.[99] RTS patients are photosensitive and develop prominent erythema and facial swelling on sun exposure early in life, which may be accompanied by blister formation. They often have sparse scalp hair, eyebrows, and eyelashes. Other clinical features include juvenile cataracts, stunted growth, skeletal abnormalities including radial bone defects, and a predisposition for cancer, in particular for osteosarcomas (32 percent of patients). Five percent of RTS patients also develop non-melanoma skin cancer.

GENE DEFECT, PATHOGENESIS, AND LABORATORY ABNORMALITIES Mutations in the helicase RecQL4 have been identified in a majority of patients with RTS.[100] Cells from RTS patients have been reported with an increased sensitivity to ionizing radiation with increased formation of chromosome gaps and breaks, suggesting a role of RECQL4 in maintaining chromosome stability.[102,103] This, however, was not confirmed in other patients, possibly reflecting heterogeneity in this disease.[104] The exact function of the RECQL4 helicase remains unclear.[105] Cells from one patient had reduced DNA repair after exposure to UVC.[106] One RTS patient had increased acute toxicity after high-dose radiotherapy after surgery and subsequent palliative chemotherapy. However, another RTS patient was reported to have a normal acute response to radiation therapy for a squamous cell carcinoma of his tongue.[107] He died 2 years later with extensive squamous cell carcinoma in the thorax, but no tumor in the oral cavity.



Fanconi Anemia

FA is an autosomal recessive disease characterized by progressive pancytopenia, growth retardation, various congenital abnormalities of the heart, kidney, and limbs, and a predisposition to cancer.[108,109] More than 1200 patients have been reported to the International Fanconi Anemia Registry.

CLINICAL FEATURES Cutaneous abnormalities are present in almost 80 percent of patients (Fig. 140-8A–D).[108,110] Hyperpigmentation is present from birth or early childhood and is diffuse and accentuated over the neck, joints, and trunk. Café-au-lait spots and achromic lesions are also present.

Hematopoietic manifestations usually have their onset before age 10 years and most commonly lead pediatricians to make the diagnosis of FA. These consist of a hypocellular bone marrow with pro-



▲ **FIGURE 140-8** Skin and oral mucous membrane findings in Fanconi anemia (**A–D**) and dyskeratosis congenita (**E–H**). **A–D.** Fanconi anemia. **A.** Congenital absence of thumb. The second finger has been surgically altered to function as a thumb. Keratotic papules are present on the palm. (**B**) Oral leukoplakia on right buccal mucosa (*arrow*). **C,D.** Dyspigmentation of Fanconi anemia. **C.** Hyperpigmentation of left axilla with discrete hyperpigmented and hypopigmented macules. **D.** Several irregular café-au lait macules, smaller fine tan hyperpigmented macules, and dozens of guttate hypopigmented macules in the lower back. **E–H.** Dyskeratosis congenita. **E.** Oral leukoplakia involving the tongue. **F.** Severe atrophy of all fingernails and thickening of the palm. **G.** Longitudinal ridging and dystrophy of several fingernails with dyspigmentation and thickening of the palm. **H.** Poikiloderma showing reticular hypo- and hyperpigmentation of the skin of the neck and chest. (A–D modified from Braun M et al: Thrombocytopenia, multiple mucosal squamous cell carcinomas, and dyspigmentation. *J Am Acad Dermatol* **54**:1056, 2006; E–H used with permission from Dr. Blanche Alter, NCI, Bethesda, MD.)



gressive decrease in the number of circulating platelets, granulocytes, and erythrocytes. Skeletal malformations are common and often include aplasia or hypoplasia of the thumb, metacarpals, or radius.[111,112] Short stature, renal deformities, strabismus, microphthalmia, hypogonadism, and central nervous system abnormalities, including hyperreflexia and mild mental retardation, are also observed. The frequency of acute myelogenous leukemia has been reported to be elevated 15,000-fold.[113–116] If patients survive aplastic anemia and/or leukemia (e.g., as a result of bone marrow transplantation) they often develop solid tumors by the fifth decade of life, mostly squamous cell carcinomas of the head and neck and the anogenital area.

GENE DEFECT, PATHOGENESIS, AND LABORATORY ABNORMALITIES FA is genetically heterogeneous with at least twelve complementation groups (FANCA to FANCM), all of which, except FANCI, have been cloned. Most of the FA proteins have been shown to act in a common DNA damage response signaling pathway, which also involves BRCA1 and BRCA2 (these genes are mutated in hereditary breast cancer; see Chap. 109).[117–120] Activation of this FA/BRCA pathway is thought to mediate DNA recombination to repair DNA strand breaks and DNA cross-links, generated, e.g., by ionizing radiation or DNA cross-linking agents.

TESTING Central to the FA/BRCA pathway is the mono-ubiquitination of the FANCD2 protein. The inability of FA cells to ubiquitinate the FANCD2 protein, as shown in Western blots after, for example, exposure to DNA cross-linking agents, is currently used as a screening tool to confirm the diagnosis of FA.

RESOURCES

Patients, physicians, and researchers may obtain information from the Fanconi Anemia Research Fund, Inc. (http://www.fanconi.org) or from Fanconi Canada (http://www.fanconicanada.org).

Dyskeratosis Congenita

Dyskeratosis congenita, the Zinsser-Cole-Engman syndrome, is an X-linked multisystem disease with cutaneous, mucosal, ocular, gastrointestinal, and hematologic abnormalities and an increased incidence of cancer (see Table 140-1). A Registry at Hammersmith Hospital in London recruited 228 families having 354 affected patients from 40 countries.[129] Affected females may have either the autosomal dominant or autosomal recessive form.

CLINICAL FEATURES The most common features are a triad of reticulated hyperpigmentation, dystrophic nails, and mucosal leukoplakia (see Fig. 140-8E–H).[130–132] During the first decade of life, patients develop reticulated poikiloderma of sun-exposed areas, with hyperpigmentation and, occasionally, bullae. Nail dystrophy is present in virtually all patients beginning at approximately age 2 to 5 years. The nails initially split easily, then develop longitudinal ridging with irregular free edges. Eventually, the nails become smaller, resulting in rudiments remaining. The fingernails are usually involved before the toenails. Other skin abnormalities include atrophic, wrinkled skin over the dorsum of hands and feet and hyperhidrosis and hyperkerato-

sis of palms and soles with disappearance of dermal ridges (absence of fingerprints).

Leukoplakia may be present in any mucosal site. The oral mucosa is the most frequent, but leukoplakia is also found in the urethra, glans penis, vagina, and rectum. Lingual hyperkeratosis may be present. Mucosal surfaces such as the esophagus, urethra, and lacrimal duct may become constricted and stenotic, resulting in dysphagia, dysuria, and epiphora. Multiple dental caries and early loss of teeth are common. Progressive pulmonary disease, including infections and fibrosis (and cirrhosis in some patients) was reported in 19 percent of affected males.[131] Approximately 20 percent of the patients had learning difficulties or mental retardation.[131] There have been several reports of intracranial calcifications, especially of the basal ganglia.[133,134] These are also seen in CS.

There is an increased incidence of neoplasia, particularly squamous cell carcinoma of the mouth, rectum, cervix, vagina, esophagus, and skin. A large British kindred had Hodgkin disease and adenocarcinoma of the pancreas.[135] Similar to FA, although hypoplasia is the main abnormality seen in bone marrow, there is a predisposition to both myelodysplasia and acute myeloid leukemia.[131]

The majority (93 percent) of patients developed bone marrow failure which was the main cause (71 percent) of early death.[131] Approximately one-half of the patients (21 of 41) developed pancytopenia under the age of 10 years with a hematologic picture similar to FA. Patients have been treated with bone marrow transplantation.[136]

LABORATORY STUDIES Chromosomes are usually normal in untreated cells; however, chromosomal abnormalities have been found in fibroblasts and bone marrow cells from a few patients.[137,138] The leukoplakia cells may show chromosomal changes presaging malignancy. Cultured skin fibroblasts have been reported to show increased frequency of chromatid breaks and gaps after x-radiation during the G_2 phase of the cell cycle. Increased chromosome breakage after x-radiation[139] or exposure to bleomycin[140] and other DNA-damaging agents[141] has been described.

A gene for dyskeratosis congenita (*DKC1*) has been cloned,[129,141,143] which is located on the q28 region of the X chromosome. The protein, dyskerin, has a nucleolar function, and a role in telomere maintenance and aging.[144–148] Mutations in the *DKC1* gene have been detected in affected patients.[129,142,149,150] There is also evidence for an autosomal form with affected females[129,131,151,152] having mutations in the *TERC* gene, which is also involved in telomere function.

KEY REFERENCES

The full reference list for all chapters is available at www.digm7.com.

4. Loeb LA: Cancer cells exhibit a mutator phenotype. *Adv Cancer Res* **72**:25, 1998
12. Bootsma D et al: Nucleotide excision repair syndromes: Xeroderma pigmentosum, Cockayne syndrome, and trichothiodystrophy, in *The Genetic Basis of Human Cancer*, second ed., edited by Vogelstein B, Kinzler KW. New York: McGraw-Hill, 2002, p 211
13. Kraemer KH, Lee MM, Scotto J: Xeroderma pigmentosum. Cutaneous, ocular, and neurologic abnormalities in 830 published cases. *Arch Dermatol* **123**:241, 1987
66. Nance MA, Berry SA: Cockayne syndrome: Review of 140 cases. *Am J Med Genet* **42**:68, 1992
78. Itin PH, Sarasin A, Pittelkow MR: Trichothiodystrophy: Update on the sulfur-deficient brittle hair syndromes. *J Am Acad Dermatol* **44**:891, 2001
87. German J: Bloom's syndrome. 20. The first 100 cancers. *Cancer Genet Cytogenet* **93**:100, 1997
93. Epstein CE et al: Werner syndrome. A Review of its symptomatology, natural history, pathologic features, genetics and relationship to the natural aging process. *Medicine* **45**:177, 1966
99. Wang LL et al: Clinical manifestations in a cohort of 41 Rothmund-Thomson syndrome patients. *Am J Med Genet* **102**:11, 2001
108. Auerbach AD: Fanconi anemia. *Dermatol Clin* **13**:41, 1995
132. Dokal I: Dyskeratosis congenita in all its forms. *Br J Haematol* **110**:768, 2000



CHAPTER 141

Tuberous Sclerosis Complex

Thomas N. Darling

EPIDEMIOLOGY

The incidence of tuberous sclerosis complex (TSC) is as high as 1 in 6000 live births.[1,2] It occurs with equal frequency in males and females and in different races and ethnicities. Hereditary transmission is evident in approximately one-third of patients. Sporadic disease occurs in about two-thirds of patients, and this is attributed to de novo mutations.[3]

ETIOLOGY AND PATHOGENESIS

TSC is caused by mutations in a tumor suppressor gene, either *TSC1* or *TSC2*.[3] Mutations in *TSC2* are observed in about three-fourths of patients, and even more commonly in de novo cases.[4,5] Patients with mutations in *TSC2* tend to exhibit a more severe phenotype.[4–7]

TSC1 maps to chromosome band 9q34. The 8.6-kb full-length transcript encodes a protein called *hamartin* or TSC1.[8] *TSC2* maps to chromosome band 16p13.3. The 5.5-kb transcript encodes a protein called *tuberin* or TSC2.[9] Immediately adjacent to *TSC2* on chromosome 16 is *PKD1*, the gene mutated in polycystic kidney disease. Some patients with TSC have severe, early-onset renal cystic disease, and most of these patients have a contiguous deletion of *TSC2* and *PKD1*.[10]

Typical of mutations in tumor suppressor genes, the mutations observed in patients with TSC are inactivating mutations located anywhere along the sequence of *TSC1* or *TSC2*. Consistent with Knudson's two-hit hypothesis, most TSC tumors show a second somatic mutation that inactivates the wild-type allele.[11,12] TSC1 and TSC2 form a complex that inhibits signaling through the mammalian target of rapamycin (mTOR) pathway (Fig. 141-1). Loss of TSC1/TSC2 function leads to increased mTOR signaling and increased cell growth. Rapamycin is a drug that inhibits its mTOR and may be useful for the treatment of internal tumors in TSC.[13]

CLINICAL FINDINGS

Clinical Criteria

The diagnosis of TSC is based on clinical criteria categorized as major or minor features (Table 141-1).[14,15] Cutaneous and oral lesions comprise 4 of 11 major

TUBEROUS SCLEROSIS COMPLEX AT A GLANCE



- Autosomal dominant syndrome with variable expressivity.
- Manifested by hamartomatous tumors in multiple organs, including brain (causing seizures), eyes, heart, kidneys, lungs, and skin.
- Skin lesions occur in nearly all individuals and are important for diagnosis.
- Skin lesions include hypomelanotic macules, "confetti" lesions, facial angiofibromas, fibrous facial plaque, shagreen patch, and ungual fibromas.
- Hypomelanotic macules appear at birth or shortly thereafter and are most useful in early diagnosis.
- Although the skin lesions are benign, they may require treatment due to symptoms or disfigurement.



features and 3 of 9 minor features. Major features are thought to have a high degree of specificity for TSC, whereas minor features are less specific or substantiated. No single feature is present in all patients, and no feature is specific for TSC. Genetic testing can be offered and may be important in particular situations (see Molecular Diagnosis).[15]

History

The medical and family history taking should include questions about seizures, mental retardation, behavioral disorders, visual problems, and tumors of the brain, heart, kidneys, lungs, and skin. Determining the ages of onset of skin lesions and their subsequent changes may assist in discriminating TSC skin lesions from similar-appearing non-TSC skin lesions. Many TSC skin lesions are not present at birth, but appear later at ages typical for the lesion.[16] For example, infants show multiple hypomelanotic macules but not angiofibromas or ungual fibromas. Adults may have multiple angiofibromas and ungual fibromas, but hypomelanotic macules may have faded or disappeared.

Cutaneous and Oral Lesions

HYPOMELANOTIC MACULES Hypomelanotic macules (Fig. 141-2) are observed in over 90 percent of children with TSC.[4,17–21] They are often present at birth or appear within the first few years of life and may fade or disappear in adulthood. The ultraviolet light of a Wood's lamp is used to improve detection, especially in lightly pigmented individuals[22] (Fig. 141-3).

Hypomelanotic macules typically measure 0.5 to 3.0 cm in diameter. They are off-white and not completely depigmented as in vitiligo.[23] Some are oval at one end and taper to a point at the other. Such lesions are called *ash-leaf spots* because of their resemblance to the leaf of the European mountain ash.[24] They number from 1 to over 20. They can be located anywhere on the body but tend to occur on the trunk and buttocks. When located on the scalp, they cause poliosis.[17]

Three or more hypopigmented macules constitutes a major feature for the diagnosis of tuberous sclerosis. One or two, and in rare individuals up to three, hypomelanotic macules occur in 4.7 percent of the general population.[25] A less common type of hypopigmentation is the "confetti" skin lesion (Fig. 141-4), which is considered a minor feature for diagnosis. It typically occurs on the legs below the knees or on the forearms, and consists of multiple hypopigmented macules 2 to 3 mm in diameter.[17,24]

FACIAL ANGIOFIBROMAS Angiofibromas appear at 2 to 5 years of age and eventually affect 75 percent to 90 percent of patients.[4,17,20,21] These 1 to 3 mm in diameter pink to red papules have a smooth surface (Fig. 141-5). They may be hyperpigmented, especially in individuals with darker pigmentation. They occur on the central face and are often concentrated in the nasolabial folds (see eFig. 141-5.1 in on-line edition), extending symmetrically onto the cheeks and to the nose, nasal opening, and chin, with relative sparing of the upper lip and lateral face. Sometimes lesions occur on the forehead, scalp, or eyelids. They may number from 1 to over 100. Lesions may coalesce to form large nodules, especially in the nasolabial folds.[17,20,22] Angiofibromas are unilateral in rare cases and may indicate a segmental or mosaic defect.[26–29]

The development of papules may be preceded by mild erythema that is intensified by emotion or heat. During puberty, angiofibromas may grow in size and number. During adulthood they tend to be stable in size, but redness may gradually diminish.[22]

Angiofibromas must be multiple to be counted as a major feature. A solitary angiofibroma is clinically and histologically indistinguishable from the fibrous papule that occurs sporadically as a single lesion in the general population.[30] Multiple angiofibromas are also observed in multiple endocrine neoplasia type 1,[31–33] and as an unusual finding in Birt-Hogg-Dubé syndrome.[34]

FIBROUS FACIAL PLAQUE The forehead plaque may be congenital or show gradual development over years.[17,35] It is present in 20 percent to 40 percent of patients.[4,17,20] It is an irregular, soft to firm, connective tissue nevus with the color of the normal surrounding skin, red, or hyperpigmented in darkly pigmented individuals (Fig. 141-6). The plaque can also be found on the scalp, cheeks, and elsewhere on the face and is therefore sometimes referred to as a fibrous facial plaque. The forehead plaque is grouped together with angiofibromas as a major feature for diagnosis.[14]

SHAGREEN PATCH The shagreen patch is observed in approximately 50 percent of patients.[4,17,20,21] It may be present in infancy but usually becomes apparent later. It is a firm or rubbery irregular plaque ranging in size from 1 to 10 cm (Fig. 141-7). The surface may appear bumpy with coalescing papules and nodules, or the patch may have the surface appearance of an orange peel. The color may be that of the surrounding skin, or it may be slightly pink or brown. There may be scattered smaller oval papules with or without a larger plaque (see eFig. 141-7.1 in on-line edition). The most common locations are on the lower back and buttocks; the patch is found less commonly on the thighs.[22]

UNGUAL FIBROMAS Ungual fibromas, also known as *Koenen's tumors*, usually appear after the first decade and eventually affect up to 88 percent of adults with TSC.[20] They are more common on the toes than on the fingers.

Ungual fibromas measure 1 mm to 1 cm in diameter. They arise from under the proximal nail fold (periungual fibromas) and under the nail plate (subungual fibromas). Periungual fibromas are red papules and nodules that are firm, pointed, and hyperkeratotic, or soft and rounded (Fig. 141-8). They press on the nail matrix and cause

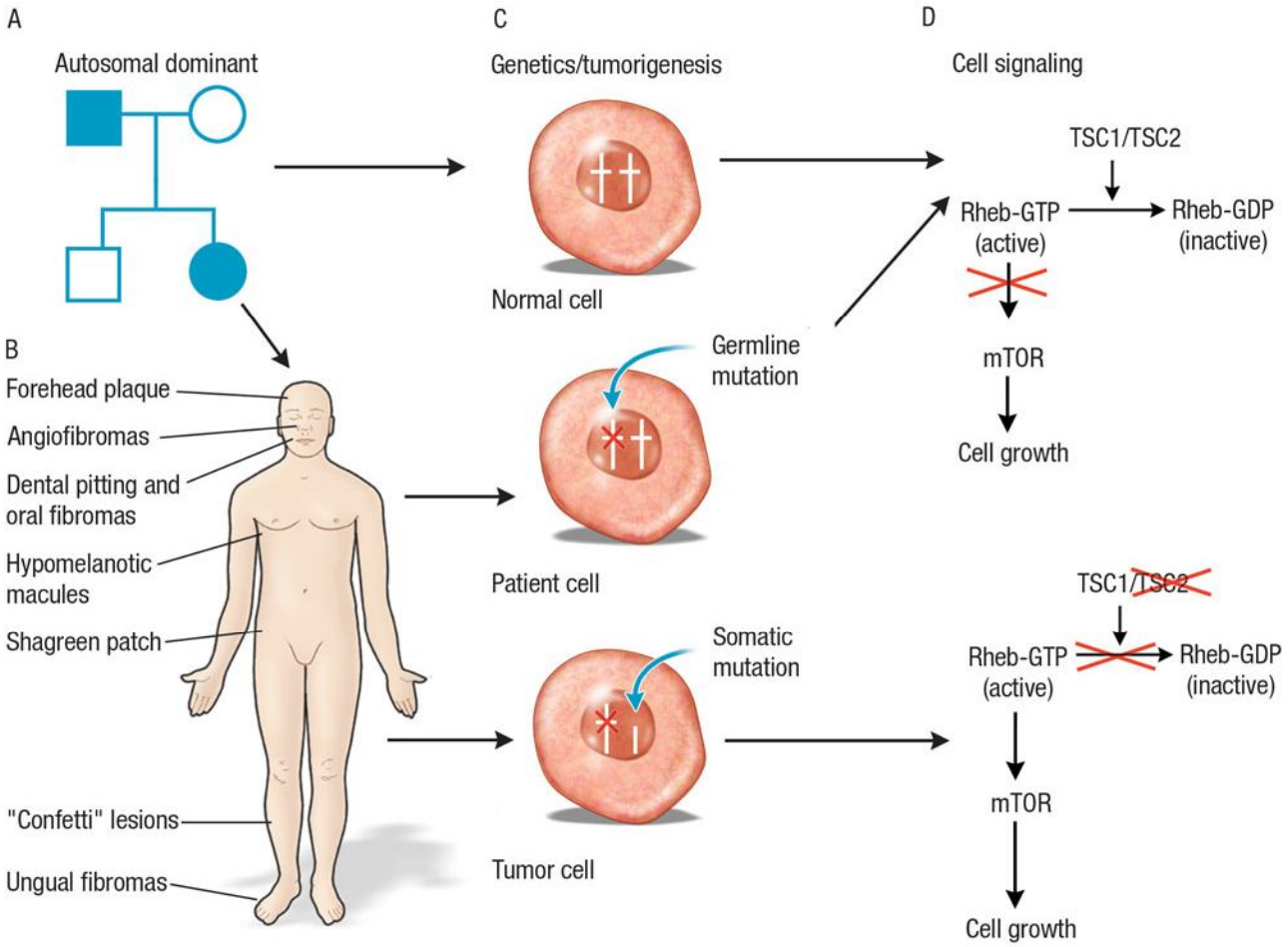



▲ FIGURE 141-1 Molecular pathogenesis of tuberous sclerosis complex (TSC). **A.** An example is shown in which a mutation in *TSC2* is passed from the father (*blue square*) to the daughter (*blue circle*), whereas the mother (*white circle*) and son (*white square*) are unaffected. **B.** Skin lesions are observed in the daughter at the indicated locations. **C.** A cell from the mother shows two normal alleles for *TSC2* on chromosome band 16p13.3. A cell from the daughter shows the *TSC2* mutation inherited from her father. A tumor from the daughter has this germline mutation and a "second-hit" mutation that inactivates the other allele, which leads to loss of heterozygosity. **D.** TSC2, in a complex with TSC1, is a guanosine triphosphatase–activating protein, converting active Ras-homolog enriched in brain (Rheb) guanosine triphosphate (GTP) to inactive Rheb guanosine diphosphate (GDP). Rheb GTP activates mammalian target of rapamycin (mTOR), a kinase that increases protein translation and cell growth, so TSC2 normally acts to inhibit cell growth. Loss of TSC2 function in tumors results in increased levels of Rheb GTP, activation of mTOR, and increased cell growth.

a longitudinal groove, and sometimes a groove forms without an evident papule[20] (see eFig. 141-8.1 in on-line edition). Subungual fibromas can be seen through the nail plate as red or white oval lesions or as red papules emerging from the distal nail plate, causing distal subungual onycholysis (see eFig. 141-8.2 in on-line edition).

Presence of a non-traumatic ungual fibroma is a major feature for diagnosis of TSC.[14] Solitary lesions (also termed *acral* or *acquired digital fibrokeratomas*) are also observed in the general population, especially after nail trauma.[36,37] Multiple acral fibromas with a myxoid stroma were reported in one patient with familial retinoblastoma.[38]

OTHER SKIN LESIONS Molluscum fibrosum pendulum (skin tags) is the name given to multiple fibroepithelial polyps in TSC. These range from soft pedunculated papules to larger firm pedunculated nodules located on the neck, axillae, trunk, and flexures (see eFig. 141-8.3 in on-line edition). They can be skin colored or hyperpigmented.[17] Skin tags are common in the general population, so these are not useful for diagnosis. Miliary fibromas are patches of multiple minute papules, usually on the neck or trunk, that appear like "gooseflesh."[22] Pachydermodactyly is a benign thickening of the proximal fingers that has been observed in a few patients with TSC.[39,40] Other lesions reported in TSC include café-au-lait macules (not six or more as in neurofibromatosis, but only one to three as in the general population), appendageal tumors (trichoepitheliomas, syringocystadenomas), lipomas, fibromyolipomas, and neurofibromas.[22]

DENTAL PITTING Multiple pits of the dental enamel are observed in up to 100 percent of TSC patients.[41–44] These pits can be tiny pinpoint lesions or larger crater-like lesions (see eFig. 141-8.4 in on-line edition). They occur on both deciduous and permanent teeth. The identification of these lesions is enhanced by using a dental plaque stain. Dental pits can also be seen in the general population, albeit with lower prevalence and at lower numbers than in TSC.[41] The presence of multiple dental pits is a minor feature for diagnosis.[14]

ORAL FIBROMAS Approximately 50 percent of TSC patients have oral fibromas[20,45] (see eFig. 141-8.5 in on-line edition). These sometimes occur in the first decade but are more common in adulthood. They are most common on the gingiva, but also occur on the buccal and labial mucosa, hard palate, and tongue.[45] Some patients have diffuse



TABLE 141-1
Diagnostic Criteria for Tuberous Sclerosis Complex (TSC)

Major features
- **Facial angiofibromas or forehead plaque**
- **Non-traumatic ungual or periungual fibroma**
- **Hypomelanotic macules (three or more)**
- **Shagreen patch (connective tissue nevus)**
- Multiple retinal nodular hamartomas
- Cortical tuber[a]
- Subependymal nodule
- Subependymal giant cell astrocytoma
- Cardiac rhabdomyoma, single or multiple
- Lymphangiomyomatosis[b]
- Renal angiomyolipomas[b]

Minor features
- **Multiple randomly distributed pits in dental enamel**
- Hamartomatous rectal polyps[c]
- Bone cysts
- Cerebral white matter migration lines[a,d,e]
- **Gingival fibromas**
- Non-renal hamartoma[c]
- Retinal achromic patch
- **Confetti skin lesions**
- Multiple renal cysts[c]

[a]When cerebral cortical dysplasia and cerebral white matter migration tracts occur together, they should be counted as one rather than two features of TSC.
[b]When both lymphangiomyomatosis and renal angiomyolipomas are present, other features of TSC should be present before a definitive diagnosis is assigned.
[c]Histologic confirmation is suggested.
[d]Radiographic confirmation is sufficient.
[e]One panel member recommended that three or more radial migration lines constitute a major feature.
Note: Cutaneous and oral lesions are in bold.
Definite TSC: Presence of either two major features or one major feature and two minor features.
Probable TSC: Presence of one major feature and one minor feature.
Possible TSC: Presence of either one major feature or two or more minor features.
Adapted from Roach ES, Gomez MR, Northrup H: Tuberous sclerosis complex consensus conference: Revised clinical diagnostic criteria. *J Child Neurol* **13**:624, 1998.

gingival overgrowth. Gingival overgrowth is a common side effect of anticonvulsants, especially phenytoin and cyclosporin, but gingival overgrowth can be observed in TSC even in patients not treated with anticonvulsants or immunosuppressive agents.[45,46] Gingival fibromas are a minor feature for diagnosis.[14] Oral fibromas in the general population are typically single and form at sites of trauma, usually on the tongue or buccal mucosa.[47]



▲ **FIGURE 141-2** Hypomelanotic ash-leaf macules on the lower leg of a child with tuberous sclerosis complex.

Related Physical Findings

Tuberous sclerosis can affect almost any organ. Only one-third of patients have the classic triad of seizures, mental retardation, and angiofibromas.

BRAIN Cerebral lesions include cortical tubers, subependymal nodules, and subependymal giant cell astrocytomas. Cerebral lesions may manifest as seizures, mental retardation, and behavioral disorders. Seizures occur in approximately 80 percent of patients, with onset common in the first 2 months and usual by the first 2 years of life. Seizures are most likely infantile spasms but can be all types except pure absence (classic petit mal).[48] Seizures are controlled with anti-epileptic drugs, and a ketogenic diet can decrease seizures.[49,50] Epilepsy surgery may be required for seizures intractable to anticonvulsant therapy.[51,52]

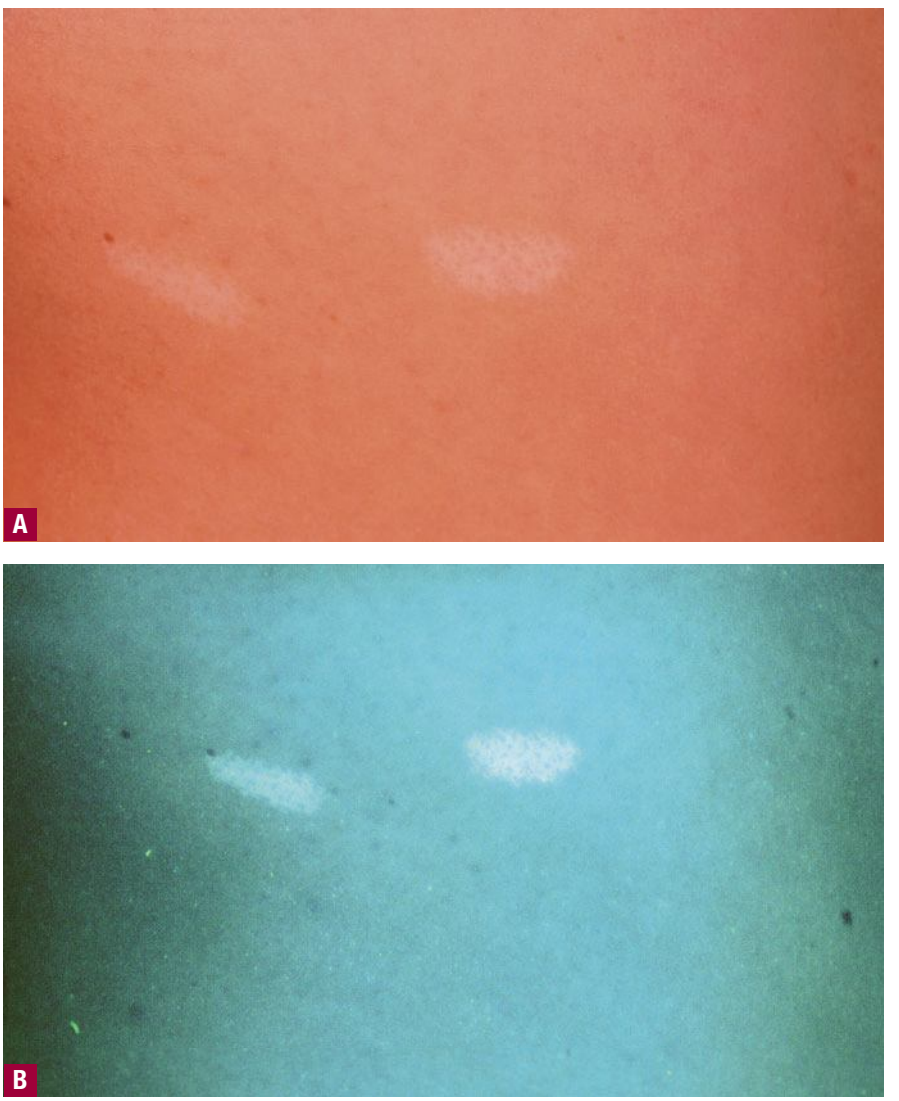

▲ **FIGURE 141-3** **A.** Hypomelanotic macules on the lateral chest of an adult with tuberous sclerosis complex. The macules may be easily overlooked. **B.** Wood's lamp accentuates the macules.



▲ **FIGURE 141-4** Confetti-like hypopigmented macules on the lower leg of an adult with tuberous sclerosis complex.

Mental retardation tends to occur in patients with seizures, but many children with seizures have no obvious neurologic impairment.

HEART Cardiac rhabdomyomas are observed in about half of infants with TSC.[56] Most of these neoplasms are asymptomatic and spontaneously regress, but in rare cases they cause fetal demise or heart failure shortly after birth.[57] Cardiac rhabdomyomas may cause dysrhythmias, commonly Wolff-Parkinson-White syndrome, noticed in utero or in the first year of life in TSC patients.[57–59]



▲ **FIGURE 141-5** Multiple facial angiofibromas on the nose, cheeks, and chin, with relative sparing of the upper lip as commonly observed in tuberous sclerosis complex.



▲ **FIGURE 141-6** The forehead fibrous plaque in tuberous sclerosis complex is often pink-red and has a bumpy surface and irregular outline.

KIDNEYS Angiomyolipomas (AMLs) are observed in approximately 75 percent TSC patients over 10 years of age.[60] Additional renal lesions include renal cysts and rarely renal cell carcinoma.[61] Polycystic kidney disease is present in 3 percent to 5 percent of patients.[56] Renal lesions can cause renal insufficiency, hypertension, and potentially fatal retroperitoneal hemorrhage. Patients may require selective embolization or partial nephrectomy.[62–65]

LUNGS Lung involvement in TSC includes lymphangioleiomyomatosis (LAM), multifocal micronodular pneumocyte hyperplasia, and clear cell tumors of the lung.

EYES Retinal astrocytic hamartomas are observed in 44 percent to 87 percent of patients.[68] The most common type is a flat, smooth, translucent, gray, non-calcified circular or oval lesion with indistinct boundaries. Also common are elevated and opaque multinodular "mulberry" lesions that have calcified, glistening nodules. Retinal astrocytic hamartomas can be indistinguishable from retinal lesions in neurofibromatosis type 1 and may appear similar to retinoblastomas. Some patients have vision loss, but blindness is rare.[69]

GASTROINTESTINAL TRACT Rectal polyps, usually asymptomatic, have been observed in 14 of 18 adults (78 percent) with TSC.[71] Histologically they are hamartomas and rarely adenomas.

OTHER ORGANS

LABORATORY TESTS

Skin Histopathologic Findings

Hypomelanotic macules have normal numbers of melanocytes, in contrast to the lesions of vitiligo, in which melanocytes are absent. The melanocytes in hypomelanotic macules have poorly developed dendritic processes, and melanosomes are decreased in numbers, size, and melanization.[23] Angiofibromas contain plump, spindle-shaped or stellate fibroblastic cells in the dermis among increased numbers of dilated vessels (see eFig. 141-8.6 in on-line edition). Collagen fibers are oriented in an onionskin pattern around follicles and vessels. The epidermis shows melanocytic hyperplasia and flattening of rete ridges. Periungual fibromas are similar, but with more extensive hyperkeratosis and a variable increase in vascularity (see eFig. 141-8.7 in on-line edition). The shagreen patch has sclerotic bundles of collagen in the reticular dermis (see eFig. 141-8.8 in on-line edition). Elastic fibers are typically reduced in amount.

Special Tests (Including Imaging Studies)

Besides dermatologic and ophthalmologic examination, the initial evaluation

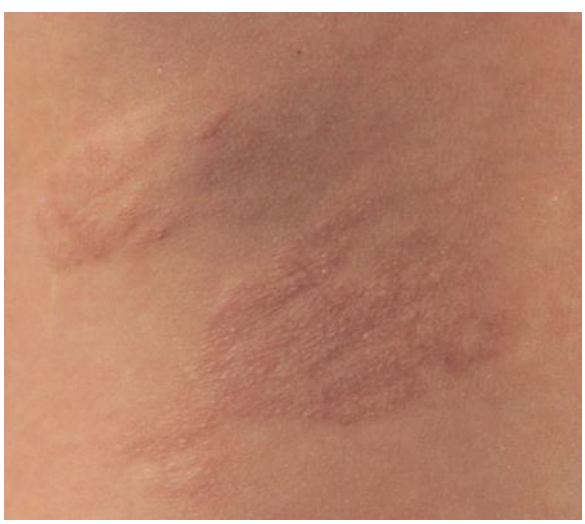

◀ **FIGURE 141-7** The shagreen patch in tuberous sclerosis complex is a firm, bumpy plaque that is usually located on the lower back.





▲ **FIGURE 141-8** Multiple periungual and subungual fibromas on the toes in a patient with tuberous sclerosis complex.



of a patient suspected to have TSC includes the following: (1) cranial computed tomography (CT) or cranial magnetic resonance imaging (MRI), (2) renal ultrasonography (or MRI or CT), and (3) electrocardiography.[60] In addition, the following tests are recommended for subsets of patients. Electroencephalography is valuable if seizures are suspected and subsequently for seizure management. In children, standardized cognitive and behavioral assessments are indicated at the time of diagnosis, in response to changes in behavior or worsening performance, and at regular intervals tailored to the individual.[53] In adult women, high-resolution chest CT is used to detect LAM. Echocardiography is indicated if the patient exhibits cardiac symptoms.[60]

After diagnosis, the patient should have periodic surveillance for the development of new lesions or changes in existing lesions. Cranial CT or MRI is recommended every 1 to 3 years in children. This may reveal the presence of a subependymal giant cell astrocytoma, which allows removal before it becomes locally invasive or causes symptoms. Similarly, renal ultrasonography is recommended every 1 to 3 years, depending on clinical suspicion and results of previous examinations. If large or numerous renal tumors are present, renal CT or MRI should be performed. Echocardiography and chest CT are indicated for cardiac and pulmonary symptoms, respectively.[60]

Box 141-1

Differential Diagnosis of Hypomelanotic Macules

- Polygonal or ash leaf
  - Nevus depigmentosus
  - Piebaldism
  - Vitiligo
  - MEN1 hypomelanotic macules
  - Nevus anemicus
- Confetti
  - Idiopathic guttate hypomelanosis (adults)
  - MEN1 confetti lesions
  - Pityriasis alba
  - Pityriasis lichenoides chronica
- Poliosis
  - Waardenburg syndrome
  - Piebaldism
  - Vitiligo
  - Vogt-Koyanagi-Harada syndrome
  - MEN1 hypomelanotic macules
  - Nevus anemicus
  - Segmental pigment mosaicism

MEN1 = multiple endocrine neoplasia type 1.

Molecular Diagnosis

Genetic testing may be useful to confirm diagnosis in individuals not meeting criteria for definite TSC.[60] It can provide additional information for genetic counseling, and it can be used in prenatal diagnosis.[15] Genetic testing may yield false-negative or inconclusive results. Extensive analysis of *TSC1* and *TSC2* fails to identify a mutation in approximately 15 percent of TSC patients.[4,5] *TSC1* and *TSC2* are large genes, and mutations may occur anywhere along the sequence. Also, sequence analysis does not identify large deletions and must be supplemented by other methods of analysis.[4,5,79] Mutation detection may also be hampered by somatic mosaicism.

Box 141-2

Differential Diagnosis of Angiofibromas

- Fibrous papules
- Multiple endocrine neoplasia type 1 angiofibromas
- Birt-Hogg-Dubé angiofibromas
- Trichoepitheliomas
- Fibrofolliculomas/trichodiscomas
- Tricholemmomas
- Syringomas
- Dermal melanocytic nevi
- Acne vulgaris
- Rosacea

Box 141-3

Differential Diagnosis of Ungual Fibroma

Most Likely

- Periungual
  - Acral fibrokeratoma
  - Superficial acral fibromyxoma
  - Epidermoid cyst
  - Pseudomyxoid cyst
  - Wart
  - Pyogenic granuloma
  - Juvenile xanthogranuloma
- Subungual
  - Acral fibrokeratoma
  - Superficial acral fibromyxoma
  - Wart
  - Subungual exostosis
  - Subungual horn
  - Familial retinoblastoma
  - Pyogenic granuloma
  - Onychomycosis
  - Psoriasis

Always Rule Out

- Subungual
  - Squamous cell carcinoma
  - Bowen disease
  - Amelanotic melanoma

DIFFERENTIAL DIAGNOSIS

Differential diagnosis for several major features of TSC are summarized in Boxes 141-1, 141-2, 141-3, and 141-4.

COMPLICATIONS

None of the skin lesions in TSC is prone to malignant degeneration, but the lesions can be a major cosmetic concern for the patient, causing social isolation and difficulties with self-esteem.[80] Angiofibromas, facial plaques, and ungual fibromas can be painful or bleed sponta-

Box 141-4

Differential Diagnosis of Shagreen Patch

Most Likely

- Familial cutaneous collagenoma
- Eruptive collagenomas
- Dermatofibrosis lenticularis disseminata (in Buschke-Ollendorf syndrome)

Consider

- Multiple endocrine neoplasia type 1 collagenomas
- Sclerotic fibroma (Cowden syndrome)
- Isolated connective tissue nevus
- Juvenile elastoma
- Nevus elasticus
- Nevus mucinosis (Hunter syndrome)

neously or in response to minor trauma. Ungual fibromas can cause nail dystrophy and eventual loss of the nail. Large facial lesions may obstruct vision or occlude the nasal passages.[81]

PROGNOSIS AND CLINICAL COURSE

Individuals with tuberous sclerosis exhibit decreased overall survival compared with the general population. The causes of premature death include renal failure, intractable seizures, obstructive hydrocephalus, cardiac outflow obstruction, arrhythmia, respiratory failure, pneumothorax, and hemorrhage from an aneurysm or a tumor, especially AMLs.[82,83] Fatal events may occur at any age. Brain and heart tumors may cause death in infancy, whereas lung and kidney tumors are more likely to cause premature death in adulthood. The prognosis for the individual patient depends on disease expressivity. Some individuals have a normal life span with few medical complications.

TREATMENT

When an infant is newly diagnosed with TSC, a major aspect of care is answering questions and addressing the concerns of the family. Unfortunately, many parents report negative experiences because of physician insensitivity and the provision of inaccurate information and inadequate support.[84] Patients should be promptly referred to other specialists and social services as needed, and genetic counseling should be offered. Families should be informed about organizations dedicated to TSC, such as the Tuberous Sclerosis Alliance (http://www.tsalliance.org).

Current treatments for TSC skin tumors are mostly surgical.

Clinical trials are in progress to test potential medical therapies for TSC tumors. Oral rapamycin caused regression of subependymal giant cell astrocytomas,[90] and its use for treatment of AMLs and LAM is being investigated. Its utility for treatment of angiofibromas is currently unknown, but the potential for serious side effects is likely to limit systemic use for these benign skin lesions, especially in children.

GENETIC COUNSELING ISSUES

It is not unusual for a child with TSC to be born to parents who do not carry the diagnosis of TSC. This may represent a de novo mutation, or it may indicate that one parent has a very mild form of TSC that has escaped detection. Both parents should be carefully screened as described earlier. If one parent has TSC, there is a 50 percent chance that subsequent children will inherit the mutation.

Prenatal testing can be performed on cells obtained by chorionic villus sampling or amniocentesis.[15,93,94] It is also possible to use high-resolution ultrasonography and ultrafast MRI to examine for TSC tumors in the fetus, but the sensitivity of these tests is unknown.[15,95–98] It should be emphasized that TSC is highly variable, even within a family, and that genetic testing does not predict disease severity in offspring. Also, this brief summary does not detail many issues surrounding genetic testing that require utmost thought and sensitivity and consultation with genetics professionals.

KEY REFERENCES

The full reference list for all chapters is available at www.digm7.com.

13. Kwiatkowski DJ, Manning BD: Tuberous sclerosis: A GAP at the crossroads of multiple signaling pathways. *Hum Mol Genet* **14 Spec No 2**:R251, 2005
15. Roach ES, Sparagana SP: Diagnosis of tuberous sclerosis complex. *J Child Neurol* **19**:643, 2004
17. Jozwiak S et al: Skin lesions in children with tuberous sclerosis complex: Their prevalence, natural course, and diagnostic significance. *Int J Dermatol* **37**:911, 1998
20. Webb DW et al: The cutaneous features of tuberous sclerosis: A population study. *Br J Dermatol* **135**:1, 1996
22. Rogers RSI, O'Conner WJ: Dermatologic manifestations, in *Tuberous Sclerosis Complex*, 3rd ed, edited by Gomez MR, Sampson JR, Whittemore VH. New York, Oxford University Press, 1999, p 160
56. Franz DN: Non-neurologic manifestations of tuberous sclerosis complex. *J Child Neurol* **19**:690, 2004
60. Roach ES et al: Tuberous Sclerosis Consensus Conference: Recommendations for diagnostic evaluation. National Tuberous Sclerosis Association. *J Child Neurol* **14**:401, 1999

CHAPTER 142

The Neurofibromatoses

Robert Listernick
Joel Charrow

EPIDEMIOLOGY

The "modern age" of neurofibromatosis began in 1981, with Riccardi's detailed clinical descriptions of the features and natural history of von Recklinghausen disease and the subsequent description of "central neurofibromatosis with bilateral acoustic neuroma."[1] With the availability of gene-based diagnosis, several distinct clinical syndromes have been identified: (1) neurofibromatosis type 1 (NF-1), also known as *von Recklinghausen disease*; (2) neurofibromatosis type 2 (NF-2), whose cardinal feature is the development of bilateral vestibular schwannomas; (3) segmental or mosaic NF-1; (4) familial café-au-lait spots; and (5) schwannomatosis. Both NF-1 and NF-2 occur equally in all ethnic groups. NF-1 occurs at an incidence of 1 in 3000 live births, whereas NF-2 is much less common, with an estimated incidence of 1 in 40,000 live births.

ETIOLOGY AND PATHOGENESIS

Genetics

NF-1 is inherited in an autosomal dominant fashion. Although the expressivity of NF-1 varies considerably, even among individuals in the same family who are genotypically identical, the disorder is considered to be 100 percent penetrant. Thus, apparent skipping of NF-1 between generations may be the result of misdiagnosis, nonpaternity, or the occurrence of a new mutation in the grandchild. Although a large number of *NF1* mutations have been described, there have been no genotype-phenotype correlations noted except for individuals who have deletions of the entire *NF1* gene. These individuals appear to have an increased risk of facial dysmorphism, mental retardation, early appearance of neurofibromas, and the presence of plexiform neurofibromas.[2] There is evidence that NF-1 is more severe when inherited from the mother rather than from the father.

The gene *NF1* is located on the long arm of chromosome 17 and encodes a protein called *neurofibromin*. Homozygosity for mutant *NF1* alleles has not been reported, probably because it is a lethal condition. *NF1* has an unusually high mutation rate, estimated at 2.4 to 10 ×

THE NEUROFIBROMATOSES AT A GLANCE



- Neurofibromatosis type 1 (NF-1), an autosomal dominant condition, occurs at an incidence of 1 in 3000 live births. Neurofibromatosis type 2 (NF-2), a separate autosomal dominant disorder, occurs at an incidence of 1 in 40,000 live births.
- NF-1 can be diagnosed clinically if two of the following features are present: six or more café-au-lait spots (larger than 0.5 cm in children, larger than 1.5 cm in adults), intertriginous freckling, two or more cutaneous neurofibromas or one plexiform neurofibroma, optic nerve glioma, characteristic bony lesion, iris Lisch nodules, or a first-degree relative with NF-1.
- Cutaneous neurofibromas are softer than the surrounding connective tissue and protrude just above the skin surface or lie just under the skin. Subcutaneous neurofibromas that arise from peripheral nerves, both under the skin and deep in the viscera, are generally much harder.
- Plexiform neurofibromas, generally present at birth or apparent during the first several years of life, may lead to disfigurement, blindness (secondary to amblyopia, glaucoma, or proptosis), loss of limb function, or organ dysfunction by compression of vital structures.
- The hallmark of NF-2 is the presence of bilateral vestibular schwannomas. Individuals with NF-2 are also at risk for the development of multiple meningiomas, schwannomas, gliomas, and neurofibromas throughout the neural axis.
- Segmental NF-1 has manifestations of NF-1, usually café-au-lait macules and neurofibromas, limited to one area of the body. This occurs as a result of a postconceptional mutation in the NF-1 gene, which leads to somatic mosaicism.



10^{-5} gametes per generation, one of the highest rates of known inherited disorders.[3] This may reflect the large size of the gene, which spans 350 kb of genomic DNA and contains 59 exons that encode a peptide containing over 2800 amino acids. An alternative hypothesis is that there is some structural property of the gene that renders it particularly susceptible to mutation. New mutations account for approximately 50 percent of cases and are usually on the paternally inherited allele. Unlike with many other dominant disorders, the frequency of new mutations does not appear to increase with advancing paternal age.

Molecular Biology

Most *NF1* mutations result in reduced intracellular levels of the *NF1* gene product, neurofibromin. This appears to be sufficient to cause most of the clinical manifestations of the disease. Tumorigenesis, including the development of benign dermal neurofibromas, appears to be dependent on inactivation of the normal *NF1* allele in somatic cells, a process referred to as *loss of heterozygosity*.[4] Loss of heterozygosity is a critical step in tumorigenesis in many inherited cancer predisposition syndromes (e.g., retinoblastoma, Li-Fraumeni syndrome), and the genes involved are called *tumor suppressor genes*. Tumorigenesis is initiated when both copies of the gene cease functioning normally, the first as a result of an inherited mutation and the second as the result of a second somatic "hit" that interferes with the function of the previously normal allele.

Neurofibromin is found in a variety of cell types, including neurons, oligodendrocytes, and nonmyelinating Schwann cells. Considerable evidence has been developed for the role of neurofibromin as a negative regulator of RAS.[5,6] The RAS gene family encodes membrane-associated, guanine nucleotide–binding proteins that are involved in the regulation of cellular proliferation, differentiation, and learning. RAS exists in an active (RAS–guanosine triphosphate) and inactive (RAS–guanosine diphosphate) state. By favoring conversion of RAS from its active state to its inactive state, neurofibromin downregulates the downstream effects of RAS, which include promoting learning, memory, synaptic plasticity, and cell growth and proliferation.[5,7] Four different forms of neurofibromin exist, resulting from alternate splicing. The type II variant includes a 21–amino acid sequence encoded by exon 23a, whereas type I does not. This sequence appears to be critical for RAS regulation and learning. In the brain, there are three major isoforms of RAS. K-RAS has been shown to be the primary target of neurofibromin activity.[6] Activation of RAS by neurofibromin stimulates G protein activity, which results in activation of adenylyl cyclase. Cyclic adenosine monophosphate and other downstream intermediates appear to play a role in cell growth, learning, and memory. Neurofibromin also associates with microtubules and plays a role in regulating γ-aminobutyric acid–ergic inhibitory neuronal activity in the hippocampus.[8]

RAS is a membrane-bound protein and requires farnesylation (addition of a C15 isoprenoid to a cysteine residue near the C-terminus) for activity, a process that is catalyzed by farnesyl transferase. Agents that inhibit farnesyl transferase cause general inhibition of the RAS pathway, much as neurofibromin does. Farnesyl transferase inhibitors reverse the proliferative phenotype in *Nf1*-deficient mouse cells and can reverse spatial learning impairments in a mouse model of *NF1* by decreasing RAS levels.[7] These observations have prompted investigations into the use of farnesyl transferase inhibitors for the treatment of NF-1–related complications, such as rapidly growing plexiform neurofibromas.

Loss of heterozygosity of the *NF1* gene in Schwann cells has been shown to be the necessary event for the development of discrete neurofibromas.[9] Furthermore, neurofibromin-deficient Schwann cells secrete a substance that stimulates mast cell migration, which, in turn, stimulates production of extracellular matrix and angiogenesis.[10] Astrocytes lacking *NF1* expression cannot form optic nerve gliomas on their own; a brain environment heterozygous for *NF1* is necessary for the development of these tumors.[11]

CLINICAL FINDINGS

A consensus development conference was held by the National Institutes of Health in 1987 to establish diagnostic criteria to promote better clinical research and better care of patients with NF-1.[12] The seven diagnostic features recognized at this conference (Table 142-1), and the recommendation that two or more of these seven features be present before a diagnosis of NF-1 is established, have proven extremely useful and continue to be applied without modification 20 years later.

Café-au-Lait Spots

Café-au-lait spots, which are flat, pigmented macules, are often the first man-

TABLE 142-1
Diagnostic Criteria for Neurofibromatosis Type 1 (NF-1)[a]

- Six or more café-au-lait macules larger than 5 mm in greatest diameter in prepubertal individuals and over 15 mm in postpubertal individuals
- Two or more neurofibromas of any type *or* one plexiform neurofibroma
- Freckling in the axillary or inguinal regions
- Optic glioma
- Two or more iris Lisch nodules
- A distinctive osseous lesion such as sphenoid dysplasia or thinning of long bone cortex with or without pseudarthrosis
- A first-degree relative (parent, sibling, or offspring) with NF-1 by the above criteria

[a]Two or more required for diagnosis.

Box 142-1
Differential Diagnosis of Syndromes Associated with Multiple Café-au-Lait Spots[a]

- Neurofibromatosis type 1
- Familial café-au-lait spots
- LEOPARD (multiple *l*entigines, *e*lectrocardiographic abnormalities, *o*cular hypertelorism, *p*ulmonary stenosis, *a*bnormalities of the genitalia, growth *r*etardation, *d*eafness) syndrome (multiple lentigines syndrome)
- Neurofibromatosis type 2
- McCune-Albright syndrome (polyostotic fibrous dysplasia)
- Tuberous sclerosis
- Fanconi anemia
- Multiple endocrine neoplasia type 2B
- Bannayan-Riley-Ruvalcaba syndrome
- Bloom syndrome
- Ataxia-telangiectasia

[a]Order based on typical numbers of macules.

ifestation of NF-1 to appear (Fig. 142-1). Frequently present at birth, they become more numerous as the infant grows. New ones may continue to appear throughout the first decade of life. Once noticed, they tend to grow in size in proportion to the overall growth of the child. Although infrequently found on the face, they may be noted anywhere on the body. The size, shape, and contour of café-au-lait spots are of no diagnostic significance, although the majority of café-au-lait spots in NF-1 are oval and have a smooth border. The oft-quoted adage that smooth-edged café-au-lait spots indicate NF-1 and irregular café-au-lait spots are more typical of McCune-Albright syndrome can be misleading (Box 142-1). When café-au-lait spots overlap each other, the area of overlap may be darker than either individual spot. When found within mongolian spots, they are typically surrounded by a more lightly pigmented halo. Individuals with large numbers of café-au-lait spots do not have "more severe" NF-1, and the location of the macules in no way predicts the location of subsequent neurofibromas.[13]

Café-au-lait spots represent collections of heavily pigmented melanocytes of neural crest origin in the epidermis. Although the cells may contain increased numbers of "giant" melanosomes, or melanin macroglobules, these are not unique to NF-1, and their presence or absence in biopsy specimens is not helpful diagnostically.



▲ **FIGURE 142-1** Café-au-lait spots. Note halo (*arrow*) around café-au-lait spot within light mongolian spot.

The diagnostic criterion for NF-1 is six or more café-au-lait spots larger than 5 mm in diameter in prepubertal individuals or 1.5 cm in adults. Of all children ultimately diagnosed with NF-1, 53 percent will have six or more café-au-lait spots by age 3 years and 97 percent by age 6 years.[14] Light brown macules that resemble café-au-lait spots are also seen with increased frequency in red-headed children, often of Irish descent. Usually such children have fewer than six macules and no other stigmata of NF-1. Individuals with multiple lentiginosis syndrome and LEOPARD (multiple *l*entigines, *e*lectrocardiographic abnormalities, *o*cular hypertelorism, *p*ulmonary stenosis, *a*bnormalities of the genitalia, growth *r*etardation, *d*eafness) syndrome (see Chap. 73) may present with café-au-lait macules during infancy or at birth and may not begin to develop lentigines until early childhood.

Intertriginous Freckling

Café-au-lait spots smaller than 5 mm are referred to as *freckles* and are commonly present in the axilla, inguinal region, and under the breasts (Fig. 142-2). Unlike ordinary freckles in these locations, these lesions are not related to sun exposure and are considered virtually pathognomonic of NF-1 (Crowe sign). Of all children ultimately diagnosed with NF-1, 81 percent will have intertriginous freckling by age 6 years.[14]

Discrete Neurofibromas (See also Chap. 127)

Neurofibromas, which consist of Schwann cells,mast cells, fibroblasts, and perineural cells, are benign nerve sheath tumors that appear as discrete masses arising from peripheral nerves.[15] Cutaneous neurofibromas protrude just above the skin surface



▲ **FIGURE 142-2** Axillary freckling and multiple small and larger (less than 1 cm) café-au-lait spots in a brown-skinned woman.



▲ **FIGURE 142-3** Cutaneous neurofibromas with overlying hyperpigmentation.



▲ **FIGURE 142-4** Multiple cutaneous neurofibromas on the back of a woman.

or lie just under the skin with an overlying violaceous hue (Fig. 142-3). They are softer than the surrounding connective tissue, often creating a "buttonholing" sensation when a finger is rubbed gently over the surface (Fig. 142-4). Subcutaneous neurofibromas that arise from peripheral nerves, both under the skin and deep in the viscera, are generally much harder (see eFig. 142-4.1 in on-line edition). If they arise from the dorsal root ganglia, they may grow through neural foramina, compressing the spinal cord and creating a "dumbbell" appearance. Subcutaneous neurofibromas in the neck may feel like a "beaded necklace" and are often confused with lymph nodes. Fewer than 20 percent of children younger than 10 years of age have cutaneous neurofibromas.[14] These lesions generally start appearing after puberty and increase in number as the patient grows older. Women who have NF-1 often comment on the appearance of cutaneous neurofibromas during pregnancy. Although it has not yet been investigated, the majority of adult patients with NF-1 likely have numerous asymptomatic deep neurofibromas involving the dorsal roots and other larger nerves. On occasion, neurofibroma-associated pruritus may be severe enough to require treatment with antihistamines.

Plexiform Neurofibromas (See also Chap. 127)

Plexiform neurofibromas, histologically similar to discrete neurofibromas, are benign peripheral nerve sheath tumors that involve single or multiple nerve fascicles, often arising from branches of major nerves.[16] They may elicit a "wormy" sensation on palpation, as one feels multiple thickened nerve fascicles. Often there is overlying hyperpigmentation ("giant café-au-lait spot") or hypertrichosis (Fig. 142-5). Most plexiform neurofibromas are present at birth or become apparent during the first several years of life. Externally visible plexiform neurofibromas are easily identified and may lead to disfigurement, blindness (secondary to amblyopia, glaucoma, or proptosis), or loss of limb function (see eFigs. 142-5.1, 142-5.2, and 142-5.3 in on-line edition). In contrast, thoracic or abdominal plexiform neurofibromas may have no external manifestations but may have equally devastating consequences due to invasion or compression of vital structures (e.g., ureters, bowel, spinal cord).

The growth rate of plexiform neurofibromas is highly variable. Periods of rapid growth alternating with long periods of quiescence are common. Malignant peripheral nerve sheath tumors, which generally arise from plexiform neurofibromas, may develop silently in deep plexiform neurofibromas and not give rise to symptoms until distant metastases have occurred. Although loss of heterozygosity at the NF-1 locus may lead to the formation of benign neurofibromas, the malignant transformation of a benign plexiform neurofibroma may be initiated by cell cycle regulators beyond the *ras* oncogene. For example, mice that have null mutations in both the NF-1 and *p53* genes uniformly develop malignant tumors.[17,18] Physicians caring for individuals with NF-1 should be alert to the development of a malignancy. Biopsy of plexiform neurofibromas should be performed if the lesions exhibit rapid growth or cause significant pain or focal neurologic dysfunction.

Optic Pathway Tumors

Approximately 15 percent of children with NF-1 will develop optic pathway tumors (OPTs); however, only one-half of these patients will ever develop symptoms, with an overall incidence of symptomatic OPT of 7 percent.[19,20] Study series of NF-1-associated OPT have identified an approximately 2:1 female predominance in patients, as well as a lower incidence in African American children. These observations suggest the possibility that either hormonal factors or modifying genes may influence the development of OPT.

The period of greatest risk for the development of symptomatic OPTs in NF-1 is during the first 6 years of life. The development of a symptomatic tumor after age 6 years is extremely unusual.[19,20] Thus, physicians caring for children with NF-1 should be sensitive to the signs and symptoms of OPT in this young age group. Approximately 30 percent of children with symptomatic OPTs will show the rapid onset of proptosis, with moderate to severe vision loss in the affected eye (see eFig. 142-5.4 in on-line edition). Another 30 percent of children will have abnormal ophthalmologic examinations, without any visual symptoms, which leads to discovery of the tumors. Because young children rarely complain of vision



▲ **FIGURE 142-5** Plexiform neurofibroma with overlying hyperpigmentation and hypertrichosis.

loss, even when it is severe, thorough annual eye examinations are imperative in all young children with NF-1. Ophthalmologic signs may include an afferent papillary defect, optic nerve atrophy, papilledema, strabismus, or defects in color vision. Finally, as many as 40 percent of children who have chiasmal tumors develop precocious puberty. Accelerated linear growth will be the first sign of precocious puberty, which underscores the need for all children with NF-1 to have annual assessments of growth using standard growth charts. Children with chiasmal tumors often have no ophthalmologic symptoms or signs. Early detection of precocious puberty is important, because both the accelerated linear growth and the development of secondary sexual characteristics can be aborted with the use of a long-acting luteinizing hormone–releasing hormone agonist.[21]

Lisch Nodules

Lisch nodules are slightly raised, well-circumscribed melanocytic hamartomas of the iris thought to be virtually pathognomonic of NF-1 (Fig. 142-6). They are best seen using a slit lamp, which is necessary to distinguish them from the more commonly encountered flat iris nevi, which are not associated with NF-1. They do not cause any functional impairment of vision. The frequency with which they are found increases with age: Although Lisch nodules are found in more than 90 percent of adults with NF-1, only 30 percent of children with NF-1 younger than 6 years of age have them.[14]

Distinctive Osseous Lesions

There are two bony lesions distinctive enough to be included in the diagnostic criteria for NF-1. The first, dysplasia of the wing of the sphenoid bone, results in poor formation of the wall and/or floor of the orbit (see eFig. 142-6.1 in on-line edition). This congenital mesodermal dysplasia may be, but is not always, clinically apparent, leading to proptosis (from herniation of meninges or brain into the orbit) or enophthalmos.



▲ **FIGURE 142-6** Lisch nodules.

Dysplasia of a long bone, characterized by congenital thinning and bowing, affects approximately 2 percent of children with NF-1. Although the tibia is most commonly affected, the femur, humerus, and other long bones may also be involved. Even when the bone is intact, thinning and bowing produce a visible deformity, and the weakened mechanical properties of the bone predispose to fracture, particularly of the weight-bearing bones. Failure of primary union after a fracture results in a "false joint," or pseudarthrosis.[22]

LABORATORY TESTS

Despite the identification of the NF-1 gene and its complete sequencing, the diagnosis of NF-1 remains primarily a clinical one. Although laboratory confirmation of the diagnosis is extremely useful in specific circumstances, in most cases it is unnecessary. Because no common mutations have been identified, molecular diagnosis can be based only on strategies that screen the entire gene for mutations. Several laboratories now offer sequencing of some or all exons and/or mutation scanning with a resulting sensitivity of as high as 95 percent. This testing is available for presymptomatic individuals and can also be applied to prenatal diagnosis of NF-1 when a mutation has been identified in an affected parent.

Inexperienced clinicians often perform biopsy on cutaneous masses in an effort to confirm the diagnosis of NF-1 in an individual with multiple café-au-lait spots or other stigmata of NF-1. Such procedures are invariably unnecessary, because the clinical diagnosis of NF-1 is quite straightforward. Biopsy of a plexiform neurofibroma should be reserved for those situations in which the physician wishes to exclude the possibility of a malignancy.

RADIOGRAPHIC EVALUATION

There has been considerable debate regarding the role of screening neuroimaging in the care of asymptomatic children with NF-1. Routine screening would be important if it led to early detection of OPT and early initiation of therapy that prevented visual deterioration. A longitudinal study of children with NF-1 failed to identify any tumors in which early detection altered the clinical course.[19] Moreover, targeted screening of very young children with NF-1, the high-risk group for the development of OPTs, failed because three children developed symptomatic tumors shortly after magnetic resonance imaging (MRI) yielded normal findings. Brainstem tumors in both children and adults with NF-1 are generally more indolent than their counterparts in individuals without NF-1, which suggests that routine screening would not be beneficial.[23] Thus, the National Neurofibromatosis Foundation Optic Pathway Task Force has recommended against routine screening neuroimaging of all children with NF-1.[24] Although there are no comparable longitudinal data for adults regarding the performance of routine MRI scans of the head and spinal cord, it seems reasonable to perform such testing only in individuals who have symptoms or signs suggestive of central nervous system pathology.

Similarly, there is debate as to whether patients with NF-1 should be screened for the presence of hidden, internal plexiform neurofibromas. Most studies have demonstrated an approximately 30 percent incidence.[25,26] Because such a strategy incurs great cost without offering any proven benefit in preventing growth of plexiform neurofibromas and subsequent long-term complications, it is not recommended.[27] However, if current chemotherapeutic trials demonstrate success in the treatment of rapidly growing tumors, their identification at an early age may become more important.

COMPLICATIONS OF NEUROFIBROMATOSIS TYPE 1

Skeletal Complications

All children with NF-1 should be regularly screened for scoliosis, beginning in early childhood. Scoliosis is the most common skeletal manifestation of NF-1, affecting 10 percent to 30 percent of patients. Scoliosis is divided into dystrophic and non-dystrophic types. Dystrophic scoliosis is the result of primary bone dysplasia and may present very early in childhood, typically resulting in a sharply angulated curve spanning relatively few vertebral bodies. It is often accompanied by extreme rotation, scalloping of the posterior margins of the vertebral bodies, vertebral wedging, defective pedicles, and enlargement of the

neural foramina and spinal canal.[22] The curvature may progress rapidly, necessitating surgery, which may be particularly complicated because of the complex, multiplanar curves, poor quality of bone, potential for nerve root and spinal cord injury, and presence of intraspinal and extraspinal neurofibromas. The non-dystrophic type of scoliosis is more common and is similar to idiopathic scoliosis in adolescents. In many children it can be managed expectantly or with bracing.

Localized regions of bony overgrowth may also occur in children with NF-1 and are often in areas free of neurofibromas. The overgrowth may affect only a single digit or a larger region such as a hand or an extremity, but true hemihypertrophy is unusual. Bony overgrowth may also occur in a region affected by a plexiform neurofibroma.



Cancer

There is little doubt that NF-1 predisposes one to an increased risk for certain cancers. In a Swedish cohort of 212 probands and their affected relatives followed for more than 40 years, malignant neoplasms or central nervous system tumors occurred in 45 percent of the probands, for a relative risk of 4 compared with that in the general population. However, when the affected relatives of the probands were examined, only the female relatives with NF-1 were found to have an increased risk of neoplasms.[28] This illustrates the tremendous bias inherent in data obtained through hospital records and disease-specific clinics. When the records of Japan's Children's Cancer Registry were reviewed, the incidence of NF-1 was 6.45 times the expected estimated rate.[29]

Malignant peripheral nerve sheath tumors arise almost exclusively from preexisting plexiform neurofibromas. Estimates of the lifetime risk for the development of this tumor vary but the rate may be as high as 13 percent.[30,31] Because the outcome of therapy is poor, physicians should be diligently aware of the early symptoms referable to these tumors, including a rapidly growing mass or unexplained pain or dysfunction. Although conventional imaging cannot identify malignant tissue within a benign plexiform neurofibroma, newer modalities such as 18-fluorodeoxyglucose positron emission tomography may be useful.[32]

Pheochromocytoma clearly is associated with NF-1, with an incidence potentially as high as 1.4 percent. In one review, the mean age at presentation was 42 years; 84 percent of patients had solitary adrenal tumors, 9.6 percent had bilateral adrenal tumors, and 6 percent had ectopic tumors in the abdominal sympathetic chain, organ of Zuckerkandl, and the bladder.[33]

Catecholamine-associated symptoms and hypertension were both present in 61 percent of patients; 22 percent of patients had neither of these findings. Malignant pheochromocytomas were found in 11.5 percent of patients, often with distant metastases at presentation. Loss of heterozygosity of the NF-1 gene has been demonstrated both in NF-1–associated and sporadic pheochromocytomas.[34,35]

There is an increased risk of chronic myelomonocytic leukemia and acute lymphoblastic leukemia in children with NF-1. In contrast to the fourfold predominance of lymphocytic leukemia generally seen in childhood, there is a clear excess of cases of myelogenous leukemia in children with NF-1.[36] Homozygous inactivation of the NF-1 gene in the bone marrow cells of children with NF-1 and malignant myeloid disorders have been identified, which suggests that the NF-1 gene plays a role in downregulating the growth of immature myeloid cells.[37]

An unusual association between juvenile xanthogranulomas, NF-1, and the development of myeloid leukemias has been reported.[38,39] Although the pathogenesis is obscure, this association also has been observed independent of NF-1. Juvenile xanthogranulomas (see Chap. 149) are yellowish papules less than 1 cm in diameter usually found on the head or trunk (see eFig. 142-6.2 in online edition). Some authors have recommended screening blood counts for individuals who have juvenile xanthogranulomas and NF-1. Although the exact magnitude of the risk is unknown, it is exceedingly low. Screening blood counts are not recommended as they provide no useful information and, in our experience, serve only to increase parental anxiety.

Rhabdomyosarcoma also occurs more frequently in individuals with NF-1[40,41] (see Chap. 127). Although a relationship between both neuroblastoma and Wilms tumor and NF-1 has been suggested, there are no strong epidemiologic data linking these tumors with NF-1. Other tumors that appear to occur with excess frequency in adults with NF-1 are somatostatinomas of the duodenum and the ampulla of Vater, and gastrointestinal stromal tumors. Compared with the tumors seen in individuals without NF-1, somatostatinomas in NF-1 patients rarely arise in the pancreas, are smaller, and generally are not associated with hormonal symptoms (i.e., diabetes, steatorrhea, and gallbladder disease).[42]

Vasculopathy

Patients with NF-1 may have a vasculopathy affecting essentially any arterial vessel. Clinical manifestations may include renal artery stenosis with hypertension, cerebral infarcts, bleeding aneurysms, and intermittent claudication of an extremity. This vasculopathy is a developmental problem not related to compression of an arteriole by a neurofibroma and appears to be acquired after birth, because the appearance of new lesions and the progression of preexisting ones have been described. Characteristic pathologic changes have been described in all layers of the vascular wall, which ultimately leads to narrowing of the arterial lumen.[43,44]

The most commonly identified vascular lesion in patients with NF-1 is in the renal artery, leading to renovascular hypertension.[45] Renal artery vasculopathy should be considered in any adult NF-1 patient with hypertension that is not easily controlled with a single antihypertensive medication. All children with NF-1 should be evaluated for this complication. Aortography with selective angiography of the renal arteries should be used to confirm the diagnosis. If the blood pressure is uncontrollable using oral antihypertensives, percutaneous transluminal angioplasty can be performed and repeated if initially unsuccessful.

Unidentified Bright Objects

Brain MRI of children with NF-1 frequently demonstrates regions of increased signal intensity on T2-weighted images, referred to as *unidentified bright objects* or UBOs. UBOs may be found in the internal capsule, basal ganglia, cortex, cerebellar hemispheres, optic tract, or brainstem. They do not enhance and are not associated with compression of surrounding tissue, features that distinguish them from neoplasms. UBOs are present in approximately 60 percent of children with NF-1 but disappear with age and are uncommon in adults. They are not associated with focal neurologic signs and are of uncertain significance. Histopathologic studies have shown that the UBOs correspond to areas of myelin vacuolization with increased water content.[46] Some studies have

found that children with NF-1 who have UBOs have significantly lower IQ and language scores, show significantly impaired visual-motor integration and motor coordination, and are at much greater risk for impaired academic achievement compared with NF-1 patients without UBOs.[47]

Intelligence and Learning Disabilities

Contrary to gross misstatements in the older literature, the mean IQ of patients with NF-1 is only 5 to 10 points lower than that of the general population and unaffected siblings.[48] However, learning disabilities, defined as discrepancies between ability (intellect) and performance, are quite common, with an estimated prevalence of 30 percent to 60 percent.[49,50] Although earlier reports suggested there might be a specific "cognitive phenotype" in NF-1 characterized by an excess of visual-perceptual disabilities, more recent studies have demonstrated that verbal deficits (e.g., reading) are at least as common as nonverbal disabilities in individuals with NF-1. These learning disabilities are lifelong and can affect adult functioning. Many children with NF-1 also have poor attention and impulse control and may be diagnosed with attention-deficit/hyperactivity disorder, which significantly interferes with school performance and learning. The use of stimulant medications may have a profound beneficial effect on the ability of these individuals to succeed academically and professionally.

TREATMENT OF NEUROFIBROMATOSIS TYPE 1

Individuals with NF-1 are best cared for within a multi-disciplinary clinic that has access to a wide range of subspecialists. The exact physician composition of the clinic is less important than the ability to obtain expeditious subspecialty consultation. All first-degree relatives should be examined for the cutaneous manifestations of NF-1 and should undergo slit-lamp examination at the first visit to ascertain the presence of Lisch nodules. Yearly visits allow the physician to identify NF-1 complications early while providing counseling and dissemination of information regarding NF-1.[13] Individuals and families can obtain further information from the websites of the two national support groups, the Children's Tumor Foundation (http://www.ctf.org) and Neurofibromatosis, Inc. (http://www.nfinc.org).

All children with NF-1 who are 10 years of age or younger should have yearly complete ophthalmologic examinations to look for signs of an OPT. These examinations should include assessment of visual acuity, color vision, and visual fields, as well as funduscopy and slit-lamp examination. Because almost all OPTs arise in children in this age group, the frequency of ophthalmologic examinations can be reduced in children older than 10 years of age. Yearly measurements of weight and height should be plotted on standardized growth charts, because the earliest indication of precocious puberty may be accelerated linear growth. Blood pressure measurements should be obtained at each visit to look for signs of renovascular hypertension. In addition, the spine should be examined each year for early signs of scoliosis.[13]

Café-au-Lait Spots

Café-au-lait spots on the face are unusual in individuals with NF-1. On occasion, they do occur, and affected individuals may seek to improve cosmesis. Attempts to remove café-au-lait spots with laser therapy have provided very mixed results. Although total disappearance of the lesion may be achieved, some studies cite a recurrence rate as high as 67 percent. Although results with use of the Q-switched ruby laser (694 nm) have been mixed, favorable reports in a limited number of cases using either the continuous-mode copper vapor laser (511 nm) or the erbium:yttrium-aluminum-garnet laser (2940 nm) have been published.[51,52] Multiple treatments of a single lesion may be more effective.

Cutaneous Neurofibromas

Discrete cutaneous neurofibromas may be removed surgically to improve cosmesis or to prevent local irritation (e.g., from brushing for lesions in the hairline or from rubbing against the shoe for those on the foot). Deeper neurofibromas may require surgical removal when they push on vital structures, such as a dorsal root neurofibroma that infiltrates the neural foramen and compresses the spinal cord. Complications of surgery include regrowth of the original tumor and nerve damage. In individuals who have severe pruritus from a large burden of cutaneous neurofibromas, antihistamines may provide symptomatic relief. Uncontrolled anecdotal case reports have suggested that ketotifen, an antihistamine and mast cell stabilizer (not currently available in the United States), has provided relief from pruritus and pain and prevented the rapid growth of new neurofibromas.[53] Use of the CO_2 laser under general anesthesia to remove hundreds of cutaneous neurofibromas has resulted in markedly increased patient quality of life and decreased pain and pruritus.[54] The residua of a flat, smooth, depigmented scar was not felt to be an impediment to such surgery by most patients.

Plexiform Neurofibromas

Until recently, the treatment of plexiform neurofibromas was limited to surgical debulking either to improve cosmesis or to prevent loss of function (e.g., upper airway obstruction, blindness). Such surgery was highly limited in its efficacy. Complete resection was impossible given the highly infiltrative nature of these tumors, and tumor regrowth was common. Thus, there has been considerable interest in the development of nontraditional chemotherapy for use against these tumors. Not surprisingly, the design of studies to test the efficacy of such agents is fraught with complications. Plexiform neurofibromas are quite different biologically from more conventional solid neoplasms. Lack of growth after treatment may be part of the natural history of the tumor rather than a true therapeutic response. In addition, tumor burden may be difficult to quantify radiographically. Plexiform neurofibromas may spread along nerve roots, sending out multiple finger-like projections, which is quite different from a single, solid tumor mass.

The aforementioned difficulties not withstanding, several phase I and II chemotherapeutic trials are in progress. The agents currently being studied include (1) pirfenidone, an antifibrotic agent that decreases proliferation of fibroblasts and collagen matrix synthesis; (2) a farnesyl transferase inhibitor that downregulates the *ras* oncogene; (3) peginterferon alfa-2b; and (4) conventional chemotherapy with a combination of methotrexate and vinblastine. If any of these studies demonstrates potential efficacy, the role of screening imaging to detect hidden plexiform neurofibromas would need to be readdressed.

Optic Pathway Tumors

Once identified, OPTs should be followed by serial MRI and ophthalmologic examinations. Treatment should be initiated only after demonstration of clear radiographic progression or deteri-



oration of vision. The goal of treatment should be to preserve vision while minimizing the side effects of therapy. Radiation therapy, although a mainstay of treatment of progressive central nervous system neoplasms not associated with NF-1, is rarely necessary in NF-1 OPT and is associated with neurocognitive and endocrinologic side effects in very young children. Rather, chemotherapy with carboplatin and vincristine has proven effective in the management of these tumors.[55]

RELATED CONDITIONS

Neurofibromatosis Type 2



NF-2 is a condition with an autosomal dominant inheritance pattern characterized by bilateral vestibular schwannomas, other schwannomas (dorsal roots of the spinal cord, peripheral nerves, and cranial nerves), meningiomas (intracranial, intraspinal, and optic nerve sheath), ependymomas and gliomas of the central nervous system, and juvenile posterior subcapsular cataracts.[56] The estimated birth incidence is 1 in 40,000 live births. Although NF-2 is much less common than NF-1, its morbidity is much greater, with patients frequently becoming paralyzed and deaf. Use of the Manchester clinical diagnostic criteria[56] has led to increased sensitivity in establishing the diagnosis, particularly in those cases without a positive family history (Table 142-2). Approximately 60 percent of patients present in adulthood with hearing loss, tinnitus, or loss of balance. The younger the age at presentation, the greater the ultimate severity of the disease. Children are more apt to present with a non–eighth nerve tumor such as an optic nerve sheath meningioma. Ophthalmologic findings include juvenile posterior subcapsular cataracts (60 percent to 80 percent of patients), retinal hamartomas, epiretinal membranes, and optic nerve sheath meningiomas.[56]

Individuals with NF-2 may have several café-au-lait spots but rarely have more than six; intertriginous freckling is not seen. The characteristic cutaneous lesion of NF-2 is the cutaneous schwannoma (see eFig. 142-6.3 in on-line edition). It is a plaque-like, slightly raised lesion with a faint violaceous hue, occasionally with hair. Less commonly, cutaneous neurofibromas, indistinguishable from those seen in NF-1, may be found.

NF-2 is caused by mutations in a gene on chromosome 22, which encodes the membrane-related protein merlin, also known as *schwannomin*. As in NF-1, the NF-2 gene is a tumor suppressor gene that downregulates cellular growth. The exact cellular pathways by which this control is exerted have yet to be delineated.

TABLE 142-2
Manchester Clinical Diagnostic Criteria for Neurofibromatosis Type 2 (NF-2)

A patient has the clinical diagnosis of NF-2 if one of the following criteria is present:

A. Bilateral vestibular schwannomas
B. First-degree family relative with NF-2 and unilateral vestibular schwannoma or any two[a] of the following: meningioma, schwannoma, glioma, neurofibroma, or posterior subcapsular lenticular opacities
C. Unilateral vestibular schwannoma and any two[a] of the following: meningioma, schwannoma, glioma, neurofibroma, or posterior subcapsular lenticular opacities
D. Multiple meningiomas (two or more) and unilateral vestibular schwannoma and any two[a] of the following: schwannoma, glioma, neurofibroma, cataract

[a]"Any two" refers to two individual tumors or cataracts.

From Evans DGR et al: Management of the patient and family with neurofibromatosis 2: A consensus conference statement. *Br J Neurosurg* **19**:5, 2005.

Segmental Neurofibromatosis Type 1

The term *segmental neurofibromatosis* refers to NF-1 with manifestations, usually café-au-lait macules and neurofibromas, that are limited to one area of the body.[57] Ruggieri and Huson have proposed the term *mosaic localized NF-1* for these cases, as an acknowledgment that the pathogenesis of this condition is a post-conceptional mutation in the NF-1 gene leading to somatic mosaicism.[58] This has been confirmed in a patient in whom the mutant NF-1 allele was present in a mosaic pattern in cultured fibroblasts from a café-au-lait macule and absent in fibroblasts from normal skin.[59]

The vast majority of patients with segmental NF-1 have café-au-lait macules or intertriginous freckling limited to one area of the body. These individuals are at risk for developing complications of NF-1 in the affected area, most commonly neurofibromas. Localized manifestations of NF-1 other than café-au-lait macules, freckling, or cutaneous neurofibromas may also represent examples of somatic mosaicism. There have been numerous reports of isolated plexiform neurofibromas, including one case in which loss of heterozygosity of the NF-1 gene in Schwann cells from the tumor was demonstrated. Because only 50 percent of cases of tibial pseudarthrosis occur in the context of NF-1, the others may actually represent cases of segmental NF-1. Patients with other examples of segmental NF-1 include a child who had a unilateral optic pathway glioma that acted biologically like an NF-1–associated tumor and individuals with isolated sphenoid bone dysplasia.

Genetic counseling of patients with segmental NF-1 is problematic. Many of these patients are misdiagnosed as having NF-1, which leads to unnecessary anxiety and inappropriate genetic counseling. In addition, gonadal mosaicism for NF-1 has been demonstrated. Patients with segmental NF-1 have had offspring with complete NF-1.

Neurofibromatosis Type 1–Noonan Syndrome

It has been recognized that there are individuals who meet the diagnostic criteria for NF-1, yet have many features of Noonan syndrome, which is characterized by hypertelorism, ptosis, downsloping palpebral fissures, low-set and posteriorly rotated ears, webbed neck, pectus deformities, and short stature. Over 50 percent of children with Noonan syndrome have cardiovascular disease, most commonly pulmonary valve stenosis. Noonan syndrome is caused by a mutation in the gene *PTPN11*. Genetic testing has shown that most individuals with LEOPARD syndrome (see Chap. 73) also have mutations in *PTPN11*. One study documented mutations in the *NF-1* gene in 16 of 17 unrelated subjects who clinically had the NF-1–Noonan phenotype; no mutations in *PTPN11* were found.[60] Thus, it appears that the vast majority of cases of NF-1–Noonan syndrome are due to mutations in *NF-1*.

Familial Café-au-Lait Spots

The occurrence of multiple café-au-lait spots without other signs of NF-1 may be inherited as an autosomal dominant trait. This condition can be diagnosed reliably only when the patient is an older child or adult who clearly lacks other stigmata of NF-1 or when there is a first-degree relative with multiple café-au-lait spots and no other features of NF-1. Intertriginous freckling is absent in most families, although exceptions have been reported. Linkage to the NF-1 gene was reported in one family and excluded in two other families.[61–63]

Schwannomatosis

It had been noted for some time that there were patients who developed multiple schwannomas (see Chap. 127) but who failed to develop other manifestations of NF-2, particularly vestibular schwannomas.[64,65] Patients with this condition, now called *schwannomatosis*, develop multiple painful schwannomas within peripheral nerves and paraspinal nerve roots. The tumors most often start appearing during the second and third decades of life. Surgical treatment of individual lesions is often necessary to manage intractable pain. In contrast to individuals with NF-2, those with schwannomatosis have a normal life span. Before a diagnosis of schwannomatosis is made, it is extremely important to exclude the possibility of NF-2 by both genetic testing and MRI scanning to look for vestibular schwannomas. Although most cases of schwannomatosis are sporadic, autosomal dominant transmission of the syndrome has been documented.

KEY REFERENCES

The full reference list for all chapters is available at www.digm7.com.

9. Zhu Y et al: Neurofibromas in NF1: Schwann cell origin and role of tumor environment. *Science* **296**:920, 2002
13. Listernick R, Charrow J: Neurofibromatosis-1 in childhood. *Adv Dermatol* **20**:75, 2004
19. Listernick R et al: Natural history of optic pathway tumors in children with neurofibromatosis type 1: A longitudinal study. *J Pediatr* **125**:63, 1994
50. Hyman SL, Shores A, North KN: The nature and frequency of cognitive deficits in children with neurofibromatosis type 1. *Neurology* **65**:1037, 2005
56. Evans DG et al: Management of the patient and family with neurofibromatosis 2: A consensus conference statement. *Br J Neurosurg* **19**:5, 2005
57. Listernick R, Mancini AJ, Charrow J: Segmental neurofibromatosis in childhood. *Am J Med Genet A* **121**:132, 2003
65. MacCollin M et al: Diagnostic criteria for schwannomatosis. *Neurology* **64**:1838, 2005



CHAPTER 143

Ectodermal Dysplasias

Virginia P. Sybert

The ectodermal dysplasias (EDs) are a group of inherited disorders that share in common developmental defects involving at least two of the major structures classically held to derive from the embryonic ectoderm—hair, teeth, nails, sweat glands. Freire-Maia and Pinheiro[1] published an exhaustive review and classification system for these disorders using a numeric system of 1 (hair), 2 (teeth), 3 (nail), and 4 (sweat glands) for characterization. This system has little use in practice, although it did allow for a rational approach to a previously chaotic field. Freire-Maia and Pinheiro laid claim to more than 150 ectodermal disorders in their most recent compilation.[2] Several other classification schemes have been suggested. Each has limited clinical application but can help in ordering thinking about these disorders.[3,4] This chapter covers only the more common of these conditions and those in which ectodermal defects are likely to bring them to a dermatologist for diagnosis and medical attention.

Fig. 143-1 is an algorithm showing the approach to the diagnosis of EDs. The first step in the algorithm for making a specific diagnosis of an ED is to determine the presence of sweating (hidrotic) or absence of sweating (hypohidrotic/anhidrotic). The involvement of other ectodermal structures and of non-ectodermally derived tissues provide further branching points in a diagnostic hierarchy. Mode of inheritance may differ within a seemingly uniform diagnostic group, and care must be taken in evaluating family members before providing recurrence risks.

Within the last few years, causal genes have been identified in many of the EDs. Given continuing discoveries, the reader is directed to the following resources: http://www3.ncbi.nlm.nih.gov/Omim (Online Catalog of Mendelian Inheritance in Humans) and http://www.genetests.org (an up-to-date listing of laboratories offering molecular testing). The OMIM (Online Mendelian Inheritance in Man) numbers with each section heading refer to the numbering system at http://www3.ncbi.nlm.nih.gov/Omim. The National Foundation for Ectodermal Dysplasias (http://www.nfed.org) is a lay support group that has numerous informative pamphlets for families and physicians, as well as a strong advocacy program for dental care, insurance coverage, and research.

HYPOHIDROTIC ECTODERMAL DYSPLASIA [ANHIDROTIC ECTODERMAL DYSPLASIA, CHRIST-SIEMENS-TOURAINE SYNDROME; OMIM #305100]

Historical Aspects

Epidemiology

X-linked hypohidrotic ED (X-LHED) occurs in all racial groups and is thought to have an incidence at birth of approximately 1 in 100,000 males.[5]

Etiology, Pathogenesis, and Genetics

X-LHED results from alterations in the gene *ectodysplasin* (*EDA, EDA1*) located at Xq12-13.[6] It codes for a transmembrane protein, ectodysplasin, which is composed of 391 amino acids and has

ECTODERMAL DYSPLASIAS AT A GLANCE



- A group of inherited disorders characterized by developmental abnormalities in two or more ectodermal structures.
- These include hair, teeth, nails, and sebaceous and sweat glands.
- There may be abnormalities in non-ectodermal structures and functions.
- Distinction is based on clinical features, mode of inheritance, and molecular findings.
- Clinically distinct disorders may be due to different mutations in the same gene (allelic heterogeneity), and clinically similar conditions may be due to mutations in different genes (locus heterogeneity).



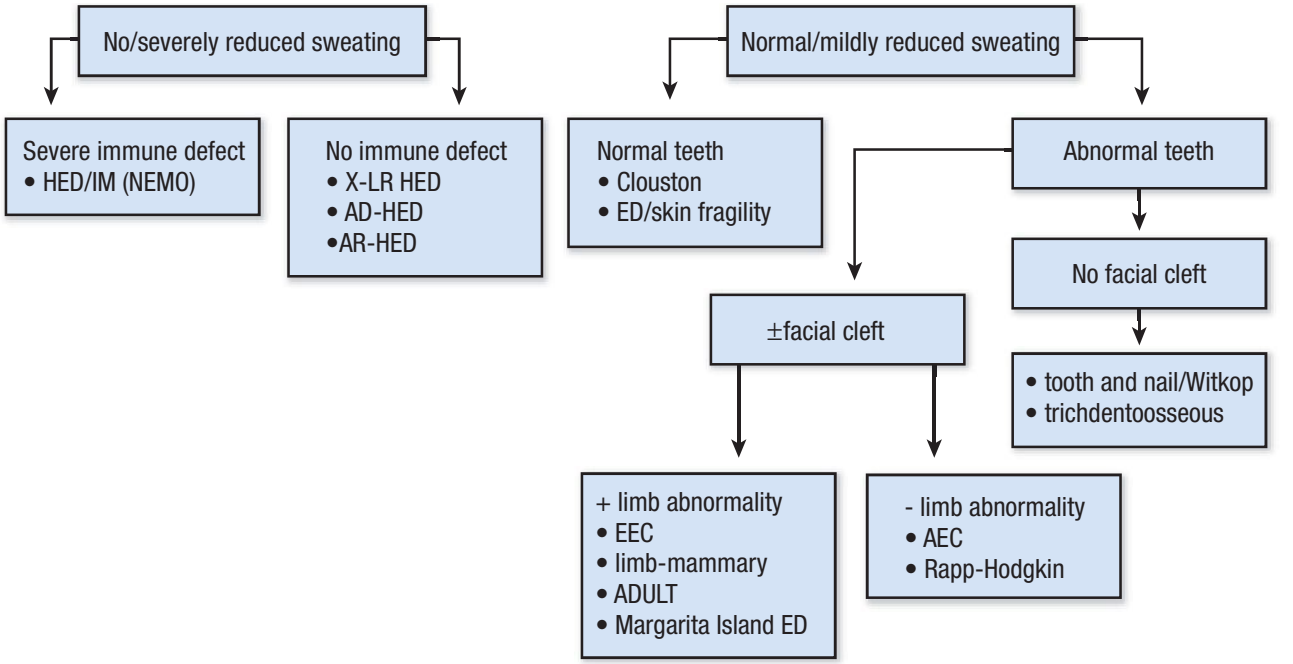

▲ **FIGURE 143-1** Approach to the diagnosis of ectodermal dysplasias. AD = autosomal dominant; ADULT = *a*cro-*d*ermato-*u*ngual-/acrimal-*t*ooth syndrome; AEC = *a*nkyloblepharon filiforme adnatum–*e*ctodermal dysplasia–*c*left palate syndrome; AR = autosomal recessive; ED = ectodermal dysplasia; EEC = ectrodactyly–ED–cleft lip/palate syndrome; HED = hypohidrotic ectodermal dysplasia; IM = immune defects; X-LR = X-linked recessive.

alternative splicing forms, the significance of which is not known. A multitude of mutations in this gene causing X-LHED has been identified. There does not appear to be a correlation between the nature of the mutation and the clinical features[7] (i.e., to date, there have been no phenotype-genotype correlations). Interfamilial and intrafamilial variation occurs to a mild degree. Ectodysplasin belongs to the tumor necrosis factor family and plays a role in regulation of the formation of ectodermal structures. It forms trimers and is expressed in keratinocytes, the outer root sheath of hair follicles, and sweat glands. It localizes to the lateral and apical surfaces of cells.

As is typical of X-linked recessive disorders, expression is full blown in affected males, and carrier females may express none, some, or all of the features of the disorder, often in a patchy distribution. The disorder can be inherited from a carrier mother or newly occur in an affected individual as the result of a de novo mutation. Approximately 70 percent of affected males inherited the mutation from a carrier mother. Between 60 percent and 80 percent of carrier females express some clinical signs of the disorder; the most frequent are patchy hypotrichosis and hypodontia.

Mutations in an autosomal gene, *EDAR,* mapped to 2q11-q13, have been implicated in an autosomal dominant form of hypohidrotic ectodermal dysplasia (HED; OMIM #129490) and in an autosomal recessive form (OMIM #224900)[8] that are clinically similar to X-LHED. Both these entities are much rarer. EDAR acts as a receptor for ectodysplasin. Mutations in yet another gene, *EDARADD,* have been identified recently in autosomal recessive HED.[9] EDARADD is an intracellular adaptor protein that assists in transmitting the signal from the activated EDA receptor to the nucleus of the cell. Individuals with autosomal dominant HED appear to have a milder defect in the ability to sweat.

Certain mutations in the X-linked *NEMO* gene, which causes incontinentia pigmenti (IP) in females, have been shown to result in males with HED and immune defects (see Chap. 144).[10,11]

Clinical Manifestations

DERMATOLOGIC Affected males may present at birth with a collodion membrane or with marked scaling of the skin,[13] similar to congenital ichthyosis. Scalp hair is usually sparse, fine, and blonde. It may thicken and darken at puberty, and secondary sexual hair may be normal. Other body hair is usually sparse or absent.

The ability to sweat is significantly compromised, and most affected males have marked heat intolerance. Sweat pores are usually undetectable on physical examination, and fingerprint ridges are effaced. The inability to sweat adequately in response to environmental heat results in an elevation of core temperature and bouts of unexplained high fevers, usually leading to an extensive workup for infectious disease, malignancy, or autoimmune disease before the correct diagnosis is recognized. In an older series of patients, mental retardation was reported as a feature of X-LHED. Currently, this is believed to have been due to damage from prolonged high fevers and convulsions and not to be an intrinsic feature of the disorder.

The nails are usually normal; reports of thin, fragile nails are not convincing, and nail dystrophy plays little role in the burden of the disorder.[14] Periorbital wrinkling and hyperpigmentation are typical and often present, albeit unappreciated, at birth (Fig. 143-2A–C). Eczema plagues more than two-thirds of affected males and is often difficult to manage. Hyperplasia of sebaceous glands, particularly on the face, can develop over time and appear as small, pearly, flesh-colored to white papules that may resemble milia.

SYSTEMIC ASSOCIATIONS Hypodontia, oligodontia, or anodontia are invariable features of X-LHED in affected males. Appreciation of hypoplastic gum ridges in an affected infant can be an early clue to the diagnosis of the disorder. Teeth that do erupt are usually peg-shaped and small (see Fig. 143-2B). The facies of the disorder are characterized by frontal bossing and a depressed midface with a

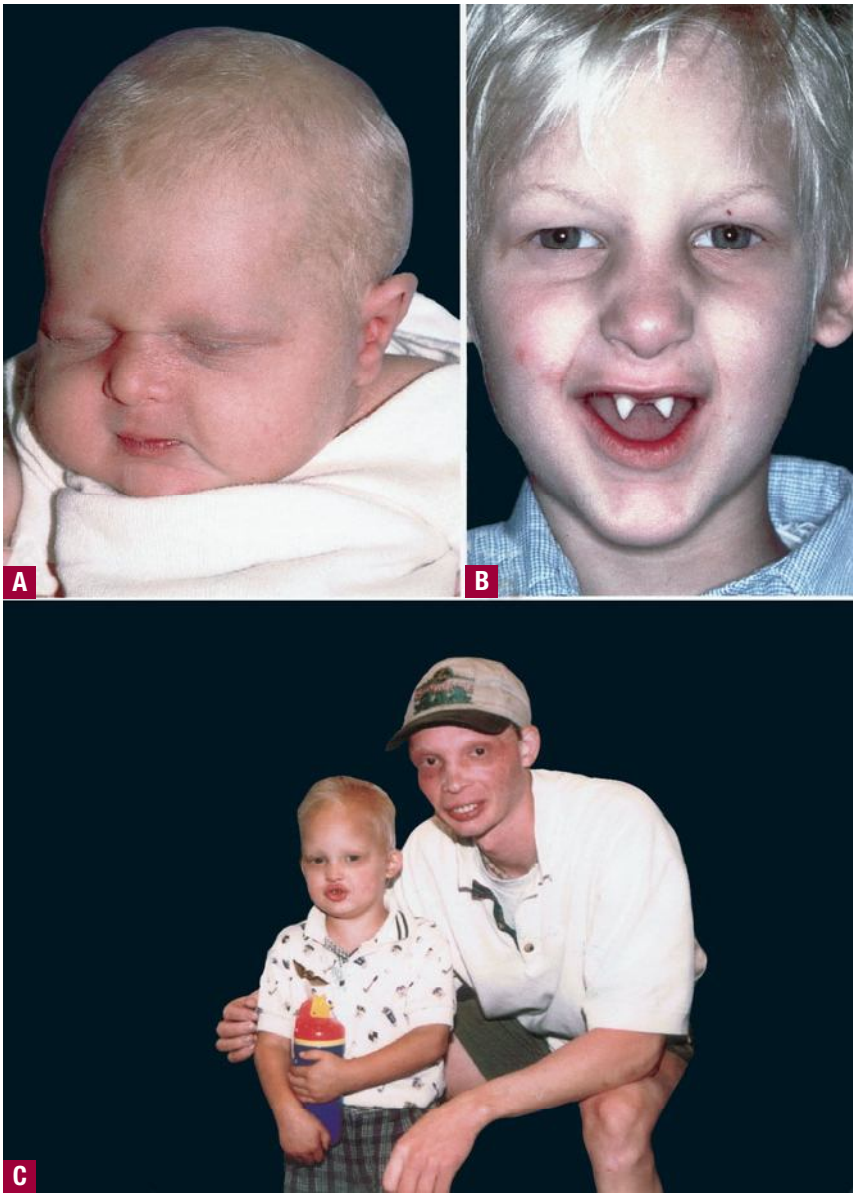

▲ **FIGURE 143-2** Hypohidrotic ectodermal dysplasia. **A.** Newborn with periorbital wrinkling, beaked nose. Diagnosis would not be suspected unless there were a positive family history. **B.** Peg-shaped teeth; fine periorbital wrinkling can be appreciated. (From Sybert VP: *Genetic Skin Disorders.* New York, Oxford University Press, 1997.) **C.** Two unrelated males with X-linked hypohidrotic ectodermal dysplasia; adult is wearing dentures; periorbital wrinkling and hyperpigmentation are evident. (Used with permission from the National Foundation for Ectodermal Dysplasias.)

saddle nose and full, everted lips. Otolaryngologic manifestations include thick nasal secretions and impaction, ozena, sinusitis, recurrent upper respiratory tract infections and pneumonias, decreased saliva production, hoarse voice, and an increased frequency of asthma. Gastroesophageal reflux and feeding difficulties may be a problem in infancy. Preliminary studies suggest that there may be failure to thrive in infancy and early childhood in as many as 20 percent to 40 percent of affected boys, with catch-up growth seen later.[15] Although several reviews have suggested that infant mortality may be increased, unbiased confirmatory data are lacking.

Female carriers for X-LHED may be affected as severely as males or show few, if any, signs of the disorder (Fig. 143-3). Heat intolerance, if present, is usually mild; adult carrier women comment that they do not sweat much or that they do not like very warm weather, but it is unusual for a female to experience fever due to inability to sweat. Typically, a few teeth may be peg-shaped or missing and scalp hair may be patchy or thin. Careful examination of the skin of carrier females often reveals a diminution in or patchy distribution of sweat pores. This sometimes can be appreciated readily just by magnification of fingertip pads or may require more sophisticated sweat testing.

VARIANTS As noted in Etiology, Pathogenesis, and Genetics, the autosomal dominant and autosomal recessive forms of HED are similar, although the autosomal dominant form may be milder. The X-linked form is by far the most common and always should be the diagnosis of default in a sporadic case.

Histopathology

The epidermis is thinned and flattened. There is a reduction in the number of sebaceous glands and hair follicles. Eccrine glands are absent or incompletely developed. Histologic evaluation of the skin is usually not necessary.

Diagnosis and Differential Diagnosis (Box 143-1)

The scaling skin at birth may result in a misdiagnosis of congenital ichthyosis. Repeated bouts of fever may be thought to have an infectious source. The diagnosis of HED is recognized readily when expected, such as when an at-risk male is born into a family in which the disorder is known to segregate. Examination for sweat pores and a Panorex view of the jaw leads quickly to the correct diagnosis. In an isolated, fully expressing female, the autosomal dominant and recessive forms of HED need to be considered. Family history, examination of parents, and molecular testing may be helpful. Mothers always should be examined fully to detect mild manifestations of the X-linked form. Molecular testing is not indicated for clinical diagnosis in most instances.

Treatment

Maintenance of cool ambient temperatures is vital to prevent hyperpyrexia. Most children do well with simple measures, such as wet T-shirts, air conditioning in home and school, wet headbands, etc. Occasionally, cooling vests allow a broader range of participation in sports and vigorous physical activity in warm climates.

Dental restoration is of primary importance, and early implementation of dentures and ultimate use of dental implants are mainstays of treatment.

Management of otolaryngologic complications, asthma, and recurrent infec-









▲ **FIGURE 143-3** Hypohidrotic ectodermal dysplasia. **A.** Female carrier of X-linked hypohidrotic ectodermal dysplasia with two affected sons. (Used with permission from the National Foundation for Ectodermal Dysplasias.) **B.** Two sisters with X-linked hypohidrotic ectodermal dysplasia manifesting to different degrees. Note periorbital hyperpigmentation, full everted lips, and sculpted noses. (From Sybert VP: *Genetic Skin Disorders*. New York, Oxford University Press, 1997.)

tions needs to be individualized. The eczema may be quite refractory to care.

The National Foundation for Ectodermal Dysplasias (http://www.nfed.org) has several pamphlets for individuals and professionals dealing with diagnosis and treatment.

Although infancy and childhood are complicated by many problems, most individuals with HED lead adult lives that allow them to function successfully in society. Heat intolerance seems to decrease due to the development of some ability to sweat in adolescence or to the development of common sense and adaptation of lifestyle, or both.

HIDROTIC ECTODERMAL DYSPLASIA (CLOUSTON SYNDROME; OMIM #129500)

Epidemiology

Hidrotic ED was first described in a French-Canadian kindred.[16] It has been reported in other ethnic groups, but the majority of affected individuals can trace their ancestry back to an original French-Canadian settler.

Box 143-1

Differential Diagnosis of Some Diagnostic Features of Ectodermal Dysplasias

- Collodion membrane
  - Lamellar exfoliation of the newborn
  - Neutral lipid storage disease
  - Non-bullous congenital ichthyosiform erythroderma
  - Lamellar ichthyosis
  - Trichothiodystrophy
  - Storage diseases (e.g., Gaucher)
  - Chondrodysplasia punctata
- Ankyloblepharon filiforme adnatum (AFA)
  - Lethal popliteal pterygium syndrome
  - Popliteal pterygium syndrome
  - Isolated AFA
  - AFA and cleft palate
- Hypodontia
  - Isolated hypodontia
  - Incontinentia pigmenti
- Skin fragility/erosions
  - Epidermolysis bullosa disorders
  - Incontinentia pigmenti
  - Acrodermatitis enteropathica
  - Plakophilin/ectodermal dysplasia
  - Congenital erythropoietic porphyria
  - LOGIC (*l*aryngeal and *o*cular *g*ranulation tissue *i*n *c*hildren from the Indian subcontinent)
- Atrophic streaks
  - Incontinentia pigmenti—stage 4
  - MIDAS (*mi*crophthalmia, *d*ermal *a*plasia, and *s*clerocornea)
  - Focal dermal hypoplasia

Etiology, Pathogenesis, and Genetics

The disorder is caused by mutations in a connexin gene, *GJB6* or *connexin-30*.[17] Different mutations in the same gene are responsible for a form of nonsyndromic autosomal dominant deafness and at least one patient with *k*eratitis-*i*chthyosis-*d*eafness (KID syndrome) (see Chap. 47). Other connexin genes show similar variability in mutation: disease correlations [e.g., mutations in *connexin-31 (GJB3)*] can cause either erythrokeratodermia variabilis (see Chap. 47) or late-onset autosomal deafness. The pathway by which allelic mutations result in such different diseases is not yet known.

Hidrotic ED is autosomal dominant with variable expression (the degree of severity can vary within and between families). Males and females are affected in equal numbers and to equal degree.



▲ **FIGURE 143-4** Hidrotic ectodermal dysplasia (Clouston syndrome) **A.** Patchy alopecia in adult. Coarseness of hair can be appreciated. **B.** Palmar hyperkeratosis. **C.** Nail dystrophy.

The gene maps to the centromeric region of the long arm of chromosome 13.

Clinical Manifestations

The scalp hair is wiry, brittle, and pale, and there is often patchy alopecia (Fig. 143-4A). This progresses in adult life and may lead to total alopecia. Body and facial hair are affected. The nails may be milky white in infancy and early childhood, gradually thickening and becoming dystrophic. The nail plates in adults are thick, short, slow-growing, separate distally from the nail bed (see Fig. 143-4C), and may cause pain. Anonychia has been reported. Not all the nails are necessarily affected to the same degree. Progressive palmar/plantar hyperkeratosis is common (see Fig. 143-4B). In contrast to HED, sweating is normal, as are the teeth. Oral leukoplakia has been reported. Conjunctivitis and blepharitis, possibly due to poor function of sparse eyelashes, are common.

Histopathology

The thickened palms and soles show orthohyperkeratosis with a normal granular layer. On electron microscopy, an increase in the number of desmosomes in the cells of the stratum corneum is found. The hair shows nonspecific changes.

Diagnosis and Differential Diagnosis (see Box 143-1)

The diagnosis is straightforward. The involvement of nails and hair and palmar/plantar thickening, in the absence of other signs of ED, are reasonably specific. Other palmar/plantar hyperkeratoses do not have similar hair changes. Orofacial clefting differentiates other forms of autosomal dominant hidrotic ED, such as ankyloblepharon filiforme adnatum (AFA)–ED–cleft palate (AEC) syndrome or Rapp-Hodgkin syndrome. Although the nail changes are similar to those of pachyonychia congenita, the hair changes are distinctive.

Treatment

Occasionally, ablation of the nail matrix is necessary for relief of pain. Wigs may provide cosmetic benefit. Treatment of the thickened palms and soles is not specific and minimally successful.

ANKYLOBLEPHARON FILIFORME ADNATUM-ECTODERMAL DYSPLASIA-CLEFT PALATE SYNDROME (HAY-WELLS SYNDROME; OMIM #106260)

Epidemiology

Described first in 1976,[18] Hay-Wells syndrome has been found in ethnically and geographically disparate families.

Etiology, Pathogenesis, and Genetics

The disorder is caused by mutations in the tumor-suppressor gene *p63*, a gene that has been implicated in the pathogenesis of ectrodactyly–ED–cleft lip/palate (EEC) syndrome, limb-mammary syndrome, *a*cro-*d*ermato-*u*ngual-*l*acrimal-*t*ooth (ADULT) syndrome, and other autosomal dominant forms of ED. Mutations that cause EEC and AEC cluster in different regions of the gene.[19,20]

AEC syndrome is an autosomal dominant disorder with complete penetrance and variable expression.

Clinical Features

DERMATOLOGIC Ninety percent of affected infants present at birth with shiny red, cracking, peeling skin and superficial erosions, similar to the appearance of a collodion membrane (Fig. 143-5A).[14] This sheds within a few weeks, and the skin underneath is dry and thin. The scalp is almost invariably involved, and many affected individuals are plagued by a chronic erosive dermatitis with abnormal granulation tissue on the scalp (see Fig. 143-5B,C).[21] Recurrent bacterial infection of the scalp is common. Patchy alopecia is the rule, and the scalp hair that is present is often wiry, coarse, and light in color. Sparseness to absence of body hair is typical. AFA—strands of skin between the eyelids—is seen in approximately 70 percent of affected infants (see Fig. 143-5D). These may tear spontaneously or require surgical lysis. Lacrimal duct atresia or obstruction is common. The nails may be normal, hyperconvex and thickened, absent, or partially dystrophic, and all changes can be found in a single individual. Sweating is usually normal, although some affected individuals describe subjective heat intolerance. Supernumerary nipples and ectopic breast tissue are seen occasionally, as is mild cutaneous syndactyly of toes two and three.

SYSTEMIC ASSOCIATIONS Cleft palate, with or without cleft lip, occurs in 80 percent of reported cases. There may be hypodontia with missing or misshapen teeth. Malformed auricles have been described in some. Recurrent otitis media and secondary conductive hearing loss are common and may be consequences of the cleft palate rather than primary. Hypospadias has been described in several affected males.

Histopathology

Some patients show a decrease in the number of sweat glands. Electron microscopy of hairs shows a defective cuticular structure. There is a decrease in the keratins of the basal and suprabasal layers of the epidermis and disorganized keratin filaments in the stratum corneum.





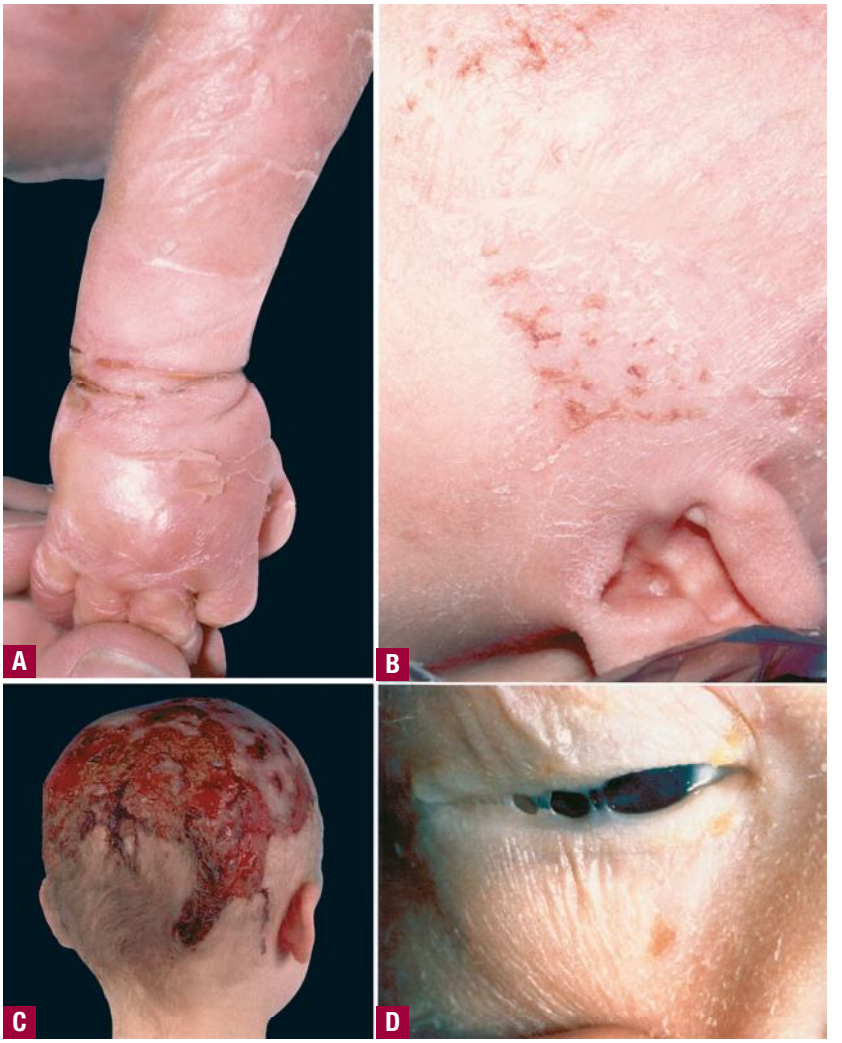

▲ **FIGURE 143-5** Ankyloblepharon filiforme adnatum–ectodermal dysplasia–cleft palate (Hay-Wells) syndrome. **A.** Newborn with peeling collodion membrane. **B.** Superficial erosion and thin skin of scalp in same patient, age 5 days **C.** Abnormal granulation tissue on scalp in older affected female. **D.** Fine strands of tissue (ankyloblepharon filiforme adnatum) between eyelids.

Diagnosis and Differential Diagnosis (See Box 143-1)

Among the autosomal dominant EDs associated with clefting, Rapp-Hodgkin syndrome lacks the ankyloblepharon and has a much lower occurrence of scalp involvement. Rapp-Hodgkin is also due to mutations in *p63*. Although the disorders have clinical distinctions, there is significant overlap and the utility of splitting rather than lumping is unclear.[22] The EEC syndrome is characterized by bony hand and foot abnormalities not seen in AEC and also lacks the ankyloblepharon. The peeling, eroded skin of the newborn can lead to misdiagnosis of epidermolysis bullosa or congenital ichthyosis. AFA can occur in the absence of syndromic associations, and strands of tissue between the eyelids have been seen in several forms of arthrogryposis, in association with chromosomal aneuploidy, and in CHANDS (*c*urly *h*air, *a*nkyloblepharon, and *n*ail *d*ysplasia *s*yndrome), an autosomal recessive form of ED.

Treatment and Prognosis

Light emollients should be used until the collodion membrane sheds. Ankyloblepharon may require surgical lysis. Ongoing ocular hygiene is important. Vigorous and meticulous but gentle scalp care with prompt treatment of infection is extremely important. Grafting of skin to the scalp is not often successful. Clefting requires a team approach for repair and follow-up for secondary issues, such as feeding difficulties, speech defects, orthodontia, and ear infections.

ECTRODACTYLY ECTODERMAL DYSPLASIA–CLEFT LIP/PALATE SYNDROME; SPLIT HAND–SPLIT FOOT–ECTODERMAL DYSPLASIA–CLEFT LIP/PALATE SYNDROME (OMIM #604292)

Historical Aspects and Epidemiology

EEC syndrome is an ED classified as a multiple congenital anomaly syndrome because it has major involvement of structures other than those derived ectodermally. EEC syndrome has occurred in all racial groups worldwide.

Etiology, Pathogenesis, and Genetics

Mutations in *p63*, a tumor-suppressor gene mapped to 3q27, have been found in most, but not all, individuals with EEC syndrome.[23] The gene is expressed widely, including in the basal cells of proliferating epithelial tissues. Mutations in the same gene cause some cases of isolated split hand–split foot disease, limb-mammary syndrome, the ADULT (OMIM #103285) syndrome, Hay-Wells syndrome and Rapp-Hodgkin syndrome. There appear to be genotype-phenotype correlations.[24] All alterations identified thus far in Hay-Wells syndrome have been missense mutations in the sterile α motif domain; in EEC syndrome, the majority of mutations result in single-amino-acid substitutions in the DNA-binding domain.[15] Frameshift mutations in *p63* cause limb-mammary syndrome, in which ectodermal structures other than the mammary gland often, but not always, appear normal. Among three unrelated families with ADULT syndrome, all shared the same point mutation in *p63*.[25]

EEC syndrome is an autosomal dominant disorder with variable expression and reduced penetrance. Intrafamilial and interfamilial differences in severity are common.

Clinical Manifestations

DERMATOLOGIC The ED may be quite mild. The hair is usually blond, coarse, and dry. It may be sparse and slow growing. Axillary and pubic hair also may be affected. The nails are dystrophic in approximately four-fifths of individuals with transverse ridging, pitting, and slow growth. Dry skin and thickening of the palms and soles can occur. Sweating is usually normal.

SYSTEMIC ASSOCIATIONS Hypodontia and premature loss of secondary teeth and

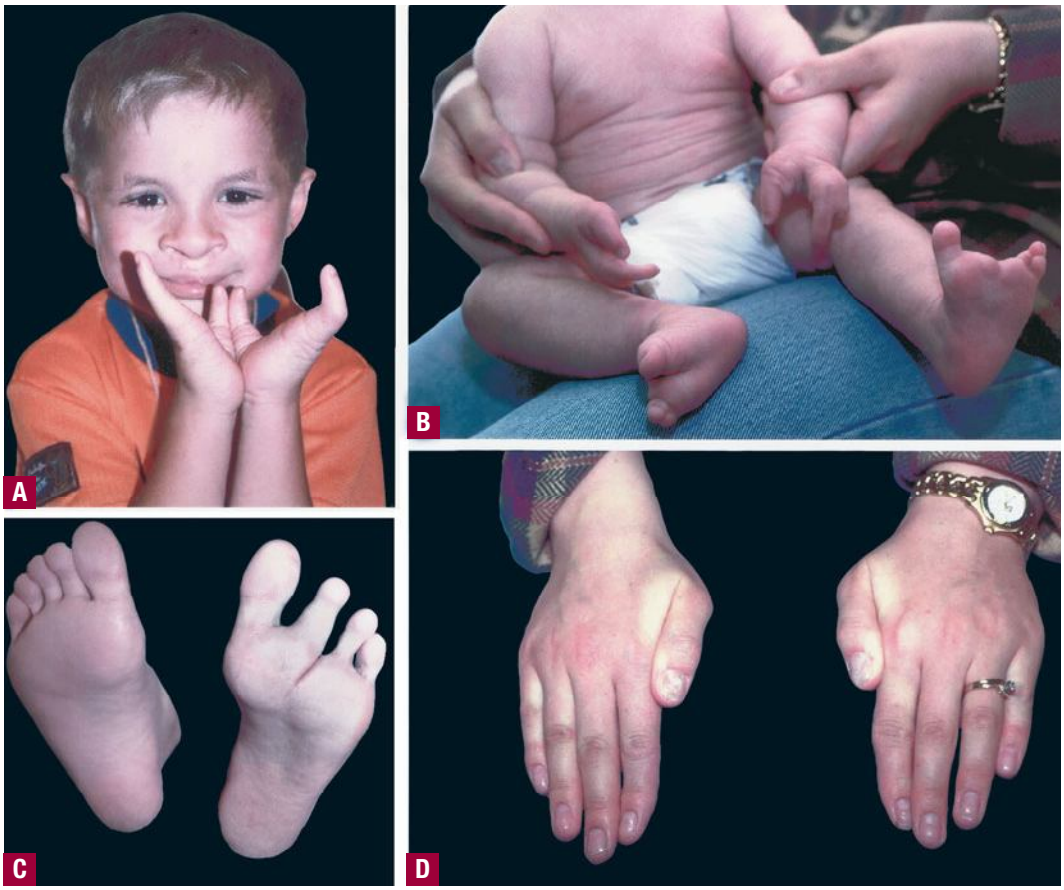

◀ **FIGURE 143-6** Ectrodactyly–ectodermal dysplasia–clefting syndrome. **A.** Mild thinness of hair. (Used with permission from the National Foundation for Ectodermal Dysplasias.) **B.** Hands and feet of affected infant. **C,D.** Feet and hands of parent of infant in (**B**) demonstrating variability of expression both among limbs and between family members. Note the nail dystrophy, especially evident on the thumbs.

the dental abnormalities associated with clefting are found in most affected individuals. Lacrimal gland abnormalities are common.

The major distinguishing feature of EEC syndrome is ectrodactyly—abnormal development of the median rays of the hands and feet (Fig. 143-6A–C). The feet are involved more frequently than the hands, and there may be asymmetry of involvement (see Fig. 143-6A–C). Cleft palate, with or without cleft lip, occurs in 70 percent to 100 percent depending on the series.[26,27] Secondary conductive hearing loss is frequent. Genitourinary abnormalities that include hydronephrosis, and structural renal or genital malformations affect one-third or more of persons with EEC syndrome. Although mental retardation has been reported, it is not believed to be an inherent feature of the disorder.

Diagnosis and Differential Diagnosis

Among disorders with limb defects that need to be considered in the differential diagnosis of EEC syndrome are the odontotrichomelic syndrome (OMIM #273400), in which there are severe absence deformities of the limbs, and aplasia cutis congenita with limb defects (Adams-Oliver syndrome, OMIM #100300), which does not have clefting or ectodermal defects other than absence of skin. Cutis marmorata telangiectatica congenital (see Chap. 106) has been described in some individuals with Adams-Oliver syndrome. Other EDs with clefting include Hay-Wells syndrome, Rapp-Hodgkin syndrome, and limb-mammary syndrome, all of which, in at least some families, appear to be allelic to EEC syndrome. Ectrodactyly with cleft palate without ED (OMIM #129830) also may be a distinct entity. There appear to be some families with EEC in whom linkage studies have suggested other causal genes located at different chromosomal loci. These genes have not yet been identified. Prenatal diagnosis by ultrasound for detection of limb abnormalities is unreliable; molecular testing may prove useful in some families.

Treatment

As for other EDs with orofacial clefting and ophthalmologic involvement, management requires a team approach. Similarly, treatment for the limb defects must be individualized. Renal ultrasound and a high index of suspicion for urinary tract problems may be appropriate.

RAPP-HODGKIN SYNDROME (OMIM #129400)

Described in 1968, Rapp-Hodgkin syndrome is an autosomal dominant disorder that shares in common with Hay-Wells syndrome cleft palate with or without cleft lip, hypohidrosis usually without episodes of frank hyperpyrexia, abnormal hair with pili torti or pili trianguli et canaliculi and progressive balding, and nail dystrophy.[28,29] The face in Rapp-Hodgkin syndrome is striking, with a short nasal columella and maxillary hypoplasia, thin upper lip, and full lower lip (Fig. 143-7A,B). The nails are thick and short, worsening with age (see Fig. 143-7C). The teeth may be conical and prone to caries (see Fig. 143-7D). The lacrimal puncta are aplastic in almost one-third of affected individuals. Hypospadias has been reported in two-fifths of affected males; labial hypoplasia and absence of the opening of the vagina have been reported in a single female. These features are also reminiscent of the EEC syndrome. Rapp-Hodgkin syndrome has proven to be due to mutations in *p63*. Scalp involvement with breakdown and granulation tissue formation appears to be far less common in patients with Rapp-Hodgkin than in AEC syndrome, and AFA is rare. Treatment is the same for these similar disorders.





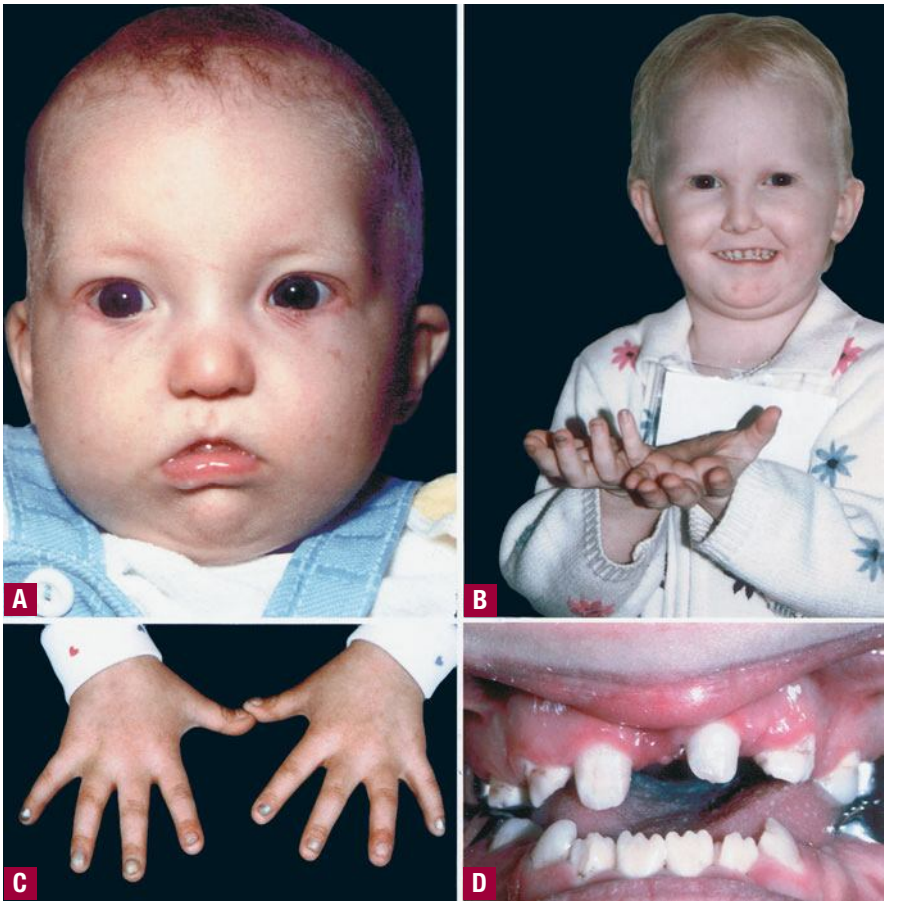

▲ **FIGURE 143-7** Rapp-Hodgkin syndrome. **A.** Affected infant at 5 months. **B.** Fine, blond, sparse hair; beginnings of nail changes on middle finger of right hand. (Used with permission from the National Foundation for Ectodermal Dysplasias.) **C.** Abnormal nails in same patient as (**A**), at age 4 and one-half years with thickened and friable nail plates. (From Sybert VP: *Genetic Skin Disorders*. New York, Oxford University Press, 1997.) **D.** Abnormal dentition, missing teeth, and peg teeth.

TOOTH AND NAIL SYNDROME (WITKOP SYNDROME; HYPODONTIA WITH NAIL DYSGENESIS; OMIM #189500)

Historical Aspects and Epidemiology

Etiology, Pathogenesis, and Genetics

A nonsense mutation in *MSX1*, a gene expressed in the developing teeth and nail beds in mice, has been found in one family with Witkop syndrome.[31] Other mutations in *MSX1* have been associated with isolated tooth agenesis or tooth agenesis with cleft palate. Tooth and nail syndrome is autosomal dominant, with variable expression and intrafamilial variability.

Clinical Manifestations

DERMATOLOGIC The nails are thin, small, and friable and may show koilonychia at birth. Toenails are usually more severely involved than fingernails (Fig. 143-8B). Nail changes improve with age and may be unappreciated in affected adults. A few individuals have reported thin, fine hair.

SYSTEMIC ASSOCIATIONS The primary teeth usually are unaffected, although they may be small. The secondary teeth may fail to erupt, and there can be partial or total absence (see Fig. 143-8A). The mandibular incisors, second molars, and maxillary canines are missing most often. No other ectodermal structures are affected.

Diagnosis and Differential Diagnosis

This is an easy condition to miss. The nail changes may be subtle. The tooth abnormalities may be mild enough to escape detection by a physician. The lack of associated features, either dermatologic or systemic, readily distinguish Witkop syndrome from other EDs. There is a presumed autosomal recessive disorder characterized by taurodontia (teeth with an elongated body and pulp chamber and short roots), absent teeth, sparse hair, and hypoplastic nails that appears similar.

Treatment and Prognosis

The nails usually require no treatment. Restorative dentistry is important.

FOCAL DERMAL HYPOPLASIA OF GOLTZ (OMIM #305600)

Epidemiology

Focal dermal hypoplasia of Goltz (FDH), first described in 1934, received its name from a report by Goltz and co-authors[32] of three patients. Subsequently, there have been over 200 case reports published.

Etiology, Pathogenesis, and Genetics

Focal dermal hypoplasia is an X-linked dominant disorder, usually lethal in

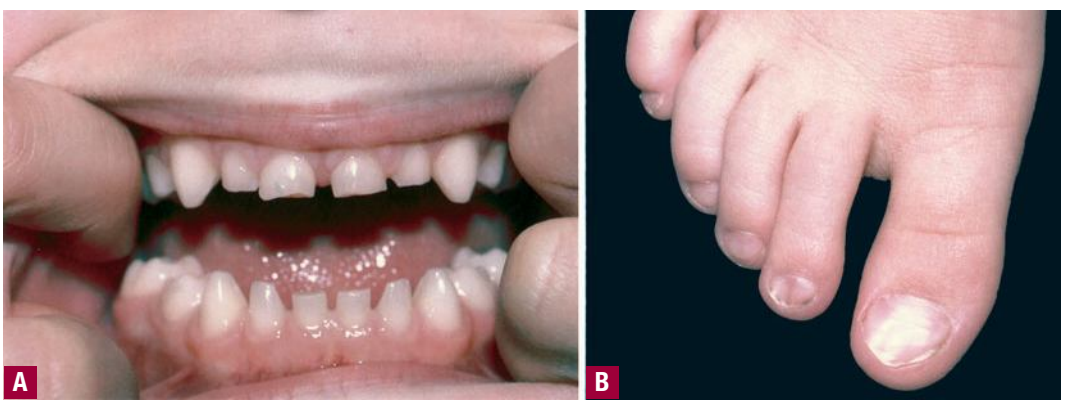

◀ **FIGURE 143-8** Tooth-nail syndrome. **A.** Primary teeth still in place; failure of adult teeth to erupt. **B.** Dystrophic toenails with flattening of nail plates.

males. Case reports of males with the condition are believed to be due to mosaicism for postzygotic mutations (as is true for incontinentia pigmenti); the presence of some normal cells allows survival in the male. The mutated gene is *PORCN*, the human homologue of the porcupine gene in drosophila. PORCN is thought to be important for palmitoylation and secretion of Wnt protein, a key regulator of the development of skin and bone.[33, 34]

Clinical Manifestations

DERMATOLOGIC The skin changes of FDH are the primary diagnostic features. There is linear, punctate, streaky cribriform atrophy (Fig. 143-9) with telangiectasia. The cribriform atrophy is marked by tiny ice pick–like depressions in the skin. These are distributed along the lines of Blaschko. Areas of thinned to absent dermis are irregularly distributed and the resultant herniations of fat appear as yellow-pink excrescences on the skin surface (see Fig. 143-9C). These are easily depressed. Papillomas that may be fleshy or vascular develop throughout life and favor the perigenital, perioral, intertriginous, and mucosal surfaces.

Other dermatologic features include patchy alopecia, brittle or sparse hair, and palmar and plantar hyperkeratoses. Some individuals have had hyperhidrosis and some have had aplasia cutis congenita.

SYSTEMIC ASSOCIATIONS The other organ systems most frequently involved in FDH are the skeletal, central nervous system, teeth, and eyes. Microphthalmia and coloboma are common and the diagnosis of FDH should prompt a full ophthalmologic evaluation. Oligodontia, tooth dysplasia, and enamel defects are common. The skeletal abnormalities are too numerous to list; the more common are vertical banding of the bones (osteopathia striata), syndactyly (both cutaneous and bony), asymmetry, and short stature. Mental retardation has been reported in approximately 15 percent of cases.

Defects in other organ systems have been described in a minority of cases, including cardiac defects, abdominal wall defects, and renal malformations. It is not certain that these are inherent features of FDH.

Diagnosis and Differential Diagnosis (See Box 143-1)

The diagnosis of FDH is relatively straightforward. Cribriform atrophy has been described in X-linked dominant Conradi-Hünermann syndrome (chondrodysplasia punctata), but ichthyosis is not a feature of FDH, and fat herniation is not part of Conradi-Hünermann. The streaky distribution of the atrophic lesions of IP is similar, as are the other system malformations, but the blistering, hyperkeratosis, and hyperpigmentation of IP are not found in FDH. In microphthalmia and linear skin defects/microphthalmia, dermal aplasia, sclerocornea, the skin defects are limited to the head and neck; there is atrophy and scarring of the skin more similar to aplasia cutis congenita and not dermal atrophy alone. The disorders do share similar ocular abnormalities.



▲ **FIGURE 143-9** Focal dermal hypoplasia of Goltz. **A.** Streaky and patchy involvement in the newborn. Note similarity to the distribution of lesions in incontinentia pigmenti. **B,C.** Same girl at age 2 showing atrophy and fat herniation. **D.** Now a young adult, erythema and atrophy, with dryness and scale, predominate. (From Sybert VP: *Genetic Skin Disorders*. New York, Oxford University Press, 1997.)



Treatment and Prognosis

There is no specific treatment for the dermatologic and systemic features of FDH. Papillomas can be excised if they interfere with function. Use of vascular lasers to decrease the erythema of telangiectatic areas may have cosmetic benefit. As with most X-linked dominant disorders, clinical involvement varies considerably, and the range in severity is marked. This makes prognostic counseling difficult early in infancy, and usually it is wiser to counsel patience and reassurance until the extent to which there is systemic involvement becomes clear. It is important to inquire about the family history of lost pregnancies (a distorted male-female ratio in offspring and increased pregnancy loss are clues to the mother being a carrier). Both mothers and fathers should be examined carefully; fathers may have subtle features, and, presumably, represent individuals with postzygotic mutations for the FDH gene.



ECTODERMAL DYSPLASIA WITH SKIN FRAGILITY (See Chap. 60)

KINDLER SYNDROME (See Chap. 60)

KEY REFERENCES

The full reference list for all chapters is available at www.digm7.com.

1. Freire-Maia N, Pinheiro M: *Ectodermal Dysplasias: A Clinical and Genetic Study*. New York, Liss, 1984
3. Lamartine J: Towards a new classification of ectodermal dysplasias. *Clin Exp Dermatol* **28**: 351, 2003.
7. Vincent MC et al: Mutational spectrum of the *ED1* gene in X-linked hypohidrotic ectodermal dysplasia. *Eur J Hum Genet* **9**:355, 2001
11. Berlin AL, Paller AS, Chan LS: Incontinentia pigmenti: A review and update on the molecular basis of pathophysiology. *J Am Acad Dermatol* **47**:169, 2002
12. Clarke A et al: Clinical aspects of X-linked hypohidrotic ectodermal dysplasia. *Arch Dis Child* **62**:989, 1987
17. Lamartine J et al: Mutations in *GJB6* cause hidrotic ectodermal dysplasia. *Nature Genet* **26**:142, 2000
20. van Bokhoven H, McKeon F: Mutations in the p53 homolog p63: Allele-specific developmental syndromes in humans.*Trends Mol Med* **8**:133, 2002
31. Jumlongras D et al: A nonsense mutation in *MSX1* causes Witkop syndrome. *Am J Hum Genet* **69**:67, 2001
32. Goltz RW: Focal dermal hypoplasia syndrome. An update. *Arch Dermatol* **128**:1108, 1992

CHAPTER 144

Genetic Immunodeficiency Diseases

Amy S. Paller
Melissa Abrams

Immunodeficiency disorders may be associated with a variety of cutaneous abnormalities, and recognition of these clinical features may allow an early diagnosis of primary immunodeficiency. Cutaneous abnormalities may include cutaneous infections, atopic- or seborrheic-like dermatitis, macular erythemas, alopecia, poor wound healing, purpura, petechiae, telangiectasias, pigmentary dilution, cutaneous granulomas, extensive warts, angioedema, and lupus-like changes (Table 144-1). Other clinical features often include failure to thrive, visceral infection, autoimmune disorders, connective tissue/rheumatologic diseases, allergic reactions, and neoplasias.

CLINICAL FINDINGS

In general, immunodeficiency should be suspected when patients have recurrent infections of increased duration and severity, particularly with unusual organisms. Incomplete clearing of infections, unexpected or severe complications of infection, or poor response to antibiotics may be associated.[1] Affected infants often grow poorly (failure to thrive). The most common non-cutaneous abnormalities are infections, diarrhea, vomiting, hepatosplenomegaly, arthritis, adenopathy or paucity of lymph nodes/tonsils, and hematologic abnormalities.

The classification of genetic immunodeficiency disorders includes (1) antibody deficiencies, (2) cellular deficiencies, (3) combined antibody and cellular deficiencies, (4) disorders of phagocytosis and cell killing, and (5) complement defects. The characteristic clinical signs of each group suggest that proper classification and laboratory tests may be used to confirm the diagnosis. The laboratory testing and clinical patterns of illness associated with each group of immunodeficiency disorders that allow their differential diagnosis are outlined in Table 144-2 and Fig. 144-1. Most important in the differential diagnosis of all genetic immunodeficiency disorders is human immunodeficiency virus (HIV) infection. In addition to the lack of HIV antigen as detected by polymerase chain reaction in patients with genetic immunodeficiency, other features help to differentiate the disorders. Patients with HIV infection tend to show an inverted CD4/CD8 ratio and hypergammaglobulinemia, in contrast to the hypogammaglobulinemia of many patients with genetic immunodeficiency.

ANTIBODY DEFICIENCY DISORDERS

X-Linked Agammaglobulinemia

EPIDEMIOLOGY X-linked agammaglobulininemia (XLA) is inherited in an X-linked fashion, and approximately 50 percent of affected boys have a family history of the disorder.[2]

ETIOLOGY AND PATHOGENESIS The underlying defect in XLA is failure of maturation of the pre-B cell to a differentiating B cell; B-cell precursors are found in the bone marrow in normal numbers. The causative gene, BTK (Bruton or B-cell tyrosine kinase) encodes a kinase (Btk)

X-LINKED AGAMMAGLOBULINEMIA AT A GLANCE

- Synonym: Bruton disease
- Early onset, recurrent bacterial infections
- Absent or barely detectable tonsillar and cervical lymph node tissue
- Profound hypogammaglobulinemia and decreased or absent peripheral B cells

TABLE 144-1
Manifestations of Genetic Immunodeficiencies

Cutaneous Manifestations	Associated Immunodeficiencies
Angioedema	• Hereditary angioedema
Atopic-like dermatitis	• IgA deficiency/IgM deficiency
	• Chronic granulomatous disease
	• Common variable immunodeficiency
	• Elevated IgM with hypogammaglobulinemia
	• Ectodermal dysplasia with immunodeficiency
	• Hyperimmunoglobulinemia E syndrome
	• Severe combined immunodeficiency
	• Wiskott-Aldrich syndrome
	• X-linked agammaglobulinemia
Cutaneous abscesses	• Chronic granulomatous disease
	• Hyperimmunoglobulinemia E syndrome
	• Leukocyte adhesion deficiency
Cutaneous granulomas	• Ataxia-telangiectasia
	• Chronic granulomatous disease
	• Chronic mucocutaneous candidiasis
	• Common variable immunodeficiency
	• Severe combined immunodeficiency, especially TAP2 deficiency
	• X-linked hypogammaglobulinemia
Cutaneous candidal infection	• Chronic mucocutaneous candidiasis
	• DiGeorge syndrome
	• Hyperimmunoglobulinemia E syndrome
	• Severe combined immunodeficiency
Eosinophilic folliculitis, infantile	• Hyperimmunoglobulinemia E syndrome
Graft-versus-host disease	• DiGeorge syndrome
	• Severe combined immunodeficiency
Lupus-like cutaneous change	• IgA deficiency
	• Chronic granulomatous disease, autosomal recessive
	• Chronic granulomatous disease, X-linked carrier
	• Common variable immunodeficiency
	• Complement deficiency, early components
	• Elevated IgM with hypogammaglobulinemia
Mucocutaneous telangiectases	• Ataxia-telangiectasia
Petechiae and/or purpura	• Chédiak-Higashi syndrome
	• Griscelli syndrome
	• Wiskott-Aldrich syndrome
Pigmentary dilution/ silvery hair	• Chédiak-Higashi syndrome
	• Griscelli syndrome
Pyoderma gangrenosum-like ulcerations	• IgA deficiency
	• Chédiak-Higashi syndrome
	• Chronic granulomatous disease
	• Hyperimmunoglobulinemia E syndrome
	• Leukocyte adhesion deficiency
	• X-linked hypogammaglobulinemia
Seborrheic-like or exfoliative dermatitis	• Ataxia-telangiectasia
	• "Leiner" phenotype: complement deficiency or dysfunction
	• Severe combined immunodeficiency
	• X-linked agammaglobulinemia
Warts, extensive	• Common variable immunodeficiency
	• Elevated IgM with hypogammaglobulinemia
	• Epidermodysplasia verruciformis (see Chap. 196)
	• IgM deficiency
	• Severe combined immunodeficiency after transplantation (mutations in *IL2RG* or *JAK3*)
	• WHIM syndrome

Ig = immunoglobulin; TAP = Transporter associated with Antigen Processing or Transporter, ATP-binding cassette; WHIM = warts, hypogammaglobulinemia, infections, myelokathexis.

TABLE 144-2
Patterns Associated with Primary Immune Deficiency

Disorder	Infection	Other
Antibody	Sinopulmonary (pyogenic bacteria)	Autoimmune disease (autoantibodies, inflammatory bowel disease)
	Gastrointestinal (enterovirus, *Giardia*)	Minimal growth retardation
	Normal handling of fungal and viral infections (exception is enterovirus)	Paucity of lymphoid tissue
Cellular	Low-grade or opportunistic infections	Growth retardation
	Pneumonia (pyogenic bacteria, *Pneumocystis*, viruses)	Graft-versus-host disease
	Gastrointestinal (viruses)	Fatal infections from live vaccines
	Skin, mucous membranes (fungi)	Malignancy
Phagocytosis and cell killing	Skin, reticuloendothelial system (*Staphylococcus*, enteric bacteria, *Aspergillus*, mycobacteria)	Ulcerative stomatitis
Complement	Alternative, late components	Early components
	Sepsis/blood-borne (streptococci, pneumococci, *Neisseria*)	Autoimmune disease (systemic lupus erythematosus, glomerulonephritis)
		C1 esterase inhibitor deficiency
		Angioedema





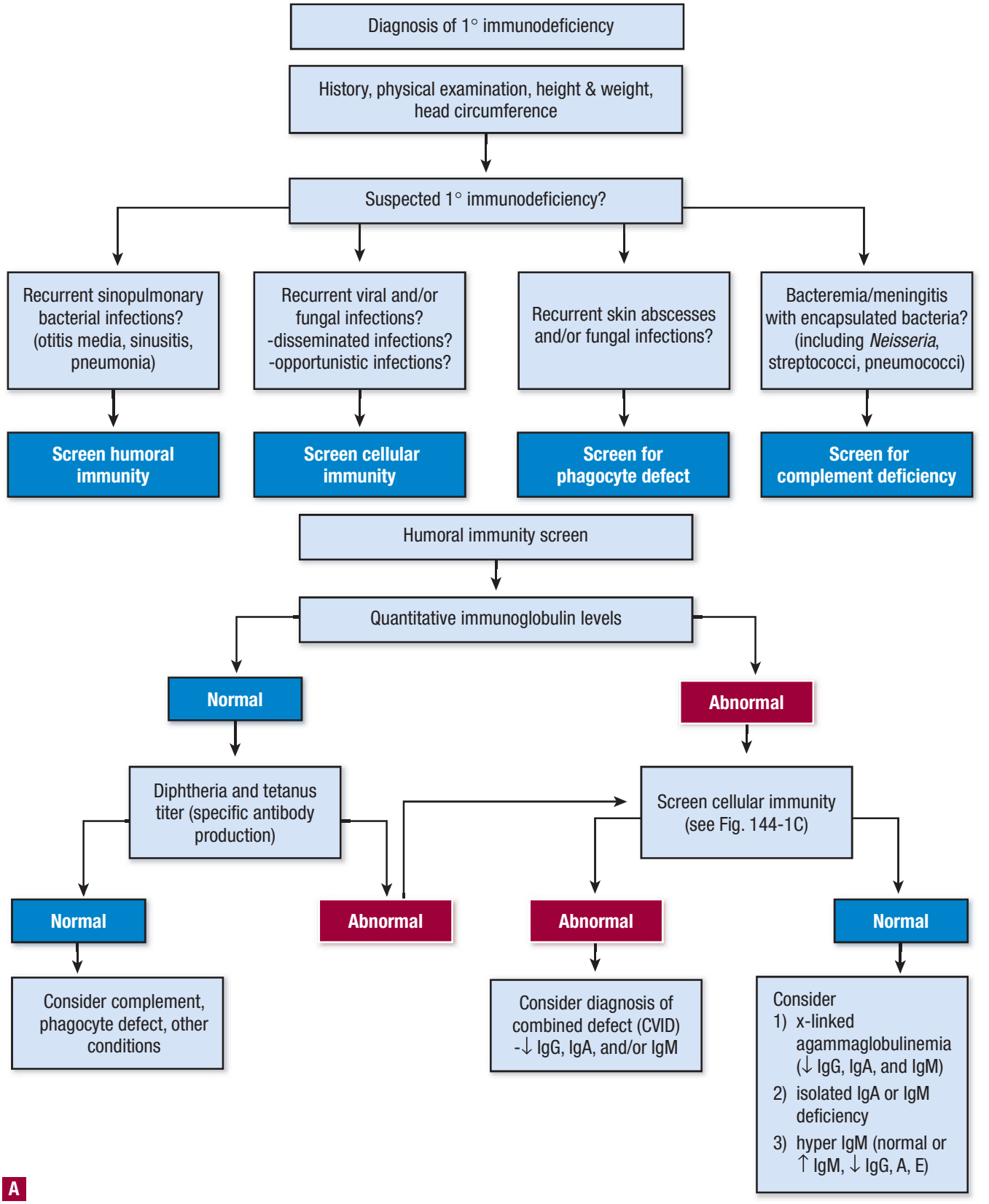

▲ **FIGURE 144-1 A–C.** Algorithm for immunodeficiency disorders in neonates and infants. *If the clinical presentation is concerning for severe combined immunodeficiency (SCID), this is a medical emergency and patient needs immediate referral to an immunologist. AT = ataxia-telangiectasia; CBC = complete blood cell count; CVID = common variable immunodeficiency; HIV = human immunodeficiency virus; Ig = immunoglobulin; NK cell = natural killer cell; NL = normal; ↓ = decreased; ↑ = increased. *(continued)*

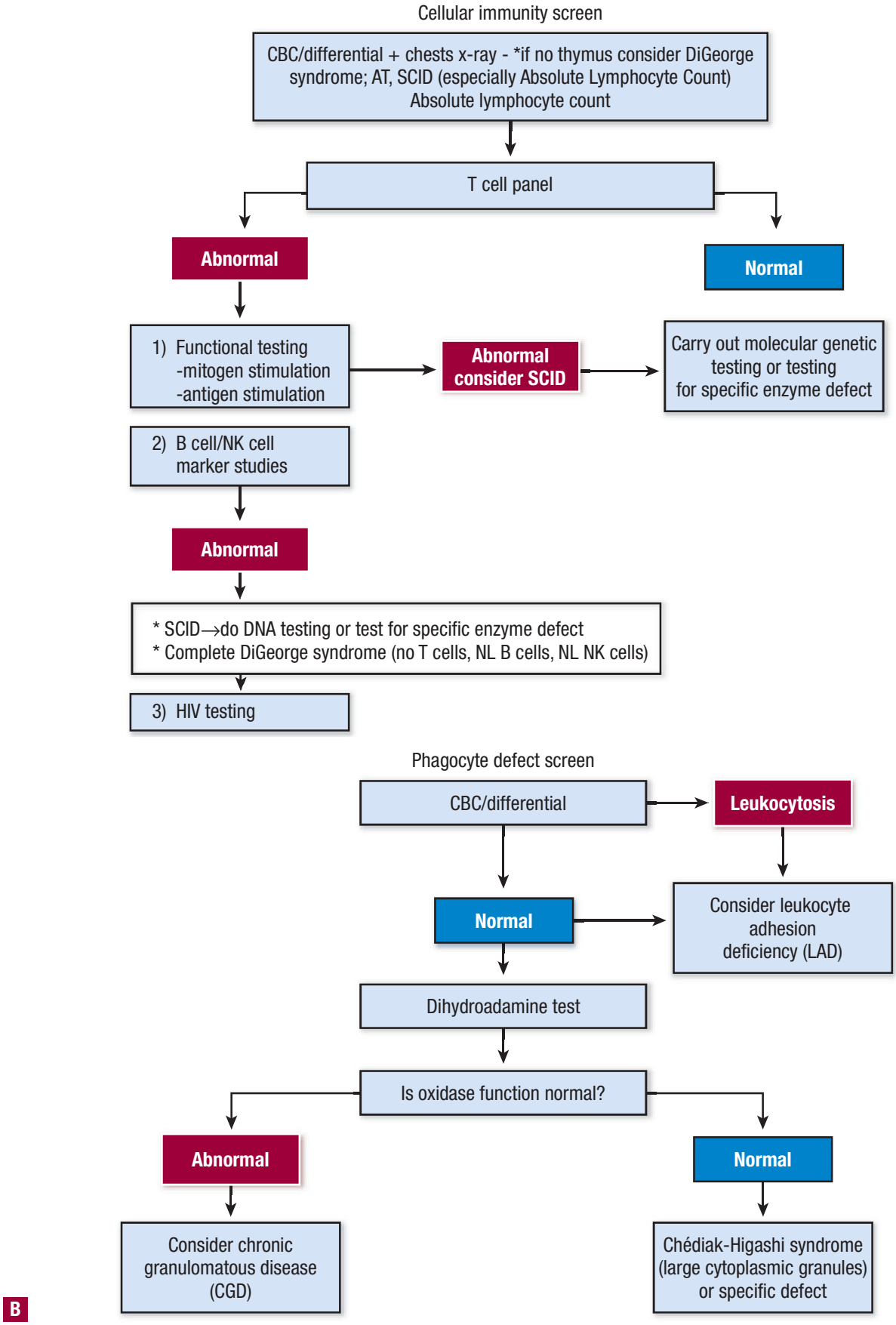

▲ FIGURE 144-1 (CONTINUED)





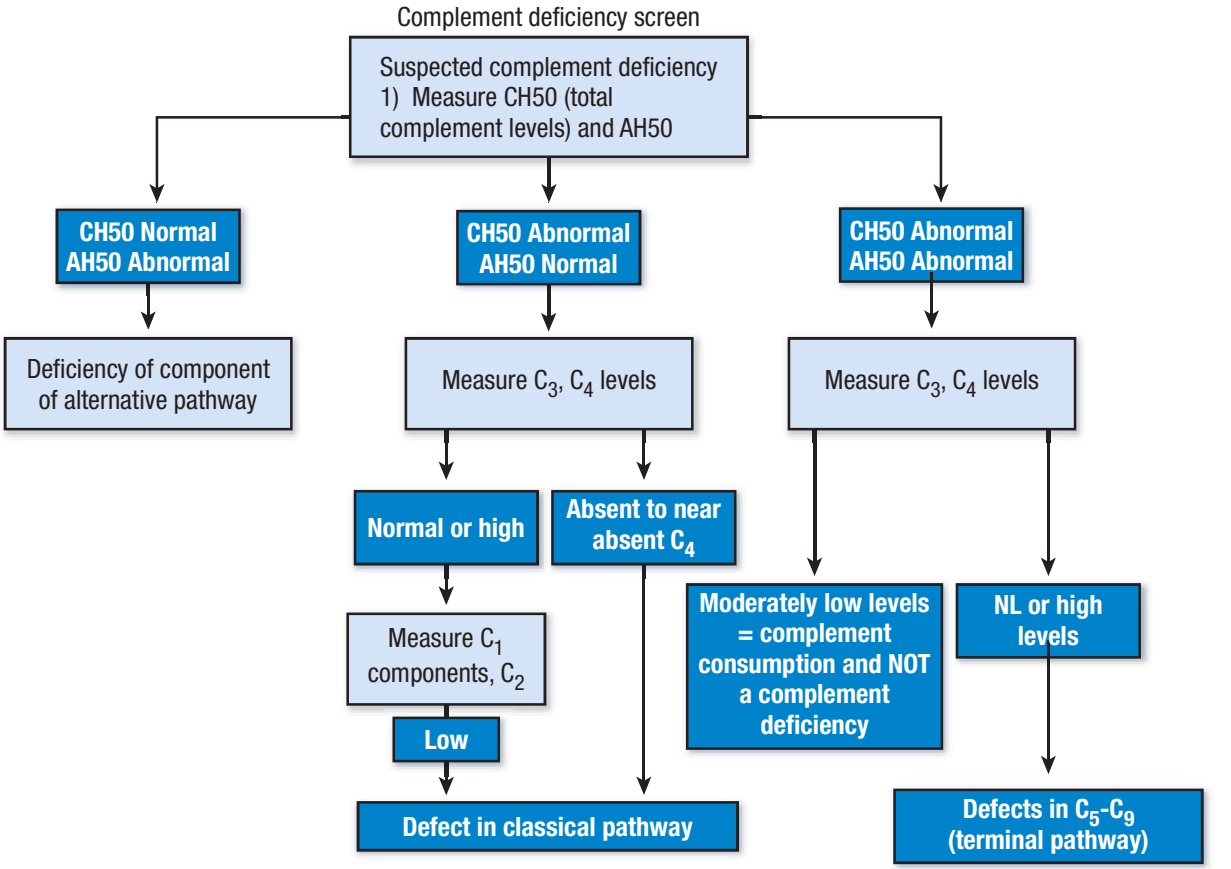

C

▲ FIGURE 144-1 (CONTINUED)

that participates in B-cell receptor intracellular signaling and is essential for B-cell maturation. Cell-mediated immunity is normal. More than 500 different mutations in Btk have been reported, and no single mutation is detected in more than 3 percent of the patients.[3] Carrier detection is possible by analyzing the patterns of X-chromosome inactivation, with selective inactivation of the abnormal X chromosome in B lymphocytes from female carriers.

CLINICAL FINDINGS XLA is characterized by recurrent pyogenic infections that often begin approximately 9 months after birth, concurrent with the disappearance of maternal immunoglobulins. These patients have absent or barely detectable tonsils and cervical lymph nodes.[4] Skin infections, especially furunculosis and impetigo, occur in 28 percent of patients and often surround body orifices. An atopic-like eczematous eruption that fails to improve with immunoglobulin therapy has been described in many affected children. Pyoderma gangrenosum and non-infectious cutaneous granulomas have been reported. Childhood exanthematous disorders are handled appropriately, but the infections may recur, owing to a failure to develop specific antibodies.

The diagnosis of XLA is made by serum concentrations of immunoglobulin G (IgG), IgA, and IgM that are far below the 95 percent confidence limits for appropriate controls (usually less than 100 mg/dL total immunoglobulin). The number of B cells in the peripheral circulation is also low (< 1 percent of normal).

TREATMENT, PROGNOSIS, AND CLINICAL COURSE Early intravenous immunoglobulin (IVIG) replacement and antibiotic use markedly reduces the risk of infections, although it may not be helpful in diminishing the risk and morbidity of chronic lung disease, chronic enterovirus infection, or of lymphoreticular malignancy (as high as 6 percent).

Common Variable Immunodeficiency

EPIDEMIOLOGY The disease prevalence of common variable immunodeficiency (CVI) is estimated at 1 in 25,000.[6] Age at first diagnosis shows a bimodal distribu-

COMMON VARIABLE IMMUNODEFICIENCY AT A GLANCE



- Heterogeneous group of disorders in which both antibody deficiency and abnormalities of T cells may be found
- Most common underlying gene defect in transmembrane activator, calcium modulator, and cyclophilin ligand interactor, which also can lead to immunoglobulin A deficiency
- May manifest during childhood, but average of onset is almost 30 years old
- Variable severity of autoimmune and infectious complications

tion with one peak between 6 and 10 years and another peak at 26 to 30 years of age, with males and females affected equally. Most cases are sporadic, but at least 10 percent are familial with a predominance of autosomal dominant over autosomal recessive inheritance.

ETIOLOGY AND PATHOGENESIS Identified genetic defects underlying CVI include defects in transmembrane activator, calcium modulator, and cyclophilin ligand interactor (TACI), inducible co-stimulator (ICOS), B-cell activation factor of the tumor necrosis factor family receptor (BAFF-R), and CD19. Each of these is critical for B-lymphocyte activation and differentiation. Altogether, mutations in these genes account for approximately 10 percent to 20 percent of patients, with defects in TACI being the most common.[6] The majority of defects have yet to be discovered.

CLINICAL FINDINGS CVI commonly presents in young adults, but 45 percent of cases are diagnosed before the age of 21 years old.[7] Patients have infections similar to those in patients with XLA, particularly sinopulmonary infections, but are less susceptible to enteroviral infections and more susceptible to *Giardia* infections. Many patients with CVI have liver disease and gastrointestinal (GI) disease, causing malabsorption syndromes. Noncaseating granulomas of skin (Fig. 144-2), lungs, liver, and spleen have been reported. Caseating granulomas of the skin and viscera, although rare, have also been described.[8,9] Extensive warts can be a major problem in individuals with CVI (Fig. 144-3). Lymphoid tissues often are enlarged, and



▲ **FIGURE 144-2** Noncaseating granulomas on the legs of a child with common variable immunodeficiency. Cultures and special stains showed no organisms.



▲ **FIGURE 144-3** The dorsal aspect of the hands were covered with recalcitrant verrucae vulgares in this girl with common variable immunodeficiency.

splenomegaly with hypersplenism is found in 25 percent of patients. Autoimmune disorders are especially frequent (11 percent to 22 percent),[7,10] particularly autoimmune thrombocytopenia, autoimmune hemolytic anemia, rheumatoid arthritis, sicca syndrome, and pernicious anemia. Alopecia areata and lupus also have been described. In 10 percent to 20 percent of patients, at least one family member is also immunodeficient, particularly with CVI or IgA deficiency.[11] The incidence of lymphoreticular malignancy and gastric carcinoma are markedly increased, particularly in the fifth and sixth decades of life.[12]

LABORATORY FINDINGS Failure in B-cell differentiation leading to impaired secretion of immunoglobulins leads to reduced serum IgG and IgA and/or IgM, two standard deviations or more below the mean.[7] The numbers of circulating B lymphocytes are usually normal. Cellular immunity is also impaired.[13] Approximately one-half of patients have T-cell dysfunction,[14] with the incidence increasing with advancing age. Patients have a lower number of circulating absolute $CD4^+$ T cells and a normal number of $CD8^+$ T cells.[15]

PROGNOSIS, CLINICAL COURSE, AND TREATMENT Periodic IVIG administration is standard treatment for CVI. Prophylactic antibiotics should be initiated in patients who continue to have infections despite immunoglobulin therapy.[16] Patients with granulomatous inflammation have a worse prognosis.[17] The mean age of death for females is 45.5 years old and for males, 40 years old. The majority die from either lymphoma or chronic sinopulmonary infections.[7]

SELECTIVE IMMUNOGLOBULIN DISORDERS

Immunoglobulin A Deficiency

Immunoglobulin M Deficiency

Hyper-Immunoglobulin M Syndrome

EPIDEMIOLOGY The disorder usually occurs in males, with X-linked inheritance in approximately 70 percent of affected individuals. Incidence is approximately 1 in 1 million live births.[20] An X-linked recessive form and two autosomal recessive forms have also been described.

PATHOGENESIS Hyper-IgM syndrome is caused by a defect of B-cell differentiation.[20] Normally, the humoral immune response begins with production of IgM and IgD antibodies. Subsequently, IgG, then IgA, and, finally, IgE antibodies are produced. The sequential production of different classes of immunoglobulins is called *class switching*. This mechanism enables the immune system to produce antibodies with different effector functions while retaining variable region specificity. In hyper-IgM syndrome, B cells are unable to switch from IgM/IgD secretion to the production of other immunoglobulin isotypes (see Chap. 36).

In contrast to the case in X-linked agammaglobulinemia, female carriers of the hyper-IgM syndrome due to mutations in CD40 ligand have random inacti-

SELECTIVE IMMUNOGLOBULIN DISORDERS AT A GLANCE

- Immunoglobulin A deficiency is usually asymptomatic; only 10 percent to 15 percent of affected individuals demonstrate clinical manifestations, especially bacterial sinopulmonary infections and autoimmune disorders.
- Most cases of hyper-immunoglobulin M syndrome have the X-linked recessive form with deficiency of CD40 ligand; common clinical features are recurrent sinopulmonary and gastrointestinal infections, oral ulcerations, and verrucae.



vation of the X chromosome in T lymphocytes because the CD40 ligand is not required for the normal development of T lymphocytes. Female carriers, in general, do not tend to show clinical manifestations. However, a female carrier who was noted to have 95 percent of her T cells expressing the mutant X chromosome had recurrent infections of the upper and lower respiratory tract[28] and another carrier had gastric lymphoma.[29]

CLINICAL FINDINGS More than one-half of patients develop symptoms of immunodeficiency and are diagnosed before age 1 year. Nearly all patients have symptoms by 4 years of age.[20] Most notable are respiratory tract infections, seen in 81 percent of patients,[20] dermatitis, an increased incidence and severity of warts, and oral ulcerations, sometimes in association with neutropenia.[30,31] Cellulitis and subcutaneous abscesses are seen in 13 percent of patients.[20] Recurrent diarrhea, central nervous system (CNS) infections and sepsis are also common. In addition to pyogenic and opportunistic infections, including *Pneumocystis carinii*, patients tend to develop autoimmune disorders of the hematopoietic system. Uncontrolled proliferation of IgM-producing plasma cells often occurs during the second decade of life, at times resulting in potentially fatal, massive infiltration of the GI tract, liver, and gallbladder. Patients with hyper-IgM syndrome also have an increased risk of cancer involving the GI tract. The sera of patients with hyper-IgM syndrome have very low amounts of IgG, IgA, and IgE, but normal or high concentrations of IgM and IgD. Despite the name, high levels of IgM are found in fewer than one-third of patients.[20]

PROGNOSIS, CLINICAL COURSE, AND TREATMENT The leading causes of death are pneumonia, encephalitis, and malignancy. The condition is treated prophylactically with intravenous γ-globulin; the autoimmune neutropenia also may respond to granulocyte-macrophage colony-stimulating factor. More than one-half of the patients benefit from prophylactic antibiotics for *P. carinii*. Allogeneic bone marrow transplantation may correct the disorder.

X-Linked Lymphoproliferative Disease (Duncan Disease)

EPIDEMIOLOGY The incidence of X-linked lymphoproliferative disease (XLP) is 1 in 3 million males.[32,33]

PATHOGENESIS XLP disease results from mutations in *SH2D1A*,[34,35] which encodes an adapter protein, signaling lymphocytic activation molecule (SLAM)-associated protein (SAP), critical to intracellular signaling pathways.[36] SAP is expressed in T cells, natural killer (NK) cells, and NKT cells.

CLINICAL FINDINGS XLP is characterized by fulminant infectious mononucleosis, dysgammaglobulinemia, and lymphoproliferative disorders.[36] Patients are also at risk for the development of autoimmune disorders. These clinical manifestations usually develop following Epstein-Barr virus (EBV) infection in boys who have previously had normal immunologic responses. With EBV infection; however, patients respond abnormally to the antigen and fail to develop EBV-specific serologic responses.

Malignant lymphomas and nonmalignant lymphoproliferative disorders, including lymphomatoid granulomatosis, Wegener granulomatosis, and necrotizing vasculitis, affect 20 percent to 30 percent of patients.[37] The majority of malignant tumors are of B-cell origin.

PROGNOSIS, CLINICAL COURSE, AND TREATMENT XLP is a fatal disease and 70 percent of patients die by the age of 10 years.[36] The median survival after development of primary EBV infection and fulminant mononucleosis is 1 to 2 months.[33] Most patients die from severe hepatitis, liver necrosis, and hepatic failure. Patients with isolated hypogammaglobulinemia treated with intravenous immunoglobulin have a better prognosis than those who develop infectious mononucleosis or lymphoma.[36]

CELLULAR DEFICIENCIES

Chronic Mucocutaneous Candidiasis

EPIDEMIOLOGY Several clinical sub-types have been defined (Table 144-3). They have varied clinical manifestations, variable immunodeficiency, and different forms of genetic inheritance. Patients with chronic mucocutaneous candidiasis (CMC) may have childhood or mature onset, familial, or sporadic occurrence, and CMC may be present with or without endocrinopathy. Patients with *a*utoimmune *p*oly*e*ndocrinopathy-*c*andidiasis-*e*ctodermal *d*ystrophy (APECED or autoimmune polyendocrine syndrome or APS, type 1) often have affected siblings. APECED and other familial forms of CMC are autosomal recessive. Autosomal dominant inheritance is seen in patients with associated keratitis.

CHRONIC MUCOCUTANEOUS CANDIDIASIS AT A GLANCE



- A heterogeneous group of disorders with altered immune responses selective to candida
- Recurrent, progressive candidal infections of the skin, nails, and mucous membranes
- May be associated with the later development of endocrinopathy [(APECED) *a*utoimmune *p*oly*e*ndocrinopathy-*c*andidiasis-*e*ctodermal *d*ystrophy]

ETIOLOGY AND PATHOGENESIS The clinical features of CMC may be seen in a variety of immunologic disorders, all characterized by ineffective defense mechanisms against *Candida*. In general, the patients with greater severity and an earlier onset of cutaneous candidal infections have more severe immunologic alterations. CMC patients have shown general dysregulation of interleukin 12 (IL-12), IL-6, and interferon-γ (IFN-γ) production,[39] resulting in an inability to mount a cell-mediated response to clear candidal organisms. Chronic infections result in production of high levels of inflammatory cytokines (IL-6) followed by anti-inflammatory cytokines (IL-10) that further reduce the production of T helper 1 (Th1)-inducing cytokines via a positive feedback loop.[39]

Humoral immunity appears normal in most patients and 25 percent to 35 percent of patients with CMC have no demonstrable immunologic defects. Many patients with CMC have associated APECED syndrome,[40] owing to mutations in the autoimmune regulator (*AIRE*) gene which maps to 21q22.3 and encodes a DNA transcription factor.[41] Mice that are deficient in AIRE do not delete organ-specific T cells in the thymus, thus promoting the development of autoimmune disease.[42] The reason for susceptibility to mucocuta-



TABLE 144-3
Classification of Patients with Chronic Mucocutaneous Candidiasis[a]

CMC Type	Inheritance/Gene Defect	Onset	Clinical Features	Associated Disorders	Non-Candidal Infections
Chronic oral candidiasis	No known genetic defect.	Middle-aged or elderly women.	Candidiasis of tongue and buccal mucosa. No esophageal, skin, or nail involvement.	Fe^{2+} deficiency	No
Familial chronic mucocutaneous candidiasis	Autosomal recessive and autosomal dominant. Males and females are equally affected.	Early childhood, often before age 2 yr.	Oral candidiasis. Limited skin and nail involvement.	No endocrinopathies	Yes
Autoimmune polyendocrinopathy-candidiasis-ectodermal dystrophy syndrome	Autosomal recessive. Mutations in the *AIRE* (autoimmune regulator) gene on 21q22.3. More common in the Finnish population, Iranian Jews, and Sardinians. Rarely, dominant form with AIRE mutations or mapped to chromosome 2p.	Candidal infections before age 5 yr. Endocrine abnormalities between 10 and 15 yr of age.	Oral and diaper area candidiasis more often than skin and nail involvement. Endocrinopathies and autoimmune disorders.	Most common endocrinopathies: Hypoparathyroidism Hypoadrenalism Other associated disorders: Thyroid disease Primary hypogonadism Hepatitis Malabsorption Pernicious anemia Alopecia areata Vitiligo Ectodermal manifestations: Dental enamel hypoplasia Pitted nail dystrophy Keratoconjunctivitis	Yes
CMC with thymoma	No known genetic basis.	Adult onset.	Mucous membrane and cutaneous candidiasis.	Malignant/benign thymomas Aplastic anemia Myasthenia gravis Hypogammaglobulinemia	No
Chronic localized candidiasis (candida granuloma)	No known genetic basis. Males and females are equally affected.	Early childhood, often before age 5 yr.	Thick, adherent candidal crusts on the scalp and face. Oral candidiasis.	None	Yes
CMC with keratitis	Autosomal dominant.	Early childhood.	Candidiasis of the oral cavity, diaper area.	Keratoconjunctivitis Alopecia Endocrine abnormalities	Yes

CMC = chronic mucocutaneous candidiasis.
[a]Chronic candidal infections have been described in patients with DiGeorge, hyperimmunoglobulinemia E, severe combined immunodeficiency, ectrodactyly-ectodermal dysplasia-clefting, and keratitis-ichthyosis-deafness syndromes; multiple carboxylase deficiency; and acrodermatitis enteropathica.

neous candidal infections is unclear. APECED must be distinguished from *i*mmune dysregulation, *p*olyendocrinopathy, *e*nteropathy, *X*-linked (IPEX) syndrome, an X-linked recessive disorder in which the abnormal development of regulatory T cells results from mutations in the *FOXP3* gene. Patients with IPEX syndrome show psoriasiform dermatitis, nail dystrophy, autoimmune endocrinopathies (overlapping with those seen in APECED syndrome), and autoimmune skin conditions such as alopecia universalis.[43]

CLINICAL FINDINGS Patients with CMC have recurrent, progressive infections of the skin, nails, and mucous membranes most commonly due to *C. albicans*.[41,44] Depending on the sub-type, the clinical presentation ranges from recurrent, recalcitrant thrush (Fig. 144-4) to mild erythematous scaling plaques (see eFig. 144-4.1 in on-line edition) with a few dystrophic nails to severe generalized, crusted granulomatous plaques (Fig. 144-5). The cutaneous plaques occur most commonly in intertriginous areas, periorificial sites, and the scalp, but they may be generalized. The nails are thickened, brittle, and discolored, and the paronychial areas are often erythematous, swollen, and tender. Scalp infections may lead to scarring and alopecia. Although the oral mucosa is the most frequent site of mucosal alteration, esophageal, genital, and laryngeal mucosae may be affected. Strictures may be formed by candidal infection at these mucosal sites. Scrapings and cultures

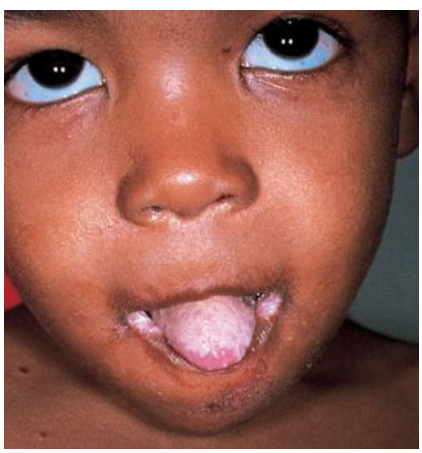

▲ **FIGURE 144-4** Recurrent thrush and candidal cheilitis in a boy with mucocutaneous candidiasis.







▲ **FIGURE 144-5** This 3-year-old child with hypothyroidism had oral thrush, intertriginous candidiasis, warty hyperkeratoses, and crusts on the scalp and face; and also, candidal onychomycosis. The warty growths shown in the photograph consisted of dried pus and serum, and grew pure cultures of *Candida*.

from cutaneous or mucosal lesions demonstrate candidal organisms.

Patients with CMC rarely develop systemic candidiasis, but 50 percent may develop recurrent or severe infections due to other organisms. In one study, 81 percent of patients with early-onset CMC also had infections with bacteria, fungi, and parasites, including bacterial septicemia.[41] Concomitant dermatophyte infections may occur.

In patients with APECED, the candidal infections tend to begin by 5 years of age, although the endocrinologic dysfunction may not be apparent until 12 to 13 years of age (see Fig. 144-5). The most commonly associated endocrinopathies are hypoparathyroidism (88 percent) and hypoadrenocorticism (60 percent). One-third of patients have candidiasis, hypoparathyroidism, and defective adrenal function. Other associated endocrinopathies or autoimmune disorders include gonadal insufficiency (45 percent), alopecia areata (20 percent), pernicious anemia (16 percent), thyroid abnormalities (12 percent), chronic active hepatitis or juvenile cirrhosis (9 percent), vitiligo, diabetes mellitus, and hypopituitarism. Chronic diarrhea and malabsorption have been reported in 25 percent of patients and usually are associated with hypoparathyroidism. Some affected patients also have pulmonary fibrosis, dental enamel hypoplasia, and keratoconjunctivitis. The "ectodermal dysplasia" features are likely to be secondary to the candidal infections or autoimmunity[44] Patients with APECED often have autoimmune antibodies, including antithyroglobulin, antimicrosomal antibodies, antiadrenal and antimelanocyte antibodies, and rheumatoid factor. Autoantibodies also have been found in patients with CMC who do not have clinical endocrinologic disease.

PROGNOSIS, CLINICAL COURSE, AND TREATMENT Candidal lesions in patients with CMC generally respond to systemically administered azole antifungal agents (itraconazole, fluconazole) or terbinafine.[45] Ketoconazole is no longer used because of the risk of hepatitis. Patients who are resistant usually respond to amphotericin B with or without flucytosine. Cutaneous granulomas often are less responsive despite clearance of infection. Recurrences are common, and the antifungal agents must be used intermittently. The drugs have no effect on the abnormal cell-mediated immunity. All patients with CMC should have an annual endocrine evaluation and patients with documented endocrinopathy or a family history of APECED should be monitored more closely. Patients who have a history of infections other than candidal should have further evaluation of their immune status.

DiGeorge Syndrome

EPIDEMIOLOGY The incidence of DiGeorge syndrome (DGS) is 1 in 4000 live births.[46] Ninety percent of the cases are associated with a deletion in chromosome 22q11.1.

ETIOLOGY AND PATHOGENESIS DGS (congenital thymic aplasia) is a member of a group of disorders that result from deletion of chromosome 22q11 (catch 22/DGS/velocardiofacial syndrome).[47] The disorder results from developmental defects of the third and fourth pharyngeal pouches due to haploinsufficiency of Tbx1, t-box transcription factor.[48]

CLINICAL FINDINGS The thymic shadow is absent or reduced at birth. Infants often have neonatal tetany with hypocalcemia due to the aplastic parathyroid glands. The cardiac anomalies are most commonly truncus arteriosus, septal defects, and abnormal aortic arch vessels. Characteristic facial features of DGS include a short philtrum, low-set malformed ears, and hypertelorism.

Many patients have recurrent mucocutaneous candidal infections as neonates, as well as increased susceptibility to viral infections, *P. carinii*, and other fungal infections. Graft-versus-host disease (GVHD) may develop in infants given nonirradiated blood products. There is an overall increased of malignancy, particularly hepatoblastoma; in a cohort of patients with DGS under the age of 14, the overall risk of malignancy was 900 per 100,000, whereas the overall risk of malignancy in children under 14 years is 3.4 per 100,000.[57]

PROGNOSIS, CLINICAL COURSE, AND TREATMENT Patients with complete DGS usually die within the first 2 years of life.[58] In rare cases, transplant of HLA-matched bone marrow or peripheral blood mononuclear cells restores T-cell function.[59] Postnatal thymus transplant restores T-cell function in patients with complete DGS.[51,60]

Cartilage-Hair Hypoplasia Syndrome

EPIDEMIOLOGY Cartilage-hair hypoplasia (CHH) syndrome is an autosomal recessive disorder that is most common in Amish and Finnish individuals.[61] There is a 4:1 female-male ratio.[62]

ETIOLOGY AND PATHOGENESIS The disorder results from mutations in RMRP, the

CARTILAGE-HAIR HYPOPLASIA SYNDROME AT A GLANCE



- Synonym: Metaphyseal chondrodysplasia McKusick type
- Autosomal recessive disorder, common in Amish and Finnish populations
- Mutations in the RNA component of a ribonucleoprotein endoribonuclease, leading to defective cell-mediated and humoral immunity
- Characterized by fine, sparse hypopigmented hair, short-limbed dwarfism
- Supportive treatment with appropriate antibiotic use, bone marrow transplant corrects immune deficiency but not dermis or cartilage



▲ **FIGURE 144-6** Sparse hypopigmented hair in a woman with cartilage-hair hypoplasia syndrome. (From Brennan TE, Pearson RW: Abnormal elastic tissue in cartilage-hair hypoplasia. *Arch Dermatol* **124**:1411, 1988, with permission.)

RNA component of a ribonucleoprotein endoribonuclease.[63]

CLINICAL FINDINGS Patients have fine, sparse, hypopigmented hair (Fig. 144-6) and metaphyseal dysostosis that results in short-limbed dwarfism. Patients may have soft, doughy skin with degenerated elastic tissue. Chronic oral fungal or viral infections as well as recurrent upper respiratory infections, otitis media, and pneumonias are related to defective cellular and humoral immunity. Associated pleiotropic features include Hirschsprung disease, deficient erythrogenesis, and an increased risk of malignancies[66] particularly non-Hodgkin lymphoma and basal cell carcinomas.

PROGNOSIS, CLINICAL COURSE, AND TREATMENT Supportive therapy with appropriate antibiotic treatment is indicated. Bone marrow transplantation, although rarely performed, has fully corrected the immune deficiency but has no influence on the course of the chondroplasia or elastic tissue. A DNA marker-based analysis provides a useful method for prenatal diagnosis.

COMBINED ANTIBODY AND T-CELL DEFICIENCY

Wiskott-Aldrich Syndrome

EPIDEMIOLOGY Wiskott-Aldrich syndrome (WAS) is an X-linked recessive disorder with an incidence of approximately 4 per million male births.[67]

PATHOGENESIS The defective gene is *WASP*, mapped to Xp11.22–11.23, which encodes WASp, a hematopoietic specific cytoplasmic protein that functions in signaling and cytoskeletal organization. WASp couples signals arising at the cell membrane with reorganization of the cellular cytoskeleton, resulting in cellular activation and promotion of cell motility. Mutations in WASp affect organization of the immunologic synapse and T-cell activation, T and B lymphocyte migration, and initiation of the primary antibody response.[68] There is a strong phenotype–genotype correlation; as classic WAS occurs when WASp is absent or truncated, while X-linked thrombocytopenia occurs when mutated WASp is expressed.[69]

WAS patients have decreased function and number of both T- and B-lymphocytes, beginning in the first years of life.[70] The lymphocytes of patients with WAS lack microvilli formed by actin bundles, resulting in defective chemotaxis and, in some patients, there is decreased expression of sialoglycoproteins (e.g., CD43 and others) on lymphocytes and platelets. Defects in humoral immunity include abnormal serum immunoglobulins and decreased antibody response to polysaccharide antigens. WAS patients also have defects in NK cell cytotoxicity, dendritic cell migration, and activation and impaired macrophage chemotaxis.[68]

CLINICAL FINDINGS The classic triad of WAS is hemorrhage due to thrombocytopenia and platelet dysfunction, recurrent pyogenic infections, and recalcitrant dermatitis, but this triad appears in only 25 percent of patients.[71] The bleeding diathesis is the most common manifestation of mutations in WAS, present in 84 percent of patients[69] and often manifests initially during the first weeks or months of life with bloody diarrhea. Epistaxis, hematemesis, hematuria, mucocutaneous petechiae, and intracranial hemorrhage also may occur. Recurrent bacterial infections begin in infancy as levels of placentally transmitted maternal antibodies diminish. These infections include furunculosis, conjunctivitis, otitis media and externa, pansinusitis, pneumonia, meningitis, and septicemia. Infections with encapsulated bacteria such as *Pneumococcus*, *Haemophilus influenzae*, and *Neisseria meningitidis* predominate. Patients are also susceptible to infections due to herpes and other viruses and to *P. carinii*.

The atopic dermatitis associated with WAS, which occurs in approximately 80 percent of patients,[67] usually develops during the first few months of life and may be quite severe. The face, scalp, and flexural areas are the most severely involved, although patients commonly have widespread involvement with progressive lichenification. The rash is often more exfoliative than that of atopic dermatitis in individuals without WAS, and excoriated areas frequently have serosanguineous crusts (Fig. 144-7). Secondary bacterial infection of eczematous lesions is common, as are eczema herpeticum (see eFig. 144-7.1 in on-line edition) and molluscum contagiosum. IgE-mediated allergic problems, such as urticaria, food allergies, and asthma, are seen in addition to the atopic dermatitis.

As many as 40 percent of patients with WAS develop an autoimmune disorder.[72] The most common are vasculitis (particularly involving the skin, GI tract, brain,

WISKOTT-ALDRICH SYNDROME AT A GLANCE



- X-linked recessive
- Mutations in Wiskott-Aldrich syndrome
- Recalcitrant dermatitis
- Recurrent pyogenic infections
- Hemorrhage due to thrombocytopenia and platelet dysfunction
- Therapy: Bone marrow stem cell transplantation





▲ **FIGURE 144-7** Severe atopic dermatitis in a boy with Wiskott-Aldrich syndrome. Note the serosanguineous crusting.



and heart) in 20 percent of patients, autoimmune hemolytic anemia in 14 percent , and IgA nephropathy in up to 10 percent of patients.[73] Other immune-mediated cutaneous manifestations are angioedema, dermatomyositis, pyoderma gangrenosum, and erythema nodosum.[72] Hepatosplenomegaly is common, and lymphadenopathy, transient arthritis, and joint effusions are present occasionally.

The thrombocytopenia of WAS is persistent, and platelet counts may range from 1000 to 80,000 platelets per μL. A platelet count of < 70,000 is required for formal diagnostic criteria. The platelets are small, and platelet aggregation is defective. Levels of IgM and sometimes, IgG, are low, and isohemagglutinins are absent. IgA, IgE, and IgD levels usually are elevated. Eosinophilia, leukopenia, and lymphopenia are also seen. Delayed hypersensitivity skin-test reactivity is diminished, and patients fail to respond to polysaccharide antigens.

PROGNOSIS, CLINICAL COURSE, AND TREATMENT Therapeutic interventions allow some patients with WAS to survive into adulthood; however, a significant proportion die before age 10 years old secondary to hemorrhage, infection, malignancies, or the complications of transplantation.[67,74,75] Thirteen percent of patients with WAS develop lymphoreticular malignancies,[71] especially non-Hodgkin lymphoma, with a predominance of extra-nodal and brain involvement. Development of autoimmune hemolytic anemia is a poor prognostic factor and associated with the development of lymphoid malignancies; overall 25 percent of patients with autoimmunity develop a malignancy[73] Ten percent of patients die from these malignancies, usually as adolescents or young adults.

Female carriers of *WAS* mutations may be detected by the selective inactivation of the abnormal X chromosome in T and B cells and in platelets. Studies of maternal X-chromosome inactivation also have been used to diagnose boys with atypical WAS. Mutation analysis allows for prenatal diagnosis.[76]

Appropriate antibiotics, immunizations, and transfusions of platelets and plasma decrease the risk of fatal infections and hemorrhage. Intravenous infusions of γ-globulin are useful in some patients. Splenectomy has been advocated to ameliorate the bleeding abnormality in patients with recurrent severe hemorrhage, but this procedure increases the risk of infection from encapsulated bacterial organisms in these patients, who cannot mount a response to vaccination. Bone marrow or stem cell transplantation is the treatment of choice for patients with recurrent problems, especially significant autoimmunity. Full engraftment results in normal platelet number and function, normal immunologic status, and clearance of the dermatitis (T lymphocyte engraftment). The 5-year survival rate with HLA-matched sibling donors is 87 percent.[71] Topical glucocorticoid preparations and systemic γ-globulin may improve the dermatitis, and chronic administration of oral acyclovir is appropriate for patients with recurrent eczema herpeticum.

Severe Combined Immunodeficiency

EPIDEMIOLOGY Severe combined immunodeficiency (SCID) includes a group of heterogeneous disorders characterized by similar clinical manifestations and immunologic deficiencies of both humoral and cell-mediated immunity.[77–79] The overall incidence of SCID is 1 in 75,000 births.[80] The mode of inheritance is either X-linked or autosomal recessive.

PATHOGENESIS All patients with SCID share most clinical features and have abnormalities of both cell-mediated and humoral immunity, although the extent of deficiency is variable. The underlying bases of SCID are quite heterogeneous, but the molecular bases correspond to integral steps in the differentiation of T cells (Table 144-4). Ninety-five percent of SCID cases have an identified gene defect.[80] X-linked SCID affects approximately 46 percent of patients,[81] and the genetic defect is a mutation in the gene encoding the γ_c chain of the IL-2 receptor, which is also shared with five other interleukin receptors, thus explaining the severity of the immunodeficiency. Several of these receptors are required for the early development of T cells, so female carriers with the mutation have nonrandom inactivation of T cells, which do not survive if the mutated allele is activated. Similarly, mutations in the gene encoding interleukin 7 receptor α chain (IL-7R) and the signaling protein Janus kinase 3 also affect cytokine receptor development. The most common form of autosomal recessive SCID (16 percent of patients) results from mutations in the gene for the purine-degradation enzyme adenosine deaminase (*ADA*).[81] Mutations in antigen receptor genes account for several other molecular defects. Ten percent of patients have defects in the recombination-activating gene 1 or 2 (*RAG1* or *RAG2*) or *Artemis* gene. These molecular defects all result in total or selective lymphopenia. Additional defects fail to completely block T-cell differentiation but the resultant T cells are functionally impaired. These include ZAP-70 deficiency,[85] CD3γ chain deficiency,[86] major histocompatibility complex (MHC) class II deficiency and MHC class I deficiency/transporter for antigen presentation (TAP) deficiency. The human homologue of the nude mouse with total alopecia and nail dystrophy has been linked to mutations in *WHN* (winged helix nude) (see Table 144-4).[87]

CLINICAL FINDINGS Infants with SCID usually fail to gain weight by 3 to 6 months of age, following the onset of recurrent sinopulmonary and skin infections. Persistent mucocutaneous candidiasis is often present at the time of

SEVERE COMBINED IMMUNODEFICIENCY AT A GLANCE

- Heterogeneous group of X-linked and autosomal recessive disorders with deficient cell-mediated and humoral immunity.
- Failure to thrive in early infancy; diarrhea; recurrent mucocutaneous candidiasis, bacterial and viral infections; risk of graft-versus-host disease.
- Transplantation may prevent death during infancy.

TABLE 144-4
Sub-Types of Severe Combined Immunodeficiency

Disorder	Gene	Lymphocyte Profile	Gene Product Function
Defects in cytokine receptor			
X-linked severe combined immunodeficiency[a,b]	*IL2RG*	T–/B+/NK–	Common γ chain of IL-2, -4, -7,-9,-15, and -21
IL-7 receptor (IL-7R) deficiency	*IL7R*	T–/B+/NK–	α chain of IL-7 receptor; stimulates Janus kinase 3
Janus protein kinase deficiency[b]	*JAK3*	T–/B+/NK–	Tyrosine kinase; primary signal transducer from common γ chain and α chain of IL-7R
Defects in cell receptor			
RAG 1 or 2[c]	*RAG1/ RAG2*	T–/B–/NK+	Required for somatic V, D, and J rearrangements during B- and T-cell development
Artemis deficiency[d,e]	*Artemis*	T–/B–/NK+	Required for DNA repair during somatic V, D, and J rearrangements during B- and T-cell development
T-cell receptor/CD3 complex deficiency	*CD3δ* and *CD3ε*	T–/B+/NK+	Facilitates expression of T-cell receptor/CD3 complex; block at pre–T-cell receptor stage of development
CD45 deficiency[82]	*PTPRC*	T–/B+/NK+	Phosphatase that regulates immune cell signaling
LIG4 syndrome[e,83]	*LIG4*	T–B–NK+	Ligase required for ATP-dependent repair of double-stranded DNA
CD8 deficiency[84]	*CD8A*	$CD4^+CD8^-$/B+/NK+	Promotes survival and differentiation of activated T cells to memory $CD8^+$ T cells
Defects in purine pathway enzymes			
ADA deficiency[a,f]	*ADA*	T–/B–/NK–	Enzyme necessary for detoxification of metabolic products of the purine salvage pathway that cause lymphocytes to undergo apoptosis
PNP deficiency	*PNP*	T–/B–/NK–	Enzyme necessary for detoxification of metabolic products of the purine salvage pathway that cause lymphocytes to undergo apoptosis: located downstream from ADA
Defects that fail to completely block T-cell differentiation. Result in functionally impaired T cells +			
ZAP-70 deficiency	*ZAP-70*	$CD4^+CD8^-$/B+/NK+	Signaling tyrosine kinase
T-cell receptor/CD3 complex deficiency	*CD3γ*	T+/B+/NK+	Chain facilitates expression of T-cell receptor/CD3 complex
MHC class II deficiency (bare lymphocyte syndrome II)	*CIITA* *RFXB* *RFX5* *RFXAP*	T+/B+/NK+ but dysfunctional CD4	Defects in the transactivating factors of MHC II molecules
MHC class I deficiency/TAP deficiency (bare lymphocyte syndrome I)	*TAP1* *TAP2*	$CD4^+CD8^-$/B+/dysregulated NK	Transporter associated with antigen processing, transports peptides to assemble the class I molecule
Defect in thymic development			
Winged helix nude deficiency	*WHN*	T–/B+/NK+	Human homologue of nude mouse with total alopecia and onychodystrophy; critical transcription factor for thymic development

ADA = adenosine deaminase; ATP = adenosine triphosphate; IL = interleukin; MHC = major histocompatibility complex; NK = natural killer cell; PNP = purine nucleoside phosphorylase; RAG = recombination activating gene; TAP = transporter associated with antigen processing.
[a]Most common severe combined immunodeficiency defects. X-linked severe combined immunodeficiency accounts for approximately 50 percent of patients. Adenosine deaminase deficiency accounts for approximately 20 percent of patients.
[b]Highest risk of human papillomavirus infections after transplantation may reflect a persistent abnormality in expression on keratinocytes despite transplantation.[176]
[c]Deletions/frameshift mutations of *RAG1*/*RAG2* genes result in severe combined immunodeficiency phenotype. Less severe mutations result in Omenn syndrome, clinically distinct from other forms of severe combined immunodeficiency. Mutations in other genes may lead to the Omenn phenotype and immunodeficiency.
[d]Common genetic defect seen in Athabascan-speaking Native Americans, the defect is called *SCIDA* in this population. Gene frequency may be as high as 2 percent. These patients have a higher incidence of oral/genital ulcers.[89]
[e]Both *Artemis* and *LIG4* mutations lead to hypersensitivity to irradiation.
[f]Eighty-five percent to 90 percent of patients present in infancy with severe immunodeficiency; one-half have skeletal deformities, neurologic symptoms, behavior problems, and decreased IQ.

diagnosis, and systemic candidal infections occur occasionally. Patients with SCID also may have chronic diarrhea and malabsorption caused by viral infections. *P. carinii* pneumonia is often a presenting feature. Although bacterial infections usually respond to systemic antibiotics, viral infections tend to be fatal. Infants with SCID lack palpable lymphoid tissue despite recurrent infections.

In addition to cutaneous bacterial and candidal infections, the most common cutaneous eruptions are morbilliform or resemble seborrheic dermatitis. In some infants with SCID, biopsy sections show GVHD (see Chap. 28). GVHD may result from the in utero exposure to maternal lymphocytes, from transfusion with nonirradiated blood products, or may follow transplantation. Patients with GVHD most commonly present acutely with morbilliform erythema, papular dermatitis, or diffuse erythroderma. The face, neck, palms, and soles are affected initially, before a generalized eruption. Severe cases are complicated by diffuse bullae or toxic epidermal necrolysis. The clinical presentation of GVHD from maternal engraftment (without transplantation) is indistinguishable from the clinical



presentation of GVHD from transplantation, but histopathologic features differ.[88] Biopsy sections from GVHD secondary to maternal engraftment show psoriasiform hyperplasia with parakeratosis and variable spongiosis in contrast to the vacuolar interface pattern observed in conventional GVHD.[88] Overall, 83 percent of SCID patients with maternal engraftment develop skin manifestations.[88] Oral and genital ulcerations are also seen in SCID, particularly in Athabascan-speaking American Indian children with a defect in the *Artemis* gene.[89] Patients with Omenn syndrome show erythroderma, hepatosplenomegaly and lymphadenopathy with eosinophilia and increased IgE production. B cells tend to be undetectable, and T cells, although often increased in number, are non-functional. Recently, Omenn syndrome has been shown to be a phenotype with several underlying genetic bases. Most patients have RAG1/RAG2 mutations, but the phenotype of Omenn syndrome has been described in patients with mutations in Artemis and IL7R.[90–92] Two individuals with CHH and another with complete DGS also showed features of Omenn syndrome.[93,94]

The sub-type of SCID is determined generally by DNA analysis, although detection of cells by fluorescence-activated cell sorting (e.g., T, B, and NK cells) and by analysis for the presence of surface markers is confirmatory. All sub-types have absent or low T-cell number and function, and total lymphocyte counts are usually < 1500 to 2000 cells (normal is 4000 to 13,500). With maternal engraftment, T lymphocyte counts may be close to normal. The number of B cells and NK cells differs depending on the genetic defect (see Table 144-4). ADA enzyme activity in leukocytes can be measured to confirm ADA-deficient SCID.

In families with a previously affected sibling of a known phenotype, prenatal detection of SCID is possible by DNA analysis, if the specific gene defect is known, by fluorescence-activated cell sorting of fetal blood with monoclonal antibodies, or by analysis of enzyme levels in cultured amniocytes. Carrier mothers of boys with X-linked SCID may be detected by the selective inactivation of the abnormal X chromosome in T and B cells.

PROGNOSIS, CLINICAL COURSE, AND TREATMENT Affected children with most forms of SCID rarely survive beyond 1 year of age without transplantation. The definitive treatment of choice for SCID is a hematopoietic stem cell transplant from HLA-identical or haploidentical T-cell depleted bone marrow.[95] Removal of post-thymic cells from parental marrow may diminish the risk of GVHD in patients with SCID without an HLA-identical donor. Bone marrow transplants done before the age of 3 months have a 95 percent survival rate, whereas after 3 months of age, the survival rate decreases to 75 percent,[96] emphasizing the importance of early diagnosis. Hematopoietic stem cell transplant does not restore complete immune reconstitution in regards to B-cell function and more than one-half of patients remain dependent on IVIG and prophylactic antibiotics. Some patients develop waning T-cell numbers years after transplant. In utero transfer of haploidentical CD34 cells and retroviral gene therapy[95] have been successful for patients with γ_c- and ADA–deficient forms of SCID. The success of gene therapy has been tempered by the development of leukemia in three patients who received retroviral gene therapy for γ_c SCID. Gene therapy is currently restricted to patients who are unlikely to survive allogenic transplantation or who have already undergone standard transplantation but do not have satisfactory T-cell immunity.[95] Patients with IL-2 deficiency have been treated with IL-2 injections. Enzyme replacement therapy with polyethylene glycol modified bovine ADA, administered subcutaneously once weekly, has resulted in clinical and immunologic improvement in patients with ADA deficiency.

Ectodermal Dysplasia with Immunodeficiency

EPIDEMIOLOGY X-linked recessive transmission is most common with an estimated incidence of 1:250,000 live male births.[97] An autosomal dominant form of ectodermal dysplasia with immunodeficiency has also been described.[98]

ETIOLOGY AND PATHOGENESIS Several genetic disorders result from gene mutations in NEMO and lead to abnormal nuclear factor κB (NF-κB) signaling (see Hypohidrotic Ectodermal Dysplasia in Chap. 143, and Incontinentia Pigmenti in Chap. 73). One of these, hypohidrotic ectodermal dysplasia with immunodeficiency, results from hypomorphic mutations in the NEMO gene [also called *ectodermal dysplasia, anhidrotic, with immunodeficiency* (EDA-ID), or *hyperimmunoglobulinemia M, immunodeficiency, X-linked with ectodermal dysplasia*]. NF-κB is recognized as a DNA-binding factor,[99] and its ability to transcribe genes is regulated by a cytoplasmic inhibitor, IκB. NF-κB signaling affects inflammation, apoptosis, development, and immunity.[100,101] NF-κB activation requires phosphorylation of IκB by IκB kinase (IKK). IKK is composed of two catalytic components (IKKα and IKKβ) and a regulatory subunit, IKKγ or NEMO. NEMO has no catalytic function, but is the structural scaffold that supports the IKK complex.[100] When NEMO is absent or defective, no functional IKK complex is formed and, as a result, NF-κB cannot translocate to the nucleus and activate gene transcription.

The hypomorphic mutations that cause EDA-ID allow early survival in males, in contrast to the large deletions in *NEMO* (usually of exons 4 to 10) that lead to incontinentia pigmenti in carrier females and fetal death in affected males (see Chap. 73).

CLINICAL FINDINGS Affected patients present with classic characteristics of hypohidrotic ectodermal dysplasia. These include the characteristic facies (Fig. 144-8), hypotrichosis or atrichia, hypohidrosis (leading to heat intolerance), hypodontia or anodontia with conical incisors, and associated dermatitis (see Chap. 143).[23,97,105–107] A subset of patients has associated osteopetrosis and lymphedema in association with severe immunodeficiency. Boys with immunodeficiency

ECTODERMAL DYSPLASIA WITH IMMUNODEFICIENCY AT A GLANCE



- Mutations in nuclear factor κB essential modulator, leading to abnormal nuclear factor κB signaling
- Characteristic facies of hypohidrotic ectodermal dysplasia
- Often severe immunodeficiency; bacterial, atypical mycobacterial, and viral infections are common
- Therapy: transplantation





▲ **FIGURE 144-8** Ectodermal dysplasia with immunodeficiency gene mutation. This boy with a hypomorphic mutation in *NEMO* showed failure to thrive, slightly exfoliative dermatitis, and the typical facial features of hypohidrotic ectodermal dysplasia. Note the small chin, the "pouty" lower lip, thin upper lip, small pinched nose with malar hypoplasia. His mother had a pigmented streak following a line of Blaschko, typical of that seen in incontinentia pigmenti. (Used with permission from Dr. Anthony Mancini.)

from NEMO mutations without the features of hypohidrotic ectodermal dysplasia have also been described.[108] Bacterial infections early in infancy are common, particularly sepsis, pneumonia, otitis, sinusitis, and lymphadenitis. Recurrent pneumonias may lead to bronchiectasis. Common pathogens include *Streptococcus pneumoniae*, *H. influenzae*, *Klebsiella*, *Salmonella*, and *Pseudomonas*. Infections with atypical mycobacteria and viruses, including cytomegalovirus (systemic and GI involvement), herpes simplex virus, molluscum contagiosum, human papillomavirus, and *P. carinii*, are also reported.[23,97,106]

The immunodeficiency is often severe, but its characteristics are variable. They may include impaired B-cell class switching with hypogammaglobulinemia (and often increased levels of IgM and/or IgA), impaired specific antibody production (particularly to polysaccharide antigens), deficient NK cell cytotoxicity, and poor cytokine production in response to CD40L signaling.[97,107] Biopsy of skin may show evidence of keratinocyte apoptosis, reflecting the dysfunction in NF-κB signaling, and must be differentiated from GVHD.

TREATMENT AND PROGNOSIS Therapy is guided by the patient's clinical and immunologic phenotype. Ectodermal dysplasia is treated supportively (see Chap. 143). Patients with impaired antibody production may benefit from IVIG. All infections (bacterial and viral) should be treated aggressively with the appropriate antibiotics/antivirals. Prophylaxis for both *P. carinii* and Mycobacterium avium intracellulare should be considered.[97] Stem cell transplantation may lead to immune reconstitution.[109] The mother and sisters of these patients should be offered genetic testing for the *NEMO* mutation and counseling.

Ataxia-Telangiectasia

EPIDEMIOLOGY Ataxia-telangiectasia (AT; Online Mendelian Inheritance in Man #208900), also called *Louis-Bar syndrome*, is an autosomal recessive disorder with an incidence of approximately 1:40,000 and a carrier rate of up to 1 percent. Carriers have an increased risk of breast cancer, hematologic malignancies,[110] and ischemic heart disease, with a reduced life expectancy of approximately 8 years.[111] These heterozygotes show increased risk of chromosomal breaks after exposure to irradiation in vitro, suggesting that mammograms in known carriers of AT are contraindicated.

ETIOLOGY AND PATHOGENESIS AT results from mutations in *ataxia-telangiectasia mutated* (*ATM*), which encodes a phosphatidylinositol 3-kinase-like serine/threonine protein kinase that plays a central role in activating apoptotic and cell cycle responses to DNA damage.[112] More than 400 different *ATM* mutations have been identified in patients with AT. The MRE11-RAD50-NBS1 (MRN) complex senses DNA breaks and recruits and activates ATM.[113] The autophosphorylated ATM monomers then phosphorylate and thus activate several targets, among them p53, BRCA1, and NBS1 and MRE11 themselves, leading to cell cycle arrest and facilitated DNA repair. The activation of ATM occurs in response to external damage, such as from ionizing radiation and radiomimetic agents (bleomycin), and in physiologic DNA breaks, such as during meiosis, telomere maintenance, and V(D)J recombination in lymphocytes.[112] These important roles of ATM explain the immunodeficiency, premature aging, progressive neurologic deterioration, and sensitivity to ionizing radiation. Oxidative stress related to ATM dysfunction has also been implicated.

Mutations in the *NBS1* and *MRE11* genes, respectively, cause Nijmegen breakage syndrome (immunodeficiency with microcephaly, chromosomal instability, and a cancer predisposition, but no ataxia[114]) and AT-like disorder (with neurologic manifestations and radiosensitivity, but no telangiectases).

CLINICAL FINDINGS Characteristic oculocutaneous telangiectases begin near the ocular canthi and progress across the bulbar conjunctivae (Fig. 144-9). These tel-

ATAXIA-TELANGIECTASIA AT A GLANCE



- Autosomal recessive disorder with mutations in *ataxia-telangiectasia mutated (ATM)*
- Early onset of ataxia with progressive neurologic deterioration; conjunctival telangiectasis first appears in pre-school years in most patients
- Sinopulmonary infections, lymphoreticular neoplasia
- Deficiency of immunoglobulin A (IgA), IgE, IgG_2, IgG_4; variable manifestations of T-cell deficiency; high levels α-fetoprotein; chromosomal breaks; sensitive to irradiation



▲ **FIGURE 144-9** Bulbar conjunctival telangiectases in a patient with ataxia-telangiectasia. (From Paller AS: Hereditary immunodeficiency disorders, in *Genetic Disorders of the Skin*, edited by Alper JC. Chicago, Mosby Year Book, 1991, p 105, with permission.)





▲ **FIGURE 144-10** Ataxia-telangiectasia. Telangiectases inside and on the helix.



angiectases usually appear when patients are 3 to 6 years of age; rarely have they been described at earlier ages. Cutaneous telangiectases subsequently may develop on the malar prominences, ears, eyelids, anterior chest, popliteal and antecubital fossae, and the dorsal aspects of the hands and feet (Fig. 144-10). The telangiectases may be subtle and resemble fine petechiae, especially in the flexural areas. The development of telangiectases may be related to sun exposure, because ocular, but not cutaneous, telangiectases develop in affected dark-skinned children. The development of telangiectases may relate, at least in part, to the sensitivity of some AT strains to ultraviolet (UV) light.[115]

Progeric changes of the skin, including xerosis and gray hair, occur in 90 percent of patients.[116] During adolescence, the facial skin may become progressively more atrophic and sclerotic, causing a mask-like appearance. Occasionally, the ears, arms, and hands also become scleroderma-tous. The hair may be diffusely gray by adolescence, and subcutaneous fat is generally lost in childhood. Recurrent severe impetigo often develops. Seborrheic dermatitis occurs in many patients, and the associated blepharitis may lead to a diagnosis of blepharoconjunctivitis rather than ocular telangiectasia. Mottled hyper- and hypopigmentation commonly occur and, together with the telangiectases and atrophy, can resemble the poikiloderma of radiodermatitis, actinic damage, or scleroderma. Other pigmentary changes include café-au-lait spots that may be found in a dermatomal distribution,[117] multiple ephelides, and vitiligo. Hypertrichosis of the arms and legs, alopecia areata, multiple warts, atopic dermatitis, keratosis pilaris, nummular eczema, and acanthosis nigricans have also been described in association with AT. Among the most common cutaneous manifestations are non-infectious cutaneous granulomas (Fig. 144-11).[117] These persistent, atrophic, and often ulcerative lesions are often mistaken for other granulomatous processes, including sarcoidosis, necrobiosis lipoidica diabeticorum, granuloma annulare, and granulomatous dermatitis.

Usually, the progressive cerebellar ataxia first becomes apparent during infancy (median age, 1.2 years old) with swaying of the head and trunk and apraxia of eye movements, often years before skin or conjunctival abnormalities develop. In childhood, dysarthric speech, drooling, choreoathetosis, and myoclonic jerks become prominent. The diagnosis of AT is usually made at a median age of 7 years, after appearance of the mucocutaneous telangiectasia. Patients usually require a wheelchair by their teenage years.

Recurrent bacterial and viral sinopulmonary infections occur in up to 80 percent of patients; these are the most common cause of death, which is usually from bronchiectasis and respiratory failure. Approximately 75 percent of patients with AT may have growth retardation and endocrine disorders, especially ovarian agenesis or testicular hypoplasia and insulin-resistant diabetes.

Neoplasia occurs in 40 percent of surviving adolescents or young adults, although lymphoid malignancy has been described as the presenting sign during infancy. Most common are lymphomas (especially B cell; 200-fold increased risk) and leukemia (especially T-cell chronic lymphocytic; 70-fold increased risk).[118,119] Basal cell carcinomas have been reported in young adults.

Among techniques to confirm diagnosis are analysis of radioresistant DNA synthesis (which demonstrates an abnormal S phase checkpoint), radiosensitivity testing with the colony survival assay, immunoblotting for the ATM protein, assessment of ATM kinase activity, and molecular genetic testing.

PROGNOSIS, CLINICAL COURSE, AND TREATMENT The therapy for AT is supportive and includes administration of antibiotics for infection, physiotherapy for pulmonary bronchiectasis, physical therapy to prevent contractures in patients with neurologic dysfunction, and sunscreens and sun avoidance to diminish actinic-like changes. Patients should be aggressively screened for malig-



▲ **FIGURE 144-11** Non-infectious granulomatous dermatitis of a patient with ataxia-telangiectasia. These persistent lesions tend to ulcerate.

nancy, especially after the first decade of life. Intralesional injections of triamcinolone have helped to promote healing of the painful associated ulcerations, although the lesions do not clear completely with treatment. Autopsy findings indicate that approximately 50 percent of the patients die from pulmonary disease, the most common cause of death. Lymphoreticular malignancies, including lymphoid leukemia, are the second most common cause of death, leading to the deaths of 15 percent of patients with AT. The remaining patients tend to die of both pulmonary disease and malignancy. Therapeutic radiation and radiomimetic chemotherapeutic agents, especially bleomycin, may lead to extensive tissue necrosis. The administration of small doses of other chemotherapeutic drugs and low-dose, fractionated radiation is the least harmful means of managing these malignancies. In a small subset of patients with milder AT, treatment with aminoglycosides increased ATM gene function.[121] Death usually occurs by late childhood or early adolescence; the oldest surviving patient died at the age of 50 years. Prenatal diagnosis is currently best achieved by DNA analysis.

DISORDERS OF PHAGOCYTOSIS AND CELL KILLING

Patients with defects in phagocyte function or cell killing typically present during infancy or childhood with recurrent, unusual, and/or difficult to clear bacterial infections. Infections commonly seen include those of skin or mucosa, lung, lymph nodes, deep tissue abscesses, or

childhood periodontitis. The most distinctive disorders of phagocytosis and cell killing are chronic granulomatous disease (CGD), leukocyte adhesion deficiencies, hyperimmunoglobulinemia E syndrome (HIES), and the silvery hair syndromes with immunodeficiency. However, several disorders with neutropenia, neutrophil dysfunction, or cytokine dysfunction also lead to a decreased ability to engulf and/or kill organisms. These are reviewed in Table 144-5.

Chronic Granulomatous Disease

EPIDEMIOLOGY CGD is a heterogeneous group of X-linked and autosomal recessive disorders. Ninety percent of patients with the disorder are male, and the overall incidence is 1 in 200,000 to 250,000 persons. X-linked disease occurs in 70 percent of affected individuals with signs and symptoms manifesting in the first year of life. Individuals with autosomal recessive disease (30 percent) present later in life with milder signs and symptoms; 56 percent of these patients have a deficiency of $p47^{phox}$ and deficiencies in $p22^{phox}$ and $p67^{phox}$ account for the remaining cases.[122]

PATHOGENESIS CGD is caused by defects in the reduced nicotinamide adenine dinucleotide phosphate (NADPH) oxidase, the enzyme complex responsible for the generation of superoxide.[123] Normal bactericidal activity after phagocytosis requires the NADPH oxidase system, which consists of NADPH, an unusual phagocyte cytochrome b (b_{558}), and cytosolic proteins. In patients with CGD, this membrane-associated NADPH oxidase system fails to produce superoxide and other toxic oxygen metabolites.

The types of microbial organisms that cause infections in patients with CGD require intracellular killing and are usually catalase-positive. Only five organisms are

CHRONIC GRANULOMATOUS DISEASE AT A GLANCE

- Group of disorders in which defective production of reactive oxygen intermediates impairs intracellular killing of microorganisms
- X-linked or autosomal recessive
- Mutations in genes that encode components of nicotinamide adenine dinucleotide phosphate oxidase system
- Pneumonias, lymphadenopathy, hepatosplenomegaly, and skin infections
- Granulomas, most commonly of lungs and liver



TABLE 144-5
Other Disorders of Phagocytosis or Cell Killing

Disorder	Genetics	Gene	Functional Consequence	Clinical Findings
Neutropenia				
Cyclic neutropenia	AD	*ELA2*	Defects in neutrophil elastase.	Cycles of neutropenia and monocytopenia, about every 3 wk. Oral ulcers and fever when low.
Severe congenital neutropenia	AD AD	*ELA1* *GF11*	Defects in neutrophil elastase lead to abnormal neutrophil trafficking. Repressor of elastase transcription leads to accumulation of elastase.	Neutropenia, myelodysplastic syndrome, and acute myelogenous leukemia. Neutropenia and lymphopenia. Myeloid progenitors in circulation.
Schwachman-Diamond syndrome (SBDS)	AR	*SBDS*	SBDS protein participates in metabolism of ribosomal RNA.	Pancytopenia with myelodysplastic syndrome and acute myelogenous leukemia. Pancreatic insufficiency. Chondrodysplasia.
WHIM[177]	AD	*CXCR4*	Receptor regulates development and migration of neutrophils; affects viral entry into cells.	Chronic cutaneous and cervical warts, antibiotic-responsive bacterial sinopulmonary infections; often low immunoglobulin levels, peripheral neutropenia in the face of bone marrow hypercellularity (myelokathexis), and distinctive neutrophil morphology.
Cytokine defects				
	AR	*IL12B*	Absence of component of IL-12 and IL-23 that stimulates IFN-γ production.	Severe mycobacterial infections. Disseminated bacille Calmette-Guérin after vaccination. Severe *Salmonella* infections.
	AR	*IL12RB1*	β1 chain of IL-12 and IL-23 receptors.	
	AR, AD	*IFNGR1*	Affects ligand binding to IFN-γ receptor.	
	AR	*IFNR2*	Affects IFN-γ receptor signaling.	
	AR, AD	*STAT1*	Affects transcription in IFN receptor signaling.	Also severe viral infections.
	AR	*STAT5B*	As in Stat1, but also growth hormone receptor signaling.	Also growth hormone insensitivity.
Defects of killing				
Myeloperoxidase deficiency	AR	*MPO*	Myeloperoxidase required for bacterial killing.	Especially *Staphylococcus aureus* and candidal infections. May be asymptomatic.
Specific granule deficiency	AR	*C/EBPE*	C/EBPε transcription factor required for granulocyte differentiation.	Recurrent bacterial infections. Neutrophils with two lobes.

AD = autosomal dominant; AR = autosomal recessive; IFN = interferon; IL = interleukin; WHIM = warts, hypoimmunoglobulinemia, infections, myelokathexis.

responsible for the overwhelming majority of infections in CGD in North America and Europe: *Staphylococcus aureus*, *Serratia marcescens*, *Burkholderia cepacia*, *Nocardia* sp., and *Aspergillus* sp.[123] The intense humoral and granulomatous responses of CGD are thought to be compensatory in the robust but ineffectual response to organisms.

CLINICAL FINDINGS Pyodermas with associated regional lymphadenopathy and dermatitis, especially around the nares and ears, usually occur during infancy and sometimes even in affected neonates. Staphylococcal abscesses are found in 40 percent of patients, particularly of the perianal area. Purulent inflammatory reactions may develop at sites of lymph node drainage or minor cutaneous trauma and heal slowly with scarring. Patients with CGD often develop chronic inflammatory granulomas, most commonly of the lungs and liver. Cutaneous granulomas are nodular and often necrotic. Granulomas can occlude vital structures, especially of the GI and genitourinary systems. Intra-oral ulcerations resembling aphthous stomatitis, chronic gingivitis, perioral ulcers, scalp folliculitis, and seborrheic dermatitis have also been described in many patients. Female carriers for X-linked CGD do not have the increased risk of infections but may have cutaneous lesions of discoid or systemic lupus erythematosus (SLE), Jessner lymphocytic infiltration of the skin, aphthous stomatitis, granulomatous cheilitis, photosensitivity, and/or Raynaud phenomenon.[126]

The lymph nodes, lungs, liver, spleen, and GI tract are the most frequent areas of non-cutaneous involvement. Suppurative lymphadenitis with abscess and fistula formation usually affects cervical nodes. Pneumonia occurs in almost all affected children and may lead to abscess formation, cavitation, and empyema. Hepatosplenomegaly has been reported in 80 percent to 90 percent of patients; more than 30 percent of patients develop hepatic abscesses, and staphylococcal liver abscesses are almost pathognomonic to CGD.

Patients with bacterial and *Nocardia* sp. infections tend to be symptomatic and frequently have leukocytosis, anemia, and elevated sedimentation rate. In contrast, lack of fever, normal erythrocyte sedimentation rate, and few symptoms are more common in *Aspergillus* sp. infections. Thus, lab values within normal limits do not rule out infection in a CGD patient. Patients not uncommonly show an increased erythrocyte sedimentation rate, hypergammaglobulinemia, leukocytosis, and mild anemia; immune functions are otherwise usually normal.

The diagnosis of CGD is made on the basis of assays that rely on superoxide production. The dihydrorhodamine flow cytometry-based test is currently favored and can readily distinguish X-linked from autosomal forms[80]; the ferricytochrome c reduction assay is another quantitative measure of the respiratory burst. The screening test for CGD is the nitroblue tetrazolium (NBT) reduction assay, in which the yellow NBT becomes its soluble, oxidized form (blue formazan) when precipitated with normal oxidative metabolism. Quantitative NBT tests and chemiluminescence assays also may be performed. Immunoblot analysis confirms the absence of the glycoprotein 91^{phox} ($gp91^{phox}$) component; because deficiency of one component of cytochrome b_{558} leads to absence of the other, sequencing of the $gp91^{phox}$ or $p22^{phox}$ gene is necessary if absence is noted by immunoblot analysis. Immunoblots that show the absence of $p47^{phox}$ or $p67^{phox}$ can be diagnostic.

Biopsy of cutaneous granulomas shows histiocytic infiltrates associated with foreign body giant cells and accumulation of neutrophils with necrosis. Although the histopathologic features of lupus erythematosus-like skin lesions in CGD patients and carriers may resemble those of lupus patients, immunofluorescence examination of lesional skin is usually negative.

PROGNOSIS, CLINICAL COURSE, AND TREATMENT Patients with X-linked CGD, $p22^{phox}$ CGD and $p67^{phox}$ CGD tend to have a more severe clinical course compared to patients with $p47^{phox}$ CGD. The mean age of diagnosis of X-linked CGD is 3 years of age, and of autosomal recessive forms 8 years of age. More than 90 percent of patients with non-$p47^{phox}$ CGD have undetectable levels of superoxide production.[82] Some patients will develop severe infections as early as infancy while others will unexpectedly develop a serious infection typical of CGD later during childhood.

Small foci of localized inflammation may not be associated with fever and may be difficult to detect without vigorous investigation of the lungs, liver, and bones by routine screening radiographs, scans, or ultrasound. Cultures should be performed to identify the infectious agent, and invasive procedures may be necessary to obtain adequate tissue samples. Patients with evidence of infection should be treated empirically with broad-spectrum parenteral antibiotics that cover *S. aureus* as well as Gram-negative organisms. Intravenous therapy should be continued for at least 10 to 14 days, followed by a several-week course of oral antibiotics. Surgical interventions (drainage, débridement) may be required for deeper infections. Trimethoprim-sulfamethoxazole therapy decreases the incidence of bacterial infection without increasing the incidence of fungal infection. Itraconazole is an effective agent for prophylaxis for fungal infections.[127] Prophylactic IFN-γ has been shown to decrease the number and severity of infections without increasing the incidence of chronic inflammatory complications in both X-linked and autosomal recessive CGD.[128] Use of IFN-γ is not accompanied by any measurable improvement in NADPH oxidase activity; its clinical benefit is related to enhanced phagocyte function and killing by non-oxidative mechanisms.[129] Leukocyte transfusions have been used for rapidly progressive, life-threatening infections. Although bone marrow transplantation has been performed in some patients with CGD, its use is limited by procedure-related toxicities, GVHD, and death; it should only be considered for those that have severe, life-threatening infections despite appropriate medical care. Systemic glucocorticoids have been helpful for patients with obstructive visceral granulomas. Stem cell gene therapy has been used for patients with the $p47^{phox}$ deficient form (Table 144-6).[84] Prenatal diagnosis has been performed by the NBT slide test and now can be based on molecular analysis.

The prophylactic administration of antibiotics and IFN-γ has reduced the mortality of CGD to about 2 percent per patient-year for autosomal CGD and 5 percent for X-linked CGD.[122] The most common causes of death are pneumonia and/or sepsis due to *Aspergillus* or *B. cepacia*.[75]

Leukocyte Adhesion Deficiency

EPIDEMIOLOGY Three autosomal recessive disorders are grouped under the term *leukocyte adhesion deficiency* (LAD). A dominant form has more recently been described in one patient [LAD type 4 (LAD4)].

ETIOLOGY AND PATHOGENESIS LAD is a rare inherited disorder that affects the



TABLE 144-6
Treatment of Chronic Granulomatous Disease

TREATMENT	INDICATION	DOSE
Trimethoprim-sulfamethoxazole[a] (dicloxacillin if allergic)	Bacterial infections	5 mg/kg/day divided bid
Itraconazole[a]	Fungal infections	100 mg/day if < 50 kg; 200 mg/day if > 50 kg
Interferon-γ[a]	Infections	50 μg/m^2 subcutaneous 3×/wk
Leukocyte transfusion	Life-threatening infections	
Bone marrow transplantation	Life-threatening infections	
Systemic glucocorticoids	Granulomas, particularly if obstructive	
Débridement /drainage/surgical intervention	Abscesses (particularly liver)	

[a]Regardless of genetic subgroup, the current recommendation is to use prophylaxis with trimethoprim-sulfamethoxazole, itraconazole, and interferon-γ.[123]

ability of neutrophils to adhere to the endothelium, tissue matrix, and microbes. Adherence is essential for the ability of leukocytes to emigrate into sites of infection and eliminate pathogens. Adherence of leukocytes relates in part to a group of cell surface glycoproteins (β_2 integrins) that share a common 95-kd β_2 subunit (CD18) encoded on chromosome 21q22.3. This β_2 subunit may be linked to three distinct α chains to form three different surface glycoproteins—the iC3b receptor (CR3), lymphocyte function–associated antigen 1, and p150,95. A mutation in the gene encoding CD18 leads to absent or deficient surface glycoproteins in LAD1. As a result, neutrophil and monocyte chemotaxis and phagocytosis are impaired.

LEUKOCYTE ADHESION DEFICIENCY AT A GLANCE



- Group of three autosomal recessive and one autosomal dominant disorder (see Table 144-6)
- Gingivitis and periodontitis
- Poor wound healing; delayed separation of the umbilical stump and development of pyoderma gangrenosum–like necrotic ulcerations after wounding
- Life-threatening bacterial and fungal infections

CLINICAL FINDINGS Patients have frequent infections of the skin and the respiratory and GI tracts, often caused by *S. aureus* or Gram-negative enteric bacteria. The skin infections are often precipitated by puncture wounds or skin surface trauma and begin as small erythematous or necrotic abscesses, progressing to large ulcerative lesions that resemble pyoderma gangrenosum, but the inflammatory response and production of purulent material are impaired (Fig. 144-12). Histopathology often reveals complete absence of tissue neutrophils. Poor wound healing leads to paper-thin or dysplastic cutaneous scars. Cellulitis of the face and perirectal area is common. Gingivitis with periodontitis results in loss of teeth. Delayed umbilical cord separation and omphalitis are also characteristic features.

Patients with LAD2 have less severe infections but have developmental delay and the Bombay (hh) erythrocyte phenotype. LAD3 is similar to LAD1 but has an associated bleeding tendency.

LABORATORY ABNORMALITIES Laboratory exams reveal a persistent leukocytosis, often out of proportion to the degree of symptoms. Diagnosis is confirmed by showing the reduction of glycoproteins with flow cytometry using monoclonal antibodies specific for the three α subunits, CD15s, and the common CD18 β subunits.

PROGNOSIS, CLINCAL COURSE, AND TREATMENT The severity of clinical involvement is proportional to the degree of glycoprotein deficiency. Patients with severe phenotypes (< 1 percent of normal expression of CD18) present in the newborn period with delayed umbilical cord separation and omphalitis. Life-threatening severe bacterial or fungal infections occur with a mortality rate of more than 75 percent before the age of 5 years old.[98] Patients with moderate phenotype (1 percent to 30 percent of normal expression of CD18) often have a milder course and are diagnosed later in life. More than one-half of these patients die between the ages of 10 and 30 years old.

Antimicrobial therapy is the mainstay of treatment. Skin abscesses/ulcers often require débridement and grafting. Bone marrow transplantation restores leukocyte function and is recommended in patients with the severe phenotype. Successful transplant of cord blood from HLA-identical siblings has also been reported.[130] Gene therapy introducing the normal CD18 subunit gene into affected hematopoietic stem cells has successfully restored CD18 expression. The ex vivo transfer of CD18 into affected cells, followed by infusion of the transduced cells, may represent another therapeutic approach.[131]

Oral fucose replacement has been helpful in some patients with LAD2. Leukocyte adhesion molecules are expressed on fetal leukocytes and make



◀ **FIGURE 144-12** Necrotic ulceration on the leg of a boy with leukocyte adhesion deficiency type 1. Note the heaped-up edge and extensive crusting. Biopsies showed almost no neutrophil invasion.



prenatal diagnosis possible by fetal blood sampling at 20-weeks' gestation.

Hyperimmunoglobulinemia E Syndrome

EPIDEMIOLOGY HIES is rare (incidence 1 in 10^6).[132] It is found equally in males and females. Most cases are sporadic or consistent with an autosomal dominant inheritance. Autosomal recessive inheritance has also been described, but patients show different associated features.

ETIOLOGY AND PATHOGENESIS The gene for HIES has been mapped to the proximal arm of chromosome 4q, although the underlying cause of HIES is still unknown.[133] A neutrophil chemotactic defect was originally implicated as primary, but recent studies indicate that neutrophil dysfunction and abnormalities of chemotaxis are variably expressed and intermittent.[134] Patients with HIES appear to have defective T-cell cytokine responses. IgE synthesis is normally enhanced by the Th2 cytokines (IL-4 and IL-13) and repressed by Th1 cytokines (IFN-γ and IL-12).[132] Given their constitutive expression of IgE, mononuclear cells from patients with HIES fail to exhibit the normal stimulation of IgE production by IL-4[135]; in addition, HIES cells cannot produce normal levels of IFN-γ even after cells are stimulated by IL-12.[136]

CLINICAL FINDINGS The clinical presentation of individual patients with HIES may vary greatly. The neonatal or infantile rash of HIES is often a papulopustular eruption with prominent crusting distributed on the scalp, face, neck, axillae, and diaper area. The most consistent finding on skin biopsy is an eosinophilic spongiotic dermatitis, sometimes centered in the dermal follicles.[137] In other infants, early candidal infections of the skin, mucosae, and nails and/or infantile atopic dermatitis (Fig. 144-13) are alternative presentations; in patients with the eosinophilic papulopustules, the atopic dermatitis commonly follows later in infancy. Superinfection of the dermatitis with *S. aureus* is very common,[138] and patients show high levels of anti-staphylococcal IgE antibodies. Staphylococcal skin infections include impetigo, furunculosis, paronychia, cellulitis, and characteristic "cold" abscesses (see Fig. 144-13) that do not demonstrate the anticipated degree of erythema, warmth, and purulence. The abscesses occur most commonly on the head and neck and in intertriginous areas.

HYPERIMMUNOGLOBULINEMIA E SYNDROME AT A GLANCE



- Synonyms: Job syndrome, Buckley syndrome, hyper-immunoglobulin E (IgE) recurrent infection syndrome.
- Most cases are sporadic or show autosomal dominant inheritance with variable penetrance.
- Classic triad: recurrent staphylococcal skin abscesses, pneumonia with pneumatocele formation, and high serum levels of IgE.
- Other common features are the atopic dermatitis, scoliosis, fractures, and dental abnormalities.
- Sporadic and autosomal dominant cases suffer from a multisystem disorder, affecting the skin, soft tissues, skeletal system, and dentition. Autosomal recessive cases have severe viral infections, lack skeletal and dental involvement, and develop severe neurologic complications.

Pulmonary bacterial pneumonia, abscesses, and empyema are the most frequent systemic infections and may result in pneumatoceles that serve as the nidus for bacterial or fungal superinfection. The most common infecting organisms are *S. aureus* and *H. influenzae*. Other than pneumonias, deep-seated infections, bacteremia, and sepsis are rare.[134]

Facial and skeletal abnormalities are common. Patients develop progressive coarsening of facial features (see Fig. 144-13), probably reflecting the skeletal defects, but the recurrent facial pustulation and lichenification from dermatitis may contribute. Distinctive facial features, including prominent forehead, a broad nasal bridge, and wide nasal tip are universally present by the age of 16 years old. Dental anomalies include retention of primary teeth and lack of eruption of secondary teeth. Osteopenia is common, and 57 percent of patients have had at least three pathologic fractures, especially of the long bones, ribs, and pelvis. Scoliosis occurs in 63 percent of adult patients and hyperextensibility of joints in 68 percent of patients.[132]



▲ **FIGURE 144-13** Coarse facial features, atopic dermatitis furuncles, and a cold abscess at the glabella in a boy with hyperimmunoglobulinemia E syndrome.

By definition, serum IgE levels must be elevated, but normal levels of IgE increase markedly during childhood. Levels of > 2000 IU/mL are seen in adolescents and adults; considerably lower levels during infancy are seen, given that the upper limit of normal in infants < 1 year old is 12.7 IU/mL and by 5 years of age is 47.1 IU/mL; an IgE level 10-fold above the 95th percentile for age is required for diagnosis. Eosinophilia of at least two standard deviations above normal (usually above 700 cells/μL) is also a clinical manifestation. The total white blood cell count is typically normal and often fails to elevate in the setting of acute infection. The most common clinical features and laboratory values of patients with sporadic or autosomal dominant HIES are summarized in Table 144-7.

Autosomal recessive disease is characterized by recurrent bacterial and viral infections, autoimmunity and devastating neurologic complications that are often fatal in childhood. Patients with autosomal recessive HIES show no tendency to form pneumatoceles and have no skeletal or dental abnormalities.[139] Eosinophilia tends to be more severe (e.g., 17,500/μL) and elevated levels of other immunoglobulin isotypes often accompany the increase in IgE level.[132]

PROGNOSIS, CLINICAL COURSE, AND TREATMENT Given the lack of correlation between serum levels of IgE, eosinophilia, and the susceptibility to severe infections, the clinical course is difficult to predict. Patients with autosomal recessive HIES have a more severe course related to the neurologic complications.[139]



TABLE 144-7
Characteristics of Hyperimmunoglobulinemia E Syndrome

	INCIDENCE (%)
Immune System	
• Dermatitis	100
• Skin abscesses	87
• Recurrent pneumonia (three or more, proved by x-ray)	87
• Pneumatoceles	77
• Mucocutaneous candidiasis	83
Skeletal System	
• Characteristic facies	83
• Wide nose	65
• Failure of dental exfoliation (> three teeth)	72
• Hyperextensibility	68
• Recurrent pathologic fractures	57
• Scoliosis (> 10°)	63
Laboratory Values	
• Immunoglobulin E > 2000 IU/mL or > 10 times the age-specific norm	97
• Eosinophilia (> 2 standard deviations above the norm)	93

Anti-staphylococcal antibiotics are effective for most cutaneous infections in patients with HIE, and oral triazole antifungals treat the mucocutaneous candidiasis. The prophylactic use of anti-staphylococcal antibiotics markedly reduces the incidence of skin abscesses and pneumonia. The cutaneous and pulmonary abscesses often require incision and drainage and may require partial lung resections. IVIG therapy has been used successfully. IVIG may influence IgE levels due to an increased immunoglobulin catabolism or neutralization of the IgE.[132] Ascorbic acid and cimetidine have decreased the number of infections and the chemotactic defect in some patients. Isotretinoin has been reported to eliminate the recurrent staphylococcal abscesses in an isolated patient without any change in immunologic status. Cyclosporin A also been used with good clinical and laboratory response.[140,141] IFN-γ has shown inconsistent effects on IgE levels and infection susceptibility. Bone marrow transplant has been attempted in two cases of typical autosomal dominant HIES with limited success.

Silvery Hair Syndromes: Chédiak-Higashi and Griscelli Syndromes (See Chap. 73)

CHÉDIAK-HIGASHI SYNDROME The silvery hair syndromes comprise a group of autosomal recessive disorders in which a peculiar metallic sheen to hair and often skin is noted. Of these, Chédiak-Higashi and Griscelli syndromes have associated immunodeficiency (Table 144-8). The other syndrome with silvery hair, Elejalde syndrome, does not have associated immunodeficiency. Elejalde syndrome may be allelic with the myosin 5a-deficient form of Griscelli syndrome (GS), with severe associated CNS dysfunction.

Epidemiology. Chédiak-Higashi syndrome (CHS) is a rare autosomal recessive disorder. Parental consanguinity is often reported, and there are approximately 300 reported cases worldwide.

Etiology and Pathogenesis. CHS is caused by mutations in the LYST gene, located on chromosome 1q42, which encodes a protein required for the final steps of vesicle trafficking and secretion.[142,143] The LYST gene is expressed in lysosomes and other secretory organelles (melanosomes, cytolytic granules, and platelet dense granules). Characteristic giant granules are thought to result from altered granule maturation and fusion.[144] Enlarged melanosomes are unable to be transferred to keratinocytes. NK cells and cytotoxic T lymphocytes do not release proteolytic enzymes necessary for target cell killing. Cytotoxic T lymphocyte–associated antigen is trapped in abnormally large vesicles rather than on the cell surface and thus may be unable to regulate T-cell activation, increasing the risk of lymphoproliferative disease.[145] Platelet dense granules are delayed in secretion of storage pools required for normal coagulation. Diminished chemotaxis of neutrophils and monocytes and delayed intracellular microorganism killing are often associated.

Clinical Findings. Patients usually first show manifestations during infancy or early childhood. Pigment abnormalities occur in 75 percent of patients, particularly the silver sheen to the hair (Fig. 144-14A). Ocular hypopigmentation may cause photophobia, and strabismus and nystagmus are common. Visual acuity does not tend to be reduced. The skin is typically fair, but slate-colored areas of pigmentation may be present. Diffuse speckled hypopigmentation and hyperpigmentation may be seen in the sun-exposed skin of dark-skinned individuals.[146]

Infections can be observed in the newborn period and continue through the lifetime of the patient. Infections most commonly involve the skin, lungs, and respiratory tract where microbes such as *S. aureus*, *S. pyogenes*, and *pneumococcus* are prevalent. Deep ulcerations resembling pyoderma gangrenosum have been described.

Neurologic manifestations include muscle weakness, cranial and peripheral neuropathy, and progressive neurologic deterioration. CHS patients have also been observed to exhibit a mild coagulation defect. Patients bruise easily, manifest petechiae, and have some mucosal bleeding, although platelet numbers remain normal.

The finding of large cytoplasmic granules in blood leukocytes is highly diagnostic. Hair shafts have evenly distributed granular pigment granules (see Fig. 144-14B), in contrast to the irregular, large pigmentary clumping of GS (see Fig. 144-14C). Skin biopsy shows pigmentary dilution in both melanocytes and keratinocytes and electron microscopy reveals giant melanosomes.

Prognosis, Clinical Course, and Treatment. Hemophagocytic syndrome, an accelerated phase of the disease that resembles lymphoma, occurs by late childhood. Hemophagocytic syndrome is characterized by widespread visceral infiltration by atypical lymphoid and histiocytic cells.

CHÈDIAK-HIGASHI SYNDROME AT A GLANCE



- Autosomal recessive disorder of vesicle trafficking that results in giant organelles, including melanosomes, leukocyte granules, and platelet-dense granules
- Mutations in LYST
- Silvery hair, often hyperpigmentation on nose and ears, and a variable degree of photophobia and nystagmus
- Recurrent pyogenic infections and a mild bleeding diathesis
- An "accelerated phase" with pancytopenia and organomegaly due to lymphohistiocytic infiltration (fatal without hematopoietic stem cell transplantation)
- Progressive neurologic deterioration
- Therapy: Transplantation



TABLE 144-8
Characteristics of Griscelli and Chédiak-Higashi Syndromes

	GRISCELLI (GS1)	GRISCELLI (GS2)	GRISCELLI (GS3)	CHÉDIAK-HIGASHI
Gene defect/ protein	*MYO5A*/myosin5a.	*RAB27A*/Rab27a.	a. *Slac2-a/mlph.* b. *MYO5A* F-exon deletion.	*LYST/lysosomal transport protein.*
Functional consequence	Intracellular organelle transport and neurotransmitter secretion; Interacts with Slac2-a/mlph.	GTPase for organelle movement and transfer. Essential for T and NK lymphocyte cytotoxic granule release and target cell death. Interacts with Slac2-a/mlph.	Interacts with both myosin 5a and Rab27 to form a protein complex essential for melanosome movement to melanocytes.	Protein required for final steps of membrane fusion and vesicle trafficking.
Tissue expression	Brain. Not in cytotoxic cells.	Cytotoxic cells. Not in brain.	Slac2-a/mlph is not in cytotoxic cells.	
Clinical features	Silvery metallic hair. Mild skin pigment dilution. Onset of neurologic disorder in infancy.	Silvery metallic hair. Mild skin pigment dilution. Severe immune disorder with hemophagocytic syndrome. Neurologic symptoms are associated with hemophagocytic syndrome and central nervous system infiltration.	Silvery metallic hair.	Silvery metallic hair and skin. Recurrent infections. Bleeding tendencies. Progressive neurologic defects. Immune disorder with hemophagocytic syndrome.
Immune defects	None.	T and NK cell function; hypogammaglobulinemia.	None.	T and NK cell function, diminished neutrophil chemotaxis and bactericidal activity.
Hair mount	Large, uneven clusters of pigment.	Same as GS1.	Same as GS1.	Granular, evenly distributed pigment.
Skin light microscopy	Pigmentary dilution in keratinocytes, accumulation of melanosomes in melanocytes.	Same as GS1.	Same as GS1.	Pigmentary dilution in both keratinocytes and melanocytes.
Skin electron microscopy	Mature melanosomes filling epidermal melanocytes.	Same as GS1.	Same as GS1.	Reduced numbers of giant melanosomes.
Leukocyte granules	None.	None.	None.	Large, cytoplasmic.

GTPase = guanosine triphosphatase; mlph = melanophilin; NK = natural killer.





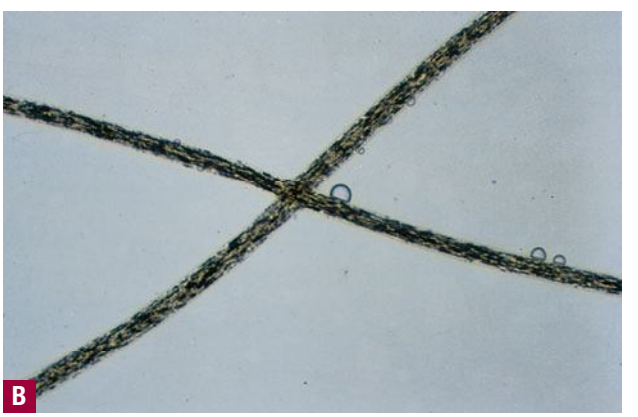

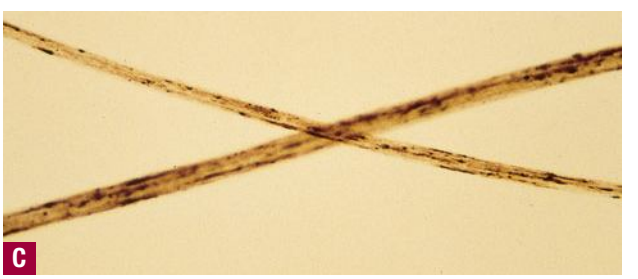

▲ **FIGURE 144-14** Silvery hair syndromes. **A.** Silvery sheen to the hair in a black infant; the patient had darkly pigmented eyes and skin. Note the accentuation of pigmentation on the ear helix. **B.** Small, evenly clumped pigment granules in the hairs of Chédiak-Higashi syndrome. **C.** Larger aggregates of irregularly spaced pigmentation in the hairs of a patient with Griscelli syndrome.

This lymphoma-like stage is precipitated by viruses, particularly by EBV infection. Hepatosplenomegaly, lymphadenopathy, pancytopenia, jaundice, fever, a leukemia-like gingivitis, and pseudomembranous sloughing of the buccal mucosa are common features.

The hemophagocytic syndrome associated with lymphohistiocytic proliferation of silvery hair syndromes needs to be distinguished from massive lymphoproliferation in other immunodeficiency disorders, particularly X-linked lymphoproliferative disorder (see Antibody Deficiency Disorders), familial hemophagocytic lymphohistiocytosis, autoimmune lymphoproliferative syndrome, and immunodeficiency due to mutations in the IL-2R. *Familial hemophagocytic lymphohistiocytosis* is a group of autosomal recessive disorders with hemophagocytosis and absence of NK cell cytotoxicity that tends to be fatal without early stem cell transplantation.[147]

The mean age of death for patients with Chédiak-Higashi syndrome is 6 years old, usually from overwhelming infection or hemorrhage during the lymphoma-like accelerated phase. Prenatal diagnosis has been achieved by examination of hair from fetal scalp biopsies and of leukocytes from fetal blood samples.

The treatment of choice for patients with Chédiak-Higashi syndrome is early transplantation, which corrects the immunologic status but does not affect the pigment abnormality nor inhibit the development of neurologic disorders that grow increasingly worse with age. Acyclovir, high-dose intravenous γ-globulin, vincristine, cyclosporine, and prednisone have been used to control the accelerated phase, but it is usually fatal. Ascorbic acid corrects the microtubular defects in vitro but has no clinical ameliorative effects.[150] Interferon has been demonstrated by some authors to partially restore NK cell function.[151]

GRISCELLI SYNDROME ***Epidemiology.*** The majority of affected patients with this autosomal recessive disorder are of Mediterranean or Middle Eastern origin and born into consanguineous families.

Etiology and Pathogenesis. Mutations in three genes may underlie GS. GS1 is caused by a mutation in the *MYO5A* gene that encodes myosin 5a, a motor protein responsible for intracellular organelle transport. *MYO5A* is abundantly expressed in brain tissue and is important for neurotransmitter secretion. It is not expressed in cytotoxic cells. GS2 is caused by a mutation in the *RAB27A* gene, which encodes Rab27a, a guanosine triphosphatase protein involved in the function of the intracellular-regulated secretory pathway. It is essential for T and NK lymphocyte cytotoxic granule release and cell death. This defective cytotoxic activity most likely leads to the uncontrolled activation of lymphocytes and macrophages in the hemophagocytic syndrome. Both *MYO5A* and *RAB27A* have been mapped to chromosome 15q21.1.[152] A third type of Griscelli syndrome (GS3) is the result of a homozygous missense mutation in *Slac2-a/mlph* (melanophilin, mlph) or a deletion of the *MYO5A* F-exon. Melanophilin encodes a member of the Rab effector family and interacts with both myosin 5a (through the F-exon) and *RAB27A* to form a triprotein complex essential for the capture and local transport of melanosomes to the melanocytes (Fig. 144-15).[152,153] All three genetic sub-types share the inability to construct this complex for melanosome transport, thus leading to the characteristic pigmentary abnormality of GS.

Clinical Findings. The pigmentary dilution of GS is often limited to the hair, characterized by a silver-gray sheen with a few cases of skin involvement.

GRISCELLI SYNDROME AT A GLANCE



- Autosomal recessive group of disorders
- Mutations in *MYO5A* (more neurologic), *RAB27A* (hemophagocytosis), or *Slac-2a*
- Silvery hair is a hallmark
- Hemophagocytosis often precipitated by Epstein-Barr virus infection
- Treatment: Transplantation

The hair shaft shows large uneven clusters of pigment (see Fig. 144-14C) and the skin shows pigmentary dilution in keratinocytes but accumulation of melanosomes in melanocytes. Electron microscopy reveals numerous stage IV melanosomes in epidermal melanocytes. In contrast to Chédiak-Higashi syndrome, smears of leukocytes do not

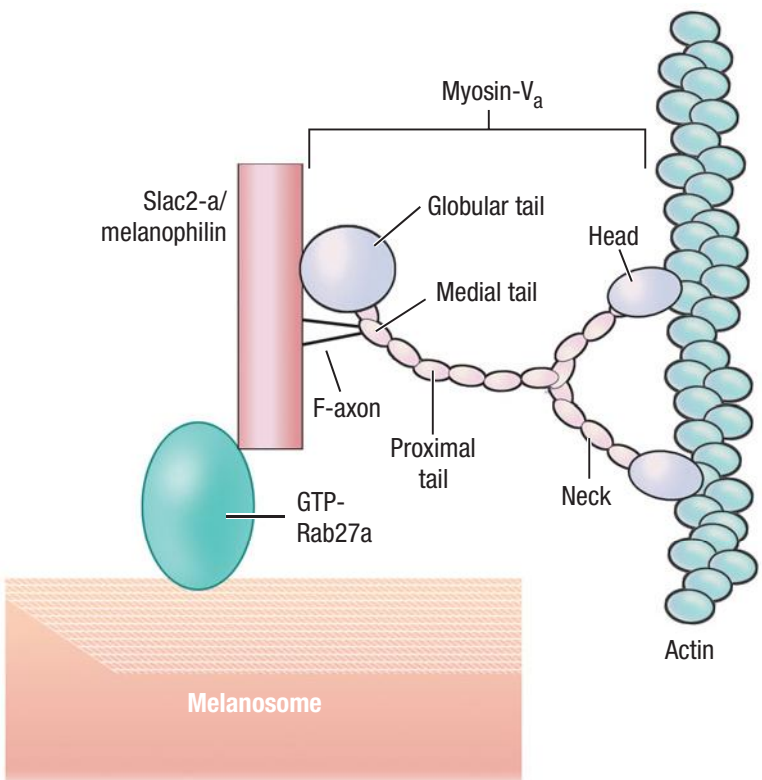

▲ **FIGURE 144-15** Protein interactions required for melanosome transfer. GTP = guanosine triphosphate. [Adapted from Menasche G et al: Griscelli syndrome restricted to hypopigmentation results from a melanophilin defect (GS3) or a MYO5A F-exon deletion (GS1). *J Clin Invest* **112**:450, 2003.]



show giant granules. The additional clinical features present in each subtype are dependent on the function and tissue expression of the defective protein. Patients with GS1 have a primary neurologic disorder that presents in infancy with hypotonia and developmental delay. Severe immune disorder characterized by hemophagocytic syndrome or an "accelerated phase of the disease" is seen in GS2. Hemophagocytic syndrome is characterized by infiltration of various organ systems by activated lymphocytes and macrophages. It develops by a mean age of 36 months, and often is precipitated by a virus, particularly EBV. Patients have fever, hepatosplenomegaly, neurologic impairment, coagulopathy, and pancytopenia.[154] Patients with GS3 present solely with the pigmentary abnormalities.



Prognosis, Clinical Course, and Treatment. GS has been uniformly fatal but now can be reversed by successful bone marrow transplantation. Eighty-five percent of patients with GS2 have mutations in the *RAB27A* gene that lead to early protein truncation. They have the most severe form of the disease with early development of hemophagocytic syndrome and rapid progression. The median survival from the onset of the accelerated phase to death in these patients is 5 months. Most patients die by 5 years of age secondary to progressive CNS disease or recurrent infections.[154] Missense mutations in the *RAB27A* gene show a milder phenotype with later age of hemophagocytic syndrome onset and a good response to chemotherapy treatment.[155] Patients with GS1 do not develop hemophagocytic syndrome. Prenatal diagnosis has been achieved by examination of hair from fetal scalp biopsies and DNA from leukocytes of fetal blood samples.[156]

COMPLEMENT DEFICIENCY DISORDERS

The complement system represents an enzymatic reaction cascade that involves three major initial pathways (classical—C1, C4, C2; lectin; and alternative—C3, factors B, D, H, and I, properdin) and a shared terminal pathway (membrane attack complex—C5–C9) (see Chap. 36). Complement proteins regulate humoral and cellular immune functions, and participate in the killing of bacterial organisms. Abnormalities of the complement system tend to manifest as increased susceptibility to bacterial organisms or autoimmune disorders.[157,158]

COMPLEMENT DEFICIENCY DISORDERS AT A GLANCE

- Deficiency or dysfunction of early complement components is associated with autoimmune disorders, particularly systemic lupus erythematosus.
- Deficiency or dysfunction of early complement components leads to risk of infections caused by encapsulated bacteria.
- Deficiency of late complement components markedly increases susceptibility to neisserial infections.

Epidemiology

The most common hereditary complement disorder is C2 deficiency, which can result from a defect in either protein synthesis (type 1) or secretion (type 2); 1 percent to 2 percent of the Caucasian population is heterozygote[159] and 0.005 percent are homozygote.[160] The deficiency is usually caused by a 28-base pair deletion in the C2 gene. Homozygous deficiencies of C1q, C1r, C1s, and C4 (C4A or C4B) are rare, but manifest with autoimmune disease more frequently than homozygous C2 deficiency. The incidence of SLE in patients with C1q, C4, and C1r is 93 percent, 75 percent, and 57 percent, respectively; whereas it is 10 percent with C2 deficiency (25 percent if homozygous).[157] Total deficiency of mannan-binding lectin (MBL) is the most common among homozygote states (approximately 3 percent), although clinical penetrance is low.[161] In addition, approximately 0.01 percent of individuals have a homozygous deficiency in the MBL-associated serum protease, which is activated by MBL binding to the surface carbohydrates of bacteria and generates classical pathway C3 convertase via cleavage of C4 and C2. Excluding deficiency of MBL; however, homozygote forms of complement deficiency represent 0.03 percent of the population. In general, heterozygotes produce sufficient complement to ensure function and remain asymptomatic, so individuals who manifest complement disorders tend to be homozygotes. Hereditary angioedema (HAE), on the other hand, manifests in heterozygotes with deficiency or dysfunction of the C1 inhibitor (C1 INH) (see Hereditary Angioedema). Despite the rarity of homozygous deficiency, the incidence of complement deficiency in patients with recurrent neisserial infection has been found to be as high as 20 percent. In patients with autoimmune disorders, such as SLE, the incidence of C2 deficiency is approximately 7 percent[159] and of MBL deficiency is increased two- to threefold. Properdin deficiency is the only X-linked complement deficiency, and all known patients are male.

Etiology and Pathogenesis

Defects involving the early components of the classical complement pathway (C1, C4, C2) manifest with an increased incidence of autoimmune disorders, especially SLE (Table 144-9). The reason for the increased incidence of autoimmune disorders and particularly lupus in patients with complement deficiency is unclear. The genes that encode C4A, C4B, C2, and factor B are localized to the MHC region on chromosome 6; just as HLA types have been linked to SLE (e.g., HLA A1, B8, DR3), gene alterations in this region may play a role in generation of autoimmunity.

The variety of recurrent infections associated with complement deficiencies underscores the key role of complement in bacterial clearance. Patients with a deficiency of the early classical components, especially C2, have a mildly increased susceptibility to infections with encapsulated bacteria. Opsonization of bacteria and fungi may be ineffective in disorders of the classical pathway because of the slow, inadequate formation of C3b. However, the development of infection is likely mitigated by the ability of the lectin and alternative pathways to generate C3, thus bypassing the early classical pathway (see Chap. 36). C5 deficiencies result in impaired generation of chemotactic factors, which may lead to inadequate neutrophil function. Individuals with C5 to C9 (membrane attack complex) deficiencies typically develop chronic recurrent neisserial infections as teenagers, reflecting the role of the terminal complement pathway in the destruction of these organisms. Similarly, the effect of properdin in stabilizing the alternative C3 convertase is critical for killing of organisms because properdin deficiency leads to fulminant neisserial infections. Manifestations of complement deficiency may also result from alterations in the regulators of the complement cascade that lead to uncon-

TABLE 144-9
Clinical Manifestations of Hereditary Deficiency or Dysfunction of Complement Components

MANIFESTATION	COMPONENT	PATHWAY	ASSOCIATIONS
Infection	C1q, C1r, C1s, C4, C2	Classical	Autoimmune disorders, especially SLE Increased encapsulated bacterial infections
	Mannan-binding lectin	Lectin	Pyogenic infections in neonates and children SLE
	Factors H, I	Inhibitors, alternative	Recurrent pyogenic infections (C3 depletion)
	Properdin	Stabilizer, alternative	Fulminant neisserial infections
	CR3	Receptor for iC3b	Leukocyte adhesion defect (see LAD type 1)
	C5–C9	Terminal (membrane attack complex)	Recurrent neisserial infections; milder with C9 deficiency
Autoimmune disorders	C1, C4, C2	Classical	Autoimmune disorders, especially SLE Increased encapsulated bacterial infections
	Mannan-binding lectin	Lectin	Pyogenic infections in neonates and children SLE
Exfoliative erythroderma	C3, C5	Shared, terminal	Failure to thrive, diarrhea, infections
Angioedema	C1 esterase inhibitor	Inhibitor, classical	Angioedema
Renal disease and/or hemolysis	Factor H	Inhibitor, alternative	Glomerulonephritis, atypical hemolytic uremic syndrome
	Decay accelerating factor (CD59)	Inhibitor, alternative	Hemolysis, thrombosis
	Membrane co-factor protein (CD46)	Inhibitor, alternative	Atypical hemolytic uremic syndrome
	C3	Shared	Membranoproliferative glomerulonephritis Severe bacterial infections

LAD = leukocyte adhesion deficiency; SLE = systemic lupus erythematosus.

trolled activation of the complement cascade (see Chap. 36).

Clinical Features

Cutaneous and joint findings of lupus erythematosus (see Chap. 156) are the most common autoimmune manifestation of deficiency of the early complement components (see Table 144-9), and often first show manifestations during childhood. Manifestations of deficiency of C2 are seen most commonly, given its prevalence, but deficiency of homozygous C1q deficiency is the strongest single genetic risk factor for SLE identified to date. In general, the lupus associated with C2 deficiency is milder than that associated with deficiency of other classical complement components (Fig. 144-16), which have an earlier onset, and increased risk of associated glomerulonephritis. In addition to patients who meet criteria for lupus erythematosus, undifferentiated connective tissue disease and vasculitis are the most common autoimmune manifestations in individuals with C2 deficiency. C2 deficiency has also been found in patients with dermatomyositis, juvenile rheumatoid arthritis, atrophoderma, Henoch-Schönlein purpura, cold urticaria, and inflammatory bowel disease.

The most common feature of lupus in persons with C2 deficiency is photosensitivity, and lesions typical of subacute cutaneous lupus are seen more often than those of acute cutaneous lupus (see Fig. 144-16) or discoid lupus. Oral ulcerations are present in approximately 50 percent of affected individuals, and cicatricial alopecia may occur. In general, the lesions may be more resistant than those of lupus without complement deficiency, but noncutaneous manifestations tend to be less



▲ **FIGURE 144-16** Systemic lupus erythematosus in a child with C4 deficiency. This boy eventually died of an overwhelming Gram-negative coccal infection.

severe. Arthralgias or arthritis is seen in 80 percent, but renal disease tends to be mild or occult. C2 deficiency lupus but also C4 deficiency lupus is unlikely to be associated with elevated antinuclear antibody titers or anti-DNA antibodies, but 75 percent of patients have detectable anti-Ro antibodies. Direct immunofluorescence may show deposition but is more likely to be negative than in lupus unrelated to C2 deficiency. Leukopenia has been described in 50 percent of affected individuals and rheumatoid factor in 40 percent.

Although most individuals with MBL deficiency show no clinical manifestations, deficiency of MBL or its associated serum protease is also associated with an increased risk of SLE, and MBL deficiency has been described with dermatomyositis. In patients with SLE, having MBL deficiency is associated with a higher risk of bacterial complications. The risk of SLE is also increased in individuals with deficiencies in C3 or regulators of the complement pathway, such as factor H or factor I (C3b inactivator). Approximately 5 percent of individuals with deficiency of the late complement components have evidence of immune complex or autoimmune disease, and these manifestations have not been described with properdin deficiency.

The bacterial organisms that cause problems in complement deficiency of classical components are encapsulated bacteria, including *Pneumococcus* and *H. influenzae*. Infections can be severe with an onset during infancy and childhood.[166,167] A recent retrospective study of 40 patients with homozygous C2 deficiency over a mean of 39 years (range, 1 to 77 years) found that severe infection was the predominant clinical manifestation[157]; 23 patients had a his-



tory of septicemia or meningitis caused by *Pneumococcus*, and in 12 the infections were recurrent. Nineteen patients had at least one episode of pneumonia, with recurrence in 10 affected individuals.

With deficiency of components of the membrane attack complex or regulators of the alternative pathway, particularly properdin deficiency, infections most commonly begin in teenage years and are caused by neisserial organisms, particularly meningococcus. Properdin deficiency is associated with fulminant meningococcal disease that can lead to death in up to 28 percent of patients and usually manifests as a single episode, but the neisserial disease with deficiency of the late complement components tends to be recurrent and of lesser severity, only occasionally leading to death.



Laboratory Abnormalities

In complement deficiencies other than HAE, total hemolytic complement (CH50) is markedly decreased (e.g., in C9 deficiency) or undetectable (most complement deficiencies). The alternative pathway lytic test (AP50) is less sensitive than the CH50, but may be useful to screen for deficiencies in the alternative pathway components. Levels of specific complement components and MBL are generally measured by enzyme-linked immunosorbent assay or radial immunodiffusion assays.[158] Although usually absent with C2 deficiency itself, anti-Ro antibodies are present in three-fourths of patients with C2 deficiency who have SLE.

Differential Diagnosis

Secondary decreases in complement levels may be seen in patients with a variety of disorders, most commonly in SLE and hypocomplementemic vasculitis. Complement levels may also be reduced by bacterial (particularly endocarditis) and viral infections, hepatic disease, myeloma, malnutrition including anorexia nervosa, and medications that may cause a lupus-like syndrome (especially hydralazine, penicillamine, and procainamide). The "Leiner phenotype" has been described in patients with HIES, SCID, and X-linked agammaglobulinemia.

Treatment

Traditional management of lupus erythematosus is appropriate for patients with complement deficiency and should be chosen based on clinical manifestations. Topical anti-inflammatory medications and sun protection may adequately treat milder cases with cutaneous findings, but antimalarial medications, systemic corticosteroids, and other immunosuppressive drugs may be required for more severe cases; given the increased risk of infections in patients with complement deficiency, careful monitoring is critical.

HEREDITARY ANGIOEDEMA

HAE is almost always inherited in an autosomal dominant fashion with a spontaneous mutation rate of 25 percent.[171] It occurs in 1 in 150,000 persons and has no racial or ethnic predilection. Seventy-five percent of patients report a positive family history. There are three types of HAE. Type I is characterized by low antigenic levels of C1 INH and affects 85 percent of patients, whereas the remainder of patients have Type II, with low functional levels but normal/high antigenic levels of C1 INH.[172] A third type of HAE does not show a deficiency of C1 INH.[173] This type of HAE was previously thought to only affect women, although recently, a family was described in which three male family members were affected.[174] One family has been identified in which the disease is transmitted as an autosomal recessive trait due to a mutation in the promoter region of the gene.[175] See Chap. 37 for a complete discussion of HAE.

KEY REFERENCES

The full reference list for all chapters is available at www.digm7.com.

1. Cunningham-Rundles C, Ponda PP: Molecular defects in T- and B-cell primary immunodeficiency diseases. *Nat Rev Immunol* **5**:880, 2005
6. Castigli E, Geha RS: Molecular basis of common variable immunodeficiency. *J Allergy Clin Immunol* **117**:740, quiz 747, 2006
44. Collins SM et al: Dermatological manifestations of autoimmune polyendocrinopathy-candidiasis-ectodermal dystrophy syndrome. *Br J Dermatol* **154**:1088, 2006
50. Bonilla FA, Geha RS: Update on primary immunodeficiency diseases. *J Allergy Clin Immunol* **117**:S435, 2006
69. Ochs HD, Thrasher AJ: The Wiskott-Aldrich syndrome. *J Allergy Clin Immunol* **117**:725, quiz 739, 2006
81. Buckley RH: The multiple causes of human SCID. *J Clin Invest* **114**:1409, 2004
106. Orange JS, Levy O, Geha RS: Human disease resulting from gene mutations that interfere with appropriate nuclear factor-kappaB activation. *Immunol Rev* **203**:21, 2005
132. Grimbacher B, Holland SM, Puck JM: Hyper-IgE syndromes. *Immunol Rev* **203**:244, 2005
152. Menasche G et al: Griscelli syndrome restricted to hypopigmentation results from a melanophilin defect (GS3) or a MYO5A F-exon deletion (GS1). *J Clin Invest* **112**:450, 2003
157. Sjoholm AG et al: Complement deficiency and disease: an update. *Mol Immunol* **43**:78, 2006

SECTION 25

SKIN MANIFESTATIONS OF BONE MARROW AND BLOOD DISORDERS

CHAPTER 145

Hematologic Diseases

Bina A. Rashid
Elizabeth Bahar Houshmand
Michael P. Heffernan

Mucocutaneous changes are often an indicator of underlying hematologic diseases. The skin and mucous membranes are highly vascular and are susceptible to abnormalities in the blood. Mucocutaneous manifestations may result from alterations in hemoglobin concentration, oxygenation, and plasma volume. Likewise, genetic diseases, such as sickle cell and thalassemia, present with significant skin changes, as do bone marrow disorders such as the leukemias and lymphomas.[1–3] This chapter focuses on the cutaneous findings associated with non-malignant hematologic disorders.[4]

Routine laboratory tests have now made it easier to detect common hematologic disorders. In some parts of the world where laboratory tests are not easily accessible or affordable, pallor, cyanosis, and jaundice are useful in detecting an underlying disease and assessing its management. In such areas of the world, anemia and other hematologic conditions are more prevalent.[5] A comprehensive listing of these associations is presented in Table 145-1. Selected associations are covered in more detail in the text. The emphasis, in this chapter, is the differential diagnosis of mucocutaneous discoloration (pallor, erythroderma, cyanosis, jaundice, and extramedullary hematopoiesis) and blood extravasation (cutaneous hemostasis and purpura).

CUTANEOUS SIGNS AND SYMPTOMS ASSOCIATED WITH HEMATOLOGIC DISEASES

Pallor

Pallor of the mucocutaneous tissue is observed most readily in the palms, nail beds, face, and conjunctivae. In these areas, the microvascular bed is visible through the skin. Pallor is the result of lowered hemoglobin content.[75,76]

There are multiple causes for pallor. They include acute and chronic hemorrhage, emotion, drugs (i.e., vasopressors), cold, shock, and pathophysiologic adjustments that lead to anemia. Cutaneous edema can also produce pallor. Treating the underlying etiology of pallor corrects both the pallor and the cause.

ANEMIA The palmar creases are a good indicator of the severity of anemia. Unless the hemoglobin level drops below the normal range, palmar creases appear pink.

The definition of anemia is dependent on the patient's age and sex. Anemias are best approached through a morphologic classification based on red blood cell (RBC) size or volume, which can be assessed by a blood smear.[77,78] This allows us to classify the anemias into microcytic, normocytic, and macrocytic anemias. Each morphologic type of anemia is associated with specific causes such as blood loss, genetic disorders, decreased red blood cell production, or increased red blood cell destruction.[79,80]

Constitutional signs and symptom of anemia include malaise, fatigue, dizziness, postural hypotension, dyspnea on exertion, and tachycardia. Obviously, these symptoms and signs become more apparent as the oxygen demand is increased. Red blood cells carry oxygen linked to hemoglobin from the lungs to tissue capillaries.[81,82] Oxygen is then released from hemoglobin according to the characteristics of the oxyhemoglobin dissociation curve.[82]

Laboratory evaluation should be based on the suspicion of the underlying cause of anemia; it includes complete blood count with white blood cell differential, iron studies (iron, total iron blood

HEMATOLOGIC DISEASES AT A GLANCE



- Mucocutaneous changes (i.e., pallor, jaundice, flushing, erythema, and cyanosis) often predict underlying hematologic pathology.
- Anemia is best differentiated by mean corpuscular volume value.
- Megaloblastic anemia of vitamin B_{12} deficiency is distinguished from folate deficiency by lack of neurologic signs in folate deficiency.
- Carcinoid tumor results in flushing, typically for 10 minutes or less; in comparison, flushing from mastocytosis lasts 30 minutes or more.
- Polycythemia vera presents with acrocyanosis, aquagenic pruritus, urticaria, Sweet syndrome, and purpura.
- The morphologic diagnosis of purpura begins with three P's: Is the lesion *p*urpuric, is it *p*rimary, and is it *p*alpable?
- Leukemia cutis is a localized or disseminated skin infiltration by leukemic cells. It is a sign of dissemination or systemic disease or relapsing leukemia.



Copyright © 2008 by The McGraw-Hill Companies, Inc. Click here for terms of use.

TABLE 145-1
Cutaneous Findings with Hematologic Associations[6–9]

Pigmentary changes
- Generalized hyperpigmentation
  - POEMS syndrome (*p*olyneuropathy, *o*rganomegaly, *e*ndocrinopathy, *M*-protein, *s*kin lesions)[10,11]
    - ~ Hyperpigmentation, 93%–98%; apparent skin thickening, 77%–85%; hypertrichosis, 78%–81%; peripheral edema, ~90%; digital clubbing, 56%; white fingernails; verrucous angiomata, telangiectasia
  - Hemochromatosis may have bronze or grayish pigmentation of the skin
  - Megaloblastic anemia of vitamin B_{12} or folate deficiency
  - Fanconi anemia[12,13]
    - ~ Begins age 4–10 yr with skin or hematologic presentation
    - ~ Generalized hyperpigmentation, especially lower trunk, flexures, neck, 85%
    - ~ Scattered darker and lighter macules within hyperpigmented areas
    - ~ Progressive hypoplastic anemia with pancytopenia
    - ~ Death from leukemia, other neoplasms, or infections 2–5 yr after onset
  - Dyskeratosis congenita[14]
    - ~ Nail dystrophy, beginning 5–13 yr of age
    - ~ Fine reticulate gray-brown hyperpigmentation, especially neck, thighs, and trunk
    - ~ Atrophic skin with telangiectasis
    - ~ Oral leukoplakia
    - ~ Mucocutaneous carcinomas, occasional pancreatic carcinoma, Hodgkin disease
    - ~ Frequent blood dyscrasias, aplasias, refractory anemias, pancytopenias
- Localized hyperpigmentation
  - Hypermelanosis and hemosiderosis may develop on the lower legs in hemolytic anemia, may develop focally in vitamin B_{12} or folate deficiency
  - Porphyria cutanea tarda, variegate porphyria, erythropoietic porphyria, occasionally hereditary coproporphyria cause hyperpigmentation, primarily in sun-exposed areas (see Chap. 149)
- Generalized hypopigmentation
  - Chédiak-Higashi (see Recurrent cutaneous infections)
  - Hermansky-Pudlak[15]
    - ~ White, red, or brown hair; cream-gray to light normal skin
    - ~ Blue-gray to brown iris
    - ~ Platelet bleeding diathesis
    - ~ Ceroid-like deposits in reticuloendothelial system, gastrointestinal tract, lung, and kidney that lead to pulmonary interstitial fibrosis, nephritis, granulomatous colitis
- Localized hypopigmentation
  - POEMS syndrome (see Generalized hyperpigmentation)
  - Pernicious anemia with vitiligo
  - Vitamin B_{12} deficiency associated with poikilodermatous hypopigmentation
  - Anemia of autoimmune hypothyroidism may be associated with vitiligo
  - Adult Gaucher disease[16]
    - ~ Brown chloasma-like macules on face, neck, and hands
    - ~ Symmetric hyperpigmentation of lower legs
  - Niemann-Pick disease[17,18]
    - ~ Indurated discolored patches, especially on checks, café-au-lait spots
    - ~ Mongolian on skin and oral mucosa
  - Porphyria cutanea tarda, variegate porphyria, erythropoietic porphyria, usually in areas of scarring

Recurrent cutaneous infections
- Neutropenia
  - Severe neutropenia (counts of 500/μL usually associated with fever, erythema without pus, painful ulcers). Causes include congenital and cyclic neutropenia; leukemia, lymphoma; marrow toxicity, failure, infiltration; and immune and autoimmune neutropenias.
- Functional leukocyte defects (counts may be low, normal, or elevated; defects identified in adherence, chemotactic response, phagocytosis, and killing)[19,20]
  - Chédiak-Higashi syndrome[15,21]
    - ~ Autosomal recessive
    - ~ Defect in cytoplasmic granule function
    - ~ Fair skin, light blond or silvery hair, and pale retina; translucent irises due to abnormal melanosomes
    - ~ Large neutrophil inclusion on Wright-stained blood smear
    - ~ Usually die in childhood
  - Griscelli syndrome[22] (see Chap. 115)
    - ~ Pigmentary dilution with silvery-gray hair
    - ~ Autosomal recessive
    - ~ Hypogammaglobulinemia, defective cell-mediated immunity
    - ~ Neutropenia, thrombocytopenia, lymphohistiocytosis, hepatosplenomegaly
    - ~ Neurologic deterioration
  - Chronic granulomatous disease of childhood (see Chap. 115)
    - ~ Leukocytes ingest bacteria normally but fail to kill them because of defects in H_2O_2 and oxygen radical production
    - ~ Multiple types, most X-linked; overall sex ration, male-female 6:1
    - ~ Skin lesions eczematous and purulent initially, transition to chronic cutaneous granulomas
    - ~ Catalase-positive microbes (e.g., *Staphylococcus aureus*, *Salmonella*, *Aspergillus*) can multiply intercellularly, whereas catalase-negative microbes (e.g., pneumococci or streptococci) that generate their own H_2O_2 are killed
    - ~ Nitroblue tetrazolium dye helpful in diagnosis
    - ~ X-linked carriers may develop lupus-like skin lesions, aphthous stomatitis, or granulomatous cheilitis
  - Myeloperoxidase deficiency
    - ~ Autosomal recessive affecting neutrophils but not eosinophils
    - ~ Functional impairment not severe
    - ~ Occasional difficulty with pyogenic infections, persistent fungal infection more common
- Membrane and cytoskeletal defects (see Chap. 115)
  - Leukocyte adherence disorders due to congenital lack of defect or some component of CD11/CD18 surface glycoproteins
    - ~ Neutrophils unable to adhere firmly to surfaces or complement-opsonized microorganisms
    - ~ Possible persistent leukocytosis
    - ~ Failure to develop much neutrophil response at inflammatory or infectious sites
  - Cytoskeletal defect in polymerizable actin[23]
    - ~ Similar presentation to leukocyte adherence defects, but with normal CD11/CD8 but impaired motility
  - Complement abnormalities
    - ~ C3 deficiency, C3b inactivator deficiency
  - Hyperimmunoglobulin E (IgE) syndrome
    - ~ Job and Buckley syndromes are subsets
    - ~ Elevated IgE, defective neutrophil chemotaxis
    - ~ No clear relationship between IgE levels and neutrophil motility defect
    - ~ Cold abscesses

(continued)

TABLE 145-1
Cutaneous Findings with Hematologic Associations[6–9] (Continued)

Recurrent cutaneous infections—*continued*
- Leiner disease
  - ~ Severe seborrheic dermatitis
  - ~ Diarrhea, failure to thrive
  - ~ Gram-negative bacterial and candidal infection during infancy
- Wiskott-Aldrich syndrome[24,25]
  - ~ X-linked
  - ~ Thrombocytopenia, small but dysfunctional platelets, hemorrhage
  - ~ Eczema
  - ~ Recurrent infections: Initially bacteria such as *Pneumococcus*, *Haemophilus influenzae*, *Neisseria meningitidis*; over time, T-cell function deteriorates and patient becomes susceptible to opportunistic viral, bacterial, and fungal infections
  - ~ Immunologic abnormalities and lymphoreticular malignancies
  - ~ CD43, a ligand for intercellular adhesion molecule-1, is defective; however, probably not primary defect because CD43 gene is on chromosome 16, not X
- Persistent or extensive herpes simplex or recurrent or disseminated herpes zoster suggest underlying immune defect or hematologic malignancy

Neutrophilic cutaneous reactions
- Acute febrile neutrophilic dermatosis (Sweet syndrome): Less than 10% of reported patients have heme association, usually acute myelogenous leukemia, myeloproliferative disorder, myelodysplastic syndrome, multiple myeloma, or monoclonal gammopathy
- Pyoderma gangrenosum: Often atypical or bullous—hematologic association similar to those in Sweet syndrome
- Antineutrophil cytoplasmic autoantibody (ANCA)–positive neutrophilic dermatosis
- Polymorphic disease with monoclonal IgA ANCA[26]
- Erythema elevatum diutinum (see Vascular disorders and coagulopathies)
- Leukocytoclastic vasculitis (see Vascular disorders and coagulopathies)

Vesiculobullous disease
- Pemphigus vulgaris: Lymphoproliferative diseases[27,28]
- Paraneoplastic pemphigus: Lymphoproliferative diseases, thymoma[29]
- Acquired immunobullous disease with skin fragility: Waldenström macroglobulinemia[30]
- Linear IgA dermatosis: Associations include Hodgkin lymphoma, non-Hodgkin lymphoma, polycythemia vera, chronic lymphocytic leukemia, plasmacytoma[31]
- IgA pemphigus: Occasional monoclonal gammopathy or myeloma, most often IgA
- Sub-corneal pustular dermatosis: IgG or IgA monoclonal gammopathy or myeloma[10,11]
- Dermatitis herpetiformis: Frequent polyclonal IgA gammopathy, occasional myeloma, lymphomas, angioimmunoblastic lymphadenopathy
- Porphyria cutanea tarda, variegate porphyria, hereditary coproporphyria, and erythropoietic porphyria (see Pruritus, prurigo, and burning, and Generalized hyperpigmentation)
- Bullous mastocytoma, bullous urticaria pigmentosa of infancy[32]
- Hypereosinophilic syndrome can induce vesiculobullous lesions[33]

Skin cancers
- Basal cell and squamous cell carcinoma increased in non-Hodgkin lymphoma and chronic lymphocytic leukemia (CLL)[34]
- Kaposi sarcoma increased in lymphoma, CLL, some immune deficiencies

Vascular disorders and coagulopathies
- Vasculitis
  - Usually cutaneous leukocytoclastic vasculitis (including urticarial vasculitis) and polyarteritis nodosa; ~5% of patients with vasculitis have an underlying malignancy[35]; lymphoproliferative disease most common, especially hairy cell leukemia, other hematologic associations include cryoglobulinemia, Hodgkin disease, non-Hodgkin lymphoma, myelodysplastic syndrome, chronic myelogenous leukemia, and multiple myeloma[27,36]
  - Erythema elevatum diutinum: Gammopathy or myeloma, frequently IgA[10,11]
  - Urticaria and angioedema
    - ~ Lymphoproliferative disease, sometimes with decreased C1-esterase inhibitor function[10]
    - ~ Cryoglobulinemia; can also cause cold-induced urticaria[10]
    - ~ Lymphocytic vasculitis: Angioblastic lymphadenopathy, non-Hodgkin lymphoma, CLL[37]
    - ~ Vasculitis panniculitis: Children, non-Hodgkin lymphoma[38]
    - ~ Hypereosinophilic syndrome[33]
- Vasculopathies and altered vascular reactivity
  - Flushing, erythroderma
  - Plethora, ruddy cyanosis
  - Erythema annulare centrifugum: Lymphoma, "malignant histiocytosis," hypereosinophilic syndrome[39]
  - Erythralgia/erythromelalgia[40–42]
    - ~ Polycythemia vera, essential thrombocytopenia; less commonly myelofibrosis, chronic myelogenous leukemia, cryoglobulinemia
  - Raynaud phenomenon
    - ~ Waldenström macroglobulinemia[10]
    - ~ Cryoglobulinemia[10]
  - Livedo reticularis[43,44]
    - ~ Plasma cell dyscrasias with hyperviscosity, cryoglobulinemia, or cold agglutinin disease, macroglobulinemia[45]
    - ~ Hyperleukocytosis
    - ~ Polycythemia vera, thrombocythemia[46]
    - ~ (for the following, see also Tables 145-2 to 145-4)
    - ~ Anti-phospholipid antibody, lupus anticoagulant[47]
    - ~ Hereditary protein C deficiency[48]
    - ~ Antithrombin III deficiency[48,49]
    - ~ Heparin-associated thrombocytopenia[50]
  - Acral cyanosis
    - ~ Coumadin or other anticoagulant-enhanced tendency for cholesterol embolization: Blue toe syndrome
    - ~ Polycythemia vera, thrombocythemia, rarely with myeloblast leukostasis syndrome of chronic myelogenous leukemia[51]
    - ~ Cryoglobulinemia[10,52]
    - ~ Cold agglutinins[10,45]
    - ~ Crystal globulin vasculopathy: Multiple meloma[53,54]
- Vascular changes
  - POEMS syndrome: Telangiectasias or angiomas
  - Langerhans cell histiocytosis: Telangiectasias, petechial hemorrhage
  - Telangiectasia macularis eruptive perstans variant of urticaria pigmentosa[32]

(continued)



TABLE 145-1
Cutaneous Findings with Hematologic Associations[6–9] (Continued)

Vascular disorders and coagulopathies—*continued*
- Bleeding or coagulopathy secondary to dysproteinemia
  - Mucocutaneous hemorrhage
    - ~ Hyperviscosity syndrome, usually Waldenström macroglobulinemia, occasionally myeloma, cryoglobulinemia[55]
    - ~ Abnormal platelet function from dysproteinemias[10]
    - ~ Factor deficiencies or inhibitors: factor V or VIII with IgM or IgA36l factor VII with IgG[10]; factor X adsorptive depletion in amyloidosis[55]
    - ~ Low-grade disseminated intravascular coagulation with protein C dysfunction secondary to IgG gammopathy[10]

Cutaneous deposition/induration[10,11]/altered texture
- AL (light-chain related) systemic amyloidosis: Papules, plaques, nodules, bullae, sclerotic plaques, urticaria-pigmentosa-like lesions, alopecia, macroglossia; occurs with idiopathic or disease-associated monoclonal gammopathies
- Nodular cutaneous amyloidosis: Local monoclonal plasma cell infiltrate; atrophic outpouchings of abdominal skin[56]
- Storage papule disease (translucent, often crusted or purpuric centers, buttocks and lower extremities): Waldenström macroglobulinemia[57]
- Cutaneous swelling associated with crystalline protein deposition: myeloma[58]
- Follicular spicules of the nose: Multiple myeloma, cryglobulinemia[59]
- Scleromyxedema variant of lichen myxedematosus: usually IgGγ gammopathy[60]
- Scleroderma: usually IgG monoclonal gammopathy, occasionally myeloma
- Niemann-Pick: Waxy induration with transient xanthomas overlying enlarged lymph nodes[18,61]
- Thickened, doughy, skin of diffuse cutaneous mastocytosis[62]
- Anetoderma: Cutaneous plasmacytoma, benign lymphoid hyperplasia[63]

Xanthomas[10,11]
- Necrobiotic xanthogranuloma with paraproteinemia
  - Usually periorbital xanthoma, typically ulcerative
  - Leukopenia
  - Monoclonal gammopathy or multiple myeloma
- Xanthoma disseminatum—occasional association with monoclonal gammopathy, multiple myeloma, Waldenström macroglobulinemia
- Generalized plane xanthomatosis
  - Multiple myeloma, monoclonal gammopathies, leukemias
  - Xanthomas and café-au-lait spots: juvenile chronic granulocytic leukemia
  - Eruptive or tuberous xanthomas rarely reports with dysproteinemias

Cutaneous sarcoidal or histiocytic tissue reactions
- Cutaneous sarcoidal reactions: Lymphoma[64]
- Multicentric reticulohistiocytosis: Lymphoproliferative disorders[65]

Epidermal changes
- Acquired ichthyosis: Lymphoproliferative malignancies, primarily Hodgkin disease[66]
- Sign of Lesser-Trélat: Lymphomas comprise one-fifth of cases[67]

Hypertrichosis
- Porphyria cutanea tarda, erythropoietic porphyria

Pruritus, prurigo, and burning
- Severe itching occurs in 1%–11% of patients with Hodgkin disease even in the absence of any visible skin lesions; occasional complication of non-Hodgkin lymphoma and leukemia[27]
- Mycosis fungoides, Sézary syndrome, or other lymphomas with skin involvement may also present as itching
- Eosinophilic folliculitis after marrow transplant or chemotherapy for heme malignancies[68]
- Aquagenic pruritus: Polycythemia vera, hypereosinophilic syndrome, myelodysplastic syndrome, juvenile xanthogranuloma[69]
- Hypereosinophilic syndrome: Pruritic, erythematous papules or nodules, and angioedematous or urticarial plaques common[33]
- Mastocytosis: Pruritic and usually pigmented papules or diffuse pruritis[32]
- Erythropoietic protoporphyria: Pruritus and burning within minutes of sun exposure; may develop urticaria, edema, erythema, purpura
- Angioimmunoblastic lymphadenopathy: Macular and popular eruptions, petechial, purpuric, nodular, ulcerative, and erythrodermic eruptions described[70,71]

Ulcerations
- Non-malignant red blood cell disorders and leg ulcers
  - α or β thalassemias
  - Hemoglobin (Hb) SS, Hb-s-β thal, Hb SC
  - Hereditary spherocytosis and elliptocytosis
  - Paroxysmal nocturnal hemoglobinuria
- Cutaneous lesions of leukemia, lymphoma, and some histiocytoses may ulcerate
- Lymphomatoid papulosis
- Polycythemia vera and essential thrombocytopenia
- Kaposi sarcoma
- Reactive hemophagocytic syndrome
- Angioimmunoblastic lymphadenopathy[70]
- Necrobiotic xanthogranuloma with paraproteinemia, xanthoma disseminatum
- Sweet syndrome
- Cryoglobulinemia[10]
- Hypereosinophilic syndrome, especially mucosal ulcerations and erosions[33,72]
- Protein C deficiency, inherited and acquired (including Coumadin necrosis, some disseminated intravascular coagulation)
- Heparin necrosis
- Anti-phospholipid antibody syndrome
- Neutropenic and immune deficiency–related infections
- Pyoderma gangrenosum or pyoderma gangrenosum–like ulcers,[73,74] Chédiak-Higashi
- Leukocyte adhesion deficiency
- Chronic granulomatous disease
- Hyperimmunoglobulinemia E
- Felty syndrome
- Acute myelogenous leukemia

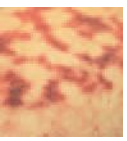

count, percent saturation of iron), ferritin, B_{12}, lactate dehydrogenase (LDH), haptoglobin, folate levels, platelet and reticulocyte counts.[83]

IRON DEFICIENCY Sixty percent to 70 percent of the body stores of iron are in the RBCs in the form of hemoglobin. Heme-containing proteins are essential for metabolic processes in virtually all cells.[84] Hemoglobin, myoglobin, and the cytochromes are all heme-containing proteins and enzymes.[85] The average life of an erythrocyte is 120 days, after which it is phagocytized by macrophages of the liver, spleen, and bone marrow. The iron is then stored in the form of ferritin to be recycled.[86,87]

Iron deficiency anemia can result from increased iron demand in the setting of inadequate iron stores. This is

most commonly seen during pregnancy when increased blood volume is necessary for the growth and development of the fetus.[90]

Clinical signs and symptoms of iron deficiency include fatigue, pallor, koilonychia, tinnitus, irritability, and pica (the craving to eat substances such as dirt, clay, ice, laundry starch, salt, or cardboard).[91] Akathisia (restless legs syndrome), blue sclera, angular stomatitis, and glossitis can also be seen. Generalized fatigue often disrupts the patient's ability to focus on daily activities at work, home, and school, resulting in poor performance.[92]

Treatment of iron deficiency anemia requires replacing lost iron and maintaining the daily iron dietary requirement. The recommended daily dose for treatment of iron deficiency is between 150 to 200 mg/day of elemental iron (325 mg ferrous sulfate = 65 mg of elemental iron), usually continued until the hemoglobin reaches a normal value.[93]

MEGALOBLASTIC ANEMIA In contrast to iron deficiency anemia, megaloblastic anemia is classified as a macrocytic anemia characterized by enlarged erythroid precursor cells. There are numerous etiologies for macrocytic anemia; folate and cobalamine (vitamin B_{12}) deficiency are the most common. Their deficiency leads to impaired purine and pyrimidine synthesis, preventing normal DNA replication. The macrocytic cells are a result of nuclear-cytoplasmic asynchronization.[94]

Clinical findings of megaloblastic anemia develop slowly and vary, depending on the level of hemoglobin concentration and the etiology. The commonly shared signs and symptoms are malaise, fatigue, palpitation, glossitis, shortness of breath, and light-headedness. Mild jaundice can also be seen when ineffective erythropoiesis leads to hyperbilirubinemia. Folate and vitamin B_{12} deficiencies are impossible to distinguish by hematologic findings; however, their clinical presentations differ as discussed below.

Vitamin B_{12} is found only in meat and dairy products, making vegetarians prone to deficiency.[98] In non-vegetarian populations (especially of Scandinavia, Turkey, and Israel), vitamin B_{12} deficiency is caused by a rare genetic disorder of malabsorption, the Imerslund-Grasbeck syndrome. Pernicious anemia (PA) is the most common cause of vitamin B_{12} deficiency. It is an autoimmune disorder that attacks intrinsic factor in the ileum, which is essential to absorb vitamin B_{12}. The second cause of PA, chronic atrophic gastritis, results in autoantibodies against gastric parietal cells, which produce intrinsic factor.

It is common to have other autoimmune disorders along with PA, such as vitiligo and Hashimoto thyroiditis.[99] Hyperpigmentation is a common cutaneous manifestation of vitamin B_{12} deficiency.[100] Hyperpigmentation is usually prominent on the knuckles of the hands and feet, especially in darkly-pigmented individuals.[101,102]

Folate is found in animal products and in green leafy vegetables. Its deficiency is usually attributed to dietary inadequacy, alcohol abuse, malabsorption, and drugs that interfere with folate metabolism, i.e., methotrexate, phenytoin, trimethoprim. The demand for folate by the placenta and fetus usually doubles. Therefore, it is now standard care to give prophylactic folic acid supplements to all pregnant women to reduce the risk of neural tube defects in newborns.[103] Exfoliative skin disease and hemolysis can also lead to folate deficiency due to increased demand. Hereditary folate malabsorption results in impaired folate transport in the gastrointestinal tract and the blood-brain barrier. Neurologic findings in vitamin B_{12} deficiency, but not folate deficiency, help to clinically distinguish between the two causes of megaloblastic anemia. Memory loss, dementia, tremor, Lhermitte's sign, irritability, atrophic glossitis, and neuropathy may occur. Specifically, patients with vitamin B_{12} deficiency develop subacute combined degeneration of the dorsal and lateral spinal columns—paresthesia (initial presentation), loss of vibration and position sense, shuffling gait, ataxia, spasticity, and paraplegia. The signs are symmetric in presentation and affect the lower extremities more than the upper extremities.

Typically, patients with folate deficiency are malnourished and often have diarrhea. Patients with alcoholism are prone to folate deficiency. Another distinguishing marker is that vitamin B_{12} deficiency takes many years to occur, given the large liver stores. Folate deficiency, on the other hand, can occur in a few months.

Correcting the underlying etiology usually resolves the anemia and reverses the signs and symptoms. Vitamin B_{12} is best administered parenterally. Prophylactic folic acid supplementation of 400 μg/day is recommended for all women of childbearing age. In folate deficient patients, 50 to 100 μg of oral folic acid is recommended with subsequent maintenance therapy.

Box 145-1

Differential Diagnosis of Flushing

- Toxins: Scombroid poisoning, drugs—ethanol, calcium channel blockers
- Rosacea
- Malignant carcinoid
- Mastocytosis
- Frey syndrome
- Fever
- Benign cutaneous flushing (blushing, exercise, temperature changes, spicy foods)
- Climacteric flushing (hot flashes)
- Chromaffin tumor
- Anaphylaxis
- Renal cell cancer
- Vasoactive intestinal polypeptide tumor
- Medullary carcinoma of thyroid
- Polyneuropathy, organomegaly, endocrinopathy, M protein, and skin changes
- Neurologic diseases (brain tumors, migraine headache, orthostatic hypotension, Parkinson)

ANEMIA OF ENDOCRINE DISORDERS Panhypopituitarism, hypothyroidism, and Addison disease are the most common endocrine disorders in association with anemia, although anemia may occur in hyperthyroidism and gonadal disease as well (see Chap. 152).

Flushing

DIFFERENTIAL DIAGNOSIS Flushing occurs as a result of cutaneous vasodilation, as opposed to pallor by vasoconstriction. Flushing associated with sweating is mediated through the sympathetic cholinergic fibers (Box 145-1; see Chap. 152).

Polycythemia Vera

The hallmark cutaneous finding of polycythemia vera (PV) is acrocyanosis (ruddy cyanosis) and plethora. Other skin findings are aquagenic pruritus, neutrophilic dermatosis and pyoderma gangrenosum, and purpura. Acrocyanosis is seen in conditions with elevated hemoglobin levels, but deoxygenated blood through the dilated vessels in the skin. Increased red cell mass is either a direct result of compensation for hypoxia or from primary disorders such as polycythemia vera. These changes lead to an increase in blood viscosity and vascular volume, resulting in a hypercoagulable state and paradoxic hemorrhage from platelet dysfunction.[114]

POLYCYTHEMIA VERA

AT A GLANCE

- Myeloproliferative disorder that involves all cell lines, with dominant erythropoietin proliferation and, subsequently, increased plasma volume and hematocrit.
- Presents with acrocyanosis, aquagenic pruritus, urticaria, and Sweet syndrome.
- Diagnostic criteria are (1) elevated red cell mass, (2) normal arterial O_2, and (3) splenomegaly.
- Treatment: Concomitant therapy of aspirin and phlebotomy, cytoreductive therapy with hydroxyurea; narrowband ultraviolet B phototherapy for pruritus.

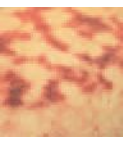

Other symptoms are headache, paresthesia, and erythromelalgia. Erythromelalgia is a thrombotic syndrome of small vessels of the hands and feet, resulting in erythema and burning pain due to congestion.[115] If not treated, this can lead to acrocyanotic ischemia and potentially gangrene of the tissue. The catastrophic symptoms include large vessel arterial cerebrovascular (stroke) or cardiovascular (myocardial infarction) events, and peripheral arterial occlusion. PV has an unusually high incidence of portal and hepatic vein thrombosis (Budd-Chiari syndrome), lower extremity deep venous thrombosis, leg ulcers, Raynaud phenomenon, and pulmonary emboli. Bleeding manifestation is assumed to be a direct cause of dysfunctional platelets or von Willebrand disease. Defective primary hemostasis manifests with ecchymosis, menorrhagia, epistaxis, gingival hemorrhage and, less frequently, gastrointestinal hemorrhage. Risk factors for PV are age (more than 60 years of age), history of thrombosis, cardiovascular risk factors (hypertension, smoking, hypercholesterolemia, diabetes), hereditary and acquired thrombophilic states (congenital deficiency of anticoagulants: antithrombin III, protein C and S; genetic mutation in factor V Leiden, prothrombin G20210A, or methylenetetrahydrofolate reductase); and acquired conditions (anticardiolipin antibodies and/or lupus anticoagulants).[116]

The major diagnostic criteria are (1) elevated red cell mass, (2) normal arterial O_2, and (3) splenomegaly. In the absence of splenomegaly, two of the following minor criteria must occur: (1) leukocytosis more than 12,000/uL, (2) thrombocytosis more than 400,000/uL, (3) leukocyte alkaline phosphatase more than 100 units, and (4) vitamin B_{12} more than 900 pg/mL. Increased platelet consumption and elevated von Willebrand factor (VWF) are associated findings with thrombosis.[117]

There is no specific therapy for PV. Treatment is directed toward preventing thrombohemorrhagic episodes and progression to myelofibrosis or leukemia.[118] Even though the role of low-dose aspirin is still under investigation, a recent randomized trial demonstrated value in using low-dose aspirin in PV. Aspirin is currently recommended in patients with ischemic stroke, myocardial infarction, and erythromelalgia. Those not benefiting symptomatically from aspirin usually require platelet cytoreduction.[119]

Phlebotomy is used to maintain hematocrit levels at less than 45 percent in males and less than 42 percent in females. Concomitant therapy of aspirin and phlebotomy is highly recommended. In high-risk patients, cytoreductive therapy with hydroxyurea may reduce recurrent thrombosis. The standardized treatment with heparin followed by anticoagulant therapy is generally used for venous thrombosis; however, recurrent venous thromboses may be prevented with hydroxyurea. Patients with severe thrombosis and/or hemorrhage benefit greatly from platelet apheresis followed by cytoreductive therapy. Narrowband ultraviolet B phototherapy provides optimum treatment for pruritus associated with PV.[120]

Cyanosis

Cyanosis refers to discoloration of the mucocutaneous tissue that results in a blue or purple tinge, particularly in the peripheral tissues such as lips, ears, and nail beds. It results from low levels of hemoglobin in the microvasculature, reducing oxygen supply to the tissues. *Central cyanosis* refers specifically to the lingual and sublingual regions, and is more reflective of reduced hemoglobin in the blood; in peripheral cyanosis (skin, hands, feet, earlobes, etc.), the cause is often vasoconstriction. Cyanosis may be difficult to detect and is often missed on physical examination. Many factors, including natural skin pigment, thickness of the skin, and blood flowing through the cutaneous capillaries, determine the degree of cyanosis.

When cyanosis is suspected, a complete and careful examination of the skin includes the mouth, conjunctivae, hands and feet, nose, and ears. Cyanosis is detectable when at least 5 grams of deoxygenated hemoglobin are circulating in the capillary blood. Total concentration of hemoglobin in respect to deoxyhemoglobin determines the presence of cyanosis. A patient with severe anemia may never present with cyanosis, whereas a patient with PV can manifest peripheral cyanosis (Box 145-2). Fluorescent light is also used to best observe cyanosis. If cyanosis is positional, an intracardiac mass must be considered.[121]

Box 145-2

Differential Diagnosis of Cyanosis

- Deoxyhemoglobin
  - Acquired and inherited methemoglobinemia
  - Sulfhemoglobinemia
  - Low oxygen-affinity hemoglobin
- Abnormal hemoglobin
  - Congenital heart defects
    - Transposition of the great vessels
    - Tetralogy of Fallot
    - Ebstein's anomaly
  - Arteriovenous fistulae, e.g., in Osler-Weber-Rendu syndrome or dyskeratosis congenital.
  - Disorders of the central nervous system, respiratory system, musculoskeletal and circulatory systems can disrupt the oxygen supply to the tissues.

The diagnostic workup for a complete assessment of cyanosis includes complete blood cell count, arterial blood gas, pulse oximetry, partial arterial pressure of oxygen (PaO_2) level, arterial oxygen saturation. Central cyanosis can be detected reliably when the arterial oxygen saturation has fallen to 85 percent, but in dark-skinned persons, it may not be detected until it has declined to 75 percent.

The causes of cyanosis are broad, but best if characterized into two groups; disorders involving deoxygenated hemoglobin and disorders of abnormal hemoglobin.[122,123] The latter includes acquired and inherited methemoglobinemia, sulfhemoglobinemia, and low oxygen-affinity hemoglobin. Abnormal hemoglobin, such as hemoglobin M (Hb M) or methemoglobinemia, is caused by oxidation of ferrous iron to ferric iron, debilitating the oxygen-carrying capacity of hemoglobin. Consequently, the affinity for oxygen in the remaining binding sites increases and the oxygen-saturation curve shifts to the left. The offending agents are nitrates (found in drinking water, drugs, and food), topical anesthetic agents (lidocaine, benzocaine, and prilocaine), drugs (i.e., dapsone,

phenazopyridine, sulfamethoxazole), and aniline dyes. Congenital methemoglobinemia is caused by deficiency in nicotinamide adenine dinucleotide (reduced form)–cytochrome b_5 reductase.[124] Treatment of choice for methemoglobinemia is intravenous methylene blue; oxygen is not useful.[125,126]

Methemoglobinemia is caused by the hemoglobin in RBCs becoming unable to bind and carry oxygen. It can be clinically suspected when cyanosis occurs in the presence of a normal PaO_2, as obtained by arterial blood gas.

Methemoglobinemia causes clinically discernible cyanosis when the absolute level of methemoglobin exceeds 1.5 g/dL; this correlates with approximately 10 percent to 15 percent methemoglobin. Sulfhemoglobin in concentrations greater than 1.5 g/dL also causes "cyanosis" with a normal PaO_2 and may be erroneously measured as methemoglobin.[127]

Offending agents in cases of acquired methemoglobinemia should be discontinued. No other therapy may be required. But if the patient is symptomatic, methylene blue, 1 to 2 mg/kg over 5 minutes, provides an artificial electron acceptor for the reduction of methemoglobin via the NADPH-dependent pathway. Response is usually rapid; the dose can be repeated in 1 hour, but frequently this is unnecessary. Caution should be exercised to avoid an overdose because large (more than 7 mg/kg) cumulative doses have been reported to cause dyspnea, chest pain, and hemolysis. Because co-oximetry detects methylene blue as methemoglobin, it cannot be used in following methemoglobin levels after treatment with methylene blue; however, the specific Evelyn-Malloy method allows for the discrimination of methemoglobin from methylene blue. Methylene blue should not be administered to patients with glucose-6-phosphate dehydrogenase deficiency.[131] If methylene blue is contraindicated, ascorbic acid can be given. RBC exchange transfusion has also been reported to be an effective treatment in symptomatic methemoglobinemic patients with co-existent glucose-6-phosphate dehydrogenase deficiency.

Sulfhemoglobinemia occurs as sulfur binds to hemoglobin, resulting in irreversible deoxyhemogobinemia. It produces cyanosis at levels of only 0.5 g/dL capillary blood. Etiologies are drugs (sulfonamides, phenacetin, acetanilide, and phenazopyridine), constipation, and purging.

Low oxygen hemoglobin-affinity occurs at altitude of 5000 m (16,000 ft) or higher and can cause hypoxemia severe enough to result in cyanosis. Emotion, cold exposure, Raynaud phenomenon, and cryoglobulins (cold agglutinins) are some nonhematologic causes of peripheral cyanosis.[132]

Disorders involving deoxygenated hemoglobin include congenital heart defects in the newborn (i.e., transposition of the great vessels, tetralogy of Fallot, and Ebstein's anomaly). X-linked dyskeratosis congenita presents with abnormal pigmentation, telangiectasias, nail dystrophy, leukoplakia; rarely, arteriovenous fistulas with central cyanosis occur. Arteriovenous fistulas are a feature of Osler-Weber-Rendu syndrome as well. Other disorders of the central nervous system, respiratory tract, and musculoskeletal and circulatory systems can also disrupt the oxygen supply to the tissues.[133]

Jaundice

Jaundice (icterus) refers to the yellowish discoloration of the skin, caused by elevated bilirubin levels. The discoloration is a direct result of the bile pigment that stains the skin, suggesting an abnormality in bilirubin clearance or increased production due to hepatobiliary disease (see Chap. 151) or a hemolytic disorder.[134] Kernicterus or permanent damage to the neonatal brain associated with hyperbilirubinemia is a serious risk.

Infiltrative Lesions/Extramedullary Hematopoiesis

Extramedullary hematopoiesis usually takes place in the spleen and liver but can also affect the skin. The dermis is a normal site of hematopoiesis during early fetal development. Cutaneous lesions of extramedullary hematopoiesis include nodules (can be sclerosing), ulcers, erythematous papules, violaceous plaques, and diffusely erythematous induration. Neonates with dermal hematopoiesis present as blueberry muffin babies with dark blue-colored to violaceous nodules. In neonates, the causes are erythroblastosis fetalis, chromosomal abnormalities, infections, congenital hemolytic anemia, thalassemia, and twin-to-twin transfusion.[139] Older individuals may show dermal hematopoiesis from hemolytic anemias, myeloproliferative syndromes such as chronic idiopathic myelofibrosis and PV, thalassemia, and osteoporosis. The histologic findings are intradermal proliferation of immature granulocytes, megakaryocytes, and erythroid and myeloid precursor cells.[140]

JAUNDICE AND EXTRAMEDULLARY HEMATOPOIESIS AT A GLANCE

- Jaundice is detectable when bilirubin levels are approximately 51 *M* (3.0 mg/dL) under non-fluorescent lighting, especially in the sclerae and sublingual region
- Differential diagnosis of jaundice: Carotenemia causes yellow pigment in palms, soles, forehead, and nasolabial folds; quinacrine leads to yellowing of skin, but not sclera.
- Extramedullary hematopoiesis: Cutaneous lesions include nodules ulcers, erythematous papules, violaceous plaques, and diffusely erythematous induration; biopsy confirms diagnosis but underlying cause needs to be determined.

HEMOSTASIS AND DIFFERENTIAL DIAGNOSIS OF PURPURA

Hemostasis

Hemostasis results from damage to the blood vessels and manifests as bleeding into the skin and soft tissues. Hemostasis has two phases, primary and secondary. Primary hemostasis is characterized by vascular contraction, platelet adhesion and activation, and subsequent development of a plug at the site of vessel injury. Vascular contraction leads to slowing of the blood flow, so the platelets can adhere to the injured site and diminish blood loss. Primary hemostasis begins immediately and is a critical mechanism involved in repairing minor defects in the microvasculature.[141] The secondary hemostasis phase promotes vascular integrity when primary hemostasis is insufficient and when larger vessels are involved. This phase maintains vasoconstriction through the secretion of prostaglandins, thromboxane, and serotonin. It also solidifies the platelet plug formed during the primary hemostasis. This occurs through a series of clotting cascade pathways that involve platelets, coagulation factors, proteins, and enzymes. Purpura, petechiae, epistaxis, and ecchymo-

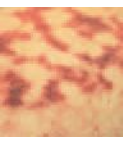

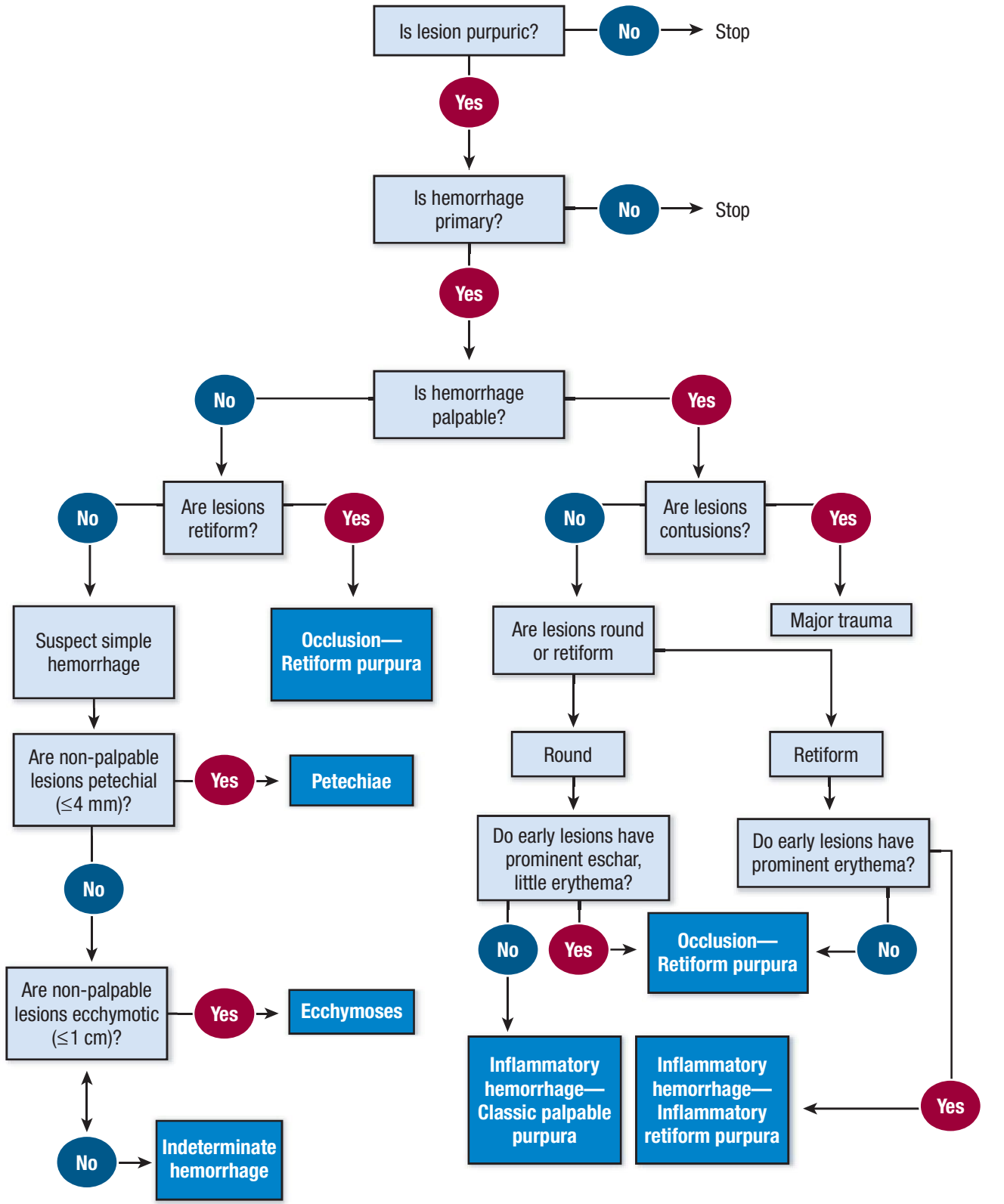

▲ **FIGURE 145-1** Algorithm for assessing purpura.

sis are commonly seen in platelet abnormalities, whereas clotting factor defects or deficiency (hemophilia A and B and von Willebrand disease) can lead to palpable ecchymoses, hematomas, hemarthrosis, or unstoppable bleeding during minor surgeries.[142] Further workup in suspected patients for disordered hemostasis requires evaluation of platelet count, bleeding time, prothrombin time, activated partial thromboplastin time, and thrombin time.[143] Additionally, peripheral blood smear, platelet release assays, and coagulation factor assays are helpful.

DIFFERENTIAL DIAGNOSIS OF PURPURA (Fig. 145-1; Tables 145-2, 145-3, and 145-4) Purpura is mucocutaneous hemorrhage measuring at least 5 to 10 mm in diameter and categorized as palpable or non-palpable. These lesions do not blanch with pressure by finger or dias-

TABLE 145-2
Partial Differential Diagnosis of Non-Palpable, Nonretiform Purpura by Size of Lesion

- Petechiae: ≤ 4 mm[144,145]
  - Platelets < 50,000/μL
    - Immune thrombocytopenia
    - Thrombotic thrombocytopenic purpura
    - Disseminated intravascular coagulation
    - Acquired thrombocytopenia (including drug-related)[145]
      - ~ Peripheral destruction (especially quinine)
      - ~ Marrow failure
      - ~ Marrow infiltration, fibrosis, failure
  - Abnormal platelet function
    - Congenital/hereditary platelet function defects[146]
    - Acquired platelet function defects
      - ~ Aspirin, nonsteroidal anti-inflammatory drugs
      - ~ Renal or hepatic insufficiency
      - ~ Gammopathy
      - ~ Myeloproliferative thrombocytosis
  - Non-platelet etiologies
    - Mildly inflammatory conditions
      - ~ Chronic pigmented purpura
      - ~ Waldenström hypergammaglobulinemic purpura
    - Intravascular pressure increase
      - ~ Valsalva-like spikes (nondependent); repetitive vomiting, coughing, childbirth
      - ~ Relatively fixed increased pressure: Ligature, strangulation, stasis
      - ~ Trauma: Usually linear arrangement
- Mid-size macules: 5–10 mm
  - Waldenström hypergammaglobulinemic purpura
  - Immunocompromised patients with sepsis
- Ecchymoses: ≥ 1 cm
  - Procoagulant defect and minor trauma[147,148]
    - Anticoagulant use
    - Vitamin K deficiency
    - Disseminated intravascular coagulation
    - Hepatic diagnosis, poor factor synthesis
    - von Willebrand disease (rarely hemophilia)
  - Poor dermal vessel support and minor trauma[149–151]
    - Actinic (senile) purpura
    - Glucocorticoid treatment, topical/systemic
    - Vitamin C deficiency—scurvy
    - Systemic amyloidosis (mostly light chain–related amyloidosis)
    - Ehlers-Danlos syndrome (some types)
    - Pseudoxanthoma elasticum
  - Other pathophysiology
    - Major trauma
    - Waldenström hypergammaglobulinemic purpura

copy, reflecting the loss of blood from vessels into the dermis. The cause of purpura can be of hematologic, dermatologic, infectious, rheumatologic, traumatic, and vascular in origin. The cause can often be determined by taking a history and performing a thorough physical examination.[178,179]

The morphologic diagnosis of purpura begins with three P's: Is the lesion *p*urpuric, is it *p*rimary, and is it *p*alpable? Manifestations of purpura include petechiae, purpuric macules, ecchymoses (Fig. 145-2), contusions, and variant presentations (target lesion, telangiectatic lesions, small angiomas, and inflammatory lesions). Purpuric lesions typically are red, blue, or a purple tone; however, greenish or yellowish hues on the skin can also be seen because of hemoglobin breakdown. Furthermore, colors help determine pathophysiology. Red-colored purpura results from saturated hemoglobin with adequate blood flow and perfusion of the cutaneous tissues.[180,181] Bright red color indicates superficial hemorrhage. Blue is indicative of restricted blood flow (presumably deoxygenated hemoglobin) and is commonly seen in hemorrhagic lesions and cyanosis. Livedo reticularis has a purplish-blue color in a net-like pattern that is a result of limited blood flow to the cutaneous tissue.

Lesions that are non-blanching are seen when there is extravasation of RBCs. Blanching of a lesion further helps to determine the erythema to hemorrhage ratio. For example, inflammation and flushing of the skin blanches completely; combination hemorrhage with inflammation blanches partially and pure hemorrhage is non-blanchable.[182]

Palpability reflects the amount of cutaneous hemorrhage, resulting in a hematoma. Obviously, the more hemorrhage, the more likely a lesion is to be palpable. Palpable purpura is due to the edema and inflammation that accompanies purpuric lesions (Fig. 145-3). The edema is often a result of inflammation or preceding microvascular ischemia.[183,184]

Retiform purpura is a branching, net-like purpura that is indicative of microvascular occlusion due to vaso-occlusive processes from cryoglobulinemia or anti-phospholipid antibodies, as well as vasculitis[185] or disseminated intravascular coagulation (DIC) (Figs. 145-4 and 145-5).

IDIOPATHIC THROMBOCYTOPENIC PURPURA

Idiopathic thrombocytopenic purpura (ITP) usually has an insidious onset in which diffuse localized petechiae are seen on the lower extremities in association with epistaxis, gingival bleeding, and menorrhagia. Treatment is based on the severity of the thrombocytopenia. ITP may be triggered by viral infection or vaccination against rubella and, rarely, measles.[186,187]

ITP is a common bleeding disorder in children caused by autoantibodies against platelet surface antigens, especially glycoproteins IIb/IIIa and Ib. It presents with increased immunoglobulin (Ig) M, IgG, and IgA autoantibodies with decreased platelet surface antigens (CD41, CD61, and CD42b).[188,189] Patients are usually asymptomatic with only ecchymoses and petechiae found on their physical examination.[190] Oral blood blisters with gastrointestinal or mucocutaneous bleeding can also occur and are referred to as *wet purpura*. As in ITP, immunothrombocytopenic purpura can be associated with recent viral illness and vaccination.[191]

ALLOIMMUNE THROMBOCYTOPENIC PURPURA Alloimmune thrombocytopenic purpura occurs when alloantibodies



TABLE 145-3
Partial Differential Diagnosis of Palpable or Retiform Purpura with Prominent Early Erythema by Lesion, Shape, and Degree of Erythema

- Palpable purpura
  - Morphology of early lesion: Prominent erythema with palpable purpura suggests inflammatory hemorrhage
  - Classic palpable purpura[144,152] (round, port-wine, partially blanchable)
  - Leukocytoclastic vasculitis and immune complex disease[152,153] (lesions usually cluster in dependent areas)
    - Small vessels only
      - ~ Idiopathic, or infection/drug-associated immunoglobulin G (IgG) or IgM complexes[154,155]
      - ~ Idiopathic IgA complexes (Henoch-Schönlein purpura, or IgA with drugs, infection
      - ~ Subacute bacterial endocarditis—hands
      - ~ Waldenström hypergammaglobulinemia
      - ~ Urticarial vasculitis—often random localization
      - ~ Pustular vasculitis—often random localization
    - Small and medium-size cutaneous vessels may be involved
      - ~ Mixed cryoglobulinemia
      - ~ Rheumatic vasculitis (lupus erythematosus, dermatomyositis, rheumatoid arthritis)
  - Leukocytoclastic vasculitis and pauci-immune vasculitis (lesions usually localize randomly)
    - Antineutrophil cytoplasmic antibodies (ANCA)–associated
      - ~ Wegener granulomatosis
      - ~ Microscopic polyangiitis
      - ~ Churg-Strauss rarely
    - Other
      - ~ Erythema elevatum diutinum—hands/feet/elbows/buttocks
      - ~ Sweet syndrome (rarely vasculitic)
  - Not leukocytoclastic (lesions usually localize randomly)
    - Small vessels only
      - ~ Erythema multiforme—acral early
      - ~ Pityriasis lichenoides et varioliformis acuta
      - ~ Chronic pigmented purpura—often legs
      - ~ Waldenström hypergammaglobulinemia—usually dependent
      - ~ Urticarial lymphocytic "vasculitis"
  - Classic target lesion
  - Usually erythema multiform—expect acral and mucosal involvement, as well as elsewhere
- Retiform purpura
  - Morphology of early lesion: Prominent erythema with retiform purpura suggests subset of inflammatory hemorrhage (and, rarely, ischemic syndromes)
  - Inflammatory retiform purpura (retiform, partially blanchable)
  - Leukocytoclastic vasculitis and immune complex disease (lesions usually cluster in dependent areas)
    - Small vessels only
      - ~ IgA (Henoch-Schönlein purpura) vasculitis[154,156]
    - Small and medium-sized cutaneous vessels may be involved
      - ~ Mixed cryoglobulinemia
      - ~ Rheumatic vasculitides
  - Leukocytoclastic vasculitis, dermal and subcutaneous vessels, pauci-immune
    - ANCA-associated—random location
      - ~ Wegener granulomatosis
      - ~ Microscopic polyangiitis
      - ~ Churg-Strauss
    - ANCA-negative syndromes
      - ~ Benign cutaneous polyarteritis nodosa, often legs
  - Nonvasculitic
    - Usually lower leg
      - ~ Livedoid vasculitis
    - Usually fingers/toes
      - ~ Chilblains (pernio)
    - Usually random location
      - ~ Pyoderma gangrenosum
      - ~ Sweet syndrome/atypical pyoderma gangrenosum

against human platelets form during blood or platelet transfusion, or maternal-fetal blood exchange, leading to posttransfusion purpura and fetal and neonatal alloimmune thrombocytopenia, respectively.[192] CD109 is a protein expressed on platelets, T lymphocytes, and endothelial cells. Antibodies against HPA-1, HPA-5, and HPA-15 on CD109 should be sought.[192]

THROMBOTIC THROMBOCYTOPENIC PURPURA Thrombotic thrombocytopenic purpura (TTP) is most commonly seen in adults, whereas hemolytic-uremic syndrome (HUS) is more commonly seen in children.[193,194] TTP can result from pregnancy, cancer, drugs (chemotherapeutic and immunosuppressives, oral contraceptives, ticlopidine, and quinine), bone marrow transplantation, and autoimmune diseases. The pathogenesis is known to be from abnormal functioning of VWF that result in platelet-fibrin thrombotic microangiopathies.[195,196] Patients have increased levels of LDH with associated schistocytes, helmet cells, and megakaryocytes; clinical signs include fever, renal (especially in HUS), and central nervous system (headache, seizures, hemiparesis, disorientation) abnormalities. HUS is commonly caused by *Escherichia coli* O157:H7 infection; it presents with bloody diarrhea and hemorrhagic colitis. Deficiency of ADAMTS13 has been shown in familial TTP. The treatment of choice is fresh frozen plasma.

Other diseases associated with thrombus formation are DIC and purpura fulminans (see the section Purpura Fulminans).[197]

PURPURA FULMINANS Purpura fulminans is a severe skin disorder associated with DIC that mainly affects children and infants. Extensive areas of skin develop blue-black hemorrhagic necrosis, and biopsy typically reveals small-vessel microthrombi and vasculitis.[198,199] Distribution of necrotic areas typically depends on the clinical setting. Patients are acutely ill with fever and hemorrhage from multiple sites, are hypotensive, and manifest typical laboratory signs of DIC. The pathogenesis of purpura fulminans is unknown, but histologic findings have been likened to the animal model of consumptive coagulopathy, the local Shwartzman reaction.[200,201] It has also been suggested that the development of purpura fulminans in meningococcemia may result from acquired defects in the protein C pathway because similar lesions are seen in two

TABLE 145-4
Differential Diagnosis of Palpable or Retiform Purpura with Minimal Early Erythema by Lesion, Shape, and Degree of Erythema

- Morphology of early lesion: Minimal erythema with retiform purpura or with necrosis suggests occlusion with ischemic hemorrhage or infarction.
- Platelet plugs[157]
  - Heparin necrosis[50,64] (distant or injection sites)
  - Myeloproliferative thrombosis[158]
  - Paroxysmal nocturnal hemoglobinuria[159,160]
  - Thrombotic thrombocytopenic purpura[161] (plugs mainly visceral vessels, skin lesions usually simple hemorrhage)
- Cold-related gelling or agglutination (lesions localize to acral, cold-exposed areas)
  - Cryoglobulinemia, usually monoclonal[52,162]
  - Cryofibrinogenemia[163,164] (often incidental finding in ill patients)
  - Cold agglutinins[165] (rarely occlusive, usually hemolytic)
- Embolization or crystal deposition (lesions localize to dependent or acral areas)
  - Cholesterol emboli[166]
  - Oxalate crystal deposition[167]
  - Both usually have extensive livedo
  - Hypereosinophilic syndrome[33]
  - Embolus from atrial myxoma, septic,[33] or marantic endocarditis
  - Crystal globulin vasculopathy[53,54]
- Local or systemic changes in coagulation control
  - Coumarin necrosis (altered protein C function)[168,169]
  - Disseminated intravascular coagulation with severe protein C deficiency or dysfunction[170]
  - Homozygous protein C or S deficiency[171,172]
  - Anti-phospholipid antibody/lupus coagulant[47]
  - Livedoid vasculitis atrophie blanche[173,174]
- Occlusion caused by organisms growing in vessel and vessel walls (usually immunocompromised host)
  - Vessel-invasive fungus (*Mucor*, *Aspergillus*, *Cephalosporium*, *Rhizopus*, etc.)
  - Ecthyma gangrenosum (*Pseudomonas*)[164]
  - Disseminated strongyloidiasis[165]
- Uncertain pathophysiology
  - Cutaneous calciphylaxis[175–177]
  - Hemoglobinopathy occlusion (sickle cell, severe thalassemia): Probably sticky reticulocyte occlusion, sickling
  - Lucio phenomenon in leprosy
  - Degos disease—not purpuric
  - Reperfusion necrosis
  - Interferon injection
  - *Loxosceles* spider bite

other protein C deficiency states, namely, neonatal purpura fulminans and warfarin-induced skin necrosis.[202]

Purpura fulminans occurs in three clinical settings. In acute sepsis-associated or secondary purpura fulminans, the initial presentation is one of overwhelming infection that is most commonly meningococcemia (see Chap. 180) but has been reported with many other Gram-positive and Gram-negative organisms.[203,204] Patients are hypotensive with reduced peripheral perfusion contributing to skin necrosis on distal extremities and elsewhere (Fig. 145-6); alternatively, skin necrosis can occur in a patchy distribution. Idiopathic purpura fulminans can manifest within 10 days of an antecedent illness, most commonly scarlet fever and varicella in children. Most skin lesions are localized to the breasts or lower half of the body. Third, purpura fulminans can be seen in association with homozygous protein C deficiency in affected neonates, in whom massive intravascular thrombosis and abdominal wall gangrene can also develop.[205,206] Acquired inhibitors of the protein C pathway can also be associated with this presentation.[207] Patients with warfarin-induced skin necrosis may present with a similar but usually less severe form of purpura fulminans and warrant consideration of protein C or protein S deficiency.[208] The mortality rate has recently been significantly reduced in purpura fulminans, largely because of more widespread use of therapeutic heparinization in these patients and aggressive transfusion support factor replacement.[209]

DISSEMINATED INTRAVASCULAR COAGULATION DIC is a syndrome characterized by a systemic activation of coagulation leading to the intravascular deposition of fibrin in the (micro) vasculature and the simultaneous consumption of coagulation factors and platelets.[210,211] The occurrence of microvascular thrombosis as a consequence of DIC is underscored by pathologic and clinical findings, demonstrating a link between DIC and organ dysfunction. Pathogenetic pathways that play a role in the development of DIC include tissue factor–dependent activation of coagulation, defective physiologic anticoagulant pathways (such as the antithrombin system and the protein C system), and impaired fibrinolysis, caused by elevated levels of plasminogen activator inhibitor type 1.[212,213] New therapeutic strategies are based on current insights into the pathogenesis of DIC, and include anticoagulant strategies (e.g., directed at tissue factor) and strategies to restore physiologic anticoagulant pathways (such as activated protein C concentrate).[214]

DIC is not a disease in itself but is always secondary to an underlying disorder. The disorders most commonly associated with DIC are listed in Table 145-5. Hyperglobulinemic purpura of Waldenström is characterized by recurring nonthrombocytopenic purpura, hy-



◀ **FIGURE 145-2** Non-palpable ecchymoses in a patient on chronic oral glucocorticoid therapy. Note the rectangular and linear lesions that suggest the minor trauma component; the distal lesion shows that the ecchymosis surrounds a linear traumatic injury. (From Piette W: Myeloma, paraproteinemias, and the skin. *Med Clin North Am* 70:155, 1986, with permission.)



▲ **FIGURE 145-3** Classic palpable purpura on the leg of a patient with immunoglobulin A vasculitis. Partial blanching of an early lesion on compression supports the clinical impression of inflammatory hemorrhage.



▲ **FIGURE 145-5** Noninflammatory retiform palpable purpura on the thigh in a patient with disseminated intravascular coagulation secondary to sepsis. None of the lesional color faded on compression. The biopsy showed multiple dermal vessels occluded by clot without inflammation.

pergammaglobulinemia, and an increased sedimentation rate.[215] Hyperglobulinemic purpura of Waldenström may present alone as a primary entity or as a secondary form associated with diseases, such as Sjögren syndrome or systemic lupus erythematosus.[216] Multiple therapies including corticosteroids, antimalarials, plasmapheresis, and other anti-inflammatory and/or immunosuppressive agents have led to variable results.[217]

The cutaneous lesions associated with scurvy are characterized by purpura that surrounds corkscrew hairs on the lower extremities (see Chap. 130). Senile purpura results from the loss of elasticity of the skin and weakened capillary walls. RBC extravasation occurs with minor trauma to the hands and other sites (see Chap. 108).[218] Solar purpura usually occurs on the extensor surfaces of the forearm. The pigmented purpuric dermatoses are discussed in detail in Chapter 169.

PALPABLE PURPURA Any process that occludes or damages the cutaneous vasculature results in purpura.

Palpable purpura is either due to vasculitis (see Chaps. 164 and 165) or vasoocclusion (embolic, systemic, and infectious; see Chap. 174). A summary of these syndromes is listed in Table 145-3. Figure 145-3 provides examples of classic palpable purpura; see Figures 145-4 and 145-5 for inflammatory retiform purpura and necrosis. Table 145-4 summarizes the most common differential diagnoses for microvascular occlusion when characterized by noninflammatory retiform, area of purpura/necrosis, and histologically by noninflammatory occlusion of dermal vessels.

LEUKEMIA CUTIS Leukemia cutis (LC) is a localized or disseminated skin infiltration by leukemic cells. It is usually a sign of dissemination of systemic disease or relapse of existing leukemia. Reported incidence varies from less than 5 percent to 40 percent, depending on the type of leukemia, both acute and chronic, including the leukemic phase of non-Hodgkin lymphoma and hairy cell leukemias. It most commonly occurs with acute monocytic leukemia, M5, and acute myelomonocytic leukemia, M4.

Pattern of presentation of skin lesions in LC is variable and may have features that overlap with other (inflammatory) eruptions. Most common lesions are small (2 to 5 mm) papules (Figs. 145-7 and 145-8), nodules (Fig. 145-9), or plaques. LC lesions are usually somewhat more pink, violaceous, or darker than normal skin, always palpable, indurated, firm, or guttate psoriasiform or lymphomatoid papulosis-like lesions, but usually not tender. They are localized or disseminated; usually on trunk (see Fig. 145-7), extremities, and face (see Fig. 145-8) but may occur at any site. They may be hemorrhagic when associated with thrombocytopenia or may ul-

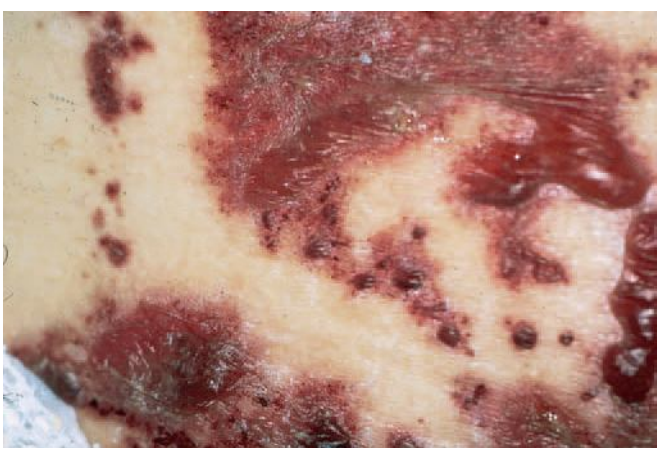

▲ **FIGURE 145-4** Inflammatory retiform palpable purpura in a patient with immunoglobulin A vasculitis. The initial erythematous phase is still present but fading in these lesions; also, blisters have formed.



▲ **FIGURE 145-6** Disseminated intravascular coagulation: Purpura fulminans. Extensive geographic areas of cutaneous infarction with hemorrhage involving the face, breast, and extremities; although the patient looked alert, she died within several days. This catastrophic event followed sepsis after abdominal surgery.

TABLE 145-5
Clinical Conditions Associated with Disseminated Intravascular Coagulation

- Sepsis/severe infection (any microorganism)
- Trauma (e.g., polytrauma, neurotrauma, fat embolism)
- Organ destruction (e.g., severe pancreatitis)
- Malignancy
  - Solid tumors
  - Myeloproliferative/lymphoproliferative malignancies
- Obstetric calamities
  - Amniotic fluid embolism
  - Abruptio placentae
- Vascular abnormalities
  - Kasabach-Merritt syndrome
  - Large vascular aneurysms
- Severe hepatic failure
- Severe toxic or immunologic reactions
  - Snake bites
  - Recreational drugs
  - Transfusion reactions
  - Transplant rejection



▲ **FIGURE 145-8** Leukemia cutis. Multiple skin-colored and erythematous papules in a 38-year-old febrile woman that had erupted approximately 1 week before this picture was taken. The patient had acute myelogenous leukemia.

cerate (see Fig. 145-9). Erythroderma may (rarely) occur. Leukemic gingival infiltration (hypertrophy) occurs with acute monocytic leukemia. Similar lesion morphologies occur with different types of leukemia or specific types of leukemia may present with a variety of morphologies.

Inflammatory disorders occurring in patients with leukemia are modified by the participation of leukemic cells in the infiltrate, resulting in unusual presentations of such disorders (e.g., psoriasis with hemorrhage or erosions/ulcerations). Also, there are a number of cutaneous inflammatory diseases that may be associated with leukemia: Sweet syndrome (see Chap. 31), bullous pyoderma gangrenosum (see Chap. 32), urticaria (see Chap. 37), and necrotizing vasculitis (see Chap. 164).

Systemic symptoms are those associated with hematologic malignancy. Not infrequently, cutaneous manifestation may be the initial presenting symptom and may contribute importantly to the diagnosis.

The diagnosis is made by suspicion and verified by skin biopsy, immunophenotyping, and B- or T-cell receptor rearrangement studies. Hematologic studies with complete analysis of bone marrow aspirate and peripheral blood smear are then needed to make the diagnosis. If cutaneous findings precede any systemic disease, careful assessment of peripheral blood smears and bone marrow biopsies must be made.

The prognosis of LC is directly related to the prognosis for systemic disease. Therapy is usually directed at the leukemia itself.



▲ **FIGURE 145-7** Leukemia cutis. Hundreds of tan-pink papules and a nodule on the trunk of a female with acute myelogenous leukemia arose during a 1-week interval. Per se, these lesions are "non-specific" and do not represent a diagnosis; but when such an eruption is seen, one should perform a peripheral blood count and a biopsy.



▲ **FIGURE 145-9** Leukemia cutis: Chloroma. Large, ulcerated, green-hued tumors (chloromas) in the inguinal and perineal regions of a female with acute myelogenous leukemia; similar lesions were also present in the axillae and on the tongue.

KEY REFERENCES

The full reference list for all chapters is available at www.digm7.com.

1. *Williams Hematology*, 7th ed, edited by Lichtman M et al. New York, McGraw-Hill, 2006
77. Bessman JD, Gilmer PR Jr, Gardner FH: Improved classification of anemias by MCV and RDW. *Am J Clin Pathol* **80**:322, 1983
83. Griner PF, Oranburg PR: Predictive values of erythrocyte indices for tests of iron, folic acid, and vitamin B12 deficiency. *Am J Clin Pathol* **70**:748, 1978
84. Weiss G, Goodnough LT: Anemia of chronic disease. *N Engl J Med* **352**:1011, 2005
96. Toh BH, van Driel IR, Gleeson PA: Pernicious anemia. *N Engl J Med* **337**:1441, 1997
100. Ridley C: Pigmentation of fingertips and nails in vitamin B_{12} deficiency. *Br J Dermatol* 97:105, 1977
102. Downham T et al: Hyperpigmentation and folate deficiency. *Arch Dermatol* **112**:562, 1976
124. Duncan PG, Kobrinsky N: Prilocaine-induced methemoglobinemia in a newborn infant. *Anesthesiology* **59**:75, 1983
144. Piette WW: The differential diagnosis of purpura from a morphologic perspective. *Adv Dermatol* **9**:3, 1994
157. Robson JK, Piette WW: The presentation and differential diagnosis of cutaneous vascular occlusion syndromes. *Adv Dermatol* **15**:153, 1999

CHAPTER 146

Cutaneous Lymphoma

Chalid Assaf
Wolfram Sterry



INTRODUCTION

Cutaneous lymphomas represent clonal proliferations of neoplastic T or B lymphocytes and rarely of natural killer (NK) cells or plasmacytoid dendritic cells. They have been recognized as a heterogeneous group with distinct variability in clinical presentation, histopathology, immunophenotyping, and prognosis.

Primary cutaneous lymphomas often show a completely different clinical behavior and prognosis than do histologically similar systemic lymphomas, which may involve the skin secondarily. Therefore primary cutaneous lymphomas require different approaches to treatment. For this reason, a new consensus classification has been created based on both the European Organisation for Research and Treatment of Cancer (EORTC) classification for primary cutaneous lymphomas and the World Health Organization (WHO) classification for tumors of hematopoietic and lymphoid tissues. This first common classification (WHO-EORTC)[1] categorizes the entities according to lineage and then according to a combination of morphology, immunophenotype, genetic features, and clinical syndromes (Table 146-1). This chapter discusses the most frequent cutaneous T-cell lymphomas (CTCLs)—mycosis fungoides (MF), Sézary syndrome (SS), primary cutaneous anaplastic large-cell lymphoma (cALCL), and lymphomatoid papulosis (LyP)—and the most frequent cutaneous B-cell lymphomas (CBCLs)—primary cutaneous follicle center lymphoma (PCFCL), primary cutaneous marginal zone lymphoma (PCMZL), and primary cutaneous diffuse large B-cell lymphoma (PCLBCL), leg type. These seven types of cutaneous lymphoma represent nearly 90 percent of all cutaneous lymphomas.[2] Rare entities occurring primarily in the skin are also described.

EPIDEMIOLOGY

Cutaneous lymphomas represent the second most common group of extranodal lymphomas after the primary gastrointestinal lymphomas.[3] The annual incidence is estimated to be 1 per 100,000.[4]

ETIOLOGY

For many years, CTCL was thought of as a disease of long-term antigen stimulation in which an initial inflammatory response in the epidermis leads to T-cell proliferation and, finally, to the emergence of a malignant clone. Despite much effort to identify a unifying antigen, the etiology remains unknown.

A viral etiology for CTCL was an attractive hypothesis given the cutaneous similarities to adult T-cell lymphoma/leukemia which is associated with human T-cell lymphotrophic virus type 1 (HTLV-1) infection (see Chap. 197). The results of studies to determine an association between CTCL and HTLV-1 are contradictory. An early study reported detection of a partially deleted HTLV-1 provirus by polymerase chain reaction (PCR) analysis in a cell line established from a patient with MF.[5] However, studies of American and European populations found no association of MF with HTLV-1 infection. PCR, Southern blot, and reverse transcriptase assays have been used, but no HTLV-1 has been demonstrated.[6–9] These data suggest that HTLV-1 does not play an important role in the etiology of CTCL and that the only reason to screen patients for antibodies is suspicion that the diagnosis is adult T-cell lymphoma/leukemia rather than MF. Epstein-Barr virus (EBV) has also been proposed as a causative pathogen.[10] Given its association with other lymphoproliferative disorders and lymphomas, such as Burkitt lymphoma, this seemed logical. However, the possibility that EBV infection can lead to the proliferation and activation of T cells in the epidermis has only been suggested and has not yet been definitively proven.

Bacterial infections have also been implicated in CTCL.[11] An association with *Staphylococcus aureus* has been suggested.[12] Of the CTCL patients studied, 75 percent had positive results for *Staphylococcus* on culture of blood or skin samples, and one-half of these cultures tested positive for *S. aureus* carrying enterotoxin genes, such as toxic shock toxin-1. The patients with positive blood culture results had SS or progressive plaque and tumor MF, but only four had monoclonal expansion of a specific Vβ gene. The results of this study, which have received support from research on microdissected tumor cells, suggested that *S. aureus* superantigen enterotoxins could provide or potentiate lymphocytic infiltration and long-term antigenic stimulation, leading to T-cell clonal expansion in CTCL.

The suggestion has been made that occupational risk factors also play a causative role in CTCL, because an indolent dermatitis often precedes the diagnosis. Exposure to carcinogens in the work environment could provide the long-term antigenic stimulation needed to initiate clonal expansion. An occupational exposure to chemicals considered hazardous was recorded in 30 percent of patients examined by the Mycosis Fungoides Study Group.[13] However, a case-control study in California and Washington state demonstrated no correlation between MF and occupation or chemical exposure.[14]

CUTANEOUS LYMPHOMA AT A GLANCE



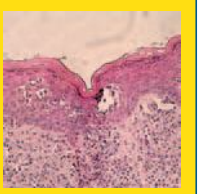

- Second most common group of extranodal lymphomas; estimated annual incidence is 1 in 100,000.
- Clonal proliferations of neoplastic T or B lymphocytes, and rarely of natural killer cells or plasmacytoid dendritic cells, arising in mid and late adulthood.
- Clinical behavior and prognosis are completely different from those of histologically similar systemic lymphomas.
- Most common form of cutaneous lymphoma is mycosis fungoides (MF), a cutaneous T-cell lymphoma, which is categorized as patch, plaque, or tumor stage. Related features include severe pruritus, alopecia, palmoplantar hyperkeratosis, and bacterial superinfection
- Histologically the patch/plaque stage of MF is characterized by an epidermotropic band-like infiltrate of neoplastic T lymphocytes with hyperconvoluted cerebriform nuclei involving the upper dermis variably with exocytosis and formation of intraepidermal Pautrier's microabscesses. The tumor stage consists of a dermal nodular infiltrate sparing the epidermis.

TABLE 146-1
WHO-EORTC Classification of Primary Cutaneous Lymphomas

Cutaneous T-Cell and NK-Cell Lymphomas
- Mycosis fungoides
- Mycosis fungoides variants and sub-types
  - Folliculotropic mycosis fungoides
  - Pagetoid reticulosis
  - Granulomatous slack skin
- Sézary syndrome
- Adult T-cell leukemia/lymphoma
- Primary cutaneous CD30-positive lymphoproliferative disorders
  - Primary cutaneous anaplastic large-cell lymphoma
  - Lymphomatoid papulosis
- Subcutaneous panniculitis-like T-cell lymphoma
- Extra-nodal NK/T-cell lymphoma, nasal type
- Provisional entities of cutaneous T-cell lymphoma
  - Primary cutaneous aggressive epidermotropic $CD8^+$ T-cell lymphoma
  - Cutaneous γ/δ T-cell lymphoma
  - Primary cutaneous $CD4^+$ small or medium-sized pleomorphic T-cell lymphoma

Cutaneous B-Cell Lymphomas
- Primary cutaneous marginal zone B-cell lymphoma
- Primary cutaneous follicle center lymphoma
- Primary cutaneous diffuse large B-cell lymphoma, leg type
- Primary cutaneous diffuse large B-cell lymphoma, other
  - Intravascular large B-cell lymphoma (provisional)
- Precursor hematologic neoplasm
- $CD4^+/CD56^+$ hematodermic neoplasm (blastic NK-cell lymphoma)

NK = natural killer; WHO-EORTC = World Health Organization and European Organisation for Research and Treatment of Cancer.

Even though the hypothesis that CTCL is a disease caused by long-term antigenic stimulation with ultimate emergence of a malignant T-cell clone appears to be logical, the etiology of CTCL, including the identity of some possible initiating events, has yet to be determined.

PATHOGENESIS

The clinical entities encompassed by the term *cutaneous T-cell lymphoma* share several components, including a T-cell clonal population, a modulated antitumor response, and an epidermal microenvironment.[3,15,16]

CTCL is a malignancy of skin-homing T cells that are primarily distinguished from other T cells by a unique cell surface receptor called *cutaneous lymphocyte-associated antigen* (CLA). CLA is expressed on memory T cells that have the ability to home to the skin by binding to E-selectin, which is expressed on vascular endothelial cells and is superinduced during cutaneous inflammation. As these T cells circulate through high endothelial venules, they respond to as yet unknown signals from the epidermis by tethering and rolling on P-selectin and E-selectin and finally extravasating into inflamed skin.

CLA is a cell surface glycoprotein that is defined by its reactivity with a monoclonal antibody, HECA-452. It has now been discovered that CLA is actually an inducible carbohydrate modification of a ubiquitously expressed T-cell surface protein, P-selectin glycoprotein ligand 1. CLA is produced by a post-translational modification of P-selectin glycoprotein ligand 1 by $\alpha(1,3)$-fucosyltransferase, which is found in lymphocytes that bind E-selectin.

CLA is also expressed on cells of myeloid lineage, including monocytes, neutrophils, and dendritic cells. Fewer than 20 percent of peripheral T cells express CLA, which suggests that these cells can be readily recruited to the skin. More than 85 percent of T cells participating in a cutaneous inflammatory response express CLA. However, CLA-expressing lymphocytes are not found in inflammatory infiltrates in the kidney, synovium, or other tissues. In vitro studies show that CLA can be induced in all peripheral blood T-cell populations, which implies that all T cells have the capacity to home to the skin, depending on as yet undetermined regulatory signals.[17]

The second similarity unifying CTCLs is the presence of a modulated antitumor response. Lesions of CTCL often have a $CD8^+$ T-cell component. Although they were once thought to be innocent bystanders in the epidermis, data have now defined the responsibility of $CD8^+$ T cells in the antitumor response. The first insight into defects in the integrity of normal T-cell function in advanced CTCL patients came from observations in patients who had been treated with extracorporeal photochemotherapy (ECP).[18] Responding patients had significantly lower CD4/CD8 T-cell ratios and higher absolute numbers of $CD8^+$ T cells in their peripheral blood at the outset of treatment than did nonresponders. In general, skin biopsy specimens of MF lesions in early stages (T1 and T2) harbor a higher proportion of $CD8^+$ cells than lesions in advanced stages. Improved long-term prognosis was correlated with the presence of these $CD8^+$ tumor-infiltrating lymphocytes (TIL) in MF.[19] It is now believed that these $CD8^+$ cytotoxic T cells play an important part in the pathogenesis of CTCL, mainly in mediating an antitumor response.

One possible mechanism for this antitumor response may be the Fas receptor/Fas ligand (FasL) pathway, which can also provide neoplasms with immune privilege and protection. Fas receptor and FasL are transmembrane proteins of the tumor necrosis factor family and are expressed on cells of lymphoid and myeloid lineage. On binding of the ligand to the receptor, a cascade of events occurs that leads to apoptosis. In melanoma, loss of Fas expression by tumor cells has been correlated with tumor progression, which suggests that the absence of this apoptotic initiator mediator leads to escape of immunosurveillance.

Aberrations of the Fas/FasL pathway have been studied in CTCL. Immunohistochemical studies of Fas and FasL expression in frozen and paraffin-embedded skin biopsy specimens from CTCL patients demonstrated loss of Fas expression in advanced MF and aggressive forms of CTCL and strong expression in early stages of MF. The Fas/FasL pathway may contribute to the immunosuppression seen in MF patients and provide immune advantage or privilege to tumor cells, rendering them immunologically tolerated.

The third unifying concept in the pathophysiology of CTCL is the participation of the epidermis as a microenvironment for malignant cells. Within the skin, cytokines have an important role in maintaining the milieu and initiating immune responses. It is well established that patients with CTCL have variable production and response to T helper 1 and 2 (Th1, Th2) cytokines. Early studies that measured the messenger RNA (mRNA) levels of Th1 and Th2 cytokines showed that, at any stage of disease, mRNA of interleukins 5 and 4 (IL-5, IL-4), Th2 cytokines, could be found, with the persistence of Th2 cytokine mRNA in skin more frequent in the tumor stage. The decline in interferon-γ (IFN-γ) and predominance in Th2 cytokines might be responsible for the loss of immunosurveillance, which allows CTCL to progress.





Other cytokines are also likely to play a role in the pathogenesis of CTCL. Culture studies and immunohistochemical analyses on skin biopsy specimens from in CTCL lesions demonstrate the presence of IL-15 and IL-7. IL-7 is a cytokine produced by keratinocytes that has been identified as a T-cell growth factor. IL-15, also produced in the skin by keratinocytes, has functional properties similar to those of IL-2, a growth-stimulating cytokine for both B and T cells and a potent T-cell chemoattractant.[16]

To better define the microenvironment and cellular components of the epidermis, a new technique of micromanipulation to obtain single immunolabeled T cells in tissue sections followed by single-cell PCR was developed.[20] When this technique is used, the exact location and immunophenotype of clonal and nonclonal (likely reactive) T cells in the different skin compartments can be determined. Once single cells are obtained, their genetic material can be precisely analyzed by PCR without reactive T-cell component contamination. This has allowed insight into the microanatomic preferences of the tumor cells. In addition, these techniques can be performed simply on skin punch biopsy specimens from patients at any stage of disease. Initial experiments with single-cell micromanipulation found that clonal $CD4^+$ T cells, especially in early stages of CTCL, were localized to the epidermis and that nonclonal $CD4^+$ T cells had a preference for the dermis rather than the epidermis. This suggests that the polyclonal $CD4^+$ T cells in the sub-epidermal infiltrate establish a barrier of lymphocyte-mediated antitumor response. Further investigations using this novel technique will bring us closer to an understanding of the unique epidermal sanctuary that harbors, preserves, and perpetuates CTCL.



▲ **FIGURE 146-1** Patch lesion of cutaneous T-cell lymphoma with poikiloderma and scale in a typical location on the breast.



▲ **FIGURE 146-2** Large plaque/patch of cutaneous T-cell lymphoma on the right flank. Annular and arcuate configurations on the border with more atrophy centrally are seen.

PRIMARY CUTANEOUS T-CELL LYMPHOMAS

CTCLs are non-Hodgkin lymphomas characterized by a dominant skin-homing T-cell clone. They represent approximately 80 percent of all cutaneous lymphomas. The most common forms are MF and SS, with an annual incidence of three or four new cases per million people. After MF and SS, the primary cutaneous $CD30^+$ lymphoproliferative disorders comprising LyP and cALCL represent the second most common group of CTCLs (approximately 30 percent).

Mycosis Fungoides

DEFINITION MF is the most frequent variant of CTCL, usually arising in mid to late adulthood (median age at diagnosis, 55 to 60 years) with a male predominance of 2:1.

CLINICAL MANIFESTATIONS ***Skin Signs.*** Clinically MF is categorized as being in the patch, plaque, or tumor stage, but patients may simultaneously have more than one type of lesion. In early patch-stage MF (Figs. 146-1, 146-2), there are single or multiple erythematous, scaly macules and patches that vary in size and are usually well defined. The color of the lesions may vary from orange to a dusky violet-red. The distribution classically favors non–sun-exposed sites, with the "bathing trunk" and intertriginous areas predominant early in the course of the disease. The eruption may be intensely pruritic or asymptomatic and occasionally may be transitory, disappearing spontaneously without scarring. Diagnosis at this stage may be difficult. Often a patient will recall a preceding "chronic dermatitis" for 10 to 20 years that may have been considered to be therapeutically resistant contact dermatitis, atopic dermatitis, psoriasis, or eczema. In any patient with a dermatosis that is refractory to the usual modalities of treatment, multiple biopsy specimens should be taken to pursue a diagnosis.

Patches may last for months or years before progressing to the plaque stage (Fig. 146-3), or plaques may arise de novo. Plaques appear as sharply demarcated, scaly, elevated lesions that are dusky red to violaceous and variably indurated (Figs. 146-4 and 146-5). Lesions in this stage may regress spontaneously or may coalesce to form large plaques with annular, arcuate, or serpiginous borders, and may clear centrally with disease activity remaining at the periphery of the lesion. There may be purpuric hyperpigmentation or hypopigmentation (Fig. 146-6) and poikiloderma (see Figs. 146-1, 146-2).

The tumor stage may occur anywhere, but tumors have a predilection



▲ **FIGURE 146-3** Patches and plaques of cutaneous T-cell lymphoma on the back and arm.



▲ **FIGURE 146-4** Confluent plaques with scaling and developing nodules.



▲ **FIGURE 146-6** In the pigmented purpuric variant of mycosis fungoides, the lesions are the typical size of mycosis fungoides lesions but are distributed in areas that are not usually affected by pigmented purpura, as shown here in the periaxillary skin. (Used with permission from Kathy Zug, MD.)



for the face (Figs. 146-7 and 146-8) and body folds: axillae, groin, antecubital fossae, and, in women, the inframammary area. These may occur in pre-existing plaques or patches of CTCL, which suggests the development of a vertical growth phase (Fig. 146-9). At this point, the neoplastic cells behave in a more biologically malignant manner, with vertical spread that leads to the clinical appearance of an expanding dermal nodule (see Fig. 146-8). De novo occurrence suggests metastatic spread by cells of a malignant T-cell clone. The nodules are reddish brown or purplish red and smooth surfaced, but they often ulcerate and may become secondarily infected (Fig. 146-10). Growth rate is variable. Patients with tumors tend to have a more aggressive form of the disease than patients with patch and plaque disease.

Erythroderma may start de novo or follow MF. The nomenclature for erythrodermic phases of CTCL varies. It has been proposed that erythroderma be defined as the involvement of 80 percent of body surface area with lesions of ill-defined borders and that patients with a history of pre-existing MF be defined as having a separate syndrome of "erythrodermic MF."

The skin is diffusely bright red with readily apparent scaling, but there may be characteristic symmetric islands of uninvolved skin (Fig. 146-11). There may be sparing of the areas of skin that are frequently folded, such as the abdomen and antecubital and axillary areas. This sparing produces a finding often called the *deck chair* or *folded luggage* sign, as shown in Fig. 146-12. Some patients with the erythrodermic form of CTCL develop tumors.

Other Symptoms. Patients may complain of fever, chills, weight loss, malaise, in-



▲ **FIGURE 146-5** Polymorphic nature of mycosis fungoides type of cutaneous T-cell lymphoma. On the right buttock is a large violaceous plaque, whereas further down the thigh is a pink psoriasiform annular lesion. Smaller atrophic lesions can also be noted in the surrounding skin.



▲ **FIGURE 146-7** Leonine facies characterized by infiltrated plaques and tumors of cutaneous T-cell lymphoma.



▲ **FIGURE 146-8** Tumor stage cutaneous T-cell lymphoma. Large tumor on the cheek.



▲ **FIGURE 146-9** A mixture of plaque and tumor stage lesions on the face of a patient with cutaneous T-cell lymphoma. **A.** Patch and plaque on the cheek and infected centrofacial ulcer. **B.** Ulcerated nodules on the trunk. **C.** Annular and crusted tumors and ulcers on the legs.

somnia secondary to the overwhelming pruritus, and poor body temperature homeostasis. There may be hyperkeratosis, scaling and fissuring of the palms and soles, alopecia, ectropion, nail dystrophy, and ankle edema, with the integument being shiny and hidebound. These changes result in pain on walking and extreme difficulty with tasks requiring manual dexterity. Such patients become cutaneous cripples, severely debilitated by the skin manifestations of this fatal disease. Pruritus is often intense, which results in excoriation, exudation, and secondary infection that may dominate the clinical picture.

DIFFERENTIAL DIAGNOSIS The differential diagnosis of MF is summarized in Box 146-1.

HISTOPATHOLOGY In the patch, plaque, and also in the erythrodermic stage, there is an epidermotropic band-like infiltrate of neoplastic T lymphocytes with hyperconvoluted cerebriform nuclei involving the upper dermis with exocytosis and formation of intraepidermal Pautrier's microabscesses (Figs. 146-13 and 146-14). In the tumor stage a nodular infiltrate in the dermis is found, and the epidermal component is much less pronounced (Fig. 146-15). Immunohistologically the malignant cells express a mature peripheral T-cell ($CD4^+$) phenotype. Partial loss of pan–T-cell antigens such as CD7 and CD3 may be a feature of MF but is not pathognomic of the disease. Analysis of T-cell receptor genes (TCR) typically shows a clonal rearrangement as demonstrated by PCR or Southern blot techniques.[21,22]

TREATMENT AND PROGNOSIS Treatment should be symptom oriented and stage adapted (see Staging of Cutaneous T-Cell Lymphoma and Principles of Treatment of Cutaneous T-Cell Lymphoma later).[23] The prognosis depends on the type and extent of skin involvement (plaques, tumors, or erythroderma), the presence of palpable lymph node involvement, and the presence of visceral disease. Overall, patients with MF limited to the skin have a 5-year survival rate of 80 to 100 percent. In contrast, patients with lymph node involvement show a 5-year survival rate of 40 percent.[24]

Mycosis Fungoides Variants

FOLLICULOTROPIC MYCOSIS FUNGOIDES Folliculotropic MF represents a distinct variant of MF characterized by preferential involvement of the head and neck by folliculotropic T-cell infiltrates, with or without mucinous degeneration of the hair follicles (Fig. 146-16B).[21,22] Previously this variant was called *follicular mucinosis* or *alopecia mucinosa*. Folliculotropic MF occurs mostly in adults but may occasionally affect children and adolescents. Pa-



▲ **FIGURE 146-10** Cutaneous T-cell lymphoma. Ulcerated, infected tumor on the digit.

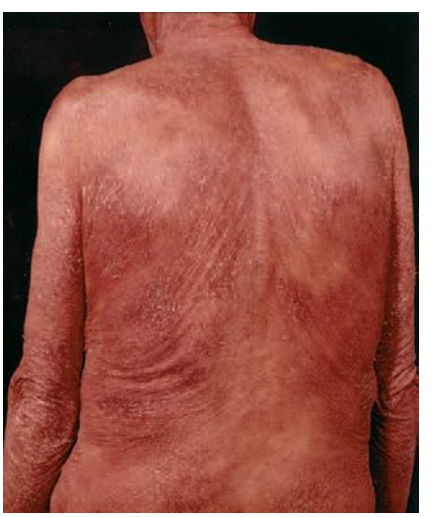

▲ **FIGURE 146-11** Cutaneous T-cell lymphoma erythroderma (in this case, Sézary syndrome). Note coppery redness and infiltration of the skin as reflected by increased skin folds and scaling.



▲ **FIGURE 146-12** In patients with cutaneous T-cell lymphoma and erythroderma, there may be sparing of areas where the skin folds, as shown here. This finding is often called the *deck chair* or *folded luggage* sign.

tients may have grouped follicular papules (see Fig. 146-16A), acneiform lesions, indurated plaques, and sometimes tumors, which usually involve the head and neck region. The occurrence of alopecia, pruritus, and secondary bacterial infections is common. Infiltrated plaques in the eyebrows with concurrent alopecia are a frequent and highly characteristic finding. Pruritus is often severe.

HYPOPIGMENTED MYCOSIS FUNGOIDES Patients with dark skin develop hypopigmented MF, a variant of patch MF. In darker-skinned individuals, this may be the most common presentation of the disease. Patients respond to therapy by repigmentation, and a relapse often presents as hypopigmentation.

PAGETOID RETICULOSIS Pagetoid reticulosis (Woringer-Kolopp disease) is a distinct variant of MF that is characterized by the presence of localized patches or plaques with an intraepidermal proliferation of neoplastic cells. Patients present with a solitary psoriasiform or hyperkeratotic patch or plaque, which is usually localized on the extremities (Fig. 146-17) and is slowly progressive. Unlike in classic MF, extra-cutaneous dissemination has not been observed.

The disseminated form (Ketron-Goodman type) is much more aggressive and is now considered to be an aggressive primary cutaneous epidermotropic $CD8^+$ T-cell lymphoma (see the section Primary Cutaneous Aggressive Epidermotropic $CD8^+$ T-Cell Lymphoma).

GRANULOMATOUS SLACK SKIN Granulomatous slack skin is a rare sub-type of MF characterized by the slow development of folds of lax skin in the major skinfolds, with a predilection for the axillae and groins (Fig. 146-18). Light microscopy reveals a dense granulomatous infiltrate in the dermis. In addition to small atypical cells with cerebriform nuclei, macrophages and numerous multinucleated giant T cells occur and palisade around necrobiotic areas, where destruction of the elastic tissue is observed. The neoplastic cells express a $CD3^+CD4^+CD8^-$ phenotype.[21,22]

Box 146-1

Differential Diagnosis of Mycosis Fungoides

PATCH/PLAQUE STAGE
- "Chronic dermatitis"
- Psoriasis
- Contact dermatitis
- Eczema
- Tinea corporis

TUMOR STAGE
- B-cell lymphoma
- Carcinoma cutis
- Sarcoidosis
- Deep fungal infection
- Atypical mycobacterial infection
- Leprosy
- Leishmaniasis
- Erythroderma
- Pityriasis rubra pilaris
- Psoriasis
- Atopic dermatitis
- Drug eruption
- Seborrhoic dermatitis

Sézary Syndrome

DEFINITION SS is a leukemic variant of CTCL that occurs exclusively in adults. It is characterized by the triad of diffuse erythroderma, generalized lymphadenopathy, and circulating malignant T cells with cerebriform nuclei, the so-called *Sézary cells*.

CLINICAL MANIFESTATIONS Clinical findings include severe scaling or fissuring of the palms and soles, alopecia, and onychodystrophy. The erythroderma may be associated with marked exfoliation, edema, and lichenification and is extremely pruritic (see Fig. 146-11).

LABORATORY FINDINGS SS demonstrates histologic features similar to those of MF.[21,22] Therefore, several diagnostic criteria proposed by the International Society for Cutaneous Lymphoma—including biopsy findings consistent with CTCL, absolute Sézary cell count in the peripheral blood of at least 1000 cells/mm^3, and, by fluorescence-activated cell-sorting analysis, an increased CD4/CD8 ratio of more than 10, a $CD7^-$ phenotype (more than 40 percent), and evidence of a circulating T-cell clone—were included

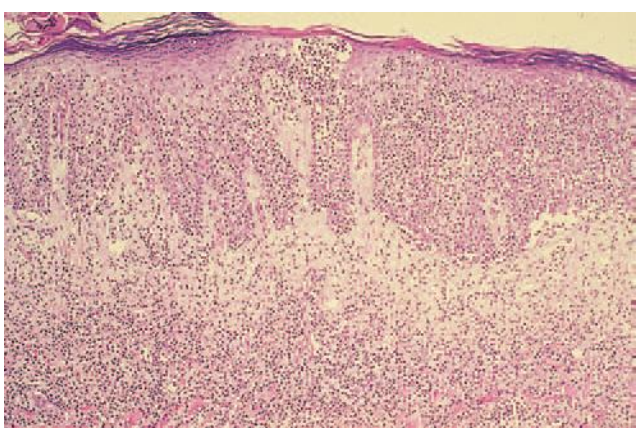

▲ **FIGURE 146-13** Dense mononuclear cell infiltrate extending from the papillary dermis into the epidermis. The epidermis is completely permeated by these cells, which form a Pautrier's abscess.



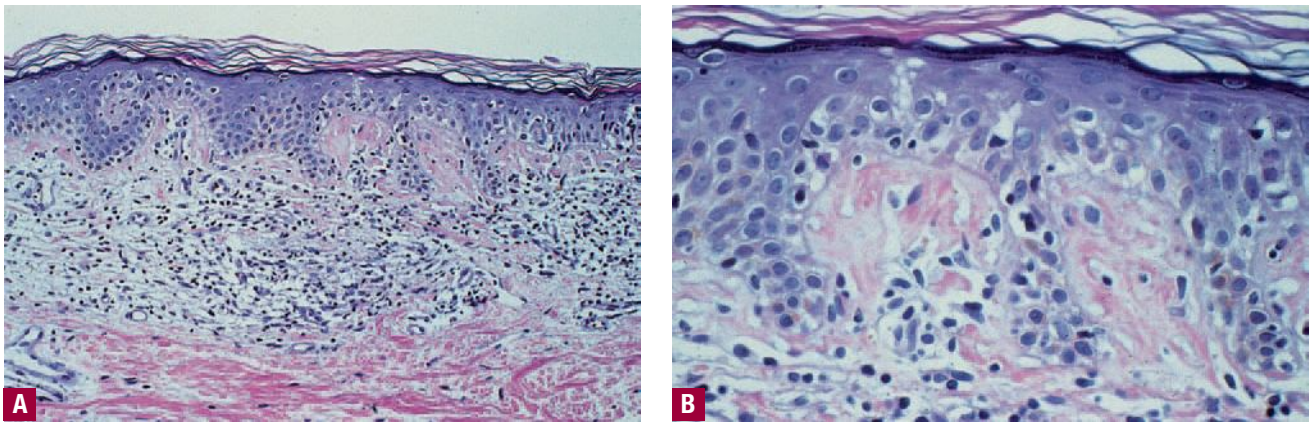

▲ **FIGURE 146-14** Patch stage of cutaneous T-cell lymphoma. **A.** Single atypical mononuclear cells in epidermis with sparse superficial perivascular infiltrate in the papillary dermis. (Hematoxylin and eosin–stained section.) **B.** High-power view of atypical cells in epidermis of same section.



in the WHO-EORTC classification.[1] Patients lacking the atypia on the peripheral blood smear or the corroborating evidence are considered to have erythrodermic CTCL.[1,2,25]

TREATMENT AND PROGNOSIS Compared with patients with patch- or plaque-stage MF, patients with SS have a markedly decreased 5-year survival rate of 33 percent. By the time the SS appears, there is very little normal immunity left. Indeed, Sézary's patients have died from infectious complications, not from progressive disease.[26]

Primary Cutaneous CD30⁺ Lymphoproliferative Disorders

Primary cutaneous CD30⁺ lymphoproliferative disorders consist of LyP and cALCL. Both entities are now recognized to form the ends of a spectrum which includes borderline cases that, on histomorphologic grounds alone, cannot be clearly assigned to LyP or cALCL.[1,2]

LYMPHOMATOID PAPULOSIS ***Definition.*** LyP was first described by Macauly in 1968. It is an uncommon chronic disorder (incidence of 1.2 to 1.9 cases in 1,000,000) characterized by recurrent self-healing crops of papules and papulonodules.[1,2]

Clinical Manifestations. Disseminated recurrent self-healing papules and papulonodules occur that may become necrotic in the center (Fig. 146-19) and often erupt over a period of months or several years. The lesions typically involve the trunk and extremities, and lesions in various stages of evolution may be present concurrently.

Histopathology. LyP shows a highly variable histologic picture that closely mimics that of malignant lymphoma.[1,2] Three major histologic types, designated as *A*, *B*, and *C*, have been recognized.[21,22] Types A and C are characterized by the presence of large atypical blasts, including mononucleated and binucleated or multinucleated cells resembling Reed-Sternberg cells characteristic of Hodgkin lymphoma. The atypical blasts express one or more T-cell antigens as well as the lymphoid activation antigen CD30 (Fig. 146-20). Although in type A these cells are embedded in a dense inflammatory background consisting of histiocytes, small lymphocytes, neutrophils, and/or eosinophils, in type C they form large sheets closely simulating cALCL. LyP type B is composed of small to medium-sized CD30⁻ T cells showing epidermotropism and thus closely resembles classic MF. Importantly, different histologic types of LyP can be present in one patient, because the histologic picture also correlates with the age of the individual lesion.

Treatment and Prognosis. Because a curative therapy is not available and none of the available treatment modalities affects the natural course of the disease, the short-term benefits of active treatment should be balanced carefully against the potential side effects. Low-dose oral methotrexate (5 to 20 mg/week) is the most effective therapy to suppress the development of new skin lesions. Treatment with psoralen plus ultraviolet A light (PUVA) has been reported to yield beneficial effects. However, after discontinuation of treatment the disease generally relapses within weeks or months. Therefore, in patients with relatively few and non-scarring lesions, long-term follow-up without active treatment should be considered.[27]

In general LyP shows a benign clinical course and a favorable 10-year survival rate of nearly 100 percent. However, in a proportion of patients, estimated at 10 percent to 20 percent of cases, LyP can precede, co-exist with, or follow malignant lymphoma, especially MF, Hodgkin lymphoma, or nodal anaplastic large cell lymphoma. In many of these cases the

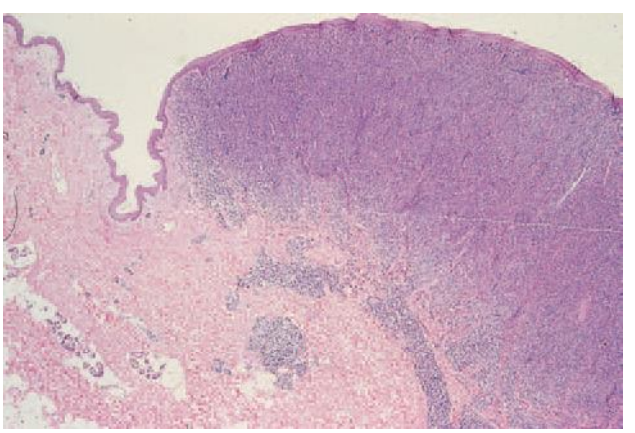

▲ **FIGURE 146-15** Low-power view of a cutaneous T-cell lymphoma tumor. The dense infiltrate extends deep into the dermis.

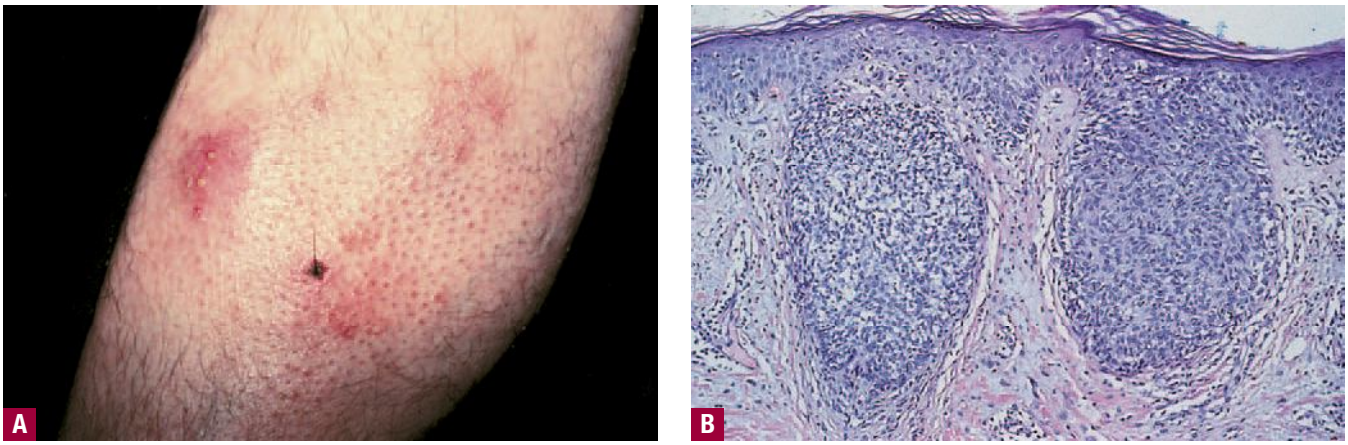

▲ **FIGURE 146-16** **A.** Folliculotropic mycosis fungoides. Note follicular localization and resulting hair loss. **B.** Outer root sheath of hair follicle is disrupted by T cells and mucin deposition, which leads to small cystic spaces.

same clonal TCR rearrangements have been found in the LyP as well as in the associated lymphoma, identifying LyP as a precursor lesion. In the majority of LyP cases, despite the sometimes extremely long course of the disease, there is no evolution of a secondary lymphoma.

CUTANEOUS ANAPLASTIC LARGE CELL LYMPHOMA ***Definition.*** The cutaneous lymphoma cALCL is characterized by large tumor cells, of which the majority express the CD30 antigen, with no evidence or history of MF or another type of primary CTCL. Regardless of the morphology of the tumor cells (anaplastic, immunoblastic, or pleomorphic large cells), the clinical presentation and behavior are identical.



▲ **FIGURE 146-17** Pagetoid reticulosis. Hyperkeratotic plaque localized on the lower leg of a male patient.

Clinical Manifestations. $CD30^+$ cutaneous large-cell lymphomas occur in adults and rarely in children and adolescents, with a male-female ratio of 1.5:1. The clinical picture is characterized by the solitary or locoregional occurrence of reddish to brownish nodules and tumors, which frequently ulcerate (Fig. 146-21A). Although secondary involvement of the regional lymph nodes is observed in roughly 25 percent of the patients, it is not necessarily associated with an unfavorable prognosis.[27]

Histopathology. A nodular or diffuse nonepidermotropic infiltrate of large cells is seen in the dermis (see Fig. 146-21B). In the majority of cases, the neoplastic cells show an anaplastic morphology with oval or irregularly shaped nuclei, prominent nucleoli, and an abundant cytoplasm. Less commonly, a pleomorphic or immunoblastic appearance is observed. Atypical mitotic figures are frequent. In the periphery of the lesions, inflammatory cells (T cells, eosinophils, and neutrophils) are present, sometimes imitating the histologic picture seen in Lyp.



▲ **FIGURE 146-18** Granulomatous slack skin. Note skinfolds due to secondary elastolysis.

By definition, at least 75 percent of the large cells are $CD30^+$. In addition, they express a $CD4^+$ phenotype with variable loss of pan–T-cell antigens such as CD2, CD3, and CD5. Cases with $CD8^+$ neoplastic cells occur rarely. Unlike nodal $CD30^+$ lymphomas, $CD30^+$ large-cell lymphomas of the skin test negative for CD15 and epithelial membrane antigen, and expression of the aplastic lymphoma kinase ALK is also absent in most cases of cALCL. Clonal TCR rearrangements are detected in most cases.[28]

For diagnosis clinico-pathologic correlation is crucial. The histologic picture may suggest Lyp, but lesions of $CD30^+$ cutaneous large cell lymphoma are clinically larger and localized, and they usually do not tend to disappear spontaneously.

Treatment and Prognosis. In cases of solitary or localized skin lesions, radiotherapy is the preferred mode of treatment. Successful treatment with PUVA in combination with IFN-α has been reported. In cases of more generalized skin lesions or extra-cutaneous dissemination, multiagent chemotherapy should be considered.[29] In contrast to extracutaneous large-cell lymphomas, $CD30^+$ cutaneous large-cell lymphomas of the skin have a favorable prognosis, with a disease-related 5-year survival rate of 90 percent.[27]

Subcutaneous Panniculitis-Like T-Cell Lymphoma

DEFINITION Subcutaneous panniculitis-like T-cell lymphoma is defined as a cytotoxic T-cell lymphoma characterized







▲ **FIGURE 146-19** Lymphomatoid papulosis. **A.** Papular papulonecrotic and modular skin lesions. Note that lesions in various stages of development are present at the same time. **B.** Lymphomatoid papulosis. Crusted erythematous papulonodule.



by the presence of primarily subcutaneous infiltrates of small, medium-sized, or large pleomorphic T cells and many macrophages, predominantly affecting the legs and often complicated by a hemophagocytic syndrome.[1]

CLINICAL MANIFESTATIONS Subcutaneous panniculitis-like T-cell lymphoma is characterized by subcutaneous nodules and plaques, which usually involve the legs and, less commonly, the trunk. Patients often have B symptoms—that is, weight loss, fever, and fatigue—which are due to a frequently associated hemophagocytic syndrome.

HISTOPATHOLOGY Histologic examination shows subcutaneous infiltrates simulating a panniculitis. Infiltrates contain a mixture of neoplastic pleomorphic cells of various sizes and macrophages. Usually, tumor cell necrosis, karyorrhexis, and erythrophagocytosis are found. Rimming of individual fat cells by neoplastic T cells is a helpful diagnostic feature. Immunophenotyping shows that the neoplastic cells express CD3, CD8, CD43, CD45RO, T cell–restricted intracellular antigen 1 (TIA-1), perforin, granzyme B, the TCR α/β , and, rarely, CD56. The neoplastic T cells show clonal TCR gene rearrangements.[21,22]

TREATMENT AND PROGNOSIS Even with aggressive chemotherapy, the disease shows a rapidly progressive course, and the prognosis is generally poor, although dissemination to extra-cutaneous sites rarely occurs. In a small number of patients the disease shows an indolent clinical course and may be controlled by systemic steroid treatment.

Extra-Nodal Natural Killer/T-Cell Lymphoma, Nasal Type

DEFINITION Extra-nodal NK/T-cell lymphoma, nasal type, is a nearly always an EBV-positive lymphoma of small, medium, or large cells, usually with an NK-cell or, more rarely, a cytotoxic T-cell phenotype. The skin is the second most common site of involvement after the nasal cavity.[1]

CLINICAL MANIFESTATIONS Extra-nodal NK/T-cell lymphoma either affects the naso-oropharynx, which leads to destruction of the nasal region (formerly described as *lethal mid-line granuloma*) or manifests in skin, subcutis, lungs, viscera, and testes. Skin lesions enclose subcutaneous tumors, erythematous plaques, ulcers, or an exanthematous eruptions with macules and papules. The clinical course is often aggravated by a hemophagocytic syndrome with pancytopenia.

HISTOPATHOLOGY This type of lymphoma shows dense infiltrates involving the dermis and, often, the subcutis. Epidermotropism may be present. Prominent angiocentricity and angiodestruction are often accompanied by extensive necrosis. Immunophenotypically the neoplastic cells strongly express cytoplasmic CD3ε, CD56, and cytotoxic proteins (TIA-1, granzyme B, perforin) but lack surface CD3, and are characteristically positive for EBV.[21,22]

TREATMENT AND PROGNOSIS Even with aggressive chemotherapy, the disease is often lethal within months.[30] A study of the EORTC cutaneous lymphoma group suggested that bone marrow transplantation may be the treatment of choice.[29]

Provisional Entities of Cutaneous T-Cell Lymphoma

In addition to the diseases discussed in the preceding sections, a number of provisional entities are included in the WHO-EORTC classification system. These primary CTCLs display characteristic histologic features, but no dis-

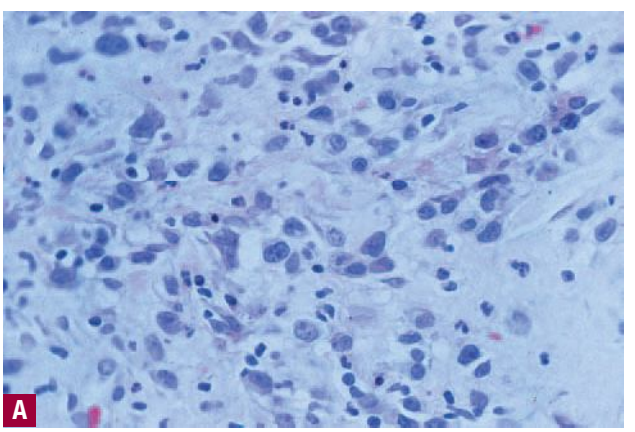

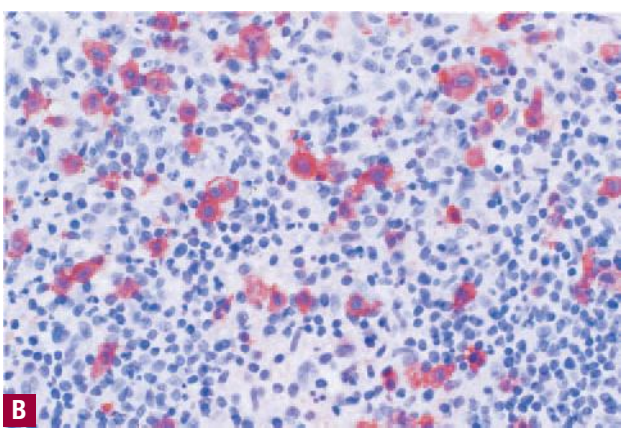

▲ **FIGURE 146-20** **A.** Lymphomatoid papulosis. Dermal infiltrate contains several large lymphoid cells with nuclei showing evenly dispersed chromatin and variably prominent nucleoli (so-called *type A cells*). **B.** Type A with large CD30$^+$ T cells (*red*) among admixed inflammatory cells.

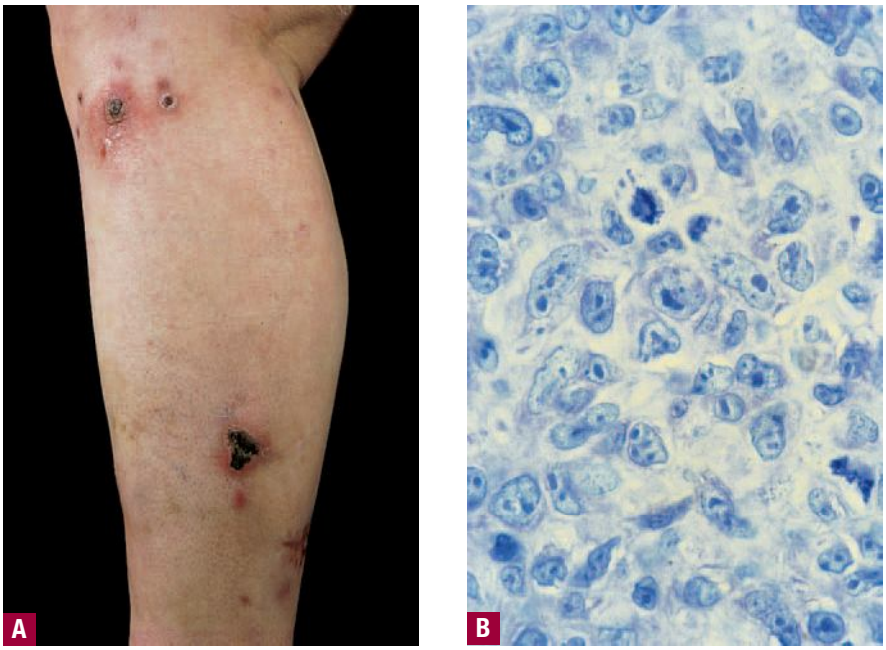

▲ **FIGURE 146-21** Primary cutaneous anaplastic large-cell lymphoma. **A.** Localized nodules, some with ulcerations. **B.** Pleomorphic large-cell lymphoma T-cell infiltrate.

tinct clinical presentation and/or outcome has been defined so far.

PLEOMORPHIC SMALL OR MEDIUM-SIZED CUTANEOUS T-CELL LYMPHOMA ***Definition.*** A neoplastic proliferation of pleomorphic, small or medium-sized T cells in the skin without any clinical signs of classic MF defines the pleomorphic, small or medium-sized CTCL.

Clinical Manifestations. Patients have one or several red-purplish papules or nodules at any location. Because histologic differentiation from MF and MF-associated follicular mucinosis can raise problems, the absence of patches and plaques in pleomorphic small or medium-sized CTCL is the decisive criterion.

Histopathology. Histologically, a dense, diffuse or nodular infiltrate containing small to medium-sized pleomorphic cells is observed within the dermis and, sometimes, the subcutis. Epidermotropism may be present. The neoplastic cells express a T-helper cell phenotype with frequent loss of pan–T-cell markers. In some cases that show a more aggressive clinical course, expression of $CD8^+$ is observed. Demonstration of an aberrant phenotype and of T-cell clonality, as well as predominance of pleomorphic T cells in the infiltrate, serve as useful criteria for the exclusion of pseudolymphomas, which often show an identical histologic pattern. MF is excluded by the absence of a dominant cerebriform tumor cell population.[31]

Therapy and Prognosis. In cases with solitary or localized lesions, radiotherapy is the preferred mode of treatment. PUVA therapy, possibly in combination with IFN-α, is useful in cases with disseminated lesions.

A 5-year survival rate of between 60 percent and 90 percent is reported for this type of lymphoma.[1,31]

PRIMARY CUTANEOUS AGGRESSIVE EPIDERMOTROPIC $CD8^+$ T-CELL LYMPHOMA ***Definition.*** Primary cutaneous aggressive epidermotropic $CD8^+$ T-cell lymphoma is a CTCL characterized by a proliferation of epidermotropic $CD8^+$ cytotoxic T cells and an aggressive clinical behavior. Differentiation from other types of CTCL expressing a $CD8^+$ cytotoxic T-cell phenotype, as observed in pagetoid reticulosis and rare cases of MF, LyP, and cALCL, is based on the clinical presentation and clinical behavior.[1]

Clinical Manifestations. Primary cutaneous aggressive epidermotropic $CD8^+$ T-cell lymphoma is characterized clinically by patches, plaques, papulonodules, and tumors mimicking those of disseminated pagetoid reticulosis and by a metastatic spread to unusual sites such as the lung, testis, central nervous system, and oral cavity, but not to the lymph nodes.

Histopathology. Histologically, band-like infiltrates consisting of pleomorphic lymphocytes or immunoblasts are observed, displaying a diffuse infiltration of an acanthotic epidermis with variable degrees of spongiosis, intraepidermal blistering, and necrosis. The neoplastic cells express the Ki67 antigen at a high frequency and are positive for CD3, CD8, CD7, CD45RA, and TIA, whereas CD2 and CD5 are frequently lost. Expression of TIA identifies these lymphomas derived from a cytotoxic T-cell subset.[29]

Treatment and Prognosis. Even with multiagent chemotherapy, the disease shows an aggressive course, and median survival is 32 months.

CUTANEOUS γ/δ T-CELL LYMPHOMA ***Definition.*** Cutaneous γ/δ T-cell lymphoma encompasses the peripheral T-cell lymphomas with a clonal proliferation of mature, activated γ/δ T cells with a cytotoxic phenotype. This group includes cases previously termed *subcutaneous panniculitis-like T-cell lymphoma with a γ/δ phenotype*.[1]

Clinical Manifestations. Patients have disseminated ulceronecrotic nodules or tumors, particularly on the extremities, but other sites may be affected as well. Involvement of mucosal and other extra-nodal sites is frequent, but involvement of lymph nodes, spleen, or bone marrow is uncommon. A hemophagocytic syndrome may occur.

Histopathology. Histologically three major patterns of involvement can be present in the skin: epidermotropic, dermal, and subcutaneous. The neoplastic cells are generally medium to large with coarsely clumped chromatin. Large blastic cells with vesicular nuclei and prominent nucleoli are infrequent. Apoptosis and necrosis are common, often with vessel invasion. Immunohistologically the tumor cells have a $\beta F1^-$, $CD3^+$, $CD2^+$, $CD5^-$, $CD7^{+/-}$, $CD56^+$ phenotype with strong expression of cytotoxic proteins. Most cases lack both CD4 and CD8, although CD8 may be expressed in some cases. In frozen sections the cells are strongly positive for TCR δ (antibody testing is not available for paraffin sections). If only paraffin sections are available, the absence of $\beta F1$ may be used to conclude a γ/δ origin.

Treatment and Prognosis. Most patients have aggressive disease resistant to multiagent chemotherapy and/or radiation therapy. Median survival is 15 months.



Staging of Cutaneous T-Cell Lymphoma

Staging of CTCL includes examination of the entire skin, chest radiography, and ultrasonography of abdominal organs and peripheral lymph nodes (cervical, axillary, and inguinal). Blood investigations are complete blood cell count, lactate dehydrogenase level, sedimentation rate, and T-cell clonality. A biopsy specimen must be taken from representative skin lesions and from enlarged lymph nodes. Staging may be completed by computed tomographic scan and/or histologic and molecular (TCR rearrangement) investigations of suspicious lymph nodes and/or visceral organs. Staging examination should be repeated at relapse and every 12 months (chest radiography every 2 to 3 years).

The aforementioned investigations allow for classification according to the tumor, lymph node, metastases (TNM) system (Table 146-2). Although the prognostic value and applicability of TNM staging for different CTCLs is controversial, the TNM scheme directs the decision-making process toward an appropriate therapeutic regimen for most CTCLs.

TABLE 146-2
Staging System for Mycosis Fungoides and Sézary Syndrome

STAGE	T (TUMOR)	N (LYMPH NODE)	M (METASTASES)
IA	T1	N0	M0
IB	T2	N0	M0
IIA	T1 or T2	N1	M0
IIB	T3	N0 or N1	M0
III	T4	N0 or N1	M0
IVA	T1–T4	N2 or N3	M0
IVB	T1–T4	N0–N3	M1

T1: patch/plaque ≤ 10% of body surface; T2: patch/plaque ≥ 10% of body surface; T3: skin tumor(s); T4: erythroderma; N0: normal nodes; N1: palpable nodes without histologic evidence of lymphoma; N2: no palpable nodes, but histologic evidence of lymphoma; N3: palpable nodes with histologic evidence of lymphoma; M0: no visceral involvement; M1: histologically confirmed visceral involvement.



Principles of Treatment of Cutaneous T-Cell Lymphoma

Every successful strategy in managing CTCL begins with goals, tumor-burden assessments, questionnaires, and a timetable. The primary goals of therapy are to improve the quality of life, to prolong life, and to cure. With a chronic disease like CTCL, surrogate markers are a necessity, and tumor burden is still the best surrogate marker for survival. Tumor-burden measurements and measures of palliation are the markers most commonly used. Skin score systems and health assessment questionnaires that evaluate both discrete and global manifestations of the disease have also provided disease activity measurements. The first staging of CTCL was done on the basis of skin involvement in a multicenter project conducted by the Mycosis Fungoides Cooperative Group[32] (see Table 146-2). The T staging provided the only underpinning for linking tumor burden with survival in that the more skin involved, from limited patch to 100 percent involvement, the worse the prognosis. In addition to skin staging, there are other factors that contribute to the heterogeneity of CTCL. This heterogeneity has undermined the usefulness of the TNM staging system. Currently, skin scores provide a measure of objective responses to therapy, and questionnaires guide the assessment of subjective responses to therapy. It has not been shown that reducing disease in a patient from T3 to T1 is accompanied by any benefit in survival, yet it is also recognized that cure is unattainable unless the patient is first in remission with a skin score of 0 by whatever skin scoring system is used. Thus, remission is the first step toward achieving a cure.

A few principles help guide therapy strategies.[23] Excellent long-term results have been reported with the localized treatment of localized disease. More widespread disease requires total skin or systemic therapy. However, it is not known at what percentage of skin surface involvement it becomes imperative to treat the entire skin. Once remission is achieved, maintenance therapy has a role in preventing relapse. Because many patients will undergo treatments that span decades, it is also important to minimize exposure to therapies that have cumulative toxicities on keratinocytes (i.e., mutagens) or the bone marrow.

With these principles in mind, one can approach the treatment of a given patient based on the patient's clinical presentation. The clinical presentation of the patient can be matched up with a successful therapy modality for both the remission-induction phase of therapy and the maintenance phase. For patients with several types of lesions, priority is given to those further down in Table 146-2. For example, a patient with both patches and tumors would be approached as a patient with tumors until those lesions are cleared.

The therapies used to help a patient with CTCL can best be categorized into skin-directed therapies, biologic response modifiers (BRMs), cytotoxic therapies, and combination therapies. Within each category, the individual modalities have unique properties that are discussed in the following sections in the context of how these modalities are used.[23]

UNILESIONAL/OLIGOLESIONAL CUTANEOUS T-CELL LYMPHOMA: SKIN-DIRECTED THERAPY The modalities considered for inducing a remission of unilesional/oligolesional disease are spot x-ray therapy, topical chemotherapy with carmustine (BCNU), and topical retinoid therapy with bexarotene. Topical glucocorticoid therapy is discussed later in the sections Maintenance Therapy and Topical Steroid Therapy. Spot radiotherapy is the most reliable and rapid method of inducing a remission of localized CTCL. Radiotherapy is widely available, and most lesions, no matter where they occur on the body (e.g., eyelid, buttock crease, ear), can be treated with this modality. There are no compliance problems, with each treatment session conducted by a professional radiotherapist. The immediate toxicity is minimal, but the long-term toxic effects of radiation dermatitis and cutaneous malignancy encourage conservative use of this modality.

The limitations of topical BCNU therapy are the systemic toxicity from absorption of the chemotherapeutic agent and local irritation. As a result, topical BCNU is used primarily for a limited body surface area. The initial protocols for BCNU administration called for an alcohol-based solution kept in the refrigerator. However, ointment-based protocols are now more common. BCNU can be easily made up in 20-mg%, 30-mg%, or 40-mg% ointments with a petrolatum base. Patients typically apply BCNU ointment at night and wash it off in the morning. Locally, a dose-related irritation

and/or hyperpigmentation may appear over the 8 to 20 weeks needed to clear lesions. Monitoring includes performing complete blood cell counts every 2 weeks to check for marrow suppression. The cumulative toxicity of BCNU is primarily structural damage with skin thinning and telangiectasias. The patient must be reliable and adherent to the regimen for this therapy to succeed.[33]

The limitations of topical bexarotene gel are also due primarily to dose-related irritant effects. Hence, bexarotene gel is typically used for lesions on less than 15 percent of body surface area, as was the case in most of the patients in the pivotal trial that led to its approval.[34] The gel is commercially available in a 1-percent formulation, so that dose intensity is varied by changing the frequency of application. Patients typically initiate therapy with nightly lesional applications of bexarotene gel. After a week, the frequency is increased to twice daily, and the patient is cautioned about the possibility of an irritant dermatitis at the site of the lesions. Complete clearance of lesions will usually occur after 12 to 16 weeks of therapy. Irritant responses can be managed by decreasing the frequency of application.[35] Successful topical bexarotene therapy also requires a patient who adheres to the treatment regimen and is willing to put up with the irritant properties of this vitamin A derivative.

DISSEMINATED PATCH/PLAQUE DISEASE Cutaneous T-cells re-circulate through the vascular system and are capable of patrolling the entire skin. When CTCL lesions are scattered, the most successful treatment strategies are those that treat the entire skin so as to extend the antilymphoma effect to the entire reach of the cutaneous T cell. Re-circulating CTCL cells are detectable even in limited disease, and such re-circulating cells are capable of restarting the disease. These cells provide some of the rationale for the use of maintenance therapy after a complete response has been achieved in the management of patients with disseminated patch/plaque disease. The total skin treatment modalities most commonly used as first-line therapy against disseminated patch/plaque disease are phototherapies, topical chemotherapy, and total skin electron-beam radiotherapy.

Phototherapies. PUVA (see Chap. 239) can produce a definite clinical response and complete remissions of long duration in patients with patch/plaque CTCL. PUVA therapy requires regular treatments, initially three to four times a week, for up to 3 months or until remission occurs. The follow-up of a patient receiving PUVA for CTCL includes an assessment to be sure there is some mild degree of phototoxicity. Otherwise, dosing of either the psoralen or the ultraviolet A light may be insufficient. Risks of the treatment include possible induction of cutaneous epithelial neoplasms and cataract formation. Therefore, all patients should be observed closely and checked regularly for the development of skin cancer. In addition, patients are advised to protect their eyes for 24 hours after PUVA therapy and to have annual ophthalmologic examinations. These precautions should be enforced early, because PUVA is a therapy that may continue for years as a maintenance treatment. Even after poor responses to conventional therapy, patients have experienced complete clearing of the skin with PUVA.[36] Maintenance therapy may be needed, however, as shown by the prolongation of clinical remission with continued PUVA.[37] For this reason, a gradual taper of therapy from thrice weekly to one session every 2 to 4 weeks after the patient has achieved a stable remission is typical.

Ultraviolet B and narrow-band ultraviolet B light are both effective in treating CTCL. These phototherapies are more convenient for patients, although their efficacy, especially for plaque disease, may not be as great as that of PUVA. Patch CTCL can often be completely cleared with ultraviolet B or narrow-band ultraviolet B light. A complete response can typically be induced with three to five treatment sessions per week. After a complete response has occurred, phototherapy can be continued on a maintenance schedule, initially at one treatment per week. The immediate adverse effects are primarily phototoxicity; the long-term toxicity is an increased risk for cutaneous malignancy.

Total Skin Topical Chemotherapy. Total skin topical chemotherapy consists of nitrogen mustard (mechlorethamine hydrochloride) applied as either an ointment or a freshly prepared aqueous solution. As an initial dose, 10 mg of the drug is dissolved in approximately 50 mL of tap water. The entire amount is then applied to the whole body surface by the patient. The patient should wear protective plastic gloves while applying the solution. A delayed hypersensitivity reaction may complicate treatment, and it is possible to desensitize patients, although their confidence in the therapy may be compromised. Ointment-based mechlorethamine, typically 10-mg% strength, may be less sensitizing and is shelf stable for a long period. Other side effects from mechlorethamine hydrochloride therapy, besides hypersensitivity reactions and primary irritant reactions, include the development of second cutaneous malignancies and hypopigmentation and hyperpigmentation. This therapy is relatively easy for the patient to use at home, but daily whole body application is required for maintenance therapy once remission is induced.



Total Skin Radiation Therapy. The radiosensitivity of cutaneous lymphomas has been therapeutically exploited by the administration of total skin electron-beam radiation. Because electrons penetrate only to the upper dermis, electron-beam therapy may be used without systemic effect. The limited penetration of the electrons is advantageous because it spares the mucous membranes, bone marrow, gastrointestinal tract, and other vital internal organs. Only those portions of the skin that are directly exposed to the beam are irradiated. Therefore, the palms, soles, scalp, axillae, and perineum may need separate exposures to ensure total body treatment. The eyelids are routinely covered with lead eye shields to protect the cornea and lens from the effects of radiation. If the eyelids are involved, 5-mm–thick contact lenses are worn between the lid and cornea within the conjunctival sac. Nail shields may also be used to prevent anonychia.

Whole body electron-beam irradiation brings about complete remission in 80 percent to 95 percent of patients. The relapse rate is highest in the later stages of CTCL, that is, in those patients with tumors, lymphadenopathy, and visceral involvement. Patients with limited plaque disease were found to have the highest relapse-free rate (42 percent at 10 years). Most relapses occurred within the first year after completion of therapy, and relapses were very rare after 3 years. The median disease-free interval was longer than 3 years in the limited plaque group, approximately 1 year for patients with generalized plaque or erythrodermic disease, and less than 6 months for patients with cutaneous tumors. The total dose of radiation is important. A dose of 30 cGy (3000 rad) or more gives higher complete remission rates and disease-free survival than do

lower doses. The major disadvantages are that this type of therapy must be provided at a specialized center and up to 3 months are required for complete treatment.

Local side effects include alopecia, atrophy of sweat glands and skin generally, radiodermatitis, and edema. When the total dose is highly fractionated, these complications are minimized and often avoided. The question is, What is the maximum radiation tolerance of the skin? When the highly fractionated approach is used, patients can receive a second course of electron-beam therapy of 36 cGy (3600 rad) to reinduce a remission. As the total radiation dose increases, so does the risk of squamous cell carcinoma and radiodermatitis. Small-field or spot orthovoltage radiotherapy using soft x-rays (60 to 100 kV with half-value layers of 1 to 1.5 mm Al) fractionated to doses of 0.75 to 5 cGy (75 to 500 rad) and total doses of 8 to 15 cGy (800 to 1500 rad) will adequately eliminate most lesions.



In many patients, a second or even third complete course of total skin electron-beam radiation can be safely given. The strategy of administering electron-beam radiation for repeat courses requires the use of a highly fractionated dose of 1 Gy per dose.

Maintenance Therapy and Topical Steroid Therapy. The concept of treating normal skin evolved from the clinical experiences with skin-directed therapies. There are two components to this approach: the treatment of normal skin during remission-induction skin-directed therapy and the treatment of normal skin during the remission maintenance phase. Topical chemotherapy, PUVA, and total skin electron-beam radiation all involve the exposure of normal skin as an integral component of their success in achieving remission. This success reflects the ability of the therapy to interrupt the critical skin-based phase of the life cycle of a re-circulating CTCL cell. Once a remission has been achieved, normal skin can be maintained with lower doses and frequencies of the therapies used to clear it. Maintenance therapies have been described with PUVA, total skin application of nitrogen mustard, ECP, and IFN. The most commonly used maintenance therapy is PUVA (see Chap. 239) or ultraviolet B irradiation (see Chap. 238). As a maintenance therapy, PUVA is initially administered at once-weekly intervals until 1 year has passed. At this point, the schedule is changed to every other week for another year, to every third week for the following year, and finally to every fourth week for 2 years. At this point, the patient should have been in remission for 5 years. Consideration should be given to stopping therapy at this point. A cure is defined as freedom from disease for 8 years off all therapy. This definition arose from the experience with nitrogen mustard treatment and total skin electron-beam radiotherapy showing that after a patient achieves a remission off therapy of 5 to 8 years, late relapse is extremely rare. This would imply that malignant cutaneous T cells re-circulate without causing lesions for up to 5 years. With 5 years of intermittent PUVA, it is less likely that one of these cells will survive, but it is still possible. After therapy has been discontinued, patients should not be considered cured unless they remain clear of disease for 8 years.

The management of suspected relapse often includes the use of topical glucocorticoids and reflects the critical role this modality can play in the treatment of suspicious lesions. Early in the course of CTCL and in a recurrence of the disease in a patient in remission, the T-cell activation process can be blunted by the aggressive use of topical glucocorticoids. Indeed, most patients have a history of using these agents before a firm diagnosis is made. A regimen for treating early lesions of MF is twice-daily applications of a class I topical glucocorticoid for 8 weeks. This regimen is one of the first-line modalities for suspected relapse, and it can help identify which patients need to undergo a 4-week "wash-out" before repeat biopsies are performed.

ERYTHRODERMA The erythrodermas of CTCL represent florid immune dysfunctions that result in total skin redness, scaling, and discomfort. It is not surprising that immune-based therapies take the forefront in the management of these disorders. The three major BRMs used in the treatment of CTCL are oral retinoids, intravenous ECP, and subcutaneous injections of IFN-α. In the clinical trials of these agents, patients have undergone monotherapy for what has usually been heavily pre-treated refractory disease. In practice, these treatments are often used as first-line monotherapy in erythroderma, and other agents are incorporated for combination therapies if the response is incomplete. With these agents, partial responses are more common than complete responses. Thus, if the goal is remission, combination therapy is used more commonly than monotherapy. If the goal is palliation, monotherapy with a BRM is often sufficient. The BRMs differ in terms of their administration, side effects, interactions with other therapy modalities, and availability.

Retinoid Therapy. The first-generation retinoids such as isotretinoin have an effect on CTCL. The more CTCL-specific retinoid bexarotene selectively binds the retinoid X receptor, whereas the other available retinoids have less specific binding patterns. In the monotherapy trials, bexarotene was dosed at 300 mg/m^2 (average dose, 450 to 675 mg/day, taken as capsules with the evening meal). Responses were seen in patients with all phases of the disease: plaques, erythroderma, and tumors. Responses paralleled the secondary end points: decreases in overall body surface area involved and in overall tumor aggregate area, and improvement in pruritus. Erythrodermic patients may experience increased desquamation during the first few weeks of oral bexarotene therapy. Improvement typically occurs by week 12 of therapy.[38]

Although there appeared to be a dose-response relationship with respect to efficacy, the higher dosages were also associated with a higher rate of adverse events and dose-limited toxicities. The most common were hyperlipidemia/hypercholesterolemia and neutropenia. Elevations in lipid levels occurred rapidly, within 2 to 4 weeks, and were associated with serious, but reversible, pancreatitis. Monitoring of lipids and the use of lipid-lowering drugs were helpful in controlling the lipid levels.[39] Dosage reductions of bexarotene capsules were also required in some patients. Drug interactions of oral bexarotene with gemfibrozil and warfarin have been observed.

Patients started on bexarotene therapy develop central hypothyroidism with low levels of thyroid-stimulating hormone and free thyroxine within weeks of starting the medication. Symptoms of hypothyroidism may be subtle and include feeling fatigued and feeling cold, which may be attributed to the CTCL. Supplementation with levothyroxine while patients are taking bexarotene alleviates the symptoms and improves tolerance of treatment.[39] The condition is reversible within weeks of stopping therapy. There is no immunosuppression with bexarotene therapy.

Patients taking bexarotene typically have monthly monitoring visits to follow lipid, liver, and thyroid parameters.

Extracorporeal Photochemotherapy. (See Chap. 239) ECP involves the photoinactivation of a portion of a patient's lymphocyte compartment with 8-methoxypsoralen in the presence of ultraviolet A light, followed by reinfusion of these cells. The treatment is performed via an intravenous line that feeds into a photoinactivation device, and the procedure typically requires the patient to remain recumbent for 3 hours. Treatments are conducted on two consecutive days every 4 weeks. Erythrodermic CTCL can be managed with ECP monotherapy,[25] but treatment of other disease stages with monotherapy has not been rigorously studied. In a multicenter study involving erythrodermic CTCL patients, approximately one-fourth had a complete response, one-fourth had no response, and the remainder had partial responses. However, it is clear that even a partial response can improve the quality of life of these patients. Improvement sometimes began as early as 6 weeks into therapy, but some patients did not show complete lesion clearance until 12 months after starting therapy. There were occasional temporary responses immediately after a 2-day cycle of therapy. On average, after 4 to 6 months there was typically a gradual and permanent decrease in erythema, scaling, and pruritus. Patients often notice more subtle changes, such as the return of body hair, loss of rigors, and a return of the ability to sweat. Partial responses may also decrease the morbidity these patients experience in terms of infectious complications. More heavily involved and inflamed skin is more readily colonized, providing both a reservoir and access point for microbes to invade the host. Thus, cutaneous improvement can also minimize complications of CTCL.

The clinical experiences with ECP for CTCL suggest that the therapeutic response may well be based in the immune system.[18] One feature is that when less than 5 percent of the malignant lymphocyte pool is photoinactivated with 8-methoxypsoralen and ultraviolet A light, clinical responses can be seen, with more than 95 percent of the malignant lymphocytes disappearing over time. It also appears that most immunocompetent patients respond. Patients who were heavily pre-treated, with longer disease durations, showed less of a response. Also, patients with more normal $CD8^+$ lymphocyte levels were responsive to ECP. In one study, total skin electron-beam radiotherapy was combined with ECP in patients with T3 and T4 disease. Comparison of patients receiving skin-directed radiotherapy plus BRM with historic controls who underwent electron-beam radiotherapy at the same institution demonstrated the impact of ECP, because patients in the skin-directed therapy plus BRM group showed significantly longer survival.[40]

Interferon-α Therapy. The most-studied IFN has been IFN-α, but clinical trials have also been done with IFN-β and IFN-γ in the treatment of CTCL. The initial studies using IFN-α as monotherapy showed rates of complete responses that varied from 10 percent to 27 percent with treatment durations of less than 6 months.[41] Again, the heterogeneity of the disease and the pre-treatments patients undergo affect outcomes and make comparisons with other modalities impossible. IFN-α is typically started at 3 million units (MU) three times a week and can be increased to a maximally tolerated dose, typically in the range of 12 MU/day. As with the other BRMs, the response to IFN is gradual, and 3 to 6 months are needed to determine the maximal response. After patients achieve a maximal response, IFN dosage can be lowered to a maintenance level of 1 MU daily.[42]

All IFNs have similar toxicities. The initial week of IFN therapy is complicated by a flu-like illness that may be accompanied by fever, myalgia, fatigue, and listlessness. As this wears off, patients are often left with a slight feeling of chronic fatigue. The long-term toxicity that causes most concern is neurologic: depression, neuropathy, dementia, and myelopathy. There are autoimmune phenomena that may occur, such as proteinuria, thrombocytopenia, and anemia. Monitoring of IFN therapy includes blood counts and urinalysis along with questionnaires assessing the impact on the patient's quality of life.

The combined-modality therapies that use IFN in the management of erythrodermas combine IFN with ECP or retinoids. If IFN monotherapy of erythroderma produces a partial response, the addition of either of these other modalities can help produce the desired goal of either complete response or increased palliation.

PRIMARY CUTANEOUS B-CELL LYMPHOMAS

Primary CBCLs are B lymphocyte–derived malignancies that develop in the skin without internal involvement at the time of diagnosis. CBCLs comprise approximately 20 percent of all cutaneous lymphomas.

In comparison with the nodal B-cell lymphomas, the majority of the CBCLs are indolent lymphomas.

Primary Cutaneous Follicle Center Cell Lymphoma

DEFINITION PCFCL can be defined as a neoplasm of clonal centrocytes (small and large cleaved follicle center cells) and centroblasts (large follicle center cells with prominent nucleoli) with or without formation of follicular centers.[1,2]

CLINICAL MANIFESTATIONS Patients with PCFCL have lesions such as non-scaling solitary or grouped papules and thick plaques or tumors, and occasionally an annular erythema can be observed in the surrounding area (Fig. 146-22A). A typical finding is the occurrence of lesions in a circumscribed area of the head and neck region.

HISTOPATHOLOGY The typical histologic finding in PCFCL is nodular or diffuse infiltrates with almost constant sparing of epidermis. In the initial lesion a mixture of centrocytes, few centroblasts, and many reactive T cells is present. In parallel with progression of the tumor, the number and size of neoplastic B lymphocytes increases. In persisting lesions large follicle center cells (centrocytes and centroblasts) dominate (see Fig. 146-22B). A follicular growth pattern or remnants of follicles are observed. The abnormal follicles contain malignant $bcl\text{-}6^+$ follicle center cells and lack tingible body macrophages. The mantle zone is reduced or absent. The typical immunophenotype of the neoplastic cells is $CD19^+CD20^+CD22^+CD79A^+$. Clonal immunoglobulin rearrangements can be detected by molecular genetic analysis. Unlike in nodular follicular lymphomas, however, the t(14;18) translocation is not present and bcl-2 protein is expressed in only a minority of cases. A clonal rearrangement of the variable part of the immunoglobulin heavy chain gene is detected in 60 percent to 80 percent of cases.[43]

TREATMENT AND PROGNOSIS Radiotherapy is the preferred mode of treatment. Che-





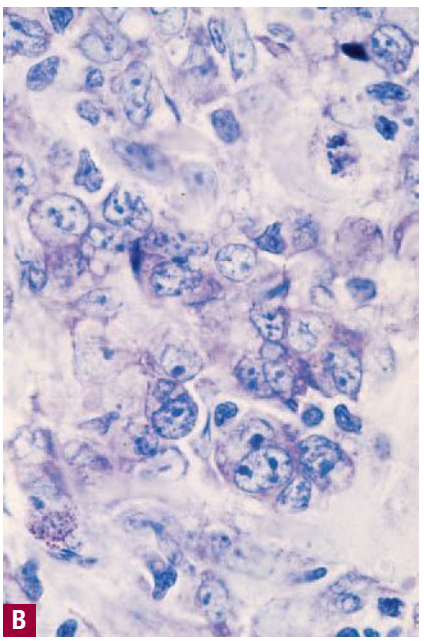

▲ **FIGURE 146-22** Primary cutaneous follicle center cell lymphoma. **A.** Tumor in the head area surrounded by erythema. **B.** The cellular infiltrate consists of a mixture of centrocytes, a number of centroblasts, and reactive T cells.

motherapy should be considered only in rare cases where more generalized skin lesions are present. Single lesions can be excised. Immune therapies such as administration of IFN-α or monoclonal antibodies against CD20 may be beneficial in cases with disseminated lesions.[10] With an estimated 5-year survival rate of 97 percent, the follicle center cell lymphoma is classified as an indolent type of primary CBCL. In untreated patients, the skin lesions increase in size over the years, but extracutaneous dissemination is uncommon.

Primary Cutaneous Marginal Zone Lymphoma

DEFINITION PCMZL is defined as a neoplastic proliferation of small lymphocytes, lymphoplasmacytoid cells, and plasma cells, which are initially localized in the marginal zone of a follicular center.[1,2]



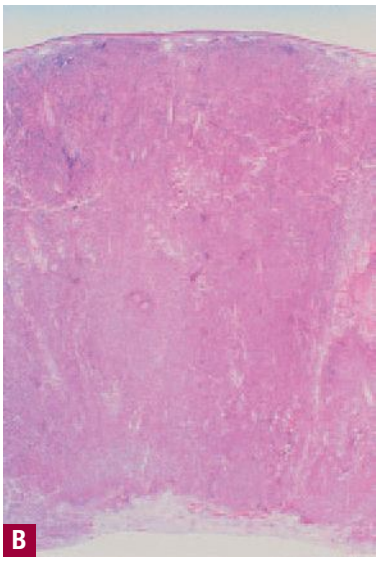

▲ **FIGURE 146-23** Primary cutaneous large B-cell lymphoma of the leg. **A.** Nodules and tumors on the right leg 3 months after disease onset. The patient died 5 months later. **B.** Lesion from the same patient showing diffuse infiltrate of large B cells with centroblasts, large centrocytes, and numerous immunoblasts.

CLINICAL MANIFESTATIONS PCMZLs are seen most commonly on the upper extremities or the trunk and occur at a median age of 55 years; they predominate in females. Patients have small red to violaceous papules, plaques, or nodules that, in contrast to the lesions of PCFCL, frequently occur in multiple locations. PCMZL accounts for 25 percent of primary CBCLs.

HISTOPATHOLOGY Histologic analysis of well-developed lesions shows dense nodular or diffuse infiltrates with sparing of the epidermis. Hyperplastic germinal centers may be observed with or without a mantle zone. Outside the germinal centers (in the marginal zone) small lymphocytes with slight nuclear irregularity and moderate amounts of cytoplasm are present. Plasmacytic differentiation of the tumor cells may occur. Monotypic expression of immunoglobulin light chains can be observed in approximately 75 percent to 85 percent of cases. Importantly, the number of neoplastic cells within the infiltrate is variable and may be very low.

The typical immunophenotype is $CD20^{+}CD79a^{+}CD5^{-}CD10^{-}$ and bcl-6^{-}. An immunoglobulin light chain restriction can frequently be found. Monoclonal immunoglobulin gene rearrangement can be demonstrated by molecular genetic methods such as PCR or Southern blotting.[43]

TREATMENT AND PROGNOSIS Radiotherapy is the treatment of choice. Immune agents such as IFN-α or monoclonal antibodies against CD20 may be administered in cases with disseminated lesions. The disease has an indolent course with an excellent prognosis, and the 5-year survival rate is 100 percent. However, local recurrences are frequently observed. Extra-cutaneous involvement is extremely rare. PCMZLs are a part of the broad group of extranodal marginal B-cell lymphomas that involve mainly mucosal sites (mucosa-associated lymphoid tissue or MALT). Just as *Helicobacter pylori* has been implicated in the development of gastric MALT-type lymphomas, it has been suggested that *Borrelia burgdorferi* is involved in the development of MALT-type lymphomas in the skin, at least in Europe.[1,23]

Primary Cutaneous Large B-Cell Lymphoma of the Leg

DEFINITION PCLBCL leg type has been specifically identified as a distinct clinical entity because of its perceived poor outcome compared with other CBCLs (particularly PCFCL). This entity shows an intermediate clinical course and is defined by tumors composed of large B cells that present exclusively on the legs.[1,2]

CLINICAL MANIFESTATIONS PCLBCL leg type affects elderly patients (over 65 years), with a predominance in females. Typically patients have solitary or clustered bluish erythematous plaques and tumors located on one or, sometimes, both legs (Fig. 146-23A). Ulceration is common and sometimes leads to the misdiagnosis of chronic venous ulceration. It is important to note that, in rare

cases, PCLBCL leg type can also arise at cutaneous sites other than the legs.

HISTOPATHOLOGY The diffuse infiltrates spare the epidermis and often extend to the subcutaneous tissue. Monotonous populations or confluent sheets of centroblasts and immunoblasts with a high mitotic rate are admixed with only a few reactive T cells (see Fig. 146-23B). The neoplastic B lymphocytes express CD20, CD79a, multiple myeloma-1/interferon regulatory factor-4 (MUM-1/IRF4), and the bcl-2 molecule. Staining for bcl-6 gives positive results in most cases, whereas results for CD10 are generally negative. A clonal immunoglobulin rearrangement is detected in most cases.[43]

TREATMENT AND PROGNOSIS This tumor belongs to the intermediate aggressive group of CBCLs. Patients develop rapidly growing painless lesions, which initially disseminate along the lymph vessels. The tumor can involve the sentinel lymph node and progress to extra-cutaneous involvement. In cases of solitary or localized skin lesions, radiotherapy may be undertaken; in all other cases and when progression is observed, multiagent chemotherapy in combination with an immunotherapy agent (e.g., CHOP [*c*yclophosphamide, *h*ydroxydaunomycin, *O*ncovin (vincristine), *p*rednisone] plus anti-CD20 antibody treatment) should be administered. An unfavorable prognosis is reported, with a 5-year-survival rate of 55 percent.[23]

Provisional Entities of Primary Cutaneous B-Cell Lymphoma

In addition to the clearly defined primary CBCLs discussed in the preceding sections, provisional entities have been included in the WHO-EORTC classification.[1]

INTRAVASCULAR CUTANEOUS B-CELL LYMPHOMA Intravascular cutaneous B-cell lymphoma is characterized by clusters of large neoplastic B cells within dermal and subcutaneous blood vessels. Occasionally, slight extravascular infiltrates of atypical cells are observed. Clinically, red to bluish, indurated plaques can be observed on the legs or trunk. Sometimes a panniculitis-like pattern can be seen. Multiagent chemotherapy is the preferred mode of treatment.

Staging of Cutaneous B-Cell Lymphoma

Staging of cutaneous B-cell lymphoma includes examination of the entire integument, chest radiography, ultrasonography of abdominal organs and lymph nodes (cervical, axillary, and inguinal), and bone marrow biopsy. A complete blood cell count, lactate dehydrogenase level, sedimentation rate, serum and immune electrophoresis, *Borrelia* serologic testing, and B-cell clonality analysis are ordered for most patients. In the event of pathologic findings, staging is completed by computed tomographic scan and/or histologic investigation of suspect lymph nodes and/or visceral organs. Staging examination should be repeated at relapse and every 12 months (chest radiography every 2 to 3 years, bone marrow biopsy at relapse only).

Principles of Treatment of Cutaneous B-Cell Lymphoma

Treatment of primary CBCLs should be adapted to the favorable prognosis of these entities, in particular of PCFCL and PCMCL. Because no curative regimen has been defined so far, therapy depends on the entity and the dissemination of the cutaneous lesions. In the case of solitary lesions, complete excision of the tumor is the treatment of choice, and, in addition, local irradiation (single dose of 3 to 4 Gy; total dose of 20 to 40 Gy) by x-ray or electron beam can be considered. When this regimen is used, long-lasting remissions can be achieved. For local treatment, intralesional application of cisplatin has also been found to induce long-lasting, complete remissions in the case of solitary lesions.

For indolent CBCLs with disseminated lesions, immunotherapeutic regimens, including the application of IFN-α or anti-CD20 antibodies, are evaluated for their efficacy.

Systemic treatment regimens are recommended in cases of large B-cell lymphomas of the leg and in other CBCLs when multiple lesions or secondary extra-cutaneous manifestations are present. Polychemotherapy (six cycles of CHOP, COP [cyclophosphamide, Oncovin (vincristine), and prednisone], or MACOP [methotrexate-leucovorin, Adriamycin, cyclophosphamide, Oncovin, prednisone]) in combination with an anti-CD20 antibody is administered. After complete remission, maintenance therapy with IFN-α may be administered for a period of 1 year. Alternatively, use of a COP regimen with longer cycle intervals of 4 to 12 weeks is possible. For stage IV disease, combined myeloablative chemotherapy and irradiation with subsequent autologous bone marrow transplantation can be taken into consideration, although only a small number of cases have been treated using this regimen so far.

PRECURSOR HEMATOLOGIC NEOPLASM

CD4+/CD56+ Hematodermic Neoplasm

DEFINITION In the WHO-EORTC classification CD4+/CD56+ hematodermic neoplasm was included for the first time as a clinically aggressive neoplasm with a high incidence of cutaneous involvement and risk of leukemic dissemination.[1] The blastic cytologic appearance and CD56 expression initially suggested an NK precursor origin. More recent studies suggest derivation from a plasmacytoid dendritic cell precursor.[30]

CLINICAL MANIFESTATIONS CD4+/CD56+ hematodermic neoplasm commonly presents in the skin as solitary or multiple nodules or tumors with or without concurrent extra-cutaneous manifestations. Approximately 50 percent of patients have nodal or bone marrow involvement at presentation. Most patients who have only skin lesions when they first come for treatment rapidly develop involvement of bone marrow, peripheral blood, lymph nodes, and extra-nodal sites.

HISTOPATHOLOGY The typical histologic characteristics are diffuse monomorphous infiltrates of medium-sized cells separated by a grenz zone from the epidermis. Perivascular patchy infiltrates and an Indian file pattern are observed occasionally. Angiotropism is uncommon. The neoplastic cells express CD4, CD43, and CD56, as well as TCL1. Tests for markers of B-/T-cell (CD20/CD3) lineage, CD30, and markers of cytotoxic cells (TIA1, granzyme B) give negative results. The cells express CD123 and blood dendritic cell antigen 2, both of which support a relationship to plasmacytoid dendritic cells. TCR genes are in germline configuration. Tumor cells test negative for EBV.

TREATMENT AND PROGNOSIS CD4+/CD56+ hematodermic neoplasm is associated with a highly aggressive clinical course and thus a poor prognosis (median survival is 14 months). Although systemic chemotherapy is the first choice for treatment of this disease, the results are often disappointing. Studies suggest that patients can best be treated with regimens



used to treat acute myeloid leukemias, including bone marrow transplantation.[30]

KEY REFERENCES

The full reference list for all chapters is available at www.digm7.com.

1. Willemze R et al: WHO-EORTC classification for cutaneous lymphomas. *Blood* **105**:3768, 2005
2. Assaf C et al: Classification of primary cutaneous lymphomas. *Front Radiat Ther Oncol* **39**:25, 2006
3. Kim EJ et al: Immunopathogenesis and therapy of cutaneous T cell lymphoma. *J Clin Invest* **115**:798, 2005
4. Weinstock MA, Gardstein B: Twenty-year trends in the reported incidence of mycosis fungoides and associated mortality. *Am J Public Health* **89**:1240, 1999
15. Girardi M, Heald PW, Wilson LD: The pathogenesis of mycosis fungoides. *N Engl J Med* **350**:1978, 2004
16. Dummer R et al: Pathogenesis of cutaneous lymphomas. *Semin Cutan Med Surg* **19**:78, 2000
18. Heald P et al: Treatment of erythrodermic cutaneous T cell lymphoma with extracorporeal photochemotherapy. *J Am Acad Dermatol* **27**:427, 1996
21. Burg G et al: WHO/EORTC classification of cutaneous lymphomas. Histological and molecular aspects. *J Cutan Pathol* **32**:647, 2005
22. Cerroni L, Gatter K, Kerl H: *Illustrated Guide to Skin Lymphoma*, 2nd ed. Boston: Blackwell Publishing, 2006
23. Trautinger F et al: EORTC consensus recommendations for the treatment of mycosis fungoides/Sézary syndrome. *Eur J Cancer* **42**:1014, 2006
24. Zackheim HS et al: Prognosis in cutaneous T-cell lymphoma by skin stage: Long-term survival in 489 patients. *J Am Acad Dermatol* **40**:418, 1999
25. Vonderheid EC et al: Update on erythrodermic cutaneous T-cell lymphoma: Report of the International Society for Cutaneous Lymphomas. *J Am Acad Dermatol* **46**:95, 2002
26. Kim YH et al: Long-term outcome of 525 patients with mycosis fungoides and Sézary syndrome: Clinical prognostic factors and risk for disease progression. *Arch Dermatol* **139**:857, 2003
27. Bekkenk MW et al: Primary and secondary cutaneous CD30(+) lymphoproliferative disorders: A report from the Dutch Cutaneous Lymphoma Group on the long-term follow-up data of 219 patients and guidelines for diagnosis and treatment. *Blood* **95**:3653, 2000
28. Kadin ME, Carpenter C: Systemic and primary cutaneous anaplastic large cell lymphomas. *Semin Hematol* **40**:244, 2003
29. Berti E et al: Primary cutaneous CD8-positive epidermotropic cytotoxic T cell lymphomas. A distinct clinicopathological entity with an aggressive clinical behavior. *Am J Pathol* **155**:483, 1999
30. Assaf C et al: CD56 hematological disorders of the skin: A multicenter study from the European Organization for Research and Treatment for Cancer (EORTC) Cutaneous lymphoma project group. *J Clin Pathol* Oct. 3, 2006 [Epub ahead of print]
31. Sterry W, Siebel A, Mielke V: HTLV1-negative pleomorphic T cell lymphoma of the skin. The clinicopathologic correlations and natural history of 15 patients. *Br J Dermatol* **126**:456, 1992
33. Vonderheid EC et al: Long-term efficacy, curative potential and carcinogenicity of topical mechlorethamine chemotherapy in cutaneous T cell lymphoma. *J Am Acad Dermatol* **20**:416, 1989
35. Zhang C, Duvic M: Retinoids: Therapeutic applications and mechanisms of action in cutaneous T-cell lymphoma. *Dermatol Ther* **16**:322, 2003
36. Herrmann JJ et al: Treatment of mycosis fungoides with photochemotherapy (PUVA): Long-term follow up. *J Am Acad Dermatol* **33**:234, 1995
39. Assaf C et al: Minimizing adverse side-effects of oral bexarotene in cutaneous T-cell lymphoma: An expert opinion. *Br J Dermatol* **155**:261, 2006
42. Ross C et al: Interferon treatment of cutaneous T cell lymphoma. *Eur J Haematol* **51**:63, 1993
43. Kerl H, Kodama, Cerroni L: Diagnostic principles and new developments in primary cutaneous B-cell lymphomas. *J Dermatol Sci* **34**:167, 2004



CHAPTER 147

Inflammatory Diseases That Simulate Lymphomas: Cutaneous Pseudolymphomas

Gary S. Wood

Cutaneous pseudolymphoma is a term used to describe skin lesions that bear a clinical and/or histopathologic resemblance to lymphoma. Over the years, a wide variety of designations have been included in this category. Some of these represent outdated synonyms, some refer to variants of the same entity, and some are misnomers for diseases now recognized to be true lymphomas. The relevant entities that are discussed in this and other chapters can be organized into several distinct disorders based on their lymphoid subset composition, pattern of cutaneous infiltration, and associated clinical findings (Table 147-1).

CUTANEOUS LYMPHOID HYPERPLASIA

Epidemiology

Cutaneous lymphoid hyperplasia (CLH) has a world-wide distribution and affects all races and ethnic groups. It occurs in both adults and children. Females are more commonly affected than males.

Etiology and Pathogenesis

CLH is characterized by a relatively dense lymphoid infiltrate, centered in the reticular dermis, that is usually B-cell rich and may resemble lymphoma clinically and/or histopathologically. Many terms are used to refer to this type of pseudolymphoma, including *Spiegler-Fendt sarcoid*, *lymphocytoma cutis*, *lymphadenosis benigna cutis*, and *cutaneous lymphoplasia*. *Cutaneous lymphoid hyperplasia* is the preferred term because it accurately describes the underlying pathophysiology of the lesion and is unlikely to be confused with terms used to describe various forms of cutaneous lymphoma.[1–5]

In most cases, CLH is idiopathic; however, some lesions are associated with exposure to foreign antigens from arthropods (bites, stings, infestations), infections (herpes zoster, *Borrelia burgdorferi*), tattoos, acupuncture, trauma, gold jewelry, vaccinations, hyposensitization injections, or medications (Figs. 147-1, 147-2, 147-3, and 147-4).[1–7] Medications that may induce CLH include phenytoin, carbamazepine, phenobarbital, β blockers, calcium channel blockers, angiotensin-converting enzyme inhibitors, allopurinol, D-penicillamine, penicillin, mexiletine chloride, cyclosporine, and agents that inhibit binding of histamine to H_1, H_2, or H_{1c} receptors. These drugs include conventional H_1 and H_2 antagonists, as well as tricyclic and nontricyclic antidepressants and phenothiazines.[8] It has been proposed that, rather than being the target of an

CUTANEOUS PSEUDO-LYMPHOMAS

AT A GLANCE



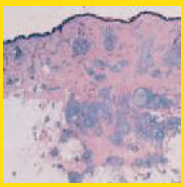

- A diverse group of skin disorders characterized by dense lymphoid infiltrates mimicking various types of cutaneous lymphomas.
- Two major immunologic categories: (1) mixed B and T cell (cutaneous lymphoid hyperplasia, Kimura disease, angiolymphoid hyperplasia with eosinophilia, Castleman disease) and (2) T cell (pseudo–mycosis fungoides, lymphomatoid contact dermatitis, Jessner's lymphocytic infiltration of the skin).
- Most are idiopathic but some are reactions to foreign antigens introduced locally or systemically.
- Usually present as violaceous, solitary, or localized papules, plaques, or nodules.
- Some cases harbor occult dominant lymphoid clones; occasional cases progress to overt cutaneous lymphomas.

immune response themselves, these latter agents may alter lymphocyte reactivity in a way that promotes a CLH response to other antigens in some individuals.[9,10]

Clinical Findings

APPROACH TO THE PATIENT Although the details of the workup for individual patients will vary with the specific type of pseudolymphoma being considered, certain data are generally important for establishing the correct diagnosis, identifying potential causative factors, and ruling out an underlying lymphoma. The clinical history taking should elicit information about the duration and symptomatology of lesions; the nature and pace of clinical progression; past treatment; local or systemic exposure to foreign antigens, including medications; and personal or family history of other lymphoproliferative disorders. It should also include a review of systems focusing on so-called *lymphoma B symptoms*, such as fever of unknown origin, unexplained weight loss, night sweats, fatigue, and malaise. A general physical examination is important, with special attention to the type and distribution of skin lesions and to the status of peripheral lymph nodes, liver, and spleen. A complete blood count with differential review, general chemistry panel, and a chest radiograph are screening tests that help to exclude extra-cutaneous involvement. Lesional skin biopsy is an essential part of the diagnostic evaluation. The use of topical and systemic glucocorticoids should be discontinued approximately 4 weeks before biopsy if possible, because these agents can attenuate lymphoid infiltrates and thereby confound their interpretation. Skin specimens should be large enough and deep enough to ensure representative sampling and to provide adequate tissue for routine histopathologic, immunohistologic, and molecular biologic studies. As with squamoproliferative skin lesions, the most diagnostic areas within cutaneous lymphoid infiltrates are often their deepest portions (Fig. 147-5). For cost effectiveness, one can often perform these biopsy studies in a sequential fashion, proceeding to the next test only if a firm diagnosis cannot be made based on the results of preceding analyses. However, rigorous characterization of a pseudolymphomatous infiltrate requires the full complement of these assays. If there is only a solitary lesion, it is generally best to obtain all biopsy material at one time, because inflammatory changes induced by the initial biopsy may interfere with the interpretation of subsequent specimens from the same locale.

TABLE 147-1
Classification of Cutaneous Pseudolymphomas

Clinicopathologic Sub-Type	Predominant Lymphoid Subset(s)	Predominant Localization	Major Associated Findings
Cutaneous lymphoid hyperplasia	B and T cell	Reticular dermis	—
Kimura disease	B and T cell	Subcutis	Lymphadenopathy
Angiolymphoid hyperplasia with eosinophilia	B and T cell	Reticular dermis	Eosinophilia
Castleman disease	B and T cell	Subcutis	Lymphadenopathy, POEMS syndrome
Pseudo–mycosis fungoides	T cell	Papillary dermis and epidermis	—
Lymphomatoid contact dermatitis	T cell	Papillary dermis and epidermis	Contact allergen
Lymphocytic infiltration of the skin (Jessner's)	T cell	Perivascular and periadnexal dermis	—

POEMS = polyneuropathy, organomegaly, endocrinopathy, M protein, and skin changes.

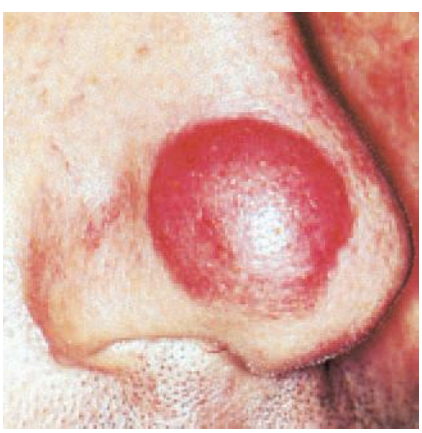

▲ **FIGURE 147-1** Cutaneous lymphoid hyperplasia. Solitary infiltrated nodule with a smooth surface in a classic location. (Lymphocytoma cutis in Lyme borreliosis.)



▲ **FIGURE 147-2** Cutaneous lymphoid hyperplasia. Involvement of the breast in a patient with elevated titers of antibodies against *Borrelia burgdorferi* spirochetes.





▲ **FIGURE 147-3** Cutaneous lymphoid hyperplasia. Multiple lesions of nodular scabies involving the genitalia.



▲ **FIGURE 147-4** Cutaneous lymphoid hyperplasia. Lymphomatoid drug reaction manifest as a generalized papulonodular eruption in a patient who was taking various neuroleptics.



In the event that there is still uncertainty as to whether the lymphoid infiltrate represents a pseudolymphoma or a lymphoma, additional workup can be helpful. This includes computed tomographic scans of the chest, abdomen, and pelvis, as well as bone marrow aspiration and biopsy. Biopsy can be performed on abnormally enlarged lymph nodes identified by physical examination or radiography and the specimens evaluated as described in the preceding paragraph for skin lesions. It is possible for patients with atypical cutaneous B-cell infiltrates manifesting as only one or a few skin lesions to have an otherwise unremarkable workup until radiographic scans of deep lymph nodes or bone marrow sampling demonstrates advanced-stage B-cell lymphoma with minor skin involvement.

HISTORY There may be a history of contact with an etiologically relevant foreign antigen; however, the majority of CLH cases are idiopathic. Lesions may be pruritic or asymptomatic. Occasionally, they may be slightly tender.[11]

CUTANEOUS LESIONS CLH presents most commonly as a solitary nodule, but it can also appear as a localized array of nodules, plaques, or papules. Generalized forms occur rarely. The head, neck, extremities, breasts, and genitalia are common sites (see Figs. 147-1, 147-2, 147-3, and 147-4). Lesions have a doughy to firm consistency and range from red-brown to violaceous in color. Lesions secondary to arthropod bites can be pruritic, ulcerated, or crusted. Occasionally, reactive lymphadenopathy may be present in the area of regional lymphatic drainage.[11,12]

Hydantoin-associated pseudolymphoma syndrome is caused by anticonvulsant drugs such as phenytoin. This syndrome is characterized by fever, lymphadenopathy, hepatosplenomegaly, arthralgia, eosinophilia, and generalized cutaneous macules and papules or, rarely, nodules.[2,3] Nodules may contain aggregates of large lymphoid cells that raise concern for lymphoma; however, both B and T cells are polyclonal. Subcutaneous lymph nodes may exhibit reactive follicular hyperplasia or atypical features suggestive of lymphoma. The macular and papular lesions of this syndrome share histopathologic features with those of hypersensitivity reactions to other drugs.

Acral pseudolymphomatous angiokeratoma of children presents as a unilateral eruption of angiomatous papules on the extremities.[13] There is a dense lymphoid infiltrate associated with histiocytes, plasma cells, and prominent, thickened capillaries.[14] This disorder is probably a variant of CLH secondary to arthropod bites.

Large cell lymphocytoma, originally reported as a cutaneous pseudolymphoma, most likely represents a mixed cell or large cell form of primary cutaneous B-cell lymphoma (CBCL).[1]

Laboratory Tests

HISTOPATHOLOGY Histopathologic examination of CLH lesions reveals a dense, nodular or diffuse lymphoid infiltrate that is concentrated in the reticular dermis (see Figs. 147-5, 147-6). It tends to be top heavy and to taper out in the lower dermis, although more widespread dermal infiltration with extension into the subcutis can sometimes be seen. In most cases, the epidermis is normal and separated from the underlying infiltrate by a narrow grenz zone of uninvolved papillary dermis. Occasionally, the epidermis may exhibit variable degrees of hyperkeratosis, parakeratosis, acanthosis, dyskeratosis, spongiosis, and basal vacuolar degeneration. Arthropod-induced reactions may show prominent epidermal hyperplasia or ulceration. Rarely, retained mouth parts may be seen associated with foreign-body granulomatous

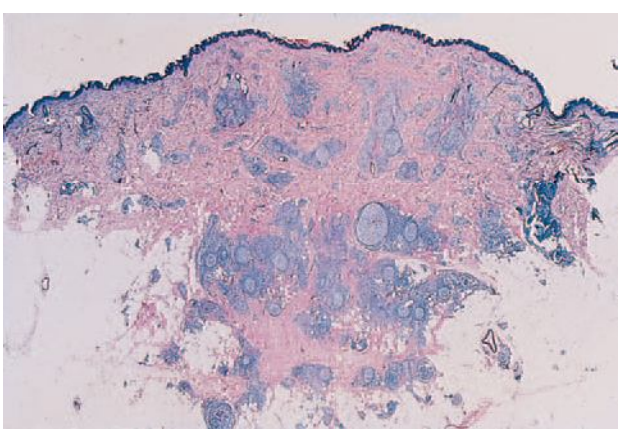

▲ **FIGURE 147-5** Cutaneous lymphoid hyperplasia. Infiltrate is wedge shaped and tapers out in its deeper portions. Note reactive lymphoid follicles containing pale germinal centers.

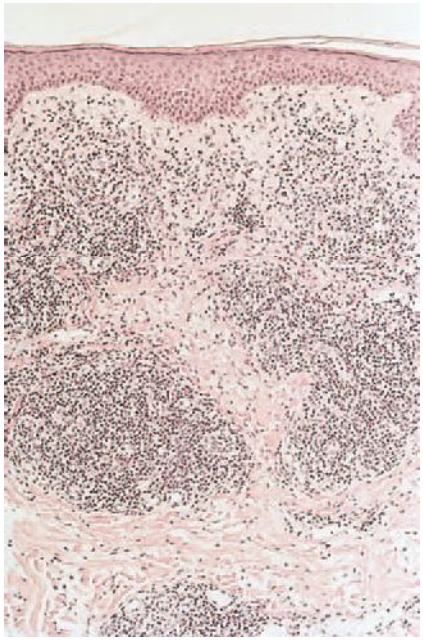

▲ **FIGURE 147-6** Cutaneous lymphoid hyperplasia. Nodular scabies. Patchy dense infiltrate composed of small lymphocytes, histiocytes, eosinophils, and plasma cells.

reactions. The dermal infiltrate is composed primarily of small mature lymphocytes, with a minor component of large lymphoid cells containing large, pale vesicular nuclei with small nucleoli (Fig. 147-7). Fewer than half of cases exhibit well-defined reactive lymphoid follicles discernible in routinely stained sections (see Figs. 147-5 and 147-8). These B-cell follicles may be either primary or secondary. The former are composed of homogeneous small lymphocytes, whereas the latter are compartmentalized into a peripheral mantle zone of small lymphocytes surrounding a germinal center composed of a heterogeneous mixture of small and large lymphoid cells with cleaved and noncleaved nuclei known as *centrocytes* and *centroblasts*. Also present in germinal centers are tingible-body macrophages, so named because they contain phagocytized debris from apoptotic lymphoid cells. Mitotic figures may be numerous within germinal centers but are usually uncommon elsewhere in the infiltrate. Various types of histiocytes, including macrophages, dermal dendritic cells, and Langerhans cells, are scattered throughout the infiltrate in variable proportions. Capillary hyperplasia and endothelial swelling are often present. Other cells are sometimes admixed, including plasma cells, eosinophils, mast cells, neutrophils, and histiocytic giant cells. The first two are particularly common in arthropod-induced reactions such as nodular scabies (see Fig. 147-6).[11,12]

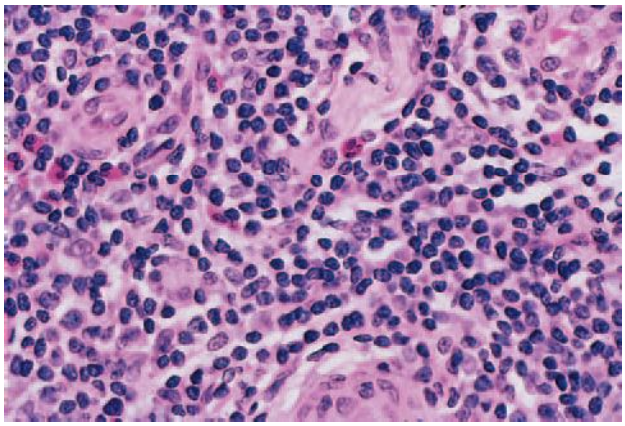

▲ **FIGURE 147-7** Cutaneous lymphoid hyperplasia. Infiltrate consists predominantly of small lymphocytes with an admixture of large lymphoid cells, histiocytes, and eosinophils.

In the less common T-cell CLH, there are only rare B cells.[1–3,15–17] Lesions may be idiopathic or secondary to drugs or arthropod bites. Sparse to moderate epidermotropism by atypical lymphoid cells may be seen. The dermal infiltrate has a nodular or diffuse pattern and may contain cerebriform cells, immunoblasts, and histiocytes mixed with a preponderance of small mature lymphocytes. The histiocytes are sometimes numerous enough to impart a vaguely granulomatous appearance.[17] The author has seen one such case presenting as multiple nodules on the trunk and extremities that was associated with rheumatoid arthritis and eventuated in T-cell lymphoma.

SPECIAL TESTS CLH is just one special case of extra-nodal lymphoid hyperplasia that may occur in a variety of organ systems. In their most well-developed form, these extra-nodal reactions re-create the immunoarchitectural features of reactive follicular lymphoid hyperplasia occurring in lymphoid tissues. CLH is generally a mixed B-cell/T-cell disorder. B cells may be organized into primary or secondary lymphoid follicles, simple clusters devoid of the follicular dendritic cell network seen in B-cell follicles, or may be randomly scattered throughout the infiltrate (Fig. 147-9).[5] A defining immunophenotypic feature of CLH is that the small, non–germinal center B cells and plasma cells are polytypic; that is, instead of restriction to only one type of immunoglobulin light chain, there is a mixture of κ-positive and λ-positive cells.[18–20] The follicular dendritic cell networks in lymphoid follicles co-express both immunoglobulin light chains because of the polytypic nature of the immunoglobulins bound to these networks (Fig. 147-10). The larger germinal center B cells are also polytypic but generally have very low levels of immunoglobulin expression, which is obscured by the more intense staining of the follicular dendritic cell networks in which they are enmeshed.[21] Consistent with their role as a site of antigen selection and apoptosis, reactive germinal centers test negative for the bcl-2 oncoprotein.[1]

Some researchers classify CLH into follicular and diffuse variants based on

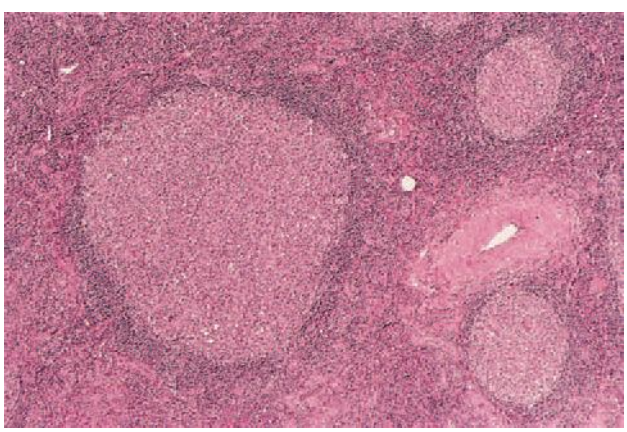

▲ **FIGURE 147-8** Cutaneous lymphoid hyperplasia. Lymphoid follicles in the dermis contain pale germinal centers surrounded by darker mantle zones.



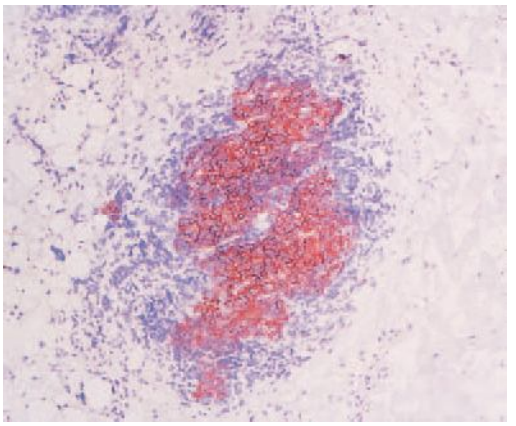

◀ **FIGURE 147-9** Cutaneous lymphoid hyperplasia. Reactive lymphoid follicle contains B cells (*blue*) enmeshed in a network of follicular dendritic cells (*red*). Frozen section immunoperoxidase-stained using the anti–dendritic reticulum cell monoclonal antibody.



the identification of lymphoid follicles in routinely stained sections. This distinction is probably not relevant biologically, because most of the apparently diffuse cases also exhibit B-cell follicles when examined immunohistologically. T cells are also present in all cases of CLH. They are found in small numbers within lymphoid follicles but are concentrated mainly between follicles, constituting an interfollicular T-cell domain. This imparts an overall compartmentalization of B and T cells in CLH lesions. The $CD4^+$ T-cell subset predominates over the $CD8^+$ subset. There is a normal pattern of T-cell antigen expression except that CD7 may be moderately deficient at times, being expressed by only 20 percent to 40 percent of T cells. Germinal center B cells, mantle zone B cells, interfollicular B cells, and plasma cells also express the same complement of cell surface differentiation antigens expressed by their counterparts in reactive lymphoid tissues.

Unlike in most nodal follicular B-cell lymphomas (Chap. 146), the t(14;18) translocation, which results in inappropriate expression of the bcl-2 oncoprotein, is absent in CLH.[1,22–24] Molecular biologic studies show that 5 percent to 33 percent of CLH cases defined by clinicopathologic and immunohistologic criteria contain occult dominant immunoglobulin gene rearrangements, which indicate the presence of a dominant B-cell clone.[1,25–29] These cases, known as *clonal CLH*, have progressed in some cases to overt B-cell lymphoma exhibiting the same dominant B-cell clone. These findings support the view that CLH, clonal CLH, and primary CBCL exist as points along a continuum of cutaneous B-cell lymphoproliferative disorders. Progression across this spectrum of disease clearly occurs in some cases, most likely as the result of serial mutations within the dominant B-cell clone. This implies that patients with persistent CLH require regular monitoring for the development of lymphoma.[19] Clonal T-cell receptor gene rearrangements have also been detected in up to one-third of CLH cases.[29,30] This may represent an expanded reactive T-cell clone within the CLH infiltrate. Evidence for this has been observed in CLH related to human immunodeficiency virus infection.[31] Other less likely possibilities include an abortive T-cell lymphoma or an evolving B-cell lymphoma bearing T-cell receptor gene rearrangements.

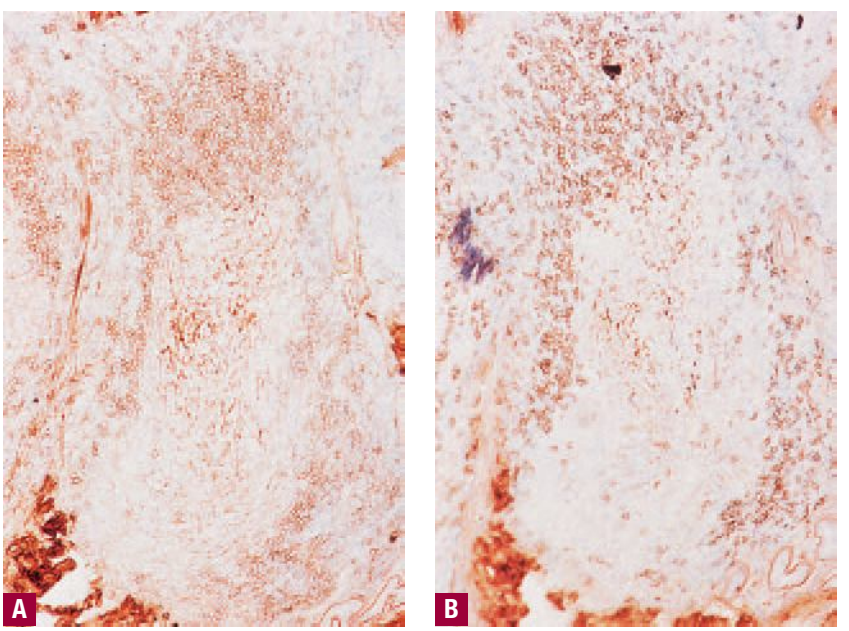

▲ **FIGURE 147-10** Cutaneous lymphoid hyperplasia. Reactive lymphoid follicle contains a germinal center surrounded by a mantle zone composed of a mixture of B cells that express either κ-immunoglobulin light chain (**A**) or λ-immunoglobulin light chain (**B**). Note that the central follicular dendritic cell network stains positive for both light chains because polytypic immunoglobulins are bound to its surface.

Differential Diagnosis

The differential diagnosis of CLH includes all of the conditions listed in Box 147-1. Many of these entities, such as granuloma faciale, Merkel cell tumor, histiocytomas, granulomas, and metastatic carcinoma, are readily distinguished from CLH by their histopathologic features.

A principal challenge in the differential diagnosis of CLH is its distinction from CBCL of either the diffuse or follicular types (see Chap. 146).[1–3,22,32] The most common variant of CBCL is diffuse large cell lymphoma, which is readily distinguished from follicular CLH on the basis of its diffuse architec-

Box 147-1

Differential Diagnosis of Cutaneous Lymphoid Hyperplasia

Most Likely

- Chronic cutaneous lupus erythematosus
- Jessner's lymphocytic infiltration of the skin
- Granuloma faciale

Consider

- Polymorphous light eruption
- Drug eruption
- Angiolymphoid hyperplasia with eosinophilia
- Deep figurate erythemas
- Metastatic carcinoma
- Merkel cell carcinoma
- Secondary syphilis
- Histiocytomas
- Infectious and inflammatory granulomas

Always Rule Out

- Cutaneous B-cell lymphoma
- Leukemia cutis

ture and monomorphous large cell composition. Differentiating follicular CLH from follicular CBCL can be difficult. Follicular CBCL tends to be more bottom heavy with adnexal infiltration and lymphoid follicles lacking the cellular heterogeneity, zonation, and macrophages typical of reactive follicles. Immunophenotyping shows that neoplastic B-cell follicles are either monotypic or immunoglobulin negative.[15–17] Cases involving cutaneous lymphoid infiltrates that are hard to classify or that contain a dominant lymphoid clone often benefit from a staging workup as described in the section Approach to the Patient. In those instances representing lymphoma, workup will sometimes reveal extracutaneous involvement, and biopsy specimens from these lesions may be easier to diagnose as lymphoma. Staging also provides useful prognostic data and is essential for appropriate management of patients with overt lymphoma.

CLH must also be distinguished from other disorders with lymphocytic infiltrates such as chronic lymphocytic leukemia, deep figurate erythemas, polymorphous light eruption, discoid lupus erythematosus, and Jessner's lymphocytic infiltration of the skin. All of these disorders tend to produce perivascular, and sometimes periadnexal, infiltrates whose density is far lower than that of the nodular or diffuse infiltrates typical of CLH. With the exception of chronic lymphocytic leukemia, these are all T-cell disorders. Chronic lymphocytic leukemia is a B-cell disorder that exhibits monotypic immunoglobulin and CD5 expression and involves the blood and bone marrow. CLH lesions rich in plasma cells must be distinguished from the lesions of secondary syphilis, plasmacytoma, myeloma, and immunocytoma. The infiltrate in secondary syphilis is generally richer in plasma cells or histiocytes than in small lymphocytes and is associated with epidermal hyperplasia, an interface inflammatory component, and positive results on serologic tests. The plasma cells in plasmacytoma and myeloma are monotypic and tend to exhibit mitotic figures, atypia, immaturity, and multinucleated forms. Monotypic immunoglobulin is also present in the tumor cells of primary cutaneous immunocytoma. This B-cell neoplasm is also known as *marginal zone lymphoma, mucosa-associated lymphoid tissue (MALT)–type lymphoma,* and *low-grade skin-associated lymphoid tissue (SALT) B-cell lymphoma*.[1,22,33] It is composed of varying proportions of small lymphocytes, plasmacytoid lymphocytes, plasma cells, and marginal zone–like B cells. The latter have monocytoid features with a halo of cytoplasm visible around their nuclei. These cells often surround clusters of small lymphocytes, imparting a "reverse reactive follicle" appearance with smaller cells centrally and the larger monocytoid cells peripherally.

It should be noted that typical reactive lymphoid follicles with germinal centers are not specific for CLH. They can be seen in some lymphomas (e.g., marginal zone lymphoma), Kimura disease, angiolymphoid hyperplasia with eosinophilia, Castleman disease, inflammatory pseudotumor of the skin, and morphea and as part of the host response to tumors such as basal cell carcinoma. The broad histopathologic differential diagnosis of CLH also includes histiocytoses, especially Rosai-Dorfman disease (sinus histiocytosis with massive lymphadenopathy; see Chap. 149), as well as so-called *small round cell tumors* such as Merkel cell carcinoma (see Chap. 120), oat cell carcinoma, neuroblastoma, and Ewing sarcoma.

Differentiation between T-cell CLH and T-cell lymphomas relies on the fact that most cases of mycosis fungoides exhibit marked epidermotropism, and most non–mycosis fungoides cutaneous T-cell lymphomas are either diffuse large cell or mixed cell types, although a pleomorphic small cell type occurs rarely. Many T-cell lymphomas show loss of one or more T-cell antigens, and most have monoclonal T-cell receptor gene rearrangements. Progression to T-cell lymphoma has been reported in occasional patients with T-cell CLH.[15,16]

Complications

One of the most challenging issues concerning cutaneous pseudolymphomas has been the nature of their relationship to true lymphomas. Many patients with CBCL have a history of prior diagnosis of biopsy specimens as CLH or atypical CLH. Patients with disorders such as lymphomatoid papulosis, lymphomatoid granulomatosis, and angioimmunoblastic lymphadenopathy with dysproteinemia have an increased risk of developing various forms of overt lymphoma.[1,2,22,33] The advent of molecular biologic methods for determining B-cell or T-cell clonality by analyzing immunoglobulin or T-cell receptor gene rearrangements, respectively, has provided important insights into the relationship between pseudolymphomas and lymphomas.[1,2,22] It appears that many forms of cutaneous pseudolymphoma represent the benign end of a lymphoproliferative continuum eventuating in true lymphoma at its malignant extreme. In between lies a spectrum of intermediate disorders that are often difficult to classify unless one conceptualizes the disorders along such a continuum. In some cases, such as the CLH-CBCL spectrum, lesions range from polyclonal CLH at the benign extreme, through an intermediate form known as clonal CLH, to overt CBCL at the malignant extreme. In other instances, such as the lymphomatoid papulosis–CD30$^+$ lymphoma spectrum, dominant clonality is already present in most cases at the clinically benign end of the spectrum. The most compelling evidence for the validity of this concept of a continuum is that case studies verify that the same dominant lymphoid clone is involved in the clonal pseudolymphomatous precursor and the subsequent overt lymphoma when they arise in the same individual. This relationship between overt neoplasia and clonal precursor lesions is not unique to cutaneous pseudolymphomas. It is also seen in the connection between other forms of extra-nodal lymphoid hyperplasia and overt lymphoma and in the relationship between monoclonal gammopathy of uncertain significance (formerly termed *benign monoclonal gammopathy*) and subsequent B-cell malignancies.

The concept of a spectrum for cutaneous pseudolymphomas and associated lymphomas has several important implications for the diagnosis, management, and pathogenesis of these disorders. First, because some cases will exhibit lesions at an intermediate point along the lymphoproliferative continuum, they may be difficult to classify neatly into a specific disease entity. It is probably more important to recognize that they belong to a particular disease spectrum, because it is the spectrum that is often the most relevant factor for determining optimal therapy as well as the magnitude and nature of the subsequent lymphoma risk. Second, because many patients with cutaneous pseudolymphomas are at increased risk for a clonally related lymphoma, they should have regular clinical follow-up, and all reasonable attempts should be made to eradicate or suppress their disease. Third, patients with pseudolymphomas probably have underlying abnormalities in the regulation of lymphoid proliferation and/or clearance (e.g., via apoptosis). Clonal evolution and concomitant clinical disease progression are likely to occur through a sequence of somatic mutations that act through these mechanisms to confer progressively increasing autonomy to the



dominant lymphoid clone. Elucidating these pathogenetic mechanisms will be important not only for developing novel therapies for cutaneous pseudolymphomas but also for improving the treatment of analogous lymphoproliferative disorders occurring in other organ systems.

Prognosis and Clinical Course

CLH lesions may resolve spontaneously or persist indefinitely. Nodular scabies (see Figs. 147-3 and 147-6) is a well-recognized form of persistent CLH. Solitary lesions sometimes regress after biopsy or may be eradicated by excision. Those lesions that are secondary to drug use usually regress when the offending agent is withdrawn.

Treatment

CLH related to infection with *B. burgdorferi* (lymphocytoma cutis; see Chap. 187) responds to antibiotic therapy with cephalosporins, as do some cases of idiopathic CLH. Glucocorticoids (topical, intralesional, systemic), cryotherapy, antimalarials, minocycline, and radiation therapy have all been used with variable success (Box 147-2). The latter is particularly effective but is usually regarded as a treatment of last resort. Laser therapy and photodynamic therapy have also been beneficial in some cases.[35,36] Local or distant recurrence can arise after any of these treatments. Cases of atypical CLH that cannot be distinguished from lymphoma are usually treated as localized lymphoma after staging rules out extra-cutaneous disease. Treatment typically involves local radiation therapy, which may be preceded by excision of the lesion.

Box 147-2

Treatment of Cutaneous Lymphoid Hyperplasia

FIRST LINE

- Excision
- Topical corticosteroids (mid to high potency twice daily)
- Intralesional corticosteroids (5–40 mg/mL, 1 mL monthly)
- Systemic antibiotics (e.g., minocycline 50–100 mg PO twice daily; cephalexin 500 mg PO twice daily)
- Topical tacrolimus[34]

SECOND LINE

- Cryotherapy
- δ-Aminolevulinic acid photodynamic therapy
- Laser therapy (e.g., pulsed dye laser)
- Hydroxychloroquine (200 mg PO twice daily)
- Systemic corticosteroids (60/40/20 mg PO taper, 5 days each)
- Local radiation therapy

Prevention

The principal preventive strategy is to avoid contact with, or ingestion of, agents known to induce CLH in those patients with a relevant clinical history. Examples include anticonvulsant medications, arthropods, gold jewelry, and hair dyes.[37–41]

KIMURA DISEASE AND ANGIOLYMPHOID HYPERPLASIA WITH EOSINOPHILIA

Epidemiology

The skin lesions of Kimura disease and angiolymphoid hyperplasia with eosinophilia (AHLE) most commonly affect young to middle-aged adults. Kimura disease is more common in Asian men, whereas AHLE is more common in women.[42,43]

Etiology and Pathogenesis

It is possible that Kimura disease represents a florid, subcutaneously deep-seated form of the same basic pathogenetic process that gives rise to classic dermal CLH. There is controversy regarding whether Kimura disease and ALHE are variants of the same disorder, although most favor the concept that they are distinct clinicopathologic entities despite some clinicopathologic overlap.[44–46] The terms *epithelioid hemangioma* and *pseudopyogenic granuloma* have been used as synonyms for ALHE. Some regard ALHE essentially as a malformation of blood vessels caused by an underlying arteriovenous shunt. They consider the CLH-like aspects of the lesional infiltrate to be a secondary feature. Those who believe that ALHE should be classified as a separate disorder argue that, compared with the lesions of Kimura disease, ALHE lesions tend to be smaller (Fig. 147-11) and more superficial (centered in the dermis rather than the subcutis) and exhibit a more prominent vascular hyperplasia, characterized by small blood vessels lined by plump endothelial cells with abundant cytoplasm and sometimes atypical nuclei (see Fig. 147-11). In addition, there is often evidence of arteriovenous anastomoses, the lymphoid infiltrate is less extensive, secondary lymphoid follicles are present in only a minority of cases, and lymphadenopathy is usually absent. Patients with both AHLE and Kimura disease have been shown to harbor dominant clonal T-cell populations in some cases.

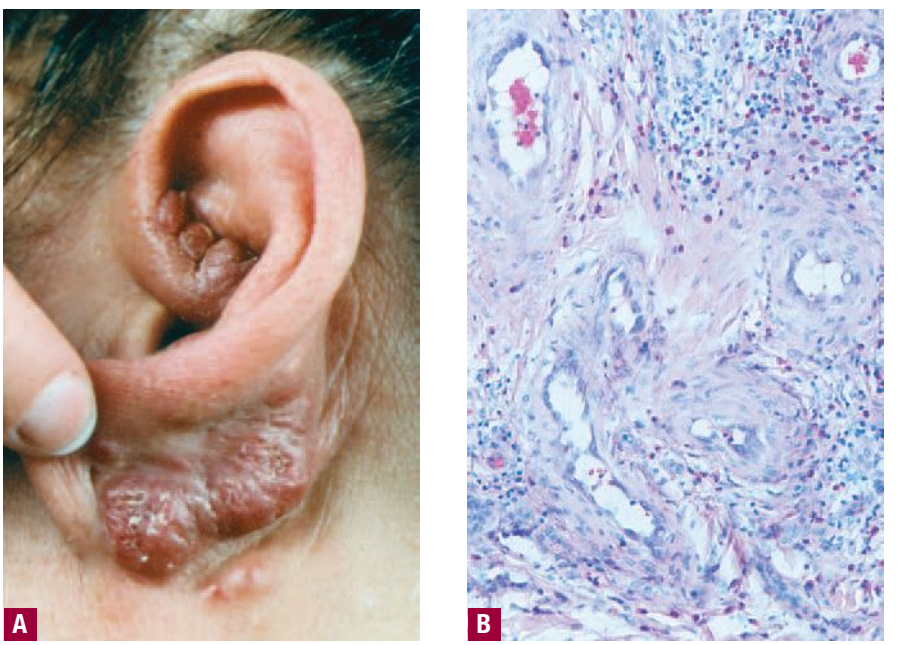

▲ **FIGURE 147-11** Angiolymphoid hyperplasia with eosinophilia. **A.** Clinically there are soft, confluent papular lesions typically located in the auricular region. **B.** Histologically blood vessels are lined by plump endothelial cells protruding into the lumen; there is vascular hyperplasia with thickened vascular walls, lymphocytic infiltrates, and prominent eosinophilia.

Clinical Findings

Kimura disease presents as solitary or multiple nodules up to 10 cm in diameter centered in the subcutis, most commonly involving the head and neck.[44–46] Peripheral eosinophilia and regional lymphadenopathy are characteristic. AHLE tends to present with multiple smaller, more superficial intradermal papulonodules that are typically unilateral. Salivary glands, lymph nodes, and other cutaneous sites can also be affected in either disorder, although such locations are more typical of Kimura disease.

Histopathologically, the dermis and/or subcutis exhibit hyperplasia of small blood vessels lined by plump endothelial cells similar to those present in the high endothelial venules of lymphoid tissues. These venules are a major point of lymphocyte trafficking between the blood and the paracortical T-cell domain of lymph nodes. Surrounding these hyperplastic vessels is a dense infiltrate composed of small lymphocytes, plasma cells, histiocytes, and eosinophils. The latter are typically prominent but may be absent in some cases. There are usually multiple secondary lymphoid follicles with prominent germinal centers, particularly in the subcutaneous lesions. In general, lesions are more superficial and the vascular features are more prominent in AHLE, whereas lesions are deeper and the lymphoid features are more prominent in Kimura disease.[42,43,47]

Differential Diagnosis

Kimura disease, which generally forms deeper, larger lesions, needs to be distinguished from CBCL, sinus histiocytosis with massive lymphadenopathy, soft tissue tumors, and subcutaneous deposits of metastatic carcinoma (Box 147-3). AHLE, which has smaller, more superficial lesions, should be differentiated from CLH, CBCL, hemangioma, angiosarcoma, pyogenic granuloma, nodular Kaposi sarcoma, bacillary angiomatosis, and bartonellosis. Many of these entities have distinctive histopathologic features. The distinguishing features of CLH and CBCL have been discussed earlier (see Differential Diagnosis under Cutaneous Lymphoid Hyperplasia).

Complications

Kimura disease has been associated with lichen amyloidosis and renal disorders such as nephrotic syndrome.[48]

Box 147-3

Differential Diagnosis of Kimura Disease and Angiolymphoid Hyperplasia (AHLE)

Most Likely

- Cutaneous lymphoid hyperplasia (both)
- Sinus histiocytosis with massive lymphadenopathy (both)
- Pyogenic granuloma (AHLE)
- Hemangioma (AHLE)

Consider

- Soft tissue tumors (both)
- Angiosarcoma (AHLE)
- Kaposi sarcoma (AHLE)
- Bacillary angiomatosis (AHLE)
- Bartonellosis (AHLE)

Always Rule Out

- Cutaneous B-cell lymphoma and other lymphomas (both)
- Metastatic carcinoma (both)

Prognosis and Clinical Course

Some cases, such as those associated with dominant T-cell clonality, have exhibited a chronic clinical course marked by multiple recurrences and resistance to treatment.

Treatment

The treatment of Kimura disease and AHLE is not well established because of the rarity of the disorders. Many approaches have been tried in only a limited number of cases. The most common and distinctive therapies are listed in Box 147-4. Topical treatments are used mainly for AHLE. Local radiation therapy has been reported to be superior to surgery and corticosteroids for treatment of Kimura disease.[43,48–50]

Box 147-4

Treatment of Kimura Disease and Angiolymphoid Hyperplasia (AHLE)

FIRST LINE

- Excision
- Topical corticosteroids (high potency twice daily)
- Intralesional corticosteroids (5–40 mg/mL, 1 mL monthly)

SECOND LINE

- Topical tacrolimus ointment (twice daily)
- Systemic corticosteroids (60/40/20 mg PO taper, 5 days each)
- Cyclosporine [microemulsion (Neoral) 2.5–4 mg/kg/day total dose divided into twice daily PO doses; use the minimum]
- Local radiation therapy
- Vinblastine (15 mg/wk IV; one report of extensive AHLE lesions treated successfully)

CASTLEMAN DISEASE

Epidemiology

Castleman disease is also known as *angiofollicular lymphoid hyperplasia* or *giant lymph node hyperplasia*.[51–54] The hyaline vascular variant is more common in younger patients, whereas the plasma cell variant tends to occur in older individuals.

Etiology and Pathogenesis

Castleman disease is a polyclonal lymphoproliferative disorder of undetermined etiology. Studies of multicentric Castleman disease demonstrate increased levels of lesional and circulating interleukins 1β and 6, which suggests that cytokine abnormalities may mediate the systemic manifestations of POEMS syndrome (*p*olyneuropathy, *o*rganomegaly, *e*ndocrinopathy, *M* protein, and *s*kin changes).[55,56] Castleman disease occurring in the setting of human immunodeficiency virus infection is associated with human herpesvirus type 8,[57,58] which has also been detected in Kaposi sarcoma (see Chap. 128) and primary effusion lymphomas.

Clinical Findings

CUTANEOUS LESIONS Castleman disease most often presents as an isolated mediastinal mass, although a multicentric form of the disease also exists. Lesions can be nodal and/or extra-nodal. Rarely, it may present as solitary or multiple, subcutaneous or cutaneous tumors in various locations.

RELATED PHYSICAL FINDINGS The plasma cell variant can be associated with polyneuropathy, organomegaly, endocrinopathy, the presence of M protein, hyperpigmentation, and hypertrichosis (POEMS syndrome).[55,59]

Laboratory Tests

Three histopathologic variants of Castleman disease exist. The more common hyaline vascular variant exhibits small, concentrically whorled, lymphoid follicles surrounded by small lymphocytes arranged in a concentric, onion-skin pattern. An extensive proliferation of capillaries is present between folli-



cles. The rarer plasma cell variant exhibits large, hyperplastic secondary lymphoid follicles associated with a highly vascular interfollicular zone rich in plasma cells. An intermediate form has also been reported.

Differential Diagnosis

The differential diagnosis of cutaneous and subcutaneous Castleman disease includes eosinophil-poor ALHE, Kimura disease, plasmacytoma, myeloma, sinus histiocytosis with massive lymphadenopathy, CLH, angioimmunoblastic T-cell lymphoma, and follicular types of CBCL (Box 147-5). All of these diseases lack the characteristic features of the lymphoid follicles seen in the two histopathologic variants of Castleman disease. These disorders also lack prominent vascular hyperplasia except for ALHE and Kimura disease, whose characteristic endothelial cells aid in their recognition, and angioimmunoblastic T-cell lymphoma, which contains large clonal atypical T cells. Plasmacytoma and myeloma contain dense sheets of atypical plasma cells and differ in their associated clinical findings. CLH is usually centered in the dermis rather than the subcutis. Most cutaneous lymphomas have a diffuse, monomorphous appearance. The rare follicular types of CBCL have distinctive features, as summarized earlier in Differential Diagnosis under Cutaneous Lymphoid Hyperplasia. Sinus histiocytosis with massive lymphadenopathy is rich in S100$^+$ histiocytes that exhibit emperipolesis (intact lymphocytes within their cytoplasm).

Complications

Castleman disease has been associated with paraneoplastic pemphigus, plane xanthomas, vasculitis, and peliosis hepatis.[60,61] Lymphomas and follicular dendritic cell sarcomas can develop in the setting of Castleman disease.

Prognosis and Clinical Course

The clinical course is usually favorable for patients with localized and extranodal lesions.

Treatment

Surgical excision is effective therapy for localized Castleman disease. Radiation and chemotherapy have been used to treat multicentric variants (Box 147-6).[62,63]

Box 147-5

Differential Diagnosis of Castleman Disease

Most Likely
- Cutaneous lymphoid hyperplasia

Consider
- Angiolymphoid hyperplasia with eosinophilia
- Kimura disease
- Plasmacytoma
- Sinus histiocytosis with massive lymphadenopathy

Always Rule Out
- Cutaneous B-cell lymphoma
- Myeloma
- Non–mycosis fungoides cutaneous T-cell lymphoma

Box 147-6

Treatment of Castleman Disease

FIRST LINE
- Excision

SECOND LINE
- Radiation therapy
- Chemotherapy

PSEUDO–MYCOSIS FUNGOIDES

Epidemiology

Eruptions mimicking mycosis fungoides occur typically in adults. Both genders can be affected.

Etiology and Pathogenesis

Pseudo–T-cell lymphomas with a band-like or mycosis fungoides–like histopathologic pattern may arise spontaneously or may occur as a T-cell infiltrate co-existing with B-cell chronic lymphocytic leukemia, as a rare variant of the eruption of lymphocyte recovery (which occurs in the setting of leukocyte reconstitution after iatrogenic marrow aplasia), or in association with ingestion of various drugs, including hydantoins, carbamazepine, propylvalerate, imatinib mesylate, and dexchlorpheniramine maleate and other antihistamines.[1–3,9,44,64,65]

Clinical Findings

HISTORY There may be a history of an associated disease or medication. Lesions may be pruritic or asymptomatic.

CUTANEOUS LESIONS The lesions present clinically as one or a few plaques on the trunk or extremities. Occasionally, several plaques or a Sézary-like syndrome develops.

Laboratory Tests

Histopathologically, there is a papillary dermal, band-like infiltrate containing mostly small and medium-sized atypical lymphocytes with clefted and cerebriform nuclei. Moderate numbers of histiocytes are admixed, but eosinophils and plasma cells are rare. The dermal-epidermal junction is obscured, and there is no grenz zone. The overlying epidermis may be hyperplastic and/or may contain a sparse to moderate atypical lymphoid infiltrate; however, compared with mycosis fungoides, epidermotropism is typically far less prominent and Pautrier's microabscess–like cell aggregates are rare. Most cases contain polyclonal T cells, although occasional cases exhibit dominant T-cell clonality.[64,66]

Differential Diagnosis

The differentiation of these pseudolymphomas from mycosis fungoides is aided by their tendency toward minimal epidermotropism in many cases, the small number of lesions, their tendency to be polyclonal, and their resolution after discontinuation of an inducing drug and/or local therapy.

Lichenoid drug eruptions caused by agents such as gold, thiazides, and antimalarials may also bear a histopathologic resemblance to atrophic forms of large plaque parapsoriasis and overt mycosis fungoides when they result in a band-like dermal lymphoid infiltrate that involves an atrophic epidermis. As in mycosis fungoides, eosinophils and plasma cells may also be present. However, these lesions lack lymphoid atypia, exhibit the clinical features of typical lichenoid drug rashes, and regress eventually after discontinuation of the causative agent. Poikilodermatous skin lesions of collagen vascular diseases and genodermatoses are distinguished from mycosis fungoides by their associated clinical and laboratory findings; by sparser infiltrates lacking atypia; and, for collagen vascular diseases, by dermal mucin, thickened epidermal basement membranes, and characteristic epidermal alterations. Chronic radiodermatitis may resemble poikilodermatous mycosis fungoides clinically but is distinguished by clinical history, sparse infiltrate, keratinocyte atypia, dermal fibrosis, and loss of adnexa.



Some cases of secondary syphilis may also mimic mycosis fungoides, showing a dense, band-like, upper dermal infiltrate that obscures the dermal-epidermal junction and invades a nonspongiotic epidermis. However, the infiltrate contains more plasma cells and fewer lymphocytes than expected in mycosis fungoides; there is no lymphoid atypia; there may be neutrophils in the epidermis; and there is a deep perivascular extension of the infiltrate that is unusual in mycosis fungoides except in the tumor phase. Furthermore, the patient's history, the clinical appearance of the lesions, serologic testing, and response to antibiotic therapy will facilitate the correct diagnosis (Box 147-7).

Three other disorders that may mimic mycosis fungoides/Sézary syndrome clinically and/or pathologically are follicular mucinosis, lymphomatoid contact dermatitis, and actinic reticuloid. Because of their distinctive features, each is discussed separately in this text.

Complications

Severe pseudo–mycosis fungoides eruptions such as erythrodermas may be associated with serious complications common to other forms of generalized exfoliative dermatitis, including local skin infection, sepsis, disrupted barrier function, and cardiovascular imbalance.

Box 147-7

Differential Diagnosis of Pseudo–Mycosis Fungoides

Most Likely
- Lichenoid drug eruption
- Psoriasis
- Tinea corporis

Consider
- Dermatomyositis
- Subacute cutaneous lupus erythematosus
- Pityriasis rubra pilaris
- Secondary syphilis
- Chronic radiodermatitis
- Genodermatoses with poikiloderma
- Alopecia mucinosa
- Actinic reticuloid
- Non–cutaneous T-cell lymphoma erythrodermas

Always Rule Out
- Mycosis fungoides
- Large plaque parapsoriasis
- Associated drug ingestion
- Associated iatrogenic marrow aplasia
- Associated B-cell chronic lymphocytic leukemia

Box 147-8

Treatment of Pseudo–Mycosis Fungoides

FIRST LINE
- Drug discontinuation (when drug induced)
- Treatment of underlying disorder (when associated with a specific disease)
- Topical corticosteroids
- Ultraviolet B and narrowband ultraviolet B phototherapy
- Psoralen plus ultraviolet A phototherapy

SECOND LINE
- Systemic corticosteroids (60/40/20 mg PO taper, 5 days each)

Prognosis and Clinical Course

Prognosis depends heavily on the clinical context and the ability to remedy the underlying cause of the pseudo–mycosis fungoides lesions. If this can be accomplished, then the lesions generally regress, although lichenoid infiltrates may require many months to resolve.

Treatment

When the disorder is drug induced, identification and withdrawal of the offending agent is the principal therapy (Box 147-8). Corticosteroids (topical or systemic) and various forms of phototherapy may also be beneficial in hastening the resolution of skin lesions. Excision can be effective for isolated or sparse lesions. When pseudo–mycosis fungoides is associated with a specific disease, treatment should be directed at that underlying disorder.

Prevention

Strategies for prevention are similar to those described for treatment.

LYMPHOMATOID CONTACT DERMATITIS

Epidemiology

Lymphomatoid contact dermatitis has been observed in adults of both genders.

Etiology and Pathogenesis

Lymphomatoid contact dermatitis was described originally in four patients with persistent allergic contact dermatitis proven by patch testing.[67] Responsible allergens include gold, nickel, and para-phenylenediamine.[68–72] The clinical and histopathologic changes in the lesions are said to resemble those of mycosis fungoides.

Clinical Findings

HISTORY Skin lesions are generally pruritic. Patients may be aware of the offending contact allergen.

CUTANEOUS LESIONS Clinically, lymphomatoid contact dermatitis is characterized by generalized red, scaly papules and plaques that may become confluent (Fig. 147-12) with resultant exfoliative erythroderma.

Laboratory Tests

Results of patch tests for a variety of common allergens, such as ethylenediamine dihydrochloride, may be positive.

Histopathologically, lymphomatoid contact dermatitis exhibits a superficial lymphocytic dermatitis that contains foci of spongiosis simulating the appearance of cutaneous T-cell lymphomas. It must be differentiated from mycosis fungoides (Fig. 147-13), usually on the basis of changes within the epidermis;



▲ **FIGURE 147-12** Lymphomatoid contact dermatitis. Erythematous papules and plaques on the forehead. Patch test with local anesthetics gave positive results.



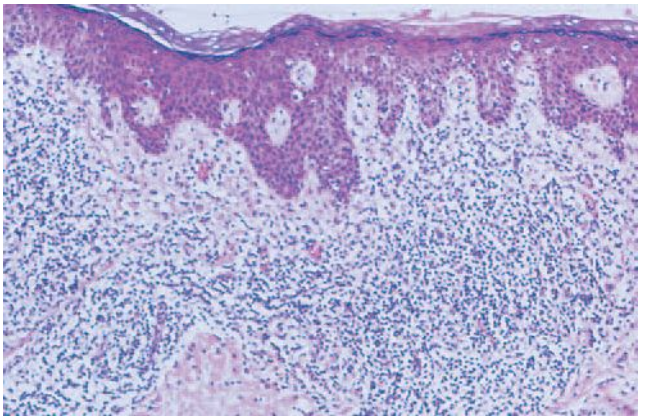

▲ **FIGURE 147-13** Lymphomatoid contact dermatitis. Dense band-like infiltrate in the upper part of the dermis and spongiotic foci in the epidermis ("spongiotic simulator" of mycosis fungoides).



specifically, in mycosis fungoides more atypical lymphocytes have a tendency to form Pautrier's microabscesses. Frequently there is edema in the papillary dermis in lymphomatoid contact dermatitis, a finding that is usually absent in mycosis fungoides. Immunohistopathologic investigations indicate that lymphomatoid contact dermatitis represents a T-cell pseudolymphoma. Examination of the cells in the infiltrate by electron microscopy reveals many atypical lymphocytes with cerebriform nuclei like those in mycosis fungoides.

Differential Diagnosis

Concern for mycosis fungoides is based mainly on the histopathologic features of the lesions. Recognition of the contact allergen is central to the correct diagnosis, aided by the microscopic distinctions noted in the preceding section. Other causes of spongiotic dermatitis and, in severe cases, erythroderma should also be considered (Box 147-9).

Box 147-9

Differential Diagnosis of Lymphomatoid Contact Dermatitis

Most Likely
- Conventional allergic contact dermatitis
- Irritant contact dermatitis

Consider
- Drug eruption
- Psoriasis
- Tinea corporis
- Non–cutaneous T-cell lymphoma erythrodermas (when extensive)

Always Rule Out
- Mycosis fungoides and Sézary syndrome
- Large plaque parapsoriasis

Complications

Although in rare cases lymphomatoid contact dermatitis has been reported to evolve into lymphoma, it is more likely that those patients had lymphoma from the outset.

Prognosis and Clinical Course

Avoidance of the responsible allergens leads to eventual resolution of the condition.

Treatment

A thorough search for the offending antigen by way of patch testing is necessary if the process of lymphomatoid contact dermatitis is to be interrupted. Topical application of glucocorticoids is beneficial (Box 147-10).

Prevention

The only relevant preventive measure for lymphomatoid contact dermatitis is avoidance of known causes.[67,73–77]

LYMPHOCYTIC INFILTRATION OF THE SKIN

Epidemiology

The vast majority of cases of lymphocytic infiltration of the skin (LIS) occur in middle-aged adults, with a roughly equal gender ratio. Children have been affected rarely. There is also a rare familial variant.[78]

Etiology and Pathogenesis

The etiology of LIS is unknown. Some regard it as a distinct disease, whereas others consider it to be a variant of lupus erythematosus or, less commonly, polymorphous light eruption, CLH, or lymphocytic lymphoma. Photo-exacerbation occurs in a minority of patients according to some observers. Immunologic investigations have shown decreased natural killer cell function as well as elevation in circulating immune complexes, the levels of which were reported to parallel disease activity.[79] Skin lesions known as *arcuate dermal erythema* may arise in female carriers of chronic granulomatous disease. These lesions resemble LIS clinically and microscopically.

Box 147-10

Treatment of Lymphomatoid Contact Dermatitis

FIRST LINE
- Elimination of responsible allergen
- Topical corticosteroids

SECOND LINE
- Topical tacrolimus or pimecrolimus

Clinical Findings

HISTORY Skin lesions are typically asymptomatic.

CUTANEOUS LESIONS LIS, which was first described by Jessner and Kanof,[80] presents as one or more erythematous plaques or nodules, generally localized to only one or a few sites on the face, neck, upper trunk, or arms.[81,82] Pustules, pruritus, and epidermal alterations are absent. In contrast to discoid lupus lesions, LIS lesions show no epidermal atrophy or follicular plugging.

Laboratory Tests

Histopathologic examination reveals a superficial and deep, perivascular and variably periadnexal infiltrate of small mature lymphocytes, often with a minor admixture of histiocytes, plasmacytoid monocytes, and plasma cells. Lymphoid follicles and eosinophils are absent. The epidermis is unremarkable. Results of direct immunofluorescence studies are negative or non-specific. Immunohistologic studies have demonstrated a predominantly HLA–DR$^-$ Leu-8$^+$ T-cell infiltrate with some B cells and histiocytes admixed. In contrast, most of the T cells in discoid lupus are HLA-DR$^+$ Leu-8$^-$.[83–85] Immunopathologic studies have shown a predominance of CD8$^+$ T cells within lesional infiltrates.

Box 147-11

Differential Diagnosis of Lymphocytic Infiltration of the Skin

Most Likely

- Chronic cutaneous lupus erythematosus
- Cutaneous lymphoid hyperplasia
- Polymorphous light eruption

Consider

- Granuloma faciale
- Infectious and inflammatory granulomas
- Erythema chronicum migrans
- Other deep figurate erythemas
- Reticular erythematous mucinosis

Always Rule Out

- Cutaneous B-cell lymphoma
- Leukemia cutis (especially B-cell chronic lymphocytic leukemia)

Box 147-12

Treatment of Lymphocytic Infiltration of the Skin

FIRST LINE

- Topical corticosteroids
- Topical tacrolimus and pimecrolimus
- Photoprotection (if historically relevant)
- Intralesional corticosteroids (5–40 mg/mL, 1 mL monthly)

SECOND LINE

- Hydroxychloroquine (100–200 mg PO twice daily)
- Systemic corticosteroids (60/40/20 mg PO daily taper, 5 days each; if effective, then as needed)
- Auranofin (3 mg PO twice daily)
- Acitretin (25–50 mg PO daily)
- Thalidomide (100 mg PO daily)

Initial studies indicate that the infiltrate lacks dominant clonality.[1,86,87]

Differential Diagnosis

The differential diagnosis of LIS includes chronic cutaneous lupus erythematosus, polymorphous light eruption, CLH, lymphocytic lymphoma and leukemia, deep figurate erythemas such as erythema chronicum migrans, granuloma faciale, and reticular erythematous mucinosis (Box 147-11). Discoid lupus generally exhibits epidermal changes, an interface inflammatory component, and a lupus band on direct immunofluorescence. The tumid variant of discoid lupus is typified by abundant dermal mucin and subtle alterations at the dermal-epidermal interface. These changes are not seen in LIS. Antinuclear antibody panel results and erythrocyte sedimentation rate are also normal. Polymorphous light eruption exhibits papillary dermal edema, which is absent in LIS. CLH contains nodular or diffuse, dermal lymphoid infiltrates that are much denser than the predominantly perivascular infiltrate of LIS. Furthermore, LIS lacks reactive B-cell follicles. Well-differentiated or small lymphocytic lymphoma/leukemia is usually a monoclonal B-cell process, and there is a peripheral lymphocytosis in the leukemic form of the disease. These findings are absent in LIS. In erythema chronicum migrans and some cases of CLH there is serologic evidence of active infection with *B. burgdorferi*, whereas this is rarely seen in LIS. Granuloma faciale is rich in neutrophils and eosinophils that are not features of LIS. Reticulated erythematous mucinosis has a reticulated clinical appearance, favors the trunk rather than the head and neck, and shows bipolar fibroblasts. These are not features of LIS.

Complications

Post-inflammatory pigmentary alterations and corticosteroid-associated skin atrophy may complicate the clinical course of LIS, especially in cosmetically sensitive locations.

Prognosis and Clinical Course

LIS has a chronic course and may show periods of spontaneous remission and eventual resolution. Lesions may recur at their original sites or elsewhere.

Treatment

LIS may respond favorably to topical or intralesional glucocorticoids, calcineurin inhibitors, antimalarials, or thalidomide; however, a persistent, indurated variant has been described that may require systemic glucocorticoid therapy to achieve remission[88] (Box 147-12).

Prevention

Photoprotection may be helpful in those cases with a history of photoexacerbation.

KEY REFERENCES

The full reference list for all chapters is available at www.digm7.com.

1. Wood G: *The Benign and Malignant Cutaneous Lymphoproliferative Disorders Including Mycosis Fungoides*. Baltimore, Williams & Wilkins, 2001
2. Gilliam AC, Wood GS: Cutaneous lymphoid hyperplasias. *Semin Cutan Med Surg* **19**:133, 2000
3. Ploysangam T, Breneman DL, Mutasim DF: Cutaneous pseudolymphomas. *J Am Acad Dermatol* **38**:877; quiz 896, 1998
9. Magro CM, Crowson AN: Drugs with antihistaminic properties as a cause of atypical cutaneous lymphoid hyperplasia. *J Am Acad Dermatol* **32**:419, 1995
17. Rijlaarsdam JU et al: Cutaneous pseudo-T-cell lymphomas. A clinicopathologic study of 20 patients. *Cancer* **69**:717, 1992
29. Nihal M et al: Cutaneous lymphoid hyperplasia (CLH): A lymphoproliferative continuum with malignant potential. *J Invest Dermatol* **114**:817, 2000
44. Chun SI, Ji HG: Kimura's disease and angiolymphoid hyperplasia with eosinophilia: Clinical and histopathologic differences. *J Am Acad Dermatol* **27**:954, 1992
54. Skelton Hea: Castleman's disease in the skin; a rare lymphoid hyperplasia not previously reported in the skin. *J Cutan Pathol* **24**:125, 1997
67. Orbaneja JG et al: Lymphomatoid contact dermatitis: A syndrome produced by epicutaneous hypersensitivity with clinical features and a histopathologic picture similar to that of mycosis fungoides. *Contact Dermatitis* **2**:139, 1976
81. Toonstra J et al: Jessner's lymphocytic infiltration of the skin. A clinical study of 100 patients. *Arch Dermatol* **125**:1525, 1989
82. Guillaume JC et al: Crossover study of thalidomide vs placebo in Jessner's lymphocytic infiltration of the skin. *Arch Dermatol* **131**:1032, 1995



CHAPTER 148

Langerhans Cell Histiocytosis

Ruggero Caputo
Carlo Gelmetti



EPIDEMIOLOGY

The prevalence of Langerhans cell histiocytosis (LCH) is internationally estimated to be from 4.0 to 5.4 per million population; however, because internal and skin lesions may not be diagnosed as LCH, this may be an underestimation. In children, the annual incidence is estimated at 0.5 per 100,000 children in the United States and at 0.5 per million worldwide. The male-female ratio is 2:1. The disease can occur in individuals of any age and can also be congenital but is more common in children aged 1 to 3 years.[1]

ETIOLOGY AND PATHOGENESIS

The pathogenesis of LCH remains a mystery despite numerous investigative efforts. In addition to genetic factors, infectious agents (especially viruses), and cellular and immune system dysfunction, including abnormalities of lymphocytes and cytokines (interleukin 1α, interleukin 10), cellular adhesion molecules, and a combination of these, have been implicated.[2] The role of genetics is not well defined. Although LCH has been reported in both monozygotic and dizygotic twins, the relative rarity of the familial occurrence does not favor a significant hereditary influence.[3]

The reactive versus neoplastic nature of LCH cells is also debated.[4] Although clonality has been demonstrated in all forms of LCH, this does not mean that the process is histologically and biologically malignant. The following features substantiate the reactive hypothesis: (1) LCH cells are highly differentiated, (2) histologically the granulomatous lesions resemble those seen in infections or foreign-body reactions, and (3) lesions may spontaneously regress. These pathogenic steps have been suggested: (1) viruses induce activation of histiocytes, (2) immunologic mechanisms produce the pathologic Langerhans cell phenotype, and (3) a cytokine-mediated storm results in LCH lesions. Many viruses (human herpesvirus 6, cytomegalovirus, adenovirus, and parvovirus) are suspected to play an etiologic role, but none has been proved to be responsible for the disease.

In contrast, the following observations support a clonal neoplastic origin of LCH: (1) bone marrow derivation and clonality of LCH cells, (2) the existence of familial cases of LCH, (3) findings of chromosomal instability with an abnormality on chromosome 7 and of p53 protein in LCH, and (4) co-occurence of LCH and a myelodysplastic marrow. Two possible explanations have been proposed for the association between LCH and myelodysplasia. The first is that the marrow dysplastic features are secondary to the infiltration of the marrow by LCH cells induced by cytokines and do not represent elements of a true myelodysplastic syndrome. A second possibility is that the abnormal marrow cells are related to the clonal LCH cells and are part of the disease process; that is, myelodysplastic cells could be arising from the same clonal cell [an anomalous pluripotent dendritic (stem) cell line]. This possibility raises the issue of whether LCH could be considered a "myeloid dendritic stem cell disorder."[5] These findings also suggest a genetic predisposition in LCH and stimulate the search for potential candidate genes in LCH. Fig. 148-1 illustrates the histiocyte developmental pathway according to Weitzman and Jaffe.[6]

CLINICAL FINDINGS

Classification

LCH is a disorder with a broad spectrum of forms: it can be local, asymptomatic with an indolent course, limited to an isolated bone lesion, or systemic and aggressive involving multiple organs and producing significant symptoms. Thus, the clinical manifestations depend on the site of the lesions and the systems involved.[7] Historically, LCH has been described under various names: Letterer-Siwe disease (LSD) is the prototype of the acute, disseminated, multisystemic form that usually appears in infants or newborns. Its course, if the disease is untreated, is fatal; Hand-Schüller-Christian disease (HSC) is the chronic, progressive, multifocal form, commonly beginning in childhood; eosinophilic granuloma (EG) is the localized, benign form; and Hashimoto-Pritzker disease (HPD) represents the benign, self-healing variant of LCH, usually present at birth or during the first few days of life. The classification system for histiocytosis defined by the Histiocyte Society is shown in Table 148-1. At present it seems realistic to describe LCH as a continuum as in Fig. 148-2, because every patient is unique with regard to the type, number, and location of lesions.

Although the historical terminology can be maintained for didactic purposes, it is more important to distinguish the forms with systemic involvement that require systemic management (multisystemic diseases or extensive LCH) from those with localized lesions that can be treated with a topical medication or observational approach (single-sys-

LANGERHANS CELL HISTIOCYTOSIS AT A GLANCE



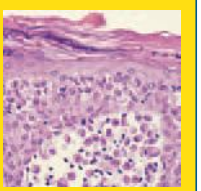

- A group of rare disorders that are considered reactive but have a broad spectrum of severity.
- The reactive versus neoplastic nature of the disease is debated. A clonal origin for the cells of Langerhans cell histiocytosis (LCH) in genetically predisposed patients is the most probable hypothesis.
- Histopathologic features consist of a dense infiltrate of histiocytes with a strong epidermotropism. The unifying element is the typical "LCH cell"—a histiocyte with an irregular vesiculated, often reniform nucleus and an abundant, slightly eosinophilic cytoplasm. These cells test positive for S100 protein, CD1a, and CD207 and contain cytoplasmic Langerhans granules.
- Cutaneous lesions vary from papules to vesicles, pustules, nodules, and ulcers. The course is also variable, with disease ranging from localized self-healing forms to generalized and fatal cases. The most common sites of involvement are the head, trunk, and skinfolds. Mucosal lesions are usually ulcerated nodules involving mainly gingival and genital regions.
- Associated manifestations include diabetes insipidus and exophthalmos. Systemic lesions may affect bones, lungs, bone marrow, liver, spleen, and lymph nodes. Aggressive forms may be treated successfully with vinblastine and other drugs.

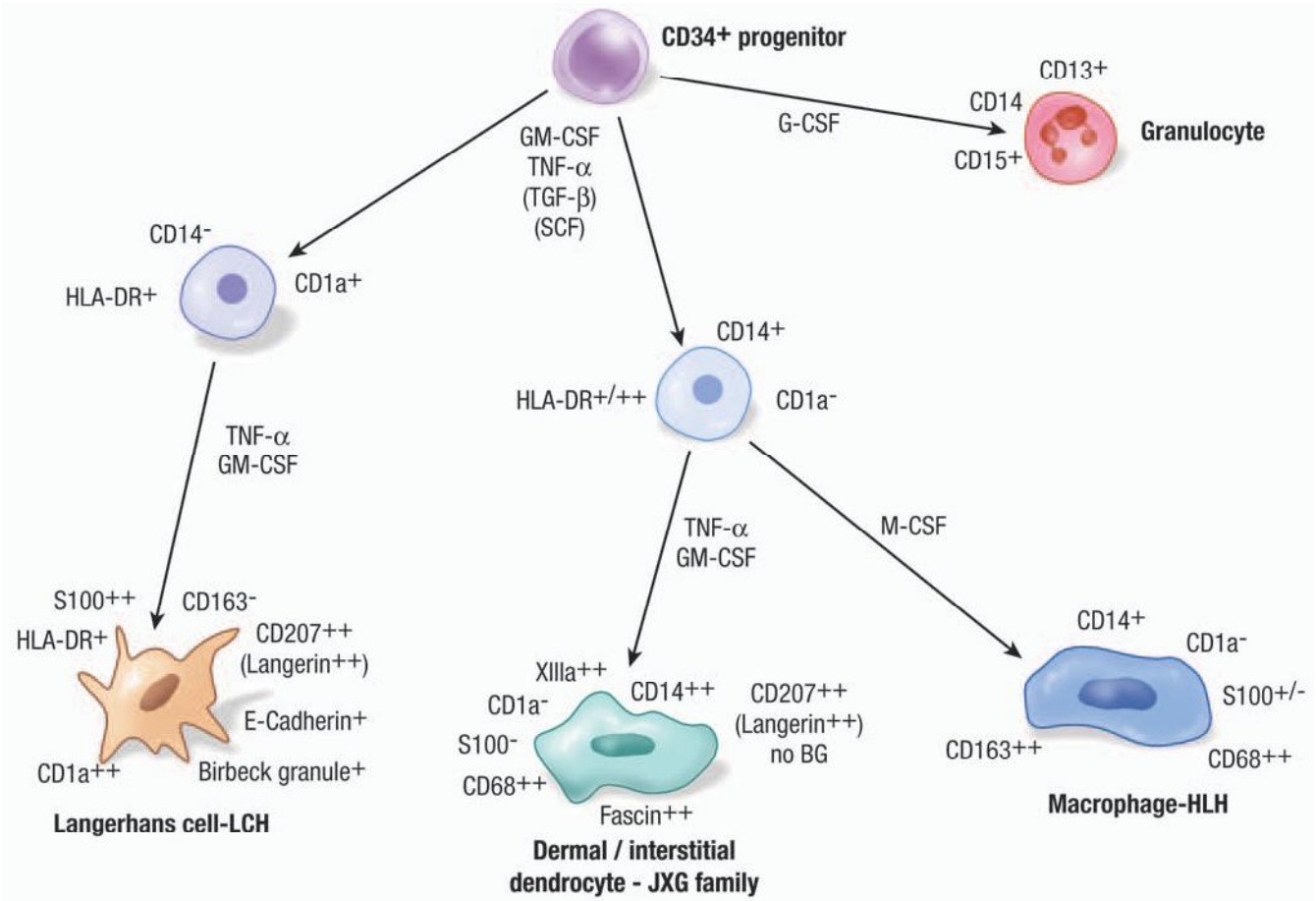

▲ **FIGURE 148-1** Schematic representation of histiocyte developmental pathway. BG = Birbeck granule; G-CSF = granulocyte colony-stimulating factor; GM-CSF = granulocyte-macrophage colony-stimulating factor; HLA = human leukocyte antigen; HLH = haemophagocytic lymphohistiocytosis; JXG = juvenile xanthogranuloma; LCH = Langerhans cell histiocytosis; M-CSF = macrophage colony-stimulating factor; SCF = stem cell factor; TGF-β = transforming growth factor-β; TNF-α = tumor necrosis factor-α. (Modified from Weitzman S, Jaffe R: Uncommon histiocytic disorders: The non–Langerhans cell histiocytoses. *Pediatr Blood Cancer* **45**:256, 2005.)

tem diseases or restricted LCH) or that are self-healing (Fig. 148-3).

History

The Writing Group of the Histiocyte Society proposed a guideline identifying confidence levels for the diagnosis of class I histiocytosis (LCH). These criteria were as follows: (1) presumptive diagnosis—light morphologic characteristics; (2) designated diagnosis—light morphologic features plus two or more supplemental positive results to stains for adenosine triphosphatase, S100 protein, α-D-mannosidase, and peanut lectin; (3) definitive diagnosis—light morphologic characteristics plus Birbeck granules in the lesional cell visible with electron microscopy and/or positive results on staining for CD1a antigen on the lesional cell[8] (Table 148-2).

Current immunostaining techniques allow the definitive diagnosis of LCH from just paraffin-embedded tissue, which avoids the need for sophisticated and expensive methods such as electron microscopy (see Table 148-2). Because the location and diffusion of the lesions have a significant influence on the course of the disease and its prognosis, various classification schemes assign scores for each organ and system involved. The former classification of LCH into three disease categories (i.e., EG, HSC, LSD) is no longer used. The present system attempts to evaluate the extent of involvement and its relationship to prognosis (Table 148-3).

TABLE 148-1
Classification System for Histiocytosis Developed by the Histiocyte Society (1987 and 2004)

Class I: Langerhans cell histiocytosis
Class II: Histiocytosis of the mononuclear phagocyte system or non–Langerhans cell histiocytosis (see Chap. 149)
- IIa: Histiocytosis involving dermal CD68+ and factor XIII+ dendrocytes (histiocytosis involving cells of dermal dendrocyte lineage)
- IIb: Histiocytosis involving cells other than Langerhans cells and cells of the dermal dendrocyte lineage

Class III: Malignant histiocytosis

Cutaneous Lesions

Cutaneous manifestations are very common in LCH and may represent the earliest sign of the disease.[9] The typical lesion is a small translucent papule, 1 to 2 mm in diameter, slightly raised, rose-yellow (Fig. 148-4A and B), and usually located on the trunk (see Fig. 148-4A and B) and scalp. The lesions frequently show scaling (see Fig. 148-4A) and may become crusted and ulcerate (see Fig. 148-4B and C). Vesicles and pustules may occur, simulating eczema, miliaria, scabies, and varicella. This is an especially common presentation during the neonatal period (first month of life). The presence of purpura is a poor prognostic sign. Although in LSD and HSC early le-



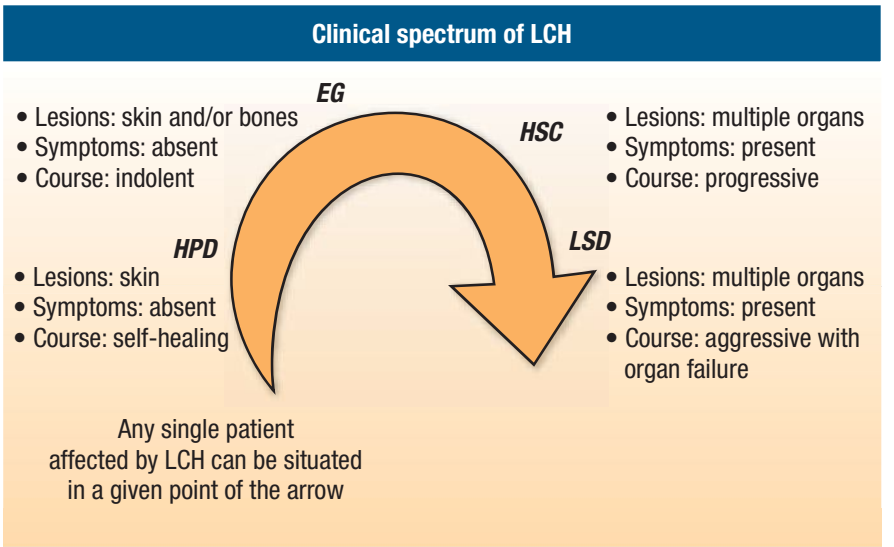

◀ **FIGURE 148-2** Clinical spectrum of Langerhans cell histiocytosis (LCH). All patients with LCH fit along this continuum. EG = eosinophilic granuloma; HPD = Hashimoto-Pritzker disease; HSC = Hand-Schüller-Christian disease; LSD = Letterer-Siwe disease.



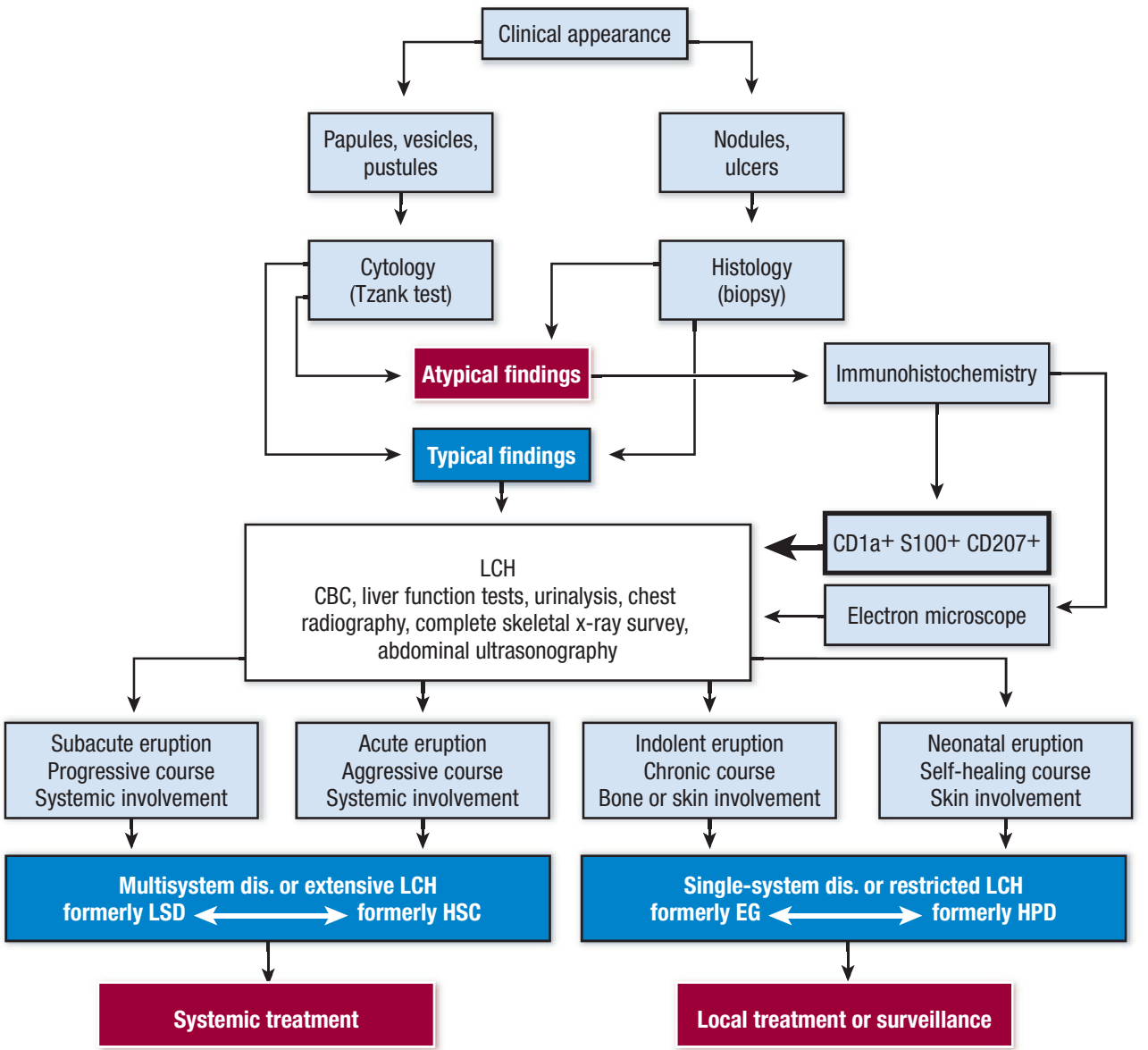

▲ **FIGURE 148-3** Approach to the patient with Langerhans cell histiocytosis (LCH). CBC = complete blood cell count; dis. = disease; EG = eosinophilic granuloma; HPD = Hashimoto-Pritzker disease; HSC = Hand-Schüller-Christian disease; LSD = Letterer-Siwe disease.

sions are similar, HPD has traditionally been characterized by the eruption of multiple or solitary elevated, firm, red-brown nodules (Fig. 148-5A) or flesh-red lesions similar to infantile angiomas; late papulonodular lesions may show elevated borders and ulcerate easily. These lesions can grow in size and number in the first few weeks of life, and some may become quite large. They then form brown crusts, which are shed and occasionally leave whitish atrophic scars after spontaneous resolution. Since the original description of the papulonodular lesions of HPD, it is clear that small reddish brown crusted papules that may resemble chickenpox are a common manifestation of "self-healing Langerhans cell histocytosis," with spontaneous clearance by 2 to 3 months of age (see Fig. 148-5B).[10]

Cutaneous lesions appear more (LSD) or less (HSC) rapidly in successive crops. The lesions tend to merge on the scalp, mimicking seborrheic dermatitis or folliculitis, and leading to alopecia, and on the folds (retroauricular, axillary, and genital), mimicking intertrigo. Occasionally, the lesions merge into plaques on the medial aspect of the chest (Fig. 148-6), the mid-back, and temporoparietal regions, and may become xanthomatous.

Mucous membrane lesions are commonly noduloulcerative and mainly involve the perioral area and gingiva (Fig. 148-7) and, especially in EG, the perigenital or perianal regions (Fig. 148-8). Although the absence of mucous membrane lesions is a key feature of HPD, oral manifestations may be the first sign of LCH: non-specific pain, aphthae, gingival bleeding, candidiasis, ulceration with loosening of the teeth, and premature eruption of the teeth can be observed.

Nail changes include fragile lamina, paronychia, subungual pustules, nail fold destruction, onycholysis, subungual hyperkeratosis, longitudinal grooving, and pigmented and purpuric striae of the nail bed (Fig. 148-9). These features are considered to be unfavorable prognostic signs. Cutaneous manifestations in elderly patients (Fig. 148-10) are similar to those seen in children.

TABLE 148-2
Diagnostic Markers for Langerhans Cell Histiocytosis

- S100 protein
- CD1a
- CD207 (langerin)

TABLE 148-3
Classification of Langerhans Cell Histiocytosis (LCH) According to Extent of Disease

- Single-system disease or restricted LCH
  - Skin lesions without any other site of involvement
  - Monostotic lesion with or without diabetes insipidus, adjacent lymph node involvement, or rash
  - Polyostotic lesions involving several bones or more than two lesions in one bone, with or without diabetes insipidus, adjacent lymph node involvement, or rash
- Multisystem disease or extensive LCH
  - Visceral organ involvement with or without bone lesions, diabetes insipidus, adjacent lymph node involvement, and/or rash but without signs of organ dysfunction of the lungs, liver, or hematopoietic system
  - Visceral organ involvement with or without bone lesions, diabetes insipidus, adjacent lymph node involvement, and/or rash but with signs of organ dysfunction of the lungs, liver, or hematopoietic system

Related Physical Findings

Malaise, weight loss, failure to thrive, nausea, myalgia, arthralgia, and fever are frequently present in aggressive forms.

Bone lesions are the most frequent manifestations of LCH (80 percent of cases), and bone involvement alone is seen in 50 percent to 60 percent of cases.[11] The lesions preferentially involve the skull, especially in the temporoparietal region, where the infiltrates lead to limited osteolytic foci that merge to form typical "map" lesions (Fig. 148-11). Because osteolysis of the lower maxillary bones is also frequent, on x-ray images the teeth appear to be floating in the mouth. Mastoid involvement is common and often symptomatic. Bone involvement can be shown by computed tomography (CT) or gadolinium-enhanced magnetic resonance imaging (MRI) and can lead to organ dysfunction such as diabetes insipidus and growth retardation. Retro-ocular bone involvement is responsible for exophthalmos. In addition, flat bones, vertebral bones, and long bones can be involved. Osteolytic lesions, either asymptomatic or accompanied by pain and functional impairment, are generally multiple and appear gradually. At times, lesions may cause a significant periosteal reaction. Extension to the adjacent tissues (e.g., muscles) can produce symptoms, which may be unrelated to the bone involvement. The onset can be insidious, and the osseous lesion can be single and may go undetected until spontaneous fracture or destruction of an organ occurs. When the lesions become symptomatic, there is localized pain, tenderness, soft tissue swelling, deformation, fracture or medullar compression (vertebra plana), or premature tooth loss.

Bone marrow involvement, which is rare and generally occurs late in aggressive forms of LCH, is characterized by the presence of numerous histiocytic cells. When thrombocytopenia, leukopenia, and anemia occur, death is almost certain.

Conventional radiography and MRI can both be used in the diagnosis of bone LCH lesions, but MRI has an advantage in the detection of muscle involvement. In addition, isotopic bone scanning can be used for multiple lesions, and scintigraphy and fluorodeoxyglucose positron emission tomography can identify active osseous lesions. Isolated bone lesions, typically with bevelled margins and without sclerosis, have the best prognosis, whereas bone lesions with multisystem involvement predict a more problematic course.

Pulmonary involvement can be more easily detected in elderly patients and is quite frequent (12 percent to 23 percent of patients).[12] Pulmonary lesions may be asymptomatic but can also cause death. Functional signs consist of dyspnea, tachypnea with rib retraction, cough, cyanosis, and thoracic pain. Other signs include mediastinal compression and pneumothorax caused by bulla formation. In chest radiographs, the lungs may show a classic "honeycomb" appearance (Fig. 148-12) or a micronodular pattern. Pulmonary function tests may reveal restrictive lung disease with decreased pulmonary volume. The diagnosis of LCH can be made if more than 5 percent of the cells in specimens obtained by bronchoalveolar lavage are Langerhans cells as indicated by immunostaining or electron microscopic examination.

Involvement of the liver and spleen is quite frequent (15 percent to 50 percent of patients). Hepatic lesions may evolve to severe fibrosis, biliary cirrhosis, and liver failure. Hepatosplenomegaly, often due to portal infiltration by Langerhans cells or Kupffer cell hyperplasia, is never the initial sign of the disease but



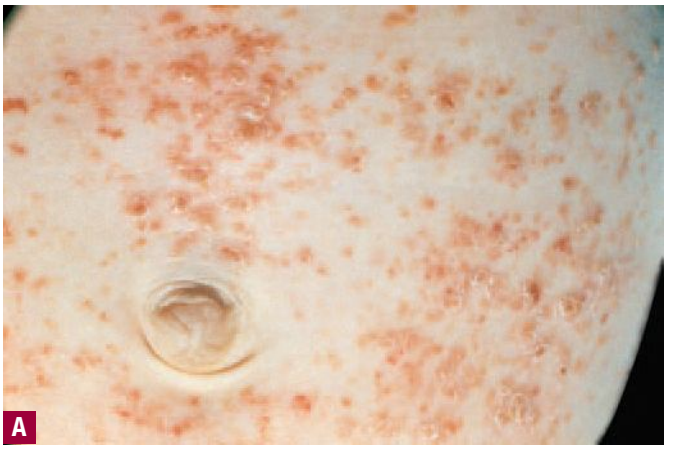





▲ **FIGURE 148-4** Extensive Langerhans cell histiocytosis. **A.** Abdominal area of infant with multiple yellowish erythematous papules covered by scale or crust. **B.** Infant with multiple ulcerated skin lesions on the trunk. **C.** Severe disease with confluent erosive and crusted lesions forming ulcers; distension of the abdomen reflects hepatosplenomegaly.



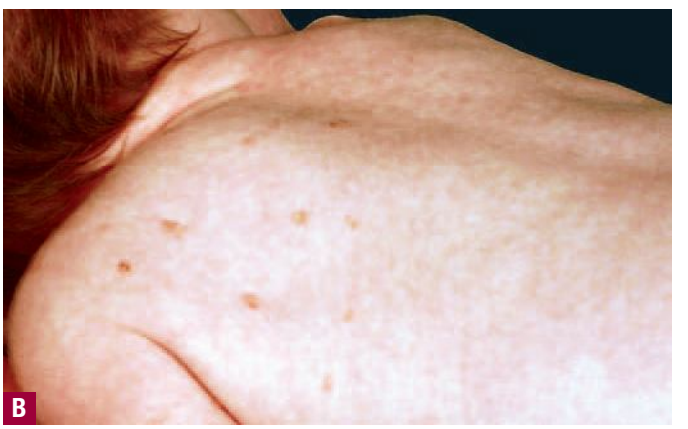

▲ **FIGURE 148-5** **A.** Hashimoto-Pritzker disease. Multiple disseminated, elevated, firm red-brown or dark red nodules (multiple form) present at birth. (From Bonifazi L et al: Congenital self-healing histiocytosis. *Arch Dermatol* **118**:267, 1982, with permission.) **B.** Resolving crusted reddish brown papules of congenital self-healing Langerhans cell histiocytosis.



▲ **FIGURE 148-6** Extensive Langerhans cell histiocytosis. The papuloscaling and papulocrusted lesions show a typical distribution on the trunk and the scalp. The involvement of the face in this patient is unusual.

is a frequent complication and is a prognostically unfavorable sign, particularly when accompanied by jaundice and ascites. Splenomegaly may increase the severity of thrombocytopenia.

Lymphadenopathy is rarely prominent but has been noted in 25 percent to 75 percent of fatal cases. Cervical lymph nodes are the most often affected. The nodes are only rarely symptomatic, but if massive, they may damage the surrounding structures. For example, enlargement of the nodes surrounding the respiratory tract may provoke cough, dyspnea, or cyanosis. Suppuration and chronic drainage can also occur.

Diabetes insipidus is present in more than 50 percent of cases and occurs more often in patients with involvement of the skull and the orbits. It should be evaluated by water deprivation testing and measurement of urinary levels of arginine vasopressin. Diabetes insipidus is easily controlled by vasopressin therapy.[13] Although diabetes insipidus is an obvious marker of skull invasion, it is not considered a prognostically unfavorable symptom. Growth retardation in children can be due to anterior pituitary involvement leading to growth hormone deficiency; however, it is more commonly caused by chemotherapy, systemic steroids, malabsorption, and general malaise. Other endocrine organs, such as the pancreas, thymus, and gonads can also be affected.[14]

Exophthalmos is present in only 10 percent to 30 percent of cases. It may be unilateral or bilateral and is due to retroocular bone infiltration by Langerhans cells. Mastoid involvement mimics an infectious mastoiditis and leads to chronic otitis media, otorrhea, and also deafness caused by the extension of the disease to the middle ear.

Gastrointestinal symptoms are nonspecific and are due to mucosal infiltration. Abdominal pain, diarrhea, vomiting, bloody stools, duodenal ulcers, and malabsorption have been described. Although conventional radiographs may show either dilated or stenotic segments, the specific diagnosis can be made by only endoscopic biopsy.[15]

Brain involvement by LCH is uncommon. Besides growth retardation, signs may include cranial nerve deficit, blurred vision, tremors, dysarthria, ataxia, spastic paraplegia or tetraplegia, and progressive intellectual deficit. Other signs, such as seizures and those related to increased intracranial pressure, are rare and depend on the site and size of the lesion. Cerebellar manifestations may appear as a first sign, followed by signs of involvement of the paraventricular cerebral white matter. CT or MRI may reveal tumor lesions as a sign of primary invasion or secondary atrophic or demyelinizing lesions.



▲ **FIGURE 148-7** Extensive Langerhans cell histiocytosis. Infiltrating lesions of the gingival tissue, which frequently leads to loss of teeth.



▲ **FIGURE 148-8** Restricted Langerhans cell histiocytosis. Noduloulcerative lesions in the vulva and on the perianal area. These lesions, although rare, are as unique as the bone lesions.

LABORATORY TESTS

The recommended laboratory evaluations for a patient with LCH are shown in Table 148-4. Other investigations that should be carried out in LCH are listed in Table 148-5.

Imaging Studies

Diagnostic imaging, from plain films to axial high-resolution CT and gadolinium-enhanced MRI, plays a major role in the diagnosis and management of LCH. As already noted, bone involvement can be investigated using isotopic bone scans to reveal multiple lesions and fluorodeoxyglucose positron emission tomography to identify active osseous lesions. These techniques may allow the precise visualization of lesions in potentially dangerous bony locations such as the skull and the spine. In the thorax, reticulonodular shadowing and honeycombing of the lung with preserved lung volume is typically revealed.[16]

Histopathologic, Immunohistochemical, and Ultrastructural Evaluation

The pathologic features of LCH provide the unifying aspect for the entire con-



▲ **FIGURE 148-9** Extensive Langerhans cell histiocytosis. All nails, save one, show purpuric striae of the nail bed. Nail changes are considered an unfavorable prognostic sign.

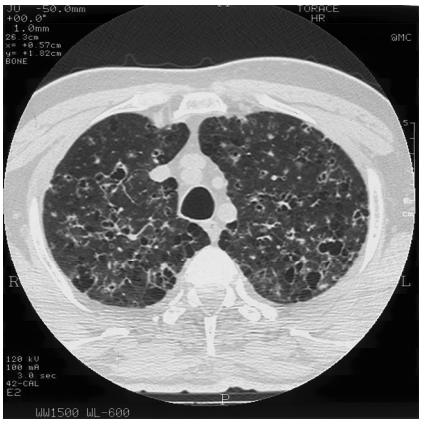

▲ **FIGURE 148-12** Extensive Langerhans cell histiocytosis. Bilateral involvement of the lungs characterized by multiple cystic cavities (honeycomb appearance). (Used with permission from E. De Juli, MD.)



tinuum of LCH disorders. The common histologic element of the different lesions is the typical "LCH cell," a cell easily identified and differentiated from the non-specific elements of the infiltrate by its size and configuration. This cell is approximately four to five times larger than small lymphocytes, has an irregular and vesiculated nucleus, is often reniform (kidney shaped), and has abundant, slightly eosinophilic cytoplasm (Figs. 148-13, 148-14, and 148-15). The histologic patterns observed in LCH are of three types: proliferative, granulomatous, and xanthomatous. A proliferative reaction is seen in early papules. It consists of an extensive epidermotropic, lichenoid infiltration of LCH cells in the upper dermis. The epidermis soon becomes compressed, thinned, invaded, and even destroyed (see Fig. 148-13). In the upper dermis, LCH cells are typically separated by edema, whereas in the lower dermis their cell membranes coalesce. In the deep dermis, the infiltrate is often localized around vessels and may invade the hypodermis. A few mitotic figures are occasionally found. Cytologic examination of LCH cells is easily accomplished by scraping early papules. The granulomatous reaction (see Fig. 148-14) consists of an aggregation of LCH cells with some multinucleated histiocytes and a varying number of eosinophils, generally in clusters. Neutrophils, lymphocytes, and plasma cells may also be present in the infiltrate. This type of reaction is seen in the chronic stages of the disease. The xanthomatous reaction is encountered mainly in HSC and consists of numerous foam cells intermingled with LCH cells and eosinophils (see Fig. 148-15). Multinucleated giant cells are frequently seen. They are mainly of the foreign-body type but occasionally may have the appearance of Touton giant cells. Lipid accumulation is considered to be a late secondary phenomenon. These different types of histologic reactions may be found simultaneously in the same patient, and the visceral lesions present in LCH show the same three types of reactions observed in the skin.

In HPD, the infiltrate appears to consist mostly of large multinucleated giant cells intermingled with typical LCH cells. In HPD, LCH cells are fewer (10 percent to 25 percent of tumor cells) and may contain dense and regularly laminated bodies. The cytoplasm of the giant cells is either acidophilic or has a "ground glass" appearance. It is usually localized in the mid and deep dermis; occasionally, the epidermis may be infiltrated and ulcerated. The LCH cells show the immunophenotype of normal Langerhans cells, expressing high levels of major histocompatibility complex class II molecules, CD1a complex, CD4, CD207 molecules, and S100 protein. Electron microscopic studies show that approximately 50 percent of the histiocytes of LCH contain



▲ **FIGURE 148-10** Extensive Langerhans cell histiocytosis in an 81-year-old woman. The diffuse papuloscaling and papulocrusted lesions on the trunk are similar to those seen in early childhood. Systemic involvement consists of hepatosplenomegaly and pulmonary lesions. (From Caputo R et al: Mucocutaneous expressions of Langerhans cell histiocytosis in adults. *Eur J Dermatol* **13**:481, 1994, with permission.)



◀ **FIGURE 148-11** Extensive Langerhans cell histiocytosis. Radiograph of the skull shows well-circumscribed osteolytic areas with a typical "map" appearance.

TABLE 148-4
Laboratory Investigations for Langerhans Cell Histiocytosis

- Complete blood count[a]
- Coagulation profile[a]
- Serum protein electrophoresis
- Erythrocyte sedimentation rate
- C-reactive protein level
- Serum glucose level
- Liver function tests[a]
- Electrolyte levels
- T- and B-cell counts and T-cell subset analysis for immunologic evaluation
- Urinalysis[a]

[a]Every 6 mo, or every month if indicator for currently involved system.

Langerhans granules (see eFig. 148-15.1 in on-line edition).[17]

DIFFERENTIAL DIAGNOSIS

The differential diagnosis for LCH is summarized in Boxes 148-1 and 148-2.

COMPLICATIONS

Intercurrent infections, mainly candidiasis and sometimes dermatophytosis,[18] are frequently observed in LCH, especially in LSD. The development of severe pyogenic abscesses has been reported in elderly patients. The results of the progressive destruction of the surrounding tissue by invading histiocytes can therefore be highly variable and multifocal. The association of LCH with malignant neoplasms, particularly solid tumors (lung tumors, celiomesenteric neuroblastoma), malignant lymphomas, or acute leukemia is not unusual. In some of these cases, LCH may be considered as a reactive process associated with malignancy. Neoplasms may also be related to chemotherapy or radiotherapy for LCH. The synchronous occurrence of LCH with leukemias may be interpreted as additional clinical evidence in favor of a common origin of monocytes and Langerhans cells.

PROGNOSIS AND CLINICAL COURSE

Although the presence of numerous lesions, either in the skin or in other tissues, generally indicates an unfavorable course, the evolution of LCH is unpredictable. The prognosis is based on clinical features and is related to the age at onset, the rate of disease progression, and the number of organ systems involved.[19] It is not related to the histopathologic features. In short, an early onset (under the age of 2 years), extensive disease, and the presence of organ failure are the three main negative prognostic indicators.

Restricted LCH or single-system disease is usually associated with a good prognosis, whereas extensive LCH or multisystem disease may be fatal.[20] However, some patients with multiple lesions have been reported to recover spontaneously. The appearance of xanthomatous lesions in the course of LCH is considered by some authors to be an expression of a shift from a disseminated aggressive form into a progressive chronic form; others believe that these lesions may represent a distinct clinical entity independent of the primary disease. Organ dysfunction (liver, bone mar-

TABLE 148-5
Procedural Investigations for Langerhans Cell Histiocytosis

SPECIFIC INVESTIGATION	INDICATION
Skin biopsy or cytology	Mandatory to determine diagnosis
Weight and height	To determine general health
Chest radiography[a]	To determine respiratory system involvement
Abdominal ultrasonography[a]	To determine gastrointestinal involvement
Endoscopy and biopsy	To investigate malabsorption
Bone marrow biopsy	To evaluate cause of anemia, leukopenia, thrombocytopenia
Liver biopsy	To determine specific infiltration and involvement
Pulmonary function tests	To investigate tachypnea; to assess before chemotherapy
Bronchoalveolar lavage	To determine specific infiltration
Lung biopsy	To exclude opportunistic infection
Brain magnetic resonance imaging	To evaluate neurologic, visual, endocrine anomalies
Endocrine evaluation	
Growth hormone level	To determine cause of short stature, hypothalamic syndrome
Thyroid-stimulating hormone level	To investigate galactorrhea, precocious puberty
Otorhinolaryngologic evaluation, audiogram	To evaluate auricular discharge, deafness
Bone scans, skeletal survey, or fluorodeoxyglucose positron emission tomography	To assess bone involvement
Urine osmolality after water deprivation	To investigate diabetes insipidus

[a]Every 6 mo, or every month if indicator for currently involved system.
Adapted from Cambazard F, Stephan JL: The histiocytoses, Langerhans cell and non–Langerhans cell histiocytosis, in *Textbook of Pediatric Dermatology*, edited by Harper J, Oranje A, Prose N. Oxford, Blackwell Publishing, 2006, p 1699.

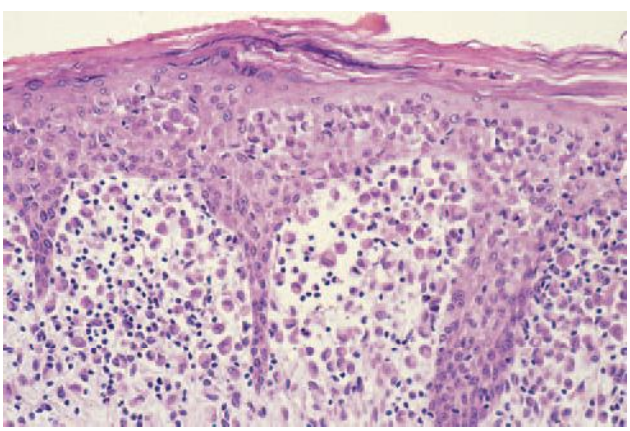

▲ **FIGURE 148-13** Langerhans cell histiocytosis (LCH). Proliferative reaction. A pure LCH cell infiltrate invades and destroys the epidermis.



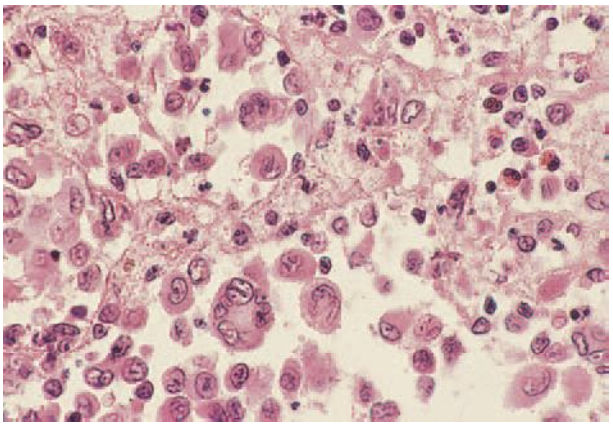

▲ **FIGURE 148-14** Langerhans cell histiocytosis (LCH). The granulomatous reaction consists of an aggregation of LCH cells with some multinucleated histiocytes and varying numbers of eosinophils, neutrophils, lymphocytes, and plasma cells. This type of reaction is seen in the chronic stage of the disease.

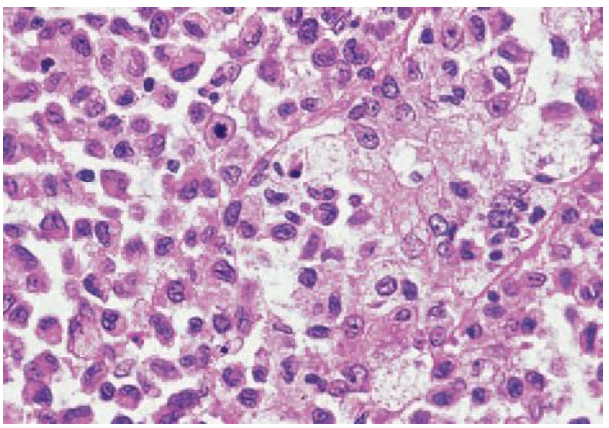

▲ **FIGURE 148-15** Langerhans cell histiocytosis (LCH). The xanthomatous reaction consists of numerous foam cells intermingled with LCH cells and is encountered mainly in Hand-Schüller-Christian disease. Mitotic figures are occasionally seen.

row, and lung), which occurs in approximately 15 percent of patients with LCH, is the most important predictor of poor outcome; however, diabetes insipidus is not a poor prognostic indicator.[21] In infants with organ dysfunction, the mortality rate may be as high as 50 percent to 65 percent. The most frequent causes of death are pulmonary and bone marrow dysfunction and intercurrent infections.

Box 148-2

Differential Diagnosis of Langerhans Cell Histiocytosis (Site Specific)

Most Likely

- Scalp
  - Seborrheic dermatitis
  - Folliculitis decalvans
  - Tinea capitis
- Face
  - Seborrheic dermatitis
  - Rosacea
- Intertriginous areas
  - Intertrigo
  - Candidiasis
  - Hidradenitis suppurativa
  - Darier disease
- Trunk
  - Lichen nitidus
  - Lichen planus
  - Miliaria
  - Non–Langerhans cell histiocytosis
  - Scabies
  - Urticaria pigmentosa
  - Varicella

Consider

- Scalp
  - Psoriasis
- Face
  - Granuloma faciale
  - Perioral dermatitis
  - Lupus miliaris faciei
- Trunk
  - Pityriasis lichenoides et varioliformis acuta
  - Psoriasis guttate
  - Dermatitis

It is impossible to attribute significance to any single sign, but jaundice, thrombocytopenia, anemia, hepatic fail-

Box 148-1

Differential Diagnosis of Langerhans Cell Histiocytosis (Lesion Specific)

	TYPE OF LESION			
	PAPULAR	**VESICOPUSTULAR**	**XANTHOMATOUS**	**NODULOULCERATIVE**
Most Likely	Seborrheic dermatitis Lichen nitidus Generalized eruptive histiocytosis Benign cephalic histiocytosis Darier disease Lichen planus	Scabies Miliaria Varicella Intertrigo Candidiasis Rosacea Folliculitis decalvans	Papular xanthoma Xanthoma disseminatum Juvenile xanthogranuloma Urticaria pigmentosa	Juvenile xanthogranuloma Urticaria pigmentosa Diffuse neonatal hemangiomatosis Blueberry muffin baby Hidradenitis Tuberculosis
Consider	Leukemia Pityriasis lichenoides chronica Hidradenitis suppurativa Psoriasis, guttate Tinea corporis, tinea capitis	Dermatitis Pityriasis lichenoides et varioliformis acuta Granuloma faciale Perioral dermatitis Lupus miliaris faciei	Hyperlipidemic xanthomatosis Granuloma annulare disseminatum	Leukemia Pyoderma gangrenosum Cherry angioma

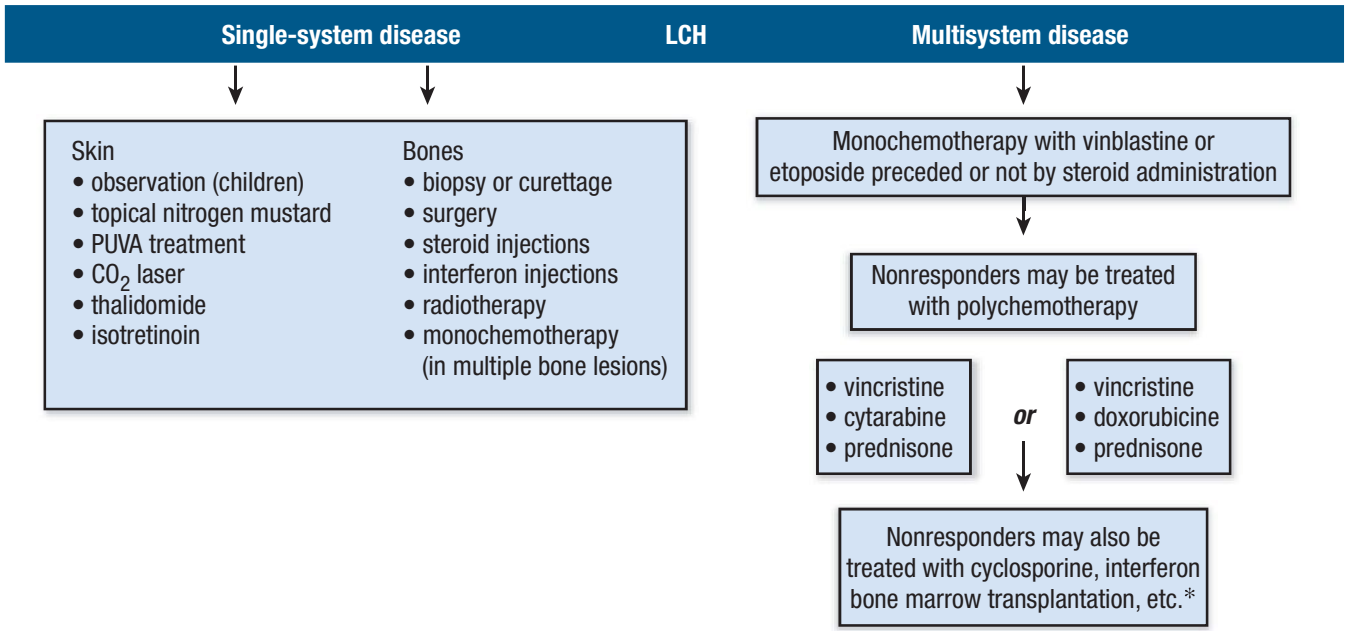

▲ **FIGURE 148-16** Treatment algorithm for Langerhans cell histiocytosis (LCH). PUVA = psoralen plus ultraviolet A light. *Others may include methotrexate, chlorambucil, cyclophosphamide, daunorubicin, procarbazine, chlormethine, β-mercaptopurine, and 2-chlorodeoxyadenosine.

ure, and nail involvement are considered unfavorable prognostic indicators. A favorable prognosis is associated with a small number of lesions, nodular lesions (as in HPD), prompt resolution of lesions, and the involvement of only one organ system (skin or bones). Multisystem LCH carries a better prognosis in adults than in children.

Liver dysfunction is considered present if there is hypoproteinemia not due to protein-losing enteropathy (less than 5.5 mg/dL total protein and/or less than 2.5 g/dL of albumin), edema, ascites, and/or hyperbilirubinemia (total serum bilirubin of more than 1.5 mg/dL). Lung dysfunction is considered present if there is cough, dyspnea or tachypnea, cyanosis, radiologically evident interstitial disease, restrictive lung disease, pneumothorax, or pleural effusion attributable to the disease rather than to infection.[22] The presence of dense areas on radiography alone is not interpreted as evidence of dysfunction. Hematopoietic dysfunction is considered present if there is anemia (less than 10 g/dL hemoglobin) not due to infection or iron deficiency, leukopenia (white blood count of fewer than 4000/μL), or thrombocytopenia (fewer than 100,000 platelets/μL). The presence of excessive numbers of histiocytes in the marrow aspirate per se is not considered as evidence of dysfunction. Hypercalcemia is also associated with a poor prognosis and is sometimes caused by bone resorption or excess prostaglandin production.[23] Finally, the rapidity and intensity of the clinical response to initial treatment is a good indicator of prognosis.

TREATMENT

Treatment strategies for LCH are chosen on the basis of the age of the patient, the extent of disease, and the location of lesions (see Fig. 148-3 and the treatment algorithm in Fig. 148-16).[24]

In single-system disease involving skin or bone, management is nonaggressive. In children with skin involvement only, observation is the best option.[25] If the lesions are persistent, topical nitrogen mustard may be an effective treatment. Therapy consists of application of this substance diluted in water to a concentration of 20 mg/dL and applied daily for 5 days. Systemic glucocorticoids or antimitotic drugs are indicated in resistant cases. In adults with skin involvement only, topical treatment with nitrogen mustard may be an effective treatment strategy. Significant improvement has been obtained with conventional psoralen plus ultraviolet A light treatment in a considerable number of cases. CO_2 laser therapy has been suggested to treat periorificial eosinophilic granuloma. The use of thalidomide at a dosage of 100 mg/day for 1 month and then 50 mg/day for 1 or 2 months may induce a remission of skin lesions. Usually the disease recurs after treatment is stopped. The effect of thalidomide seems to be a result of its immunomodulatory and anti-inflammatory properties.[26] In one case, a complete remission of skin lesions was obtained after oral isotretinoin therapy. The patient was treated with 1.5 mg/kg daily for 8 months and remained free of recurrence and visceral involvement for 5 years.

For patients with bone involvement only, surgery (excision or curettage) is the treatment of choice if the lesions are accessible (see eFig. 148-16.1 in on-line edition). In children, glucocorticoid injections into selected sites may prevent surgical trauma to developing teeth or the growth plate of long bones.[27] In adults, radiotherapy is indicated for involvement of vertebrae, the sella turcica, and weight-bearing bones with risk of spontaneous fracture. In children, radiotherapy must be reserved for cases that fail to respond to other measures to avoid the risk of long-term effects. In the case of multiple bone lesions, monochemotherapy is suggested as with multiorgan involvement.

The management of patients with multisystem disease is controversial. Currently, monochemotherapy with vinblastine or etoposide with or without glucocorticoids is probably the most suitable treatment.[28] Vinblastine is given intravenously at doses of 0.1 to 0.2 mg/kg (6.5 mg/m^2) once weekly for 1 to 3 months. Re-administration of the alkaloid should be instituted only when new lesions appear. Etoposide is administered at a dose of 200 mg/m^2 orally or



intravenously for 3 consecutive days every 3 to 4 weeks for at least three to four courses. Both vinblastine and etoposide are well tolerated and cause only a few toxic effects; however, cumulative doses of etoposide exceeding 4000 mg/m^2 carry a significant risk of causing acute myeloid leukemia. Therefore, this drug is not the first choice in children and should be reserved for the treatment of LCH that is severe and resistant to other therapies. In the event of relapse, retreatment with the same type of monochemotherapy results in complete clearing in 60 percent of cases. Finally, methylprednisolone (30 mg/kg intravenously on 3 consecutive days) may be the initial therapeutic approach.

Only patients for whom monochemotherapy is not effective should be given multiagent regimens including vincristine, cyclophosphamide, doxorubicin, and chlorambucil. In refractory and advanced cases of LCH, cyclosporine and interferon-α2, and 2-chlorodeoxyadenosine have been used. Allogenic bone marrow transplantation or autotransplantation with CD1a-depleted bone marrow has been successful in some patients.

KEY REFERENCES

The full reference list for all chapters is available at www.digm7.com.

2. Nezelof C, Basset F: An hypothesis Langerhans cell histiocytosis: The failure of the immune system to switch from an innate to an adaptive mode. *Pediatr Blood Cancer* **42**:398, 2004
7. Stockschlaeder M, Sucker C: Adult Langerhans cell histiocytosis. *Eur J Haematol* **76**:363, 2006
11. Hicks J, Flaitz CM: Langerhans cell histiocytosis: Current insights in a molecular age with emphasis on clinical oral and maxillofacial pathology practice. *Oral Surg Oral Med Oral Pathol Oral Radiol Endod* **100**:S42, 2005
12. Al-Trabolsi HA et al: "Primary" pulmonary Langerhans cell histiocytosis in a two-year-old child: Case report and literature review. *J Pediatr Hematol Oncol* **28**:79, 2006
13. Ghirardello S et al: Current perspective on the pathogenesis of central diabetes insipidus. *J Pediatr Endocrinol Metab* **18**:631, 2005
14. Amato MC et al: Endocrine disorders in pediatric-onset Langerhans cell histiocytosis. *Horm Metab Res* **38**:746, 2006
15. Hait E et al: Gastrointestinal tract involvement in Langerhans cell histiocytosis: Case report and literature review. *Pediatrics* **118**:e1593, 2006 [Epub Oct. 9, 2006]
16. Azouz EM et al: Langerhans' cell histiocytosis: Pathology, imaging and treatment of skeletal involvement. *Pediatr Radiol* **35**:103, 2005
17. Henter JI, Tondini C, Pritchard J: Histiocyte disorders. *Crit Rev Oncol Hematol* **50**:157, 2004
24. McClain KL: Drug therapy for the treatment of Langerhans cell histiocytosis. *Expert Opin Pharmacother* **6**:2435, 2005
25. Ricart J et al: Congenital self-healing reticulohistiocytosis: Report of a case and review of the literature. *Acta Paediatr* **93**:426, 2004



CHAPTER 149

Non–Langerhans Cell Histiocytosis

Carlo Gelmetti
Ruggero Caputo

Non–Langerhans cell histiocytosis (NLCH), or class II histiocytosis, represents a broad group of different disorders characterized by the proliferation of histiocytes other than Langerhans cells[1] (Table 149-1).

Most of these cells share the same immunophenotypes, but the resulting disorders differ in clinical presentation and course. Although all NLCH disorders are considered reactive with no clinical evidence of malignancy, some forms, as with class I histiocytosis (Langerhans cell histiocytosis, or LCH), can be invasive and therefore are not necessarily biologically benign. Patients have been described who have developed both LCH and an NLCH, particularly juvenile xanthogranuloma (JXG) or benign cephalic histiocytosis (BCH),[2–4] and overlap between JXGs and BCH has also been described.[5]

Several attempts have been made to classify NLCH,[6] but none has been universally accepted.[7,8]

It is not possible to perfectly correlate the histologic features and the immunophenotype with either the clinical presentation or the course of a single disease. As a practical guide one could suggest that infantile forms with individual papulonodular lesions tend to be almost all purely cutaneous and self-healing [e.g., JXG, generalized eruptive histiocytosis (GEH), BCH], whereas the adult forms with coalescing plaque-like lesions tend often to be systemic and progressive/aggressive [e.g., Erdheim-Chester disease (ECD); necrobiotic xanthogranuloma (NXG); sinus histiocytosis with massive lymphadenopathy (SHML)]. An approach to the patient with NLCH is outlined in Fig. 149-1.

This chapter discusses only disorders of significance to the general dermatologist. Forms that are very rare (e.g., indeterminate cell histiocytosis) or that have been described in a single patient (e.g., fat-storing hamartoma of dermal dendrocytes) are not considered.

TABLE 149-1
Disorders Categorized as Non–Langerhans Cell Histiocytosis (with Abbreviations)

Juvenile xanthogranuloma	JXG
• Papular xanthoma	PX
Generalized eruptive histiocytosis	GEH
• Benign cephalic histiocytosis	BCH
Xanthoma disseminatum	XD
• Erdheim-Chester disease	ECD
Multicentric reticulohistiocytosis	MRH
• Solitary cutaneous reticulohistiocytosis	SRH
• Diffuse cutaneous reticulohistiocytosis	DRH
Progressive nodular histiocytosis	PNH
Necrobiotic xanthogranuloma	NXG
Sinus histiocytosis with massive lymphadenopathy	SHML

Note: Major disorders are in bold. The other forms are considered variants of these diseases.

EPIDEMIOLOGY

JXG accounts for 80 percent to 90 percent of cases of NLCH. All of the other NLCHs are rare. The authors have encountered almost 300 cases in the past 35 years. There is no sexual or racial predilection. JXG appears within the first year of life in approximately 80 percent of cases; in 20 to 35 percent of cases, it is congenital.[9,10] Approximately 30 adult cases are reported in the literature. There is a slight male predominance among in-

NON–LANGERHANS CELL HISTIOCYTOSIS

AT A GLANCE



- A broad enigmatic group of different and only partially related disorders characterized by the proliferation of histiocytes involving cells other than Langerhans cells.
- The disorders classified as non–Langerhans cell histiocytosis (NLCH), as a whole, are not rare and can be observed everywhere without sexual or racial predilection. Most cases are seen in infants and run a benign, self-healing course lasting a few years.
- The primary histopathologic feature is a dense, diffuse infiltrate that is less epidermotropic than in Langerhans cell histiocytosis and composed of occasionally foamy macrophages intermingled with lymphocytes, plasma cells, eosinophils, and sometimes Touton giant cells. In typical cases, histiocytes are $CD68^+$ but $CD1a^-$ and $CD207^-$.
- Cutaneous lesions range from papules to nodules. The number as well as the size of lesions is variable from one single small lesion to numerous nodules and plaques. Lesions become more or less xanthomatous in the absence of metabolic disorders.
- The most common sites of involvement are the head, trunk, and skinfolds. Mucosal lesions are rare and can be confused with trivial problems.
- Systemic manifestations such as ocular involvement, diabetes insipidus, and joint and visceral impairment are rare in juvenile xanthogranuloma, by far the most common NLCH, but are common in the rarer forms of NLCH.

dividuals with solitary JXG lesions and a strong male predominance among those with multiple cutaneous lesions.[9] Papular xanthoma (PX), considered a variant of JXG, is a rare disorder; fewer than 20 cases have been described. The onset of PX in children is usually during the first year of life. The disease seems to be more frequent in males. GEH is rare, with approximately 40 cases described, of which 10 were in children. It may start at any age, with reports of onset ranging from 3 months to 58 years. BCH is also rare. Over the past 3 decades, approximately 30 cases have been described, with the same incidence in boys and girls. The age of onset is 5 to 34 months (mean, 13.5 months). Progressive nodular histiocytosis (PNH) is an exceptional form described in a few children and adults. Xanthoma disseminatum (XD) is rare (approximately 100 published cases) and affects males more frequently than females. The random nature of the disorder does not permit an exact evaluation of either familial involvement or morbidity. In approximately 60 percent of patients, onset is before age 25 years. ECD is also rare, and only about 60 cases have been described in 70 years. Multicentric reticulohistiocytosis (MRH) is an uncommon disorder but has been observed in more than 100 individuals reported up to 1990, with the purely cutaneous forms seen in more than 50 patients. Caucasians are affected in more than 85 percent of cases, and women are more frequently affected than men (female-male ratio of 3:1). In general MRH affects adults 40 years of age, but the disease may appear during adolescence and rarely in childhood (pure cutaneous forms).

NXG has been described in approximately 60 cases. The age of onset of NXG ranges from 17 to 85 years, and the disease shows no gender predilection. SHML is also a relatively rare disease; approximately 365 cases have been studied. The disease has a worldwide distribution with increased incidence in blacks from Africa and the West Indies. There is no gender predilection. Any age group may be affected, but 80 percent of cases occur in the first or second decade of life.

ETIOLOGY AND PATHOGENESIS

The pathogenesis of NLCH is unknown. MRH may represent an abnormal histiocytic reaction to different stimuli. In forms with solitary lesions, local trauma may play a role, whereas in diffuse forms, the association with internal malignancies and autoimmune diseases suggests an immunologic basis for the initiation of the reaction.

PNH is a progressive disease with no tendency to involute spontaneously. It is thought to entail proliferation of mature spindle-shaped cells and may represent an evolution of another form of NLCH. According to some authors, MRH may evolve from a less developed form of NLCH such as GEH or adult JXG. It has also been suggested that urokinase released by the activated histiocytes may play a role in the extracellular matrix degradation leading to erosion of cartilage and adjacent bone. The origin and function of the pleomorphic cytoplasmic inclusions that are frequently present in the histiocytes forming the infiltrate in this disease are still debated. They may result from a peculiar kind of endocytosis or from the expression of an exocytosis phenomenon. These unique granules have already been described in several cases of reticulohistiocytosis, and if their presence is confirmed by subsequent observations, they could represent the ultrastructural marker.

The cause of NXG and its link to paraproteinemia are uncertain. It has been suggested that serum immunoglobulins complexed with lipid become deposited in the skin, eliciting a giant cell foreign-body reaction. Another hypothesis is that the paraproteinemia is the primary phenomenon, and a secondary proliferation of macrophages with receptors for the Fc portion of immunoglobulin G occurs. It has also been proposed that the paraprotein in NXG has functional features of a lipoprotein that may bind to lipoprotein receptors of histiocytes and induce granuloma formation. The cause of SHML remains obscure. Two main etiologies have been proposed: a disturbance of cell-mediated immunity and a primary infection (Epstein-Barr virus, *Klebsiella*).

HISTORY

JUVENILE XANTHOGRANULOMA

Clinical Findings

CUTANEOUS LESIONS JXG is a benign, self-healing disorder that is characterized by asymptomatic yellowish papulonodular lesions of the skin and other organs in the absence of a metabolic disorder. Lesions consist of an infiltrate of histiocytes with a progressively greater degree of lipidation.

In JXG two main clinical forms can be distinguished, a papular and a nodular form. In both the lesions are initially orange-red or red-brown but quickly turn yellowish. The papular form (Fig. 149-2) is characterized by numerous (up to





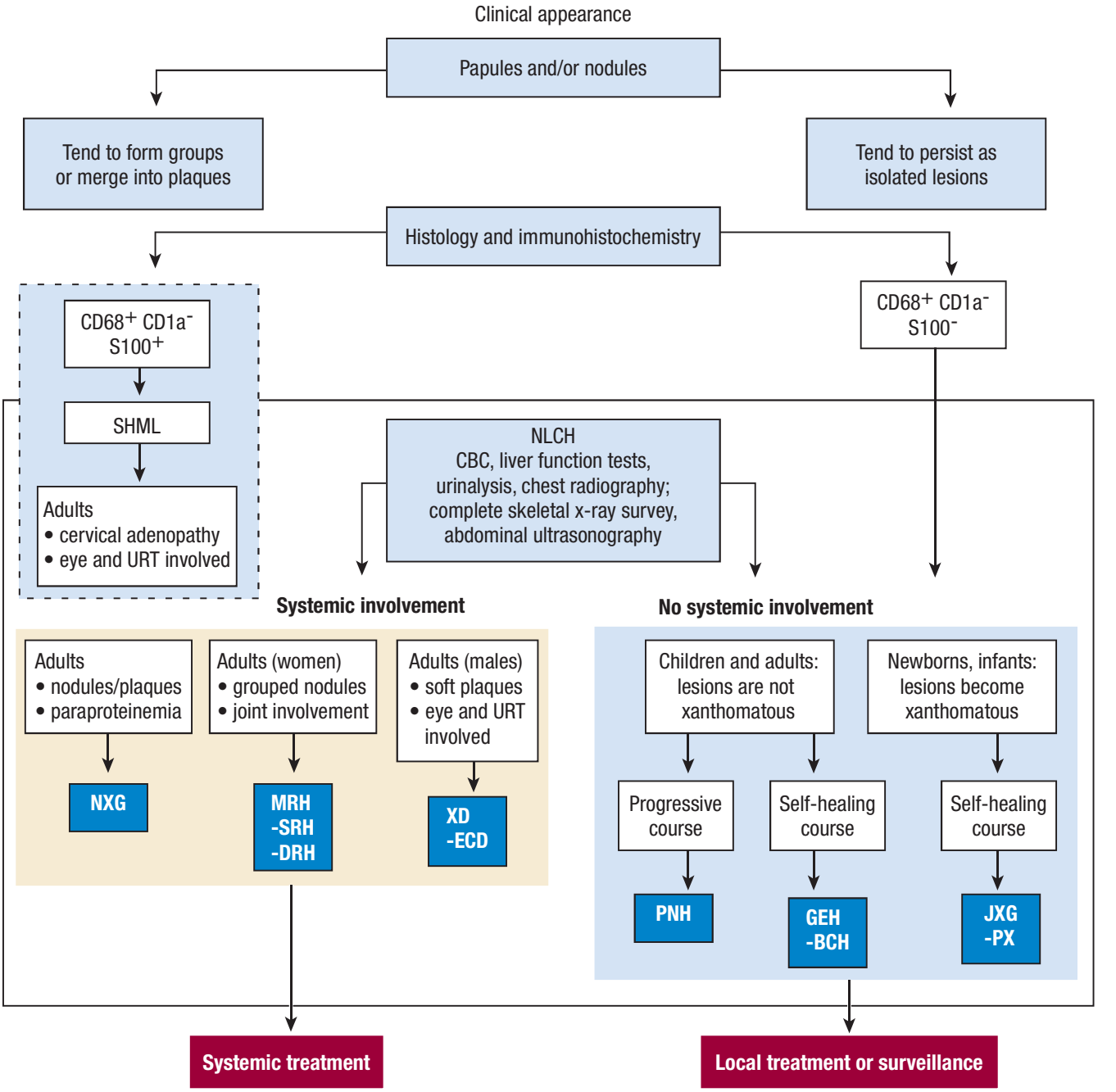

▲ **FIGURE 149-1** Approach to the patient with non–Langerhans cell histiocytosis (NLCH). BCH = benign cephalic histiocytosis; CBC = complete blood count; DRH = diffuse cutaneous reticulohistiocytosis; ECD = Erdheim-Chester disease; GEH = generalized eruptive histiocytosis; JXG = juvenile xanthogranuloma; MRH = multicentric reticulohistiocytosis; NXG = necrobiotic xanthogranuloma; PNH = progressive nodular histiocytosis; PX = papular xanthoma; SRH = solitary cutaneous reticulohistiocytosis; SHML = sinus histiocytosis with massive lymphadenopathy; URT = upper respiratory tract; XD = xanthoma disseminatum.

100) firm hemispheric lesions 2 to 5 mm in diameter. These lesions are irregularly scattered throughout the skin but are located mainly on the upper part of the body. PX is considered to be a form of JXG in which the lesions rapidly become xanthomatous. PX lesions range from 2 to 12 mm and show a generalized distribution with no tendency to merge into plaques. The nodular form (Fig. 149-3) is less frequent and occurs as one or a few lesions. Such nodules are generally round, 10 to 20 mm in diameter, and translucent, and might show telangiectases on their surface. The term *giant juvenile xanthogranuloma* is applied to lesions larger than 2 cm. Unusual clinical variants have been also reported. The mixed form is characterized by the simultaneous presence of both small and large nodules. The term *juvenile xanthogranuloma en plaque* defines a group of JXG lesions with a tendency to coalesce into a plaque as the only expression of the disease. In one study, 67 percent of 174 cases involved solitary papular lesions, and an additional 16 percent showed solitary nodular lesions.[9] Multiple cutaneous lesions were noted in 7 percent of affected individuals, a solitary extra-cutaneous lesion in 5 percent, and multiple cutaneous and visceral-systemic lesions in an additional 5 percent.

RELATED PHYSICAL FINDINGS Ocular involvement is the most typical extracutaneous manifestation. It may precede or follow the cutaneous lesions. Ocular JXGs are usually unilateral and



▲ **FIGURE 149-2** Juvenile xanthogranuloma. Papular form.

may lead to hemorrhage and glaucoma.[11,12] An extremely rare extra-cutaneous manifestation of the papular variant is central nervous system (CNS) involvement. The nodular form of JXG may occasionally be related to systemic lesions of the lungs, bones, kidneys, pericardium, colon, ovaries, and testes. Juvenile chronic myelogenous leukemia has been observed in association with this variant of JXG. Café-au-lait macules and JXGs occur together in 20 percent of individuals with papular JXGs and can be considered an excellent marker of neurofibromatosis type 1 (NF-1) (see Chap. 142) during the first years of life, even in the absence at that age of other reliable markers of NF-1.[13] Although the presence of JXGs in children has been said to be a marker of chronic myelogenous leukemia with and without concurrent NF-1,[14] few children with café-au-lait macules and JXGs show evidence of leukemia.[15]

Laboratory Tests

No abnormalities in laboratory test results are usually found in JXG except in the very rare cases in which juvenile chronic myeloid leukemia is associated with JXG.

Histopathologic and Ultramicroscopic Findings

Biopsy sections of JXG lesions show a feature that is common to many NLCHs, that is, a nonepidermotropic histiocytic infiltrate lacking Langerhans granules. Early lesions of JXG are characterized by a monomorphous, non–lipid-containing histiocytic infiltrate that occupies at least the upper half, and sometimes the entire thickness, of the dermis. Mature lesions (Fig. 149-4) contain foam cells, foreign-body giant cells, and Touton giant cells, mainly distributed in the superficial dermis and on the border of the infiltrate. Lymphocytes, eosinophils, and neutrophils are variably associated. Older lesions may show fibrosis. In mature lesions, fat stains yield positive results. The majority of JXG lesional biopsy sections stain positive for CD68/Ki-M1P and factor XIIIa but negative for CD1a and S100 protein.[10]

Under the electron microscope, the histiocytes that characterize the early stage of the disease exhibit pleomorphic nuclei, are rich in pseudopods, and contain many elongated and irregular dense bodies. Clusters of comma-shaped bodies can occasionally be observed. In older lesions, there is a predominance of foam cells, the cytoplasm of which is completely filled with lipid vacuoles, cholesterol clefts, and myeloid bodies. Touton giant cells are extremely large and sometimes contain more than 10 nuclei. Lipid material fills the periphery, whereas mitochondria and lysosomes predominate at the center.

The lesions of PX are composed almost entirely of foam cells and Touton giant cells. There is no evidence of a primitive histiocytic phase, and inflammatory cells are scarce or absent. Ultrastructurally, the cytoplasm is completely filled with lipid vacuoles without a limiting membrane, myeloid bodies, and lysosomal inclusions. Comma-shaped bodies are not found in these histiocytes.

Differential Diagnosis

The differential diagnosis of JXG is summarized in Box 149-1.

Complications

Eye involvement of a JXG lesion can cause a major visual problem leading to

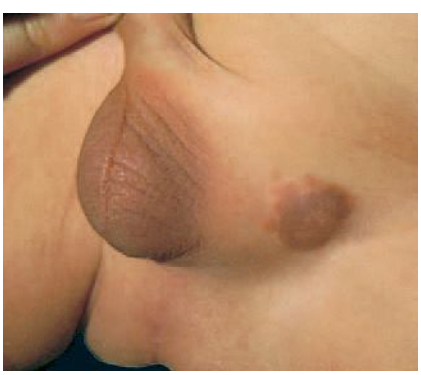

▲ **FIGURE 149-3** Juvenile xanthogranuloma. Nodular form.

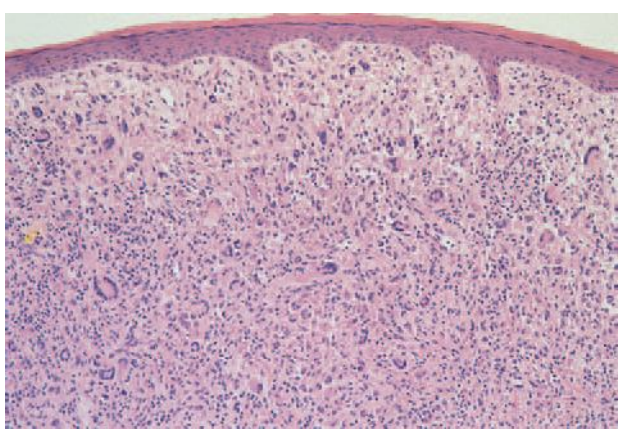

▲ **FIGURE 149-4** Juvenile xanthogranuloma. Histopathologic features. A mature lesion containing foam cells, foreign-body giant cells, and Touton giant cells.



Box 149-1

Differential Diagnosis of Juvenile Xanthogranuloma

PAPULAR

Most Likely

- Papular xanthoma
- Xanthoma disseminatum
- Tuberous xanthoma (hyperlipemic)
- Sarcoidosis (lichenoid form)
- Papular mastocytosis

Consider

- Benign cephalic histiocytosis
- Generalized eruptive histiocytosis
- Diffuse cutaneous reticulohistiocytosis
- Eruptive Spitz nevi
- Molluscum contagiosum
- Leukemia

NODULAR

Most Likely

- Hashimoto-Pritzker disease
- Nodular mastocytoma
- Spitz nevus

Consider

- Dermatofibroma
- Solitary cutaneous reticulohistiocytosis
- Giant molluscum contagiosum



severe secondary glaucoma. Lesions compatible with JXG have been described in many other organs as well, including lungs, spleen, liver, testes, pericardium, gut, kidney, and even the CNS, and in rare cares can lead to death. Patients may respond to multiagent chemotherapeutic regimens used to treat LCH.

Prognosis and Clinical Course

The cutaneous lesions of JXG tend to flatten with time. Each lesion evolves separately; thus, lesions at different stages of development may be seen in the same patient. Both cutaneous and visceral lesions disappear spontaneously, usually within 3 to 6 years. The patient's general health is not impaired, and physical and mental development is normal. Metabolic disturbances have not been identified. In the absence of associated conditions, prognosis is good.

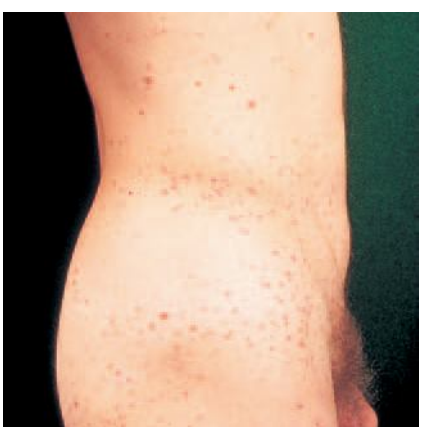

▲ **FIGURE 149-5** Generalized eruptive histiocytosis in an adult.

GENERALIZED ERUPTIVE HISTIOCYTOSIS

Clinical Findings

The skin lesions of GEH consist of an asymptomatic eruption of round or oval papules that are firm, pink or dark red, and range in size from 3 to 10 mm[16] (Fig. 149-5). These lesions appear in successive crops and are usually numerous (in the hundreds). In adults, the lesions are symmetrically distributed and may involve the mucous membranes, whereas in children the lesions are irregularly scattered over the entire body and the mucous membranes are spared.

BCH may evolve into GEH and therefore is now considered a limited form of the latter. BCH manifests as asymptomatic, slightly raised, round or oval, orange-red or red-brown lesions, 2 to 8 mm in diameter, that are initially localized on the upper part of the face, mainly around the eyelids, forehead, and cheeks[17] (Fig. 149-6; see eFig. 149-6.1 in on-line edition). Other lesions subsequently appear over the entire head, the auricles (particularly on the posterior side), the occipital region, and the neck. A few lesions may appear on the shoulders and arms. The number of early lesions varies considerably, from 2 to more than 100, and new ones continue to appear for many months. GEH and BCH do not, in general, show other features, lead to abnormalities in laboratory test results, or have known complications. However, diabetes insipidus has been reported in association with BCH from infiltration of the pituitary stalk,[18] as has been described more commonly in LCH (see Chap. 148) and XD (see the section Xanthoma Disseminatum later).



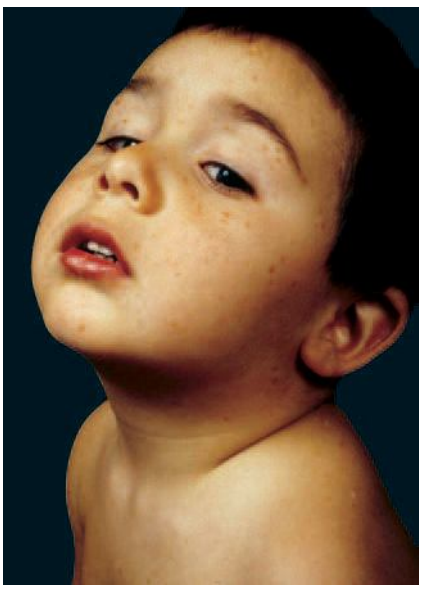

▲ **FIGURE 149-6** Benign cephalic histiocytosis. Note the distribution on the face.

Histopathologic and Ultramicroscopic Findings

The lesions of GEH (Fig. 149-7) show a dense, monomorphous, non-xanthomatous histiocytic infiltrate in the papillary and midportion of the dermis, with a few lymphocytes. The histiocytes contain a nucleus with scanty chromatin and an abundant light, poorly limited cytoplasm. These cells are often arranged in nests around vessels. Older lesions in children may contain rare foam cells and few multinucleated giant cells with peripheral nuclei. By conventional microscopy, lesions of BCH cannot be distinguished from GEH lesions. In GEH, electron microscopy shows the tumor cells to contain a large number of dense and regularly laminated bodies, often clustered together. Occasionally, worm-like bodies are found. In BCH, many coated vesicles with a diameter ranging from 500 to 1500 nm are seen in all the histiocytes. Clusters of comma-

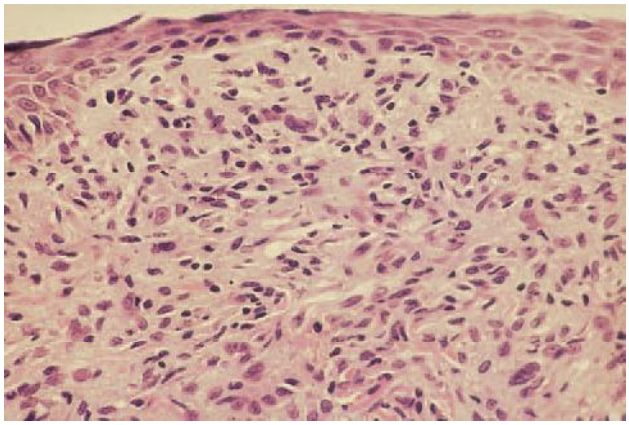

▲ **FIGURE 149-7** Generalized eruptive histiocytosis. Histopathologic features. Dense monomorphous histiocytic infiltrate in the papillary and mid-dermis, intermingled with a few lymphocytes.

shaped bodies are present in nearly one-fourth of the histiocytes. The comma-shaped bodies are formed by two electron-dense membranes of approximately 6 nm, separated by a light space of approximately 8 nm. Where the infiltrate is more dense, desmosome-like junctions may be observed among the histiocytes.

Differential Diagnosis

The disorders from which GEH should be differentiated are listed in Box 149-2.

Prognosis and Clinical Course

In GEH, new crops of lesions may continue to appear for years. Slowly the disease subsides spontaneously without a trace or leaving anetoderma-like macules. Spontaneous regression of lesions occurs months to years after the onset of BCH. Regression of lesions starts characteristically where papules first appeared. The papules begin to flatten, and then, after a short period of hyperpigmentation, the lesions disappear without leaving scars.

Box 149-2

Differential Diagnosis of Generalized Eruptive Histiocytosis

Most Likely

- Papular xanthoma
- Xanthoma disseminatum
- Multicentric reticulohistiocytosis
- Indeterminate cell histiocytosis
- Sarcoidosis (lichenoid form)
- Juvenile xanthogranuloma[a]
- Papular mastocytosis[a]

Consider

- Granuloma annulare disseminatum

[a]Children.

PROGRESSIVE NODULAR HISTIOCYTOSIS

Clinical Findings

PNH is a histiocytic disorder of skin and mucous membranes with a progressively deforming course. Cutaneous lesions consist of the eruption of hundreds of lesions of two different types: superficial papules and deep nodules. The most common lesions are yellow to orange papules, 2 to 10 mm in diameter, that are randomly scattered over the body without localization in the flexural areas. These lesions may be present in the oral, laryngeal, and conjunctival mucosae. The deep lesions are dermal nodules ranging from 1 to 5 cm, with overlying telangiectasia, mainly located on the trunk. Café-au-lait spots, arthritis, and diabetes insipidus are absent. PNH has been described in a child with a hypothalamic tumor, probably histiocytic.[19] Another patient with PNH had hepatosplenomegaly, hypothyroidism, hypocholesterolemia, hyperuricemia, and chronic myeloid leukemia, but the relationship between these features and the PNH was not established.[20]

Histopathologic and Ultramicroscopic Findings

The histopathologic features of PNH are those of a xanthogranuloma with a predominance of storiform, spindle-shaped histiocytes that are positive for macrophage/dendritic cell line markers (CD68), and negative for CD1a and S100. Electron microscopic examination reveals histiocytes with a large indented nucleus.

Differential Diagnosis

The differential diagnosis for PNH is summarized in Box 149-3.

Box 149-3

Differential Diagnosis of Progressive Nodular Histiocytosis

Most Likely

- Multicentric reticulohistiocytosis
- Papular xanthoma
- Xanthoma disseminatum
- Generalized eruptive histiocytosis
- Sarcoidosis
- Lepromatous leprosy

Consider

- Nodular mastocytoma

Prognosis and Clinical Course

In PNH new lesions continue to develop during successive years with no sign of spontaneous involution. Despite the progressive nature of the lesions, patients remain in good health.

XANTHOMA DISSEMINATUM

Clinical Findings

CUTANEOUS LESIONS XD is a rare, benign, normolipemic form of NLCH affecting the skin and mucous membranes. It is frequently associated with diabetes insipidus. The cutaneous manifestations consist of hundreds of papules that are red-brown at first and then become yellowish. They symmetrically involve the eyelids, trunk, face, and proximal extremities and, in flexures and folds, tend quickly to merge, forming soft plaques (Fig. 149-8). ECD is considered a variant of XD that has visceral manifestations and is progressive.



▲ **FIGURE 149-8** Xanthoma disseminatum.



RELATED PHYSICAL FINDINGS In approximately 50 percent of cases of XD, xanthomatous lesions may also be observed on the mouth, pharynx, larynx, conjunctiva, and cornea. Symptoms of dyspnea and dysphagia are not uncommon. Vasopressin-sensitive transitory diabetes insipidus may be present, but polyuria and polydipsia are generally mild. Osteolytic lesions have been reported in only a few patients. XD may be associated with multiple myeloma, Waldenström macroglobulinemia, and monoclonal gammopathy. In ECD the most common sign is chronic bone pain, usually mild and localized in the lower limbs. Extraosseous involvement can affect almost every organ, including the lungs, liver, kidney, heart and CNS.[21,22]



Laboratory Tests

A normal lipid profile is present in this disease, but slightly elevated levels of serum cholesterol or triglycerides have been found in a few cases. In some cases, multiple myeloma, Waldenström macroglobulinemia, and monoclonal gammopathy have been detected. When lesions affect the CNS, magnetic resonance imaging may show foci of abnormally high signal intensity. In ECD, radiographs show symmetric sclerosis typically affecting the long bones of the lower limbs with involvement of the diaphyseal and metaphyseal regions.

Histopathologic and Ultramicroscopic Findings

In the early stage of XD, biopsy specimens show a mixture of histiocytes, foam cells, and inflammatory cells; later, foam cells predominate and Touton giant cells are frequently present (Fig. 149-9). Siderosis is often observed. The proliferating cells resemble those of JXG ultrastructurally, but the plasma membranes of foam cells show many microvilli. Lesional skin sections in ECD show an infiltrate of lipid-laden histiocytes intermingled with Touton giant cells and eosinophils, surrounded by fibrosis.

Differential Diagnosis

The disorders from which XD should be differentiated are listed in Box 149-4.

Complications

In XD organ involvement may lead to a variety of complications, particularly conjunctival inflammation and respiratory obstruction. Seizures, diabetes insipidus, and growth retardation have also been described. Chronic bone pain is the hallmark of ECD.

Prognosis and Clinical Course

Based on the evolution and prognosis of reported cases, three clinical variants of XD have been distinguished: a self-healing form, a persistent form, and a progressive form (ECD).[23] The persistent form is the most frequent one. Prognosis is usually good, but respiratory tract involvement may lead to dyspnea and dysphagia. Tracheotomy has been required in a few cases. In ECD the prognosis is poor because of the high risk of visceral involvement, particularly pulmonary fibrosis.[24]

MULTICENTRIC RETICULOHISTIOCYTOSIS

Clinical Findings

CUTANEOUS LESIONS MRH is characterized by the association of a cutaneous and mucosal eruption with severe arthropathy and other visceral symptoms. The papulonodular lesions range in diameter from a few millimeters to 2 cm and are round, translucent, and yellow-rose or yellow-brown (Figs. 149-10, 149-11). Grouping of lesions into plaques can give a cobblestone appearance, but lesions are generally scattered and isolated (see eFig. 149-11.1 in on-line edition). They do not tend to ulcerate and are pruritic in about one-third of cases. These lesions preferentially affect the fingers (see Fig. 149-10), the palms and backs of the hands, the juxta-articular regions of the limbs, and the head (see Fig. 149-11). Small scattered lesions may be found on the trunk. Periungual papules (see Fig. 149-10), arranged around the nail folds, resemble "coral beads"[25] and have been noted in approximately 40 percent of cases. Severe involvement of the face may lead to a leonine facies. Xanthomatous lesions are found in 30 percent of cases. Periarticular nodules, resembling rheumatoid nodules, may occasionally be seen. Erythematous, photodistributed macules and papules have been observed in approximately 15 percent of cases and may be confused with dermatomyositis. Nail changes, including brittleness, longitudinal ridging, and atrophy, may occur. Almost 50 percent of affected patients have specific nodular lesions of the oral, nasal, and pharyngeal mucosae.

Two different sub-types without joint or visceral manifestations have been described: solitary cutaneous reticulohistiocytosis (or reticulohistiocytoma cutis) and diffuse cutaneous reticulohistiocytosis. Solitary cutaneous reticulohistiocytosis is characterized by a single firm, rapidly growing nodule varying in color from yellow-brown to dark red (Fig. 149-12). Its most common location is the head, but it may be found in almost any cutaneous site. It occurs without evidence of systemic involvement, and its onset may be preceded by trauma.

Box 149-4

Differential Diagnosis of Xanthoma Disseminatum

Most Likely

- Chronic disseminated Langerhans cell histiocytosis
- Tuberous xanthoma (hyperlipemic)
- Papular xanthoma

Consider

- Juvenile xanthogranuloma
- Generalized eruptive histiocytosis
- Multicentric cutaneous reticulohistiocytosis
- Progressive nodular histiocytosis

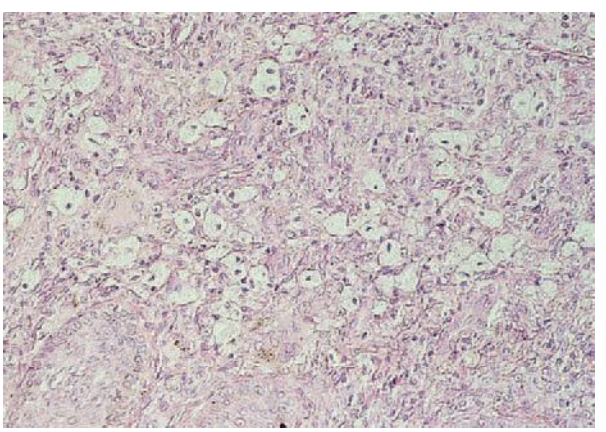

▲ **FIGURE 149-9** Xanthoma disseminatum. Histopathologic features. The lesions are characterized by a mixture of histiocytes, inflammatory cells, and foam cells. Touton giant cells are present.



▲ **FIGURE 149-10** Hands of a patient with active skin lesions of multicentric reticulohistiocytosis. Note the periungual array of some of the nodules, resembling "coral beads."

Diffuse cutaneous reticulohistiocytosis is a purely cutaneous form characterized by the eruption of firm, smooth, asymptomatic papulonodular lesions, 3 to 10 mm in diameter, scattered diffusely over the skin. The color of early lesions is pinkish yellow, whereas older lesions show a red-brown color.

RELATED PHYSICAL FINDINGS In MRH, severe chronic diffuse polyarthritis with arthralgias is the initial sign of the disease in up to two-thirds of cases.[26] The lesions symmetrically involve the hands (80 percent of cases), knees (70 percent), wrists (65 percent), and less frequently the shoulders, ankles, elbows, hips, feet, and spine. The osteoarticular lesions show a progressive destructive course for 6 to 8 years and then become stable.[27] Involvement of the muscles (myositis, myotonia, and myoatrophy), cardiopulmonary system (pericarditis, cardiac insufficiency, pleuritis, pulmonary infiltration), eyes (exophthalmos, conjunctival infiltration), gastrointestinal system (gastric ulcer), thyroid gland (thyroid nodules), and submandibular salivary glands have occasionally been reported, but histologic documentation of involvement at these sites is rare. Fever, weight loss, and weakness can be present. The term *familial histiocytic dermatoarthritis* is used to indicate a particular form of MRH characterized by familial occurrence and typical ocular involvement (glaucoma, uveitis, and cataracts). Internal malignancy may be associated in 15 percent to 27 percent of cases. Solid tumors such as bronchial, breast, gastric, and cervical carcinomas are most common. Lymphomas and myelodysplastic syndromes have been found less frequently, and malignant melanoma has been reported in three cases. Whether MRH can be interpreted as a true paraneoplastic disease is not clear. Whatever the nature of the association, the incidence of internal neoplasia is such that patients who come for treatment of MRH should be investigated for concomitant internal neoplasm. MRH has been described in association with autoimmune diseases, systemic vasculitis, tuberous sclerosis, sclerosing lesions of the leg, and tuberculosis.



▲ **FIGURE 149-11** Mucocutaneous nodular infiltrate on the perioral and perinasal areas, as well as the oral and nasal mucosae in a patient with multicentric reticulohistiocytosis.



▲ **FIGURE 149-12** Solitary cutaneous reticulohistiocytosis.

Laboratory Tests

In MRH, elevated erythrocyte sedimentation rate and anemia have been observed in about half of patients and hypercholesterolemia in one-third of cases. An increase in immunoglobulin G and the presence of cryoglobulinemia and cold agglutinins have occasionally been reported. Rheumatoid factor is usually not detected. Radiographically, the joint lesions of MRH are characterized by bilateral, symmetrical, sharply circumscribed, and rapidly progressive erosions that spread from the margins to the joint surfaces, often with concomitant separation of the bone ends but without subchondral sclerosis.

Histopathology and Ultramicroscopic Findings

The histologic findings in MRH and its sub-types are identical. Histologically, the early lesions may be composed of histiocytes and lymphocytes, and therefore may be confused with other cutaneous histiocytoses. Older lesions show the presence of numerous large, mononucleated or multinucleated histiocytes with an abundance of eosinophilic, homogeneous cytoplasm containing fine granules that has a ground-glass appearance (Fig. 149-13). The number of giant cells may vary, and the diameter of these cells may reach 100 nm. The nuclei of the multinucleated cells may be arranged haphazardly or they may align along the periphery or cluster in the center. Plasma cells and eosinophils are sometimes present. Fragmentation and clumping of collagen and elastic fibers have been reported. At times, connective tissue and cell phagocytosis may be seen. Histochemically, the granular material in histiocytes and giant cells stains with periodic acid-Schiff after diastase digestion, Sudan black, and scarlet red, which indi-



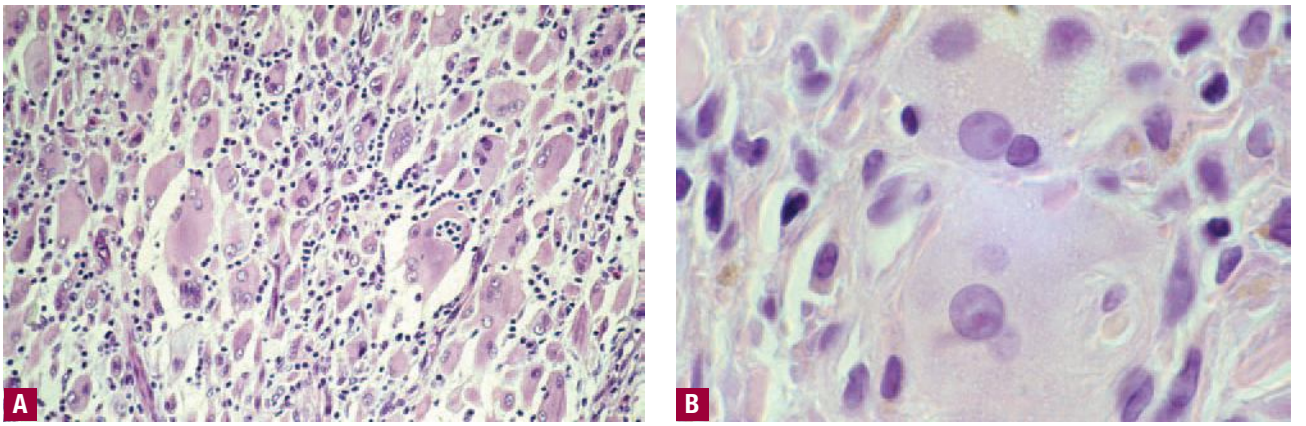

▲ **FIGURE 149-13** Photomicrographs of a lesion of multicentric reticulohistiocytosis. Note the histiocytic infiltrate (**A**) and multinucleated giant cells with aggregated nuclei and ground-glass cytoplasm (**B**).



cates the presence of glycolipids and/or glycoproteins and neutral fat.[28]

Differential Diagnosis

The differential diagnosis for MRH is summarized in Box 149-5.

Complications

Complications occurring in MRH are mainly due to visceral involvement of the disease. Lesions in the upper airway may lead to dysphonia and/or dysphagia. Cardiopulmonary manifestations are more frequently reported and may also be fatal. In addition, bones and all the visceral organs may be affected, which leads to weight loss and pyrexia that complicate the potentially mutilating inflammatory polyarthritis.

Prognosis and Clinical Course

The purely cutaneous forms of reticulohistiocytosis may involute spontaneously. It is possible that the diffuse, purely cutaneous form is an early stage of MRH before the appearance of joint and visceral lesions. In MRH, the mucocutaneous course does not parallel the articular course. The mucocutaneous lesions have an unpredictable course and may remit spontaneously. In half of the patients, the osteoarticular manifestations become stable, whereas in the other half, they cause progressive destruction. The prognosis is favorable for cutaneous forms. The prognosis for MRH is related to the severity of the osteoarticular manifestations, the presence of visceral involvement, and underlying neoplasms if present.

Box 149-5

Differential Diagnosis of Multicentric Reticulohistiocytosis

Most Likely

- Rheumatoid arthritis
- Dermochondrocorneal dystrophy
- Familial histiocytic dermatoarthrosis
- Lipodermoarthrosis
- Progressive nodular histiocytosis

Consider

- Farber lipogranulomatosis
- Xanthoma disseminatum
- Lipoid proteinosis
- Lepromatous leprosy
- Sarcoidosis
- Self-healing cutaneous mucinosis
- Fibroblastic rheumatism

NECROBIOTIC XANTHOGRANULOMA

Clinical Findings

CUTANEOUS LESIONS In NXG, early cutaneous lesions consist of indurated papulonodules varying in color from red-orange to violaceous or yellow and involving the dermis and subcutaneous tissue. These lesions slowly enlarge into plaques with well-demarcated edges, ranging in diameter from a few to 25 cm. There is central atrophy with telangiectasias or areas of ulceration (Fig. 149-14). Most cases are asymptomatic, but pain or a burning sensation may be noted. The lesions are usually multiple and involve, in order of frequency, the face, trunk, and extremities. The periorbital area is the site of predilection and is involved in 85 percent of cases. The oral mucosa is occasionally involved. Hepatosplenomegaly has been observed in approximately 20 percent of patients.

RELATED PHYSICAL FINDINGS NXG may be associated with myeloma, arthropathy, hypertension, neuropathy, neoplastic syndrome, primary biliary cirrhosis, and Graves disease.

Laboratory Tests

Ninety percent of patients with NXG have paraproteinemia (immunoglobulin G κ or λ light chains), especially in cases with associated myeloma. Cryoglobulinemia has been found in approximately 40 percent of cases. Other abnormal laboratory test results may include an elevated sedimentation rate, neutropenia, leukopenia, anemia, and decreased levels of CH50.

Histopathologic and Ultramicroscopic Findings

The histopathologic picture of NXG is characteristic and consists of a granulomatous infiltrate involving the whole dermis and subcutis composed of a mixture of lymphocytes, epithelioid cells, foam cells, and Touton giant cells. Areas of severe, clearly defined necrosis are sharply delineated from the surrounding granuloma. Typically, cholesterol crystals are located within the necrobiotic areas. Numerous, atypical, very large, bizarrely angulated, multinucleated giant cells may be seen adjacent to the areas of necrosis. Dense, well-defined lymphoid nodules, occasionally containing a germinal center, may be present in the dermis or subcutis. Touton cell panniculitis may involve the entire fat lobules. Occasionally, a granulomatous infiltrate may surround some vessels. Ultrastructurally, cells are rich in lipid droplets, cholesterol clefts, and myeloid bodies and are similar to those observed in JXG.

Differential Diagnosis

The disorders from which NXG should be differentiated are listed in Box 149-6.

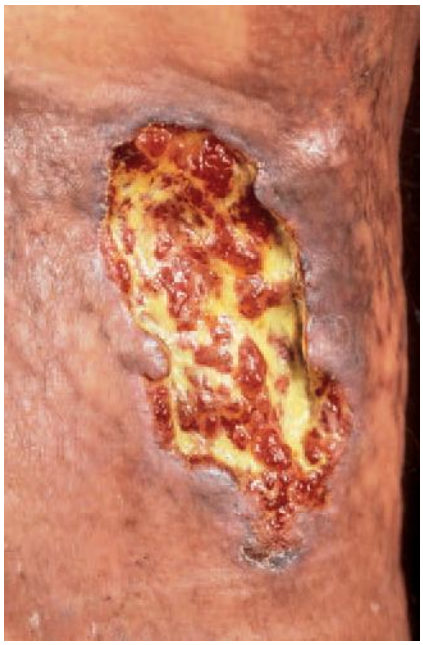

▲ **FIGURE 149-14** Necrobiotic xanthogranuloma on the calf. Note "granulomatous" periphery of the lesion, with central ulceration and necrotic material at the base.

Complications

In NXG the periorbital involvement may lead to ocular complications such as lagophthalmos, conjunctivitis, keratitis, scleritis, uveitis, corneal ulceration, and even loss of ocular function. Nausea, vomiting, epistaxis, back pain and Raynaud phenomenon have also been recorded.

Prognosis and Clinical Course

NXG has a chronic, often progressive course that is characterized by the appearance of new lesions and ulcerations. The prognosis in given cases is difficult to predict and depends on extra-cutaneous involvement and the presence of visceral tumors such as multiple myeloma.

Box 149-6

Differential Diagnosis of Necrobiotic Xanthogranuloma

Most Likely

- Granuloma annulare
- Necrobiosis lipoidica
- Xanthoma disseminatum
- Multicentric reticulohistiocytosis

Consider

- Juvenile xanthogranuloma
- Hyperlipemic xanthoma

SINUS HISTIOCYTOSIS WITH MASSIVE LYMPHADENOPATHY (ROSAI-DORFMAN DISEASE)

Clinical Findings

CUTANEOUS LESIONS SHML is a benign, generally self-limited disease confined mainly to cervical lymph nodes. Cutaneous manifestations are observed in approximately 10 percent of patients and are polymorphic (Fig. 149-15). They may occur as yellowish macules and patches, reddish-brown papules, and plaques and nodules that may become eroded or ulcerated. In one patient, firm purple nodules and tumors as large as 10 cm in diameter were noted, but in most instances the lesions are much smaller, multiple, widespread, and asymptomatic. Periocular involvement of SHML can result in lobulated induration of the eyelids. Cutaneous lesions may be the initial manifestation and sole presenting feature of the disease. Massive bilateral cervical lymphadenopathy, usually painless, is the hallmark of the condition.[29] Less commonly, axillary, mediastinal, inguinal, and preauricular lymph nodes may be affected.

RELATED PHYSICAL FINDINGS SHML is usually accompanied by fever. Extra-nodal disease occurs in approximately 25 percent of patients and may be the initial manifestation of the disorder. The extra-nodal non-cutaneous sites most commonly affected are the eye, upper respiratory tract, liver, spleen, testes, skeleton, and nervous system. Involvement of the gastrointestinal tract is rare. An elderly woman with hematochezia was found to have SMLH of the rectum presenting as a rectal mass.[30]

Laboratory Tests

SHML is usually accompanied by an elevated erythrocyte sedimentation rate, leukocytosis with neutrophilia, and polyclonal hypergammaglobulinemia. Less frequent findings include moderate anemia (60 percent), lymphopenia, elevated titers of Epstein-Barr virus, and, in one case,[31] elevated *Klebsiella* antibody titers. Axial post-contrast computed tomography can highlight the lymphadenopathy.

Histopathologic and Ultramicroscopic Findings

Histopathologically, the skin lesions of SHML are characterized by a diffuse dermal infiltrate composed predominantly of histiocytes with large vesicular nuclei and abundant pale cytoplasm. Some histiocytes are foamy, multinucleated, or both.



▲ **FIGURE 149-15** Sinus histiocytosis with massive lymphadenopathy.

Histiocytes are sometimes aggregated in clusters resembling lymph node sinuses. Lymphocytes, plasma cells, and polymorphonuclear leukocytes, typically eosinophils, may be intermixed in the infiltrate. Emperipolesis (phagocytosis of leukocytes, especially lymphocytes) is a constant feature. In electron microscopic views most of the histiocytes are rich in phagosomes and may contain clusters of comma-shaped bodies.

Differential Diagnosis

The differential diagnosis for SHML is summarized in Box 149-7.

Complications

Extra-nodal SHML lesions have led to bilateral anterior granulomatous uveitis and may mimic neurofibromatosis, meningioma, pachymeningitis, and chronic ankle arthritis.[32,33]

Prognosis and Clinical Course

In most patients, SHML has a benign course with spontaneous regression over a period of months to years. Usually the extra-nodal lesions regress first,

Box 149-7

Differential Diagnosis of Sinus Histiocytosis with Massive Lymphadenopathy

Most Likely

- Abscesses
- Hodgkin disease
- Tuberculosis

Consider

- Sarcoidosis
- Leukemia
- Acquired immunodeficiency syndrome

whereas adenopathy may persist for years. A worse prognosis results mainly from the associated immunologic abnormalities.

TREATMENT

Most forms of NLCH, such as JXG, do not require treatment because the disease is asymptomatic and self-healing. When treatment is necessary, as in XD, ECD, MRH, NXG, or SHML, therapy options are few and treatment is often unsuccessful.

Treatment of XD is usually not helpful. Vasopressin is necessary for the associated diabetes insipidus. Radiotherapy, cryotherapy, corticosteroids, and antiblastic chemotherapy have been attempted with palliative results in the more disfiguring forms.

Therapy for MRH has frequently been disappointing. Anti-inflammatory agents such as aspirin, indomethacin, and pyrazolones have shown little effect. Systemic corticosteroids may be effective on articular lesions, but only for a short period of time. Dexamethasone pulse therapy led to a dramatic response in one case.[34] Azathioprine is of no benefit alone but in association with prednisolone may have a beneficial effect on both skin and joint lesions. Antimitotic agents (mainly cyclophosphamide and chlorambucil) have been reported to induce regression of lesions in only a few patients. Oral methotrexate seems to be the most effective. Etanercept has been used successfully to treat both cutaneous and articular symptoms. Generally, solitary cutaneous lesions are surgically excised.

In NXG, intermittent glucocorticoid treatment can induce a partial response. Low dosages of alkylating agents, such as chlorambucil or melphalan, may lead to remission of the paraproteinemia and skin lesions but do not prevent the evolution to multiple myeloma. Temporary remission of skin lesions has been obtained with radiation therapy and with plasmapheresis.[35]

As a rule, because the vast majority of lesions of SHML heal spontaneously, no treatment is necessary.[36] In rare instances, a space-occupying lesion will interfere with the function of an organ, and then treatment with systemic glucocorticoids or with various chemotherapeutic regimens might be useful.[37]

PREVENTION

At present, because the causes of all of the forms of NCLH are unknown, the possibility of preventing such diseases does not exist. As in LCH, future directions include complete genome hybridization and derivation of a gene expression profile.

KEY REFERENCES

The full reference list for all chapters is available at www.digm7.com.

1. Henter JI, Tondini C, Pritchard J: Histiocyte disorders. *Crit Rev Oncol Hematol* **50**:157, 2004
8. Weitzman S, Jaffe R: Uncommon histiocytic disorders: The non–Langerhans cell histiocytoses. *Pediatr Blood Cancer* **45**:256, 2005
16. Seward JL, Malone JC, Callen JP: Generalized eruptive histiocytosis. *J Am Acad Dermatol* **50**:116, 2004
23. Alexander AS et al: Xanthoma disseminatum: A case report and literature review. *Br J Radiol* **78**:153, 2005
25. Luz FB et al: Multicentric reticulohistiocytosis. *J Eur Acad Dermatol Venereol* **15**:524, 2001
29. Coras B et al: Rosai-Dorfman disease with cutaneous manifestation (sinus histiocytosis with massive lymphadenopathy). *Eur J Dermatol* **16**:293, 2006



CHAPTER 150

Biology of Mast Cells and the Mastocytosis Syndromes

Melody C. Carter
Dean D. Metcalfe

BIOLOGY OF MAST CELLS

Mast cells are the primary effector cells in immunoglobulin E (IgE) mediated inflammatory reactions. They are implicated in both acquired and innate immune responses, wound healing, fibrosis, angiogenesis, and autoimmune diseases.

Mast Cell Distribution and Identity

Mast cells are widely distributed, long-lived cells found predominately in connective and mucosal tissues and often in proximity to blood vessels, nerves, and lymphatic tissues.[1] Mast cells are abundant in the skin, respiratory tract, gastrointestinal tract, and genitourinary tract. The cytoplasmic granule content, cell size, and susceptibility to pharmacologic agents vary with specific location. All human mast cells contain tryptase, histamine, and proteoglycans, including heparin and chondroitin sulfate E. Mast cells are classically identified in tissue by toluidine blue or Giemsa dye that stains the cytoplasmic granules, and more recently, by immunohistochemistry using an antibody that recognizes mast cell tryptase. Human mast cells are classically divided into two types. Mast cells that contain tryptase and chymase are referred to as *TC mast cells* (MC_{TC}). Such cells tend to be located in submucosal tissues. Increased numbers of these cells are found in fibrotic diseases.[2] Mast cells that contain tryptase but not chymase are referred to as *T mast cells* (MC_T) and are increased in allergic and parasitic diseases. MC_T cells are decreased in the gastrointestinal mucosa in patients infected with human immunodeficiency virus.[3] A third mast cell phenotype has been described. These mast cells are located in the skin, lymph nodes, and intestinal submucosa and contain only chymase.[4,5]

MAST CELLS AT A GLANCE



- Mast cells are derived from pluripotent stem cells.
- Stem cell factor is required for proliferation and survival.
- Mast cells release both pre-formed and generated mediators when activated.
- Activation occurs both in innate and acquired immune responses.

Development and Differentiation

Mast cells arise from a $CD34^+$, KIT^+ pluripotent progenitor stem cell. Cross-

linking KIT by stem cell factor (SCF) is essential for these precursor cells to differentiate into mast cells. Mature mast cells require SCF for survival. Other cytokines that regulate SCF-dependent mast cell differentiation and proliferation include interleukin 13 (IL-13), IL-4, IL-5, and interferon-γ (IFN-γ). IL-3 shares a number of signal transduction pathways with SCF but has minimal direct effects on human mast cell proliferation except in early cultures. IL-4 enhances mast cell function when added to mature cultures. For example, IL-4 increases FcεRI expression on mast cells and subsequently potentiates spontaneous and antigen-stimulated degranulation release. In contrast, when IL-4 is added during SCF-dependent mast cell differentiation, it inhibits cell division and decreases final mast cell numbers. In developing mast cells, IFN-γ inhibits mast cell proliferation and influences mast cell phenotype and function. Although mature mast cells express the IFN-γ receptor, IFN-γ has a minimal effect on mature mast cell activation.[6]

Mast Cell Activation and Mediators

Antigen-dependent aggregation of FcεRI-bound IgE on the surface of mast cells is a primary mechanism of activation of mast cells and subsequent release of preformed pro-inflammatory mediators, as well as of newly synthesized mediators (Table 150-1). Non–IgE-driven signals that activate mast cells include Toll-like receptor ligands such as lipopolysaccharide and nucleic acids, the anaphylatoxins C3a and C5a, and certain chemokines and cytokines.[7]

PRE-FORMED SECRETORY MEDIATORS Preformed secretory granular mediators are released in response to aggregation of the high-affinity IgE receptor, activation through complement receptors, or activation by cytokines. Mast cell tryptase is released upon activation of mast cells, along with histamine, heparin, chymase, and carboxypeptidase A.

Tryptase is the most abundant human mast cell protein and exists in two forms that show 90 percent homology, α and β tryptases. Proforms of tryptase are believed to be secreted from mast cells and account for background serum tryptase levels. The biologic function of tryptase has not been completely defined, but it appears to activate protein cascade systems, enhance vasopermeability, and alter airway smooth muscle reactivity. Tryptase has the capability to cleave fibronectin, vasoactive intestinal peptide, and kininogens. It is also a growth factor for epithelial cells and fibroblasts. The total tryptase level in blood is used as an indirect parameter of mast cell burden and mast cell activation. Baseline tryptase levels are generally elevated in patients with systemic mastocytosis (SM). Increased serum tryptase levels are also observed within 15 minutes of onset of anaphylaxis with a peak level seen at 1 to 2 hours, although this is not consistent.[8]

The mast cell protease, chymase, converts angiotensin I to angiotensin II.[9] The vasoactive properties produced by angiotensin II may contribute to transient hypertension in some individuals during mast cell activation reactions. Carboxypeptidase A similarly converts angiotensin I to angiotensin II.[10]

Histamine is stored in all mast cells, as well as basophils, and released with cell activation. The biologic effects of histamine are mediated through activation of H_1, H_2, H_3, and H_4 receptors. H_1 receptors are located on epithelial cells as well as vascular and perivascular cells and mediate vascular permeability and instability, bronchial and intestinal smooth muscle contraction, edema, pruritus, and flushing. H_2 receptors are present on epithelial cells in the gastrointestinal tract and are associated with gastric hypersecretion. H_3 receptors are found in the brain and gastrointestinal tract and may be associated with certain neurologic effects such as headache. H_4 receptors are expressed predominately on bone marrow cells and are present on eosinophils and mast cells.[11–17] H_4 receptor function in humans is not well understood. Although the expression of H_4 receptors is low in most tissues, its expression on mast cells, eosinophils, and T cells implies it has a role in inflammatory and immune responses.

TABLE 150-1
Selected Mast Cell Mediators

Mediators	Biologic Effects	Possible Consequences
Pre-formed		
Histamine	Vasodilation, increased vascular permeability, gastric hypersecretion, bronchoconstriction	Hypotension, flushing, urticaria, abdominal pain; (peptic, colic) diarrhea, malabsorption
Heparin	Anticoagulant, inhibition of platelet aggregation	Prolonged bleeding time
Tryptase	Endothelial cell activation, fibrinogen cleavage, mitogenic for smooth muscle cells	Osteoporosis/osteopenia, disruption of cascade systems (clotting, etc.)
Chymase	Converts angiotensin I to II, lipoprotein degradation	Hypertension
Newly synthesized		
Leukotrienes	Increased vascular permeability, bronchoconstriction, vasoconstriction	Bronchospasm, hypotension
Prostaglandins	Vasodilatation, bronchoconstriction	Flushing, urticaria
Cytokines		
Stem cell factor	Growth and survival of mast cells, chemotaxis of KIT^+ cells	Mast cell hyperplasia, focal aggregates
Tumor necrosis factor-α	Activation of vascular endothelial cells, cachexia, fatigue	Weight loss, fatigue
Transforming growth factor-β	Enhanced production of connective tissue components	Fibrosis
IL-5	Eosinophil growth factor	Eosinophilia
IL-6	Growth and survival of mast cells	Fever, bone pain, osteoporosis/osteopenia
IL-16	Lymphocyte accumulation	Focal aggregates

IL = interleukin.





Heparin stabilizes and regulates secretory granule proteases. In addition, it binds to antithrombin III, inhibiting activation of the clotting cascade. Heparin binding also regulates and stabilizes cytokines and growth factors. Heparin-mediated effects include bleeding diathesis, osteopenia, and osteoporosis.

NEWLY SYNTHESIZED MEDIATORS Newly formed, membrane-derived lipid mediators, produced by mast cell activation, include prostaglandin D_2 (PGD_2), cysteinyl leukotrienes, and platelet-activating factor (PAF). These mediators have profound effects in both the immediate and late allergic reactions.[18,19] Receptors for PGD_2 are present on vascular and perivascular cells and mediate effects including bronchospasm, vasodilation, vasopermeability, and inhibition of platelet aggregation.[20] Flushing in response to niacin is mediated by PGD_2.[21] Cysteinyl leukotrienes increase vascular permeability and cause bronchoconstriction.[22–24] These mediators also are responsible for the long-lasting wheal and flare in response to injection of antigen in human skin.[23,24] Leukotrienes are believed to contribute to abdominal symptoms in patients with SM.

PAF is a potent inducer of bronchoconstriction mediated through microvascular leakage in the airways and the subsequent development of submucosal edema. Numerous cells synthesize PAF, including endothelial cells, neutrophils, and macrophages. PAF reproduces many aspects of inflammation by functioning as a chemotactic agent for eosinophils,[25] neutrophils,[26] and mast cells.[27]

Mast cells similarly produce and release a number of cytokines that may contribute to the pathologic features of mastocytosis. Tumor necrosis factor causes cachexia and vascular instability. Transforming growth factor-β contributes to tissue fibrosis, abnormal bone remodeling, osteopenia, and eosinophilia.[28] IL-4 is implicated in IgE synthesis and the development of a T helper 2 phenotype. IL-5 is instrumental in the recruitment and survival of eosinophils that contribute to tissue damage. IL-6 has been linked to the pathogenesis of osteoporosis[29] and is elevated in the plasma of patients with SM.[30–32] Evidence for the mast cell's role in innate immunity is shown by the production of IL-1β, IL-6, and other chemokines in response to pathogens and their products.[4,33,34]

MASTOCYTOSIS

Mastocytosis is a condition characterized by mast cell hyperplasia in one or more of the following organs: the bone marrow, liver, spleen, lymph nodes, gastrointestinal tract, and skin. Clinically, the disease is often accompanied by evidence of constitutive mast cell activation. This evidence includes pruritus, flushing, urtication, abdominal pain, nausea, vomiting, diarrhea, musculoskeletal pain, vascular instability, headache, and neuropsychiatric difficulties. Mastocytosis may present at any age and demonstrates a slight male-to-female predominance. The prevalence of the disease is unknown, and familial occurrence appears unusual.

TABLE 150-2
World Health Organization Classification of Mastocytosis[a]

VARIANT TERM	ABBREVIATION	SUBVARIANTS
Cutaneous mastocytosis	CM	Urticaria pigmentosa Diffuse CM Mastocytoma of skin
Indolent systemic mastocytosis	ISM	Smoldering SM Isolated bone marrow mastocytosis
Systemic mastocytosis with an associated clonal hematologic non-mast cell lineage disease	SM-AHNMD	SM-acute myelogenous leukemia SM-myelodysplastic syndrome SM-myeloproliferative disease SM-chronic myelomonocytic leukemia SM-non-Hodgkin lymphoma
Aggressive systemic mastocytosis	ASM	
Mast cell leukemia Mast cell sarcoma Extra-cutaneous mastocytoma	MCL	Aleukemic MCL

[a]For details of the WHO classification of mastocytosis, see Valent P et al: *World Health Organization Classification of Tumours: Pathology and Genetics of Tumours of the Haematopoietic and Lymphoid Tissues*, edited by Jaffe ES et al. Lyon, IARC Press, 2001.

MASTOCYTOSIS AT A GLANCE



- The hallmark of mastocytosis is a pathologic accumulation of mast cells.
- Mastocytosis occurs at any age.
- The skin is the most commonly involved organ system.
- Classification of mastocytosis is critical for selection of appropriate therapy.

MASTOCYTOSIS SYNDROMES

Mastocytosis represents a disease spectrum characterized by a diverse phenotypic expression, along with pathologic and genetic findings that affect prognosis. Table 150-2 represents an updated consensus classification of the variants of mastocytosis, adopted by the World Health Organization (WHO) in 2001.[35] The most common forms are cutaneous mastocytosis (CM) and indolent SM (ISM), both of which have a good prognosis. The prognosis in patients with other variants is less optimistic. In children, the skin is the most common organ involved and is usually the only clinical manifestation of the disease, particularly with a mastocytoma or limited urticaria pigmentosa (UP). SM occurs much more commonly in adults and rarely in children. It is diagnosed on the basis of bone marrow histopathology outlined by the WHO consensus panel (Table 150-3). ISM is diagnosed when criteria for mastocytosis are met, and there is no evidence of an associated clonal hematologic disorder or severe liver disease, hypersplenism, or significant lymphadenopathy. In most cases, symptomatic management is adequate for CM and ISM.

SM with an associated clonal hematologic non-mast cell lineage disease (SM-AHNMD) is rarely observed in children. In this group, examination of the bone marrow and peripheral blood reveals the hematologic abnormality. The prognosis for these patients is determined by the course of the associated hematologic dis-

MASTOCYTOSIS SYNDROMES AT A GLANCE

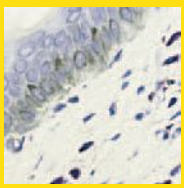

- Prevalence unknown, considered an unusual disorder.
- Generally benign in children.
- In adults, most commonly associated with a somatic mutation in KIT, the receptor for stem cell factor that promotes mast cell proliferation.
- Cutaneous manifestations may occur alone or in association with systemic disease.
- Cutaneous findings consist of hyperpigmented macules, papules, or nodules, or a diffuse infiltration of the dermis.
- Related features may be flushing, pruritus, hypotension, nausea, dyspepsia, and diarrhea.
- Most common extra-cutaneous tissues involved are the bone marrow, liver, spleen, and lymph nodes.
- May be associated with myeloproliferative and myelodysplastic disorders.
- Treatment depends upon variant of disease.

order. Patients with aggressive SM (ASM)[36] have poor prognostic features, including impaired liver function, hypersplenism, and malabsorption, but they do not have a distinctive hematologic disorder or mast cell leukemia (MCL).

TABLE 150-3
Diagnostic Criteria for Systemic Mastocytosis (Major and One Minor or Three Minor Criteria Are Needed)[a]

Major
- Multifocal dense infiltrates of mast cells in bone marrow and/or other extra-cutaneous organs

Minor
- More than 25% of the mast cells in bone marrow aspirate smears or tissue biopsy sections are spindle shaped or display atypical morphology.
- Detection of a codon 816 c-kit point mutation in blood, bone marrow, or lesional tissue.
- Mast cells in bone marrow, blood, or other lesional tissue expressing CD25 or CD2.
- Baseline total tryptase level of greater than 20 ng/mL.

[a]For details of the WHO classification of mastocytosis, see Valent P et al: *World Health Organization Classification of Tumours: Pathology and Genetics of Tumours of the Haematopoietic and Lymphoid Tissues*, edited by Jaffe ES et al. Lyon, IARC Press, 2001.

Patients with ASM have rapidly increasing mast cell numbers and are difficult to manage medically. Their prognosis is less favorable than that of patients with ISM. MCL is a rare variant of SM. MCL is characterized by multiorgan failure and in bone marrow smears; mast cells represent greater than 20 percent of the nucleated cell population. Mast cells also account for 10 percent or more of peripheral blood nucleated cells.[37,38] Mast cell sarcomas are rare; they have localized destructive growth, and distant spread is possible. Mast cells in these tumors are highly atypical and immature. Extra-cutaneous mastocytomas are very rare, usually localized to the lung, and consist of mature mast cells.



▲ **FIGURE 150-1** Mastocytoma on the sole of a child.

Clinical Manifestations

All categories of mastocytosis share clinical features caused by the excess production of mast cell–dependent mediators, although some aspects of disease may predominate in a specific category. The skin, gastrointestinal tract, lymph nodes, liver, spleen, bone marrow, and skeletal system are responsible for the most significant management problems. The respiratory tract, genitourinary, and endocrine systems are seldom involved. Furthermore, patients with mastocytosis do not suffer from recurrent bacterial, fungal, or viral infections, even though mast cells release mediators such as histamine that inhibit immune responses in vitro.

Solitary mastocytomas are brownish nodules, which, when traumatized, may cause systemic symptoms such as flushing and hypotension (Fig. 150-1). The onset is generally before age 6 months, and it is unusual to develop subsequent skin lesions more than 2 months after the presentation of the initial lesion.[39]

UP is the most common skin manifestation of cutaneous disease in both adults (Fig. 150-2) and children (Fig. 150-3;



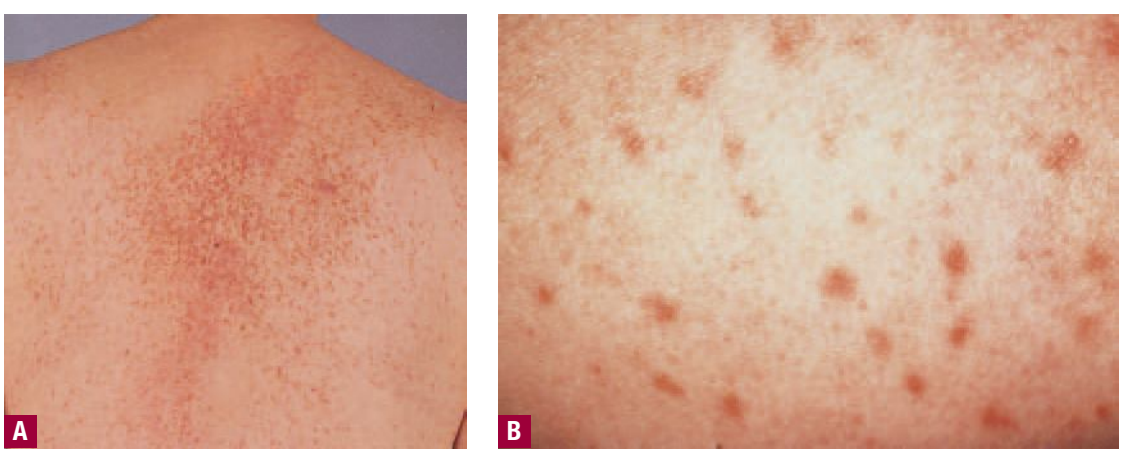

▲ **FIGURE 150-2** Urticaria pigmentosa in an adult with indolent systemic mastocytosis. **A.** Hundreds of lentigo-like macules are seen on the back of this adult. If vigorously rubbed, these lesions will show urtication and become erythematous, raised, and pruritic. **B.** Close-up.





▲ **FIGURE 150-3** Urticaria pigmentosa in a child with cutaneous disease only.



▲ **FIGURE 150-5** Diffuse cutaneous mastocytosis in a child.

see eFig. 150-3.1 in on-line edition) but the size and number are more variable in children with CM and typically more uniform in adults and children with systemic disease (Fig. 150-4). UP lesions are seen in greater than 90 percent of patients with ISM and in fewer than 50 percent of patients with SM-AHNMD or ASM. The lesions of UP are yellow-tan to reddish-brown macules or slightly raised papules scattered over the body with generally less involvement of the sun-exposed areas. Also generally spared are the palms, soles, face, and scalp. Mild trauma, including scratching or rubbing of the lesions, usually causes urtication and erythema around the macules; this is known as *Darier sign*. Many infants or young children have limited disease with few complaints, except for recurrent wheals at the same location. These often occur at sites of friction at the site of the lesion(s) such as at the edge of the diaper area.

Diffuse CM (DCM) is seen initially almost exclusively in infants (Fig. 150-5), although it may persist into adult life. The skin may be thickened with a peau d'orange appearance with a reddish-brown discoloration without discrete lesions. Dermographism with formation of hemorrhagic blisters is common.

Telangiectasia macularis eruptiva perstans is observed in fewer than 1 percent of patients with mastocytosis and is seen almost exclusively in adults. It appears as red-brown telangiectatic macules with irregular borders (see eFig. 150-5.1 in on-line edition). The occurrence of Darier sign and pruritus is variable, and this form of mastocytosis is least likely to blister.

Bullae in mastocytosis may erupt spontaneously or in association with infection and immunization and necessitate distinguishing mastocytosis from other bullous diseases of childhood (Fig. 150-6; Box 150-1). Mastocytosis may also be exacerbated by changes in climatic temperature, skin friction, and ingestion of hot beverages, spicy foods, alcohol, or certain drugs. Formation of bullae is a characteristic limited to pediatric-onset cutaneous disease. With mastocytoma, the tendency to blister usually abates after the first few years and, with UP, by puberty in the majority of affected children. The diagnosis is confirmed by characteristic skin histopathology (Fig 150-7).

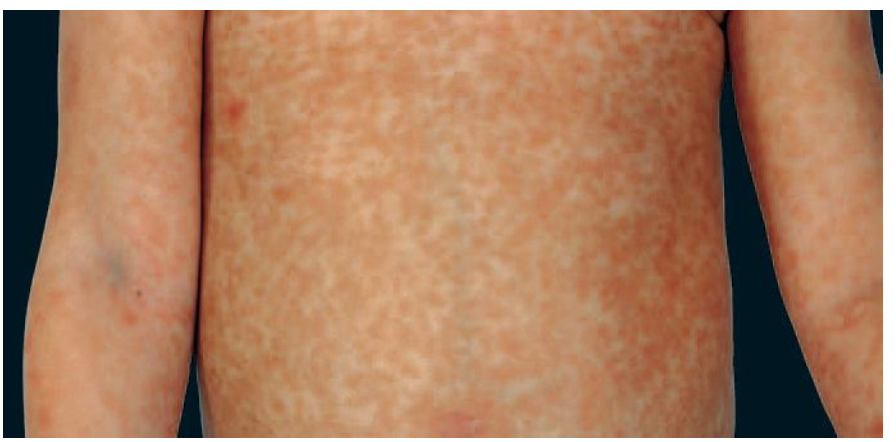

▲ **FIGURE 150-4** Urticaria pigmentosa systemic pediatric-onset disease.

Related Clinical Findings

Non-cutaneous disease is quite uncommon during childhood, although gastrointestinal involvement is the most frequent non-cutaneous feature. Gastric hypersecretion caused by elevated plasma histamine with resultant gastritis and peptic ulcer disease is the most common problem in both children and adults.[40] Diarrhea and abdominal pain are also frequent. Malabsorption is limited to a subset of patients with advanced disease. Significant hepatic disease in adults and children with ISM is relatively infrequent. Serious manifestations of hepatic

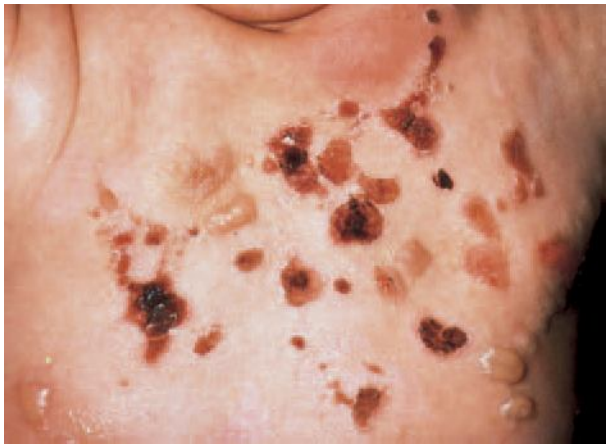

▲ **FIGURE 150-6** Bullous eruption on the back of a child with diffuse cutaneous mastocytosis.

and splenic involvement, including portal hypertension and ascites associated with liver fibrosis,[41] are more common in patients who have SM-AHNMD or ASM. Splenic involvement is present in about one-half of patients with mastocytosis with evidence of systemic disease.[42,43] Markedly increased splenic weights (greater than 700 g) generally occur in patients who fit into unfavorable categories of mastocytosis, including ASM or SM-AHNMD. Anemia, leukopenia, thrombocytopenia, and eosinophilia may occur in association with systemic disease and suggest SM-AHNMD, ASM, or MCL.

Patients with mastocytosis sometimes experience flushing or vascular collapse, even if there is widespread cutaneous involvement. In occasional patients, such reactions may be provoked by triggers of mast cell release, including alcohol, aspirin, narcotics, iodinated contrast media, insect stings, or other significant allergic triggers, exercise, or infections. Cutaneous responses to intradermal histamine are unchanged in patients with UP.[44]

Musculoskeletal pain affects 19 percent to 28 percent of patients. In patients with severe or advanced disease, pathologic fractures may occur. Neuropsychiatric abnormalities have been reported.[45,46] These include decreased attention span, memory impairment, headache, and irritability. Depression as a consequence of chronic disease or possibly mediated by mast cell products is a possibility. There is no clear psychopathology that exists in children with mastocytosis.[45]

Biopsies and Laboratory Testing

In patients with UP, mast cells are found in increased numbers in the dermal papillae beneath UP macules and papules, particularly near blood vessels (see Fig. 150-7).[47] Mast cells may distribute in a band-like infiltrate of the papillary dermis (see eFig. 150-7.1 in on-line edition) or appear as nodular infiltrates from the papillary dermis to subcutaneous tissues. On average, there is a 15- to 20-fold increase in mast cells beneath those lesions, but in occasional patients, only a two- to fourfold increase in mast cells is found. These observations highlight the importance of correlating the gross skin examination with skin mast cell numbers and to avoid the diagnosis of UP solely on the basis of small increases in dermal mast cells. Mast cells may also be found in increased numbers in the normal-appearing skin between lesions of UP.

Mast cell infiltration in DCM is observed around blood vessels and throughout the dermis. In patients with DCM, the band-like infiltrates may be indistinguishable from some lesions of UP or from tissue obtained from mastocytomas. Cutaneous mast cell hyperplasia in patients with telangiectasia macularis eruptiva perstans is present around the capillary venules of the superficial plexus. The biopsy of these lesions reveals increased numbers of perivascular mast cells. However, mast cell numbers are relatively low.

Histologic sections of jejunal biopsies show moderate blunting of the villi; however, significant mast cell hyperplasia is uncommon. Biopsies of affected spleen most commonly show a peritrabecular distribution of mast cell infiltrates and fibrosis. Eosinophilic infiltrates are also noted, as are areas of extramedullary hematopoiesis. Bone marrow lesions typically consist of multifocal clusters or aggregates of tryptase-positive mast cells, often interspersed with eosinophils, and T and B lymphocytes (Fig. 150-8; see eFig. 150-8.1 in online edition). Systemic pediatric-onset disease is infrequently associated with the classic bone marrow pathology seen in adult-onset SM. The mast cell aggregates may be poorly defined with less than 15 mast cells per aggregate and distributed along perivascular and/or peritrabecular areas.

The most common chemical abnormality is an elevated level of alkaline phosphatase, which must be distinguished from bone-derived alkaline phosphatase, which may also be ele-

Box 150-1

Differential Diagnosis of Cutaneous Mast Cell Disease

Most Likely

- Diffuse or localized hyperpigmented macules
  - Café-au-lait spots
  - Neurofibromatosis
  - Albright syndrome
  - Multiple cutaneous lentiginosis
- Bullous lesions
  - Chronic bullous disease of childhood
  - Linear immunoglobulin A dermatosis
- Solitary or multiple papules or nodules
  - Congenital nevus
  - Juvenile xanthogranuloma

Consider

- No lesions
  - Idiopathic flushing
- Diffuse or localized hyperpigmented macules
  - Post-inflammatory hyperpigmentation
  - Secondary syphilis
  - Chronic urticaria
  - Atopic dermatitis
- Bullous lesions
  - Staphylococcal infection
  - Drug eruption
  - Incontinentia pigmenti
  - Bullous pemphigoid
- Solitary or multiple nodules

Always Rule Out

- No lesions
  - Identifiable causes of anaphylaxis
  - Idiopathic anaphylaxis
- Diffuse or localized hyperpigmented macules or papules
  - Secondary syphilis
  - Addison disease
  - Lentigo
- Bullous lesions
  - Bullous impetigo of infancy
  - Incontinentia pigmenti
- Solitary or multiple nodules
  - Leukemia
  - Lymphoma
  - Neuroblastoma



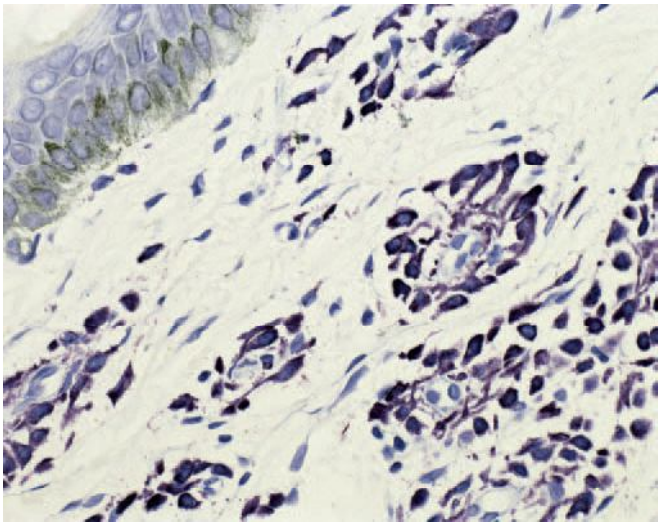

▲ **FIGURE 150-7** Histopathology of urticaria pigmentosa, toluidine blue.



vated. Despite the infrequency of significant hepatic disease, liver function tests are somewhat above normal in about one-half of all patients with extra-cutaneous disease.[41] Elevated levels of plasma[48,49] or urinary histamine or histamine metabolites,[50] PGD_2 metabolites in the urine,[51] or serum tryptase[52] isolation are not diagnostic, but do raise the index of suspicion of SM. Other surrogate markers of disease are serum IL-6 levels,[31] and soluble SCF receptor (CD117) and IL-2 receptor (CD25) levels. The levels of the latter receptors are highly correlated with the severity of bone marrow pathology.[53]

Bone marrow infiltration with mast cells may induce bone changes that cause radiographically detectable lesions, particularly in adults. The proximal long bones are most often affected, followed by the pelvis, ribs, and skull. Skeletal scintigraphy (bone scan) is more sensitive than a radiographic survey in detecting and locating active lesions.[54] Roentgenographic abnormalities of the gastrointestinal tract fall into three major categories: peptic ulcers; abnormal mucosal patterns such as mucosal edema, multiple nodular lesions, coarsened mucosal folds, or multiple polyps; and motility disturbances.

Diagnosis (Fig. 150-9)

Mastocytosis is diagnosed on the basis of history, clinical manifestations, histopathology, and laboratory evaluation, and categorized using the classification schema from the WHO consensus panel. Biopsy in the pediatric patient is not needed if the clinical features of skin lesions are typical and Darier sign is positive. Mastocytosis in a prepubertal child is generally benign and does not require extensive evaluation to detect systemic involvement if the history and physical examination suggest no evidence of involvement beyond the skin. In contrast, the presence of non-cutaneous features or disease onset in adolescents or adults necessitates full evaluation, particularly performing a complete blood count and serum tryptase level (see Fig. 150-9 and Table 150-3).

CM is confirmed by a lesional skin biopsy (see Clinical Manifestations). Blind skin biopsies must be interpreted with caution because other skin conditions, including atopic dermatitis, and recurrent episodes of anaphylaxis may be associated with a two- to fourfold increase in dermal mast cells.[47] Similarly, this type of increase may also be seen at skin sites involved in scleroderma,[55] chronic urticaria,[56] and prolonged antigenic contact.[57] Other diseases with similar cutaneous characteristics must be considered in the differential diagnosis of mastocytosis (see Box 150-1). In adults suspected of having SM, the diagnosis of a carcinoid tumor or pheochromocytoma should be ruled out. Note that patients with mastocytosis do not excrete increased amounts of 5-hydroxyindoleacetic acid. Patients with carcinoid tumor or pheochromocytoma do not have histologic evidence of significant mast cell proliferation and should have normal serum tryptase levels.[52]

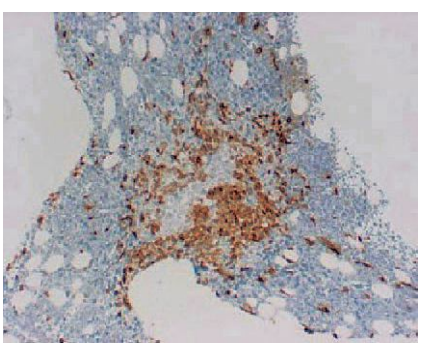

▲ **FIGURE 150-8** Classic mastocytosis bone marrow lesion (100×), tryptase stain.

Mastocytosis should be suspected in patients without skin lesions if they have one or more of the following: unexplained ulcer disease or malabsorption, radiographic or ^{99}technetium bone scan abnormalities, hepatomegaly, splenomegaly, lymphadenopathy, peripheral blood abnormalities, or unexplained flushing or hypotension. This constellation of symptoms is not unique to mastocytosis and may occur in other disease processes (Box 150-2). SM is usually diagnosed by performing a bone marrow biopsy and aspirate with demonstration of the major criterion, a classic lesion consisting of multifocal dense mast cell aggregates, and one minor criterion. Mastocytosis may also be diagnosed if three minor criteria are present (see Table 150-3). Minor criteria include atypical mast cell morphology, detection of codon 816 mutations in Kit, expression of CD2 and/or CD25 by bone marrow aspirate mast cells, and a total serum tryptase of > 20 ng/mL. A bone marrow biopsy in those with pediatric-onset disease is not recommended unless there is evidence of systemic disease as demonstrated by hepatosplenomegaly, lymphadenopathy, unexplained peripheral blood abnormalities, or an elevated serum tryptase (> 20 ng/mL). The most specific technique for identifying mast cells is immunostaining with anti-tryptase monoclonal antibody. In trephine core bone marrow biopsies, decalcification interferes with subsequent attempts to visualize mast cell granules with metachromatic stains, thereby necessitating immunostaining to detect tryptase.

Other tissue specimens, such as lymph nodes, spleen, liver, and gastrointestinal mucosa, define the extent of mast cell involvement, but are usually obtained only as dictated by necessity. For example, gastrointestinal biopsies are obtained only if a gastrointestinal workup is indicated, and lymph nodes are biopsied only if lymphoma is considered.

Treatment

The management of patients with all variants of mastocytosis includes counseling patients and care providers as to

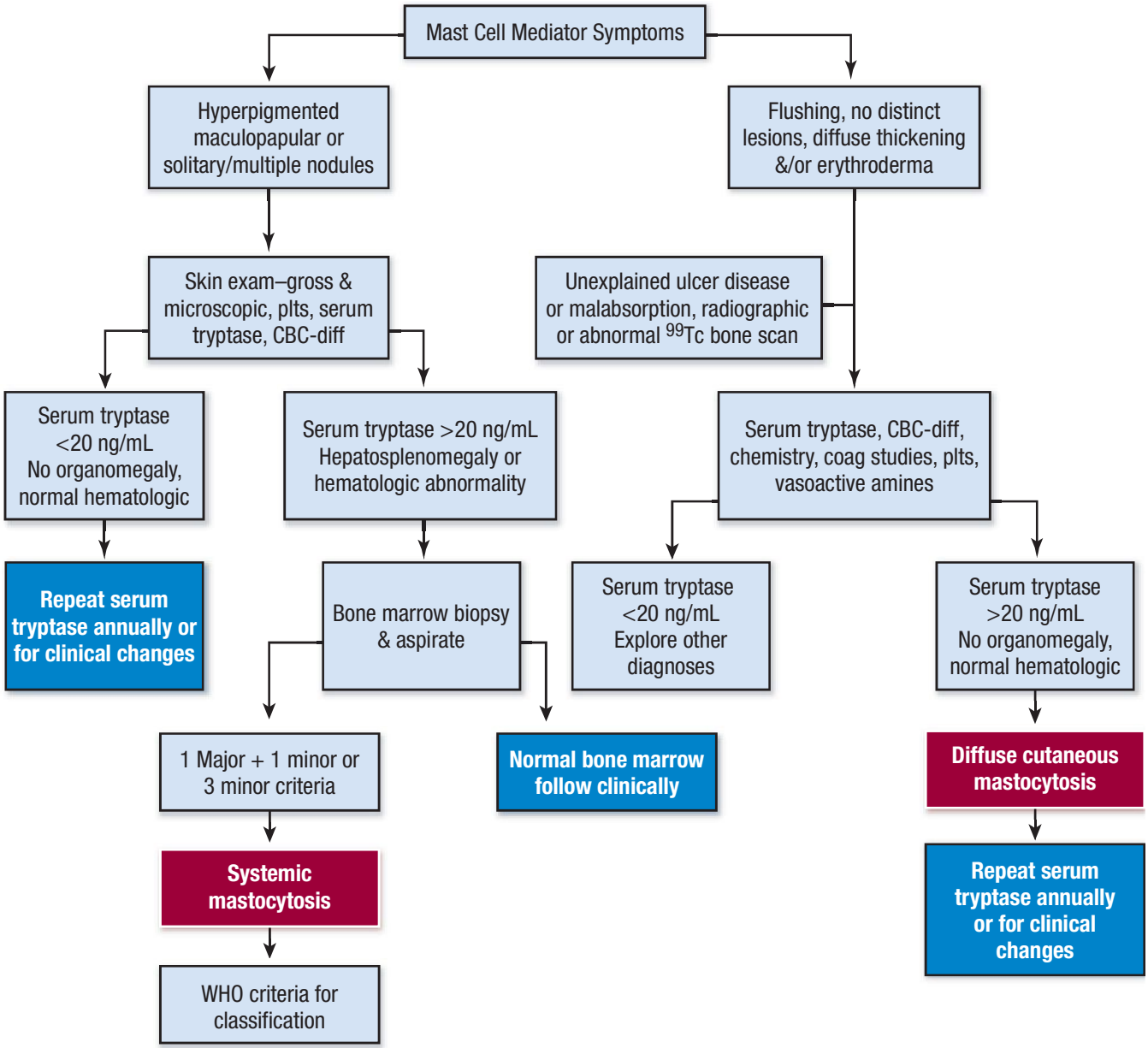

▲ **FIGURE 150-9** Algorithm for a diagnostic evaluation of new-onset mastocytosis (especially in adolescents and adults). CBC = complete blood cell count; Tc = technetium; WHO = World Health Organization. [a]For details of the WHO classification of mastocytosis, see Valent P et al: *World Health Organization Classification of Tumours: Pathology and Genetics of Tumours of the Haematopoietic and Lymphoid Tissues*, edited by Jaffe ES et al. Lyon, IARC Press, 2001.

the features of disease, avoidance of factors provoking mediator release, management of chronic symptoms such as pruritus and gastric hypersecretion, treatment of acute episodes of vascular collapse and, when indicated, cytoreductive therapy to address the sequelae of disabling organ infiltration by mast cells and to track any associated hematologic disorder (Boxes 150-3 and 150-4).

There is currently no generally recognized safe and effective mast cell ablative therapy, nor are there effective mast cell stabilizing drugs. The treatment of mastocytosis is in part focused on symptomatic relief. In young children with mastocytomas that become reactive intermittently or in children with UP that is minimally symptomatic, no therapy is needed. Having alcohol-free diphenhydramine at home, however, is recommended. Chronic administration of H_1 antihistamines (hydroxyzine, cetirizine, and fexofenadine) is helpful in reducing pruritus, flushing, and reflex tachycardia by controlling vascular tone and permeability.[58] H_2 antihistamines, in addition to H_1 blockers, may assist in controlling pruritus, flushing, and wheal formation. H_2 antagonists (cimetidine or ranitidine) are also used in the management of excess gastric secretion, which results in gastritis and peptic ulcer disease.

If gastrointestinal symptoms persist, proton pump inhibitors may be effective in relieving symptoms of diarrhea and gastric hypersecretion.[58] Disodium cromoglycate (cromolyn sodium) inhibits the degranulation of mast cells and may have some efficacy in the treatment of mastocytosis, particularly in relieving gastrointestinal complaints in children.[59] Cromolyn sodium does not lower plasma or urinary histamine levels in patients with mastocytosis. Both ketotifen and azelastine, antihistamines with mast cell-stabilizing properties, help by relieving the pruritus and wheal-ing associated with mastocytosis (not available in systemic formulations in the



Box 150-2

Differential Diagnosis of Systemic Mastocytosis without Skin Lesions[a]

- Gastrointestinal
  - Peptic ulcer disease
  - Ulcerative colitis
  - Gluten-sensitive enteropathy
  - Hepatitis
  - Parasitic disease
- Cardiovascular
  - Allergy
  - Idiopathic anaphylaxis
  - Cardiac disease
  - Vasculitis
- Endocrine
  - Adrenal tumor
  - Vasoactive intestinal polypeptide tumor
  - Carcinoid syndrome
- Medullary thyroid carcinoma
  - Gastrinoma
  - Diabetes mellitus
- Neoplastic/oncologic
  - Hypereosinophilic syndrome
  - Lymphoma
  - Myeloma
  - Histiocytosis
  - Bone tumor metastases

[a]Note: Some forms of mast cell disease may not show cutaneous manifestations. These include aggressive systemic mastocytosis, mast cell leukemia, systemic mastocytosis with an associated clonal hematologic non-mast cell lineage disease, and isolated bone marrow mastocytosis.



United States). However, neither drug appears to offer an advantage over a standard antihistamine such as hydroxyzine.[60,61] Low-dose aspirin has been used in some patients to reduce flushing, tachycardia, and syncope. However, aspirin must be used with caution, as it may cause vascular collapse in some patients with mastocytosis and exacerbate peptic ulcer disease. Anti-leukotrienes are effective in some patients in controlling symptoms of flushing, diarrhea, and abdominal cramping.[58]

It is known that glucocorticoids decrease tissue mast cell numbers by reducing the production of SCF by resident cells in the skin.[62] Potent topical glucocorticoids, such as 0.05 percent betamethasone dipropionate ointment, under plastic-film occlusion for 8 hours per day over 8 to 12 weeks can be used to treat extensive cutaneous disease. Mast cell numbers decrease as the lesions clear. These lesions eventually recur after discontinuation of therapy,[63] although the treatment may lead to improvement in the cutaneous lesions for up to 1 year. Topical calcineurin inhibitors may also improve the appearance

Box 150-3

Treatment for Cutaneous Mastocytosis

	TOPICAL	PHYSICAL	SYSTEMIC
First line	Emollients		H_1 (± H_2) antihistamines
Second line	Topical glucocorticoids Calcineurin inhibitors	Psoralen and ultraviolet A light (adults only) Laser for telangiectasia macularis eruptiva perstans	Leukotriene antagonist
Third line		Surgical excision (mastocytoma)	Glucocorticoids Low-dose aspirin

Note: Avoidance of triggering factors such as heat, friction, or drugs.

and tendency to wheal of mast cell lesions. Oral glucocorticoids have demonstrated some efficacy in patients with malabsorption and ascites.[64] After control is achieved, glucocorticoid therapy should be tapered to the lowest effective dose. Systemic corticosteroids can also be administered for treating severe CM that is not responsive to antihistamines alone. A 1-month course may be sufficient to cause improvement for a prolonged period.

Musculoskeletal pain, seen in approximately 25 percent of patients with SM, is managed with aspirin and nonsteroidal anti-inflammatory drugs, while using caution to avoid patients who are aspirin sensitive. Osteoporosis should be treated with calcium and vitamin D supplementation and, when appropriate, the addition of estrogen replacement or bisphosphonates as determined by monitoring bone density.

Epinephrine is used to treat episodes of vascular collapse or bronchoconstriction with respiratory distress. Patients with extensive mastocytosis should carry epinephrine, be prepared to self-administer this drug, and have a plan for emergency management. If subcutaneous epinephrine is insufficient, intensive therapy for vascular collapse should be instituted. Patients with recurrent episodes of vascular collapse may be prophylactically placed on H_1 and H_2 antihistamines to lessen the severity of attacks. Episodes of vascular collapse may be spontaneous but have also occurred after stings from insects or after administration of iodinated contrast media. In the latter case, premedication is recommended before such procedures.

Methoxypsoralen with ultraviolet A light relieves pruritus and whealing after 1 to 2 months of treatment.[65,66] Improvement is associated with a temporary decrease in dermal mast cells. Pruritus recurs within 3 to 6 months after treatment is stopped. Photochemotherapy should be used only in instances of extensive cutaneous disease that do not respond to other forms of therapy. Some patients report a diminution in the number or intensity of cutaneous lesions after exposure to natural sunlight.

Cytoreductive therapy is considered in patients with associated organopathy as seen in SM-AHNMD, ASM, and MCL. The risk-benefit must be carefully considered due to the dose-limiting toxicities of these drugs. IFN-α may be considered for ASM with and without associated hematologic malignancy. In a prospective study,[67] IFN-α was most efficacious in ameliorating symptoms associated with mast cell mediator release. In other reports, variable clinical responses included a reduction in bone

Box 150-4

Treatment of Non-Cutaneous Mastocytosis Symptoms

	GASTROINTESTINAL	CARDIOVASCULAR	MUSCULOSKELETAL
First line	H_2 antihistamines, oral cromolyn	Intramuscular epinephrine (anaphylaxis)	Calcium supplement ± vitamin D supplement
Second line	Proton pump inhibitors Leukotriene antagonist Anticholinergics	Glucocorticoids (prophylaxis)	Bisphosphonates Nonsteroidal anti-inflammatory drugs
Third line	Glucocorticoids		

Note: Cytoreductive therapy is restricted to patients with aggressive variants of mastocytosis (systemic mastocytosis with an associated clonal hematologic non-mast cell lineage disease, aggressive systemic mastocytosis, and mast cell leukemia).

marrow infiltration,[68–72] regression of ascites and hepatomegaly, improvement in skin lesions, and improved bone density.[67,69,73] Improvement was often transitory. 2-Chlorodeoxyadenosine may be considered in patients with progressive disease that is refractory to interferon-α. Its use is restricted by the associated myelosuppression. 2-Chlorodeoxyadenosine has been shown to be efficacious in reducing ascites, mediator-associated symptoms, and bone marrow mast cell burden.[74]

Tyrosine kinase inhibitors such as imatinib inhibit growth of neoplastic cells through receptors such as KIT, ABL, and PDGFR tyrosine kinases[75] and was also found to be successful in the treatment of a patient with a transmembrane mutation in KIT at the F522C position.[76] Imatinib does not appear to inhibit mast cells expressing the D816V mutation. PKC412, disatinib, and AMN107 are tyrosine kinase inhibitors that demonstrated in vitro inhibition of mast cell lines with and without the D816V mutation. PKC412 inhibitory effects were superior in the D816V$^+$ cell line as compared to AMN107.[77] PKC412, disatinib, and AMN107 are in clinical trials to determine their efficacy in mastocytosis.

Splenectomy may improve survival in patients with forms of mastocytosis that have a poor prognosis.[78] Radiotherapy has been used to treat refractory bone pain in advanced disease.[79] Nonmyeloablative bone marrow transplantation may be considered for gravely ill patients, although a recent report using this therapy in three patients with advanced SM showed no sustained improvement despite inducing a graft versus mast cell state.[80]

Prognosis

Pediatric-onset cutaneous disease usually has a favorable prognosis and at least 50 percent of cases of childhood-onset UP reportedly resolve by adulthood.[81,82] Furthermore, children born of mothers with ISM reportedly are free of disease.[83] Adults with UP usually progress gradually to systemic disease and rarely develop hematologic disease.[83] DCM may be associated with ISM. Older patients with UP who experience fading of their lesions continue to exhibit bone marrow lesions typical of their diagnosis, whether ISM or SM-AHNMD.[84] Patients with SM-AHNMD have a variable course dependent on the prognosis of their hematologic disorder. With MCL, mean survival is generally less than 6 months. With ASM, mean survival is 2 to 4 years without therapy. The prognosis appears to improve with aggressive symptomatic management.

KEY REFERENCES

The full reference list for all chapters is available at www.digm7.com.

6. Kulka M, Metcalfe DD: High-resolution tracking of cell division demonstrates differential effects of TH1 and TH2 cytokines on SCF-dependent human mast cell production in vitro: Correlation with apoptosis and Kit expression. *Blood* **105**:592, 2005
35. Valent P et al: *World Health Organization Classification of Tumours: Pathology and Genetics of Tumours of the Haematopoietic and Lymphoid Tissues*, edited by Jaffe ES et al. Lyon, IARC Press, 2001
52. Schwartz LB et al: The alpha form of human tryptase is the predominant type present in blood at baseline in normal subjects and is elevated in those with systemic mastocytosis. *J Clin Invest* **96**:2702, 1995
53. Akin C et al: Analysis of the surface expression of c-kit and occurrence of the c-kit Asp816Val activating mutation in T cells, B cells, and myelomonocytic cells in patients with mastocytosis. *Exp Hematol* **28**:140, 2000
58. Valent P et al: Mastocytosis: Pathology, genetics, and current options for therapy. *Leuk Lymphoma* **46**:35, 2005
76. Akin C et al: A novel form of mastocytosis associated with a transmembrane c-kit mutation and response to imatinib. *Blood* **103**:3222, 2004
80. Nakamura R et al: A pilot study of nonmyeloablative allogeneic hematopoietic stem cell transplant for advanced systemic mastocytosis. *Bone Marrow Transplant* **37**:353, 2006



This page intentionally left blank

SECTION 26

SKIN MANIFESTATIONS OF INTERNAL ORGAN DISORDERS

CHAPTER 151

The Skin and Disorders of the Alimentary Tract, the Hepatobiliary System, Kidney, and Cardiopulmonary System

Graham A. Johnston
Robin A. C. Graham-Brown

Diseases of the skin frequently indicate, or associate with, diseases of the alimentary tract, the hepatobiliary system, the kidneys, and the cardiopulmonary system. Just as a full physical examination should be part of a full dermatologic assessment, it is important to examine the skin in a patient presenting with a systemic problem. This chapter is presented in the same order that a physician performing a full physical examination might approach the patient. The cutaneous manifestations that indicate internal disease are discussed for each step of the examination.

GENERAL SKIN CHANGES

Alterations in Skin Quality

The presence of pallid, dry, rough, scaly skin that is usually itchy in patients with malabsorption, chronic renal disease, or chronic hepatic disease is non-specific. Asteatotic eczema may develop. Some patients itch without any visible abnormality of their skin.

CARDIAC DISEASE ***Ehlers-Danlos Syndrome.*** (See Chap. 139) Hyperelastic velvety skin that rebounds to the original position after being stretched, "cigarette-paper" scars, and hyperextensible joints are characteristic of the Ehlers-Danlos syndrome. Mitral and tricuspid prolapse, dilatation of the aorta and pulmonary artery, arterial rupture, myocardial infarction, and emphysema may accompany this syndrome.[1]

Cutis Laxa. Progressive looseness of the skin with pendulous folds and droopy eyelids may be associated with generalized hyperelastosis, leading to aortic dilatation and rupture, congestive heart failure, or cor pulmonale with pulmonary artery stenosis and progressive emphysema.

Pseudoxanthoma Elasticum. The skin of patients with pseudoxanthoma elasticum is thick, lax, and yellowish, especially over the axillae, antecubital area, and neck. Yellow patches may occur on mucous membranes, especially the labia. The arteries may be calcified, and the aortic and mitral valves thickened. Angina pectoris and claudication are frequent symptoms.[2]

Progeria. In Werner syndrome (progeria), the skin appears atrophic and tight: there is marked loss of subcutaneous tissue, with leg ulceration and coronary atherosclerosis; death by myocardial infarction at an early age is common.

LIVER DISEASE In chronic liver disease, hormone-induced changes of the skin include loss of forearm, axillary, and pubic hair in both sexes. Men may experience a decreased rate of growth of facial hair, pectoral alopecia, and female pubic hair distribution, as well as loss of libido, testicular atrophy, and oligospermia. Striae distensae occur in both men and women (Fig. 151-1). Gynecomastia, together with Dupuytren contracture and swelling of the parotid gland, is

DISORDERS OF THE ALIMENTARY TRACT, THE HEPATOBILIARY SYSTEM, KIDNEY, AND CARDIOPULMONARY SYSTEM AT A GLANCE



- A full physical examination should be part of a full dermatologic assessment.
- It is important to examine the skin in a patient presenting with a systemic problem.
- Look for generalized changes in skin quality first.
- Then examine specific organ systems systematically.
- The majority of causes of jaundice can be found on clinical history and examination.
- In both abdominal pain and gastrointestinal bleeding, there can be cutaneous findings that suggest the underlying cause.
- Some cardiopulmonary syndromes have specific dermatologic clues.
- Remember dermatologic drugs as a cause of systemic symptoms.



Copyright © 2008 by The McGraw-Hill Companies, Inc. Click here for terms of use.



▲ **FIGURE 151-1** Widespread striae in a 16-year-old boy with chronic active hepatitis.



associated with cirrhosis. Many of these changes occur more commonly in those with alcoholic cirrhosis.

Patients with chronic alcoholism also develop a "pseudo-Cushing syndrome," even in the absence of liver disease; signs include facial mooning, truncal obesity, and proximal muscle wasting.[3] These changes may regress if the patient discontinues alcohol.

Patients with chronic liver disease often have telangiectatic changes, mainly on light-exposed skin. Numerous tiny telangiectases sometimes give the impression of a diffuse, almost exanthematic redness. They are known as "dollar paper markings" after the small threads visible in paper money held up against the light. They fade on pressure with a glass slide and rarely pulsate.

RENAL DISEASE The skin of patients with chronic renal failure (CRF) is typically dry, often with ichthyosis-like scaling. This may result in part from altered vitamin A metabolism in CRF[4–6] along with the fluid volume shifts of dialysis.

Color Changes

Skin color is altered in CRF. The skin is pale from anemia and often exhibits a distinctive gray-yellow hue due to accumulation of carotenoid and nitrogenous pigments (urochromes) in the dermis.

CYANOSIS An increase in the absolute amount of desaturated (reduced) hemoglobin results in a purple-blue discoloration of the skin. Cyanosis is classified into "central" and "peripheral" types: the terms referring to the level of arterial oxygen saturation rather than the anatomic source of cyanosis. Thus, central cyanosis occurs in states that produce low arterial oxygen saturation, such as congenital heart disease with intracardiac or intrapulmonary right-to-left shunting, or severe lung disease. Peripheral cyanosis occurs when there is normal arterial oxygen saturation but reduced blood flow, such as low-output cardiac failure and local vasoconstriction. Pulmonary embolism may result in a combination of central cyanosis caused by intrapulmonary shunting and peripheral cyanosis caused by low cardiac output.

Central cyanosis is usually visible on warm areas of the skin such as the tongue, oral mucosae, and conjunctivae. Peripheral cyanosis is seen on cooler areas such as the nose, lips, earlobes, and fingertips. In the anemic patient, detection of cyanosis may be impossible because the absolute amount of reduced hemoglobin is not increased. Cyanosis fades when pressure is applied because the coloration is within the blood vessels.

ERYTHEMA Redness of the skin is caused by an increase in the amount of saturated hemoglobin, an increase in the diameter or actual number of skin capillaries, or a combination of these factors. Edema of the face, arms, and hands associated with redness and/or cyanosis may indicate obstruction of the superior vena cava due to mediastinal disease.

Polycythemia may produce the characteristic "ruddy" complexion, but may also cause a peculiar ruddy cyanosis. This is most pronounced on the tongue, lips, nose, earlobes, conjunctivae, and fingertips. It is due to increased amounts of saturated hemoglobin producing erythema, with increased amounts of desaturated hemoglobin producing cyanosis because of the inability of the body to fully oxygenate the increased absolute amounts of hemoglobin. The absence of nail clubbing may help differentiate patients with polycythemia vera from those patients with cardiopulmonary disease who develop secondary polycythemia. In addition, the hypervolemic state of polycythemia vera is associated with increased stroke volume and may lead to high-output cardiac failure. Pulmonary emboli may result from venous thrombosis secondary to hyperviscosity.

FLUSHING Paroxysmal intense flushing of the face, neck, chest, and abdomen, often with telangiectases of the face and neck, may occur in patients with carcinoid tumors (see Chap. 154), systemic mastocytosis (see Chap. 150), and pheochromocytoma (see Chap. 154), and Sipple syndrome.

PIGMENTARY CHANGES In addition to jaundice (see Jaundice below), both diffuse and circumscribed pigmentary changes may occur in chronic liver disease. A diffuse muddy gray color in patients with long-standing cirrhosis is due to basal cell melanin.

Cirrhosis. Melanosis is common in primary biliary cirrhosis (PBC) and may be an early presenting sign. It initially involves exposed areas, but it gradually becomes generalized. Blotchy, circumscribed areas of dirty brown pigmentation are also occasionally evident. Accentuation of normal freckling and areolar pigmentation can occur. Localized linear pigmentation may appear in the creases of the fingers and palms. Pigmentation resembling chloasma may localize to the perioral and periorbital areas. Guttate hypomelanosis, a condition in which small white macules, sometimes with a central spider, appear on the skin of the buttocks, back, thighs, and forearms, may occur in cirrhosis and, rarely, in PBC.[7] The yellow and orange lesions of dermal, subcutaneous, and tendon xanthomas and also xanthelasma (see Chap. 135) are common in PBC and can be extensive.

Hemochromatosis. The generalized metallic gray or bronze-brown color of the skin in hemochromatosis can be striking. There is accentuation in sun-exposed and traumatized skin, and occasionally there is buccal and conjunctival pigmentation.[8]

The etiology and pathogenesis of hyperpigmentation in chronic liver disease remain obscure. The pigmentation in PBC is due predominantly to the presence of excess melanin with no stainable iron. In hemochromatosis, pigmentation results not only from the presence of hemosiderin in the skin, but also from excess melanin. After phlebotomy, histologic siderosis and pigmentation decrease, even though melanosis remains histologically.

Vitamin Deficiency. (See Chap. 130) Pellagra gives rises to lichenified and often deeply pigmented skin in sun-exposed sites and can develop in patients with alcoholic liver disease. Vitamin B_{12} deficiency causes pigmentation of the distal extremities in a glove and stocking distribution. Diffuse hyperpigmentation occurs in folate deficiency. Kwashiorkor produces generalized depigmentation.

JAUNDICE (Table 151-1) In jaundice, raised plasma bilirubin produces a generalized coloration of the skin, mucous

TABLE 151-1
Functional Classification of Jaundice

- Unconjugated hyperbilirubinemia
  - New and infant
    - "Physiologic"—functional hepatic immaturity
    - Hemolysis—Rh, ABO, sepsis, drug factors
    - Prematurity
    - Transient familial hyperbilirubinemia—maternal steroid inhibitors
    - Crigler-Najjar syndrome—glucuronyl transferase deficiency (hereditary)
  - Adult
    - Excess bilirubin production
      - ~ Hemolysis
        Congenital
        Acquired
      - ~ Dyserythropoietic—"shunt" hyperbilirubinemia
    - Deficient conjugation
    - Familial
      - ~ Constitutional hepatic dysfunction (Gilbert syndrome)
      - ~ Crigler-Najjar syndrome type II
    - Acquired
      - ~ Posthepatic
      - ~ Associated disease—cardiac, enteric, metabolic
      - ~ Drug-induced
  - Diagnostic features
    - Serum-conjugated bilirubin less than 15% of total
    - Absence of bilirubinuria
    - Low to normal urine urobilinogen
    - Absence of other liver function disturbances
    - Normal morphologic features of liver
- Conjugated hyperbilirubinemia
  - Hepatic cell damage
    - Acute—viral, toxic, anoxic, metabolic
    - Chronic—cirrhosis, metabolic
  - Impaired bile excretion
    - Extra-hepatic obstruction
    - Intrahepatic cholestasis—atresia, viral, drugs, hormones, pregnancy, benign recurrent cholestasis
  - Familial (defect confined to bilirubin excretion)
    - Dubin-Johnson syndrome—excretory defect and cell pigment
    - Rotor syndrome—excretory defect and no pigment
  - Diagnostic features
    - Serum-conjugated bilirubin more than 15% of total
    - Bilirubinuria common
    - Urine urobilinogen often elevated
    - Other liver functions often abnormal in hepatic cell damage and impaired bile excretion
    - Characteristic morphologic abnormalities of liver

membranes, and other body tissues varying in hue from faint golden to dark green-yellow. Both jaundice and pigmentation are most prominent in extrahepatic biliary obstruction and in PBC.

Pathogenesis. Jaundice results from increased cellular or connective tissue binding of bilirubin and its metabolites in the skin. Bilirubin has an affinity for elastin, but circulates almost exclusively as a tightly bound complex with albumin. Eighty-five percent of bilirubin comes from the degradation of heme, the remainder from other heme-containing proteins such as myoglobin and cytochromes. Jaundice results from an imbalance between the tissue production and hepatic clearance of bilirubin.

Tissue-serum equilibration is slow, and so the intensity of clinical jaundice often fails to reflect the concurrent serum bilirubin level. Hyperbilirubinemia may, therefore, antedate the onset of detectable jaundice, and jaundice may persist despite falling or normal serum bilirubin levels. The correlation between skin color and serum pigment levels is especially poor in newborns. The intensity of jaundice and levels of serum bilirubin in patients with biliary atresia, acquired bile duct obstruction, or defective bilirubin conjugation tend to stabilize despite continued pigment production. Hyperbilirubinemia and jaundice secondary to raised intrahepatic pressure may occur in patients in congestive cardiac failure.

Clinical Features. Clinically detectable jaundice appears when sufficient amounts of bilirubin become tissue-bound. Involvement of the sclerae differentiates jaundice from other causes of skin pigmentation, including carotenemia, the yellow skin pigmentation produced by quinacrine and busulfan, and lycopenemia due to the ingestion of tomato juice.

The urine becomes dark yellow and then brown as conjugated serum bilirubin rises. Because most of the brown color of normal feces is produced by urobilins derived from degradation of bilirubin in the intestine, the jaundice of impaired bilirubin excretion or bile obstruction is associated with "clay-colored" stools. Degradation of bilirubin occurs with exposure to ultraviolet radiation, which is the rationale for phototherapy to prevent kernicterus in severe neonatal jaundice.

The jaundice of biliary obstruction resolves after the obstruction is relieved. Jaundice in patients with acute hepatitis resolves spontaneously. The jaundice of chronic liver disease may improve after transplantation. Jaundice in chronic active hepatitis can decrease after glucocorticoid therapy. Neonatal jaundice may respond to phototherapy (see Chap. 238).

Pruritus

CHOLESTATIC PRURITUS ***Pathogenesis of Cholestatic Pruritus.*** One of the most common and distressing symptoms of hepatobiliary disease is pruritus. Although retained cutaneous bile acids have been implicated, there is a poor correlation between the plasma bilirubin and the severity of pruritus. However, the partial relief of itching by bile salt chelating resins and the disappearance of pruritus when liver cells fail suggest that the liver manufactures at least one of the agents contributing to pruritus.

Opiate agonists, such as morphine, induce pruritus. Animal studies show that the intracerebral presence of morphine induces pruritus that is reversed by the opiate antagonist nalaxone,[9] demonstrating that opiate agonists induce scratching



of central origin. In addition, the administration of the opioid antagonist, nalmefene, to patients with PBC produces a reaction similar to that of opiate withdrawal, and the injection of plasma from patients with PBC into monkeys produces pruritus. Taken together, these studies suggest that opioidergic tone increases in cholestasis.[9] These studies do not indicate which agent contributes to the pruritus of cholestasis and whether it originates peripherally (e.g., in the liver) or centrally.[10]

Clinical Features. Pruritus ranges from mild and transient to severe and prolonged. Pruritus more commonly occurs in conditions causing cholestasis. Pruritus may be debilitating in patients with PBC, mechanical biliary obstruction, or intrahepatic obstruction. However, in viral hepatitis, itching is frequently missed as an early sign of the disease until it occurs in the later, icteric phase. Drugs, especially erythromycin, oral contraceptives, phenothiazines, chlorpropamide, para-aminosalicylic acid, and nitrofurantoin, induce cholestasis accompanied by pruritus. Pruritus is the presenting symptom in more than 50 percent of cases of PBC and may precede jaundice by months or even years.

Pruritus may be transient or continuous and may occur without jaundice. It is usually most marked on the extremities and only rarely involves the neck and face, and genitalia. There is little correlation between the severity of cholestasis and the severity of perceived pruritus, and a spontaneous decrease in the intensity of pruritus may signal the development of hepatocellular failure rather than improvement. Scratching does not relieve the pruritus of cholestasis, and there may be no visible skin changes except excoriations, although in chronic cases lichenified plaques, nodular prurigo, or perforating collagenoses occur.

Management. Pruritus rapidly decreases when cholestasis secondary to mechanical bile duct obstruction is relieved. Drugs to relieve cholestasis, such as ursodeoxycholic acid, do not consistently relieve pruritus, nor do the anion exchange resins cholestyramine and colestipol, which are thought to bind intestinal pruritogens and prevent them making their way to the skin.

Hepatic enzyme inducers, including phenobarbital and rifampicin, may induce the metabolism of pruritogens: the latter has been shown to be relatively efficacious in randomized controlled trials.[11] Antihistamines or topical steroids have no proven efficacy, but sedating antihistamines or ultraviolet light can help. Trials of plasmapheresis and charcoal hemoperfusion are inconclusive.

Neurotransmitter receptor antagonists, such as oral nalmefene, may be useful in the long-term control of the pruritus of cholestasis[12]; intravenous naloxone has short term efficacy,[13] as has oral naltrexone.[14]

RENAL PRURITUS The incidence of renal pruritus is reported to be as high as 90 percent of patients undergoing hemodialysis.[15–17]

Pathogenesis of Renal Pruritus. Renal pruritus is thought to be caused by a combination of increased serum histamine, vitamin A, and parathyroid hormone (PTH); mast cell hyperplasia; peripheral polyneuropathy; and xerosis.[16–18] Clinically the skin may appear normal or demonstrate a variety of lichenified or hyperkeratotic lesions.[19]

Management. Topical moisturizers alleviate pruritus associated with xerotic skin. Topical glucocorticoids and ultraviolet phototherapy[20–22] are often used to suppress inflammation in treated areas. Topical capsaicin depletes substance P from nerve endings, thereby suppressing itch sensation.[23] Improving the efficacy of dialysis and/or changing the dialysate concentration may help to alleviate pruritus.[24] Some patients have responded to treatments with intravenous lidocaine, heparin, and cholestyramine.[23] Surgical options include subtotal parathyroidectomy, electric needle stimulation, and renal transplantation. Erythropoietin lowers plasma histamine concentrations with subsequent improvement in pruritus.[25] Preliminary studies indicate that oral evening primrose oil,[26] endocannibinoids,[27] and topical tacrolimus ointment[28] may each have a therapeutic effect.

Alterations in Sweating

Sweating may be prominent in a number of cardiopulmonary states such as acute myocardial infarction, cardiogenic shock, left ventricular failure, massive pulmonary emboli, and pulmonary edema. Pallor and clamminess or coldness of the extremities and exposed surfaces are also often found. Excessive sweating may suggest pheochromocytoma when associated with hypertension.

The sodium and chloride content of sweat is increased in patients with cystic fibrosis and may lead to an increase in skin wrinkling after immersion, as when bathing.[29]

Skin Changes in Malignancy

Many skin changes occur in association with malignancies. Dry skin (acquired ichthyosis) with asteatotic dermatitis as well as hyperpigmentation may occur in malignancy.

DERMATOMYOSITIS (See Chap. 152) Adult-onset dermatomyositis is associated with underlying malignant disease in a significant minority of cases.[30] Blind computed tomography scans may help uncover occult malignancy in these patients.[31] Pancreatic, gastric, and colorectal cancers are the third most common after bronchogenic and ovarian cancers in Europe and North America. In China, nasopharyngeal carcinoma is common. The rash and myopathy can regress after removal of the tumor.

Interstitial lung disease occurs[32] with bronchiolitis obliterans, subcutaneous emphysema, and spontaneous pneumothorax. Upper pharyngeal weakness can lead to chronic aspiration, and exertional dyspnea can occur because of weakness of the respiratory muscles. Lung disease is associated with Anti-Jo-1 antibodies.

ACANTHOSIS NIGRICANS In two-thirds of patients with acanthosis nigricans and cancer, the tumor is gastric. The changes may regress if the tumor, usually an adenocarcinoma of the stomach or bowel, is removed.

HYPERTRICHOSIS LANUGINOSA Excessive growth of lanugo hair is a rare complication of gastrointestinal cancer.

OTHER SKIN CHANGES IN MALIGNANCY (See Chap. 154) Diverse cutaneous paraneoplastic syndromes may arise from underlying tumors.[33] They may precede, coincide with, or follow the diagnosis of cancer and often indicate a poor prognosis. They include reactive erythemas, such as erythema gyratum repens and necrolytic migratory erythema; the vascular dermatoses (Trousseau syndrome); and papulosquamous disorders, including tripe palms (Fig. 151-2), palmar hyperkeratosis, acquired ichthyosis, pityriasis rotunda, Bazex syndrome, florid cutaneous papillomatosis, the sign of Leser-Trélat, and extra-





▲ **FIGURE 151-2** Patient with "tripe hands" due to adenocarcinoma of the jejunum.

mammary disease. Migratory superficial thrombophlebitis occurs in association with neoplasia, particularly carcinoma of the pancreas. Glucagonoma is one of the amine precursor uptake and decarboxylation cell tumors. It usually arises in the islet cells of the pancreas and occurs in association with a distinctive necrolytic migratory erythema.

Any tumor may metastasize to the skin. The scalp is a common site. Metastases at the umbilicus (Sister Joseph nodules) occur particularly with carcinoma of the stomach, colon, or ovary (Fig. 151-3).

Erythroderma (See Chap. 23)

The systemic effects of erythroderma can be considerable. Patients can develop hypothermia, hypoalbuminemia, hypovolemia, secondary sepsis, the initial stages of renal failure, and high-output cardiac failure with secondary effects on hepatic function. Death from sepsis, cardiac failure, adult respiratory distress syndrome, and capillary leak syndrome occur.[34]

SPECIFIC ORGAN AND SYSTEM CHANGES

Nails (See Chap. 87)

Lindsey's, or half-and-half, nails are normal in their distal 50 percent and white in the proximal 50 percent and found in CRF.

In malabsorption or malnutrition, nails grow more slowly, become brittle, and may develop fissures.[35,36] Multiple pigmented bands can appear. Koilonychia often indicates iron deficiency, even without anemia. White nails, thought to be due to selenium deficiency, have occurred with total parenteral nutrition.

Flushing of the nail beds that is synchronous with the heartbeat is a sign of aortic regurgitation called *Quincke pulsation*.

NAIL CHANGES IN LIVER DISEASE Nail abnormalities are a less constant physical sign than spider nevi or liver palms. In cirrhosis, however, a number of changes may occur: clubbing, curved nails, thickened nails, longitudinally ridged nails, white nails, watch-glass deformity, flattened nails, white bands, striations, and brittleness.[36]



▲ **FIGURE 151-3** Umbilical metastasis (Sister Joseph nodule) from intra-abdominal adenocarcinoma.



▲ **FIGURE 151-4** Terry's white nails in a patient with cirrhosis.

White nails may occasionally be seen in healthy individuals or in association with systemic disease, including congestive heart failure, diabetes, cryoglobulinemia, Raynaud syndrome, and systemic sclerosis. Intensely white nails (Terry's nails) are characteristic of cirrhosis (Fig. 151-4).[37] Thumbs and forefingers are often most affected. The whiteness does not alter with nail growth or with compression of digital vessels and is thought to be due to the opacity of the nail plate itself. The so-called *watch-glass deformity* may accompany white nails (Fig. 151-5).

Azure lunulae, a bluish color of the lunular portion of nails, occurs in hepatolenticular degeneration (Wilson disease). Azure lunulae and corneal changes resembling Kayser-Fleischer rings may also be evident in patients with argyria or after treatment with busulfan or antimalarials.[36]

The characteristic nail changes of lichen planus (see Chap. 26), including longitudinal ridging, pterygium formation, and permanent nail loss, occur both with and without skin changes in PBC (see Cutaneous Manifestations of Primary Biliary Cirrhosis).

Splinter hemorrhages also occur in cirrhosis. Flat or spoon nails are less common in patients with liver disease. The nails are flat or concave, pale in color, and frequently show longitudinal ridging. In hemochromatosis, koilonychia is probably the most common of the nail abnormalities, but it is not related to anemia.[36]

NAIL CLUBBING Nail clubbing most commonly occurs in patients with bron-





▲ **FIGURE 151-5** Flat white nails with slight convex watch-glass deformity, showing a distal pink band in a patient with liver disease.



▲ **FIGURE 151-7** Yellow nail syndrome. There is thickening, increased curvature, and yellowish discoloration of all fingernails. This patient had lymphedema of the extremities and bronchiectasis with multiple recurrent respiratory infections.



chogenic carcinoma, suppurative lung disease, endocarditis, and congenital heart disease, but it may be idiopathic or familial (Fig. 151-6). Clubbing is quite common in all forms of cirrhosis, especially PBC and chronic active hepatitis. Signs include beaking or distal curvature of the nail. There may be loss of the angle between the nail and cuticle. Sponginess or "floating" of the nail when pressure is applied is also characteristic, and the size of the terminal tuft may increase.

Anatomically, there is an increased thickness of the nail bed. This is due to edematous infiltration of the soft parts of the terminal segment followed by hyperplasia of the dermal fibrovascular tissue with increased vascularity.[36]

YELLOW NAIL SYNDROME Yellow nail syndrome is the triad of yellow nails, primary lymphedema, and pleural effusion. The characteristics of the nails include thickening, transverse ridging, diminished growth, increased curvature with a "hump," and onycholysis. The lunulae and cuticles may be absent. The color may vary from pale yellow to green (Fig. 151-7). The nail changes are secondary to congenitally hypoplastic lymphatics,[38] leading to lymphedema, which is characteristically slowly progressive and somewhat asymmetric, with induration and hyperkeratosis extending to the thighs. Periodic lymphangitis is frequent and may contribute to the swelling.

Respiratory findings include sinusitis, bronchiectasis, and pleural effusions. Patients may have frequent upper respiratory infections and pneumonia. The appearance of pulmonary features and lymphedema may be late, and lymphoma or sarcoma has been reported.

Fingers: Erythromelalgia

Erythromelalgia (labile hyperthermia) is a chronic clinical syndrome that is characterized by recurrent attacks of burning pain in the hands and/or feet with redness and warmth.[39] There may be swelling that extends to the elbows and knees. Erythromelalgia may be primary or secondary to a disorder such as atherosclerosis, hypertension, and polycythemia. Symptoms are thought to be caused by vascular dysfunction, including arteriovenous shunting and reduced capillary perfusion with subsequent tissue hypoxemia.[40] Management includes analgesia, controlling secondary and underlying factors, and use of drugs such as aspirin and calcium channel blockers.[41] A possible role for high-dose oral magnesium has been proposed[42] and the use of a combination gel of 1 percent amitriptyline and 0.5 percent ketamine to treat refractory erythromelalgia pain.[43]



◀ **FIGURE 151-6** Clubbing of fingernails.

Hands

HYPERTROPHIC OSTEOARTHROPATHY Hypertrophic osteoarthropathy often has clubbing as a feature, but in addition there is associated arthralgia and/or arthritis of the fingers, wrists, knees, and ankles. There is a painful periostitis with subperiosteal new bone formation on x-ray. There may be pitting edema, shiny skin, increased sweating, and paronychial thickening. Hypertrophic osteoarthropathy is most often secondary to malignant tumors of the chest.

Pachydermoperiostosis, a primary form, is frequently familial. Its onset is around puberty, and it has a number of cutaneous manifestations. Distinctive thickening and furrowing of the skin of the scalp, forehead, and cheeks may create leonine facies. Other features include excessive sweating, especially of the hands and feet, severe seborrhea of the scalp and face, and dermatitis of the hands and feet. Familial clubbing alone may also be found and may represent a partial expression of this syndrome. Thyroid acropachy (see Chap. 152) may mimic osteoarthropathy but is most often painless.

REFLEX SYMPATHETIC DYSTROPHY The shoulder-hand syndrome is a painful

periarthritis or adhesive capsulitis of the shoulder ("frozen shoulder"), usually on the left side, associated with erythema, increased sweating, shiny induration, edema, tenderness, pain, and immobility of the ipsilateral hand. Reduction of finger flexion, loss of movement, temperature changes, sensory disturbances, and hair/nail growth changes have been reported.[44] Neurotrophic ulcerations of the fingers and thickening of the palmar aponeurosis with nodules and/or Dupuytren contracture may be late sequelae.[45] Predisposing conditions include arterial embolization, cerebrovascular accidents, and protective disuse of the arms for any reason.[46]

Palms: Palmar Erythema

There are two clinical forms of palmar erythema. In the first (Fig. 151-8), there is an exaggeration of normal mottling; the hands are warm and bright red, especially on the palm, the dorsae of the hands, the fingers, and the nail bases. In the second, there is well-demarcated redness of the hypothenar eminence that gradually spreads to the fingertips and then to other areas of the palm. The soles of the feet may show similar changes. The mottling blanches on pressure and flushes synchronously with the pulse rate under a glass slide. Patients may complain of throbbing or tingling. "Liver palms" occur not only in liver disease, but also in pregnancy and thyrotoxicosis. An accompanying change in those with cirrhosis is atrophy of the muscles of the thenar and hypothenar eminence. This is of myogenic rather than neurogenic origin.[47]



▲ **FIGURE 151-8** Palmar erythema showing the characteristic blotchy redness.



▲ **FIGURE 151-9** Spider nevi in a patient with cirrhosis.

Face: Spider Nevus

The spider nevus, or spider angioma, is the most representative and classic vascular lesion of chronic liver disease. Clinically, it has a central arteriole from which numerous small, twisted vessels radiate (Fig. 151-9). Spider nevi range in size from a pinhead to 2 cm. Larger lesions can be seen to pulsate when pressed with a glass slide. Pressure over the central arteriole causes blanching of the whole lesion. Spider nevi are characterized by the abnormal permanent dilatation of end vessels. Histologically, spider nevi consist of a central ascending arteriole ending in a thin-walled ampulla beneath the epidermis from which small arterial branches radiate outward into the papillary dermis.[3]

Spider nevi are most common on the face, neck, and upper part of the chest (i.e., over the region drained by the superior vena cava; see Fig. 151-9). They may be seen in 15 percent of healthy adults and not infrequently in children, where they tend to affect the hands and fingers. They may appear in large numbers during pregnancy, but usually disappear after parturition. They may also be seen in thyrotoxicosis or due to oral contraceptives.

In liver disease, spider nevi can regress with improvement of the underlying condition, although they are more likely to persist. Spider nevi are more common in patients with alcoholic cirrhosis than in those with viral or idiopathic cirrhosis. In alcoholic cirrhosis, they are associated with the presence of esophageal varicosities, and their presence may be a useful predictive marker for the future risk of esophageal bleeds.[48]

Traditionally, vascular spider nevi and palmar erythema (see Palms: Palmar Erythema) have been attributed to estrogen excess, particularly because they also occur during pregnancy and because estrogens have an enlarging, dilating effect on the spiral arterioles of the endometrium. This also explains the spider nevi seen in men receiving estrogen therapy for prostatic cancer. Patients with nonalcoholic cirrhosis have been shown to have higher plasma estradiol–testosterone ratios and substance P levels than healthy controls do,[49] and levels of substance P or vascular endothelial growth factor[50] may have an etiopathogenic role. In alcoholic cirrhosis, the presence of alcoholism and elevated serum bilirubin are both important predictors of the presence of spider nevi.[51]

Eyes

Corkscrew scleral vessels (tortuous small arteries that traverse the margins of the ocular sclerae) can develop in patients with chronic liver disease.

Mouth and Esophagus: Dysphagia

When dermatologic diseases extend into the pharynx and esophagus, dysphagia may occur. Symptoms resulting from infections of the esophagus occur in patients taking oral or inhaled glucocorticoids or in those who have an immunodeficiency. *Candida albicans* is the most frequent pathogen, although opportunistic viruses can also be responsible.

Extensive esophageal involvement, with blisters, erosions, and strictures, can occur in hereditary epidermolysis bullosa, particularly in the recessive dystrophic and junctional forms.[52] The acquired immunobullous disorders can affect mucosae. Dysphagia is most troublesome in cicatricial pemphigoid where half of patients have pharyngeal involvement and up to 13 percent esophageal involvement.[53]

Esophageal lichen planus has been reported only in women, typically middle-aged with oral involvement. Therapeutic dilatation can lead to a Koebner-like exacerbation of the stricture.[54] Esophageal involvement also occurs in Darier disease, sometimes in association with esophageal carcinoma,[55] and in acanthosis nigricans. The mucosae may be extensively involved in Stevens-Johnson syndrome and toxic epidermal necrolysis.

In Behçet disease, isolated mucosal ulcers can occur at any point along the gastrointestinal tract.[56] A typical site is the ileocecal region. Oral ulceration, occurring at least three times in a 12-



month period, is usually evident on the nonkeratinized epithelium and can be difficult to distinguish from the mouth ulceration associated with Crohn disease.

In Plummer-Vinson (Paterson-Kelly) syndrome, a postcricoid web is associated with koilonychia, angular stomatitis, a sore tongue, and, usually, iron deficiency. Up to 10 percent of patients with a postcricoid web develop carcinoma at the site. Tylosis is exceedingly rare, but 95 percent of patients develop esophageal cancer.[57]

Up to 90 percent of patients with systemic sclerosis have gastrointestinal involvement, but this is sub-clinical in one-third. Dyspepsia due to gastroparesis is common; decreased peristalsis, esophageal dilation, and stricture formation occur. Gastric antral vascular ectasia is a rare manifestation that may cause significant bleeding.[58] In dermatomyositis and polymyositis, decreased esophageal motility and difficulty swallowing are indications for urgent treatment with the systemic administration of glucocorticoids and immunosuppressive drugs. Vasculitic ulcers in the mouth and pharynx infrequently occur in systemic lupus erythematosus (SLE).



Ears

EARLOBE CREASE The presence of a diagonally positioned skin crease along the earlobe, either unilateral or bilateral, suggests an increased risk for coronary artery disease in men younger than 60 years of age.[59]

RELAPSING POLYCHONDRITIS (See Chap. 160) Relapsing polychondritis is characterized by inflammation and destruction of cartilage and connective tissues, including those of the cardiopulmonary system. It is idiopathic but is frequently associated with other immunologic disorders such as SLE. Auricular chondritis with pain, swelling, and redness of the pinna but complete sparing of the lobes is characteristic. Respiratory tract involvement may begin with hoarseness or tenderness of the anterior trachea. Degeneration of the laryngeal, tracheal, and/or bronchial rings may lead to progressive insufficiency or to sudden collapse. Cardiac involvement includes degeneration of the aortic ring with valvular insufficiency and aneurysmal dilatation. "Floppy" mitral valve syndrome also occurs. Pericardial and myocardial abnormalities have been reported.

Hair

EFFECTS OF NUTRITION Malnutrition causes hair to grow more slowly, fall out more easily, and become gray. The hair root diameter and the proportion of anagen hairs decrease. Lanugo hair may develop. Kwashiorkor, a form of protein-energy malnutrition, causes hair to become hypopigmented, varying from red-yellow to white, and curly. There may be alternating bands of pale and dark hair.[35] Total parenteral nutrition has been associated with hair loss and pigmentation of remaining hair. Type II vitamin D–dependent rickets is associated with alopecia totalis.

MALE BALDING Frontoparietal male pattern baldness is more prevalent in men admitted with nonfatal myocardial infarction.[59] Vertex hair loss may be more strongly associated with cardiovascular risk factors such as hypertension and hypercholesterolemia.[60]

Cardiovascular System (Table 151-2)

Cardiac output frequently increases in patients with cirrhosis, and total peripheral resistance may decrease.

CORONARY HEART DISEASE: FAMILIAL HYPERLIPIDEMIA (See Chap. 135) Familial hyperlipidemias comprise a group of metabolic disorders with elevated plasma cholesterol and/or triglycerides and are associated with a high incidence of coronary heart disease. Cutaneous xanthomata are also seen and are also associated with a high incidence of coronary heart disease.

CARDIOMYOPATHY: NAXOS DISEASE Naxos disease is an autosomal recessive mutation in desmoplakin, a desmosomal protein important in cell adhesion.[61] Generalized striate keratoderma are seen, particularly on the palmoplantar epidermis (see Chap. 48), with woolly hair and dilated left ventricular cardiomyopathy leading to arrhythmias, heart failure, and early sudden death.

ATRIAL MYXOMA Atrial myxomas, the most common primary tumors of the heart, are benign hamartomatous intracardiac tumors. The cardiopulmonary findings include, in order of frequency, congestive heart failure, mitral murmur, chest pain, pulmonary edema, and pulmonary emboli. Additionally, valvular insufficiency, constrictive pericarditis, conduction blocks, and arrhythmias may occur.

TABLE 151-2
Diseases with Both Cutaneous and Cardiac Involvement

- Joint and connective tissue diseases
  - Rheumatoid arthritis
  - Systemic lupus erythematosus
  - Reiter syndrome
  - Behçet disease
  - Systemic scleroderma
  - Dermatomyositis
  - Rheumatic fever
  - Ehlers-Danlos syndrome
  - Cutis laxa
  - Marfan syndrome
  - Periarteritis nodosa
  - Multicentric reticulohistiocytosis
- Metabolic diseases
  - Hemochromatosis
  - Amyloidosis
  - Fabry disease
  - Carcinoid tumors
  - Myxedema
  - Hyperlipidemias
  - Hyperthyroidism
- Nevoid or genetic disorders
  - Progressive lentigines (Moynahan syndrome)
  - Watson syndrome
  - Neurofibromatosis
  - Tuberous sclerosis
  - LEOPARD syndrome
  - NAME/LAMB/Carney complex
  - Danoff syndrome
- Infectious diseases
  - Varicella
  - Gonococcemia
  - Subacute and acute bacterial endocarditis
  - Chagas disease
  - Diphtheria
  - Miscellaneous (protozoal, viral, rickettsial, and bacterial infections)
- Diseases of uncertain etiology
  - Sarcoidosis
  - Whipple disease
  - Kawasaki disease
  - Degos disease

LAMB = *l*entigines, *a*trial *m*yxoma, and *b*lue nevi; LEOPARD = *l*entigines, *e*lectrocardiogram conduction defects, *o*cular hypertelorism, *p*ulmonary stenosis, *a*bnormalities of genitalia, *r*etardation of growth, and sensorineural *d*eafness; NAME = *n*evi, *a*trial *m*yxoma, and neurofibroma *e*phelides. Modified and reprinted with permission from *Dermatologic Capsule & Comment*, edited by Fitzpatrick TB. September 1987, p 9.

Variable murmurs can be an important clue. Other systemic findings include fever, cachexia, arthralgia, clubbing, hypergammaglobulinemia, and leukocytosis.

The cutaneous manifestations of atrial myxomas may be dramatic. In addition to



▲ **FIGURE 151-10** Lentiginous lesions in the atrial myxoma syndrome complex. This child has the LAMB syndrome (*l*entigines, *a*trial myxoma, *m*ucocutaneous myxomas, and *b*lue nevi).

biphasic digital color changes on cold exposure, skin lesions may simulate collagen vascular disease or vasculitis with tender, violaceous, non-blanching, annular, and serpiginous lesions of the digital pads, as well as splinter hemorrhages presenting as a systemic vasculitis or infective endocarditis. Characteristic pruritic, erythematous papules as well as cyanosis and ecchymosis of the extremities may also occur. Histologically, myxomatous emboli with large pale cytoplasm and stellate nuclei may be found among occluded blood vessels. Mucocutaneous pigmented lesions, including lentigines (Fig. 151-10), melanocytic nevi, and dermal myxomatous nodules, have been described (NAME/LAMB/Carney complex).[62]

LEOPARD SYNDROME Multiple lentigines syndrome is an autosomal dominant disorder comprising *l*entigines, *e*lectrocardiogram conduction defects, *o*cular hypertelorism, *p*ulmonary stenosis, *a*bnormalities of genitalia, *r*etardation of growth, and sensorineural *d*eafness (LEOPARD syndrome). Electrocardiographic features include axis deviation, prolonged P-R interval, bundle branch block, and complete heart block. Hypertrophic cardiomyopathy appears to be the most common anatomic abnormality. Subaortic stenosis is the most common valvular lesion.

SUBACUTE BACTERIAL ENDOCARDITIS The cutaneous manifestations of bacterial endocarditis include Osler's nodes, Janeway lesions, subungual splinter hemorrhages, cutaneous purpura and petechiae, and conjunctival petechiae (Roth's spots).

Petechiae are the most common manifestation with small, red or violaceous non-blanching macules especially on the heels, shoulders, and legs.



▲ **FIGURE 151-11** Osler's nodes (*arrows*).

Osler's nodes and Janeway lesions may both present as erythematous or hemorrhagic macules, papules, or nodules (Fig. 151-11). However, although Osler's nodes are exquisitely painful, tender, and located distally on the digital tufts, Janeway lesions are non-tender and located proximally on the palms and soles. Histologically, Osler's nodes are a perivasculitis or necrotizing vasculitis without microabscess formation or other evidence of infection or emboli, whereas Janeway lesions have been described as a vasculitis with microabscess formation. Both are found in patients with other conditions, particularly SLE, gonococcemia, hemolytic anemia, and typhoid fever.

COLLAGEN VASCULAR DISEASE AND THE HEART ***Systemic Lupus Erythematosus.*** Pericarditis may be more common in patients with drug-induced lupus or photosensitive discoid lesions. Myocarditis is often undiagnosed and may be associated with prolonged P-R intervals, heart block, and arrhythmias. Valvular heart disease in patients with SLE, most often of the Libman-Sacks type, is frequently associated with anti-phospholipid antibodies.[63] Diastolic murmurs may occur with mitral stenosis or aortic insufficiency, but the onset of a new diastolic murmur should provoke a search for subacute infective endocarditis. Splinter hemorrhages, Osler's nodes, Janeway lesions, and Roth's spots may occur in SLE *per se* without infection. SLE is associated with complete heart block in newborns because of placental transfer of maternal antibodies, especially the anti-Ro antibody.[64] The newborn infants of patients with SLE or of clinically normal but Ro-antibody–positive mothers may also have distinctive evanescent eruptions, including prominent telangiectasia and periorbital erythema.[64]

Systemic Sclerosis. Acute or chronic pericarditis is an important feature of systemic sclerosis. Pericardial effusions may be occult, and constrictive pericarditis and tamponade may occur. Additionally, small-vessel involvement of the myocardium may lead to fibrosis.[65] Fibrosis of the conduction system may cause arrhythmias and sudden death.

Respiratory System

PULMONARY ARTERIOVENOUS FISTULAS Pulmonary arteriovenous fistulas are congenital abnormalities of capillary development that may not become clinically apparent until late adolescence. Osler-Weber-Rendu disease[66] is an autosomal dominant trait, characterized clinically by punctate, linear, or spider-like telangiectasias of the skin, especially the upper body, oral and nasal mucous membranes, and nail beds (Fig. 151-12). The radiating arms surrounding an elevated punctum are the most characteristic feature, especially on the lips and tongue. They are distinguished from spider nevi in that they do not pul-



▲ **FIGURE 151-12** Osler-Weber-Rendu disease. Note the punctate and splinter-like telangiectasia on the lips and tongue.



sate. Recurrent epistaxis is the most frequent presenting symptom and may begin in early childhood or adolescence. The liver and gastrointestinal and central nervous systems can be involved (see Disorders of Both Skin and Liver), and recurrent hemorrhage may result. Bleeding may be enhanced by an associated von Willebrand disease. In those with an arteriovenous fistula of the lungs, pulmonary bruits accentuated by inspiration can be heard.

In cirrhosis, arteriovenous shunting may occur within the lungs (the hepatopulmonary syndrome),[67] liver, and extremities. These arteriovenous malformations, including spider nevi, may regress after transplantation.[68]



LARVA MIGRANS (See Chap. 207) Cutaneous larva migrans may cause mild respiratory symptoms and be associated with transient pulmonary infiltrates and a peripheral eosinophilia (Löffler syndrome). Visceral larva migrans, or toxocariasis, may lead to granulomatous involvement of the liver, lungs, heart, muscle, brain, and eyes. Marked eosinophilia, hyperglobulinemia, pneumonitis with wheezing, recurrent bronchitis, fever, and tender hepatomegaly frequently occur. Skin lesions may present as patchy urticaria or erythematous papular eruptions.

FAT EMBOLISM SYNDROME Petechiae, respiratory insufficiency, and cerebral dysfunction after long bone fracture are termed the *fat embolism syndrome*. Petechiae alone after fractures should suggest this syndrome. The petechiae are most common on the neck, axillae, shoulders, chest, and conjunctivae and often appear before other manifestations. They begin on the second or third day after injury and appear in crops. When widespread, they tend to herald more significant cerebral and pulmonary dysfunction. Histologically, fat globules are present within the dermal and pulmonary vessels. Respiratory involvement includes cyanosis, hemoptysis, and pulmonary edema. Jaundice and thrombocytopenia may occur.[69]

LIPOID PROTEINOSIS (HYALINOSIS CUTIS ET MUCOSAE) (See Chap. 137) Skin changes include confluent, waxy papules, plaques, and scarring, particularly on the face. The tongue is enlarged. Oropharyngeal and laryngeal mucous membranes are usually affected early in the course of the disease, during infancy or childhood. Hoarseness due to laryngeal infiltration is often the initial finding and may progress to obstruction and respiratory insufficiency. The trachea and main stem bronchus may be thickened and studded with warty projections.

MULTICENTRIC RETICULOHISTIOCYTOSIS (See Chap. 149) Multicentric reticulohistiocytosis is an uncommon disorder presenting with characteristic mucocutaneous lesions consisting of deeply set, firm, small papules, and a deforming arthritis in association with systemic symptoms such as fever, malaise, weight loss, and myopathy. Neurofibroma-like, soft, sessile, larger lesions have been reported as has an association with malignancy.[70] The cardiopulmonary complications include pleural effusions, pulmonary infarctions, pericarditis, angina pectoris, myocardial infarction, and congestive heart failure.

SARCOIDOSIS (See Chap. 153) Cardiac involvement in sarcoidosis may be occult and results from myocardial or conduction system granulomata. Ventricular arrhythmias and conduction disturbances present as palpitations and syncope. Congestive heart failure and chest pain occur as do cardiomyopathy or cor pulmonale. The prognosis for patients with cardiac involvement is unfavorable. Sarcoidosis affecting the pulmonary system may be suggested by lupus pernio with involvement of the hilar nodes, bronchi, and/or alveoli resulting in obstructive and/or restrictive dysfunction and respiratory failure.[71] Indwelling vascular catheters can, rarely, disintegrate into pieces that embolize into small pulmonary vessels and lymphatics, causing granulomatous changes and dyspneic symptoms. These lesions have also been reported in the skin.[72]

AMYLOIDOSIS (See Chap. 133) Systemic amyloidosis may cause waxy induration of the skin, and, when stroked, the skin may become hemorrhagic ("pinch purpura"). A biopsy of clinically normal skin might demonstrate amyloid deposition within the vessels in up to 50 percent of patients.

Cutaneous involvement occurs most often in the primary and myeloma-associated types, and therefore serves as a marker for cardiopulmonary involvement. Congestive heart failure with cardiomegaly or a restrictive cardiomyopathy occur. Pathologically, there is infiltration of the endocardium, myocardium, pericardium, valves, and coronary vessels.[73] Senile amyloidosis may also affect the heart but is often asymptomatic.

Respiratory tract involvement is also most common in primary and myeloma-associated types. Macroglossia may impede respiration; the larynx and trachea may become infiltrated, causing stridor; and bronchial and parenchymal involvement cause asthma-like symptoms.

LYMPHOMATOID GRANULOMATOSIS (See Chap. 146) Lymphomatoid granulomatosis is a rare angiocentric and angiodestructive, Epstein-Barr virus-associated B-cell lymphoproliferative disorder, varying from an indolent process to an aggressive large cell lymphoma. The skin is the extrapulmonary organ most commonly involved. The disease also affects the lungs, heart, central nervous system, and kidneys. Although many patients remain asymptomatic, cough, dyspnea, and chest pain may occur. Chest x-rays show transient infiltrates, which may progress to nodules that cavitate and cause profuse hemoptysis.

COLLAGEN VASCULAR DISEASE AND THE LUNGS The pulmonary complications of the various collagen vascular diseases may sometimes be associated with a specific cutaneous sign or constellation of features.

Rheumatoid Arthritis. Extra-articular manifestations of rheumatoid arthritis, especially in the lungs, appear to correlate with subcutaneous nodules and vasculitic skin lesions. Skin lesions are also associated with high-titer rheumatoid factor, hypocomplementemia, cryoimmunoglobulinemia, and hypereosinophilia. These occur more commonly in men with long-standing disease but may not correlate with current arthritis activity. The pulmonary symptoms include cough and hemoptysis.

Systemic Lupus Erythematosus. (See Chap. 156) Pleuritis may be present in one-half of patients with SLE, and pleural effusions also occur. Parenchymal lung involvement in SLE is usually a result of secondary factors such as infections or pulmonary emboli. Primary lung involvement in SLE may be classified as (1) diffuse interstitial pneumonitis, (2) acute pneumonitis, (3) intrapulmonary hemorrhage, (4) diaphragm dysfunction with decreased lung volume, (5) pulmonary hypertension with cor pulmonale, and (6) fibrosing alveolitis.[74]

Systemic Sclerosis. (See Chap. 158) Raynaud phenomenon, telangiectases, and dilated and distorted capillary loops of the nails are cutaneous clues. Exertional dyspnea chronic, nonproductive cough,

and pleuritic chest pain indicate lung involvement.[75] Pulmonary hypertension with cor pulmonale and congestive heart failure may develop independently of parenchymal disease. Esophageal dysmotility causing aspiration pneumonia is associated with a higher incidence of interstitial lung disease.[76]

Gastrointestinal System

On examining the abdomen in patients with cirrhosis, portal-systemic collateral vessels may be seen and are a clue to the existence of portal hypertension. Often, the umbilical vein is dilated and visible in the epigastrium, an occurrence more common than the well-recognized, but rare, caput medusae.

GASTROINTESTINAL BLEEDING Hematemesis, melena, or passing of fresh blood in the stools are signs of gastrointestinal bleeding (Table 151-3). The characteristic picture of hereditary hemorrhagic telangiectasia is of a familial pattern of epistaxis with telangiectases on mucosal surfaces (see Fig. 151-12) and arteriovenous malformations in multiple organs.[66] Hemorrhage from the gut, usually from the stomach or duodenum, occurs in up to 40 percent of patients and at an average age of 55 years.

Most cases of blue rubber bleb nevus syndrome (see Chap. 173) are sporadic, but there are families with autosomal dominant inheritance. The gastrointestinal venous malformations look and feel as their name suggests and project into the gut lumen, particularly that of the small intestine. In contrast to cutaneous lesions, they bleed easily, causing chronic anemia and, less commonly, acute hemorrhage.[77]

In the autosomal dominant vascular type of the Ehlers-Danlos syndrome, type IV, rupture of the bowel, often involving the sigmoid colon, accounts for one-quarter of all complications and 8 percent of all deaths.[1] Diverticula and hernias may also occur.

Thirteen percent of patients with pseudoxanthoma elasticum experience gastrointestinal bleeding, usually from the stomach. This is often the first clinical manifestation of the disease.[78]

The gut, particularly the small intestine, is a common site for Kaposi sarcoma. Although involvement is commonly asymptomatic, severe bleeding may occur.

Gastrointestinal bleeding in a patient with a dermatologic disease may be due to drug therapy. The systemic administration of glucocorticoids commonly causes dyspepsia; less commonly, it causes gastric erosions, ulceration, and hemorrhage. Methotrexate may cause enteritis, gastrointestinal ulceration, and hemorrhage.

ABDOMINAL PAIN (Table 151-4) Involvement of the sensory roots of the vertebrae T6-L1 in herpes zoster may produce abdominal pain even before skin lesions appear. Occasionally, herpes zoster in the distribution of S2, S3, and S4 is associated with perineal pain and disturbances of urination and defecation.

Acute attacks of urticaria or angioedema may present as abdominal pain. Edema of the bowel wall and mucosal thickening, often in association with free peritoneal fluid, is evident ultrasonographically, which avoids unnecessary surgery in acute cases.[79] This is especially true in hereditary angioedema where colicky abdominal pain and life-threatening laryngeal edema occur and require treatment with injection of purified C1 inhibitor concentrate[80] (see Chap. 37).

It is only in the rare variegate porphyria that skin involvement and attacks of abdominal pain co-exist (see Chap. 132). The skin shows changes identical to those in porphyria cutanea tarda (PCT). Pregnancy or drugs such as estrogen and griseofulvin may precipitate acute attacks. Although the detection of urinary uroporphyrin and fecal protoporphyrin indicates the diagnosis, plasma fluorescence with emission maxima at 626 nm is more sensitive in revealing the condition, even in patients who are in remission.[81]

One-third of patients with systemic mastocytosis (see Chap. 150) have gastrointestinal involvement. Symptoms include vomiting, abdominal pain, malabsorption, diarrhea, peptic ulceration, and gastrointestinal bleeding. Patients with more aggressive disease may develop hepatosplenomegaly with ascites and lymphadenopathy.[82–85]

Anderson-Fabry Disease (Angiokeratoma Corporis Diffusum). (See Chap. 136) Anderson-Fabry disease is a rare X-linked recessive multisystem lysosomal storage disorder caused by a deficiency of α-galactosidase A. Signs include severe, painful neuropathy; and progressive renal, cardiovascular, and cerebrovascular dysfunction. Gastrointestinal symptoms include abdominal pain and diarrhea. The diagnosis may be missed without the skin signs. Angiokeratomas may not appear until adolescence and, even then, can be subtle. Assay of α-galactosidase A is possible not only in established cases, but also before birth, and female carriers often are identifiable. Treatment with intravenous infusions of α-galactosidase A is safe and efficacious.[86]

Vasculitis. (See Chaps. 164 and 165) Henoch-Schönlein purpura is palpable, especially on the legs and buttocks, and may occur in conjunction with joint swelling. Up to 76 percent of patients have gastrointestinal involvement, ranging from colicky abdominal pain, nausea, and vomiting to bloody diarrhea, intussusception, and pancreatitis. Renal involvement is common, especially in patients with bloody stools.[87] Upper gastrointestinal endoscopy reveals multiple raised erythematous lesions or ulceration that resolves after systemic treatment with glucocorticoids.[88]

TABLE 151-3
Skin Abnormalities in Patients with Gastrointestinal Bleeding

- Congenital malformations of blood vessels
  - Hereditary hemorrhagic telangiectasia
  - Blue rubber bleb nevi
- Inherited defects of connective tissue
  - Ehlers-Danlos syndrome
  - Pseudoxanthoma elasticum
  - Kaposi sarcoma
  - Vasculitis
  - Polyposis
  - Ulcerative colitis and Crohn disease
  - Gastrointestinal tumors
  - Drugs used to treat skin disease

TABLE 151-4
Skin Abnormalities in Patients with Abdominal Pain

- Herpes zoster
- Angioedema
- Porphyria
- Fabry disease
- Vasculitis
  - Henoch-Schönlein purpura
  - Collagen vascular diseases
  - Malignant atrophic papulosis
- Polyposis
  - Gardner syndrome
  - Peutz-Jeghers syndrome
  - Cronkhite-Canada syndrome
  - Neurofibromatosis
  - Ulcerative colitis
- Inflammatory bowel disease: ulcerative colitis and Crohn disease
- Pancreatitis
- Gastrointestinal tumors
  - Metastases
  - Dermatomyositis
  - Acanthosis nigricans
  - Hypertrichosis lanuginosa



Malignant atrophic papulosis is an idiopathic, systemic, obliterative vasculopathy. The characteristic skin lesions are recurrent crops of porcelain-white atrophic papules with an elevated erythematous border. These may have been present for years with no other apparent disease, although gut vessels are involved in half of the cases.[89] Clinically bleeding, abdominal pain, diarrhea, malabsorption, and bowel perforation with peritonitis occur.

Polyposis. True polyps are rare except in the colon and rectum. Polyp-like lesions that are hamartomatous or inflammatory occur in all parts of the gut. The term *hamartoma* implies a non-neoplastic tumor composed of tissue elements normally present in that organ. The hamartomatous polyposis syndromes (e.g., Peutz-Jeghers, Cronkhite-Canada) should be distinguished from the adenomatous polyposis syndromes (e.g., Gardner). In many of these syndromes, hamartomatous polyps of the gastrointestinal tract coexist with adenomas, and adenomas may develop within hamartomatous polyps, contributing to the frequent occurrence of adenocarcinoma in most of these syndromes.[90]

Gardner syndrome is an autosomal dominant disorder characterized by cutaneous cysts and pre-malignant adenomatous polyps, particularly in the colorectum. Duodenal and hepatic carcinoma can also occur. The cutaneous lesions frequently pre-date the gastrointestinal lesions and include solitary or multiple epidermoid cysts, fibromas, lipomas, pilomatricomas, facial osteomas, and distinctive ocular lesions.[91]

Peutz-Jeghers syndrome is autosomal dominant and characterized by small, darkly pigmented macules around the mouth, on the lips, buccal mucosa, and digits. A histologically unique type of hamartomatous polyp occurs, mainly in the small intestine, which predisposes to recurrent intussusception. Bleeding is relatively rare, but up to 2 percent of patients develop adenocarcinoma of the stomach, duodenum, and colon.[90] There is also an increased risk of malignancy in general.[92]

In Cronkhite-Canada syndrome, there is patchy alopecia and characteristic nail changes.[90] Inflammatory polyps are present in the stomach and bowel, and abdominal pains with a severe protein-losing enteropathy are common.

Both ulcerative colitis and Crohn disease present with abdominal pain, gastrointestinal bleeding, or diarrhea. Ulcerative colitis predisposes to carcinoma of the colon. The skin complications of the two diseases are similar, although some occur with different frequencies. Up to one-half of patients with pyoderma gangrenosum may have inflammatory bowel disease, although only 12 percent of patients with ulcerative colitis and 2 percent of patients with Crohn disease will develop the condition.[93] The severity and extent of ulceration in pyoderma gangrenosum may be linked to the activity of the underlying disease, and pyoderma gangrenosum can heal with effective treatment of the underlying bowel disease. Erythema nodosum is well recognized.

Oral granulomatous nodules are common in Crohn disease, where they may coalesce to give a "cobblestone" appearance. Crohn disease is one cause of granulomatous cheilitis, which may predate bowel disease by several years. Granulomas may also occur in the perineum, at colostomy and ileostomy sites, and in association with scars, sinuses, and fistulas. Very rarely, granulomas occur at sites not contiguous with the bowel, such as the trunk and limbs: the so-called *"metastatic" cutaneous Crohn disease*.[94] Aphthous ulcers may be a presenting feature. Bruising of the skin around the umbilicus (Cullen's sign) or in the flanks (Grey Turner's sign) are well-known features of acute pancreatitis, but occur in less than 3 percent of cases.[95] Chronic pancreatitis may cause tender, subcutaneous nodular areas of fat necrosis that may ulcerate.

GASTRIC BYPASS SURGERY Gastric bypass surgery or reduction with jejunoileal and jejunocolic anastomoses is used to treat morbid obesity. Dryness of the skin, hair loss, recurrent fever, arthralgia, and inflammatory and vasculitic skin lesions have been reported postoperatively. "Bowel bypass syndrome without bowel bypass" is recognized as the same constellation of symptoms but with other gastrointestinal disorders.[96]

CUTANEOUS EFFECTS OF MALABSORPTION OF SPECIFIC NUTRIENTS (See Chap. 130) Vitamin deficiency can follow intestinal surgery, pancreatic disease, malabsorption syndromes, and malnutrition, including malnutrition associated with alcoholism (Table 151-5).[35]

- Vitamin A deficiency causes xerotic wrinkled skin covered with fine scales, occasionally accompanied by deep erosions (dermomalacia).

TABLE 151-5
Malabsorption and Skin Disease

- Skin changes due to malabsorption
  - Non-specific
    - Acquired ichthyosis and pruritus
    - Hair and nail changes
    - Hyperpigmentation
    - Skin texture and elasticity
    - Eczematous and psoriatic rashes
    - Jejunoileal and jejunocolic anastomoses
  - Specific nutrients
    - Zinc
    - Essential fatty acids
    - Vitamins
- Malabsorption due to skin disease
  - Dermatogenic enteropathy
  - Collagen vascular disease
  - Dermatitis herpetiformis and celiac disease

- Deficiency of vitamin B_3 causes pellagra with its triad of diarrhea, dermatitis, and dementia.
- Vitamin B_{12} (cyanocobalamin) deficiency is common in ileal malabsorption syndromes such as pancreatic disease. There is a symmetric "glove and stocking" hyperpigmentation, but a lemon yellow pallor to the skin elsewhere.
- Vitamin C deficiency classically causes follicular keratoses, hemorrhage, and corkscrew hairs.
- Malabsorption of vitamin K occurs in obstructive jaundice and leads to impaired coagulation, resulting in cutaneous hemorrhage with ecchymoses and purpura.
- A diffuse hyperpigmentation, cheilitis, and perineal ulceration or dermatitis can occur in folic acid deficiency states. Theoretically, drugs used for dermatologic diseases such as methotrexate, a folate antagonist, can exacerbate folic acid deficiency.
- Iron deficiency presents with angular stomatitis, smooth painful tongue, and fragile/brittle nails, which have longitudinal ridging and lamellation. In marked iron deficiency, anemia koilonychia, a spoon-like convexity of the nails, develops. Hair changes include diffuse scalp alopecia with brittle, split hairs. All take a long time to resolve on replacement therapy.
- Zinc deficiency can result from acrodermatitis enteropathica, malabsorption, or a lack of zinc in long-term parenteral nutrition. Acrodermatitis enteropathica usually presents at weaning or in very early infancy



with dermatitic or vesicobullous lesions of the hands, on the feet, and around the mouth and anus, together with progressive alopecia and "failure to thrive."

MALABSORPTION DUE TO SKIN DISEASE Malabsorption can result from poor intestinal peristalsis in systemic sclerosis or chronic obliteration of mesenteric vessels in polyarteritis and other forms of vasculitis. In diffuse scleroderma and systemic sclerosis, 8 percent of patients develop malabsorption or recurrent intestinal pseudo-obstruction, usually within 3 years of disease onset.[65,97] Vasculopathy interferes with peristalsis and leads to malabsorption by allowing bacterial colonization higher up the bowel than is usual.

Small-bowel tumors produce a variety of hormones and vasoactive amines, of which the best characterized is serotonin. The most common tumors are in the appendix, rectum, and ileum, where they are usually multiple. Episodic flushing, wheezing, or diarrhea does not occur until the vasoactive amines reach the systemic circulation. Therefore, flushing usually indicates metastasis to the lymph nodes or liver or a primary tumor at a different site (e.g., lung or ovary).[98,99]

Hepatobiliary System

Skin lesions occurring in association with liver disease are usually not specific to a particular disease. The most florid cutaneous lesions appear in patients with chronic active hepatitis or alcoholic liver disease, but may also occur in physiologic states, such as spider nevi, in pregnant women. There may be no visible skin changes in patients with severe liver disease and, conversely, dramatic cutaneous manifestations may develop in those with minimal hepatic dysfunction.

HEPATITIS AND THE SKIN Cutaneous striae may appear in patients with chronic hepatitis, whatever the underlying cause and even before glucocorticoid therapy (see Fig. 151-1). Pyoderma gangrenosum, urticaria, vasculitis, acne, scleroderma, and splinter nail hemorrhages occur, depending on the underlying cause of the hepatitis.

The clinical features of infection with the different hepatotropic viruses that cause acute viral hepatitis are similar. In the pre-icteric phase, malaise, lethargy, nausea, and abdominal pain occur. A discrete, transient, maculopapular, urticarial, or petechial rash may develop, together with arthritis or arthralgia. These symptoms may worsen with the appearance of jaundice, dark urine, and pale stools. Malaise and fatigue may persist for some time after resolution of the disease.

Hepatitis A. Transmission of hepatitis A virus takes place via the fecal-oral route. Although relapses occur, hepatitis A does not progress to chronic hepatitis.

Hepatitis B. Hepatitis B virus (HBV) is transmitted by percutaneous and permucosal routes. It is endemic in many countries, and health care professionals are at risk. A recombinant DNA vaccine is available, but has been associated with cutaneous side effects.[100–102] Five percent of HBV-infected subjects become carriers, and 90 percent of infants born of infected mothers develop chronic infection.

There are four main cutaneous associations of hepatitis B: (1) a serum sickness-like syndrome, (2) cryoglobulinemia, (3) polyarteritis nodosa, and (4) papular acrodermatitis of childhood. The serum sickness-like syndrome occurs in approximately 10 percent of patients in the pre-icteric phase of acute hepatitis B infection. Urticaria may be the predominant or sole feature, but is usually accompanied by a low-grade fever, arthralgia of the peripheral joints, proteinuria, and hematuria. There may be vasculitis.

Both HBV and hepatitis C virus (HCV) infection are associated with cryoglobulinemia, although HCV infection is more common. Mixed cryoglobulinemia in HCV infection is usually of type III,[103] and the cryoglobulinemia may indicate the presence of active viral replication.[104] Patients develop recurrent purpura, acrocyanosis, arthralgia, lymphadenopathy, peripheral neuropathy, and hepatosplenomegaly. Renal involvement is common. Histopathologically, there is a necrotizing vasculitis.[104]

Polyarteritis nodosa can occur in the acute phase of HBV infection, or it may not present for several years. Circulating immune complexes containing hepatitis B surface antigen and immunoglobulin occur. Leukocytoclastic vasculitis may develop.

Papular acrodermatitis (Gianotti-Crosti syndrome) usually affects children. The appearance of monomorphic, flat-topped, erythematous papules on the face and limbs is characteristic. This eruption is self-limiting and asymptomatic in most, but may be accompanied by lymphadenopathy.[105] Other infectious agents and immunizations have been implicated in papular acrodermatitis.[106] Sweet syndrome has recently been reported with both acute[107] and chronic HBV infection.

Hepatitis C. The majority of cases of posttransfusion hepatitis have been due to HCV infection, but screening has reduced the number of new cases dramatically. Cutaneous manifestations of acute and chronic HCV infection include leukocytoclastic vasculitis, usually due to cryoglobulinemia (see Hepatitis B); cutaneous necrosis[104]; pruritus[108]; acquired angioedema[109]; PCT; erythema nodosum; urticaria; erythema multiforme; and polyarteritis nodosa.[110]

Lichen planus occurs more commonly in patients infected with HCV,[111] although studies disagree on the incidence.[112] There is an increased frequency of the HLA-DR6 allele in Italian patients with HCV-associated oral lichen planus,[113,114] suggesting that host factors may play a part in this association.

DISORDERS OF BOTH SKIN AND LIVER (Table 151-6) Argininosuccinic aciduria is a rare autosomal recessive disorder characterized by ataxia, seizures, severe mental retardation, hepatomegaly with liver dysfunction, and brittle hair. Dermatomyositis may be the presenting sign of a primary[115] or secondary hepatic tumor. In eruptive neonatal angiomatosis, multiple angiomas may occur anywhere on the skin surface; in addition, vascular lesions may occur in internal organs, including the liver. Both acute and chronic phases of graft-versus-host reactions may have prominent effects on both skin and liver, most commonly in patients receiving bone marrow transplants. In hereditary hemorrhagic telangiectasia, arteriovenous fistulas can cause shunting, and "cirrhosis" (i.e., multiple small telangiectatic hepatic vessels) occurs.[66] Several of the histiocytoses, including Langerhans cell histiocytosis and malignant histiocytosis, may involve both skin and liver. Immunodeficiency states may result in multiple infections of skin and liver. Examples include congenital disorders (e.g., ataxia-telangiectasia, Chédiak-Higashi syndrome, chronic granulomatous disease) and acquired disorders (e.g., acquired immunodeficiency syndrome).

Hepatomegaly occurs in systemic mastocytosis.[82–85] In Kawasaki disease, children may develop upper abdominal pain associated with hepatobiliary



TABLE 151-6
Diseases with Both Cutaneous and Hepatic Involvement

- Argininosuccinic aciduria
- Dermatomyositis
- Drug reactions
- Eruptive neonatal angiomatosis
- Graft-versus-host disease
- Hereditary hemorrhagic telangiectasia (Osler-Weber-Rendu disease)
- Histiocytoses
- Immunodeficiency states
- Mastocytosis
- Mucocutaneous lymph node syndrome (Kawasaki disease)
- Porphyrias
  - Porphyria cutanea tarda
  - Variegate porphyria
  - Erythropoietic (erythrohepatic) porphyria
  - Hereditary coproporphyria
- Sarcoidosis
- Syphilis
- Systemic lupus erythematosus
- Tuberous sclerosis
- Vinyl chloride disease



changes, non-specific elevation of liver enzyme levels due to vasculitic changes, or bile duct inflammation.[116] Sarcoidal infiltration of the liver may accompany the cutaneous signs of sarcoidosis. Hepatic granulomas may also occur in tuberculosis, glandular fever, and syphilis, or as a side effect of drugs such as phenylbutazone, allopurinol, and the sulfonamides. True syphilitic hepatitis is rare and presents with pruritus and cholestatic jaundice.

Patients with SLE can have abnormal liver tests.[117] The most common cause is drug-induced hepatitis. Thrombotic conditions, including Budd-Chiari syndrome and venoocclusive disease, occur with or without lupus anticoagulant. Rare abnormalities include nodular regenerative hyperplasia, perihepatitis, and hepatic or splenic rupture. Autoimmune hepatitis, PBC,[118] granulomatous hepatitis, cryptococcal infection, porphyria, or idiopathic portal hypertension[119] may also occur.

Cholestatic hepatitis occurs as a rare complication of Stevens-Johnson syndrome and may precede the skin signs.[120]

Angiomyolipomas are frequently seen on ultrasound examination of the livers of patients with tuberous sclerosis, but are usually asymptomatic. Liver function abnormalities are common in patients with vinyl chloride disease and may be associated with hepatosplenomegaly, cirrhosis, and, rarely, angiosarcoma.

Cutaneous Manifestations of Primary Biliary Cirrhosis. The basis for a diagnosis of PBC is a clinical picture of a middle-aged female with jaundice and pruritus, cholestatic liver function tests, antimitochondrial antibodies, and histologic changes in the liver of inflammatory duct destruction with fibrosis and cirrhosis. Severe itching may antedate other features of biliary cirrhosis by months or years.

The combination of the CREST syndrome (*c*alcinosis cutis, *R*aynaud phenomenon, *e*sophageal dysfunction, *s*clerodactyly, and *t*elangiectasia) and PBC occurs more often than would be expected by chance and has been termed *Reynolds syndrome*. Patients have a higher incidence of anticentromere antibodies (especially the antiprotein C isotype) and Sjögren syndrome.[121]

Lichen planus has a well-recognized association with PBC and may occur in either the presence or the absence of penicillamine treatment for PBC. It can resolve following liver transplantation.[122] Cutaneous xanthomas also occur with PBC. Rarely, both lichenoid and xanthomatous changes appear in the same lesion.[123]

EFFECTS OF SKIN DISEASE ON THE LIVER

Several systemic complications occur as a consequence of skin disease, and some of them reflect abnormalities of hepatic function.

Extensive Loss of Skin. Patients may lose large areas of skin because of thermal burns, immunobullous disease, or toxic epidermal necrolysis. In experimental animal models, extensive thermal injury results in a halving of the hepatic arterial blood flow.[124] Postburn sepsis amplifies this injury and induces portal hypertension.[125] This may, in turn, account for a gut barrier dysfunction (the so-called *dermatogenic enteropathy*), but research has not convincingly demonstrated this relationship in humans with extensive skin disease.

Psoriasis. The high incidence of abnormalities of the liver architecture in patients with psoriasis has been attributed to alcohol misuse. Psoriasis is more common than expected in alcoholic cirrhosis than in cirrhosis due to other causes.[8,126] Those who misuse alcohol are said to have a unique, acral, distribution of psoriasis.[8] Alcohol appears not only to trigger psoriasis, especially in men, but also to influence the course of the disease, as heavy drinkers have more severe, extensive, inflamed disease. Patients who decrease alcohol consumption may decrease the extent of their disease and increase their response to treatment.[126]

Dermatitis Herpetiformis. Results of liver function tests are sometimes abnormal in patients with dermatitis herpetiformis[127] and can also occur secondary to treatment or as a result of associated conditions.[128]

Skin Cancer. Primary cutaneous neoplasms, including melanoma, squamous cell carcinoma, Merkel cell tumor, and Kaposi sarcoma, occasionally metastasize to the liver.

HEPATOTOXIC EFFECTS OF DRUGS USED IN THE TREATMENT OF SKIN DISEASE

Several drugs used in managing patients with skin disease are hepatotoxic (Table 151-7). Many others, such as antimalarials or terbinafine, warrant caution in patients with hepatic impairment.

Patients who have psoriasis and who are undergoing long-term treatment with methotrexate have a high frequency of liver fibrosis and cirrhosis,[129] especially if their total doses exceed 1.5 g (see Chaps. 18 and 228). Those with a history of alcohol misuse, impaired renal function, diabetes, and obesity are at higher risk. Diagnosis of fibrosis is histologic and requires liver biopsy. The morbidity of liver biopsy can be as high as 10 percent, and the mortality up to 0.1 percent.[130] In hepatic fibrosis, the synthesis of predominantly type III collagen is increased, and the amino terminal propeptide of type III procollagen (PIIINP) is cleaved off and released into the circulation.[131,132] Because it is now possible to measure serum PIIINP levels accurately, this test has become a valuable non-invasive marker of active hepatic fibrogenesis during methotrexate treatment of psoriasis.[133] Thus, the number of liver biopsies taken in patients with normal serial serum PIIINP levels can be reduced to a minimum.[134]

Renal System

The cutaneous manifestations of renal disease are primarily encountered in patients with CRF. In contrast, only two skin changes—edema and uremic frost—occur in acute renal failure (ARF). Edema is a particular feature of ARF with nephrotic syndrome. Uremic frost results from eccrine deposition of urea crystals on the skin surface of individuals with severe uremia. It is now rare

TABLE 151-7
Hepatotoxic Drugs Used in the Treatment of Skin Diseases

Drug	Indication	Side Effect
Azathioprine	Bullous disorders, dermatomyositis	Raised liver enzymes
Cyclosporin	Psoriasis, dermatitis	Raised liver enzymes
Cyproterone acetate	Hirsutism and virilization	May worsen pre-existing dysfunction
Danazol	Hereditary angioedema	May worsen pre-existing dysfunction and porphyria
Dapsone	Dermatitis herpetiformis, erythema elevatum diutinum, granuloma faciale, and others	May cause dapsone syndrome (rash, eosinophilia fever hepatitis). Avoid in porphyria
Griseofulvin	Fungal infections	May worsen pre-existing liver disease
Ketoconazole	Fungal infections	Raised liver enzymes and hepatitis
Methotrexate	Psoriasis, sarcoidosis	Cirrhosis
Minocycline	Acne	Hepatitis
Retinoids	Acne, psoriasis, disorders of keratinization	Elevated liver enzymes, increases hepatotoxicity of methotrexate
Stanozolol	Hereditary angioedema	May worsen pre-existing dysfunction and porphyria
Terbinafine	Fungal infections	Hepatitis

because of the wide availability of acute hemodialysis.

CALCIFICATION Metastatic calcification of the skin in CRF results from secondary or tertiary hyperparathyroidism. Abnormally elevated levels of PTH may trigger deposition of crystalline calcium pyrophosphate in the dermis, subcutaneous fat, or arterial walls.[135] Vascular calcification is common in patients with long-term CRF and seldom symptomatic. Occasionally, however, calcified vessels may thrombose acutely, resulting in a syndrome that has been called *calciphylaxis*. This acute thrombosis produces livedoid areas that are excruciatingly painful due to ischemia, and quickly become hemorrhagic and ulcerate (Fig. 151-13). Calciphylaxis is associated with a high mortality, particularly when the skin of the trunk is involved.[135] PTH is usually markedly elevated. The serum calcium and phosphate levels, and the calcium-phosphate product, are frequently only minimally elevated and may be normal. Treatment of calciphylaxis includes analgesia débridement of gangrenous tissue, and parathyroidectomy.[135,136]

In addition to vascular calcification and calciphylaxis, nodular calcification may occur in the skin and fat of patients with CRF. These calcium deposits are identical to calcinosis cutis in other disorders such as tumoral calcinosis or CREST syndrome. The involved skin may ulcerate, but this process occurs in a subacute fashion, without livedo or ischemic pain.

BULLOUS DISEASE OF HEMODIALYSIS (See also Chaps. 91 and 132) PCT has been described in patients with CRF undergoing hemodialysis.[137] Although the etiology of this phenomenon is still unclear, inadequate clearance of plasma-bound porphyria precursors by urine excretion or hemodialysis[138] may lead to porphyrin deposition in the skin manifested clinically as photosensitivity and subepidermal bullae.[139–141] Patients undergoing hemodialysis may also produce or be exposed to compounds that alter normal heme synthesis.

Bullous dermatosis of dialysis or pseudoporphyria may occur in up to one-fifth of patients undergoing hemodialysis[137,139,141] This condition is often clinically indistinguishable from PCT with marked skin fragility and blister formation on sun-exposed skin. However, hypertrichosis is less common, and plasma porphyrin levels are typically normal.[137,139] Pseudoporphyria may also occur in some patients taking tetracycline, nabumetone, nalidixic acid, furosemide, and phenytoin.[139]

When treating PCT or pseudoporphyria, phlebotomy can reduce iron levels in the liver, allowing new hepatic uroporphyrinogen decarboxylase to be formed.[142] However, patients with end-stage renal disease often have significant anemia and cannot tolerate phlebotomy. Intravenous erythropoietin[141] may both lower total body iron stores and support phlebotomy as needed.[140,142] Chloroquine effectively clears porphyrins from the liver. In patients with CRF, however, porphyrins may not be effectively cleared by hemodialysis or excreted in the urine.[141] Deferoxamine may lower serum porphyrin levels in some patients.[140] Others may require renal transplantation to obtain complete resolution of symptoms.[140]

ACQUIRED PERFORATING DERMATOSES (See Chap. 67) Acquired perforating dermatosis can occur in association with CRF and diabetes mellitus.[143] This condition occurs in up to 10 percent of patients undergoing hemodialysis[47,144,145] and appears to be distinct from the four primary perforating disorders: elastosis perforans serpiginosa, Kyrle disease, perforating folliculitis, and reactive perforating collagenosis.[146] Clinically, patients develop hyperkeratotic papules with a central, crust-filled crater on the trunk and extensor surfaces, often in a linear distribution.[144] Simultaneous trans-epidermal elimination of both collagen and elastic fibers has been detected.[145]

Proposed mechanisms for the etiology of this process include diabetic microangiopathy, dysregulation of vitamin A or vitamin D metabolism, abnormality of collagen or elastic fibers, or inflammation and connective tissue degradation caused by dermal deposition of substances such as uric acid and calcium pyrophos-



◀ **FIGURE 151-13** Calciphylaxis. (Used with permission from Suzanne N. Granados, MD.)



phate.[147] Many authorities regard this entity as a response to trauma caused by scratching in chronic renal pruritus. Successful treatment depends on addressing the underlying etiology of pruritus. Topical and intralesional glucocorticoids, topical and systemic retinoids, cryotherapy, and ultraviolet light may be useful.[144,145]

NEPHROGENIC FIBROSING DERMOPATHY Nephrogenic fibrosing dermopathy (NFD), a recently described disorder,[148] resembles scleromyxedema in some of its aspects.[149] To date, NFD has been found only in patients with renal disease. Most affected individuals have been on hemodialysis, and many have restarted dialysis after failure of a renal transplant. NFD also has been described in a few patients with ARF. Clinically, patients progressively develop erythematous, sclerotic dermal plaques on the arms and legs, with sparing of the head and neck. Pruritus is a common feature. The histopathology of NFD similarly resembles that of scleromyxedema, with proliferation of fibroblasts in the dermis and subcutaneous septae, accompanied by increased dermal and septal collagen and mucin.[150] The etiology of NFD is unknown. All patients described have had persistent disease (even though renal failure resolved in some cases).

Lower Limbs

In acquired clotting defects, such as thrombocytopenia and vascular fragility, purpuric lesions, ranging from pinpoint-sized spots to large ecchymoses, occur. They may be transient and recurrent, and they are sometimes accompanied by follicular hyperkeratosis.[3]

CHOLESTEROL EMBOLI In patients with advanced atherosclerosis of the abdominal aorta, cholesterol crystals may microembolize to the lower extremities, particularly after invasive vascular procedures or surgery. The pulses may remain normal. Patients complain of pain in the legs, buttocks, and low back, as well as myalgia, restless legs, and abdominal symptoms. Livedo reticularis may affect the lower abdomen and back, buttocks, and legs. Ulcers on the legs and feet, surrounded by an erythematous or violaceous halo and a small scab, may be present. Digital cyanosis and gangrene may simulate necrotizing vasculitis (Fig. 151-14). Indurated plaques and nodules are firm, violaceous, painful, and necrotic in the center. Deep skin biopsy of areas of livedo reticularis or adjacent to nodules or ulceration reveal occlusions of arterioles by multinucleated, foreign-body, giant cells and fibrosis surrounding biconvex, needle-shaped clefts corresponding to the cholesterol crystal microemboli.[151]



◀ **FIGURE 151-14** Cholesterol emboli: blue toe and infarctions.

POSTBYPASS SKIN CHANGES Coronary artery bypass surgery is commonly performed using the superficial veins of the legs as donor-graft sites. Dermatitis has been reported to occur along the saphenous vein graft scars on the medial aspect of the legs 2 to 6 months after surgery. Patients have no history of venous stasis, thrombophlebitis, ankle edema, or skin disease. Examination reveals a reddish-brown, scaling and fissured dermatitis along the distal part of a well-healed saphenous vein graft scar. The dermatitis responds to topical steroids, but recurrence is usual, and most patients require continued treatment. The cause may be due to postoperative thrombophlebitis and stasis dermatitis.

Recurrent cellulitis may develop in the healed vein graft many months after surgery. Erythema may extend along the entire vein graft site, accompanied by pain and tenderness. Swelling may be significant. β-Hemolytic streptococcus has been isolated. The presence of tinea pedis has been reported, and patients should be assessed and treated before surgery.

KEY REFERENCES

The full reference list for all chapters is available at www.digm7.com.

1. Pepin M et al: Clinical and genetic features of Ehlers-Danlos syndrome type IV, the vascular type. *N Engl J Med* **342**:673, 2000
8. Smith KE, Fenske NA: Cutaneous manifestations of alcohol abuse. *J Am Acad Dermatol* **43**:1; quiz, 16; 2000
9. Jones EA, Bergasa NV: Evolving concepts of the pathogenesis and treatment of the pruritus of cholestasis. *Can J Gastroenterol* **14**:33, 2000
30. Hill CL et al: Frequency of specific cancer types in dermatomyositis and polymyositis: A population-based study. *Lancet* **357**:96, 2001
35. Ryan AS, Goldsmith LA: Nutrition and the skin. *Clin Dermatol* **14**:389, 1996
36. Tosti A: The nail in systemic disease, in *Diseases of the Nails and Their Management*, edited by Baran R. Oxford, Blackwell Scientific Publications, 1994
41. Davis MD, Rooke T: Erythromelalgia. *Curr Treat Options Cardiovasc Med* **8**:153, 2006
56. Pickering MC, Haskard DO: Behçet's syndrome. *J R Coll Physicians Lond*, **34**:169, 2000
58. Sjögren RW: Gastrointestinal features of scleroderma. *Curr Opin Rheumatol* **8**:569, 1996
63. Moder KG, Miller TD, Tazelaar HD: Cardiac involvement in systemic lupus erythematosus. *Mayo Clin Proc* **74**:275, 1999
64. Krafchik BR: Neonatal lupus erythematosus. *Adv Exp Med Biol* **455**:23, 1999
66. Haitjema T et al: Hereditary hemorrhagic telangiectasia (Osler-Weber-Rendu disease): New insights in pathogenesis, complications, and treatment. *Arch Intern Med* **156**:714, 1996
74. Keane MP, Lynch JP 3rd: Pleuropulmonary manifestations of systemic lupus erythematosus. *Thorax* **55**:159, 2000
76. Marie I et al: Esophageal involvement and pulmonary manifestations in systemic sclerosis. *Arthritis Rheum* **45**:346, 2001
91. Tsao H: Update on familial cancer syndromes and the skin. *J Am Acad Dermatol* **42**:939; quiz, 970; 2000
92. Doxey BW, Kuwada SK, Burt RW: Inherited polyposis syndromes: Molecular mechanisms, clinicopathology, and genetic testing. *Clin Gastroenterol Hepatol* **3**:633, 2005
97. Steen V: Targeted therapy for systemic sclerosis. *Autoimmun Rev* **5**:122, 2006
98. Kulke MH, Mayer RJ: Carcinoid tumors. *N Engl J Med* **340**:858, 1999
110. Hadziyannis SJ: Skin diseases associated with hepatitis C virus infection. *J Eur Acad Dermatol Venereol* **10**:12, 1998
134. Zachariae H: Have methotrexate-induced liver fibrosis and cirrhosis become rare? A matter for reappraisal of routine liver biopsies. *Dermatology* **211**:307, 2005
148. Cowper SE, Bucala R, LeBoit PE: Case 35-2004: Nephrogenic fibrosing dermopathy. *N Engl J Med* **352**:1723; author reply, 1723, 2005



CHAPTER 152

Diabetes Mellitus and Other Endocrine Diseases

Andrea A. Kalus
Andy J. Chien
John E. Olerud

DIABETES MELLITUS

Epidemiology

Diabetes mellitus (DM) is a major cause of morbidity and mortality in the United States. More than 19 million Americans have the disease, and approximately 11 percent ($92 billion) of all health care expenditures in the United States were directly attributable to the medical care of diabetes in 2002.[1,2] Men and women diagnosed with diabetes at age 40 years are expected to lose 12 and 14 life-years, respectively.[3] Of great importance, major studies show that tight glycemic control decreases retinopathy, neuropathy, nephropathy, and, possibly, coronary artery disease, all of which remain the major contributors to morbidity and mortality.[4,5] Likewise, tight glycemic control may have a beneficial effect on a subset of skin-related, diabetes-associated disorders.

Diabetes is characterized by a state of relative or complete insulin deficiency, leading to gross defects in glucose, fat, and protein metabolism. In type 1 diabetes (formerly insulin-dependent DM), an insufficiency of insulin occurs through a gradual, immune-mediated destruction of β islet cells in the pancreas, marked by autoantibodies. In type 2 diabetes (formerly non–insulin-dependent DM), chronic hyperglycemia occurs mainly through end-organ insulin resistance followed by a progressive decrease in pancreatic insulin release associated with aging. A fasting blood glucose level of ≥ 126 mg/dL or a random value of ≥ 200 mg/dL on two separate occasions confirms the diagnosis of diabetes. A genetic predisposition and a strong association with obesity exist in type 2 diabetes. In both types of diabetes, abnormalities of insulin and elevated blood glucose levels lead to metabolic, vascular, neuropathic, and immunologic abnormalities. Affected organs include the cardiovascular, renal, and nervous systems, the eyes, and the skin.

DIABETES MELLITUS AT A GLANCE



- The incidence of diabetes in America is increasing steadily with the epidemic of obesity.
- Eleven percent of health care expenditures in America are diabetes related.
- Metabolic abnormalities in glucose and insulin relate directly to diabetic thick skin, limited joint mobility, eruptive xanthomas, and acanthosis nigricans.
- Neuropathy, vasculopathy, and immune dysfunction associated with diabetes contribute directly to lower extremity ulcers and certain cutaneous infections.
- Diabetes-associated skin conditions without a known pathogenesis include: necrobiosis lipoidica, granuloma annulare, diabetic dermopathy, acquired perforating dermatosis, and bullosis diabeticorum.

Etiology and Pathogenesis

Nearly all patients with diabetes have cutaneous findings related to their condition, including those listed in Table 152-1. Some diabetes-associated skin conditions are a direct result of the related metabolic changes such as hyperglycemia and hyperlipidemia. Progressive damage to the vascular, neurologic, or immune systems also contributes significantly to skin manifestations. The mechanisms for other diabetes-associated skin conditions remain unknown.

Hyperglycemia leads to nonenzymatic glycosylation (NEG) of various structural and regulatory proteins, including collagen. Although NEG occurs normally with aging, the process is greatly accelerated in diabetes.[6,7] NEG leads to the formation of advanced glycation end products (AGEs) that are responsible for decreases in both acid solubility and enzymatic digestion of cutaneous collagen. Disorders such as diabetic thick skin and limited joint mobility (LJM) are thought to result directly from accumulation of AGEs.[8] Studies show that the degree of cutaneous AGEs correlates strongly with retinopathy, nephropathy, and other microvascular complications of diabetes.[9]

Derangements of immunoregulatory mechanisms also occur in diabetes. Hyperglycemia and ketoacidosis diminish chemotaxis, phagocytosis, and bactericidal ability of white blood cells.[10] Historically, infections were a major cause of death in the diabetic patient. This has changed dramatically with improved glucose control and antibiotic use. Despite these improvements, certain infections, such as malignant external otitis, necrotizing soft tissue infections, and the devastating disease of mucormycosis, occur more frequently in patients with diabetes.[11]

TABLE 152-1
Approach to Patient with Diabetes

Cutaneous findings in diabetes
- Acanthosis nigricans
- Limited joint mobility and scleroderma-like syndrome
- Scleredema diabeticorum
- Eruptive xanthomas
- Bacterial infections (streptococcal, malignant external otitis, necrotizing fasciitis)
- Fungal infections (candidal, onychomycosis, mucormycosis)
- Foot ulcers
- Necrobiosis lipoidica
- Granuloma annulare
- Diabetic dermopathy
- Acquired perforating disorders
- Bullosis diabeticorum

Related features
- Retinopathy
- Nephropathy
- Neuropathy
- Cardiovascular disease
- Peripheral vascular disease
- Hyperlipidemia
- Hypertension

Diagnosis
- In the absence of symptoms, the diagnosis must be confirmed by two separate abnormal tests, fasting blood glucose of ≥ 126 mg/dL or random value of ≥ 200 mg/dL.
- Hemoglobin A1C is increasingly being used in conjunction with fasting plasma glucose for the diagnosis of diabetes mellitus.

Management
- Diet and exercise.
- Referral to primary care provider or endocrinologist for medical management with either oral hypoglycemic agents or insulin.
- Always perform a foot examination.
- Address modifiable risk factors.





Metabolic abnormalities, including hyperinsulinemia, as is seen in early insulin-resistant type 2 diabetes, can contribute to cutaneous manifestations as well. The action of insulin on the insulin-like growth factor-1 (IGF-1) receptor appears to mediate the abnormal epidermal proliferation and resulting phenotype of acanthosis nigricans.[12] Dysregulated lipid metabolism occurs with diabetes-associated insulin deficiency. The activity of lipoprotein lipase (LPL) is directly dependent on insulin,[13] making insulin central to the processing of triglyceride-rich chylomicrons and very-low-density lipoproteins. In insulin-deficient diabetic patients, defective lipid processing can lead to massive hypertriglyceridemia, manifesting in the skin as eruptive xanthomas. Naturally, disorders of lipid processing also play an integral role in the vasculopathies of diabetes.

Macro- and microangiopathy contribute significantly to the cutaneous complications of diabetes. In patients with diabetes, there is increased "leakiness" or vessel wall permeability, decreased vascular responsiveness to sympathetic innervation, and less ability to respond to thermal and hypoxemic stress.[10] In combination with arteriosclerosis of large vessels, these microvascular abnormalities contribute to the formation of diabetic ulcers. In addition, a loss of cutaneous sensory innervation occurs with diabetes, predisposing patients to infection and injury. The loss of neuroinflammatory cell signaling plays a causal role in non-healing, lower extremity ulcers.[14] Patients with diabetes who lack lower extremity vibratory perception have a 15.5-fold increased probability of leg amputation.[15]

The cutaneous disorders associated with DM are characterized in the following section by disorders with evidence for metabolic, vascular, neurologic, or immunologic pathogenesis induced by glucose and insulin abnormalities and by disorders associated with diabetes, but without a clear pathogenesis (see Cutaneous Disorders of Diabetes Mellitus Associated with Metabolic, Vascular, Neurologic, or Immunologic Abnormalities).

CUTANEOUS DISORDERS OF DIABETES MELLITUS ASSOCIATED WITH METABOLIC, VASCULAR, NEUROLOGIC, OR IMMUNOLOGIC ABNORMALITIES

Acanthosis Nigricans (See Chap. 154)

EPIDEMIOLOGY Acanthosis nigricans is probably the most readily recognized skin manifestation of diabetes. Acanthosis nigricans is common in the general population, and most cases are linked to obesity and insulin resistance. In some cases, increased androgen production is also identified.[16,17] Drug-related and idiopathic acanthosis nigricans or familial acanthosis nigricans have been reported.[18] In general, though, acanthosis nigricans should be considered a prognostic indicator for developing type 2 diabetes.[19] In a large, population-based study from Galveston, Texas, acanthosis nigricans was present in 7 percent of school-age children.[17] This percentage increased to 66 percent of children who weighed 200 percent of their ideal body weight. In this study, fasting insulin levels correlated with the presence and severity of skin findings. The rate of acanthosis nigricans varies among different ethnic groups. In the Galveston study, despite similar obesity rates, the prevalence was lower in whites (0.5 percent) and Hispanics (5 percent) than in African American children (13 percent).[17] This finding suggests a possible genetic predisposition or increased sensitivity of the skin to hyperinsulinemia among certain populations.[19] Although historical data have emphasized the relationship between acanthosis nigricans and malignancy, a true association is rare. Only when the onset is particularly rapid, the clinical findings are florid, or in the non-obese or non-diabetic adult with acanthosis nigricans is an evaluation for malignancy beyond routine age appropriate screening warranted (see Chap. 154). In one author's experience with seeing more than 12,000 patients with cancer, only two developed acanthosis nigricans.[20]

ETIOLOGY AND PATHOGENESIS Advances are taking place in understanding the pathogenesis of acanthosis nigricans. Insulin clearly plays a central role in the presentation of acanthosis nigricans. In a subset of women with hyperandrogenism and insulin resistance with acanthosis nigricans, loss of function mutations in the insulin receptor or anti-insulin receptor antibodies can be found (type A and type B syndrome).[21] It is postulated that excess growth factor stimulation in the skin causes the aberrant proliferation of keratinocytes and fibroblasts that results in the phenotype of acanthosis nigricans.[16] In states of insulin resistance and hyperinsulinemia, acanthosis nigricans may result from excess insulin binding to IGF-1 receptors on keratinocytes and fibroblasts.[12] IGF-1 receptors are expressed on basal keratinocytes and are upregulated in proliferative conditions.[22] Studies show that high concentrations of insulin stimulate fibroblast proliferation through IGF-1 receptors in vitro.[23] Other members of the tyrosine kinase receptor family, including the epidermal growth factor receptor and the fibroblast growth factor receptor, have been implicated in acanthosis nigricans. Several genetic syndromes [Crouzon and SADDAN (*s*evere *a*chondroplasia with *d*evelopmental *d*elay and *a*canthosis *n*igricans)] with mutations in fibroblast growth factor receptor 3 result in acanthosis nigricans in the absence of hyperinsulinemia or obesity. Implicating this growth factor receptor in the pathogenesis of acanthosis nigricans.[22] In several reports of acanthosis nigricans associated with malignancy, evidence suggests that transforming growth factor-β released from the tumor cells may stimulate keratinocyte proliferation via the epidermal growth factor receptors.[24,25] Support for the role of different growth factors in the pathogenesis of acanthosis nigricans continues to accrue.

In addition to the direct effects of hyperinsulinemia on keratinocytes, insulin also appears to augment androgen levels in women. High insulin levels stimulate the production of ovarian androgens and ovarian hypertrophy with cystic changes.[21] Although associated with elevated androgen levels, the acanthosis nigricans in women with polycystic ovarian syndrome (PCOS) does not respond reliably to antiandrogen therapy, implicating the relative importance of hyperinsulinemia over hyperandrogenism in acanthosis nigricans. Several drugs have also been reported to cause acanthosis nigricans, including systemic glucocorticoids, nicotinic acid, and estrogens such as diethylstilbestrol.[16]

CLINICAL FINDINGS: CUTANEOUS LESIONS Clinically, acanthosis nigricans presents as brown to gray-black papillomatous cutaneous thickening in the flexural areas, including the posterolateral neck, axillae, groin, and abdominal folds. The distribution is usually symmetric. The affected skin has a dirty, velvety texture. In some cases, oral, esophageal, pharyngeal, laryngeal, conjunctival, and anogenital mucosal surfaces may be involved. In general, however, the back of the neck is the most consistently and severely affected area[19] (Fig. 152-1). The development of superimposed acrochordons in involved areas is well described (Fig. 152-2). In particularly florid cases, involvement on the back of the hands over the knuckles and even on the palms can be seen. When the palms are involved, the rugated appearance of



◀ **FIGURE 152-1** Acanthosis nigricans involving the neck.

the palmar surface has been called *tripe palms* and is usually associated with acanthosis nigricans seen in the setting of malignancy (see Chap. 154). In the majority of cases, the most important factor in diagnosing acanthosis nigricans is recognizing the usually associated hyperinsulinemia, which is a known risk factor for type 2 diabetes.

The histopathology of clinical lesions demonstrates papillomatosis and hyperkeratosis but minimal acanthosis. Hyperpigmentation of the basal layer has been variably demonstrated and the brown color of the lesions is attributed to the hyperkeratosis by most.[26,27]

TREATMENT Treatment of acanthosis nigricans is generally ineffective. Topical treatment with calcipotriol,[28] salicylic acid, urea, systemic and topical retinoids have all been used with anecdotal success.[29] When identifiable, treatment of the underlying cause may be beneficial. Improvement or resolution does occur with weight loss in some obese patients.[12,16] Medications that improve insulin sensitivity, such as metformin, have a theoretic benefit. Removal of an offending medication generally results in clearance of the skin.[30] In patients with acanthosis nigricans in association with malignancy, there is usually improvement following treatment of the underlying malignancy. The skin finding may present before or after the diagnosis of malignancy is made. When it is associated with malignancy, a tumor of intra-abdominal origin, usually gastric, is seen in the majority of cases[31] (see Chap. 154). It has been repeatedly described that patients' skin improves with chemotherapy and remits with recurrences.



▲ **FIGURE 152-2** Acanthosis nigricans involving the axilla with numerous acrochordons.

Diabetic Thick Skin

Several specific syndromes are associated with localized thickening of the skin in diabetes. The common underlying pathogenesis involves biochemical alterations in dermal collagen and mucopolysaccharides. The clinical syndromes are a result of increased deposition and improper degradation of these constituents, likely related to the formation of AGEs.

Limited Joint Mobility and Scleroderma-Like Syndrome

Diabetic LJM, or cheiroarthropathy, presents as tightness and thickening of the skin and periarticular connective tissue of the fingers, resulting in a painless loss of joint mobility. Initial involvement of the distal interphalangeal joints of the fifth digit usually progresses proximally to involve all fingers. Larger joints of the elbow, knee, and foot may be affected. The actual joint space, however, remains uninvolved, so that LJM is not a true arthropathy. This disorder is characterized by the "prayer sign," which is an inability to approximate the palmar surfaces and interphalangeal joint spaces with the hands pressed together and fingers separated (Fig. 152-3). In addition to joint contractures, the skin may appear thickened, waxy, and smooth with apparent loss of adnexa, resembling skin changes in scleroderma.

Thirty percent to fifty percent of adult patients with type 1 diabetes have LJM, and it is common in type 2 diabetes as well. LJM is associated with increased duration of diabetes and poor glucose



▲ **FIGURE 152-3** Limited joint mobility in a 31-year-old male patient with type 1 diabetes mellitus. The patient is unable to approximate the palmar surface of the proximal and distal interphalangeal joints with palms pressed together (known as the "*prayer sign*"). **A.** Ulnar view; only fingertips are approximated. **B.** Radial view; straining to press palms together.



control.[32,33] One longitudinal prospective study showed a 2.5-fold increase in the risk of LJM for every unit increase in the glycosylated hemoglobin.[33] In addition, it appears that LJM may be correlated with the presence of microvascular disease.[34]

Most important, the evidence indicates that intensive insulin therapy is central in prevention and, possibly, treatment of LJM and scleroderma-like syndrome. Long-term tight glycemic control leads to decreased skin AGEs,[9] and tight glycemic control is associated with delayed onset and severity of LJM.[33] On the basis of improvements in diabetes management, a fourfold reduction in the frequency of LJM over the last 20 years was reported.[35] Treatment for LJM is difficult and should focus on tight control of blood sugar as well as physical therapy to preserve active range of motion.



Although the scleroderma-like skin changes can occur independently, they often occur together with LJM in patients with diabetes. The scleroderma-like syndrome is not associated with systemic sclerosis but does correlate with the duration of diabetes, the severity of joint contractures, and retinopathy.[36] It seems likely that the historical description of "diabetic hand syndrome" represents a combination of LJM and the scleroderma-like syndrome.

Scleredema Diabeticorum (See Chap. 159)

Recognized in 1970 as a syndrome,[37,38] scleredema of diabetes (scleredema diabeticorum) presents with the insidious onset of painless, symmetric induration and thickening of the skin on the upper back and neck. Spreading to the face, shoulders, and anterior torso may occur. The skin retains a nonpitting, woody, *peau d'orange* quality. Identical changes occur with postinfectious scleredema, usually associated with streptococcal pharyngitis. In scleredema associated with infection, however, the onset is often sudden, and the symptoms usually remit over time. Scleredema diabeticorum affects 2.5 percent to 14 percent of patients with diabetes.[39,40] Scleredema diabeticorum is a disease of long-standing diabetes associated with obesity. Most patients have type 2 diabetes. This disorder has not been reported in children.

The pathogenesis of scleredema diabeticorum is postulated to be unregulated production of extracellular matrix molecules by fibroblasts, leading to thickened collagen bundles and increased deposition of glycosaminoglycans (GAGs, mainly hyaluronic acid). Studies using in vitro fibroblast analysis from involved skin have variably demonstrated increased synthesis of GAGs and type I collagen.[41] However, most of these reports involved non-diabetic patients with paraproteinemia and are based on small numbers of cases.

Patients with scleredema diabeticorum may experience decreased sensation to pain and light touch over the affected areas and difficulties with upper extremity and neck range of motion. Extreme cases may result in full loss of range of motion. Unlike in LJM and scleroderma-like syndrome, the presence of scleredema does not correlate with retinopathy, nephropathy, neuropathy, or principal vascular disease.[39] However, no large-scale prospective studies have been done. Most patients with scleredema diabeticorum become insulin dependent, are difficult to treat, and have multiple complications of diabetes.[41] Treatment for scleredema diabeticorum is usually unsuccessful. Case reports describe treatment with radiotherapy, low-dose methotrexate, bath psoralen and ultraviolet A light (PUVA), extracorporeal photopheresis, factor XIII, and prostaglandin E_1.[38,42,43]

Eruptive Xanthomas (See Chap. 135)

Eruptive xanthomas present clinically as 1- to 4-mm, reddish-yellow papules on the buttocks and extensor surfaces of the extremities (Fig. 152-4). The lesions occur in crops and may coalesce into plaques over time. Although eruptive xanthomas are generally asymptomatic, there is often underlying severe hypertriglyceridemia (> 1000 mg/dL) and potentially undiagnosed diabetes. Histologic and biochemical studies show that lipoproteins (mainly chylomicrons) in the blood permeate cutaneous vessel walls and accumulate in macrophages in the dermis.[44] Initially, triglycerides predominate in the skin lesions but, because triglycerides are mobilized more easily than cholesterol, the lesions contain progressively more cholesterol as they resolve.[44] Whether this mechanism plays a role in the atherosclerosis of large arteries is unknown.

Insulin is an important regulator of LPL activity. The degree of enzymatic dysfunction and subsequent clearing of serum triglycerides is proportionate to the amount of insulin deficiency and hyperglycemia.[13] Clearance of plasma lipoproteins depends on adequate insulin.[45] In uncontrolled diabetes, this inability to metabolize and clear triglyceride-rich chylomicrons and very-low-density lipoproteins can lead to plasma triglyceride levels in the thousands. Uncontrolled diabetes is a common cause of massive hypertriglyceridemia.

In addition to eruptive xanthomas, triglyceride levels above 4000 may cause lipemia retinalis. On funduscopic examination, lipemia retinalis appears as pale pink to white retinal arterioles and venules. The fundus may have a milky hue. Untreated, severe hypertriglyceridemia may also present clinically with abdominal pain, hepatosplenomegaly, pancreatitis, or dyspnea from decreased pulmonary diffusing capacity and abnormal hemoglobin oxygen affinity.[46] Treatment of hypertriglyceridemia involves strict dietary fat restrictions and control of the underlying diabetes. LPL activity returns to normal after treatment with long-term insulin or oral glucose-lowering agents.[13] The eruptive xanthomas respond rapidly and usually resolve completely in 6 to 8 weeks.[47]

Cutaneous Infections

In diabetic patients, there is not strong evidence for an increased susceptibility to



◀ **FIGURE 152-4** Eruptive xanthomas appear as yellow-orange papules and plaques on a male patient with type 2 diabetes mellitus. (Used with permission from Greg Raugi, MD.)

infections in general, but several skin infections do occur more commonly, with greater severity, or with a greater risk for complications in patients with DM. Joshi et al. have reviewed this subject.[11]

Much research has been undertaken on the pathogenesis of immune dysfunction in diabetes. Although some studies could not detect defects at the cellular level,[48] other studies show that leukocyte chemotaxis, adherence, and phagocytosis are impaired in patients with diabetes, especially during hyperglycemia and diabetic acidosis.[49] Further studies show that cutaneous T-cell function and response to antigen challenge are also decreased in diabetes.[11]

BACTERIAL INFECTIONS Diabetics are at a higher risk for contracting certain bacterial infections, including group A and group B streptococcal infections, necrotizing fasciitis, and malignant otitis media. The relation between diabetes and staphylococcal infections is controversial.

Group B Streptococcal Infections. (See Chap. 177) Group B streptococcus (*Streptococcus agalactiae*), a major cause of morbidity in neonates and pregnant women, is also a significant source of invasive bacterial infection in nonpregnant adults. Both retrospective and prospective population-based studies identify diabetes as a risk factor in these infections.[50,51] In a study of 424 nonpregnant adults with invasive group B streptococcal infection, 30 percent of cases occurred in patients with diabetes. The most common sites of infection were skin, soft tissue, and bone (cellulitis, foot ulcers, and decubitus ulcers).[51] In young adults, the presence of diabetes increases the risk of group B streptococcal infection 30-fold.[51] Despite therapy, approximately 20 percent of these cases are fatal.[50,51] In pregnancy, maternal diabetes (but perhaps not gestational diabetes alone)[52] increases the risk even more.[53]

Group A Streptococcal Infections. (See Chap. 177) In a prospective population-based surveillance of invasive group A streptococcal disease, the risk of infection was 3.7-fold greater in diabetics. Soft tissue infections were the most common clinical presentation for all patients.[54]

Staphylococcal Infections. (See Chap. 177) Historically, *Staphylococcus aureus* skin infections were associated with diabetes. Past recommendations even suggested testing patients with recurrent furunculosis or folliculitis for diabetes.[55] In a review, however, Breen and Karchmer[56] concluded that current data do not permit estimation of proportional risk of staphylococcal infections in patients with diabetes. They suggested that only subsets of patients with diabetes have increased staphylococcal carriage rates.[56]

Malignant External Otitis. Invasive "malignant" otitis externa is an uncommon, life-threatening infection of the external auditory canal with potential cranial bone and intracranial involvement. *Pseudomonas aeruginosa* is usually implicated, and preceding aural irrigation with tap water may play an etiologic role[57] (see Chap. 180). This painful infection, which occurs in older patients with diabetes, is characterized by purulent discharge, unilateral facial swelling, hearing loss, and granulation tissue in the ear canal. The presentation is surprisingly without fever.[11] This infection occurs almost exclusively in diabetics. Diagnosis is often delayed, and mortality rates are as high as 20 percent to 40 percent despite appropriate antibiotic therapy.[58] Surgical débridement of necrotic tissue in addition to antibiotic therapy is important. The extent of tissue involvement can be assessed using magnetic resonance imaging or computed tomography imaging studies, and early consultation with an otolaryngologist will facilitate the evaluation and management.[11]

Necrotizing Fasciitis. (See Chap. 179) Ten percent to sixty percent of all cases of necrotizing fasciitis occur in patients with diabetes.[59] Necrotizing fasciitis is a life-threatening bacterial infection of the soft tissues with spread along fascial planes. The perineum, trunk, abdomen, and upper extremities are most commonly involved.[10] Clinical presentation includes erythema, swelling, induration, necrosis, and possible bullae formation. The degree of pain and toxicity are often out of proportion to the severity of the findings. Although most cases are caused by polymicrobial infections (*Escherichia coli*, *Bacteroides*, *Peptostreptococcus*, and *Clostridium* sp.), approximately 10 percent of cases are monomicrobial, often due to streptococcal species.[11,60] Treatment includes urgent surgical débridement and appropriate broad spectrum antibiotics. Mortality rates of 40 percent have been reported.[11]

FUNGAL AND YEAST INFECTIONS ***Candidal Infections.*** (See Chap. 189) Most authors believe that mucocutaneous *Candida* infections occur more frequently among patients with diabetes, especially those with poorly controlled disease.[61] Intertrigo (axillary, inguinal, web space), vulvovaginitis, balanitis, paronychia, onychomycosis, glossitis, and angular cheilitis are most common. In one study, the clinical diagnosis of candidal paronychia was made in 9.6 percent of 250 diabetic women, compared to only 3.4 percent of non-diabetic women.[62] In addition to symptomatic vaginal yeast infections, asymptomatic carriage rates are also elevated in patients with diabetes.[61] Postmenopausal females with recurrent vulvo-vaginal candidiasis should undergo screening for diabetes. Treatment for candidal infections includes topical and oral antifungals. Patients with candidal paronychia should avoid wetting of the nails and use drying agents (e.g., 15 percent sulfacetamide in 50 percent ethanol, three to four drops, applied four times per day, and after each time hands get wet).[10]



Dermatophyte Infections. (See Chap. 188) Although two studies failed to show an overall increased prevalence of dermatophyte infections in patients with diabetes compared with control subjects,[63,64] Gupta et al.[65] demonstrated that the rate of toenail onychomycosis was 2.77 times greater for patients with diabetes as compared with controls. Onychomycosis has recently been demonstrated to be a significant predictor of foot ulcers in diabetics.[66] In patients with diabetes, aggressive diagnosis and treatment of tinea foot infections are important because of the potential portal of entry for subsequent bacterial infections.

Rhinocerebral Mucormycosis. (See Chap. 190) Rhinocerebral mucormycosis is caused by Zygomycetes (*Mucor* and *Rhizopus* sp.). It often presents with headache, fever, and lethargy, in addition to nasal congestion and facial-ocular pain and swelling. Subsequent findings include unilateral proptosis, ophthalmoplegia, and palate or nasocutaneous necrosis. Seventy-five percent to eighty percent of all cases occur in patients with diabetes,[67] and diabetic ketoacidosis is the most important risk factor.[11] Ketoacidosis reportedly blunts the normal inhibitory activity of serum against *Rhizopus*.[68] Amphotericin B and surgical débridement are the treatments of choice. Voriconazole, caspofungin, and other azoles are ineffective against the Zygomycetes. The investigational triazole, posaconazole, may be efficacious in these infec-

tions.[69] Mortality rates for mucormycosis are reportedly as high as 50 percent.[70] *Mucor* species have also been observed, complicating skin ulcers on the legs and hands of patients with DM.[61]

Diabetic Ulcers

EPIDEMIOLOGY Foot ulcers are a significant problem for patients with diabetes, occurring in 15 percent to 25 percent of diabetic patients.[71] Patients with diabetes have an estimated increased risk of lower extremity amputation that is 10 to 30 times greater than the general population. Lower-extremity ulcers were the proximal cause of amputation in 67 of 80 patients (84 percent) in a study by Pecoraro et al.[72] In diabetic patients with foot ulcers, 14 percent to 24 percent will eventually undergo amputation.[73] The attributable cost of treating a diabetic foot ulcer, excluding the cost of amputation, was estimated to be $28,000 in a 1999 U.S. study.[74]

ETIOLOGY AND PATHOGENESIS Many of the factors previously described in this chapter contribute to the pathogenesis of diabetic ulcers. Peripheral neuropathy, pressure, and trauma are felt to play prominent roles in the development of diabetic ulcers. Neuropathy (associated with uncontrolled hyperglycemia) is one of the major predictors of diabetic ulcers.[15] Patients with diabetes also suffer the loss of cutaneous sensory nerves.[75] The subsequent diminished neuroinflammatory signaling via neuropeptides to keratinocytes, fibroblasts, endothelial cells, and inflammatory cells may adversely affect wound healing.[76] Excessive plantar pressure develops from foot deformities (Charcot arthropathy), as a result of LJM related to NEG, and from callus formation. Ill-fitting shoes and socks were the most common reasons for foot ulcers in a study of 314 diabetic patients with ulcers.[77] By wearing running shoes, patients with diabetes had a measurable reduction of calluses in one study.[78] Callus formation is a sign of excess friction and often precedes foot ulcers. Once an ulcer develops, peripheral vascular disease and intrinsic wound healing disturbances contribute to adverse outcomes. Known factors associated with foot ulceration in the setting of diabetes include previous foot ulceration, prior lower extremity amputation, long duration of diabetes (> 10 years), impaired visual acuity, onychomycosis, and poor glycemic control. Boyko and colleagues have recently published a prediction model for foot ulceration based on the relative contributions of these factors.[66]



▲ **FIGURE 152-5** "Diabetic foot." Two larger ulcers overlying the first right and second left metacarpophalangeal joints in a 56-year-old man with diabetes of 20 years' duration. There is significant sensory neuropathy and peripheral vascular disease.

CLINICAL FINDINGS Callus formation precedes necrosis and breakdown of tissue over bony prominences of feet, usually on great toe and sole, over first and/or second metacarpophalangeal joints. Ulcers are surrounded by a ring of callus and may extend to underlying joint and bone (Fig. 152-5). Complications are soft tissue infection and osteomyelitis.

TREATMENT Treatment of diabetic ulcers requires modification of factors that contribute to ulcer formation, for example, stasis dermatitis, leg edema, and skin infection. Standard therapy for neuropathic diabetic ulcers includes débridement, off-loading (often non–weight bearing), moist wound care, and protective dressings (Fig. 152-6).

There has been substantial interest in developing adjunctive therapies for diabetic ulcers, including growth factors and skin replacement products, but data have not supported their use as a replacement for standard wound care. Recombinant platelet-derived growth factor for the topical treatment of diabetic foot ulcers demonstrates a modest benefit if used with adequate off-loading, débridement, and control of infection.[79] A large multicenter, clinical trial of a bilayered living skin equivalent[80] showed 56 percent healing at 12 weeks as compared with 38 percent healing for standard care. The most favorable published results for a monolayered living skin equivalent and platelet-derived growth factor (Becaplermin) show roughly comparable improvement in healing to that reported for bilayered living skin equivalents (Graftskin) when each is compared with standard care or placebo.[81] However, these technologies await definitive analysis of cost effectiveness compared with standard older approaches. Although studies are not available at this time to support their routine use, these biologic approaches may have a role in the treatment of large ulcers (> 2 cm) or ulcers poorly responsive to standard therapy.

PREVENTION Ulcer prevention is the most important intervention physicians and other health care professionals can provide for diabetic patients. An excellent review of ulcer prevention was recently published by Singh et al.[71] Optimizing glycemic control is well supported to prevent the neuropathy that is so intimately associated with foot ulceration. In a recent study, the risk of a foot ulcer increased in nearly direct proportion to every 1 percent increase in hemoglobin A1C.[66] Foot examinations, including Semmes-Weinstein 10-g monofilament testing for neuropathy and clinical assessment for peripheral vascular disease, should be performed regularly in all patients with diabetes. If tinea pedis is present, it should be treated to prevent the associated skin barrier disruption. Smoking cessation should be encouraged. Patients should be counseled about the importance of daily foot care (Table 152-2).

Specialized ulcer care teams have published impressive results on the prevention and healing of ulcers.[82] This multidisciplinary team approach is becoming more important in the treatment of diabetic ulcers in large population centers. Patients with a history of ulceration are at high risk for reulceration (34 percent at 1 year, 61 percent at 3 years, and 70 percent at 5 years).[83] Intensifying education (formal foot care classes) and prevention efforts in this group along with lifelong surveillance is required.

DISORDERS ASSOCIATED WITH DIABETES MELLITUS BUT OF UNKNOWN PATHOGENESIS

Necrobiosis Lipoidica

EPIDEMIOLOGY AND PATHOGENESIS Coined by Urbach in 1932 as *necrobiosis lipoidica diabeticorum*, this disorder was named after characteristic histologic findings and was first described in patients with diabetes. Because not all patients have concurrent diabetes, the shortened term, *necrobiosis lipoidica* (NL), is preferred. Epidemiologic

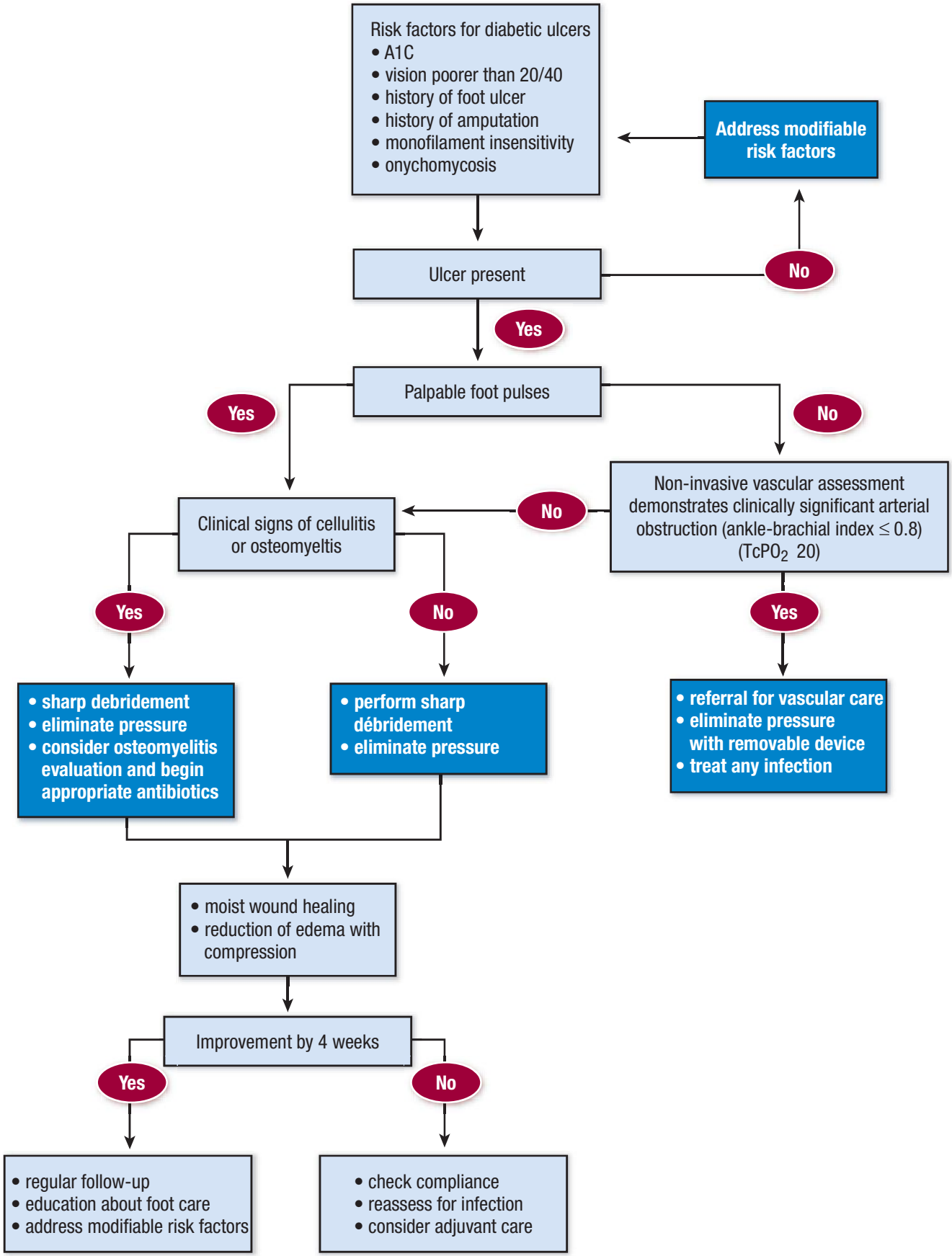

▲ **FIGURE 152-6** Approach to the care of the diabetic foot and diabetic ulcers. A1C = hemoglobin A1C; $TcPO_2$ = transcutaneous oxygen tension.[178]



TABLE 152-2
General Foot Care Guidelines for Patients with Diabetes

- Examine feet every day, including areas between the toes.
- Regular washing of feet with careful drying, especially between the toes.
- Water temperature should always be less than 37°C (98.6°F) and checked first with the hand rather than the foot.
- Barefoot walking in- or outdoors and wearing of shoes without socks is discouraged.
- Daily inspection and palpation of the inside of the shoes for irregular surfaces or foreign objects.
- If vision is impaired, patients should not try to treat their feet (e.g., nails) by themselves.
- Emollients should be used for dry skin but not between the toes.
- Change stockings daily.
- Wearing of stockings with seams inside out or preferably without any seams at all.
- Nails should be cut straight across.
- Corns and calluses should not be cut by patients but by a health care provider.
- The patient must ensure that the feet are examined regularly by a health care provider.
- The patient should seek early health care attention for any blister, cut, scratch, sore, ingrown toenail, or dermatitis.



data show that the mean age of onset is around 30 years, with women representing three times more cases than men.[84] The most often quoted statistics concerning the association of NL with diabetes are from a 1966 retrospective study at the Mayo Clinic. Of 171 patients with NL, two-thirds had diabetes at diagnosis, and another 5 percent to 10 percent had glucose tolerance abnormalities.[84] However, in a 1999 study of 65 patients with NL, only 11 percent had diabetes after 15 years of follow-up.[85] Conversely, the prevalence of NL has been found to be only 0.3 percent to 3.0 percent in patients with diabetes.[84] Although lacking full concordance, NL definitely has a strong association with diabetes and remains a valid marker of the disease. The pathogenesis of this skin disease is unclear. Many etiologic mechanisms have been proposed and reviewed.[86] Evidence suggests that the degree of hyperglycemia and diabetic control does not correlate with the presence of NL.[87]

CLINICAL FINDINGS: CUTANEOUS LESIONS Classically, NL presents with one to several sharply demarcated yellow-brown plaques on the anterior pretibial region (Fig. 152-7). The lesions have a violaceous, irregular border that may be raised and indurated. Initially, NL often presents as red-brown papules and nodules that may mimic sarcoid or granuloma annulare (GA). Over time, the lesions flatten, and a central yellow or orange area becomes atrophic, and commonly telangiectasias are visible, taking on the characteristic "glazed-porcelain" sheen. Aside from the shins, other sites of predilection include ankles, calves, thighs, and feet. Fifteen percent of patients develop lesions on the upper extremities and trunk that tend to be more papulonodular. Although pain and pruritus have been reported, most lesions are asymptomatic. Anesthesia of the plaques does occur.[88]

The clinical course is often indolent, with spontaneous remission in less than 20 percent of cases.[10] Over time, the plaques tend to stabilize, and formation of new lesions tapers off. However, the possibility of ulceration, a poor spontaneous remission rate, and cosmetic concerns lead patients to seek treatment. Ulceration, the most serious complication, occurs in approximately 13 percent to 35 percent of cases on the legs.[84,86] A few cases of squamous cell carcinoma arising in chronic ulcerative lesions of NL have been reported.[89] Multiple reports document the association of NL with GA and sarcoidosis.[90]

TREATMENT Treatment for NL is disappointing. At this time, only case reports and small, uncontrolled trials provide the basis for treatment decisions (see ref. 86). Early application of potent topical glucocorticoids might slow progression.[86] Although some authors[84] report improvement with intralesional injection of glucocorticoids to the active border, the risk of ulceration with this treatment modality should be considered. A few case reports and one series of six patients[91] showed benefit with short-term systemic glucocorticoids. Aspirin and dipyridamole have produced variable results.[86] Anecdotal reports exist that support the use of topical retinoids and topical PUVA. Treatment with fumaric acid esters in 18 patients was reported to improve lesions clinically and histologically.[92]

Given the generally benign nature of the lesions, physicians should consider the adage "do no harm." Focus should be on prevention of ulcers. When ulceration occurs in patients with NL, the same wound care principles apply as for all diabetic ulcers. Healing of ulcerated lesions with cyclosporine has been demonstrated in several patients.[93] Surgical excision down to fascia and split-thickness skin grafting remain as the last resort for very recalcitrant ulcers in NL.[94]

Granuloma Annulare (See Chap. 43)

EPIDEMIOLOGY AND PATHOGENESIS The association of GA with diabetes is weaker than that of NL. Although most patients with GA are in good health, without underlying systemic illness, an association with diabetes is supported in the literature. Dabski and Winkelmann[95] found diabetes in 10 percent of 1353 patients with localized GA and 21 percent of 100 patients with generalized GA. An additional small retrospective case-control study showed an increased prevalence of diabetes among patients with GA (18 percent) as compared with the prevalence in age-matched controls (8 percent).[96] Furthermore, there is an impression that diabetes is found more frequently in patients with adult onset GA and in those with general-

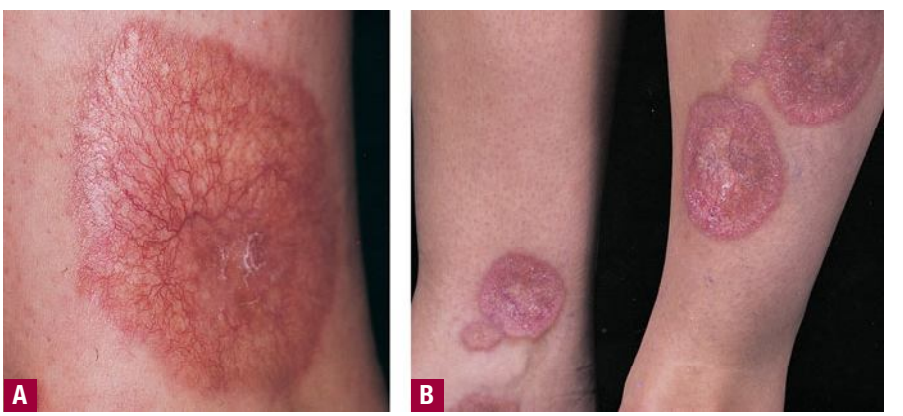

▲ **FIGURE 152-7** Necrobiosis lipoidica. **A.** A single orange plaque with atrophy of the overlying epidermis and arborizing telangiectasias is seen on the lower leg of a juvenile with diabetes mellitus; the crust marks an area of early ulceration. **B.** Older lesions with striking central atrophy involving both the dermis and epidermis.

ized or perforating GA, and that these patients tend to experience a more chronic, relapsing course of GA. The pathogenesis is unclear.

CLINICAL FINDINGS AND TREATMENT Clinical findings and treatment of GA are discussed in the on-line version and in Chap. 43.

Diabetic Dermopathy

ETIOLOGY AND PATHOGENESIS Atrophic skin lesions of the lower extremity, or shin spots, were first characterized and proposed as a cutaneous marker for diabetes in 1964.[100] Shortly after, Binkley coined the term *diabetic "dermopathy"* to correlate the pathologic changes with those of retinopathy, nephropathy, and neuropathy.[101] Since that time, controversy has existed about the disorder's etiology, specificity for diabetes, and association with other microangiopathic complications of diabetes.

The prevalence of shin spots in ambulatory patients with diabetes varies. In a population-based study from Sweden, diabetic dermopathy was found in 33 percent of patients with type 1 diabetes and in 39 percent of patients with type 2 diabetes, compared with 2 percent of controls.[102] In other studies, the prevalence rate for individuals without diabetes ranges from 1.5 percent for healthy medical students to 20 percent for a group of non-diabetic endocrine patients.[103] Diabetic dermopathy occurs more often in patients with an increased duration of diabetes and is more frequent in men.[103]

It is likely that the lesions are related to antecedent trauma. Lithner[104] induced diabetic dermopathy on the legs of diabetic patients with heat and cold injury, whereas non-diabetic control subjects healed without residual change. When questioned, most patients think that the changes are caused by injury, but they are often unable to detail preceding trauma.

CLINICAL FINDINGS, DIAGNOSIS, AND TREATMENT Diabetic dermopathy presents as small (< 1 cm), atrophic, pink to brown, scar-like macules on the pretibial areas (Fig. 152-8). The lesions are asymptomatic and clear within 1 to 2 years with slight residual atrophy or hypopigmentation.[100] The appearance of new lesions gives the sense that the pigmentation and atrophy are persistent.

An association seems to exist between diabetic dermopathy and the more serious complications of diabetes. In a study of 173 patients with diabetes, the incidence of shin spots correlated with the duration of diabetes and the presence of retinopathy, nephropathy, and neuropathy.[105] Diabetic dermopathy does not, however, correlate with obesity or hypertension in patients with diabetes.[103] No treatment is necessary for the individual atrophic tibial lesions. They are asymptomatic and are not directly associated with an increase in morbidity.



◀ **FIGURE 152-8** Diabetic dermopathy with hyperpigmented macules on the anterior lower legs.

Acquired Perforating Disorders (See Chap. 67)

The acquired perforating disorders comprise an overlapping group of disorders characterized by trans-epidermal elimination or "spitting" of altered dermal constituents. Included in this group are Kyrle disease, reactive perforating collagenosis, perforating folliculitis, and elastosis perforans serpiginosa.[106]

Clinically, these lesions appear as pruritic, keratotic papules mainly on the extensor surfaces of the extremities. Papules and nodules with a perforating component may also occur on the trunk and face. Many are follicular and contain a prominent central keratotic plug. The papules may be grouped, or coalesce to form verrucous plaques. Treatment for the perforating disorders is usually unsuccessful. Retinoic acid, topical glucocorticoids, and PUVA are partially successful.[107]

Bullosis Diabeticorum

ETIOLOGY AND PATHOGENESIS The abrupt, spontaneous development of blisters on the lower extremities without other demonstrable cause is a rare characteristic skin manifestation of diabetes. The pathogenesis of diabetic bullae is unknown. Patients with bullosis diabeticorum (BD) do not have a history of antecedent trauma or infection. One study found a decreased threshold to suction-induced blister formation in patients with diabetes.[108] Reduced suction blister time is also observed with increasing age in non-diabetic subjects.[109] Although a history of antecedent trauma is not elicited, this finding suggests a role of increased skin fragility in diabetic bullae. Perhaps the formation of AGEs leads to increased fragility.

CLINICAL FINDINGS, DIAGNOSIS, AND TREATMENT BD is characterized by the abrupt onset of bullae on the lower extremities, usually the toes, feet, and shins, arising in normal skin. Occasionally, the distal upper extremities are involved. The blisters are usually painless and not pruritic. Healing occurs within 2 to 5 weeks and rarely leaves scarring. The condition may recur as successive crops of bullae over many years. Studies of affected individuals excluded other blistering skin disorders, and revealed no abnormalities of porphyrin metabolism.[108] Histopathologic examination of the bullae shows an inconsistent level of separation varying from intraepidermal to sub-epidermal.[109] No immunopathologic features are consistently observed (Box 152-1).

BD runs a benign course without involvement of large body surface areas.

Box 152-1

Differential Diagnosis and Evaluation of Bullosis Diabeticorum

DIFFERENTIAL DIAGNOSIS

- Bullous impetigo
- Bullous pemphigoid
- Epidermolysis bullosa acquisita
- Porphyria cutanea tarda
- Bullous erythema multiforme
- Insect bite reaction

LABORATORY TESTS

- Skin biopsy for histology and immunofluorescence
- Bacterial cultures
- Screening for porphyrins



The only serious complication is that of secondary infection, which should be managed with culture and appropriate antibiotics if suspected. Otherwise, therapy is supportive. The real importance of this disorder is that of correct diagnosis because several of the blistering skin diseases have a high rate of morbidity and require potentially toxic systemic treatments. Even a negative workup is important. The patient should be educated, reassured, and good wound care implemented.

THYROID DISEASE

Epidemiology



Worldwide estimates of the prevalence of goiter (enlargement of the thyroid gland) range from 200 million to 800 million affected people. The majority of these worldwide cases are secondary to iodine deficiency. However, in industrialized countries where salt is routinely iodized, the main causes of goiter are autoimmune thyroiditis and nodular thyroid disease. The overall incidence of hyperthyroidism in the U.S. population is estimated at approximately 1 percent, but may be four to five times higher in older women.[110] Graves disease accounts for 60 percent to 80 percent of all cases of hyperthyroidism and was first described by Caleb Parry in 1825 (and later by Robert Graves in 1835) as an association between goiter, palpitations, and exophthalmos.[111] Although the incidence of Graves disease is similar between whites and Asians, it appears to be lower in blacks.[111] *Toxic adenoma* and *toxic multi-nodular goiter* refer to the hyperplastic growth of thyroid tissue that is functioning independent of thyrotropin (TSH) regulation, resulting in increased levels of thyroid hormone. Toxic multinodular goiter has been reported to be more common in areas of low iodine intake, particularly in patients older than the age of 50 years.[112] Population-based screening with laboratory testing found hypothyroidism in 4.6 percent of the U.S. population, although > 90 percent of individuals with tests consistent with hypothyroidism were normal clinically.[110]

The majority of thyroid disease is acquired, but thyroid disease can also be congenital. Congenital hypothyroidism is the most common treatable cause of mental retardation, and occurs in up to 1 in 3000 neonates worldwide due to either an absent or anatomically defective gland, inborn errors of thyroid metabolism, or iodine deficiency.[113] Congenital hyperthyroidism is much less common, and although 0.2 percent of pregnant women have Graves disease, only about 1 percent of the resultant neonates will have hyperthyroidism, with most cases resulting from the transfer of maternal thyroid-activating autoantibodies.[114]

Etiology and Pathogenesis

The metabolic regulation of every cell in the body relies on thyroid hormones, which is synthesized primarily in the thyroid gland. Hyperthyroidism (also known as *thyrotoxicosis*) results from the excess levels of thyroid hormones with resultant hypermetabolism, whereas hypothyroidism (or myxedema) is characterized by hypometabolism secondary to diminished levels of thyroid hormone. Thyroid hormones act on target tissues by activating cytoplasmic receptors that subsequently translocate to the nucleus and activate specific thyroid-responsive genes.[115] Thyroid hormone synthesis is heavily dependent on iodine and, consequently, changes in iodine intake can result in both hyperthyroidism and hypothyroidism.

Synthesis of thyroid hormone is regulated by the pituitary via release of TSH in response to hypothalamic release of thyrotropin-releasing hormone (TRH). TSH acts on the thyroid gland by binding a G-protein–coupled receptor (TSH-R) to trigger thyroid hormone synthesis and release. Aberrant activation of TSH-R is thought to underlie the hyperthyroidism seen in Graves disease, where almost all patients have long-acting thyroid-stimulator auto-antibodies that bind and activate TSH-R.[116] Release of TSH is, in turn, stimulated by TRH, which also acts via a G-protein–coupled receptor. Administration of recombinant TRH followed by measurement of the response in TSH levels provides a useful test for distinguishing whether hypothyroid disease results from dysfunction of the hypothalamic-pituitary axis or the thyroid gland. Levels of TSH and TRH are both tightly controlled by circulating levels of thyroxine (T_4) and triiodothyronine (T_3), which provide feedback regulation. Persistent stimulation of the thyroid leads to the hypertrophy of the gland, known as *goiter* (Fig. 152-9).

The great majority of thyroid hormone in the blood is bound by plasma proteins, including thyroid-binding globulin, which is the major determinant of protein binding, and to a lesser extent transthyretin (formerly called *prealbumin*) and albumin. A variety of medical conditions and medications can alter levels of thyroid hormone binding proteins or peripheral conversion of T_4 to T_3 (which is responsible for most of thyroid hormone's effects), and subsequently alter the tissue availability of thyroid hormone independent of changes in thyroid hormone synthesis (Table 152-3). Thyroid hormone levels can be affected by a variety of medications, including several that are prescribed by dermatologists (Table 152-4).[117]

Hyperthyroidism can be broadly classified into two categories: high radioiodine (radioactive iodine) uptake and low radioiodine uptake. The presence of high radioiodine uptake indicates increased synthesis of thyroid hormone, while diminished or absent radioiodine uptake suggests either an extra-thyroidal source of thyroid hormone or the destruction of thyroid tissue with concomitant release of pre-formed thyroid hormone into the circulation. Evidence suggests that genetic predisposition as well as environmental factors, including infection, may play a role in the pathogenesis of autoimmune thyroid disease.[118] In the case of toxic adenoma, molecular studies have identified a high prevalence of TSH-R mutations, result-

THYROID DISEASE AT A GLANCE



- The most common cause of hyperthyroidism is Graves disease, characterized by the triad of autoimmune thyroid disease, eye disease, and thyroid dermopathy (pretibial myxedema).
- Toxic multinodular goiter is another cause of hyperthyroidism that should be considered, particularly in elderly individuals.
- Serious signs of thyrotoxicosis include atrial fibrillation and fever.
- Hashimoto thyroiditis and thyroid ablation for treatment of hyperthyroidism are the two most common causes of hypothyroidism.
- The best screening test for thyroid disease is thyrotropin, which is elevated in hypothyroidism and depressed or absent in hyperthyroidism.

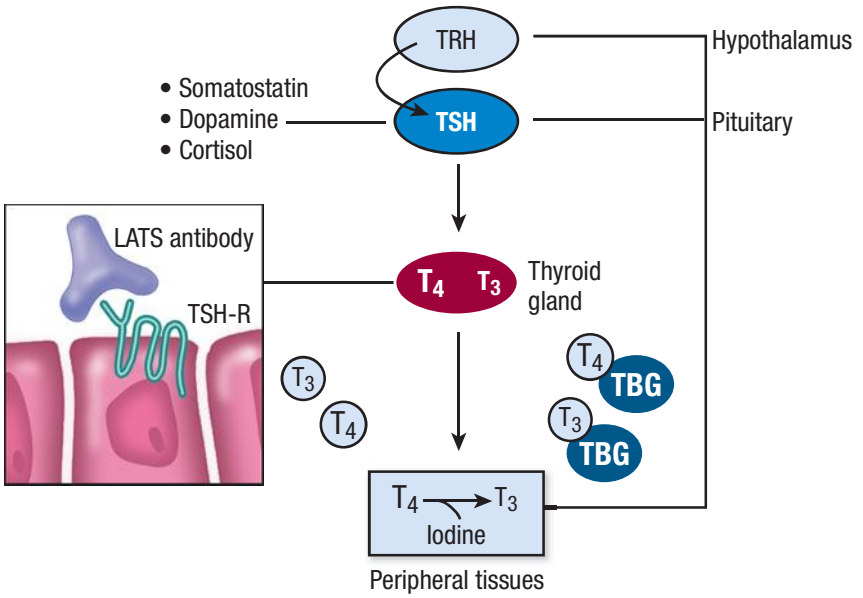

▲ **FIGURE 152-9** The hypothalamic-pituitary-thyroid axis. LATS = long-acting thyroid-stimulator; T_3 = triiodothyronine; T_4 = thyroxine; TBG = thyroid-binding globulin; TRH = thyrotropin-releasing hormone; TSH = thyrotropin; TSH-R = thyrotropin G-protein–coupled receptor.

ing in a receptor that triggers thyroid hormone synthesis in the absence of bound TSH.[119]

Although some of the cutaneous findings seen in hyperthyroidism are indirect consequences of thyroid hormone's actions on other tissues, most of the skin manifestations of thyroid disease result from the direct effects of thyroid hormones on the keratinized epithelium of the epidermis, hair, and nails as well as effects on stromal cells in the dermis. Thyroid hormones are essential for optimal epidermal proliferation both in vitro and in vivo.[120] Thyroid hormones regulate genes involved in keratinocyte proliferation and also stimulate the expression of certain keratins.[120]

TABLE 152-3
Medical Conditions That Can Affect Thyroid Hormone Levels

Increased thyroid-binding globulin
- Pregnancy
- Infectious/chronic active hepatitis
- Biliary cirrhosis
- Acute intermittent porphyria

Decreased thyroid-binding globulin
- Chronic liver disease
- Severe systemic illness
- Active acromegaly
- Nephrosis

Decreased peripheral conversion of thyroxine to triiodothyronine
- Fasting/malnutrition
- Systemic illness
- Physical trauma
- Postoperative state

Approximately 95 percent of cases of hypothyroidism are thought to arise from defects in the thyroid gland itself, whereas the remaining cases result from defects in the hypothalamic-pituitary axis. Ironically, the most common cause of hypothyroidism without a goiter is the surgical or radioiodine-induced ablation of the thyroid gland for the treatment of Graves thyrotoxicosis. Cretinism occurs with untreated congenital hypothyroidism and does not have a goiter. The most common cause of hypothyroidism with a goiter in North America is Hashimoto thyroiditis. Less common causes of hypothyroidism include inherited defects in hormone synthesis or the ingestion of drugs that inhibit hormone synthesis, such as lithium or aspirin. Bexarotene, a retinoid-X-receptor agonist (see Chap. 229) used to treat cutaneous T-cell lymphoma, causes a central hypothyroidism with a decrease in TSH, followed by low levels of T_3 and T_4.[121] In rare cases, hypothyroidism can occur from decreased secretion of TSH, such as with pituitary failure, a tumor of the pituitary region, or postpartum pituitary necrosis (Sheehan syndrome). Inadequate secretion of TRH by the hypothalamus is another very rare cause of hypothyroidism.

Clinical Findings

CUTANEOUS MANIFESTATIONS OF HYPERTHYROIDISM (Table 152-5) Signs and symptoms of hyperthyroidism and hypothyroidism are variably present and

TABLE 152-4
Medications Affecting Thyroid Hormone Levels

Drugs that affect thyroid hormone secretion
- Lithium (decreases secretion)
- Iodide (can increase or decrease secretion)
- Amiodarone (can increase or decrease secretion)

Drugs that increase serum thyroid-binding globulin concentrations
- Estrogens/tamoxifen
- Heroin/methadone
- Fluorouracil

Drugs that decrease serum thyroid-binding globulin concentrations
- Androgens
- Anabolic steroids
- Slow-release nicotinic acid
- Glucocorticoids

Drugs that increase hepatic metabolism of thyroid hormone
- Phenobarbital
- Rifampin
- Phenytoin
- Carbamazepine

Drugs that decrease deiodination of thyroxine to triiodothyronine
- Propylthiouracil (used to treat hyperthyroidism)
- Amiodarone
- β Blockers
- Glucocorticoids
- Certain radiographic contrast dyes

Drugs that decrease thyrotropin
- Bexarotene

Adapted from Surks MI, Sievert R: Drugs and thyroid function. *N Engl J Med* **333**:1688, 1995.

summarized in Table 152-6. The skin changes of hyperthyroidism have been likened to infant's skin and described as soft, warm, and velvety in texture. Pruritus can be a manifestation of thyroid disease, and laboratory screening for thyroid disease is often included in working up patients experiencing diffuse pruritus with no obvious rash. Scalp hair in hyperthyroid patients is described as soft and fine, and in certain cases may be accompanied by a diffuse non-scarring alopecia analogous to telogen effluvium. Patients with hyperthyroidism frequently have nail changes that are commonly described as soft, shiny, and brittle nails with an increased rate of growth. A small percentage of patients with hyperthyroidism will have Plummer's nails, which exhibit a concave shape with distal onycholysis (see Chap. 87). Plummer's nails can also be found in a variety of other conditions and are not pathognomonic for hyperthyroidism. Vitiligo appears to





TABLE 152-5
Approach to Patient with Hyperthyroidism

Cutaneous findings in hyperthyroidism
- Soft, velvety, infant-like skin
- Thyroid dermopathy
- Soft, fine with diffuse non-scarring alopecia
- Facial flushing
- Palmar erythema
- Hyperpigmentation
- Plummer's nails
- Thyroid acropachy
- Hyperpigmentation

Related features
- Hyperhidrosis
- Atrial fibrillation
- Ophthalmopathy
- Goiter
- High-output cardiac failure
- "Thyroid storm"

Diagnosis
- Best initial test is serum thyrotropin
- Other tests include serum free triiodothyronine, thyroxine, and antithyroid antibodies
- Radioactive iodine uptake and imaging

Management
- Appropriate surgical and endocrine consultation
- Propanolol for symptomatic treatment
- Propylthiouracil to inhibit thyroid hormone metabolism
- Methimazole to inhibit thyroid hormone synthesis
- Radioiodine ablation of the thyroid gland

be over-represented in patients with Graves disease, but not in patients with other forms of hyperthyroidism. Vitiligo may often predate the diagnosis of thyroid disease and does not improve with the treatment of the hyperthyroidism (see Chap. 72).

Thyroid dermopathy is most commonly seen with Graves disease but has been reported in hypothyroid patients as well. Pretibial thyroid dermopathy (in the past referred to as *pretibial myxedema*) is a classic manifestation of hyperthyroidism and Graves disease (Fig. 152-10). The term *thyroid dermopathy* is used in this chapter because the lesions can occur at any site on the body, are not limited to the pretibial region, and the name does not suggest myxedema as a cause.[122] Although there are reports of hyperthyroid patients who have presented with thyroid dermopathy as their initial finding, thyroid dermopathy is usually a later manifestation of thyroid disease. Almost all patients with thyroid dermopathy also have thyroid ophthalmopathy, another late manifestation of hyperthyroidism.[123] The clinical appearance of thyroid dermopathy can be quite varied. Classically, thyroid dermopathy occurs bilaterally as painless non-pitting nodules and plaques with variable coloring and a waxy, indurated texture (see Fig. 152-10). The distribution can range from very circumscribed to diffuse, but by far the most common location is on the extensor surfaces of the legs.[123] Some cases can exhibit a peau d'orange appearance as well. An extreme form of diffuse thyroid dermopathy has been termed the *elephantiasic* variant, which occurs in less than 1 percent of patients with Graves disease and is characterized by progressive thickening and gray-black hyperpigmentation of the pretibial skin accompanied by a woody, firm edema with nodule formation.[122] Biopsies of thyroid dermopathy reveal a thickened dermis with splayed collagen fibrils and abundant mucin, usually hyaluronic acid, in the interstitial space.

The exact pathophysiology underlying thyroid dermopathy is still unclear. Histologically, increased amounts of hyaluronic acid are seen in the dermis and the subcutis, leading to the hypothesis that fibroblasts or other cells in the dermis may be synthesizing increased levels of GAGs secondary to stimulation by activating autoantibodies. However, antibodies that bind TSH-R on fibroblasts can be seen in patients with and without thyroid dermopathy, indicating that other determinants are likely involved. The presence of dependent edema in the lower extremities may also contribute somehow to either the



▲ **FIGURE 152-10** Hyperthyroidism with thyroid dermopathy in a classic location on the anterior shins. Note that infiltrated plaques extend to the calf and are partially hyperkeratotic. An isolated nodule is also present on the dorsum of the foot.

TABLE 152-6
Symptoms, Clinical Findings, and Complications of Thyroid Disease

Symptoms, Clinical Findings, and Complications of Hyperthyroidism	Symptoms, Clinical Findings, and Complications of Hypothyroidism
Symptoms	Symptoms
• Unintentional weight loss	• Unexplained weight gain
• Heat intolerance/sweating	• Fatigue
• Palpitations	• Cold intolerance
• Agitation/emotional lability	• Constipation
• Multiple daily loose stools	• Dry skin
• Pruritus	• Muscle weakness
• Weakness	• Carpal tunnel syndrome
• Oligomenorrhea in women	• Hoarseness
Clinical findings and complications	• Decreased body temperature
• Goiter	• Facial swelling
• Tachycardia	• Menorrhagia in women
• Atrial fibrillation	Clinical findings and complications
• High-output cardiac failure	• Goiter
• Fine tremor	• Cold, doughy skin
• Hot sweaty extremities	• Bradycardia
• Ophthalmopathy	• Facial and finger swelling
• Agitation/confusion	• Slowed relaxation of deep tendon reflexes
• Muscle weakness/wasting	• Hair loss/lateral eyebrow loss
• "Thyroid storm" with fever, confusion, dehydration, and eventual death, if untreated	• Pericardial effusion
	• Myocardial infarction or congestive heart failure with aggressive thyroid hormone replacement
	• Coma and death without treatment



▲ **FIGURE 152-11** Graves disease. Note the proptosis of the eyes, thyroid acropachy, and the thyroid dermopathy on the pretibial region.

fibroblast stimulation or hyaluronic acid accumulation, and thus account for the tendency of thyroid dermopathy to occur in this anatomic site.

Thyroid acropachy refers to digital clubbing, soft-tissue swelling of the hands and feet, and the presence of characteristic periosteal reactions.[122] This very rare clinical finding is also associated with thyroid dermopathy and exophthalmos, and almost always presents after the diagnosis and treatment of hyperthyroidism (Fig. 152-11). Like thyroid dermopathy, thyroid acropachy has also been reported in hypothyroid conditions. Clubbing occurs most frequently on the first, second, and fifth metacarpals, the proximal phalanges of the hand, and the first metatarsal and proximal phalanges of the feet.[122] The radiologic findings are characterized by a lamellar periosteal reaction of the hands or wrists, with long bones only rarely involved. Because increased osteoblastic activity has been observed in the diaphyseal parts of small bones, the use of bone scan has been suggested as a sensitive way to aid in diagnosis.[124] The mechanisms underlying thyroid acropachy remain unknown, although interestingly, a large case series identified a disproportionately high percentage of smokers (80 percent) in patients with thyroid acropachy.[125]

The effects of thyroid hormone excess on other organ systems can also result in cutaneous findings. Hyperpigmentation similar to Addison disease has been seen with hyperthyroid disease, with resultant pigment in the palmar creases, gingiva, and buccal mucosa that is usually more prominent in individuals with darker skin. It has been postulated that the hyperpigmentation may be the result of increased corticotropin (ACTH) resulting from accelerated cortisol metabolism.[122] The cardiovascular effects of thyroid hormone excess include atrial fibrillation, increased cardiac output, and decreased peripheral vascular resistance, resulting in increased blood flow to the skin along with facial flushing and palmar erythema. The overall increased metabolism, along with changes in peripheral blood flow and temperature dysregulation, can also result in a generalized hyperhidrosis as well as high-output cardiac failure similar to that seen with Paget disease of bone.

There is extensive literature regarding the association between thyroid disease and urticaria[126] (see Chap. 37). Several studies have found a much higher incidence of thyroid disease in patients with chronic urticaria compared with control populations, although the mechanism behind this association remains unclear. Other dermatologic conditions have been reported in association with Graves disease, including dermatitis herpetiformis, Sweet syndrome, pemphigoid gestationis, vitiligo, pemphigus vulgaris, anetoderma, and mid-dermal elastolysis.[122]

CUTANEOUS MANIFESTATIONS OF HYPOTHYROIDISM (Table 152-7) In hypothyroidism, decreased core temperature and increased peripheral vasoconstriction cause the skin to be cool and pale. The skin is also xerotic, and the stratum corneum is poorly hydrated. Histologically, the epidermis is thin, and there is hyperkeratosis with follicular plugging. The generalized distribution of these findings can help distinguish these changes from those of atopic dermatitis and keratosis pilaris, which tend to be more prominent on the extremities. A fine wrinkling can also be seen. A yellow-orange discoloration of the skin can be seen secondary to the accumulation of β-carotene in the stratum corneum, possibly secondary to increased circulating carotene from diminished hepatic conversion of β-carotene to vitamin A.

Myxedema is the most classic finding associated with hypothyroidism and is distinct from the thyroid dermopathy seen with Graves disease. Myxedema occurs as a result of dermal accumulation

TABLE 152-7
Approach to the Patient with Hypothyroidism

Cutaneous findings
• Myxedema
• Cool temperature
• Doughy, dry skin with fine wrinkling
• Yellow-orange carotenemia
• Dry, brittle hair
• Slow growth of hair and nails
Related features
• Macroglossia
• Broadened nose, thickened lips, puffy eyelids
• Impaired wound healing
• Cretinism with congenital cases
• "Myxedema coma"
Diagnosis
• Best initial test is serum thyrotropin
• Other tests include serum free triiodothyronine and thyroxine
Management
• Appropriate endocrine consultation
• Oral thyroxine (usually in the range of 75–150 μg/day)
• Careful follow-up for heart, lung, and adrenal disease



of mucopolysaccharides, namely hyaluronic acid and chondroitin sulfate, and tends to resolve with treatment of the hypothyroidism. The myxedema tends to be generalized but can appear more striking in the extremities. Characteristic facial changes can be seen, including a broadened nose, thickened lips, puffy eyelids, and macroglossia with a smooth and clumsy tongue (Fig. 152-12). The skin can be doughy, swollen, and waxy, but without pitting. Wound healing is impaired in hypothyroidism.

The hair in hypothyroidism is coarse, dry, and brittle with slowed growth. Hair loss in the scalp can be either diffuse or patchy. Hypothyroidism can result in increased numbers of hair follicles in telogen, as well as telogen effluvium when the onset of hypothyroidism is abrupt. There can be loss of eyebrow hair in a characteristic pattern involving the outer third (see Fig. 152-12). Although body hair can be diminished, hypothyroidism can also result in increased lanugo hair on the back, shoulders, and extremities. The nails in hypothyroidism grow slowly and can be thickened and brittle with longitudinal and transverse striations. In patients with a goiter, hoarseness can result secondary to compression of the recurrent laryngeal nerve. With large goiters, tracheal or esophageal displacement can be seen. In extreme cases, large retrosternal goiters can cause Pemberton's sign, characterized by facial plethora suggestive of compression when patients raise their arms above their head.





▲ **FIGURE 152-12** Hypothyroidism. This patient has many of the characteristic features of hypothyroidism, including dry, pale skin; the absence of hair on the lateral third of the eyebrow; and puffiness of the face and lips due to accumulation of mucopolysaccharides in the dermis. The nose is broadened; the tongue is large, smooth, red, and clumsy; and there is drooping of the eyelids. Also, note the lack of facial expression that is the most pathognomonic of any of the features.

Hashimoto thyroiditis has been associated with several other dermatologic disorders, including alopecia areata, connective tissue disease (including lupus and dermatomyositis), bullous pemphigoid, dermatitis herpetiformis, and chronic mucocutaneous candidiasis (CMC).[127–131]

Laboratory Tests

The diagnosis of thyroid-related cutaneous disease is often suspected clinically, although in certain instances a skin biopsy may prove helpful in confirming the diagnosis. The clinical diagnosis of thyroid disease is confirmed by thyroid function tests. Serum levels of TSH are recommended as an initial screen, and any abnormalities in TSH should be followed up with measurements of serum T_4 and free T_3 to confirm whether the abnormal TSH truly reflects a thyroid disorder. Other tests that can be useful include in vitro T_3 resin uptake and measurements of antithyroid antibodies. This combination of tests will diagnose the vast majority of patients with suspected thyroid disease.

Treatment

The mainstay of treatment for the cutaneous findings of thyroid disease is normalization of thyroid function, either through replacement of thyroid hormone for hypothyroidism or through ablation of thyroid function for hyperthyroidism. Thyroid dermopathy and thyroid acropachy can be a chronic problem even in patients who are treated effectively for their thyroid disease, and the current treatment options can be classified as either experimental or palliative at best. Complete or partial remission of cutaneous findings can be seen even in the absence of any localized topical treatment.[132] Reported treatments of thyroid dermopathy include topical corticosteroids, systemic corticosteroids, intralesional corticosteroids, intralesional octreotide, intravenous (IV) immunoglobulin, plasmapheresis, compression therapy, and even surgical excision.[132,133] The success of these therapies is still controversial and based on small uncontrolled case series or anecdotal reports.

PARATHYROID DISEASE

AT A GLANCE



- The most common cause of hypercalcemia in outpatients is hyperparathyroidism, while the most common cause of hypercalcemia in hospitalized patients is malignancy.
- The most common causes of hypocalcemia are vitamin D deficiency and surgically induced hypoparathyroidism.
- Calciphylaxis is most commonly seen in the setting of secondary hyperparathyroidism of renal failure.

Epidemiology

The annual incidence of primary hyperparathyroidism has decreased in the past two decades to about 20 cases per 100,000, potentially reflecting a decrease in the use of ionizing radiation to the neck, which is a known risk factor for developing primary hyperparathyroidism.[134] The majority of cases occur in individuals older than 45 years of age, with an approximate 2:1 female-male predominance. In the outpatient setting, parathyroid disease accounts for almost all cases of hypercalcemia. In hospitalized patients, parathyroid disease accounts for approximately one-third of all cases of hyperparathyroidism, while the majority of other cases are accounted for by malignancy. Together, hyperparathyroidism and malignancy account for greater than 90 percent of all cases of hypercalcemia.

Etiology and Pathogenesis

Parathyroid hormone (PTH) is secreted by the parathyroid gland in response to low levels of serum calcium and acts as one of the main regulators of calcium levels in the body. Elevations of PTH (hyperparathyroidism) are associated with hypercalcemia, whereas decreased levels of PTH (hypoparathyroidism) are associated with hypocalcemia. PTH acts through varying mechanisms that include the stimulation of vitamin D production, stimulation of calcium absorption in the gastrointestinal tract, regulation of renal absorption of calcium and phosphate, and direct regulation of calcium mobilization from bone. Circu-

lating free calcium acts on the parathyroids via a G-protein–coupled receptor to control the release of PTH. Released PTH then acts in target tissues by binding another G-protein–coupled receptor, the PTH receptor, resulting in changes in calcium metabolism. Because problems with PTH result primarily in alterations of circulating calcium, it is not surprising that the skin manifestations of parathyroid disease are primarily changes resulting from calcium dysregulation. The skin is likely a site of PTH action, although the exact effects of PTH on skin are not understood. Keratinocytes express a PTH-related peptide (PTHrP) that has been implicated in regulating keratinocyte growth and differentiation and utilizes the same receptors as PTH.[135–138] Although PTHrP has been associated with normal wound healing, elevated PTHrP can also be seen in the setting of certain squamous cell carcinomas.[137,139,140] The elevated PTHrP with squamous cell carcinoma can result in malignancy-related hypercalcemia in these patients.

Primary hyperparathyroidism results from abnormal function of the parathyroid gland, resulting in increased levels of PTH. In 80 percent of diagnosed cases, the cause of hyperparathyroidism is a result of either parathyroid hyperplasia, parathyroid carcinoma, or parathyroid adenoma. Pseudohyperparathyroidism occurs when PTH or a PTH-like molecule (for instance PTHrP) is secreted from a non-parathyroid tissue such as occurs in malignancy.

Secondary hyperparathyroidism occurs most commonly in the setting of renal disease. Resistance of end organs to PTH results in hypersecretion of PTH and consequent hypocalcemia and hyperphosphatemia. Secondary hyperparathyroidism is found in almost all patients with chronic renal failure requiring dialysis. Secondary hyperparathyroidism can also be associated with idiopathic hypercalciuria as well as with certain medications, including oral contraceptives and long-term furosemide therapy. In renal patients with long-term secondary hyperparathyroidism, hyperplastic parathyroid tissue can become autoactivated, resulting in tertiary hyperparathyroidism. This condition is characterized by persistent hypersecretion of PTH and resultant osteomalacia despite hypercalcemia.

Primary hypoparathyroidism occurs primarily from iatrogenic causes such as the removal of the parathyroid glands during a thyroidectomy. There are also several genetic and non-genetic congenital causes of primary hypoparathyroidism, although these are much less common. Secondary hypoparathyroidism refers to decreased PTH secretion secondary to a primary process that causes hypercalcemia.

TABLE 152-8
Physical Findings Associated with Hypercalcemia and Hypocalcemia

Hypercalcemia
- Anorexia
- Nausea and vomiting
- Constipation
- Hypotonia
- Lethargy and coma

Hypocalcemia
- Increased neuromuscular irritability and tetany
  - Chvostek's sign: induced tetany of the facial muscles induced by tapping on the zygoma
  - Trousseau sign of hypocalcemia: carpal spasm with inflation of blood pressure cuff above systolic value
- Peripheral and perioral paresthesias
- Seizures
- Bronchospasm/laryngospasm
- Lengthening of QT interval on electrocardiogram

Clinical Findings

Parathyroid disease most often presents in the setting of altered calcium metabolism. The physical findings and symptoms associated with hyper- and hypocalcemia are shown in Table 152-8. As for hypercalcemia and hyperparathyroidism, skin manifestations are rarely seen but can be impressive and dramatic. An approach to a patient with suspected hyperparathyroidism is outlined in Table 152-9. Cutaneous calcinosis (sometimes referred to as *calcinosis cutis* or *metastatic calcinosis*) is thought to be related to elevated calcium and phosphate[141] (see Chap. 138). Subcutaneous calcifications can be found in a symmetric distribution, often overlying large joints or in linear arrayed papules and plaques that are normally of skin color and hard on palpation (Fig. 152-13). These lesions can be pruritic. Chronic urticaria has been associated with hyperparathyroidism as well.[142] Signs of hyperparathyroidism in association with cutaneous skin tumors, such as angiofibromas, collagenomas, and lipomas, should engender a workup for multiple endocrine neoplasia type 1 (MEN1), which is caused by mutations in the MEN1 gene and characterized by tumors of the anterior pituitary, the pancreas, and the parathyroid. The finding of somatic (non-germline) mutations and loss of heterozygosity of the MEN1 gene in 20 percent to 30 percent of spontaneous parathyroid tumors further supports a role for this gene in parathyroid oncogenesis.[143] The differential diagnosis is of hypercalcemia is shown in Box 152-2.

TABLE 152-9
Approach to the Patient with Suspected Hyperparathyroidism

Cutaneous findings
- Cutaneous (metastatic) calcinosis
- Calciphylaxis

Related disorders
- Renal disease
- Multiple endocrine neoplasia type 1 with angiofibromas, collagenomas, and lipomas
- History of head/neck irradiation

Diagnosis
- Serum calcium and serum parathyroid hormone
- With suspected malignancy, serum parathyroid hormone-related peptide

Management
- Identify underlying cause of hyperparathyroidism.
- Appropriate endocrine, surgery, and nephrology consultation.
- Hospitalization for acute cases with hypercalcemia.
- Aggressive fluid management to treat hypercalcemia, with forced diuresis.
- Phosphate replacement as warranted.
- Dialysis for acute renal failure.
- Calciphylaxis warrants aggressive management of wounds and infection.
- Surgical parathyroidectomy.

Calciphylaxis is a rare but life-threatening cutaneous condition associated



▲ **FIGURE 152-13** Papules of cutaneous calcinosis are arranged in a linear array in the skin overlying the mandible.





Box 152-2

Differential Diagnosis of Hypercalcemia

- Increased parathyroid hormone
  - Solitary adenoma
  - Multiple adenomas (i.e., multiple endocrine neoplasia type 1)
  - Tertiary hyperparathyroidism with renal failure
- Increased parathyroid hormone-related peptide
  - Squamous cell carcinoma
  - Renal carcinoma
  - Bladder carcinoma
  - Human T-cell leukemia virus type 1
  - Breast cancer
  - Lymphoma
- Increased 1,25-vitamin D
  - Sarcoidosis
  - Excess ingestion
- Increased bone resorption of calcium
  - Myeloma
  - Lymphoma
  - Breast cancer
- Renal failure
  - Secondary hyperparathyroidism
  - Tertiary hyperparathyroidism
  - Vitamin D intoxication
  - Milk-alkali syndrome (susceptibility to hypercalcemia with ingestion of calcium-based antacids and milk)

with hyperparathyroidism. Calciphylaxis occurs most often in the setting of chronic renal failure and secondary hyperparathyroidism, although there are reports of calciphylaxis associated with primary hyperparathyroidism and normal renal function. Although the name may falsely imply an immune etiology, calciphylaxis actually results from calcium deposition in the walls of small- to medium-sized vessels, resulting in vascular occlusion and skin necrosis. Clinically, patients present initially with violaceous patches that may exhibit a mottled or reticular pattern. Subsequently, involved areas can become indurated and painful, with eventual ulceration and eschar formation that proceeds to tissue gangrene (Fig. 152-14; see Fig. 151-13). Both the trunk and extremities can be involved. A calcium-phosphate product (serum calcium × serum phosphate) of greater than 70 mg/dL has often been cited as a predisposing risk factor. The histologic finding of calcium deposits in vessel walls coupled with compatible clinical findings is diagnostic. Calciphylaxis has a very poor prognosis, with reported mortality rates up to 80 percent, usually from infection. Parathyroidectomy and aggressive management of wounds and infections has

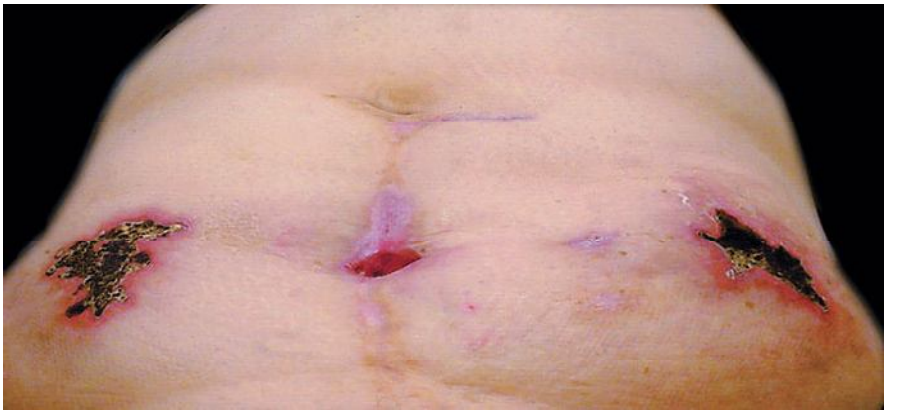

▲ **FIGURE 152-14** Calciphylaxis in a patient with chronic renal failure. Note the stellate-shaped necrotic plaques on the abdomen and the scars from peritoneal dialysis. Often the thighs and buttocks are also involved. A deep biopsy that includes subcutaneous fat can help make the diagnosis if it demonstrates the characteristic findings of calcification in the media of small- and medium-sized vessels. Histologically, subcutaneous calcium deposits and fat necrosis can also be seen.

been successful in treating some cases. There is not compelling evidence to support the use of hyperbaric oxygen, but there are small case series reporting successful treatment of calciphylaxis using hyperbaric oxygen, suggesting use for this often life-threatening condition.[144,145]

Hypoparathyroidism is associated with scaly, hyperkeratotic, and edematous puffy skin (Table 152-10). Paresthesias secondary to hypocalcemia can be seen. Patchy alopecia and generalized thinning of the hair have been reported. Nails can be brittle with transverse ridging. Hypoparathyroidism has been associated with psoriatic flares, which is interesting in light of the response of psoriasis to calcipotriene.[146] These skin abnormalities often resolve with normalization of serum calcium levels, suggesting that they are due to changes in calcium homeostasis rather than deficiency of PTH.

Hypoparathyroidism in the setting of familial autoimmune polyglandular syndrome type 1 has been associated with chronic mucocutaneous candidiasis (CMC) and adrenal failure.[147] The CMC can precede the diagnosis of hypoparathyroidism, although the CMC does not improve significantly with treatment of the hypoparathyroidism with calcium and vitamin D. Other findings in these patients include dental enamel hypoplasia, vitiligo, and the cutaneous manifestations of adrenal failure (see under Addison Disease).

Hypoparathyroidism in the setting of elevated serum PTH is known as *pseudohypoparathyroidism* or *PTH-resistant hypoparathyroidism*. Although several variants of pseudohypoparathyroidism have been described, perhaps the best-characterized is Albright's hereditary osteodystrophy.[148] These patients present with a constellation of findings that include short stature, obesity, rounded facies, dental hypoplasia, and shortened bones of the hands and feet. Characteristic shortening of the fourth metacarpal leads to a dimpling of the fourth knuckle, known as *Albright's sign*. These patients can also have subcutaneous ossifications and calcifications.

Laboratory Tests

The diagnosis of parathyroid disease can be made with measurements of se-

TABLE 152-10
Approach to the Patient with Suspected Hypoparathyroidism

Cutaneous findings
- Scaly, hyperkeratotic, puffy skin
- Patchy alopecia with hair thinning
- Brittle nails with transverse ridging

Related findings
- Paresthesias
- Neuromuscular irritability
- Bronchospasm or laryngospasm
- Electrocardiogram changes

Diagnosis
- Serum calcium and serum parathyroid hormone
- Serum magnesium levels to rule out hypomagnesemia
- Electrocardiogram to rule out QT elongation

Management
- Vitamin D or vitamin D metabolites (i.e., calcitriol at 0.2–1.0 μg/day)
- Calcium supplementation at 2–3 g of elemental calcium per day
- Magnesium supplementation when appropriate

rum calcium levels and serum levels of PTH. In the case of hypercalcemia related to malignancy, measurement of PTHrP may also be useful in the workup.

Treatment

The main treatment for hyperparathyroidism is partial or total parathyroidectomy (see Table 152-9). For hypoparathyroidism, treatment focuses on correction of serum calcium and phosphate (see Table 152-10). In the setting of acute hypercalcemia, aggressive fluid and electrolyte management are essential, because cardiorespiratory failure may result from dehydration.

DISORDERS OF THE ADRENAL GLAND

Cushing Syndrome

Excessive production of endogenous cortisol manifests clinically as Cushing syndrome. Similar findings are seen from chronic exogenous administration of glucocorticoids (see Chap. 225). In the normal physiology of the hypothalamic-pituitary-adrenal axis, corticotropin-releasing hormone is secreted from the hypothalamus and stimulates the production of corticotropin, also known as *ACTH*, by the anterior pituitary. ACTH is synthesized as part of a larger precursor molecule, proopiomelanocortin (POMC). This relationship of POMC to ACTH is important in diseases of the adrenal gland and the resulting skin manifestations. POMC is processed into several peptides, including melanocyte-stimulating hormone (MSH) and ACTH, which stimulates the production of cortisol from the adrenal cortex. In a classic negative feedback manner, cortisol inhibits corticotropin-releasing hormone and ACTH production.

EPIDEMIOLOGY, ETIOLOGY, AND PATHOGENESIS The overall incidence of Cushing syndrome is about 10 persons per million per year, with a female predominance.[149] Cushing syndrome is divided into two categories. The first is caused by inappropriately high secretion of ACTH, usually from a pituitary microadenoma. It is given the unique name of *Cushing disease*. The excess ACTH drives glucocorticoid production in the adrenals. Rarely ectopic, or non-pituitary, production of ACTH results in Cushing syndrome. This clinical presentation is most often associated with a pulmonary carcinoid tumor, although numerous other tumor types have been reported.[150] The second category of Cushing syndrome results from excess cortisol produced by the adrenal cortex independent of regulation by the pituitary or hypothalamus. This is usually due to an adrenal adenoma, which may be benign or malignant, or is the result of generalized hyperplasia of the adrenal gland. Cushing syndrome can be seen in the McCune-Albright syndrome[151] and in association with primary pigmented nodular adrenocortical disease in the Carney complex.[152]

CLINICAL FINDINGS: CUTANEOUS LESIONS The clinical presentation of Cushing syndrome may be subtle (Table 152-11). Skin findings may be present, and if careful attention is paid to the relationship of skin findings and systemic complaints, one may consider the diagnosis early in the clinical course. Common skin complaints are easy bruisability and skin thinning. Mild hypertrichosis often of the lanugo type and acne may occur. Frank hirsutism and severe acne raise the possibility of a concurrent androgen-secreting tumor. The development of multiple violaceous striae wider than 1 cm on the abdomen or proximal extremities is highly suggestive of Cushing syndrome (Fig. 152-15). The width and color of these striae differentiate them from the commonly seen striae in pregnancy or with weight gain. Relatively dramatic changes in fat distribution often occur along with a generalized gain in weight. There is an increase in central obesity and concurrent thinning of the arms and legs with loss of muscle mass. Increased facial fat results in a rounded appearance of the face, often with increased redness and telangi-

ADRENAL GLANDS AND THE SKIN AT A GLANCE



- Excessive production of cortisol manifests as Cushing syndrome and results from pituitary oversecretion of corticotropin or excess production of cortisol by the adrenal cortex.
- Destruction of the adrenal gland with loss of glucocorticoids, mineralocorticoids, and adrenal androgens is known as Addison disease.
- Although many etiologies of Addison disease are described, the most common cause is autoimmune destruction with detectable circulating autoantibodies.

TABLE 152-11
Approach to the Patient with Cushing Syndrome

Cutaneous findings in Cushing syndrome
- Increased central adiposity (moon facies and buffalo hump) with thinning of the extremities
- Skin thinning and easy bruisability
- Violaceous striae
- Acanthosis nigricans
- Increased dermatophyte and candidal skin and nail infections
- Rarely, hyperpigmentation

Related features
- Diabetes
- Hypertension
- Osteoporosis
- Irregular menses

Diagnosis
- Measurement of cortisol in serum and urine
- Failure to suppress cortisol production with dexamethasone suppression tests

Management
- Appropriate endocrine and surgical consultation
- Surgical removal of pituitary or adrenal adenoma
- Adrenal enzyme inhibitors
- Radiation therapy



▲ **FIGURE 152-15** Abdominal striae in a patient with Cushing syndrome. Note gynecomastia. This patient has psoriasis and was treated with corticosteroids.



ectasias. This appearance has been referred to as a moon facies. In addition to truncal obesity, there is an increase in the size of the dorsocervical fat pad, known as a *buffalo hump* and increased fat in the supraclavicular fossae. Men may experience gynecomastia.

Although unusual, hyperpigmentation can occur in cases of Cushing syndrome caused by massive increased ACTH production either from the pituitary or, more commonly, an ectopic source.[153] ACTH itself, in addition to MSH derived from POMC, contributes to increased melanin synthesis. This is similar to the hyperpigmentation more commonly associated with Addison disease. Acanthosis nigricans may be seen because Cushing syndrome contributes to insulin resistance, and, often, patients develop diabetes. The immunosuppressive effects of glucocorticoids result in increased dermatophyte and candidal nail and skin infections. Women may experience irregular menses or amenorrhea. Additional extra-cutaneous signs and symptoms of Cushing syndrome include hypertension, osteoporosis, and decreased muscle mass and strength.[154]



LABORATORY TESTS Diagnostic confirmation of Cushing syndrome requires demonstration of excess cortisol production. Cortisol production varies throughout the day and, as a rule, should be examined in the early morning when it is usually at its highest value. The average daily cortisol level can be measured using a 24-hour urine collection. Any abnormal test should be repeated two or three times for confirmation. If the urine or serum levels are elevated, failure to suppress the 8 A.M. serum cortisol level or 24-hour urine cortisol with a low-dose dexamethasone suppression test is confirmatory. Additional testing, including a high-dose dexamethasone suppression test, can be useful to determine if the source of the excess cortisol production is from the pituitary or elsewhere. Hypercortisolism may be present in patients without true Cushing syndrome. This is known as *pseudo-Cushing syndrome* and can be caused by obesity, major depressive disorders, and chronic alcohol abuse. With further testing, these patients can usually be identified.

TREATMENT The primary treatment of Cushing disease is surgical removal of the ectopic focus of ACTH production or adenoma in the pituitary or adrenal gland. Cure is achieved in the majority of patients, but resistant disease requires radiation in the case of pituitary disease or medical therapy with adrenal enzyme inhibitors.[153] Historically, Cushing syndrome was treated with bilateral adrenalectomy. This frequently resulted in Nelson syndrome, which is characterized by unchecked ACTH production from an enlarging pituitary adenoma with resulting hyperpigmentation. Pituitary radiation can be helpful in these cases.[155]

Addison Disease

EPIDEMIOLOGY, ETIOLOGY, AND PATHOGENESIS Destruction of the adrenal glands and the resulting life-threatening deficiency of glucocorticoids, mineralocorticoids, and adrenal androgens is known as *Addison disease*. It occurs at an estimated prevalence rate of 120 per million in Western countries.[156] It is suspected that many more cases remain undiagnosed. Historically, the most common cause was tuberculosis infection, but now autoimmune destruction as part of the autoimmune polyglandular syndromes 1 and 2 is the most common etiology. In autoimmune cases, enzymes of the adrenal cortex, including 21-hydroxylase and 17-hydroxylase, are target autoantigens, and circulating autoantibodies can be detected. Subsequent lymphocytic infiltration of the adrenal gland with damage and scarring results.

Infectious causes of adrenal insufficiency remain the next most common etiology. Tuberculosis is still a major problem in many areas of the world. Atypical mycobacterial infection can also cause adrenal insufficiency. This is seen more commonly in immunosuppressed patients. Addison disease is increasingly recognized in patients with acquired immunodeficiency syndrome and, in these patients, infections with cytomegalovirus is the most recognized cause. Fungal infections have also been associated with Addison disease, including histoplasmosis, blastomycosis, paracoccidioidomycosis, coccidioidomycosis, and cryptococcosis. In the setting of an acute bacterial infection, bilateral adrenal infarction due to adrenal hemorrhage is known as the *Waterhouse-Friderichsen syndrome*. Classically this is due to meningococcal infection, although other infections have been reported.[157] Other rare causes of Addison disease include drugs, congenital adrenal hypoplasia, and infiltrative disorders, including amyloidosis, sarcoidosis, and metastatic carcinomas. The surgical treatment of Cushing syndrome can be an additional cause of adrenal insufficiency.

TABLE 152-12
Approach to the Patient with Addison Disease

Cutaneous findings in Addison disease
• Hyperpigmentation of skin and mucous membranes
• Longitudinal pigmented bands in the nails
• Vitiligo
• Decreased axillary and pubic hair in women
• Calcification of auricular cartilages in men
Related features
• Abdominal pain
• Electrolyte abnormalities (hyponatremia and hyperkalemia)
• Postural hypotension
• Anorexia and weight loss
• Shock, coma, and death, if untreated
Diagnosis
• Failure to respond adequately to corticotropin stimulation test
Management
• Lifelong replacement therapy of glucocorticoids and mineralocorticoids

CLINICAL FINDINGS: CUTANEOUS LESIONS (Table 152-12) The clinical and cutaneous manifestations of adrenal insufficiency are not usually present until 90 percent of the gland function is destroyed.[156] The most recognized cutaneous manifestation is the hyperpigmentation of skin and mucous membranes. This occurs after long-standing adrenal insufficiency and would not be present in an acute presentation of adrenal crisis unless it is superimposed on a history of chronic adrenal insufficiency. The skin pigmentation is accentuated in sun-exposed areas, flexural folds, and skin creases, including the creases on the palms (Fig. 152-16). Pigment may develop in scars and longitudinal pigmented bands may appear in the nails. These pigment changes are a consequence of low cortisol levels and the resulting loss of negative regulatory feedback on the hypothalamus and pituitary. This results in unchecked production of POMC, ACTH, and MSH, which increase melanogenesis. As mentioned previously (see Epidemiology, Etiology, and Pathogenesis under Addison Disease), the disease is often associated with autoimmunity, and vitiligo can be seen in 10 percent to 20 percent of patients.[158] Axillary and pubic hair may be sparse in women, due to the loss of adrenal androgens. This does not occur in men because adequate androgen levels are maintained by the testes. Unique to men is the reported calcification of the auricular cartilages.[159] Extra-





▲ **FIGURE 152-16** **A.** This patient with Addison disease demonstrates the characteristic hyperpigmentation of the skin with accentuation in sun-exposed areas. **B.** Palmar creases are also hyperpigmented compared to a normal hand.

cutaneous symptoms include weakness, anorexia, weight loss, abdominal pain, and postural hypotension due to electrolyte abnormalities.

LABORATORY TESTS Acute adrenal crisis can occur in the setting of chronic adrenal insufficiency and can be life threatening. The primary treatment is glucocorticoid replacement and, in an acute crisis, a blood sample should be obtained for measurement of cortisol, but therapy with 100 mg IV hydrocortisone should be instituted immediately. In chronic adrenal insufficiency, the diagnosis is confirmed using the cosyntropin stimulation test. This involves the IV administration of synthetic corticotropin (ACTH) and the measurement of stimulated cortisol in the blood 30 minutes later. Inability to produce adequate cortisol is diagnostic. Chronic replacement therapy is necessary and may require adjustments for illness or severe stress. With treatment, there is a gradual improvement in the skin changes.

ESTROGEN AND PROGESTERONE

Epidemiology

The most commonly encountered cause of estrogen excess is the pharmacologic use of estrogens for birth control, treatment of dysfunctional uterine bleeding, and as post-menopausal hormone replacement. Up to one-third of childbearing age women in the United States use oral contraceptives.[160] Ovarian, testicular, or hypothalamic tumors can also cause estrogen excess. Estrogen deficiency occurs most commonly as a result of menopause, which occurs on average at about 50 years of age. Other less common causes of estrogen deficiency include pituitary or gonadal failure. Exercise-induced amenorrhea is also associated with a concomitant estrogen deficiency.

Etiology and Pathogenesis

Estrogen receptors are found throughout the skin, including on keratinocytes, sebaceous glands, eccrine and apocrine glands, in hair follicles, in dermal fibroblasts, and in melanocytes. Estrogens bind to cytosolic receptors that subsequently translocate to the nucleus and activate gene transcription. Estrogen receptors are found in greater numbers in women compared with men. The main observations regarding the effects of estrogen on skin come from studies of post-menopausal women, in whom estrogen deprivation leads to skin wrinkling, xerosis, and atrophy. Increased epidermal and dermal thickness, increased water-holding capacity, changes in lipid composition of the stratum corneum, and improvement in skin laxity all occur with estrogen replacement, highlighting the important effects of this hormone throughout the skin.[161] Estrogen deprivation has also been reported to hinder wound healing, which subsequently improves with estrogen replacement. Estrogens have also been reported to suppress sebaceous gland function and also tend to inhibit hair growth.

The most potent naturally occurring estrogen is estradiol, which is the principal estrogen secreted by the ovary. Estrone, another estrogen secreted by the ovaries, is synthesized primarily in peripheral tissues from the conversion of androstenedione. In the menstrual cycle, estradiol levels peak at mid-cycle immediately preceding ovulation, and then again near the end of the cycle around day 24 before falling to baseline

ESTROGEN AND SKIN AT A GLANCE



- Exogenous estrogen, either through oral contraceptives or hormone replacement, is the most common cause of estrogen excess.
- Wrinkling, xerosis, and atrophy are signs of estrogen deficiency.
- Triple-ingredient preparations are first-line therapy for treating melasma if patients are not content with covering cosmetics.

before menses. During pregnancy, the main estrogen is estriol, which is synthesized by the placenta. Progesterone is the main hormone secreted by the corpus luteum, and peak levels are seen after ovulation, remaining elevated until just before menses. Gonadal hormones are not entirely specific, and progesterone is able to cross-react by binding to androgen receptors to exert androgenic or anti-androgenic effects.

Clinical Findings and Diagnosis: Cutaneous Manifestations of Estrogen Excess and Deficiency

Estrogen can have both beneficial and undesired effects. Estrogen replacement therapy in post-menopausal women can reverse epidermal atrophy and restore cutaneous collagen. The inhibitory actions of estrogen on sebum production can lead to improvement of acne with oral contraceptive therapy, particularly with the use of estrogen-dominant preparations. Despite circulating estriol during pregnancy, the relative androgen excess due to elevated progesterone can actually exacerbate acne in some patients. Telogen effluvium characterized by diffuse loss of scalp or body hair can occur after delivery or discontinuation of oral contraceptives. Both pregnant women and patients taking synthetic estrogen can be more prone to certain side effects of estrogen, including telangiectasias, palmar erythema, spider angiomas, and pigmentary changes.



Melanocytic lesions, including preexisting nevi and malignant melanoma, can darken during pregnancy. Hyperpigmentation of the nipples, linea nigra, and genitalia can be seen. Melasma, sometimes referred to as the *mask of pregnancy*, presents as irregularly shaped, hyperpigmented patches on the forehead, cheeks, nose, upper lip, chin, and neck (Fig. 152-17). Although melasma may improve after delivery, it can reoccur with subsequent pregnancies. When caused by oral contraceptives, melasma can still persist even after discontinuation of the medication.

Acanthosis nigricans can be associated with estrogen excess. In clinical states characterized by elevated estrogen levels, including pregnancy and the use of oral contraceptives, increased hair growth over the face, breasts, and extremities can be seen. This phenomenon may be a result of the complex interplay of estrogens and androgenic hormones rather than a direct effect of increased estrogen levels on the hair follicles themselves. Estrogen and progesterone dermatitis has been described in the literature and is characterized by a polymorphous eruption marked by cyclical pre-menstrual flares that may include pruritus. The diagnosis may be made by separate subcutaneous injection of both estrogen and progesterone in the skin of the forearm, checking within 15 to 60 minutes for reactions ranging from erythema to a wheal.[162] Oral contraceptives have been implicated as a cause of erythema nodosum.

Estrogen deficiency from either menopause or pituitary failure can result in hot flashes, epithelial atrophy of the genitalia, and decreased breast size. Certain medications, such as danazol, leuprolide, and clomiphene citrate, can induce a pharmacologic menopause that presents with flushing. Flushing episodes accompanied by uncomfortable heat lasting several minutes can occur in younger women immediately before or during their period when estrogen levels are at their lowest.



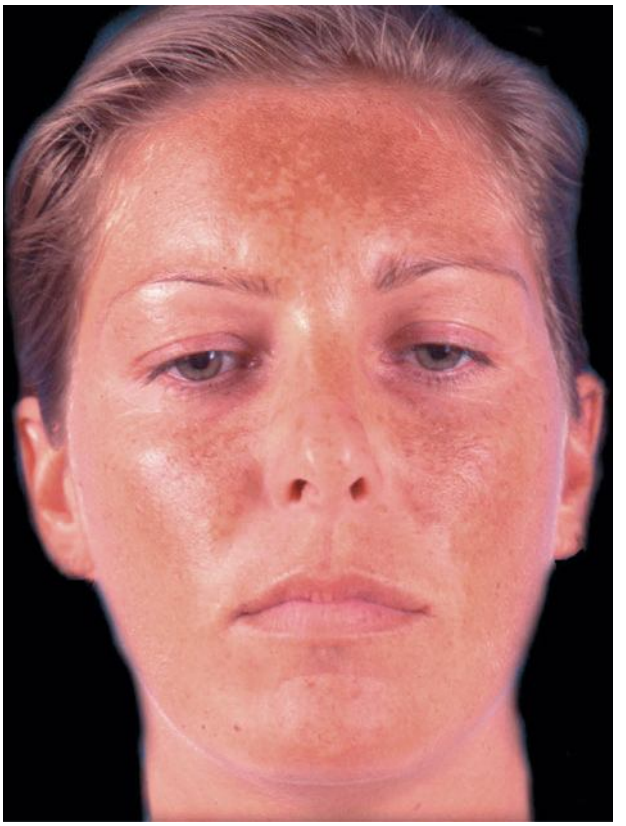

◀ **FIGURE 152-17** Melasma is demonstrated in a symmetric pattern on the face of a young woman. The upper lip is also a common site of involvement.

Treatment

The Pigmentary Disorders Academy generated a consensus statement on the treatment of melasma and recommended the use of fixed "triple-ingredient" combinations as first-line therapy.[163] Topical retinoids, corticosteroids, azelaic acid, and hydroquinone-based bleaching creams have been used in various combinations to treat melasma. Kligman's formula, first developed in 1975, is the classic triple-ingredient melasma preparation consisting of 5 percent hydroquinone, 0.1 percent tretinoin, and 0.1 percent dexamethasone in a hydrophilic ointment. Dual ingredient combinations or single agents are reasonable alternatives. For refractory cases, chemical peels (i.e., glycolic acid or trichloroacetic acid) in combination with topical therapy can be tried. Lasers can also be considered but seem to be of limited usefulness. Given the exacerbation of hyperpigmentation with sun exposure, the consistent use of broad-spectrum sunscreens is also important for melasma treatment.

Although estrogen therapy can reverse some of the epithelial atrophy seen during menopause, the risks and benefits of hormone replacement therapy must be weighed on an individual basis. Low-dose clonidine has been reported as an effective treatment for menopause-related flushing. There has been controversy regarding the use of estrogen therapies in patients with systemic lupus erythematosus, although two recent, well-designed trials suggest that these therapies can be used safely in most patients with systemic lupus erythematosus whose disease is stable.[164,165]

ANDROGENIC HORMONES

Epidemiology

In males, cutaneous manifestations of androgen excess occur most commonly with either the onset of sexual maturation or with androgen replacement therapy. Androgen-secreting tumors are a less common cause of androgen excess. In women, androgen excess can occur due to congenital adrenal hyperplasia (CAH) secondary to deficiency of enzymes in adrenal enzymes such as 21-hydroxylase (also called *CYP21*), which accounts for almost 90 percent of CAH in the United States.[166] Deficiency of CYP21 is inherited as an autosomal recessive trait and results in accu-

ANDROGENS AND SKIN AT A GLANCE



- The peripheral conversion of testosterone to 5 α-dihydrotestosterone is important for the pathophysiology of androgenic alopecia.
- Hirsutism secondary to androgen excess has a characteristic distribution that includes the beard area, chest, back, and suprapubic region.

mulation of 17-hydroxyprogesterone. Although progestins in oral contraceptives are listed as potential causes of hirsutism due to their chemical similarity to testosterone, they likely do not cause androgenic effects at clinically used doses based on data from animal studies. PCOS occurs in about 5 percent of pre-menopausal women in the United States and is characterized by insulin resistance, polycystic ovaries, and the presence of androgenic cutaneous findings, including acne, hirsutism, and androgenic alopecia. PCOS is also associated with the metabolic syndrome, which is characterized by lipid abnormalities, diabetic predisposition, and heart disease. Androgenic alopecia affects approximately one-half of men older than age 40 years, and potentially as many women as well, with most patients showing signs of alopecia by age 30 (see Chap. 86).

Etiology and Pathogenesis

Like estrogen receptors, androgen receptors are also present throughout the skin. In men, androgens are synthesized in the testis and adrenals, whereas in women androgens are secreted by the ovaries and adrenals. In addition to testosterone, progesterone, dehydroepiandrosterone (DHEA), and DHEA sulfate (DHEA-S) are all natural androgens that can lead to cutaneous findings when they are present in excess.[167] Testosterone is subsequently converted in peripheral target tissues to the active metabolite 5 α-dihydrotestosterone (5α-DHT) by the enzyme 5α-reductase. Unlike testosterone, which can be aromatized to form estrogen, 5α-DHT cannot be aromatized and thus retains purely androgenic properties. In addition, 5α-DHT binds the androgen receptor with greater affinity than testosterone.

Androgens are significant regulators of hair growth and sebaceous gland function. Androgens have also been implicated in wound healing, epidermal differentiation, and the regulation of dermal fibroblasts. Androgen receptors have a trophic distribution throughout the body that is most evident with the appearance of "male pattern" hair growth on the face, chest, and back, as well as areas of hair loss on the scalp. Both estrogens and androgens can be bound by sex hormone binding globulin (SHBG, also called *TEBG* for *t*estosterone-*e*strogen-*b*inding *g*lobulin). SHBG levels are decreased by synthetic progestins found in oral contraceptives (i.e., norgestrel, norethindrone, norgestimate, desogestrel), as well as in obesity, acromegaly, hypothyroidism, and hyperinsulinemia. The decreased SHBG results in higher levels of circulating androgens and accounts, in part, for why androgenic findings can be associated with these conditions.

Clinical Findings and Diagnosis: Cutaneous Manifestations of Androgen Excess

Androgen-related skin conditions are commonly seen in dermatology practice. Although our knowledge regarding acne pathogenesis is still incomplete, at least part of acne's pathophysiology involves the response of sebaceous glands to androgens. In most males and females, acne tends to subside after adolescence (see Chap. 78). Cases of persistent acne should elicit a differential diagnosis that includes causes of persistent androgen excess, including CAH, PCOS in women, or an androgen-secreting tumor (Fig. 152-18), in addition to rosacea and chemically induced acne. In the appropriate clinical setting, laboratory studies may be helpful in determining the source of androgen excess (see Table 152-13). Performance-enhancing anabolic steroids are derivatives of testosterone, and the resulting androgen excess can manifest as acne.

There is some genetic variation underlying the response of hair follicles to androgens as evidenced by the varying degrees of hirsutism seen among women with different ethnic backgrounds but similar serum androgen levels. Hirsutism secondary to androgen excess occurs in a characteristic distribution involving the beard region of the face, the chest, the upper back, and the suprapubic area.

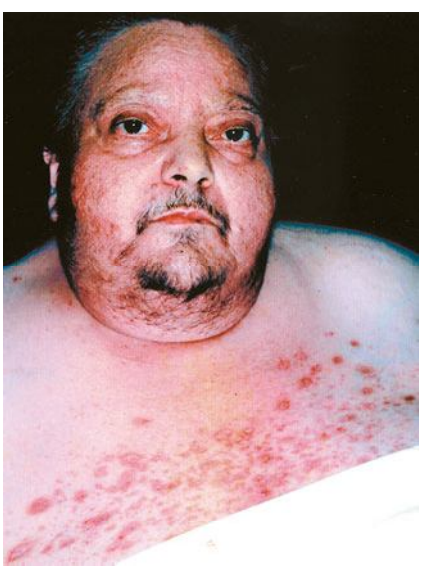

▲ **FIGURE 152-18** Hyperandrogenism manifests clinically in this woman with an androgen-secreting adrenal tumor. Note the characteristic facial hair, the receding hairline, and the acneiform eruption on the chest.

TABLE 152-13
Approach to the Female Patient with Suspected Hyperandrogenism

History and physical findings concerning for hyperandrogenism
- Sudden onset of acne
- Severe acne refractory to conventional treatments
- Irregular menstrual periods
- Hirsutism

Laboratory evaluation (most accurate when patient is off oral contraceptives for 4–6 weeks and if tests are drawn before menses)
- Dehydroepiandrosterone sulfate: screens for adrenal androgen source
  - > 8000 ng/mL may suggest adrenal tumor
  - 4000–8000 ng/mL may suggest congenital adrenal hyperplasia
- Testosterone: screens for ovarian source
  - 150–200 ng/dL can occur in polycystic ovarian syndrome
  - Some adrenal tumors can also secrete testosterone
- Luteinizing hormone–follicle stimulating hormone ratio
  - > 2–3 can be consistent with polycystic ovarian syndrome

Adapted from Thiboutot D: Acne: Hormonal concepts and therapy. *Clin Dermatol* **22**:419, 2004.

Ironically, although androgens can cause hair excess, they are also responsible for male-pattern alopecia as well. Scalp hairs are eventually converted first to indeterminate hairs and then to vellus hairs. Clinically, scalp hairs become thinner until they are replaced by nonpigmented vellus hairs. In men, the pattern is characteristic and consists of symmetric recession of the hairline and the temples along with hair loss on the vertex. In women, the hairline is usually preserved, and the pattern is mostly diffuse thinning without an area of frank baldness. Although androgenetic alopecia can be acquired in patients with androgen excess, it is most commonly an incompletely characterized genetic disorder that appears to be inherited in an autosomal dominant manner (see Chap. 86).

Treatment

In women whose acne appears to be hormonally related, the use of anti-andro-



gens, including the diuretic spironolactone or the oral contraceptive drospirenone, may prove more effective than conventional topical and oral acne medications. These drugs act as competitive inhibitors of DHT binding to androgen receptors. Specific 5α-reductase inhibitors, such as finasteride, can be used to treat androgenetic alopecia, although this medication is contraindicated in women of child-bearing age due to possible effects on development of genitalia and gonads in the male fetus.

When patients have an excess of adrenal androgens such as DHEA-S, the use of low-dose glucocorticosteroids (such as prednisone, 2.5 to 5.0 mg/day) can be used for suppressive therapy, and the efficacy of therapy can be monitored by measuring serum DHEA-S levels. Cyproterone acetate is an antiandrogen that is not available in the United States, although it has shown promise in the treatment of acne when used in other countries in oral contraceptive preparations. Flutamide is a nonsteroidal androgen receptor antagonist that is rarely used due to the risk of fatal hepatitis as well as concerns about effects on fetal development in women of child-bearing age.[168]



DISORDERS OF GROWTH HORMONE

Acromegaly

Growth hormone (GH) is secreted by the pituitary in a pulsatile fashion and reaches its maximum rate during puberty and then declines over time. The pulsatile pattern of secretion is equally important to the amount of hormone for normal function. Secretion of GH is primarily regulated by GH-releasing hormone (GHRH) and somatostatin.[169] Recently, the natural GH secretagogue ghrelin, produced in the stomach, has been discovered to have potent GH-releasing properties and may be involved in a separate pathway of GH regulation.[169,170] GHRH stimulates the release of GH, whereas somatostatin has an inhibitory effect. The target of these regulatory factors is the GHRH receptor in the pituitary. The peripheral effects of GH are largely indirectly mediated through production of IGF-1 in the liver and stimulation of the IGF-1 receptor. GH contributes significantly to linear growth in children, increases protein synthesis, mobilizes stored triglycerides, and antagonizes the action of insulin (Fig. 152-19).

ETIOLOGY AND PATHOGENESIS Excessive production of GH is almost always due to a pituitary adenoma. In children, this results in pituitary gigantism, whereas in adults, excessive GH manifests as the clinical syndrome acromegaly. This syndrome is diagnosed in about 3 to 4 people per million every year.[171] Very rarely, acromegaly is caused by a GH-producing tumor in the hypothalamus or by an ectopic non-endocrine tumor such as small cell lung cancer or carcinoid tumor.[172] GH-producing adenomas are present in 8 percent of patients with Carney complex, an inherited disorder with multiple lentigines and multiple endocrine abnormalities.[173]

GROWTH HORMONE AT A GLANCE



- Growth hormone plays a central role in longitudinal growth.
- In children, deficiency manifests as short stature while gigantism occurs from oversecretion of growth hormone before puberty, when the growth plates in long bones are still open.
- The disease acromegaly occurs in adults after the growth plates have closed.
- Acromegaly results from oversecretion of growth hormone, usually due to a pituitary adenoma.

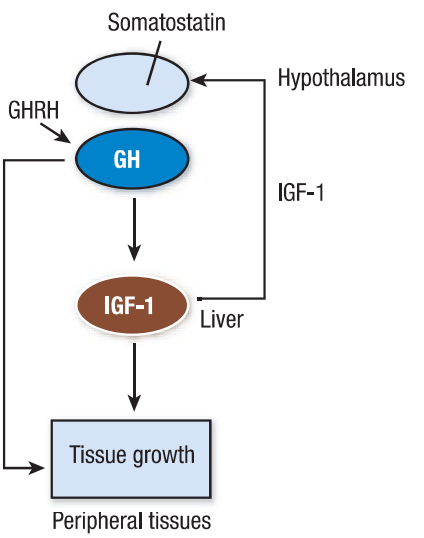

▲ **FIGURE 152-19** Effects and regulation of growth hormone (GH). GHRH = growth hormone releasing hormone; IGF-1 = insulin-like growth factor-1.

TABLE 152-14
Approach to the Patient with Acromegaly

Cutaneous findings in acromegaly
- Enlargement of hands and feet with a doughy texture
- Increased ring, glove, shoe, and hat size
- Jaw enlargement with separation of teeth (prognathism)
- Macroglossia
- Cutis vertices gyri
- Acanthosis nigricans
- Hirsutism
- Hyperhidrosis
- Brittle thick nails

Related features
- Diabetes
- Hypertension
- Hyperlipidemia

Diagnosis
- Elevated serum insulin-like growth factor-1 levels
- Failure to suppress growth hormone levels by oral glucose-tolerance test

Management
- Appropriate endocrine and surgical consultation
- Surgical removal of adenoma by transphenoidal resection
- Somatostatin analogues or growth hormone receptor antagonists for residual disease
- Radiation therapy is an option for resistant cases

CLINICAL FINDINGS: CUTANEOUS LESIONS (Table 152-14) The clinical manifestations of acromegaly include the overgrowth of bone and connective tissue, metabolic effects, and localized tumor mass effects. The onset is insidious, and the average age at the time of diagnosis is 40 to 45 years old, but often the condition has been present for many years before the diagnosis.[174] The metabolic effects include diabetes, hypertension, and hyperlipidemia. There is a gradual coarsening of the features and increased head, hand, and foot size. This acral pattern of overgrowth may be noticed as increasing shoe, ring, glove, or hat size (Fig. 152-20A). Macroglossia can be seen. The skin becomes thickened, almost doughy, with deep grooves prominent on the forehead and around the nasolabial folds (Fig. 152-20B). On the scalp, cutis verticis gyrata may develop. Heel pads and the pads of the digits become thickened. Nails are thickened and brittle, and some patients develop hirsutism. Hyperhidrosis and malodor are common complaints. Many patients de-

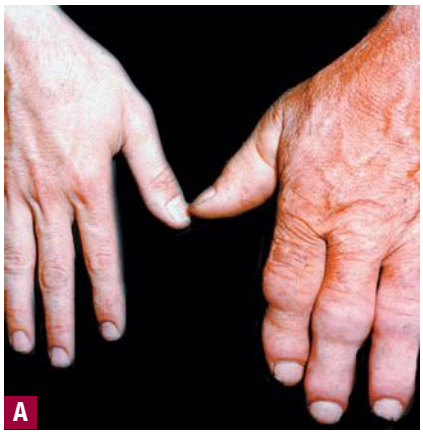

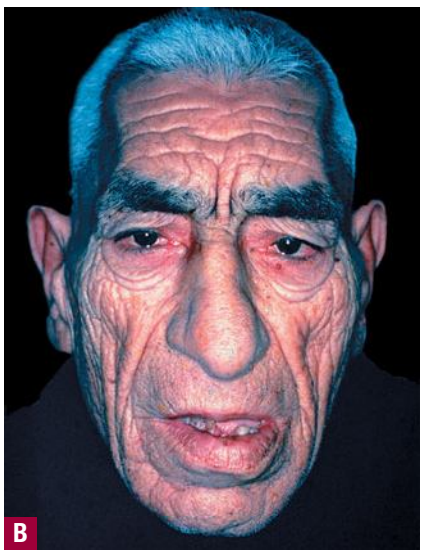

▲ **FIGURE 152-20** **A.** Acral enlargement is a prominent feature of acromegaly and is easily demonstrated in comparison with a normal hand. **B.** Patients develop deep grooves on the forehead and around the nasolabial folds. When jaw enlargement is present, spaces between the teeth can be seen. (Reprinted from Braverman I, Saunders WB: *Skin Signs of Systemic Disease*, 3rd ed, 1997, with permission.)

velop acanthosis nigricans and multiple acrochordons with or without frank diabetes. Retinal angioid streaks can be seen in acromegaly (as well as in osteogenesis imperfecta and pseudoxanthoma elasticum) (see Chap. 139). Histologically, there is a dense deposition of GAGs in the papillary and superficial reticular dermis. Often, coarse collagen bundles with normal elastin and increased numbers of fibroblasts are seen in the dermis.

LABORATORY TESTS Measurement of the serum GH level is highly variable and unreliable diagnostically because of the pulsatile pattern of secretion. Plasma IGF-1 levels are very much dependent on GH and fairly stable during any 24-hour period. Serum IGF-1 can be used as a surrogate measurement of GH. As a screening test for acromegaly, IGF-1 levels will be elevated. Further workup with assistance from a consulting endocrinologist may include an oral glucose tolerance test. In the proper clinical setting failure to suppress the GH level to < 1 ng/mL within 1 or 2 hours after 75 to 100 g of oral glucose is diagnostic for acromegaly.[175]

TREATMENT Because most cases of GH excess are due to a pituitary adenoma, surgical removal is the primary therapy. This is most commonly accomplished through a selective transsphenoidal resection.[176] Residual disease after surgery is more common in larger adenomas and may be higher than 30 percent for tumors larger than 1 cm. The inhibitory effect of somatostatin on GH secretion is harnessed for therapy. Somatostatin analogues, including octreotide, are used for the medical treatment of residual disease after surgery and are increasingly being considered as potential primary therapy. The somatostatin analogues alone have demonstrated the ability to reduce the size of tumors and to control IGF-1 levels in select patients. In resistant cases, radiation therapy can be considered.

Growth Hormone Deficiency and Panhypopituitarism

GH deficiency can occur in children or adults and be inherited or acquired. The primary clinical manifestation of this deficiency occurs in children as abnormal short stature. This can be corrected by the administration of GH. The clinical presentation of GH deficiency in adults includes decreased lean body mass, decreased strength and exercise capacity in part due to decreased sweating, and a loss of general vitality. Replacement therapy in adults is a complex discussion and beyond the scope of this chapter. Recently, practice guidelines have been established by the Endocrine Society for the assessment and treatment of GH deficiency in adults.[177] In the setting of panhypopituitarism, there is total loss of all pituitary function, including GH (Table 152-15). These patients usually present with a combination of symptoms either due to a space-occupying lesion in the pituitary or to hormone dysregulation. These symptoms may be a manifestation of any number of endocrine systems that are regulated at the level of the pituitary including features of hypothyroidism. Skin findings that have been described in these patients include fine wrinkling of the skin, decreased pigmentation, and decreased to absent pubic and axillary hair (Fig. 152-21).

TABLE 152-15
Causes of Hypopituitarism

- Mass lesions: nonfunctioning pituitary adenoma, cyst, craniopharyngioma, metastasis
- Infectious causes: tuberculosis, histoplasmosis
- Pituitary infarction: known as *Sheehan syndrome* when occurs with childbirth
- Pituitary apoplexy: sudden hemorrhage into the pituitary
- Lymphocytic hypophysitis
- Infiltrative disorders: hemochromatosis, sarcoidosis, Langerhans cell histiocytosis
- Head trauma
- Surgery or radiation



▲ **FIGURE 152-21** In this patient with panhypopituitarism, fine wrinkling and pale skin can be seen as well as other features suggestive of hypothyroidism. Her decreased pigmentation is contrasted by that of her nurse on the right. Patients with panhypopituitarism often present with findings of multiple endocrine disorders.



KEY REFERENCES

The full reference list for all chapters is available at www.digm7.com.

1. Cowie CC et al: Prevalence of diabetes and impaired fasting glucose in adults in the U.S. population: National Health And Nutrition Examination Survey 1999–2002. *Diabetes Care* **29**:1263, 2006
3. Narayan K.M et al: Lifetime risk for diabetes mellitus in the United States. *JAMA* **290**:1884, 2003
5. Gaede P, Pedersen O: Intensive integrated therapy of type 2 diabetes: Implications for long-term prognosis. *Diabetes* **53**:S39, 2004
10. Olerud JE: Diabetes and the skin, in *Ellenburg & Rifkin's Diabetes Mellitus*, 6th ed, edited by Porte D Jr, Sherwin RS, Baron A. New York, McGraw-Hill, 2003, p 895
11. Joshi N et al: Infections in patients with diabetes mellitus. *N Engl J Med* **341**: 1906, 1999
22. Torley D, Bellus GA, Munro CS: Genes, growth factors and acanthosis nigricans. *Br J Dermatol* **147**:1096, 2002
31. Kebria MM et al: Malignant acanthosis nigricans, tripe palms and the sign of Leser-Trélat, a hint to the diagnosis of early stage ovarian cancer: A case report and review of the literature. *Gynecol Oncol* **101**:353, 2006
66. Boyko EJ et al: Prediction of diabetic foot ulcer occurrence using commonly available clinical information: The Seattle Diabetic Foot Study. *Diabetes Care* **29**:1202, 2006
69. van Burik JA et al: Posaconazole is effective as salvage therapy in zygomycosis: A retrospective summary of 91 cases. *Clin Infect Dis* **42**:e61, 2006
71. Singh N, Armstrong DG, Lipsky BA: Preventing foot ulcers in patients with diabetes. *JAMA* **293**:217, 2005
73. Consensus Development Conference on Diabetic Foot Wound Care: 7-8 April 1999, Boston, Massachusetts. American Diabetes Association. *Diabetes Care* **22**:1354, 1999
79. Wieman TJ, Smiell JM, Su Y: Efficacy and safety of a topical gel formulation of recombinant human platelet-derived growth factor-BB (becaplermin) in patients with chronic neuropathic diabetic ulcers. A phase III randomized placebo-controlled double-blind study. *Diabetes Care* **21**:822, 1998
80. Veves A et al: Graftskin, a human skin equivalent, is effective in the management of noninfected neuropathic diabetic foot ulcers: A prospective randomized multicenter clinical trial. *Diabetes Care* **24**:290, 2001
81. Edmonds M et al: New treatments in ulcer healing and wound infection. *Diabetes Metab Res Rev* **16**:S51, 2000
86. Lowitt MH, Dover JS: Necrobiosis lipoidica. *J Am Acad Dermatol* **25**:735, 1991
95. Dabski K, Winkelmann RK: Generalized granuloma annulare: Clinical and laboratory findings in 100 patients. *J Am Acad Dermatol* **20**:39, 1989
99. Setterfield J, Huilgol SC, Black MM: Generalised granuloma annulare successfully treated with PUVA. *Clin Exp Dermatol* **24**:458, 1999
111. Weetman AP: Graves' disease. *N Engl J Med* **343**:1236, 2000
112. Laurberg P et al: High incidence of multinodular toxic goitre in the elderly population in a low iodine intake area vs. high incidence of Graves' disease in the young in a high iodine intake area: Comparative surveys of thyrotoxicosis epidemiology in East-Jutland Denmark and Iceland. *J Intern Med* **229**:415, 1991
118. Prabhakar BS, Bahn RS, Smith TJ: Current perspective on the pathogenesis of Graves' disease and ophthalmopathy. *Endocr Rev* **24**:802, 2003
120. Safer JD, Crawford TM, Holick MF: Topical thyroid hormone accelerates wound healing in mice. *Endocrinology* **146**:4425, 2005
122. Ai J, Leonhardt JM, Heymann WR: Autoimmune thyroid diseases: Etiology, pathogenesis, and dermatologic manifestations. *J Am Acad Dermatol* **48**:641, quiz 660, 2003
125. Fatourechi V, Ahmed DD, Schwartz KM: Thyroid acropachy: Report of 40 patients treated at a single institution in a 26-year period. *J Clin Endocrinol Metab* **87**:5435, 2002
126. Dreskin SC Andrews KY: The thyroid and urticaria. *Curr Opin Allergy Clin Immunol* **5**:408, 2005
127. Biro E et al: Association of systemic and thyroid autoimmune diseases. *Clin Rheumatol* **25**:240, 2006
132. Schwartz KM et al: Dermopathy of Graves' disease (pretibial myxedema): Long-term outcome. *J Clin Endocrinol Metab* **87**:438, 2002
134. Wermers RA et al: Incidence of primary hyperparathyroidism in Rochester, Minnesota, 1993-2001: An update on the changing epidemiology of the disease. *J Bone Miner Res* **21**:171, 2006
141. Walsh JS, Fairley JA: Calcifying disorders of the skin. *J Am Acad Dermatol* **33**:693, quiz 707, 1995
143. Heppner C et al: Somatic mutation of the MEN1 gene in parathyroid tumours. *Nat Genet* **16**:375, 1997
144. Basile C et al: Hyperbaric oxygen therapy for calcific uremic arteriolopathy: A case series. *J Nephrol* **15**:676, 2002
146. Lee Y et al: Hypocalcaemia-induced pustular psoriasis-like skin eruption. *Br J Dermatol* **152**:591, 2005
147. Makitie O et al: Bone health in autoimmune polyendocrinopathy-candidiasis-ectodermal dystrophy (APECED): Findings in 25 adults. *Clin Endocrinol* (Oxf) **64**:489, 2006
149. Beauregard C, Dickstein G, Lacroix A: Classic and recent etiologies of Cushing's syndrome: Diagnosis and therapy. *Treat Endocrinol* **1**:79, 2002
150. Ilias I et al: Cushing's syndrome due to ectopic corticotropin secretion: Twenty years' experience at the National Institutes of Health. *J Clin Endocrinol Metab* **90**:4955, 2005
156. Ten S, New M, Maclaren N: Clinical review 130: Addison's disease 2001. *J Clin Endocrinol Metab* **86**:2909, 2001
161. Hall G, Phillips TJ: Estrogen and skin: The effects of estrogen, menopause, and hormone replacement therapy on the skin. *J Am Acad Dermatol* **53**:555, quiz 569, 2005
163. Rendon M et al: Treatment of melasma. *J Am Acad Dermatol* **54**:S272, 2006
168. Thiboutot D: Acne: Hormonal concepts and therapy. *Clin Dermatol* **22**:419, 2004
175. Melmed S: Medical progress: acromegaly. *N Engl J Med* **355**:2558, 2006
176. Melmed S et al: Guidelines for acromegaly management. *J Clin Endocrinol Metab* **87**:4054, 2002
177. Molitch ME et al: Evaluation and treatment of adult growth hormone deficiency: An endocrine society clinical practice guideline. *J Clin Endocrinol Metab* **91**:1621, 2006
178. Boulton A et al: Neuropathic diabetic foot ulcers. *N Engl J Med* **351**:48, 2004



CHAPTER 153

Sarcoidosis

Richard M. Marchell
Bruce Thiers
Marc A. Judson

Sarcoidosis is a multisystem granulomatous disease of unknown cause. The lung is the most commonly affected organ, but the skin is frequently involved.[1] The first descriptions of sarcoidosis in the late 1800s were limited to its skin manifestations.[1] The term *sarcoidosis* is derived from Caesar Boeck's 1899 report of what he described as "multiple benign sarkoid of the skin," because he believed the lesions resembled sarcomas but were benign.[2]

EPIDEMIOLOGY

Sarcoidosis occurs worldwide and affects all ages and races. Disease onset is most often in the third decade of life, although a smaller second peak occurs in people older than 50 years.[1] The prevalence rate is slightly higher in women.[1] Sarcoidosis is more frequent away from the equator. The highest prevalence of sarcoidosis is found in Denmark, Sweden, and, in the United States, in persons of African descent.[1] In the United States, the lifetime risk of sarcoidosis is 2.4 percent in African Americans and 0.85 percent in Caucasians.[3] The age-adjusted annual incidence rate of sarcoidosis in the United States is 35.5 per 100,000 for African Americans and 10.9 per 100,000 for Caucasians.[3] The

SARCOIDOSIS AT A GLANCE



- Sarcoidosis is a systemic granulomatous disease of unknown cause that primarily affects the lungs, but often involves the skin.
- The highest prevalence of sarcoidosis is in Denmark and Sweden; in the United States, it is higher in persons of African descent.
- The most common sites of cutaneous sarcoidosis are the head and neck. Scar tissue at all sites can be affected.
- The most common cutaneous form of sarcoidosis, the papular form, is characterized by translucent yellow-red papules with an "apple jelly" appearance on diascopy.
- Noncaseating, "naked" granulomas on biopsy are quite suggestive, but not specific for the diagnosis.
- Erythema nodosum is the main nonspecific cutaneous manifestation of sarcoidosis, and heralds a good prognosis.

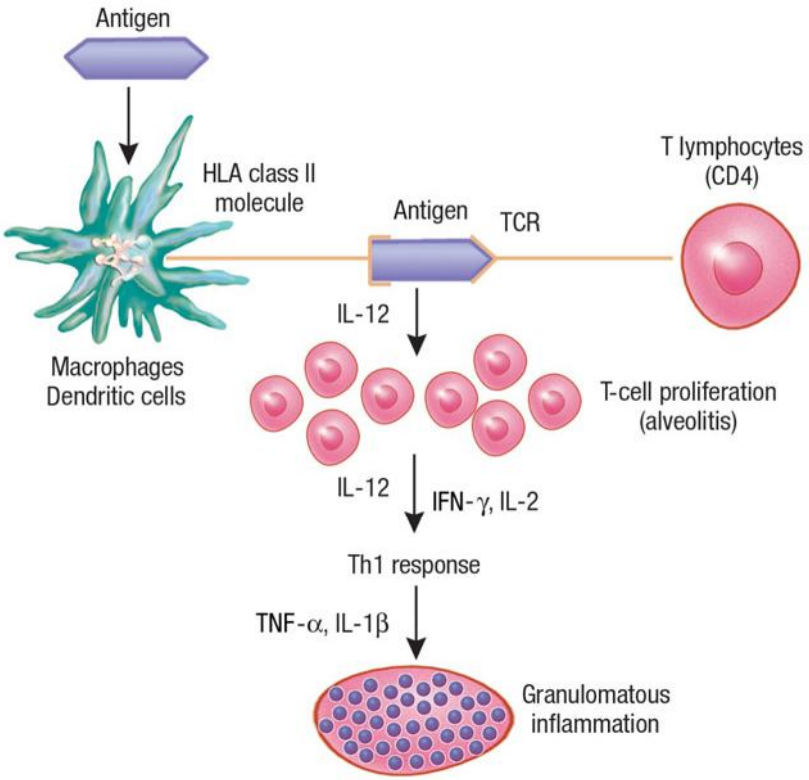

▲ **FIGURE 153-1** Proposed immunopathogenesis of sarcoidosis. An antigen, presently unknown, is engulfed and processed by an antigen-presenting cell (macrophage or dendritic cell). The processed antigen is presented to a T-cell receptor (TCR) of a T lymphocyte via an HLA class II molecule. Once the HLA receptor and TCR have bound the processed antigen, numerous lymphokines and cytokines of the T helper 1 (Th1) class are released that lead to T-cell proliferation, recruitment of monocytes, and eventual granuloma formation. A few of these lymphokines and cytokines are shown, with those released by the antigen-presenting cells on the left and those released by lymphocytes on the right. IFN = interferon; IL = interleukin; TNF = tumor necrosis factor.



frequency and severity of the disease also vary between different ethnicities and races. African Americans tend to have more severe disease, whereas Caucasians are more likely to present with asymptomatic disease.[4,5] African Americans are also more likely to have extrapulmonary disease,[6] require treatment,[7] develop new organ involvement,[8] and have a lower rate of clinical recovery than Caucasians.[5,8] The disease is more common in life-long nonsmokers.[9]

ETIOLOGY AND PATHOGENESIS

The current understanding is that the development of sarcoidosis requires at least three major events: (1) exposure to antigen(s), (2) acquired cellular immunity directed against the antigen and mediated through antigen-presenting cells and antigen-specific T lymphocytes, and (3) the appearance of immune effector cells that promote a nonspecific inflammatory response.[10] The identity of the putative antigen(s) of sarcoidosis is unknown.

Presumably, antigen-presenting cells such as macrophages recognize, process, and present the processed antigen to $CD4^+$ T cells of the T helper 1 type. The processed antigen is presented to these lymphocytes via HLA (major histocompatibility complex)-class II molecules on the antigen-presenting cells that have undergone enhanced expression from exposure to the sarcoidosis antigen and possibly interferon-γ (IFN-γ).[10,11] These activated macrophages produce interleukin (IL)-12, which induces lymphocytes to shift toward a T helper 1 profile and causes T lymphocytes to secrete IFN-γ. These activated T cells release IL-2 and chemotactic factors that recruit monocytes and macrophages to the site of disease activity. IL-2 and other cytokines also expand various T-cell clones. IFN-γ further activates macrophages and transforms them into giant cells.[11] Tumor necrosis factor (TNF), IL-2, and other cytokines may also be important in stimulating macrophages.[12] Fig. 153-1 displays the major features of the presumed immunopathogenesis of sarcoidosis.

A variety of candidate antigens have been suggested as provocative agents for the cascade of immunologic events that eventuate in sarcoidosis. Infectious agents such as mycobacteria,[13] *Propionibacterium acnes*,[14] and *Chlamydia*[15] have been associated with sarcoidosis. Mineral dusts, such as silica, iron,[16] and titanium,[17] also have been associated with sarcoidosis as have combustible wood products because the disease has been found more commonly in individuals who use wood stoves.[18] Interestingly, firefighters have been found to be at greater risk of developing sarcoidosis.[19]

Genetics play a major role in determining susceptibility to sarcoidosis, as it is more common in relatives of an affected person than in individuals in the general population.[20] Genes coding for HLA class II antigens are thought to be prime candidates for a role in the development of the disease because these molecules present exogenous peptides to $CD4^+$ T-cell receptors. Numerous studies in various ethnic groups have shown a relationship of HLA antigens to the development of disease, protection from disease, good prognosis, poor prognosis, acute disease, chronic disease, and various phenotypic expressions of sarcoidosis.[21]

The interplay of antigenic and genetic factors suggests that there may be multiple causes of sarcoidosis. Patients may have to experience a specific interaction between one or several exposures and be genetically programmed to one or several abnormal immunologic responses. Each putative antigen may be associated with a specific HLA class II molecule and T-cell receptor.

CLINICAL FINDINGS

History

The diagnosis of sarcoidosis is often delayed for months to years because symptoms are non-specific and can relate to involvement of any organ.[22]

Thirty to sixty percent of patients with pulmonary sarcoidosis are asymptomatic.[23] Other than the lung, the skin, eye, liver, and peripheral lymph nodes are commonly involved. Consequently, sarcoidosis should be considered in a patient with skin lesions and concomitant pulmonary symptoms, eye complaints, right upper quadrant abdominal pain, or peripheral lymphadenopathy. In addition, the cytokines associated with the granulomatous inflammation of sarcoidosis may cause constitutional symptoms such as fever, night sweats, malaise, and weight loss.

Cutaneous lesions of sarcoidosis may occur before, coincident with, or after systemic involvement. Specific cutaneous lesions are usually asymptomatic. Pruritus and pain are rare. Cosmetic disfigurement is the most common complaint. Erythema nodosum associated with sarcoidosis is indistinguishable from erythema nodosum unassociated with sarcoidosis (see Chap. 68).

Cutaneous Lesions

Classically, lesions are divided into two categories: specific and non-specific. Specific lesions have granulomas on biopsy. Non-specific skin findings are reactive and do not exhibit sarcoidal granulomas.

SPECIFIC LESIONS ***Skin.*** Specific sarcoidal lesions most often are found on the head and neck (Figs. 153-2, 153-3, and 153-4) but may occur symmetrically or asymmetrically on any part of the skin and mucosa. Almost all morphologies have been reported, including macules, papules, patches, plaques, and nodules. Alopecia occurs with scalp involvement, and nail changes also occur. Specific lesions of sarcoidosis may be scaly, telangiectatic, or atrophic. Despite the diversity in appearance, there are several clinical presentations that are classically associated with cutaneous sarcoidosis.

The most common presentation is the papular form (see Figs. 153-2, 153-3, and 153-4). These firm, 2- to 5-mm papules often have a translucent red-brown or yellow-brown appearance. The yellow-brown color has been likened to "apple jelly" and is accentuated with diascopy (Fig. 153-5). In addition to the color change, the underlying granulomas have a nodular quality that can also be appreciated with diascopy. The apple jelly appearance and nodules are not pathognomonic for sarcoidosis, as other granulatomous skin conditions, such as lupus vulgaris (see Chap. 184), may exhibit similar diascopic properties. Epidermal changes may or may not be present, but often the lesions have a waxy appearance, which reflects mild epidermal atrophy. Papular lesions occur most commonly on the face and neck, with a predilection for periorbital skin (see eFig. 153-5.1 in on-line edition). Annular plaques (Fig. 153-6), non-annular plaques (Fig. 153-7 and see eFig. 153-7.1 in on-line edition), and nodules (Fig. 153-8) may develop from these papular lesions and may or may not retain the classic translucent quality of the papules.



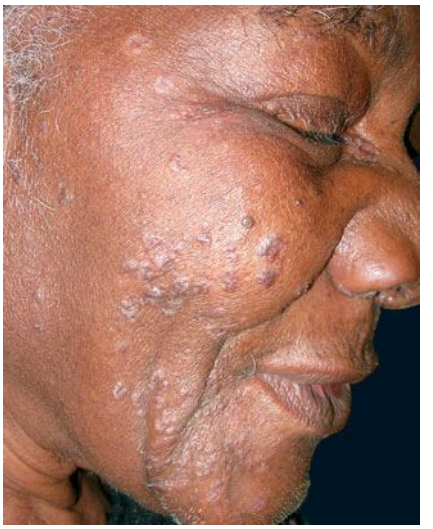

▲ **FIGURE 153-4** Cutaneous sarcoidosis of the face. Symmetric papules on cheeks.

Lupus pernio describes the relatively symmetric, violaceous, indurated plaques and nodules that occur on the nose, earlobes, cheeks, and digits (Figs. 153-9, 153-10, and 153-11). This clinical variant of sarcoidosis is distinctive and has been associated with systemic involvement. Lupus pernio is associated with a higher prevalence of upper respiratory tract disease.[24] Lupus pernio lesions may directly extend into the nasal sinus,



▲ **FIGURE 153-2** Cutaneous sarcoidosis of the face. Micropapular form.



▲ **FIGURE 153-3** Cutaneous sarcoidosis of the face. Papular form. Some of the papules have enlarged to small plaques.

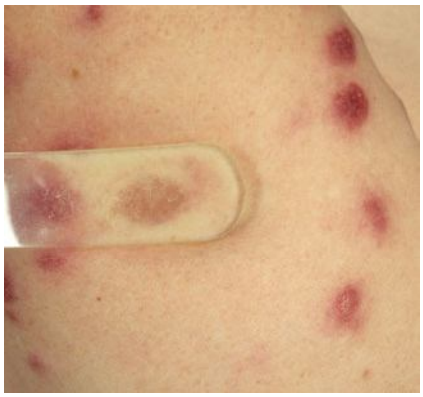

▲ **FIGURE 153-5** Diascopy highlights the "apple jelly" coloration of cutaneous sarcoidosis.

leading to epistaxis, nasal crusting, and sinus bone involvement.

Angiolupoid lesions are pink papules and plaques with prominent telangiectasias that usually occur on the face (see eFig. 153-11.1 in on-line edition) and may be a variant of lupus pernio, as both lesions usually appear on the face and can be violaceous.[25,26] However, angiolupoid lesions tend to be less numerous than the papular and lupus pernio forms.[26]

Rarely, sarcoidosis can present as persistent subcutaneous nodules (Darier-Roussy sarcoid).[27] The nodules may be tender or painless and preferentially occur on the extremities.

Scars. Cutaneous sarcoidosis occurs preferentially within scar tissue, at traumatized skin sites, and around embedded foreign material such as silica. Scars become inflamed and infiltrated with sarcoidal granulomas (Fig. 153-12). Inflammation of old scars (see eFig. 153-12.1 in on-line edition) may parallel or precede systemic disease activity. Infiltrated scars may be tender or pruritic. Scar sarcoidosis may be the only cutaneous finding in a patient with systemic sarcoidosis; therefore, it is important to closely examine scar tissue in patients suspected of having the disease. The presence of sarcoidal granulomas surrounding foreign material does not establish the diagnosis of sarcoidosis, nor does foreign material in the presence of granulomas exclude the diagnosis.[28] Other signs of systemic or cutaneous involvement are required to confirm the diagnosis.



▲ **FIGURE 153-7** Plaques of cutaneous sarcoidosis on the neck and upper back.

Scalp. Alopecia occurs with involvement of the scalp and may be scarring or non-scarring (see eFig. 153-12.2 in on-line edition).[29–32] Biopsy shows noncaseating granulomas. Its reversibility is dependent on the degree of destruction of hair follicles.

Nails. Sarcoidosis may cause nail plate deformation and discoloration, but the incidence is very low.[33] There may be clubbing, subungual hyperkeratosis, and even nail plate destruction. Nail manifestations may result from granulomas in the nail matrix or from involvement of adjacent bone.



▲ **FIGURE 153-8** Nodular sarcoidosis in the face. In Caucasians, lesions of sarcoidosis are often red or purple.

Mucous Membranes. Sarcoidal granulomas may cause papules and plaques of the mucosal surfaces and tongue. Sarcoidosis is one cause of Mikulicz syndrome, the bilateral enlargement of the lacrimal (see eFig. 153-12.3 in on-line edition), parotid, sublingual, and submandibular glands.

Additional Presentations. A myriad of additional clinical presentations have also been reported. These include ichthyosis,[34] erythroderma,[29] ulcerations (see eFig. 153-12.4 in on-line edition),[35] morpheaform plaques,[36] lichen niditus–like papules,[37] folliculitis-like lesions,[38] psoriasiform plaques,[39] hypopigmented areas,[40] gyrate erythema,[41] verrucous lesions,[38] faint erythema, penile (see eFig. 153-12.5



▲ **FIGURE 153-6** Cutaneous sarcoidosis with an annular configuration.



▲ **FIGURE 153-9** Lupus pernio along the nasal rim.





▲ **FIGURE 153-10** Violaceous lupus pernio lesions on cheek and nose.



in on-line edition) and vulvar lesions,[42,43] palmar erythema,[44] discoid lupus–like plaques,[45] lower extremity edema,[46] lesions mimicking polymorphous light eruption,[38] and pustular lesions.[38]

NON-SPECIFIC LESIONS Erythema nodosum (see Chap. 68) is the main non-specific cutaneous manifestation of sarcoidosis (prevalence of approximately 17 percent). Erythema nodosum with bilateral hilar adenopathy, arthralgias, and fever is frequently the initial manifestation of sarcoidosis and is called *Löfgren syndrome*. These patients tend to have an acute form of sarcoidosis with eventual resolution.

Other non-specific cutaneous manifestations of sarcoidosis are much less common. Non-specific erythematous eruptions resembling viral exanthems or drug reactions without histologic evidence of granulomatous inflammation occur rarely with acute sarcoidosis. Additionally, patients with sarcoidosis may have pruritus



▲ **FIGURE 153-11** Violaceous lupus pernio on distal fingers.



▲ **FIGURE 153-12** Sarcoidosis arising in old facial scars sustained after car accident.

without granulomatous infiltration, leading to prurigo nodules.[25] Erythema multiforme had been regularly cited as a non-specific cutaneous manifestation of sarcoidosis,[38] but reports of histologically proven erythema multiforme with interface dermatitis associated with sarcoidosis are virtually nonexistent in the literature,[25,38,47,48] and any association is probably coincidental. Erythroderma and lower extremity swelling have been described as both specific and non-specific lesions of sarcoidosis.[25,46,49,50]

Related Clinical Findings

LUNGS The lung is the most common organ involved with sarcoidosis. Findings on pulmonary examination are usually absent. Patients with pulmonary sarcoidosis are often asymptomatic, with the disease detected on a screening chest radiograph. Common symptoms include dyspnea, cough, chest pain, and wheezing. The chest radiograph is abnormal in more than 90 percent of patients with sarcoidosis. Bilateral hilar adenopathy is noted in 50 percent to 85 percent of cases (see eFig. 153-12.6 in on-line edition). Pulmonary parenchymal infiltrates are seen in 25 to 60 percent of cases.

Chest computed tomography (CT) reveals more thoracic disease than can be appreciated on the chest radiograph. CT is superior to the chest radiograph in detecting thoracic involvement with sarcoidosis, but there is insufficient evidence that CT has a clinical role in the management of pulmonary sarcoidosis.[51]

In sarcoidosis patients with normal lung parenchyma on chest radiograph, pulmonary function tests are abnormal in 20 to 40 percent of cases. When the chest radiograph is abnormal, pulmonary function tests are abnormal in 50 to 70 percent of cases.

EYES The eyes are involved in one-fourth to three-fourths of sarcoidosis patients.[52] Eye involvement with sarcoidosis is potentially vision-threatening, and the patient may be asymptomatic. For this reason, every patient diagnosed with sarcoidosis requires an ophthalmologic examination.[52] Redness, burning, itching, or dryness are the most common ocular symptoms when present. Any portion of the eye may be involved, and eye involvement may be the first manifestation of the disease.[52] Uveitis is the most common ocular manifestation and can lead to cataracts and glaucoma. Other ocular manifestations include conjunctivitis, lacrimal gland involvement causing keratoconjunctivitis sicca (dry eyes), and optic neuritis, which may rapidly lead to loss of vision. Heerfordt syndrome includes fever, parotid gland enlargement, facial palsy, and anterior uveitis.[1]

LIVER Hepatic involvement is common at disease onset but usually does not cause signs or symptoms.[53] Although histologic evidence of hepatic sarcoidosis is present in more than one-half of sarcoidosis patients,[54] signs of organ dysfunction due to hepatic sarcoidosis are far less common.[53] Hepatomegaly, abdominal pain, and pruritus are present in only 15 to 25 percent of patients with hepatic sarcoidosis. An increased serum alkaline phosphatase level occurs in approximately one-third of patients,[55] but it is rarely associated with permanent hepatic dysfunction and therefore does not mandate treatment.[53,55] Treatment is required in the rare patient with significant symptoms, evidence of synthetic dysfunction, or hyperbilirubinemia. Rarely, hepatic sarcoidosis may lead to a primary biliary cirrhosis–type picture, and portal hypertension may develop.[56]

HEART Clinical evidence of cardiac involvement is found in only 5 percent of sarcoidosis patients,[57] although myocardial granulomas have been found in approximately 25 percent of patients at autopsy.[58] Most clinical problems are related to cardiac arrhythmias or left ventricular dysfunction.[59] Sudden death may occur. Congestive heart failure may result when the myocardium is massively infiltrated with granulomas. Because of the potential lethal nature of heart involvement with sarcoidosis, an electrocardiogram is recommended for every patient diagnosed with the disease.[1]

NERVOUS SYSTEM Any portion of the central nervous system or peripheral nervous system may be affected by sarcoidosis. Neurosarcoidosis has a predilection for the base of the brain, and cranial neuropathies are the most common manifestation.[60] The facial nerve is the cranial nerve most frequently involved.[60] In fact, it is common for Bell palsy to be the first manifestation of sarcoidosis and resolve completely before other manifestations of the disease occur. Mass lesions may develop in the brain or spinal cord. Aseptic meningitis and peripheral neuropathy are other neurologic manifestations of sarcoidosis.[61]

OTHER ORGANS The sinuses and upper airway are commonly involved with sarcoidosis, a condition known as *SURT*: *s*arcoidosis of the *u*pper *r*espiratory *t*ract.[62] Nasal SURT is often associated with lupus pernio skin lesions and may cause epistaxis and severe nasal crusting. Sarcoidosis of the spleen is not rare.[63] Sarcoidosis may also cause a disorder in calcium metabolism that results from activated sarcoidal macrophages demonstrating an increase in 1-α hydroxylase activity. This enzyme converts 25-hydroxyvitamin D to 1,25-dihydroxyvitamin D, the active form of the vitamin, an increase of which may result in hypercalcemia, hypercalciuria, and nephrolithiasis.[64] Sarcoidosis may be associated with a reduction in any blood cell line. Leukopenia may result from bone marrow involvement or from splenic sequestration. Thrombocytopenia may result from bone marrow involvement, splenic sequestration, or from an idiopathic thrombocytopenic purpura–like syndrome related to the hypergammaglobulinemia often seen in patients with sarcoidosis.[65]

LABORATORY TESTS

Table 153-1 lists clinical, imaging, and laboratory tests recommended when a diagnosis of sarcoidosis is entertained. These tests screen for involvement of various organs. A careful history and physical examination should be performed to detect signs and symptoms of organ involvement as well as to obtain a history suggesting another granulomatous disease (e.g., exposure to tuberculosis, endemic fungi, beryllium exposure).

Additional laboratory tests that assess disease activity are listed in the following sections. Although controversial, these tests are not routinely recommended because active granulomatous inflammation in sarcoidosis may remit spontaneously and therefore does not mandate treatment.

TABLE 153-1
Recommended Initial Evaluation of Patients with Sarcoidosis

1. History (occupational and environmental exposure, symptoms)
2. Physical examination
3. Posteroanterior chest x-ray
4. Pulmonary function tests: Spirometry, DL_{CO}, and KL_{CO}
5. Peripheral blood counts: White blood cells, red blood cells, platelets
6. Serum chemistries: Calcium, liver enzymes (alanine aminotransferase, aspartate aminotransferase, alkaline phosphatase), creatinine, blood urea nitrogen
7. Urine analysis
8. Electrocardiogram
9. Routine ophthalmologic examination
10. Tuberculin skin test

DL_{CO} = diffusing capacity of lung for carbon monoxide; KL_{CO} = diffusing capacity per liter alveolar volume.
Adapted from American Thoracic Society/European Respiratory Society: Statement on sarcoidosis. Joint Statement of the American Thoracic Society (ATS), the European Respiratory Society (RS) and the World Association of Sarcoidosis and Other Granulomatous Diseases (WASOG) adopted by the ATS Board of Directors and the ERS Executive Committee, February 1999. *Am J Respir Crit Care Med* **160**:736, 1999, with permission.

Angiotensin-Converting Enzyme

The epithelioid cell of the sarcoidal granuloma secretes angiotensin-converting enzyme[66]; therefore, serum angiotensin-converting enzyme (SACE) levels reflect the total granuloma burden in sarcoidosis. Clinical data concerning SACE in sarcoidosis suggest that an elevated SACE level is insufficiently specific for the diagnosis of sarcoidosis to rest on it alone and insufficiently sensitive to exclude the diagnosis.[67] However, SACE may be useful as an adjunct in the diagnosis of the disease. Because SACE reflects the total body granuloma burden, SACE levels may be useful to monitor the course of sarcoidosis. Initial SACE levels are not different between patients who deteriorate and those who improve[68]; thus, SACE levels should not be used as a basis for treatment decisions.

Gallium Scan

The mechanism of gallium-67 uptake in sarcoidosis is not completely understood. It is thought that inflammatory processes cause hyperemia and increased capillary permeability of gallium. Gallium also accumulates in macrophages and, to a lesser extent, in T lymphocytes, which are major participants in the granulomatous inflammation of sarcoidosis. Sarcoidosis may cause gallium uptake in thoracic and extrathoracic sites, although typically not in areas of skin involvement. Gallium scanning has not been found to be useful for monitoring the clinical course of sarcoidosis, but it may have a role in identifying organs with sarcoid involvement (see discussion of panda and lambda sign under Diagnosis section).

PATHOLOGY

The epithelioid granuloma of sarcoidosis usually contains a compact collection of mononuclear phagocytes. The granulomas typically are surrounded by a paucity of lymphocytes ("naked granulomas"), but varying degrees of lymphocytic inflammation may be present (Fig. 153-13 and see eFig.153-13.1 in on-line edition).[66] Epithelioid cells, which are themselves transformed monocytes, are commonly present within the sarcoidal granuloma. Multinucleated giant cells of the Langhans type result from the fusion of epithelioid cells. Although central fibrinoid necrosis is not uncommon, gross necrosis is not a characteristic feature of sarcoid granulomas and suggests an alternative diagnosis, such as tuberculosis, fungal infection, or vasculitis.[66] Mycobacterial and fungal diseases must always be considered as alternative diagnoses; therefore, stains and cultures for mycobacteria and fungi should be routinely performed on biopsy specimens. Table 153-2 lists the major pathologic differential diagnoses of sarcoidosis on skin biopsy.

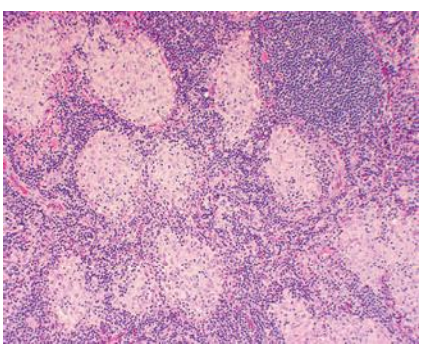

▲ **FIGURE 153-13** Histologic specimen of sarcoidosis demonstrating noncaseating granulomatous inflammation with multinucleated giant cells and a surrounding zone of lymphocytes.



TABLE 153-2
Major Pathologic Differential Diagnosis of Sarcoidosis on Skin Biopsy

- Tuberculosis
- Atypical mycobacteriosis
- Fungal infection
- Reaction to foreign bodies: Beryllium, zirconium, tattooing, paraffin, etc.
- Rheumatoid nodules

Adapted from American Thoracic Society/European Respiratory Society: Statement on sarcoidosis. Joint Statement of the American Thoracic Society (ATS), the European Respiratory Society (RS) and the World Association of Sarcoidosis and Other Granulomatous Diseases (WASOG) adopted by the ATS Board of Directors and the ERS Executive Committee, February 1999. *Am J Respir Crit Care Med* **160**:736, 1999, with permission.



A clinically important aspect of the pathology of sarcoidosis involves the development of fibrosis. Dense bands of fibroblasts may encase the ball-like granulomas. This fibrotic response can produce tissue destruction and organ dysfunction that is often irreversible.[10] Currently available chemotherapeutic agents for sarcoidosis can effectively treat the granulomatous inflammatory response but not the fibrotic reaction.

DIAGNOSIS

The diagnosis of sarcoidosis requires a compatible clinical picture, histologic demonstration of noncaseating granulomas, and exclusion of other diseases capable of producing similar histology or clinical features.[1] Because sarcoidosis is a diagnosis of exclusion, the diagnosis can never be confirmed with 100 percent certainty.

Normally, the diagnosis of sarcoidosis requires a compatible clinical picture, histologic demonstration of noncaseating granulomas, and exclusion of other diseases capable of producing similar histology or clinical features (Fig. 153-14). Alternatively, the diagnosis can be assumed without biopsy when the clinical presentation is typical for the disease and is not explained by an alternative cause

The presence of noncaseating granulomas in a single organ does not conclusively establish the diagnosis of sarcoidosis because sarcoidosis is, by definition, a systemic disease that should involve multiple organs.[70] Isolated skin granulomas should not be assumed to represent sarcoidosis, and efforts must be made to exclude alternative diagnoses (see Table 153-2). Although a confirmed diagnosis of sarcoidosis requires proof of granulomatous involvement in at least two separate organs, histologic confirmation is usually not required in the second organ.[71]

Certain disease presentations are so specific for the diagnosis of sarcoidosis (e.g., Löfgren syndrome,[72] Heerfordt syndrome, and asymptomatic bilateral hilar adenopathy) that the diagnosis may be accepted without a tissue biopsy.

Asymptomatic Bilateral Hilar Adenopathy

Asymptomatic hilar adenopathy on chest radiograph almost always represents sarcoidosis.[73] It has been suggested that histologic confirmation of sarcoidosis may not be required in asymptomatic patients with bilateral hilar adenopathy, provided the physical examination, complete blood cell count, and routine blood tests are all normal and there is no prior history of malignancy.[23] In such cases, chest radiographs should be monitored at 3- to 6-month intervals, and a biopsy should be performed if there is significant change in the chest radiograph.[23]

Panda and Lambda Sign on Gallium-67 Scan

The presence of panda sign (bilateral lacrimal and parotid gland uptake) and lambda sign (bilateral hilar and right paratracheal uptake) on gallium-67 scanning is highly specific for sarcoidosis and may obviate the need for invasive diagnostic procedures. However, these signs are both positive in only a small percentage of sarcoidosis patients.

NATURAL HISTORY AND PROGNOSIS

The granulomatous inflammation of sarcoidosis can remit spontaneously or with therapy. Therefore, the general prognosis of sarcoidosis is good.[70] Pulmonary sarcoidosis resolves, improves, or stabilizes in 60 to 90 percent of patients even without treatment.[75] Remissions often occur within the first 6 months after diagnosis, although it may take 2 to 5 years.[76] The prognosis is generally favorable for liver and peripheral lymph node sarcoidosis as well. The skin lesions may resolve with or without scarring or pigmentary changes.

Almost all severe impairment from sarcoidosis is the result of the development of fibrosis. As mentioned previously, this is probably the result of hyalinization of granulomatous inflammation. Presently it is unclear if this is the result of inadequate treatment or a host propensity for a brisk fibrotic response. Such cutaneous fibrosis may result in permanent scarring and disfigurement. Rarely, cutaneous lesions may ulcerate or destroy nearby bone or cartilage; this most commonly occurs in patients with lupus pernio.

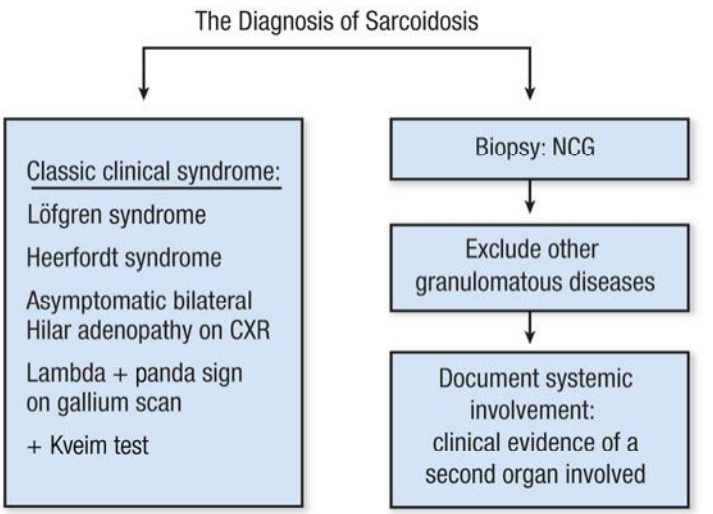

▲ **FIGURE 153-14** Approach to patient with sarcoidosis. Diagnostic algorithm. Usually the diagnosis is made by following the pathway on the right: A tissue biopsy demonstrates noncaseating granulomatous inflammation with a compatible clinical picture, alternative causes of granulomatous inflammation are excluded (including tuberculosis), and there is clinical evidence of systemic (multiorgan) granulomatous inflammation. On occasion, the diagnosis can be assumed without biopsy confirmation if the clinical presentation is very specific for sarcoidosis. These clinical presentations are listed on the left side of the pathway. CXR = chest x-ray; NCG = noncaseating granulomas.

TABLE 153-3
Prognosis for Sarcoidosis

	Good	Poor
Erythema nodosum	+	
African descent		+
Extrathoracic disease		+
Stage I vs. II–III CXR	+	
Age > 40 years		+
Splenic involvement		+
Lupus pernio		+
Disease duration > 2 years		+
FVC < 1.5 L		+
Stage IV CXR/aspergilloma		+

CXR = chest x-ray; FVC = forced vital capacity. Adapted from Judson MA et al: Sarcoidosis, in *Diffuse Lung Disease, A Practical Approach*, edited by Baughman RP, DuBois RM, Lynch JP. London, Arnold Publishers, 2004, p 109, with permission.

Because sarcoidosis is a systemic disease, the prognosis is not solely related to pulmonary involvement. In the United States, three-fourths of sarcoidosis deaths result from pulmonary involvement. Sarcoidosis of the heart and central nervous system accounts for most of the remaining deaths.[77]

There is no current laboratory or radiologic test that can predict the outcome of sarcoidosis. Skin lesions are not a reliable indicator of prognosis, but several useful associations have been documented. Patients with cutaneous lesions are more likely to have chronic systemic sarcoidosis than sarcoidosis patients without skin involvement.[78] Erythema nodosum with fever and arthralgias portends a good prognosis.[79] Patients with Löfgren syndrome have a more than 80 percent rate of spontaneous remission, generally within 4 to 6 weeks.[1] Lupus pernio indicates chronic disease and is associated with upper respiratory tract involvement, pulmonary fibrosis, and bony cysts.[1] Table 153-3 reviews various clinical features that are associated with the prognosis of sarcoidosis.

TREATMENT

Because sarcoidosis often spontaneously remits and therapy may be associated with significant side effects, it is not mandatory to treat the disease.[80] Treatment is indicated when there is evidence of progressive organ damage.[80] Table 153-4 shows suggested indications for treatment of various organs with sarcoidosis involvement. Tests of disease activity that are discussed in preceding sections are rarely used to determine the need for therapy. This is because the presence of active granulomatous inflammation from sarcoidosis does not imply that the disease will be progressive or lead to significant fibrosis and permanent organ damage.

Topical/Intralesional Therapy

Cutaneous sarcoidosis, including lupus pernio, may be improved with prolonged application (longer than 8 weeks) of class I topical steroids, but intralesional injections of triamcinolone are generally more effective. Topical tacrolimus reportedly has been effective for skin disease in several cases as well.[81–83]

Systemic Corticosteroids

In general, corticosteroids are the drug of choice for the treatment of sarcoidosis. The recommended initial dose for pulmonary sarcoidosis is 20 to 40 mg of prednisone equivalent/day.[1,80] Cardiac and neurologic sarcoidosis may require higher initial doses, up to 60 to 80 mg of prednisone equivalent/day.[1] The corticosteroid dose can often be tapered to 0.1 to 0.2 mg/kg of prednisone equivalent/day over a few months.[1,80] It is unusual for patients with pulmonary sarcoidosis to require a maintenance corticosteroid dose of more than 15 mg of prednisone equivalent/day, although more may be required for sarcoidosis of the skin, heart, or nervous system. An attempt should be made to taper the corticosteroid dose within 9 to 12 months of the initiation of therapy.[80] Cardiac sarcoidosis may be an exception to this rule if the patient has had previous life-threatening manifestations of cardiac involvement. If life-threatening arrhythmias have occurred, placement of an internal defibrillator is indicated.[59,84,85]

Immunosuppressive Medications

If the patient cannot be successfully weaned from corticosteroids, adjunctive immunosuppressive medications can be used.[80] Most of these are inadequate as monotherapy but are effective as corticosteroid-sparing agents. The appropriate doses for sarcoidosis are listed in Table 153-5 and discussed in the following sections.

METHOTREXATE After corticosteroids, methotrexate is the next most studied agent for sarcoidosis. It is usually corticosteroid-sparing, and corticosteroids can be discontinued in one-fourth of cases.[86] The drug requires careful monitoring of liver function tests and blood cell counts. Folic acid may be given in conjunction

TABLE 153-4
Indications for Treatment by Organ

	No Treatment	Treatment
Lung		
No symptoms	X	
Normal pulmonary function	X	
Worsening pulmonary symptoms/function		X
Severe pulmonary symptoms/function		X
Skin		
Asymptomatic	X	
Scarring or infiltrative (e.g., lupus pernio)		X
Cosmetically unacceptable to patient		X
Neurologic		
Other than facial nerve (Bell palsy)		X
Cardiac		
Symptomatic		X
Liver		
Asymptomatic, elevated alkaline phosphase	X	
Synthetic dysfunction (international normalized ratio increased, albumin decreased)		X
Cholestatic symptoms		X
Spleen		
Hypersplenism		X
Eye		
Anterior uveitis		Topical (eyedrops)
Other manifestations		X



TABLE 153-5
Sarcoidosis Chemotherapy

AGENT	DOSE/COMMENT
Corticosteroids	
Topical	Localized skin lesions: Ultrapotent topical steroids or intralesional injections Anterior uveitis: Eyedrops
Prednisone equivalent	20–40 mg/day, then taper Consider higher dose for cardiac, neurologic involvement
Methotrexate	10–25 mg/wk. Monitor LFTs, CBC. Consider adjunctive folate.
Hydroxychloroquine	200–400 mg/day. Check glucose-6 phosphodiesterase. Monitor ophthalmology examinations.
Chloroquine	250–1000 mg/day. Check glucose-6 phosphodiesterase. Monitor ophthalmology examinations.
Tetracyclines	Minocycline: 200 mg/day Doxycycline: 200 mg/day Primarily for non-lupus pernio skin disease
Pentoxifylline	400 mg tid
Thalidomide	50–200 mg/day. Very sedating; give qhs. Peripheral neuropathy common
Leflunomide	100 mg/day for 3 days loading, then 10 mg/day. Can increase to 20 mg/day. Monitor CBC and LFTs
Infliximab	5 mg/kg IV q6wk. Need pre-treatment purified protein derivative skin test and close monitoring for tuberculosis.
Cyclophosphamide	500–1000 mg IV q3–4wk. Monitor CBC and urinalysis. Stop if hematuria develops. Patients must be informed of carcinogenicity. Only for severe life-threatening disease (e.g., neurosarcoidosis).

CBC = complete blood cell count; LFTs = liver function tests.



with methotrexate. Approximately 10 percent of sarcoidosis patients taking methotrexate develop cirrhosis, even if their liver function tests are normal.[87] Therefore routine liver biopsies should be considered after 2 g of total therapy (usually after 2 years).[87] Low-dose methotrexate, 10 mg to 25 mg a week, is used for the treatment of cutaneous sarcoidosis.[88] Cutaneous improvement may be noted within 1 month, but maximal therapeutic benefit often does not occur until at least 6 months after the initiation of treatment.

HYDROXYCHLOROQUINE/CHLOROQUINE Antimalarial drugs are useful for skin and joint sarcoidosis, and hypercalcemia.[89,90] Antimalarial agents are not highly effective for pulmonary disease, often take several months to be effective, and cannot be used in patients with glucose-6 phosphodiesterase deficiency. Either drug, especially chloroquine, can cause retinal damage.[91] Patients taking antimalarial agents must therefore have regular ophthalmologic examinations.

CYCLOPHOSPHAMIDE Cyclophosphamide is effective for many forms of sarcoidosis. However, because of its significant side-effect profile, including its carcinogenic potential, it is usually only used for severe or potentially life-threatening disease.

TETRACYCLINE DERIVATIVES Minocycline and doxycycline have been reported to improve skin sarcoidosis in case series. These drugs may take more than 2 years to be effective.[92] Although the efficacy of these drugs suggests that sarcoidosis may be caused by an infectious agent, the tetracyclines also modify the immune response by suppressing activity of macrophages and T lymphocytes.[93]

TUMOR NECROSIS FACTOR ANTAGONISTS TNF is a cytokine that is secreted in macrophages associated with sarcoidal granulomas.[9] Antagonists of TNF have been shown to be useful for the treatment of sarcoidosis. Pentoxifylline,[94] thalidomide,[95] and infliximab[96] have been the most studied. Infliximab appears to be particularly useful for the treatment of lupus pernio, and it may be superior to other TNF antagonists, as a study of etanercept failed to show benefit for sarcoidal uveitis.[97] A tuberculin skin test is required before the use of TNF antagonists, and patients taking the drugs must be monitored closely for the development of tuberculosis. Adalimumab has also been reported to treat sarcoidosis effectively.[98]

OTHER AGENTS Azathioprine,[99] mycophenolate mofetil,[100] leflunomide,[101] and cyclosporine[102] have been reported to be useful for the treatment of systemic sarcoidosis in case reports or small case series. Allopurinol,[103] isotretinoin,[104] and fumaric acid esters[105] have been reported to be effective for sarcoidal skin disease. Resolution of sarcoidal skin manifestations after phototherapy and photodynamic therapy has also been described.[106]

Surgical Treatment

Electrodesiccation, pulse dye laser therapy, carbon dioxide laser therapy, and reconstructive surgical procedures have all been used successfully to improve the cosmetic disfigurement of cutaneous sarcoidosis, but these interventions do not have any effect on disease progression.

PREVENTION

As the cause of sarcoidosis remains unknown, prevention is currently impossible.

ACKNOWLEDGMENT

Several clinical photographs were contributed by Lawrence Lieblich, M.D.

KEY REFERENCES

The full reference list for all chapters is available at www.digm7.com.

1. American Thoracic Society/European Respiratory Society: Statement on sarcoidosis. Joint Statement of the American Thoracic

Society (ATS), the European Respiratory Society (RS) and the World Association of Sarcoidosis and Other Granulomatous Diseases (WASOG) adopted by the ATS Board of Directors and the ERS Executive Committee, February 1999. *Am J Respir Crit Care Med* **160**:736, 1999
6. Baughman RP et al: Clinical characteristics of patients in a case control study of sarcoidosis. *Am J Respir Crit Care Med* **164**:1885, 2001
10. Newman LS et al: Sarcoidosis. *N Engl J Med* **336**:1224, 1997
21. Martinetti M et al: HLA and sarcoidosis: New pathogenic insights. *Sarcoidosis Vasc Diff Lung Dis* **19**:83, 2002
23. Lynch JP et al: Pulmonary sarcoidosis. *Clin Chest Med* **18**:755, 1997
28. Callen JP: The presence of foreign bodies does not exclude the diagnosis of sarcoidosis. *Arch Dermatol* **137**:485, 2001
70. Judson MA et al: Sarcoidosis, in *Diffuse Lung Disease, A Practical Approach*, edited by Baughman RP, DuBois RM, Lynch JP. London, Arnold Publishers, 2004, p 109

CHAPTER 154

Cutaneous Manifestations of Internal Malignant Disease: Cutaneous Paraneoplastic Syndromes

Christine A. DeWitt
Lucinda S. Buescher
Stephen P. Stone

PARANEOPLASTIC DERMATOSES

Some cutaneous manifestations of cancer are paraneoplastic syndromes [i.e., dermatoses (often unique)] secondary to the cancer. There is an evolving consensus of what constitutes a true paraneoplastic syndrome.[1] There are two essential criteria: (1) the dermatosis must develop only after the development of the malignant tumor, even though some tumors may be asymptomatic and occult, and (2) both the dermatosis and the malignant tumor follow a parallel course in that complete removal of the cancer results in clearing of the dermatosis, and recurrence of the cancer causes relapse of the dermatosis. A suggested classification of clinicopathologic categories is included in Table 154-1.

Epidemiology

Changes of the skin can be markers of an internal malignancy, but the exact prevalence is unknown. This is in part due to the complexity of disease variation in some cases and the rarity of occurrence in others. Age, sex, and risk factors for developing a paraneoplastic dermatosis correlate with the overall risk for the respective internal malignancy.

The specific relationship of the cancer with the marker can be variable. For instance, hypertrichosis lanuginosa acquisita can be a marker for many different malignant neoplasms, whereas necrolytic migratory erythema (NME) is nearly specific for a glucagon-producing tumor of the pancreas. The specific correlations with internal malignancies for each paraneoplastic dermatosis are listed in Table 154-1.

Etiology and Pathogenesis

These manifestations are grouped by their major clinical manifestations. Unfortunately, our lack of knowledge prevents a more pathophysiologic approach.

Proven association of the cutaneous eruption with a tumor can be more easily made when the supposed manifestation is very rare, and the tumor is also very uncommon. It becomes a major problem, however, when the manifestation is very common, such as the seborrheic keratoses in Leser-Trélat sign, and the presumed association is with a wide spectrum of commonly occurring neoplasms. In this situation, anecdotal reports abound.

HYPERKERATOTIC DERMATOSES

Acanthosis Nigricans (See Chap. 152)

The term *acanthosis nigricans* was originally proposed by Unna, although the first cases were malignancy-associated and described independently by Pollitzer and by Janovsky in 1890. Curth clinically classified acanthosis nigricans into malignant, benign, syndromic acanthosis nigricans, or pseudoacanthosis nigricans (obesity-related).[2]

EPIDEMIOLOGY The majority (80 percent) of acanthosis nigricans occurs idiopathically or in benign conditions such as endocrinopathies and/or heritable diseases.[3] Malignancy-associated acanthosis nigricans is rare. It was present in 1 of 35 patients with intrathoracic or intra-abdominal malignancies,[4] and in 2 of 12,000 cancer patients. Although reported in all age groups, at least 80 percent of malignancy-related acanthosis nigricans occurs in individuals over the age of 40 years.[3]

PARANEOPLASTIC DERMATOSES AT A GLANCE





- Skin can be a marker for internal malignancy:
  - Epi-phenomenon
  - Familial cancer syndromes
  - Direct tumor extension
- Paraneoplastic dermatoses follow a parallel course with the malignancy and allow early diagnosis and monitoring.
- Dermatoses with high associations with internal malignancy include tripe palms, Bazex syndrome, paraneoplastic pemphigus, erythema gyratum repens, necrolytic migratory erythema, and hypertrichosis lanuginosa acquisita.
- Weakly associated with internal malignancy are acanthosis nigricans, acquired ichthyosis, and multiple seborrheic keratoses.
- Management of the dermatosis is the treatment of the malignancy.



ACANTHOSIS NIGRICANS AT A GLANCE



- Acanthosis nigricans is a cutaneous marker, most commonly of insulin resistance and less frequently of genetic disorders and malignancy.
- Characterized by symmetric hyperpigmented, hyperkeratotic, verrucous plaques that bestow a velvety texture on intertriginous skin and occasionally mucocutaneous areas.
- Darker skin pigmentation, insulin resistance, and obesity are more commonly associated with benign acanthosis nigricans.
- Malignant acanthosis nigricans often appears rapidly in older individuals and can involve atypical sites such as mucosal surfaces.



ETIOLOGY AND PATHOGENESIS Although the precise etiology of benign acanthosis nigricans remains unclear, there is evidence that insulin plays a significant role. The pathogenesis of malignancy-associated acanthosis nigricans is even less clear. A humoral factor produced by the tumor is likely, given cases in which the skin disorder improved or resolved following treatment of the malignancy. Elevated urinary transforming growth factor-α (TGF-α) and increased expression of epidermal growth factor (EGF) receptors in lesional skin were noted in a patient with acanthosis nigricans, acrochordons, Leser-Trélat sign, and melanoma. The enhanced expression of this cytokine and its receptor normalized after removal of the melanoma, and the acanthosis nigricans, acrochordons, and seborrheic keratoses improved postoperatively.[5] A separate case, with gastric cancer, was also shown to express TGF-α and EGF receptors.[6]

More recently, a pathogenic role has been proposed for a tyrosine kinase receptor expressed on the basal cells of the epidermis. In several inherited human skeletal dysplasias associated with acanthosis nigricans, such as craniosynostoses and dwarfing chondrodysplasias, activating mutations in the fibroblast growth factor receptor 3 (FGFR3) can be observed, whereby FGFR3 has an inhibitory affect on bone formation.[7] In other studies, FGFR3 has oncogenic affects in such malignancies as multiple myeloma, bladder, and cervical carcinoma. With respect to the role of FGFR3 on the epidermis, animal models with activating mutations develop benign epidermal tumors resembling acanthosis nigricans and seborrheic keratoses.[8]

CLINICAL FINDINGS (See Chap. 152) The clinical hallmark of acanthosis nigricans is development of gray-brown, velvety plaques that may start as a dirty appearance. The hyperpigmentation is later accompanied by hypertrophy, increased skin markings, and papillomatosis. Pruritus can be a problem in some patients. The most commonly involved locations are the axillae, neck, external genitalia, groin, face, inner thighs, antecubital and popliteal fossae, umbilicus, and perianal area. Acrochordons may develop, superimposed on the acanthosis nigricans or on other locations (see Fig. 152-2).

TABLE 154-1
Clinical Characteristics of the Paraneoplastic Dermatoses

Paraneoplastic Dermatosis	Major Internal Malignancy	% with Cancer	Approach to the Patient	Unique Features
Hyperkeratotic diseases				
Acanthosis nigricans[a]	Adenocarcinomas: intra-abdominal; gastric (50%–60%)	Unknown	CBC, CMP, fasting blood glucose; upper endoscopy or CT scan of abdomen if history supports	Later age, rapid course, and oral involvement more common in malignancy-associated. Usually with insulin resistance.
Acquired ichthyosis[a]	Hodgkin lymphoma (70%–80%)	Unknown	CBC, CXR; consider CT of abdomen to rule out lymphoma	Spares flexures, palms, soles; up to 30% of cases may occur in patients with acquired immunodeficiency syndrome
Tripe palms	Lung CA most common; gastric CA second	> 90%	CBC, CMP, CT of chest and abdomen	Co-exists with acanthosis nigricans in 75%
Leser-Trélat sign	Adenocarcinomas: GI (47%); lymphoproliferative (20%)	Unknown	CBC, imaging of GI tract	Early onset, eruptive nature, and pruritus are paraneoplastic features; co-exists with acanthosis nigricans in 20%
Bazex syndrome[a]	SCC of upper aerodigestive tract	Nearly 100%	ENT examination; CXR; thoracoabdominal CT	Acral papulosquamous lesions (ears, nose), paronychia, onychodystrophy
Collagen-vascular diseases				
Dermatomyositis[a]	Women: ovarian and breast CA; Men: GI and respiratory tract CA	25%–30%	CBC, CMP, CXR; up to date cancer screenings, bimanual exam in women; abdominal CT to rule out ovarian CA in selected cases	Patients older than in idiopathic form; males predominate; refractory or flaring of previously well-controlled disease may signal malignancy
Progressive systemic sclerosis	Lung; SCC of the tongue (25× increased risk)	3%	Annual oral examination; pulmonary function test	Decreased pulmonary CO diffusion (< 70%) risk factor for lung CA
Reactive erythemas				
Erythema gyratum repens[a]	Bronchial CA (32%)	82%	CXR, upper GI evaluation, mammogram	"Wood-grain" patterned erythema

(continued)

TABLE 154-1
Clinical Characteristics of the Paraneoplastic Dermatoses (Continued)

Paraneoplastic Dermatosis	Major Internal Malignancy	% with Cancer	Approach to the Patient	Unique Features
Necrolytic migratory erythema	Pancreatic α-cell tumor	Nearly 100%	Abdominal CT	Not parallel to malignancy
Neutrophilic dermatoses				
Sweet syndrome[a]	AML and lymphoma (85%)	20%	CBC with differential bone marrow bx if multiple abnormalities seen; skin bx for histology and culture	Neutrophilia and fever may not be present in patients with hematologic malignancy; presentation often more severe in this form
Pyoderma gangrenosum	AML most frequent; multiple myeloma second	7%	Same as Sweet syndrome; SPEP/UPEP	Atypical presentation more common with malignancy; may be on a continuum with Sweet syndrome; IgA paraproteinemia 10%–18%
Dermal proliferative diseases				
Multicentric reticulohistiocytosis	No specific cancer type or location	28%	CBC, CMP, CXR	Not parallel to malignancy
Necrobiotic xanthogranuloma	IgG paraproteinemia with 10 percent progressing to multiple myeloma	80% (gammopathy)	CBC, CMP, SPEP/UPEP	Periorbital involvement especially with necrosis
Disorders with dermal deposition				
Scleromyxedema	Monoclonal gammopathy of undetermined significance; rare multiple myeloma	80% (gammopathy)	CBC, CMP, ECG, CXR; thyroid studies; SPEP/UPEP	Most have IgG-λ monoclonal gammopathy; only rarely convert to multiple myeloma but poor prognosis if it occurs
Systemic amyloidosis	Multiple myeloma, thyroid or multiple endocrine neoplasia	13%–26% (multiple myeloma)	Bx of clinically involved skin, rectal or abdominal fat tissue; SPEP/UPEP	Macroglossia, pinch purpura, carpal tunnel clue to systemic amyloidosis; 1-yr mean survival in patients with multiple myeloma
Bullous disorders				
Paraneoplastic pemphigus	Lymphoproliferative (75%): non-Hodgkin (42%), CLL (29%)	Nearly 100%	CBC, CMP, CXR, CT abdomen	Parallels benign, but not malignant tumors
Dermatitis herpetiformis	GI (78%) and non-Hodgkin lymphoma	4%	Colonoscopy with mucosal bx	Occurs significantly more in patients who do not follow a gluten-free diet
Other changes				
Hypertrichosis lanuginosa acquisita	Men: lung, colorectal; women: colorectal, lung, or breast	Nearly 100%	CXR, colonoscopy, mammogram	Excessive downy hair initially concentrated on face, spreading caudally
Trousseau syndrome (migratory thrombophlebitis)	Lung and pancreatic carcinoma	50%	CBC, CXR, CT of abdomen	Responds best to low-molecular-weight heparin

AML = acute myelogenous leukemia; bx = biopsy; CA = cancer; CBC = complete blood count; CLL = chronic lymphocytic leukemia; CMP = complete metabolic panel; CT = computed tomography; CXR = chest x-ray; ECG = electrocardiogram; ENT = ear, nose, and throat; GI = gastrointestinal; Ig = immunoglobulin; SCC = squamous cell carcinoma; SPEP = serum protein electrophoresis; UPEP = urine protein electrophoresis.
[a]Dermatoses established to closely parallel course of malignancy.

Several inherited syndromes have acanthosis nigricans described as a feature of the disease. Those that have been reported are listed in Table 154-2.

The lesions of malignant and benign acanthosis nigricans are indistinguishable. However, there are subtle differences regarding the age of onset, distribution, and speed of onset that may assist in recognizing the paraneoplastic form. The benign form typically presents at a younger age and has a gradual progression of flexural surfaces (see Chap. 152). Concerns for malignancy-associated acanthosis nigrans should arise when a rapid appearance of the lesions in an older individual along with atypical sites such as the oral mucosa is involved (Fig. 154-1).

Many consider tripe palms and Leser-Trélat sign (see sections Tripe Palms and Leser-Trélat Sign) to be along a spectrum of malignant acanthosis nigricans given the high degree of co-occurrence and histologic similarities. Florid cutaneous papillomatosis is also a part of this same spectrum. It presents as a rapid appearance of verrucous papillomas that are identical in appearance to typical viral warts. This phenomenon occurs with malignant acanthosis nigricans and, in a large series, had a 100 percent correlation with an internal malignancy, most commonly gastric adenocarcinoma.[9]

Many types of malignancies have been reported in association with malignant acanthosis nigricans. A review of the literature has shown up to 90 percent of patients have an associated intra-abdominal adenocarcinoma, of which approximately 60 percent are gastric.[10]

Histopathology of acanthosis nigricans classically shows hyperkeratosis



TABLE 154–2
Syndromes Associated with Acanthosis Nigricans

- Acromegaly
- Addison disease
- Alström syndrome[a]
- Ataxia-telangiectasia
- Bartter syndrome
- Beare-Stevenson syndrome
- Benign encephalopathy
- Bloom syndrome
- Capozucca syndrome
- Chondrodystrophy with dwarfism
- Costello syndrome
- Crouzon syndrome
- Cushing syndrome
- Dermatomyositis
- Diabetes insipidus
- Donohue syndrome (leprechaunism)[a]
- Down syndrome
- Edwards syndrome[a]
- Gigantism
- HAIR-AN syndrome (hyperandrogenism, insulin resistance, and acanthosis nigricans)[a]
- Hashimoto thyroiditis
- Hepatic cirrhosis
- Hirschowitz syndrome
- Hypothyroidism
- Laurence-Moon-Bardet-Biedl syndrome
- Lawrence-Seip syndrome (congenital lipodystrophy)[a]
- Lipoatrophic diabetes[a]
- Lupoid hepatitis
- Lupus erythematosus
- MORFAN syndrome (mental retardation, overgrowth, remarkable facies, and acanthosis nigricans)
- Phenylketonuria
- Pituitary hypogonadism
- Pituitary tumors
- Prader-Willi syndrome
- Pseudoacromegaly[a]
- Pyramidal tract degeneration
- Rabson-Mendenhall syndrome[a]
- Rud syndrome[a]
- Scleroderma
- Stein-Leventhal syndrome (polycystic ovarian disease)[a]
- Streak gonads
- Type A syndrome of insulin resistance[a]
- Type B syndrome of insulin resistance[a]
- Werner syndrome
- Wilson disease (hepatolenticular degeneration)

[a]Associated with insulin resistance.

and epidermal papillomatosis. There is only slight acanthosis and, in some places, atrophy can be seen. Other features that can be observed include pseudocyst formation and increased melanin pigmentation. The dermis is usually devoid of inflammatory cells with the exception of mucosal acanthosis nigricans, which may have a mixed infiltrate of lymphocytes, plasma cells, and occasional neutrophils. The pathologic differential diagnosis includes confluent and reticulated papillomatosis of Gougerot and Carteaud, seborrheic keratosis, and epidermal nevus.

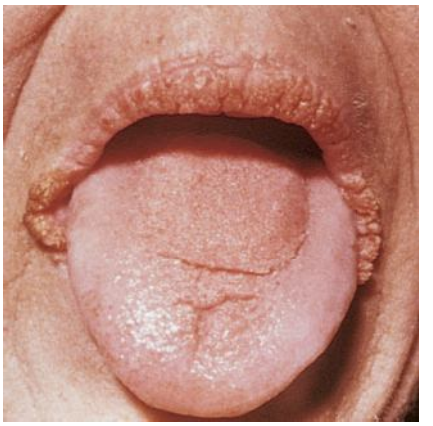

▲ **FIGURE 154-1** Acanthosis nigricans involving the lips, with minimal hyperpigmentation. (All rights reserved. Reprinted with permission from the American Academy of Dermatology.)

DIFFERENTIAL DIAGNOSIS

COMPLICATIONS The cutaneous complications of acanthosis nigricans are most often of cosmetic concern. With time, severe papillomatosis and acrochordon formation can lead to frictional irritation and can be quite problematic. Of most concern with these patients, however, is an undiagnosed endocrinopathy or malignancy.

PROGNOSIS AND CLINICAL COURSE The malignant form may also parallel the course of the underlying malignancy. Unfortunately, most associated malignancies present at an advanced stage, and thus the median survival rate for those with malignant acanthosis nigricans has been reported to be from 10 to 24 months.[11]

TREATMENT Management of any co-occurring disease or malignancy often improves and may even resolve acanthosis nigricans. Topical keratolytics, including the retinoids, and oral retinoids can reduce the appearance of acanthosis nigricans. Other oral medications reported to show improvement include dietary fish oil, metformin, and cyproheptadine, possibly by inhibition of tumor-secreted growth factors in the case of the latter.[2]

PREVENTION Unfortunately for those with acanthosis nigricans associated with inherited conditions and malignancy, there is no effective prevention.

Acquired Ichthyosis (See Chap. 47)

The sudden onset of ichthyosis in an adult may indicate an occult malignant tumor, most often Hodgkin lymphoma. However, patients with acquired immunodeficiency syndrome can represent up to 30 percent of patients with acquired ichthyosis.[12] Diffuse rhomboidal scaling is observed on extensor surfaces and typically spares skin folds, palms, and soles. Erythema is often present in the ichthyotic fissures. Although the ichthyosis usually occurs as a late manifestation of a lymphoma, it may precede the diagnosis by several years and typically parallels the course of the malignancy.

Tripe Palms

EPIDEMIOLOGY Tripe palms is a rare paraneoplastic dermatosis with approximately 100 cases reported in the literature. The association with malignancy is high, with a greater than 90 percent occurrence.

ETIOLOGY AND PATHOGENESIS Specific mechanisms of development have not been fully elucidated. Similar to acanthosis nigricans, there is limited evidence for the role of TGF-α in the pathogenesis of tripe palms, and that normalization of this cytokine results in clinical improvement.[13]

Other investigations have shown melanocortin-1 and EGFs to be upregulated in malignancy-associated tripe palm.[14,15] However, there is evidence that these are not uniformly present.[16]

CLINICAL FINDINGS The name originated from the description in the first reported case in 1963 whereby the patient suggested his hands looked similar to the rugose surface of the bovine stomach (Fig. 154-2).[17] Based on clinical similarities and frequency of co-occurrence, many consider this to be a form of palmar acanthosis nigricans. Indeed, tripe palms have also been called "*acanthosis nigricans of the palms*" and "*acanthosis palmaris*." The honeycombed and corrugated thickening of the palms may be associated with periungual tender-

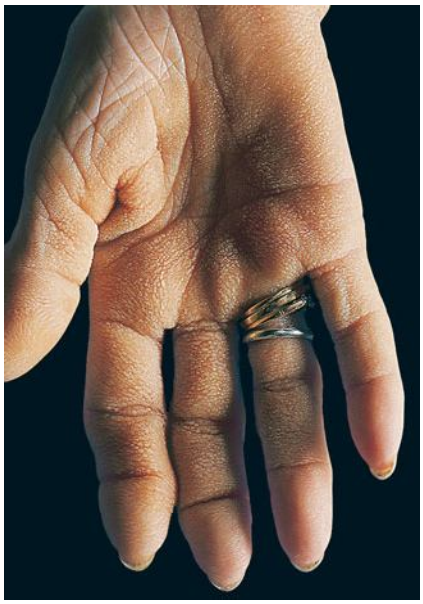

▲ **FIGURE 154-2** Tripe palm. The palmar ridges show maximal accentuation, thus mimicking the mucosa of the stomach of a ruminant.

ness. Normal dermatoglyphic ridges are accentuated.

Histopathology of tripe palms includes hyperkeratosis, acanthosis, and papillomatosis. These features closely resemble those pathologic findings observed in acanthosis nigricans and seborrheic keratoses.

The majority (75 percent) of patients will have concomitant acanthosis nigricans. In patients with only tripe palms, pulmonary carcinoma (53 percent) is the most frequent malignancy. In patients with both tripe palms and acanthosis nigricans, gastric carcinoma (35 percent) is the most common, followed by lung carcinoma (11 percent).[18]

DIFFERENTIAL DIAGNOSIS

COMPLICATIONS This is often a complication itself of underlying malignancy.

PROGNOSIS AND CLINICAL COURSE A complete malignancy workup should be performed in patients with tripe palms due to the high association and because it is the initial presenting sign in 40 percent of patients that have an undiagnosed malignancy.

TREATMENT There is no specific therapy for tripe palms. Similar to acanthosis nigricans, there are anecdotal reports of improvement with oral retinoids alone and in combination with metformin.[19] It has been reported that approximately 30 percent will resolve with treatment of the underlying tumor.[20] However, there are many cases whereby a remission of the cancer has had no effect.

PREVENTION There is no way to prevent the development of tripe palms. Patients should be up to date with standard cancer screenings. An expanded cancer investigation is warranted if no co-existence of malignancy is noted at the time of diagnosis.

Leser-Trélat Sign

EPIDEMIOLOGY Leser-Trélat sign is a rare paraneoplastic dermatosis that occurs with equal frequency between men and women and among different races. Similar to the occurrence of malignancy, this sign is more common in older individuals.

Controversy has surrounded this as a true diagnosis due to the extremely common nature of benign seborrheic keratoses and furthermore, occurring in the age group most susceptible to malignancy. In a large population based study of 1752 consecutive cases of seborrheic keratoses, there was no statistical evidence of an increased incidence of internal malignancy compared to the general population. Subanalysis of those presenting with eruptive seborrheic keratoses also failed to demonstrate an increased risk of internal malignancy.[21] In another study of 82 patients with seborrheic keratoses and a recent solid tumor, a comparison with age- and sex-matched controls did not demonstrate a difference in either the clinical features or numbers of seborrheic keratoses.[22] As such, large epidemiologic studies have not provided the evidence needed to conclusively define this sign as a true paraneoplastic dermatosis.

Although large studies have not shown a statistical difference, there exists evidence to demonstrate that this sign may signify an internal malignancy. First, there are cases of eruptive seborrheic keratoses in patients in their 20s, an age group that rarely exhibits these lesions. Further workup in both cases led to a diagnosis of an internal malignancy.[23,24] Clinically, Leser-Trélat sign often co-exists with malignant acanthosis nigricans, a more established paraneoplastic phenomenon. Additionally, alterations in growth factor expression differ from control patients. Together, this provides evidence that the Leser-Trélat sign is a legitimate but extremely uncommon paraneoplastic dermatosis.

LESER-TRÉLAT SIGN AT A GLANCE



- Rapid and eruptive increase in numbers and size of seborrheic keratoses.
- Pruritus common.
- Often with malignant acanthosis nigricans.
- Adenocarcinomas of the gastrointestinal tract are most common malignancy, followed by lymphoproliferative malignancies.
- Differential diagnosis includes seborrheic keratoses, verruca vulgaris, dermatosis papulosa nigra, melanocytic nevi, and warty dyskeratomas.

ETIOLOGY AND PATHOGENESIS Similar to the other hyperkeratotic paraneoplastic dermatoses, an exact pathogenesis has yet to be elucidated. However, similar to acanthosis nigricans, evidence also exists with the Leser-Trélat sign that an alteration in growth factor homeostasis is contributory. In several instances, a state of increased growth factor expression has been observed with increased urinary levels of the growth factors EGF and TGF-α detected in patients with an underlying malignancy and eruptive seborrheic keratoses. Subsequently, growth factor levels decreased following primary tumor resection.[25]

It is not known if the tumors are the primary source or are inducing a secondary secretion of such growth factors as TGF-α and EGF. In an analysis of a patient with pancreatic carcinoma and Leser-Trélat sign, the tumor cells expressed low levels of EGF while the hyperkeratotic lesions of seborrheic keratoses expressed increased EGF.[26] In a comparison of Leser-Trélat lesional skin and that of control seborrheic keratoses, increased levels of the growth factor homologs EGF and human EGF receptor 2/neu were detected in the downward branching epithelial strands.[27] In addition to increased levels of growth factor expression, lesional skin in paraneoplastic acanthosis nigricans and seborrheic keratoses has alterations in the extracellular matrix.[28] It is unknown what the



direct impact of growth factor signaling has on the skin. Proposed ideas include either inducing a hyperproliferative state primarily or by altering the surrounding environment such as via the extracellular matrix. These similar mechanisms further support the idea of a continuum between acanthosis nigricans and the Leser-Trélat sign.

CLINICAL FINDINGS Clinical features signifying a paraneoplastic phenomenon include patients with widespread eruptive seborrheic keratoses. Pruritus is a significant feature occurring in 43 percent.[3] Co-occurrence with other hyperkeratotic paraneoplastic dermatoses is common, with 20 percent having acanthosis nigricans, including a report of oral acanthosis nigricans, the Leser-Trélat sign, and tripe palms co-existing in the same patient.[10,29] The rapid occurrence of pruritic eruptive seborrheic keratoses, especially in a setting of acanthosis nigricans, should alert the clinician to a potential internal malignancy.

Adenocarcinomas account for the majority of malignancies described with the Leser-Trélat sign; 47.7 percent involve the gastrointestinal tract.[26] The second most common malignancy is lymphoproliferative disorders and includes leukemias, lymphomas, Sézary syndrome and mycosis fungoides. Involvement of other organs such as the pancreas, kidneys, and lungs has been reported in several cases as well. In a series of 44 patients with lung cancer, the Leser-Trélat sign was observed in 2.27 percent.[30]

Typically defined by a concurrent malignancy, the Leser-Trélat sign has also been reported in non-neoplastic tumors, human immunodeficiency virus, conditions of erythroderma, and in association with the chemotherapeutic drug cytarabine.[31–34] The term *pseudo-sign of Leser-Trélat* has been used to designate non-malignancy–associated eruptive seborrheic keratoses that presents identically to its paraneoplastic counterpart. Unfortunately, these examples do not help to further define an already confusing and controversial clinical entity.

DIFFERENTIAL DIAGNOSIS

COMPLICATIONS As with many paraneoplastic dermatoses, sudden reappearance may herald tumor recurrence, although this particular sign only occasionally parallels the malignancy.

PROGNOSIS AND CLINICAL COURSE This sign can develop from 5 months before to 9.8 months after the diagnosis of malignancy and, once diagnosed, the prognosis is poor, with an average survival time of 10.6 months.[35] This eruption parallels the course of the underlying malignancy in some cases, but not as a general rule.

TREATMENT Treatment should be directed towards the underlying tumor. If the lesions are symptomatic or cosmetically concerning to the patient, other options for treatment include standard therapies for seborrheic keratoses such as α hydroxy acids, retinoids, trichloroacetic acid, cryosurgery with or without curettage, dermabrasion, laser, and shave excision.

PREVENTION There is no effective prevention other than keeping up with age-appropriate cancer screenings.

Paraneoplastic Acrokeratosis of Bazex

EPIDEMIOLOGY Bazex established an association between this uniquely distributed papulosquamous eruption and underlying malignancy. In fact, he considered the characteristic cutaneous presentation a pathognomonic sign of internal malignancy.[36] There have been more than 100 cases reported in the medical literature. Patients are typically men over the age of 40 years old. Acrokeratosis paraneoplastica is unrelated to Bazex-Dupre-Christol, which is a genodermatosis characterized by congenital hypotrichosis, follicular atrophoderma, and basal cell carcinomas arising at an early age.

ETIOLOGY AND PATHOGENESIS The mechanism by which this characteristic eruption occurs is still speculative. One theory proposes that antibodies mounted against the tumor cross-react with keratinocyte or basement membrane antigens (similar to those found in paraneoplastic bullous pemphigoid).[37] Other theories include a T-cell mediated immune response to tumor-like antigens in the epidermis or excessive expression of autocrine growth factors from the tumor resulting in epidermal hyperplasia.[38–40]

CLINICAL FINDINGS The name, *acrokeratosis paraneoplastica*, is aptly descriptive because characteristic lesions are located acrally and exhibit hyperkeratosis. The plaques are usually erythematous to violaceous with overlying scale. Almost all patients have lesions affecting the ears and nails during the disease. Nearly two-thirds will demonstrate involvement of the nose and fingers, and over one-half have lesions on the hands and feet, especially volar surfaces.[41] Other clinical findings include hyperpigmentation and bullae. Bullae, when present, are most common on the hands and feet.

Three stages of skin lesions parallel the growth and dissemination of the underlying tumor. In the first stage, the helices, nose, fingers, and toes are usually affected in a symmetric fashion. Early lesions are macular and not clearly demarcated, simulating a non-specific dermatitis. They may exhibit crust in addition to scale. The eruption is classically asymptomatic, but pruritus may be a problem. Paronychia is the first sign of nail involvement (Fig. 154-3). In most cases, the responsible tumor is occult at this stage and remains so for an average of 11 months.[41]

During the second stage, the tumor exhibits symptoms, due to local extension or metastatic spread, and the skin eruption becomes more extensive. The cheeks display the typical red to purple scaly or crusted plaques. The palms and soles develop a keratoderma that often spares the central volar surfaces but may lead to painful fissures (Fig. 154-4). Nail plate changes include yellowing, thickening, onycholysis, and ridging, both horizontal and vertical.

The final stage is observed when the tumor goes untreated or fails to respond

ACROKERATOSIS PARANEOPLASTICA OF BAZEX AT A GLANCE



- Distribution of cutaneous lesions is symmetric and characteristically involves the helices, nose, cheeks, digits, nails.
- Lesions evolve from non-specific dermatitis and paronychia to inflammatory plaques, acral keratoderma, and nail plate changes.
- Skin lesions often pre-date detection of internal malignancy.
- Upper aerodigestive tract malignancy most common.





◀ **FIGURE 154-3** Distal edema of toes, painful generalized paronychia, and distal subungual hyperkeratosis in early acrokeratosis paraneoplastica.

to treatment. All of the above signs and symptoms persist while the papulosquamous lesions begin to appear on the trunk, elbows, knees, and dorsal hands and feet. Rarely, vesicles and bullae may be present, most commonly on the fingers, hands, and feet. Nail changes can be quite variable, ranging from the typical thickening to nail atrophy and loss.

The main differentiation to be made in diagnosis is psoriasis, especially acral variants. The distinguishing clinical feature, which is nearly always present in acrokeratosis paraneoplastica, is involvement of the helices of the ears (Fig. 154-5) and the tip of the nose. Knees and elbows may develop plaques but it occurs late in the disease. Typically, Bazex is treatment resistant unlike other diseases considered in the differential.

Mucosal squamous cell carcinoma of the head and neck is the most frequently associated malignancy in acrokeratosis paraneoplastica and is markedly over-represented when compared with the cancer statistics in the general population. Tumors in the oropharynx or larynx and cervical squamous cell lymph node metastases of an occult primary malignancy make up more than 60 percent of cancers associated with Bazex syndrome but only 7 percent of cancer patients without Bazex. The lung[42] and esophagus were the next most frequent site of tumors (15 percent and 10 percent, respectively), though not always squamous cell carcinomas.[41]

Histologically, some psoriasiform features are present, including hyperkeratosis, parakeratosis, and a superficial lymphohistiocytic infiltrate, but other nonpsoriasiform changes also exist. These include vacuolar degeneration with melanin-containing macrophages in the dermis and dyskeratotic keratinocytes.[41]

DIFFERENTIAL DIAGNOSIS (Box 154-1)

COMPLICATIONS The keratoderma affecting volar surfaces may develop fissures. On the feet, this can lead to painful ambulation. Secondary infection occurs. Paronychia is usually painful and may be debilitating.



▲ **FIGURE 154-4** Keratoderma characteristically spares central aspects of plantar (and palmar) surfaces in acrokeratosis paraneoplastica.



▲ **FIGURE 154-5** Characteristic helical inflammation with scale in acrokeratosis paraneoplastica.[45] (Used with permission from Peter Karl Kohl.)

Box 154-1

Differential Diagnosis of Acrokeratosis Paraneoplastica

Most Likely
- Psoriasis
- Dermatitis (seborrheic, eczematous, or contact)
- Dermatophytosis/onychomycosis

Consider
- Mycosis fungoides
- Drug eruption
- Cutaneous lupus erythematosus
- Keratoderma blenorrhagicum (reactive arthritis)
- Arsenical keratoses

Always Rule Out
- Internal malignancy
- Dermatophyte infection

PROGNOSIS AND CLINICAL COURSE The skin eruption is expected to resolve with treatment of the underlying malignancy and can reappear with tumor recurrence. For some patients the cutaneous lesions, but more commonly the nail dystrophy (ridging and subungual hyperkeratosis), may persist despite (presumed) successful tumor eradication.

TREATMENT Adequate treatment of the underlying malignancy usually results in improvement of acrokeratosis paraneoplastica and recurrence of the eruption heralds tumor recurrence. The skin lesions are typically resistant to standard therapies for hyperkeratotic conditions, and few treatments specific for the cutaneous component of acrokeratosis paraneoplastica have been reported. Retinoids have been used with variable success.[43] Isolated reports suggest benefit from oral psoralen and ultraviolet A phototherapy, topical salicylic acid, and corticosteroids.[44]

PREVENTION There is no effective prevention other than keeping up with age-appropriate cancer screenings.

COLLAGEN-VASCULAR DISEASE

Dermatomyositis (See Chap. 157)

Dermatomyositis can be a marker for internal neoplasia, and the development of the dermatomyositis can predate the diagnosis of the cancer. The clinical manifestations of dermatomyositis appear to be the same with and without a malignant tumor, although Basset-Sequin et al.[45] noted that cutaneous necrosis and an elevated erythrocyte sedimentation rate appeared to be markers for those





▲ **FIGURE 154-6** **A.** Serpiginous parallel bands on axilla and arm. (Used with permission from Michael Adler.) **B.** "Wood-grained" pattern of erythema and slight scale in a woman with breast cancer. (Used with permission from Barbara Resnick.)

with cancer and a reduced survival. Men over the age of 50 years old have an elevated risk of malignancy.[46] The most common cancers are ovarian, lung, pancreatic, stomach, colorectal, and lymphoma.[47] Although dermatomyositis in an adult is strongly associated with concurrent cancer, polymyositis alone is much less strongly associated.[48]

The cancers are usually identifiable by history and physical examination. Adults with dermatomyositis should be examined thoroughly for evidence of an associated malignant tumor, including all recommended cancer screenings. The diagnosis of malignancy is usually made within 1 year, but can be several years later. In children, dermatomyositis is not statistically linked to malignancy.

Progressive Systemic Sclerosis (See Chap. 158)

Systemic scleroderma is not commonly associated with internal malignancy. In a Japanese review of 8327 patients with systemic sclerosis, the frequency of malignancy was 5.4 percent in men and 2.8 percent in women (overall, 3.1 percent).[49] Several population-based studies have been performed to determine the incidence of malignancy with mixed results. Some have detected no increase in overall malignancy incidence as compared with the general population, although others have detected a small, but statistically significant increased risk.[50] In a nested cohort comparing patients diagnosed with systemic sclerosis before the age of 60 years and after the age of 75 years, not surprisingly, there was an increased frequency of all malignancies in the older age, but especially esophageal and oropharyngeal cancer.[51,52]

Lung cancer has been the most often associated malignancy, but there is also a nearly 25-fold increased risk of squamous cell carcinoma of the tongue.[53] Almost all patients with associated lung tumors have very advanced systemic scleroderma, particularly older patients with advanced interstitial lung disease. Evidence suggests the association is most likely one of a lung tumor developing secondary to the chronic pulmonary fibrosis.

REACTIVE ERYTHEMAS

Erythema Gyratum Repens (See Chap. 42)

This particular annular ("gyratum" is Latin for circle) erythema is nearly always indicative of internal malignancy and is one of the most dramatic skin diseases in both its appearance and evolution. Affected individuals are often Caucasian men (2:1) in their 60s. Numerous serpiginous bands are arranged in a parallel configuration of concentric red swirls over most of the body. This presentation is occasionally referred to as a "wood-grained" appearance (Fig. 154-6A). Even more striking is the relatively rapid rate at which lesions migrate ("repens" is Latin for creeping), estimated at 1 cm per day.[54] A slight scale may be found along the trailing edge of erythema (see Fig. 154-6B). The hands, feet, and face are commonly spared, except for occasional volar hyperkeratosis. Ichthyosis is present in many cases. Pruritus is universal and may be severe.

An underlying malignancy is associated with erythema gyratum repens more than 80 percent of the time. This distinctive migratory eruption appears 4 to 9 months before the diagnosis of malignancy in approximately 80 percent of cases. Approximately one-third of patients will manifest a lung cancer, whereas 8 percent have esophageal cancer, and 6 percent have breast cancer. Individual case reports of many other types of associated tumors are published, as well as 6 percent of cases with an unknown primary. In those individuals with erythema gyratum repens who did not have a detectible underlying malignancy, concurrent conditions included tuberculosis, pregnancy, and bullous dermatoses, among others.[54]

The exact etiology of erythema gyratum repens is unknown, but it has been suggested that the tumor may induce a chemical alteration of the normal components of the surrounding tissue. Molecular mimicry ensues as the inflammatory response directed against the tumor cross-reacts with benign cutaneous proteins. This theory is supported by documentation of immunoglobulin G (IgG) and C3 deposition at the basement membrane of affected skin and bronchial basement membrane in one case associated with lung cancer.[54] Migration characterizes all of the figurate erythemas, but is notably rapid in erythema gyratum repens, and the mechanism for this is not clear, although recent studies have focused on fibroblast activity. Inflammatory cells and/or fibroblasts may mediate ground substance alterations which may localize the inflammation that orchestrates the movement of the infiltrate in a patterned mode.[55,56]



◀ **FIGURE 154-7** The glucagonoma syndrome, necrolytic migratory erythema. Flaccid and papulovesicular lesions (**A**) with erosions, crusting, and fissures around the orifices, and (**B**) appearing as geographic, circinate "necrolytic migratory erythema" in the groin. (**A** and **B** are not the same patient.)

The treatment for erythema gyratum repens is to locate and treat the primary malignancy. With adequate control of the cancer, the rash usually abates, but this may not be possible in cases that are widely metastatic at the time of diagnosis. Unfortunately, the eruption is often treatment resistant, although variable results occur with systemic steroids.[57] Topical steroids, vitamin A, and azathioprine have not been beneficial.[58–60] The eruption has been known to resolve immediately before death, possibly due to generalized ante mortem immunosuppression.[55]

Necrolytic Migratory Erythema

EPIDEMIOLOGY NME is virtually pathognomonic for pancreatic glucagonoma and is present in more than two-thirds of patients at the time of tumor diagnosis.[61] When the characteristic eruption occurs without underlying pancreatic malignancy, the condition is referred to as *pseudoglucagonoma syndrome*. Glucagonomas are rare, with an estimated 400 cases cited in the literature.[62] There is no sexual predilection, and it most commonly affects people in their sixth decade.[63]

ETIOLOGY AND PATHOGENESIS Most of the signs and symptoms can be attributed to the metabolic effects of excess glucagon. Amino acid levels are depressed due to glucagon stimulating consumption of amino acid substrates for gluconeogenesis and increasing amino acid oxidation.[64] With insufficient amino acids, epidermal protein deficiency and necrolysis ensue. Reduced amino acid levels (histidine, tryptophan) can cause painful, erythematous eroded skin, especially in intertriginous areas in several nutritional disorders. Glucagon also increases cutaneous levels of arachidonic acid, which likely increases downstream inflammatory mediators (prostaglandins and leukotrienes).

CLINICAL FINDINGS The skin lesions of NME are polymorphous, but erosions and crusts are usually apparent. Primary lesions are erythematous patches that eventuate into plaques that develop central bullae. The blisters erode rapidly, form crust, and eventually resolve. The erythematous and eroded annular patches and plaques coalesce into large geographic areas. The eruption disappears and reappears spontaneously over the course of weeks. Pruritus and pain are common symptoms. The distribution of NME is characteristic and includes intertriginous areas (groin, perineum, buttocks, lower abdomen), the central face (especially perioral) and distal extremities (Fig. 154-7). Mucosal involvement manifests as angular cheilitis, atrophic glossitis and stomatitis. Dystrophic nails may accompany the syndrome.

NECROLYTIC MIGRATORY ERYTHEMA AT A GLANCE



- Painful, eroded, crusted intertriginous and facial skin eruption.
- Highly suggestive of pancreatic malignancy (glucagonoma).
- Half of tumors are metastatic at the time of diagnosis.
- Pseudoglucagonoma syndrome occurs in absence of glucagonoma.
- Skin improves with treatment of underlying nutritional aberrations.

The features of glucagonoma syndrome are weight loss, sore mouth, diarrhea, weakness, mental status changes, and diabetes mellitus.[62] Weight loss is the most common presenting sign. Laboratory abnormalities include a dramatically elevated serum glucagon, usually well over 1000 pg/mL (normal range 50 to 150 pg/mL). Most patients have hyperglycemia and a normochromic normocytic anemia. Abnormal liver function is present, and serum levels of amino acids, total protein, albumin, and cholesterol are low. Occasionally, zinc levels are deficient.

Pseudoglucagonoma syndrome presents identically, but the α-cell pancreatic tumor is not present, which may explain why the serum glucagon levels are not elevated to the same degree. Underlying diseases identified in patients with the pseudo-syndrome are liver disease, pancreatitis, celiac sprue, inflammatory bowel disease, acrodermatitis enteropathica, pellagra, and non-pancreatic malignancies.[62]

The histology of NME is characteristic. Acute lesions demonstrate a striking degree of epidermal necrosis in the upper layers of the stratum spinosum. Neutrophils may be abundant in the necrotic layer, and frank separation from the underlying intact epidermis may occur. Chronic lesions also show a psoriasiform dermatitis with parakeratosis and loss of the granular layer. The constellation of hyperkeratosis, architectural disorder, and scattered degenerating keratinocytes may be seen in other nutritional deficiencies, graft-versus-host disease, connective tissue disorders, and phototoxic drug eruptions.[65]

DIFFERENTIAL DIAGNOSIS (Box 154-2)

COMPLICATIONS Nearly all patients suffer from weight loss; malaise and anemia are a result of the catabolic effects of glucagon. Gastrointestinal symptoms, such as abdominal pain, diarrhea, and anorexia, may be debilitating. Neuro-psychiatric



Box 154-2

Differential Diagnosis of Necrolytic Migratory Erythema

Most Likely

- Dermatitis (seborrheic, eczematous, or contact)
- Drug eruption

Consider

- Pemphigus (foliaceus, erythematosus)
- Acrodermatitis enteropathica
- Essential fatty acid deficiency
- Vitamin deficiency (especially B_2, B_3, B_6)
- Amino acid deficiency (histidine, tryptophan)
- Cutaneous lupus erythematosus

Always Rule Out

- Glucagonoma (abdominal computed tomography)
- Liver disease
- Pancreatitis
- Nutritional deficiencies (zinc, vitamin, amino and fatty acids)
- Malabsorption
- Inflammatory bowel disease



features occur in approximately 20 percent of patients and may present as depression, dementia, psychosis, agitation, ataxia, and decreased cognitive function.[66] Venous thrombosis occurs in up to 30 percent of patients with glucagonoma.[67]

PROGNOSIS AND CLINICAL COURSE If the glucagonoma is not metastatic and can be completely resected at the time of diagnosis, symptoms of the syndrome will resolve. Unfortunately, by the time of diagnosis, tumors are frequently large and metastatic in most cases. Fortunately, the tumors are slow-growing, and patients may experience symptom improvement with surgically decreasing the tumor burden, although survival may not be affected by the procedure. Chemotherapy has been disappointingly ineffective.[62]

TREATMENT The underlying cause for hyperglucagonemia must be addressed to eradicate the painful skin disease. For patients with glucagonoma, resection of the tumor is important for symptom relief. Measures to correct nutritional deficiencies and glucagon levels have provided relief for many patients. Intravenous somatostatin (a glucagon antagonist) has been shown to improve the cutaneous symptoms of the syndrome.[68] Supplementation to correct zinc, amino acid, or fatty acid deficiencies has been shown to be beneficial in some cases.

PREVENTION None known.

NEUTROPHILIC DERMATOSES

Sweet Syndrome (See Chap. 31)

Many authors have suggested that the neutrophilic dermatoses, Sweet syndrome and pyoderma gangrenosum, represent a continuum when associated with an underlying malignancy. In approximately 40 percent of patients with malignancy-associated Sweet syndrome, a diagnosis of cancer is made within 1 month of the dermatoses.[69] Two-thirds of the time, cutaneous manifestations occur before the diagnosis of malignancy and is seen most commonly with acute myelocytic leukemia but also may be associated with other leukemias, myelodysplastic syndrome, multiple myeloma, and lymphoma.[70] Of note, patients with an underlying hematologic malignancy may have a normal neutrophil count that is, in actuality, a relative neutrophilia.

Much less commonly, associations have also been reported with solid tumors such as cancers of the genitourinary tract, embryonal carcinoma of the testes, ovarian carcinoma, gastric carcinoma, and adenocarcinoma of the breast, prostate, and rectum.[71] Unlike many of the other paraneoplastic dermatoses, the neutrophilic dermatoses respond to systemic corticosteroids and other standard treatments regardless of the course of the underlying malignancy.

Pyoderma Gangrenosum (See Chap. 32)

Overall, there is a low incidence of malignancy in patients with pyoderma gangrenosum but the incidence increases up to 27 percent in those presenting with atypical features such as hemorrhagic bullae, superficial and/or rapid appearance, involvement of the upper extremities/hands, and scarring. Similar to Sweet syndrome, the most common underlying malignancy is hematologic with acute myelogenous leukemia the most common followed by multiple myeloma.[72]

Another unexplained co-occurrence in patients with pyoderma gangrenosum is an IgA paraproteinemia, occurring in 10 percent to 18 percent of patients. By itself, this is not a malignancy. However, studies of individuals with monoclonal gammopathy of undetermined significance show an increased risk of malignant transformation occurring at a rate of approximately 1 percent, and can be as high as 40 percent at 25 years. Those with IgA gammopathies have a higher probability of malignant transformation.[73,74] Therefore, careful monitoring is warranted in these patients as well. A parallel course to the underlying malignancy has not been well established with this paraneoplastic dermatosis.

DERMAL PROLIFERATIVE DISORDERS

Multicentric Reticulohistiocytosis (See Chap. 149)

Though malignancy has been diagnosed in many patients with multicentric reticulohistiocytosis, no one malignancy predominates. Neoplasms that have been reported most commonly include melanoma, hematologic malignancies, and carcinomas of the breast, colon, ovaries, cervix, and stomach.[12] The natural course of the disease is generally one of spontaneous remission after several years of activity that resides with permanent joint destruction. While active though, treatment options for multicentric reticulohistiocytosis have only been partially effective, and the course of the disease does not consistently parallel the activity of the underlying malignancy.

Necrobiotic Xanthogranuloma (See Chap. 149)

This non-Langerhans cell histiocytosis is a rare disease that has a high association with hematologic abnormalities. In the majority (80 percent) of patients with necrobiotic xanthogranuloma, an IgG paraproteinemia can be detected with an approximate 10 percent conversion to multiple myeloma. Periorbital involvement is seen in 85 percent of patients and ulceration is more common in this particular xanthoma.[75] Other malignant associations include chronic lymphocytic leukemia, Hodgkin lymphoma, and non-Hodgkin lymphoma.[3]

DERMAL DEPOSITION

Scleromyxedema (See Chap. 159)

Scleromyxedema is the generalized form of papular mucinosis (lichen myxedematosus) and is more severe than its localized counterpart with particular predilection for face, arm, and hand involvement. Systemic organ involvement is more common, and the majority (80 percent) of patients with scleromyxedema has an IgG-λ light chain monoclonal gammopathy of undetermined significance. Serum protein electrophoresis should be performed in conjunction with thyroid studies to rule out thyroid dysfunction and myxedema. Fortunately, the paraproteinemia only rarely

converts to multiple myeloma, but when it occurs, it portends a poor prognosis. Other rare malignancies to co-occur include Waldenström macroglobulinemia, leukemia, or Hodgkin or non-Hodgkin lymphoma.[3] It is uncertain if treatment of scleromyxedema with agents such as melphalan triggers malignant transformation.[76] The course of the disease is usually progressive with major cardiac and pulmonary involvement, and there is no established marker for those most likely to progress to malignancy.

Systemic Amyloidosis (See Chap. 133)

The amyloid sub-type in primary systemic amyloidosis most commonly associated with internal malignancy is the amyloid light chain.

Multiple myeloma is the most common malignancy, seen in 13 percent to 26 percent of patients and, once diagnosed, has an extremely poor prognosis, with a mean survival of 1 year. Other malignancies reported include Hodgkin lymphoma and gastric, breast, and renal cell carcinoma.[12,77,78] The purely cutaneous variants of amyloidosis are not significantly associated with malignancy but familial cutaneous lichenoid amyloidosis has been reported in association with multiple endocrine neoplasia type 2A.[79] All patients with skin lesions of systemic amyloidosis should have a serum and urine electrophoresis performed.

BULLOUS DISORDERS

Paraneoplastic Pemphigus (See Chap. 53)

The signature clinical finding is the early onset of severe refractory oral mucosal involvement. Other sites of involvement can include the ocular, respiratory, and gastrointestinal epithelium. Because nearly every patient with paraneoplastic pemphigus has an associated malignancy, if there is no diagnosed malignancy at the time of presentation, an extensive workup is required. There are occasional instances whereby the association is with a benign tumor. The most common malignancy associated is non-Hodgkin lymphoma. The next most common in frequency are chronic lymphocytic leukemia, Castleman disease, and thymoma.

Dermatitis Herpetiformis (See Chap. 59)

Dermatitis herpetiformis and celiac disease are independent risk factors for gastrointestinal lymphoma. There is no indication that there is a greater than expected number of patients with dermatitis herpetiformis developing tumors other than intestinal lymphoma.[80] The incidence of lymphoma has been reported as between 1 percent and 4 percent developing 2 to 31 years after the diagnosis.[81,82] Interestingly, the increased risk is observed only in adults and the incidence ratio decreases with every calendar year after diagnosis, ultimately reaching null.[83]

The most commonly associated malignancy is enteropathy-associated T-cell lymphoma of the gastrointestinal tract but patients are also at risk to develop B-cell lymphoma both in and out of the gastrointestinal tract and non-Hodgkin lymphoma.[81,84] The relative risk of non-Hodgkin lymphoma associated with dermatitis herpetiformis is 5.4 (95 percent, CI 2.2 to 11.1) in males, less in females.[84] It is often observed that affected patients with lymphoma are less compliant with a gluten-free diet as compared to those without malignancy.[81]

Bullous Pemphigoid (See Chap. 54)

Case-control studies have failed to show a significant increased risk of a malignant tumor in patients with bullous pemphigoid other than that associated with the age of the patient.[85] However, a Japanese cohort of patients with bullous pemphigoid had a 5.8 percent prevalence of neoplasia versus 0.61 percent of controls.[86] In younger patients, bullous pemphigoid under the age of 60 years old was observed in 9.5 percent of patients in a retrospective review of 74 patients, and there are anecdotal reports of patients clearing when the concomitant tumor is treated.[87]

MISCELLANEOUS

Hypertrichosis Lanuginosa Acquisita

Acquired hypertrichosis lanuginosa (described by Fretzin[88] as *malignant down*) is a rare condition characterized by the relatively sudden appearance of long, fine, non-pigmented lanugo (Latin for "down") hairs. The lanugo most frequently appears on the face and ears early in the course (Fig. 154-8). The hairs may grow to an extraordinary length; eyebrows and eyelashes may grow to inches long. The long fine hairs may also be seen on the trunk and limbs, including the axillae. Epithelial proliferation of the oral mucosa may cause glossodynia, hypertrophy of the papillae of the tongue, mucosal pigmentation, and disturbances of taste or smell.[89,90] Symptoms in the mouth are similar to those seen in various vitamin deficiencies, and one case has been reported with decreased vitamins A and B_1 and niacinamide levels.[91]



▲ **FIGURE 154-8** Hypertrichosis lanuginosa acquisita in a 19-year-old woman with pancreatic carcinoma.

This condition is frequently paraneoplastic and nearly always pre-dates the diagnosis of malignancy. The most commonly associated malignancies are located in the lung and colon. Breast and uterine adenocarcinomas, lymphoma, and urinary bladder transitional carcinomas have also been found in patients with acquired hypertrichosis lanuginosa as have other malignancies.[89,90] Unfortunately, tumors are usually widespread by the time hypertrichosis manifests and, thus, this paraneoplastic condition portends a poor prognosis.

Hypertrichosis lanuginosa may also be seen in other disorders. These include acquired immunodeficiency syndrome (most characteristically hypertrichosis and trichomegaly of the eyelashes),[92] anorexia nervosa, thyrotoxicosis, and porphyria cutanea tarda. The condition may be a consequence of medications such as cyclosporin, phenytoin, penicillin, spironolactone, corticosteroids, or minoxidil.[90]

Trousseau Syndrome

In general, malignancy predisposes to alterations in the clotting cascade, resulting in a combined state of hemorrhage and

hypercoagubility. Approximately 11 percent of all cancer patients will develop migratory thrombophlebitis during the course of their disease, and up to 23 percent will have evidence at autopsy.[93,94] Trousseau syndrome is an acquired coagulopathy presenting as migratory thrombophlebitis often in a setting of underlying malignancy. Both the arterial and venous vasculature can be affected and can lead to devastating complications such as pulmonary embolism, stroke, limb necrosis, and organ ischemia.

The human oncogene MET induces increased production of plasminogen activator inhibitor type 1 and cyclooxygenase 2 in some models and may be part of the mechanism linking the hypercoagulable and hemorrhagic state with malignancy.[95]

The most common malignancy reported with Trousseau syndrome is lung carcinoma. However, this most likely reflects the frequency with which it occurs in the general population. The less common pancreatic cancer has a more striking association, with 42 percent having evidence of pulmonary embolism. Furthermore, certain characteristics of tumors have been shown to correlate with an increased risk for the development of Trousseau syndrome. These features include adenocarcinoma, metastatic progression, and involvement of the gallbladder, gastrointestinal, and/or pulmonary systems.[94]

Treatment is best achieved with eradication of the underlying malignancy. To manage the embolic sequelae in Trousseau syndrome, anticoagulation can be achieved with the use of heparin. Low-molecular weight heparin is the treatment of choice, as unfractionated heparin exhibits strong neutralization in the presence of tumor cells.[96]

FAMILIAL CANCER SYNDROMES

It is important for clinicians to recognize cutaneous features of genetic conditions that predispose to internal malignancy. In several cases, cutaneous features predate the development of malignancy and increased surveillance may improve the survivability in these patients.

For malignancies associated with a genodermatosis, there may be an increased risk for family members to develop cancer. Appropriate genetic testing may elicit the carrier state of each relative in question and can assist with genetic counseling of the patient and the patient's family.

The characteristic cutaneous findings and the major associated internal malignancy for the genodermatoses with cancer susceptibility are listed in Table 154-3.[97–103,106]

TABLE 154–3
Genetic Conditions Involving the Skin and Associated with Malignancy

Syndrome	Cutaneous Findings	Major Associated Internal Malignancy	Minor Associated Internal Malignancy
Autosomal dominant			
Birt-Hogg-Dubé syndrome[98]	Fibrofolliculomas, trichodiscomas, acrochordons	Renal carcinoma (12%)	—
Bloom syndrome	Short stature, poikiloderma, CALMs	Acute leukemias/lymphoma[a] Gastrointestinal carcinoma[a]	Wilms' tumor, medulloblastoma, osteogenic sarcoma
Carney complex[106]	Mucocutaneous myxomas, nevi, ephelides, blue nevi	Myxomas (cardiac, 53%; skin, 33%) Sertoli cell testicular cancer (33% males) Primary pigmented nodular adrenocortical disease (26%; benign, causes Cushing syndrome)	Other testicular cancers, breast and thyroid tumors, and melanotic schwannomas
Cowden disease[97]	Trichilemmomas, acral keratoses, oral papillomas, sclerotic fibromas	Breast cancer (22%) Hamartomatous intestinal polyps (60%) Thyroid abnormalities (62%; includes follicular thyroid carcinoma, goiter, and adenoma)	Transitional cell and renal cell carcinomas, glioblastoma multiforme, liposarcoma; lung, hepatocellular, pancreatic, uterine, and ovarian cancer
Gardner syndrome[97]	Epidermoid cysts, fibromas, pilomatricomas	Intestinal polyposis and colorectal adenocarcinoma (near 100%)	Follicular or papillary thyroid cancer, adrenal adenomas and adenocarcinomas, and hepatoblastoma
Gorlin syndrome[97]	Multiple basal cell carcinomas, epidermoid cysts, milia, palmar and plantar pits	Medulloblastoma (10%) Meningiomas (5%)	Ovarian fibromas, fibrosarcomas, cardiac fibromas, ovarian desmoids
Howel-Evans syndrome[100]	Palmoplantar keratoderma	Esophageal carcinoma (up to 90%)	
Maffucci syndrome	Venous malformations	Chondrosarcoma (20%)	Angio- and lymphangiosarcoma, fibrosarcoma, osteosarcoma
MEN1 syndrome[97,99]	Angiofibromas, collagenomas, CALMs, lipomas, hypopigmented macules, gingival papules, necrolytic migratory erythema	Parathyroid adenomas (90%) Gastrinomas (54%; includes Zollinger-Ellison syndrome) Anterior pituitary tumors (10%–30%)	Insulinomas, glucagonomas, foregut carcinoids, pheochromocytoma
MEN2a syndrome[97,99]	Scapular macular or lichen amyloidosis	Medullary thyroid carcinoma (90%) Pheochromocytomas (50%) Parathyroid tumors (20%–30%)	
MEN2b/3 syndrome[97,99]	Mucosal neuromas, CALMs, marfanoid habitus, mucosal/intestinal ganglioneuromas	Medullary thyroid carcinoma (90%) Pheochromocytoma (50%)	

(continued)

TABLE 154–3
Genetic Conditions Involving the Skin and Associated with Malignancy (Continued)

Syndrome	Cutaneous Findings	Major Associated Internal Malignancy	Minor Associated Internal Malignancy
Muir-Torre syndrome[97]	Sebaceous tumors, keratoacanthomas	Colorectal carcinomas (51%) Genitourinary cancers (25%)	Breast, head and neck, and small intestine carcinomas, hematologic malignancies
Neurofibromatosis type 1[97]	CALMs, neurofibroma, plexiform neurofibroma, axillary freckling, Lisch nodules	Optic gliomas (66%) Neurofibrosarcoma (3.5%) Chronic myelomonocytic leukemia (if associated with juvenile xanthogranuloma; 221× increased risk)	Astrocytomas, non-Hodgkin lymphoma, acute lymphoblastic leukemia, pheochromocytoma, carcinoid
Neurofibromatosis type 2[97]	Schwannomas, neurofibroma, CALMs, plexiform neurofibroma	Bilateral vestibular schwannomas (near 100%) Spinal tumors (90%; usually schwannomas) Meningiomas (50%)	Gliomas, astrocytomas, intramedullary ependymomas
Peutz-Jeghers syndrome[97]	Perioral and mucosal lentigines	Polyps (near 100%) Gastrointestinal carcinoma (13%)	Variety of solid tumors
Reed syndrome[101]	Cutaneous leiomyomas	Uterine leiomyoma (98%) Renal carcinoma (type II papillary renal cell)	
Tuberous sclerosis	Ash leaf macules, shagreen patches, facial angiofibromas, periungual fibromas	Intracranial cortical/subcortical tubers (near 100%) Cardiac rhabdomyomas (50%) Renal angiomyolipomas (49%)	Wilms' tumor, pancreatic carcinoma, parathyroid adenoma
Autosomal recessive			
Ataxia-telangiectasia	Telangiectasias	Leukemia/lymphomas (38%) Breast cancer (increased risk in heterozygotes)	
Bloom syndrome[97,102]	Short stature, CALMs, poikiloderma	Acute leukemia[a] Lymphoma[a] Gastrointestinal adenocarcinoma[a]	Wilms' tumor, medulloblastoma, osteogenic sarcoma
Chédiak-Higashi syndrome[102]	Silver hair, slate-gray skin, ecchymoses	Lymphoma-like accelerated phase (85%)	
Fanconi anemia[103]	Short stature, CALMs microcephaly, thumb and/or radial ray anomalies	Acute myeloid leukemia (9%)	Myelodysplastic syndrome, gynecologic malignancies
Griscelli syndrome	Silver hair, pigmentary dilution	Lymphoma-like accelerated phase (in the majority)[a]	
Rothmund-Thompson syndrome[97]	Poikiloderma, nail dystrophy, photosensitivity hypotrichosis	Osteogenic sarcomas[a]	
Werner syndrome[97,102]	Premature aging, short stature, bird-like facies	Sarcomas (10%; soft tissue, bone) Thyroid cancer[a]	Meningiomas, adenocarcinomas; acrolentiginous melanoma in Japan
Xeroderma pigmentosum[97]	Photosensitivity, actinic keratoses, squamous cell carcinoma, basal cell carcinoma, melanoma, lentigines, dermatoheliosis	Ocular cancers Lung and gastric carcinomas (10–20× increased risk)	Sarcomas, leukemia
X-linked recessive			
Dyskeratosis congenita	Leukoplakia, alopecia, reticulate pigmentation, nail dystrophy	Mucosal squamous cell carcinoma[a]	
Wiskott-Aldrich syndrome	Eczema, petechiae	Lymphoreticular malignancy (20%; non-Hodgkin lymphoma)	
X-linked icthyosis[102]	Adherent brown scales	Testicular cancer (from associated cryptorchidism)	
Miscellaneous			
Beckwith-Wiedemann syndrome	Capillary malformation, macroglossia, earlobe creases	Wilms' tumor[a] Hepatoblastoma[a]	Adrenal cortical carcinoma, rhabdomyosarcoma
Epidermal nevus syndrome	Epidermal nevi, hemangiomas, CALMs, capillary malformation	Wide variety (usually ecto- and mesoderm derived)	
Familial melanoma (dysplastic nevus syndrome)[97]	Multiple dysplastic nevi, melanomas	Pancreatic cancer (22× increased risk)	Lung, laryngeal, and breast carcinomas

CALMs = café-au-lait macules; MEN = multiple endocrine neoplasia.
[a]Frequency unable to be reported due to rarity of the genodermatoses and/or a specific malignancy.







▲ **FIGURE 154-9** **A.** Carcinoma erysipelatoides. Intralymphatic spread of mammary carcinoma that manifests as erysipelas-like erythema. **B.** Carcinoma en cuirasse involving both breasts and thoracic wall.

DIRECT TUMOR INVOLVEMENT OF THE SKIN

Cutaneous Metastases

Direct involvement of the skin by metastatic spread from a distant primary tumor is perhaps the most unquestioned sign of internal malignancy. The overall incidence of cutaneous involvement is approximately 5 percent.[104] In a review of over 100,000 cancer patients, skin involvement was the first sign of internal malignancy in 7.8 percent.[105] The most common malignancies to metastases to the skin in women are breast, colon, and melanoma. In men, the most common are lungs, colon, and melanoma.

Several clinical and pathologic features can aid in determining the source of the metastasis. Metastatic breast cancer can present as an erysipelas-like eruption known as *carcinoma erysipelatoides* (Fig. 154-9A). Usually asymptomatic, this type of breast cancer can be painful. Another clinical variant is the leather-like skin change of sclerosing metastatic breast cancer known as *carcinoma en cuirasse*, which may later present as nodules and ulceration (see Fig. 154-9B). Carcinoma en cuirasse can be progressive for many years, even decades, in the absence of any apparent systemic involvement.

Metastases from malignant melanoma are usually pigmented (Fig. 154-10). Often there is a bluish tint to the lesion, even if it is deep in the skin. However, even if the primary tumor was pigmented, the metastases can be amelanotic. The reverse is also true.

Other tumors that commonly metastasize to skin include tumors of the lung (Fig. 154-11), stomach, kidney, and ovary. The scalp is quite commonly involved by metastases from lung, kidney, and breast tumors. Alopecia may result. The face and neck may be involved by metastases from oropharyngeal carcinomas. Metastases from renal and thyroid carcinoma may be pulsatile and may have a bruit.

A proposed diagnostic truncated immunohistochemical battery includes cytokeratin 7, cytokeratin 20, and S-100. When administered to a cohort of patients with lung, colorectal, bladder, renal cell carcinoma, and melanoma, there was an overall diagnostic accuracy of 83.3 percent. Other useful markers include antithyroid transcription factor (lung), human melanoma black-45 (melanoma), prostate-specific antigen (prostate), estrogen/progesterone receptors (breast), and mucicarmine (salivary gland).[105]

Generally cutaneous metastases herald a poor prognosis because evidence of systemic spread to other sites is usually quickly apparent. The average survival time of patients with cutaneous metastases is approximately 7.5 months.[105]

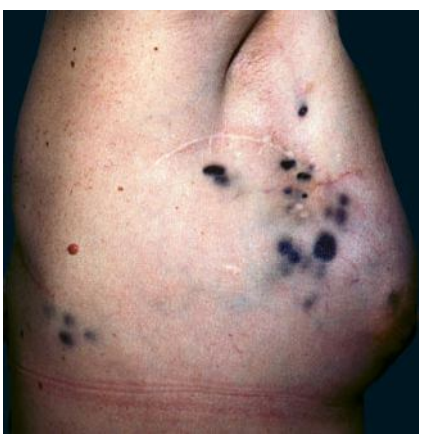

▲ **FIGURE 154-10** Deeply pigmented cutaneous metastases from melanoma.

Leukemia and Lymphoma Cutis (See Chaps. 145 and 146)

Involvement of the skin with lymphoma cells is quite common, particularly in the case of a T-cell lymphoma. T-cell leukemias frequently have skin involvement, and this involvement may manifest itself as a diffuse erythroderma, as is seen in Sézary syndrome.

B-cell lymphomas also can involve the skin, with Hodgkin lymphoma being the most common. B-cell lymphoma involvement of the skin is usually manifested by the development of one or more papules or nodules that may be ulcerated and form arcuate lesions. Alopecia also can be caused by lymphoma. Alopecia mucinosa is involvement of



▲ **FIGURE 154-11** Metastatic lung cancer presenting as a forehead nodule.

the hair follicles by lymphoma, with associated mucin deposition.

Aside from the erythroderma seen in T-cell leukemia, other lymphocytic, myeloid, and myelomonocytic leukemias can have cutaneous manifestations. The most common of these are the infiltrations of the skin produced by monocytic or myelomonocytic leukemia, which can produce a leonine facies in addition to other infiltrative plaques. Involvement of the skin can be a presenting feature in myelomonocytic leukemia, although it generally occurs late in the course of the disease.

When assessing a solitary nodule that is histologically lymphoma but in the absence of any definable systemic disease, it is important to consider benign cutaneous lymphoid infiltrates in the differential diagnosis.

Paget and Extramammary Paget Disease (See Chap. 121)

Paget disease of the nipple is an erythematous scaling eruption indicating ductal carcinoma of the underlying breast. Extramammary Paget disease, which can occur in the anogenital skin, similarly may be associated with an underlying adenocarcinoma. The underlying carcinoma may be of apocrine or eccrine sweat gland origin, or can be from the rectum or urethra.

KEY REFERENCES

The full reference list for all chapters is available at www.digm7.com.

3. Chung VQ et al: Clinical and pathologic findings of paraneoplastic dermatoses. *J Am Acad Dermatol* **54**:745, 2006
7. Torley D, Bellus GA, Munro CS: Genes, growth factors and acanthosis nigricans. *Br J Dermatol* **147**:1096, 2002
12. Cohen PR, Kurzrock R. Mucocutaneous paraneoplastic syndromes. *Semin Oncol* **24**:334, 1997
41. Bolognia JL, Brewer YP, Cooper DL: Bazex syndrome (acrokeratosis paraneoplastica). An analytic review. *Medicine* **70**:269, 1991
54. Eubanks LE, McBurney E, Reed R: Erythema gyratum repens. *Am J Med Sci* **321**:302, 2001
62. Remes-Troche JM et al: Necrolytic migratory erythema: A cutaneous clue to glucagonoma syndrome. *J Eur Acad Dermatol Venereol* **18**:591, 2004
90. Hovenden AL: Hypertrichosis lanuginosa acquisita associated with malignancy. *Clin Dermatol* **11**:99, 1993
97. Tsao H: Update on familial cancer syndromes and the skin. *J Am Acad Dermatol* **42**:939, 2000
105. Saeed S, Keehn CA, Morgan MB: Cutaneous metastasis: A clinical, pathological, and immunohistochemical appraisal. *J Cutan Pathol* **31**:419, 2004



This page intentionally left blank

SECTION 27

THE SKIN IN VASCULAR AND CONNECTIVE TISSUE AND OTHER AUTOIMMUNE DISORDERS

CHAPTER 155

Mechanisms of Autoimmune Disease

Insoo Kang
Joe Craft

Autoimmune diseases, including rheumatoid arthritis (RA) and systemic lupus erythematosus (SLE), are relatively common disorders.[1] Although the underlying etiologies of these illnesses are still elusive, they arise in the context of a break in the immune tolerance to self.[2,3] The mechanisms for abrogation of immune self-tolerance appear to be multifactorial, including genetic and environmental, that work in concert to initiate the eventual hallmarks of disease: unregulated immune activation against self-antigens and subsequent tissue destruction. Immune activation against self-antigens is clinically manifest by the presence of autoantibodies and autoreactive T cells.[1,2] Based on their autoantigenic targets, autoimmune diseases can be classified into organ-specific and systemic autoimmune processes. For example, Graves disease, with its autoantibodies against the thyroid-stimulating hormone receptor, is a typical example of organ-specific autoimmune disease as is type 1 diabetes mellitus (DM) with its autoantibodies and autoreactive T cells directed against components of pancreatic β cells, whereas SLE with its characteristic autoantibodies against ubiquitous nuclear antigens is a good example of a systemic autoimmune disease. Although adaptive immune cells, such as B cells and T cells, recognize self-antigens and, hence, dominate the phenotype of the patient with autoimmunity, other immune components, including antigen-presenting cells (APCs) and complement, are involved in various steps from initiation of the autoimmune response to tissue destruction.[4–6]

GENETICS

Autoimmune Diseases Are Polygenic

Autoimmune diseases are polygenic, involving both major histocompatibility complex (MHC) and non-MHC genes.[7,8] Yet, the concordance rate of autoimmune diseases in monozygotic twins is not 100 percent, ranging from 10 percent to 50 percent, including in RA and SLE,[6,7] indicating a significant role for non-genetic factors in the development of these disorders. Nevertheless, genetic influences are strong. For instance, the contribution of alleles of MHC to the development of autoimmunity has been known for more than 30 years. An increased frequency of HLA (human leukocyte antigen)-DR4 has been observed in some patients with RA.[8] Using more sophisticated molecular techniques, the sequence of genetic alleles encoding HLA loci have been typed, with the resultant demonstration that the *HLA-DRB1* gene is highly polymorphic, and such polymorphisms can affect the binding of peptides to HLA molecules and the contacts between the T-cell receptor (TCR) and the HLA molecule.[8] Thus, the associations between autoimmune diseases and particular HLA molecules can be explained by a model where disease susceptibility is determined by differences in the ability of different HLA alleles to present autoantigenic peptides to autoreactive T cells.[2,8]

Non-Major Histocompatibility Complex Associations with Autoimmune Diseases

The association of non-MHC genes with autoimmune diseases is well established.[1,7] These genes include those involved in autoantigen clearance, apoptosis, cell signaling, cytokine production, and the expression of co-stimulatory molecules.[1,2,7] For instance, complement components are required for proper clearance of immune complexes, and an increased incidence of homozygous C4 deficiency is found in patients with SLE who have immune complex deposits in damaged organs such as the kidneys.[6]

MECHANISMS FOR AUTOIMMUNE DISEASES AT A GLANCE

- Autoimmune diseases are relatively common disorders and can be divided into organ-specific and systemic autoimmune diseases based on the autoantigens targeted by immune cells.
- Although the underlying etiologies of these illnesses are still elusive, they arise in the context of a break in the immune tolerance to self.
- The mechanisms for abrogation of immune self-tolerance appear to be multifactorial, including genetic and environmental, that lead to unregulated immune activation against self-antigens and subsequent tissue destruction.
- B cells and T cells recognize self-antigens and dominate the phenotype of the patient with autoimmunity, although other immune components including antigen-presenting cells and complement are involved in various steps from initiation of the autoimmune response to tissue destruction.



Copyright © 2008 by The McGraw-Hill Companies, Inc. Click here for terms of use.

Autoimmune Regulator

A gene called *autoimmune regulator* (*AIRE*) has been identified as a candidate gene responsible for the development of autoimmune diseases.[9,10] AIRE is a transcriptional factor that regulates the ectopic expression of proteins, normally expressed in peripheral tissues, in the thymus, allowing for thymic expression of the latter and subsequent negative selection of self-reactive thymocytes before they migrate as mature T cells to the secondary lymphoid organs such as the spleen and lymph nodes. An alteration in thymic expression of *AIRE* can lead to increased generation of autoreactive T cells due to their impaired negative selection.[11] Indeed, patients with mutations of the *AIRE* gene develop a syndrome called *autoimmune polyendocrinopathy candidiasis ectodermal dystrophy* or *autoimmune polyglandular syndrome 1* (*APS-1*) that is characterized by chronic mucocutaneous candidiasis, hypoparathyroidism, and Addison disease.[12] In addition, patients with this condition often have other organ-specific autoimmune diseases, including type 1 DM, autoimmune thyroid diseases, gonadal failure, vitiligo, alopecia areata, dystrophy of dental enamel and nails, and pernicious anemia.[12]

Cytotoxic T-Lymphocyte Antigen-4

An increased incidence of autoimmune diseases has been reported in individuals with a particular variant of genes that affect T-cell activation. These include cytotoxic T-lymphocyte antigen-4 (CTLA-4) gene and protein tyrosine phosphatase 22 gene (PTPN22; see Protein Tyrosine Phosphatase 22).[1,13] CTLA-4 is a key immunoregulatory molecule that restrains T-cell activation. It is expressed on T cells upon TCR stimulation by antigen on APC and competes with CD28, a positive co-stimulatory molecule also on T cells, for binding to CD80 and CD86 expressed on APC.[14] By contrast to CD28 engagement by CD80 and CD86, binding of CTLA-4 to the latter molecules inhibits T-cell activation. The association of SLE and RA with single nucleotide polymorphisms (SNPs) in the *CTLA-4* promoter and coding region has been reported. These polymorphic sites include –1722 position of the *CTLA-4* promoter and +49 position of exon-1,[15,16] although the functional consequence of such gene polymorphisms is not clear yet. CTLA-4 polymorphisms also have been linked to autoimmune endocrinopathies; for example, a decrease in the alternate splice product of *CTLA-4* that is the soluble form of CTLA-4 is found in individuals with CTLA-4 SNP CT60 G/G, which is linked with increased susceptibility to Graves disease, autoimmune hypothyroidism, and type 1 DM.[17] This finding suggests a possible functional role for CTLA-4 polymorphisms in autoimmune diseases (Fig. 155-1).

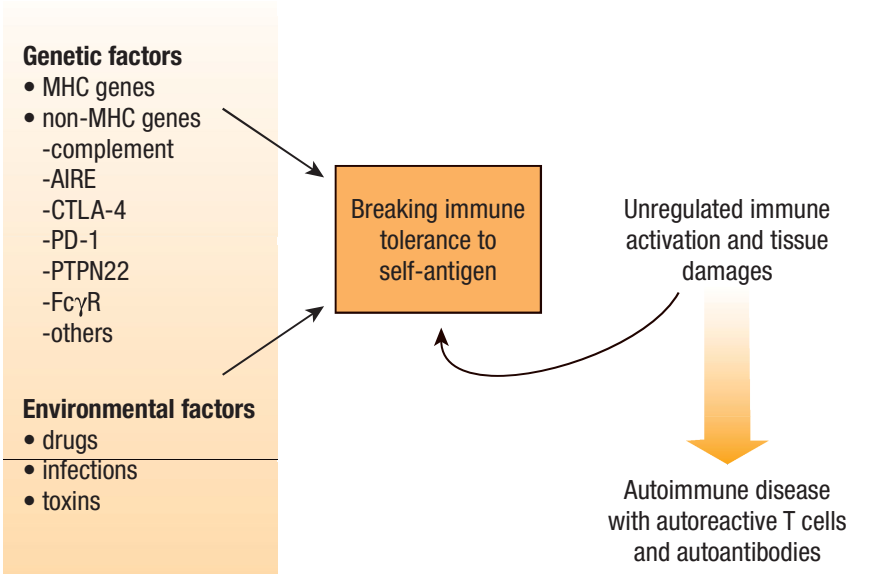

▲ **FIGURE 155-1** Mechanisms for development of systemic autoimmune disease. The figure shows potential mechanisms for initiation of systemic autoimmune diseases, in this case, systemic lupus erythematosus, including genetic and environmental factors that work in concert to initiate breaking immune tolerance to self-antigen. Subsequently, unregulated immune activation and tissue damages arise, leading to the development of autoimmune disease with autoreactive T cells and autoantibodies. AIRE = autoimmune regulator; CTLA-4 = cytotoxic T-lymphocyte antigen-4; FcγR = receptor for immunoglobulin G Fc portion; MHC = major histocompatibility complex; PD-1 = programmed cell death 1; PTPN22 = protein tyrosine phosphatase 22. See details in text.

Programmed Cell Death 1

In a manner analogous to CTLA-4, a protein called *programmed cell death 1* (PD-1) is expressed on T cells providing an inhibitory signal upon their activation. This molecule is also expressed on other immune cells including B cells and myeloid cells.[1,18] PD-1 is encoded by the *PDCD1* gene, with a SNP in its fourth intron associated with autoimmunity, including SLE and RA.[19–21] Of interest, this disease-associated SNP impairs the binding of the hematopoietic runt-related transcription factor 1 (RUNX1), presumably leading to aberrant expression of *PDCD1* gene and subsequently uncontrolled T-cell activation.[19] The association of genetic polymorphisms of CTLA-4 and PD-1, molecules involved in regulating T-cell activation, with autoimmune diseases supports the notion that regulation of T-cell activation by these co-stimulatory molecules is a critical checkpoint for the development of autoimmunity.

Protein Tyrosine Phosphatase 22

The *PTPN22* gene is another gene that is associated with autoimmune diseases.[1] A variant of the *PTPN22* gene, which encodes a tryptophan at codon 620 (620W) instead of an arginine (wild-type), has been found to be associated with an increased risk of RA, SLE, type 1 DM, and Graves disease (reviewed in ref. 1). Such a mutation appears to have functional consequences, as the *PTPN22* gene encodes lymphoid tyrosine phosphatase that modulates the activation of Lck and other kinases involved in TCR signaling.[22] Indeed, the *PTPN22* 620W allele appears to potentially increase the inhibition of TCR activation by downregulating Lck activation.[22] Thus, it still needs to be clarified how this allele promotes the development of autoimmunity.

Receptors for Immunoglobulin G Fc Portion

In addition to genes expressed by T cells, those involved in humoral immune responses also appear to be associated with autoimmunity. The receptors for immunoglobulin G (IgG) Fc portion (FcγR) are expressed on B cells, macrophages, monocytes, granulocytes, and dendritic cells (DCs). There are eight genes identified for the human FcγR: *FCGRIA*, *FCGRIB*,

FCGRIC, *FCGRIIA*, *FCGRIIB*, *FCGRIIC*, *FCGRIIIA*, and *FCGRIIIB*.[23] The binding of FcγRs to IgG, except for that to FcγRIIb, results in a broad spectrum of activating cellular responses including phagocytosis, cytolysis, cytokine production, and degranulation that lead to inflammation. By contrast, FcγRIIb physiologically serves as an inhibitory receptor that downregulates the effector function of cells.[23] An increased frequency of some variants of *FCGR* genes has been reported in humans with autoimmune diseases, including SLE and RA (reviewed in ref. 23).[24–27] FcγRIIa with an arginine at position 131 has a higher response to IgG1 than Fc–γRIIa with a histidine at the same position, suggesting that FcγRIIa gene polymorphisms have physiologic relevance.[27] Of interest, FcγRIIa with an arginine has been reported as a susceptibility factor for SLE in some ethnic groups.[23,28] Similarly, a variant of FcγRIIIa with a phenylalanine at position 158 may be a susceptibility factor for SLE and RA.[24,26] In addition, genetic polymorphisms of the inhibitory FcγRIIb have been reported in patients with SLE,[25,29,30] The best known such polymorphism is a substitution of an isoleucine at position 232 (187 by counting from the N-terminus of the mature protein) with a threonine.[25,29,30] The latter genotype is more commonly reported in patients with SLE. Although the biologic implication of such an alteration on the development of SLE is as yet unclear, functioning inhibitory FcγRs are necessary for dampening autoimmunity in murine lupus.[31]

Overall, genetic studies on MHC genes and non-MHC genes support the notion that some patients with autoimmune diseases have an increased genetic risk for the development of autoimmune diseases secondary to genetic alterations affecting immune cell function. However, such alterations are not always observed in patients with autoimmune diseases, and ethnic differences in genetic susceptibility are not uncommon. These findings indicate that autoimmune diseases are polygenetic and that environment factors are also involved in their development.

TOLERANCE AND AUTOIMMUNITY

Central Tolerance

Intact mechanisms of self-tolerance are necessary to prevent the development of autoimmune diseases.[2] Self-tolerance is generated and maintained through the capacity of the immune system to distinguish self-reactive B and T cells from non–self-reactive cells. These processes begin during the development of lymphocytes in the bone marrow and thymus, respectively.[3] Such selective processes are controlled by the binding affinity of antigen receptors to self-antigens during lymphocyte development. B and T cells expressing antigen receptors with affinity for self-antigens are altered, either becoming nonreactive to antigenic stimuli (through a process called *anergy induction*) or changing their antigen receptors so that they no longer bind self-antigens (a process called *receptor editing*, largely operative in self-reactive B cells), or if they bind too strongly to self, they are simply killed via apoptosis. These interventions lead to central tolerance to self-antigens.[3] A defect in central tolerance can cause autoimmune diseases as evidenced by the development of APS-1 in humans with an alteration in the *AIRE* gene (see Genetics) that is involved in negatively selecting autoreactive T cells.[32,33]

Peripheral Tolerance

Despite removing or modifying autoreactive lymphocytes in the thymus and bone marrow by selective processes, some lymphocytes reactive to self-antigens still mature and enter the peripheral immune system; (i.e., negative selection is not perfect, probably because if it were, potentially beneficial T and B cells would never make it past central selection in the thymus and bone marrow, respectively). These autoreactive T and B cells that escape central selection can potentially be activated upon recognition by self-antigens; thus, peripheral tolerance mechanisms need to be available to avoid the development of autoimmunity. Such mechanisms are several, and involve minimizing contacts of autoreactive cells with self-antigens (ignorance of the self-reactive lymphocyte), not providing appropriate signals for their activation, terminating activated autoreactive cells by regulatory molecules such as PD-1 or CTLA-4 and/or actively suppressing autoimmune responses by other T cells.[2] In critical organs like the brain, eyes, and gonads, immunologic ignorance is a principle mechanism for avoidance of autoreactivity via the provision of anatomical barriers separating the tissue and lymphocytes. Activation of the latter can be further prevented by the relative paucity of APCs in these organs and the minimal expression of MHC molecules in these tissues.[34,35] These sites are termed *immunologically privileged sites* because even tissue grafts do not elicit immune responses in these tissues. Immunologically privileged sites have additional mechanisms that prevent immune activation. These include production of transforming growth factor-β (TGF-β), which can suppress immune responses such as in the anterior chamber of the eyes, and constitutive expression of Fas ligand that induces apoptosis of infiltrating activated lymphocytes.[34,35]

Nevertheless, because autoantigens are expressed on some tissues and autoreactive lymphocytes are present in the circulation, there is still a reasonable chance for these cells to recognize autoantigens expressed by MHC molecules on APC. However, such an autoantigenic signal through potentially self-reactive antigen receptors is not enough to activate lymphocytes, as additional signals (second signals) provided by APCs, such as CD80 and CD86, to CD28 on T cells are required for proper activation.[14,26] When proper co-stimulation is not provided by APCs, autoreactive T cells that are only signaled through the TCR undergo apoptosis or become anergized. As CD80 and CD86 upregulation on APCs requires an inflammatory stimulus provided to the APC such as that provided by a pathogen during infection, APC presentation of self-antigens in the absence of inflammation does not lead to autoreactive T-cell activation. By contrast, peptides of pathogens lead to cellular activation as they are presented to the immune system in the appropriate inflammatory context. Of course, this regulatory control on autoimmunity may be bypassed if, in a similar manner, self-antigens are presented at a site of inflammation. Fortunately, this appears to be a relatively unusual event, and autoimmunity invoked by this mechanism is typically avoided.

Autoreactive lymphocytes that manage to become activated in the periphery can be also deleted by apoptosis (programmed cell death) and/or their activation terminated by inhibitory molecules expressed on autoreactive lymphocytes. Fas and Fas ligand expressed on T cells are largely responsible for the former process.[37,38] The latter process can be achieved through CTLA-4 and PD-1 expressed on activated T cells that inhibit and downregulate T-cell activation.[14,18] The potential roles for CTLA-4 and PD-1 in controlling autoimmunity have been demonstrated by mouse studies where these genes have been genetically eliminated, for example, with resultant autoimmunity.[39,40] In addition,



genetic polymorphisms in these molecules have been reported to be associated with autoimmune diseases including SLE and RA (see Genetics). More important, there have been attempts to treat autoimmune diseases by modulating CTLA-4 and PD-1 inhibitory pathways.[41,42] Indeed, abatacept, a recombinant fusion protein comprising the extracellular domain of human CTLA-4 and a fragment of the Fc domain of human IgG1, is available for the treatment of RA.[41] This drug, like CTLA-4, competes with CD28 for CD80 and CD86 binding, blocking T-cell activation and thus selectively modulating T cell activation. The activation of autoreactive lymphocytes is also actively suppressed through other mechanisms. The most appealing such mechanism is immune suppression through subsets of T cells called *regulatory T cells* (*Tregs*), discussed in Regulatory T Cells.



Regulatory T Cells

The concept that certain T cells can regulate immune responses dates back to the early 1970s. These cells, which Gershon initially called *suppressor cells*,[43] remained largely undefined and their mechanism of suppression not identified. After their original discovery, they remained out of vogue until more than a decade later when others, including Sakaguchi, reported modulation of immune responses by $CD4^+$ T cells expressing CD25 [interleukin 2 (IL-2) receptor α chain][44] as well as by T cells producing TGF-β and IL-10.[45–47] Cells with immune regulatory functions are now called *Tregs*. Several subsets of Tregs have been identified thus far, including (1) naturally occurring $CD4^+$ $CD25^+$ Tregs expressing the transcriptional repressor protein forkhead box P3 (Foxp3); (2) $CD4^+$ T cells producing IL-10, called *type 1 Tregs* (*Tr1*); (3) $CD4^+$ T cells producing TGF-β, named *T helper 3 cells* (*Th3*); and (4) $CD8^+$ T cells producing IL-10 or TGF-β (reviewed in refs. 48 and 49).

$CD4^+$ $CD25^+$ Regulatory T Cells

Among the best characterized Tregs are naturally occurring $CD4^+$ $CD25^+$ $Foxp3^+$ cells that are produced in the thymus. The potential role for these Tregs in controlling the development of autoimmunity was initially demonstrated by studies where mouse T-cell suspensions were transferred into congenic athymic nude mice. If the latter animals received such suspensions depleted of $CD4^+$ $CD25^+$ T cells, they developed an autoimmune syndrome including thyroiditis, gastritis, insulitis, sialoadenitis, adrenalitis, oophoritis, glomerulonephritis, and polyarthritis.[44] By contrast, athymic nude mice that received whole T-cell suspensions did not develop autoimmunity, indicating a role for $CD4^+$ $CD25^+$ T cells in preventing autoimmune diseases.[44] Subsequently, the inhibitory effects of $CD4^+$ $CD25^+$ Tregs in different types of animal models of autoimmune diseases, including collagen-induced arthritis and autoimmune diabetes, were documented.[50,51] Yet, not all $CD4^+$ $CD25^+$ T cells have immunoregulatory functions as CD25 is upregulated upon T-cell activation. Thus, the search for other markers that specifically identify these cells has been extensive, and has led to the identification of CD38, CD103, CTLA-4, glucocorticoid-induced tumor necrosis factor (TNF) receptor, lymphocyte activation gene, and Foxp3[52] as potential markers as well as contributors to function. The most promising of this group is Foxp3. Disruption of its gene in mice results in autoimmune diseases,[53,54] whereas overexpression of Foxp3 in T cells induces expansion of $CD4^+$ T cells with immunosuppressive function.[53–55] Furthermore, $CD4^+$ CD25- T cells transfected with FoxP3 acquire immunosuppressive function.[53,54]

Although the exact mechanism(s) by which naturally occurring $CD4^+$ CD25 Tregs suppress autoreactive T cells is not fully understood, cell-to-cell contact is necessary, and CTLA-4 appears to be required.[56] CTLA-4 expressed on Tregs interacts with CD80 and CD86 expressed on APC as well as on the target T cells[57,58]; although CD80 and CD86, ligands for CTLA-4, are conventionally expressed on APC, as noted above under Cytotoxic T-Lymphocyte Antigen-4, they have also been found on activated $CD4^+$ T cells.[57,58] These molecules likely interact with CTLA-4 expressed on $CD4^+$ $CD25^+$ T cells, providing "outside-in" signaling, leading to immune suppression. This notion is supported by the study of graft-versus-host disease (GVHD), in which $CD4^+$ $CD25^-$ T cells with or without expression of CD80 and CD86 were transferred into lymphopenic recombination-activating gene 2 (RAG2)-deficient mice, together with $CD4^+$ CD25+ T cells.[57,58] Mice that received $CD4^+$ $CD25^+$ T cells as well as $CD4^+$ $CD25^-$ T cells with expression of CD80 and CD86 developed no GVHD. By contrast, mice that received $CD4^+$ $CD25^+$ T cells and $CD4^+$ $CD25^-$ T cells deficient in CD80 and/or CD86 expression developed GVHD. These findings indicate that $CD4^+$ $CD25^+$ Tregs expressing CTLA-4, via interaction with CD80, can modulate activated T cells and CD86 expressed on activated T cells.

By contrast to animal studies, the data on $CD4^+$ $CD25^+$ Tregs in human autoimmune diseases is relatively minimal. In patients with type 1 DM, a typical example of organ-specific autoimmune diseases, the frequency of $CD4^+$ $CD25^+$ Tregs has been shown to be significantly lower than in healthy controls and patients with type 2 DM, suggesting a role for these cells in disease development.[59] However, differences in the frequency of $CD4^+$ $CD25^+$ Tregs has not been reported in patients with type 1 DM compared with healthy controls,[60] although the inhibitory function of such cells was impaired in such patients.[61] Similarly, there was no difference in the frequency of $CD4^+$ $CD25^+$ T cells and their functional markers, including Foxp3, among patients with APS-II characterized by Addison disease, type 1 DM, and autoimmune thyroid disease, as well as control patients with single autoimmune endocrinopathies and normal healthy donors.[62] However, $CD4^+$ $CD25^+$ Tregs from APS-II patients were defective in their suppressive capacity.[62] These findings suggest that patients with autoimmune endocrinopathies, including type 1 DM and APS-II, may have an alteration in the suppressive function of $CD4^+$ $CD25^+$ Tregs.

A role for $CD4^+$ $CD25^+$ Tregs in the development of SLE and RA, typical systemic autoimmune diseases, has also been explored. In pediatric patients with SLE, an inverse correlation between the frequency of $CD4^+$ $CD25^+$ Tregs with disease activity and levels of anti-double-stranded DNA (anti-dsDNA) antibodies has been reported.[63] Similarly, decreased numbers of $CD4^+$ $CD25^+$ Tregs were found in adult patients with SLE, although there was no significant correlation found between the levels of $CD4^+$ $CD25^+$ Tregs and disease activity.[64] These observations suggest a potential role for $CD4^+$ $CD25^+$ Tregs in the development of SLE. In RA, $CD4^+$ $CD25^+$ Tregs from both peripheral blood and synovial fluid have been studied.[65–67] The frequency of $CD25^+$ $CD4^+$ Tregs in the latter fluid was higher than that in peripheral blood,[66,67] although there was no significant difference in the numbers of $CD4^+$ $CD25^+$ Tregs in peripheral blood between patients and controls.[66,67] Of interest, $CD4^+$ $CD25^+$ Treg cells in RA have been shown to have compromised function in the suppression of inflammatory cytokines from $CD4^+$ $CD25^-$

T cells.[68] Furthermore, such impairment was reversed after treating patients with anti–TNF-α therapy. These findings suggest that patients with RA have a functional, but not a numerical, defect in $CD4^+$ $CD25^+$ Tregs.

Other Regulatory T Cells

In contrast to $CD4^+$ $CD25^+$ Tregs that naturally occur, other regulatory T cells can be induced in vivo and in vitro (reviewed in ref. 49). These cells include Tr1, Th3 ($CD4^+$ T cells producing large amounts of TGF-β), $CD28^+$ T cells that develop in the setting of immune stimulation such as that initiated by chronic infections. For instance, humans chronically infected with hepatitis C or Epstein-Barr viruses (EBVs), or with *Mycobacterium tuberculosis* or the nematode *Onchocerca volvulus*, may develop pathogen-specific Tr1 cells that produce large amounts of IL-10 that can suppress antigen-specific or non-specific T-cell responses.[69–72] These cells can also be generated after ingestion of a foreign antigen via the oral route.[45] The immunosuppressive mechanisms employed by Tr1 and Th3 cells are dependent on IL-10 and TGF-β production rather than direct cell-to-cell contact as in natural Tregs.[49]

$CD8^+$ T cells may also have immunosuppressive activity.[48] Mice deficient in $CD8^+$ T cells develop experimental autoimmune encephalomyelitis (EAE), an animal model of multiple sclerosis.[73] However, EAE in the same animals was milder when they received adoptive transfers of $CD8^+$ $CD28^-$ T cells. Moreover, $CD8^+$ $CD28^-$, but not $CD8^+$ $CD28^+$, T cells suppressed in vitro interferon-γ (IFN-γ) production by $CD4^+$ T cells specific for myelin oligodendrocyte glycoprotein, an autoantigen in EAE. Such suppression required cell-to-cell contact and was mediated by inhibition of upregulation of co-stimulatory molecules on APCs that led to decreased co-stimulation of $CD4^+$ T cells. Of interest, $CD8^+$ T cells with suppressor activity have been suggested to have a potential role in improving lupus-like disease in mice.[74] Decreased levels of pathogenic anti-dsDNA antibodies with a resultant increase in survival were found in lupus-prone [New Zealand Black (NZB) x New Zealand White (NZW)]F_1 mice when injected with an artificial peptide called pConsensus that was developed based on T-cell stimulatory V_H sequences found in (NZB x NZW)F1 anti-DNA antibodies. This protection depended in part on the generation of peripheral TGF-β– and Foxp3-expressing inhibitory $CD8^+$ T cells, and suggested that $CD8^+$ T cells with regulatory activity could be a potential way to modulate autoimmune diseases.

INNATE IMMUNITY AND AUTOIMMUNITY: DENDRITIC CELLS AND TOLL-LIKE RECEPTORS

Various cells of the innate immune system appear to be involved in the regulation of autoimmunity, including DCs, natural killer cells, γδ T cells, natural killer T cells, and even mast cells.[75–80] Among the best characterized are DCs, or professional APCs.[81] DCs present antigens to T cells for their activation, but their requirement to provide co-stimulation via CD80 and CD86 limits autoreactive T-cell activation in the absence of inflammatory signals. Interaction of CD80 on DCs and CD28 on T cells polarizes TCR-triggered naive T cells into Th1 cells producing IFN-γ. In addition, activated DCs produce multiple cytokines including IL-12, TNF-α and IL-6 that can promote inflammation. DCs express Toll-like receptors (TLRs), or pattern recognition receptors that recognize various pathogen-associated molecular structures including lipopolysaccharide, double-stranded RNA, single-stranded RNA, and hypomethylated cytosine and guanosine sequence (CpG) DNA.[82] Thus, microorganisms can potentially promote autoimmunity and inflammation through these receptors by activating DCs.[81] Activated DC can also affect $CD4^+$ $CD25^+$ Treg function. Microbial activation of TLRs blocks the suppressive effect of $CD4^+$ $CD25^+$ Treg cells, allowing activation of pathogen-specific adaptive immune responses.[83] This block of suppressor activity is dependent in part on IL-6, which was induced by TLRs upon recognition of microbial products.

DCs and TLRs are also likely involved in the development of SLE. Ronnblom and Alm have demonstrated that immune complexes in lupus serum containing autoantibodies associated with apoptotic fragments of cells including DNA or RNA can stimulate plasmacytoid DCs (pDCs) to produce IFN-α with resultant autoimmune inflammation.[4,5] Such events can be mediated by TLRs,[84,85] pDCs express TLR9 that recognize CpG DNA[82]; thus, immune complexes in lupus serum containing CpG DNA and anti-DNA antibodies can stimulate pDC to produce IFN-α, which promotes autoimmunity (see Interferon-α and Autoimmunity). This notion is supported by two studies showing that murine B-cell hybridomas with specificity to rheumatoid factor or DNA activate B cells by engaging both IG receptors and TLR9.[86,87] A similar concept has been raised by recent studies demonstrating the role of TLR7 and TLR8 in cellular responses to single-strand RNA,[88,89] because antibodies against small nuclear RNA and protein complexes are often found in lupus patients.[84,85]

ENVIRONMENTAL FACTORS AND AUTOIMMUNITY

Drugs and Autoimmunity

Certain drugs can induce autoimmune diseases, with potentially protean clinical manifestations.[90] Among the best-known inducers of autoimmunity are procainamide and hydralazine, which can lead to drug-induced lupus in a minority of patients who take these agents. Although the exact mechanisms that promote procainamide- and hydralazine-induced lupus are not fully understood, recent studies suggest that alterations in DNA methylation, a process critically involved in gene regulation, by these drugs could be responsible for the development of lupus.[91,92] Procainamide and hydralazine can decrease DNA methylation in T cells, resulting in increased expression of genes, such as lymphocyte function-associated antigen, which can potentially promote autoimmunity.[93,94] Evidence from mice also suggests that procainamide may alter central (thymic) tolerance in T-cell selection, leading to escape of autoreactive T cells into the periphery.[95]

Interferon-α and Autoimmunity

Ironically, drugs that modulate the immune system, for example IFN-α, can also induce autoimmunity. In patients treated with IFN-α for hepatitis C or for malignancies, drug-induced lupus with nephritis and antineutrophil cytoplasmic antibodies–associated vasculitis have been reported.[84,85,90] In fact, the potential role of IFN-α in the pathogenesis of lupus was suggested in late 1970s by a study reporting increased serum levels of IFN-α in lupus patients.[96] This notion has been recently revived by several groups that have demonstrated increased expression of IFN-induced genes in peripheral blood cells from lupus patients, using microarray analyses.[97,98]

IFN-α can affect innate and adaptive immune cell function. Although it has antiproliferative effects on T cells,[99] at



the same time, it enhances IG isotype switching by stimulating DCs.[100] IFN-α also induces maturation of DCs and drives monocytes to become more effective in stimulating T cells, including those that are potentially autoreactive.[101–103] The results of studies in mice also provide evidence for a role of this cytokine in the development of lupus. Administration of poly(inosine-cytosine), a synthetic double-stranded RNA and strong IFN-α inducer, accelerated development of disease in lupus-prone (NZB x NZW)F_1 mice.[104] Lupus-prone mice lacking receptors for type I IFN, including IFN-α, had reduced anti-dsDNA antibodies and disease activity.[105]



Toxins and Autoimmunity

Environmental chemicals and toxins also have been reported as a potential cause for autoimmune diseases.[106] Probably the best-known chemical is crystalline silica, which has been reported to be associated with the development of systemic sclerosis.[106] In addition to this condition, there are patients with SLE and RA who were exposed to crystalline silica,[106] although such epidemiologic data is difficult to provide evidence for causation. On the other hand, lupus-prone (NZB x NZW)F_1 mice exposed to silica have increased levels of anti-nuclear antibodies, with decreased survival compared with mice not exposed to this chemical.[107] Although the exact mechanism for the development of autoimmune diseases after crystalline silica exposure is unknown, this chemical could serve as an adjuvant promoting immune responses with an increase in the production of pro-inflammatory cytokines such as TNF-α.[108] Although there are case reports of autoimmune diseases associated with the exposure to toxic chemicals as well as animals with autoimmune diseases aggravated by such chemicals, additional studies are needed to define the causal relationship between chemical exposure and autoimmunity.

Infections and Autoimmunity

Infection has been suggested as a possible causative factor for autoimmunity. Postulated mechanisms include: (1) release of inflammatory cytokines such as IFN-α by APCs that can modulate immune responses, (2) production of cross-reactive antibodies or T cells that can recognize both autoantigens and foreign antigens (molecular mimicry), and (3) polyclonal activation of autoreactive T cells by superantigens.[2] However, these possible mechanisms are not yet proven. Nevertheless, a variety of infectious organisms, including virus and bacteria, have been linked to autoimmune diseases,[109] including EBV as a trigger for SLE. The prevalence of EBV infection as determined by measuring anti-EBV antibodies is higher in patients with SLE compared with healthy controls,[110,111] and patients with SLE have increased EBV viral loads in peripheral blood and altered T-cell immune responses to EBV compared with healthy controls.[112] These findings suggest that the immune control of EBV is altered in SLE, although it is not clear whether such an alteration is the cause or the consequence of SLE. An intriguing question is why only a small fraction of individuals develop autoimmunity even though infections that may be associated with autoimmunity, such as EBV, are very common in the population. One likely answer is diversity in the genetic background among individuals, which can lead to different immune responses to the same infectious organisms and possible development of autoimmune diseases.

PATHOGENESIS OF TISSUE DAMAGE IN AUTOIMMUNITY

The mechanisms involved in tissue damages in autoimmune diseases are similar to those that are used in eradicating invading foreign organisms. Autoantibodies can directly bind to autoantigens that are expressed on cells, which results in destruction of cells (type II antibody-mediated hypersensitivity reaction).[2] Autoimmune hemolytic anemia and autoimmune thrombocytopenia, which can be seen in SLE, are good examples of cell destruction by this mechanism.[113] Some autoantibodies can bind autoantigens and activate the complement cascade, which leads to the recruitment of inflammatory cells and subsequent tissue damage (type III immune complex-mediated hypersensitivity reaction).[113] For instance, autoantibodies against chromatin and ribonucleoproteins appear to have a pathogenic role in lupus.[114] The deposition of immune complexes of these autoantibodies with their respective autoantigens in target organs, such as in the kidney, leads to activation of complement and Fc receptor binding with subsequent tissue injury.[115,116] Although autoreactive T cells are required for the development of autoimmune diseases and autoantibodies,[117,118] it is still unclear whether autoreactive T cells are directly involved in damaging tissues in systemic autoimmune syndromes such as SLE. Whereas, their role in directly promoting tissue injury in organ-specific autoimmune syndromes, such as type 1 DM and multiple sclerosis, are much better established.

Taken together, although the mechanisms for development of autoimmune diseases have not been fully dissected, the key impairment is a break in immune tolerance against self that leads to unregulated immune activation and tissue damages. Both genetic and environmental factors are accountable for this phenomenon by affecting various types of components in the immune system that include innate and adaptive immune cells, cytokines, and complement. A better understanding of the mechanisms that underlie the development of autoimmune diseases will be essential for developing specific treatments by selectively targeting the defect(s) in immune tolerance against self.

KEY REFERENCES

The full reference list for all chapters is available at www.digm7.com.

1. Pearce SH, Merriman TR: Genetic progress towards the molecular basis of autoimmunity. *Trends Mol Med* **2**:90, 2006
2. Janeway C et al: Autoimmunity and transplantation, in *Immunobiology: The Immune System in Health and Disease*. New York, Garland Science Publishing, 2005, p 557
3. Goodnow CC et al: Cellular and genetic mechanisms of self tolerance and autoimmunity. *Nature* **7042**:590, 2005

23. Takai T: Fc receptors and their role in immune regulation and autoimmunity. *J Clin Immunol* **1**:1, 2005

48. Beissert S et al: Regulatory T cells. *J Invest Dermatol* **1**:15, 2006
49. Mills KH: Regulatory T cells: Friend or foe in immunity to infection? *Nat Rev Immunol* **11**:841, 2004

85. Crow MK, Kirou KA: Interferon-alpha in systemic lupus erythematosus. *Curr Opin Rheumatol* **5**:541, 2004

CHAPTER 156

Lupus Erythematosus

Melissa I. Costner
Richard D. Sontheimer

LUPUS ERYTHEMATOSUS: A CHALLENGE TO DEFINE AND TREAT

Lupus erythematosus (LE) is the root designation for a diverse array of illnesses that are linked together by the development of autoimmunity directed predominately at the molecular constituents of nucleosomes and ribonucleoproteins. Some patients present with life-threatening manifestations of systemic LE (SLE); whereas others, who are affected with what likely represents the same basic underlying disease process, express little more than discoid LE (DLE) skin lesions throughout their illness. It is convenient to conceptualize LE as a clinical spectrum ranging from mildly affected patients with only localized DLE skin lesions to those at risk of dying from the systemic manifestations of LE such as nephritis, central nervous system disease, or vasculitis. The pattern of skin involvement expressed by an individual patient with LE can provide insight about the position on the spectrum where the patient's illness might best be placed.

The nomenclature and classification system originally devised by James N. Gilliam divides the cutaneous manifestations of LE into those lesions that show characteristic histologic changes of LE (LE-specific skin disease) and those that are not histopathologically distinct for LE and/or may be seen as a feature of another disease process (LE–non-specific skin disease). The term *cutaneous LE* (CLE) is often used synonymously with "LE-specific skin disease" as an umbrella designation for the three major categories of LE-specific skin disease: acute cutaneous LE (ACLE), subacute cutaneous LE (SCLE), and chronic cutaneous LE (CCLE). This will be the framework used in our discussion of the extraordinarily diverse set of cutaneous lesions that occur in patients with LE (Table 156-1).

The essence of LE is in its heterogeneity, and the challenge for those who treat it is to recognize clinically useful patterns within the mosaic of features that constitute this protean illness. An overview of the systemic manifestations of LE can be seen in the American College of Rheumatology's (ACR) classification criteria for SLE,[1] which are presented in Table 156-2, and from the outline of the systemic manifestations of SLE presented in Table 156-3. It should be noted that a study to refine SLE criteria, including addressing definition of CLE, is ongoing.[2]

EPIDEMIOLOGY

The epidemiology and socioeconomic impact of LE in general,[3] and CLE specifically,[4] have been reviewed. Skin disease is the second most frequent clinical manifestation of LE after joint inflammation. As many as 45 percent of patients with CLE experience some degree of vocational handicap.

Malar, or butterfly rash (localized ACLE), has been reported in 20 percent to 60 percent of large cohorts of patients with LE. Limited data suggest that the maculopapular or SLE rash of generalized ACLE is present in about 35 percent to 60 percent of patients with SLE. ACLE, like SLE in general, is much more common in women than men (8:1). All races are affected; however, the early clinical manifestations of ACLE can be overlooked in a dark-skinned individual.

Patients presenting with SCLE lesions constitute 7 percent to 27 percent of LE patient populations. SCLE is primarily a disease of white females, with the mean age of onset in the fifth decade.

The most common form of CCLE, a classic DLE skin lesion, is present in 15 percent to 30 percent of SLE populations selected in various ways. Approximately 5 percent of patients presenting with isolated localized DLE subsequently develop SLE. It has been suggested that SLE is sevenfold more common than DLE. Although DLE can occur in infants and the elderly, it is most common in individuals between 20 and 40 years of age. DLE has a female-male ratio of 3:2 to 3:1, which is much lower than that of SLE. All races are affected, but investigations suggest that DLE might be more prevalent in blacks.

ETIOLOGY AND PATHOGENESIS

The cause(s) of and pathogenetic mechanisms responsible for LE-specific skin disease are not fully understood, although recent work has provided many new insights. The pathogenesis of LE-specific skin disease is inextricably intertwined with SLE pathogenesis. Simply put, SLE is a disorder in which the interplay between host factors (susceptibility genes, hormonal milieu, etc.) and environmental factors [ultraviolet (UV) radiation, viruses, drugs] leads to loss of self-tolerance, and induction of autoimmunity. This is followed by activation and expansion of the immune system, and eventuates in immunologic injury

LUPUS AT A GLANCE



- A group of heterogeneous illnesses that have in common the development of immunity to particles of self-DNA, with skin-only disease at one end of the spectrum and severe visceral involvement at the other.
- Skin lesions may be specific to lupus or non-specific and are be seen in other conditions as well.
- Acute cutaneous lupus erythematosus (malar rash) is almost always associated with underlying visceral involvement, subacute cutaneous lupus patients meet systemic lupus erythematosus criteria about 50 percent of the time, and chronic cutaneous lupus (discoid lupus erythematosus, lupus panniculitis, chilblain lupus, and tumid lupus erythematosus) patients most often have skin-only or skin-predominant disease.
- Discoid lupus erythematosus causes scarring and can be permanently disfiguring. Subacute cutaneous lupus and acute cutaneous lupus erythematosus are highly photosensitive and are characteristically non-scarring.
- Lupus erythematosus–non-specific skin lesions include non-scarring alopecia, mouth ulcers, photosensitivity, Raynaud phenomenon, and vasculitis/vasculopathy, among others. They often herald a systemic lupus erythematosus flare.
- Treatment consists of sunscreens, local and systemic (short-term) glucocorticoids, antimalarials, retinoids, immunosuppressives, thalidomide, and biologic therapies.
- Lupus erythematosus occurs much more commonly in women (9:1 female-male ratio).





TABLE 156-1
The Gilliam Classification of Skin Lesions Associated with Lupus Erythematosus

I. LE-specific skin disease [cutaneous LE (CLE)]
- A. Acute cutaneous LE (ACLE)
  - 1. Localized ACLE (malar rash; butterfly rash)
  - 2. Generalized ACLE (lupus maculopapular lupus rash, SLE rash, rash, photosensitive lupus dermatitis)
- B. Subacute cutaneous LE (SCLE)
  - 1. Annular SCLE (lupus marginatus, symmetric erythema centrifugum, autoimmune annular erythema, lupus erythematosus gyratus repens)
  - 2. Papulosquamous SCLE (disseminated DLE, subacute disseminated LE, superficial disseminated LE, psoriasiform LE, pityriasiform LE, and maculopapular photosensitive LE)
- C. Chronic cutaneous LE (CCLE)
  - 1. Classic discoid LE (DLE)
    - a. Localized DLE
    - b. Generalized DLE
  - 2. Hypertrophic/verrucous DLE
  - 3. Lupus profundus/lupus panniculitis
  - 4. Mucosal DLE
    - a. Oral DLE
    - b. Conjunctival DLE
  - 5. Lupus tumidus (urticarial plaque of LE)
  - 6. Chilblain LE (chilblain lupus)
  - 7. Lichenoid DLE (LE/lichen planus overlap, lupus planus)

II. LE–non-specific skin disease
- A. Cutaneous vascular disease
  - 1. Vasculitis
    - a. Leukocytoclastic
      - (1) Palpable purpura
      - (2) Urticarial vasculitis
    - b. Periarteritis nodosa–like cutaneous lesions
  - 2. Vasculopathy
    - a. Degos disease–like lesions
    - b. Secondary atrophie blanche (livedoid vasculitis, livedo vasculitis)
  - 3. Periungual telangiectasia
  - 4. Livedo reticularis
  - 5. Thrombophlebitis
  - 6. Raynaud phenomenon
  - 7. Erythromelalgia (erythermalgia)
- B. Non-scarring alopecia
  - 1. "Lupus hair"
  - 2. Telogen effluvium
  - 3. Alopecia areata
- C. Sclerodactyly
- D. Rheumatoid nodules
- E. Calcinosis cutis
- F. LE–non-specific bullous lesions
- G. Urticaria
- H. Papulonodular mucinosis
- I. Cutis laxa/anetoderma
- J. Acanthosis nigricans (type B insulin resistance)
- K. Erythema multiforme
- L. Leg ulcers
- M. Lichen planus

LE = lupus erythematosus; SLE = systemic lupus erythematosus.
From Sontheimer RD: The lexicon of cutaneous lupus erythematosus—A review and personal perspective on the nomenclature and classification of the cutaneous manifestations of lupus erythematosus. *Lupus* **6**:84, 1997, with permission from Stockton Journals, Macmillan Press, Ltd.

to end organs and clinical expression of disease (Fig. 156-1).

Host Factors

SUSCEPTIBILITY GENES A genetic contribution to susceptibility to LE is supported by an increased sibling risk (as much as 20-fold) and by increased disease concordance in monozygotic twins. This heterogeneous disease is likely polygenic, with different genetic abnormalities predisposing to different clinical phenotypes of disease. This idea has been supported by Liu and Mohan,[5] whose congenic mouse model has suggested a multi-step process, in which LE is initiated by one gene and is further exacerbated by additional susceptibility loci or genes. For example, breach of immune tolerance to nuclear antigens mediated by the Sle1 gene appears to be essential for the development of lupus in the inbred New Zealand mouse. However, Sle1 by itself does not lead to the development of fatal lupus, rather only modest serologic autoreactivity. In contrast, Sle1 in epistasis with Sle3,5 or lpr genes mediates highly penetrant fatal glomerulonephritis.[5]

In humans, the genetic association between LE-specific skin disease and serologically determined major histocompatibility complex (MHC) class II DR specificities is well known. For example, patients with SCLE and overlapping features of Sjögren syndrome are more likely to have the HLA-DR3, DQA1*0501, DQB1*0502 haplotype. Significant increases of HLA-B7, -B8, -DR2, -DR3, and -DQA0102 and a significant decrease in HLA-A2 have been reported for patients with DLE. The combination of HLA-DR3, HLA-DQA0102, and HLA-B7 conferred the maximum relative risk (7.4) for DLE. Although there is a strong theoretical basis that MHC alleles can act as disease susceptibility genes by shaping the T-cell repertoire, it is also increasingly recognized that HLA class II alleles are more closely associated with specific autoantibody and clinical phenotypes of disease. In addition, genetic linkage studies in multiplex families have suggested that discoid LE skin lesions in African American SLE patients are linked to a candidate region at 11p13.[6]

Other susceptibility genes outside the MHC region that have been implicated. These include interleukin 1 (IL-1) receptor antagonist and tumor necrosis factor-α (TNF-α). Werth and colleagues[7] found a substantial increase in the prevalence of a promoter polymorphism of TNF-α (-308A) in patients with SCLE. Additionally, they found that there was a striking synergy between UVB and added IL-1α (a photo-induced cytokine) in the induction of transcription of the TNF-α -308A promoter.[7] This finding suggests that this polymorphism may directly contribute to the photosensitivity of patients with SCLE. An alternate explanation is that TNF-α may be a marker allele for the extended HLA-A01,B08, DRB1*0301 haplotype that is associated with a number of autoimmune conditions, including SCLE.[8]

Genetic deficiency of the early complement components C1q, C4, and to a lesser extent, C2 predispose patients to the development of lupus.[9] In fact, complete congenital deficiency of C1q is the strongest single genetic risk factor yet identified for the development of photosensitive SLE.[10]

SEX HORMONES One of the most striking clinical observations in SLE is the disease's female predilection. Indeed, there is a lifetime female-male ratio of 9:1. This sexually dimorphic prevalence is likely due to the effect of sex hormones on the immune system. High levels of estrogen and progesterone promote humoral autoreactivity. Patients with lupus metabolize estrogens differently and have up to a 20-fold increase in the fraction of high-potency to low-potency estrogens when compared with healthy controls. High levels of estrogen have been shown to cause patients with SLE to have an increase in (1) the number of self-reactive lymphocytes that bypass developmental deletion, (2) an increase in CD4/CD8 ratio (favoring humoral responsiveness), and (3) the number of B cells leaving the

TABLE 156-2
The 1982 Revised Criteria for Classification of Systemic Lupus Erythematosus[a]

CRITERION	DEFINITION
1. Malar rash	Fixed erythema, flat or raised, over the malar eminences, tending the spare the nasolabial folds
2. Discoid rash	Erythematous raised patches with adherent keratotic scaling and follicular plugging; atrophic scarring may occur in older lesions
3. Photosensitivity	Skin rash as a result of unusual reaction to sunlight, by patient history or physician observation
4. Oral ulcers	Oral or nasopharyngeal ulceration, usually painless, observed by a physician
5. Arthritis	Non-erosive arthritis involving two or more peripheral joints, characterized by tenderness, swelling, or effusion
6. Serositis	a. Pleuritis—convincing history of pleuritic pain or rub heard by a physician or evidence of pleural effusion *or* b. Pericarditis—documented by electrocardiogram or rub or evidence of pericardial effusion
7. Renal disorder	a. Persistent proteinuria— > 0.5 g/day or greater than 3+ if quantitation not performed *or* b. Cellular casts—may be red cell, hemoglobin, granular, tubular, or mixed
8. Neurologic disorder	a. Seizures—in the absence of offending drugs or known metabolic derangements (e.g., uremia, ketoacidosis, or electrolyte imbalance) *or* b. Psychosis—in the absence of offending drugs or known metabolic derangements (e.g., uremia, ketoacidosis, or electrolyte imbalance)
9. Hematologic disorder	a. Hemolytic anemia—with reticulocytosis *or* b. Leukopenia— < 4000 μL total on two or more occasions *or* c. Lymphopenia— < 1500/μL on two or more occasions *or* d. Thrombocytopenia— < 100,000 μL in the absence of offending drugs
10. Immunologic disorder	a. Anti-DNA—antibody to native DNA in abnormal titer *or* b. Anti-Sm—presence of antibody to Sm nuclear antigen *or* c. Positive finding of anti-phospholipid antibodies based on (1) an abnormal serum level of immunoglobulin G or immunoglobulin M anticardiolipin antibodies, (2) a positive test result for lupus anticoagulant using a standard method, or (3) a false-positive serologic test for syphilis known to be positive for at least 6 mo and confirmed by *Treponema pallidum* immobilization or fluorescent treponemal antibody absorption test
11. Anti-nuclear antibody	An abnormal titer of anti-nuclear antibody by immunofluorescence of an equivalent assay at any point in time and in the absence of drugs known to be associated with "drug-induced lupus" syndrome

[a]The proposed classification is based on 11 criteria. For the purpose of identifying patients in clinical studies, a person shall be said to have systemic lupus erythematosus if any 4 or more of the 11 criteria are present, serially or simultaneously, during any interval or observation.
From Tan EM et al: The 1982 revised criteria for the classification of systemic lupus erythematosus. *Arthritis Rheum* **25**:1271, 1982, copyright 1982, with permission of the American College of Rheumatology.

bone marrow that express high-affinity recognition of self-DNA.[11]

Androgens, on the other hand, shift the cytokine profile to that of a T helper 1 (Th1) cell-mediated immune response. Both males and females with SLE have decreased availability of testosterone, dihydrotestosterone, dehydroepiandrosterone (DHEA), and DHEA sulfate. Additionally, androgen-deficient males with Klinefelter syndrome have a higher incidence of Th2-driven autoimmune disease including SLE. These observations led investigators to study the use of exogenous DHEA for the treatment of SLE flares. Administration of 200 mg of DHEA for 7 to 12 months reduced corticosteroid requirements and the frequency of disease flares.[12] A controversy exists regarding the use of exogenous estrogens in patients with SLE. Oral contraceptives have been thought to produce disease flares. However, a large multicenter trial showed that estrogens are safe and do not cause worsening of SLE in both post- and pre-menopausal women.[13]

Higher prolactin levels are associated with the presence of high anti-DNA titers and an accelerated autoimmune disease course among females with SLE. Although high estrogen levels explain pregnancy-related increases in SLE disease severity, the continuation of the disease exacerbation into the postpartum period may be due to increased prolactin associated with lactation.

Environmental Factors

Genetic predisposition for a lupus diathesis does not, in itself, produce disease. Rather, it appears that induction of autoimmunity in such patients is triggered by some inciting event, likely an environmental exposure. Drugs, viruses, UV light, and, possibly, tobacco, have been shown to induce development of SLE.

ULTRAVIOLET RADIATION UV radiation (UVR) is probably the most important environmental factor in the induction phase of SLE and especially of LE-specific skin disease. Early studies demonstrated that CLE lesions could be provoked in the clinically normal skin of patients with both SLE and CLE by repeated delivery of high doses of UVB radiation to the same test site. More recent studies argue that UVA radiation can also induce CLE lesions.

UV light likely leads to self-immunity and loss of tolerance because it causes apoptosis of keratinocytes, which in turn, makes previously cryptic peptides available for immunosurveillance (see below under Apoptosis and Complement). UVB radiation has been shown to displace autoantigens such as Ro/SS-A and related autoantigens, La/SS-B, and calreticulin, from their normal locations inside epidermal keratinocytes to the cell surface.[14]

UV light causes an exaggerated release of immune mediators in patients with SLE. Recent work by Meller and colleagues[15] shows that UVB irradiation induces the release of CCL27 (cutaneous T cell-attracting chemokine), which upregulates the expression of chemokines that activate autoreactive T cells and interferon-α (IFN-α), producing dendritic cells (DCs), which likely play a central role in lupus pathogenesis (see Dendritic Cells and Interferon-α).[15] UV light may



TABLE 156-3
Overview of the Extracutaneous Manifestations of Systemic Lupus Erythematosus

- General
  - Fever, fatigue, malaise, weight loss
- Musculoskeletal
  - Symmetric small joint arthralgia, arthritis, (non-deforming and deforming), morning stiffness
  - Myalgia, myositis
  - Tendinitis
  - Avascular (aseptic) bone necrosis
- Hematologic
  - Anemia
    - Normocytic, normochromic
    - Hemolytic
  - Leukopenia
    - Lymphopenia
    - Granulocytopenia
  - Thrombocytopenia
- Cardiopulmonary
  - Pleurisy, pleural effusions, aseptic pneumonitis, pulmonary, hemorrhage
  - Pericarditis, tachycardia, cardiomegaly, congestive heart failure, arrhythmias, conduction defects, coronary arteritis, Libman-Sacks endocarditis
- Renal
  - Mesangial glomerulitis (WHO class II)
    - Mild proteinuria
  - Focal proliferative glomerulonephritis (WHO class III)
    - Proteinuria, hematuria, occasionally nephrotic syndrome, hypertension
  - Diffuse proliferative glomerulonephritis (WHO class IV)
    - Proteinuria, hematuria, red cell casts, renal insufficiency, nephrotic syndrome, hypertension
  - Membranous glomerulonephritis (WHO class V)
    - Severe proteinuria, nephrotic syndrome
- Neuro-psychiatric
  - Peripheral neuropathy, transverse myelitis, Guillain-Barré syndrome
  - Chorea, choreoathetosis
  - Seizures
  - Headaches (severe, migraine-like)
  - Brain infarcts secondary to cerebral arteritis
  - Organic brain syndrome
    - Psychosis due to diffuse cerebritis
  - Psychological
    - Depression
- Gastrointestinal
  - Anorexia, nausea, vomiting, abdominal pain
  - Bowel infarction/perforation secondary to mesenteric vasculitis
  - Pancreatitis
  - Peritonitis, ascites
  - Hepatomegaly, chronic active hepatitis
- Ocular
  - Conjunctivitis, episcleritis
  - Blindness secondary to central retinal artery occlusion
  - Cytoid bodies
  - Keratoconjunctivitis sicca
- Lymphatic system
  - Lymphadenopathy
  - Splenomegaly

WHO = World Health Organization.



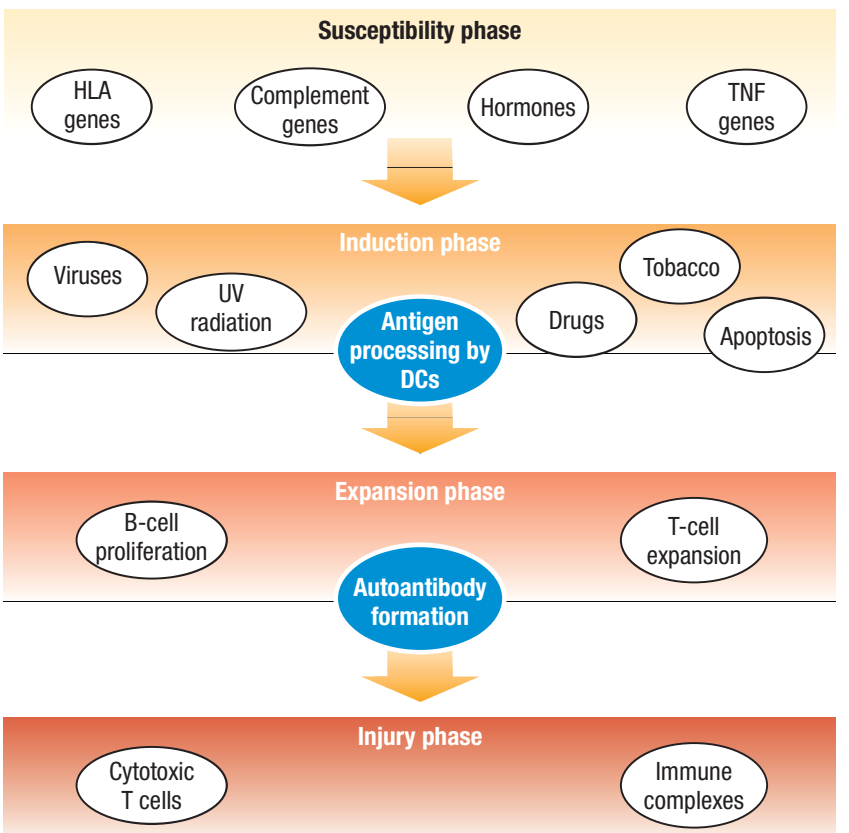

◀ **FIGURE 156-1** Model of systemic lupus erythematosus pathogenesis. DCs = dendritic cells; TNF = tumor necrosis factor; UV = ultraviolet.

additionally have an early critical role in the induction phase by directly altering cellular DNA. UV light may affect immunoregulatory cells, which normally help suppress "abnormal" patterns of cutaneous inflammation.

TOBACCO EXPOSURE A recent, large, case-control study reported that smokers are at a greater risk of developing SLE than are nonsmokers and former smokers. Investigators suggest that this fact may be related to lipogenic aromatic amines, which are contained in tobacco smoke. Two abstracts from the Baltimore Lupus Cohort suggest an increased frequency of DLE in smokers, and several authors have shown that patients with LE-specific skin disease who smoke are less responsive to antimalarial treatment.[16,17,18]

DRUGS Numerous drugs have been implicated in inducing various features of SLE (see Drug-Induced Cutaneous Lupus Erythematosus). A mechanism for drug-induced LE by which the provocative agent induces T-cell DNA hypomethylation inducing altered repair of DNA has been proposed. A decrease in the amount of methylation of DNA correlates with increased biologic autoreactivity of lymphocytes. The drugs that induce CLE can be linked by their photosensitizing properties. It has been suggested that these drugs cause an increase in keratinocyte apoptosis, exposure of previously intracellular peptides on epidermal cell surfaces, and enhance pro-inflammatory cytokines such as TNF-α and IFN-α.[19]

VIRUSES There has been much speculation about the role of infectious agents, particularly viruses, in the induction of SLE and CLE. Infections of all types have long been known to exacerbate SLE. Infection by α viruses, such as Sindbis, rubella, and cytomegalovirus, appears able to induce cell surface expression of Ro/SS-A and related autoantigens in cells undergoing virus-induced apoptosis. Seroconversion to Epstein-Barr virus (EBV) among patients with SLE is nearly universal, and recent data have demonstrated that patients with SLE have defective control of latent EBV infection that probably stems from altered T-cell responses against EBV.[20]

Key Constituents in the Pathogenesis of Lupus

DENDRITIC CELLS AND INTERFERON-α DCs have a key role in antigen recognition and stimulation of the immune system. They perform a watchdog-like role in all peripheral tissues in an immature state. Immature DCs are essential to the maintenance of peripheral tolerance to self-antigens. They constantly sample their environment, capture self-antigens released in normal tissue turnover (apoptosis), and in the absence of inflammation, primarily act as housekeepers, keeping self-antigens in check. In the company of inflammation or microbes, they mature and move to draining lymph nodes, where they present antigen to T cells via MHCs. With appropriate co-stimulatory molecules, T- and B-cell activation ensues, with subsequent launching of an adaptive immune response.[21]

DCs develop from precursor monocytes and have two different lineages, myeloid DCs, which then differentiate into immature and mature DCs and plasmacytoid DCs. Plasmacytoid DCs are found in lymphoid organs, such as bone marrow, spleen, tonsils, and lymph nodes, and are noteworthy for producing large amounts of IFN-α in response to many viruses and certain bacteria. They have recently been found to infiltrate LE-specific skin lesions as well. IFN-α causes monocytes to differentiate into myeloid DCs, which are able to capture circulating apoptotic cells. These can then present self-antigens to autoreactive CD4 T cells and also support B-cell proliferation and differentiation, leading to the clinical expression of LE.[22]

Recent findings place IFN-α at the center of immunologic abnormalities observed in SLE, and suggest that IFN-α and IFN-α–producing cells are novel potential therapeutic targets. It is well established that levels of IFN-α are increased in the serum of SLE patients, and recombinant IFN-α, when administered as a therapy to patients with malignancy or hepatitis infection, can induce SLE, and even neonatal lupus in one case.[23,24]

More recently, several important studies using microarray data, have revealed a genomic "signature" of upregulated IFN-α–inducible genes from peripheral blood mononuclear cells of SLE patients, as well as from lesions of LE-specific skin disease.[25] Additionally, it has been shown that IFN-α increases as patients' disease flares. Recent studies have shown that local production of type I IFNs in CLE induces Th1-biased inflammation via induction of IFN-inducible chemokines, with recruitment of pathogenic T lymphocytes into the skin.[26] In short, there has been convergence of data from several studies, leading to the suggestion that IFN-α plays a central role in the pathogenesis of lupus.

It seems that LE patients produce IFN-α in an unabated fashion, either as a consequence of complex genetic alterations or because of a persistent stimulus such as a virus. Regardless of the mechanisms leading to its excess, IFN-α turns on the adaptive immune system through the activation of myeloid DCs, leading to a break of tolerance to self-antigens and activation of autoreactive T and B cells.

TOLL-LIKE RECEPTORS Toll-like receptors (TLRs) are important in innate immunity and have a potent microorganism-sensing capacity. They do so by recognizing bacterial DNA (unmethylated cytosine and guanosine dinucleotides sequence motifs). It appears that circulating DNA/anti-DNA complexes trigger TLR signaling, which then induces (1) proliferation of autoreactive B cells, and (2) IFN-α secretion from DCs. Lupus mice that lack TLR9 do not produce double-stranded DNA (dsDNA) antibodies. Thus, blocking the TLRs may have therapeutic implications in lupus.

APOPTOSIS AND COMPLEMENT In SLE, the rate of in vitro apoptosis of peripheral blood mononuclear cells is increased. In CLE, there is an additional abundance of apoptotic keratinocytes, especially in response to UVR.[27] Regulated cell death is accomplished by endonuclease degradation of DNA, whereby apoptotic cells remain intact while they are dying. If clearance of apoptotic material is not expeditious, apoptotic cells become necrotic, with dissolution of the cellular membrane and release of previously sequestered intracellular contents (e.g., ribonucleoproteins, dsDNA, and Ro/SS-A antigens). Patients with lupus have dysregulation of both apoptosis and apoptotic cell clearance. Normally, complement proteins bind to apoptotic cells, which are then disposed of by "housekeeping" macrophages. When complement proteins are deficient (a common characteristic of patients with lupus) and are not present on apoptotic cells, the apoptotic cells are then recognized by DCs that are able to stimulate the adaptive immune response, rather than housekeeping macrophages. These DCs subsequently process the apoptotic cells and present antigens, which leads to a break in self-tolerance followed by activation of the immune cascade.[28]

TUMOR NECROSIS FACTOR-α TNF is likely involved in the pathogenesis of cutaneous lupus. TNF induces apoptosis



through the FAS-associated death domain. TNF has been shown to be elucidated by keratinocytes exposed to UVR. It induces HLA-DR expression on keratinocytes and causes stimulation of an adaptive immune response. It also stimulates release of nuclear factor κB, which causes upregulation of pro-inflammatory adhesion molecules. TNF is produced in large amounts by epidermal keratinocytes in patients with SCLE.[29] It stands to reason that inhibition of TNF likely will help cutaneous lupus.

However, there have also been several reports of the development or worsening of cutaneous lupus while on anti-TNF therapy; and the development of dsDNA antibodies and lupus-like syndromes is well described with drugs such as etanercept and infliximab. Banchereau and colleagues have shown that TNF regulates IFN-α production in vitro by inhibiting the generation of plasmacytoid DCs.[30] As mentioned above under Dendritic Cells and Interferon-α, overexpression of IFN-α is thought to be a key event in immune dysregulation in lupus. Thus, too much TNF may induce lesions of cutaneous lupus, whereas not enough may do the same and may even lead to unmasking of SLE or the development of a drug-induced lupus-like illness.



T CELLS T cells play a key role in both the induction and expansion phases in the development of SLE. T cells are involved in the development of both central and peripheral tolerance. Self-antigens are presented by DCs to autoreactive T cells. Binding of the surface signaling molecules, such as the T-cell receptor, to their ligands leads to T-cell activation. In SLE, and in CLE, T cells display markers of increased activation, increased numbers of DR^+ antigens.[31,32] T cells also provide cognate help to autoreactive B cells, leading to production of autoantibodies. For example, SLE patients demonstrate increased production of T-cell–dependent immunoglobulin G (IgG) anti-dsDNA antibodies. Last, T cells facilitate tissue damage in end organs, and may be of particular importance in CLE. Recent investigations have highlighted the relevance of cytotoxic lymphocytes in tissue damage in SLE, including in CLE. One group of authors found that scarring skin lesions of DLE are characterized by high numbers of skin-homing cytotoxic lymphocytes associated with expression the IFN-α–induced protein MxA.[32]

B CELLS B cells are involved in the expansion phase of LE pathogenesis, in that they can present antigen to autoreactive T cells and further amplify T-cell activation. The production by B cells of autoantibodies against nuclear antigens is the hallmark of SLE.[33] Several of these autoantibodies are thought to be directly pathogenic, including dsDNA and Ro/SS-A antibodies. Such autoantibodies likely play a direct role in the injury phase of LE. They form immune complexes, which may cause tissue damage by means that include direct cell death, cellular activation, opsonization, and the blocking of target molecule function. B cells may not be as important in CLE as they are in other manifestations of the disease, as supported by the suggestion that anti–B-cell therapies such as Rituximab are less effective for CLE.

Clearly, there are several key constituents involved in the pathogenesis of LE. The sheer number of potential players in disease development is one the main reasons for the highly variable expression of the disease. Recent data uncovering convergence points (i.e., IFN-α) in the pathogenetic expression of disease have already led to early development of new drugs for LE. Additionally, the complexity of the pathogenesis of LE suggests that multiple pharmacotherapeutics (a layering of drugs with different pathomechanisms) may be required to treat patients with recalcitrant disease.

CLINICAL FINDINGS (Fig. 156-2)

Cutaneous Lesions

Table 156-4 compares the key clinical, histopathologic, and laboratory features of patients presenting with ACLE, SCLE, and CCLE (classic DLE) skin lesions. It is important to distinguish among the subtypes of LE-specific skin disease, because the type of skin involvement in LE can reflect the underlying pattern of SLE activity. In fact, the designations acute, subacute, and chronic, in regard to CLE, refer to the pace and severity of any associated SLE and are not necessarily related to how long individual lesions have been present. For example, ACLE almost always occurs in the setting of acutely flaring SLE, whereas CCLE often occurs in the absence of SLE or in the presence of mild smoldering SLE. SCLE occupies an intermediate position in this clinical spectrum. Subclassification, although important for assigning risk, is sometimes difficult, as it is not uncommon to see more than one sub-type of LE-specific skin disease in the same patient, especially in patients with SLE.

ACUTE CUTANEOUS LUPUS ERYTHEMATOSUS Although ACLE localized to the face is the usual pattern of presentation, ACLE can assume a generalized distribution. Localized ACLE has commonly been referred to as the *classic butterfly rash* or *malar rash of SLE* (Fig. 156-3). In localized ACLE, confluent symmetric erythema and edema are centered over the malar eminences and bridges over the nose (unilateral involvement with ACLE has been described). The nasolabial folds are characteristically spared. The forehead, chin, and V area of the neck can be involved, and severe facial swelling may occur. Occasionally, ACLE begins as small macules and/or papules on the face that later may become confluent and hyperkeratotic. Generalized ACLE presents as a widespread morbilliform or exanthematous eruption often focused over the extensor aspects of the arms and hands and characteristically sparing the knuckles (Fig. 156-4A). Although perivascular nail fold erythema and telangiectasia can occur (see Fig. 156-4B), they are considerably more common and occur in more exaggerated forms in dermatomyositis (see Fig. 157-5). Generalized ACLE has been indiscriminately referred to as the *maculopapular rash of SLE*, *photosensitive lupus dermatitis*, and *SLE rash*. An extremely acute form of ACLE is rarely seen that can simulate toxic epidermal necrolysis (TEN). This form of LE-specific vesiculobullous disease results from widespread apoptosis of epidermal keratinocytes, and eventuates in areas of full-thickness epidermal skin necrosis, which is subsequently denuded. It can be differentiated between true TEN because it occurs on predominantly sun-exposed skin and has a more insidious onset.[34] Mucosa may or may not be involved, as in TEN.

ACLE is typically precipitated or exacerbated by exposure to UV light. This form of CLE can be quite ephemeral, lasting only hours, days, or weeks; however, some patients experience more prolonged periods of activity. Post-inflammatory pigmentary change is most prominent in patients with heavily pigmented skin. Scarring does not occur in ACLE unless the process is complicated by secondary bacterial infection. ACLE occasionally occurs in conjunction with SCLE; however, the simultaneous occurrence of ACLE and active DLE is unusual. Both localized and generalized ACLE wax and wane in par-

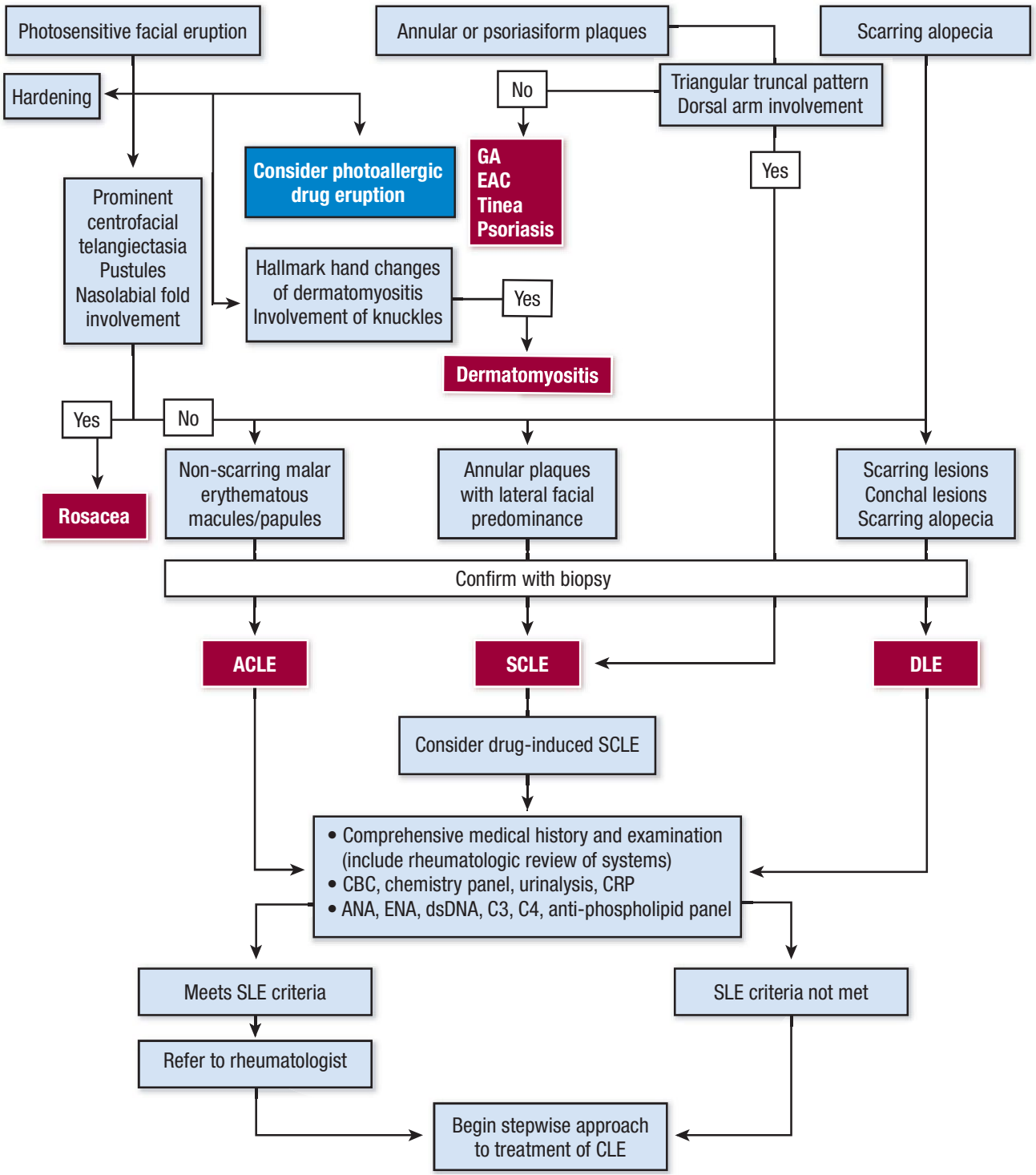



▲ **FIGURE 156-2** Approach to the patient with skin lesions suspicious for cutaneous lupus erythematosus. ACLE = acute cutaneous lupus erythematosus; ANA = anti-nuclear antibody; CBC = complete blood cell count; CLE = cutaneous lupus erythematosus; CRP = C-reactive protein; DLE = discoid lupus erythematosus; dsDNA = doubled-stranded DNA; EAC = erythema annulare centrifugum; ENA = extractable nuclear antibody; GA = granuloma annulare; SCLE = subacute cutaneous lupus erythematosus; SLE = systemic lupus erythematosus.

allel with underlying SLE disease activity, including LE nephritis.

SUBACUTE CUTANEOUS LUPUS ERYTHEMATOSUS A number of names have been used to describe SCLE skin lesions: *symmetric erythema centrifugum*; *disseminated DLE*; *autoimmune annular erythema*; *subacute disseminated LE*; *superficial disseminated LE*; *psoriasiform LE*; *pityriasiform LE*; *maculopapular photosensitive LE*; and *lupus erythematosus gyratum repens*. A disease presentation dominated by SCLE lesions marks the presence of a distinct subset of LE having characteristic clinical, serologic, and genetic features. Although a finding of circulating autoantibodies to the Ro/SS-A ribonucleoprotein particle strongly supports a diagnosis of SCLE, the presence of this autoantibody specificity is not required to make a diagnosis of SCLE.

SCLE initially presents as erythematous macules and/or papules that evolve

TABLE 156-4
Comparison of the Major Types of Lupus Erythematosus–Specific Skin Disease

Disease Features	ACLE	SCLE	Classic DLE
Clinical features of skin lesions			
Induration	0	0	+++
Dermal atrophy	0	0	+++
Pigment changes	+	++	+++
Follicular plugging	0	0	+++
Hyperkeratosis	+	++	+++
Histopathology			
Thickened basement membrane	0	+	+++
Lichenoid infiltrate	+	++	+++
Periappendageal inflammation	0	+	+++
Lupus band			
Lesional	++	++	+++
Non-lesional	++	+	0
Anti-nuclear antibodies	+++	++	+
Ro/SS-A antibodies			
By immunodiffusion	+	+++	0
By ELISA	++	+++	+
Anti–double-stranded DNA antibodies	+++	+	0
Hypocomplementemia	+++	+	+
Risk for developing systemic lupus erythematosus	+++	++	+

ACLE = acute cutaneous lupus erythematosus; DLE = discoid lupus erythematosus; ELISA = enzyme-linked immunosorbent assay; SCLE = subacute cutaneous lupus erythematosus; +++ = strong association; ++ = moderate association; + = weak association; 0 = negative, no association.
Reprinted from Sontheimer RD, Provost TT: Lupus erythematosus, in *Cutaneous Manifestations of Rheumatic Diseases*, edited by Sontheimer RD, Provost TT. Baltimore, Williams & Wilkins, 1996, with permission from Williams & Wilkins Publishers.



into hyperkeratotic papulosquamous or annular/polycyclic plaques (Fig. 156-5). Whereas most patients have either annular or papulosquamous SCLE, a few develop elements of both morphologic varieties. SCLE lesions are characteristically photosensitive and occur in predominantly sun-exposed areas (i.e., upper back, shoulders, extensor aspects of the arms, V area of the neck, and, less commonly, the face). SCLE lesions typically heal without scarring but can resolve with long-lasting, if not permanent, vitiligo-like leukoderma and telangiectasias.

Several variants of SCLE have been described. On occasion, SCLE lesions present initially with an appearance of erythema multiforme (see Chap. 38). Such cases are similar to Rowell syndrome (erythema multiforme–like lesions occurring in patients with SLE in the presence of La/SS-B autoantibodies). As a result of intense injury to epidermal basal cells, the active edge of an annular SCLE lesion occasionally undergoes a vesiculobullous change that can subsequently produce a strikingly crusted appearance. Such lesions can mimic Stevens-Johnson syndrome/TEN (see Chap. 39). Pathogenesis is similar to that described above for TEN-like ACLE.[34] Rarely, SCLE presents with exfoliative erythroderma or displays a curious acral distribution of annular lesions. Pityriasiform and exanthematous variants of SCLE have been reported. The skin lesions of neonatal LE (transient, photosensitive, non-scarring LE-specific skin lesions in neonates who have received IgG anti-Ro/SS-A, and, occasionally, other autoantibody specificities transplacentally) share many features with SCLE.

Between 15 percent and 20 percent of patients with SCLE lesions may also develop ACLE or classic DLE at some point. ACLE skin lesions tend to be more transient than SCLE lesions and heal with less pigmentary change. They are also more edematous and less hyperkeratotic than SCLE lesions. ACLE more commonly affects the malar areas of the face, whereas SCLE focuses more on the neck, shoulders, upper extremities, and trunk. When the face is involved, it is most often the lateral face, with sparing of the central, malar regions. DLE lesions occurring in the context of SCLE are generally associated with a greater degree of hyper- and hypopigmentation, atrophic dermal scarring, follicular plugging, and adherent



▲ **FIGURE 156-3** Localized acute cutaneous lupus erythematosus. Erythematous, slightly edematous, sharply demarcated erythema is seen on the malar areas in a "butterfly" distribution.



▲ **FIGURE 156-4** Generalized acute cutaneous lupus erythematosus. **A.** Well-demarcated patches of erythema with fine overlying scale on the dorsal aspect of the hands, fingers, and periungual areas. Note the characteristic sparing of the knuckles, which are preferentially involved in dermatomyositis. **B.** Close-up view of periungual erythema and grossly visible telangiectasia. Although these lesions can be seen in lupus erythematosus, they are more typical of dermatomyositis.



▲ **FIGURE 156-5** Subacute cutaneous lupus erythematosus (SCLE). **A.** Annular SCLE on the upper back of a 38-year-old woman. Note the central areas of hypopigmentation in which no dermal atrophy is present. **B.** Papulosquamous SCLE over the extensor aspect of the forearm of a 26-year-old woman.



scale. A consistent clinical difference is that DLE lesions are characteristically indurated, whereas SCLE lesions are not; this difference reflects the greater depth of inflammation seen histopathologically in DLE lesions.

Approximately one-half of patients with SCLE meet the ACR's revised criteria for the classification of SLE. However, manifestations of severe SLE, such as nephritis, central nervous system disease, and systemic vasculitis, develop in only 10 percent to 15 percent of patients with SCLE. It has been suggested that the papulosquamous type of SCLE, leukopenia, high titer of anti-nuclear antibody (ANA) (> 1:640), and anti-dsDNA antibodies are risk factors for the development of SLE in a patient presenting with SCLE lesions.

SCLE can overlap with other autoimmune diseases, including Sjögren syndrome, rheumatoid arthritis, and Hashimoto thyroiditis. Other disorders that have been anecdotally related to SCLE are Sweet syndrome, porphyria cutanea tarda, gluten-sensitive enteropathy, and Crohn disease. There has also been the suggestion that SCLE can be associated with internal malignancy (breast, lung, gastric, uterine, hepatocellular, and laryngeal carcinomas) as well as with Hodgkin lymphoma.[35]

CHRONIC CUTANEOUS LUPUS ERYTHEMATOSUS Classic DLE lesions, the most common form of CCLE, begin as red-purple macules, papules, or small plaques and rapidly develop a hyperkeratotic surface. Early classic DLE lesions typically evolve into sharply demarcated, coin-shaped (i.e., discoid) erythematous plaques covered by a prominent, adherent scale that extends into the orifices of dilated hair follicles (Fig. 156-6).

DLE lesions typically expand with erythema and hyperpigmentation at the periphery, leaving hallmark atrophic central scarring, telangiectasia, and hypopigmentation (Fig. 156-7). DLE lesions at this stage can merge to form large, confluent, disfiguring plaques. DLE in persons of certain ethnic backgrounds, such as Asian Indians, can present clinically as isolated areas of macular hyperpigmentation. When present on hair-bearing skin (scalp, eyelid margins, eyebrows), DLE causes scarring alopecia, which can lead to disfigurement and markedly impact quality of life. Follicular involvement in DLE is a prominent feature. Keratotic plugs accumulate in dilated follicles that soon become devoid of hair. When the adherent scale is lifted from more advanced lesions, keratotic spikes similar in appearance to carpet tacks can be seen to project from the undersurface of the scale (i.e., the "carpet tack" sign). DLE lesions can be difficult to diagnose in Caucasian patients because the characteristic peripheral hyperpigmentation is often absent. Such lesions are often confused with actinic keratoses, squamous cell carcinoma, or acne.

DLE lesions are most frequently encountered on the face, scalp, ears, V area of the neck, and extensor aspects of the arms. Any area of the face, including the eyebrows, eyelids, nose, and lips, can be affected. A symmetric, hyperkeratotic, butterfly-shaped DLE plaque is occasionally found over the malar areas of the face and bridge of the nose. Such le-



▲ **FIGURE 156-6** Classic discoid lupus erythematosus. Typical early erythematous plaque on the forehead demonstrating hyperkeratosis and accentuation of follicle orifices in a 60-year-old man with a 25-year history of cutaneous lupus erythematosus. The lesion had been present for 3 months; no dermal atrophy was present at this stage.

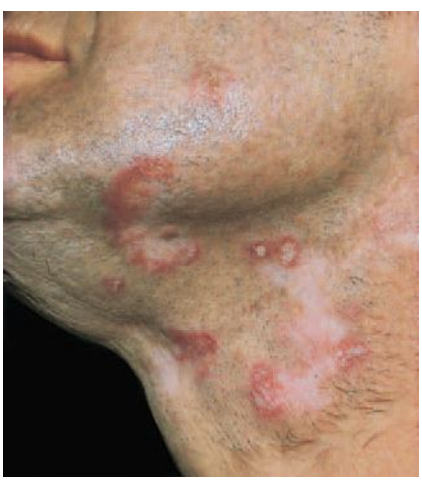

▲ **FIGURE 156-7** Classic discoid lupus erythematosus. Sharply demarcated, round-to-ovoid, slightly indurated, erythematous plaques on the neck and face. Most plaques show a mild degree of hyperkeratosis, and some show dermal atrophy. Noninflamed areas of hypopigmentation and scarring mark the sites of prior lesions that have resolved.

sions should not be confused with the more transient, edematous, minimally scaling ACLE erythema reactions that occur in the same areas. Facial DLE, like ACLE and SCLE, usually spares the nasolabial folds. It may be difficult to distinguish early lesions of malar DLE from ACLE, but induration and recalcitrance to topical steroids/calcineurin inhibitors favors the former diagnosis. When DLE lesions occur periorally, they resolve with a striking acneiform pattern of pitted scarring. DLE characteristically affects the external ear, including the outer portion of the external auditory canal (Fig. 156-8A). Such lesions often present initially as dilated, hyperpigmented follicles. The scalp is involved in 60 percent of patients with DLE; irreversible, scarring alopecia resulting from such involvement has been reported in one-third of patients (see Fig. 156-8B). The irreversible, scarring alopecia resulting from DLE differs from the reversible, non-scarring alopecia that patients with SLE often develop during periods of systemic disease activity. This type of hair loss, so-called *lupus hair*, may be telogen effluvium occurring as the result of flaring systemic disease.



Localized DLE lesions occur only on the head or neck, whereas generalized DLE lesions occur both above and below the neck. DLE lesions below the neck most commonly occur on the extensor aspects of the arms, forearms, and hands, although they can occur at virtually any site on the body. The palms and soles can be the sites of painful, and at times disabling, erosive DLE lesions. On occasion, small DLE lesions occurring only around follicular orifices appear at the elbow and elsewhere (follicular DLE). We have observed that elbow/extensor arm lesions seem to co-occur with acral finger lesions of DLE, and that patients with this combination of findings more frequently have active systemic disease. DLE activity can localize to the nail unit. The nail can be impacted by other forms of CLE as well as SLE, producing nail fold erythema and telangiectasia, red lunulae, clubbing, paronychia, pitting, leukonychia striata, and onycholysis.

DLE lesions can be potentiated by sunlight exposure but to a lesser extent than ACLE and SCLE lesions. DLE, as well as other forms of LE skin disease activity, can be precipitated by any form of cutaneous trauma (i.e., the Koebner phenomenon or isomorphic effect).

The relationship between classic DLE and SLE has been the subject of much debate.[5] The following summary points can be made: (1) 5 percent of patients presenting with classic DLE lesions subsequently develop unequivocal evidence of SLE; and (2) patients with generalized DLE (i.e., lesions both above and below the neck) have somewhat higher rates of immunologic abnormalities, a higher risk for progressing to SLE, and a higher risk for developing more severe manifestations of SLE than patients with localized DLE.







▲ **FIGURE 156-8** Classic discoid lupus erythematosus (DLE) and mucosal DLE in a 45-year-old African American woman with a 20-year history of untreated cutaneous lupus erythematosus. **A.** Characteristic involvement of the ear shows lesions with atrophy and post-inflammatory hyperpigmentation as well as inflammatory red plaques on the scalp with post-inflammatory hypopigmentation. **B.** Confluent lesions on the scalp have resulted in extensive scarring alopecia. **C.** Plaques of DLE on the palatal mucosa showing morphologic features similar to those of cutaneous lesions.

The following have been suggested as risk factors for the development of SLE in patients with DLE: generalized lymphadenopathy; SCLE/ACLE skin lesions; LE–non-specific skin lesions such as vasculitis, diffuse non-scarring alopecia, periungual nail fold telangiectasia, Raynaud phenomenon; unexplained anemia; marked leukopenia; false-positive tests for syphilis; persistently positive high-titer ANA assay; anti–single-stranded DNA antibody; hypergammaglobulinemia; an elevated erythrocyte sedimentation rate (especially > 50 mm/hour); positive, sun-protected, non-lesional lupus band test (LBT) and elevated levels of soluble IL-2 receptor.

Roughly one-fourth of patients with SLE develop DLE lesions at some point in the course of their disease, and such patients tend to have less severe forms of SLE. Fig. 156-9 illustrates the relative risks for systemic disease activity that are associated with the clinical varieties of LE-specific skin disease.

Hypertrophic DLE, also referred to as *hyperkeratotic* or *verrucous DLE*, is a rare variant of CCLE in which the hyperkeratosis normally found in classic DLE lesions is greatly exaggerated. The extensor aspects of the arms, the upper back, and the face are the areas most frequently affected. Overlapping features of hypertrophic LE and lichen planus have been described under the rubric *lupus planus*. The entity *lupus erythematosus hypertrophicus et profundus* appears to represent a rare form of hypertrophic DLE, affecting the face with the additional features of violaceous/dull red, indurated, rolled borders and striking central, crateriform atrophy. The name for this clinical entity is ambiguous because LE panniculitis is not characteristic of its histopathology. Patients with hyper-

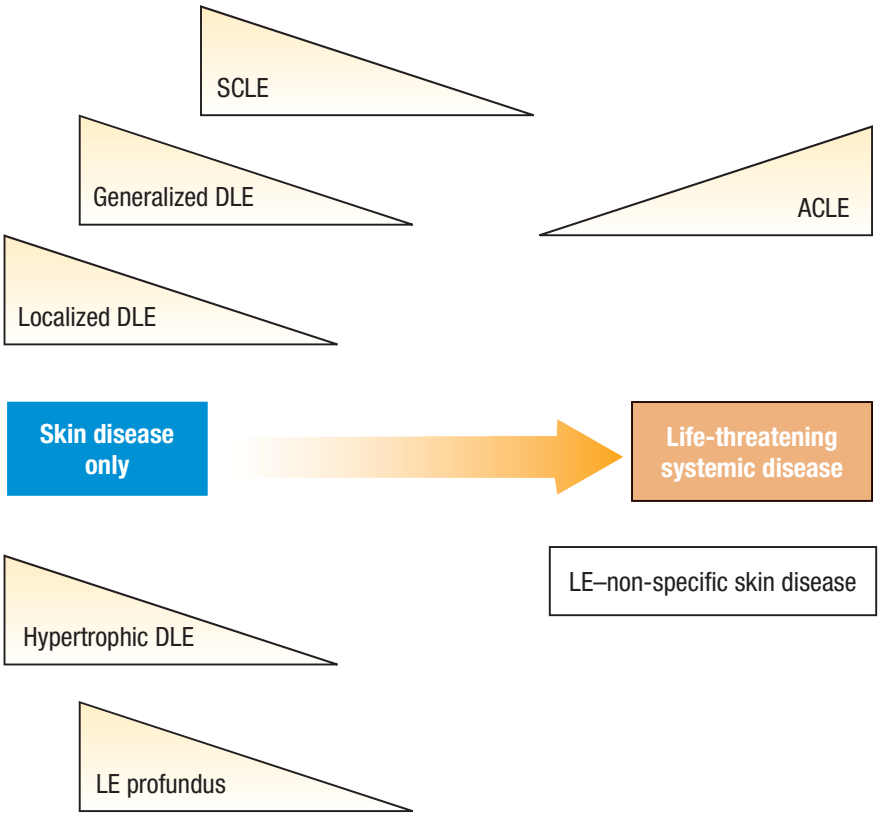

▲ **FIGURE 156-9** Relative risk for co-existence of or progression to systemic lupus erythematosus in patients presenting with various forms of lupus erythematosus (LE)–specific skin disease. The spectrum of LE is depicted as a disease continuum ranging from skin disease alone to life-threatening systemic disease. ACLE = acute cutaneous lupus erythematosus; DLE = discoid lupus erythematosus; SCLE = subacute cutaneous lupus erythematosus.

trophic DLE probably do not have a greater risk for developing SLE than do patients with classic DLE lesions.

Patients with DLE in a linear configuration following Blaschko's lines have been described. This rare sub-type of DLE appears most frequently in children and seems to be associated with a low incidence of associated SLE.[36]

Mucosal DLE occurs in approximately 25 percent of patients with CCLE. The oral mucosa is most frequently affected; however, nasal, conjunctival, and genital mucosal surfaces can be targeted. In the mouth, the buccal mucosal surfaces are most commonly involved, with the palate (see Fig. 156-8C), alveolar processes, and tongue being sites of less frequent involvement. Lesions begin as painless, erythematous patches that evolve to chronic plaques that can be confused with lichen planus. Chronic buccal mucosal plaques are sharply marginated and have irregularly scalloped, white borders with radiating white striae and telangiectasia. The surfaces of these plaques overlying the palatal mucosa often have a honeycomb appearance. Central depression often occurs in older lesions, and painful ulceration can develop. Rarely, oral mucosal DLE lesions can degenerate into squamous cell carcinoma, similar to long-standing cutaneous DLE lesions. Any degree of nodular asymmetry within a mucosal DLE lesion should be evaluated for the possibility of malignant degeneration. Chronic DLE plaques also appear on the vermilion border of the lips. At times, DLE involvement of the lips can present as a diffuse cheilitis, especially on the more sun-exposed lower lip.

DLE lesions may present on the nasal, conjunctival, and anogenital mucosa. Perforation of the nasal septum is more often associated with SLE than DLE. Conjunctival DLE lesions affect the lower lid more often than the upper lid. Lesions begin as focal areas of nondescript inflammation most commonly affecting the palpebral conjunctivae or the lid margin. Scarring becomes evident as lesions mature, and the permanent loss of eyelashes and ectropion can develop, producing considerable disability.

The risk for systemic disease activity in patients with LE and mucosal involvement is a function of the type of mucosal lesion present. Chronic mucosal DLE plaques are seen most commonly in patients with LE who do not have life-threatening manifestations of SLE. However, transient superficial oral or nasal mucosal ulcerations with a relatively non-specific histopathology occur in patients with active SLE. Mucosal lesions of this type represent one of the 11 revised ACR classification criteria for SLE.

DRUG-INDUCED CUTANEOUS LUPUS ERYTHEMATOSUS Drug-induced lupus shares symptoms and laboratory characteristics with idiopathic SLE, and numerous drugs have been implicated in inducing various features of SLE [e.g., procainamide, hydralazine, isoniazid, chlorpromazine, phenytoin, minocycline, and most recently, anti-TNF medications].[37] Classic drug-induced SLE is associated with antihistone antibodies and manifests similarly to SLE but without cutaneous involvement.

Drugs can also induce or exacerbate lupus-specific skin lesions. Drug-induced SCLE has been convincingly associated with exposure to hydrochlorothiazide, calcium channel blockers, angiotensin-converting enzyme inhibitors, and cinnarizine. Recently, there have been accounts of patients with terbinafine-induced SCLE. Other drugs reported to precipitate SCLE include piroxicam, D-penicillamine, sulfonylureas, oxprenolol, parenteral gold therapy, griseofulvin, naproxen, spironolactone, IFN-β, ranitidine, efalizumab, propylthiouracil, carbamazepine, systemic 5-fluorouracil, lansoprazole, bupropion, acebutolol, and tiotropium inhaled. Both SCLE and DLE skin lesions have been induced in patients on anti-TNF therapy.[30,38] SCLE has recently been reported with use of leflunomide for rheumatoid arthritis.[39]

LESS COMMON SUB-TYPES OF LUPUS ERYTHEMATOSUS–SPECIFIC SKIN DISEASE LE profundus/LE panniculitis (Kaposi-Irgang disease) is a rare form of CCLE typified by inflammatory lesions in the lower dermis and subcutaneous tissue. Approximately 70 percent of patients with this type of CCLE also have typical DLE lesions, often overlying the panniculitis lesions. Some have used the term *LE profundus* to designate those patients who have both LE panniculitis and DLE lesions, and *LE panniculitis* to refer to those having only subcutaneous involvement. Typical subcutaneous lesions present as firm nodules, 1 to 3 cm in diameter. The overlying skin often becomes attached to the subcutaneous nodules and is drawn



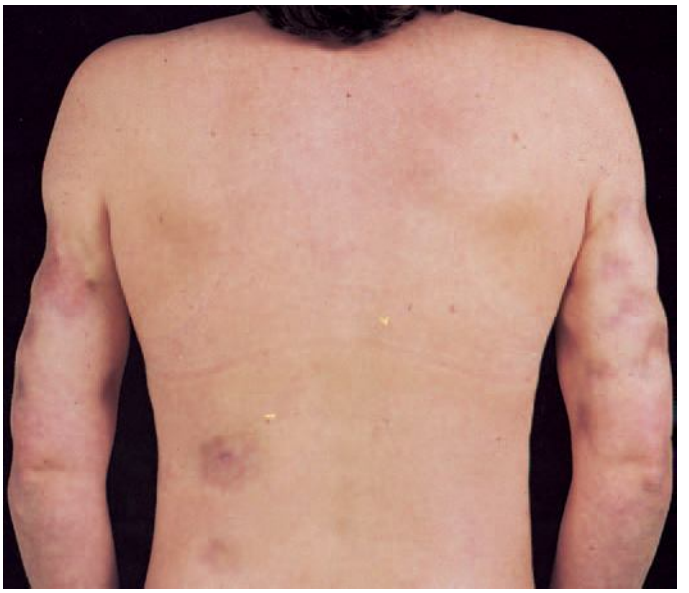



▲ **FIGURE 156-10** Lupus erythematosus panniculitis. Lupus panniculitis has resulted in large, sunken areas of overlying skin; erythema and atrophy of the skin are present.

inward to produce deep, saucerized depressions (Fig. 156-10). The head, proximal upper arms, chest, back, breasts, buttocks, and thighs are the sites frequently affected. LE panniculitis, in the absence of overlying DLE, may produce breast nodules that can mimic carcinoma clinically and radiologically (lupus mastitis). Confluent facial involvement can simulate the appearance of lipoatrophy. Dystrophic calcification frequently occurs in older lesions of LE profundus/LE panniculitis, and pain associated with such calcification can, at times, be the dominant clinical problem. Roughly 50 percent of patients with LE profundus/panniculitis have evidence of SLE. However, the systemic features of patients with LE panniculitis/profundus tend to be less severe, similar to those of patients with SLE who have DLE skin lesions.

Chilblain LE/perniotic LE lesions initially develop as purple-red patches, papules, and plaques on the toes, fingers, and face, which are precipitated by cold, damp climates and are clinically and histologically similar to idiopathic chilblains (pernio) (see Chap. 93). As they evolve, these lesions usually assume the appearance of scarred atrophic plaques with associated telangiectases. They may resemble old lesions of DLE or may mimic acral lesions of small vessel vasculitis. Histologic findings include a superficial and deep lymphocytic vascular reaction in addition to fibrin deposition in reticular, dermal-based blood vessels. Patients with chilblain LE often have typical DLE lesions on the face and head. It is possible that chilblain LE begins as a classic acral, cold-induced lesion that then koebnerizes DLE lesions, thus explaining the spectrum of clinicohistologic findings, which seem to vary based on when, in the course of the lesion, the biopsy sample is taken.

Chilblain LE appears to be associated with anti–Ro/SS-A antibodies.[40] A recent study suggests that persistence of lesions beyond the cold months, a positive ANA, or presence of one of the other ACR criteria for SLE at the time of diagnosis of chilblain lesions helps to distinguish chilblain LE from idiopathic chilblains.[41] Approximately 20 percent of patients presenting with chilblain LE later develop SLE. Chilblain LE is an under-recognized entity, yet it is likely that it is one of the most common causes of digital lesions in patients with LE. A recent study by Bouaziz et al.[42] examined digital lesions in a cohort of 50 such patients. A clinical diagnosis of vasculitis was suggested by the referring physician in 36 percent of cases. However, the vast majority of patients were found to have LE-specific skin lesions, especially chilblain LE and atrophic scarring DLE.[42]

Lupus erythematosus tumidus (LET; tumid LE) is a variant of CCLE in which the dermal findings of DLE, namely excessive mucin deposition and superficial perivascular and periadnexal inflammation, are found on histologic evaluation. The characteristic epidermal histologic changes of LE-specific skin disease are only minimally expressed, if at all. This results in succulent, edematous, urticaria-appearing plaques with little surface change (Fig. 156-11). The paucity of epidermal change often produces confusion concerning the diagnosis of LET as a form of CLE.

Recently, there have been several reports of patients with this clinico-pathologic presentation that have helped to alleviate some of this confusion. Ruiz and Sanchez[43] reported four patients who had firm diagnoses of classic DLE and/or SLE in addition to red-violet plaques on the upper body; histologic examination showed the dermal changes that occur in LE-specific skin disease. Kuhn et al.[44] reported a cohort of 40 patients with similar clinical and histologic features who were markedly photosensitive and who had a very high response rate to antimalarial therapy.[44] This cohort had a very low incidence of SLE, further suggesting that LET is a subset of CCLE. The authors noted that unlike classic DLE, however, LET lesions tend to resolve completely without either scarring or atrophy.[44,45] A third study, a review of 26 patients, confirmed that patients with LET have little clinically overt epidermal involvement, intense photosensitivity, a benign course, absence of systemic disease, good response to antimalarial treatment, and a tendency to recur.[46]



▲ **FIGURE 156-11** Lupus erythematosus tumidus. Note succulent, indurated plaques.

Some authors have suggested the Jessner lymphocytic infiltrate overlaps with LET, in that both (1) have similar clinical and histologic findings, (2) occur with other forms of CLE and SLE, and (3) rarely present with visceral organ involvement of SLE. They further propose that LET, Jessner lymphocytic infiltrate, papulonodular mucinosis, and reticular erythematous mucinosis are all dermal variants of LE-specific skin disease and, as such, should be included in the current classification scheme.[47]

VESICULOBULLOUS SKIN CHANGE IN LUPUS ERYTHEMATOSUS Vesiculobullous skin change in LE is a very confusing subject. As with non-bullous LE skin disease, vesiculobullous skin lesions in patients with LE can be divided on the basis of histopathology into those that are LE-specific and those that are LE–non-specific (Table 156-5). Bullae may develop in ACLE and SCLE as a manifestation of particularly aggressive liquefactive degeneration of the epidermal basal layer, resulting in basal cell dissolution and simulating the clinical and histopathologic appearance of TEN. Vesiculo-bullous changes can develop at the active edge of annular SCLE lesions, and sub-epidermal bullous changes occasionally develop in DLE lesions.

The cutaneous entity described as bullous SLE is an example of LE–non-specific bullous skin change. Patients who typically have or subsequently develop active SLE including nephritis occasionally develop a severe vesiculobullous eruption. Histopathologically, marked neutrophilic infiltration with papillary microabscess formation is present similar to that of dermatitis herpetiformis (DH) and the inflammatory variant of epidermolysis bullosa acquisita (see Chap. 58). However, the direct immunofluorescence findings are more typical of those of LE. Type VII collagen autoantibodies are present in some patients. Although the vague term *bullous SLE* is most often used to describe such lesions, more descriptive terms such as *DH-like vesiculobullous LE* or *epidermolysis bullosa acquisita–like vesiculobullous LE* seem more appropriate, inasmuch as other forms of bullous skin lesions can occur in patients with SLE.

Other bullous skin diseases that have been linked anecdotally to LE include bullous pemphigoid, pemphigus erythematosus (see Senear-Usher syndrome in Chap. 52), DH, and porphyria cutanea tarda. It is not clear whether there is a primary association between these bullous skin disorders and LE, or whether their co-existence is the result of chance alone.

TABLE 156-5
Proposed Classification Scheme for Vesiculobullous Skin Disorders Encountered in Patients with Lupus Erythematosus

LE-Specific Vesiculobullous LE
- Acute cutaneous LE
  - Toxic epidermal necrolysis–like acute cutaneous LE
- Subacute cutaneous LE
  - Toxic epidermal necrolysis–like SCLE
  - Vesiculobullous annular subacute cutaneous LE
- Chronic cutaneous LE
  - Bullous discoid LE

LE–Non-Specific Vesiculobullous LE
- "Bullous systemic LE" (proposed alternative terms: *dermatitis herpetiformis–like LE–non-specific skin disease*; *epidermolysis bullosa acquisita–like LE–non-specific skin disease*; *LE–non-specific vesiculobullous eruption of SLE*)
- Vesiculobullous skin disorders anecdotally reported to occur in LE patients but whose relationship to LE has not yet been firmly established
  - Bullous pemphigoid
  - Dermatitis herpetiformis
  - Pemphigus erythematosus
  - Porphyria cutanea tarda

LE = lupus erythematosus.
From Sontheimer RD: The lexicon of cutaneous lupus erythematosus—A review and personal perspective on the nomenclature and classification of the cutaneous manifestations of lupus erythematosus. *Lupus* **6**:84, 1997, with permission from Stockton Journals, Macmillan Press, Ltd.

Lupus Erythematosus–Non-Specific Skin Lesions

A large number of cutaneous lesions that are found in LE patients are not specific for LE; that is, they also occur in patients that don't have or never develop LE and do not share the histologic features of LE-specific skin disease. Such skin lesions are usually found in the context of SLE or a significant risk thereof. These LE–non-specific skin lesions are listed in Table 156-1.

LUPUS ERYTHEMATOSUS–NON-SPECIFIC LESIONS AS DIAGNOSTIC CRITERIA FOR SYSTEMIC LUPUS ERYTHEMATOSUS As with some forms of LE-specific skin disease (e.g., ACLE), the presence of non-specific skin lesions may be an indicator of underlying SLE activity. In studies looking at skin lesions in patients with SLE, higher activity scores were seen in association with photosensitivity, Raynaud phenomenon, oral ulcers, non-scarring alopecia (all lupus non-specific lesions), in addition to malar rash and cicatricial alopecia.[48–50]

The high prevalence rates of these conditions in SLE has led to their past and/or present inclusion in the ACR criteria for diagnosis of SLE. Photosensitivity, defined clinically as an *abnormal response to UVR*, appears to be a relatively sensitive indicator of SLE. Several different studies have documented between 50 percent and 93 percent incidence rates of photosensitivity in patients with SLE. Because of the frequency of photosensitivity in SLE, all patients should be taught the importance of protecting skin from UVR. Oral ulcers are present in roughly 25 percent to 45 percent of SLE patients[51,52] and up to 25 percent of DLE patients.[53] Although these lesions can show LE-specific histopathologic changes on biopsy, particularly in DLE patients, they often are non-specific. LE–non-specific alopecia, diffuse non-scarring alopecia that is different than the scarring alopecia associated with DLE, has been referred to as *lupus hair* and presents as course, dry hair that has increased fragility. It often results in broken hairs and may be more prominent over the frontal hairline. This likely has considerable overlap with a diffuse non-scarring alopecia caused by telogen effluvium.

CUTANEOUS VASCULAR REACTIONS Reactions that are focused on the cutaneous vasculature are important to recognize in patients with SLE, as they can frequently indicate underlying systemic vascular pathology. Raynaud phenomenon (see Chap. 171) is the most common vascular reaction in lupus patients: one study documented Raynaud phenomenon in 39.6 percent of patients with SLE.[54] Additionally, it has been shown that Raynaud phenomenon seems to herald a worse prognosis and is associated with higher disease activity scores.[48,50] The presence of Raynaud phenomenon in patients with SLE may correlate with an increase in DLE lesions on the hands. Skin changes that can be seen in association with chronic severe Raynaud phenomenon include focal ulcerations on the fingertips and periungual areas that result in pitted scarring on resolution, prominent nail fold capillary ectasia and drop out, punctate cuticular hemorrhage due to incompetent nail fold capillaries, fingertip tuft atrophy, digital calcinosis, and pterygium inversus unguium.



Patients with SLE often develop vessel pathology in the form of vasculitis. In SLE, all sizes of vessels may be affected.[55] When leukocytoclastic vasculitis (LCV) presents in patients with SLE, other causes of LCV, such as medications and infections, should be excluded before a diagnosis of primary lupus-associated LCV is assigned. Urticarial vasculitis is not uncommon in SLE patients and presents as tender urticarial papules and plaques, often over bony prominences, which last longer than 24 hours. Involvement of medium and/or large vessels may present as purpuric plaques with stellate or retiform borders with or without cutaneous necrosis and ulceration, or subcutaneous nodules. LE–non-specific vasculitis must be distinguished from vasculopathy due to thromboembolism because it may present with similar clinical findings. LE–non-specific vasculopathy is most commonly the result of antiphospholipid antibodies.



Livedo reticularis should be considered as a separate LE–non-specific cutaneous vascular reaction, although it has clear overlap with vasculopathy. It manifests as net-like, blanchable, complete or incomplete, red-purple rings on the extremities and is the result of impeded flow of blood through vessels. Macular erythema over the hyper- and hypothenar eminences of the palms has been reported in lupus patients. Reticulated palmar erythema can also be a sign of vasculopathy associated with anti-phospholipid antibodies. Dilated capillaries of the nail folds have been found in LE patients but less frequently than in patients with dermatomyositis (including clinically amyopathic dermatomyositis) or systemic sclerosis. Erythromelalgia (erythermalgia) is characterized by intense burning pain in the feet and hands, accompanied by local macular erythema and warmth. It differs from Raynaud phenomenon in that it worsens with exposure to heat instead of cold. It may be seen as an isolated clinical entity or in association with several different underlying illnesses, including SLE. Telangiectasia and erythema of the proximal nail fold were found in 76 percent of patients who had both DLE and SLE, but none in patients with DLE in the absence of SLE, suggesting that it, too, is a rather sensitive indicator for systemic disease activity.[54]

OTHER LUPUS ERYTHEMATOSUS–NON-SPECIFIC SKIN LESIONS Urticaria is sometimes associated with LE and is thought to be a manifestation of the immune dysregulation of the disease process. One study found chronic urticaria in 44 percent of 73 SLE patients.[51] SLE patients may present with LE–non-specific cutaneous mucinosis. Patients may develop indurated erythematous papules, nodules, or plaques, typically on the trunk and/or arms. Histopathologic examination of these lesions reveals diffuse dermal mucin deposits. A number of nail changes have been noted in LE patients, including leukonychia, nail pitting or ridging, onycholysis, onychomadesis, and red lunula.[56–58]

Other conditions seen more commonly in the setting of LE that are on the list of LE–non-specific skin lesions include lichen planus, acanthosis nigricans, cutis laxa, anetoderma, multiple dermatofibroma, acquired ichthyosis, and interstitial granulomatous dermatitis.[59–64]

TABLE 156-6
Autoantibodies Associated with Unselected Systemic Lupus Erythematosus

Antigen	Autoantibody Frequency (%) ID	SPA/RIA	Molecular Specificity	Clinical Association
High disease specificity for SLE				
dsDNA		60	Native DNA	LE nephritis
Sm	25		Ribonucleoprotein	—
rRNP	10		Ribosomal P protein	CNS LE
PCNA	3		Cyclin	—
Low disease specificity for SLE				
ssDNA		60	Denatured DNA	Risk for SLE in patients with DLE
Histones		50	Histones	Drug-induced SLE
U1RNP	25		Ribonucleoprotein	Overlap CTD (MCTD)
Ro/SS-A	25	50	Ribonucleoprotein	SLCE, SSj, neonatal LE
La/SS-B	10	20	Ribonucleoprotein	SSj, SCLE
Ku	10		Transcription factor	Overlap CTD

CNS = central nervous system; CTD = connective tissue disease; DLE = discoid lupus erythematosus; dsDNA = doubled-stranded DNA; ID = immunodiffusion; MCTD = mixed CTD; PCNA = proliferating cell nuclear antigen; RIA = radioimmunoassay; RNP = ribonucleoprotein; SCLE = subacute cutaneous lupus erythematosus; SLE = systemic lupus erythematosus; SPA = solid phase immunoassay (i.e., enzyme-linked immunoassay); ssDNA = single-stranded DNA; SSj = Sjögren syndrome.
Reprinted from Sontheimer RD, Provost TT: Lupus erythematosus, in *Cutaneous Manifestations of Rheumatic Diseases*, edited by Sontheimer RD, Provost TT. Baltimore, Williams & Wilkins, 1996, with permission from Williams & Wilkins Publishers.

LABORATORY TESTS

Table 156-4 summarizes the major laboratory findings associated with the varieties of LE-specific skin disease, and Table 156-6 presents the autoantibody associations of SLE. Because of the strong association between ACLE and SLE, the laboratory features of ACLE are those associated with SLE (high-titer ANA, anti–dsDNA, anti-Sm, hypocomplementemia).

The laboratory markers for SCLE are the presence of anti-Ro/SS-A (70 percent to 90 percent) and, less commonly, anti-La/SS-B (30 percent to 50 percent) autoantibodies. ANA are present in 60 percent to 80 percent of patients with SCLE, and rheumatoid factor is present in approximately one-third. Other autoantibodies in patients with SCLE include false-positive serologic tests for syphilis (VDRL rapid plasma reagin) (7 percent to 33 percent), anticardiolipin (10 percent to 16 percent), antithyroid (18 percent to 44 percent), anti-Sm (10 percent), anti–ds-DNA (10 percent), and anti-U1 ribonucleoprotein (10 percent). Patients with SCLE, particularly those with systemic involvement, may have a number of laboratory abnormalities, including anemia, leukopenia, thrombocytopenia, elevated erythrocyte sedimentation rate, hypergammaglobulinemia, proteinuria, hematuria, urine casts, elevated serum creatine and blood urea nitrogen, and depressed complement levels (resulting from genetic deficiency or increased complement consumption).

ANA are present in low titer in 30 percent to 40 percent of patients with DLE; however, fewer than 5 percent have the higher ANA levels that are characteristic of patients with overt SLE (> 1:320). Antibodies to single-stranded DNA are not uncommon in DLE, but antibodies to dsDNA are distinctly uncommon. Precipitating antibodies to U1RNP are sometimes found in patients whose disease course is dominated by DLE lesions; however, such patients usually have only mild manifestations of SLE or overlapping connective tissue

disorders such as mixed connective tissue disease. Precipitating Ro/SS-A and La/SS-B autoantibodies are rare in patients with DLE; low levels of anti–Ro/SS-A antibody detected by enzyme-linked immunoassay are more common. A small percentage of patients with DLE have low-grade anemia, biologic false-positive serologic tests for syphilis (VDRL rapid plasma reagent), positive rheumatoid factor tests, slight depressions in serum complement levels, modest elevations in γ globulin, and modest leukopenia. It has been suggested that such findings are risk factors for the development of SLE. ANA are present in 70 percent to 75 percent of patients with LE profundus/panniculitis, but anti–dsDNA antibodies are rare.

The laboratory findings associated with SLE, as well as with CLE, in both adults and newborns, have been reviewed.[65–67]

HISTOPATHOLOGY

The LE-specific skin disease histopathology is a distinctive constellation of hyperkeratosis, epidermal atrophy, vacuolar basal cell degeneration, dermal-epidermal junction basement membrane thickening, dermal edema, dermal mucin deposition, and mononuclear cell infiltration of the dermal-epidermal junction and dermis, focused in a perivascular and periappendageal distribution (Fig. 156-12). Variable degrees of these features are encountered in the different forms of LE-specific skin disease (see Chap. 6). Differences of opinion exist as to whether ACLE, SCLE, and DLE lesions can be distinguished reliably on the basis of their histopathologic appearances alone.[65,68,69]

Acute Cutaneous Lupus Erythematosus

The histopathologic changes in ACLE lesions are generally less impressive than those in SCLE and DLE lesions, and are mainly those of a cell-poor interface dermatitis. The lymphohistiocytic cellular infiltrate is relatively sparse. Some authors have noted an increase in the number of neutrophils in the infiltrate. A mild degree of focal vacuolar alteration of basal keratinocytes can be seen, in addition to telangiectases and extravasation of erythrocytes. One may see individually necrotic keratinocytes, and in its most severe form, ACLE can display extensive epidermal necrosis similar to TEN. The upper dermis usually shows pronounced mucinosis and may be very helpful in distinguishing ACLE from other causes of a cell-poor interface dermatitis. It is uncommon to see basement membrane zone thickening, follicular plugging, or alteration of epidermal thickness in ACLE, although epidermal atrophy is sometimes present.[69]

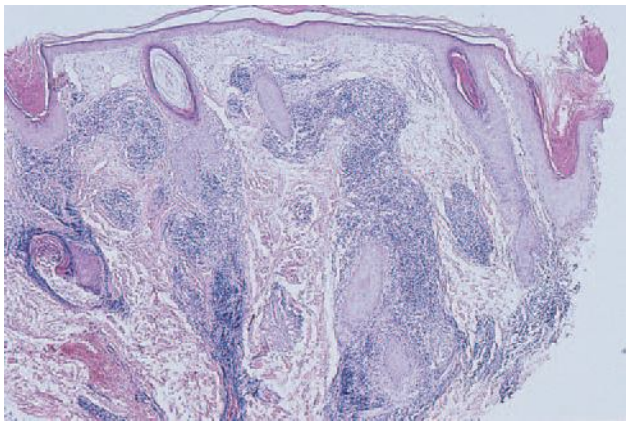

▲ **FIGURE 156-12** Histopathology of lupus erythematosus–specific skin disease. Histology of a discoid lupus erythematosus lesion demonstrating marked basal cell layer damage with vacuolization and irregularity of basal cell size. Mild hyperkeratosis is present.

Subacute Cutaneous Lupus Erythematosus

SCLE also frequently presents as an interface dermatitis, with foci of vacuolar alteration of basal keratinocytes alternating with areas of lichenoid dermatitis. Pronounced epidermal atrophy is often present. SCLE is in the differential diagnosis of atrophic lichenoid dermatitis, along with atrophic lichen planus and lichenoid drug eruptions. Dermal changes include edema, prominent mucin deposition, and sparse mononuclear cell infiltration usually limited to areas around blood vessels and periadnexal structures in the upper one-third of the dermis. Lesser degrees of hyperkeratosis, follicular plugging, mononuclear cell infiltration of adnexal structures, and dermal melanophages might help distinguish SCLE lesions from DLE lesions. It has not been possible to differentiate papulosquamous from annular SCLE by histopathologic criteria alone.[68]

Chronic Cutaneous Lupus Erythematosus

In classic DLE lesions, epidermal changes include hyperkeratosis, variable atrophy, and interface changes similar to those described for SCLE. The epidermal basement membrane is markedly thickened. Dermal changes include a dense mononuclear cell infiltrate composed primarily of CD4 T lymphocytes and macrophages predominantly in the periappendageal and perivascular areas, melanophages, and dermal mucin deposition. The infiltrate is often quite dense and typically extends well into the deeper reticular dermis and/or subcutis, which may help to distinguish it from ACLE or SCLE. In chronic scarring DLE lesions, the dense inflammatory cell infiltrate subsides and is replaced by dermal fibroplasia. A folliculotropic variant of DLE, in which the inflammatory infiltrate is predominantly around hair follicles, has been described, as have lymphomatoid variants, in which there are extremely dense infiltrates that may contain atypical lymphoid cells.[69]

Less Common Sub-Types of Lupus Erythematosus–Specific Skin Disease

The histopathology of hypertrophic DLE lesions is similar to that of classic DLE lesions except for a much greater degree of epidermal acanthosis and hyperkeratosis. At times, prominent acanthosis may simulate keratinocytic neoplastic processes such as squamous cell carcinoma.

In LE panniculitis (see Chap. 68), the absence of the characteristic epidermal and dermal changes of LE can make the histologic diagnosis difficult. In LE panniculitis, subcutaneous tissue displays a lobular lymphocytic panniculitis with perivascular infiltration with lymphocytes, plasma cells, and histiocytes in the deep dermis and subcutaneous fat (including lymphoid nodule formation); vessel wall thickening and invasion by



mononuclear cells (lymphocytic vasculitis); absence of polymorphonuclear leukocytes; hyaline fat necrosis; prominent fibrinoid degeneration of collagen; and mucinous degeneration and calcification in old, established lesions. Except for the differences related to the absence of hair follicles and stratum corneum in mucous membranes, the microscopic changes of mucosal DLE are highly reminiscent of those in cutaneous DLE lesions.

Chilblain LE shows an interface dermatitis, with superficial and deep perivascular lymphocytic infiltration much like classic DLE. However, a lymphocytic vasculitis and fibrin within the lumina of dermal blood vessels are present in addition.[68,69] In tumid LE, the dermal changes of DLE are present, namely a variable perivascular mononuclear infiltrate with prominent mucin between collagen bundles; but the classic epidermal changes that occur in other forms of LE-specific skin disease are not present.[43,45] Histopathologic changes in vesiculo-bullous lesions of LE are noted above under Vesiculobullous Skin Change in Lupus Erythematosus.



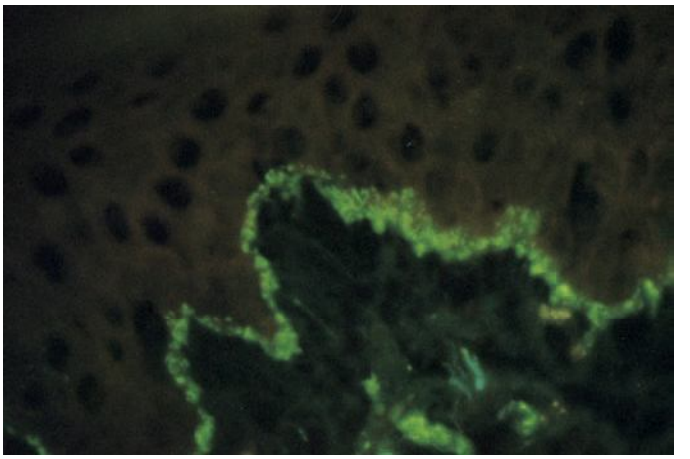

▲ **FIGURE 156-13** Immunopathology of lupus erythematosus–specific skin disease. Direct immunofluorescence examination of a discoid lupus erythematosus lesional skin biopsy showing a continuous band of granular fluorescence at the dermal-epidermal junction as a result of staining with fluorescein isothiocyanate-conjugated goat anti-immunoglobulin G.

IMMUNOHISTOLOGY

Immunohistology is often helpful in confirming a diagnosis of LE-specific skin disease and has been shown to boost the sensitivity and specificity of diagnosis.[69] Because it is not uncommon to see negative immunofluorescence studies in patients with acute, subacute, and chronic LE, and false-positive studies in healthy individuals, immunohistology must be interpreted in the context of clinical and histologic findings in a given patient.

IgG, IgA, IgM and complement components (C3, C4, Clq, properdin, factor B, and the membrane attack complex C5b-C9) deposited in a continuous granular or linear band-like array at the dermal-epidermal junction have been observed in the lesional and non-lesional skin of patients with LE since the early 1960s (Fig. 156-13). However, debate about terminology in this area continues to cloud the field.[65] Some restrict the use of the term *lupus band test* to refer to the examination of non-lesional skin biopsies for the presence of this band-like array of immunoreactants at the dermal-epidermal junction. Others qualify the LBT as being either "lesional" or "non-lesional." Less confusion might exist if the terms *lesional LBT* (lesional lupus band) and *non-lesional LBT* (non-lesional lupus band) were uniformly adopted.

Acute Cutaneous Lupus Erythematosus

The sparse data that exist suggest that 60 percent to 100 percent of ACLE lesions display a lesional lupus band. However, the realization that sun-damaged skin from otherwise healthy individuals can display similar immunopathology has diluted the clinical value of this finding.

Subacute Cutaneous Lupus Erythematosus

Initial studies indicated that approximately 60 percent of patients with SCLE had lesional lupus bands. A "dust-like particle" pattern of IgG deposition focused around epidermal basal keratinocytes has been suggested to be more specific for SCLE by reflecting the presence of in vivo-bound Ro/SS-A autoantibody.

Chronic Cutaneous Lupus Erythematosus

Early reports suggested that more than 90 percent of classic DLE lesions had lesional immunoreactants at the dermal-epidermal junction, often extending along the basement membrane of the hair follicle, but subsequent studies report somewhat lower rates. Lesions on the head, neck, and arms are positive more frequently (80 percent) than those on the trunk (20 percent). The lesional lupus band also appears to be a function of the age of the lesion being examined, with older lesions (> 3 months) being positive more often than younger ones. Ultrastructural localization of immunoglobulin at the dermal-epidermal junction confirms that these proteins are deposited on the upper dermal collagen fibers and along the lamina densa of the epidermal basement membrane zone.

In LE profundus, immunoglobulin and complement deposits are usually found in blood vessel walls of the deep dermis and subcutis. Immunoglobulin deposits at the dermal-epidermal junction may or may not be present, depending on the site biopsied, the presence or absence of accompanying SLE, and the presence or absence of overlying changes of DLE at the dermal-epidermal junction.

Non-Lesional Lupus Band Test

There has been much debate over the past three decades regarding the diagnostic and prognostic significance of an immunoglobulin/complement band at the dermal-epidermal junction of non-lesional skin taken from patients with LE.[65,68] When totally sun-protected non-lesional skin (e.g., buttocks) is sampled, the diagnostic specificity for SLE appears to be very high when three or more immunoreactants are present at the dermal-epidermal junction. Prospectively ascertained follow-up data also suggest that the presence of a non-lesional LBT correlates positively with risk for developing LE nephritis. However, the non-lesional LBT has fallen out of favor as a clinical tool largely because

Box 156-1

Differential Diagnosis of Lupus Erythematosus

Most Likely	*Consider*	*Always Rule Out*
ACLE	ACLE	ACLE
• Localized	• Localized	• Generalized
~ Acne rosacea	~ Seborrheic dermatitis	~ Toxic epidermal necrolysis
~ Dermatomyositis	~ Polymorphous light eruption	DLE
• Generalized	~ Photoallergic contact dermatitis	• Tinea incognito
~ Drug hypersensitivity reaction	• Generalized	Cutaneous T-cell lymphoma
~ Photoallergic/phototoxic drug reactions	~ Dermatomyositis	• Lupus panniculitis
~ Viral exanthems	SCLE	~ Infectious panniculitis (deep fungal/atypical mycobacterial organisms)
SCLE	• Papulosquamous	~ Calciphylaxis
• Papulosquamous	~ Photoallergic/photo lichenoid drug eruption	
~ Photosensitive psoriasis	• Annular	
• Annular	~ Erythema gyratum repens	
~ Erythema annulare centrifugum	DLE	
~ Granuloma annulare	• Early DLE/LET	
DLE	~ Granuloma faciale	
• Early DLE/LET	~ Sarcoidosis	
~ Polymorphous light eruption	~ Jessner benign lymphocytic infiltration of the skin	
~ Acne	~ Pseudolymphoma	
• Fully Evolved DLE/Hypertrophic DLE	~ Lymphoma cutis	
~ Squamous cell carcinoma	~ Lupus vulgaris	
~ Actinic keratosis	~ Urticaria	
~ Keratoacanthoma	~ Urticarial vasculitis	
• Lupus panniculitis	• Fully evolved/hypertrophic DLE	
~ Morphea profundus	~ Prurigo nodularis	
	~ Hypertrophic lichen planus	
	• Lupus panniculitis	
	~ Subcutaneous sarcoidosis	
	~ Traumatic panniculitis	
	~ Eosinophilic fasciitis	

ACLE = acute cutaneous lupus erythematosus; DLE = discoid lupus erythematosus; LET = lupus erythematosus tumidus; SCLE = subacute cutaneous lupus erythematosus.



the information gained has not been proven to be of significantly greater value than the results of more readily available serologic assays such as antibody to dsDNA.

DIFFERENTIAL DIAGNOSIS

(Boxes 156-1 and 156-2)

PROGNOSIS AND CLINICAL COURSE

Acute Cutaneous Lupus Erythematosus

Both localized and generalized forms of ACLE lesions flare and abate in parallel with underlying SLE disease activity. Therefore, the prognosis for any given patient with ACLE is dictated by the pattern of the underlying SLE. Both 5-year (80 percent to 95 percent) and 10-year (70 percent to 90 percent) survival rates for SLE have progressively improved over the past four decades as a result of earlier diagnosis made possible by more sensi-

Box 156-2

Complications

- ACLE/SCLE
  - Associated flaring SLE with potentially organ-threatening involvement
  - Ulceration with risk for superinfection
  - Progression to TEN-like ACLE/SCLE
  - Post-inflammatory hyperpigmentation
- DLE
  - Associated flaring SLE with potentially organ-threatening involvement (especially if disseminated)
  - Scarring/disfigurement, including scarring alopecia
  - Ulceration with risk for superinfection
  - Post-inflammatory hyperpigmentation
  - LE panniculitis
  - Dystrophic calcification
  - Depressed atrophic disfigurement
  - Lupus mastitis
- LE–non-specific skin disease
- Vasculitis/vasculopathy
  - Associated systemic involvement with life- or organ-threatening involvement
  - Cutaneous necrosis/ulceration
- Raynaud phenomenon
  - Digital ulceration/dry gangrene/loss of digits

ACLE = acute cutaneous lupus erythematosus; DLE = discoid lupus erythematosus; LE = lupus erythematosus; SCLE = subacute cutaneous lupus erythematosus ; SLE = systemic lupus erythematosus; TEN = toxic epidermal necrolysis.

tive laboratory testing and improved immunosuppressive treatment regimens. Ominous prognostic signs in SLE are hypertension, nephritis, systemic vasculitis, and central nervous system disease.

Subacute Cutaneous Lupus Erythematosus

Because SCLE has been recognized as a separate disease entity for only two decades, the long-term outcome associated with SCLE lesions has yet to be determined. It is the authors' experience that most patients with SCLE have intermittent recurrences of skin disease activity over long periods of time without significant progression of systemic involvement (we are aware of only one death directly attributable to SLE in approximately 150 patients with SCLE). Other patients enjoy long-term if not permanent remissions of their skin disease activity. A few patients have experienced unremitting cutaneous disease activity.



It has also been the authors' experience that approximately 15 percent of the patients with SCLE develop active SLE, including lupus nephritis. This subgroup of patients is marked by the presence of papulosquamous SCLE, localized ACLE, high-titer ANA, leukopenia, and/or antibodies to dsDNA. Long-term follow-up studies of SCLE are required to determine the true risk of severe systemic disease progression in patients presenting with SCLE skin lesions. CCLE lesions, typically classic DLE, have also arisen in patients initially presenting with SCLE.

Evidence suggests that overlap occurs between SCLE and Sjögren syndrome. Patients with SCLE who develop Sjögren syndrome are at risk for developing the extraglandular systemic complications associated with Sjögren syndrome, including vasculitis, peripheral neuropathy, autoimmune thyroiditis, renal tubular acidosis, myositis, chronic hepatitis, primary biliary cirrhosis, psychosis, lymphadenopathy, splenomegaly, and B-cell lymphoma.

Chronic Cutaneous Lupus Erythematosus

Most patients with untreated classic DLE lesions suffer indolent progression to large areas of cutaneous dystrophy and scarring alopecia that can be psychosocially devastating and occupationally disabling. However, with treatment, skin disease can be largely controlled. Spontaneous remission occurs occasionally, and the disease activity can recrudesce at the sites of older, inactive lesions. Rebound after discontinuation of treatment is typical, and slower taper of medications during periods of inactivity is recommended. Squamous cell carcinoma occasionally develops in chronic smoldering DLE lesions.

Death from SLE is distinctly uncommon in patients who present initially with localized DLE. As discussed in Epidemiology, patients presenting with localized DLE have only a 5 percent chance of subsequently developing clinically significant SLE disease activity. Generalized DLE and persistent, low-grade laboratory abnormalities appear to be risk factors for such disease progression. Unrecognized squamous-cell carcinoma developing within a long-standing DLE skin lesion could be a cause of morbidity and mortality.

Outcomes Measures

The recent development of a validated instrument to measure activity of CLE, the Cutaneous Lupus Erythematosus Area and Severity Index, has made it possible to objectively follow patients' disease course and response to therapy. The instrument has separate scores for damage (scarring) and activity which is important, because one would not expect a "burned-out" scarred area to normalize with drugs that were meant to abate LE activity.[70] The creation of this utility tool is timely because the U.S. Food and Drug Administration has recently called for new drug development for lupus, including disease in which only one organ is affected (i.e., skin-only DLE). A Brazilian group has recently used the Dermatology Life Quality Index and SF-36 to measure quality of life in patients with CLE. Both questionnaires showed that patients with active skin lesions had lower quality of life and that patients with associated alopecia were particularly impacted.[71]

TREATMENT

The initial management of patients with any form of CLE should include an evaluation to rule out underlying SLE disease activity at the time of diagnosis. All patients with CLE should receive instruction about protection from sunlight and artificial sources of UVR and should be advised to avoid the use of potentially photosensitizing drugs such as hydrochlorothiazide, tetracycline, griseofulvin, and piroxicam. With regard to specific medical therapy, local measures should be maximized and systemic agents used if significant local disease activity persists or systemic activity is superimposed.

ACLE lesions usually respond to the systemic immunosuppressive measures required to treat the underlying SLE disease activity that so frequently accompanies this form of CLE (e.g., systemic glucocorticoids, azathioprine, cyclophosphamide). Increasing evidence suggests that aminoquinoline antimalarial agents such as hydroxychloroquine can have a steroid-sparing effect on SLE, and these drugs can be of value in ACLE. The local measures discussed in Local Therapy below can also be of value in treating ACLE. Because the lesions of SCLE and CCLE are often found in patients who have little or no evidence of underlying systemic disease activity, unlike the lesions of ACLE, nonimmunosuppressive treatment modalities are preferred for SCLE and CCLE (Table 156-7). For the most part, SCLE and CCLE lesions respond equally to such agents.

Local Therapy

SUN PROTECTION Advise patients to avoid direct sun exposure, wear tightly woven clothing and broad-brimmed hats, and regularly use broad-spectrum, water-resistant sunscreens [SPF ≥ 30 with an efficient UVA blocking agent such as a photostabilized form of avobenzone (Parsol 1789), micronized titanium dioxide, micronized zinc oxide, or Mexoryl SX]. UV-blocking films should be applied to home and automobile windows, and acrylic diffusion shields should be placed over fluorescent lighting. Corrective camouflage cosmetics such as Dermablend® and Covermark® offer the dual benefit of being highly effective physical sunscreens as well as aesthetically pleasing cosmetic masking agents. An in-depth discussion of practical and theoretical photoprotection and local therapy for autoimmune connective tissue skin disease such as diabetes mellitus has been discussed by Ting and Sontheimer (see Chap. 223).[72]

LOCAL GLUCOCORTICOIDS Although some prefer intermediate-strength preparations, such as triamcinolone acetonide 0.1 percent, for sensitive areas such as the face, superpotent topical class I agents, such as clobetasol propionate 0.05 percent or betamethasone dipropionate 0.05 percent, produce the greatest benefit in CLE. Twice-daily application of the superpotent preparations to lesional skin for

TABLE 156-7
Therapeutic Options for Lupus Erythematosus–Specific Skin Disease

	Drug	Dose
First line	Topical glucocorticoids Topical calcineurin inhibitor Intralesional: triamcinolone acetonide	Class I steroid qd–bid for 2 wk alternating with class IV pimecrolimus, 1% bid; tacrolimus, 0.1% bid 2.5–10.0 mg/cc
Second line (low threshold for use if scarring, widespread lesions, systemic symptoms)	Hydroxychloroquine Chloroquine Quinacrine (if monotherapy fails, add quinacrine to either hydroxychloroquine or chloroquine)	6.5 mg/kg/day ideal body weight 3.5 mg/kg/day ideal body weight 100 mg daily (available at compounding pharmacies)
Short courses only (2–16 wk) (must have patient on concomitant alternative agent to prevent rebound on discontinuation)	Prednisone Thalidomide	5–60 mg/day 50 mg qd–200 mg/day; taper to 50 mg qod on response
Third line (safer immunosuppressives)	Azathioprine Mycophenolate mofetil Methotrexate	1.5–2.5 mg/kg/day 2.5–3.5 g/day 7.5–25 mg PO or SQ/wk
Worth consideration	Dapsone Accutane or Acitretin Gold	50–200 mg/day 0.5–2 mg/kg/day 10–50 mg/day Work up to 50 mg weekly, taper after 1 g
Fourth line (limited by side effects)	Cyclophosphamide Clofazimine	1.5–2.0 PO mg/kg/day
Investigational (some currently available)	Efalizumab (Raptiva) Leflunomide (Arava) Anti-tumor necrosis factor agents Rituximab (Rituxan) Abatacept Epratuzumab Anti–interferon-α agents	

2 weeks followed by a 2-week rest period can minimize the risk of local complications such as steroid atrophy and telangiectasia. Ointments are more effective than creams for more hyperkeratotic lesions such as hypertrophic DLE. Occlusive therapy with glucocorticoid-impregnated tape (e.g., flurandrenolide) or glucocorticoids with plastic food wrap (e.g., Saran or Glad Press-N-Seal) can potentiate the beneficial effects of topical glucocorticoids but also carries a higher risk of local side effects. Class I or class II topical glucocorticoid solutions and gels are best for treating the scalp. Unfortunately, even the most aggressive regimen of topical glucocorticoids by itself does not provide adequate improvement for most patients with SCLE and CCLE.

TOPICAL CALCINEURIN INHIBITORS Pimecrolimus 1 percent cream and tacrolimus 0.1 percent ointment have demonstrated variable efficacy in the treatment of ACLE, DLE, and SCLE.[73–75]

INTRALESIONAL GLUCOCORTICOIDS Intralesional glucocorticoids (e.g., triamcinolone acetonide suspension, 2.5 to 5.0 mg/mL for the face with higher concentrations allowable in less sensitive sites) are more useful in the management of DLE than SCLE. Intralesional glucocorticoids themselves can produce cutaneous and subcutaneous atrophy (deep injections into the subcutaneous tissue enhances this risk). A 30-gauge needle is preferred because it produces only mild discomfort on penetration, especially when injected perpendicularly to the skin. The active borders of lesions should be thoroughly infiltrated. Intralesional therapy is indicated for particularly hyperkeratotic lesions or lesions that are unresponsive to topical glucocorticoids, but most patients with CLE have too many lesions to be managed exclusively by intralesional glucocorticoid injections.

Systemic Therapy

ANTIMALARIALS One or a combination of the aminoquinoline antimalarials can be effective for approximately 75 percent of patients with CLE who have failed to benefit adequately from the local measures described in Local Therapy.[65] The risks of retinal toxicity should be discussed with the patient, and a pre-treatment ophthalmologic examination should be performed. However, the risk of antimalarial retinopathy is extremely rare if recommended daily dose maximum levels of these agents are not exceeded (hydroxychloroquine, 6.5 mg/kg/day based on ideal body weight; chloroquine, 4 mg/kg/day). Patients should have follow-up ophthalmologic evaluations every 6 to 12 months while on therapy.

Hydroxychloroquine sulfate (Plaquenil), 400 mg/day by mouth, should be given for the first 6 to 8 weeks of treatment to reach equilibrium blood levels. Once an adequate clinical response has been achieved, the daily dose should be decreased to a maintenance dose of 200 mg/day for at least 1 year to minimize chances of recurrence (some authorities recommend even longer periods of inductive treatment). If no response is seen after 8 to 12 weeks, quinacrine hydrochloride, 100 mg/day (currently available in the United States only through compounding pharmacies), can be added to the hydroxychloroquine without enhancing the risk of retinopathy (quinacrine does not cause retinopathy). If, after 4 to 6 weeks, adequate clinical control has not been achieved, consideration should be given to replacing the hydroxychloroquine with chloroquine diphosphate (Aralen), 250 mg/day. In Europe, chloroquine is generally felt to be more efficacious than hydroxychloroquine in treating CLE, perhaps due to the earlier therapeutic responses that might occur as a result of the shorter time period required to reach equilibrium blood levels with chloroquine as compared to hydroxychloroquine. Hydroxychloroquine and chloroquine should not be used simultaneously because of enhanced risk for retinal toxicity.

Multiple side effects other than retinal toxicity are associated with the use of antimalarials. Quinacrine is associated with



a higher incidence of side effects, such as headache, gastrointestinal intolerance, hematologic toxicity, pruritus, lichenoid drug eruptions, and mucosal or cutaneous pigmentary deposition, than is either hydroxychloroquine or chloroquine. Quinacrine commonly produces a yellow discoloration of the entire skin and sclera in fair-skinned individuals, which is completely reversible when the drug is discontinued. Quinacrine can produce significant hemolysis in patients with glucose-6-phosphate dehydrogenase deficiency (this adverse effect has also been reported to occur rarely with hydroxychloroquine and chloroquine). Each of the aminoquinoline antimalarials can produce bone marrow suppression, including aplastic anemia, although this effect is exceedingly rare with the current dosage regimens. Toxic psychosis, grand mal seizures, neuromyopathy, and cardiac arrhythmias occurred with the use of high doses of these drugs in the past; these reactions are uncommon with the lower daily dose regimens used today.



Before therapy with hydroxychloroquine and chloroquine is begun, complete blood cell counts, as well as liver and renal function tests, should be performed; these tests should be repeated 4 to 6 weeks after therapy has been initiated, and every 4 to 6 months thereafter. A screen for hematologic toxicity when quinacrine is used is recommended more often. Patients with overt or sub-clinical porphyria cutanea tarda are at particularly high risk for developing acute hepatotoxicity, which often simulates an acute surgical abdomen, when treated with therapeutic doses of antimalarials for CLE. It is also recommended to check urine levels of β–human chorionic gonadotropin initially in women with childbearing potential, although recent evidence indicates that the risk to pregnant women of currently recommended dose regimens of antimalarials is minimal.

NONIMMUNOSUPPRESSIVE OPTIONS FOR ANTIMALARIAL-REFRACTORY DISEASE Some patients with refractory CLE (SCLE more than DLE) respond to diaminodiphenylsulfone.[76] An initial dose of 25 mg by mouth twice daily can be increased up to 200 to 400 mg/day, if necessary. Significant dose-related hemolysis and/or methemoglobinemia can result from the use of diaminodiphenylsulfone, especially in individuals deficient in glucose-6-phosphate dehydrogenase activity, and, therefore, complete blood counts and liver function tests should be performed regularly. Isotretinoin, 0.5 to 2.0 mg/kg/day, and acitretin, 10 to 50 mg/day, have also been used in this setting, but their efficacy is limited by their side effects (teratogenicity, mucocutaneous dryness, hyperlipidemia). In addition, breakthrough of CLE activity has been a problem with the long-term use of retinoids.

Thalidomide (see Chap. 236) (50 to 200 mg/day) is strikingly effective for CLE that is refractory to other medications. Numerous studies have cited response rates between 85 percent and 100 percent, with many patients experiencing complete remission.[77] However, strict prescribing regulations put in place in the United States in 1998 because of severe teratogenicity, make thalidomide challenging to dispense to women of childbearing potential. Sensory neuropathy is another toxicity associated with thalidomide, and 25 percent to 75 percent of patients with CLE develop peripheral neuropathy while taking the drug. Most cases are reversible when therapy is stopped. Neuropathy seems to correlate with total treatment times so that short courses are preferred. Relapses after the drug is stopped are common. Excess somnolence as well as constipation and other minor side effects sometimes limit its use, although these effects usually abate with lower daily doses.[78] Thromboembolism is a serious adverse event that can happen in patients with a pre-existing hypercoagulable state (e.g., presence of anti-phospholipid antibodies). Oncologists who use thalidomide for multiple myeloma frequently initiate concomitant anticoagulation therapy to prevent this side effect. Lenalidomide (Revlamid, Celgene) is a thalidomide analog that is more efficacious but has similar rates of teratogenicity, peripheral neuropathy, thromboembolism, and also has the additional potential side effect of profound leukopenia.

Other drugs reported to be of value in the treatment of refractory CLE are gold and clofazimine; however, the benefit varies from case to case and both of these agents are associated with the risk of significant side effects. Vitamin E, phenytoin, sulfasalazine, danazol, DHEA, and phototherapy (UVAI phototherapy, photopheresis) have also been reported in uncontrolled trials to be of value in CLE.

SYSTEMIC GLUCOCORTICOIDS Every effort should be made to avoid the use of systemic glucocorticoids in patients with LE limited to the skin. However, in occasional patients who have especially severe and symptomatic skin disease, intravenous pulse methylprednisolone has been used. In less acute cases, moderate daily doses of oral glucocorticoids (prednisone, 20 to 40 mg/day, given as a single morning dose) can be used as supplemental therapy during the loading phase of therapy with an antimalarial agent. The dose should be reduced at the earliest possible time because of the complications of long-term glucocorticoid therapy, especially avascular (aseptic) bone necrosis, a side effect to which patients with LE are particularly susceptible.

Because steroid-induced bone loss occurs most rapidly in the first 6 months of use, all patients who do not have contraindications should begin agents to prevent osteoporosis with the initiation of steroid therapy. An excellent review describing current recommendations for prevention of bone loss and other side effects of systemic glucocorticoids has been published.[39] When the disease activity is controlled, the daily dosage should be reduced by 5- to 10-mg decrements until activity flares again or until a daily dosage of 20 mg/day is achieved. The daily dose should then be lowered by 2.5-mg decrements (some physicians prefer to use 1-mg dose decrements below 10 mg/day). Alternate-day glucocorticoid therapy has not been successful in suppressing disease activity in most patients with CLE or SLE. Prednisolone rather than prednisone should be used in patients who have significant underlying liver disease, because prednisone requires hydroxylation in the liver to become biologically active. Any amount of prednisone given as a single oral dose in the morning has less adrenal-suppressing activity than the same amount given in divided doses throughout the day. However, any given amount of this drug, taken in divided doses, has a greater LE-suppressing activity than does the same amount of drug given as a single morning dose.

OTHER IMMUNOSUPPRESSIVES Azathioprine (Imuran) (1.5 to 2.0 mg/kg/day orally) can play a glucocorticoid-sparing role in the severely affected patient with CLE. Mycophenolate mofetil (MMF) (2.5 to 3.0 g/day orally) is a purine analogue similar to azathioprine, but with more specific inhibition of the de novo pathway in lymphocytes. This characteristic may allow for more efficacy and less toxicity in treating severe, recalcitrant CLE, and such results have been reported in several studies.[79–82] Although one study describes inefficacy of

MMF in CLE,[83] one of the authors (M.I.C.) has noted complete or partial response in most patients treated with an average daily dose of 3 g of MMF. Strict observance of dietary restrictions seems to enhance efficacy. Methotrexate (7.5 to 25.0 mg orally 1 day per week) is effective for severe refractory CLE. A double-blind, randomized, placebo-controlled trial in patients with SLE showed that moderate doses of methotrexate (15 to 20 mg weekly) effectively controlled cutaneous and articular activity and permitted a reduction in prednisone dose.[84] Leflunomide is an inhibitor of de novo pyrimidine synthesis that is approved for the treatment of rheumatoid arthritis. Several small series have reported beneficial results in SLE patients. However, there have also been reports of leflunomide-induced cutaneous lupus, thus this drug should be used carefully in patients with LE.[39]

Other immunosuppressives that have been used anecdotally include cytosine arabinoside and cyclosporine. Immunotherapy with high-dose intravenous γ globulin has also been used.

BIOLOGIC THERAPIES (See Chap. 235) There have been reports documenting efficacy of anti-TNF medications (etanercept, adalimumab, infliximab) in the treatment of recalcitrant CLE, particularly SCLE.[85–87] However, these agents are also well known to induce both SLE and CLE, highlighting the importance of TNF homeostasis in patients predisposed to LE.[30,38]

Rituximab, a genetically engineered chimeric monoclonal antibody directed against the CD20 antigen found on the surface of developing B cells, has been studied systematically in SLE and might also have use in CLE.[88] Epratuzumab, a monoclonal antibody against CD22 B-cell antigen, is another drug initially developed for non-Hodgkin lymphoma, and is being studied in murine lupus.[89] B-lymphocyte stimulator (BLyS) is a recently discovered member of the TNF cytokine family. BLyS is made by monocytes and macrophages with subsequent release when these cells are activated. BLyS binds to a receptor found only on B cells, which stimulates maturation into antibody-secreting plasma cells. A fully human monoclonal antibody directed against BLyS, belimumab, inhibits the biologic activity of BLyS. Belimumab was initially studied in murine lupus models, resulting in increased survival. A phase II trial showed improvement in patients with high titer dsDNA antibodies.[89]

Abatacept is a fully human recombinant fusion protein that selectively modulates T-cell activation by blocking co-stimulation via the B7 (CD80/86):CD 28 pathway. This results in decreased T-cell activation, proliferation, cytokine secretion, and subsequent autoantibody production without depletion of T or B cells. It has effectively prevented SLE onset in several murine models. Two observational studies are planned.[39] Modulation of T-cell activation by blocking co-stimulization is likely the same way efalizumab might impact recalcitrant CLE.

Efalizumab, a recombinant humanized monoclonal IgG1 antibody directed against CD11a/LFA-1, has been recently reported to be effective in SCLE.[90] In addition, a series of 15 therapeutically refractory DLE patients have been informally reported to have experienced good to excellent clinical responses to efalizumab with minimal adverse effects (personal communication, Dr. Mark Goodfield, September 2006). There is currently an ongoing phase II clinical trial in the United States of efalizumab in scalp DLE. Interestingly, there has been one report noting induction of SCLE in a patient treated with efalizumab for erosive lichen planus.[91]

As previously discussed under Dendritic Cells and Interferon-α, abnormal regulation of IFN-α appears to play a central role in the pathogenesis of both cutaneous and systemic manifestations of LE. A phase I clinical trial is currently underway in the United States that examines the clinical efficacy of a monoclonal antibody to IFN-α (MEDI-545-MedImmune) in LE skin lesions of various sub-types occurring in the context of SLE.

Surgical and Cosmetic Therapy

DLE lesions can produce permanent scarring alopecia, cosmetically disturbing dermal atrophy, and pigmentary changes. Patients so affected often ask about the possibility of cosmetic correction of these changes. Surgical interventions such as hair transplantation and dermabrasion carry finite risks because CLE is characterized by a tendency for non-specific mechanical trauma, including surgical incision or laser ablation, to exacerbate disease activity (i.e., Koebner phenomenon/isomorphic effect). Some patients tolerate scar revision techniques, including dermabrasion, if they are on maintenance systemic therapy (e.g., antimalarials). Anecdotal reports of the successful management of active CLE with argon and pulsed dye laser therapy have appeared. Resurfacing of atrophic scars with the erbium:yttrium-aluminum-garnet laser or carbon dioxide resurfacing laser has been reported to be beneficial.[92,93] The injection of atrophic lesions with collagen or other similar materials should be avoided.

PREVENTION

Predicting and preventing the initial clinical manifestation of LE, whether it is skin disease or systemic, is not feasible at this time. However, as many LE patients exhibit worsening of their skin disease activity with UV light exposure, physical protection from sunlight and artificial sources of UV light as well as the regular use of broad-spectrum sunscreens having a SPF of 30 or greater should be encouraged.

KEY REFERENCES

The full reference list for all chapters is available at www.digm7.com.

1. Tan EM et al: The 1982 revised criteria for the classification of systemic lupus erythematosus. *Arthritis Rheum* **25**:1271, 1982
3. Watanabe T, Tsuchida T: Classification of lupus erythematosus based upon cutaneous manifestations. Dermatological, systemic and laboratory findings in 191 patients. *Dermatology* **190**:277, 1995
5. Liu K, Mohan C: What do mouse models teach us about human SLE? *Clin Immunol* **119**:123, 2006
7. Werth VP, Bashir M, Zhang W: Photosensitivity in rheumatic diseases. *J Investig Dermatol Symp Proc* **9**:57, 2004
22. Pascual V, Banchereau J, Palucka AK: The central role of dendritic cells and interferon-alpha in SLE. *Curr Opin Rheumatol* **15**:548, 2003
39. Dooley MA, Ginzler EM: Newer therapeutic approaches for systemic lupus erythematosus: Immunosuppressive agents. *Rheum Dis Clin North Am* **32**:91, 2006
49. Zecevic RD et al: Skin lesions—An indicator of disease activity in systemic lupus erythematosus? *Lupus* **10**:364, 2001
65. Sontheimer RD, Provost TT: Lupus erythematosus, in *Cutaneous Manifestations of Rheumatic Diseases*, edited by Sontheimer RD, Provost TT. Baltimore, Williams & Wilkins 1996, p 1
70. Albrecht J et al: The CLASI (Cutaneous Lupus Erythematosus Disease Area and Severity Index): An outcome instrument for cutaneous lupus erythematosus. *J Invest Dermatol* **125**:889, 2005
72. Ting WW, Sontheimer RD: Local therapy for cutaneous and systemic lupus erythematosus: Practical and theoretical considerations. *Lupus* **10**:171, 2001



CHAPTER 157

Dermatomyositis

Richard D. Sontheimer
Melissa I. Costner

The idiopathic inflammatory myopathies (IIMs) are a heterogeneous group of genetically determined autoimmune disorders that predominately target the skeletal musculature and/or skin and typically result in symptomatic skeletal muscle weakness and/or cutaneous inflammatory disease (Table 157-1). This group of diseases was previously referred to as *polymyositis/dermatomyositis* (PM/DM). Among the IIMs, DM is of special interest to the dermatologist due the universal presence of a hallmark pattern of cutaneous inflammation. DM is the only IIM that expresses a characteristic pattern of primary cutaneous inflammation.

In this chapter, the term *classic DM* is used to refer to DM as traditionally defined (i.e., the concurrence of myositis resulting in clinically significant proximal muscle weakness and a set of hallmark inflammatory skin lesions occurring in a specific anatomical distribution). Also of interest to the dermatologist is the subgroup of patients who express the hallmark cutaneous manifestations of DM

TABLE 157-1
Dermatomyositis (DM)–Related Terminology Used in This Chapter[a]

TERM	DEFINITION
Amyopathic DM[b]	Subset of DM characterized by biopsy-confirmed hallmark cutaneous manifestations of classical DM occurring for 6 mo or longer with no clinical evidence of proximal muscle weakness and no serum muscle enzyme abnormalities. If more extensive muscle testing is carried out, the results should be within normal limits [if such results are positive or abnormal, the patient should be classified as having "hypomyopathic dermatomyositis" (see below)]. Exclusion criteria for amyopathic DM for the purpose of clinical studies include the following: 1. Treatment with systemic immunosuppressive therapy for 2 consecutive months or longer within the first 6 mo after skin disease onset (such therapy could prevent the development of clinically significant myositis). 2. Use of drugs known to be capable of producing isolated DM-like skin changes (e.g., hydroxyurea, statin cholesterol-lowering agents) at the time of onset of the cutaneous DM changes.
Classic DM	Presence of the hallmark cutaneous manifestations of DM, proximal muscle weakness, and objective evidence of muscle inflammation characteristic of DM.
Clinically amyopathic DM (CADM)	Functional umbrella designation that refers both to amyopathic DM and to hypomyopathic DM. This designation emphasizes that the predominant clinical problem is skin disease in affected patients.
DM sine myositis	Historic term synonymous with *clinically amyopathic DM*.
DM-specific skin disease	Clinicopathologic pattern of skin changes appearing only in DM (analogous to the concept of "lupus erythematosus–specific skin disease" proposed by Gilliam in 1975).[113]
Hallmark cutaneous lesions/changes of DM	Skin lesions that alone or in combination are seen only in patients with some form of DM (synonymous with *DM-specific skin disease*).
Hypomyopathic DM	DM-specific skin disease but no clinical evidence of muscle disease (i.e., no muscle weakness) but sub-clinical evidence of myositis on laboratory, electrophysiologic, and/or radiologic evaluation.
Idiopathic inflammatory dermatomyopathies (IIDMs)	More inclusive term used to designate the spectrum of illness that has conventionally been referred to as the *idiopathic inflammatory myopathies* and *dermatomyositis/polymyositis*.

[a]Derivation of new term discussed elsewhere.[1,2]
[b]Both adult-onset and juvenile-onset amyopathic DM and hypomyopathic DM can be subcategorized as "provisional" or "confirmed" when patients have biopsy-confirmed hallmark cutaneous manifestations of DM without muscle weakness and with normal muscle enzyme levels for ≥ 6 mo (provisional) or 24 mo (confirmed).[112]

DERMATOMYOSITIS AT A GLANCE



- Dermatomyositis (DM) is thought to evolve through multiple sequential phases: (1) a genetically determined susceptibility phase, (2) an induction phase triggered by an environmental stimulus (e.g., ultraviolet light, infection) involving loss of tolerance to self-antigens in skin and skeletal muscle, (3) an autoimmune expansion phase, and (4) an injury phase involving multiple immunologic effector mechanisms.
- All clinical types of the idiopathic inflammatory dermatomyopathies are rare, orphan diseases.
- Some clinical subphenotypes of DM such as clinically amyopathic DM have been underdiagnosed in the past, often being confused with isolated forms of cutaneous lupus erythematosus.
- Clinical features are a function of age of onset (e.g., juvenile-onset classic DM: vasculopathy, dystrophic calcification; adult-onset classic DM: associated occult malignancy, interstitial lung disease).
- The sine qua non of DM is a hallmark constellation of inflammatory skin changes presenting as patchy or confluent, macular, violaceous erythema that assumes a highly characteristic anatomic distribution and is often photoaccentuated. With time, additional diagnostic skin changes appear, including Gottron papules, prominent periungual nail fold microvascular changes, and poikiloderma atrophicans vasculare.
- Joint disease (arthritis/arthralgia), pulmonary disease (interstitial lung disease, aspiration pneumonia), esophageal disease (dysphagia), vasculopathic injury of multiple organ systems (gastrointestinal system, central nervous system, eye), and cardiac disease (conduction defects, cardiomyopathy) may be related features.
- Pathologic features include the following: In skin—a cell-poor interface dermatitis with dermal mucin accumulation; in muscles—a characteristic pattern of inflammatory myositis.



for prolonged periods (6 months or longer) without developing clinically evident muscle weakness. This pattern of DM expression is referred to as *clinically amyopathic DM* (CADM); this term is synonymous with the predominately historical designation, *dermatomyositis sine myositis*.

On occasion, other organ systems, such as the lungs (interstitial lung disease), joints (arthritis), and heart (cardiomyopathy, conduction defects), are targeted by inflammatory injury in IIM patients. In addition, differences exist between classic DM presenting in adults and that presenting in children. For example, juvenile-onset classic DM is associated with higher rates of vasculopathy/vasculitis resulting in the complication of dystrophic calcification, whereas adult-onset classic DM is associated with a significantly increased risk of internal malignancy and interstitial lung disease.

The diagnostic criteria for DM under the current consensus IIM classification system have not allowed for the inclusion of cutaneous-only or cutaneous-predominant subsets of DM, such as amyopathic DM and hypomyopathic DM, which together are referred to here as CADM. A more inclusive disease category designation, "idiopathic inflammatory dermatomyopathies" (IIDM), has been proposed by one of the authors (R.D.S.) as an alternative to the "IIM" designation because it allows for the inclusion of these cutaneous subsets of DM[1] (Table 157-2). For further discussion, the reader is referred to several comprehensive reviews of all aspects of DM,[1–16] including a historical perspective emphasizing the cutaneous manifestations of DM.[2]

Thus, IIDM represents a heterogeneous group of clinical disorders that can be conveniently conceptualized as a continuum of illness with subgroups of patients who share common clinical and immunologic features at distinct positions along this spectrum (Fig. 157-1).

TABLE 157-2
Comprehensive Classification of Idiopathic Inflammatory Dermatomyopathies

Dermatomyositis (DM)
- Adult onset
  - Classic DM
    - ~ Classic DM alone
    - ~ Classic DM with malignancy
    - ~ Classic DM as part of an overlap connective tissue disorder
  - Clinically amyopathic DM
    - ~ Amyopathic DM
    - ~ Hypomyopathic DM
- Juvenile onset
  - Classic DM
  - Clinically amyopathic DM
    - ~ Amyopathic DM
    - ~ Hypomyopathic DM

Polymyositis (PM)
- PM alone
- PM as part of an overlap connective tissue disorder
- PM associated with internal malignancy[a]

Inclusion Body Myositis

Other Clinical-Pathologic Subgroups of Myositis
- Focal myositis
- Proliferative myositis
- Orbital myositis
- Eosinophilic myositis
- Granulomatous myositis

[a]Although population-based European studies have now clearly confirmed that adult-onset classic DM is associated with a significant risk for internal malignancy, if such a relationship exists for PM, it is much weaker.

EPIDEMIOLOGY

Classic Dermatomyositis

Cutaneous involvement occurs in 30 percent to 40 percent of adults and in 95 percent of children with IIDM. By definition, skin disease is absent in patients with PM and present in 100 percent of patients with classic DM and CADM. Skin disease activity can precede muscle disease activity in classic DM by weeks to several months.

Classic DM can occur from infancy to adulthood and most frequently presents in the fifth and sixth decades (PM is extremely rare in children). The incidence of classic IIDM between 1963 and 1982 was estimated to be 5.5 cases per million. The incidence probably is higher, inasmuch as this study[16a] was based only on hospital inpatient–ascertained diagnoses and did not include cases of CADM. Black women during their childbearing years were affected most frequently, and DM might be underdiagnosed in blacks because of the more subtle coloration of inflammatory changes in their skin. More recent reports from Asia have indicated that individuals of those ethnic backgrounds with classic DM are more likely to be male than female (females are affected twice as often as males in white populations). DM-associated interstitial lung disease appears to occur more commonly in Japanese patients than in other ethnic groups. Familial concordance occurs rarely, and concordant disease expression has been reported in identical twins.

The epidemiology of juvenile-onset classic DM in the United States has been reviewed.[17] For children 2 to 17 years of age, the estimated annual incidence rates from 1995 to 1998 in the United States ranged from 2.5 to 4.1 cases per million children, and the 4-year average annual rate was 3.2 per million children. Estimated annual incidence rates by race were 3.4 for white non-Hispanics, 3.3 for African American non-Hispanics, and 2.7 for Hispanics. Girls were affected more than boys (ratio of 2.3:1). Cutaneous ulceration occurring as a result of infarctive vasculopathy and subsequent calcification is more common in the childhood form of the disease.

Environmental factors have been implicated as disease triggers. Seasonality has been noted in both juvenile-onset and adult-onset classic DM, which suggests the possibility of an infectious etiology. DM- and PM-like syndromes

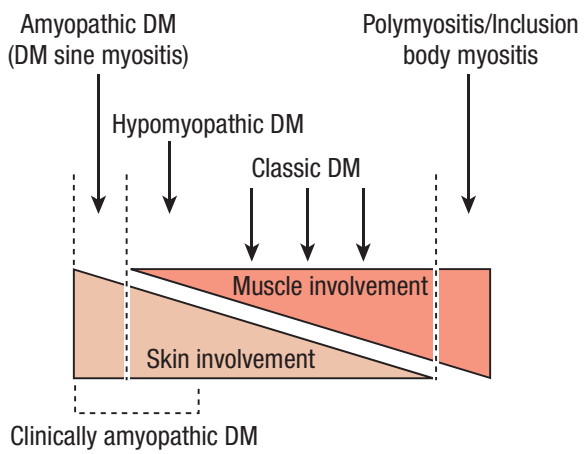

▲ **FIGURE 157-1** Graphic representation of the relationships between the cutaneous and muscular manifestations of the idiopathic inflammatory dermatomyopathies, including the nosologic entities within this spectrum of illness. DM = dermatomyositis.



have been reported in patients infected with coxsackievirus, parvovirus B19, Epstein-Barr virus, human immunodeficiency virus, and human T-cell leukemia virus type 1.

Approximately 50 percent of DM patients experience an exacerbation of their skin disease activity as a result of exposure to sunlight. It has been suggested that the intensity of global surface ultraviolet radiation may modulate the clinical and immunologic expression of autoimmune disorders such as the IIDM.[18]

In addition, exposure to drugs such as hydroxyurea, penicillamine, statin-type cholesterol-lowering agents, niflumic acid/diclofenac, phenytoin, tryptophan, and practolol can induce skin changes that mimic both classic DM and CADM.[1,19]



Clinically Amyopathic Dermatomyositis

The prevalence of CADM in the United States is unknown, because no such population-based studies concerning this question have yet been carried out.

A systematic review of the published literature on adult-onset CADM has been presented.[24] Two hundred ninety-one reported cases of adult-onset CADM (18 years or older) in over 19 countries were analyzed. The average duration of DM skin disease was 3.74 years [range, 6 months (by definition) to 20 years], and 73 percent of cases were females. Among 37 patients with hypomyopathic DM who were identified, the average duration of disease was 5.4 years, and none had developed clinically significant weakness at the time the case reports were published. Thirty-seven of the reported CADM patients developed muscle weakness longer than 6 months after onset of their skin disease (15 months to 6 years). The data for such patients were subanalyzed under the designation "CADM evolving to classic DM." Somewhat surprisingly, 36 of 291 (13 percent) of the identified reported patients with adult-onset CADM developed interstitial lung disease.

Very little information currently exists about the incidence of juvenile-onset CADM. In a retrospective analysis of data for all children with DM seen at an academic medical center in Pennsylvania between 1968 and 1998, 2 of 16 (12 percent) were categorized as having CADM.[25] A systematic review of the published literature on juvenile-onset CADM has recently been performed that included 69 cases of juvenile-onset CADM reported from 1963 to 2005.[26] Of these, 38 (56 percent) could be subclassified as juvenile-onset amyopathic DM and 12 (18 percent) as juvenile-onset hypomyopathic DM. In 18 (26 percent) of the patients identified as having juvenile-onset CADM, the disorder was reported to have subsequently evolved into juvenile-onset classic DM. Overall, the mean age at diagnosis was 10.5 years (range, 2 to 17 years), with a nearly equal number of males and females affected. The mean follow-up time was 3.9 years.

As previously mentioned (see Classic Dermatomyositis), certain drugs can induce cutaneous DM-like skin changes in the absence of systemic manifestations of IIDM.[1,19] Such drug-induced syndromes can simulate CADM. Long-term hydroxyurea therapy for chronic myelogenous leukemia can produce a DM-like cutaneous eruption that is clinically and histopathologically similar to that of idiopathic DM-specific skin disease.[27] However, muscle weakness and other systemic symptoms are absent. Painful leg ulcers are often seen in association, as are xerosis and cutaneous atrophy. This symptom complex usually occurs only after the patient has been treated with hydroxyurea for long periods (2 to 10 years). The presence of concurrent therapy with hydroxyurea has been proposed as the exclusion criterion for CADM.[1] The other drug class most frequently implicated in this regard has been the statin-type cholesterol-lowering agents.

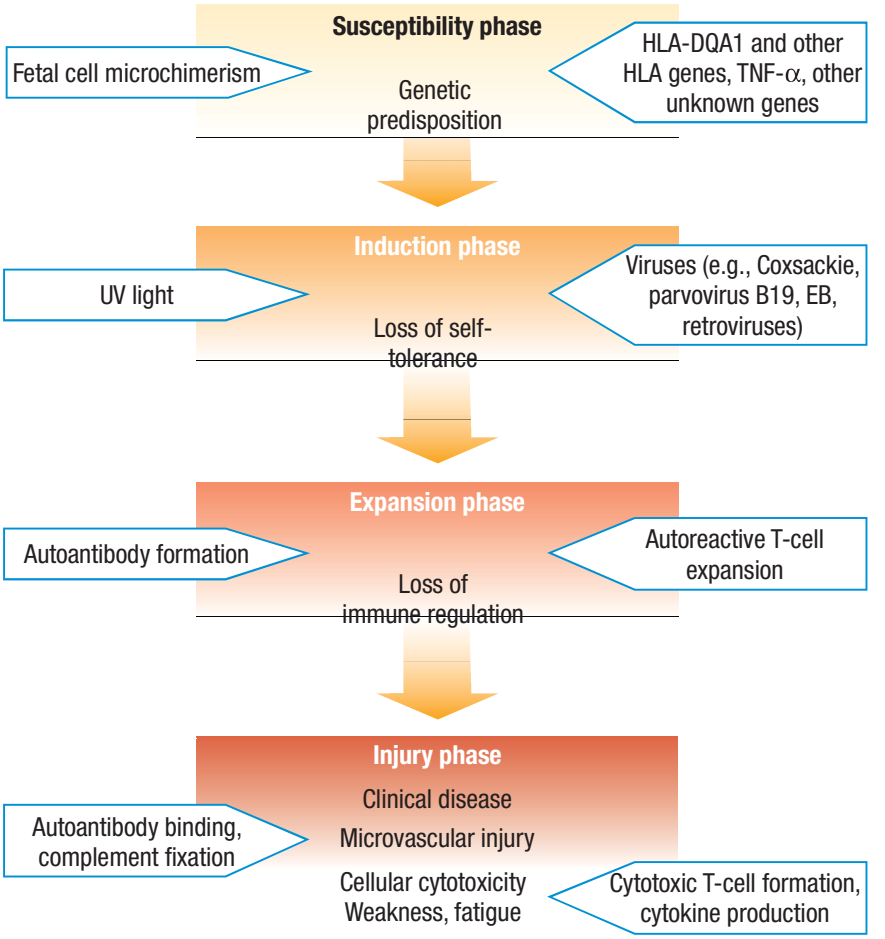

▲ **FIGURE 157-2** Etiology and pathogenesis of dermatomyositis: Current concepts. See text for discussion. EB = Epstein-Barr; TNF-α = tumor necrosis factor-α; UV = ultraviolet.

ETIOLOGY AND PATHOGENESIS

The inflammatory nature of the muscle and skin manifestations coupled with the characteristic humoral autoimmune abnormalities has led to the hypothesis that DM results from a genetically determined, aberrant autoimmune response to environmental agents. Fig. 157-2 presents a summary overview of current thought in this area. Like other systemic autoimmune diseases involving autoantibody production such as systemic lupus erythematosus (SLE), DM is thought to evolve through multiple sequential phases: the susceptibility phase, the induction phase, the expansion phase, and the injury phase.

TABLE 157-3
Autoantibodies in the Idiopathic Inflammatory Dermatomyopathies

Autoantibody	Median Prevalence[a]	Molecular Specificity	Clinical Association
High Specificity for DM/PM			
155 kd and/or Se	20–80%	Uncharacterized polypeptides	Classic DM, clinically amyopathic DM (?)
140 kd	53%	Uncharacterized polypeptides	Clinically amyopathic DM (?)
Jo-1	20%	Histidyl tRNA synthetase	PM, antisynthetase syndrome
Mi-2	15%	Helicase nuclear proteins	Shawl sign, cuticular overgrowth
SRP	5%	Signal-recognition particle	Fulminant DM/PM, cardiac involvement
PL-7	3%	Threonyl tRNA synthetase	Antisynthetase syndrome
PL-12	3%	Alanyl tRNA synthetase	Antisynthetase syndrome
OJ	Rare	Isoleucyl tRNA synthetase	Antisynthetase syndrome
EJ	Rare	Glycyl tRNA synthetase	Antisynthetase syndrome, possibly increased frequency of skin changes
Fer	Rare	Elongation factor 1α	—
Mas	Rare	Small RNA	—
KJ	Rare	Translation factor	—
Low Specificity for DM/PM			
ANA (most common nuclear immunofluorescence patterns—specked and nucleolar)	40%		Clinically amyopathic DM (80%)
ssDNA	40%		SLE, SSc
PM-Scl (PM-1)	40%	Ribosomal RNA processing enzyme	Overlap with scleroderma
Ro (52-kd Ro)	15%	RNP	Overlap with SSJ, SCLE, neonatal LE/CHB, SLE
U1RNP	10%	U1RNP	Overlap connective tissue disease
Ku	3%	DNA end-binding repair protein complex	Overlap with scleroderma
U2RNP	1%	U2RNP	Overlap with scleroderma

ANA = anti-nuclear antibody; CHB = chronic hepatitis B; DM = dermatomyositis; LE = lupus erythematosus; PM = polymyositis; ssDNA = single-stranded DNA; SLE = systemic lupus erythematosus; SRP = signal recognition particle; SSc = systemic sclerosis; SSJ = Sjögren syndrome; tRNA = transfer RNA.
[a]Using current assay techniques.

The susceptibility phase of DM is thought to result largely from a genetic predisposition. DM is one of the human autoimmune diseases that is linked to the 8.1 ancestral haplotype (HLA-A1, C7, B8, C4AQ0, C4B1, DR3, DQ2).[28] PM and DM have been specifically associated with HLA-B8, DR3, and DRw52, especially in white patients. This association is likely a result of linkage disequilibrium with HLA-DQA1*0501. The production of antisynthetase antibodies such as Jo-1 is strongly linked to HLA-DR3 and even more strongly linked to its super-typic specificity HLA-DRw52.

A single nucleotide polymorphism in the tumor necrosis factor-α promoter (TNF-α308A), which is also a component of the 8.1 ancestral haplotype, has been associated with disease chronicity, calcinosis, and high levels of TNF-α in a cohort of white patients with juvenile-onset classic DM.[29] This same TNF-α promoter polymorphism has been associated with photosensitive subacute cutaneous LE.[32] This same TNF-α promoter polymorphism has been associated with photosensitive subacute cutaneous LE.[30] In addition, several gene polymorphisms associated with low production of mannose-binding protein, a molecule involved in the physiologic clearance of apoptotic cells, have been associated with adult DM.[31] There has also been a single case report of adult-onset CADM that evolved to classic DM in a young Japanese woman who was shown to be genetically deficient in the fifth component of complement.[32]

The cutaneous manifestations of DM are precipitated or exacerbated by natural and artificial sources of ultraviolet light. Approximately 50 percent of patients with DM experience photosensitivity. The action spectrum appears to include both ultraviolet B and ultraviolet A light. Environmental stimuli, including ultraviolet radiation and infection, could represent inductive factors in DM leading to loss of self-tolerance. Various types of infections have been circumstantially implicated as causative factors in DM. These include infection with RNA viruses such as coxsackievirus, echovirus, and human retroviruses (i.e., human T-cell leukemia/lymphoma virus type 1 and human immunodeficiency virus). Nonviral pathogens such as *Toxoplasma gondii* have also been implicated. However, repeated attempts to confirm persistent myotropic infection by viruses or other pathogens have not been successful.

The expansion phase of DM is marked by autoantibody production signaling the loss of normal immune regulation. DM is associated with the production of a number of specific autoantibodies that probably predates by some period the first evidence of clinical disease activity (Table 157-3). Whether these autoantibodies are truly pathogenetic or represent only a by-product of muscle injury is unknown. It has been suggested that CADM might be associated with a specific autoantibody profile (antibodies to 140-kd, 155-kd, and Se antigens).[33,34]

It is thought that autoantibodies, immune complexes, and/or autoreactive T cells play a major role in the tissue injury phase of DM. Cell-mediated immune activity against muscle autoantigens is thought to be primarily responsible for the muscle injury that occurs in PM. Both myocytotoxic $CD3^+$ T-cell clones and non–HLA-restricted myocytotoxic cells of other lineages have been identified in the peripheral blood of patients with inflammatory myopathies.[35] Little has been done in the past experimentally to date to probe for T-cell–mediated cytotoxic epidermal or dermal cell injury in DM skin lesions.





Predominately humoral autoimmune mechanisms targeting the microvasculature have been implicated in the pathogenesis of muscle injury in DM. Microvascular ischemia is an early feature of DM muscle involvement. Components of the C5 to C9 membrane attack complex are regularly found in the walls of microvessels in muscle biopsy specimens from DM patients.

There is not always good agreement between the degree of muscle weakness or fatigue experienced by patients with classic DM and the degree of inflammation noted in muscle biopsy specimens and the elevation of serum muscle enzyme levels. This observation has led to the idea that inflammatory cytokines might be capable of mediating metabolic disturbances within muscle that can exacerbate muscle weakness and fatigue.[36] As with other rheumatic diseases such as systemic sclerosis, maternal microchimerism has been observed in children with juvenile classic DM.[37] The pathogenetic significance of the presence of alloreactive maternal lymphoid cells in the circulation, muscle, and skin of patients with juvenile DM is unknown.

The pathogenesis of cutaneous inflammation in classic DM and CADM and has received little attention, owing in part to the lack of an experimental animal model of this pattern of cutaneous inflammation. Histopathologic analysis of cutaneous DM reveals three general abnormalities: (1) a cell-poor interface dermatitis, (2) a vasculopathy of dermal microvessels, and (3) prominent dermal mucin deposition. These histopathologic elements can be precipitated or exacerbated by exposure to ultraviolet radiation.

The predominate infiltrating cell types in hallmark inflammatory DM skin lesions are activated macrophages and CD4 memory phenotype T cells (45RO) that are focused around microvessels in the dermis.[39] Plasmacytoid dendritic cells, a potent cellular source of interferon-α, have been shown to be present in substantial numbers in affected DM muscle[40,41] and skin tissue.[42] In addition, products of genes induced by interferon-α/β, including the myxovirus-resistance protein A (MxA) and the CXCL10 chemokine ligand (syn. IP10), are also highly overexpressed in DM muscle tissue[39] and skin tissue.[42] These observations have been used to support a hypothesis that T cells bearing the CXCR3 chemokine receptor are recruited into the skin of DM patients by CXCL10 after the local cutaneous generation of type I interferons (α/β) by activated plasmacytoid dendritic cells. The recruited CXCR3 receptor-bearing T cells then produce a T helper 1–biased immune effector reaction that results in features of cutaneous DM, including the characteristic interface dermatitis and microvascular endothelial cell injury.[42]

The dermal microvasculature is more prominently altered in cutaneous DM than in cutaneous lupus erythematosus (LE). It has been suggested that humoral factors can produce microvascular injury by triggering local activation of complement with deposition of C5 to C9, perhaps through endothelial-specific autoantibodies. Class II histocompatibility antigen expression by dermal endothelial cells is decreased in DM skin lesions, and this cell type appears to display an activation phenotype with respect to expression of adhesion molecules (intercellular adhesion molecule 1, vascular cell adhesion molecule 1, and E-selectin). The net effect of microvascular injury in cutaneous DM is dropout of microvessels, which results in microvascular ischemia.

CLINICAL FINDINGS

Approach to the Patient

The approach to a new patient with cutaneous DM is presented in Fig. 157-3.

History

In 60 percent of patients with classic DM, the cutaneous lesions and muscle weakness present simultaneously. In 30 percent of patients, the cutaneous findings appear before the onset of muscle weakness. In 10 percent, muscle weakness precedes the appearance of skin lesions. The onset of cutaneous disease is typically accompanied by pruritus and/or a burning skin sensation. Sensitivity to sunlight or artificial sources of ultraviolet light is often present. Muscle weakness initially affects the shoulder and hip girdle musculature, presenting clinically as difficulty raising the arms above the head and arising from a sitting position. Weakness can be accompanied by muscle pain and tenderness.

Cutaneous Lesions

HALLMARK SKIN LESIONS Table 157-4 presents the hallmark cutaneous manifestations of DM (to date, no recognizable differences in the clinical, histopathologic, and immunopathologic manifestations of classic DM and CADM have been reported). Some of these lesions, such as Gottron sign of DM (Fig. 157-4) and Gottron papules (see Fig. 157-4; Fig. 157-5), are pathognomic of this disease, whereas others, such as periorbital, confluent, macular, violaceous (heliotrope) erythema/edema and grossly visible periungual telangiectasia associated with dystrophic cuticles, are highly characteristic.

The primary skin change of DM is a highly characteristic, often pruritic, symmetric, confluent, macular violaceous erythema variably affecting the skin overlying the extensor aspect of the fingers, hands, and forearms; the arms, deltoid areas, posterior shoulders, and neck (the shawl sign); the V area of the anterior neck and upper chest; and the central aspect of the face, periorbital areas, forehead, and scalp (Figs. 157-6 and 157-7). Central facial involvement can occasionally simulate the appearance of seborrheic dermatitis with nasolabial fold involvement. The lateral aspects of the hips and thighs (holster sign) are also frequently involved.[44] Lesions such as poikiloderma atrophicans vasculare (poikilodermatomyositis) (see eFig. 157-7.1 in on-line edition) and calcinosis cutis are often present in patients with DM but may also appear in patients with cutaneous T-cell lymphoma (poikiloderma atrophicans vasculare) and scleroderma (SCL; calcinosis cutis). In addition, overlapping features of cutaneous DM and cutaneous SCL (see Chap. 158) can occur in the same individual (sclerodermatomyositis).

Table 157-5 presents the characteristic anatomic distribution of the hallmark cutaneous manifestations of DM. There is very little published information on the prevalence of involvement in these different anatomic locations. In some series reported by dermatologists, Gottron papules have been more commonly seen than periorbital heliotrope erythema, which by many outside of dermatology is felt to be the hallmark cutaneous manifestation of DM.

The violaceous hue of the cutaneous inflammation in lightly pigmented individuals is a striking clinical finding that usually is evident from the outset of disease activity. This hue helps to distinguish cutaneous DM from cutaneous LE, in which it is a late finding when present. It has been suggested that edema associated with the DM skin disease indirectly produces the violaceous hue by displacing the hyperemic cutaneous vasculature more deeply into the dermis. One might also speculate that this could result from the deoxygen-

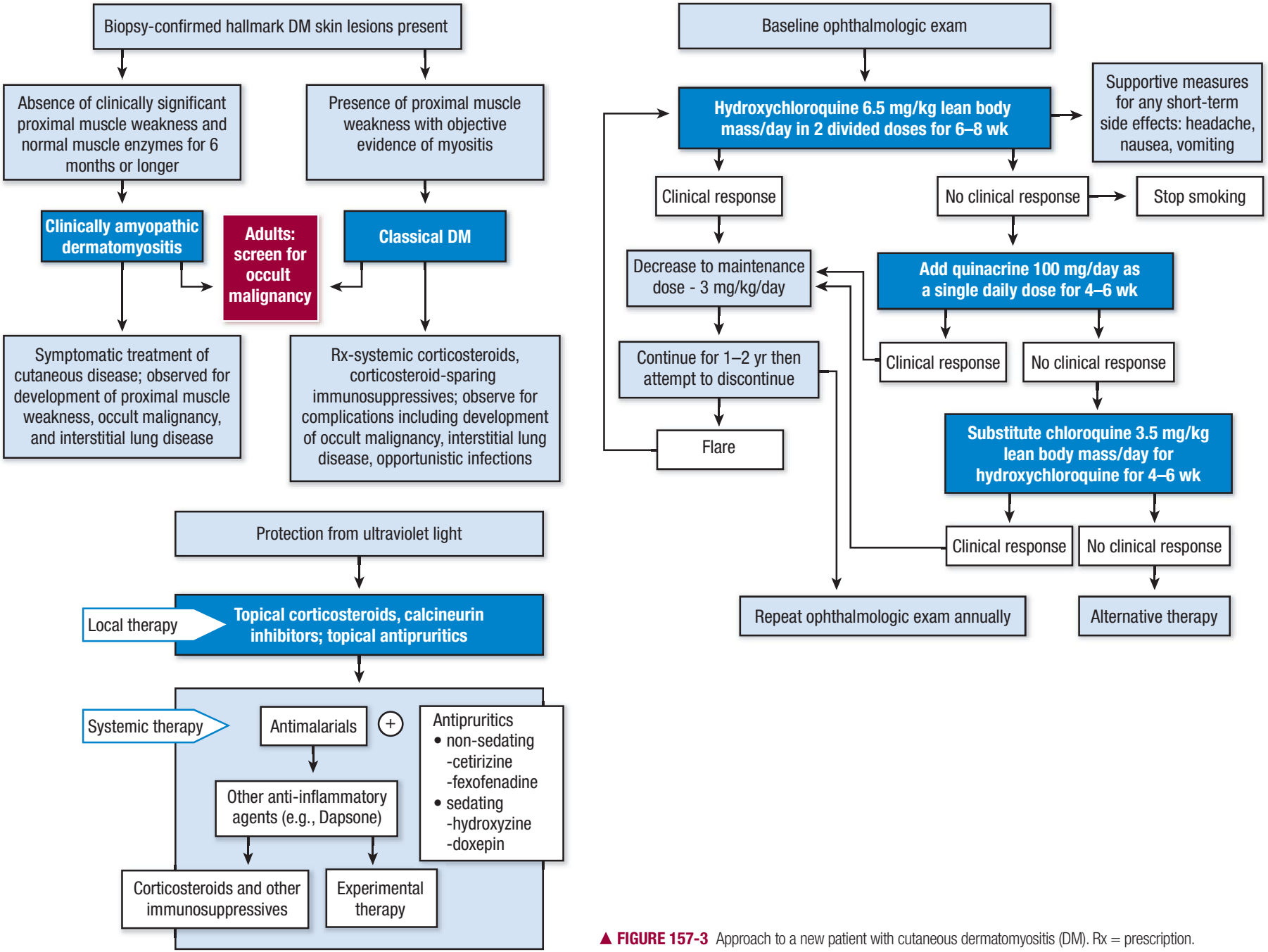

▲ **FIGURE 157-3** Approach to a new patient with cutaneous dermatomyositis (DM). Rx = prescription.



TABLE 157-4
Classic Cutaneous Manifestations of Dermatomyositis (DM)

Pathognomonic

1. Gottron papules
   Papules with a violaceous hue typically overlying the dorsal-lateral aspect of interphalangeal and/or metacarpophalangeal joints. When typically fully formed, these papules become slightly depressed at the center, which can assume a white, atrophic appearance. Associated lacy scale and telangiectasia can be present.
2. Gottron sign of DM
   Symmetric confluent macular violaceous erythema with or without associated edema overlying the dorsal aspect of the interphalangeal/metacarpophalangeal joints, olecranon processes, patellae, and medial malleoli.

Characteristic

1. Periorbital confluent macular violaceous (heliotrope) erythema with or without associated edema of the eyelids and periorbital tissue.
2. Grossly visible periungual telangiectasia with or without dystrophic cuticles and cuticular hemorrhage.
3. Symmetric confluent macular violaceous erythema overlying the dorsal aspect of the hands and fingers (where it can track along the extensor tendons), extensor aspects of the arms and forearms, deltoids, posterior shoulders and neck (shawl sign), V area of anterior neck and upper chest (V sign), central aspect of the face and forehead, and scalp.
4. Mechanic's hand lesion
   Bilaterally symmetric confluent hyperkeratosis having the appearance of that produced by manual labor distributed along the ulnar aspect of the thumb and radial aspect of the fingers; also prominent on the index and middle fingers with occasional extension to the palmar surfaces.

Compatible with dermatomyositis

1. Poikiloderma atrophicans vasculare (poikilodermatomyositis)
   Circumscribed violaceous erythema with associated telangiectasia, hypopigmentation, hyperpigmentation, and superficial atrophy most commonly found over the posterior shoulders, back, buttocks, and V area of the anterior neck and chest. Often asymmetric.
2. Calcinosis cutis

Adapted from Euwer RL, Sontheimer RD: Dermatomyositis, in *Cutaneous Manifestations of Rheumatic Disease,* edited by Sontheimer RD, Provost TT. Baltimore, Williams & Wilkins, 1996, p 73, and Euwer RL, Sontheimer RD: Dermatologic aspects of myositis. *Curr Opin Rheumatol* **6**:583, 1994, with the permission of Current Sciences and Williams & Wilkins.



ation of blood flowing through an abnormal dermal microvascular bed. In this regard, it is interesting to note that cutaneous DM often presents in the skin over joints that is frequently stretched and thus often made to become transiently ischemic under normal physiologic conditions.

A striking clinical feature that helps to distinguish cutaneous DM from cutaneous LE is pruritus, which can be so severe in DM as to be disabling, even in the absence of systemic involvement. In addition to pruritus, DM patients often described severe burning, painful sensations associated with the DM skin inflammation. Some work has suggested that severe DM skin disease can have a greater impact on quality of life than other skin diseases such as psoriasis and atopic dermatitis for which aggressive systemic immunomodulatory therapies are often used.[48]

A number of other skin changes can be encountered in patients with DM. Hyperkeratosis may follow the onset of the confluent, macular, violaceous erythema; however, the scale in DM skin lesions is usually less prominent than that in subacute cutaneous LE and discoid LE. Secondary skin changes in DM skin lesions include excoriation with secondary infection and ulceration. Sub-epidermal vesicles and/or bullae occasionally occur in areas of particularly intense cutaneous inflammation. Post-inflammatory pigmentary changes, both hyperpigmentation and hypopigmentation, occur. Older lesions may have white lacy markings somewhat similar to those of Wickham's striae in lichen planus. Another similarity between cutaneous DM and lichen planus is the characteristic violaceous hue. Mucinous infiltration, a common histologic finding in the dermis of DM skin lesions, can be clinically prominent, producing an infiltrated, glistening appearance. Superficial erosions and ulcers can subsequently develop over the face and eyelids as well



▲ **FIGURE 157-4** Hand of a 30-year-old woman with a 15-year history of amyopathic dermatomyositis (DM). Note the confluent macular violaceous erythema, most pronounced over the metacarpophalangeal/interphalangeal joints, extending in a linear array overlying the extensor tendons of the hand and fingers. These changes, referred to as *Gottron sign*, are a hallmark cutaneous feature of DM. Early Gottron papules, an extension of Gottron sign, can be seen over the distal interphalangeal joints along with periungual erythema and dystrophic cuticles. In DM, the violaceous erythema is centered over the metacarpophalangeal/interphalangeal joints, whereas in lupus erythematosus these areas are relatively spared.



▲ **FIGURE 157-5** Fingers of an elderly woman with classic dermatomyositis (DM). Note the fully formed Gottron papules over the distal interphalangeal joints, a hallmark cutaneous feature of DM. Prominent grossly visible nail fold telangiectasias are also present, along with dystrophic cuticles. The combination of Gottron papules and nail fold changes such as these is pathognomic for DM. Such changes are seen to an equal degree in classic DM and amyopathic DM.



▲ **FIGURE 157-6** The confluent, macular, violaceous erythema of the V area of the upper chest and neck (V sign), when persistent over time, can evolve into poikilodermatous skin changes. Less evident in this photograph are periorbital edema and confluent, macular, violaceous (heliotrope) erythema of the upper eyelids. Note the absence of involvement of the malar areas, which are often involved in lupus erythematosus.

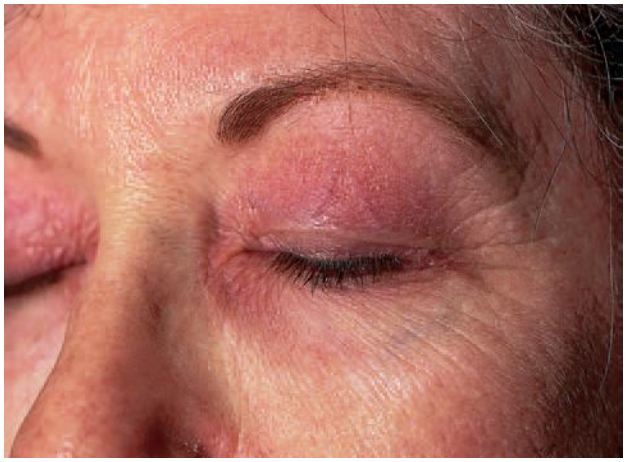

▲ **FIGURE 157-7** Periorbital confluent, macular, violaceous (heliotrope) erythema most prominent on the upper eyelids. Like Gottron papules and Gottron sign, this is a hallmark cutaneous feature of dermatomyositis.

as in other areas affected by intense and protracted inflammation. Deep, irregular, retiform ulcers can also develop in areas of poikiloderma in both adults and children. It has been suggested that the penetrating ulcers reflecting vasculopathy can be a bad prognostic sign in both juvenile-onset and adult-onset DM.

Clinical experience suggests that, as with cutaneous LE/SLE, the activity of IIDM can be precipitated or exacerbated by emotional and physical stress, although there is scant published evidence. Strenuous physical exertion can be detrimental to patients who have active myositis.

Magnetic resonance imaging (MRI) may identify edema/inflammation in skin, subcutaneous tissue, and fascia resulting from vasculopathy and vasculitis in patients with classic juvenile DM.[49] In approximately 80 percent of the 26 children studied, MRI abnormalities indicating skin, subcutaneous, and/or fascial edema were observed. Clinical skin disease activity scores correlated positively with MRI skin edema scores. Five children developed soft tissue calcification in areas previously found to be edematous by MRI after 4- to 9-month follow-up intervals. These observations suggest that the assessment of soft tissue by MRI could be of value in predicting risk for developing calcification and in monitoring treatment to prevent or minimize it.

Dystrophic calcification appears to be quite uncommon in both adult- and juvenile-onset CADM (see Fig. 138-1). Little relationship was found between MRI indices of edema/inflammation in the superficial (skin and subcutaneous tissue) and deep (fascial and muscle) tissue compartments of patients with juvenile-onset classic DM.[49]

DM can develop as a component of an overlap connective tissue disorder. Most common are overlaps with SLE (see Chap. 156) and systemic sclerosis (see Chap. 158). Raynaud phenomenon, sclerodactyly, sclerosis of the skin, and the characteristic hyperpigmentation can all be present in the latter setting. The term *sclerodermatomyositis* describes

TABLE 157-5
Anatomic Distribution of Hallmark Cutaneous Manifestations of Dermatomyositis

ANATOMIC LOCATION	LESIONS
Scalp	CMVE; non-scarring diffuse alopecia
Face	
Periorbital region	CMVE (usually most intense on the upper eyelids), edema
Malar eminences	CMVE sparing or involving the nasolabial fold[114]
Forehead, chin	CMVE
Neck and shoulders	
Anterior	CMVE evolving to poikiloderma
Posterior	CMVE (shawl sign)
Upper extremities	
Arms, forearms	CMVE on the extensor aspects
Elbows	CMVE usually most intense in this location (Gottron sign of dermatomyositis)
Hands, fingers	
Dorsal aspect	CMVE usually most intense over the extensor tendons and metacarpophalangeal/interphalangeal joints (Gottron sign), Gottron papules overlying the dorsal-lateral aspect of the metacarpophalangeal/interphalangeal joints, relative sparing of the dorsal aspects of the phalanges, periungual nail fold telangiectasia (often grossly visible), cuticular microvascular hemorrhage, dystrophic/ragged cuticles
Palmar aspect	Mechanic's hand lesion, mucinous plaques centered over the flexural creases
Trunk	CMVE evolving to large areas of poikiloderma (poikiloderma atrophicans vasculare) commonly seen over the flanks and lower back
Lower extremities	
Thighs	CMVE (holster sign)
Knees	CMVE (Gottron sign)
Lower legs, feet	CMVE, often focal, centered over the medial malleoli; Gottron sign overlying the medial malleoli

CMVE = confluent, macular, violaceous, erythema.



the disorder in patients who present with DM and who develop striking features of SCL 6 months to 3 years later. In addition, myositis occurs in approximately 5 percent of patients who test positive for anti–Ro/SSA autoantibody (most of whom have Sjögren syndrome (see Chap. 162). The cutaneous manifestations of DM are not usually found in this setting.

The highly pruritic/burning scaling scalp involvement in patients with adult-onset classic DM and CADM that can be associated with non-scarring alopecia[50] has also been found to occur in approximately 25 percent of patients with juvenile-onset DM.[25] Localized scalp involvement can at times be the presenting manifestation of DM.



OTHER ASSOCIATED SKIN LESIONS

Systemic Features

Table 157-6 outlines the systemic manifestations and associations of classic IIDM. Most of the extramuscular systemic features associated with classic DM have not been reported in CADM except for arthritis and interstitial lung disease.

MUSCLE DISEASE Muscle involvement typically presents as symmetric weakness of the proximal muscles of the extremities. Lower-extremity weakness manifested as difficulty in performing routine activities of daily living, such as rising from a chair or bathtub and climbing stairs, is often the initial clinical finding. Weakness of the upper extremities soon follows, often manifested by difficulty in raising the arms above the head to perform routine activities such as combing the hair. Pain or tenderness in the affected muscle groups commonly occurs. Some patients experience a fulminant disease course that results in disabling weakness within a few weeks. Weakness involving the upper one-third of the esophagus and/or the laryngopharyngeal muscles may present as dysphagia or a hoarse voice (dysphonia), respectively.

Confirmation that proximal muscle weakness is caused by the inflammatory myositis of IIDM can be difficult, because so many other clinical disorders produce proximal muscle weakness (Table 157-7). The diagnosis can be supported by demonstration of characteristic elevations in serum levels of muscle enzymes (CK, aldolase) as well as identification of diagnostic changes in electromyography (EMG) results, muscle imaging, and muscle biopsy specimens. Some patients with CADM have low-grade, sub-clinical muscle disease (i.e., hypomyopathic DM). However, in some patients who express the hallmark cutaneous manifestations of DM, no symptoms of muscular weakness have developed for up to 28 years (unpublished personal observation, R.D.S.).

Inclusion-body myositis is a pathologically distinctive type of steroid-resistant myositis that more commonly affects the distal muscle groups of men in an asymmetric pattern. Cutaneous involvement is not seen with this disorder or with classic PM.

A retrospective analysis encompassing all patients with DM seen at the Mayo Clinic between 1976 and 1994 revealed that 32 (4 percent) of 746 patients conformed to the definition of CADM[57]; 27 had amyopathic DM and 5 had what can be classified as hypomyopathic DM. Follow-up information was available on 16 of the patients with amyopathic DM. Ten had no muscle weakness after 2 to 10 years, four had no weakness at 1 year, and two developed weakness within 5 years after diagnosis. None of the three patients classified as having hypomyopathic DM showed evidence of muscle weakness 8 to 17 years after diagnosis. Thus, of these 19 patients with CADM, only 2 developed clinical evidence of myositis after prolonged periods of time. Therefore, the presence of sub-clinical muscle abnormalities at the time of diagnosis of CADM does not necessarily portend the subsequent development of clinically significant muscle disease.

For the definition of CADM to be fulfilled, clinical evidence of muscle weakness should not be present. Muscle strength testing is graded on a scale of 1 to 5, where 0 = no muscle action; 1 = trace contraction; 2 = visible contraction but with inability to overcome gravity; 3 = fair contraction with ability to overcome gravity; 4 = contraction with ability to offer some resistance; 5 = muscle contraction that cannot be overcome by the evaluator. The examination should focus on the proximal muscle groups that control the neck, shoulders, and hips. Manual muscle testing is reproducible; variables such as pain, contractures, voluntary effort, and motivation may influence the ability of an individual to exert maximal muscle effort.

PULMONARY DISEASE Among the most feared nonmuscular systemic manifestations of IIDM is pulmonary disease. Lung function can be compromised in a number of ways in patients with classic DM: by a restrictive lung defect resulting from

TABLE 157-6
Systemic Manifestations/Associations of Dermatomyositis/Polymyositis

- Musculoskeletal
  - Myositis with proximal weakness
  - Muscle atrophy and contracture[a]
  - Muscular calcification[a]
- Cardiac
  - Cardiomyopathy
  - Conduction defects
- Respiratory
  - Dysphonia
  - Diffuse interstitial pneumonitis/fibrosis
  - Aspiration pneumonia
  - Respiratory failure from muscle weakness
- Gastrointestinal
  - Proximal dysphasia
  - Large bowel infarction/perforation secondary to vasculopathy[a]
- Ophthalmologic
  - Retinopathy[a]
- Internal malignancy[b]

[a]Usually limited to juvenile dermatomyositis.
[b]Not significantly increased in juvenile dermatomyositis.

TABLE 157-7
Conditions That Can Simulate the Proximal Muscle Weakness of Dermatomyositis/Polymyositis

- Infectious myopathies
  - Human immunodeficiency virus 1, human T-cell lymphotrophic virus 1, coxsackievirus, echovirus, influenza virus, adenovirus, hepatitis B virus, Epstein-Barr virus
- Other myopathies
  - Inclusion-body myositis, rheumatic disease vasculitis, muscular dystrophies, metabolic myopathies
- Neurologic disorders
  - Myasthenia gravis, amyotrophic lateral sclerosis, Guillain-Barré syndrome
- Endocrine disorders
  - Hypothyroidism and hyperthyroidism, Cushing syndrome, diabetic neuropathy, hypokalemia
- Drug-induced myopathies
  - Alcohol, antimalarials (vacuolar myopathy), colchicine, glucocorticoids, cyclosporine, street drugs (cocaine, heroin), lipid-lowering agents (lovastatin, simvastatin, gemfibrozil, clofibrate, niacin), D-penicillamine, zidovudine, isotretinoin/etretinate

Adapted from Euwer RL, Sontheimer RD: Dermatomyositis, in *Cutaneous Manifestations of Rheumatic Disease,* edited by RD Sontheimer, TT Provost. Baltimore, Williams & Wilkins, 1996, p 73, with the permission of Williams & Wilkins.

respiratory muscle weakness; by aspiration pneumonia secondary to gastrointestinal reflux and impaired esophageal muscle function; by opportunistic infections; or by interstitial pneumonitis related to the underlying autoimmune disease process. In addition, some systemic drugs used to treat DM can produce pulmonary complications (e.g., methotrexate hypersensitivity pneumonitis).

Interstitial pneumonitis resulting from both classic DM and CADM has been reviewed.[61,62] Between 5 percent and 40 percent of patients with classic DM develop interstitial lung disease [high-resolution chest computed tomographic (CT) scan can identify lung involvement earlier than can routine chest radiography]. This complication presents clinically with symptoms of nonproductive cough and exertional dyspnea that are accompanied by bibasilar fine crackling rales. Pulmonary function test results show a restrictive pattern with reduced diffusion capacity. Several clinical patterns of interstitial lung disease have been described: usual interstitial pneumonia, non-specific interstitial pneumonia, diffuse alveolar damage, and bronchiolitis obliterans with organizing pneumonia.

Interstitial lung disease can present clinically as an acute/subacute type or a chronic type. In the acute/subacute type, patients experience severe, rapidly progressive dyspnea and progressive hypoxemia within a month of the onset of lung involvement. In such cases, the lung disease is often resistant to treatment, and patients are at risk for death. In the chronic type, patients experience a much slower pace of progressive dyspnea. Interstitial lung disease can also be identified by chest CT and/or pulmonary function tests in the complete absence of symptoms. It has been suggested that interstitial lung disease associated with the myositis-specific autoantibodies (antisynthetases) can occasionally occur in the absence of skin and muscle disease.[63] In some individuals, interstitial lung disease occurs before the clinical appearance of myositis. Patients with classic DM who have the antisynthetase syndrome (the presence of Jo-1, PL-7, PL-12, or other synthetase autoantibodies; arthritis; Raynaud phenomenon) have increased risk of developing interstitial lung disease. The antisynthetase syndrome and interstitial pneumonitis occur also in children with classic DM. Interstitial pneumonitis and air leakage were observed in one child with classic juvenile DM.[64]

Interstitial pneumonitis of various sub-types is increasingly being recognized as a potential complication of CADM.[24,65] Published data indicate that the prevalence of interstitial pneumonitis in CADM is approximately 13 percent.[24] A disproportionately high percentage of patients with CADM and interstitial lung disease has been reported in Japan related to the fact that interstitial pneumonitis appears to be an especially common complication of classic DM in the Japanese. Curiously, the acute/subacute pattern of disease presentation with rapidly progressive dyspnea, progressive hypoxemia, treatment resistance, and fatal outcome has been observed in CADM patients who develop interstitial pneumonitis.[66]

In most cases, interstitial pneumonitis has occurred in patients with CADM in the absence of antisynthetase autoantibodies such as Jo-1, which are considered to be markers for interstitial lung disease risk in patients with classic DM and the antisynthetase syndrome. However, it has been suggested that newly observed autoantibodies to 140-kd and 155-kd autoantigens that appear to be highly specific for classic DM and CADM might serve as a marker for interstitial lung disease in Japanese CADM patients.[34]

The appearance of symptoms of interstitial pneumonitis, especially the acute/subacute type, in a patient with any form of DM should be considered a medical emergency, and the assistance of a pulmonary medicine specialist should be obtained as soon as possible to ensure proper diagnosis and therapy. Aggressive multidrug systemic immunosuppressive therapy is typically required in such cases, and the patient is often admitted to a pulmonary intensive care unit.[67]

ARTHRITIS Arthritis occurs in 20 percent to 65 percent of patients with juvenile-onset classic DM.[68] Typically, this is a nonerosive arthritis involving knees, wrists, elbows, and fingers. It is seen early in the course of the disease. For some patients, arthritis can be a major symptomatic problem. Arthritis also occurs in some patients with juvenile-onset CADM. In one study, three of five patients with juvenile CADM followed over an average of 4.9 years were reported to have arthritis, whereas 49 of 80 children with classic DM had arthritis.[68]

Relationship Between Cutaneous and Systemic Manifestations

There is little correlation between skin and muscle disease activity in DM. In patients who have clinically significant skin and muscle disease at the outset of their illness and in whom all evidence of disease activity is suppressed by systemic immunosuppressive therapy, DM skin disease activity can return unaccompanied by muscle disease activity once treatment has been discontinued. The intensity of cutaneous symptoms, associated disability, and resistance to treatment in this setting can be marked.

Attempts have been made to correlate the periungual microvascular changes in patients with adult and juvenile classic DM as assessed by nail fold capillaroscopy (i.e., dilatation, tortuosity, budding or arborization, and avascularity) with the systemic manifestations of this disease process, including myositis. However, the periungual nail fold capillary changes in patients with CADM are qualitatively similar to and as prominent as those in patients with classic DM.[69] Thus, no simple relationship exists between the degree of abnormality of periungual nail fold vascular changes and myositis activity in DM patients. Both of the authors have observed that the disappearance or improvement of periungual telangiectasia often heralds remission or at least marked improvement of disease.

HISTOPATHOLOGY

The earliest histologic appearance of cutaneous DM is similar to that of normal skin except for periodic acid-Schiff–positive thickening of the basement membrane; a smudgy, homogeneous appearance of the papillary dermis; and increased dermal mucin and edema. No lymphocytic infiltrate is seen at this stage, and vacuolar alteration of basal keratinocytes, pigment incontinence, and colloid body formation are variably present.

Biopsy specimens from more advanced skin lesions (i.e., scaling violaceous erythema) show changes similar to or indistinguishable from those of LE. These changes include hyperkeratosis, epidermal atrophy, and effacement of the rete ridges. An interface dermatitis with vacuolar degeneration of the basal keratinocytes and a sparse, superficial, patchy, or band-like perivascular lymphocytic infiltration can also be seen, along with thickening of the basement membrane and pigment incontinence. The dermis is often pale as a result of the accumulation of edema and mucin.

In poikiloderma, these same features are encountered except that ectatic dermal vessels are present. Hyperkeratosis, acanthosis, undulating papillomatosis,



vacuolar alteration of basal keratinocytes, thickened basement membrane, variable lymphocytic exocytosis, and increased mucin deposition in the epidermis are seen in Gottron papules, although the histologic features of such lesions are often non-specific. Lipomembranous (membranocystic) changes previously thought to be specific for sclerosing panniculitis have been noted in the histopathologic examination of punched-out ulcers of DM.

Band-like granular deposits of immunoglobulin and complement along the dermal-epidermal junction, sub-epidermal cytoid bodies, dermal connective tissue staining, and epidermal cytoplasmic staining have been described in DM skin lesions. Lesional dermal-epidermal junction immunoglobulin and complement bands reportedly occur in 5 percent to 86 percent of patients, depending on the site of biopsy, with the nail fold being a high-prevalence area. However, similar findings can be observed in actinically exposed skin of otherwise normal individuals. It has been suggested that components of the complement membrane attack complex (C5 to C9) are more often present in the dermal microvessels than at the dermal-epidermal junction in cutaneous DM lesions, whereas the opposite occurs in cutaneous LE lesions. However, there is no general agreement at this time as to the validity of this point of distinction.



LABORATORY TESTS

Classic Dermatomyositis

MUSCLE ENZYMES An elevation in the serum level of CK is the most sensitive and specific laboratory indicator of muscle disease activity in IIDM. Ninety percent of patients with classic IIDM have elevated levels of CK at some point. The elevated CK activity is caused primarily by the CK-MM isoenzyme (muscle form of CK); however, elevations caused by the CK-MB isoenzyme (muscle and brain form of CK) are also seen. Elevated levels of CK can be associated with some of the disorders listed in Table 157-7 (e.g., other myopathies, hypothyroidism, and ingestion of certain drugs), as well as with strenuous physical exertion and needle trauma (intramuscular injection, EMG needle insertion). Enzymatic detection of CK activity can at times be inhibited by serum factors. Levels of CK may become elevated before the development of weakness and can normalize several weeks before the return of normal strength during treatment. Patients with IIDM who have normal CK levels may have a worse prognosis with respect to pulmonary disease and associated malignancy. Levels of CK are usually normal in patients with glucocorticoid-induced myopathy.

Serum aldolase level is a somewhat less sensitive indicator than CK for active myositis in IIDM. However, aldolase level is occasionally elevated in the presence of a normal CK level, especially in juvenile DM. Levels of transaminases (aspartate aminotransferase, alanine aminotransferase) and lactic dehydrogenase can also be elevated in active myositis, but these values are less useful clinically because of their low degree of specificity. Elevations of transaminase levels during treatment with methotrexate may reflect the activity of myositis as well as drug-induced hepatotoxicity. Urinary creatine excretion can also be used to monitor the status of myositis. However, the specificity is low because urinary creatine excretion can also be elevated in steroid myopathy. Serum myoglobin levels can also be elevated in severe IIDM.

AUTOANTIBODIES Elevated anti-nuclear antibody (ANA) levels with human tumor cell substrates are found in 60 percent to 80 percent of patients with both classic DM and CADM.[24] Autoantibodies of known molecular specificity in DM are now categorized into two groups: myositis-specific autoantibodies and myositis-associated autoantibodies.[70,71a] Myositis-specific autoantibodies include the antisynthetases [Jo-1, PL-7, PL-12, OJ, Mi-2, and signal-recognition particle (SRP)]. PM/Scl, Ro/SSA (Ro52, Ro60), and U1RNP represent the major myositis-associated autoantibodies. Table 157-3 lists the molecular specificities and clinical correlations of these autoantibodies. The fact that none of the myositis-specific autoantibodies occurs with a prevalence greater than one in five patients with DM makes routine testing for these autoantibodies of little clinical use.

Among the most frequently encountered myositis-specific autoantibodies are those that target the various aminoacyl transfer RNA synthetases. Of these antisynthetase autoantibodies, autoantibodies to Jo-1 (histidyl transfer RNA synthetase) are the most common and are found in 20 percent of patients with classic IIDM overall and 30 percent to 40 percent of adult patients with PM. Fever, interstitial lung disease, polyarthritis, Raynaud phenomenon, and incomplete response to therapy occur more often in patients who produce these antibodies (antisynthetase syndrome), as does the mechanic's hand skin lesion. Patients who produce Jo-1 antibodies less frequently display the classic cutaneous manifestations of DM.

SRP antibodies occur in 5 percent of patients with PM and are more common in those who exhibit acute-onset, severe, treatment-resistant forms of classic IIDM with cardiac involvement. Such patients rarely have any type of skin involvement. Autoantibodies to Mi-2, a nuclear protein complex containing histone deacetylase and nucleosome remodeling activities, are seen almost exclusively in patients with classic DM. Mi-2 antibody is found in 5 percent to 10 percent of patients with classic IIDM overall and in 15 percent to 20 percent of patients with classic DM. This autoantibody is associated with more treatment-responsive forms of classic DM as well as with the shawl sign and prominent cuticular changes. The clinical correlations of the myositis-specific autoantibodies found in adults (e.g., Jo-1) also occur in children with classic IIDM. IIDM autoantibodies that currently have less clinical significance are also listed in Table 157-3. An autoantibody to a 155-kd nuclear antigen (transcriptional intermediary factor-1 gamma [syn. ref fused gene 7]) has recently been reported to be highly specific for classic DM and CADM. In classic DM patients, this antibody has been suggested to be associated with an increased risk for internal malignancy.[71b]

OTHER LABORATORY ABNORMALITIES The erythrocyte sedimentation rate is elevated in about one-half of patients with classic IIDM, but it does not closely correlate with disease activity. Rheumatoid factor levels are elevated in 20 percent of cases, more often in patients with overlap disease. Levels of other serum factors such as neopterin and factor VIII–related antigen (von Willebrand factor) and $CD19^+$ B cells[29] have been reported to correlate with disease activity in children with classic DM. Messenger RNA for the interferon-α–induced protein MxA has been reported to be upregulated in peripheral blood mononuclear cells of patients with juvenile-onset classic DM and to correlate positively with muscle disease activity in that setting. Elevated levels of other markers of vascular activation, including

soluble forms of vascular cellular adhesion molecule 1 and E-selectin, have also been reported to occur in the circulation of patients with classic DM. KL-6 is a human mucin core protein 1 class mucin that is preferentially expressed on type II pneumocytes. KL-6 has been proposed to be a sensitive serum marker for the presence of interstitial pneumonia in the setting of classic DM in Japanese patients (reviewed in ref. 72). However, the laboratory assay for this marker has yet to become generally available in the United States.

Clinically Amyopathic Dermatomyositis

By definition, the levels of CK and other muscle enzymes are normal in CADM. Approximately two-thirds of patients reported as having CADM have tested positive for ANA.[24] However, such patients do not appear to produce myositis-specific or myositis-associated antibodies. Preliminary studies have indicated that several new autoantibodies (140 kd, 155 kd, and Se) might serve as serologic markers for CADM patients provided their disease specificity can be confirmed.[33,34,73]

When the results of immunoblot and immunoprecipitation studies using HeLa cell extracts were combined, 16 (89 percent) of 18 white adult patients with CADM showed autoantibodies to the 155-kd autoantigen and/or the Se autoantigen. With the exception of the 155-kd autoantigen, the molecular identities of these autoantigens have not yet been revealed. If these preliminary results can be corroborated, they could provide a useful clinical tool for confirming a diagnosis of CADM. In addition, it has been suggested that a newly observed autoantibody specific to a 140-kd autoantigen might also serve as a marker for interstitial lung disease in Japanese CADM patients.[34]

As in classic DM, serum levels of KL-6 are also suggested to correlate with the activity of interstitial pneumonia in patients with CADM.[74]

Special Tests (Including Imaging Studies)

ELECTROMYOGRAPHY The EMG changes of myositis include a myopathic pattern of the motor unit action potential, a myopathic recruitment pattern, increased insertional activity, and increased spontaneous activity. EMG changes of myositis can be erratically distributed. EMG recordings from the paraspinous muscles can be abnormal when those from the limb girdle musculature are normal. As many as 10 percent of patients with biopsy-documented myositis have normal EMG findings.

MUSCLE BIOPSY Muscle fiber degeneration/regeneration, perifascicular atrophy, and capillary injury are frequently present in the muscle biopsy specimens of patients with IIDM. A perivascular infiltrate of T lymphocytes and histiocytes and, occasionally, of B lymphocytes, plasma cells, and eosinophils is also seen. Biopsy specimens from patients with DM often show CD4 T cells and B cells in the perivascular areas, whereas CD8 T cells preferentially associate with damaged muscle fibers in patients with PM. The capillary density in muscle specimens from patients with DM is decreased. Inflammation may be absent in up to 25 percent of biopsy specimens from patients with otherwise typical muscle disease by clinical, EMG, or biochemical criteria.

An occlusive vasculopathy is a striking aspect of the pathology of juvenile-onset classic DM. Phlebitis and arteritis leading to intimal hyperplasia, fibrinous occlusion of vessels, and infarction of the involved tissues can be seen. The muscles, gastrointestinal tract, and nerves are particularly affected. This vasculopathy in muscles is noninflammatory and occurs predominately in the capillaries. There is a spectrum of endothelial changes from swelling to obliteration to necrosis. In muscles this occlusive vasculopathy is most commonly seen in small vessels, resulting in microvascular ischemia. The local production of interferon-induced angiostatic ELR-negative CXC chemokines has been implicated as a pathogenetic factor in the vasculopathy of juvenile-onset DM.[75]

MUSCLE IMAGING Myositic inflammation can be highly focal. A number of non-invasive techniques are currently being examined for their ability to localize affected muscle groups. MRI is the method of choice for diagnostic imaging of muscle abnormalities in patients with myositis.[76] However, the MRI signal associated with myositis is not specific for IIDM muscle involvement. The possibility that MRI-guided needle biopsy could obviate the need for the more costly and invasive open muscle biopsy is being explored. In addition, MRI and phosphorus 31 magnetic resonance spectroscopy are also useful in assessing the status of muscle disease activity during treatment with systemic glucocorticoids and other immunosuppressive drugs. These procedures are expensive and cannot be used in some individuals with metallic implants. Less costly approaches to monitoring muscle disease activity, such as power Doppler and gray-scale ultrasonography and ultrasonography with contrast material are being examined.[77]

Functional metabolic changes in muscles identified by magnetic resonance spectroscopy have been especially evident on exercise in some patients with amyopathic DM (such patients would better be classified as having hypomyopathic DM). Artificial neural networks have been proposed as an effective way to analyze the multichannel functional data that result from phosphorus 31 magnetic resonance spectroscopy examination.[78] A central issue in this area is whether the subtle muscular abnormalities that can be identified with these sensitive imaging systems have true prognostic value.

DIFFERENTIAL DIAGNOSIS (Box 157-1)

In the earlier stages, cutaneous DM might be confused with contact dermatitis, seborrheic dermatitis, lichen planus, psoriasis, polymorphic light eruption, and atopic dermatitis. In the later stages, when the more typical cutaneous manifestations of DM have evolved, the greatest challenge can be to distinguish the skin involvement of DM from that of cutaneous LE, especially acute cutaneous LE and subacute cutaneous LE (Table 157-8).

Periorbital heliotrope erythema and edema can occasionally be observed in SLE, but fully formed Gottron papules are never seen as a cutaneous manifestation of LE. It has been the authors' experience that, excluding the rare occurrence of hydroxyurea- or statin-induced DM-like skin changes, the concurrent presence of Gottron papules and grossly visible periungual nail fold telangiectasia is pathognomic of DM skin disease. Pruritus or related dysesthetic symptoms such as burning pain are typical of DM skin inflammation, whereas the various forms of LE-specific skin disease are characteristically not pruritic.

The pattern of involvement over the hands also differs; in LE the skin over the dorsal interphalangeal and metacarpophalangeal joints is spared, and the hair-bearing skin between these joints is preferentially involved. The opposite is true for DM: the skin overlying the dor-





Box 157-1

Differential Diagnosis of Dermatomyositis (DM)

CLASSIC DM

Most Likely

- Few illnesses can be confused with the fully expressed combination of hallmark skin changes and proximal weakness seen in classic DM. However, treatment with certain drugs, such as statin lipid-lowering agents, has been reported to be capable of triggering the appearance of both the cutaneous and muscle manifestations of DM.

Consider

- There are a number of causes of proximal muscle weakness other than myositis (see Table 157-7). It is possible that co-occurrence of one of these other causes of proximal muscle weakness with a common dermatologic condition mimicking the early manifestations of cutaneous DM could be confused with classic DM.

CLINICALLY AMYOPATHIC DM

Most Likely

- Cutaneous lupus erythematosus (acute cutaneous lupus erythematosus or subacute cutaneous lupus erythematosus, but not discoid lupus erythematosus)

Consider

- Seborrheic dermatitis
- Contact dermatitis
- Lichen planus
- Psoriasis
- Polymorphic light eruption
- Atopic dermatitis
- Overlap connective tissue disease
- DM-like skin changes induced by drugs (e.g., hydroxyurea, statins)

TABLE 157-8
Comparative Features of Skin Involvement on Dermatomyositis and Lupus Erythematosus

	DERMATOMYOSITIS	LUPUS ERYTHEMATOSUS
Distribution		
Face		
Malar eminences	+	++
Eyelids, periorbital areas	++	+
Scalp	++	++
Oral mucosa	+	++
Extensor arms, forearms	++	++
Hands		
Dorsal aspect	++	++
Palmar aspect	+	+
Dorsal fingers	+	++
Knuckles	++	+
Periungual telangiectasia	++	+
Color of skin lesions		
Violaceous	++	+
Red, pink	+	++
Alopecia	+	++
Hyperkeratosis	+	++
Gottron papules	++	0
Pruritus	++	+
Pathology		
Dermal mucinosis	++	++
Intense mononuclear cell infiltrate	+	++
Immunopathology		
Dermal-epidermal junction immunoglobulin, complement band	+	++
Dermal microvessel C5 to C9 deposits	++	+
Laboratory findings		
Anti-nuclear antibodies	++	++
Anti–Ro/SSA	+	++
Anti–native DNA	0	++
Anti-Sm	0	++
Elevated erythrocyte sedimentation rate	+	++
Malignancy association	++	0

++ = frequently seen; + = occasionally seen; 0 = absent.
From Euwer RL, Sontheimer RD: Dermatomyositis, in *Cutaneous Manifestations of Rheumatic Disease,* edited by Sontheimer RD, Provost TT. Baltimore, Williams & Wilkins, 1996, p 73, with the permission of Williams & Wilkins.

sal interphalangeal and metacarpophalangeal joints is preferentially affected (see Fig. 157-4). When extensive, however, the linear streaking of violaceous erythema that tracks over the extensor tendons of the hands and fingers can sometimes obscure this point of differential diagnosis.

Poikiloderma commonly occurs in DM patients. Various forms of "poikilodermatous" cutaneous LE have also been reported. However, it has been the authors' personal experience that most of the patients with "poikilodermatous LE" that have been referred to them have turned out to have CADM. For most physicians outside of dermatology, the absence of clinically evident muscle weakness reflexively prevents further consideration of cutaneous DM, no matter how typical the skin features might be. This confusion is exacerbated by the fact that the majority of CADM patients test positive for ANA.

In addition, multicentric reticulohistiocytosis (see Chap. 149) has been reported to masquerade as DM. However, the "string of pearls" papules that occur in the periungual areas in multicentric reticulohistiocytosis can be clearly distinguished from the periungual inflammatory changes of DM by clinical and pathologic examination. Many conditions other than IIDM can be associated with proximal muscle weakness.[79] Table 157-7 outlines these disorders.

As previously noted (see Epidemiology), drugs such as hydroxyurea, penicillamine, niflumic acid/diclofenac, phenytoin, tryptophan, and practolol have been reported in rare cases to produce an eruption with clinical similarities to the hallmark cutaneous features of DM. In addition, statin-type lipid-lowering drugs (atorvastatin, fluvastatin, lovastatin, pravastatin, rosuvastatin, simvastatin) and other classes of lipid-lowering drugs (fenofibrate, gemfibrozil) are well known to produce a drug-induced myositis and/or rhabdomyolysis that can simulate the myositis seen in DM. Considering the high rate of usage of these drugs, however, confirmed reports of statins' and other lipid-lowering drugs' triggering the hallmark cutaneous manifestations of DM are quite rare. To prove that a case of classic DM or CADM is drug induced would require a rechallenge with the suspected drug once the cutaneous and/or muscle manifestations of DM have remit-

ted. Few patients or physicians would be willing to do this, and the ethics of such an attempt could be questioned. In addition, most cases of classic DM induced by lipid-lowering drugs are likely to be treated with prednisone and/or steroid-sparing systemic immunosuppressives in addition to cessation of the offending drug. Therefore, without a drug challenge, the argument can be made that the appearance of DM and treatment with potentially triggering drugs was merely fortuitous. More study of the epidemiology and pathogenesis of lipid-lowering drug–induced DM is needed.

COMPLICATIONS

Cutaneous Ulceration

Cutaneous ulcers are more common in juvenile than in adult classic DM and appear to be quite rare in both juvenile and adult CADM. The skin can ulcerate in DM as a result of a number of different mechanisms. Superficial erosion/ulceration can develop from vesiculobullous changes occurring within intensely inflamed DM skin lesions. Retiform ulcers can result from skin breakdown in poikilodermal areas. Deep penetrating ulcers can result from cutaneous infarction secondary to vasculopathy. The skin can ulcerate as a result of pressure from underlying calcium deposits. In addition, leg ulcers are a component of the clinical constellation of hydroxyurea-induced DM skin changes. Because of their frequent association with vasculopathy, deeply penetrating cutaneous ulcers have traditionally been thought to be a poor prognostic sign. One of the authors (M.I.C.) has noted that deeply penetrating ulcers may correlate with pulmonary involvement in DM.

Systemic Vasculopathy

Clinical manifestations of systemic vasculopathy are seen most often in patients with juvenile-onset classic DM. This can result in perforation of the gastrointestinal tract, ocular damage, and central nervous system damage.

Calcinosis

Extraosseous calcification is also more common in children than in adults with classic DM. As with cutaneous ulceration and systemic vasculopathy, calcinosis is seen less commonly in both children and adults with CADM. The higher rate of vasculopathy that occurs in juvenile DM is thought to be a forerunner of dystrophic calcification. Approximately 25 percent of children with classic DM have dystrophic calcification at the time of diagnosis, and 40 percent to 50 percent develop calcinosis sometime during the course of their illness.

DM patients experience several different patterns of calcinosis. In adults, cutaneous calcification often presents as firm dermal and/or subcutaneous papules or nodules that are often most prominent around the elbows and hands. Large subcutaneous tumoral deposits can also occur over the trunk of adults. Such lesions can be filled with a liquid suspension of calcium crystals (i.e., "milk of calcium"). Four types of calcification have been described in children with DM: (1) a superficial pattern consisting of small, firm nodules and plaques in the skin; (2) periarticular subcutaneous nodules (calcinosis circumscripta); (3) deposition along fascial planes in muscles (calcinosis universalis) (see eFig. 157-7.2 in on-line edition); and (4) a severe "exoskeleton" pattern of deposition in the subcutaneous tissue. Calcinosis cutis or calcium deposition in muscles and tendons is more common in the late phases of the disease in children. The TNF-α308A promoter polymorphism might represent a risk factor for developing calcinosis.[29] The complications of calcinosis, such as ulceration and sepsis, are a significant cause of both morbidity and mortality in patients with juvenile classic DM.

Internal Malignancy

Population-based studies document that adult-onset classic DM is associated with a higher than expected risk for internal malignancy.[80–84] Relative risks for malignancy range from 2.4 in males with DM to 3.4 in females with DM. The risk for malignancies was negligible in patients with PM. During the 5-year period after the diagnosis of DM, the risk of a woman developing ovarian cancer in these studies was 16.7-fold higher than the risk for women without DM. In a more recent study, the standardized incidence ratio for malignancy in adult patients with DM was 6.5.[81] In the first year after diagnosis, the relative risk for malignancy in patients with DM was 26.0. Females with DM in this study had a 32-fold higher risk of developing ovarian carcinoma. This study also found that PM was not associated with an increased risk of cancer and that the treatment of DM with cytotoxic drugs did not increase the risk of malignancy. Because of the risk of ovarian cancer in females with DM, it has been suggested that all women with DM (classic DM and CADM) undergo an initial comprehensive gynecologic examination and repeat examinations at 6- to 12-month intervals for at least the first 2 years after the diagnosis. Determination of serum levels of cancer antigen-125 and transvaginal ultrasonography have been recommended for females with DM who have intact ovaries. It is an unfortunate fact, however, that there is no foolproof way to screen for early ovarian cancer.

Tumors other than ovarian carcinoma have been reported with DM, including melanoma, mycosis fungoides, and Kaposi sarcoma. Carcinomas are more frequent than sarcomas, and lymphoproliferative malignancies are uncommon. Except for ovarian cancer in women, no preponderance of specific types of cancer is seen in whites with IIDM. Asian males most frequently develop nasopharyngeal carcinoma.[80,81]

The diagnosis of cancer is most often made by history, review of systems, physical examination, and routine laboratory and radiologic testing. Debate exists about the routine use of surveillance imaging techniques, such as chest, abdominal, and pelvic CT and/or MRI in this setting. Age appears to be a factor in malignancy risk. There is not a significant risk of occult malignancy in patients with juvenile-onset classic DM, whereas individuals 50 years of age or older at the time of onset of classic DM appear to have a definite increased risk of malignancy (20 percent to 30 percent). The leading cause of death in patients with IIDM who have malignancy is metastatic spread of the malignancy rather than complications directly related to the myositis. In patients with malignancy, the myositis and cutaneous manifestations are less responsive to systemic glucocorticoid therapy. In a few well-documented cases, definitive therapy for the malignancy resulted in resolution of the DM disease activity, and a recurrence of the cancer was associated with the reappearance of DM activity.

Older age, greater extent and severity of skin disease [i.e., intense generalized erythema ("malignancy suffusion"), blistering, ulceration], and elevated CK levels appear to enhance the risk of malignancy in adults with classic DM. It has been suggested that other systemic manifestations of DM, such as interstitial lung disease, are negatively correlated with risk for internal malignancy.[22]



All routine age- and sex-directed malignancy surveillance guidelines should be followed.

There are no population-based data concerning the risk of internal malignancy in patients with CADM. In a systematic review of the world literature, 291 reported cases of adult-onset CADM were identified,[24] and only 14 percent of these cases were associated with internal malignancy. However, publication bias could be at play here. It has been the personal experience of one of the authors (R.D.S.) that internal malignancy has been virtually absent in the approximately 100 patients with adult-onset CADM in whose care he has been personally involved at three different U.S. academic medical centers over the past three decades.[24] Population-based studies will be required to resolve the question of risk of malignancy in CADM. Until then, it is recommended that the same approach to occult malignancy surveillance be used for patients with CADM as is used for patients with classic DM.



Opportunistic Infections and Lymphoma

Early initiation of aggressive systemic immunosuppression is required for both juvenile-onset and adult-onset classic DM. Because DM frequently pursues a chronic and/or recurring course, such patients frequently are exposed to the consequences of long-term use of specific immunosuppressive regimens, including a panoply of opportunistic systemic infections (bacterial, mycobacterial, viral, fungal) and opportunistic infection–induced lymphoma (Epstein-Barr virus infection).[86,87a]

Effects of Pregnancy

Classic DM and CADM can occur for the first time during pregnancy, and pregnancy can be a complicating factor for pre-existing classic or DM and CADM. DM presenting in the first trimester of pregnancy is thought to have a worse effect on maternal health and fetal outcome than DM presenting in the second or third trimesters. The impact of pregnancy on DM is generally thought to be a function of the state of DM disease activity and maternal overall health status.

CADM has been reported to occur for the first time during the third trimester of pregnancy. However, one of the authors (R.D.S.) has personally observed two sisters with long-standing CADM who both experienced spontaneous clearing of their DM skin disease activity during the second and third trimesters of multiple pregnancies with consistent relapse of skin disease activity within the first 3 months after delivery of a healthy newborn.

PROGNOSIS AND CLINICAL COURSE

Classic Dermatomyositis

Reported mortality rates vary from 25 percent to 80 percent, depending on the case mix and the medical era in which the cases were collected. In the past two decades, the mortality rate has decreased considerably because of the more aggressive use of glucocorticoids and other immunosuppressives and better supportive medical care.[87b] The 5- and 8-year survival rates for 76 patients with IIDM studied in the 1980s were 80 percent and 73 percent, respectively. Global survival rates for the IIDMs have been more reported to be 95 percent, 92 percent, and 89 percent for 1, 5, and 10 years, respectively. Pulmonary and cardiac complications were the most frequent causes of death. Cancer-associated myositis had the worst prognosis, whereas juvenile-onset and overlap myositis had the best. Five- and 10-year survival rates were 94.2 percent and 89.4 percent for patients with primary PM and 90.1 percent and 86.4 percent for those with primary DM.[88] Individuals who receive early systemic treatment for their disease have a better prognosis. The early, aggressive use of glucocorticoids has reduced the mortality rate in children to less than 10 percent.

The presence of antisynthetase antibodies and TNF-α308A allele may represent risk factors for disease chronicity and severity in juvenile-onset classic DM.[29] African American children with DM tend to have more aggressive disease than do white or Hispanic children. Calcinosis remains a primary cause of both disease morbidity and mortality in patients with juvenile classic DM.

Certain types of skin lesions have also been said to correlate with a poor outcome. Ulcers arising over violaceous indurated plaques on the trunk with or without indurated papules were reported to be more frequent in adults with DM who developed a malignancy. Necrotic/ulcerative skin disease is thought to an unfavorable prognostic feature overall. The mechanic's hand lesion has been suggested to be associated with an increased risk for interstitial lung disease in classic DM.

Prognosis in both adults and children with classic DM is associated with the types of autoantibodies produced. The presence of antisynthetase autoantibodies (Jo-1, PL-7, PL-12) has been correlated with incomplete response to therapy and interstitial lung disease. As noted earlier (see Antibodies) SRP antibodies have been found in patients with acute-onset, severe, and treatment-resistant forms of disease with frequent cardiac involvement. Autoantibodies to Mi-2 are associated with more treatment-responsive forms of DM. PM-SCL has been associated with overlapping features of DM and systemic sclerosis. The presence of the 155-kd autoantibody might possibly indicate a significantly increased risk for occult malignancy.

The causes of death in DM vary depending on the age of onset of disease. In juvenile-onset classic DM, death is more commonly seen with complications of vasculopathy (e.g., bowel perforation, central nervous system involvement) and severe widespread dystrophic calcification (ulceration with sepsis). In adult-onset classic DM, death is more common from occult malignancy, cardiac involvement, and pulmonary involvement or complications (aspiration pneumonia related to esophageal dysfunction, restrictive ventilatory insufficiency due to involvement of muscles of breathing, interstitial lung disease). Patients with both juvenile-onset and adult-onset DM can also die of complications of prolonged systemic immunosuppressive therapy (e.g., opportunistic infection with viruses, bacteria, mycobacteria, and fungi).

Clinically Amyopathic Dermatomyositis

Data are not available to allow adequate discussion of mortality in either adult-onset or juvenile-onset CADM. Individual reports of death from occult malignancy and interstitial lung disease in adult-onset CADM have appeared.[24]

Insufficient long-term follow-up data are available to assess prognosis and clinical course in adults or children with CADM. All six patients in one cohort with adult-onset disease who initially had only skin disease and who were treated conservatively ultimately developed muscle disease.[89] In another cohort, none of the five adults with CADM treated aggressively with high-dose systemic glucocorticoids developed clinical evidence of myositis.[90] Both of these small case series could have suffered from case selection/publication bias.

A systematic review of adult-onset CADM identified 291 cases among which there was a 13 percent incidence of interstitial lung disease and 14 percent incidence of associated internal malignancy.[24] However, this compilation of individual case reports and small case series is likely to have also been affected by reporter bias. Population-based studies of the epidemiology and management of CADM are greatly needed to address this and other clinical issues relating to this sub-type of DM.

One study has suggested that patients with juvenile-onset DM who have only the cutaneous manifestations are usually not treated aggressively and may frequently develop pathologic calcifications.[60] This report is contrary to the findings of other studies of CADM in both children[59] and adults,[20,57] which have indicated that this mode of presentation is usually not associated with a high rate of subsequent dystrophic calcification. One study, indicating that both rheumatologists and dermatologists tend to be conservative in treating patients with CADM,[59] also reported that a high percentage of patients with juvenile-onset CADM enjoy spontaneous remission without systemic immunosuppressive treatment.

TREATMENT

A search of the Cochrane Library revealed a single systematic review of the efficacy of steroid-sparing immunosuppressant and immunomodulatory treatments for DM and PM.[91] This review identified seven potentially relevant randomized controlled trials, none of which had DM skin disease activity as the primary endpoint. Therefore, by necessity, the following discussion of the clinical management of DM skin disease is the product of published anecdotal observation by others, expert opinion by others, and the personal clinical experience of the authors.

The treatment of CADM patients differs from that of classic DM patients only in the absence of the need to treat symptomatic inflammatory myositis. The cutaneous manifestations of classic DM and CADM respond similarly to aggressive systemic immunosuppressive therapy; however, this therapy is difficult to justify in cases of CADM when nonimmunosuppressive topical and systemic measures might be of benefit.

Local Treatment

Patients with either classic DM or CADM should avoid excessive sun exposure and use effective broad-spectrum sunscreens. An in-depth discussion of practical and theoretical photoprotection and local therapy for autoimmune connective tissue skin disease such as DM has been presented elsewhere.[92] However, efforts should be made to insure that vitamin D deficiency does not occur, especially in growing children.

Topical glucocorticoids (classes I and II) can dampen cutaneous inflammation and pruritus, and such agents can be used safely for prolonged periods of time when administered cyclically (2 weeks of daily treatment followed by 2 weeks off treatment). However, these agents alone usually cannot fully suppress DM skin disease activity. Daily use of a medicated shampoo followed by application of a topical class I and II glucocorticoid solution, gel, spray, or foam to the affected areas can provide relief for scalp pruritus. Xerosis is often present, especially in the elderly, and effective moisturization regimens can be of value in managing the pruritus often experienced by patients with DM. Topical antipruritic agents such as combinations of menthol/phenol/camphor, pramoxine, and doxepin can provide short-term relief.

Pulsed dye laser therapy has been advocated for the cosmetic treatment of the residual poikilodermatous skin changes that can follow in the wake of active cutaneous DM.[93]

Systemic Treatment

When nonimmunosuppressive systemic therapy is possible, its use should be maximized. Non-sedating or sedating antihistamines can be used during the day as appropriate. Doxepin, a tricyclic antidepressant, is a potent H_1 and H_2 receptor–blocking antihistamine. When given at bedtime in doses of 10 to 50 mg titrated to the degree of somnolence the next morning, this long-acting antihistamine can ameliorate the pruritus and excoriation that often occur during sleep. The addition of cimetidine 200 to 400 mg four times daily for its histamine H_2 receptor–blocking ability can also be helpful. With the appropriate precautions, oral naltrexone and mirtazapine may be used to treat the intractable pruritus and burning sensations that can be seen in this setting.

ANTIMALARIALS Hydroxychloroquine sulfate (6 mg/kg given as two divided doses per day) has been used to treat DM skin disease. Some experienced clinicians have reported that hypersensitivity reactions to hydroxychloroquine occur at higher frequencies in DM patients than in other patient groups.[94]

Some DM patients will respond better to a combination of hydroxychloroquine and quinacrine, 100 mg/day, or to chloroquine (3.5 mg/kg/day) and quinacrine (100 mg/day)[95] than to hydroxychloroquine alone (see Fig. 157-3). However, even combination antimalarial therapy will not adequately control the cutaneous symptoms of many DM patients. Precautions should be taken to minimize the risk of retinal toxicity with hydroxychloroquine or chloroquine and of hematologic toxicity with quinacrine. If extrapolation from the experience gained from patients with cutaneous LE is valid, patients with DM who smoke cigarettes may be less responsive to antimalarial therapy than those who do not smoke. It should be remembered that on rare occasion antimalarials can contribute to muscular weakness by causing a toxic vacuolar myopathy. Other nonimmunosuppressive systemic therapies that have been suggested to be of benefit in cutaneous DM include dapsone[96,97] and anti-estrogen therapy.[98]

SYSTEMIC GLUCOCORTICOIDS Systemic glucocorticoids remain the traditional first-line therapy for classic DM. Early intervention with systemic glucocorticoids is associated with a better overall prognosis. In adults, prednisone (prednisolone for those with decreased liver function) is given orally in divided doses of 1.0 to 1.5 mg/kg/day, whereas in children the dosage is 1 to 2 mg/kg/day. Significant improvement of muscle strength, normalization of muscle enzyme levels, and improvement in cutaneous inflammation are the endpoints of therapy. Most patients require 1 to 3 months of full-dose treatment with prednisone. When symptoms improve, the dose can be consolidated from a divided dose to a single daily dose given in the morning to reduce the risk of adrenal suppression and other glucocorticoid side effects. The glucocorticoid dosage can then be progressively decreased. Treatment should be continued for 12 to 24 consecutive months to minimize the chance for recurrence. Attention should be paid from the outset to managing the side effects of long-term systemic glucocorticoid use such as osteoporosis. Calcium loss from bones starts within the first 3 months after initiation of systemic corticosteroid therapy.

In acutely ill patients, intravenous pulse therapy with methylprednisolone can be



used. This approach has become increasingly popular in the management of juvenile DM. Alternate-day glucocorticoid administration usually does not provide adequate relief during active phases of the disease. The cutaneous lesions of DM can be refractory to high-dose, long-term glucocorticoid therapy in some patients. Other patients have recrudescent disease activity only in the skin after complete suppression of muscle disease with systemic immunosuppressive therapy.

Systemic glucocorticoids and other systemic immunosuppressives can be used to treat disabling skin disease activity in patients with CADM. However, it remains to be determined whether early aggressive immunosuppressive treatment of CADM might prevent the subsequent development of clinically significant myositis in the minority of CADM patients in whom this occurs.



Approximately 25 percent of patients with classic DM do not respond adequately to systemic glucocorticoids within the first 2 months of treatment. Azathioprine (2 to 3 mg/kg/day), cyclophosphamide (1 to 2 mg/kg/day), methotrexate (7.5 to 50 mg/week), chlorambucil (2 to 6 mg/day), cyclosporine (3 to 5 mg/kg/day), and mycophenolate (1 to 3 g/day) have been used in this setting in patients who cannot tolerate the side effects of prolonged high-dose glucocorticoid therapy.

METHOTREXATE, CYCLOSPORINE, AND CYCLOPHOSPHAMIDE Methotrexate (7.5 to 25.0 mg) given once weekly by mouth has been successful in the treatment of patients with classic DM and some patients affected primarily by the cutaneous manifestations of DM. Higher dosages can be given subcutaneously or intravenously; administration by the intramuscular route may cause spurious elevation of muscle enzyme levels. Cyclosporine and cyclophosphamide have each been reported to be of benefit in treating severe complications of interstitial lung disease in patients with CADM, especially when started before frank respiratory failure has developed.[99,100] In children, oral cyclophosphamide (2 to 4 mg/kg/day) has traditionally been used in cases that could not be managed satisfactorily with systemic glucocorticoids. High-dose intravenous γ globulin therapy has been used in both children and adults in this setting and has the advantage of low toxicity. Plasmapheresis and leukapheresis appear to have little additional value in the management of IIDM.

ANTI–TUMOR NECROSIS FACTOR-α AND OTHER IMMUNOBIOLOGIC AGENTS Based on experimental evidence indicating a role for TNF-α in the pathogenesis of the muscle inflammation in classic DM, anti–TNF-α therapy has been used anecdotally to treat both the muscular and cutaneous manifestations of DM. A small number of cases of severe, therapy-resistant DM have been successfully treated with etanercept (Enbrel) or infliximab (Remicade).[101] More systematic study is needed to define the value of this treatment. Such therapy would have to be used with caution because of the possibility of its uncovering other patterns of systemic autoimmunity (e.g., SLE). In addition, anecdotal reports have appeared suggesting benefit from the use of efalizumab, an inhibitor of T-cell co-stimulation, and rituximab, a depletor of memory B cells, in patients with therapeutically refractory DM.[102,103] B cells have also been implicated in the pathophysiology of DM. Studies of therapy with rituximab (a CD20 B cell–depleting antibody) have provided encouraging results in patients whose disease responded poorly to other treatments.[103,104]

Because levels of enzymatic indicators of muscle inflammation tend to normalize quite quickly after systemic therapy is begun, other surrogate markers of DM systemic disease activity are used by some to guide therapy. Such markers include the von Willebrand factor antigen, $CD19^+$ B cells, and neopterin (reviewed in ref. 29). Serum levels of KL-6 have also been suggested to reflect DM interstitial lung disease activity.

Additional Management

Medical treatment of dystrophic calcification in DM is very challenging. Aluminum hydroxide antacids and diltiazem are currently used to treat this problem with less than ideal results. Other agents that can be tried include probenecid (250 mg/day), potassium para-aminobenzoic acid (15 to 25.0 g/day), warfarin (1 mg/day), ethylenediaminetetraacetic acid, and colchicine (1.2 to 1.8 mg/day). The bisphosphonates, such as alendronate, might be of value.[105] The surgical removal of symptomatic cutaneous or subcutaneous calcium deposits can be considered as a last resort. There is a theoretical basis for considering therapies such as sodium thiosulfate chelation[106,107] and extracorporeal lithotripsy[108,109] for the management of calcinosis cutis.

Passive range-of-motion exercise should be provided early in the disease course to prevent disabling joint contractures, especially in children. Once disease activity is suppressed medically, an active exercise program can facilitate the return of normal strength.

Surveillance for the detection of occult malignancy was discussed earlier in Internal Malignancy. In addition, changes in the clinical status of the respiratory, cardiovascular, and gastrointestinal systems should be evaluated carefully for the possibility of systemic disease activity in these target organs.

Treatment of Clinically Amyopathic Dermatomyositis

Current approaches to the treatment of adults and children with CADM are based on anecdotal observations of individual cases or a relatively small case series. One approach has been to treat patients with CADM aggressively from the outset with systemic glucocorticoids in the hope that progression to systemic involvement might be delayed or prevented.[90] This approach is supported by studies of patients with both juvenile- and adult-onset classic DM, which indicate that early systemic immunosuppressive treatment can lessen long-term disability from muscle dysfunction and complications such as calcification. However, in the large majority of published reports to date, a more conservative approach has been taken to the treatment of CADM.[24,26,110] This approach is validated by reports of patients with CADM who go 10 to 28 years and longer without any sign of disease activity or damage other than in the skin.[1,57,58,111]

Until it is confirmed that adult patients with CADM do not have a significantly increased risk of internal malignancy, they should be evaluated for this potential complication in a manner similar to for patients with classic DM. Because internal malignancy has not been reported to be associated with juvenile-onset classic DM or CADM, it can be assumed that routine evaluation for internal malignancy is not indicated in this population.

PREVENTION

Predicting and preventing the initial clinical manifestation of DM, whether it is skin disease or muscle weakness, is not feasible at this time. However, because many DM patients exhibit worsening of their skin disease activity with

ultraviolet light exposure, physical protection from sunlight and artificial sources of ultraviolet light as well as the regular uses of broad-spectrum sunscreens with a sun protection factor of 30 or higher should be encouraged.

It has been suggested that once the initial features of classic DM have become clinically manifested, early aggressive systemic immunosuppressive therapy can minimize subsequent complications, such as calcinosis and muscle atrophy, and thereby decrease morbidity and mortality. In this context, it has been questioned whether early systemic immunosuppressive therapy in patients with CADM might decrease or eliminate the risk of subsequently development of clinically significant muscle weakness. However, to date, only a minority of CADM patients have been observed to develop muscle weakness after 6 months. Therefore, most authorities currently think that, because of the risks associated with early aggressive systemic immunosuppressive therapy, its use in CADM patients is unwarranted.

KEY REFERENCES

The full reference list for all chapters is available at www.digm7.com.

5. Sontheimer RD et al: Dermatomyositis, in *Cutaneous Manifestations of Rheumatic Diseases*, edited by Sontheimer RD, Provost TT. Baltimore, Williams & Wilkins, 2004, p 65
24. Gerami P et al: A systematic review of adult-onset clinically-amyopathic dermatomyositis: A missing link in the spectrum of the idiopathic inflammatory myopathies. *J Am Acad Dermatol* **54**:597, 2006
25. Peloro TM et al: Juvenile dermatomyositis: A retrospective review of a 30-year experience. *J Am Acad Dermatol* **45**:28, 2001
29. Pachman LM et al: TNFalpha-308A allele in juvenile dermatomyositis: Association with increased production of tumor necrosis factor alpha, disease duration, and pathologic calcifications. *Arthritis Rheum* **43**:2368, 2000
34. Sato S et al: Autoantibodies to a 140-kd polypeptide, CADM-140, in Japanese patients with clinically amyopathic dermatomyositis. *Arthritis Rheum* **52**:1571, 2005
42. Wenzel J et al: Type I interferon-associated skin recruitment of CXCR3+ lymphocytes in dermatomyositis. *Clin Exp Dermatol* **31**:576, 2006
48. Hundley JL et al: Cutaneous symptoms of dermatomyositis significantly impact patients' quality of life. *J Am Acad Dermatol* **54**:217, 2006
75. Fall N et al: Association between lack of angiogenic response in muscle tissue and high expression of angiostatic ELR-negative CXC chemokines in patients with juvenile dermatomyositis: Possible link to vasculopathy. *Arthritis Rheum* **52**:3175, 2005
80. Sigurgeirsson B et al: Risk of cancer in patients with dermatomyositis or polymyositis. A population-based study. *N Engl J Med*. **326**:363, 1992
103. Levine TD: Rituximab in the treatment of dermatomyositis: An open-label pilot study. *Arthritis Rheum* **52**:601, 2005
104. Noss EH, Hausner-Sypek DL, Weinblatt ME: Rituximab as therapy for refractory polymyositis and dermatomyositism. *J Rheumatol* **33**:1021, 2006
110. Plamondon S, Dent PB: Juvenile amyopathic dermatomyositis: Results of a case finding descriptive survey. *J Rheumatol* 27:2031, 2000



CHAPTER 158

Scleroderma (Systemic Sclerosis)

Christopher P. Denton
Carol M. Black

Systemic sclerosis (SSc) is a prototypic multisystem disease that has hallmark cutaneous manifestations but which has the highest case-specific mortality of any of the autoimmune rheumatic diseases. This high mortality and an associated severe morbidity make diagnosis important. SSc also serves as a valuable model for organ-specific fibrotic processes and disease. The clinical diversity of SSc makes classification important. Although not curable, there have been substantial advances in therapy for organ-based complications of SSc, and this represents a major therapeutic advance. The sporadic nature of complications that affect only a minority of cases has stimulated interest in risk-stratification. In addition to being of clinical importance, this also may have impact on studies of pathogenesis and genetics, as distinct pathogenic mechanisms may be predominant in different organ systems.

It is important to distinguish SSc from the localized forms of scleroderma (lcSSc) and also from scleroderma-like conditions, including fasciitis and scleromyxedema. Formal diagnostic criteria are not well established, although the clinical features that lead to the diagnosis of SSc are clear. Classification criteria have mostly focused on the differentiation of SSc from other forms of connective tissue disease. With this in mind, it is important to note that up to 20 percent of cases of SSc may have overlap features.

SCLERODERMA AT A GLANCE



- A multisystem disease characterized by sclerosis of skin in which high mortality and an associated severe morbidity make diagnosis important.
- Clinical features that are almost always present include Raynaud phenomenon and skin sclerosis.
- The extent of skin sclerosis defines each major disease subset.
- It is important to distinguish systemic sclerosis from the localized forms of scleroderma and also from scleroderma-like conditions, including fasciitis and scleromyxedema.

EPIDEMIOLOGY

SSc is an uncommon disease that has proven difficult to ascertain in epidemiologic studies. Estimated prevalence is between 1 and 2 cases per 10,000 of the population, with an annual incidence of new cases approximately 10-fold less than this. Contrasting estimates of frequency in population-based surveys are likely to reflect methodologic challenges of assessing a rare and clinically diverse disease. Although there have been substantial differences between estimates of frequency of SSc in different populations, this may well reflect methodology of individual studies. There is likely to be particular bias in hospital-based series in which more severe cases are likely to be over-represented. This may explain the lower frequency of lcSSc

cases in hospital-based series compared with population-based estimates.

Although a genetic component to etiopathogenesis is likely and evidence supports genetic factors in severity and susceptibility, there is also strong evidence supporting environmental factors as triggers for the disease. This probably underlies the clusters that have been reported in Italy and associated with the mining industry in North America and South Africa.

A major advance for SSc epidemiology has been the recruitment of large cohorts of cases in multicenter registries in a number of different countries. These registries may provide a valuable tracking tool to identify SSc cases and facilitate population-based analysis of environmental and genetic factors influencing the disease phenotype and outcome in SSc.



ETIOLOGY AND PATHOGENESIS

SSc is a complex disease. The pathogenesis involves multiple cell types interacting through a variety of mechanisms that are dependent on microenvironment and key mediators. Major facets of the disease include inflammation, vasculature, and connective tissue–producing cells. Genetic factors are likely to be important, as in other complex disease. However, few genetic factors have been robustly described. The clinical heterogeneity of SSc makes it likely that distinct pathogenetic mechanisms predominate in particular patients or subsets of disease. Similarly, it is likely that the balance of different mechanisms differs at different stages of SSc.

Genetic Factors

The best evidence for a genetic contribution to SSc comes from studies that report familial clustering and from the limited twin studies that have been undertaken. Some support is provided from genetic association studies that have usually used a candidate gene approach. Most success has been observed in genetic analysis of individual components of the disease such as autoantibody profiles. These appear to have a strong genetic determinant, and this may underlie the apparent mutual exclusivity of the SSc hallmark reactivities. It has been demonstrated that the ability to mount an immune response to a particular SSc-associated antigen is restricted by major histocompatibility complex haplotype. Observation from a large number of studies examining genetic markers has identified a number of candidate genes. However, as with other complex diseases, in very many instances, it has not proven possible to replicate initially promising data. Studies of genetically homogeneous populations have been especially informative, including those of the Choctaw nation of Native Americans. It is, however, of interest that some of the associations are very plausible in terms of molecular pathogenesis. It is likely that epistasis and the effect of multiple modifier genes confound simple genetic association studies in SSc, just as in other complex diseases.[1] Reported genetic associations are summarized in Table 158-1.

TABLE 158-1
Summary of Recent Genetic Association Studies in Systemic Sclerosis (SSc)

POLYMORPHISM	CLINICAL ASSOCIATION	REFERENCE
CXCR2	SSc	Renzoni et al. 2000
Tumor necrosis factor-863A	Anti-centromere antibodies	Sato et al. 2004
Interleukin 10	Anti-centromere antibodies	Hudson et al. 2005
SPARC	SSc	Zhou et al. 2002
SPARC	No association	Lagan et al. 2005
Macrophage chemoattractant protein-1	SSc	Karrer et al. 2005
TGF-β1	SSc	Crilly et al. 2002
TGF-β1	No association	Ohtsuka et al. 2002
TGF-β1	No association	Sugiura et al. 2003
ACE	SSc	Fatini et al. 2002
Fibrillin-1	SSc	Tan et al. 2001
COL1A2	SSc	Hata et al. 2000

ACE = angiotensin-converting enzyme; CXCR = chemokine receptor 2; SPARC = secreted protein, acidic and rich in cysteine; TGF = transforming growth factor.

Immune Events

There is substantial evidence of inflammatory change in the skin and lung of cases of SSc. One example is the presence of highly specific hallmark autoantibodies. These are summarized in Table 158-2. The first inflammatory infiltrates in lesional skin are predominantly cells of the monocyte lineage. Later, T lymphocytes predominate, and these demonstrate sub-populations of memory cells. The potential role of autoantibodies in pathogenesis is a fascinating and exciting area. The majority of SSc cases have positive anti-nuclear antibodies. These include a number of hallmark reactivities as well as autoantibodies that occur in other autoimmune rheumatic diseases (e.g., anti-cyclic citrullinated peptide, rheumatoid factor) and antibodies that may have functional significance that are directed against cell surface antigens. Functional impact of these antibodies remains an area of investigation. Several studies suggest that antigens recognized by hallmark SSc autoantibodies may be

TABLE 158-2
Clinical Association of Hallmark Autoantibodies in Systemic Sclerosis (SSc)

REACTIVITY	TARGET ANTIGEN	FREQUENCY	CLINICAL ASSOCIATION
Centromere	CENP proteins	60% lcSSc, 2% dcSSc	Limited skin sclerosis, severe gut disease, isolated pulmonary arterial hypertension
Scl-70	Topoisomerase-1	40% dcSSc, 15% lcSSc	Diffuse skin sclerosis, pulmonary fibrosis
RNAP	RNA polymerase III	25% dcSSc, 2% lcSSc	Diffuse skin sclerosis, hypertensive renal crisis
nRNP	U1-RNP	15% SSc	Overlap features of SLE, arthritis
PM-Scl		l5% SSc	Myositis-systemic, sclerosis overlap

dcSSc = diffuse cutaneous systemic sclerosis; lcSSc = localized cutaneous systemic sclerosis; SLE = systemic lupus erythematosus.

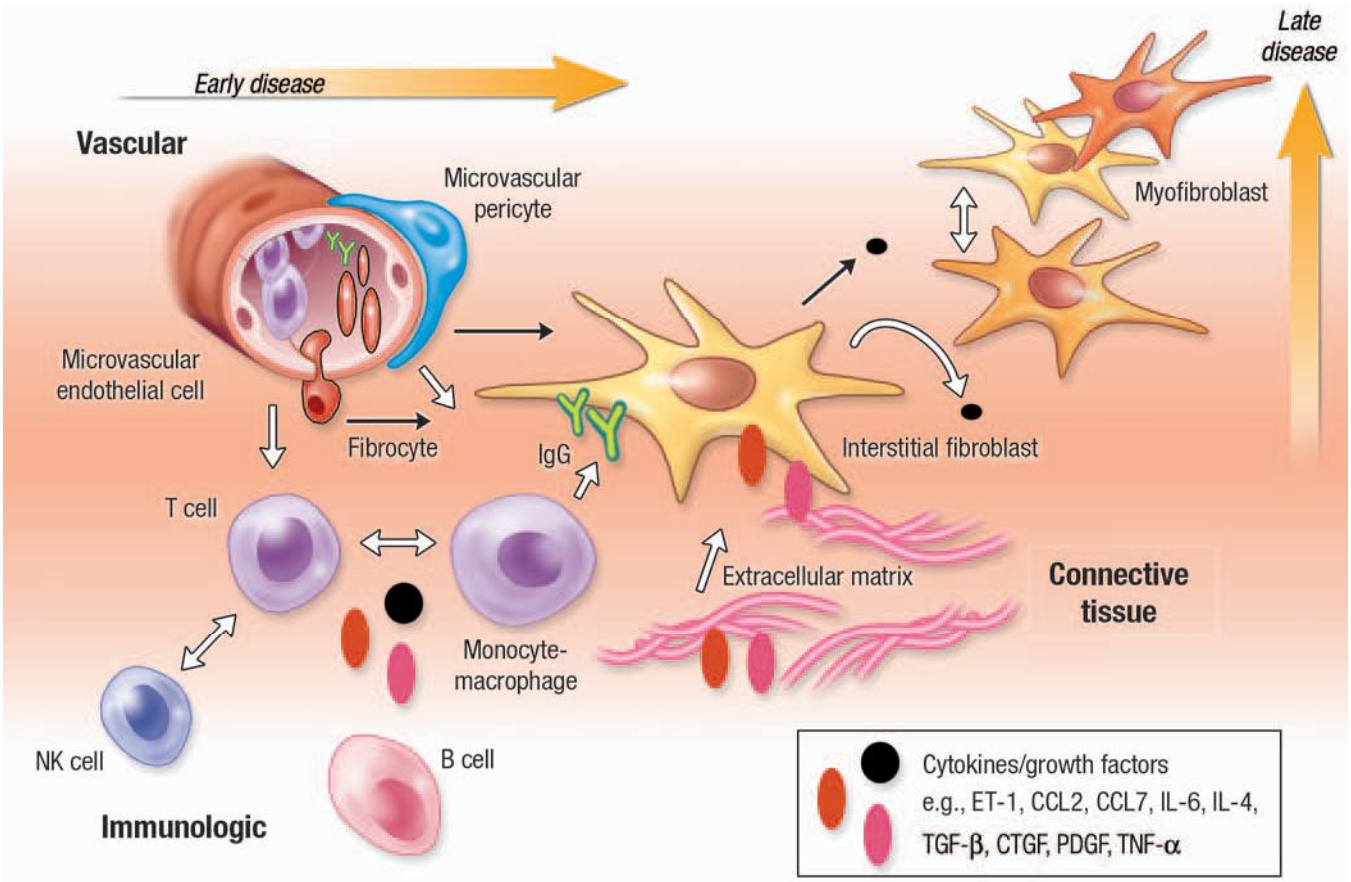

▲ **FIGURE 158-1** Pathogenesis of systemic sclerosis. The schematic shows how the development of systemic sclerosis results from a complex interplay between cells within the immune system, including adaptive and innate compartments, the vasculature, and the connective tissue. Cell-matrix interactions are also potentially important. Early vascular events lead to later development of a relatively autonomous population of activated fibroblasts and myofibroblasts that contract soft tissue and deposit excessive extracellular matrix. These cells may develop from resident connective tissue fibroblasts; transdifferentiation from other cell types, including activated microvascular pericytes; and recruitment of circulating progenitor cells (fibrocytes). The contribution of each lineage to the fibrotic lesion is unclear. Many growth factors and cytokines are implicated as mediators of this process, and complex reciprocal networks may lead to a profibrotic microenvironment. Potential disease-modifying therapies could target individual mediators alone or in combination [e.g., tumor growth factor-β (TGF-β), endothelin (ET-1), connective tissue growth factor (CTGF), platelet-derived growth factor (PDGF)] or modulate immune cells (e.g., cyclophosphamide) or the endothelial cell (e.g., prostacyclin analogues). The extracellular matrix may be an important repository for mediators that are later released and play a key role in pathogenesis. CCL = CC chemokine ligand; Ig = immunoglobulin; IL= interleukin.

expressed on the cell surface. The best evidence of functional significance is for anti-endothelial cell autoantibodies and for anti-fibroblast–reacting antibodies. Recent reports suggest the presence of anti-fibrillin autoantibodies and stimulatory autoantibodies reacting with platelet-derived growth factor receptors, although this observation requires further confirmation. Microchimerism and graft-versus-host disease mechanisms have been suggested in some cases, although the relatively high frequency of microchimerism in healthy individuals or other disease states suggests that this may be contributory rather than causal if it has a role in SSc.

Vasculopathy

Vascular abnormalities are universal in SSc—they manifest as changes in the microcirculation evidenced by structural damage to the nail fold capillaries and as vasospastic responses in Raynaud phenomenon. Vascular change underlies some of the major complications of SSc, including pulmonary arterial hypertension (PAH), scleroderma renal crisis (SRC), and digital vasculopathy.

Fibrosis

SSc is a prototypic multisystem fibrotic disease. Deposition of excessive extracellular matrix in specialized organs is responsible for much of the morbidity and mortality of the disease. Fibrous connective tissue is deposited by activated fibroblasts and myofibroblasts. From an early stage in the disease, there appears to be established an autonomous population of fibroblasts that produce excessive extracellular matrix. The initiators of this process include a number of key cytokines and growth factors that may represent logical therapeutic targets.

A schematic summarizing pathogenetic mechanisms in SSc is shown in Fig. 158-1.

CLINICAL FINDINGS

The heterogeneity of SSc arises from the range of disease manifestations that vary in extent and severity between patients. However, some clinical features that are almost always present, including Raynaud phenomenon (see Chap. 171) and skin sclerosis. The extent of skin sclerosis defines each major disease subset. Each subset has particular features, although there are common features to both. It is also important to consider cases in which there are features of



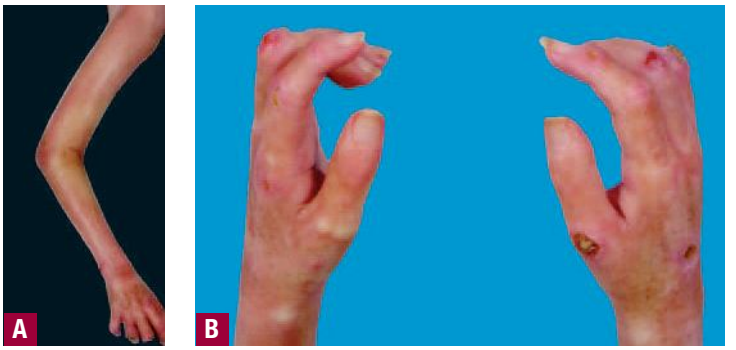

▲ **FIGURE 158-2** **A,B.** Diffuse cutaneous systemic sclerosis. Skin sclerosis in diffuse cutaneous systemic sclerosis extends proximal to the elbows and knees, and often involves the chest and abdominal wall. Severe soft-tissue contractures may arise, and ulceration occurs, especially over extensor surfaces. Skin sclerosis score typically is maximum within the first 18 months of disease. Raynaud phenomenon may develop after onset of skin changes.



one or more additional autoimmune rheumatic diseases; these cases are designated *overlap syndromes*. The two major subsets of SSc are illustrated in Figs. 158-2 to 158-5, and features are summarized in Table 158-3.

Although the two major subsets of SSc are classified according to the presence or absence of proximal skin involvement, in practice, many other clinical differences exist. This includes the duration of Raynaud phenomenon at onset of the other clinical features of SSc. This is typically only a few months in diffuse cutaneous systemic sclerosis (dcSSc) but often spans several years in lcSSc. In addition, the frequency and timing of different visceral manifestations of SSc differs between major subsets. There is, however, some overlap between subsets in terms of organ-based disease, and the extent and severity of skin sclerosis, assessed by modified Rodnan skin score, varies such that lcSSc may have only minor sclerodactyly or may have severe sclerotic changes extending to the elbows. An intermediate subset has been proposed but is not generally recognized. It is also important to recognize that proximal skin involvement can occur in morphea (see Chap. 62).

Autoantibody-based classification of SSc has been proposed, and there is evidence from association studies that this may be clinically meaningful, as indicated in Table 158-2. Moreover, genetic association analysis using a candidate gene approach has demonstrated association between serologically based subsets of SSc that are more strong than with SSc overall. The significance of this remains uncertain, and it should be noted that a genetic basis for autoantibody reactivity has been well described, leading to the suggestion that the serologic subsets may be more genetically homogeneous than unselected SSc cases or clinically defined subsets of SSc.



▲ **FIGURE 158-3** **A–D.** Localized cutaneous systemic sclerosis. Skin sclerosis in localized cutaneous systemic sclerosis is confined to the face, neck, and extremities. Vascular changes are prominent, including telangiectasis. Raynaud symptoms often pre-date skin sclerosis by several years. Skin score tends to slowly rise but does not exceed 18 based on the maximal number of sites involved. Vascular abnormalities that occur include critical ischemia, digital ulceration, and gangrene, ultimately leading to autoamputation.



▲ **FIGURE 158-4** Localized cutaneous systemic sclerosis showing involvement of the face that has a mask-like appearance, with inability of opening the mouth, sclerodactyly, and ulcerations.

The clinical manifestations of SSc depend to a large extent on the subset and stage of disease. Typical constellations exist for the two major subsets and form the basis for discriminating between lcSSc and dcSSc. Thus, most cases of lcSSc occur after a substantial pre-existing period of Raynaud phenomenon. Typical presenting features are those of oesophageal reflux and dysmotility and swelling or skin textural changes in the extremities. Other manifestations reflect individual patterns of internal organ disease. A very small proportion of cases develops vascular, immunologic, and organ-based fibrotic features of SSc but do not show skin sclerosis. These cases constitute approximately 1 percent of SSc cases and are termed *SSc sine scleroderma*. In all other patients, the extent and severity of skin sclerosis can be assessed by the modified Rodnan skin score. Usually, 17 sites are assessed and skin thickness is categorized to grade 1, 2, or 3, corresponding to mild, medium, and severe, according to palpation of the

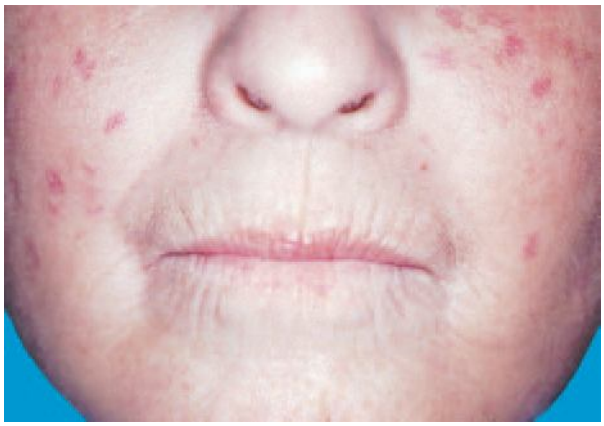

▲ **FIGURE 158-5** Radial furrowing around the mouth and mat-like telangiectases are prominent on the cheeks in a patient with scleroderma.

TABLE 158-3
Clinical Features of the Major Systemic Sclerosis (SSc) Subsets

- Localized cutaneous SSc
  - Long pre-existing history of Raynaud phenomenon
  - Skin sclerosis spares proximal sites
  - Often anti-centromere antibodies–positive (but any reactivity possible)
  - Includes classic CREST (*c*alcinosis cutis, *R*aynaud phenomenon, *e*sophageal dysfunction, *s*clerodactyly, and *t*elangiectasia) syndrome
  - High frequency of visceral disease including isolated pulmonary arterial hypertension
  - Pulmonary fibrosis and gastrointestinal tract involvement common
  - Low frequency of scleroderma renal crisis
- Diffuse cutaneous SSc
  - Proximal skin sclerosis (upper arms, thighs, chest and abdomen)
  - Close temporal relationship between onset of Raynaud and skin sclerosis
  - Prominent inflammatory features during first 24 mo of disease
  - High frequency of pulmonary fibrosis, cardiac involvement, and scleroderma renal crisis
  - Often Scl-70 or anti-RNAPIII positive (but any reactivity can occur)
- Overlap SSc
  - Features of scleroderma together with those of another autoimmune rheumatic disease
  - Poly- or dermatomyositis
  - Systemic lupus erythematosus
  - Sjögren syndrome
  - Vasculitis
  - Polyarthritis
  - Anti-nuclear antibody testing often shows speckled nucleolar staining with specificity for nRNP, fibrillarin, or PM-Scl
  - May demonstrate additional serologic features of systemic lupus erythematosus, rheumatoid arthritis, Sjögren

skin by a trained examiner. Skin score at baseline correlates with disease severity and outcome in dcSSc.

Cases of dcSSc have a more abrupt onset, with major inflammatory symptoms including swelling of the extremities. Typically, the vascular manifestation of Raynaud phenomenon is delayed compared with lcSSc and may occur simultaneous with the onset of other features of the disease or at a later time point. The first presentation is typically with arthralgia, stiffness, and swelling of the extremities that may reflect increased vascular permeability. Later, the features of skin sclerosis develop. For classification purposes, any involvement of the proximal limbs or trunk defines the case as dcSSc. In addition to Raynaud and skin sclerosis of the extremities, other common features of early stage dcSSc are weight loss, constitutional symptoms, and gastrointestinal manifestations, including oesophageal reflux and dysmotility, and postprandial bloating.

The clinical features of established SSc are diverse and reflect the multiple patterns of internal organ involvement and the consequences of progression of the underlying pathologic processes of vasculopathy, inflammation, and fibrosis. Particular consideration must be given to the hallmark complications of hypertensive SRC, PAH, pulmonary fibrosis (PF), and gastrointestinal dysmotility. Overlap syndromes have especially variable clinical features reflecting the underlying pathology of these conditions. Many of the symptoms and signs are seen to a lesser extent in isolated SSc but are more severe.

Some symptoms are especially common in SSc and raise important differential diagnostic questions. These are considered in Table 158-4.

TABLE 158-4
Cardinal Symptoms in Systemic Sclerosis: Potential Mechanisms Underlying Morbidity in Systemic Sclerosis

- Chest pain
  - Reflux esophagitis
  - Esophageal spasm
  - Pericarditis
  - Cardiac arrhythmia
  - Pulmonary arterial hypertension
  - Miscellaneous—chest infection, chest wall inflammation
- Breathlessness
  - Interstitial pulmonary fibrosis
  - Pulmonary arterial hypertension
  - Pleural or pericardial effusion
  - Cardiac involvement
  - Anemia (e.g., from gastric antral vascular ectasia)
  - Physical deconditioning due to reduced activity
  - Miscellaneous—chest infection, myositis
- Altered bowel habit
  - Constipation with overflow
  - Small intestinal bacterial overgrowth
  - Pancreatic exocrine insufficiency
  - Pseudo-obstruction
  - Obstruction due to inspissated feces
  - Sigmoid volvulus
- Impaired exercise capacity
  - Cardiorespiratory complications
  - Physical deconditioning due to reduced activity
  - Contractures of skin and soft tissue
  - Lower extremity ulcers
  - Muscle weakness/myositis

HISTOPATHOLOGY

The histopathology of SSc shows fibrosis of the lower two-thirds of the dermis and the subcutaneous fibrous trabeculae (Fig. 158-6). Panniculitis may also be a prominent feature in the early stages, whereby subcutaneous fat is replaced by a fibrous connective tissue. In the dermis, the collagen bundles appear pale, homogenous, and swollen, and there may be a sparse perivascular lymphocytic infiltrate. In later stages, pilosebaceous units and eccrine glands disappear, and there may be an effacement of the rete ridges.

Vessels of all sizes may be involved in SSc. In the early stages, there may be only dilatation of capillaries, then endothelial proliferation and complete occlusion of vessels.

DIFFERENTIAL DIAGNOSIS

The diagnosis of SSc is clinical. Although there are classification criteria that were developed to facilitate distinction of SSc



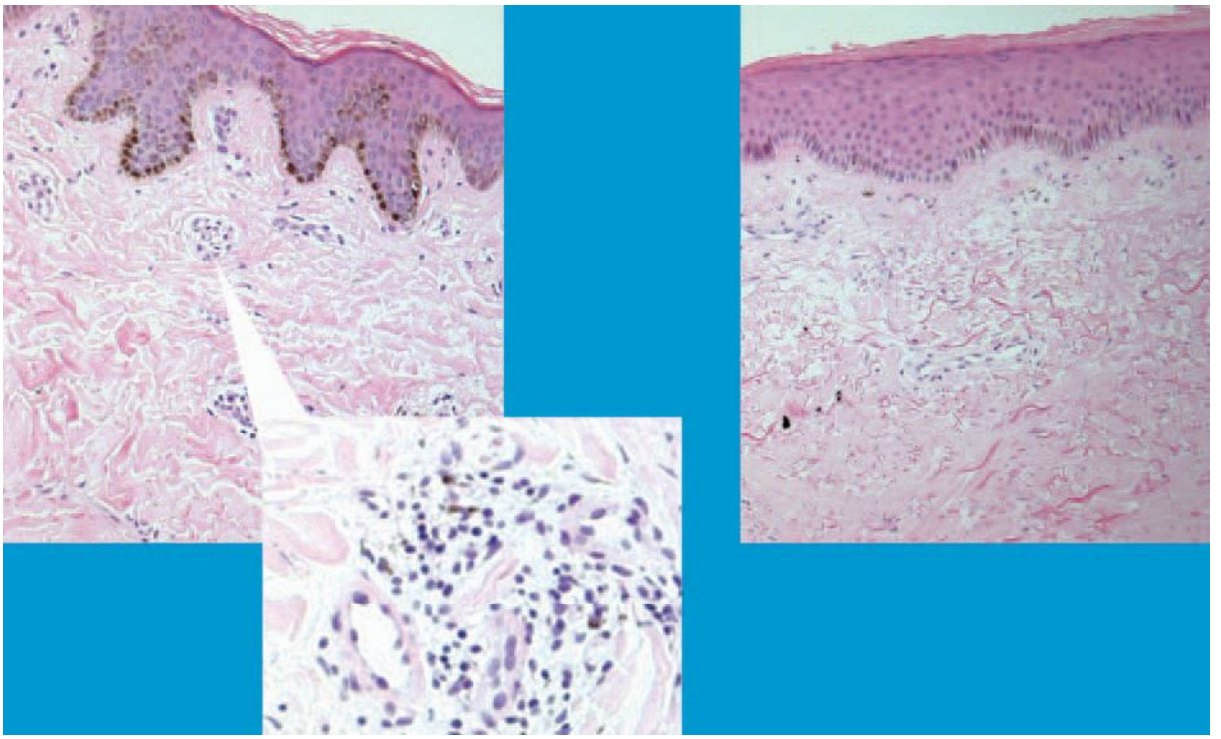



▲ **FIGURE 158-6** Histologic appearance of skin in early and late-stage diffuse cutaneous systemic sclerosis (dcSSc). In dcSSc there is perivascular mononuclear cell infiltrate at the early stages of disease. This precedes the development of skin sclerosis. Perivascular changes are shown at high power in the left panel. Later stage disease is accompanied by skin sclerosis and a low density of blood vessels and absence of inflammatory cells. At this stage, there may be associated epidermal changes with thickening and loss of secondary skin structures, including hair follicles and sweat glands. Absence of the rete ridges is also characteristic at the later stages of dcSSc. Similar changes are predicted in localized cutaneous SSc, but this is rarely biopsied due to limited skin sclerosis and concerns about healing.

from other connective tissue diseases, no formal diagnostic criteria have been developed. The main differential diagnosis is with other conditions within the scleroderma spectrum and with the scleroderma overlap syndromes. In addition it is critical to distinguish other causes of skin sclerosis. Box 158-1 summarizes important differential diagnosis for SSc. In cases of established SSc, the most important aspects of differential diagnosis relate to differentiation of the diverse manifestations of SSc. For example, there are multiple SSc-related causes for dyspnea, chest pain, or gastrointestinal symptoms that need to be correctly diagnosed.

COMPLICATIONS AND COURSE

See the section Organ-Based Treatment Strategies.

TREATMENT

Disease-Modifying Treatment

The three facets of SSc are potentially amenable to therapeutic modulation, and this raises the possibility of true disease-modifying treatment. At present, vascular therapies and immunomodulation have the widest range of candidate therapies. These approaches are summarized in Tables 158-5 and 158-6. Antifibrotic treatment remains much more of a challenge. Some encouragement is provided by recent clinical trials of idiopathic PF. However, at present there is no proven antifibrotic agent. Further details about possible treatment approaches are provided in Table 158-7. A simplified schematic for integrating putative disease-modifying therapy with programs of screening and surveillance that permit timely intervention in SSc is shown in Fig. 158-7 with organ-based strategies that currently form the basis of the majority of SSc therapeutics. Possibilities for targeted disease modifying therapy depend on the availability of therapeutic agents and a clear understanding of their role in pathogenesis.[2]

Organ-Based Treatment Strategies

There has been much more success in the field of organ-based therapeutics in SSc. The individual complications together with an overview of treatment options are listed below.

DIGITAL VASCULOPATHY AND ITS COMPLICATIONS Approximately 50 percent of patients with SSc are troubled by digital ulceration associated with vasculopathy at some point in their disease history. This is the major external feature of structural vessel disease. Other complications include critical digital ischaemia, paronychia, and finger pulp loss. Tender and painful pitting scars are very frequent and may, on occasion, progress to ulcers. Raynaud phenomenon per se does not lead to these structural and trophic changes that serve to distinguish cases with underlying connective tissue disease. Treatment requires optimal therapy for Raynaud, including agents that may have the potential for vascular remodeling, such as angiotensin receptor–blocking drugs. Parenteral prostacyclin derivatives are widely used. These help to heal digital ulcers and may prevent recurrent lesions. Prostacyclin derivatives by continued intravenous infusion are the mainstay of therapy for critical digital ischaemia. Anti-platelet agents such as aspirin or clopidogrel are used especially in critical digital ischaemia. Nebulized iloprost has been reported to be beneficial in some cases, but formal trial data are not available. More recently, there has been enthusiasm about use of therapies that are effective for PAH in digital vasculopathy. Thus bosentan, an oral

Box 158-1

Differential Diagnosis of Systemic Sclerosis

OTHER DISORDERS WITHIN THE SCLERODERMA SPECTRUM

- Localized scleroderma
  - Generalized morphea
  - Multiple plaque morphea

ACRAL VASOSPASM

- Raynaud phenomenon
  - Primary Raynaud phenomenon
  - Other autoimmune rheumatic disorders
    - ~ Systemic lupus erythematosus
    - ~ Rheumatoid disease
    - ~ Dermato/polymyositis
- Other vascular disease
  - Hematologic
    - ~ Cryoglobulinemia
    - ~ Cold agglutinin disease
    - ~ Hyperviscosity syndrome
  - Systemic vasculitis
  - Buerger disease (thromboangiitis obliterans)
  - Macrovascular disease

OTHER CAUSES FOR SKIN SCLEROSIS

- Infiltrative disorders
  - Amyloidosis
  - Scleromyxedema
  - Scleroderma of Buschke
  - Lichen sclerosis et atrophicus
- Metabolic disorders
  - Myxoedema
  - Porphyria cutanea tarda
  - Congenital porphyrias
  - Acromegaly
  - Phenylketonuria
- Inflammatory
  - Eosinophilic fasciitis
  - Chronic graft-versus-host disease
  - Sarcoidosis

dual specificity endothelin receptor antagonist, has been demonstrated in two large controlled trials to significantly reduce the number of new digital ulcers occurring, compared with placebo.[3] No positive effect on healing of established ulcers has been demonstrated. Other agents, such as phosphodiesterase type 5 inhibitors sildenafil and tadalafil, have also been used for treatment of Raynaud, and digital ulcers but prospective clinical trial data are not available. Surgical treatments include digital microarteriolysis, which can benefit single fingers with refractory ulcers. Whenever possible, surgical amputation of digits is avoided, and prolonged treatment with parenteral prostacyclin and potent analgesia may help with this. Lumbar sympathectomy may be helpful for lower

TABLE 158-5
Immunomodulatory Strategies for Treatment of Systemic Sclerosis

Agent	Clinical Trial Data	Reference
Cyclosporin A	Open study, 10 patients. Improvement in skin score.	Clements et al. 1993
Methotrexate	Placebo-controlled trial, 30 patients. Significant improvement in skin score. Larger North American study inconclusive.	van den Hoogen et al. 1996, Pope et al. 2001
Cyclophosphamide	Minor effect on lung function tests but significant benefit for skin and disability in Scleroderma Lung Study of oral cyclophosphamide for 12 mo.	Tashkin et al. 2006
Immunoablation/ stem cell transplantation	Ongoing studies in United States and Europe.	Tyndall et al. 1997, Furst et al. 1997
Extracorporeal photopheresis	Variable reports. Open study, 6/16 cases showed improvement.	Krasagakis et al. 1998
Anti-thymocyte globulin	Open study, 13 patients. With mycophenolate mofetil. Skin score improved.	Stratton et al. 2001
Oral tolerization to type I collagen	Favorable pilot data. Trial ongoing in United States.	Carbone et al. 2004
Mycophenolate mofetil	Retrospective cohort study of over 100 systemic sclerosis cases suggests benefit.	Nihtyanova et al. 2007

TABLE 158-6
Therapies for Raynaud Phenomenon and Digital Ischemia in Systemic Sclerosis

Intervention	Evidence	Reference
Calcium channel blockers	Several studies confirm benefit of this class of drug for Raynaud phenomenon.	Kahan et al. 1985
Angiotensin-converting enzyme inhibitors	Anecdotal support for benefit in Raynaud phenomenon and proven efficacy in scleroderma renal crisis.	Challenor 1994
Angiotensin receptor blockers	Study suggests superiority over nifedipine in small trial.	Dziadzio et al. 1999
Antioxidant agents	Study suggests benefit for probucol, a synthetic antioxidant, in Raynaud phenomenon. Antioxidant vitamins not helpful in clinical trials.	Denton et al. 1999, Herrick et al. 2000
Prostacyclin analogues	Intravenous iloprost effective for Raynaud phenomenon and healing digital ulcers. Oral iloprost not effective at low dose, and side effects limit higher dose treatment.	Wigley et al. 1994
α-Adrenergic blockers	Preliminary studies suggest benefit compared with placebo.	Wise et al. 2004
Endothelin receptor blockade	Two large placebo-controlled studies show reduction in new digital ulcer formation on bosentan. No effect on healing of established ulcers.	Korn et al. 2004
Anticoagulants	One study suggests benefit for low-molecular-weight heparin.	Denton et al. 2000
Serotonin reuptake inhibitors	Small study suggested benefit over nifedipine and favorable side-effect profile.	Coleiro et al. 2001
Phosphodiesterase type 5 inhibitors	Uncontrolled studies of sildenafil and tadalafil suggest benefit for Raynaud phenomenon.	Fries et al. 2005
Nitrate formulations	Uncontrolled trials suggest benefit for Raynaud phenomenon. Vasodilator side effects may limit usefulness.	Teh et al. 1995



TABLE 158-7
Potential Antifibrotic Strategies for Treatment of Systemic Sclerosis

AGENT	CLINICAL TRIAL DATA	REFERENCE
D-Penicillamine	High- vs. low-dose study in United States. 134 patients, no apparent benefit.	Clements et al. 1999
Relaxin	Placebo-controlled dose-escalation study (30 patients stable scleroderma) encouraging. Improved global assessment score. Large phase III study negative. Considered ineffective.	Seibold et al. 2000
Interferon-γ	Open study (44 patients) showed minor improvements in skin sclerosis.	Grassegger et al. 1998
Anti–TGF-β strategies	Pilot studies of anti–TGF-β1 antibodies (44 patients) showed no efficacy. No high-dose toxicity observed. Anti–TGF-β1–3 in development as blocking single isoform unlikely to be effective. Other strategies being considered, including anti–connective tissue growth factor and small molecule inhibitors.	Denton et al. 2007

TGF = tumor growth factor.



limb Raynaud or ulceration. Generally, a temporary procedure is performed initially to determine likely benefit from a definitive sympathectomy. In cases of critical digital ischemia, anti-platelet therapies are often given, with anecdotal reports of the benefit of clopidogrel in preventing digital infarction.

SCLERODERMA RENAL DISEASE Although hypertensive SRC is the most devastating renal complication of SSc, there are other patterns of disease. Studies suggest that a chronic vasculopathy with reduced glomerular filtration rate is frequent. In addition, there is evidence of an increase in fibrillar collagen deposition within the renal interstitium in SSc. Finally, cases with overlap SSc may manifest inflammatory glomerular disease, including glomerulonephritis or vasculitic changes. These are usually associated with serologic features of these diseases.

However, SRC remains the most devastating renal manifestation. It occurs overall in 10 percent to 15 percent of dcSSc and 1 percent to 2 percent of lcSSc cases during the course of disease. Many cases occur within the first 12 months of disease, and in up to one-fourth of patients with SRC the diagnosis of SSc is made at the time of the renal presentation. Typically, cases present with accelerated phase hypertension and progressive renal impairment. End-organ damage can result in encephalopathy with generalized seizures or flash pulmonary edema. Microangiopathic anemia is common, and sometimes disseminated intravascular coagulation develops. Overall, approximately two-thirds of cases of SRC presenting to a specialist center require renal replacement therapy. Of these, approximately one-half of cases eventually recover sufficiently to discontinue dialysis. This can occur over 24 months after the crisis, and so decisions about renal transplantation should be postponed until that time. The possibility of late recovery distinguishes SRC from other causes of end-stage renal failure. These outcomes are possible through the use of angiotensin-converting enzyme inhibition as routine therapy for SRC. Before their availability, the mortality from established SRC was more than 90 percent at 12 months; this is dramatically improved, but outcome still has room for improvement. Patient and physician education forms an important part of this.

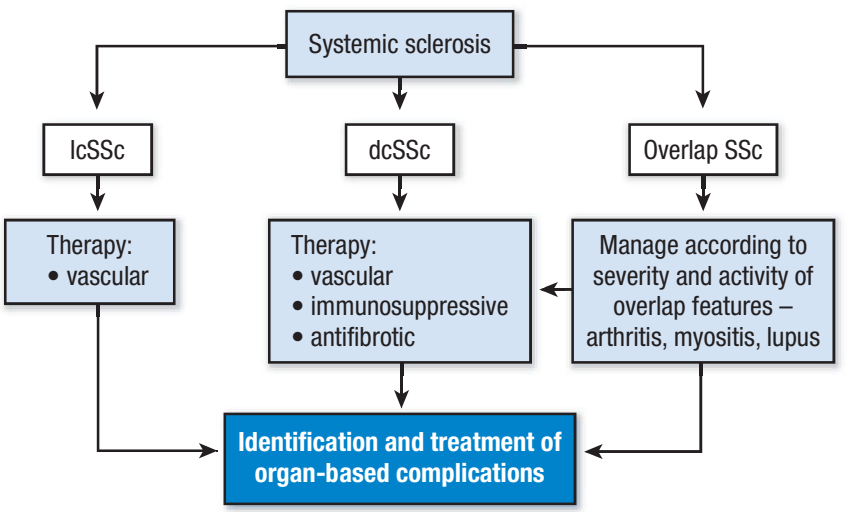

▲ **FIGURE 158-7** Algorithm summarizing current approach to management of systemic sclerosis (SSc). The principles of therapy for SSc include accurate diagnosis and treatment according to the disease subset, the presence of overlap features, and the likely predominant pathologic process according to the stage of disease. In all cases, screening for and treatment of organ-based complications has a major role in successful management. Education of patients and a multidisciplinary team, including specialist nurses, physiotherapists, occupational therapists and many subspecialty physicians, and surgeons, are central to providing appropriate care for severe cases of SSc. dcSSc = diffuse cutaneous systemic sclerosis; lcSSc = localized cutaneous systemic sclerosis.

PULMONARY ARTERIAL HYPERTENSION PAH is currently the most common cause of disease-related death in SSc. It occurs in both limited and diffuse cutaneous subsets, although the most typical cases are those of lcSSc associated with isolated PAH. This condition has substantial similarities to idiopathic PAH. Current classification of pulmonary hypertension is shown in Table 158-8. Thus, two patterns of disease occur in SSc. Most cases have PAH, but there are some patients with late-stage extensive interstitial lung fibrosis in SSc that develop a true secondary PH. It is increasingly appreciated that a group of cases with some lung fibrosis [that can be detected by high-resolution computed tomography (HRCT) in up to 50 percent of SSc cases] have predominantly PAH and that this group may respond to standard PAH therapies. There have been substantial advances in the treatment of PAH over the past decade.[4] This has significantly increased the options for therapy of SSc-associated PAH, and this, in turn,

TABLE 158-8
Revised World Health Organization Classification of Pulmonary Hypertension

- Group I: Pulmonary arterial hypertension
  - Idiopathic
  - Familial
  - Related conditions: Connective tissue disease, congenital left-right shunt, portal hypertension, human immunodeficiency virus infection, drugs/toxins, other diseases
  - Associated with significant venous or capillary involvement
    - Pulmonary venoocclusive disease
    - Pulmonary-capillary hemangiomatosis
    - Persistent pulmonary hypertension of the newborn
- Group II: Pulmonary venous hypertension
  - Left-sided atrial or ventricular disease
  - Left-sided valvular heart disease
- Group III: Pulmonary hypertension associated with hypoxemia
  - Chronic obstructive pulmonary disease
  - Interstitial lung disease
    - Chronic exposure to high altitude
- Group IV: Pulmonary hypertension due to chronic thrombotic and/or embolic disease
  - Proximal pulmonary thromboembolic obstruction
  - Distal thromboembolic obstruction
- Group V: Miscellaneous
  - Sarcoidosis, vascular compression

Adapted from Simonneau et al: Clinical classification of pulmonary hypertension. *J Am Coll Cardiol* **43**:5, 2004.

has raised the profile and priority of PAH in SSc. Most cases are treated with oral agents: either bosentan (an endothelin receptor antagonists) or sildenafil (a phosphodiesterase 5 inhibitor) once they are significantly functionally limited (New York Heart Association class III). Later, if progression takes place, combination oral treatment or introduction of parenteral prostacyclin is used, by either intravenous or subcutaneous route. Inhaled delivery systems for iloprost are available.

PULMONARY FIBROSIS Although PAH is probably responsible for more deaths that lung fibrosis in SSc, lung fibrosis remains an important complication. Most cases fall histologically into the classification of non-specific interstitial pneumonia. Interestingly even those cases that have a usual interstitial pneumonia histologic or HRCT pattern have a much more favorable outcome than cases of idiopathic PF. Treatment of SSc-PF remains challenging.[5] Adding to a substantial body of uncontrolled or retrospective data suggesting benefit for cyclophosphamide in SSc-PF, the results of two randomized double-blind placebo-controlled trials have recently been reported. Both show a modest placebo-subtracted benefit for cyclophosphamide.[6] For change in forced vital capacity (percent predicted), this was statistically significant for the Scleroderma Lung Study comparing oral cyclophosphamide with placebo, and was a strong trend ($p = 0.06$) in the trial of intravenous cyclophosphamide followed by oral azathioprine. At present, most centers use cyclophosphamide as treatment for severe or progressive SSc-PF, defining the extent and severity by pulmonary function tests and HRCT. Extent of disease by HRCT and a history of progressive restrictive abnormality on pulmonary function tests is the best predictor of future decline in lung function and generally used to make decisions about therapy. Other therapies that are in use include carbocysteine and low dose corticosteroids. The place of other immunosuppressive strategies remains uncertain and requires evaluation in prospective multicenter clinical trials. It is noteworthy that despite strong theoretic rationale as a treatment for lung fibrosis, the endothelin receptor antagonist bosentan was not superior to placebo in a recent large multicenter study of SSc-PF cases. Recent trials in idiopathic PF of pirfenidone, etanercept, and interferon-γ that have shown some signals of efficacy and are under further evaluation for this disease.

GASTROINTESTINAL COMPLICATIONS Involvement of the gastrointestinal tract is very frequent in SSc. More than 90 percent of cases have esophageal involvement with dysmotility and reflux. This can respond very well to proton pump inhibitors and agents that increase lower oesophageal sphincter tone such as domperidone. Mid-gut involvement takes many forms. Pseudo-obstruction requires conservative management initially but may require parenteral nutritional supplementation. Small intestinal bacterial overgrowth can be treated using broad-spectrum antibiotics, and pancreatic insufficiency may require enzyme supplements. Large bowel involvement is a major challenge. Anorectal incontinence sometimes responds well to an implanted sacral nerve stimulator or to less elaborate approaches such as bioplastic injection to increase the internal anal sphincter bulk. Associated rectal prolapse may require additional surgical intervention. Chronic constipation, sometimes with overflow diarrhea, is a common problem. An adjustment to diet and judicious use of stimulating, softening, or bulking aperients is recommended, but an individualized approach with substantial patient involvement is generally the most successful approach. On occasion, defunctioning colostomy is needed, but this is only appropriate in a very limited number of cases.

MYOSITIS One of the challenges of treating myositis is the need to balance the risk and benefit of corticosteroid therapy in SSc and the definition of the pathologic basis for muscle involvement in SSc. Fibrosis, atrophy, and inflammation can all occur. Steroid doses should be minimized. Imaging and electromyogram can be helpful in distinguishing different patterns of pathology.

CARDIAC COMPLICATIONS Cardiac involvement from SSc is an important contributor to mortality but remains one of the least well understood and poorly recognized of the internal organ complications of SSc. A large number of studies confirm that radionuclide imaging, electrophysiologic, and functional abnormalities are frequent in SSc, but the significance of these findings is uncertain. Hemodynamically significant cardiac involvement occurs in up to 10 percent of cases of dcSSc. An inflammatory component of myocarditis may respond to immunosuppression, and so an operational approach to management of cardiac scleroderma is indicated in Fig. 158-7. This is not based on data but could form the basis for prospective evaluation of the significance of impaired left ventricular ejection fraction and elevated circulating troponin levels in SSc. Cardiac magnetic resonance imaging, tissue Doppler, and assessment of diastolic dysfunction by conventional two-dimensional echocardiography are all potential strategies for assessing cardiac involvement in SSc.

There have been many advances in SSc, including a better appreciation of the diversity of the condition, improved understanding of the underlying pathologic mechanisms, and major progress in treating organ-based complications. This includes the accumulation of robust clinical trial data that demonstrate effectiveness or lack of benefit of individual therapies and in validation of measures of disease assessment.[7] Furthermore, there have been major steps forward in developing effective patient organizations and



in the development of networks to better understand this disease.

SCLERODERMA-LIKE DISORDERS

Scleroderma-like disorders have been reported in association with numerous environmental toxins and drugs. These agents include solvents (vinyl chloride, benzene, toluene, epoxy resins), drugs (bleomycin, cardiopa, pentazocine, cocaine, docetaxel, metaphenylenediamine), and miscellaneous substances.

SSc was reported to occur in underground coal and gold miners. In male patients with silicosis who are older than 40 years of age, the likelihood of developing SSc is approximately 190 times greater than in males not exposed to silica, and 50 times greater than in males without silicosis but exposed to silica dust.[8] Most epidemiologic studies have failed to show a significant association between silicone gel implants and other silicone products and the development of scleroderma.[9]

An unusual form of scleroderma characterized by Raynaud phenomenon, morphea-like skin changes, capillary abnormalities of the nail fold (similar to those in SSc), osteolysis of the distal phalanges, and hepatic and PF may occur in workers exposed to polyvinyl chloride. Bleomycin also produces PF, Raynaud phenomenon, and cutaneous changes indistinguishable from those of SSc.[10] The development of these changes appears to be dose dependent and is reversible on discontinuation of the drug.

Collectively, chemical exposures account for a small fraction of scleroderma cases. Large epidemiologic studies have not yet revealed a significant role for toxins and drugs in scleroderma.

Scleroderma-like skin changes may also be associated with scleromyxedema, porphyria cutanea tarda, and graft-versus-host disease. Similar skin changes, primarily in the legs, have been described in the carcinoid syndrome, but these entities are clearly separable from scleroderma per se.

Other syndromes that cause scleroderma-like skin changes, such as eosinophilic fasciitis (Shulman syndrome), the eosinophilia myalgia syndrome, and toxic oil syndrome are discussed in Chap. 35. Scleromyxedema is discussed in Chap. 159.

KEY REFERENCES

The full reference list for all chapters is available at www.digm7.com.

1. Assassi S, Tan FK: Genetics of scleroderma: Update on single nucleotide polymorphism analysis and microarrays. *Curr Opin Rheumatol* **17**:761, 2005
2. Denton CP, Black CM: Targeted therapy comes of age in scleroderma. *Trends Immunol* **26**:596, 2005
3. Korn JH et al: Digital ulcers in systemic sclerosis: Prevention by treatment with bosentan, an oral endothelin receptor antagonist. *Arthritis Rheum* **50**:3985, 2004
4. Hachulla E, Coghlan JG: A new era in the management of pulmonary arterial hypertension related to scleroderma: Endothelin receptor antagonism. *Ann Rheum Dis* **63**:1009, 2004
5. Steen VD. The lung in systemic sclerosis. *J Clin Rheumatol* **11**:40, 2005
6. Tashkin DP et al: Scleroderma Lung Study Research Group. Cyclophosphamide versus placebo in scleroderma lung disease. *N Engl J Med* **354**:2655, 2006
7. Merkel PA et al: Current status of outcome measure development for clinical trials in systemic sclerosis. Report from OMERACT 6. *J Rheumatol* **30**:1630, 2003



CHAPTER 159

Scleredema and Scleromyxedema

Roger H. Weenig
Mark R. Pittelkow

Disorders characterized by excessive mucin deposition, increased collagen production, and fibrocyte hyperplasia are historically categorized as mucinoses, sclerosing disorders, and fibrosing disorders, respectively. The fibrocyte (fibroblast) is central in the pathogenesis of each of these conditions. Thus, shifting the focus from products and consequences of disordered fibroblast activity (e.g., mucin, collagen, fibrosis) to the cell of origin, the fibroblast, and the mechanisms that stimulate specific fibroblast dysfunction provides a better understanding of the histopathogenesis of these diseases and also lays a foundation for the development of more effective treatments for these incapacitating conditions. In some disorders, a singular fibroblast activity predominates, such as excessive mucin or collagen production [pretibial myxedema (see Chap. 152) and sclerodermoid disorders (see Chap. 158) respectively]. In others, a combination of excessive mucin and collagen production occurs (scleredema, this chapter) or excessive mucin production and fibrocyte hyperplasia ensues [scleromyxedema (this chapter) and nephrogenic fibrosing dermopathy (see Chap. 151)].

Fibroblasts are derived from CD34-positive hematopoietic precursors that originate in the bone marrow and populate the skin during development and wound repair. The chief role of the skin fibroblast is to deposit collagen, elastin, and ground substance, the major constituents of the dermis and pannicular septae and the substrates to which the epidermis and skin appendages attach and integrate (see Chap. 61).

The stimuli that cause fibroblasts to overproduce mucin or collagen, or to proliferate or aberrantly immigrate into skin are varied. Infectious triggers, inflammatory states, diabetes mellitus, drugs, genetic mutations, and toxins as well as specific mediators such as eicosanoids, growth factors, cytokines, chemokines, immunoglobulins-paraproteins, and other circulating factors have been implicated, but the precise mechanisms that result in fibroblast pathology (fibropathy) are poorly characterized. Some of these stimuli may recruit bone marrow–derived fibroblast precursors to the skin; others may act directly on fibroblasts already residing in the skin.

This chapter discusses scleredema and scleromyxedema. Other diseases relevant to cutaneous fibrocytes are discussed separately in other chapters and are listed in Table 159-1.

SCLEREDEMA

Scleredema was described by Buschke in 1902[1] and is also designated as *scleredema of Buschke* or *scleredema adultorum*, although the latter is a misleading term because children or adolescents can develop the condition.

Epidemiology

Scleredema is rare, although the precise incidence and prevalence are unknown. Men and women are affected with

SCLEREDEMA AT A GLANCE



- Acute skin induration characterized by dermal mucinosis and mild sclerosis.
- Disease associations:
  - Post-infectious scleredema of youth.
  - Diabetes mellitus–associated scleredema of adulthood.
  - Paraproteinemia-associated scleredema.
  - In rare cases, hyperparathyroidism, connective tissue disease, human immunodeficiency virus infection.
- Histopathology: pan-dermal thickening with broad collagen bundles separated by mucin deposits, chiefly hyaluronate.
- Clinical course:
  - Post-infectious: usually resolves in 1 to 2 years.
  - Diabetes mellitus associated: may improve with better control of diabetes, but a prolonged course is expected.
- Treatment: therapy for underlying disease, ultraviolet A1 light; psoralen plus ultraviolet A light.

equal frequency. More than half of cases of scleredema occur in childhood or adolescence, most commonly after an upper respiratory tract infection.[2] Streptococcal infection is most commonly identified, but other infectious agents have also been implicated. Disease development in adulthood in association with adult-onset diabetes mellitus is the second most common presentation of scleredema. Uncommonly, scleredema occurs in association with paraproteinemia or multiple myeloma, and this association possibly is becoming more common as other causes diminish in frequency with better treatment and management of underlying disease.

Pathogenesis

Type I collagen and hyaluronate appear to be the major fibroblast products whose production is increased in scleredema-affected skin.[3–5] The precise mechanism(s) for increased collagen and glycosaminoglycan production in scleredema is not known. Stimulation of fibrocytes by immunoglobulin may be related to the pathogenesis of scleredema, particularly in cases associated with infectious agents or a paraproteinemia. Serum from a patient with scleredema associated with paraproteinemia was able to increase collagen production by cultured fibroblasts in vitro.[6] However, the factor(s) involved has not been elucidated. Other soluble circulating cytokines and small molecule mediators likely also play critical roles.

Clinical Findings

The clinical findings of scleredema are distinctive. An acute onset of non-pitting induration of neck, shoulders, and upper back skin may be followed by involvement of the face and arms. Characteristically, the affected skin appears smooth and waxy, with tense dermal induration and prominent follicular ostia, at times imparting a *peau d'orange* appearance (Fig. 159-1). In general, however, skin changes are better felt on palpation than seen. The skin of the upper trunk (especially the back) is a favored site for scleredema, but more widespread involvement may be observed. The affected and unaffected skin blend imperceptibly. Scleredema involving the esophagus, bone marrow, nerve, liver, or salivary glands has been described rarely.[7,8] Patients may report symptoms of restricted motion of joints, the tongue, or eyes, as well as muscular weakness or tenderness. However, investigations to identify internal organ involvement by scleredema are infrequently pursued.

Histopathology

Punch biopsy specimens of affected skin have a non-tapered (square) appearance on low-power microscopic examination. The proportion of dermis is very significantly increased in comparison to adjacent non-affected skin (Fig. 159-2A). There is a decreased number or higher placement of eccrine units. Fibroblasts are normal in number and morphology.

TABLE 159-1
Selected Fibroblast Disorders

	CHAPTER
Excessive collagen production by fibroblasts—*sclerosing disorders*	
• Scleroderma	158
• Morphea	62
• Sclerodermoid graft-versus-host disease	28
• Sclerodermoid porphyria cutanea tarda	132
• Eosinophilic fasciitis	35
• Sclerodermoid drug reactions (to bleomycin, epoxy resin, pentazocine)	35
• Lipodermatosclerosis (sclerosing panniculitis)	68
• Collagenoma	64
• Fibroblast hyperplasia—*fibrosing disorders*	
• Fibromatosis (Dupuytren contracture, Peyronie disease)	64
• Excessive collagen and mucin production by fibroblasts—*scleromucinoses*	
• Scleredema	159
• Fibroblast hyperplasia and excessive mucin production by fibroblasts—*fibromucinoses*	
• Lichen myxedematosus and scleromyxedema	159
• Nephrogenic fibrosing dermopathy	151
• Toxic oil syndrome	35
• Eosinophilia-myalgia syndrome	35
• Fibroblast hyperplasia and excessive collagen production by fibroblasts—*fibrosclerosing disorders*	
• Juvenile hyaline fibromatosis	64
• Gingival fibromatosis	74
• Excessive mucin production by fibroblasts—*mucinoses*	
• Pretibial myxedema	152
• Generalized myxedema	152
• Localized myxedema	152
• Reticular erythematous mucinosis and plaque-like mucinosis	147
• Connective tissue disease	156, 157, 158, 162
• Degos disease	172





▲ **FIGURE 159-1** Scleredema showing waxy, non-pitting induration of back skin.



The collagen bundles are slightly thickened and separated from each other by subtle deposits of mucin. Stains for mucin (Alcian blue, colloidal iron) are recommended to identify the mucin deposits (see Fig. 159-2B).

Prognosis and Clinical Course

Post-infectious scleredema usually abates in 1 to 2 years. Scleredema associated with adult-onset diabetes tends to be protracted, although some patients appear to improve with better glucose control. Gammopathy-associated scleredema is more chronic and can be resistant to many therapies.

Treatment

Antibiotics do not appear to affect the course of post-infectious scleredema. Treatment of the associated disease (e.g., improved glucose control or treatment of paraproteinemia) may lead to improvement. Ultraviolet A1 phototherapy has been reported effective in a few adult patients,[9,10] as has bath–psoralen plus ultraviolet A phototherapy.[11] Treatment with methotrexate did not provide benefit in a series of cases of scleredema. Scleredema has responded to local radiotherapy or electron-beam irradiation. Scleredema associated with monoclonal gammopathy has responded to extracorporeal photopheresis.

SCLEROMYXEDEMA

Historical Aspects

Lichen myxedematosus/scleromyxedema and scleredema are related conditions characterized by dermal fibroplasias and excess mucin production. Lichen myxedematosus presents with scattered small, whitish cream to red papules on the trunk and extremities, whereas confluent papules forming large areas of thickened, indurated skin typify scleromyxedema. A monoclonal paraproteinemia, usually of immunoglobulin G κ, is frequently associated with lichen myx-

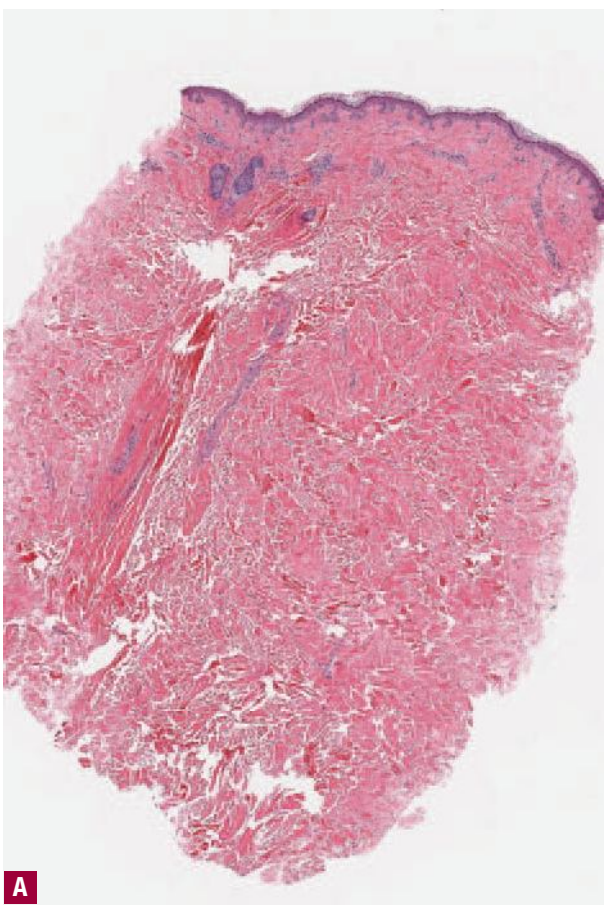

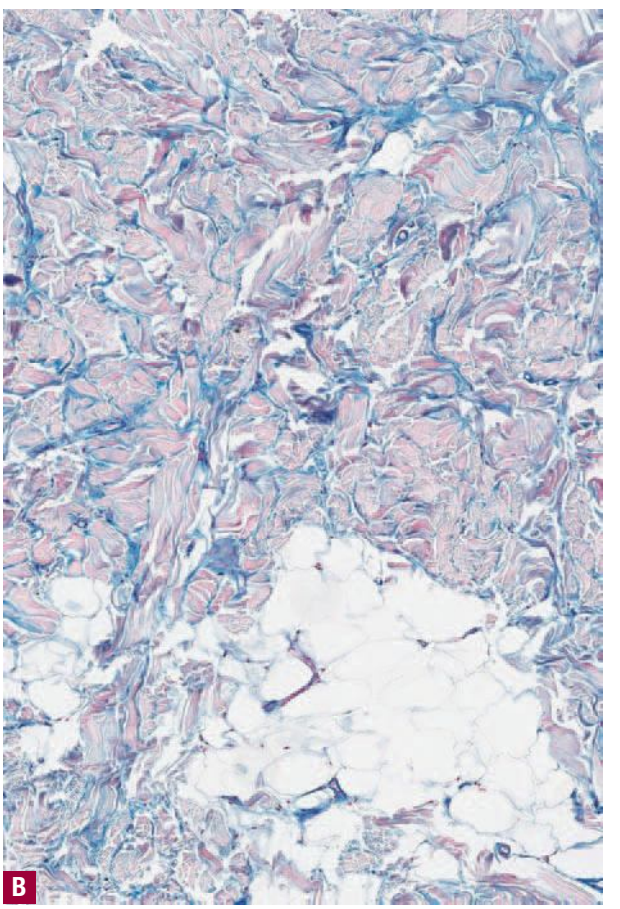

▲ **FIGURE 159-2** Photomicrograph of scleredema showing a mild increase in the thickness of dermal collagen bundles separated by clear spaces (**A**), and mucin deposition identified in clear spaces by Alcian blue stain (**B**).

SCLERO-MYXEDEMA AT A GLANCE



- Chronic, progressive condition characterized by dermal fibrosis and mucinosis with normal thyroid function.
- Usually associated with paraproteinemia.
- Clinical variants:
  - Generalized, confluent lichenoid eruption (scleromyxedema).
  - Discrete papular (rarely nodular) eruption on the trunk or extremities (lichen myxedematosus).
    - Papular mucinosis of infancy.
    - Papular mucinosis of adulthood.
    - Self-healing papular mucinosis.
    - Acral persistent papular mucinosis.
    - Nodular variant.
  - Localized or generalized lichenoid plaques (but distinct from plaque-like mucinosis/reticulated erythematous mucinosis).
  - Urticarial plaques.
- Histopathology: superficial to mid-dermal fibroplasia and mucinosis.
- Clinical course: chronic progressive course and poor outcome in generalized cases; localized and self-healing forms have a better prognosis.
- Treatment: correction of paraproteinemia through melphalan therapy, bone marrow transplantation.

edematosus and almost universally observed in scleromyxedema.

Epidemiology

Lichen myxedematosus/scleromyxedema constitutes a rare spectrum of disease that affects men and women with equal frequency and shows an onset of symptoms in mid to later life.

Pathogenesis

The pathogenesis of scleromyxedema is unknown. Most patients with scleromyxedema have a monoclonal gammopathy (paraproteinemia), usually of the immunoglobulin G κ type and defined as being of "undetermined significance." Excessive hyaluronate production and fibroblast proliferation are observed, but support for a direct effect of the monoclonal protein on fibroblasts is lacking.[15,16] Indirect mechanisms of development appear to include circulating cytokines, inflammatory mediators, and fibroblast precursor cell lineages that migrate from the blood, take up residence in the dermis and, in more extensive cases, in other tissues, and synthesize mucin.



▲ **FIGURE 159-3** Scleromyxedema showing marked nodular induration of facial skin with accentuated skinfolds.

Clinical Findings

Several distinct clinical presentations, and hence nosologic designations, have been recognized. Although there is considerable clinical overlap and patients may show progression from limited to widespread involvement, it is useful to distinguish localized from generalized disease as well as presentation with discrete papules from presentation with confluent plaques. The generalized lichenoid eruption consists of numerous minute (1- to 3-mm) papules scattered on the extremities and the trunk. Scleromyxedema presents with confluent lichenoid plaques. Individual lesions and plaques may exhibit marked erythema or hyperpigmentation. The face is involved in most cases, which leads to significant deformity (Fig. 159-3). The trunk and extremities are usually affected (Fig. 159-4A), and the result is often decreased flexibility and range of motion in the involved areas (see Fig. 159-4B).

A monoclonal paraproteinemia of undetermined significance, usually of immunoglobulin G κ, is identified in most patients. Paraproteinemia is less common in localized variants. Progression to multiple myeloma occurs rarely.

Muscle weakness, contractures, restrictive lung disease, upper airway involvement, pulmonary hypertension, esophageal dismotility, and neurologic disorders (seizures, motor impairment, carpal tunnel syndrome, depression, memory loss, aphasia, peripheral neuropathy, and psychosis) have been reported in association with scleromyxedema.[17] Thyroid function is normal.

Histopathology

Regardless of the clinical presentation, the histopathologic findings of lichen myxedematosus/scleromyxedema are identical and demonstrate superficial to mid-dermal mucin deposition with admixed fibroblast proliferation (Fig. 159-5). The disease spectrum of scleromyxedema is histologically distinct from other mucinoses as well as sclerosing and fibrosing conditions. Nephrogenic fibrosing dermopathy (see Chap. 151) shows close histologic resemblance to scleromyxedema. The pannicular septa are the focus for histologic distinction: they are always involved in nephrogenic fibrosing dermopathy and never involved in scleromyxedema. Moreover, scleromyxedema tends to be restricted to the upper half of the dermis, whereas nephrogenic fibrosing dermopathy becomes more prominent in the lower dermis then extends to the pannicular septa.

Prognosis and Clinical Course

Localized, self-healing variants are usually confined to the skin and self-limiting. However, prospective follow-up and caution is advised, because some cases fitting the criteria for localized disease have been associated with internal organ involvement or progression to more generalized disease (so-called *atypical papular mucinosis*). Scleromyxedema usually follows a chronic and progressive clinical course, and the outcome is poor. Respiratory failure, cerebral disease, and infection usually lead to a gradual decline and death.

Treatment

Melphalan has been used for decades to treat scleromyxedema with variable efficacy.[18–20] Other therapies directed



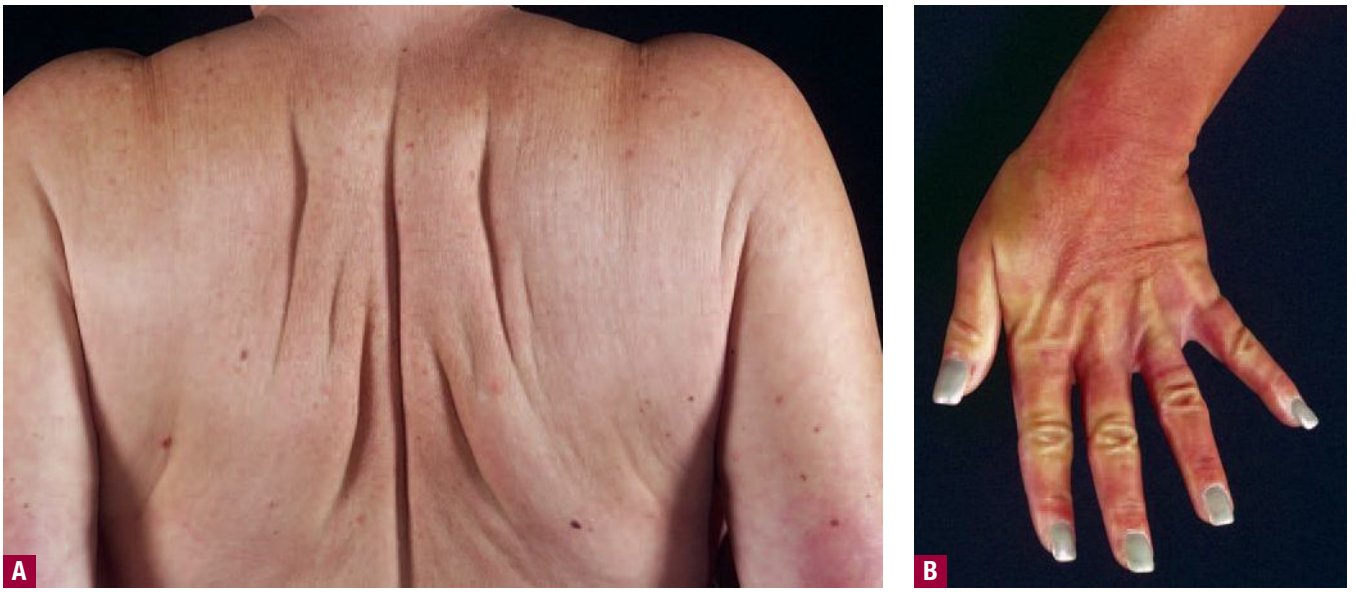

▲ **FIGURE 159-4** Scleromyxedema. **A.** Thickened, bound-down skin of the back. **B.** Confluent lichenoid papules and indurated skin of the hand and wrist.

toward quantitatively reducing or ameliorating the effects of the paraproteinemia have shown variable results. Agents or therapies with reported efficacy include glucocorticoids,[21] intravenous immunoglobulin,[22] thalidomide,[23] interferon-α,[24] retinoids, psoralen plus ultraviolet light,[25] electron-beam radiation, plasmapheresis, and extracorporeal photopheresis.[21–26] Autologous peripheral blood stem cell transplantation has resulted in dramatic remission of scleromyxedema in a number of patients with severe disease.[27,28]

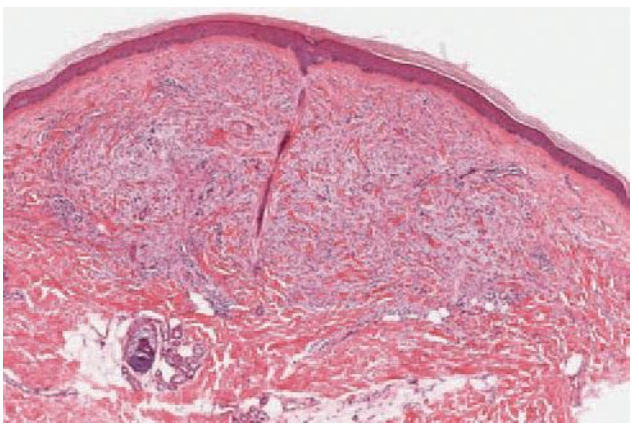

▲ **FIGURE 159-5** Scleromyxedema showing superficial to mid-dermal fibroplasias and increased mucin deposits.

KEY REFERENCES

The full reference list for all chapters is available at www.digm7.com.

3. Oikarinen A et al: Scleredema and paraproteinemia. Enhanced collagen production and elevated type I procollagen messenger RNA level in fibroblasts grown from cultures from the fibrotic skin of a patient. *Arch Dermatol* **123**:226, 1987
7. Wright RA, Bernie H: Scleredema adultorum of Buschke with upper esophageal involvement. *Am J Gastroenterol* **77**:9, 1982
15. Harper RA, Rispler J: Lichen myxedematosus serum stimulates skin fibroblast proliferation. *Science* **199**:545, 1978
18. Feldman P et al: Scleromyxedema. A dramatic response to melphalan. *Arch Dermatol* **99**:51, 1969
21. Rayson D et al: Scleromyxedema: A complete response to prednisone. *Mayo Clin Proc* **74**:481, 1999
22. Lister RK et al: Scleromyxedema: Response to high-dose intravenous immunoglobulin (hdIVIg). *J Am Acad Dermatol* **43**:403, 2000
27. Lacy MQ et al: Successful treatment of scleromyxedema with autologous peripheral blood stem cell transplantation. *Arch Dermatol* **141**:1277, 2005

CHAPTER 160

Relapsing Polychondritis

Camille Frances

RELAPSING POLYCHONDRITIS AT A GLANCE





- Relapsing polychondritis is a rare multisystem autoimmune disease with both autoantibodies and cellular immune reactions to different cartilage proteins.
- More than 30 percent of patients have an associated disease, mainly of autoimmune or hematologic origin.
- Recurrent episodes of chondritis lead to progressive destruction of cartilaginous structures.
- Other proteoglycan-rich structures such as eyes, blood vessels, or inner ear may be affected.
- Dermatologic manifestations occur frequently, especially in association with myelodysplasia.

EPIDEMIOLOGY

The incidence of relapsing polychondritis (RP) has been estimated to be 3.5 per 1 million in Rochester, Minnesota.[1] The peak age for disease onset is the fifth decade; however, development of the disease may occur in young children and in the elderly.[2] The male-female ratio has been estimated to be from 1.1:1.0 to 1.3:1.0.[3] Although most cases have been reported in Caucasians, there is no evidence supporting a role for ethnic or geographic factors.

ETIOLOGY AND PATHOGENESIS

Several lines of evidence have been accumulated that suggested the role of autoimmunity in RP. More than 30 percent of patients have an associated disease, mainly of autoimmune origin.

The role of the humoral immune response was based on the presence of antibodies to collagen type II in the acute phase of RP. Antibody titers seemed to correlate with the severity of symptoms. Other antibodies were also detected in patients with RP: antibodies to type IX and type XI collagen, minor collagens which represent 5 percent to 10 percent of cartilage collagens, antibodies to matrilin-1, an extracellular matrix protein, predominantly expressed in upper respiratory tract cartilage; and antibodies to cartilage oligomeric matrix protein, another cartilage protein. Several animal models have been described in which immunization with these various cartilage proteins induced a variety of chondritis manifestations that mimic those seen in patients.[4] A role for immune complexes and subsequent activation of the complement system is suggested by examination of tissue lesions, which usually shows the presence of granular deposits of immunoglobulins and the C3 component of complement associated with $CD4^+$ lymphocytes and plasma cells. A role for T cells in RP pathogenesis, although less well studied, has also been demonstrated in patients and in animal models with specificity against the same cartilage proteins. T-cell clones isolated from a RP patient were found to be specific for a peptide corresponding to residues 261 to 273 of the type II collagen and were restricted to either the DRBI*0101 or the DRBI*0401 allele.[5] A significant near twofold increase in DR4 antigen frequency was found in RP patients as compared to that in healthy controls, but the genotyping of DR-4 positive patients and controls did not show predominance of any DR4 sub-type. Genetic susceptibility was also confirmed by animal models.

CLINICAL FINDINGS

Disease onset is usually sudden with characteristic chondritis, with arthritis or ocular inflammation occurring less frequently. Non-specific initial symptoms, such as fever or weight loss, are rare.

Attacks of chondritis usually occur in a relapsing and remitting pattern. Inflammatory episodes generally last a few days or weeks and may subside spontaneously or with treatment; recurrences after weeks or months occur and subsequently result in cartilage destruction. Auricular chondritis is the most frequent sign, occurring in 85 percent of patients, causing pain, redness, and swelling of the cartilaginous portion of the pinna, sparing the non-cartilaginous lobe (Fig. 160-1). Biopsy of the auricular cartilage is not needed to make a correct diagnosis. After several attacks, the pinna may become soft and floppy, looking like a cauliflower (Fig. 160-2); sometimes it is stiff due to calcifications. Nasal chondritis (65 percent) is less inflammatory, presenting with nasal pain, stuffiness, rhinorrhea, and, sometimes, epistaxis. The characteristic saddle-nose deformity (Fig. 160-3) may appear with or without previous clinical inflammatory episodes.



▲ **FIGURE 160-1** Relapsing polychondritis. Painful inflammation of the cartilaginous portion of ear.

OTHER ORGAN INVOLVEMENT

Respiratory tract chondritis, though uncommon at presentation, occurs in up to 50 percent of patients, and may be lethal. The respiratory involvement results in complaints of hoarseness, nonproductive persistent cough, dyspnea, and wheezing. Complications include



▲ **FIGURE 160-2** Relapsing polychondritis. Soft and floppy ear with a "cauliflower" appearance.



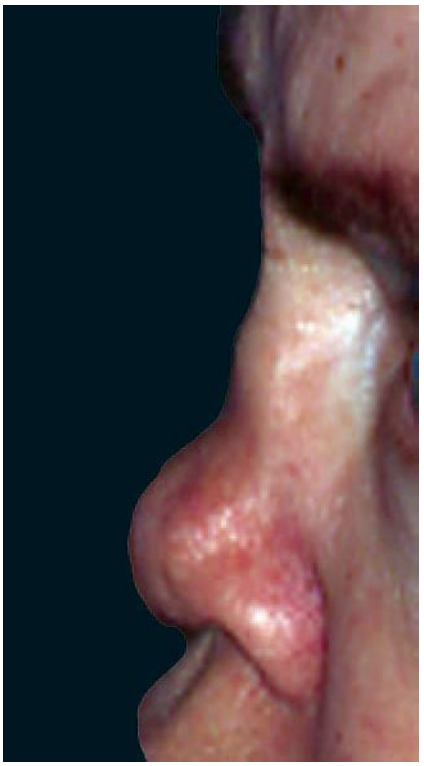

▲ **FIGURE 160-3** Relapsing polychondritis. Saddle nose deformity.

upper airway collapse, obstructive respiratory insufficiency, and secondary infections. Costochondritis (35 percent) causes parietal pains that may also compromise respiration.

Joint pain is a common presenting feature in RP (30 percent). Large and small joints of the peripheral or axial skeleton may be affected (> 70 percent). Arthritis is intermittent, migratory, asymmetric, seronegative, and usually nonerosive.

Nearly 60 percent of patients develop ocular inflammation. Episcleritis and scleritis (see eFig. 160-3.1 in on-line edition) are the most common manifestations, followed by keratoconjunctivitis sicca, iritis, retinopathy, keratitis. Rarely corneal perforation, retinal vasculitis, and optic neuritis lead to blindness.

Conductive hearing loss is secondary to stenosis of the external auditory canal, eustachian tube chondritis, or serous otitis media, while perception hearing loss may occur as a consequence of sensorineural involvement. Symptoms of vestibular dysfunction, such as dizziness, ataxia, nausea, and vomiting, are usually acute and improve with time.

The spectrum of cardiovascular manifestations is wide, including different cardiac tissues (aortic and/or mitral regurgitation, impairment of the conduction system, pericarditis) and all types of vessels (thoracic and abdominal aortitis leading to aneurysms, Takayasu-like aortic arch syndrome, medium and large vessels vasculitis, leukocytoclastic vasculitis, thrombophlebitis). Lesions are inflammatory and/or thrombotic. Some, but not all, thrombotic manifestations have been linked to anti-phospholipid syndrome. Large vessel vasculitis tends to occur after several years of smoldering and often, occult disease, despite immunosuppressive therapy.

Dermatologic manifestations are sometimes the presenting feature of RP (12 percent), and ultimately become apparent in more than one-third of patients.[6] They are non-specific including nodules on the limbs (see eFig. 160-3.2 in on-line edition), purpura (see eFig. 160-3.3 in on-line edition), oral or complex aphthosis (see eFig. 160-3.4 in on-line edition), papules, sterile pustules (see eFig. 160-3.5 in on-line edition), superficial phlebitis, livedo reticularis, ulcerations on the limbs, and distal necrosis (see eFig. 160-3.6 in on-line edition). They appear concomitantly or in the absence of attacks of chondritis. Pathologic features include inflammatory or thrombotic vascular lesions, neutrophil infiltrates as in neutrophilic dermatoses, and inflammation of the dermis or subcutis. Patients with and without dermatologic manifestations have similar clinical manifestations of RP. However, the frequency of dermatologic manifestations (> 90 percent), age of onset of chondritis, and male-female ratio seems higher when RP is associated with myelodysplasia.[6]

LABORATORY FINDINGS

Histopathology

Histopathology of affected cartilage shows perichondrial inflammation and the loss of the normal cartilaginous basophilia.

Other Laboratory Tests

Laboratory findings in RP are nonspecific, consistent with acute or chronic inflammation. Urinalysis may be abnormal in the presence of renal involvement (mesangial expansion, immunoglobulin A nephropathy, tubulointerstitial nephritis, or necrotizing glomerulonephritis).

Pulmonary function tests, including inspiratory and expiratory flow volume curves, should be performed systematically to detect occult pulmonary involvement, which may be confirmed by computed tomography of the respiratory tract. Three-dimensional or spiral magnetic resonance imaging may provide better resolution. Although not routinely available, autoantibodies to type II, IX, and XI collagen and to matrilin I can be found in patients with RP. Urinary type II collagen neoepitope measurement may be a useful tool to follow the evolution of disease.[7]

Box 160-1

Empirical Diagnostic Criteria[a]

- Bilateral auricular chondritis
- Non-erosive seronegative inflammatory polyarthritis
- Nasal chondritis
- Ocular inflammation
- Respiratory chondritis
- Audiovestibular damage

[a]For the diagnosis of relapsing polychondritis, patients must have one of the following: at least three of the above clinical criteria, one or more of the above clinical criteria and biopsy confirmation of cartilage inflammation, or chondritis at two or more separate anatomic locations with response to steroids and/or dapsone.
Data from Michet CJ et al: Relapsing polychondritis—Survival and predictive role of early disease manifestations. *Ann Intern Med* **104**:74, 1986.

DIAGNOSIS (Box 160-1)

DIFFERENTIAL DIAGNOSIS (Box 160-2)

PROGNOSIS AND CLINICAL COURSE

The clinical course of RP is progressive with intermittent flares. The number of different organs involved, the severity of involvement, and the response to treatment are unpredictable. Common causes of death are respiratory or cardiovascular complications and secondary infections. Patients have an increased risk of developing lethal myelodysplastic malignancies.

TREATMENT

Because of the highly variable course of RP, individualized therapy is the key to optimum management. General therapeutic guidelines are based on retrospective analyses of series of patients or isolated case reports. Nonsteroidal anti-inflammatory drugs, colchicine, or dapsone may be useful for patients with mild auricular or nasal chondritis, arthralgia, or mild arthritis. More serious mani-

Box 160-2

Differential Diagnosis of Relapsing Polychondritis

AURICULAR CHONDRITIS
- Bacterial cellulitis
- Leishmaniasis
- Leprosy
- Traumatisms (rugbyman, boxer)

NASAL CHONDRITIS
- Sinusitis
- Infectious perichondritis
- Wegener granulomatosis
- Congenital syphilis

MAIN DISEASES ASSOCIATED WITH RELAPSING POLYCHONDRITIS AND/OR WITH CLINICALLY SIMILAR MANIFESTATIONS
- Autoimmune diseases
  - Rheumatoid arthritis
  - Systemic lupus erythematosus
  - Sjögren syndrome
  - Mixed connective tissue disease
  - Thyroid autoimmune disease
  - Diabetes mellitus
- Hematologic disorders
  - Myelodysplastic syndromes
  - Immunoglobulin A myeloma
  - Others
- Skin diseases
  - Vitiligo
  - Psoriasis
  - Alopecia areata
  - Lichen planus
- Vasculitides
  - Leukocytoclastic
  - Wegener granulomatosis
  - Polyarteritis nodosa
  - Microscopic polyangiitis
  - Churg-Strauss syndrome
  - Behçet disease
  - MAGIC syndrome
  - Takayasu arteritis
- Intestinal diseases
  - Crohn disease
  - Ulcerative colitis
- Others
  - Ankylosing spondylitis
  - Reiter syndrome

MAGIC = mouth and genital ulcers with inflamed cartilage.

festations require oral corticosteroids in doses of 0.3 to 1.0 mg/kg of body weight according to the severity of disease. Pulse intravenous steroids are prescribed for acute airway obstruction, and/or before surgical intervention (tracheostomy, aortic aneurysm repair, cardiac valve replacement). Long-term corticosteroids decrease the frequency and severity of recurrences although it does not prevent vital organ involvement. Many kinds of immunosuppressants have been used with some success as disease-modifying and steroid-sparing agents. Methotrexate, azathioprine, cyclophosphamide, and cyclosporine A are most commonly used. The beneficial effects of new biologic therapies such as anti-CD4 monoclonal antibodies, antitumor necrosis factor agents, and of autologous stem cell transplantation have been reported in isolated cases. One child was successfully treated with daily oral fetal bovine type II collagen.

REFERENCES

1. Kent PD et al: Relapsing polychondritis. *Curr Opin Rheumatol* **16**:56, 2004
2. Michet CJ et al: Relapsing polychondritis—Survival and predictive role of early disease manifestations. *Ann Intern Med* **104**:74, 1986
3. Letko E et al: Relapsing polychondritis: A clinical review. *Semin Arthritis Rheum* **31**:384, 2002
4. Hansson AS et al: Cartilage-specific autoimmunity in animal models and clinical aspects in patients—focus on relapsing polychondritis. *Arthritis Res* **4**:296, 2002
5. Buckner JH et al: Identification of type II collagen peptide 261-273-specific T-cell clones in a patient with relapsing polychondritis. *Arthritis Rheum* **46**: 238, 2002
6. Frances C et al: Dermatologic manifestations of relapsing polychondritis. *Medicine (Baltimore)* **80**:173, 2001
7. Kraus VB et al: Urinary type II collagen neoepitope as an outcome measure for relapsing polychondritis. *Arthritis Rheum* **48**:2942, 2003



CHAPTER 161

Rheumatoid Arthritis, Rheumatic Fever, and Gout

Christina L. Haverstock
Joseph L. Jorizzo

This chapter discusses common rheumatologic diseases that have predominantly musculoskeletal presentations; however, all of these conditions have cutaneous manifestations.

RHEUMATOID ARTHRITIS

Rheumatoid arthritis (RA) is a systemic inflammatory autoimmune disease that is characterized by a debilitating chronic, symmetric polyarthritis with significant extra-articular manifestations, which include rheumatoid nodules, pyoderma gangrenosum, granulomatous dermatitis, vasculitis, and internal organ involvement. The disease process is often progressive, resulting in limitation of joint function. Ultimately there may be a resultant decline in functional status, possibly leading to premature death. Permanent remission is unusual.

Epidemiology

Approximately 1 percent of the adult population in North America and Northern Europe are affected with RA, with great variation in prevalence in other parts of the world.[1] Approximately 70 percent of patients follow a chronic disease course with exacerbations and remissions, 25 percent have intermittent disease with brief attacks of inflammation followed by remissions, and approximately 5 percent have an aggressive, malignant form with multiple extra-articular manifestations.[2] RA is more common in females than males, ratio from 2:1 to 3:1, and has a peak onset at 50 years of age.[1]

Etiology and Pathogenesis

The exact etiology of RA remains unknown. The initial onset of joint symptoms is likely multifactorial. Genetics plays at least some role in the development, severity, and outcome of the disease in certain patients.[3] Furthermore, an association between extra-articular disease and HLA-DR1 and -DR4 genes has been noted in some populations.[4]

Mechanical stress on joints may initiate an inflammatory response creating an imbalance between the rapid response to trauma and the need to pro-

RHEUMATOID ARTHRITIS AT A GLANCE



- Affects roughly 1 percent of the world population.
- Chronic disfiguring inflammatory condition.
- Genetics and environment play a role in etiology.
- Symmetric arthritis of the proximal interphalangeal and metacarpalphalangeal joints.
- Skin findings include: Granulomatous dermatitis, vasculitis, rheumatoid nodules, pyoderma gangrenosum, and Bywaters lesions.
- Treatment based on severity of disease.



TABLE 161-1
1987 American College of Rheumatology Revised Criteria for the Classification of Rheumatoid Arthritis (Modified)

CRITERION	DEFINITION
Morning stiffness	Morning stiffness in and around the joints, lasting at least 1 h before maximal improvement.
Arthritis of three or more joint areas	At least three joint areas simultaneously afflicted with soft-tissue swelling or joint fluid observed by a physician. The possible areas are (right or left): PIP, MCP, wrist, elbow, knee, ankle, and MTP joints.
Arthritis of hand joints	At least one area swollen in a wrist, MCP, or PIP joint.
Symmetric arthritis	Simultaneous involvement of the same joint areas on both sides of the body (bilateral involvement of PIP, MCP, or MTP acceptable without perfect symmetry).
Rheumatoid nodules	Subcutaneous nodules over bony prominences or extensor surfaces or in juxta-articular regions (observed by a physician).
Serum rheumatoid factor	Abnormal amount of serum rheumatoid factor by any method while the result has been positive in 5% of control subjects.
Radiographic changes	Erosions or unequivocal bony decalcification localized in or most marked adjacent to the involved joints.

MCP, metacarpophalangeal; MTP, metatarsophalangeal; PIP, proximal interphalangeal.
From Arnett FC et al: The American Rheumatism Association 1987 revised criteria for the classification of rheumatoid arthritis. *Arthritis Rheum* **31**:315, 1988.

tect self from damage. Patients with seropositive RA (positive rheumatoid factor) have circulating and tissue-bound immune complexes. B cells produce autoantibodies in some RA patients. After binding to antigen, these autoantibodies result in complement fixation and recruitment of polymorphonuclear leukocytes, which result in joint destruction. Possible antigens in RA include heat shock proteins, collagen, and cyclic citrullinated peptides.[5]

Patients with seronegative RA (negative rheumatoid factor) may not create autoantibodies, but other immune mechanisms are involved. This theory led to the recognition that T cells are important players in the etiology of this disease. In the SKG mouse model, autoreactive T cells are preferentially selected, leading to inflammatory arthritis similar to RA. T cells also activate other cells via cytokines, including osteoclasts, which play a major role in the bone resorption seen in RA. Effector cytokines of the T cell include interferon-γ, interleukin 1, interleukin 17, and tumor necrosis factor (TNF)-α, many of which have been, or are being, used as therapeutic targets to treat RA.[2,5]

Lastly, joints have unique anatomic and physiologic qualities that render them targets for immune and inflammatory assault. Cartilage is subject to repetitive mechanical stress, retains antigens and pro-inflammatory cytokines, and has a limited capacity for regeneration. Once proteolytic enzymes cause erosions, narrowing of the joint space, and mechanical instability, rheumatoid inflammation may become self-sustaining.[6]

Clinical Features

RA often begins with general constitutional symptoms such as fatigue, anorexia, vague musculoskeletal complaints, and generalized weakness. It may be weeks or months before the characteristic synovitis presents. It is in these early stages that definite diagnosis is most difficult, despite a thorough patient evaluation. However, early diagnosis and treatment are essential because most of joint damage is thought to occur early in the disease process. The American College of Rheumatology has guidelines for the diagnosis of RA (Table 161-1).[7] For a patient to be diagnosed with RA, four of the seven criteria must be present, and the first four criteria listed must be present for at least 6 weeks. Extra-articular manifestations may help to delineate the disease process early and may signify a more serious disease process requiring the initiation of aggressive therapy.[8,9]

ARTICULAR MANIFESTATIONS The articular manifestations of RA relate to an inflammatory synovitis that can affect the synovial lining of joints, tendons, and bursae. Synovial inflammation usually results in warmth but not erythema of the affected area. There is significant pain in association with stretching of the joint capsule. Hand and foot involvement forms the basis of the disease in most patients. Although the initial manifestations in the hand may be asymmetric, the clinical course subsequently takes on a symmetric and diffuse pattern. There is characteristic involvement of the proximal interphalangeal (PIP) and metacarpophalangeal joints with sparing of the distal interphalangeal (DIP) joints. The pattern of joint involvement is highly suggestive of the diagnosis.

Chronic inflammation may result in irreversible structural damage of the joint, including cartilage destruction and bony erosion. Late structural deformities may result from soft-tissue contractures or from bony ankylosis. Characteristic deformities include radial deviation of the hand with ulnar deviation of the digits, the "swan neck" deformity from hyperextension of the PIP joint and compensatory flexion of the DIP joint, and the boutonnière deformity from flexion contracture of the PIP joint and extension of the DIP joint. Similar structural deformities can occur in the feet, and all can be debilitating. Involvement of the thoracic and lumbar spine in RA is exceptional. Although the shoulder joint is often affected, it is soft-tissue structures, which include the ro-

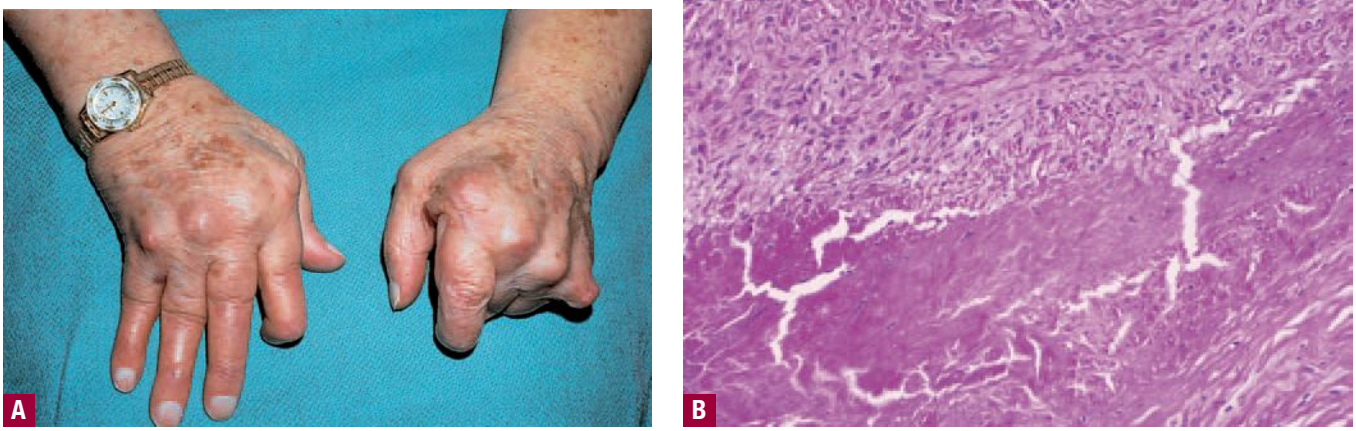

▲ **FIGURE 161-1** Rheumatoid nodules. **A.** Severely affected joints of a patient with rheumatoid arthritis with overlying rheumatoid nodules. **B.** Histopathologically, rheumatoid nodules are palisaded granulomas in the deep reticular dermis surrounding degenerated collagen.



tator cuff tendons and muscles and the subacromial bursa, that are usually involved in the patient's symptomatology.

DERMATOLOGIC MANIFESTATIONS Extra-articular manifestations occur in more aggressive or extensive forms of RA.[8,9] The most common dermatologic finding in RA is the rheumatoid nodule. The classic rheumatoid nodule is a subcutaneous nodule that occurs in approximately one-fourth of patients with RA (Fig. 161-1A). More than 90 percent of patients with rheumatoid nodules have seropositive RA. The usual location is over pressure points such as the olecranon, the extensor surface of the forearms, and the Achilles tendon; but they have been described in almost every location, including viscera.[9] The main histologic findings (see Fig. 161-1B) are palisaded granulomas in the deep dermis or subcutaneous tissues with fibrinoid degeneration of collagen, a multitude of neutrophils, and neutrophilic dust, with surrounding fibrosis and proliferation of vessels. The main differential diagnoses histopathologically include subcutaneous granuloma annulare, necrobiosis lipoidica, foreign body or infectious granulomatous reaction, and epithelioid sarcoid.[10]

Though rheumatoid nodules are benign, they can lead to complications, including ulceration, infection, joint effusion (rheumatoid chyliform bursitis), and fistulas (fistulous rheumatism). All conditions may lead to the need for surgical excision.[9]

Rheumatoid vasculitis has an estimated annual incidence of less than 1 percent, most often affects patients with seropositive disease, and is believed to affect 1 in 8 males with RA, versus 1 in 38 females.[11] Small- to medium-sized vessels are primarily affected, often with associated peripheral neuropathy (including motor), digital gangrene, nail fold infarcts, and palpable purpura (see Chap. 164).[9,12] Some patients may have nail fold telangiectasias, with minute digital ulcerations or petechiae and digital pulp papules (Bywaters lesions) (Fig. 161-2). These papules are a manifestation of mild vasculitis and typically occur without systemic signs of vasculitis. Histopathology of skin biopsy specimens usually shows leukocytoclastic vasculitis with neutrophilic infiltration of the vessel wall, fibrinoid necrosis, and hemorrhage without palisaded granulomatous reaction.[10] Cutaneous small vessel vasculitis mostly involves postcapillary venules and may affect arterioles and larger vessels of the viscera, heart, and central nervous system. The spectrum of clinical lesions reported in rheumatoid vasculitis is wide and varies with the size and location of the vessels involved and with the extent of the disease (see Chaps. 164 and 165). Unfortunately, the presence of vasculitis, especially at the onset of the disease, portends a poor outcome.[13] Patients with evidence of vasculitis affecting the skin should be started on aggressive therapy and followed closely for other organ involvement.[6]

Rheumatoid vasculitis can present as lower-extremity ulcers; however, pyoderma gangrenosum (see Chap. 32) should be suspected if deep liquefying ulcers with a characteristic purple, undermined border occur in patients with RA. The ulcers may occur at any site but are most common on the lower extremities and abdomen. Pyoderma gangrenosum occurs more frequently and more severely in females and may take years to heal. Leg ulcers may also appear in patients with Felty syndrome, a combination of chronic RA, hypersplenism, and leukopenia (Fig. 161-3).[9]

Rheumatoid neutrophilic dermatosis is a very rare cutaneous manifestation in patients with severe RA. First described by Ackerman in 1978, these lesions are



▲ **FIGURE 161-2** Bywaters lesions. Note the purpuric papule on the dorsal finger.





▲ **FIGURE 161-3** Felty syndrome. A refractory ulcer on the foot of a patient with rheumatoid arthritis and hypersplenism.

usually chronic, erythematous, and urticaria-like plaques and papules that are sharply marginated (Fig. 161-4A). Histopathologically, these lesions have a dense infiltrate of neutrophils without leukocytoclasia, in the setting of a mixed infiltrate and papillary edema (see Fig. 161-4B).[10] It may be difficult to differentiate rheumatoid neutrophilic dermatosis from acute febrile neutrophilic dermatosis (Sweet syndrome) (see Chap. 31).

Other vasculitis syndromes, such as erythema elevatum diutinum (see Chap. 166) and livedo vasculitis (segmental hyalinizing vasculitis), have also been described in patients with RA. Skin manifestations such as palmar erythema, erythromelalgia, autoimmune bullous diseases such as epidermolysis bullosa acquisita (see Chap. 58), yellow nail syndrome (see Chap. 87), erythema multiforme (see Chap. 38), erythema nodosum (see Chap. 68), and urticaria (see Chap. 37) also have been reported in patients with RA.[8]

NON-DERMATOLOGIC EXTRA-ARTICULAR MANIFESTATIONS In addition to systemic vasculitis, which can affect numerous organ systems, there are multiple non-dermatologic extra-articular manifestations of RA. Table 161-2 lists the more common ones.

TABLE 161-2
Non-Dermatologic Extra-Articular Manifestations of Rheumatoid Arthritis

TYPE	MANIFESTATIONS
Ocular	Keratoconjunctivitis sicca, scleritis, episcleritis, scleromalacia
Renal	Amyloidosis and vasculitis
Hematologic	Anemia, thrombocytosis, lymphadenopathy, Felty syndrome
Neurologic	Entrapment neuropathy, cervical myelopathy, mononeuritis multiplex (vasculitis), peripheral neuropathy
Lung	Pleural effusions, pulmonary fibrosis, bronchiolitis obliterans, rheumatoid nodules, vasculitis
Cardiac	Pericarditis, premature atherosclerosis, vasculitis, nodules, aortic root dilatation

Differential Diagnosis (Box 161-1)

Laboratory Findings

There is no one specific histologic, radiographic, or laboratory test that conclusively permits the diagnosis of RA. Rheumatoid factor, an autoantibody that reacts with the Fc portion of immunoglobulin G (IgG), is found in sera of 85 percent of patients with RA. Rheumatoid factor should not be used as a definitive screening tool because it can be found in other disease processes (sarcoidosis, liver diseases, pulmonary fibrotic processes, and cryoglobulinemia). It is also found in approximately 5 percent of the unaffected population.[12] A false-positive rheumatoid factor can be caused by many factors, including chronic bacterial infections such as infective endocarditis, tuberculosis, and Lyme disease, as well as by viral diseases such as rubella and infectious mononucleosis.[6]

Treatment

Because the exact cause of RA is unknown, treatment has been directed against various components of the in-



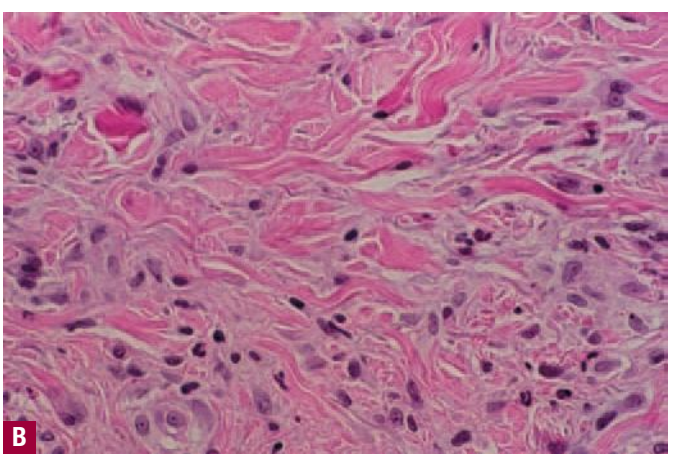

▲ **FIGURE 161-4** Rheumatoid neutrophilic dermatosis. **A.** Lesions are erythematous urticarial papules often coalescing into plaques in a patient with rheumatoid arthritis. **B.** Histopathologically, there is an interstitial mixed dermal infiltrate predominated by neutrophils without leukocytoclasis. This is often accompanied by papillary edema.

Box 161-1

Differential Diagnosis of Rheumatoid Nodules

Consider

- Subcutaneous granuloma annulare
- Foreign body granuloma
- Infectious granuloma
- Sarcoid granuloma
- Myxoid cyst
- Traumatic epidermal cyst
- Xanthoma

Rule Out

- Epithelioid sarcoma
- Fibromatous nodules in Lyme borreliosis

flammatory process. No single therapy is the treatment of choice. In the past, most patients with early disease were started on nonsteroidal anti-inflammatory drugs until joint erosions were evident.

These medications are useful to alleviate symptoms. They do not alter disease progression.

Furthermore, new understanding of disease mechanism and the chronic disabling nature of RA has resulted in a shift to earlier use of disease-modifying anti-rheumatic drugs (DMARDs). New guidelines released by the American College of Rheumatology in 2002[13] advocate this switch.[14] DMARDs decrease inflammation (confirmed by a reduction in acute phase reactants), reduce or prevent joint damage, and modify the disease process.[2] The use of DMARDs is now recommended early in the disease course, when joint damage has already occurred or is imminent. Multiple medications fall into this category (Table 161-3). They may be used alone or in combination, but their use may be limited by loss of efficacy or systemic toxicity. Medications are often used in combination, but the decision about which drug to use is often individualized and determined by the clinical severity and loss of function and resultant disability, along with concerns about the safety profile of each given patient.

TABLE 161-3
Disease-Modifying Anti-Rheumatic Drugs

- Methotrexate
- Hydroxychloroquine
- Gold salts
- Sulfasalazine
- Azathioprine
- Cyclosporine
- Cyclophosphamide
- Leflunomide
- D-Penicillamine

Systemic glucocorticoids are potent anti-inflammatory agents but have a serious side-effect profile when used in large doses over long periods of time. They are not a good option alone for RA, but are sometimes used in a low dose with other DMARDs. Methotrexate has been used as a very effective DMARD for many years.

The newest additions to the anti-rheumatic armamentarium are the biologic response modifiers, which act to inhibit the pro-inflammatory cytokines that play a role in RA. The best known commercially available members of this category are the anti–TNF-α agents. TNF-α is a pro-inflammatory agent released by macrophages and T cells contributing to synovitis and joint destruction.

There are three anti–TNF-α drugs currently approved by the U.S. Food and Drug Administration for the treatment of RA: etanercept, infliximab, and adalimumab. Etanercept is a recombinant human TNF dimeric receptor fusion protein consisting of the ligand-binding portion of the human 75-kd TNF receptor linked to the Fc portion of human IgG1. This treatment is given as a subcutaneous injection twice per week. Infliximab is a chimeric (mouse/human) IgG1 monoclonal antibody to TNF-α. It is given intravenously every 6 to 8 weeks. Last, adalimumab, the newest of these agents, is a human IgG1 monoclonal antibody that binds membrane bound and soluble TNF-α.[15] Etanercept, infliximab, and adalimumab render TNF-α biologically inactive, thereby significantly decreasing the synovitis and retarding the progression of joint destruction.[16]

There are a number of limitations to the use of biologic response modifiers. They are expensive, ranging between 18,000 to 30,000 dollars per year, and both etanercept and adalimumab require the patient to self-administer injections. Not all patients are willing to do this. Infliximab, on the other hand, is an infusion, which inherently requires that the patient have more time from work/home and lends itself to the possibility of infusion reactions. In addition, there needs to be an infusion center nearby where the patient can receive therapy. Most patients receiving TNF-α blocking agents have failed therapy with one or a combination of the previously mentioned DMARDs. Inhibiting the normal host immune response has led to concern about re-activation of tuberculosis, increased susceptibility to other infections, and predisposition to the development of malignancy. The true risk of malignancy is difficult to establish because patients with RA are thought to have a higher incidence of lymphoid malignancy than the normal population and some have shown that the incidence of lymphomas may in fact be increased in patients taking anti–TNF-α drugs.[17] As with all medications, knowing your patient's medical history is the key to proper use of these medications. They should not be used in patients with concurrent serious infection or in those predisposed to serious infections (patients with poorly controlled diabetes). Extreme caution and consultation with the hematologist-oncologist should be used before prescribing these medications to patients with a recent history of malignancy.

In conclusion, the dermatologist and rheumatologist must function as a cohesive team in the treatment of patients with cutaneous manifestations of RA, which often present during phases of intense disease activity. Patients need their underlying rheumatic disease to be treated aggressively, but proven treatments for these associated dermatologic processes, such as pyoderma gangrenosum, cryoglobulins, vasculitis, and others, should not be forgotten. These specific treatment regimens are beyond the scope of this chapter.

RHEUMATIC FEVER

Acute rheumatic fever (ARF) is a delayed sequel to group A β-hemolytic streptococcal (GAS) infection of the oropharynx. It is an inflammatory disease that can affect the heart, joints, central nervous system, skin, and subcutaneous tissues. There are no specific diagnostic tests, rather it is a clinical diagnosis made on the basis of certain criteria. Treatment of the underlying infection leads to prevention of rheumatic fever.

Epidemiology

ARF is rare and most commonly occurs in children 5 to 15 years of age after clinically severe tonsillopharyngeal infections. However, it has been reported in patients of all ages and in those with asymptomatic disease. The incidence of rheumatic fever has dropped precipitously since the 1950s with widespread recognition of disease and treatment with penicillin. It has been nearly eradicated from the developed world but remains a serious health problem in developing countries.[2] The World Health Organization es-



timates that 15.6 million people worldwide are affected by rheumatic heart disease, and that 233,000 people die annually either from rheumatic heart disease or acute renal failure as a result of complicated GAS infection.[18]

Pathogenesis

The exact mechanism by which ARF results from an infection with group A streptococcal bacteria is unclear, but it is thought to be an exaggerated immune response to infection. Some strains of streptococcus are more likely to cause ARF than others. For instance, pharyngeal strains are much more likely to cause ARF than extrapharyngeal strains responsible for impetigo or cellulitis. Molecular mimicry has also been implicated in the etiology of ARF. M protein has structural similarity to cardiac myosin. Studies have demonstrated that rats immunized with streptococcal M protein develop myocarditis. Oddly, however, the morbidity and mortality of rheumatic fever results from valvular disease rather than acute carditis.[18] Familial clustering of disease, and the linkage of HLA-DR4 and -DR2 to ARF in Caucasian and African American patients demonstrates that host properties also affect the susceptibility of individual patients in the development of disease.[2]

Clinical Features

The clinical features of ARF vary widely and are largely outlined in the Jones criteria used to aid in diagnosis of the disease. The Jones criteria, updated in 1992,[19] emphasize five characteristic major manifestations: polyarthritis, carditis, chorea, subcutaneous nodules, and erythema marginatum (Box 161-2). Non-specific signs of systemic inflammation are considered minor criteria and include arthralgia, fever, elevated acute phase reactants, and a prolonged P-R interval by echocardiogram.

Diagnosis is based on the presence of two major criteria and one minor criteria plus evidence of preceding infection with group A streptococcus. If, however, chorea and carditis are present then demonstration of antecedent strep infection is not required to make the diagnosis.[19]

Rheumatic carditis usually involves the endocardium, myocardium, and pericardium and almost always is associated with a murmur, either mitral or aortic regurgitation.[18] Carditis, if present, usually presents in the first 3 weeks of the illness. There has been much debate about the use of echocardiography to aid in diagnosis of rheumatic heart disease without clinical evidence of a murmur; however, thus far its routine use has not been advocated. Its use has been accepted in patients with polyarthritis where other diagnostic criteria have not yet been met and in indistinguishable heart murmurs.[18]

Migratory polyarthritis can affect any joint but most often involves the large joints. Early administration of anti-inflammatory medications does mitigate the arthritis and may therefore mask it. In addition, post-streptococcal reactive arthritis exists and can confound the picture.[18] The diagnosis of chorea is based entirely on clinical signs, which include fleeting local muscular weakness, emotional lability, personality changes, and erratic, jerky, purposeless movements. Chorea does not occur in adult men.

The dermatologic manifestations of ARF are characteristic but rare. Subcutaneous nodules are small, painless, and localized over bony prominences and in tendon sheaths. Typically, they last for 1 to 2 weeks and spontaneously resolve. Erythema marginatum begins as an erythematous macule or papule extending outward while the central skin returns to normal. The border is pink and serpiginous, is not indurated, and blanches with pressure (Fig. 161-5). Patients are often unaware of its presence.[6] Histopathologically, there is a sparse superficial perivascular infiltrate of lymphocytes and neutrophils.[10]

Treatment

Treatment is directed at eradication of GAS from the oropharynx. Penicillin is the antibiotic of choice, is inexpensive, and can be administered orally or intramuscularly. Oral therapy should be continued for at least 10 days.[6] Penicillin-allergic patients can be treated with cephalosporins or macrolide antibiotics.[20] Due to the high rate of recurrence in previously affected people, antibiotic prophylaxis is recommended, especially in endemic areas.

The acute inflammatory process is largely treated symptomatically. Anti-inflammatory medications including salicylates and nonsteroidal agents are effective for the arthritis, fever, and arthralgia. However, salicylates alone have not been shown to be effective in decreasing the incidence of rheumatic heart disease after ARF. Corticosteroids are believed to be beneficial in the treatment of carditis; though this has never been shown in a randomized controlled trial. Lastly, intravenous Ig has also been tested but not shown any benefit.[18] Approximately 80 percent of patients who fulfill the criteria for this disorder recover spontaneously.

Box 161-2

The Jones Criteria for Rheumatic Fever, Updated 1992

MAJOR CRITERIA
- Carditis
- Migratory polyarthritis
- Sydenham chorea
- Subcutaneous nodules
- Erythema marginatum

MINOR CRITERIA
- Clinical
  - Fever
  - Arthralgia
- Laboratory
  - Elevated acute phase reactants
  - Prolonged P-R interval

plus

Supportive evidence of a recent group A streptococcal infection (e.g., positive throat culture or rapid antigen detection test; and/or elevated or increasing streptococcal antibody test)

From Guidelines for the diagnosis of rheumatic fever. Jones Criteria, 1992 update. Special Writing Group of the Committee on Rheumatic Fever, Endocarditis, and Kawasaki Disease of the Council on Cardiovascular Disease in the Young of the American Heart Association. *JAMA* **268**:2069, 1992.





▲ **FIGURE 161-5** Erythema marginatum of rheumatic fever. Enlarging and shifting transient annular and polycyclic lesions.

GOUT

Gout is a clinical syndrome caused by a group of heterogeneous diseases characterized by deposition of monosodium urate crystals in synovial fluid and joints with or without hyperuricemia, renal disease, and nephrolithiasis. Classically, the presentation is that of an acute lower extremity peripheral joint inflammatory synovitis. The most commonly affected sites are the first metatarsophalangeal joint and the ankle.[6]

Epidemiology

Gout affects approximately 5 million Americans and has historically been described as a disease that affects men; however, it also affects women. Recent epidemiologic studies demonstrate that on average, women develop gout a decade later than men, and that female patients with gout are more likely to have renal insufficiency or to be taking diuretics.[21] Obesity has been linked to gout, and both diseases have increased in incidence over the past two decades. Alcohol has long been recognized as a risk factor for gout, but only recently has consumption of purine rich foods such as meat and seafood has been shown to correlate positively with serum urate levels and gout. It has also been shown that eating low fat dairy products may be protective.[22] Gouty attacks in children are so uncommon that this diagnosis should prompt an evaluation for a malignant or genetic cause.

Pathogenesis

Hyperuricemia is a risk factor for gout, but acute gouty arthritis can occur in patients with normal serum uric acid levels. Patients with serum uric acid levels greater than 7 mg/dL have a 22 percent chance of developing gout over a 5-year period, demonstrating that many patients with elevated serum uric acid levels may never have gouty arthritis.[6]

Uric acid is the end product of purine catabolism. Humans lack the enzyme uricase, which breaks down uric acid into a more water-soluble product. When the plasma monosodium urate level exceeds its limit of solubility, it is more likely to precipitate in tissues. Hyperuricemia results from either overproduction or underexcretion of uric acid. Ninety percent of affected patients are underexcreters.[6]

Table 161-4 presents a classification of hyperuricemia. Less than 10 percent of patients with hyperuricemia or gout excrete excessive quantities of uric acid in a 24-hour urine collection. It is usually in this group that identifiable and inherited derangements in mechanisms regulating protein nucleotide synthesis, specifically a deficiency of hypoxanthine-guanine phosphoribosyltransferase, glucose-6-phosphatase, or fructose-1-phosphatase, either partial or complete, can be found. These are genetically inherited by X-linked and autosomal recessive means (in the latter two); therefore, family history or early presentation may be a clue. The Lesch-Nyhan syndrome, well described but very rare, is an extremely severe form of hypoxanthine-guanine phosphoribosyltransferase deficiency associated with mental retardation, gout, and self-mutilation.[6]

TABLE 161-4
Classification of Hyperuricemia

- Overproduction of uric acid
  - Primary hyperuricemia
    - Idiopathic
    - Hypoxanthine-guanine phosphoribosyltransferase deficiency
    - Phosphoribosylpyrophosphate synthetase superactivity
  - Secondary hyperuricemia
    - Excessive dietary purine intake
    - Increased nucleotide turnover (e.g., myeloproliferative and lymphoproliferative disorders, hemolytic disease, psoriasis)
- Diminished excretion of uric acid
  - Primary hyperuricemia
    - Idiopathic
  - Secondary hyperuricemia
    - Diminished renal function
    - Inhibition of tubular urate secretion by competitive anions (e.g., keto- and lactic acidosis)
  - Enhanced tubular urate reabsorption
    - Dehydration, diuretics
  - Miscellaneous
    - Hypertension
    - Hyperparathyroidism
    - Certain drugs (e.g., cyclosporine, pyrazinamide, ethambutol, low-dose salicylates)
    - Lead nephropathy

Uric acid underexcretion is idiopathic in patients with hyperuricemia. The anatomic appearance and physiologic function of the kidney appear normal; however, alteration of renal tubular function in these patients by many drugs can precipitate gouty attacks. These pharmacologic agents include loop diuretics, low-dose cyclosporine, and salicylates.

Precipitating causes of an acute gouty attack are not well understood. Studies have shown the presence of intracellular monosodium urate crystals in synovial fluid of asymptomatic patients, suggesting that inflammation in gout is chronic. There must be an unidentified trigger in the acute attack that incites a more robust inflammatory response. Monocytes are present and secrete cytokines, including TNF-α, interleukin 1, interleukin 6, and interleukin 8. Neutrophils are then attracted to the site as well, ingest the crystals, and release multiple inflammatory mediators, initiating further inflammation and tissue damage.[6]

Clinical Manifestations

It is felt that gout occurs in four stages: asymptomatic hyperuricemia, acute gouty arthritis, intercritical gout (between gouty attacks), and chronic tophaceous gout.[6]

Patients are often asymptomatic for years, requiring no therapeutic intervention in the absence of other evidence of disease (for example, nephrolithiasis or renal insufficiency).

Acute gouty arthritis usually occurs in middle age and primarily affects a single joint in the lower extremities, the first metatarsophalangeal being the most common site of initial involvement (podagra). Clinically, the affected joint is erythematous and exquisitely tender to palpation. This may be confused with a sprain, a septic joint, or cellulites. Cytokine release can lead to fever and systemic symptoms, confounding the picture further. Further differential diagnoses include other forms of arthritis (psoriatic, reactive arthritis osteoarthritis, or RA) and pseudogout (chondrocalcinosis).[6]

Intercritical gout describes the interval that occurs between attacks of gout, an interval of between 6 months to 2 years. As attacks continue, they tend to be polyarticular, more severe, and of longer duration. Chronic tophaceous gout describes gout where patients rarely have asymptomatic periods. Urate crystals may be found in the soft tissues, cartilage, and tendons (Fig. 161-6A).[6] They have been reported in a variety of unusual places as well, including the nasal dorsum.[23] They may be confused with rheumatoid nodules, and aspiration or biopsy may prove useful.

Laboratory Presentation and Pathology

Laboratory analysis may reveal elevated uric acid levels, but this finding is not necessary for the diagnosis. Leukocytosis and





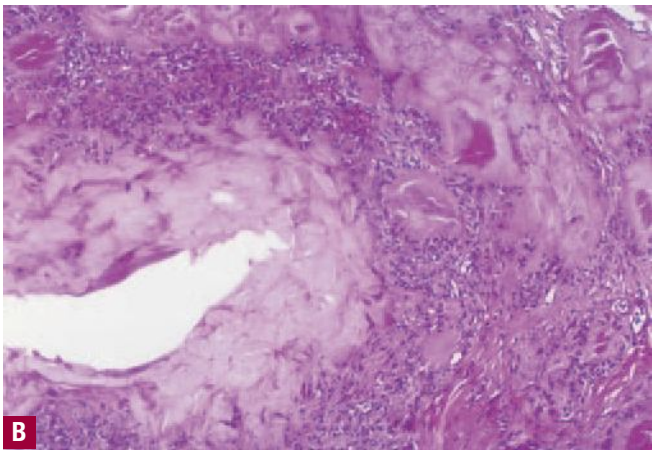

▲ **FIGURE 161-6** Gouty tophi. **A.** Tender nodules overlying joints and tendons, which may drain chalky white material. **B.** Histopathology shows granulomatous "fluffy" appearing infiltrate surrounding radially arranged needle-like spaces.



elevated sedimentation rate are often seen during acute arthritic attacks. Accurate diagnosis rests on the demonstration of intracellular, negatively birefringent, needle-shaped crystals by polarized microscopy. Histopathologic examination of a gouty tophus reveals granulomatous inflammation surrounding yellow-brown urate crystals or needle-like spaces in a radial arrangement, representing crystals dissolved during processing (see Fig. 161-6B; Fig. 161-7).[10]

Treatment

The goal of therapy in acute gouty attacks is analgesia and reduction in inflammation. The main options to choose from are the nonsteroidal anti-inflammatory drugs, colchicine, and corticosteroids. Indomethacin has been shown in randomized controlled trials to decrease pain, as has colchicine; however, the adverse gastrointestinal side effect of colchicine is often a deterrent for its use. Indomethacin can precipitate acute renal failure in patients with underlying renal disease. Corticosteroids, both oral and intra-articular, are also believed to be effective. Because patients with gout are older and often have many co-morbidities, therapy should be individualized. Treatment should continue for 7 to 10 days after the acute attack, and prophylactic therapy may be continued for 3 to 6 months.[6]



▲ **FIGURE 161-7** Gouty tophi on helix.

In patients with only one gouty attack, a conservative management approach can be used. This includes avoidance of drugs that decrease the excretion of uric acid such as thiazide or loop diuretics, aspirin, pyrazinamide, or niacin. Patients should maintain adequate hydration, lose weight, control hypertension and hyperlipidemia, and make diet adjustments by decreasing purine intake. Effectiveness of limiting cholesterol, fat, meat, and alcohol has never been studied, but should be advocated to avoid the need for lifelong oral therapy.[6,24]

Uric acid–lowering therapy is probably necessary in patients in whom the diagnosis of gout has been established, and who have had more than one gouty attack or are suffering from chronic tophaceous gout. It is also indicated in patients with history of gout and renal calculi, extremely high values of serum uric acid, high serum uric acid levels in the setting of a known familial history of gout (for example, where there is a known deficiency of one of the relevant enzymes previously described), and prophylaxis for patients receiving acute courses of chemotherapy.

The goal of urate-lowering drugs is to maintain the serum urate level consistently at less than 6 mg/dL. Uricosuric therapy is ideal in younger patients (age less than 60 years) with normal kidneys who are underexcreters of uric acid. Uricosurics include probenecid and sulfinpyrazone. The major risks associated with these medicines include hypersensitivity reactions and increased risk of uric acid nephrolithiasis (avoided by alkalinizing the urine). Unfortunately, most patients with gout do not fit this "ideal" situation.

For all other patients, the xanthine oxidase inhibitor allopurinol is used. It decreases production of uric acid, and is indicated for patients with nephrolithiasis, renal impairment, those who failed uricosuric agents, with myeloproliferative disorders on chemotherapy, and patients with hyperuricemia due to enzyme abnormalities. Dosages must be reduced in patients with renal failure. Twenty percent of patients taking allopurinol report side effects, and 5 percent discontinue medication as a result. Side effects include dyspepsia, headache, diarrhea, a pruritic papular eruption, thrombocytopenia, and hepatic function abnormalities. Allopurinol hypersensitivity syndrome is rare and includes fever, urticaria, leukocytosis, eosinophilia, interstitial nephritis, acute renal failure, granulomatous hepatitis, and toxic epidermal necrolysis.

KEY REFERENCES

The full reference list for all chapters is available at www.digm7.com.

1. Alamanos Y, Drosos AA: Epidemiology of adult rheumatoid arthritis. *Autoimmun Rev* **4**:130, 2004
5. Firestein GS: Immunologic mechanisms in the pathogenesis of rheumatoid arthritis. *J Clin Rheum* **11**:S39, 2005.
6. Harris ED et al: *Kelley's Textbook of Rheumatology.* Philadelphia, Elsevier Saunders, 2005, Chs. 65–68, 87, and 103

9. Sayah A, English JC, III: Rheumatoid arthritis: A review of the cutaneous manifestations. *J Am Acad Dermatol* **53**:191, 2004
10. Ackerman AB et al: *Histological Diagnosis of Inflammatory Skin Disease,* 2d ed. Philadelphia, Williams and Wilkins, 1997
18. Carapentis JR, McDonald M, Wilson NJ: Acute rheumatic fever. *Lancet* **366**:155, 2005.
24. Sutaria S, Katbamna R, Underwood M: Effectiveness of interventions for the treatment of acute and prevention of recurrent gout—A systematic review. *Rheum* **10**:1093, 2006

CHAPTER 162

Sjögren Syndrome

Stamatina Danielides
Gabor Illei

EPIDEMIOLOGY

Sjögren syndrome (SS) is one of the most common rheumatic autoimmune diseases. SS affects predominantly women with a female to male ratio of 9:1. Women are most commonly diagnosed in their fifth or sixth decade, but it can affect individuals of any age and sex.

SS has a worldwide distribution. In most studies the estimated prevalence rate in the adult general population is between 0.1 percent and 0.8 percent in mainly Caucasian populations. However, one study in the United Kingdom showed a prevalence rate of 3.3 percent, whereas another study in Japan showed only a 0.02 percent prevalence rate. The estimated annual incidence rate was consistently approximately 0.005 percent in several studies.[1]

PATHOGENESIS

The pathogenesis of SS is still largely unknown. In a genetically predisposed individual, various environmental factors, such as viral infections, may lead to epithelial cell activation and a protracted inflammatory response with features of autoimmunity. Autoreactive lymphocytes and autoantibodies are considered important in this process, although the pathogenic role of any particular autoantibody is still undefined. Abnormal apoptosis may be important in several ways. First, increased apoptosis of epithelial cells may lead to functional defects and provide autoantigens, whereas the prolonged survival of B and T cells through upregulation of anti-apoptotic signals may be involved in sustaining a self-perpetuating autoimmune process. Decreased apoptosis of lymphocytes may also contribute to the increased frequency of lymphoma in SS patients.

Immunogenetic Factors

The role of genetic factors in SS was recognized in family studies where first degree relatives of patients had an increased prevalence of SS.[2] Such family clustering was further observed among first-degree relatives of individuals with anti-Ro/SSA antibodies regardless of their clinical diagnoses [SS or systemic lupus erythematosus (SLE) or even healthy controls].[3] There is a well-established association between SS or anti-Ro/SSA and anti-La/SSB antibodies with HLA class II genes.[4] The first HLA class II associations described with primary SS were with DR3 and DR2 in European populations.[5] This genetic association predominantly involves antibody-positive but not antibody-negative Sjögren patients. Several small studies suggested an association between anti-Ro/SSA and anti-La/SSB antibodies and molecularly defined HLA-DR and HLA-DQ alleles, especially DRB1*0301, DRB1*15, and DQB1*0201.

Genes other than those of the HLA loci may also be associated with an increased risk of disease. Associations with a number of cytokine gene polymorphisms, such as interleukin (IL) 6, IL-10, tumor necrosis factor (TNF)-α and the IL-1 receptor antagonist, have been reported, but none of these have been confirmed to date.[4]

Environmental Factors

The inciting event in the pathogenesis of SS is not known, and it may not be a single event. The strong predominance of females suggests gender-specific predisposing factors. Although sex hormones are obvious targets, there is no conclusive proof yet that the difference in the pathogenesis between males and females is due to sex hormones alone. Viral infections have also been proposed as inciting events. This theory is strongly supported by the fact that chronic inflammation of the salivary glands has been observed with chronic hepatitis C and human immunodeficiency virus infections, and such infections cause a disease with a clinical spectrum very similar to SS. The fact that some viruses, such as Epstein-Barr virus (EBV), are known to replicate in oropharyngeal and lacrimal glands led to the hypothesis that these viruses may be involved in Sjögren pathogenesis. In fact, genetic material from EBV was detected by DNA hybridization in SS salivary tissue, but it was also found in normal individuals. Further experiments have identified an unusual strain of EBV containing a deletion in the genome in salivary gland specimens from Chinese SS patients.[6] Similarly, in a Japanese cohort, defective human T-lymphotropic virus-I genome was isolated from salivary gland tissue.[7] Other viruses, such as coxsackievirus[8] or endogenous retrovi-

SJÖGREN SYNDROME AT A GLANCE



- Chronic autoimmune disease characterized by chronic inflammation involving the exocrine glands.
- Salivary and lacrimal glands are predominantly affected leading to dry mouth and dry eyes.
- May occur alone (primary Sjögren syndrome), or may co-exist with other systemic connective tissue disorders (secondary Sjögren syndrome).
- Systemic manifestations, such as fatigue, arthritis, vasculitis, interstitial pulmonary disease, peripheral or central neuropathy, and autonomic nervous dysfunction may accompany glandular involvement.
- Patients with systemic manifestations are at higher risk of lymphoma.
- Treatment of sicca symptoms is mainly symptomatic, whereas management of extraglandular manifestations is similar to other autoimmune diseases.



ruses have also been proposed as causative agents. However, there is no proof, to date, that any of these viruses play a pathogenic role in SS.

Epithelial Cell Activation and Chronic Inflammation

Sections of salivary and lacrimal glands in SS are characterized by periductal mononuclear infiltrates. The majority of the infiltrating cells are $CD4^+$ T lymphocytes, whereas $CD8^+$ cytotoxic T cells are found in smaller numbers. Activated B lymphocytes are also present, including immunoglobulin-secreting cells.

Inflammation seems to target glandular epithelial cells, and recent research has demonstrated the central role of epithelial cell activation in initiating the recruitment of the inflammatory infiltrate.[9] In animal models, changes in epithelial cells occur before the appearance of lymphocytes in the salivary glands. Initial events include the expression of HLA class II molecules and various activation markers, such as the costimulatory molecules CD80 and CD86, on the surface of acinar and ductal[10] salivary epithelial cells. These molecules are crucial in regulating the interaction between antigen-presenting cells and lymphocytes. Their expression in acinar and tubular[11,12] epithelial cells suggests that epithelial cells in SS act as antigen-presenting cells and actively participate in lymphocyte activation. Another important step is the upregulation of adhesion molecules and chemokines, all of which contribute to the recruitment of inflammatory cells, such as T and B lymphocytes, macrophages, and dendritic cells. The activation of lymphocytes leads to abnormal cytokine and chemokine expression, perpetuating the chronic inflammatory process characterized by a complex interaction between activated epithelial cells, the innate and acquired immune system. Extraglandular manifestations occur as a result of similar lymphocytic infiltrations at other organs. This is described by some as *autoimmune epithelitis* to better reflect the systemic nature of the disease. Some epithelial cells express Fas and Fas ligand[13] and as a consequence undergo apoptosis; others may be destroyed by perforin, granzymes, and other cytotoxins produced by lymphocytes. However, in most patients, only partial destruction of the glands is noted. Local production of cytokines, autoantibodies, metalloproteinases, and other inflammatory mediators may contribute to the dysfunction of the remaining epithelial cells by various mechanisms. For example, it has been shown that TNF interferes with the intracellular trafficking of aquaporin-5, one of the water channels required for saliva production.

Autoantibodies

Autoantibodies are the hallmarks of systemic autoimmune diseases, including SS. The best-defined autoantibodies in SS are the anti-Ro/SSA and anti-La/SSB antibodies.[14] Both are targeted against ribonucleoprotein antigens. Anti-Ro/SSA recognizes two RNA binding proteins (the 52-kd or the 60-kd protein), whereas anti-La/SSB antibodies recognize RNA polymerase III. Anti-Ro/SSA antibodies are found in over 70 percent of patients with SS, but are not specific for SS and are frequently found in SLE and other autoimmune diseases even when there are no symptoms or signs of oral or ocular dryness. Anti-La/SSB is more specific; it is present in 50 percent of patients with primary SS or SS/SLE but is rarely seen in other diseases. The pathogenic role of these antibodies is not yet defined, but, because Ro and La are expressed on the surface of apoptotic epithelial cells, it is possible that an immune response against these antigens contributes to inflammation in the gland. The most compelling in vivo evidence for a pathogenic role of these autoantibodies comes from newborns with fetal heart block born to women with anti-Ro/SSA and/or anti-La/SSB antibodies. These antibodies can cross the placenta and bind to Ro and La antigens located on the cell surface of fetal myocardial tissue, leading to fetal heart block. Other autoantibodies, such as anti-nuclear antibodies and rheumatoid factor, are frequently present in patients with both primary and secondary SS. Although they lack specificity, they are markers of a systemic autoimmune response and thus can help distinguish SS from other causes of salivary or lacrimal gland dysfunction.

In recent years, research has focused on identifying antibodies more specific for SS, such as anti-α-fodrin and anti-muscarinic acetylcholine receptor antibodies, but the results have been controversial. The major stimulus for saliva production is the binding of acetylcholine to muscarinic acetylcholine receptors. The hypothesis that oral and ocular dryness could result from antibodies antagonizing the muscarinic acetylcholine receptor-3, is intriguing. These antibodies have been demonstrated to play an essential role in eliciting glandular dysfunction in the NOD mouse model of SS, possibly through an inhibitory effect on the receptor.[15] In humans, however, results are still contradictory as multiple attempts to detect these antibodies with conventional immunologic methods have been fruitless.[16]

CLINICAL MANIFESTATIONS

Exocrine Gland Involvement

The dominating feature of SS is exocrine gland dysfunction, leading to the classic sicca symptoms of xerostomia (oral dryness) and xerophthalmia or keratoconjunctivitis sicca (dry eyes).

XEROSTOMIA Oral dryness is the principal symptom of SS. Before attributing dry mouth to SS, other possible common causes, such as dehydration, diabetes, viral infections, or drug treatment, should be excluded. In SS, hyposalivation is persistent and continuous throughout day and night and can significantly compromise quality of life. The oral manifestations of SS result from the loss of lubricating and antimicrobial properties of saliva. Patients with SS often have increased incidence of caries, even with excellent oral hygiene leading to increased number of decayed, missed, and filled teeth. A characteristic feature of caries in SS is that it is primarily located at the cervical and incisal regions of the teeth. Oral mucosal surfaces are dry and ulcerations may be evident; ulcerations are particularly common in SS patients with dentures, in proximity to the mucosal surface that makes contact with the denture. Physical examination may reveal a red, dry, and fissured tongue with a characteristic atrophy of the filiform papillae or angular cheilitis. Reduced salivation causes difficulty in chewing and swallowing dry foods; dryness of the tongue and oral mucosa leads to an altered sense of taste and at times produces a burning discomfort, especially when eating acidic or spicy foods.

Reduction of saliva flow can lead to an increased susceptibility to infections. Fungal infections, especially oral candidiasis of the oral cavity, are common and can be manifested as pseudomembranous or erythematous mucosal lesions. They can be asymptomatic or present as burning pain.

Bilateral salivary gland enlargement may occur in the parotid glands of SS patients. It is usually non-tender, and it



Box 162-1

Differential Diagnosis of Parotid Gland Swelling

Bilateral	Viral infections	Mumps
		Epstein-Barr, cytomegalovirus, coxsackie
		Human immunodeficiency virus, human T-lymphotropic virus-I
		Hepatitis C
	Immune mediated	Sjögren syndrome
		Sarcoidosis
		Amyloidosis
	Endocrine/metabolic	Diabetes mellitus
		Hyperlipoproteinemia
		Chronic pancreatitis
		Acromegaly
	Other	Alcohol
		Recurrent parotitis of the childhood
Unilateral	Bacterial infections	
	Neoplasms	Mainly lymphomas
	Sialothithiasis	

can be recurrent or chronic (Box 162-1). Painful, unilateral parotid enlargement should raise the suspicion of an infection (Fig. 162-1) or a salivary gland stone. In cases of persistent unilateral parotid gland enlargement, the presence of lymphoma should be excluded (see Box 162-1).

KERATOCONJUNCTIVITIS SICCA Ocular dryness is the other dominant feature of SS. A burning and itching sensation in the eyes, commonly exacerbated by smoke, is caused by lack of tear production. Patients frequently complain of intolerance to contact lenses. Paradoxically, the quantity of tears produced during crying may not be affected. Physical evaluation shows corneal injection and mucous discharge in the lower fornix. Enlarged lachrymal glands have been described in Sjögren patients, but occur less commonly than enlarged salivary glands. The constellation of symptoms and signs indicating dry eyes constitutes keratoconjunctivitis sicca.



▲ **FIGURE 162-1** Acute infectious parotitis. Note the asymmetric swelling of the left parotid gland.

OTHER SICCA MANIFESTATIONS *Cutaneous xerosis*, a term used to describe dryness of the skin, is very common in SS, with a frequency varying between 23 percent to 68 percent. The most common symptoms of xerosis are non-specific pruritus, burning sensation and a pin-prick–like feeling. Physical examination reveals roughness, fine scaling, and loss of elasticity of the skin. The pathogenesis of xerosis is unknown. Impairment of the sweat glands is considered an important factor because decreased sweating has been reported in SS patients. A recent study has indicated that xerosis may be related to increased epidermal proliferation with disturbed epidermal differentiation.[17]

Dryness of the upper respiratory tract can cause epistaxis, hoarseness, and bronchial hyper-responsiveness. Another common complaint in women with SS is vaginal dryness, which may lead to an increased incidence of vaginal infections and dyspareunia.

Non-Exocrine Gland Involvement

SKIN INVOLVEMENT Cutaneous manifestations common extraglandular features of SS (Table 162-1).[18] They are generally divided as vasculitic and nonvasculitic lesions.

Vascular Lesions. Raynaud phenomenon is probably the most common abnormality. It can be seen in 15 percent to 35 percent of patients and can precede sicca symptoms by many years. Although Raynaud is usually mild in SS, it is a marker of a subgroup with increased risk of extraglandular manifestations.[19]

TABLE 162-1
Cutaneous Manifestations of Sjögren Syndrome

Vascular	• Raynaud phenomenon
	• Cutaneous vasculitis
	  • Non-palpable purpura
	  • Palpable purpura
	  • Urticarial vasculitis
	  • Necrotizing vasculitis
	• Annular erythema
	• Erythema multiforme
	• Erythema perstans
	• Erythema nodosum

Nonvascular	• Oral
	  • Dry mucous membranes
	  • Papillary atrophy of the tongue
	  • Candidiasis
	  • Angular cheilosis
	• Eyelid dermatitis
	• Alopecia
	• Vitiligo

Cutaneous vasculitis (CV) in SS presents most commonly as flat or palpable purpura (Fig. 162-2). CV appears as recurrent crops of round, pink, macular, or patchy lesions. After a few days, the lesions turn dull purple, then brown, finally leaving a pale brown stain. Flat purpura is most commonly seen in patients with hyperglobulinemia, whereas palpable purpura represents dermal vasculitis and typically involves the lower extremities and buttocks (see Chap. 164). In contrast to simple purpura, palpable purpura does not blanch when pressure is applied to the skin. Histopathologically, CV can be divided in two groups. Neutrophilic inflammatory vascular disease is characterized by a predominantly neutrophilic infiltrate, fibrinoid necrosis, occlusion of the lumen and extravasation of red blood cells and is indistinguishable from the classical leukocytoclastic vasculitis (see Chap. 164). On the other hand, mononuclear inflammatory vascular disease is characterized by a mononuclear inflammatory infiltrate with invasion of the blood vessel walls. Fibrinoid necrosis is present but less prominent. The clinical presentation of these two forms are indistinguishable, but neutrophilic inflammatory vascular disease is associated more strongly with markers of systemic au-







▲ **FIGURE 162-2** Cutaneous vasculitis in primary Sjögren syndrome. Biopsy showed leukocytoclastic vasculitis.

toimmunity, such as anti-nuclear antibodies and anti-Ro/SSA and anti-La/SSB antibodies, hypergammaglobulinemia, rheumatoid factor, and hypocomplementemia. Cryoglobulinemic vasculitis can also be seen among Sjögren patients and has the same cutaneous manifestations (see Chap. 170).

Urticarial vasculitis is the second most frequent form of CV in SS and presents as pruritic wheals with erythema (see Chap. 37). In contrast to true urticaria, individual lesions last for more than 24 hours and often resolve with hyperpigmentation. Biopsy of the skin lesions demonstrates a perivascular neutrophilic infiltrate accompanied by leukocytoclasia. Cutaneous purpura is an important marker of more severe disease in SS because it has been associated with an increased risk of lymphoma development and mortality.

Necrotizing vasculitis initially presents as palpable purpuric lesions of the lower extremities, which may ulcerate, finally resolving within 1 to 4 weeks. They heal with atrophy or scar tissue formation. This form of CV has been observed more frequently among patients with more active disease; it has been associated with arthritis, Raynaud phenomenon, peripheral neuropathy, fever, and pulmonary or glomerular involvement.

Annular erythema is found among Asian patients who have anti-Ro/SSA antibodies. Characteristic lesions are annular erythematous plaques with elevated borders and central clearing. They are localized on the face, arms, back, trunk, and proximal thighs. Lesions are similar to subacute cutaneous lupus but seem to represent a distinct clinical and histopathologic entity.

A painful nodular eruption of the anterior surface of the lower extremities, suggesting erythema nodosum (see Chap. 68) may occur in patients with sicca manifestations. Because erythema nodosum in SS patients is rare, its presence should raise suspicion for sarcoidosis. Erythema multiforme–like lesions and superficial ill-defined patches (erythema perstans) have also been described in SS.

Nonvascular Cutaneous Manifestations. Xerostomia predisposes to angular cheilitis, which presents as recurrent, symmetric, itching fissures. Eyelid dermatitis is defined by the presence of erythematous, infiltrated and lichenificated lesions of the eyelids associated with itching and foreign body sensation. Alopecia and vitiligo can also be seen in SS, albeit infrequently. Despite multiple case reports describing cutaneous B- and T-cell lymphomas in SS patients, they are, in fact, rare.

NON-CUTANEOUS EXTRAGLANDULAR MANIFESTATIONS

Musculoskeletal. A symmetric non-erosive polyarthritis can frequently be seen in primary SS. The distinction from rheumatoid arthritis may be difficult; the absence of rheumatoid factor and anti-CCP antibodies would favor SS over RA. Arthralgias and myalgias are common complaints but true myositis is rare in primary SS.

Visceral Manifestations. Tracheobronchitis sicca and interstitial pneumonitis are the most common lung manifestations of SS. Patients may also develop mucosa-associated lymphoid tissue (MALT) lymphoma in the lungs. Genitourinary manifestations include interstitial cystitis, renal tubular acidosis, interstitial nephritis, and, rarely, glomerulonephritis. Dysphagia due to xerostomia and esophageal dysmotility is common. *Helicobacter pylori* is associated with an increased risk of MALT lymphomas, therefore, SS patient with gastritis should be checked for *H. pylori* and treated if found positive. SS is associated with various other diseases, such as celiac disease, primary biliary cirrhosis, and hypothyroidism. Because of these associations, a high index of diagnostic suspicion is warranted to identify and treat these conditions.

Neurologic Manifestations. Nervous system involvement is reported in approximately 20 percent of patients with SS. The most common manifestations are peripheral axonal or ganglionic polyneuropathies and autonomic dysfunction. Sensorimotor neuropathies present with symmetric anesthesia and dysesthesia of the extremities in a glove and stocking distribution, whereas motor dysfunction is usually minor. Less frequently, patients may also present with a pure sensory neuropathy. Another entity that has been described to occur frequently among SS patients is a ganglionopathy involving the sensory ganglia of the posterior column. This starts with unilateral peripheral paresthesias evolving over months to years to deep sensory impairment, positive Romberg's sign, generalized areflexia, and ataxia.[20] An asymmetric motor and sensory neuropathy can signal vasculitis of small- and medium-sized vessels. Cranial neuropathies are also frequent among SS patients. The most common form is unilateral trigeminal neuropathy; it usually spares the ophthalmic division, thus preserving the corneal reflex. Other cranial neuropathies may lead to Bell palsy (facial nerve), neural deafness and vestibular dysfunction (vestibule-cochlear), and diplopia (oculomotor, trochlear, abducent nerve).

Lymphoproliferative Disease. The incidence of lymphoma in Sjögren patients is increased 15- to 44-fold, according to various studies,[21] and 4 percent to 8 percent of SS patients develop lymphoma. Most of these are indolent, extra-nodal, marginal-zone, B-cell lymphomas of MALT, but higher grade lymphomas are also seen.

A variety of clinical and laboratory features have been correlated to an increased risk of lymphoma development. Recurrent or persistent salivary gland swelling, palpable purpura, low complement levels, low CD4 counts, and persistently elevated inflammatory markers indicate an increased disease activity and increased risk for lymphoma development.[25]

DIAGNOSIS

The diagnosis of SS is based on the clinical constellation of xerostomia, keratoconjunctivitis sicca, and features of autoimmunity, such as anti-nuclear antibodies and/or anti-Ro/SSA and anti-

TABLE 162-2
Revised International Classification Criteria for Sjögren Syndrome

I. Ocular symptoms: A positive response to at least one of the following questions:
1. Have you had daily, persistent, troublesome dry eyes for more than 3 mo?
2. Do you have a recurrent sensation of sand or gravel in the eyes?
3. Do you use tear substitutes more than three times a day?

II. Oral symptoms: A positive response to at least one of the following questions:
1. Have you had a daily feeling of dry mouth for more than 3 mo?
2. Have you had recurrently or persistently swollen salivary glands as an adult?
3. Do you frequently drink liquids to aid in swallowing dry food?

III. Ocular signs—that is, objective evidence of ocular involvement defined as a positive result for at least one of the following two tests:
1. Schirmer's test, performed without anaesthesia (≤5 mm in 5 min)
2. Rose bengal score or other ocular dye score (≥4 according to van Bijsterveld's scoring system)

IV. Histopathology: In minor salivary glands (obtained through normal appearing mucosa) focal lymphocytic sialoadenitis, evaluated by an expert histopathologist, with a focus score ≥1, defined as a number of lymphocytic foci (which are adjacent to normal appearing mucous acini and contain more than 50 lymphocytes) per 4 mm^3 per glandular tissue

V. Salivary gland involvement: Objective evidence of salivary gland involvement defined as a positive result for at least one of the following diagnostic tests:
1. Unstimulated whole salivary flow (< 1.5 mL/15 min)
2. Parotid sialography showing the presence of diffuse sialectasias (punctuate, cavitary or destructive pattern), without evidence of obstruction in the major ducts
3. Salivary scintigraphy showing delayed uptake, reduced concentration and/or reduced excretion of tracer

VI. Autoantibodies: Presence in the serum of the following autoantibodies: antibodies to Ro/SSA, La/SSB or both

Modified from Vitali C et al: Classification criteria for Sjögren's syndrome: A revised version of the European criteria proposed by the American-European Consensus Group. *Ann Rheum Dis* **61**:554, 2002.

La/SSB antibodies. In patients with severe symptoms the diagnosis is straightforward, but in patients with milder symptoms, or those without the typical autoantibody profile, the diagnosis can be difficult. Moreover, several sets of diagnostic criteria were developed and used by various groups, adding to the confusion. Recently, an international consensus group agreed on a set of criteria, and this revised American-European classification system has been widely accepted (Table 162-2).[26] Six features are taken into consideration: subjective complaints, objective evidence of dry eyes or dry mouth, objective evidence of salivary gland involvement, and the presence of specific autoantibodies in the serum. For the diagnosis of primary SS, at least four criteria should be present, and at least one of them should be either evidence of lymphocytic infiltration or the presence of autoantibodies. Patients with a co-existing connective tissue disease are labeled secondary SS. Exclusions include other diseases and medications that may cause sicca symptoms.

To establish subjective symptoms of dry eyes and dry mouth, a validated uniform questionnaire is used. A variety of non-invasive methods can be used to diagnose reduced salivary flow in clinical practice. The most commonly used method is sialometry, which involves measurement of the total unstimulated and stimulated saliva produced from salivary glands in a time period of 15 minutes (unstimulated or stimulated whole salivary flow). The whole unstimulated salivary flow is considered abnormal if it is less than 1.5 mL in 15 minutes. Salivary gland scintigraphy assesses saliva production by measuring the secretion of a radioisotope (99m technetium-sodium pertechnetate) into the oral cavity. Salivary scintigraphic changes correlate significantly with sialometric values and provide the same functional information.[27] Given the high cost and the exposure to radiation, their routine use is not justified. Sialography is an imaging method based on retrograde injection of contrast media into the parotid duct. Dilatations of salivary ducts and sialolithiases are the most common findings.

However, none of the above diagnostic procedures is specific for SS. The most reliable objective diagnostic feature is seen on biopsy of the minor salivary gland. A small incision is made on the inner surface of the lip, and a minor salivary gland tissue sample is collected. Evidence of a focal, periductal infiltrate composed of T and B lymphocytes and few plasma cells is the histologic hallmark of SS (Fig. 162-3). The degree of lymphocytic infiltration is evaluated semi-quantitatively by means of a focus scoring system. Evidence of more than one focus is considered indicative of SS, and a focus is considered a conglomeration of at least 50 lymphocytes per 4 mm^3 of glandular tissue. Atrophy and fat tissue are other findings that may be present in SS patients, but are also present among healthy, elderly individuals. Although salivary gland biopsy provides important clues that may lead to definitive diagnosis, some controversy still exists regarding its sensitivity and specificity. Some patients with primary SS diagnosed on the basis of reduced salivary flow and evidence of anti-SSA and anti-SSB antibodies have no lymphocytic infiltration in biopsy specimens of minor salivary glands. In addition, some healthy individuals may demonstrate lymphocytic foci in their salivary glands.

The diagnosis of keratoconjuctivitis sicca is based on the demonstration of decreased tear production, corneal damage, or both. Tear production is measured by Schirmer's test. This is performed by placing a standardized paper strip in the inferior fornix of each eye and measuring the length of filter paper that becomes wet after 5 minutes. The European-American classification system uses a cut-off value of 5 mm in 5 minutes, below which the diagnosis of dry eyes is made. An alternative method is staining with a dye (rose bengal or lissamine green) that preferentially stains the devitalized cornea and conjunctiva. This staining is evaluated through the van Bijsterveld's scoring system; a score of 4 or more indicates keratoconjunctivitis sicca. These tests have a high sensitivity but low specificity; they identify ocular dryness, but cannot attribute abnormal findings to SS.

PROGNOSIS

There are two patterns of primary SS that define two distinct disease categories with very different clinical risks. Patients with low C4 levels and/or palpable purpura early in their disease course may be classified as a high-risk disease syndrome (type I). This group comprises approximately 20 percent of the primary SS diagnoses and carries a significantly increased risk of lymphoproliferative disease and also has an increased mortality rate. Most severe extraglandular manifestations also occur in this group. Patients without these two predictors (80 percent of all primary SS diagnoses) may be reassured that they have a low-risk ("type II") form of primary SS that carries no in-



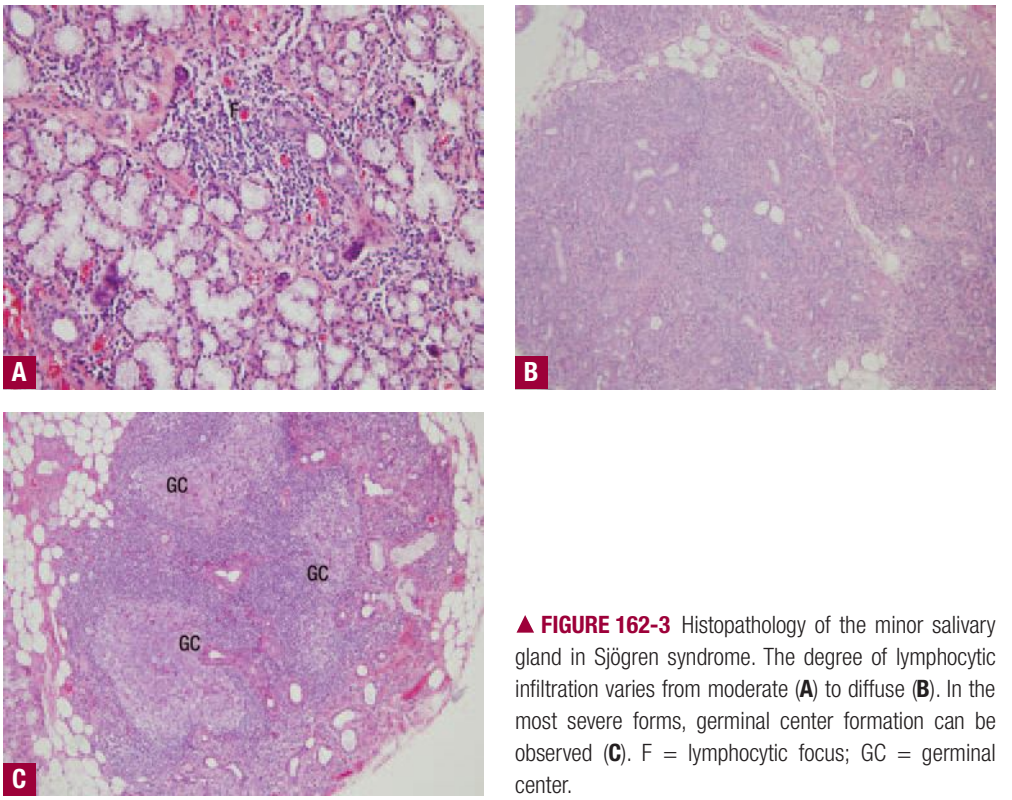

▲ **FIGURE 162-3** Histopathology of the minor salivary gland in Sjögren syndrome. The degree of lymphocytic infiltration varies from moderate (**A**) to diffuse (**B**). In the most severe forms, germinal center formation can be observed (**C**). F = lymphocytic focus; GC = germinal center.



creased risk of death and in general has a more benign course dominated by sicca symptoms.[25]

TREATMENT

Treatment of Dry Mouth (Table 162-3)

The treatment of oral dryness is largely symptomatic.[28] Although various artificial saliva preparations are available, the mainstay of replacement therapy consists of frequent sips of water or other sugar-free fluids. Patients should be encouraged to use sugar-free candies and chewing gums to increase saliva production. Sugar-containing foods should be avoided because they contribute to the increased risk of dental caries and oral candidiasis. Meticulous dental hygiene is essential for SS patients to prevent or treat dental caries. The mainstay of prevention is the use of various fluoride applications including prescription-strength toothpaste, fluoride gels, and oral rinses. Oral candidiasis is treated with oral and systemic antifungal therapy. To prevent candidiasis, patients should not wear dentures at night, and the dentures should be soaked in 2 percent chlorhexidine. Nystatin or clotrimazole cream can be used to treat angular cheilitis.

If dry mouth is not adequately controlled with replacement methods, pharmacologic therapy with secretagogue drugs is an option. Two drugs are approved for this indication: pilocarpine (5 mg four times a day) and cevimeline (30 to 60 mg three times/day). Both act on muscarinic receptors and increase exocrine gland secretion. They are contraindicated in narrow-angle glaucoma and uncontrolled asthma. Cholinergic side effects, such as excessive sweating, urinary frequency, flushing, and headaches, are common for both agents. Tolerability can be increased if treatment is started at a lower dose, which is then gradually increased (see Table 162-3).

Treatment of Dry Eyes (See Table 162-3)

Many tear substitutes are available and are commonly used by patients to alleviate ocular dryness. Preservative-free preparations are preferred, especially if used more than four times a day. Methylcellulose-containing ointments may provide longer relief, but their use is limited to nighttime use by the risk for blurred vision. Cyclosporin ophthalmic solution (0.05 percent, one drop every 12 hours) has recently been approved for the treatment of keratoconjunctivitis sicca. Topical corticosteroids are rarely needed and should only be prescribed by ophthalmologists. Infections may present with aggravation of symptoms or increased mucus secretion, and should be promptly treated with topical antibiotics.

A frequently used surgical option is the occlusion of the puncta to block tear

TABLE 162-3
Management of Sicca Symptoms in Sjögren Syndrome

Xerostomia	• Frequent water • Mechanical stimulation of salvia secretion (sugar-free gum and candies) • Artificial saliva • Meticulous oral hygiene • Caries prevention with fluoride-containing toothpaste and rinses • Aggressive treatment of candidiasis with topical and systemic antifungals • Sialogogues: pilocarpine (5 mg orally three times/day) or cevimeline (30–60 mg orally three times/day)
Xerophthalmia	• Frequent use of preservative-free artificial tears • Nighttime use of moisturizing ointments • Topical cyclosporine A ophthalmic solution (0.05%, one drop every 12 h) • Surgical: Punctual plug placement • Sialogogues

drainage and consequently increase moisture. The occlusion can be transient by the insertion of collagen or silicone plugs, or permanent by electrocautery.

Pilocarpine and cevimeline can be effective for dry eyes, too, especially in patients with the most severe dryness.[29]

Treatment of Extraglandular Manifestations

The treatment of musculoskeletal manifestations of SS is similar to those of other systemic rheumatologic diseases.[28] Because of reduced saliva production and esophageal dysmotility, these patients have reduced tolerance to nonsteroidal anti-inflammatory drugs. Antimalarial drugs, such as hydroxychloroquine, are effective for arthralgia/arthritis, myalgia, and fatigue.[30] They also decrease erythrocyte sedimentation rate, serum γ globulin, and C-reactive protein values. Dryness of eyes and mouth may also improve slightly in some cases.[31] Visceral manifestations such as vasculitis, pneumonitis, glomerulonephritis, and neurologic manifestations are treated with corticosteroids and immunosuppressive drugs, in doses similar to those used in systemic lupus erythematosus. Steroid-sparing immunosuppressive drugs include methotrexate, leflunomide, and azathioprine. Pulse cyclophosphamide is reserved for the most severe manifestations. Primary biliary cirrhosis should be treated with ursodeoxycholic acid.

Treatment of lymphoma in SS is the same as in the general population. Most SS-associated lymphomas are low-grade B-cell lymphomas localized to the exocrine glands. For these, watchful waiting may be the most appropriate approach. Higher grade lymphomas require more aggressive treatment with a cytotoxic regimen and/or radiation therapy.

Targeted Therapy

Several randomized case-control studies have focused on therapy for SS using biologic agents, such as the TNF-blocking agents infliximab[32]and etanercept,[33] but none of the studies showed clinical benefit. There is increasing interest in therapies targeting B cells, such as monoclonal antibodies against CD20 (rituximab) or CD22 (epratuzumab).[34] Other potential targets for biologic therapy include cytokines such as IL-6 and BlyS (BAFF), interferons, adhesions molecules, and chemokines. However, even if effective, systemic immunomodulatory therapy may be associated with unwanted side effects and may not be justified in patients with primary SS whose disease is limited to exocrine glands. An alternative approach is to develop a localized form of immunotherapy by using gene therapy restricted to the salivary and lacrimal glands. This approach would most likely alter the abnormal immune response locally but may avoid the systemic side effects.[35]

KEY REFERENCES

The full reference list for all chapters is available at www.digm7.com.

1. Alamanos Y et al: Epidemiology of primary Sjögren's syndrome in north-west Greece, 1982–2003. *Rheumatology (Oxford)* **45**:187, 2006
4. Sawalha AH et al: The genetics of primary Sjögren's syndrome. *Curr Rheumatol Rep* **5**:324, 2003
9. Fox RI: Sjögren's syndrome. *Lancet* **366**:321, 2005
16. Dawson L et al: Antimuscarinic antibodies in Sjögren's syndrome: Where are we, and where are we going? *Arthritis Rheum* **52**:2984, 2005
18. Roguedas AM et al: Cutaneous manifestations of primary Sjögren's syndrome are underestimated. *Clin Exp Rheumatol* **22**:632, 2004
26. Vitali C et al: Classification criteria for Sjögren's syndrome: A revised version of the European criteria proposed by the American-European Consensus Group. *Ann Rheum Dis* **61**:554, 2002
28. Mavragani CP, Moutsopoulos NM, Moutsopoulos HM: The management of Sjögren's syndrome. *Nat Clin Pract Rheumatol* **2**:252, 2006



This page intentionally left blank

SECTION 28

THE SKIN IN INFLAMMATORY AND OTHER VASCULAR DISORDERS

CHAPTER 163

Endothelium in Inflammation and Angiogenesis

Peter Petzelbauer
Lisan S. Peng
Jordan S. Pober

OVERVIEW OF THE VASCULAR SYSTEM

The blood vascular system is formed by a continuous series of hollow tubes that carry blood from the heart to the tissues and back again. Blood exits the heart through the aorta, a large elastic artery, which gives rise to a series of diverging, progressively narrower muscular arteries and arterioles that deliver the blood to all organs of the body. The terminal arterioles arborize into an interconnecting network of microvessels, mostly capillaries, which nourish and cleanse the peripheral tissues. The capillary network empties into a series of converging venules and progressively larger veins that ultimately return the blood to the heart. All segments of this vascular system, as well as the heart itself, are lined by a simple, one-cell-thick layer of epithelium-like cells called *endothelium* (Fig. 163-1). All of these endothelial cells (ECs) share common features and functions, and hence may be collectively described as one cell type. However, endothelia from one segment of the vascular system may differ in significant ways from the endothelia at other anatomic sites. Blood vessel ECs also differ in a number of ways from lymphatic ECs, which are not discussed in this chapter.

All blood vessel ECs must perform three important constitutive functions. First, vascular ECs must maintain homeostasis of the blood, which consists of roughly equal volumes of fluid (plasma) and cellular elements (erythrocytes, leukocytes, and platelets). The plasma contains the proteins of the coagulation system, which have the capacity to self-assemble into an insoluble matrix of fibrin (i.e., to form an intravascular thrombus or an extravascular clot) when placed in contact with tissue cells or extracellular matrix. In addition, both the leukocytes and the platelets have membrane receptors that trigger cellular activation on contact with the extravascular environment. The EC lining acts to prevent intravascular activation both of the coagulation system and of these responsive cellular elements, yet it keeps both systems poised to appropriately respond to wounding or infection.

The second function that must be performed by ECs is to form a barrier that separates circulating blood from the tissues. The barrier formed by ECs permits limited passage of fluid and solutes, allowing the blood to nourish the tissues while displaying "permselectivity" for macromolecules and presenting a virtually impenetrable barrier for blood cells (except at specialized sites of high permeability and leukocyte trafficking). In other words, vascular ECs regulate rather than completely prevent interactions between blood and tissues.

The third constitutive function performed by ECs is to regulate the extent of local blood flow. Because ECs are arranged in alignment with flow, their contraction is a mechanism of opening gaps between cells, which thus enhances permeability but does not alter flow (see Fig. 163-1). However, ECs indirectly regulate flow by acting on smooth muscle cells, which are arranged radially around the vessels. Their contraction narrows the vessel lumen, reducing flow. ECs control smooth muscle cell tone (i.e., the degree of contraction of smooth muscle cells), which regulates the size of the vessel lumen and flow. ECs do so principally by the generation of smooth muscle cell relaxants [i.e., vasodilators like nitric oxide (NO), prostaglandin E_2 or prostaglandin I_2 (PGI_2), and endothelium-derived hyperpolarizing factor] or contractants (i.e., vasoconstrictors like endothelins) or by

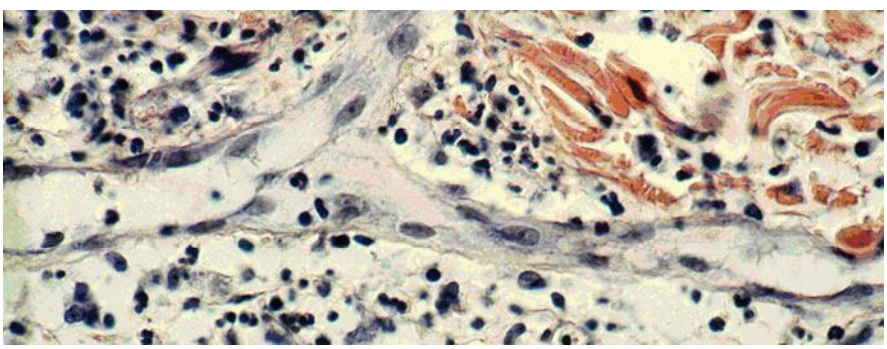

▲ **FIGURE 163-1** Endothelium. In this postcapillary venule, endothelial cells are seen to line a channel. Nuclei are seen en face and in cross-section, and activated endothelial cells appear to have an edematous cytoplasm, which increases their visibility. This specimen is from an inflammatory lesion (Sweet syndrome; see Chap. 31) without signs of vessel damage.

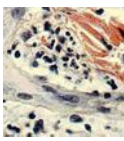

Copyright © 2008 by The McGraw-Hill Companies, Inc. Click here for terms of use.

ENDOTHELIUM AT A GLANCE

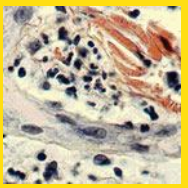

- All blood vessel endothelial cells (ECs) perform three important constitutive functions:
  - Maintaining homeostasis of the blood
  - Forming a barrier that separates circulating blood from the tissue
  - Regulating the extent of local blood flow
- The cutaneous vasculature is divided into a superficial vascular plexus and a deep vascular plexus. The superficial vascular plexus is formed by parallel pairs of arterioles and venules that are connected via capillary loops that extend into the dermal papillae.
- ECs participate in innate and adaptive immune responses.
- Tumor necrosis factor-α and interleukin-1β are important modulators of EC function.
- Vascular ECs contribute to inflammation through distinctive patterns of adhesion molecule expression. In the skin, E-selectin, vascular adhesion molecule 1, and intercellular adhesion molecule 1 may be particularly important.
- Microvessels of the skin in situ basally express major histocompatibility complex (MHC) class I and II molecules at their luminal surfaces and may present antigen in an MHC-restricted manner to T cells.
- In the healthy adult, blood vessels are stable structures with very slow turnover of ECs. In chronic inflammation, tissue injury, wound healing, and tumor growth new vessels are formed (angiogenesis) and existing vessels undergo remodeling.
- Keratinocytes produce a wide range of angiogenic factors, including members of the fibroblast or transforming growth factor protein family, platelet-derived growth factor, and vascular endothelial growth factor, as well as chemokines like cutaneous T cell–attracting chemokine. Vascular remodeling is a prominent feature of psoriasis.

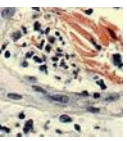

catalyzing the generation of vasoconstrictors from plasma protein–derived mediators (like angiotensin II). In the latter case, ECs express angiotensin-converting enzyme, which catalyzes the generation of angiotensin II from inactive angiotensin I and simultaneously degrades bradykinin, a plasma protein–derived agonist that acts on ECs to generate NO.

In addition to these constitutive functions, ECs may respond to mediators generated during inflammation or injury to acquire additional inducible functions. This activation of ECs is discussed later in the chapter.

STRUCTURE AND FUNCTION OF THE SKIN VASCULATURE

Approximately three decades ago Irwin Braverman described the organization of the vascular network of human skin, which he summarized in 1989.[1] Specifically, he noted that the human vascular system of the dermis consists of two interconnected systems—a superficial and a deep vascular plexus—with additional vascular networks surrounding sweat glands and hair follicles[2,3] (Fig. 163-2). The superficial vascular plexus (SVP) is comprised of paired arterioles and venules that form an interconnected network of vessels coursing on a plane parallel to and just beneath the epidermal surface.[3] Capillaries arise from the arterioles, extend upward within the papillary dermis at sites between the epidermal rete ridges, and then loop back down to the venules forming arcade-like structures. The basement membrane of the arterioles appears homogeneous by electron microscopy, whereas that of the venules is multi-layered. In normal skin, most of the capillary loop is invested with a basement membrane that resembles that of the arteriole. The capillaries acquire a venule-like investiture only at the level of the deepest rete just proximal to the anastomosis with the venule of the SVP.[2] There are no ultrastructural differences between capillary loops at different sites of the skin. Inflammatory leukocytes extravasate through the venule-like portions of the capillary and through the venule proper but only rarely infiltrate through the arteriole-like portions of the capillary or the arteriole itself.

The arterioles and venules of the SVP are connected by short, straight vessels to the arterioles and venules of a deeper planar network of anatomizing vessels called the *deep vascular plexus* (DVP) (see Fig. 163-2). The plane of the DVP is parallel to that of the SVP and courses above the boundary between the reticular dermis and the underlying subcutis (see Fig. 163-2). The DVP is fed through penetrating vessels from the subcutis. The DVP is drained by valve-containing veins into the subcutaneous fat. Valves are typically located where the small vessels join the larger ones, which implies a functional role in forward propulsion of blood. The vessel wall in the SVP consists of discontinuous layers of elastic fibers and smooth muscles. The DVP contains arterioles and venules of larger caliber consisting of three layers: an intima, a media, and an adventitia. Capillary networks connecting the arterioles and venules of the DVP provide nourishment for the adnexal structures within the reticular dermis. The venules of the DVP serve as portals of entry for leukocytes associated with inflammation of the adnexa or for inflammation within the reticular dermis itself, as occurs in erysipelas.

Dermal microvessels are surrounded by flat adventitial cells, ultrastructurally most closely resembling a fibroblast, called *veil cells*.[1] Veil cells are external to the wall, demarcating the vessel from the surrounding dermis. These cells test negative for lymphocyte markers and negative for HLA-DR and CD1a expression. They express glycoprotein Ib α, von Willebrand factor (vWF) receptor, and factor XIIIa, a coagulation transglutaminase, and are sometimes called *XIIIa-positive dendrocytes*. Interestingly, factor XIIIa–positive dendrocyte rarefaction is found in the classic type of Ehlers-Danlos syndrome, but the significance of this finding is not clear.

Dermal microvessels, especially capillaries, contain, in addition to ECs, a population of contractile mesenchymal cells called *pericytes*. Unlike veil cells, pericytes are an integral component of the vessel wall. They extend long cytoplasmic processes over the abluminal surface of the ECs and make interdigitating contacts. The coverage of ECs by pericytes varies considerably among different microvessel types, and the location of pericytes on the microvessel is not random but appears to be functionally determined. At points of contact, communicating gap junctions, tight junctions, and adhesion plaques are present. Specifically in the postcapillary venule, there is an intimate interdigitation between pericytes and ECs, with one pericyte making contact with two to four ECs.

Because pericytes are rich in contractile proteins and have complex interdigitations with ECs in postcapillary venules, it is assumed that they are responsible, at least in part, for gap forma-

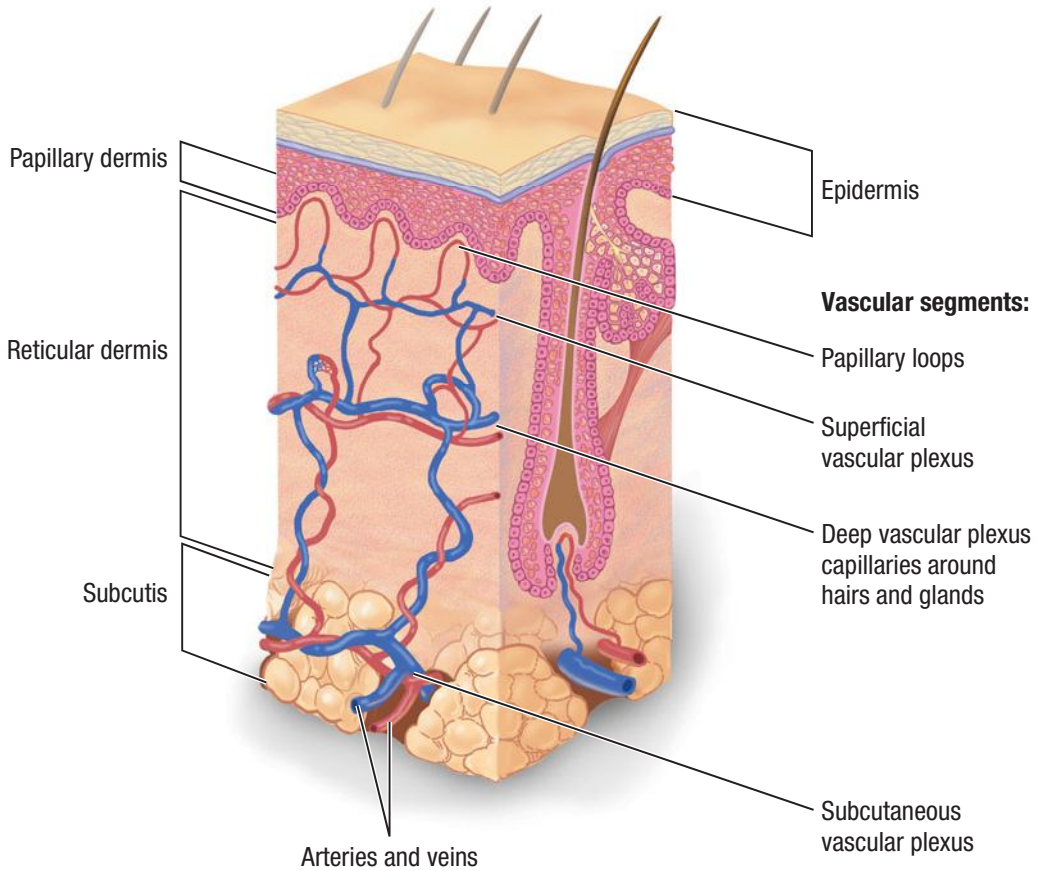

▲ **FIGURE 163-2** Schematic diagram of the architecture of the skin vasculature.

tion in response to, for example, histamine or bradykinin (although cultured ECs are capable of contraction in the absence of pericytes). Moreover, interaction between pericytes and ECs is important for the maturation, remodeling, and maintenance of the vascular system via the secretion of growth factors or modulation of the extracellular matrix. There is also evidence that pericytes are involved in the transport across the blood-brain barrier and the regulation of vascular permeability.

MORPHOLOGY AND MOLECULAR MARKERS

General Morphology

ECs usually appear as flattened epithelium-like cells, with a thickness typically less than 10 μm and a surface area covering up to 1000 μm^2 (see Fig. 163-1). In large vessels, ECs have an elongated shape, especially in regions of laminar flow, and have their long axis oriented in the direction of blood flow. ECs located in regions of disturbed flow (i.e., at branch points of the arterial tree) are often polygonal rather than elongated. Cultured ECs are typically polygonal but elongate when flowing medium is passed over them for periods of 24 hours or more.[4] These observations led to the conclusion that shear stress, the force imparted by viscous drag of flowing liquid, is responsible for inducing a cytoskeletal rearrangement and the change of shape from polygonal to elongated. Interestingly, the microtubular organizing center of ECs, located near the nucleus, is always oriented toward the heart (i.e., upstream of the nucleus in arteries and downstream of the nucleus in veins) regardless of the direction of blood flow.[5] The basis for this phenomenon is unknown. Moreover, ECs have an apical/luminal polarization, integrin receptors for matrix macromolecules are concentrated on the basal/abluminal surface, and adhesion molecules for leukocytes are almost exclusively displayed on their apical surface, which faces the lumen of the blood vessel.[6]

Specialized Organelles of Endothelial Cells

The ultrastructure of a postcapillary venule is shown in Fig. 163-3. ECs have a number of characteristic organelles. The best described are Weibel-Palade bodies (WPBs), fenestrae, and the caveolar system. WPBs are elongated, membrane-bound organelles that display longitudinal striations by electron microscopy. WPBs are distributed randomly throughout the cytoplasm in vascular ECs of most vertebrates. WPBs constitutively contain vWF (also called *factor VIII-related antigen*), P-selectin (CD62P),[7] lysosomal-membrane–associated glycoprotein 3 (or CD63),[8] 1,3-fucosyltransferase VI,[9] interleukin 8 (IL-8),[10] and angiopoietin 2.[11] The longitudinal striations within the WPBs are formed by highly polymerized forms of vWF, reaching sizes of up to 20,000 kd. On release, vWF polymers may attach to the basement membrane and stabilize platelet adhesion to the subendothelial matrix, particularly in high-velocity arterial flow. Although vWF is commonly used as an EC marker (see Molecular Markers of Endothelial Cells), it is also found in megakaryocytes, which appear to lack a physiologic mechanism of release, synthesizing vWF only for storage within the α granules of their platelet progeny. P-selectin is rapidly translocated to the cell surface as the WPB fuses with the plasma membrane, where it mediates leukocyte adhesion to ECs (see Leukocyte Adhesion). CD63 is a

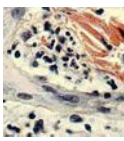

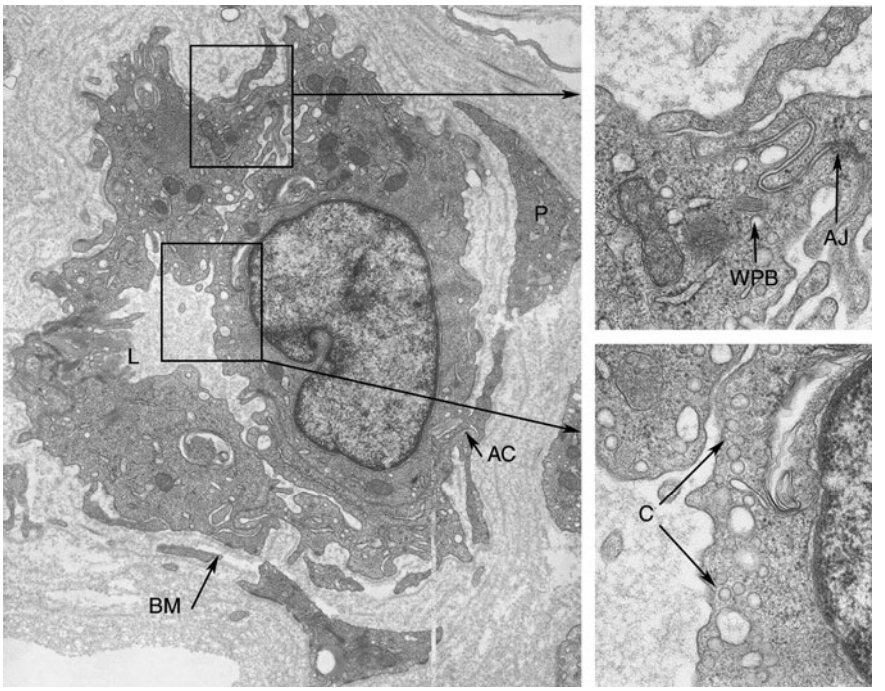

▲ **FIGURE 163-3** Ultrastructure of a postcapillary venule. AC = area of contact between endothelial cell and pericyte; AJ = adherens junction; BM = basement membrane; C = caveolae; L = lumen; P = pericyte; WPB = Weibel-Palade body.

53-kd lysosomal membrane glycoprotein belonging to the tetraspanin superfamily; its function in the WPB is unknown.

Blood vascular ECs usually form a continuous monolayer, and most transendothelial transport takes place in the junctions between cells. One important exception is in the fenestrae of capillaries in lymph nodes, capillaries in the intestinal mucosa, renal glomerular ECs, and hepatic and bone marrow sinusoids. Fenestrae are 175 nm in diameter, are grouped into structures resembling sieve plates, and occupy 6 percent to 8 percent of the surface capillaries. They are specialized annular patches of attenuated cytoplasm and membrane characterized by an increased concentration of anionic lipids.[12] Fenestrated capillaries are much more permeable to water and small-molecular-size solutes than those of the continuous type. The anionic charge probably precludes the trans-fenestral passage of anionic plasma proteins. Fenestrae are unique to ECs. Various factors, such as pressure, alcohol, serotonin, nicotine, and infection, change the number and diameter of fenestrae. However, even ECs of the continuous type may become transiently fenestrated.

All ECs appear to contain numerous vesicles subjacent to the plasmalemma, both luminal and abluminal. Although such structures were originally interpreted as vesicles caught in the process of budding off or fusing to the membrane, on careful examination most of these vesicles turned out to have narrow tubular connections to the plasma membrane. These flask-shaped invaginations are called *caveolae*, literally "little caves," and are part of the surface membrane, either as a single caveola or as more complex racemose invaginations. In situ, they may account for 50 percent or more of the plasma membrane surface area of ECs. Caveolae are made in a late Golgi compartment and represent a stable membrane unit built up around caveolins, cholesterol, and glycosphingolipids. ECs are rich in caveolins 1 and 2, whereas cardiac myocytes and skeletal muscle fibers express caveolin 3. The lipid constituents of caveolae are the same as those of lipid rafts, but the latter lack caveolins and are flat. Caveolins bind to cholesterol and are required for caveolae formation; for example, the expression of caveolin 1 in cells normally lacking caveolae causes the formation of caveolae. Surprisingly, cultured ECs normally retain expression of caveolin 1 but lose their caveolae, with cholesterol and glycosphingolipids dispersing into submicroscopic lipid rafts on the now simplified plasma membrane.

Caveolae serve for vesicular transport and represent a platform for the assembly of signaling complexes at the surface of the cell. Caveolins interact with a variety of downstream signaling molecules, including Src-family of tyrosine kinases, p42/44 mitogen-activated protein kinase, and endothelial NO synthase (eNOS). They hold these signal transducers in the inactive conformation until activation by an appropriate stimulus. For example, the amount of caveolin is inversely related to NO production by eNOS.[13] Mice lacking caveolin 1 have impaired NO and calcium signaling in the cardiovascular system, which causes aberrations in EC-dependent relaxation, contractility, and maintenance of myogenic tone.[14]

Caveolin 1 is associated with a number of growth factor receptors. For these receptors, the invaginated structure of caveolae provides an optimal environment for receptor function, forming a more stable signaling complex and allowing for cross-talk with other receptors. The entire structure is stabilized by the caveolar coat, a function that results in reduced endocytosis and a more prolonged signal. The epithelial growth factor (EGF) receptor was one of the first receptors shown to be enriched in the caveolin-containing, low-density fraction of cells. Subsequently, it was shown that the high-affinity nerve growth factor receptor (TrkA), the insulin receptor, the platelet-derived growth factor (PDGF) receptor, and transforming growth factor (TGF) receptors I and II also associate with caveolae.[15] In addition, cytokine receptors like the tumor necrosis factor (TNF) receptor 1 (CD120a) also localize to caveolae.[16]

Endothelial Junctions

Neighboring ECs connect to each other by forming interdigitating protrusions connected by junctions. Junctions possess different degrees of complexity along the vascular tree, reflecting different permeability for proteins and cells. Intercellular tight (occluding) junctions constitute the anatomic basis for the tightly regulated interfaces of the blood-testis and blood-brain barriers.[17] They consist of a continuous belt-like meshwork of six anastomosing junctional strands, which prevent the transport of macromolecules into the tissue. The transmembrane protein occludin, linked to ZO-1 cytoplasmic proteins, appears to provide the molecular basis of this function. In addition, junctional adhesion molecules, called *JAMs*, members of the immunoglobulin superfamily, form homophilic adhesion sites in tight junctions and play a role in the generation of cell polarity, keeping luminal proteins from diffusing to the abluminal cell surface and vice versa.[18] Arterial

ECs also possess tight junctions; however, they consist of only one or two junctional strands. Tight junctions are virtually absent in postcapillary venules.

Adherens junctions are found in all vascular ECs (see Fig. 163-3). They are multimeric protein structures principally organized by CD144 [also called *cadherin 5* or *vascular endothelial cadherin (VE-cadherin)*]. Other junctional proteins may be recruited into this structure by association to VE-cadherin such as CD31 (also called *platelet/endothelial cell adhesion molecule 1* or *PECAM-1*)[19] or junctional adhesion molecule C (*JAM-C*). These adherens junction proteins appear to be involved in three different cell functions. First, they participate in capillary tube formation. Indirect evidence for the role of the transmembrane molecules PECAM-1 and VE-cadherin in vessel formation comes from investigations of malignant endothelial tumors with primitive or abortive vascular (luminal) differentiation, which have little to no VE-cadherin or PECAM-1 expression. Blocking VE-cadherin and PECAM-1 interactions with monoclonal antibodies inhibits vessel formation.[20] VE-cadherin–negative ECs derived by gene targeting fail to organize in vessel-like structures.[21] Whereas VE-cadherin appears critical for initial formation of blood vessels, for maintenance and remodeling of blood vessels a receptor-type phospho-tyrosine phosphatase called *VE-PTP* appears essential. VE-PTP binds to VE-cadherin via the extracellular domain and supports adhesive functions of VE-cadherin.[22] Second, PECAM-1 and VE-cadherin participate in the regulation of leukocyte transendothelial migration. Third, PECAM-1 and VE-cadherin may indirectly regulate cell growth by regulating the free cytoplasmic pool of β-catenin. ECs also express a neuronal cadherin, N-cadherin. However, this protein is localized outside the junction and appears to be nonfunctional.

The existence of a third type of junction in ECs has been demonstrated by transfer of microinjected small-molecular-weight tracers between adjacent ECs, which indicates the presence of gap junctional interendothelial communications. In EC, the gap junctional proteins are connexin-43, connexin-37, and connexin-40. Interestingly, ECs also may form hetero–gap junctions with pericytes or smooth muscle cells in the vessel wall and sometimes with adherent leukocytes.

A fourth kind of junction is particularly abundant in EC-related stellate cells that form the three-dimensional filter meshwork of the lymph node sinus. Stellate cells do not form a normal endothelial layer but are characterized by numerous thin filopodia-like processes forming a closely interwoven meshwork. They are connected by cell junctions with a unique molecular composition and are called *complexus adhaerens*. In lymph nodes they are integrated into a larger structural system termed *syndesmos*. They contain VE-cadherin, α- and β-catenin, protein $p120^{ctn}$, afadin, desmoplakin and plakoglobin, and tight junction proteins claudin-5 and ZO-1.

Endothelial Cell–Matrix Interactions

ECs rest on a basal lamina, which is formed by EC itself and by surrounding cells. It consists of laminin-1, collagens, fibronectin, nidogen (entactin), and heparan sulfate proteoglycans. Interaction with these matrix molecules is essential for maintaining normal endothelial function. For example, the laminin A chain peptide supports endothelial branching and formation of new capillaries.[23] Furthermore, a 20-kd C-terminal fragment of collagen XVIII specifically inhibits endothelial proliferation and angiogenesis,[24] which suggests that collagen XVIII is also a positive regulator of vessel growth. On the other hand, EC–collagen V interactions inhibit endothelial attachment and growth. ECs interact with these components of the basal lamina by numerous transmembrane adhesion molecules. The complexities of these interactions have only been partially characterized. Members of the integrin family are particularly important for this function. For example, $\alpha_6\beta_1$, $\alpha_2\beta_1$, $\alpha_5\beta_1$, and $\alpha_V\beta_3$ receptor complexes are important for endothelial attachment to, and migration on, laminin, collagen, and tenascin, and therefore serve important roles in angiogenesis. In addition, integrin binding to matrix proteins also has a multitude of intracellular effects on the organization of the endothelial actin skeleton and on signaling processes within the cell.[25] Endothelial cell growth factors have been shown to differentially upregulate the biosynthesis of α_2, α_5, β_1, and β_3 integrins, serving the different needs of endothelium during growth, spreading, and new vessel formation. Moreover, integrins show certain tissue- and vessel-restricted expression; for example, $\alpha_1\beta_1$ is found only in small blood vessels and capillaries but not in large-vessel ECs. Matrix proteins such as thrombospondins may also serve as inhibitors of angiogenesis.[26]

Molecular Markers of Endothelial Cells

ECs display a number of molecular markers that result in a characteristic profile detectable with antibodies, lectins, and other ligands (Table 163-1). In addition to containing molecules expressed on all endothelium, the skin vasculature shows several site-specific characteristics. Postcapillary venules of the SVP are $CD36^-$ and thus distinct from capillaries of the DVP and from capillaries of other tissues, which are $CD36^+$.[27] CD36 antigen is a cellular receptor for thrombospondin, collagen, low-density lipoproteins, long-chain fatty acids, and platelet-agglutinating protein p37.[28] Moreover, CD36 functions as one of the receptors that mediates the adhesion of *Plasmodium falciparum*–infected erythrocytes to microvascular EC. The functional consequences of the disparate CD36 expression on SVP and DVP endothelium are unknown. Microvessels are best characterized by expression of the PAL-E (pathologische anatomie Leiden-endothelium) antigen (which is identical with plasmalemmal vesicle 1 or fenestrated endothelial-linked structure protein),[29] N-cadherin, and CXCR4, and by their surrounding by smooth muscle actin–positive cells. This distinguishes them from lymphatic vessels, which express prospero-related homeobox 1, lymphatic vessel endothelial hyaluronan receptor 1, podoplanin, beta-chemokine receptor D6, and vascular endothelial growth factor receptor 3 (VEGFR-3).

Postcapillary venules of the skin express Toll-like receptor (TLR) family members and CD32 molecules (FcγRIIa).[30] CD32 binds complexed immunoglobulin G and is thought to function in the elicitation of type III (immune complex–mediated) hypersensitivity as well as in immune complex clearing. ECs of postcapillary venules express significantly higher levels of the histamine H_1 receptor than other ECs. Histamine produces increased albumin leakage and induces rolling of leukocytes, mediated in part by P-selectin expressed on the EC surface. Proteinase-activated receptor 2 expression at this site also plays a role in inflammatory reactions. Proteinase-activated receptor 2–activating peptides increase leukocyte rolling and adhesion to postcapillary venules. Finally, postcapillary vessels of the skin in situ constitutively express major histocompatibility complex (MHC) class I and II molecules at their luminal surfaces, which implies that ECs may directly participate in the

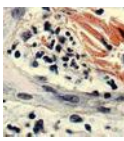

TABLE 163-1
Molecular Markers of Endothelium

Marker	Location/Function	Expression Profile
vWF	WPB, biosynthetic organelles (Golgi, ER)	EC, megakaryocytes, platelets
CD31	Adhesion molecule, transmigration	EC, platelets, leukocytes
CD143 (angiotensin-converting enzyme)	Secreted then bound to cell surface	EC, macrophages
CD141	Anticoagulant thrombomodulin	EC, trophoblast of the placenta
Reactivity with the lectin UEA-1	Blood group H antigens	EC, erythrocytes, specialized epithelia
VEGFR-1 and VEGFR-2	Receptor tyrosine kinase	EC, macrophages, hematopoietic stem cells, motor neurons (R2)
Tie-1 and Tie-2	Receptor tyrosine kinase	EC, hematopoietic stem cells, peripheral nervous tissue (Tie-2)
ICAM-2	Adhesion molecule	EC
CD40, CD54, CD58, CD105	—	EC, broad expression pattern
CD9, CD13, CD31, C1q and C5a receptors, complement regulatory proteins	Common embryologic origin of the angioblast and the hematopoietic stem cell	EC, hematopoietic cells
CD26, CD40, CD44, CD47, CD54, CD58, CD146	—	EC, broadly expressed on other cell types
Class II MHC molecules	Antigen presentation	Constitutive on skin and kidney microvessels
Endoglin (CD105)	Surface receptor	EC, stromal cells
PAL-E antigen	Caveolae	Microvessels and veins
CD34	Proteoglycan, adhesion molecule	Microvessels, hematopoietic cells
CD36	Proteoglycan	Microvessels except brain and some skin ECs
CD32	Fc receptor	Liver and skin microvessels, leukocytes
P-selectin	Pre-stored in WPB	EC
VCAM-1 (CD106)	Inducible adhesion molecule	EC, macrophages, follicular-dendritic cells
E-selectin (CD62E)	Inducible adhesion protein	EC
MAdCAM-1	Adhesion molecule, sialomucin	Microvessels of intestine and breast
GlyCAM-1	Adhesion molecule, sialomucin	Lymph nodes, high endothelial venules
Peripheral node addressins (antibody MECA-79)	L-selectin ligands	EC of peripheral nodes and skin
ICAM-3	Adhesion molecule	Tumor vessels

EC = endothelial cell; ER = endoplasmic reticulum; GlyCAM = glycosylation-dependent cell adhesion molecule; ICAM = intercellular adhesion molecule; MAdCAM = mucosal addressin cell adhesion molecule; MHC = major histocompatibility complex; PAL-E = pathologische anatomie Leiden-endothelium; UEA = ulex europaeus agglutinin; VCAM = vascular adhesion molecule; VEGFR = vascular endothelial growth factor receptor; vWF = von Willebrand factor; WPB = Weibel-Palade body.

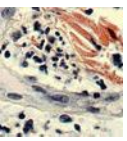

elicitation of antigen-driven immune responses. As discussed later (see Role of Endothelium in Adaptive Immunity), skin microvessels in cell culture appear able to process and present antigen in an MHC-restricted manner to T cells.[31]

ENDOTHELIUM IN INFLAMMATION

Innate Immunity

Innate immunity, also called *natural* or *native immunity*, comprises the host's defense systems against microbes that are independent of T and B lymphocytes and their receptors for specific antigens (see Chap. 10). The innate immune system is much older in evolutionary terms than the T- and B-cell–specific immune system (often called *adaptive immunity* to distinguish it from innate immunity), and elements of innate immunity have been found in invertebrates such as sponges and starfish. The humoral component primarily involves the complement system. The primary cellular effectors of innate immunity in humans are neutrophils, mononuclear phagocytes, and natural killer cells, but ECs also participate. For example, exposure to lipopolysaccharide, a major cell wall constituent of Gram-negative bacteria, results in endothelial activation through a receptor complex consisting of TLR-4, CD14, and MD2. Then, recruitment of the adaptor protein myeloid differentiation factor (MyD88) to the ligand-activated TLR-4 receptor initiates an MyD88-dependent pathway that culminates in the early activation of nuclear factor kappa B and the mitogen-activated protein kinases. In parallel, an MyD88-independent pathway results in a late-phase activation of nuclear factor kappaB.[32,33] ECs also express TLR-2, which serves as a signaling receptor for Gram-positive cell wall components, and intracellular TLRs that respond to various types of nucleic acids typically encountered during infections by viruses. Certain vascular beds express the macrophage mannose receptor (CD206), a receptor for oligosaccharides on the cell wall of bacteria, yeasts, and

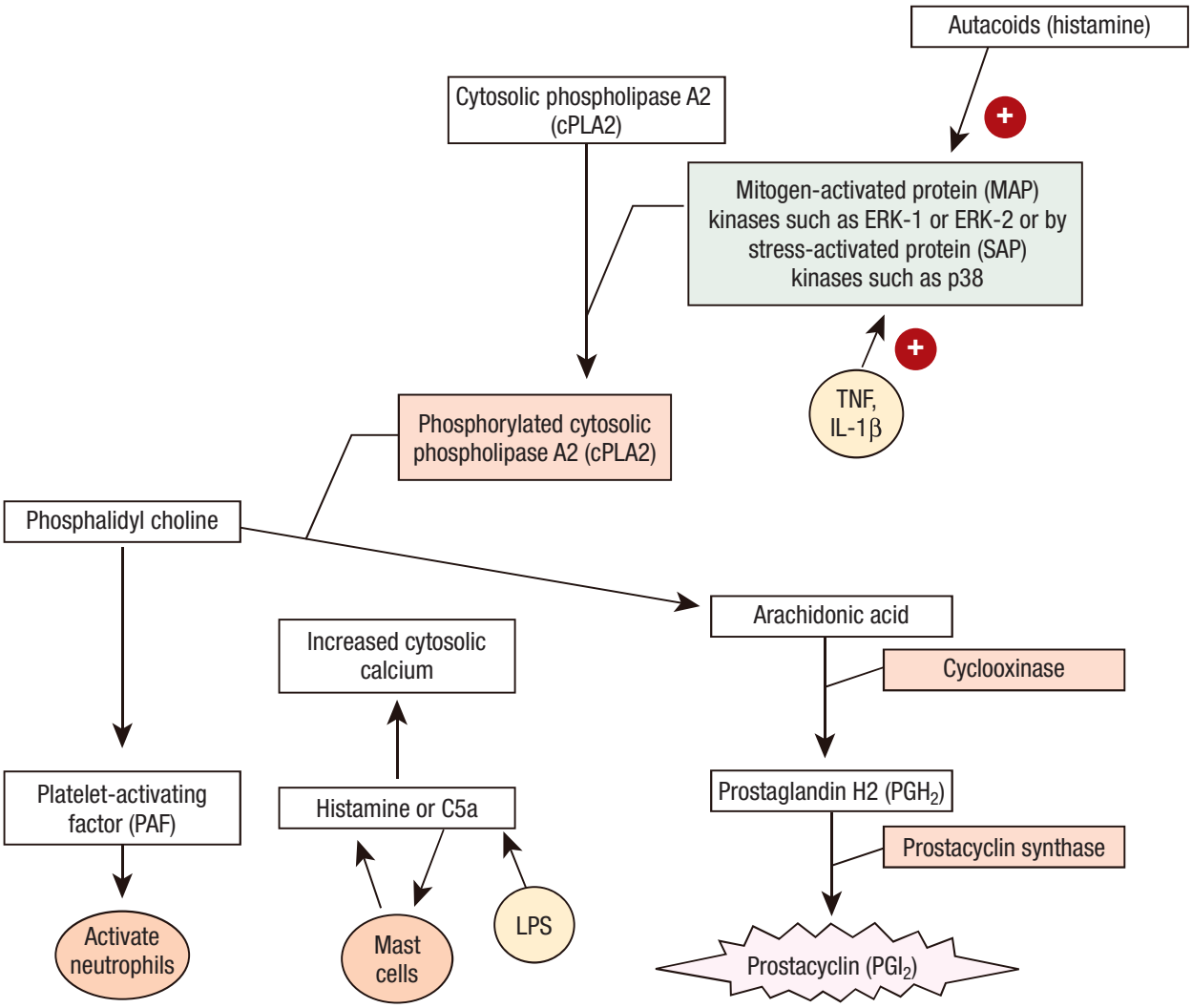

▲ **FIGURE 163-4** Prostaglandin I_2 (PGI_2) synthesis. ERK = extracellular signal–regulated kinase; IL = interleukin; LPS = lipopolysaccharide; TNF = tumor necrosis factor.

parasites. Other receptors of the innate immune system include a variety of lectin-type molecules, such as mannose-binding protein or galactins that recognize bacterial carbohydrates. Mannose-binding protein may stimulate the alternative pathway of complement activation.

TNF and IL-1β are central effector cytokines of the innate immune response. In general, endothelial responses to TNF and IL-1 are similar and are considered together. At least five changes in the phenotype of ECs that promote inflammation, collectively called *endothelial activation*, have been described.

SYNTHESIS OF VASODILATORS TNF- or IL-1β–treated ECs increase production of vasodilators such as PGI_2 and NO. They relax smooth muscle cell tension, thereby producing vasodilation and increasing tissue perfusion. PGI_2, also called *prostacyclin*, is synthesized in ECs by a series of three sequential enzyme-catalyzed reactions.[34] ECs express one isoform of prostaglandin H synthase, PGHS-1, also called *cyclooxygenase 1*, that is constitutively active. Treatment of ECs with TNF or IL-1β dramatically increases PGHS activity by inducing de novo expression of a second isoform, PGHS-2, which is also called *cyclooxygenase 2*. This response markedly increases the capacity to make prostaglandin H_2 from arachidonic acid and subsequently PGI_2 (Fig. 163-4). Pharmacologic reduction in the generation of PGI_2 is thought to contribute to the anti-inflammatory actions of aspirin and nonsteroidal anti-inflammatory drugs that inhibit PGHS activity. NO is produced by conversion of arginine to citrulline through eNOS (Fig. 163-5). Although TNF may reduce eNOS expression by destabilizing its messenger RNA, it also increases eNOS activity by inducing phosphorylation by protein kinase B (also known as *Akt*) and by increasing synthesis of necessary co-factors, such as tetrahydrobiopterin.

LEUKOCYTE ADHESION (Tables 163-2 and 163-3) TNF- or IL-1β–treated ECs exhibit changes in the cell surface that favor the initial capture, rolling, and, ultimately, firm adhesion and spreading of leukocytes (Fig. 163-6). Adhesion is a prelude to extravasation of leukocytes into the tissues. Capture and rolling are typically mediated by selectins expressed on the leukocyte or on the EC.[35] There are three structurally related selectin proteins: L-selectin (CD62L), E-selectin (CD62E), and P-selectin (CD62P). In the presence of flowing blood, the leukocyte is propelled in the direction of blood flow, rapidly breaking and reforming selectin-mediated attachments. This results in rolling of the leukocyte along the EC surface (see Fig. 163-6). It should be noted that the ligands involved in selectin-mediated adhesion that participate in the initial capture may not be the same as those involved in rolling; for example, neutrophils may switch from L-selectin to E-selectin ligand-1 as the principal E-selectin ligand during

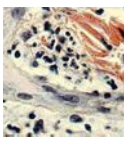

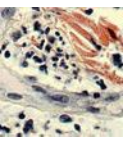

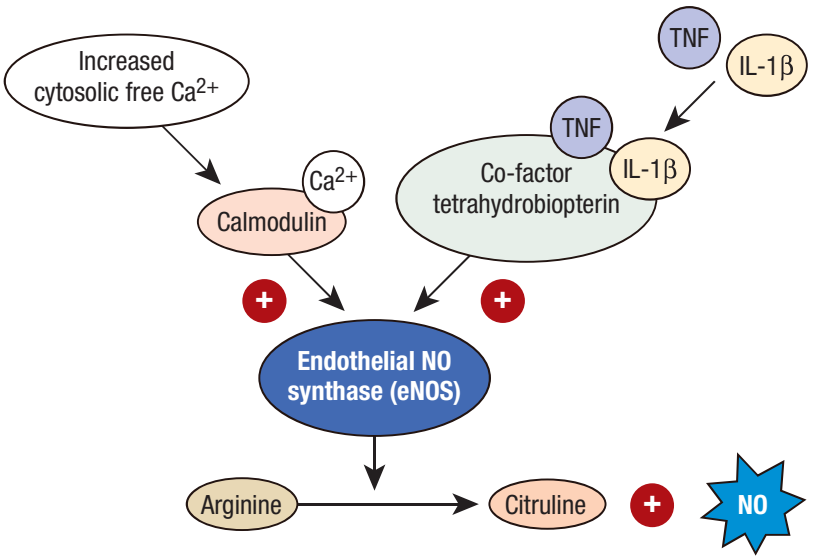

▲ **FIGURE 163-5** Nitric oxide (NO) synthesis. IL = interleukin; TNF = tumor necrosis factor.

these two phases of the interaction.[36,37] Studies using blocking monoclonal antibodies or adhesion molecule knockout mice have confirmed that selectins are required for neutrophil rolling and subsequent recruitment in vivo, although E- and P-selectin functions may be redundant (i.e., both molecules must be knocked out or inhibited for complete loss of rolling).

Firm adhesion of leukocytes to ECs is generally mediated by leukocyte integrins. Leukocytes use two different types of integrins to interact with ECs. The first of these are the CD18 or β_2 integrins, including lymphocyte function-associated antigen-1 ($\alpha_L\beta_2$ or CD11a/CD18) and Mac-1 ($\alpha_M\beta_2$ or CD11b/CD18). The adhesion mediated by LFA-1 or Mac-1 recognition of intercellular adhesion molecule 1 (ICAM-1) is much stronger than that mediated by selectins, so that once these molecules have engaged ICAM-1, leukocytes no longer roll. In the case of neutrophils, integrin engagement results in a gradual slowing of rolling velocity. In contrast, lymphocytes abruptly convert from rolling to firm adhesion. Once adherent, leukocytes spread out and then slowly crawl along the EC surface until they reach a cell junction, where they undergo diapedesis through the vessel wall into the tissues (see Fig. 163-6). It is likely that LFA-1–mediated attachment, disengagement, and reattachment to ICAM-1 play a role in the spreading, crawling, and diapedesis of leukocytes. Although ICAM-1 is initially (at 4 hours after treatment with TNF) upregulated diffusely on the luminal surface of the EC, it tends to preferentially localize to the intercellular junctions over the first few days.[6] Studies with blocking antibodies in knockout mice confirm that β_2 integrins and ICAM-1 play a major role in leukocyte adhesion to ECs and in subsequent recruitment.

The second group of integrins on leukocytes that mediate attachment to ECs are the α4 integrins (CD49d), which may pair with either β_1 (CD29) to form very late antigen-4 (VLA-4) ($\alpha_4\beta_1$) or with β_7 to form lymphocyte Peyer's patch adhesion molecule (integrin $\alpha_4\beta_7$). The principal EC ligand for VLA-4 is vascular adhesion molecule 1 (VCAM-1). This immunoglobulin superfamily mem-

TABLE 163-2
Adhesion Molecules

ADHESION MOLECULE	EXPRESSION	LIGAND	FUNCTION
Selectins			
L-selectin (CD62L)	Leukocytes	Sialylated and fucosylated carbohydrates displayed on, for example, CD34, MAdCAM-1, or GlyCAM-1	Tether, rolling
E-selectin (CD62E)	EC	Sialylated Lewis X or A moieties such as CLA displayed on ESL-1, L-selectin or PSGL-1[58]	Tether, rolling
P-selectin (CD62P)	EC, platelets	Glycans and sulfated sialomucins displayed on PSGL-1[95]	Tether, rolling
Integrins			
LFA-1 ($\alpha_L\beta_2$ or CD11a/CD18)	Leukocytes	ICAM-1, ICAM-2[96]	Firm adhesion, diapedesis
Mac-1 ($\alpha_M\beta_2$ or CD11b/CD18)	Leukocytes	ICAM-1[96]	Firm adhesion, diapedesis
VLA-4 ($\alpha_4\beta_1$)	Monocytes, T cells, eosinophils, and basophils	VCAM-1	Firm adhesion
LPAM-1 ($\alpha_4\beta_7$)	Lymphocytes	VCAM-1, MAdCAM-1, fibronectin	Adhesion
$\alpha_1\beta_1$, $\alpha_2\beta_1$	EC	Collagens, laminins	Angiogenesis
$\alpha_V\beta_3$, $\alpha_V\beta_5$	EC	Fibronectin, vitronectin, fibrinogen, osteopontin, TSP	Angiogenesis
$\alpha_5\beta_1$	EC	Fibronectin	Angiogenesis
Junctional Proteins			
PECAM-1 (CD31)	EC, leukocytes	PECAM-1	Transmigration
CD99	EC, leukocytes	CD99	Transmigration
JAM-1, JAM-2, JAM-3	EC	Integrins	Transmigration
VE-cadherin	EC	E1 fragments of fibrin	Transmigration

CLA = cutaneous lymphocyte antigen; EC = endothelial cell; GlyCAM = glycosylation-dependent cell adhesion molecule; ICAM = intercellular adhesion molecule; JAM = junctional adhesion molecule; LFA = lymphocyte function–associated antigen; LPAM = lymphocyte Peyer's patch adhesion molecule; MAdCAM = mucosal addressin cell adhesion molecule; PECAM = platelet/endothelial cell adhesion molecule; PSGL = P-selectin glycoprotein ligand; TSP = thrombospondin; VCAM = vascular adhesion molecule; VE-cadherin = vascular endothelial cadherin; VLA = very late antigen.

TABLE 163-3
Phenotype of Postcapillary Venules of the Superficial Vascular Plexus

Constitutive Markers in Normal Skin	Phenotypic Alterations in Acute Inflammation	Phenotypic Alterations in Chronic Inflammation
vWF	E-selectin (CD62E) high	E-selectin (CD62E) low
PECAM-1 (CD31)	P-selectin (CD62P)	P-selectin (CD62P)
CD34	VCAM-1 (CD106) low	VCAM-1 (CD106) high
VE-cadherin (CD144)	CXCR4 downregulated	MECA-79 reactive epitopes
N-cadherin	CCR10 high	HECA-452 reactive epitopes
PAL-E		
CXCR4		
CD32		
CCR10 low		
CD36 negative		

N-cadherin = neuronal cadherin; PECAM = platelet/endothelial cell adhesion molecule; PAL-E = pathologische anatomie Leiden-endothelium; VCAM = vascular adhesion molecule; VE-cadherin = vascular endothelial cadherin; vWF = von Willebrand factor.

ber is not expressed on resting ECs under normal circumstances but is upregulated by TNF or IL-1β with a time course similar to that observed for ICAM-1. VCAM-1 may be selectively upregulated by IL-4, a cytokine associated typically with certain types of adaptive rather than innate immunity. Although VCAM-1 expression is not responsive to interferon-γ (IFN-γ) itself, IFN intensifies TNF-induced VCAM-1 expression.[38] Interestingly, VCAM-1 may support initial tethering and rolling of some leukocytes (e.g., of T cells but not of neutrophils), as well as firm adhesion, depending on whether the affinity/avidity of the leukocyte VLA-4 is increased by leukocyte activation. Both VLA-4 and VCAM-1 knockout mice are embryonically lethal mutations and shed no light on inflammatory processes; however, antibody-blocking experiments confirm a role for these molecules in leukocyte recruitment in vivo.[39]

LEUKOCYTE ACTIVATION TNF- or IL-1β–treated ECs promote the activation of tethered or rolling leukocytes, triggering the transition from selectin-mediated low-affinity attachment to integrin-mediated firm adhesion and the transition from spherical, immotile leukocytes to spreading, migrating forms. In some experiments, engagement of selectins appears to be adequate by itself to trigger some of these changes, but most experiments indicate the requirement for a distinct signal. One candidate activator is the lipid mediator platelet-activating factor (PAF), which can be displayed in the EC plasma membrane. PAF synthesis is initiated by cytosolic phospholipase A2 activation, that is, the same reaction that provides arachidonic acid for PGI_2 synthesis. (In ECs, PAF contains acyl lipids rather than the alkyl lipids favored by leukocytes.) It has been reported that IL-1α (but not IL-1β) may promote PAF synthesis in ECs, but most studies emphasize the role of autacoids (e.g., histamine), rather than cytokines, as inducers of PAF synthesis.

The chemokines constitute an important group of TNF- or IL-1β–induced leukocyte activators that are defined by the presence and number of amino acids between two N-terminal cysteine residues (i.e., CC, CXC, etc.) (see Chap. 12). Chemokines induce migration and/or activation of various types of leukocytes through interaction with a group of seven transmembrane G protein–coupled receptors. The CXC chemokines (such as IL-8) are particularly important for neutrophil activation, and CC chemokines (such as MCP-1) are important for monocyte activation. IL-8 is stored in WPBs and released on stimulation with histamine or thrombin. Both IL-8 and MCP-1 are synthesized and secreted by TNF- or IL-1β–treated ECs. Furthermore, ECs can display their secreted chemokines in a complex with cell surface proteoglycans in a manner that renders them bioavailable to tethered or rolling leukocytes. The bound chemokines displayed by ECs could be made by ECs or could be captured and displayed once made by tissue cells or leukocytes. In addition, there is a transmembrane protein form of a chemokine called *fractalkine* that has its chemokine domain presented at the top of a mucin-like stalk. Fractalkine can be induced in vascular ECs and functions as an adhesion molecule. Accumulating evidence suggests that fractalkine mediates vascular injury in glomerulonephritis, allograft rejection, and atherosclerotic disease.[40–42] Chemokines may also play a role in activation and recruitment of specific lymphocyte subsets, as discussed later.

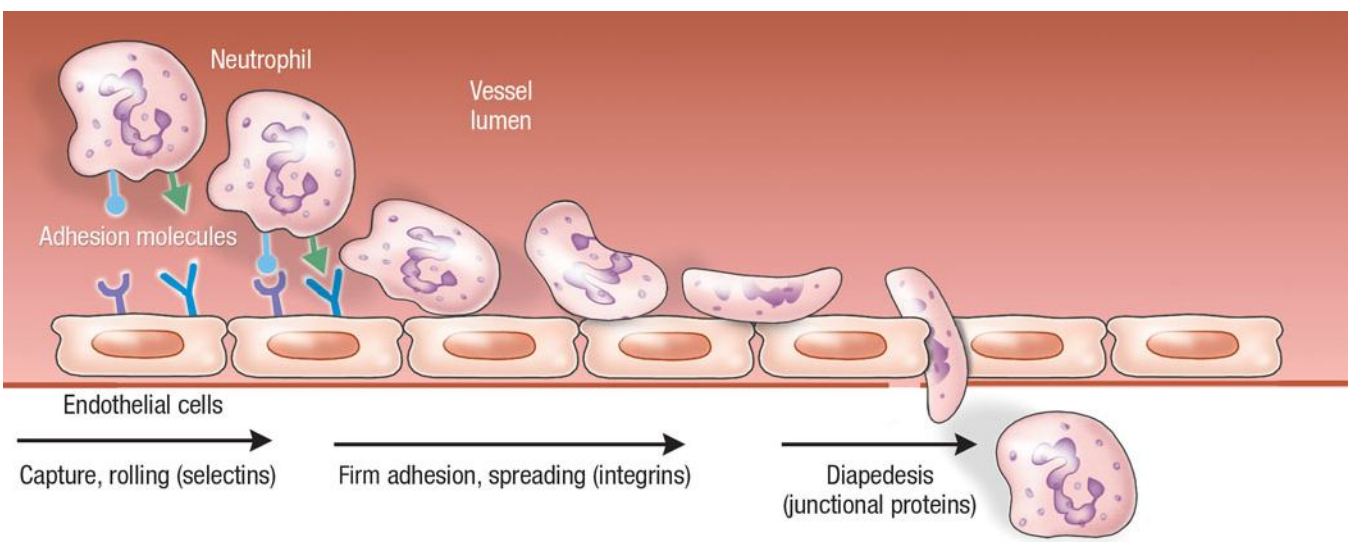

▲ **FIGURE 163-6** Leukocyte adhesion.

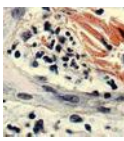

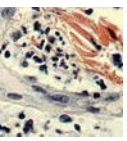

EXTRAVASATION OF LEUKOCYTES The interaction between TNF- and IL-β–treated ECs and leukocytes results in degradation of cellular and extracellular matrix barriers that normally separate leukocytes from the tissue space. The endothelial junctions contain proteins such as PECAM-1 (CD31) that appear to contribute to leukocyte transmigration, and as noted earlier, activated ECs also concentrate adhesive ligands, such as E-selectin, ICAM-1, and VCAM-1, at these same junctions. The details of interaction between leukocytes and ECs during diapedesis in vivo are incompletely defined. The principal pathway for extravasation appears to be through the intercellular junctions (see Table 163-2). Antibodies to PECAM-1 inhibit this process. However, in PECAM-1 knockout mice, effects on leukocyte transmigration appear to be mouse strain specific. The EC junctional protein CD99 plays a role in transmigration of monocytes and perhaps other types of leukocytes as well. VE-cadherin interacts with leukocytes through an interposed fragment of fibrin, which is formed through thrombin-induced fibrinogen activation followed by plasmin or urokinase digestion.[43] JAM proteins, also localized at endothelial junctions, interact with leukocytes by binding to integrins. The integrin LFA-1 mediates neutrophil and T-cell adhesion to JAM-1; the integrin $\alpha_4\beta_1$ mediates leukocyte adhesion to JAM-2. JAM-2–$\alpha_4\beta_1$ interactions appear to be dependent on interactions between JAM-2 and JAM-3. JAM-3 binds to CD11b/CD18 on neutrophils, and this interaction is thought to be important for neutrophil transepithelial migration.

In certain instances, leukocytes may extravasate through the EC body. The early stages of this process appear to involve phagocytosis of the leukocyte through membrane extensions enriched in ICAM-1 and VCAM-1. The factors that determine whether leukocytes use the intercellular or transcellular pathway are unknown. In addition, the rapid transmigration of T cells, but not other leukocyte subsets, appears to depend on the presence of venular levels of shear stress; the role that shear stress plays in this process is also unknown. TNF- or IL-1β–treated ECs secrete and activate matrix metalloproteinases (MMPs), which degrade the condensed region of connective tissue matrix, that is, the basement membrane that underlies the endothelial monolayer. ECs may also trigger leukocytes to synthesize or release MMPs, and the signals for this release may be cytokine-inducible molecules such as VCAM-1 or chemokines.[44]

VASCULAR LEAKAGE AND PROVISIONAL MATRIX Extravasation of plasma proteins into the tissue is a hallmark of inflammation. Autacoids such as histamine allow this to occur rapidly and transiently by causing ECs to contract their actin cytoskeleton, opening gaps between cells. VEGF may function similarly but also appears to have its primary effects on increasing fluid transit through vesiculo-vacuolar organelles. In contrast, TNF- or IL-1β–treated ECs permit the non-specific extravasation of fluid and plasma proteins, commonly called *vascular leak*, only after a delay of several hours in a process that depends on new protein synthesis. The loss of permselectivity (vascular leak) is a hallmark of inflammation. The principal purpose of this response is to allow plasma proteins, such as fibronectin and fibrinogen, to deposit in the tissues, where they form a provisional matrix that can be used by motile leukocytes. This is important because circulating leukocytes typically lack receptors that allow them to interact with the normal extracellular matrix, composed largely of interstitial collagens.

Collectively, these five TNF- or IL-1β–mediated responses of ECs promote the development of an inflammatory infiltrate initially comprised of neutrophils and later of mononuclear phagocytes. The infiltrating leukocytes serve to phagocytose the eliciting microbes and clean up damaged tissue. Infiltrating phagocytes also can cause tissue damage through the same mediators and enzymes they use to eradicate microbes (e.g., reactive oxygen intermediates, NO, and matrix-degrading enzymes such as elastase and MMPs). These mechanisms can and often do injure local ECs, which is manifested by EC retraction and/or denudation and often accompanied by intravascular thrombosis. Intravascular thrombi exacerbate tissue ischemia and injury. Fortunately, TNF- or IL-1β–treated ECs become more resistant to injury through expression of protective gene products such as detoxifying agents for reactive oxygen intermediates like manganese-superoxide dismutase and hemoxygenase; protease inhibitors like plasminogen activator inhibitor-1 and tissue inhibitors of metalloproteinases; and cytoprotective genes such as the zinc finger protein A20 and Bcl-related antiapoptotic genes such as A1. These protective responses allow ECs to survive many inflammatory reactions without triggering thrombosis and consequent tissue infarction.

The acquisition of cytoprotective features has been observed in the ECs of organ grafts that have evaded transplant rejection.[45] However, these protective responses are not always adequate. Moreover, some other TNF- or IL-1β–mediated endothelial responses, for example, induction of procoagulant proteins such as tissue factor coupled with loss of anticoagulant proteins such as thrombomodulin, may actually exacerbate tissue and vascular injury. This combination of neutrophil recruitment and activation with alterations in the endothelial coagulation system may underlie the tissue injury seen in the local Shwartzman reaction or in Gram-negative septicemia.

In summary, ECs, through their responses to cytokines, can contribute to host defense reactions mediated by the innate immune system. However, these same effector mechanisms may lead to endothelial injury and exacerbate tissue damage.

Role of Endothelium in Adaptive Immunity

As noted earlier in the chapter (see Molecular Markers of Endothelial Cells), ECs of microvessels constitutively express MHC molecules. To date, the only known function of class I and class II MHC molecules is to present peptides to T cells. Vascular ECs not only express MHC molecules but also express the proteins involved in generating peptides and loading these peptides into nascent class I and class II molecules.[46] The expression of class I genes (and the gene encoding the associated β2-microglobulin molecule), as well as the proteins involved in peptide generation and class I MHC molecule peptide loading, are all upregulated by cytokines, particularly by IFNs (IFN-α, IFN-β, and IFN-γ), and by TNF.[47] Under basal culture conditions human ECs do not express class II MHC molecules or the proteins responsible for peptide loading of class II molecules, but these proteins are induced by IFN-γ. In humans, class II molecules are basally expressed on microvascular cells in vivo.[47,48] It is unclear whether this "constitutive" expression depends on low levels of circulating IFN-γ or is truly constitutive.

The typical diameter of a capillary lumen is less than 10 μm; that is, nar-

rower than the diameter of a circulating lymphocyte. Consequently, circulating T cells are forced to encounter antigenic peptides complexed to both class I and class II MHC molecules displayed on the endothelial surface during the course of normal circulation. A key question is what effect this encounter has on the T cell. On recognition of peptide–MHC molecule complexes, T cells may become activated, may remain unchanged (a state called *immunologic ignorance*), or may become inactivated and unable to respond to future encounters (i.e., enter a state of anergy).

Studies of the consequences of T-cell recognition of antigen presented by ECs have largely used cell culture systems. In humans, such experiments often use the allogeneic response or polyclonal activators because the frequency of T cells specific for particular antigens is too low for most detection systems. In mice, investigators may use animals with transgenic expression of particular T-cell receptors so that every T cell can be stimulated by a single antigen or peptide. In vitro experiments using human cells suggest that naive T cells ignore antigens presented by ECs (or may become anergized), whereas resting memory T cells or recently activated T blasts respond by cytokine gene expression and a limited degree of proliferation. This limitation correlates with the observation that human ECs are deficient in expressing certain co-stimulatory molecules, for example, CD80 and CD86, and primarily co-stimulate T cells with LFA-3 (CD58).[49] Naive T cells poorly express CD2, the receptor for LFA-3. Another factor may be that naive T cells lack the expression of adhesion molecules necessary to attach firmly to ECs. In addition to constitutive expression of LFA-3, human ECs display inducible expression of ligands for inducible T-cell co-stimulator, CD137, and CD134 that are typically associated with the stimulation or reactivation of memory T cells.

Several non-exclusive roles have been proposed for presentation of antigen by ECs if it were to occur in vivo. The first is the maintenance of immunologic memory. Long-lived memory T cells may require periodic low-affinity signaling to survive, and the expression of MHC molecules bearing self-peptides by ECs may provide such low-affinity signals as these cells pass through the microcirculation. The second role might come into play when there is re-infection by a particular pathogen. In this case, ECs may present microbe-derived peptides in association with MHC molecules, providing an antigen-specific signal to circulating memory T cells that pathogen is present. This mechanism, if present, would serve to contribute to the efficiency of immune surveillance. This is a potentially important function, because T cells specific for any one antigen, even among memory T cells expanded by prior encounter with antigen, are rare (less than 1 in 10,000 to 100,000). Presentation of antigen by ECs could markedly increase the likelihood that antigen is recognized in a timely manner and that memory T cells are recruited to sites of danger. A third possibility involves the post-thymic induction and activation of $CD4^+25^+$forkhead box P3 regulatory T cells.[50] It has been shown that in mice alloantigen presentation by vascular ECs to $CD4^+$ T cells induces such regulatory T cells, which could be important for induction of tolerance. However, it must be noted that mouse ECs usually do not express class II MHC molecules in vivo and that cultured human T cells preferentially activate $CD4^+$ effector cells rather than regulatory T cells.

T cells may differentiate into specialized cytokine-producing subsets. For $CD4^+$ T cells, such responses may become polarized into T helper 1 (Th1) responses, dominated by T cells that produce IFN and lymphotoxin, or into T helper 2 (Th2) responses, dominated by T cells that produce IL-4 and IL-5. The Th1 subset favors recruitment and activation of mononuclear phagocytes and (in mice, at least) production of antibody isotypes that opsonize bacteria for phagocytosis. The Th2 subset favors recruitment and activation of eosinophils, favors production of antibody isotypes that target parasites for eosinophil-mediated killing, and triggers mast cells and basophils to release vasoactive mediators and cytokines. More recently, it has been appreciated that some effector $CD4^+$ T cells may selectively secrete IL-17, a pro-inflammatory cytokine, or IL-10 or TGF-β, inhibitory cytokines that downregulate T-cell responses. The biology of these T-cell subsets is less well understood.

It is possible that cytokines released by Th1 or Th2 cells differentially shape EC activation patterns. For example, IFN-γ combined with lymphotoxin causes prolonged expression of E-selectin, an important ligand for Th1 T cells. Th1 cells, but not Th2 cells, are able to bind to P-selectin and E-selectin, and migration of Th1 cells into inflamed skin is blocked by antibodies against P- and E-selectin.[51] P-selectin glycoprotein ligand 1 appears to functions as P- and E-selectin ligands for Th1 cells, which correlates with increased expression of the α3-fucosyltransferases in Th1 cells.[51,52] In contrast, Th2-derived IL-4 increases VCAM-1 expression while suppressing E-selectin, a cell surface molecule that favors eosinophil and possibly also Th2-cell recruitment. In other words, T cell–derived cytokines may modify the innate EC responses in a way that biases leukocyte recruitment toward recruitment of specific effector cells. Finally, differential expression of chemokine receptors may also account for selective recruitment of T-cell subsets. For example, CCR5 and, to a lesser degree, CXCR3 are preferentially found on Th1 cells, whereas CCR4, CCR8, and, more controversially, CCR3 and CXCR4 are preferentially found on Th2 cells.

SKIN MICROVESSELS IN INFLAMMATION AND REPAIR

Skin Microvessels in Cutaneous Inflammation

It is clear that vascular ECs are important participants in the development of inflammatory responses. It has now been elucidated that tissue-specific differences in ECs may partly determine the unique patterns of inflammation observed in different organs. One mechanism by which vascular ECs may contribute to tissue-specific inflammatory patterns is through distinctive patterns of adhesion molecule expression, which results in selective recruitment and diapedesis of circulating leukocytes bearing the proper ligands. In the skin, E-selectin, VCAM-1, and ICAM-1 may be particularly important in this process, and they have been extensively evaluated in normal and disease states[27,53–55] (see Table 163-3).

The induction of E-selectin appears to be particularly important in cutaneous inflammatory reactions. In addition to being readily inducible by cytokines and uniformly associated with leukocytic infiltration, E-selectin may play a role in the selective recruitment of lymphocytes to cutaneous sites of inflammation through binding to the cutaneous lymphocyte antigen (CLA).[56,57] CLA is a carbohydrate moiety on the surface of T cells closely related to sialylated Lewis X, which has homology to the core structure of P-selectin glycoprotein-1.[58] By using the identifying monoclonal an-

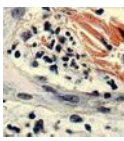

tibody HECA-452, CLA has been found on 80 percent to 90 percent of skin infiltrating lymphocytes compared with 5 percent to 10 percent at other peripheral sites. CLA is also present on circulating precursor Langerhans cells and presumably plays a role in their eventual localization to the skin. The expression of E-selectin in cultured dermal microvascular ECs is relatively persistent compared to endothelium derived from other sources. This persistent expression of E-selectin in vivo has been proposed to be responsible for the preferential homing of CLA-positive lymphocytes to the skin. Work in a chimeric human mouse model of inflammation suggests that CLA-positive lymphocytes specifically migrate through the superficial, as opposed to the deep, vascular plexus.[59] It is unlikely that E-selectin–CLA interactions alone are sufficient for the homing of lymphocytes to the skin. The transmigration of CLA-positive lymphocytes across activated ECs is dependent on interactions with VCAM-1 and ICAM-1, in addition to E-selectin.

The induction of E-selectin on cutaneous microvessels also appears to play a role in immediate hypersensitivity reactions in atopic individuals. These reactions are characterized by an immunoglobulin E–dependent biphasic response. Within minutes after exposure, the relevant antigen cross-links immunoglobulin E, which is bound to the high-affinity FcRε receptors on the surface of mast cells, and results in histamine release. Histamine-dependent stimulation of ECs leads to vasodilation and increased vascular permeability, which produces the classic wheal-and-flare response that typically resolves within 30 to 90 minutes. This reaction, known as the *early-phase response*, is not accompanied by endothelial E-selectin upregulation or inflammatory cell recruitment. The late-phase reaction begins 3 to 4 hours after antigen challenge and is characterized by the infiltration of eosinophils, neutrophils, and mononuclear cells into the inflamed area. Granulocytes are most prominent at 6 to 8 hours, and by 24 to 48 hours the cellular infiltrate consists largely of mononuclear cells. The expression of E-selectin, which indicates endothelial activation, is detectable at the onset of infiltration. Although this E-selectin induction may simply be due to cytokine release from infiltrating inflammatory cells, there is evidence that the necessary mediators are first released from skin-resident cells. In skin organ culture, the addition of antigen either before or during the culture period results in significant E-selectin expression without inflammatory infiltrate.[60]

VCAM-1 may play a role in the specific homing of leukocytes to the skin through binding to the integrin $\alpha_4\beta_7$ on the surface of lymphocytes. This integrin is associated with the specific localization of lymphocytes to the gut through binding to mucosal addressin cell adhesion molecule 1 (Madcam)-1 on ECs of intestinal microvessels.[55] Another ligand for $\alpha_4\beta_7$ includes fibronectin. $\alpha_4\beta_7$ has been found to be expressed on a high percentage of intraepidermal lymphocytes, particularly in cutaneous T-cell lymphoma (CTCL) and, to a lesser degree, in spongiotic dermatitis.[55] Interestingly, in CTCL, the expression of $\alpha_4\beta_7$ strongly correlated with the expression of integrin $\alpha_E\beta_7$. $\alpha_E\beta_7$ is also found on a high percentage of gut (intraepithelial) and intraepidermal lymphocytes.

In chronic inflammatory conditions such as psoriasis and CTCL, the cutaneous microvascular endothelium develops a "high endothelial venule" morphology similar to that seen in peripheral lymph nodes. This is accompanied by the expression of peripheral lymph node addressin identified by the antibody MECA-79, which serves as an L-selectin ligand. This has led to the speculation that peripheral node addressins in chronic T cell–mediated skin diseases are responsible for sustained lymphocyte recruitment. Interestingly, there is MECA-79 reactivity in the perifollicular vessels in noninflamed skin.[61] This constitutive expression in normal skin may serve a function in continuous lymphocyte recirculation.[62]

Chemokines also play a role in the selective homing of T cells to the skin. CCR4 is expressed at high levels by CLA-positive memory T cells. The CCR4 receptor TARC is constitutively expressed on ECs in cutaneous postcapillary venules. In vitro TARC triggers CLA-positive T cells that are rolling on E-selectin to firmly adhere ICAM-1. Another skin-associated chemokine, CCL27 (cutaneous T cell–attracting chemokine), is produced by keratinocytes and also preferentially attracts CLA-positive memory T cells.[63]

New Vessel Formation in the Skin

DEFINITION OF ANGIOGENESIS AND VASCULOGENESIS In the healthy adult, blood vessels are stable structures with very slow turnover of ECs. In settings of chronic inflammation, tissue injury, or tumor growth, new vessels may be formed and existing vessels may undergo remodeling. Much of the process of vessel formation has been learned by the study of the formation of the vascular system during embryogenesis. In the embryo, ECs arise from angioblasts,[64,65] which migrate from their site of origin (initially blood islands, later liver, and ultimately bone marrow) to peripheral tissues, where they form primitive blood vessels (vasculogenesis). Subsequently, new blood vessels arise from pre-existing ones (angiogenesis). Mesenchymal cells are then recruited into the vessel wall, where they subsequently differentiate into smooth muscle cells and pericytes, as part of a process called *vascular remodeling*. New vessels can be formed in the adult as part of chronic inflammation or as part of the repair of injured tissues. In the adult, most new vessels develop through angiogenesis, but this may be supplemented by hematogenic "seeding" of endothelial progenitor cells, mesoangioblasts, and multipotent adult progenitor cells derived from the adult bone marrow (vasculogenesis).[66,67] Transgenic and genetic knockout animal models have revealed that vasculogenesis and angiogenesis are largely regulated by growth factors and their specific receptor tyrosine kinases.[68]

REGULATION OF ANGIOGENESIS AND VASCULOGENESIS (Table 163-4) Molecules of the VEGF family, VEGF A through E, and their receptors, VEGFR-1 (Flt-1), VEGFR-2 (KDR or Flk-1), and VEGFR-3 (Flt-4), are required to initiate the formation of primitive vessels. Mice with a targeted disruption of VEGF or VEGFR-2 genes fail to develop a vasculature. VEGFR-1 knockout mice have immature leaky vessels. Disruption of VEGFR-3 results in the disorganization of large vessels and lymphatic hypoplasia. A missense mutation in VEGFR-3 occurs in primary human lymphedema.[68–70] Fibroblast growth factors 1 and 2 (FGF-1 and FGF-2, also called *acidic* and *basic FGF*, respectively) mainly signal through FGF receptor I.[71] Knockout mice die before vasculogenesis starts; thus specific evaluation of FGF function in vascular development is not possible in these animals. Both FGF-1 and FGF-2 are potent EC mitogens but also act on smooth muscle cells and fibroblasts. FGFs "synergize" with VEGF in stimulation of cultured EC mitogenesis and in bioassays of angiogenesis. In the adult, FGF-1 and FGF-2 are stored in the cytoplasm of a variety of cells, which is consistent with the fact that these proteins lack the signal sequences required for efficient secretion. Stored FGFs are released when cells are injured, acting as "wound hormones" to

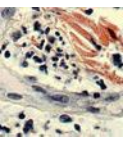

TABLE 163-4
Molecules Important in Vasculogenesis and Angiogenesis

MOLECULE	FUNCTION	RECEPTOR
VEGF family • Five splice variants (VEGF A–E) • Homolog PlGF	Specific mitogen for ECs	Family of closely related receptor tyrosine kinases • VEGFR-1 (Flt-1) binds VEGF A and B, PlGF • VEGFR-2 (KDR or Flk-1), main mediator of VEGF-induced vascular development and angiogenesis, binds all isoforms of VEGF • VEGFR-3 (Flt-4) binds VEGF C and D
FGF-1 and FGF-2	Involved in vasculogenesis and angiogenesis in embryonic development	FGFR-I
Angiopoietins • Ang-1 • Ang-2 • Murine Ang-3 • Human Ang-4	Ang-1 positively affects vascular stability Ang-2 is a competitive inhibitor of Ang-1	Tie-1 and Tie-2 receptor tyrosine kinases • Tie-2 mediates dialog between primitive mesenchymal cells and EC of immature vessels • Tie-1 ligands not known
PDGF	Secreted by ECs, acts on mesenchymal cells to promote migration, matrix biosynthesis, and differentiation	Receptor tyrosine kinase
TGF-β	Secreted by ECs, acts on mesenchymal cells to promote migration, matrix biosynthesis, and differentiation	Protein serine/threonine kinase Endoglin (CD105) important for vascular development
TSP-1	Anti-angiogenic, inhibits MMP-9, activates TGF-β	Integrin $\alpha_V\beta_3$ CD36

Ang = angiopoietin; EC = endothelial cell; FGF = fibroblast growth factor; FGFR = fibroblast growth factor receptor; KDR = kinase insert domain protein receptor; MMP = matrix metalloproteinase; PDGF = platelet derived growth factor; PlGF = placental growth factor; TGF = transforming growth factor; TSP = thrombospondin; VEGF = vascular endothelial growth factor; VEGFR = vascular endothelial growth factor receptor.

stimulate local angiogenesis and connective tissue growth.[71] Other polypeptide factors have also been found to act on ECs in vivo and in vitro, including epidermal growth factor,[72] heparin-binding EGF–like growth factor,[73] and hepatocyte growth factor (HGF)/scatter factor (SF).[74]

For vascular remodeling and stabilization, tyrosine kinase receptors 1 (Tie-1) and 2 (Tie-2; Tek) are required. Tie-2 mediates the dialogue between mesenchymal cells and the endothelium of the immature blood vessel through binding to angiopoietins (Ang-1, Ang-2, murine Ang-3, and its human ortholog Ang-4). In humans, Tie-2 mutations cause venous malformations typified by enlarged vascular channels lacking smooth muscle cells. Ang-2 appears to be a competitive inhibitor of Ang-1, and Ang-2 overexpression results in a phenotype resembling an Ang-1 knockout animal.[75] Ligands for Tie-1 are not known, but knockout of this receptor results in defective vascular maturation later in embryonic development.[68,76] The eph family of receptor tyrosine kinases (ephA1 to ephA8 and ephB1 to ephB6) and their corresponding ephrin ligands (ephrin-A1 to ephrin-A5 and ephrin-B1 to ephrin-B3) are membrane bound and appear to mediate bidirectional cell-to-cell signaling. Mice lacking ephrin-B2 and its ephB4 receptor have lethal defects in early angiogenic remodeling.[77] During vascular development ephrin-B2 marks the ECs of early arterial vessels and ephB4 marks the ECs of early veins.[78]

PDGF and TGF-β are secreted by ECs and promote migration of mesenchymal cells, matrix biosynthesis, and differentiation.[79] PDGF acts through a receptor protein tyrosine kinase; TGF-β signals through a protein serine/threonine kinase. TGF-β also uses nonsignaling receptors that present TGF-β to the signaling receptor, for example, endoglin (CD105). A truncation mutation in the endoglin gene in humans causes a hereditary form of vascular malformations (hereditary hemorrhagic telangiectasia type I)[80] and endoglin knockout mice die of defective vascular development.

Matrix glycoproteins such as fibronectin and laminin and receptors for matrix glycoproteins such as β_1 and β_3 integrins are also believed to play a role in vasculogenesis and angiogenesis.[81] This seems intuitive, because neither ECs nor mesenchymal cells can survive unless they interact with matrix proteins via integrin receptors. Knockout of most of these molecules causes early embryonic death, which prevents a direct test of their role in vascular embryology. An exception is the β_3 integrin knockout mouse, which shows normal development but enhanced tumor angiogenesis. Coagulation factors, like tissue factor or coagulation factor V, are implicated in vasculogenesis by observations of defective vascular development in knockout mice.[82] It is thought that these defects are an indirect result of defective thrombin production, because knockout of the thrombin receptor PAR-1 produces similar phenotypes.

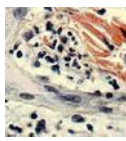

CUTANEOUS ANGIOGENESIS AND VASCULOGENESIS Cutaneous angiogenesis and vasculogenesis occur in wound healing, inflammation, and tumorigenesis. New vessel formation in the skin differs in several ways from that in other organs. Skin harbors hair follicles, which, besides having a role in forming hair shafts, appear to play a role in new vessel formation. The follicle contains a distinct population of presumptive follicular stem cells that express nestin, also a marker for neural stem cells. These nestin-expressing follicle cells are located in the follicular bulge region. During the follicular growth cycle, they differentiate into the various cell types of the hair follicle and, in addition, can form a variety of epidermal cells. It has been shown that these nestin-positive cells can also develop into cutaneous blood vessels that originate from hair follicles and form a follicle-linked vascular network. The quantitative contribution of hair follicle–derived angiogenesis compared with conventional angiogenesis through local sprouting and/or hematogenic seeding of endothelial progenitors is still unknown.

Skin endothelium is also unique by virtue of its close proximity to keratinocytes, which form the overlying epidermis coating. Keratinocytes have been shown to express a wide range of angiogenic factors, including members of the fibroblast or TGF protein family, platelet PDGF, or VEGF.[83,84] Under conditions of injury, hypoxia, or inflammation, keratinocytes produce and release these growth factors. Concomitantly, VEGFR-2 is upregulated on ECs, which augments endothelial responses to VEGF.[85] Ang-1 and Ang-2 are also upregulated during in-

jury, which is consistent with the role they are thought to play in the destabilization, followed by stabilization, of the vasculature. This allows a window for VEGF-mediated sprouting and elongation, followed by Ang-1–mediated remodeling.[68] FGF-2 is released in cutaneous wounds and is derived from ECs and from infiltrating macrophages. Antibodies against FGF-2 inhibit wound angiogenesis nearly completely.[86]

Adhesion molecules are necessary for physiologic angiogenesis in the skin. The expression of integrin $\alpha_V\beta_3$ on the tips of growing capillaries appears to facilitate endothelial migration and to be required for wound healing. In an in vivo model in which human skin placed on immunodeficient mice was wounded, blocking antibodies directed to CD31 and VE-cadherin reduced wound vascularization and healing.[20] In a similar model, blocking antibodies directed against $\alpha_V\beta_3$ inhibited angiogenesis and wound healing.[87] Administering $\alpha_V\beta_3$ inhibitors reduces granulation tissue formation and wound-induced angiogenesis, which suggests that $\alpha_V\beta_3$ is required for proper wound healing. In contrast, mice lacking β_3 integrins show enhanced wound healing with complete re-epithelialization several days earlier than do wild-type mice,[88] apparently due to an increase in TGF-β1 and enhanced dermal fibroblast infiltration into wounds of β_3-null mice. This suggests that the role of β_3 integrins is complex and that these molecules may influence both angiogenic and anti-angiogenic effects.

Angiogenesis is also necessary in skin tumorigenesis to maintain adequate nutritive supply. Skin tumors are known to produce angiogenic factors such as VEGF, FGF-2, EGF, and HGF/SF.[89] Some of these growth factors play a role in the pathogenesis of both benign and malignant skin tumors. There is a significant vascular contribution to the growth and metastasis of cutaneous melanoma and increased number of vessels in primary melanomas compared with severely atypical nevi. This vascular proliferative response appears to be in part mediated by FGF-2, which is produced by melanoma cells. Antisense oligonucleotides directed against FGF-2 inhibit the proliferation of both primary and metastatic melanoma.[90] HGF/SF and VEGF are also produced by melanoma cells and also contribute to vascularization. Peptide growth factors also appear to play a role in the pathogenesis of vascular tumors. The spindle cells of Kaposi sarcoma also produce large amounts of VEGF (see Chap. 128). When human ECs are cultured in the presence of HGF/SF, they acquire a Kaposi sarcoma cell–like morphology. In hemangiomas high levels of FGF-2 and VEGF characterize the proliferative phase. However, there is also abundant FGF-2 expression in the involuting phase.

VASCULAR REMODELING IN THE SKIN Vascular remodeling plays a role in the pathogenesis of some inflammatory skin diseases, notably psoriasis (see Chap. 18). Psoriatic vessels become tortuous and elongated, and the normally well-defined boundary between capillary ECs resting on an arteriole-like homogenous basement membrane and ECs on a venule-like laminated basement membrane becomes unclear. The intrapapillary portions of capillaries acquire a venular phenotype.[91] It is unknown whether this is due to metaplasia from arteriolar to a venular endothelium or to an elongation of the postcapillary venule. Light-microscopic investigations on eruptive guttate psoriatic lesions demonstrated that vascular alterations are the first ultrastructurally detectable alterations within the dermal compartment. These alterations consist of gap formation within postcapillary venules, EC hypertrophy with a cuboidal shape similar to that seen in high endothelial venules, and compression of the vascular lumen, all of which precedes the invasion of inflammatory cells into the tissue.[91] This morphologic alteration is accompanied by altered endothelial function. For example, there is increased blood flow in perilesional psoriatic skin even in the absence of any microscopically detectable changes.[92] The role angiogenic factors play in vascular remodeling in psoriasis has been partly characterized. It has been suggested that these vascular alterations may, in part, be mediated by increased production of VEGF by keratinocytes. There is also increased expression of VEGFR-1 and VEGFR-2 on the papillary dermal microvascular ECs.[93] VEGF appears to directly upregulate expression of ICAM-1, VCAM-1, and E-selectin. The VEGF-mediated vascular leak and adhesion molecule upregulation can be inhibited by concurrent overexpression of Ang-1. The role of angiogenesis in inflammatory processes has been further exemplified by the anti-inflammatory effects of angiogenesis inhibitors.[94]

CONCLUSION

The skin vascular system is unique in several respects. It is organized into functionally distinct vascular segments: the loops within the tips of the papillae, the SVP and the DVP, and the subcutaneous vascular plexus. These segments may individually or conjointly respond to exogenous or endogenous stimuli, thereby influencing skin disease expression. Due to their proximity to the epidermis, ECs of the SVP may directly respond to keratinocyte-derived factors like cutaneous T cell–attracting chemokine or VEGF, which results in an altered vascular architecture, phenotype, and function. Moreover, skin EC may be directly exposed to environmental antigens. In this context, the constitutive expression of HLA class II molecules by postcapillary venules implies that ECs play a role in antigen presentation, which may increase the likelihood that antigen is recognized in a timely manner to efficiently recruit memory T cells to sites of danger.

KEY REFERENCES

The full reference list for all chapters is available at www.digm7.com.

1. Braverman IM: Ultrastructure and organization of the cutaneous microvasculature in normal and pathologic states. *J Invest Dermatol* **93**:2S, 1989
2. Braverman IM, Yen A: Ultrastructure of the human dermal microcirculation. II. The capillary loops of the dermal papillae. *J Invest Dermatol* **68**:44, 1977
27. Petzelbauer P et al: Heterogeneity of dermal microvascular endothelial cell antigen expression and cytokine responsiveness in situ and in cell culture. *J Immunol* **151**:5062, 1993
35. Pober JS, Cotran RS: Immunologic interactions of T lymphocytes with vascular endothelium. *Adv Immunol* **50**:261, 1991
37. Springer TA: Adhesion receptors of the immune system. *Nature* **346**:425, 1990
39. Albelda SM et al: Adhesion molecules and inflammatory injury. *FASEB J* **8**:504, 1994
47. Choi J et al: T lymphocyte–endothelial cell interactions. *Annu Rev Immunol* **22**:683, 2004
56. Berg EL et al: The cutaneous lymphocyte antigen is a skin lymphocyte homing receptor for the vascular lectin endothelial cell-leukocyte adhesion molecule 1. *J Exp Med* **174**:1461, 1991
63. Pober JS et al: Human endothelial cell presentation of antigen and the homing of memory/effector T cells to skin. *Ann N Y Acad Sci* **941**:12, 2001
68. Yancopoulos GD et al: Vascular-specific growth factors and blood vessel formation. *Nature* **407**:242, 2000
93. Detmar M et al: Overexpression of vascular permeability factor/vascular endothelial growth factor and its receptors in psoriasis. *J Exp Med* **180**:1141, 1994

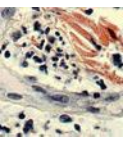

CHAPTER 164

Cutaneous Necrotizing Venulitis

Nicholas A. Soter
Jose L. Diaz-Perez

Necrotizing angiitis or vasculitis comprises a diverse group of disorders that combine segmental inflammation with necrosis of the blood vessels. The vascular damage may result from immunologic and/or other inflammatory mechanisms. Clinical syndromes are based on criteria that include the gross appearance and the histologic alterations of the vascular lesions, the caliber of the affected blood vessels, the frequency of involvement of specific organs, and laboratory abnormalities. Necrotizing vasculitis may be a primary disease, may develop as a feature of a systemic disorder, or may be idiopathic.

Necrotizing vasculitis in the skin involves predominantly venules and is known as *cutaneous necrotizing venulitis* (CNV) and *leukocytoclastic vasculitis.* The occurrence of CNV in association with systemic involvement of the small blood vessels has been termed *hypersensitivity angiitis* or *vasculitis, systemic polyangiitis,* and *microscopic polyangiitis* (see Chap. 165). CNV may occur in association with an underlying chronic disease, may be precipitated by infections or drugs, or may develop for unknown reasons (Table 164-1). Although immunoglobulin A (IgA)–mediated small-vessel necrotizing vasculitis has been proposed as a nosologic entity, at the present time an immunopathobiologic classification of CNV is not possible. Systemic forms of necrotizing vasculitis that affect larger blood vessels are considered in Chap. 165.

TABLE 164-1
Cutaneous Necrotizing Venulitis

- Associated chronic disorders
  - Rheumatoid arthritis
  - Sjögren syndrome
  - Systemic lupus erythematosus
  - Hypergammaglobulinemic purpura
  - Paraneoplastic vasculitis
  - Cryoglobulinemia
  - Ulcerative colitis
  - Cystic fibrosis
  - Antineutrophil cytoplasmic or antiphospholipid antibody syndromes
- Precipitating events
  - Bacterial, viral, and mycobacterial infections
  - Therapeutic and diagnostic agents
- Idiopathic disorders
  - Henoch-Schönlein syndrome
  - Acute hemorrhagic edema of childhood
  - Urticarial vasculitis and variants
  - Erythema elevatum diutinum
  - Nodular vasculitis
  - Livedoid vasculitis
  - Genetic complement deficiencies
  - Eosinophilic vasculitis
  - Idiopathic

EPIDEMIOLOGY

The age of patients has a limited influence on CNV. The associated chronic disorder usually determines the age of the affected individual. In children, CNV is most commonly described as the Henoch-Schönlein syndrome or acute hemorrhagic edema of childhood. Antineutrophil cytoplasmic antibody (ANCA)–associated vasculitides are most common in patients older than 50 years of age.

ETIOLOGY AND PATHOGENESIS

Experimental studies in animal models and observations in humans implicate immune complexes as a major pathobiologic mechanism in the production of CNV. Data obtained in animal models suggest that the localization in venules is related to vasoactive amines and subsequent vasopermeability alterations. Additional factors that are operative in the localization of immune complexes include endothelial–cell surface receptors and the defective clearance of immune complexes by the reticuloendothelial system.

The most frequently postulated mechanisms in the production of CNV are the local deposition of circulating immune complexes formed during antigen excess or the formation of immune complexes in situ in the skin. Immune complexes may activate the complement system and lead to the generation of C5a anaphylatoxin, which attracts neutrophils. In turn, the neutrophils release lysosomal enzymes that damage tissue. The neutrophil superoxide-generating system may produce reactive oxygen products, which also cause tissue injury. The generation of the chemoattractant leukotriene (LT) B_4 from infiltrating neutrophils enhances the influx of neutrophils. An infiltrate composed predominantly of neutrophils in the lesional skin of patients with CNV is consistent with tissue damage induced by immune complexes that activate the complement system. In the Henoch-Schönlein syndrome, the fragmentation of neutrophils was attributed to apoptosis on the basis of the detection of in-

CUTANEOUS NECROTIZING VASCULITIS AT A GLANCE



- Signature lesions are erythematous papules that do not blanch when the skin is pressed and are known as *palpable purpura.*
- Palpable purpura persists for 1 to 4 weeks and resolves at times with transient hyperpigmentation and/or atrophic scars.
- Macules, papules, urticaria/angioedema, pustules, vesicles, ulcers, necrosis, and livedo reticularis may also be present.
- May even be characterized by episodes of recurrent and chronic urticaria and angioedema.
- Lesions may occur anywhere on the skin but are most common on the lower extremities or over dependent areas, such as the back and gluteal regions.
- May be associated with connective-tissue diseases, notably rheumatoid arthritis, Sjögren syndrome, systemic lupus erythematous, and hypergammaglobulinemic purpura.
- There may be many precipitating causes but infections and drugs are most common.
- The most widely recognized subgroup of idiopathic cutaneous necrotizing vasculitis is the Henoch-Schönlein syndrome, otherwise known as *anaphylactoid purpura.*
- Histologic criteria include necrosis of the blood vessels with the deposition of fibrinoid material and dermal cellular infiltrates that consist of neutrophils with nuclear debris, mononuclear cells, and extravasated erythrocytes.



ducible nitric oxide synthase and nitrotyrosine in the infiltrates and the detection of interleukin 8 on vascular endothelial cells.[1]

In patients with CNV, circulating immune complexes have been demonstrated in serum as mixed-type cryoglobulins and indirectly by assays that detect C1q precipitins, materials that bind to complement receptors on human lymphocytoid (Raji) cells, materials that bind to monoclonal rheumatoid factor, and substances that function in the antibody-dependent cellular cytotoxicity inhibition assay. The presence of immune complexes is inferred from the occurrence of serum hypocomplementemia with activation of the classic activating pathway and by the detection of increased plasma levels of C4a and C3a anaphylatoxins.



Immune complexes have been detected in lesional tissues by ultrastructural observation as electron-dense subendothelial deposits; and the membrane-attack complex, C5b-9, of the complement system has been detected on the surface of endothelial cells and infiltrating neutrophils. Decay-accelerating factor, a regulatory complement protein that prevents the assembly of the membrane-attack complex, is not present on the surface of endothelial cells of the upper dermal microvasculature. Tissue immune complexes also have been detected by direct immunofluorescence techniques as deposited immunoglobulins and complement proteins. In time-course studies of the evolution of cutaneous vascular lesions, immune reactants have been identified in lesions less than 24 hours old. Antigens have been identified in only a few instances as bacterial, viral, mycobacterial, or rickettsial proteins by direct immunofluorescence techniques or by the polymerase chain reaction.

A role for lymphocytes, mononuclear cells, and Langerhans cells in the production of CNV is suggested by a perivenular infiltrate in skin lesions that is rich in lymphocytes with large and hyperchromatic nuclei, and by a prominence of mononuclear cells in the vascular skin lesions of patients with CNV and Sjögren syndrome. The lymphocytes express CD3, CD4, CD1a, CD36, intercellular adhesion molecule-1, and lymphocyte function–associated antigen-1. Lymphocytes may be activated by immune complexes, by cellular immune mechanisms, or by primary activation in autoimmune disease to produce lymphokines. Endothelial cells also can present antigens to and activate T lymphocytes. Activated macrophages secrete chemokines and lysosomal enzymes. γ/δ T cells have been detected in CNV with a neutrophil-rich pattern and with a documented infectious etiology.[2] In these specimens, a 72-kd heat shock protein was expressed by endothelial cells and antigen-presenting cells.

The participation of mast cells in CNV is suggested by hypogranulated mast cells with shed extracellular granules, by a decreased number of mast cells in biopsy specimens of skin lesions, and by the development of vascular lesions after the intracutaneous injection of histamine in patients with active episodes of CNV. Mast cells can be activated directly by immune complexes through FcγRIII or by complement fragments acting through their specific receptors. Through the production of histamine, prostaglandin D_2, and cysteinyl LTs, the mast cell could alter venular permeability; interendothelial cell gaps have been noted in venules in patients with CNV. Eosinophils and neutrophils could be recruited by mast cell–derived chemotactic factors. The neutral proteases and acid hydrolases of mast cells may facilitate tissue damage, and the release of tumor necrosis factor (TNF)-α may increase expression of E-selectin on endothelial cells, thereby facilitating neutrophil recruitment.

Evidence for the role of the mast cell is provided by time-course analyses of the sequential histopathologic changes in individuals with physical urticaria. In a patient with circulating immune complexes and hypocomplementemia, in whom cold and trauma elicited CNV, initial mast cell degranulation was followed by the infiltration by neutrophils with an influx of eosinophils and basophils, the deposition of fibrin, and venular endothelial-cell necrosis. A postulated sequence of events would be the activation of the mast cell by physical stimuli, the release of vasoactive mediators, the deposition of circulating immune complexes with activation of the complement system, the influx of neutrophils, and the development of CNV. Another example of the time course of necrotizing venulitis in human skin has been provided in an individual with exercise-induced vasculitis.[3] At 3 hours, the number of mast cells decreased and the eosinophil was the next cell to appear around the venules with the deposition of eosinophil peroxidase. TNF-α levels were elevated, and E-selectin was expressed on endothelial cells. Subsequently, an influx of neutrophils appeared with the deposition of neutrophil elastase and the development of CNV.

Early in the course of necrotizing venulitis, endothelial cells show increased expression of intercellular adhesion molecule-1 and E-selectin without the expression of vascular cell adhesion molecule (VCAM)-1 in response to TNF-α (see Chap. 163). Because E-selectin is an adhesion molecule for neutrophils and for skin-homing, memory T lymphocytes, the increase in E-selectin is consistent with the appearance of an infiltrate of neutrophils that express CD11b within the first 24 hours.[4]

In skin biopsy specimens from patients with idiopathic cutaneous vasculitis, hypersensitivity vasculitis, urticarial vasculitis, and Henoch-Schönlein syndrome, E-selectin was detected on endothelial cells of lesions less than 48 hours old and was associated with an infiltrate of neutrophils expressing CD11b. The endothelial cells expressed HLA-DR and very-late activating antigen-1 but not P-selectin, and the perivascular cells demonstrated VCAM-1 and HLA-DR. Diminished cutaneous fibrinolytic activity with reduced release of plasminogen activator from venular endothelial cells occurs in patients with CNV; the subsequent reduction in fibrinolytic activity leads to fibrin deposition. Increased levels of plasma thrombomodulin, tissue-type plasminogen activator, and plasminogen activator inhibitor-1 were detected in patients with Henoch-Schönlein syndrome.[5,6]

Cutaneous nerve fibers can release neuropeptides, such as substance P, neurokinin A, and calcitonin gene-related peptide, that cause vasodilation (see Chap. 101). Substance P activates mast cells and macrophages and increases fibrinolytic activity mediated by plasminogen activator. Calcitonin gene-related peptide induces expression of E-selectin on endothelial cells and is chemotactic for T lymphocytes.

Eosinophils are minor infiltrating cells in CNV except in eosinophilic vasculitis. Eosinophils could produce LTC_4 and platelet-activating factor, which increase vascular permeability. Eosinophil granule proteins are toxic to endothelial cells and cause the release of chemical mediators from mast cells.

Associations have been recognized between small-vessel necrotizing vasculitis and ANCAs, which have specificity for proteins of the cytoplasmic granules of neutrophils and the lysosomes of monocytes. Two forms are recognized: cytoplasmic (c-ANCAs) and perinuclear

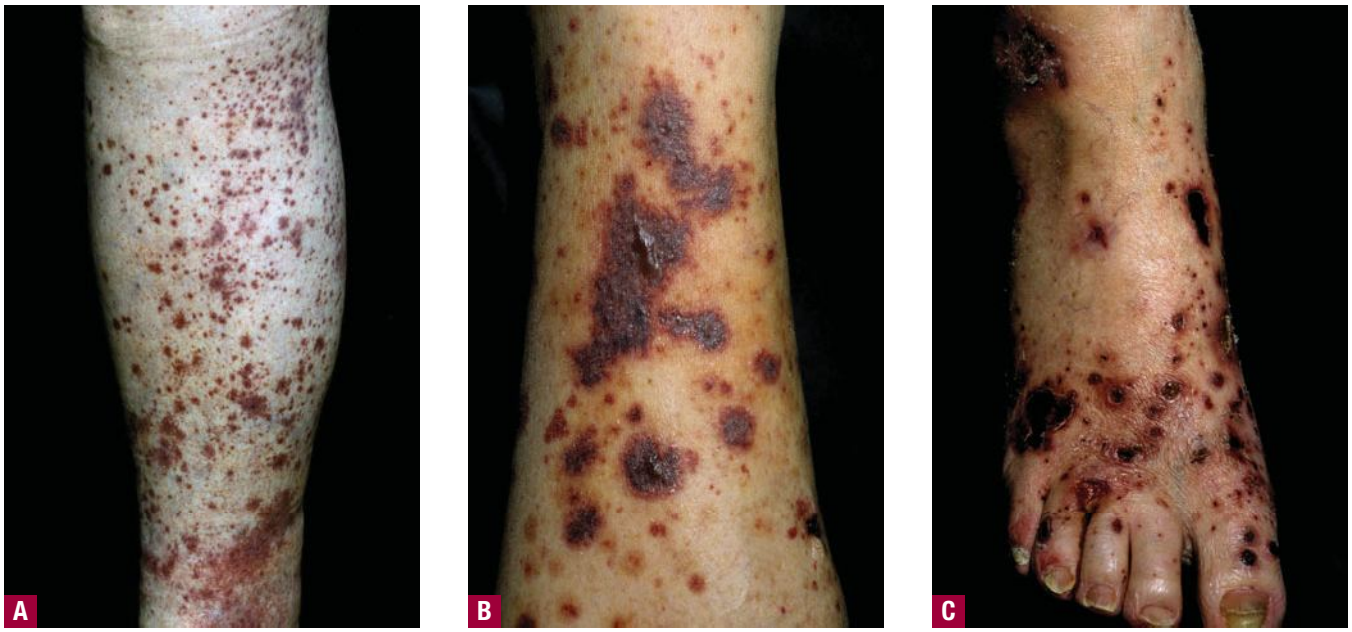

▲ **FIGURE 164-1** **A.** Palpable purpura on the lower leg in a patient with Henoch-Schönlein syndrome. **B.** Palpable purpura with more severe tissue damage leading to hemorrhagic vesicles and bullae. **C.** With even more tissue damage, multiple necrosis and subsequent ulcers develop.

(p-ANCAs). In patients with necrotizing vasculitis, most c-ANCAs are specific for proteinase 3 and most p-ANCAs are specific for myeloperoxidase. Antiendothelial cell antibodies have been detected in the sera of patients with systemic vasculitis, rheumatoid arthritis with vasculitis, microscopic polyangiitis, and Sneddon syndrome.

An increased prevalence of the HLA haplotype HLA-A11, Bw35 in patients with CNV and associated connective tissue disorders suggests that genetic factors may be operative.

CLINICAL FINDINGS

The skin lesions of CNV are polymorphous; however, erythematous papules that do not blanch when the skin is pressed, which are known as *palpable purpura,* are the signature lesions (Fig. 164-1A). Macules, papules, urticaria/angioedema, pustules, vesicles, hemorrhagic blisters (see Fig. 164-1B), necrosis and ulcers (see Fig. 164-1C), and livedo reticularis may be present. Occasionally, there is subcutaneous edema below the area of the dermal lesions.

The eruption most often appears on the lower extremities or over dependent areas such as the back and gluteal regions. The lesions may occur anywhere on the skin but are uncommon on the face, palms, soles, and mucous membranes. The clinical lesions are episodic and may recur over weeks to years. Palpable purpura persists for 1 to 4 weeks and resolves at times with transient hyperpigmentation and/or atrophic scars. Lesional symptoms include pruritus or burning and, less commonly, pain.

An episode of cutaneous vascular lesions may be attended by fever, malaise, arthralgias, or myalgias irrespective of a defined underlying or associated disease. Systemic involvement of the small blood vessels most commonly occurs in the synovia, gastrointestinal tract, voluntary muscles, peripheral nerves, and kidneys.

Associated Chronic Disorders

CNV is associated with connective-tissue diseases, notably rheumatoid arthritis, Sjögren syndrome, systemic lupus erythematosus (SLE), and hypergammaglobulinemic purpura. It rarely occurs in mixed connective-tissue disease, relapsing polychondritis, and scleroderma. In patients with rheumatoid arthritis and CNV, the development of vascular lesions is related to the severity of the disease, which is generally but not always seropositive. Subcutaneous nodules, as well as cutaneous ulcers, may be present. Patients with rheumatoid arthritis often have involvement of larger vessels with associated peripheral neuropathy, nail fold infarcts, and digital gangrene.

In patients with SLE, the vasculitis is associated with exacerbations of the underlying disease. Vasculitis, however, is rare in patients with subacute cutaneous lupus erythematosus. Approximately 5 percent of women with necrotizing vasculitis without connective-tissue disease have anti-Ro antibodies, and their infants may be born with neonatal lupus erythematosus.

In patients with Sjögren syndrome, the vascular lesions are located predominantly on the lower extremities and appear after exercise. Both hyperpigmentation and cutaneous ulcers are common features. Hypergammaglobulinemic purpura occurs in older women and may be associated with Sjögren syndrome, SLE, or a lymphoproliferative disorder. Dermatomyositis in children, but not in adults, may be associated with vasculitis of the gastrointestinal tract.

Paraneoplastic vasculitis is used to describe CNV with associated malignant conditions, including Hodgkin disease, lymphosarcoma, adult T-cell leukemia, mycosis fungoides, myelofibrosis, acute and chronic myelogenous forms of leukemia, IgA myeloma, diffuse large-cell leukemia, hairy-cell leukemia, squamous-cell bronchiogenic carcinoma, prostatic carcinoma, renal carcinoma, and colon carcinoma. However, the association between CNV and neoplasia is rare. It is not necessary to evaluate all patients with CNV for associated malignant conditions.

Cryoglobulins (see Chap. 170), especially mixed types II and III, may be found in patients with idiopathic CNV and in patients with CNV associated with connective-tissue diseases, lymphoproliferative disorders, and hepatitis A, B, and C virus infections, although hepatitis C virus is the most common infection, especially when also associated with cryoglobulinemia.[7,8] CNV oc-

curs in patients with cystic fibrosis, inflammatory bowel diseases of the colon, and Behçet disease.[9]

Both ANCAs and anti-phospholipid antibodies are associated with various forms of necrotizing vasculitis. ANCAs are present in patients with microscopic polyangiitis and cutaneous vasculitis with hepatitis C virus infection (see Chap. 165). The most common cutaneous feature in patients with ANCAs is palpable purpura. Microscopic polyangiitis is associated with small-vessel systemic vasculitis that involves the cutaneous venules and arterioles, kidneys with necrotizing and crescentic glomerulonephritis, and p-ANCAs. A male patient has experienced microscopic polyangiitis restricted to the skin and ANCAs for 20 years without progression to systemic vascular disease.[10]



Anti-phospholipid antibodies, either anticardiolipin antibodies and/or lupus anticoagulant, occur in patients with autoimmune and connective-tissue diseases and as an idiopathic disorder. Livedo reticularis is the most frequently recognized cutaneous finding.[11] Anti-phospholipid antibodies of the IgA class were detected in 6 of 10 patients with idiopathic CNV, and anti-phospholipid antibodies have been detected in some individuals with livedoid vasculitis.[12] A female patient with anti-phospholipid antibodies and cutaneous nodules that demonstrated vasculitis and thrombosis on biopsy has been reported.

Precipitating Infections and Drugs

Infections and drugs precipitate episodes of CNV. The most commonly recognized infectious agents are group A hemolytic streptococci, *Staphylococcus aureus, Mycobacterium leprae,* and hepatitis B and C viruses. Transient episodes of urticaria may occur early in the course of hepatitis B virus infection and represent immune complex–induced vasculitis; episodes of palpable purpura may occur in patients with chronic active hepatitis. Cutaneous vasculitis was identified in patients with hepatitis A and C infections.[13] Cutaneous vasculitis has been recognized in a limited number of individuals with human immunodeficiency virus infection; the skin lesions consisted of palpable purpura, at times with a follicular localization, and cutaneous ulcers.

Erythema nodosum leprosum (see Chap. 186), which appears as cutaneous nodular lesions in lepromatous leprosy, is a form of necrotizing vasculitis involving capillaries, venules, arterioles, small- to medium-sized arteries, and veins. The vascular lesions occur spontaneously or are precipitated by the administration of chemotherapeutic agents. They may be accompanied by fever, malaise, arthralgias, lymphadenopathy, and polyneuritis.

Necrotizing vasculitis caused by the direct invasion of the blood vessel wall occurs in *Neisseria meningitidis* bacteremia, in Rocky Mountain spotted fever, and in infections localized at the site of a catheter.

Palpable purpura is one of the less common forms of drug reactions (see Chap. 40). The most commonly incriminated therapeutic agents are penicillin, sulfonamides, thiazides, allopurinol, hydantoins, and nonsteroidal anti-inflammatory agents. Propylthiouracil[14] and hydralazine may cause vasculitis in association with ANCAs. Cutaneous vasculitis has occurred after the administration of streptokinase, radiocontrast media, monoclonal antibodies, granulocyte colony-stimulating factor, staphylococcal protein A column immunoadsorption therapy, drug additives, and etanercept.[15]

Idiopathic Disorders

HENOCH-SCHÖNLEIN SYNDROME The most widely recognized subgroup of idiopathic CNV is the Henoch-Schönlein syndrome, formerly known as *anaphylactoid purpura*. It occurs predominantly in children, with a peak incidence at 5 to 6 years of age, but it may occur in adults.[16,17] A history of a recent upper respiratory tract infection, especially streptococcal, is obtained in up to 75 percent of individuals; however, Henoch-Schönlein syndrome has been associated with other infections. Sites of involvement include the skin, synovia, gastrointestinal tract, and kidneys. Symptoms may be colicky abdominal pain, melena, arthralgia, and hematuria. Long-term morbidity from progressive renal disease occurs in 5 percent of patients. The spread of purpura to the upper parts of the trunk is a predictive factor for renal involvement.[16]

ACUTE HEMORRHAGIC EDEMA OF CHILDHOOD This uncommon disorder, which often goes unrecognized or has been confused with Henoch-Schönlein syndrome, affects infants and children younger than 2 years of age, but it has been reported in one adult. The lesions appear as painful, edematous petechiae and ecchymoses that affect the head and distal portions of the extremities. Facial edema may be the initial sign. The skin lesions may be associated with a target-like appearance and may develop bullae and necrosis. Infection, drugs, or immunization may be triggering factors. Acute hemorrhagic edema of childhood is distinguished from Henoch-Schönlein syndrome by its occurrence in children aged 4 months to 2 years, lack of systemic features, and resolution within 1 to 3 weeks without sequelae.

URTICARIAL VASCULITIS Episodes of recurrent and chronic urticaria and angioedema may be a clinical manifestation of CNV.[18,19] Known as *urticarial vasculitis,* this edematous form of necrotizing venulitis occurs in patients with serum sickness, connective-tissue disorders, an IgM_K M component, infections, and physical urticarias; after the administration of potassium iodide and nonsteroidal anti-inflammatory agents; and as an idiopathic disorder. Single case reports exist of patients with urticarial vasculitis and colon carcinoma, IgA myeloma, polycythemia vera, Muckle-Wells syndrome, and Cogan syndrome. Infections include hepatitis B and C viruses and infectious mononucleosis. The term *hypocomplementemic urticarial vasculitis syndrome* has been used to describe patients with more severe systemic manifestations and an autoantibody to Clq.

The skin lesions appear as erythematous, occasionally indurated, wheals that may contain foci of purpura (Fig. 164-2; see Fig. 165-2 and Chap. 165). Other skin manifestations include angioedema, macular erythema, livedo reticularis, nodules, and bullae. Although the individual urticarial lesions may last for fewer than 24 hours, they often persist for up to 3 to 5 days. The lesions are



▲ **FIGURE 164-2** Urticarial vasculitis. Some of the wheals have been marked 24 hours previously to show persistent character of the urticarial lesions.

TABLE 164-2
Extracutaneous Manifestations of Urticarial Vasculitis

- General features
  - Fever
  - Malaise
  - Myalgia
- Specific organ involvement
  - Lymphadenopathy
  - Hepatosplenomegaly
  - Synovia (arthralgia, arthritis)
  - Kidneys (glomerulitis, glomerulonephritis)
  - Gastrointestinal tract (nausea, vomiting, pain, diarrhea)
  - Respiratory tract (laryngeal edema, shortness of breath, chronic obstructive pulmonary disease, and, less commonly, interstitial pulmonary disease)
  - Eyes (conjunctivitis, episcleritis, iridocyclitis, uveitis)
  - Central nervous system (headache, benign intracranial hypertension)

pruritic or possess a burning or painful quality; they usually resolve without residua, although some individuals may develop contusions or hyperpigmentation as a result of hemosiderin deposition in the tissue. The episodes of urticaria are chronic, range in duration from months to years, and vary in frequency. Approximately 70 percent of affected individuals are women. The prevalence of this disorder remains unknown. General features include fever, malaise, and myalgia; the lymph nodes, liver, and spleen may be enlarged (Table 164-2).

Episodic arthralgias are a major clinical manifestation and affect the elbows, wrists, fingers, knees, ankles, and toes. Arthritis with necrotizing venulitis apparent in biopsy specimens of the synovial tissue occasionally develops. Urticarial vasculitis is associated with Jaccoud syndrome.[20] Renal involvement occurs as a diffuse glomerulitis or glomerulonephritis; however, progression to severe impairment of renal function is rare. Gastrointestinal tract manifestations include nausea, vomiting, diarrhea, and pain. Laryngeal edema may occur. Chronic obstructive pulmonary manifestations and, less frequently, interstitial lung disease may develop. Conjunctivitis, episcleritis, iridocyclitis, and uveitis develop in some individuals. Rarely, cardiac valvular involvement may occur.[21] There is one report of an individual becoming blind. Headaches and pseudotumor cerebri (benign intracranial hypertension) reflect central nervous system involvement.

The natural history of urticarial vasculitis is unknown, although individuals have been described with historic episodes of cutaneous lesions for up to 25 years. In one series of patients followed for 1 year, 40 percent experienced complete resolution of skin lesions; in another series of individuals followed for as long as 14 years, resolution occurred in only one patient. Sjögren syndrome and SLE have developed. Deaths have been reported from pulmonary disease, sepsis, and myocardial infarction.

The prevalence of urticarial vasculitis in individuals with chronic idiopathic urticaria is unknown, although series have reported rates ranging from 1 percent to 50 percent. Most of these data have been reported from tertiary referral centers, and the prevalence is most likely less than 1 percent.

Necrotizing vasculitis of cutaneous venules has been described in isolated instances of dermographism, cold urticaria, delayed pressure urticaria, solar urticaria, and exercise-induced urticaria.[3] However, the prevalence of necrotizing vasculitis in patients with physical urticaria is unknown, and the importance of this histologic finding for prognosis and therapy remains to be elucidated. Individuals with these physical urticarias have provided experimental models for time-course studies of the evolution of necrotizing vasculitis in human skin.

Schnitzler syndrome consists of episodes of urticarial vasculitis that occur in association with a monoclonal IgM_K M component. Associated features include fever, lymphadenopathy, hepatosplenomegaly, bone pain with osteosclerosis, and a sensorimotor neuropathy. Evolution into a lymphoplasmacytic malignant condition has been reported in 15 percent of patients.[22]

ERYTHEMA ELEVATUM DIUTINUM Erythema elevatum diutinum occurs as symmetric, persistent, red-purple or red-brown plaques that are predominantly disposed over the joints of extensor surfaces and over the gluteal area (see Chap. 166).

NODULAR VASCULITIS Nodular vasculitis (see Chap. 68) appears as tender, red, subcutaneous nodules over the lower extremities, especially the calves, without systemic manifestations (Fig. 164-3; see Fig. 68-5 and Chap. 68). At times, lesions develop on the thighs, buttocks, trunk, and arms, and ulcerated nodules are present. Recurrent episodes are common. It is more common in women and has a peak incidence in individuals between 30 and 40 years of age. Erythema induratum is a form of nodular vasculitis, that has been associated with *M. tuberculosis* infection, as demonstrated by polymerase chain reaction amplification for *M. tuberculosis* DNA in skin biopsy specimens.[23] Various sizes of blood vessels, including venules, are affected.[24]



▲ **FIGURE 164-3** Nodular vasculitis with ulceration on lower legs (see Fig. 68-5).

LIVEDOID VASCULITIS Livedoid vasculitis (Fig. 164-4), known also as *livedoid vasculopathy*, *livedo vasculitis*, *segmental hyalinizing vasculitis*, and *atrophie blanche*, occurs as recurrent, painful ulcers of the lower extremities in association with a persistent livedo reticularis (*livedo racemosa*) that often is deep purple in color (see Fig. 165-6 and Chap. 165). Healing results in sclerotic pale areas surrounded by telangiectases that are designated atrophie blanche (Fig. 164-5). Many patients have arteriosclerosis or stasis of the lower extremities, and mononeuritis multiplex has been identified in a single patient.[25] Livedoid vasculitis is more common in women, may occur in patients with SLE who develop central nervous system features, and has been reported in two patients with protein C deficiency.[26] Atrophie blanche, however, probably represents the end stage of a variety of forms of vascular damage in the skin (see Chap. 175). Elevation of fibrinopeptide A levels may occur in blood. Pathogenesis has focused on a hypercoagulable state with fibrin thrombi in the lumina of the superficial blood vessels. Some consider this condition a thrombogenic vasculopathy rather than a small-vessel vasculitis. Anti-phospholipid antibodies have been detected in a few individuals.[12]

Sneddon syndrome[27,28] is a condition in which livedo reticularis and livedoid vasculitis are associated with ischemic cerebrovascular lesions, hypotension,





▲ **FIGURE 164-4** Livedoid vasculitis with recurrent extremely painful irregular ulcers and a background of livedo reticularis.



and extracerebral arterial and venous thromboses (see Fig. 174-9 in Chap. 174). Anti-endothelial cell antibodies were detected in the serum in 35 percent of individuals; anti-phospholipid antibodies, anti-β_2-glycoprotein antibodies, and anti-prothrombin antibodies[29] were detected in some patients.

GENETIC COMPLEMENT DEFICIENCIES Genetic C2 deficiency has been recognized in association with CNV in three children, and a C4 deficiency was present in one child with CNV. Deficiencies of C4A and C4B isotypes were found in some children and adults with Henoch-Schönlein syndrome. A partial C4B deficiency with C4 A1, A3, B1, and a null allele B*QO was reported in a 51-year-old woman with CNV.[30]



▲ **FIGURE 164-5** Atrophie blanche over the medial malleolus with bizarre, porcelain white atrophy, telangiectasia, and punctate ulcers.

EOSINOPHILIC VASCULITIS Eosinophilic vasculitis has been described as an idiopathic syndrome in individuals with recurrent, pruritic, and purpuric papular skin lesions, urticarial plaques, and angioedema. Skin biopsy specimens showed an infiltrate composed of eosinophils expressing CD40[31] and VCAM-1 on endothelial cells of involved vessels. Eosinophilic vasculitis also has been described in some individuals with a hypereosinophilic syndrome[31] (see Chap. 35) and in others with connective-tissue disorders.[32,33]

IDIOPATHIC Individuals with CNV who do not meet the criteria for recognized syndromes are classified as idiopathic.

LABORATORY FINDINGS

The laboratory evaluation of patients with CNV depends on information obtained from the history and physical examination (Table 164-3). An elevated erythrocyte sedimentation rate is the most consistent abnormal laboratory finding. The platelet count is usually normal. Other abnormalities reflect either a co-existent chronic disorder or the involvement of additional organ systems. Occasionally, leukocytosis, anemia, thrombocytosis, an abnormal urine sediment, circulating immune complexes, rheumatoid factor, and antinuclear antibodies have been reported in idiopathic disease.

TABLE 164-3
Laboratory Evaluation of Cutaneous Necrotizing Venulitis

- Erythrocyte sedimentation rate
- White blood cell count with differential analysis
- Platelet count
- Urinalysis
- 24-Hour urine protein and creatinine clearance
- Blood chemistry profile
- Serum protein electrophoresis
- Hepatitis B antigens and hepatitis A and C antibodies
- Cryoglobulins
- CH50
- Anti-nuclear antibody
- Rheumatoid factor
- Antineutrophil cytoplasmic antibodies
- Anti-phospholipid antibodies
- Circulating immune complexes
- Skin biopsy

Serum complement levels are usually normal. Hypocomplementemia may develop in patients with concomitant connective tissue diseases or cryoglobulinemia and reflects the associated disease or the composition of the cryoglobulin. Hypocomplementemia also occurs in some individuals with idiopathic CNV and in 40 percent of individuals with urticarial vasculitis.

In some patients with the hypocomplementemic urticarial vasculitis syndrome, a low-molecular-weight 7s C1q precipitin, identified as an IgG autoantibody against the collagen-like region of C1q, was detected. The antigen-antibody interaction involves the $F(ab')_2$ fragment of IgG. Autoantibodies to vascular endothelial cells were detected in patients with the hypocomplementic urticarial vasculitis syndrome, in patients with SLE and urticarial vasculitis, and in patients with urticarial vasculitis alone.[34] In a single patient with Schnitzler syndrome, autoantibodies against dermal microvascular endothelial cells, mast cells, and the FcεRIα receptor were detected.[35] In Henoch-Schönlein syndrome, serum IgA1 levels are elevated. In patients with CNV, various types of circulating immune complexes and IgA ANCAs[36] have been described. IgG autoantibodies against IgE also have been identified in four of eight patients with urticarial vasculitis.

HISTOPATHOLOGY

In skin biopsy specimens of palpable purpura and urticarial vasculitis stained

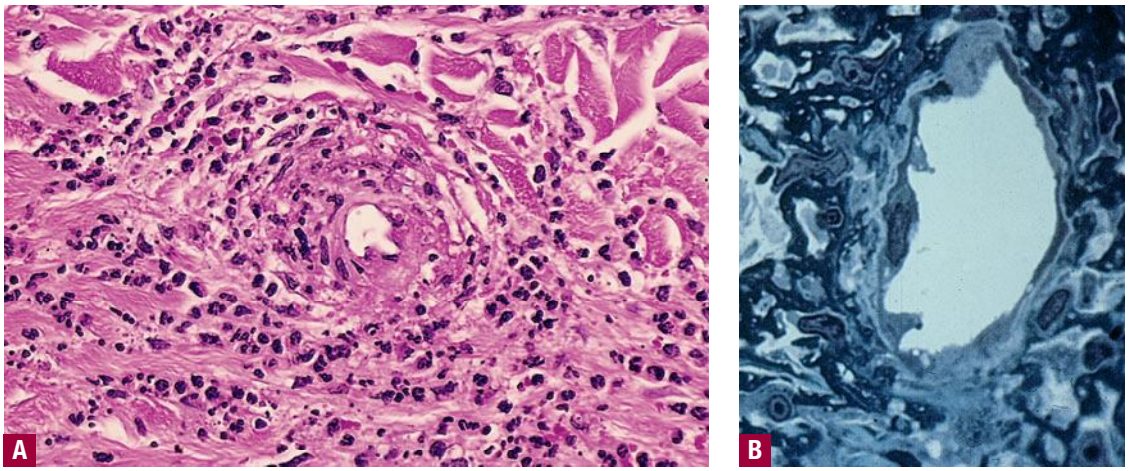

▲ **FIGURE 164-6** **A.** Perivenular infiltrate of neutrophils with fibrin deposition. (Hematoxylin and eosin stain, ×50 in original magnification.) **B.** Endothelial cell necrosis of venule with perivenular fibrin and neutrophils. (1-μm section, Giemsa stain, ×1000 in the original magnification.)

with hematoxylin and eosin (Fig. 164-6A), the histologic criteria requisite for the diagnosis of CNV include necrosis of the blood vessels with the deposition of fibrinoid material and dermal cellular infiltrates that consist of neutrophils with nuclear debris, mononuclear cells, and extravasated erythrocytes. The dermal inflammatory infiltrates vary in intensity and are usually perivenular in location but at times are dispersed widely. The fibrinoid material consists of fibrin, necrotic endothelial cells, and deposited immunoreactants.

Studies with 1-μm–thick sections (see Fig. 164-6B) show two distinct cellular patterns in CNV: one rich in neutrophils and the other in lymphocytes. Neither pattern appears to be the result of evolution of the tissue changes associated with the dynamic nature of the cellular infiltrate. Although the infiltrate of neutrophils regresses with the persistence of an infiltrate of mononuclear cells, repeat biopsy specimens in some patients consistently demonstrated an infiltrate of mononuclear cells. In a time-course study over 6 days of the evolution of experimentally induced CNV in a patient with physical urticarias, the number of infiltrating neutrophils decreased without a concomitant increase in lymphocytes, although the number of monocyte-macrophages was increased at 48 hours and 72 hours. Other features in both cell patterns of CNV include hypogranulated mast cells, macrophages containing debris, and the perivenular and interstitial deposition of fibrin. Venular alterations in both cell patterns consist of endothelial cell swelling, activation of nuclei, wrinkling of nuclear membranes, necrosis (see Fig. 164-6B), and basement membrane reduplication and thickening. The arterioles are not affected. Some patients with connective-tissue disorders and cutaneous vasculitis have an infiltrate of inflammatory cells composed of eosinophils with deposited major basic protein and decreased numbers of mast cells.[32]

By direct immunofluorescence techniques, fibrin deposition in venules is routinely identified in biopsy specimens, whereas the deposition of immunoglobulins and complement proteins varies widely. IgG is the most commonly deposited immunoglobulin, although IgM and IgA also have been detected. IgA is deposited about blood vessels in the skin, intestines, and kidneys in the Henoch-Schönlein syndrome and has become an immunopathologic marker of this condition. In the skin in Henoch-Schönlein syndrome, IgA1 is the dominant subclass deposited.[37] C3 is the only complement protein that has been sought with frequency.

DIFFERENTIAL DIAGNOSIS

Thrombocytopenia may result in purpura; however, these lesions are flat. Other causes of non-palpable cutaneous purpura include local trauma to the skin of aged individuals with vascular fragility, chronic sun exposure, and endogenous or iatrogenic hypercorticism. Erythema elevatum diutinum may resemble Kaposi sarcoma (see Chap. 128) or multicentric reticulohistiocytosis (see Chap. 149). Scurvy may appear as hemorrhagic, follicular papules over the lower extremities. Various infectious agents may be associated with hemorrhagic skin lesions that arise from disseminated intravascular coagulation or septic emboli. The cutaneous manifestations of disseminated intravascular coagulation, known as *purpura fulminans,* appear as extensive areas of purpura with a slate-gray color (see Chap. 145). These lesions occur in patients with acute meningococcemia but also with gram-positive coccal sepsis; skin biopsy specimens show thrombosis but not necrotizing venulitis. Septic emboli occur as finite numbers of hemorrhagic pustules, papules, and vesicles distributed over acral areas. Rarely, echo and coxsackievirus infections may cause purpuric papules. Rocky Mountain spotted fever typically begins as purpuric papules over the ankles and wrists that spread to include the trunk. Cholesterol embolization includes purpura, livedo reticularis, ulcers, and nodules.

The progressive pigmentary purpuric dermatoses (purpura simplex) (see Chap. 169), which include a number of disorders, appear as macular, petechial, pigmented, or lichenoid lesions.

The differential diagnosis of cutaneous nodules includes erythema nodosum, panniculitis, superficial forms of thrombophlebitis, fat necrosis associated with pancreatic disease, and systemic vasculitides, such as polyarteritis nodosa, Wegener granulomatosis, and Churg-Strauss syndrome.

TREATMENT

Therapeutic approaches may be divided into removal of the antigen, treatment of an underlying disease, and treatment of CNV. Treatment of necrotizing vasculitis consists of prevention of the deposition of immune complexes, suppression of the inflammatory response, modulation of underlying immunopathologic mechanisms, and local therapy. When the eruption is associated with a precipitating event, withdrawal of the medication or treatment of the in-



TABLE 164-4
Algorithm for Treatment of Cutaneous Necrotizing Venulitis

- Phase one
  - H_1 Antihistamines
  - Nonsteroidal anti-inflammatory agents
  - Colchicine
  - Hydroxychloroquine sulfate
  - Dapsone
- Phase two
  - Systemic glucocorticoids
  - Azathioprine
  - Cyclophosphamide
  - Intravenous gammaglobulin
  - Cyclosporine
  - Plasmapheresis



fection results in resolution of the cutaneous lesions. If a co-existent chronic disease is present, treatment of the underlying disease may be associated with improvement in the cutaneous vascular lesions. In many cases, CNV is a self-limited condition, and double-blind, placebo-controlled, prospective trials of therapeutic agents are usually lacking.

The treatment of CNV can be divided into two phases (Table 164-4), each of which depends on an analysis of the cutaneous disability as well as the toxicity and side effects of the therapeutic agents. H_1 antihistamines are used in patients with palpable purpura to alleviate lesional symptoms and perhaps to reduce tissue deposition of circulating immune complexes. Nonsteroidal anti-inflammatory agents are combined with the H_1 antihistamine. Depending on the therapeutic response, colchicine or hydroxychloroquine sulfate can be added to or substituted for these agents. However, colchicine was shown to have no significant therapeutic effect in a prospective, randomized, controlled trial. If there is no benefit, dapsone can be used. If there still is no therapeutic response, a major decision must be made because the medications to be considered in the second phase (systemic glucocorticoids, azathioprine, methotrexate, cyclophosphamide, plasmapheresis, cyclosporine,[38] and intravenous immunoglobulin[39]) are associated with more serious side effects. Although all of these agents have been reported to benefit some patients, controlled clinical trials are not available. The administration of interferon-α is associated with clearing of cutaneous vasculitis in patients with hepatitis C virus infection.

The treatment of urticarial vasculitis is similar to that of palpable purpura. Additional case reports exist on the treatment of patients with intramuscular gold therapy, cyclophosphamide-dexamethasone pulse therapy,[40] mycophenolate mofetil,[41] and psoralen plus ultraviolet A photochemotherapy.[42]

In patients with erythema elevatum diutinum, dapsone is the drug of choice. Plasma exchange plus chlorambucil was a successful treatment for one individual with erythema elevatum diutinum and a monoclonal IgA paraprotein.[43] The treatment of nodular vasculitis consists of empiric trials of a variety of therapeutic agents that include a saturated solution of potassium iodide, nonsteroidal anti-inflammatory drugs, colchicine, and systemic glucocorticoids. Thalidomide is the treatment of choice for erythema nodosum leprosum.

In the treatment of livedoid vasculitis, support stockings are useful. Empiric trials of aspirin and dipyridamole, colchicine, dapsone, danazol,[44] low-dose heparin, systemic glucocorticoids, nicotinic acid, low-molecular-weight dextran, phenformin and ethylestrenol, nifedipine, and pentoxifylline are used. Infusions of prostacyclin, prostaglandin E_1, and intravenous immunoglobulin[45] have been used successfully in one patient each.

KEY REFERENCES

The full reference list for all chapters is available at www.digm7.com.

7. Cohen P, Guillevin L: Vasculitis associated with viral infections. *Presse Med* **33**:1371, 2004
8. Trejo O et al: Cryoglobulinemia: Study of etiologic and clinical and immunologic features in 443 patients from a single center. *Medicine (Baltimore)* **80**:252, 2001
16. Tancrede-Bohin E et al. Shöenlein-Henoch purpura in adult patients: Predictive for IgA glomerulonephritis in a retrospective study of 57 cases. *Arch Derm* **133**:438, 1997
17 Trapani S et al: Henoch Schönlein purpura in childhood: Epidemiological and clinical analysis of 150 cases over a 5-year period and review of literature *Semin Arthritis Rheum* **35**:143, 2005
36. Rovel-Guitera P et al: IgA antineutrophil cytoplasmic antibodies in cutaneous vasculitis. *Br J Dermatol* **143**:99, 2000
37. Egan CA et al: IgA1 is the major IgA subclass in cutaneous blood vessels in Henoch-Schönlein purpura. *Br J Dermatol* **141**:859, 1999
41. Worm M et al: Mycophenolate mofetil is effective for maintenance therapy of hypocomplementaemic urticarial vasculitis. *Br J Dermatol* **143**:1324, 2000

CHAPTER 165

Systemic Necrotizing Vasculitis

Carmen E. Gota
Brian F. Mandell

EPIDEMIOLOGY

Vasculitic syndromes are uncommon. The overall annual incidence is estimated to be between 10 and 42 cases per million per year. Takayasu arteritis (TA) occurs preponderantly in young females. Kawasaki disease and Henoch-Schönlein purpura are the most common types of childhood vasculitis, and temporal arteritis [giant cell arteritis (GCA)] occurs in patients generally older than 55 years of age. Small vessel vasculitis, predominantly cutaneous, occurs at all ages; but the underlying etiology differs between children and older adults.

ETIOLOGY AND PATHOGENESIS

Blood vessels may be affected by a number of diverse processes, including the hypercoagulability syndromes, Raynaud vasospasm, myointimal proliferation with occlusion (e.g., scleroderma), embolic occlusion, congenital or acquired dysplasias (e.g., Marfan syndrome, fibromuscular dysplasia), atherosclerosis, and inflammation. Vascular damage and remodeling results from contributions of both the attacking immune cells and the responding blood vessel wall, which is not just an innocent bystander. Rather, the vessel wall response to the injury can be both regenerative and maladaptive.

Blood vessels targeted by an inflammatory insult have limited ways of responding to injury: increased permeability may lead to edema and purpura, attenuation of the vessel wall may lead

SYSTEMIC VASCULITIS AT A GLANCE



- Heterogenous group of rare inflammatory conditions in which blood vessel walls are primarily targeted by an inflammatory reaction.
- Etiology unknown; geographic, environmental, and genetic factors are important.
- Incidence up to 42 cases per million per year.
- Diagnosis established in patients with multiple but variable organ involvement; supported by laboratory or radiologic studies and histologic evidence of inflammatory reaction in blood vessels.
- Cutaneous involvement can occur in any of the primary systemic vasculitic syndromes.
- Cutaneous features are often not sufficient to provide complete diagnosis and staging.
- Classification:
  - Primary process (no cause or association)
  - Secondary
    - Drug ingestion
    - Infection
    - Systemic, non-vasculitic disease
    - Malignancy
    - Local factors (e.g., trauma)
- Primary vasculitis is a diagnosis of exclusion after causes of secondary vascular inflammation have been ruled out.
- Determinants of prognosis and treatment include the specific vasculitic syndrome, whether critical organs are involved, the severity of involvement, and the rate of disease progression.
- Treatment often requires steroids and the use of other immunosuppressive drugs.

to aneurysm formation or hemorrhage, and intimal proliferation or thrombosis may cause stenosis or occlusion with tissue ischemia or infarction.

Several pathogenetic mechanisms have been implicated in generating a vasculitic process. Immune complex deposition has been found to be associated with many vasculitic syndromes, especially those involving small vessels. The antigens implicated in the process include medications, foods, infections (e.g., hepatitis B and C, bacterial endocarditis), and endogenous or tumor antigens. The immune complexes trigger an inflammatory response with the participation of complement activation products, neutrophils, and lymphocytes.

Antineutrophil cytoplasmic antibodies (ANCAs) are found in small vessel vasculitides such as Wegener granulomatosis (WG), Churg-Strauss syndrome (CSS), and microscopic polyangiitis (MPA). Whether ANCAs directly participate in the pathogenesis of these vasculitides remains debatable.

CLINICAL FINDINGS

History and Physical Examination

The first step in the diagnosis of a vasculitic syndrome is to perform a detailed patient history and physical examination to evaluate and document specific organ involvement (Fig. 165-1). Special attention should be paid to finding evidence of inflammation in the eyes, ears, nose, paranasal sinuses, mouth, trachea, joints, intestine, kidneys, or peripheral nerves. The presence of adenopathy, periungual capillary abnormalities, cardiac abnormalities, asymmetric peripheral pulses, or abdominal and subclavian bruits provide other diagnostic clues. The principal clinical clue to the diagnosis of a specific vasculitic disorder is the pattern of organ involvement.

Cutaneous Involvement in Systemic Vascultis

Systemic and localized vasculitis often affects the skin and subcutis, likely due in part to their large vascular bed, structure of the postcapillary venules, hemodynamic factors (e.g., stasis in lower extremities), and environmental influences (e.g., cold exposure; see Chap. 164).[1] Physical signs of vasculitis include urticaria (Fig. 165-2), palpable purpura (Fig. 165-3; see Chap. 164), infiltrative erythema, ulcers (Fig. 165-4), digital ischemia (Fig. 165-5), livedo reticularis (Fig. 165-6), and nodules. In the presence of cutaneous vasculitis, a thorough evaluation for systemic involvement is mandatory. In addition to a detailed history and physical examination, urinalysis looking for the presence of blood, protein, and cellular casts; blood testing to evaluate for anemia, elevated creatinine, and/or transaminases; and a chest x-ray looking for lung infiltrates are simple methods to screen for clinical emergencies such as rapidly progressing glomerulonephritis and alveolar hemorrhage.

LABORATORY, RADIOLOGIC, AND HISTOPATHOLOGY TESTING

The inflammatory process per se is often associated with laboratory and clinical abnormalities, but these, however prominent, tend to be non-specific (e.g., elevated erythrocyte sedimentation rate, anemia, fatigue, fevers) and do not substantially aid in distinguishing vasculitis from other inflammatory or proliferative diseases. Although it is reasonable to include a few "basic" laboratory tests in the initial evaluation, more specialized studies should be obtained only after a focused differential diagnosis is generated. Initial studies should include a complete blood count with differential, serum creatinine, transaminases, and a dipstick and microscopic urinalysis. The urinalysis should ideally be a fresh morning sample. It should be immediately examined by a physician; urine that has been allowed to sit for several hours before analysis does permit identification of cellular casts that may rapidly degenerate ex vivo. Red blood cell casts are highly supportive of the presence of glomerulonephritis. A clinical axiom is that the primary vasculitides are almost never associated with leukopenia or thrombocytopenia. The presence of these laboratory findings should suggest alternative diagnoses such as systemic lupus erythematosus (SLE), vasculitis associated with malignancy, disseminated intravascular coagulation, infection, or drug-induced cytopenias. Some disorders that may mimic or are associated with a vasculitis are shown in eTable 165-0.1 in on-line edition.

The value of indiscriminate testing for anti-nuclear antibodies, rheumatoid factor, and angiotensin-converting enzyme to look for the presence of possible "immune" disease is arguable, at best. These studies should be primarily used as aids in supporting a tenable clinical diagnosis. Angiographic and selected serologic studies may provide support for certain diagnoses, but are not by themselves pathognomonic for any specific form of vasculitis.

Histopathologic diagnosis is desirable and often required. The term *vasculitis* reflects conditions in which inflammatory cells significantly damage





Detailed history and physical

Systemic
- fever, night sweats
- weight loss
- arthralgias/arthritis
- myalgias

EAR, NOSE, AND THROAT
- chronic sinusitis
- otitis media and/or interna
- saddle nose
- nasal septal perforation
- nasal crusting
- epistaxis
- subglottic stenosis

Ophthalmologic
- conjunctivitis
- anterior and/or posterior uveitis
- retinal vasculitis
- anterior optic nerve ischemia
- proptosis

Cardiovascular
- pericarditis
- myocarditis
- myocardial ischemia
- carotidynia
- bruits
- strokes
- asymmetric blood pressure
- absent pulses

Gastrointestinal
- ischemic bowel
- acalculous cholecystitis

Cutaneous
- palpable purpura
- periungual capillary lesions
- digital infarcts
- skin ulcers
- nodules
- panniculitis
- oral ulcers
- gums hypertropy (WG)
- desquamation of hands and feet (Kawasaki)
- fissuring of lips (Kawasaki)

Pulmonary
- infiltrates
- nodules
- cavitary lesions
- alveolar hemorrhage

Renal
- glomerulonephritis
- hypertension
- rise in creatinine

Neurologic
- mononeuritis multiplex
- sensory motor neuropathy
- seizures
- cranial nerve palsy
- confusion, dementia

Laboratory data

Initial studies
- Westergren sedimentation rate
- C-reactive protein
- complete blood count with differential
- creatinine
- transaminases
- urinalysis for protein, blood, cellular casts

Useful serologic studies
- hepatitis B, C, HIV
- complement levels
- cyroglobulins
- ANCA

Laboratories to exclude other etiologies
- drug screen
- blood cultures
- lupus serologies
- antiphospholipid antibodies
- lupus anticoagulant

Radiologic imaging
- X-rays
- CT scans
- MRIs
- angiograms

Histopathologic diagnosis

Rule in vasculitis

Rule out vasculitis mimics

▲ **FIGURE 165-1** Algorithm for diagnosis of vasculitides. ANCA = antineutrophil cytoplasmic antibody; CT = computed tomography; HIV = human immunodeficiency virus; MRI = magnetic resonance imaging; WG = Wegener granulomatous.

vessels and not merely traverse through them to enter the surrounding tissue.

The type of lesion chosen for skin biopsy has a great impact on the diagnostic yield of the biopsy. The optimal time for skin biopsy is 24 to 48 hours after the appearance of a vasculitic lesion. In the first 24 hours, the affected vessels show fibrin deposits and neutrophilic infiltration of the vessel wall, surrounding hemorrhage, and nuclear debris. After 24 hours, neutrophils are replaced by lymphocytes and macrophages. Biopsies of lesions more than 48 hours old may show perivascular lymphocyte-rich infiltrates. The choice of a shave biopsy, punch biopsy, or excisional biopsy affects which vessels are examined, as the type of vessel is dependent on location within the skin and subcutis (the deeper the skin, the larger the vessel).[2]

The diagnosis of vasculitis can be unequivocally made if there are inflammatory infiltrates in the walls of vessels accompanied by fibrin deposition within and around the vessel wall, a finding called *fibrinoid necrosis*. These changes co-exist with signs of endothelial damage in the form of endothelial swelling



▲ **FIGURE 165-2** Urticarial vasculitis (see Chap. 164). Urticarial lesions change their morphology only slowly, are persistent (24 to 72 hours), may be associated with purpura, and resolve with pigmentation.

or sloughing (see Chap. 164).[2] Identification of qualitative pathologic changes in affected organs (pattern of necrosis, presence of granulomas, eosinophilic infiltration) further delineates the differential diagnosis.

DIFFERENTIAL DIAGNOSIS

The differential diagnosis of the systemic vasculitides often includes distinct or co-existent coagulopathy, occult malignancy, or infection, particularly deep-seated abscess, viral hepatitis, or bacterial endocarditis. Thus, an approach directed towards ruling in a specific form of vasculitis should be pursued, in addition to ruling out specific alternatives.



▲ **FIGURE 165-4** Leg ulcer in a patient with polyarteritis nodosa.

CLASSIFICATION OF VASCULITIDES

There is no universally accepted classification system for vasculitis, although several different schemes have been proposed based on clinical and histopathologic features. The most widely used diagnostic classification systems are based on the caliber of affected blood vessels (Table 165-1),[3] pattern of organ involvement, and the presence or absence of granulomas and/or eosinophilic infiltration. Such schemes are useful in providing a diagnostic framework to distinguish clinical disorders with distinct differences in prognosis and response to treatment. Classification systems provide useful constructs for communication and the design of research protocols. The American College of Rheumatology classification criteria (1990)[4] and definitions based on a consensus conference at Chapel Hill (1993)[5] are the most commonly used sets of agreed-on classification criteria and definitions for vasculitis in current practice. These schemes emphasize distinction between fully expressed vasculitic syndromes; they are less useful in diagnosing early and evolving systemic vasculitic disorders.

Some authors have proposed a prime diagnostic role for the presence or absence of specific serum ANCAs, particularly antibodies to proteinase 3 (PR3-ANCA) and myeloperoxidase (MPO-ANCA). We believe that the role of these tests at the present time is to support a rationally developed clinical diagnosis, not to define one. In patients who do not neatly fit into a well-defined diagnostic category, these serologic tests should not supplant an attempt to obtain a tissue diagnosis if the latter is feasible.



▲ **FIGURE 165-5** Digital gangrene in a patient with type I cryoglobulinemia.



▲ **FIGURE 165-3** Leukocytoclastic vasculitis after administration of granulocyte macrophage colony-stimulating factor for aplastic anemia.

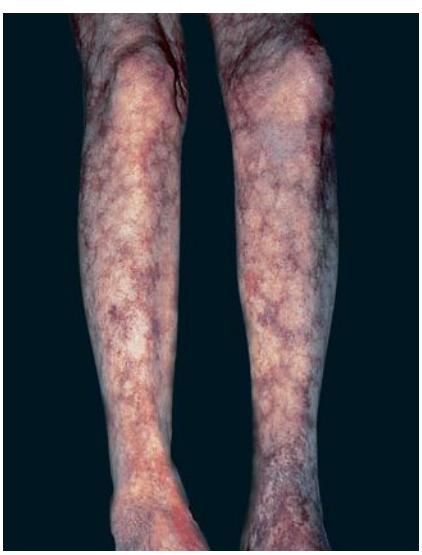

▲ **FIGURE 165-6** Livedo reticularis.



TABLE 165-1
Classification of Primary Systemic Vasculitides According to the Size of the Blood Vessels

- Predominantly large vessels
  - Takayasu arteritis
  - Giant cell arteritis
  - Cogan syndrome
  - Behçet disease
- Predominantly medium-sized vessels
  - Polyarteritis nodosa
  - Buerger disease
  - Kawasaki disease
- Predominantly small vessels
  - Antineutrophil cytoplasmic antibody–associated vasculitides
    - Wegener granulomatosis
    - Churg-Strauss syndrome
    - Microscopic polyangiitis
  - Cryoglobulinemic vasculitis
  - Cutaneous leukocytoclastic angiitis
  - Hypocomplementemic urticarial vasculitis
  - Henoch-Schönlein purpura
  - Erythema elevatum diutinum
  - Goodpasture syndrome
  - Renal limited vasculitis



SPECIFIC VASCULITIC SYNDROMES

Small Vessel Vasculitis

Small vessel vasculitis involves arterioles, capillaries, and venules.[6] There may be co-existent medium-vessel disease, but the small vessel component is usually the predominant manifestation. The vasculitic process may be limited to the skin or may affect the skin along with visceral involvement such as pulmonary hemorrhage, intestinal ischemia or hemorrhage, or glomerulonephritis. Therefore, a primary cutaneous small vessel vasculitis should be a diagnosis of exclusion after systemic involvement has been ruled out (see Chap. 164).

Small vessel vasculitis can occur as an isolated primary cutaneous disorder or be secondary to another process (Table 165-2).

Palpable purpura tends to occur in crops of lesions of similar age (see Figs. 164-1A and 165-3). Small vessel vasculitis/purpura is generally more pronounced in gravitydependent areas. One exception is vasculitis due to cryoglobulinemia, especially in association with lymphoma.

Cutaneous vasculitis of the legs may be associated with such striking edema as to suggest nephrotic syndrome. Findings such as livedo reticularis (see Fig. 165-6) may be seen in patients with peripheral vascular disease of various etiologies. Both systemic and localized forms of small vessel vasculitis occur, and in addition to histopathology, immunohistology and autoimmune serology are important for full definition of the disorders in this group.

TABLE 165-2
Classification of Small Vessel Vasculitis

- Primary
- Secondary
  - Drug allergy
  - Infections
    - Bacterial endocarditis
    - Viral infections; (e.g., hepatitis B or C, parvovirus B19, cytomegalovirus, Epstein-Barr virus)
    - Disseminated *Neisseria*, *Rickettsiae* infections
  - Defined systemic autoimmune disorders (e.g., Sjögren syndrome, systemic lupus erythematosus, dermatomyositis, rheumatoid arthritis)
  - Malignancies
    - Hematologic
    - Lymphoid
    - Solid organ malignancies
  - Systemic vasculitic syndromes

There are mainly three immunopathologic types of small vessel vasculitis: antibody mediated (e.g., Goodpasture syndrome), immune complex mediated (e.g., Henoch-Schönlein purpura (Table 165-3), essential cryoglobulinemic vasculitis, urticarial vasculitis (Table 165-4), and ANCA-associated, pauci-immune vasculitides (WG, CSS, MPA).

Therapy of isolated cutaneous vasculitis is directed at the underlying process if one can be identified. Infections should be treated. Suspected offending agents, such as drugs, should be withdrawn. If no inciting agent is found, the choice of therapy depends on the severity of organ involvement (Table 165-5).

The primary systemic vasculitides include WG, CSS, and MPA. These conditions are also referred to by some investigators as *ANCA-associated vasculitides*. This term emphasizes similarities between these conditions, including the predominant involvement of small- and medium-sized vessels, the similar renal histology (focal segmental glomerulonephritis without immune complexes), and the association with ANCA.

Wegener Granulomatosis

WG is a relatively uncommon, potentially lethal disease that is characterized by necrotizing granulomatous inflammation and vasculitis of small- and medium-sized vessels. Diagnosis mandates systemic therapy, usually with two drugs. Multiple organs are often involved, with a predilection for the upper and lower respiratory tracts, eye, and the kidney.[7] Males and females of all ages can be affected. Upper airway disease tends to be particularly striking, but is often initially attributed for months or even years to "routine" sinus disease until other manifestations of WG are recognized.

TABLE 165-3
Henoch-Schönlein Purpura

- More common in children than in adults, often after a respiratory tract infection
- Annual incidence, 20/100,000 children/yr
- Clinical manifestations in children
  - Cutaneous (leukocytoclastic vasculitis)
    - Purpura
    - Urticarial rash with local edema
  - Gastrointestinal (intestinal vasculitis, intussusception)
    - Colicky abdominal pain
    - Gastrointestinal bleeding
  - Renal disease (glomerulonephritis)
    - Hematuria and proteinuria
    - Nephritic syndrome
    - Acute renal failure
- Clinical manifestations in adults
  - Joint symptoms more common
  - Renal disease, more severe
- Confirmation of diagnosis of Henoch-Schönlein purpura
  - Evidence of tissue deposition in the skin or kidney of immunoglobulin A by immunofluorescence microscopy
- Overall outcome (generally good)
  - Complete recovery
  - Recurrent episodes of purpura and nephritis
  - Persistent disease
- Treatment
  - No specific therapy (most patients)
  - Corticosteroids (arthritis, abdominal pain)
  - Immunosuppressive drugs (nephritis with crescents)
  - Plasmapheresis (severe disease)

The clinical manifestations in WG are summarized in Table 165-6.

The clinical presentation of dermatologic lesions in WG is highly variable, including palpable purpura (Fig. 165-7A), tender subcutaneous nodules, papules, pustules, livedo reticularis, infarction of the fingertips, pyoderma gangrenosum, gingival hyperplasia, and necrotic ulcers in the nasal and oral mucosa (see Fig. 165-7B). Necrotic papules of the limbs, though not a frequent or a specific manifestation, are suggestive of WG. The skin biopsy may reveal necrotizing vasculitis, granulomatous vasculitis, or ex-

TABLE 165-4
Urticarial Vasculitis

- Episodes of urticaria are accompanied by histopathologic features of leukocytoclastic vasculitis
- Prevalence of 5% in patients with urticaria
- Histopathology
  - Leukocytoclastic vasculitis
  - Immunofluorescence: Deposits of immunoglobulins, complement, or fibrin within vessel walls
- Clinical presentation
  - Cutaneous (see Fig. 165-2)
    - Burning, tender, painful, or pruritic lesions
      Wheals or serpentine papules
      Angioedema
    - Persistence 24–72 h
    - Residual effects
      Purpura
      Hyperpigmentation
  - Systemic
    - Arthralgias/arthritis
    - Abdominal pain
- Etiology
  - Idiopathic
  - Underlying autoimmune disorder (systemic lupus erythematosus or Sjögren syndrome)
  - Immunoglobulin M paraproteinemia (Schnitzler syndrome)
  - Viral infections (hepatitis, acute Ebstein-Barr viral infection)
  - Henoch-Schönlein purpura
- Hypocomplementemic urticarial vasculitis syndrome
  - Urticaria > 6 mo
  - Hypocomplementemia
  - Dermal venulitis by biopsy
  - Arthralgia or arthritis
  - Uveitis, episcleritis
  - Glomerulonephritis
  - Recurrent abdominal pain
  - Angioedema
  - Obstructive lung disease
- Treatment
  - Moderate doses of daily corticosteroids
  - Colchicine
  - Dapsone
  - Nonsteroidals
  - Antimalarials
  - Immunosuppressive drugs

travascular granulomas, and, occasionally, palisading granulomas.

Return of cutaneous manifestations with drug tapering almost always portends a systemic flare.

The diagnosis of WG should be considered in patients with otherwise unexplained inflammation of the upper or lower respiratory tract, eye, or glomerulonephritis. Suspicion of WG should be increased when multiple organ involvement is demonstrated, the upper airway disease is destructive, or pulmonary nodules (especially with cavities) are demonstrated by radiography. Any combination of organ involvement is conceivably possible, but most patients exhibit upper airway involvement at the time of diagnosis. If the entire clinical picture is compatible with WG, and alternative diagnoses have been appropriately ruled out, the finding of cytoplasmic ANCA with anti-PR3 specificity in the patient's serum is sufficient to make the diagnosis and initiate therapy. However, if there are any atypical features or special concerns regarding the initiation of immunosuppressive therapy or if the patient does not respond appropriately to therapy, tissue documentation of the diagnosis is mandatory (see eFig. 165-7.1 in on-line edition). Because WG generally requires glucocorticoid plus cytotoxic drug therapy, it should be distinguished from other inflammatory disorders, including other vasculitic syndromes, which may be effectively treated with a less toxic approach.

TABLE 165-5
Principles of Treatment in Primary Small Vessel Vasculitis

- Cutaneous involvement only
  - Nonsteroidal anti-inflammatory drugs
  - Colchicine
  - Pentoxifylline
  - Dapsone
  - Thalidomide
  - Short-term, low-dose corticosteroids
- Visceral involvement
  - Higher dose corticosteroids
  - Immunosuppressive therapy (e.g., methotrexate, azathioprine, cyclophosphamide)

The most recent therapeutic approaches in WG have separated treatment into two phases: induction, where active disease is placed in remission, and maintenance. In most cases, initial remission occurs within 3 to 6 months (Table 165-7). For severe, life-, or organ-threatening disease, cyclophosphamide should be used as an induction therapy along with corticosteroids.

Corticosteroids may induce symptomatic improvement in the upper airway, lungs, skin, and musculoskeletal system, but only rarely produce remission. Corticosteroids alone essentially never control aggressive renal disease. Even if improvement follows single drug treatment with corticosteroids, tapering usually results in a flare in the disease. Despite immunosuppression, the relapse rate in WG is approximately 50 percent. We do not routinely use sequential cytoplasmic ANCA measurements to dictate changes in immunosuppressive therapy. Local nasal and sinus care and otolaryngoscopic evaluations are a routine part of the therapy of patients with WG and upper airway disease.

Churg-Strauss Syndrome (Allergic Angiitis and Granulomatosis)

CSS, like WG, affects small- to medium-sized arteries and veins.[8] There are clinical similarities to WG in terms of the pattern of organ involvement and pathology. This is especially true in regard to upper and lower airway disease and glomerulonephritis. CSS differs most strikingly from WG in that the former usually occurs in patients with a history of atopy, asthma, or allergic rhinitis, which is often ongoing. In the prevasculitic atopy phase, as well as during the systemic phase of the illness, eosinophilia is characteristic and often of striking degree (1000 eosinophils/mm^3 or more). When eosinophilia is present in WG, it is usually more modest (500/mm^3 or less).

Systemic features of CSS include some combination of pulmonary infiltrates, cardiomyopathy, coronary arteritis, pericarditis, polyneuropathy (symmetric or mononeuritis multiplex), ischemic bowel disease, eosinophilic gastroenteritis, ocular inflammation, nasal perforations, glomerulonephritis, and cutaneous nodules and/or purpura (Table 165-8).

The skin is involved in about half of patients with CSS. Strauss, Churg, and Zak divided the clinical findings in allergic granulomatosis into three categories: erythematous maculopapules resembling erythema multiforme, hemorrhagic lesions ranging from petechiae to extensive ecchymosis, often associated with wheals, and cutaneous and subcutaneous nodules. It has been suggested that the initial small vessel vasculitis evolves into a pattern of inflammation with granulomas that coalesce into the palpable nodules. The histopathologic features of the first two types were non-specific; however, the pathologic changes in the third type, cutaneous and subcutaneous nodules consisting of necrotic collagen in the center surrounded by a palisading granuloma, were thought to be suggestive for allergic granulomatosis. Similar nodules can be found in WG, SLE, or rheumatoid arthritis. Additional clinical findings in



TABLE 165-6
Clinical Manifestations in Wegener Granulomatosis

Organ Involvement	Symptoms and Signs	Histopathology	Useful Tests
Upper airway disease	Pansinusitis, often destructive Nasal crusting Epistaxis Septal perforation Saddle nose deformity Otitis media Ear chondritis Neurosensorial hearing loss Subglottic stenosis	Nasal tissue biopsy Low yield for specific diagnosis	CT of the sinuses
Lower airway and lungs	Diffuse alveolar hemorrhage Lung infiltrates Lung nodules Cavitary lesions	Open lung biopsy Highest yield for diagnosis but not specific Areas of necrosis in "geographic pattern," giant cell granulomas, vasculitis (see eFig. 165-7.1A,B in on-line edition) Diffuse alveolar hemorrhage with capillaritis and hemosiderin-laden macrophages	CT scan of the chest Bronchoscopy with bronchoalveolar lavage cultures to exclude infections Transbronchial biopsy (very low yield for specific diagnosis)
Renal involvement	Glomerulonephritis Acute renal failure	Renal biopsy Focal segmental glomerulonephritis with variable proliferative changes Rapidly progressive crescentic glomerulonephritis No immune complex deposition (pauci-immune) helps distinguish from systemic lupus erythematosus, Goodpasture syndrome, viral etiologies	Urinalysis; serum creatinine, 24-h protein collection
Ocular	Orbital pseudotumor Nasolacrimal duct stenosis Conjunctivitis Scleritis Uveitis Retinal vasculitis		CT or magnetic resonance imaging of the orbit
Musculoskeletal	Arthralgias Migratory or fixed polyarthritis		Rheumatoid factor frequently positive; x-rays: no erosions
Neurologic	Peripheral neuropathy Oculomotor involvement by retro-orbital mass impingement Central nervous system involvement uncommon		Electromyogram
Cutaneous involvement	Acute indolent deep inflammatory masses Palpable purpura Pyoderma-like ulcerations Gingival hyperplasia Papules Ulcers Panniculitis and subcutaneous nodules	Skin biopsy No pathognomonic histopathology Leukocytoclastic vasculitis Granulomatous vasculitis	
Gastrointestinal	Ulcerations Ischemic bowel		
Cardiovascular	Cardiac ischemia Conduction abnormalities Pericarditis		

CT = computed tomography.



CSS include ulcers, livedo reticularis, facial edema, and deep pannicular vasculitis.

Histologically, cutaneous lesions can be divided into three categories: extravascular granulomas, leukocytoclastic vasculitis with or without prominent eosinophilic infiltration, and cutaneous polyarteritis nodosa (PAN).

Histopathology of involved skin, nerve, lung, heart, and gastrointestinal tract typically exhibits a vascular or extravascular granulomatous inflammation, with a prominent eosinophilic infiltrate and vasculitis. Vasculitis in a given tissue section may be granuloma-

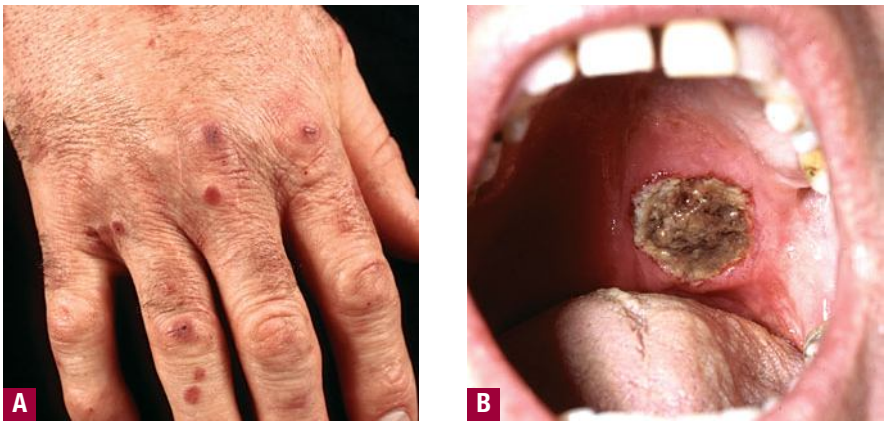

▲ **FIGURE 165-7** Wegener granulomatosis. **A.** Palpable purpura, which has a more pronounced papular component than in the more common types of leukocytoclastic vasculitis. **B.** Deep ulcer on the soft palate.

tous or nongranulomatous. Granulomas can be found in tissue at areas separate from the demonstrable vasculitis. Eosinophilic infiltrates are more striking than in WG. Neither abundant eosinophils, granulomas, nor giant cells are found in classic PAN. However, the pathology of these nodules is not by itself sufficient to make a diagnosis of CSS because similar pathology can be seen in lymphoma and sarcoidosis.

CSS is generally a corticosteroid-responsive disease. Some patients are able to be withdrawn from steroids. However, bronchial asthma and sinus disease may require ongoing therapy, even if the vasculitic component of the disease has remitted. It seems appropriate to extend the principles for treatment of WG to all ANCA-associated vasculitides. Cyclophosphamide should be added to glucocorticoids for remission induction in all patients who present with disease manifestations that threaten the patient's life or the function of a vital organ. For patients with less severe disease, methotrexate, azathioprine, or mycophenolate mofetil can be used as glucocorticoid-sparing therapies.

Polyarteritis Nodosa and Microscopic Polyangiitis

Attempts to neatly separate these two forms of necrotizing medium/small-sized vessel arteritis have not been universally accepted, and older literature frequently combined these disorders. A recent international consensus conference proposed that the diagnosis of these disorders be based on the absence of granulomatous inflammation in both, and the lack of involvement of arterioles, capillaries, venules, and glomerular capillaries in classic PAN. MPA involves vessels ranging in size from capillaries and venules to medium-sized arteries. Glomerulonephritis, particularly rapidly progressive glomerulonephritis, and alveolar hemorrhage are particularly common in MPA, and by definition absent in PAN. Antibody to myeloperoxidase, a type of perinuclear ANCA, is detected in 60 percent of sera from patients with MPA. It may well be that some cases of classic PAN do involve the smaller vessels, and until it can be demonstrated that the two syndromes have distinct pathophysiologies, attempts to clearly distinguish MPA from PAN remain imperfect. Hepatitis B and C infections have been associated with a classic PAN-like syndrome as well as MPA-like disease.

Given the diagnostic nuances and disagreements, it is not surprising that a clear-cut distinction cannot be provided in terms of prognosis or response to therapy between the two syndromes. Most important, because the distinction between these two syndromes is still being defined, it is difficult to interpret the clinical descriptions of the older studies on PAN, which included patients with both classic PAN and MPA. This accounts for some of the wide variation in the reported frequency of cutaneous, pulmonary, or glomerular involvement in PAN.

Constitutional symptoms, such as fever, asthenia, and myalgias, are common in both PAN and MPA. Elevated acute phase reactants, thrombocytosis, leukocytosis, and the anemia of inflammatory disease are also common. MPA is typically manifest by purpura; crescentic necrotizing, segmental glomerulonephritis; and/or alveolar hemorrhage in conjunction with small- and medium-sized vessel vasculitis in other organ systems.

It is important to note that alveolar hemorrhage in MPA and other entities may manifest as dyspnea, pulmonary infiltrates, and anemia in the absence of hemoptysis. Peripheral neuropathy with symmetric mixed motor and sensory



TABLE 165-7
Treatment of Wegener Granulomatosis (WG)

Drug	Indication	Dose	Side Effects	Comments
Cyclophosphamide (Cytoxan)	Remission induction: severe disease; life-threatening or major organ-threatening disease (e.g., alveolar hemorrhage, acute glomerulonephritis, mononeuritis multiplex)	2 mg/kg/day PO	Infections, cytopenias, bladder cancer, leukemia	Dramatically increased survival in WG patients compared to steroids alone
Methotrexate	Remission induction: systemic disease; not life-threatening or major organ-threatening; remission maintenance	0.3 mg/kg/wk PO, SC, IV	Pneumonitis, elevation in transaminases, cytopenias	Should be avoided in patients with renal insufficiency
Azathioprine (Imuran)	Remission maintenance	2 mg/kg/day PO	Cytopenias, pneumonitis, hypersensitivity	
Mycophenolate mofetil (CellCept)	Remission maintenance	2 g/day PO	Cytopenias, infections	
Leflunomide (Arava)	Remission maintenance	20–40 mg/day PO	Diarrhea, hepatotoxicity	



TABLE 165-8
Clinical Manifestations in Churg-Strauss Syndrome

- Pulmonary manifestations
  - Asthma
    - Disease-defining feature
    - 99% of cases
    - Precedes the onset of vasculitis
  - Pulmonary infiltrates
    - Transient, patchy
  - Alveolar hemorrhage
  - Nodules
    - Uncommon
    - Rarely cavitate
  - Pleural effusions
    - Common
    - Abundant eosinophils
- Neurologic involvement
  - Mononeuritis multiplex
  - Symmetric polyneuropathy
- Cutaneous involvement
  - Nodules and papules on the extensor surfaces of joints (Churg-Strauss granulomas)
  - Cutaneous extravascular granulomatous lesions
    - Histopathology: Palisading granulomas with central necrosis
  - Palpable purpura
    - Histopathology: Leukocytoclastic vasculitis without prominent eosinophilic infiltration
  - Erythematous maculopapules
- Cardiac disease: Common, may be severe, leading cause of mortality
  - Eosinophilic myocarditis
  - Valvular heart disease
  - Small vessel coronary vasculitis
  - Pericarditis
- Gastrointestinal involvement
  - Eosinophilic gastroenteritis
  - Mesenteric vasculitis

components or mononeuritis multiplex pattern is common. Upper airway and ocular inflammation may occur, which occasionally makes distinction from WG difficult. Purpura and/or splinter hemorrhages are commonly found in MPA.

Classic PAN may present with hypertension and/or renal insufficiency with a bland urine sediment on microscopic analysis. Renal ischemia may result from inflammation, stenosis, or occlusion of pre-glomerular muscular arteries. Peripheral neuropathy, testicular pain/epididymitis, and ischemic myalgias occur fairly frequently. Both PAN and MPA may cause ischemia in the heart and gastrointestinal tract. PAN is associated with the development of 1- to 5-mm microaneurysms in the mesenteric, hepatic, or renal arteries in perhaps 40 percent of cases. Microaneurysms can also occur in MPA, WG, CSS, Behçet, SLE, and other disorders affecting medium-size vessels.

Skin manifestations occur in 15 percent of cases. Subcutaneous inflammatory, bright red to bluish nodules (0.5 to 2.0 cm) are violaceous, become confluent to form painful subcutaneous plaques, and are accompanied by livedo reticularis (see Fig. 165-6); "starburst" livedo is pathognomonic and marks a cluster of nodular lesions (Fig. 165-8). Ulcers follow ischemia nodules (see Fig. 165-4) and are usually found bilaterally on lower legs and thighs. Other areas: arms, trunk, head, neck, buttocks. Livedo reticularis may extend to trunk. The duration is from days to months and resolves with residual violaceous or postinflammatory hyperpigmentation. Skin lesions in systemic and cutaneous PAN are identical.

When the clinical picture of PAN or MPA is recognized, it is imperative to be certain that it is not secondary to, or associated with, infection with hepatitis B or C. The presence of hepatitis B or C infection does not seem to dramatically alter the presentation of the PAN or MPA syndrome, although membranous glomerulonephritis, liver failure, and thrombocytopenia are more likely to occur with viral hepatitis infection. Infection with parvovirus B19 and human immunodeficiency virus should also be excluded.

The diagnosis of these disorders should ideally be based on histopathology and clinical pattern of disease. In the patient with a urine sediment analysis suggestive of glomerulonephritis or neuropathy, a renal biopsy or biopsy of a clinically involved nerve may support the diagnosis of MPA. The presence of serum perinuclear ANCA with anti-myeloperoxidase specificity further supports the clinical diagnosis, but is not specific for this disease. The renal biopsy tissue in MPA, as in WG, is negative for immune complexes by immunofluorescent staining and electron microscopy—so called *pauciimmune glomerulonephritis*. Lung biopsy in the setting of pulmonary infiltrates or hemorrhage may demonstrate "capillaritis," but yields less specific pathology than in WG. Biopsy is most useful to rule out alternative pulmonary diagnoses. The diagnosis of classic PAN is often more difficult in the setting of dominant but non-specific constitutional symptoms and the absence of easily accessible disease-affected tissue such as nerve. Biopsy of skin lesions can be diagnostic when segmental necrotizing arteritis is found (Fig. 165-8B). Biopsy of clinically uninvolved tissue (i.e., asymptomatic muscle) is not usually fruitful. Several diagnostic algorithms have been proposed. If biopsy is not indicated due to the absence of accessible involved tissue, complete abdominal angiography should be considered to evaluate the medium-size vessels. The sensitivity and specificity of this procedure is not well defined, especially in the absence of abdominal complaints. Angiography is generally avoided, whenever possible,

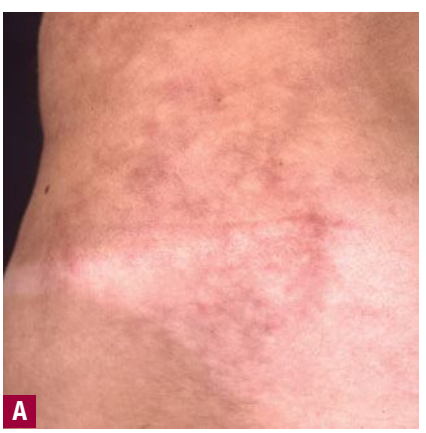

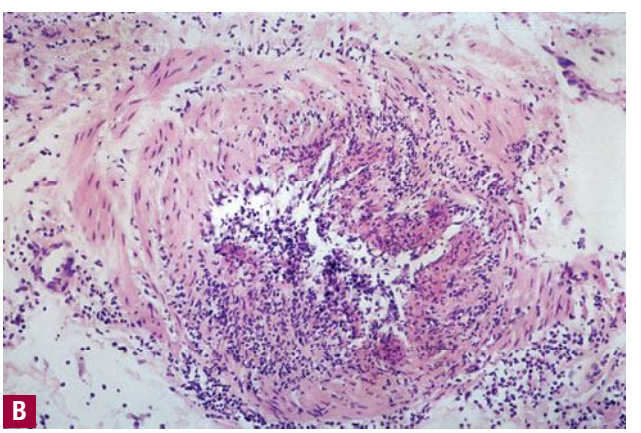

◀ **FIGURE 165-8** **A.** "Starburst" livedo is pathognomonic for polyarteritis nodosa and marks a cluster of nodular lesions. **B.** Histopathology of skin lesions in polyarteritis nodosa showing segmental necrotizing arteritis.

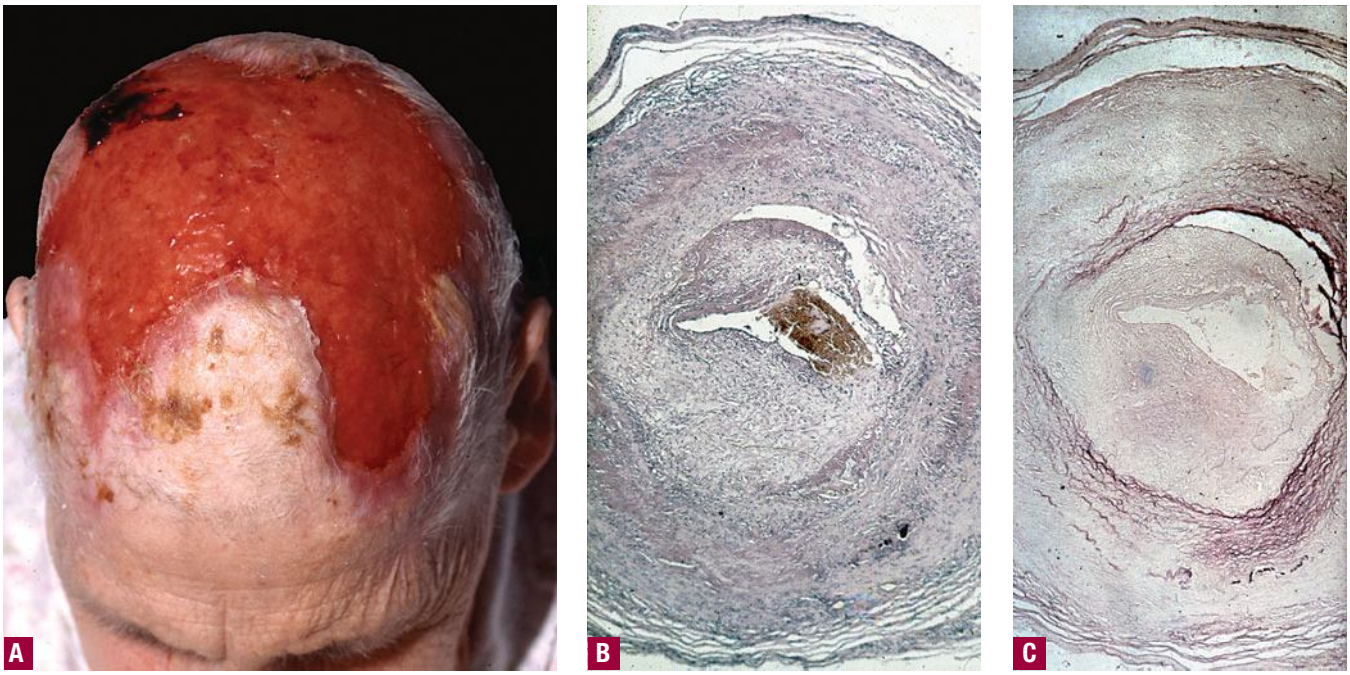

▲ **FIGURE 165-9** **A.** Temporal arteritis. Necrosis of the scalp first manifests with a black eschar, which is adherent, but later shed, leaving a deep ulcer that may extend to the bone and, later, granulates under corticosteroid therapy as shown here. **B.** Histopathology of the temporal artery shows necrosis of the media, inflammatory infiltrates consisting of lymphocytes, and giant cells. There is also subintimal proliferation of fibroblasts and fibrosis. **C.** Elastic tissue stain reveals destruction of the lamina interna and externa.

in the setting of progressive or significant renal insufficiency.

Treatment of both PAN and MPA is still somewhat empiric. Corticosteroids in high doses remain the initial mainstay of therapy for both PAN and MPA. Corticosteroids alone may be sufficient therapy in patients who do not have critical organ involvement, defined as renal insufficiency, gastrointestinal ischemia, cardiomyopathy, dense peripheral neuropathy, and central nervous system involvement. Such patients have increased risk of morbidity or mortality and are usually treated with glucocorticoids and an additional immunosuppressive agent such as cyclophosphamide. Although this is common practice, the use of initial combination therapy in this setting has not been formally studied. Patients with MPA may be more likely to suffer relapses after a course of treatment than those with PAN.

When active hepatitis B or C infection is present, a relatively short course of steroids should be considered, based on disease severity, in conjunction with antiviral therapy, and, perhaps, apheresis. Controlled studies have not been conducted to objectively assess the value of adding apheresis to the combination of antiviral and corticosteroid therapy. The possibility of drug-induced MPA or PAN syndromes should always be considered. Common drugs include propylthiouracil, hydralazine, leukotriene inhibitors, sulfasalazine, minocycline, D-penicillamine, ciprofloxacin, phenytoin, and allopurinol.

Large Vessel Arteritis (Takayasu Arteritis and Temporal Arteritis)

TA and GCA are the most common inflammatory diseases of the aorta and its major branches. Similar vascular targeting may occur in Behçet disease (see Chap. 167), Cogan syndrome, and sarcoidosis (see Chap. 153). These diseases are readily distinguished by their associated extravascular features. GCA and TA have similar histology but differ in the age of onset. GCA generally affects individuals older than 55 years of age. TA preferentially affects women in their first through third decades of life. GCA and TA can be associated in some patients with the syndrome of polymyalgia rheumatica. Polymyalgia rheumatica is characterized by proximal muscle pain and stiffness with nocturnal and early morning worsening. There may be a subjective sense of weakness, without true weakness on examination; serum muscle enzyme levels are normal. The clinical findings in GCA are presented in Table 165-9. Skin lesions in GCA are scalp tenderness, cyanosis of extremities, and scalp necrosis, which may be extensive (see Fig. 165-9A).

Diagnosis of GCA is generally made by biopsy of the superficial temporal artery. Pathology of GCA usually reveals chronic mononuclear cell infiltrates, giant cells, and necrosis of the media (see Fig. 165-9B and C). There are isolated reports of GCA overlap syndromes also involving medium-sized vessels of the viscera, but generally this disease is not associated with small (capillary, venule) blood vessel inflammation.

TA (pulseless disease) is also a chronic inflammatory disease affecting the aorta and its major branches. Although it is usually recognized in younger, predominantly female patients of reproductive age, it can also occur in young children and older patients of either sex. TA is

TABLE 165-9
Clinical Manifestations in Giant Cell Arteritis

General	Fever, night sweats, weight loss
Musculoskeletal	Polymyalgia rheumatica
Ischemic symptoms	Masticatory muscle claudication, tongue claudication, scalp tenderness, retinal ischemic syndromes, limb claudication
Cutaneous manifestations	Extremity cyanosis, pallor; scalp necrosis

more commonly associated with aortic and aortic branch vessel stenoses and aneurysms than GCA. It is uncertain whether TA and GCA are distinct or the same disorder with modified expression in different age groups. The characteristic features of the disease reflect the ischemia produced by the inflammatory stenoses of the aorta and its major branches.

Diagnosis is usually made by arteriographic demonstration of stenotic and obstructive lesions; aneurysms are less commonly observed. The entire arch as well as abdominal aorta and renal vessels should be evaluated; central arterial pressure should be obtained at the time of angiography and compared with simultaneously obtained arm and leg pressures. The role for vascular magnetic resonance imaging in the evaluation and follow up of these patients is currently under investigation. Pathologic documentation is more difficult to obtain in TA, but the histopathology is similar to that described in GCA.

Initial therapy of both TA and GCA is with corticosteroids. GCA is generally quite steroid responsive, although the choice of the most appropriate initial dose remains controversial. Different authors have advocated an initial daily dose of between 20 mg and 1 mg/kg, with tapering of the corticosteroids over 8 to 12 months. Measurement of acute phase reactants provides an imperfect marker of disease activity and an imperfect guide to steroid tapering. If significant steroid side effects occur, or if patients relapse on tapering, a "second line" agent such as methotrexate is often (empirically) added to the corticosteroids. TA is less consistently responsive to initial corticosteroid therapy than GCA, but this has not been carefully studied. Some authors have advocated earlier use of methotrexate therapy in TA to reduce the long-term toxicity risks of corticosteroids. Other drugs, such as cyclophosphamide, azathioprine, and the newer anti-tumor necrosis factor drugs, etanercept and infliximab, have been used with variable but generally less than hoped for success. Vascular reconstructive surgery or angioplasty are adjunctive therapeutic options in some patients.

SOME CAVEATS AND GENERAL COMMENTS CONCERNING THE TREATMENT OF PATIENTS

The systemic vasculitides are potentially life threatening and often require potent anti-inflammatory and immunosuppressive therapy. After the initiation of therapy, there is a prolonged window of increased susceptibility to opportunistic infection. The greatest risks occur in patients with marked neutropenia or lymphopenia. One must be particularly wary about attributing new problems to "flares" in the underlying disease without considering the possibility of a new or recrudescent infection. Varicella zoster may present with fever and pain before the appearance of the tell-tale vesicles. Pneumocystis carinii, cytomegalovirus, systemic fungal infections, or reactivation of mycobacterial disease are observed more frequently than in the normal host. Significant immunosuppression from steroids and other medications frequently is associated with mucosal candidiasis, less commonly molluscum contagiosum, and, rarely, Kaposi sarcoma. Methotrexate may cause a flu-like illness after each dose. Methotrexate, azathioprine, or cyclophosphamide may cause leukopenia and, less often, other cytopenias. Steroids can cause a significant amount of facial and truncal acne, which, especially in younger patients, must be addressed to encourage compliance with therapy. Cutaneous complications, including allergic purpura, can also result from adjunctive medications for hypertension, epilepsy, or arthritis. Reactions to thrombolysis or angiographic studies may include urticaria as well as the cholesterol embolization syndrome in patients with atherosclerosis (see Chap. 174). Drug-induced pneumonitis has been reported with the use of immunosuppressive agents, especially with methotrexate and cyclophosphamide.

REFERENCES

1. Langford CA: 15. Vasculitis. *J All Clin Immunol* **111**:S602, 2003
2. Carlson JA, Ng BT, Chen KR: Cutaneous vasculitis update: Diagnostic criteria, classification, epidemiology, etiology, pathogenesis, evaluation and prognosis. *Am J Dermatopathol* **27**:504, 2005
3. Saleh A, Stone JH: Classification and diagnostic criteria in systemic vasculitis. *Best Pract Res Clin Rheumatol* **19**:209, 2005
4. Bloch DA et al: The American College of Rheumatology 1990 criteria for the classification of vasculitis. Patients and methods. *Arthritis Rheum* **33**:1068, 1990
5. Jennette JC et al: Nomenclature of systemic vasculitides. *Arthritis Rheum* **37**:187, 1994
6. Mandell BF, Hoffman GS: Differentiating the vasculitides. *Rheum Dis Clin North Am* **20**:409, 1994
7. Molloy ES, Langford CA: Advances in the treatment of small vessel vasculitis. *Rheum Dis Clin North Am* **32**:157, 2006
8. Keogh KA, Specks U: Churg-Strauss syndrome. *Semin Resp Crit Care Med* **27**:148, 2006
9. Liang P, Hoffman GS: Advances in the medical and surgical treatment of Takayasu's arteritis. *Curr Opin Rheumatol* **17**:16, 2005



CHAPTER 166

Erythema Elevatum Diutinum

Nneka I. Comfere
Lawrence E. Gibson

Erythema elevatum diutinum (EED) is a chronic leukocytoclastic vasculitis (LCV) that was initially described by Hutchinson in 1888 and subsequently by Bury in 1889. The name *EED* was first used by Radcliff-Crocker and Williams who separated it into two groups.[1–3] The Bury type tended to occur more commonly in younger women with a history of underlying rheumatologic disease, and the Hutchinson type tended to occur in elderly males.

EPIDEMIOLOGY

The incidence of EED is unknown; however, it appears to be a rare disease. There is no significant mortality associated with EED. It presents predominantly in males, in the fourth to sixth decade of life.

PATHOGENESIS

The pathogenesis of EED is not entirely clear; however, the prevailing and traditional theories are based on immune complex deposition within vessel walls, complement fixation, inflammation, and subsequent vascular destruction.[1] The various disease associations seen in EED (see Co-Occurring Diseases) have provided further understanding of the underlying pathomechanism of EED.

ERYTHEMA ELEVATUM DIUTINUM

AT A GLANCE





- Rare disease; unknown incidence.
- A chronic leukocytoclastic vasculitis typified by a distinctive clinical pattern.
- Symmetric, erythematous, violaceous, or yellow-brown papules/nodules/plaques.
- Most common sites of involvement are the extensor surfaces of the hands, fingers, elbows, knees, legs, and Achilles tendon. Trunk is usually spared.
- Co-occurring diseases include monoclonal paraproteinemias, lymphoproliferative disorders, chronic infection, autoimmune conditions, and connective tissue diseases.
- Pathology consists of leukocytoclastic vasculitis in early stage lesions and a granulation-tissue–like response with fibrosis in later stages.



▲ **FIGURE 166-1** Erythema elevatum diutinum. Nodular lesions on dorsal hand present for several years.



Antineutrophil cytoplasmic antibodies (ANCA) of the immunoglobulin G (IgG) type have proven useful for the diagnosis and monitoring of disease activity in various systemic vasculitides, including Wegener granulomatosis (WG), microscopic polyangiitis (MPO), polyarteritis nodosa, and Churg-Strauss syndrome.[4]

There are reports in the literature documenting the occurrence of IgA ANCAs in patients with neutrophil-driven dermatoses such as Henoch-Schönlein purpura, inflammatory bowel disease, and various cutaneous vasculitides, including EED.[6,7] It seems likely that abnormal functioning or activation of the neutrophil, which is the primary inflammatory cell in EED, may represent the central event. Most importantly, some of the neutrophilic dermatoses, including EED, have been associated with underlying paraproteinemias (monoclonal and polyclonal IgA gammopathies)[8] and hematologic malignancies. The severity of EED does not, however, appear to be dependent on the total paraprotein levels. Nevertheless, immunoelectrophoresis screening for monoclonal gammopathies as a marker of EED has been recommended.[9] Hence, IgA ANCAs against yet unidentified neutrophilic antigenic targets may prove to be useful clinical markers in EED.[10]

In a recent analysis of the clinical, histopathologic, and immunohistochemical features in six patients with EED by Wahl et al.,[9] the vascular endothelium of EED was immunoreactive for CD31, CD34, vascular endothelial growth factor, and factor VIIIa but nonimmunoreactive for factor XIIIa, transforming growth factor-β, and latency-associated nuclear antigen of human herpesvirus 8. The staining properties of the endothelium in EED were compared to endothelial staining in similar lesions, including LCV, urticarial vasculitis, dermatofibromas, and capillary hemangiomas. No significant differences in the immunohistochemical staining properties were observed. The authors concluded that the chronic and recurrent nature of EED is the primary means of distinguishing it from other entities that are similar clinically and histologically.[9]

CLINICAL FEATURES

EED typically presents as multiple, persistent, symmetric, and erythematous to violaceous papules/nodules/plaques on the extensor surfaces of the hands (Fig. 166-1), elbows (Fig. 166-2), wrists, knees (Fig. 166-3), ankles, Achilles tendons, fingers (Fig. 166-4) and toes, buttocks (see eFig. 166-4.1 in on-line edition), face, ears, legs, forearms, and genitals.[1] The trunk, however, is usually spared, but may be involved rarely.[11] Other atypical sites of involvement include the retroauricular and palmoplantar regions.[1,11,2] Overlying epidermal changes, such as vesiculation or ulceration, may be present. Lesions may be exacerbated by cold exposure and may become more raised, erythematous, and firm in the evening.[12–14]

With time, the lesions may become firmer and develop a yellowish-brown coloration, resembling xanthomata (see Fig. 166-2). These eventually heal with dyspigmentation. The onset of new lesions may be associated with symptoms of pruritus, burning, stinging sensations, paresthesias, or may be completely asymptomatic. Constitutional symptoms,



▲ **FIGURE 166-2** Multiple erythematous scaly papules coalescing into plaques on extensor elbow.



▲ **FIGURE 166-3** Crusted brown and violaceous papules over knee and anterior thigh.



including fever and arthralgias, are seen commonly.[1,15]

The clinical presentation of EED in human immunodeficiency virus (HIV)–infected individuals is somewhat different and can mimic lesions of Kaposi sarcoma and bacillary angiomatosis usually seen in immunosuppressive states.[16] Nodular lesions have been reported in HIV-infected patients.

LABORATORY FINDINGS

Histopathology

Histopathologic findings are predominantly those of a chronic LCV, with thickening of blood vessel walls, mural and luminal neutrophilia, vascular occlusion, fibrinoid necrosis of vessel walls, endothelial cell swelling, leukocytoclasia, and dermal neutrophilia with lymphocytes (Fig. 166-5). Epidermal changes of hyperkeratosis, acanthosis, ulceration, subepidermal edema, and bulla formation may also be observed.[1,3,17]

The histopathologic features characteristic for EED are not usually all present within the same lesion. There is an evolution of the pathologic features that can be seen with progression from the early stages into the later stages of disease.

Early stage lesions are characterized by leukocytoclastic vasculitis with a moderately dense perivascular inflammatory infiltrate consisting of neutrophils, leukocytoclastic debris, macrophages, and histiocytes (see eFig. 166-5.1 in on-line edition). Fibrin deposition is also evident within the vascular walls. At this stage, the histologic differential diagnosis is broad and includes all the potential causes of LCV. However, the histologic features of EED at this early stage may mimic those of dermatitis herpetiformis. The distinguishing feature for dermatitis herpetiformis includes a limitation of the neutrophilic infiltrate to the papillary dermis, whereas in EED the infiltrate tends to be more diffuse. Other entities to consider in the differential diagnosis include the neutrophilic dermatoses, such as Sweet syndrome, bowel bypass syndrome, and rheumatoid neutrophilic dermatitis, none of which has LCV as a predominant feature.[18] Clinicopathologic correlation is necessary to establish the diagnosis in the early stages of disease.

With progression of disease, a granulation tissue–like response with fibroplasia and capillary proliferation becomes the predominant feature[1,3] (see eFigs. 166-5.1 and 166-5.2 in on-line edition). The infiltrate is increasingly composed mostly of histiocytes, some with phagocytosed nuclear debris. At this stage, the histopathologic features (see eFig. 166-5.3 in on-line edition) may be indistinguishable from other fibrosing lesions, such as a solitary sclerotic fibroma, fibrous histiocytomas, and dermatofibrosarcoma protuberans, or vascular lesions such as pyogenic granuloma, Kaposi sarcoma, and bacillary angiomatosis.[1,18,19] In the later stages of disease, xanthomatization is occasionally observed. This is characterized by the presence of both intra- and extracellular cholesterol deposits within infiltrating histiocytes and the dermis as demonstrated by ultrastructural studies.[1,20]

Direct immunofluorescence findings of lesional skin are generally non-diagnostic and range from few to many blood vessels within the superficial to mid-dermis, with variable staining with various conjugates, including IgG, IgM, C3, and fibrinogen.[15,21]

Other Laboratory Findings

(See Co-Occurring Diseases and Table 166-1)

CO-OCCURRING DISEASES

EED has been reported in association with a wide range of disease processes (see Table 166-1). Notable associations include chronic bacterial infections, especially streptococcal infections; HIV infection; underlying monoclonal and polyclonal gammopathies; and connective tissue diseases. Some of these dis-



▲ **FIGURE 166-4** Smooth, flesh-colored to slightly erythematous papules on extensor fingers over proximal interphalangeal joints.

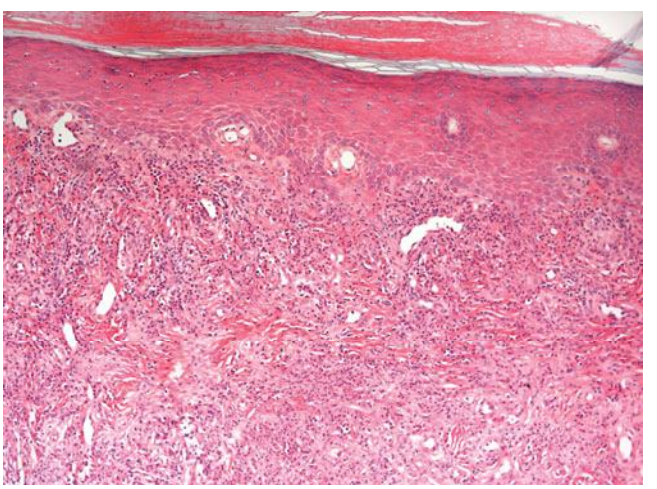

▲ **FIGURE 166-5** Early stage lesion of erythema elevatum diutinum: Focal leukocytoclastic vasculitis with a fairly dense perivascular and interstitial infiltrate composed of neutrophils, lymphocytes, histiocytes, and leukocytoclastic debris. Mild capillary proliferation is also evident.

TABLE 166-1
Co-Occurring Entities

Infectious Diseases	Inflammatory Diseases	Connective Tissues Diseases/Autoimmune Conditions	Malignancy	Medications	Miscellaneous
Chronic bacterial infections	Crohn disease	Cutaneous lupus erythematosus	Polycythemia vera	Rifampin	Pulmonary infiltrates
HIV, HIV-2	Mixed cryoglobulinemia	Relapsing polychondritis	Myelodysplasia	Pyrazinamide	Pleural effusions
Human herpesvirus 6	Pyoderma gangrenosum	Rheumatoid arthritis	IgA/IgG paraproteinemia (monoclonal gammopathy/ MGUS/myeloma)	Isoniazid	Mosquito bites
Measles virus		Systemic lupus erythematosus	Hairy cell leukemia	Streptomycin	Insulin-dependent diabetes mellitus
Streptococcal infection/rheumatic fever		Myasthenia gravis	Chronic lymphocytic leukemia		Hyperimmunoglobulinemia D syndrome
Syphilis		Celiac disease	B-cell lymphoma		Hypereosinophilic syndrome
Tuberculosis		Dermatitis herpetiformis	Lymphadenopathy-associated virus/human T-cell lymphotrophic virus type 3		Acro-osteolysis
Hepatitis B		Autoimmune keratolysis of the eye			Hemophilia Peripheral ulcerative keratitis

HIV = human immunodeficiency virus; Ig = immunoglobulin; MGUS = monoclonal gammopathy of undetermined significance.

ease associations have provided further insight into the pathogenesis of EED.

The most frequent disease association with EED is IgA paraproteinemia. Lesions of EED have been noted to flare with increased IgA levels. Hence, IgA paraprotein levels have been proposed to be a useful clinical marker in EED.[22] Other notable associations have included chronic bacterial, viral, and parasitic infections. Bacterial infections, especially streptococcal infections, have been associated with EED, and typical skin lesions have been reproduced or exacerbated by the intradermal injection of streptococcal antigens.[1,3,22] Juxta-articular nodules of EED have been observed in patients with HIV infection. The histopathology of these nodules usually reveals a predominance of fibrosis rather than a neutrophilic infiltrate, probably secondary to the advanced/chronic stage of such lesions.[16,23,24] The role of infectious agents in the etiopathogenesis of EED is still unclear, but evidence suggests that perhaps these agents serve as antigenic triggers of a hypersensitivity response that manifests as EED.

Connective tissue diseases and autoimmune diseases have also been seen in association with EED.

TREATMENT

As is the case with cutaneous vasculitis, treatment is aimed at alleviating discomfort associated with the lesions, diminishing damage to the skin, and eradication/minimization of underlying/associated conditions. Reports in the literature on treatment options are primarily anecdotal or based on experience in small case series. Management of EED remains challenging due to the chronic and recurrent nature of the disease. In general, treatment of the underlying cause or infectious process may result in resolution of lesions.[1] Dapsone- and sulfone-based therapies are considered first-line treatment choices for EED.[1,3,15,25] Dramatic and rapid response is usually seen within 48 hours of initiation of therapy, with near complete resolution of lesions within weeks to months.[25] However, lesions may recur with discontinuation of therapy.[1,22] The responsiveness of EED and other neutrophil-driven dermatoses to dapsone and sulfonamides is not completely known but is thought to be secondary to its inhibitory effects on neutrophil chemotaxis and function.[14] In patients with HIV infection, treatment with a combination of antiretroviral agents and dapsone or sulfonamides may be beneficial.[1] Other reported treatments with variable success in EED include niacinamide and tetracycline,[26] colchicine,[27] intralesional, potent topical or oral corticosteroids,[3] phenformin,[28,29] clofazimine,[13] and cyclophosphamide.[5]

CONCLUSION

EED is a distinctive form of cutaneous vasculitis. It is the clinical pattern combined with the chronicity of this process that is unique to EED. Repeated antigenic stimulation or infection appears to play a key role in the pathogenesis. Although microscopic features of early lesions are shared with other cutaneous vasculitides, in the chronic phase of the disease, the microscopic pattern may resemble various other entities characterized by granulation response and healing skin. It is important to search for an underlying disease and to evaluate patients carefully for infection. Otherwise, treatment recommendations are anecdotal and similar to those used for other cutaneous vasculitides.

KEY REFERENCES

The full reference list for all chapters is available at www.digm7.com.

1. Gibson LE, El-Azhary R: Erythema elevatum diutinum. *Clin Dermatol* **18**:295, 2000
7. Rovel-Guitera P et al: IgA antineutrophil cytoplasmic antibodies in cutaneous vasculitis. *Br J Dermatol* **143**:99, 2000
9. Wahl CE, Bouldin MB, Gibson LE: Erythema elevatum diutinum: Clinical, histopathologic, and immunohistochemical characteristics of six patients. *Am J Dermatopathol* **27**:397, 2005



10. Ayoub N et al: Antineutrophil cytoplasmic antibodies of IgA class in neutrophilic dermatoses with emphasis on erythema elevatum diutinum. *Arch Dermatol* **140**:931, 2004
15. Yiannias JA, el-Azhary RA, Gibson LE: Erythema elevatum diutinum. A clinical and histopathologic study of 13 patients. *J Am Acad Dermatol* **26**:38, 1992
22. Woody CM, Lane JE, Davis LS: Erythema elevatum diutinum in the setting of connective tissue disease and chronic bacterial infection. *J Clin Rheumatol* **11**:98, 2005
24. LeBoit PE, Cockerell CJ: Nodular lesions of erythema elevatum diutinum in patients infected with the human immunodeficiency virus. *J Am Acad* **28**:919, 1993

CHAPTER 167

Adamantiades-Behçet Disease

Christos C. Zouboulis



Adamantiades-Behçet disease is a multisystem inflammatory disease of unknown etiology, classified as systemic vasculitis involving all types and sizes of blood vessels and characterized clinically by recurrent oral aphthous and genital ulcers, skin lesions, and iridocyclitis/posterior uveitis, occasionally accompanied by arthritis and vascular, gastrointestinal, neurologic, or other manifestations[1,2] (Fig. 167-1).

HISTORICAL ASPECTS

EPIDEMIOLOGY

Adamantiades-Behçet disease presents a worldwide occurrence with varying prevalence, being endemic in the eastern and central Asian and the eastern Mediterranean countries (along the so-called Silk Road) and rare in northern European countries, central and southern Africa, the Americas, and Australia.[4] A prevalence of 80 to 420 patients per 100,000 inhabitants has been reported in Turkey;[5] 7 to 30 patients per 100,000 inhabitants in the rest of the Asian continent (Japan, 14 to 31:100,000; Korea, 7.3:100,000; northern China, 14:100,000; Saudi Arabia, 20:100,000; Iran, 17:100,000) and 1.5 to 7.5:100,000 in southern Europe. In northern Europe (0.27 to 1.18:100,000) and the United States (0.12 to 0.33:100,000), the disease is rare.[4] In countries with several ethnic populations, including Turkmen and Mongol descents, the latter are mainly affected. The increasing prevalence of the disease is due to its chronic character. Its annual incidence is low; 0.75 to 1.0 new cases per 100,000 inhabitants were assessed in Japan (1990) and Germany (2005).[6] Adamantiades-Behçet disease most often affects patients in their 20s and 30s; however, early and late onsets (first year of life to 72 years) have been reported. Juvenile disease rates are 2 percent to 21 percent in different ethnic groups; its prevalence was estimated to be 0.17:100,000 in France. In contrast to old Japanese and Turkish reports of male predominance, the male to female ratio drastically decreased in the last 20 years. Currently, both genders are equally affected; a male predominance is still observed in Arab populations, whereas female predominance is evident in Korea, China, some northern European countries, and the United States.

ETIOLOGY AND PATHOGENESIS

The etiology of the disease remains unknown, although genetic factors, infectious agents, environmental pollution, immunologic mechanisms, and endothelial and clotting factors have been implicated and studied intensively.[7,8] The endemic occurrence along the historical Silk Road, the major involvement of certain ethnic groups (mostly of Turkmen and Mongol descent), and associated immunogenetic data support the hypothesis that the disease followed the migration of these old nomadic tribes. On the other hand, the wide variation of the disease prevalence in the same ethnic group in association with different geographic areas of residence indicates an additional environmental triggering factor. Therefore, transfer of genetic material and/or of an unknown exogenous agent may have been responsible for the expansion of the disease.

Genetics and Immunogenetics

There is no specific mode of Mendelian transmission in Adamantiades-Behçet disease.[7,8] Familial occurrence with regional differences has been reported, being more frequent in Korea (15 percent) than in Japan or China (2 percent to 3 percent) and in Arab countries, Israel, and Turkey (2 percent to 18 percent) than in Europe (0 percent to 5 percent). An earlier disease onset in children compared with their parents and a higher frequency of familial cases in juveniles than in adults has been observed.

ADAMANTIADES-BEHÇET DISEASE AT A GLANCE





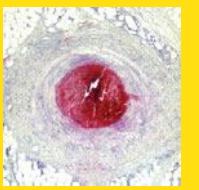

- Rare disease with worldwide distribution but strongly varying prevalence; certain ethnic groups are mainly affected.
- A genetically determined disorder with a probable environmental triggering factor.
- Multisystem occurrence, with oral aphthous ulcers, genital ulcers, papulopustules, erythema nodosum–like lesions, uveitis, and arthropathy as most common signs.
- Inflammatory disease representing a neutrophilic vascular reaction or vasculitis.
- Chronic relapsing progressive course and potentially poor prognosis (especially in males with systemic presenting signs; mortality, 0 percent to 6 percent).

A significant association exists between the disease and human leukocyte antigen (HLA)-B51 in Japan, the Middle East, and the Mediterranean countries; however, this relationship is not as strong in Western countries. The allele also seems to be associated with a more severe prognosis.[9] Its exact role in the disease mechanism is still unknown; however, it may be involved in the disease development through specific antigen presentation, molecular mimicry with microbial antigens, or participation in linkage disequilibrium with a presently unknown susceptibility gene.[10]

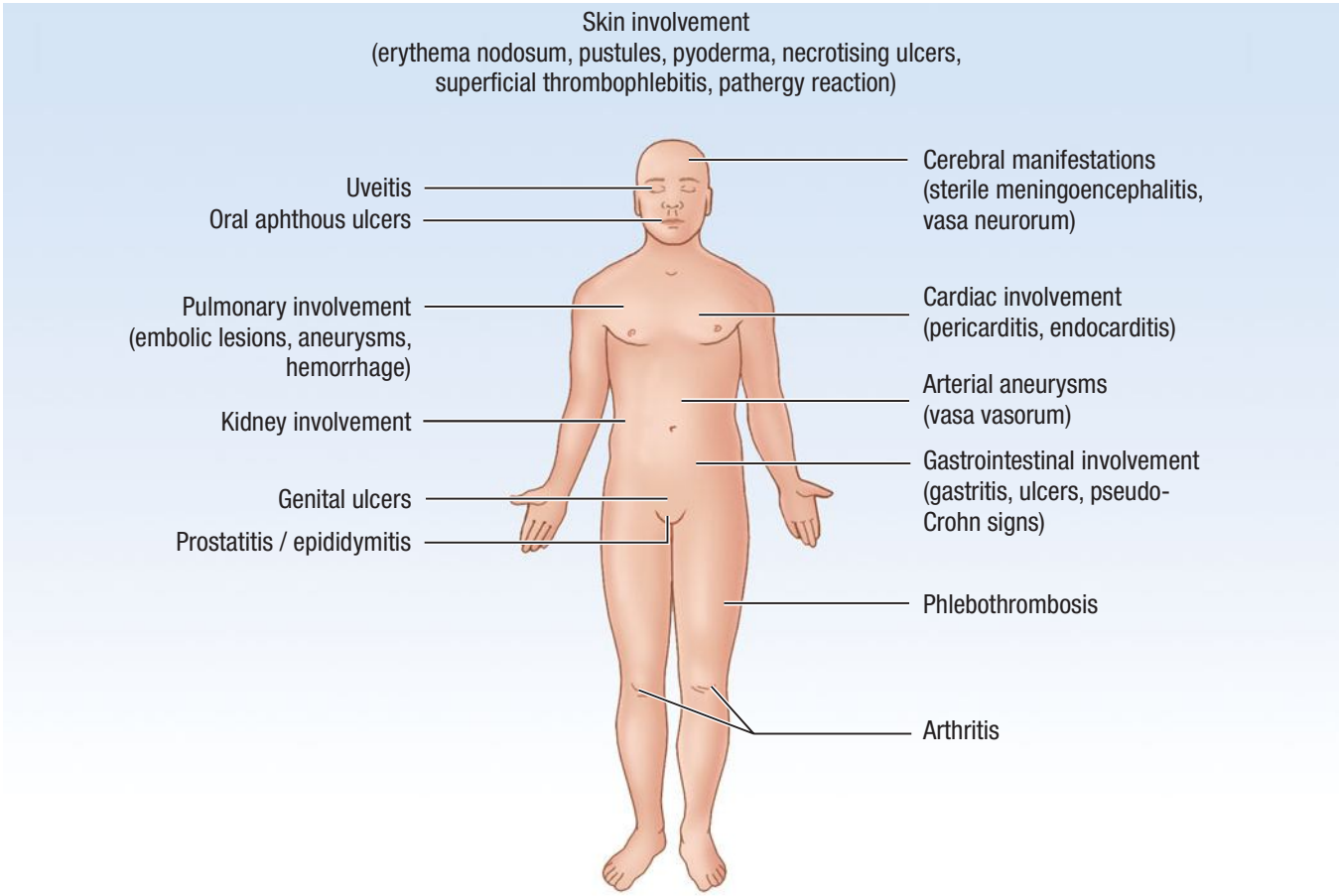

▲ **FIGURE 167-1** Adamantiades-Behçet disease: A multisystem disorder.

Infectious Precipitants

Adamantiades-Behçet disease is not considered contagious, as no horizontal transmission has ever been reported. However, viral and bacterial infections have been implicated in initiating immunopathologic pathways, leading to the onset of the disease.[7,8]

VIRAL AGENTS Early theories of the pathogenesis of Adamantiades-Behçet disease proposed a viral or other infectious etiology.[3] Partial transcription of herpes simplex virus type 1 (HSV-1) DNA in patients' peripheral blood lymphocytes was reported.[7] HSV-1 DNA was detected in patients' saliva and oral and genital ulcers, and HSV-1 antibodies were found in patients' serum.

BACTERIAL AGENTS The disease activity has been known to correlate with bacterial infection, particularly streptococci.[7] *Streptococcus sanguinis* dominates the flora of the oral mucosa in patients with the disease and appears to be the most relevant *Streptococcus* strain as a provoking factor for initiation of the disease.[13] *Streptococcus* antigens and anti-streptococcal antibodies are frequently found in the oral mucosa and serum of patients. The involvement of immunoglobulin A protease–producing *S. sanguinis* is proposed as an explanation for a chronic infection leading to initiation of Adamantiades-Behçet disease. High titers of the immunogenic *S. sanguinis* antigen KTH-1 have been detected in patients. In addition, exposure of the patients to *Streptococcus* antigens may be a major provoking factor for disease activity. The lipoprotein of *Mycoplasma fermentas* MALP-404 was found in the serum of patients with Adamantiades-Behçet disease but not in healthy controls.[14] Interestingly, MALP-404 contains a peptide motif, which can be presented by HLA-B51.

Immunologic Mechanisms

Immunologic mechanisms are considered to play a major role in the pathogenesis of Adamantiades-Behçet disease.[7,8,11,12] The disease has currently been classified among the autoinflammatory disorders,[15] which are caused by primary dysfunction of the innate immune system.

AUTOIMMUNE MECHANISMS The major microscopic finding at most sites of active disease is an immune-mediated occlusive vasculitis. The pathergy reaction (see Clinical Findings) is induced by the rapid accumulation of neutrophils (hyperchemotaxis) and later by T lymphocytes and monocytes/macrophages at the needle prick sites. T cells in the peripheral blood and in the involved tissues are increased, and a predominant T helper 1 immune response induced by interleukin (IL)-12 has recently been demonstrated.[16] Patients' lymphocytes also express CD29 molecules and bind to endothelial cells in active disease. In addition to defective T-cell immunity, B-cell activation is impaired. Circulating immune complexes, together with enhanced neutrophil migration, may be involved; diversity of T cells indicates that specific T-cell responses to several antigens may lead to the variety of symptoms.[17] Tropomyosins and the 160-kd polypeptide kinectin have been detected as autoantigens in Adamantiades-Behçet disease.[18,19]

HEAT SHOCK PROTEINS Increased levels of heat shock protein (HSP)–specific antibodies in serum have been found in Adamantiades-Behçet disease.[20] T cells respond to 60-kd HSP, and four different



peptide determinants within 60-kd HSP identified by T-cell epitope mapping have been suggested to be involved in the pathogenesis of the disease.

CYTOKINE MEDIATORS Various pro-inflammatory cytokines, such as IL-1, -8, -12, and -17 and tumor necrosis factor-α, are elevated in the sera of patients with Adamantiades-Behçet disease. In particular, IL-8 seems to play an important role, can also be released by endothelial cells, has a potent effect on the inflammatory response, and is a sensitive marker of disease activity.[21] Cytokine release may be dependent on the involved organ.



ENDOTHELIAL CELLS The endothelium seems to be the primary target; however it may just be subject to the bizarre behavior of the immune system.[22] An immunoglobulin M–type, 47-kd cell surface HSP against endothelial α-enolase was identified in the serum of patients with Adamantiades-Behçet disease.[23] Plasma endothelin-1 concentrations were found significantly increased, perhaps indicating vasoconstriction and being the direct result of elevated synthesis by injured vascular endothelial cells. Thrombomodulin, a cell surface glycoprotein of vascular endothelium, which is also increased in the plasma of patients with active disease, potentially damages the endothelial cells.

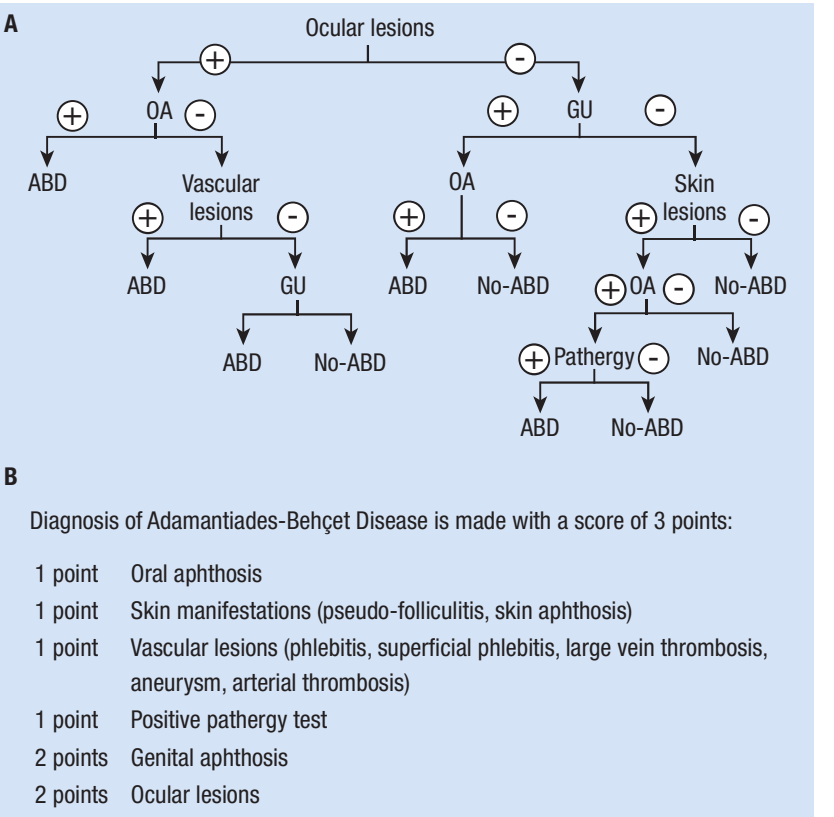

▲ **FIGURE 167-2** Revised International Criteria for Behçet's Disease (International Team for the Revision of ICBD; coordinator: F. Davatchi) according to (**A**) the classification tree format, and (**B**) the traditional format. ABD = Adamantiades-Behçet disease; GU = genital ulcer; OA = oral aphthous ulcer. (From Zouboulis CC et al: Evaluation and revision of the International Criteria for Behçet's Disease (ICBD). Abstracts of the 21st World Congress of Dermatology, Buenos Aires, Argentina, 2007, in press, with permission.)

CLINICAL FINDINGS

Adamantiades-Behçet disease is a chronic, recurrent, multisystem, and, occasionally, life-threatening disorder.[1,6] Recurrent oral aphthous ulcers, recurrent genital ulcers, skin manifestations, ocular lesions, and arthritis/arthropathy are the most frequent clinical manifestations. Vascular, gastrointestinal, neurologic, psychiatric, pulmonary, renal, and cardiac manifestations; epididymitis; and other findings can also occur. The clinical picture usually develops within a few months after the presenting sign; both an acute multisystem presentation and long-term development of the disease over years are possible.

Approach to the Patient with Oral Ulcers, Genital Ulcers, or Iridocyclitis/Posterior Uveitis

Diagnosis of Adamantiades-Behçet disease is based on clinical signs, as pathognomonic laboratory test or histologic characteristics are absent. There are several sets of diagnostic criteria, the most popular of them being the criteria of the International Study Group[24] and those of the Behçet Disease Research Committee of Japan.[25] However, there have been several problems with these criteria, including their performance in selectivity and specificity, so that both of them have currently been revised[2,26] (Fig. 167-2; Table 167-1).

Mucocutaneous Lesions

Recurrent oral aphthous and genital ulcers are the most frequently observed mucosal manifestations. Oral aphthous ulcers are the presenting sign in more than 80 percent of the cases.[1,6,12] Although recurrent aphthous stomatitis is a common disorder, only a few patients progress to Adamantiades-Behçet disease, and it is not possible to determine in whom or when the transition may occur. Typically, lesions are multiple, painful, 1 to 3 cm in diameter, and sharply margined with a fibrin-coated base and surrounding erythema (Fig. 167-3). Oral aphthous ulcers usually heal without scarring (92 percent). Genital ulcers may not recur as often and usually heal with a characteristic scar (64 percent to 88 percent; Fig. 167-4). Spontaneous healing of aphthae occurs within 4 days to 1 month; genital ulcers may persist longer. Large oral ulcerations can also be associated with problems such as pharyngeal involvement, dysphagia, and dyspnea or fistulae involving the pharynx, larynx, trachea, or esophagus. Genital ulcers can occur on the penis, scrotum, vagina, labia, and urethra, and also in the anal, perineal, and inguinal regions.

Skin lesions that should be accepted as diagnostically relevant in Adamantiades-Behçet disease should be confined to pustular vasculitic lesions (including pathergy lesions), erythema nodosum–like lesions, Sweet-like lesions, pyoderma gangrenosum–like lesions, and palpable purpuric lesions of necrotizing venulitis (see Fig. 167-6). All of these lesions are characterized in their early stages by a neutrophilic vascular reaction. Acneiform lesions or follicle-based pustules should not be considered relevant.[27]

Systemic Lesions

Ocular involvement is the major cause of morbidity in patients with Adamantiades-Behçet disease. The most diagnostically relevant lesion is posterior uveitis (also called *retinal vasculitis*), which can lead to blindness (Fig. 167-5A).

TABLE 167-1
Revised Diagnostic Criteria of the Behçet's Disease Research Committee of Japan[a]

- Main points
  - Main symptoms
    - Recurrent oral aphthous ulcers
    - Skin lesions
      - a. Erythema nodosum (see eFig. 167-8.1B)
      - b. Superficial thrombophlebitis
      - c. Papules
      - Skin hypersensitivity
    - Ocular lesions
      - a. Iridocyclitis or sequelae
      - b. Posterior uveitis or sequelae
  - Genital ulcers
  - Additional symptoms
    - Arthritis without deformity or sclerosis
    - Epididymitis
    - Gastrointestinal lesions represented by ileocecal ulcerations
    - Vascular lesions
    - Central nervous system lesions moderate or severe
- Criteria for diagnosis of disease types
  - Complete types: Four main symptoms
  - Incomplete types: Three main symptoms or two main and two additional symptoms or typical ocular lesions and another main symptom or two additional symptoms
  - Suspected disease: Typical main symptoms not fulfilling the criteria for an incomplete type
  - Special lesions: Certain gastrointestinal, vascular, and nervous system lesions
- Clinical laboratory data contributing to the diagnosis (not essential)
  - Negative or positive pathergy test
  - Negative or positive prick test to vaccinate for streptococci
  - Inflammatory response
  - Positive HLA-B51
  - Other pathologic findings
- Additional points
  - Non-typical symptoms should not be diagnosed as Behçet disease.
  - One of the criteria (a) to (c) of the skin lesions and (a) or (b) of the ocular lesions is enough for the diagnosis of the relevant symptom if the lesion occurs frequently.

[a]In abbreviated form.
From Suzuki Kurokawa M, Suzuki N: Behçet's disease. *Clin Exp Med* **4:**10, 2004, with permission.



◀ **FIGURE 167-3** Single (**A**) and multiple (**B**) oral aphthous ulcers. (**A** from Altenburg A et al: Epidemiology and clinical manifestations of Adamantiades-Behçet disease in Germany—Current pathogenetic concepts and therapeutic possibilities. *J Dtsch Dermatol Ges* **4:**49, 2006, with permission.)

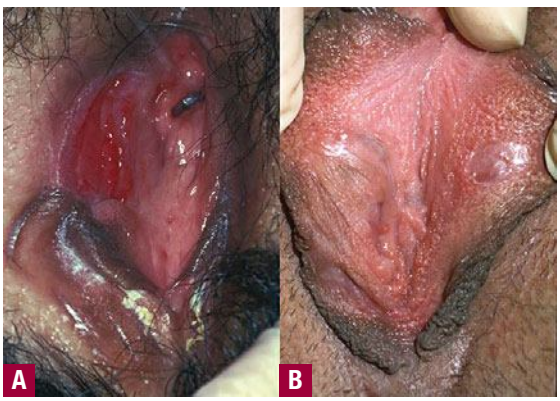

◀ **FIGURE 167-4** Genital ulcer (**A**) healing with a demarcated flat scar (**B**).



reous involvement, chronic cystoid macular edema, and possible—presumably also vasculitic—involvement of the optic nerve can result in vision loss. Recurrent vasculitic changes can ultimately lead to ischemic optic nerve atrophy.

The characteristic arthritis is a non-erosive, asymmetric, sterile, seronegative oligoarthritis; however, symmetric polyarticular involvement is common. Joint manifestations frequently occur first in one knee or ankle and then the other as migratory monoarthritis, then in both joints simultaneously, and finally affecting nearly all joints. An HLA-B27–positive, erosive sacroiliitis has to be excluded.

Systemic vascular involvement can be significant and includes venous occlusions and varices, arterial occlusions, and aneurysms, often being migratory. Cases of large-vein thrombosis (inferior vena cava, cranial venous sinuses) or large-artery aneurysms are potentially fatal.[1,6] Arterial involvement is rather rare and usually presents in the form of thromboses and, less often, of aneurysms, resulting from multicentric arteritis. Pulmonary artery aneurysms are the principal feature of pulmonary involvement in Adamantiades-Behçet disease, occasionally resulting in coughing and hemoptysis. Cardiac involvement can include myocarditis, coronary arteritis, endocarditis, and valvular disease. A wide spectrum of renal manifestations can occur, varying from minimal change disease to proliferative glomerulonephritis and rapidly progressive crescentic glomerulonephritis. Immune complex deposition is thought to be responsible for the underlying pathogenesis in some cases of glomerulonephritis. Gastrointestinal complaints can be a symptom for aphthae throughout the gastrointestinal tract and can rarely result in perforation and peritonitis (0.5 percent). Inflammatory bowel disease has to be excluded. Sterile prostatitis and epididymitis can be present in male patients without genital ulcers.

Significant neurologic manifestations occur in approximately 10 percent of patients and may be delayed in onset. Meningoencephalitis, cerebral venous sinus thrombosis, benign intracranial hypertension, cranial nerve palsies, brainstem lesions, and pyramidal or extrapyramidal

Other ocular lesions include anterior uveitis, hypopyon (pus in the anterior chamber of the eye, which is now—due to early treatment—uncommon; see Fig. 167-5B), and secondary complications such as cataract, glaucoma, and neovascular lesions.[28] Retinal inflammation can lead to vascular occlusion and, ultimately, tractional retinal detachment. Severe vit-

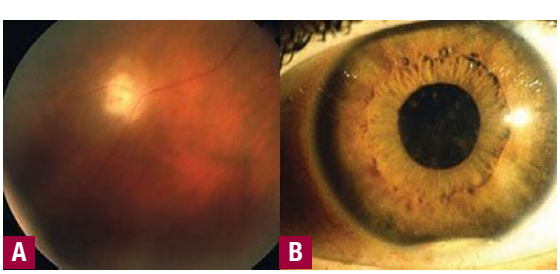

◀ **FIGURE 167-5** **A.** Posterior uveitis. **B.** Hypopyon-iritis. (From Altenburg A et al: Epidemiology and clinical manifestations of Adamantiades-Behçet disease in Germany—Current pathogenetic concepts and therapeutic possibilities. *J Dtsch Dermatol Ges* **4:**49, 2006, with permission.)

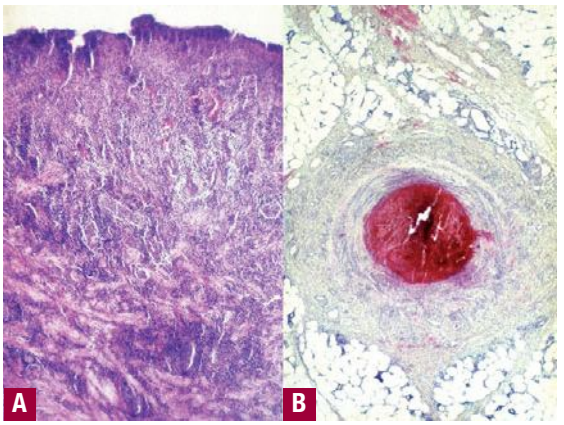

▲ **FIGURE 167-6 A.** Abundant mixed inflammatory infiltrate dominated by neutrophils in an oral ulcer of Adamantiades-Behçet disease. **B.** Vessel thrombosis in an erythema nodosum–like lesion.



lesions have been described. Poor prognosis is associated with a progressive course, relapses after treatment, repeated attacks, and cerebellar symptoms or parenchymal disease. Neurologic manifestations usually present with severe headache. Further symptoms include gait disturbance, dysarthria, vertigo, and diplopia as well as hyperreflexia, epileptic seizures, hemiplegia, ataxia, or a positive Babinski reflex. Psychiatric symptoms, such as depression, insomnia, or memory impairment, are also signs of neurologic involvement.

HISTOPATHOLOGY

Characteristic histopathologic features of Adamantiades-Behçet disease are vasculitis and thrombosis (Fig. 167-6). Biopsies from early mucocutaneous lesions show a neutrophilic vascular reaction with endothelial swelling, extravasation of erythrocytes, and leukocytoclasia or a fully developed leukocytoclastic vasculitis with fibrinoid necrosis of blood vessel walls.[1,6] Although there are reports of lesions that consist primarily of a lymphocytic perivasculitis, most of these lesions are likely older. The neutrophilic vascular reaction should be considered the predominant histopathologic finding.[27] Aneurysms can also develop in large arteries as a result of vasculitis of the vasa vasorum with penetration of the lamina elastica.

SPECIAL TESTS

Pathergy Test

A positive pathergy test (hyper-reactivity reaction) manifests within 48 hours as an erythematous papule (> 2 mm) or pustule at the site of a skin needle prick or after intracutaneous injection of 0.1 mL isotonic salt solution using a 20-gauge needle without prior disinfection of the injection site (see eFig. 167-6.1A in on-line edition). The skin prick is generally placed at an angle of 45° 3 to 5 mm intracutaneously on the volar forearm. Erythema without infiltration is considered a negative finding. Provoked oral aphthae and genital ulcers after injection or injury (such as chorioretinitis in the corneal region of the eye after photocoagulation of the ocular fundus region) can also be considered as positive pathergy phenomenon. Broader pathergy phenomena also include the occurrence of aneurysms around vascular anastomoses as well as local recurrence of ulcers after resection of affected bowel segments. Although a positive pathergy reaction is a sign of Adamantiades-Behçet disease, it is not pathognomic, as it can also occur in patients with pyoderma gangrenosum, rheumatoid arthritis, Crohn disease, and genital herpes infection.

Radiologic Findings

Scintigraphic evidence of arthritis is found in 50 percent of the patients.[6] Cranial magnetic resonance imaging allows documentation of hypodense or atrophic changes in the brain. Electroencephalographic detection of diffuse α waves is considered a positive finding. Vascular lesions can be detected by angiography.

DIFFERENTIAL DIAGNOSIS

(Box 167-1)[6,29]

Box 167-1

Differential Diagnosis of Adamantiades-Behçet Disease

- Oculocutaneous/mucocutaneous syndromes
  - Erythema multiforme exudativum and variants, including Stevens-Johnson syndrome
  - Vogt-Koyanagi-Harada syndrome
  - Reiter disease
  - Bullous autoimmune diseases: Pemphigus vulgaris, cicatricial mucous membrane pemphigoid, epidermolysis bullosa acquisita
  - Viral infections (herpes, coxsackie, echo)
  - Syphilis
- Articulomucocutaneous syndromes
  - Systemic lupus erythematosus
  - MAGIC syndrome (*m*outh *a*nd *g*enital ulcers with *i*nflamed *c*artilage)
  - Yersiniosis
  - Arthropathic psoriasis
- Gastrointestinal/mucocutaneous syndromes
  - Ulcerative colitis, Crohn disease
  - Tuberculosis
  - Bowel-associated dermatitis-arthritis syndrome
- Aphthae
  - Recurrent aphthous stomatitis (RAS)
  - Cyclic neutropenia
  - Herpes simplex infection
- Genital ulcers
  - Ulcus vulvae acutum (Lipschütz ulcer)
  - Herpes simplex infection
  - Sexually transmitted infections
- Uveitis
  - Other forms of uveitis
- Arthritis
  - Ankylosing spondylitis
  - Juvenile rheumatoid arthritis
- Central nervous system manifestation
  - Multiple sclerosis
  - Neuro-Sweet disease
- Lung manifestation
  - Sarcoidosis

Adapted from Altenburg A et al: Epidemiology and clinical manifestations of Adamantiades-Behçet disease in Germany—Current pathogenetic concepts and therapeutic possibilities. *J Dtsch Dermatol Ges* **4:**49, 2006 and Rogers RS 3rd: Pseudo-Behçet's disease. *Dermatol Clin* **21:**49, 2003.

CLINICAL COURSE AND PROGNOSIS

The clinical course of Adamantiades-Behçet disease is variable. There can be a delay of up to several years before the diagnosis is made, and this may influence the prognosis. Mucocutaneous and joint manifestations usually occur first. Recurrent erythema nodosum and HLA-B51 positivity are risk factors for the development of superficial thrombophlebitis and vision loss,[9,30,31] and superficial thrombophlebitis, ocular lesions, and male gender are risk factors for the development of systemic vessel involvement.[9,30,32] A severe course, including blindness, meningoencephalitis, hemoptysis, intestinal perforation, and severe arthritis, occurs in approximately 10 percent of patients. Blindness can often be prevented with early aggressive therapy of posterior uveitis. Lethal outcome

Box 167-2

Topical Treatment of Oral Aphthous Ulcers

- Mild diet
- Avoidance of hard, spicy, or salty nutrients and irritating chemicals, such as toasted bread, nuts, oranges, lemons, tomatoes, spices (pepper, paprika, curry), alcohol- or CO_2-holding drinks, mouthwashes, toothpastes containing sodium lauryl sulfate[a]
- Topical treatment of the aphthous oral ulcers includes:
  - Caustic solutions (silver nitrate, 1%–2%; tinctura myrrha, 5%–10% weight/volume; H_2O_2, 0.5%; methyl violet, 0.5%) 1–2 ×/day
  - Antiseptic and anti-inflammatory preparations (amlexanox, 5% in oral paste[a]; triclosan, 0.1% mouthwash solution and in toothpastes[a]; amyloglucosidase- and glucoseoxidase-containing toothpastes[a]; hexetidine, 1%, chlorhexidine, 1%–2% mouthwash solutions; benzydamine; camomile extracts) 3% diclofenac in 2.5% hyaluronic acid,[a] tetracycline mouthwash (as glycerine solution 250 mg/5 mL glycerine) 2 min 4–6 ×/day[a] (caveat: pregnancy), doxymycine in isobutylcanoacrylate[a]
  - Corticosteroids (triamcinolone mucosal ointment, dexamethasone mucosal paste, betamethasone pastilles) 4 ×/day or during the night (ointment/paste) or intrafocal infiltrations with triamcinolone suspension 0.1–0.5 mL per lesion
  - Anaesthetics (lidocaine, 2%–5%; mepivacaine, 1.5%; tetracaine, 0.5%–1% gels or mucosal ointments) 2–3 ×/day (caveat: allergy)
  - 5-Aminosalicylic acid (5% creme) 3 ×/day (reduces the duration of lesions and the pain intensity)
  - Cyclosporin A, 500 mg solution for mouthwash 3 ×/day (effective as topical immunosuppressive drug)
  - Sucralfate suspension, 5 mL × 4/day[a] (for oral aphthous and genital ulcers)
- A close association of smoking with a decrease of recurrences of oral aphthous ulcers has been described.

[a]Small, randomized, double-blind, placebo-controlled trial against placebo.

has been seen in 0 percent to 6 percent of affected patients in different ethnic groups. Central nervous system and pulmonary and large vessel involvement, as well as bowel perforation, are the major life-threatening complications; death may also result as a complication of immunosuppressive therapy. Markers of severe prognosis include HLA-B51 positivity, male gender, and early development of systemic signs.[9] Onset in childhood does not necessarily predict a poor prognosis. Spontaneous remissions of certain or all manifestations of the disease have been observed. Ophthalmic and neurologic sequelae are leading causes of morbidity, followed by severe vascular and gastrointestinal manifestations, and their effects on morbidity may be cumulative.

TREATMENT

The choice of treatment for patients with Adamantiades-Behçet disease depends on the site and severity of the clinical manifestations of the disease. Recurrent aphthae are most often treated with palliative agents, such as mild diet, avoidance of irritating agents, and potent topical glucocorticoids and local anesthetics[33,34] (Box 167-2). For the topical treatment of genital ulcers and skin lesions, corticosteroid and antiseptic creams can be applied for up to 7 days. Painful genital ulcerations can be managed by topical anaesthetics in cream. Corticosteroid injections (triamcinolone, 0.1 to 0.5 mL/lesion) can be helpful in recalcitrant ulcerations.

Patients with mucocutaneous lesions resistant to topical treatment, those with systemic involvement, and patients with markers of poor prognosis are candidates for systemic treatment. Several compounds have been found effective in randomized, double-blind, placebo-controlled trials[35–44] (Box 167-3). Additional treatments have been successful in studies with a lower grade of evidence.[2,12,33,45–47] Oral and intravenous

Box 167-3

Systemic Treatment of Adamantiades-Behçet Disease[a]

DRUG	DOSE	INDICATION	RCT
Methylprednisolone	40 mg/every 3 wk IM	Erythema nodosum (but not orogenital ulcers)	36
Rebamipide	300 mg/day PO (caveat: pregnancy, lactation)	Oral ulcers	37
Colchicine	1-2 mg/day PO (caveat: pregnancy, lactation—induces oligozoospermia)	Erythema nodosum, arthritis, genital ulcers, (oral ulcers in females)	38
Dapsone	100 mg/day PO (caveat: pregnancy, lactation—methemoglobin increase: ascorbic acid, 500 mg/day)	Oral ulcers, genital ulcers, skin lesions, pathergy test	39
Azathioprine	2.5 mg/kg/day (caveat: pregnancy, lactation, severe liver disease, bone marrow depression, severe infection, children)	Recent onset ocular disease	40
Interferon-α 2a	6×10^6 IU/3 ×/wk SC (caveat: pregnancy, lactation—induces psychotic signs, psoriasis, myopathy)	Oral ulcers, genital ulcers, papulopustular lesions	41
Thalidomide	100 mg/day (caveat: pregnancy, lactation—induces polyneuropathy: minimized at 25 mg/day)	Oral ulcers, genital ulcers, papulopustular lesions	42
Cyclosporin A	10 mg/kg/day PO (against colchicine, 1 mg/day PO) (caveat: lactation, renal insufficiency—induces pathologic central nervous system findings)	Ocular manifestations, oral ulcers, skin lesions, genital ulcers	43
Etanercept	25 mg/2 ×/wk PO (caveat: pregnancy, lactation)	Oral ulcers, nodular lesions, papulopustular lesions (not pathergy test)	44

[a]Evidence grade A—randomized, double-blind, placebo-controlled trial (RCT) against placebo except otherwise mentioned.



prednisolone can be combined with other immunosuppressants, colchicine, dapsone, sulfasalazine, or interferon-α. A synergistic effect with cyclosporin A has been described in patients with ocular involvement. Prednisolone is one of the few medications that can be used during pregnancy. Colchicine can be combined with immunosuppressants and interferon-α. A rapid relapse often occurs after discontinuing cyclosporin A, interferon-α, or dapsone.[46,47]

PREVENTION

- Patients with severe or progressive recurrent aphthous stomatitis should be followed up for years as potential candidates for Adamantiades-Behçet disease, particularly those patients with familial occurrence of the disease.
- Patients with suspected Adamantiades-Behçet disease should be referred early for specialist advice.
- Male patients with systemic involvement as a presenting sign and/or an early age of onset should be treated systemically because of the poor prognosis.

KEY REFERENCES

The full reference list for all chapters is available at www.digm7.com.

1. McCarty MA, Garton RA, Jorizzo JL: Complex aphthosis and Behçet's disease. *Dermatol Clin* **21**:41, 2003
2. Suzuki Kurokawa M, Suzuki N: Behçet's disease. *Clin Exp Med* **4**:10, 2004
3. Zouboulis CC, Keitel W: A historical review of early descriptions of Adamantiades-Behçet's disease. *J Invest Dermatol* **119**:201, 2002
4. Zouboulis CC: Epidemiology of Adamantiades-Behçet's disease, in *Immunology of Behçet's Disease*, edited by Zierhut M, Ohno S. Lisse, Swets & Zeitlinger, 2003, p 1
7. Zouboulis CC, May T: Pathogenesis of Adamantiades-Behçet's disease. *Med Microbiol Immunol* **192**:149, 2003
33. Zouboulis CC: Adamantiades-Behçet's disease, in *European Handbook of Dermatological Treatments*, 2nd ed, edited by Katsambas AD, Lotti TM. Berlin Heidelberg, Springer, 2003 p 16
35. Pipitone N et al: New approaches in the treatment of Adamantiades-Behçet's disease. *Curr Opin Rheumatol* **18**:3, 2006



CHAPTER 168

Kawasaki Syndrome

Donald Y. M. Leung
H. Cody Meissner
Anne W. Lucky

Kawasaki syndrome (KS) is an acute multisystem vasculitis that primarily affects infants and young children. Although KS was originally described as a benign illness of early childhood, it is now recognized that this disease is the leading cause of acquired heart disease in children in the United States and Western Europe. Children with KS who do not receive appropriate treatment within the first 10 days of onset of fever have a 20 percent to 25 percent risk of developing coronary artery abnormalities. Early recognition and prompt treatment with the combination of intravenous immunoglobulin (IVIG) and aspirin (ASA) reduce the prevalence of coronary artery abnormalities to less than 5 percent. Thus, acute KS must be diagnosed early and treated promptly. A diagnosis of classic KS is based on the presence of fever plus at least four of five criteria listed in Table 168-1.[1] Atypical or incomplete KS may be diagnosed in a patient with fever and fewer than four criteria.

HISTORICAL ASPECTS

KS, originally called *mucocutaneous lymph node syndrome*, was first recognized and described in Japan in 1967 by Dr. Tomisaku Kawasaki.[2] He reported his experience with 50 children who had been seen during the preceding 6-year period at the Tokyo Red Cross Medical Center. These children appeared to manifest a constellation of findings distinct from any previously described disease. After this description, numerous cases were reported throughout Japan. Dr. Kawasaki's first description of the disease in the English language appeared in 1974. In 1976, the syndrome was first reported in the United States by Melish, Hicks, and Larson in a group of 12 children from Honolulu seen between 1971 and 1973. Since then, KS has been recognized worldwide in children of every racial group. The Kawasaki Disease Research Committee published the fifth revised edition of its diagnostic guidelines in 2005.[3]

TABLE 168-1
Diagnostic Criteria for Kawasaki Syndrome

Fever of 5 or more days without other explanation, and at least four of the five following criteria[a]:

- Bilateral painless bulbar nonexudative conjunctival injection
- One of the following changes in the oropharynx: Injected or fissured lips, injected pharynx, or strawberry tongue
- One of the following extremity changes: Erythema of the palms or soles, edema of the hands or feet, or periungual desquamation
- Polymorphous exanthem
- Acute non-suppurative cervical lymphadenopathy (≥ 1.5 cm in diameter)

[a]A diagnosis of atypical Kawasaki syndrome can be made when less than four criteria are present if coronary artery aneurysms are present.

EPIDEMIOLOGY

Although KS occurs worldwide in children of all racial groups, it is most prevalent in Japan and in children of Japanese ancestry.[4] KS is primarily an illness of young children, with approximately 80 percent of patients being younger than 5 years of age. The ratio of males to females is about 1.5:1.0. The incidence rate is the highest for Japanese children between 6 and 12 months of age, with equal numbers in the first and second years of life. Secondary cases of KS rarely occur in the same school, day care center, or household. Thus, person-to-person transmission of the disease appears to be unlikely. In Japan, the recurrence rate of KS is reported to be 3.9 percent and the proportion of sibling cases 1.4 percent. In those cases of patients whose parents had KS in their childhood in Japan (0.2 percent of more than 32,000 cases) there was a higher rate of sibling cases, a greater likelihood to experience recurrence, additional need for IVIG, and more coronary abnormalities 1 month after onset.[5] The rate of recurrence is highest within the first 12 months after the first episode. These studies suggest a common exposure to an infectious agent in genetically predisposed individuals.

The incidence of KS in Japan increased from 1967 to the mid-1980s.

KAWASAKI SYNDROME AT A GLANCE



- Most common cause of acquired heart disease in children, with highest prevalence in those of Japanese ancestry.
- Major features of acute Kawasaki syndrome include
  - Fever
  - Acute multisystem vasculitis
  - Polymorphous exanthem
  - Bilateral bulbar nonexudative conjunctival injection
  - Inflammation of the oropharynx
  - Erythema of the palms or soles, edema of the hands or feet, or periungual desquamation
  - Acute non-suppurative cervical lymphadenopathy (≥ 1.5 cm in diameter)
- Complications of Kawasaki syndrome include
  - Coronary artery abnormalities, including aneurysms
  - Myocarditis
  - Arthralgia and arthritis
  - Urethritis
  - Aseptic meningitis
- Prompt treatment with the combination of intravenous immunoglobulin and aspirin reduces the prevalence of coronary artery abnormalities.

Nationwide epidemics, with wave-like spread of cases, occurred in 1979, 1982, and in late 1985 to early 1986. Since the mid-1980s, the incidence of KS in Japan has increased steadily such that the incidence rate in 1998 was more than 1.5 times higher than that in 1987.[6] The endemic annual incidence of KS is approximately 111 cases per 100,000 children younger than age 5 years. Both the endemic and the epidemic form of KS in Japan occurs most commonly in the late winter and spring, with another period of slightly increased incidence during late fall. KS has been increasingly recognized in other Asian countries as well. In Taiwan between 1966 and 2002, the epidemiology was similar, with an annual incidence of 146 per 100,000 and a peak in the summer months.

Epidemiologic findings in the United States and Europe reveal striking similarities to those in Japan. KS has been reported in all parts of the United States and Europe, occurring sporadically or as temporally limited community-wide epidemic outbreaks. The highest incidence of KS in the United States has been reported from Hawaii, with a hospitalization rate of 47.7/100,000 children < 5 years of age. Within the continental United States estimates of the incidence of KS range from 9 to 19/100,000 children. The peak age is 18 to 24 months of age. More than 80 percent of cases occur in patients younger than 5 years of age, and most cases occur in patients younger than 2 years of age. Infants younger than 12 months of age, and particularly those younger than 6 months of age, appear to be at an increased risk of developing coronary artery abnormalities. In the United States, the prevalence of KS is highest among Asians, intermediate in blacks, and lowest in whites. Regardless of the racial group affected, however, the clinical picture is similar. Although antecedent respiratory illness and exposure to rug cleaning have been associated with KS, neither has been consistently identified as a risk factor.

ETIOLOGY AND PATHOGENESIS

Considerable evidence suggests that KS is a condition that results from immune activation.[7] First, the acute phase of KS is characterized by increased numbers of activated helper T cells and monocyte/macrophages, as well as a marked polyclonal B-cell activation. Second, there is increased production of multiple proinflammatory cytokines. Serum levels of interleukin (IL)-1, tumor necrosis factor (TNF)-α, IL-6, adrenomedullin, and vascular endothelial growth factor have been reported to correlate with the development of coronary artery abnormalities.[8,9] Third, the histologic lesion in coronary arteries and other medium-sized arteries suggests a role for immune-mediated vascular injury (see Pathology). Fourth, the acute phase of KS is associated with the appearance of circulating antibodies that are cytotoxic against cardiac myosin and vascular endothelial cells pre-stimulated with IL-1, TNF-α, or interferon-γ.[10] Finally, successful treatment of patients with IVIG plus ASA reduces the immune activation associated with this disease.[11] In contrast, KS patients treated with ASA alone have prolonged T- and B-cell activation.

At present, however, there is no consensus regarding the etiology of KS. It is widely hypothesized that KS represents immune activation in response to an infectious agent based on the acute, self-limited nature of this disease, seasonal incidence, geographic clustering of outbreaks, and the unique susceptibility of young children. Despite this consensus of opinion, extensive serologic, tissue culture, ultrastructural, and molecular evaluations have failed to define a single triggering agent. A few years ago, evidence suggested that the disorder was associated with a novel human coronavirus infection.[12] Using polymerase chain reaction, the virus was detected in 73 percent of 11 affected children, but only 4.5 percent of controls. Other investigators have not been able to confirm this observation, which may merely reflect the frequent clustering of cases.[13] The discussion now focuses on whether the infectious agent that triggers the immune activation in KS is a conventional antigen or whether it elaborates a superantigen. Evidence to support both possibilities continues to accrue.

In support of the theory that superantigens may be etiologic are the clinical findings in acute KS (see Table 168-1), including fever, that significantly overlap with bacterial toxin-mediated diseases such as toxic shock syndrome (TSS) or scarlet fever. The activation of T cells and monocytes/macrophages found in acute KS is characteristic of diseases caused by bacterial toxins that act as superantigens.[14] Staphylococcal enterotoxins, TSS toxin-1 (TSST-1), and streptococcal pyrogenic exotoxins (SPEs) are prototypic superantigens that stimulate a large proportion (up to 35 percent) of T cells in a human leukocyte antigen (HLA)-DR–dependent yet unrestricted manner. These bacterial toxins bind directly to conserved amino acid residues outside of the peptide antigen binding groove on major histocompatibility complex (MHC) class II molecules and selectively stimulate T cells expressing specific T-cell antigen receptor (TCR) β chain variable gene segments.

To determine whether the immune activation during acute KS results from stimulation by superantigen(s), T lymphocytes of 19 children with KS were analyzed for TCR Vβ gene usage.[15] Patients with acute KS demonstrated marked expansion of Vβ2 and, to a lesser extent, Vβ8-positive T cells. In





contrast, cells from control subjects showed no evidence for overexpression of TCR Vβs. During the convalescence phase of KS, percentages of Vβ2-positive and Vβ8-positive T cells returned to normal levels. This selective expansion of circulating Vβ2-positive T cells is similar to the changes observed in T cells from patients with staphylococcal TSS, an illness with many clinical similarities to acute KS.

Since the initial description, there have been confirmatory and non-confirmatory reports of Vβ2 expansion in acute KS.[16–26] The ability to find Vβ2-positive T-cell abnormalities in the peripheral blood of patients with acute KS may depend on the timing of the blood collection, as superantigens stimulate the expression of homing receptors, thereby triggering the migration of T cells into inflamed tissues.[16] If superantigens are involved, T-cell activation observed in the peripheral blood of acute KS is most likely mediated by a superantigen that induces Vβ2-positive T-cell expansion based on the high frequency of response but extensive β-chain junctional diversity.[27] Selective expansion of Vβ2-positive T cells in the small intestinal mucosa of patients with acute KS[28] suggests that the gastrointestinal tract may be the primary site of entry for a superantigen-secreting organism causing acute KS. One study identified potential superantigen-producing bacteria in 13 of 16 patients with acute KS (from rectal or pharyngeal, not skin, cultures), but only 1 of 15 control patients ($p < 0.0001$)[29]; of 13 toxin (superantigen)-positive cultures from patients with KS, 11 were TSST-1, secreting *Staphylococcus aureus*, and 2 of 13 were streptococci, producing streptococcal pyrogenic exotoxin B (SPEB) and SPEC. Importantly, TSST-1 and SPEB are known to possess Vβ2 stimulatory activity, whereas SPEC has both Vβ2 and Vβ8 stimulatory activity. These studies further suggest a gastrointestinal site of infection and superantigen[28] and that several superantigens may be involved.

An alternative hypothesis is that a conventional antigen-driven response leads to KS, with the respiratory tract as the site of entry.[30–33] One group has identified oligoclonal immunoglobulin A antibodies in arterial tissue from fatal cases of KS. Human antibodies, synthesized to target prevalent immunoglobulin A genes from patient arterial samples, have detected antibodies in the respiratory epithelium of 10 of 13 patients with KS and none of the nine controls; these antibodies were also detected in inflamed tissues from 17 children with KS. In the ciliated bronchial epithelia of affected children, this KS-associated protein localizes to cytoplasmic inclusion bodies that resemble aggregates of viral protein and nucleic acid.

CLINICAL MANIFESTATIONS

Dermatologic Features

The mucocutaneous manifestations of KS are varied, and not all children exhibit each feature. The major diagnostic criteria for KS are listed in Table 168-1.[1–4] KS is a triphasic illness beginning with an acute phase that lasts 7 to 14 days, followed by a subacute phase of approximately 25 days, and a convalescent phase that lasts nearly 70 days. The cardinal feature of the acute phase is a prolonged high fever that frequently spikes to 40°C (104°F) and is associated with a toxic appearance in virtually all patients. In the absence of anti-inflammatory therapy, the duration of fever is usually 1 to 2 weeks.

Approximately 90 percent of children with KS develop an exanthem in the first days of their acute febrile illness (Fig. 168-1). The eruption favors the trunk and proximal extremities but can be generalized. It can be quite variable, having been described as macular, papular, morbilliform, scarlatiniform, urticarial, and even "target-like," resembling erythema multiforme. The initial rash may be indistinguishable from an acute viral exanthem or adverse drug reaction. It is rarely pustular, vesicular, or bullous.[25] Recently, plaque-type and pustular psoriatic lesions have been described



▲ **FIGURE 168-1** A generalized morbilliform eruption appearing early in the febrile course of a 5-year-old boy with Kawasaki syndrome.



▲ **FIGURE 168-2** Generalized erythema and early desquamation in the perigenital and perineal area of a 4-year-old girl with Kawasaki syndrome. This feature occurs early in the illness and involves 67 percent of affected children.

in the acute phase.[26] There are no diagnostic histologic features.

One of the earliest signs of KS is a characteristic perineal eruption (Fig. 168-2). In one study of 58 children, 67 percent had the perineal eruption.[34] Onset is usually within the first 6 days of the illness and presents as diffuse macular or plaque-type blanching erythema involving part or all of the perineal skin. These involved areas can be warm and tender. Within 48 hours, the erythematous areas begin to desquamate. This desquamation occurs earlier than that of the palms and soles.

In 90 percent of patients, a bilateral, nonexudative, conjunctival injection begins shortly after the onset of fever and generally involves the bulbar conjunctivae more severely than the palpebral conjunctivae. Conjunctival vessels become engorged and dilated. There is no purulent discharge or crusting of the eyelashes, as is seen in bacterial conjunctivitis. Conjunctival injection is associated with anterior uveitis in approximately 83 percent of patients examined within the first weeks of illness.

Oral mucosal findings are very characteristic of KS and occur in almost all cases. The lips become "cherry" red, dry, and often cracked, producing small hemorrhagic fissures. In contrast to staphylococcal scalded-skin syndrome, there is no radial crusting of the perioral skin. There are no punctate ulcerations, as are seen in herpes gingivostomatitis or aphthae, and no diffuse erosions with confluent hemorrhagic crusts, as are seen in erythema multiforme or Stevens-Johnson syndrome (see Chaps. 38 and 39). The tongue has been described as "strawberry," with hypertrophied papillae and



▲ **FIGURE 168-3** Erythema and edema of the distal fingertips are characteristic of the early phase of Kawasaki syndrome.

hyperemia that is indistinguishable from that seen with streptococcal scarlet fever, but only about one-half of the cases seem to have this feature. Diffuse erythema of the oral mucosa is common.

Edema and erythema of the distal aspects of the hands and feet with fusiform swelling of the fingers are also noted in almost all cases (Fig. 168-3). Onset is usually within a few days of the start of illness. These hyperemic areas are subject to desquamation within 2 to 3 weeks after onset of fever during the subacute phase. The desquamation characteristically begins at the tips of the fingers and toes and may develop either fine peeling or shedding of thick "casts" of palmar and plantar skin, similar to that seen in scarlet fever (Fig. 168-4).

Generalized fine desquamation, especially in the areas of the skin that had previously been erythematous, is also common at this time. Recurrent skin peeling, especially in those children with nasal staphylococcal colonization, may occur for several years, usually after upper respiratory tract infections. Because of the severe systemic nature of the illness and the prolonged high fever, it is not surprising that some children develop telogen effluvium, with significant but transient hair loss 6 to 12 weeks after the acute phase of the illness. Similarly, Beau's lines of the nails and/or shedding of the nails have been observed weeks to months later. Transient episodes of psoriasis have been described 4 to 12 weeks after the acute phase, but none of these children has developed chronic psoriasis.[23,26] Lymphadenopathy is the least frequent finding and is seen in less than 75 percent of patients. The adenopathy generally consists of a single, enlarged, nonsuppurative cervical node measuring at least 1.5 cm. When present, adenopathy usually occurs in the anterior cervical triangle, is nonfluctuant, and is either non-tender or only slightly tender. Erythema and induration at a site of vaccination with bacille Calmette-Guérin have been described in Japan and seen elsewhere.



▲ **FIGURE 168-4** Desquamation starting at the tips of the fingers occurs 10 to 18 days after the onset of illness, as illustrated in this 3-month-old infant with Kawasaki syndrome.

Approximately 10 percent of cases do not fit the diagnostic criteria nor do they appear to have another disease. These cases have been labeled *atypical, incomplete,* or *suspected KS*.

Systemic Associations

Table 168-2 lists other associated clinical features of KS. Arthralgia and arthritis occur in approximately one-third of patients. During the acute phase, the arthritis usually involves the small joints, such as the interphalangeal joints, whereas involvement of the large weight-bearing joints is more likely to occur in the second and third weeks of the illness. Urethritis associated with sterile pyuria is frequently present in acute KS. Infants with KS often are more irritable than children with other febrile exanthems. Aseptic meningitis may be present and usually is associated with mild mononuclear cell pleocytosis of the cerebrospinal fluid and with normal glucose and protein. Hydrops of the gallbladder may be present with or without obstructive jaundice. Diarrhea, vomiting, abdominal pain, cranial nerve palsies, tympanitis, and infarction of organs in which the vascular supply is compromised by thrombosis also may be presenting signs. Sensorineural hearing loss also has been associated with KS.

During the convalescent phase, there is generally a paucity of physical findings. Patients who suffer cardiovascular complications from this illness may have persistent cardiac abnormalities, including chronic myocardial dysfunction, aortic or mitral regurgitation, and cardiac arrhythmias. Occasionally, a patient may experience clinical exacerbation, with recurrence of fever and other acute clinical signs, such as rash and conjunctival injection, after they had appeared to resolve. This occurs most often within a few weeks of onset of illness and may be associated with an increased risk of coronary artery disease.

TABLE 168-2
Associated Clinical Features of Kawasaki Syndrome

- Cardiovascular abnormalities, including myocarditis, arterial aneurysms, pericarditis, aortic or mitral regurgitation, ventricular arrhythmias
- Arthralgia and arthritis
- Urethritis with sterile pyuria
- Aseptic meningitis
- Hydrops of the gallbladder
- Diarrhea, vomiting, or abdominal pain
- Sensorineural hearing loss
- Uveitis
- Hepatic dysfunction

Cardiac Manifestations

Abnormal cardiac findings are a hallmark of KS. Myocarditis is frequently observed during the first week after onset of fever. Pericardial effusion may develop toward the latter part of the acute phase and is secondary to myopericarditis. It is rare that these patients progress to cardiac tamponade, and the pericardial effusion generally resolves spontaneously. Rarely, congestive heart failure may occur as a result of myocarditis in the acute phase. During the subacute stage, congestive heart failure is usually caused by myocardial dysfunction secondary to ischemia or infarction.

Coronary artery ectasia or aneurysms occur in nearly 25 percent of patients with KS who are not treated with IVIG. Dilatation of the coronary arteries may be detected by echocardiography beginning 7 days after the onset of fever, usually peaking 3 or 4 weeks into the illness. A minority of patients (approximately 5 percent) may suffer from aortic or mitral regurgitation due to valvulitis, transient papillary muscle dysfunction, or as a complication of myocardial infarction.

On cardiac examination, patients with acute KS often present with tachycardia and gallop rhythms, both in excess of the fever and anemia associated with the illness. In a minority of patients, a pericardial friction rub, dysrhythmias, aortic



and mitral regurgitation, the findings of congestive heart failure, and the appearance of peripheral arterial aneurysms appear during the latter part of the acute phase or during the subacute phase.

LABORATORY FINDINGS

During the acute phase of KS, patients develop a leukocytosis with a predominance of mature and immature neutrophils. A normocytic, normochromic anemia without evidence of hemolysis or reticulocytosis presents during the first week of illness and persists until the inflammatory process subsides. Increased platelet turnover occurs together with marked hypercoagulability in the acute phase. Thrombocytosis is a characteristic feature of KS and peaks typically in the third week after onset of fever at between 500,000 and 1 million/mm^3. Elevation of liver transaminases, usually two- to threefold, is common in the acute phase, usually with a cholestatic profile of elevated bilirubin and alkaline phosphatase. Sterile pyuria caused by urethritis is observed in up to 75 percent of patients during the first week of illness. Early in the disease, acute-phase reactants, such as C-reactive protein and serum α_1-antitrypsin, are increased with the onset of fever and persist for 6 to 10 weeks. Similarly, erythrocyte sedimentation rates are uniformly elevated in patients with acute KS. Elevation of the latter typically persists after resolution of fever, a feature that may help to distinguish KS from common viral illness. Although patients with KS have a polyclonal B-cell activation, their sera do not contain the usual autoantibodies associated with collagen vascular disease (i.e., no rheumatoid factor or anti-nuclear or anti-DNA antibodies). Low serum albumin levels (< 3.5 g/dL) are reported to be a risk factor for the development of coronary artery aneurysms and poor clinical outcome.[35]

Electrocardiographic changes may be present in more than one-half of patients with acute KS. These abnormalities can include prolonged PR interval, left ventricular hypertrophy, abnormal Q waves, ventricular dysrhythmias, and non-specific ST-T wave changes. Two-dimensional echocardiography has been used extensively for the assessment of ventricular function, the anatomy of the proximal coronary arteries, and the presence of a pericardial effusion. Recommendations from the American Heart Association for patients with uncomplicated KS suggest echocardiographic evaluation at the time of diagnosis, at 2 weeks, and at 6 to 8 weeks. Magnetic resonance imaging of proximal coronary artery segments may be useful in selected patients. Cardiac stress testing may demonstrate reversible ischemia in children with coronary artery aneurysms. Coronary arteriography is generally reserved for the patient with persistent abnormalities on echocardiograms or any patient with symptoms of myocardial ischemia. Angiography is useful for visualization of coronary artery stenoses and to determine the extent of collateral artery formation.

PATHOLOGY

Extensive gross and microscopic studies have been carried out at autopsy of KS patients who have died in different phases of their illness. The case fatality rate for KS is approximately 0.4 percent, with most deaths occurring secondary to the cardiovascular complications of this disease. The pathology of this syndrome has been classified into four stages, according to the duration of illness at death.[36] Stage 1 (0 to 9 days after onset) is characterized by acute vasculitis and perivasculitis of small blood vessels. Microscopically, the acute vascular lesion in KS is associated with evidence for endothelial activation and endothelial cell damage.[36,37] The lesion is also associated with the infiltration of both neutrophils and mononuclear cells. The mononuclear cells consist of activated T cells and monocytes/macrophages.[38] MHC II antigens are expressed on the coronary arterial endothelium in acute KS but not in normal controls. Interferon-γ is a potent in vivo inducer of class II MHC antigens, and IL-1, as well as TNF-α, plays an important role in the induction of leukocyte adhesion molecules. The induction of class II MHC antigens on endothelial cells, as well as the observation of leukocyte adhesion to endothelial cells in the vascular lesion of KS, suggests that cytokine-induced endothelial antigens play an important role in the pathogenesis of this disease. In the larger arteries, the initial inflammation involves the intima and the vasa vasorum without inflammation of the media. Pericarditis, myocarditis, inflammation of the atrioventricular conduction system, and endocarditis with valvulitis are also present.

Stage 2 (12 to 25 days after onset) is characterized by a marked infiltration of inflammatory cells into the media of the coronary arteries as well as other medium-sized arteries, and aneurysms with thrombosis begin to form. At this stage, it is presumed that the formation of aneurysms is occurring as the result of destruction of the blood vessel walls that follows release of proteolytic enzymes and inflammatory mediators into the media. In stage 3 (28 to 31 days), the acute inflammatory process regresses, and granulation of the coronary arteries is noted. In stage 4 (40 days to 4 years), scar formation, organization of thrombi, intimal proliferation, and neoangiogenesis continue to occur for several years after onset of the disease. This process can result in severe stenosis of the coronary arteries as well as other medium-sized arteries.

It is worth emphasizing that although coronary arteries are invariably involved in this disease, almost any other medium- or large-sized blood vessel may be involved when examined at autopsy. Aneurysm formation has been reported in the femoral, iliac, renal, axillary, and brachial arteries. KS is a systemic vasculitis that can affect most small- and medium-sized blood vessels. Cutaneous vasculitis, however, is not a prominent feature of KS.

DIAGNOSIS AND DIFFERENTIAL DIAGNOSIS

According to the guidelines set forth by the American Heart Association,[1] the patient with KS should have fever lasting 5 or more days without other reasonable explanation and satisfy at least four of the five following criteria (see Table 168-1): (1) bilateral nonexudative conjunctival injection; (2) at least one of the following mucous membrane changes: injected or fissured lips, diffuse injection of the oral and pharyngeal mucosa, or "strawberry tongue"; (3) at least one of the following peripheral extremity changes: erythema of the palms or soles, edema of the hands or feet during the acute phase, or periungual desquamation during the convalescent phase; (4) polymorphous exanthem; and (5) acute non-suppurative cervical lymphadenopathy (> 1.5 cm in diameter). In incomplete cases, patients with fever for ≥ 5 days and fewer than four of the principal symptoms can be diagnosed as having KS when coronary artery disease is detected by two-dimensional echocardiography or coronary angiography. In some children with prominent findings, KS can be diagnosed before 5 days of fever.[3] Therapy with IVIG and ASA should be initiated whenever the diagnosis of KS is made.

Males younger than 6 months of age are at particularly high risk for incomplete KS and have a high risk of coronary artery abnormalities. *Incomplete KS* is used to describe patients with fever for at least 5 days and at least two criteria for



KS, and no other reasonable explanation for the illness can be found. The laboratory findings are similar to those in patients with classic KS. Incomplete KS is more common in young infants, perhaps accounting for the increased risk of coronary artery abnormalities that has been described in infants < 6 months of age. The diagnosis of incomplete KS should be considered in any infant with unexplained fever for ≥ 5 days and even one of the principal features. Findings that should trigger the search for another diagnosis include discrete intraoral ulcerations, exudative conjunctivitis, and generalized lymphadenopathy, which is rarely seen in acute KS.

KS has clinical features compatible with infection, hypersensitivity reactions, or exposure to environmental toxins. It has a variety of mucocutaneous manifestations, some of which are characteristic, but many of which are shared with these other infectious and reactive disorders. As KS may resemble a multitude of skin eruptions, a site-specific differential diagnostic ladder is helpful (Box 168-1). The correct diagnosis of KS hinges on recognizing the cumulative combination of mucocutaneous, systemic, and laboratory findings. Considerations that help in eliminating certain viruses, such as measles and influenza, from the differential diagnosis include local epidemiology, vaccination history, and culture results. Viral upper respiratory tract illness, particularly due to adenovirus, may mimic the features of KS.

Because KS is based on diagnostic criteria that use clinical characteristics that overlap with other illnesses, diagnostic dilemmas can arise, particularly in atypical cases that do not completely fulfill the diagnostic criteria but that are associated with the development of coronary artery abnormalities. The decision to initiate therapy in children who do not satisfy the criteria for classic KS can be supported by laboratory results showing acute phase reactants (elevated white blood cell count, elevated sedimentation rate), an ultrasound showing a pericardial effusion, or a slit-lamp examination showing anterior uveitis.

Box 168-1

Differential Diagnosis of Cutaneous Manifestations of Kawasaki Disease (Site Specific)

Most Likely

- Lips
  - Stevens-Johnson syndrome/erythema multiforme
  - Staphylococcal scalded-skin syndrome
- Skin
  - Erythema multiforme
  - Drug reaction
  - Staphylococcal scalded-skin syndrome
  - Scarlet fever
  - Toxic shock syndrome
- Lymph nodes
  - Bacterial/tuberculous infection
- Eyes
  - Conjunctivitis
- Tongue
  - Scarlet fever
- Groin
  - Staphylococcal scalded-skin syndrome
  - Streptococcal infection
- Fingers
  - Scarlet fever (late desquamation)

Consider

- Lips
  - Cheilitis
- Skin
  - Viral exanthem (e.g., roseola, rubeola)
  - Drug reaction
  - Dilantin hypersensitivity
- Eyes
  - Leptospirosis
- Groin
  - Candidiasis

Always Rule Out

- Lips
  - Stevens-Johnson syndrome
  - Staphylococcal scalded-skin syndrome
- Skin
  - Staphylococcal scalded-skin syndrome
  - Erythema multiforme
  - Drug reaction
  - Toxic shock syndrome
- Tongue
  - Scarlet fever
- Groin
  - Staphylococcal scalded-skin syndrome
  - Streptococcal infection

TREATMENT

Current management is aimed at reducing inflammation in the myocardium and coronary artery wall, and at preventing coronary thrombosis (Fig. 168-5). The combined use of IVIG and ASA has formed the basis of treatment of KS for nearly 20 years. ASA is used in the acute stage of illness to decrease the intensity of vasculitis and to provide inhibition of platelet aggregation. ASA will not alter the risk of coronary artery disease, although the dose may affect the duration of fever.[39] High-dose ASA (80 to 100 mg/kg/day in four divided doses) is recommended to maintain adequate serum salicylate levels because of reduced absorption and increased clearance during the acute stage of illness. After the child has been afebrile for 48 to 72 hours, a switch to low-dose ASA (3 to 5 mg/kg/day) can be made and continued until 6 to 8 weeks after onset of illness in the absence of coronary artery abnormalities. ASA therapy is continued indefinitely if coronary artery aneurysms develop and persist. Digitalis and diuretics are used as needed in the patient with congestive heart failure. In patients at risk for cardiovascular complications, some physicians add dipyridamole, 1 mg/kg body weight per day, to further inhibit platelet aggregation. Therapy of the mucocutaneous manifestations of the disease is entirely symptomatic and includes emollients for desquamating skin and antihistamines for pruritus.

No definitive prospective study has demonstrated that high-dose ASA therapy prevents coronary artery abnormalities. In contrast, several randomized multicenter studies have demonstrated that high-dose (greater than 1 g/kg) IVIG in combination with ASA therapy is safe and effective in reducing the prevalence of coronary artery abnormalities.[40–43] IVIG both reduces the overall prevalence of coronary artery abnormalities and prevents the formation of giant aneurysms, the most serious form of coronary abnormality caused by KS. Abnormalities of left ventricular systolic function and contractility also improve more rapidly in children treated in the acute phase with high-dose IVIG together with ASA than in those children treated with ASA alone.[44]

The efficacy of IVIG in prevention of coronary artery abnormalities is dose-dependent, although the optimal dose of IVIG has not been firmly established. Administration of IVIG, 2 g/kg over 10 to 12 hours as a single dose, has benefit over the earlier regimen of a 400 mg/kg dose for 4 days in terms of more rapid elimination of fever and less coronary artery disease at 2 weeks follow-up (although there is not a statistically significant difference at 7 weeks follow-up). The current standard is 2 g/kg plus salicylate before day 10 of fever, which will reduce the risk of coronary artery disease from about 20 percent to < 5 percent. The mechanism of action of IVIG is not known.

Approximately 85 percent of children treated within 10 days after onset of illness will experience prompt defervescence and resolution of signs of inflammation in response to IVIG and ASA therapy. Optimal management has not been established for children who demonstrate ongoing or recrudescent fever and other signs of inflammation 24 to 72 hours or





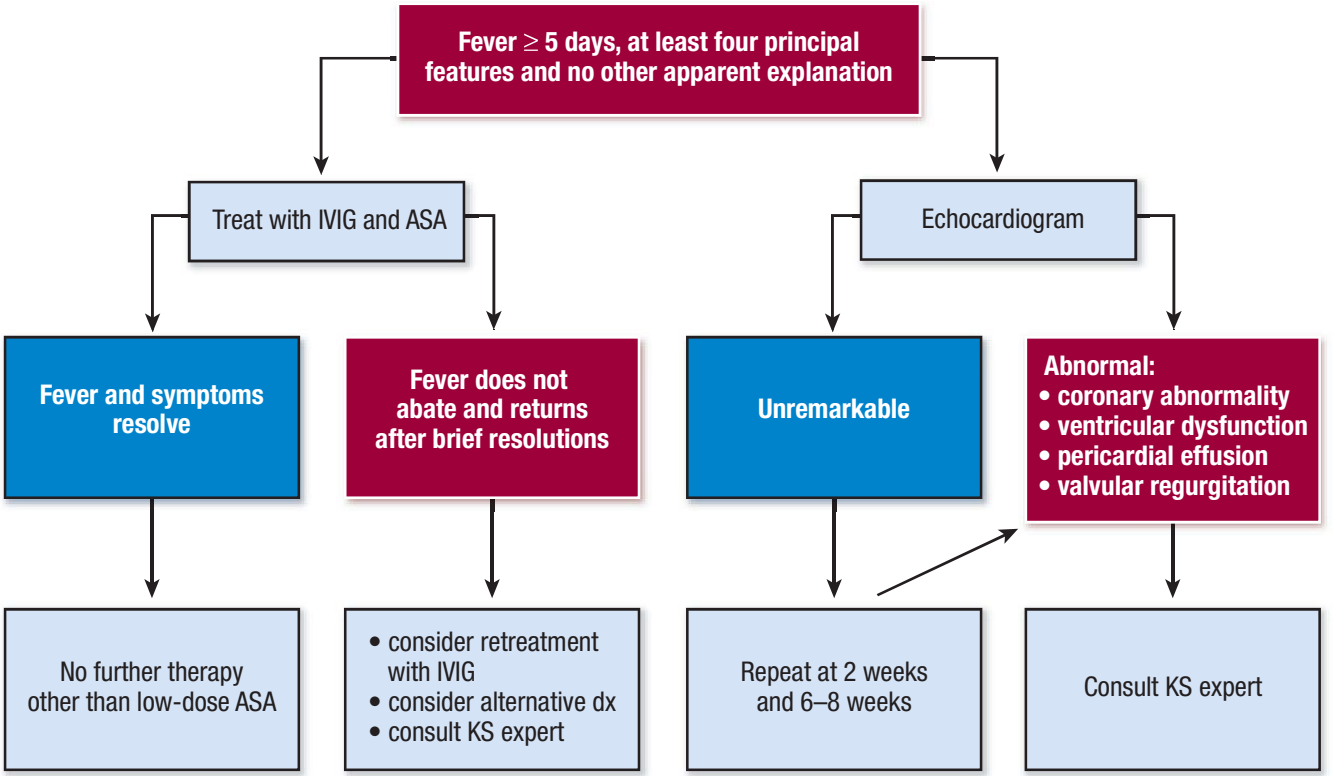

▲ **FIGURE 168-5** Approach to the patient with suspected Kawasaki syndrome (KS). ASA = aspirin; dx = diagnosis; IVIG = intravenous immunoglobulin.

longer after treatment.[45] For symptomatic children in whom the diagnosis of KS is still considered to be likely after one dose of IVIG, generally a second dose of IVIG, 2 g/kg, is administered because ongoing fever correlates with the presence of proinflammatory cytokines and an ongoing risk of coronary artery ectasia or aneurysm formation. In some instances a third dose of IVIG may be appropriate, although complications have been reported after large doses of γ globulin.

If fever persists after two or three doses of IVIG, intravenous methylprednisolone (pulse doses of 30 mg/kg for 3 days) can be considered. At present, the use of systemic steroids in the treatment of KS is controversial. Several studies from Japan report that patients treated with steroids alone or in combination with ASA have a higher frequency of coronary aneurysms and of subsequent myocardial infarction and death.[46] A more recent study of four patients with KS resistant to IVIG suggested a response to high-dose pulse methylprednisolone therapy (30 mg/kg once daily for 1 to 3 days).[47] In 1999, Shinohara et al. reviewed the experience with prednisolone in children with KS.[48] The authors concluded that prednisolone resulted in a shorter duration of fever and a lower prevalence of coronary artery aneurysms. However, this study was a retrospective review of patients who received different doses and different schedules of IVIG than what is currently used in the United States. Several small case series report either oral or intravenous corticosteroid use in patients with unresponsive disease despite at least two adequate doses of IVIG.[49,50] These reports suggest an improvement in symptoms without detectable progression of coronary artery abnormalities. The small number of patients studied prevents an accurate assessment of the impact of steroids on coronary artery abnormalities. Until controlled studies are available, corticosteroids should not be used routinely in patients with KS.

Other interventions that have been used in acute KS refractory to more than one dose of IVIG include plasma exchange, ulinastatin (human trypsin inhibitor), abciximab (platelet glycoprotein IIb/IIIa receptor inhibitor), infliximab (monoclonal antibody against TNF-α), and cyclophosphamide. The role of these agents in patients with refractory KS is not known.

Patients who develop coronary artery aneurysms must be monitored closely for the long-term cardiac sequelae of KS.[51] Stress echocardiography and coronary angiography may be indicated in patients with evidence of myocardial ischemia. For the KS patients with obstructive changes in one or more coronary arteries, anticoagulant therapy may be required. For more severe cardiovascular symptoms, the options include the use of intravenous streptokinase or urokinase when a thrombus is present, balloon angioplasty, and/or coronary artery bypass grafting.[52,53]

PROGNOSIS

The major long-term morbidity in KS is related to cardiovascular complications from this disease. The majority of children (50 percent to 67 percent) with arterial aneurysms will show angiographic regression within 1 to 2 years after onset of disease.[54] The likelihood of resolution of the aneurysms appears to be determined by the initial size of the aneurysm, with smaller aneurysms having a greater likelihood of regression. Some studies, however, indicate that there is evidence of persistent abnormal vascular wall morphology and vascular dysfunction at the site of regressed coronary aneurysms in patients with previous KS.[55] Patients with giant aneurysms—that is, those with a maximum diameter larger than 8 mm—have the worst prognosis. The majority of patients with giant aneurysms progress to stenosis or obstruction. Nearly all late deaths from KS occur in this subgroup of patients.

The peak time of death is 3 to 4 weeks after onset of the acute illness. Death can occur as early as during the first week of illness and as late as more than 10 years after the acute illness. During stage 1 of KS,

patients usually die of acute myocarditis or cardiac arrhythmia caused by inflammation of the atrioventricular conduction system. In stage 2 of the disease, death can result from rupture of the coronary arteries or myocarditis, including lesions of the atrioventricular conduction system, or myocardial insufficiency caused by thrombosis of the coronary arteries. Sudden death late in the illness (stage 3) or years after recovery from acute KS (stage 4) may occur as the result of myocardial infarction in children with residual coronary artery aneurysms and stenoses.

Children without known cardiac sequelae during the first month of KS appear to return to their previous state of health without cardiac impairment. A study of patients many years after resolution of acute KS, however, using high-resolution ultrasound to study endothelium-dependent vascular responses, showed evidence of persistent endothelial dysfunction, even in patients without detectable early coronary artery involvement.[56] Increased blood pressure, adiposity, and higher fasting triglyceride levels have also been reported in patients with previous KS. Thus, it is generally recommended that children with KS be followed over the long term by a cardiologist to rule out the development of myocardial dysfunction, late-onset valvular regurgitation, or premature coronary artery disease.

KEY REFERENCES

The full reference list for all chapters is available at www.digm7.com.

1. Diagnostic guidelines for Kawasaki disease. *Circulation* **103**:335, 2001
2. Kawasaki T: Acute febrile mucocutaneous syndrome with lymphoid involvement with specific desquamation of the fingers and toes in children. *Arerugi* **16**:178, 1967
3. Ayusawa M et al: Revision of diagnostic guidelines for Kawasaki disease [the 5th revised edition]. *Pediatr Int* **47**:232, 2005
4. Burns JC: Kawasaki disease. *Adv Pediatr* **48**:157, 2001
7. Leung DY, Schlievert PM, Meissner HC: The immunopathogenesis and management of Kawasaki syndrome. *Arthritis Rheum* **41**:1538, 1998
26. Eberhard BA et al: Psoriatic eruption in Kawasaki disease. *J Pediatr* **137**:578, 2000
42. Newburger JW et al: A single intravenous infusion of gamma globulin as compared with four infusions in the treatment of acute Kawasaki syndrome. *N Engl J Med* **324**:1633, 1991
51. Fulton DR, Newburger JW: Long-term cardiac sequelae of Kawasaki disease. *Curr Rheumatol Rep* **2**:324, 2000



CHAPTER 169

Pigmented Purpuric Dermatoses

Theresa Schroeder-Devere

The pigmented purpuric eruptions are a group of dermatoses characterized by petechiae, pigmentation, and, occasionally, telangiectasia in the absence of associated venous insufficiency or hematologic disorders (Table 169-1). Synonyms include *persistent pigmented purpuric dermatitis*, *purpura simplex*, and *purpura pigmentosa chronica*. They are found most commonly on the lower extremities; however, the lesions may involve the upper body and rarely become generalized. There are reports of palm, sole, genital, and oral mucosal involvement. These benign, generally asymptomatic eruptions tend to be chronic, with remissions and flares. They share common histopathology features, including capillaritis, erythrocyte extravasation, and hemosiderin deposition.

EPIDEMIOLOGY

Pigmented purpuric eruptions are rare. There seems to be no ethnic or gender predisposition, and most patients are in their 30s and 40s (see Table 169-1), but children may be affected.

PATHOGENESIS

There are three different views of the pathogenesis of pigmented purpuric eruptions. The first is that they are due to a disturbance or weakness of the cutaneous blood vessels, leading to capillary fragility and erythrocyte extravasation. However, this does not account for the inflammatory infiltrate common to these disorders. The second proposed mechanism is humoral immunity. This suggested pathogenesis is supported by direct immunofluorescent studies showing vascular deposition of C3, C1q, immunoglobulin M, or immunoglobulin A. However, several cases have not shown these deposits. The third proposed mechanism is cellular immunity.[1,2] The infiltrate in pigmented purpuric dermatoses consists of lymphocytes, macrophages, and Langerhans cells. This inflammatory infiltrate leads to vascular fragility and subsequent leakage of erythrocytes. Aiba and Tagami used immunohistologic studies in eight cases of Schamberg disease to demonstrate that the dermal infiltrate was predominantly composed of helper-inducer T cells and OKT6-reactive cells,[3] whereas the epidermis showed intercellular staining with human leukocyte antigen (HLA)-DR antibody and OKT6 antibody. Based on this study, they concluded that a cellular immune reaction, specifically the Langerhans cell, likely plays an important role in the pathogenesis.

Pigmented purpuric dermatoses may be induced by drugs (Table 169-2),[4–14] but other causes have also been implicated (Table 169-3).[15–22] The mechanism behind drug-induced or other

PIGMENTED PURPURIC DERMATOSES AT A GLANCE



- A group of dermatoses characterized by petechiae, pigmentation, and, occasionally, telangiectasia.
- Are found most commonly on the lower extremities; however, the lesions may involve the upper body and rarely become generalized.
- Are benign, generally asymptomatic eruptions that tend to be chronic with remissions and flares.
- Share common histopathology features, including capillaritis, erythrocyte extravasation, and hemosiderin deposition.
- Clinical variation between eruptions led to their subclassification into eponymic groups.
- Frequent overlap may make differentiation difficult.

TABLE 169-1
Pigmented Purpuric Eruptions

	Schamberg	Majocchi	Gougerot and Blum	Doucas and Kapetanakis	Itching Purpura	Lichen Aureus
Average age	40s	30s	40s	40s	50s	20s–30s
Sex	M > F	F > M	M > F	F > M	M > F	M > F
Onset	Insidious	Abrupt	Insidious	Abrupt	Abrupt	Abrupt
Primary lesion	Red-brown macule	Annular purpuric, telangiectasia	Lichenoid papule	Red-brown macule + scale	Red-brown macule	Orange-brown papule or plaque

F = female; M = male.

causes may be immune-mediated; however, this is unproven. Gravity and increased venous pressure may account for the lesions localizing to the lower extremities.



TYPES OF PIGMENTED PURPURIC DERMATOSES

Progressive Pigmentary Dermatosis (Schamberg Disease)

Schamberg first described in 1901 a pigmented eruption on the legs of a 15-year-old boy that consisted of irregularly shaped reddish-brown patches with "pin head sized reddish puncta, closely resembling grains of cayenne pepper."[23]

Although described in children and adolescents, the average age of onset of Schamberg disease is in the fifth decade.[24] The lesions tend to develop insidiously on either or both lower legs. Lesions can involve the trunk or the upper extremities (Figs. 169-1 and 169-2). Schamberg disease is generally asymptomatic and persistent. Remissions and flares can occur indefinitely.

TABLE 169-2
Drugs Implicated in Pigmented Purpuric Dermatoses

- Acetaminophen
- Aminoglutethimide
- Bezafibrate
- Carbamazepine
- Carbromal
- Carbutamide
- Chlordiazepoxide
- Diltiazem
- Topical fluorouracil
- Furosemide
- Glipizide
- Infliximab
- Interferon-α
- Medroxyprogesterone acetate
- Meprobamate
- Raloxifene
- Tartrazine (food additive)
- Thiamine
- Trichlormethiazide

Purpura Annularis Telangiectodes (Majocchi Purpura)

The original case of purpura annularis telangiectodes, described by Majocchi in 1896, was a 21-year-old man with annular patches of follicular and punctate reddish-brown macules, with telangiectasias and purpura on the lower extremities.[25] The annular pattern is the distinctive characteristic of this sub-type (Fig. 169-3). The individual lesions may have central hypopigmentation and slight atrophy, with peripheral telangiectasias. Linear and irregularly shaped patterns may also occur. The lesions most often present symmetrically on the lower extremities; however, the upper extremities and trunk may be involved. The lesions are asymptomatic and usually last several months with relapses and remissions. This sub-type occurs more commonly in young adult females.

TABLE 169-3
Other Implicated Causes of Pigmented Purpuric Dermatoses

- Contact dermatitis
  - Disperse dyes
  - Paraphenylenediamine
  - Black rubber
  - Cobalt
  - Benzoyl peroxide
  - Epoxy resin
  - Methylmethacrylate
  - Eutectic mixture of local anesthetics
- Venous stasis/acroangiodermatitis
- Step aerobics
- Rheumatoid arthritis
- Diabetes mellitus
- Benign hyperglobulinemic purpura (of Waldenstrom)/dysproteinemic purpura
- Hodgkin disease
- Hepatitis B, C
- Odontogenic infection
- Polycythemia
- Purpuric mycosis fungoides

Pigmented Purpuric Lichenoid Dermatosis (Gougerot and Blum)

In 1925, Gougerot and Blum reported a pigmented eruption on the lower extremity of a 41-year-old man.[26] The distinguishing feature of this sub-type is the primary lesion, a reddish-brown polygonal or round lichenoid papule, in association with purpura or telangiectasia. Individual papules frequently coalesce into plaques with or without overlying scale. The term *lichenoid* describes the clinical appearance rather than a histologic feature. The color and morphology of the lesions can be mistaken clinically for Kaposi sarcoma (Fig. 169-4). Like the other sub-types, this eruption is found on the lower extremities and, occasionally, the arms. It occurs in males more often than females and has a chronic course.



▲ **FIGURE 169-1** Pigmented purpuric dermatosis: Schamberg disease. Multiple, discrete, and confluent non-palpable, non-blanching purpuric lesions of many months' duration on the legs. Acute microhemorrhages resolve with deposition of hemosiderin, creating a disfiguring dark-brown peppered stain.



▲ **FIGURE 169-2** "Cayenne pepper" appearance of Schamberg disease. (Used with permission from S. Mallory, MD.)

Eczematid-Like Purpura of Doucas and Kapetanakis

Doucas and Kapetanakis reported a group of patients with an asymptomatic seasonal eruption occurring in the spring and summer.[27] Its distinguishing quality is the mild scale overlying the typical patches and pinpoint erythematous macules. These spread rapidly over a period of 15 to 30 days, involving the legs and, occasionally, the upper body. This eruption fades without treatment over several months to years.

Itching Purpura (Disseminated Pruriginous Angiodermatitis)

The acute onset and widespread involvement of orange-brown to purpuric macules with severe pruritus distinguishes itching purpura (Fig. 169-5).[28,29] It usually appears first on the lower extremities and may become generalized. This disorder also has a chronic course, but there can be spontaneous remissions. Middle-aged men are most commonly affected.



▲ **FIGURE 169-3** Pigmented purpuric dermatosis: Majocchi disease. Multiple non-palpable, non-blanching purpuric lesions arranged in annular configurations and associated with tiny telangiectasias. Note brownish discoloration of older lesions.



▲ **FIGURE 169-4** Lichenoid dermatosis of Gougerot and Blum. (Used with permission from S. Mallory, MD.)

Lichen Aureus (Lichen Purpuricus)

Marten first coined the term "lichen purpuricus" in 1958,[30] and Calnan later termed the same eruption "lichen aureus."[31] In this condition, *lichen* refers to the clinical and histopathologic descriptions. A dense, band-like, dermal, inflammatory infiltrate differentiates lichen aureus from the other pigmented purpuric dermatoses. Clinically, there are circumscribed areas of confluent gold to copper-orange to, less commonly, purple macules or papules (Fig. 169-6). Although these lesions may be intensely pruritic, they are typically asymptomatic. They are most commonly unilateral and localized on the lower extremities, but they can affect the forearms and trunk. This disorder has a predilection for young adults, with a peak incidence in the second and third decades. The lesions tend to be chronic, remaining stable or progressing slowly. Spontaneous resolution rarely occurs in adults, but in children the eruption may be self-limited.



▲ **FIGURE 169-5** Disseminated pruriginous angiodermatitis (itching purpura). (Used with permission from S. Mallory, MD.)

Unilateral Linear Capillaritis (Segmental Pigmented Purpura)

Riordan et al. reported a linear and pseudodermatomal distribution of pigmented purpura in four young men (average age, 22 years).[32] The patients all had a macular, pigmented, unilateral eruption involving the foot, leg, or buttock. Clinically, the lesions most closely represented lichen aureus; however, the pathology did not show a lichenoid infiltrate. Furthermore, all four cases resolved spontaneously in approximately 2 years, unlike the typically chronic course of lichen aureus. There are also several reported cases of segmental or zosteriform lichen aureus and Schamberg disease. Two cases have been associated with trauma, and one case preceded the development of localized morphea.[33–45]

Granulomatous Pigmented Purpura

Saito and Matsuoka reported a granulomatous variant of pigmented purpuric dermatosis in 1996,[46] and Wong reported two additional cases.[47] The



▲ **FIGURE 169-6** Lichen aureus. (Used with permission from S. Mallory, MD.)



mean age of onset was 59 years; all patients were of Asian descent, and all occurred only on the dorsum of the feet. Histopathologic examination showed a dense mononuclear cell infiltrate with granulomas in the papillary dermis, thickened capillaries, and hemosiderin deposits. The duration of the lesions ranged from 2 months to 20 years.

Pigmented Purpuric Dermatosis/ Mycosis Fungoides Overlap

Some cases of persistent pigmented purpuric dermatoses have eventually been diagnosed as mycosis fungoides. In fact, the first patient diagnosed with lichen aureus in the United States was later diagnosed with mycosis fungoides. Is there a relationship between the two disorders, or are these cases of mycosis fungoides merely mimicking pigmented purpura clinically? Some evidence supports the idea that lichenoid variants of pigmented purpuric dermatoses may be precursors of mycosis fungoides, with similar histologic findings and clonal populations of lymphocytes.[48–55] Long-term follow-up of these patients is needed to determine if their lesions will evolve into mycosis fungoides.



HISTOPATHOLOGY

The pigmented purpuric dermatoses share similar histopathology. In early lesions, a lymphocytic perivascular infiltrate is found in the papillary dermis with extravasated erythrocytes (Fig. 169-7). The epidermis may show spongiosis and parakeratosis, especially in the pigmented purpuric lichenoid dermatitis of Gougerot-Blum and in the eczematid-like purpura of Doucas and Kapetanakis. In older lesions, there is less inflammation, and extravasated red cells may no longer be present. Hemosiderin is deposited primarily in macrophages. In lichen aureus, the mononuclear infiltrate in the upper dermis is distributed in a band-like fashion with a grenz zone.

DIAGNOSTIC STUDIES

Diagnosis is generally made clinically and supported by histopathologic examination. No consistent laboratory abnormalities have been identified. The clinical measurement of capillary fragility by application of a sphygmomanometer (Hess test) does not appear to be reliable, because some reports show an increased capillary fragility in pigmented purpuric eruptions, and others were normal. Review of the patient's medical history, medications, and potential contact allergens is advised. Skin biopsy may be indicated to rule out vasculitis, especially if the lesions are papular. Mycosis fungoides should be considered if the lesions are chronic and unremitting.

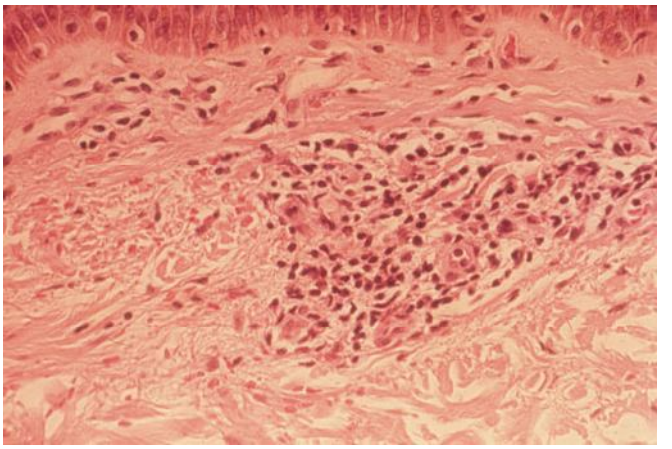

▲ **FIGURE 169-7** Pigmented purpuric dermatosis showing superficial perivascular lymphocytes and extravasated erythrocytes.

DIFFERENTIAL DIAGNOSIS

(Box 169-1)

MANAGEMENT

Treatment is often ineffective, and most treatments are anecdotal. If the eruption is induced by a drug or contact allergen, discontinuation of the causative drug or contact allergen can lead to complete resolution. However, residual pigmentation may persist for years. Oral bioflavonoid (rutoside, 50 mg bid) and ascorbic acid (500 mg bid) given to three patients with chronic pigmented purpura in an open trial led to clearance in all three patients within 4 weeks.[56] Corticosteroids have been reported to be successful; in particular, triamcinolone spray or potent topical (fluorinated) steroids. Systemic corticosteroids and cyclosporine are often effective but are not indicated due to the benign nature of the disorder.[57] With both topical and systemic steroids, recurrence of the lesions is the rule when steroids are discontinued. Treatment with topical pimecrolimus twice daily cleared lichen aureus lesions in a 10-year-old boy.[58] In a pilot study, calcium dobesilate, 500 mg twice daily, was given to nine patients for 3 months.[59] Seven patients had some mild to moderate improvement that was sustained at 1 year after cessation of therapy. Griseofulvin, 500 mg to 750 mg daily, improved existing lesions within a week and stopped new lesions within a mean of 33 days in an open trial of six patients.[60] Colchicine, 0.5 mg twice daily, cleared a 28-year-old woman with recalcitrant Schamberg disease.[61] Minocycline has also been reported to be beneficial.

Pentoxifylline, which inhibits T-cell adherence to endothelial cells and keratinocytes, may be helpful. A randomized, investigator-blinded trial compared pentoxifylline, 400 mg thrice daily, with topical betamethasone dipropionate cream, 0.05 percent twice daily, for 2 months. Patients treated with pentoxifylline had significantly greater improvement than those treated with the topical steroid. However, the response was not sustained after discontinuation of the medication.[62] Psoralen and ultraviolet A light and narrow band ultraviolet B have both been reported to clear lesions.[63–66] The phototherapy-induced immunosuppression of cell-mediated response is the proposed mechanism. Supportive stockings should be worn when lesions are on lower extremities.

Box 169-1

Differential Diagnosis of Pigmented Purpuric Dermatoses

- Contact dermatitis
- Cutaneous necrotizing vasculitis
- Stasis dermatitis and purpura
- Angioma serpiginosum
- Kaposi sarcoma (Gougerot-Blum)

KEY REFERENCES

The full reference list for all chapters is available at www.digm7.com.

3. Aiba S, Tagami H: Immunohistologic studies in Schamberg's disease: Evidence for cellular immune reaction in

lesional skin. *Arch Dermatol* **124**:1058, 1988
24. Torrelo A et al: Schamberg's purpura in children: a review of 13 cases. *J Am Acad Dermatol* **48**:31, 2003
39. Pock L, Capkova S: Segmental pigmented purpura. *Ped Derm* **19**:517, 2002
46. Saito R, Matsuoka Y: Granulomatous pigmented purpuric dermatosis. *J Dermatol* **23**:551, 1996
54. Toro JR et al: Persistent pigmented purpuric dermatitis and mycosis fungoides: Stimulant, precursor, or both: A study by light microscopy and molecular methods. *Am J Dermatopathol* **19**:108, 1997
56. Reinhold U et al: Treatment of progressive pigmented purpura with oral bioflavonoids and ascorbic acid: An open pilot study in 3 patients. *J Am Acad Dermatol* **41**:207, 1999
62. Panda S: Oral pentoxifylline vs topical betamethasone in Schamberg disease: a comparative randomized investigator-blinded parallel-group trial. *Arch Dermatol* **140**:491, 2004

CHAPTER 170

Cryoglobulinemia and Cryofibrinogenemia

Milan J. Anadkat
Lynn A. Cornelius
Thomas J. Lawley

CRYOGLOBULINEMIA

Epidemiology

Cryoglobulins are circulating immunoglobulins complexed with other immunoglobulins or proteins that reversibly precipitate in the cold. Wintrobe and Buell first noted the existence of cryoproteinemia as a clinical entity in 1933.[1] They noted precipitates of varying size within sera stored at low temperature that disappeared during incubation at 37°C (98°F). Lerner and Watson coined the term *cryoglobulins* in 1947.[2] They also performed the first large-scale examination of patient sera for cryoglobulins and identified precipitates in 11 percent of the specimens examined. Incidence rates vary, however, depending upon the patient population examined.

Etiology

The classification of cryoglobulinemia described by Brouet et al.[3] consists of three distinct groups: types I, II, and III, based upon immunoglobulin type (Table 170-1). Type I cryoglobulins consist of a single monoclonal immunoglobulin, typically immunoglobulin G (IgG) or IgM. Patients with type I cryoglobulinemia usually have an underlying hematologic malignancy, such as multiple myeloma or B-cell lymphoma. These patients may present with occlusive vasculopathy or may not exhibit any specific clinical manifestations.

TABLE 170-1
Types of Cryoglobulin[a]

- Simple (single-component) cryoglobulins (type I)
  - IgG
  - IgM
  - IgA
  - Immunoglobulin light chain
  - Complexed to other proteins
- Mixed cryoglobulins
  - IgM rheumatoid factors
    - Monoclonal (type II)
    - Polyclonal (type III)

Ig = immunoglobulin.
[a]The M components seen in types I and II cryoglobulinemias are most frequently IgM molecules, and it has been estimated that approximately 10% of all Waldenström macroglobulins are cryoprecipitable. IgM type I cryoglobulins are approximately 1.5 times more prevalent than IgG type I cryoglobulins. Thus, significant skewing exists among type I cryoglobulins in the IgM isotype, especially considering that, overall, IgM accounts for only about 15% of gammopathies, a number that reflects closely the contribution of this isotype to the total vascular body pool of immunoglobulins. This skewing toward IgM is even more striking among type II cryoglobulins, which are almost invariably IgMκ molecules utilizing the VκIII subgroup and selective V-region heavy- and light-chain genes.
Reproduced with permission from Kallemucukkal U, Gorevic, PD: Evaluation of cryoglobulins. *Arch Pathol Lab Med* **123**:119, 1999.

Mixed (type II and type III) cryoglobulins are immune complexes consisting of a rheumatoid factor (RF, the antibody), usually IgM, complexed with IgG (the antigen). Type II cryoglobulins are single monoclonal immunoglobulins (usually IgM) that co-precipitate with polyclonal IgG. Type III cryoglobulins are polyclonal immunoglobulins that form cryoprecipitates with polyclonal IgG or a nonimmunoglobulin serum component. These monoclonal (type II) or polyclonal (type III) RF-IgG complexes usually occur with a concomitant disease process such as connective tissue disease, infection, hepatic disease, or lymphoproliferative disease. Patients with mixed cryoglobulinemia typically present with vasculitis.

CRYOGLOBULINS AT A GLANCE



- Cryoglobulins are circulating immunoglobulins complexed to other immunoglobulins or proteins that reversibly precipitate in cold temperatures.
- Type I cryoglobulins consist of a single monoclonal immunoglobulin, typically immunoglobulin G (IgG) or IgM.
- Patients with type I cryoglobulinemia present with a noninflammatory occlusive vasculopathy.
- Mixed (type II and III) cryoglobulinemia is an immune complex disease resulting in an inflammatory vasculitis and glomerulonephritis.
- Type II cryoglobulinemia consists of a monoclonal antibody, usually IgM, complexed with polyclonal IgG. Type III cryoglobulinemia consists of polyclonal antibodies that precipitate with either polyclonal IgG or another serum component.
- Purpura, typically at a distal site, is the cutaneous hallmark of cryoglobulinemia. Livedo reticularis, acrocyanosis, ulceration, or gangrene may also be seen.

The term *essential cryoglobulinemia* is reserved for instances of mixed cryoglobulinemia without an identifiable underlying disease. A majority of patients with essential mixed cryoglobulinemia were historically found to have evidence of chronic active hepatitis or cirrhosis, but the exact triggering antigen was unable to be localized. In 1977, Levo et al. identified hepatitis B surface antigen, hepatitis B surface antibody, or Dane particles within patients' sera and



cryoprecipitates, and implicated the hepatitis B virus as the causative agent.[4] Later studies invalidated these findings, however.[5,6] In the early 1990s, authors first began to describe a relationship between hepatitis C virus (HCV) and the presence of mixed cryoglobulinemia.[7–10] The prevalence of HCV antibody and/or RNA in serum samples of patients with the diagnosis of essential mixed cryoglobulinemia ranged from 44 percent to 96 percent of patients studied, as documented by recombinant immunoblot assay or polymerase chain reaction, respectively.[11] Chronic HCV infection may result in either type II or type III cryoglobulinemia; however, type II cryoglobulins are the most commonly isolated precipitates. It is now believed that the vast majority of historical cases previously classified as essential cryoglobulinemia actually represent instances of HCV-associated mixed cryoglobulinemia. Patients with type I cryoglobulinemia may be seropositive for HCV at a low incidence. By definition; however, the cryoprecipitate does not contain the virus or antibody.

It is unclear why only select patients with chronic HCV develop mixed cryoglobulinemia. The role of host factors such as immunoglobulin subsets has been shown to be insignificant thus far. Some propose that a specific viral phenotype may predispose to vasculitis, most notably HCV genotype 2a.[12] Others postulate that HLA sub-types play a role in the development of HCV-associated mixed cryoglobulinemia. Cacoub et al. examined 158 HCV infected patients and found an increased risk of mixed cryoglobulinemic vasculitis in patients with HLA-DR11 phenotype; conversely, a decreased incidence of vasculitis was seen in patients with HLA-DR7.[13]

Pathogenesis

TYPE I CRYOGLOBULINS Type I cryoglobulins are monoclonal immunoglobulins, typically IgG or IgM, although IgA and Bence Jones proteins have been identified. In a review of 86 patients with cryoglobulinemia, Brouet et al.[3] reported that 25 percent of patients had only monoclonal cryoglobulins with a predominance of IgM immunoglobulin. A larger cohort study of 443 patients was conducted by Trejo et al.,[14] in which 90 cryoprecipitates were analyzed, revealing 34 percent of patients with type I disease; IgGκ and IgMκ were equally represented. Complement components are not routinely found within type I cryoprecipitates. Type I cryoglobulins, even when present in large amounts, may not result in signs or symptoms of disease.

Type I cryoglobulins demonstrate a self-association of monoclonal immunoglobulins at temperatures ranging from 0° to 30°C (32° to 86°F) or more. Monoclonal cryoglobulins are present in substantial amounts, often ranging from 1 to 30 mg/mL. They may precipitate as a gel, a flocculent precipitate, or in some instances as crystals. The specific physical forces involved in causing precipitates of type I cryoglobulins seem to include temperature-induced conformational changes, deficient carbohydrate side chains, and nucleation reactions.

The large molecular size of IgM monoclonal cryoglobulins may predispose these immunoglobulins to precipitation; some believe that cryoprecipitation may represent an extension of normal immunoglobulin solubility. In certain monoclonal IgG cryoprecipitates, earlier work suggested that the cryoprecipitate determinant resided in the variable region of the immunoglobulin, because the activity could be retained in the F(ab′)2 fragment.[15] Some idiotypic relatedness may exist among monoclonal IgG cryoglobulins, suggesting similar variable region structures and, possibly, similar antigenic specificity.[16]

MIXED CRYOGLOBULINS Types II and III cryoglobulins are typically present in relatively small amounts. These monoclonal (type II) or polyclonal (type III) RF-IgG complexes usually occur with a concomitant disease process such as connective tissue disease, infection, hepatic disease, or lymphoproliferative disease. The exception, as mentioned earlier, is the occurrence of "essential" mixed cryoglobulinemia, where an underlying disease process cannot be identified.

Type II cryoglobulins consist of two immunoglobulin components, one of which is monoclonal. The most common scenario is that of a monoclonal IgM RF complexed with a polyclonal IgG. Some evidence suggests that there is an increased prevalence of κ light chains in the monoclonal IgM, and that the monoclonal IgM has restricted specificity for IgG. A typical monoclonal spike is not always apparent on immunoelectrophoresis in type II cryoglobulinemias, even at relatively high serum concentrations. IgG monoclonal RFs are identified in a small percentage of patients with type II cryoglobulinemia, and IgA monoclonal RFs are rare.

Certain monoclonal IgM idiotypes have been preferentially associated with type II mixed cryoglobulinemia. Chronic HCV infection drives a non-malignant monoclonal B-cell expansion that typically regresses with antiviral therapy. These B cells produce a monoclonal IgM with polyreactive RF activity. This monoclonal IgM clone displays cross-reactivity with the Wa^+ idiotype, which is encoded by the Ig heavy chain variable gene V_H1-69 and the light chain variable gene V_L kv325.[17] HCV infection-driven lymphocyte proliferation may result in lymphocyte transformation into a B-cell non-Hodgkin lymphoma, which is characterized by the production of a monoclonal IgM cryoglobulin with RF activity. Specific VH and VL genes also encode the majority of antibodies expressed in these tumors, notably V_H1-69 and V_L kv325.

Type III cryoglobulins usually occur in low concentration and consist of polyclonal immunoglobulin complexes or polyclonal immunoglobulin-nonimmunoglobulin cryoprecipitates. These cryoglobulins are found in association with diseases that may involve the formation of immune complexes; IgM-IgG cryoglobulins are the most frequent scenario. The finding of complement system components, particularly C1q,[18] provides evidence for the immune complex nature of this phenomenon. Indeed, these cryoglobulins may activate complement in vitro, and patients with type III cryoglobulinemia often have decreased serum complement levels. Both autologous and exogenous antigens have been found associated with polyclonal immunoglobulins in this disease.

Analysis of types II and III cryoglobulins often reveals the presence of complement in addition to immunoglobulins. More specifically, type II cryoprecipitates may fix complement, where in type III disease, complement may be an integral component of the cryoprecipitate. Early work on the complement system in cryoglobulinemia revealed decreased "functional complement activity" (CH50), C1, C4, and C2.[19] A number of clinical studies have since identified patients with mixed cryoglobulinemia with depressed levels of C3, along with decreased levels of CH50, C2, and C4.[14] Similar studies have shown that patients with HCV-associated cryoglobulins demonstrate a higher frequency of hypocomplementemia than do patients without HCV. Cold-dependent activation of complement is common in the setting of HCV[20] and may itself affect CH50 levels in these patients.



TABLE 170-2
Clinical and Laboratory Findings with Cryoglobulinemia

- Type 1[a]
  - Severe cold-dependent symptomatology, including
    - Raynaud syndrome
    - Acrocyanosis of the digits or helices of the ears
    - Gangrene in the absence of other known causes of vascular occlusion
    - Livedoid vasculitis
    - Gelling of blood on blood drawing
    - Pathologic evidence of occlusive vasculopathy due to immunoglobulins
- Type II
  - Clinical presentation of
    - Cutaneous vasculitis-purpura/leg ulcers
    - Arthralgias/arthritis
    - Immune-complex nephritis
    - Neuropathy
  - Renal disease characterized histologically by
    - Membranoproliferative glomerulonephritis
    - Hyaline inclusions in glomeruli, positive for immunoglobulin M
    - Vasculitis
    - Congophilic-negative fibrillar inclusions in glomeruli by electron microscopy
  - Sjögren syndrome complicated by nephritis, glomerulonephritis, or gammopathy
  - Chronic hepatitis with extra-hepatic clinical manifestations
  - High-titer rheumatoid factor activity in the absence of rheumatoid disease
  - Markedly depressed levels of C4
- Type III
- Chronic infections (e.g., bacterial endocarditis) complicated by vasculitis, nephritis
  - Extra-articular manifestations of rheumatoid arthritis
  - Vasculitis and/or nephritis complicating:
    - Known rheumatic diseases
    - Chronic inflammatory liver diseases
    - Chronic inflammatory bowel diseases

[a]Many patients with type I cryoglobulins do not manifest specific symptomatology, suggesting that other factors may be important to the clinical expression of disease.
Reproduced with permission from Kallemucukkal U, Gorevic PD: Evaluation of cryoglobulins. *Arch Pathol Lab Med* **123**:119, 1999.



▲ **FIGURE 170-1** Leukocytoclastic vasculitis in a patient with mixed cryoglobulinemia manifested as palpable purpura and acrocyanosis. Patient with tuberculosis, positive anti-nuclear antibody, and hepatitis.

Clinical Findings (Table 170-2)

HISTORY Cryoglobulinemia may be painless (type I) or painful (type II or III) and typically appears as a shower of purpura, especially over the distal extremities. Patients should be questioned regarding the onset of their lesions and associated symptoms. Interestingly, cold sensitivity is not an invariable feature of cryoglobulinemia. A thorough review of the medical history will help to exclude similar vasculopathies in Differential Diagnosis. A targeted review of systems will guide the physician towards potential complications (arthralgias, visual changes, hematuria) or underlying disease triggers (i.e., infection, connective tissue disease, etc.).

CUTANEOUS LESIONS Purpura is considered to be a cutaneous hallmark of cryoglobulinemia. It is usually located distally, most typically on the lower extremities. Showers of these lesions may occur spontaneously, provoked by cold exposure or induced by long periods of standing or sitting. The appearance of purpura is usually preceded by local pricking sensations or paresthesia, not frank pain. Resultant ulcerations characteristically appear above the malleoli and often spontaneously regress.

Noninflammatory purpura, with histologic evidence of an amorphous eosinophilic precipitate within the vasculature, is characteristically seen in type I cryoglobulinemia and less commonly occurs in types II and III disease. Raynaud phenomenon is frequently evident, involving the hands, feet, ears, nose, or lips. Acrocyanosis, livedo reticularis, arterial thrombosis, and gangrene have also been reported to occur with type I cryoglobulinemia.[14,21]

Leukocytoclastic vasculitis (see Chap. 164), presenting clinically as palpable purpura, is the characteristic hallmark of mixed cryoglobulinemia (Fig. 170-1). The lesions are intermittent in nature (typically lasting 3 to 10 days) and usually are non-pruritic. Cutaneous manifestations such as Raynaud phenomenon, cutaneous vasculitis, psoriasis, porphyria cutanea tarda, lichen planus, urticaria, urticarial vasculitis, and cold urticaria have also been described.[22–24]

RELATED PHYSICAL FINDINGS The clinical picture of cryoglobulinemia is often heterogeneous. The organ systems typically affected in cryoglobulinemia are the skin, kidneys, liver, and musculoskeletal and nervous systems. Patients may also have serum cryoprecipitates in the absence of clinical symptoms. Typically, type I cryoglobulins are associated with thrombotic vasculopathy, presenting as acrocyanosis, retinal hemorrhage, Raynaud phenomenon, or arterial thrombosis. Renal disease and peripheral neuropathy are much less common.

Types II and III cryoglobulins are associated with arthritis, arthralgias, renal disease, and neurologic symptoms. Few studies exist comparing HCV-positive and HCV-negative cryoglobulinemic patients. Most believe that cutaneous and systemic disease is much more severe in HCV-positive patients, but more recent studies have found little difference between the two cohorts. The most recent comparison by Rieu et al. of 49 patients with symptomatic cryoglobulinemia found HCV-positive patients to differ only by increased transaminase levels and more severe arthralgias.[25]

Renal Disease. Early reports indicated that up to 60 percent of patients with essential mixed cryoglobulinemia have, or will develop, renal involvement.[15] Later studies have demonstrated a slightly lesser frequency.[26] Pathologic evaluation classically reveals predominantly a membranoproliferative glomerulonephritis. In fact, a specific membranoproliferative



"cryoglobulinemic glomerulonephritis" has been recognized in association with HCV-induced type II cryoglobulinemia having characteristic findings.[27] The initial clinical presentation of membranoproliferative glomerulonephritis may include diastolic hypertension, edema, or frank renal failure. Laboratory findings may include proteinuria, hematuria, pyuria, and red call casts. In contrast to skin, immunofluorescence is typically positive and reflects the immunoglobulin and/or complement components identified in the isolated cryoprecipitate.

Other Physical Findings. Articular manifestations, more common in types II and III cryoglobulinemia, rarely present as distinct arthritis, but rather as arthralgias. The knees, hips, metacarpophalangeals, and proximal interphalangeals are the most commonly affected sites.

Hepatic involvement was initially described in a majority of patients with "essential" mixed cryoglobulinemia, as discussed earlier (see Etiology); these patients are now recognized to have positive hepatitis B or C serologies. Hepatomegaly and splenomegaly may be evident, as well as liver function abnormalities. Histologic evaluation of transcutaneous liver biopsies reveals a variety of findings: microsteatosis, portal lymphoid aggregates, sinusoidal cell hyperplasia, intralobular necrosis, and changes consistent with active chronic hepatitis, or cirrhosis.

Neurologic symptoms are typically peripheral and believed to occur secondary to epineural vasculitis. Peripheral neurologic disease can present with one of two distinct forms. The majority of affected patients develop a progressive, chronic distal sensory polyneuropathy of the lower legs. Conversely, an acute mononeuritis multiplex may result with loss of strength, often manifesting as a foot-drop. Central nervous system involvement, such as transient dysarthria, hemiplegia, or confusion, is less common.

Other constitutional manifestations, such as fever, weight loss, asthenia, or diffuse abdominal pain, may also occur.

ASSOCIATED DISEASES (Table 170-3) Lymphoproliferative disease, autoimmune disorders, and infectious etiologies are the most frequently associated diseases. Human immunodeficiency virus infection may be present, usually co-existent with HCV. Lymphoproliferative diseases, such as macroglobulinemia and lymphomas, are associated with types I and II cryoglobulins; autoimmune disorders and HCV are associated with types II and III (see Pathogenesis). Autoimmune disorders, especially rheumatoid arthritis, systemic lupus erythematosus, and Sjögren syndrome, are associated with 15 percent of patients with type I and with 26 percent of patients with mixed cryoglobulinemia.[14]

TABLE 170-3
Disease Associations

- Type I
  - Multiple myeloma
  - Waldenström macroglobulinemia
  - Other lymphoproliferative diseases with M components
- Type II
  - Chronic hepatitis C virus infection[a]
  - Sjögren syndrome
  - Waldenström macroglobulinemia
  - Chronic lymphocytic leukemia
  - Non-Hodgkin lymphoma
  - Autoimmune diseases
  - Cold agglutinin disease
- Type III
  - Chronic infections
    - Viral (Epstein-Barr virus, cytomegalovirus, human immunodeficiency virus, hepatitis viruses)
    - Bacterial (subacute bacterial endocarditis, leprosy, spirochetal)
    - Fungal, parasitic
  - Autoimmune diseases
    - Systemic lupus erythematosus
    - Rheumatoid arthritis
    - Inflammatory bowel diseases
    - Biliary cirrhosis

[a]The authors believe that the majority of cases previously designated as essential cryoglobulinemia actually represented undiagnosed hepatitis C infection.
Reproduced with permission from Kallemucukkal U, Gorevic PD: Evaluation of cryoglobulins. *Arch Pathol Lab Med* **123**:119, 1999.

Laboratory Tests

Kallemuchikkal and Gorevic described the isolation and characterization of cryoglobulins in detail.[28] When cryoglobulinemia is suspected, blood is drawn with a syringe warmed to 37°C (98.6°F) and left to clot at the same temperature. Serum obtained by centrifugation of the blood at 37°C (98.6°F) is then refrigerated at 4°C (39.2°F) for several days. If positive, a cryoprecipitate will form at the base of the test tube (Fig. 170-2). Initial screening includes the determination that the precipitate is capable of resolubilization when the serum is re-warmed. Once formed, the cryoprecipitate is isolated, resuspended in saline at 37°C (98.6°F), and the protein components are characterized by immunofixation. Most type I cryoprecipitates will be evident within 24 hours, whereas mixed type III cryoglobulins may require several days of cold incubation for precipitation. Therefore, it is important to hold serum for approximately 1 week before final determination is made of the presence of a cryoprecipitate. Cryoglobulins may become associated with serum lipids and remain suspended during centrifugation, thereby obscuring the formation of a visible precipitate.[29] Conversely, in patients undergoing heparin therapy, an insoluble cryoprecipitate may form with other serum proteins, specifically fibronectin.[30]



▲ **FIGURE 170-2** Whitish cryoprecipitates after keeping tube at 4°C (39.2°F) for 48 hours and centrifugation.

Once a cryoprecipitate is identified, additional serum studies may aid in their further determination. Although not always present, serum protein electrophoresis may demonstrate the presence of a monoclonal spike, suggesting a gammopathy consistent with type I or II cryoglobulins. Detection of cryoglobulin can be increased by collecting the sample, and running the electrophoresis, at 37°C (98.6°F). Serum immunofixation will characterize an identified monoclonal spike, which involves electrophoretic serum protein separa-

tion on an agarose gel, followed by incubation with antisera specific to immunoglobulin classes and light-chain types. This method is highly sensitive for immunotyping a monoclonal gammopathy.[31] Quantitative immunoglobulin determination may aid in further identification of cryoglobulin-associated diseases (i.e., lymphoproliferative diseases).

The concentration of cryoglobulins may be expressed as a percentage of the volume of the total collected serum (cryocrit), or, alternatively, as the concentration of protein in the dissolved cryoprecipitate (expressed in milligrams per milliliter). Type I cryoglobulins are typically present in concentrations greater than 5 mg/mL. In contrast, type III cryoglobulins are usually present in lesser amounts (i.e., cryocrit < 1 percent).[32] Symptom severity does not necessarily reflect cryoprotein concentration in the serum or the temperature at which cryoprecipitation takes place.[33] Isolated cryoglobulin precipitates are typed by immunofixation, immunoblotting, two-dimensional gel electrophoresis, and capillary zone electrophoresis.[28] Immunofixation methods are the most sensitive and most widely used.

Differential Diagnosis (Box 170-1)

Box 170-1

Differential Diagnosis of Cryoglobulinemia and Cryofibrinogenemia

- Autoimmune disease
  - Lupus erythematosus
  - Scleroderma
  - Dermatomyositis
  - Rheumatoid arthritis
  - Anti-phospholipid antibody syndrome
- Hematologic disease
  - Protein C or S deficiency
  - Disseminated intravascular coagulation
  - Thrombotic thrombocytopenic purpura
  - Idiopathic thrombocytopenic purpura
- Vasculopathies
  - Thromboangiitis obliterans
  - Leukocytoclastic vasculitis
  - Henoch-Schönlein purpura
  - Cholesterol emboli
  - Septic emboli
- Infectious etiologies
  - Hepatitis C
  - Rocky mountain spotted fever
  - Meningococcus
- Drug-related reactions
  - Raynaud
    - Bleomycin
    - Ergot
  - Livedo reticularis
    - Amantadine
  - Purpura
    - Warfarin
    - Heparin

Treatment

Treatment of cryoglobulinemia is based on the severity of disease presentation. Mild cutaneous symptoms may not require therapeutic intervention. Nonsteroidal anti-inflammatory drugs may improve dermatologic and articular manifestations. More severe visceral involvement, particularly renal disease, may require corticosteroid therapy in conjunction with cytotoxic agents. Melphalan, chlorambucil, or cyclophosphamide may benefit some patients with underlying lymphoproliferative disorders. Rituximab, a chimeric monoclonal anti-CD20 antibody proven to be efficacious against B-cell lymphomas, has been shown to be efficacious in type II disease,[34] but has questionable benefit in type I disease.[35]

Plasmapheresis has been used in patients with rapidly progressive disease refractory to conventional therapy, but a postpheresis rebound in disease activity may occur. Plasma exchange successfully decreases the hyperviscosity seen in type I disease and is usually instituted together with immunosuppressive or cytotoxic agents in an attempt at better disease control as well as avoidance of rebound. Cryofiltration is a method of combining a refrigerated membrane unit with pheresis and has been used in patients refractory to more conventional therapy.[36]

Patients with HCV-associated cryoglobulinemia have experienced only marginal success with interferon-α (IFN-α) monotherapy.[37–39] There also exist concerns regarding potential complications of IFN in the setting of systemic cryoglobulinemia, such as neuropathy, renal crisis, or delayed ulcer healing.[40] Other studies attempting to combine IFN-α with ribavirin have provided improved results. The current standard of treatment for patients with chronic HCV infection is with combination polyethylene glycol-IFN-α and ribavirin; the resultant antiviral response achieved with this regimen over 18 to 24 months makes it the best choice for HCV-mediated vasculitis, as well.[41] Similarly, patients with mixed cryoglobulinemia in the setting of chronic hepatitis B may show benefit with lamivudine.[42]

CRYOFIBRINOGENEMIA

Epidemiology

Cryofibrinogenemia is an extremely uncommon disorder characterized by precipitation of patients' native fibrinogen or fibrin by-products. Symptomatic disease due to cryofibrin precipitates is even more rare. One study by McKee et al. reported the prevalence of essential cryofibrinogenemia as 3 percent (among 135 healthy residents) in Oklahoma City.[43] The same study noted the prevalence of secondary cryofibrinogenemia among 665 hospitalized patients to be 13 percent; samples from these patients were observed for 48 hours. Another study by Smith et al. examined 36,000 hospitalized patients and noted the prevalence of secondary disease at only 3.4 percent; blood samples from this study were only followed for 24 hours, however.[44] Secondary cryofibrinogenemia has a female predilection, reportedly occurring at a female-male ratio of 4:1.[44] Whether this is due to the higher incidence of connective tissue disease in women has not yet been validated. An age or racial predilection does not appear to exist, however.

Such epidemiologic data on primary and secondary cryofibrinogenemia are somewhat outdated, and interpretation of findings is often difficult. In fact, most authors recommend observing blood samples for 72 hours to detect cryofibrinogens, and, as with the studies cited above, a majority of prior studies failed to follow this protocol. In addition, the characteristics of hospitalized patients have changed over the years

CRYO-FIBRINOGENS AT A GLANCE

- Cryofibrinogens are protein complexes that precipitate in both cooled serum and plasma. They consist of fibrin, fibrinogen, or fibrin split products complexed with albumin, plasma proteins, or immunoglobulins.
- Cryofibrinogenemias are classified as either primary, with no known etiology or precipitating underlying disease, or secondary.
- The cutaneous findings of cryofibrinogenemia are similar to those of cryoglobulinemia.



with an increase in immunosuppressed patients and a variation in infectious disease etiologies. Whether this changes the current epidemiology of cryofibrinogenemia is unclear.

Etiology

Korst and Kratochvil first described cryofibrinogens in 1955.[45] Cryoprecipitates are cold, insoluble complexes of fibrinogen, fibrin, and fibrin split products with albumin, fibronectin (cold-insoluble globulin), factor VIII, immunoglobulins (rare in patients with isolated disease), and other plasma proteins.[46,47] Cryoprecipitates may, in fact, be composed of normal plasma proteins demonstrated on freeze thawing of plasma.[15] Heparin may produce false-positive precipitates (heparin-precipitable fraction) through the formation of heparin-fibronectin cryoprecipitable complexes, the formation of which may be further enhanced by the presence of fibrinogen.[15]

Cryofibrinogenemia is classified as primary, without known etiology or disease association, or secondary. Secondary cryofibrinogenemia may occur in patients with connective tissue disease, infections, malignancies, and thromboembolic disorders and is more frequently found in patients with associated cryoglobulinemia.[45] Diabetes, hyperglycemia, chronic lung disease, hypothyroidism, and acute myocardial infarction have been described as disease associations, as has pregnancy and the use of oral contraceptive agents.[43,48–52] In one study of patients with associated cryoglobulinemia,[46] immunoglobulins were a predominant constituent of the cryofibrinogen precipitate, and, not surprisingly, of the same class as that characterizing the cryoglobulinemia. Similarly, fibronectin was found in the cryoglobulin cryoprecipitate.

Pathogenesis

Cryofibrinogen products clot with thrombin and then reversibly precipitate in the plasma on cooling to 4°C (39.2°F). The precipitate then dissolves readily upon re-warming to 37°C (98.6°F). They represent cryoproteins in plasma that has been anticoagulated following blood draw with oxalate, citrate or ethylenediaminetetraacetic acid (as opposed to heparin). The proteins consumed in the clotting process are the necessary substrates for formation of cryofibrinogens and therefore, the precipitate requires whole plasma. Cryofibrinogens, unlike cryoglobulins, cannot precipitate in cooled serum. Plasma levels of cryofibrinogens may range from 0.05 g/L to > 1 g/L.[46] In patients with isolated cryofibrinogenemia, and in those with co-existent cryoglobulinemia, plasma fibrinogen levels may be elevated.

The exact mechanism responsible for the formation of cryofibrinogens is not known. The current hypothesis is based upon findings of increased α_1-antitrypsin and α_2-macroglobulinemia in patients with cryofibrinogenemia.[44,50] α_2-Macroglobulin seems to be elevated more frequently.[53] These proteins inhibit the major plasma fibrinolytic agent, plasmin, resulting in an accumulation of protein cryoprecipitates (fibrinogens, fibrin, etc.). Both α_1-antitrypsin and α_2-macroglobulinemia can readily be identified by serum protein electrophoresis.

Clinical Findings

Patients with cryofibrinogenemia, as with cryoglobulinemia, typically present with cutaneous disease. The symptoms of cryofibrinogenemia are due to thrombotic occlusion of small- and medium-sized dermal vessels and resultant ischemia.[46] By definition, essential disease occurs in otherwise healthy individuals. Given the limited number of reported cases, the clinical presentation is not well defined, but likely emulates secondary disease. Patients presenting with cryofibrinogenemia typically report a temporal association between exposure to cold and an onset of symptoms. Non-specific general complaints of fever and malaise are common. The clinical phenotype of cutaneous lesions varies in severity from purpura, livedo reticularis, or ecchymoses to ulceration, ischemia, and gangrene. Cryofibrinogenemia may clinically simulate calciphylaxis, presenting in patients with end-stage renal disease (see Chap. 151). Any body site may be affected, but those maintaining a cooler temperature are more likely to be involved: hands, feet, buttocks, ears, or nose.

Non-cutaneous thrombotic events may also occur irrespective of the cryofibrinogen level (seen in approximately 25 percent of patients with secondary disease).[43] Cerebrovascular accidents, myocardial infarction, thrombophlebitis, pulmonary emboli, and retinal artery thrombosis have been reported, and correlate directly with the level of circulating cryofibrinogen. In contrast, spontaneous bleeding may occur in select patients due to depletion of clotting factors.

The histologic features of cryofibrinogenemia are similar in both cutaneous lesions and systemic disease,[54] with eosinophilic refractile deposits within vessel lumina and extension to the vessel intima, secondary to occlusive thrombi composed of cryofibrinogen precipitates. Distinction from type I cryoglobulinemia is difficult, but the presence of an accompanying granulomatous reaction, either extravascular granulomatous foci or granulomatous vasculopathy, is more characteristic of cryofibrinogenemia. Types II and III cryoglobulins, in contrast, typically elicit a lymphocytic or leukocytoclastic vasculitis. Cryofibrinogen precipitates may also be distinguished by their cylindrical configuration, which is often displayed within the vessel lumina.

Laboratory Testing

When cryofibrinogenemia is suspected, blood should be collected in tubes containing oxalate, citrate, or ethylenediaminetetraacetic acid as the anticoagulant. Tubes containing heparin should not be used given the risk of false-positives. On collection, the blood should be stored at 37°C (98.6°F) until centrifuged. Centrifugation performed after the sample has been allowed to cool results in false-negatives, as cryofibrinogens will precipitate with the red blood cell fraction. After centrifugation, plasma is stored at 4°C (39.2°F) and observed for the formation of a precipitate for up to 72 hours. A sample should also be drawn without anticoagulant, with the blood allowed to clot, to exclude the presence of precipitable cryoglobulinemia. As stated earlier, cryoglobulins form in both cooled serum and plasma and must be excluded when making a laboratory diagnosis of cryofibrinogenemia.

Differential Diagnosis (See Box 170-1)

Treatment

There is no regularly effective treatment for cryofibrinogenemia. Avoidance of exposure to cool environments is likely to be only partially effective. Various therapeutic interventions and pharmacologic agents have been proposed. Systemic steroids have shown limited benefit as monotherapy, but case reports cite improvement in clinical disease when combined with immunosuppressant therapy, most notably azathioprine.[55,56] Oral streptokinase has been reported to decrease disease activity; however, streptokinase is only available as an intravenous infusion in the



United States. Stanazolol is an androgenic steroid with fibrinolytic activity, presumed due to alteration of liver protein synthesis. It has been described to benefit patients in a few case reports.[57–59] Last, plasmapheresis, cryofiltration apheresis, and warfarin have been reported with varying success rates. The treatment of secondary cryofibrinogenemia should target the underlying disease or associated condition.

KEY REFERENCES

The full reference list for all chapters is available at www.digm7.com.

13. Cacoub P et al: Influence of HLA-DR phenotype on the risk of hepatitis C virus-associated mixed cryoglobulinemia. *Arthritis Rheum* **44**:2118, 2001
17. Carbonari M et al: Hepatitis C virus drives the unconstrained monoclonal expansion of VH1-69-expressing memory B cells in type II cryoglobulinemia: A model of infection-driven lymphomagenesis. *J Immunol* **174**:6532, 2005
25. Rieu V et al: Characteristics and outcome of 49 patients with symptomatic cryoglobulinemia. *Rheumatology* **41**:290, 2002
34. Zaja F et al: Efficacy and safety of rituximab in type II mixed cryoglobulinemia. *Blood* **101**:3827, 2003
41. Cacoub P et al: PEGylated interferon alfa-2b and ribavirin treatment in patients with hepatitis C virus-related systemic vasculitis. *Arthritis Rheum* **52**:911, 2005

CHAPTER 171

Raynaud Phenomenon

John H. Klippel

EPIDEMIOLOGY

Studies of the epidemiology of Raynaud phenomenon are biased by under-reporting (most patients with primary Raynaud never seek medical attention) and studies done by investigators interested in the secondary forms of the disorder. Surveys indicate that Raynaud phenomenon affects up to 10 percent of the general population.[1,2] Primary Raynaud phenomenon is estimated to be approximately twice as common as secondary Raynaud.[3] Symptoms most often first develop in the teenage years, and most series show a female predominance of the disorder (female-male = 4:1). Increases in the frequency and severity of attacks during menses suggest that female sex hormones may be involved in the pathogenesis.[4] Differences in seasonal skin temperatures, marital status, alcohol use, age, and smoking between women and men have also been suggested to contribute to the sex differences.[5,6] Familial aggregation has been identified in a number of studies and suggests the contribution of genetic factors.[7] Other associations reported in epidemiologic studies include living in a cold climate, occupation, cardiovascular disease, low body-mass index, and use of vibratory tools.

ETIOLOGY AND PATHOGENESIS

The pathophysiology of the vasospasm is complex and only partially understood. Studies show significant reductions of peripheral blood flow throughout all phases of central body cooling and re-warming, suggesting impairments of central thermoregulatory control mechanisms.[8] The principal mechanisms thought to contribute to the development of Raynaud phenomenon include a local defect of a digital blood vessel, causing abnormal vascular reactivity or reduced blood flow; an enhanced localized production of vasoconstrictors or reduced production of vasodilators; hyperreactivity of the sympathetic nervous system; and abnormal properties of the blood that compromise distal perfusion.

The results of gross histologic examinations of digital arteries in patients with primary Raynaud phenomenon are normal. Structural abnormalities of the digital microvasculature are frequently seen in patients with secondary forms of Raynaud phenomenon, particularly in the connective tissue diseases. Studies show a range of pathology, including intimal hyperplasia, narrowing or total occlusion of arteries, or thrombi. In most patients with systemic sclerosis, there exists evidence of activation and damage of the endothelium, fibrinolysis, and platelet activation.[9] Microcirculatory flow studies with laser Doppler in patients with scleroderma have shown marked reductions in blood flow and hand temperature during an attack, with prominent abnormalities during re-warming—findings that suggest a failure of the arteriovenous anastomoses to open.[10]

Serotonin is also incriminated as an important mediator in the induction of ischemic attacks of Raynaud phenomenon. Patients have an increased sensitivity to intra-arterial infusions of serotonin, and S2-serotonergic antagonists relieve but do not prevent the induction of attacks.

The evidence of direct central sympathetic nervous system hyperactivity is strongest in vibration-induced injury, in which the use of a vibration tool in one hand produces vasospasm in the other hand.[11] Similarly, vasospasm can be inhibited by proximal nerve blockade in patients with vibration-induced injury. In general, most studies of the sympathetic nervous system in patients with primary or other secondary forms of Raynaud phenomenon have failed to detect evidence of sympathetic hyperactivity. The results of microelectrode studies of skin sympathetic nervous activity during cold pressor tests are normal, and plasma levels of catecholamines are not increased in the venous drainage of the hands of patients with Raynaud phenomenon.

RAYNAUD PHENOMENON AT A GLANCE



- Affects 10 percent of the population; 4:1 female-male ratio.
- Chronic episodic attacks of digital ischemia provoked by exposure to cold or emotional stress.
- Classified into primary (idiopathic) and secondary (underlying disease or cause present) forms; severity ranges from mild/benign to severe with loss of digital tissues.
- Connective tissue diseases—particularly systemic sclerosis—are the most common forms of secondary Raynaud.
- Both non-pharmacologic and drug therapies are used to reduce the frequency and severity of attacks.







▲ **FIGURE 171-1** Ischemic phase of attack of Raynaud phenomenon with marked pallor of the ring and little fingers of the left hand and little finger of the right hand.

Consistent abnormalities in plasma fibrinogen, cold agglutinins, platelets, or cryoglobulins have not been demonstrated in primary Raynaud phenomenon, but are important in certain secondary cases, particularly scleroderma. Levels of von Willebrand's factor and soluble thrombomodulin, thromboxane B_2 and β-thromboglobulin, and tissue plasminogen activator inhibitor-1 are increased in patients with scleroderma, when compared to levels in patients with primary Raynaud phenomenon.[9]

Genetic studies with microsatellite markers of extended families affected with primary Raynaud phenomenon have identified several potential candidate genes.[12]

CLINICAL FINDINGS

A careful history and physical examination are important in the evaluation of a patient with suspected Raynaud phenomenon.

History

The history is important to elicit a clear description of the attacks and to screen for evidence of signs and symptoms suggestive of a secondary cause. Patients complain of episodic attacks of well-demarcated, white or blue digits induced by exposure to cold and sometimes by emotional stimuli (Fig. 171-1). Often only a portion of the digit is affected, and the thumbs are typically spared. A classic tricolor change of pallor, cyanosis, and hyperemia described in most textbooks is rarely volunteered by patients; most describe only blanching of the digits accompanied by numbness. During the attacks, one or more fingers or toes may be numb and be described as "dead." On re-warming, the digits may become bright red, and throbbing pain may occur. When pain is a prominent symptom in the ischemic phase, a secondary cause should be suspected. Attacks last minutes to hours. The fingers and toes are most commonly involved; however, the attacks may involve the nose, earlobes, or nipples.

A careful review of systems is important to screen for symptoms of connective tissue disease (arthralgias, arthritis, dysphagia, heartburn, rash, photosensitivity, skin changes, muscle weakness, shortness of breath, or sicca), a drug-related etiology, symptoms of obstructive arterial diseases (intermittent claudication), and exposure to vibratory tools or continuous finger trauma.

Cutaneous Lesions

Attacks of Raynaud phenomenon, presumably stress induced, are commonly witnessed during the course of the history or physical examination. There is well-demarcated blanching or cyanosis of the digits extending from the tip to various levels of the digit (see Fig. 171-1). The digits distal to the line of ischemia are cold, while the proximal skin is pink and warmer. On re-warming, blanched digits may become cyanotic, because of the slow blood flow, and then bright red, because of reactive hyperemia. Persistent ischemic discoloration of digits suggests a secondary cause.

The digits should be carefully examined for trophic or ischemic changes, which are signs of prolonged or severe attacks of Raynaud phenomenon. The skin may become atrophic, thin, and tight (sclerodactyly), with loss of hair over the dorsal surfaces. The nails may become brittle and deformed. Ulcerations, which can be extremely painful, particularly at night, may develop on the finger pads or around the nail bed. The ulcers heal slowly, leave characteristic small, pitted scars (Fig. 171-2), and may become infected. Gangrene of the distal aspects of the digit is rare.

Related Physical Findings

The physical examination should pay attention to all pulses, and blood pressure should be obtained in both arms. Allen's test is useful to assess arterial and capillary function of the hands; abnormalities imply structural disease of the microcirculation and raise the suspicion of a secondary form of Raynaud phenomenon. The radial and ulnar arteries are simultaneously compressed by the examiner's thumbs while the patient opens and closes the fist to induce blanching of the palm. Selective arterial filling is judged by the rate of color return as pressure is sequentially released from the radial and ulnar arteries. Vascular



▲ **FIGURE 171-2** Loss of pulp of the pad of the digit with pitting scars and ulcerations from chronic, severe Raynaud phenomenon.

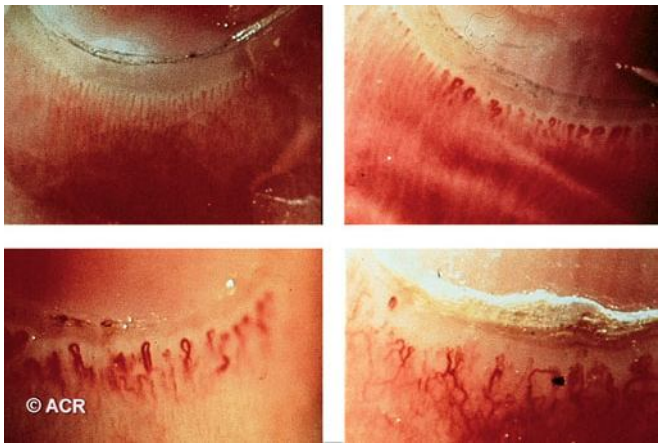

▲ **FIGURE 171-3** Nail fold capillary microscopy, in a patient with scleroderma, showing capillary drop out with enlarged, dilated, tortuous capillary loops.

obstruction from the thoracic outlet syndrome should be assessed by the Adson maneuver, which tests for diminution in the radial pulse with exaggerated movements of the neck and shoulder. A careful neurologic examination should be performed to detect evidence of sympathetic hyperactivity, abnormal reflexes, muscular weakness or atrophy, or compression of the median nerve within the carpal tunnel. Skin changes, such as telangiectases, changes in skin texture, rashes, or purpura, provide valuable clues to the presence of a connective tissue or hyperviscosity disorder.

LABORATORY TESTS

In all patients, a complete blood count, erythrocyte sedimentation rate, urinalysis, and anti-nuclear antibody test should be obtained. Additional laboratory studies should be directed by findings elicited by the history and physical examination. In patients with abnormal anti-nuclear antibody levels, tests for antibodies to specific nuclear antigens, such as Sm antigen or topoisomerase or centromere antigens, are helpful to detect early systemic lupus erythematosus or scleroderma (see Chaps. 156 and 158). A routine chest radiograph should be obtained to look for a cervical rib or evidence of interstitial lung disease.

Nail fold capillary microscopy is considered to be a useful procedure to distinguish primary from secondary Raynaud phenomenon.[13] Although mild capillary abnormalities may be observed in patients with primary Raynaud phenomenon, patients with connective tissue diseases may have enlarged, deformed capillary loops surrounded by avascular areas (Fig. 171-3).[14] Serial studies reveal progressive decreases in the total number of nail fold capillary loops in secondary, but not primary, forms of Raynaud phenomenon.[15] The patency of small arteries can be assessed by Doppler techniques. Digital subtraction arteriography should be reserved for selected patients with prolonged, severe ischemia for whom arterial reconstruction is a consideration.

DIFFERENTIAL DIAGNOSIS

Raynaud phenomenon is subdivided into primary (idiopathic) and secondary forms based on whether an underlying cause or disease association can be identified.

Primary Raynaud Phenomenon

Primary Raynaud phenomenon is a disorder in which known causes of attacks of peripheral vasospasm cannot be found. Criteria for the diagnosis of primary Raynaud phenomenon have been developed by Allen and Brown[16] and LeRoy and Medsger[17] (Table 171-1).

Several studies have examined the long-term outcome of patients with primary Raynaud phenomenon.[3,18,19] Progression to a secondary form of Raynaud phenomenon, most commonly a connective tissue disease such as scleroderma, occurs in approximately 15 percent of patients during the first decade after onset. Variables predictive of a transition to a secondary form include nail fold capillary abnormalities, hand swelling, positive Allen's test, and anti-nuclear antibodies.

Secondary Raynaud Phenomenon

CONNECTIVE TISSUE DISEASES The connective tissue diseases are the most common cause of secondary Raynaud phenomenon (Table 171-2). Among patients with scleroderma, 80 percent to 90 percent manifest Raynaud phenomenon and/or persistent vasospasm. It is the presenting symptom in about one-third of patients and may be the only manifestation of the disease for years. Raynaud phenomenon occurs in about one-third of patients with systemic lupus erythematosus, idiopathic inflammatory myopathies, and systemic vasculitis. Although patients with rheumatoid arthritis often complain of cold hands with mottled red and white areas, true Raynaud phenomenon appears to be no more common in persons with rheumatoid arthritis than in the general population. Arteriograms of patients with connective tissue diseases usually show digital and sometimes, ulnar or radial artery obstructions.

TABLE 171-1
Criteria for Primary Raynaud Phenomenon

- Vasospastic attacks precipitated by exposure to cold or emotional stimuli
- Bilateral involvement of extremities
- Normal vascular examination with symmetric peripheral pulses and normal nail fold capillary microscopy
- Absence of gangrene or, if present, limited to the skin of the fingertips
- No evidence of an underlying disease, drug, or occupational exposure that could be responsible for vasospastic attacks
- Negative anti-nuclear antibody test
- Normal erythrocyte sedimentation rate
- History of symptoms for at least 2 yr

Combined criteria of Allen and Brown[16] and Le Roy and Medsger.[17]

OCCUPATIONAL Raynaud phenomenon may be occupational in origin. It is especially common in individuals who use vibratory tools (e.g., air hammers, chain saws, rivet guns) and in those whose occupation requires prolonged exposure of the extremities to cold temperatures (e.g., butchers, ice cream workers, fish packers). Prevalence rates correlate with the vibration level of the tool and the duration of exposure; they can be as high as 90 percent in high-risk occupations such as logging or mining.[20]

NEUROLOGIC DISORDERS Any neurologic condition that produces permanent disuse of a limb can be associated with sympathetic nervous system disturbances to that limb. Patients often develop persistent vasospasm with coldness, paleness or cyanosis, and even ulcerations of the limb, and Raynaud phenomenon may occur. Thermoregulatory abnormalities may be



TABLE 171-2
Secondary Raynaud Phenomenon

- Connective tissue disease
  - Scleroderma
  - Systemic lupus erythematosus
  - Dermatomyositis and polymyositis
  - Undifferentiated connective tissue disease
  - Systemic vasculitis
  - Sjögren syndrome
  - Eosinophilic fasciitis
- Obstructive arterial disease
  - Atherosclerosis
  - Thromboangiitis obliterans (Buerger disease)
  - Thromboembolism
  - Thoracic outlet syndrome
- Neurologic disorders
  - Carpal tunnel syndrome
  - Reflex sympathetic dystrophy
  - Hemiplegia
  - Poliomyelitis
  - Multiple sclerosis
  - Syringomyelia
- Drugs and toxins
  - β-Adrenergic blockers
  - Ergotamines
  - Oral contraceptives
  - Methysergide
  - Bleomycin and vinblastine
  - Clonidine
  - Bromocriptine
  - Cyclosporine
  - Amphetamines
  - Fluoxetine
  - Interferon-α
- Occupation/environmental exposure
  - Vibration injury (lumberjacks, pneumatic hammer operators)
  - Post-traumatic injury (hypothenar hammer syndrome, crutch pressure)
  - Vinyl chloride disease
  - Cold injury
  - Hyperviscosity disorders
    - Cryoproteins
    - Cold agglutins
    - Macroglobulins
    - Polycythemia
    - Thrombocytosis
- Miscellaneous
  - Hypothyroidism
  - Infections (bacterial endocarditis, Lyme disease, viral hepatitis)
  - Neoplasms
  - Primary pulmonary hypertension
  - Arteriovenous fistula
  - Intra-arterial injections



a prominent feature of reflex sympathetic dystrophy syndrome.[21] Nerve root pressure or nerve entrapment may produce Raynaud phenomenon. It is often present in patients with carpal tunnel syndrome and typically involves the first, index, and middle fingers, digits innervated by the median nerve. In addition, Raynaud phenomenon may occur as a result of neurovascular compression at the thoracic outlet. The compression may be caused by cervical ribs; abnormalities of the scalenus anticus muscle; bony abnormalities of the cervical vertebrae, clavicle, or first rib; or shoulder compression syndromes (the costoclavicular or hyperabduction syndrome).

DRUGS AND TOXINS Propranolol, one of the most widely used β-adrenergic blockers for cardiovascular diseases and migraine headaches, is probably the most frequently used drug responsible for Raynaud phenomenon. Ergot preparations and methysergide used to treat migraine headaches may produce vasospasm. Intra-arterial use of many medications and recreational drugs can result in toxicity to endothelial cells with irreversible structural damage to the microvasculature of the extremities and be responsible for severe Raynaud phenomenon. The chemotherapeutic agents bleomycin and vinblastine also may cause the phenomenon.[22]

HYPERVISCOSITY Patients with hyperviscosity from cryoglobulinemia, macroglobulins, cold agglutinins, and polycythemia can exhibit Raynaud phenomenon. Cryoglobulins are most commonly present in patients with multiple myeloma, but they also occur in patients with rheumatic diseases, chronic infections, leukemia, and lymphoma, and as an idiopathic condition.

MISCELLANEOUS The most common endocrine disturbance associated with Raynaud phenomenon is hypothyroidism; symptoms usually remit with thyroid hormone replacement. Raynaud phenomenon may be a feature of various infectious disorders, including subacute bacterial endocarditis, Lyme disease, and viral hepatitis, presumably a reflection of systemic vasculitis. Peripheral vasospasm may also occur in association with malignant tumors, including pheochromocytoma, carcinoid, and ovarian carcinoma.

The major forms of vascular ischemia that must be distinguished from Raynaud phenomenon are cold digits, chilblain (pernio), livedo reticularis, and acrocyanosis (see Chap. 93). Many patients complain of cold, sometimes painful digits without color changes. This condition likely represents one extreme of the spectrum of normal sympathetic nervous system activity. Chilblain is an inflammatory condition of the skin of the extremities induced by cold. Patients develop a bluish-red discoloration and edema, typically involving the lower limb and associated with warmth, erythema, and burning. In severe cases, hemorrhagic lesions, bullae, or ulcers may develop, and secondary infections may supervene. The lesions last from 7 to 10 days, often leaving a residual pigmentation of the skin. Livedo reticularis is a bluish discoloration of the skin of the extremities with a characteristic lacy, irregular appearance. The bluish discoloration becomes more intense on exposure to cold and may disappear in a warm environment. Most patients are entirely asymptomatic, although livedo reticularis may be a feature of the antiphospholipid syndrome, in which patients are at increased risk for venous and arterial thromboses, thrombocytopenia, and pregnancy losses. In acrocyanosis, the hands, and, less commonly, the feet, develop a persistent bluish discoloration. The blue color is intensified by exposure to cold and is converted into a purplish or red color by warming; a pallor phase is absent. The skin is cold, and the palms are often wet and clammy from sweat. Trophic changes or ulcerations are rarely observed.

TREATMENT

The management of Raynaud phenomenon is guided by the frequency and severity of attacks and the complications from ischemia (Table 171-3). Secondary forms of Raynaud phenomenon require treatment directed at the underlying medical disorder, discontinuation of drugs causing the vasospasm, or occupational modifications.

General Measures

Mild Raynaud phenomenon is generally easy to control with lifestyle changes to minimize exposure to the cold; dressing warmly with loose-fitting, layered clothing; and keeping the thermostat a few degrees higher than normal. Limiting time spent outdoors in winter, wearing insulated gloves, and using hand or foot warmers are usually helpful. Patients should be taught to recognize and terminate attacks promptly by returning to a warmer environment and applying local heat to the hands (e.g., by placing their hands in warm water or by using a hair dryer). Patients should be strongly encouraged to stop smoking and to avoid

TABLE 171-3
Management of Raynaud Phenomenon

Infrequent or mild attacks	Preventive measures
	Cessation of smoking
Frequent or severe attacks	Calcium channel blockers (nifedipine, diltiazem)
	Anti-adrenergic drugs (prazosin, reserpine)
	Topical nitroglycerin
Acute, severe ischemia	Intravenous prostaglandin E_1 or prostacyclin
	Digital sympathectomy
	Microvascular surgery
Digital ulcers	Antiseptic soaks, antibiotic ointments, occlusive dressing
	Calcium channel blockers (maximal doses)
	Intravenous prostaglandin E_1 or prostacyclin
Gangrenous, infected ulcers	Analgesics
	Antibiotics
	Surgical débridement
	Amputation

secondhand smoke, because nicotine induces cutaneous vasoconstriction. Stress modification and social support are valuable aspects of treatment to minimize vasoconstriction induced by hyperactivity of the sympathetic nervous system. Counseling, training in relaxation, or medications may be helpful. Some patients benefit from conditioning programs such as biofeedback training.

Digital ulcers from Raynaud phenomenon can be extremely painful and typically take weeks or months to heal completely. Pain control is an important part of therapy, because pain can lead to additional vasospasm and more ischemia. On occasion, narcotic pain medications may be necessary to control symptoms. The finger should be soaked in a tepid antiseptic solution (e.g., half-strength hydrogen peroxide) twice daily to soften or loosen the crust or eschar. After drying, an antibiotic ointment is applied to the ulcer, and the digit is covered with an occlusive dressing. Maximum drug therapy with a calcium channel blocker should be used throughout treatment. Infection is a common complication of digital ulcers and is typically manifest by increasing pain, erythema, swelling, or purulent drainage. Cultures usually demonstrate *Staphylococcus* sp., and treatment with dicloxacillin or cephalosporins is usually effective.

Drug Therapy

Various drugs have been used to treat Raynaud phenomenon, including vasodilators, platelet inhibitors, serotonin antagonists, and fibrinolytics. Drug therapy is usually reserved for patients with prolonged or frequent attacks that fail to respond to conservative measures. In general, improvements with drug therapy are more pronounced in patients with primary Raynaud phenomenon, presumably as a consequence of fixed, structural damage in patients with secondary forms.

Sympatholytic drugs, including reserpine, methyldopa, phenoxybenzamine, and tolazoline, have been used in management, although they have not been well studied. In a pilot study, the selective serotonin reuptake inhibitor fluoxetine reduced the frequency and severity of Raynaud attacks.[25] Additional drug therapies reported to be beneficial in the treatment of Raynaud phenomenon include low molecular weight heparin,[26] prazosin,[27] the angiotensin II receptor antagonist losartan,[28] and stanozolol.[29] The calcium channel blockers are by far the most widely used and effective drugs for treating Raynaud phenomenon.[23,24] Vasodilating properties vary among different agents. Nifedipine (10 to 20 mg tid or qid) reduces the severity and frequency of attacks; the long-acting preparation of nifedipine is better tolerated but may be less effective. Diltiazem (60 mg tid or qid) may be substituted if nifedipine is ineffective or not well tolerated. Side effects of calcium channel blockers include fluid retention, light-headedness, and heartburn; these may limit therapy.

Topical nitroglycerin paste (2 percent) and a sustained-release transdermal glyceryl patch are helpful in selected patients.[30] Intravenous prostaglandin E_1 and prostacyclin (PGI_2) and iloprost (a PGI_2 analog) have been shown to have beneficial effects in patients with severe Raynaud phenomenon; however, the vasodilatory effects are not sustained and long-term therapy is required.[31–34] Oral prostaglandins are currently available only as investigational agents.

Sympathectomy

Sympathectomy may be a consideration for the management of patients with refractory, disabling attacks or with an acutely ischemic digit that is unresponsive to other measures. A positive vasodilator response to a stellate ganglion block or epidural infusion should be documented before a permanent procedure is done. Lumbar sympathectomy has an important role in the management of severe Raynaud phenomenon of the feet, and selective digital sympathectomy may be used to relieve pain and heal digital ulcers in patients with ischemic digits.[35] The long-term effects of sympathectomy are poor, with up to two-thirds of patients reporting no benefit at the end of 1 year. Newer procedures for thoracic sympathectomy, including percutaneous radio frequency[36] and thoracoscopic procedures,[37] have been advocated as technically easier to perform with fewer complications and more promising long-term results.

Severe Vasospasm

Severe vasospasm with prolonged ischemia (dead-white finger) poses a threat of gangrene and amputation; it is considered a medical emergency. The patient should be hospitalized and the affected extremity put to rest. Nifedipine (10 to 20 mg tid) should be started immediately, as well as prostaglandin E_1 (6 to 10 ng/kg/minute) or PGI_2 (0.5 to 2 ng/kg), given by continuous intravenous infusion for several hours over 3 consecutive days. Intra-arterial phentolamine or tolazoline may reverse acute vasospasm, but monitoring of vital signs is essential, and these drugs need to be used with great caution. A digital (or stellate ganglion) block with lidocaine hydrochloride or bupivacaine hydrochloride (without epinephrine) relieves pain and produces a chemical sympathectomy that may reverse vasoconstriction. Sympathectomy (thoracic, lumbar, or digital) should be considered in patients who have a positive response. Arterial reconstruction should be reserved for patients with angiographically documented occlusive vascular disease.[38]

KEY REFERENCES

The full reference list for all chapters is available at www.digm7.com.

2. Gelber AC et al: Symptoms of Raynaud's phenomenon in an inner-city African-American community: Preva-



lence and self-reported cardiovascular comorbidity. *J Clin Epidemiol* **52**:441, 1999
16. Allen EV, Brown GE: Raynaud's disease: A critical review of minimal prerequisites for diagnosis. *Am J Med Sci* **183**:187, 1932
17. LeRoy EC, Medsger TA Jr: Raynaud's phenomenon: A proposal for classification. *Clin Exp Rheumatol* **10**:485, 1992
18. Spencer-Green G. Outcome in primary Raynaud phenomenon: A meta-analysis of the frequency, rates, and predictors of transition to secondary diseases. *Arch Intern Med* **158**:595, 1998
19. Hirschi M et al: Transition from primary Raynaud's phenomenon to secondary Raynaud's phenomenon identified by diagnosis of an associated disease. *Arthritis Rheum* **54**:1974, 2006
24. Thompson AE, Pope JE: Calcium channel blockers for primary Raynaud's phenomenon: A meta-analysis. *Rheumatology* **44**:145, 2005
38. Tomaino MM et al: Surgery for ischemic pain and Raynaud's phenomenon in scleroderma: A description of treatment protocol and evaluation of results. *Microsurgery* **21**:75, 2001



CHAPTER 172

Malignant Atrophic Papulosis (Degos Disease)

Dan Lipsker
Jean-Hilaire Saurat

In the early 1940s, Köhlmeier first described malignant atrophic papulosis, whereas Degos, Delort, and Tricot recognized it as a specific entity a year later.[1–3] We now know that the clinically distinctive lesion of the so-called *Degos disease* is a marker of a cutaneous thrombo-obliterative vasculopathy rather than of a specific disease per se. Indeed, such lesions can be found in at least two distinctive clinical settings: as an apparent idiopathic disease, either classic Degos disease or its benign variant, or as a surrogate clinical finding in some connective tissue diseases such as the anti-phospholipid syndrome, lupus erythematosus, dermatomyositis, and systemic sclerosis.

EPIDEMIOLOGY

Classic Degos disease is rare, with less than 200 reported cases. It almost always occurs in Caucasians, but cases have been observed in African American patients and in Japan. The disease most commonly presents between the third and fourth decades, but can occur at any age. Men are more often affected than women (ratio, 3:1). The majority of cases are sporadic, but familial cases have been described, and most of these cases are consistent with an autosomal dominant pattern of inheritance.[4]

ETIOLOGY AND PATHOGENESIS

The etiology of Degos disease is unknown. The histopathologic findings in patients with malignant atrophic papulosis suggest a primary vaso-occlusive process. Thus, a vascular coagulopathy and/or endothelial cell damage should be considered as the major pathogenic mechanism. A combination of prothrombotic factors possibly play a role in triggering the full-blown disease. Extensive studies of prothrombotic factors were performed in some patients with Degos disease, and no single abnormality was repeatedly identified. All patients should be screened for the presence of anti-phospholipid antibodies/lupus anticoagulant and cryoglobulins, although Assier et al. did not find the former in their series of 15 patients.[5] Inhibition of fibrinolysis and platelet abnormalities, including increased platelet adhesiveness and spontaneous aggregation, were reported in some patients.[5–8]

The lesions of Degos disease should be viewed as a cutaneous marker indicative of intraluminal thrombosis. Several disease processes may converge to produce those clinical and histologic findings.

CLINICAL FINDINGS (Fig. 172-1)

History

Patients seek medical advice for the appearance of small cutaneous lesions that usually are neither pruritic nor painful. In some patients, history and/or review of systems will reveal signs indicative of extra-cutaneous involvement: abdominal pain, diarrhea, melena, nausea, blurred vision, hemiparesis, paresthesia or any other sign indicative of an ischemic event. History can also give a clue to previous thromboembolic or obstetrical events suggestive of the anti-phospholipid antibody syndrome.

Cutaneous Lesions

Cutaneous lesions start as crops of 2 to 10 mm, largely asymptomatic or mildly pruritic, fleshy or rose-colored macules that soon become round, smooth, often dome-shaped firm papules (Fig. 172-2). Some lesions display central umbilication and/or necrosis (Fig. 172-3). These lesions evolve over days or weeks to porcelain-white, atrophic papules with a rim of rosy erythema and/or telangiectases (Fig. 172-4). A fully developed lesion therefore closely resembles lesions of atrophie blanche. In time, the reddish border disappears, and only a varicelliform white scar remains. Usually, the lesions are separated from each other, but they may coalesce, leading to polycyclic atrophic areas or to skin ulcerations.

The lesions are localized on the trunk and limbs. Palms, soles, face, scalp, and genitalia are usually spared, although there are exceptions. A linear distribution

MALIGNANT ATROPHIC PAPULOSIS AT A GLANCE



- A rare, primary vaso-occlusive disorder, affecting mainly the skin, the gastrointestinal tract, and the central nervous system.
- Diagnosis relies on clinico-pathologic evaluation.
- Characterized by numerous typical porcelain-white, atrophic papules, with a rim of rosy erythema and/or telangiectases.
- Pathology shows a wedge-shaped area of dermal necrosis with edema and mucin deposition.
- Benign forms without extra-cutaneous involvement are possible.

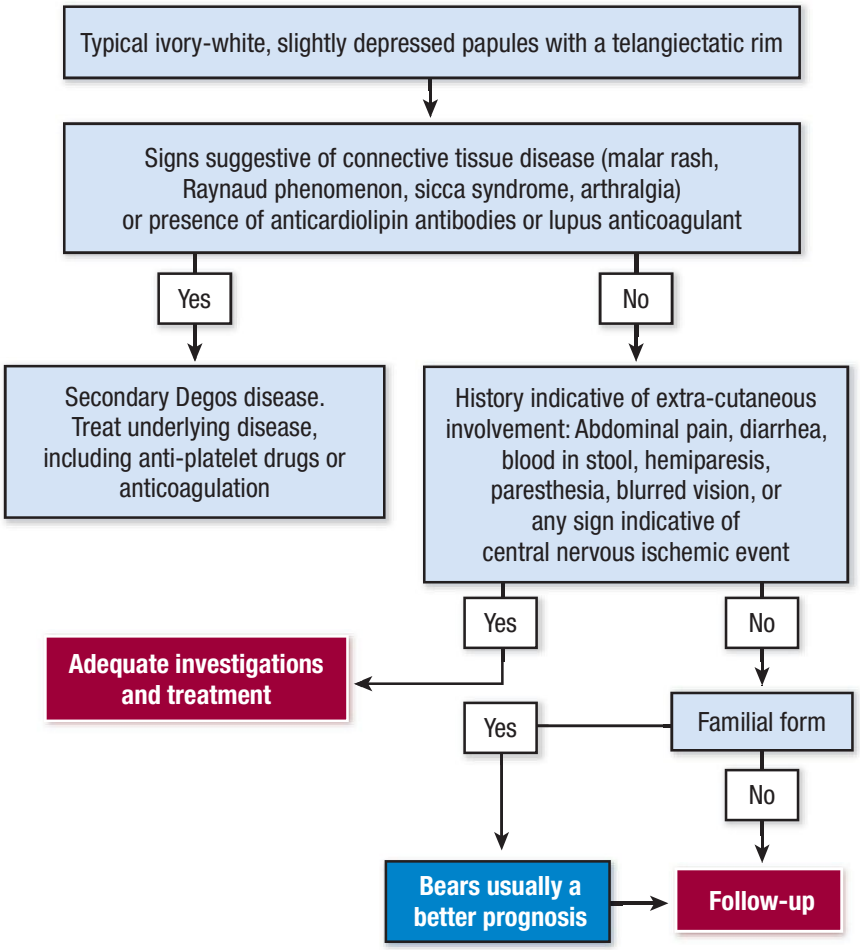

▲ **FIGURE 172-1** Approach to the patient with malignant atrophic papulosis.

was reported.[9] Eye involvement is possible, and the most common manifestation is an avascular patch on conjunctivae, but sclerae, episclera, retina, choroids, and optic nerves may be affected (see eFig. 172-4.1 in on-line edition).

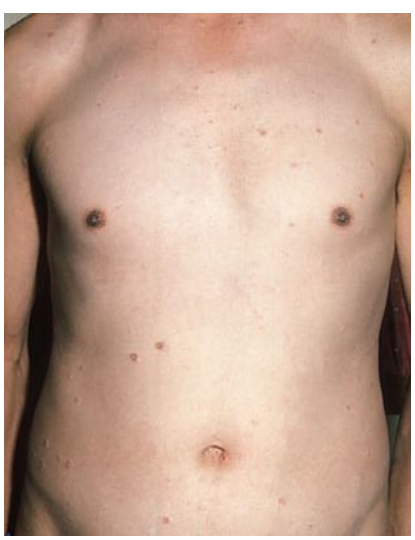

▲ **FIGURE 172-2** Numerous typical papules of Degos disease in a young man.

CLASSIC DEGOS DISEASE In classic Degos disease, the number of cutaneous lesions varies from a few to more than one hundred. Cutaneous findings usually precede the systemic manifestations that may involve the gastrointestinal tract, with bowel perforation and peritonitis, and/or the central nervous system, with hemorrhagic or ischemic stroke. Rarely, cutaneous lesions occur simultaneously or after gastrointestinal or central nervous system involvement. Postmortem studies have revealed small vessel thrombotic involvement of many organs, including kidney, bladder, prostate, liver, pleura, pericardium, lung, and eyes.[10] Some patients with classic Degos disease have anti-phospholipid antibodies, and this raises the possibility of a relationship with a primary anti-phospholipid syndrome.

BENIGN DEGOS DISEASE A benign form of Degos is now widely recognized. In this form, only skin involvement is found, and most of the familial cases are benign.[4] Development during pregnancy has been reported in a patient



▲ **FIGURE 172-3** Papule with central ulceration in patient with Degos disease.

with anti-phospholipid antibodies,[11] as well as a case occurring in a patient with acquired immunodeficiency syndrome.[12] A patient developing Degos disease after interferon injections, a drug known to induce atrophie blanche–like lesions[13] and microangiopathy,[14] is known to the authors (L. Thomas, personal communication). There is no clear-cut distinction between the classic and the benign form of Degos disease, and there is no way by which one can predict which patients will or will not develop visceral involvement.

DEGOS DISEASE–LIKE LESIONS OR SECONDARY DEGOS DISEASE Degos disease–like lesions can occur in patients with known lupus erythematosus, especially those with anti-phospholipid antibodies, dermatomyositis, and systemic sclerosis.[15,16]

LABORATORY TESTS

Histopathology

Clinically, fully developed lesions reveal a cell-poor, wedge-shaped area of slight to severe dermal necrosis with dermal edema and copious mucin deposition, extending from the papillar dermis to the deep part of the reticular dermis



▲ **FIGURE 172-4** Typical pathognomonic papules of Degos disease with a porcelain-white center and an erythematous raised border.

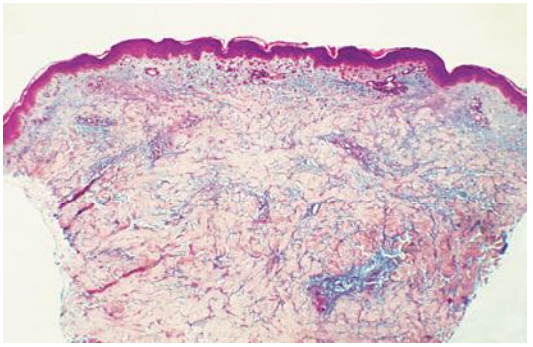

◀ **FIGURE 172-5** A wedge-shaped area of dermal necrosis, poor in cells, with copious mucin deposition, extending from the papillar dermis to the deep part of the reticular dermis (hematoxylin-eosin-safran-Astra blue, ×40).

(Fig. 172-5). At the base of the lesion, occluded vessels with occasional thrombosis, thickened vessel walls, proliferating endothelial cells, and sparse perivascular lymphocytic infiltrate can be found (Fig. 172-6). Yet, a full-blown leukocytoclastic neutrophilic vasculitis is never found in patients with malignant atrophic papulosis. This entity should therefore not be classified as vasculitis. Numerous secondary, epidermal changes can be found: hyperkeratosis, interface dermatitis, scattered necrotic keratinocytes, and atrophy. An associated sclerosing panniculitis was reported in one patient.[17] Results of direct immunofluorescence studies have been inconsistent. Electron microscopy occasionally revealed tubuloreticular aggregates within endothelial cells of uncertain significance.

Because some of those histopathologic findings, such as mucinous infiltration of the dermis, interface dermatitis, and perivascular lymphocytic dermal infiltrate, are shared by lupus erythematosus and dermatomyositis, Degos disease is considered by some authors as a possible variant of lupus erythematosus.[18]

Other Laboratory Tests and Special Tests

There is no diagnostic or prognostic marker of the disease. A search for antinuclear antibodies, lupus anticoagulant, and anticardiolipin antibodies should be performed in each patient. An extensive exploration of hemostasis will sometimes reveal abnormalities.

Clinical evaluation can confirm secondary Degos disease if signs suggestive of connective tissue disease or antiphospholipid syndrome are present. If clinical evaluation reveals signs of intestinal or cerebral involvement (pain, diarrhea, hemiparesis, blurred vision, paresthesia), imaging studies including cerebral magnetic resonance imaging and/or endoscopic evaluation/laparoscopy are mandatory.

DIAGNOSIS

The diagnosis is usually established clinically, because of the distinguished lesion. A confirmatory biopsy should always be performed.

DIFFERENTIAL DIAGNOSIS

(Box 172-1)

COMPLICATIONS

Death related to an ischemic cerebral or gastrointestinal event is the major complication of Degos disease. Gastrointestinal hemorrhage, perforation, and peritonitis are the most frequent complications of the disease and are the major ominous events. Neurologic complications, including hemiparesis, aphasia, multiple cranial nerve involvement, monoplegia, sensory disturbances, and seizures, are less common. Rarely, progressive neurologic involvement can lead to death, especially in children. Exceptionally, death can result from respiratory failure or myocardial infarction.

Box 172-1

Differential Diagnosis

Most Likely

- Atrophie blanche

Consider (although unlikely, other diseases with white and/or necrotic papules)

- Cutaneous lichen sclerosus
- Pityriasis lichenoides
- Lymphomatoid papulosis
- Syphilids, tuberculids
- Cutaneous Kikuchi disease
- Clear cell papulosis
- Calcinosis cutis
- Fiboelastolytic papulosis of the neck
- White lentiginosis

Always Rule Out

- Connective tissue disease with Degos lesions

PROGNOSIS AND CLINICAL COURSE

Although absence of visceral involvement 2 years after diagnosis portends a better prognosis, systemic involvement can occur up to many years after initial cutaneous lesions and thus, it is impossible to predict the outcome. Lethality is above 50 percent if patients present with extra-cutaneous involvement, and most of these patients die within 2 to 3 years mainly because of severe intestinal involvement. Familial Degos disease bears a better prognosis.[4]

TREATMENT

Due to the rarity of Degos disease, there are no controlled clinical trials, but only anecdotal reports. Yet, in some aspects, Degos disease resembles livedoid vasculopathy, and, therefore, some treatments reported to be efficient in patients with the former entity are worth trying.

Secondary Degos disease occurring in patients with known connective tissue disease should involve, in our opinion, the introduction of anti-platelet agents in addition to the standard treatments otherwise required by those patients.

Patients with classic Degos disease should be screened for all known preventable cardiovascular risk factors. Patients should cease smoking, and their lipid levels should be screened and lowered, if necessary, using statins.

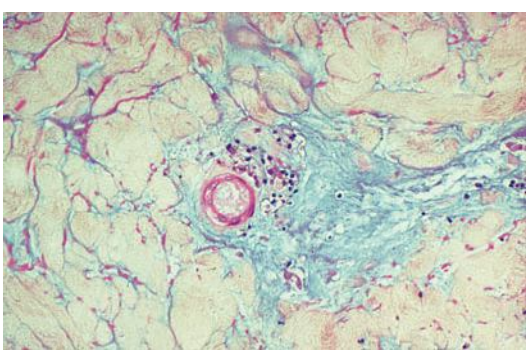

◀ **FIGURE 172-6** At the base of the dermal lesion, in the deep part of the reticular dermis, important mucin deposition and a slight lymphocytic infiltrate around a blood vessel (hematoxylin-eosin-safran-Astra blue, ×200).

Box 172-2

Treatment of Malignant Atrophic Papulosis (Degos Disease)

First line	Aspirin (100–325 mg) and dipyridamole (3 × 400 mg)
Second line	Heparin and other anticoagulation strategies
Adjunctive measures	Control of cardiovascular risk factors

First-line treatment of patients with Degos disease should include platelet aggregation inhibitors (aspirin, clopidogrel, dipyridamole) (Box 172-2). A substantial number of patients responded to aspirin and dipyridamole.[6,7,12] A number of anecdotal treatments, including antibiotics, chloroquine, immunosuppressive agents, phenylbutazone, and fibrinolytics, have been reported with variable success. Systemic steroids have been reported to exacerbate the disease and should not be prescribed.[19] Heparin and other anticoagulation strategies such as anti-vitamin K (warfarin, fluindione) have variable success rates. Yet, by analogy to livedoid vasculopathy, low-molecular-weight heparin as well as the newer anticoagulants might warrant a trial in the acutely ill patient not responding to anti-platelet agents.[20]

KEY REFERENCES

The full reference list for all chapters is available at www.digm7.com.

2. Degos R, Delort J, Tricot R: Dermatite papulosquameuse atrophiante. *Bull Soc Fr Dermatol Syphiligr* **49**:148, 1942
5. Assier H, Chosidow O, Piette JC et al: Absence of antiphospholipid antibodies and anti-endothelial cell antibodies in malignant atrophic papulosis: A study of 15 cases. *J Am Acad Dermatol* **33**:831, 1995
16. High WA et al: Is Degos' disease a clinical and histological end point rather than a specific disease? *J Am Acad Dermatol* **50**:895, 2004
18. Ball E, Newberger A, Ackerman AB: Degos' disease is a distinctive pattern, chiefly of lupus erythematosus, and not a specific disease. *Dermatopathol Pract Concept* **7**:370, 2001



CHAPTER 173

Vascular Malformations

Laurence M. Boon
Miikka Vikkula

EPIDEMIOLOGY

Vascular malformations are believed to be due to errors of development of vessels that occur during the fourth and tenth weeks of intrauterine life. Most vascular malformations are sporadic, although several families with inherited forms have been identified. They are very heterogeneous and affect about 0.3 percent of the population. Vascular malformations are mostly congenital, even if they may be diagnosed only later in life.

ETIOLOGY AND PATHOGENESIS

Although several genes have been identified as the cause of inherited forms of vascular malformations, the etiology of the most common sporadic lesions is unknown.[1,2] Histologically, vascular malformations consist of enlarged, tortuous vessels with quiescent endothelium. In contrast to hemangioma, there is no parenchymal mass nor cellular proliferation.

CLASSIFICATION

For many years, vascular anomalies were grouped under the term *angioma*, hampering precise classification and leading to incorrect diagnosis and improper management. For example, the term *hemangioma* has been used both for vascular malformations, often of the venous type (cavernous hemangioma) as well as for vascular tumors (strawberry hemangioma). This nomenclature changed in 1982 with the development of a biologic classification by Mulliken and Glowacki. It divided vascular anomalies into two major categories: vascular tumors (with cellular proliferation; hemangioma being the most common) (see Chap. 126) and vascular malformations (structural anomalies of blood vessels) that are subsequently subdivided, depending on the affected vessel type, into arterial, capillary, lymphatic, or venous malformations (VMs).[3,4] In 1996, this classification was adopted and further developed by the International Society for the Study of Vascular Anomalies (Table 173-1).[5] Vascular malformations mostly affect only one vessel type, yet combined malformations also exist. They are named according to the affected vessel types, (e.g., capillary-venous or veno-lymphatic malformation). In addition to isolated forms, vascular malformations occur in syndromes such as Klippel-Trénaunay (capillary-lymphatico-venous malformation with limb hypertrophy), Maffucci syndrome (multiple enchondromas associated with multiple venous anomalies and high incidence of malignancy)[6] or Parkes Weber syndrome (high-flow vascular malformation of the extremity with soft tissue hypertrophy).[7]

VASCULAR MALFORMATIONS AT A GLANCE



- Worldwide prevalence: Roughly 0.3 percent
- Congenital, diversified but localized and well-demarcated lesions of malformed vessels of various types: Capillary, venous, lymphatic, arteriovenous
- Histologically consist of enlarged, tortuous vessels of various types
- Can be isolated, combined, or part of a syndrome
- Management: Multidisciplinary approach

CLINICAL FINDINGS

Vascular malformations grow proportionately with the patient. Usually they do not regress. Most frequently, they are well demarcated and localized (Fig. 173-1). In rare instances, they can be the stigmata of deep lesions. Vascular malformations are rheologically divided into slow-flow (capillary, lymphatic, venous, and combined) and fast-flow (arterial, arteriovenous, and combined). Doppler ultrasound is the best non-invasive radiologic examination that provides

TABLE 173-1
Classification of Vascular Anomalies

VASCULAR TUMORS (SEE CHAP. 126)	VASCULAR MALFORMATIONS

• Hemangioma
  • Hemangioma of infancy
  • Congenital
  • Rapidly involuting congenital hemangioma
  • Non-involuting congenital hemangioma
• Hemangioendotheliomas
  • Kaposiform hemangioendothelioma
  • Tufted angioma
• Angiosarcoma (see Chap. 128)
	• Capillary
	  • Capillary malformation (port-wine stain)
	  • Telangiectasia (hereditary benign telangiectasia; essential telangiectasia)
	  • Hereditary hemorrhagic telangiectasia
	  • Capillary malformation-arteriovenous malformation
	  • Sturge-Weber syndrome
	• Venous
	  • Venous malformation
	  • Familial form: Cutaneo-mucosal venous malformation
	  • Glomuvenous malformation
	  • Blue rubber bleb nevus or Bean syndromes
	• Lymphatic
	  • Lymphatic malformation
	  • Primary lymphoedemas
	• Arterial
	  • Arteriovenous malformation
	  • Capillary malformation-arteriovenous malformation
	  • Arteriovenous fistula
	• Syndromic malformations
	  • Slow-flow
	  • Klippel-Trénaunay syndrome (capillary-lymphatico-venous malformation)
	  • Maffucci syndrome
	  • Fast-flow
	  • Parkes Weber syndrome

clues to the differentiation of the various types. Magnetic resonance imaging (MRI) details the extension and precise location of the lesion (Table 173-2).[8]

TREATMENT

Treatment of vascular malformations depends on the affected vessel type, the location of the lesion, and the symptoms. As many lesions are extensive, patients should be aware that a complete cure is often not possible. Treatment is difficult and can have severe complications. Extensive and/or complex lesions should always be managed by a multi-disciplinary team.

CAPILLARY MALFORMATIONS

Epidemiology

Capillary malformation (CM), commonly called *port-wine stain*, is a slow-flow vascular malformation with an incidence of 0.3 percent (Fig. 173-2).[9] Other blanchable pinkish patches, known as *stork bite*, *angel's kiss*, *salmon patch*, or *nevus flammeus neonatorum*, are often confused with CM. They are located on the nape of the neck (81 percent), the eyelids (45 percent), or the glabella (33 percent).[10] When located on the occiput, it is called *unna nevus* (see eFig. 173-2.1 in on-line edition.). These patches have a much higher incidence (42 percent) in white infants than in black infants (31 percent).[11] These lesions disappear spontaneously at around the ages of 1 to 4 years.

CMs are mainly sporadic, although there are well-documented pedigrees showing autosomal dominant inheritance.[12] When inherited, they are usually multiple and part of the CM-AVM phenotype, a newly recognized entity that associates atypical CM with arteriovenous malformation (AVM) (see Arteriovenous Malformations).[13–15] No sex preponderance is noted.

Etiology and Pathogenesis

Etiology of CM is currently unknown. Facial CM is thought to be due to clonal expansion of abnormal cells originating from the neural crest.[16] The identification of the affected gene (RASA1) in CM-AVM (see Arteriovenous Malformations) might help unravel the cause of the more common sporadic CM. Histologically, CM is characterized by dilatation of normal numbers of capillaries of the papillary and upper reticular dermis combined with areas of increased number of normal looking capillaries (see Fig. 173-2). Endothelial cells are flat. Factor VIII, fibronectin, and basement membrane protein are normal but S100 staining shows abnormal innervation.[17,18]

CAPILLARY MALFORMATIONS AT A GLANCE



- Worldwide occurrence: Roughly 0.1 percent to 0.2 percent of the population affected.
- Congenital no-flow malformations of the capillary bed.
- Pinkish-red to purple in color. Tend to darken and thicken with time.
- In most cases, a cosmetic problem.
- Can be part of syndromes, such as Sturge-Weber or Klippel-Trénaunay.
- Pathology: Capillaries that are increased in size and number with abnormal innervation.

Clinical Findings

CUTANEOUS LESIONS (Fig. 173-3; See Fig. 173-2) CM is a red homogenous congenital lesion that is often unilateral, sometimes bilateral, but usually not median. CMs involve skin and subcutis and, sometimes, mucosa. Their color varies from pinkish-red to deep purple with a geographic contour or a dermatomal distribution. Lesions are flat and painless, do not bleed spontaneously, and are never warm on palpation. They can extend throughout the entire body. Fifty percent of CMs are located on the face where they follow the distribution of the trigeminal nerve: ophthalmic branch V1 (front and upper eyelid), maxillary branch V2 (lower eyelid, cheek, and upper lip) (see Fig. 173-3B), or mandibular V3 (lower lip, chin, and mandible). In combination with another vascular malformation, CM can be part of a syndrome, such as Sturge-Weber, phakomatosis pigmento-vascularis, Klippel-



▲ **FIGURE 173-1** Vascular malformations of various vessel types: (**A**) capillary malformation of left lower extremity and genitalia; (**B**) subcutaneous lymphatic malformation invading the cubital nerve; (**C**) extensive venous malformation of right lower extremity causing pain, swelling, and coagulopathy; (**D**) arteriovenous malformation of sole; and (**E**) note nidus of the lesion on arteriography.



Trénaunay, Servelle-Martorell, etc. None of these syndromes is inherited. In rare instance, CM can be the cutaneous hallmark of occult spinal dysraphism, especially if located in the lumbosacral area.[19]

Sturge-Weber Syndrome. Sturge-Weber syndrome (SWS) is a neuro-oculocutaneous syndrome consisting of a CM located on the ophthalmic branch of the trigeminal nerve, a homolateral leptomeningeal capillary-venous malformation, often on the parieto-occipital area, and choroid "angioma" causing glaucoma and, sometimes, buphthalmos and retinal detachment (Fig. 173-4). Calcifications are frequently seen on the choroid plexus, and anomalies of the venous drainage of the encephalon can occur.[20] This malformation can cause epilepsy, leading to neural death, cerebral atrophy, and mental retardation.

Phakomatosis Pigmento-Vascularis.

Klippel-Trénaunay Syndrome. Klippel-Trénaunay syndrome (KTS) is an eponym used for the presence of a capillary-lymphatico-venous malformation located on the extremity with hypertrophy of the affected limb (Fig. 173-5). Venous varicosities on the lateral side of the leg, first described by Servelle, are very common and is specific for this syndrome in 80 percent of cases.[23] It is thought to be due to the persistence of embryologic veins. Valvular incompetence of deep venous system is common. Lower extremities are most commonly affected (95 percent), although upper limb, thorax, abdomen, and genitalia can also be involved. Lymphatic dermal vesicles cause frequent oozing. Lymphedema can be seen and tends to progress with time. Infection is common after trauma or secondary to small ulceration. VM is often seen in the underlying muscles. Hypertrophy of the limb is another sign of this disorder. It is already present at birth and occasionally evolves after puberty. Evolution towards ulceration, infection, bleeding, and thrombosis is common. Protein-losing enteropathy can be seen with abdominal involvement. Pulmonary embolism can sometimes lead to death.

IMAGING STUDIES No imaging studies are mandatory except in some rare situations. If a so-called *CM* is painful, warm,

TABLE 173-2
Clinical Characteristics of Vascular Malformations

	Capillary Malformation	Venous Malformation	Lymphatic Malformation	Arteriovenous Malformation
Skin color	Pinkish-red to purple	Normal–bluish-purple GVM: red (neonates) to dark blue-purple (adult)	Normal–yellowish-purple	Normal–red
Aspect	Flat	Flat–raised	Raised–vesicular	Flat–raised
Temperature	Normal	Normal	Normal	Warm
Palpation	Normal	Compressible GVM: Nodular, painful	Firm, non-compressible	Thrill, bruit
Associations	Hypertrophy	Phleboliths, deformation	—	Ulceration, deformation
Radiology	No-flow	Slow-flow	Slow-flow, cyst	Fast-flow
Histology	Dilated capillaries D2–40 negative	Thin-walled venous channels Relative lack of vascular smooth muscle cells GVM: glomus cells D2–40 negative	Cystic lymphatic channels D2–40 positive	Arterialized veins D2–40 negative
Etiology	?	VMCM: TIE-2 GVM: Glomulin	Lymphatic malformation: ? Primary lymphoedema: SOX18, VEGFR-3, FOXC2	Arteriovenous malformation: ? CM-AVM: RASA1
Treatment	Pulsed-dye laser	Sclerotherapy, surgery	Surgery, sclerotherapy	Embolization followed by surgical resection of nidus

CM-AVM = capillary malformation-arteriovenous malformation; FOXC2 = forkhead box C2; GVM = glomuvenous malformations; SOX18 = SRY-Box 18; VEGFR-3 = vascular endothelial growth factor receptor 3; VMCM = cutaneo-mucosal venous malformations.



or spontaneously bleeds, Doppler ultrasound is indicated to exclude the diagnosis of a fast-flow malformation such as an AVM, a Parkes Weber syndrome, or a proliferating hemangioma. CM located in the frontopalpebral area, especially if the inner part of the upper eyelid is involved, can be part of SWS. Therefore, a brain MRI and an ophthalmic examination have to be performed during the first months of life and repeated once a year until puberty, even if normal at younger age.[24] MRI of the spinal cord is needed in presence of a lumbosacral CM. In patients with phakomatosis pigmento-vascularis, ophthalmologic, neurologic, and orthopedic follow-up is mandatory due to the common association of CM with systemic lesion. In patients with KTS, leg length is evaluated radiologically after the age of 2 years and, if abnormal, followed once a year until the end of puberty. Doppler ultrasound evaluation of the venous status is



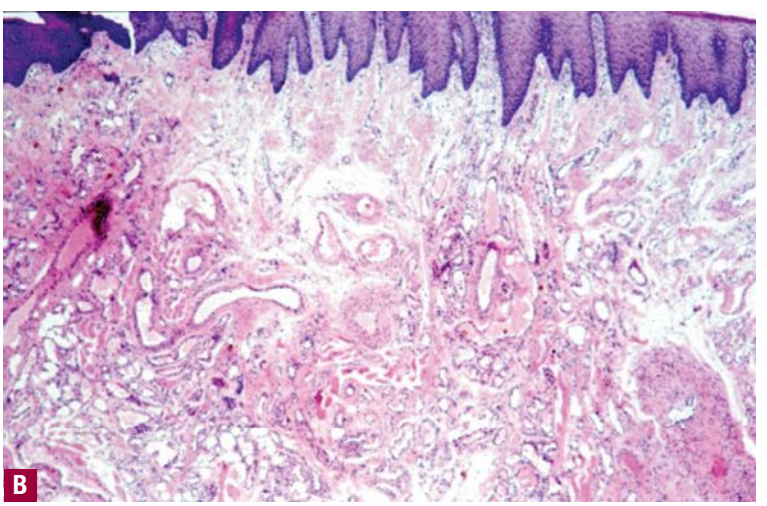

◀ **FIGURE 173-2** **A.** Extensive capillary malformation of upper extremity. **B.** Histologically, capillary malformation is characterized by dilated capillaries of normal number on the papillary and upper reticular dermis in combination with areas of increased number of normal-looking capillaries (hematoxylin and eosin staining).



▲ **FIGURE 173-3** Several aspects of capillary malformations: (**A**) light red lesions involving half of the body, (**B**) dark red lesions on the face with mucosal involvement and soft tissue hypertrophy, and (**C**) more localized on shoulder and arm.

mandatory to identify varicose veins in KTS. MRI is sometimes useful before management of the lesion.[23]

Differential Diagnosis (Box 173-1)

Complications

The major concern for a patient affected with CM is esthetic due to the visible discoloration. Hypertrophy of soft tissue can occur with time, especially when CM is located on V2 and V3 dermatomes or on the extremities. In rare instances, CM can be the stigmata of underlying anomalies such as lumbar dysraphism when located on the sacrum.

Prognosis and Clinical Course

CM never regresses. It is present at birth and slowly thickens and darkens with time. It often becomes raised and nodular.[31] Pyogenic granuloma can occur with time as well as soft tissue or bony hypertrophy (Fig. 173-6C).[32]

Treatment

Many treatment approaches have been used for CM, such as electrocoagulation, tattooing, dermabrasion, cryosurgery, and cosmetic makeup. Camouflage using Covermark is still effectively used (see eFig 173-6.1 in on-line edition). Laser treatment is the gold standard for most CM. Pulsed-dye laser with its specific wavelength (585 nm) and a short-pulse duration (400 ms) currently gives the best results in infants and children. There are few complications. Multiple sessions (6 to 12) are needed, and general anesthesia is usually necessary as the procedure is painful. Laser treatment is more efficient on the cervico-facial and trunk area than on the extremities. Early treatment during childhood does not reduce the number of laser sessions.[33] The use of a dynamic cooling system to avoid heating the epidermis allows increasing the laser fluences, resulting in optimal lightening of the lesion.[34] Recurrence can occur after cessation of therapy. Laser treatment has no impact on associated hypertrophy. Contour resection is needed mainly to treat complications such as pyogenic granuloma or lip hypertrophy.

Treatment of patients with KTS is conservative and mainly consists of

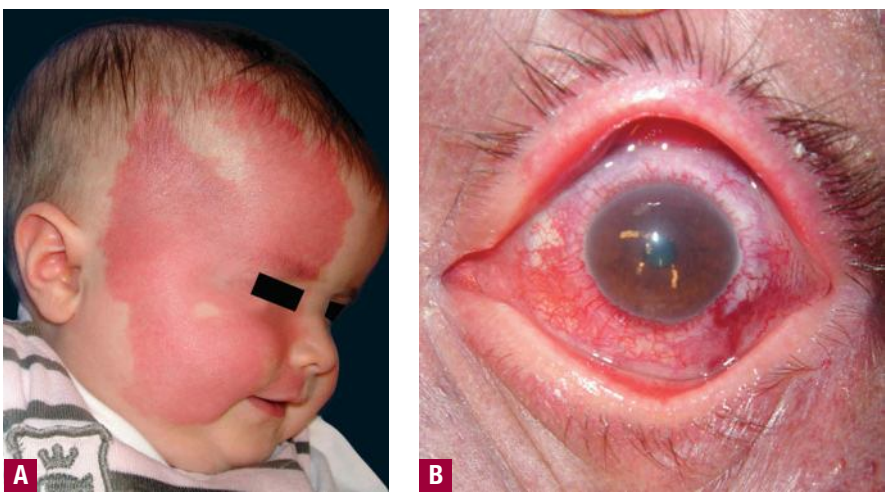

▲ **FIGURE 173-4** Extensive right facial capillary malformation (**A**) involving the ophthalmic and maxillary branches of the trigeminal nerve in a 6-month-old girl affected with Sturge-Weber syndrome. Choroid capillary-venous malformation (**B**) causing vision loss in a 50-year-old man with Sturge-Weber syndrome.



▲ **FIGURE 173-5** Capillary-lymphatico-venous malformation of the right lower extremity with soft tissue hypertrophy (Klippel-Trénaunay syndrome).



Box 173-1

Differential Diagnosis

DIFFERENTIAL DIAGNOSIS OF CAPILLARY MALFORMATION

Most Likely

- Faint pinkish median patch
  - Unna nevus
  - Nevus flammeus neonatorum
- Multiple, inherited
  - CM of CM-AVM
- Telangiectatic patch
  - CMTC[25]
  - HHT[26]
  - Essential telangiectasia
  - Unilateral nevoid telangiectasia
- Warm on palpation
  - Proliferating hemangioma
  - AVM
  - AVF
- Ulcerated or painful
  - AVM
  - AVF

Rule Out

- Small, multiple
  - Mastocytosis
  - CM of CM-AVM
  - Tufted angioma[27]

DIFFERENTIAL DIAGNOSIS OF CAPILLARY MALFORMATION (SITE-SPECIFIC)

Most Likely

- Occiput
  - Unna nevus
- Glabella, upper eyelid, nape of neck
  - Stork bite, angel's kiss, salmon patch

Consider

- Extremity
  - CMTC
  - Klippel-Trénaunay syndrome
  - Parkes Weber syndrome
- Faint on trunk
  - M-CM[28]

Rule Out

- Scalp
  - Adams-Oliver syndrome[29]
  - Multiple telangiectasia near canthus
  - Ataxia telangiectasia[30]

AVF = arteriovenous fistula; AVM = arteriovenous malformation; CM = capillary malformation; CM-AVM = capillary malformation-arteriovenous malformation; CMTC = cutis marmorata telangiectatica congenita; HHT = hereditary hemorrhagic telangiectasia; M-CM = macrocephaly cutis marmorata.

elastic stockings to alleviate pain due to venous congestion. Surgical resection of varicose veins cannot be done if the deep venous system is abnormal (aplasia, incompetence). In the presence of leg discrepancy, an early adapted shoe lift is needed to prevent scoliosis, and is followed by epiphysiodesis. If cutaneous bleeding occurs from capillary-lymphatic cutaneous vesicles, neodymium:yttrium-aluminum-garnet laser coagulation, sclerotherapy, or skin grafting can be helpful.

Prevention

In patients with SWS, ophthalmic follow-up, started immediately after birth and continued until the end of puberty, is essential, as visual impairment will depend on the promptness of treatment. Prophylactic anti-epileptic medication to prevent neural cell death has been advocated by some clinicians.[35,36]

VENOUS ANOMALIES

Epidemiology

Venous anomalies are the most common vascular malformations referred to specialized centers.[37] They are mainly sporadic, although 1 percent are inherited cutaneo-mucosal venous malformations

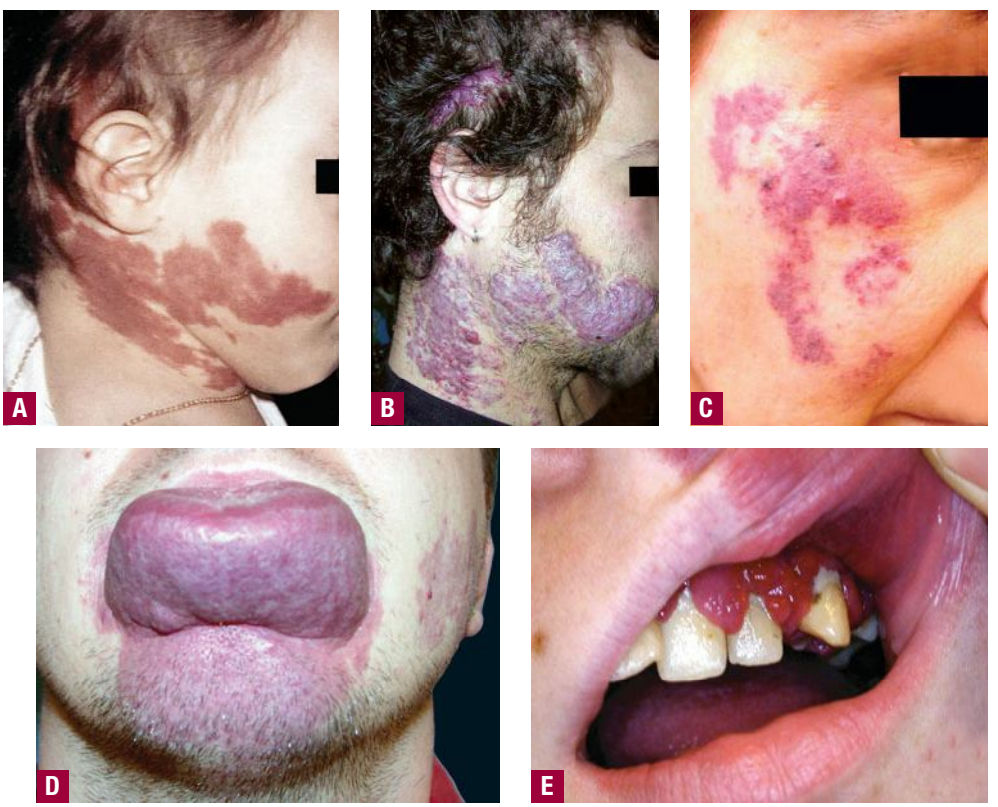

◀ **FIGURE 173-6** Clinical course of capillary malformation: Darkening and thickening with time: (**A**) at age of 6 months, and (**B**) at age of 33 years. **C.** Development of pyogenic granuloma, (**D**) soft tissue, and (**E**) mucosal hypertrophy.

VENOUS MALFORMATIONS AT A GLANCE





- Most common referrals to specialized centers for vascular anomalies. Incidence unknown, but lower than for capillary malformation.
- Congenital slow-flow malformation of the venous bed.
- Bluish in color, localized or extensive, solitary or multifocal.
- Compressible on palpation, presence of phleboliths.
- Histologically consists of ectatic venous-like channels with anomalies in mural cells.
- Mainly sporadic but can be inherited as an autosomal dominant trait.
- Inherited venous anomalies: Cutaneo-mucosal venous malformation (1 percent), glomuvenous malformation (> 5 percent).
- Syndromic venous malformation: Klippel-Trénaunay, blue rubber bleb nevus, Maffucci.

(VMCM), and 5 percent are inherited glomuvenous malformations (GVM). No sex preponderance is reported.[38] Both VMCM and GVM have an age-dependent variation in penetrance, which reaches its maximum by 20 years of age (87 percent for VMCM and 92.7 percent for GVM).[39] Large VMCMs and GVMs are present at birth. However, 17 percent of affected individuals develop new small lesions over time.[38]

VM is a congenital defect on the skin or mucosa, but can involve any structure (subcutis, muscles, bones, and nerves) and any organ, [central nervous system, gastrointestinal (GI) tract]. Fifty percent of VMs are located in the cervicofacial area and 37 percent on the extremities. VMs are mainly isolated, but can be part of complex vascular disorders of unknown etiology, such as KTS, and Maffucci and blue rubber bleb nevus (BRBN) syndromes.

Histology

VMs consist of ectatic vascular channels of venous type with flat endothelium and thin walls due to a variable number of mural smooth muscle cells that stain positive for smooth muscle cell-α-actin.[40] In contrast, GVM is characterized by distended venous channels surrounded by mural glomus cells that are aberrant smooth muscle cells. Glomus cells are round or polygonal instead of elongated like the normal vascular smooth muscle cells.[41] By immunohistochemistry, glomus cells stain positively for smooth muscle cell-α-actin and vimentin, whereas they are negative for desmin, von Willebrand factor and S100 neuronal marker.[42] By in situ hybridization, they are also negative for glomulin.[43]

Pathogenesis

The pathogenesis of sporadic VM is unknown. However, identification of the defective gene for inherited VMCM could help understand the cause of VM.[44]

Clinical Findings (Table 173-3; Fig. 173-7; and see eFig. 173-7.1 in on-line edition)



VMs are usually solitary, but can be multifocal, suggesting an inheritable disorder. Cutaneous VMs are congenital light-to-dark bluish lesions. Deep VM has a normal overlying skin color and is often diagnosed only at puberty or later in life with the onset of pain. Cutaneous VMs are detected early because they are usually clinically visible. Size varies from small spongy blebs to large lesions of several centimeters in diameter. VMs can easily be emptied by compression or by positioning in a nondependent position. Skin temperature is normal. There is no thrill or bruit. Depending on size and location, VMs can cause pain,

TABLE 173-3
Venous Abnormalities

	Venous Malformation	Cutaneo-Mucosal Venous Malformation	Glomuvenous Malformation	Blue Rubber Bleb Nevus	Maffucci Syndrome
Location	50% head and neck	Extremities, mucosa	70% extremities	Especially palms and soles	Extremities
Skin color	Normal–bluish-purple	Bluish	Bluish–red-purple	Bluish–dark blue	Normal–bluish
Aspect	Flat–raised	Raised dome-shaped	Raised, cobblestone, plaque-like, hyperkeratotic	Dome shaped, nipple-like	Exophytic
	Single large	Multiple, small	Multiple	Multiple, small, often +1 large lesion	Multiple, important deformation of hands and feet
Palpation	Phleboliths	Compressible	Non-compressible, painful	Firm, rubbery, spongy	Firm
Associated	Coagulopathy	—	—	Visceral venous malformation, coagulopathy	Multiple enchondromas, high risk of cancer
Radiologic	Phleboliths	Venous channels	No phlebolith	Venous channels	Venous channels, enchondromas
Tissue involved	Often deep location	Cutis and subcutis	Cutis and subcutis	Often deep component	Deep location
Histology	Thin-walled venous channels	Thin-walled venous channels	Glomus cells	Thin-walled venous channels	Spindle cells, hemangioendothelioma
Inheritance	Sporadic	Autosomal dominant	Autosomal dominant	Sporadic	Sporadic
Cause	?	Gain of function mutation in TIE-2	Loss of function mutation in glomulin	?	?





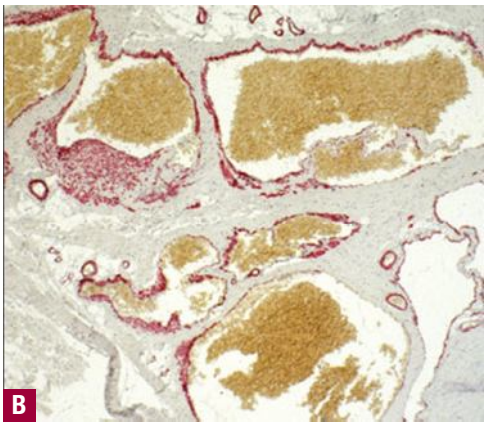





◀ **FIGURE 173-7** **A.** Venous anomalies: Extensive hemifacial venous malformation (VM) causing soft-tissue hypertrophy and lip deformation in a 6-month-old boy. **B.** Histologically, VM consists of ectatic venous-like channels with anomalies in mural cells (hematoxylin and eosin). **C.** Superficial glomuvenous malformation of the inner thigh. Note the presence of mural glomus cells on histology (hematoxylin and eosin). **D.** Mucosal VM involving the lower lip and the floor of the mouth.

particularly in the morning on awakening, anatomic distortion, and even threaten life because of bleeding, expansion, or obstruction of vital structures. Palpation is not painful unless thrombosis occurs.[38] Local thrombosis is responsible for acute pain that lasts for 10 days and causes phleboliths, which can be identified by palpation or by radiography. VM never cause pulmonary embolism. Facial VM is usually unilateral, causing asymmetry and progressive deformation and possibly dental malalignment (see Fig. 173-7 and eFig. 173-7.1 in on-line edition). Migraine is a common feature if VM is located in the temporal muscle. Oropharyngeal VM can impair speech whereas pharyngeal or laryngeal location will compromise the airway and cause snoring and even sleep apnea. On extremities, VMs often involve muscles and joints (see eFig. 173-7.1). They cause muscle weakness, hypotrophy, and sometimes, hypertrophy, resulting in leg length discrepancy which is less severe than in KTS. Intra-articular bleeding, if the malformation is located in the knee joint, leads to early-onset arthrosis.[47] Genital VM often occurs with limb VM and can be responsible for dyspareunia**.** GI VM is often diagnosed in patients with chronic anemia.

FAMILIAL CUTANEO-MUCOSAL VENOUS MALFORMATIONS

GLOMUVENOUS MALFORMATION (Fig. 173-8) Five percent of patients with venous anomalies seen at multi-disciplinary vascular anomaly centers are GVMs [Online Mendelian Inheritance in Man (OMIM) #138000]. GVM, previously known as *glomangioma* or *(multiple) glomus tumor*, is a vascular malformation of venous type. It should not be confused with solitary glomus tumor, a painful 3- to 6-mm papule commonly located in the nail bed (see Fig. 87-17). Clinically, these lesions resemble VM but can often be distinguished by color, appearance, consistency, and painfulness to palpation.[38] GVM varies from pink to purplish-dark blue in color. They are usually raised, nodular, hyperkeratotic, and multifocal (see Fig. 173-8). They are present at birth and slowly expand during childhood. Plaque-like GVM can be present at birth as a telangiectatic, red, flat lesion, which is only slightly bluish at the periphery. Thus, they mimic capillary-venous malformations. Within months, the lesion will become more raised and purple, like typical GVM.[48] GVMs are mainly located on the extremities (see Fig. 173-8), involve skin and subcutis, but rarely mucosa. In contrast to VM, GVM cannot be completely emptied by compression. They do not lead to intestinal hemorrhage, which distinguishes them from patients with BRBN syndrome (OMIM #112200).[49]

BLUE RUBBER BLEB NEVUS SYNDROME (BEAN SYNDROME) When a patient has both cutaneous and visceral VMs, the diagnosis of BRBN syndrome is most likely. This syndrome is usually sporadic, although some families with autosomal inheritance have been reported. They could be familial VMCM. The cutaneous VMs of BRBN are distinct, characterized by multiple, small (0.1 to 0.5 cm) spongy, and rubbery blebs often located on the palms and soles (Fig. 173-9).[50] Often a patient has one large VM that is present at birth and multiple small lesions disseminated all over the body. More lesions appear with time. The VMs are usually asymptomatic, but, occasionally, they can become tender and painful. GI lesions, commonly located in the small intestine, are sessile







◀ **FIGURE 173-8** Two glomuvenous malformations on the extremity: (**A**) small nodule, (**B**) extensive but superficial with cobblestone appearance, and (**C**) as seen on T2-weighted image.

or polypoid, causing chronic and severe iron-deficiency anemia. In rare instances, BRBN can involve other organs such as lungs, spleen, liver, kidneys, bladder, or even the brain.

FAMILIAL CEREBRAL "CAVERNOUS" MALFORMATION

MAFFUCCI SYNDROME Maffucci syndrome is a rare sporadic disorder that associates venous-type lesions with multiple enchondromas and a high incidence of malignancy (30 percent to 90 percent). There is no gender predilection. Enchondromas that are abnormal intraosseous and subperiosteal cartilaginous overgrowths in the hand, foot, and long bones, usually appear first, leading to an initial diagnosis of Ollier disease.[57] The venous-type lesions are multiple, located more commonly on the hand (89 percent) and foot (61 percent) but can be anywhere (Fig. 173-10). They are bluish exophytic nodules. These venous ectasias are often characterized as hemangioendotheliomas with spindle cells.[6] Skeletal deformation and spontaneous fracture as well as secondary dwarfism are common in patients with Maffucci syndrome.

CEREBRAL DEVELOPMENTAL VENOUS ANOMALY

Laboratory Tests

Localized intravascular coagulopathy (LIC) can be associated with VM. It is characterized by elevated D-dimers and split fibrin degradation products, normal-to-low fibrinogen, and normal platelet counts. The phenomenon can decompensate into disseminated intravascular coagulation after, for example, surgery, sclerotherapy, pregnancy, and puberty, resulting in severe bleeding due to consumption of clotting factors.[60,61] This coagulation disorder is different from the Kasabach-Merritt phenomenon seen with kaposiform hemangioendothelioma (see Chap. 126).[62,63]

Imaging Study

Doppler ultrasound is the easiest way to confirm the clinical diagnosis of a VM by demonstrating a slow-flow, ill-defined vascular lesion that is compressible on palpation, in contrast to lymphatic malformation or hemangioma. Presence of phleboliths, easily identified on plain radiography, is the hallmark of VM and, in contrast, never present in GVM (see eFig. 173-10.1 in on-line edition).[64] Computed tomography scan detects skeletal defects that can be seen in about 20 percent of craniofacial VM. MRI with spin-echo T1- and T2-weighted sequences is the gold standard to evaluate extension and exact location of VMs (see eFig. 173-10.1 in on-line edition).[65] Arteriography is normal, as arteries are not affected by the malformation. The VM lesion is seen in late venous phase. Phlebography, always done before sclerotherapy, has limited diagnostic use compared with Doppler and MRI.



▲ **FIGURE 173-9** Hyperkeratotic, small, rubbery blebs characteristic of blue rubber bleb nevus syndrome.





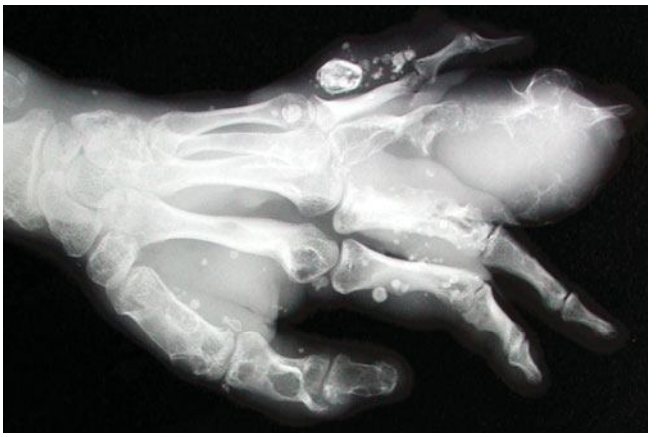

▲ **FIGURE 173-10** Exophytic venous-like lesions of hand associated with multiple enchondromas (as seen on plain radiography) specific of Maffucci syndrome.



Differential Diagnosis (Box 173-2)

Cutaneous VMs are usually diagnosed by clinical examination on the basis of their bluish color and the fact that they are compressible on palpation. However, not all bluish lesions are VMs.

Prognosis and Clinical Course

VMs are present at birth and exhibit progressive ectasia with age. A rapid expansion can be observed after trauma, partial resection, or hormonal modulation at puberty, or during pregnancy or antiovulatory therapy. Deep VMs often become painful at puberty. If not treated, cervicofacial VM can cause chronic respiratory obstructive syndrome.

Treatment

Indications for treatment include esthetic preference, pain, or functional impairment. VMs can be treated conservatively or medically, and more aggressively with either sclerotherapy or surgical resection. VM in an extremity is conservatively managed by a custom-made elastic compressive garment. Aspirin (80 mg/day) can alleviate chronic pain due to local and painful thrombosis. Low-molecular-weight heparin is much more efficient in case of LIC (high D-dimer). The commonly used dosage is 100 anti-Xa/kg/day for adults and 30 anti-Xa/kg/day in children. Reduction of pain and D-dimers are seen within 10 days. The treatment can be continued for several months and is mandatory before any surgery to avoid decompensation into disseminated intravascular coagulopathy during or after surgery. It will also improve sclerotherapy results.

Small cutaneous VMs can be injected, at any site, with a sclerosant, such as 1 percent sodium tetradecylsulfate. For large VMs, fluoroscopic guidance and general anesthesia are mandatory during percutaneous sclerotherapy. Sclerotherapy is potentially dangerous and requires the skills of an experienced interventional radiologist.[66] Several sessions are usually necessary (see eFig. 173-10.2 in on-line edition). For GVM, sclerotherapy is less effective.

Small, well-localized symptomatic VMs can be surgically excised (see eFig. 173-10.3 in on-line edition). The risk of recurrence after subtotal surgery can be reduced by preoperative sclerotherapy.[44] Laser (argon, pulsed-dye, neodymium:yttrium-aluminum-garnet) has been used with variable results.[67] GI VM of BRBN can be managed by endoscopic cauterization, sclerosis, or bowel resection if necessary.[68] GVMs are best treated by surgical resection.[49]

LYMPHATIC MALFORMATIONS

Epidemiology

Lymphatic malformation (LM) is a congenital disorder of unknown incidence. It consists of vesicles or large cysts filled with lymphatic fluid. Macrocystic LM can be diagnosed in utero as early as the first trimester of pregnancy.[69] However, most LMs are diagnosed during infancy,

Box 173-2

Differential Diagnosis

DIFFERENTIAL DIAGNOSIS OF VENOUS MALFORMATION

Most Likely

- Bluish subcutaneous mass, non-compressible
  - Infantile hemangioma
  - Lymphatic malformation
- With multiple enchondromas
  - Maffucci syndrome

Consider

- Hyperkeratotic
  - GVM, if on extremity
  - HCCVM of CCM

Rule Out

- Superficial, collateral normal veins
  - Deep venous insufficiency iatrogenic stenosis or congenital agenesis
  - Bluish nonvascular lesion such as bluish nevus

DIFFERENTIAL DIAGNOSIS OF VENOUS MALFORMATION (SITE-SPECIFIC)

Consider

- Base of the nose
  - Normal prominent veins
- Scalp or forehead
  - Sinus pericranii
- Subungual
  - Solitary glomus tumor
- Cheek
  - Bluish nevus
- Brain
  - Developmental venous anomaly
  - CCM

Rule Out

- Neck; deep mass
  - Thyroglossal duct
  - Bronchogenic cyst

CCM = cerebral cavernous malformation; GVM = glomuvenous malformation; HCCVM = hyperkeratotic cutaneous capillary-venous malformation.

LYMPHATIC MALFORMATIONS AT A GLANCE



- Worldwide occurrence is unknown.
- Congenital sporadic no-flow malformations of the lymphatic vessels.
- Primary lymphedema can be inherited as an autosomal trait.
- Lymphatic malformations consist of micro- or macrocysts filled with lymphatic fluid.
- Infection is the most common complication that can lead to septicemia.
- Histologically consist of dilated lymphatic channels with flat endothelium that stains for D2–40.

before the age of 2 years. Some can manifest only at puberty or during adulthood. Macrocystic LMs are often located on the neck, axilla, chest wall, or groin, whereas microcystic lesions are commonly seen in the face. LMs occur sporadically in contrast to primary lymphoedema that can be inherited as an autosomal dominant trait in up to 20 percent of cases. Rare families with recessive inheritance have also been identified.[70] Primary lymphoedema is divided into congenital (present at or soon after birth) (Milroy disease, OMIM #153100) and late onset (present at puberty) (Meige disease, OMIM #153200). It can be isolated or part of a syndrome, such as Turner and Noonan syndromes.[71]

Etiology and Pathogenesis

LMs are errors in morphogenesis of the lymphatic vessels. The etiology is unknown. In contrast, several genes have been identified that lead to or cause lymphoedema. Milroy disease is caused by a mutation that leads to loss of phosphorylation of vascular endothelial growth factor receptor 3 (VEGFR-3),[72,73] whereas lymphoedema distichiasis is caused by loss of function mutations in the FOXC2 transcription factor. Hypotrichosis-lymphoedema-telangiectasia, which has an autosomal dominant or recessive pattern of inheritance, is caused by mutations in *SOX18*.[70]

Histologically, LMs are characterized by dilated, flat, endothelium-lined channels of variable wall thickness. No blood cells are seen in these spaces, except after intracystic bleeding (Fig. 173-11) or in the presence of a combined lymphatico-venous malformation. Macrocystic LM shows single or multiple lymphatic cysts surrounded by thick fibrous membrane. These cysts do not communicate with each other. Endothelial cells express specific lymphatic markers, such as podoplanin, D2–40, VEGFR-3.[74] Lymphoedema is characterized by abnormalities in collecting lymphatic vessels in the affected limb (VEGFR-3 and FOXC2 patients) and extensive dermal fibrosis.

Clinical Findings

LMs are composed of microcysts (previously *lymphangioma circumscriptum*; Fig. 173-12) and/or macrocysts (larger than 1-cm diameter; previously known as "cystic hygroma") that grow proportionally with the child. They are filled with clear or serosanguineous fluid (see Fig. 173-12). Macrocystic LM manifests as a soft, multi-lobulated, well-defined mass, whereas microcystic LMs are ill-defined and often invade adjacent structures. Skin can be normal in color or, due to intracystic bleeding, have a bluish discoloration (see Fig. 173-12.1 in on-line edition). Dermal LMs can manifest as small millimeter-sized vesicles, clear (see Fig. 173-12 and eFig. 173-12.1 in on-line edition), or dark red (if intracystic bleeding) that can bleed and become purple and nodular (see Fig. 173-11A).

Facial asymmetry, especially of the mandible, is commonly associated with microcystic LM (see eFig. 173-12.1 in on-line edition). Intraorbital LM is responsible for ocular dystopia and exophthalmia as well as orbital enlargement. LM on the tongue impairs speech and produces oozing and halitosis. Airway obstruction is common when affecting the base of the tongue or the cervicofacial area.[75] Extension into the pleura can occur and cause chylothorax. Abdominal lesions are associated with chylous ascites. Extensive limb LM can cause elephantiasis.

ANGIOKERATOMA CIRCUMSCRIPTUM Angiokeratoma circumscriptum, or capillary-LM, is a combined, well-demarcated lesion often located on the extremity.





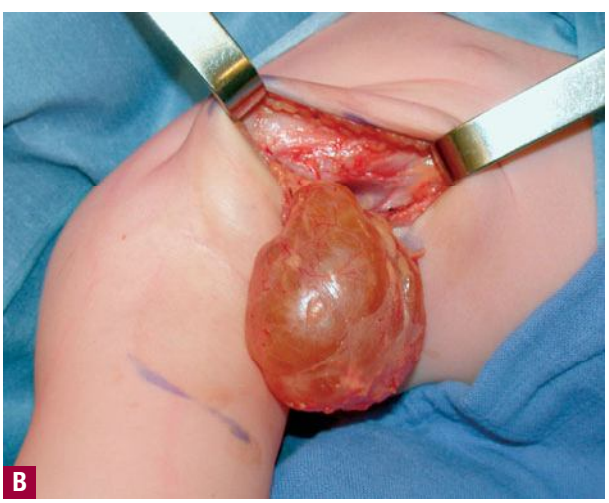

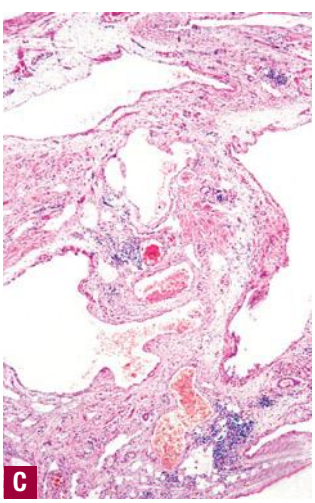

▲ **FIGURE 173-11** **A.** Microcystic, dermal lymphatic malformation (LM) consisting of clear and dark red vesicles. **B.** Intraoperative view of a macrocystic LM of the axilla showing a well-delineated cyst filled with clear lymph fluid. **C.** Histologically, LM consists of dilated lymphatic channels with flat endothelium (hematoxylin and eosin).



▲ **FIGURE 173-12** Lymphatic malformation. Frog-spawn–like confluent grouped "vesicles" filled with a serosanguineous fluid.



This lesion is pink to bluish-red in color, slightly raised, and usually hyperkeratotic (Fig. 173-13). Dilated capillaries and lymphatic vessels located on the superficial dermis and associated with hyperkeratosis can be seen histologically. Clinically, angiokeratoma circumscriptum (see Fig. 173-13), angiokeratoma of Mibelli (circumscribed, dark-red, and hyperkeratotic plaques on the distal extremities; see eFig. 173-13.1 in on-line edition), and angiokeratoma of Fordyce (very common hyperkeratotic, blue-black papules on the scrotum of elderly males; see eFig. 173-13.2 in on-line edition) are recognized (see Table 136-2). They have to be differentiated from the angiokeratomas of Fabry disease (see Chap. 136).

GORHAM-STOUT SYNDROME

LYMPHEDEMA Lymphedema is characterized by swelling of the affected body part, usually the lower extremity, and is caused by accumulation of lymphatic fluid into the extracellular space due to intrinsic lymphatic dysfunction (Fig. 173-14).

Congenital Lymphedema. Congenital lymphedema, or Milroy disease, is suspected in the presence of swelling of the dorsum of the feet with familial history of lymphedema. Lymphedema is present at birth, often bilateral, and affects the lower limbs below the knees.[77] Rare occurrence of pleural effusion and chylous ascites has been observed.[78] Other features can be associated with congenital lymphedema, such as hydrocele (37 percent of males), prominent veins (23 percent), upslanting toenails (14 percent), papillomatosis (10 percent), or urethral abnormalities in males (4 percent). Cellulitis is a common complication affecting 20 percent of cases.[77]

Meige Disease. Meige disease, or pubertal-onset lymphedema, represents 80 percent of primary lymphedema. It is usually isolated and more common in women. In two specific forms, the causative genetic alterations have been identified.

Lymphedema-Distichiasis Syndrome.

Hypotrichosis-Lymphedema-Telangiectasia Syndrome.

Turner Syndrome.

Lymphedema with Yellow Nails.

Imaging Studies

Doppler ultrasound shows anechoic or hypoechoic and homogeneous cysts that are not compressible. On MRI, macrocystic LMs are hypointense on T1- and hyperintense on T2-weighted sequences. In the presence of a large cyst, fluid level is seen, showing intracystic bleeding. Microcystic LM shows an ill-defined mass with abnormal enhancement.[65]

Laboratory Tests

For pure LM, no diagnostic test exists. In extensive, combined, lymphaticovenous malformation, LIC, as in VM, can be seen. Therefore, blood tests, including D-dimer levels, fibrinogen, and platelet counts, should be done for each patient.

Differential Diagnosis (Box 173-3)

Complications

LM can suddenly enlarge in response to fever, cough, or viral or bacterial infection or to intralesional bleeding (see eFig. 173-14.1 in on-line edition). Recurrent cellulitis is the major complication, as it can evolve into septicemia if not promptly treated. Local redness and warmth will appear, and the lesion will become painful. Visceral LM can cause protein-loosing enteropathy and hypoalbuminemia.

Prognosis and Clinical Course

LM usually grows with the child and often causes asymmetry with bony overgrowth. Increase in size can be seen during infection or intralesional bleeding. Episodic reports of spontaneous involution exist. As the regression is usually seen after local infection, it could be that this evolution is due to post-inflammatory sclerosis.

Treatment

Intralesional bacterial infection as well as early cellulitis should be managed with prolonged antibiotics first given in-



▲ **FIGURE 173-13** Capillary-lymphatic malformation (angiokeratoma circumscriptum) on the lower extremity, causing oozing. It is purple-red in color and slightly raised, with hyperkeratosis.



▲ **FIGURE 173-14** Various types of congenital primary lymphedema characterized by lymphedema of lower limb, below the knees (**A**), with papillomatosis (**B**), and with upslanting toenails (**C**), that can evolve into elephantiasis (**D**).

travenously. Pain medication and anti-inflammatory drugs may be required. Immune-modifying medications, such as interferon and corticosteroids, are not effective. Neodymium:yttrium-aluminum-garnet laser or carbon dioxide laser photocoagulation has been used to treat dermal LM vesicles that cause oozing (see eFig. 173-14.2 in on-line edition). Macrocystic LM is treated with fluid aspiration followed by percutaneous, intralesional injection of sclerosing agents performed by an interventional radiologist. Several sclerosing agents have been used, such as sodium tetradecyl sulfate, pure ethanol, OK432 (extract from a killed strain of group A *Streptococcus pyogenes*: Picibanil), doxycycline, or bleomycin. Side effects include fever, erythema, and edema.[83,84]

Surgical resection is another alternative for LM.[85] Results depend on the anatomical site and extension of the lesion (see eFig. 173-14.3 in on-line edition). Recurrence is frequent because it is difficult to differentiate LM from adjacent normal tissue. This leads to either incomplete resection or unnecessary sacrifice of normal structures. One should always try to treat completely one region at a time.[86]

Lymphedema is best treated with elastic stocking, massage, and pneumatic compression devices. Family and patient education regarding the etiology and treatment is necessary, as lymphedema can be inherited.

ARTERIOVENOUS MALFORMATIONS AT A GLANCE

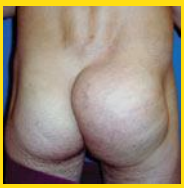
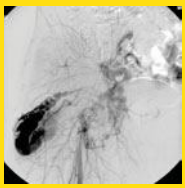

- Worldwide occurrence: Rare, but exact frequency unknown
- Congenital fast-flow malformations that can be hidden until puberty
- Histologically consist of direct communications between arteries and veins
- Usually sporadic, but can have a genetic predisposition as in capillary malformation-arteriovenous malformation or hereditary hemorrhagic telangiectasia
- Can be part of syndromes such as Parkes Weber or PTEN hamartoma tumor syndrome
- Most difficult vascular malformations to treat; need a multi-disciplinary approach

ARTERIOVENOUS MALFORMATIONS

Fast-flow cutaneous vascular malformations are mainly AVMs and rarely arteriovenous fistula (AVF). AVF is usually traumatic. AVM is characterized by the presence of a "nidus," the epicenter of the lesion that is composed of direct communications between multiple feeding arteries and draining veins without intervening normal capillary bed. Histologically, AVM consists of distorted arter-

Box 173-3

Differential Diagnosis

DIFFERENTIAL DIAGNOSIS OF LYMPHATIC MALFORMATION

Most Likely

- Rapid growth after birth
  - Fibro- or rhabdomyosarcoma[81]

Consider

- Subcutaneous mass
  - Infantile hemangioma
  - Venous malformation
  - Teratoma[82]
  - Fibrosarcoma

DIFFERENTIAL DIAGNOSIS OF LYMPHATIC MALFORMATION (SITE-SPECIFIC)

Rule Out

- Vulvar
  - Acquired lymphangiectasia due to radiotherapy
  - Acquired lymphangiectasia due to Crohn disease



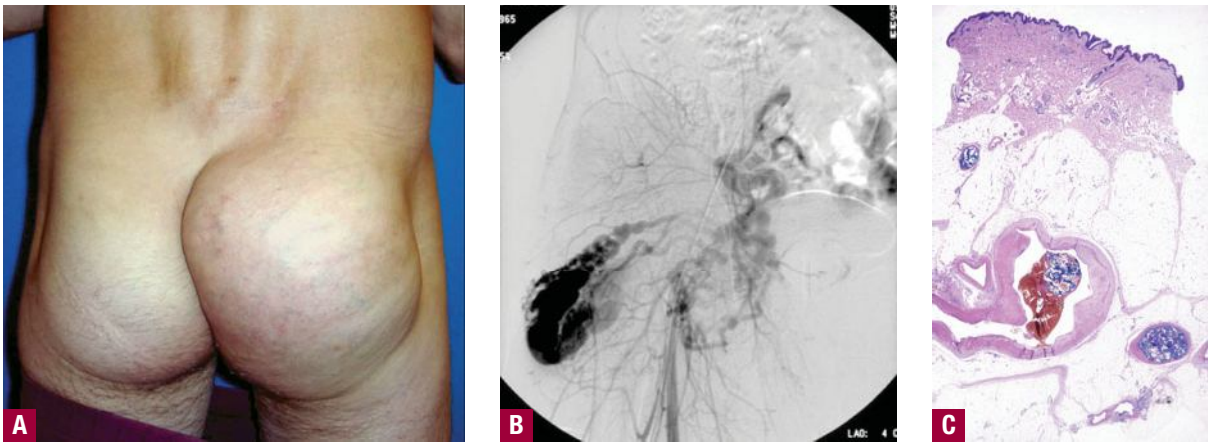

▲ **FIGURE 173-15** Extensive arteriovenous malformation deforming the right buttock (**A**). Arteriography showing the nidus of the malformation (**B**). Histology shows a direct connection between artery and vein, with thrombotic material secondary to the embolization procedure (**C**).



ies and veins with thickened muscle walls due to arteriovenous shunting and fibrosis (Fig. 173-15).

Epidemiology

The incidence of AVM is unknown. It is a rare, usually sporadic, fast-flow vascular malformation. It can affect any tissue and any organ. Seventy percent of AVMs are located on the head and neck area. AVMs are present at birth but often manifest later in life during puberty or after trauma. They never regress.

Etiology and Pathogenesis

The etiology of AVM is unknown. An underlying predisposing genetic defect exists for these fast-flow vascular malformations when part of CM-AVM (OMIM #608354), HHT (OMIM #187300), or PHTS (OMIM #153480 and #158350). The newly recognized CM-AVM entity associates multiple, small, atypical CMs with fast-flow lesions (AVM or AVF). CM-AVM is inherited as an autosomal dominant disorder with a penetrance of about 95 percent.[13–15] It is caused by loss-of-function mutations in the *RASA1* gene.[13] The high intrafamilial phenotypic variability could be explained by the necessity of a second hit, a somatic mutation, to occur. Prevalence of CM-AVM is unknown.

TABLE 173-4
Schobinger Classification of Arteriovenous Malformation

Stage 1	Local mass, blush or red stain Doppler ultrasound: Increased vascularization
Stage 2	+ Prominent draining veins, pulsation, thrill Doppler ultrasound: Arteriovenous shunting
Stage 3	+ Dystrophic changes
Stage 4	+ Congestive heart failure

Clinical Findings

During childhood, AVM is often mistaken for a CM or a hemangioma, as, at birth, AVM usually manifests as a faint, ill-defined macular red stain. However palpation reveals its fast-flow component as it is warm. About one-third of AVMs are present at birth, another one-third appear during childhood or at puberty, and the rest in adulthood. Puberty and trauma usually trigger the growth of an AVM. AVMs are staged using the Schobinger classification (Table 173-4). AVMs manifest as cutaneous, red-to-purple warm masses with a thrill, a bruit, or a pulsation of increased amplitude. They worsen with time, evolving from stage I to III or even IV, never regressing spontaneously (Fig. 173-16).

CAPILLARY MALFORMATION-ARTERIOVENOUS MALFORMATION CM-AVM manifests as multiple atypical CM associated with fast-flow lesions in 18 pecent to 20 percent of patients: AVM, AVF, or Parkes Weber syndrome. The expressivity is highly variable within families, from small, asymptomatic CMs to life-threatening AVM. In contrast to sporadic CM, CMs in CM-AVM are often multiple and randomly distributed. Their size is variable: from a few millimeters to several centimeters in diameter. They are round-to-oval, pink, red or brown, and sometimes with a narrow pale halo (Fig. 173-17). The lesions are well circum-



▲ **FIGURE 173-16** Stage 2 arteriovenous malformation (AVM) (**A**) evolving into stage 3 AVM (**B**).



◀ **FIGURE 173-17** Small atypical capillary malformations of capillary malformation-arteriovenous malformation (**A–D**). Note the pale halo (**D**).



scribed and blanch on pressure with a glass. Some of them are present at birth, whereas others appear later. They grow with the child and are asymptomatic. Fast-flow lesions (AVM or AVF) are either cutaneous, subcutaneous, with or without intramuscular and intraosseous involvement, or intracerebral.[13–15] About 10 percent to 15 percent of the CM-AVM individuals have Parkes Weber syndrome either on the lower (two-thirds) or the upper extremity (one-third). The AVMs can be asymptomatic but complications occur, depending on their location and size.

HEREDITARY HEMORRHAGIC TELANGIECTASIA Hereditary hemorrhagic telangiectasia (HHT) manifests as multiple cutaneous and mucosal telangiectasias that are associated with visceral, pulmonary, and cerebral fast-flow lesions. Epistaxis is a common clinical sign.[26]

PTEN HAMARTOMA TUMOR SYNDROME PTEN hamartoma tumor syndrome (PHTS) regroups patients with Bannayan-Riley-Ruvalcaba syndrome (BRRS) and Cowden syndrome, as 60 percent and 81 percent of them, respectively, have a mutation in the PTEN gene.[59] These patients typically have macrocephaly, penile freckling, multiple developmental venous anomalies in the brain, fast-flow vascular malformations (54 percent) and an increased risk of malignancy. The vascular malformations are often multifocal (57 percent) and musculoskeletal, and associated with ectopic fat deposition and disruption of the normal tissular architecture.[59]

PARKES WEBER SYNDROME Parkes Weber syndrome (OMIM #608355) was first described by F. Parkes Weber in 1918. This condition is characterized by a large, congenital, cutaneous, vascular stain on an extremity in association with soft tissue and skeletal hypertrophy of the affected limb, and with underlying multiple arteriovenous microfistulas.[7] The affected extremity is longer and larger than the contralateral one. The signs and symptoms worsen with age. When young, these patients can develop congestive heart failure.

BONNET-DECHAUME-BLANC SYNDROME

COBB SYNDROME

Imaging Studies

Ultrasonography and color Doppler show no mass, but an aggregation of high-velocity arterial and pulsatile venous flow with low resistance. Vessels are tortuous. On extremities, noninvasive follow-up is performed by comparing the arterial outflow of the affected limb with the unaffected one. Computed tomography-scan has been replaced by MRI, which better shows the extent of AVM and allows differentiation from hemangioma and VM. Flow voids, corresponding to fast-flow vessels, are pathognomonic of AVM. Arteriography is needed before any treatment to determine feeding arteries and the nidus (see Fig. 173-15).

Differential Diagnosis (Box 173-4)

Prognosis and Clinical Course

AVMs tend to worsen with time, causing local destruction and/or life-threatening bleeding. Puberty and trauma trigger growth. Bony hypertrophy is a common feature that causes common facial asymmetry. AVM of an extremity commonly causes peripheral ischemia due to blood flow steel phenomenon. Cardiac failure is rare (Schobinger stage IV), especially during childhood. Improper management due to misdiagnosis, or ligation of feeding arteries or partial resection of the nidus, can have dramatic consequences and expansion

Box 173-4

Differential Diagnosis

DIFFERENTIAL DIAGNOSIS OF ARTERIOVENOUS MALFORMATION

Most Likely

- At birth
  - Congenital hemangioma
  - Infantile fibrosarcoma
  - Other sarcoma
- Rapid growth after birth
  - Infantile hemangioma

Rule Out

- On top of a scar
  - Sarcoidosis

DIFFERENTIAL DIAGNOSIS OF ARTERIOVENOUS MALFORMATION (SITE-SPECIFIC)

Rule Out

- Ear, nose
  - Lupus erythematosus tumidus
  - Sarcoidosis
  - Dabska tumour
- Lip
  - Melkersson-Rosenthal syndrome



of the AVM (see Fig. 173-16). The CMs in CM-AVM are harmless, and usually of only cosmetic importance.

Treatment

This fast-flow vascular malformation is the most complex and difficult vascular anomaly to treat. Its management is multi-disciplinary. AVM should be followed by periodic evaluation. In a limb AVM or multiple AVFs, elastic stockings can stabilize the lesion and protect the skin. The goal of cure of an AVM is based on obliteration (by embolization) and complete removal of the nidus or the epicenter. Early intervention for "quiescent AVM" (stage 1) is debatable but should be considered only if complete resection is possible. In contrast to AVF, superselective arterial embolization alone is only palliative and is done only in unresectable complicated AVM. The embolized particles need to reach the epicenter of the lesion to avoid refilling of the nidus through new collaterals.[92] Direct puncture of the nidus is another possibility in patients with previous arterial ligation or embolization.[93] Surgical resection is usually done only after embolization to minimize perioperative bleeding.[94] AVM needs to be widely excised. Reconstruction often necessitates microsurgical free flap transfer.[95] At least 5-year follow-up by annual Doppler ultrasound and/or MRI is mandatory after any treatment. For patients with Parkes Weber syndrome, the treatment should be as conservative as possible (e.g., elastic stockings). Epiphysiodesis may be necessary to control leg length discrepancy. However, this procedure can sometimes aggravate the AVM.[7]

ACKNOWLEDGMENTS

Studies by the authors were partially supported by the Interuniversity Attraction Poles initiated by the Belgian Federal Science Policy, network 5/25 and 6/05; Concerted Research Actions (A.R.C.) - Convention No 02/07/276 of the Belgian French Community Ministry; the National Institute of Health, Program Project P01 AR048564-01A1; EU FW6 Integrated project LYMPHANGIOGENOMICS, LSHG-CT-2004-503573; and the F.N.R.S. (Fonds national de la recherche scientifique) (to M.V., a "Maître de recherches du F.N.R.S.").

The authors thank Ms. Liliana Niculescu for secretarial help.

KEY REFERENCES

The full reference list for all chapters is available at www.digm7.com.

1. Brouillard P, Vikkula M: Genetic causes of vascular malformations. *Hum Mol Genet* 2007, in press
7. Enjolras O, Chapot R, Merland JJ: Vascular anomalies and the growth of limbs: A review. *J Pediatr Orthop B* **13**:349, 2004
14. Boon LM, Mulliken JB, Vikkula M: RASA1: Variable phenotype with capillary and arteriovenous malformations. *Curr Opin Genet Dev* **15**:265, 2005
38. Boon LM et al: Glomuvenous malformation (glomangioma) and venous malformation: Distinct clinicopathologic and genetic entities. *Arch Dermatol* **140**:971, 2004
40. Wassef M, Enjolras O: [Superficial vascular malformations: Classification and histopathology]. *Ann Pathol* **19**:253, 1999
44. Hein KD et al: Venous malformations of skeletal muscle. *Plast Reconstr Surg* **110**:1625, 2002
47. Vikkula M et al: Vascular dysmorphogenesis caused by an activating mutation in the receptor tyrosine kinase TIE2. *Cell* **87**:1181, 1996
86. Greene AK et al: Periorbital lymphatic malformation: Clinical course and management in 42 patients. *Plast Reconstr Surg* **115**:22, 2005
92. Burrows PE, Fellows KE: Techniques for management of pediatric vascular anomalies, in *Current Techniques in Interventional Radiology*, edited by Cope C. Philadelphia, Current Medicine, 1995, p 11
94. Wu JK et al: Auricular arteriovenous malformation: Evaluation, management, and outcome. *Plast Reconstr Surg* **115**:985, 2005

CHAPTER 174

Cutaneous Changes in Peripheral Vascular Arterial Disease

Mandeep Dhadly
Steven M. Dean
Robert T. Eberhardt

OBSTRUCTIVE PERIPHERAL ARTERIAL DISEASE

Epidemiology

Although atherosclerotic obstructive peripheral arterial disease (PAD) has a prevalence of only 3 percent in patients age 40 to 59 years old, this rises to 15 percent in the age group older than 65 years. Nationwide, this translates into approximately 9 million cases in the United States in 2005, and this number is expected to increase along with the aging demographics of our population.[1,2] PAD is often unrecognized clinically and almost one-half of all patients are asymptomatic. Gender predisposition shows preponderance in males, although the incidence in females rises rapidly after menopause. Anatomically, superficial femoral artery disease predominates, with development of symptoms typically in the seventh decade. Interestingly, symptoms from aorto-iliac disease usually present a decade earlier.

Etiology and Pathogenesis

Atherosclerotic risk factors are similar to those identified for coronary artery disease. Diabetes mellitus and smoking are the most significant and are associated with a fourfold and doubling of relative risk, respectively. Patients with diabetes mellitus develop the disease at an earlier age than non-diabetics and have more severe and progressive disease. The anatomic distribution of obstruction differs from non-diabetics with less aorto-iliac involvement and more extensive disease of the runoff vessels below the knees; however, superficial femoral artery disease is similar in both populations. Approximately 50 percent of patients have hyperlipidemia. PAD is also more commonly encountered in patients with hypertension.

The pathologic findings in atherosclerosis occur in large- and medium-sized arteries, and are morphologically diverse, with focal accumulation of lipids and lipoproteins, mucopolysaccharides and collagen, smooth muscle cells and macrophages, and calcium deposits in variable quantities. Localized areas of intimal thickening secondary to smooth muscle cell proliferation and lipid-laden macrophages are seen in early stages with disruption of the internal elastic lamina. The media is often atrophic with thin strands of smooth muscle, lipid pools, collagen tissue, and calcium deposits. Enlarging plaques encroach on the lumen despite dilation of the artery, and the plaques may ulcerate. Hemorrhages occur in the arterial wall. Thrombi may form and occlude the narrowed arterial lumen.

The etiology of atherosclerosis is complex and multifactorial, but progressive buildup of plaque narrows the vessel lumen, and complete occlusion may develop acutely secondary to thrombosis. Because disease progression is usually over an extended time period, collateral blood vessels have time to develop and are usually robust. Tissue perfusion to the affected limb is often adequate at rest, but the blood pressure distal to the occlusions decreased secondary to high resistance and limited flow through collateral vessels. Dermatologic changes imply severe compromise of tissue perfusion, often secondary to tandem high-grade stenoses or occlusions present at multiple levels in the arterial tree.

Clinical Findings (Fig. 174-1)

HISTORY The classical symptom of intermittent claudication is usually described as pain, fatigue, or tiredness in the muscles distal to the diseased vascular segment on walking. The discomfort tends to be highly reproducible and precipitated by the same level of exertion. Resolution within several minutes of rest is an expected finding. Patients with inadequate collateral circulation may complain of cold extremities, hyperesthesia, rest pain, discolored toes, or skin breakdown. Rest pain typically affects the foot and may interfere with sleep or necessitate sleeping with the leg in a dependent position. Peripheral edema may then occur.

Acute limb ischemia secondary to vessel thrombosis or embolism presents more dramatically with severe pain, usually persistent at rest, pallor, pulselessness, paresthesias, and paralysis (the five Ps). Poikilothermia (a cold extremity) may be added to this pentad of clinical findings (Box 174-1). The presence of neurologic symptoms indicates severe ischemia and need for emergent evaluation.

CUTANEOUS FINDINGS The cutaneous findings in PAD will vary depending on the severity of arterial obstruction and tissue ischemia (Table 174-1). Limbs in patients with intermittent claudication may appear normal although associated clinical findings include hair loss, coldness, and cyanosis, or thickened and malformed toe nails. In patients with severe ischemia, the skin is apt to be atrophic, dry, and shiny. In patients with rest pain, the foot is usually bright red and cold in dependency. Ulcerations most often start at the tips of the toes or on the heel of the foot and are extremely painful except when diabetic neuropathy is also present (Fig. 174-2). Ulcers occasionally start on the lower calves or lateral aspect of the heel. They frequently demonstrate irregular borders and a pale base. The heels may show cracks in the skin with nu-

OBSTRUCTIVE PERIPHERAL ARTERIAL DISEASE AT A GLANCE



- Most commonly due to atherosclerosis of the vessels supplying the lower extremity
- Affects 15 percent of the U.S. adult population over the age of 65 years
- Stenosis or obstruction of the large arteries to the lower extremities leading to supply demand mismatch, initially with exertion but may progress to occur at rest
- Intermittent claudication with exertional muscle pain or fatigue, critical limb ischemia with rest pain or tissue compromise, and acute limb ischemia
- Cutaneous findings from hypoperfusion ranging from dry skin, hair loss, and malformed toenails to ulceration and gangrene





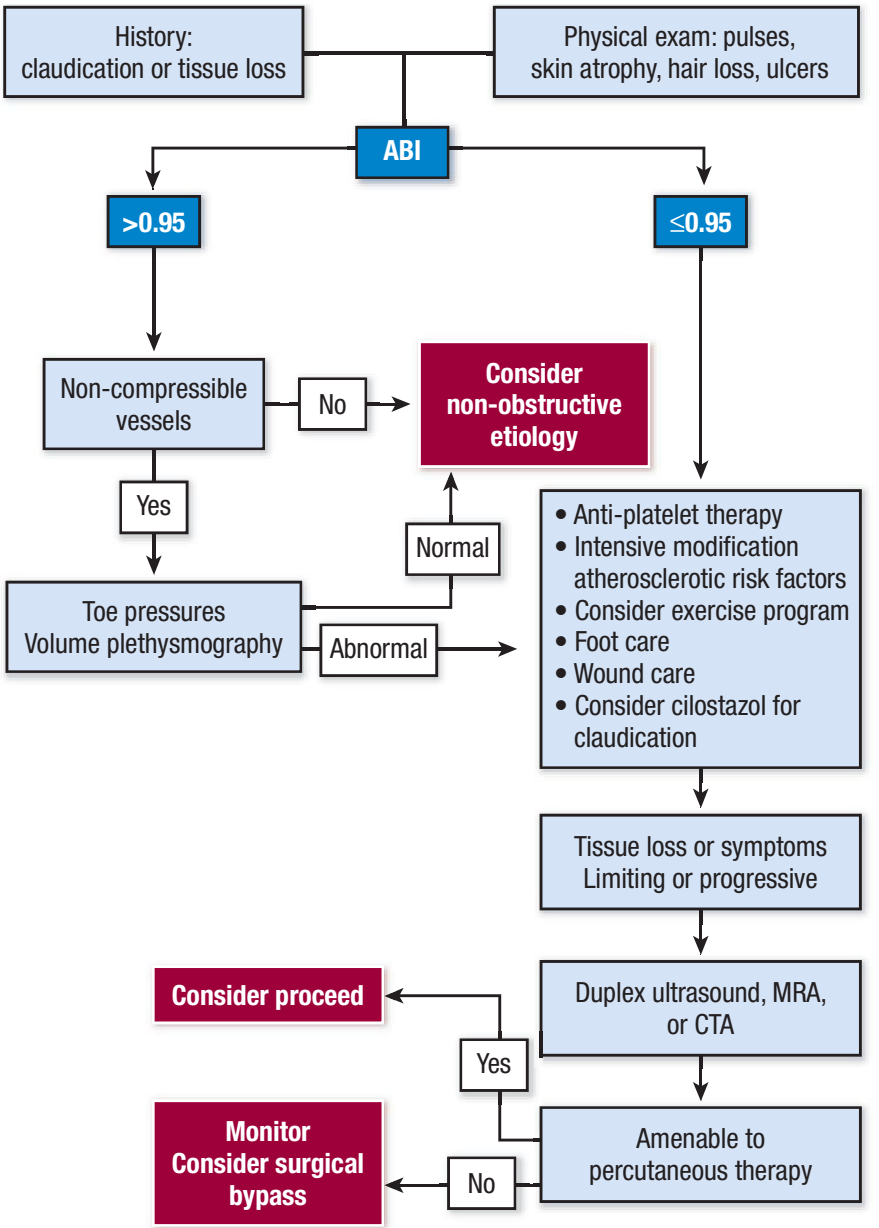

▲ **FIGURE 174-1** Approach to patient algorithm for suspected peripheral arterial obstructive disease. ABI = ankle-brachial index; CTA = computed tomographic angiography; MRA = magnetic resonance angiography.

merous fissures. When gangrene occurs, usually one or more toes become black, dry, and mummified (Fig. 174-3). Superimposed infection is a major concern, and important associated signs include purulent discharge or decay (wet gangrene) or surrounding tissue erythema and swelling.

Box 174-1

Acute Limb Ischemia: Six Ps

- Pain
- Pallor
- Pulselessness
- Paresthesia
- Paralysis
- Poikilothermia

RELATED PHYSICAL FINDINGS The hallmark characteristic is decreased or absent pulses distal to the stenotic arterial segment, and there may be bruits on auscultation over the diseased segment of vessel secondary to turbulent flow. The collateral circulation to limbs affected by PAD can be evaluated by simple bedside exam. With the patient supine, elevation of the limb at a 45° angle for 2 minutes should not produce pallor. Collateral circulation is deemed inadequate if the toes and feet become pale. The patient then assumes a sitting position with the legs dependent and the times for filling of the foot veins and flushing of the feet measured. The veins should fill within 20 seconds and the feet flush immediately in a warm environment. When these times exceed 30 seconds, the collateral circulation is deemed inadequate, and the patient must be observed frequently for the development of rest pain, ulcers, or gangrene. Venous filling times are of limited value when varicose veins co-exist.

TABLE 174-1
Cutaneous Findings in Peripheral Arterial Disease

- Pallor
- Coolness of the extremities
- Dependent rubor
- Subcutaneous atrophy
- Hair loss
- Brittle toenails
- Absence of sweating
- Ulceration
- Gangrene
- Tenderness
- Regional edema

Special Tests

A simple objective test comparing systolic blood pressure in the arms and ankles is sufficient to document the severity of arterial obstruction. The ankle systolic pressure in the supine position should be equal to or greater than the brachial artery systolic pressure. An ankle-to-arm systolic pressure ratio is calculated (ankle-brachial index, or ABI); values greater than 0.95 are considered normal, whereas those less than 0.4 are indicative of severe disease. This information is of prognostic use for determination of wound healing or the need for revascularization. One important caveat to note is that occasional patients with heavily calcified or "non-compressible" vessels, most commonly diabetics, may have falsely elevated ABIs despite the presence of significant PAD. Under this circumstance, alternate tests, including toe pressures (as smaller vessels are rarely affected) or segmental volume plethysmography, are helpful. Duplex ultrasound scanning can be time-consuming, but further helps to define physiology. Magnetic resonance imaging (MRI) or computed tomography angiographies are competitive technologies used to demonstrate precise anatomic location and extent of disease in the arteries but supply limited hemodynamic information. MRI is usually preferred because of



▲ **FIGURE 174-2** Peripheral arterial obstructive disease. Mottled erythema of right foot with bluish discoloration of the digits. Incipient necrosis on toe and ankle. Necrosis was also present on lateral aspect of the heel. (Image provided with permission from Dr. Joseph Raffetto, VA Boston Health Care System, West Roxbury, MA.)



▲ **FIGURE 174-3** Necrotic toe in a patient with peripheral arterial obstructive disease. There is marked dependent rubor of the toes and distal aspect of the foot.



lack of ionizing radiation or need for iodine-based contrast dye, but may not be tolerated by claustrophobic individuals. Conventional catheter-based arteriography is usually reserved for definitive evaluation in patients about to undergo vascular surgery or as a necessary component of percutaneous angioplasty or stenting procedures (Fig. 174-4).

Differential Diagnosis

The diagnosis of PAD can usually be made by the typical history of intermittent claudication and palpation for diminished or absent pulses in the limbs. The ABI is usually diminished, although occasional patients may have normal values at rest. When the diagnosis remains in doubt, a helpful provocative maneuver to increase blood flow is to exercise the patient. Post-exercise blood flow may be limited by the arterial obstructive disease, and repeat ABI will then be diminished. The differential diagnosis of PAD includes both local factors and systemic disorders (Box 174-2). Arterial obstructive disease is just one of several potential etiologies for the development of a foot ulcer (Box 174-3). In some patients with diabetes mellitus or other disease resulting in neuropathy, ulcers may develop on the heel, toes, or anterior calf in the presence of normal pulses. These painless (neurotropic) ulcers are due to repetitive trauma not noticed by the patient because of the peripheral neuropathy. Surrounding callus formation is a typical finding.

Thromboangiitis obliterans also causes intermittent claudication, ulcers, and gangrene. It occurs in a younger age group (onset of symptoms before age 45 years old) and is often associated with superficial thrombophlebitis and vasospasm. In contrast to PAD, it affects medium and smaller arteries and the upper extremities more commonly.

Occlusive vascular disease confined to focal anatomic locations in young patients with minimal traditional risk fac-



▲ **FIGURE 174-4** **A.** Contrast angiography demonstrating extensive peripheral artery occlusive disease involving the bilateral iliac arteries with stenoses and occlusions. **B.** Recanalization of the iliac arteries after placement of bilateral iliac artery stents.

Box 174-2

Differential Diagnosis of Obstructive Peripheral Arterial Disease

LOCAL FACTORS
- Trauma (including iatrogenic)
- Arterial dissection
- Cystic adventitial disease
- Thrombosed popliteal artery aneurysm
- Arterial entrapment syndromes
- Extrinsic compression

SYSTEMIC DISEASE
- Primary thrombotic disorder (thrombophilia)
- Embolism
- Thromboangiitis obliterans
- Fibromuscular dysplasia
- Vasculitic disorders (particularly giant cell arteritis or Takayasu arteritis)



tors for atherosclerosis should raise suspicion for alternative etiologies. For example, popliteal artery occlusion may occur secondary to entrapment by calf muscles or cystic adventitial disease. In the latter condition, adventitial cysts of unclear etiology compress the vessel lumen, most commonly in the popliteal artery (85 percent) or rarely, in the external iliac or femoral arteries, presenting as intermittent claudication. Surgical excision of the cysts usually alleviates symptoms although, in the event of complete vessel occlusion, an interposition graft may be necessary.

Neurogenic claudication (pseudoclaudication) is often a difficult diagnosis to distinguish and is due to compression or intermittent ischemia of the lower spinal cord or cauda equina with exercise. Etiologic factors are prolapsed intervertebral discs, congenital stenosis, or hypertrophic bony ridging of the spinal canal. In contrast to PAD, leg pain may occur in the erect position without exercise and be affected by changes in posture, neurologic signs may be present before or after exercise, and peripheral pulses are normal. Dilemmas in diagnosis and management can occur when both conditions co-exist. MRI or computed tomography scan of the spine is used to confirm the diagnosis.

Box 174-3

Differential Diagnosis of Foot Ulcers
- Obstructive peripheral arterial disease
- Microvascular disease
- Chronic venous insufficiency
- Neuropathic (particularly diabetic)
- Infection (diabetes or fungal)
- Trauma

Box 174-4

Treatment of Obstructive Peripheral Arterial Disease

	SYMPTOM RELIEF	RISK REDUCTION
First line	Exercise regimen Cilostazol (Pletal)	Smoking cessation Statin therapy (target low-density lipoprotein < 100 mg/dL) Aspirin Glycemic control Antihypertensive therapy
Second line	Pentoxifylline (Trental) Percutaneous revascularization (angioplasty, stent, atherectomy, cryotherapy) Surgical revascularization (endarterectomy or bypass)	Other lipid therapy Clopidogrel (Plavix)

Complications

The major direct complications of PAD relate to limb loss from progressive severe ischemia or superimposed infection. In patients with rest pain or tissue loss, the risk of infection is high and wound healing slow or absent. Under these circumstances, the need for revascularization is more urgent to avoid the need for amputation. Superimposed infection needs to be aggressively treated with antibiotics, wound débridement, and local foot care and, if rapidly progressive, presents a medical emergency.

Prognosis and Clinical Course

Peripheral vascular outcomes in patients with intermittent claudication as a consequence of PAD tend to be relatively benign, with studies showing that 60 percent to 90 percent of such patients remained stable over a period of 5 to 9 years. Occasional patients show spontaneous improvement in symptoms, most likely secondary to enhanced collateral blood flow, although plaque regression is possible. Patients with diabetes mellitus, however, tend to have progressive disease, and their amputation rate is fourfold greater than for patients without diabetes. In patients with diabetic neuropathy, trauma to the limbs must be avoided, and special shoes may be required. Ongoing smokers also have greater amputation and vascular graft occlusion rates than nonsmokers.

In contrast with the limb-related outcomes, because patients with PAD often have advanced atherosclerosis present in multiple vascular beds, the risk of associated cardiovascular morbidity and mortality is high.[1,2] The 5-year mortality in patients with intermittent claudication is 30 percent, with death largely attributed to cardiovascular causes. In addition, another 20 percent of patients will incur a nonfatal myocardial infarction or stroke.

Treatment

For patients with intermittent claudication, an exercise program is the treatment of choice (Box 174-4).[2] Patients are instructed to exercise to the threshold of tolerable pain, briefly rest, and then exercise again for a total duration of 30 to 60 minutes a day in excess of their normal activity. The exercise period must be performed in one session, with walking being the preferred modality. Drawing on data from several studies, approximately 80 percent of patients may be expected to show significant improvements in exercise tolerance through these techniques. Patients should be further instructed to keep their feet warm, clean, and dry; and extremes of temperature should be avoided because ischemic tissue is more susceptible to burning and to frostbite than normal tissue. Cuts or severe bruises of the limbs or feet should be treated immediately. Conventional vasodilators appear to have no value in treatment.

Two agents have been approved for the indication of intermittent claudication in the United States. Cilostazol, a phosphodiesterase inhibitor with antiplatelet and vasodilatory properties, has been shown in several studies to have consistent benefits on treadmill walking distance and quality of life.[2] However, its benefits are limited by high frequency of side effects, principally gastrointestinal symptoms or headaches. Furthermore, it is contraindicated in patients with congestive heart failure. Pentoxifylline affects red cell deformability and blood viscosity but has been shown

to be ineffective in the treatment of claudication in recent studies.[2] Propionyl-L-carnitine is an agent with metabolic effects, actively under study in the United States for this indication.

Endovascular intervention with angioplasty or stenting is highly effective for aorto-iliac disease and is often indicated for moderate, or lifestyle-limiting claudication. Angioplasty or stenting of the superficial femoral artery is technically feasible but limited in applicability by high restenosis rates, particularly in the setting of long occlusions, a common scenario in this location. Despite this limitation, it is a valid therapeutic option for patients with focal disease, severe claudication, or tissue loss. Endovascular management of infra-popliteal (below the knee) disease is associated with extremely high restenosis rates, and is usually a temporizing measure to allow increased blood flow for wound healing. Surgical bypass techniques are effective but are generally high-risk procedures in a population with frequent co-morbidities and are usually reserved for patients with severe intermittent claudication or rest pain, or to allow healing of ulcers and gangrene. Sympathectomy is not of value for intermittent claudication, but may allow small ulcers or areas of gangrene to heal. In patients with rest pain, ulcers, or gangrene who are technically unrevascularizable or very high risk for surgery, treatment options are limited. A period of rest with legs dependent may improve some patients, but amputation is a frequent outcome. Parenterally administered prostacyclin or prostaglandin E_1 despite some favorable reports of success, has not yet been thoroughly evaluated and is an expensive mode of therapy.

Dry gangrene of the digits or lower limbs should be allowed to spontaneously demarcate. Soaking or ointments are unnecessary. The edges of the gangrenous areas should be kept open if possible and observed frequently for infection. Pain medication is usually necessary for 2 to 3 months with digital gangrene. A conservative approach and patience will save many digits and extremities. Infected (wet) gangrenous areas must be actively débrided and appropriate antibiotics administered. Amputations may be necessary.

Prevention

The grim statistics regarding cardiovascular outcomes in these patients emphasize the need for aggressive secondary prevention by modifying appropriate cardiovascular risk factors when possible. Tobacco smoking is absolutely contraindicated. Hypertension and diabetes mellitus should be controlled, and hyperlipidemias should be treated with a target low-density lipoprotein < 100 mg/dL (or < 70 mg/dL with uncontrolled or multiple risk factors) as per recent guidelines for secondary prevention. Evidence is accumulating that aggressive lipid management will prevent progression of PAD, in addition to prevention of myocardial infarction and stroke. Similarly, anti-platelet use with aspirin is well established for prevention of cardiovascular events. The use of thienopyridines such as clopidogrel (Plavix) may be of additional benefit, but may be associated with higher bleeding rates (particularly with combined therapy) and expense. Use, therefore, must be individualized.

ATHEROMATOUS EMBOLISM

Epidemiology

The epidemiology of atheromatous embolism is poorly defined due to underreporting and difficulties establishing a clinical diagnosis.[3] Routine autopsy series of the adult population suggest an incidence of atheromatous embolism of between 0.15 percent and ~4 percent. The incidence increases dramatically in the presence of severe atherosclerotic disease. Atheromatous embolism has been found in more than 20 percent of deaths following cardiac surgery or angiography. However, it should be emphasized that the rate of clinically detected atheromatous embolism appears to be reasonably low (less than 1 percent).

Etiology and Pathogenesis

The pathogenesis of atheromatous embolism involves the occlusion of small arteries and arterioles by atheromatous debris (or so-called *cholesterol crystals*) that are dislodged from a proximal atherosclerotic plaque, with this material inciting an inflammatory cascade characterized by leukocyte infiltration followed by monocytes. This inflammatory process leads to further occlusion with thrombus formation, endothelial cell proliferation, and intimal fibrosis, which may result in ischemia, infarction, and necrosis. The clinical picture is characterized by impaired perfusion of the skin and muscle due to small vessel occlusion, although nearly any organ of the body may be involved.

ATHEROMATOUS EMBOLISM AT A GLANCE



- Atheromatous embolism is the embolization of small pieces of atheromatous debris from the more proximal arteries to the smaller arteries.
- Synonyms include *cholesterol embolism*, *atheroembolism*, *blue toe syndrome*, and even *pseudovasculitis syndrome*.
- More common with advanced age and after invasive procedures.
- Manifestations include blue or discolored toes, livedo racemosa, gangrene, necrosis, ulceration, and fissure.
- Renal failure and stroke from systemic involvement.
- Diagnosis confirmed by cholesterol clefts in skin or muscle biopsies.
- Treatment focuses on prevention during invasive procedures and elimination of the embolic source. Medical therapy may include anti-platelet therapy and statin agents, while the use of anticoagulation is controversial and often avoided.

The major risk factor for the development of atheromatous embolism is atherosclerotic disease of the thoracic or abdominal aorta. The risk is higher with more extensive atheroma burden (defined by increased thickness above 4 mm) or unfavorable plaque features such as protruding mobile plaque. Co-existent vascular disease including coronary artery disease, PAD, and even an abdominal aortic aneurysm is a risk factor. The more traditional atherosclerotic risk factors also increase the risk of atheromatous embolism, with older age (more than 60 years old) being prominent.

Atheromatous embolism often occurs after an invasive procedure. Angiography, endovascular procedures, and both cardiac and vascular surgeries may create mechanical trauma to the vessel and destabilize an atherosclerotic plaque. Anticoagulation, primarily with Coumadin, and even thrombolytic therapy are potential risk factors. It has been postulated that anticoagulation may de-



lay the healing of irregular or ulcerated plaque. Embolic events may occur spontaneously although minor stressors such as coughing or straining may be provocative factors.

Clinical Findings

HISTORY There is a wide spectrum of clinical manifestations depending upon the affected organs. The clinical presentation ranges from subtle clinical findings to catastrophic systemic embolic complications. However, lower extremity involvement is extremely common with manifestations of discolored or ulcerated painful toes and tender calf muscles. This is more common after invasive cardiovascular procedures. Depending on the source for the embolization, nearly any organs of the body may be involved. Involvement of the ascending aorta may result in systemic complications including transient ischemic attacks, strokes, or other retinal manifestations, while involvement of the descending or abdominal aorta may lead to renal failure, mesenteric ischemia, or hemorrhagic pancreatitis. In addition, constitutional symptoms including fever and weight loss may be seen due to hypermetabolism associated with the inflammatory process.

CUTANEOUS LESIONS The dermatologic manifestations are often the presenting complaint (Table 174-2). The most common of these findings are related to tissue or digital ischemia and include cyanosis, necrosis, gangrene, ulcerations, and fissures. The finding of tender, cool, blue, or purple toes with normal pulses, found in the "blue toe syndrome," is common (Fig. 174-5A). About 50 percent of patients will have livedo racemosa, which typically involves the foot and leg but may extend into the trunk or buttocks. Erythematous lesions are often seen on the lateral aspect of the foot and calcaneal region. Although advance ischemic manifestations such as ulcers or gangrene may be present (see Fig. 174-5B), the surrounding areas are normally perfused tissue. There may be other cutaneous manifestations, often hemorrhagic in nature, including petechiae, ecchymosis, purpura, and splinter hemorrhages. Raised painful erythematous nodules may occur that are probably inflammatory in origin.







▲ **FIGURE 174-5** **A.** Typical appearance of blue toes due to multiple atheromatous emboli to the lower limbs in a patient with extensive atheromatous disease of the aorta. **B.** Development of ulceration of the tip of the toes due to atheromatous embolism with a faint reticular pattern on the forefoot typical of livedo racemosa.

TABLE 174-2
Cutaneous Findings in Atheromatous Embolism

- Blue or purple toes
- Livedo racemosa
- Gangrenous digits
- Ulcers
- Fissures
- Nodules
- Petechiae
- Purpura
- Splinter hemorrhages

RELATED PHYSICAL FINDINGS Examination of the vascular system often reveals normal pedal and proximal pulses, but systolic bruits may be heard on auscultation over the aorta or common femoral arteries. Tenderness of skeletal muscles, particularly in the calf, may be detected. Funduscopic examination revealing Hollenhorst plaques is a specific but insensitive finding because most atheromatous emboli arise from a source distal to the aortic arch. Fever may be present.

Laboratory Tests

The laboratory tests are typically nonspecific and depend upon the organ involved and the severity of disease. An elevated erythrocyte sedimentation rate, thrombocytopenia, hypocomplementemia, leukocytosis, and anemia may all been seen due to the systemic inflammatory response. With renal involvement azotemia, proteinuria, microscopic hematuria, eosinophilia, and even eosinophiluria may be seen. Transient eosinophilia has been reported in up to 80 percent of those with renal involvement. Involvement of the gastrointestinal tract may lead to anemia and blood in the stools. Injury to the liver, gallbladder, or pancreas may lead to abnormal liver function tests and elevated pancreatic enzymes.

Special Tests

Contrast angiography may demonstrate diffuse atherosclerotic involvement of the vessels proximal to the lesions but is typically avoided due to the risk of precipitating further embolic events. Noninvasive imaging techniques such as computed tomographic angiography or magnetic resonance angiography are useful to evaluate for atherosclerotic disease within the aorta or other large vessels. Although stenotic atherosclerotic disease is the most common finding, aneurysmal disease may also be present. Transthoracic echocardiography is often helpful to evaluate for a cardiac source, but the more definitive transesophageal echocardiography can also assess the thoracic aorta for plaque.

Histologic findings are useful to confirm a suspected diagnosis. Cholesterol crystals are birefringent under polarized light. However, due to the solubility of cholesterol with typical solvents used in processing of tissue for histopathology, cholesterol crystals appear as empty clefts. Skin, muscle, or renal biopsies may reveal these characteristic elongated, needle-shaped clefts in small arterial vessels. There may also be inflammatory infiltrates, intimal thickening, and perivascular fibrosis as well as giant cells. The sensitivity of the biopsy depends upon the site. Muscle biopsy seems to be the most sensitive test, reportedly being positive in > 95 percent of cases, but is technically difficult, painful, and risky to obtain. The sensitivity of skin biopsy has varied from 40 percent to 90 percent. Skin biopsies offer maximum yield when

Box 174-5

Differential Diagnosis in Atheromatous Embolism

- Anti-phospholipid antibodies
- Atrial myxoma
- Calciphylaxis
- Chilblains (or pernio)
- Cryoglobulinemia
- Heparin-induced thrombocytopenia
- Malignancies
- Multiple myeloma
- Nonbacterial thrombotic endocarditis
- Polyarteritis nodosa
- Subacute bacterial endocarditis
- Thrombocytopenia, polycythemia
- Thrombotic embolism
- Vasculitis
- Warfarin-induced skin necrosis

obtained directly from areas of suspected emboli, such as those with livedo racemosa, but should be cautiously obtained or avoided in areas of more overt ischemic injury.

Differential Diagnosis

The diagnosis of atheromatous emboli is suggested by blue or ulcerated painful digits, livedo racemosa, petechiae, and tender calf muscles in the presence of normal pulses. Definitive diagnosis can be made by skin, muscle, or even renal biopsies. Several other entities must be considered in the differential diagnosis of atheromatous embolism (Box 174-5).

Complications

There are numerous ischemic complications depending upon the organ involved. These include the kidneys, mesenteric circulation, and central nervous system. Renal atheroembolic disease is a consequence of showering of emboli to the renal parenchymal branch vessels. An intense inflammatory process may ensue, producing glomerular sclerosis, tubular atrophy, and interstitial fibrosis. Although there is a variable timing of onset and progression of disease, there typically is a several-week delay after the inciting event before the development of renal dysfunction. New onset of hypertension or overt renal failure may ensue. It is rare to develop gross hematuria or frank renal infarction. The development of renal failure is one of the more ominous complications with a high mortality in affected individuals.

The central nervous system is another feared site of involvement with atheromatous embolism. There is the obvious concern for ischemic manifestations such as transient ischemic attacks, stroke, and paralysis. However, other less readily apparent manifestations may result, such as a confusional state or a progressive neurologic decline.

The gastrointestinal tract is perhaps the third most common organ system involved with atheromatous embolism. The manifestations may be non-specific abdominal complaints such as abdominal pain, nausea, vomiting, or diarrhea. More overt ischemic manifestations may be seen with gastrointestinal bleeding or bowel infarction. The colon is the most common site in the gastrointestinal tract to be affected. Establishing a diagnosis may be difficult as endoscopy findings are often non-specific, and biopsy may miss the classic findings. Splenic infarction, cholecystitis, gangrene of the gallbladder, pancreatitis, and pancreatic necrosis have also been reported.

Prognosis and Clinical Course

The outcome depends upon the organ system affected with the emboli. Early reports suggested an extremely poor prognosis with a mortality of more than 50 percent. This figure appears to have been an overestimation as more recent estimates range from 20 percent to 30 percent for 1-year mortality. The poorest outcomes have been reported in those with emboli arising from a suprarenal location.

The syndrome usually subsides, and lesions heal following successful surgical or medical treatment, although spontaneous resolution may occur. Recurrent embolism may result in limb loss in the absence of surgical or interventional management options. In the "malignant multisystem" disease, most patients die within 1 year if treatment is unsuccessful. The prognosis is extremely poor in the presence of systemic complications, particularly renal failure or stroke. The development of end-stage renal disease due to atheromatous embolism is a strong predictor of death.

Treatment

Early recognition is essential to minimize end organ damage and improve the clinical outcomes.[3] Preventing further ischemic insult, supportive care, and removal of the atheromatous source are the mainstays of therapy. Elimination of the source of the emboli can often be accomplished by surgical bypasses or endarterectomy although many of these patients have contraindications to major surgery. Endovascular procedures with covered stents may also be considered; however, this approach may carry significant risk with the potential to exacerbate further embolization.

Medical therapies have not been well studied, and recommendations are based on the results from small series or anecdotal reports. Anti-platelet agents such as aspirin and dipyridamole are most often tried and, if successful, therapy should be continued long-term. Antithrombotic therapy such as subcutaneous heparin or low-molecular-weight heparin may be beneficial with some, suggesting that these agents may reduce the secondary small vessel thrombosis. Warfarin is usually avoided due to potential for exacerbating the process, but this concern has limited basis. There is even a proposed beneficial effect of long-term anticoagulation to prevent embolic events in those with extensive mobile aortic atheroma. The use of statins may aid in plaque stabilization and has clear established benefits in prevention of cardiovascular ischemic events in those with vascular disease. Other agents such as iloprost and cilostazol have limited evidence to suggest benefit but have been tried in those with renal dysfunction and cutaneous lesions, respectively. Systemic corticosteroids are not recommended.

Prevention

Primary prevention in high-risk patients, targeted to avoid the development of atherosclerotic plaque, should be performed. Once atherosclerosis develops, avoiding unnecessary invasive procedures is advised. When angiography is necessary, newer techniques with the use of soft-tipped guidewires and more flexible catheters help to reduce the risk. In addition, protective devices such as filters, baskets, and balloon occlusion have been used. Surgical techniques have also been refined with less aortic manipulation and circulation arrest, which may help to minimize the chance of developing this disorder.

THROMBOANGIITIS OBLITERANS (BUERGER DISEASE)

Epidemiology

The prevalence of this disease is greatest in the Mediterranean, the Middle



THROMBO-ANGIITIS OBLITERANS

AT A GLANCE



- Rare inflammatory occlusive disease affecting medium and small arteries and veins, most commonly in the extremities.
- Predominantly affects males, age 20 to 40 years old.
- Extremely strong association with smoking; often abates with smoking cessation.
- Clinical manifestations include ischemia, cold sensitivity, or claudication of foot, leg, or hand.
- Ischemic ulcers, peripheral cyanosis, gangrene, or superficial thrombophlebitis.



East, and Asia.[4] Males are afflicted with a higher prevalence than females, although an increased incidence in females has occurred in recent years, likely reflecting the pattern of tobacco use. Patients are usually between the ages of 20 and 40 years old. Over the last three decades, there has been a marked decline in the reported prevalence of thromboangiitis obliterans in the United States, possibly reflecting the impact from adoption of strict diagnostic criteria for this disease entity, although declining smoking prevalence may also play a role.

Etiology and Pathogenesis

The etiology of thromboangiitis obliterans remains unknown.[4] The disease almost exclusively occurs in smokers and often abates with the cessation of tobacco smoking. An increased cellular sensitivity to types I and III collagen has been reported in comparison to a group of normal individuals and patients with atherosclerotic disease. Tissue ischemia is produced by an inflammatory reaction involving medium and small arteries of the extremities and superimposed obstruction by thrombi. Despite the inflammatory process, thromboangiitis obliterans is considered serologically silent, and even during active disease, erythrocyte sedimentation rate and C-reactive protein levels are usually normal. In one report, serum anti-endothelial cell antibody titers were found to be high, and impaired endothelial-dependent vasodilation to acetylcholine has been demonstrated to occur even in non-obstructed limbs. Veins may also be involved. Occasionally, cardiac, intestinal, and cerebral vessels are involved.

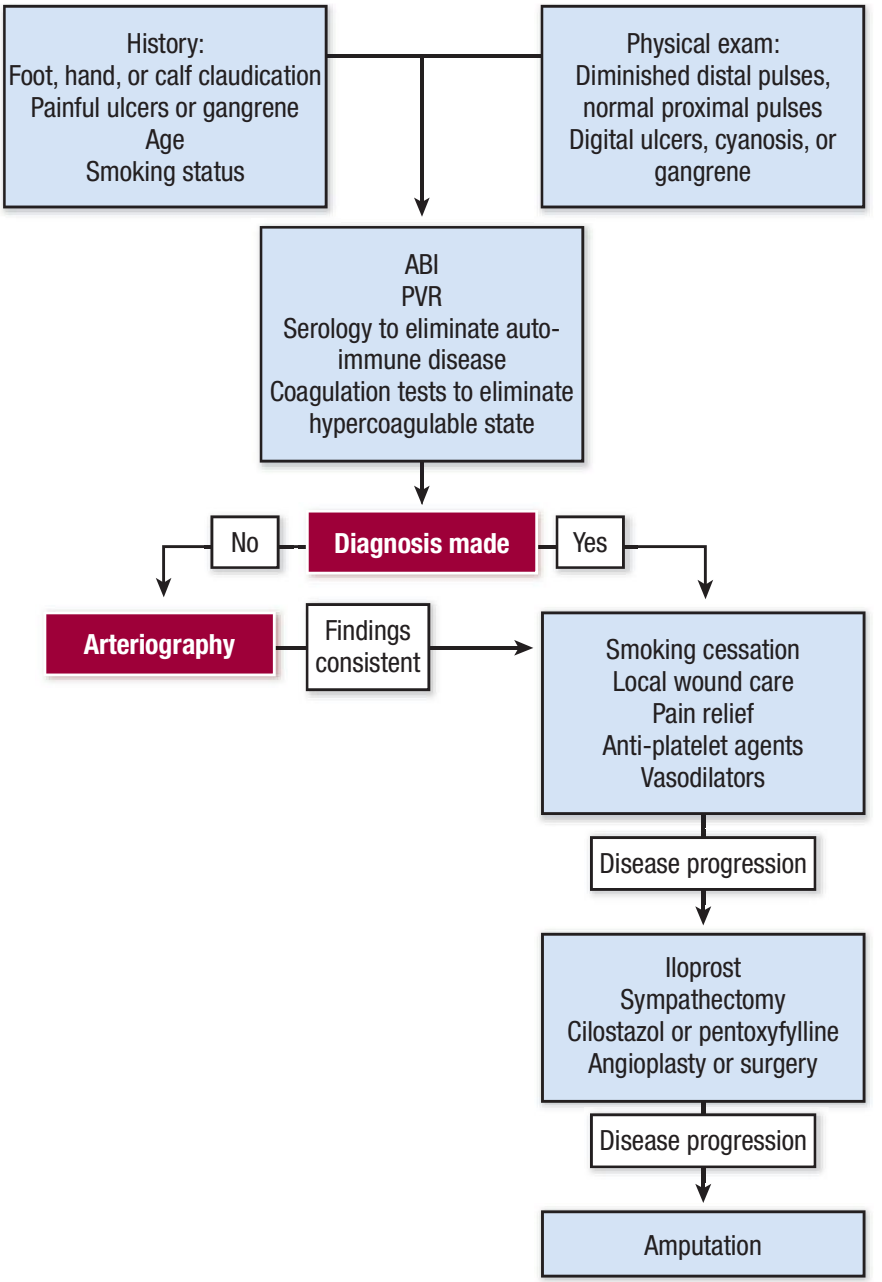

▲ **FIGURE 174-6** Approach to patient algorithm for suspected thromboangiitis obliterans. ABI = ankle-brachial index; PVR = pulse-volume recording.

Clinical Findings (Fig. 174-6)

HISTORY The most common initial complaints are claudication of the foot or lower calf, digital cyanosis or gangrene, or rest pain. Involvement of multiple limbs is usual. Patients may present with ulcers of the toes or fingers. Although the lower extremities are affected most often, more than one-third of patients have upper-extremity involvement. Ulcerations or gangrenous areas are characteristically extremely painful. Superficial thrombophlebitis, often migratory, may occur in up to 40 percent of patients. Cold sensitivity or even classical Raynaud phenomenon may be observed.

CUTANEOUS FINDINGS The cutaneous findings of thromboangiitis obliterans are sim-



▲ **FIGURE 174-7** Necrotic toe in a patient with thromboangiitis obliterans; this appearance may be seen with other arterial occlusive processes.

ilar to that of PAD. Common findings include ulceration or gangrene of digits (feet worse than hands) (Fig. 174-7), peripheral cyanosis or Raynaud phenomenon, and superficial thrombophlebitis, often migratory, with indurated red nodules.

RELATED PHYSICAL FINDINGS Physical examination may reveal cyanotic, ulcerated, or gangrenous, and very painful digits. The dorsalis pedis, posterior tibial, and ulnar pulses are often absent. During episodes of thrombophlebitis, small indurated red, tender nodules will be found, which follow the course of superficial veins and are common on the thigh or calf. Typical changes of Raynaud phenomenon, with well-demarcated pallor or cyanosis of the digits, may be seen on exposure to cold; one or more extremities may be involved. Sensory abnormalities reflecting ischemic neuropathy have been observed in advanced cases. Nail fold examination with capillaroscopy may reveal multiple dilated capillary loops.

Laboratory and Special Tests

There are no specific blood studies. Classical findings on contrast arteriography include segmental occlusions of medium and small blood vessels interspersed with normal appearing wall segments. Corkscrew configuration of collateral vessels originating from the occluded vessels are a classic finding; however, this is non-specific, as it may be seen with other disorders. More proximal and larger caliber vessels are usually spared.

Pathology

In the acute stage, there is a pan-vasculitis of arteries and veins; the diagnostic finding is arterial thrombi with foci of microabscesses and giant cells. In contrast to systemic vasculitis (see Chap. 165) and atherosclerosis, normal architecture is usually well preserved, and there is no early disruption of the internal elastic lamina.[5] In the chronic stage, only fibrotic obliteration of the arteries may be observed. The diagnosis can then only be surmised in the absence of hallmark pathologic changes to support atherosclerosis.

Differential Diagnosis

The same differential diagnoses as for PAD must be considered in thromboangiitis obliterans (see Box 174-2). In particular, the disease must be distinguished from distal arterial obstructive disease often seen in diabetes mellitus or end-stage chronic kidney disease. Other considerations include autoimmune disease, particularly scleroderma or CREST syndrome (*c*alcinosis cutis, *R*aynaud phenomenon, *e*sophageal dysfunction, *s*clerodactyly, and *t*elangiectasia), and ergotamine abuse.

The diagnosis should be considered in young male smokers presenting with symptoms and signs of distal extremity ischemia, migratory thrombophlebitis, or Raynaud phenomenon. An abnormal Allen test (with compromised perfusion of the fingers and blanching secondary to an occluded ulnar artery or incomplete palmar arch following manual compression of the radial artery) in a young smoker with lower extremity ulceration is very suggestive of this disease. The distal nature of disease and associated upper extremity involvement are particularly helpful clues to differentiate from atherosclerotic PAD. Arteriographic findings may support the diagnosis but only biopsy of an artery or vein during the active phase of the disease showing the characteristic pathologic picture is truly diagnostic. Atherosclerosis is the major differential but tends to occur in an older age group, usually more than 45 years of age, and larger vessels are involved. Raynaud phenomenon (see Chap. 171) is infrequent, and upper extremities are rarely involved. Occasional patients with long-standing diabetes mellitus or end-stage renal disease may exhibit arteriosclerosis affecting medium-sized and distal vessels, but these diagnoses are usually obvious. Raynaud phenomenon associated with scleroderma or CREST syndrome may present with a similar picture, but systemic symptoms, proximal skin changes, and presence of anti-nuclear antibodies will assist in the diagnosis.

Complications

Major clinical complications of this disease include amputation or superimposed infection of ischemic tissue. Rarely, involvement of other vessels may result in myocardial infarction, stroke, or mesenteric ischemia.

Prognosis and Clinical Course

The disease often continues to progress unabated in patients who continue to smoke. Amputations of digits or even extremities may be necessary. The course of the disease is marked by exacerbations and remissions, but usually becomes quiescent after many years. However, in those who manage to quit smoking, remission is common and progression to amputation unusual unless critical limb ischemia with tissue loss is already present. Patients generally have a normal life expectancy.

Treatment

There is no specific treatment (Box 174-6) other than smoking cessation. Local wound care is imperative, and adequate analgesic therapy is emphasized. In the absence of data from large randomized

Box 174-6

Treatment of Thromboangiitis Obliterans

	IMPROVE BLOOD FLOW	SYMPTOM RELIEF
First line	Smoking cessation	Local wound care Analgesics
Second line	Anti-platelet agents Oral vasodilators Cilostazol (Pletal) Pentoxifylline (Trental)	
Third line	Iloprost Angioplasty Surgical endarterectomy or bypass	Sympathectomy Amputation



trials, anti-platelet agents and vasodilators may play a role and are usually initiated. Similarly, pentoxifylline or cilostazol, both agents used for improving walking distances in claudicants with atherosclerotic disease, may be tried. In one study, daily infusions of iloprost, a prostaglandin analog, were shown to relieve rest pain, heal ulcers, and prevent amputation more frequently than aspirin. Bypass surgery or angioplasty have been reported but are suboptimal therapeutic options because of the small size and distal location of the vessels affected. Sympathectomy may help patients with a prominent vasospastic component. Vascular endothelial growth factor gene therapy may prove of value, but has not been well studied yet.



Prevention

The only preventive measure is never to smoke.

LIVEDO RETICULARIS AND LIVEDO RACEMOSA

Epidemiology

Livedo reticularis is typically a primary disorder that affects young to middle-aged females (20 to 50 years of age) who are otherwise healthy.[6,7] Amantadine-induced livedo reticularis is also more common in females. The epidemiologic factors of livedo racemosa are dependent on the underlying condition. The distinction between livedo racemosa and livedo reticularis is an evolving concept, which is not universally quoted, and is not referenced in most of the older literature.

Etiology and Pathogenesis

In both disorders, the characteristic ring-like mottling results from (patho)physiologic changes with the cutaneous microvascular system. Anatomically, the dermis is perfused via perpendicularly oriented ascending arterioles. Individual arterioles arborize into a capillary bed at the skin surface. Ultimately, the capillary beds empty into a conical appearing, peripherally located subpapillary venous plexus.

Pathophysiologically, livedo arises from either deoxygenation or venodilatation within the venous plexus. Decreased arteriolar perfusion is the predominant cause of deoxygenation within the venous plexus. Diminished arteriolar flow can result from vasospasm, hyperviscosity, and/or thrombosis. Physiologic arteriolar vasospasm produces the reversible cutaneous discoloration of livedo reticularis. Protracted arteriolar vasospasm, thrombosis and/or hyperviscosity underlie the pathologic skin changes of livedo racemosa. Venodilatation of the venous plexus may be provoked by hypoxia or autonomic dysfunction.

Amantadine-induced livedo reticularis has traditionally been ascribed to catecholamine provoked arteriolar vasospasm; however, an interaction between amantadine and *N*-methyl-D-aspartic acid receptors in the skin may be responsible in some unexplained fashion.

Livedoid vasculopathy is a rare ulcerative sub-type of livedo racemosa due to fibrinolytic abnormalities and microcirculatory thrombosis.

LIVEDO RETICULARIS AND LIVEDO RACEMOSA AT A GLANCE





- Livedo is an ischemic dermopathy characterized by a violaceous reticular or "net-like" mottling of the skin.
- Imperative to differentiate benign livedo reticularis from pathologic livedo racemosa.
- Livedo reticularis is a primary disorder affecting young to middle-aged females that is benign. The livid conical discoloration is symmetric, reversible, and uniform.
- Livedo racemosa is a secondary disorder that is pathologic and permanent. The livid conical discoloration is asymmetric, irreversible, and "broken."
- Anti-phospholipid antibody testing should be obtained on all patients presenting with livedo racemosa.

Clinical Findings

HISTORY With the exception of a subjective feeling of coldness, the majority of patients with livedo reticularis are asymptomatic. Patients often present with concerns regarding their skin discoloration. A minority describe mild pain and numbness. Livedo racemosa–associated symptoms are related to the causative secondary disorder (e.g., livedoid vasculopathy provokes painful ulcerations).



▲ **FIGURE 174-8** Symmetric and relatively uniform, conical rings of primary, reversible livedo reticularis (cutis marmorata).

CUTANEOUS LESIONS In livedo reticularis, a symmetric, fishnet-like red or purple mottling surrounds a pallorous conical core (Fig. 174-8). This discoloration is aggravated by cold exposure and may completely dissipate with warming. The livid rings are most pronounced on the lower extremities yet the abdomen and upper extremities can be affected.

In contradistinction to the symmetric and uniform reticular pattern of livedo reticularis, the discoloration of livedo racemosa is asymmetric, irregular, and "broken" (Fig. 174-9). Although it may improve with warming, it does not resolve. Attendant skin manifestations of livedo racemosa may include purpura, nodules, macules, ulcerations, and/or atrophie blanche type scarring.

In both livedo reticularis and racemosa, the skin is palpably cool.

RELATED PHYSICAL FINDINGS Livedo reticularis and livedo racemosa are often associated with vasospastic digits or acrocyanosis. With exception of the characteristic skin changes, the examination in livedo reticularis is otherwise unremarkable. Patients with livedo racemosa may have concurrent abnormal physical findings related to their underlying disease (e.g., aphasia and lateralizing neurologic signs associated with Sneddon syndrome).

Laboratory and Special Tests

In livedo reticularis, laboratory testing is typically negative and consequently is un-



▲ **FIGURE 174-9** Permanent and "broken" rings of secondary livedo racemosa on the buttocks and thighs in a woman who had cerebrovascular thrombosis. This is an example of Sneddon syndrome.

warranted. An anti-phospholipid antibody panel should be obtained on all patients presenting with livedo racemosa. A complete thrombophilia panel is warranted in the rare patient with livedoid vasculopathy (see Chap. 164). The need for additional laboratory analysis in a patient with livedo racemosa should be directed by the clinical assessment.

A skin biopsy is not required in livedo reticularis as the findings are non-specific. A large punch or wedge biopsy of the deep reticular dermis and subcutaneous fat is sometimes helpful in identifying the secondary cause of livedo racemosa. The biopsy findings are highly variable and reflect the associated livedo racemosa etiology. For instance, cholesterol clefts suggest atheroembolic disease, calcification of the vessels and interstitium indicate calciphylaxis, non-inflammatory arteriolar obstruction occurs with Sneddon syndrome, livedoid vasculopathy is associated with extensive fibrin deposition and microthrombi (see Chap. 164), whereas fibrinoid necrosis is present in polyarteritis nodosa (see Chap. 165).

Differential Diagnosis

The diagnosis of livedo is easily made by identifying the characteristic mottled skin discoloration. It is paramount that the clinician distinguish between livedo reticularis and livedo racemosa. Once a diagnosis of livedo racemosa is established, the secondary cause should be sought (Table 174-3).

Prognosis and Clinical Course

The prognosis for livedo reticularis is excellent as this is primarily a cosmetic condition. Livedo racemosa–associated prognosis is less favorable and parallels the associated disease. Of interest, livedo racemosa has been identified as a marker for predicting multisystem thrombosis in the anti-phospholipid antibody syndrome. Additionally, up to 40 percent of patients manifest livedo racemosa as the initial sign of the anti-phospholipid antibody syndrome.[7] Livedoid vasculopathy tends to be a relapsing condition marked by recurrent painful ulcerations and subsequent atrophie blanche type scars.

Treatment

Other than cold avoidance, medical treatment for primary livedo reticularis is typically unwarranted. As a last resort, vasodilator therapy may be tried in the patient that is socially inhibited by the cosmetic appearance of the disorder.

Therapy of livedo racemosa should be directed towards the underlying disorder. Patients with livedo racemosa and the anti-phospholipid antibody syndrome with thrombosis require anticoagulation. Treatment of livedoid vasculopathy is often unsatisfactory but potentially beneficial medications include anticoagulants, anti-platelet agents, immunosuppressants, pentoxifylline, danazol, and tissue plasminogen activator. Alternatively, hyperbaric oxygen and psoralen and ultraviolet A light therapy have also been successfully utilized to treat livedoid vasculopathy.

TABLE 174-3
Conditions Associated with Livedo Racemosa

- Anti-phospholipid antibody syndrome
- Sneddon syndrome
- Livedoid vasculopathy
- Vasculitis (especially polyarteritis nodosa)
- Collagen vascular disease
- Myeloproliferative syndromes (polycythemia vera, essential thrombocytosis)
- Paraproteinemias
- Cryoglobulinemia/cryofibrinogenemia/cold agglutinin disease
- Atheroembolic disease
- Calciphylaxis
- Hyperoxaluria
- Atrial myxoma
- Erythema ab igne
- Chronic pancreatitis
- Infections

ERYTHROMELALGIA (ERYTHERMALGIA)



Epidemiology

This is a rare disorder with limited epidemiologic data available.[8] In Norway, the incidence is estimated to be 0.25 for 100,000 population with a prevalence of 2 per 100,000. Primary erythromelalgia has a greater male prevalence and may occur at any age. In contrast, secondary erythromelalgia has an equal sex distribution and occurs mostly after the third decade.

Etiology and Pathogenesis

The etiology and pathogenesis of the erythromelalgia are unknown. Several mechanisms have been postulated for

ERYTHRO-MELALGIA AT A GLANCE



- Intense, burning pain with marked erythema, typically of the lower extremity.
- Typically intermittent. May be precipitated by exercise.
- Primary disorder or secondary to a myeloproliferative disorder.
- Cutaneous manifestations are often a result of attempts to alleviate the symptoms with immersion and thermal injury.
- Aspirin may be effective for secondary erythromelalgia.

primary erythromelalgia, including arteriovenous shunting and a small fiber neuropathy. It has been speculated that precapillary sphincters may be constricted while arteriovenous shunts are open, leading to an increased total perfusion but a deficient nutritive blood flow. Substances produced by local hypoxia lead to increased local blood flow, warmth, redness, and pain. In contrast, the genetics of erythromelalgia appears to be supporting a neuropathic basis. A mutation in a voltage-gated sodium channel of sensory nerves has been reported in inherited erythromelalgia.

Secondary erythromelalgia occurs in polycythemia, thrombocythemia, and autoimmune disorders and is hypothesized to be caused by platelet breakdown products based on the response to aspirin therapy.



Clinical Findings

HISTORY The disorder is characterized by red, hot, painful extremities with characteristic intense burning pain. It most commonly affects the lower extremities but may affect the upper extremities as well as other body parts, such as the face and ears. Involvement is usually symmetric although it can be unilateral in secondary cases. The symptoms are typically intermittent in nature but may be constant. Their onset may be gradual or abrupt, precipitated by activities, such as exercise or dependency of the limb, or ambient temperature or the use of heavy blankets at night. In contrast, cold exposure (e.g., standing on a cold floor) or immersion in ice water often relieves flares.

A few patients have been described who have both erythromelalgia and Raynaud phenomenon. During the hyperemic phase of Raynaud phenomenon, patients often complain of erythromelalgic-like symptoms. It is postulated that both syndromes have a common basis in a dysfunction of the regulation of vasomotor tone.

CUTANEOUS LESIONS Examination during attacks reveals warm, red, extremely sensitive extremities with normal pulses (Fig. 174-10). Between flares, the extremities may appear normal. The constant use of ice water leads to maceration of the skin, secondary infection, ulcers, and necrosis.

Pathology

The pathology of the primary disease is unknown. In the secondary syndrome caused by thrombocythemia or polycythemia fibromuscular dysplasia, internal elastic membrane splitting, and thrombotic occlusions of arterioles are present.

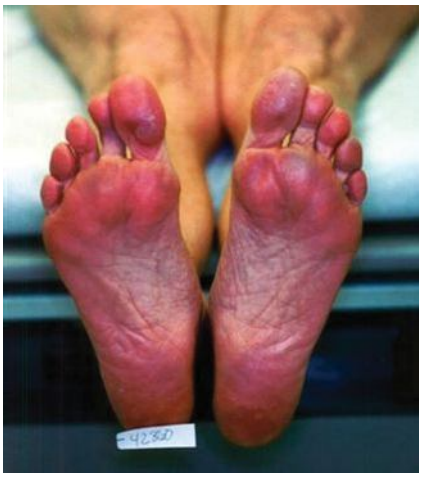

▲ **FIGURE 174-10** Intense erythema of the feet with associated burning pain typical of erythromelalgia.

Laboratory and Special Tests

There are no confirmatory tests. It has been reported that warm water immersion at 32° to 36°C (89.6° to 96.8°F) may induce attacks. Secondary disease must be evaluated with a complete blood cell count and anti-nuclear antibodies, to help distinguish autoimmune diseases. Nerve conduction studies may be necessary to rule out neuropathies.

Differential Diagnosis

The diagnosis must be made from the history and clinical manifestations. Skin injury is sometimes present from the constant cold-water immersion. The main differential diagnosis is regional complex pain syndrome (or reflex sympathetic dystrophy) during the early warm phase, but this is usually unilateral, and there is a history of trauma.

Complications

Complications are often related to treatment used by patients to provide relief of symptoms. Immersion or thermal injury may ensue due to prolonged soaks in ice water. This may lead to trophic changes of the skin, ulcers, and infection and even the need for amputation.

Prognosis and Clinical Course

The natural history of erythromelalgia is extremely variable.[9] Symptoms may be mild for several years or totally disabling within weeks. It has been reported that with long-term follow-up, symptoms were worse in 32 percent, unchanged in 27 percent, improved in 31 percent, and resolved in 10 percent of patients. Many patients become unable to work or carry on daily activities. As a result of the profound impact upon their life with intractable symptoms, patients have been known to commit suicide. There is a decrease in survival compared with age- and gender-matched controls.

Treatment

There are limited data available to guide therapy, primarily based upon case reports or small series.[9] Behavioral modifications should include efforts to keep the limbs cool and avoid the use of ice water or prolonged soaking. Additional measures including biofeedback and even hypnosis have been tried. Pharmacologic therapy has varied but often has focused on vasoactive drugs and drugs that affect the nervous system. Most vasoactive drugs, including calcium-channel blockers and β blockers, have been minimally effective in treating this disorder. Drugs used to treat neuropathy, such as serotonin reuptake inhibitors, tricyclic antidepressants, and gabapentin, have been used and may provide some relief. Aspirin is often of great benefit but only in secondary cases. Topical therapies, such as lidocaine patch or capsaicin cream, may reduce the pain. The prostaglandin E_1 analog misoprostol has been evaluated in a double-blind, crossover trial and found to be superior to placebo. Numerous other agents, including lorazepam, cycloheptadine, methysergide, piroxicam, and pizotifen, have been tried in selected cases. Surgical or medical sympathectomies have also been tried but have been found to have mixed results.

Prevention

There are no established measures to prevent the development of erythromelalgia. The focus has been to prevent flares once the disorder occurs. The key to prevention is to avoid exacerbating factors and to prophylactically cool the involved extremity. The other preventive measures are to prevent the development of secondary complications often as a result of prolonged soaking in ice water. It is important to limit the duration of soaking and to use cool, not ice-cold, water.

REFERENCES

1. Hirsch AT et al: ACC/AHA 2005 guidelines for the management of patients with peripheral arterial disease (lower extremity, renal, mesenteric, and abdominal aortic): A collaborative report from the American Association for Vascular Surgery/Society for Vascular Surgery, Society for Cardiovascular Angiography and Interventions, Society for Vascular Medicine and Biology, Society of Interventional Radiology, and the ACC/AHA Task Force on Practice Guidelines (Writing Committee to Develop Guidelines for the Management of Patients With Peripheral Arterial Disease). *J Am Coll Cardiol* **47**;1239, 2006
2. Hiatt WR: Medical treatment of peripheral arterial disease and claudication. *N Engl J Med* **344**:160, 2001
3. Liew YP, Bartholomew JR: Atheromatous embolization. *Vasc Med* **10**:309, 2005
4. Olin JW, Shih A: Thromboangiitis obliterans (Buerger's disease). *Curr Opin Rheumatol* **18**:18, 2006
5. Olin JW: Thromboangiitis obliterans (Buerger's disease). *N Engl J Med* **343**:864, 2000
6. Kraemer M, Linden D, Berlit P: The spectrum of differential diagnosis in neurological patients with livedo reticularis and livedo racemosa. *J Neurol* **252**:1155, 2005
7. Toubi E et al: Livedo reticularis is a marker for predicting multi-system thrombosis in antiphospholipid syndrome. *Clin Exp Rheum* **23**:499, 2005
8. Cohen JS: Erythromelalgia: New theories and new therapies. *J Am Acad Dermatol* **43**:841, 2000
9. Davis MD, Rooke T: Erythromelalgia. *Curr Treat Options Cardiovasc Med* **8**:153, 2006

CHAPTER 175

Cutaneous Changes in Venous and Lymphatic Insufficiency

Claude S. Burton
Craig N. Burkhart
Lowell A. Goldsmith

CHRONIC VENOUS DISEASE

Chronic disease of the peripheral veins includes a spectrum of diseases ranging from edema and tenderness to venous ulceration (Table 175-1).

Anatomy

Epidemiology

Chronic venous disease is extremely common. Although estimated costs and time lost from work have not been objectively assessed in over two decades, estimates state that 6 to 7 million people in the United States have evidence of venous stasis and that it accounts for 1 percent to 3 percent of the total health care budgets in countries with developed health care systems.[1]

Risk factors for chronic venous disease include heredity, age, female sex, obesity, pregnancy, prolonged standing, and greater height.[2]

Etiology and Pathogenesis

Venous ulcer occurs after failure of the calf muscle pump (Fig. 175-1). The heart pumps blood down to the foot; the calf muscle pump (when upright), returns venous blood to the heart. Venous blood from the skin and subcutis collects in the superficial venous system including the greater and lesser saphenous veins and its tributaries, moves through the fascia in a series of "perforating" or "communicating" veins, and fills the muscle-enveloped deep venous system. With muscle contraction, the deep veins are compressed; one-way valves in the deep system allow the now high pressure flow to move against gravity, and one-way valves in the perforators close to prevent pressure injury in the skin (see Fig. 175-1). In all patients with venous disease there is failure of these one-way valves and this can result in varicose veins (Fig. 175-2). The severity of venous disease is influenced by the number and distribution of incompetent valves and is worsened by any impairment of leg muscle function or ankle joint range of motion—all critical components of the calf muscle pump.

TABLE 175-1
Common Signs and Symptoms of Peripheral Venous Disease

Symptoms
- Leg fullness
- Aching discomfort
- Heaviness
- Nocturnal leg cramps
- Bursting pain on standing

Signs

Very early
- Tenderness to palpation

Early
- Edema
- Hyperpigmentation
- Stasis dermatitis
- Varicose veins

Late
- Venous ulcers
- Atrophie blanche
- Lipodermatosclerosis
- Acroangiodermatitis of Mali
- Post-phlebitic syndrome

VENOUS DISEASE AT A GLANCE



- One percent to 3 percent of U.S. health care expenses are for peripheral venous diseases and their complications.
- Venous ulcers are the most common chronic wound in humans.
- Risk factors include genetics, obesity, female gender, pregnancy, occupations requiring prolonged standing, surgery, trauma, and malignancies.
- Peripheral venous disease should be considered part of a spectrum including
  - Early signs: Tenderness, edema, hyperpigmentation, and varicose veins.
  - Late signs: Atrophie blanche, lipodermatosclerosis, and venous ulcers.
- Venous ulcers are located exclusively below the knee after venous pump failure, most often secondary to prior thrombosis.
- Treatment for all stages includes leg elevation, compression, treatment of infection, and dermatitis.
- Deep venous disease is associated with thromboembolism.





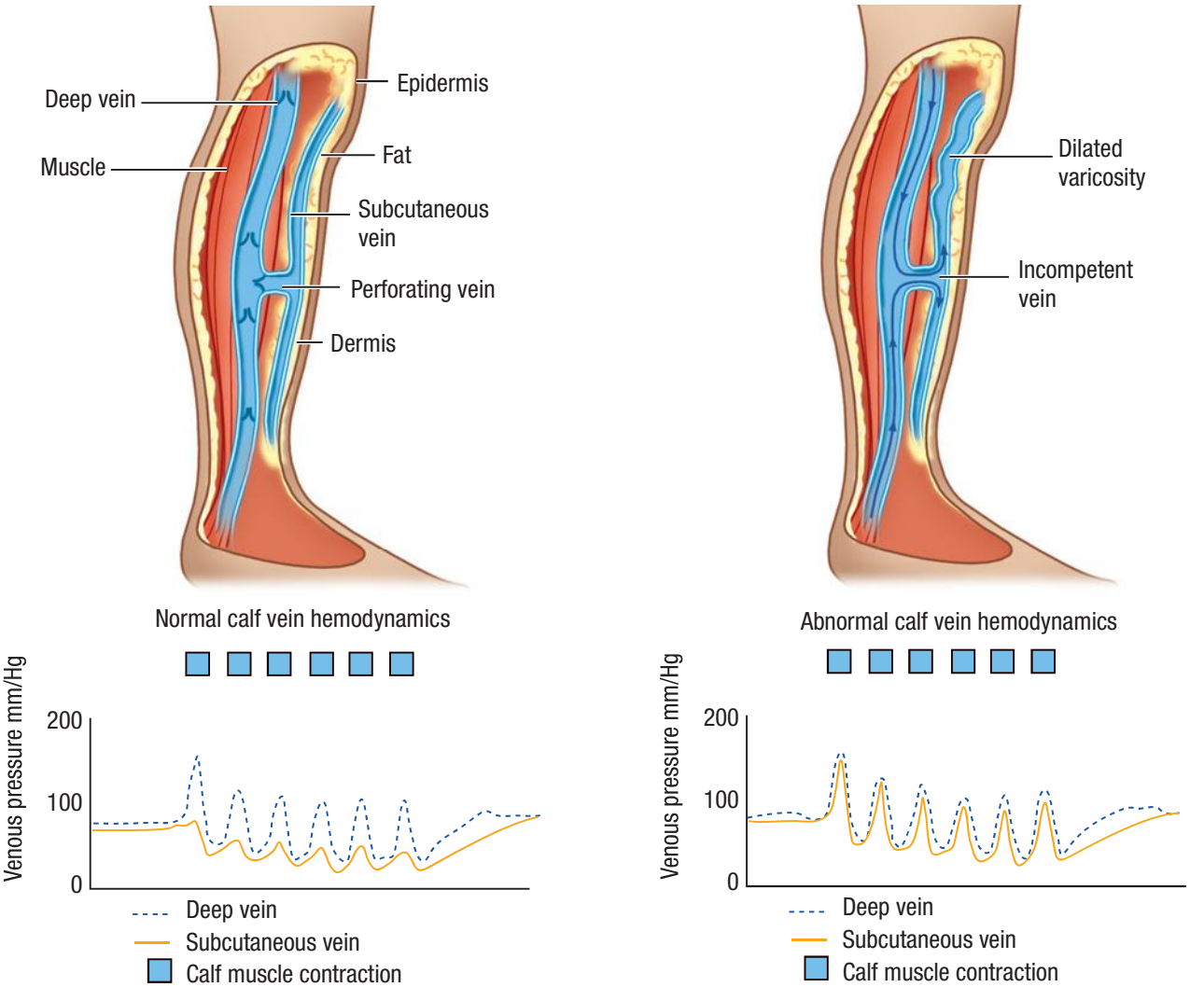

▲ **FIGURE 175-1** Anatomy and hemodynamics of the calf muscle pump in normal individuals and in patients with venous insufficiency. The latter is characterized by high pressure reflux from deep veins into the superficial veins and small vessels of the skin.

Any obstruction to venous return (thrombosis, radiation fibrosis, etc.), or elevation of tight atrial pressure (pulmonary hypertension, heart failure, etc.), further compromises venous return. A detailed description of the anatomy and hemodynamics of the venous system of the lower extremities is found in Chap. 250.

The most common cause of valvular failure is thrombosis. The nidus for venous thrombosis is typically the valve cusp, and when the thrombus is lysed by plasmin, valve function is often lost as well. Calf muscle pump failure after deep venous thrombosis (DVT) is often referred to as the *post-phlebitic syndrome*.[6]

Once valves fail, especially those in the perforators, high pressure blood in the deep system refluxes into the unsupported veins of the skin, leading to soft tissue injury, inflammation, and eventually fibrosis, as the subcutaneous fat is replaced by scar in a process described by the term *lipodermatosclerosis* (see the section Cutaneous Lesions).

Clinical Findings

HISTORY An approach to the analysis of patients with ulcers is in Fig. 175-3.

Trauma frequently triggers the nonhealing venous ulcer. The events preceding ulceration happen insidiously over many years and may be ignored by the patient. A history of thrombosis may be missing because most episodes of lower extremity venous thrombosis are clinically silent. Relevant inquiry related to thrombosis risk should include a family history of similar problems (suggesting perhaps a familial thrombotic tendency), any episode of leg immobilization including knee or hip surgery and fractures, and any head injury associated with loss of consciousness.

Most patients complain of leg swelling, and many have been given diuretics, though the edema of venous disease, unlike the edema in salt-retaining states, like heart failure, cirrhosis, and nephritic syndrome, does not respond to diuretics. An edematous leg not responsive to diuretic therapy is a strong clue to the diagnosis. Venous ulcers may or may not be painful.

CUTANEOUS LESIONS All of the clinical syndromes described are secondary to the initial valvular syndrome and are grouped into clinical categories. Once there is venous valvular failure, a rather predictable series of changes occur in the skin. The earliest (though not universal) physical finding is soft tissue tenderness, even of normal appearing skin, discovered when checking for the presence of edema by palpation. Its association with other cutaneous signs of chronic venous disease is common.

The soft tissue injury that precedes ulceration begins in the subcutis, and visible changes may not appear for some time. Frequently one notes the ap-



▲ **FIGURE 175-2** Extensive varicose veins on the calf and thigh.

pearance of petechial lesions, which have the appearance of cayenne pepper sprinkled about the gaiter area. As the hemoglobin in the petechial lesions breaks down, the iron remains in the skin as hemosiderin and may lead to impressive discoloration (Fig. 175-4).

Stasis dermatitis, characterized by erythema, scaling, pruritus, erosions, oozing, crusting, and occasional vesicles may occur during any stage of chronic venous insufficiency (see Fig. 175-4). It typically occurs in the medial supramalleolar region where microangiopathy is most intense. Over time, lesions may lichenify. As 58 percent to 86 percent of patients with venous leg ulcers develop contact sensitization to topical therapies, it is important to evaluate for coexisting allergic contact dermatitis.

In lipodermatosclerosis (sclerosing panniculitis, hypodermatitis sclerodermiformis) pliable subcutaneous fat is gradually replaced by fibrosis, and the skin begins to feel indurated. This is a fibrosing panniculitis (see Chap. 68) characterized by a bound-down, indurated plaque that begins at the medial ankle and extends circumferentially around the entire leg.[7] As the fibrosis increases, it may constrict and strangle the lower leg further, impeding venous and lymphatic flow and leading to brawny edema above and below the fibrosis. These late changes resemble an inverted champagne bottle (Fig. 175-5).

Varicose veins, especially noticeable when the patient is standing, and smaller



▲ **FIGURE 175-4** Bilateral venous disease with dermatitis and extensive hemosiderosis.

varicosities appear about the dorsum of the foot and ankle (see Chap. 250). Although they are usually asymptomatic, patients may complain of symptoms of aching, cramping, itching, fatigue, and swelling that are worse with prolonged standing (see Fig. 175-2).

Atrophie blanche (livedo vasculitis, segmental hyalinizing vasculitis) refers to skin overlying areas of fibrosis that often appears porcelain white and atrophic. Fully established lesions of atrophie blanche consist of irregular, smooth, atrophic plaques with surrounding hyperpigmentation and telangiectasias (Fig. 175-6). Although mostly related to venous stasis, atrophie blanche may also be associated with an underlying disorder of coagulation (e.g., antiphospholipid syndrome, inherited coagulopathies) or autoimmune disease (e.g., scleroderma, lupus erythematosus).[8]

Occasionally, acute inflammation of the subcutaneous fat develops in patients with venous disease, and histologically one finds an acute septal panniculitis in this setting (see Chap. 68).

Though ulceration is classically located in the gaiter area (see Fig. 175-5), *venous ulcers* have been described anywhere below the knee. Venous ulcers are typically tender, shallow, irregular, red-based ulcers that are always located below the knee (Fig. 175-7). They are usually located on the medial ankle or along the line of the long or short saphenous veins. Clinical distinction should be made with other common ulcers of

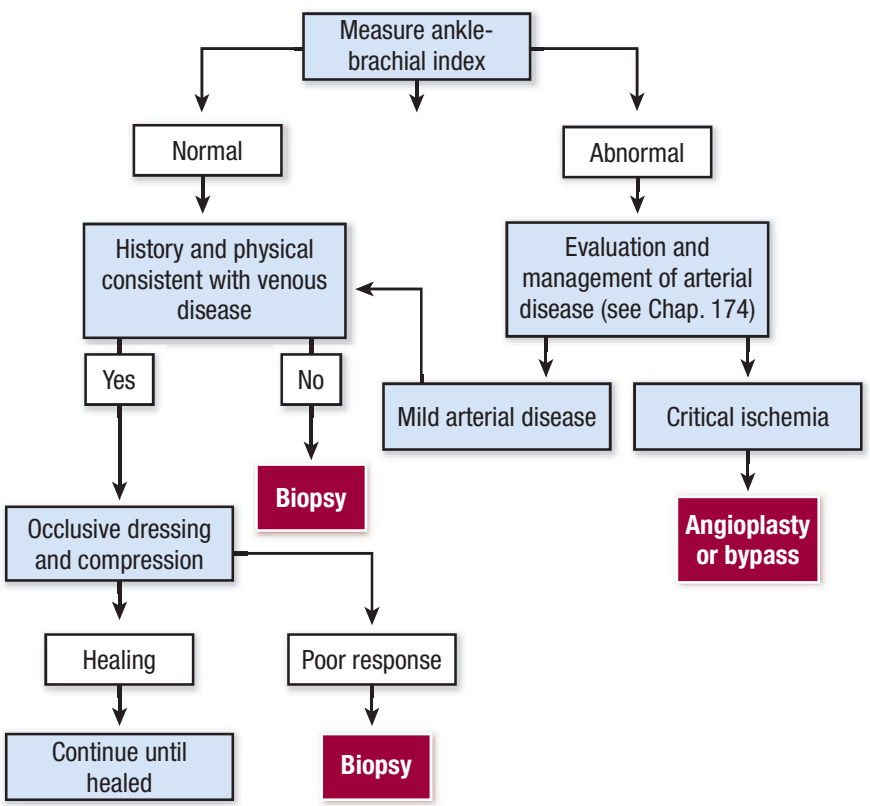

▲ **FIGURE 175-3** Approach to patient with lower extremity venous insufficiency.







▲ **FIGURE 175-5** Venous ulceration in an area of lipodermatosclerosis, hemosiderosis, inflammation, and varicosities on the foot. Note lipodermatosclerosis constricts lower leg below the calf ("inverted champagne bottle").

the lower extremity as discussed later in this chapter and as shown in Box 175-1.

Histopathology

Laboratory Tests and Imaging Studies

It is crucial to evaluate arterial blood flow. A useful bedside screening test is to calculate the ratio of the systolic blood pressure in the ankle (as measured by Doppler) to the systolic pressure in the brachial artery (also measured by Doppler). This "ankle/brachial index" is greater than or equal to one in normal individuals. Anything less than one is an indication of peripheral arterial disease. The lower the ratio, the more severe the arterial obstruction (see Fig. 175-3). An ankle/brachial index is reliable except in the presence of calcified vessels, which are non-compressible and therefore a true systolic pressure cannot be measured. Having excluded arterial disease as a cause of ulceration, a clinical diagnosis is sufficient for the initiation of empiric therapy in most cases. When the diagnosis is in doubt, skin biopsy may be useful. Functional testing of calf muscle pump function and venous valvular function using plethysmography is occasionally useful. Duplex Doppler ultrasonography can be useful to document valvular incompetence and to evaluate patients for possible sclerotherapy or surgery (see Chap. 250).



▲ **FIGURE 175-6** Atrophie blanche with irregular porcelain-white atrophic scars, small ulcerations, and crusting.

Differential Diagnosis (See Box 175-1)

Complications

Recurrent ulceration is frequent. Any open wound provides a portal of entry for bacteria, and cellulitis, though infrequent, may develop at any time. Given that venous dermatitis may be extremely pruritic, and that these patients are easily sensitized to the topical agents they apply, contact dermatitis, especially due to topical antibiotics, is common. The skin is easily excoriated and may become infected.[10] The advent of methicillin-resistant *Staphylococcus aureus* is a threat to this population. The dermatitis of venous disease may become generalized as an id reaction and may rarely produce an exfoliative erythroderma (see Chap. 17). Many of these individuals are predisposed to thrombi, and recurrent episodes of venous thrombosis are not uncommon.



▲ **FIGURE 175-7** Venous ulceration with stasis dermatitis, edema, and varicosities.

All patients with advanced venous disease have some degree of lymphatic impairment, though lymphatic impairment may also result from inherited defects in lymphatic development or destruction of lymphatics after cellulitis/lymphangiitis, surgical interruption, or radiation.[11] Loss of lymphatic drainage from the lower leg may lead to verrucous changes and cutaneous hypertrophy, elephantiasis nostras (see Acquired Lymphedema).

Prognosis and Clinical Course

The prognosis for healing areas of ulceration and inflammation is excellent in the absence of comorbid illness that interferes with healing. The vast majority of uncomplicated patients respond well to ambulatory outpatient therapy as outlined in the section Treatment. Permanent changes include hemosiderosis and fibrosis that develop before the initiation of therapy. Loss of valvular function is irreversible. In the absence of continual lifelong cutaneous support in the form of inelastic wraps or elastic stockings, skin and soft tissue injury continues.

Treatment

Treatment of chronic venous insufficiency is outlined in Box 175-2.

Box 175-1

Differential Diagnosis of Leg Ulcers

- Vascular diseases
  - Arterial (hypertensive atherosclerotic, vasospastic)
  - Venous (venous stasis ulcer)
  - Lymphedema
- Metabolic disorders
  - Diabetes mellitus
  - Necrobiosis lipoidica diabeticorum
  - Porphyria cutanea tarda
  - Gout
  - Pancreatitic (pancreatitis, carcinoma)
- Infections
  - Bacterial (especially *Staphylococcus aureus, Streptococcus*)
  - Spirochetal (syphilis)
  - Fungal (deep fungal, mycetoma)
  - Opportunistic in immunocompromised
  - Viral
- Vasculitis
  - Hypersensitivity vasculitis
  - Polyarteritis
  - Systemic lupus erythematosus
  - Rheumatoid vasculitis
  - Wegener granulomatosis
  - Lymphomatoid granulomatosis
- Lymphedema
  - Congenital
  - Post-infectious
  - Postsurgical
  - Postirradiation
- Drugs
  - Halogens (bromide, iodide)
  - Ergotism
  - Drug-induced vasculitis
  - Anticoagulant necrosis (Coumadin, heparin)
  - Hydrea
- Hematologic abnormalities
  - Hypercoagulable states (protein C, S, antithrombin III deficiency, activated protein C resistance, prothrombin gene polymorphism)
    - Lupus anticoagulant syndrome
    - Paroxysmal nocturnal hemoglobinuria
  - Sickle cell anemia
  - Thalassemia
  - Polycythemia vera
  - Leukemia
  - Dysproteinemia (cryoglobulinemia, macroglobulinemia)
- Tumors
  - Cutaneous (basal cell cancer, squamous cell cancer, sarcoma, malignant melanoma, Merkel cell)
  - Secondary (metastatic carcinoma, lymphoma)
  - Kaposi sarcoma
- Miscellaneous
  - Pyoderma gangrenosum
  - Trauma (including factitial)
  - Burns
  - Pressure ulcers, neuropathic ulcers
  - Insect bites (brown recluse spider)
  - Ulcerative lichen planus
  - Bullous diseases (epidermolysis bullosa)
  - Sweet syndrome
  - Idiopathic

Box 175-2

Treatment of Chronic Venous Insufficiency

- Mechanical
  - Leg elevation
  - Compression stockings
  - Compression bandages
  - Intermittent pneumatic compression pumps
- Drug therapy
  - Aspirin
  - Pentoxifylline
  - Topical steroids (for stasis dermatitis)
  - Horse chestnut seed extract
- Dressings
  - Wet and dry non-adherent dressings
  - Occlusive hydrocolloid or gel dressings
  - Zinc paste–impregnated bandages (Unna boot)
- Surgery
  - Sclerotherapy
  - Long saphenous vein stripping
  - Saphenofemoral/saphenopopliteal junction disconnection
  - Calf varicosity avulsions
  - Subfascial endoscopic perforator vein ligation
  - Endovenous laser therapy
  - Radiofrequency ablation

Given the limitations of bed rest as an effective therapy, the focus is now on an ambulatory outpatient approach to the management of venous ulceration. Most experts agree on the essential role of compression in treating chronic venous insufficiency.[12] Hence, unless there are contraindications (arterial occlusive disease or abnormal ankle-arm indexes), compression therapy should remain part of any treatment regimen for chronic venous disease.

Toward the end of the nineteenth century, Paul Gerson Unna recognized that by providing a compression bandage to the distal extremity he could heal venous ulcers in an ambulatory patient population using zinc impregnated gauze wrap, the "Unna boot." Though the literature over the years continued to document the success of this approach, it proved difficult to achieve graduated compression with this wrap, and compliance was poor. Eventually, the addition of a self-adherent second layer (Coban™, for example) over a zinc wrap was introduced as the "Duke boot" and has proven to be easy to apply with reproducible graduated inelastic compression (Fig. 175-8) bandaging to counter the outflow from perforator incompetence is the cornerstone of venous ulcer management.[13]

The dressings should be changed weekly, or more often for heavily exudating wounds. New tissue is vulnerable to the cytotoxic effects of most topical antiseptics, and these agents are to be avoided. One should not put anything in a wound that you would not be willing to put in your eye. A gentle rinse with tap water or saline is sufficient. It is preferable to have the patient supine during dressing changes if at all possible.

Mechanical therapy is the mainstay of treatment for all clinical manifestations of chronic venous insufficiency.

Each pharmaceutical therapy targets a specific clinical aspect of chronic venous insufficiency. Diuretics may be used in the short term for treating severe edema. Horse chestnut seed extract (often standardized to 50 mg escin twice daily) is an herbal remedy that appears to be safe and effective as a short-term treatment for leg pain and swelling.[17] Aspirin (300 to 325 mg/day)[18] and pentoxifylline[19] may improve healing of chronic venous ulcers. Finally, topical steroids and emollients aid resolution of stasis dermatitis.

Although all wounds harbor potential pathogens, there is no evidence that routine use of antibiotics is helpful in patients with venous ulcer. If cellulitis is suspected, empiric therapy with coverage for *S. aureus* and *Streptococci* is warranted. Topical antibiotics, especially mupirocin, are useful for folliculitis due to *S. aureus* and *Streptococci.* With the increasing incidence of community acquired methicillin-resistant *S. aureus* in this population, culture and sensitivity are suggested for suspected skin and soft tissue infections.

Venous disease is progressive and irreversible. Patients must be educated about the need for continual hemody-







▲ **FIGURE 175-8** Compression bandage using a zinc paste primary layer (Unna boot) followed by Coban™ at full stretch.

namic support after the wound has healed. Graduated stockings that provide a minimum of 30 to 40 mmHg at the ankle should be carefully fitted to all patients and worn for their lifetime. It is a mistake to place elastic stockings on edematous limbs, especially those that are tender. One should use compression bandaging until all edema, inflammation, and tenderness have resolved before fitting the patient with stockings.

In carefully selected cases, sclerotherapy or surgical techniques, especially endovenous ablation, may close incompetent perforators and correct the hemodynamic abnormalities that lead to venous ulcer (see Chap. 250).[20,21]

Prevention

Prevention of venous thrombosis prevents venous insufficiency. Because many thrombotic traits are genetic, it is likely those patients at extra risk for thrombosis may be identified and treated for this risk before an event, and efforts to prevent thrombosis during elective surgery and hospitalization should reduce the numbers of post-phlebitic limbs. Once a patient develops venous thrombosis, elastic compression stockings are the only proven method to reduce the risk of post-thrombotic syndrome.[22]

Valvular failure may develop during pregnancy. Therefore the use of supportive stockings throughout maternity, although not proven, can be recommended. If one's occupation or lifestyle involves long periods of immobility (long-distance flights appear to be especially risky), stockings are advisable.

OTHER VENOUS DISEASES

DVT is important for at least two reasons: The thrombosed veins are the sources of pulmonary embolisms, and the thrombosed leg may progress to chronic venous disease that has already been discussed. Superficial thrombophlebitis has associations with internal diseases as well.

Deep Vein Thrombosis

EPIDEMIOLOGY

ETIOLOGY AND PATHOGENESIS

CLINICAL FINDINGS Clinical diagnosis of DVT is unreliable. Swelling, pain, discoloration, warmth, and/or superficial venous dilation may be seen in the involved extremity; less than one-third of patients suspected of having a DVT on clinical grounds have the disease.[26]

LABORATORY TESTS

TREATMENT Details of anticoagulation management in these cases should be in conjunction with the appropriate consultants. Primary prevention follows the same procedures discussed above for peripheral vascular disease.

Superficial Venous Thrombosis and Phlebitis

EPIDEMIOLOGY

ETIOLOGY AND PATHOGENESIS

CLINICAL FINDINGS Superficial phlebitis is the clinical finding of pain, tenderness, induration, and/or erythema in a superficial vein often associated with a palpable cord. These signs may be due to inflammation, infection, and/or thrombosis. Various eponyms are used for phlebitis in certain locations. For example, *Mondor disease* (sclerosing lymphangitis) refers to superficial phlebitis of the breast or dorsal penile vein, and *superficial thrombophlebitis* usually refers to superficial phlebitis of a lower extremity vein. Clinically, a thrombus is suggested by superficial phlebitis with a palpable cord that persists after a limb is raised.

LABORATORY TESTS Due to the possibility of co-existing occult DVT in patients with superficial venous thrombosis, some experts recommend compression ultrasound for all patients with lower extremity superficial venous thrombosis. However, this recommendation has not been explicitly tested in any trial and clinical judgment should guide further testing.

TREATMENT

LYMPHEDEMA

Lymphedema is a consequence of prolonged edema; edema is an interference of the physiologic movement of fluid from capillaries through the interstitial spaces and back into lymphatics. In edema, the equilibrium is shifted and more fluid remains in the interstitial space—when this becomes chronic, inflammatory cells and their cytokines lead to an irreversible state.

Dysfunction of the lymphatic system because of genetic or congenital defects or related to infection, surgery, or external trauma leads to functional impairment of the tissue clearing ability and progression to clinical signs of lymphedema. The differential diagnosis of lymphedema is extensive but can be logically approached.

In all the clinical disorders discussed, edema may be transient and pitting with pressure but, with time, becomes fixed and accompanied by dermal sclerosis and epidermal hyperplasia.

Anatomy and Physiology of the Lymphatic System

Lymphedema-Related Genetic Diseases

Primary lymphedema (types I and II) is estimated at 1 in 6000. Other types are even rarer. A continuously updated

LYMPHEDEMA AT A GLANCE

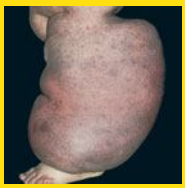

- Lymphatics are essential for the clearing of extravascular fluids and debris and as transport of immunocompetent cells during the initiation of an immune response.
- Specific markers of lymphatic endothelia exist.
- Genetic defects causing lymphedema in childhood or early adult life are often caused by defects in a vascular growth factor receptor (*VEGFR3*) and *FoxC2*, a transcription factor.
- Lymphedema acquired in adult life is often related to chronic venous disease, after mastectomy with radiation and node removal, and, in certain geographic locations, filariasis.
- Cellulitis may complicate all forms of lymphedema and should be aggressively treated.

source on these diseases is Online Mendelian Inheritance in Man (OMIM; http://www.ncbi.nlm.nih.gov/omim/).

TYPE I LYMPHEDEMA (MILROY SYNDROME, OMIM #153100) ***Etiology and Pathogenesis.*** Type I lymphedema, an autosomal dominant disease characteristically has a mutation in *VEGFR3* (also called the *FLT4 gene*). Penetrance is relatively high (80 percent). There is a 2.3:1.0 female predominance in pedigrees; this sex ratio may be due to a more severe disease in males that leads to hydrops fetalis and fetal death.

CLINICAL AND RADIOLOGIC FINDINGS Lymphedema is almost always from birth and is confined to the legs with deep creases over the toes and small deformed ("ski jump") toenails and is characterized hypoproteinemia from intestinal loss of albumen, chylous ascites, and scrotal edema.[32]

Lymphangiography demonstrates dysplastic lymphatics in both clinically affected and clinically normal extremities, emphasizing the complexity of the pathophysiology, leading ultimately to disease. Prenatal ultrasound can show edematous legs in the fetus.

TYPE II LYMPHEDEMA (FORK-HEAD FAMILY TRANSCRIPTION FACTOR DEFECTS) ***Etiology and Pathogenesis.*** The fork-head family transcription factor defects have in common mutations in a transcription factor, the fork-head transcription factor, FoxC2 [MFH1 (mesenchyme forkhead-1); fork-head is the name of a *Drosophila* trait]. FoxC2 is inherited as an autosomal dominant trait. The concept of type II lymphedema can be enlarged to include four syndromes with similar molecular defects: Lymphedema-late onset (Meige syndrome), lymphedema-distichiasis syndrome, lymphedema and ptosis syndrome, and the hereditary forms of lymphedema with the yellow nail syndrome. Mutations have included nonsense and frameshift mutations inactivating FoxC2.

Clinical Findings. **MEIGE SYNDROME (OMIM #153200).** Edema develops around puberty, later than type I disease, and facial puffiness with deep creases and wrinkling may occur. Lymphedema *praecox* (Latin for *premature*) should not be used for this disease as it only leads to further nosologic confusion. Lymphangiosarcoma may be associated. Late onset-type II disease has decreased or absent axillary nodes and decreased lymphatics above the inguinal ligament on scintilymphangiography.

Other rare syndromes with lymphedema exist.

GENETIC DISORDERS AFFECTING BOTH LYMPHATICS AND VEINS

ACQUIRED LYMPHEDEMA ***Epidemiology.*** Chronic edema in a community sample in London had a prevalence of 1.33 per 1000 and was 5.4 per 1000 for those older than the age of 65 years.[36] Twenty-five percent of chronic edema was related to malignancy; and 29 percent of patients had at least one episode of cellulitis over the year before the survey; 70 percent to 80 percent of patients were female.

Worldwide lymphedema due to filariasis is estimated to affect between 90 and 100 million individuals (see Chap. 207). The microfilaria invade lymphatics, reproduce within the lymphatics, and damage local lymphatics and regional nodes, often resulting in hydroceles and scrotal swelling, classic components of filarial elephantiasis. In endemic areas, children may have subclinical disease that may be important to treat.[37]

Other infectious diseases with lymphedema are much less common and include lymphogranuloma venereum with elephantiasis of the penis and scrotum, granuloma inguinale (see Chaps. 203 and 204), and tuberculosis (see Chap. 184).

Etiology and Pathogenesis. There are two major etiologies to non-hereditary lymphedema on a worldwide basis—venous disease of the legs (discussed earlier in this chapter) and postcancer, especially carcinoma of the breast–related lymphedema.

Clinical Findings. Acquired lymphedema is often painless and leaves legs feeling heavy and the patient tired. Although the limb swells during the day, indentations from socks can be seen on the leg at nighttime, returning toward normal during the night, but the leg stays swollen, and initially concerns may be cosmetic in nature. The foot is often involved first and initially lesions pit with pressure. With time, lesions become woody or lardaceous and do not pit. The toe contours are lost (Fig. 175-9). Kaposi-Stemmer sign, a feature of chronic lymphedema, describes the skin over the proximal digit of the second toe that cannot be elevated; in edema the skin can be elevated.

Unilateral lymphedema suggests localized obstructing factors, but bilateral lymphedema can be due to obstruction in the pelvis or abdomen.

Inflammation with redness, pain, and swelling is not lymphedema but can be pyogenic infection, most commonly with *S. aureus* or *Streptococcus pyogenes*. Systemic antibiotics should be started before waiting for red lymphangitic streaking. A common complication is contact dermatitis from the use of topical antibiotics or multiple emollients and anti-inflammatory creams.

Special Tests.

Complications. Prolonged lymphedema leads to fibrosis and epidermal hyperplasia with verrucous hyperkeratosis (Fig. 175-10). Ulceration rarely occurs, although the edema and hyperkeratotic changes may be profound. Lymphangiosarcoma, the Stewart-Treaves syndrome when associated with postmastectomy lymphedema, is the common lesion in chronically lymphedematous locations (see Chap. 128).

Prognosis and Clinical Course. Careful, symmetric measurement at ankles, calves, and thighs should be made.

Treatment. Diuretics may worsen the condition and should not be used as a primary treatment for lymphedema. El-





▲ **FIGURE 175-9** Lymphedema of the left leg in a 47-year-old fireman. The extreme swelling began at birth and was painless. Note the lack of stasis pigmentation or ulceration. The patient functioned normally at work and wanted no treatment.



evation, massage, and sequential compression followed by elastic stockings can be used (see Treatment under Chronic Venous Disease). Various surgical approaches have been tried. In patients with primary and secondary lymphedema in the absence of venous or arterial disease, manual lymphatic drainage and sequential pneumatic pumps, in addition to compression wraps and garments, may be useful.

Cellulitis or recurrent lymphangitis is a significant problem in lymphedematous sites, and there is both a rationale and results that encourage long-term antibiotic use (e.g., 2.4 million units of benzathine-penicillin G intramuscularly every 2 weeks).[39]



▲ **FIGURE 175-10** Verrucous skin changes in chronic lymphedema.

Microsurgery of lymphatics to bypass obstructed nodes can be considered if nonsurgical treatments are not successful. This surgery consists of the formation of multiple end-to-end lymphatic-venous anastomoses.[40]

Excisional or suction-assisted lipectomy (liposuction) may be an option in selected patients.

Prevention. Any patient with lymphedema, whatever the cause, should keep their feet dry, nails trimmed, and prevent and aggressively treat pyogenic infection. Lymph moves faster during limb activity and exercise (e.g., walking should be encouraged).

LOCALIZED AREAS OF LYMPHEDEMA

Lymphedema is common in some locations, face and penis especially; low-grade infection is usually invoked as the cause.

In puffy hand syndrome, intravenous drug use with injections into hands or feet is associated with lymphedema. The condition is not drug specific.

KEY REFERENCES

The full reference list for all chapters is available at www.digm7.com.

2. Bergan JJ et al: Chronic venous disease. *N Engl J Med* **355**:488, 2006
3. McGuckin M et al: Validation of venous leg ulcer guidelines in the United States and United Kingdom. *Am J Surg* **183**:132, 2002
4. Margolis DJ et al: Venous leg ulcer: Incidence and prevalence in the elderly. *J Am Acad Dermatol* **46**:381, 2002
12. Douglas WS, Simpson NB: Guidelines for the management of chronic venous leg ulceration. Report of a multidisciplinary workshop. British Association of Dermatologists and the Research Unit of the Royal College of Physicians. *Br J Dermatol* **132**:446, 1995
21. Chaby G et al: Refractory venous leg ulcers: A study of risk factors. *Dermatol Surg* **32**:512, 2006
31. Cueni LN, Detmar M: New insights into the molecular control of the lymphatic vascular system and its role in disease. *J Invest Dermatol* **126**:2167, 2006
32. Brice G et al: Milroy disease and the VEGFR-3 mutation phenotype. *J Med Genet* **42**:98, 2005
33. Brice G et al: Analysis of the phenotypic abnormalities in lymphoedema-distichiasis syndrome in 74 patients with FOXC2 mutations or linkage to 16q24. *J Med Genet* **39**:478, 2002



Disease Due to Microbial Agents, Infestations, Bites, and Stings

Copyright © 2008 by The McGraw-Hill Companies, Inc. Click here for terms of use.



SECTION 29

BACTERIAL DISEASE

CHAPTER 176

General Considerations of Bacterial Diseases

Timothy G. Berger

Bacterial infection of the skin may be thought of in four major categories: (1) primary skin infection, (2) secondary infection of a primary skin disease (e.g., infected atopic dermatitis), (3) the skin lesions as manifestations of primary infection in some other organ system, usually the blood, and (4) reactive skin conditions resulting from bacterial infection (e.g., erythema nodosum due to streptococcal pharyngitis). It is important to remember that the cutaneous changes associated with infection are not always suppurative but may present as a vasculitis or a hypersensitivity response (e.g., lesions in subacute bacterial endocarditis or erythema nodosum).

The importance of the skin as a mirror of systemic infection cannot be overemphasized, especially when classic clinical findings are distorted as in immunocompromised patients. The timely recognition of the cutaneous clues of bacteremia may provide the early warning to consider life-threatening infections due to organisms such as *Pseudomonas aeruginosa*, *Vibrio vulnificus*, *Salmonella typhi*, *Staphylococcus aureus*, and *Neisseria meningitidis*.

◀ Erysipelas. Painful, edematous erythema with sharp margination on both cheeks and the nose. There is tenderness, and the patient has fever and chills.

PATHOGENESIS OF BACTERIAL INFECTION OF THE SKIN

The development and evolution of bacterial infection involve three major factors: (1) the portal of entry, (2) the host defenses and inflammatory response to microbial invasion, and (3) the pathogenic properties of the organism.

Portal of Entry

The efficacy of the intact and functioning epidermis to resist direct bacterial invasion is illustrated by the high prevalence of septicemia in low-birthweight, premature infants who lack an effective epidermal barrier.[1] Because normal intact pediatric and adult skin is relatively resistant to infection, most infections occur when there is disruption of the skin barrier. Maceration, shaving, chronic wounds, excoriation of pruritic insect bites, and disruption of the epidermal barrier by other pathogens are the primary avenues by which bacteria can breach the skin barrier. For example, lower leg cellulitis in the otherwise healthy person without venous incompetence or a leg ulcer is a consequence, most commonly, of interdigital maceration or tinea pedis.[2]

The character of the cutaneous inflammatory response to bacteria will be influenced by how the organisms reach the involved area. Local inflammation and suppuration commonly accompany direct bacterial infection of the skin. In septicemia, the vascular wall is often the primary site of skin involvement; hemorrhage or thrombosis with infarction is the initial manifestation. Certain bacteria can produce bacteremia or distant lesions without evoking an obvious inflammatory response at the portal of entry [e.g., *Yersinia pestis*, *Streptobacillus moniliformis* (rat-bite fever)], even in a nonimmunosuppressed host. Occasionally, a devastating *S. pyogenes* septicemia has followed closely on an innocuous pinprick or abrasion that has not induced a significant local lesion.

BACTERIAL SKIN DISEASES AT A GLANCE

- Bacteria cause disease by direct invasion of tissues, by secreting toxins, and by causing immunologic consequences that result in disease.
- The innate immune system is critical in the adequate handling of bacterial entry into the skin.
- The virulence and pathogenicity of bacteria is related to their ability to avoid activating the innate immune system or resisting killing within immune effector cells.
- Immunosuppression, especially neutropenia, puts the host at high risk for bacterial infections; some infections are rare except in the immunocompromised host.
- Treatment of bacterial infection needs to consider the nature of the host and that of the infecting bacterium to be successful.

Natural Resistance of the Skin

The normal skin of healthy individuals is highly resistant to invasion by the wide variety of bacteria to which it is constantly exposed. It is difficult to produce localized infections such as impetigo, furunculosis, or cellulitis if the integument is intact.[3] Pathogenic organisms such as *S. pyogenes* (group A streptococcus, GAS) and *S. aureus* produce characteristic lesions of cellulitis and furunculosis in hosts with normal defenses usually

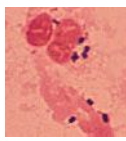

Copyright © 2008 by The McGraw-Hill Companies, Inc. Click here for terms of use.

because there is a disruption of the normal skin barrier. The presence of a silk suture reduces by a factor of 10,000, in the case of *S. aureus*, the number of organisms needed to produce an abscess in the human skin.[4]

Bacteria are unable to penetrate the keratinized layers of normal skin and, when applied to the surface, rapidly decrease in number. Maceration and occlusion, which result in increased pH, higher carbon dioxide content, and higher epidermal water content, result in dramatic increases in bacterial flora.[5] Some bacteria, such as those that are Gram negative, can only be found in such sites, suggesting that normal skin conditions prevent them from colonizing the skin. The relative dryness of normal skin specifically contributes to the marked limitation of growth of bacteria, especially Gram-negative bacilli. Lipids found on the skin surface have antibacterial properties.[1] Reduction of skin surface lipids with topical solvents prolongs the survival time of *S. aureus* on the skin. The free fatty acids, linoleic and linolenic acids, are more inhibitory for *S. aureus* than for coagulase-negative staphylococci, a component of the normal skin flora. Sphingosine, glucosylceramides, and *cis*-6-hexadeconic acid have been demonstrated to have antimicrobial activity against *S. aureus*. Bacterial interference (the suppressive effect of one bacterial species on colonization by another) exerts a major influence on the overall composition of the skin flora.

The organisms that characteristically survive and multiply in various ecologic niches of the skin constitute the "normal cutaneous flora." As an example, the distribution of different species of coagulase-negative staphylococci varies among different anatomic areas, and their relative numbers can depend on age. In adults, *S. epidermidis* is the principal staphylococcal species isolated from the scalp, face, chest, and axilla. Gram-negative bacilli are relatively rare as components of the normal resident skin flora, with the exception of members of the *Acinetobacter calcoaceticus-baumannii* complex, found on approximately 25 percent of normal adults, primarily in axillae, groins, and toe webs.[6]

ANTIMICROBIAL PEPTIDES Human skin contains a wide range of proteins with inherent antimicrobial properties. These antimicrobial peptides (AMPs) are expressed on the skin surface as well as in eccrine sweat and saliva.[7] Activated keratinocytes produce AMPs. The AMPs produced in keratinocytes are delivered to the skin surface in the lamellar bodies, and their appearance on the skin surface is closely tied to the production of normal skin stratum corneum lipids (see Chap. 45). These small proteins have as a characteristic physical property the presence of an amphipathic organization, with one portion being cationic and capable of binding to microbial membranes, and another being hydrophobic allowing for insertion into the bacterial lipid membrane. The insertion into the membrane results in membrane disruption and microbial death. A second principle of AMPs is that they are processed after release by enzymes on the skin surface, resulting in multiple peptides each with different activities and different targets. The third principle of AMPs is that they not only kill microbes directly, but they are also potent activators of the host immune response. The two major AMPs studied to date on the skin are the cathelicidins (LL-37) and the defensins. The marked decrease of these molecules on the inflamed skin of patients with atopic dermatitis explains the susceptibility of atopic patients to infections with *S. aureus*, herpes simplex virus, and vaccinia virus.[8] T helper 2 cytokines specifically suppress the production of these AMPs, explaining why psoriatic skin has normal or elevated AMP content and is less susceptible to bacterial and viral infections.[9]

SPECIFIC FEATURES OF HOST INFLAMMATORY RESPONSE TO CUTANEOUS INFECTION

The adaptive immune system, which requires the development of targeted cells and antibodies, is highly effective in protecting humans from infection once the effector cells and antibodies have been produced. However, this takes days, and bacteria replicate and invade in hours. The discovery of the "innate" immune system explains the ability of organisms to mount an effective and targeted immune response to microbes before the adaptive immune system comes into play (see Chap. 10). The innate immune system is present in plants, invertebrates, and vertebrates. This system relies on a series of "pattern recognition receptors" that recognize "pathogen-associated molecular patterns" that are not present on "self."[10] Binding of the pattern recognition receptors to the pathogen-associated molecular patterns results in opsonization and activation of the complement system as well as induction of inflammatory signaling pathways. This process involves at least three pattern recognition receptors: (1) the AMPs discussed in Antimicrobial Peptides, (2) Toll-like receptors (TLRs), and (3) the complement system. These three systems all engage bacteria once they enter the skin and, by intercommunication and by signaling neutrophils and other immune cells, are vital in bringing to the site of infection the cells required to destroy the pathogen.

TLRs are a repertoire of pattern recognition receptors (see Chap. 10).[11] They occur on cell membranes and recognize certain exogenous ligands that are unique to invading microorganisms and not found in the host. They play a prominent role as primary sensors for invading pathogens. For instance, TLR5 recognizes flagellin, unique to flagellated bacteria, and TLR2 recognizes the peptidoglycan on the surface of Gram-positive bacteria. These structural elements of the invading organism are essential for its pathogenicity and therefore are hard to eliminate on an evolutionary basis. The TLRs not only engage the invader but they also orchestrate what type of immune response is generated for that specific pathogen. TLRs do this by instructing antigen-presenting cells that have engaged the organism to secrete appropriate cytokines to generate the desired immunologic milieu and eventual adaptive immune response (see Chap. 10). Alternative downstream signaling pathways can result in different immune responses from engagement of the identical TLRs.

Complement (see Chap. 36) is activated when mannin-binding lectin binds to carbohydrate patterns on bacteria and activates C2 and C4.[12] Activation of C3 liberates C3a and C3b. C3b on membranes leads to opsonization and enhanced phagocytosis. In addition, the cleavage of C5 leads to C5a, a potent activator of neutrophils and a stimulator of pro-inflammatory cytokines, including interleukin 1 (IL-1) and IL-8. The "membrane attack complex" is formed by completion of the complement cascade and kills invading microbes. Not surprisingly, complement components also modulate the immune system, and alter TLR stimulation of some activation pathways. Through an extensive repertoire of outcome options, the human host has the ability to develop an organism-specific response to a wide variety of infectious agents that the host has not previously encountered. In addition, the innate immune system through complement and TLR orchestrates the adaptive immune system to appropriately respond to the invading microbe. This elaborate innate immune response explains the variety of rather distinctive

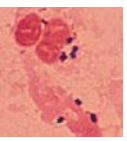

clinical responses to various bacterial infections that have been described. The infectious agent, the anatomic site of the infection, and the attendant inflammatory response pattern create the clinical lesion.

Pathogenicity of the Microorganism

To effectively invade a host, the microbe must initially gain access. *S. aureus* uses teichoic acid and other surface proteins that promote adherence to the nasal mucosa. The bacteria are then available to contaminate any breaches in the skin, binding to fibronectin in wounds. The disease-producing capacity of bacteria is termed *virulence*. The genetic material encoding virulence factors and toxins are carried on mobile genetic elements called *pathogenicity islands*. Bacteriophages carry genetic elements from one bacterium to the next (Panton-Valentine leukocidin for example). Panton-Valentine leukocidin is a cytotoxin directed against human immune cells. It is associated with deep-seated and more inflammatory furunculosis. In addition, many bacterial species contain DNA elements within their own genome that specifically are designed to escape, inactivate, or suppress the host's innate immune response, especially by resisting killing by neutrophils and excreted products. These gene products that respond to the host's immune attack are usually composed of a two-protein interaction cascade involving a sensor and a response protein. This is called a *two-component gene regulatory system*. In the case of *S. aureus*, numerous specific substances target each element of the innate immune attack by the host. Staphylokinase (SAK) inactivates defensins. Aureolysin A cleaves LL-37. The *oatA* gene encodes a membrane protein that imparts lysozyme resistance. *S. aureus* is catalase positive, and the yellow pigment of *S. aureus* (carotenoids) protects it from oxidative killing by neutrophils. SAK also activates plasminogen to plasmin. Surface plasmin cleaves C3b and immunoglobulin G, removing important opsonic molecules from the bacterial surface. Chemotaxis inhibitory protein of *S. aureus* binds to C5a blocking neutrophil activation. Staphylococcal complement inhibitor binds to C3 convertase on the bacterial surface preventing it from cleaving C3 and activating the complement cascade. SAKS, chemotaxis inhibitory protein of *S. aureus*, and staphylococcal complement inhibitor are carried on the same pathogenicity islands.[13–16]

Although it is useful to distinguish between disease caused by toxins and those caused by direct invasion and virulence factors, most bacterial infections result from the combination of the invasive and toxigenic properties of the organism. Examples in which locally secreted toxins are instrumental in creating the characteristic lesions are infections with *S. aureus* (bullous impetigo), *Corynebacterium diphtheriae*, and *Bacillus anthracis* (see Chap. 178). Systemic manifestations of toxin secretion are seen in staphylococcal scalded skin syndrome and tetanus. In the case of *C. perfringens*, elaboration of a variety of extracellular toxins and enzymes (α-toxin or lecithinase, proteases, collagenases) appears to play an important role in the rapidly spreading skin lesions and the systemic manifestations of clostridial myonecrosis (see Chap. 179). *S. pyogenes*, specifically GAS, also contains numerous genes that help it evade the innate immune system. These include those within the genome, such as the M protein, which prevents phagocytosis by neutrophils, and those transmitted on prophages such as exotoxin A. The production of DNase SdaD2 protects GAS from extracellular killing by neutrophils in neutrophil extracellular traps and is important in skin infections. Tissue invasion and systemic spread are enhanced by streptokinase. GAS streptokinase is active only against human plasminogen, which may be critical in restricting GAS infection to humans. The proclivity of streptococcus to share the genetic material containing these virulence factors across strains has blurred the restrictions of streptococcal types to certain disease patterns. Now, for instance, in some regions, group G streptococcus is a major cause of pharyngitis and contains the same virulence genes that gave GAS the ability to cause this condition.[17,18]

Gram-negative bacteria (*Escherichia coli*, *S. typhi*, *N. meningitidis*, *N. gonorrhoeae*, *Brucella melitensis*, and others) contain endotoxin, complex phospholipid-polysaccharide macromolecules [lipopolysaccharides (LPS)] as an integral part of the bacterial cell envelope (see Chap. 180). Endotoxins, unlike exotoxins, are released only upon breakdown of the bacterial cell. Their toxicity appears to be linked principally to the lipid fraction, whereas their antigenic determinants reside with the polysaccharide component. Much is now known of the mechanisms by which LPS exerts its biologic effects in systemic infections due to Gram-negative bacteria or in major localized infections that may also be capable of producing the sepsis syndrome. The effects are both toxic and immunologic. The two cytokines most important in the toxic and pro-inflammatory effects of LPS are produced by LPS-activated macrophages: tumor necrosis factor (TNF) and IL-1. TNF initiates a pro-inflammatory cytokine cascade (see Chap. 11). TNF activates the coagulation system through its effects on vascular endothelium and decreases blood pressure and tissue perfusion by reducing myocardial contractility and by relaxing smooth muscle. High circulating levels of TNF are demonstrable in patients with meningococcemia and other forms of severe sepsis.[19] Infusion of high concentrations of purified TNF alone can produce shock and death. The ability of LPS, through TNF production, to induce leukocyte adherence to capillary endothelium and to induce fibrin deposition has been suggested as the basis for development of the hemorrhagic necrotic skin lesions (with or without direct bacterial invasion) that sometimes occur during the course of Gram-negative bacillary bacteremias and particularly in meningococcemia. Purpura fulminans develops in 10 percent to 20 percent of cases of marked meningococcal sepsis, and severe cases may develop thrombosis of large vessels with infarction of digits (see Chaps. 145 and 180).

Changing Patterns of Bacterial Infections of the Skin

Three factors have resulted in an increase in the prevalence and virulence of bacterial infections. First, we have discovered new pathogens such as *Bartonella* sp., that were not previously known to cause human disease (see Chap. 182). Second, bacteria themselves have become more difficult to treat via the acquisition of virulence factors and antibiotic resistance. Third, there are an ever increasing number of immunocompromised patients due to increasing numbers of the elderly and debilitated, the human immunodeficiency virus-infected, and the iatrogenically immunosuppressed. In addition to the usual pathogens, a variety of "non-pathogenic" members of the cutaneous microflora are capable of producing disease in debilitated patients and in individuals with altered humoral or cellular defenses. For example, ecthyma gangrenosum due to local or systemic destructive invasion of the skin is seen virtually always in the setting of neutropenia (see

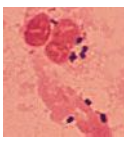

Chap. 180). In the immunocompetent host, a transient, self-healing folliculitis is caused by the same organism. *B. henselae* causes cat-scratch disease, a self-healing disorder in the immunocompetent host (see Chap. 182). In the acquired immunodeficiency syndrome patient with advanced immunosuppression (CD4 < 50) bacillary angiomatosis and systemic involvement, fatal without treatment, is seen (Chaps. 182 and 198).

Influence of Hypersensitivity to Bacterial Antigens on Inflammatory Reaction in Skin

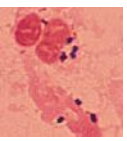

The ability of bacteria to induce immunologic events on the part of the host explains certain syndromes. The flares of atopic dermatitis induced by *S. aureus* may be due to shifts in cytokine profile in the lesions induced by the bacterial infection. Similarly, streptococcal infection of the pharynx can induce an immunologic response that triggers psoriasis via activation of the immune system.

Neutrophilic Conditions as a Cutaneous Response to Systemic Infection

Inflammatory changes in and about small blood vessels in the skin may occur in a variety of bacteremic infections in the absence of obvious localization of bacteria at these sites. The papular and petechial lesions of chronic meningococcemia, and at times in disseminated gonococcal infection (see Chaps. 180 and 205) and the development of leukocytoclastic vasculitis following adequate treatment of endocarditis (probably induced by circulating immune complexes) are examples. The lesions of Sweet syndrome (see Chap. 31) and early erythema nodosum (see Chap. 68) can have prominent tissue neutrophilia, even though the initiating infection (e.g., streptococcal pharyngitis) is distant. The Osler nodes and petechiae of subacute bacterial endocarditis, caused by viridans streptococci, probably provide the best examples of this association of small-vessel vasculitis with bacteremia (see Chap. 181). Histologically, these lesions are more suggestive of vasculitis than of emboli. The occasional development of such lesions in profusion, localized to the lower extremities, supports the concept of cutaneous vascular inflammation rather than embolization.

CLASSIFICATION OF BACTERIAL INFECTIONS OF THE SKIN

The discovery of specific bacteria as the cause of skin infections has led in most cases to classification of skin diseases based on the pathogenic bacteria rather than by morphology. In many cases, however, the infectious agent will be identified by culture, and the results not known for at least 1 day. In addition, impetigo (see Chap. 177), cellulitis, and necrotizing fasciitis (see Chap. 179) are three examples where multiple pathogens are capable of causing the same clinical pattern and require treatment decision based on the most likely pathogens. Therefore, morphologic classification of skin lesions is still important and can guide initial diagnostic testing and empiric antibiotic treatment. To this end, the classification of skin findings caused by bacterial infections as (1) primary infections (pyodermas), (2) secondary infections, (3) cutaneous manifestations of systemic bacterial disease, and (4) reactive conditions resulting from distant infection, seems warranted. Primary bacterial infections are produced by the invasion of ostensibly normal skin by a single species of pathogenic bacteria. In such infections, there is usually no doubt as to the primary etiologic role of the specific agent in the pathogenesis of the lesion. Treatment aimed at the bacterial pathogen almost universally results in cure of the lesion. Impetigo, erysipelas, and furunculosis (see Chap. 177) are familiar examples of primary cutaneous infections. In contrast, secondary infections develop in areas of already damaged skin. Although the bacteria present did not produce the underlying skin disorder, their proliferation and subsequent invasion of surrounding areas may aggravate and prolong the disease. Such secondary infection may occur when the integrity of the skin has been broken, or the local immune milieu is altered by the primary skin condition, allowing for infection by bacteria. In contrast to the primary infections, the secondary infections at times show a mixture of organisms on culture, and not infrequently, it is impossible to determine which if any play the major role. It is important to know in which conditions recovery of a bacterial pathogen is important, and in which it is less predictable of response to antibiotic treatment. In flares of atopic dermatitis (see Chap. 14), the finding of numerous *S. aureus* on the skin surface is often associated with improvement of the dermatitis with antibiotic treatment. In contrast, even experts in the field disagree on the significance of culturing bacterial "pathogens" from chronic leg ulcers. In the case of secondary infections, the morphology of the primary skin disease may be minimally altered, and the presence of an exacerbating bacterial pathogen may only be suspected by poor response to treatment or an otherwise unexplained flare of the condition.

DIAGNOSTIC STRATEGIES

Direct Examination of Aspirates and Biopsies

Identification of bacteria from skin lesions may provide important information as to the cause of cutaneous infections. Examination of a Gram-stained smear of material from a suspected skin infection can guide decisions on early antibiotic therapy before a cultural diagnosis is made. For these reasons, bacteriologic investigation is an important part of the initial evaluation of patients with skin lesions and includes (1) appropriate sampling, (2) interpretation of Gram-stained smears, and (3) use of selective growth media for culturing.

Gram staining provides a very rapid method of examining a sample for number and type of bacteria, as well as for the character of the inflammatory exudate. Obtaining an appropriate specimen for microscopic study and culture requires care to avoid contamination. Results of needle aspiration of cellulitis and erysipelas are generally unrewarding. Aspirates from the advancing edge of cellulitis yielded positive cultures in only 10 percent of patients, and culture of skin punch biopsy specimens taken from the leading edge were positive in only 15 percent to 20 percent of patients,[20,21] perhaps higher in patients with diabetes mellitus and neoplastic disease. A higher yield (about 50 percent) for positive cultures has been reported in aspirates obtained from the point of maximal inflammation than that obtained from the leading edge of cellulitis (5 percent) in children.[22] Findings on needle aspiration, when positive, can provide an immediate useful guide to therapy. If sterile saline is injected into a lesion that initially yields no aspirate, bacteriostatic agent-free solutions should be employed. In circumstances in which no data are available from needle aspiration, a surgical biopsy may yield information that is lifesaving. In the bioterrorism-associated outbreak of anthrax infections in the United States, rapid specific diagnosis of cutaneous disease was accomplished by

punch biopsy of an erythematous, indurated plaque and tissue Gram stain demonstrated Gram-positive rods, confirmed as *B. anthracis* by immunohistochemical analysis (see Chap. 178).[23] Local lesions of the skin and subcutaneous tissues in immunocompromised patients should always be biopsied if aspiration fails to define a pathogen. Encouraging results have been reported in patients with suspected necrotizing fasciitis (see Chap. 179) who had biopsies done to confirm the diagnosis early in the course of this devastating infection.[24]

Other Diagnostic Procedures

FLUORESCENT ANTIBODY The practical use of this procedure in bacterial diseases of the skin is currently of limited applicability. Spirochetes can be demonstrated (by the direct or indirect techniques) in chancres, (see Chap. 200). *N. gonorrhoeae*, *Actinomyces israelii*, *Legionella* sp., *Francisella tularensis*, *B. anthracis*, and *Y. pestis* have been identified by this rapid direct fluorescent antibody staining method. Its greatest use is in the specific diagnosis of uncommon but serious infections.[25]

OTHER IMMUNOLOGIC METHODS A variety of serologic tests may be helpful in the diagnosis of bacterial infections of the skin, particularly in those where the cutaneous manifestations are secondary to systemic disease (e.g., "rose spots" of typhoid fever). Bartonella infections are routinely diagnosed in this manner. As with any serologic test, a fourfold or greater rise in titer during the course of the illness is considered significant.

POLYMERASE CHAIN REACTION Polymerase chain reaction technology can be applied to diagnosis of material obtained on skin punch biopsy of lesional tissue or aspirates from a vesiculo-bullous lesion just as it has been used in diagnosis of infection in body fluids (cerebrospinal fluid, pleural fluid, blood). Appropriate precautions to exclude contamination during the acquisition of the specimen must be taken. The use of this procedure is most helpful when one particular bacterial species is being considered, and appropriate primers are available. Such was the case in a patient with a cutaneous lesion during the bioterrorism-induced anthrax outbreak.[25]

ANTIBIOTIC THERAPY (See Chap. 231)

The selection of the appropriate antibiotic should be made initially on the basis of the appearance of the skin lesion, the characteristics of any systemic illness, and a Gram-stained smear of material from a lesion, if available. Culture results and susceptibility testing of the isolated pathogen(s) are usually available within 48 hours. Additional epidemiologic factors (current hospitalization or residence in a nursing home, recent antibiotic use, neutropenia, and immunocompromise) should be considered in the choice of initial antimicrobial therapy. Also, it is important to make the choice based on the latest data from the local area and from frequently updated sources in view of the rapidly changing patterns of antimicrobial resistance of various bacterial species.

Dosage: Methods of Administration—Excretion

Primary cutaneous infections of mild to moderate severity can be treated with local measures, topical drugs, oral antibiotics, or by a combination of these methods. Extensive infections of the skin, with or without systemic manifestations, should be vigorously treated with parenteral antibiotics in adequate dosages. In the immunocompromised host, parenteral treatment of cutaneous infections is virtually always recommended.

A number of factors must be considered in administering antibiotics: oral treatment may be limited by absorption and gastrointestinal disturbances; hypotension and extensive skin disease can prohibit the intramuscular route; and the proper drug selected may be suitable for administration only by a specific route. The excretory pattern of a given antibiotic should always be considered to avoid toxic accumulation in the face of specific organ malfunction (e.g., hepatic or renal impairment).

Toxicity

The toxicity of antibiotics should be considered on an individual basis but some problems are applicable to all antibiotics. Hypersensitivity reactions are relatively common and can include skin rashes, fever, or more severe manifestations such as acute anaphylaxis or exfoliative erythrodermas. The penicillins and sulfonamides are particularly likely to produce these problems. Questions regarding previous drug allergy should be asked whenever any antibiotic is to be administered. All antibiotics can alter the indigenous flora, especially broad-spectrum agents such as the cephalosporins. Gastrointestinal disturbances and oral mucous membrane lesions are the major problems encountered with alteration of the flora. There are numerous other potential untoward reactions (renal, hematologic, hepatic, nervous system) to antibiotics that may represent acceptable risks if the reasons for use of these drugs are compelling. It is the physician's responsibility to be aware of the usual and unusual manifestations of toxicity of any of the antibiotics used and to be alert to possible novel effects in individual patients.

Antibiotic Resistance Because of "R" Factors (See Chap. 231)

Transferable resistance to multiple antibiotics has emerged as a widespread problem. Extrachromosomal genetic elements (R plasmids) in bacteria are the basis for much of such resistance.[26] Prolonged antibiotic therapy may select R-factor–carrying members of the indigenous flora (e.g., in the gastrointestinal tract), which may subsequently transfer this property to a potential pathogen. In this way, antibiotic resistance to chloramphenicol, tetracycline, and kanamycin conferred by a plasmid in *E. coli* can be transferred during mating to a *Klebsiella* or *Salmonella* strain.

Topical Antibacterial Agents (See Chap. 218)

Topical antibacterial agents are frequently used to prevent, as well as to suppress, bacterial growth in open lesions and surgical wounds. In the case of sutured dermatologic wounds, topical antibiotics have limited effect in reducing wound infections.[27] Topical neomycin and bacitracin not infrequently precipitate contact dermatitis. Contact dermatitis is especially common when these topical antibiotics are applied to venous insufficiency leg ulcers.

Among the most useful topical antibacterial agents are acetic acid (1 percent to 5 percent for *Pseudomonas* nail and toe web infections and bacitracin (500 units per milliliter or gram) for selected superficial *S. aureus* and streptococcal lesions. Neomycin (0.5 percent ointment) and gentamicin (0.17 percent cream) may be useful in selected patients when mixed Gram-negative bacteria require local suppression. Mupirocin (2 percent ointment) has antibacterial activity against various streptococci and *S. aureus*. A number of broad-spectrum antiseptics are also avail-

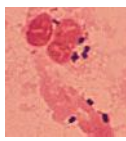

able for topical use. Povidone-iodine (Betadine) is effective against most Gram-positive and Gram-negative bacteria but does not persist in the skin to provide a residual action. Chlorhexidine gluconate (4 percent solution) combines broad antibacterial properties with prolonged action. An alcoholic preparation is especially effective, is not appreciably absorbed into the blood, and generally is not irritating to the skin. These broad-spectrum antiseptics can be used prophylactically or to treat local wounds and superficially infected dermatoses.

KEY REFERENCES

The full reference list for all chapters is available at www.digm7.com.

1. Elias PM: Defensive functions of the stratum corneum: Integrative aspects, in *Skin Barrier*, edited by Elias PM, Feingold KR. New York, Taylor & Francis Group, 2006, p 5
2. Bjornsdottir S et al: Risk factors for acute cellulitis of the lower limb: A prospective case-control study. *Clin Infect Dis* **41**:1416, 2005
7. Izadpanah A et al: Antimicrobial peptides. *J Am Acad Dermatol* **52**:381, 2005
8. de Jongh GJ et al: High expression levels of keratinocyte antimicrobial proteins in psoriasis compared with atopic dermatitis. *J Invest Dermatol* **125**:1163, 2005
11. Kang SSW et al: Toll-like receptors: Applications to dermatologic disease. *J Am Acad Dermatol* **54**:951, 2006
13. Rooijakkers SHM et al: Staphylococcal innate immune evasion. *Trends Microbiol* **13**:596, 2005
17. Currie BJ: Group A streptococcal infections of the skin: Molecular advances but limited therapeutic progress. *Curr Opin Infect Dis* **19**:132, 2006
25. Roche KJ et al: Cutaneous anthrax infection. *N Engl J Med* **345**:1611, 2001



CHAPTER 177

Superficial Cutaneous Infections and Pyodermas

Noah Craft
Peter K. Lee
Matthew T. Zipoli
Arnold N. Weinberg
Morton N. Swartz
Richard Allen Johnson

Normal human skin is colonized soon after birth by a large number of bacteria that live as commensals on the epidermis and epidermal appendages. Coagulase-negative staphylococci (*Staphylococcus epidermidis*) are inoculated during vaginal passage and coryneform bacteria take up residence on neonatal skin shortly after birth. Within several weeks after birth, the flora of neonatal skin is similar to that of adults (see Chap. 176).

The majority of the primary and secondary pyodermas (cutaneous bacterial infections) are caused by either *S. aureus* or group A streptococcus. These bacteria cause a broad clinical spectrum of infection ranging from superficial pyodermas to invasive soft-tissue infections (STIs; see Chap. 179) depending on the organism, the anatomic location of infections, and on host factors.

STAPHYLOCOCCAL SKIN INFECTIONS

Epidemiology

Staphylococci are classified into two major groups: the coagulase-negative staphylococci and coagulase-positive (*S. aureus*) staphylococci. Individuals carry a minimum of 10 to 24 combined temporary and resident strains of *S. epidermidis*, the most common coagulase-negative strain. *S. epidermidis* is a common colonizer of the skin but is capable of causing superficial and invasive infections (particularly about implants and catheters).

S. aureus permanently colonizes the anterior nares in 20 percent of the population. Carriage is transient or intermittent in other individuals. Approximately 60 percent of healthy individuals have occasional carriage of *S. aureus* at some site.[1] Other sites of colonization include the axillae, perineum, pharynx, and hands. Conditions predisposing to *S. aureus* colonization include atopic dermatitis, diabetes mellitus (insulin-dependent), dialysis (hemo- and peritoneal), intravenous drug use, liver dysfunction, and human immunodeficiency virus (HIV) infection.

S. aureus is an aggressive pathogen and the most common cause of primary pyodermas and STIs, as well as of secondary infections on disease-altered skin. *S. aureus* in pyodermas or STIs can invade the bloodstream, producing bacteremia, metastatic infection such as osteomyelitis, and acute infective endocarditis. Some strains of *S. aureus* also produce exotoxins, which can cause constellations of cutaneous and systemic symptoms such as staphylococcal scalded-skin syndrome (SSSS) and staphylococcal toxic shock syndrome (TSS).

PYODERMAS AT A GLANCE



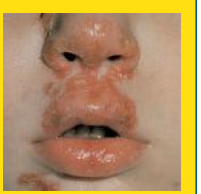

- Bacterial skin infections (pyodermas) are primarily caused by *Staphylococcus aureus* and *Streptococcus* sp.
- Twenty percent of individuals are continuously colonized with *S. aureus*, and occasional carriage is found in 60 percent of healthy people. This represents a common source of many infections.
- Contributing factors: Immunosuppression, atopic dermatitis, pre-existing tissue injury, and inflammation.
- Local manifestations include: Folliculitis, furunculosis, ecthyma, and impetigo.
- Systemic reactions include: Staphylococcal toxic shock syndrome and scarlatiniform eruption.
- Not particularly localized to one anatomic area.
- Pathology: Abundant neutrophilic infiltration admixed with lymphocytes.
- Treatment: Topical, oral, or parenteral antibiotics: Change predisposing conditions, if possible. When planning therapy, consider local and current antimicrobial resistance patterns.

Transfer of organisms to patients occurs predominantly via the hands of personnel rather than through the air. This appears to be particularly true in newborn nurseries. Any individuals with open staphylococcal infections are high-risk potential carriers and transmitters of infection. Nasal carriage of *S. aureus* appears to be a major risk factor for wound infection after cardiac surgery, resulting in higher mortality rates and longer postoperative stays.[2] The rate of *S. aureus* bacteremia is also higher in nasal carriers of *S. aureus*.[3] Good nursery technique, careful handling of patients, strict hand-washing procedures, and isolation of patients with open draining staphylococcal infections are important in the reduction of transmission of staphylococci. In older adults, *S. aureus* accounts for 9 percent of nosocomial infections and follows only *Escherichia coli, Pseudomonas aeruginosa*, and enterococci in prevalence.[4]

Etiology and Pathogenesis

Colonization by *S. aureus* may be transient or represent a prolonged carrier state. *S. aureus* produces many cellular components and extracellular products that may contribute to its pathogenicity. Host factors such as immunosuppression, glucocorticoid therapy, and atopy may play a major role in the pathogenesis of staphylococcal infections. Preexisting tissue injury or inflammation (surgical wound, burn, trauma, dermatitis, retained foreign body) is of major importance in the pathogenesis of staphylococcal disease.

Some strains produce one or more exoproteins, including the staphylococcal enterotoxins (SEA, SEB, SECn, SED, SEE, SEG, SEH, and SEI), the exfoliative toxins (ETA and ETB), TSS toxin-1 (TSST-1), and leukocidin. These toxins have unique potent effects on immune cells and other biologic effects as well, ultimately inhibiting host immune response.

TSST-1 and the staphylococcal enterotoxins are also known as *pyrogenic toxin superantigens*. These molecules act by binding directly to constitutively expressed HLA-DR molecules (major histocompatibility complex II) on antigen-presenting cells without antigen processing. Although conventional antigens require recognition by all five elements of the T-cell–receptor complex, superantigens require only the variable region of the β chain. As a result, 5 percent to 30 percent of resting T cells may be activated, whereas the "normal" antigenic response is only 0.0001 to 0.01 percent of T cells.[5] Non-specific T-cell activation leads to massive systemic release of cytokines, especially interleukin 2, interferon-γ, and tumor necrosis factor-β from T cells and interleukin 1 and tumor necrosis factor-α from macrophages.[6] Superantigen stimulation of T cells also results in activation and expansion of lymphocytes expressing specific T-cell–receptor variable region of the β chain. They may activate B cells, leading to high levels of immunoglobulin E (IgE) or autoantibodies.[7] Also, there is evidence that superantigens selectively induce cutaneous lymphocyte-associated antigen on T cells, thereby "homing" them to the skin.[8]

There are several other mechanisms by which *S. aureus* evades immune clearance. Approximately 60 percent of *S. aureus* strains secrete the chemotaxis inhibitory protein of staphylococci, which inhibits neutrophil chemotaxis. Additionally, protein A, staphylokinase, capsular polysaccharide, fibrinogen binding protein, and clumping factor A all act to aid in avoidance of being opsonized and phagocytosed. Staphylokinase and aureolysin bind and cleave antimicrobial peptides respectively, resulting in increased survival in vitro and probably in vivo.[1]

DRUG RESISTANCE A major problem in treating staphylococcal infections has been the emergence of antibiotic-resistant strains. With ever-increasing use of penicillins, methicillin-resistant *S. aureus* (MRSA) strains have become a major epidemiologic problem since the 1980s. Resistance to methicillin indicates pan-resistance to all β-lactam antibiotics. Recently, intermediate-level resistance of MRSA to vancomycin has emerged and constitutes a potential further problem in treatment. Although *S. aureus* infection prevalence has not changed much, in some countries the percentage of MRSA isolates of these infections has significantly increased. Those at higher risk for acquiring colonization or infection with MRSA are adults older than 65 years of age, the chronically ill, those with prolonged hospitalizations (especially surgical), exposure to others with MRSA, and prior antibiotic therapy. The main MRSA reservoirs are health care workers and hospitalized patients with subsequent transmission primarily through direct contact.[9]

Attempts to eradicate MRSA have generally been unsuccessful. Treatment of anterior nares and wounds with mupirocin ointment has been shown to decrease *S. aureus* colonization but in one study did not decrease the rate of transmission to a roommate in a long-term care facility.[10] Although there are many other reports of the use of topical mupirocin to reduce colonization of MRSA and methicillin-sensitive *S. aureus*, indiscriminate use of topical mupirocin must be avoided because significant mupirocin resistance has already emerged.

IMMUNITY The primary defense against *S. aureus* infections is the innate immunity provided by neutrophils. A major component of the innate response is antimicrobial peptides. These peptides can be found in various locales and include dermicidin, LL-37, protegrin, α-defensins and β-defensins, lactoferricin, and cascocidin. However, *S. aureus* also has the ability to thwart the immune system in several ways. One of the main virulence factors of *S. aureus* is the production of adhesins that facilitate binding to host epithelial cell surfaces. The almost universal presence in adults of circulating antibodies to one or more cell-wall antigens or extracellular toxins substantiates the high prevalence of staphylococcal infections. However, these antibodies are not the primary determinants of resistance to such infections. Recent evidence demonstrates that *S. aureus* can invade and survive in many types of host cells, suggesting that a cell-mediated immune response is required for killing intracellular organisms.

Clinical Findings

SUPERFICIAL STAPHYLOCOCCAL PYODERMAS Pyodermas are infections in the epidermis, just below the stratum corneum or in hair follicles. In industrialized nations, *S. aureus* is the most common cause of superficial pyodermas (Table 177-1), but group A streptococcus continues to be a common cause of pyoderma in developing countries. Untreated, pyodermas can extend to the dermis, resulting in ecthyma and furuncle formation.

Impetigo. Two clinical patterns of impetigo are recognized: bullous and non-bullous. Bullous impetigo is caused by *S. aureus*. Currently, in industrialized nations, non-bullous impetigo is most commonly caused by *S. aureus* and less often by group A streptococcus. Group A streptococcus remains a common cause of non-bullous impetigo in developing nations.



TABLE 177-1
Infections and Toxin Syndromes Involving the Skin and Soft Tissues Caused by *Staphylococcus aureus*

Sites of colonization (carrier state)
- Anterior nares
- Throat
- Axillae, perineum
- Hands
- Involved skin in individuals with atopic dermatitis

Sites of colonization in neonates (and sites of infection)
- Skin
- Umbilicus
- Circumcision site
- Conjunctivae

Superficial pyodermas
- Primary pyodermas
  - Skin
    - Impetigo
    - Bullous impetigo
    - Erythema
    - Botryomycosis
  - Hair follicles
    - Superficial folliculitis (follicular or Bockhart impetigo)
    - Folliculitis (sycosis barbae)
    - Furuncle (boil)
    - Carbuncle
  - Intertriginous sites
    - Perianal dermatitis
  - Digital infections
    - Paronychia
    - Blistering distal dactylitis
  - After skin disruption
    - Trauma (physical, thermal)
    - Foreign body (intravascular catheter, prosthetic device)
- Secondary pyodermas
  - Impetiginization of dermatoses such as atopic dermatitis, herpes simplex (superinfection)
  - Pyodermas associated with systemic disease
  - Job syndrome
  - Chédiak-Higashi syndrome
  - Chronic granulomatous disease

Invasive infections
- Lymphangitis, lymphadenitis
- Erysipelas
- Cellulitis
- Streptococcal gangrene
- Pyomyositis
- Bacteremia, septicemia

Metastatic skin infections associated with bacteremia (often *S. aureus* acute infections endocarditis)
- Abscesses (superficial and deep)
- Septic vasculitis (pustular purpura)

Purpura fulminans
- Disseminated intravascular coagulation associated with staphylococcal bacteremia
- Meningococcemia-like syndrome

Staphylococcal toxin–associated syndromes
- Staphylococcal scarlet fever
- Staphylococcal scalded-skin syndromes
- Staphylococcal toxic-shock syndrome



NON-BULLOUS IMPETIGO. The non-bullous type of impetigo accounts for more than 70 percent of cases of this form of pyoderma. It occurs in children of all ages as well as in adults. Intact skin is usually resistant to colonization or impetiginization, possibly due to absence of fibronectin receptors for teichoic acid moieties on *S. aureus* and group A streptococcus. Production of bacteriocins, produced by certain *S. aureus* strains (phage group 71) and highly bactericidal to group A streptococcus, may be responsible for the isolation of only *S. aureus* from some lesions initially caused by streptococci.

History. In a typical sequence, *S. aureus* spreads from nose to normal skin (approximately 11 days later) and then develop into skin lesions (after another 11 days). Lesions commonly arise on the skin of the face (especially around the nares) or extremities after trauma. Nasal carriers of *S. aureus* can present with a very localized type of impetigo confined to the anterior nares and the adjacent lip area (Fig. 177-1); pruritus or soreness of the area is a common complaint (Fig. 177-2). Conditions that disrupt the integrity of the epidermis, providing a portal of entry of impetiginization, include insect bites, epidermal dermatophytoses, herpes simplex, varicella, abrasions, lacerations, and thermal burns.

Differential Diagnosis. See Box 177-1 for differential diagnosis of non-bullous impetigo.

Cutaneous Lesions. The initial lesion is a transient vesicle or pustule (see Fig. 177-2) that quickly evolves into a honey-colored crusted plaque that can enlarge to greater than 2 cm in diameter (see Fig. 177-1). Surrounding erythema may be present. Constitutional symptoms are absent. Regional lymphadenopathy may be present in up to 90 percent of patients with prolonged, untreated infection. Untreated, the lesions may slowly enlarge and involve new sites over several weeks. In some individuals, lesions resolve spontaneously. In others, the lesions extend into the dermis, forming an ulcer (see Staphylococcal Ecthyma).

BULLOUS IMPETIGO. Three types of skin eruptions can be produced by phage group II *S. aureus*, particularly strains 77 and 55: (1) bullous impetigo, (2) exfoliative disease (SSSS), and (3) nonstreptococcal scarlatiniform eruption (staphylococcal scarlet fever). All three represent varying cutaneous responses to extracellular exfoliative toxins ("exfoliatin") types A and B produced by these staphylococci (see Chap. 178). Exfoliative toxin A acts as a serine protease of desmoglein 1, the desmosomal cadherin that is also the target of autoantibodies in pemphigus foliaceus.[11]



▲ **FIGURE 177-1** *Staphylococcus aureus:* Impetigo. Erythema and crusting on the nose and moustache area (**A**), which can spread to involve the entire centrofacial region (**B**).

In a study of bullous impetigo, 51 percent of patients had concurrent *S. aureus* cultured from the nose or throat, and 79 percent of cultures grew the same strain from both sites.

Cutaneous Lesions. Bullous impetigo occurs more commonly in the newborn and in older infants, and is characterized by the rapid progression of vesicles to flaccid bullae (Fig. 177-3). Decades ago, extensive bullous impetigo (archaic term: *pemphigus neonatorum* or *Ritter disease*) occurred in epidemics within neonatal nurseries.

Bullae usually arise on areas of grossly normal skin. The Nikolsky sign (sheet-like removal of epidermis by shearing pressure) is not present. Bullae initially contain clear yellow fluid that subsequently becomes dark yellow and turbid (see Fig. 177-3A), and their margins are sharply demarcated without an erythematous halo. The bullae are superficial, and within a day or two, they rupture and collapse, at times forming thin, light-brown to golden-yellow crusts (see Fig. 177-3B). So-called *bullous varicella* represents superinfection by *S. aureus* (phage group II) of varicella lesions (bullous impetiginization).

Laboratory Tests. Gram stain of exudates from bullous impetigo reveals Gram-positive cocci in clusters. *S. aureus* belonging to phage group II can be cultured from the contents of intact bullae.

Histologically, the lesions of bullous impetigo show vesicle formation in the sub-corneal or granular region, occasional acantholytic cells within the blister, spongiosis, edema of the papillary dermis, and a mixed infiltrate of lymphocytes and neutrophils around blood vessels of the superficial plexus.

Differential Diagnosis. See Box 177-2 for differential diagnosis of bullous impetigo.



▲ **FIGURE 177-2** *Staphylococcus aureus:* Nasal carriage with impetigo. Erythema with a small pustule on the tip of the nose and nares in individual whose nares are colonized by *S. aureus*.

Box 177-1

Differential Diagnosis of Non-Bullous Impetigo

Consider

- Seborrheic dermatitis
- Atopic dermatitis
- Allergic contact dermatitis
- Epidermal dermatophyte infections
- Tinea capitis
- Herpes simplex
- Varicella
- Herpes zoster
- Scabies
- Pediculosis capitis

Always Rule Out

- Herpes simplex
- Herpes zoster
- Scabies

PROGNOSIS AND CLINICAL COURSE. Untreated, invasive infection can complicate *S. aureus* impetigo with cellulitis, lymphangitis, and bacteremia, resulting in osteomyelitis, septic arthritis, pneumonitis, and septicemia. Exfoliatin production can lead to SSSS in infants and in adults who are immunocompromised or have impaired renal function.

TREATMENT. Local treatment with mupirocin ointment or cream, removal of crusts, and good hygiene is sufficient to cure most mild to moderate cases (Box 177-3).[12] Systemic antibiotics may be required in extensive cases. The frequency of isolation of group A streptococcus makes such therapy a reasonable approach in most patients who have a significant degree of involvement. There is no role for general disinfectant treatments or bacitracin.[13]

Staphylococcal impetigo responds quite promptly to appropriate treatment. In an adult with extensive or bullous lesions, dicloxacillin (or similar penicillinase-resistant semi-synthetic penicillin), 250 to 500 mg orally (PO) four times daily (qid), or erythromycin (in the penicillin-allergic patient), 250 to 500 mg PO qid, should be given. Treatment should be continued for 5 to 7 days (10 days if streptococci are isolated). Also, a single course of oral azithromycin (in adults 500 mg on the first day, 250 mg daily on the next 4 days) has been shown to be equally as effective as dicloxacillin for skin infections in adults and children. For impetigo caused by erythromycin-resistant *S. aureus*, which is commonly isolated from impetigo lesions of children, amoxicillin plus clavulanic acid [25 mg/kg/day given three times a day (tid)],





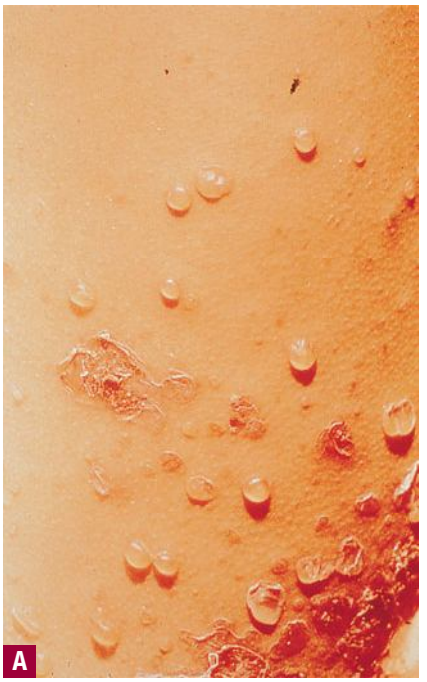

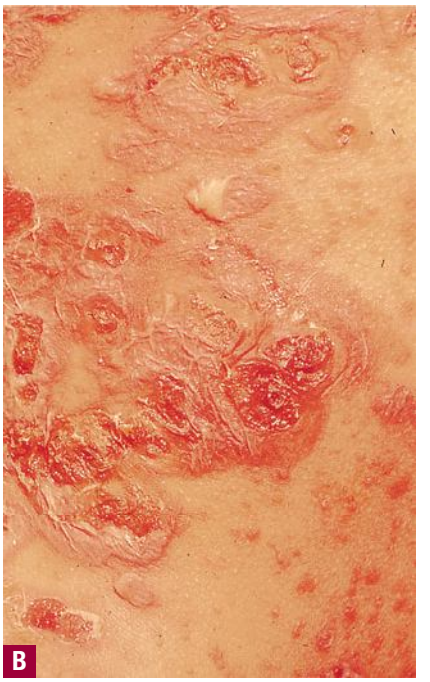

▲ **FIGURE 177-3** *Staphylococcus aureus:* Bullous impetigo. **A.** Multiple vesicles with clear and turbid contents that (**B**) rapidly coalesce to form flaccid bullae.

cephalexin (40 to 50 mg/kg/day), cefaclor (20 mg/kg/day given tid), cefprozil (20 mg/kg once daily), or clindamycin (15 mg/kg/day tid or qid) given for 10 days are effective alternative therapies.

Staphylococcal Ecthyma. Ecthyma is a cutaneous pyoderma characterized by thickly crusted erosions or ulcerations. Ecthyma is usually a consequence of neglected impetigo and classically evolves in impetigo occluded by footwear and clothing. It thus is a lesion typically occurring in the homeless and soldiers in combat on maneuver in a humid and hot climate. *S. aureus* and/or group A streptococcus can be isolated on culture. Untreated staphylococcal or streptococcal impetigo can extend more deeply, penetrating the epidermis, producing a shallow crusted ulcer (Fig. 177-4). Ecthymatous lesions can evolve from a primary pyoderma or within a preexisting dermatosis or site of trauma. Ecthyma gangrenosum is a cutaneous ulcer caused by *P. aeruginosa* and resembles staphylococcal or streptococcal ecthyma (see Chap. 180).

Ecthyma occurs most commonly on the lower extremities of children, or neglected elderly patients, or individuals with diabetes. Poor hygiene and neglect are key elements in pathogenesis. Multiple ecthymatous ulcers on the ankle and dorsum of the foot were the most common pyodermas seen during wartime in tropical climates.[14]

The ulcer has a "punched out" appearance when the dirty grayish-yellow crust and purulent material are débrided. The margin of the ulcer is indurated, raised, and violaceous (see Fig. 177-4), and the granulating base extends deeply into the dermis. Untreated ecthymatous lesions enlarge over weeks to months to a diameter of 2 to 3 cm or more.

The lesions are slow to heal, requiring several weeks of antibiotic treatment for resolution. Problems of spread by autoinoculation or by insect vectors and of post-streptococcal sequela (glomerulonephritis) are the same as with impetigo.

Management of ecthyma is the same as for staphylococcal impetigo (see Box 177-3).

Folliculitis. Folliculitis is a pyoderma that begins within the hair follicle, and is classified according to the depth of invasion (superficial and deep), and microbial etiology (Table 177-2).

SUPERFICIAL FOLLICULITIS. Superficial folliculitis has also been termed *follicular* or *Bockhart impetigo*. A small, fragile, dome-shaped pustule occurs at the infundibulum (ostium or opening) of a hair follicle, often on the scalps of children and in the beard area (Fig. 177-5), axillae, extremities, and buttocks of adults. Isolated staphylococcal folliculitis is common on the buttock of adults. *Periporitis staphylogenes* refers to secondary infection of miliaria of the neonate by *S. aureus*. Staphylococcal blepharitis is an *S. aureus* infection of the eyelids, presenting with scaling or crusting of the eyelid margins, often with associated conjunctivitis; the differential diag-

Box 177-2

Differential Diagnosis of Bullous Impetigo

Consider

- Contact dermatitis
- Bullous insect bites
- Bullous tinea
- Bullous fixed drug reaction
- Bullous drug eruption
- SSSS
- Thermal burns
- Pemphigus vulgaris
- Bullous pemphigoid
- Erythema multiforme
- Dermatitis herpetiformis

Always Rule Out

- Herpes simplex
- Varicella
- Bullous tinea
- Bullous fixed drug reaction
- Bullous drug eruption
- SSSS

SSSS = staphylococcal scalded-skin syndrome.
Note: Any of these disorders may occur primarily and become secondarily impetiginized with *Staphylococcus aureus* or group A streptococcus.

Box 177-3

Treatments for Impetigo[a]

	TOPICAL		SYSTEMIC	
First line	Mupirocin	bid	Dicloxacillin	250–500 mg PO qid for 5–7 days
	Fusidic acid (not available in United States)	bid	Amoxicillin plus clavulanic acid; cephalexin	25 mg/kg tid; 250–500 mg qid
Second line (penicillin allergy)			Azithromycin	500 mg × 1, then 250 mg daily for 4 days
			Clindamycin	15 mg/kg/day tid
			Erythromycin	250–500 mg PO qid for 5–7 days

[a]Washing and hygiene are important in all regimens.



▲ **FIGURE 177-4** *Staphylococcus aureus:* Ecthyma. Multiple thickly crusted ulcers on the leg of a patient with diabetes and renal failure. Ecthymatous lesions were also present on the other leg, the arms, and the hands.

nosis includes seborrheic dermatitis and rosacea of the eyelid.

S. aureus folliculitis must be differentiated from other folliculocentric infections. Also, three non-infectious, inflammatory, follicular disorders are more common in black men: pseudofolliculitis barbae, which occurs on the lower beard area (Fig. 177-6); folliculitis keloidalis or acne keloidalis nuchae, on the nape of the neck; and perifolliculitis capitis, on the scalp. *S. aureus* can cause secondary infection in these inflammatory disorders. Exposure to mineral oils, tar products, and cutting oils can cause an irritant folliculitis. Acne vulgaris, drug-induced acneform eruptions, rosacea, hidradenitis suppurativa, acne necrotica of the scalp, and eosinophilic folliculitis of HIV disease must be distinguished from infectious folliculitis as well. Also, "hot tub" folliculitis may be caused by *P. aeruginosa* (see Chap. 180).

DEEP FOLLICULITIS. Sycosis barbae is a deep folliculitis with perifollicular inflammation occurring in the bearded areas of the face and upper lip (Fig. 177-7). If untreated, the lesions may become more deeply seated and chronic. Local treatment with warm saline compresses and local antibiotics (mupirocin or topical clindamycin) may be sufficient to control infection. More extensive cases require systemic antibiotic therapy. Dermatophytic folliculitis must be differentiated from *S. aureus* folliculitis. In fungal infections, hairs are usually broken or loosened, and there are suppurative or granulomatous nodules rather than pustules. Also, in dermatophytic folliculitis plucking of hairs is usually painless (see Chap. 188).

Lupoid sycosis is a deep, chronic form of sycosis barbae associated with scarring, usually occurring as a circinate lesion. A central cicatrix surrounded by pustules and papules gives the appearance of lupus vulgaris (see Chap. 184).

TABLE 177-2
Classification of Infectious Folliculitis

- Bacterial folliculitis
  - *Staphylococcus aureus* folliculitis
    - Periporitis staphylogenes
    - Superficial (follicular or Bockhart impetigo)
    - Deep (sycosis) [may progress to furuncle (boil) or carbuncle]
  - *Pseudomonas aeruginosa* folliculitis ("hot tub" folliculitis)
  - Gram-negative folliculitis (occurs at the site of acne vulgaris, usually the face, with long-term antibiotic therapy)
  - Syphilitic folliculitis (secondary; acneform)
- Fungal folliculitis
  - Dermatophytic folliculitis
    - Tinea capitis
    - Tinea barbae
    - Majocchi granuloma
  - *Pityrosporum* folliculitis
  - *Candida* folliculitis
- Viral folliculitis
  - Herpes simplex virus folliculitis
  - Follicular molluscum contagiosum
- Infestation
  - Demodicidosis



▲ **FIGURE 177-6** Pseudofolliculitis barbae. Multiple papules in the lower beard area caused by ingrowing of the curved hair shaft in a black man who shaves. If pustules are present, secondary *Staphylococcus aureus* infection must be ruled out.

Furuncles and Carbuncles. A furuncle or boil is a deep-seated inflammatory nodule that develops around a hair follicle, usually from a preceding, more superficial folliculitis and often evolving into an abscess. A carbuncle is a more extensive, deeper, communicating, infiltrated lesion that develops when suppuration occurs in thick inelastic skin when multiple, closely set furuncles coalesce.

FURUNCLES. Furuncles arise in hair-bearing sites, particularly in regions subject to friction, occlusion, and perspiration, such as the neck, face, axillae, and buttocks. They may complicate pre-existing lesions such as atopic dermatitis, excoriations, abrasions, scabies, or pediculosis, but occur more often in the absence of any local predisposing causes. In addition, a variety of systemic host factors is associated with furunculosis: obesity, blood dyscrasias, defects in neutrophil function (defects in chemotaxis associated with eczema and high levels of IgE, defects in intracellular killing of organisms as in



◀ **FIGURE 177-5** *Staphylococcus aureus:* Superficial folliculitis. Multiple pustules confined to the beard area.



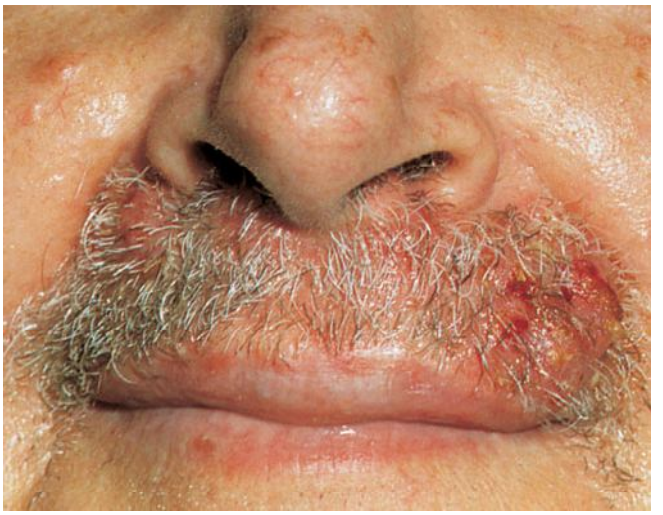

▲ **FIGURE 177-7** Sycosis barbae. Deep staphylococcal folliculitis of the mustache region.



chronic granulomatous disease of childhood), treatment with glucocorticoids and cytotoxic agents, and immunoglobulin deficiency states. The process is often more extensive in patients with diabetes. The majority of patients with problems of furunculosis appear to be otherwise healthy.

Cutaneous Lesions. A furuncle starts as a hard, tender, red folliculocentric nodule in hair-bearing skin that enlarges and becomes painful and fluctuant after several days (i.e., undergoes abscess formation; Fig. 177-8A). Rupture occurs, with discharge of pus and often a core of necrotic material. The pain surrounding the lesion then subsides, and the redness and edema diminish over several days to several weeks. Furuncles may occur as solitary lesions or as multiple lesions in sites such as the buttocks (see Fig. 177-8B).





▲ **FIGURE 177-8** **A.** Furuncle of the upper lip. The lesion is nodular, and the central necrotic plug is covered by purulent crust. Several small pustules are seen lateral to the center of the lesion. **B.** Multiple furuncles. Multiple abscesses on the buttocks of long standing in a young man with inflammatory bowel disease. The lesions healed with scarring after a prolonged course of dicloxacillin.

Differential Diagnosis. See Box 177-4 for differential diagnosis of furunculosis.

CARBUNCLES. A carbuncle is a larger, more serious inflammatory lesion with a deeper base, characteristically occurring as an extremely painful lesion at the nape of the neck, the back, or thighs (Fig. 177-9). Fever and malaise are often present, and the patient may appear quite ill. The involved area is red and indurated, and multiple pustules soon appear on the surface, draining externally around multiple hair follicles. The lesion soon develops a yellow-gray irregular crater at the center, which may then heal slowly by granulating, although the area may remain deeply violaceous for a prolonged period. The resulting permanent scar is often dense and readily evident.

LABORATORY TESTS. Extensive furunculosis or a carbuncle may be associated with leukocytosis. *S. aureus* is almost always the cause. Histologic examination of a furuncle shows a dense polymorphonuclear inflammatory process in the dermis and subcutaneous fat. In carbuncles, multiple abscesses, separated by connective-tissue trabeculae, infiltrate the dermis and pass along the edges of the hair follicles, reaching the surface through openings in the undermined epidermis. The diagnosis is made on the basis of the clinical appearance. Gram stain of pus, clusters of Gram-positive cocci, or isolation of *S. aureus* on culture confirms the diagnosis.

PROGNOSIS AND CLINICAL COURSE. The major problems with furunculosis and carbuncles are bacteremic spread of infection and recurrence. Lesions about

Box 177-4

Differential Diagnosis of Furunculosis

- Cystic acne
- Kerion (see Chap. 188)
- Hidradenitis suppurativa
- Ruptured epidermal inclusion cyst
- Furuncular myiasis
- Apical dental abscess
- Osteomyelitis



▲ **FIGURE 177-9** Carbuncle. This lesion represents multiple confluent furuncles draining pus from multiple openings.

the lips and nose raise the specter of spread via the facial and angular emissary veins to the cavernous sinus. Invasion of the bloodstream may occur from furuncles or carbuncles at any time, in an unpredictable fashion, resulting in metastatic infection such as osteomyelitis, acute endocarditis, or brain abscess. Manipulation of such lesions is particularly dangerous and may facilitate spread of infection via the bloodstream. Fortunately, these complications are not common. Recurrent furunculosis is a troublesome process that may continue for many years.

Treatment. Simple furunculosis may be aided by local application of moist heat. A carbuncle or a furuncle with surrounding cellulitis, or one with associated fever, should be treated with a systemic antibiotic (as for impetigo; see Box 177-3). For severe infections or infections in a dangerous area, maximal antibiotic dosage should be employed by the parenteral route. If MRSA is implicated or suspected in serious infections, vancomycin (1.0 to 2.0 g intravenously daily in divided doses) is indicated. Antibiotic treatment should be continued for at least 1 week.

When the lesions are large, painful, and fluctuant, then incision and drainage is critical. If the infection is recurrent or complicated by co-morbidities, a culture can be sent. Antimicrobial therapy should be continued until all evidence of inflammation has regressed and altered appropriately as culture results become available. Draining lesions should be covered to prevent autoinoculation and diligent hand washing performed. Patients with recurrent furunculosis present a special and frequently exasperating problem (Table 177-3).

TABLE 177-3
Management of Recurrent Furunculosis

- Careful evaluation for underlying causes.
  - Systemic processes: Previously discussed.
  - Specific localized predisposing factors: Industrial exposure to chemicals, oils; poor hygiene; obesity; hyperhidrosis; ingrown hairs; pressure from tight clothing or belts.
  - Sources of staphylococcal contact: Pyogenic infections in the family, contact sports such as wrestling, autoinoculation.
  - Nasal carriage of *Staphylococcus aureus*: This is the site from which dissemination of the organism may occur to other body sites. The frequency of nasal carriage varies: 10%–15% in infants 1 yr of age, 38% in college students, 50% in hospital physicians and military trainees.
- General skin care: The aim of these measures is to reduce the numbers of *S. aureus* on the skin. General skin care of both hands and body with water and soap is important (an antimicrobial soap solution, such as 4% chlorhexidine solution, may be used to decrease staphylococcal skin colonization). The patient should avoid trauma to the skin as well as potential skin irritants such as strong soaps and deodorants. A separate washcloth (and towel) should be used and carefully washed in hot water before use.
- Care of clothing: Loose, lightweight, porous clothing should be worn as much as possible. Large numbers of staphylococci are frequently present on the sheets and underclothing of patients with furunculosis and may cause re-infection of the patient and infection of other members of the family. In problem cases, it is not unreasonable to recommend that these items be carefully and separately washed in boiling water and changed daily.
- Care of dressings: Dressings should be changed frequently if purulent drainage collects. They should be carefully discarded in a paper bag that can be sealed and disposed of immediately.
- General measures: Despite the above measures, some patients continue to have recurrent cycles of lesions. Sometimes, the problem can be ameliorated or abolished by removing the patient from the regular routine of work. This is particularly pertinent in individuals who are under considerable emotional stress and physical fatigue. A vacation for several weeks, ideally in a cool, dry climate, may help considerably by providing rest and also the time needed for carrying out the program of careful skin care.
- Measures aimed at elimination of nasal (and skin) carriage of *S. aureus* (methicillin-susceptible or methicillin-resistant):
  - Local use of ointment in the nasal vestibule reduces nasal carriage of *S. aureus* and secondarily reduces the "shedding" of organisms on the skin, a process that may contribute to recurrent furunculosis. Intranasal application of a 2% mupirocin calcium ointment in a white, soft, paraffin base for 5 days can eliminate *S. aureus* nasal carriage in 70% of healthy individuals for up to 3 mo. In immunocompetent staphylococcal carriers with recurrent skin infections, a 5-day course of nasal mupirocin ointment every month for 1 yr resulted in positive nasal cultures in only 22% of patients as compared with 83% in the placebo group. The nasal culture–negative patients also had significantly fewer skin infections during the treatment period. Staphylococcal resistance to mupirocin was observed in only 1 patient out of 17. Prophylaxis with fusidic acid ointment in the nares twice daily every fourth week for the patient and family members who are nasal carriers of the infecting strain (along with peroral anti-staphylococcal antibiotic for 10–14 days for the patient) has been used with some success.
  - Oral antibiotics (e.g., rifampin, 600 mg orally daily for 10 days) have been effective in eradicating *S. aureus* from most nasal carriers for periods of up to 12 weeks. Such a use of rifampin for a brief period to eradicate nasal carriage of *S. aureus* and interrupt a continuing cycle of recurrent furunculosis might be reasonable in a patient in whom other measures have failed. However, selection of rifampin-resistant strains can occur rapidly with such therapy. The addition of a second drug (dicloxacillin for methicillin-susceptible *S. aureus*; trimethoprim-sulfamethoxazole, ciprofloxacin, or minocycline for methicillin-resistant *S. aureus*) has been used to reduce the emergence of rifampin resistance and to treat recurrent furunculosis.





▲ **FIGURE 177-10** *Staphylococcus aureus* abscess. A large painful abscess on the heel of a patient with diabetes improved clinically; however, the severe pain persisted. X-ray films of the heel revealed a broken-off sewing needle. The patient had sensory neuropathy and was unaware of stepping on this foreign body.



Abscess. As discussed in Furuncles and Carbuncles, abscesses caused by *S. aureus* commonly occur in folliculocentric infections—that is, folliculitis, furuncles, and carbuncles. Abscesses can also occur at sites of trauma, foreign bodies, burns, or sites of insertion of intravenous catheters. The initial lesion is an erythematous nodule. If untreated, the lesion often enlarges, with the formation of a pus-filled cavity (Fig. 177-10).

The initial and most important treatment of an abscess is incision and drainage and antibiotic treatment as for furuncles.

Botryomycosis. (See Chap. 190) Botryomycosis is a rare pyogenic disease, possibly related to a balance between numbers of organisms and host defenses, presenting as a purulent chronic, subcutaneous infection. Predisposing factors include trauma, immunosuppression (HIV disease, hyper-IgE syndrome), chronic alcoholism, and diabetes mellitus. Lesions (usually solitary) can occur in skin, bone, and liver.



▲ **FIGURE 177-11** *Staphylococcus aureus* botryomycosis. A plaque on the chest had been present for several months in this human immunodeficiency virus–infected individual. The diagnosis was confirmed on lesional biopsy findings and culture.

Cutaneous botryomycosis usually presents as a solitary lesion or a few lesions, often occurring in the genital area. The lesion has the gross appearance of a ruptured epidermal inclusion cyst (an erythematous circumscribed tender nodule), or prurigo nodularis (Fig. 177-11). In the majority of reported cases, a foreign body (fish bone, broom straw, etc.) has played a role in initiating or perpetuating the lesion. For diagnosis and treatment, see Chap. 185.

Staphylococcal Paronychia. Individuals exposed to hand trauma or chronic moisture are predisposed to staphylococcal paronychia, as well as to other causes of paronychia (e.g., *Candida, Pseudomonas, Streptococcus,* dermatophytes). *S. aureus* is the major infectious cause of acute paronychia, usually around the fingernails, often originating from a break in the skin, such as a hangnail. Clinically, skin and soft tissue of the proximal and lateral nail fold are red, hot, and tender, and, if not treated, can progress to abscess formation (Fig. 177-12).

In contrast, chronic or recurrent paronychia caused by *C. albicans* is an infection of the space created by separation of the proximal dorsal nail plate and the undersurface of the proximal nail fold. Candidal paronychia is most common in individuals who have their hands in water for a great deal of time (see Chap. 189)

Management of paronychia caused by *S. aureus* includes oral and topical antibiotics, and incision and drainage of abscesses.



▲ **FIGURE 177-12** *Staphylococcus aureus* paronychia. An abscess is seen in the dorsum of the finger, beginning in a small break in the cuticle. In contrast, *Candida* paronychia is a space infection, occurring in the space created by the separation of the proximal dorsal nail plate and the overlying proximal nail fold.

Staphylococcal Whitlow (Felon). A whitlow is a purulent infection or abscess involving the bulbous distal end of the finger. The most common causes are *S. aureus* and herpes simplex virus. The portal of entry of *S. aureus* is a traumatic injury or possible extension of an acute paronychia. This infection is usually very painful. An obvious portal of entry is often apparent. The finger bulb is red, hot, tender, and edematous, with possible abscess formation (Fig. 177-13). In contrast, individuals with herpetic whitlows usually have a history of lesions occurring in the same site and present with grouped hemorrhagic vesicles, which may be-



▲ **FIGURE 177-13** *Staphylococcus aureus* whitlow (felon). A pyogenic granuloma arose 1 week after trauma to the bulb of the thumb. A week later, the bulb became swollen, erythematous, and very tender. Abscess formation is seen with loculation of pus. X-ray films showed early osteomyelitis complicating the whitlow.

come confluent and form a single bulla (see Chap. 193). Management of a staphylococcal whitlow requires surgical drainage of loculated abscess(es) within the tissue and intravenous antibiotic therapy. X-ray examination of the involved finger is indicated to determine the presence of osteomyelitis.

SYNDROMES CAUSED BY STAPHYLOCOCCAL EXOTOXINS SSSS, staphylococcal scarlatiniform eruption, TSS, recalcitrant erythematous, desquamating disorders (red disorders) and recurrent toxin-mediated perineal erythema are syndromes caused by staphylococcal exotoxins and are discussed in Chap. 178.

STREPTOCOCCAL SKIN INFECTIONS

General Features

EPIDEMIOLOGY Group A streptococci are usually spread by transfer of organisms from an infected person or carrier through close personal contact. The major source of such spread is from patients with infections in the upper respiratory tract. Approximately 10 percent of the normal population carry group A streptococcus asymptomatically—a higher percentage of adults than of children in the oropharynx and less commonly in the nares and anus. Although the carriage rate of group A streptococcus on normal skin is less than 1 percent, a variety of skin lesions and puerperal sepsis may also be the source of intrahospital spread of infection. Group A streptococci introduced into the operating room in the form of a minor skin infection, or even through perianal carriage by a surgeon or anesthetist, may be responsible for an epidemic of streptococcal wound infections.

The major factor in the spread from a carrier or an infected person is the proximity to the individual disseminating the organisms. Because many patients with group A streptococcal (GAS) skin infections harbor the same organism in their pharynxes, they are, for both reasons, potential sources for spread of infection in a hospital. Particular care must be taken to prevent spread of infection by isolating such patients until antibiotic therapy has rendered them noncontagious.

The overall incidence of streptococcal disease has surged since the mid-1980s.[15] Reports of invasive GAS infections often associated with shock and multiorgan failure have increased globally. Localized epidemics continue to appear and, during such outbreaks, the carrier and infection rates in the community increase. After recovery (without antibiotic treatment) from streptococcal pharyngitis, some individuals may carry the organism for prolonged periods. The carrier state may also occur in the absence of overt antecedent infection. Fifteen percent to twenty percent of schoolchildren carry group A streptococci in the throat.

ETIOLOGY AND PATHOGENESIS The Lancefield classification of streptococcal groups (A to T) is based on the C carbohydrate antigens of the cell wall. Although essentially all GAS strains are β-hemolytic streptococci, not all streptococci producing β-hemolysis belong to group A. Because serologic grouping of streptococci is not generally available, a reasonably accurate presumptive test for group A streptococci is necessary. Bacitracin disk ("Taxos S") sensitivity has been widely used; group A streptococci are, almost without exception, susceptible to the low concentration of bacitracin contained in the disk, whereas streptococci of other groups are often resistant. Subtyping of group A streptococci can be performed according to their M protein antigenicity (see below). Certain M protein serotypes appear to correlate with greater virulence of the organism. The M protein inhibits phagocytosis, promotes adherence to host cells and allows bacterial growth in human blood.[16] The M protein is highly polymorphic, with more than 150 variants coded for by the *emm* gene. Other virulence factors are cell surface molecules, including the hyaluronic acid capsule, C5a peptidase, opacity factor, and streptococcal inhibitor of complement. Secreted proteins playing a role in virulence include streptolysins O and S, cysteine proteinase, pyrogenic exotoxins, streptokinase, hyaluronidase, and other enzymes. It should be noted that horizontal gene transfer in GAS strains is a very common event. This transfer results in the rapid development of new and more virulent strains.[17]

The primary invasive streptococcal pyodermas are due almost exclusively to group A streptococcus, which is usually considerably more invasive than of other streptococci. Non-suppurative post-infectious complications have been limited mostly to those produced by group A streptococcus. Thus, GAS infections merit antibiotic treatment and eradication.

The hallmarks of invasive GAS infection are profuse edema, rapid spread through tissue planes, and a relatively thin exudative response. Infection may spread via the lymphatic or hematogenous routes and result in a fulminant clinical course.

The presence of streptococci of groups other than A in skin lesions may represent either surface colonization or actual secondary infection in pre-existing dermatoses. Group C and group G streptococci have occasionally been implicated in impetiginous lesions, secondarily infected dermatitis, wound infections with lymphangitis, and even in erysipelas and cellulitis (see Chap. 179). Streptococci of groups B and D have been isolated from infections of skin lesions secondary to ischemia or venous stasis and have particularly involved the perineal area and operative wound sites. As with most secondary infections, those due to group B and group D streptococci are frequently mixed infections with enteric bacteria or *S. aureus*. Group B streptococci may cause cellulitis and otitis in neonates and, sometimes, in adults. Group L streptococci (often carried by pigs, cattle, and poultry) have been responsible for impetigo, secondarily infected wounds, and paronychias in meat handlers.

The incidence of invasive complications (lymphangitis, suppurative lymphadenitis, bacteremia) of streptococcal infections of the skin has decreased in the antibiotic era. Other than these pyogenic complications, a variety of non-suppurative complications (acute rheumatic fever, acute glomerulonephritis, erythema nodosum) may follow GAS infections. Distinct differences exist between acute rheumatic fever and acute glomerulonephritis in the site of the antecedent infection, the length of the latent period, and the streptococcal serotypes involved. Acute rheumatic fever may be a complication of GAS pharyngitis or tonsillitis, but it does not occur after streptococcal skin infections. In contrast, acute nephritis may follow infection of either the skin or the upper respiratory tract. The latent period between streptococcal pharyngitis and the onset of rheumatic fever is 2 to 3 weeks; whereas the latent period for pharyngitis-associated nephritis is approximately 10 days. A longer latent period of approximately 3 weeks is characteristic of acute nephritis associated with streptococcal pyoderma.

Group A streptococci are classified into over 80 sub-types, based on the antigenicity of their M proteins (fibrillar structures extending out from the cell surface). Although there is as yet no strong evidence



of an association between infection with any specific group A serotypes and the subsequent development of rheumatic fever, several serotypes (particularly mucoid strains of types 1, 3, and 18) have been implicated in a few outbreaks of streptococcal sore throat complicated by this sequela.[18] However, there is a clear relationship between infection with certain serotypes and the subsequent occurrence of nephritis—the so-called *nephritogenic serotypes*. Type 12 is the classic serotype responsible for pharyngitis-associated acute nephritis, but other serotypes, such as 1, 4, 25, and 49, have been implicated. The pyoderma-associated nephritogenic strains generally belong to different serotypes: types 2, 49, 42, 55, 56, 57, and 60.[19,20] Unlike the pharyngitis strains, the pyoderma serotypes produce lipoproteinase or opacity factor, illustrating a fundamental difference between the two.[15] The skin rather than the pharynx is the principal site of antecedent streptococcal infection causing nephritis, and impetigo is now the most common form of such predisposing skin infections.

The frequency of acute glomerulonephritis after infection with a known nephritogenic strain is 10 percent to 15 percent; the frequency of rheumatic fever after an unrecognized or inadequately treated pharyngeal infection by any serotype of group A streptococcus is 2 percent to 3 percent or less. The distinction between nephritogenic and other strains of streptococci that might be associated with rheumatic fever can be seen in studies from Trinidad, a hyperendemic area for pyoderma-associated nephritis. There the streptococcal serotypes causing outbreaks of nephritis differed from the serotypes associated with sporadically occurring cases of acute rheumatic fever in the same population.[18]

It has been suggested that several biologic properties are associated with broad categories of group A streptococci. Most M proteins fall into one of two antigenic classes based on the presence (class I) or absence (class II) of a highly conserved antigenic domain. Almost all rheumatic fever outbreak–associated strains belong to serotypes of class I and require a precursor nasopharyngeal infection. However, because many class I serotypes are associated with impetigo as well, and because class II serotypes are responsible for both upper respiratory and skin infections, the class of M protein alone is not a determinant of tissue tropism. Current evidence indicates differences among class I organisms that may relate to their capacities to induce rheumatic fever: Class I nasopharyngeal isolates appear to lack human IgG-binding activity, whereas nearly all impetigo isolates of the same class bear human IgG receptors.[21]

As in *S. aureus*, there are several GAS superantigens that have been identified. These include streptococcal pyrogenic exotoxin (or erythrogenic exotoxin) A to C, F, and G to J, streptococcal superantigen, and streptococcal mitogenic exotoxin Z. These superantigens are associated with disease.[22]

ANTIBODY RESPONSE AND IMMUNITY The immune response to GAS infection depends to a large measure on the site of infection. *Streptococcal infection* is usually defined as a positive throat culture with a serologic response to group A streptococcus and the streptococcal carrier state by a positive throat culture and no serologic response. After streptococcal pharyngitis, specific antibodies develop to many of the extracellular enzymes of the streptococci. Eighty-five percent of patients with acute rheumatic fever and a proven preceding streptococcal infection have an elevated or increasing antistreptolysin O titer. The serologic demonstration of an antecedent streptococcal infection in this situation can be increased to virtually 100 percent by the simultaneous testing for several other antibodies (antihyaluronidase, anti-DNase B). Antibodies to extracellular products, with the exception of antibody to the erythrogenic toxin of scarlet fever, appear to have no effect on the manifestations of illness. Streptococcal immunity is type specific (but not group specific), long-lasting, and depends on the production of bactericidal antibodies to the specific M proteins of the over 80 different serotypes of group A organisms. Although recurrent pharyngeal infections caused by the same serotype are most unusual, repeated clinical infections caused by different types are not uncommon. Early treatment of streptococcal upper respiratory tract disease with antibiotics may suppress the appearance of type-specific antibody (and immunity), as well as the development of antibody to the extracellular products of the organism.

In contrast to pharyngeal infections, the antistreptolysin O response with streptococcal skin infections or pyoderma-associated nephritis is weak. To define the latter serologically, anti-DNase B titers are much more reliable. Although pyoderma strains of streptococci produce M proteins, and although type-specific antibody may develop in patients with pyoderma-associated nephritis, the frequency of production of such antibodies and their role in protection against re-infection are unclear. Although pharyngeal re-infection with the same streptococcal serotype is probably unusual, some evidence suggests that the same serotype can be associated with repeated episodes of pyoderma.

TABLE 177-4
Infections and Toxin Syndromes Caused by Group A Streptococci

- Superficial pyodermas
  - Nonintertriginous skin
    - Impetigo
    - Ecthyma
    - Blistering distal dactylitis
  - Intertriginous skin
    - Perianal streptococcal cellulites
    - Streptococcal vulvovaginitis
    - Streptococcal intertrigo
- Invasive infections
  - Acute lymphangitis
  - Erysipelas
  - Cellulitis
  - Streptococcal gangrene
  - Bacteremia, septicemia
- Toxin-associated syndrome
  - Scarlet fever
  - Streptococcal toxic-shock–like syndrome
  - Streptococcal gangrene
- Non-suppurative complications
  - Rheumatic fever
  - Glomerulonephritis
- Other associated cutaneous reaction patterns
  - Erythema nodosum
  - Erythema multiforme
  - Guttate-pattern psoriasis
  - Vasculitis

Specific diseases caused by group A (and other) streptococci are listed in Table 177-4. Streptococcal pyodermas include all types of superficial streptococcal skin infections except erysipelas—that is, impetigo, ecthyma, and secondary infections of pre-existing skin lesions (e.g., insect bites, abrasions, eczema). Streptococcal intertrigo such as streptococcal perianal "cellulitis" can occur primarily or secondarily in underlying conditions such as inverse psoriasis.

Impetigo

EPIDEMIOLOGY Impetigo caused by group A streptococcus is a highly communicable infection and occurs predominantly in preschool-aged children (usually before the age of 2 years except in highly endemic areas). It is more common in warmer, more humid climates than in



temperate zones. Its peak seasonal incidence is in the later summer and early fall. Non-group A (groups B, C, and G) streptococci may be responsible for rare cases of impetigo; group B streptococci are associated with impetigo in the newborn. Whereas many different serotypes of group A streptococci may cause pharyngitis, a limited number of newly described types predominate in impetigo (types 49, 52, 53, 55, 56, 57, 59, and 61).

ETIOLOGY AND PATHOGENESIS Group A streptococci appear on normal skin of children approximately 10 days before the development of impetigo, and they are not recovered from the nose and throat of the same patients until 14 to 20 days after skin acquisition of the organism. Streptococci are recovered from the respiratory tract of approximately 30 percent of children with skin lesions, but there is no clinical evidence of streptococcal pharyngitis. Thus, the sequence of spread in a given patient is from normal skin to lesions and eventually to the respiratory tract.[23] In contrast, the sequence of spread of *S. aureus* (in cases of impetigo in which it is the only organism isolated) is from nose, to normal skin, to skin lesions (see Impetigo).

When exposed to an infectious contact, pre-existing lesions, such as scabies, varicella, or eczema, predispose to the appearance of infected lesions. Crowding, poor hygiene, and neglected minor skin trauma contribute to the spread of streptococcal impetigo in families. Minor outbreaks have also occurred among athletes involved in contact sports. Although the majority of cases occur in children, particularly of preschool age, young adults are also affected. The inflammatory process of impetigo is superficial, with a unilocular vesicopustule located between the stratum corneum above and the stratum granulosum below. This is usually situated near the opening of a hair follicle. Organisms, as well as leukocytes and cell debris, fill the vesicle.

CLINICAL FINDINGS ***Cutaneous Lesions.*** Impetigo caused by group A streptococcus presents as a crusted superficial infection of the skin; an initial vesicular phase has been described but is rarely detected. Lesions are clinically indistinguishable from impetigo caused by *S. aureus*, with the exception of bullous impetigo (see Non-Bullous Impetigo and Figs. 177-1 to 177-3). Pruritus and burning may occur, but the lesions are usually painless. Systemic response is minimal unless complications occur.

Laboratory Tests. A slight leukocytosis may occur. A Gram-stained smear of early vesicle fluid reveals Gram-positive cocci in chains. Culture of the weeping area or of the area beneath an unroofed crust reveals group A streptococci or a mixture of streptococci and *S. aureus* (particularly from older crusted lesions).

PROGNOSIS AND CLINICAL COURSE Untreated, the process may persist and new lesions may develop over the course of several weeks; thereafter, the infection tends to resolve spontaneously unless there is some underlying cutaneous disorder such as eczema. Untreated, some lesions become chronic and deeper, such as ecthyma (see Staphylococcal Ecthyma). Complicating erysipelas, cellulitis, or bacteremia are unusual. The major serious sequela is acute post-streptococcal glomerulonephritis.

TREATMENT Topical treatment (removal of dirt, crusts, and debris by soaking with soap and water) is a valuable adjunct. Mupirocin ointment appears to be as effective as parenteral or oral penicillin for treatment of impetigo.[24]

In superficial pyodermas known to be caused by group A streptococcus, penicillin is the drug of choice, administered either as a single injection of long-acting benzathine penicillin (300,000 to 600,000 units for children; 1.2 million units for adults) or orally (25,000 to 100,000 units/kg/day in divided doses q6h for 10 days). Although penicillin treatment clears the lesions of GAS impetigo and prevents recurrence for a short time, streptococci can persist on or newly colonize unaffected skin in spite of this therapy. Erythromycin (30 to 50 mg/kg/day PO in divided doses q6h for children; 250 to 500 mg PO q6h for adults administered for 10 days) is a suitable alternative drug in patients allergic to penicillin. However, it should be noted that 20 percent or more of GAS strains became resistant to erythromycin in areas (Japan, Finland) where this antibiotic had been extensively used for a variety of indications.[25] There is still no evidence to suggest that treatment of GAS pyoderma can prevent subsequent nephritis in any individual. Although the latent period after impetigo is longer than that after pharyngeal infection, the mildness of the illness delays or negates the seeking of medical attention.

Practically, however, the majority of cases of non-bullous impetigo are caused by *S. aureus*, and topical or systemic antimicrobial treatment should be directed at that pathogen (see Box 177-3).

Streptococcal Ecthyma

See Staphylococcal Ecthyma.

Intertriginous Streptococcal Infections

Streptococcal pyodermas occur much less commonly in occluded sites such as the perineum/perianal region, vulva/vagina, axillae (Fig. 177-14), inframammary region, groin, preputial sac, and web spaces of the feet. Perianal (group A) streptococcal "cellulitis" occurs principally in children, presenting with intense perianal erythema (Fig. 177-15), pain on defecation, blood-streaked stools associated with anal fissures, and chronicity if untreated.[26] It is often confused with psoriasis, candidiasis, seborrheic dermatitis, inflammatory bowel disease, pinworm infection, or a behavioral problem. The infection can also involve the penis and vulva. Treatment options include oral antibiotics or topical mupirocin. Guttate psoriasis has also occurred in children, associated with perianal streptococcal infection.[27]

BLISTERING DISTAL DACTYLITIS Group A streptococcus is responsible for the majority of cases of blistering distal dactyli-



▲ **FIGURE 177-14** Group A streptococcus intertrigo. A sharply marginated erythematous and oozing plaque in the axilla, which was also present in the other axilla, inframammary area, and inguinal folds, was painful in this human immunodeficiency virus–infected woman.







▲ **FIGURE 177-15** Group A streptococcus intertrigo—perianal streptococcal cellulitis. Well-demarcated erosive erythema in the perianal region and perineum in an 8-year-old boy who complained of soreness.

tis, also called *bulla repens*, usually occurring in children and adolescents. However, group B streptococcus can also cause this infection. A large, tense blister develops, filled with seropurulent fluid, over the volar skin pad of distal fingers or toes (Fig. 177-16). The blisters are often surrounded by an erythematous base. The lesion may be more proximally located on the finger or extend to involve the nail folds. Group A streptococcus may be cultured from the vesicle fluid. Blistering distal dactylitis may be treated with oral penicillins or erythromycin and release of subungual pus is often required. Staphylococcal blistering distal dactylitis has been reported with an identical clinical picture.[28]



▲ **FIGURE 177-16** Group A streptococcus blistering dactylitis. A blister is seen on a toe adjacent to the nail fold; the patient also had group A streptococcal intertrigo of an abdominal skin fold.

ACUTE LYMPHANGITIS Acute lymphangitis is an inflammatory process involving the subcutaneous lymphatic channels. It is most often caused by group A streptococci, but occasionally may be caused by *S. aureus*; rarely, STIs with other organisms, such as *Pasteurella multocida* or herpes simplex virus may be associated with acute lymphangitis.

CLINICAL FINDINGS ***History.*** The portal of entry is commonly a wound on an extremity, an infected blister, or a paronychia. The systemic manifestations of infection may occur either before any evidence of infection is present at the site of inoculation or after the initial lesion has subsided. The patient may notice pain over an area of redness proximal to the original break in the skin. Systemic symptoms are often more prominent than expected from the degree of local pain and erythema.

An unusual spread of streptococcal infection of the thumb (paronychia) or of the interdigital webs between the thumb and index finger may occur occasionally. Lymphatic drainage from this area can bypass the lymph nodes at the elbow and drain into the axillary nodes, which, in turn, communicate with the subpectoral nodes and the pleural lymphatics. As a consequence, subpectoral abscesses and pleural effusion can develop. The subpectoral infection may dissect downward and appear over the lower chest and upper abdomen as an area of cellulitis. This is a very serious illness. The clinical clues to the development of this sequence of events are provided by the location of the original infection on the thumb or medial surface of the index finger and the early occurrence of axillary pain.

Cutaneous Lesions. Red linear streaks, which may be a few millimeters to several centimeters in width, extend from the local lesion toward the regional lymph nodes, which are usually enlarged and tender (Fig. 177-17).

DIFFERENTIAL DIAGNOSIS In the upper extremities, acute lymphangitis usually can be differentiated from subacute or chronic sporotrichoid syndrome caused by organisms such as *Sporothrix schenckii*. In the lower extremities, superficial thrombophlebitis may produce somewhat similar linear areas of tender erythema. The absence of a portal of entry and of tender regional adenopathy is helpful in distinguishing this process from lymphangitis.



▲ **FIGURE 177-17** Acute lymphangitis of forearm due to *Staphylococcus aureus*. There is a tender linear streak extending proximally from a small area of cellulitis on the volar wrist.

LABORATORY TESTS The peripheral white blood cell count is elevated, with a marked increase in polymorphonuclear cells. The offending organism cannot be cultured from the skin, as the infection is restricted to the lymphatic channels. However, the primary portal of entry or a suppurative lymph node, if overt infection is present, may reveal the etiologic agent.

PROGNOSIS AND CLINICAL COURSE The frequent development of bacteremia with metastatic infection in various organs makes this a potentially serious disease. The infection responds readily to penicillin therapy if instituted promptly.

Invasive Streptococcal Infections

Erysipelas, cellulitis, and streptococcal gangrene are invasive streptococcal infections and are discussed in Chap. 179.

Streptococcal Toxin Syndromes

Scarlet fever and toxic streptococcal syndromes are streptococcal toxin syndromes and are discussed in Chap. 178.

Cutaneous Manifestations of Subacute Bacterial Endocarditis (See Chap. 181)

Post-Streptococcal (Group A) Non-Suppurative Cutaneous Sequelae

ERYTHEMA NODOSUM (See Chap. 68)

ERYTHEMA MARGINATUM (CUTANEOUS LESIONS OF ACUTE RHEUMATIC FEVER) (See Chap. 161)

PURPURA FULMINANS (See Chaps. 145 and 181)

OTHER SKIN LESIONS ACCOMPANYING OR FOLLOWING GROUP A STREPTOCOCCAL INFECTIONS ***Erythema Multiforme–Like Lesions.*** Round erythematous macules, up to 1.5 cm in diameter, some developing bright borders and subsequently showing clearing in the center, may occur during bacteremia caused by group A streptococci (or *S. aureus*) in infants and young children (see Chap. 38).

Acute Guttate Psoriasis. Rarely, erythematous, papulosquamous, guttate psoriasiform lesions may develop during or after GAS pharyngitis or skin infections. Children appear to be most commonly affected. Clearing of the lesions may occur within weeks of antimicrobial therapy of the streptococcal infection. Although the temporal relation of the two processes is striking, a direct causal connection has not been established, but the role of superantigens in guttate psoriasis is the subject of current research (see Chap. 18).[29,30]

Management of Group A Streptococcal Skin Infections

GENERAL PRINCIPLES Penicillin G is the drug of choice in the treatment of known GAS skin infections. When the etiology is not known immediately (e.g., in cellulitis) and when *S. aureus* is also a distinct consideration, a semi-synthetic penicillin (nafcillin or oxacillin) should be employed initially. Penicillin treatment should be continued for at least 10 days to ensure eradication of the infection. Prophylactic penicillin therapy is indicated for close family contacts (particularly children) of patients with streptococcal pharyngitis.

Box 177-5

Treatment of Streptococcal Pyodermas[a]

	TOPICAL (for mild impetigo)	SYSTEMIC	
First line	Mupirocin bid	Penicillin V	250–500 mg PO qid for 5–7 days
		Dicloxacillin (if *S. aureus* is suspected)	250–500 mg qid for 5–7 days
Second line (penicillin allergy)		Azithromycin	500 mg × 1 then 250 mg daily for 4 days
		Clindamycin	15 mg/kg/day tid
		Erythromycin	250–500 mg PO qid for 5–7 days

[a]Washing and hygiene are important in all regimens.

ANTIMICROBIAL THERAPY Mild instances of infections, such as impetigo, scarlet fever, or certain cases of erysipelas and cellulitis, may be treated with oral penicillin V (250 to 500 mg qid). When staphylococcal infection is suspected, dicloxacillin (250 to 500 mg PO qid) should be substituted. In adults allergic to penicillin, erythromycin (250 to 500 mg PO qid) is a reasonable alternative. Other alternatives include azithromycin, clarithromycin, and clindamycin (Box 177-5).

PREVENTION OF SPREAD Patients hospitalized with GAS infections should be isolated until the organisms have been eradicated by antibiotic treatment. Individuals with recurrent episodes of GAS infections can be treated with dicloxacillin or erythromycin, 250 mg twice daily (penicillin-allergic individuals), as secondary prophylaxis.

Soft-Tissue Streptococcal Infections (See Chap. 179)

Cutaneous Infections Caused by Micrococcus: Pitted Keratolysis

Pitted keratolysis involves the stratum corneum of the web spaces and plantar surface. Originally named *keratoma plantare sulcatum* by Castellani in 1910, this disease has become more commonly called by its current name after Taplin and Zaias coined it in 1967. The disease was first seen in those who went barefooted during the rainy season.

ETIOLOGY AND PATHOGENESIS The likely causative organism is *Micrococcus sedentarius*, which is a Gram-positive staphylococcus-related bacterium that invades the stratum corneum softened by sweat and moisture. *Corynebacterium* sp. may also be involved. Pitted keratolysis tends to be much more severe in tropical climates than in temperate ones.

Pitted keratolysis occurs in adults and children of both sexes, but adult males with sweaty feet are most susceptible (96 percent of cases).[31] Sliminess of the skin, often manifest by the foot sticking to the socks, is also a common complaint (70 percent of cases). The feet are typically very malodorous (89 percent) and may be mildly pruritic (8 percent).

CLINICAL MANIFESTATIONS Pitted keratolysis presents as a superficial erosion of the stratum corneum, composed of numerous small crateriform pits coalescing to form a large discrete defect with serpiginous borders on the plantar surface of the foot. The pits are usually larger than 0.7 mm in diameter, but at times are smaller than 0.5 mm. The pits have elongated configurations along the plantar furrows and are located predominantly on the pressure-bearing areas, such as the ventral aspect of the toe, ball of the foot, and the heel, but they are also seen on non–pressure-bearing areas.[31] The web spaces between the toes are also commonly involved sites, and may be the only manifestation (Fig. 177-18). The diagnosis is made clinically.

DIFFERENTIAL DIAGNOSIS Interdigital tinea pedis can present with erosive lesions in the web spaces. Erythrasma in the web spaces is usually hyperkeratotic but can be erosive.

LABORATORY FINDINGS Gram-staining of scrapings may detect the microorganism more readily than potassium hydroxide examination. Histologically, the organisms are present in the walls and bases of the crateriform defects in the upper layer of the stratum corneum. The organisms appear as coccoid and filamentous forms with branches and septa.





▲ **FIGURE 177-18** Pitted keratolysis. The web spaces between the toes are sharply eroded. Interdigital tinea pedis and erythrasma may occur concurrently.



TREATMENT Prophylactic measures are aimed at keeping the feet as dry as possible. Inert antiseptic foot powders often help. Aluminum chloride 20 percent solution is an effective astringent. A benzoyl peroxide wash and 5 percent gel are effective therapy in most cases as well. Other commonly used topical adjunctive agents include clindamycin and erythromycin solutions.

Infections Caused by Corynebacterium

ERYTHRASMA Erythrasma is a common superficial bacterial infection of the skin characterized by well-defined but irregular reddish brown patches, occurring in the intertriginous areas, or by fissuring and white maceration in the toe clefts.

Etiology and Epidemiology. *C. minutissimum*, the etiologic agent of erythrasma, is a short, Gram-positive rod with subterminal granules. The infection is more common in tropical than in temperate climates. In a study in a temperate climate, 20 percent of randomly selected subjects were found to have erythrasma by Wood's lamp examination. The generalized disease is much more common in the tropics. Erythrasma is more common in men and may occur in asymptomatic form in the genitocrural area.

Clinical Findings. **HISTORY.** Symptoms vary from a completely asymptomatic form, through a genitocrural form with considerable pruritus, to a generalized form with scaly lamellated plaques on the trunk, inguinal area, and web spaces of the feet. When pruritic, irritation of lesions may cause secondary changes of excoriations and lichenification.

CUTANEOUS LESIONS. The most common site of involvement is the web spaces of the feet, where erythrasma presents as a hyperkeratotic white macerated plaque (Fig. 177-19), especially between the fourth and fifth toes. In the genitocrural, axillary, and inframammary regions, the lesions present as well-demarcated, reddish-brown, superficial, finely scaly, and finely wrinkled patches (Fig. 177-20). In these sites, the patches have a relatively uniform appearance as compared with tinea corporis or cruris, which often have central clearing.

Wood's lamp examination of erythrasma reveals a coral-red fluorescence caused by coproporphyrin III. The fluorescence may persist after eradication of the *Corynebacterium* as the pigment is within a thick stratum corneum.

DIFFERENTIAL DIAGNOSIS. Tinea versicolor is distinguished from erythrasma by the lesions on the trunk being most numerous at nonintertriginous sites. Tinea cruris tends to have an active scaling border with central clearing. Inverse psoriasis usually presents as sharply demarcated plaques with a shiny red color in the intergluteal cleft, inguinal folds, and axillae.

LABORATORY FINDINGS. Culture of the specific *Corynebacterium* in abundance from the lesion corroborates the diagnosis. Gram-stained imprints of the horny layer of the skin show rod-like, Gram-positive organisms in large numbers.

The diagnosis is strongly suggested by the location and superficial character of the process, but must be confirmed by demonstration of the characteristic "coral-red" fluorescence with Wood's lamp illumination.

PROGNOSIS AND CLINICAL COURSE. The disease may remain asymptomatic for years or may undergo periodic exacerbations. Relapses occasionally occur even after successful antibiotic treatment.

TREATMENT. For localized erythrasma, especially of the web spaces of the feet, benzoyl peroxide wash and 5 percent gel are effective in most cases. Clindamycin (2 percent solution) or azole creams are several of the many effective topical agents. For widespread involvement, oral erythromycin is effective. A 1 g single dose of clarithromycin has been used successfully.[32] For secondary prophylaxis, an antibacterial benzoyl peroxide bar when showering is effective.



▲ **FIGURE 177-19** Erythrasma. Hyperkeratosis with a yellowish hue in the web space of the foot. The three lateral web spaces of both feet were involved. The potassium hydroxide preparation was negative; the Wood's lamp examination showed a bright coral red fluorescence.



▲ **FIGURE 177-20** Erythrasma. Well-demarcated reddish-brown patches in the axilla (**A**) and groin (**B**). The potassium hydroxide preparations were negative; the Wood's lamp examination showed a bright coral red fluorescence.



TRICHOMYCOSIS AXILLARIS AND PUBIS

Trichomycosis axillaris, a bacterial infection of the hair shaft (not fungal as the name implies), is characterized by what appears to be nodular thickenings on the hair shaft, composed of colonies of aerobic *Corynebacterium*. The condition occurs both in the axillae and pubic areas, and not just in the axillae, as the name implies. The bacteria produce various pigments, giving the nodules a range of colors. In a study from the United Kingdom, axillary infection was noted in 27 percent of adult male students; in hospitalized mentally retarded patients, the finding was present in 42 percent of male patients and in 7 percent of female patients (many of the females had no axillary hair).[33]



▲ **FIGURE 177-21** Trichomycosis axillaris. Tan-yellow concretions on the hair shafts of the axilla.

Trichomycosis is asymptomatic except for the patient's concern regarding the lesions themselves and because they are malodorous. The concretions on the hair shaft are usually a tan color but may be reddish, yellow, or black (Fig. 177-21). Lesions are most dense in and may be present only in the central portion of the axillary hair. The same lesions may occur in the pubic hair as well.

The diagnosis is usually made on the basis of the physical findings. The concretions can be visualized using a potassium hydroxide preparation. Pediculosis pubis infestation with multiple eggs on the hair shaft should be ruled out.

The involved hair can be removed by shaving. Benzoyl peroxide wash and gel are effective as treatment and prevention against recurrence of trichomycosis.

KEY REFERENCES

The full reference list for all chapters is available at www.digm7.com.

1. Foster TJ: Immune evasion by staphylococci. *Nat Rev Microbiol* **3**:948, 2005
4. Bradley SF: *Staphylococcus aureus* infections and antibiotic resistance in older adults. *Clin Infect Dis* **34**:211, 2002
5. Manders SM: Toxin-mediated streptococcal and staphylococcal disease. *J Am Acad Dermatol* **39**:83, 1998
6. McCormick JK, Yarwood JM, Schlievert PM: Toxic shock syndrome and bacterial superantigens: An update. *Annu Rev Microbiol* **55**:77, 2001
9. Hryniewicz W: Epidemiology of MRSA. *Infection* **27**:S13 1999
11. Amagai M et al: Toxin in bullous impetigo and staphylococcal scalded-skin syndrome targets desmoglein 1. *Nat Med* **6**:1275, 2000
12. Gisby J, Bryant J: Efficacy of a new cream formulation of mupirocin: Comparison with oral and topical agents in experimental skin infections. *Antimicrob Agents Chemother* **44**:255, 2000
13. Koning S et al: Interventions for impetigo. *Cochrane Database Syst Rev* CD003261, 2004
15. Cunningham MW: Pathogenesis of group A streptococcal infections. *Clin Microbiol Rev* **13**:470, 2000
17. Currie BJ: Group A streptococcal infections of the skin: Molecular advances but limited therapeutic progress. *Curr Opin Infect Dis* **19**:132, 2006
29. Leung DY et al: Evidence for a streptococcal superantigen-driven process in acute guttate psoriasis. *J Clin Invest* **96**:2106, 1995
31. Takama H et al: Pitted keratolysis: Clinical manifestations in 53 cases. *Br J Dermatol* **137**:282, 1997

CHAPTER 178

Gram-Positive Infections Associated with Toxin Production

Jeffrey B. Travers
Nico Mousdicas



Skin infections with the Gram-positive bacteria *Staphylococcus aureus* and group A streptococcus (*Streptococcus pyogenes*) are an important source of morbidity and even mortality. These bacteria produce toxins that can induce characteristic syndromes, including staphylococcal scalded-skin syndrome (SSSS) and toxic shock syndrome (TSS). Moreover, the production of these toxins is thought to underlie the ability of infection with these bacteria to initiate and/or propagate inflammatory skin diseases.

EPIDEMIOLOGY

All conditions discussed here are relatively rare but have high morbidity, and some have considerable mortality.

FACTORS IN TOXIN-MEDIATED DISEASE

Staphylococcal and streptococcal pathogenicity is due to the production of a range of immunomodulatory proteins including toxins, exoenzymes, and adhesins.[1] Among the best characterized are the toxins (Table 178-1).

Many risk factors play a role in the ability of a toxin-forming *Staphylococcus* or *Streptococcus* to produce disease. The development of disease is related to the resistance of the host to infection and to the virulence of the organism. Host resistance depends, among other factors, on intact skin and mucous membranes functioning as barriers to invasion and the host's ability to mount an immune response (e.g., neutralizing antibodies) against such toxins. Colonization by virulent *Staphylococcus* or *Streptococcus* toxin–producing organisms exposed to optimal, focal conditions for growth and toxin production (e.g., menstruation + tampon use or abscess) allows these bacteria to initiate and/or propagate infection.

Minor defects in these barriers such as those produced by superficial excoriations, toe web fungal infections or alternatively, major defects produced by surgery, trauma, burns, or foreign substances (packing, sutures, intravascular catheters, shunts) increase the risk of infection. The role of host response cannot be overstated. For example, if a patient has an underlying immunodeficiency and cannot produce adequate neutralizing antibodies or, as in chronic granulomatous disease where neutrophils lack the oxidative burst to destroy catalase-positive bacteria (e.g., *S. aureus*), the patient is at increased risk for colonization and infection by toxin-producing bacteria. Finally, the types of immune cells that are activated play an important role in the subsequent host response, especially as it relates to toxins that act as superantigens. The ability of a superantigen to activate numerous T cells is based upon the variable region of the T-cell receptor. This could result in various types of responses depending on the specificity of the individual T cell that happened to become activated. Table 178-2 provides an overview of Gram-positive coccal toxin related diseases.

DISEASES CAUSED BY EXFOLIATIVE TOXINS: STAPHYLOCOCCAL SCALDED-SKIN SYNDROME

S. aureus–mediated production of exfoliative toxin also results in a spectrum of blistering skin disorders ranging from localized bullous impetigo (see Chap. 177) to a severe generalized form, SSSS. The syndrome is a generalized exanthematous disease consisting of cutaneous tenderness and widespread superficial blistering and denudation.

Etiology and Pathogenesis

Exfoliative toxins (ETs) are made by certain strains of *S. aureus* (usually phage group 2). Exfoliatin A and B (ETA and

GRAM-POSITIVE INFECTIONS ASSOCIATED WITH TOXIN PRODUCTION AT A GLANCE



- Caused by *Staphylococcus aureus* and/or group A streptococcus toxin–producing bacteria
- Three characteristic syndromes (all with skin manifestations):
  - Predominantly cutaneous
    - Local: Bullous impetigo
    - Generalized: Staphylococcal scalded skin syndrome
  - Cutaneous and systemic
    - Local: Recurrent toxin mediated erythema—(recurrent perineal erythema)
    - Generalized: Recalcitrant erythematous desquamating disorder
    - Other abortive hybrids of predominantly systemic manifestations disorder
  - Predominantly systemic
    - Generalized: Toxic shock syndrome *Staphylococcus* (predominantly) or *Streptococcus*
    - Scarlet fever—*Streptococcus* (predominantly) or *Staphylococcus*

TABLE 178-1
Toxins and Diseases Due to *Staphylococcus aureus* and Group A Streptococcus

BACTERIA	TOXIN	TOXIN TYPE	CLINICAL DISEASE
Staphylococcus aureus	Exfoliatin type A	Epidermolytic	Bullous impetigo SSSS
	Exfoliatin type B	Epidermolytic	SSSS Bullous impetigo
	TSS toxin 1	Superantigen	TSS (menstrual > non-menstrual), food poisoning
	Staphylococcal enterotoxins A–C	Superantigen	TSS (non-menstrual > menstrual), food poisoning
Streptococcus pyogenes	Streptococcal pyrogenic exotoxins A, C	Superantigen	TSS (non-menstrual), scarlet fever

SSSS = staphylococcus scalded-skin syndrome; TSS = toxic shock syndrome.

TABLE 178-2
Gram-Positive Coccal Infections Associated with Toxin Production

Caused by *Staphylococcus aureus* and/or group A streptococcus toxin–producing bacteria

- Characteristic syndromes (all with skin manifestations): can be divided into three categories depending on the predominant clinical presentation
  - Predominantly cutaneous
    - Local: Bullous impetigo
    - Generalized: Staphylococcal scalded-skin syndrome
  - Intermediate cutaneous and systemic
    - Local: Recurrent toxin-mediated erythema (recurrent perineal erythema)
    - Generalized
      - ~ Recalcitrant erythematous desquamating disorder
      - ~ Other abortive hybrids of predominantly systemic manifestations
  - Predominantly systemic
    - Generalized
      - ~ Toxic shock syndrome—*Staphylococcus* (predominantly) or *Streptococcus*
      - ~ Scarlet fever—*Streptococcus* (predominantly) or *Staphylococcus*

Predominantly Cutaneous	Intermediate Cutaneous and Systemic	Predominantly Systemic
• Exfoliative toxins	• Unidentified toxins	• Superantigens
Clinical Features		
• Erythema local or generalized • Tenderness • Nikolsky sign • Bullae • Exfoliation	• Erythema generalized • Fever and hypotension • Desquamation • Mucosal involvement • Prolonged disease • Some but not all toxic shock syndrome criteria met • Recurrences	• Erythema generalized with or without sandpaper characteristics • Toxic • Fever and hypotension • Mucosal involvement • Swelling of hands and feet • Organ failure • Exfoliation or desquamation
Foci of Bacterial Colonization/Infection		

• Bullous impetigo
  • Local skin
• Staphylococcus scalded-skin syndrome
  • Conjunctiva
  • Middle ear
  • Nasopharyngeal
  • Umbilical stump
  • Carbuncle or boil
	• Recurrent perineal erythema
	  • Nasopharyngeal
	• Recalcitrant erythematous desquamating disorder
	• Human immunodeficiency virus–associated
	• Non-human immunodeficiency virus–associated
	  • Search for occult *Staphylococcus*/*Streptococcus* infection
		• Toxic shock syndrome—*Staphylococcus aureus*
		  • Menstrual-associated
		  • Vagina
		  • Non-menstrual
		  • Surgical wounds
		  • Sinusitis
		  • Osteomyelitis
		  • Influenza
		  • Intravenous drug use
		  • Burn wounds
		  • Gynecologic-postpartum
		• Toxic shock syndrome–*Streptococcus*
		  • Skin in 80% of cases
		  • Cellulitis
		  • Necrotizing fasciitis
		• Scarlet fever–streptococcal
		  • Nasopharyngeal
		  • Surgical wounds
		  • Uterine infections
		  • Special clinical features of scarlet fever
		  • Circumoral pallor
		  • White and red strawberry tongue
		  • Forschheimer's spots
		  • Pastia's sign
		• Scarlet fever–staphylococcal
		  • All arise from skin (e.g., furuncle/carbuncle)
		  • Special clinical features of staphylococcus, scarlet fever
		  • Absences of pharyngitis in a patient with generalized erythroderma with sandpaper texture



ETB) are two serologically distinct proteins produced by *S. aureus*.[2] ETs are serine proteases that bind to the cell adhesion molecule desmoglein 1 and cleave it, resulting in a loss of cell-cell adhesion.[3] Consistent with the expression pattern of desmoglein 1, which is expressed in the upper part of the epidermis, the epidermolysis takes place



usually between the stratum spinosum and granulosum. This results in a very thin-walled, flaccid blister that is easily disrupted, exhibiting a positive Nikolsky sign. The pathophysiology of ET resembles that of the autoimmune blistering disease pemphigus foliaceus, with desmoglein 1 targeted in both diseases. Presumably, staphylococcal bacteria have evolved this toxin to allow the bacteria to proliferate and spread beneath the barrier of the skin. There are two forms of ET-mediated disease: localized bullous impetigo and systemic SSSS. Recent studies suggest that the majority of cases of localized bullous impetigo are due to ETA, and systemic forms such as SSSS are due to ETB, possibly due to a lower titer of anti-ETB neutralizing antibodies in the general population.[4] Although some reports suggest that ET can also act as superantigens (see Diseases Caused by Superantigenic Toxins) in addition to their epidermolytic activities,[5] this has recently been called into question.[6]

Clinical Features

LOCALIZED FORM (BULLOUS IMPETIGO) Infection of the upper part of the skin (epidermis) by *S. aureus* or *S. pyogenes* results in impetigo contagiosa (Figs. 178-1 and 178-2). Impetigo, which may account for up to 10 percent of all pediatric skin disease consists of honey-colored crusts on an erythematous base. Approximately one-fourth of cases of impetigo are bullous with local ET-expressing staphylococcus without hematogenous dissemination. As is the case with SSSS, bullous impetigo is usually a disease of children (see Chap. 177), although adult cases can also occur. The early lesions of bullous impetigo are cloudy vesicles or bullae surrounded by an erythematous rim (see Fig. 178-2). These blisters often rupture leaving superficial erosions. Lesions at various stages can often be seen. The lesions tend to be found around exposed parts of the body and around orifices (see Fig. 178-1). Diagnosis is usually based upon clinical appearance. In contrast to SSSS, confirmation of diagnosis can be easily obtained by aspiration of blister fluid for Gram stain and cultures will reveal *S. aureus*.



▲ **FIGURE 178-1** Bullous impetigo in a child. Blisters are initially filled with cloudy fluid and later rupture, resulting in erosions and crusting.



◀ **FIGURE 178-2** Bullous impetigo in a child. Note blisters filled with cloudy fluid and lesions that have ruptured, leading to erosions and crusting.

GENERALIZED FORM The clinical features of SSSS were first described in 1878 by the German physician Gotfried Ritter von Rittershain, who reported almost 300 cases of "dermatitis exfoliativa neonatorum" among young children.[7] Outbreaks of SSSS tend to occur in clusters as a consequence of cross-infection. Typically neonatal or maternity hospital staff colonized or infected with ET-producing staphylococci are the source of these outbreaks. Although more commonly seen in infants/children, SSSS can also be seen in adults. The risk factors for adults include a compromised immune response allowing for growth of the *S. aureus* and possibly impaired amounts of toxin-neutralizing antibodies or renal insufficiency, which decreases the clearance of the toxin. Affected individuals initially have a faint, orange-red macular exanthem or uniform erythema (Fig. 178-3) sparing mucosal surfaces in association with a purulent conjunctivitis, otitis media, nasopharyngeal infection, or, occasionally, pyogenic skin infection such as bullous impetigo or that which arises from an umbilical stump or boil (carbuncle). These are the staphylococcal foci from which the toxin is released. Periorificial (see Fig. 178-3A) and flexural (see Fig. 178-3B) accentuation of the exanthema is often noted.

Although the early rash is not distinctive in appearance, the concomitant cutaneous tenderness is usually present at this early stage. Tenderness can be often so severe that infants will refuse to lie down or allow anyone to hold them. Within 1 to 2 days the rash progresses from an exanthematous scarlatiniform to a blistering eruption (Fig. 178-4; see Fig. 178-3C and eFig. 178-4.1 in on-line edition). Very superficial tissue paper–like wrinkling of the epidermis, which is characteristic, progresses to large flaccid bullae in flexural and periorificial surfaces. A positive Nikolsky sign can be elicited by stroking the skin, which results in a superficial blister (see Fig. 178-4A and B and eFig. 178-4.1 in on-line edition). Large sheets of the epidermal surface are typically shed, revealing a moist underlying erythematous base. At this stage, the disease looks very worrisome, resembling a generalized scalding burn. Although fevers are often present and outwardly the signs of SSSS may look serious, the infants and children do not usually appear toxic unless they have developed complications such as septicemia or pneumonia. The cutaneous process usually resolves spontaneously or faster with antibiotics and superficial desquamation, with healing complete within 5 to 7 days (Fig. 178-5; see eFig. 178-5.1 in online edition). Cultures obtained from an intact blister are usually sterile consistent with the pathogenesis of a hematogenously disseminated toxin originating from a distant focus of infection.

Although most cases of SSSS occur in infants and children, the syndrome can also rarely be seen in adults, particularly when there is renal failure (see eFig. 178-5.2 in on-line edition). Histopathology shows acantholysis in the granular layer and sub-corneal cleft formation in early lesions (Fig. 178-6B) and an intact viable epidermis with shedding of the stratum corneum in the desquamative stage.

INTERMEDIATE (ABORTIVE) FORMS In addition to localized bullous impetigo and generalized SSSS, intermediate forms of



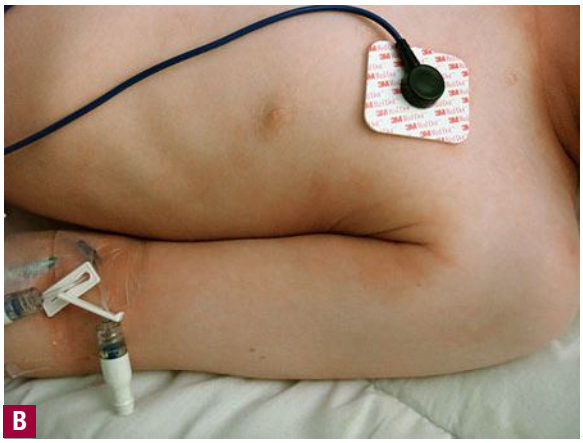



▲ **FIGURE 178-3** Staphylococcal scalded-skin syndrome. Pictures of early staphylococcal scalded-skin syndrome demonstrating the development of indistinct erythema (**A**, **B**) with positive Nikolsky sign (**C**) and superficial erosions.







▲ **FIGURE 178-4** Staphylococcal scalded-skin syndrome (SSSS). Pictures of later SSSS demonstrating (**A**) the same patient in Fig. 178-3A 24 hours later with erythema, more superficial blisters with desquamation of large sheets. **B.** Superficial erosions around the eye with underlying denuded skin. **C.** Characteristic crusting with superficial erosions noted on face of this 10-month-old child with SSSS.







▲ **FIGURE 178-5** Late stage of staphylococcal scalded-skin syndrome. Generalized desquamation with large sheets.

staphylococcal-mediated eruptions, in which blistering can be apparent, can be encountered. One scenario is localized bullous impetigo that evolves to produce regionally limited bullae and denuded areas that may or may not actually harbor *S. aureus*. A possibly abortive form of SSSS has been described. It is known as the *scarlatiniform variant* and has features of the early erythrodermic and final desquamative stages yet very little blister formation is present (see Staphylococcal Scarlet Fever).[8] Again, because *S. aureus* bacterial strains can produce both exfoliative and other superantigenic toxins, and ETs could have superantigenic activity,[5] it is not surprising that overlap syndromes with features of toxic shock and scalded skin can infrequently be observed.

Diagnosis and Differential Diagnosis

All forms of SSSS are characterized by intraepidermal cleavage with splitting beneath and within the stratum granulosum. The cleavage space may contain either partially or totally unattached acantholytic cells. However, the remainder of the epidermis is usually unremarkable, and the dermis contains few inflammatory cells (see Fig. 178-6B). In localized bullous impetigo, more inflammatory cells, including neutrophils, can be often visualized (see Fig. 178-6A).

The principal diagnostic problem is distinguishing generalized SSSS from toxic epidermal necrolysis (TEN) (see Chap. 39). It should be noted that the cases that represented Lyell's first description of TEN actually included some that were probably SSSS.[9] The age distribution between SSSS (neonates, children) and TEN tends to be different, yet much overlap occurs. In contrast to TEN, SSSS never has mucosal erosions. Using a Tzanck smear that will show acantholytic cells in SSSS but not in TEN (see eFig. 178-6.1 in on-line edition) and the use of frozen sections that can rapidly differentiate the superficial subgranular acantholysis in SSSS versus the characteristic full-thickness epidermal necrosis and dermal-epidermal separation seen in TEN aid in the differential diagnosis.

Treatment and Prognosis

Therapy for bullous impetigo may include topical mupirocin ointment therapy alone and/or oral antibiotics. Prognosis for recovery is excellent. Therapy for SSSS should be directed toward eradication of *S. aureus*, which generally requires hospitalization and intravenous anti-staphylococcal antibiotics. For uncomplicated cases, oral antibiotics can usually be substituted after several days. The use of suitable antibiotics combined with supportive skin care and management of potential fluid and electrolyte abnormalities due to the widespread disruption of barrier function will usually be sufficient to ensure rapid recovery. Neonates benefit from incubators to maintain body temperature and humidity. The use of non-adherent dressings, including petrolatum-impregnated gauze, to the widespread areas of superficial blistering are helpful. Antibiotic mupirocin ointment applied several times per day to clearly impetiginized areas, including the original source, is often a helpful adjunct to systemic antibiotic therapy.

Major complications of SSSS are serious fluid and electrolyte disturbances. The mortality in uncomplicated pediatric SSSS is very low (2 percent) and is not usually associated with sepsis. Adult mortality is higher (approximately 10 percent) due to concomitant morbidity factors and increased likelihood of sepsis.

DISEASES CAUSED BY SUPERANTIGENIC TOXINS

Etiology and Pathogenesis

Superantigens are a group of microbial and viral proteins that differ in several important respects from conventional peptide antigens (Fig. 178-7).[10,11] First,

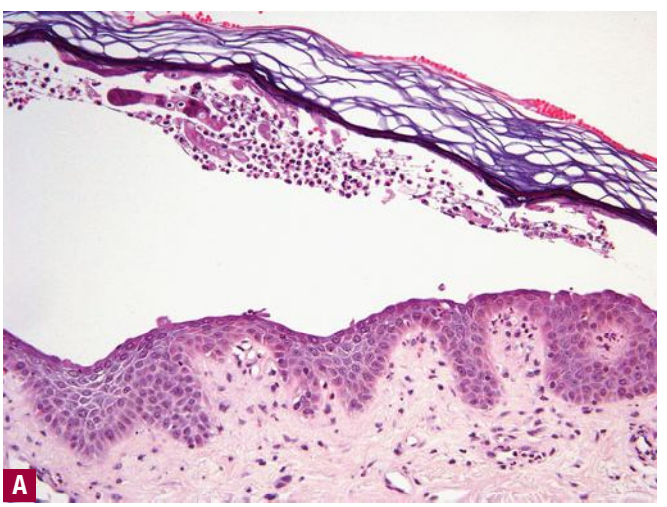

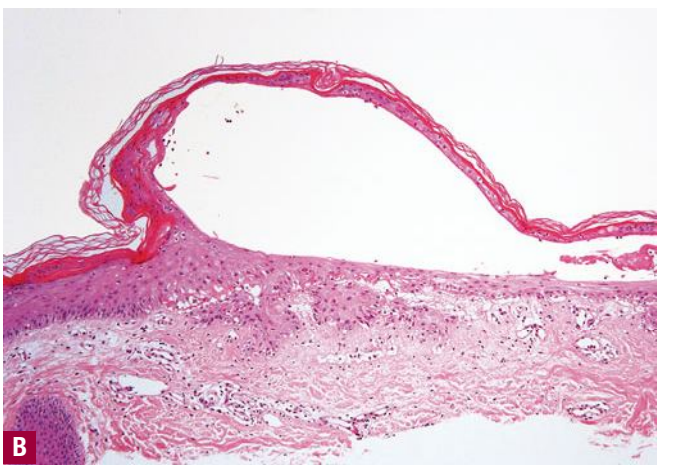

▲ **FIGURE 178-6** Histology of **A.** Bullous impetigo (200×) versus (**B**) staphylococcal scalded-skin syndrome (100×). In both conditions, the intraepidermal cleavage induced by the epidermolytic toxin occurs within or just below the stratum granulosum. Note paucity of cells in generalized disease (staphylococcal scalded-skin syndrome) (**B**) in comparison to the large numbers of leukocytes found in the localized form (bullous impetigo) (**A**). In both, cleavage occurs in the granular layer and is due to acantholysis. Note free-floating acantholytic cells in **A** and compacted acantholytic cells in the blister roof of **B**.

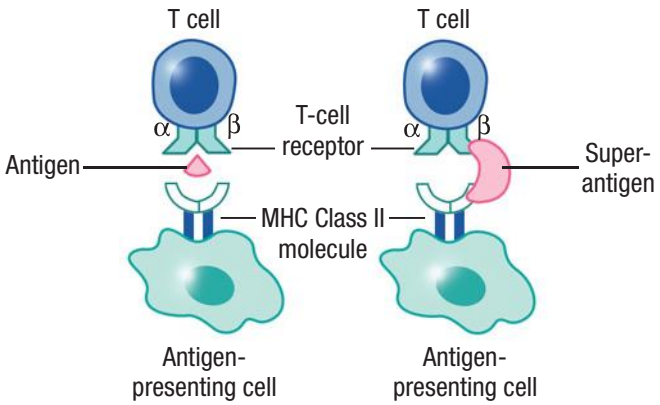

▲ **FIGURE 178-7** T-cell activation in the presence of nominal peptide antigens (*left*) or superantigens (*right*). The peptide antigen binds in the groove of the major histocompatibility complex (MHC) class II molecule and activates only antigen-specific T cells through the T-cell receptor. In contrast, a superantigen is a large globular protein that binds to the MHC class II molecule outside the antigen-binding groove and directly cross-links the MHC class II molecule and the Vβ chain of the T-cell receptor, leading to polyclonal T-cell activation.

unlike conventional protein antigens, which are taken up and processed by antigen presenting cells, superantigens exert their effects as globular intact proteins. Similar to peptide antigens, they are presented by class II major histocompatibility complex (MHC) molecules; however, they do not interact with the MHC peptide β-antigen binding groove, but instead bind to conserved amino acid residues that are on the outer walls of the peptide antigen-binding groove. Thus, whereas recognition of conventional peptide antigens by the T-cell receptor is restricted by MHC alleles, recognition of superantigens is generally not MHC restricted. Second, superantigens primarily recognize and bind to the variable region of the T-cell receptor β chain (Vβ). This is in contrast to nominal peptide antigens, which require recognition by all five variable elements (i.e., Vβ, Dβ, Jβ, Vα, Jα) of the T-cell receptor. Therefore, the responding frequency of a superantigen for resting T cells is several orders of magnitude greater (up to 20 percent to 30 percent) than a conventional peptide antigen (0.01 percent to 0.1 percent) The unique ability of a superantigen to bind directly to (and signal through) MHC class II molecules, and cross-link (and thus activate) a large percentage of T cells expressing relevant T-cell receptor Vβ chains, provides an explanation for the potent immune stimulation seen with these molecules. Of note, in comparison to nominal antigens, superantigen-mediated T-cell activation tends to generate increased numbers of T cells expressing the skin homing receptor cutaneous lymphocyte antigen (CLA).[12] Given that CLA-positive T cells are the T-cell type that traffics readily to the skin, the increased numbers of CLA-positive T cells generated by these agents is thought to be responsible for the high propensity of cutaneous manifestations in these conditions. Superantigens lead to a massive release of cytokines, including tumor necrosis factor-α, interleukin 1, and interleukin 6. This cytokine "storm" is in great part responsible for a capillary leak syndrome and accounts for the majority of the clinical manifestations seen in superantigen-mediated diseases. The prototypical disease due to superantigens is TSS caused by staphylococcal or streptococcal toxins. Although specific syndromes such as TSS and scarlet fever have characteristic findings, overlap syndromes have been described. Because the individual clinical findings are the summation of amount and type(s) of toxins and the types of cells responding to activation, it should not be surprising that heterogeneity in clinical presentations occurs.

Unlike syndromes associated with ETs that usually do not have significant systemic symptoms, those due to superantigens are characterized by systemic manifestations. Superantigen-mediated toxin syndromes can be divided into intermediate cutaneous and systemic and predominantly systemic due to the relative amounts of systemic toxicity. Disorders which have predominantly systemic manifestations are scarlet fever and the most ominous toxin-mediated disease, TSS. The intermediate cutaneous and systemic category includes syndromes such as recalcitrant erythematous desquamating disorder (REDD) and toxin-mediated erythema, which are less systemic versions of TSS and scarlet fever, respectively. All of these superantigen-mediated disorders are diagnosed based upon clinical findings and can be due to toxins produced by either *S. aureus* or group A streptococcus (see Table 178-2).

Toxic Shock Syndrome (See Table 178-2)

TSS is an inflammatory response characterized by fever, rash, hypotension, and multiorgan involvement representing the severe end of the spectrum of superantigen-mediated diseases. Although first described in 1978 in a series of children with *S. aureus* infection,[13] TSS became more broadly recognized with reports of epidemics associated with use of highly absorbent tampons in menstruating women in the early 1980s.[14] Presumably, the tampon served as a nidus for infection: the blood added protein and neutralized the normally bacteriocidal acidic vaginal pH. Since the first descriptions of the disease, TSS has been shown to be associated with many types of staphylococcal and streptococcal infections.



CLINICAL FINDINGS ***Staphylococcal Toxic Shock Syndrome.*** The most common staphylococcal toxin associated with TSS is TSS toxin-1 (TSST-1), and it is the predominant toxin associated with menstrual-associated cases. TSST-1 appears unique among superantigens in its ability to cross mucosal surfaces. With the removal of highly absorbent tampons from the market along with patient education, the incidence of menstruation-associated TSS decreased steadily, and at present the incidence of non-menstrual TSS exceeds that of menstrual-associated cases. Non-menstrual TSS is associated with postsurgical wounds, sinusitis, osteomyelitis, influenza, intravenous drug use, burn wounds, and gynecologic infection (especially in the postpartum period). Other staphylococcal toxins, including staphylococcal enterotoxins B and C (SEB and SEC), can also be found, and the latter two superantigenic toxins comprise approximately 50 percent of non-menstrual TSS. The host response is an important factor in the development of TSS, as studies have shown an increased susceptibility in patients who do not have neutralizing antibodies against TSST-1.[15]

The symptoms of TSS begin with the acute onset of fever, sore throat, and my-





▲ **FIGURE 178-8** Toxic shock syndrome (TSS). Patient in intensive care unit with TSS due to *Staphylococcus aureus*. Note patient's eruption is non-specific erythema around intertriginous areas and face. The eruption associated with staphylococcal TSS varies and could be morbilliform, scarlatiniform, or even pustular.

algia. Diarrhea is common, and vomiting may also occur. The rash is most often a macular erythema but a scarlatiniform type can also sometimes be seen. The eruption usually begins on the trunk and spreads to extremities and can involve palms and soles (Fig. 178-8). If the patient is hypotensive, the eruption tends to be more prominent on the trunk than extremities. Symptoms of hypotension include orthostatic dizziness, fainting, or overt shock. Nonpurulent conjunctival hyperemia, pharyngeal inflammation, and strawberry tongue (see Scarlet Fever) are invariably present. Signs of decreased mentation can also occur. The rash will desquamate within 1 to 2 weeks after it appears. The Centers for Disease Control and Prevention criteria for TSS are listed in Table 178-3. Cases of lesser severity that do not meet the full definition probably do occur frequently, especially with earlier recognition and treatment. In nonmenstruation cases, especially those associated with postoperative infections, the classic signs of a localized infection such as erythema, pain, and purulence can be absent. This is often in contrast to streptococcal TSS.

Streptococcal Toxic Shock Syndrome. Streptococcal TSS was described in the late 1980s as a disease similar to staphylococcal TSS, but caused by invasive group A streptococcus. Recent reports have suggested streptococcal TSS is more commonly encountered than the staphylococcal form. The majority of cases of streptococcal TSS are due to streptococcal pyrogenic exotoxin A (SPEA), yet other superantigenic toxins including SPEB, SPEC, and involvement of other non–group A streptococcus have also been reported. Although not associated with tampon use, streptococcal TSS can result from nearly any type of group A streptococcal infection. The most common types of infections appear to be wounds, and streptococcal TSS has been well described as a complication of varicella and influenza A. However, in many cases the route of infection cannot be determined. In contrast to staphylococcal TSS, disease induced by group A streptococcus is from skin in 80 percent of cases. The initial presentation is skin pain that is localized to an extremity in many cases. The localized pain often progresses over several days to localized erythema (see Chap. 179) and edema. Cellulitis associated with necrotizing fasciitis and myositis with concomitant streptococcal invasion of the bloodstream then develop. It should be noted that blood cultures are positive in more than one-half of patients with streptococcal TSS, in contrast to only one-tenth of patients with staphylococcal TSS. Thus, a patient with signs of TSS and a localized cellulitis should suggest streptococcal TSS as soft-tissue infections are not usually seen with staphylococcal TSS. Although very young, elderly, diabetic, or immunocompromised patients would be more

TABLE 178-3
Centers for Disease Control and Prevention Case Definition of Staphylococcal Toxic Shock Syndrome

Major Criteria (all four must be met)	Multisystem Involvement (three or more must be met)	Normal Test Results (if performed)

• Fever
  • Temperature > 38.9°C (102°F)
• Rash
  • Diffuse macular erythroderma
• Desquamation
  • 1–2 wk after onset of illness, particularly on palms/soles
• Hypotension
  • Systolic blood pressure < 95 mm Hg for adults, or less than fifth percentile by age for children < 16 yr of age, or orthostatic syncope
	• Gastrointestinal
	  • Vomiting or diarrhea at onset of illness
	• Muscular
	  • Severe myalgia or creatine kinase level twice upper limit of normal
	• Mucous membrane
	  • Oropharyngeal, conjunctival, or vaginal hyperemia
	• Renal
	  • Blood urea nitrogen or creatinine level twice upper limit of normal, or > 5 white blood cells per high-power field in urine in absence of urinary tract infection
	• Hepatic
	  • Total bilirubin, aspartate aminotransferase, or alanine aminotransferase level at least twice upper limit of normal
	• Hematologic
	  • Platelets < 100,000/mm^3
	• Central nervous system
	  • Disorientation or alterations in consciousness without focal neurologic signs when fever and hypotension are absent
		• Blood, throat, or cerebrospinal fluid cultures (blood cultures may be positive for *Staphylococcus aureus*)
		• No rise in titer in antibody tests for Rocky Mountain spotted fever, leptospirosis, or measles

susceptible to streptococcal TSS, the majority of cases have occurred in otherwise healthy adults.

DIFFERENTIAL DIAGNOSIS The differential diagnosis of staphylococcal TSS includes septic shock, staphylococcal exfoliative syndromes, Rocky Mountain spotted fever, viral hemorrhagic shock, measles, leptospirosis, and Stevens-Johnson syndrome. Although Kawasaki syndrome has many similar clinical findings, including swelling of extremities and desquamation of palms and soles during convalescence, Kawasaki syndrome differs in that the course of fever is prolonged, and there is absence of diarrhea and hypotension. Streptococcal-mediated syndromes including scarlet fever and especially streptococcal TSS can mimic staphylococcal TSS.

In a patient with fever, rash, and hypotension, a thorough search for possible sites of staphylococcal and streptococcal infection is critical. Surgical wounds should be carefully examined even if no clinical signs of infection are apparent. Vaginal examination and removal of tampon or other foreign body should be done, and vaginal irrigation with saline or povidone iodine has been recommended.

TREATMENT AND PROGNOSIS The treatment of TSS is supportive (and usually in the intensive care setting) and focused on eradicating the offending *S. aureus*. Large doses of a β-lactamase–resistant, antistaphylococcal antibiotics (e.g., nafcillin) have been used historically. Because these agents have been known to increase TSST-1 in vitro (probably as a result of cell lysis), concomitant clindamycin (which will inhibit bacterial protein toxin production) is often prescribed. Because of the increasing frequency of methicillin-resistant staphylococci in the community, vancomycin is often recommended. β-lactamase–resistant penicillins are of lesser value, not only because of emerging resistance, but also they are less effective with high levels of bacteria (in contrast to clindamycin or vancomycin). Todd has recommended a combination of vancomycin and clindamycin for suspected serious staphylococcal infections pending culture and sensitivity.[16] Recently intravenous immunoglobulin (IVIG; which presumably acts in part via neutralizing antibodies against toxins) has been used and appears to have significant promise.[17] At present, IVIG is used in severe or recalcitrant cases. Contraindications to IVIG include previous hypersensitivity to it or immunoglobulin A deficiency. Systemic corticosteroids are controversial and probably have less impact than considered as superantigen-mediated immune cell activation is associated with corticosteroid resistance.

Staphylococcal TSS is clearly a life-threatening disease but the mortality rate is only approximately 5 percent, most likely because the majority of cases occur in otherwise healthy young individuals. Unfortunately, recurrence can be seen in up to 20 percent. Women who have had TSS should avoid using tampons during menstruation as it will increase the likelihood of re-infection. Diaphragms and contraceptive sponges should also be avoided in this population.

The treatment of streptococcal TSS is similar to that for staphylococcal TSS. For cases associated with necrotizing fasciitis/myositis, rapid recognition and surgical débridement are imperative. IVIG is becoming increasingly recognized as an important part of treatment of streptococcal TSS, especially because the mortality rate in this disease can be greater than 30 percent.[18]

Recalcitrant Erythematous Desquamating Disorder (See Table 178-2)

A new presentation of a toxin-mediated disorder, termed *recalcitrant erythematous desquamating disorder*, was first described in 1992.[19] The clinical findings include fever and hypotension. The rash of REDD consists of diffuse macular erythema with delayed desquamation. Other findings in common with TSS include ocular and oral mucosal injection and strawberry tongue. Staphylococci producing TSST-1, staphylococcal enterotoxin A or B (SEA, SEB), have been isolated from various places, including nasal sinuses, soft tissues, or blood. Although the majority of patients described to date have had acquired immunodeficiency syndrome, some REDD patients without acquired immunodeficiency syndrome have been reported. In contrast to TSS, this is a prolonged disease (measured in weeks to several months) in which only several of the TSS criteria are met. The diagnosis is often established by careful examination for occult colonization and/or infection in a susceptible individual.

Scarlet Fever (see Table 178-2)

Scarlet fever is a syndrome characterized by exudative pharyngitis, fever, and scarlatiniform rash. It is most commonly due to pyrogenic exotoxin-producing group A streptococcus, although staphylococcal infections can produce a similar-appearing disease. The exact mechanism by which toxins produce the symptom complex is unclear. Compelling studies by Schlievert demonstrated that the scarlatiniform eruption could only be induced in mice that were previously sensitized against toxins. This suggests that a combination of conventional delayed type and superantigen-mediated processes are occurring.[20] It should be noted that streptococcal toxins, especially SPEA, have areas of significant homology with collagen, which could provide a mechanism for rare autoimmune sequelae of streptococcal scarlet fever, including renal failure and rheumatic fever.[21] Scarlet fever is no longer the major public health threat it was in the past because of antibiotic treatment and because most streptococcal isolates causing scarlet fever express the less virulent SPEB and SPEC rather than SPEA.



CLINICAL FINDINGS ***Streptococcal Scarlet Fever.*** Streptococcal scarlet fever is a childhood disease that occurs most commonly in winter and early spring. It is estimated that up to 10 percent of childhood group A streptococcal pharyngitis patients develop scarlet fever. Approximately 12 hours to 5 days after exposure, an abrupt prodrome consisting of pharyngitis, headache, vomiting, abdominal pain, and fever develops. The rash appears 1 to 2 days after onset of the illness, first on the neck and then extending to the trunk and extremities, although it spares the palms and soles. The exanthem texture is usually coarse, like fine-grade sandpaper, and the erythema blanches with pressure (Fig. 178-9). The skin can be mildly pruritic but usually is not painful. A few days after generalization of the exanthem, the rash becomes more intense around skin folds and lines of confluent petechiae, due to increased capillary fragility (Pastia's sign), can be seen. The generalized exanthem begins to fade 3 to 4 days after onset and a desquamative phase begins, usually starting on the face. Peeling from the palms and fingers and, sometimes, soles occurs approximately 1 week later and can last for up to 1 month (see Fig. 178-9D).

Oral findings of streptococcal scarlet fever include edematous, erythematous tonsils sometimes covered with a yellow, gray, or white exudate. Tender anterior cervical lymphadenopathy is



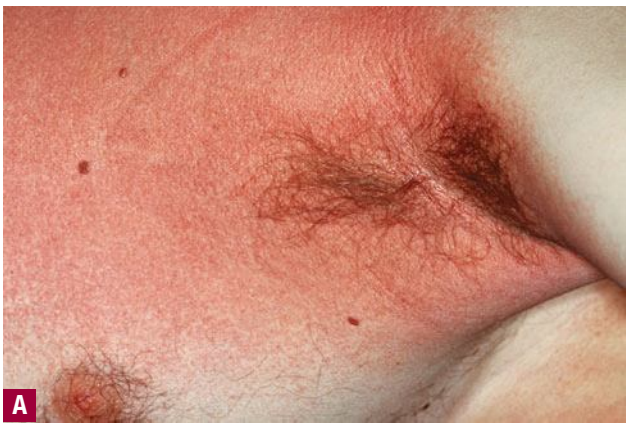







▲ **FIGURE 178-9** Scarlet fever. **A.** Exanthematous rash with a sandpaper texture in the axilla. **B.** Exanthematous rash with a sandpaper feel on the chest. **C.** Perioral pallor and strawberry tongue. **D.** Post-streptococcal desquamation.

common. Petechiae and punctate red macules are seen on the soft palate and uvula (Forschheimer's spots). A flushed face with circumoral pallor is also commonly noted (see Fig. 178-9C). In scarlet fever, the tongue demonstrates characteristic changes. During the first 2 days of the disease, the tongue has a white coat through which the red and edematous papillae project (white strawberry tongue). After 2 days, desquamation occurs, resulting in a red tongue with prominent papillae (red strawberry tongue) (see Fig. 178-9C).

The diagnosis of scarlet fever is made by the characteristic clinical signs and confirmed by the rapid streptococcal test or throat culture. Scarlet fever usually follows a benign course, and any undue morbidity or mortality is likely due to suppurative complications, including peritonsillar abscess, sinusitis, pneumonia, and meningitis or nonsuppurative complications associated with immune-related rheumatic fever or glomerulonephritis. The risk of acute rheumatic fever following an untreated group A streptococcal infection has been estimated to be approximately 3 percent in epidemics and 0.3 percent in endemic circumstances. Glomerulonephritis can occur in up to 10 percent to 15 percent after infection with nephritogenic group A streptococcal strain. In addition to pharyngitis, group A streptococcus can cause scarlet-fever-like eruptions from skin (often surgical wounds) or uterine infections.

Scarlet fever is treated by antibiotics (penicillin or erythromycin for a 10-day course) and supportive care. Fever usually abates within 12 to 24 hours after initiation of antibiotic therapy. Recurrences are common.

Staphylococcal Scarlet Fever. Staphylococcal scarlet fever, also known as *scarlatiniform erythroderma or rash*, was first described almost 90 years ago and, until recently, was considered to be a milder or abortive form of SSSS. Patients usually develop a generalized erythroderma with a roughened, sandpaper-like texture very much like in streptococcal scarlet fever. However, the exanthem of staphylococcal scarlet fever tends to be more tender than corresponding streptococcal scarlet fever. Systemic signs including malaise and fever are invariably present. Within a few days of initiation of the rash, thick flakes develop, and the entire skin desquamates over the subsequent week. Unlike generalized SSSS, the scarlatiniform eruption is not associated with the formation of bullae or superficial exfoliation and can be very difficult to differentiate from other infectious erythrodermal causes such as TSS and streptococcal scarlet fever. Scarlet fever induced by staphylococci differs from streptococcal-mediated disease by the lack of pharyngitis. A recent study by Wang and colleagues examined the clinical characteristics and toxin detected in 20 children with staphylococcal scarlet fever.[22] They found that all of the patient's staphylococcal infections arose from the skin; 16 of 20 cases from furuncles/carbuncles; two each from abscesses or wound infections. All of the *S. aureus* strains expressed SEB. Of note, SEB shows significant protein sequence homology with SPEA, a known exotoxin associated with streptococcal scarlet fever. Yet other studies have implicated other staphylococcal enterotoxins.[23] One explanation for this heterogeneity of toxins associated with this disorder is that the diagnosis is made upon clinical grounds. It is indeed possible that staphylococcal scarlet fever represents an incomplete form of TSS, in which toxins spread from the skin, thus activating the skin-associated lymphoid

tissue rather than mucosal-associated lymphoid tissue. Because most cases of streptococcal scarlet fever arise from a pharyngitis, the lack of a pharyngitis in a patient with characteristic rash and other clinical signs of scarlet fever should alert the clinician to look for a localized nidus of infection (e.g., furuncle) that could be cultured to establish the diagnosis.

DIFFERENTIAL DIAGNOSIS The diagnosis of scarlet fever is made on clinical grounds with supporting positive bacterial cultures. The differential diagnosis should include other toxin-mediated disorders including SSSS. Although Kawasaki syndrome (see Chap. 168) has many similar clinical findings including mucosal involvement (e.g., strawberry tongue), swelling of extremities, and desquamation of palms and soles during convalescence, Kawasaki syndrome differs in that the course of fever is prolonged and cultures would be expected to be negative. Atypical drug hypersensitivity reactions can have some cutaneous features, but would lack the mucosal signs. There is usually a history of offending drug and peripheral eosinophilia. Scarlet fever from group A streptococcus can usually be differentiated from that induced by *S. aureus* as the usual nidus of infection in streptococcal scarlet fever is from a pharyngitis while the staphylococcal variant usually has its infectious nidus in the skin.

TREATMENT AND PROGNOSIS The treatment of scarlet fever includes antibiotics to eradicate the offending bacteria. If the localized nidus of infection is an abscess or furuncle/carbuncle, it should be drained. Acute rheumatic fever or glomerulonephritis is not associated with staphylococcal scarlet fever. For situations in which more systemic signs resemble TSS, the treatment should be that of TSS.

Toxin-Mediated Erythema (Recurrent Toxin-Mediated Perineal Erythema)

(See Table 178-2)

In 1996, Manders and colleagues recognized a previously unreported toxin-mediated disorder, they termed *recurrent toxin-mediated perineal erythema*.[24] Recurrent toxin-mediated perineal erythema is characterized by a striking diffuse macular perineal erythema that occurs within 24 to 48 hours after a pharyngitis with a toxin-producing group A streptococcus or *S. aureus*. Clinical findings seen in scarlet fever, including a strawberry tongue, as well as erythema, edema, and later, palmoplantar desquamation, are commonly found in recurrent perineal erythema. Fever, hypotension, and other systemic signs of scarlet fever or TSS are characteristically absent although diarrhea is a common feature. Recurrences are more frequently found in this localized form. It has been proposed by Manders that that the term *toxin-mediated erythema* be used to describe the following clinical settings in which a toxin-producing *Staphylococcus* or *Streptococcus* can be found: recurrent erythroderma associated with a preceding bacterial pharyngitis, isolated episodes of toxin-mediated erythema without recurrences, and patients with episodic mild hypotension, fever, and typical mucocutaneous findings in the absence of full criteria for TSS.[25]

Diseases Initiated and/or Exacerbated by Superantigens

In addition to the ability of superantigens to induce characteristic diseases including TSS, scarlet fever, and gastroenteritis, recent evidence is accumulating which indicates that these potent immunomodulatory agents can initiate or exacerbate other skin disorders.

PSORIASIS (See Chap. 18) Psoriasis is an autoimmune T-cell–driven keratinocyte hyperproliferative disease involving skin and rarely joints. Superantigens have been implicated in psoriasis in at least two settings: the guttate (acute eruptive) form and in situations where psoriasis flares in response to secondary infection.[11]

AUTOECZEMATIZATION (ID) RESPONSE (See Chap. 17)

ATOPIC DERMATITIS (See Chap. 14) Secondary infection with *S. aureus* or group A streptococcus is a well-known trigger of atopic dermatitis. It is estimated that *S. aureus* can be cultured from essentially all subjects with atopic dermatitis.[28] Recent studies have demonstrated that skin from subjects with active atopic dermatitis has decreased levels of antimicrobial proteins.[29] This lack of antimicrobial proteins may provide one explanation for the almost universal bacterial infection associated with flaring atopic dermatitis.



KEY REFERENCES

The full reference list for all chapters is available at www.digm7.com.

1. Dinges MM, Orwin PM, Schlievert PM: Exotoxins of *Staphylococcus aureus*. *Clin Micrbiol Rev* **13**:16, 2000
10. McCormick JK, Yarwood JM, Schlievert PM: Toxic shock syndrome and bacterial superantigens: An update. *Annu Rev Microbiol* **55**:77, 2001
11. Leung DY et al: The role of superantigens in human diseases: Therapeutic implications for the treatment of skin diseases. *Br J Dermatol Suppl* **53**:17, 1998
14. Shands KN et al: Toxic shock syndrome in menstruating women: Association with tampon use and *Staphylococcus aureus* and clinical features in 52 cases. *N Engl J Med* **303**:1436, 1980
16. Todd JK: Staphylococcal infections. *Peds Rev* **26**:444, 2005
27. Travers JB et al: Epidermal HLA-DR and the enhancement of cutaneous reactivity to superantigenic toxins in psoriasis. *J Clin Invest* **104**:1181, 1999
29. Ong PY et al: Endogenous antimicrobial peptides and skin infections in atopic dermatitis. *N Engl J Med* **347**:1151, 2002

CHAPTER 179

Soft-Tissue Infections: Erysipelas, Cellulitis, Gangrenous Cellulitis, and Myonecrosis

Arturo Saavedra
Arnold N. Weinberg
Morton N. Swartz
Richard Allen Johnson



EPIDEMIOLOGY

Soft-tissue infections (STIs) account for roughly 10 percent of inpatient hospitalizations in North America, and their healthcare cost has been steadily increasing.[1] STIs are characterized by clinical findings that include an acute, diffuse, tender, spreading, edematous, suppurative inflammation of the dermis, subcutaneous or muscular tissues, often associated with systemic symptoms of malaise, fever, chills, and local pain. These infections are usually caused by β-hemolytic streptococci (primarily group A), *Staphylococcus aureus,* and, in deep fascia and muscle, by mixed anaerobic and facultative Gram-positive and Gram-negative organisms, including histotoxic *Clostridia*. There is less predictability in immunocompromised hosts where organisms may include a range of traditional and rare pathogens, usual commensals, yeast, fungi, and parasites. Because traditional patterns of symptoms and physical findings may be lacking or non-specific in immunocompromised patients, determining an etiologic diagnosis is especially important.[2] In both immunocompetent and compromised hosts, bullae, necrosis, or gas-forming bacterial infections signal urgency in establishing the location of infection and in defining the cause.

ETIOLOGY AND PATHOGENESIS (Table 179-1)

Intact skin plays a critical role in the defense against a wide range of pathogens. The details of the host–pathogen interaction are poorly understood but appear to involve barrier function, bacterial factors, and host factors. Importantly, diminished immune status [diabetes, cancer, renal failure, neutropenia, or (human immunodeficiency virus (HIV)] as well as circulatory compromise make the host susceptible to increased frequency of STIs (see Chap. 176).

Recently, the molecular interaction of strains, such as group A streptococcus (GAS) and *C. perfringens*, with the coagulation system have been elucidated. Injectable exotoxins from M-type 1 invasive streptococcus induce the aggregation of platelets and neutrophils, mostly secondary to streptolysin O and mediated by platelet P-selectin.[3] Via stabilization of glycoprotein IIb/IIIA, intravascular aggregates of platelets and neutrophils occlude vessels that may contribute to the rapid clinical progression and tissue destruction in myositis and necrotizing fasciitis. In *C. perfringens*, through the activity of α-toxin, phospholipase C-mediated upregulation in glycoprotein IIb/IIIA may lead to similar effects. The role of the coagulation and fibrinolytic system in causing ischemia during the course of these infections has been reviewed by Bryant.[4] In addition, the role of streptolysin S in mediating STIs caused by streptococcus G as well as the role of the Panton-Valentine leukocidin (PVL) determinant in soft-tissue and pulmonary infection by community-acquired, methicillin-resistant *S. aureus* (CA-MRSA), has recently been fortified.[5,6]

CLINICAL FINDINGS

History

STIs usually present at an antecedent lesion or site, including dermatitis, stasis ulcer, puncture wound, animal bites, percutaneous catheters, or trauma. In addition, surgical wounds after excision, electrodesiccation, and curettage or cosmetic procedures can serve as a nidus for infection. Less commonly, bacteremia, osteomyelitis, or visceral infections such as diverticular abscess may lead to seeding of the skin and soft tissues. With onset of infection, patients often experience local pain and tenderness along with variable degrees of erythema and systemic symptoms (fever, chills, and malaise). Erythema may rapidly intensify and spread. Local pain is often severe and, in the absence of erythema, should raise suspicions of early deep-seated infection. In some individuals, systemic symptoms may antedate localizing complaints and signs of STIs. In a study of 50 patients with cellulitis, only 26 percent had fever higher than 38°C (100.4°F). A potential portal of entry was identified in 66 percent of patients: 50 percent of those with upper extremity and 67 percent of those with lower extremity cellulites.[7] Patients with early gangrenous cellulitis may experience severe pain out of proportion to the appearance of the local area.

SOFT-TISSUE INFECTIONS AT A GLANCE



- Approximately 10 percent of hospitalizations in North America are due to soft-tissue infections.
- Routine organisms can be treated by empiric therapy but high index of suspicion for resistant organisms should be maintained for cases that do not improve or present in areas where resistant strains have been reported.
- Newer antibiotics are currently available or undergoing testing to treat resistant infections caused by methicillin-resistant strains or vancomycin-resistant strains.
- Though unnecessary in uncomplicated cases, aspiration, wound cultures, and blood cultures are required for identification of etiologic organisms.
- Nonnecrotizing soft-tissue infections are treated with antibiotics, drainage, and supportive measures.
- Necrotizing soft-tissue infections require surgical treatment.
- Radiographic imaging may be helpful in crepitant infections but should not delay surgical therapy in cases where necrotizing infections are suspected.

Skin Signs

ERYSIPELAS Erysipelas is a distinct type of superficial cutaneous cellulitis with marked dermal lymphatic vessel involvement caused by group A β-hemolytic streptococcus (very uncommonly group C or G streptococcus) and rarely caused by *S. aureus*. In the newborn, group B streptococci can cause erysipelas.[8,9] Lymphedema, venous stasis, web intertrigo, and obesity are risk factors in the adult patient.

In the absence of underlying edema or other skin abnormalities, erysipelas

TABLE 179-1
Etiology of Soft-Tissue Infections

Type of Infection	Most Common Cause(s)	Uncommon Causes
Erysipelas	Group A streptococcus	Group B, C, and G streptococcus, *Staphylococcus aureus*
Cellulitis	*S. aureus,* group A streptococcus	Group B, C, and G streptococcus*; Streptococcus iniae*; *Pneumococcus*; *Haemophilus influenzae* (children); *Escherichia coli; Proteus*, other Enterobacteriaceae; *Campylobacter jejuni*; *Moraxella; Cryptococcus neoformans; Legionella pneumophila, L. micdadei*; *Bacillus anthracis* (anthrax); *Aeromonas hydrophila; Erysipelothrix rhusiopathiae; Vibrio vulnificus, V. alginolyticus, V. cholerae* non-01
Cellulitis in children	*S. aureus,* group A streptococcus	Group B streptococcus (neonates)
Facial/periorbital cellulitis	*S. aureus,* group A streptococcus	*Neisseria meningitides, H. influenzae* (young children)
Perianal cellulitis	Group A streptococcus	*S. aureus*
Cellulitis second degree to bacteremia	*Pseudomonas aeruginosa*	*V. vulnificus; S. pneumoniae;* group A, B, C and G streptococcus
Crepitant cellulitis	Histotoxic *Clostridia* sp., (*C. perfringens, C. septicum)*	*Bacteroides* sp.; Peptostreptococci; *E. coli*, Enterobacteriaceae
Cellulitis associated with water exposure	*E. rhusiopathiae (erysipeloid)*	*V. vulnificus, Aeromonas hydrophila, Mycobacterium marinum* (nodular lymphangitis), *M. fortuitum* complex
Gangrenous cellulitis (infectious gangrene)		
NF		
Streptococcal gangrene	Group A streptococcus	Groups B, C, and G streptococcus
Nonstreptococcal NF	Mixed infection with one or more anaerobes (*Peptostreptococcus* or *Bacteroides)* plus at least one facultative species (non–group A streptococci; members of the Enterobacteriaceae such as *Enterobacter, Proteus,* etc.)	
Synergistic necrotizing cellulitis[a]	Polymicrobial with facultative and anaerobic organisms that originate in the intestine; one-third of patients have positive blood cultures, usually a coliform, *Bacteroides*, or *Peptostreptococcus*	
Facultative	Coliforms: *E. coli*, *Proteus*, *Klebsiella*	
Anaerobes	*Bacteroides, Peptostreptococcus, Clostridium, Fusobacterium*	
Fournier gangrene	Similar to nonstreptococcal NF (type I)	
Clostridial soft-tissue infections	*C. perfringens,* other histotoxic clostridial species	
Anaerobic cellulitis		
Anaerobic myonecrosis (gas gangrene)		
Spontaneous, nontraumatic anaerobic myonecrosis	*C. septicum* (bacteremic)	
Nonclostridial anaerobic cellulitis	Various *Bacteroides* sp., peptostreptococci, peptococci	
Progressive bacterial synergistic gangrene (Meleney gangrene)	Mixed bacterial infection	
Ulcer base	*S. aureus*	*Proteus* sp., other Gram-negative bacilli
Advancing margin	Microaerophilic or anaerobic streptococci	
Gangrenous cellulitis in the immunosuppressed individual	*P. aeruginosa* (ecthyma gangrenosum) *Mucor*, *Rhizopus*, *Aspergillus*	*Bacillus* sp., other bacterial and fungal sp.

[a]Essentially the same as nonstreptococcal necrotizing fasciitis (NF) but with some involvement of adjacent skeletal muscle.

usually begins on the face or a lower extremity, heralded by pain, superficial erythema, and plaque-like edema with a sharply defined margin to normal tissue (Fig. 179-1). These findings are often described as *peau d'orange* appearance. In the presence of antecedent edema or other anatomic abnormalities, the margin between normal and diseased soft tissue may be obscure, much as in primary cellulitis. There may not be an obvious portal of entry, and skipped areas may confuse the nature of the process. Facial erysipelas is less frequent than lower extremity disease and begins unilaterally but may spread by contiguity over the nasal prominence to involve the face symmetrically (Fig. 179-2). The oropharynx may be a portal of entry, and throat culture may show GAS. Inflammatory edema may extend to the eyelids, but orbital complications are rare. Fever may precede local signs, and, occasionally, before distal extremity





▲ **FIGURE 179-1** Erysipelas. There is painful, warm erythema of the lower extremity with well-defined borders.



findings, patients complain of groin pain caused by swelling of a femoral node. Lymphangitis and abscess are very rare, but the process may spread rapidly from the initial lesion. Occasionally, in addition to rapid spread of the erythematous, edematous plaque, bullae may form in the involved area.[10]

Recurrent erysipelas is associated with saphenous vein harvest (occasionally in association with tinea pedis) and lymphedema complicating mastectomy with axillary node dissection. In these cases, erysipelas presents with edema and erythema along lines of venectomy or nodal dissection. In addition, resultant lymphedema from a previous episode of erysipelas is a risk factor for recurrence, particularly on the lower extremities. Congenital lymphedema (Milroy disease) may also lead to recurrent erysipelas.

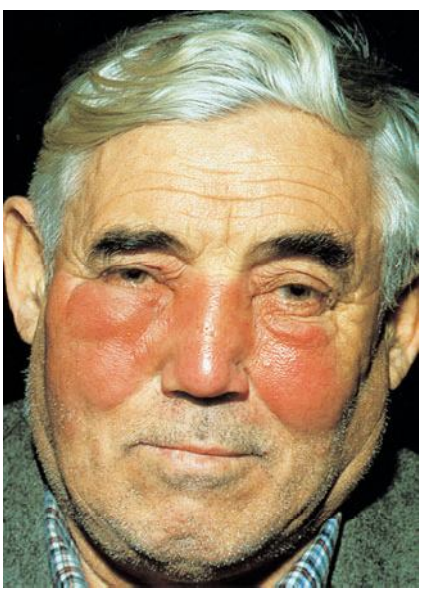

▲ **FIGURE 179-2** Erysipelas. Painful, edematous erythema with sharp margination on both cheeks and the nose. There is tenderness, and the patient has fever and chills.



◀ **FIGURE 179-3** Cellulitis. The lower extremity is swollen, erythematous, and tender; there is blistering and crusting.

ACUTE CELLULITIS Cellulitis extends deeper into the dermis and subcutaneous tissue. *S. aureus* and GAS are by far the most common etiologic agents, but occasionally other bacteria are identified (e.g., group B streptococci in the newborn, pneumococci, Gram-negative bacilli, and in immunocompromised individuals, a variety of other microorganisms, including yeasts and molds). *Escherichia coli* and other Enterobacteriaceae and anaerobes are involved in cellulitis, especially in association with extremes of age, prolonged hospitalization, percutaneous intravascular lines, diabetes, immunocompromised states, and glucocorticoids.[11] Liposuction and "skin popping" are reported risk factors that may also lead to cellulitis from less common organisms.

Though cellulitis has many of the features of erysipelas (erythema, tenderness, pain), it can be differentiated from erysipelas by the lack of distinct margins between affected and normal skin, a deeper, firmer form of tender induration, fluctuance, and, occasionally, the presence of crepitus on palpation. In some cases of cellulites, the overlying epidermis undergoes bulla formation or necrosis, resulting in extensive areas of epidermal sloughing and superficial erosion (Figs. 179-3 and 179-4A,B). Alternatively, with or without antibiotic therapy, infection may localize in the soft tissue with dermal and subcutaneous abscess formation, necrosis, and fasciitis (Fig. 179-5). Regional lymphadenopathy may be associated with cellulitis on an extremity. In older individuals, thrombophlebitis may complicate lower leg cellulitis.

Similar to erysipelas, recurrent cellulitis has been reported after mastectomy. Cellulitis of the ipsilateral arm can be recurrent due to associated lymphedema caused by axillary lymph-node dissection and irradiation.[12] Cellulitis at the site of saphenous vein grafting for coronary artery bypass may also recur.

SURGICAL WOUND INFECTIONS Surgical wound infections are the most common adverse events in hospitalized patients undergoing surgery and are classified as incisional (superficial) or deep.[13] Incisional wound infections involve the skin, subcutaneous tissue, and/or muscle (see Fig. 179-4B). Deep infections involve structures adjacent to the surgical wound that were entered or exposed during the procedure, such as subfascial layers, viscera, and/or spaces within the peritoneum, thorax, or joints. Up to 80 percent of wound infections are incisional. A wound is considered to be infected if there is drainage of purulent material and evidence of inflammation. Incisional infections present with erythema, pain, tenderness, and local swelling and, often, with low-grade fever. Purulent drainage reveals neutrophils and cultures most often grow *S. aureus.* Separation of the margins of the wound is usual and this allows appropriate drainage. Deep-wound infections may be more subtle and delayed and often present as fever of uncertain cause. Progressive bacterial synergistic gangrene and other variants of gangrenous cellulitis can arise in surgical wounds or around sutures (see the section Gangrenous Cellulitis, Infection Gangrene, and Crepitant Soft-Tissue Wounds).

The complications of superficial and deep-wound infections include poor healing, bacteremia, the local and systemic effects of prolonged hospitalization, poor nutrition, residual compromised tissue integrity, and the consequence of prolonged antibiotic therapy in a hospital setting. Additionally, wounds infected with toxin-producing *S. aureus* or GAS may result



▲ **FIGURE 179-4** **A.** Cellulitis after puncture trauma. The forearm is swollen, erythematous, and tender; there is abscess formation, blistering, and crusting. **B.** Cellulitis arising at the site of a surgical excision: *Staphylococcus aureus.* Note discharge of pus.

in systemic complications such as toxic shock syndrome or scarlet fever (see Chap. 178).

CELLULITIS COMPLICATING A PRESSURE ULCER Pressure ulcers, particularly those located in the sacrum in elderly, frail, malnourished individuals, become contaminated by a variety of facultative and anaerobic microorganisms from the skin and the bowel, including *S. aureus,* enterococci, *Pseudomonas aeruginosa,* and *Bacteroides fragilis*. In addition to pain and cellulites, the ulcer can be undermined and may eventually be complicated by bacteremia, often polymicrobial, or the underlying bone can become infected. Similar to other open wounds, the identity of the active pathogen(s) may be difficult to determine.

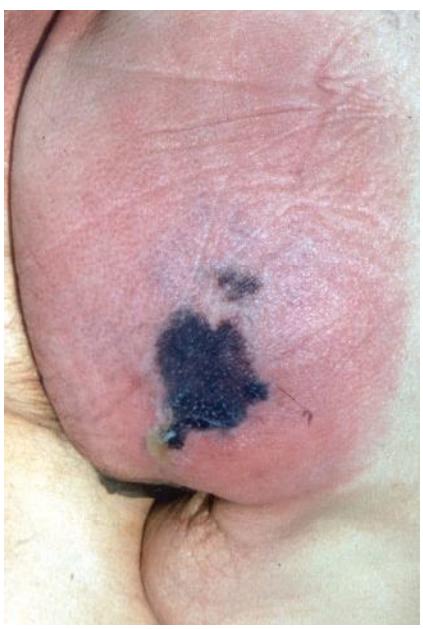

▲ **FIGURE 179-5** Gangrenous cellulitis: Necrotizing fasciitis. Note the black necrotic plaque, resembling a third-degree burn, and an erythematous margin. There is severe systemic toxicity.

CELLULITIS ARISING AT SITES OF ANIMAL BITES Domestic dog and cat bites are frequent and can give rise to painful, necrotizing cellulitis caused by *Pasteurella multocida, Capnocytophaga canimorsus* (especially in asplenic individuals), and a host of other aerobes and anaerobes from the animal's mouth or the skin of the infected individual. Dog bites are often accompanied by a crush injury that devitalizes tissues. The bite of cats can inject organisms (via sharp incisors) deep into tissues, including joint spaces, tendon sheaths, or below the periosteum of bone (see Chaps. 183 and 209).

Human bites have a higher incidence of infection than do animal bites because of the mix of oral bacteria (aerobes and anaerobes), as well as the crush injury imparted along with the bite. Organisms include various streptococci, *S. aureus, Eikenella*, *Corynebacterium*, and the anaerobic peptostreptococci and peptococci.

GANGRENOUS CELLULITIS, INFECTIOUS GANGRENE, AND CREPITANT SOFT-TISSUE WOUNDS These STIs are characteristically rapidly developing, progressive, and accompanied by constitutional symptoms, severe pain, and tenderness, with changes in overlying skin that progress to bulla formation and frank necrosis. The process can be in the superficial or deep fascia with secondary changes in the overlying soft tissues. Palpation may reveal tenderness or gas in the area of involvement. This section focuses on the various types of necrotizing fasciitis and other necrotizing STIs, with and without gas formation, excluding myonecrosis (Table 179-2).

Streptococcal Gangrene, Including Type II Necrotizing Fasciitis. In streptococcal gangrene, a monomicrobial infection, the pathogen is almost always a GAS, although groups C and G isolates, as well as other microorganisms, are infrequently identified. Occasionally, in newborns but also in patients early postpartum, group B streptococci have been recovered. *Streptococcus pneumoniae* necrotizing fasciitis is rarely reported and behaves like GAS infections.[14] In addition, monomicrobial necrotizing fasciitis caused by both health care–acquired MRSA (HA-MRSA) and CA-MRSA, have been reported (see the section Methicillin-Resistant *Staphylococcus aureus*). Recently, 14 cases of CA-MRSA in patients with intraoperative findings consistent with necrotizing fasciitis, myonecrosis, or both, have been reported.[15]

Patients may be immunocompromised by age or illness such as diabetes, alcoholism, or cirrhosis, but are usually healthy individuals. The location of the necrotizing lesion is most often an extremity and rarely, the face. A small area of involvement may underestimate the deep extent of the infection. Pain, erythema, and edema with rapid formation of bullae, constitutional symptoms with high fever, and toxicity are characteristic of early progression. There is bacteremia in approximately two-thirds of patients and evolution of necrosis of the overlying skin can



TABLE 179-2
Findings in Gangrenous Cellulitis and Infectious Gangrene

Factor	Progressive Bacterial Synergistic	Synergistic Necrotizing Cellulitis	Streptococcal Gangrene	Clostridial Myonecrosis (Gas Gangrene)	Necrotizing Infections in Immunosuppression
Etiology	Streptococci, *Staphylococcus aureus*	Mixture of organisms: *Bacteroides*, peptosreptococci, or *Escherichia coli*	Group A streptococci or enteric bacteria	*Clostridium perfringens*	*Rhizopus, Mucor, Absidia, Pseudomonas aeruginosa*
Predisposing conditions	Surgery or draining sinus	Diabetes	Diabetes or abdominal surgery	Trauma	Diabetes, corticosteroid use, immunosuppression, burns
Fever	Minimal	Moderate	High	Moderate to high	Low in fungal, high in pseudomonal
Pain	Prominent	Prominent	Prominent	Prominent	Mild
Anesthesia	Absent	Absent	May occur	Absent	May occur
Crepitus	Absent	May occur	Absent	Present	Absent
Course	Slow	Rapid	Very rapid	Extremely rapid	Rapid

Modified with permission from Swartz MN, Pasternack MS: Cellulitis and subcutaneous tissue infections, in *Principles and Practice of Infectious Diseases*, edited by Mandell GL et al. Elsevier, Philadelphia, 2000, p 1183.



be rapid and dramatic, revealing deeper structures, including tendon sheaths and muscle. Though lymphangitis is rare, metastatic abscesses can occur. A streptococcal toxic shock–like syndrome often accompanies this infection, referred to in the lay press as a *flesh-eating bacterial process*. With bulla formation, the diagnosis is apparent from a Gram stain of an aspirate. As the process evolves, necrosis and eschar formation precede sloughing of tissues. Early symptoms of local pain eventually evolve to anesthetic areas and progressive toxicity is often accompanied by mental depression. Treatment with penicillin and clindamycin as well as surgical débridement and supportive therapy can be lifesaving, but the prognosis remains poor.[11,16] Chapter 178 provides a detailed discussion of the streptococcal toxic shock–like syndrome, its prognosis, and therapy.

Type I Necrotizing Fasciitis. Type I necrotizing fasciitis, a polymicrobial infection, is caused by a mix of facultative and anaerobic microbes, often delivered into the subcutaneous tissues after surgery, bowel perforation secondary to neoplasm or diverticulitis, trauma, or parenteral drug abuse via skin-popping. It often occurs in patients compromised by diabetes or malnutrition. Organisms include at least one anaerobic organism recovered in a mix of facultative microbes: nongroupable streptococci, enterococci, anaerobic streptococci and staphylococci, *Bacteroides* sp., and Enterobacteriaceae including *E. coli,* as well as various aquatic bacteria. Often, three to five species contribute to the infection, which may have a slower pace than GAS in evolving to a full-blown process with cutaneous manifestations.[17,18]

Type I necrotizing fasciitis most commonly occurs on an extremity, abdominal wall, perineum, or about operative wounds (see Fig. 179-5). Clinically, it is indistinguishable from streptococcal gangrene. Although the initial pace of the illness may be slower, it is important to recognize that when this infection presents in the thigh (dissection along the psoas muscle) or abdominal wall, it may be secondary to an intestinal source (occult diverticulitis, rectosigmoid neoplasm). The involved area may be painful at first and then evolve with objective findings: swelling, erythema, warmth, and tenderness. The process is often more extensive than the overlying skin changes would suggest. Within several days, the skin color becomes purple, bullae develop, and frank cutaneous gangrene ensues (Fig. 179-6). At this stage, the involved area is no longer tender but has become anesthetic as a result of occlusion of small blood vessels and destruction of superficial nerves in the subcutaneous tissues. Crepitus is often present, particularly in patients with diabetes mellitus or if gas-forming anaerobes, such as *Bacteroides* sp., are causative.[11,18] Though not universally used, the Laboratory Risk Indicator for Necrotizing Fasciitis has been devised from retrospective analysis of cases and tested in a secondary analysis of small clinical trials, with reported negative predictive value of 95 percent and high specificity.[19]

Fournier Gangrene. Fournier gangrene is a localized variant of necrotizing fasciitis involving the scrotum and perinis.[11,20,21] It is usually caused by the same mix of facultative and anaerobic organisms that are associated with type I necrotizing fasciitis. In rare cases, GAS as the single pathogen has been implicated, and this may be related to rectal ring carriage or to oral-genital sex. The average age at onset is 50 to 60 years of age. Most men have underlying diseases or history of procedures. These include diabetes mellitus, ischiorectal abscess, perineal fistula, bowel disease (rectal or colon carcinoma, diverticulitis), scrotal or penile trauma, prior hemorrhoidal or urogenital surgery, pressure ulcers of the scrotum and perineum (e.g., alcoholics



▲ **FIGURE 179-6** Type I necrotizing fasciitis with progressive gangrene of the pubic, perigenital, and perianal tissue.



▲ **FIGURE 179-7** Fournier gangrene. There is painful erythema with marked edema, superficial desquamation, and areas of necrosis in the inferior aspect of the scrotum.

sitting in a drunken stupor), paraphimosis and, rarely, obscure causes, such as dissection of pancreatic secretions through the retroperitoneum and into the scrotum in acute pancreatitis.

The onset of Fournier gangrene can be insidious, with a discrete area of edema, erythema, and necrosis on the scrotum, progressing to advancing skin necrosis rapidly over 1 to 2 days (Fig. 179-7). Pain, swelling, and crepitus in the scrotum, perineum, or suprapubic region may be marked. Foul-smelling drainage occurs, indicating a contribution from anaerobes. Purplish discoloration of the scrotum, an initial "red flag," progresses to frank gangrene. The infection tends to be superficial, limited to skin and subcutaneous tissue and extending to the base of the scrotum, but it may spread to the penis, perineum, and abdominal wall along fascial planes. The testes, glans penis, and spermatic cord are usually spared, as they have a separate blood supply. The infection may progress and invade the abdominal panniculus in obese patients, especially those with diabetes mellitus, leading to rapid and extensive destruction of tissue and requiring wide débridement and prolonged hospitalization.

Cervical Necrotizing Fasciitis and Craniofacial Necrotizing Fasciitis. Cervical necrotizing fasciitis is a type I infection (polymicrobial etiology), but GAS can be the single etiologic agent in rare cases, particularly in the setting of peritonsillar abscess formation. Most commonly, cervical necrotizing fasciitis originates from dental or pharyngeal sources. Crepitus may develop as the infection spreads to the face. This is in contradistinction to necrotizing fasciitis that starts in the face (craniofacial necrotizing fasciitis), which is most commonly caused by GAS after a traumatic episode. Cervical necrotizing fasciitis carries a much higher mortality rate than the craniofacial variant.

Synergistic Necrotizing Cellulitis (Necrotizing Cutaneous Myositis, Synergistic Non-Clostridial Anaerobic Myonecrosis). Synergistic necrotizing fasciitis is unique in that all soft-tissue structures, including muscle, can be involved in a painful, progressive, polymicrobial infection that is highly lethal. The poor prognosis relates to the demography of the usual patient: frail, elderly, diabetic, wasted, or obese, and almost always with compromising cardiovascular and renal disease. The process may begin slowly, evolving over 7 to 10 days with mild symptoms, primarily pain. Individuals are often afebrile or have only low-grade fever, lacking systemic toxicity in the early stages. The initial skin lesion is a small area of necrosis or reddish-brown blister with extreme local tenderness; the superficial appearance belies the widespread destruction of the deeper tissues. Skin sinuses (with surrounding areas of blue-gray gangrene) form, draining a foul-smelling thin pale "dishwater" exudate containing fragments of necrotic fat. Gram stain of the drainage reveals both Gram-positive and Gram-negative organisms and rare or absent neutrophils. Extensive gangrene of the superficial tissues and fat can be visualized by direct inspection through open skin areas or with skin incisions. Gas can be palpated in the tissues in approximately one-fourth of patients. Organisms frequently isolated included anaerobes (streptococci and/or bacteroides) and facultative bacteria, especially Enterobacteriaceae (*E. coli, Proteus, Klebsiella)*. Coagulase-negative staphylococci have also been reported.[22,23]

The most common site of involvement in approximately one-half of the cases is the perineum. The major predisposing causes are peri-rectal and ischiorectal abscesses. These localized infections track to the deeper structures of the pelvis, leading to a severe infection. A more superficial form involves the buttocks without extension to deeper muscles; 40 percent of individuals have involvement of the thigh and leg. Some infections arise in the adductor compartment of the thigh, often extending from an infected amputation stump or diabetic gangrene. The remaining 10 percent of cases are often associated with severe vascular disease and diabetes and are found on the lower abdomen, distal leg, and, rarely, on the neck.

Even with rapid surgical and medical interventions, the mortality rate remains in the 40 to 50 percent range, in part because of accompanying diseases. Incision, drainage, extensive débridement, and amputation are the aggressive actions that must be taken in concert with antibiotics (including one directed at bacteroides) guided initially by the Gram stain.[11]

Progressive Bacterial Synergistic Gangrene (Meleney Gangrene). Progressive bacterial synergistic gangrene typically occurs in association with wire stay sutures in a drain site after an abdominal operation (ileostomy, colostomy), in an incision in the chest wall after abdominal or thoracic infection (empyema), at the exit site of a fistulous tract, or in a chronic ulcer. The infection usually is recognized as one or more shaggy, painful ulcers developing within a week or two of the procedure, especially in proximity to wires or other foreign bodies.[11,24,25] *S. aureus* and the anaerobic streptococci are most commonly implicated. Though controversial, a role for *Entamoeba histolytica* has been proposed.

Gangrenous Cellulitis in the Immunocompromised Individual. The microorganisms associated with necrotizing cutaneous infections in the normal host are joined by a variety of other traditionally pathogenic and non-pathogenic bacteria, as well as fungi in compromised patients. In the presence of thermal burns, bacteremic *P. aeruginosa* may colonize normal skin, producing ecthyma gangrenosum (see Chap. 180), or may be attracted to burn areas, leading to extensive bacteremic *Pseudomonas* gangrenous cellulitis. Mucormycotic gangrenous cellulitis can engraft onto thermal burns or complicate percutaneous catheter areas in immunosuppressed individuals.[26] In the immunocompromised host, it becomes mandatory to biopsy any necrotic cellulitic lesions and to be alert to the possibility of a wide range of bacterial, viral, fungal, and even parasitic pathogens.

Nonclostridial Crepitant Cellulitis. The patient with nonclostridial crepitant cellulitis may have experienced a traumatic or surgical injury that was inadequately



débrided or had an underlying local infection, a poorly performed needle stick, or skin popping for delivery of illicit drugs.[27] Underlying diabetes, glucocorticoid or nonsteroidal anti-inflammatory drug (NSAID) use, and granulopenia may be present. The clinical presentation is often insidious, with low-grade fever, mild pain, and tenderness, but with early palpable gas and edema. Anaerobic non-spore–forming isolates may include *Bacteroides* sp. or peptostreptococci, often with facultative Gram-negative bacilli. In uncontrolled diabetes, the presence of gas may result from metabolism of glucose by *E. coli, Klebsiella, Aeromonas,* and other microorganisms (see Chap. 180).



CLOSTRIDIAL SOFT-TISSUE INFECTIONS The histotoxic clostridia are responsible for a variety of infections that involve the subcutaneous and muscular tissues, with changes in the overlying skin that can be abrupt and dramatic. Clostridial anaerobic cellulitis is an infection of the more superficial subcutaneous zone, usually in tissues that are already devitalized, and, rarely, involving the deep fascia or muscle. Clostridial myositis, or gas gangrene, is a process that is anatomically in the muscle layer but with significant changes in the skin and subcutaneous tissues via interference with vascular and lymphatic structures. The histotoxic clostridia primarily involved in these infections include the human gut commensal *C. perfringens* and the environmentally resident *C. septicum*. *C. perfringens* is present in approximately 90 percent of normal colons but *C. septicum* is rarely found, perhaps only in 5 percent of asymptomatic individuals. Newer and traditional bacteriologic techniques allow for easy identification of these obligate anaerobes.[28]

ANAEROBIC CELLULITIS Anaerobic cellulitis is an infection of devitalized tissue usually caused by *C. perfringens* with or without other bacteria, occurring in a dirty or inadequately débrided wound several days after injury or after a needle stick or surgery. The onset is more gradual than in anaerobic myonecrosis (gas gangrene). The clostridia are able to grow in the wound and extend rapidly through tissue planes with attendant formation of large quantities of gas that is readily palpable. A thin, dark-gray to brown, foul, serous discharge is produced. Gram stain of the drainage reveals short, plump, blunt-ended, Gram-positive rods with a variable number of polymorphonuclear leukocytes and, occasionally, other bacterial forms. Unlike gas gangrene, there is relatively little local pain or edema, change in overlying skin, or toxemia. At surgery, the muscles appear normal, but gas may be readily evident throughout the exudate. Anaerobic cellulitis can be distinguished from anaerobic myonecrosis by inspection of muscle to avoid needless mutilating surgery and amputations. Treatment consists of opening the wound, removing necrotic debris, and administering antibiotics (penicillin and either clindamycin or metronidazole). Occasionally, bacteremic *C. septicum* can spread to subcutaneous tissues. These patients are toxic, unstable, and, usually, the suspicion of *C. septicum* is raised on finding subterminal spores in large Gram-positive bacilli.[29]

Recently, infection by *C. sordellii* and *C. novyi* has been reported in intravenous drug users. Patients develop toxic shock and necrotizing fasciitis, though fever is not universally seen. The organism can usually be cultured from wounds, but blood cultures may remain negative. Before these reports, most of these cases were associated with childbirth or medical abortion.[30]

ANAEROBIC MYONECROSIS (GAS GANGRENE) Anaerobic myonecrosis is a rapidly progressing, toxemic, potentially lethal infection involving muscle but with secondary changes in the overlying skin. Gas gangrene may also occur in the uterus, intraperitoneal viscera, as well as the brain and eye in the absence of bacteremia. The infection may develop as a complication of muscle injury, a traumatic dirty wound with extensive muscle and soft-tissue damage, including injectable drugs,[31] or after surgery on the bowel or gallbladder. *C. perfringens* is the most common pathogen and also part of the normal flora but rarely associated with spontaneous gas gangrene. Two toxins appear most important in pathogenesis. α-Toxin (phospholipase C/lecithinase) hydrolyzes cell membrane and increases capillary permeability and platelet aggregation. θ-Toxin (perfringolysin O), though non-essential for disease, appears to inhibit recruitment of polymorphonuclear leukocytes, explaining their paucity in biopsies of infected muscle tissue.[4] Group A and anaerobic streptococcus, as well as bacteroides, *E. coli* and *Klebsiella*, have also been reported.

The incubation period of anaerobic myonecrosis is often short (12 to 24 hours) but may be delayed, rarely developing after anaerobic cellulitis. The first symptom is usually severe local pain followed by fever, tachycardia, and hypotension. Gas formation is present but not prominent in subcutaneous tissues, and may be completely obscured by edema of the superficial tissues. The skin often takes on a dark yellow or bronze discoloration with tense blebs or bullae containing dark brown fluid. A serosanguineous exudate can be expressed from the wound or aspirated from a bullous lesion. Gram stain of the exudate reveals plump Gram-positive rods and rare or absent white blood cells even with a systemic leukocytosis. The overlying skin may develop patchy necrosis and desquamation. At surgery, the process in the muscle is evident, with gray pallor, absence of bleeding, presence of gas and failure of muscle to respond to direct stimuli. Removal of devitalized tissue, antibiotics, and supportive therapy must be quickly undertaken, and amputation can be lifesaving in limb involvement. Antitoxin is no longer available and hyperbaric oxygen is reserved for involvement of areas not amenable to débridement but is not recommended as monotherapy.[28]

SPONTANEOUS, NONTRAUMATIC ANAEROBIC MYONECROSIS In the absence of an external wound, septicemic gas gangrene may occur spontaneously, usually caused by *C. septicum* and often associated with hematologic malignancies or occult colon cancer, especially in the cecal area. Spontaneous *C. septicum* gas gangrene is a fulminant disease, with a mortality approaching 100 percent and marked by a precipitous onset and progression, often with subcutaneous gas, myonecrosis, and high-grade septicemia. In addition, the organism may be aerotolerant and thus lacks susceptibility to hyperbaric oxygen. Progression is more rapid than in other forms of anaerobic myonecrosis, and no controlled treatment trials exist for this disease. Overlying skin of an involved area becomes red-brown and the epidermis sloughs early in the illness.[29]

Recently, spontaneous gas gangrene from *E. coli* has been reported. All three patients were cirrhotic, and no obvious source of bacteremia, such as gastrointestinal perforation, was noted.[32] In addition, sterile, spontaneous diabetic myonecrosis is important to consider in the differential diagnosis, though patients are usually not febrile and do not appear toxic. This entity is most common in women with late-stage diabetes complicated by nephropa-

thy and retinopathy and usually affects the quadriceps and thigh muscles, occasionally with little, if any rise, in muscle enzymes.

LABORATORY STUDIES

Smears of Pus, Exudate, and Aspirates

The typical appearance of an STI coupled with epidemiologic and clinical data may guide antimicrobial therapy but is not completely reliable, particularly in patients who are immunocompromised by diseases or their therapies. Immediate and more substantial clues can come from aspiration of complicated, fluctuant lesions or bullae and from swabs of open lesions using the Gram stain, fungal stains, and other direct methods, including immunofluorescence (see Chap. 176).

Though not indicated in routine or uncomplicated cases, nonbacteriostatic saline can be injected into the advanced border of the infected site, followed by aspiration of tissue fluid that is then subjected to staining. Successful identity of pathogens is accomplished between 7 percent and 33 percent of the time, but cultures of the material in addition to blood cultures is a vital part of the search for the etiologic agent in all STIs.[1,33] Sampling the most inflamed area of the lesion, rather than the advancing edge, may increase the yield of cultures.[12] Open lesions such as postsurgical, traumatic, and pressure ulcers, may contain multiple organisms, some of which may be significant whereas others are contaminants.[34] The Gram stain may help initially to identify the most significant morphologic and staining bacteria but often a biopsy as well as the inflammatory cell type of the lesion, followed by cultures, special stains, and pathologic investigation, proves most helpful compared to study of surface material. Biopsy for tissue culture may have a much higher yield in establishing a pathogen than needle aspiration. Pathogens are more likely to be seen microscopically and cultured from abscesses, surgical wounds, bullae, and deeper tissue exudates from necrotizing fasciitis and myonecrosis.

Bacteremia is uncommon in cellulitis and positive blood cultures are only noted 4 percent of the time. Therefore, routine blood cultures do not appear to be cost effective in routine care of the immunocompetent host. If cellulitis is complicated by lymphedema, the diagnostic yield of blood cultures rises to 30 percent. In addition, high fever, chills, buccal and periorbital cellulitis, or exposure to salt- or freshwater sources, are indications for ordering blood cultures.[12] Identification of the responsible pathogen is the gold standard in effective antimicrobial therapy of STI (see Chap. 176 for a discussion of other methods, many noncultural, currently used or developed to identify a responsible pathogen).[35]

Imaging

Routine imaging is generally not necessary in uncomplicated cases. Infections with anaerobic organisms, especially *Clostridia* and bacteroides, may lead to gas formation, which can then be visualized radiographically. Conventional x-ray of anaerobic cellulitis may reveal pockets of gas confined to superficial tissues and is usually readily palpable. True gas gangrene (clostridial myositis) can be distinguished from anaerobic cellulitis by the linear feathery appearance of gas infiltrating through groups of muscle fibers, although palpation may not reveal crepitus.[11,28] Lack of gas pattern on x-ray does not rule out necrotizing fasciitis or myonecrosis caused by non-gas–producing organisms such as *S. pyogenes*, however. In addition, if underlying osteomyelitis or source of bacterial seeding to the skin is suspected plain films or computed tomography are indicated.

Magnetic resonance imaging has gained favor as a technique in diagnosing STIs. In a recent study, 23 patients with acute STIs underwent magnetic resonance imaging evaluation. T2-weighted images best highlighted the cutaneous disease process. In patients with pyomyositis or subcutaneous abscesses, a spindle-shaped or round, well-defined area of high signal intensity was observed in the muscle or fat, respectively. Patients with necrotizing fasciitis had deep dermal, well-defined, dome-shaped areas of increased signal. Patients with nonnecrotizing cellulitis had smaller, heterogeneous areas of increased signal.[36] However, it is important to note that radiographic testing should never delay open surgical examinations in cases with high-index of suspicion where definite diagnosis and curative therapy can be obtained.

HISTOPATHOLOGY

In addition to direct stains and cultures pathologic investigation with special staining can be very useful. Direct immunofluorescent techniques have been reported to identify streptococcal pathogens in 19 of 27 cases of erysipelas and in 10 of 15 cases of cellulites.[37] Lesional skin punch biopsy is often helpful in ruling out a cellulitis-simulating non-infectious inflammatory lesion or a co-existing diagnosis such as erythema nodosum, vasculitis, or eosinophilic cellulitis. For instance, in ecthyma gangrenosum (caused by *P. aeruginosa*), a septic vasculitis is seen with epidermal necrosis and Gram-negative bacilli occasionally seen in vessel walls.

Histologically, erysipelas is characterized by intense edema, marked lymphatic and vascular dilatation of the superficial dermis, and a profuse infiltration of tissue spaces and lymphatic channels with streptococci and neutrophils. The streptococci are not found in the blood vessels themselves, but their presence in the lymphatics produces an inflammatory reaction about these vessels. The dermis is markedly edematous and there is infiltration with neutrophils, and mononuclear cells, mostly centered around vessels. Histiocytes and granulation tissue may be seen in chronic lesions. The epidermis is only secondarily involved, primarily with edema.

Deep incisional biopsy and histopathologic examination on frozen section has been shown to improve diagnosis and decrease mortality in necrotizing fasciitis by rapidly establishing the diagnosis and thus defining the need for surgical débridement.[38] Indications for an open exploration and a biopsy include confusion, pain and tenderness, tachycardia, tachypnea, ketoacidosis/hyperglycemia, bullous or gangrenous skin changes, bronzing of the skin, spreading areas of anesthesia, thin reddish discharge with undermining of wound edges, crepitus, and an abscess with multiple tracts.

In streptococcal gangrene, the prominent angiitis and focal dermal necrosis with spread along fascial planes suggest that the disease is fundamentally gangrene of the subcutaneous tissues followed by necrosis of the overlying skin. Microscopically, fibrinoid necrosis is present in the media of many arteries and veins passing through the edematous and damaged fascia.[39] Fibrin thrombi are present. The epidermis, dermis, skin appendages, and even fascial planes in the area of gangrene undergo coagulation necrosis. Numerous polymorphonuclear leukocytes and mononuclear cells infiltrate the lesion, and the up-



per layers of the dermis contain large numbers of Gram-positive cocci.

DIFFERENTIAL DIAGNOSIS

The differential diagnosis of erysipelas, cellulitis, necrotizing cellulitis, and myonecrosis includes other infections, as well as non-infectious inflammatory disorders that have features that may be confused with STI (Box 179-1). Most notably, these include Sweet syndrome, lymphoma, carcinoma erysipeloids, and spontaneous, sterile diabetic myonecrosis.[40–42]



Specific Bacterial Species Associated with Soft-Tissue Infection

PERSON-TO-PERSON SPREAD **Staphylococcus aureus *and Groups A, B, C, and G β-Hemolytic Streptococcus.*** (See Chap. 177)

***Enterobacteriaceae,* Haemophilus influenzae, Neisseria meningiditis, *and* Pseudomonas aeruginosa.** (See Chap. 180)

Streptococcus pneumonia. *S. pneumoniae* is a rare cause of cellulitis and necrotizing fasciitis, perhaps occurring more frequently in recent years and behaving similar to GAS STI.[43,44] Predisposing or associated conditions include chronic alcoholism, drug abuse, HIV, connective-tissue disorders, glucocorticosteroids, and the use of NSAIDs.[14] Bacteremia is an underlying mechanism in approximately one-half of the cases described, but relative or absolute penicillin resistance in STIs does not appear to be a factor.

Specific Bacterial Species Associated with Aqueous Environments. *Aeromonas* sp. and *Vibrio* sp. (see Chap. 183).

Specific Bacterial Species Associated with Soil Exposure. *Clostridium* sp. (primarily, excluding endogenous *C. perfringens,* the most frequently isolated pathogen) were discussed earlier in this chapter.

Specific Bacterial Species Associated with Animal Exposure. (See Chap. 183) *S. iniae, Erysipelothrix rhusiopathiae, Bacillus anthracis,* and *P. multocida* are associated with animal exposure.

Specific Bacterial Species Associated with Bioterrorism. (See Chap. 213) *B. anthracis*, *C. botulinum*, *Yersinia pestis*, and *Francisella tularensis* comprise category A disease agents. These agents can easily disseminate from person to person and result in high mortality rates. Category B agents, which include *Brucella* sp., *C. perfringens,* as well as several other bacteria considered to be food and water safety threats, are defined as those with moderate ability to disseminate but lead to lower mortality rates compared with category A agents (see Chap. 213).

Box 179-1

Differential Diagnosis of Erysipelas, Acute Cellulitis, and Necrotizing Soft-Tissue Infections

	NON-INFECTIOUS	INFECTIOUS
Erysipelas and cellulitis	Dissecting cellulitis of the scalp Acne conglobata Hydradenitis suppurativa Acute allergic contact dermatitis Erythema nodosum Eosinophilic cellulitis Giant urticaria and angioedema Fixed drug eruption Deep venous thrombosis Lipodermatosclerosis Vasculitis such as polyarteritis Kawasaki disease Familial Mediterranean fever Gout Deep venous thrombosis Sweet syndrome Pyoderma gangrenosum Inflammatory breast carcinoma (carcinoma erysipeloids) Lymphoma	Osteomyelitis of the maxillary or frontal bones secondary to paranasal sinusitis Extension of subperiosteal infection from long bone osteomyelitis Erythema migrans Erythema infectiosum (human parvovirus B19) Early herpes zoster
Necrotizing soft tissue	Factitial ulcers Pyoderma gangrenosum Calciphylaxis Ischemic necrosis (atherosclerosis obliterans or thromboembolism) Fixed drug eruption warfarin necrosis, heparin necrosis Pressure ulcer Brown recluse spider bite Spontaneous sterile diabetic myonecrosis	Purpura fulminans Amebic (*Entamoeba histolytica*) gangrene after bowel surgery

***Methicillin-Resistant* Staphylococcus aureus.** Antibiotic resistance is of increasing concern particularly in the case of MRSA, which accounts for a large number of STIs that are not responsive to empiric therapy. Most of these resistant strains were initially thought to be acquired from health care settings such as hemodialysis centers, after prolonged hospitalizations, or after use of indwelling catheters. HA-MRSA was initially treated with vancomycin, and most infected patients were hospitalized because oral formulations are poorly absorbed and do not achieve sufficient concentrations in soft tissue. With the advent of linezolid (see the section Treatment), which is available orally, more of these infections are now treated in the outpatient setting.

Though still a controversial issue, CA-MRSA strains are thought to be "escaped" nosocomial isolates. Up to 18 percent of people with CA-MRSA had a history of hospitalizations 12 months before infection and up to 85 percent of patients with CA-MRSA have at least one risk factor for acquiring HA-MRSA.[47] Novel multi-resistant strains also include *S. sciuri* and *S. haemolyticus*, which have also been reported in STIs.[52]

Vancomycin-Resistant Enterococcus. Vancomycin-resistant enterococcus is usually acquired as a nosocomial pathogen and less frequently causes STIs when compared with its ability to colonize skin and wounds. In a recent study, only 5 percent of enterococcal infections involved the skin or soft tissue.[53]

Mycobacterium *Species.* *Mycobacterium fortuitum* complex species are rapid growers

and include *M. fortuitum, M. chelonae,* and *M. abscessus* (see Chap. 184). These organisms are widely distributed in soil, dust, and water. Inoculation can occur via puncture wounds (injection or traumatic) or surgical procedures (augmentation mammoplasty, median sternotomy, percutaneous catheterization); rarely, primary cellulitis occurs without recognizable skin trauma.[54,55] Contaminated gentian violet used for skin marking has been the source in some outbreaks. *M. fortuitum*–complex STIs characteristically occur several weeks after the inciting injury and appear as indolent wound infections (nodules, ulcers, granulomatous papules, or verrucous plaques). In immunocompromised individuals, *M. fortuitum* can disseminate hematogenously to skin (multiple recurring abscesses on the extremities) and joints. Treatment regimens are complex, require careful susceptibility testing, and may include excisional biopsies.

Box 179-2

Antimicrobial Treatment of Necrotizing Infection of Skin, Fascia, and Muscle

ORGANISM	DRUG OF FIRST CHOICE	ALTERNATIVE DRUGS
Mixed infection	Ampicillin/sulbactam Imipenem/cilastatin, meropenem Ticarcillin/clavulanate	Cefoxitin, clindamycin, or metronidazole + an aminoglycoside
Streptococcus (A, C, G, B)	Penicillin G + clindamycin for toxic shock syndrome or necrotizing fasciitis	Ceftriaxone + clindamycin Vancomycin, linezolid, daptomycin
Enterococcus (systemic infection)	Penicillin G or ampicillin + Gentamicin or streptomycin	Vancomycin + gentamicin or streptomycin, linezolid Quinupristin/dalfopristin, or daptomycin
Staphylococcus aureus	Nafcillin (or oxacillin) Vancomycin (for methicillin-resistant strains) Linezolid, daptomycin	Cefazolin or amoxicillin/clavulanic acid, clindamycin, quinupristin/dalfopristin,
Clostridium perfringens	Penicillin G + clindamycin	Metronidazole and imipenem or meropenem, Ceftriaxone Chloramphenicol

PROGNOSIS AND CLINICAL COURSE

Uncomplicated erysipelas remains confined primarily to the lymphatics and subcutaneous tissues, occasionally complicated by bleb formation and, rarely, by the presence of an abscess. Even in the days before antibiotic therapy, it was often a self-limited process, subsiding over 7 to 10 days. Occasionally, untreated erysipelas or cellulitis may be complicated by bacteremia with metastatic infection in various organs. Prompt treatment prevents both suppurative and non-suppurative complications. However, in young infants and elderly debilitated patients and in individuals receiving glucocorticoids, the disease may progress with devastating rapidity to a fatal outcome.

Erysipelas has a tendency to recur in the same area, probably a result of the predisposing effects of chronic lymphatic obstruction, persistent edema, and even elephantiasis-like swelling caused by earlier infections. Such recurrent infections may produce persistent swelling of the lips (macrocheilia), cheeks (particularly the lax tissues beneath the eyes), lower extremities, or even abdomen. Chronic lymphedema of the lower extremities secondary to recurrent erysipelas may result in elephantiasis nostra verrucosa (see Chap. 175). Early therapy and prolonged elevation of the affected area can help to preserve better tissue resistance to reinfection. Some patients with frequent recurrences in the same area benefit from prophylactic antibiotics, usually monthly benzathine penicillin injections.[56]

Acute cellulitis, with or without abscess formation, has a tendency to spread through the lymphatics and bloodstream and may be a serious disease if not treated early. In older patients, involvement of a lower extremity may be complicated by thrombophlebitis. In patients with chronic edema, the process may spread extremely rapidly and recovery may be slow, despite drainage and sterilization of the lesions by antibiotics.

The mortality rate for necrotizing fasciitis is high (reported to be approximately 40 percent greater when complicated by streptococcal toxic shock–like syndrome; see Chap. 178). Early diagnosis and aggressive treatment of necrotizing fasciitis is the most important factor in determining outcome.[57] Overall, clostridial infections have a mortality of 20 percent to 70 percent, depending on the location of the process, with myonecrosis associated with the more lethal prognosis. Spontaneously occurring gas gangrene tends to have an even more ominous mortality, approaching 100 percent, because of its rapid onset, without an obvious predisposing traumatic or surgical wound and the association with an underlying malignancy. The mortality for synergistic necrotizing cellulitis is at least 50 percent, the patient usually succumbing to septic shock and circulatory collapse.

In assessing prognosis, the wide ranges described for these infections depends on the underlying health and immune status of the patients. Early recognition and definition of etiologic agents guides appropriate antibiotic usage, as well as surgical decisions. Many of these infections are life threatening, and, therefore, urgent evaluation and therapy can improve prognosis.

TREATMENT

Antibiotics

See Box 179-2 for therapeutic guidelines for necrotizing infections.

Mild cases of early erysipelas can be treated on an outpatient basis with either intramuscular procaine penicillin (600,000 units twice daily) or with oral penicillin V, 500 mg every 6 h. Dicloxacillin (500 mg four times a day) as well as the oral cephalosporins are also effective, particularly if clinical findings make exclusion of acute cellulitis difficult. Macrolides and clindamycin can be used in penicillin-allergic individuals, but increasing resistance of *S. pyogenes* to erythromycin has been reported.[58,59]

Individuals with more extensive streptococcal infections and with underlying medical problems such as diabetes mellitus should be hospitalized and treated with intravenous aqueous penicillin G (1 to 2 million units every 4 to 6 hours). In severe streptococcal skin infections (e.g., extensive erysipelas, cellulitis, or streptococcal gangrene), parenteral aqueous penicillin G should be administered in higher doses. In the ill patient in whom a staphylococcal etiology is identified, a penicillinase-resistant



semi-synthetic penicillin (e.g., nafcillin) should be used and/or vancomycin substituted in the penicillin-allergic individual. In the patient with a questionable penicillin allergy, cefazolin 1 g intravenously every 8 hours) may be chosen. Vancomycin (1 g intravenously twice a day) is the drug of choice in patients who have a methicillin-resistant organism or a prior history of an immediate type reaction (immunoglobulin E mediated) to a penicillin or a cephalosporin.

With the advent of resistant organisms, particularly MRSA, newer agents have been approved by the U.S. Food and Drug Administration for the treatment of STIs and include linezolid (an oxazolidinone), quinupristin-dalfopristin (a streptogramin combination antibiotic), and daptomycin. Though some resistant strains have already been reported after use of linezolid (600 mg twice a day), it has been shown to reduce hospital stay when compared with vancomycin in the treatment of MRSA skin and STIs.[60,61] It is also useful in treating infections caused by vancomycin-resistant enterococcus, though resistance to *Enterococcus faecium* has been reported. In addition, its oral formulation of equal bioavailability makes it useful in outpatient treatment of documented resistant infections. Use of quinupristin-dalfopristin is limited to required intravenous infusions of large volume. Daptomycin (4 mg/kg/day) is bactericidal and has been shown to be equivalent to vancomycin in the treatment of skin and STIs. In addition, given its novel mechanism of action, which is poorly understood but includes disruption of bacterial membrane electric potential, less chance for bacterial resistance is postulated.[62] Tigecycline, a minocycline derivative, has been approved and is in use. In addition, oritavancin and dalbavancin, new glycopeptides with long half-lives that belong to the same class as vancomycin, as well as ramoplanin, a glycolipodepsipeptide, are in development and testing and have shown activity against resistant Gram-positive organisms, particularly *S. aureus*.[63]

The quinolones moxifloxacin and gatifloxacin have been approved by the U.S. Food and Drug Administration for treatment of uncomplicated STIs.[63] On the other hand, meropenem used as monotherapy has been shown to be equally effective to imipenem-cilastatin in the treatment of complicated skin and STIs.[64] Of note, in complicated cases, fluctuant lesions or any fluid collections should be drained in addition to treating with antibiotics.

Treatment decisions for patients with crepitant or gangrenous STI, including necrotizing fasciitis, anaerobic cellulitis, and myonecrosis, must be based on a rapid or presumptive identification of the etiologic agent(s) (see Box 179-2).

Local Measures

Care of the local lesions of erysipelas and cellulitis includes bed rest and elevation of the involved area to reduce local edema. Cool, sterile saline dressings decrease the local pain and are particularly indicated in the presence of bullous lesions. The application of moist heat may aid in the localization of an abscess in association with cellulitis, but it should not be used in a patient with arterial insufficiency of the involved extremity.

Surgical Intervention

Treatment of necrotizing STIs requires early and complete surgical débridement of necrotic tissue in combination with appropriate drainage and high-dose antibiotics. Inspection of the deep fascia can confirm the presence of fat necrosis and preservation of the deep aponeurosis overlying muscle and provide material for bacterial and pathologic study.[41] Re-exploration and débridement should be performed as necessary to ensure that all necrotic tissue has been removed and pockets of pus are drained.

When synergistic necrotizing cellulitis is considered a more likely diagnosis than an abscess, it becomes essential to explore the involved area, including careful assessment of the area of necrosis in the deep subcutaneous tissues as well as inspection of the underlying muscle.

Anaerobic clostridial cellulitis is treated with surgical débridement of all devitalized tissue. The use of hyperbaric oxygen drenching, particularly in patients with far-advanced disease involving the trunk in whom surgical excision would be mutilating, appears to have a place in current therapy.

The surgical approach to clostridial or streptococcal myonecrosis requires rapid evaluation, appropriate antibiotics with penicillin and metronidazole or clindamycin and exploration and débridement of affected muscle. Amputation of a limb can be rapidly accomplished and may be lifesaving in selected patients. Spontaneous myonecrosis and anaerobic cellulitis caused by *C. septicum* or other histotoxic clostridia may benefit from exposure to hyperbaric oxygen because bacteremia is frequently present, toxin production may be halted, and tissues still viable may be protected by an oxygen barrier.[66]

Other Therapies

Other adjunctive considerations in treatment of STI include the use of intravenous γ globulin for type II necrotizing fasciitis caused by GAS, particularly in the setting of toxic shock syndrome. However, evidence for its benefit in the absence of toxic shock syndrome is lacking. Tefibazumab, a humanized monoclonal antibody raised against microbial surface compounds, is currently in trials for staphylococcal infection in newborns. A vaccine against *S. aureus* has also been developed for use in hemodialysis patients but has only shown a temporary effect.[47] Recombinant human activated protein C has been used in severe sepsis related to these STIs.[67,68] Patients with poor granulocyte production may benefit from granulocyte colony-stimulating factor administration. There is some evidence from the recent literature and from speculative observation that NSAIDs should be avoided in patients suspected of incubating or expressing early bacterial infections, as they may interfere with leukocyte chemotaxis (inhibition of lipoxygenase), decrease the inflammatory response (through decreased leukotriene production), and blur cardinal symptoms of infection (fever and pain) by inhibition of prostaglandin action.[14] Though these observations and speculations argue for more thoughtful and cautious use of NSAIDs in fragile patients, further study is needed in this controversial area. A recent case control study including 21 children with necrotizing fasciitis and 19 children with STI without necrosis, did not find an increased risk of infection in those taking ibuprofen for short-term use.[69]

Given the newly described role of the coagulation system in causing platelet and neutrophil aggregation that leads to hypoperfusion, a role for calcium channel blockers and inhibitors of glucoprotein IIb/IIIa in STIs has been suggested.[4] In addition, the role of photodynamic therapy in halting quick spread and in treating STI has been postulated.[70]

PREVENTION

Prevention, education of health care providers, adherence to infection-control measures, and judicious use of antimi-



crobials are paramount, particularly in preventing bacterial resistance. Decolonization strategies to prevent outbreaks have been attempted with oral and topical antibiotics, but their effectiveness in some resistant strains remains to be proven, and development of further resistance from these protocols is a feared complication.[51]

KEY REFERENCES

The full reference list for all chapters is available at www.digm7.com.

1. Vinh DC, Embil JM: Rapidly progressive soft tissue infections [Review]. *Lancet Infect Dis* **5**:501, 2005
3. Bryant AE et al: Vascular dysfunction and ischemic destruction of tissue in Streptococcus pyogenes infection: The role of streptolysin O-induced platelet/neutrophil complexes. *J Inf Dis* **192**:1014, 2005
4. Bryant AE: Biology and pathogenesis of thrombosis and procoagulant activity in invasive infections caused by group A streptococci and *Clostridium perfringens* [review]. *Clin Microbiol Rev* **16**:451, 2003
12. Swartz M: Cellulitis. *N Engl J Med* **350**:904, 2004
28. Swartz MN: Myositis, in *Principles and Practice of Infectious Diseases*, 5th ed., edited by Mandell GL, Douglas RG, Dolin R: New York, Churchill Livingstone, 2000, p 1058
45. Fridkin SK et al: Methicillin-resistant *Staphylococcus aureus* disease in three communities. *N Engl J Med* **352**:1436, 2005
50. Kowalski TJ, Berbari EF, Osmon DR: Epidemiology, treatment, and prevention of community-acquired methicillin-resistant *Staphylococcus aureus* infections [review]. *Mayo Clin Proc* **80**:1122, 2005
52. Shittu A et al: Isolation and molecular characterization of multiresistant *Staphylococcus sciuri* and *Staphylococcus haemolyticus* associated with skin and soft tissue infections. *J Med Microbiol* **53**:51, 2004
59. Stevens DL et al: Practice guidelines for the diagnosis and management of skin and soft tissue infections. *Clin Infect Dis* **41**:1373, 2005
63. Schweiger ES, Weinberg JM: Novel antibacterial agents for skin and skin structure infections [review]. *J Am Acad Dermatol* **50**:331, 2004



CHAPTER 180

Gram-Negative Coccal and Bacillary Infections

Morton N. Swartz

Many of the characteristic cutaneous manifestations of infection with Gram-negative organisms are due to direct microbial invasion of the skin or subcutaneous tissues. In addition, responses of host cytokines, chemokines, receptor molecules, and other effector cells and factors may contribute to fever, hypotension, and a variety of cutaneous manifestations.[1–4]

INFECTIONS DUE TO *NEISSERIA MENINGITIDIS* (MENINGOCOCCUS)

Three clinical syndromes associated with cutaneous involvement occur in meningococcal disease: meningitis, acute meningococcemia, and chronic meningococcemia. Skin lesions are frequently the most dramatic manifestations of these infections. The presence of areas of purpura or gross hemorrhage is associated with higher numbers of organisms in the bloodstream and indicates a poorer prognosis than for a petechial eruption. The epidemiology, pathogenesis, and clinical presentations of these processes have been reviewed.[1,3,4]

Bacteriology and Pathogenesis

Neisseria are aerobic, encapsulated, Gram-negative, bean-shaped cocci. *N. meningitidis* grows well on blood-enriched media in 5 percent to 10 percent CO_2. With potentially mixed bacterial exudates, these organisms should be grown on a selective medium (e.g., modified Thayer-Martin). They can be distinguished from *N. gonorrhoeae* by their fermentation of both glucose and maltose rather than of glucose alone. Meningococci are separable on the basis of capsular antigens, of which A, B, C, Y, and W-135 are the major human pathogenic groups. Outer membrane proteins that can identify serotypes are helpful in epidemiologic studies.[3] In an epidemic of meningococcal disease a shift of capsular group can occur (e.g., from group B to group C and vice versa), which facilitates evasion of host antibodies.[5]

Skin lesions associated with meningococcemia result from damage to small dermal blood vessels. Light and electron microscopy reveal bacteria within endothelial and polymorphonuclear cells in needle aspirate or punch biopsy specimens.[9,10] Endothelial damage, thrombosis, and necrosis of the vessel walls occur. Immunoglobulins and complement are present, even in early lesions.[3,9] Edema, infarction of overlying skin, and extravasation of red blood cells are responsible for the characteristic macular, papular, pustular, petechial, hemorrhagic, and bullous lesions. Many of the cutaneous hemorrhagic lesions may be caused directly by the effects of lipopolysaccharide (LPS) endotoxin or indirectly by stimulation of lease of outer membrane vesicles (blebs) has been observed on electron microscopy of meningococci in the plasma of patients with very high levels of circulating endotoxin in fatal meningococcal septicemia.[11] Another contribution to the dermal inflammatory vascular injury, independent of immune complexes and cytokine activity, may be the interaction be-

MENINGOCOCCUS INFECTIONS AND THE SKIN AT A GLANCE



- In the United States up to 2800 cases of meningococcal disease occur annually.
- Skin lesions associated with meningococcemia result from damage to small dermal blood vessels.
- Three clinical syndromes are associated with meningococcal disease: meningitis, meningococcemia, and chronic meningococcemia.
- Purpura and gross hemorrhage correlate with higher numbers of organisms in the bloodstream and indicate a poorer prognosis.

tween vascular endothelium (intercellular adhesion molecule 1) and an adhesion glycoprotein (CD18) on leukocytes, the so-called *dermal (localized) Shwartzman reaction* (LSR).[12] Mouse neutrophils express a surface protein, gp 49 B1, that prevents neutrophil-dependent vascular injury in response to LPS; humans have a leukocyte analog. The LSR requires a priming dose of LPS followed by a systemic challenge 18 to 24 hours later. A single intradermal injection of LPS into gp 49 B1–null mice produces an exaggerated microangiopathy in the LSR not seen in wild-type gp 49 B1 mice.[13] LSR and the generalized Shwartzman reaction (in which both doses of LPS are administered systemically) serve as models for the thrombohemorrhagic vasculopathy, purpura fulminans, of meningococcal sepsis. The profound effects on small blood vessels, caused directly by bacterial invasion or indirectly by LPS, host cytokines, or LSR, may lead to diminished blood volume, lowered cardiac output, anoxia, myocardial failure, hypotension, acidosis, and diffuse intravascular coagulation (DIC).[4] Purpura fulminans, the cutaneous manifestation of DIC (see Chap. 145), occurs in 10 percent to 20 percent of children with meningococcal septic shock and is associated with functional impairment of protein C activation. The latter is thought to result from (1) downregulation of thrombomodulin and endothelial protein C receptor on endothelial surfaces to which protein C binds for its activation, (2) shedding of thrombomodulin from the endothelial surface, and (3) enzymatic cleavage of the thrombin-coupled protein C activation complex.[14]

Meningococci can be isolated from blood in chronic meningococcemia, usually during periodic fevers and rash, and joint manifestations. This form of meningococcal infection has been linked to absence of terminal complement components in several patients and to an isolated immunoglobulin A (IgA) deficiency in one patient, associations that may provide insights into pathogenic mechanisms.[15,16] Absence of bacteria, bacterial antigenic material, and granulocytic inflammation distinguishes chronic from acute infection. Skin biopsy findings in an infant revealed leukocytoclastic vasculitis, an exception to the usual absence of vascular damage seen in chronic meningococcemia.[16] The chronic course of the disease, the lack of endotoxin-like manifestations, and the potential for eventual complications such as meningitis or endocarditis suggest that an unusual host-parasite relationship is central to this rare infection.

Epidemiology

Humans are the only known natural hosts of *N. meningitidis*. Nasopharyngeal carrier rates vary with age: 1 percent in young children, 5 percent in those 14 to 17 years of age, and 20 percent to 40 percent in adults. In the United States there are 1400 to 2800 cases of meningococcal disease annually. In schools and military camps, or when a carrier of a new strain develops disease in a day care or family setting, carrier rates can increase dramatically.[17,18]

Globally, group A strains have been responsible for epidemics of meningitis, especially in sub-Saharan Africa. In Europe and the Americas, groups B and C have predominated, and in the United States, a recent surge in group Y disease has been reported.

In most industrialized countries a few clonal serogroup B electrophoretic types (e.g., ET-5 strains) have predominated during recent decades. Similarly, clonal complex ET-37 strains, usually expressing the serogroup C capsule but sometimes expressing serogroup B, W-135, or Y, are found around the world.[3] Adult family members probably introduce the organism into the household, but secondary cases are most frequently spread from ill children to other family members in the same age group, especially under crowded conditions.[19] Household spread is 500 to 800 times more frequent than the occurrence of secondary cases in the community, and there is an increased incidence of secondary cases in day care centers where large numbers of susceptible children congregate.[4,20] Absence of the spleen has been associated with fulminant meningococcal disease.

Immunity to meningococci increases with age, and protective bactericidal antibodies, both IgG and IgM, are found in 70 percent to 95 percent of young adults. Newborns are often resistant to meningococcal disease until they are 3 to 6 months of age.[21]

The quadrivalent vaccine containing polysaccharides of groups A, C, Y, and W-135 had been the only licensed vaccine against meningococcal disease until 2005. Its inadequate protective efficacy in infants led to the development of protein polysaccharide conjugate vaccines that appear to have the same protective efficacy as the currently available *Haemophilus influenzae* type b conjugate.[3,4] The group B capsular polysaccharide, a polysialic acid polymer similar to fetal neural tissue, does not induce protective immunity. Efforts continue to develop a vaccine using outer membrane proteins of group B organisms.[22]

Acute Meningococcemia and Meningitis

CLINICAL MANIFESTATIONS ***History.*** The disease often follows a mild upper respiratory tract infection associated with headache, grippe-like complaints, nausea, and muscle soreness. These symptoms can be so short-lived that fever, obtundation, and other manifestations of meningitis are the initial findings. In fulminant meningococcemia, vomiting, stupor, precipitous development of a hemorrhagic rash, and hypotension may be evident within a few hours of the onset of symptoms. Milder cases develop at a slower pace.

Cutaneous Lesions. Skin findings in acute meningococcal infections are characteristically petechial, but transient macular or papular lesions (Fig. 180-1A), which can resemble those seen in viral exanthems, may be evident.[23] The petechiae are small and irregular with a "smudged" appearance. Although most often located on the extremities and trunk, lesions can also be found on the head (see Fig. 180-1B), palms, soles, and mucous membranes. Extensive hemorrhagic lesions with central necrosis (suggillations) and bullae can develop. Gangrenous hemorrhagic areas (indistinguishable from purpura fulminans; see Chap. 145) can appear in severe meningococcemia, often with DIC (see Fig. 180-1C). Skin lesions and bacteremia are rarely seen with meningococcal pneumonia.[24] Cellulitis has been noted occasionally, especially in children with meningococcal conjunctivitis (see Primary Meningococcal Conjunctivitis).

Other Physical Findings. Patients with meningitis display signs of meningeal irritation and altered consciousness. Cranial nerve palsies, long-tract signs, seizures, and alterations in vital signs associated with changes in intracranial pressure may be present.

Obtundation and hypotension without meningeal signs, associated with the syndrome of DIC, are characteristic features of fulminant meningococcemia. Rarely, meningococcemia may result in septic foci in other areas: (1) septic arthritis, (2) purulent pericarditis with enlarging cardiac silhouette and findings of tamponade, and (3) bacterial endocardi-





▲ **FIGURE 180-1** *Neisseria meningitidis* infection. Acute meningococcemia. **A.** Transient macular and papular lesions on the upper chest. **B.** Discrete pink-to-purple macules and papules, as well as purpura, on the face of a young child. These lesions represent early diffuse intravascular coagulation (DIC). **C.** Map-like gray-to-black areas of cutaneous infarction are seen in this child with DIC.

tis. More commonly, a delayed immune complex–mediated syndrome results in a sterile arthritis, pericarditis, or episcleritis.[3] The acute arthritis-dermatitis syndrome, characterized by petechiae and nontraumatic arthritis, has traditionally been identified with disseminated *N. gonorrhoeae* infection (see Chap. 205). There has been a decline of gonococcal cases and an increase in cases of this syndrome caused by *N. meningitidis*.[25]

LABORATORY FINDINGS A polymorphonuclear leukocytosis is present in peripheral blood and cerebrospinal fluid (CSF) in meningitis. The CSF glucose value is commonly reduced. Characteristic organisms may be seen on Gram-stained smears of fluid, and meningococci are usually isolated from the CSF. *N. meningitidis* may be isolated from the blood of approximately one-third of patients with meningitis and from almost 100 percent of patients with acute meningococcemia. Demonstration of organisms in cutaneous lesions has been variable, and the presence of Gram-negative commensal organisms on the skin requires cautious interpretation. Reports describe positive results for 50 percent to 80 percent of aspirates, skin film samples, and punch biopsy specimens of petechial lesions.[9,26]

In patients already exposed to antimicrobial agents, the development of rapid, accurate, and inexpensive procedures for detection of soluble antigens in the CSF has been a major advance. The latex agglutination method and enzyme-linked immunosorbent assay methods are sensitive and very specific, but their clinical usefulness in most situations has been questioned.[27] Rapid diagnosis using polymerase chain reaction (PCR) testing is available in research settings.[28]

HISTOPATHOLOGY Endothelial swelling is seen, a perivascular infiltrate of polymorphonuclear leukocytes is present, thrombi occlude capillaries and postcapillary venules, and the walls of capillaries and venules are destroyed, as in leukocytoclastic vasculitis (see Chap. 164).

DIFFERENTIAL DIAGNOSIS Meningococcal infection warrants consideration in a patient with fever and a petechial or purpuric eruption, even in the absence of clinical meningitis (Box 180-1). Occasionally, the characteristic rash is absent, which delays consideration of meningococcal disease.

COURSE AND PROGNOSIS Untreated, acute meningococcal disease usually ends fatally. With treatment, recovery occurs in 90 percent of patients with meningitis.

In severe meningococcemia, especially with the rapid emergence of cutaneous hemorrhages, hypotension, and

Box 180-1

Differential Diagnosis of Acute Meningococcemia

- Acute bacteremias and endocarditis: In endocarditis, mucous membrane and conjunctival lesions, as well as subungual "splinter" hemorrhages, occur. Very infrequently, numerous petechial and purpuric lesions occur in patients with acute *Staphylococcus aureus* endocarditis. Usually, a few skin lesions in a patient with acute *S. aureus* endocarditis are purulent purpura. In acute gonococcemia, the skin lesions are usually acral, nodular, hemorrhagic, and few in number (see Chap. 205). Occasional patients with *Haemophilus influenzae* or *Streptococcus pneumoniae* bacteremia develop petechial eruptions.
- Cutaneous necrotizing vasculitis (see Chap. 164): Here, lesions are usually palpable. Renal involvement and hypertension may be present.
- Enteroviral infections: Fever, petechial eruptions, and aseptic meningitis are frequent features.
- Rocky Mountain spotted fever: The history of exposure to ticks in an endemic area, absence of an antecedent respiratory infection, and delay in appearance of the rash are clues (see Chap. 199).
- Toxic shock syndrome (see Chap. 178).
- Purpura fulminans (see Chaps. 145 and 181).
- Weil disease (leptospirosis) (see Chap. 183).

DIC, the entire course from onset to death can be measured in hours. In patients with sepsis-associated DIC, cutaneous thrombotic hemorrhages on the distal extremities may lead to skin and digital necroses that necessitate amputation.[29] Rarely, young children with meningococcal sepsis, shock, and DIC suffer thrombotic injury that causes growth plate arrest.[30] Myocardial dysfunction often occurs in meningococcal septic shock and is associated with high circulating levels of interleukin 6.[31] These cases are often associated with massive adrenal hemorrhage (*Waterhouse-Friderichsen syndrome*). Children who die from meningococcal septic shock have relatively low cortisol levels (but not in the range expected in adrenal insufficiency).[32] The mortality rate for meningococcal septic shock approaches 100 percent. Gradations in the severity of meningococcal disease make it difficult to assign an accurate prognosis, although a bedside predictive model has been proposed.[4,33]



Chronic Meningococcemia

CLINICAL MANIFESTATIONS ***History.*** The manifestations of chronic meningococcemia are vague at onset but tend to establish a pattern over a period of weeks or months.[15,34] Initially, there may be an acute febrile illness, but it wanes and leaves the patient with intermittent muscle aches, joint soreness, mild headache, and anorexia with weight loss. The simultaneous emergence of a localized rash with several days of fever and joint soreness are characteristic. As fever recedes, the rash fades, and the patient may be totally free of skin manifestations for days or weeks. This pattern of recurring fever and rash may last from a few weeks to 6 or 8 months. Untreated cases may eventually evolve into acute meningococcemia, meningitis, or endocarditis. Rare case reports relate this syndrome to the absence of a terminal component of complement, a finding also observed in some sporadic and recurrent acute meningococcal infections.[15]

Cutaneous Lesions. Skin lesions are usually distributed about one or more painful joints or on pressure areas in contrast to the acral distribution in gonococcemia. They may vary in appearance and size (1 to 20 mm) from one crop of lesions to the next and include (1) pale to rose-colored macular and papular lesions (the most common type), (2) slightly indurated and tender erythema nodosum–like nodules, (3) petechiae of variable size, (4) petechiae with vesicular or pustular centers, (5) hemorrhage (minute) with an areola of paler erythema, and (6) grossly hemorrhagic areas with pale blue-gray centers.

Other Physical Findings. Aside from the rash, the physical findings of chronic meningococcemia are minimal except for occasional joint swelling and tenderness.

HISTOPATHOLOGY The skin lesions differ pathologically from those in acute meningococcemia in that bacteria are absent, and fluorescent antibody techniques do not detect meningococcal antigens. Also, thrombi do not occlude capillaries and venules, endothelial cell swelling is absent, and the perivascular infiltrate consists of mixed polymorphonuclear and mononuclear cells.

DIAGNOSIS AND DIFFERENTIAL DIAGNOSIS During febrile periods, blood cultures frequently reveal meningococci and provide the specific diagnosis. No data are available on the use of antigen detection procedures.

A number of diseases with periodic fever, skin lesions, and joint involvement resemble chronic meningococcemia:

- Subacute bacterial endocarditis: A prolonged febrile course with a pleomorphic petechial rash, joint symptoms, and no overt focus make subacute bacterial endocarditis an important consideration. A prominent heart murmur, evidence of renal impairment, and blood cultures help establish the diagnosis.
- Acute rheumatic fever: When fever is prolonged, joint findings are prominent, and macular and papular rashes appear, the diagnosis may be acute rheumatic fever (see Chap. 161).
- Henoch-Schönlein purpura: The petechial hemorrhagic rash in Henoch-Schönlein purpura is more often symmetric, usually only on the lower extremities, and does not have the periodicity of the rash of chronic meningococcemia (see Chap. 164).
- Rat-bite fever, also referred to as *Haverhill fever*, may be acute (mimicking acute meningococcemia) or chronic (resembling chronic meningococcemia). Intermittent fever, rash, and joint manifestations are hallmarks of an illness that follows a rodent bite or ingestion of contaminated milk (see Chap. 183).
- Erythema multiforme: The iris-type configuration of lesions suggests erythema multiforme (see Chap. 38).
- Gonococcemia (chronic): The cutaneous and joint manifestations of chronic gonococcemia may continue for many days or weeks (see Chap. 205), and tenosynovitis in gonococcemia can be an important clue.

COURSE AND PROGNOSIS Some patients with chronic meningococcemia recover spontaneously without specific therapy, whereas others develop serious systemic complications, such as endocarditis or meningitis. The prognosis for treated infection is excellent.

Primary Meningococcal Conjunctivitis

N. meningitidis is responsible for up to 2 percent of cases of bacterial conjunctivitis. The source of infection is either direct inoculation of airborne organisms from close contact with carriers or manual contact with secretions from the patient's own nasopharynx.[35]

Treatment and Prophylaxis

CHEMOTHERAPY Widespread emergence of sulfonamide-resistant strains approximately 40 years ago has complicated therapy for meningococcal infections. Initially, these strains belonged predominantly to serogroup B, but in recent years, they have been from serogroups A to C. Penicillin G, or ampicillin, has supplanted the sulfonamides as the treatment of choice for acute meningococcal infections.

The usual adult dosage of penicillin G for meningococcal meningitis is 4 million units given intravenously (IV) every 4 hours for 7 days. Penicillin, 6 to 12 million units divided into four to six daily doses, given IV for 7 to 10 days, should be effective therapy for chronic meningococcemia. In highly penicillin-allergic adults, administration of chloramphenicol (1 g IV every 6 hours) is preferable to risking cross-reactions with a third-generation cephalosporin. In Europe and the United States, where meningococci relatively resistant to penicillin have been isolated (30 percent or more), a third-generation cephalosporin (e.g., ceftriaxone or cefotaxime) should be considered for initial therapy.[37] All meningococcal isolates from blood, CSF, or other normally sterile body cavities should be tested for penicillin susceptibility.[4] Immune complex–associated complications (fever, sterile arthritis, vasculitis, pericarditis, episcleritis) can occur in

15 percent of patients 4 to 10 days after initiation of antimicrobial therapy for severe meningococcal disease.[38]

SUPPORTIVE THERAPY Although it has been postulated that hypotension in acute meningococcemia may be due to adrenal failure associated with Waterhouse-Friderichsen syndrome (adrenal hemorrhage), blood cortisol levels and corticosteroid secretion rates have been found to be elevated or in the low normal range (not in the range associated with adrenal insufficiency).

The modern treatment of shock in sepsis begins with a number of well-accepted measures, including antibiotic selection, drainage procedures for abscesses, appropriate use of volume expanders, administration of β-adrenergic–stimulating drugs such as dopamine or isoproterenol, correction of severe acidosis, and, in selected patients, use of peripheral vasodilators. Therapies still considered experimental include those that neutralize host cell–mediated cytokines (e.g., interleukin 1, tumor necrosis factor)[1] and protein C.[39] Although numerous studies of glucocorticoid therapy have been completed, results have been variable, and on balance glucocorticoids do not appear to be indicated for septic shock.

Because of the impaired conversion of protein C to its activated form through the downregulation of thrombomodulin by inflammatory cytokines during sepsis, intravenous recombinant human activated protein C (drotrecogin alfa activated) has been used as ancillary treatment in a large randomized trial involving patients with severe sepsis (but none with meningococcal sepsis) accompanied by dysfunction of at least one organ.[39] The mortality rate was reduced from 30.8 percent in the placebo group to 24.7 percent in those receiving drotrecogin alfa. The incidence of serious bleeding was 3.5 percent in the drotrecogin alfa group compared with 2.0 percent in the placebo group. Any patients with meningococcal infection with DIC should be closely monitored for increased bleeding.[40] Severe meningococcal infections can be complicated by the syndrome of DIC. The basis for the diagnosis is usually a composite of associated hematologic abnormalities, including thrombopenia and hypofibrinogenemia, prolongation of the prothrombin time and partial thromboplastin time, and the presence of fibrin split products. If bleeding occurs, it may be necessary to administer fresh frozen plasma. Treatment for each case must be individualized, because therapy may be harmful and produce more problems than the DIC syndrome. Data on the use of heparin in treating DIC remain unconvincing, and because of potential adverse effects, this drug is no longer recommended. Investigators continue to study antibodies to various cytokines whose levels are elevated in meningococcal septicemia and immunomodulatory therapies.[41]

CHEMOPROPHYLAXIS There is a critical need for reliable chemoprophylaxis to rapidly protect children exposed in a day care nursery, contacts in crowded household, and institutional groups, because secondary cases can emerge, often within 24 to 48 hours of an index case.[17,42]

Currently recommended prophylactic drug regimens for children and adults favor rifampin, 600 mg orally twice daily for 2 days (age adjusted for children).[20] Rifampin resistance occurs, however, and reports have documented the development of invasive meningococcal disease.[37] Fortunately, ciprofloxacin and ofloxacin are effective single-dose substitutes, and ceftriaxone is available for parenteral single-dose use in children as well as adults.[43]

IMMUNIZATION Polysaccharide vaccines (groups A, C, Y, and W-135 *N. meningitidis*) are safe and effective in preventing meningococcal disease in adults and in children older than 2 years of age.[20]

Protein-conjugated meningococcal vaccine, MCV-4 (groups A, C, Y and W-135), is available in the United States.[4] The Centers for Disease Control and Prevention recommends routine vaccination of young adolescents (11 to 12 years old) with MCV-4. Elucidation of the complete genome of *N. meningitidis* has identified several conserved proteins that, in an experimental mouse model, have been protective against challenge with all pathogenic *N. meningitidis* organisms.

INFECTIONS DUE TO *PSEUDOMONAS AERUGINOSA*

Bacteriology and Pathogenesis

Pseudomonas aeruginosa is a nonfermentative, obligately aerobic, Gram-negative bacillus. Some strains produce a blue pigment (pyocyanin), a water-soluble yellow-green substance (fluorescein), or black pyomelanin. With Wood's lamp, the presence of organisms in lesions of skin or nails can be detected if the infecting strain produces fluorescein. The pigments impart a characteristic greenish color to the surrounding growth media or the tissue substrate involved in clinical disease (e.g., "green nail" syndrome, Fig. 180-2). In addition, an odor of grapes, characteristic of trimethylamine, often accompanies the growth of these microorganisms.

Organisms gain entry at sites of maceration, dermatophytic foci, trauma, or foreign bodies (e.g., indwelling venous catheters), or via aspiration into the respiratory tract. Infections in otherwise healthy individuals are unusual; when they occur, the involved regions are often areas with increased moisture (e.g., toe webs, the external auditory canal). Infection may begin in the base of the nail in persons who frequently have their hands or feet in water. This can progress to paronychia, followed by development of a green-blue discoloration of the nail due to local pigment production. The ability of this organism to infect healthy, but moistened, skin is evidenced by the occurrence of disseminated papules and pustules on areas

PSEUDOMONAS AERUGINOSA INFECTIONS AND THE SKIN AT A GLANCE



- The ubiquitous Gram-negative bacillus *Pseudomonas aeruginosa* can cause serious infections, usually in individuals who have altered defenses, who are receiving intense antibiotic therapy, or who are in the hospital.
- Cutaneous manifestations of *Pseudomonas* infections are common and characteristic.
- These cutaneous manifestations may represent the overt finding in septicemia (ecthyma gangrenosum) or may be the localized focus of serious infections of the ear.
- *Pseudomonas* infection can produce trivial cutaneous lesions involving the nails, toe webs, other skin areas, and external auditory canal.





▲ **FIGURE 180-2** *Pseudomonas aeruginosa* infection. "Green nails." This 36-year-old bartender noted a greenish yellow discoloration of 8 of 10 fingernails during the preceding year. Several of the fingers show chronic candidal paronychia as well.



of skin of people immersed in hot tubs ("hot tub folliculitis," Fig. 180-3), wading pools, and swimming pools.[44] These ubiquitous organisms can sometimes be aggressive secondary invaders in open wounds, in decubitus and other skin ulcerations, or in association with thermal burns. Rarely, a superficial pyoderma due solely to *Pseudomonas* is engrafted on a generalized or localized dermatitis, such as tinea pedis or eczema, producing irregular pustular areas with macerated borders.[44,45] Serious invasive infections occur in debilitated patients; malnourished infants; individuals whose normal bacterial flora has been suppressed by antibiotics; patients with neoplastic diseases, granulocytopenias, or impaired circulating or cellular immunity, including that associated with acquired immunodeficiency syndrome (AIDS)[46]; and individuals requiring mechanical respiratory assistance. These organisms frequently colonize body surfaces and survive exposure to antibiotics. *P. aeruginosa* can spread widely via the bloodstream, producing a disseminated infective vasculitis in which organisms can appear in the adventitia and media of vessels without luminal clots. Occasionally, features of the generalized Shwartzman reaction are found, but less frequently than in infections due to *N. meningitidis* or Enterobacteriaceae.

Epidemiology

Because *P. aeruginosa* is widely distributed in nature, it is not surprising that it may contaminate plants, vegetables, hot tubs, and swimming and wading pools. Moist regions of skinfolds and the external auditory canal are the most common sites of colonization (3 percent to 5 percent of cases). *P. aeruginosa* is found in small numbers in the feces of 10 percent to 20 percent of the population.



▲ **FIGURE 180-3** *Pseudomonas aeruginosa* infection. "Hot tub folliculitis." This 22-year-old woman noted the appearance of erythematous, pruritic papules and pustules on the trunk, buttocks, and upper thighs several days after bathing in a hot tub. The eruption resolved without antibiotic therapy.

Any activity that leads to excessive local moisture—laundry work, dishwashing, or hiking for long periods in wet terrain—will enhance the growth of these organisms. Moist or weeping cutaneous lesions (e.g., thermal burns) encourage the growth of *Pseudomonas* as well as of other Gram-negative bacteria. Increased environmental humidity is frequently associated with overgrowth of these organisms. Synthetic sponges easily become contaminated with Gram-negative bacteria and have served as vehicles of transmission.

Systemic infection with *P. aeruginosa* depends primarily on altered susceptibility of the host rather than on spread from individual to individual or on increased pathogenicity. However, exceptions may be seen in newborn nurseries, respiratory care units, and occasionally urology wards, where dissemination from a primary source may occur. Neutropenic or immunocompromised hospitalized patients are more likely to become colonized and develop invasive disease.

Local and Secondarily Infected Lesions

Pseudomonas produces a number of characteristic lesions. In addition, colonization by these organisms complicates other skin diseases and open wounds.[51]

CLINICAL MANIFESTATIONS ***History.*** Painful paronychial lesions, with or without characteristic green discoloration of the nails, occur most often in women with a history of continual immersion of the hands in water with soaps and detergents. People with toe web infection characteristically work in an atmosphere of high humidity, often have wet feet, and experience soreness and scaling of web tissues. There are numerous reports of the appearance of skin rashes in healthy individuals within 1 to 5 days after the use of public bathing facilities such as therapeutic or recreational whirlpools, hot tubs, or swimming pools (see Fig. 180-3). *P. aeruginosa* organisms have been isolated in large numbers from pool water. The rash usually clears without therapy within 1 week but is often accompanied by malaise, low-grade fever, external otitis, and mastitis.[44] *P. aeruginosa* folliculitis has also occurred after shower or bath exposure or exposure to contaminated bath articles.[45] Hot-foot syndrome caused by *P. aeruginosa* contamination of a wet surface exemplifies the organism's opportunism in infecting the ventral surfaces of feet abraded by a roughened floor.[52]

Cutaneous Lesions. In addition to a tender paronychial lesion, patients with green nail syndrome may have a nail that is partly or entirely green. The color may be in horizontal bands, representing intermittent activity of the infection at the nail base (see Fig. 180-2). Individuals with toe web *Pseudomonas* infections have thick, macerated, scaling, foul-smelling discolored areas between the toes. Hot-foot syndrome is characterized by tender, painful, red plantar nodules that develop within 1 to 2 days of exposure to an abrasive wet surface, such as a wading pool.[52]

In external otitis the lesion has a swollen, macerated appearance in the local area without involving the eardrum. Often referred to as *swimmer's ear*, the condition produces intense swelling and discoloration with excruciating pain on movement of the pinna. If the skin is traumatized, local infection can spread to the pinna, producing perichondritis and chondritis with intense tender swelling. Cartilaginous necrosis may result unless immediate drainage with through-and-through incisions and appropriate antibiotic therapy are instituted. Organisms other than *P. aeruginosa*, including *Staphylococcus aureus* and streptococci, may be causal.[53] The most severe form of *Pseudomonas* infection, malignant external

otitis, has a high mortality rate if therapy is delayed or inadequate. It usually occurs in elderly people with diabetes but may also be seen in healthy elderly people after surgery or minor trauma, such as water irrigation of the external canal, and in patients with AIDS.[54] The onset and early progression are insidious, with swelling, erythema, moderate discharge, and pain without fever or constitutional symptoms. As the surface breaks down, *Pseudomonas* invades the soft tissues at the junction of cartilage and bone; the process then advances to involve cartilage, mastoid, and temporal bone. Inflammation at the stylomastoid and jugular foramina can lead to seventh nerve palsy followed by palsy of the ninth to eleventh nerves. Diagnosis is made clinically if granulation tissue can be seen erupting at the cartilage-bone interface in the posterior inferior canal wall. The pinna is often swollen, and pain is intense.[55]

In patients who develop folliculitis the rash can be localized if only a limb has been immersed, or generalized, or in intertriginous areas. The rash begins as erythematous papules, evolves to papulopustules (see Fig. 180-3), and eventually heals with fine desquamation and occasional pigmented macules. Pruritus and pain may accompany the lesions along with localized areas of mastitis and external otitis. Serotype 0-11 of *P. aeruginosa* is most commonly involved.[56]

A small outbreak of *P. aeruginosa* 0-11 folliculitis occurred in granulocytopenic patients in a cancer treatment center, but the lesions in these patients, in contrast to those in healthy individuals with swimming pool folliculitis, rapidly became widespread and progressed to bullae, which became necrotic (ecthyma gangrenosum–like) unless systemic antibiotic treatment was begun immediately.[57] Thus, ecthyma gangrenosum (see Septicemia and Cutaneous Involvement) can result from progression of initial folliculitis in an immunocompromised patient as well as from *P. aeruginosa* bacteremia.

Although gangrene of the genitalia and perineum (Fournier gangrene) is almost always caused by a polymicrobial (facultative species and anaerobes) or group A streptococcal infection, exceptional cases have been attributed to *P. aeruginosa*.[58] Necrotizing fasciitis generally has similar causes, but in rare cases monomicrobial *P. aeruginosa* necrotizing fasciitis has occurred, usually involving the vulva or abdominal wall, in children with acute lymphoblastic leukemia.[59] Such patients are febrile; the infected area is painful, erythematous, and edematous, with subsequent skin necrosis; and bacteremia is present. Necrotizing fasciitis due to *P. aeruginosa* has also occurred in an immunocompetent infant (see Chap. 179).[60]

In secondarily infected skin areas, irregular, superficial pustular lesions may be superimposed on underlying skin disease; the margins of these regions are usually sharply defined and may exhibit the characteristic grape-like odor and pigmented exudate.[56] *P. aeruginosa* infection of a chronic ulcer occasionally progresses to *Pseudomonas* cellulitis.[61]

DIAGNOSIS AND DIFFERENTIAL DIAGNOSIS Nail and skin lesions resulting from *Pseudomonas* infection are recognized by the characteristic pigment. The organisms can be identified as thin Gram-negative rods, or a mixed infection (e.g., with *Candida*) may be observed. Fluorescence, demonstrated with a Wood's lamp, can support the diagnosis. Occasionally, *Aspergillus* infection of the nails produces a greenish color, and there is usually no associated paronychia. A subungual hematoma may superficially resemble *Pseudomonas* nail infection.

COURSE AND PROGNOSIS Patients with minor *Pseudomonas* infections (e.g., onychia and paronychia, toe web inflammation, whirlpool-associated skin rash, and external otitis) usually improve rapidly with topical therapy and drying of the affected area. Malignant external otitis requires the systemic administration of antibiotics directed against *Pseudomonas*, including a fluoroquinolone with or without meropenem or ceftazidime. High dosages and prolonged therapy are combined with surgical débridement to limit spread to bone and nervous system.[49,62]

Septicemia and Cutaneous Involvement

CLINICAL MANIFESTATIONS ***History.*** In individuals with suspected *Pseudomonas* septicemia, history taking is most frequently centered around the underlying problem and antecedent therapy. A premature infant may have required resuscitation and treatment of a non-specific pneumonitis before developing high fever, obtundation, and macular or hemorrhagic vesicular skin lesions. Infants may present initially with omphalitis or severe diarrhea, followed by septicemia and skin lesions. Urinary tract infections complicating exstrophy of the bladder may predispose the infant to bacteremia. In adults, there is usually a background of antibiotic therapy, immunoglobulin deficiency, diabetes mellitus, treatment with glucocorticoid hormones or antitumor agents, or the use of percutaneous catheters. Frequently, the patient is granulopenic, has already had a significant febrile illness, and may still be receiving antibiotics when one of the characteristic cutaneous manifestations develops. The local lesions are rarely painful. Occasionally, hemorrhagic manifestations may develop secondary to platelet reduction or DIC.

Pseudomonal involvement of the gastrointestinal tract, particularly in the tropics, may produce the picture of an acute enteric infection, with headache, high fever, diarrhea, and rose spots (Shanghai fever) resembling typhoid fever. The same enteric syndrome with ecthyma gangrenosum has occurred in previously healthy infants.[63]

Cutaneous Lesions. Skin lesions, the most characteristic physical findings in *Pseudomonas* septicemia, consist of four types[64]:

1. *Vesicles and bullae*. Singly or in clusters, these lesions spread in random fashion over the skin. They become hemorrhagic as they evolve. Occasionally in infants they may be surrounded by large erythematous halos and be mistaken for erythema multiforme.
2. *Ecthyma gangrenosum*. This lesion starts with an erythematous or purpuric macule and develops rapidly into a hemorrhagic bulla that ruptures; becomes a gunmetal gray, infarcted lesion with surrounding erythema (Fig. 180-4); and evolves into a necrotic black or gray-black eschar and surrounding erythema (Fig. 180-5).



▲ **FIGURE 180-4** *Pseudomonas aeruginosa* infection. Ecthyma gangrenosum. Gunmetal gray, painless, infarcted lesions with surrounding erythema.





▲ **FIGURE 180-5** *Pseudomonas aeruginosa* infection. Ecthyma gangrenosum. This 32-year-old man with human immunodeficiency virus infection noted the onset of a very tender plaque on the right buttock associated with fever and malaise. **A.** Five-day-old lesion with a central infarcted, necrotic area surrounded by erythema. **B.** At 5 weeks, the lesions had improved after ciprofloxacin treatment, which was discontinued because of an adverse drug reaction. Without antibiotic treatment, the necrotic area enlarged and was associated with bacteremia. Eventually, the lesion re-epithelialized, but the patient died of pseudomonal pneumonia.

Frequently, the lesion is in the anogenital or axillary region. Noma neonatorum, a gangrenous process of the nose, eyelids, oral cavity, or anal area and genitalia, occurs in premature newborns and other infants.[65] It is similar in appearance to noma, which occurs in young debilitated infants. Whereas the infecting agent in noma is *Fusobacterium*, noma neonatorum is caused by *P. aeruginosa*.

3. *Gangrenous cellulitis*. Sometimes presenting as a sharply demarcated, superficial, painless, necrotic lesion, gangrenous cellulitis may resemble a decubitus ulcer. However, it is located in a nonpressure area and may complicate a prior area of injury, such as a thermal burn. Also, it may begin abruptly, producing local pain, swelling, and erythema, and involving deep subcutaneous tissue and fascia. Local injury or bacteremia may introduce the infection.
4. *Macular or papular nodular lesions*. These lesions are small, oval, and painless, located predominantly over the trunk. They resemble the rose spots of typhoid fever.

Another cutaneous manifestation of *Pseudomonas* septicemia, usually occurring after days or weeks, is suppurative panniculitis. The lesions are red, warm, and sometimes fluctuant, but often situated deeply enough to feel solid. Surgical incision reveals suppuration, and *P. aeruginosa* can be isolated.[64,66] A variation of this manifestation consists of numerous red, nonfluctuant, hot, nontender, subcutaneous nodules that may be accompanied by other characteristic lesions, such as hemorrhagic bullae and ecthyma gangrenosum. Such lesions may be treated successfully by combination antipseudomonal antibiotic therapy.

Other lesions that may appear in systemic *Pseudomonas* infection include petechiae, ecchymoses, dermal Shwartzman-like reactions, and purpura fulminans.

Other Physical Findings. Patients with *Pseudomonas* septicemia frequently exhibit physical findings associated with their underlying diseases: malnutrition, mucous membrane ulcerations, glossitis secondary to antibiotic therapy and granulocytopenia, urinary tract infections, proctitis, adenopathy, hepatosplenomegaly, and hemorrhagic bronchopneumonia.

LABORATORY FINDINGS Hematologic examination may reveal leukocytosis or leukopenia, based on the underlying illness. Platelet levels may be diminished, and levels of fibrinogen and other clotting factors may be reduced in association with DIC, liver disease, or profound malnutrition.

Characteristically, in *Pseudomonas* septicemia aspirated material from bullae, areas of cellulitis, and papular or nodular lesions reveals numerous organisms but few leukocytes, even in patients with leukocytosis. Cultures of these lesions and of blood show *Pseudomonas*.

PATHOLOGY The distinctive finding in *Pseudomonas* lesions is a necrotizing vasculitis in which a myriad of bacteria invade the walls of small arteries and veins.[67] Extravasation occurs around the vessels, edema and bland necrosis in the perivascular and adventitial regions are extensive, and blood flow supplied by the affected vessel is decreased. Organisms tend to spread along the exterior surfaces of vessels and invade the skin. Similarly, bacterial invasion of the blood vessel walls in lungs, liver, and other organs produces nodular necrotic lesions.

DIAGNOSIS AND DIFFERENTIAL DIAGNOSIS Ecthyma gangrenosum skin lesions in an acutely ill patient suggest the diagnosis of *Pseudomonas* septicemia. The finding of abundant Gram-negative rods with rare granulocytes in vesicle fluid or in association with gangrenous or hemorrhagic cellulitis constitutes further presumptive evidence.

The differential diagnosis of *Pseudomonas* septicemia includes other infections that can produce ecthyma gangrenosum and other skin lesions through direct involvement of blood vessels (e.g., those caused by *N. meningitidis*, *Aeromonas hydrophila*, *Escherichia coli*, *Klebsiella pneumoniae*, *Citrobacter freundii*, *Morganella* sp., *Vibrio vulnificans*, *Burkholderia cepacia*, *Stenotrophomonas maltophilia*, *Moraxella* sp., and fungi of the *Aspergillus*, *Fusarium*, and *Rhizopus* groups).[68] *Chromobacter violaceum*, a saprophyte present in water and soil in tropical and subtropical (e.g., southeastern United States) environments, is a rare cause of ecthyma gangrenosum in the setting of chronic granulomatous disease of childhood, a condition predisposing to infections with this microorganism.[69] Pyoderma gangrenosum and gangrenous herpes simplex may mimic ecthyma gangrenosum.[70]

COURSE AND PROGNOSIS *Pseudomonas* septicemia is frequently the terminal event in a patient with malignant disease or altered defense mechanisms. Therapy may be effective and recovery complete in some instances when septicemia occurs in patients with more favorable underlying problems, such as urinary tract infections, or in patients with venous catheters.

TREATMENT AND PROPHYLAXIS ***Local Infections.*** Superficial skin and toe web infections and onychia usually respond to application of acetic acid, silver nitrate, or gentian violet compresses two to three times daily between long periods of drying. Paronychia is best treated by surgical drainage, nail trimming, and application of 4 percent thymol in chloroform. Acetic acid, polymyxin (0.1 percent) in acetic acid, or glucocorticoids with neomycin are effective for otitis externa. When acetic acid is used topically on chronic ulcers, a 2 percent to 5 percent solution is often effective.[71] In addition, topical silver nitrate (0.5 percent) or silver sulfadiazine may eradicate these organisms in burn patients (see Chap. 94).

Systemic Infections. *Pseudomonas* septicemia requires early systemic bactericidal antimicrobial therapy. Effective agents include the aminoglycosides (gentamicin, tobramycin, amikacin). One of these drugs is combined with ceftazidime or cefepime or an antipseudomonal penicillin and given IV to patients who are acutely ill. In the presence of hypotension or any renal impairment, the dosage of aminoglycoside must be reduced; aminoglycoside serum levels should guide therapy.

In addition to the parenteral administration of antibiotics, surgical drainage is appropriate for nodular and fluctuant lesions. Acute *P. aeruginosa* gangrenous cellulitis/fasciitis requires débridement (often extensive), sometimes with a surgical "second look" 1 or 2 days later. Investigations involving the experimental use of human immune globulins with activity against *P. aeruginosa* or specific *Pseudomonas* exotoxin A antibody preparations are ongoing.[50] The markedly granulocytopenic patient with *P. aeruginosa* gangrenous cellulitis presents a particularly difficult problem, and very prompt surgical débridement in addition to treatment with antimicrobials and granulocyte colony-stimulating factor is required.

SKIN INFECTIONS DUE TO OTHER *PSEUDOMONAS* SPECIES

P. putrefaciens, now renamed *Shewanella putrefaciens*, is a rare cause of cellulitis, particularly chronic infected ulcers of the lower extremities.[72] The natural habitat of the organism is water and soil, and it is a rare cause of cellulitis and bacteremia after contamination of a laceration.[73]

INFECTIONS DUE TO *HAEMOPHILUS INFLUENZAE*

Bacteriology and Pathogenesis

H. influenzae is a small, pleomorphic Gram-negative coccobacillus with fastidious growth requirements, including the presence of heme and nicotinamide nucleoside. There are rough and encapsulated forms, the latter of which are divided into six types (a through f) based on capsular polysaccharide antigens.

Most invasive infections with *H. influenzae*, including meningitis, epiglottitis, and cellulitis, are caused by encapsulated type b strains (Hib). Rough strains do not cause cellulitis but are involved in acute otitis media, exacerbations of chronic bronchitis, and pneumonia.[74] A hyperacute disease, Brazilian purpuric fever, characterized by fever, purpura, and shock, is caused by nontypeable *H. influenzae* biogroup aegyptius strains producing an extracellular hemagglutinin that may be a virulence factor.[75]

Most Hib skin infections are preceded by an upper respiratory tract infection or acute otitis media. The characteristic localization of the cellulitis to the upper part of the body argues for the sequence of upper respiratory tract infection, fallout onto or invasion of the skin locally, and then bacteremia. This sequence is evident in adult as well as in pediatric cases. A primary bacteremic mechanism with secondary localization in the skin would be favored by a more random and widespread distribution of lesions than is seen. Localization of a subclinical bacteremia could follow trauma and has been suggested as a possible predisposing event.

Epidemiology

Humans are the only known natural host for *H. influenzae*. These potentially pathogenic bacteria are carried in the oropharynx and nasopharynx, especially in children up to age 5 years, as part of the normal indigenous flora. However, early immunization using conjugate Hib vaccines has markedly decreased nasopharyngeal carrier rates, increased herd immunity, and caused a dramatic decline in invasive clinical disease.[76] Cellulitis, meningitis, pneumonia, and epiglottitis have all but disappeared in vaccinated populations.

HAEMOPHILUS INFECTIONS OF THE SKIN AT A GLANCE



- *Haemophilus influenzae* cellulitis involves the face, neck, or upper extremities.
- Most cases occur in young children (6 to 24 months of age), but the infection can occur in adults.
- Because of immunization with *H. influenzae* conjugate vaccines, invasive *H. influenzae* disease has nearly disappeared in industrialized countries, but it persists as a major problem in developing countries.

Clinical Manifestations

HISTORY Typically, a nonimmunized young infant or child develops an area of swelling and discoloration on the face or arm after several days of coryza and abruptly rising temperature. Rarely, a similar process occurs in adults as a complication of upper respiratory tract infection.[79]

CUTANEOUS LESIONS The typical lesion is a single, circumscribed, indurated area usually located on the face, neck, upper chest, or upper extremity. Although described in infants as characteristically blue-red to purple-red and surrounded by a zone of edema, the early lesion may be an area of pale edema or erythema (Fig. 180-6). The margins are indistinct, in contrast to the sharply defined borders of erysipelas. Regional adenopathy is rarely present. Occasionally, in children with Hib buccal cellulitis, erythematous buccal mucosal lesions appear on the side of the affected cheek, which suggests direct bacterial spread from the oropharynx into buccal soft tissues.[80]

When *H. influenzae* cellulitis occurs in adults, the infection follows a striking sequence: Marked pharyngitis at first, high fever, then rapidly progressive anterior neck swelling, tenderness, erythema, and dysphagia.[79]

OTHER PHYSICAL FINDINGS Associated otitis media, sinusitis, or epiglottitis as well as pneumonia may occur; occasionally, metastatic infections such as septic arthritis or meningitis develop.



▲ **FIGURE 180-6** Cellulitis caused by *Haemophilus influenzae*. Erythema and edema of the face in a child. (Used with permission from Richard A. Johnson, MD.)



Laboratory Findings

The white blood cell count is elevated, usually in the 20,000/mm^3 range. Results of blood cultures are positive in approximately 50 percent of cases. Aspiration and culture of specimens taken from the margin of the cellulitis have yielded positive results in about half of patients.

Diagnosis and Differential Diagnosis

H. influenzae cellulitis should be suspected when a child aged 3 to 24 months develops an acute facial (buccal) cellulitis with high fever. Immediate confirmation of the diagnosis may be possible from inspection of Gram-stained smears of an aspirate of the lesion. Although upper body cellulitis caused by other microorganisms is more common in adults, Hib also should be considered in patients with respiratory infections, especially adults or young children not fully immunized.[77]

Streptococcal (group A, C, or G) or pneumococcal cellulitis may produce discoloration of the skin similar to that in Hib infection. Erysipelas, which occurs rarely in infants, is usually homogeneously erythematous, and the margins of the plaque-like swelling are distinct, whereas the lesion borders in *H. influenzae* cellulitis are indefinite. The presence of pustules or boils is helpful in identifying *S. aureus* as the etiologic agent.

Course and Prognosis

Most patients do well with antibiotic therapy, even though the disease is often associated with bacteremia. The abrupt onset of high fever and easily observed cellulitis indicates the urgency of the situation. Constant vigil must be maintained for suppurative complications in the upper airways, meninges, lungs, bones, joints, and other organs.

Treatment and Prophylaxis

Third-generation cephalosporins (ceftriaxone or cefotaxime) are currently the drugs of choice in the treatment of Hib disease because of their activity against both ampicillin-susceptible and β-lactamase–producing strains of *H. influenzae* and because of their efficacy in treating any complicating meningeal spread of infection. Infections caused by β-lactamase–negative isolates can be treated with ampicillin given IV in four to six divided doses daily. Because 30 percent to 45 percent of Hib strains show plasmid-mediated ampicillin resistance, however, therapy should begin with a third-generation cephalosporin.

The use of Hib conjugate vaccine (capsular polysaccharide covalently linked to a protein moiety) has dramatically decreased the incidence of invasive Hib disease in the developed world.[76] These vaccines stimulate the production of protective antibodies when given to infants before 6 months of age.

CUTANEOUS MANIFESTATIONS OF *SALMONELLA* INFECTIONS (ENTERIC FEVER)

Bacteriology and Pathogenesis

Isolation of salmonellae from stool is made difficult by the fact that, when present, they represent only a small part of the fecal flora. Extragastrointestinal isolates are easier to identify, because they are usually pure cultures of a given *Salmonella* sp. The use of selective media (e.g., MacConkey agar, *Salmonella-Shigella* agar) that inhibit the growth of Gram-positive organisms, as well as many Gram-negative species, facilitates isolation of the organisms from stool. Salmonellae are Gram-negative bacilli that do not ferment lactose. In stool bacteriologic testing, initial selection of non–lactose-fermenting colonies is followed by biochemical and serologic (agglutination) procedures for identification. There are over 2400 serovars determined by surface and flagellar antigens. Modern molecular biology has established a revised nomenclature, with *S. enterica* the single species, and all others serovars (serotypes) of this single species (e.g., *S. enterica* serotype Typhimurium). Because habits are difficult to change, organisms are usually still referred to as familiar species [e.g., *S. typhi*, *S. paratyphi* (A, B or C), *S. enteritidis*] rather than as serotypes of *S. enterica*.

Epidemiology

People acquire *S. typhi* and other *Salmonella* species causing enteric fever by ingestion of contaminated water or food, often during travel in developing countries. A history of recent travel and of suspicious food or water encounters should be sought in a patient with appropriate clinical manifestations.

Humans are the only hosts for *S. typhi* and *S. paratyphi*. The chronic carrier state that may follow clinical typhoid fever is almost always asymptomatic, except for manifestations of gallbladder disease if cholelithiasis and active cholecystitis are present. Other serotypes of *Salmonella* occasionally can produce an enteric fever syndrome similar to, but usually milder than, that of typhoid fever. Unlike *S. typhi*, these other *Salmonella* serotypes are ubiquitous in nature (occurring in animals, reptiles, and poultry).

SALMONELLA INFECTIONS AND THE SKIN AT A GLANCE

- *Salmonella* organisms are widespread in nature.
- Carried by cold- and warm-blooded animals, they contaminate foods derived from animals and are global in distribution.
- *Salmonella* infections manifest as gastroenteritis, enteric fever, or septicemia.
- Rose spots are the classic skin lesions of systemic *Salmonella* infection.
- These lesions occur in 10 percent to 60 percent of natural (untreated) typhoid fever cases but less frequently in cases of enteric fever caused by other *Salmonella* sp.

Clinical Manifestations

HISTORY Symptoms begin several days to several weeks after the ingestion of contaminated water or food. Headache, fever, generalized aching, abdominal discomfort, cough, and constipation are common. Delirium or mental torpor is not unusual, especially with high fever. Heart rate may be slower than expected for the magnitude of the fever. Symptoms increase in intensity, and fever often reaches 39.4°C to 40.6°C (103°F to 105°F) by the end of the first week. During the second week, rose spots may appear on the trunk, and diffuse abdominal cramping becomes prominent, sometimes accompanied by diarrhea.

CUTANEOUS LESIONS After 7 to 10 days of high fever, the rose spots characteristic of *S. typhi* infection may appear. These lesions are 2- to 3-mm, slightly raised, nontender, pink maculopapules that blanch on pressure. Appearing in crops of approximately 10 to 20 lesions, they are often located between the nipple area and the umbilicus on the anterior trunk, rarely on the back or extremities. Without therapy, the spots usually become brownish as they fade and disappear in 3 to 4 days. New lesions emerge over the ensuing 2 to 3



weeks in untreated patients. Their presence in 63 percent of a group of 62 patients should encourage careful observation for this subtle rash.[82] Early institution of antimicrobial therapy may be responsible for the decreasing incidence of rose spots. The rash is less frequently reported in people of color, but this may be because of the difficulty in detecting the small lesions on dark skin. Rose spots occur infrequently in enteric fevers caused by other *Salmonella* sp.

Other skin changes have been noted during the acute phase of enteric fever. Erythema typhosum, an erythematous confluent rash, may occur during the first week. Erythema nodosum and urticarial lesions have been observed. In several reports from the Indian subcontinent, subcutaneous and cutaneous abscesses and skin ulcers have been described.[83,84] It is distinctly uncommon to observe herpes labialis in enteric fever.

OTHER PHYSICAL FINDINGS During the time cutaneous lesions are appearing, the patient may be disoriented and have signs of pneumonia. The abdomen is often distended, tympanitic, and diffusely tender, with some localization to the right lower quadrant. The spleen is often enlarged but may be difficult to palpate because of abdominal distension and guarding.

Laboratory Findings

Leukopenia is often present, but values range from 3000 to 20,000/mm^3. The percentage of mononuclear cells may be increased, and atypical lymphocytes can appear in small numbers, which suggests a viral illness. Thrombocytopenia and, rarely, hemolysis may occur. During the initial week of illness, blood culture results are usually positive for *Salmonella*. During the second week, or when diarrhea begins, stool culture results become positive for *Salmonella*, and the white blood cell count may increase. Isolation of *S. enterica* serotype Typhi from the blood is the gold standard for diagnosis of typhoid fever.

Histopathology

Histologic examination of a rose spot reveals gross dilatation of capillaries. There is considerable edema and abundant pericapillary infiltration with macrophages. Organisms may be present within these cells.[87]

Diagnosis and Differential Diagnosis

The diagnosis of *Salmonella* enteric fever may be difficult in a sporadic case, especially if the characteristic rash and gastrointestinal symptoms have not yet appeared and there is no history of travel in an endemic area. Headache, cough, and high fever are not very specific findings. However, when these symptoms are associated with delirium, relative bradycardia, and leukopenia with increased numbers of circulating mononuclear cells, the diagnosis of enteric fever should be considered. The diagnosis is usually made by performing blood cultures, which yield positive results for *Salmonella* in approximately 80 percent of untreated cases during the first 10 days. Results of Widal's tests are usually negative during the early phase of the illness. Likewise, enteric fever due to *S. enterica* serotypes other than serotype Typhi can usually be diagnosed through blood cultures. Culture of other material (e.g., bone marrow, rose spots) may be important, especially in patients who have had prior antibiotic therapy. PCR testing of blood may have a role in the latter.

Differential diagnosis includes a wide range of diseases. Prominent cough and severe headache in the early phases may suggest a viral or atypical pneumonia. Typhus and Rocky Mountain spotted fever can usually be excluded by geographic and epidemiologic considerations, serologic studies, the characteristic petechial component of the rash, and its distribution on the distal parts of the extremities. Miliary tuberculosis may begin as an acute febrile illness with similar symptoms, leukopenia, and splenomegaly. The diagnosis may be delayed until a secondary complication such as meningitis occurs. Infectious mononucleosis is suggested by headache, fever, lymphadenopathy, splenomegaly, and a blood profile with leukopenia and some atypical mononuclear cells.

Malaria and toxoplasmosis are two parasitic illnesses that deserve consideration. Epidemiologic information plus intermittency of symptoms usually suggest the former. In generalized toxoplasmosis, manifestations may be very similar to those of early enteric fever: prominent cough, high fever, lymphadenopathy and a truncal rash. The rash tends to be more florid than in enteric fever and has a petechial component. Diagnosis usually requires identification of *Toxoplasma gondii* in biopsy material or a rising antibody titer.

Course and Prognosis

The response of patients with enteric fever to antibiotic therapy is usually gradual, with 3 to 6 days needed for the temperature to return to normal. With prolonged treatment, the incidence of relapse has declined. The major complications in the pre-antibiotic era were bowel perforation and hemorrhage. Although rare, these complications still occur and are responsible for 75 percent of mortality. Deaths have been reduced from 10 percent to 1 percent to 2 percent with antibiotic therapy, although mortality is higher in immunocompromised patients. After recovery from typhoid fever, 1 percent to 4 percent of patients continue to harbor organisms in the gallbladder and to excrete them in the stools, becoming a potential source for spread.

Treatment and Prevention

The emergence of multidrug-resistant *Salmonella*, including *S. typhi*, in many areas of the world has essentially eliminated the use of chloramphenicol, ampicillin, and trimethoprim-sulfamethoxazole as first-line antimicrobials.[88] The fluoroquinolones (ciprofloxacin, ofloxacin) are active against drug-susceptible and multidrug-resistant *S. typhi* or other salmonellae causing enteric fever. Blood cultures become sterile promptly on treatment with ciprofloxacin, and this drug has become the treatment of choice for typhoid fever. Ciprofloxacin is administered in 500- to 750-mg doses given orally (or 400 mg given IV) every 12 hours in adults for 7 to 14 days. Ceftriaxone and cefotaxime are alternatives.

Skin Infections Due to Nontyphoidal *Salmonella* Serotypes

Skin infections due to nontyphoidal *Salmonella* serotypes are uncommon and usually take the form of pustular lesions, cellulitis, or bacteremic subcutaneous abscesses. Very uncommonly, *Salmonella* necrotizing fasciitis has been reported, usually in the setting of immunosuppression.[90]

INFECTIONS WITH OTHER GRAM-NEGATIVE BACILLI THAT HAVE CUTANEOUS MANIFESTATIONS

Bacteriology and Pathogenesis

Epidemiology

Cellulitis usually follows contamination of adjacent tissues by bowel contents or a breakdown of skin. Predisposing conditions include (1) bowel perforation, (2) co-



OTHER GRAM-NEGATIVE BACILLARY INFECTIONS AND THE SKIN

AT A GLANCE





- An acute cellulitis, with or without production of gas, may be caused by *Escherichia coli*, *Proteus* sp., *Klebsiella* sp., *Enterobacter* sp., *Serratia marcescens*, and other organisms.
- These infections occur often but not exclusively in the very elderly; in individuals with diabetes; in patients after trauma surgery, bowel or perineal inflammation; and in immunocompromised individuals.
- The infectious process may be limited to the superficial soft tissues or found primarily in the deep fascia.[91]
- Drug addicts develop such infections after "skin popping," which lead to cellulitis and necrotizing fasciitis.
- Rhinoscleroma is a granulomatous infection caused by *K. pneumoniae* subspecies *rhinoscleromatis*. It has a slowly progressive course and may involve the upper airway and tracheobronchial tree.

lon surgery, (3) chronic edema, (4) vascular insufficiency, (5) injection of addictive drugs,[92] (6) decubitus ulcers, (7) presence of percutaneous lines, and (8) superficial perineal dermatitis. Poorly controlled diabetes, altered host defenses, and poor nutrition often further predispose to such infections in these patients. Crepitant (gas-containing) cellulitis results from infection with gas-forming strains of bacteria (*E. coli*, *Klebsiella*, *A. hydrophila*), especially in patients with diabetes, or in the presence of *Bacteroides* sp. or anaerobic streptococci.[94,95]

Clinical Manifestations (See Chap. 179)

HISTORY Diabetes mellitus, malnutrition, or a chronic condition (e.g., paraplegia with decubitus ulcers) is usually present at the time of infection. The onset may be insidious or abrupt. Pain, often severe, frequently precedes local skin changes, especially if the infection is at the level of the deep fascia. High fever, shaking chills, increasing pain, and falling blood pressure may follow. Rectal or perineal pain can indicate a local process that may be especially devastating in a patient deficient in granulocytes.

CUTANEOUS LESIONS In the early stages, the skin is rarely discolored beyond a pink hue, and vesicles or bullae are almost never present. At this juncture, unless pain is present, the process may easily be overlooked. As the cellulitis progresses, edema and redness increase; tenderness, crepitus, and hemorrhagic bullae may develop; and areas of cutaneous gangrene may appear (see Figs. 179-5 and 179-6). The cellulitis may remain localized to the skin and superficial subcutaneous tissues, but progression to the deep fascia with necrosis of fat and increasing pain and toxicity suggests a diagnosis of necrotizing fasciitis[100] (see Chap. 179). Although most cases of Gram-negative bacillary necrotizing fasciitis are polymicrobial in etiology, a striking monomicrobial form caused by *Klebsiella* sp. occasionally occurs, almost always in individuals with diabetes mellitus.[101] *Klebsiella* necrotizing fasciitis results from direct inoculation or commonly from hematogenous spread from another site.

SUPERFICIAL NASAL LESIONS *K. pneumoniae* subspecies *rhinoscleromatis* is the etiologic agent of a hypertrophic, granulomatous infection of the external nares known as *rhinoscleroma*. It often produces changes in the overlying nasal skin (Fig. 180-7) and the contiguous surfaces of the respiratory, sinus, and posterior pharyngeal regions. Most cases seen in the United States have been in patients who have emigrated from specific areas of eastern and central Europe, Africa, the Near East, and parts of Central and South America.[102] Dissemination of the organism is by prolonged close contact. Infected individuals can shed organisms for years. The disease has been reported in patients with AIDS.[103] As in leprosy, the disease rarely becomes clinically apparent until early adulthood. Patients complain of fetid, purulent nasal discharge, epistaxis and obstructive symptoms, cutaneous nasal masses, and eventual scarring of

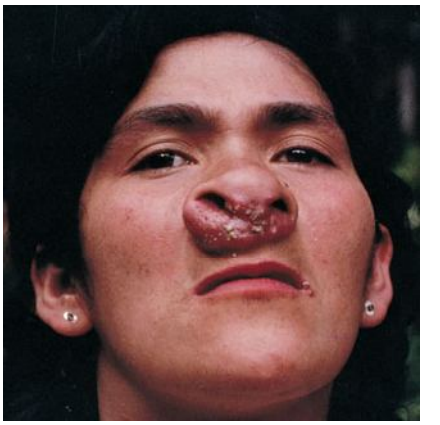

▲ **FIGURE 180-7** *Klebsiella pneumoniae* subspecies *rhinoscleromatis* infection. Rhinoscleroma. The nasal passages and nose are infected, which results in obstructed respiration.

nasal passages. Diagnosis depends on biopsy-based identification of characteristic vacuolated Mikulicz cells and isolation of the organism on routine cultures. Untreated, rhinoscleroma has a slowly progressive course over many years and may extend to involve any portion of the upper airway and tracheobronchial tree.[104]

K. pneumoniae subspecies *rhinoscleromatis* is susceptible to ciprofloxacin, 250 to 500 mg administered twice daily for 1 to 3 months. Alternatively, the combination of rifampin plus trimethoprim-sulfamethoxazole for 6 months may be used.

OTHER PHYSICAL FINDINGS The clinical course is often dominated by systemic manifestations of the underlying illness or decreased mental alertness, hypotension, and dehydration. Abdominal distension and other manifestations of localized or generalized peritonitis may be present. Extreme tenderness of the rectum, with or without a mass, can indicate the local source of a perineal process.

Laboratory Findings

The leukocyte count is usually elevated but may be markedly diminished in the presence of Gram-negative septicemia. Elevated blood glucose values and findings of ketoacidosis are not unusual. In crepitant cellulitis, radiographs or magnetic resonance imaging of the soft tissue may show the depth and extent of the gas-forming process.[105]

Pathology

Edema, gangrene of overlying skin, fat necrosis, and exudate containing poly-

morphonuclear leukocytes are usually present. Gas may be evident in the subcutaneous tissues. Blood vessels are often involved in a necrotic, obliterative, inflammatory reaction.[100] Underlying muscle is usually not involved unless there is septicemia associated with major vascular thrombosis or there is myonecrosis due to an organism such as *A. hydrophila.*

Diagnosis and Differential Diagnosis

A bacteriologic diagnosis can be made by analysis of specimens from needle aspiration of the cellulitis or an overlying bleb. Several Gram-positive as well as Gram-negative organisms may be present. When gas is present, anaerobic cocci and *Clostridia* must also be considered. A foul, fetid odor may accompany the presence of anaerobes in the exudate. Radiologic and surgical evaluation can be helpful in determining a descriptive diagnosis such as crepitant cellulitis or necrotizing fasciitis.

Course and Prognosis

The process may be indolent and may respond quickly to effective antibiotic therapy. In obese diabetic patients with perineal lesions, the progression of necrotizing fasciitis may be astonishingly rapid, even with vigorous antibiotic and surgical therapy. When the process is located centrally, in the perineal-gluteal area, the mortality rate is often as high as 50 percent. Infection of an extremity is frequently treated by antibiotics, drainage, and débridement, or by amputation, with more favorable results. The course is often prolonged and complex.

Treatment

Immediate antibiotic therapy and surgical drainage, guided by Gram-stained smears of the exudate and determinations of the extent of the process, are essential. Incision and drainage of focal collections associated with cellulitis are indicated. In necrotizing fasciitis, débridement of involved skin and subcutaneous tissues should be extended until normal fascia is reached. The adjunctive use of hyperbaric oxygen therapy for necrotizing fasciitis is controversial but may have some rationale in selected cases with a polymicrobial etiology in which anaerobes play an important role.[106] Judgment and experience are vital in surgical decisions.

Patients with necrotizing fasciitis or gangrenous cellulitis should receive initial combination antimicrobial therapy (modified by specific findings of Gram-stained smears and culture): ampicillin, gentamicin and clindamycin; ampicillin, gentamicin, and metronidazole; ampicillin-sulbactam plus gentamicin; or meropenem or imipenem plus gentamicin. Fluoroquinolones can substitute for aminoglycosides in patients with renal impairment. If *P. aeruginosa*, *Klebsiella*, or *Serratia* is suspected in certain hospital-acquired infections, tobramycin or amikacin may be preferred to gentamicin, and a broad-spectrum penicillin (e.g., ticarcillin-clavulanate) or ceftazidime added in place of ampicillin if *Pseudomonas* is a major pathogen. If methicillin-susceptible *S. aureus* is suspected, nafcillin is included; if resistant enterococci or methicillin-resistant staphylococci are suspected, then vancomycin is included.

KEY REFERENCES

The full reference list for all chapters is available at www.digm7.com.

2. Kingston ME, Mackey D: Skin clues in the diagnosis of life-threatening infections. *Rev Infect Dis* **8**:1, 1986
4. Rosenstein NE et al: Meningococcal disease. *N Engl J Med* **344**:1378, 2001
14. Faust SN et al: Dysfunction of endothelial protein C activation in severe meningococcal sepsis. *N Engl J Med* **345**:408, 2001
15. Ploysangam T, Sheth AP: Chronic meningococcemia in childhood: Case report and review of the literature. *Pediatr Dermatol* **13**:483, 1996
38. Goedvolk CA et al: Immune complex associated complications in the subacute phase of meningococcal disease: Incidence and literature review. *Arch Dis Child* **88**:927, 2003
44. Agger WA, Mardan A: *Pseudomonas aeruginosa* infections of intact skin. *Clin Infect Dis* **20**:302, 1995
55. Ruskin J, Yu VL: Malignant external otitis: Insights into pathogenesis, clinical manifestations, diagnosis and therapy. *Am J Med* **85**:391, 1988
56. Silvestre JF, Betlloch MI: Cutaneous manifestations due to *Pseudomonas* infection. *Int J Dermatol* **38**:419, 1999
79. McDonnell WM et al: *Haemophilus influenzae* type B cellulitis in adults. *Am J Med* **81**:709, 1986
81. Peques DA et al: *Salmonella* species including *Salmonella typhi*, in *Principles and Practice of Infectious Diseases*, 6th ed, edited by Mandell GL, Bennett JE, Dolin R. New York, Wiley, 2005, p 2636



CHAPTER 181

The Skin in Infective Endocarditis, Sepsis, Septic Shock, and Disseminated Intravascular Coagulation

Laura Korb Ferris
Joseph C. English III



INFECTIVE ENDOCARDITIS

Epidemiology

In the United States, the incidence of native valve endocarditis is 1.7 to 6.2 cases per 100,000 person-years. The highest rate of infective endocarditis (IE) is seen in intravenous drug users, with an incidence estimated at 150 to 2000 per 100,000 person-years. The risk of prosthetic valve IE decreases with time after valve implantation and the cumulative risk is approximately 2 to 3 percent after 60 months.[1]

Etiology and Pathogenesis

IE can be subdivided by native valve versus prosthetic valve infection. The causative organisms in most cases of IE are staphylococci or streptococci, implicating skin as the initial site of infection in many cases. Native valve endocarditis occurs most commonly in the setting of valvular disease or in people who use intravenous drugs. Rheumatic valve disease has been replaced by aortic stenosis and mitral regurgitation as the most common settings in which native valve endocarditis is encountered. At sites of endothelial injury, a sterile thrombus can occur, which is particularly susceptible to seeding of bacteria from transient episodes of bacteremia. This can result in the development of valvular vegetations that can cause local tissue destruction and embolic events.

Intravenous drug users are particularly susceptible to IE even though most have no pre-existing structural heart disease. More than one-half of the cases of IE in injection drug users are right sided, involving the tricuspid valve. The most common causative organism is *Staphylococcus aureus*.

Prosthetic valve endocarditis can be classified as early (in the first 2 months after valve replacement) or late (2 months or later). The newly placed prosthetic valve is particularly susceptible to bacterial colonization because the process of endothelialization does not occur until 2 to 6 months after surgery. Early prosthetic valve endocarditis is most commonly caused by *S. epidermidis* followed by *S. aureus*. Late prosthetic valve endocarditis can be due to a variety of organisms including the so-called *HACEK organisms* (*Haemophilus parainfluenzae, H. aphrophilus, Actinobacillus actinomycetemcomitans, Cardiobacterium hominis, Eikenella corrodens,* and *Kinsella kinasae*).

Most cases of nosocomial endocarditis are secondary to indwelling catheters or to surgical procedures and are caused by streptococci. However, nosocomial endocarditis in dialysis patients is most commonly due to *S. aureus*. Other less common causes of IE include fungi, *pseudomonas,* and *Coxiella burnetii*.

Clinical Findings

HISTORY Patients with IE generally present with non-cardiac complaints of fever, malaise, and anorexia. The presence of a murmur that is new or has changed in character is often present. Unexplained fever in a patient with a prosthetic heart valve should prompt an evaluation for endocarditis. The Duke criteria (Table 181-1)[2] are helpful in making the diagnosis of IE.

CUTANEOUS LESIONS Cutaneous signs of IE are non-specific but may help the clinician in making the appropriate diagnosis. Cutaneous findings are caused either by embolic events, thrombosis or focal vasculitis.

Splinter hemorrhages (Fig. 181-1) are 1- to 2-mm red-brown longitudinal streaks under the nail plate. They are seen in approximately 15 percent of patients with IE and are considered to be of greater diagnostic value if proximally located. Splinter hemorrhages associated with IE are the result of small capillary vasculitis or from microemboli. In the absence of other signs or symptoms of IE, the mere presence of splinter hemorrhage is not specific enough evidence to warrant a workup. Crops of petechiae are commonly seen in the buccal membrane, soft palate, and extremities.

Janeway lesions are painless, irregular, non-blanchable, erythematous maculopapules that appear on the palms and soles and last days to weeks (see eFig. 181-1.1 in on-line edition). Histologically, thrombi are found in small vessels in the absence of vasculitis. Neutrophilic microabscesses can be seen in the dermis with occasional gram-positive organisms. Osler nodes present as painful red papulo-nodules with a pale center on the fingertips lasting days to weeks (see eFig. 181-1.2 in on-line edition). Osler nodes are painful, perhaps due to involvement of the glomus bodies located in the fingertips. Histologically, neutrophilic microabscesses are present in the dermis, and arteriolar microemboli may contain gram-positive cocci.

Septic emboli of valvular vegetation fragments can cause ischemia of distal extremities. Toes are most commonly involved, followed by fingers, and this condition presents as reticulated pur-

INFECTIVE ENDOCARDITIS, SEPSIS, SEPTIC SHOCK, DISSEMINATED INTRAVASCULAR COAGULATION, AND THE SKIN AT A GLANCE



- Infective endocarditis: staphylococcal or streptococcal bacteria most common cause in intravenous drug use setting.
- Sepsis: gram-positive bacteria most common cause; tenth leading cause of death in the United States.
- Disseminated intravascular coagulation: most commonly from sepsis; results from systemic activation of the coagulation cascade.
- Cutaneous manifestations of these entities include: splinter hemorrhages, Janeway lesions, Osler nodules, erythroderma, cellulitis, purpura, hemorrhage, purpura fulminans, and skin necrosis.

TABLE 181-1
Modified Duke Criteria for Infective Endocarditis[2]

- *Clinically definite case* is defined as fulfilling two major, one major plus three minor, or 5 minor criteria
- *Clinically suspicious case* is defined as fulfilling one major and one minor, or three minor criteria
- Major criteria
  - Microbiologic
    - Two separate blood cultures positive for typical microorganism
      or
    - Persistently positive blood culture for typical microorganism
      or
    - Single positive blood culture for *Coxiella burnetii* or a phase I immunoglobulin G antibody titer to *Coxiella burnetii* greater than 1:800
  - Evidence of endocardial involvement
    - New valvular regurgitation
      or
    - Positive echocardiogram showing oscillating echogenic intracardiac mass at the sire of endocardial injury, a periannular abscess, or new dehiscence of a prosthetic valve
- Minor criteria
  - Predisposition to infective endocarditis
  - Fever
  - Vascular phenomena such as Osler nodes or Roth spots
  - Immunologic factors such as a positive rheumatoid factor or glomerulonephritis
  - Serologic evidence of active infection not meeting microbiologic major criteria

pura similar to that seen in cholesterol emboli syndrome (see Chap. 174). Although this condition generally resolves without sequelae, tissue necrosis or gangrene can result.

RELATED PHYSICAL FINDINGS The most common non-cutaneous finding in IE is fever. Signs and symptoms related to the bacterial infection and septic emboli may include splenomegaly, microscopic hematuria, pneumonitis, cerebral vascular accident, meningoencephalitis, brain abscess, retinal hemorrhages (Roth spots), acute abdomen, myocardial infarction, pericarditis and congestive heart failure, arthralgias and arthritis, or chronic wasting disease.

Laboratory Tests

A positive blood culture is the most helpful laboratory test in making the diagnosis of IE. Other tests that may be abnormal in this setting include a positive rheumatoid factor, elevated erythrocyte sedimentation rate, C-reactive protein, leukocytosis, or a urinalysis showing hematuria.



◀ **FIGURE 181-1** Globular proximal splinter hemorrhage and several distal linear splinter hemorrhages in a patient with infective endocarditis. (Photo used with permission from William James, MD, and James Fitzpatrick, MD.)

Special Tests

Echocardiography allows the visualization of the valves and can provide information as to the level of myocardial involvement. Transthoracic echocardiography is less invasive and less expensive than transesophageal echocardiography. However, the sensitivity and specificity of transthoracic echocardiography are 60 percent to 70 percent and 98 percent, respectively, whereas the sensitivity of transesophageal echocardiography is 75 percent and 95 percent without a compromise in specificity.

Differential Diagnosis

The differential diagnosis of splinter hemorrhages is reviewed in Box 181-1. Janeway lesions and Osler nodes can be similar in appearance to septic emboli and neutrophilic eccrine hidradenitis.

Complications

Cardiac complications of IE include congestive heart failure, extension of disease to the myocardium, and pericarditis. Embolic complications include stroke, mycotic intracranial aneurysms, and splenic abscess.[1]

Prognosis and Clinical Course

The overall mortality for IE has dropped by approximately 50 percent over the past 40 years and is currently approximately 28 percent.[2] Prognosis depends on age, the nature of the responsible microorganism, the presence of emboli, and the extent of cardiac damage. Early diagnosis and treatment improve outcome.

Treatment

Appropriate antibiotic therapy should be initiated in suspected cases of IE after blood cultures have been drawn. Long-term (4 to 6 weeks) parenteral antibiotics, usually with a penicillin derivative, are used to treat streptococcal or staphylococcal IE. Antibiotic treatment has been shown to reduce the risk of subsequent embolism. Treatment of IE caused by other organisms is reviewed elsewhere.[1] Indications for surgical treatment include persistent bacteremia despite 7 days of parenteral antibiotic therapy, prosthetic valve endocarditis, the presence of large vegetations, severe valvular dysfunction, and infection with *Pseudomonas*, *C. burnetii*, or fungus.[3]

Prevention

Currently, prophylactic antibiotics for skin surgery are not indicated for procedures performed on non-infected, surgically scrubbed skin regardless of cardiac

Box 181-1
Differential Diagnosis of Splinter Hemorrhage[15]

- Trauma
- Atopic dermatitis
- Psoriasis
- Thyrotoxicosis
- Internal malignancy
- Drug-induced
- Vascular endothelial growth factor receptor inhibitors[16]
- Tetracyclines
- Scurvy
- Trichinosis
- Idiopathic



history. When a patient falls into a high or moderate risk category and is to have a procedure that involves a clean, contaminated body area (such as the oral cavity, groin, or axilla) or a contaminated or infected wound, antibiotic prophylaxis is recommended.[4]

SEPSIS AND SEPTIC SHOCK

Epidemiology

Sepsis, most commonly from gram-positive bacteria, is the tenth leading cause of death in the United States. A review of approximately 750 million hospitalizations over 22 years in the United States showed that sepsis accounts for 1.3 percent of all hospital admissions. The incidence of sepsis has been steadily increasing since 1971 although the mortality rate has been dropping.[5]

Etiology and Pathogenesis

The prevailing presumption has been that sepsis is a result of uncontrolled activation of the inflammatory response to pathogens. Sepsis is often characterized by an initial burst of immunologic activation, including a surge in tumor necrosis factor-α production. This is thought to be mediated by binding of specific pathogen-associated molecules to Toll-like receptors found on cells of the immune system. Toll-like receptors activate signaling through transcription factors such as nuclear factor-κB that activate the expression of a cascade of inflammatory cytokines. However, this is followed by a relative decrease in immunity with impaired delayed type hypersensitivity, a loss of critical cells of the immune response including B cells, $CD4^+$ helper T cells, and dendritic cells, and the inability to clear infection.

Sepsis is often complicated by impaired organ function. Autopsy studies revealed that even in the setting of profound organ dysfunction, cell death is minimal and not sufficient to account for the clinical picture. Thus, sepsis appears to activate a state of cellular hibernation in which cells reduce their activities to only those required for cell survival. This would explain why organ function is often regained in those patients who recover from sepsis.[6]

Clinical Findings

HISTORY The septic patient is usually febrile, or in some cases hypothermic, with tachycardia and tachypnea. Patients with severe sepsis can also have dysfunction of major organ systems and those in septic shock develop hypotension that is refractory to the administration of fluid.



◀ **FIGURE 181-2** Proximal nail fold purpura from leukocytoclastic vasculitis due to *Clostridium difficile* sepsis.

CUTANEOUS LESIONS The causative organism in sepsis is not always identifiable by routine culture. In some cases, the cutaneous examination can provide clues to the identity of the responsible pathogen, providing a valuable clinical tool in the management of the septic patient.

Erythroderma in the septic patient suggests staphylococcal or streptococcal toxic shock syndrome (TSS). Patients with TSS are usually young and otherwise healthy. Patients with staphylococcal TSS are much more likely to be erythrodermic but much less likely to have positive blood culture than are patients with streptococcal TSS. Streptococcal TSS is commonly associated with a soft tissue infection.

The finding of pustules on the skin of a septic patient, particularly in the neonate or immunocompromised individual, may be suggestive of fungal infection, particularly with *Candida* species. Congenital candidiasis, most often seen in infants born to mothers with vaginal candidiasis, is generally a skin-limited disease. However, in the septic infant with pustules, candidemia should be considered.

The vasculitis and coagulopathy that can occur in the septic patient may cause purpura, sometimes prominent in the nail fold small capillaries (Fig. 181-2). Purpura is particularly prominent in those patients with thrombocytopenia. Such infections are seen most commonly in oncology patients undergoing bone marrow transplantation. In the immunocompromised host, opportunistic fungal infection, such as with *Aspergillus* sp., *Fusarium* sp., and *Candida* sp., often presents as erythematous papules, petechiae, or pustules that progress to purpuric lesions (Fig. 181-3).

Pustules due to disseminated gonococcemia are acrally located, typically tender and a characteristic gun-metal gray color, hemorrhagic, or black and are most commonly seen in the otherwise healthy adolescent or young adult (see eFig. 181-3.1 in on-line edition). Gram stain of the pustule reveals intracellular gram-negative diplococci. In its most extreme form, meningococcemia can cause purpura fulminans (see the section Cutaneous Lesions). Pustules may also be secondary to a local inoculation site, as in the case of staphylococcal sepsis.

A more aggressive local soft tissue infection, necrotizing fasciitis, can be associated with positive blood cultures later in the course of the disease due to hematogenous seeding by the organisms. Clinically, necrotizing fasciitis is rapidly progressive, initially painful, and accompanied by fever and leukocytosis



▲ **FIGURE 181-3** Petechiae from *Fusarium* sepsis in an immunosuppressed patient.

(see Chap. 179). Blood cultures are frequently positive. After several days, the involved area may become anesthetic secondary to destruction of cutaneous nerves.[8] Cellulitis is characterized by intense local inflammation in the presence of relatively few infectious organisms and blood cultures are rarely positive (see Chap. 179). Most commonly occurring on the legs, the affected extremity is typically erythematous, hyperemic, and edematous. The most common causes of cellulitis are *S. aureus* and group A *Streptococcus*. Rarely, anaerobic organisms, including clostridial species and other anaerobic bacteria species such as *Bacteroides*, *Peptostreptococcus* or *Peptococcus,* are the causative organism. In immunosuppressed patients, *Cryptococcus neoformans* can also cause cellulitis, particularly in the setting of AIDS. Patients with liver compromise can develop cellulitis from *Vibrio vulnificus*, a gram-negative bacterium that lives in warm marine environments and becomes concentrated in filter-feeding shellfish. Infection occurs either via consumption of contaminated organisms such as raw oysters, or through contact with infected water. Mortality rates exceed 40 percent in those with *V. vulnificus* sepsis.[7]

Ecthyma gangrenosum (see Chap. 180) begins as an erythematous papule that expands and eventually becomes a necrotic bulla. Lesions are most commonly seen between the umbilicus and the knees. Classic ecthyma gangrenosum represents cutaneous seeding of bacteria, usually *Pseudomonas aeruginosa*, from a hematogenous source and is seen almost exclusively in neutropenic patients, often in association with an underlying malignancy. Non-classic cases have been reported with *Aeromonas hydrophila, E. coli, Citrobacter freundii*, and *Corynebacterium diphtheriae*, fungal infection, including *Candida, Aspergillus, Fusarium,* and mucormycosis-causing species, and even herpes simplex virus.[9]

RELATED PHYSICAL FINDINGS *Sepsis* is defined as infection plus systemic inflammation and is characterized by hyper- or hypothermia, tachycardia, and tachypnea. Sepsis is further subdivided into *severe sepsis*, which is defined as infection with systemic inflammation and organ dysfunction. The organ systems commonly affected in sepsis include the renal, hepatic, central nervous, pulmonary, gastrointestinal, and cardiovascular systems. Septic shock occurs when patients with severe sepsis also have hypotension (systolic blood pressure less than 90) refractory to fluid administration.

Laboratory Tests

The septic patient generally has a white blood cell count greater than 12×10^9/L or less than 4×10^9/L or a bandemia of greater than 10 percent. Elevated C-reactive protein and procalcitonin levels are common. Organ dysfunction can manifest as low cardiac output, elevated creatinine, thrombocytopenia, and elevated international normalized ratio or prothrombin time, or hyperbilirubinemia.[10] Blood cultures can be helpful in guiding treatment of the septic patients, however, only 30 percent to 50 percent of septic patients have positive blood cultures.[11]

Special Tests

Special tests, including imaging studies and culture of suspected involved tissue, can sometimes be helpful in identifying the source of infection in the septic patient.

Differential Diagnosis

The differential diagnosis of skin findings in the septic patient is reviewed in Box 181-2.

Complications

Complications of sepsis include death, loss of limbs due to hypoperfusion, and permanent organ dysfunction.

Prognosis and Clinical Course

The survival rate in sepsis in 2000 was 17.9 percent and organ failure occurred in 33.6 percent of patients with sepsis.[5]

Treatment

Treatment of sepsis is usually done in an intensive care unit and involves the use of antimicrobial drugs, chosen empirically or based on the culture of a particular microorganism, and supportive care to preserve organ function.

Prevention

The prevention of sepsis in a hospital setting is achieved by the implementation of basic infection control measures, including routine hand washing and the minimization and regular replacement of indwelling catheters. In patients who are immunocompromised, particularly in the setting of organ transplantation or AIDS, the use of prophylactic antibiotics can help to reduce the incidence of sepsis.

Box 181-2

Differential Diagnosis of Skin Findings in the Septic Patient

- Erythroderma
  - Staphylococcal or streptococcal scalded-skin syndrome
  - Drug reaction
  - Cutaneous T-cell lymphoma
  - Psoriasis
- Papules
  - Drug reaction
  - Contact dermatitis
- Pustules
  - Candidemia
  - Disseminated gonococcemia
  - Folliculitis
  - Miliaria
  - Steroid acne
  - Acute generalized exanthematous pustulosis
- Purpura
  - Invasive fungal infection, especially in thrombocytopenic patient
  - Disseminated intravascular coagulation
  - Vasculitis (infectious, neoplastic, drug-induced, or autoimmune)
  - Trauma-induced
  - Heparin or Coumadin necrosis
  - Thrombotic thrombocytopenic purpura
  - Cryoglobulinemia
- Cellulitis
  - Infectious cellulitis
  - Necrotizing fasciitis
  - Stasis dermatitis
- Ecthyma gangrenosum
  - Pseudomonal ecthyma gangrenosum
  - Nonpseudomonal bacterial or fungal ecthyma gangrenosum
  - Herpes simplex infection in immunosuppressed patient
  - Necrotizing vasculitis
  - Cryoglobulinemia

DISSEMINATED INTRAVASCULAR COAGULATION

Epidemiology

The incidence of disseminated intravascular coagulation (DIC) is not known. Approximately 15 percent of septic patients may develop DIC.

Etiology and Pathogenesis

DIC represents systemic activation of the coagulation cascade. This leads to fi-



TABLE 181-2
Settings in Which Disseminated Intravascular Coagulation Can Occur

- Sepsis
- Trauma
- Malignancy
- Obstetric complication (amniotic fluid embolism, placental abruption)
- Vascular abnormalities
- Hepatic failure
- Immunologic reaction to drugs or toxins
- Transfusion reactions
- Transplant reaction
- Protein C or S deficiency



brin deposition in the vasculature, which can cause organ ischemia and death. In addition, the consumption of platelets and coagulation factors can lead to bleeding. DIC occurs most commonly secondary to an underlying disorder as listed in Table 181-2.

In DIC, coagulation activation is a tissue factor–dependent (i.e., extrinsic or factor VIIa pathway). Inflammatory cytokines such as tumor necrosis factor-α promote damage to endothelial cells and activation of mononuclear cells. These cells then produce tissue factor, which binds to factor VIIa and activates downstream coagulation cascades. Thrombin generation is amplified by defective anticoagulant mechanisms and results in increased fibrin deposition. The fibrin that is generated fails to be degraded by the fibrinolytic system. In the healthy state, antithrombin regulates thrombin activity. In DIC, antithrombin levels are low due to continuous consumption, degradation by neutrophil elastase and impaired synthesis due to liver failure in some settings. Fibrinolysis is inhibited by plasminogen activator inhibitor type 1 (PAI-1). Studies show that individuals with high plasma levels of PAI-1 are at higher risk of mortality in DIC. This correlates with a mutation in PAI-1 that is associated with higher PAI-1 plasma concentrations. Thus, some individuals may be genetically predisposed to fatal outcomes from DIC due to a point mutation in PAI-1.[12]

The infection most commonly associated with DIC is meningococcal sepsis. However, DIC has been reported after viral and other bacterial infections. Many recent reports suggest an emergence of sepsis due to staphylococcus, particularly those isolates containing exotoxins including staphylococcal enterotoxin serotypes B and C, TSS toxin-1, and Panton-Valentine leukocidin, a leukocyte toxin believed to be important in the pathophysiology of skin and soft-tissue infections and necrotizing pneumonia, as a factor in initiating DIC.[13]

Clinical Findings

HISTORY DIC is always secondary to an underlying condition or disorder and thus the patient generally first presents with the antecedent condition. Often, patients with DIC develop simultaneous bleeding, thrombosis, and multiorgan failure. The onset of DIC in the neonatal period is suggestive of protein C or S deficiency.

CUTANEOUS LESIONS The most characteristic cutaneous finding in DIC is noninflammatory purpura with extensive microvascular occlusion referred to as *purpura fulminans* (Fig. 181-4). Patients have diffuse bleeding, hemorrhagic necrosis of tissue, and skin necrosis (see eFig. 181-4.1 in on-line edition). Patients with purpura fulminans may present with ischemic digits or extremities (see eFig. 181-4.1 in on-line edition; see also Chap. 145) that, left untreated, can progress to gangrene.

RELATED PHYSICAL FINDINGS In its most extreme form, patients with DIC develop the Waterhouse-Friderichsen syndrome, most commonly seen in meningococcal sepsis (see Chap. 180). This is a syndrome of multiorgan failure characterized by a petechiae or purpura, coagulopathy, cardiovascular collapse, and bilateral adrenal hemorrhage.



▲ **FIGURE 181-4** Purpura fulminans from *Escherichia coli* sepsis.

Laboratory Tests

DIC is characterized by laboratory evidence of massive activation of the coagulation cascade and the destruction of platelets. Platelet counts are generally less than 100,000. Because of the high conversion of fibrinogen to fibrin, soluble fibrin monomers and the D-dimer assay are usually elevated. The prothrombin time is usually prolonged to at least 1.2 times the upper limit of normal as well. Several scoring systems exist that assign numeric values to particular laboratory findings and allow the calculation of a single numeric score that is helpful in predicting the presence of and mortality from DIC as reviewed elsewhere.[12]

Differential Diagnosis

The differential diagnosis of DIC includes other conditions causing small- and mid-size vessel thrombotic occlusions leading to organ failure and microangiopathic hemolysis. This includes thrombocytopenic thrombotic purpura, the hemolytic uremic syndrome, and the HELLP (*h*emolysis, *e*levated *l*iver enzymes, *l*ow *p*latelets) syndrome seen in obstetric patients.

Complications

Complications of DIC include tissue necrosis and infection, often requiring amputation of limbs or digits, multiorgan failure (particularly the Waterhouse-Friderichsen syndrome), and death.

Prognosis and Clinical Course

The mortality risk is doubled in patients with DIC who are septic or have experienced trauma.

Treatment

Because DIC is always secondary to another condition, the most important factor in the management of DIC is treatment of the underlying cause. However, replacement of components consumed during DIC and inhibition of the coagulation cascade has an important role as well. Despite the conventional wisdom that replacement of platelets and coagulation factors in the patient with DIC adds "fuel to the fire," more recent clinical trials have not shown this to be the case. These stud-

ies have demonstrated a survival benefit to treating patients with DIC with low-dose heparin. Finally, activated protein C, which works by enhancing thrombomodulin activity, has been shown to significantly reduce mortality in patients with DIC.[12]

There is very little published experience regarding the treatment of the cutaneous necrosis seen in DIC. Skin necrosis secondary to DIC is similar to that seen in full thickness cutaneous burns. Possible excision of necrotic tissue and coverage with autografts, and/or amputation of extremities are treatment options.[14]

Prevention

Most interventions in DIC are aimed at minimizing organ damage and bleeding. Prevention of DIC itself can be achieved by the prompt diagnosis and treatment of its causes, particularly sepsis.

KEY REFERENCES

The full reference list for all chapters is available at www.digm7.com.

1. Mylonakis E, Calderwood CB: Infective endocarditis in adults. *N Engl J Med* **345**:1318, 2001
5. Martin GS et al: The epidemiology of sepsis in the United States from 1979 through 2000. *N Engl J Med* **348**:1546, 2003
6. Hotchkiss RS, Karl IE: The pathophysiology and treatment of sepsis. *N Engl J Med* **348**:138, 2003
8. Valeriano-Marcet J, Carter JD, Vasey FB: Soft tissue disease. *Rheum Dis Clin North Am* **29**:77, 2003
9. Reich HL et al: Nonpseudomonal ecthyma gangrenosum. *J Am Acad Dermatol* **50**:S114, 2004
10. Riedemann NC, Guo RF, Ward PA: The enigma of sepsis. *J Clin Invest* **112**:460, 2003
12. Levi M: Disseminated intravascular coagulation: What's new? *Crit Care Clin* **21**:449, 2005



CHAPTER 182

Bartonellosis

Timothy G. Berger
Francisco G. Bravo

Bartonella are aerobic, fastidious, Gram-negative bacilli, with the remarkable capacity for intraerythrocyte persistence and the production of bacteremia. The number of identified *Bartonella* sp. has been rapidly expanding. The genus includes three important species that are human pathogens: *B. henselae,* the cause of most cases of cat-scratch disease (CSD) as well as some cases of bacillary angiomatosis (BA), hepatic and splenic peliosis (cystic blood-filled spaces in hepatic lobules or the splenic parenchyma), and endocarditis; *B. quintana,* the cause of trench fever, urban trench fever, BA, and endocarditis; and *B. bacilliformis,* the cause of Oroya fever and verruga peruana. Other potential human pathogens are *B. elizabethae* and *vinsonii,* which cause endocarditis, *B. grahamii,* a cause of neuroretinitis, and *B. washoesis*, which causes myocarditis (Table 182-1).[1] Infections caused by most *Bartonella* are associated with arthropod vectors that may simultaneously carry several species. Asymptomatic bacteremia rates in primary vertebrate (reservoir) hosts may exceed 50 percent. This suggests high prevalence of infection and prolonged and persistent bacteremia as characteristics of *Bartonella* infection.

The genus *Bartonella* contains organisms previously in the genuses *Rochalimaea* and *Grahamella*. *Bartonella* organisms are small aerobic, fastidious, pleomorphic, Gram-negative bacteria; they are difficult to culture from clinical samples. Initial clinical isolates grow slowly and visible colonies may not be detected for weeks, but subsequent passages grow much more rapidly. The organisms are short rods, ranging from 0.3 to 0.5 μm wide by 1.0 to 1.7 μm long. The organisms are best visualized in tissue using modified silver stains (Warthin-Starry). Polymerase chain reaction (PCR) and immunohistochemistry can also detect infection.[2,3]

BARTONELLOSIS AT A GLANCE

- Cat-scratch disease, trench fever/bacteremia, and Oroya fever are caused by these bacteria.
- *Bartonella* sp. are able to live inside erythrocytes, explaining the presence of bacteremia in many of the clinical conditions.
- Bacillary angiomatosis occurs in immunosuppressed hosts, especially acquired immunodeficiency syndrome patients.
- Diagnosis often made by histologic examination or serology due to the difficulty in culturing these bacteria.

CAT-SCRATCH DISEASE

Epidemiology

Approximately 29.2 million households (31 percent) in the United States own a cat, averaging close to two cats per household, for a total household cat population of 57 million. This large population of domestic cats explain the more than 22,000 cases of CSD reported annually. CSD affects persons of all ages, although 60 percent to 90 percent of cases are reported in children and young adults. CSD is seen worldwide and does not appear to have a racial prevalence. Most patients with CSD recall a history of cat contact, but this is not absolute (90.3 percent to 99.1 percent). The incidence of CSD is slightly higher in males and it occurs seasonally, mostly between July and October.[4–6]

CSD is associated with exposure to a cat, usually a kitten. The method of spread from cat to human is usually a scratch or bite. In California, 39.5 percent of cats are bacteremic for *B. henselae* with a single sampling, indicating a very high

CAT-SCRATCH DISEASE AT A GLANCE



- Vast majority of cases caused by *Bartonella henselae*
- Transmitted by the scratch or bite of a cat
- Most common cause of localized, chronic lymphadenopathy in children
- Diagnosis established serologically

TABLE 182-1
***Bartonella* Species and the Diseases They Cause**

Species	Human Disease	Risk Group	Reservoir	Vector
Bartonella henselae	Cat-scratch disease	IC	Cat	Cat flea[a]
	Bacillary angiomatosis	ICD	Cat	Cat flea[a]
	Endocarditis	IC	Cat	
B. quintana	Trench fever	IC	Human	Body louse
	Urban trench fever and endocarditis	IC, alcoholic, homeless	Human	Body louse
	Bacillary angiomatosis	ICD	Human	Body louse
B. bacilliformis	Oroya fever	IC	Human	Sandfly
	Verruga peruana			
B. elizabethae	Endocarditis			
B. vinsonii	Endocarditis			
B. grahamii	Neuroretinitis			
B. washoesis	Myocarditis			

IC = immunocompetent; ICD = immunocompromised.
[a]The cat flea transmits *B. henselae* from cat to cat, but not cat to human.

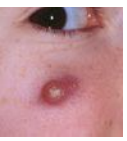

infection rate. Bacteremic cats were more likely to be stray cats, young (less than 1 year old), and flea-infested. Seroprevalence for *B. henselae* is as high in pet cats as in shelter and feral cats.[7] The seroprevalence of *B. henselae* among pet cats in North America is 27 percent overall but highly variable, with a higher seroprevalence in warm rainy regions. When the geographic seroprevalence of *B. henselae* is compared with predicted estimates of cat flea populations based on temperature and humidity, there is considerable overlap, supporting the role of the cat flea (*Ctenocephalides felis*) as the arthropod vector maintaining infection in cats. *B. henselae* can be transmitted from cat to cat via the cat flea, cat fleas contain *Bartonella* organisms after feeding on infected cats, cat flea feces contains viable *Bartonella,* and cats can be experimentally infected by the intradermal injection of infected cat flea feces.[8] The cat flea has not been demonstrated to spread *Bartonella* infection from cats to humans. Rather, cats' claws and teeth may be contaminated by infected flea feces during scratching and grooming allowing for transmission to humans by scratches.

Etiology and Pathogenesis

B. henselae causes the vast majority (more than 95 percent) of cases of CSD. There is one infectious genotype in the United States and two types in Europe, but the disease caused by all is clinically identical. In the immunocompetent host, the organism is, in the majority of cases, well controlled by the immune system, with containment in the primary skin papule and draining lymph node.

Clinical Findings

CUTANEOUS LESIONS The clinical spectrum of CSD has expanded since serologic diagnosis has become possible. Typical CSD exhibits two components, the primary inoculation papule and adenopathy proximal to the inoculation site. The papule appears at the site of inoculation within 3 to 10 days of exposure and progresses through an edematous or vesicular and crusted stage. The primary inoculation papule lasts 1 to 3 weeks. The lymphadenopathy, seen in at least 90 percent of patients with typical CSD, develops on average 2 weeks after inoculation (range, 3 to 50 days; Fig. 182-1). The inoculation papule is still present in 60 percent to 90 percent when the adenopathy develops, making it a valuable diagnostic finding.[9] The most commonly affected lymph nodes are axillary, cervical, and submandibular, with 98 percent of patients having involvement of only one anatomic region. The nodes are generally firm, tender and between 1 and 5 cm in diameter (Fig. 182-2). The lymphadenopathy usually remits spontaneously after several months, although in 20 percent of cases, the adenopathy lasts longer than 6 months. Recurrences are uncommon.

Suppuration of clinical significance occurs in less than 10 percent of cases, but when affected nodes are followed with ultrasonography, suppuration is found to be the natural course of resorption of affected nodes in nearly all cases.[9] Surgical drainage is seldom necessary.

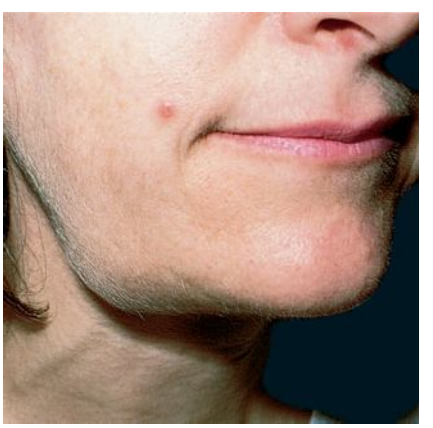

▲ **FIGURE 182-1** Cat-scratch disease. Primary lesion adjacent to mouth with associated submandibular lymphadenopathy in a woman.

RELATED PHYSICAL FINDINGS With improved diagnosis, atypical cases of CSD have increased from fewer than 5 percent of cases to more than 30 percent of cases in some series.[10] The exact prevalence of these atypical presentations is not known, as they are often reported as single cases, and the total number of CSD cases from which they come is unknown. In one pediatric series, atypical mononucleosis with pharyngitis and bilateral cervical adenopathy and thrombocytosis was a common presentation of *B. henselae* infection.[11] Fever of unknown origin with or without endocarditis, hepatic and splenic granulomatosis, and massive lymph node enlargement resembling lymphoma are uncommon presentations.[10] Involvement of the terminal ileum may rarely mimic inflammatory bowel disease and intra-abdominal lymphadenopathy may very rarely obstruct the portal vein.[12,13] Ocular complications of *B. henselae* infection have been frequently reported and include neuroretinitis, focal retinochoroiditis, arterial and venous occlusion, iridocyclitis, and mac-

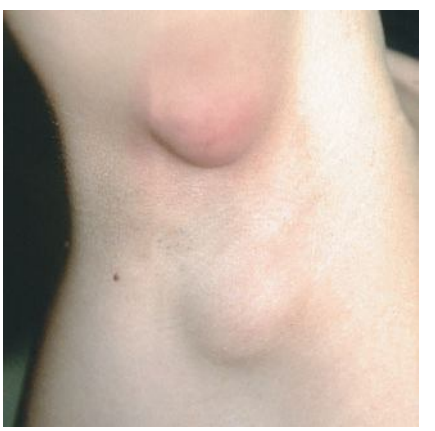

▲ **FIGURE 182-2** Bartonellosis: cat-scratch disease with axillary adenopathy. Acute, very tender, axillary lymphadenopathy in a child; cat scratches were present on the dorsum of the ipsilateral hand. (Used with permission from Howard Heller, MD.)

ular hole.[14,15] The most common neurologic complication of CSD is acute encephalopathy, presenting with seizures in 66 percent and status epilepticus in 10 percent of patients.[16–18]

In one study, up to 20 percent of immunocompetent patients with serologically confirmed CSD had PCR positivity for *B. henselae* in peripheral blood, suggesting bacteremia may be common.[19] Not surprisingly, hematogenous dissemination of *B. henselae* complicating CSD in immunocompetent persons has been reported to affect bone (osteomyelitis), liver and spleen, lungs (pneumonia, pleural effusion, pulmonary nodules), and the optic nerve.[20–22] These lesions may be markedly symptomatic, or, in one case of pulmonary involvement, completely asymptomatic.[20] *B. henselae,* not infrequently causes endocarditis in persons with known valvular heart disease, usually affecting the aortic valve, and 90 percent of patients require valvular surgery as a consequence of severe damage.[23]

Reactive conditions of the skin and joints may be seen in patients with CSD. Two percent of CSD patients develop erythema nodosum.[24] Three percent of patients with CSD suffer a rheumatoid factor–negative arthropathy of the larger joints of the extremities.[25] These patients are older than 20 years of age and two-thirds are female. Twenty percent have lesions of erythema nodosum. In 80 percent the arthropathy resolved in 6 weeks, but in 20 percent there is a more chronic course averaging 2.5 years.

Laboratory Tests

Routine laboratory findings are nonspecific and usually not helpful except to exclude other diseases. Patients with CSD may have a slightly elevated white blood cell count and elevated erythrocyte sedimentation rate during the acute phase. Blood cultures are rarely positive when using current testing techniques. PCR of affected lymph nodes may be positive in 30 percent of cases. Between 80 and 90 percent of cases of CSD have positive serology for *B. henselae* at the time of presentation, and many of the seronegative cases are positive 2 to 8 weeks later. Serologic testing has replaced the CSD skin test as the confirmatory test of choice in cases of CSD.

Histopathology

Histopathologic examination of CSD lymph node lesions is not specific. Lymph nodes undergo three stages in the formation of a granuloma: (1) enlargement with hypertrophy of the germinal centers and thickening of the cortex; (2) formation of granulomas with invasion of lymphocytes and epithelioid cells; and (3) necrosis and infiltration with neutrophils—all of which may be simultaneously present within a single lymph node. Abscess formation may occur. Organisms can be detected in lymph nodes and primary skin lesions, often in clumps or filaments, usually in or adjacent to areas of necrosis.

In primary skin lesions, microscopic examination reveals necrosis of the epidermis and upper dermis, and dermal inflammation ranging from neutrophil and macrophage infiltration to granuloma formation. Conjunctival lesions have similar histologic findings. In a few cases, conjunctival lesions produce proliferating blood vessels and a homogenous eosinophilic to basophilic granular appearance in the background—features similar to those of BA.

Differential Diagnosis (Box 182-1)

Treatment

Virtually all cases of CSD remit spontaneously without therapeutic intervention. In a retrospective study of 202 patients with CSD who were treated with antibiotics, commonly prescribed antibiotics, including macrolides, tetracycline derivatives, and cephalosporins, were ineffective.[23] However, antibiotic susceptibility studies have shown that *B. henselae* is highly sensitive to macrolides, tetracycline derivatives, and second- and third-generation cephalosporins, and is variably sensitive to quinolones. The failure of antibiotics in classic CSD in the immunocompetent host may relate to the small infectious burden and the frequent initiation of therapy once the disease is already improving spontaneously (in its lymphatic phase). In a recent prospective randomized trial, azithromycin for 5 days was demonstrated to reduce the lymph node volume during the first 30 days of observation. Half of azithromycin-treated patients reached 20 percent of baseline lymph node volume by 1 month, as opposed to 7 percent of untreated patients. However, there was no difference in any other symptoms or findings, or in the long-term outcome, and some treated patients had increases in lymph node size after treatment.[9] For complicated CSD of the eye or central nervous system, doxycycline 100 mg twice daily plus rifampin 300 mg twice daily is recommended.

Box 182-1

Differential Diagnosis[26]

Most Likely
- Atypical *Mycobacteria* (especially *M. marinum*)
- Sporotrichosis

Consider
- Syphilis
- Tularemia
- Primary inoculation tuberculosis

Rule Out
- Lymphoma

TRENCH FEVER, URBAN TRENCH FEVER, AND BACTEREMIA/ENDOCARDITIS

Epidemiology

B. quintana is the etiologic agent of trench fever, a disease that affected more than 1 million troops of the German and Allied armies during World War I.[27] In the last three decades, *B. quintana* has been identified as a cause of bacteremia and endocarditis in the United States and France (urban trench fever).[23,27] Virtually all of the patients are human immunodeficiency virus–negative, homeless, alcoholic men. Moreover, in cities where urban trench fever has been described, from 15 percent to 50 percent of the indigent alcoholic inner-city male population has serologic evidence of infection with *B. quintana*.[28]

TRENCH FEVER, URBAN TRENCH FEVER, AND BACTEREMIA/ ENDOCARDITIS AT A GLANCE

- Infection transmitted by the body louse
- Etiology: *Bartonella quintana*
- Systemic symptoms: headache, fever, and shin and back pain
- Endocarditis



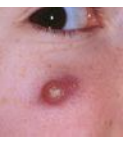

Etiology and Pathogenesis

Trench fever is caused by *B. quintana*. As opposed to most other *Bartonella* species, humans are the only known reservoir for this organism. The disease is transmitted from human to human by the human body louse (*Pediculus humanus corporis*). Close body contact and unsanitary conditions are associated with outbreaks. The incubation period ranges from 5 to 20 days. The organism can be isolated from patients with the disease and can be transmitted from person to person by direct inoculation or through lice. Recovered patients may be bacteremic for weeks.[27] Bartonella are the only bacterial pathogens able to invade and live inside the human erythrocyte. This may be the reservoir of bacteria in persistently infected persons.[1]

Clinical Findings

Classic trench fever is characterized by a fever lasting approximately 1 week, followed by recurrent fevers every 4 to 8 days, most commonly every 5 days (quintana fever). Clinically, patients complain of severe headaches and neck, back, and shin pain (shin bone fever). There are no specific cutaneous manifestations. Although significant morbidity is associated with the disease, fatalities are rare.

Laboratory Tests

Treatment

For uncomplicated bacteremia, 4 weeks of doxycycline 100 mg bid plus gentamicin 3 mg/kg/day intravenously for 2 weeks is recommended.[1] For documented *Bartonella* endocarditis, doxycycline 100 mg bid for 6 weeks plus gentamicin 3 mg/kg/day for 2 weeks is recommended.[1]

BARTONELLA INFECTION IN THE IMMUNOSUPPRESSED (BACILLARY ANGIOMATOSIS; PELIOSIS OF THE LIVER AND SPLEEN)

Epidemiology

BA is most commonly seen in patients with acquired immunodeficiency syndrome (AIDS) and a CD4 count less than 50 cells/mm^3, with an incidence of 1.2 cases per 1000 at-risk patients (see Chap. 198).[30] Patients with other forms of immunosuppression, including patients with leukemia and recipients of organ transplants, have been reported.[31] Uncommonly, human immunodeficiency virus–negative and nonimmunosuppressed persons develop BA.[32] In the cases of BA in immunocompetent persons, however, although the lesions were proliferative vascular papules, they were limited in number, the affected persons had limited or no systemic involvement and a benign course. There is no predisposition in terms of race, sex, or age.

BACILLARY ANGIOMATOSIS AT A GLANCE



- Etiology: *Bartonella henselae* and *B. quintana*
- Acquired from infected cats
- Most commonly in patients with acquired immunodeficiency syndrome but also in other forms of immunosuppression
- Pyogenic granuloma–like and subcutaneous nodules
- Hyperpigmented plaques in African Americans
- May be associated with hepatic and systemic lesions
- Treatment: erythromycin or doxycycline

Etiology and Pathogenesis

Both *B. henselae* (the CSD bacillus) and *B. quintana* (the agent of trench fever) have been identified as causative agents of BA. At one end of the clinical spectrum, classic CSD is seen in young, immunocompetent hosts as a limited infection. At the other end, BA is seen in patients who are severely immunocompromised as a systemic disease. Thus, it is the immunocompetence of the host and the bacterial load that dictates the clinical manifestations of the disease. Moreover, immunocompromised patients with BA develop an angioproliferative response in response to intracellular hypoxia. The presence of intracellular bacilli induces hypoxia-inducible factor-1 that in turn induces vascular endothelial cell growth factor, leading to vascular proliferation.[29] BA caused by *B. henselae* is acquired from infected cats and is a manifestation of CSD in the immunocompromised host. Peliosis hepatitis is exclusively associated with *B. henselae* infection.[33] In contrast, patients with BA caused by *B. quintana* develop subcutaneous masses and lytic bone lesions.

Clinical Manifestations

CUTANEOUS LESIONS The incubation period for BA is unknown. In AIDS patients, the clinical constellation includes fever, cutaneous or subcutaneous vascular lesions, lymphadenopathy, and/or abdominal symptoms. The most common cutaneous morphologies of BA are (1) pyogenic granuloma–like lesions, (2) subcutaneous nodules, and (3) hyperpigmented indurated plaques. The same patient may have several morphologies. Lesions resembling pyogenic granuloma can range in size from 1 mm to many centimeters and are dusky-red in color with a collarette of scale and peripheral satellite lesions (Fig. 182-3). The lesions are firm, bleed easily, and are often tender. They occur on skin and mucosa. Subcutaneous nodules can range from distinct nodules to diffuse swell-



◀ FIGURE 182-3 Bacillary angiomatosis. Multiple, grouped, dusky-red, and violaceous papules and nodules that resemble pyogenic granulomas.

Box 182-2

Differential Diagnosis of Bacillary Angiomatosis

Most Likely
- Pyogenic granuloma
- Kaposi sarcoma
- Angioma

Consider
- Chronic herpes simplex
- Hypertrophic scars
- Nocardiosis

Always Rule Out
- Amelanotic melanoma
- Squamous cell carcinoma
- Basal cell carcinoma
- Dermatofibroma protuberans
- Merkel cell carcinoma

ings with or without induration and are also often tender. Hyperpigmented plaques are most commonly seen in African Americans with BA and are oval in shape; they are several centimeters in diameter with indistinct borders. Large, fungating masses rarely occur. Patients with BA may have few to thousands of lesions with the number of lesions gradually increasing over time. Additional immunosuppression with chemotherapeutic agents may be followed by a shower of miliary skin lesions.

RELATED PHYSICAL FINDINGS In addition to cutaneous lesions, other organ systems may be affected. Hepatic and splenic vascular lesions can occur concomitantly with or independently of cutaneous lesions and can be a cause of significant blood loss and anemia. *Bartonella* infection, especially that caused by *B. quintana,* can affect bone and soft tissues. Lesions of the central nervous system have been reported and can result in neurologic and psychiatric disorders. Bacteremia, chronic fevers, and pulmonary and gastrointestinal lesions have also been reported. Radiologic studies usually identify areas of systemic involvement. Ocular vascular proliferative lesions can produce loss of vision.[34]

There are several reports of patients with other cutaneous diseases concomitant with BA, as well as the simultaneous existence of BA and another infection within the same lesion. Several patients have been reported with both BA and Kaposi sarcoma. Cytomegalovirus, Epstein-Barr virus, *Cryptococcus neoformans,* and *Mycobacterium avium-intracellulare* have been found within lesions of BA.

Differential Diagnosis (Box 182-2)

Laboratory Findings

Patients with AIDS and BA are anemic and may have elevated liver function tests (characteristically, lactic acid dehydrogenase and alkaline phosphatase are more elevated than hepatocellular enzymes). Blood cultures are positive for *Bartonella* sp. in approximately one-half of BA patients. *B. henselae* and *B. quintana* can be cultured from skin lesions. The organisms grow slowly and may not be detected without prolonged culture (more than 1 month). PCR of affected tissue is virtually always positive if lesions are histologically characteristic. The vast majority of cases are diagnosed histologically, with identification of the causative bacteria by Warthin-Starry staining.

Histopathology

Lesions of BA have the general features of a lobular capillary hemangioma (pyogenic granuloma) (Fig. 182-4), but in contrast to a pyogenic granuloma, the endothelial cells are often larger and polygonal; they may have marked atypia. There is a prominent inflamma-



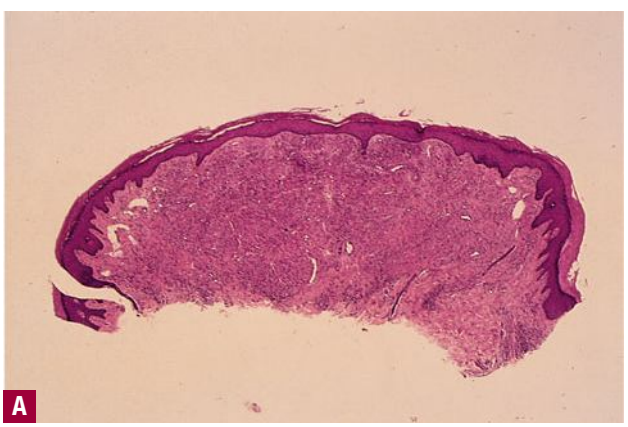

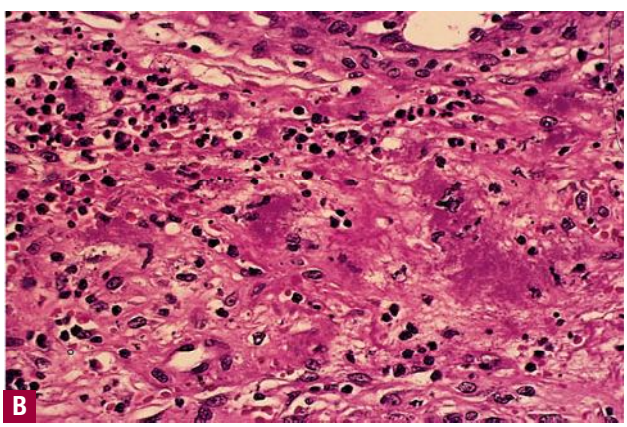

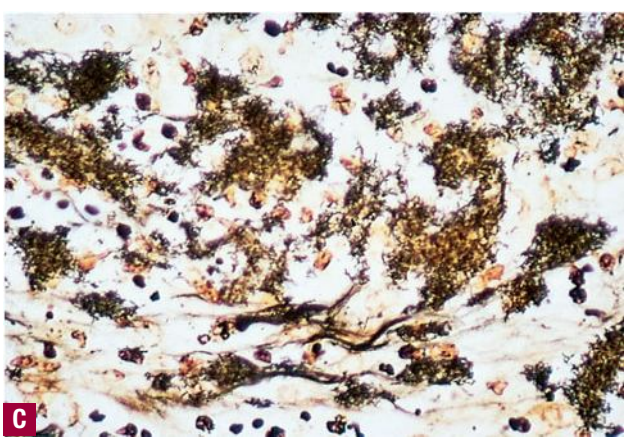

▲ **FIGURE 182-4** Histology of bacillary angiomatosis. **A.** Low-power magnification showing the architectural features of a lobular capillary hemangioma. **B.** High-power magnification showing new capillary formation and endothelial cells with cytological atypia, a prominent inflammatory infiltrate, and leukocytoclastic debris. **C.** Warthin-Starry stain showing numerous pleomorphic bacteria. (Used with permission from P. LeBoit, MD.)

tory infiltrate, with significant numbers of neutrophils as well as leukocytoclastic debris (see Fig. 182-4B). Polymorphonuclear leukocytes (PMNs) are scattered throughout the lesion, as opposed to classic pyogenic granuloma lesions in which the PMNs are at or near the surface, even if the pyogenic granuloma is eroded and impetiginized. There is usually a finely granular pink to purple material in areas of PMN infiltration adjacent to blood vessels. This represents large clumps of bacteria, best visualized with a modified Warthin-Starry stain (see Fig. 182-4C). Standard tissue Gram stain and the Warthin-Starry stain used for syphilis do not stain the organisms. If the diagnosis cannot be confirmed with special stains, electron microscopy may be used. The lack of spindle cells, atypically shaped vascular channels, and hyaline globules distinguish BA from Kaposi sarcoma. Lesions of BA in tissues other than liver show similar histologic features.

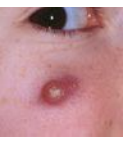

Clinical Course

In the immunocompromised host, the natural history of untreated BA is gradually progressive disease, with increasing numbers of skin lesions and involvement of many visceral organs. Untreated, severely immunocompromised patients might die of their infection.

Treatment

Erythromycin, 500 mg four times a day, or doxycycline, 100 mg twice a day for 3 months, is the treatment of choice for BA. Other antibiotics thought to be effective are minocycline, tetracycline, chloramphenicol, azithromycin, and roxithromycin. For peliosis hepatis, 4 months of treatment is recommended. Some patients require life-long suppressive therapy. Relapses have been reported, especially with shorter treatment courses.[33] A Jarisch-Herxheimer reaction not uncommonly occurs after initiation of therapy. Most patients respond rapidly to antibiotic therapy. The rapid disappearance of the vascular lesions may relate to the effects of the macrolides and tetracyclines on protein synthesis, stopping the production of vascular growth factors. If patients are not treated for a sufficient period, they are likely to relapse, despite the fact that their skin lesions vanish after a few weeks of treatment. The additional treatment is required to sterilize visceral or hematologic reservoirs of bacteria.

OROYA FEVER AND VERRUGA PERUANA

Epidemiology

Oroya fever and verruga peruana are restricted to the South American Andes, from 2°5' latitude north to 13° south of the equator, including southern Colombia, parts of Ecuador, and Peru. Most cases have been reported in regions of altitude ranging from 500 to 3200 meters above sea level. Recent epidemics have been reported in previously nonendemic areas of Peru, suggesting the endemic area is expanding to lower highland jungle areas near the Amazon basin.[35] Sea surface temperature warming is associated with higher minimum daily temperatures, and an increase in the arthropod vectors. El Niño–related climate changes resulted in up to a four-fold increase in *B. bacilliformis* infection in some geographic regions.[36] Humans are the only known reservoir for *B. bacilliformis,* and asymptomatic bacteremia occurs in 0.5 percent of persons in endemic regions. In one endemic area, the annual incidence of infection was 12.7 percent in the overall population, 38 percent in children, and 1 percent in those 60 years of age or older. Cases cluster in households.[35]

Etiology and Pathogenesis

The disease was named after Daniel Carrión, who, as a Peruvian medical student in 1885, inoculated himself with a lesion of verruga peruana and died of the acute phase of Oroya fever, showing that both diseases are caused by the same agent. The causative organism of these diseases is *B. bacilliformis*. The arthropod vector is most commonly a sandfly, particularly *Lutzomyia verrucarum*.

Clinical Manifestations

Endemic bartonellosis had been considered a biphasic disease with an acute form (acute hematic bartonellosis or Oroya fever) and a chronic form with skin lesions called *verruga peruana*. With the ability to culture the causative organism and do serologic testing, the disease spectrum has expanded. In a prospective study in an endemic area, 1 percent of patients presented with acute hematic disease, 37 percent with verruga peruana and symptoms of acute hematic disease, 32 percent with verruga peruana without systemic symptoms, and 20 percent have asymptomatic infection with seroconversion only.

OROYA AND VERRUGA PERUANA AT A GLANCE

- Etiology: *Bartonella bacilliformis*
- Arthropod vector: Sandfly—*Lutzomyia*
- Geographically restricted to South American Andes and lower highland jungles
- Biphasic disease: Acute hematic bartonellosis (Oroya fever) and verruga peruana

After an incubation period between 10 and 210 days (average, 60 days), the acute stage (acute hematic bartonellosis) develops. Patients have severe fevers, headache, abdominal pain, malaise, adenopathy, and a profound paleness. Other signs of hemolysis may also be present. Patients may develop signs of neurologic involvement, including coma. During the acute state, the patients are extremely susceptible to superinfection, either bacterial (classically *Salmonella*) or parasitic (classically *Toxoplasma*). After acute hematic bartonellosis, the patients may experience recurring episodes of fever and transitory bone, joint, and muscle pain.

Patients often present with the eruptive lesions of verruga peruana having had no preceding acute phase. Verruga peruana are highly vascular lesions, identical to BA (see Fig. 182-4). Three patterns of cutaneous lesions have been described: miliary, nodular, and mular. In the miliary form, lesions are about 3 mm in diameter (Fig. 182-5). Mular lesions are larger, fewer in number, and either sessile or pedunculated, with su-



▲ **FIGURE 182-5** Bartonellosis (verruga peruana). Multiple small papules on the extremities. The lesions may ulcerate.

perficial erosion. Nodular lesions are deep dermal or subcutaneous papules and nodules may not have overlying erythema. Mucosal lesions may occur.

Laboratory Findings

During the acute hemolytic phase, a profound anemia may be present. Red blood cell counts can fall below 106/mm^3 (two-thirds of patients have a hematocrit below 20). Oroya fever is one of the few bacterial diseases in which the agent can actually be seen on peripheral blood smears. However, only one-third of patients have positive smears.

Histopathology

Lesions of verruga peruana are histologically identical to those of BA, showing the distinct angioproliferative pattern with areas of neutrophilic collection within the stroma. The pattern of proliferation varies with the type of lesion. In miliary lesions, it is in the papillary and superficial reticular dermis, and in nodular and mular lesions, it is in the deeper dermis. Old verrugas tend to lose the inflammatory component, retaining the vascular frame. At that point, the lesion may look very similar to a pyogenic granuloma. In contrast to BA, the purple bodies of bacteria are hardly seen in verruga peruana lesions. However, the organisms can be seen in the tissue with modified silver stain techniques.

Box 182-3

Differential Diagnosis of Verruga Peruana

Most Likely
- Pyogenic granuloma
- Bacillary angiomatosis

Consider
- Cutaneous tuberculosis
- Nocardiosis

Always Rule Out
- Angiosarcoma
- Skin cancer (especially melanoma)

Differential Diagnosis (Box 182-3)

Treatment

Untreated, Oroya fever is a fatal disease in 40 percent to 90 percent of cases. Because of the frequent concomitant infection with *Salmonella,* the treatment of choice for Oroya fever is chloramphenicol (50 to 75 mg/kg/day, maximum 3 g/day) for 14 days plus a β-lactam antibiotic. Ciprofloxacin, 500 mg bid for 10 days, also appears effective. Rifampin, 10 mg/kg/day for 14 days, is the treatment of choice for verruga peruana, although the macrolides and tetracyclines are also effective. Ciprofloxacin, 500 mg bid for 7 to 10 days, is an alternative.[1] Verruga peruana may also regress spontaneously.

KEY REFERENCES

The full reference list for all chapters is available at www.digm7.com.

1. Rolain JM et al: Recommendations for treatment of human infections caused by *Bartonella* species. *Antimicrob Agents Chemother* **48**:1921, 2004
6. Reynolds MG et al: Epidemiology of cat-scratch disease hospitalizations among children in the United States. *Pediatr Infect Dis J* **24**:700, 2005
7. Guptill L et al: Prevalence, risk factors, and genetic diversity of *Bartonella henselae* infections in pet cats in four regions of the United States. *J Clin Microb* **42**:652, 2004
18. Massei F et al: *Bartonella henselae* infection associated with Guillain-Barré syndrome. *Pediatr Infect Dis J* **25**:90, 2006
28. Guibal F et al: High seroprevalence to *Bartonella quintana* in homeless patients with cutaneous parasitic infestations in downtown Paris. *J Am Acad Dermatol* **44**:219, 2001
35. Chamberlin J et al: Epidemiology of endemic *Bartonella bacilliformis:* A prospective cohort studying a Peruvian mountain valley community. *J Infect Dis* **186**:983, 2002



CHAPTER 183

Miscellaneous Bacterial Infections with Cutaneous Manifestations

Scott A. Norton

This chapter focuses on a group of unrelated bacterial diseases that are rarely encountered in a conventional urban or suburban setting but are acquired after a distinctive environmental exposure, such as saltwater immersion, animal bites, handling of an infected animal carcass, or travel to specific areas around the world. Several of these diseases present primarily as cutaneous disorders with rare systemic involvement (e.g., erysipeloid); others present primarily as systemic disorders with rare cutaneous involvement (e.g., brucellosis). Several of the pathogens can be aerosolized and disseminated for respiratory transmission, naturally or with human intervention. The ease of dissemination and the potential virulence of several organisms makes them suitable for intentional spread as biologic weapons. The intentional spread of these diseases is discussed in greater detail in Chap. 213.

In this chapter, these infections are grouped by their most common, natural means of transmission to humans: atraumatic exposure to animals, animal bites, and contact with contaminated water (Fig. 183-1).

ANTHRAX

Etiology and Epidemiology

Anthrax is a zoonotic infectious disease caused by *Bacillus anthracis*, a large aerobic, spore-forming Gram-positive rod.[1] Anthrax occurs naturally in ruminant mammals, such as sheep, cattle, and goats. Human disease is seen most often in agrarian, livestock-dependent regions. Consequently, human anthrax usually follows agricultural or industrial exposure, either through direct handling of infected animals or contaminated soil or through the processing of hides, wool, hair, or meat.[2] The clinical presentation of human anthrax depends on the route of inoculation. In 95 percent of human cases, the disease is acquired through percutaneous inoculation of anthrax spores. Human anthrax can also be acquired as inhalational and gastrointestinal disease. Each form has distinctive clinical, epidemiologic, and prognostic features.[3] Anthrax has potential as a class A bioweapon (Table 183-1; see also Chap. 213).

Clinical Findings

HISTORY After an incubation period of 1 to 7 days, patients may experience low-grade fever and malaise and develop a

ANTHRAX AT A GLANCE



- A large Gram-positive rod, *Bacillus anthracis*, changes into dormant spores under environmentally harsh conditions. Spores are infectious particles that revert to active bacillary form in host tissues.
- Natural pathogen of livestock, especially sheep, goats, and cattle. Most human disease is occupationally related to exposure to live animals or animal products.
- Cutaneous anthrax is the most common form and is associated with the lowest morbidity. Inhalational and gastrointestinal anthrax are more virulent and frequently lethal.
- Cutaneous lesions arise from percutaneous spore inoculation, usually unnoticed. They present as painless edematous papules or plaques that develop jet-black central eschars.
- The organism is a Centers for Disease Control and Prevention Category A bioweapon in aerosolizable micro-powder form. There is no human-to-human transmission.

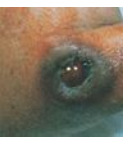

painless papule at the exposed site. As the lesion enlarges, the surrounding skin becomes increasingly edematous. Pain, if present, is usually due to edema-associated pressure or secondary infection.

CUTANEOUS LESIONS Cutaneous anthrax develops when spores enter minor breaks in the skin, especially on exposed parts of the hands, legs, and face (Fig. 183-2). In the hospitable environment of human skin, spores revert to their rod forms and produce their toxins. A dermal papule, often resembling an arthropod bite reaction, develops over several days, and then progresses through vesicular, pustular, and escharotic phases. Lesions are surrounded by varying degrees of edema. Depending on the manner of inoculation, one to several lesions may appear, and there may be regional lymphadenitis, malaise, and fever. Individual lesions may appear pustular, leading to the name "malignant pustule," but they do not suppurate. In anthrax, true pustules are rare; a primary pustular lesion is unlikely to be cutaneous anthrax.

The lesion enlarges into a glistening pseudobulla that becomes hemorrhagic with central necrosis and may be umbilicated (see Fig. 183-2). The necrotic ulcer is usually painless, which is an important feature in differentiating it from a brown recluse spider bite. There may be small satellite papules and vesicles that may extend along lymphatics in a sporotrichoid manner. An area of brawny, non-pitting edema ("malignant edema") often surrounds the main lesion. Lesional progression is due to toxins and is unaffected by antibiotic therapy. Fatigue, fever, chills, and tender regional adenopathy may cause an ulcero-glandular syndrome. The eschar dries and separates in 1 to 2 weeks.[9–13]

RELATED PHYSICAL FINDINGS Cutaneous anthrax may cause fever, tachycardia, and hypotension.

Histopathology

The prominent features are hemorrhagic edema, dilated lymphatics, and epidermal necrosis. Bacilli may be found in the eschar. Anthrax is toxin mediated and induces scant inflammatory infiltrate. Immunohistochemical stains are quite useful.[14]

Treatment

Naturally occurring anthrax is treated with penicillin or doxycycline. Weaponized anthrax, on the other hand, may be resistant to these antibiotics, and, therefore, a fluoroquinolone is recommended for the initial treatment of confirmed or suspected bioterrorism-associated anthrax, even in pregnant women and children. Once drug sensitivities have been established, the patient may be switched to another antibiotic as clinically indicated. Antibiotics will kill activated *B. anthracis* bacilli but will not alter tissue damage already caused by toxins.[15,16]

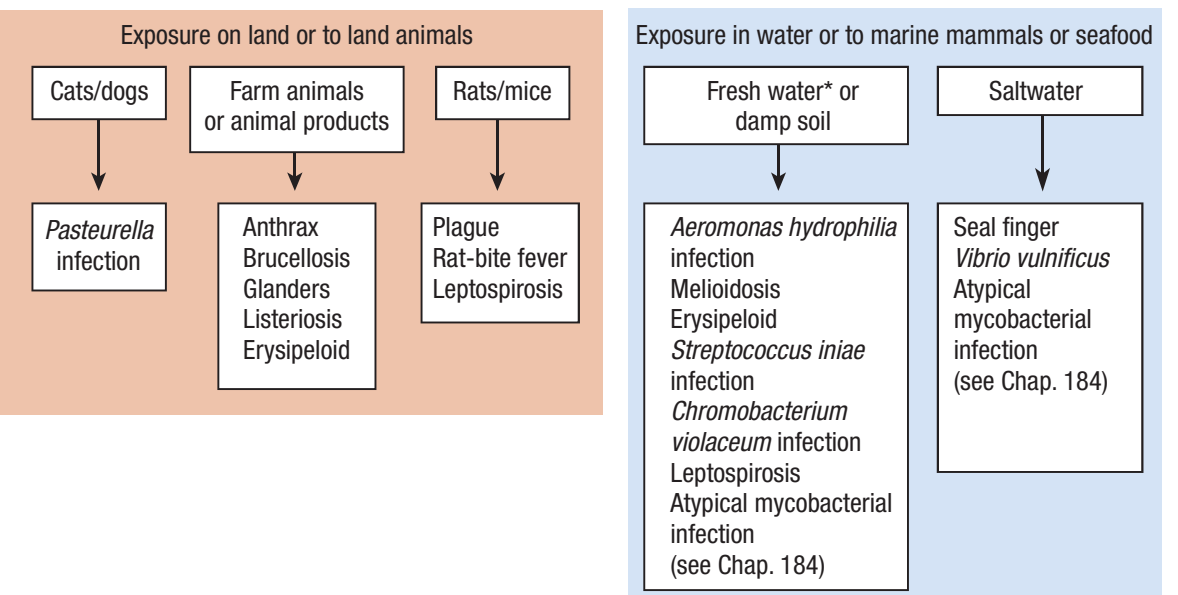

▲ **FIGURE 183-1** Algorithm for identifying cutaneous infections usually contracted in specific environmental settings. *Brackish water may harbor the same organisms.

TABLE 183-1
Overview of Bacterial Infections

Infection	Expected Demographic Distribution	Typical Presentation (Skin)[a]	Typical Exposure	Bioweapon Potential[b]	Treatment
Anthrax	Worldwide, especially developing agrarian areas	Painless edematous plaque with central black ulcer or eschar	Goats, sheep, cattle, or products made from them	A	PCN, doxy, ciprofloxacin
Tularemia	North America, Europe	Ulcero-glandular: painful papule that ulcerates and forms eschar	Tick bites, rabbits, rodents	A	Streptomycin, genta, TCN
Plague	Worldwide, especially United States Southwest, India	Buboes (tender regional lymphadenopathy) followed by purpura and gangrene	Flea bites, spread from infected rodents	A	Streptomycin, genta, doxy
Brucellosis	Worldwide, especially developing agrarian areas	Variable; skin manifestations present in < 5% of patients	Cattle, sheep, goats, or untreated milk	B	Doxy plus genta or rifampin
Glanders	Rare and focal in Asia, Middle East	Nodule with cellulitis that ulcerates; later, deep abscesses and sinuses	Donkeys, mules, horses	B	Sulfadiazine, genta, doxy
Pasteurella infection	Worldwide	Rapid onset of cellulitis at bite site followed by necrosis	Dog or cat bite	NR	Amoxicillin plus CA
Rat-bite fever (streptobacillary)	Worldwide, especially Asia	Morbilliform eruption with fever followed by arthritis	Rats or their excreta	NR	Amoxicillin plus CA
Seal finger	Cool coastal regions worldwide	Extremely painful nodule on finger	Seals or sea lions	NR	TCN
Listeriosis	Worldwide	In neonates, generalized petechiae, papules, and pustules	In neonates, infected mother with transfer in utero or shortly after birth	NR	Ampicillin or PCN IV
Vibrio vulnificus infection	Worldwide	Necrotizing fasciitis, hemorrhagic bullae often beginning as a wound infection	Warm saltwater or brackish water or undercooked seafood	NR	Doxy and ceftazidime IV, débridement of lesions
Aeromonas hydrophila infection	Worldwide	Cellulitis evolving to abscess formation, often beginning as a wound infection	Fresh or brackish water, contaminated fish	NR	Third-generation cephalosporins, fluoroquinolones
Melioidosis	Wet tropical areas, especially Southeast Asia and northern Australia	Indolent abscesses; suppurative parotitis (in children)	Wet soil (classically rice paddies), flooded regions	B	Ceftazidime plus TMP-SMX IV, then amoxicillin CA
Erysipeloid	Worldwide	Tender violaceous plaque on hand at site of injury	Contaminated fish, shellfish, poultry, meat, and animal products	NR	PCN, ampicillin, third-generation cephalosporin
Streptococcus iniae infection	Worldwide, especially freshwater fish farms	Rapid onset of hand cellulitis following a puncture wound	Contaminated farm-raised fish	NR	PCN, cephalosporin
Leptospirosis	Worldwide, especially the tropics	Papules, petechiae, jaundice	Contaminated freshwater, moist soil, or animal urine	NR	Doxy, PCN
Diphtheria	Worldwide where immunization is not practiced	Pustule or superinfected abrasion, evolving to an ulcer with gray membrane at base	Asymptomatic human carriers	NR	PCN IV or erythromycin plus antitoxin

A = highest (systemic disease, often fatal); B = substantial (severe systemic disease, sometimes fatal); CA = clavulanic acid; doxy = doxycycline; genta = gentamicin; NR = not rated; PCN = penicillin; TCN = tetracycline; TMP-SMX = trimethoprim-sulfamethoxazole.
[a]For many entities, multiple presentations are possible depending on the route of inoculation (percutaneous entry, oral ingestion, or inhalation). See text.
[b]If aerosolized, per criteria of the Centers for Disease Control and Prevention.

Prognosis and Clinical Course

TULAREMIA (*FRANCISELLA TULARENSIS* INFECTIONS)

Etiology and Epidemiology

Tularemia is a zoonotic infectious disease caused by *Francisella tularensis*, a pleomorphic Gram-negative coccobacillus found in many species of mammals, most important, lagomorphs (rabbits and hares) and rodents, and in their immediate environments. The bacteria are highly infectious, can be transmitted in many ways, and cause at least eight different patterns of disease.

Tularemia occurs solely in temperate and cold regions of the Northern Hemisphere. The most common form in the United States is ulcero-glandular disease in which organisms are inoculated directly into the skin by minor trauma or by bites of infected arthropods that maintain the enzootic cycle. Before 1950, most U.S. infections occurred in hunters





▲ **FIGURE 183-2** Anthrax. The classic cutaneous lesion of a primary infection in anthrax is a painless papule that evolves into a hemorrhagic bulla with surrounding brawny non-pitting edema. Note the typical localization on the hand. The name *anthrax* comes from the Greek word ανθραξ *(anthrax)*, meaning coal, which refers to the coal-black hue of the lesions of cutaneous anthrax.

who handled infected rabbits and hares. Two incidence peaks each year corresponded with summer and winter hunting seasons. Currently, 100 to 200 U.S. cases occur each year, mostly in Arkansas, Missouri, Oklahoma, and South Dakota, with transmission of the organism largely via tick bites. The most common tick vectors are *Dermacentor* sp., *Amblyomma americanum*, and, in Europe, *Ixodes* sp.[20,21]

Clinical Findings

HISTORY Duration of incubation varies with size of inoculum, ranging from 2 to 10 days. All forms of tularemia present as a sudden flu-like illness characterized by fever, headache, malaise, and myalgias.

CUTANEOUS LESIONS In ulcero-glandular tularemia, a painful red papule appears at the inoculation site (Fig. 183-3). It enlarges rapidly and evolves into a necrotic chancriform ulcer often covered by a black eschar. Regional lymph nodes are large and tender.[24] Bacteremia may cause sepsis and virulent pneumonia.

RELATED PHYSICAL FINDINGS In oculoglandular tularemia, organisms are introduced directly into the conjunctivae, for example, after handling an infected tick or rabbit. This causes purulent conjunctivitis with pain, edema, and local adenopathy. In a recent outbreak in Bulgaria, more than 90 percent of cases were oropharyngeal, reflecting transmission via contaminated well water.

TULAREMIA AT A GLANCE



- Caused by *Francisella tularensis*, a Gram-negative coccobacillus found in rabbits, rodents, other mammals, and their immediate environments in temperate and cold regions of North America.
- Has diverse clinical presentations related to route of transmission. Ulcero-glandular disease after tick bites is most common.
- Bacteria are easily aerosolized and highly infectious in small inocula; therefore, tularemia poses risks of laboratory accidents or use as a bioweapon.

Swallowing the organism may cause ulcerative pharyngotonsillitis with cervical adenopathy or may cause "typhoidal" tularemia.[23] Pulmonary tularemia may be primary (i.e., due to inhalation of organisms) but is more often due to bacteremic spread from another focus.

Laboratory Findings

Histopathology

The pathogen survives intracellularly in phagocytes, and small granulomas develop in lymph nodes, liver, and spleen. Some lesions may caseate and progress to frank abscess formation. Hepatic granulomas may resemble tuberculosis or brucellosis.

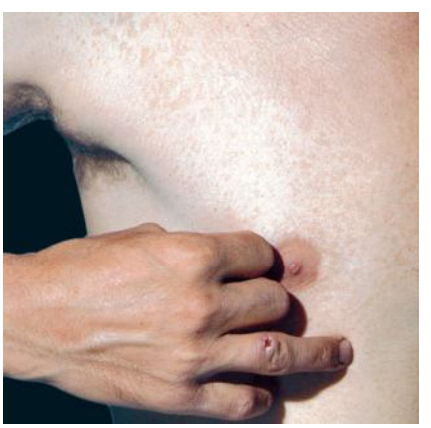

▲ **FIGURE 183-3** Tularemia. A chancre-like ulcer with raised margins on the dorsum of the fourth digit with accompanying axillary lymphadenopathy. The rash on the chest is unrelated and is pityriasis versicolor.

Differential Diagnosis

Treatment

A presumptive diagnosis of tularemia on clinical and epidemiologic grounds is sufficient to initiate treatment while awaiting serologic confirmation (see Table 183-1). Streptomycin is effective against all forms of tularemia when started promptly. Gentamicin appears to be an acceptable alternative. Patients improve within 24 to 48 hours, but treatment should continue for at least 7 to 10 afebrile days. Tetracycline and chloramphenicol are other acceptable alternatives but should be given for longer periods to reduce the risk of relapse.

Prognosis, Clinical Course, and Complications

Prevention

PLAGUE

Etiology and Epidemiology

Plague is a severe, acute, febrile zoonosis caused by the aerobic Gram-negative bacillus *Yersinia pestis*. Plague exists in an enzootic cycle, infecting humans through contact with rodent reservoirs or flea vectors. Human plague has three clinical forms: (1) bubonic; (2) bubonic-septicemic, a more virulent form due to secondary bacteremia and sepsis; and (3) pneumonic (fulminant disease due to respiratory spread). Distal purpura and gangrene associated with septicemic plague likely gave rise to the term *black death*.

In this country, human disease is almost always transmitted by fleas. Direct handling of infected rodents, rabbits, or their carcasses can also transmit plague. Some cases are transmitted by direct contact with pet dogs or cats that became ill after contact with infected wild animals. Between 1990 and 2005, 107 plague cases, more than 80 percent bubonic, were reported in the United States, averaging 7 per year, mostly in summertime. In western states, winter cases are often linked with handling of animal carcasses while hunting. In recent years, epizootics have occurred among prairie dogs, and sporadic human cases were seen on several Indian reservations. Rarely, bactere-

PLAGUE AT A GLANCE

- Focal enzootic sites worldwide, including the southwestern United States. Human disease is caused by bites from infected fleas or direct contact with rodent reservoirs.
- The bubonic form is the most common, producing large tender lymph nodes (buboes) proximal to the site of flea bite. All forms can lead to sepsis, distal gangrene (origin of the term *black death*), and death.
- Pneumonic plague due to respiratory spread of aerosolized *Yersinia pestis* has a high mortality and is a possible weapon of bioterrorism.

mic bubonic disease may evolve into pneumonic plague and further initiate respiratory spread to others.[27,28]

The flea associated with epidemic plague in the Old World is *Xenopsylla cheopis*, but fleas in other genera (e.g., *Anomiopsyllus*, *Aetheca*, *Pulex*) are also vectors in the United States.

Because *Y. pestis* can be aerosolized, is devastatingly lethal, and can spread from person to person, it is considered a Category A biologic weapon (see Table 183-1). *Y. pestis* produces an intracellular toxin and virulence factors (see Chap. 213).

Clinical Findings

HISTORY Bubonic plague incubates for roughly 2 to 6 days, followed by the sudden onset of high fever, prostration, malaise, myalgias, backache, and tachycardia. Primary pneumonic plague has a shorter incubation time.

CUTANEOUS LESIONS In bubonic plague, the initial skin lesion is related to the flea bite and may appear as papular urticaria. However, the hallmark of bubonic plague is prominent, exquisitely tender regional lymphadenopathy with extensive subcutaneous edema.

Any form of plague can lead to overwhelming endotoxic septicemia accompanied by disseminated intravascular coagulopathy (DIC) (see Chap. 145). Subsequent purpura and gangrene are most severe on distal extremities.[29]

RELATED PHYSICAL FINDINGS Primary septicemic plague lacks buboes and presents with typical Gram-negative sepsis. Many patients also have severe abdominal pain, nausea, vomiting, and bloody diarrhea. Pneumonic plague has an abrupt onset with high fever, tachycardia, tachypnea, chest pain, and dyspnea. Within 24 hours of onset, the patient is critically ill and producing bloody sputum laden with *Y. pestis*. Meningitis may complicate all forms of plague.

Laboratory Findings

Organisms can be cultured from lymph node aspirates, cerebrospinal fluid (CSF), sputum, and, in pneumonic plague, tracheal washes. In septicemic plague, bacilli can sometimes be seen on stained buffy coat smears. Leukocytosis occurs in all forms of the disease. Renal failure and DIC may occur in severe cases. Bacteria can be cultured on standard blood agar media. Direct fluorescent antibody assays, enzyme-linked immunosorbent assay, and polymerase chain reaction testing are useful when available, but serologic tests are less reliable.[29,30] Histopathologically, acute inflammatory changes are seen in the involved nodes. Immunohistochemical stains of tissue biopsy specimens may show organisms.[31]

Differential Diagnosis

Treatment

Because the drug of choice, streptomycin, is not widely available, another aminoglycoside antibiotic, gentamicin, is the preferred treatment (although the U.S. Food and Drug Administration has not approved it for this indication) (see Table 183-1). Doxycycline and fluoroquinolones are also effective. Patients with pneumonic plague must be placed in respiratory isolation to prevent further transmission. A course of treatment, irrespective of medication, is 10 days. Ordinarily, buboes should not be drained until they are well localized and antibiotic therapy has been started.[32]

Prognosis and Clinical Course

Prevention

BRUCELLOSIS

BRUCELLOSIS AT A GLANCE

- Zoonosis transmitted by contact with infected animals or consumption of contaminated dairy products.
- May be transmitted via aerosolized bacteria, hence the concern regarding the use of *Brucella* in bioterrorism.
- Usually presents with undulant fever and can involve all organ systems, especially the joints, reproductive organs, liver, and central nervous system. Endocarditis can be fatal.
- Cutaneous lesions are seen in fewer than 5 percent of patients, usually children. Variable morphologies include vasculitis, erythema nodosum, panniculitis, abscesses, and polymorphous papules, pustules, and papulosquamous lesions. Children with acute brucellosis may have a violaceous papulonodular eruption primarily on the trunk and lower extremities.

Etiology and Epidemiology

Brucellosis is caused by any of four species of *Brucella*, which ordinarily infect livestock, especially cattle, sheep, and goats. It is transmitted to humans by contact with infected animals or animal products, ingestion of contaminated dairy products, and, rarely, by inhalation of aerosolized bacteria. Worldwide there are approximately 500,000 human cases per year. The highest incidence is in underdeveloped agrarian areas where there are poor health controls for herds and where people consume raw dairy products. These regions include East Africa, grazing areas of upland South and Central America, and the belt of nations extending from Spain and Portugal across the Mediterranean basin, through Asia from Turkey and the Middle East, and across the former Soviet republics to Mongolia. Domesticated animals are reservoirs for *Brucella*, and the four species that infect humans are *B. melitensis* ("from Malta," where the disease was first described), *B. suis*, *B. abortus*, and *B. canis*.[33–36]

In the United States, brucellosis has largely been eliminated by proper animal husbandry practices. Still, there are 100 to 200 cases annually, mostly in travelers who ate raw dairy products in endemic areas or in people who consume illegally imported unpasteurized Mexican dairy products. Those at high risk include herders, farmers, veterinarians, and abattoir workers. Hunters who handle carcasses of large game such as deer, elk, and wild pigs are also at risk.

Clinical Findings

HISTORY The incubation period varies and is usually 1 to 3 weeks, but may be 2 months or longer. The disease presents either as an acute febrile, flu-like bactere-



mic syndrome or as a chronic disease with non-specific signs and symptoms such as weakness, anorexia, headache, and low-grade fever. Relapses occur in approximately 15 percent of patients, often after an ineffective antibiotic regimen.

CUTANEOUS LESIONS Skin manifestations occur in fewer than 5 percent of patients and are more common in children than in adults. Furthermore, skin lesions, when present, vary widely, appearing as vasculitis, erythema nodosum, panniculitis, abscesses, and polymorphous papules, pustules, and papulosquamous lesions. Children with acute cutaneous brucellosis typically have a violaceous papulonodular eruption primarily on the trunk and lower extremities. Rarely, *Brucella*-related osteomyelitis or suppurative lymph nodes may create cutaneous abscesses or sinuses.[37–41]

RELATED PHYSICAL FINDINGS Brucellosis can involve every organ system, although there are no pathognomic clinical findings. Joints, reproductive organs, liver, and the central nervous system are, in order, the most frequently involved. Nearly all patients have a characteristic undulant fever (alternating pattern of several febrile days followed by several afebrile days). Arthritis can be axial (e.g., sacroiliitis) or peripheral. The disease shows a predilection for reproductive organs, which leads to miscarriages, stillbirths, mastitis, prostatitis, orchitis, and epididymitis. Spinal osteomyelitis is well described, and endocarditis can be fatal. Persistent neuro-psychiatric findings occur in 5 percent of patients.

Laboratory Findings

Histopathology

The papulonodular eruption shows focal perivascular and periadnexal lymphohistiocytic granulomatous inflammation. Macular lesions have a non-specific mild lymph perivascular infiltrate. The panniculitis usually shows septo-lobular inflammation with abundant plasma cells. Hepatic and splenic lesions contain small, noncaseating granulomas. Caseation necrosis and calcification may occur in *B. suis* infections.[34,36]

Differential Diagnosis

Treatment

Brucellosis requires prolonged multidrug therapy with antimicrobials that penetrate into cells. Standard therapy consists of doxycycline combined with either streptomycin or gentamicin. Similar results are found with a combination of doxycycline and rifampin (see Table 183-1). Treatment should last at least 6 weeks; shorter courses carry a risk for relapse.

Prognosis and Clinical Course

Prevention

GLANDERS

Etiology and Epidemiology

Glanders is a rare zoonosis caused by the Gram-negative bacillus *Burkholderia mallei* (formerly *Pseudomonas mallei*). Glanders occurs mostly in horses, mules, donkeys, and related species, and exists focally in Asia and the Middle East. The disease is usually fatal in donkeys and mules but may cause a chronic suppurative condition, called *farcy*, in horses. Human cases are usually the result of direct exposures to animal reservoirs. In endemic areas, animal handlers, veterinarians, and abattoir workers have the greatest risks of exposure.[43,44]

Clinical Findings

HISTORY Human glanders may present in several ways, depending whether the disease is transmitted via cutaneous inoculation or respiratory inhalation[45,46]: acute localized infection, chronic cutaneous infection, acute pulmonary disease, and septicemia. Most cases are acquired transcutaneously, and a local ulcer develops within 1 to 5 days. Regional lymph nodes may then enlarge, producing a ulcero-glandular syndrome.

CUTANEOUS LESIONS In acute glanders, a nodule surrounded by cellulitis appears at the site of inoculation (see Table 183-1). Local swelling and suppuration occur, the lesion ulcerates, and regional lymphadenopathy develops. The ulcer is painful and has irregular edges with a gray-yellow base. Nodules rapidly develop along lymphatics that drain the initial lesion. These become necrotic and ulcerated, forming sinuses. Widespread dissemination quickly follows, with multiple nodular necrotic abscesses in subcutaneous tissues and muscle. Lesions frequently coalesce into gangrenous areas.

During bacteremic spread, patients have fevers, rigors, and night sweats. The characteristic eruption is composed of crops of papules, bullae, and pustules. These may be generalized or localized to the face and neck, in which case involvement of the nasal mucosa, either initially or by secondary spread, is prominent. Mucopurulent, bloody nasal discharge is common. Infection may spread to the paranasal sinuses, pharynx, and lungs.

In chronic glanders, cutaneous and subcutaneous nodules appear on the extremities and occasionally on the face. The lesions ulcerate, and draining sinuses develop. Ulceration of the hard palate and perforation of the nasal septum can occur. If the organisms are inhaled, pulmonary disease may produce pneumonia, pulmonary abscesses, or pleural effusions. Septicemic glanders is usually fatal.

GLANDERS AT A GLANCE

- Rare zoonosis caused by the Gram-negative bacillus *Burkholderia mallei* (formerly *Pseudomonas mallei*), found focally in Asia and the Middle East.
- Animal glanders occurs in horses, mules, and donkeys. Humans are infected through direct occupational exposure to animal reservoirs.
- Most human cases are acquired by direct inoculation into skin or contact of open skin with an infected animal or its secretions. Inhalational transmission is rare.
- A cutaneous ulcer develops after a 1- to 5-day incubation period, followed by several presentations: ulcero-glandular syndrome, localized abscesses (acute or chronic), or bacteremic dissemination (often fatal).

Laboratory Findings

Histopathologic examination of the skin and other involved organs shows a suppurative, necrotic process containing numerous intracellular and extracellular bacteria. Chronic glanders causes granulomatous changes.

Differential Diagnosis

Treatment

The Centers for Disease Control and Prevention recommends treatment with sulfadiazine, although in vitro data indicate that *B. mallei* is susceptible to ceftazidime, gentamicin, doxycycline, imipenem, and ciprofloxacin. Patients with subcutaneous or visceral abscesses

may require treatment for up to 1 year.[45–47] Because the disease has largely disappeared, few evidence-based recommendations are available.

Prognosis, Clinical Course, and Complications

Prevention

PASTEURELLA MULTOCIDA INFECTIONS

Etiology and Epidemiology

Pasturella multocida is a small, ovoid, Gram-negative rod that can cause local skin infection with regional adenitis after a superficial animal bite, scratch, or lick,[48] or septic arthritis and osteomyelitis after a deeper animal bite. Respiratory infections unassociated with trauma occur in rare cases, and bacteremia may accompany meningitis or osteomyelitis.

P. multocida commonly colonizes the oropharynx and nasopharynx of healthy cats, dogs, rats, mice, livestock, and poultry. Nearly all patients with *P. multocida* infection have had animal exposure, most commonly a dog or cat bite. Cat teeth are often longer and sharper than those of dogs and therefore may penetrate more deeply to cause septic arthritis or osteomyelitis. Compromising conditions such as cirrhosis, malignancy, and chronic obstructive pulmonary disease co-exist in most severe cases.[49–53]

Clinical Findings

HISTORY Local pain and swelling occur within a few days of an animal bite or contact exposure. Fever is uncommon.

CUTANEOUS LESIONS Redness, swelling, ulceration, and seropurulent drainage develop at the bite site. Cellulitis may progress rapidly and extensively, producing lymphangitis. Local necrosis may follow, and necrotizing fasciitis with septic shock has been reported.[49,54]

RELATED PHYSICAL FINDINGS Regional adenopathy may be present. Deep bites may introduce organisms into a joint or beneath periosteum and cause septic arthritis or osteomyelitis.

Laboratory Findings

Mild leukocytosis is present. After several weeks, a radiograph of underlying bone may show osteomyelitis. The organism is Gram negative, and Wright-Giemsa stain reveals a bipolar appearance. Histopathologically, an acute pyogenic response is seen.[50]

PASTEURELLA MULTOCIDA INFECTIONS AT A GLANCE

- Normal flora in oropharynx of many domestic animals. Most human infections are due to dog or cat bites.
- Local pain and swelling appear rapidly, usually less than 2 days after exposure.
- Gram-negative organism; nevertheless, infection is treated with penicillin or presumptively with amoxicillin/clavulanic acid.

Differential Diagnosis

Treatment

Because most animal bite wounds show polymicrobial contamination, an amoxicillin/clavulanic acid preparation should be started after a dog or cat bite. Although *P. multocida* is a Gram-negative organism, most strains are susceptible to penicillin, which is the drug of choice if only *Pasteurella* is cultured. If one suspects that the bite reached periosteum, parenteral penicillin should be given until the local lesion is well healed. *P. multocida* is also susceptible to doxycycline, later-generation cephalosporins, and trimethoprim-sulfamethoxazole (see Table 183-1).

Prognosis and Clinical Course

Prevention

RAT-BITE FEVER

Etiology and Epidemiology

The term *rat-bite fever* applies to two clinically similar zoonoses that are both attributable to contact with rats or their excreta. The more common form is caused by *Streptobacillus moniliformis*, a pleomorphic Gram-negative rod found in the nasopharyngeal flora of most wild and laboratory rats, which are asymptomatic carriers. Carnivores that prey on wild rodents may also transmit infection. Infections with *S. moniliformis* arise in two ways: direct contact with infected animals, usually through a bite, or ingestion of food or drink contaminated by rat urine, feces, or other secretions.[56] In both forms, patients have an acute flu-like infection characterized by a clinical triad of fever, polyarthralgias or arthritis, and rash. In 1926, an outbreak in Haverhill, Massachusetts, caused by consumption of milk tainted by rat excreta led to the designation *Haverhill fever* or *erythema arthriticum epidemicum*.

The other pathogen implicated in rat-bite fever is *Spirillum minus*, a Gram-negative spirochete. Spirillary rat-bite fever differs in its geographic distribution, incubation period, and milder arthritis. It occurs almost exclusively in East Asia. Its Japanese name is *sodoku*.[57]

RAT-BITE FEVER AT A GLANCE

- Rat-bite fever refers to two clinically similar zoonoses caused by *Streptobacillus moniliformis* and *Spirillum minus*.
- Infection is usually acquired through rat bite or ingestion of rat-contaminated food or drink.
- The disease is characterized by the classic triad of fever, polyarthralgias, and rash.

Clinical Findings

HISTORY Streptobacillary disease has an asymptomatic incubation period of 1 to 7 days, and, in rare cases, as long as 3 weeks. Often, the rat bite has healed by the time a flu-like illness begins with fever, chills, headache, stiff neck, and myalgias. A rash begins to appear several days later. Spirillary rat-bite fever has an incubation period of longer than 14 days.

CUTANEOUS LESIONS Approximately 75 percent of patients with streptobacillary fever develop a morbilliform eruption, usually 2 to 3 days after the fever. Individual lesions can be macular, morbilliform, or petechial. Lesions are most prominent on the palms, soles, and around joints but may become generalized, resembling measles.[58–60] Notably, when the rash appears, the rat bite has usually healed and only rarely shows evidence of infection, inflammation, or regional adenopathy. A week or so after resolution of the disease, the palms and soles have a characteristic desquamation



that may resemble Kawasaki disease. In contrast, the bite producing spirillary fever is usually tender, red, indurated, or ulcerated when the rash appears.[61] Cutaneous lesions are larger and are prominent on the abdomen, thus resembling the rose spots of typhoid.

RELATED PHYSICAL FINDINGS Within a week of the febrile symptoms, arthritis usually develops, predominantly involving large joints. The arthritis may be an asymmetric polyarthritis resembling rheumatoid arthritis but is rarely suppurative. Regional lymphadenopathy may be present.

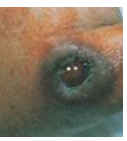

Laboratory Findings

Differential Diagnosis

Treatment

The treatment of choice for someone who becomes ill after a rat bite is amoxicillin/clavulanic acid. In patients allergic to penicillins, doxycycline is acceptable. Once *S. moniliformis* is identified, penicillin is the drug of choice. In general, rat bites should be cleansed promptly and thoroughly. Tetanus immunization status should be checked. Although there are no established guidelines, one might consider a prompt prophylactic course of penicillin or doxycycline after any rat bite.[56]

Prognosis, Clinical Course, and Complications

Prevention

SEAL FINGER

Etiology and Epidemiology

Seal finger is an occupational zoonosis that occurs only after direct contact with seals, sea lions, and similar marine mammals (order Pinnipedia), transmitted via bites or through open skin after handling seals or their carcasses. Seal finger is characterized by intensely painful red nodules, usually on the distal phalanx. Untreated, it can evolve into tenosynovitis, osteitis, and joint destruction.[62,63] Although this has not been fully confirmed, seal finger appears to be caused by a group of *Mycoplasma* that is part of the normal oropharyngeal flora of pinnipeds.[64]

SEAL FINGER AT A GLANCE

- Occupational zoonosis after contact with seals or sea lions. Occurs worldwide in marine environments.
- Usually presents as an exquisitely painful nodule on the distal phalanx of the finger that may progress to tenosynovitis or joint destruction.
- The pathogen is likely to be a marine *Mycoplasma* found in the seal's normal oropharyngeal flora. The infection responds quickly to tetracyclines.

Clinical Findings

People at risk include hunters, zookeepers, and marine biologists. Seal finger is common in coldwater coastal areas around Scandinavia, Greenland, Newfoundland, and similar environments in the Southern Hemisphere. Most cases occur during the spring sealing season. Incubation is usually approximately 4 days, rarely as long as 2 weeks. A furuncle-like lesion appears at the inoculation site, followed by severe pain, marked swelling, and stiffness.[65–67]

Differential Diagnosis

Treatment

Seal finger does not respond to the β-lactam antibiotics frequently prescribed presumptively for cellulitis caused by *Staphylococcus*, *Streptococcus*, or *Erysipelothrix*. The lack of response to β-lactams further suggests seal finger. Tetracyclines are the treatment of choice and must be continued for 4 to 6 weeks (see Table 183-1). Older accounts describe occasional sealers who amputated their own fingers to rid themselves of the excruciatingly painful digit.[62]

LISTERIOSIS (*LISTERIA MONOCYTOGENES* INFECTIONS)

Etiology and Epidemiology

Listeria monocytogenes is an anaerobic Gram-positive bacillus found widely in soil, water, vegetation, and the gut flora of humans and other animals. Exposure to this organism occurs through fecal-oral contamination, but the disease has an opportunistic nature, appearing in very young, very old, pregnant, or immunocompromised individuals. *L. monocytogenes* is found in the feces of many domestic and wild animals and birds, and is therefore widespread in the environment. Typically, livestock become infected by eating manure-contaminated silage; this can cause abortions, septicemia, and a peculiar form of encephalitis called *circling disease*.[68]

Human listeriosis is uncommon but occurs in three typical settings: sporadic disease in pregnant women and neonates; sporadic disease in acquired immunodeficiency syndrome patients; and food-borne outbreaks. Humans usually become infected by eating contaminated, unpasteurized, or improperly pasteurized dairy products. In adults, the disease can present as septicemia, meningitis, vaginal infection, pneumonitis, or oculoglandular syndrome and can cause miscarriages and stillbirths.[45] Infantile listeriosis presents acutely with septicemia, meningitis and meningoencephalitis, and septic granulomatosis.

The highest incidence of human listeriosis is seen among infants in the perinatal period, which suggests that the transmission occurs in utero or at birth. One-fourth of adult cases occur in pregnant women. Many other adult cases occur in patients with altered cellular immunity, such as those with Hodgkin disease, leukemia, or acquired immunodeficiency syndrome or those who have undergone organ transplantation. Hepatic disorders such as cirrhosis and iron overload also predispose to infection.

LISTERIOSIS AT A GLANCE

- Caused by anaerobic Gram-positive bacillus transmitted in fecal-oral manner through consumption of contaminated dairy products.
- Human listeriosis is most common in pregnant women, neonates, and patients with acquired immunodeficiency syndrome, and in food-borne outbreaks. May cause miscarriages, stillbirths, and virulent neonatal infections.
- Generalized petechiae, papules, or pustules may be seen in neonatal listeriosis, especially in meconium-stained newborns.

Clinical Findings

HISTORY Early-onset neonatal listeriosis develops in infants infected in utero by

untreated bacteremic mothers shortly before labor begins. Findings are evident at birth or become apparent within the first few days. These neonates are acutely ill and have generalized pustular, papular, or petechial skin lesions. Late-onset neonatal listeriosis occurs several weeks after a healthy birth, is presumably acquired postpartum, and usually presents as meningitis.[70,71]

Listeriosis from food-borne organisms usually causes outbreaks of acute gastroenteritis in families or communities. Patients have fever, vomiting, and non-bloody diarrhea, but this form lacks skin lesions.

CUTANEOUS LESIONS In septic infants, cutaneous lesions appear as generalized petechiae, papules, or pustules. Veterinarians or farmers who handle infected bovine fetuses may develop an acute febrile illness with headache, malaise, and regional adenopathy. Tender red papules develop on exposed surfaces and may evolve into pustules over 2 to 3 days. These contain the characteristic Gram-positive rods.

RELATED PHYSICAL FINDINGS

Laboratory Findings

L. monocytogenes is a small pleomorphic bacillus that often appears coccoid in infected tissues and body fluids. Pustules, meconium, CSF, or blood cultures reveal the characteristic Gram-positive rods. The organism is β-hemolytic when cultured on sheep blood agar and exhibits a characteristic tumbling motility when grown in broth. In adults with meningitis, the CSF contains neutrophils, but about one-third of meningitic infants have a mononuclear response.

Histopathology

Differential Diagnosis

Treatment

Neonates with listeriosis should be treated with intravenous ampicillin (or penicillin) (see Table 183-1).

Prognosis, Clinical Course, and Complications

Prevention

VIBRIO VULNIFICUS INFECTIONS AT A GLANCE

- Non-cholera *Vibrio* organisms are found in warm saltwater worldwide. Exposures occur via percutaneous injury, often minor (e.g., while ocean fishing) or via ingestion of filter-feeding shellfish, which concentrate organisms.
- Severe illness presents with necrotizing fasciitis, hemorrhagic bullae, and hypotensive shock. Cirrhosis and other liver diseases predispose to a virulent, often fatal, course.

VIBRIO VULNIFICUS INFECTIONS

Etiology and Epidemiology

Vibrio are facultatively anaerobic, pleomorphic, Gram-negative rods found in marine waters, estuaries, brackish lakes, and their sediments wherever the water temperature is above 20°C (68°F). The most well-known vibriosis is cholera, caused by antigenic strains of *V. cholerae*. Although cholera organisms do not infect the skin, many other *Vibrio* do. The most important of these, *V. vulnificus*, can cause fulminant cellulitis, myositis, necrotizing fasciitis, and death.[72]

People become infected with *V. vulnificus* through oral or percutaneous exposure. After eating contaminated raw or undercooked seafood, people who have chronic liver disease or diabetes mellitus, or who are otherwise immunocompromised, are at risk for primary septicemia. Percutaneous infections are acquired by handling raw seafood, by entering saltwater with an open wound, or by experiencing skin trauma while in or around saltwater. Immunocompromised individuals are again at increased risk for secondary septicemia.[73,74]

V. vulnificus lives in warm seawater, where it colonizes the skin of fish and is concentrated in filter-feeding shellfish, such as oysters. Infections are particularly common along the Gulf of Mexico and, because of global warming, are now found in increasingly higher latitudes, such as on the Baltic Sea.[75–77]

Clinical Findings

HISTORY There is nearly always a history of contact with saltwater, injury while ocean fishing, or consumption or handling of shellfish. After oral exposure, primary septicemia often begins with watery diarrhea, fever, chills, nausea, vomiting, and abdominal pain. People with wound infections usually recall an open skin lesion present before the saltwater exposure or a percutaneous injury during the exposure. *Vibrio* cellulitis is painful and has a rapid onset within 12 to 24 hours of exposure. Secondary bacteremia with sepsis may occur several days later.[79]

CUTANEOUS LESIONS Infected wounds may present as pustules, lymphangitis, or cellulitis. These infections may be mild or may develop into rapidly progressive, painful cellulitis with extensive skin necrosis, myositis, and necrotizing fasciitis (Fig. 183-4). Secondary bacteremia may cause metastatic cutaneous lesions.[73,80] In septic patients, large hemorrhagic bullae commonly arise on the extremities or trunk and usually progress to necrotic ulcers and



▲ **FIGURE 183-4** *Vibrio vulnificus* cellulitis with hemorrhagic plaque and bullae on the legs of an older diabetic patient with cirrhosis.



necrotizing fasciitis (see Table 183-1; see also Chap. 179).

RELATED PHYSICAL FINDINGS *V. vulnificus* septicemia causes high fever, tachycardia, and hypotension. One-third of patients develop Gram-negative septic shock.

Laboratory Findings

Differential Diagnosis

Treatment

Primary or secondary septicemia due to *V. vulnificus* (or other *Vibrio* sp.) requires prompt management of hypotensive shock, parenteral administration of antibiotics, and vigorous débridement of necrotic lesions. Amputation of the affected limb may be necessary. The antibiotics of choice are a combination of doxycycline and ceftazidime (see Table 183-1). Alternatives to doxycycline include chloramphenicol, ciprofloxacin, and minocycline. Alternatives to ceftazidime include cefotaxime. Application of compresses with modified Dakin's solution (0.025 percent sodium hypochlorite) may help arrest the progression of the cutaneous lesions.[81]

Prognosis, Clinical Course, and Complications

Prevention

OTHER CUTANEOUS *VIBRIO* INFECTIONS

AEROMONAS HYDROPHILA INFECTIONS

Etiology and Epidemiology

Aeromonas hydrophila is a facultatively anaerobic, Gram-negative bacillus that causes opportunistic human infections. Except for the freshwater habitat of *Aeromonas*, its taxonomic, ecologic, and epidemiologic profiles resemble those of *Vibrio* sp. Aeromonads are found in fresh and brackish water worldwide and are natural pathogens of many aquatic animals, including fish, amphibians, and reptiles. Human *Aeromonas* infections are usually associated with exposure to contaminated fresh or brackish water. The organism is typically linked with gastroenteritis,[82] but in an increasing number of cases, it has been implicated in skin, soft-tissue, and muscle infections, as well as in septicemic disease. An increasing number of soft-tissue infections are associated with the medical use of leeches.[83,84]

AEROMONAS HYDROPHILA INFECTIONS AT A GLANCE

- Caused by a facultatively anaerobic Gram-negative bacillus found in fresh and brackish water worldwide.
- Usually presents as cellulitis after exposure to fresh or brackish water but may cause necrotizing fasciitis or myonecrosis.
- Sepsis risk in cirrhotic and immunocompromised patients.

Clinical Findings

HISTORY The key historical feature is the contact of open skin with fresh or brackish water. In healthy individuals, *Aeromonas* infections may remain localized, but compromised hosts are at risk for severe soft-tissue and septicemic disease.[54,85]

CUTANEOUS LESIONS The most common presentation is cellulitis associated with a laceration, often followed by abscess formation or spread to deeper subcutaneous tissues. Myonecrosis or necrotizing fasciitis may mimic clostridial gas gangrene in its rapid onset (1 to 2 days after exposure) and swift progression with severe pain, marked swelling, serosanguineous bullae, crepitation, and systemic toxicity. The exudate often has a foul or fishy odor. Occasionally, bacteremia produces ecthyma gangrenosum–like lesions.[54,87,88]

RELATED PHYSICAL FINDINGS

Laboratory Findings

Gram-stained aspirates from abscesses or bullae may contain Gram-negative bacilli. Wound cultures yield multiple microbes in more than 50 percent of cases, and specimens should be plated on both sheep blood agar and MacConkey's agar. Blood cultures are rarely positive for the organism. A radiograph may detect gas in deeper soft tissues.

Differential Diagnosis

Prognosis and Clinical Course

Treatment

Prompt surgical exploration and débridement are essential, guided radiographically, if possible. *A. hydrophila* produces β-lactamase and is resistant to first-generation penicillins and cephalosporins. Most isolates are susceptible to third-generation cephalosporins, fluoroquinolones, and aminoglycosides (but not streptomycin). Consideration must be given to the polymicrobial nature of these infections, so results of Gram staining and culture should guide antimicrobial selection. Two other less pathogenic species of *Aeromonas*, *A. caviae* and *A. sobria*, have similar antibiotic sensitivity profiles.[54,87]

Prevention

MELIOIDOSIS

Etiology and Epidemiology

Melioidosis is caused by *B. pseudomallei* (formerly *P. pseudomallei*), a motile, pleomorphic, Gram-negative aerobic bacillus. The organism is a natural saprophyte found in freshwater and damp soil in the humid tropics. Melioidosis infects humans, a variety of birds, and domestic and wild mammals in endemic areas, but animals are not regarded as reservoirs for human infection. Although sporadic cases occur pantropically, melioidosis has its greatest incidence in Southeast Asia, especially Singapore and northeastern Thailand, and in coastal areas of Australia's Northern Territory. Apart from rare laboratory-acquired infections, cases of melioidosis in the United States and Europe have occurred only in people previously exposed in endemic areas.[89–91]

Most cases of melioidosis are transmitted by exposure of open skin to contaminated soil or water. The frequency of pulmonary disease suggests that melioidosis may also be acquired by inhalation of contaminated droplets, soil, or dust.[92,93]

During the Vietnam War, extensive immersion in rice paddies and similar conditions led to cases of melioidosis among American servicemen. Several cases were Vietnam veterans whose disease appeared decades later, and the only plausible exposure was to rice paddies long before.[101]

MELIOIDOSIS AT A GLANCE

- Caused by *Burkholderia pseudomallei* (formerly *Pseudomonas pseudomallei*), a Gram-negative aerobic bacillus that lives as a saprophyte in freshwater and damp soil.
- Occurs in humans and animals, primarily in wet tropical areas such as Southeast Asia and coastal northern Australia. People who develop melioidosis elsewhere usually had prior exposure in endemic areas.
- Rice farmers, particularly if compromised by diabetes mellitus or chronic renal disease, are most susceptible.
- The disease is acquired after exposure to contaminated soil or water, either directly via the skin or through inhalation of particulate soil or dust.
- Clinical presentation ranges from focal indolent cutaneous and subcutaneous abscesses to fulminant pneumonia with septicemia.
- On the Centers for Disease Control and Prevention's Category B list of possible bioweapon agents.

Direct human-to-human transmission is rare. *B. pseudomallei* is infectious when aerosolized and is regarded as a Category B bioweapon for its potential use on livestock or humans. If an individual without characteristic travel or exposure history develops melioidosis, or if there is a cluster of cases, deliberate exposure may have occurred.[102]

Clinical Findings

HISTORY Melioidosis has two principal clinical presentations: (1) acute melioidosis with suppurative skin lesions, pneumonia, or septicemia; and (2) chronic melioidosis, the more common form of the disease, with involvement of the lungs, skin (subcutaneous abscesses and draining sinuses), bones, joints, liver, and spleen. Approximately 50 percent of cases involve the lungs, caused either by inhalation of pathogens or by bacteremia from a cutaneous exposure, although most patients have no obvious breaks in the skin. Human immunodeficiency virus infection does not appear to increase either the risk of acquiring the disease or its severity.[89,103]

The incubation period can be as brief as 2 to 3 days. Acute pneumonic melioidosis usually starts abruptly with fever, chills, cough, dyspnea, and chest pain. Acute septicemic melioidosis may also arise from a cutaneous focus. In one-half the patients, no source for the bacteremia can be identified, but many individuals have minor abrasions on their feet.[90]

CUTANEOUS LESIONS Cutaneous manifestations are non-specific. Acute septicemia may follow minor cutaneous disease. Disseminated disease can produce multiple superficial pustules or, more rarely, ecthyma gangrenosum or necrotizing fasciitis. In chronic melioidosis, draining sinuses and subcutaneous abscesses, particularly of the scalp, are common. In children, a common presentation is acute suppurative parotitis, usually unilateral, associated with parotid pain and fever.[89–91,104–107]

RELATED PHYSICAL FINDINGS

Laboratory Findings

Differential Diagnosis

Treatment

Antibiotic susceptibility must be determined for each isolate. The combination of ceftazidime plus trimethoprim-sulfamethoxazole is the initial therapy of choice. After a 10- to 14-day course of intravenous antibiotics, oral antibiotics, usually amoxicillin/clavulanic acid, should be continued for 2 to 6 months (or longer in the case of osteomyelitis or multiple suppurative foci) to reduce the risk of relapse.[91,110] Abscesses should be drained surgically, but only after the patient is taking appropriate antibiotics to help prevent bacteremia.

Prognosis, Clinical Course, and Complications

Prevention

ERYSIPELOID

Etiology and Epidemiology

Erysipeloid, an acute infection of traumatized skin caused by *E. rhusiopathiae* (formerly *E. insidiosa*), occurs most frequently in fishermen, butchers, kitchen workers, and others who handle raw fish, poultry (especially turkey), and meat products.[13] The disease occurs primarily during the summer months.

ERYSIPELOID AT A GLANCE



- An occupational zoonosis caused by *Erysipelothrix rhusiopathiae* and associated with percutaneous trauma while handling raw fish or poultry.
- Classic dermatologic presentation is localized non-suppurative purple-red plaques on the dorsal hands. Rare chronic and bacteremic forms exist.

E. rhusiopathiae is a thin, Gram-positive, microaerophilic, nonmotile bacillus that is hardy enough to survive putrefaction of tissue and exposure to saltwater or freshwater. The organism is found in rats, birds, the slime on saltwater fish, and crabs and other shellfish, and is associated with poultry, meats, hides, and bones.

Clinical Findings

HISTORY The patient is usually employed in the fishing or animal product industry. After inoculation, there is an incubation period of 2 to 7 days. Initially, burning pain occurs at the injured site, then a violaceous dermal plaque develops. Lymphangitis and regional adenopathy occasionally occur, as well as low-grade fever and malaise. Bacteremia and endocarditis are rare but serious sequelae. Untreated, erysipeloid usually heals on its own within 3 weeks.

CUTANEOUS LESIONS The distinctive erysipeloid lesion is usually on a finger or the back of the hand; is violaceous, warm, and tender; and has well-defined, raised margins with an angular or polygonal border (Fig. 183-5). It often involves the web spaces but spares the terminal phalanges and does not progress beyond the wrist. The borders usually expand, whereas the central region clears without desquamation or ulceration. Rarely, multiple lesions distant from the original site of injury arise, presumably through bacteremic spread. Post-inflammatory hyperpigmentation may persist after the lesion resolves.

RELATED PHYSICAL FINDINGS Arthritis may be associated with the local lesion, and,





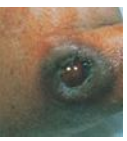

▲ **FIGURE 183-5** Erysipeloid. Characteristically, the violaceous, sharply marginated lesion is composed of macules and plaques and is located on the hand.

in rare cases, distant joints are involved. Sepsis produces typical peripheral stigmata, including signs of endocarditis.[112]

Laboratory Findings

Histopathology

Differential Diagnosis

Treatment

The treatment of choice for erysipeloid is high-dose penicillin or ampicillin for 7 to 10 days. Patients who cannot take penicillins may be treated with a third-generation cephalosporin, imipenem, or ciprofloxacin (see Table 183-1). This recommendation is based primarily on in vitro studies, not clinical experience. If arthritis, septicemia, or endocarditis is present, the penicillin dosage should be increased and the drug should be administered intravenously for several weeks.[112]

Prognosis, Clinical Course, and Complications

Prevention

STREPTOCOCCUS INIAE INFECTIONS

Etiology and Epidemiology

S. iniae is a recently recognized Gram-positive coccus that colonizes the skin of freshwater fish, particularly those raised in intense aquaculture.

STREPTOCOCCUS INIAE INFECTIONS AT A GLANCE

- Caused by a recently recognized streptococcal species that colonizes or infects freshwater fish, such as tilapia, grown in intense aquaculture.
- Most human clinical cases present as cellulitis of the hand after an accidental puncture wound during preparation of live fish for cooking.
- Bacteremia commonly occurs.

In humans, *S. iniae* infection usually causes hand cellulitis after the handling of live freshwater fish, particularly farm-raised tilapia (*Tilapia* sp. and *Oreochromis* sp.). Most cases have been reported in cities in China and in Asian communities in North America, particularly Toronto, where the practice of buying live fish for home preparation, rather than buying fresh fish that have already been killed and cleaned, is common.[117]

Clinical Findings

HISTORY AND CUTANEOUS LESIONS The key element in the history is the rapid onset of hand cellulitis within 1 to 3 days after the handling of live farm-raised fish. Lymphangitis and fever are early features, but neither skin necrosis nor bullae occur.[118]

RELATED PHYSICAL FINDINGS Bacteremia frequent complicates *S. iniae* cellulitis and may lead to septic arthritis, meningitis, osteomyelitis, and endocarditis.[118]

Laboratory Findings

Differential Diagnosis

Prognosis and Treatment

The infection will respond within 2 to 4 days to penicillin, the treatment of choice. The pathogen is also susceptible to cephalosporins, macrolides, quinolones, and vancomycin but is resistant to tetracyclines. Treatment should be maintained for 10 days or longer if there are extra-cutaneous complications.[118]

Prevention

CHROMOBACTERIUM VIOLACEUM INFECTIONS

Chromobacterium violaceum is a facultatively anaerobic, Gram-negative, motile, flagellated bacillus found as a saprophyte in tropical and sub-tropical freshwater and soil. It is rarely pathogenic except to people with disorders of neutrophil function, especially inherited chronic granulomatous disease. Infection occurs after open skin is exposed to a contaminated source, such as stagnant or muddy water. Nearly all U.S. cases have occurred in southeastern states during the summer months. After exposure, cellulitis and fevers soon develop. Pustules and nodules may appear, followed by regional adenopathy. The organisms may disseminate hematogenously, causing ecthyma gangrenosum, visceral abscesses, abdominal pain, septic shock, and death.

LEPTOSPIROSIS

Etiology and Epidemiology

Leptospirosis is a waterborne zoonosis caused by *Leptospira interrogans*. The disease is found worldwide, except in the polar regions, wherever animal urine can contaminate bodies of freshwater. Rodents are the most important reservoirs, although over 160 species of mammals are known to harbor *Leptospira*, including wild, farm, pet, and laboratory animals. Infected humans can also serve as transient reservoirs, particularly in urban slums in the wet tropics. Reservoir animals excrete leptospires in their urine, which contaminate the environment. Humans generally acquire the disease through broken skin after direct contact with an infected animal or exposure to contaminated water or soil. People are infected less commonly through mucous membranes, ingestion of contaminated water, or inhalation of fomites.[123–128]

Clinical Findings

HISTORY Patients usually have had recent occupational or recreational contact with contaminated water or mud. Most human infections are asymptomatic, self-limited, and detectable only on serologic surveys. Ill patients have one of two clinical forms of the disease: a mild anicteric form that resolves without complications, or a severe, icteric form (Weil disease).

After several relatively asymptomatic days, the second phase of illness begins

LEPTOSPIROSIS AT A GLANCE

- Waterborne zoonosis with worldwide distribution caused by serovars of *Leptospira interrogans*, which are excreted in urine of reservoir animals, especially rodents. Outbreaks during rainy seasons or after flooding in areas with poor sanitation.
- Most human cases are mild or sub-clinical. In severe cases there may be fever, hepatic and renal failure, jaundice, hemorrhage, and death.
- Cutaneous findings include jaundice, conjunctival suffusion, petechiae, and non-specific papules.

with low-grade fever. In severe cases rash, meningitis, uveitis, and hepatic and renal failure may develop.

CUTANEOUS LESIONS In the first week of illness, the conjunctivae become suffused (red but not exudative). Skin lesions occur in fewer than 50 percent of cases. These consist of non-specific macules, papules, urticaria, and petechiae, mostly on the trunk. Desquamation and infarcts have been observed on the hands or feet of some infected children. Weil disease has prominent hepatic (jaundice) and renal (hematuria, azotemia) components. Hemorrhages occur in a variety of organs, including the skin, and petechiae are common on the palate. A variant called *pretibial fever* or *Fort Bragg fever*, caused by *L. interrogans* serovariant *autumnalis*, has a distinctive rash that appears on the fourth or fifth day of illness, consisting of slightly raised, 1- to 5-cm, tender, erythematous papules on the shins. The rash subsides within 4 to 7 days.[128]

RELATED PHYSICAL FINDINGS

Laboratory Findings

Differential Diagnosis

Treatment

Public health authorities in endemic areas recommend starting antibiotic therapy early, perhaps presumptively, to reduce the risk of severe disease while laboratory confirmation is awaited. Doxycycline is effective and can be taken prophylactically for short-term exposure in a hyperendemic area. Penicillin has also been recommended, although controlled studies are lacking, and it may precipitate a Jarisch-Herxheimer reaction (see Table 183-1).

Prognosis, Clinical Course, and Complications

Prevention

DIPHTHERIA

Etiology and Epidemiology

Diphtheria is an acute febrile illness caused by *Corynebacterium diphtheriae* that in 90 percent of cases affects the pharynx and mucous membranes of the upper respiratory tract. The clinical manifestations of diphtheria are caused by (1) acute membranous obstruction of the airway, and (2) the tardive effects of a potent exotoxin on the myocardium and on cranial and peripheral nerves. The classic oropharyngeal lesion is a gray, leathery membrane along the tonsils and soft palate. Cutaneous diphtheria, which is far less common, can present either as a primary skin lesion or as a secondary infection of an existing break in the skin. Cutaneous diphtheria occurs most commonly in people living in or returning from tropical areas.[131]

Although diphtheroids are widespread in nature, humans are the only natural host for *C. diphtheriae*, which colonizes the pharynx of asymptomatic individuals. Disease occurs when a nonimmune person, usually someone very young or very old, is infected by a toxigenic strain of *C. diphtheriae*. Epidemics occur when such strains become widespread among nonimmune individuals. Diphtheria has been largely controlled in Western nations by routine childhood immunization, which is directed against diphtheria's exotoxin, not against the bacteria itself.

Clinical Findings

HISTORY Classic diphtheria presents with pharyngitis and low-grade fever 2 to 5 days after exposure to a carrier or, much more rarely, to fomites. A thick or leathery grayish white membrane adheres to pharyngeal walls and tonsillar pillars, and usually spreads asymmetrically onto the soft palate and uvula. As the disease progresses, the patient's neck becomes painful and swollen. There is often a unilateral bloody nasal discharge. Patients appear to have a toxic process, and ensuing tracheal

DIPHTHERIA AT A GLANCE

- Classic diphtheria produces adherent gray membranous pharyngeal lesions, which may cause lethal airway obstruction. Exotoxin may cause latent peripheral neuritis or lethal cardiomyopathy.
- Cutaneous diphtheria usually affects the legs and begins as tender pustules that break down to punched-out ulcers covered by gray membranes. It is primarily found in the tropics or in travelers returning from these areas.
- Diphtheria can be prevented with toxoid immunization. It is treatable with antibiotics and antitoxin.

edema may obstruct the airway, causing lethal suffocation.

Cutaneous diphtheria typically affects the lower extremity, involves one or more sites, and may occur with or without concomitant pharyngeal disease. In roughly one-third of patients with cutaneous diphtheria, the same strain of *C. diphtheriae* can be recovered from the respiratory tract, which suggests inadvertent autoinoculation as the cause of the skin lesions.

CUTANEOUS LESIONS There are two types of skin involvement. The first is primary cutaneous diphtheria, which starts acutely as a tender pustule and then breaks down to form an enlarging oval punched-out ulcer with a gray membrane at the base (see Table 183-1). Later, the membrane becomes dark brown, and the ulcer's border acquires edematous, rolled, bluish margins.[131,133,134]

Wound diphtheria is a secondary infection by *C. diphtheriae* of an existing break in the skin. This type accounts for almost all cases of cutaneous diphtheria reported in the United States. Pre-existing skin lesions affected include those caused by abrasions, chronic dermatoses (e.g., eczema or scabies), and common pyodermas already infected with *Staphylococcus* or *Streptococcus*. A painful ulcer is partly covered by a brownish gray membrane, drains pus, and is surrounded edema and erythema. In the outbreak in Seattle among indigent alcoholics, co-infection with *S. pyogenes* occurred in 73 percent of diphtheritic skin lesions.[132] *C. diphtheriae* has been recovered from lesions resembling impetigo, ecthyma, and infected insect bites. Whether these are truly infected or merely colonized is not clear.



Mucosa of the nose, conjunctivae, or vagina can exhibit membranous diphtheria, although these cases are quite rare.

RELATED PHYSICAL FINDINGS

Laboratory Findings

C. diphtheriae can be isolated from either the skin ulcer or pharyngeal membrane. It is a Gram-positive, club-shaped rod that exhibits metachromatic bipolar granules on staining with methylene blue. The organism grows well on standard culture media, but other bacteria may obscure it. Therefore, selective media such as Löffler or tellurite agar should be used. The histopathologic features of cutaneous diphtheria are non-diagnostic, and the membrane is composed of coagulation necrosis and inflammatory cells. Not all strains of *C. diphtheriae* produce diphtheria toxin, so it is recommended that the pathogen be sent to a reference laboratory to determine the toxigenicity of the particular strain.

Differential Diagnosis

Treatment

Pharyngotonsillar diphtheria requires treatment with antibiotics (to kill the bacteria) and antitoxin (to neutralize the exotoxin). Treatment should be started on clinical suspicion without awaiting culture confirmation, because toxin produced in the interim might damage the myocardium irreversibly.

Cutaneous diphtheria must be treated with antibiotics and antitoxin (see Table 183-1). The antibiotic of choice is high-dose intravenous penicillin or, for those unable to take penicillin, erythromycin. Diphtheria antitoxin, available from the Centers for Disease Control and Prevention, is administered intravenously after careful testing for horse serum hypersensitivity. Injection of antitoxin subcutaneously around and under the ulcer, along with superficial application to the lesion, may be beneficial, but data are incomplete. After antitoxin and antibiotics are administered, the membrane should be débrided and the ulcer kept clean. Patients with either form of the disease should be isolated for roughly 14 days.

Prognosis, Clinical Course, and Complications

Prevention

OTHER CUTANEOUS DIPHTHEROID INFECTIONS

KEY REFERENCES

The full reference list for all chapters is available at www.digm7.com.

1. Hart CA, Beeching NJ: A spotlight on anthrax. *Clin Dermatol* **20**:365, 2002
21. Hayes EB: Tularemia, in *Tick-Borne Diseases of Humans*, edited by Goodman JL, Dennis DT, Sonenshine DE. Washington, DC, ASM Press, 2005, p 207
34. Pappas G et al: Brucellosis. *N Engl J Med* **352**:2325, 2005
53. Talan DA et al: Clinical presentation and bacteriologic analysis of infected human bites in patients presenting to emergency departments. *Clin Infect Dis* **37**:1481, 2003
54. Vinh DC, Embil JM: Severe skin and soft tissue infections and associated critical illness. *Curr Infect Dis Rep* **8**:375, 2006
59. Freels LK, Elliott SP: Rat bite fever: Three case reports and a literature review. *Clin Pediatr (Phila)* **43**:291, 2004
73. Ulusarac O, Carter E: Varied clinical presentations of *Vibrio vulnificus* infections: A report of four unusual cases and review of the literature. *South Med J* **97**:163, 2004
90. Peacock SJ: Melioidosis. *Curr Opin Infect Dis* **19**:421, 2006
117. Lau SK et al: Invasive *Streptococcus iniae* infections outside North America. *J Clin Microbiol* **41**:1004, 2003
119. Brown KL et al: Ecthyma gangrenosum and septic shock syndrome secondary to *Chromobacterium violaceum*. *J Am Acad Dermatol* **54**:S224, 2006

CHAPTER 184

Tuberculosis and Infections with Atypical Mycobacteria

Gerhard Tappeiner

The genus *Mycobacterium* is estimated to cause more suffering for humans than all other bacterial genera combined. Twenty-five years ago it was assumed that tuberculosis would become extinct in the developed countries, because its incidence decreased at an average rate of 6 percent in the United States and 10 percent in Europe between 1953 and 1985. However, by 1983 tuberculosis was declared a "global emergency" by the World Health Organization because of a sharp increase in incidence elsewhere (e.g., a doubling in sub-Saharan Africa) largely due to the human immunodeficiency virus infection pandemic, poverty, and social disruption. One-third of the world's population is thought to be infected. In the United States, the figure is estimated at 15 million. Currently, an estimated 8 million new cases of tuberculosis and 3 million tuberculosis-related deaths occur each year, 98 percent of them in developing countries. There are also 1.5 million new cases and 500,000 deaths per year among children. Tuberculosis has the highest morbidity and mortality rates of all infectious diseases and is thought to be responsible for 25 percent to 30 percent of avoidable deaths.

The so-called *atypical mycobacteria* (mycobacteria other than *M. tuberculosis*, or MOTT) cause skin disease more frequently than does *M. tuberculosis*. They exist in various reservoirs in the environment. Among these organisms are obligate and facultative pathogens as well as non-pathogens. In contrast to the obligate pathogens, the latter do not cause disease by person-to-person spread.

CLASSIFICATION OF MYCOBACTERIA[1]

MYCOBACTERIA AND THE ACQUIRED IMMUNODEFICIENCY SYNDROME PANDEMIC

The pandemic of acquired immunodeficiency syndrome (AIDS), with its profound and progressive suppression of cellular immune functions, has led to a resurgence of tuberculosis and the appearance or recognition of new mycobacterial pathogens. The *M. avium-intracellulare* complex is the most common cause of disseminated bacterial infections in patients with AIDS in the United States, but is much less frequently so in Europe. In AIDS patients *M. kansasii* is more common than *M. tuberculosis*. The incidence of tuberculosis

TUBERCULOSIS AT A GLANCE



- Infection with *Mycobacterium tuberculosis* (and other very closely related strains, the "*M. tuberculosis* complex") and the inflammatory reaction of the host define the disease (tuberculosis, or TB).
- One-third of the world's population is infected with TB. Nine million new infections and 2 million disease-related deaths occur per year. TB is the main cause of death of patients infected with human immunodeficiency virus. In the United States, there are 10.8 cases per 100,000 in black non-Hispanic individuals and 1.3 cases per 100,000 in white non-Hispanic individuals.
- TB usually affects the lung, but virtually all other organ systems may be involved.
- TB of the skin is a relatively rare manifestation with a wide spectrum of clinical findings depending on the source of infection and the immune status of the host.
- Diagnosis is based on clinical manifestations, histopathologic analysis, demonstration of the relevant mycobacteria in tissue or in culture and host reaction to *M. tuberculosis* antigen.
- Treatment is with standard multidrug regimens; cases of multidrug-resistant TB or extensively multidrug-resistant TB require special attention.
- Course and prognosis depend on the immune status of the host. Treatment is curative except for patients with a breakdown of the immune system.

in patients with AIDS is almost 500 times that in the general population.

The sharp increase in pulmonary and bacteremic or disseminated mycobacterial infections has not been paralleled by an equal increase in skin disease. Cutaneous disease in AIDS patients is frequently caused by MOTT.

TUBERCULOSIS OF THE SKIN

Definition and Classification

Tuberculosis of the skin is caused by *M. tuberculosis*, *M. bovis*, and, under certain conditions, bacille Calmette-Guérin (BCG), an attenuated strain of *M. bovis* originally developed for vaccination. Classification is based on the mode of infection and the immunologic state of the host (Table 184-1).

TABLE 184-1
Classification of Cutaneous Tuberculosis

	Host Immune Status	Clinical Disease
Exogenous infection	Naive	Primary inoculation tuberculosis
	Immune	Tuberculosis verrucosa cutis
Endogenous spread	High	Lupus vulgaris
		Scrofuloderma
	Low	Acute miliary tuberculosis
		Orificial tuberculosis
		Metastatic tuberculous abscess (tuberculous gumma)
Tuberculosis due to bacille Calmette-Guérin	Naive	Normal primary complex–like reaction
		Perforating regional adenitis
		Postvaccination lupus vulgaris
Tuberculids	Not clear	Tuberculids:
		Lichen scrofulosorum
		Papulonecrotic tuberculid
		Facultative tuberculids:
		Nodular vasculitis
		Erythema nodosum

Epidemiology

Mycobacteria are neither very virulent nor very infectious. Tuberculosis of the skin has a worldwide distribution. Once more prevalent in regions with a cold and humid climate, it now occurs mostly in the tropics. In European and North American countries, the incidence of skin tuberculosis has declined steadily over the past decades, paralleling the decreasing incidence of pulmonary tuberculosis. So far, there has been no increase in skin tuberculosis proportional to the resurgence of pulmonary tuberculosis.

The two most frequent forms of skin tuberculosis are lupus vulgaris (LV) and scrofuloderma. In the tropics, LV is rare, whereas scrofuloderma and verrucous lesions predominate. LV is more than twice as common in women than in men, whereas tuberculosis verrucosa cutis is more often found in men. Generalized miliary tuberculosis is seen in infants (and adults with severe immunosuppression or AIDS), as is primary inoculation tuberculosis. Scrofuloderma usually occurs in adolescents and the elderly, whereas LV may affect all age groups.

Etiology and Pathogenesis

THE MYCOBACTERIUM Mycobacteria multiply intracellularly and are initially found in large numbers in the tissue.

M. tuberculosis, *M. bovis*, and, under certain conditions, the attenuated BCG organism cause all forms of skin tuberculosis.

In LV, the bacteria often have a virulence as low as that of the BCG. Large numbers of bacteria can be found in the lesions of a primary chancre or of acute miliary tuberculosis; in the other forms, their number in the lesions is so small that it may be difficult to find them.

M. tuberculosis may become dormant in the host tissue.

New diagnostic tools are emerging.[4,5]

THE HOST The human species is quite susceptible to infection by *M. tuberculosis*, with big differences among populations and individuals. Populations that have been in long-standing contact with tuberculosis are, in general, less susceptible than those that have come into contact with mycobacteria more recently. Age, state of health, environmental factors, and particularly the immune system are of importance. In Africans, tuberculosis frequently takes an unfavorable course, and tuberculin sensitivity may be more pronounced than in whites.

TUBERCULIN REACTION (KOCH PHENOMENON) An extract of *M. tuberculosis* (tuberculin) was shown to produce a different skin reaction in sensitized individuals than in naive individuals, and this difference became the basis of a widely used diagnostic test. This reaction is a delayed-type hypersensitivity reaction, induced by mycobacteria during primary infection. This "old tuberculin" has now been replaced by purified protein derivative



(PPD). More recently, purified species-specific antigens have been developed.

Local intradermal injection (the method most widely used) leads to the local tuberculin reaction, which usually reaches its maximum intensity after 48 hours. It consists of a sharply circumscribed area of erythema and induration, and in highly hypersensitive recipients or after large doses, a pallid central necrosis may appear.

In an attempt to quantify the tuberculin reaction, an assay to measure specific antigen-driven interferon-γ synthesis by whole blood cells has been developed. Its usefulness remains to be determined.[6]

Tuberculin sensitivity usually develops 2 to 10 weeks after infection and persists throughout life. The state of sensitivity of an individual infected with *M. tuberculosis* is of considerable significance in the pathogenesis of tuberculosis skin lesions.

In patients with clinical tuberculosis, an increase in skin sensitivity usually indicates a favorable prognosis, and in tuberculous skin disease accompanied by high levels of skin sensitivity, the number of bacteria within the lesions is small. Tuberculin sensitivity is not necessary for immunity, however, and sensitivity and immunity do not always parallel each other. There is evidence that a high degree of tuberculin sensitivity may even be antagonistic to protection.

ROUTE OF INFECTION Cutaneous inoculation leads to a tuberculous chancre or to tuberculosis verrucosa cutis, depending on the immunologic state of the host.

Spread of mycobacteria may occur by continuous extension of a tuberculous process in the skin (scrofuloderma), by way of the lymphatics (LV), or by hematogenous dissemination (acute miliary tuberculosis of the skin or LV).

Histopathology

The hallmark of tuberculosis and infections with some of the slow-growing atypical mycobacteria is the tubercle: an accumulation of epithelioid histocytes with Langhans-type giant cells among them and a varying amount of caseation necrosis in the center, surrounded by a rim of lymphocytes and monocytes. Although this tuberculoid granuloma is highly characteristic of several forms of tuberculosis, it may be mimicked by deep fungal infections, syphilis, and leprosy, as well as other diseases. As in leprosy, the histopathologic features of skin tuberculosis may be reflective of the host's immune status.

Polymerase Chain Reaction Procedure

The polymerase chain reaction (PCR) procedure has been used increasingly to ascertain the presence of mycobacterial DNA in skin specimens.[7] Although the detection of specific DNA in tissues has yielded valuable information and will conceivably gain importance in the future, interpretation of the results of these tests in individual patients is still problematic.[8] In one study,[9] samples from 16 of 20 patients with sarcoidosis contained mycobacterial DNA, both tuberculous and nontuberculous. In another study[7] of patients with confirmed or highly probable cutaneous tuberculosis or with erythema induratum, PCR testing showed 100 percent sensitivity and specificity in multibacillary disease, but only 55 percent combined sensitivity and specificity in paucibacillary disease, and showed an 80 percent correlation with response to antituberculosis therapy.

SKIN DISEASES CAUSED BY *MYCOBACTERIUM TUBERCULOSIS/BOVIS* INFECTION

Infection with *M. tuberculosis* used to be thought to result in characteristic clinical features.[10] However, with increasing numbers of cases in immunocompromised individuals and improved diagnostic tools, many quite uncharacteristic manifestations have been discovered.

Primary Inoculation Tuberculosis (Tuberculous Chancre, Tuberculous Primary Complex)

Tuberculous chancre and affected regional lymph nodes constitute the tuberculous primary complex in the skin. The condition is believed rare, but its incidence may be underestimated. In some regions with a high prevalence of tuberculosis and poor living conditions, primary inoculation tuberculosis of the skin is not unusual. Children are most often affected. Sites of predilection are the face, including the conjunctivae and oral cavity, as well as the hands and lower extremities.

PATHOGENESIS Tubercle bacilli are introduced into the tissue at the site of minor wounds. Oral lesions may be caused by bovine bacilli in nonpasteurized milk and occur after mucosal trauma or tooth extraction. Primary inoculation tuberculosis is initially multibacillary but becomes paucibacillary as immunity develops.



▲ **FIGURE 184-1** Primary inoculation tuberculosis. Note tuberculous chancre on the thigh and regional lymphadenopathy. A positive tuberculin reaction is noted on the arm.

CLINICAL MANIFESTATIONS The chancre initially appears 2 to 4 weeks after inoculation and presents as a small papule, crust, or erosion with little tendency to heal. A painless ulcer develops, which may be quite insignificant or may enlarge to a diameter of more than 5 cm (Fig. 184-1). It is shallow with a granular or hemorrhagic base studded with miliary abscesses or covered by necrotic tissue. The ragged edges are undermined and of a reddish blue hue. As the lesions grow older, they become more indurated, with thick adherent crusts.

Wounds inoculated with tubercle bacilli may heal temporarily but break down later, giving rise to granulating ulcers. Mucosal infections result in painless ulcers or fungating granulomas. Inoculation tuberculosis of the finger may present as a painless paronychia. Inoculation of puncture wounds may result in subcutaneous abscesses.

Slowly progressive, regional lymphadenopathy develops 3 to 8 weeks after the infection (see Fig. 184-1) and may rarely be the only clinical finding. After weeks or months, cold abscesses may develop that perforate to the surface of the skin and form sinuses. The lymph nodes draining the primary glands may also be involved. Body temperature may be slightly elevated. The disease may take a more acute course, and in half the patients, fever, pain, and swelling simulate a pyogenic infection.

HISTOPATHOLOGY Early, there is an acute non-specific inflammatory reaction in both skin and lymph nodes, and mycobacteria are easily detected by Fite stain. After 3 to 6 weeks, the infiltrate and the regional lymph nodes acquire a tuberculoid appearance and caseation may occur.



Box 184-1

Differential Diagnosis of Primary Inoculation Tuberculosis

- Syphilis
- Tularemia
- Bartonellosis
- Sporotrichosis
- Other mycobacterioses

DIAGNOSIS Any ulcer with little or no tendency to heal and unilateral regional lymphadenopathy in a child should arouse suspicion. Acid-fast organisms are found in the primary ulcer and draining nodes in the initial stages of the disease. The diagnosis is confirmed by bacterial culture. The PPD reaction is negative initially and later converts to positive (see Fig. 184-1).

The differential diagnosis encompasses all disease with a primary complex (Box 184-1).

COURSE Untreated, the condition may last up to 12 months. Rarely, LV develops at the site of a healed tuberculous chancre. The regional lymph nodes usually calcify.

The primary tuberculous complex usually produces immunity, but reactivation of the disease may occur. Hematogenous spread may give rise to tuberculosis of other organs, particularly of the bones and joints. It may also lead to acute miliary disease with a fatal outcome. Erythema nodosum occurs in approximately 10 percent of cases.

Tuberculosis Verrucosa Cutis (Warty Tuberculosis)

PATHOGENESIS Tuberculosis verrucosa cutis is a paucibacillary disorder caused by exogenous re-infection (inoculation) in previously sensitized individuals with high immunity.

Inoculation occurs at sites of minor wounds or, rarely, from the patient's own sputum. Members of professional groups handling infectious material are at risk. Children may become infected playing on contaminated ground.

CLINICAL MANIFESTATIONS AND COURSE Lesions usually occur on the hands or, in children, on the lower extremities as a small asymptomatic papule or papulopustule with a purple inflammatory halo. They become hyperkeratotic and are often mistaken for a common wart. Slow growth and peripheral expansion lead to the development of a verrucous plaque with an irregular border (Fig. 184-2). Fissures discharging pus extend into the underlying brownish red to purplish infiltrated base. The lesion usually is solitary, but multiple lesions may occur. Regional lymph nodes are rarely affected.



▲ **FIGURE 184-2** Tuberculosis verrucosa cutis on the back of the hand.

Lesions progress slowly and, if untreated, persist for many years. Spontaneous involution eventually occurs, leaving an atrophic scar.

HISTOPATHOLOGY The most prominent histopathologic features are pseudoepitheliomatous hyperplasia with marked hyperkeratosis, a dense inflammatory infiltrate, and abscesses in the superficial dermis or within the pseudoepitheliomatous rete pegs. Epithelioid cells and giant cells are found in the upper and middle dermis. Typical tubercles are uncommon, and the infiltrate may be non-specific.

DIFFERENTIAL DIAGNOSIS (Box 184-2)

Lupus Vulgaris

LV is an extremely chronic, progressive form of cutaneous tuberculosis occurring in individuals with moderate immunity and a high degree of tuberculin sensitivity.

Box 184-2

Differential Diagnosis of Tuberculosis Verrucosa Cutis

- Warts or keratoses
- Hyperkeratotic lupus vulgaris
- Blastomycosis
- Chromomycosis
- Bromoderma
- Lesions due to other mycobacteria
- Hypertrophic lichen planus
- Tertiary syphilis

Once common, LV has declined steadily in incidence. It has always been less common in the United States than in Europe. Females appear to be affected two to three times as often as males; all age groups are affected equally.

PATHOGENESIS LV is a postprimary, paucibacillary form of tuberculosis caused by hematogenous, lymphatic, or contiguous spread from elsewhere in the body. Spontaneous involution may occur, and new lesions may arise within old scars. Complete healing rarely occurs without therapy.

CLINICAL MANIFESTATIONS Lesions are usually solitary, but two or more sites may be involved simultaneously. In patients with active pulmonary tuberculosis, multiple foci may develop. In approximately 90 percent of patients, the head and neck are involved. LV usually starts on the nose, cheek, earlobe, or scalp and slowly extends onto adjacent regions. Other areas are rarely involved.

The initial lesion is a brownish red, soft or friable macule or papule with a smooth or hyperkeratotic surface. On diascopy the infiltrate exhibits a typical apple jelly color. Progression is characterized by elevation, a deeper brownish color (Fig. 184-3A), and formation of a plaque (see Fig. 184-3B). Involution in one area with expansion in another often results in a gyrate outline border. Ulceration may occur. Hypertrophic forms appear as a soft nodule (see eFig. 184-3.1 in on-line edition) or plaque with a hyperkeratotic surface (see eFig. 184-3.2 in on-line edition). Involvement of the nasal or auricular cartilage may result in extensive destruction and disfigurement (Fig. 184-4). Atrophic scarring, with or without prior ulceration, is characteristic, as is recurrence within a scar. Fibrosis may be pronounced and mutilating.

The mucosae may be primarily involved or become affected by the extension of skin lesions. Infection is manifest as small, soft, gray or pink papules, ulcers, or friable granulating masses. Dry rhinitis is often the only symptom of early nasal LV, but lesions may also destroy the cartilage of the nasal septum. Scarring of the soft palate and laryngeal stenosis also occur.

After a transient impairment of immunity, particularly after measles (thus the term *lupus postexanthematicus*), multiple disseminated lesions may arise simultaneously in different regions of the body as a consequence of hematogenous spread from a latent tuberculous







▲ **FIGURE 184-3** **A.** Slightly raised, brownish plaque of lupus vulgaris. **B.** Large plaque of lupus vulgaris of 10 years' duration involving the cheek, jaw, and ear.

focus. During and after the eruption, a previously positive tuberculin reaction may become negative but will usually revert to positive as the general condition of the patient improves.

HISTOPATHOLOGY The most prominent histopathologic feature is the formation of typical tubercles. Secondary changes may be superimposed: epidermal thinning and atrophy or acanthosis with excessive hyperkeratosis or pseudoepitheliomatous hyperplasia. Acid-fast bacilli are usually not found. Non-specific inflammatory reactions may partially conceal the tuberculous structures. Old lesions are composed chiefly of epithelioid cells and may be impossible to distinguish from sarcoidal infiltrates (see eFig. 184-4.1 in on-line edition).

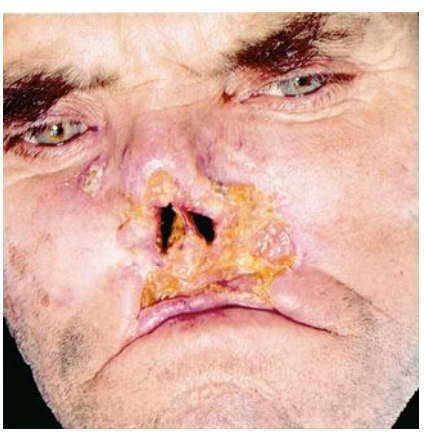

▲ **FIGURE 184-4** Lupus vulgaris of long duration that has led to the destruction of the nose. Ulcerating squamous cell carcinoma has developed on the upper lip.

DIAGNOSIS Typical LV plaques may be recognized by the softness of the lesions, brownish red color, and slow evolution. The apple jelly nodules revealed by diascopy are highly characteristic; finding them may be decisive, especially in ulcerated, crusted, or hyperkeratotic lesions. The result of the tuberculin test is strongly positive except during the early phases of postexanthematic lupus. Bacterial culture results may be negative, in which case the clinical diagnosis can usually be supported by positive PCR results for *M. tuberculosis* (Box 184-3).

COURSE LV is a very long-term disorder and without therapy progresses over many years to functional impairment and disfiguration (see Fig. 184-4). Long-standing LV may lead to the development of carcinoma (see Fig. 184-4). Squamous cell carcinomas outnumber basal cell carcinomas by far, and the risk of metastases is high. In 40 percent of patients there is associated tuberculous lymphadenitis, and 10 percent to 20 percent have active pulmonary tuberculosis or tuberculosis of the bones and joints.[11] Pulmonary tuberculosis is 4 to 10 times more frequent in patients with LV than in the general population.

Scrofuloderma (Tuberculosis Colliquativa Cutis)

Scrofuloderma is subcutaneous tuberculosis leading to cold abscess formation and a secondary breakdown of the overlying skin. It may be either multibacillary or paucibacillary.

Scrofuloderma represents contiguous involvement of the skin overlying another site of infection (e.g., tuberculous lymphadenitis, tuberculosis of bones and joints, or tuberculous epididymitis). Prevalence is higher among children, adolescents, and the aged.

Box 184-3

Differential Diagnosis of Lupus Vulgaris

- Sarcoidosis
- Lymphocytoma
- Discoid lupus erythematosus
- Tertiary syphilis
- Leprosy
- Blastomycosis or other deep mycotic infections
- Lupoid leishmaniasis

CLINICAL MANIFESTATIONS Scrofuloderma most often occurs in the parotidal, submandibular, and supraclavicular regions and may be bilateral. It first presents as a firm, subcutaneous nodule, usually well defined, freely movable, and asymptomatic. As the lesion enlarges it softens. After months, liquefaction with perforation occurs, causing ulcers and sinuses (Fig. 184-5). The ulcers are linear or serpiginous with undermined, inverted, bluish edges and soft, granulating floors. Sinusoidal tracts undermine the skin. Clefts alternate with soft nodules. Scar tracts develop and bridge ulcerative areas or even stretches of normal skin. Tuberculin sensitivity is usually pronounced.

HISTOPATHOLOGY Massive necrosis and abscess formation in the center of the lesion are non-specific. However, the periphery of the abscesses or the margins of the sinuses contain tuberculoid granulomas.

DIAGNOSIS If there is an underlying tuberculous lymphadenitis or bone and joint disease, the diagnosis usually presents no difficulty (Box 184-4). Positive results on culture confirm the diagnosis.

COURSE Spontaneous healing does occur, but the course is very protracted and it may be years before lesions have been completely replaced by scar tissue. Presence of the typical cribriform scars permits a correct diagnosis, even after the process has become quiescent. LV may develop at or near the site of scrofuloderma.



▲ **FIGURE 184-5** Scrofuloderma in the clavicular region. Note abscess formation, ulceration, and extrusion of purulent and caseous material.

Box 184-4

Differential Diagnosis of Scrofuloderma

- *Mycobacterium avium-intracellulare* lymphadenitis
- *M. scrofulaceum* infection
- Syphilitic gummas
- Sporotrichosis
- Actinomycosis
- Severe forms of acne conglobata
- Hidradenitis suppurativa

Metastatic Tuberculous Abscess (Tuberculous Gumma)

Orificial Tuberculosis (Tuberculosis Ulcerosa Cutis et Mucosae)

PATHOGENESIS Orificial tuberculosis is a rare form of tuberculosis of the mucous membranes and orifices that is caused by autoinoculation of mycobacteria from progressive tuberculosis of internal organs.

The underlying disease is far advanced pulmonary, intestinal, or, rarely, genitourinary tuberculosis. Mycobacteria shed from these foci in large numbers are inoculated into the mucous membranes.

CLINICAL MANIFESTATIONS A small yellowish or reddish nodule appears on the mucosa and breaks down to form a soft ulcer with a typical punched-out appearance, undermined edges, and circular or irregular border (Fig. 184-6). The ulcer floor often exhibits multiple yellowish tubercles and bleeds easily. The surrounding mucosa is edematous and inflamed. Lesions may be single or multiple and are extremely painful, resulting in dysphagia.

The tongue is most frequently affected, particularly the tip and the lateral margins, but the soft and hard palates are also common sites. In advanced cases the lips are involved, and the oral condition often represents an extension of ulcerative tuberculosis of the pharynx and larynx. In patients with intestinal tuberculosis, lesions develop around the anus, and in females with active genitourinary disease, the vulva is involved.



▲ **FIGURE 184-6** Orificial tuberculosis in advanced cavitary pulmonary tuberculosis.

HISTOPATHOLOGY There is a massive non-specific inflammatory infiltrate and necrosis, but tubercles with caseation may be found deep in the dermis. Mycobacteria are easily demonstrated.

DIFFERENTIAL DIAGNOSIS (Box 184-5)

COURSE Orificial tuberculosis is a symptom of advanced internal disease and usually portends a fatal outcome.

Acute Miliary Tuberculosis of the Skin (Tuberculosis Cutis Miliaris Disseminata)

Sequelae of Bacille Calmette-Guérin Inoculation

Vaccination with attenuated bovine BCG appears to protect infants and young children from the more serious forms of tuberculosis, but its ability to prevent disease in adults remains uncertain. In the United States guidelines for BCG immunization have been developed.

In the normal course of BCG vaccination, an infiltrated papule develops after approximately 2 weeks, attains a size of approximately 10 mm after 6 to 12 weeks, ulcerates, and then slowly heals, leaving a scar. Vaccination may provoke an accelerated reaction in a previously infected person. The regional lymph nodes may enlarge but usually heal without breaking down. Tuberculin sensitivity appears 5 to 6 weeks after vaccination.

The true incidence of complications caused by the BCG organism[12] is difficult to ascertain, but it is extremely low in comparison to the great number of vaccinations performed in Europe in the past 50 years. Problems include the following:

Box 184-5

Differential Diagnosis of Orificial Tuberculosis

- Syphilitic lesions (not painful)
- Aphthous ulcers
- Squamous cell carcinoma

- Lupus vulgaris at or near the vaccination site (latency of months to years)
- Koch phenomenon in individuals sensitive to tuberculin [see Tuberculin Reaction (Koch Phenomenon)]
- Regional adenitis, sometimes severe and with systemic symptoms, more often in children
- After deep injection, local abscesses, excessive ulceration
- Scrofuloderma with suppuration for 6 to 12 months
- Generalized tuberculid-like reactions (rare)
- Generalized adenitis, osteitis, organ tuberculosis (e.g., in the joints) occasionally

Nonfatal generalized complications occurr in 1 or 2 persons per million; a perforating regional adenitis appeared in 2 percent of vaccinated children in Denmark; and the incidence of postvaccination LV is estimated to be from 5 to 10 per million. Fatal disease caused by generalized BCG tuberculosis occurs in 1 in 10 million immunizations.

THE TUBERCULIDS

Lichen scrofulosorum, erythema induratum, papulonecrotic tuberculids, lupus miliaris disseminatus faciei, and other eruptions with rather exotic designations were originally included in the tuberculids (Table 184-2).

With the sharp decline in incidence and the effective treatment of tuberculosis in developed countries, the tuberculids also became rare. This does not apply to areas in which tuberculosis is still common, however, and with the recent resurgence of tuberculosis associated with AIDS in some Western countries, some tuberculids are also being observed again.

The pathogenic relationship of the tuberculids to tuberculosis is still poorly understood. Although there is no doubt that such a relationship exists for some tuberculids, in other cases it appears highly unlikely.

PCR testing revealed *M. tuberculosis* DNA in skin lesions of erythema induratum/nodular vasculitis and papulonecrotic tuberculid in one series of patients,[13] but in another results were uniformly negative.[14] Thus, *M. tuberculosis* infection may be responsible directly or indirectly for some cases of these diseases but not all, and the usefulness of lesional PCR testing may vary among clinical settings. Consistent with this statement, antituberculosis drugs are beneficial in some cases but not all; spontaneous involution may occur, and some patients appear to respond well



TABLE 184-2
Tuberculids

TERMINOLOGY/RELATIONSHIP TO TUBERCULOSIS	ENTITIES
Tuberculids: conditions in which *Mycobacterium tuberculosis/bovis* appears to play a significant role	Lichen scrofulosorum Papulonecrotic tuberculid
Facultative tuberculids: conditions in which *M. tuberculosis/bovis* may be one of several pathogenic factors	Nodular vasculitis/erythema induratum of Bazin Erythema nodosum
Non-tuberculids (conditions formerly designated as tuberculids; there is no relationship to tuberculosis)	Lupus miliaris disseminatus faciei Rosacea-like tuberculid Lichenoid tuberculid



to other therapies. It should be noted that, although not considered a tuberculid, sarcoidosis has been postulated to result from an immunologic reaction to mycobacterial antigens.[15]

The following discussion includes only those conditions for which a preponderance of the evidence supports a tuberculous etiology (see Table 184-2).

Lichen Scrofulosorum

EPIDEMIOLOGY AND PATHOGENESIS Lichen scrofulosorum is an uncommon lichenoid eruption ascribed to hematogenous spread of mycobacteria in an individual strongly sensitive to *M. tuberculosis*. Usually associated with chronic tuberculosis of the lymph nodes, bones, or pleura, it has also been observed after BCG vaccination and in association with *M. avium-intracellulare* infections.[16]

CLINICAL MANIFESTATIONS Lesions are usually confined to the trunk and occur most often in children and adolescents with active tuberculosis. The lesions are asymptomatic, firm, follicular or perifollicular flat-topped yellowish or pink papules, sometimes with fine scale. Lichenoid grouping is pronounced, and lesions may coalesce to form rough, discoid plaques. Lesions persist for months, but spontaneous involution eventually occurs. Antituberculosis therapy results in complete resolution within weeks.

HISTOPATHOLOGY Superficial tuberculoid granulomas develop around hair follicles or independent of the adnexa. Mycobacteria are not seen in the sections and cannot be cultured from biopsy material.

Box 184-6
Differential Diagnosis of Lichen Scrofuloderma

- Lichen planus
- Lichen nitidus
- Lichenoid secondary syphilis
- Micropapular forms of sarcoidosis

DIFFERENTIAL DIAGNOSIS (Box 184-6)

Papulonecrotic Tuberculid

Papulonecrotic tuberculid is a symmetric eruption of necrotizing papules, appearing in crops and healing with scar formation, that occurs preferentially in children or young adults. It is rarely reported but may not be uncommon in populations with a high prevalence of tuberculosis.

PATHOGENESIS As a rule, bacteria cannot be demonstrated in lesions. In most cases, the tuberculin test shows a positive reaction, and associated pulmonary or extrapulmonary tuberculosis is common. LV has been reported to evolve with papulonecrotic tuberculid. Lesions are reported to respond promptly to antituberculosis therapy whether or not a tuberculous focus is identified.

In studies of skin lesions in patients with papulonecrotic tuberculid, *M. tuberculosis* DNA was detected in approximately 50 percent of patients.[17–19] *M. kansasii* infection was documented in one patient.[20]

Some cases of papulonecrotic tuberculid have been associated with discoid lupus erythematosus, arthritis, or erythema nodosum and may therefore be triggered by antigens unrelated to *M. tuberculosis*.

CLINICAL MANIFESTATIONS Sites of predilection are the extensor aspects of the extremities, buttocks, and lower trunk (Fig. 184-7), but the eruption may become widespread. Distribution is symmetric and consists of disseminated crops of livid or dusky red papules with a central depression and an adherent crust over a crater-like ulcer. There is spontaneous involution, which leaves pitted scars.

HISTOPATHOLOGY Characteristically, a wedge-shaped necrotic area in the upper dermis extends into the epidermis. The inflammatory infiltrate surrounding this necrotic area may be nonspecific but is usually tuberculoid. Involvement of the blood vessels is a cardinal feature and consists of an obliterative and sometimes granulomatous vasculitis leading to thrombosis and complete occlusion of the vascular channels.

DIFFERENTIAL DIAGNOSIS (Box 184-7)

Nodular Vasculitis/Erythema Induratum of Bazin (See Chap. 68)

Erythema Nodosum (See Chap. 68)

TREATMENT OF CUTANEOUS TUBERCULOSIS

In general, the management of cutaneous tuberculosis is similar to that of tuberculosis of other organs.[21–24] Chemotherapy is usually the treatment of choice (Table 184-3), but ancillary measures may be required. Vaccines against *M. tuberculosis* are under development.[2]

Although they are not yet established as a therapeutic option, cytokines such



▲ **FIGURE 184-7** Papulonecrotic tuberculid on the forearm.

Box 184-7

Differential Diagnosis of Papulonecrotic Tuberculid

- Pityriasis lichenoides et varioliformis acuta
- Leukocytoclastic necrotizing vasculitis
- Lichen urticatus
- Prurigo
- Secondary syphilis

as interleukin 2, interferon-γ, interleukin 12, and granulocyte-macrophage colony-stimulating factor may help to control intracellular pathogens and thereby shorten the duration of therapy and overcome drug resistance.[25] The immunomodulatory drug thalidomide (see Chap. 236) may prove to be useful in controlling problems related to the inflammatory response that may follow treatment of multibacillary infection and could become a useful adjunctive drug, as it is in the treatment of leprosy.

Special Considerations in Treating Tuberculosis of the Skin

In contrast to systemic infection, for which triple-drug therapy is recommended, tuberculosis verrucosa cutis and localized forms of LV without evidence of associated internal tuberculosis may be treated with isoniazid alone for up to 12 months. Total doses of 80 to 140 g may be required. Because viable mycobacteria have been found in clinically healed lesions, treatment should be continued for at least 2 months after complete involution of the lesions. Surgical intervention is quite helpful in scrofuloderma, because it reduces morbidity and shortens the required length of chemotherapy. Small lesions of LV or tuberculosis verrucosa cutis are also best excised, but tuberculostatics should be given concomitantly. Plastic surgery is important as a corrective measure in cases of longstanding LV with mutilation.

DISEASES CAUSED BY MYCOBACTERIA OTHER THAN *M. TUBERCULOSIS*

MOTT were identified as human pathogens in 1938 (*M. fortuitum*), in 1948 (*M. ulcerans*), and in 1954 (*M. marinum*). Overshadowed by the infectious disease burden due to *M. leprae* and *M. tuberculosis*, however, the pathogenic potential of slow-growing MOTT species has been recognized only in recent decades. Because MOTT infections usually closely mimic infections with *M. tuberculosis* and the bacteria have strict and often unusual requirements for culture, they are still probably underdiagnosed.

Identification of Mycobacteria Other Than *M. tuberculosis*

As with other infectious diseases, the diagnosis of mycobacterial infection depends on the identification of the microorganism isolated from the host. Specimens for culture should be sent to a special laboratory familiar with the special growth requirements of these organisms.

Antigens for intradermal skin testing (PPDs) for many of the clinically relevant mycobacterial species have been prepared in analogy to PPD from *M. tuberculosis*, but their accessibility is very limited and they are therefore little used.

Histopathologic analysis is supportive but cannot distinguish among mycobacterial species, because all share similar histopathic features.[26]

Treatment is summarized in Table 184-4. Importantly, some MOTT organisms are resistant to standard tuberculosis therapy. PCR testing for mycobacterial DNA is not yet reliable enough to play a role in the diagnosis of disease but can sometimes be useful in distinguishing among species.

TABLE 184-3
Therapy Guidelines for *Mycobacterium tuberculosis* Infections

	Option 1		Option 2			Option 3
Antituberculosis Drugs	Initial 8 wk	Then 16 wk	Initial 2 wk	Then 6 wk	Then 16 wk	9 mo
Rifampin 10 mg/kg	Daily	2–3×/wk	Daily	Daily	Daily	3×/wk
Isoniazid 5 mg/kg	Daily	2–3×/wk	Daily	Daily	Daily	3×/wk
Pyrazinamide 30 mg/kg	Daily		Daily	Daily		3×/wk
Ethambutol 15 mg/kg	Daily		Daily	2×/wk		3×/wk
or						
Streptomycin 15 mg/kg						

Total duration of treatment is 6 mo except in patients with human immunodeficiency virus infection, in whom treatment duration is at least 9 mo.
Proof of culture conversion cannot be expected in the majority of cases of tuberculosis of the skin.

DISEASES CAUSED BY MYCOBACTERIA OTHER THAN *M. TUBERCULOSIS* AT A GLANCE



- A heterogeneous group of diseases caused by a variety of obligate or facultatively pathogenic mycobacteria other than those of the *Mycobacterium tuberculosis* complex.
- Involvement depends on the type of mycobacterium, the route of infection, and the immune status of the host.
- Various organs may be involved.
- Mycobacteria other than *M. tuberculosis* (MOTT) are more often the cause of skin disease than *M. tuberculosis*.
- Diagnosis relies on histopathologic analysis and the results of culture.
- Incidence is unknown, but endemic areas exist for certain types of MOTT.
- Treatment is unlike that of tuberculosis, and no strict international guidelines have been developed. Effective antibiotics are known for each mycobacterial species but should be checked by sensitivity testing.

Pathology and Pathogenesis

MOTT are widely distributed in nature and are usually commensals or saprophytes rather than pathogens. Atypical mycobacteria are usually acquired from environmental sources such as water or soil, and their role in disease reflects their natural distribution and, possibly, local lifestyles. These organisms are thought to cause mycobacterial skin disease more often than does *M. tuberculosis*. Cases tend to be sporadic, but certain types of exposures may lead to small community outbreaks.[1,3] Any organ or organ system may be affected



TABLE 184-4
Treatment of Infections with Mycobacteria Other Than *M. tuberculosis*

Treatment	*Mycobacterium* Species							
	ULCERANS	*MARINUM*	*KANSASII*	*AVIUM-INTRACELLULARE*	*SCROFULACEUM*	*HAEMOPHILUM*	*CHELONAE*	*FORTUITUM*
Amikacin			+				+	+
Ansamycin				+				
Azithromycin				+				
Cefoxitin								+
Ciprofloxacin								+
Clarithromycin				+	+		+	
Clofazimine	+			+				
Co-trimoxazole	+							
Cycloserine			+					
Dapsone	+							
Doxycycline		+					+	
Erythromycin							+	
Ethambutol[a]	+	+	+	+				
Ethionamide			+	+				
Imipenem								+
Isoniazid[a]			+	+	+			
Kanamycin			+					
Minocycline	+	+	+	+		+[b]		
Rifampicin[a]	+	+	+	+	+			
Rifamycin			+	+		+		
Streptomycin[a]	+		+	+				
Tobramycin								+
Surgery	+				+		+	+

[a]Usual antituberculosis drugs.
[b]Alone or in combination with ciprofloxacin or rifampicin.

TABLE 184-5
Organ Involvement in Infections with Atypical Mycobacteria

Mycobacterial Species	Organ Involvement	
	Skin, Subcutis	Lymph Nodes, Other Organs
Mycobacterium tuberculosis/bovis complex (including *M. africanum* and bacille Calmette-Guérin)	+	+
M. marinum	+	–
M. ulcerans	+	–
M. gordonae	+	–
M. haemophilum	+	–
M. kansasii	+	+
M. avium-intracellulare complex (including *M. scrofulaceum*)	+	+
Fast growers: *M. fortuitum*, *M. chelonae*, *M. abscessus*	+	–



(Table 184-5), but MOTT seem much less likely to disseminate than *M. tuberculosis*, and infections usually run a more benign and limited course. As a rule, MOTT are much less responsive to antituberculosis drugs but may be sensititve to other chemotherapeutic agents.

Only two organisms, *M. ulcerans* and *M. marinum*, produce a characteristic clinical picture. An immunosuppressed state of the host or damage to a particular organ (e.g., in *M. kansasii* infection of the lung) facilitates these infections.

New mycobacterial pathogens are described from time to time, which suggests that their full pathogenic potential is not yet appreciated.

Skin Infections with Mycobacteria Other Than *M. tuberculosis*

MYCOBACTERIUM ULCERANS The natural habitat of *M. ulcerans* is still not known, and it has never been found outside the human body, but *M. ulcerans* infection occurs in wet, marshy, or swampy areas and seems to have to do with contaminated water. *M. ulcerans* is the third most frequent mycobacterial pathogen, after *M. tuberculosis* and *M. leprae*.

Clinical Manifestations. The disease is found most often in children and young adults, and affects females more often than males. A subcutaneous nodule gradually enlarges and eventually ulcerates. A blister may develop before ulceration. The ulcer is deeply undermined, and necrotic fat is exposed (Fig. 184-8). The preceding nodule as well as the ulcer is painless, and the patient continues to feel well. The lesions may occur anywhere on the body but tend to be limited to the extremities in adults. They may be large, involving a whole limb. The ulceration may persist for months and years, and healing and progression of the ulceration may occur in the same patient. This process may lead to appreciable and sometimes disabling scarring and lymphedema. Neither lymphadenopathy nor any constitutional signs appear at any time unless the disease process is complicated by bacterial superinfection.



▲ **FIGURE 184-8** *Mycobacterium ulcerans* infection in a child in Uganda. The knee bears an ulcer with an infiltrated undermined margin and a base of necrotic adipose and connective tissue. (Used with permission from M. Dietrich, MD.)

Box 184-8

Differential Diagnosis of *Mycobacterium ulcerans* Lesions

- Early lesions
  - Foreign body granuloma
  - Phycomycosis
  - Nodular fasciitis
  - Panniculitis
  - Nodular vasculitis
  - Sebaceous cyst
  - Appendageal tumor
- Late lesions
  - Necrotizing cellulitis
  - Blastomycosis or other deep fungus infection
  - Pyoderma gangrenosum
  - Suppurative panniculitis

Differential Diagnosis. (Box 184-8)

MYCOBACTERIUM MARINUM (MYCOBACTERIUM BALNEI) *M. marinum* occurs in freshwater and saltwater, including swimming pools and fish tanks.

Clinical Manifestations. Risk factors for *M. marinum* infection are a history of trauma and water- or fish/seafood-related hobbies and occupations. The disease begins as a violaceous papule at the site of a trauma 2 to 3 weeks after inoculation. Patients may have a nodule or a psoriasiform or verrucous plaque at the site of inoculation, usually the hands, feet, elbows, or knees (Fig. 184-9). The lesions may ulcerate. Usually the lesions are solitary, but occasionally sporotrichoid spread occurs. They may heal spontaneously within 1 to 2 years, with residual scarring. Occasionally the lesions are suppurative rather than granulomatous and may be multiple in both normal or immunosuppressed hosts.

Differential Diagnosis. (Box 184-9)

MYCOBACTERIUM KANSASII *M. kansasii* is the atypical mycobacterium most closely related to *M. tuberculosis*. It is usually acquired from the environment. Endemic areas include Texas, Louisiana, the Chicago area, California, and Japan. Skin disease caused by *M. kansasii* usually occurs in adults and is more common in individuals with underlying immunosuppression caused by Hodgkin disease, treatment for organ transplantation, or AIDS. Inoculation is usually attributable to minor trauma such as a puncture wound.

Clinical Manifestations. *M. kansasii* infection may present in several forms. Most frequently, there are papules in a sporotrichoid distribution. Sometimes, subcutaneous nodules extend to deeper structures and may result in a carpal tunnel syndrome or joint disease. An ulcerated plaque may also develop as a metastatic lesion. Disseminated disease caused by *M. kansasii* infection occurs in immunosuppressed patients, and such patients have cellulitis and abscesses rather than granulomatous lesions. The most commonly affected organ is the lung, usually in patients with other pulmonary conditions (silicosis, emphysema). Infection may also cause cervical lymphadenopathy. As with *M. tuberculosis*, *M. kansasii* present in nasopharyngeal secretions can lead to periorificial cutaneous infection. These infections usually progress slowly, although a chronic stable lesion or even spontaneous regression may occur. Drug therapy should be initiated as soon as the diagnosis is made.



▲ **FIGURE 184-9** **A.** *Mycobacterium marinum* infection on the back of the hand. Granulomatous nodular lesion with central ulceration at the site of inoculation. (Used with permission from A. Kuhlwein, MD.) **B.** Verrucous, violaceous plaque with central spontaneous clearing occurring at the site of an abrasion sustained in a fish tank. The lesion was caused by *M. marinum*.

Box 184-9

Differential Diagnosis of *Mycobacterium marinum* Lesions

- Other mycobacterial infections
- Blastomycosis
- Coccidioidomycosis
- Histoplasmosis
- Sporotrichosis
- Nocardiosis
- Tertiary syphilis
- Yaws

Differential Diagnosis. (Box 184-10)

MYCOBACTERIUM SCROFULACEUM *M. scrofulaceum* is widely distributed in the environment.

Clinical Manifestations. The usual manifestation of *M. scrofulaceum* infection is cervical lymphadenitis, frequently unilateral, in children, mainly between the ages of 1 and 3 years. Submandibular and submaxillary nodes are typically involved, rather than the tonsillar and anterior cervical nodes as is characteristic for *M. tuberculosis* infection. There are no constitutional symptoms. Involved lymph nodes enlarge slowly over several weeks and eventually ulcerate and develop fistulae. There rarely is evidence of lung or other organ involvement. In most cases, the disease is benign and self-limited.

Differential Diagnosis. The differential diagnosis includes other forms of bacterial lymphadenitis; viral infections, including mumps and mononucleosis; and malignancy, including solid tumors, lymphoma, and leukemia.

MYCOBACTERIUM AVIUM-INTRACELLULARE *M. avium-intracellulare* encompasses organisms with a wide variety of microbiologic and pathogenic properties. Well over 20 sub-types can be separated by immunologic techniques, although this is not necessary for clinical purposes.

Box 184-10

Differential Diagnosis of *Mycobacterium kansasii* Lesions

- Sporotrichosis
- Tuberculosis
- Other granulomatous infections of the skin



These organisms are usually grouped together with *M. scrofulaceum* in the so-called *M. avium-intracellulare–scrofulaceum* complex but are separated here for clinical reasons. Whereas *M. scrofulaceum* produces only a benign, self-limited lymphadenopathy with no organ involvement, *M. avium-intracellulare* infection usually causes lung disease or, less frequently, osteomyelitis. It may also produce a cervical lymphadenitis with sinus formation that is clinically indistinguishable from tuberculous scrofuloderma.

Clinical Manifestations. Primary skin disease caused by *M. avium-intracellulare* has been reported in rare instances, presenting as single or multiple painless, scaly yellowish plaques, sometimes resembling LV, or as subcutaneous nodules with a tendency to ulceration and a slowly progressive, chronic course. Sometimes, skin involvement occurs secondary to disseminated infection with *M. avium-intracellulare*. Skin lesions have included generalized cutaneous ulcerations, granulomas, infiltrated erythematous lesions on the extremities, pustules, and soft-tissue swelling. *M. avium-intracellulare* infections are an important cause of morbidity in patients with AIDS (see Chap. 198).

MYCOBACTERIUM SZULGAI, MYCOBACTERIUM HAEMOPHILUM, MYCOBACTERIUM GENAVENSE *M. szulgai*, *M. haemophilum*, and *M. genavense* are rarely found to cause human disease in cases of otherwise unexplained cervical lymphadenitis, cellulitis, draining nodules and plaques, bursitis, pneumonia and subcutaneous granulomatous eruptions.

MYCOBACTERIUM FORTUITUM, MYCOBACTERIUM CHELONAE, MYCOBACTERIUM ABSCESSUS *M. fortuitum*, *M. chelonae*, and *M. abscessus*, three species of fast-growing, facultative pathogenic mycobacteria, were previously grouped in the *M. fortuitum* complex but are now recognized as distinct species. These organisms seem to be widely distributed and can commonly be found in soil and water. Contamination of various materials, including surgical supplies, occurs but does not always result in clinical disease.

Clinical Manifestations. *M. fortuitum*, *M. chelonae*, and *M. abscessus* cause similar clinical diseases. Infection usually follows a puncture wound or a surgical procedure. The disease manifests itself as a painful red infiltrate at the site of inoculation; there are no signs of dissemination and no constitutional symptoms. Cold postinjection abscesses, especially in the tropics, may also be caused by fast-growing mycobacteria.

The lesion is a dark red nodule, often with abscess formation and clear fluid drainage. Healthy children and adults may become infected, but disseminated disease usually occurs in hemodialysis patients or other immunologically compromised individuals. The disease course consists of multiple recurrent episodes of abscesses on the extremities or a generalized macular and papular eruption. Internal organs may be involved.

Histopathology. There is simultaneous occurrence of polymorphonuclear leukocyte microabscesses and granuloma formation with foreign body–type giant cells, the so-called *dimorphic inflammatory response*. There is usually necrosis but no caseation. Acid-fast bacilli may occasionally be found within microabscesses.

Diagnosis and Treatment. Organisms of the *M. fortuitum* complex may be identified by special laboratories to permit a rational treatment.

KEY REFERENCES

The full reference list for all chapters is available at www.digm7.com.

1. Rastogi N et al: The mycobacteria: An introduction to nomenclature and pathogenesis. *Rev Sci Tech* **20**:21, 2001
5. Pai M, Kalantri S, Dheda K: New tools and emerging technologies for the diagnosis of tuberculosis: Part I. Latent tuberculosis. *Expert Rev Mol Diagn* **6**:413, 2006
6. Tsiouris SJ et al: Results of a tuberculosis-specific IFN-γ assay in children at high risk for tuberculosis infection. *Int J Tuberc Lung Dis* **10**:939, 2006
8. Barbagallo J et al: Cutaneous tuberculosis: diagnosis and treatment. *Am J Clin Dermatol* **3**:319, 2002
10. Zouhair K et al: Cutaneous tuberculosis in Morocco. *Int J Infect Dis* **11**:209, 2007 [Epub, Jul. 5 2006]
21. Taylor Z et al: Controlling tuberculosis in the United States. Recommendations from the American Thoracic Society, CDC, and the Infectious Diseases Society of America. *MMWR Recomm Rep* **54**:1, 2005
24. Iseman MD: Tuberculosis therapy: Past, present and future. *Eur Respir J* **Suppl 36**:87s, 2002



CHAPTER 185

Actinomycosis, Nocardiosis, and Actinomycetoma

Francisco G. Bravo
Roberto Arenas
Daniel Asz Sigall

Actinomyces and *Nocardia* are a group of filamentous bacteria belonging to the same class, Actinobacteria, and same order, Actinomycetales. They cause human disease with prominent skin involvement. Microorganisms under this category were wrongly classified as fungi for a long time, because of their tendency to produce branching filaments, mimicking radiating hyphae (form the Greek *actino*, meaning *sun*). Their taxonomy is still evolving, resulting in continuous reclassification of different species in old and new families. Anaerobic endogenous *Actinomyces*, part of our normal respiratory, intestinal, and genito-urinary flora, will cause localized suppurative disease with fistula formation that is analogous to the lumpy jaw of cattle. Aerobic environmental *Nocardia* sp. causes diseases ranging from cellulitis to paronychia to abscesses, with the most striking presentation being a lymphocutaneous, sporotrichoid syndrome. In addition, other aerobic environmental species of *Nocardia* and *Actinomyces* will cause one of the two known forms of mycetoma, the actinomycetoma.

The sulfur granule or grain, a clumping of filamentous bacteria seen in infected living tissue, is considered characteristic of the infection by these microorganisms, but is not always present and is also not specific (Table 185-1). Practicing dermatologists should be aware of the various morphologic variants of these diseases, so that measures may be taken to ensure the appropriate culturing techniques required for isolation.

ACTINOMYCOSIS AT A GLANCE



- Worldwide distribution, relatively uncommon.
- Actinomyces are part of normal upper respiratory, intestinal, and genitourinary flora.
- *Actinomyces israelii* is the most common causative agent, usually as a polymicrobial infection, mixed with Gram-positive cocci and anaerobes.
- Classical presentation is a chronic, localized infiltrative process with abscess fistula formation and draining sinuses.
- Most common location is cervico-facial (related to dental pathology), followed by abdominal, pelvic, and chest wall involvement.
- Pathologic findings include a chronic inflammatory infiltrate with granulation tissue or granuloma formation.
- Grains (sulfur granules) are characteristic but neither invariably present nor pathognomonic.

ACTINOMYCOSIS

Epidemiology

Described by Israel in 1878, the disease has a worldwide distribution. It is more commonly seen in males, ages 20 to 60 years old, with females affected at a younger age. In the pre-antibiotic era, the incidence in the Netherlands and Germany was 1:100,000 inhabitants/year; in the 1970s, the reported incidence in Cleveland, Ohio, was 1:300,000 inhabitants/year, and in 1984, in Cologne, Germany, it was estimated to be 1:40,000 inhabitants/year.[1] Recently, an increased incidence of genitourinary actinomycosis has been described in females, related to the use of intrauterine devices (IUDs). Nowadays, there is a tendency to subtle cases with more limited involvement, many of them circumscribed to the oral cavity. Diagnosis in such circumstances requires a high index of suspicion.

Etiology and Pathogenesis

The term *actinomycosis* implies disease produced by endogenous, anaerobic, or microaerophile, Gram-positive, non-spore–forming bacteria, belonging to the families Actinomycetaceae and Propionibacteriaceae, of the order Actinomycetales; and Bifidobacteriaceae, of the order Bifidobacteriales.[1] Their normal habitat is human and animal mucosal surfaces, with considerable host specificity, from the mouth to the upper respiratory, gastrointestinal, and female genital tract. Species known to cause disease in humans include *A. israelii*, *A. naeslundii*, *A. gerencseriae*, *A. viscosus*, *A. odontolyticus*, and *A. meyeri*, as well as *Propionibacterium propionicum* and *Bifidobacterium dentium*. The disease in most cases is mixed with other microorganisms sharing the same habitat, so it should be considered a synergistic infection, with the *Actinomyces* playing the role of guiding organism, defining the course, the symptoms, and the ultimate prognosis. Accompanying organisms may vary in number, from one to nine different species, and may include coagulase negative staphylococci, *Staphylococcus aureus*, α- and β-hemolytic streptococci, microaerophile and anaerobic streptococci, *Fusarium* and *Bacteroides* sp., and even *Propionibacterium* sp. other than *P. propionicum*.[1] This concomitant flora may be in part responsible for the course of the process. If pyogenic bacteria are involved, such as *S. aureus* or β-hemolytic streptococci, the lesion will be acutely inflammatory and painful. If, on the contrary, anaerobes predominate, the course will be subacute and insidious. A particular more chronic course is seen when *A. israelii* or *A. gerencseriae* is accompanied by *Actinobacillus actinomycetemcomitans*. In recent years, with better culturing techniques, more than one *Actinomyces* have been isolated from one single lesion in several patients, underlying the possibility that single bacterial isolation, common in the past, was a technical artifact.

The infection has its portal of entry at a break on a mucous membrane. Most of

TABLE 185-1
Infectious Diseases with Production of Grains

DISEASE	ACTINOMYCOSIS	NOCARDIOSIS	ACTINOMYCETOMA	EUMYCETOMA	BOTRYOMYCOSIS
Clinical pattern	Lump with draining sinuses	Sporotrichoid, cellulitis	Lump with draining sinuses	Lump with draining sinuses	Lump with draining sinuses
Site	Cervico-facial, thorax, abdomen, pelvic	Extremities (upper > lower)	Feet, back, extremities	Feet mainly	Hand, head, feet
Source	Endogenous flora	Environment	Environment	Environment	Endogenous and environment
Most common causing agent	*Actinomyces israelii*	*Nocardia brasiliensis* *N. asteroides*	*N. brasiliensis* *Actinomadura madurae* *A. pelletieri* *Streptomyces somaliensis*	*Madurella mycetomatis* *M. grisea* *Pseudallescheria boydii*	*Staphylococcus aureus* *Escherichia coli* *Pseudomonas aeruginosa*
Presence of grains, clinically or in tissue	Common	Rare (only disseminated)	Always	Always	Always
Content of grain	Filamentous bacteria	Filamentous bacteria	Filamentous bacteria	Hyphae	Cocci
Staining	Gram positive	Gram positive Weak acid-fast bacillus	Gram positive Weak acid-fast bacillus (only if *Nocardia*)	Periodic acid-Schiff, Grocott	Gram positive





cervical and facial cases originate from periapical abscesses or after dental procedures. Thoracic cases represent involvement of the chest wall by continuity either from pleural or lung disease acquired by obstruction or aspiration. The same mechanism of spreading applies to disease of the abdominal wall, secondary to gut or genital pathology, following appendicitis, diverticulitis, surgery, or trauma. Perineal disease occurs as a consequence of involvement of the internal organs of the pelvis, secondary to use of an intravaginal device or IUD. The only exception to the endogenous origin of the infection is hand involvement that follows fist or bite trauma.[2]

In tissue, the bacteria cluster in filamentous aggregates, the so-called *sulfur granules* (grains; see Table 185-1). They are commonly surrounded by acute and chronic inflammation, usually neutrophils, granulation tissue, and fibrosis. Granuloma formation is unusual. The fistula formation may give way to drainage of granules, although under no circumstances should their presence be considered by itself specific for this disease.

Clinical Findings

Actinomycosis should always be suspected when dealing with one of three features: a mass-like inflammatory infiltrate of the skin and subcutaneous tissue, sinus formation with drainage, and a relapsing or refractory clinical course after short-term therapy with antibiotics. Actinomycotic granules may be seen macroscopically.

Cervical actinomycosis is the most frequent form of disease,[3] accounting for approximately 55 percent of cases. Commonly, there is a history of poor dental hygiene, dental or periodontal disease, dental procedure, surgery, or penetrating trauma through the oral mucosa. Most of the infections start as a periapical abscess. The most common location is on the jaw angle and high cervical area (60 percent), followed by the cheek (16 percent), the chin (13 percent), and less commonly, the temporo-mandibular joint and the retro-mandibular area. The lesion starts as a solid mass in any of those locations, and initially may be confused with a neoplastic process (Fig. 185-1). It may eventually progress to form recurring abscesses and later will spread to adjacent structures, with no sparing of anatomic planes. Propagation to lymph nodes is uncommon but eventually may involve the orbit, cranium, spine, and even vascular structures. The lesion is sometimes reported as painless, but pain may be present, as well as fever and leukocytosis. With extension to the skin surface, sinus tracts appear (Fig. 185-2). The overlying skin may have a purplish red hue. Trismus may develop. Bone involvement is present in 10 percent of cases, mostly the jaw. More limited disease may produce a mass or an ulcer, affecting any structure in the mouth or the nasopharyngeal region. Extension to the ear may present as chronic otitis media or mastoiditis. In addition to orbital involvement, there are reported cases of lacrimal canaliculitis and endophthalmitis.



▲ **FIGURE 185-1** Cervico-facial actinomycosis. A solid mass on the mandibular angle that can be confused with a neoplastic process.



▲ **FIGURE 185-2** Typical cervico-facial actinomycosis: a lump with sinus formation. (Used with permission from Wilson Delgado, DDS; and Lepoldo Meneses, DDS; Universidad Peruana Cayetano Heredia, Lima.)

Thoracic actinomycosis comprises 15 percent of cases. The common source of infection is the aspiration of microorganism from the oropharynx, although other routes are possible, such as propagation of cervico-facial disease to the mediastinum. The disease may involve the lung, pleura, mediastinum, and chest wall. The course is indolent, with chest pain, fever, weight loss, cough, and less frequently, hemoptysis, mimicking tuberculosis. Radiologically, the disease will present as a mass or pneumonia, with pleural involvement by continuity. Relevant to dermatologists, up to 26 percent of cases will have chest wall involvement,[4] with the developing of a cutaneous abscess and sinus formation (Fig. 185-3). Parenchymal, pleural, and chest wall disease occurring together will make actinomycosis a most likely diagnosis. Mediastinal actinomycosis may show either as anterior chest wall disease (rarely sternum involvement), or paraspinal abscess. Involvement of breast tissue and breast implants has also been described.

Abdominal actinomycosis represents about 20 percent of all cases. It presents as a consequence of spreading from the gastrointestinal tract or from the female genital tract, linked to IUD use. Appendicitis and diverticulitis is a common precipitating event. Any organ in the peritoneal cavity may be affected; by continuity, the disease may spread to the abdominal wall. An inflammatory mass may appear in the skin surface of the abdominal region or the perineum, with later development of sinuses. In the perianal area, multiple abscesses and fistula formation may occur. From there on, spreading to buttocks, thigh, scrotum, or groin may follow.

Primary pelvic disease most commonly originates from ascending infection from the female genital tract and less common, following abdominal disease. The role of IUD as a risk factor has been well established and is usually associated to prolonged use, 8 years on average.

Punch or fist actinomycosis represents a particularly uncommon but interesting clinical presentation.[2] It usually follows blunt trauma of a closed fist against an adversary's mouth; similar findings may originate from a human bite. It usually involves the proximal phalanges and



▲ **FIGURE 185-3** Thoracic actinomycosis from a patient who died from disseminated disease.

metacarpal bones. First a soft tissue infection, it will eventually spread to the bony structures. Grains are commonly seen in this particular form.

Actinomycosis of the central nervous system (CNS) may present as brain abscess, meningitis, meningoencephalitis, subdural empyema, actinomycoma, and spinal abscess. It is usually secondary to hematogenous spread.

Laboratory tests considered useful include direct examination of draining material, culture, and biopsy. Direct examination will show the presence of filamentous *Actinomyces* on Gram stain. The isolation of *Actinomyces* in culture should be considered diagnostic, if coming from a sterile site. However, positive culture rates are as low as 35 percent in some series. The processing should be done in anaerobic conditions, and when all techniques available today are used, the percentage of isolates that cannot to be identified is as low as 2.8 percent.[1]

The presence of granules, either microscopically or macroscopically, is very relevant, especially if obtained from tissues not connected to mucosal surfaces. Grains are usually yellow (hence the name *sulfur granules*), but can be white, pinkish gray, gray, or brown. In tissue samples, special stains, such as Brown-Brenn, Gram, Giemsa, or Gomori stains, are required to demonstrate filamentous structures. The number of grains is usually scanty: only one single granule was identified from 25 percent of specimens in a study of 181 cases.[3] The Splendore-Hoeppli phenomenon, a rim of eosinophilic material, may surround the granules in tissue cuts. The lack of staining with Fite modified acid-fast stain separates *Actinomyces* from *Nocardia* sp. Eumycetoma granules stain positive with periodic acid-Schiff and Gomori, whereas granules from Botryomycosis should show clumps of bacteria. Direct immunofluorescent staining is available for some species, including *A. israelii* (see Table 185-1).

Differential Diagnosis

Depending on the site affected, the differential diagnosis will include infections such as tuberculosis, non-infectious inflammatory processes such as hidradenitis and inflammatory bowel disease, and neoplasia (Box 185-1).

Box 185-1

Differential Diagnosis of Actinomycosis (Site-Specific)

Most Likely

- Face: tuberculosis, odontogenic abscesses, parotid tumors
- Chest: tuberculosis, neoplasm, pyogenic infections
- Abdomen and pelvis: tuberculosis, inflammatory bowel disease, hidradenitis suppurativa, neoplasm

Consider

- Face: lupus panniculitis, granuloma inguinale
- Pelvis: granuloma inguinale

Prognosis and Therapy

There is general agreement that the treatment of actinomycosis requires high-dose antibiotics to be given for a long period. The treatment of choice is penicillin G, 18 to 24 million units intravenously for 2 to 6 weeks, followed by oral penicillin or amoxicillin, to be given for 6 to 12 months. Cervico-facial disease or any more limited disease can receive a shorter course of therapy. A good rule to follow is to give therapy until full resolution of clinically evident disease. Alternative treatment for those allergic to penicillin includes tetracycline, doxycycline, erythromycin, and clindamycin. Imipenem has been used successfully as short-term therapy. Chloramphenicol is the alternative to penicillin in cases of CNS involvement. Risk factors for death or relapse include duration of disease longer than 2 months, lack of antibiotic therapy or surgical therapy, and needle aspiration rather than open drainage or excision.

With early diagnosis and more limited disease, as compared to the bulky disease of the past, treatment can be shorter: 30 days for cervico-facial disease and 3 months for pelvic or thoracic disease.[5] Periapical actinomycosis can be successfully treated with curettage and 10 days of antibiotic therapy.

Surgery is indicated for bulky disease involving the chest, abdomen, pelvis, and CNS. It should be directed to resection of necrotic tissue, excision of sinus tracts, draining of empyemas and abscesses, and curettage of bone, always accompanied by antibiotic therapy.

Antibiotics that are effective against synergistic microbes that accompany the *Actinomyces* can reasonably be included in the initial therapy.

Prevention

Good oral hygiene and prevention of periodontal disease may decrease colonization by *Actinomyces*. Physicians dealing with patients using an IUD should be aware of the risk of developing the disease.

NOCARDIOSIS AT A GLANCE



- Aerobic Gram-positive filamentous bacteria.
- Worldwide distribution, environmentally acquired infection, due to primary traumatic inoculation.
- Pulmonary infections mostly in immunocompromised patients and skin infections mostly in immunocompetent patients.
- Skin disease mostly caused by *Nocardia brasiliensis*; less commonly *N. asteroides*, *N. otidiscaviarum*, and *N. farcinica*.
- Cutaneous nocardiosis can take the form of either cellulitis or more characteristic lymphocutaneous nodules in a sporotrichoid pattern; skin lesions also occur in disseminated disease.
- Diagnosis is based on Gram stain of clinical specimen showing thin, gram-positive branching bacteria, weakly positive with acid-fast staining; microbiologic isolation of *Nocardia* sp. is diagnostic, but requires keeping cultures under observation 5 to 7 days.
- Treatment: sulfonamides.

NOCARDIOSIS

Epidemiology

The *Nocardia* sp. are aerobic, Gram-positive, filamentous, higher bacteria found worldwide in soil and decaying organic plant matter. They can be found in house dust, beach sand, garden soil, and swimming pools. They are able to cause disease in many organs, including the skin. Approximately 1000 cases of nocardiosis occur annually in the United States.[6] Cutaneous disease comprises 5 percent to 22 percent of all cases.[6] A higher incidence of primary cutaneous nocardiosis in Europe may be explained on the basis of more frequent isolation of *N. brasiliensis* in the environment. Patients have also been described in India and Argentina.[4] Disease occurs most commonly in males.

Immunocompromised patients account for 50 percent of cases, mostly pulmonary,



systemic, and CNS infections. They are commonly seen in transplant patients, patients with acquired immunodeficiency syndrome (AIDS)[4] or malignancy, or those receiving steroids. Primary cutaneous disease is most commonly seen in immunocompetent patients and has been reported rarely in children in United States, mostly in the south and southwestern part of the country.[7]

Etiology and Pathogenesis

The *Nocardia* sp. of medical importance include *N. asteroides*, most commonly associated with lung and systemic disease, and *N. brasiliensis*, most commonly associated with skin infection. Other species include *N. farcinica*, *N. otidiscaviarum*, *N. nova*, *N. pseudobrasilensis*, *N. transvalensis*, and *N. abscessus*. It is only recently that many of this species have been completely separated, especially those of the *N. asteroides* group, including *N. farcinica* and *N. nova*. It is interesting to note that *Nocardia* sp. belong to a subgroup of bacteria called the *aerobic nocardioform actinomycetes* that also include *Mycobacterium*, *Corynebacterium*, *Rhodococcus*, and *Gordona*. All these microorganisms have mycolic acid as constituent of their cell wall, which explains the varying acid fastness on appropriate staining. The proposed etiologic agent for Whipple disease, *Tropheryma whippelii*, also belongs to this group.

The usual inflammatory response in infected tissue is neutrophilic, with branching, beading filamentous bacteria within abscesses. Sulfur granules are uncommon in primary cutaneous nocardiosis; they have been described in disseminated disease. They are more commonly seen when the clinical picture is that of mycetoma (see Actinomycetoma).

Clinical Findings

Cutaneous involvement by *Nocardia* can manifest either as cellulitis or more characteristically, as lymphocutaneous nodules in a sporotrichoid pattern. Disseminated disease can also present in the skin as a consequence of hematogenous spread. In most series, skin disease is second only to pulmonary involvement in frequency. Mycetoma due to *Nocardia* is discussed in Clinical Findings under Actinomycetoma.

Predisposing factors for primary cutaneous nocardiosis include soil or sand exposure while gardening or farming; or superficial injury from domestic shrubbery, outdoor falls, or accidents. The frequent history of thorn injury or gardening may suggest incorrectly a diagnosis of sporotrichosis. Cat scratches or insect bites may be also the portal of entry, especially in children.[7]

The most common cause of primary cutaneous nocardiosis is *N. brasiliensis*, but *N. asteroides*, *N. otidiscaviarum*, *N. nova*, and *N. farcinica* have also been implicated. Most patients are immunocompetent, but *Nocardia* cutaneous infection may also occur in the context of immunosuppression. A recent series of nocardial infection in AIDS patients showed skin lesions in 11 percent of cases, most commonly cutaneous abscesses and suppurative adenitis.[4]

The disease has been also described in ulcerative bullous, linear/keloid, and nodulo-pustular forms (Fig. 185-4A) that may evolve into the more specific sporotrichoid pattern (see Fig. 185-4B). Patients may also present acutely with eccrine hidradenitis, or chronically with hyperkeratotic plaques. Cutaneous nocardiosis may begin suddenly, reactivate after months to years, or follow a chronic course for up to 10 years. A case of simultaneous infection in a husband and wife has also been described. Very rarely, pure cutaneous disease may lead to systemic illness. The cellulitic form most commonly affects the lower extremities, as compared to sporotrichoid form, in which the upper extremities are most commonly involved. Children frequently present with cellulitis, abscesses, and lymphadenitis affecting lower extremities and trunk; 20 percent of cases will have lesions at multiple sites.[7]

Lymphocutaneous forms may account for 24 percent of all *Nocardia* cutaneous infections (see Fig. 185-4). The first case proven to be due to *N. brasiliensis* was described by Alarcon[9]; the patient developed acute nodular suppurative lymphadenitis after injuring the finger with a rose thorn. Although the upper extremity is the most common location, disease of lower extremity and cervico-facial region have also been reported. A common history is appearance of a solitary papule or nodule on the upper limbs, 2 to 4 weeks after cutaneous inoculation. Then, proximal nodules develop along lymphatic drainage. The primary lesion is initially warm and tender, then becomes fluctuant and later ulcerates. Macroscopic grains may be seen, but draining sinuses are rare. Systemic symptoms are mild. Regional lymphadenitis is common but lymphangitis is unusual.

Sternal wound infections usually develop 1 month after thoracic surgery.



▲ **FIGURE 185-4** **A.** Early lesions of lymphocutaneous nocardiosis. **B.** Lymphocutaneous nocardiosis: typical sporotrichoid pattern. (Used with permission from Marcia Karam, Daniel Asz, and Roberto Arenas, Hospital Manuel Gea González, Mexico City.)

The symptoms include erythema, clear-to-purulent drainage, wound dehiscence, and/or fever. Diabetes mellitus seems to be the only identifiable risk factor. At least in one outbreak, the hands of an anesthesiologist were culture positive for *N. farcinica*. In another case of sternal osteomyelitis and mediastinal abscess, the patient's occupation (carrying wooden crates loaded with vegetables) may have been the source of infection, in the absence of chest surgery or trauma.

Pulmonary disease is the most common form of clinical infection, but, compared to primary cutaneous diseases, is often due to different species (*N. asteroides* predominates). The disease may take the form of an acute pneumonia or a chronic process with bronchopneumonia, abscesses, and development of cavities. Ten percent of pulmonary infections disseminates to the skin.

Bacteremia due to *Nocardia* is seen in patients with concomitant malignancy, and *N. asteroides* is the agent most commonly isolated. Cutaneous or subcutaneous nodules and abscesses occur in many patients, and the skin may be the portal of entry in some cases. Catheter-associated nocardemia is well documented.

Laboratory tests considered useful include direct examination of clinical specimens, culture, and biopsy. The impor-



tance of direct microscopic examination for the presence of granules cannot be overemphasized. Organisms are detected as Gram-positive, branched filamentous "hyphae," and branching at right angles is diagnostic. Acid-fast stains, including Fite-Faraco and the modified Kinyoun technique, show the filamentous bacteria. For isolation, cultures should be kept for up to 2 to 3 weeks. The microorganisms grow satisfactorily on most of the non-selective media used for isolation of bacteria, mycobacterium, and fungi. Because slow growth of *Nocardia* colonies over 2 days to 2 weeks on routine culture media allows bacterial overgrowth, isolation of this organism from soil and non-sterile sites may be difficult. *Nocardia* do not survive the digestive procedures used routinely in mycobacterial culture. Thayer-Martin and buffered charcoal-yeast extract agar may be used and pre-treatment of specimens with a low pH potassium chloride-hydrochloric acid solution for 4 minutes is required.

Patterns described on histology include monocytic infiltrates, fibrinopurulent exudates, granuloma formation, chronic granuloma formation, chronic nodular dermatitis, microabscess formation, and cocco-bacillary organisms; the presence of granules has been described in disseminated cases.[6]

Differential Diagnosis

In cases of cellulitis, the differential diagnosis is extensive, including both infections and non-infectious etiologies. However, in the lymphocutaneous form, the differential diagnosis can be approached more systematically. The sporotrichoid pattern should be differentiated from the more acute ulceroglandular syndrome, as is seen in tularemia and cat-scratch disease (Box 185-2).

Prognosis and Clinical Course

Primary cutaneous nocardiosis is usually subacute or chronic but has a good prognosis when treated appropriately. However, the disease has the potential to disseminate; sternal wound infections may be complicated with osteomyelitis.[6] Systemic disease, especially sepsis, has a high mortality rate, 44 percent to 85 percent, if the patient is nocardemic.[8]

Treatment

The treatment of *Nocardia* infection is appropriate antimicrobial therapy and surgical drainage and débridement. Factors to consider include site and severity of infection, the immune status of the host, potential for interactions and the species of *Nocardia* involved. Current standard for sensitivity testing is by the broth microdilution method.

Sulfonamides, alone or in combination with trimethoprim (TMP), are the cornerstone of therapy for *Nocardia* infections, but are ineffective against *N. otidiscaviarum*.[8] For primary cutaneous nocardiosis of mild to moderate intensity, sulfonamide (either sulfadiazine or sulfisoxazole) alone has been considered adequate therapy[8] but other authors consider TMP-sulfamethoxazole (SMX) the treatment of choice, despite lack of controlled trials. This is based on synergistic activity of both drugs in vitro against *Nocardia*. The commercially available preparation has a fixed ratio of 1:5, and the dose recommended at the present time is 5 to 10 mg/kg TMP and 25 to 50 mg/kg SMX in two to four divided doses. For primary cutaneous nocardiosis, 5 mg/kg of TMP should be sufficient. Clinical improvement should be seen within 3 to 10 days, and 1 to 4 months of treatment should be curative for sporotrichoid nodules and cutaneous ulcers. Prolonged therapy is required for immunosuppressed patients. Minocycline 100 to 200 mg twice a day is considered the alternative treatment in cases of sulfonamide hypersensitivity or poor tolerance.

In more severe cases or disease involving other organs, a combination of sulfonamide with a second agent is recommended. The second-line drugs most recommended are amikacin, imipenem, and ceftriaxone. Alternative second-line drugs include amoxicillin-clavulanate and linezolid. Immunosuppression is a good indication for a two-drug regimen, including amikacin; 88 percent cure rate has been reported when this drug is used.[6] Sternal infections due to *N. asteroides* have responded to oral ofloxacin therapy.[8] *N. farcinica* has a high degree of resistance to various antibiotics, especially third-generation cephalosporin and imipenem, and combined therapy is highly recommended. Extended treatment for extra-cutaneous nocardiosis, with parenteral therapy followed by an oral regimen is necessary. Surgery is indicated in cases of abscesses (drainage) or extensive necrosis (débridement). Spontaneous resolution or good clinical response despite inappropriate therapy has been seen in children with *Nocardia* cellulitis or lymphadenitis.[7]

Box 185-2

Differential Diagnosis of Lymphocutaneous Nocardiosis

Most Likely
- Sporotrichosis
- *Mycobacterium marinum* infection
- Leishmaniasis
- Pyoderma due to *Staphylococcus aureus*

Consider
- Cryptococcosis
- Tuberculosis
- *M. kansasii chelonae* and *M. fortuitum*
- Cysticercosis

Rule Out
- Epithelioid sarcoma
- Metastatic disease

Prevention

The low incidence of *Nocardia* infections in immunodeficient states does not justify prophylactic use of antibiotics. AIDS patients receiving TMP-SMX for *Pneumocystis* are already protected against *Nocardia*.

ACTINOMYCETOMA (See also Chap. 190)

Epidemiology

Mycetomas are chronic infections of the skin, underlying tissues, sometimes bones, and rarely viscera, caused by both bacteria (actinomycetomas) and fungi (eumycetomas).[10] Only actinomycetoma is discussed further in this chapter (for eumycetomas, see Chap. 190). The disease has a worldwide distribution but it is more frequent in the tropics, especially in India, Sudan, Somalia, Mexico, and Venezuela. *A. pelletieri* and *A. madurae* are common agents in Senegal.[11] Occasional cases are seen in the United States, particularly in the South.[10] Actinomycetoma affect mainly men, and the age ranges from 16 to 40 years old, but frequency before 15 years of age is similar in both sexes.[12]

Etiology and Pathogenesis

Microorganisms reported to cause actinomycetomas include *N. brasiliensis*, *Actinomadura madurae*, *A. pelletieri*, *Streptomyces somaliensis*, and less commonly, *N. asteroides*, *N. otitidiscaviarum*, *Nocardiopsis dassonvillei*, and *N. transvalensis*.[13] *N. pseudobrasiliensis*, *N. veterana* and *N.*



ACTINO-MYCETOMA AT A GLANCE



- Actinomycetoma is caused by bacteria, as opposed to eumycetoma, which is caused by fungi.
- More commonly seen in the tropics.
- Several microorganisms cause the disease. Some species are specific for some geographic areas. In the Americas, *Nocardia brasiliensis* predominates.
- More common in men and in lower extremities.
- Characterized by inflammation, tumefaction, and discharging sinus tracts.
- Macroscopic or microscopic grains are usually white. Gram staining shows filamentous bacteria.



mexicana have been reported recently as agents in human actinomycetoma; and *N. pseudobrasiliensis* has also been associated with invasive or disseminated infections. The infection most commonly affects people living in rural areas in developing countries.

Recent taxonomic studies (using DNA hybridization and ribosomal RNA gene sequencing) have confirmed marked heterogeneity among the genera of aerobic actinomycetes.

In North America (Mexico), South America, and Australia, *N. brasiliensis* is the leading cause of actinomycetomas; in Africa, Saudi Arabia, and India, *S. somaliensis* and *A. madurae* predominate; this species is also identified as the etiologic agent in 10 percent to 15 percent of cases in Mexico and Venezuela.[14]

Clinical Findings

Actinomycetoma is a chronic, localized, slowly progressive, painless disease of the skin and subcutaneous tissue. The pathologic process begins with a minor traumatic injury. Walking barefooted or wearing sandals may be considered a risk factor for these infections in rural communities. The lower limbs are involved in 64 percent of the cases (Fig. 185-5), the foot being the most common site (Fig. 185-6). The lower leg, knee, and thigh, as well as the hand, forearm, (Figs. 185-7 and 185-8), face, neck, and abdominal wall, may also be affected. In Mexico, the upper back (Figs. 185-9 and 185-10) is involved in 17 percent to 25 percent of cases in relation to occupational activity, such as firewood collection. Actinomycetoma caused by *Nocardia* sp. is a very inflammatory process characterized by tumefaction, destructive granuloma with a nodular appearance, deformity, and discharging sinus tracts with communicating channels that exudate pus. Ulceration, crusting, and scarring are also observed.[10] Mycetoma due to *A. madurae*, *A. pelletieri*, and *S. somaliensis* are less inflammatory with smaller sinus tracts; *A. madurae* is mainly seen in women with plantar involvement.[14] With all these agents, the granules may be seen with the naked eye (see Table 185-1), usually in a cream color; the exception will be *A. pelletieri*, in which the granules are red.



▲ **FIGURE 185-5** Actinomycetoma of the lower leg. Multiple, indolent, coalescing nodules.



▲ **FIGURE 185-6** Mycetoma of the foot produced by *Nocardia* sp.: typical location, with multiple draining sites.

The course is chronic and progressive, with potential involvement of bones, lung, and abdominal viscera. In women, mycetomas increase in size during pregnancy and spontaneously improve after delivery. Advanced cases may cause functional disability. Atypical clinical forms include the cryptic mycetoma (without sinus tracts), the so-called *minimycetoma* (single or multiple small lesions observed mainly in children and adolescents), and the occasional inguinal "metastatic" lesions from a primary mycetoma of the foot.[10]

Skin biopsy plays an important role in the diagnosis of actinomycetoma. Typically, in hematoxylin and eosin stained tissue sections, there is a suppurative reaction characterized by the presence of polymorphonuclear cells, fibrosis, neovascularization, and rarely, a granulomatous reaction with a tuberculoid granuloma.[10] *Nocardia* infection is characterized by granules 30 to 200 μm in diameter, partially basophilic to amphophilic, with an amorphous eosinophilic radially arranged material on the periphery (the so-called *Splendore-Hoeppli phenomenon*). Granules of *A. madurae* are soft and bigger (1 to 3 mm diameter), purple with a cartographic shape and an eosinophilic fringe (Fig. 185-11). *A. pelletieri* granules are firm and red with a diameter of 200 to 500 μm. Granules of *S. somaliensis* are rounded, hard, pale, and



▲ **FIGURE 185-7** Mycetoma of the hand and wrist caused by *Nocardia brasiliensis*. Note gross deformity. (Used with permission from Roberto Arenas, MD, Hospital Manuel Gea González, Mexico City.)



▲ **FIGURE 185-8** Radiograph from patient in Fig. 185-6 shows associated marked destruction of bones and underlying soft tissues. (Used with permission from Roberto Arenas, MD, Hospital Manuel Gea González, Mexico City.)

1.5 to 10.0 mm of diameter.[10] These organisms stain in tissue with Gomori methenamine silver, periodic acid-Schiff, and the Brown-Brenn modification of the Gram stain.

Clinical specimens should be sent for direct examination (Gram stain) and culture. On direct examination, *Nocardia* granules are microscopic with a yellowish color. Granules produced by other agents are macroscopic: those of *A. madurae* are white, yellow, or cream whereas grains from *A. pelletieri* are red and those of *S. somaliensis* are cream to brown color. Fine needle aspiration cytology has been reported as a good diagnostic tool.



▲ **FIGURE 185-9** Mycetoma of the shoulder caused by *Nocardia brasiliensis*. (Used with permission from Maria Cecilia Albornoz, MD, Instituto de Biomedicina, Caracas.)

The microorganisms can be cultured on Sabouraud's dextrose agar or Lowenstein-Jensen at room temperature; *Nocardia* strains are white-yellow hard colonies. Microscopically, its very thin filaments are Gram-stain positive and acid fast with the Kinyoun's stain. *A. madurae* produce slowly growing beige or pink colonies; *A. pelletieri* colonies are red. *S. somaliensis* produce beige or tanned colonies. All *Actinomyces* and *Streptomyces* sp. are acid-fast negative.[10]

Biochemistry can be used for identification. *N. brasiliensis* hydrolyzes casein and tyrosine, but not xanthine; *N. otitidiscaviarum* is negative to casein and tyrosine and positive to xanthine testing; *N. asteroides* is negative to all these tests.

An enzyme-linked immunosorbent assay has been described for the diagnosis of mycetoma due to *N. brasiliensis*; it has been proposed as a method to assess the response to therapy. This test detects antibodies against two immunodominant antigens (24 and 26 kd). An additional advantage of this particular assay might be its demonstrated cross-reactivity with *N. asteroides*.[15]

Differential Diagnosis

The differential diagnosis includes other infections causing fistulae; for example, eumycotic mycetoma, actinomycosis, botryomycosis, scrofuloderma, and atypical mycobacterial infections (Box 185-3). Botryomycosis is a condition that can mimic actinomycetoma and eumycetoma, both clinically and histologically. The disease can be caused by several organisms, most commonly *S. aureus*, *Escherichia coli*, *Pseudomonas aeruginosa*, *Proteus vulgaris*, *Actinobacillus* sp., *Streptococcus* sp., Gram-negative cocco-bacilli, *Propionibacterium* acne, and other anaerobic bacteria. The cutaneous form accounts for 75 percent of the cases; visceral involvement, mainly the lung, is rare. The disease is characterized by localized areas of infiltration, with mass effect and draining sinuses. Extension to the underlying structures, including bone, is not uncommon. Most commonly affected areas are exposed surfaces, such as hands, head, and feet. Patients usually have a predisposing factor such as local trauma, a foreign body, diabetes or human immunodeficiency virus. Botryomycosis is also characterized by the presence of granules, which can be seen macroscopically and microscopically. As in mycetoma, the center of the granule will show agglomeration of the causal agent, most commonly, Gram-positive cocci. Splendore-Hoeppli phenomenon may also be seen around the granules.

Treatment

Therapy for patients with actinomycetoma should be individualized. Eco-



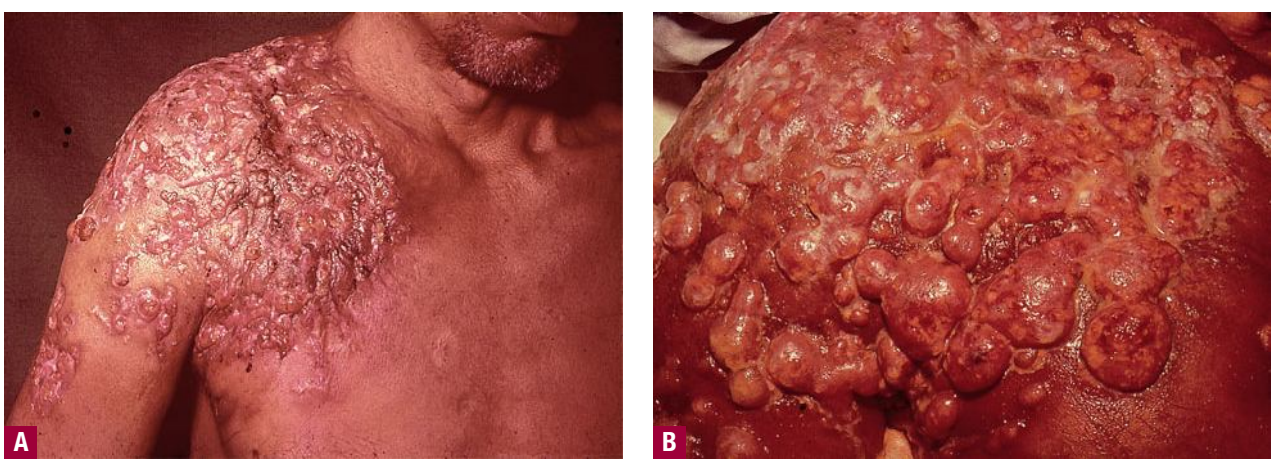

▲ **FIGURE 185-10** **A.** Huge scapulothoracic mycetoma caused by *Nocardia brasiliensis*. Note multiple fistulae. **B.** Close-up. Note doughnut-shaped masses and purulent drainage. (**B,** Used with permission from Maria Cecilia Albornoz, MD, Instituto de Biomedicina, Caracas.)

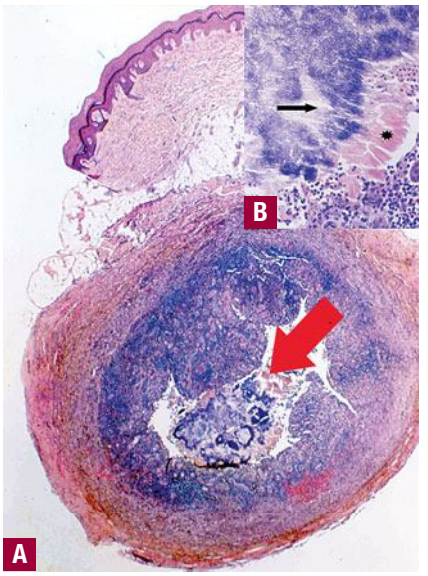



▲ **FIGURE 185-11** **A.** Skin biopsy of an *Actinomadura* mycetoma shows the granule (*red arrow*) inside the inflammatory reaction (hematoxylin and eosin, 20×). **B.** The contrast between the blue fibrillary material (*black arrow*), representing bacteria, and the eosinophilic proteinaceous material of the Splendore-Hoeppli phenomenon (*star*) (hematoxylin and eosin, 100×).

nomic considerations may influence the choice of therapy, particularly in developing countries. The treatment of choice in actinomycetoma caused by *N. brasiliensis* is diaminodiphenylsulfone (Dapsone) 100 to 200 mg/day (3 to 5 mg/kg) plus TMP-SMX 160/800 mg twice a day for several months in initial cases; the treatment should continue for up to 2 years.[10] Dapsone can also be combined with streptomycin, 1 g/day; clofazimine, 100 mg/day; rifampin, 300 mg twice/day; tetracycline, 1 g/day; or isoniazid, 300 to 600 mg/day; alternative drugs include kanamycin and phosphomycin.

Box 185-3

Differential Diagnosis of Actinomycetoma

- Eumycotic mycetoma
- Actinomycosis
- Botryomycosis
- Scrofuloderma
- Atypical mycobacterial infections

Some resistant cases have been treated with amoxicillin, 500 mg, plus clavulanic acid, 125 mg/day for 5 months.

Amikacin alone or combined with imipenem are powerful antibiotics used as alternative treatments for severe or multi-resistant mycetomas, especially those with bone and visceral involvement. In adults, amikacin is administered 15 mg/kg/day (500 mg intramuscularly twice a day) for 3 weeks; ototoxicity and nephrotoxicity may develop.[16] Patients treated with intravenous imipenem must be hospitalized and treated with a dose of 500 mg three times a day for 3 weeks. It is possible to repeat this cycle several times.[17]

Ramam et al.[18] used a two-step regimen consisting of an intensive phase of therapy with intravenous penicillin (1,000,000 IU every 6 hours) plus intravenous gentamicin (80 mg twice a day), and oral TMP-SMX (80 to 400 mg twice a day) for 5 to 7 weeks. Linezolid, a new oxazolidinone, has shown in vitro antimicrobial activity against *N. brasiliensis*; it also has demonstrated efficacy in patients with nocardiosis. Its main disadvantage of this alternative is the cost. It is available as intravenous and oral preparations.

Patient follow-up is always important, and improvement can be monitored by clinical assessment as well as by laboratory tests: hemoglobin level, white cell count, C-reactive protein, erythrocyte sedimentation rate, enzyme-linked immunosorbent assay (when available), biopsy, and culture.

Amputation is not indicated in actinomycetoma because the very low risk of lymphangitic or hematogenous dissemination. Functional impairment is common with osseous, pulmonary, or abdominal visceral involvement. The disease may be fatal.

KEY REFERENCES

The full reference list for all chapters is available at www.digm7.com.

1. Pulverer G, Schutt-Gerowitt H, Schaal KP: Human cervicofacial actinomycoses: Microbiological data for 1997 cases. *Clin Infect Dis* **37**:490, 2003
5. Sudhakar SS, Ross JJ: Short-term treatment of actinomycosis: Two cases and a review. *Clin Infect Dis* **38**:444, 2004
6. Lederman ER, Crum NF: A case series and focused review of nocardiosis: Clinical and microbiologic aspects. *Medicine (Baltimore)* **83**:300, 2004
7. Fergie JE, Purcell K: Nocardiosis in South Texas children. *Pediatr Infect Dis J* **20**:711, 2001
8. Lerner PI: Nocardiosis. *Clin Infect Dis* **22**:891, 1996
10. Arenas R, Lavalle P: Mycetoma (Madura foot), in *Tropical Dermatology*, edited by Arenas R, Estrada R. Georgetown, Landes, 2001, p 51
12. Bonifaz A et al: Actinomicetomas en niños y adolescentes. *Monografías en Dermatología* **19**:17, 2006
14. Davila MR et al: Epidemiología de los micetomas por Actinomadura madurae en el Estado de Guanajuato, México. *Monografías en Dermatología* **19**:24, 2006
17. Fuentes A et al: Actinomicetoma por *Nocardia* sp. Tratamiento con imipenem solo o combinado con amikacina en 5 casos graves o resistentes. *Gac Med Mex* **142**:247, 2006

CHAPTER 186

Leprosy

Thomas H. Rea
Robert L. Modlin

HISTORICAL ASPECTS

EPIDEMIOLOGY

Now primarily a disease of developing countries, leprosy is endemic in all continents, except Antarctica. In the Americas, only Canada and Chile are not endemic areas, with Texas and Louisiana having endemic foci in the United States. The southernmost nations of Europe have a very low incidence, while leprosy is endemic in many Pacific islands. India has two-thirds of the world's leprosy burden.

During the 1990s, the prevalence of leprosy fell by 90 percent because patients completing a course of multiple-drug therapy have been considered to be cured, but the incidence of the disease, which varies in direct proportion to case-finding efforts, has yet to be reduced convincingly.

In all populations studied, lepromatous disease is more common in men than in women by a 2:1 ratio. If leprosy is common, the "tuberculoid" forms dominate; if leprosy is uncommon, the "lepromatous" forms predominate.[9] Leprosy is said to be a disease of rural incidence, but of urban prevalence. The median age of onset is less in tuberculoid than in lepromatous patients, but in both groups, leprosy is predominantly a young person's disease, the medial age of onset being less than 35 years old. However, old age does not protect. The incubation time for tuberculoid leprosy is up to 5 years and for lepromatous disease may be 20 years or longer.

LEPROSY AT A GLANCE



- Definition: A chronic granulomatous infection and its sequelae, caused by *Mycobacterium leprae.*
- Involvement: Primarily skin and nerves, but also other organs or systems, including eyes, respiratory tract, lymph nodes, testicles, and joints.
- Diagnosis: Requires demonstration of acid-fast bacilli in tissue or a characteristic peripheral nerve abnormality.
- Incidence: Approximately 500,000 new cases yearly, worldwide.
- Long-term morbidity: Despite curative antibacterial treatment, one-fourth to one-third of patients will have a debilitating and permanent neurologic deficit.
- A clinical challenge: Diverse manifestations result from a granulomatous spectrum, and are further increased by superimposed, reactional states.
- An immunologic opportunity: Leprosy is an exemplary model for the understanding of cell-mediated immunity in humans.

The preponderance of opinion supports the traditional view that *Mycobacterium leprae* is transmitted from human-to-human, but *M. leprae* causes lepromatous-like illness in wild armadillos[10]; evidence of armadillo exposure is a risk factor for leprosy in people,[11] and the presence of an *M. leprae*–like organism on sphagnum moss[12] suggest that nonhuman sources for *M. leprae* may be important. The route of infection is unproven, but current evidence favors respiratory transmission; evidence for congenital and percutaneous transmission has been presented, but examples are rare.[13] In leprosy endemic areas, sub-clinical infection is common, as judged by serologic studies identifying *M. leprae*–specific antibodies,[14] but the incidence of overt disease is, by comparison, very small, with most individuals mounting a curative immunologic response.

ETIOLOGY AND PATHOGENESIS

M. leprae, the cause of leprosy, is a non-cultivable, Gram-positive, obligate, intracellular, acid-fast bacillus. The genome of *M. leprae* (3.27 megabases) is notably shorter than that of *M. tuberculosis* (4.41 megabases). The *M. leprae* genome codes for only 1600 genes, *M. tuberculosis* codes for 4000. The two species share 1439 genes in common. In *M. leprae*, only one-half of its genome is coding sequence; this evident gene deletion and decay leaves *M. leprae* with few respiratory enzymes,[6] which explains the failure to cultivate the organism and its obligatory intracellular environment.

In tissues or smears, *M. leprae* is quantified by the biopsy index (BI), a logarithmic scale as to the numbers of bacilli per oil immersion field (OIF): a BI of 6 is 1000 or more bacilli/OIF; a BI of 5 is 100 to 1000/OIF; a BI of 4 is 10 to 100/OIF; a BI of 3 is 1 to 10/OIF; a BI of 2 is 1 bacillus/1 to 10 OIFs; a BI of 1 is 1 bacillus/10 to 100 OIFs; and a BI of 0 is no bacilli in 100 OIFs. Because a BI of 6 indicates 10^9 bacilli per gram of granuloma, tissue with a BI of 0, may have as many as 10^3 organisms per gram.

A patient is considered to be "paucibacillary" if no acid-fast bacilli are found in tissue or smears, and to be "multibacillary" if one or more acid-fast bacilli are found.

M. leprae, like *Treponema pallidum*, is not toxic, the clinical manifestations of leprosy being produced by the host's responses to the *M. leprae*, or, alternatively, by the accumulation of enormous numbers of bacteria, as in signs of diffuse infiltration.

The cell-wall–associated lipoproteins, ligands for the Toll-like receptor 2/1 heterodimer, probably initiates the host's first response to invading *M. leprae*, which is the innate immune response. This response is perhaps important in determining the eventual outcome of the host-parasite interaction.[15] Phenolic glycolipid I is a major species-specific and immunogenic constituent of the highly nonpolar outer layer of the bacillus. Entry into nerves is mediated by the binding of the species-specific trisaccharide in phenolic glycolipid I to laminin-2 in the basal lamina of Schwann cell-axon units,[16] providing a rationale for why *M. leprae* is the only bacterium known to invade peripheral nerves.

A twin study has provided compelling evidence that both genetic and environmental factors are important in determining disease susceptibility and disease expression.[17] A region on chromosome 10p 13, including the PARK2 and PACRG loci for susceptibility to Parkinson disease, has been found to also contain a risk factor for susceptibility to leprosy.[18] This includes both tuberculoid and lepromatous forms, and has been identified in several, but not in all, genetically diverse groups. Major histocompatibility complex class II antigens influence tuberculoid versus lepromatous disease expression, but not disease susceptibility.[19]

CLINICAL FINDINGS

History

For physicians practicing in nonendemic areas, learning that the patient has risk factors for leprosy, (i.e., birth or residence in an endemic area, or a blood relative with leprosy) may lead to a correct diagnosis of leprosy.

Historic data or symptoms that should elicit further suspicion of leprosy include complaints referable to peripheral neuropathy, persistent nasal stuffiness, ocular symptoms, and, in young men, loss of sexual drive or infertility.

Cutaneous and Neural Lesions in the Granulomatous Spectrum

THE GRANULOMATOUS SPECTRUM The in-depth description of the granulomatous spectrum of leprosy was by Ridley and his associates, based on clinical and histologic changes.[3,20] Ridley's construct is a six-member spectrum, ranging from high to low resistance, TT (polar tuberculoid), BT (borderline tuberculoid), BB (borderline), BL (borderline lepromatous), LLs (subpolar lepromatous), and, finally, LLp (polar lepromatous):

TT←BT↔BB↔BL↔LLs LLp

Conceptually, TT and LLp are clinically stable, but, between the poles, the host's granulomatous posture may change, as indicated by the arrows, upgrading (or reversing) to a posture of higher resistance, often with devastating inflammation, or downgrading to a posture of lower resistance, usually silent but occasionally inflammatory. BT patients may upgrade to TT, thus, becoming stable, but LLs patients do not downgrade to LLp nor do LLp patients upgrade. (When the term *LL* is used, it includes both LLs and LLp patients.) The pathogenesis of the granulomatous spectrum is widely accepted as being mediated by a type IV immunologic reaction, cell-mediated immunity (CMI) or delayed-type hypersensitivity (DTH).



The classification is determined primarily by clinical and histologic changes, bacillary numbers being a secondary consideration.

In comparison of pre-Ridley and Ridley terminology, "tuberculoid" corresponds to TT and BT, "borderline" or "dimorphic" to BB and BL, and "lepromatous" to LLs and LLp. In virtually all TT patients, and in most BT cases, acid-fast bacilli cannot be found, whereas in BB, BL, LLs, and LLp, bacilli are demonstrable with ease. Ridley's construct is useful in classifying patients, especially for immunity.



PERIPHERAL NERVE CHANGES Five types of peripheral nerve abnormalities are common in leprosy:

1. Nerve enlargement (usually perceived as asymmetry), particularly in those close to the skin, such as the great auricular, ulnar, radial cutaneous, superficial peroneal, sural, and posterior tibial,
2. Sensory impairment in skin lesions,
3. Nerve trunk palsies either with signs and symptoms of inflammation or without such overt manifestations, that is, silent neuropathy,[21] often with both sensory and motor loss (weakness and/or atrophy) and, if long-standing, also with contracture,
4. Stocking-glove pattern of sensory impairment (S-GPSI), a withering away, so to speak, of the type C fibers, involving heat and cold discrimination before loss of pain or light touch, beginning in acral areas and, over time, extending centrally but sparing the palms, at least for a while, and
5. Anhidrosis on palms or soles, suggesting sympathetic nerve involvement.

Polar Tuberculoid Leprosy. In TT, leprosy immunity is strong, as manifested by spontaneous cure and the absence of downgrading to a posture of less host resistance. The primary skin lesion of TT is a plaque, often assuming an annular configuration secondary to peripheral propagation and central clearing (Fig. 186-1). The border of the plaque or both borders of the annulus are sharply marginated. Typically, the lesion is firmly indurated, elevated, erythematous, scaly, dry, hairless, and hypopigmented, but considerable variation is encountered (see eFigs. 186-1.1 and 186-1.2 in on-line edition).

A nearby sensory nerve may or may not be enlarged, but the lesion itself is characteristically hypesthetic and anhidrotic, with an upper limit of 10 cm in lesion diameter. Skin lesions are often solitary, particularly in those patients who are TT de novo, as contrasted to those who upgrade to TT from BT, where multiple lesions, usually no more than three, may be found. In both groups, immunity is sufficient to affect cure, but antibiotic therapy is recommended.



▲ **FIGURE 186-1** A solitary, anesthetic, and annular lesion of polar tuberculoid leprosy, which had been present for 3 months. Its sharp margins, erythema, and scale are more evident than its elevation. The central red dots are the sequelae or "footprints" of testing for pinprick perception when it is absent. (If present, the patient withdraws, preventing overtly purpuric consequences.)

Histologically, the de novo lesions are small tubercles with large lymphocytic mantles. The upgrading lesions have abundant Langhans giant cells, and exocytosis into the epidermis, in addition to lymphocytic mantles.

Borderline Tuberculoid Leprosy. In BT disease, immunologic resistance is strong enough to restrain the infection, in that the disease is limited and bacillary growth retarded, but the host response is insufficient to self-cure (see eFigs. 186-1.3 through 186-1.5 in on-line edition). These patients are somewhat unstable—resistance may increase, upgrading to TT, or decrease, downgrading to BL.

The primary skin lesions of BT are plaques and papules. As in TT, an annular configuration is common, and both borders are sharply marginated, but annular lesions or plaques may have sharply marginated satellite papules (Fig. 186-2). Hypopigmentation may be conspicuous in darkly pigmented patients. In contrast to TT, typically there is little or no scaling, less erythema, less induration, and less elevation, but lesions may become much larger (see eFig. 186-1.3 in on-line edition), that is, well over 10 cm in diameter, a single lesion sometimes involving an entire extremity over time. Multiple, asymmetric lesions are the rule, but solitary lesions are not rare. Impaired sensation in skin lesions is the rule and nerve trunk involvement, enlargement, or palsies, usually asymmetric and affecting no more than two nerves, are common. Nerve abscesses, when they occur, are most often seen in males with BT disease (see eFig. 186-1.5 in on-line edition).

Histologically, lymphocytic mantles are less well developed, Langhans cells are less common or absent, and any exocytosis is focal. Acid-fast bacilli and plasma cells are rare; if present, a DTH reaction [see Delayed-Type Hypersensitivity Reaction (Jopling's Type I Reaction; Upgrading, Reversal, or Downgrading Reactions)] should be suspected.

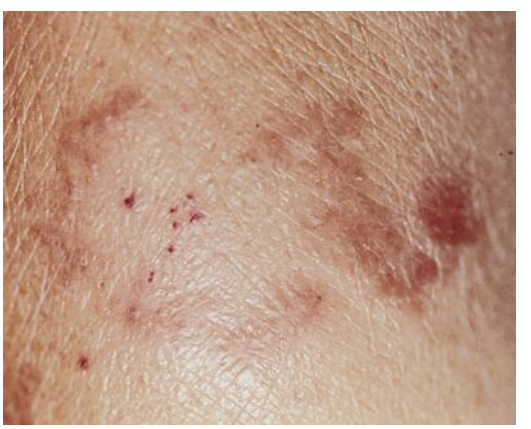

◀ **FIGURE 186-2** One of several lesions of borderline tuberculoid leprosy, which had an incompletely annular configuration with satellite papules. Compared to the polar tuberculoid lesion in Fig. 186-1, there is less erythema, no evident scales, but sharp margination, and the footprints of absent pinprick perception are also seen.



▲ **FIGURE 186-3** A characteristic borderline or dimorphic lesion, which is an indurated and elevated annular plaque that has a well-defined "tuberculoid" interior margin but a poorly defined "lepromatous" exterior margin. Having both morphologies, it is termed "dimorphic." (From Demis DJ: *Clinical Dermatology*, 23rd revision, vol 3, unit 16–29, 1996, p 14. Used with permission from Lippincott Williams & Wilkins.)



▲ **FIGURE 186-5** Two different host reaction patterns in lepromatous leprosy disease as shown in two ears. In the ear on the left, the diffuse infiltration has become so extensive that the skin of the ear has been thrown into folds, but with no nodule formation. (From Demis DJ: *Clinical Dermatology*, 23rd revision, vol 3, unit 16-16, 1996, page 16. Used with permission from Lippincott Williams & Wilkins.) On the helix of the ear on the right are four nodular lepromatous leprosy lesions, arranged chronologically, so to speak, with the most recent one on top, and the oldest near the bottom. The two top nodules have more poorly defined nodules than do the two older lesions at the bottom. The skin between the nodules is also diffusely infiltrated but has produced no clinically evident changes.

Borderline Leprosy. BB is the immunologic midpoint or mid-zone of the granulomatous spectrum, being its most unstable area, with patients quickly up- or downgrading to a more stable granulomatous posture with or without a clinical reaction. Characteristic skin changes are annular lesions with sharply marginated interior and exterior margins, large plaques with islands of clinically normal skin within the plaque, giving a "Swiss cheese" appearance, or the classic dimorphic lesion. Because of instability, the BB posture is short-lived, and such patients are rarely seen; for example, we have yet to see a nonreactional patient meeting both clinical and histologic criteria.

Borderline Lepromatous Leprosy. In BL disease, resistance is too low to significantly restrain bacillary proliferation, but still sufficient to induce tissue-destructive inflammation, especially in nerves. Thus, patients with BL have the worst of both worlds.

The BL category is highly variable in its clinical expression (Fig. 186-3; see eFigs. 186-3.1 through 186-3.3 in on-line edition). Although seen in only one-third of BL patients, the classic dimorphic lesion (one having both morphologies) is the most characteristic, having an annular configuration with a poorly marginated outer border (lepromatous-like) but a sharply marginated inner one (tuberculoid-like; see Fig. 186-3). Poorly or sharply marginated plaques, with "punched out" or "Swiss cheese" sharply marginated areas of normal skin in the interior of the plaque, are also characteristic. Annular lesions with sharply marginated exterior and interior borders are not uncommon. If they occur, lepromatous-like, poorly defined papules and nodules may be numerous, but are usually accompanied by some sharply marginated lesions elsewhere (Fig. 186-4).

Lesions range in number from solitary (something happens first, the tip of an iceberg) to numerous and widespread. Generally speaking, the annular and plaque lesions, however numerous, are asymmetric, but the lepromatous-like nodules, if numerous, are symmetric. Nerve trunk palsies have their highest prevalence in BL disease but are variable in number, ranging from none to serious deficits, both motor and sensory, in all four extremities. Involvement of both median and ulnar nerves, often symmetrical, is characteristic. If disease is extensive, BL patients may have S-GPSI.

Histologically, one classic response is a dense lymphocytic infiltrate confined to the space occupied by the macrophages (see eFig 186-4.1 in on-line edition). Another classic response is lamination of the perineurium with a lymphocytic infiltrate. The pattern may be that of chronic inflammation. Macrophages may be foamy or undifferentiated. Acid-fast bacilli are easily found.

Lepromatous Leprosy. In LL disease, the lack of CMI toward *M. leprae* permits unrestricted bacillary replication and widely disseminated multiorgan disease. Diffuse dermal infiltration is always present subclinically and, in diffuse non-nodular LL, may be overtly manifested by enlargement of ear lobes, widening of the nasal root, and fusiform swelling of the fingers, the latter mimicking a rheumatic illness. Poorly defined nodules are the most common lesions, usually up to 2 cm in diameter, and are symmetrically distributed (Fig. 186-5; see eFig. 186-5.1 in on-line edition). The skin may be thrown into folds, producing leonine facies, often in conjunction with nodular lesions. Dermatofibroma-like (histoid) lesions, usu-

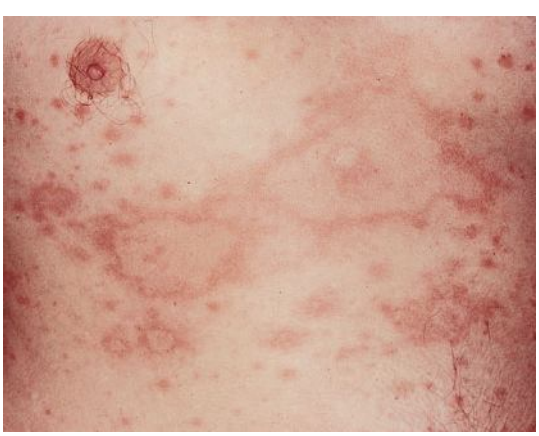

◀ **FIGURE 186-4** Multiple lesions in a patient with borderline lepromatous leprosy. The annular lesions vary in size and are asymmetrically distributed. In contrast, the poorly defined papular and nodular lesions are roughly symmetric. Impairment of sensation was present in most lesions.





▲ **FIGURE 186-6** Multiple dermatofibroma-like (histoid) lesions, which are solitary and confluent, in a patient with subpolar lepromatous leprosy. Their uniformly sharp margins and erythema are in contrast to most of the lesions in Fig. 186-5.



ally multiple, are sharply marginated, erythematous papules or nodules, sometimes confluent into plaques; first identified in relapsing patients as "histoid" leprosy, these are not unusual as presenting lesions in our patients (Fig. 186-6; see eFig. 186-6.1 in on-line edition). Less common presenting skin lesions include digitate, barely indurated patches of erythema (Fig. 186-7), which, in light-skinned patients, are sometimes followed by a mild hyperpigmentation; in dark-skinned patients, multiple hypopigmented macules may arise in such lesions, with melanin concealing the erythema. Also, dermal infiltrate may mimic a shagreen patch (see eFig. 186-7.1 in on-line edition).

Hair loss is common on the eyebrows, where it may progress laterally to medially, or be patchy, but also affects the eyelashes and extremities (see eFig. 186-7.2 in on-line edition). Scalp involvement is rare, likely because of the higher skin temperature. S-GPSI is common and may be so severe as to lead to debilitating trophic changes of the hands or feet.

Histologically, LLs and LLp have many features in common:

1. Nodular lesions have abundant dermal macrophages, foamy or undifferentiated, a sprinkling of lymphocytes, and a thin epidermis above a grenz zone.
2. Clinically, normal skin in usually infiltrated; if scant, in a perivascular distribution.
3. Dense "pseudofollicular" aggregates of lymphocytes may be B cells.[22]
4. Endothelial and Schwann cell acid-fast bacilli are common.
5. Plasma cells and mast cells are inconstantly increased.
6. Foreign-body giant cells may be found in old lesions. In LLs the perineurium in laminated but not infiltrated. In LLp the perineurium is undisturbed.

Indeterminate Leprosy. *Indeterminate leprosy* is a term with nearly as many meanings as it has users. We prefer the definition of Khanolkar,[23] designating an early lesion, appearing before the host makes a definitive immunologic commitment to cure or to an overt granulomatous response. Clinically, the indeterminate lesion is a hypopigmented macule or patch, with or without an associated sensory deficit in or nearby, and acid-fast bacilli, if found, are present in very small numbers. Such lesions are rare in our clinic. The term is inappropriately used to describe lesions rich in bacilli but having neither typical tuberculoid or lepromatous histological patterns, usually BL or LL.

Related Physical Findings

Insensitivity of the cornea is common in all forms of leprosy. In BL and LL disease, numerous changes in the cornea and anterior chamber are possible, iritis being a common serious change, occurring de novo or in association with reactions. Also, in LL, beading of the corneal nerves is common and may be a helpful diagnostic sign.

In all LL patients and in BL patients with extensive disease, wide dissemination of the infection is the rule. In the upper respiratory tract, involvement is from the tip of the nose through the vocal cords, manifesting as rhinitis, septal perforation, nasal collapse, and hoarseness from vocal cord nodules. As judged by elevated follicle-stimulating hormone and luteinizing hormone levels, testicular involvement is common in LL men, less so in BL men, and is clinically manifested by complaints of impotence and infertility, and by atrophy on examination. Involvement of liver, spleen, peripheral lymph nodes, and bone marrow is common, but clinically evident injury is rare.

PREGNANCY AND POSTPARTUM Pregnancy is said to be a precipitating factor for leprosy in 10 percent to 25 percent of women patients, presumably because of altered immunity. When pregnant, LL and BL patients are predisposed to develop erythema nodosum leprosum (ENL, see Erythema Nodosum Leprosum), but postpartum, they are predisposed to develop DTH reactions [see Delayed-Type Hypersensitivity Reaction (Jopling's Type I Reaction; Upgrading, Reversal, or Downgrading Reactions)], putatively due to reduced immunity in the former and restored immunity in the latter.[24] Untreated, lactating BL and LL patients have viable bacilli in their milk, but no risk has been identified in infants ingesting such bacilli.[25] Dapsone in mother's milk may produce hemolysis in the baby.

ACQUIRED IMMUNODEFICIENCY SYNDROME In acquired immunodeficiency syndrome or human immunodeficiency virus pa-



▲ **FIGURE 186-7** These multiple, barely palpable, erythematous, and asymptomatic lesions had been erupting over the previous 2 months in a subpolar lepromatous patient. With treatment, as lesions remitted, they became mildly hyperpigmented. Here, the accentuation of the normal skin markings are in contrast to their effacement in the lesions in Fig. 186-6.

tients, leprosy has not been regarded as an opportunistic infection. For example, in one study, acquired immunodeficiency syndrome or human immunodeficiency virus did not appear to influence disease expression (tuberculoid vs. lepromatous), but was associated with recurrent DTH reactions [see Delayed-Type Hypersensitivity Reaction (Jopling's Type I Reaction; Upgrading, Reversal, or Downgrading Reactions)] (see eFig. 186-7.3 in on-line edition).[26] However, recent reports of leprosy being diagnosed as DTH reactions in the setting of highly active antiretroviral therapy suggests that current views may need revision.[27]

RELAPSING LEPROSY Multibacillary patients who are non-compliant or whose disease develops drug resistance are prone to relapse. Such individuals present in several ways, including (1) a reprise of their initial presentation, (2) florid dermatofibroma-like lesions (histoid lesions), (3) a reactional state, and (4) a posture of higher resistance than their initial presentation, for example, an initially LLs patient having BL or even BT disease.

Reactional States

Generically, the reactional states of leprosy are distinctive, tissue destructive, inflammatory processes, putatively immunologically driven, that greatly increase the morbidity of the disease and, because of the experience required for optimal patient care, justify leprology as a clinical subspecialty. When present, a reactional state is superimposed upon the underlying granuloma, but the reactional state usually dominates the clinical picture. When the immune reaction intensifies, tissue injury may ensue. Too often, the reactional states are dismissed as complications of treatment, but they may occur before treatment is initiated or after it has been completed.

DELAYED-TYPE HYPERSENSITIVITY REACTION (JOPLING'S TYPE I REACTION; UPGRADING, REVERSAL, OR DOWNGRADING REACTIONS) DTH reactions are particularly common in BL patients, but are not rare in LLs, BB, or BT patients.[28,29] Patients may upgrade to a more resistant granulomatous posture, remain unchanged, or downgrade to a less-resistant posture.

Clinically, DTH reactions are characterized by the abrupt conversion of previously torpid plaques to tumid lesions, and by new tumid lesions arising in clinically normal skin with or without an abrupt onset of neuritis. A purplish color is characteristic, but may be subtle (Fig. 186-8). Iritis and lymphedema (elephantiasis graecorum) may be concomitant changes.[29] Morphologic variants include annular, concentric, and eczemaous changes (see eFig. 186-7.3 and eFigs. 186-8.1 through 186-8.5 in on-line edition). Rarely, lesions are solitary, as can happen in BT upgrading to TT, and are often multiple or occasionally myriad, as in BL or LLs upgrading to BT. Neuritis ranges from mild to severe and can be disastrous if multiple nerves are involved. DTH reactions are often a mode of presentation, and DTH reactions occurring soon after presentation may well have been DTH reactions from the beginning. Most common in the first year of treatment, DTH reactions may occur up to 7 years or longer after starting therapy, or well after treatment has stopped. The diagnosis of a DTH reaction is primarily clinical, but histologic confirmation, if available, should be sought, where the most common finding is edema. Other microscopic changes include epithelioid differentiation of macrophages, a mixture of Langhans and foreign-body types of giant cells, and a thickened epidermis.



▲ **FIGURE 186-8** Some of the initial presenting lesions in a patient with a delayed-type hypersensitivity reaction who had borderline lepromatous leprosy. The tumidity, purplish hues, and sharp margination strongly suggest a reversal reaction. The lesions were neither painful nor tender. The differences between these lesions and those shown in Figs. 186-3 and 186-4 emphasize that the delayed-type hypersensitivity reaction, not the underlying borderline lepromatous disease, dominates the clinical picture. The patient also had an irreversible foot drop of recent onset.

ERYTHEMA NODOSUM LEPROSUM (JOPLING'S TYPE II REACTION) ENL occurs most often in LL, in up to 75 percent of cases, but is not rare in BL patients. It is important to appreciate that ENL is not erythema nodosum occurring in leprosy; it is a leprosy-specific response, which has some features in common with erythema nodosum (see Chap. 68). It may occur before, during, or after chemotherapy. The median time of onset is almost 1 year after onset of treatment. Clinically, this reaction is characterized by crops of painful and tender bright-pink, dermal and subcutaneous nodules arising in clinically normal skin, in association with fever, anorexia, and malaise (Fig. 186-9; see eFigs. 186-9.1 through 186-9.5 in on-line edition). Lesions may be targetoid, vesicular, pustular, ulcerative, or necrotic. Of the other organs involved, arthralgias and arthritis are more common in ENL than are neuritis, adenitis, orchitis/epididymitis, or iritis, but each may rarely be the initial presentation. Involvement of both upper and lower extremities is the rule, and facial lesions occur in one-half of the patients. A neutrophilic leukocytosis is often present, occasionally leukemoid in degree. Severe episodes can be associated with an abrupt fall in hematocrit, up to 5 g/dL, easily mistaken for dapsone-induced hemolysis. The improvement in response to thalidomide is dramatic in greater than 90 percent of patients, perhaps qualifying as a diagnostic criterion. When ENL is the presenting mode of leprosy, there may be little or no stigmata of the underlying multibacillary disease. ENL may be precipitated by pregnancy or pyogenic infections.

Although episodes of ENL may be occasional or sporadic, in the more severely involved patients, episodes can be frequent to virtually unremitting. In the latter, brawny induration of the anterior thighs and lateral portion of the arms is characteristic, perhaps a reversible fibrosis. The course of ENL may be



▲ **FIGURE 186-9** Lesions of erythema nodosum leprosum in a patient with lepromatous leprosy. The bright-pink color is characteristic. These lesions are edematous, and pustule formation is suggested. The lesions are painful and tender.



prolonged, and the median required duration of anti-inflammatory treatment is approximately 5 years.

The diagnosis of ENL, if considered, is usually not difficult, as the clinical and histologic features are characteristic and the response to thalidomide is often dramatic.

Histopathologically, the signature cell of ENL is the neutrophil, which may be abundant, scant, or absent, if an old lesion is sampled (see eFigs. 186-9.6 through 186-9.8 in on-line edition). Other common features include an increase in lymphocytes, a thickened epidermis, and a lobular panniculitis. Vasculitis is uncommon. The usual histologic pattern is a "bottom heavy" infiltrate, preferring the deep dermis and subcutis.



LUCIO PHENOMENON Most prevalent in Mexico and the Caribbean region, Lucio phenomenon is restricted to patients with so-called *Latapi lepromatosis* (Lucio leprosy) that consists of diffuse cutaneous infiltration, as well as a purplish suffusion of the hands and feet, telangiectatic mats or eruptive telangiectasias, nasal septum perforation, total alopecia of eyebrows and eyelashes, and, often, S-GPSI.[30] Firm subcutaneous nodules are palpable but not visible. Ocular sparing is the rule.

Lucio phenomenon usually occurs in well-developed, untreated Latapi lepromatosis. Hemorrhagic infarcts arise in crops and have the serrated margins characteristic of septic infarcts (Fig. 186-10; see eFigs. 186-10.1 and 186-10.2 in on-line edition). Lesions are painful but not tender to palpation. Lesions usually crust and may heal with stellate scaring. Ulceration is common, especially below the knees. Lesions vary in size and extent, ranging from a few small lesions on the ankles to many large lesions, placing life in peril. With dapsone alone, lesions may worsen, but in our experience, with one exception, new lesions ceased within 1 week of beginning rifampin.[31] Microscopic changes include ischemic necrosis of the epidermis, deep dermal vessel occlusion by endothelial proliferation, and heavy parasitization of endothelial cells by acid-fast bacilli (see eFig. 186-10.3 in on-line edition).



▲ **FIGURE 186-10** Lesions of the Lucio reaction, which show the characteristic hemorrhagic infarcts and serrated borders. An erythematous halo is characteristic, but is usually gone within 1 week, reflecting microbicidal treatment or aging of the lesion. Lesions are painful but not tender. The patient has Latapi lepromatosis as manifested by diffuse infiltration, total alopecia of the eyelashes and brows, perforation of the nasal septum, no nodular lesions, and severe stocking-glove pattern of sensory impairment. (From Quisimoro FP et al: Lucio's phenomenon: An immune complex deposition syndrome in lepromatous leprosy. *Clin Immunol Immunopathol* **9**:185, 1978.)

HISTOPATHOLOGY

LABORATORY TESTS

Immunopathology and Immunology

Investigation into the immunology of leprosy offers three promises: (1) a better understanding of the disease itself; in particular, the immunopathogenesis of the granulomatous spectrum and the reactional states; (2) eradication or control of the disease by vaccination; and (3) a probe of CMI in humans that, when understood in the model of leprosy, will illuminate other disease processes.

CELLULAR IMMUNITY The great diversity of leprosy is exemplified by comparing its two polar forms. The high-resistance TT form is characterized by few lesions, rare organisms, epithelioid cell granulomas, and a tendency to self-cure. TT leprosy appears to be an entirely different disease than the low-resistance LL form, which manifests wide dissemination, abundant acid-fast bacilli, foamy macrophages, and, if untreated, relentless progression. A sharp margin on a plaque is the inscription of anti–*M. leprae* DTH on the skin; a nerve trunk palsy is its inscription on a peripheral nerve.

The observations of a positive lepromin skin test in tuberculoid subjects and unresponsiveness in lepromatous patients was the first objective and reproducible evidence that host immunity was the mechanism of polar diversity. Lymphocyte transformation tests provided an in vitro correlate of the lepromin skin test[4] and substantial evidence that mediation of polar diversity was through the cellular-immune response. On the contrary, antibody responses to *M. leprae* were found to be stronger in LL patients, indicating the humoral immunity does not lead to resistance to disease.

Immunophenotypic studies established an important difference between the lymphocyte subsets infiltrating skin lesions in tuberculoid versus lepromatous patients, with the former having a predominance of the CD4 subset (CD4/CD8 = 2:1), but the latter having a predominance of the CD8 subset (CD4/CD8 =1:2).[33] The skewing of T-cell subsets in lesions was independent of those in the peripheral blood, because all patients had a normal CD4/CD8 ratio of 2:1. Therefore, it is important to study the immune response of patients at the site of disease activity, that is, in skin lesions.

Reverse transcriptase-polymerase chain reaction studies of messenger RNA (mRNA) cytokine profiles in polar tissues have provided a functional explanation for their immunopathology. Tuberculoid lesions have a type 1 [T helper 1 (Th1) or Th1-like] pro-inflammatory profile, in particular, abundant mRNA coding for interleukin 2 (IL-2), interferon-γ (IFN-γ), and IL-12, but scant mRNA coding for IL-4 or IL-10. In contrast, lepromatous tissues have a type 2 (Th2 or Th2-like) anti-inflammatory profile, in particular, abundant IL-4 mRNA and IL-10 mRNA, but little mRNA coding for the type 1 cytokines.[34] Furthermore, $CD4^+$ T cells in tuberculoid lesions were shown to produce IFN-γ, whereas CD8 T cells in lepromatous lesions accounted for the production of IL-4.[35] The presence of type 1 cytokines likely results in strong T-cell and macrophage activation, the result being CMI to localize the infection. On the other hand, the type 2 cytokines found in lepromatous lesions likely lead to the strong antibody responses, but concomitantly inhibit T-cell and macrophage responses, resulting in progression of the infection. The importance of this paradigm is reflected in experiments designed to

augment CMI in lepromatous patients, where intradermal administration of recombinant IFN-γ to lepromatous patients reduced the number of bacilli-infiltrating tissues.[36] The decision by the host as to which cytokine profile to make, that is, type 1 or type 2, may rest with the response of the innate immune system to *M. leprae*. Cytokines produced by the innate immune system may profoundly affect the adaptive T- or B-cell responses,[37] and, in particular, the Toll-like receptors of the innate system are triggered by mycobacterial lipoproteins, causing the release of IL-12, a key inducer of the type 1 cytokine response.[15]

ANTIBODY IMMUNITY ENL is widely regarded as mediated by immune complexes. There are large amounts of anti–*M. leprae* antibodies in both LL and BL patients, but these antibodies do not confer disease protection. Also, the blood of BL and LL patients contains abundant antigens, including intact bacilli, up to 10^5/mL. Therefore, it is readily conceivable that BL and LL patients should be subject to immune complex–mediated tissue injury. The best direct support for the hypothesis that ENL is immune complex–mediated is the presence of split complement products in serum, which is consistent with extravascular complement activation within tissues.[40] Inferential evidence is that of neutrophil infiltration, suggesting an Arthus phenomenon, and an excess of glomerulonephritis in ENL patients. Also, the cytokine profile in ENL is type 2, despite a preponderance of the $CD4^+$ subset.[39] However, evidence for immune complex mediation is not yet persuasive—it has been difficult to reproduce, and it is confounded by a number of observations, including human leukocyte antigen HLA-DR framework antigen in lesional epidermis,[41] an increase in IFN-γ containing cells as determined by hybridization studies,[42] an excess of IL-2–staining cells as compared with LL tissue,[43] and the precipitation of ENL by the administration of recombinant IFN-γ.[44] Perhaps both immune complexes and cellular immunity are important in the pathogenesis of ENL.

Little is known concerning the immunopathogenesis of the Lucio reaction. Extant evidence favors immune complex mediation.[45] The abundant acid-fast bacilli in endothelial cells could be the optimum location for presentation of antigen to antibody. Its mechanism does appear to differ from that of ENL, in that there is little epidermal expression of HLA-DR framework antigen.[41,45]

Other Laboratory Tests

Most laboratory changes occur in LL or extensive BL disease. Hyperglobulinemia is the most common, giving an elevated sedimentation rate. A biologic false-positive serologic test for syphilis, anemia of chronic disease, and mild lymphopenia are also common. Clinically insignificant anti-phospholipid antibodies are present in 50 percent of LL patients, and may give rise to a lupus anticoagulant or agglutination of sheep erythrocytes (Rubino factor).[46] If examined, the stained smear of the buffy coat shows bacilli up to 10^5/mL. Elevated serum lysozyme and angiotensin-converting enzyme values reflect the extensive accumulation and activation of macrophages synthesizing these proteases. Proteinuria, not uncommon, is associated with a focal glomerulonephritis, seen mostly in patients with ENL. As manifested by high-serum follicle stimulating hormone and luteinizing hormone but low testosterone levels, the testicles are involved in a majority of men with LL, but in a minority of men with BL.

DIFFERENTIAL DIAGNOSIS

As a polymorphous disease, one approach to its differential diagnosis is by emphasizing the types of primary and secondary lesions found in leprosy as well as in the conditions that may mimic leprosy or be mimicked by leprosy.

Primary Lesions

- Macules and patches. The hypopigmentation of pityriasis alba and indeterminate leprosy mimic each other. Faintly indurated BL plaques may mimic patches. Telangiectasias may be eruptive, presenting as mats on the face and upper trunk.
- Papular to nodular lesions. In the dermis, leprosy may mimic or be mimicked by dermatofibromas, eruptive histiocytomas, lymphomas, sarcoidosis, and other granulomas. Eruptive and recurrent inflammatory subcutaneous nodules may be ENL, erythema nodosum, erythema induratum, vasculitis, etc. Palpable but not visible subcutaneous nodules in Latapi lepromatosis may mimic lipomas.
- Plaques. Erythematous plaques may mimic mycosis fungoides. Plaques without pigmentary change may be wheal-like in appearance, causing confusion with urticaria. Hypopigmented plaques may mimic papulosquamous eruptions. Islands of normal skin within a plaque may suggest psoriasis.
- Polymorphous vesiculobullous eruptions. Lesions mimicking autoimmune blistering disease may occur in ENL. Up to 30 percent of LL patients have an antibody directed to desmoglein 1. Immunoglobulin M is not uncommon at the epidermal basement membrane in LL.
- Annular lesions. Leprosy may mimic or be mimicked by annular erythemas, sarcoidosis, syphilis, or tinea.

Secondary Lesions

- Infarcts. Lucio phenomenon lesions and necrotic ENL mimic septic infarcts.
- Ulcers. Ulcers occur in Lucio phenomenon, ENL, neurotrophic ulcers of the plantar surface, and as leg ulcers secondary to venous insufficiency, a consequence of endothelial cell infection.

Clinical Constellations

- Systemic lupus erythematosus–like changes. Fusiform fingers, swan neck deformity, biologic false-positive serologic test for syphilis, anti-phospholipid antibodies, lupus anticoagulant, etc.
- Vasculitis. A true vasculitis may occur in ENL, Lucio phenomenon, and Latapi lepromatosis. Clinically, granulomatous leprosy lesions may mimic vasculitis.

Microscopic Constellations

- Common and uncommon patterns. Granulomatous responses are the common tissue reactions in leprosy, with epithelioid differentiation of macrophages being characteristic of TT, BT, and BB, and undifferentiated or foamy macrophages being the hallmark of BL, LLs, and LLp. Microscopic changes in BB are said to consist of epithelioid differentiation of macrophages, very few lymphocytes, no giant cells, but many acid-fast bacilli. Uncommon patterns can occur, sometimes dominating the histologic picture, and are (1) chronic inflammation, particularly in BL and indeterminate disease; (2) lobular panniculitis in ENL; (3) vasculitis in ENL, Lucio phenomenon, and Latapi



lepromatosis; and (4) normal skin in BL or LL. At the level of the low-power objective, normal skin, a patchy infiltrate involving both the papillary and reticular dermis, or a bizarre "sausage-shaped" infiltrate (following neurovascular bundles) should prompt inclusion of leprosy in the differential diagnosis.

DIAGNOSIS

Criteria for Diagnosis

A firm diagnosis of leprosy requires the satisfaction of one of two criteria: a consistent peripheral nerve abnormality or the demonstration of acid-fast bacilli in tissues. In nonendemic areas, the diagnosis is often difficult, but only because the possibility of leprosy is not considered. There is no test or series of tests that will prove that the patient does not have leprosy.

Because *M. leprae* does not grow in cell-free media, demonstration of mycobacteria by their acid-fast property is used most commonly in diagnosis. Acid-fast bacilli in tissue sections are best shown by carbolfuchsin staining, using modifications of the Ziehl-Neelsen method, collectively called Fite-Faraco stains. *M. leprae*, like *Nocardia* species, is only weakly acid-fast. In smears, either the Ziehl-Neelsen method or auramine-rhodamine staining with fluorescent microscopy is satisfactory. Because of characteristic clinical and histologic changes, positive specification of *M. leprae* is rarely required.

Characteristic histologic changes are extremely helpful in suggesting or corroborating a diagnosis of leprosy, but, excepting the presence of epithelioid cell granulomas within nerves, are not absolutely diagnostic.

False Negatives

False Positives

Alternative Methods

Alternative methods of establishing a diagnosis have been pursued but, at present, are of limited value. *M. leprae*–specific antibodies are most prevalent in multibacillary cases, in which diagnosis is readily made by clinical criteria, and in endemic areas, high antibody titers are far more prevalent than the disease, thus further restricting their use.[14] Reverse transcriptase-polymerase chain reaction may be negative in up to one-half of paucibacillary cases, making a positive signal of value but a negative signal of no help. PCR should be helpful in the diagnosis of patients with lesions having acid-fast bacilli but no stigmata of leprosy and negative cultures.[47] Lepromin skin testing, because of the high rate of positive reactions in unaffected adults, is not useful in diagnosis, but can be of value in classification of patients. All TT and most BT (85 percent in our experience) are positive (3 mm or more of induration at 21 days) and BB through LLp are negative (< 3 mm). Gene expression profiling may provide new tests for the diagnosis and/or classification of leprosy.[22]

COMPLICATIONS

The complications of leprosy, as contrasted to the injury resulting directly from the host's response to *M. leprae*, arise for peripheral nerve injury or venous insufficiency. Approximately one-fourth to one-third of newly diagnosed patients with leprosy have, or will eventually have, some chronic disability secondary to irreversible nerve injury, usually of the hands or feet, or from eye involvement. Collapse of the nose in LL is from the contracture of the scar tissue, which has replaced the bone and cartilage.

Ocular Disability

Exposure keratitis may result from a variety of factors including a dry eye, corneal insensitivity, and lagophthalmos. The keratitis and the anterior chamber lesions, most commonly iritis, may result in blindness.

Disability of Hands and Feet

Weakness from loss of innervation of muscles is a self-evident cause of disability. Loss of protective sensation is less obvious, but no less real. When a sharp or hot object cannot be perceived as such, injury occurs. Because this injury is more severe than if sensation were normal, infection is more apt to occur. Because the infection can produce no painful signal, the part is not rested, allowing the infection to become extensive before help is sought. Repetitive cycles of injury and infection, permitted by loss of protective pain sensation, is the source of severe tissue destruction in leprosy. Contracture secondary to muscle weakness or scar formation may produce further deformity. Charcot's joints are another source of deformity. Dryness of palm or soles from sympathetic involvement further compounds these problems.

Venous insufficiency, secondary to endothelial involvement of deep vein valves, leads to stasis dermatitis and leg ulcers.

Management and prevention of the problems arising from nerve injury require the skills of orthopedic surgeons, ophthalmologists, podiatrists, plastic surgeons, physical therapists, orthotists, and occupational therapists.

PROGNOSIS AND CLINICAL COURSE

In untreated leprosy, the only patients who will self-cure are those with TT, or BT patients who upgrade to TT. Otherwise, the disease will be progressive, with morbidity occasioned by nerve injury and a reactional state. BT, BB, BL, and LLs may upgrade, BT, BB and BL may downgrade, and BL, LLs and LLp may develop ENL.

Treatment arrests much of disease activity, but S-GPSI may progress. Peripheral neuritis of recent onset may improve with corticosteroid treatment. Like the post-polio syndrome, late-arising sensory impairment is sometime seen and is difficult to understand and to manage.

TREATMENT

Medical management is directed at the infection itself, and, if present, at a reactional state[8] (Boxes 186-1 and 186-2). As mentioned in Etiology and Pathogenesis, a patient is considered to be "paucibacillary" if no acid-fast bacilli are found in tissue or smears and to be "multibacillary" if one or more acid-fast bacilli are found. Please see Box 186-1 for the different regimens recommended by the World Health Organization (WHO)[48] and the U. S. Public Health Service (USPHS).[49,50]

The rationale for recommending three drug regimens is that rifampin (bactericidal) will kill all susceptible organisms, including those resistant to dapsone (bacteriostatic), and dapsone will eventually eliminate all susceptible organisms, including those resistant to rifampin. Clofazimine (weakly bactericidal, mainly bacteriostatic) is added to obviate the risk of primary dapsone resistance. The absence of routine follow-up in the WHO recommendations per-

Box 186-1

Antibacterial Treatment of Leprosy Recommendations

RECOMMENDING ORGANIZATION	DISEASE TYPE	RIFAMPIN	DAPSONE	CLOFAZIMINE	DURATION	FOLLOW-UP
World Health Organization	PB	600 mg/mo	100 mg/day	—	6 mo	No mandated follow-up. To return prn.
	MB	600 mg/mo	100 mg/day	50 mg/day 300 mg/mo	1 yr	No mandated follow-up. To return prn.
U.S. Public Health Service	PB	600 mg/day	100 mg/day	—	1 yr	At 6 mo intervals for 5 yr.
	MB	600 mg/day	100 mg/day	50 mg/day	2 yr	At 6 mo intervals for 10 yr.

OTHER MICROBICIDAL AGENTS	DOSE
Clarithromycin	500 mg/day
Minocycline	100 mg/day
Levofloxacin	500 mg/day

MB = multibacillary or 1 or more acid-fast bacilli found on smear of biopsy; PB = paucibacillary or no acid-fast bacilli found on smear or biopsy.

haps reflects expectations of a low relapse rate, as well as a low rate of post-treatment reactional states. The presence of semi-annual follow-up visits for up to 10 years in the USPHS recommendations perhaps reflects a differing opinion as to the frequency of non-compliance, bacterial relapse, and post-treatment reactional states.

The rate of relapse after completion of a triple drug regimen is controversial. Most observers concur with the WHO[51] that relapse is rare. A small but growing minority have presented evidence that relapse is a serious problem, approaching 20 percent 10 years after stopping treatment in patients with a BI of 3 or more.[52–55] Shetty et al.[55] have reported on relapses, have reviewed the other reports, and have offered reasons for the controversy. One group reported relapses beginning 6 years after completion of 2 years of triple drug therapy.[54] Two groups reported relapse after smear negativity had occurred.[54,55] Also, a 1-year course of treatment had a higher relapse rate than did a 2-year course.[53] The reported relapses are not considered to be re-infection. Opinion varies as to how to cope with this problem. The WHO plan depends upon the patient's self-referral. The USPHS recommendations would allow resumption of treatment based upon a physician's evaluation. Another approach is to continue dapsone alone indefinitely, after completing multiple drug therapy.

In addition to rifampin, a number of antibiotics have potent bactericidal activity, including minocycline, clarithromycin, and the fluoroquinolones, ofloxacin and levofloxacin. Taking a single dose of three drugs, rifampin, ofloxacin, and minocycline, is being studied as treatment for paucibacillary disease, but the relapse rate has not been determined.[56] Because of their expense, the use of the above agents on a daily basis is prohibitive in the areas where leprosy is common and health care funds scarce. Also, it is not known if some combinations of these potent microbicidal agents, an attractive idea a priori and by analogy to tuberculosis, would have any advantage over the WHO and USPHS recommendations, but they were well tolerated in a small trial.[57]

Because the incidence of primary dapsone resistance is low in our multibacillary patient population,[58] we often use the combination of rifampin, 600 mg daily, and dapsone, 100 mg daily, for 2 to 3 years. Then the choice of continuing dapsone indefinitely or confronting an uncertain relapse rate is discussed with the patient.

In reversal reactions (see Box 186-2), because of the risk of permanent nerve damage, prompt institution of prednisone therapy (0.5 to 1.0 mg/kg/day) is recommended. The dose of prednisone is titrated against overt nerve tender-

Box 186-2

Medical Management of Reaction States

	THALIDOMIDE	PREDNISONE OR PREDNISOLONE	DURATION	OTHER AGENTS OF UNPROVEN VALUE
Reversal reactions (type 1 reactions)	Of no value	0.5–1.0 mg/kg. Rifampin may increase their catabolism. Taper slowly. Alternate-day treatment may be well tolerated.	Usually needed for 6 mo–2 yr. May be longer or shorter.	Nonsteroidal anti-inflammatory agents
Erythema nodosum leprosum (type II reactions)	The most efficacious drug if available and not contraindicated Initially 1 dose of 100–200 mg qd hs Maintainable dose range 50 mg every other day to 500 mg daily	If thalidomide not available, 0.5–1.0 mg/kg/day.	Median duration of treatment is approximately 5 yr. Can persist for 10 yr.	Pentoxifylline
Lucio phenomenon (usually ceases with use of a microbicidal agent)	Of no value	May be helpful.	—	Plasmapheresis reported as helpful in unremitting patients



ness, the patient's symptoms, and careful sensory evaluation of hands and feet, for example with graded Semmes-Weinstein filaments. Therapy should be tapered slowly and the patient cautioned that 6 months or more of prednisone may be needed. If the response of a neuritis to prednisone is not prompt, then rest, enforced with splinting of affected extremities, is advised.

In ENL (see Box 186-2), thalidomide (see Chap. 236) is dramatically effective in a majority of patients if available and not interdicted by its teratogenic effects. The needed dose ranges over one order of magnitude. We usually start with 100 to 200 mg nightly and, if it is only partially effective, we may add prednisone in a 0.5 to 1.0 mg/kg range, tapering the prednisone over the subsequent 6 to 8 weeks. Alternatively, we increase the dose of thalidomide until obtaining a therapeutic or toxic affect, having gone as high as 600 mg at bedtime. Thalidomide is slowly tapered as dictated by abolition of systemic symptoms or morbidity from skin lesions but not the complete disappearance of skin lesions. If thalidomide cannot be used, then corticosteroids may be needed. Management with nonsteroidal anti-inflammatory agents, clofazimine, or pentoxifylline has been found useful by some, but have been disappointing in our hands.

ADVERSE EFFECTS OF DRUGS USED IN LEPROSY

Adverse reactions to dapsone (see Chap. 226) in the short term include the dapsone syndrome, a rare, potentially fatal infectious mononucleosis-like condition, and three kinds of hemolytic anemia, almost universally from a direct membrane effect, uncommonly from a glucose-6-phosphate deficiency, and rarely from an idiosyncratic response. In the long term, dapsone is associated with peripheral neuropathy, usually motor with a sensory component, and, rarely, bone marrow suppression, especially agranulocytosis.

The serious problem with rifampin is hepatotoxicity. Red urine is alarming but banal. As a P_{450} inducer, rifampin may lessen the effect of other drugs, for example, oral contraceptives and corticosteroids. Once-monthly use is rarely associated with severe hemolysis or acute renal failure.

Clofazimine produces skin darkening from the clofazimine itself in the near-term and from a ceroid-lipofuscin pigment in the long-term (see eFig. 186-10.22 in on-line edition).[59] At usual doses of 50 to 100 mg a day, gastrointestinal intolerance, dry skin, and acquired ichthyosis are common. Prolonged administration of large doses may produce a novel enteropathy secondary to mucosal and enteric lymph node drug accumulation. Accumulation in the spleen may predispose to rupture.

Thalidomide (see Chap. 236), infamous for teratogenicity, may produce constipation and dizziness. Neuritis, a common side effect in non-leprosy patients, appears to be rare in ENL patients. An idiosyncratic intolerance is uncommon.

Long-term use of minocycline may be limited by hyperpigmentation, more common in leprosy than in acne, perhaps related to the large accumulation of macrophages in leprosy. We have seen both diffuse hyperpigmentation and intense hyperpigmentation at the site of lesions, usually on the legs or feet (see eFig. 186-10.23 in on-line edition).

Corticosteroids, in addition to their well-known side effects, may also exacerbate co-existing diseases, for example, tuberculosis, hepatitis B, and some parasitic conditions.

PREVENTION

Protocols endeavoring to control leprosy by vaccination usually consist of bacille Calmette-Guérin alone, viable bacille Calmette-Guérin in combination with killed *M. leprae*, or killed *M. leprae* alone.[60] Most studies support a reduction in leprosy incidence, roughly one-third in tuberculoid cases, considerably less in lepromatous. The recent observation that lipid and lipoglycan antigens are presented to T cells ($CD4^-$, $CD8^-$, $CD3^+$) by $CD1^+$ cells opens the door to entirely new vaccination protocols.[61] Other preventive measures, such as isolation of patients or treatment of patient contacts with antimicrobials, have been disappointing.

KEY REFERENCES

The full reference list for all chapters is available at www.digm7.com.

6. Cole ST et al: Massive gene decay in the leprosy bacillus. *Nature* **409**:1007, 2001
10. Truman R: Leprosy in wild armadillos. *Lepr Rev* **76**:198, 2005
15. Krutzik SR et al. TLR activation triggers the rapid differentiation of monocytes into macrophages and dendritic cells. *Nature Med* **11**:653, 2005
18 Mira T et al. Susceptibility to leprosy is associated with PARK2 and PACRG. *Nature* **427**:636, 2004
27. Trindade MA et al. Leprosy and HIV co-infection. *Lepr Rev* **76**:162, 2005
28. Scollard DM et al. The continuing challenges of leprosy. *Clin Microbiol Rev* **19**:338, 2006
32. Rea TH, Levan NE: Lucio's phenomenon and diffuse non-nodular lepromatous leprosy. *Arch Dermatol* **114**:1023, 1978
50. Moschella SL. An update on the diagnosis and treatment of leprosy. *J Am Acad Dermatol* **51**:417, 2004
51. World Health Organization: Health Topics, http://www.who.int/topics/en/
55. Shetty VD et al: Clinical, histological and bacteriological study of 52 referral MB cases relapsing after MDT. *Lep Rev* **76**:241, 2005



CHAPTER 187

Lyme Borreliosis

Meera Mahalingam
Jag Bhawan
Anne-Marie Chomat
Linden Hu

Lyme borreliosis, or Lyme disease, is the most commonly reported arthropod-borne illness in both the United States and Europe.[1] It was first recognized in the 1970s after epidemiologic investigations of a clustering of cases of oligoarthritis among children in eastern Connecticut established a probable microbial etiology for the disease.[2] In 1981, Burgdorfer isolated a new spirochetal bacterium, *Borrelia burgdorferi*, from the midgut of the *Ixodes dammini* tick (now *I. scapularis*).[3] Recovery of the organism subsequently from cutaneous lesions, cerebrospinal fluid (CSF), and blood specimens of patients with Lyme disease in both the United States[4,5] and Europe[6–8] definitively linked the disease with *B. burgdorferi*.

EPIDEMIOLOGY

In the United States, the Centers for Disease Control and Prevention (CDC) initiated surveillance for Lyme disease in 1982, and the Council of State and Territorial Epidemiologists made Lyme disease a nationally notifiable disease in 1991. Since 1982, there have been more than 200,000 cases reported to the CDC. In 2003, the number of new cases in the United States was 21,273 (national incidence 7.22 cases per 100,000 people). There is believed to be significant under-reporting of Lyme disease, and the real number of new cases each year in the United States is actually thought to approach 150,000. In 2003, approximately 95 percent of cases occurred in 12 states located in the northeastern, mid-Atlantic, and north central regions: Connecticut, Delaware, Maine, Maryland, Massachusetts, Minnesota, New Hampshire, New Jersey, New York, Pennsylvania, Rhode Island, and Wisconsin. All states except Hawaii, Montana, and Oklahoma reported cases in 2002.[1]

Lyme disease is also widely distributed in Europe, with an estimated 120,000 new cases each year.[9] The highest reported frequencies occur in forested areas of central and Northern Europe (Germany, Austria, Slovenia, and Sweden).[10,11] The infection is also found in eastern Russia, China, Korea, and Japan.[12]

ETIOLOGY

Organism

Borrelia burgdorferi sensu lato, the agent of Lyme borreliosis, belongs to the eubacterial phylum of Spirochaetales, which are vigorously motile, corkscrew-shaped bacteria. The borrelial genome is made up of a linear chromosome and more than 20 circular and linear plasmids, the largest number known for any bacteria.[13] Some of the plasmids can be considered minichromosomes, as they are required for survival of the organism. Among the interesting characteristics of the organism are the large number of lipoproteins (more than 150) encoded by the genome. *B. burgdorferi*'s genome encodes no toxins or other identified virulence factor. *Borrelia* also lack biosynthetic machinery to produce many essential nutrients (e.g., amino acids, fatty acids) suggesting that *B. burgdorferi* is highly dependent on its hosts for obtaining crucial nutrients.[14]

Eleven *Borrelia* sp. have been described worldwide within the *B. burgdorferi sensu lato* complex. Only three—*B. burgdorferi sensu stricto*, *B. afzelii*, and *B. garinii*—have been confirmed to be pathogenic in humans and to cause Lyme borreliosis, although other species are under investigation for their relationship to human diseases (including *B. bissettii*[15,16] and *B. lonestari*[17]).

In the United States, the etiologic agent of Lyme disease is exclusively *B. burgdorferi sensu stricto*. *B. afzelii* and *B. garinii* cause the majority of Lyme disease in Europe, although *B. burgdorferi sensu stricto* is also present.[18] In Asia, only *B. afzelii* and *B. garinii* have been confirmed to exist.

Enzootic Life Cycle of the Agent of Disease

B. burgdorferi is maintained in nature through a cycle involving small rodents, birds, and ticks of the *Ixodes* species.[19,20] Although not important reservoirs for *B. burgdorferi*, deer are an important feeding source for adult ticks and reductions in deer populations can lead to significant decreases in the tick population.[21]

Ixodes ticks have a 2-year, three-stage (larval, nymphal, and adult) life cycle. Larval ticks acquire *B. burgdorferi* organisms by taking a blood meal from an infected animal and maintain the infection during the subsequent molting to the nymphal and adult stages. *B. burgdorferi* remain dormant in the tick's midgut between feedings.[22] Each tick life stage takes one blood meal: larval ticks feed in late summer, nymphal ticks feed the subsequent spring and early summer, and adult ticks feed in the fall and early winter. The major reservoirs for *B. burgdorferi* are small rodents and birds that are fed on by larval and nymphal ticks. Adult ticks feed on larger mammals (e.g., deer) that are not important reservoirs for *B. burgdorferi*. Humans are incidental hosts not important in maintaining *B. burgdorferi* in the wild. Most cases of human illness occur in the late spring and summer months when the nymphs are most active and human outdoor activity is greatest.

Of clinical relevance, certain *Ixodes* ticks are vectors of other tick-borne illnesses in addition to Lyme disease: *I. scapularis* ticks in the United States and *I. ricinus* ticks in Europe may transmit *Babesia microti* (a red blood cell parasite) or *Anaplasma phagocytophilum* (formerly referred to as the agent of human granulocytic ehrlichiosis).[23,24] *I. ricinus* in Europe and *I. persulcatus* in Asia are also vectors of tick-borne encephalitis virus.[25]

Pathogenesis

Once in the host's skin, *B. burgdorferi* begins to spread from the initial inoculation site rapidly into the bloodstream where it disseminates to multiple sites.

LYME DISEASE AT A GLANCE


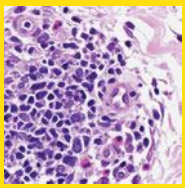

- Lyme disease is caused by *Borrelia burgdorferi*, a spirochete.
- Clinical course can be prolonged and may involve multiple organ systems.
- Cutaneous hallmarks are erythema migrans and acrodermatitis chronica atrophicans.
- Diagnosis is typically made on clinical grounds and/or serologic testing.
- Early treatment with antibiotics (doxycycline, amoxicillin, or cefuroxime) is highly successful.



Time from inoculation to dissemination varies from as little as 3 days to weeks.[5]

B. burgdorferi has developed strategies to adapt to and survive in markedly different microenvironments.[26] The organism expresses a variety of proteins during its life cycle, facilitating binding to different host proteins, migration within host tissues, transmission, and evasion of the host immune response.[27,28] A well-documented example of host adaptation is the variable expression of outer-surface proteins (Osp) A and C. OspA, primarily expressed while the spirochete is dormant in the tick's midgut,[29] is thought to serve as an anchor by binding the tick midgut protein, TROSPA.[30] When the tick engorges on a host, *B. burgdorferi* down-regulates OspA, releases from the midgut, and begins to multiply and travel to the salivary glands. This process takes between 24 and 48 hours, which explains why removal of the tick before 24 hours of attachment prevents transmission of disease.[31]

As the organism downregulates OspA, it upregulates OspC, which facilitates migration from the tick's gut to its salivary glands. OspC binds to a tick salivary protein, Salp15, which protects the organism from clearance by host immune defenses.[32] Immunosuppressive characteristics of tick saliva also aid in the establishment of early infection. *B. burgdorferi* also bind host factor H to protect itself from complement-mediated killing.[33,34] Specificity of strains of *B. burgdorferi* for factor H from different animal species may, in part, explain differences in host range between the species. *B. burgdorferi* have been shown to upregulate host proteases such as matrix metalloproteinases in the skin and joints which may play a role in pathogenesis by digesting extracellular matrix proteins and allowing dissemination, but this requires further clarification.[35]

Immunology

Both innate and acquired immune defenses have important roles in the control of *B. burgdorferi* infection; however, neither can typically eradicate the disease.[36,37] Phagocytosis, both complement-mediated and non–complement-mediated, is the first line of host defense against *B. burgdorferi*.[38,39] Natural antibodies (polyclonal IgM antibodies) may also function as a first line of defense against *B. burgdorferi*, killing spirochetes in the tick midgut during the blood meal and limiting pathogen burden before the development of a specific adaptive immune response.

Once inside the host, *B. burgdorferi* is a strong inducer of inflammation. Its outer surface lipoproteins are potent inflammatory stimuli.[40–42] Recognition of borrelial lipoproteins occurs through binding to Toll-like receptor 1 and 2 heterodimers, which initiates a cascade of intracellular signaling events culminating in the production of pro-inflammatory cytokines, chemokines, and other molecules important in host defense. Studies using Toll-like receptor–deficient mice have shown that other signaling pathways are also activated by *B. burgdorferi* and result in release of inflammatory mediators. Among the other innate immune receptors recognizing *B. burgdorferi* and mediating inflammation are integrin receptors.[43,44]

Development of a specific humoral immune response generally occurs over weeks to months.[45,46] The IgM response usually peaks between 3 and 6 weeks after disease onset and may remain elevated for months to years; the immunoglobulin G (IgG) response usually follows the IgM response by several weeks so that approximately 90 percent of patients have detectable IgG levels 4 to 6 weeks into the infection. The development of the humoral antibody response typically heralds a significant decrease in the number of organisms and decrease in the level of inflammation. Of note, the acquired humoral response is not typically protective against reinfection, in part due to significant sequence variability in protective antigenic epitopes between *B. burgdorferi* strains and the lack of expression of less variable protective antigens (e.g., OspA) in the mammalian host.[47]

CLINICAL MANIFESTATIONS

The clinical course of Lyme disease is typically described in stages that parallel that of another spirochetal disease, syphilis: early-localized, early-disseminated, and late-disseminated. Localized disease closely follows the bite of an infected tick and is characterized by the erythema migrans (EM) rash with or without constitutional symptoms. Early-disseminated Lyme disease presents days to months after onset of infection as a number of distinct clinical entities affecting the skin, joints, nervous system, and heart. Late-disseminated Lyme disease typically presents in only a subgroup of untreated patients months to years later, and manifests as chronic symptoms localized most often to the skin, joints, and nervous system. A minority of patients go on to develop prolonged post-treatment syndromes. These include a syndrome of antibiotic-resistant arthritis thought possibly to be autoimmune in nature, and, separately, a constellation of symptoms with similarities to fibromyalgia and chronic fatigue syndrome. The relationship of these latter symptoms to infection with *B. burgdorferi* is still debatable.

The disease caused by each species of *B. burgdorferi* is largely the same but certain clinical manifestations are more closely associated with infection due to a particular species.[18,48] For instance, *B. burgdorferi sensu stricto* is the most arthritogenic of the three Borrelia species.[49] For this reason, Lyme arthritis is the most frequent presentation of late Lyme disease in North American patients. Similarly, because *B. afzelii* is the species that has most often been associated with late skin manifestations; some dermatologic conditions [e.g., acrodermatitis chronica atrophicans (ACA) and borrelial lymphocytoma] are nearly exclusively found in Europe. Finally, *B. garinii*, the most neurotropic of the three species, causes a wide range of neurologic abnormalities.

Early Cutaneous Manifestations of Lyme Disease

ERYTHEMA MIGRANS ***Clinical Features.*** In early case reports, EM lesions were reported in 50 percent to 80 percent of patients with Lyme disease. More recent studies have shown lower rates of EM, likely due to improved patient education. Definite history of tick bite at the site of the lesion is obtained in only a small proportion of patients.[53] The lesion itself is believed to be the result of the direct presence of the spirochete, corroborated by reports showing aspiration and cultivation of the organism from the lesion. EM lesions develop within 3 to 30 days of the tick bite (median, 7 days).[54]

EM may be seen anywhere on the body but is most common on the lower extremities, inguinal and axillary regions of adults (Fig. 187-1), and on the face in children ("slapped cheek" appearance) reflecting sites of predilection of the tick.[2] Although no definite sex predilection has been noted in the United States, women are reported to be more commonly affected in European studies.[8]

The skin lesion has a characteristic and pathognomonic appearance (see Fig. 187-1) of an expanding erythema en-



▲ **FIGURE 187-1** Lyme borreliosis. Erythema migrans in the groin with expanding margin at the site of the tick bite of a week's duration. (Reprinted with permission from *Dermatopathology Interactive Atlas*, edited by Bhawan J, Sau P, Byers HR, 2001; http://www.dermpathatlas.com.)

circling the bite site, with the transition between the central zone and periphery being less well demarcated than between that of the periphery and adjacent skin.[53] The border is usually confluent and not patchy. Cases in which the erythema appears stationary or even linear are reported.[5] Typically described as round, the lesion in reality is more oval with the "long line of the oval parallel to the lines of least skin tension" (Langer lines) (see Fig. 187-1).[55] As migration of the lesion proceeds, distortion of this configuration occurs.[56] The center fades after a few weeks leaving only the annular border erythematous (see eFigs. 187-1.1 and 187-1.2 in on-line edition). In very large lesions, only a portion of the erythematous border can be seen (see eFig. 187-1.3 in on-line edition). Uncommon presentations include the entire lesion being homogenously erythematous ("solidly erythematous") (10 percent), forms with marked central necrosis, minimal size EM (size of the ring less than 5 cm at initial presentation) (2 percent), and the vesicular variant (5 percent).[57–59]

The lesion in itself is usually asymptomatic, but 50 percent of patients report mild tingling or itching.[60] Systemic manifestations, reported in approximately 50 percent of patients, may appear before, during, or after the classic rash.[53,56]

EM has an excellent prognosis, attributable in part to the activation of proinflammatory cytokines such as interferon-γ.[61] EM usually heals spontaneously, but may persist for as long as 6 to 12 months; median duration of the rash in the United States is approximately 4 weeks and in Europe is approximately 10 weeks.[8,18,60]

Multiple EM-like lesions occur in between 1 percent and 17 percent of patients.[53] The reported prevalence of multiple lesions is believed to be higher in the United States (25 percent to 48 percent) than in Europe (8 percent or less).[62] The spatial relationship of multiple lesions to the initial lesion indicates that they may be the consequence of hematogenous dissemination. Secondary EM lesions number from 2 to more than 80, usually occur away from the original lesion, and are usually smaller and less migratory (occur in "crops" of similar size, color, and shape) in comparison to classic EM.[53] Lesions are usually asymptomatic and if untreated spontaneously resolve over weeks to months. Like the primary lesion, secondary EM expands over days to weeks resulting in both solid and annular erythema. Primary EM may still may be present but more often a primary lesion is not found. Constitutional symptoms are usually more severe than those associated with classic EM.[57]

Histopathologic Features. Histopathologic findings vary with the biopsy site[56] and age of the lesion. Biopsies of early lesions show papillary dermal edema and a mixed infiltrate of lymphocytes, neutrophils, a few plasma cells, and a few eosinophils (Fig. 187-2). Biopsies of older lesions display a variably dense perivascular and interstitial infiltrate of lymphocytes and plasma cells (Fig. 187-3). Helpful, albeit non-specific, clues include the

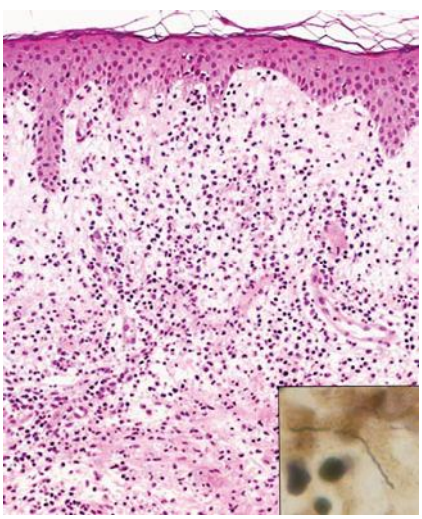

▲ **FIGURE 187-2** Histopathology of erythema migrans. Papillary dermal edema, mixed infiltrate of lymphocytes, neutrophils, few plasma cells, and few eosinophils (hematoxylin and eosin stain). *Inset* shows a spirochete in same biopsy stained with Warthin-Starry stain (oil immersion). (Reprinted with permission from *Dermatopathology Interactive Atlas*, edited by Bhawan J, Sau P, Byers HR, 2001.)

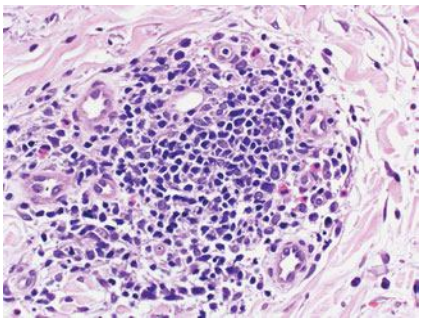

▲ **FIGURE 187-3** Histopathology of erythema migrans. Dense nodular perivascular lymphoid cell infiltrate with many plasma cells and few eosinophils in a biopsy from a later stage of erythema migrans. (Hematoxylin and eosin stain, ×40.)

presence of plasma cells and mast cells in the infiltrate.[63] The presence of plasma cells and eosinophils in the same specimen is reported to be much less common than the presence of either alone.[56]

Immunohistochemical studies indicate the infiltrate to be composed of $CD4^+$ T lymphocytes with the exception of those seen in association with HIV infection in which the infiltrate is mainly $CD8^+$ T lymphocytes, reflective of the CD4 lymphopenia of HIV infection.[64]

Histopathologic features of multiple lesions of EM are identical to primary EM.

Diagnosis. The diagnosis of EM is typically made on clinical appearance in patients in an endemic area. From biopsy specimens, spirochetes are best located in the papillary dermis and may be short or elongate at this stage of the disease (see Fig. 187-2 inset).[56] Direct detection of the spirochete from biopsy specimens by culture or by polymerase chain reaction (PCR) typically has good sensitivity but is usually unnecessary.[65]

Diagnosis and Differential Diagnosis. Atypical lesions exist and broaden the clinical differential diagnosis to include cellulitis, tinea, contact dermatitis, or a fixed drug reaction (Table 187-1). The differential diagnosis of vesicular EM includes poison ivy, contact dermatitis, cellulitis, herpes simplex, and impetigo.

Late Cutaneous Manifestations of Lyme Disease

ACRODERMATITIS CHRONICA ATROPHICANS

Clinical Features. Observed mainly in elderly patients in Europe, ACA has an insidious onset and appears to have predilection for females.[66] Rare cases of ACA have been reported in children.[67] The time interval from the spirochete inocu-



TABLE 187-1
Cutaneous Manifestations of Lyme Disease

	Onset	Diagnosis/Differential Diagnosis
Common Manifestations		
Erythema migrans	Weeks to months (early)	Arthropod bite, erythema multiforme granuloma annulare, urticaria, erysipelas, brown recluse spider bite, fixed drug eruption
Acrodermatitis chronica atrophicans	Months to years (late)	Venous insufficiency, lichen sclerosus, scleroderma, physiologic age-related atrophy, corticosteroid-induced atrophy
Uncommon Manifestations		
Cutaneous scleroborrelioses	Months to years (late)	
Morphea		Primary morphea
Lichen sclerosus et atrophicus		Primary lichen sclerosus et atrophicus
Periarticular fibrous nodules		Rheumatoid nodule, gouty tophi
Progressive facial hemiatrophy		Primary progressive facial hemiatrophy/Parry-Romberg syndrome
Eosinophilic fasciitis		Primary eosinophilic fasciitis/Shulman syndrome
Cutaneous atrophoborrelioses	Months to years (late)	
Anetoderma		Primary anetoderma
Cutaneous lymphoborrelioses	Months to years (late)	
B-cell dominant (including B-cell lymphoma)		Arthropod bite reaction, response to vaccination, granulomas, neoplasm
T-cell dominant		Pityriasis lichenoides, polymorphous light eruption
Other cutaneous lesions	Weeks to months to years (early or late)	
Panniculitis		Erythema nodosum
Granuloma annulare		Insect bite reaction
Erythema multiforme		Drug eruption
Syphilis-like papulo-squamous eruption		Secondary syphilis



lation to the onset of symptoms of ACA is extremely difficult to evaluate. Most patients do not recall the specific tick bite that initiated the disease.[8,68] That the spirochete can survive for decades is favored by reports indicating transmission of the disease from ACA patients even after 20 years.[8]

An inflammatory phase characterizes the early clinical stages of this biphasic disease.[69] The inflammatory phase presents as a bluish-red discoloration on the extensor aspect of fingers, hands, joints, and lower extremities (see eFigs. 187-3.1 and 187-3.2 in on-line edition). Joints usually involved include the elbows and knees. Infiltrated purple bands of varying widths may be observed adjacent to involved joint(s). Associated findings include a cushion-like ("doughy") swelling of the dorsum of the hands and feet (see eFig. 187-3.2 in on-line edition).[69] The extremities are most commonly involved, although extensive lesions on the trunk have also been documented. Lesions typically extend from the distal to the proximal portion of the extremity involved. Although the erythema and swelling initially vary in intensity ("waxes and wanes"), swelling of the posterior aspect of the lower extremities is believed by some to be particularly indicative of Lyme disease.[60]

Cutaneous atrophy (Fig. 187-4) characteristic of the later clinical stage is not an obligatory sequel to the inflammatory phase of ACA.[69] Rarely, coexistence of both kinds of lesions at different sites in the same patient has been documented. The atrophic phase is characterized by lesions with a "cigarette paper-like" appearance and a prominence of superficial veins (see Fig. 187-4).



▲ **FIGURE 187-4** Acrodermatitis chronica atrophicans. Typical end-stage cutaneous atrophy with prominence of superficial veins.

Extracutaneous Features. Central and peripheral nervous system involvement has also been documented in approximately 45 percent of patients with ACA. Thirty percent to 45 percent of patients suffer from a polyneuropathy, often most pronounced in the limb with cutaneous involvement.[62] Chronic joint and bone involvement, attributed to persistence of spirochetes in cutaneous lesions, is most often seen in patients with long-standing ACA or an untreated lesion of EM/ACA and is typically restricted to the extremity involved. The characteristic symptom, exhibited in approximately one-third of patients in one study, was a swollen or painful foot and heel.[62] Other symptoms include subluxation of small joints, bursitis, arthritis, and cortical thickening of bone. Solitary or multiple fibrotic lesions near joints, particularly in the olecranon area, may develop in some patients.[69]

Histologic Features. All three species of *B. burgdorferi* that infect humans have been found in ACA lesions.[71] Histopathologic features of biopsied lesions vary with the clinical phase of ACA. In inflammatory lesions, three layers are typically described: an atrophic epidermis, a zone of uninvolved papillary dermis, and a layer of inflammatory cells composed of lym-

phocytes and plasma cells.[72] The presence of plasma cells in the infiltrate is documented mainly from studies from Europe, as American reports indicate that few or no plasma cells are found.[68,69] The infiltrate may be deep with extension into the subcutis.[60] Occasionally, interface dermatitis has been reported. Unusual findings include the presence of vacuoles, either singly or in groups, at different levels of the dermis.[73] Although some believe these represent mature adipocytes, others believe them to be an expression of lymphedema, given that they are mainly observed from biopsies of markedly edematous sites. In favor of the latter hypothesis is the absence of such vacuoles from the same site post-treatment.

Phenotypic studies indicate the lymphocytes in the infiltrate are mainly of the CD4 phenotype, favoring the concept that ACA is a T cell–mediated immune response.[74] Further in support of this theory is the expression of adhesion molecules, such as intracellular adhesion molecule-1, on endothelial cells, lymphocytes, and basal keratinocytes in the inflammatory infiltrate.[75] Chronicity of the lesions may be partially explained by down-regulation of major histocompatibility complex class II molecules on Langerhans cells.[76]

Diagnosis and Differential Diagnosis. Lesions of ACA are notoriously overlooked or misinterpreted. In those with a relevant clinical history, the onset appears to be related to an untreated lesion of EM and/or neurologic manifestations. In one study, a history of EM months to years earlier on the same side was found in approximately 18 percent of patients.[76] Differential diagnoses are listed in Table 187-1.

Detection of the spirochete substantiates the infective etiology, further supported by positive serologic findings. The latter are of great utility in the diagnosis of ACA. Antibodies to *B. burgdorferi* can be detected in almost all (100 percent) of patients with ACA even years after treatment.

CUTANEOUS SCLEROBORRELIOSES ***Clinical Features.*** Sclerotic skin lesions clinically indistinguishable from primary lichen sclerosus et atrophicus (LSA) or morphea (see eFig. 187-4.1 in on-line edition) develop not only in association with other dermatoborrelioses [approximately 10 percent of patients with ACA and borrellial lymphocytoma (see Uncommon Cutaneous Manifestations of Lyme Disease)] but also in the absence of other cutaneous manifestations of Lyme disease.[57,77,78]



▲ **FIGURE 187-5** Lyme borreliosis. Fibrotic nodules and multiple large, firm subcutaneous nodules on both elbows.

Periarticular ("ulnar") fibrous nodules (Fig. 187-5), described in association ACA, may also occur in the absence of dermatoborrelioses.[79] They usually present as hard nodules on the elbows, knees, and on the lateral aspect of the digits near joints and have been reported to be provoked by trauma, surgery, and electromagnetic radiation.[80]

Uncommon sclerotic disorders associated with Lyme disease include progressive facial hemiatrophy (Parry-Romberg syndrome) and eosinophilic fasciitis (Shulman syndrome) (see Chap. 135).[81] In support of an infectious etiology is the clinical similarity of the cutaneous lesions, positive history of tick bite, and, in rare cases, anti-borrelial serologic evidence and positive culture and PCR from lesions.[82,83] Eosinophilic fasciitis associated with borrelial infection has been termed *borrelial fasciitis*, reflective of the infectious nature of these lesions.[81] However, patients with borrelial fasciitis lack the peripheral blood eosinophilia typical of patients with Shulman disease.

Histologic Features. A unifying feature of LSA- and morphea-like scleroborrelioses is the abundance of plasma cells in the inflammatory infiltrate.[69] Unusual histologic findings include a scleromyxedema-like picture with increased dermal mucin and fibroblast proliferation.[79]

Histopathologic examination of a periarticular fibrous nodule reveals relatively well-circumscribed nodules of broad hyalinized bundles of collagen with macrophages and plasma cells.[80,84] Adjacent capillaries may be occluded by similar deposits.

Progressive facial hemiatrophy and eosinophilic fasciitis show variable dermal sclerosis, loss of appendages, and a perivascular infiltrate composed predominantly of lymphocytes and plasma cells with scattered histiocytes.[60] In borrelial fasciitis, eosinophilic infiltration of the fascial planes is not as impressive as in "idiopathic" Shulman disease.[81]

Diagnosis and Differential Diagnosis. (See Table 187-1) In the absence of other dermatoborrelioses, definitive diagnoses can only be made by positive evidence of infection in the form of identification of the spirochete in tissue sections (identification of the organism in periarticular nodules has been reported to be positive despite the lengthy spatial relationship from the initial tick bite), positive cultures, or positive serology.[85] Conflicting evidence regarding serologic findings in patients with scleroderma or LSA-like lesions exists.[78] Although some reports indicate a high frequency of elevated titers of anti-*Borrelia* antibodies (8 of 15 cases), others suggest that such serologic evidence is minimal.

CUTANEOUS ATROPHOBORRELIOSES ***Clinical Features.*** Atrophic lesions indistinguishable from primary anetoderma (see Chap. 65) may also occur in the absence of other dermatoborrelioses.[69,85] When associated with ACA, these lesions are usually seen at the periphery of an extensive lesion.[86]

Histologic Features. Biopsy specimens from atrophic or anetoderma-like skin lesions show abnormal elastic tissue fibers in association with a perivascular infiltrate of lymphocytes with occasional histiocytes, neutrophils, or eosinophils.[69] Spirochetes are found with difficulty in histologic sections.

Diagnosis. Definitive diagnosis is made by identification of the spirochete in tissue sections, positive cultures, or positive serology in combination with a compatible clinical presentation.[85]

Uncommon Cutaneous Manifestations of Lyme Disease

CUTANEOUS LYMPHOBORRELIOSES (B- AND T-CELL LYMPHOID HYPERPLASIAS) ***Clinical Features.*** Lymphocytic infiltrates associated with *Borrelia* are the least com-

mon of the cutaneous hallmarks of Lyme disease (1 percent) and may present either as single borrelial lymphocytoma (lymphadenosis benigna cutis) or as multiple lesions.[60] The coexistence of lymphocytoma with other dermatoborrelioses led to the suggestion of a unifying causative organism, favored by the development of EM-like lesions following passive inoculation of an infiltrate from a lesion of LABC.[8,87] Lymphocytoma has been reported solely in Europe. However, all three species of *B. burgdorferi sensu lato* have been associated with lymphocytoma so it is unclear whether the lack of U.S. cases is related to strain differences.[71]

More common in children than in adults, lymphocytoma clinically presents as a nodulo-papular lesion in the ear lobes (Fig. 187-6) and scrotum (see eFig. 187-6.1 in on-line edition) in children and the nipple-areolar area in adults.[57] The precise reason for this predilection is not known but is believed to be tissue temperature related.[60] Other locations occur (see eFig. 187-6.2 in online edition). As with the other dermatoborrelioses, most patients are not aware of a preceding tick bite. The incubation period varies anywhere from a few weeks to 10 months. The duration of an untreated solitary lesion can vary from months to years (average, 5 years). Spontaneous resolution may occur, but typically lesions resolve more rapidly with antibiotic therapy.[62] Lesions of multiple lymphocytomas can be entirely subcutaneous, may last for decades, and typically have no specific site predilection or associations with other dermatoborrelioses.

Discoid lesions "starting as small papules and expanding peripherally with central clear" that wax and wane have also been described in association with borrelial infection.[88] The name given for these lesions is *benign lymphocytic infiltrates* of the skin (Jessner-Kanof) (see Chap. 147). More common in men, they tend to be located on the face, neck, and upper trunk. Annular lesions clinically resembling EM have also been described.



▲ **FIGURE 187-6** Borrelial lymphocytoma of ear lobe, 3 months' duration.

Several reports suggest an association of low-grade cutaneous B-cell lymphoma with *B. burgdorferi* infection.[89,90] Clinical presentation of *Borrelia*-associated B-cell lymphoproliferative disease is varied and consists of multiple ill-defined, slowly progressive plaques and nodules presenting on the trunk, extremities, or both, of usually older patients. The highest frequency of infection with *Borrelia* has been found in marginal zone lymphoma (20 percent to 52 percent), followed by follicular center lymphoma (15 percent to 26 percent) and diffuse large B-cell lymphoma (15 percent to 16 percent; see Chaps. 146 and 147).[89,91] That antigenic drive by *Borrelia* may be a pathogenic factor in more than one subtype is supported by the association of *B. burgdorferi* with multiple subtypes of cutaneous B-cell lymphoma. Demonstration of the organism in the skin before development of overt cutaneous B-cell lymphoma serves to confirm the temporal progression of *B. burgdorferi*-associated B-cell lymphoproliferative disease. Clinical regression of marginal zone lymphoma after eradication of *B. burgdorferi* argues in favor of a benign process.[90,92,93]

Histologic Features. Histopathologic findings of benign B- and T-cell dominant hyperplasias are essentially similar to benign lymphoid hyperplasias (Fig. 187-7) secondary to an arthropod bite, vaccination, or other causes (see Chap. 147). Definitive classification of *Borrelia*-associated B-cell lymphoma is confounded by the immunohistochemical profile: expression of CD5 and CD10 (common acute lymphoblastic leukemia antigen), antigens typically associated with centrocytic lymphoma, are absent in *Borrelia*-associated B-cell lymphoma.[89]

Diagnosis and Differential Diagnosis. (See Table 187-1) Positive history of tick bite and presence of other dermatoborrelioses are helpful, given that the histologic findings of cutaneous lymphoborrelioses are not diagnostic. Direct evidence of an infective etiology has been provided from studies demonstrating the presence of fragmented spiral forms suggestive of *B. burgdorferi* in lesions of benign lymphocytic infiltrates[88] and has been confirmed by immunofluorescence using species-specific monoclonal antibodies. Spirochetes may be cultured directly from biopsy specimens or *B. burgdorferi* DNA may be detected by PCR. High titers of anti-borrelial antibodies have been reported in more than 50 percent of patients with LABC solitaria.[87] The common denominator in patients with *Borrelia*-associated lymphoma appears to be a high titer of antibodies, typical of the chronic stage of the infection, against *B. burgdorferi*.[89]

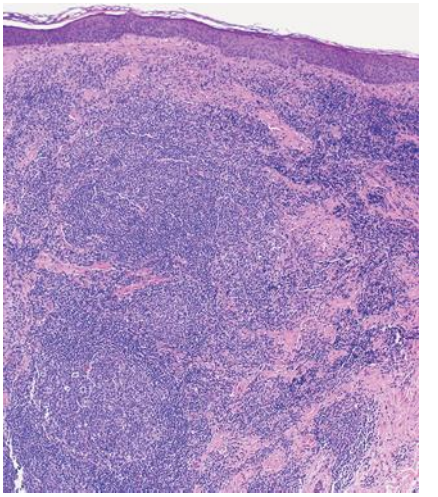

▲ **FIGURE 187-7** Cutaneous borrelial lymphocytoma with definitive history of tick bite. Nodular and diffuse dense lymphohistiocytic infiltrate with prominent germinal center (hematoxylin and eosin stain).

OTHER CUTANEOUS LESIONS Other cutaneous lesions reported in patients with documented Lyme disease include panniculitis, vasculitis, granuloma annulare, erythema multiforme, and a syphilis-like papulo-squamous eruption (see Table 187-1), but *B. burgdorferi* has not been directly recovered from any of these lesions.

Non-Cutaneous Manifestations of Lyme Disease

NERVOUS SYSTEM MANIFESTATIONS *B. burgdorferi* can cause early-disseminated neurologic disease in 10 percent to 15 percent of patients in the United States who have not received antibiotics.[94] Meningitis, cranial neuropathy, and radiculopathy are the most common neurologic manifestations and can manifest as soon as 1 week after EM.[95] Facial palsy is the most characteristic neuropathy of early Lyme disease in the United States, occurring in 40 percent to 50 percent of patients with borrelial neurologic involvement, usually within 4 weeks after onset of EM. Bilateral facial palsy should immediately raise suspicion for Lyme disease, as it is uncommon in most other causes of facial palsy. Involve-

ment of other cranial nerves has been reported, but is relatively rare.[95] The triad of lymphocytic meningitis, cranial palsy (often facial), and radiculoneuritis, known as *Bannwarth syndrome*, is pathognomonic for Lyme disease. It is frequently reported in Europe but is rare in the United States.[96,97] Acute or subacute myelitis leading to spastic paraparesis and CSF pleocytosis, mononeuritis, and a Guillain-Barré-like syndrome may also occur in early disseminated disease.[95,98] Late neurologic manifestations include encephalomyelitis, encephalopathy, and chronic polyneuropathies.[98,99]

CARDIAC MANIFESTATIONS Cardiac involvement occurs in 4 percent to 10 percent of untreated patients in the United States and in 0.3 percent to 4.0 percent of European patients. It usually occurs within several weeks after the onset of infection, although it can occur as early as 1 week and as late as 7 months into the infection.[100,101] Within the heart, *B. burgdorferi* has a predilection for the atrioventricular node, resulting in atrioventricular block. Acute myopericarditis and left ventricular dysfunction can also occur, but are usually self-limited and mild, only sometimes resulting in transient cardiomegaly or pericardial effusion.[102] *B. burgdorferi* has been isolated from endomyocardial biopsy samples from several European patients with chronic dilated cardiomyopathy, a complication observed less frequently in the United States.[103,104]

MUSCULOSKELETAL MANIFESTATIONS Early musculoskeletal manifestations of *B. burgdorferi* infection are typically nonspecific. Inflammatory arthritis is the most frequent clinical sign of late-disseminated Lyme disease in the United States, occurring in 50 percent to 70 percent of patients with untreated or incompletely treated infection. It usually presents 1 or more months after the onset of Lyme disease as asymmetric mono- or oligoarthritis of large joints, most often of the knee.[94] Migratory arthritis is also relatively common.[5,49] Bouts of arthritis are generally frequent and short at first, becoming longer and less frequent with time, each lasting from several days to 1 year.

OTHER MANIFESTATIONS OF LYME DISEASE Ophthalmic complications in the form of conjunctivitis, keratitis, iridocyclitis, retinal vasculitis, chorioiditis, and optic neuropathy are rare manifestations of Lyme disease. They are believed to be the direct result of tissue inflammation by *B. burgdorferi* and are usually associated with other signs and symptoms of disease.[105,106] The eye may also be affected by extraocular manifestations of Lyme disease, such as cranial nerve pareses and orbital myositis. Findings in other organ systems (gastrointestinal, lymphatic, respiratory, urinary, and genital) have been reported, but the associations with borrelial infection are loose.

PERINATAL LYME DISEASE Studies in both human and animal models indicate that *B. burgdorferi* can cross the placenta during the initial spirochetemia, but evidence of a fetal immune response or an adverse neonatal outcome are not definitively established.[107]

LYME DISEASE IN CHILDREN Other than differences in localization of EM lesions (more typically in the head and neck), pediatric Lyme disease is similar to that of adults. Of note, however, in children optic nerve involvement may lead to blindness.[108]

PROGNOSIS AND CLINICAL COURSE

All manifestations of Lyme disease resolve over time, even in the absence of antibiotic therapy. Antibiotic therapy can hasten resolution of some (EM, arthritis), but not all (facial palsy, radiculitis) manifestations, and antibiotic therapy can clearly abort late manifestations.

Dual infection with *B. burgdorferi* and either of *Babesia microti* or *Anaplasma phagocytophilum* occurs at different frequencies depending on the geographic location, and may alter the clinical presentation of Lyme disease in some patients. Some studies suggest more severe disease in patients who are co-infected, but this remains uncertain.[109-111]

COMPLICATIONS

A small number of patients have symptoms that persist for years despite appropriate antibiotic therapy. Up to 10 percent of patients with Lyme arthritis treated with appropriate antibiotics may have continued arthritis that persists for years.[112,113] Arthritis in these patients does typically respond to immunosuppressive agents (methotrexate, antitumor necrosis factor therapies), which has led to suggestions that these patients may have an autoimmune syndrome. Molecular mimicry of borrelial antigens with host proteins has been proposed as one possible mechanism, but this remains unproven.[114]

There have been many reports of patients who develop a fibromyalgia-like syndrome including profound fatigue, depression, myalgias, polyarthralgias without arthritis, and paresthesias, as well as neurocognitive difficulties involving memory, concentration (particularly auditory), and decreased mental flexibility (i.e., impaired verbal fluency) after infection with *B. burgdorferi*.[41,115,116] This syndrome is often referred to as *chronic Lyme disease*. The linkage of these symptoms with *B. burgdorferi* infection remains controversial and several large epidemiologic studies have shown that patients who have contracted Lyme disease are no more likely to suffer from these symptoms than persons in the general population.[117,118]

DIAGNOSIS OF LYME DISEASE

Physical findings, a history of potential exposure, known tick bites, or symptoms consistent with the typical multisystem presentation of Lyme disease can all be helpful in making a diagnosis. In the presence of classic EM or of Bannwarth syndrome, the diagnosis of Lyme disease can be made on clinical grounds alone. Diagnostic conundrums arise in presentations that involve other compatible skin, cardiac, neurologic, or musculoskeletal symptoms in the absence of a history of EM or tick exposure.

Laboratory Tests

DIRECT DETECTION OF *B. BURGDORFERI* The gold standard for diagnosis of Lyme disease is culture of *B. burgdorferi*. However, the need for specialized media and the slow growth of the organism make it impractical in most clinical settings. *B. burgdorferi* can readily be cultured from biopsies of EM and ACA[65] as well as from CSF samples in patients with meningitis.[119,120] Recent studies have also demonstrated that the organism can be recovered from the blood in up to 50 percent of untreated adult patients with EM.[121] However, cultures are generally insensitive in patients with extracutaneous manifestations of Lyme borreliosis, particularly in later stage disease.

PCR assays are very sensitive in detecting *B. burgdorferi* DNA in skin biopsy and synovial fluid specimens from patients with EM and Lyme arthritis, respectively.[122] However, PCR testing for *B. burgdorferi* DNA has not been approved by the U.S. Food and Drug Ad-



ministration (FDA), and its routine use is not recommended.[7]

SEROLOGIC DIAGNOSIS OF LYME DISEASE

Immunologic diagnosis is the main laboratory modality used to support a clinical diagnosis of Lyme disease. In the United States, the FDA has approved more than 70 different immunoassays for Lyme disease[123]—mainly enzyme-linked immunoabsorbent (ELISA) and Western immunoblot assays. ELISA tests use whole-cell lysates of *B. burgdorferi sensu lato* or, less commonly, purified *B. burgdorferi* antigens to capture either anti-*B. burgdorferi* IgG and/or IgM antibodies present in a given sample. Although relatively specific, ELISA tests are associated with a high rate of false-positive results.[124,125] Patients with autoimmune diseases (lupus, rheumatoid arthritis), Epstein-Barr virus, bacterial endocarditis, and other tick-borne diseases appear to be at an increased risk for false-positive IgM serologic testing; syphilis, *H. pylori*, systemic lupus erythematosus, ehrlichiosis, and babesiosis cause false-positive IgG serologic testing.[125–127] A newer ELISA test that uses only a small peptide of the constant region of *B. burgdorferi* VlsE protein appears to have greater specificity than traditional whole cell ELISA testing. This test, also known as the *C6 peptide test*, measures only IgG antibody, but IgG antibody to the C6 peptide develops early in the course of disease and sensitivity of the assay in patients with early disease has been equivalent to that seen with IgM whole cell ELISA tests.[128,129] Western immunoblot assays are more specific because they enable detection of antibodies to individual components of *B. burgdorferi*. Currently, there are no widely accepted standard tests or criteria for serodiagnosis of Lyme disease in either Europe or Asia, in part because of the presence of multiple strains of *B. burgdorferi* that have only partial antigen cross-reactivity.

Other Available Tests for the Diagnosis of Lyme Disease.

Current Recommendations for Use of Serologic Testing for Lyme Disease. Because of its limitations, particularly high false-positive results within the general population, serologic testing should be initiated based on the pre-test probability of disease and serve only to support a clinical diagnosis.[7] It is most helpful in patients with an intermediate pre-test probability of Lyme disease—namely those who reside in endemic areas and who present with signs and symptoms consistent with, but not diagnostic of, Lyme disease (e.g., facial palsy, arthritis, or atrioventricular nodal conduction abnormalities in the absence of an EM lesion). [Patients who reside in areas of high endemicity and have clear EM lesions should be diagnosed on clinical grounds alone without laboratory testing. Testing should be avoided in patients with low suspicion for disease (patients not living in endemic areas, or with non-specific systemic symptoms, or after a tick bite) as the rates of false-positive tests greatly outnumber true positive tests in this setting.] One algorithm for workup of patients presenting with an eruption suspicious for EM is shown in Fig. 187-8.

Once the decision is made to obtain serologic testing, current recommendations are for two-stage testing, starting with a highly sensitive ELISA test first. If the ELISA is negative, the likelihood of Lyme disease is low, and further testing is not generally recommended. However, if the test is positive or indeterminate, a Western immunoblot assay with high specificity should be used to confirm the results. The specificity of this two-step approach is thought to be 99 percent to 100 percent in late-stage Lyme disease.[133] If testing is negative early in the course of disease, the tests can be repeated in 3 to 4 weeks (antibiotic therapy, if given very early, may abort antibody development). It is important to note that in patients with untreated disease for longer than 1 month, IgM testing should not be performed. A positive IgM Western blot with a negative IgG Western blot in this setting is considered a negative result due to the high false positivity rate of IgM testing. Seronegativity in patients suspected of having late Lyme disease practically excludes the diagnosis.[7] Finally, because IgG and IgM antibody titers may persist for years despite antibiotic therapy,[134,135] persistent seropositivity is not in itself an indication of treatment failure, nor is it proof of recent infection or re-infection. Currently, there is no test that allows confirmation of successful clearance of the organism after treatment.

TREATMENT RECOMMENDATIONS

Treatment is indicated for all stages of Lyme disease, even though most manifestations resolve over time without therapy. Patients may not be asymptomatic at the time of completion of the antibiotic course but this is not an indication for extending length of therapy; symptoms generally continue to improve steadily over time. Of note, Jarisch-Herxheimer reactions (fevers, chills, and worsening arthralgias and myalgias) are sometimes reported after the initial dose of antibiotics; the reaction is thought to be caused by host reaction to the dying organisms.

The Infectious Disease Society of America has published guidelines for the treatment of all manifestations of Lyme disease,[136] although many of the recommendations are based on expert opinion and not on rigorously controlled clinical trials. Treatment patterns differ in different countries, but no data suggest differences in either the efficacy of specific antibiotics or in the optimal duration of therapy between patients in North America and Europe.

Treatment of all of the cutaneous manifestations of Lyme disease should initially be with oral antibiotics (Table 187-2). Doxycycline is generally considered as first-line therapy, because it has excellent penetration into the central nervous system and is also effective against *A. phagocytophilum,* the agent of human granulocytic ehrlichiosis. Amoxicillin should be used in children and pregnant women. Cefuroxime is a more expensive first-line agent. These three agents have been found to be equally effective.[25,136–138] Macrolides are second-line agents and some evidence suggests that they are less effective than the first-line agents.[136] Duration of therapy is generally recommended to be 14 to 21 days; a recent study showed similar outcomes in patients with EM treated with either a 10- or a 20-day course of oral doxycycline.[139]

Intravenous antibiotics (ceftriaxone, cefotaxime, or penicillin G) may be recommended for patients with cutaneous manifestations that are accompanied by neurologic disease (meningitis, encephalopathy) or high degree heart block. Intravenous antibiotics are also sometimes used for patients with refractory ACA or arthritis.

Treatment of patients with non-specific fibromyalgia-like disease after infection with *B. burgdorferi* is controversial. There are no controlled trials supporting the use of long-term antibiotic therapy.[140]

PREVENTION

Prompt removal of the tick is the most effective measure in preventing disease, as the tick must usually be attached for

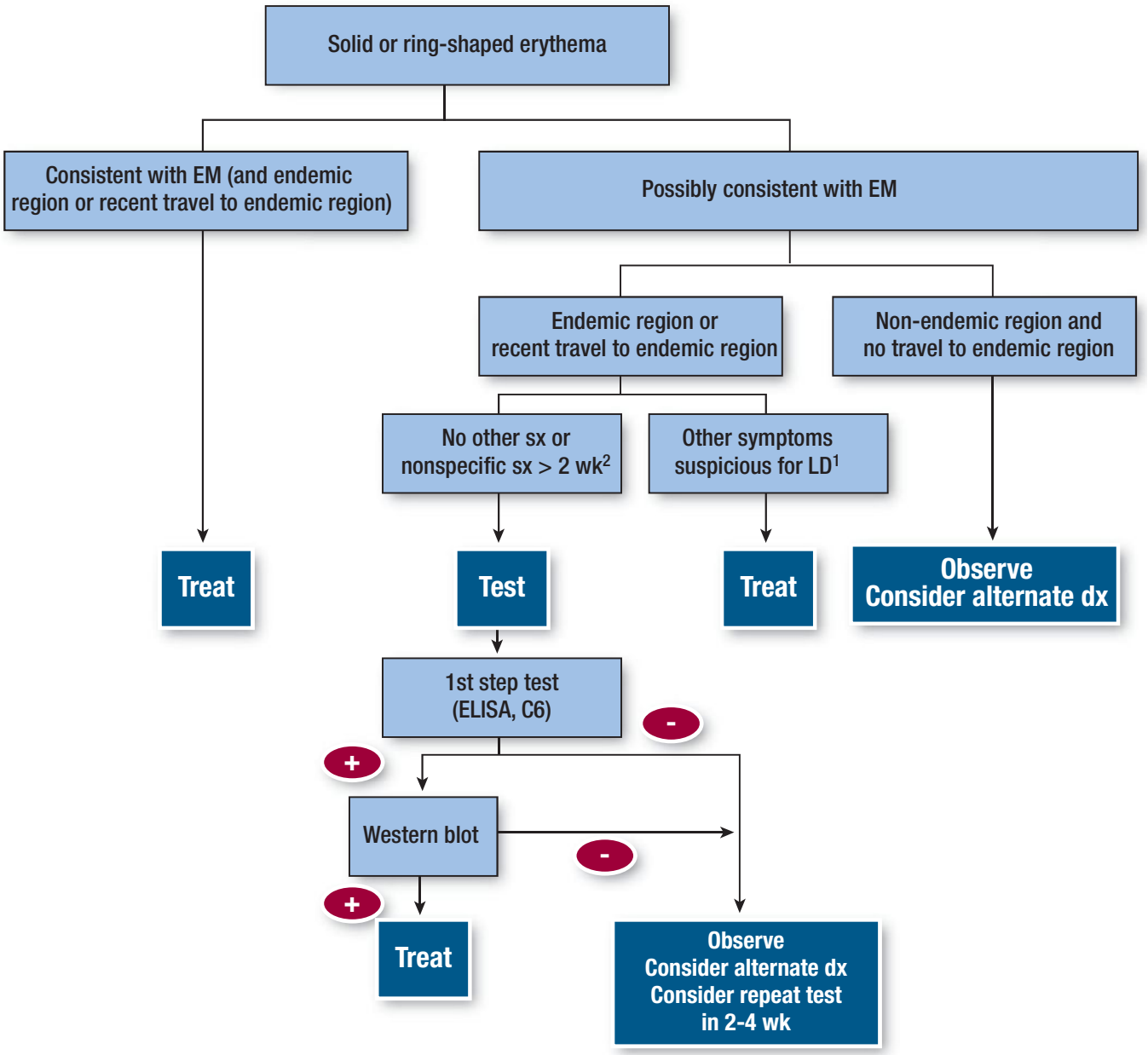

▲ **FIGURE 187-8** Approach to patient with erythema migrans (EM). [1]Bell palsy, radiculoneuritis, meningitis, arthritis. [2]Fever, chills, fatigue. dx = diagnosis; ELISA = enzyme-linked immunosorbent assay; LD = Lyme disease; sx = symptoms; dx = diagnosis.

24 to 48 hours for transmission to occur. For adult or nymphal *I. scapularis* ticks that have attached for longer than 36 hours within an endemic area, a single 200-mg dose of doxycycline within 72 hours of tick removal is 87 percent effective in preventing early cutaneous manifestations.[136,141]

In 2002, the only FDA-approved Lyme disease vaccine for humans, a recombinant form of OspA, was withdrawn by the manufacturer despite an 80 percent efficacy in preventing Lyme disease in North America.[142,143] Withdrawal of the vaccine was related to concerns linking the emergence of autoimmune arthritis with host immune responses to OspA.[144] Recently, trials of an OspA vaccine lacking the epitope thought to be linked to autoimmune arthritis have begun in Europe.[145]

Available preventive measures in Lyme disease endemic areas include use of repellents, such as DEET or picaridin, or permethrin treatment of clothing; routine checks for ticks; and landscaping practices to create an inhospitable environment for ticks (removing brush and leaf litter, creating buffer zones of wood chips or gravel between forest and lawn, and application of pesticides to yards). Novel approaches under investigation include biologic agents (fungi) to kill the ticks, the use of devices to target acaricides to rodents and deer without harming them, and the development of vaccines to eradicate disease in the wild reservoirs. The control of infection on a larger scale by the eradication of deer or widespread use of acaricides have had limited public acceptance.[1,146]

TABLE 187-2
Treatment of Lyme Disease

Presentation[a]			Treatment (Alternate)	Treatment Length (Days)	Comments
Early Lyme Disease	Skin	Erythema migrans	A (B)	14 (14–21)	Can consider treating for 10 days if using doxycycline.
		Lymphocytoma	A (B)	14 (14–21)	
	Cardiac	1st and 2nd degree AV block	A (B)	14 (14–21)	Consider IV antibiotics, temporary pacemaker if symptomatic.
		3rd degree AV block	C (D)	14 (14–21)	Consider temporary pacemaker.
	Neuro	Cranial nerve palsy	A (B, C)	14 (14–21)	Consider lumbar puncture to exclude central nervous system involvement.
		Meningitis	C (D)	14 (14–28)	
		Radiculopathy	C[b] (D)	14 (14–28)	Response to treatment usually is slow and may be incomplete; do not repeat antibiotics unless objective relapse.
Late Lyme Disease	Skin	Acrodermatitis	A (B)	21 (14–28)	
	Rheum	Arthritis	A (B, C/D)	28	If persistent or recurrent joint swelling, repeat 28-day course of oral antibiotics or 14–28-day course of IV ceftriaxone. If arthritis persists despite two courses of antibiotics: non-steroidal anti-inflammatory drugs, disease-modifying anti-rheumatic drugs, arthroscopic synovectomy.
	Neuro	Encephalopathy	C (D)	28 (14–60)	Use 14–28 days initially. If no improvement, may consider a second course of similar duration
		Radiculopathy	C (D)	14 (14–28)	

Treatment (doses will need to be adjusted in children):
A: First line oral: Doxycycline[c] (100 mg PO bid), or Amoxicillin[d] (500 mg PO tid), or Cefuroxime (500 mg PO bid)
B: Alternative oral[e]: Azithromycin (500 mg PO qd), or Erythromycin (500 mg PO qid), or Clarithromycin (500 mg PO bid)
C: First line parenteral: Ceftriaxone (2 g IV qd)
D: Alternative parenteral: Penicillin G (18–24 M units/day divided into doses given q4h),[f] or Cefotaxime (2 g IV q8h), or Doxycyline (200–400 mg/day IV in 2 divided doses)

[a]If several manifestations of Lyme disease are present, the route (PO or IV) and length of therapy should be as for the manifestation with the longest and most aggressive (e.g., IV > PO) recommendation.
[b]According to some small studies, oral doxycycline has been found to be effective.
[c]Also effective against *A. phagocytophilum*, the agent of human granulocytic ehrlichiosis. Relatively contraindicated during pregnancy or lactation and for children younger than 8 years.
[d]Preferred choice in children and pregnant women.
[e]Reserved for patients who are intolerant of first-line agents.
[f]Assuming normal renal function.



KEY REFERENCES

The full reference list for all chapters is available at www.digm7.com.

25. Steere AC: Lyme disease. *N Engl J Med* **345**:115, 2001
35. Zhao Z et al: Selective up-regulation of matrix metalloproteinase-9 expression in human erythema migrans skin lesions of acute Lyme disease. *J Infect Dis*. **188**:1098, 2003
60. Duray PH, Asbrink E, Weber K: The cutaneous manifestations of human Lyme disease: a widening spectrum. *Adv Dermatol* **4**:255, 1989
61. Mullegger RR et al: Differential expression of cytokine mRNA in skin specimens from patients with erythema migrans or acrodermatitis chronica atrophicans. *J Invest Dermatol* **115**:1115, 2000
62. Asbrink E, Hovmark A: Early and late cutaneous manifestations in Ixodes-borne borreliosis (erythema migrans borreliosis, Lyme borreliosis). *Ann N Y Acad Sci* **539**:4, 1988
63. Duray PH: Clinical pathologic correlations of Lyme disease. *Rev Inf Dis* **11**:S1487, 1989
65. Berger BW et al: Cultivation of *Borrelia burgdorferi* from erythema migrans lesions and perilesional skin. *J Clin Microbiol* **30**:359, 1992
72. Duray PH: The surgical pathology of human Lyme disease. An enlarging picture. *Am J Surg Pathol* **11**:47, 1987
81. Granter SR, Barnhill RL, Duray PH: Borrelial fasciitis: Diffuse fasciitis and peripheral eosinophilia associated with *Borrelia* infection. *Am J Dermatopathol* **18**:465, 1996
83. Abele DC, Anders KH: The many faces and phases of borreliosis. I. Lyme disease. [erratum appears in *J Am Acad Dermatol* 24:663, 1991]. *J Am Acad Dermatol* **23**:167, 1990
90. Goodlad JR et al: *Borrelia burgdorferi*-associated cutaneous marginal zone lymphoma: a clinicopathological study of two cases illustrating the temporal progression of *B. burgdorferi*–associated B-cell proliferation in the skin.[see comment]. *Histopathol* **37**:501, 2000

SECTION 30

FUNGAL DISEASES

CHAPTER 188

Superficial Fungal Infection: Dermatophytosis, Onychomycosis, Tinea Nigra, Piedra

Shannon Verma
Michael P. Heffernan

MYCOLOGY

Fungal infection can be superficial, subcutaneous, or systemic, depending on characteristics of the organisms and of the host. This chapter concentrates on the superficial fungal infections, which are confined to the stratum corneum, hair, and nails. They can be subdivided into infections that induce an inflammatory response, such as those caused by the dermatophytes, and those that result in minimal to no inflammation, such as those caused by the piedras.

DERMATOPHYTES

The dermatophytes are a group of taxonomically related fungi. Their ability to form molecular attachments to keratin and use it as a source of nutrients allows them to colonize keratinized tissues, including the stratum corneum of the epidermis, hair, nails, and the horny tissues of animals.[1] Superficial infection caused by a dermatophyte is termed *dermatophytosis*, whereas *dermatomycosis* refers to a fungal infection by any fungi.

Historical Aspects

Epidemiology

Numerous ways of classifying superficial fungi exist, including habitat and pattern of infection. Geophilic "earth-loving" organisms originate in the soil and only sporadically infect humans, usually by direct contact with the soil. These infections are usually spread by spores, which can live for years in blankets and grooming tools. Infections produced by these organisms are usually inflammatory. Strains of *Microsporum gypseum*, the most common geophilic pathogen cultured from humans, are more virulent than those from the soil, accounting for occasional epidemic spread under appropriate conditions.[2]

Zoophilic ("animal-loving") species are usually found on animals, but are also transmitted to humans. Domestic animals and pets are a common source of these infections in urban areas (e.g., *M. canis* in cats and dogs). Transmission may occur through direct contact with a specific animal species or indirectly when infected animal hair is carried on clothing or present in contaminated buildings or feed. Exposed areas such as the scalp, beard, face, and arms are favored sites of infection. Although human infection with zoophiles is often suppurative, animal infection may be clinically silent, demonstrating the unique adaptation of fungi to their animal hosts.[3] Inflammatory dermatophytoses are most commonly produced by zoophilic dermatophytes.

Anthropophilic ("man-loving") species have adapted to humans as hosts. Unlike the sporadic geophilic and zoophilic infections, anthropophilic infections are often epidemic in nature. They are transmitted from person to person via direct contact or fomites. Infections with these species can vary from asymptomatic to markedly inflammatory due to variability in virulence as well as host susceptibility. Kerion formation, suppuration, or other manifestations of inflammatory tinea facilitate early diagnosis. Noninflammatory disease, in contrast, results in a clinically silent "carrier" state that serves to delay diagnosis and propagate the infection.

Host variability also affects presentation. Immunocompromised individuals

SUPERFICIAL FUNGAL INFECTIONS AT A GLANCE



- Dermatophytes: Fungi capable of colonizing keratinized tissues.
- Dermatophytes can be divided into geophilic, zoophilic, and anthropophilic organisms.
- Dermatophytes come from the genera *Epidermophyton*, *Microsporum*, and *Trichophyton*.
- Tinea capitis, tinea barbae, tinea corporis, tinea manuum, tinea pedis, tinea cruris, and onychomycosis are all caused by dermatophytes.
- Oral antifungals include griseofulvin, itraconazole, fluconazole, and terbinafine.
- Tinea nigra is a superficial dermatophyte infection that may mimic acral lentiginous melanoma.
- Piedra, which consists of white and black forms, is an asymptomatic fungal infection of the hair shaft.



Copyright © 2008 by The McGraw-Hill Companies, Inc. Click here for terms of use.

TABLE 188-1
Laboratory Characteristics of Dermatophytes That Cause Tinea Capitis

ECTOTHRIX	ENDOTHRIX
Yellow-green fluorescence	Dull gray-green fluorescence
Microsporum audouinii	*Trichophyton schoenleinii*
M. canis	
M. ferrugineum	
No fluorescence	No fluorescence
M. fulvum	*T. gourvillii*
M. gypseum	*T. soudanense*
T. megninii	*T. tonsurans*
T. mentagrophytes	*T. violaceum*
T. rubrum	*T. yaoundei*
T. verrucosum	

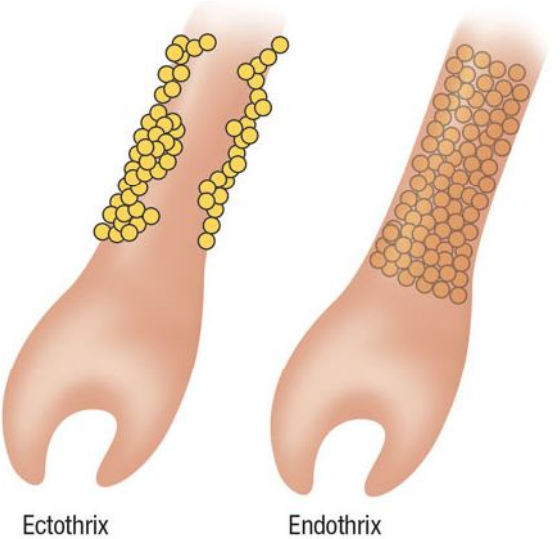

◀ **FIGURE 188-1** Graphic demonstration of ectothrix (*left*) and endothrix hair involvement.



are more susceptible to severe or refractory dermatophytoses, and advances in chemotherapy and transplant medicine have led to an increase in opportunistic infections by previously non-pathogenic dermatophytes.[4] Interestingly, only the severity of dermatophytosis is increased with human immunodeficiency virus disease, not the prevalence.[5] Age, sex, and race are additional important epidemiologic factors, as dermatophyte infections are five times more prevalent in males than females. However, *Trichophyton tonsurans* tinea capitis is more common in female adults than male adults, and most common in African American children. There is no evidence currently to support linkage of dermatophyte susceptibility to any of the ABO groups, nor is there evidence that diabetic patients are especially susceptible. Diabetes may, however, affect the course of established infections.[6]

Patterns of human travel may rapidly influence the distribution of endemic fungi, as illustrated by *T. tonsurans*. Within the past quarter century, it has replaced *M. audouinii* as the predominant cause of tinea capitis in the United States, correlating well with the immigration of Mexican and Caribbean populations. The relative resistance of *T. tonsurans* to griseofulvin has also contributed to its predominance.[3]

Finally, local customs can influence rates of dermatophytoses. For example, the use of macerating occlusive footwear has made tinea pedis and onychomycosis much more common in industrialized nations.[5]

Diagnostic Procedures

A clinical diagnosis of a dermatophyte infection can be confirmed by microscopic evaluation or culture. Although microscopic evaluation can provide evidence of fungal infection within minutes, it does not often allow for speciation or for identification of the susceptibility profile of the infectious agent. Microscopic evaluation may also yield false-negative results, and fungal culture should be performed when a dermatophyte infection is suspected clinically.

MICROSCOPIC EXAMINATION ***Hair.*** Examination of lesions involving the scalp or beard with a Wood's lamp may reveal the fluorescent pteridine of certain pathogens (Table 188-1). If so, hairs that fluoresce should be selected for further examination. However, it is important to note that although the ectothrix organisms *M. canis* and *M. audouinii* will fluoresce on Wood's light examination, the endothrix organism, *T. tonsurans*, will not fluoresce. *T. tonsurans*, which is now the most common cause of tinea capitis in the United States, thus limits the use of Wood's light examination. Hairs must be plucked, not cut, put on a microscopic slide with 10 percent to 20 percent potassium hydroxide (KOH), covered with a coverslip and slightly warmed. Low-power microscopy will reveal two possible patterns of infection (Fig. 188-1):

1. Ectothrix—small or large arthroconidia forming a sheath around the hair shaft; or
2. Endothrix—arthroconidia within the hair shaft.

Skin and Nails. Skin samples should be taken by scraping with the dull edge of a scalpel outward from the advancing margins of a lesion. Nail specimens must include clippings of the entire thickness of dystrophic areas of nail, as proximal from the distal edge as possible.

In a 10 percent to 20 percent KOH preparation, dermatophytes have septate and branching hyphae without constriction (Fig. 188-2); however, culture is required for speciation, as all dermatophyte species appear identical.

CULTURE PROCEDURES Speciation of superficial fungi is based on the macroscopic, microscopic, and metabolic characteristics of the organism. Sabouraud's dextrose agar (SDA) is the most commonly used isolation medium and serves as the basis for most morphologic descriptions. However, contaminant saprobes (organisms that feed on dead or decaying matter) grow rapidly on this medium, masking true pathogens. This necessitates the addition of cycloheximide (0.5 g/L) and chloramphenicol (0.05 g/L) to make the medium highly selective for the isolation of dermatophytes. Commercial versions of this agar exist. Dermatophyte test medium contains the pH indicator phenol red; it remains amber with the growth of most saprophytes, but turns red when dermatophyte proteolytic activity increases the pH to 8 or above. Nondermatophytes turn the medium yellow due to their acidic byproducts. Identification of isolated fungi is facilitated by the use of potato dextrose agar, which stimulates the production of conidia and pigment. Finally, species of *Trichophyton* are often differentiated by their nutritional requirements, revealed on *Trichophyton* agar numbers 1 through 7.

It is essential that each laboratory use standardized media, of which several

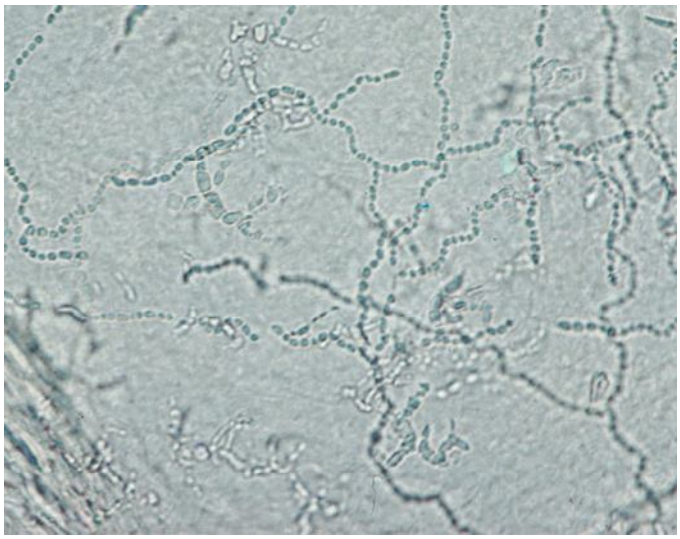

▲ **FIGURE 188-2** Microscopic examination of skin scrapings (scales) revealing septate, branching hyphae.

commercial variants are available. Cultures are incubated at room temperature (26°C [78.8°F]) for up to 4 weeks before being discarded as no growth. With more than 40 known dermatophytes, proper identification requires a suitable reference source.[7] Table 188-2 lists the characteristics of the most common pathogens.

Pathogenesis

Dermatophytes can survive solely off of human stratum corneum, which provides a source of nutrition for the dermatophytes and for the growing fungal mycelia.[8] Dermatophyte infections involve three main steps: adherence to keratinocytes, penetration through and between cells, and the development of a host response.



TABLE 188-2
Characteristics of the Most Common Dermatophytes

Organism	Colony Morphology		Microscopic Appearance
Epidermophyton floccosum 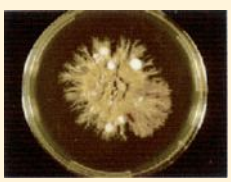	Flat feathery colonies with a central fold and yellow to dull gray-green pigment. Yellow to brown reverse pigment.	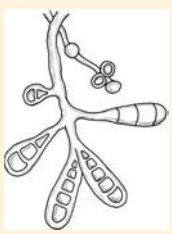	No microconidia, numerous thin and thick-walled, club-shaped macroconidia.
Microsporum audouinii 	Flat and white to gray with widely spaced radial grooves. Tan to salmon reverse pigment. Salmon-pink pigment on PDA. No growth on polished rice.		Terminal chlamydoconidia and pectinate (comb-like) hyphae.
M. canis 	Flat, white to light yellow, coarsely hairy, with closely spaced radial grooves. Yellow to orange reverse pigment. Yellow on PDA. Growth on polished rice.	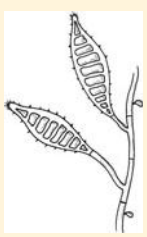	Few microconidia, numerous thick walled and echinulate macroconidia with terminal knobs.
M. gypseum 	Flat and granular with tan to buff pigment, no reverse pigment.	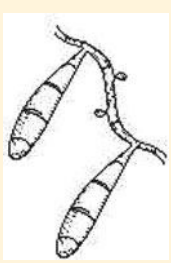	Few microconidia, numerous thin-walled macroconidia without knobs.

(continued)

TABLE 188-2
Characteristics of the Most Common Dermatophytes (Continued)

Organism	Colony Morphology	Microscopic Appearance
Trichophyton mentagrophytes 	White to creamy with a cottony, mounded surface. None to light brown reverse pigment. No pigment on PDA. Urease positive.	 Clustered round microconidia, rare cigar-shaped macroconidia, occasional spiral hyphae. Hair perforation positive.
T. rubrum 	Mounded white center with maroon periphery. Maroon reverse pigment. Cherry red on PDA. Urease negative.	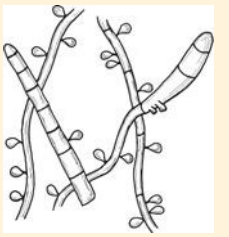 Few tear-shaped microconidia, rare pencil-shaped macroconidia. Hair perforation negative.
T. schoenleinii 	Heaped or folded and whitish. Colorless to yellow-tan reverse pigment.	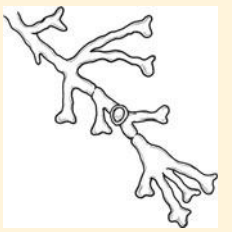 Knobby antler-like hyphae (favic chandeliers), numerous chlamydoconidia.
T. tonsurans 	Suede-like center with feathery periphery, white to yellow or maroon color. Reverse pigment usually dark maroon, sometimes none to yellow. Partial thiamine requirement.	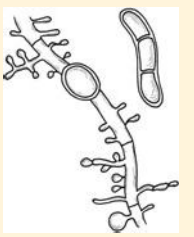 Numerous multiform microconidia and rare cigar-shaped macroconidia.
T. verrucosum 	Small and heaped, although sometimes flat, white to yellow-gray. Reverse pigment none to yellow. Requires thiamine and usually inositol for growth.	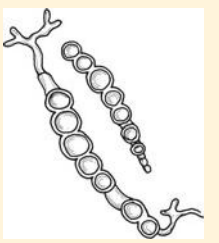 Chains of chlamydoconidia on SDA. Long and thin "rat-tail" macroconidia with thiamine.
T. violaceum 	Waxy and heaped, deep purplish-red. Purple reverse pigment. Partial thiamine requirement.	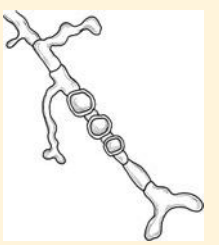 Irregular hyphae with intercalary chlamydoconidia. No micro- or macroconidia on SDA, rare micro- and macroconidia with thiamine.

PDA = potato dextrose agar; SDA = Sabouraud's dextrose agar.
Used with permission from David Ellis, PhD.



ADHERENCE Superficial fungi must overcome several obstacles in order for the arthroconidia, the infectious element, to adhere to keratinized tissue. They must resist the effects of ultraviolet light, variation in temperature and moisture, competition from normal flora, and sphingosines produced by keratinocytes. Fatty acids produced by sebaceous glands are fungistatic, particularly those with chain lengths 7, 9, 11, and 13. The presence of these fatty acids in postpubertal children may account for the dramatic decrease in tinea capitis infections after puberty.

PENETRATION After adherence, spores must germinate and penetrate the stratum corneum at a rate faster than desquamation. Penetration is accomplished by the secretion of proteinases, lipases, and mucinolytic enzymes, which also provide nutrients to the fungi.[8] Trauma and maceration also facilitate penetration and are important factors in the pathogenesis of tinea pedis. Fungal mannans in the cell wall of dermatophytes may also decrease the rate of keratinocyte proliferation. New defenses emerge once the deeper layers of epidermis are reached, including competition for iron by unsaturated *transferrin* and possibly inhibition of fungal growth by progesterone.

DEVELOPMENT OF A HOST RESPONSE The degree of inflammation is influenced both by the patient's immune status and by the organism involved. Immune detection and chemotaxis of inflammatory cells may occur through several mechanisms. Some fungi produce low-molecular-weight chemotactic factors much like those produced by bacteria. Others activate complement via the alternative pathway, creating complement-derived chemotactic factors.

Antibody formation does not appear to be protective in dermatophyte infections, as patients with widespread infections may have elevated antibody titers.[9] Alternatively, type IV, or delayed-type hypersensitivity (DTH), plays a pivotal role in combating dermatophytoses. This arm of cellular immunity is maintained by interferon-γ secretion from type 1 T-helper lymphocytes. In patients without previous exposure to a dermatophyte, primary infection causes minimal inflammation, and a trichophytin skin test is negative.[10] The infection produces mild erythema and scale, the result of increased keratinocyte turnover. It is hypothesized that dermatophyte antigen is then processed by epidermal Langerhans cells and presented in local lymph nodes to T lymphocytes. The T lymphocytes undergo clonal proliferation and migrate to the infected site to attack the fungus. At this time, the lesion becomes abruptly inflammatory, and the epidermal barrier becomes permeable to transferrin and migrating cells. Soon, the fungus is cleared, and the lesion spontaneously resolves. The trichophytin skin test is now positive, and clearing of a second infection will be more rapid.

Dermatophytid reactions, which occur in 4 percent to 5 percent of patients, are inflammatory eczematous allergic skin reactions at sites distant from the primary fungal infection.[11] Unlike the primary lesion, these are KOH examination and culture negative. These reactions may take the form of follicular papules, erythema nodosum, vesicular id of the hands and feet, erysipelas-like, erythema annulare centrifugum, or urticaria (see Chap. 17).[12–16] Although the precise mechanism is unknown, these reactions are associated with a DTH response to the trichophytin test and may involve a local DTH response to systemically absorbed fungal antigen.[11,17]

Genetics

In households afflicted with *T. concentricum* and *T. rubrum*, relatives are more likely to be infected than conjugal partners, even with equal exposure to the fungus. Specific factors facilitating infection are unknown.

DERMATOPHYTOSES

Tinea Capitis

Tinea capitis is a dermatophytosis of the scalp and associated hair. It may be caused by any pathogenic dermatophyte from the genera *Trichophyton* and *Microsporum* excepting *T. concentricum*. The most common cause worldwide is *M. canis*, whereas in the United States *T. tonsurans* is most prevalent followed by *M. canis*.[18]

EPIDEMIOLOGY The incidence of tinea capitis remains unknown, but it is most commonly found in children aged 3 to 14 years old. It is uncommon in adults. For unknown reasons, tinea capitis is more common in children of African descent. Transmission is increased with decreased personal hygiene, overcrowding, and low socioeconomic status. Organisms responsible for tinea capitis have been cultured from fomites such as combs, caps, pillowcases, toys, and theater seats. Even after shedding, hairs may harbor infectious organisms for more than 1 year.[19] Asymptomatic carriers are common, making tinea capitis difficult to eradicate.[20]

PATHOGENESIS Ectothrix dermatophytes (see Table 188-1) typically establish infection in the perifollicular stratum corneum, spreading around and into the hair shaft of mid- to late-anagen hairs before descending into the follicle to penetrate the cortex of the hair. Arthroconidia then reach the cortex of the hair and are transported upward on its surface. Microscopically, only the ectothrix arthroconidia may be visualized on plucked hairs, although intrapilary hyphae are present as well.

The pathogenesis of endothrix infections is the same except that arthroconidia remain within the hair shaft, replacing the intrapilary keratin and leaving the cortex intact. As a result, the hair is very fragile and breaks at the surface of the scalp where support from the follicular wall is lost, leaving behind a tiny black dot. Thus, "black dot" tinea capitis is observed.

CLINICAL FINDINGS The clinical appearance of tinea capitis depends on its etiology (Table 188-3).

TABLE 188-3
Organisms Associated with Clinical Types of Tinea Capitis[a]

INFLAMMATORY	NONINFLAMMATORY	BLACK DOT	FAVUS
• *Microsporum audouinii*	• *M. audouinii*	• *Trichophyton tonsurans*	• *M. gypseum*
• *M. canis*	• *M. canis*	• *T. violaceum*	• *T. schoenleinii*
• *M. gypseum*	• *M. ferrugineum*		• *T. violaceum*
• *M. nanum*	• *T. tonsurans*		
• *T. mentagrophytes*			
• *T. schoenleinii*			
• *T. tonsurans*			
• *T. verrucosum*			

[a]Note that a single organism may have more than one presentation.





▲ **FIGURE 188-3** Tinea capitis caused by *Microsporum audouinii*.



Noninflammatory, Human, or Epidemic Type. The noninflammatory pattern of tinea capitis is seen most commonly with the anthropophilic ectothrix organisms such as *M. audouinii* or *M. canis*. This form of tinea capitis is also known as the *seborrheic* form secondary to prominent scaling.[21] Inflammation is minimal. Hairs in the affected area turn gray and lusterless secondary to their sheath of arthroconidia and break off just above the level of the scalp (Fig. 188-3). Often there is no noticeable hair loss. Frequently, however, these lesions appear as well-defined, round hyperkeratotic, scaly areas of alopecia, due to the breaking off of hairs (gray patch type; Fig. 188-4). Appearance is like a "wheat field." Remaining hairs and scales exhibit green fluorescence under Wood's light (see Table 188-1). Lesions usually occur on the occiput.[19]



▲ **FIGURE 188-4** Tinea capitis "gray patch" type. A large, round hyperkeratotic plaque of alopecia due to breaking off of hair shafts close to the surface, giving the appearance of a mowed wheat field on the scalp of a child. Remaining hair shafts and scales exhibit a green fluorescence when examined with a Wood's lamp. *Microsporum canis* was isolated on culture.

Inflammatory Type. The inflammatory type of tinea capitis is usually seen with zoophilic or geophilic pathogens, with common examples being *M. canis* and *M. gypseum*. Inflammatory tinea capitis is the result of a hypersensitivity reaction to the infection. The spectrum of inflammation ranges from a pustular folliculitis to kerion (Fig. 188-5), which is a boggy, inflammatory mass studded with broken hairs and follicular orifices oozing with pus.[22] Such inflammation often results in scarring alopecia. Inflammatory lesions are usually pruritic, and may be associated with pain, posterior cervical lymphadenopathy, fever, and additional lesions on glabrous skin.

"Black Dot" Tinea Capitis. The "black dot" form of tinea capitis is caused by the anthropophilic endothrix organisms *T. tonsurans* and *T. violaceum*. This is the least inflammatory form of tinea capitis. Hair loss may or may not occur. When it does, hairs broken at the level of the scalp leave behind grouped black dots in the areas of alopecia (Fig. 188-6). Diffuse scaling is again typically present, but inflammation varies from minimal to pustular folliculitis or furuncle-like lesions to kerion.[20] Affected areas are usually multiple or polygonal with poorly demarcated, finger-like margins. Normal hairs commonly remain within patches of alopecia.



▲ **FIGURE 188-5** Kerion of the scalp.



▲ **FIGURE 188-6** "Black dot" tinea capitis caused by *Trichophyton tonsurans*.

DIFFERENTIAL DIAGNOSIS (Box 188-1)

HISTOPATHOLOGY In tinea capitis, methenamine silver and periodic acid-Schiff (PAS) stains reveal hyphae around and within the hair shaft. The dermis demonstrates a perifollicular infiltrate of mixed lymphocytes, histiocytes, plasma cells, and eosinophils. Follicular disruption leads to an adjacent foreign-body giant cell reaction.

Markedly inflammatory lesions, such as a kerion, demonstrate a more intense infiltrate of polymorphonuclear leukocyte abscesses within the dermis and follicle.[23] Organisms are difficult to visualize, but fungal antigens are detectable with immunofluorescent techniques.[24]

Tinea Favosa

Tinea favosa or favus (Latin, "honeycomb") is a chronic dermatophyte infection of the scalp, glabrous skin, and/or nails characterized by thick yellow

Box 188-1

Differential Diagnosis of Tinea Capitis

Most Likely

- Seborrheic dermatitis, atopic dermatitis, impetigo and pustular or plaque psoriasis, bacterial pyodermas, folliculitis decalvans, and perifolliculitis capitis abscedens et suffodiens

Consider

- Alopecia areata, trichotillomania, pseudopelade

Rule Out

- Syphilis, lupus erythematosus

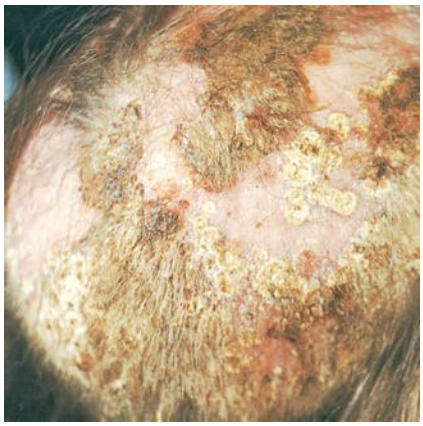

▲ **FIGURE 188-7** Favus caused by *Trichophyton schoenleinii*. Note the numerous yellow scutula.

crusts (scutula) within the hair follicles, which lead to scarring alopecia.

EPIDEMIOLOGY Favus is usually acquired before adolescence and extends into adulthood.[25] Associated with malnutrition and poor hygiene, it has become geographically limited in the past century, as it is now seen almost exclusively in Africa, the Middle East, and parts of South America.[26] Even in these regions, its incidence is dramatically declining.

ETIOLOGY *T. schoenleinii* is the most common cause of human favus, with *T. violaceum* and *M. gypseum* occurring as rare isolates.[26] Although favus occurs in poultry, mice, and horses, there are very few reports in the literature of human favus caused by an organism responsible for animal favus.[27]

CLINICAL FINDINGS Early favus (usually the first 3 weeks of infection) is characterized by patchy follicular erythema with slight perifollicular scaling and mild matting of the hair. Progressive hyphal invasion distends the follicle, first producing a yellowish-red papule, then a yellow concave crust often centered about a single dull, dry hair (Fig. 188-7) that is less brittle than that of endothrix infections. The scutulum may reach 1 cm in diameter, engulfing surrounding hairs and coalescing with other scutula to form large adherent mats with an unpleasant cheese-like or musky odor. Over several years, the lesions advance peripherally, leaving central, atrophic clearings of alopecia.[26]

LABORATORY TESTS *T. schoenleinii* exhibits subtle, grayish-green fluorescence along the entire hair with Wood's lamp examination (see Table 188-1). Microscopy with KOH preparation reveals hyphae arranged lengthwise around and within the hair shaft, rare arthroconidia, and vacant air spaces.[26]

Tinea Barbae

EPIDEMIOLOGY Tinea barbae is by definition seen only in males. Largely transmitted by contaminated barbers' razors in the past, improved sanitation has reduced its incidence. Tinea barbae is now more often contracted by direct exposure to cattle, horses, or dogs, and is thus most commonly seen in rural settings among farmers or ranchers.

ETIOLOGY Tinea barbae is most commonly caused by the zoophilic organisms *T. mentagrophytes* and *T. verrucosum*, and, uncommonly, *M. canis*. Among the anthropophilic organisms, *T. megninii*, *T. schoenleinii*, and *T. violaceum* may cause tinea barbae in endemic areas, while *T. rubrum* is an infrequent cause.[26]

CLINICAL FINDINGS Tinea barbae is typically unilateral and more often involves the beard area than the moustache or upper lip. Three forms exist.

Inflammatory Type. Usually caused by *T. mentagrophytes* and *T. verrucosum*, inflammatory tinea barbae (Fig. 188-8) is analogous to kerion formation in tinea capitis. The lesions are nodular and boggy with a crusting seropurulent discharge.[28] Hairs in this area are lusterless, brittle, and easily epilated to demonstrate a purulent mass about the root. Perifollicular pustulation may coalesce to form sinus tracts and abscess-like collections of pus, eventuating in a scarring alopecia.[26]



▲ **FIGURE 188-9** Circinate tinea barbae has an advancing border of tiny papules, vesicles, and scaling.

Superficial Type. Caused by the less inflammatory anthropophiles, this form of tinea barbae closely resembles bacterial folliculitis, with mild diffuse erythema and perifollicular papules and pustules (see Fig. 188-8B). Hairs that are dull and brittle make endothrix infection with *T. violaceum* a more likely etiology than *T. rubrum*.

Circinate Type. Much like tinea circinata of glabrous skin, circinate tinea barbae exhibits an active, spreading vesiculopustular border with central scaling and relative sparing of the hair (Fig. 188-9).[28]

DIFFERENTIAL DIAGNOSIS (Box 188-2)

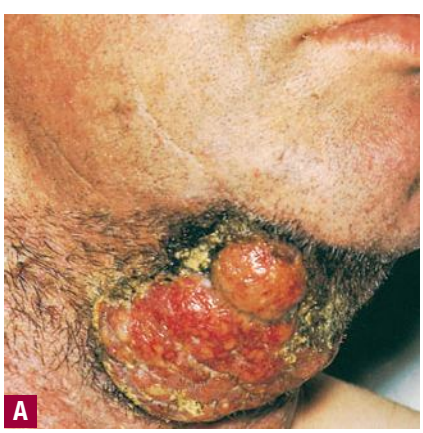



◀ **FIGURE 188-8** **A.** Tinea barbae, kerion. Sharply demarcated red nodule studded with multiple yellowish pustules. The surface is edematous and weeping. Note hairs have been lost from this nodule. **B.** Superficial tinea barbae. Scattered follicular papules and pustules easily mistaken for *Staphylococcus aureus* folliculitis.



Box 188-2

Differential Diagnosis of Tinea Barbae

Most Likely

- Bacterial folliculitis (sycosis vulgaris), perioral dermatitis, candidal folliculitis, pseudofolliculitis barbae, acne vulgaris/rosacea, contact dermatitis

Rule Out

- Halogenoderma, herpes simplex

Tinea Corporis (Tinea Circinata)

Tinea corporis refers to all dermatophytoses of glabrous skin except the palms, soles, and groin.



EPIDEMIOLOGY Tinea corporis may be transmitted directly from infected humans or animals, via fomites, or via autoinoculation from reservoirs such as *T. rubrum* colonization of the feet.[1] Children are more likely to contract zoophilic pathogens, especially *M. canis* from dogs or cats. Occlusive clothing and a warm, humid climate are associated with more frequent and severe eruptions.[29]

The occlusive clothing, frequent skin-to-skin contact, and minor trauma (mat burns) of competitive wrestling create an environment in which dermatophytes flourish. Numerous outbreaks of "tinea corporis gladiatorum" have resulted, mostly caused by *T. tonsurans*.[30]



▲ **FIGURE 188-10** Annular tinea corporis on the thigh. Note multiple, confluent annular lesions with a scaly and partially vesicular border. This type of lesion is usually seen with zoophilic dermatophytic infection.

Tinea imbricata, caused by *T. concentricum*, clinically appears as a plaque consisting of concentric erythematous rings. It is largely limited to areas of the Far East, South Pacific, and South and Central America.

ETIOLOGY Although any dermatophyte can cause tinea corporis, the most common cause is *T. rubrum*. *T. mentagrophytes*, *M. canis*, and *T. tonsurans* are also common pathogens.[3] *T. rubrum* and *T. verrucosum* are the most likely candidates in cases with additional follicular involvement.[28] Tinea imbricata is caused by *T. concentricum*.



▲ **FIGURE 188-11** Tinea corporis with typical "ringworm-like" configuration.

CLINICAL FINDINGS Table 188-4 presents the many variants of tinea corporis. The classic presentation is an annular lesion with scale across the entire erythematous border. The border is often vesicular (Fig. 188-10) and advances centrifugally. The center of the lesion is usually scaly but may exhibit clearing. Lesions may be serpiginous and annular ("ringworm"–like; Fig. 188-11). Concentric vesicular rings suggest tinea incognito caused by *T. rubrum*, whereas the concentric rings of tinea imbricata demonstrate little to no vesiculation.[1] *T. rubrum* infections may also present as large,

TABLE 188-4
Variants of Tinea Capitis

Name	Etiology	Clinical Description
Noninflammatory		
Tinea circinata	Any dermatophyte (usually *Trichophyton rubrum, T. mentagrophytes, Microsporum canis*)	Annular lesions with central clearing and an active, spreading border
Bullous tinea corporis	Usually *T. rubrum*	Spongiotic or sub-corneal vesicles/pustules; may be herpetiform
Tinea imbricata	*T. concentricum*	Widespread; multiple concentric, polycyclic scaly lesions with minimal inflammation
Inflammatory		
Kerion of glabrous skin	Zoophilic organisms	Similar to kerion of scalp or beard
Majocchi granuloma	*T. rubrum, T. violaceum, T. tonsurans, T. mentagrophytes*	Perifollicular, granulomatous nodules mostly on the scalps of children; often without pustulation, and associated with underlying disease
Nodular granulomatous perifolliculitis of the legs	*T. rubrum*	Variant of Majocchi granuloma affecting the lower two-thirds of women's legs; unilateral; *T. rubrum* is also present on the nails and feet
Agminate folliculitis	Zoophilic organisms	Well-defined erythematous plaques studded with perifollicular pustules
Subcutaneous abscess (tinea profunda)	*T. mentagrophytes, T. violaceum, T. tonsurans, T. rubrum, M. audouinii*	Deep subcutaneous nodules are present; rarely with lymph node involvement or hematogenous spread
Mycetoma	*M. audouinii, M. canis, M. ferrugineum, T. mentagrophytes, T. tonsurans, T. violaceum, T. verrucosum*	Subcutaneous masses
Tinea faciale	Usually *Trichophyton* species, occasionally *M. canis*	3%–4% of tinea corporis, erythematous, scaly plaques with or without active borders; telangiectasia, atrophy, and photo-exacerbation may mimic lupus erythematosus
Tinea incognito	Any dermatophyte infection modified by glucocorticoids	Atypical with possible absence of inflammation, scaling, or symptoms; dermal nodules or kerion-like lesions may be present



◀ **FIGURE 188-12** Polycyclic pattern of tinea corporis resembling psoriasis.

confluent polycyclic or psoriasiform plaques (Fig. 188-12).

Majocchi granuloma is an infection usually caused by *T. rubrum*, which occurs when fungal hyphae invade hairs and hair follicles. It is classically seen in women who shave their legs and appears as inflamed folliculocentric papules.

DIFFERENTIAL DIAGNOSIS (Box 188-3)

Tinea Cruris

Tinea cruris is a common dermatophytosis of the groin, genitalia, pubic area, perineal, and perianal skin. The designation is a misnomer, because in Latin "cruris" means of the leg. It is the second-most common dermatophytosis worldwide.

EPIDEMIOLOGY Much like tinea corporis, tinea cruris spreads via direct contact or fomites, and is exacerbated by occlusion and warm, moist climates. It is three times more common in men than in women, and adults are affected more commonly than children. Again, autoinfection from distant reservoirs such as tinea pedis caused by *T. rubrum* or *T. mentagrophytes* is common.[1]

Box 188-3

Differential Diagnosis of Tinea Corporis

Most Likely

- Erythema annulare centrifugum, nummular eczema, granuloma annulare

Consider

- Psoriasis, lichen planus, seborrheic dermatitis, pityriasis rosea, pityriasis rubra pilaris, polymorphous light eruption, contact dermatitis, acne rosacea

Rule Out

- Mycosis fungoides, secondary syphilis, lupus erythematosus, dermatomyositis, candidal or deep fungal infections, mycobacterial infections or blastomycosis

ETIOLOGY Most tinea cruris is caused by *T. rubrum* and *Epidermophyton floccosum*, with the latter being most often responsible for epidemics.[26] *T. mentagrophytes* and *T. verrucosum* are also less commonly involved.

CLINICAL FINDINGS Tinea cruris usually appears as multiple erythematous papulovesicles with a well-marginated, raised border. Pruritus is common, as is pain with maceration or secondary infection. *E. floccosum* tinea cruris is more likely to display central clearing, and is most often limited to the genitocrural crease and the medial upper thigh. In contrast, *T. rubrum* infections are often coalescent with extension to the pubic, perianal, buttock, and lower abdominal areas (Fig. 188-13). The genitalia are typically unaffected.[26]

DIFFERENTIAL DIAGNOSIS (Box 188-4)

Tinea Pedis and Tinea Manus

Tinea pedis is a dermatophytosis of the feet, whereas tinea manus affects the palmar and interdigital areas of the hand.

Box 188-4

Differential Diagnosis of Tinea Cruris

Most Likely

- Psoriasis, seborrheic dermatitis, candidiasis, erythrasma, lichen simplex chronicus

Consider

- Familial benign pemphigus, Darier-White disease

EPIDEMIOLOGY Present worldwide, tinea pedis and tinea manus are the most common dermatophytoses. The prevalence of tinea pedis is approximately 10 percent, primarily attributable to modern occlusive footwear, although increased worldwide travel has also been implicated.[26] The incidence of tinea pedis is higher among those using communal baths, showers, or pools.

Tinea manus may be acquired by direct contact with an infected person or animal, the soil, or autoinoculation.[31] However, it is nearly always associated with tinea pedis[26] and occurs most commonly in the hand used to excoriate the feet.

ETIOLOGY Tinea pedis and tinea manus are caused predominantly by *T. rubrum* (most common), *T. mentagrophytes*, and *E. floccosum*.

CLINICAL FINDINGS Tinea pedis may present as any of four forms, or a combination thereof.

Chronic Intertriginous Type (Interdigital Type). The most common presentation of tinea pedis, the chronic intertriginous



▲ **FIGURE 188-13** Tinea cruris. Scaling erythematous plaque with sharp margins in the unguinal and pubic region.





▲ **FIGURE 188-14** Tinea pedis, interdigital. The area is macerated and has opaque white scales and some erosions.



▲ **FIGURE 188-16** "Two feet–one hand" presentation of *Trichophyton rubrum*.



type, begins as scaling, erosion, and erythema of the interdigital and subdigital skin of the feet, particularly between the lateral three toes. Under appropriate conditions, the infection will spread to the adjacent sole or instep, rarely involving the dorsum.[26] Occlusion and bacterial co-infection soon produce the interdigital maceration, pruritus, and malodor of dermatophytosis complex (Fig. 188-14) or "athlete's foot."[32]

Chronic Hyperkeratotic Type. Usually bilateral with patchy or diffuse scaling limited to the thick skin, soles, and the lateral and medial aspects of the feet, this is also known as "moccasin-type" tinea pedis (Fig. 188-15). *T. rubrum*, the most common etiology, produces very few minute vesicles, leaving collarettes of scale less than 2 mm in diameter. Erythema is variable.[1]

Unilateral tinea manuum commonly occurs in association with hyperkeratotic tinea pedis, resulting in the "two feet–one hand syndrome" (Fig. 188-16). When tinea manus extend to the dorsum of a hand, it assumes the clinical pattern of tinea corporis (see eFig. 118-16.1 in online edition). Oral antifungals are often required for treatment due to the high incidence of concomitant onychomycosis and relapse.[33]

Vesiculo-Bullous Type. The vesiculo-bullous type of tinea pedis, typically caused by *T. mentagrophytes*, features tense vesicles larger than 3 mm in diameter, vesiculopustules, or bullae on the thin skin of the sole and periplantar areas (Fig. 188-17). It is rarely reported in childhood, but the most common etiologic agent in childhood is *T. rubrum*.[34]

Acute Ulcerative Type. Rampant bacterial co-infection, most often from Gram negatives in combination with *T. mentagrophytes*, produces vesiculopustules and large areas of purulent ulceration on the plantar surface. Cellulitis, lymphangiitis, lymphadenopathy, and fever are frequently associated.

The vesiculo-bullous and acute ulcerative types commonly produce a vesicular id reaction, either as a dyshidrotic-like distribution on the hands or on the lateral foot or toes.

DIFFERENTIAL DIAGNOSIS (Box 188-5)

LABORATORY TESTS For vesiculo-bullous lesions, examination of the roofs yields the highest rate of positivity on KOH examination.

PATHOLOGY Histologically, hyperkeratotic tinea pedis or tinea manuum is char-



▲ **FIGURE 188-15** Tinea pedis. Superficial white scales in a moccasin-type distribution. Note arciform pattern of the scales, which is characteristic.



▲ **FIGURE 188-17** Tinea pedis: Bullous type. Ruptured vesicles, bullae, erythema, and erosion on the plantar aspect of the great toe. Hyphae were detected on potassium hydroxide preparation obtained from the roof of the inner aspect of the bulla. In some cases, superficial white onychomycosis may also be seen with this *Trichophyton mentagrophytes* infection.

Box 188-5

Differential Diagnosis of Tinea Manus et Pedis

Most Likely

- Interdigital: Psoriasis, soft corns, bacterial co-infection, candidiasis, erythrasma
- Hyperkeratotic: Psoriasis, hereditary or acquired keratodermas of the palms and soles, dyshydrosis
- Vesiculo-bullous: Pustular psoriasis, palmoplantar pustulosis, bacterial pyodermas

Consider

- Pityriasis rubra pilaris, contact dermatitis, peridigital dermatitis, atopic dermatitis

Rule Out

- Reiter syndrome

acterized by acanthosis, hyperkeratosis, and a sparse, chronic, superficial perivascular infiltrate in the dermis. Vesiculo-bullous forms display spongiosis, parakeratosis, and sub-corneal or spongiotic intraepithelial vesiculation. With both types, foci of neutrophils are occasionally seen in the stratum corneum. PAS or methenamine silver staining demonstrates fungal organisms.

ONYCHOMYCOSIS

Onychomycosis denotes any infection of the nail caused by dermatophyte fungi, nondermatophyte fungi, or yeasts. *Tinea unguium*, however, refers strictly to dermatophyte infection of the nail plate. Onychomycosis is the most prevalent nail disease and accounts for approximately 50 percent of all onychopathies. The four clinical types of onychomycosis are: (1) distal subungual onychomycosis, (2) proximal subungual onychomycosis (PSO), (3) white superficial onychomycosis (WSO), and (4) candidal onychomycosis.

Epidemiology

Onychomycosis is a common infection, with a prevalence estimated in population-based studies at 2 percent to 8 percent, which is likely an underestimate. The Achilles project estimates the prevalence of onychomycosis in Europe at approximately 27 percent,[35] and North American studies show an incidence of 13.8 percent.[36] The increasing prevalence of this disease may be secondary to tight shoes, increasing numbers of immunosuppressed individuals, and increased use of communal locker rooms. Onychomycosis is also increasing in children, accounting for 20 percent of the superficial mycoses diagnosed in children in one study.[37]

The dermatophytosis commonly begins as tinea pedis before extending to the nail bed, where eradication is more difficult. This site then serves as a reservoir for recurrent skin infections, particularly in the setting of a hot and humid environment created by occlusion or tropical climates.[1]

Etiology

The dermatophytes cause the great majority of onychomycosis. *T. rubrum* is responsible for approximately 71 percent of all tinea unguium cases, and *T. mentagrophytes* adds another 20 percent. *T. tonsurans* and *E. floccosum* are also well-known causative agents.[35] Table 188-5 categorizes the most likely causative dermatophytes according to patterns of concurrent infection in other areas.[38]

Yeasts are the source of approximately 5 percent of onychomycosis (see Chap. 189), the majority of which is caused by *Candida albicans* and occurs in conjunction with chronic mucocutaneous candidiasis. The nondermatophyte molds *Acremonium, Aspergillus, Fusarium, Onychocola canadensis, Scopulariopsis brevicaulis,* and *Scytalidium dimidiatum* account for approximately 4 percent of onychomycosis, with *S. brevicaulis* as the most frequently identified mold pathogen.[39] The nondermatophyte molds appear to have a predilection for antecedently diseased or aged nails.[28]

Clinical Findings

The most common form of onychomycosis may be caused by any of the organisms listed above. It begins with invasion of the stratum corneum of the hyponychium and distal nail bed, forming a whitish to brownish-yellow opacification at the distal edge of the nail (Fig. 188-18). The infection then spreads proximally up the nail bed to the ventral nail plate. Hyperproliferation of the nail bed in response to the infection creates subungual hyperkeratosis, and progressive invasion of the nail plate results in an increasingly dystrophic nail.

TABLE 188-5
Causative Organisms According to Anatomic Patterns

- Tinea unguium + tinea pedis and/or tinea corporis
  - *Trichophyton rubrum*
  - *T. mentagrophytes var. interdigitale*
  - *Epidermophyton floccosum*
- Tinea unguium + tinea capitis or favus
  - *T. tonsurans*
  - *T. violaceum*
  - *T. megninii*
  - *T. schoenleinii*
- Tinea unguium + tinea imbricata
  - *T. concentricum*



▲ **FIGURE 188-18** Distal subungual onychomycosis.

PSO (Fig. 188-19) results primarily from *T. rubrum* and *T. megninii* infection of the proximal nail fold, and is evident as a white to beige opacity on the proximal nail plate. This opacity gradually enlarges to affect the entire nail, and subungual hyperkeratosis, leukonychia, proximal onycholysis, and destruction of the entire nail unit may be seen. *T. rubrum* causes PSO almost exclusively in those infected with human immunodeficiency virus.[5] WSO (Fig. 188-20) is a direct invasion of the dorsal nail plate resulting in white to dull yellow sharply bordered patches anywhere on the surface of the toenail. It is usually caused by *T. mentagrophytes*, although nondermatophyte molds such as *Aspergillus*,



▲ **FIGURE 188-19** Proximal subungual onychomycosis in a patient with acquired immunodeficiency syndrome; Kaposi sarcoma is also seen on the fourth toe.





▲ **FIGURE 188-20** White superficial onychomycosis.



Scopulariopsis, and *Fusarium* are also known etiologies. *Candida* species invade via the hyponychial epithelium to affect the entire thickness of the nail plate.[40]

Differential Diagnosis (Box 188-6)

Laboratory Tests

Because onychomycosis is responsible for only 50 percent of dystrophic nails, laboratory diagnostic confirmation is often helpful before treatment with an oral antifungal. KOH examination, nail biopsy, and fungal culture on SDA (with and without antimicrobials) are most useful. However, microscopy is often negative even when there is a high clinical suspicion of onychomycosis, and nails with positive microscopy often yield negative cultures. As most false-negatives are caused by sampling error, the simplest measures to maximize yield are to maximize sample size and perform repeat collections.[41]

Finally, because of the difficulty in discerning pathogens from contaminants, the following guidelines should be followed: (1) if a dermatophyte is isolated on culture, it is a pathogen; (2) if a non-dermatophyte mold or yeast is cultured, it is considered significant only if hyphae, spores, or yeast cells are seen on microscopic examination; and (3) confirmation of an infection by a nondermatophyte requires repeated isolation, classically defined as at least 5 of 20 inocula without concurrent isolation of a dermatophyte.[42] Studies have shown that PAS examination of nail clippings is the most sensitive diagnostic test for onychomycosis, whereas culture is the most specific test.[43]

Box 188-6

Differential Diagnosis of Onychomycosis

Most Likely

- Psoriasis, hand eczema

Consider

- Pachyonychia congenita, Darier disease, lichen planus, acquired and congenital leukonychias, onychogryphosis

Rule Out

- Exfoliative dermatitis, Norwegian scabies, Reiter syndrome

Box 188-7

Treatment of Dermatophytes

DISEASE	TOPICAL TREATMENT	SYSTEMIC TREATMENT
Tinea capitis	Only as adjuvant Selenium sulfide Zinc pyrithione Povidone iodine Ketoconazole	Griseofulvin, 20–25 mg/kg/day Fluconazole, 6 mg/kg/day Itraconazole, 3–5 mg/kg/day Terbinafine, 3–6 mg/kg/day
Tinea barbae	Only as adjuvant Topical antifungals	Griseofulvin, 1 g/day Itraconazole, 200 mg/day Terbinafine, 250 mg/day Fluconazole, 200 mg/day
Tinea corporis/cruris	Allylamines Imidazoles Tolnaftate Butenafine Ciclopirox	Adults: Fluconazole, 150 mg/wk Itraconazole, 100 mg/day Terbinafine, 250 mg/day Griseofulvin, 500 mg/day Children: Griseofulvin, 10–20 mg/kg/day Itraconazole, 5 mg/kg/day Terbinafine, 3–6 mg/kg/day
Tinea pedis/manuum	Allylamine Azole Ciclopirox Benzylamine Tolnaftate Undecenoic acid	Adults: Terbinafine, 250 mg/day Itraconazole, 200 mg twice/day Fluconazole, 150 mg/wk Children: Itraconazole, 5 mg/kg/day
Onychomycosis	Ciclopirox Amorolfine	Terbinafine, 250 mg/day Itraconazole, 200 mg/day Fluconazole, 150–300 mg once/wk

Histopathology

Hyphae are seen lying between the nail laminae parallel to the surface, with a predilection for the ventral nail and nail bed stratum corneum.[44] The epidermis may show spongiosis and focal parakeratosis, and there is a minimal dermal inflammatory response. In WSO, the organisms are present superficially on the dorsal nail and display unique "perforating organs" and "eroding fronds." Candidal onychomycosis displays invasion of pseudohyphae throughout the entire nail plate, adjacent cuticle, granular layer, and stratum spinosum of the nail bed, and the hyponychial stratum corneum.[40]

TREATMENT OF DERMATOPHYTES (Box 188-7)

Tinea Capitis/Favus

Multiple systemic and topical antifungals are available with efficacy against the dermatophytes. Infections involving hair-bearing skin necessitate oral antifungals as the dermatophytes penetrate the hair follicle. The standard treatment of tinea capitis in the United States has been and continues to be griseofulvin. The oral triazole (itraconazole, fluconazole) and allylamine (terbinafine) antifungals also appear to be safe, effective, and have the advantage of shorter treatment durations.

GRISEOFULVIN (See Chap. 233) Griseofulvin is still the only oral treatment approved by the U.S. Food and Drug Administration for tinea capitis. The previously recommended pediatric dosage was 10 to 20 mg/kg/day for 6 to 8 weeks taken with a fatty meal to facili-

tate absorption.[19] However, a reported high failure rate with this treatment has caused most experts to now recommend 20 to 25 mg/kg/day of the microsize form and 15 mg/kg/day of the ultramicrosize form for 8 weeks, although this recommendation is not based on clinical trials.[45]

The disadvantages of griseofulvin include poor compliance because of cost and length of treatment, its bitter taste in liquid form, photosensitivity, headache, and gastrointestinal side effects.[18] It also potently induces cytochrome P_{450} enzymes.[46] No laboratory tests are required for the duration of treatment used for tinea capitis.

FLUCONAZOLE (See Chap. 233) Available as both tablets and a pleasant-tasting liquid, fluconazole at doses of 6 mg/kg/day for 20 days is 89 percent effective in curing *T. tonsurans* tinea capitis.[47] Other effective treatment options include once-weekly dosing of 8 mg/kg fluconazole for 8 to 16 weeks and 6 mg/kg for 2 weeks followed by an additional week of therapy 4 weeks later, if clinically indicated.[48]

Absorption of fluconazole is not affected by meals, and gastrointestinal side effects exist but are uncommon. Hepatitis has been reported but occurs less frequently than with ketoconazole.[46]

ITRACONAZOLE (See Chap. 233) At doses of 3 to 5 mg/kg/day, itraconazole effectively eradicates tinea capitis caused by either *Microsporum* or *Trichophyton* species in 4 to 6 weeks.[49] Pulse therapy at 5 mg/kg/day for 1 week/month for one to three pulses is also effective.

Possible adverse effects of itraconazole include gastrointestinal upset, diarrhea with liquid itraconazole, and peripheral edema, especially when used in conjunction with calcium channel blockers. Like fluconazole, hepatotoxicity occurs at much lower rates than with ketoconazole.[46] However, there are reports of hepatic failure in patients treated with itraconazole. Itraconazole has also rarely been linked to congestive heart failure.

TERBINAFINE (See Chap. 233) Doses of 3 to 6 mg/kg/day of terbinafine can cure *Trichophyton* tinea capitis in 2 to 4 weeks, but 4 to 8 weeks of treatment are required for eradication of *Microsporum*.[18] A randomized comparison of 4 weeks of terbinafine to 8 weeks of griseofulvin showed no statistically significant difference overall. However, a subgroup with *Trichophyton* infection responded better to terbinafine, while *M. audouinii* infections responded better to griseofulvin.[50]

Terbinafine also produces gastrointestinal side effects and, rarely, hepatitis. Although it has fewer cytochrome P_{450} effects than the other oral antifungals, tricyclic antidepressant toxicity has occurred with concomitant terbinafine use as a result of CYP2D6 inhibition.[46] Like itraconazole, there are reports of liver failure in patients using this drug.

ADJUVANT THERAPY (See Chap. 219) A number of shampoos have been shown to help eradicate dermatophytes from the scalp of children, and their use is recommended by most experts. Selenium sulfide (1 percent and 2.5 percent), zinc pyrithione (1 percent and 2 percent), povidone iodine (2.5 percent), and ketoconazole (2 percent) are all commonly used. Common recommendations are to use these shampoos 2 to 4 times weekly for 2 to 4 weeks.[45] With markedly inflammatory tinea capitis, oral glucocorticoids may reduce the incidence of scarring. Although there is no consistent evidence for differences in cure rates, oral glucocorticoids are beneficial in relieving pain and swelling. The usual dose of prednisone is 1 to 2 mg/kg each morning for the first week of therapy.

Household transmission may be prevented through the treatment of infected family members or animals and disinfection of the environment. The use of ketoconazole 2 percent shampoo or selenium sulfide 2.5 percent by all household members three times weekly also reduces transmission by decreasing the shedding of spores.[18]

Tinea Barbae

Like tinea capitis, oral antifungals are essential in the treatment of tinea barbae. Griseofulvin at 1 g daily, itraconazole 200 mg daily for 2 to 4 weeks, terbinafine 250 mg daily for 2 to 4 weeks, or fluconazole 200 mg daily for 4 to 6 weeks are all effective treatment plans. Inflammatory *T. verrucosum*, *T. mentagrophytes*, and *M. canis* infections usually resolve without treatment in 2 to 4 weeks.[26] Systemic glucocorticoids are helpful for severe inflammatory lesions.[28]

Tinea Corporis/Tinea Cruris

For isolated lesions on the glabrous skin, topical agents such as the allylamines, imidazoles, tolnaftate, butenafine, or ciclopirox are effective. Most are applied twice daily for 2 to 4 weeks. Oral antifungals are reserved for widespread or more inflammatory lesions. Comparative studies in adults show fluconazole, 150 mg weekly for 4 to 6 weeks, itraconazole, 100 mg daily for 15 days, and terbinafine, 250 mg daily for 2 weeks, to be as effective as griseofulvin, 500 mg daily for 2 to 6 weeks, with no significant differences in adverse events.[51] Safe and effective regimens for children include ultramicrosize griseofulvin, 10 to 20 mg/kg/day for up to 6 weeks, itraconazole, 5 mg/kg/day for 1 week,[52] and terbinafine, 3 to 6 mg/kg/day for 2 weeks.

Tinea Pedis

Mild interdigital tinea pedis without bacterial involvement can be treated topically with an allylamine, azole, ciclopirox, benzylamine, tolnaftate, or undecenoic acid.[53] Topical terbinafine for 1 week is 66 percent effective.[54]

The newer oral antifungals have replaced griseofulvin as the treatments of choice for severe or refractory tinea pedis when accompanied by onychomycosis. The dosing schedule of terbinafine is 250 mg daily for 2 weeks. Effective regimens of itraconazole for adults are 200 mg twice daily for 1 week, 200 mg daily for 3 weeks, or 100 mg daily for 4 weeks,[51] whereas children should receive 5 mg/kg/day for 2 weeks.[52] Fluconazole, 150 mg weekly for 3 to 4 weeks or 50 mg daily for 30 days, is also effective.[51] Associated onychomycosis is common; if present, treatment of the onychomycosis is necessary to prevent recurrence of tinea pedis.

Maceration, denudation, pruritus, and malodor obligate a search for bacterial co-infection by Gram stain and culture. Antibiotics should be started once bacterial infection is documented and chosen based on sensitivity studies.

Finally, because vesiculo-bullous tinea pedis is the result of a T-cell–mediated immune reaction, symptomatic relief with topical or systemic corticosteroids may be warranted during the beginning of antifungal treatment.[55]

Onychomycosis

Treatment of onychomycosis depends both on the severity of nail involvement and on the causative fungus. Onychomycosis can be divided into cases with and without matrix area involvement. In cases without matrix area involvement, topical treatment alone can be sufficient for treatment, whereas oral and combination treatments are recommended for



cases with matrix involvement. Ciclopirox is sometimes an effective topical agent for tinea unguium (8 percent lacquer) applied daily for 48 weeks. When used for mild to moderate disease, it is 7 percent effective in achieving mycologic cure and clear nails.[56] It also has efficacy against *Candida* sp. and some molds.[57] Despite its much poorer efficacy compared with the newer oral antifungals, topical ciclopirox avoids the risk of drug interactions, an important consideration for chronic therapy in a mostly older population. Amorolfine is another agent specifically prepared for use as a nail lacquer. It is the first member of a new class of antifungal drugs, the morpholine derivatives. It has activity against the yeasts, dermatophytes, and molds that cause onychomycosis and has shown efficacy when applied once weekly.[57]

Oral antifungals may be used for refractory, severe, or nondermatophytic onychomycosis, or when a shorter treatment regimen or higher chance for clearance or cure is desired. Selecting an antifungal should be based primarily on the causative organism, potential adverse effects, and risk of drug interactions.

Terbinafine is fungicidal against dermatophytes, *Aspergillus*, and *Scopulariopsis*, but demonstrates variable activity against *Candida* sp. A course of 250 mg daily for 6 weeks is effective for most fingernail infections, while a minimum 12-week course is required for toenail infections. Most adverse effects are gastrointestinal, and cytochrome P_{450} interactions are insignificant. There is good evidence that a 3-month continuous regimen of terbinafine is the most effective oral treatment for fungally infected toenails available today.[58]

Itraconazole is fungistatic against dermatophytes, nondermatophyte molds, and yeasts. Safe and effective schedules include pulse dosing at 400 mg daily for 1 week per month or a continuous dose of 200 mg daily, both of which require 2 months of treatment for fingernails and at least 3 months for toenails.[39] Children may receive 5 mg/kg/day.[52] Elevated liver enzymes occur in 0.3 percent to 5.0 percent of patients, returning to normal within 12 weeks of discontinuation. Although itraconazole has a broader spectrum of activity than terbinafine, studies have shown a significantly lower rate of cure with itraconazole and higher relapse rates than seen with terbinifine.[59]

Fluconazole is fungistatic against dermatophytes, some nondermatophyte molds, and *Candida*. The usual dosage is 150 to 300 mg once per week for 3 to 12 months, although 450 mg weekly may be used in refractory onychomycosis.

Griseofulvin is no longer considered standard treatment for onychomycosis because of its adverse effects, drug interactions, prolonged treatment course, and low cure rates. Final options for refractory cases include surgical avulsion or chemical removal of the nail with 40 percent urea compounds in combination with topical or oral antifungals.

Combination therapies have been shown to have a more effective clearance rate than either oral or topical treatments alone. Oral terbinafine combined with ciclopirox nail lacquer was shown in one study to increase mycological cure rates from 65 percent with terbinafine alone to 88 percent for the combination.[60] A similar study of terbinafine and amorolfine nail lacquer showed improved cure rates from 37 percent for terbinafine alone to 72 percent for combination therapy.[61]

TINEA NIGRA

Tinea nigra is a superficial dermatomycosis, usually of the palmar stratum corneum, caused by *Hortaea werneckii* (formerly named *Phaeoannellomyces werneckii* and *Exophiala werneckii*).[62]

Epidemiology

Tinea nigra usually occurs in tropical or sub-tropical areas, including Central and South America, Africa, and Asia. It is infrequent in the United States and Europe. Of the approximately 150 cases reported in North America since 1950, the majority were associated with tropical travel.[63] However, endemic foci exist in the coastal southeastern United States and Texas. Person-to-person transmission is rare.[64] Tinea nigra has a female/male predilection of 3:1.

Etiology

Nearly always caused by *H. werneckii*, other dematiaceous fungi such as *Stenella araguata* may produce the same clinical picture. Such dematiaceous fungi are commonly found in soil, sewage, and decaying vegetation.[64] Tinea nigra arises after inoculation subsequent to trauma and has a typical incubation period of 2 to 7 weeks.

Clinical Findings

Tinea nigra is found on otherwise healthy people and presents as an asymptomatic, mottled brown to greenish-black macule with minimal to no scale (Fig. 188-21). It is frequently misdiagnosed as acral lentiginous melanoma. The macule is painless and discrete and is often darkest at the advancing border.



▲ **FIGURE 188-21** Tinea nigra palmaris. An irregular, brownish-black macule on the palm caused by *Hortaea werneckii*. (Used with permission from Stuart Salasche, MD.)

Differential Diagnosis (Box 188-8)

Laboratory Tests

KOH examination of scrapings from the lesion reveals brown to olive-colored thick, branching hyphae and oval to spindle-shaped yeast cells occurring singly or in pairs with a central transverse septum. Cultures may be performed on SDA with cycloheximide and chloramphenicol and grow within 1 week. Growth is initially yeast-like and brown to shiny black, appearing as the typical two-celled yeast forms under microscopic examination. With time, mycelial

Box 188-8

Differential Diagnosis of Tinea Nigra

Most Likely

- Junctional nevus, melanoma

Consider

- Chemical exposure

Rule Out

- Addison disease, syphilis, pinta, melanoma



growth predominates as aerial hyphae create a fuzzy grayish-black colony.

Treatment

Tinea nigra responds easily to topical therapy with a keratolytic (Whitfield's ointment, 2 percent salicylic acid), tincture of iodine, or azole antifungal.[63] Treatment should be continued for 2 to 4 weeks after clinical resolution to prevent relapse. Ketoconazole twice daily is curative, as is itraconazole and miconazole or once daily terbinafine; however, systemic therapies are rarely indicated.[62,64]

PIEDRA

Piedra is an asymptomatic fungal infection of the hair shaft also known as *trichomycosis nodularis*. Black piedra is caused by *Piedraia hortae*, whereas white piedra is caused by pathogenic species of the *Trichosporon* genus, namely *Trichosporon asahii*, *T. ovoides*, *T. inkin*, *T. mucoides*, *T. asteroides*, and *T. cutaneum*.[62]

Epidemiology

Black piedra is seen commonly in humans and primates of tropical areas such as South America, the Pacific Islands, and the Far East, and less commonly in Africa and Asia. Scalp hair is most commonly affected. Infestation is encouraged for religious and esthetic reasons by some indigenous cultures.[63] *P. hortae* is present in the soil and in stagnant water and crops.

White piedra is most common in temperate and semi-tropical climates such as South America and Asia, the Middle East, India Africa, and Japan and occurs infrequently in the United States and Europe. It affects facial, axillary, and genital hair more commonly than the scalp.[28] Person-to-person transmission is rare, and infection has not been associated with travel to endemic areas.[65] *T. inkin* is found more commonly on pubic hair and *T. ovoides* on head hair. *T. asahii* can be present in the soil, air, water, vegetation, sputum, and on body surfaces.

Clinical Findings

Black piedra is characterized by firmly attached, hard, brown-black nodules on the hair shaft that vary from microscopic to a few millimeters in size, and are gritty to palpation.[63] Black piedra weakens the hair shaft, often resulting in broken hairs. Scalp hairs are most typically affected, and nodules are most commonly seen on the frontal scalp.

White piedra consists of softer and less adherent whitish to beige nodules that may be discrete or coalesce into sleeve-like structures. Broken hairs are sometimes present but are less common than with black piedra. White piedra can be easily detached from the hair shaft because it affects the outer lipid layers.

Diagnosis

Microscopy immediately differentiates piedra from nits, hair casts, developmental hair shaft defects, and trichomycosis axillaris. In addition, the nodules of trichomycosis axillaris are usually smaller and may fluoresce under a Wood's lamp.

Laboratory Tests

Nodules of black piedra examined with KOH display a periphery of aligned hyphae and a well-organized center of thick-walled cells packed closely together, sometimes termed *pseudoparenchyma*. These nodules are mostly outside of the hair shaft. *P. hortae* grows well, albeit slowly, on most laboratory media and is uninhibited by cycloheximide.

The nodules of white piedra have a less organized and more intrapilar appearance than do the nodules of black piedra, with hyphae arranged perpendicularly to the hair shaft.[63] *T. asahii* thrives on SDA and is inhibited by cycloheximide.

Treatment

Shaving the infected hair is often curative and is the best treatment for both black and white piedra. Shaving may be augmented by the use of a topical azole antifungal. Because of the high rate of relapse and evidence for intrafollicular organisms in white piedra, some authors suggest using an additional systemic antifungal in this disease such as oral itraconazole.[65]

KEY REFERENCES

The full reference list for all chapters is available at www.digm7.com.

13. Frieden IJ, Howard R: Tinea capitis: Epidemiology, diagnosis, treatment, and control. *J Am Acad Dermatol* **31**:S42, 1994
18. Elewski BE: Treatment of tinea capitis: Beyond griseofulvin. *J Am Acad Dermatol* **40**:S27, 1999
31. Richardson MD, Warnock DW: Dermatophytosis, in *Fungal Infection: Diagnosis and Management.* Oxford, Blackwell, 1997, p 59
40. Zaias N: Onychomycosis. *Arch Dermatol* **105**:263, 1972
46. Smith EB: The treatment of dermatophytosis: Safety considerations. *J Am Acad Dermatol* **43**:S113, 2000
48. Gupta AK et al: Tinea capitis: An overview with emphasis on management. *Pediatr Dermatol* **16**:171, 1999
51. Rand S: Overview: The treatment of dermatophytosis. *J Am Acad Dermatol* **43**:S104, 2000
58. Crawford F et al: Oral treatments for toenail onychomycosis: A systematic review. *Arch Dermatol* **138**:811, 2002
63. Rippon JW: Superficial infections, in *Medical Mycology: The Pathogenic Fungi and the Pathogenic Actinomycetes,* 3rd ed. Philadelphia, Saunders, 1988, p 154



CHAPTER 189

Yeast Infections: Candidiasis and Tinea (Pityriasis) Versicolor

Matthew P. Janik
Michael P. Heffernan

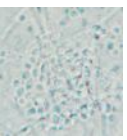

CANDIDIASIS

Candidiasis (or *candidosis*) refers to a diverse group of infections caused by *Candida albicans* or by other members of the genus *Candida*. These organisms typically infect the skin, nails, mucous membranes, and gastrointestinal tract, but they also may cause systemic disease.

Etiology

The genus *Candida* is a heterogeneous group of approximately 200 yeast species.[1] Many species of *Candida* are opportunistic human pathogens, although the majority do not infect humans. All species within the genus *Candida* share the ability to produce pseudomycelia (Fig. 189-1), with the exception of *C. glabrata*. *Candida* do not possess morphologic or biochemical characteristics that would classify them in the genera of imperfect yeast, which are unicellular for the majority of their life cycle, nor do they produce ascospores or teliospores. Other species of *Candida* cause clinical disease under certain circumstances, such as immunosuppression, prolonged hospitalization, and previous antibiotic use.[2,3] These infections may be systemic or localized. *C. albicans* is a dimorphic yeast that is responsible for 70 percent to 80 percent of all candidal infections, which makes it the most common cause of superficial and systemic candidiasis.[2] Epidemiologic studies indicate that the relative prevalence of *C. albicans* in clinical isolates is declining, and other species such as *C. glabrata, C. tropicalis, C. krusei,*[1,4] *C. dubliniensis,*[5] and *C. parapsilosis*[1,6] are increasingly encountered as pathogens. The different species of *Candida* can be identified in the laboratory by microscopic examination of yeast morphology. Polymerase chain reaction assays and enzyme-linked immunosorbent assays for species differentiation are now becoming more readily available.[1,7]

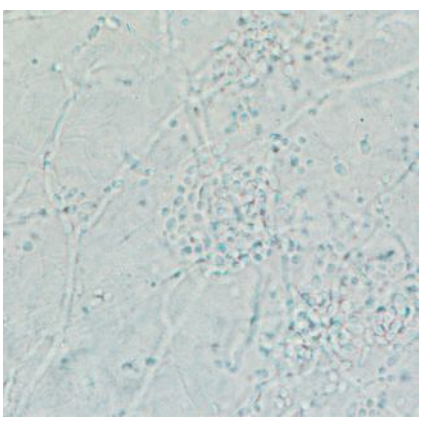

▲ **FIGURE 189-1** *Candida* in potassium hydroxide preparation. Pseudomycelia in clusters of grape-like yeast cells.

YEAST AT A GLANCE

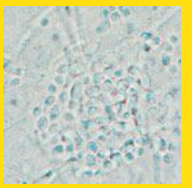

- *Candida albicans* accounts for 70 percent to 80 percent of all candidal infections.
- Clinically lesions are erythematous, macerated patches with satellite vesicopustules.
- *Candida* sp. are seen as typical budding yeasts with hyphae or pseudohyphae.
- *Malassezia furfur* and *M. globosa* most frequently cause tinea versicolor, hypopigmented or hyperpigmented macules with fine scales on the chest, back, abdomen, and proximal extremities.
- *Malassezia* sp. are long and have short, septate, and occasionally branching hyphae with a "spaghetti and meatballs" appearance.

Pathogenesis

C. albicans is often found as a saprophyte and colonizes the mucous membranes of warm-blooded animals. In up to 50 percent of normal individuals, the oropharynx is colonized.[3] In addition, *C. albicans* exists as a commensal organism in the vaginal mucosa of 20 percent to 25 percent of asymptomatic, healthy women[8] and up to 30 percent of pregnant women.[9] The yeast is rarely isolated from normal human skin except occasionally from intertriginous areas. Likewise, the organism is infrequently found in soil, vegetation, and air samples.

Factors predisposing to *Candida* infection are outlined in Table 189-1.

TABLE 189-1
Factors Predisposing to *Candida* Infections

- Mechanical factors
  - Trauma (burns, abrasions)
  - Local occlusion, moisture, and/or maceration
  - Dentures
  - Occlusive dressings or garments
  - Obesity
- Nutritional factors
  - Avitaminosis
  - Iron deficiency (chronic mucocutaneous candidiasis)
  - Generalized malnutrition
- Physiologic alterations
  - Extremes of age
  - Pregnancy
  - Menses
- Systemic illnesses
  - Down syndrome
  - Acrodermatitis enteropathica
  - Endocrine disease
    - Diabetes mellitus
    - Cushing disease
    - Hypoadrenalism
    - Hypothyroidism
    - Hypoparathyroidism
  - Uremia
  - Malignancy (especially hematologic, thymoma)
  - Immunodeficiency
    - Acquired immunodeficiency syndrome
    - Severe combined immunodeficiency syndrome
    - Myeloperoxidase deficiency
    - Chédiak-Higashi syndrome
    - Hyperimmunoglobulinemia E syndrome
    - Chronic granulomatous disease
    - DiGeorge syndrome
    - Nezelof syndrome
- Iatrogenic causes
  - Indwelling catheters and intravenous lines
  - X-ray irradiation
  - Medications
    - Glucocorticoids
    - Other immunosuppressive agents
    - Antibiotics (especially broad spectrum, metronidazole)
    - Tranquilizers
    - Oral contraceptives (especially estrogen dominant)
    - Colchicine
    - Phenylbutazone

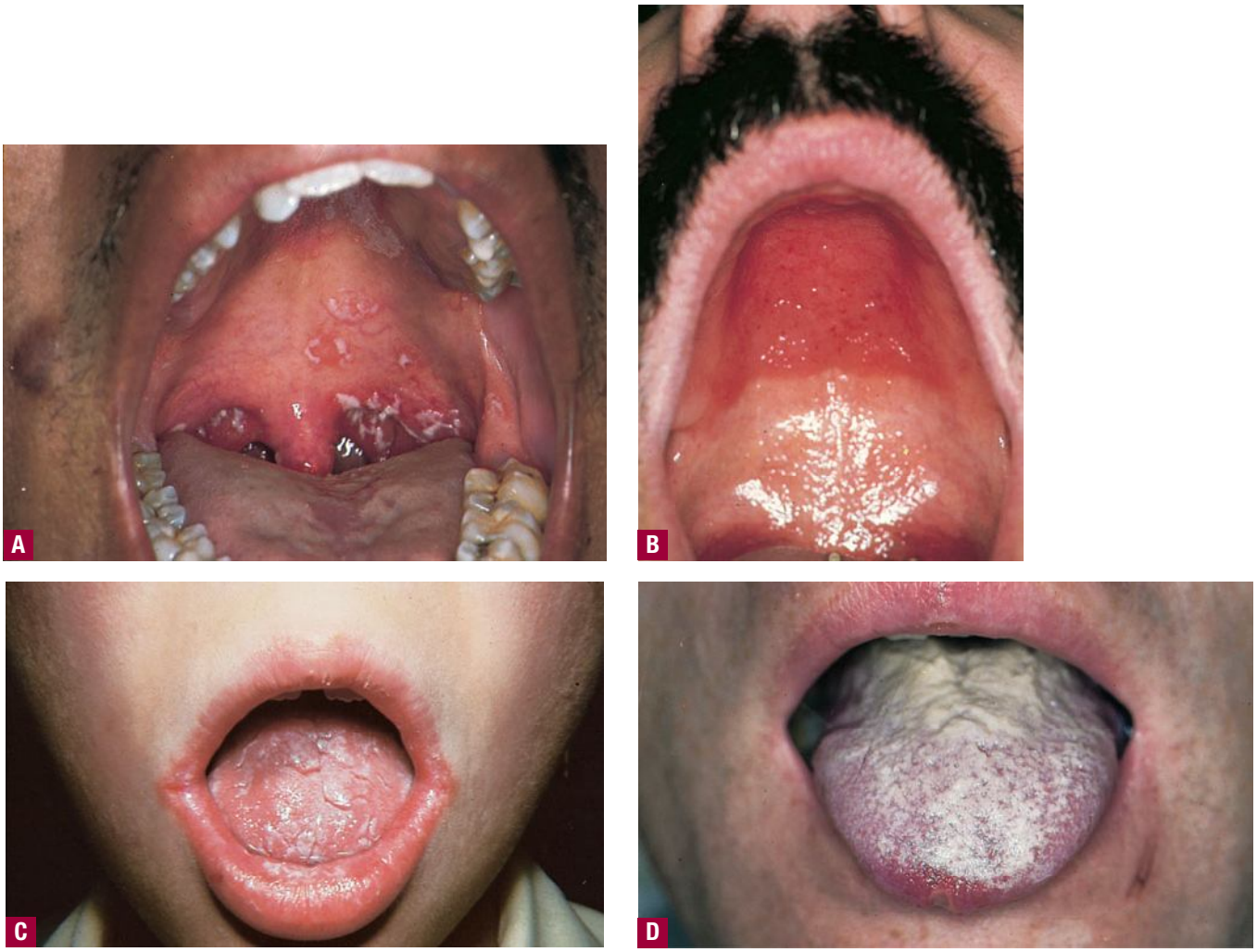

▲ **FIGURE 189-2** **A.** Pseudomembranous candidiasis or thrush. Note the characteristic white patches on the palate. **B.** Atrophic candidiasis under dentures. Edema and erythema at the site of contact with dentures. **C.** *Candida* perlèche with erythema and fissuring at the corners of the mouth. **D.** Hyperplastic candidiasis of the tongue.

Clinical Manifestations

The cutaneous and mucosal manifestations of candidiasis can be divided into several distinct clinical syndromes.

ORAL CANDIDIASIS Acute pseudomembranous candidiasis or thrush is the most common form of oral candidiasis. Predisposing factors include diabetes mellitus, systemic steroid use, antibiotic use, pernicious anemia, malignancies, radiotherapy to head and neck, and cell-mediated immunodeficiency[3,10,11] (see Table 189-1). Up to one-third of patients infected with human immunodeficiency virus develop oral candidiasis, and over 90 percent of patients with acquired immunodeficiency syndrome develop oral candidiasis over the course of their disease.[12] Oral candidiasis appears as discrete white patches that may become confluent on the buccal mucosa, tongue, palate, and gingivae (Fig. 189-2A). This friable pseudomembrane resembles milk curds and consists of desquamated epithelial cells, fungal elements, inflammatory cells, fibrin, and food debris (see Figs. 189-2A, C, and D). Scraping the patches exposes a brightly erythematous surface underneath. Microscopic examination of this material reveals masses of tangled pseudohyphae and blastospores (see Fig. 189-1). In severe cases, the mucosal surface may ulcerate.

Acute atrophic candidiasis (erythematous candidiasis) commonly occurs after sloughing of the thrush pseudomembrane.[10] This condition is associated with broad-spectrum antibiotic therapy, glucocorticoid use, and human immunodeficiency virus infection[3] (see Chap. 198). The most common location is on the dorsal surface of the tongue, where there are patchy depapillated areas with minimal pseudomembrane formation. There is both an asymptomatic and symptomatic variant, the later of which is characterized by burning or pain.[13]

Chronic atrophic candidiasis (denture stomatitis) (see Fig. 189-2B) is a common form of oral candidiasis seen in 24 percent to 60 percent of those wearing dentures.[14] Female patients are affected more commonly than males. Clinical findings of chronic erythema and edema of the palatal mucosa that contacts the dentures as well as angular cheilitis are present. Presumably, the chronic low-grade trauma and occlusion provided by dentures predispose to candidal colonization and subsequent infection.[15]

Candidal cheilosis (angular cheilitis), so-called *perlèche*, is characterized by erythema, fissuring, maceration, and soreness at the angles of the mouth (see Fig. 189-2C). This condition is commonly encountered in habitual lip lickers, usually in the young, and in elderly patients with sagging skin at the oral commissures. Loss of dentition, poorly fitting dentures, malocclusion, and riboflavin deficiency may be predisposing factors.

Box 189-1

Differential Diagnosis of Oral Candidiasis

Most Likely

- Lichen planus
- Herpetic infection
- Erythema multiforme
- Pernicious anemia

Consider

- Mucositis due to chemotherapy
- Lupus erythematosus
- Histoplasmosis
- Salicylate toxicity

Rule Out

- Glucagonoma
- Zink deficiency
- Pemphigus vulgaris

Cheilosis is often associated with chronic atrophic candidiasis due to denture wear.[10]

The differential diagnosis of oral candidiasis is summarized in Box 189-1.

VAGINAL AND VULVOVAGINAL CANDIDIASIS (See also Chap. 76) Approximately three-fourths of all women will experience an episode of vulvovaginal candidiasis (VVC) in their lifetime. *C. albicans* causes 80 percent to 90 percent of cases of VVC, and *C. glabrata* is the next most common species involved.[16] Risk factors for VVC include diabetes mellitus, steroid use, presence of an intrauterine device, wearing of tight-fitting and synthetic clothing, and immunosuppression.[17] A retrospective study conducted by MacDonald et al.[18] also showed a clear relationship between the use of oral antibiotics and subsequent VVC. These factors disrupt the vaginal lactobacilli that normally inhibit overgrowth of *Candida*.[16]

Patients generally present with a thick vaginal discharge associated with burning, itching, and occasional dysuria. Examination shows whitish plaques on the vaginal wall with underlying erythema and surrounding edema that can extend to the labia and perineum.

Recurrent VVC is defined as four or more episodes per year. Recurrent VVC occurs in up to 5 percent of women.[16] Changes in the hormonal environment, such as pregnancy and the luteal phase of the menstrual cycle, can induce a relapse of VVC. Use of a genital cleansing solution or douche is also associated with recurrent candidiasis. The mechanism may be an allergy or hypersensitivity response that increases susceptibility to *Candida*. If none of these factors is involved, one must suspect use of antibiotics, immunosuppression, or diabetes.[19] Frequent sexual intercourse may predispose women to recurrent VVC. This is assumed to be due to both vaginal abrasions sustained during intercourse and semen allergy.[20]

***CANDIDA* OF MALE GENITALIA: BALANITIS AND BALANOPOSTHITIS** *Candida* sp. cause 30 percent to 35 percent of infectious balanitis. Factors predisposing to balanitis include candidal vaginal infection in sexual partners, diabetes mellitus, and an uncircumcised state. *C. albicans* balanitis presents as small papules or fragile papulopustules on the glans or in the coronal sulcus (Fig. 189-3).These break to leave superficial erythematous erosions with a collarette of whitish scale. Infection may spread to the scrotum and inguinal areas. In diabetic or immunosuppressed patients, a severe edematous, ulcerative balanitis may occur. Occasionally, patients complain of a transient erythema and burning occurring shortly after intercourse.

CUTANEOUS CANDIDIASIS *C. albicans* has a predilection for colonizing moist, macerated folds of skin. Intertrigo is the most common clinical presentation on glabrous skin. Usual locations for intertrigo include the genitocrural, axillary, gluteal, interdigital, and inframammary (Fig. 189-4) areas and between folds of skin on the abdominal wall. Predisposing conditions include obesity, wearing of occlusive clothing, diabetes mellitus, and occupational factors.[21] Cutaneous candidiasis appears as pruritic, erythematous, macerated skin in intertriginous areas with satellite vesicopustules. These pustules break open, leaving an erythematous base with a collarette of easily detachable necrotic epidermis.



▲ **FIGURE 189-3** Candidiasis: balanoposthitis. Multiple discrete pustules on the glans penis and inner aspect of the foreskin.

Cutaneous candidal infection is diagnosed by the typical appearance of skin lesions and the presence of satellite vesicopustules. The clinical diagnosis should be confirmed by KOH examination and culture of skin scrapings. See Box 189-2 for the differential diagnosis of intertriginous candidiasis.

Several clinical variants of *Candida* intertrigo deserve special mention. Candidal diaper dermatitis is caused by yeast colonization from patients' gastrointestinal tracts. Chronic occlusion by wet diapers furthers the infection. Lesions appear first in the perianal area and spread to the perineum and inguinal creases, which show pronounced erythema[22] (see Fig. 189-4C). *Erosio interdigitalis blastomycetica* refers to interdigital candidal or polymicrobial infection of the hands or feet; because of anatomic considerations, it usually affects the third or fourth interspace (see Fig. 189-4D). *Candida* miliaria often affects the back in bedridden patients. Lesions start as isolated vesicopustules that contain yeast. *Candida* also can colonize and infect the skin around wounds covered by occlusive dressings (Fig. 189-5). Broad-spectrum topical antibiotics also contribute to *Candida* wound infections.[23]

Candidal paronychia is common in individuals whose hands are habitually involved in wet work (e.g., housekeepers, bakers, fishermen, bartenders). Typically there is redness, swelling, and tenderness of the paronychial area with prominent retraction of the cuticle toward the proximal nail fold (Fig. 189-6). Occasionally, pus can be expressed. Secondary nail changes include onycholysis and transverse depressions of the nail plate (Beau's lines) with a brownish or green discoloration along the lateral borders.[24,25] Candidal paronychia should be differentiated from bacterial paronychia or paronychia associated with hypoparathyroidism, celiac disease, acrodermatitis enteropathica (see Chap. 130), reactive arthritis syndrome (see Chap. 20), acrokeratosis paraneoplastica, and retinoid therapy.

DISSEMINATED CANDIDIASIS The incidence of disseminated candidiasis is steadily rising as more immunosuppressed patients are living longer. The organisms responsible include *C. albicans, C. tropicalis, C. glabrata,* and *C. parapsilosis.*[26] These organisms may gain hematogenous access from the oropharynx or gas-









▲ **FIGURE 189-4** Candidal intertrigo. **A.** Erythematous, eroded, pustular papules coalescing to plaques involving the scrotum and inguinal area with satellite lesions. Collarette-like scales where pustules have eroded. **B.** Confluent and discrete erythematous, eroded areas with pustular and erosive satellite lesions. **C.** Red, partially eroded plaques on the vulva surrounded by a delicate collar in an infant. Outside the main lesions are a few pustular satellite lesions. **D.** Erosio interdigitalis blastomycetica. Erythematous eroded areas between the fingers occurring in a waitress.

Box 189-2

Differential Diagnosis of Intertriginous Candidiasis

Most Likely

- Bacterial intertrigo
- Dermatophytosis (e.g., tinea cruris)
- Psoriasis
- Contact dermatitis
- Erythrasma
- Seborrheic dermatitis

Consider

- Familial benign pemphigus
- Flexural Darier disease
- Leiner disease

Rule Out

- Glucagonoma
- Extramammary Paget disease
- Secondary syphilis
- Zinc deficiency

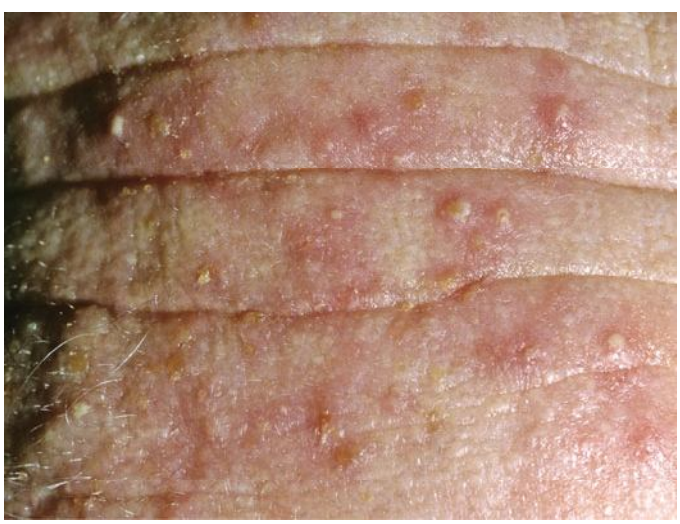

▲ **FIGURE 189-5** *Candida* miliaria on the forehead of a diabetic patient that arose after use of a semi-occlusive dressing for headache.





◀ **FIGURE 189-6** Chronic onychia and paronychia caused by *Candida albicans*. **A.** Note the warm but not hot, slightly tender, edematous nail fold with some onycholysis. This is very often misdiagnosed as staphylococcal paronychia. **B.** This is a chronic inflammatory condition with pustulation of the nail fold that also can involve the nail plate.

trointestinal tract when the function of the mucosal barrier is compromised (e.g., by mucositis secondary to chemotherapy) or through contaminated intravenous catheters. Multiple organs are involved.[27] Skin lesions occur in some patients with disseminated infection. The recognition of such lesions may be important in early diagnosis, because antemortem blood culture results are negative in a high percentage of patients with autopsy-proven systemic candidiasis.[27]

The characteristic skin lesions are 0.5- to 1.0-cm erythematous papules with a hemorrhagic or pustular center (Fig. 189-7). The eruption is located on the trunk and extremities and has a varying number of lesions. Associated findings include fever and myalgias.[28] Necrotic cutaneous lesions also have been encountered in these patients.



▲ **FIGURE 189-7** Invasive candidiasis with candidemia. Multiple erythematous papules on the hand of a febrile patient with granulocytopenia associated with treatment of acute myelogenous leukemia. The usual source of the infection is the gastrointestinal tract. *Candida tropicalis* was isolated on blood culture. Candidal forms were seen in lesional skin biopsy specimens.

The differential diagnosis of disseminated candidiasis is provided in Box 189-3.

CHRONIC MUCOCUTANEOUS CANDIDIASIS

Chronic mucocutaneous candidiasis (CMC) consists of several clinical syndromes characterized by chronic, treatment-resistant, superficial candidal infections of the skin, nails, and oropharynx. There is virtually no propensity for disseminated visceral candidiasis. In many cases there are specific abnormalities in cell-mediated immunity; in others, the defects are more global. The clinical findings of CMC can be exhibited in a unique spectrum of disease.

There are multiple more or less distinct clinical syndromes of CMC (Table 189-2).[29–31] In general, the various syndromes may be familial or sporadic. When they present in childhood, lesions are detected before the age of 3 years. Oral lesions or diaper dermatitis appear first, followed by angular cheilitis (perlèche), lip fissures, nail and paronychial involvement, vulvovaginitis, and cutaneous involvement. Cutaneous lesions may appear with an erythematous, serpiginous border or areas of brownish desquamation on a background of mild erythema (Fig. 189-8).

Nail involvement is characterized by markedly thickened and dystrophic nail plates whose entire thickness is invaded by *Candida*. The paronychial areas are red and edematous, there may be pus, and the fingertips are often bulbous (see Fig. 189-6B).

There are multiple conditions that have been associated with CMC. Most notably these include candidal esophagitis or laryngitis, endocrinopathies (usually hypoparathyroidism, hypoadrenalism, and hypothyroidism), diabetes mellitus, vitiligo, and iron deficiency. Recurrent pyogenic, viral, or other fungal infections also may occur. When CMC first appears in adulthood, it is often associated with a thymoma.[32]

Box 189-3

Differential Diagnosis of Disseminated Candidiasis

Most Likely

- Bacterial sepsis (e.g., gonococcal, meningococcal, staphylococcal)

Consider

- Pityrosporum folliculitis
- Deep fungal infections (e.g., cryptococcosis, torulopsosis, or sporotrichosis)

Always Rule Out

- Disseminated fungal infections (e.g., aspergillosis)
- Disseminated herpes infection

Laboratory Findings

Direct microscopic examination of specimens for the presence of yeast and isolation of yeast in culture are needed to diagnose infection definitively. In superficial candidal infections, the diagnosis can be made by examining skin scrapings and observing typical budding yeasts with hyphae or pseudohyphae (see Fig. 189-1). *C. albicans* grows readily on Sabouraud's agar with added antibiotics and is usually recommended for isolation. Whitish mucoid colonies grow within 2 to 5 days.

In systemic candidiasis with skin lesions, the diagnosis usually can be made from histopathologic examination and culture of appropriate skin biopsy specimens. Blood culture results often are negative in this setting.[26] Serologic studies using immunodiffusion, counterim-

TABLE 189-2
Classification of Chronic Mucocutaneous Candidiasis

Clinical Syndrome	Inheritance	Age at Onset	Distribution of Lesions	Endocrinologic Abnormality	Associated Findings	Notes
Chronic oral candidiasis	Sporadic	Any	Mucosa of tongue, lips, buccal cavity; perlèche; no skin or nail involvement	None	Esophagitis	Denture stomatitis is a variant.
Chronic candidiasis with endocrinopathy	Autosomal recessive	Childhood	Mucous membranes, skin, and/or nails	Frequent (hypoadrenalism, hypothyroidism, hypoparathyroidism, or polyendocrinopathy)	Alopecia totalis, thyroiditis, vitiligo, chronic hepatitis, pernicious anemia, gonadal failure, malabsorption, diabetes mellitus	Endocrinopathy may be delayed in onset.
Chronic candidiasis without endocrinopathy	Autosomal recessive	Childhood	Mucous membranes, perlèche, and nail involvement; less common skin involvement	None	Blepharitis, esophagitis, laryngitis	—
	Autosomal dominant	Childhood		None	Dermatophytosis, loss of teeth, recurrent viral infections	—
Chronic localized mucocutaneous candidiasis	Sporadic	Childhood	Mucous membranes, skin, and/or nails	Occasionally	Pulmonary infections, esophagitis	Hyperkeratotic lesions (*Candida*), granuloma.
Chronic diffuse candidiasis	Autosomal recessive	Childhood	Widespread on mucous membranes, skin and nail involvement	None	—	Erythematous, serpiginous skin lesions.
		Adolescence	Widespread on mucous membranes, skin and nail involvement	None	History of frequent course of antibiotics	—
Chronic candidiasis with thymoma	Sporadic	Adulthood (after third decade)	Mucous membranes, nails, and skin	None	Thymoma, myasthenia gravis, aplastic anemia, neutropenia, hypogammaglobulinemia	Chronic mucocutaneous candidiasis often precedes diagnosis of thymoma.

munoelectrophoresis, and latex agglutination methods may be somewhat helpful in the diagnosis; however, false-negative and false-positive reactions are common. More promising are techniques to detect circulating candidal antigens (e.g., mannan or enolase) or metabolic products (e.g., arabinitol), which show encouraging sensitivities and specificities in serial testing.[33]

Microscopic Studies

Because *Candida* sp. may infect virtually any organ system, specimens for laboratory examination will vary from body fluids to surgical biopsy samples. Direct microscopic examination for the presence of yeast provides rapid evidence to support the clinical diagnosis. Body fluids such as urine and cerebrospinal fluid should be centrifuged and the sediment examined directly to increase the probability of finding yeast. Sputum, surgical biopsy specimens, and tissue scrapings must be treated with a clearing agent such as 10 percent KOH and ink before the material is examined. *Candida* appears as oval budding cells, elongated filamentous cells connected end to end (pseudohyphae), or septate hyphae (see Fig. 189-1).

Pathology

Superficial candidiasis is characterized by sub-corneal pustules. Organisms are seldom seen within the pustule but can be visualized in the stratum corneum with the aid of a periodic acid-Schiff (PAS) stain. The histologic examination of a candidal granuloma shows marked papillomatosis and hyperkeratosis and a dense dermal infiltrate consisting of lymphocytes, granulocytes, plasma cells, and multinucleated giant cells. In systemic candidal infections with skin involvement, biopsy specimens show focal areas of yeast in the dermis and within blood vessels. Organisms can be identified using PAS or methenamine silver stains. There may be a surrounding mononuclear cell infiltrate, leukocytoclastic vasculitis, or microabscess formation.

Treatment

Treatment options are available and effective for each of the candidal infections.

ORAL CANDIDIASIS In cases of uncomplicated oral candidiasis, nystatin suspension (400,000 to 600,000 units four times per day) or clotrimazole troches (10 mg dissolved in the mouth five times per day) are effective. However, in recurrent cases, oral azoles (see Chap. 233) are proven to be more effective.

CANDIDAL VULVOVAGINITIS AND BALANITIS Two therapeutic options exist when dealing with candidal vaginitis. There are many topical imidazoles that are effective, such as butoconazole, miconazole, and clotrimazole, available over the counter, and tioconazole, econazole,



▲ **FIGURE 189-8** Mucocutaneous candidiasis. Well-demarcated serpiginous lesions with massive scaling. Lesions look like psoriasis.

and terconazole available by prescription (see Chap. 219). They may be used for 3 or 7 days.[34] All these topical agents are safe to use during pregnancy.[35] Oral fluconazole, itraconazole, and ketoconazole offer efficacy similar to that of topical therapy (see Chap. 233). Prophylactic regimens can be used to prevent recurrent cases. A weekly clotrimazole 500-mg tablet intravaginally or fluconazole 150 mg/week orally has been shown to prevent recurrences.[34] The recommended treatment for candidal balanitis is topical clotrimazole cream or a single 150-mg dose of fluconazole.

INTERTRIGO Intertrigo has been treated successfully with topical antifungals including nystatin and topical imidazole creams. Miconazole powder can be use to dry moist intertriginous areas.

CANDIDAL PARONYCHIA Chronic paronychia due to *Candida* is resistant to therapy. All wet work should be minimized, and a topical imidazole in solution form is the ideal treatment.[36] Four percent thymol in chloroform or absolute alcohol is drying and may be a suitable alternative. Oral ketoconazole also may be used.[37]

DISSEMINATED CANDIDIASIS Amphotericin B is available in newer lipid-based formulations. Also, caspofungin is available for treating disseminated candidiasis (see Chap. 233).[38]

PITYROSPORUM INFECTIONS OF THE SKIN: PAPULOSQUAMOUS TINEA VERSICOLOR, *PITYROSPORUM* FOLLICULITIS, AND INVERSE TINEA VERSICOLOR

The genus *Malassezia* currently includes nine species of lipophilic basidiomycetous yeast: *M. furfur, M. pachydermatis, M. sympodialis, M. globosa, M. restricta, M. slooffiae, M. obtusa, M. dermatis,* and *M. equi*.[39] Previously, *M. furfur, M. pachydermatis,* and *M. sympodialis* were the only members of the genus. In 1996, a new taxonomic classification based on morphology, ultrastructure, and molecular biology was proposed[40] that added four new species. More recently, it was projected that the possible identification of new species *M. japonica, M. nana,* and *M. yamatoensis* may bring the total to 12.[41] These yeasts cause a wide spectrum of superficial cutaneous disease, including tinea (pityriasis) versicolor, *Pityrosporum* folliculitis, and seborrheic dermatitis, while contributing to atopic dermatitis and psoriasis.[39]

Etiology and Pathogenesis

M. furfur can be cultured from diseased and normal skin and is considered part of the normal flora, particularly in sebum-rich areas of the skin.[42] *M. furfur* is a dimorphic, lipophilic organism that grows in vitro only with the addition of C12 to C14 fatty acids such as olive oil and lanolin. Under appropriate conditions, it converts from the saprophytic yeast to the predominantly parasitic mycelial morphologic form associated with clinical disease. Factors responsible for mycelial transition include a warm, humid environment, oral contraceptive use, heredity, systemic corticosteroid use, Cushing disease, immunosuppression, hyperhidrosis, and a malnourished state.[42,43]

The species of *Malassezia* can be differentiated by their nutritional requirements, morphology, and molecular biology.[39,40] *M. pachydermatis* is the one member of the genus *Malassezia* without an absolute requirement for exogenous lipids. This is due to its ability to produce phospholipase, which directly correlates with skin infection.[44] Although previously recognized as a zoophilic organism, it has been identified only recently as a human pathogen. In one study, *M. pachydermatis* caused a series of infections in a neonatal care nursery, where it was presumably spread to patients from health care workers whose pet dogs were colonized with the fungus.[45] It was later proven that the vast majority of dog owners tested positive for *M. pachydermatis* on their hands.[46] Other members of the genus, including *M. sympodialis* and *M. slooffiae*, are part of the normal skin flora.[47] A few studies also linked *M. sympodialis* with neonatal cephalic pustulosis, a skin disorder also known as *neonatal acne*.[48,49]

M. furfur has long been identified as the fungus causing tinea versicolor. However, studies now indicate that *M. globosa* may be involved in the pathogenesis of this disease. In patients with tinea versicolor, when the organism was identified, the vast majority of lesions were associated with *M. globosa*.[39]

Tinea versicolor is an opportunistic infection of the skin. Experimental inoculation of *Malassezia* under occlusion can cause infection.[42] The resulting increase in humidity, temperature, and CO_2 tension appear to be important factors that make the skin susceptible to infection.[50] When the occlusion is terminated, healing occurs, although the organism is not eradicated from the skin and can be cultured from clinically uninvolved areas.[51] It also may colonize follicular structures, and a high recurrence rate is expected.

The yeast may filter the rays of the sun and interfere with normal tanning.[51]



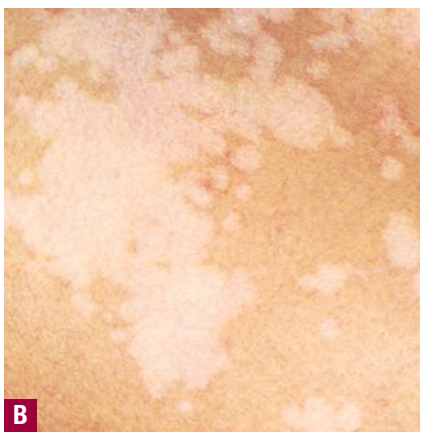

▲ **FIGURE 189-9** Tinea versicolor. **A.** These lesions are darker because of hyperemia secondary to inflammatory response and increased melanin. **B.** There are sharply marginated, uniformly hypopigmented macules with fine, sometimes barely perceptible scales, which are easily scraped off with a glass slide. When the lesions are very large, as on the left, they can be confused with vitiligo.

Mayser et al.[52] discussed a specific compound synthesized by *Malassezia* called *pityriacitrin* that absorbs ultraviolet light.[52] Other metabolites of *M. furfur* such as azaleic acid, a dicarboxylic acid, can cause hypopigmentation by inhibiting tyrosinase and injuring melanocytes.[51,53] The long-standing damage to melanocytes due to these by-products may explain why most hypopigmented lesions persist for months and some persist for years.[53]

Clinical Features

Cutaneous infections with *Malassezia* may take three forms: (1) papulosquamous tinea versicolor, (2) folliculitis, and (3) inverse tinea versicolor. The most common presentation is scaly hypopigmented or hyperpigmented macules observed in characteristic areas of the body, including the chest, back, abdomen, and proximal extremities (Fig. 189-9). Less common areas of involvement include the face, scalp, and genitalia. The characteristic scale is described as dust-like or furfuraceous. This characteristic feature of the disease can be produced by lightly scraping a scalpel blade over the involved skin.[53] The color of the lesions varies from almost white to reddish brown or fawn colored. The presenting complaint is usually a cosmetic one, because lesions often fail to tan with sun exposure. Pruritus is mild or absent.

The differential diagnosis of papulosquamous tinea versicolor is presented in Box 189-4.

In *Malassezia (Pityrosporum)* folliculitis, lesions typically appear on the back, chest, and sometimes the extremities in adolescents (Fig. 189-10A). Pruritus is more common than with typical tinea versicolor. The primary lesion is a perifollicular, erythematous, 2- to 3-mm papule or pustule. Only appropriate culture and KOH examination can distinguish this infection from a bacterial folliculitis. Frequently, biopsy with special stains for fungus is necessary, but *Malassezia* can often be recognized in follicles even in hematoxylin and eosin–stained sections (see Fig. 189-10B). Diabetes mellitus, glucocorticoid use, antibiotic therapy, and use of immunosuppressive medications can predispose to this disorder.[39] There have also been cases of recalcitrant acne vulgaris and concurrent *Pityrosporum* folliculitis.[54] See Box 189-5 for the differential diagnosis of *Pityrosporum* folliculitis.

Box 189-4

Differential Diagnosis of Papulosquamous Tinea Versicolor

Most Likely
- Pityriasis alba
- Pityriasis rosea
- Seborrheic dermatitis
- Dermatophyte infections

Consider
- Vitiligo
- Psoriasis
- Pityriasis rubra pilaris
- Confluent and reticulated:
  - Papillomatosis of Gougerot and Carteaud

Always Rule Out
- Secondary syphilis





▲ **FIGURE 189-10** **A.** *Pityrosporum* folliculitis on the anterior chest. **B.** Histopathology. Note the organisms in the follicular ostia on staining with hematoxylin and eosin.

The lesions of *inverse tinea versicolor* are encountered predominantly in flexural areas.[55] These lesions are sharply demarcated confluent erythematous patches that can be confused with inverse psoriasis, seborrheic dermatitis, erythrasma, candidiasis, and dermatophytic infections.

Box 189-5

Differential Diagnosis of *Pityrosporum* Folliculitis

Most Likely
- Bacterial folliculitis
- Acne vulgaris

Consider
- Candidal folliculitis
- Eosinophilic folliculitis

Always Rule Out
- Disseminated candidiasis
- Pustular drug eruption

Each of the cutaneous variants has an equal sex distribution and tends to flare during the summer months, presumably due to increased heat and humidity. These infections are also more common in tropical climates. Although the disease can occur at any age, it favors late adolescence and early adulthood when sebaceous glands are most active.[39,42]

Laboratory Findings

To identify the *Malassezia* yeast forms, scale from involved skin should be scraped onto a glass slide and treated with 10 percent KOH. Alternatively, cellophane tape can be used to pick up skin scales from the lesion. The tape is mounted on a glass slide with methylene blue, and the organism is selectively stained.[56] The microscopic appearance of the yeast is classically described as "spaghetti and meatballs" (Fig. 189-11).

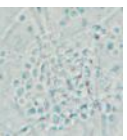

Pathology

In tinea versicolor, the organisms inhabit the stratum corneum. There is usually no dermal infiltrate. Yeast may be observed with hematoxylin and eosin staining alone. PAS staining is confirmatory. Microscopic examination reveals clusters of oval budding yeast cells 3.5 × 4.5 μm long with short, septate, and occasionally branching hyphae (see Fig. 189-11). In *Pityrosporum* folliculitis, organisms are noted in widened follicular ostia mixed with keratinous material (see Fig. 189-10B). Rupture of the follicular wall can occur with a resulting mixed inflammatory and foreign-body giant cell response.

Diagnosis

The clinical appearance of tinea versicolor is usually characteristic, and KOH examination is confirmatory. A Wood's lamp examination may show yellowish fluorescence of involved skin.

Treatment and Prognosis

TINEA VERSICOLOR Multiple topical products are useful in treating tinea versicolor. The most widely used has been 2.5 percent selenium sulfide shampoo, which is applied daily for 2 weeks and left on for at least 10 minutes, then washed off. Subsequently, applying the drug once or twice per month will usually prevent recurrence. All the topical azole antifungals have been effective in the treatment of tinea versicolor. Ketoconazole 2 percent shampoo is lathered on affected areas and left for 5 minutes; this treatment is repeated for 3 consecutive days.[57] Topical terbinafine 1 percent solution applied twice daily to lesions for 7 days has yielded cure rates of more than 80 percent.[58]

Although topical therapy is ideal for localized lesions, systemic treatment may be necessary for patients with extensive disease or frequent recurrences, or for whom topical agents have failed.[59] Oral ketoconazole (200 mg daily for 7 days) or oral itraconazole (200 to 400 mg daily for 3 to 7 days) is almost universally effective. Even one dose of itraconazole 400 mg by mouth has been shown to be more than 75 percent effective and in one study was just as effective as itraconazole given for 1 week.[60] Fluconazole is also effective and can be administered as a single dose of 400 mg.[57]

***PITYROSPORUM* FOLLICULITIS** *Pityrosporum* folliculitis also can be treated successfully with systemic therapy. Although there are few controlled trials, oral ketoconazole (200 mg daily for 4 weeks), fluconazole (150 mg weekly for 2 to 4 weeks), and itraconazole (200 mg daily for 2 weeks) are useful systemic agents in the treatment of this condition.[39,56]

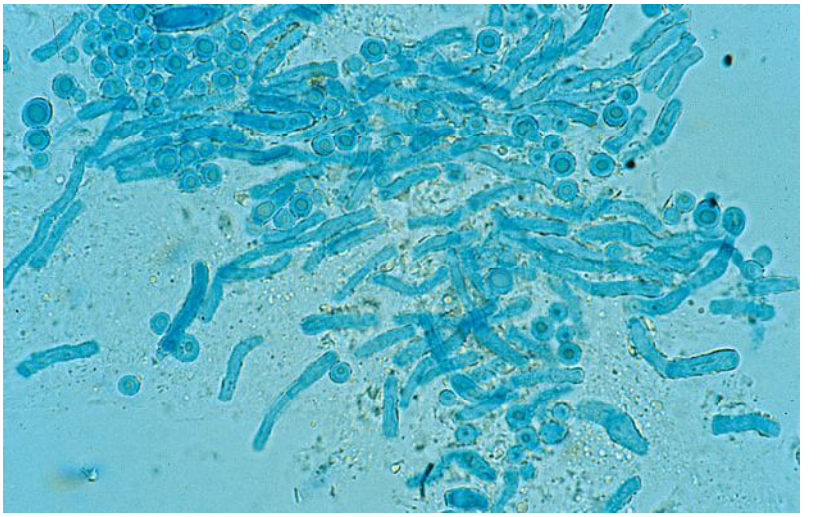

▲ **FIGURE 189-11** "Spaghetti and meatballs" appearance of *Malassezia* in a KOH preparation.

KEY REFERENCES

The full reference list for all chapters is available at www.digm7.com.

1. Segal E: *Candida*, still number one—What do we know and where are we going from there? *Mycoses* **48 Suppl 1**:3, 2005
3. Farah CS et al: Oral candidosis. *Clin Dermatol* **18**:553, 2000
10. Appleton SS: Candidiasis: Pathogenesis, clinical characteristics, and treatment. *J Calif Dent Assoc* **28**:942, 2000
19. Owen MK, Clenney TL: Management of vaginitis. *Am Fam Physician* **70**:2125, 2004
32. Kirkpatrick CH: Chronic mucocutaneous candidiasis. *J Am Acad Dermatol* **31**:S14, 1994
34. Owen MK, Clenney TL: Management of vaginitis. *Am Fam Physician* **70**:2125, 2004
39. Gupta AK et al: Skin diseases associated with *Malassezia* species. *J Am Acad Dermatol* **51**:785, 2004
43. Gupta AK, Bluhm R, Summerbell R: Pityriasis versicolor. *J Eur Acad Dermatol Venereol* **16**:19, 2002
52. Mayser P et al: Pityriacitrin—an ultraviolet-absorbing indole alkaloid from the yeast *Malassezia furfur*. *Arch Dermatol Res* **294**:131, 2002
60. Kose O et al: Comparison of a single 400 mg dose versus a 7-day 200 mg daily dose of itraconazole in the treatment of tinea versicolor. *J Dermatolog Treat* **13**:77, 2002

CHAPTER 190

Deep Fungal Infections

Roderick J. Hay

Deep fungal infections comprise two distinct groups of conditions, the subcutaneous and systemic mycoses. Neither are common, and the subcutaneous mycoses, with some exceptions, are largely confined to the tropics and sub-tropics. In recent years, the systemic mycoses have become important opportunistic infectious complications in immunocompromised patients, including those with acquired immunodeficiency syndrome (AIDS) and patients receiving treatment for malignancies. They also include a group of primary respiratory infections, such as histoplasmosis and coccidioidomycosis, which may affect otherwise healthy individuals and those with underlying illness. The fungi that cause these respiratory infections are usually dimorphic or exist in a different morphologic phase (e.g., yeast or mold) at different stages of their life cycle.

Patients with subcutaneous fungal infections often present to a physician with signs of skin involvement. By contrast, patients with systemic mycoses only occasionally have skin lesions, either following direct involvement of the skin as a portal of entry or after dissemination from a deep focus of infection. There are a number of excellent texts about fungi and the diseases they cause.[1–4]

Treatment of these conditions remains difficult in many cases, although there is now a wide range of antifungal drugs with different modes of action (see eFig. 190-0.1 in on-line edition.)

SUBCUTANEOUS MYCOSES

The subcutaneous mycoses, or mycoses of implantation, are infections caused by fungi that have been introduced directly into the dermis or subcutaneous tissue through a penetrating injury, such as a thorn prick. Although many are tropical infections, some, such as sporotrichosis, are also prevalent in temperate climates; any of these infections may present as an imported disease in a patient who has originated from an endemic area, sometimes after a lapse of many years. The most common subcutaneous mycoses are sporotrichosis, mycetoma, and chromoblastomycosis. Rarer infections include lobomycosis and subcutaneous zygomycosis.

Sporotrichosis

Sporotrichosis is a subcutaneous or systemic fungal infection caused by the dimorphic fungus *Sporothrix schenckii*.[5,6] The fungus occurs in the natural environment, presumably in mold form, but develops as a yeast in infections. The most frequent site of this infection is the dermis or subcutis. There is also a systemic form of sporotrichosis whose clinical features range from pulmonary infection to arthritis or meningitis. One important characteristic of the diagnosis of cutaneous lesions is the scarcity of organisms in tissue, making confirmation of the diagnosis by microscopy potentially difficult.[6] Sometimes in tissue, fungal cells are surrounded by an eosinophilic refractile fringe, the asteroid body, that is a characteristic of the organism, although a similar phenomenon may occur with other infectious organisms (e.g., Schistosome eggs).

EPIDEMIOLOGY Infections occur in both temperate and tropical countries. They are seen in North, South, and Central America, including the southern United States and Mexico, as well as in Africa, Egypt, Japan, and Australia (see eFig. 190-0.2 in on-line edition).[6] The countries where the highest rates of infection occur are Mexico, Brazil, and South Africa. However, sometimes hyperendemic areas are found where large numbers of cases occur.[7] In the United States, infections are most common in the midwestern river valleys. Infections are now rare in much of Europe. In nature, the fungus grows on decaying vegetable matter such as plant debris, leaves, and wood. Although it is usually a cause of sporadic infection, *S. schenckii* also may affect groups of workers exposed to the organism, such as those using straw as a packing material, gardeners, forestry workers, and those whose recreational activities bring them into contact with plant debris. The organism is thought to be introduced into the skin through a local injury.

CLINICAL FINDINGS One important feature of the infection is the development of clusters of cases in defined geographic areas. For instance, there was a major outbreak of sporotrichosis in the South African gold mines from 1941 to 1944.

The two clinical varieties of sporotrichosis are the subcutaneous and systemic forms of disease.[5,8,9] Subcutaneous sporotrichosis is by far the more common and includes two main forms: lymphangitic and fixed infections. The lymphangitic form is the more common and usually develops on exposed skin sites such as hands or feet. The first sign of infection is the appearance of a dermal nodule that breaks down into a small ulcer. Draining lymphatics become inflamed and swollen, and a chain of secondary nodules develops along the course of the lymphatic (Fig. 190-1); these also may break down and ulcerate. In the fixed variety, which accounts for about 15 percent of cases, the infection remains localized to one site, such as the face, and a granuloma develops that subsequently may ulcerate. Satellite nodules may form around the rim of the primary lesion. Other clinical variants of subcutaneous sporotrichosis may mimic mycetoma, lupus vulgaris, and chronic venous ulceration. In some cases, deep extension of the infection may affect joints or tendon sheaths. Patients with AIDS who develop sporotrichosis often have multiple cutaneous lesions[9] without prominent lymphatic involvement, but deep infections, such as arthritis, are also reported.

In the much rarer systemic form of sporotrichosis, lesions can develop almost anywhere, although chronic lung nodules, with cavitation, arthritis, and meningitis have been described most frequently. These may co-exist with cutaneous lesions of sporotrichosis.

DIFFERENTIAL DIAGNOSIS Conditions commonly confused with sporotrichosis are

SUBCUTANEOUS MYCOSES AT A GLANCE



- Are usually sporadic
- Are contracted in the tropics and sub-tropics
- May cause chronic disability
- Are best diagnosed by histopathology, except for sporotrichosis
- Often require months of successful antifungal treatment







▲ **FIGURE 190-1** Sporotrichosis. An ulcerated nodule is seen on the thumb, with proximal lymphangitic spread represented by subcutaneous nodules. (Used with permission from Takeji Nishikawa, MD.)

mycobacterial (see Chap. 184) and primary cutaneous *Nocardia* infections (see Chap. 185) and leishmaniasis (see Chap. 206). The nontuberculous mycobacterial infection due to *Mycobacterium marinum* (fish-tank granuloma), in particular, closely resembles lymphangitic sporotrichosis.

LABORATORY TESTS The best sources of diagnostic material are smears, exudates, and biopsies. *S. schenckii* is seen very rarely in direct microscopic examination because yeasts are usually present only in small numbers; the organism can be isolated readily on Sabouraud's agar. In primary culture, the fungus grows as a mold, with compact, white colonies that darken with age. Microscopically, the hyphae produce small oval or triangular conidia either on specialized hyphae or elsewhere on the mycelium. Ideally, the organism should be converted to yeast phase on enriched media such as brain-heart infusion agar at 37°C (98.6°F) to complete the identification.

Pathologically, sporotrichosis causes a mixed granulomatous reaction with neutrophil microabscesses. The fungus, if present, is usually in the form of small (3 to 5 μm) cigar-shaped or oval yeasts that may, on occasion, be surrounded by a thick, radiating eosinophilic fringe forming the distinctive asteroid body. Organisms are usually sparsely distributed in lesions, and it may be necessary to scan several sections to identify one yeast. An intradermal sporotrichin skin test is available in some countries and may have a role to play in allowing the physician to identify the most appropriate laboratory investigations to instigate.

TREATMENT Although spontaneous remissions may occur, most patients are treated with antifungal chemotherapy.[10] Potassium iodide (saturated solution), 4 to 6 mL tid, is effective in the cutaneous types of sporotrichosis and should be continued for 3 to 4 weeks after clinical cure. The daily dose is built up slowly from 1 mL tid over 2 to 3 weeks to avoid side effects such as hypersalivation and nausea. This is an inexpensive form of therapy, but it is unpalatable. Alternative treatments include itraconazole, 200 mg daily, and terbinafine, 250 mg daily, which are better tolerated, and intravenous amphotericin B for deep infection. In all cases, treatment is continued for at least 1 week after clinical resolution.

Mycetoma (Maduromycosis, Madura Foot)

Mycetoma is a chronic localized infection caused by different species of fungi or actinomycetes. It is characterized by the formation of aggregates of the causative organisms, known as *grains*, that are found within abscesses. These either drain via sinuses onto the skin surface or involve adjacent bone, causing a form of osteomyelitis. Grains are discharged onto the skin surface via these sinuses. The disease advances by direct spread, and distant metastatic sites of infection are very rare. Mycetomas caused by species of fungi are known as *eumycetomas*, and those caused by aerobic actinomycetes or filamentous bacteria are known as *actinomycetomas* (see Chap. 185). The organisms are usually soil or plant saprophytes[11] that are only incidental human pathogens.

EPIDEMIOLOGY Mycetomas are mainly, but not exclusively, found in the dry tropics where there is low annual rainfall (see eFig. 190-1.1 in on-line edition).[11,12] They are sporadic infections that are seldom common, even in endemic areas.[13] Occasionally, nonimported cases are reported from temperate climates, although in these cases, the most common organism is *Scedosporium apiospermum*. Actinomycetomas due to *Nocardia* sp. are most common in Central America and Mexico. In other parts of the world, the most common organism is a fungus, *Madurella mycetomatis*. The actinomycete *Streptomyces somaliensis* is isolated most often from patients originating from Sudan and the Middle East. The causative organisms of mycetoma have been isolated from either soil or plant material, including Acacia thorns, in endemic areas.

The organisms are implanted subcutaneously, usually after a penetrating injury. It is unusual to find any underlying predisposition in patients with mycetoma, and the persistence of the organism after the initial inoculation appears to be related to its ability to evade host defenses through a variety of adaptations such as cell wall thickening and melanin deposition.[14]

CLINICAL FINDINGS The clinical features of both fungal and actinomycete mycetomas are very similar.[12] They are most common on the foot, lower leg, or hand, although head or back involvement also may occur. Infection of the chest wall is most characteristic of *Nocardia* infections (see Chap. 185). The earliest stage of infection is a firm, painless nodule that spreads slowly with the development of papules and draining sinus tracts over the surface (Fig. 190-2). Local tissue swelling, chronic sinus formation, and later bone involvement distort and deform the original site of infection (Figs. 190-3 and 190-4). Lesions are seldom painful except in the late stages and where sinus tracts are about to emerge onto the skin surface. Dissemination from the initial site is exceptionally rare, although local lymphadenopathy may occur.

X-ray changes include periosteal erosion and proliferation, as well as the development of lytic lesions in the bone. Bone scans or magnetic resonance imaging may identify bone lesions at an earlier stage.

DIFFERENTIAL DIAGNOSIS Chronic bacterial or tuberculous osteomyelitis may re-



▲ **FIGURE 190-2** Mycetoma. Brawny edema and crusted papules on the plantar surface.



▲ **FIGURE 190-4** Mycetoma. Chronic fibrotic involvement of the foot with lymphatic spread to the popliteal fossa.

semble mycetoma. Actinomycosis (see Chap. 185) is also similar but usually develops close to certain sites, such as the mouth or the cecum, where the causative organisms are sometimes commensal.

LABORATORY TESTS Finding the mycetoma grains is the key to establishing the diagnosis, and these are generally discharged from the openings of sinus tracts. However, they also may be obtained by removing the surface crust from a pustule or sinus tract with a sterile needle and gently squeezing the edges. Grains are 250- to 1000-μm white, black, or red particles that can be picked out with the naked eye (Table 190-1). Direct microscopy of grains is important because it will show whether the grain is composed of the small actinomycete or broader fungal filaments. In general, it is not possible to distinguish the fine actinomycete filaments in potassium hydroxide (KOH) mounts or, for that matter, in hematoxylin and eosin–stained material. In addition, black grains are always caused by fungi; red grains, by actinomycetes (see Table 190-1).

Final identification requires isolation of the causal agent in culture. In view of the number of possible species, a series of different culture media and conditions of incubation should be used. Morphologic and physiologic characteristics are used to distinguish between the genera and species. There are now a few examples where the organism has been identified using specific primers through use of the polymerase chain reaction. Serology is diagnostically helpful only in some cases (e.g., in *S. somaliensis)*, and even then, more as a guide to therapeutic response.

Histologically, there is a chronic inflammatory reaction with neutrophil abscesses and scattered giant cells and fibrosis.[11] Grains (50 to 250 μm) are found in the center of the inflammation. Their size and shape may help in the identification, although with nonpigmented eumycetomas, this is seldom sufficient (Fig. 190-5).

TREATMENT Of the fungal causes of mycetoma, some cases of *M. mycetomatis* infection respond to ketoconazole, 200 mg daily, over several months. For the others, a trial of therapy with griseofulvin, terbinafine, or itraconazole is worth attempting. However, responses to chemotherapy are unpredictable, although antifungals may slow the course of infection. Surgery, usually amputation, is the definitive procedure and may have to be used in advanced cases. However, the value of major surgery in a disfiguring but nonlife-threatening infection has to be weighed against the availability of appropriate prosthetic limbs.

Actinomycetomas (see Chap. 185) generally respond to antibiotics such as a combination of dapsone with streptomycin or sulfamethoxazole-trimethoprim plus rifampin or streptomycin. Amikacin also may be used in recalcitrant *Nocardia* infections. The responses in all but a few cases are good.[15]



▲ **FIGURE 190-3** Eumycetoma caused by *Scedosporium* leading to significant distortion of the forefoot.

Chromoblastomycosis (Chromomycosis)

Chromoblastomycosis is a chronic fungal infection of the skin and subcutaneous tissues caused by pigmented or dematiaceous fungi that are implanted into the dermis from the environment. In the ensuing inflammation, they form thick-walled single cells or cell clusters (sclerotic or muriform bodies), and these may elicit a marked form of pseudoepitheliomatous hyperplasia often accompanied by trans-epidermal elimination of organisms. The infection can be caused by a number of different pigmented fungi, the most common being *Phialophora verrucosa, Fonsecaea pedrosoi, F. compactum, Wangiella dermatitidis,* and *Cladophialophora carrionii*.[16]

EPIDEMIOLOGY The fungi that cause chromoblastomycosis can be isolated in the environment from wood, plant debris, or soil.[17] The vast majority of infections are caused by *F. pedrosoi* and *C. carrionii*. As with other subcutaneous mycoses, infection follows implantation through a tissue injury. The infection is



TABLE 190-1
Macroscopic and Histopathologic Features of Mycetoma Grains

Organisms	Hematoxylin and Eosin Section Appearances
Eumycetoma	
Dark grains	
Madurella mycetomatis	Cement present, vesicles sometimes prominent
M. grisea	Cement absent, compact outer layer
Leptosphaeria senegalensis	Cement in outer zone, dark periphery with vesicular center
Exophilia jeanselmei	Cement absent, often hollow
Pyrenochaeta romeroi	Cement lacking, compact outer layer
Pale grains	
Fusarium sp., *Acremonium, Scedosporium apiospermum, Aspergillus nidulans, Neotestudina rosati*	Compact, pigment lacking, interwoven fungal filaments (*S. apiospermum* may have prominent vesicles)
Actinomycetoma	
Pale (white to yellow) grains	
Actinomadura madura	Basophilic-stained fringe in layers
Nocardia brasiliensis	Small, pale blue, eosinophilic fringe
Yellow to brown grains	
Streptomyces somaliensis	Grains fractured, basophilic or pink
Red to pink grains	
A. pelletieri	Small, basophilic layers



found as a sporadic condition in Central and South America, although rarely in North America. It occurs in the Caribbean region, Africa (particularly Madagascar), Australia, and Japan (see eFig. 190-5.1 in on-line edition). It also may occur as an imported infection outside the usual endemic areas. The disease is most frequent in male rural workers.

CLINICAL FINDINGS The initial site of the infection is usually on the feet, legs, arms, or upper trunk. The clinical features vary.[17] The initial lesion is often a warty papule that expands slowly over months or years (Figs. 190-6 and 190-7). Alternatively, lesions may be plaque-like with an atrophic center. The more common verrucous form spreads slowly and locally. Individual lesions may be very thick and often develop secondary bacterial infection. Satellite lesions around the initial site of infection are local extensions of the infection and usually are produced by scratching. Complications of chromoblastomycosis include local lymphedema, leading to elephantiasis and squamous carcinomas in some chronic lesions.

DIFFERENTIAL DIAGNOSIS The disease must be differentiated from chronic tropical lymphedema with hyperplasia (mossy foot). Other chronic verrucous lesions, such as tuberculosis and blastomycosis, are often more extensive. The identification of organisms in the lesions of chromoblastomycosis is essential.

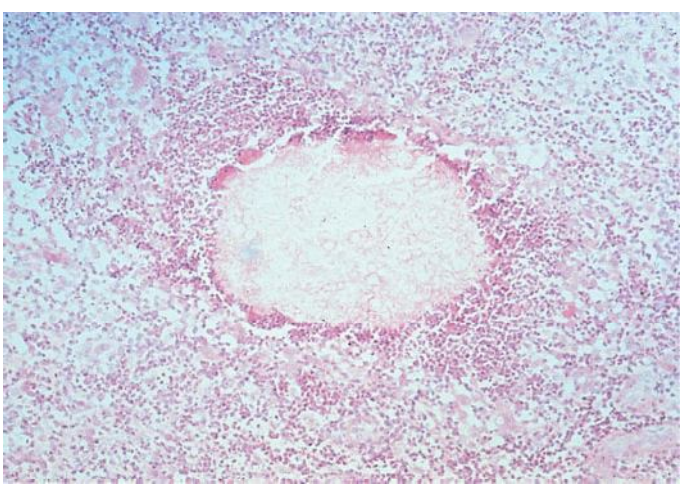

▲ **FIGURE 190-5** Pale eumycetoma grain (hematoxylin and eosin stain).



▲ **FIGURE 190-6** Chromoblastomycosis. A solitary, large, verrucous plaque surrounded by a halo of erythema is seen on the calf. (Used with permission from Ted Rosen, MD, and Howard Rubin, MD.)

LABORATORY TESTS The typical sclerotic or muriform fungal cells can be seen in skin scrapings taken from the surface of lesions, particularly areas where there is a small dark spot on the skin surface, using KOH mounts. The lesions also should be biopsied because the pathologic changes and presence of muriform cells are typical. The histology shows a mixed granulomatous response, with small neutrophil abscesses and often exuberant epidermal hyperplasia.[18] The organisms, which are often seen either in giant cells or in neutrophil abscesses, appear singly or in small groups of brown pigmented cells, often with a single or double septum and thick cell wall.

In culture, these fungi are very similar in gross macroscopic appearance, producing black colonies with a downy surface. Their cultural identification depends on demonstrating the presence of different but specific types of sporulation, and either single or multiple sporulation mechanisms may be seen in each organism. Accurate differentiation between the different fungi may be difficult. At this stage, the choice of treatment does not depend critically on correct identification of the organisms, although there may be differences in the speed of response to azole drugs (see following section Treatment).

TREATMENT The main treatments for chromoblastomycosis are itraconazole, 200 mg daily, with or without flucytosine, 30 mg/kg qid (in a patient with normal renal function)[19]; terbinafine, 250 mg daily[20]; and, in extensive cases, intravenous amphotericin B (up to 1



◀ **FIGURE 190-7** Close-up view of chromoblastomycosis. Note hyperkeratosis with pigmentation.

mg/kg daily). Lesions can be spread by surgery, which should be used only as an adjunctive therapy after drug treatment. The local application of heat may be helpful in some instances. The responses of these fungi to different antifungal agents do not appear to differ significantly, although there is some evidence that *C. carrionii* responds more rapidly to terbinafine and itraconazole. In any event, treatment is continued until there is clinical resolution of lesions, which usually takes several months. Extensive lesions often respond poorly to treatment.

Pheohyphomycosis (Phaeomycotic Cyst, Cystic Chromomycosis)

Phaeohyphomycosis is a rare infection characterized by the formation of subcutaneous inflammatory cysts. It is caused by dematiaceous fungi, the most common of which are *Exophiala jeanselmei* and *W. dermatitidis*, but some 103 species have been described as causal agents.[21] However, unlike in chromoblastomycosis, these organisms form short, irregular, pigmented hyphae in tissue. The infection may occur in any climatic area, although it is more common in the tropics. It also may appear in immunosuppressed patients, particularly those receiving long-term glucocorticoid therapy. The lesions present as cysts and may be mistaken for other similar structures such as Baker's cysts. The diagnosis is usually made after surgical excision. Histologically, the cyst wall consists of palisades of macrophages and other inflammatory cells surrounded by a fibrous capsule, and the fungal hyphae are found in the macrophage zone. Although the fungi in tissue lesions are usually pigmented, this is not always the case; cystic lesions caused by non-pigmented fungi being called hyalohyphomycotic cysts. The treatment is surgical excision, although relapse can occur, particularly in immunocompromised patients.

Lobomycosis (Keloidal Blastomycosis, Lobo Disease)

Lobomycosis is an uncommon infection seen in Central and South America, often in remote rural areas. The source of the organism is unknown, although similar lesions have been found on freshwater dolphins. Lobomycosis is characterized by the appearance of keloid-like skin lesions on exposed sites.[22] Although it cannot be cultured in vitro, it is caused by a fungus, *Lacazia loboi*, that forms chains of rounded cells in tissue, each joined by a small tubule. Lesions may occur anywhere on the body but usually are found on exposed parts such as the legs, arms, and face. They can spread from site to site by autoinoculation. Antifungal drugs are not effective, and surgical removal is the main treatment.

Subcutaneous Zygomycosis [Basidiobolomycosis, Subcutaneous Phycomycosis and Conidiobolomycosis, (Rhino)-Entomophthoromycosis]

Subcutaneous zygomycosis is a rare tropical subcutaneous mycosis characterized by the development and spread of a chronic, firm swelling involving subcutaneous tissue. There are two main varieties caused by different organisms.[23] The first, most often caused by *Basidiobolus ranarum* (*B. haptosporus*), is more common in children. It occurs in a wide variety of countries and environments from South America to Africa and Indonesia. The organism can be found in plant debris and in the intestinal tracts of reptiles and amphibians. Lesions usually develop around limb girdle sites and present with a firm, slowly spreading, woody cellulitis. The second form, caused by *Conidiobolus coronatus*, is seen in adults. The organism can be isolated from soil, plant debris, and some insects. The early infection starts in the region of the inferior turbinates of the nose. Spread involves the central part of the face, and once again, the swelling is hard and painless. It may cause very severe deformity of the nose, lips, and cheeks. These infections are distinct to those caused by other zygomycete fungi.

Histopathologically, a chronic granulomatous response with large numbers of eosinophils can be seen. The fungi are present as large, strap-like hyphae without cross walls or septa. They are also often surrounded by refractile eosinophilic material (Splendore-Hoeppli phenomenon). The organisms can be cultured readily on Sabouraud's agar. Lesions usually respond to oral treatment with potassium iodide, given in similar doses to those used in sporotrichosis (see Treatment under Sporotrichosis). Ketoconazole (400 mg daily) and itraconazole (100 to 200 mg daily) also may be useful in this condition, although experience to date is limited to a few cases.

Rhinosporidiosis

Rhinosporidiosis is a chronic infection caused by the organism *Rhinosporidium seeberi*, which causes the development of polyps affecting the mucous membranes. The organism has never been cultured, and it is now thought to be an aquatic protist and a member of the Mesomycetozoa. Rhinosporidiosis is seen most often in southern India and Sri Lanka. Cases also have been described in South America, the Caribbean, and South Africa. Exposure to water (lakes, pools) has been associated with the infection. The main site affected is the nasal mucosa, but the conjunctival mucosa also may be affected.[24] The infection causes the development of large polyps that are studded with white flecks; these are small cysts or sporangia containing small spores. These are best seen in histopathologic sections, where the large sporangia or spore sacs in different phases of development are readily seen. The only treatment is surgical excision.

SYSTEMIC MYCOSES

The systemic mycoses are fungal infections whose initial portal of entry into the body is usually a deep site such as the lung, gastrointestinal tract, or paranasal sinuses. They have the capacity to spread via the bloodstream to produce a generalized infection. In practice, there



ENDEMIC AND OPPORTUNISTIC SYSTEMIC MYCOSES

AT A GLANCE

- Where the patient has lived or visited is important for correct diagnosis.
- A careful history relevant of underlying disease states and their treatment is critical.
- Erythema nodosum may be caused by some endemic mycoses (e.g., coccidioidomycosis).
- Skin biopsy is important in making the diagnosis.
- Positive fungal culture must be interpreted with caution, as the organism identified may simply be colonizing the site.
- Warn the laboratory if you are sending material from a suspected endemic mycosis case for culture, as these are dangerous pathogens and require containment facilities.
- Treatment usually requires prolonged therapy often with intravenous drugs such as amphotericin B, voriconazole, or caspofungin.



TABLE 190-2
Underlying Predisposition and Opportunistic Systemic Mycoses

PREDISPOSITION	INFECTION
Neutropenia (whatever cause) functional neutrophil defects	Aspergillosis, oropharyngeal, and/or systemic candidiasis, zygomycosis, infections due to rare organisms
CD4 lymphopenia (e.g., acquired immunodeficiency syndrome)	Oropharyngeal candidiasis, cryptococcosis, and endemic respiratory mycoses such as histoplasmosis, nocardiosis
Diabetes mellitus	Zygomycosis
Heart valve surgery	Various but mainly *Candida albicans* and non-*albicans Candida* sp.
Abdominal surgery	Candidiasis

are two main varieties of systemic mycosis: the opportunistic mycoses and the endemic respiratory mycoses.

The chief opportunistic systemic mycoses seen in humans are systemic or deep candidiasis, aspergillosis, and systemic zygomycosis. These affect patients with severe underlying disease states, such as AIDS, or with neutropenia associated with malignancy, solid-organ transplants, or extensive surgery. Where combination antiretroviral therapy is used, the incidence of systemic mycoses in patients infected with human immunodeficiency virus (HIV) has dropped considerably. In the neutropenic patient in particular, other fungi also may cause infection occasionally. Different underlying conditions predispose to different mycoses, and a scheme for this is shown in Table 190-2. Generally, skin involvement is not common with most of these opportunistic infections, which can occur in any climate and environment. The clinical manifestations of the opportunistic mycoses are also variable because they depend on the site of entry of organism and the underlying disease.

The endemic respiratory mycoses are histoplasmosis (classic and African types), blastomycosis, coccidioidomycosis, paracoccidioidomycosis, and infections due to *Penicillium marneffei*. The clinical manifestations of these infections are affected by the underlying state of the patient, and many develop in the presence of particular immunodeficiency states, notably AIDS. However, they follow similar clinical patterns in all infections. These infections also may affect otherwise healthy individuals. They have well-defined endemic areas determined by factors that favor the survival of the causative organisms in the environment, such as climate. The usual route of infection is via the lung (Fig. 190-8).

In practice, because of the tendency for both groups of infections to develop in predisposed patients, the distinction between opportunistic and endemic mycoses is blurred. This is particularly the case with cryptococcosis, which shares clinical and pathologic features of the two main types of respiratory systemic mycoses but is mainly seen now in AIDS patients.

Histoplasmosis

Fungi of the dimorphic genus *Histoplasma* cause a number of different infections in animals and humans. These range from equine farcy, or equine histoplasmosis, a disseminated infection of horses caused by *Histoplasma farciminosum* to two human infections known as *classic* or *small-form histoplasmosis* and *African histoplasmosis*. These are caused, respectively, by two variants of *H. capsulatum*: *H. capsulatum* var. *capsulatum* and *H. capsulatum* var. *duboisii*. They can be distinguished because their respective yeast phases differ in size, the *capsulatum* variety producing cells from 2 to 5 μm in diameter and the *duboisii* form producing cells of 10 to 15 μm in diameter. The other important differences are in their epidemiology and clinical manifestations. They also show minor antigenic differences that are apparent in serodiagnosis but their mycelial phases are identical. The two types of human infections will be referred to as *histoplasmosis* and *African histoplasmosis* because this nomenclature is used most widely.

SMALL-FORM OR CLASSIC HISTOPLASMOSIS OR HISTOPLASMOSIS CAPSULATI Histoplasmosis results from infection with the dimorphic fungus *H. capsulatum* var. *capsulatum*. A sexual state of this fungus, *Ajellomyces capsulatus*, also has been described. The infection starts as a pulmonary infection that, in most individuals, is asymptomatic and heals spontaneously, the only evidence of exposure being the development of a positive intradermal skin test reaction to a fungal antigenic extract, histoplasmin.[25] However, in addition, there is a symptomatic disease that includes respiratory infections and acute or chronic pulmonary histoplasmosis, as well as a disseminated infection that may spread to affect the skin or mucous membranes. Direct inoculation into the skin may occur as a result of a laboratory accident.

Epidemiology. Histoplasmosis occurs in many countries from the Americas to Africa, India, and the Far East (see eFig. 190-8.1 in on-line edition). In the United States, it is endemic in the Mississippi and Ohio River valleys, where often more than 80 percent of the population may have acquired the infection asymptomatically. Exposure rates are usually lower in all other endemic areas, although high rates are also found in northern South America and some Caribbean islands. Histoplasmosis is not found in Europe. *H. capsulatum* is an envi-

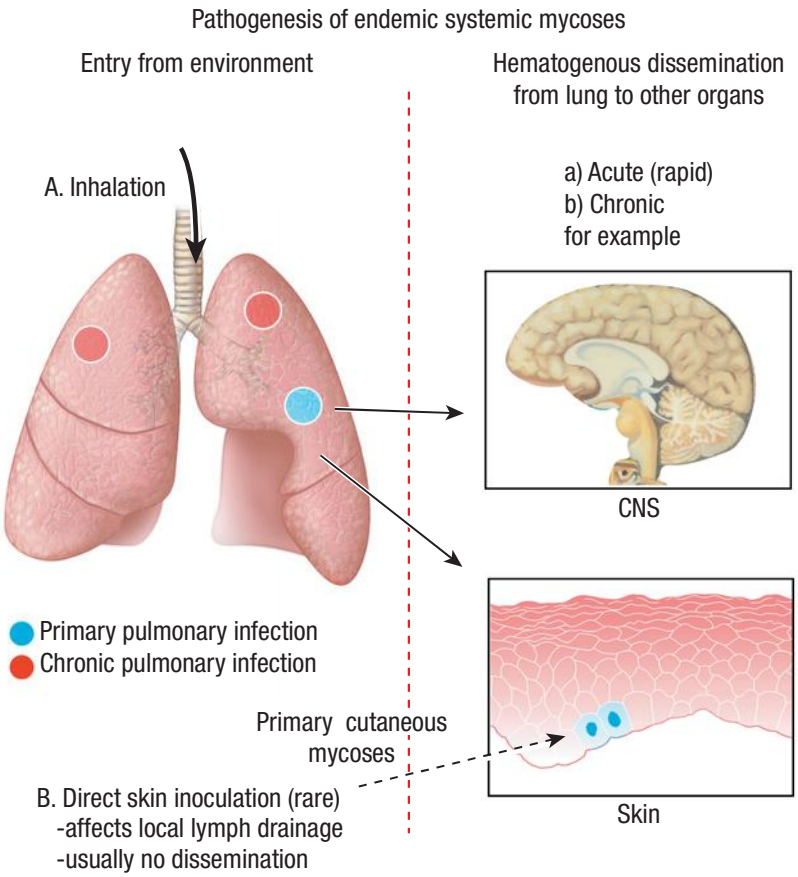

▲ **FIGURE 190-8** The route of infection and dissemination to the skin of the endemic (respiratory) mycoses. CNS = central nervous system.

ronmental saprophyte that can be isolated from soil, particularly when it is contaminated with bird or bat excreta. The disease is acquired by inhalation of spores, and epidemics of respiratory infection may occur in persons exposed to a spore-laden environment when exploring caves or cleaning sites heavily contaminated with bird droppings, such as bird roosts or barns. Although any person can acquire histoplasmosis through inhalation, it causes a distinctive disseminated infection in patients with disease affecting cellular immune capacity, such as AIDS or lymphoma.[26,27]

Clinical Findings. The spectrum of histoplasmosis includes asymptomatic as well as benign symptomatic infections and a progressive disseminated variety with bloodstream spread to multiple organs.[25] Skin lesions may develop as a result of immune-complex formation in the primary infection (erythema multiforme) or from direct spread after dissemination from the lungs; rarely, infections may develop at a point of inoculation into the skin.

Asymptomatic forms of histoplasmosis are, by definition, without signs or symptoms, but those exposed usually have a positive histoplasmin skin test. The percentage of skin test reactors in the community indicates the chances of exposure, and, in endemic areas, this may range from 5 percent to 90 percent. Occasionally, asymptomatic pulmonary nodules removed at surgical exploration or autopsy are found to contain *Histoplasma*.

ACUTE PULMONARY HISTOPLASMOSIS. In acute pulmonary histoplasmosis, patients are often exposed to large quantities of spores such as may be encountered in a cave or after cleaning a bird-infested area. Patients present with cough, chest pain, and fever, often with accompanying joint pains and rash—toxic erythema, erythema multiforme, or erythema nodosum. These skin rashes are not common, occurring in fewer than 15 percent of patients, but they may be precipitated by treatment of the acute infection. On chest x-ray, there is often diffuse mottling, which may calcify with time.

CHRONIC PULMONARY HISTOPLASMOSIS. Chronic pulmonary histoplasmosis usually occurs in adults and presents with pulmonary consolidation and cavitation, closely resembling tuberculosis. Skin involvement is not seen.



▲ **FIGURE 190-9** Histoplasmosis, disseminated. Multiple erythematous keratotic papules and small plaques resembling guttate pattern psoriasis are seen on the chest and arm of a man with advanced human immunodeficiency virus disease. (Used with permission from J. D. Fallon, MD.)

ACUTE DISSEMINATED HISTOPLASMOSIS. In patients with acute disseminated histoplasmosis, there is widespread dissemination to other organs such as the liver and spleen, lymphoreticular system, and bone marrow. Patients present with progressive weight loss and fever. This form is the type that is most likely to occur in untreated AIDS patients, who often develop skin lesions as a manifestation of disseminated infection (Fig. 190-9).[28] There are papules, small nodules, or small molluscum-like lesions that subsequently may develop into shallow ulcers. These skin lesions are more common in HIV positive patients than in others with disseminated histoplasmosis. Diffuse micronodular pulmonary infiltrates also may develop. Patients have progressive and severe weight loss, fever, anemia, and hepatosplenomegaly.

The distinction between acute and chronic dissemination in histoplasmosis is somewhat artificial because these merely represent extremes of behavior, with progression occurring over a few months, on the one hand, and over several years, on the other. Intermediate forms occur, and other organs such as the meninges and heart may be affected.

CHRONIC DISSEMINATED HISTOPLASMOSIS. Chronic disseminated histoplasmosis may appear months or years after a patient has left an endemic area. The most common clinical presenting features are oral or pharyngeal ulcer-

ation or adrenal insufficiency (Addison disease) due to adrenal infiltration. The mouth ulcers are often large, irregular, and persistent and may affect the tongue as well as the buccal mucosa. The patients otherwise may appear well, but it is important to investigate them for evidence of infection elsewhere (e.g., by abdominal computed tomography scan). Adrenal infection in particular should be excluded.

PRIMARY CUTANEOUS HISTOPLASMOSIS. Primary cutaneous histoplasmosis is rare and follows inoculation of the organism into the skin, for instance, after accidental laboratory- or postmortem room–acquired infection. The primary lesion is a nodule or indurated ulcer, and there is often local lymphadenopathy.



Differential Diagnosis. The organism is the same size as a number of others causing deep mycoses such as *P. marneffei* and small forms of *Blastomyces* and *Cryptococcus* (see Laboratory Tests). It is also similar in size to *Leishmania* sp., and in the tropics, kala-azar is an important part of the differential diagnosis. These observations emphasize the importance of carrying out appropriate laboratory tests to confirm the diagnosis.

Laboratory Tests. The diagnosis of histoplasmosis is established by identifying the small intracellular yeast-like cells of *Histoplasma* in sputum, peripheral blood, bone marrow, or biopsy specimens. *Histoplasma* must be separated from *P. marneffei* because the two organisms are of a similar size, although the latter shows characteristic septa formation. The identity of the organism should be confirmed by culture; it grows as a mold at room temperature. The white, cottony colonies develop at room temperature on Sabouraud's glucose agar to produce two types of spores, the larger (8 to 15 μm), rounded, tuberculate macroconidia being typical; the smaller microconidia are infectious. Confirmation of the identity should be obtained by demonstrating the production of diffusing exoantigen by an immunodiffusion assay (exoantigen test). Mycelial-phase cultures of *H. capsulatum* are very infectious, and laboratories receiving specimens should be warned about the suspected diagnosis.

The intradermal histoplasmin skin test is an epidemiologic tool that is of no help in diagnosis. In patients with disseminated histoplasmosis, it is often negative. By contrast, serology is often useful in diagnosis. A rising complement-fixation titer indicates dissemination. Precipitins detected by immunodiffusion are also valuable because the presence of antibodies to specific H and M antigens correlates well with active or recent infection.[28] A new development, particularly helpful in AIDS patients, has been serologic tests for the detection of circulating *Histoplasma* antigens.[29] In histopathologic sections, *H. capsulatum* is an intracellular parasite often seen in macrophages. The cells are small (2 to 4 μm in diameter) and oval in shape with small buds (Fig. 190-10). Mycelial forms are seen rarely in tissue.

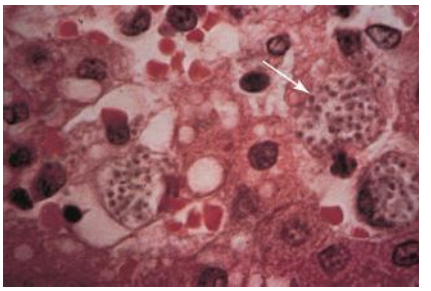

▲ **FIGURE 190-10** Histoplasmosis, disseminated. Lesional biopsy specimen shows dermal macrophages packed with dozens of tiny yeast forms of *Histoplasma capsulatum* (*arrow*).

AFRICAN HISTOPLASMOSIS (LARGE-FORM HISTOPLASMOSIS OR HISTOPLASMOSIS DUBOISII) African histoplasmosis is sporadic and uncommon even in AIDS patients.[30] It is seen in patients from areas south of the Sahara and north of the Zambezi River in Africa. Infections seen outside Africa are all imported. The most common clinically involved sites are the skin and bone, although lymph nodes and other organs, including the lungs, may be affected. Skin lesions range from small papules resembling molluscum contagiosum to cold abscesses, draining sinuses, or ulcers. It is not clear if there is an asymptomatic form of African histoplasmosis as in classic histoplasmosis. The diagnosis is confirmed by culture and microscopy (direct microscopy or histopathology). The organisms of *H. capsulatum* var. *duboisii* are different from the smaller *capsulatum* forms. They are usually 10 to 15 μm in diameter, slightly pear-shaped, and clustered in giant cells. *Histoplasma* serology, using conventional tests, is often negative in African histoplasmosis.

Treatment. The choice of therapy for histoplasmosis depends on the severity of the illness. For patients with some disseminated or localized forms of the disease, oral itraconazole (200 to 400 mg daily) is highly effective. It also has been used for long-term suppressive treatment of the disease in AIDS patients after primary therapy either with itraconazole or amphotericin B.[31] However, there is now evidence that provided CD4 counts do not fall in patients on highly active antiretroviral therapy (HAART) therapy (see Chap. 198), suppressive treatment can be discontinued. In AIDS, some patients receiving treatment for histoplasmosis, an immune reconstitution syndrome has been reported after commencing HAART therapy with intestinal obstruction, uveitis, and arthralgia. Intravenous amphotericin B (up to 1 mg/kg daily) is given to patients with widespread and severe infections and is the main alternative used. Ketoconazole and fluconazole are also effective in many cases. In African histoplasmosis, itraconazole is also the treatment of choice, but once again, in severe cases amphotericin B may be used.[30]

Blastomycosis (North American Blastomycosis, Gilchrist Disease)

Blastomycosis is a chronic mycosis caused by the dimorphic pathogen *B. dermatitidis*.[32] Its chief sites of involvement are the lungs, but disseminated forms of the infection may affect skin, bones, central nervous system, and other sites.

EPIDEMIOLOGY Blastomycosis is found in North America and Canada.[33] Most cases, though, come from the Great Lakes region and southern states of the United States. It also occurs sporadically in Africa, with the largest numbers of cases coming from Zimbabwe,[34] and cases also have been reported from the Middle East and India (see eFig. 190-10.1 in on-line edition).

It is thought that the natural habitat of *Blastomyces* is in some way related to wood debris and is close to rivers or lakes or in areas subjected to periodic flooding. However, it is difficult to isolate *Blastomyces* from the natural environment.[35] Blastomycosis also may affect domestic animals such as dogs.

CLINICAL FINDINGS As with histoplasmosis, there is a sub-clinical form of the infection; its prevalence has not been defined in detail because of lack of a commercial *Blastomyces* skin test antigen and the extent of antigenic cross-reactivity with fungi such as *Histoplasma*. Primary cutaneous blastomycosis is also very rare and follows trauma to the skin and the subsequent

introduction of fungus, for instance, in laboratory workers or pathologists.[36] After inoculation, an erythematous, indurated area with a chancre appears in 1 to 2 weeks with associated lymphangitis and lymphadenopathy.

Pulmonary blastomycosis is very similar in clinical presentation to pulmonary tuberculosis.[33,36,37] There may be no symptoms, or there may be low-grade fever, chest pain, cough, and hemoptysis, and unlike histoplasmosis, it often co-exists with disseminated disease. Skin lesions are a common presenting feature of disseminated blastomycosis.[36,38] They are often symmetric and usually affect the face and extremities. The early lesion is a papule or nodule, which may ulcerate and discharge pus. With time, this enlarges to form a hyperkeratotic lesion, often with central ulceration and/or scarring (Figs. 190-11 and 190-12). Oral lesions are less common. Multiple skin lesions are often found in disseminated infection. Other patients may present with nodules and abscesses, and in many patients lesions of different morphologies are present. African patients with blastomycosis have a higher frequency of skin and bone involvement.[34] Although blastomycosis can affect almost any organ, other common sites for dissemination include the bone, the epididymis, and the adrenal gland. Less commonly, there is widespread rapid dissemination with multiple organ involvement, and *B. dermatitidis* can produce a form of adult respiratory distress syndrome. Skin lesions in widespread disseminated disease are usually papules, abscesses, or small ulcers. Widespread blastomycosis has been described in AIDS patients, but it is not common.[39]



▲ **FIGURE 190-11** Blastomycosis. Inflammatory plaque with ulceration resembling pyoderma gangrenosum on the calf. (Used with permission from Elizabeth M. Spiers, MD.)



▲ **FIGURE 190-12** Blastomycosis. Chronic verrucous plaque on the cheek.

DIFFERENTIAL DIAGNOSIS The chronic skin granulomas must be differentiated from those due to tuberculosis, other deep mycoses, non-melanoma skin cancers, pyoderma gangrenosum, and drug reactions due to bromides and iodides.

LABORATORY FINDINGS The fungus can be found in KOH mounts of pus, skin scrapings, or sputum as thick-walled, rounded refractile spherical cells with broad-based buds (Fig. 190-13). In culture, the fungus grows as a mycelial fungus at room temperature. It produces small, rounded, or pear-shaped conidia. At higher temperature [37°C (98.6°F)] and on enriched media, it produces yeast forms with the characteristic buds. In tissue sections, the typical organisms with broad buds may be found although it may be necessary to search several fields to find the characteristic cells. These are often found in giant cells or surrounded by neutrophils (Fig. 190-14). Precipitating antibodies to *B. dermatitidis* are often present in the sera of infected patients, and a characteristic precipitin line, the E band, has been described in a high proportion of proven cases; there is also an enzyme-linked immunosorbent assay for blastomycosis. However, one of the problems with serodiagnosis in blastomycosis is the presence of a high number of false-positive reactions in uninfected persons and cross-reactivity with other fungi.

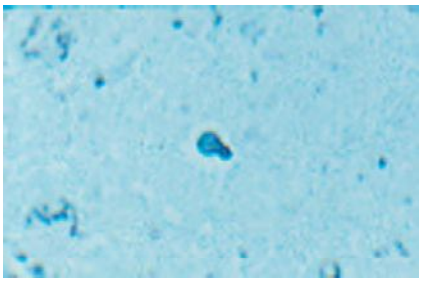

▲ **FIGURE 190-14** Blastomycosis. Lesional biopsy specimen shows a budding yeast form (Gomori methenamine silver stain).

TREATMENT Treatment is similar to that used for histoplasmosis; itraconazole (200 to 400 mg daily) is used in the less severe forms of the infection or when there is only localized spread. Treatment is usually given for at least 6 months. Follow-up surveillance is necessary because relapse can occur, particularly where there are deep sites of infection or the patient is immunosuppressed. Amphotericin B (up to 1 mg/kg daily) is generally used for the treatment of widespread disseminated forms of blastomycosis.

Coccidioidomycosis (Coccidioidal Granuloma, Valley Fever, San Joaquin Valley Fever, Desert Rheumatism)

Coccidioidomycosis is the infection caused by the fungus *Coccidioides immitis*.

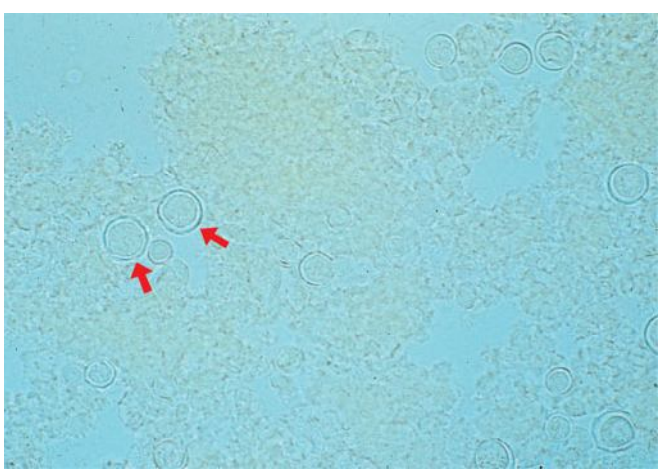

▲ **FIGURE 190-13** Direct preparation (potassium hydroxide) of *Blastomyces* (*arrows*).



It shows an unusual form of dimorphism, with a mold form at room temperature and the development of large, spore-containing structures, spherules, in infected tissue. As with other endemic mycoses, there are asymptomatic, acute and chronic pulmonary, and disseminated forms. The disease can affect otherwise healthy individuals or predisposed patients, including those with AIDS.

EPIDEMIOLOGY *C. immitis* is endemic in some semidesert areas of the southwestern states of the United States (e.g., California, Arizona, New Mexico, and Texas) and in parts of Mexico and Central and South America (see eFig. 190-14.1 in online edition). The climate of the endemic areas is marked by very high summer temperatures and low annual rainfall, demonstrated by a characteristic vegetation with cacti and mesquite bushes. Skin tests with coccidioidin show that the incidence of exposure in endemic areas may be as high as 95 percent. The fungus is found in soil and can affect other animals as well as humans. Exposure may result from a brief visit to an endemic area, and local weather can determine exposure rates.[40] For instance, dust storms may cause infection in large numbers of individuals. The usual route of infection is respiratory, although direct implantation into the skin can occur rarely.

CLINICAL FINDINGS As with other systemic mycoses, there is an asymptomatic or sub-clinical form of coccidioidomycosis that is common in endemic areas, judging by the percentages of skin test reactors to coccidioidin in the healthy population. The primary pulmonary form, which is the most common clinical type, presents as a chest infection with fever, cough, and chest pain. Complications such as pleural effusion may occur. Erythema multiforme or erythema nodosum,[40] often accompanied by arthralgia or anterior uveitis, occurs from the third to the seventh week in about 10 percent to 15 percent of patients and is more common in females. Sometimes an early, generalized, macular and erythematous rash is seen in some patients.

The chronic pulmonary form of the disease presents with chronic cough and resembles tuberculosis. Skin lesions normally do not occur in this phase.

In the rare primary skin infection,[41] after inoculation, there is an indurated nodule that develops 1 to 3 weeks after local trauma. This is followed by regional lymphadenopathy. Disseminated coccidioidomycosis develops in fewer than 0.5 percent of infected individuals. It is mainly seen in patients from certain ethnic backgrounds (American blacks, Filipinos, or Mexicans), in pregnant women, and in immunosuppressed patients, including those with AIDS.[42,43] In disseminated disease, lesions may develop in the skin, subcutaneous tissues, bones, joints, and all organs. The skin lesions (Fig. 190-15) are papules, nodules, abscesses, granulomas, ulcers, or discharging sinuses in which there is underlying bone or joint disease. Some lesions appear as flat plaques with central atrophy. Meningitis is an important complication of dissemination and is usually not associated with signs of infection in other sites. In AIDS patients, persistent pneumonia, skin lesions, and widespread dissemination can all occur.





▲ **FIGURE 190-15** Coccidioidomycosis, disseminated. Two intact and ulcerated papules/nodules are seen on the cheek and nose of this comatose patient with coccidioidomycotic meningitis. (Used with permission from Francis Renna, MD.)

DIFFERENTIAL DIAGNOSIS Physicians in endemic areas should be aware of the connection between erythema nodosum and coccidioidomycosis. It also may occur in visitors to endemic areas after only a short stay.

LABORATORY TESTS A characteristic of the laboratory findings is the ability of *C. immitis* to form spore-containing spherules. These are large (up to 250 μm) and can be seen in KOH mounts of sputum, cerebrospinal fluid (CSF), or pus. In culture, colonies of *C. immitis* are mycelial, fast-growing, white, and cottony. On microscopy, there are chains of arthrospores at intervals on the older mycelium. *C. immitis* in the mold phase is highly infectious, and cultures should be handled carefully.

Serologic tests are of value in the diagnosis and prognosis of coccidioidomycosis.[44] Precipitins develop in about 90 percent of infected individuals within 2 to 6 weeks but are short-lived; complement-fixing antibodies are characteristic of more severe infections and, in active infection, increase to a maximum after 6 months. Skin tests with coccidioidin are of little value in diagnosing infections. Spherulin is an antigen obtained from spherules of *C. immitis* and may be better than coccidioidin for detecting sensitization. However, in severe infections, cutaneous anergy to both is common.

Spherules containing large endospores can be seen in tissue sections, although there are a variety of less distinct intermediate stages in spherule formation that also can be seen. Before endospores form, the cytoplasm of the immature spherule is basophilic and subsequently breaks up into spores. Mycelium is seen rarely in histopathologic sections.

TREATMENT No specific therapy apart from rest is necessary in the primary pulmonary infection, and there is little evidence that the symptoms are either improved or shortened by giving an oral azole drug, even though it is widespread practice. For disseminated disease, treatment is still unsatisfactory, but amphotericin B (1 mg/kg daily), itraconazole (200 to 400 mg daily), or fluconazole (200 to 600 mg daily) can all be given.[45] Experience with the newer antifungal agents, such as voriconazole and posaconazole, is limited at present. It is important to follow patients carefully, given the frequency of relapse. Meningitis, arthritis, and progressive disseminated infection involving multiple sites are all particularly refractory to therapy. Generally, soft-tissue coccidioidomycosis (skin and joint) has a better prognosis, and the mortality in patients who present with soft tissue lesions is low.

Paracoccidioidomycosis (South American Blastomycosis, Paracoccidioidal Granuloma)

Paracoccidioides brasiliensis is a dimorphic fungus that causes a respiratory infection with a tendency to disseminate to the mucous membranes and lymph nodes. It is confined to Central and South America.[46]

EPIDEMIOLOGY Paracoccidioidomycosis has been reported from most Latin

American countries, but the infection is found most commonly in parts of Brazil, Colombia, and Argentina. The infection does not occur in the United States, although it has been reported in Mexico (see eFig. 190-15.1 in on-line edition). Exposure rates can be estimated by skin test reactivity and appear to be equal in both males and females, although the prevalence of positive reactors in endemic areas seldom exceeds 25 percent; work with a skin test derived from purified glycoprotein 43 antigen generally demonstrates that exposure rates are higher than previously believed. The active infection is seen predominantly in males. The mechanism is thought to be connected to the presence of a cytoplasmic estrogen receptor on the fungus, and in vitro, estradiol suppresses the conversion of mycelium to yeast.[47] The ecologic niche of the organisms is unknown, but the condition is much more frequent in rural areas; exposure has been associated with proximity to water or areas of high atmospheric humidity.[48]

CLINICAL FINDINGS There are a number of different clinical patterns of paracoccidioidomycosis infection that depend on the predominant site of clinical involvement. These include the lung (pulmonary form), the mucous membranes (mucocutaneous form), and the lymph nodes (lymphatic form). Many patients have a mixed type of infection with involvement of different organ groups.[46]

Patients rarely present with an acute form of pulmonary infection although this has been observed rarely and reported to subside while dissemination occurs. More usually, pulmonary infection tends to be chronic and slowly progressive with weight loss and chronic cough. The lesions may be bilateral and nodular on chest x-ray, and there is often extensive fibrosis. Other sites of involvement include mucocutaneous areas. Oral or circumoral lesions are common in the mucocutaneous forms of paracoccidioidomycosis; lesions also occur in the nose, conjunctivae, or around the anus. These lesions may be small granulomas or ulcers. They heal with scarring, which may cause considerable deformity.

The cervical lymph nodes are sometimes enlarged, tender, and tethered to the overlying skin; they rarely suppurate. Other systemic sites of involvement include the spleen, intestines, lungs, and liver. Paracoccidioidomycosis is uncommon in AIDS patients, although there is a widespread variety that is a more rapidly progressive form of disseminated infection occurring in young adults or older children without recognizable predisposition.[49]

DIFFERENTIAL DIAGNOSIS Differential diagnosis includes tuberculosis, leishmaniasis, and other deep mycoses.

LABORATORY TESTS Sputum, exudates, and scrapings can be screened using KOH. They show numbers of round yeasts with a characteristic form of multiple budding in which a parent cell is surrounded by large numbers of smaller buds. The organism is dimorphic and produces a cottony mycelial-phase growth on primary isolation at room temperature. Once again, the characteristic yeast phase can be induced on enriched media such as brain-heart infusion agar at 37°C (98.6°F). Serology is very helpful in confirming the diagnosis, the main tests being the immunodiffusion assay and a complement-fixation test. Recently, antibodies to a 43-kd antigen have been found to be highly specific for this infection in immunoblotting. There is also an antigen-detection test useful in monitoring patients with disseminated disease. Histopathologically, there is a mixed granulomatous response with fibrosis. The organisms can be seen with special fungal stains such as methenamine silver (Grocott modification). In tissue, the characteristic budding pattern can be seen, although it may be necessary to search several fields to find the most typical structures (Fig. 190-16). In widespread infections, masses of small yeast forms may be mistaken for *Histoplasma*.

TREATMENT The treatment of choice in most cases is itraconazole, which can produce remissions in 3 to 6 months.[50] Ketoconazole is an alternative. Relapses can occur, and, where possible, patients should be reviewed periodically after primary therapy. In very extensive infections and in severely ill patients, such as those with the progressive disseminated type of infection, intravenous amphotericin B may be necessary. Severe pulmonary or intra-oral fibrosis may remain after treatment.

Infections Due to *Penicillium marneffei* (Penicilliosis, Penicilliosis Marneffei)

P. marneffei infection is a more recently recognized disease found in Southeast Asia. *P. marneffei* is a member of the common genus *Penicillium*.[51] It shows an unusual pattern of dimorphism in that it develops yeast-like cells that reproduce with septal formation, dividing the cells into two. It is inhaled via the lungs, and it is not known whether there is a primary cutaneous form of the infection.

EPIDEMIOLOGY The natural source of *P. marneffei* is unknown. Infections are confined to Southeast Asia, particularly Thailand, South China, and Vietnam (see eFig. 190-16.1 in on-line edition). However, there are reports in other Asian countries, including northeast India, and imported cases are seen in Europe and the United States. Natural infections are known to occur in bamboo rats of the genus *Cannomys*, which are large burrowing rodents. The infection affects otherwise healthy individuals as well as those with immune defects and is most common after the rainy season.[52] Patients with AIDS appear to be particularly susceptible to this infection.

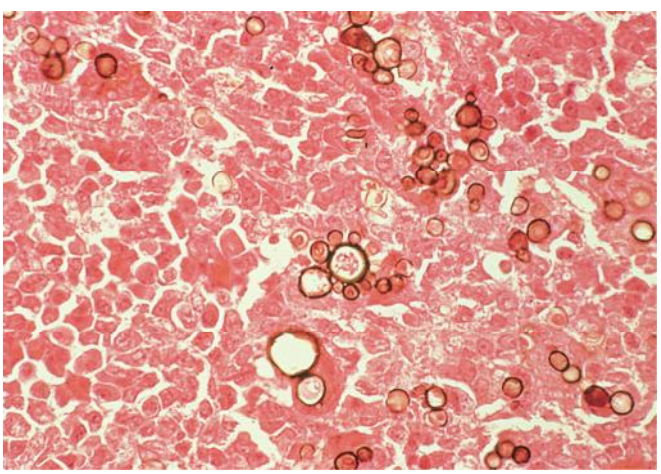

▲ **FIGURE 190-16** Biopsy of oral mucosal lesion showing multiple budding *Paracoccidioides brasiliensis*.



CLINICAL FINDINGS There has been no work to demonstrate that there is a sub-clinical form of *Penicillium* infection, even though this is likely. Patients usually present with localized pulmonary or disseminated disease. The chest signs are those of chronic pulmonary disease.[53,54] More than 50 percent of AIDS patients with this infection have multiple skin lesions, which are umbilicated papules that may enlarge and ulcerate. They are usually widely scattered on the face and trunk. Other organs, including the liver, gastrointestinal tract, spleen, and bone marrow, may be affected.



DIFFERENTIAL DIAGNOSIS The main differential diagnosis is with other disseminated mycoses, such as histoplasmosis and cryptococcosis, which also can be found in the endemic area in AIDS patients. Biopsy and, when necessary, culture will distinguish between the different causes.

LABORATORY TESTS *P. marneffei* forms characteristic yeast-like cells that are divided by a septum in tissue and are best seen in histopathologic sections stained with methenamine silver. These cells are small (2 to 4 μm) and difficult to see in blood films or skin or bone marrow smears, but they may be highlighted with stains such as leishmanin. In culture, *P. marneffei* is a green or grayish mold that produces typical *Penicillium* conidiophores and a diffusible red pigment. There is no commercial serologic test as yet, although antigen detection systems and polymerase chain reaction have both been used in diagnosis.

TREATMENT In severe cases, amphotericin B is necessary. In many cases, however, there is a good response to itraconazole (200 to 400 mg daily). In AIDS patients, this is continued after initial therapy to prevent relapse.[54]

Cryptococcosis (Torulosis, European Blastomycosis)

Cryptococcosis is the infection caused by the encapsulated yeast *C. neoformans*. Although the main portal of entry is through inhalation into the lungs, the disease usually presents with signs of extrapulmonary dissemination such as meningitis. Cutaneous lesions can develop as a result of dissemination or, rarely, through inoculation. It is associated with HIV infection.[55]

EPIDEMIOLOGY Cryptococcosis has a worldwide distribution although exposure rates probably differ markedly in different countries. *C. neoformans* has three variants: (1) *C. neoformans* var. *neoformans*, (2) *C. neoformans* var. *grubii*, and (3) *C. neoformans* var. *gattii*.

These correspond to three clusters of serotypes: (1) D, (2) A, and (3) B or C.[56] The *neoformans* and *grubii* varieties can be isolated from pigeon excreta and are more common in AIDS patients; the *gattii* form is found in the debris of certain eucalyptus trees in the tropics and California, but it is less often isolated from AIDS patients. Two sexual varieties called *Filobasidiella neoformans* and *F. bacillispora* correspond to the *neoformans/grubii* and *gattii* varieties, respectively. Patients with certain immunodeficiency states caused by AIDS, malignant lymphomas, sarcoidosis, collagen disease, carcinoma, and those receiving systemic glucocorticoid therapy are particularly susceptible. The incidence of cryptococcosis in patients with established AIDS varies in different countries from 3 percent to 6 percent in the United States, to 3 percent in the United Kingdom, to more than 12 percent in parts of Africa (e.g., Zaire). Strains of serotype D are more likely to be found in skin lesions, which occur in 10 percent to 15 percent of cases of disseminated cryptococcosis.

CLINICAL FINDINGS The advent of the AIDS epidemic has affected the epidemiology of cryptococcosis considerably, and in areas such as northern Thailand, it is one of the main secondary complications of HIV infection.[55] There is probably a sub-clinical form of cryptococcosis because unaffected individuals may have positive skin tests. However, the most common clinical manifestation of disease is meningoencephalitis. This presents with classic signs of meningismus, changes in consciousness, mental changes, and nerve palsies. In AIDS patients, these signs may be only weakly expressed. Pulmonary infection can be found in about 10 percent of those with meningitis. Chest signs include the appearance of nodular shadows, cavitation, and pleural effusion. Patients with AIDS often present with fever and mild headache and few other features of infection.[55] Cutaneous lesions may develop in about 10 percent of cases but are seldom pathognomonic.[57–60] Acneiform papules or pustules progressing to warty or vegetating, crusted plaques, ulcers, and hard infiltrated plaques or nodules are characteristic of widespread systemic infection (Fig. 190-17). Cold abscesses, cellulitis, and nodular lesions also occur. In otherwise healthy patients or those with sarcoidosis, lesions may be solitary, and in such patients, they may be the only clinical manifestation of infection.



▲ **FIGURE 190-17** Cryptococcosis, disseminated. Multiple, discrete, skin-colored papules and nodules resembling molluscum contagiosum are seen on the face of a male with advanced human immunodeficiency virus disease. (Used with permission from Loïs Vaillant, MD.)

In primary cutaneous cryptococcosis with direct inoculation of organisms into the skin, the skin lesions are usually solitary nodules that break down and ulcerate. Local lymphadenopathy also develops. The term *primary cutaneous cryptococcosis* is also used loosely to describe solitary lesions of cryptococcosis, but in many such cases there is also evidence of dissemination to other internal organs. It is important to investigate all patients who present with cutaneous lesions for evidence of dissemination to other sites.[58]

DIFFERENTIAL DIAGNOSIS Cryptococcal skin lesions may mimic a range of other conditions, particularly other systemic mycoses in AIDS patients. It is important to biopsy and culture suspicious lesions in immunocompromised patients.

LABORATORY TESTS Cryptococci are large (5 to 15 μm), budding cells with capsules that are best observed by direct microscopy of India ink or Nigrosin mounts (Fig. 190-18). The organism is not difficult to grow in culture. Various biochemical features, such as the production of urease and the ability to pigment on Guizotia seed medium, are characteristic. Serologic tests are rapid and specific. The main test is an antigen-detection assay using latex agglutination or enzyme-linked immunosorbent assay, and this is

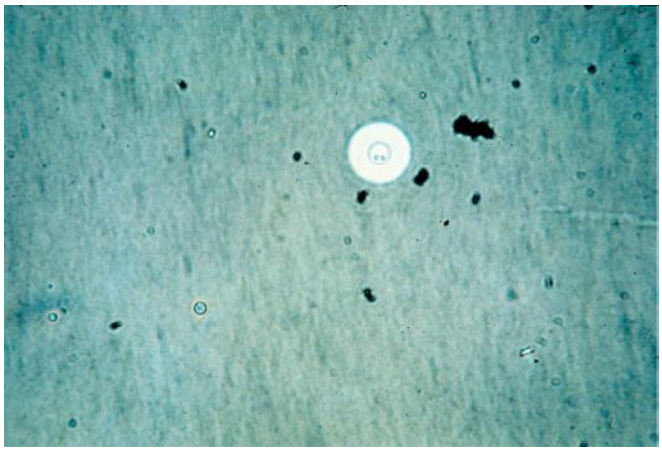

▲ **FIGURE 190-18** Cryptococcosis. India ink preparation of cerebrospinal fluid.

simple and very rapid to perform on blood or CSF. Very high titers are found in AIDS patients in serum and CSF. Non-AIDS patients with single, localized skin lesions are often antigen-negative.

In tissue sections, the large pleomorphic yeasts stimulate either a granulomatous reaction or very little inflammation. The capsules of the cells can be stained using the mucicarmine or Alcian blue stains.

TREATMENT The most frequently used drug regimen in the non-AIDS patient is intravenous amphotericin B combined with flucytosine. In patients with single skin lesions and no other signs of infection, alternatives such as fluconazole or itraconazole can be used. In AIDS patients, there is a very high relapse rate, and the usual policy is to give a 10- to 14-day course of amphotericin B with or without flucytosine, followed by long-term fluconazole.[61] However, it may be possible to stop long-term suppressive therapy in patients receiving HAART. Fluconazole given on its own is an alternative approach.

Cutaneous Aspects of Systemic Opportunistic Mycoses

Skin lesions are not common with the opportunistic fungal infections, but they can occur in some, particularly in certain predisposed groups. When they occur, their presence may be very helpful because it is possible to biopsy easily accessible lesions in order to establish the diagnosis.

Systemic Candidiasis (See Chaps. 189 and 198)

Systemic candidiasis follows dissemination of *Candida* sp. from the gastrointestinal tract or via the bloodstream. Skin lesions may occur particularly in two situations: (1) In neutropenic patients, there is often a severe disseminated disease with widespread skin nodules and associated muscle pains,[62] and (2) in intravenous drug abusers, candidiasis may present with a follicular, pustular rash in the beard area and scalp. Other lesions include retinal and vitreal deposits and abscesses around the costochondral junctions.[63]

Systemic candidiasis is usually treated with intravenous amphotericin B (conventional or lipid-associated) or fluconazole. Resistance to some azole drugs, such as fluconazole and ketoconazole, is more common with certain non-*albicans Candida* sp., and these antifungal agents should be avoided in infections caused by these species.

Zygomycosis (Mucormycosis, Phycomycosis)

Zygomycosis is a rare disease caused by zygomycete fungi such as *Rhizomucor*, *Absidia*, and *Rhizopus*. *Cunninghamella bertholletiae* and *Saksenaea vasiformis* are less common causes. Zygomycetes cause disease in patients with poorly controlled diabetes, neutropenia, or renal disease. Direct invasion through abrasions has been reported following trauma due to a natural disaster (e.g., during a mud slide or tsunami).[64] They can invade necrotic burned areas or involve the facial skin secondary to invasive infection of the paranasal sinuses (Fig. 190-19). Zygomycete infections also have been caused by close apposition of the skin with contaminated dressing materials in the case of *R. rhizopodiformis*[65] or with wooden tongue depressors in the case of *R. microsporus*.[66] The zygomycete fungi have a tendency to invade blood vessels, causing widespread infarction. Infections may respond to intravenous amphotericin, and recent results with lipid-associated amphotericin B formulations have been encouraging.

Other Opportunistic Mycoses

Other fungi causing systemic infections also may produce skin lesions in the process of bloodstream dissemination. The best known of these organisms are *Aspergillus*, *Scedosporium*, *Trichosporon*, and *Fusarium*. Skin infection is seen mainly in severely immunocompromised patients such as those with neutropenia.

Aspergillus may produce large necrotic lesions such as ecthyma gangrenosum, but smaller papules and cold abscesses also can occur.[67] *Fusarium* infections may produce widely distributed target-like lesions that may undergo central necrosis and, in some cases, digital cellulitis and superficial white onychomycosis.[68] Treatment for all these infections is usually amphotericin B.

LABORATORY FINDINGS Laboratory confirmation of the diagnosis is fraught with difficulties chiefly because many of the organisms are also commensals in human sites; because they occur in severely ill patients, the capacity to produce diagnostic antibody titers is compromised. The interpretation of laboratory data is consequently difficult and has to be related to the clinical state of the patient. Ideally, a histologic diagnosis should be made, although biopsy may be impossible because of the risk of bleeding. In many cases, the diagnosis of a systemic mycosis is presumptive, and treatment therefore is given empirically.

Actinomycosis and Nocardiosis

Actinomycosis is an infection caused by filamentous bacteria that form large granules (sulfur granules) in abscess cavities. Draining sinuses communicate from the center of the abscess to the skin or mucosal surface. Nocardiosis is an acute and chronic infection also caused by filamentous bacteria. These lead to localized skin, subcutaneous, and systemic infections. Actinomycosis and nocardiosis are discussed in detail in Chap. 185 and in the on-line version.



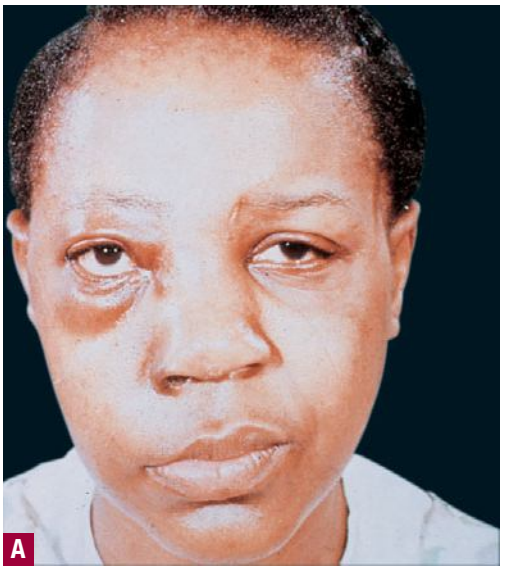



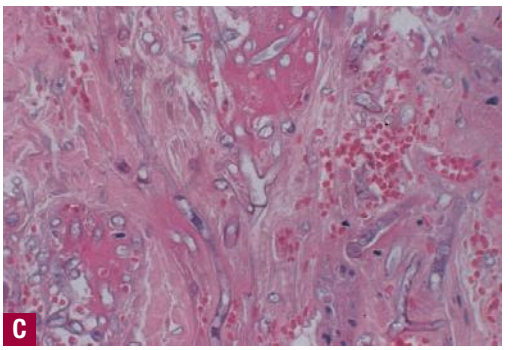

▲ **FIGURE 190-19** Mucormycosis. **A.** The face of this young woman with diabetes mellitus shows proptosis, unilateral facial edema, and a right-sided facial palsy associated with infection beginning in the right maxillary sinus. **B.** Ulcer. **C.** Hyphae in tissue.



KEY REFERENCES

The full reference list for all chapters is available at www.digm7.com.

2. Merz WG, Hay RJ: *Topley and Wilson's Microbiology and Microbial Infections: Medical Mycology*. London, Hodder Arnold, 2005
4. Dismukes WE et al: *Clinical Mycology*. New York, Oxford University Press, 2003
6. Bustamante B, Campos PE: Sporotrichosis: A forgotten disease in the drug research agenda. *Expert Rev Anti Infect Ther* **2**:85, 2004
11. Fahal AH: Mycetoma: A thorn in the flesh. *Trans R Soc Trop Med Hyg* **98**:3, 2004
16. Esterre P. Chromoblastomycosis, in *Topley and Wilson's Microbiology and Microbial Infections: Medical Mycology,* edited by Merz WG, Hay RJ. London, Hodder Arnold, 2004, p 356
28. Gutierrez ME et al: Disseminated histoplasmosis in patients with AIDS in Panama: A review of 104 cases. *Clin Infect Dis* **40**:1199, 2005
33. Bradsher RW et al: Blastomycosis. *Infect Dis Clin N Am* **17**:21, 2003
42. Crum NF et al: Coccidioidomycosis: A descriptive survey of a reemerging disease. Clinical characteristics and current controversies. *Medicine* **83**:149, 2004
46. Franco M et al: *Paracoccidioidomycosis*. Boca Raton, FL, CRC Press, 1994
54. Supparatpinyo K et al: Disseminated *Penicillium marneffei* infection in southeast Asia. *Lancet* **344**:110, 1994
58. Murakawa GJ et al: Cutaneous cryptococcus infection and AIDS: Report of 12 cases and review of the literature. *Arch Dermatol* **132**:545, 1996

SECTION 31

VIRAL AND RICKETTSIAL DISEASES

CHAPTER 191

Viral Diseases: General Considerations

Ammar M. Ahmed
Vandana K. Madkan
Natalie Mendoza
Stephen K. Tyring
Douglas R. Lowy

Skin lesions are a prominent feature of many viral diseases. These lesions are either a direct result of viral replication in the epidermis or a secondary effect of viral replication elsewhere in the body. In the latter case, the cutaneous manifestations may be the first or most prominent sign of a systemic infection that requires thorough evaluation and appropriate diagnostic testing. Although most viral infections with skin lesions are mild and self-healing, occasionally severe illness and even life-threatening complications can develop, especially in immunocompromised populations.[1] Fortunately, recent advances in laboratory testing have shortened the time for diagnosis of a number of viral infections. To complement advances in diagnosis, there are several effective antiviral agents for treating certain viral diseases with cutaneous manifestations, and other potential antiviral agents are in clinical trials. Consequently, making the correct diagnosis in viral infection has important implications for therapy as well as for prognosis. It may also contribute to the surveillance and control of infectious disease within a community. Preventive vaccines are of monumental importance. They have nearly or completely eradicated several viral infections, most notably smallpox, and the emerging development of new vaccines against other viruses could dramatically reduce their morbidity and associated health care costs.

DEFINITION

Viruses form a diverse group of infectious, acellular organisms that share a distinctive composition and a unique mode of replication.[2–5] Although certain viruses encode a small number of enzymes, viruses do not possess functional ribosomes or other cellular organelles. They multiply only inside host cells, where they make use of the cellular synthetic apparatus to produce their components. It is because their replication depends on the host cell that viruses are often referred to as *obligate intracellular parasites*.

The most important element of a virus is its genetic information (the viral *genome*), which may be either DNA or RNA, depending on the type of virus.[6,7] The life cycle of a virus may be divided into two parts. In one part, the virus exists as an extracellular particle (also called a *virion*), in which the viral genetic information is surrounded by a highly organized protein coat (the *capsid*) that can be seen by electron microscopy. The virion serves to transmit the viral genetic information, functionally intact, to a susceptible host or to spread the infection within an infected host. In the second part of the viral life cycle, the viral genetic information is present inside a cell, where it is usually found in a nonparticulate form. The duration of this intracellular phase is extremely variable, from a few hours in acute infections to years when a virus establishes latency.

VIRAL DISEASES AT A GLANCE



- Cutaneous lesions are an extremely common, and often the only, manifestation of many viral infections.
- Viruses can produce skin lesions either by direct replication in the epidermis, as is the case with papillomaviruses, poxviruses, and several herpesviruses, or as a secondary manifestation of replication elsewhere in the body.
- The direct effects of viral replication on epidermal cells and the inflammatory response of cell-mediated immunity combine to produce cutaneous lesions.
- Neoplastic transformation or viral latency followed by reactivation occurs with certain viruses.
- Laboratory diagnosis is by viral culture, microscopy, detection of viral nucleic acids or viral antigens, and/or serologic testing.
- Many effective antiviral drugs exist, and others are currently in development.
- Preventive techniques, most notably vaccines, have to date been the most effective means for controlling viral infection.

CLASSIFICATION

Viruses that infect animals are divided into several large families according to the size, shape, and structure of the virion and the type of viral nucleic acid within it, as shown in Table 191-1. Viruses of a given family can be identified

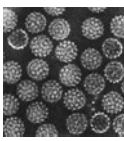

Copyright © 2008 by The McGraw-Hill Companies, Inc. Click here for terms of use.

TABLE 191-1
Selected Animal Virus Groups

Group	Size (nm)	Symmetry	Envelope	Nucleic Acid	Capsid Assembly	Examples of Viruses
Herpesvirus	120–200	Icosahedral	Yes	DNA	Nucleus	Herpes simplex virus (types 1 and 2), varicella-zoster virus, cytomegalovirus, EBV, KSHV/HHV-8
Papillomavirus	50–55	Icosahedral	No	DNA	Nucleus	Papillomaviruses
Polyomavirus	45–50	Icosahedral	No	DNA	Nucleus	SV40
Poxvirus	240 × 300	Complex	No	DNA	Cytoplasm	Molluscum contagiosum, orf, milker's nodules virus, variola virus, vaccinia virus
Retrovirus	80–120	?	Yes	RNA	Cytoplasm	HIV, HTLV
Paramyxovirus	150–300	Helical	Yes	RNA	Cytoplasm	Measles virus, mumps virus
Togavirus	40–60	Icosahedral	Yes	RNA	Cytoplasm	Rubella virus, some arboviruses
Parvovirus	20	Icosahedral	No	DNA	Nucleus	Erythema infectiosum
Hepadnavirus	40–50	Icosahedral	No	DNA	Nucleus	Hepatitis B virus
Adenovirus	70–80	Icosahedral	No	DNA	Nucleus	Multiple human serotypes
Picornavirus	20–30	Icosahedral	No	RNA	Cytoplasm	Enterovirus (coxsackievirus, echovirus, poliovirus), rhinovirus
Bunyavirus	90–100	Helical	Yes	RNA	Cytoplasm	Some arboviruses
Arenavirus	85–120	?	Yes	RNA	Cytoplasm	Lassa virus
Coronavirus	80–120	Helical	Yes	RNA	Cytoplasm	Several human serotypes
Orthomyxovirus	80–120	Helical	Yes	RNA	Cytoplasm	Influenza types A + B + C
Rhabdovirus	70–80	Helical	Yes	RNA	Cytoplasm	Rabies virus
Reovirus	50–80	Icosahedral	No	RNA	Cytoplasm	Rotavirus, reovirus

EBV = Epstein-Barr virus; HHV-8 = human herpesvirus-8; HIV = human immunodeficiency virus; HTLV = human T-cell lymphotropic virus; KSHV = Kaposi sarcoma–associated herpesvirus.

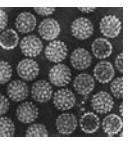

by physical methods such as the size and shape of their virions by electron microscopy, by antigenic cross-reactivity, or by nucleic acid homology. Although viruses are grouped principally according to their virion morphology and nucleic acid composition, a given family of viruses usually shares functional, genetic, biochemical, and immunologic features. Within a given family, viruses may be further classified according to their relatedness at the nucleic acid level, their antigenic cross-reactivity, and the host cells that they infect.

In certain virus families (such as herpesviruses and retroviruses), the capsids are located inside a virion envelope (composed of lipid, protein, and carbohydrate), which is required for infectivity (see Table 191-1). The viral envelope is sensitive to drying, so that infectivity is lost on dry surfaces. The virions of other viruses (e.g., papillomaviruses) do not possess an envelope, so their capsids are called *naked*. Because the capsid proteins are usually stable in dry environments, viruses whose virions lack an envelope typically remain infectious for long periods after drying.

Fig. 191-1 shows examples of virions from the three main families of viruses that multiply in the epidermis (papillomaviruses, herpesviruses, and poxviruses). The viral genomes of these three families are composed of DNA. As noted earlier, papillomaviruses possess naked (nonenveloped) capsids, and herpesviruses have enveloped virions. Poxvirus virions are large, have a very complex structure, and are enveloped, but their envelope is not required for their virions to be infectious. Hence, poxviruses can remain infectious after drying.

VIRAL REPLICATION

The viral replication cycle, which has been studied in detail in tissue culture, involves several more or less sequential steps: attachment (adsorption), penetration, uncoating, biosynthesis, virion assembly, and release. Attachment of virions to cells involves a specific interaction between the viral capsid or envelope (for those viruses that possess enveloped virions) and receptors on the cell surface. For example, human immunodeficiency virus (HIV) enters cells via an interaction between viral envelope protein and two classes of receptors: cellular CD4 receptors and chemokine receptors.[8] Cells that lack the appropriate cell surface receptors for a particular virus will not be infected by that virus. Although most people are quite susceptible to HIV infection, rare individuals who lack the appropriate chemokine receptors or who have modified versions of them may be relatively resistant to HIV infection or the development of acquired immunodeficiency syndrome.[9,10]

After the virion penetrates into the cell, cellular enzymes degrade the envelope and capsid (uncoating), which begins the nonparticulate phase of the virus life cycle. During biosynthesis, the viral genome instructs the infected cell to produce the proteins encoded by the viral genes. Nonvirion proteins (proteins that are not structurally incorporated into the mature virion) of certain viruses may redirect the cell to synthesize proteins required by the virus at the expense of those required for normal function of the cell. Many tumor viruses, including papillomaviruses, encode nonvirion proteins that increase cell growth and lead to inappropriate control of cell division.

Each virus has its characteristic site of replication within the cell. Papillomaviruses and herpesviruses are assembled

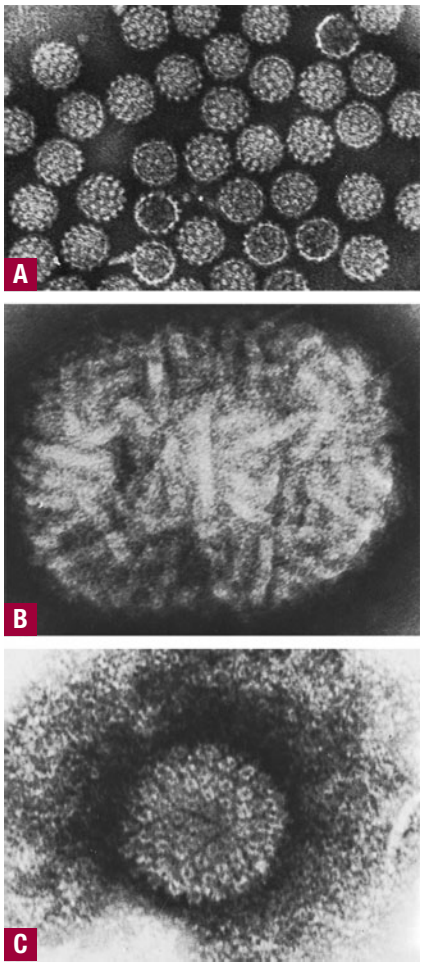

▲ **FIGURE 191-1** Electron micrographs of negatively stained virions (×200,000). **A.** Papillomavirus: multiple nonenveloped human papillomavirus (wart) virions showing capsid subunits (capsomeres). **B.** Poxvirus: single molluscum contagiosum virus virion, showing complex tubular structures. **C.** Herpesvirus: single varicella-zoster virus virion showing capsid inside envelope. (Parts A and B used with permission from AF Howartson, JD Almeida, and MG Williams. Part C by permission of Almeida JD et al: Morphology of varicella (chicken pox) virus. *Virology* **16**:353, 1962.)

in the nucleus (Figs. 191-2 and 191-3). Poxviruses, which are the only DNA viruses that replicate in the cytoplasm, synthesize their virions in organized cytoplasmic "viral factories" (Fig. 191-4). The virions of most viruses, including papillomaviruses, herpesviruses, and poxviruses, are released after cell death and lysis. However, enveloped viruses whose virions are assembled at the cell surface (such as retroviruses and paramyxoviruses) are released by budding from intact cells; with these viruses, productive infection and release of virions may or may not be accompanied by toxic effects on the infected cell.

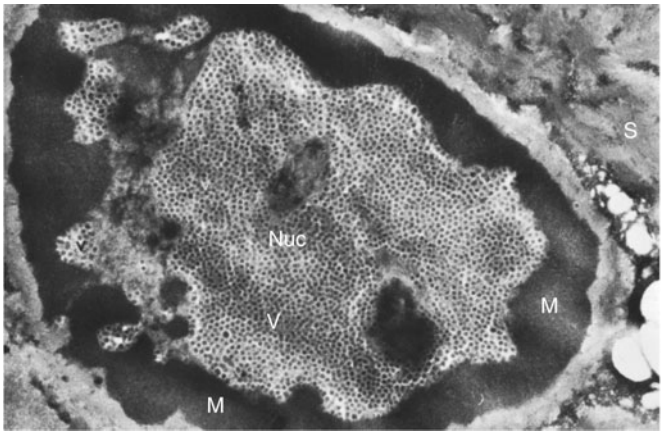

▲ **FIGURE 191-2** Papillomavirus-infected cell. Electron micrograph (×20,000). Nucleus (Nuc) of a stratum corneum cell, filled with papillomavirus virions (V); chromatin is marginated (M). Mature keratin can be seen in an adjacent cell (S).

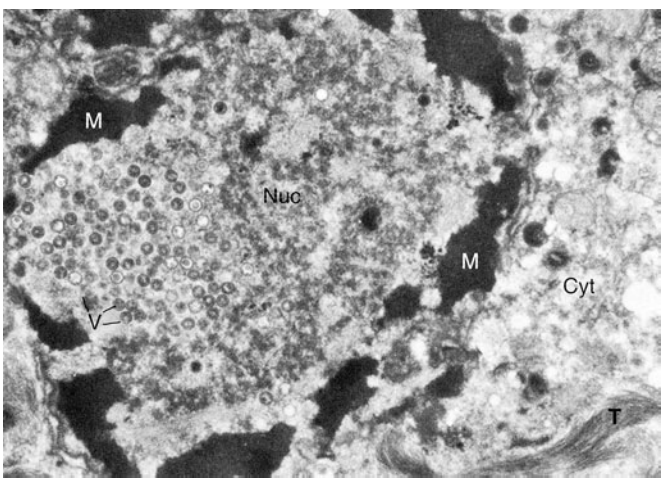

▲ **FIGURE 191-3** Cell infected with varicella-zoster virus (a herpesvirus). Electron micrograph (×24,000). Portion of cell of the stratum spinosum. The nucleus (Nuc) contains varicella-zoster virions (V). Chromatin is marginated at (M). Virions (V) and tonofilaments (T) are shown in the cytoplasm (Cyt).

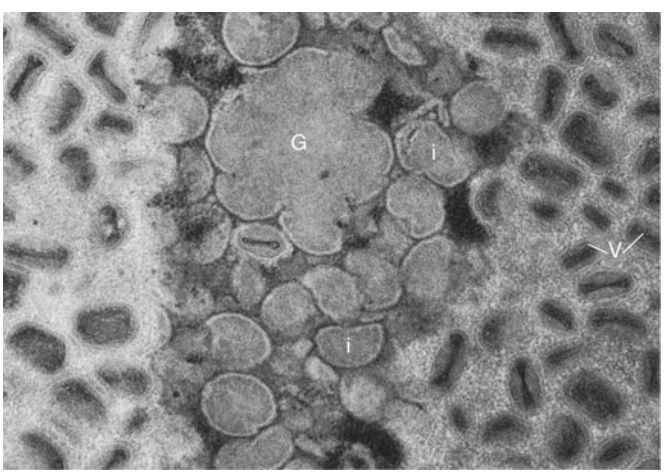

▲ **FIGURE 191-4** Cell infected with molluscum contagiosum (a poxvirus). Electron micrograph (×45,000). Cytoplasm of a spinosum cell filled with mature molluscum contagiosum virions (V), immature virus forms (i), and viroplasm in a gyrate pattern (G).

Typically, hundreds or thousands of new virions are produced from each infected cell, and they, in turn, infect previously uninfected cells. One cycle of viral replication may last from 3 to 36 hours, depending on the virus and cell

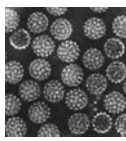

involved. Interruption of any step will prevent the development of new infectious virions.

Each virus can infect and replicate in only a limited number of cell types. The spectrum of susceptible cells depends on the virus. Human papillomaviruses (see Chap. 196) can productively infect a very narrow range of cells, namely, certain differentiating human epidermal cells. Other viruses can infect a much broader range of cells. Herpes simplex viruses (HSVs) (see Chap. 193) can replicate in many different human and nonhuman cell types.

Even within a given tissue, a virus may be infectious only for cells with a specific degree of differentiation. The important role of the differentiated state of the cell in determining whether or not a virus will undergo replication is seen in the skin lesions of molluscum contagiosum (see Chap. 195). Because molluscum contagiosum virus (MCV) particles are sometimes found in cells of the upper dermis, the virus must be capable of attachment to and penetration of these cells. MCV does not, however, replicate in dermal cells, which indicates that an intracellular block to MCV synthesis exists in the dermal cells. MCV particles are also found in the basal layer of epidermal cells, but synthesis of new viral components does not begin until the cells reach the suprabasal layers. This observation implies that MCV replication can take place only in partially differentiated epidermal cells.

CELLULAR CONSEQUENCES OF VIRAL INFECTION

Typically, infected cells develop gross and often characteristic cytopathic changes and eventually die. Infections of this type are termed *cytocidal* or *lytic*. However, as mentioned earlier, certain enveloped viruses can replicate without causing irreversible damage to the host cell. Two other phenomena seen in certain noncytocidal infections are neoplastic transformation[11,12] and viral latency.[13,14] Tumor viruses, when they transform cells, alter the normal control of cellular proliferation. In general, tumor viruses (such as the polyomavirus SV40) do not synthesize new virions in neoplastically transformed cells, although such transformation requires the continued expression of a portion of the viral genome. It is interesting to note that SV40 is exclusively cytocidal for some cell types (permissive infection), induces transformation exclusively in other cells (nonpermissive infection), and induces both types of infection in still other cell types (semipermissive infection), which again underlines the importance of the host cell in affecting the outcome of infection. Epidermal cells are semipermissive for papillomavirus infection. Virus-induced neoplasia is discussed in greater detail in Chap. 111.

Viral latency is a common mechanism for evading the host immune response. Latently infected cells either produce very small numbers of new virions so that spread to uninfected cells is minimal or they synthesize no virions but retain an intact and potentially inducible viral genome.

PATHOGENESIS OF VIRAL INFECTIONS IN THE SKIN

There are three general patterns of viral infection.[14] The most typical is that of acute infection followed by viral clearance, usually by immune mechanisms. This pattern occurs frequently with viruses that produce exanthemas, such as measles. Another pattern is that of acute infection followed by latent infection, which may then be followed by viral reactivation. In viruses with cutaneous manifestations, this pattern occurs often with HSV (see Chap. 193), varicella-zoster virus (VZV) (see Chap. 194), and papillomavirus (see Chap. 196). A third pattern is that of chronic infection, as occurs with HIV. Active subacute or chronic infections lasting months to years can also occur with papillomaviruses and MCV, even in immunocompetent hosts.

Transmission of an infecting virus to a susceptible individual can occur through several routes. In warts, herpes simplex, chickenpox, herpes zoster, molluscum contagiosum, and smallpox, viral shedding from human skin lesions represents an important source in the transmission of virus to other people. For other viruses with cutaneous manifestations, respiratory secretions, blood, genital secretions, or animal vectors are involved in carrying virus to susceptible individuals. The skin, specifically, is affected by three different routes: direct inoculation, systemic infection, or local spread from an internal focus. The skin lesions that result may be produced by the direct effect of virus replication on infected cells, the host response to the virus, or the interaction of replication and host response.

The viruses of warts, molluscum contagiosum, vaccinia, orf, milker's nodules, and (primary) herpes simplex, all of which infect the skin by direct inoculation, replicate in the epidermis. Their viral cytopathic effects account for the appearance of early lesions. The immune system presumably contributes to the evolution of these lesions by inducing an inflammatory response. The incubation period is generally short, because the lesions develop at the site of inoculation. For warts, however, the incubation period is longer, presumably because the virus replicates slowly or cell-to-cell spread of virus occurs to only a limited extent.

In systemic infections, the skin is infected during viremia, so that the dermis is generally infected earlier than the epidermis. It is not known how the distribution of viral exanthemas is determined. In chickenpox (see Chap. 194) and smallpox (see Chap. 195), the damage from cytocidal infection of the skin is a direct cause of the lesions. In contrast, there is suggestive evidence from patients with impaired cellular immunity that the lesions of rubella and measles (see Chap. 192) result at least partly from a cell-mediated immune response to the virus. The basis of most exanthemas associated with enteroviral infections remains to be established; there is significant cytocidal viral replication in the skin in hand-foot-and-mouth disease (see Chap. 192).

Recurrent herpes simplex and herpes zoster represent the local spread of virus to the skin after reactivation of the latent virus present in sensory nerve ganglia. Cytocidal infection clearly plays an important role in these lesions, although lesions may contain less virus than during primary infection, presumably because of immunity.

HOST RESPONSE

The severity of illness induced by a particular virus varies considerably from person to person. Although the size of the viral inoculum and the portal of entry play some role, it is believed that host factors usually account for most of this variation. Both immunologic and nonimmunologic responses appear to be important,[14–17] and both innate and adaptive immunity play key roles in the coordinated immune response.[18] Conversely, viral infection may have significant direct and indirect effects on the immune system, especially infection with those viruses that target lymphoid cells, such as Epstein-Barr virus and HIV.[8]

Antibody responses to viral infection represent the major host defense against

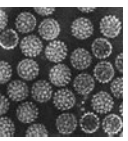

re-infection by the same virus.[19] The prophylactic administration of type-specific antibodies can prevent or modify some primary viral infections, even in patients with impaired cellular immunity. There are several mechanisms by which antibodies may inhibit the spread of virus. These include neutralization of virus through prevention of viral attachment to target cells (which may be increased by complement), enhancement of viral uptake by phagocytic cells, and complement-mediated immune lysis of infected cells. However, humoral immunity is thought not to contribute to the recovery from most primary viral infections, because viral infection of patients with isolated deficiencies of humoral immunity usually follows a normal course.

Specific cell-mediated immunity (CMI) is also elicited during viral infections and influences the course of many viral infections. CMI controls viral spread and promotes clearance of the virus, although it may sometimes increase the degree of cellular pathology (as in the eruption of measles). Patients with impaired CMI often have difficulty handling primary or recurrent viral infection. Such patients are at risk of developing severe primary virus infections, problematic reactivations of dormant viruses such as VZV and cytomegalovirus, and persistent warts, herpes simplex eruptions, and other viral cutaneous lesions. Virus-specific cytotoxic lymphocytes, natural killer cells, and antibody-dependent cell-mediated cytotoxicity all can inhibit infection under experimental conditions, and these are thought to be the primary players in clearing viral infections.

Inflammatory cells may produce some of their antiviral effects via the production of interferons, a unique family of closely related cytokines that are active against viruses.[20] Interferon, which can be induced by foreign RNA or DNA (including viral nucleic acids), is secreted into the extracellular fluid. Resistance to viral infection is induced in those cells that come in contact with the interferon. Virtually all viruses are capable of inducing interferon and are susceptible to its action, but viruses differ greatly in their degree of interferon induction and in their sensitivity to its effects. Interferon is responsible for recovery in several types of viral infection in mice, and the presence of interferon correlates with the recovery phase of several human viral infections. Genetic factors may also play a role in determining the outcome of viral infections. In animal models, cellular genes can determine the susceptibility to viral infection at several levels, including virion attachment to cells, viral replication, and viral-induced immune responses.[21]

CLINICAL MANIFESTATIONS

Viral infections can produce a wide spectrum of mucocutaneous lesions, from single papules to generalized pustulation to large, fungating tumors. Table 191-2 lists the viruses that most commonly cause a number of distinguishable skin lesions. There are several cutaneous eruptive diseases that appear to be viral exanthemas based on clinical presentation and seasonable variability but for which a specific viral cause has never been proven. Asymmetrical periflexural exanthem of childhood and pityriasis rosea (see Chap. 41) are two such diseases (although some evidence does link pityriasis rosea to infection with human herpesvirus 7).[22]

Even during a single episode of viral infection, the observable lesions often change considerably as they evolve. For example, in many infections due to HSV, VZV, or coxsackievirus, the lesions begin as papules with erythema, progress to frank vesicles, and are followed by pustules, crusts, or shallow ulcers. In certain viral infections the lesions are very specific (e.g., the verrucous papules seen with papillomavirus infection), and a diagnosis can be made without any further testing. In other viral infections the lesions are either extremely non-specific (e.g., urticaria or erythema multiforme) and cannot be accurately distinguished from lesions of nonviral etiology, or semi-specific for a limited number of viral diagnoses (e.g., the vesicles seen in HSV, VZV, coxsackievirus, and echovirus infections). In both of these circumstances additional diagnostic procedures may help clarify the cause. Evaluation of systemic signs and symptoms is crucial in formulating a differential diagnosis of skin eruptions and is particularly valuable in infections by viruses that do not replicate in the epidermis, such as Epstein-Barr virus and cytomegalovirus.

TABLE 191-2
Viral Exanthems

TYPE OF RASH	ASSOCIATED VIRUS
Macular/maculopapular	Rubella Echovirus (especially 9, 16) Coxsackievirus (especially A5, A9, A16, B5) Epstein-Barr virus (infectious mononucleosis) Human herpesvirus 6 (roseola) Rubeola virus Arbovirus (dengue fever) Parvovirus B19 (erythema infectiosum) Hepatitis B and C viruses Human immunodeficiency virus 1
Papular	Human papillomaviruses Orf virus Human herpesvirus 8 (Kaposi sarcoma) Milker's nodule virus Molluscum contagiosum Human immunodeficiency virus 1
Patches	Epstein-Barr virus (oral hairy leukoplakia)
Petechial/purpuric	Coxsackieviruses A5, A9 Hemorrhagic fever viruses Rubella virus (congenital infection) Cytomegalovirus (congenital infection) Echovirus 9 Epstein-Barr virus
Urticarial	Human immunodeficiency virus 1 Hepatitis B virus Coxsackieviruses A5, A9 Epstein-Barr virus
Vesicular/vesiculopustular	Varicella-zoster virus Vaccinia virus Variola virus Herpes simplex virus types 1 and 2 Coxsackievirus (hand-foot-and-mouth disease) (herpangina) Vesicular stomatitis virus Echovirus

From Tyring SK: Cutaneous virology, in *Mucocutaneous Manifestations of Viral Diseases,* edited by Tyring SK. New York, Marcel Dekker, 2002, p 3, with permission.

DIAGNOSIS OF VIRAL INFECTIONS

Five major approaches are used in the laboratory to diagnose viral infection: viral culture, microscopy, detection of viral nucleic acids, detection of viral antigens, and serologic testing.[23–25] As with all laboratory tests, the results must be interpreted in the context of the clinical setting. Coincidental infection with a virus unrelated to the illness should always be considered. For many viruses, considerable progress has been made in the development of relatively rapid assays that are sensitive and specific.[23,24,26] Most of these newer assays

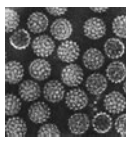

depend on the ability to detect small amounts of viral nucleic acids and/or viral antigens.

Culture of the virus has represented the traditional gold standard for viral diagnosis. Virus isolation is most useful if the suspected pathogen can be readily propagated and positive results can be obtained in a short time. If necessary, more precise identification of the cultured virus can be carried out with specific tests for viral nucleic acid or viral antigen. Culture techniques for HSV are quite sensitive, with diagnostic changes in cells often appearing within 1 to 2 days of inoculation. The closely related VZV is much more difficult to grow in culture, which frequently leads to false-negative results.

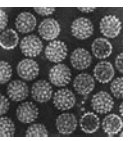

When virus isolation is to be attempted, specimens should be obtained as early in the disease as possible. In vesicular conditions, fluid from an early vesicle is often a good source of virus. Lesional specimens are less likely to give positive results with nonvesicular exanthemas. Specimens are collected in a sterile tube with 2 to 5 mL of a buffered isotonic balanced salt solution containing penicillin and streptomycin. Preferably, they should be transported on ice immediately to the laboratory. If this is not practical, specimens should be frozen [at –70°C (–94°F), if possible]. The suspected pathogen(s) should be indicated, because it may determine the type of cell culture or test animal to be inoculated.

The direct identification of a virus in clinical specimens can theoretically be accomplished more quickly than identification through tests that rely on culturing the virus. This approach may be especially useful for detecting those viruses difficult to propagate in culture and those such as papillomaviruses for which no reproducible culture system is available. Direct analysis may identify characteristic cells, as with Tzanck smears for herpesviruses (this test will not distinguish between HSV and VZV) or characteristic inclusion bodies, as in MCV-infected cells. For those lesions that contain large numbers of viral particles, electron microscopy of a lesion or its extract may provide morphologic identification of the virus,[25] although this method is labor intensive and not readily available.

Whereas culture systems confront virus-specific constraints, any virus should theoretically be detectable by recognition of viral nucleic acid if there is sufficient knowledge of the viral genome to design specific probes and primers. The use of such assays has had a progressively greater impact on direct identification, initially through Southern hybridization and in situ hybridization, and more recently through application of the polymerase chain reaction (PCR).[23,24,26] This latter technique, which can specifically amplify minute quantities of viral nucleic acid, has revolutionized diagnostic virology. Assays based on PCR and related techniques are extremely sensitive, often being able to detect as few as 1 infected cell in 10,000, and highly specific. The main pitfall of PCR is that its great sensitivity makes it very susceptible to yielding false-positive results via cross-contamination with minute quantities of viral nucleic acid. However, meticulous attention to detail and appropriate controls can usually overcome this potential liability. In situ PCR, which combines the sensitivity of PCR with histologic localization, is an even more sophisticated technique for viral detection.

Rapid diagnostic tests for viral antigens are useful and widely available. Fluorescent antibody detection is commonly used to identify and distinguish between HSV-1, HSV-2, and VZV infections. Radioimmunoassay, enzyme-linked immunosorbent assay, immunoelectron microscopy, and immunoperoxidase techniques are other methods of identifying viral antigen by the use of virus-specific antibody.

Serologic studies to detect viral antibodies may be important for epidemiologic purposes, for identification of infection with viruses such as HIV and hepatitis B virus, and for those situations in which acute sera contain diagnostic antibodies, as with heterophile antibodies in infectious mononucleosis. In general, the most accurate serologic method of diagnosing acute viral illness is comparison of immunoglobulin G antibody titers from acute and convalescent sera, which limits its use in that setting to making a retrospective diagnosis. A single positive titer for immunoglobulin M antibody can also suggest acute illness. Acute specimens should be taken as early in the illness as possible and convalescent specimens 2 to 4 weeks later. Serum should be separated immediately from the coagulated blood and refrigerated or preferably frozen at –20°C (–4°F) until antibody tests can be run simultaneously on both specimens. A fourfold or greater rise in antibody titer between acute and convalescent sera generally indicates recent infection. A variety of assays are used to measure antibody levels, each detecting a certain type of antigen-antibody reaction, with the type of virus partly determining the utility of any particular assay.

THERAPY AND PREVENTION

Most antiviral drugs are virostatic, not virocidal. More than 40 drugs are now approved for the treatment of viral infections, and several of these have a key role in the treatment of cutaneous viral infections. Viral enzyme inhibitors, chemotherapeutic agents, and immunomodulatory drugs are among the systemic and topical medications used to treat such infections. Although significant progress has occurred in antiviral therapy in recent decades, especially in the treatment of infections by HIV, herpesviruses, and influenza virus, prophylaxis of viral infection has thus far proved more successful than the specific treatment of established infection for most viruses. Vaccines have been extremely useful in the prevention of a variety of viral illnesses[19,27,28] and represent one of the premier medical achievements of the twentieth century. In 2006, the U.S. Food and Drug Administration approved two new antiviral vaccines: a prophylactic VZV vaccine for the prevention of herpes zoster in persons 60 years of age and older, and a prophylactic vaccine against genital human HPV infection in women for prevention of cervical cancer caused by HPV-16 and HPV-18 and genital warts caused by HPV-6 and HPV-11. In addition to the numerous viral vaccines that are currently licensed for use, investigational vaccines are currently being developed for HSV, cytomegalovirus, dengue virus, West Nile virus, and HIV, among others.[29] Recombinant DNA techniques are making it possible to develop effective, non-infectious subunit vaccines composed only of viral protein (as with the vaccines against HPV and hepatitis B virus), rather than traditional vaccines, which contain either an attenuated strain of the pathogen or an inactivated preparation of the entire virus.[30,31] In addition to vaccines that induce active immunity, the passive administration of type-specific antibody soon after exposure is useful in select clinical situations, for example, in immunocompromised children exposed to varicella. Sensitive procedures for the detection of hepatitis B virus, hepatitis C virus, and HIV in potential blood donors has drastically reduced the incidence of transmission of these agents by transfusion. Other public health measures such as safer sex, single use of needles, control of mosquitoes, and proper hand washing continue

to be paramount in the prevention of viral disease.

KEY REFERENCES

The full reference list for all chapters is available at www.digm7.com.

1. Rebora A: Life-threatening cutaneous viral diseases. *Clin Dermatol* **23**:157, 2005
9. Dean M et al: Genetic restriction of HIV-1 infection and progression to AIDS by a deletion allele of the CKR5 structural gene. *Science* **273**:1856, 1996
10. Smith MW et al: Contrasting genetic influence of CCR2 and CCR5 variants on HIV-1 infection and disease progression. *Science* **277**:959, 1997
14. Ahmed R et al: Persistence of viruses, in *Fields Virology*, 3d ed, edited by Fields BN, Knipe DM, Howley PM. New York, Lippincott–Raven Publishers, 1996, p 219
21. Brahic M et al: Immunogenetics of the host response to viral infections, in *Immunology of Infectious Diseases*, edited by Kaufmann SHE, Sher A, Ahmed R. Washington, DC, ASM Press, 2002, p 421
29. Huang DB, Wu JJ, Tyring SK: A review of licensed viral vaccines, some of their safety concerns, and the advances in the development of investigational viral vaccines. *J Infect* **49**:179, 2004

CHAPTER 192

Exanthematous Viral Diseases

Leah Belazarian
Mayra E. Lorenzo
Nicole C. Pace
Susan M. Sweeney
Karen M. Wiss

MEASLES

Epidemiology

Measles, or rubeola, has a worldwide distribution and remains a leading public health burden, with 30 to 40 million cases and 530,000 deaths in 2003.[1] The risk of mortality is highest in developing countries, with most deaths due to complications of the disease.

Before the development of a vaccine, measles epidemics occurred every 2 to 5 years during winter and spring months in children 5 to 9 years old.[2,3] There continues to be a decline in the number of reported cases in the United States each year as vaccination strategies have improved, particularly in immigrant populations. During 2004, a total of 37 cases were reported to the Centers for Disease Control and Prevention by local and state health departments.[4] Improved immunization programs in developing countries have also prevented outbreaks and reduced measles-associated morbidity and mortality.

Etiology and Pathogenesis

Measles virus, a member of the Paramyxoviridae family, is a heat-labile virus with an RNA core and outer lipoprotein envelope.[2,3] Measles is spread by direct or airborne contact with infectious droplets. The incubation period is typically 8 to 12 days, with patients being contagious from 1 to 2 days before onset of symptoms to 4 days after appearance of the rash.[3] Both humoral and cell-mediated immunity are needed to control measles virus infection. Immunoglobulin M (IgM) antibodies are detected initially with onset of the rash, followed by a rise in measles-specific IgG titers. The humoral response controls viral replication and confers antibody protection, whereas the cell-mediated response eliminates infected cells.[2] A transient immunosuppression occurs during measles virus infection, causing depressed delayed-type hypersensitivity and T-cell counts as well as an increased risk of bacterial infections.[2] This process, as well as long-term immunity against measles, is not well understood but may be due to a weak T helper 1 response to the virus.[5]

Clinical Findings

HISTORY The prodrome is typically characterized by fever [up to 40°C to 40.5°C (104°F to 105°F)], malaise, conjunctivitis (palpebral, extending to lid margin), coryza, and cough (brassy or barking), which may last up to 4 days.[2,3] Koplik spots, the pathognomonic enanthem of measles, begin as small, bright red macules that have a 1- to 2-mm blue-white speck within them. They are typically seen on the buccal mucosa near the second molars (Fig. 192-1) 1 to 2 days before and lasting 2 days after the onset of the rash (see eFig. 192-1.1 in on-line edition).[2,3] Individuals with pre-existing partial immunity (e.g., patients who received exogenous immunoglobulin) may have less severe symptoms but a prolonged incubation period (14 to 20 days). Conversely, immunosuppressed patients may have more severe disease and can present without the typical rash.[3]

MEASLES AT A GLANCE



- Rubeola.
- Epidemic disease; worldwide distribution.
- Fever, malaise, conjunctivitis, coryza, cough, Koplik spots.
- Generalized erythematous macules and papules that spread from the forehead and behind the ears to the trunk and extremities; begins to fade in 4 to 5 days.
- More severe disease in immunocompromised or malnourished individuals.

CUTANEOUS LESIONS The exanthem is characterized by erythematous, non-pruritic, macules and papules that begin on the forehead and behind the ears (Fig.

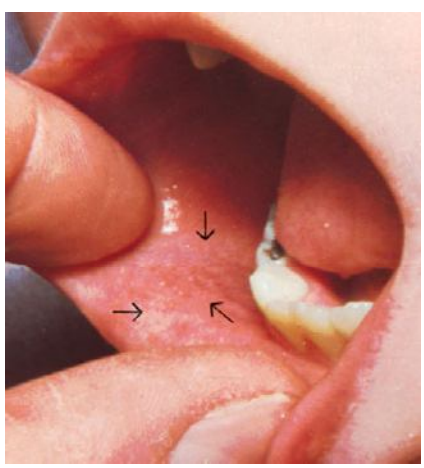

▲ **FIGURE 192-1** The pathognomonic Koplik spots appear as tiny white lesions surrounded by an erythematous halo "grains of sand." They precede the generalized rash by 1 to 2 days.





▲ **FIGURE 192-2** The rash appears behind the ears, on the forehead, and face and spreads slowly downward over the neck, shoulders, trunk, and then distally over the upper and lower extremities.



192-2). The rash quickly progresses to involve the neck, trunk, and extremities (Fig. 192-3). The hands and feet are involved. Lesions may coalesce, especially on the face and neck (see eFig. 192-3.1 in on-line edition). The rash usually peaks within 3 days and begins to disappear in 4 to 5 days after the order of its appearance. Desquamation may occur as the rash resolves.

RELATED PHYSICAL FINDINGS The entire illness may last up to 10 days, with some individuals also having vomiting, diarrhea, abdominal pain, splenomegaly, pharyngitis, and generalized lymphadenopathy.[2] Immunosuppressed patients are at higher risk for pneumonitis, encephalitis, and other fatal complications.[2,6] Viral shedding may also be more persistent in these individuals.[7]

Atypical measles infection is rare, but seen in individuals who received formalin-inactivated measles vaccine (1963 to 1967) and were subsequently exposed to wild-type virus.[2] Symptoms are often more severe with high fever, interstitial pneumonia, pleural effusions, extremity edema, hepatitis, and hyperesthesias occurring more commonly. Coryza, conjunctivitis, and Koplik spots are usually not present. The rash may be maculopapular, hemorrhagic, vesicular, or urticarial and spreads centripetally, making it difficult to distinguish from Rocky Mountain spotted fever.[2]

Laboratory Tests

Laboratory abnormalities may include monocytosis, leucopenia, and thrombocytopenia. During the prodrome stage, virus can be found in nasopharyngeal secretions, blood, and urine. The pharyngeal virus shedding ends by the second day of the rash. Virus may be seen in the urine until 4 days after rash onset. Viral culture has a low sensitivity for finding the virus. Indirect enzyme-linked immunoassay (ELISA), polymerase chain reaction (PCR), and real-time (RT)-PCR assays can detect measles virus in clinical specimens such as nasopharyngeal secretions, blood, and urine.[8] Serologic studies demonstrate measles virus infection with a documented increase in IgM and/or IgG antibody titers. IgM increases with the onset of the rash and lasts approximately 1 month whereas IgG appears 2 weeks after rash onset and peaks 4 to 6 weeks later.[3,9] Many laboratories may have access to viral immunofluorescence tests that quickly detect measles in throat or nasopharyngeal specimens.[10] In the United States, measles should be reported to the local health department.

Differential Diagnosis (Box 192-1)

Complications

Age-specific rates of complications are highest among children less than 5 years old and adults over 20 years. The most common complications of measles virus infection are otitis media, pneumonia, laryngotracheobronchitis, and diarrhea.[3,11] Hepatitis, thrombocytopenia, and encephalitis occur less commonly. Thrombocytopenia-associated purpura may be severe. Pneumonia is the most common fatal complication of measles in children and the most common complication overall in adults.[2,12] The disease severity is worse in immunocompromised and malnourished individuals,



▲ **FIGURE 192-3** Measles. Classic morbilliform exanthem with red papules spreading from forehead and postauricular to neck, trunk, and then extremities.

Box 192-1

Differential Diagnosis of Measles

Most Likely

- Drug hypersensitivity reaction
- Rubella

Consider

- Rocky Mountain spotted fever (atypical cases)
- Henoch-Schönlein purpura (atypical cases)
- Other viral infection (parvovirus, enterovirus, adenovirus, human herpesvirus-6, Epstein-Barr virus)

Always Rule Out

- Kawasaki disease
- Graft-versus-host disease (recent bone marrow transplant)

often resulting in the development of Hecht giant cell pneumonia.[13]

Prognosis and Clinical Course

Clinical diagnosis of measles is typically made with onset of the characteristic rash as the prodromal symptoms can mimic influenza-like illnesses. Uncomplicated measles is self-limited, lasting 10 to 12 days. Malnutrition, immunosuppression, poor health, and inadequate supportive care can worsen the prognosis in any patient. In developing nations, measles is a major cause of infant mortality.

Treatment

Treatment for measles in the majority of cases is supportive. Patients with secondary bacterial infections need to be treated with appropriate antibiotics. Ribavirin may be considered, as it has been shown to inhibit measles virus in tissue culture and reduce the severity and duration of measles in some cases.[2,3,18] In trials with patients with subacute sclerosing panencephalitis, however, no benefit was noted with the use of ribavirin.

Malnutrition and vitamin A deficiency can depress cell-mediated immunity in children, increasing the risk and severity of childhood infections. Measles virus infection decreases serum levels of vitamin A and can lead to higher risk of mortality from disease. Vitamin A supplementation is recommended for all children with measles who live in communities where vitamin A deficiency is known or where measles fatality rate is 1 percent.[3,19] In the United States, supplementation is considered for children 6 months to 2 years who are hospitalized with measles and its complications or for children more than 6 months of age who are at risk for vitamin A deficiency (immunodeficiency, severe malnutrition).[3] More recent studies of vitamin A have led to some controversy regarding its use.[20]

All individuals at risk (children less than 1 year of age, pregnant women, unimmunized, immunocompromised, exposed to measles virus) should receive immunoglobulin prophylaxis within 6 days of exposure.[3] If given within 72 hours of exposure, the individual will not be infected with the virus.[2] Healthy individuals should receive 0.25 mL/kg of intramuscular immunoglobulin, and immunocompromised patients require 0.5 mL/kg.[3] Exposed patients (excluding pregnant women and those with impaired immune systems) should also be given the measles vaccine 5 months later to confer lasting protection (Box 192-2).

Box 192-2

Treatments for Measles

- First line
  - Supportive care
  - Treat secondary infections
  - Vitamin A[a]
  - Immune globulin, IM[a]
  - Measles vaccine
- Second line
  - Ribavirin[a]

[a]In select cases, please see text.

Prevention (Immunizations)

The incidence of measles has decreased worldwide as a direct result of immunization. A single dose of the live attenuated measles vaccine produces detectable levels of antibody in 95 percent of individuals, conferring lifelong immunity.[2,3]

Common potential side effects of measles vaccine include fever and transient morbilliform rash that resolve without treatment. Less common adverse reactions include thrombocytopenia and transient neurologic reactions.[3,22]

Measles vaccine administration is contraindicated in individuals who have a moderate to severe illness as well as those allergic to eggs or neomycin. It is also contraindicated in pregnant women and those with impaired immune systems [cancer, non–human immunodeficiency virus (HIV) immune deficiency disease, immunosuppressive therapy]. Patients off chemotherapy or immunosuppressive medications for 3 months can receive the measles vaccine.

There have been many unconfirmed, unsubstantiated but widely publicized reports suggesting a potential link between measles-mumps-rubella (MMR) vaccine and the development of autism and possibly inflammatory bowel disease. Current scientific evidence does not support a causal link between MMR vaccine and autism or inflammatory bowel disease.[23]

RUBELLA

Epidemiology

Rubella virus has a worldwide distribution with outbreaks occurring most frequently in late winter and early spring months.[27] School-aged children, adolescents, and young adults most often develop the disease. Epidemics occasionally occur in developing countries, especially where vaccines are unavailable.

Since introduction of the rubella vaccine in the United States in 1969, the incidences of rubella and congenital rubella syndrome have drastically declined with no widespread epidemics occurring in the United States. Occasional outbreaks have largely been attributed to failure to vaccinate susceptible individuals.

RUBELLA AT A GLANCE



- German measles, 3-day measles.
- Epidemic disease; worldwide distribution.
- Short prodrome; rash of 2- to 3-day duration.
- Enlargement of cervical, suboccipital, and postauricular glands.
- High risk of fetal malformations with congenital infection (microcephaly, congenital heart disease, deafness), particularly in the first trimester.

Etiology and Pathogenesis

Rubella is an enveloped RNA virus in the Togaviridae family.[27,31] The virus is spread through direct or droplet contact from nasopharyngeal secretions.[27] Infected individuals shed virus for 5 to 7 days before and 14 days after onset of disease,[31] with viremia unlikely after the rash occurs. In most individuals, infection leads to lifelong immunity.

Congenital rubella occurs when a nonimmunized, susceptible, pregnant woman is exposed to the virus. Transplacental infection of the fetus occurs during the viremic stage. The risk is greatest to a fetus exposed to the virus in the first trimester. Congenitally infected infants may shed the virus through urine, blood, and nasopharyngeal secretions for up to 12 months after birth, thus being a potential source of viral exposure to other susceptible individuals.[27,31]

Clinical Findings

HISTORY Primary rubella infection is typically a mild, sub-clinical disease,



particularly in adults.[27,31] The prodrome is characterized by low-grade fever, myalgias, headache, conjunctivitis, rhinitis, cough, sore throat, and lymphadenopathy; symptoms that may last up to 4 days and often resolve with appearance of rash. Up to 50 percent of children with primary rubella infection may have a sub-clinical infection[32] or present only with lymphadenopathy or rash (no prodrome).[31] Conversely, older adults may have more severe and persistent prodromal symptoms that may make distinction from rubeola difficult in some situations. The presence of Koplik spots in the mouth favors rubeola. As the prodrome resolves and the rash begins to appear, some patients develop an enanthem consisting of tiny red macules on the soft palate and uvula (Forschheimer spots).[33] This enanthem is not diagnostic for rubella.



CUTANEOUS LESIONS The exanthem, occurring 14 to 17 days after exposure, is characterized by pruritic pink to red macules and papules that begin on the face, quickly progressing to involve neck, trunk, and extremities (Fig. 192-4 and At a Glance image).[31] Lesions on the trunk may coalesce, whereas those on the extremities often remain more discrete. The rash usually begins to disappear in 2 to 3 days, unlike rubeola, which can be more persistent and clears the head and neck first. Desquamation may follow resolution of the rash.

RELATED PHYSICAL FINDINGS Lymphadenopathy is usually most severe in the posterior cervical, suboccipital, and postauricular lymph nodes and is noted up to 7 days before the rash appears.[27] Enlargement of the nodes may persist for several weeks.

Adults, particularly women (up to 70 percent), may develop arthritis with rubella infection.[27] Both small and large joints may be affected. Joint symptoms often first appear as the rash fades and can last several weeks. In some individuals, the symptoms may become persistent or recurrent. Joint swelling may progress to form a joint effusion.



▲ **FIGURE 192-4** Rubella. Erythematous macules and papules appearing initially on the face and spreading to trunk, arms, and legs within 24 hours.

Laboratory Tests

Serum complete blood cell count usually shows leukopenia with relative neutropenia. Increased numbers of atypical lymphocytes or abundant plasma cells may be noted as well. Patients with meningeal involvement have lymphocytes in the cerebrospinal fluid (CSF). Viral culture (nose, throat, blood, urine, CSF, synovial fluid) is sensitive but often difficult due to the unstable nature of the virus.[31] Diagnosis is typically made using serology to detect rubella-specific IgM antibody (up to 8 weeks after infection) or to document a fourfold rise in antibody titer in acute and convalescent-phase serum.[27,33] Hemagglutination-inhibition, complement fixation, immunofluorescence assay, and ELISA are some of the methods used to detect antibodies.[31,33] As with measles, rubella cases should be reported to local health departments.

Congenital Rubella Syndrome

Women who are infected with rubella during pregnancy may only exhibit minor clinical symptoms. The effects, however, of rubella infection on the fetus can be profound,[31] with the greatest risk of fetal malformation in the early stages of pregnancy. Up to 85 percent of fetuses exposed to rubella within the first 4 weeks develop serious sequelae such as: microcephaly with mental retardation, congenital heart disease (ventricular septal defect, patent ductus arteriosus), sensorineural deafness, cataracts, low birth weight and fetal death.[27,31,33]

Diagnosis of congenital rubella infection is obtained by isolating rubella virus in the throat, urine, or CSF of the affected neonate. Serologic testing is not as sensitive but is easily available for confirmatory testing.[31]

Differential Diagnosis (Box 192-3)

Box 192-3

Differential Diagnosis of Rubella

Most Likely

- Drug hypersensitivity reaction
- Rubeola (measles)

Consider

- Other viral infection (enterovirus, adenovirus, parvovirus, human herpesvirus-6)

Always Rule Out

- Streptococcal scarlet fever

For differential diagnosis of congenital rubella syndrome with blueberry muffin lesions, see Box 192-9.

Complications

Rarely, rubella infection may lead to encephalitis (1 in 6000 cases),[33] with mortality rates varying from 0 percent to 50 percent.[33] Other rare complications include: peripheral neuritis, optic neuritis, myocarditis, pericarditis, hepatitis, orchitis, and hemolytic anemia.[31] Transient thrombocytopenia has been described in 1 in 3000 children (usually girls); first appearing within days of rash onset and lasting days to months.[31,35] Recently, a case of rubella-associated hemophagocytic syndrome in an infant was described.[36]

Prognosis and Clinical Course

Rubella is typically a self-limited disease. Infants who have congenital rubella are infectious until viral shedding from the nasopharynx and urinary tract ends. The majority of infants (85 percent) infected in utero excrete virus in the first month of life; 1 percent to 3 percent continue to excrete virus in the second year of life.[27,33] Pregnant women caring for these infants are at risk for developing rubella. Clinical course depends on how severely affected the fetus is from intrauterine infection.

Treatment

Treatment of primary, uncomplicated rubella is supportive. In nonpregnant individuals, rubella vaccine administration within 3 days of exposure may theoretically prevent illness, though this is yet to be proven.[27] Immune globulin is not routinely recommended as post-exposure prophylaxis of rubella-susceptible pregnant women. Limited data indicate that intramuscular immune globulin (0.55 mL/kg) may decrease clinically apparent infection from 87 percent to 18

percent if given to an exposed, susceptible pregnant woman.[27] However, absence of clinical signs after administration of immune globulin does not assure that congenital infection did not occur.

Neonates with congenital rubella syndrome require supportive care as well as appropriate attention to significant health issues. These infants are contagious and should be isolated to prevent transmission to susceptible individuals.[27,31] Contact isolation is recommended for these infants until they are at least 12 months old or if repeated cultures are negative after 3 months of age.

Prevention (Immunizations)

Rubella vaccine is typically administered as part of a three-fold vaccine (MMR) at 12 to 15 months of age and again at 4 to 6 years of age. Seroconversion after a single dose of MMR vaccine occurs in 95 percent individuals.[27] It is imperative that individuals at risk for rubella infection are immunized, such as health care workers, military recruits, college students, and recent immigrants.[27] Individuals are considered immune to rubella if they have documented vaccination with a live MMR on or after their first birthday, serologic evidence of rubella immunity, or were born after 1957 (except women of childbearing age).[33]

Potential adverse reactions to rubella vaccine occur in susceptible individuals and include: fever, morbilliform rash, lymphadenopathy, and arthralgia.[27]

Pregnant woman should not be immunized with rubella to minimize risk to the fetus. Any woman receiving the rubella vaccine should not become pregnant for 28 days. Infants of vaccinated breast-feeding mothers may become infected with rubella via breast milk. Typically they develop a mild erythematous exanthem of macules and papules with no serious effects.[33] As rubella infection confers lifelong immunity, a woman who is re-exposed during pregnancy has a low risk of having her fetus contract congenital rubella. Concern about possible infection can be addressed by looking for IgM antibodies in fetal serum (cordocentesis).

ERYTHEMA INFECTIOSUM AND PARVOVIRUS B19 INFECTION

Epidemiology

Erythema infectiosum (fifth disease) is worldwide in distribution, can occur throughout the year, and can affect all ages. It tends to occur in epidemics, especially associated with school outbreaks in the late winter and early spring. Serologic studies show increasing prevalence of antibodies with age. Various studies indicate that from 15 percent to 60 percent of children 5 to 19 years of age and 30 percent to 60 percent of adults are seropositive.[37] Seroprevalence increases to greater than 90 percent in the elderly.[37] Previous infection with B19 seems to confer lifelong immunity.

The incubation period for erythema infectiosum is from 4 to 14 days.[38] After intranasal inoculation of parvovirus-infected serum to healthy volunteers, low-grade fever and non-specific complaints occurred at the time of viremia, 6 to 14 days after inoculation, and the rash appeared at day 17 or 18.[39]

Parvovirus B19 is thought to be transmitted primarily by the respiratory route via droplet aerosol during the viremic phase, and B19 DNA has been found in respiratory secretions of viremic patients.[39] After the rash of erythema infectiosum appears, B19 is not found in respiratory secretions and is usually not present in the serum. This suggests that persons with erythema infectiosum are infectious only before the onset of the rash.

PARVOVIRUS B19 AT A GLANCE



- Causes erythema infectiosum, fifth disease.
- Fifth disease in children with "slapped cheeks" followed by an erythematous, lacy eruption on the trunk and extremities.
- Symmetric polyarthritis, particularly of the small joints.
- Causes papular purpuric gloves-and-socks syndrome with pruritic erythema, edema, and petechiae of the hands and feet, fever, and oral erosions in adolescents.
- Aplastic crisis in patients with increased red blood cell turnover, chronic anemia in immunocompromised persons, and fetal hydrops.

The virus seems to be effectively spread after close contact. The secondary attack rate among susceptible household contacts is approximately 50 percent. Transmission may occur via blood transfusion, from blood products, and vertically from mother to fetus.[40] The transmission of B19 through blood transfusion is particularly problematic because the nonenveloped virus is not killed by the solvent detergents or heat that are used to inactivate HIV and hepatitis viruses.[41]

Etiology and Pathogenesis

The B19 virus belongs to the family Parvoviridae and the genus *Parvovirus*.[42] B19 lacks an envelope and contains single-stranded DNA. It is the smallest single-stranded DNA–containing virus known to infect humans, measuring 18 to 26 μm in diameter. Parvoviruses are widespread in veterinary medicine, but animal parvoviruses are not thought to be transmissible to humans.[41]

The pathogenesis of erythema infectiosum is unknown, but the mechanism may involve immune complexes. The more serious manifestations of parvovirus infection relate to the fact that the virus infects and lyses erythroid progenitor cells. Evidence suggests that the blood group P antigen (globoside) is a receptor of parvovirus. Because some individuals lack P antigen, they are not susceptible to infection with B19.[43] In patients with increased red blood cell destruction or loss who depend on compensatory increase in red cell production to maintain stable red cell indices, B19 infection may lead to transient aplastic crisis. Such patients include those with anemia associated with acute or chronic blood loss. When parvovirus infects the erythroblasts in a developing fetus with decreased red cell survival, the result may be hemolysis and anemia.[44] Anemia may trigger congestive heart failure, edema (fetal hydrops), and possibly fetal death.

Clinical Findings

PARVOVIRUS B19 IN CHILDREN Most infections caused by B19 are asymptomatic and unrecognized. Fifth disease, the most common clinical picture associated with the virus, usually begins with nonspecific symptoms such as headache, coryza, and low-grade fever approximately 2 days before the onset of the rash.[45] Patients may have headache, pharyngitis, fever, malaise, myalgias,



coryza, diarrhea, nausea, cough, and conjunctivitis coinciding with the rash. Approximately 10 percent of children with erythema infectiosum develop arthralgias or arthritis. Large joints are affected more often than small joints.[45] Occasionally, children may present with chronic joint complaints suggestive of juvenile rheumatoid arthritis.[46]

The characteristic rash begins with confluent, erythematous, edematous plaques on the malar eminences, the "slapped cheeks" (Fig. 192-5). As the facial rash fades over 1 to 4 days, pink to erythematous macules or papules appear on the trunk, neck, and extensor surfaces of the extremities. These lesions have some central fading, giving them a lacy or reticulated appearance (Fig. 192-6).[45] The rash can be morbilliform, confluent, circinate, or annular, and there have been reports of palmar and plantar involvement.[38] The eruption typically lasts 5 to 9 days, but can recur for weeks or months with triggers such as sunlight, exercise, temperature change, bathing, and emotional stress. In some outbreaks, pruritus is a major feature of the rash in children.[38]

There have been occasional reports of parvovirus B19 associated with vascular purpura, including Henoch-Schönlein purpura.[47] An enanthem consisting of erythema of the tongue and pharynx and red macules on the buccal mucosa and palate can occur.

PARVOVIRUS B19 IN ADULTS Acute arthropathy is the primary manifestation of B19 viral infection in adults.[48] It occurs mainly in women and affects the small joints of the hands, the knees, other joints, such as the spine and costochondral joints, are involved. This symmetric polyarthritis is usually of sudden onset and is self-limited but can be persistent or recurrent for months. It may mimic Lyme arthritis or rheumatoid arthritis.



▲ **FIGURE 192-5** Erythema infectiosum. Child with the characteristic "slapped cheek."



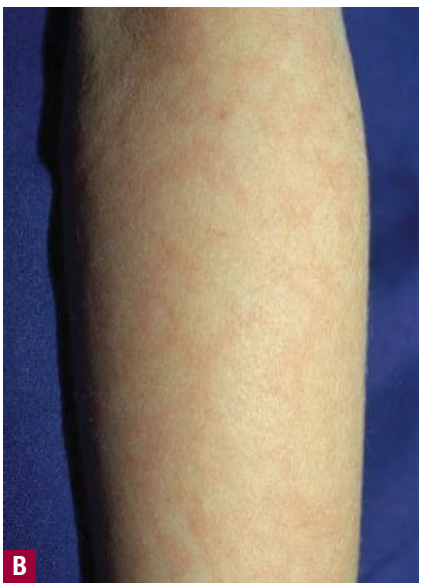

▲ **FIGURE 192-6** Erythema infectiosum. **A.** Lacy, reticulated macules and papules on proximal extremities. **B.** Lacy macules on leg.

The constitutional symptoms are usually more severe in adults than in children.[49] Fever, adenopathy, and a mild arthritis without a rash is the usual course. Women are more likely than men to have joint complaints and rash, whereas men often present with only a flu-like illness.[48] Some adults may have fatigue, malaise, and depression for weeks after the infection. Asymptomatic infection can certainly occur in adults as well as in children. In one outbreak, 26 percent of adults were reported to be asymptomatic.[48] Parvovirus B19 can cause numbness and tingling of the fingers with or without other features of fifth disease.[50] Pruritus that is sometimes severe can occur with or without a rash. It has been suggested that if pruritus is a complaint in a patient with acute-onset arthritis, parvovirus should be considered as a possible cause.

The rash in adults, if present at all, is usually macular and blotchy or lacy, often on the extremities, and rarely demonstrates the characteristic slapped-cheek appearance.[48] Other cutaneous manifestations associated with B19 infection in adults include purpura, vesicles and pustules, palmo-plantar desquamation, a morbilliform exanthem with Koplik spots, and livedo reticularis.

PAPULAR PURPURIC GLOVES-AND-SOCKS SYNDROME In 1990,[51] a unique syndrome of pruritic erythema and edema of the hands and feet with petechiae, fever, and oral erosions was described. This rare exanthem, now known as *papular, purpuric gloves-and-socks syndrome,* seems to affect teenagers and adults. However, it can affect children also.[52] Patients usually have mild prodromal symptoms of fatigue and low-grade fever, myalgias, and arthralgias. Subsequently, itchy, painful, symmetric edema and erythema of the distal hands and feet occurs.[53] Purpuric papules appear on the hands and feet with abrupt demarcation at the wrists and ankles. The enanthem, if present, arises on the lips, soft palate, and buccal mucosa. The syndrome resolves spontaneously within 2 weeks. Although many viruses have been implicated as causative agents for papular, purpuric gloves-and-socks syndrome, B19 is the virus proven to cause the syndrome.[54]

Laboratory Tests

In patients with erythema infectiosum, laboratory results are usually normal, including reticulocyte count, hematocrit, and tests of liver and renal function. Patients with aplastic crisis have reticulocytopenia and anemia, the severity of which depends on the degree of the underlying anemia. Reticulocytopenia, anemia, lymphopenia, neutropenia, and thrombocytopenia can occur in healthy individuals with B19 infection, although these are usually not significant enough to cause clinical symptoms. The erythrocyte sedimentation rate is rarely elevated, and rheumatoid factor has been positive in some cases of parvovirus-associated arthritis.

Detection of recent infection is usually performed with assays for IgM antibody. Radioimmunoassay or ELISA techniques can detect IgM within a few days after

onset of illness. IgM can be measured for up to 6 months in many cases, although there is a decline in titer in the second month after onset. IgG can be identified with the same techniques by the seventh day of illness and lasts for years and is therefore best for documenting past infection. Parvovirus antibody is often not detectable in immunodeficient persons. B19 virus can be detected in serum during viremia by a variety of techniques including radioimmunoassay, counterimmunoelectrophoresis, and ELISA. The most specific tests are dot-blot hybridization[55] and the PCR,[56] which may allow identification of B19 DNA in serum, urine, respiratory secretions, CSF, and bone marrow. B19 DNA can be detected with PCR for up to 4 months after the onset of illness.[57]

Special Tests

Differential Diagnosis (Box 192-4)

Complications

As more attention is focused on parvovirus B19, an increasing number of complications are recognized. Sub-clinical infection is quite common. However, this virus can be responsible for a variety of hematologic, rheumatologic, and neurologic abnormalities.

Box 192-4

Differential Diagnosis of Parvovirus B19 Infection

Most Likely
- Erythema infectiosum
- Drug reaction
- Enteroviral infection
- Erysipelas on the cheek
- Papular purpuric gloves-and-socks syndrome
- Hand-foot-mouth disease

Consider
- Erythema infectiosum
- Roseola
- Rubella
- Measles
- Collagen vascular disease (systemic lupus erythematosus, dermatomyositis)
- Papular purpuric gloves-and-socks syndrome
- Atypical measles

Always Rule Out
- Erythema infectiosum
- Scarlet fever
- Papular purpuric gloves-and-socks syndrome
- Rocky Mountain spotted fever
- Kawasaki disease

TRANSIENT APLASTIC CRISIS Parvovirus B19 is the most common cause of transient aplastic crisis in patients with chronic hemolytic anemias.[59] This has been demonstrated in sickle cell anemia, hereditary spherocytosis, heterozygous β-thalassemia, pyruvate kinase deficiency, and autoimmune hemolytic anemia, as well as in other conditions of decreased red cell production or increased red cell destruction. The aplastic crisis may be the initial manifestation of the underlying hematologic disease.[60]

CHRONIC B19 INFECTION In immunocompromised patients, B19 infection can cause a serious, prolonged anemia from persistent lysis of red blood cell precursors.[62] Parvovirus-related chronic anemia has been reported in HIV-infected patients, as well as in transplant recipients and those with congenital immunodeficiencies, acute leukemias, lupus erythematosus, and during the first year of life without immunodeficiency. These patients respond dramatically to intravenous γ globulin, suggesting that antibody is the main defense to human parvovirus infection.[63]

FETAL B19 INFECTION Fetal infection with B19 may result in either an unaffected fetus or spontaneous abortion (especially in the first half of pregnancy), hydrops fetalis in the second half of pregnancy, congenital anemia, and even late fetal death.[64] Nonimmune fetal hydrops is the most common complication of intrauterine infection with B19. Because B19 virus can infect erythroid precursors, extensive hemolysis can occur in the fetus, leading to severe anemia, tissue anoxia, high-output heart failure, and generalized edema. The fetus may show ultrasonographic evidence of subcutaneous edema, ascites, pleural effusion, pericardial effusion, placental edema, and polyhydramnios. The overall risk of fetal death is not clearly known, but recent studies suggest that this risk is approximately 6.5 percent with maternal infection.[64] The risk of fetal death for a woman with unknown serologic status is estimated to be less than 2.5 percent after a household exposure and less than 1.5 percent after a significant work exposure. It seems that in B19-infected pregnant women, most fetuses are not infected; if they are infected, usually there is not an adverse outcome.[65] Furthermore, approximately one-half of women of childbearing age are immune to parvovirus infection because of prior infection.

OTHER COMPLICATIONS

Prognosis and Clinical Course

Parvovirus B19 infection in healthy individuals is self-limited. The rash of erythema infectiosum and the parvovirus arthropathy usually resolve in 1 to 2 weeks, but can recur or persist for months. If untreated, transient aplastic crisis can be fatal, but most patients recover in 1 week. Chronic anemia from B19 usually resolves if treated with γ globulin. Fetal hydrops can lead to fetal death if not treated.

Treatment

There is no specific treatment available for parvovirus B19 infection. Erythema infectiosum is a benign condition, and usually no treatment is necessary. Supportive therapy for relief of fatigue, malaise, pruritus, and arthralgia may be needed. The chronic anemia of persistent B19 infection may be treated successfully with commercially available intravenous immunoglobulin, which contains neutralizing anti-B19 antibodies. Transient aplastic crisis, which can be life-threatening, may require oxygen therapy and blood transfusion.

Serologic testing for B19 IgG and IgM should be offered to pregnant women who are exposed to parvovirus B19. Infected pregnant women are followed by frequent ultrasonograms. Evidence of hydrops fetalis warrants umbilical cordocentesis to check for anemia, viral DNA, IgG, and IgM. The management of infected fetuses is controversial. Some physicians advocate observation because spontaneous resolution is common. Fetuses with severe anemia and compromise are usually managed with intrauterine exchange transfusion, but this procedure does carry risk (Box 192-5).

Box 192-5

Treatments for Parvovirus B19 Infections

Erythema infectiosum	Supportive treatment of fatigue, malaise, pruritus, arthralgias.
Chronic anemia	IV immune globulin.
Transient aplastic crisis	Oxygen and/or blood transfusion may be necessary.
Hydrops fetalis	Possible intrauterine exchange transfusion.



Prevention

There is currently no vaccine to prevent parvovirus B19 infection. Candidate vaccines are in clinical trials.[76] It is not known whether immunoglobulin given around the time of exposure prevents infection or alters the course of the disease.

Because patients with erythema infectiosum are no longer infectious by the time they develop the illness, control measures directed toward these individuals are not likely to be effective. If these persons are hospitalized, no special precautions need to be taken. Because the virus is transmitted before the rash appears, the disease is easily spread in situations of close prolonged contact such as schools, day care centers, workplaces, and homes.

Patients with aplastic crisis or immunosuppression with chronic B19 anemia may have high-titer viremia and are particularly infectious. These individuals should be placed in respiratory and contact isolation if hospitalized, and pregnant health care providers should not care for them directly. Hospital workers are at risk of contracting nosocomial infections from these patients[77] and could spread the virus to patients if adequate precautions are not taken.



EPSTEIN-BARR VIRUS

Epidemiology

Epstein-Barr virus (EBV) is a worldwide pathogen with more than 90 percent of adults latently infected.[78] In developed countries, most cases of primary infection occur during adolescence or early adulthood, and clinically may present as infectious mononucleosis.[79] Primary infection may occur during childhood; however, is often sub-clinical, probably because children are better able to clear the infection. In developing countries, most of the population is infected during childhood, thus infectious mononucleosis is much less common.

EBV is transmitted primarily by saliva through close contact.[80] Viral replication occurs during primary infection, allowing infectious viral particles to be shed from the oropharynx. There are also reports of EBV acquired via blood transfusion.[81] It is also thought that EBV may be transmitted through breast milk[82] and genital secretions.[83]

Etiology and Pathogenesis

EBV, also called *human herpesvirus 4 (HHV-4)*, belongs to the Herpesviridae family and is approximately 180 to 200 nm in diameter.[80] The double-stranded DNA genome encodes approximately 100 proteins and is enclosed within a capsid. The capsid is surrounded by an envelope, composed primarily of glycoprotein gp350. CD21 is present on the surface of B cells and binds with gp350, allowing entry of EBV into the cell.

EBV infects B lymphocytes directly within the oral mucosa or infects mucosal epithelial cells, which then infect the B lymphocytes.[84–86] The infected B cells are activated, and their population is expanded. These B lymphocytes allow dissemination of the virus throughout the lymphoreticular system.[87] A clonal expansion of cytotoxic T lymphocytes allows recovery from primary infection and is the source of the atypical lymphocytes associated with EBV infection.[88] Symptoms are likely a result of this immunologic response.

EBV establishes an indefinite latent infection within the B cells, during which time low levels of the latent proteins are produced.[87] The previously linear DNA forms a circular structure, called an *episome*. Thereafter, B cells may re-activate and re-infect the oropharynx; replication and shedding of the viral DNA allows transmission of the virus to new hosts.[80,87]

EPSTEIN-BARR VIRUS AT A GLANCE



- Human herpesvirus 4.
- In developed countries, primary infection most often occurs during adolescence/early adulthood.
- Infectious mononucleosis characterized by the triad of fever, lymphadenopathy, and pharyngitis.
- Morbilliform exanthem with primary infection; most common after administration of ampicillin/amoxicillin.
- Oral hairy leukoplakia, nasopharyngeal carcinoma, Burkitt lymphoma, Hodgkin disease, Kikuchi histiocytic necrotizing lymphadenitis, and certain types of cutaneous T-cell lymphoma associated with Epstein-Barr virus infection.

Clinical Findings

HISTORY There is an incubation period of 30 to 50 days. Primary infection with EBV in adolescents and adults typically results in infectious mononucleosis, or the "kissing disease." The classic triad of fever, lymphadenopathy, and pharyngitis are noted in more than 50 percent of patients.[80] The fever may range from 37.5°C (99.5°F) to 40.5°C (104.9°F) and lasts 1 to 3 weeks. Lymphadenopathy is tender and characteristically found in the posterior cervical chain. Examination of the posterior pharynx may vary from mild erythema to grossly enlarged tonsils with white exudates.[87]

CUTANEOUS LESIONS Seventy percent to 100 percent of patients with infectious mononucleosis develop an eruption when antibiotics, specifically ampicillin, are administered.[85] Similar rashes have been reported with other antibiotics, such as amoxicillin, cephalexin, erythromycin, and levofloxacin. The rash typically begins 7 to 10 days after the initial administration of antibiotics. A pruritic, erythematous, morbilliform, or scarlatiniform eruption is noted on the trunk and extremities. The rash has been described as *copper-colored*. Coalescence may be observed on the extensor surfaces and dependent areas. (Fig. 192-7A,B and see eFig. 192-7.1 in on-line edition). The palms, soles, or oral mucosa may be involved. Clearance, which is usually within 7 days,[89] is accompanied by prominent desquamation.[90] The rash is thought to be a result of EBV-induced antibodies that are produced in response to the administered drug; these antibodies subsequently form immune complexes, which fix complement.[85] This exanthem does not usually indicate a permanent allergy to the medication.[91]

An exanthem due to EBV alone may also occur in a minority of cases (approximately 5 percent to 15 percent).[85,89] This rash is also morbilliform and pruritic; however, usually it commences during the first few days of illness and resolves faster, typically in 1 to 6 days.[89,90] Periorbital and eyelid edema may be seen in up to 50 percent of those with infectious mononucleosis.[92] In approximately 25 percent of cases, an enanthem is noted. Six to 20 petechiae, measuring 0.5 to 1.0 mm, may be visualized at the junction of the hard and soft palate. Lesions may coalesce forming larger lesions.

Erythema multiforme, erythema nodosum, acrocyanosis, erythema annulare centrifugum, pityriasis lichenoides, palmar dermatitis, cold urticaria, and granuloma annulare have all been re-





▲ **FIGURE 192-7** **A.** Epstein-Barr virus mononucleosis. Copper-colored papules on trunk and extremities after taking oral amoxicillin. **B.** Closer view of rash with Epstein-Barr virus mononucleosis. (Used with permission from Helmut Hintner, MD.)

ported during infection with EBV.[90] Genital ulcers have also been observed during primary infection with EBV (Fig. 192-8).[93] Typically occurring after the onset of fever and lymphadenopathy, ulcers are painful, deep, and red-violaceous in color. The base of the ulcer can be clear, seropurulent, or with granulation tissue. The ulcers heal in approximately 2 weeks, and treatment is symptomatic.



▲ **FIGURE 192-8** Two scrotal ulcerations in a patient with documented Epstein-Barr virus infection.

EBV is currently the most common cause of Gianotti-Crosti syndrome (GCS; see Chap. 106).[94] In children, primary infection with EBV is often mild or asymptomatic; as a result, typical features of infectious mononucleosis may not be observed.[90]

RELATED PHYSICAL FINDINGS Associated symptoms and signs may include fatigue, rigors, headache, and hepatosplenomegaly.[95]

Laboratory Tests

Most patients with infectious mononucleosis demonstrate a lymphocytosis, often with lymphocytes accounting for more than 50 percent of the absolute white blood cell count.[96] Atypical lymphocytes are a hallmark, typically more than 10 percent atypical lymphocytes; most of these cells represent activated T cells responding to infected B cells.[80] Mild, transient neutropenia[97] and thrombocytopenia[98] are common. Transaminases are elevated in more than 80 percent of patients with infectious mononucleosis.[99]

The presence of heterophile antibodies confirms most cases of infectious mononucleosis.[88] Heterophile antibodies recognize antigens on the erythrocytes from a number of different species including horses, sheep, bulls, and humans; however, they do not recognize EBV. They are thought to be a result of polyclonal stimulation during the viral infection,[100] and can occasionally be detected (false positives) in other illnesses such as lymphoma, hepatitis, or autoimmune disease.[88] Heterophile antibodies typically appear within 1 week of the onset of symptoms, peak within 2 to 5 weeks, and may persist for up to 1 year. They are not the ideal diagnostic test in children less than 4 years old, as sensitivity is quite low.[95] In the past, the Paul-Bunnell test had been used with sheep erythrocytes.[88,96] Currently, the more sensitive monospot test is used, which is a latex agglutination assay with horse erythrocytes to look for heterophile antibodies. Up to 10 percent of patients with EBV mononucleosis never develop heterophile antibodies; this is referred to as *heterophile-negative mononucleosis*.

A number of antibodies specific to EBV develop in the course of disease as well.[88,95] Measurement of these specific antibodies may be warranted if infectious mononucleosis is suspected and heterophile antibodies are negative. IgM and IgG antibodies form to viral capsid antigen (VCA) and are both present at onset of disease. IgM VCA antibodies wane after approximately 3 months; IgG VCA antibodies persist for life and are a marker for previous infection. IgG antibodies to EBV nuclear antigen develop 6 to 12 weeks into the course of disease and also persist for life. IgG to early antigen develops at the onset of disease and is made up of two subsets of antibodies, anti-D and anti-R. The presence of anti-D antibodies suggests recent infection, although 30 percent of patients do not produce antibodies at all. Anti-R antibodies have no clinical significance. Thus, primary infection may be most easily diagnosed in the presence of IgM and IgG VCA antibodies as well as negative IgG EBV nuclear antigen antibodies.[101]

Histopathology

The morbilliform exanthem associated with EBV demonstrates non-specific histopathologic findings.[102] There is usually a mild perivascular infiltrate of inflammatory cells. Specific cutaneous manifestations may show their characteristic pathologies.

Differential Diagnosis (Box 192-6)

Complications

Complications of infectious mononucleosis occur in approximately 20 percent of patients and include airway obstruction, autoimmune hemolytic anemia or thrombocytopenia, neutropenia,[87] myocarditis, and hepatitis.[80] Neurologic complications occur in approximately 5 per-

Box 192-6

Differential Diagnosis of Infectious Mononucleosis

Most Likely

- Group A streptococcal infection
- Cytomegalovirus mononucleosis
- Toxoplasmosis

Consider

- Viral hepatitis
- Measles
- Rubella
- Enterovirus
- Adenovirus

Always Rule Out

- Primary exanthem of human immunodeficiency virus
- Drug rash with eosinophilia and systemic symptoms syndrome



Box 192-7

Treatment for Epstein-Barr Virus Infectious Mononucleosis

First line	Fever, throat discomfort, myalgias, headache. Splenomegaly.	Acetaminophen/nonsteroidal anti-inflammatory drugs. Avoid contact sports until spleen size normalizes to prevent splenic rupture.
Second line	Impending airway obstruction, thrombocytopenia, hemolytic anemia.	Systemic corticosteroids.

cent of patients.[87] Examples include encephalitis, meningitis, and Guillain-Barré syndrome.[80] The risk of splenic rupture is estimated at 0.1 percent and is spontaneous in greater than one-half of cases.[103] Between 3 percent and 30 percent of patients with infectious mononucleosis also have concomitant group A streptococcal pharyngitis.[96] Finally, in some patients, fatigue and hypersomnia can persist up to 6 months.[104]

Prognosis and Clinical Course

Recovery from infectious mononucleosis is typically gradual over 2 to 3 weeks without specific treatment.[88] Disease may be more protracted in older adults. Chronic active EBV infection occurs rarely.[80] It begins as a primary EBV infection and persists for more than 6 months with severe illness and histologic evidence for organ disease. EBV DNA or antigens can be demonstrated from tissue, and usually EBV antibody titers are significantly elevated.

Treatment

Treatment for uncomplicated infectious mononucleosis is symptomatic (Box 192-7).[95] Acetaminophen or nonsteroidal anti-inflammatory agents may be useful in treating the fever or throat discomfort. Because splenomegaly is often an associated finding, contact sports should be avoided until the spleen has returned to its normal size to avoid splenic rupture.

Systemic corticosteroids may decrease the duration of fever or pharyngeal symptoms, but in general, are not recommended for uncomplicated disease.[79]

Prevention

Because infectious mononucleosis is often mistaken for a bacterial infection, antibiotics may initially be used to treat. Antibiotics should be avoided in infectious mononucleosis as an exanthem is much more likely to occur in this setting.

Vaccinations are currently being investigated and may prove to be helpful in preventing EBV infections in the future, particularly in high-risk patients.[80]

Oral Hairy Leukoplakia (See Chap. 198)

Lymphoproliferative Disease and Malignancy

The latent infection established by EBV has been linked to the development of several malignancies, including nasopharyngeal carcinoma, Burkitt lymphoma, and Hodgkin lymphoma.[80] EBV-associated malignancies occur mainly in patients who are immunocompromised due to HIV infection, congenital immunodeficiencies, or those who receive immunosuppressant therapy such as organ transplant recipients. It is thought that the latent infection of B cells allows transformation and immortalization, allowing the development of a neoplasm to occur.[113] Different EBV genes are expressed in each type of malignancy and the biology is quite complex.

Kikuchi Histiocytic Necrotizing Lymphadenitis

GIANOTTI-CROSTI SYNDROME

Epidemiology

GCS, also known as *infantile papular acrodermatitis* and *papular acrodermatitis of childhood,* is a common, self-limited dermatosis seen worldwide. It affects infants and children between the ages of 6 months and 12 years with the peak age of presentation being 1 to 6 years of age. In children, there is neither an ethnic nor sexual predilection.[128,129] There have been only scattered case reports in adults.

Etiology and Pathogenesis

GCS is a cutaneous reaction pattern associated with viruses, bacteria, and vaccines. Historically, it was thought to be induced exclusively by hepatitis B, but over time other infectious triggers were identified. When hepatitis B is the causative agent, sub-type ayw is most frequently seen.[130] Associated triggers include hepatitis B and EBV most commonly, but other associated viruses include cytomegalovirus, enterovirus, respiratory syncytial virus, rotavirus, adenovirus, echovirus, pox virus, poliovirus, coxsackie virus, parvovirus, HIV, hepatitis A, hepatitis C, and parainfluenza virus. Bacterial pathogens include *Mycoplasma pneumoniae, Borrelia burgdorferi, Bartonella henselae,* and group A β-hemolytic streptococcus. Immunizations that have been associated include influenza, diphtheria, tetanus, pertussis, bacillus Calmette-Guérin, *Haemophilus influenzae* type b, and oral polio vaccine. The exact pathogenesis of GCS is not known but may be due to a viral antigenemia or circulating immune complexes.[131] Virus-like particles have been seen in cytoplasmic vacuoles and lysosomes in lesional skin.[132]

GIANOTTI-CROSTI SYNDROME AT A GLANCE



- Papular acrodermatitis of childhood.
- Common, self-limited dermatosis.
- Monomorphic dome-shaped or flat-topped papules symmetrically distributed on face and extensor extremities.
- Associated with multiple viral triggers and immunizations.
- Historically associated with hepatitis B infection, but now more often triggered by Epstein-Barr virus.

Clinical Findings

HISTORY Before the onset of the exanthem, a non-specific prodrome of upper respiratory tract infection with fever and pharyngitis plus low-grade fever may be present.

CUTANEOUS LESIONS Typically, patients develop multiple coalescing, monomorphous, flat-topped or dome-shaped, red-brown papules and papulovesicles (Fig. 192-9 and see eFig.192-9.1 in on-line edition). Lesions can be pruritic and, rarely, hemorrhagic. Papules vary from 1 to 10 mm in diameter (see Fig. 192-9C)[133] and are distributed symmetrically on the cheeks, extensor surfaces of the extremities, and the buttocks. The trunk, palms, and soles are usually, but not al-







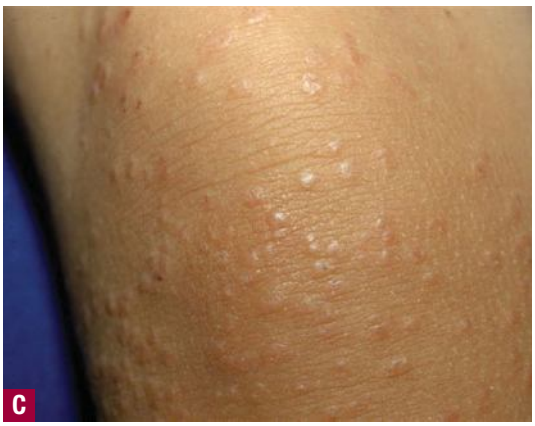

▲ **FIGURE 192-9** Monomorphous crusted papules on face (**A**) and extensor extremities (**B**) in a patient with Gianotti-Crosti syndrome. **C.** Flat-topped, 2- to 4-mm papules with very uniform appearance.

Box 192-8

Differential Diagnosis of Gianotti-Crosti Syndrome

Most Likely
- Papular urticaria
- Pityriasis rosea

Consider
- Erythema multiforme
- Lichen planus
- Lichenoid drug eruption
- Pityriasis lichenoides et varioliformis acuta
- Molluscum contagiosum
- Hand-foot-mouth disease
- Follicular eczema
- Erythema infectiosum

Always Rule Out
- Infectious mononucleosis
- Henoch-Schönlein purpura
- Scabies

ways, spared. Occasionally, the small papules coalesce into large plaques. Cutaneous lesions evolve over a few days and last for 2 to 8 weeks.

RELATED PHYSICAL FINDINGS Constitutional symptoms, including malaise, low-grade fevers, and diarrhea, are sometimes seen at time of presentation, but are usually mild. Patients can develop lymphadenopathy, especially of the cervical, axillary, and inguinal chains.[134]

Laboratory Tests

In most patients, the diagnosis is established on clinical findings and no further diagnostic testing is necessary. In patients with hepatomegaly, further diagnostic testing, including complete blood cell count and liver enzymes, may be warranted. Lymphocytosis or lymphopenia are common and do not require further diagnostic evaluation. If there are elevations in the liver enzymes, evaluation for hepatitis or EBV should be performed. If hepatitis is suggested, checking anti–hepatitis A IgG and IgM, hepatitis B surface antigen and core antibody, and anti–hepatitis C IgG is indicated.

Differential Diagnosis (Box 192-8)

Complications

Complications are rare with the majority of cases having a self-limited and mild course. On rare occasions, when GCS is associated with hepatitis B infection, chronic liver disease with subsequent liver failure can occur.[131]

Prognosis and Clinical Course

In the vast majority of cases, GCS is a self-limited, benign process. The course is quite variable, with the skin findings lasting anywhere from 5 days to 12 months.[134,135] Lesions heal without scarring, and, rarely, post-inflammatory hypopigmentation or hyperpigmentation is seen. Lymphadenopathy can last for several months.[130] In cases associated with hepatitis B, an anicteric viral hepatitis evolves and may not be seen until 2 weeks after cutaneous lesions are seen. Most of the time, the hepatitis is self-limited.

Treatment

No treatment is necessary in the majority of cases. In some patients, medium potency topical steroids may decrease the duration of lesions when applied once daily for 1 to 2 weeks. However, patients should be monitored closely because worsening of findings with topical steroid use has been documented.[136] In severe cases, systemic, pulsed corticosteroids may be administered.[137] Oral antihistamines or topical anti-itch lotions may diminish severe pruritus.

Prevention

There is no known way to prevent GCS.

HUMAN CYTOMEGALOVIRUS

Epidemiology

Human cytomegalovirus (HCMV) is ubiquitous around the world. The seroprevalence in the population increases with age, with 10 percent to 20 percent of children infected before they reach puberty.[138] By adulthood, the prevalence of HCMV is 40 percent to 100 percent. For unclear reasons, there is a higher prevalence in developing countries and areas of low socioeconomic status. HCMV is the most common congenital viral infection in humans with an incidence of 0.2 percent to 2.2 percent of live births in the United States.[139] Five percent to 17 percent of congenital infections exhibit neurodevelopmental sequelae.[140] Nearly all HIV-infected patients are infected with HCMV.[141] It is a significant cause of morbidity in bone marrow transplant (BMT) and solid organ transplant (SOT) patients, with 50 percent to 90 percent of patients infected.[139]

Etiology and Pathogenesis

HCMV, which corresponds to HHV-5, is a member of the Herpesviridae family,



CYTOMEGALOVIRUS AT A GLANCE



- Human herpesvirus 5.
- High prevalence in the population.
- Establishes latent infection and capable of re-activation in immunosuppressed states.
- Primary infection is mainly asymptomatic; it is the cause of severe morbidity and mortality in utero and in immunocompromised patients.
- Petechiae and blueberry muffin syndrome with congenital infection.
- Congenital infection is major cause of hearing loss.
- Infected cells are cytomegalic with intranuclear inclusions.



and the prototype of the β-Herpesviridae subfamily. The 230-kbp virion is composed of a double-stranded DNA linear genome encapsulated in an icosahedral capsid enclosed in a lipid bilayer membrane, which contains multiple membrane glycoproteins.[139] HCMV is distinguished by its salivary gland tropism, slow growth, and species specificity.

Humans are the only known reservoir for HCMV, and transmission occurs from person to person. Close contact is required as the virion is labile to heat and drying.[139] Transmission can also occur via saliva, fomites, sexual activity, blood transfusions, organ transplantation, intrauterine perinatal exposure, and breast milk.[85,142,139]

The virus disseminates throughout the body in leukocytes via the bloodstream. It can infect various organs depending on the age of the host.[140] As with other herpesviruses, HCMV establishes latency in the host after recovery from acute primary infection. HCMV remains latent in $CD34^+$ myeloid progenitor cells in bone marrow.[143] Productive infection can result in cell lysis, but organ dysfunction during symptomatic infection is a combination of infected cell dysfunction and the inflammatory response to the infection.[144]

Infection of cells results in cytomegaly and nuclear inclusions, hence the name *cytomegalovirus*. These "protozoan" cells were noted by Ribbert in 1881 in organs of a stillborn. The disease later became known as *cytomegalic inclusion disease*. In 1960, the term *cytomegalovirus* was proposed to replace salivary gland virus and salivary inclusion disease virus.[145]

Clinical Findings

CONGENITAL HUMAN CYTOMEGALOVIRUS INFECTION ***History.*** Congenital HCMV (cytomegalic inclusion disease of the newborn) occurs mostly in children of primiparous women with primary infection during pregnancy. Fifty-five percent of maternal primary HCMV infections results in intrauterine HCMV infection of the fetus, and approximately one-third of those are symptomatic.[146] Re-activation or secondary HCMV infection of a HCMV-immune woman during pregnancy rarely results in symptomatic HCMV infection for the baby.[146]

Cutaneous Lesions. Cutaneous findings in the newborn include a petechial rash secondary to thrombocytopenia, jaundice due to hepatitis and blueberry muffin lesions (Fig. 192-10) from dermal erythropoiesis. In one study, approximately 70 percent of children with symptomatic congenital HCMV infections had petechiae and jaundice.[147] Dermal erythropoiesis, also known as *thrombocytopenic purpura* or *blueberry muffin syndrome*, can also be seen with congenital rubella,[148] toxoplasmosis, and blood dyscrasias. These purpuric lesions are present at birth and evolve during the first 24 to 48 hours of life. They are papular and range from 2 to 10 mm in diameter. Lesions are initially dark blue to violaceous and fade to red or copper-brown. They regress during the first 6 weeks of life despite continued presence of the virus. Histology shows plaque-like aggregates of nucleated cells and non-nucleated erythrocytes in the reticular dermis.[149]

Related Physical Findings. Related findings include hepatosplenomegaly in virtually all newborns, microcephaly, periventricular calcifications, ventriculomegaly, encephalitis, chorioretinitis, hearing loss or neurodevelopmental sequelae, intrauterine growth retardation, and postnatal failure to thrive. Studies show that 22 percent to 65 percent of symptomatic and 6 percent to 23 percent of asymptomatic children have hearing loss after congenital HCMV infection.[150]



▲ **FIGURE 192-10** Newborn with congenital human cytomegalovirus infection: Blueberry muffin baby. (From Groark SP, Jambel RM: Violaceous papules and macules in a newborn. Dermal erythropoiesis associated with congenital cytomegalovirus infection. *Arch Dermatol* **114**:116, 1989, with permission.)

PERINATAL HUMAN CYTOMEGALOVIRUS INFECTIONS ***History.*** Perinatal infection with HCMV is very different from congenital HCMV infection, without diffuse visceral or central nervous system involvement.[146] Transmission of the virus occurs via cervical secretions, breast milk, or blood transfusions between 4 and 16 weeks of age. It is usually asymptomatic, although it may be manifested by self-limited lymphadenopathy, hepatosplenomegaly, or afebrile pneumonitis.

Cutaneous Lesions. There are usually no cutaneous findings with perinatal HCMV infection. Uncommon presentations for HCMV infection in infants and children include scleroderma, GCS,[128,151] gray pallor, hepatosplenomegaly with self-limited respiratory deterioration in preterm infants,[152] and cutaneous vasculitis.[152]

HUMAN CYTOMEGALOVIRUS INFECTION IN IMMUNOCOMPETENT ADULTS AND CHILDREN ***History.*** Although primary HCMV infection in the immunocompetent patient is usually asymptomatic, some can present with an infectious mononucleosis-like picture.[153] Approximately 10 percent of infectious mononucleosis cases are caused by HCMV. Symptoms and signs are indistinguishable from EBV-induced mononucleosis, including fever, malaise, splenomegaly, hepatitis, peripheral, and atypical lymphocytosis. Unlike EBV mononucleosis, HCMV-induced mononucleosis patients do not typically have pharyngitis and lymphadenopathy.[154] Given the lack of heterophile anti-

bodies, HCMV mononucleosis is also known as *heterophile-negative mononucleosis*. *Post-perfusion syndrome* is the term used when HCMV mononucleosis occurs between 3 to 6 weeks after exposure to blood products.[155]

Cutaneous Lesions. A few patients with HCMV mononucleosis develop a rubelliform or morbilliform eruption; if given ampicillin, 80 percent to 100 percent develop a morbilliform rash within 1 week (see eFig. 192-10.1 in on-line edition).[156] There have been reports of erythema nodosum[157] and urticaria[85] associated with acute HCMV mononucleosis.

HUMAN CYTOMEGALOVIRUS AND THE IMMUNOCOMPROMISED ***History.*** Immunocompromised patients are at risk for HCMV primary infection as well as reactivation resulting in persistent viremia and disseminated systemic disease.[158] Immunosuppressive agents such as azathioprine and cyclophosphamide alone can re-activate HCMV disease, as can systemic corticosteroids in conjunction with other immunosuppressive agents.

SOLID ORGAN TRANSPLANT RECIPIENTS. SOT recipients not infected with HCMV receive an organ from an HCMV-positive individual are at highest risk of developing HCMV disease post-transplantation. Other risk factors include therapy with anti–T-cell antibody (OKT3)[159] and those who undergo HHV-6 seroconversion.[160] Initial infection of the transplanted organ is followed by pneumonitis, enteritis, hepatitis, retinitis, and central nervous system disease.[161]

BONE MARROW TRANSPLANT PATIENTS. The risk of HCMV disease in BMT patients is lower with the use of seronegative donors and use of leukocyte-depleted blood products.[162] Risk factors for re-activation include a seropositive recipient, graft-versus-host disease (GVHD), and T-cell depletion of allograft. Pneumonitis has a 60 percent to 80 percent mortality without treatment and 50 percent mortality with antiviral treatment and cytomegalovirus immune globulin.

HUMAN IMMUNODEFICIENCY VIRUS–INFECTED PATIENTS. HCMV retinitis was seen in up to 25 percent of HIV-infected patients before the use of highly active antiretroviral therapy (HAART).[163] Now, immune recovery vitreitis with posterior segment inflammation is seen as CD4 counts recover after initiation of HAART.[164] Encephalopathy, peripheral polyradiculopathy, pneumonitis,[161] and colitis[165] may occur.



▲ **FIGURE 192-11** Infant with acquired immunodeficiency syndrome and diaper dermatitis–like disseminated human cytomegalovirus. (From Thiboutot DM et al: Cytomegalovirus diaper dermatitis. *Arch Dermatol* **127**:396,1991, with permission.)

Cutaneous Lesions. Cutaneous manifestations of HCMV disease in immunocompromised patients are rare compared with involvement of other organs. Perianal and rectal ulceration are most common (Fig. 192-11).[166] Also seen are indurated hyperpigmented nodules or plaques,[167] papular and purpuric eruptions,[166] vesiculobullous lesions,[168] purpura, petechiae,[169] indurated plaques, and nodules (see eFig. 192-11.1 in on-line edition). Verrucous and necrotic nodules have been reported in HIV-infected patients.[158] Some of these cutaneous manifestations may be caused by infection of the endothelium of cutaneous blood vessels.[170]

Laboratory Tests

The gold standard for diagnosis of HCMV infection is viral culture from blood using human fibroblasts. Infection is determined by cytopathic effect. However, it takes days to several weeks to see the cytopathic effect in culture. The diagnosis of congenital HCMV infection can be made by detection of virus in urine or saliva via culture or PCR (Fig. 192-12).[172]

The characteristic histologic feature of cytomegalovirus (CMV) infection is cytomegalic cells with nuclear inclusions (Fig. 192-13). In the skin, enlarged endothelial cells with large intranuclear inclusions and a clear halo are seen in small dermal vessels.[173] Histologic diagnosis is specific but sensitivity is low.[174]

Various fast and reliable methods for detection of HCMV antigens and nucleic acids in cells and tissue are available. These include HCMV antigenemia assay (detects pp65 in peripheral blood neutrophils), hybrid capture assay (detects HCMV DNA in leukocytes), and quantitative and qualitative PCR.[119]

In immunocompetent individuals, IgM is usually positive during primary infection. The reported sensitivity of commercially available ELISA for HCMV IgM varies. Rheumatoid factor and EBV-IgM may yield false-positive results.[175] IgG may be negative during active infection, but subsequent fourfold rise in IgG titer is indicative of infection.

The diagnosis of invasive CMV disease can be challenging because the presence of the virus does not mean causality given that the virus establishes latency after primary infection.

Differential Diagnosis (Boxes 192-9 and 192-10)

Complications

Possible complications of postnatal HCMV infection include interstitial pneumonia, hemolytic anemia, splenic infarction, thrombocytopenia and hemolytic anemia, hepatitis, Guillain-Barré syndrome, meningoencephalitis, myocarditis, arthritis, and gastrointestinal/genitourinary syndromes (i.e., colitis, esophagitis, cervicitis, and urethral syndromes).[140,146]

Prognosis and Clinical Course

HCMV disease in immunocompetent individuals is usually self-limited. In immunocompromised patients with systemic HCMV disease, the prognosis is poor and mortality 85 percent.[176]

Treatment

HCMV infection in immunocompetent hosts is usually asymptomatic or self-limited, not requiring treatment with antiviral drugs. Ganciclovir, valacyclovir, foscarnet, and cidofovir have been approved for systemic treatment of HCMV disease.[177] HAART is effective in suppressing HCMV viremia and preventing CMV retinitis in acquired immunodeficiency syndrome patients without end-organ disease.[178] Ganciclovir and valacyclovir are also used for HCMV prophylaxis.[40,177]

None of these drugs is recommended for treatment of symptomatic congenital HCMV infection.





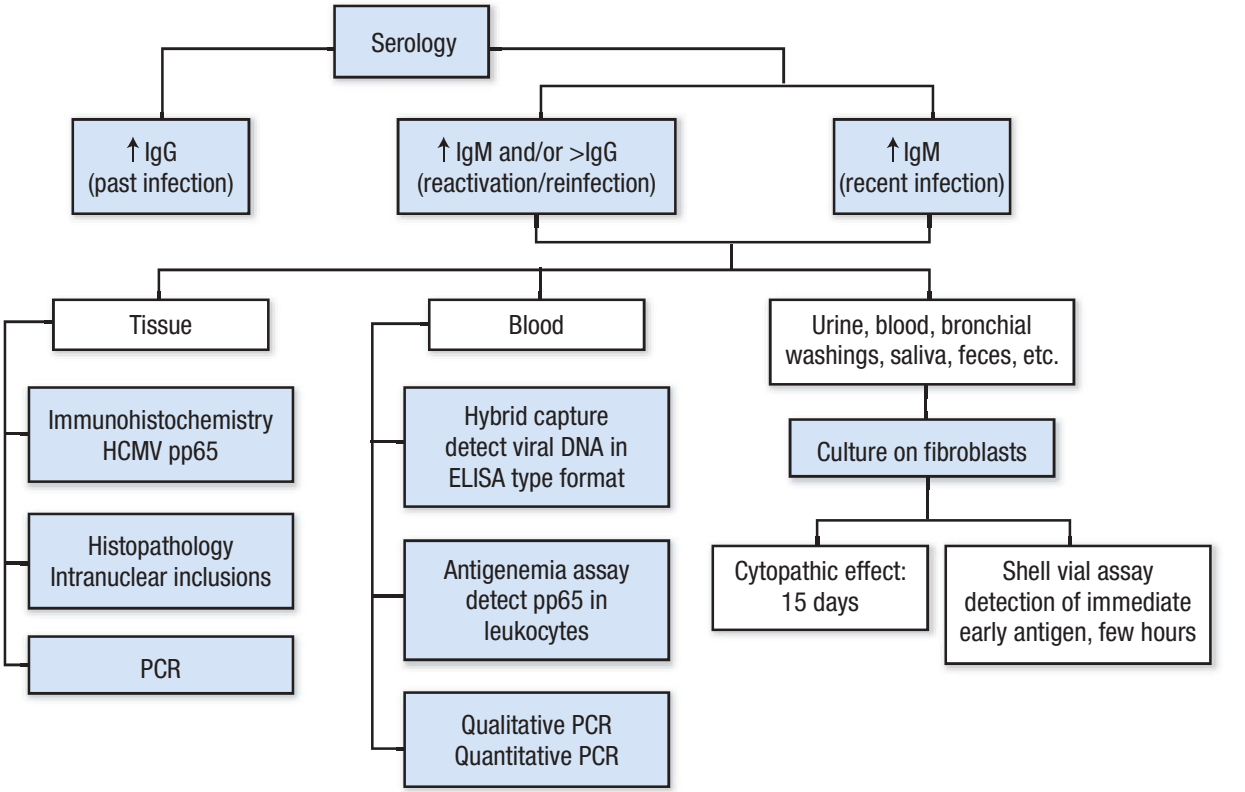

▲ **FIGURE 192-12** Algorithm demonstrating the various methods for diagnosis of active human cytomegalovirus (HCMV) infection. ELISA = enzyme-linked immunosorbent assay; Ig = immunoglobulin; PCR = polymerase chain reaction.

Prevention

Prevention of HCMV infection in transplanted patients can be achieved with use of blood and tissues from HCMV-negative donors.[162] Preemptive (at time of high risk for disease but before symptoms) or prophylactic treatment can be used for immunocompromised individuals at risk of infection from blood transfusions or organ transplantation with ganciclovir.[146] Risk factors evaluated for preemptive therapy include CMV viremia and GVHD. The use of prophylactic versus preemptive therapy remains controversial.[179,180]

HUMAN HERPESVIRUS 6

Epidemiology

HHV-6 has been identified as a causative agent for exanthem subitum (ES), also known as *roseola infantum* and *sixth disease*.[181] ES is usually seen in children ages 6 months to 4 years.[182–184] The seroprevalence of HHV-6 in the adult population is greater than 95 percent.[185] Seroprevalence is high in the first few weeks of life and subsequently declines as maternal antibodies wane. It rises again by 1 year of age, with its peak between 3 to 5 years of age, and declines with advancing age.[184,186–188] There is a discrepancy between the seropreva-

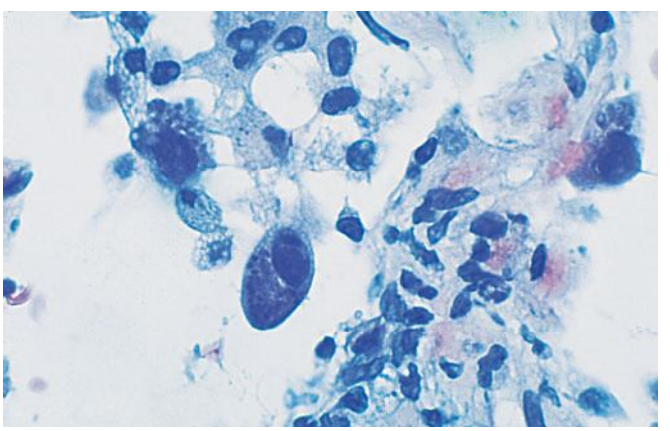

▲ **FIGURE 192-13** Intracellular inclusions in a cell infected by human cytomegalovirus. (From Konstadt JW et al: Disseminated cytomegalovirus infection with cutaneous involvement in a heart transplant patient. *Clin Cases Dermatol* **2**:2, 1990, with permission.)

Box 192-9

Differential Diagnosis of Congenital Human Cytomegalovirus (Blueberry Muffin Syndrome)

Most Likely

- Causes of dermal (extramedullary) hematopoiesis
  - Congenital infection
    - Rubella
    - Toxoplasmosis
    - Herpes simplex virus infection
    - Enterovirus
  - Twin-twin transfusion syndrome
  - Hereditary spherocytosis
  - Rhesus and ABO incompatibility

Consider

- Langerhans cell histiocytosis
- Neonatal lupus erythematosus

Always Rule Out

- Congenital leukemia
- Neuroblastoma with skin metastases

Box 192-10

Differential Diagnosis of Human Cytomegalovirus Mononucleosis

Most Likely

- Epstein-Barr virus mononucleosis

Consider

- Toxoplasmosis
- Viral hepatitis

Always Rule Out

- Lymphoma

lence of HHV-6 and the incidence of ES, mainly thought to be due to the varied clinical manifestations of HHV-6 infection and sub-clinical HHV-6 infection.[189] Primary HHV-6 infection in children can result in a sub-clinical infection or an acute febrile illness without cutaneous manifestations.[190,191]

There is seasonal variation of HHV-6 infection with highest incidence in spring; summer and fall epidemics have also been reported.[85]

Etiology and Pathogenesis

HHV-6 is a member of the β-Herpesviridae subfamily. There are two distinct variants by restriction enzyme analysis, HHV-6a and -6b.[192] They are different in their immunologic, biologic,[193] and genetic[192] characteristics. HHV-6b causes ES, but it is unclear what diseases, if any, are caused by HHV-6a.[194]

The cellular receptor for HHV-6 is CD46.[195] The mode of transmission is proposed to be via nasopharyngeal viral shedding from healthy individuals.[196] Airborne transmission is likely via saliva.[197] HHV-6 has been isolated from the saliva of healthy individuals[182,184] and viral shedding is intermittent, not associated with changes in antibody titers.[184] HHV-6 DNA is found in the cervix of infected women,[198] raising the question of possible perinatal infection, although children of mothers with positive swabs do not acquire early HHV-6 infection. HHV-6 DNA has also been found in fetal tissue from spontaneous abortions.[199,200] HHV-6 is not transmitted through breast milk.[85] Transmission in transplant patients can occur via the grafted organ.[201,202] The incubation period for HHV-6 infection is 5 to 15 days, with an average of 10 days. Viremia in immunocompetent children lasts 3 to 4 days in ES, whereas viremia from HHV-6 re-activation in allogeneic BMT patients lasts weeks.[203]

HHV-6 replicates in salivary glands,[204] where it can establish a persistent infection.[185] It is tropic for $CD4^+$ T lymphocytes in vitro[205,206] and establishes latency in human peripheral blood monocytes/macrophages[207] and early bone marrow progenitors.[208] HHV-6 genome is able to integrate into the host cell DNA at the ends of chromosomes 1, 17, and 22.[185]

HHV-6 can re-activate from latency in immunosuppressed individuals.[85,201,209] A synergistic effect on disease of HHV-6 and CMV has been described in renal transplant recipients.[210,211] HIV and HHV-6 also appear to be synergistic.[146] The clinical importance of this finding remains to be elucidated. Unlike in transplant patients, there does not seem to be one specific clinical syndrome of HHV-6 infection in HIV-infected patients.[185]

HUMAN HERPESVIRUS 6 AT A GLANCE

- Causes exanthema subitum (roseola infantum, sixth disease).
- Febrile seizures often without rash in children.
- High seroprevalence in general population by 1 year of age.
- Re-activation in immunocompromised individuals is cause of morbidity.

Clinical Findings

HISTORY Primary infection with HHV-6 results in an acute febrile illness typically in children 6 months to 1 year of age.[185] The fever lasts approximately 3 to 7 days[185] and can be followed by the characteristic rash of roseola in a minority of children.[191,212,213]

HHV-6 infection is seen in 40 percent to 50 percent of transplant recipients (BMT more than SOT) and peaks at 2 to 4 weeks post-transplantation. Approximately one-half of these infections result in symptomatic disease with bone marrow suppression.[214]

CUTANEOUS LESIONS ***Exanthem Subitum.*** Palpebral edema can be evident from the first to third day of fever, resulting in a "sleepy" appearance, and resolves after a day of the exanthema.[215] Erythematous papules on the soft palate (Nagayama spots) may precede the viral exanthema.[215] The exanthem is seen from 1 day before to 1 to 2 days after the fever fades and lasts for 3 to 5 days.[215] It is characterized by rose red macules or papules 2 to 5 mm in diameter, surrounded by a white halo. These are distributed mainly on the neck and trunk and sometimes on the face and proximal extremities (Fig. 192-14).[140] Desquamation is not usually seen.

Transplant Recipients. A rash similar to acute GVHD has been described in pediatric patients undergoing BMT who have HHV-6 re-activation.[216,217] Fever and/or rash are the most common manifestations of HHV-6 infections in SOT recipients.[185]

Human Immunodeficiency Virus Patients. HHV-6 can be an opportunistic pathogen in HIV patients, causing encephalitis and pneumonitis in some cases.[185] But most case reports do not show one consistent clinical syndrome in HIV patients.[185]



▲ **FIGURE 192-14** **A,B.** Exanthem subitum in an infant showing truncal pink macules and some papules that appeared 1 day after defervescence.



Rosai-Dorfman Disease. (See Chap. 149) HHV-6 genome has been detected in tissue from patients with sinus histiocytosis with massive lymphadenopathy or Rosai-Dorfman disease,[218] and immunohistochemical studies suggest a possible pathogenic involvement.[219]

RELATED PHYSICAL FINDINGS Patients with ES may have high fever, malaise, inflamed tympanic membranes, conjunctival injection, gastrointestinal and respiratory tract symptoms, cervical lymphadenopathy, and bulging fontanelle.[215,220]

A mononucleosis-like infection, which is EBV- and CMV-negative, has been attributed to HHV-6 in children and adults.[140]



Laboratory Tests

Although laboratory results may be variable in HHV-6 primary infection, one can see leukopenia (between 3000 to 6000 cells/mm^3) with an increased percentage of lymphocytes between days 3 and 6 of the illness. White blood cell count elevation can be seen at the beginning of the febrile phase.

HHV-6 infection is usually benign and self-limited; however, in atypical cases, serologic studies may be valuable. This can be done by ELISA or by indirect immunofluorescence. Anti–HHV-6 IgM antibodies are a marker of recent infection or re-activation, but 5 percent of adults may be IgM seropositive at any time. IgM develops after 5 to 7 days of infection, peaks at 2 to 3 weeks, and disappears in 2 months. IgM alone is not reliable.[221] A fourfold IgG increase between acute and convalescent sera IgG indicates active infection.

Laboratory tests vary in their ability to distinguish latent virus from actively replicating virus. PCR detection of HHV-6 DNA in cell-free serum, plasma, or CSF indicates active replication, whereas a positive PCR from cellular material does not indicate active replication because the virus can be found latent in cells. Viral culture is not used routinely because it is technically difficult and may take more than 1 week. A combination of a positive serum IgM with positive PCR of whole blood DNA in patients older than 3 months of age has excellent specificity and sensitivity, and positive and negative predictive value for primary infection.[190,222] Although not routinely available, quantitative PCR allows fast, sensitive, and absolute quantitation of viral load, making it a method of choice.

Complications

Febrile seizures are thought to occur in 10 percent of children with primary HHV-6 infection.[185] Rarely, encephalitis has been reported in children with fatal or severe sequelae such as hemiparesis.[190] Although usually a benign infection, rare complications include hepatitis, hemophagocytic syndrome, pneumonitis, and thrombocytopenia.[185,189] Hemophagocytic syndrome has been reported on re-activation of HHV-6 in an immunocompetent adult.[223]

HHV-6 infection or re-activation in the immunocompromised can also result in hepatitis,[202] pneumonitis,[224,225] bone marrow suppression,[226,227] and graft dysfunction or rejection.[211] Re-activation of HHV-6 in the immunocompromised host can result in encephalitis and/or encephalopathy.[185] There have been reports of fulminant multifocal demyelinating disease in both immunocompetent and immunocompromised patients. The contribution of HHV-6 infection to progressive multifocal leukoencephalopathy or multiple sclerosis is being studied.[185]

Prognosis and Clinical Course

ES is benign and self-limiting. Treatment may be necessary for atypical cases with complications and in immunosuppressed patients. Primary infection can be fatal in the immunocompromised host.

Treatment

There are no controlled clinical trials, and no compounds have been formally approved for treatment of HHV-6 infection. The same drugs used for HCMV treatment and prophylaxis have been used for HHV-6. The activities of various antiviral compounds against HHV-6 have been tested in vitro.[228,229] Several case reports support the clinical effectiveness of ganciclovir in HHV-6 treatment and prophylaxis.[185] Foscarnet and cidofovir might also prove to be useful.[185] New antiherpesvirus drugs are being developed, although most are not active against HHV-6.[185] Further studies are needed before treatment and prophylaxis can be recommended.

Prevention

Prophylaxis with ganciclovir may prevent HHV-6 re-activation in BMT and stem cell transplant recipients,[230] but low-dose prophylaxis may facilitate the development of resistance. Preemptive therapy (treatment after systemic detection of virus but before clinical symptoms of disease) has been proposed instead.[185]

HUMAN HERPESVIRUS 7 AT A GLANCE

- Causes a small subset of cases of exanthem subitum.
- Primary infection typically occurs later in life than human herpesvirus 6 infection.

HUMAN HERPESVIRUS 7

Epidemiology

In seroconversion studies, 10 percent of ES cases are caused by HHV-7.[231] Primary infection occurs during childhood, but later than[232] and at a slower rate than infection with HHV-6[233]; both viruses are ubiquitous in adulthood. HHV-7 can be isolated from saliva samples of healthy seropositive adults.[234]

Etiology and Pathogenesis

HHV-7 is a member of the β-Herpesviridae family. It has significant homology to HHV-6; however, it is serologically and biologically distinct. It was initially isolated from CD4$^+$ T lymphocytes from a healthy adult.[235] CD4 has been identified as the cellular receptor for HHV-7.[236]

HHV-7 establishes persistent infection in salivary glands,[237] and transmission might be through saliva.[189] Latent virus can be activated in vitro from peripheral blood mononuclear cells[238] and its DNA can be found in CD4$^+$ T cells. Similar to many other herpesviruses,[239,240] HHV-7 can downregulate expression of CD4[241] and major histocompatibility complex class I,[242] which may play a role in establishment of latency or pathogenesis. Re-activation of HHV-7 occurs more often than re-activation of HHV-6.[233]

Clinical Findings

EXANTHEM SUBITUM HHV-7 causes a small subset of ES cases. When HHV-7 is associated, ES tends to occur later in life than when HHV-6 is associated.[190] The rash associated with HHV-7 is

lighter in color and occurs later in the course of the disease than HHV-6–associated ES.[243]

PITYRIASIS ROSEA (See Chap. 41) HHV-7 DNA has been isolated from skin biopsy specimens, peripheral blood mononuclear cell, and plasma of patients with pityriasis rosea and not controls.[244] However, these findings have not been confirmed by other studies.[245–247] It is possible that the inflammatory milieu in pityriasis rosea activates HHV-7 and HHV-6 within the lesions, but there is no evidence for causality.

LICHEN PLANUS HHV-7 DNA and virion-like structures have been found in lesional lichen planus skin samples compared to non-lesional skin and psoriatic skin samples.[248] Although suggestive, further studies are needed to establish a causal relationship.

HHV-7 has also been found to be the associated with febrile seizures in children.[249]

Laboratory Tests

There is limited cross-reactivity between HHV-7 and HHV-6 in serologic studies.[250] Due to high prevalence, a single positive IgG is not sufficient to establish a diagnosis. Culture from peripheral blood mononuclear cells takes 1 to 3 weeks, and it is not widely available. PCR is more widely available and is useful for timely diagnosis. Diagnosis of active infection by PCR can only be made from acellular material such as CSF, serum, or plasma, because the virus is latent in peripheral blood mononuclear cells and tissue. Immunohistochemical studies for viral antigens in biopsy specimens can be performed.[251]

Differential Diagnosis (Box 192-11)

Complications

Complications of HHV-7–associated ES include acute hemiplegia and febrile seizures with CSF findings consistent with encephalitis[252] and hepatitis.

Prognosis and Clinical Course

Exanthem subitum is a self-limiting disease, which does not require specific antiviral treatment. Disease in immunocompromised can be more serious and require treatment.

Box 192-11

Differential Diagnosis for Human Herpesvirus-6– and Human Herpesvirus-7–Associated Exanthem Subitum

Most Likely
- Human herpesvirus–associated exanthemsum subitum
- Drug hypersensitivity reaction
- Enterovirus (including coxsackie, echovirus)

Consider
- Rubella (German measles)
- Measles/rubeola
- Adenovirus
- Epstein-Barr virus
- Fifth disease (erythema infectiosum, parvovirus)

Always Rule Out
- Scarlet fever
- Kawasaki disease

Treatment

Treatment for HHV-7 has not been evaluated in clinical trials but could be guided by treatment recommendations for HHV-6.

ENTEROVIRUSES

Human enteroviruses may cause a variety of exanthems and clinical syndromes. They are small, single-stranded RNA picornaviruses and include echovirus, coxsackievirus A and B, enterovirus, and poliovirus.[253] Most enteroviral infections are benign. However, non-polio enteroviruses are the most common cause of aseptic (viral) meningitis.[254] Enteroviruses can also cause life-threatening infections with encephalitis, myocarditis, and sepsis.[254] Two distinct enteroviral exanthems include hand-foot-mouth disease (HFMD) and herpangina, which are discussed in the sections Hand-Foot-Mouth Disease and Herpangina. Enteroviral infections are seen throughout the year, but many epidemics occur in the summer and fall. The viruses are primarily spread via the fecal-oral route.

The exanthems seen with enteroviruses are often non-specific and not very dramatic, with small pink macules and papules that resolve in a few days. Petechiae and purpura are frequently present (Fig. 192-15A,B). When a petechial rash due to an enterovirus accompanies high fever and meningeal signs and symptoms, the clinical picture may mimic meningococcemia.

Hand-Foot-Mouth Disease

EPIDEMIOLOGY HFMD is a disease with worldwide distribution that is usually self-limited. There is a slight male predominance. Children less then 10 years of age are most frequently affected and infected adults rarely show signs of infection. Similar to exanthems caused by other enteroviruses, HFMD occurs more during summer and fall in temperate climates and throughout the year in the tropics.[171,255–261] Outbreaks may be sporadic or in epidemics. The largest recorded epidemic was in Taiwan in 1998. This epidemic affected over 120,000 people and caused 78 deaths.[262]

Transmission is via fecal-oral route and, less commonly, respiratory inhalation. There is a high transmission rate among household contacts as has been documented with studies of epidem-



▲ **FIGURE 192-15** **A,B.** Purpuric macules and papules in a 4-year-old girl with enteroviral infection.



HAND-FOOT-MOUTH DISEASE AT A GLANCE



- Viral exanthem seen mostly commonly in children in summer and fall.
- Erosions in the mouth and papulovesicles on the palms and soles.
- Caused by enteroviruses including coxsackievirus A16 and enterovirus 71.
- Self-resolving without serious sequelae in the majority of cases but may have serious complications when caused by enterovirus 71.



ics.[263] Once inhaled or ingested, virus replication ensues in the oropharynx and/or gastrointestinal tract with subsequent viremia. The incubation period of HFMD is believed to be short, lasting 3 to 6 days, with viral shedding lasting up to 5 weeks.[263]

ETIOLOGY AND PATHOGENESIS HFMD is caused by a number of non-polio enteroviruses, including coxsackieviruses A5, A7, A9, A10, A16, B1, B2, B3, B5, echoviruses, and other enteroviruses. The most common causes are coxsackie A16 and enterovirus 71. Enteroviruses belong to the Picornaviridae family, which are single-stranded RNA viruses.

CLINICAL FINDINGS ***History.*** After an incubation phase of 3 to 6 days, affected individuals may complain of a low-grade fever, malaise, abdominal pain, and upper respiratory tract symptoms.

Cutaneous Lesions. Nearly all cases of HFMD have painful oral lesions. These are generally few in number and are found on the tongue (Figs. 192-16A and 192-17A), buccal mucosa, hard palate, and, less frequently, the oropharynx. The lesions start as bright pink macules and papules that progress to vesicles with surrounding erythema. These quickly erode and form yellow to gray erosions surrounded by an erythematous halo. The time between vesicle and erosion is short, and most patients have erosions by the time they visit their physician.

Cutaneous peripheral lesions are present in two-thirds of patients and appear soon after the oral lesions.[264] The lesions are most common on the palms, soles (see Figs. 192-16B,C and 192-17B,C), sides of hands and feet, buttocks (see eFig. 192-17.1 in on-line edition) and, occasionally, external genitalia, and on the face and legs. They evolve similarly to the oral lesions, starting as red macules that become clear oval, elliptical (football-shaped), or triangular vesicles with surrounding red halos (see Figs. 192-16 and 192-17) The number of lesions ranges from few to numerous. After crusting, they heal in 7 to 10 days.

Related Physical Findings. HFMD usually begins with a non-specific prodrome, including low-grade fever [38°C to 39°C (100.4°F to 102.2°F)] that lasts 1 to 2 days, malaise, and, occasionally, abdominal pain or upper respiratory tract symptoms. Sore throat or sore mouth is common and may lead to poor oral intake and dehydration. Cervical and submandibular lymphadenopathy may be present.

LABORATORY TESTS No laboratory tests are indicated. If an epidemic is suspected, stool and throat cultures may be helpful in determining the strain and, therefore, possible complications.

SPECIAL TESTS Historically, enteroviral infection was verified by viral culture, which lacked sensitivity, and suckling mouse inoculation, which detected neutralizing antibodies. Recently, PCR has been found to be very effective in detection and identification of enterovirus serotypes. PCR may be very useful if it becomes widely available.







▲ **FIGURE 192-16** **A.** Toddler with vesicles and surrounding erythema on the tongue from hand-foot-mouth disease. **B,C.** Elliptical, "football-shaped" vesicles with halo of erythema on the palms and soles in the same patient.







▲ **FIGURE 192-17** **A.** Hand-foot-mouth disease is clinically identical in adults. Shallow ulcerations on the tongue that are part of the oral lesions of hand-foot-mouth disease caused by coxsackievirus A16 infection. **B,C.** Vesicular lesions on the fingers and feet.

DIFFERENTIAL DIAGNOSIS (Box 192-12)

COMPLICATIONS Patients rarely experience complications from HFMD. One rare complication, called *eczema coxsackium*, occurs in individuals with eczema. These patients develop disseminated cutaneous viral infection similar to that seen in eczema herpeticum.[265] The most common serious complication associated with HFMD is aseptic meningitis. Aseptic meningitis is rarely life-threatening, and patients do not develop permanent sequelae. Epidemics in Taiwan of enterovirus 71 have resulted in severe disease with encephalitis, encephalomyelitis, polio-like syndromes, myocarditis, pulmonary edema, pulmonary hemorrhage, and death.[259,260,266] Serious complications are less frequent in cases associated with coxsackievirus A16 than with enterovirus 71.[259]

Box 192-12

Differential Diagnosis of Hand-Foot-Mouth Disease

Most Likely
- Herpangina

Consider
- Varicella
- Aphthous stomatitis
- Drug eruption
- Erythema multiforme

Always Rule Out
- Herpes gingivostomatitis

PROGNOSIS AND CLINICAL COURSE HFMD is usually a benign, self-limited illness that resolves within 7 to 10 days. Occasionally, cases associated with more prolonged fever, systemic symptoms, diarrhea, and joint pains have been reported.[267]

PREVENTION During epidemics, public health measures should be instituted to decrease morbidity. Measures such as universal precautions, dissuading attendance at childcare centers or kindergarten, and isolating affected individuals have been suggested.[268]

Herpangina

EPIDEMIOLOGY Herpangina is a self-limited enanthem seen in children around the world. There is no ethnic or sexual predilection. Children are affected most commonly between 3 and 10 years of age. Most outbreaks in temperate climates are seen in the summer and fall. Herpangina is caused by multiple types of coxsackie viruses (most frequently sub-types A8, A10, and A16), echoviruses, and enteroviruses.[269] Transmission is via fecal-oral, respiratory inhalation, or oral-oral spread in the majority of cases.

ETIOLOGY AND PATHOGENESIS Enteroviruses belong to the family of Picornaviridae, which are single-stranded RNA viruses. Herpangina may occur sporadically or in epidemics. Epidemics have been traced to coxsackievirus A types 1, 2, 3, 4, 5, 6, 8, 10, 22, and B1 as well as echovirus types 16 and 25 and enterovirus 71. Replication ensues in the pharynx and gastrointestinal tract, with subsequent viremia. The incubation period is about 4 days,[270] and viral shedding may continue for days to months.

CLINICAL FINDINGS ***History.*** The presenting signs and symptoms of herpangina are sudden onset of fever, chills, sore throat, headache, abdominal pain, vomiting, and body aches. The fever ranges from 37.5°C to 41.5°C (99.5°F to

HERPANGINA AT A GLANCE



- A viral enanthem seen in small children in summer and fall in temperate climates.
- Papulovesicles on the tonsillar pillars, uvula, and soft palate that progress to erosions.
- Caused by enteroviruses, including coxsackievirus and echoviruses.
- Self-resolving over several days without serious sequelae in the majority of cases.



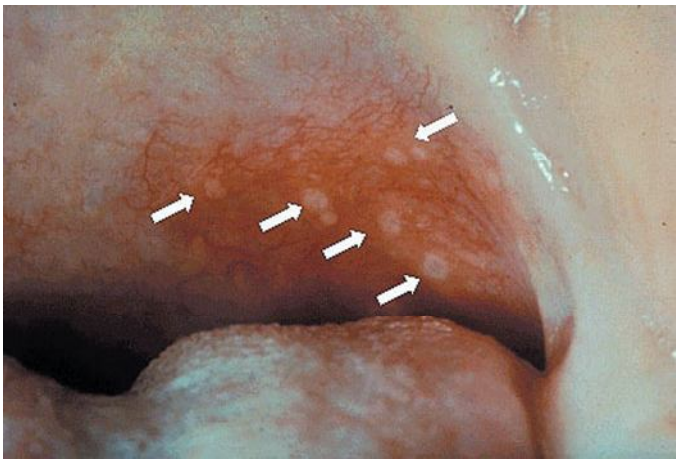

▲ **FIGURE 192-18** Typical appearance of the oropharyngeal lesions of herpangina (*arrows*). Acute, multiple papulovesicular lesions quickly progress to form shallow ulcerations with brisk marginal erythema.



106.7°F). There may be a prodrome of listlessness, irritability, and anorexia a few hours before the onset of fever.

Cutaneous Lesions. Lesions are 1 to 2 mm, yellow-white papulovesicles with surrounding erythema that progress to erosions (Fig. 192-18). They are seen most frequently on the anterior pillars of the tonsillar fauces (or tonsillar pillars), followed by the uvula, tonsils and soft palate. They are less frequently seen on the tongue and buccal mucosa. The number of lesions may vary from very few to numerous. Resolution occurs over 5 to 10 days.

LABORATORY TESTS No laboratory tests are indicated.

SPECIAL TESTS Historically, enteroviral infection has been verified by viral culture that lacked sensitivity and suckling mouse inoculation looking for neutralizing antibodies. Recently, PCR has been found to be very effective in detection and identification of enterovirus serotypes. PCR could be very useful if it were to become widely available.[271]

DIFFERENTIAL DIAGNOSIS (Box 192-13)

COMPLICATIONS Occasionally, patients suffer febrile seizures associated with the fever that is present in the first few days of infection. There have been rare case reports of serious complications, including myocarditis, encephalitis, meningitis, and pulmonary edema.

TREATMENT The main goal of treatment is pain management. Viscous lidocaine, antihistamine mouthwashes, and allopurinol mouthwash may be of benefit in relieving symptoms.

PROGNOSIS AND CLINICAL COURSE The fever rarely lasts longer then 4 days, whereas oral lesions spontaneously resolve several days after their eruption. The prognosis is good, and the course is most often benign.

PREVENTION Once infected, a person has lifelong immunity to that particular strain. Recurrence of herpangina may occur but would be from one of the other strains.

ROTAVIRUS

Epidemiology

Rotavirus is a major cause of diarrheal illness in children under 2 years of age.[272] Rotaviral infections occur worldwide, affecting children in both developing and developed countries.[273] In the United States, the peak of rotaviral infections occurs in the winter. Typically, rotavirus appears in the southwestern United States in November and reaches the Northeast by March.

Rotavirus is transmitted primarily by the fecal-oral route.[274] It has also been postulated that transmission via respiratory droplets and contaminated water is possible. The virus may survive on hands for at least 4 hours, and, in addition, 10 infectious rotaviral particles may be all that is needed to transmit the infection. Once transmitted, viral shedding may commence as early as 48 hours before the development of symptoms and continue for 4 to 7 days thereafter. Asymptomatic shedding is also common.[275] Because of frequent diaper changing and contact between infected toddlers, day care centers often have outbreaks.[274] The fact that soap and water alone are relatively ineffective in removing virus from contaminated hands allows easier transmissibility.[276]

Children between the ages of 6 months and 2 years are most often affected. There is a male predominance that is poorly understood.[277] Adults can also become infected; they are often household members of infected children.[278]

Box 192-13

Differential Diagnosis of Herpangina

Most Likely
- Hand-foot-mouth disease

Consider
- Infectious mononucleosis
- Lymphonodular pharyngitis
- Aphthous stomatitis
- Oral candidiasis
- Varicella
- Diphtheria
- Nutritional deficiency
- Hematologic disorders

Always Rule Out
- Herpetic gingivostomatitis

ROTAVIRUS AT A GLANCE

- Occurs worldwide; peak occurs in the winter.
- Transmission occurs primarily by fecal-oral route; major cause of diarrhea in children under age 2 years of age.
- Belongs to the Reovirus family.
- Skin manifestations may include exanthems, Gianotti-Crosti syndrome, and acute hemorrhagic edema of infancy.

Etiology and Pathogenesis

Rotaviruses belong to the family Reoviridae and the genus *Rotavirus*.[279]

The pathogenesis of skin manifestations associated with rotavirus is unknown, largely because there have been few reports of associated skin findings with varied morphologies.

Clinical Findings

HISTORY After an incubation period of 1 to 3 days, symptoms of rotaviral infection commence.[274] Typically, fever and vomiting are followed by non-bloody diarrhea (often 10 to 12 episodes per day), which occasionally results in moderate to severe dehydration.[277,282,283] Respira-

tory symptoms and otitis media may be present. It has been noted that rotavirus is associated with respiratory symptoms and otitis media in up to 50 percent of cases.[274] In general, illness is less severe in adults.[278] Vomiting and diarrhea are usually present; however, fever and respiratory symptoms are absent.[278]

CUTANEOUS LESIONS Rotaviral infections are not associated with specific dermatologic manifestations; however, several clinical pictures have been reported. A generalized exanthem possibly related to rotavirus has been described.[284,285] Pink-red macules and papules appear 3 to 6 days after the onset of the diarrhea and as defervescence occurs. The asymptomatic rash progresses from the trunk to the extremities and, finally, to the face within hours. The exanthem then fades over approximately 3 days in the same order as it appeared.

Other dermatologic manifestations have been described. GCS occurs in response to a number of different viruses. Two toddlers had GCS with diarrhea 4 and 7 days before the eruption, and rotavirus was isolated from the stool cultures.[286] A third case of Gianotti-Crosti was reported without gastrointestinal symptoms.[287] Rotavirus was isolated from the stool culture, and all other suspected viruses yielded negative results. A child with acute hemorrhagic edema of infancy was found to be associated with a rotaviral infection.[287]

RELATED PHYSICAL FINDINGS It has been noted that rotavirus is associated with respiratory symptoms and otitis media in up to 50 percent of cases.[274]

Laboratory Tests

Laboratory values may be unremarkable; however, it is not unusual to find a mild hyperchloremic metabolic acidosis.[288] Occasionally, liver transaminases may be mildly elevated. Hypernatremia, elevated albumin, and elevated uric acid, when detected, are likely the result of dehydration. Fecal leukocytes may be detected; however, they are usually not significant.[288]

Special Tests

Differential Diagnosis

The diagnosis of rotaviral infection is usually made on clinical grounds in conjunction with identification of rotavirus as the etiologic agent. In general, rotaviral infection is clinically indistinguishable from other enteric viruses; however, diarrhea associated with rotavirus may be more severe and more frequently involve vomiting and fever.[274] Diagnoses that may be considered include enterovirus, ES, adenovirus, and rubella.

Complications

Rotaviral infections may lead to persistent gastrointestinal symptoms, including diarrhea, gastroparesis, and lactose deficiency. Immunosuppressed patients and malnourished patients in developing countries are most at risk for protracted disease.[293] In addition, there have been many associated conditions/syndromes reported, including seizures,[294] encephalopathy,[295] aseptic meningitis,[296] hepatic abscess,[297] acute myositis,[298] pneumonia,[299] sudden infant death syndrome,[300] Reye syndrome,[301] biliary atresia,[302] and Kawasaki disease.[303] It has also been suggested that rotaviruses have been associated with necrotizing enterocolitis[304] and intussusception.[305]

Prognosis and Clinical Course

Rotaviral infection in the United States resolves, on average, within 5 to 7 days, without any sequelae.[282,288] In developing countries, where poverty and malnutrition are common, children are most likely to experience chronic symptoms.[293] Death from rotaviral infection is not uncommon in developing countries due to dehydration.[280]

Treatment

Because there are no specific antiviral agents directed against the rotavirus, therapy is aimed at correcting dehydration and electrolyte imbalance. Oral rehydration is necessary. The World Health Organization recommends the oral rehydration solution, which consists of an isotonic salt solution with glucose supplementation or oral rehydration solution light, which has reduced osmolarity.[306] Intravenous fluids may be necessary if the patient is unable to rehydrate orally or if there is severe dehydration and should ideally consist of lactated Ringer or normal saline. Antibiotics are ineffective, and antimotility agents are not recommended for young children.

Prevention

Infection control is an important means of preventing rotaviral infections.[306] It is important to disinfect contaminated surfaces with quaternary ammonium compounds that contain 40 percent alcohol[274,306] or chlorhexidine gluconate in 70 percent ethanol.[274] Because of the morbidity and mortality associated with rotaviral infections in the developing and developed world, the development of a safe and effective vaccine has become a priority over the past 20 years.[307]

UNILATERAL LATERO-THORACIC EXANTHEM AT A GLANCE



- Asymmetric periflexural exanthem of childhood.
- Children 1 to 5 years of age.
- Pink papules that start in a large flexural region, become bilateral, but remain asymmetric.
- Probably viral etiology.

UNILATERAL LATEROTHORACIC EXANTHEM

Epidemiology

Unilateral laterothoracic exanthem (ULE), also known as *asymmetric periflexural exanthem of childhood,* has a seasonal variation and occurs most frequently in late winter and early spring.[308] It typically occurs in children from 1 to 5 years of age but may be seen from 8 months to 10 years. Rare cases in adults have been reported.[309] There is a slight female predominance.

Etiology and Pathogenesis

The etiology is unknown, but because of its seasonality and associated viral symptoms, a viral trigger is suspected. The distinct clinical presentation may be a manifestation of a variety of infectious agents. The pathogenesis is also unknown.







▲ **FIGURE 192-19** **A.** Asymmetric erythematous exanthem in left axilla consistent with unilateral laterothoracic exanthem. **B.** Coalescence of tiny, pink, rough papules in axilla with left axillary lymphadenopathy.



Clinical Features

HISTORY Mild upper respiratory tract, low-grade fever, or gastrointestinal tract symptoms precede the eruption in a majority of patients.

Conjunctivitis and fatigue may be present.

CUTANEOUS LESIONS The lesions are usually 1- to 2-mm pinpoint, pruritic, pink papules that begin in a large flexural region like the axillae or groin and spread centrifugally (Fig. 192-19). A variety of morphologies have been described, including macules, papules, morbilliform, annular, scarlatiniform, and annular. The initial lesion is often a pink papule with a surrounding pale halo.[308] The eruption typically becomes bilateral and more widespread, but a unilateral and asymmetric distribution remains. The eruption is often quite pruritic.

RELATED PHYSICAL FINDINGS Lymphadenopathy is seen in 70 percent of patients. This often manifests as a large (1 to 3 cm) mobile lymph node at the site where the rash starts.

Box 192-14

Differential Diagnosis of Unilateral Laterothoracic Exanthem

Most Likely
- Allergic or irritant contact dermatitis
- Scarlet fever

Consider
- Other viral exanthems

Always Rule Out
- Herpes zoster
- Atopic dermatitis

Laboratory Tests

No laboratory tests are indicated.

Differential Diagnosis (Box 192-14)

Complications

There has not been documentation of complications after ULE.

Prognosis and Clinical Course

The rash typically lasts from 2 to 6 weeks but may last as long as 2 months. Resolution is spontaneous and without scarring.

Treatment

Treatment for ULE is typically focused on controlling pruritus. This can be done with topical corticosteroids, antiitch lotions, and oral antihistamines.

Prevention

There is no known way to prevent ULE.

KEY REFERENCES

The full reference list for all chapters is available at www.digm7.com.

2. Stalkup JR: A review of measles virus. *Dermatol Clin* **20**:209, 2002
3. Pediatrics, A.A.o., Measles, in *Red Book: 2003 Report of the Committee on Infectious Diseases*, edited by Pickering L. American Academy of Pediatrics: Elk Grove, IL, 2003, p 419
27. Pediatrics, A.A.o., Rubella, in *Red Book: 2003 Report of the Committee on Infectious Diseases*, edited by Pickering L. American Academy of Pediatrics: Elk Grove Village, IL, 2003, p 536
31. Vander Straten MR, Tyring SK: Rubella. *Dermatol Clin* **20**:225, 2002
45. Feder HM Jr, Anderson I: Fifth disease. A brief review of infections in childhood, in adulthood, and pregnancy. *Arch Intern Med* **149**:2176, 1989
64. Levy R et al: Infection by parvovirus B 19 during pregnancy: A review. *Obstet Gynecol Surv* **52**:254, 1997
80. Cohen JI: Epstein-Barr virus infection. *N Engl J Med* **343**:481, 2000
85. Ikediobi NI, Tyring SK: Cutaneous manifestations of Epstein-Barr virus infection. *Dermatol Clin* **20**:283, 2002
119. Gandhi MK, Khanna R: Human cytomegalovirus: Clinical aspects, immune regulation, and emerging treatments. *Lancet Infect Dis* **4**:725, 2004
129. Brown J, Rentiers R: The Gianotti-Crosti syndrome: A distinctive exanthem. *Can Med Assoc J* **4**:773, 1969
133. Brandt O et al: Gianotti-Crosti syndrome. *J Am Acad Dermatol* **54**:136, 2006
154. Horwitz CA et al: Clinical and laboratory evaluation of cytomegalovirus-induced mononucleosis in previously healthy individuals. Report of 82 cases. *Medicine (Baltimore)* **65**:124, 1986
166. Lee JY: Cytomegalovirus infection involving the skin in immunocompromised hosts. A clinicopathologic study. *Am J Clin Pathol* **92**:96, 1989
169. Lesher JL Jr: Cytomegalovirus infections and the skin. *J Am Acad Dermatol* **18**:1333, 1988
170. Pariser RJ: Histologically specific skin lesions in disseminated cytomegalovirus infection. *J Am Acad Dermatol* **9**:937, 1983
185. De Bolle L, Naesens L, De Clercq E: Update on human herpesvirus 6 biology, clinical features, and therapy. *Clin Microbiol Rev* **18**:217, 2005
187. Leach CT, Sumaya CV, Brown NA: Human herpesvirus-6: Clinical implications of a recently discovered, ubiquitous agent. *J Pediatr* **121**:173, 1992
231. Hidaka Y et al: Exanthem subitum and human herpesvirus 7 infection. *Pediatr Infect Dis J* **13**:1010, 1994
259. Chang LY et al: Comparison of enterovirus 71 and coxsackie-virus A16 clinical illnesses during the Taiwan enterovirus epidemic, 1998. *Pediatr Infect Dis J* **6**:1092, 1999
262. Ho M et al: An epidemic of enterovirus 71 infection in Taiwan. Taiwan Enterovirus Epidemic Working Group. *N Engl J Med* **4**:929, 1999
267. Fields JP et al: Hand, foot, and mouth disease. *Arch Dermatol* **6**:243, 1969
274. Dennehy PH: Transmission of rotavirus and other enteric pathogens in the home. *Pediatr Infect Dis J* **19**:S103, 2000
285. Patrizi A et al: Exanthem in children with rotavirus infection. *JEADV* **8**:145, 1997
308. McCuaig CC et al: Unilateral laterothoracic exanthem. A clinicopathologic study of forty-eight patients. *J Am Acad Dermatol* **34**:979, 1996

CHAPTER 193

Herpes Simplex

Adriana R. Marques
Stephen E. Straus

EPIDEMIOLOGY

Herpes simplex virus (HSV) infections are very common and are caused by two closely related types of HSV. Their main clinical manifestations are mucocutaneous infections, with HSV type 1 (HSV-1) being mostly associated with orofacial disease, whereas HSV type 2 (HSV-2) is usually associated with perigenital infection.

The incidence of primary infection with HSV-1, which is responsible for the vast majority of recurring labial herpes, is greatest during childhood, when 30 percent to 60 percent of children are exposed to the virus. Rates of infection with HSV-1 increase with age, and the majority of persons age 30 or older are seropositive for HSV-1.[1,2] From 20 percent to 40 percent of the population have had episodes of herpes labialis.[3] The frequency of recurrent episodes is extremely variable, and, in some studies, averages about once per year,[4] but there is evidence that the frequency and severity of recurrent HSV-1 disease decrease over time.

Acquisition of HSV-2 correlates with sexual behavior and the prevalence of the infection in the pool of one's potential sexual partners. Antibodies to HSV-2 are rare in people before the onset of intimate sexual activity and rises steadily thereafter. HSV-2 seroprevalence in the United States is 22 percent in persons 12 years of age or older.[5]

Although most patients infected with HSV-1 or HSV-2 are asymptomatic, they still can transmit the virus. Studies using DNA polymerase chain reaction (PCR) assays show that rates of detecting HSV-2 DNA in genital secretions of people who have never recognized herpes outbreaks (asymptomatic persons) are similar to the rates of shedding viral DNA in persons who have experienced symptomatic genital herpes but who are not symptomatic at the moment of testing (sub-clinical shedding).[6] It is estimated that more than 70 percent of transmission of HSV-2 is associated with asymptomatic and sub-clinical reactivation and shedding.[7] The average risk of transmission for couples discordant for genital herpes (i.e., one partner has genital herpes and the other does not) varies from 5 percent to 10 percent per year.[7,8] As with other sexually transmitted infections, the rate of acquisition of HSV-2 infection is higher for women than for men (6.8 vs. 4.4 cases per 100 person-years; relative risk, 1.55). Asymptomatic HSV-2 infection is more common among men and persons who are also seropositive for HSV-1, suggesting that prior infection with HSV-1 reduces one's likelihood of experiencing symptomatic HSV-2 infection.[9] Studies have shown that genital HSV infections significantly increase the risk for acquisition and transmission of human immunodeficiency virus (HIV).[10]

ETIOLOGY AND PATHOGENESIS

The Virus

HSV-1 and HSV-2 are members of the Herpesviridae family, a group of lipid-enveloped double-stranded DNA viruses responsible for a wide variety of common human infections. Both serotypes of HSV and the closely related varicella-zoster virus (VZV) are members of the α-Herpesviridae virus subfamily. α-Herpesviruses infect multiple cell types in culture, grow rapidly, and efficiently destroy the host cells. Infection in the natural host is characterized by lesions in the epidermis, often involving mucosal surfaces, with spread of virus to the nervous system and establishment of latent infections in neurons, from which virus periodically re-activates.

HSV-1 and HSV-2 have a high degree of genetic and antigenic homology. Both genomes are approximately the same size, are linear, and consist of two regions of unique sequence, each of which is bounded by a pair of inverted repeat elements. An analysis of herpesvirus phylogeny estimated that the two HSV types diverged from an ancestral protoherpesvirus approximately 8 million years ago.[11]

Herpesvirus replication is a carefully regulated, multi-step process. Shortly after infection, five "immediate-early" genes are transcribed. The proteins encoded by these genes stimulate the synthesis of about a dozen "early" proteins that are required for genome replication. Most current antiviral drugs interact with two of these proteins, the thymidine kinase (TK) and the viral DNA polymerase enzyme. After DNA replication, the remaining set of more than 60 "late" HSV-2 genes is expressed. They encode virion structural components and proteins needed for their proper assembly.

In vivo, HSV infections can be divided into three stages: acute infection,

HERPES SIMPLEX AT A GLANCE



- Herpes simplex viruses (HSVs) are common human DNA viral pathogens that intermittently re-activate. After replication in the skin or mucosa, the virus infects the local nerve endings and ascends to the ganglia where it becomes latent until re-activation.
- There are two types of HSV: HSV-1 and HSV-2. HSV-1 is mostly associated with orofacial disease, whereas HSV-2 usually causes genital infection, but both can infect oral and genital areas and cause acute and recurrent infections.
- Most of the adult population is seropositive for HSV-1, and the majority of infections are acquired in childhood. About one-fourth of adults are infected with HSV-2 in the United States. Acquisition of HSV-2 correlates with sexual behavior.
- Most primary HSV infections are asymptomatic or not recognized, but they can also cause severe disease. Most recurrences are not symptomatic (asymptomatic shedding), with most transmissions occurring by asymptomatic shedding.
- Genital herpes is the most prevalent sexually transmitted disease worldwide and is the most common cause of ulcerative genital disease, and it is an important risk factor for acquisition and transmission of human immunodeficiency virus.
- HSV can also cause diseases involving the eye, central nervous system, and neonatal infection. Cellular immunity defects are a risk factor for severe and disseminated disease.
- Diagnosis is made by viral culture, polymerase chain reaction and serology, depending on the clinical presentation.
- Treatment is with acyclovir, valacyclovir, or famciclovir. Regimens and dosages vary with the clinical setting. Resistance is rare in other than immunocompromised patients.



establishment and maintenance of the latency, and re-activation of virus. During acute infection, virus replicates at the site of inoculation on mucocutaneous surfaces, resulting in primary lesions from which virus rapidly spreads to infect sensory nerve terminals, where it travels by retrograde axonal transport to neuronal nuclei in regional sensory ganglia. In a subset of infected neurons, a latent infection is established in which viral DNA is maintained as an episome and HSV gene expression is severely restricted: of all of the viral genes, only one is abundantly transcribed during latency. In the last stage, replication re-activates with concomitant anterograde axonal transport of newly assembled virus to a peripheral site, at or near the original portal of entry (Fig. 193-1).

HSV-1 re-activates most efficiently and frequently from trigeminal ganglia, while HSV-2 re-activates primarily from sacral ganglia. The rate of re-activation of HSV appears to be influenced by the quantity of latent viral DNA in the ganglia.[12] In addition to the quantity of latent virus being a determinant of the relative rate of HSV re-activation, there are type-specific sequences within the HSV genome that appear to influence recurrence rates in particular anatomic sites.[13] In addition to viral genes, host factors strongly influence HSV re-activation. Re-activation is induced in experimentally infected animals by exposure to ultraviolet irradiation, by hyperthermia, by local trauma, and by other physiologic stressors. These model systems emulate well what occurs in similarly stressed humans.



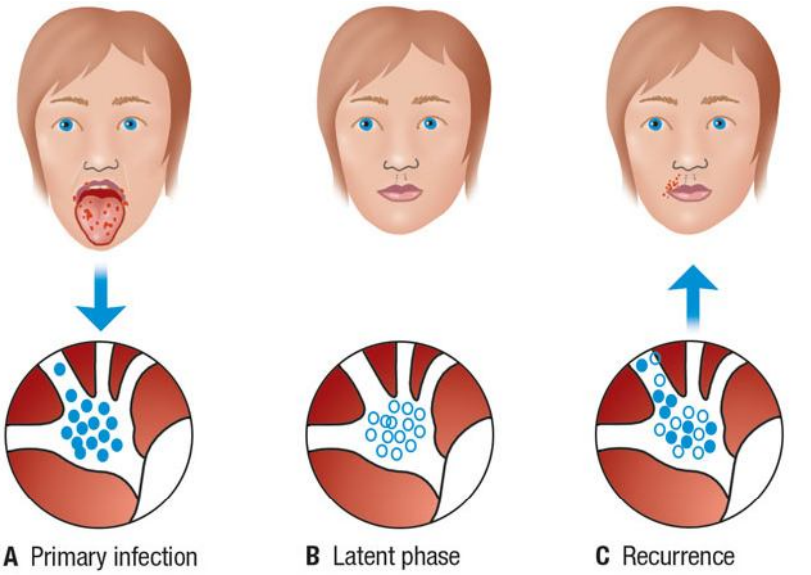

▲ **FIGURE 193-1** Herpes labialis. **A.** With primary herpes simplex virus infection, virus replicates in the oropharyngeal epithelium and ascends peripheral sensory nerves into the trigeminal ganglion. **B.** Herpes simplex virus persists in a latent phase within the trigeminal ganglion for the life of the individual. **C.** Various stimuli initiate re-activation of latent virus, which then descends sensory nerves to the lips or perioral skin, resulting in recurrent herpes labialis.

Immune Response

Host immunity to HSV clearly influences the risk of acquiring the infection, the severity of disease, and the frequency of recurrences. The risk of severe HSV disease and the recurrence rate correlates with the level of cellular immune competence of the host. Patients with mild decreases in cellular immunity may experience only an increased number of recurrences and a slower resolution of lesions, while severely compromised patients are more likely to develop disseminated, chronic, or drug-resistant infections.

Studies of humans and mice have implicated a role for both $CD8^+$ and $CD4^+$ T lymphocyte subsets, for natural killer cells, and for inflammatory cytokines like interferon-γ in mediating protection against HSV. However, the contribution of each cell subset and cytokine in the control of HSV infection has not been clearly defined.

Patients with defects in humoral immunity have no increase in HSV disease severity, but the humoral immune response is important in reducing virus titers at the site of inoculation and in regional neural tissues during primary infection. Animals are effectively protected from disseminated and neurologic disease by passive transfer of polyclonal or monoclonal antibodies and by antibody responses elicited actively through vaccination. Moreover, the transfer of HSV-specific antibodies from the mother to the child is a key factor in protecting against neonatal herpes.

The roles of immunity in sustaining latency and in limiting re-activation of HSV are less clear. There is evidence that constant immune surveillance and engagement are required to maintain latency, mainly by HSV-specific $CD8^+$ lymphocytes and low levels of viral proteins produced in neurons.[14] Other findings implicate immunity, predominantly CD4 and CD8 lymphocytes, in defining whether virus once re-activated would spread and become clinically evident.

CLINICAL FINDINGS

The clinical manifestations of HSV infection depend on the site of infection and, as indicated in Immune Response, the immune status of the host. Primary infections with HSV, namely those that develop in persons without pre-existing immunity to either HSV-1 or HSV-2, are usually more severe, frequently with systemic signs and symptoms, and they have a higher rate of complications, than recurrent episodes.

Orofacial Infections

Herpetic gingivostomatitis (Fig. 193-2) and pharyngitis are mostly commonly associated with a primary HSV-1 infection. The symptoms of primary oral herpes may resemble those of aphthous stomatitis and include ulcerative lesions involving the hard and soft palate, tongue, and buccal mucosa, as well as neighboring facial areas. Patients with pharyngitis exhibit ulcerative and exudative lesions of the posterior pharynx that can be difficult to differentiate from streptococcal pharyngitis. Other common symptoms are fever, malaise, myalgias, pain on swallowing, irritability, and cervical adenopathy.

Re-activation of virus from these primary infections involves the perioral facial area, mainly the lips, with the outer one-third of the lower lip being the most commonly affected (Fig. 193-3). Other facial locations include the nose, chin, and cheek, and account for less than 10 percent of the cases (Fig. 193-4). Two-thirds of labial lesions involve the vermilion border, while the rest occur at the junction of the border with the skin.



▲ **FIGURE 193-2** Primary herpetic gingivostomatitis. (Used with permission from Clyde S. Crumpacker, MD.)

In patients with frequent recurrences, lesions may differ slightly in location with each episode. Immunocompetent patients tend not to experience recurrent intra-oral lesions, but can present with clusters of tiny vesicles and ulcers on the gingivae and anterior hard palate that are mildly symptomatic. Prodromal symptoms precede herpes labialis in 45 percent to 60 percent of episodes.[1] Patients experience pain, burning, or itching at the site of the subsequent eruption. Even in the immunocompetent patient, the severity of recurrent herpes labialis is extremely variable and may vary from that of prodromal symptoms alone without the subsequent development of lesions (aborted episodes) to extensive disease induced by severe local sunburn.

The progression of the classical herpes lesions has been divided according to the following stages based on their features: prodromal, erythema, and papule (the developmental stages); vesicle, ulcer, and hard crust (disease stages); followed by dry flaking and residual swelling (resolution stages). The lesions usually resolve within 5 to 15 days.

Trigger factors for oral herpes recurrences include emotional stress, illness, exposure to sun, trauma, fatigue, menses, chapped lips, and the season of the year.[15] Other well-documented triggers include exposure to ultraviolet irradiation, trigeminal nerve surgery, oral trauma, epidural administration of morphine, and abrasive, laser, and chemical facial cosmetic procedures. The exact mechanism by which these diverse factors trigger HSV re-activation is unknown.

HSV-2 causes a primary orofacial infection that is indistinguishable from that associated with HSV-1 except that it is usually in adolescents and young adults and following genital–oral contact. Moreover, HSV-2 orolabial infections are 120 times less likely to re-activate than is orolabial HSV-1 disease.



◀ **FIGURE 193-3** Herpes simplex virus infection: Recurrent herpes labialis. Grouped and confluent vesicles with an erythematous rim on the lips 24 hours after onset of symptoms.



▲ **FIGURE 193-4** Recurrent facial herpes simplex with grouped vesicles and crusting. (Used with permission from Clyde S. Crumpacker, MD.)

Genital Infection

Genital herpes is the major clinical presentation of HSV-2 infection, but it may also result from HSV-1 in 10 percent to 40 percent of the cases, primarily ones following oral–genital contact. Because of their epidemiology, acquisition of HSV-1 in a person with prior HSV-2 infection is unusual, but HSV-2 acquisition in the presence of previous HSV-1 infection is common, and infection of the genital tract with both HSV-1 and HSV-2 has been described. Patients with previously known HSV-1 genital infection who develop frequent genital herpes recurrences should be tested for HSV-2 infection.[16]

The clinical courses of acute first-episode genital herpes among patients with HSV-1 and HSV-2 infections are similar. These infections are associated with extensive genital lesions in different stages of evolution, including vesicles, pustules, and erythematous ulcers that may require 2 to 3 weeks to resolve (Fig. 193-5). In males, lesions commonly occur on the glans penis or the penile shaft; in females, lesions may involve the vulva, perineum, buttocks, vagina, or cervix. There is accompanying pain, itching, dysuria, vaginal and urethral discharge, and tender inguinal lymphadenopathy. Systemic signs and symptoms are common and include fever, headache, malaise, and myalgias. Herpetic sacral radiculomyelitis, with urinary retention, neuralgias, and constipation, can occur. HSV cervicitis occurs in more than 80 percent of women with primary infection. It can present as purulent or bloody vaginal discharge, and examination reveal areas of diffuse or focal friability and redness, extensive ulcerative lesions of the exocervix, or,



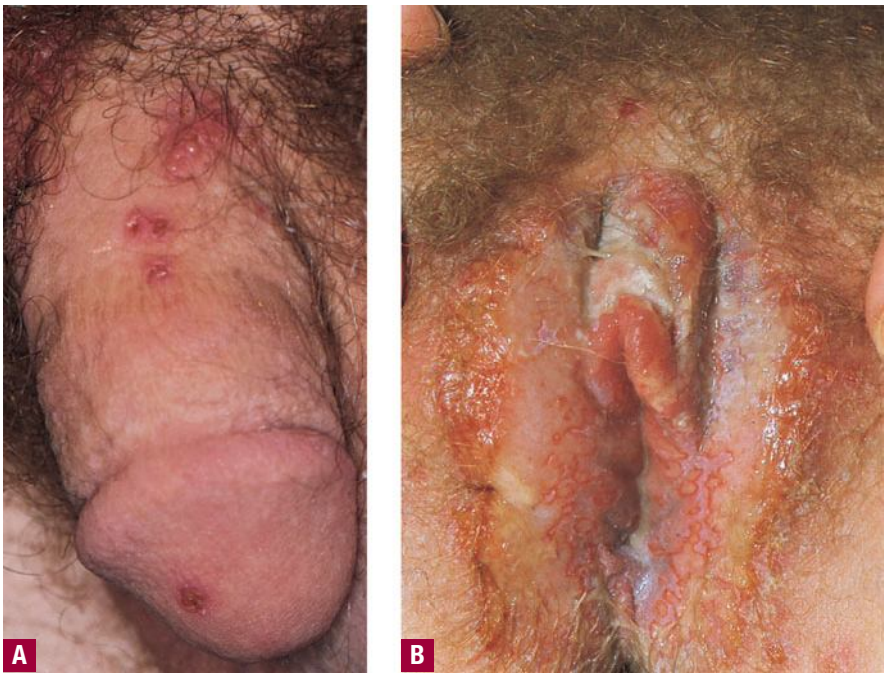

▲ **FIGURE 193-5** **A.** Primary genital herpes with vesicles. (Used with permission from Clyde S. Crumpacker, MD.) **B.** Primary herpetic vulvitis.

rarely, necrotic cervicitis. Cervical discharge is usually mucoid, but it is occasionally mucopurulent.

The rates of recurrence for genital HSV-2 infections vary greatly among individuals and over time within the same individual. Infections caused by HSV-2 re-activate approximately 16 times more frequently than HSV-1 genital infections, and average 3 to 4 times per year, but may appear virtually weekly.[3] Recurrences tend to be more frequent in the first months to years after first infection. The classical clinical manifestations of recurrent HSV-2 infection include multiple small but grouped vesicular lesions in the genital area (Fig. 193-6), but it can occur anywhere that can be covered by a pair of boxer shorts (see eFig. 193-6.1 in on-line edition), and the lesions may recur always at the same site or change location. The recurrence of genital lesions may be heralded by a prodrome of tenderness, itching, burning, or tingling, and the outbreaks are less severe than primary infection. Without treatment, the lesions usually heal in 6 to 10 days. Herpetic cervicitis is less common in recurrent disease, occurring in 12 percent of the patients. It may present without external lesions. Signs and symptoms that are less classical for genital HSV infection and which may divert one from the correct diagnosis include small erythematous lesions, fissures, pruritus, and urinary symptoms. HSV can cause urethritis, usually manifested only as a clear mucoid discharge, dysuria, and frequency. Occasionally, HSV can be associated with endometritis, salpingitis, or prostatitis. Symptomatic or asymptomatic rectal and perianal infections are common. Herpetic proctitis presents with anorectal pain, anorectal discharge, tenesmus, and constipation, with ulcerative lesions of the distal rectal mucosa. Genital herpes can recur at non-genital sites as well.



▲ **FIGURE 193-7** Herpes simplex virus infection: Herpetic whitlow. Painful, grouped, confluent vesicles on an erythematous edematous base on the distal finger were the first (and presumed primary) symptomatic infection.

Other Cutaneous Infections

HSV can infect any skin site. The common theme among virtually all of these cutaneous presentations is the requirement that virus has penetrated otherwise normal and well-keratinized tissues. Herpetic whitlow (Fig. 193-7) is the infection of the fingers by HSV acquired by direct inoculation or by direct spread from mucosal sites at the time of primary infection. Thus, a typical presentation of whitlow would be in children who suck their fingers during a





▲ **FIGURE 193-6** **A.** Genital herpes: Recurrent infection of the penis. Group of vesicles with early central crusting on a red base arising on the shaft of the penis. This "textbook" presentation, however, is much less common than small asymptomatic erosions or fissures. **B.** Genital herpes: Recurrent vulvar infection. Large, painful erosions on the labia. Extensive lesions such as these are uncommon in recurrent genital herpes in an otherwise healthy individual.

primary gingivostomatitis outbreak. It is also a well-documented occupational hazard for medical personnel. It is usually caused by HSV-1, but HSV-2 whitlow may develop as a manifestation of primary inoculation following manual–genital contact with an infected partner. The infected region becomes erythematous and edematous. Lesions are usually present at the fingertip and can be pustular and very painful. Fever and local lymphadenopathy are common. Whitlow is often misdiagnosed as a bacterial paronychial infection, but the surgical drainage, often needed for a bacterial infection, is unnecessary and potentially harmful, while antiviral therapy speeds healing. Whitlow may recur.

Cutaneous herpes can be transmitted between athletes involved in contact sports, such as wrestling (herpes gladiatorum) and rugby (herpes rugbiaforum or scrum pox), and may do so as outbreaks or small epidemics among team members. In these instances, multiple herpetic lesions may appear across the thorax, ears, face, arms, and hands, caused by facilitation of infection by trauma to the normally keratinized skin sustained during the practice of the sport. Concomitant ocular herpes can occur.

Eczema herpeticum (Kaposi varicelliform eruption; Fig. 193-8) results from a widespread infection following inoculation of virus to skin damaged by eczema. It is usually a manifestation of primary HSV-1 infection in a child with atopic dermatitis, and the expression of cathelicidins in the skin may be a factor in controlling susceptibility to eczema herpeticum in these patients.[17] Mycosis fungoides, Sézary syndrome, Darier disease, various bullous diseases of the skin (particularly if patients are receiving immunosuppressive therapy), and burns of second or third degree can also be complicated by cutaneous dissemination of HSV. The severity of eczema herpeticum ranges from mild to fatal, with mortality rates of up to 10 percent being reported before antiviral therapy was available. Mortality was usually primarily caused by bacterial superinfection and bacteremia. Common pathogens include *Staphylococcus aureus*, *Streptococcus*, and *Pseudomonas*. In a typical severe primary attack, several days after exposure vesicles develop in large numbers over the areas of active or recently healed atopic dermatitis, particularly the face, and continue to appear in crops for several days more. The vesicles become pustular and markedly umbilicated. Patients commonly have high fever and adenopathy. Viremia with infection of internal organs can be fatal. Recurrences are usually far milder than these first infections. Arriving at the correct diagnosis can be delayed because of secondary impetiginization of the lesions, but it always should be considered in children with infected eczema, particularly if the child is more ill systemically than one might anticipate with impetigo. Eczema herpeticum of the young infant is a medical emergency, and early treatment with acyclovir can prove lifesaving.



▲ **FIGURE 193-8** **A.** Herpes simplex virus infection: Eczema herpeticum on face. Confluent and discrete crusted erosions associated with erythema and edema of the face of a woman with atopic dermatitis. **B.** Herpes simplex virus infection: Eczema herpeticum on neck. Confluent crusted erosions with peripheral vesicle on neck and face in the setting of atopic dermatitis.

Recurrent HSV infection is the most common precipitating event in cases of recurrent erythema multiforme (see Chap. 38). HSV-associated erythema multiforme is usually an acute, self-limited, recurrent disease. The duration of the disease is usually about 3 weeks. The lesions are usually disseminated and symmetric, occurring on acral extremities and face, and there is grouping of the lesions over the elbow and knees, as well as nail fold involvement; photodistribution and isomorphic phenomenon can occur. Mucosal involvement is usually mild and restricted to the mouth. Constitutional symptoms are rare, and the skin lesions heal without scarring.

LABORATORY TESTS

The method of choice for diagnosis of HSV infection depends on the clinical presentation. In many instances, the history and clinical findings may be sufficient, but the social, emotional, and therapeutic implications of a diagnosis dictate that it be confirmed by laboratory testing when possible. For patients with lesions, virus isolation by cell culture is the method of choice. In culture, HSV causes typical cytopathic effects, and most specimens will prove positive within 48 to 96 hours after inoculation. The sensitivity of the culture depends on the quantity of the virus in the specimen. Even in the most experienced centers, only approximately 60 percent to 70 percent of fresh genital lesions are culture-positive. Isolation of the virus is most successful when lesions are cultured during their vesicular stage and when specimens are taken from immunocompromised patients or from patients suffering from a primary infection.

PCR is more sensitive than viral isolation and has been extensively used for the diagnosis of central nervous system infections and in neonatal herpes. It may also be useful for the detection of HSV in late-stage ulcerative lesions. Both viral culture and PCR assays enable typing of the isolate as HSV-1 or HSV-2. This information helps to predict the frequency of re-activation after a first-episode of HSV infection.

Direct fluorescent antibody staining of lesion scrapings and antigen detection assays can also be used but sensitivity is somewhat lower than that of viral culture.[18] The Tzanck smear can be helpful in the rapid diagnosis of herpesviruses infections, but it is less sensitive than culture and staining with fluorescent antibody, with positive results in fewer than 40 percent of culture-proven cases. It is performed by scraping the base of a freshly ruptured vesicle and staining the slides with Giemsa or Wright stain (the Papanicolaou staining method can also be used), followed by



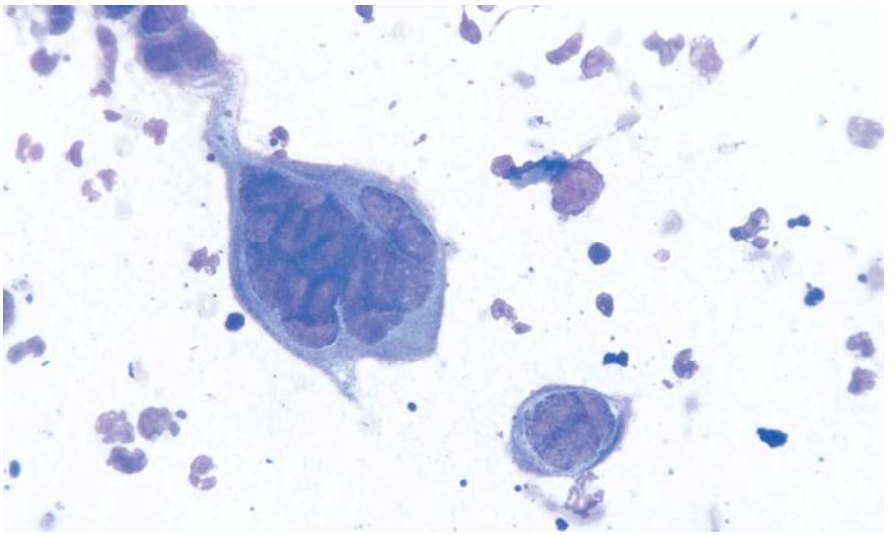

▲ **FIGURE 193-9** Herpes simplex virus: Positive Tzanck smear. A giant, multinucleated keratinocyte on a Giemsa-stained smear obtained from a vesicle base. Compare size of the giant cell to that of neutrophils also seen in this smear. Another smaller multinucleated acantholytic keratinocyte is seen as well as acantholytic keratinocytes. Identical findings are present in lesions caused by varicella-zoster virus.



▲ **FIGURE 193-10** Herpes simplex virus infection: Chronic ulcer in an immunocompromised host. Multiple, slowly spreading, deep ulcers with central necrosis and hemorrhagic crusts on the lips, cheeks, and nose of a woman with leukemia.



examination for the multinucleated giant cells that are diagnostic of herpetic infection (Fig. 193-9). Both HSV and VZV will cause these changes. In the skin biopsy specimens, the epithelial cells are enlarged, swollen, and often separated. Multinucleated cells with intranuclear eosinophilic inclusion bodies (Cowdry type A inclusions) can be seen.

Serologic detection of antibodies to HSV can be helpful in certain settings, but the results are often misinterpreted. Its main function is in differentiating a primary episode from a recurrent infection (Table 193-1). A positive serologic test result can be useful in patients with recurrent, genital lesions that are not present at times of examination and, therefore, a positive culture cannot be obtained. Serologic testing can also be helpful for counseling patients with initial episodes of disease and their partners, especially during pregnancy, and in counseling partners of patients with genital herpes about their risk of acquiring HSV.

Until recently, serologic testing for HSV was seriously deficient because of substantial cross-reactivity between HSV-1 and HSV-2 antigens. HSV-1 and HSV-2 infections could be distinguished by Western blot assay, but this assay is expensive and only available in a few research laboratories. Recently, simple kits for type-specific serologic assays based on antigenic differences between HSV-1 and HSV-2 glycoprotein G, have become available.[19] These tests should be used by practitioners who are prepared to counsel patients about the meaning of the test results in terms of the natural history of the disease, available treatment regimens, disease transmission, and the emotional and social implications of the diagnosis.[20]

COMPLICATIONS

Immunocompromised Host

All manifestations of HSV infection seen in the immunocompetent host can also be seen in immunocompromised patients but they are usually more severe, more extensive, and difficult to treat; and, for many of them, recurrences are more frequent as well. Patients with defects of T-cell immunity are at particular risk for progressive mucocutaneous or visceral infections but, the degree of dissemination depends on the level of immunodeficiency of the host. Recurrent and persistent ulcerative HSV lesions are among the most common and defining opportunistic infections in patients with acquired immunodeficiency syndrome (Fig. 198-10). Genital herpes is very common in patients with HIV and can be persistent and severe. Oropharyngeal HSV in immunocompromised patients can present with widespread involvement of skin (see Fig. 193-10), the mucosa, and extremely painful, friable, hemorrhagic, and necrotic lesions, similar to the mucositis caused by cytotoxic agents or other infectious agents. The lesions can spread locally to involve the esophagus. Esophagitis presents with odynophagia, dysphagia, substernal pain, and multiple ulcerative lesions. Esophagitis can also arise directly by re-activation of HSV and its spread to the esophagus

TABLE 193-1
Classification of Herpes Simplex Infections According to Viral Isolation and Paired Serologic Test Results

Classification	Virus Isolated	Serology (Acute)		Serology (Convalescent)	
		HSV-1	HSV-2	HSV-1	HSV-2
Primary HSV-1	HSV-1	–	–	+	–
Primary HSV-2	HSV-2	–	–	–	+
Primary HSV-1 plus previous HSV-2 infection[a]	HSV-1	–	+	+	+
Primary HSV-2 plus previous HSV-1 infection	HSV-2	+	–	+	+
Recurrent HSV-1	HSV-1	+	– or +	+	– or +
Recurrent HSV-2	HSV-2	– or +	+	– or +	+

HSV = herpes simplex virus; – = negative; + = positive.
[a]Rare.

via the vagus nerve. Tracheobronchitis and pneumonitis can also occur by spreading of the virus from oropharyngeal HSV.

HSV can re-activate from visceral ganglia of the autonomic nervous system or disseminate hematogenously to other visceral organs (causing pneumonitis, hepatitis, and pancreatitis) and other portions of the gastrointestinal tract, as well as causing adrenal necrosis. Most of these severe infections are caused by HSV-1, but HSV-2 can do so as well. Few are ever diagnosed except at autopsy.

Ocular Infections

HSV is a leading cause of recurrent keratoconjunctivitis and its associated corneal opacification and visual loss. It is usually caused by HSV-1, except in neonates in whom HSV-2 is more prevalent. The majority of HSV eye disease is caused by re-activation of the virus in the trigeminal ganglia, but primary infections of the eye can also occur. Usually, the initial manifestation of herpetic eye disease is a superficial infection of the eyelids and conjunctiva (blepharoconjunctivitis), or corneal surface (dendritic or geographic epithelial ulcer). Deeper involvement of the cornea (stromal keratitis) or anterior uvea (iritis) represents more serious forms of the disease and can cause permanent visual loss. Acute retinal necrosis is a rare but rapidly progressive disease characterized by retinal arteriolar sheathing, uveitis, and peripheral retinal opacification with variable pain and visual loss. Bilateral involvement may occur, and retinal detachments are common. It is usually associated with HSV-1 infection, but HSV-2 retinitis has been described, and VZV causes a similar process.[21]

Neurologic Disorders

All HSV infections involve the nervous system, as neurons are the sole proven site of virus latency. Neurologic manifestations of HSV infections, however, are not universal, but highly variable in their presentation and severity. HSV meningitis is manifested by headache, fever, and mild photophobia, with lymphocytic pleocytosis in the cerebrospinal fluid (CSF). Most cases result from HSV-2 infection. It resolves spontaneously in 2 to 7 days. It is usually seen in association with primary genital HSV-2 infection. Recurrent lymphocytic meningitis (Mollaret meningitis) is associated with recurrent HSV-2 infection, often without symptomatic genital disease. Involvement of the sacral nerves with autonomic nervous system dysfunction, numbness, pelvic pain, tingling, urinary retention, constipation, and CSF pleocytosis has been reported in association with HSV infection. Symptoms usually resolve in a few days, but in some cases, the neurologic residua take weeks to months to disappear, occasionally becoming permanent. Rare cases of transverse myelitis and Guillain-Barré syndrome after HSV infection have been reported. Bell palsy is an acute, peripheral facial paresis of unknown cause and is thought to result from inflammation and subsequent mechanical compression of the facial nerve in the temporal bone. Re-activation of HSV and VZV are implicated in the pathogenesis of the disease.[22]

HSV encephalitis is the most commonly identified acute, sporadic viral encephalitis in the United States, accounting for 10 percent to 20 percent of all cases. Nearly all of the cases arising after the neonatal period (see Neonatal Herpes) are caused by HSV-1. HSV encephalitis usually presents with acute onset of focal neurologic symptoms and fever. Involvement of the temporal lobe is a characteristic feature of this disease, but overall, it is difficult to differentiate HSV encephalitis clinically from other viral encephalitides. PCR of the CSF for HSV DNA is the most sensitive non-invasive technique to help in the diagnosis. Brain biopsies had been the gold standard method to establish the diagnosis until the advent of PCR. However, even with therapy, neurologic sequelae are frequent, especially in persons older than 35 years of age. Patients with presumed HSV encephalitis should be treated empirically with intravenous acyclovir until the diagnosis is confirmed or an alternative diagnosis is made.

Neonatal Herpes

The neonate is a special category of immune-deficient host. The incidence of neonatal herpes is approximately 1 in 3500 live births. Seventy percent of neonatal HSV cases are caused by HSV-2 inoculated directly by infectious genital secretions at the time of delivery. The category of maternal infection plays a significant role in defining the risk of neonatal herpes. Primary genital herpes is associated with a risk of neonatal infection of 33 percent to 50 percent for vaginally delivered babies. Risk of transmission to a neonate is highest in women who develop primary herpes in the third trimester. This is because primary infections are usually associated with prolonged excretion of high titers of virus, and there will have been no time for the mother to mount an immune response against the virus and transfer protective antibodies to the child. In contrast, recurrent maternal infection is associated with a risk of transmission of less than 3 percent.[23] Other risk factors for development of neonatal herpes include vaginal delivery, use of invasive monitors, isolation of HSV-1, and isolation of HSV from the cervix.[24] Prolonged rupture of the membranes is also a risk factor.

Neonatal herpes infections manifest in one of three forms: skin, eye, and mouth involvement; encephalitis; or disseminated disease. The latter two forms account for more than 50 percent of cases of neonatal herpes. It is important to remember that more than 20 percent of neonates with neurologic and disseminated disease do not develop cutaneous vesicles. Without therapy, the overall mortality of neonatal herpes is 65 percent, and fewer than 10 percent of untreated neonates with central nervous system infection will develop normally. With current therapeutic modalities, most babies with skin, eye, and mouth disease survive and have normal development at 1 year. For treated babies with encephalitis, mortality is 4 percent, with about 30 percent developing normally after 1 year. For babies with disseminated disease, mortality is 30 percent, with about 80 percent of the survivors apparently developing normally after 1 year.[25]

TREATMENT

All sexually active persons should be educated regarding the nature and risks of acquiring and transmitting sexually transmitted infections, including HSV. Studies show that about one-half of the patients with asymptomatic HSV-2 infection have mild, unrecognized disease and can be taught to recognize their symptoms and signs of genital herpes. Also, patients should be counseled regarding safer sex practices. It must be emphasized that the majority of transmission occurs in asymptomatic phases and from people who have no classical lesions. Patients with genital herpes should be counseled to refrain from sexual intercourse during outbreaks and for 1 to 2 days after and to use condoms between outbreaks. Suppressive antiviral therapy is also an option for individuals concerned about



transmission to a partner (see Antiviral Therapy under Prevention).

Pregnant women who are known to have genital herpes should be reassured that the risk of transmitting herpes to the baby during childbirth is extremely low. Recommendations for the management of pregnant women with recurrent genital herpes include clinical evaluation at delivery, with delivery by cesarean section indicated if there are signs and symptoms of active infection (including prodrome).[24] But cesarean section delivery may not reliably prevent neonatal HSV infection when membranes are ruptured for long periods (≥ 24 hours). Women with primary HSV infection during pregnancy, particularly during the second and third trimesters, should be treated with antiviral therapy. For women at or beyond 36 weeks of gestation who are at risk for recurrent HSV infection, suppressive antiviral therapy also may be considered.[26] The role of culturing the mother and/or the baby for HSV is controversial. Current recommendations include culturing for HSV at the time of delivery in women with a history of genital herpes. Women with active genital lesions at delivery and their babies should be cultured serially. Cultures should be taken from eye, oronasopharynx, and suspected sites every 2 to 3 days during the first 4 weeks of life. Preemptive therapy with intravenous acyclovir has been recommended for neonates born vaginally or after prolonged rupture of membranes to a woman with a clinically apparent first episode of genital herpes at delivery.[26]

Women who are known by history and serologic tests not to have genital herpes should be counseled about signs and symptoms of HSV and how to avoid acquiring the infection during pregnancy. Serology is helpful in counseling a couple in which the male partner has recurrent genital herpes and the pregnant wife is susceptible.

Antiviral Therapy (See Chap. 232)

Many HSV infections require no specific treatment at all. Keeping the lesions clean and dry while they heal by themselves may be all that is required. Treatment is warranted for infections that are likely to prove protracted, highly symptomatic, or complicated. Acyclovir, an acyclic guanosine analogue, was the first compound shown to prevent replication of a virus at concentrations far below those that affect cellular nucleic acid synthesis. This finding was a key factor in establishing antiviral chemotherapy as a major medical intervention. Acyclovir has a highly favorable therapeutic index because of its preferential activation in infected cells and preferential inhibition of the viral DNA polymerase. It must be phosphorylated to be active, and it requires the viral TK for efficient monophosphorylation. Acyclovir inhibits HSV-1 and HSV-2 replication by 50 percent at a concentration of 0.1 and 0.3 μg/mL (range, 0.01 to 9.9 μg/mL), respectively, but is toxic at concentrations of > 30 μg/mL. Any strain that requires more than 3 μg/mL of acyclovir to be inhibited is said to be relatively drug-resistant.

Valacyclovir, the L-valyl ester of acyclovir, is an oral prodrug of acyclovir that achieves three- to fivefold higher bioavailability after oral administration, and it can be used in a more convenient dosage regimen. Famciclovir is the well-absorbed oral form of the related guanosine analogue penciclovir. Similar to acyclovir, famciclovir is converted by phosphorylation to its active metabolite penciclovir-triphosphate. The efficacy and adverse effect profile of famciclovir is comparable to that of acyclovir. Penciclovir 1 percent cream is approved by the U.S. Food and Drug Administration (FDA) for the treatment of herpes simplex labialis. Docosanol 10 percent cream is approved by the FDA for over-the-counter treatment of recurrent herpes labialis. Docosanol is a long-chain saturated alcohol that inhibits entry of lipid-enveloped virus into the cell. It decreased the healing time by 18 hours when compared with placebo.[27]

The current recommendations for antiviral treatment depend on the clinical disease, on host immune status, and whether one is treating a primary or recurrent episode or considering suppressive therapy. Box 193-1 describes the dosages and regimens for these different scenarios. For disseminated or severe herpes infections, the treatment of choice remains intravenous acyclovir 5 to 10 mg/kg every 8 hours. Some experts use acyclovir 15 to 20 mg/kg intravenously every 8 hours for life-threatening HSV infection, including encephalitis. The dose of intravenous acyclovir for neonatal herpes is 20 mg/kg per dose given every 8 hours.

For first episodes of genital HSV-2 infections, oral acyclovir, famciclovir, and valacyclovir all speed the healing and resolution of symptoms, and decrease viral shedding. When compared with placebo, acyclovir decreases time to healing from 16 to 12 days, the duration of pain from 7 to 5 days, and the duration of constitutional symptoms from 6 to 3 days.[28] Valacyclovir was compared with acyclovir in the treatment of primary episodes and shown to be equivalent.[29] But antiviral treatment of initial herpes episodes does not decrease subsequent recurrences, probably because HSV establishes latent infection within hours after inoculation and days before symptoms evolve.

Treatment of recurrent episodes of genital herpes with famciclovir, acyclovir, or valacyclovir has been shown to reduce the time of healing from about 7 to 5 days, time of cessation of viral shedding from 4 to 2 days, and duration of symptoms from 4 to 3 days when compared with placebo. Valacyclovir and acyclovir are equivalent,[30,31] and it is likely that famciclovir, if tested, would be as well.

For persons with frequent or complicated genital recurrences, long-term suppressive therapy with acyclovir or its analogues is the most effective management strategy.[32,33] Because genital herpes is not progressive in the normal host and because the rate of recurrences varies over time and may decrease after some years, it is wise to recommend a "holiday" from treatment every year or so to reassess the person's continuing need for treatment.

The use of antiviral suppressive therapy during the late phase of pregnancy to avoid neonatal herpes has also been advocated, but a formal study of the approach would require a very large number of participants because of the rare incidence of neonatal herpes. A more achievable goal is to decrease the need for cesarean deliveries caused by herpes recurrences during labor. Although analyses have been favorable for the use of acyclovir in late pregnancy (beginning at 36 weeks) to prevent clinical recurrences, cesarean sections due to genital herpes, and the risk of HSV viral shedding at delivery,[34,35] further research is needed before a recommendation can be made.

Orolabial HSV infections warrant antiviral treatment less often than do the genital infections. Primary HSV gingivostomatitis should be treated with oral acyclovir. The pediatric dose is 15 mg/kg of acyclovir suspension orally five times a day for 7 days. When it is started within 3 days of onset of the disease, this regimen decreases the duration of oral and extra-oral lesions, fever,



Box 193-1

Recommended Regimens for the Treatment of Herpes Simplex Infections

		ACCEPTABLE REGIMEN ALTERNATIVES[a]			
DISEASE		**ADULTS**	**PEDIATRIC[b]**	**DURATION**	**COMMENTS**
Orofacial herpes	Primary infection	Acyclovir, 200 mg orally five times a day. Acyclovir, 400 mg orally three times a day. Valacyclovir, 1000 mg orally two times a day. Famciclovir, 250 mg orally three times a day.	15 mg/kg of acyclovir orally five times a day.[59]	7–10 days or until resolution of symptoms.	IV acyclovir for severely ill individuals. No studies have been done in adults: Regimens are extrapolated from their effectiveness in primary genital herpes.
	Recurrent infection: Episodic treatment	Topical penciclovir, 1% cream q2h while awake.[36] Topical docosanol 10% cream five times a day.[27] Acyclovir, 400 mg orally five times a day.[60] Famciclovir, 500 mg orally two or three times a day.[37,61] Valacyclovir, 2000 mg orally twice a day for 1 day.[62] Famciclovir, 1500 mg single dose or 750 mg twice a day for 1 day.[38]		4–5 days or until lesions are healed. Valacyclovir and famciclovir were used for only 1 day.	Generally not warranted.
	Recurrent infection: Prophylaxis	Acyclovir, 400 mg orally twice a day.[40]			Start just before and during precipitating event, such as intensive ultraviolet exposure.
	Recurrent infection: Suppression of confirmed frequent recurrences	Acyclovir, 400 mg orally twice a day.[39]	There are no pediatric studies, but children with confirmed frequent recurrences may benefit from suppressive oral acyclovir therapy.		
Genital herpes	Primary infection	Acyclovir, 200 mg orally five times a day.[28] Acyclovir, 400 mg orally three times a day.[63] Valacyclovir, 1000 mg orally twice a day.[29] Famciclovir, 250 mg orally three times a day.	Acyclovir, 40–80 mg/kg/day orally divided in three to four doses (maximum 1 g/d).[64]	7–10 days or clinical resolution occurs.	
	Recurrent infection	Acyclovir, 400 mg orally three times a day. Acyclovir, 200 mg orally five times a day.[30] Acyclovir, 800 mg orally twice a day.[65] Valacyclovir, 500 mg orally twice a day.[31,66] Valacyclovir, 1000 mg orally once a day.[66] Valacyclovir, 1000 mg orally twice a day.[67,68,c] Famciclovir, 500,[c] 250, 125 mg orally twice a day.[61,69,70] Famciclovir, 1000 mg orally twice a day for 1 day (patient initiated).[71]	Acyclovir, 1000 mg/day orally in three to five divided doses.[72]	5–10 days or until clinical resolution occurs.	

(continued)



Box 193-1

Recommended Regimens for the Treatment of Herpes Simplex Infections (Continued)

		ACCEPTABLE REGIMEN ALTERNATIVES[a]			
DISEASE		**ADULTS**	**PEDIATRIC[b]**	**DURATION**	**COMMENTS**
Genital herpes (continued)	Suppression of recurrences	Acyclovir, 400 mg orally twice a day.[73] Acyclovir, 800 mg orally once a day.[74] Valacyclovir, 500, 1000 orally once a day.[75,d] Valacyclovir, 250 mg orally twice a day.[73,d] Valacyclovir, 500 mg twice a day or 1000 mg orally once a day.[67,68,c] Famciclovir, 250 orally twice a day.[76,77] Famciclovir, 125 mg, 250 mg orally three times a day.[78]	Acyclovir, 400–1000 mg/day orally in two to three divided doses.[72]		Duration of the therapy is controversial. Some authorities will offer treatment for 1 yr and then reassess the need to resume it.
	Suppression of recurrences in pregnant women	Acyclovir, 400 mg orally three times a day from 36 wk to delivery.[79,80]			Use is controversial.
	Reduction of transmission	Valacyclovir, 500 mg orally once a day.[8]			Safer sex practices should continue to be used.
Ocular herpes	Therapy	1% trifluridine drop—1 drop q2h during day and q4hs during night (maximum, 9 drops/day).[81] 0.1% IDU drop and 0.5% ointment—drop hourly during the day and q2h during night. Ointment q2h during day and q4h during night.[81] 3% vidarabine ointment—q3h during day.[81] Acyclovir, 400 mg orally five times a day.[81] Valacyclovir, 1000 mg orally 2 times a day.[82]			Undertake in consultation with an ophthalmologist. Trifluridine's corneal and conjunctival toxicity is similar to IDU's. IDU can cause corneal epithelial toxicity, follicular conjunctivitis and scarring, and closure of tear outflow channels. Vidarabine causes less corneal and conjunctival toxicity than IDU.
	Suppression of recurrences	Acyclovir, 400 mg orally twice a day.[83]	Acyclovir, 80 mg/kg/day orally in three divided doses (maximum, 1g/day) may be of benefit.[72]		Undertake in consultation with an ophthalmologist.
Other cutaneous herpes (herpes gladiatorum, herpetic whitlow, etc.)	Treatment	Acyclovir, 200 mg orally five times per day. Acyclovir, 400 mg orally three times a day. Valacyclovir, 1000 mg orally twice a day. Famciclovir, 250 mg orally three times a day.	Acyclovir, 40–80 mg/kg/day orally divided in three to four doses (maximum, 1 g/day).[72]	7–10 days or until resolution of symptoms.	No studies have been done. Regimens are extrapolated from the treatment of genital herpes. Consider suppressive antiviral therapy for patients with frequent recurrences.
Neonatal herpes			IV acyclovir, 20 mg/kg every 8 h.[84]	14–21 days.	The value of long-term suppression after initial treatment is being evaluated.
Disseminated infection		IV acyclovir, 10–15 mg/kg three times a day.	IV acyclovir, 10 mg/kg three times daily.[26]	14–21 days.	
Encephalitis		IV acyclovir, 10–15 mg/kg three times a day.	IV acyclovir, 10 mg/kg three times daily.[26]	14–21 days.	

(continued)



Box 193-1

Recommended Regimens for the Treatment of Herpes Simplex Infections (Continued)

	ACCEPTABLE REGIMEN ALTERNATIVES[a]			
DISEASE	**ADULTS**	**PEDIATRIC[b]**	**DURATION**	**COMMENTS**
Eczema herpeticum	Acyclovir, 200 mg orally five times a day. Acyclovir, 400 mg orally three times a day. Valacyclovir, 1000 mg orally twice a day. IV acyclovir, 10–15 mg/kg three times a day.	Acyclovir, 40–80 mg/kg/day orally divided in three to four doses (maximum, 1.2 g/d). IV acyclovir, 10 mg/kg three times daily.[72]	14–21 days.	No studies have been done. Use IV acyclovir in severely ill individuals. Consider suppressive antiviral therapy for patients with recurrences. Ocular involvement should be treated in consultation with an ophthalmologist.

IDU = idoxuridine.
[a]The doses are for patients with normal renal function.
[b]Oral dosage of acyclovir in children should not exceed 80 mg/kg/day. Children 40 kg and above should receive the adult dose.
[c]Human immunodeficiency virus patients.
[d]The high once-a-day and twice-daily doses of valacyclovir are more effective in patients who present with more than 10 recurrences per year.
Note: Neither valacyclovir nor famciclovir is approved by the U.S. Food and Drug Administration for use in children.



and eating and drinking difficulties. Valacyclovir and famciclovir may be equally effective, but they have not been studied in this setting and are not currently approved for use in children. Severely ill children may need to be hospitalized for hydration, and intravenous acyclovir may be necessary.

Treatment of recurrent herpes labialis with antiviral drugs in immunocompetent hosts has shown only modest benefits so far. The infections are inherently briefer and less symptomatic than genital herpes. Treatment is only effective if used very early in the disease, especially in the prodromal or erythema lesion stages. Patients who wish treatment should have the medication available and be vigilant for the earliest signs and symptoms of a recurrence. When treatment is felt to be required, the therapy of choice is penciclovir 1 percent cream every 2 hours while awake, for 4 days.[36] Treatment should be initiated as early as possible. When initiated within 1 hour of first symptom of recurrence, penciclovir sped the healing of lesions (4.8 days vs. 5.5 days) and decreased the duration of pain (3.5 days vs. 4.1 days). This regimen is approved by the FDA. Docosanol 10 percent cream is approved by the FDA for over-the-counter treatment of herpes simplex labialis. It is to be applied five times a day at the first sign of recurrence of herpes simplex labialis. There has been no direct comparison with topical penciclovir. Oral acyclovir, 400 mg five times a day for 5 days, affords marginal benefit if begun in the earliest hour or two of the outbreak. Famciclovir, 500 mg three times a day for 5 days, when started within 48 hours after experimental ultraviolet radiation, decreased the median time to healing from 6 to 4 days[37] but is not useful for the more usual sporadic cases of herpes labialis. A 1-day regimen of valacyclovir (2 g twice daily for 1 day) decreased the mean duration of cold sore episodes by 1 day when compared with placebo, if started in the prodrome period. Similarly, a single dose of famciclovir reduced time to healing of herpes labialis lesions by approximately 2 days compared with placebo.[38] Creams and ointments containing 5 percent and 10 percent acyclovir are not beneficial in recurrent herpes labialis.

The use of suppressive acyclovir for herpes labialis is controversial. In one small study, oral acyclovir, 400 mg twice a day, was effective in decreasing recurrences of herpes labialis.[39] In studies with skiers (and therefore significant and anticipated sun exposures), acyclovir 400 mg twice a day, was shown to reduce recurrences in one study,[40] whereas acyclovir, 800 mg bid, failed to prevent recurrences in another study.[41] Both perioperative famciclovir (125 or 250 mg orally twice daily given 1 to 2 days before to 5 days after the procedure) and valacyclovir (500 mg twice daily for 14 days, starting either a day before or the day of the procedure) appeared to reduce the recurrence of orofacial HSV in patients undergoing facial laser resurfacing.[42,43] Valacyclovir has also been shown to suppress recurrences of herpes gladiatorum.[44]

Herpetic eye disease should always be treated in consultation with an ophthalmologist. Options usually involve topical antivirals. These include idoxuridine, vidarabine, and trifluridine. Topical antivirals are effective in shortening the duration of dendritic and geographic keratitis, and are used to prevent corneal epithelial disease in patients with blepharitis and conjunctivitis, as well as patients on topical steroid therapy for corneal stromal inflammation and iridocyclitis. Oral acyclovir is also effective for dendritic and geographical epithelial keratitis. Suppressive acyclovir therapy reduces the rates of all types of recurrent ocular HSV disease, and it is most important for patients with a history of HSV stromal keratitis because it can prevent additional episodes and potential loss of vision.

Antiviral Resistance

The specter of drug resistance hangs over the family of antiherpes drugs, as it does over all other classes of antimicrobials. However, virtually all clinically relevant drug resistance has been seen in immunocompromised patients. The primary mechanism of acyclovir resistance is selection of viral mutants defective or deficient in TK expression. Most mutants that are TK deficient are somewhat attenuated in virulence in vivo.

The treatment of resistant HSV infection is complicated. First, one must make the diagnosis. Very few people who claim to be "resistant" to one of the antiviral drugs actually harbor resistant virus. There is a common misconception that treatment prevents all recurrences, now and forever. One should suspect resistance only in people who continue to have culture-proven outbreaks of unaltered frequency and se-

verity, especially if the lesions do not heal by themselves. When resistance is suspected, virus should be recovered and tested specifically for sensitivity to acyclovir. These tests are expensive but now widely available through commercial reference laboratories. Second, the options for patients with true resistance are few and far from ideal due to the lack of alternatives that are safe and easy to administer. Foscarnet, an organic analogue of inorganic pyrophosphate, inhibits replication of all known herpesviruses in vitro and does not require activation by TK or other kinases, and therefore can be effective in the treatment of acyclovir-resistant HSV. Foscarnet requires intravenous therapy and can cause numerous adverse reactions including nephrotoxicity, electrolytes disturbances, anemia, and seizures. Also, foscarnet-resistant herpesvirus strains have been described.

Cidofovir is an acyclic nucleoside phosphonate with broad-spectrum activity against a wide variety of DNA viruses, including herpesviruses. Being a nucleotide (rather than nucleoside) analog, it does not require the viral TK for its intracellular phosphorylation to the active form. Cidofovir has been tested in cases of acyclovir-resistant HSV and topical cidofovir has been used with success to treat progressive herpetic lesions.[45] Intravenous cidofovir is associated with considerable nephrotoxicity and requires the co-administration of saline hydration and probenecid. There is one report of a patient with acyclovir-resistant genital herpes that responded to imiquimod 5 percent cream,[46] but imiquimod caused severe inflammation in some patients with recurrent herpes labialis.[47]

PREVENTION

Strategies to prevent HSV infection have proved inadequate to address the growing epidemic of genital herpes. HSV infection can be prevented by total abstinence, as indicated by very low seroprevalence rates in cloistered nuns. Condoms reduce rates of transmission if used routinely.[48] Other than these public health approaches, most efforts involve antiviral therapy and vaccines directed at genital herpes.

Antiviral Therapy

Acyclovir, famciclovir, and valacyclovir all decrease both symptomatic and subclinical shedding of HSV-2, from about 8 percent of the days in the placebo group to 0.3 percent to 0.6 percent of the days in the treatment group, when assessed by culture.[49–52] Recently, valacyclovir 500 mg once daily was shown to be effective in reducing the transmission of HSV-2 between partners by 48 percent, and reduced clinical disease in the susceptible partner by 75 percent[8] in a randomized, placebo-controlled trial involving immunocompetent, heterosexual couples in stable relationships. This therapy can be recommended for individuals concerned about transmission to a partner, in conjunction with the use of condoms. Regarding other groups (e.g., homosexual couples, non-monogamous individuals, immunocompromised, and persons with asymptomatic HSV-2 infection), it is uncertain if the use of antiviral therapy (and which regimen) would be the most adequate to decrease transmission.

Vaginal microbicides are also being studied, mostly focusing in decreasing HIV transmission, but some of the compounds also have anti-HSV activity and may also affect HSV transmission.[53]

Vaccines

The best public health strategy to reduce infection and morbidity associated with HSV infection is development of effective vaccines. Unfortunately, no vaccine has proved to protect adequately against acquisition of HSV (prophylactic) or to reduce the number of recurrent episodes (therapeutic), although there are hopeful developments in these directions.

Recombinant glycoprotein vaccines containing immunogenic HSV proteins have been developed and tested by multiple pharmaceutical and biotechnological companies. In a preliminary study, a recombinant HSV-2 glycoprotein D vaccine with alum adjuvant decreased the frequency of symptomatic outbreaks in patients with genital herpes. A modified form of the vaccine (with added glycoprotein B and a lipid emulsion adjuvant known as *MF59*) was not found, in larger studies, to decrease the number of recurrences in patients with genital herpes, but it was able to decrease the duration and severity of a subsequent study outbreak of genital herpes.[54] Two phase III studies of the effect of this vaccine (one in monogamous seronegative partners of individuals with genital herpes, and the other in seronegative persons attending clinics for sexually transmitted diseases) failed to prevent acquisition of genital herpes infection or disease.[55] A recombinant gD2 vaccine that uses monophosphoryl lipid-A as adjuvant was protective against HSV-2 genital disease (but had limited protection against infection) in HSV-1 and HSV-2 seronegative women but not in males or HSV-1 seropositive females.[56] A double-blind, randomized controlled study in HSV-1 and HSV-2 seronegative women is under way.

A major theoretical limitation of recombinant HSV vaccines is their inability to induce broad and protective cellular immune responses. To better do so, investigators have turned their attention to DNA-based and genetically engineered live vaccines. Replication-defective viruses are capable of only a single round of replication, and therefore have no pathogenic potential while potentially inducing the full spectrum of immune responses. Also, these mutant constructs open the possibility of engineering agents with additional genes that encode antigens from other infectious agents, envisioning a vaccine that can protect against multiple infections. The use of replication-defective HSV mutants has been tested with success as a candidate vaccine in animal models.[57] Recently, a glycoprotein H–deficient virus had no effect on reducing HSV reactivation and clinical disease among individuals with recurrent genital HSV-2 infection.[58] Another replication-defective mutant, defective in ICP8 (a single-strand DNA binding protein) and part of the helicase/primase complex, has demonstrated to be immunogenic and protective in animals[57] but has not been tested in humans yet. DNA vaccines for HSV have also shown promising results in animal models. Phase I studies are being conducted.

KEY REFERENCES

The full reference list for all chapters is available at www.digm7.com.

1. Spruance SL et al: The natural history of recurrent herpes simplex labialis: Implications for antiviral therapy. *N Engl J Med* **297**:69, 1977
4. Lafferty WE et al: Recurrences after oral and genital herpes simplex virus infection. Influence of site of infection and viral type. *N Engl J Med* **316**:1444, 1987
6. Wald A et al: Reactivation of genital herpes simplex virus type 2 infection in asymptomatic seropositive persons. *N Engl J Med* **342**:844, 2000
10. Freeman EE et al: Herpes simplex virus 2 infection increases HIV acquisition in men and women: Systematic review and meta-analysis of longitudinal studies. *AIDS* **20**:73, 2006



14. Khanna KM et al: Immune control of herpes simplex virus during latency. *Curr Opin Immunol* **16**:463, 2004
20. Patel R: Supporting the patient with genital HSV infection. *Herpes* **11**:87, 2004
23. Brown ZA et al: The acquisition of herpes simplex virus during pregnancy. *N Engl J Med* **337**:509, 1997
25. Kimberlin DW: Neonatal herpes simplex infection. *Clin Microbiol Rev* **17**:1, 2004
48. Wald A et al: The relationship between condom use and herpes simplex virus acquisition. *Ann Intern Med* **143**:707, 2005
52. Koelle DM, Wald A: Herpes simplex virus: The importance of asymptomatic shedding. *J Antimicrob Chemother* **45**:1, 2000

CHAPTER 194

Varicella and Herpes Zoster

Stephen E. Straus
Michael N. Oxman
Kenneth E. Schmader

EPIDEMIOLOGY

Epidemiology of Varicella

Varicella is distributed worldwide, but its age-specific incidence differs in temperate versus tropical climates and in populations that have received varicella vaccine. In temperate climates in the absence of varicella vaccination, varicella is endemic, with a regularly recurring seasonal prevalence in winter and spring, and periodic epidemics that depend on the accumulation of susceptible persons. In Europe and North America in the pre-vaccination era, 90 percent of cases occurred in children younger than 10 years of age and fewer than 5 percent in individuals older than the age of 15.[1] From 1988 to 1995, there were approximately 11,000 hospitalizations and 100 deaths caused by varicella each year in the United States.[2] The risk of hospitalization and death was much higher in infants and adults than in children, and most varicella-related deaths occurred in previously healthy people.[3] In tropical and semi-tropical countries, the mean age of varicella is higher and susceptibility among adults to primary varicella-zoster virus (VZV) infection is significantly greater than in temperate climates. High levels of susceptibility to varicella among adult immigrants from tropical climates are well documented in the U.S. military, where up to 40 percent of recruits from Puerto Rico and the Philippines have been seronegative. This is important for hospitals, where susceptible health care workers may pose a significant risk of nosocomial varicella.

Widespread use of the varicella vaccine has markedly altered the epidemiology of varicella. In the United States, vaccine coverage rates among susceptible children increased from 0 percent in 1995, when varicella vaccine was licensed, to 88 percent in 2004.[4] This has resulted in a marked decline in varicella cases and varicella-related hospitalizations. From 1995 through 2000, varicella cases reported to the Centers for Disease Control and Prevention (CDC) declined by 71 percent to 84 percent, depending on surveillance area, and by 2002 the incidence of varicella had decreased from 2.63 to 0.92 cases/1000 person years.[5,6] The decline was greatest among children aged 1 to 4 years, but cases declined in all age groups, including infants and adults. The annual varicella-related hospitalization rate in the United States declined from more than 0.5 per 10,000 from 1993 to 1995 to 0.1 per 10,000 by 2001. The decline in varicella-related hospitalization rates was greatest among 0- to 4-year-old children, but rates also declined among youths aged 5 to 19 years and adults.[7]

Varicella is highly contagious. Attack rates of 87 percent among susceptible siblings in households and nearly 70 percent among susceptible patients on hospital wards have been reported. More than 95 percent of cases of varicella are clinically apparent, although occasionally the exanthem may be so sparse and transient as to pass unnoticed. A typical patient is infectious for 1 to 2 days (rarely, 3 to 4 days) before the exanthem appears, and for 4 or 5 days thereafter, that is, until the last crop of vesicles has crusted. The immunocompromised patient, who may experience many successive crops of lesions for 1 week or more, is infectious for a longer period of time. The mean incubation period of varicella is 14 or 15 days, with a range of 10 to 23 days. It is often prolonged in patients who develop varicella after passive immunization with varicella-zoster immune globulin (VZIG) or zoster immune plasma, or active post-exposure immunization with live attenuated Oka strain varicella vaccine.[8]

The major route by which varicella is acquired and transmitted is thought to be the respiratory tract, but infection may also be spread by direct contact. Varicella crusts are not infectious, and the duration of infectivity of droplets containing virus is probably quite limited. Although the infectiousness of patients with varicella is thought to depend largely upon virus shed from the mucous membranes of the upper respiratory tract, VZV has only rarely been cultured from pharyngeal secretions; however, it can be detected in the oropharynx of the majority of patients using polymerase chain reaction–based assays.[9]

Natural varicella (i.e., varicella caused by wild-type VZV) generally confers lifelong immunity to the disease. Re-exposure to the virus boosts humeral and cell-mediated immune responses but rarely leads to clinical illness. Most reported second attacks of varicella involve incorrect diagnoses; others may represent cutaneous dissemination in patients with herpes zoster (see Epidemiology of Herpes Zoster). With severe immunocompromise, re-infections manifested as varicella have been observed. In addition, persons who develop modified varicella (e.g., because they are infected early in infancy in the presence of maternal antibody or have been immunized with live attenuated varicella vaccine) may respond to exogenous exposure by developing a second, usually mild, episode of breakthrough varicella.

Epidemiology of Herpes Zoster

Herpes zoster occurs sporadically throughout the year without seasonal prevalence. The occurrence of herpes zoster is independent of the prevalence of varicella, and there is no convincing evidence that herpes zoster can be acquired by contact with other persons with varicella or herpes zoster. Rather, the incidence of herpes zoster is determined by factors that influence the host-virus relationship.

One strong risk factor is older age (Fig. 194-1A). The incidence of herpes zoster is 1.5 to 3.0 per 1000 person years in all ages and 7 to 11 per 1000 per year in persons over 60 years of age in European and North American studies.[10–17] It is estimated that there are more than a million new cases of herpes zoster in the United States each year, more than one-



VARICELLA AND HERPES ZOSTER AT A GLANCE





- Varicella (chickenpox) and herpes zoster (shingles) are distinct clinical entities caused by the varicella-zoster virus.
- Varicella, an acute, highly contagious exanthem that occurs most often in childhood, is the result of primary infection of a susceptible individual.
- The rash usually begins on the face and scalp and spreads rapidly to the trunk. Lesions are scattered rather than clustered, and progress from rose-colored macules to papules, vesicles, pustules, and crusts. In varicella, lesions in all stages are usually present on the body at the same time.
- In normal children, serious complications are rare. In adults and in immunologically compromised persons, varicella is more likely to be associated with life-threatening complications.
- Where use of varicella vaccine in susceptible children and adults is widespread, the incidence of varicella is markedly reduced.
- Herpes zoster is characterized by unilateral, dermatomal pain and rash as the result of the reactivation of endogenous varicella-zoster virus that had persisted in latent form within sensory ganglia after an earlier attack of varicella.
- The erythematous, maculopapular, and vesicular lesions of herpes zoster are clustered rather than scattered because virus reaches the skin via sensory nerves.
- Herpes zoster is most common in older adults and immunosuppressed individuals.
- Pain is the most important clinical manifestation of herpes zoster, and the most common complication is chronic pain or postherpetic neuralgia.
- Antiviral therapy and analgesics aid acute pain control; lidocaine patch (5 percent), gabapentin, pregabalin, opioids, and tricyclic antidepressants reduce postherpetic neuralgia.
- The zoster vaccine reduces the incidence of herpes zoster by one-half and the incidence of postherpetic neuralgia by two-thirds.



half of which occur in persons 60 years of age or older, and this number increase as the population ages.[11,14]

Another major risk factor is cellular immune dysfunction. Immunosuppressed patients have a 20 to 100 times greater risk of herpes zoster than immunocompetent individuals of the same age. Immunosuppressive conditions associated with high risk of herpes zoster include human immunodeficiency virus (HIV) infection, bone marrow transplant, leukemia and lymphoma, use of cancer chemotherapy, and use of corticosteroids. Herpes zoster is a prominent and early "opportunistic infection" in persons infected with HIV, in whom it is often the first sign of immune deficiency. Thus, HIV infection should be considered in individuals who develop herpes zoster.

Other factors reported to increase the risk of herpes zoster include female sex,[17] physical trauma in the affected dermatome,[18] interleukin 10 gene polymorphisms,[19] and black race,[16,17] but confirmation is required. Exposure to children and contact with cases of varicella have been reported to confer protection against herpes zoster.[17,20]

Second episodes of herpes zoster are uncommon in immunocompetent persons, and third attacks are very rare. Persons suffering more than one episode may be immunocompromised. Immunocompetent patients suffering multiple episodes of herpes zoster–like disease are likely to be suffering from recurrent zosteriform herpes simplex virus (HSV) infections.[21]

Patients with herpes zoster are less contagious than patients with varicella. The rate at which susceptible household contacts develop varicella after exposure to herpes zoster appears to be about one-third of the rate observed after exposure to varicella.[11] Virus can be isolated from vesicles and pustules in uncomplicated herpes zoster for up to 7 days after the appearance of the rash, and for much longer periods in immunocompromised individuals. Patients with uncomplicated dermatomal zoster appear to spread the infection by means of direct contact with their lesions. Patients with disseminated herpes zoster may, in addition, transmit the infection in aerosols, so that airborne precautions, as well as contact precautions, are required for such patients.

The effect of the marked reduction in the incidence of varicella, due to widespread varicella vaccination of children, on the epidemiology of herpes zoster is unclear. In the long term, the incidence of herpes zoster is likely to decline as the cohorts of children now receiving the vaccine become adults; vaccine virus-associated herpes zoster will probably be less frequent and less severe in older adults than wild-type virus–associated herpes zoster because the vaccine virus is highly attenuated. In the short term, the incidence of herpes zoster could increase because a decline in the incidence of varicella will reduce the adult population's exposure to VZV, thereby reducing immune boosting, hastening the age-related decline in immunity to VZV, and thus increasing the age-specific risk of herpes zoster. However, recent studies of herpes zoster in populations with high rates of varicella vaccination have shown little or no increase in the incidence of herpes zoster.[6,12,22]

ETIOLOGY AND PATHOGENESIS

VZV is a member of the herpesvirus family.[23] Other members pathogenic for humans include HSV-1 and HSV-2; cytomegalovirus; Epstein-Barr virus; human herpesvirus-6 (HHV-6) and HHV-7, which cause roseola; and Kaposi sarcoma–associated herpesvirus, also called *HHV-8*. All herpesviruses are morphologically indistinguishable and share a number of properties, including the capacity to establish latent infections that persist for life.

The VZV genome encodes approximately 70 unique genes, most of which have DNA sequence and functional homology to genes of the other herpesviruses. Immediate early gene products regulate VZV replication. Early gene products, such as the virus-specific thymidine kinase and the viral DNA polymerase, support viral replication. Late genes encode virus structural proteins that serve as targets of antibody and cellular immune responses.

There is only one VZV serotype. Although viruses isolated from individual cases of varicella or herpes zoster worldwide are basically similar, minor variations in their nucleotide sequences allow one to distinguish wild-type from vaccine virus strains, and to "fingerprint" viruses isolated from individual patients.

Pathogenesis of Varicella

Entry of VZV is through the mucosa of the upper respiratory tract and oropharynx. Initial multiplication at this portal of entry results in dissemination of small amounts of virus via the blood and lymphatics (the primary viremia). This virus is cleared by cells of the reticuloendothelial system, the major site of virus replication during the remainder of the incubation period.

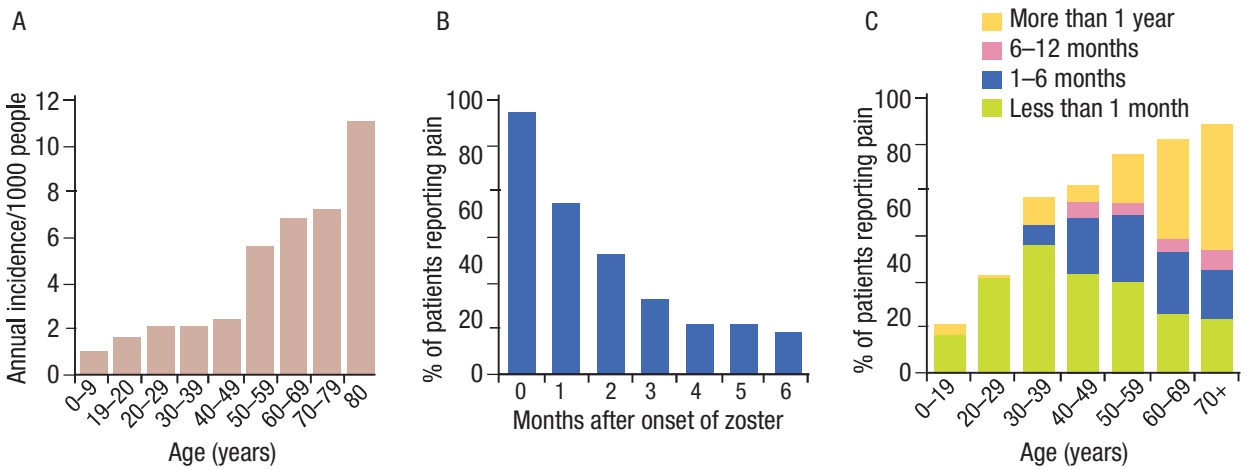

▲ **FIGURE 194-1** **A.** The epidemiology of herpes zoster and postherpetic neuralgia. The annual incidence of herpes zoster per 1000 persons in a general medical practice. **B.** The percentage of patients with pain persisting after the onset of the herpes zoster rash. These data are from the placebo recipients in one large, double-blind treatment study. **C.** The proportion of patients with postherpetic neuralgia according to age. (From Kost RG, Straus SE: Postherpetic neuralgia: Pathogenesis, treatment, and prevention. *N Engl J Med* **335**:32, 1996, with permission.)



The incubating infection is partially contained by innate host defenses (e.g., interferon, natural killer cells) and by developing VZV-specific immune responses. In most individuals, virus replication eventually overwhelms these developing host defenses, so that approximately 2 weeks after infection, a much larger (secondary) viremia and associated symptoms and lesions occur. Skin lesions appear in successive crops, reflecting a cyclic viremia, which in the normal host is terminated after approximately 3 days by VZV-specific humeral and cellular immune responses. Virus circulates in mononuclear leukocytes, primarily lymphocytes. Even in uncomplicated varicella, the secondary viremia results in the sub-clinical infection of many organs in addition to the skin. Effective host immune responses terminate viremia and limit the progression of varicella lesions in the skin and other organs. Humeral immunity to VZV protects against varicella. People with detectable serum antibody do not usually become ill after exogenous exposure. Cell-mediated immunity to VZV also develops during the course of varicella, persists for many years, and protects against severe infections.[24]

Pathogenesis of Herpes Zoster

During the course of varicella, VZV passes from lesions in the skin and mucosal surfaces into the contiguous endings of sensory nerves and is transported centripetally up the sensory fibers to the sensory ganglia. In the ganglia, the virus establishes a latent infection that persists for life. Herpes zoster occurs most often in dermatomes in which the rash of varicella achieves the highest density—those innervated by the first (ophthalmic) division of the trigeminal nerve and by spinal sensory ganglia from T1 to L2 (Fig. 194-2).

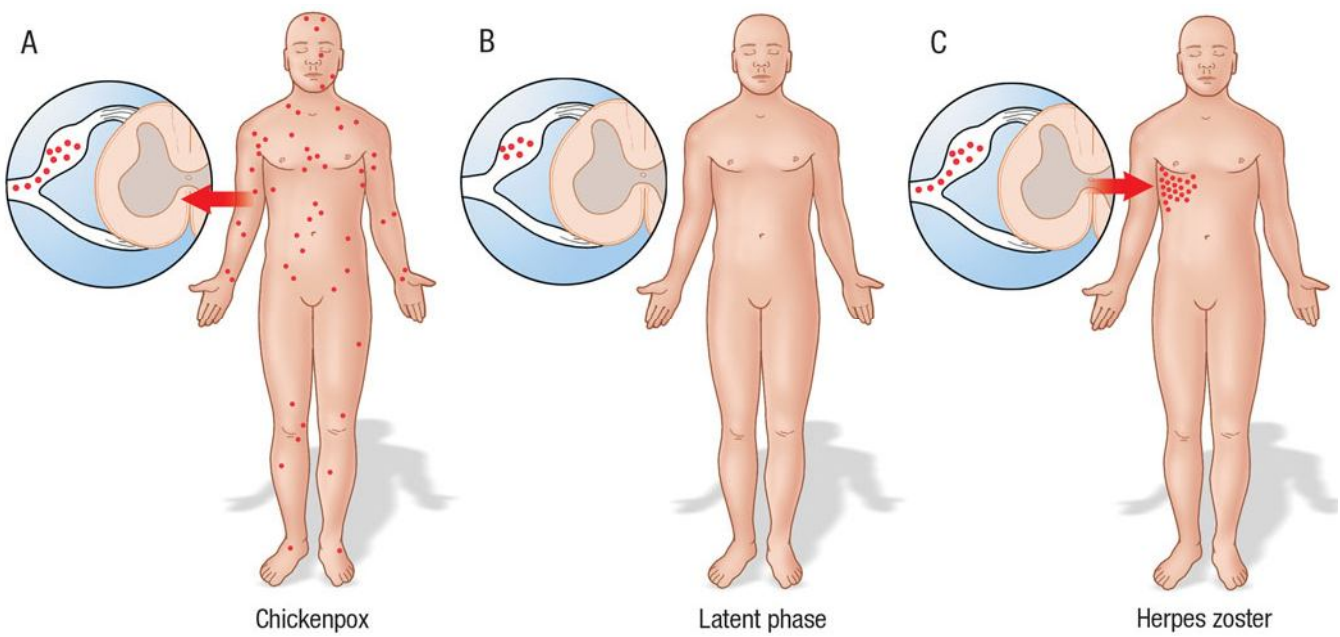

▲ **FIGURE 194-2** Varicella and herpes zoster. **A.** During primary varicella-zoster virus (VZV) infection (varicella or chickenpox), virus infects sensory ganglia. **B.** VZV persists in a latent phase within ganglia for the life of the individual. **C.** With diminished immune function, VZV re-activates within sensory ganglia, descends through sensory nerves, and replicates in skin.



Although the latent virus in the ganglia retains its potential for full infectivity, re-activation is sporadic and infrequent, and infectious virus does not appear to be present during latency. The mechanisms involved in re-activation of latent VZV are unclear, but re-activation has been associated with immunosuppression; emotional stress; irradiation of the spinal column; tumor involvement of the cord, dorsal root ganglion, or adjacent structures; local trauma; surgical manipulation of the spine; and frontal sinusitis (as a precipitant of ophthalmic zoster). Most important, though, is the decline in VZV-specific cellular immunity that occurs with increasing age.[25]

VZV may also re-activate without producing overt disease. The small quantity of viral antigens released during such contained re-activations would be expected to stimulate and sustain host immunity to VZV.[26]

When VZV-specific cellular immunity falls below some critical level, re-activated virus can no longer be contained.[11] Virus multiplies and spreads within the ganglion, causing neuronal necrosis and intense inflammation, a process that is often accompanied by severe neuralgia.[27] Infectious VZV then spreads antidromically down the sensory nerve, causing intense neuritis, and is released from the sensory nerve endings in the skin, where it produces the characteristic cluster of zoster vesicles. Spread of the ganglionic infection proximally along the posterior nerve root to the meninges and cord results in local leptomeningitis, cerebrospinal fluid pleocytosis, and segmental myelitis. Infection of motor neurons in the anterior horn and inflammation of the anterior nerve root account for the local palsies that may accompany the cutaneous eruption, and extension of infection within the central nervous system (CNS) may result in rare complications of herpes zoster (e.g., meningoencephalitis, transverse myelitis).

Pathogenesis of Pain in Herpes Zoster and Postherpetic Neuralgia

Pain is a major symptom of herpes zoster. It often precedes and generally accompanies the rash, and it frequently persists after the rash has healed—a complication known as *postherpetic neuralgia* (PHN). A number of different but overlapping mechanisms appear to be involved in the pathogenesis of pain in herpes zoster and PHN (Fig. 194-3).[28,29]

Injury to the peripheral nerve and to neurons in the ganglion triggers afferent pain signals. Inflammation in the skin triggers nociceptive signals that further amplify cutaneous pain. The abundant release of excitatory amino acids and neuropeptides induced by the sustained barrage of afferent impulses during the prodrome and acute phase of herpes zoster may cause excitotoxic injury and the loss of inhibitory interneurons in the spinal dorsal horn. Damage to neurons in the spinal cord and ganglion, and to the peripheral nerve, is important in the pathogenesis of PHN. Damaged primary afferent nerves may become spontaneously active and hypersensitive to peripheral stimuli, and also to sympathetic stimulation. Excessive nociceptor activity and ectopic impulse generation may, in turn, sensitize CNS neurons, augmenting and prolonging central responses to innocuous as well as noxious stimuli. Clinically, these mechanisms result in allodynia [pain and/or unpleasant sensations elicited by stimuli that are normally not painful (e.g., light touch)] with little or no sensory loss.

The anatomic and functional changes responsible for PHN appear to be established early in the course of herpes zoster. This would explain the correlation of initial pain severity and the presence of prodromal pain with the subsequent development of PHN, and the failure of antiviral therapy to fully prevent PHN (see Treatment).

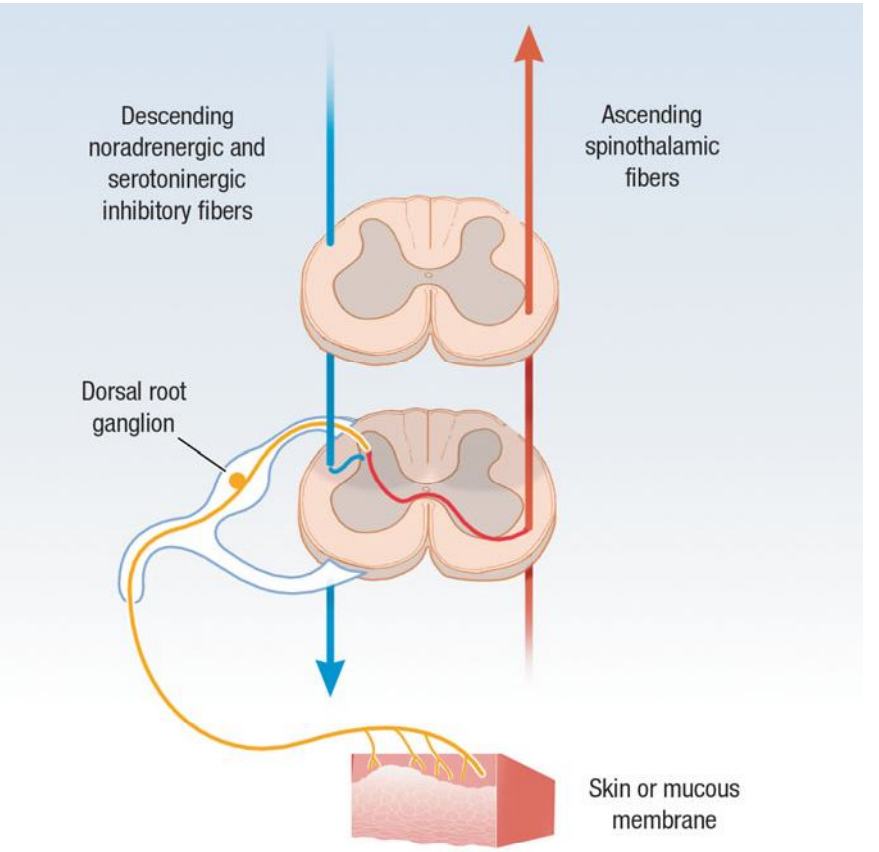

▲ **FIGURE 194-3** Pathway of normal pain perception. Noxious stimuli activate free nerve endings in the skin to generate signals that are conveyed through unmyelinated C fibers (*red*) and small Aδ fibers to the neuronal bodies in the segmental dorsal root ganglia, then proximally to the dorsal horn of the spinal cord, where they form synapses with second-order neurons. Spinal cord neurons are subject to powerful descending inhibitory signals from the brain (*blue*), mediated by the biogenic amines serotonin and norepinephrine. Drugs that potentiate the central effects of biogenic amines, such as tricyclic antidepressant drugs, may act by enhancing these descending pathways. Endogenous opiates also contribute to descending inhibitory input. The net result of peripheral afferent input and descending inhibitory input is projected cephalad, joining other ascending fibers in the contralateral spinothalamic tract (*orange*). Information from the spinothalamic tract is integrated with input from brainstem and cortical areas for the perception of specific aspects of pain as well as more general affective components of pain perception.

CLINICAL FINDINGS

Clinical Findings of Varicella

PRODROME OF VARICELLA In young children, prodromal symptoms are uncom-



▲ **FIGURE 194-4** Varicella. **A.** A full spectrum of lesions—that is, erythematous papules, vesicles ("dewdrops on rose petals"), crusts, and erosions at sites of excoriation—is seen in a child with a typical case of varicella. **B.** A wider range of lesions, including many large pustules, is seen in a 21-year-old woman who was febrile as well as "toxic" and had varicella pneumonitis.

mon. In older children and adults, the rash is often preceded by 2 to 3 days of fever, chills, malaise, headache, anorexia, severe backache, and, in some patients, sore throat and dry cough.

RASH OF VARICELLA In unvaccinated persons, the rash begins on the face and scalp and spreads rapidly to the trunk, with relative sparing of the extremities (Fig. 194-4). New lesions appear in successive crops, but their distribution remains central. The rash tends to be denser in the small of the back and between the shoulder blades than on the scapulae and buttocks and more profuse on the medial than on the lateral aspects of the limbs. It is not uncommon to have a few lesions on the palms and soles, and vesicles often appear earlier and in larger numbers in areas of inflammation, such as diaper rash or sunburn.

A striking feature of varicella lesions is their rapid progression, over as little as 12 hours, from rose-colored macules to papules, vesicles, pustules, and crusts (see Fig. 194-4). The typical vesicle of varicella is 2 to 3 mm in diameter and elliptical, with its long axis parallel to the folds of the skin. The early vesicle is superficial and thin-walled, and it is surrounded by an irregular area of erythema, which gives the lesions the appearance of a "dewdrop on a rose petal." The vesicular fluid soon becomes cloudy with the influx of inflammatory cells, which convert the vesicle to a pustule (see Fig. 194-4). The lesion then dries, beginning in the center, first producing an umbilicated pustule and then a crust. Crusts fall off spontaneously in 1 to 3 weeks, leaving shallow pink depressions that gradually disappear. Scarring is rare unless the lesions were traumatized by the patient or superinfected with bacteria. Healing lesions may leave hypopigmented spots that persist for weeks to months.

Vesicles also develop in the mucous membranes of the mouth, nose, pharynx, larynx, trachea, gastrointestinal tract, urinary tract, and vagina. These mucosal vesicles rupture so rapidly that the vesicular stage may be missed. Instead, one sees shallow ulcers 2 to 3 mm in diameter.

A distinctive feature of varicella is the simultaneous presence, in any one area of the skin, of lesions in all stages of development. Careful prospective studies have shown that the average number of lesions in healthy children ranges from 250 to 500; secondary cases resulting from household exposure are more severe than primary cases resulting from exposure at school, presumably because more intense and prolonged exposure at home results in a higher virus inoculum.

Fever usually persists as long as new lesions continue to appear, and its height is generally proportional to the severity of the rash. It may be absent in mild cases or rise to 40.5°C (105°F) in severe cases with extensive rash. Prolonged fever or recurrence of fever after defervescence may signify a secondary bacterial infection or another complication. The most distressing symptom is pruritus, which is usually present throughout the vesicular stage.

The varicella vaccine alters the natural history of the rash. A small percentage of vaccinees develop breakthrough varicella after exposure to people with active VZV infections. The usual breakthrough rash is predominately maculopapular with fewer lesions (i.e., less than 60) and fewer vesicles than the rash of natural varicella. The incidence and severity of fever is also less than that in natural varicella.[30]

Clinical Findings of Herpes Zoster

PRODROME OF HERPES ZOSTER Pain and paresthesia in the involved dermatome often precede the eruption by several days and vary from superficial itching, tingling, or burning to severe, deep, boring, or lancinating pain. The pain may be constant or intermittent, and it is often accompanied by tenderness and hyperesthesia of the skin in the involved dermatome. The pre-eruptive pain of herpes zoster may simulate pleurisy, myocardial infarction, duodenal ulcer, cholecystitis, biliary or renal colic, appendicitis, prolapsed intervertebral disk, or early glaucoma, and this may lead to serious misdiagnosis and misdirected interventions. Prodromal pain is uncommon in immunocompetent persons younger than 30 years of age, but it occurs in the majority of persons with herpes zoster over the age of 60 years. A few patients experience acute segmental neuralgia without ever developing a cutaneous eruption—a condition known as *zoster sine herpete*.

RASH OF HERPES ZOSTER The most distinctive feature of herpes zoster is the localization and distribution of the rash, which is nearly always unilateral and is generally limited to the area of skin innervated by a single sensory ganglion (Fig. 194-5). The area supplied by the trigeminal nerve, particularly the ophthalmic division, and the trunk from T3 to L2 are most frequently affected; the thoracic region alone accounts for more than one-half of all reported cases, and lesions rarely occur distal to the elbows or knees.[11,15]

Although the individual lesions of herpes zoster and varicella are indistinguishable, those of herpes zoster tend to evolve more slowly and usually consist of closely grouped vesicles on an erythematous base, rather than the more discrete, randomly distributed vesicles of varicella. This difference reflects intraneural spread of virus to the skin in herpes zoster, as opposed to viremic spread in varicella. Herpes zoster lesions begin as erythematous macules and papules that often first appear where superficial branches of the affected sensory nerve are given off, for example, the posterior primary division and the lateral and anterior branches of the anterior primary division of spinal nerves. Vesicles form within 12 to 24 hours and evolve into pustules by the third day. These dry and crust in 7 to 10



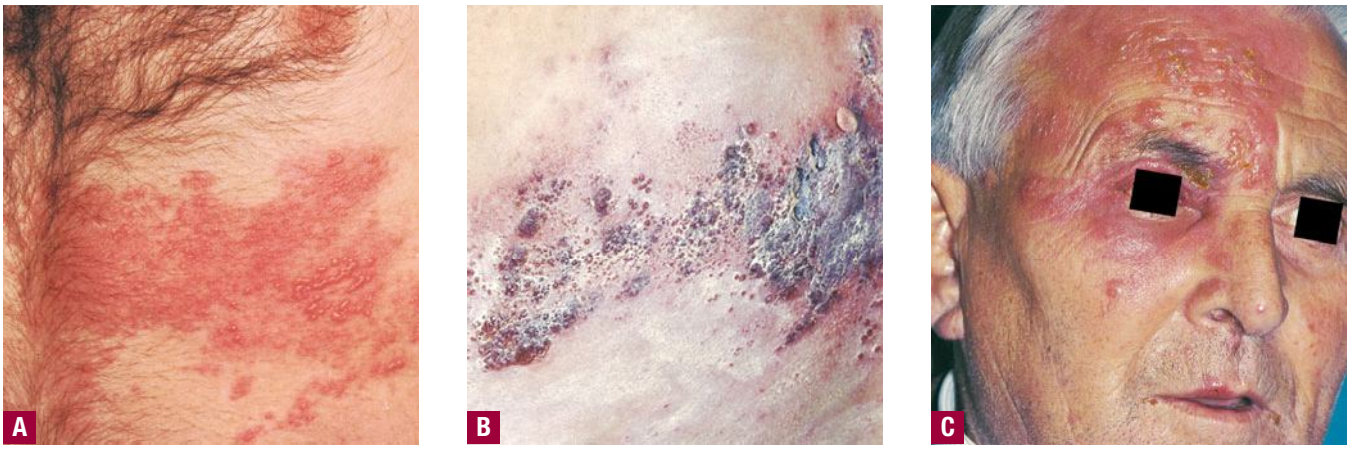

▲ **FIGURE 194-5** Herpes zoster. **A.** Early involvement of a thoracic dermatome with erythema within the dermatome and areas of grouped vesicle formation. **B.** Later involvement with crusted sites on the back, where the eruption first appeared, and many confluent hemorrhagic vesicles and bullae on the lateral chest wall, where the eruption appeared more recently; some vesicles are also seen outside the involved dermatome, representing hematogenous dissemination, a not uncommon occurrence. **C.** Ophthalmic zoster. Note the involvement of the tip of the nose, which frequently signals involvement of the eye.

days. The crusts generally persist for 2 to 3 weeks (see Fig. 194-5B). In normal individuals, new lesions continue to appear for 1 to 4 days (occasionally for as long as 7 days). The rash is most severe and lasts longest in older people, and is least severe and of shortest duration in children.

Between 10 percent and 15 percent of reported cases of herpes zoster involve the ophthalmic division of the trigeminal nerve (see Fig. 194-5C).[31] The rash of ophthalmic zoster may extend from the level of the eye to the vertex of the skull, but it terminates sharply at the midline of the forehead. When only the supratrochlear and supraorbital branches are involved, the eye is usually spared. Involvement of the nasociliary branch, which innervates the eye as well as the tip and side of the nose, provides VZV with direct access to intraocular structures. Thus, when ophthalmic zoster involves the tip and the side of the nose, careful attention must be given to the condition of the eye. The eye is involved in 30 percent to 40 percent of patients with ophthalmic zoster. Corneal sensation is generally impaired and when impairment is severe, it may lead to neurotrophic keratitis and chronic ulceration.

Herpes zoster affecting the second and third divisions of the trigeminal nerve (Fig. 194-6) as well as other cranial nerves may produce symptoms and lesions in the mouth, ears, pharynx, or larynx. The so-called *Ramsay Hunt syndrome* (facial palsy, in combination with herpes zoster of the external ear or tympanic membrane, with or without tinnitus, vertigo, and deafness), results from involvement of the facial and auditory nerves.

PAIN OF HERPES ZOSTER Although the rash is important, pain is the cardinal problem posed by herpes zoster, especially in the elderly. Most patients experience dermatomal pain or discomfort during the acute phase (30 days from rash onset) that ranges from mild to severe. Patients describe their pain or discomfort as burning, deep aching, tingling, itching, or stabbing. For some patients, the pain intensity is so great that words such as *horrible* or *excruciating* are used to describe the experience. Acute herpes zoster pain is associated with decreased physical functioning, emotional distress, and decreased social functioning.[32]

HERPES ZOSTER IN THE IMMUNOCOMPROMISED HOST Except for PHN, most serious complications of herpes zoster occur in immunocompromised persons. These complications include necrosis of skin and scarring (Fig. 194-7) and cutaneous dissemination with an incidence as high as 25 percent to 50 percent. Approximately 10 percent of patients with cutaneous dissemination also manifest widespread (Fig. 194-8), often fatal, visceral dissemination, particularly to the lungs, liver, and brain.[33]

HIV-infected patients are fairly unique in their tendency to suffer multiple recurrences of herpes zoster as their HIV infection progresses; herpes zoster may recur in the same or different dermatomes or in several contiguous or non-contiguous dermatomes. Herpes zoster in patients with acquired immunodeficiency syndrome (AIDS) may be severe, with cutaneous and visceral dissemination. Patients with AIDS may also develop chronic verrucous, hyperkeratotic (Fig. 194-9), or ecthymatous cutaneous lesions caused by acyclovir-resistant VZV.

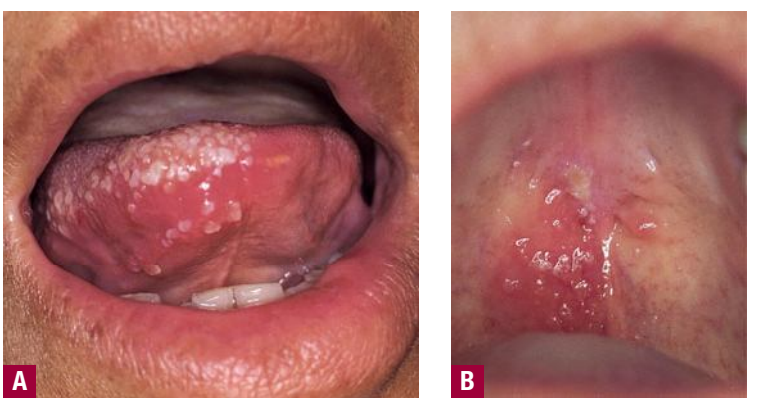

▲ **FIGURE 194-6** Cephalic herpes zoster with facial palsy (Hunt syndrome). A 60-year-old woman with right-sided facial palsy and vesicles on her (**A**) tongue and (**B**) soft palate.

DIAGNOSIS OF VARICELLA

Varicella can usually be diagnosed readily on the basis of the appearance and evolution of its characteristic rash (see Fig. 194-4), particularly when there is a history of exposure within the preceding 2 to 3 weeks.





▲ **FIGURE 194-7** **A.** Acute, necrotic herpes zoster involving the first and second distributions of the fifth cranial nerve in a woman with lymphoma receiving cytotoxic chemotherapy. **B.** Dense scar formation and temporal muscle wasting several weeks later. (From Straus SE et al: Varicella-zoster infections: Biology, natural history, treatment and prevention. *Ann Intern Med* **108**:221, 1988 with permission.)



▲ **FIGURE 194-8** The back of a patient with chronic lymphocytic leukemia and disseminated herpes zoster. (From Straus SE et al: Varicella-zoster infections: Biology, natural history, treatment and prevention. *Ann Intern Med* **108**:221, 1988 with permission.)



◀ **FIGURE 194-9** Chronic verrucous lesions of herpes zoster despite long-term acyclovir treatment in a patient with advanced acquired immunodeficiency syndrome. (Used with permission from David Paar, MD.)

Disseminated herpes zoster may be mistaken for varicella when there is widespread dissemination of VZV from a small, painless area of herpes zoster or from the affected sensory ganglion in the absence of an obvious dermatomal eruption. This is not infrequent in profoundly immunosuppressed, seropositive persons (see Fig. 194-7).

Disseminated HSV infections may resemble varicella; however, there is often an obvious concentration of lesions at and surrounding the site of the primary or recurrent infection (e.g., the mouth or external genitalia), and there may be marked toxicity and encephalitis.

The remaining differential diagnoses of varicelliform rashes are listed in Box 194-1. The character, distribution, and evolution of the lesions, together with a careful epidemiologic history, usually differentiate these diseases from varicella. When any doubt exists, the clinical impression should receive laboratory confirmation.

DIAGNOSIS OF HERPES ZOSTER

In the pre-eruptive stage, the prodromal pain of herpes zoster is often confused with other causes of localized pain. Once the eruption appears, the character and dermatomal location of the rash, coupled with dermatomal pain or discomfort, usually makes the diagnosis obvious (see Figs. 194-5 and 194-6).

A cluster of vesicles, particularly near the mouth or genitals, may represent herpes zoster, but it may also be a recurrent HSV infection.[12] Zosteriform herpes simplex is often impossible to distinguish from herpes zoster on clinical grounds. A history of multiple recurrences at the same site is common in herpes simplex

Box 194-1

Differential Diagnosis

VARICELLA

Most Likely
- Vesicular exanthems of coxsackie viruses and echoviruses
- Impetigo
- Insect bites
- Contact dermatitis

Consider
- Papular urticaria
- Erythema multiforme
- Drug eruptions
- Disseminated herpes simplex
- Scabies

Always Rule Out
- Secondary syphilis
- Disseminated herpes zoster
- Dermatitis herpetiformis
- Smallpox and other poxviruses

HERPES ZOSTER

Most Likely
- Zosteriform herpes simplex
- Contact dermatitis
- Insect bites
- Burns

Consider
- Papular urticaria
- Erythema multiforme
- Drug eruptions
- Scabies

Always Rule Out
- Bullous pemphigoid
- Pemphigus vulgaris
- Dermatitis herpetiformis
- Epidermolysis bullosa herpetiformis

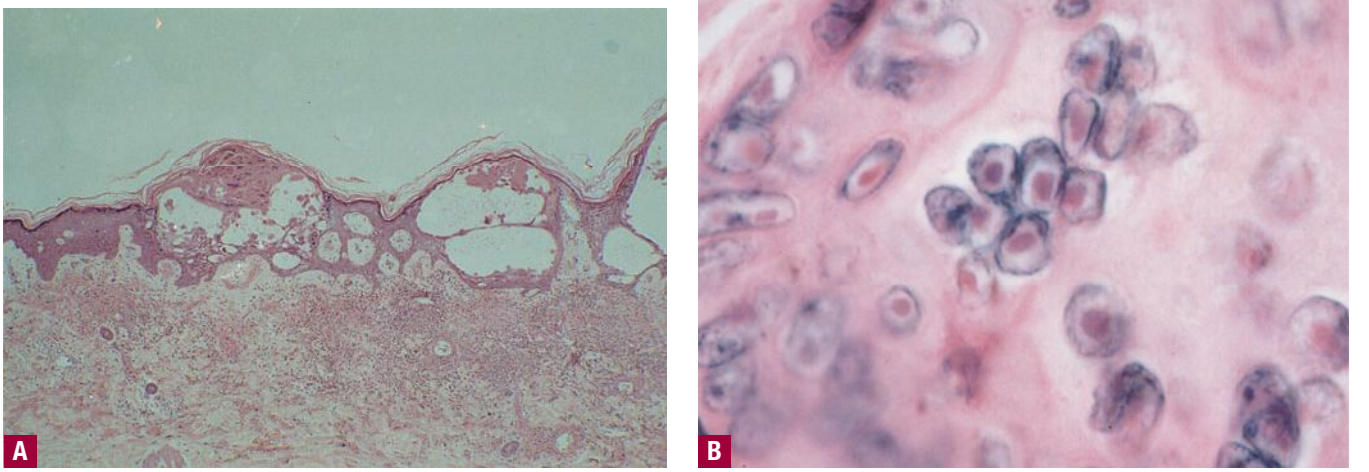

▲ **FIGURE 194-10** Herpes zoster, histopathology. **A.** Intraepidermal vesicle, acantholysis, reticular degeneration; underlying dermis shows edema and vasculitis. **B.** Multinucleated giant cells with characteristic nuclear changes.

but does not occur in herpes zoster in the absence of profound and clinically obvious immune deficiency.

Box 194-1 lists other considerations in the differential diagnosis of herpes zoster.

LABORATORY TESTS

The lesions of varicella and herpes zoster are indistinguishable by histopathology (Fig. 194-10). The presence of multinucleated giant cells and epithelial cells containing acidophilic intranuclear inclusion bodies (see Fig. 194-10B) distinguishes the cutaneous lesions produced by VZV from all other vesicular eruptions (e.g., those caused by variola and other poxviruses, and by coxsackie viruses and echoviruses) except those produced by HSV (see Fig. 193-9 in Chap. 193). These cells can be demonstrated in Tzanck smears prepared at the bedside; material is scraped from the base of an early vesicle, spread on a glass slide, fixed in acetone or methanol, and stained with hematoxylin-eosin, Giemsa, Papanicolaou, or Paragon multiple stain.

Punch biopsies provide more reliable material for histologic examination than Tzanck smears and facilitate diagnosis in the prevesicular stage and in atypical lesions such as the chronic verrucous lesions produced by acyclovir-resistant VZV in patients with AIDS (see Fig. 194-9).

The definitive diagnosis of VZV infection, as well as the differentiation of VZV from HSV, is accomplished by the isolation of virus in cell cultures inoculated with vesicle fluid, blood, cerebrospinal fluid or infected tissue, or by the direct identification of VZV antigens or nucleic acids in these specimens. Virus isolation is the only technique that yields infectious VZV for further analysis, such as determination of its sensitivity to antiviral drugs; however, VZV is extremely labile, and only 30 percent to 60 percent of cultures from proven cases are generally positive. To maximize virus recovery, specimens should be inoculated into cell culture immediately. It is important to select new vesicles containing clear fluid for aspiration, because the probability of isolating VZV diminishes rapidly as lesions become pustular. VZV is almost never isolated from crusts.

VZV can be isolated and propagated in vitro in monolayer cultures of a variety of human (and certain simian) cells. The cytopathic effects induced by the replicating virus in such cell cultures are characterized by the formation of acidophilic intranuclear inclusion bodies and multinucleated giant cells similar to those seen in the cutaneous lesions of the disease. These changes are indistinguishable from those produced by HSV, but whereas HSV rapidly spreads to infect the remaining cells in the culture, the cytopathic effect of VZV remains focal. Cytopathic effects of VZV are generally not apparent until several days after specimen inoculation. Modifications of the cell culture assay in which vesicle fluid or lesion scrapings are centrifuged onto cells growing on coverslips at the bottom of thin glass-walled "shell" vials followed 24 to 72 hours later by fixation and staining with fluorescein- or enzyme-labeled monoclonal antibodies to VZV proteins, can confirm the presence of VZV relatively quickly, well before cytopathic effects are evident in conventional cell cultures.[34]

Immunofluorescent or immunoperoxidase staining of cellular material from fresh vesicles or prevesicular lesions has become the diagnostic method of choice in many centers; it can detect VZV significantly more often and faster than virus culture, even relatively late in the disease when cultures are no longer positive.[34] Enzyme immunoassays provide another rapid and sensitive method for antigen detection.

Detection of VZV DNA in clinical specimens after amplifications by polymerase chain reaction provides the greatest assay sensitivity, very high specificity, and rapid turn-around time. It has revolutionized the diagnosis of VZV infections.[34,35]

Serologic tests permit the retrospective diagnosis of varicella and herpes zoster when acute and convalescent sera are available for comparison.[34] These assays can also identify susceptible individuals who may be candidates for isolation or prophylaxis. The technique most commonly used is a solid-phase enzyme-linked immunosorbent assay. This assay, however, often lacks sensitivity and specificity and does not detect antibody in people who are immune, and sometimes yield false-positive results in susceptible individuals. Several more sensitive techniques have been developed to measure humoral responses to VZV. These include an immunofluorescence assay for antibody to VZV-induced membrane antigens (fluorescent antibody to membrane antigen) that reliably distinguishes immune from susceptible adults and a latex agglutination test that is comparable in sensitivity and specificity to fluorescent antibody to membrane antigen assays but is much simpler to perform.[36]

COMPLICATIONS

Complications of Varicella

In the normal child, varicella is rarely complicated. The most common complication is the secondary bacterial infection of skin lesions, usually by staphylococci or streptococci, which may produce impetigo, furuncles, cellulitis, erysipelas, and, rarely, gangrene.[37] These local infections often lead to scarring and, rarely, to septicemia with metastatic infection of other organs. Bullous lesions may develop when vesicles are superinfected by staphylococci that produce exfoliative toxins. Invasive group A streptococcal infections are particularly virulent. In the absence of varicella vaccination, up to one-third of invasive group A streptococcal infections are associated with varicella; they usually occur within 2 weeks of the onset of the varicella rash.[38] Widespread varicella vaccination appears to have markedly reduced the percentage of invasive group A streptococcal hospitalizations associated with varicella in the United States.[39]

Secondary bacterial pneumonia, otitis media, and suppurative meningitis are rare complications and typically respond to appropriate antibiotic therapy. However, bacterial superinfection is common and potentially life-threatening in leukopenic patients. Other complications reflect a basic defect in the capacity of the host to limit VZV replication and dissemination.[40]

In adults, fever and constitutional symptoms are more prominent and prolonged, the rash of varicella is more profuse, and complications are more frequent.[40] High rates of complications have been reported in adults not born in the United States (i.e., adults born in Mexico).[41] Primary varicella pneumonia is the major complication of adult varicella. Some patients are virtually asymptomatic, but others develop severe respiratory embarrassment, with cough, dyspnea, tachypnea, high fever, pleuritic chest pain, cyanosis, and hemoptysis 1 to 6 days after onset of the rash. The severity of the symptoms usually exceeds the physical findings, but the roentgenogram typically reveals diffuse, peribronchial nodular densities throughout both lung fields with a tendency to concentrate in the perihilar regions and at the bases. The mortality in adults with frank varicella pneumonia has been estimated to be between 10 percent and 30 percent, but it is less than 10 percent if immunocompromised patients are excluded.[42]

TABLE 194–1
Complications of Herpes Zoster

CUTANEOUS	VISCERAL	NEUROLOGIC
• Bacterial superinfection	• Pneumonitis	• Postherpetic neuralgia
• Scarring	• Hepatitis	• Meningoencephalitis
• Zoster gangrenosum	• Esophagitis	• Transverse myelitis
• Cutaneous dissemination	• Gastritis	• Peripheral nerve palsies
	• Pericarditis	• Motor
	• Cystitis	• Autonomic
	• Arthritis	• Cranial nerve palsies
		• Sensory loss
		• Deafness
		• Ocular complications
		• Granulomatous angiitis (causing contralateral hemiparesis)

Varicella during pregnancy is a threat to both mother and fetus.[43] Disseminated infection and varicella pneumonia may result in maternal death, but neither the incidence nor the severity of varicella pneumonia appear to be significantly increased by pregnancy. The fetus may die as a consequence of premature labor or maternal death caused by severe varicella pneumonia, but varicella during pregnancy does not, otherwise, substantially increase fetal mortality. Nevertheless, even in uncomplicated varicella, maternal viremia can result in intrauterine (congenital) VZV infection, and a characteristic constellation of congenital abnormalities.[43] Perinatal varicella (i.e., varicella occurring within 10 days of birth) is more serious than varicella in infants infected even a few weeks later.

The morbidity and mortality of varicella are markedly increased in immunocompromised patients. In these patients, continued virus replication and dissemination result in a prolonged high-level viremia, a more extensive rash, a longer period of new vesicle formation, and clinically significant visceral dissemination. Immunosuppressed and glucocorticoid-treated patients may develop pneumonia, hepatitis, encephalitis, and hemorrhagic complications of varicella, which range in severity from mild febrile purpura to severe and often fatal purpura fulminans and "malignant" varicella.

CNS complications of varicella occur in fewer than 1 in 1000 cases; they include several distinct syndromes. Varicella-associated Reye syndrome (acute encephalopathy with fatty degeneration of the liver) typically occurs 2 to 7 days after the appearance of the rash. In the past, from 15 percent to 40 percent of all cases of Reye syndrome occurred in association with varicella, particularly when aspirin was administered for fever, with mortality as high as 40 percent.[44] Acute cerebellar ataxia is more common than the other neurologic complications of varicella, occurring in 1 in 4000 cases, and is more benign.[45] Encephalitis is much less common, occurring in 1 in 33,000 cases, but it frequently causes death or permanent neurologic sequelae. The pathogenesis of cerebellar ataxia and encephalitis remains obscure, but in many cases it is possible to detect VZV antigens, VZV antibodies, and VZV DNA in the cerebrospinal fluid of patients, suggesting direct infection of the CNS.[35]

Although elevated aminotransferase levels are common, clinical hepatitis is rare except as a complication of progressive varicella. Other rare complications of varicella include myocarditis, glomerulonephritis, orchitis, pancreatitis, gastritis and ulcerative lesions of the bowel, arthritis, Henoch-Schönlein vasculitis, optic neuritis, keratitis, and iritis. The pathogenesis of many of these complications has not been delineated, but direct parenchymal or endovascular VZV infection, or vasculitis induced by VZV antigen-antibody complexes, appear to be responsible in most cases.

Complications of Herpes Zoster (Table 194-1)

The sequelae of herpes zoster include cutaneous, ocular, neurologic, and visceral complications. Most complications of herpes zoster are associated with the spread of VZV from the initially involved sensory ganglion, nerve, or skin, either via the bloodstream or by direct neural extension. The rash may disseminate after the initial dermatomal eruption has become apparent. When immunocompetent patients are carefully examined, it is



not uncommon to have at least a few vesicles in areas distant from the involved and immediately adjacent dermatomes. The disseminated lesions usually appear within a week of the onset of the segmental eruption and, if few in number, are easily overlooked. More extensive dissemination (with 25 to 50 lesions or more), producing a varicella-like eruption (generalized herpes zoster; see Fig. 194-7), occurs in 2 percent to 10 percent of unselected patients with localized zoster, most of whom have immunologic defects as a result of acquired immunodeficiency, as seen with HIV infection, underlying malignancy (particularly lymphomas), or immunosuppressive therapy. If the rash spreads widely from a small, painless area of herpes zoster, the initial dermatomal presentation may go unnoticed, and the ensuing disseminated eruption may be mistaken for varicella.

When the dermatomal rash is particularly extensive, as it often is in severely immunocompromised patients, there may be superficial gangrene with delayed healing and subsequent scarring (see Fig. 194-7B). Secondary bacterial infection may also delay healing and cause scarring.

The eye is involved in 20 percent to 70 percent of patients with ophthalmic zoster, with a wide range of possible complications.[31] VZV is also the principle cause of acute retinal necrosis, a fulminant sight-threatening disease observed primarily in otherwise healthy individuals.[46]

Herpes zoster may be attended by a variety of neurologic complications (see Table 194-1), of which PHN is the most common and important.[47] PHN has been variably defined as any pain after rash healing or any pain 1 month, 3 months, 4 months, or 6 months after rash onset, with most recent definitions focusing on 90 to 120 days after rash onset.[48,49] In clinic and community studies, the overall incidence of PHN is 8 percent to 15 percent, depending on the definition (see Fig. 194-1).[28,50,51] Age is the most significant risk factor for PHN (see Fig. 194-1). Clinically significant pain lasting 3 months or more is rare in immunocompetent persons younger than 50 years of age, but complicates 12 percent to 15 percent of cases of herpes zoster in persons 60 years of age and older.[14] Other risk factors for PHN include the presence of prodromal pain, severe pain during the acute phase of herpes zoster, greater rash severity, more extensive sensory abnormalities in the affected dermatome and, possibly, ophthalmic (as opposed to thoracic or abdominal) herpes zoster.[52] Increasing age, greater acute pain severity, presence of prodromal pain, and greater rash severity have each been reported to be independent predictors of PHN.[49] The positive predictive value of each factor alone was low, but, together, the positive predictive value was almost 50 percent. Conversely, 90 percent to 95 percent of patients with herpes zoster who had none of these risk factors developed PHN. PHN usually remits spontaneously over several months but, as with PHN itself, the risk of long-lasting PHN also increases with increasing age.

Patients with PHN may suffer from constant pain (described as *burning, aching, throbbing*), intermittent pain (*stabbing, shooting*), and/or stimulus-evoked pain, including allodynia (*tender, burning, stabbing*). Allodynia (pain elicited by stimuli that are normally not painful) is a particularly disabling component of the disease that is present in approximately 90 percent of patients with PHN. Patients with allodynia may suffer severe pain after even the lightest touch of the affected skin by things as trivial as a breeze or a piece of clothing. These subtypes of pain may produce disordered sleep, depression, anorexia, weight loss, chronic fatigue, and social isolation, and they often interfere with dressing, bathing, general activity, traveling, shopping, cooking, and housework.

TREATMENT

Antiviral Agents

The nucleoside analogues acyclovir, famciclovir, valacyclovir, and brivudin and the pyrophosphate analog foscarnet show efficacy in treating VZV infections. Acyclovir is a guanosine analog that is selectively phosphorylated by VZV thymidine kinases (it is a poor substrate for cellular thymidine kinase) and thus is concentrated in infected cells. Cellular enzymes then convert acyclovir monophosphate to acyclovir triphosphate, which interferes with viral DNA synthesis by inhibiting viral DNA polymerase. VZV is approximately 10-fold less sensitive to acyclovir than HSV (see Chap. 232).

Two prodrugs, valacyclovir and famciclovir, are better and more reliably absorbed than acyclovir after oral administration. Thus, they produce much higher blood levels of antiviral activity and permit less frequent dosing than acyclovir.

Because of their superior pharmacokinetics and the lower sensitivity of VZV compared with HSV, famciclovir, or valacyclovir are preferred to acyclovir for oral therapy of VZV infections. Acyclovir-resistant varicella and herpes zoster have been documented in patients with advanced AIDS (see Fig. 194-9). Because of the mechanism of acyclovir resistance in VZV (mutations in the viral thymidine kinase gene), these infections are cross-resistant to ganciclovir, valacyclovir, famciclovir, and penciclovir. They usually respond to foscarnet, 40 mg intravenously every 8 hours; however, the infections commonly recur after treatment has ended.

Treatment of Varicella

TOPICAL THERAPY In normal children, varicella is generally benign and self-limited. Cool compresses or calamine lotion locally, oral antihistamines, and tepid baths with baking soda or colloidal oatmeal (3 cups per tub of water) may relieve itching. Creams and lotions containing glucocorticoids and occlusive ointments should not be used. Antipyretics may be needed, but salicylates must be avoided because of their association with Reye syndrome.[44] Minor bacterial infections are treated with warm soaks. Bacterial cellulitis requires systemic antimicrobial therapy that is effective against *Staphylococcus aureus* and group A β-hemolytic streptococcus.

ANTIVIRAL THERAPY ***Normal Children.*** (Table 194-2) A large randomized, controlled trial of acyclovir treatment of healthy children 2 to 12 years of age found that early treatment (within 24 hours of the appearance of rash) with oral acyclovir (20 mg/kg four times a day for 5 days) modestly reduced the maximum number of lesions, the time to cessation of new lesion formation, and the duration of the rash, fever, and constitutional symptoms when compared with placebo.[53] Treatment initiated more than 24 hours after rash onset was not effective. Because varicella is a relatively benign infection in children and the clinical benefits of treatment are modest, it does not require routine acyclovir treatment.[54] However, many have favored its use when cost is not a concern, when it can be begun in time to benefit the patient (within 24 hours of rash onset), and when there is a perceived need to speed resolution of the infection so that parents can comfortably return to work. Because secondary cases among susceptible children in the household are generally more severe



TABLE 194–2
Treatment of Varicella in the Normal and Immunocompromised Patient

PATIENT GROUP	REGIMEN
Normal	
Neonate	Acyclovir, 500 mg/m^2 q8h × 10 days
Child	Symptomatic treatment alone, or acyclovir, 20 mg/kg PO qid × 5 days
Adolescent, adult, or glucocorticoids used	Acyclovir, 800 mg PO 5×/day × 7 days
Pneumonia, pregnancy	Acyclovir, 800 mg PO 5×/day × 7 days, or acyclovir, 10 mg/kg IV q8h × 7 days
Immunocompromised	
Mild varicella or mild compromise	Acyclovir, 800 mg PO 5×/day × 7–10 days
Severe varicella or severe compromise	Acyclovir, 10 mg/kg IV q8h × 7 days or longer
Acyclovir resistant (advanced acquired immunodeficiency syndrome)	Foscarnet, 40 mg/kg IV q8h until healed

than the index cases, and because early initiation of treatment is more readily accomplished in secondary cases, treatment with acyclovir seems reasonable for such secondary cases.

Normal Adolescents and Adults. A randomized, controlled trial of acyclovir treatment of healthy adolescents 13 to 18 years of age found that early treatment with oral acyclovir (800 mg five times a day for 5 days) reduced the maximum number of lesions and time to cessation of new lesion formation compared with placebo.[55] A randomized, placebo-controlled trial of oral acyclovir in healthy young adults with varicella showed that early treatment (within 24 hours of rash onset) with oral acyclovir (800 mg five times a day for 7 days) significantly reduced the time to crusting of lesions, the extent of disease, and duration of symptoms and fever.[42] Thus, routine treatment of varicella in adults seems reasonable. Although not tested, it is likely that famciclovir, 500 mg orally every 8 hours, or valacyclovir, 1000 mg orally every 8 hours, would be convenient and appropriate substitutes for acyclovir in normal adolescents and adults. Many physicians do not prescribe oral acyclovir in uncomplicated varicella during pregnancy because the risk to the fetus of treatment is unknown. Other physicians recommend oral acyclovir for infections in the third trimester when organogenesis is complete, when there may be a heightened risk of varicella pneumonia, and when infection can be spread to the newborn. Intravenous acyclovir is often considered for pregnant women with varicella who have extensive cutaneous and/or systemic disease.

Complications of Varicella in Normal Persons. Uncontrolled trials in immunocompetent adults with varicella pneumonia suggest that early treatment (within 36 hours of hospitalization) with intravenous acyclovir (10 mg/kg every 8 hours) may reduce fever and tachypnea and improve oxygenation.[56] Other serious complications of varicella in the immunocompetent host, such as encephalitis, meningoencephalitis, myelitis, and ocular complications, should be treated with intravenous acyclovir.

Immunocompromised Patients. Controlled trials in immunocompromised patients with varicella demonstrated that treatment with intravenous acyclovir decreased the incidence of life-threatening visceral complications when treatment was initiated within 72 hours of rash onset.[57] Immune compromise, however, is a continuum ranging from minimal to severe. Intravenous acyclovir has been the standard of care for varicella in patients with substantial immunodeficiency. Although oral therapy with famciclovir or valacyclovir might suffice for patients with mild degrees of immune impairment, there are no controlled clinical trials to guide the decision.

Treatment of Herpes Zoster

TOPICAL THERAPY During the acute phase of herpes zoster, the application of cool compresses, calamine lotion, cornstarch, or baking soda may help to alleviate local symptoms and hasten the drying of vesicular lesions. Occlusive ointments should be avoided, and creams or lotions containing glucocorticoids should not be used. Bacterial superinfection of local lesions is uncommon and should be treated with warm soaks; bacterial cellulitis requires systemic antibiotic therapy. Topical treatment of the herpes zoster rash with antiviral agents is not effective.

ANTIVIRAL THERAPY The major goals of therapy in patients with herpes zoster are to (1) limit the extent, duration, and severity of pain and rash in the primary dermatome; (2) prevent disease elsewhere; and (3) prevent PHN.

Normal Patients. Table 194-3 lists the current recommendations for treatment of herpes zoster. Randomized controlled trials indicate that oral acyclovir (800 mg five times a day for 7 days), famciclovir (500 mg every 8 hours for 7 days), and valacyclovir (1 g three times a day for 7 days) reduce time to rash healing, and the duration and severity of acute pain in older adults with herpes zoster who are treated within 72 hours of rash onset. In some studies, the duration of chronic pain was also reduced, but the U.S. Food and Drug Administration (FDA) has not approved these agents for the prevention of PHN.[28,58,59] Randomized controlled trials comparing acyclovir with valacyclovir, acyclovir with famciclovir, and valacyclovir with famciclovir demonstrated equivalent results in rash healing, acute pain, and the duration of chronic pain.[60–62] All three drugs are acceptable

TABLE 194-3
Treatment of Herpes Zoster in the Normal Immunocompromised Patient

PATIENT GROUP	REGIMEN
Normal	
Age < 50 yr	Symptomatic treatment only, or acyclovir, 800 mg/PO 5×/day × 7 days
Age ≥ 50 yr, or with ophthalmic involvement	Acyclovir, 800 mg PO 5×/day × 7 days, or valacyclovir, 1 g PO q8h × 7 days, or famciclovir, 500 mg PO q8h × 7 days
Immunocompromised	
Mild compromise, or human immunodeficiency virus	Acyclovir, 800 mg PO 5×/day × 7–10 days, or valacyclovir or famciclovir
Severe compromise	Acyclovir, 10 mg/kg IV q8h × 7–10 days
Acyclovir resistant (advanced acquired immunodeficiency syndrome)	Foscarnet, 40 mg/kg IV q8h until healed



agents for older adults, with cost and dosing schedule determining the choice of agent. However, the reduced sensitivity of VZV compared with HSV, and the higher and more reliable blood levels of antiviral activity achieved, make famciclovir or valacyclovir preferable to acyclovir for oral treatment of herpes zoster.

Because of the lower risk of PHN, antiviral therapy is less valuable or necessary for treatment of uncomplicated herpes zoster in healthy people younger than 50 years of age. The use of antiviral agents is unproven if treatment is initiated more than 72 hours after rash onset. Nevertheless, we believe that it is prudent to initiate antiviral therapy even if more than 72 hours have elapsed after rash onset in patients who have ophthalmic zoster or who continue to have new vesicle formation.[59]

Ophthalmic zoster represents a special therapeutic challenge because of the risk of ocular complications. Examination by an ophthalmologist should be sought in most cases. Oral acyclovir has been shown in a randomized, controlled trial to be effective in preventing ocular complications of ophthalmic zoster.[63] Famciclovir and valacyclovir appear to have efficacy comparable to that of acyclovir in the treatment of ophthalmic zoster, and are preferred for the reasons cited above.[64,65]

Immunocompromised Patients. A randomized, double-blind, placebo-controlled trial in immunocompromised patients with herpes zoster showed that intravenous acyclovir (500 mg/m^2 every 8 hours for 7 days) halted progression of the disease, both in patients with localized herpes zoster and in patients with cutaneous dissemination before treatment.[66] Acyclovir accelerated the rate of clearance of virus from vesicles and markedly reduced the incidence of visceral and progressive cutaneous dissemination. Pain subsided faster in acyclovir recipients, and fewer reported PHN, but these differences were not statistically significant. Clinical trials comparing intravenous acyclovir with intravenous vidarabine for the treatment of herpes zoster in immunocompromised patients showed that acyclovir was significantly more effective and less toxic.[33,66] In patients with mild immunocompromise and localized herpes zoster, oral acyclovir, valacyclovir, or famciclovir usually suffices.[67,68] A randomized, controlled trial of oral famciclovir versus oral acyclovir in patients with localized herpes zoster after bone marrow or organ transplantation or cancer chemotherapy showed that the two treatments were equivalent in rash healing and loss of acute pain and that both were well tolerated.[68]

ANTI-INFLAMMATORY THERAPY The possibility that PHN might be caused by inflammation of the sensory ganglion and contiguous neural structures provided the rationale for the use of glucocorticoids during the acute phase of herpes zoster in an attempt to further reduce acute pain and prevent PHN. Randomized controlled trials, however, showed that the addition of glucocorticoids to acyclovir did not change the incidence of chronic pain.[69,70] However, glucocorticoids did reduce acute pain in most trials, and in one trial of acyclovir and prednisone, the time to uninterrupted sleep, return to baseline daily activity, and cessation of analgesic therapy was reduced in patients who received glucocorticoids.[70] Consequently, some experts advocate oral glucocorticoids for otherwise healthy older adults whose rash is complicated by moderate to severe pain and who have no contraindications to glucocorticoids. Others believe that the common adverse effects of glucocorticoids argue against their routine use in older patients with herpes zoster. The authors agree and do not recommend the use of glucocorticoids in this setting. Glucocorticoids, in combination with effective antiviral therapy, may improve motor outcomes and acute pain in VZV-induced facial paralysis and cranial polyneuritis, where compression of affected nerves may contribute to disability.

ANALGESICS Greater severity of acute pain is a risk factor for PHN, and acute pain may contribute to central sensitization and the genesis of chronic pain. Therefore, aggressive pain control is both reasonable and humane. The severity of acute herpes zoster pain should be determined using simple standardized pain scales. Clinicians should prescribe nonopiate or opiate analgesics with the goal of limiting the severity of pain to less than 3 or 4 on a 0 to 10 scale, and to a level that does not interfere with sleep. The choice, dosage, and schedule of drugs are governed by the patient's pain severity, underlying conditions, and response to specific drugs. If pain control remains inadequate, regional or local anesthetic nerve blocks should be considered for acute pain control.[71] Although carefully managed opiates, anticonvulsants, and tricyclic antidepressants (TCAs) have demonstrated efficacy in established PHN, their effectiveness when administered during the acute phase of herpes zoster in reducing the incidence, duration, or severity of PHN is not known. This needs to be evaluated in rigorous clinical trials. A randomized controlled trial demonstrated that a single epidural injection of corticosteroids and local anesthetics in the acute phase of herpes zoster did not prevent the subsequent development of PHN.[71]

Treatment of Postherpetic Neuralgia

Once established, PHN is difficult to treat.[28] Fortunately, it resolves spontaneously in most patients, although this often requires several months (see Fig. 194-1). Clinicians have advocated a wide range of treatments, including many oral and topical medications, epidural injection of local anesthetic and glucocorticoids, acupuncture, biofeedback, subcutaneous injections of triamcinolone, trans-epidermal electric nerve stimulation, spinal cord stimulators, and systemic administration of a variety of compounds, but most have not been validated by controlled trials. However, the topical 5 percent lidocaine patch, gabapentin, pregabalin, opioids, and TCAs have been shown in randomized, controlled trials to be effective in patients with PHN. On average, these agents provide adequate pain relief (defined as reduction of pain to below 4 on a 0 to 10 point scale or by 50 percent on a visual analog or Likert scale) in 30 percent to 60 percent of patients. These modalities are now recommended as first-line, evidence-based pharmacotherapy for PHN in practice management guidelines.[72,73]

TOPICAL THERAPY Topical anesthesia delivered by means of a 5 percent lidocaine patch has been shown in controlled clinical trials to produce significant pain relief in patients with PHN. The 10 cm × 14 cm lidocaine patch contains 5 percent lidocaine base, adhesive, and other ingredients on a polyester backing. It is easy to use and is not associated with systemic lidocaine toxicity.[74] Up to three patches are applied over the affected area for 12 hours a day. The disadvantages of the patch are application site reactions, such as skin redness or rash, and substantial cost. EMLA (eutectic mixture of local anesthetics) cream applied once a day over the affected area under an occlusive dressing is an alternative method of delivering topical anesthesia.

Capsaicin (*trans*-8-methyl-*N*-vanillyl-6-nonenamide), an extract of hot chili peppers, is a chemical known to deplete substance P, an important endogenous neuropeptide that acts as a chemomediator of nociceptive impulses from the



periphery to the CNS. A small clinical trial of topical capsaicin for 4 weeks in patients with PHN demonstrated significant effects of this therapy on pain, with 75 percent of patients experiencing substantial pain relief.[75] Unfortunately, the ointment burns too much to be tolerated by many patients. In the authors' experience, capsaicin is rarely effective in patients with PHN.

ORAL AGENTS Gabapentin has been shown to produce moderate or greater pain relief in 41 percent to 43 percent of patients with PHN compared to 12 percent to 23 percent in patients receiving placebo.[76,77] Frequent adverse effects of gabapentin include somnolence, dizziness, and peripheral edema. Pregabalin has been shown to produce 50 percent or greater pain relief in 50 percent of patients with PHN compared to 20 percent in placebo recipients.[78] Dizziness, somnolence, and peripheral edema were the most common adverse effects reported with this medication.[78,79] Pregabalin has a less complicated dose titration schedule and a faster onset of action than gabapentin.

TCAs have been shown to produce moderate to good pain relief in 44 percent to 67 percent of elderly patients with PHN in several randomized, controlled trials.[72,73] Nortriptyline and desipramine are preferred alternatives to amitriptyline because they cause fewer cardiac adverse effects, sedation, cognitive impairment, orthostatic hypotension, and constipation in the elderly.[80]

Treatment with scheduled opioids may also reduce PHN. In a randomized, placebo-controlled crossover trial of sustained-release oxycodone in patients with PHN, patients reported significant pain relief when treated with opioid compared to placebo.[81] In a crossover study in patients with PHN, both controlled-release morphine and TCAs provided significant pain relief compared to placebo.[82] In this trial, patients preferred treatment with opioid analgesics to either TCAs or placebo despite a greater incidence of adverse effects and more drop-outs during opioid treatment. In a randomized controlled trial, combination therapy with morphine and gabapentin produced greater pain relief than each agent alone and placebo but with greater adverse effects.[83]

PREVENTION

Prevention of Varicella

VARICELLA VACCINE Several studies conducted in Europe, Japan, and the United States from the early 1970s through the early 1990s demonstrated that live attenuated (Oka strain) VZV vaccines were immunogenic and efficacious in protecting susceptible children against varicella. Although breakthrough cases of varicella were observed after subsequent exposure to wild-type VZV, they were relatively mild.[84] Similar results were obtained in adults when two doses were given 4 to 8 weeks apart. Vaccinated children and adults developed breakthrough varicella caused by wild-type VZV at a rate of 1 percent to 3 percent per year compared to an attack rate of 8 percent to 13 percent per year in unvaccinated children. On the basis of these data, the FDA licensed the Oka/Merck varicella vaccine in the United States in 1995.

The Advisory Committee on Immunization Practices (ACIP) and the American Academy of Pediatrics recommend varicella vaccine for (1) routine childhood immunization, one dose at 12 to 18 months of age; (2) susceptible, immunocompetent children older than 13 years of age, adolescents, and adults, using two doses, 4 to 8 weeks apart; (3) susceptible individuals at high risk for exposure or transmission, including susceptible health care workers, family of immunosuppressed individuals, teachers of children, day care workers, residents and staff in institutional settings, nonpregnant women of childbearing age, and college students; (4) post-exposure prevention and outbreak control; and (5) day care and school entry.[85] The ACIP issued expanded recommendations for varicella vaccine in 2005 to promote wider use for adolescents and adults, in HIV-infected children, and a second dose for outbreak control. These recommendations are under review by the CDC and Department of Health and Human Services (http://www.cdc.gov/vaccines/vpd-vac/varicella/default.htm).

The immunity to varicella induced by varicella vaccine is not as solid as that induced by wild-type VZV infection, and the duration of vaccine-induced immunity is not yet known. However, a high percentage of children followed long-term have remained seropositive.[86] Recent experience in clinical practice indicates that vaccine efficacy in children is modestly lower than that reported in clinical trials, and outbreaks of breakthrough varicella in schools and day care centers do occur.[87–90] In a prospective, population-based study, vaccine effectiveness for prevention of all disease was 78.9 percent (95 percent confidence interval; 69.7 percent to 85.3 percent); for prevention of moderate disease, it was 92 percent (50 to 500 lesions); and for prevention of severe disease and physician visits, it was 100 percent.[89] Interestingly, cases of breakthrough varicella in household settings were half as contagious as cases of varicella in unvaccinated persons, although the minority of breakthrough cases with 50 lesions or more were as contagious as cases in unvaccinated persons. In adults, approximately 20 percent of vaccinees lose detectable antibodies to VZV over time, but continue to be partially protected—breakthrough varicella is characterized by mild disease rather than severe varicella.[87–90]

In 2006, the ACIP recommended routine administration of a second "booster" dose of the varicella vaccine to increase the proportion of the population protected and the duration of immunity.[91] The second dose may be especially important because of the approval by the FDA in 2005 of a combined measles, mumps, rubella and varicella vaccine for routine immunization of children 12 months to 12 years of age.

More than 15,000 adverse events after varicella vaccination were reported to the FDA's Vaccine Adverse Event Reporting System and the CDC from March 1995 through December 2001, over 95 percent of which were non-serious events, mainly minor rashes and injection site reactions.[92] Serious adverse events were rare and, in the majority, a causal relationship between the reported serious adverse event and varicella vaccine could not be established.

Herpes zoster has been reported in vaccinees, but it occurred at a significantly lower frequency than herpes zoster in persons of similar age following varicella caused by wild-type VZV. Cases of laboratory-confirmed herpes zoster in vaccinees from several studies included some cases caused by re-activation of the vaccine virus and others caused by re-activation of wild-type virus acquired before vaccination as a consequence of unrecognized varicella.

POST-EXPOSURE PROPHYLAXIS AND INFECTION CONTROL Patients with varicella and herpes zoster may transmit VZV to susceptible individuals. No preventive measures are recommended for a normal child who has been exposed to varicella or herpes zoster. On the other hand, it is desirable to prevent or modify varicella in high-risk immunocompromised individuals.

Passive immunization with VZIG was an effective preventive strategy but the production of VZIG has been discontinued in the United States. An in-



TABLE 194-4
Criteria for the Use of Investigational Varicella-Zoster Immune Globulin for the Prophylaxis of Varicella

- Immunocompromised patients.
- Neonates whose mothers have signs and symptoms of varicella around the time of delivery (i.e., 5 days before to 2 days after).
- Premature infants born at ≥ 28 wk of gestation who are exposed during the neonatal period and whose mothers do not have evidence of immunity.
- Premature infants born at < 28 wk of gestation or who weigh ≤ 1000 g at birth and were exposed during the neonatal period, regardless of maternal history of varicella disease, or vaccination. Pregnant women.



vestigational VZIG, VariZIG, is available under an investigational new drug application submitted to the FDA. The investigational VariZIG is a purified human immune globulin preparation made from plasma containing high levels of anti-varicella antibodies (immunoglobulin class G). This product can be requested for patients who have been exposed to varicella and who are at increased risk for severe disease and complications.[93] The patient groups recommended by ACIP to receive VariZIG are listed in Table 194-4.

Active immunization with the live attenuated varicella vaccine is also effective in preventing illness or modifying varicella severity in children if used within 3 days after exposure.[94] Whereas protection afforded by zoster immune globulin is transient, varicella vaccine induces long-lasting (active) immunity to VZV and protection against subsequent exposures.

Chemoprophylaxis with acyclovir also has been studied in susceptible children after household exposure to varicella. Children who received post-exposure treatment with acyclovir experienced fewer and less severe cases of varicella than children in the control group.[95] However, appropriate timing is critical, but poorly defined immunity to varicella may not be achieved, especially with early post-exposure treatment, and there are always fears that resistant strains will be selected by promiscuous application of this approach. Hence, post-exposure antiviral chemotherapy is not recommended for routine use in children.

Infection control practices for VZV increase in importance with the age and compromised immune status of the exposed, susceptible individual. There is no need to prevent exposure of susceptible normal children to VZV, but careful isolation procedures should be enforced to prevent infection of susceptible immunocompromised patients, newborn infants, and adults, particularly women of childbearing age. Exposure of susceptible immunocompromised patients to VZV warrants reduction in the dosage of glucocorticoids and other immunosuppressive drugs, and administration of investigational VariZIG. Hospital and long-term care facility personnel without a clear history of varicella or herpes zoster should be tested for antibody to VZV so that appropriate leave from work can be instituted after VZV exposure. In hospitals, airborne and contact precautions are recommended until all lesions are crusted for patients with varicella, immunocompromised patients with localized herpes zoster, and any patient with disseminated herpes zoster.[96] Contact precautions are recommended for immunocompetent patients with localized herpes zoster.

Prevention of Herpes Zoster: Zoster Vaccine

Until universal varicella vaccination greatly reduces the number of people latently infected with wild-type VZV, prevention of herpes zoster must be aimed at preventing re-activation and spread of the latent virus. Long-term suppressive acyclovir treatment is only practical in immunocompromised patients at proven risk of developing herpes zoster within a defined time period, for example, in the year after bone marrow or solid organ transplantation. Other strategies must be devised for the general population.

One approach to the prevention of herpes zoster is the stimulation of immunity to VZV, which wanes in the elderly and in other high-risk individuals.[25] Studies of healthy adults older than 55 years of age with a history of varicella have demonstrated an increase in VZV-specific T lymphocytes and humoral immunity after vaccination with live attenuated VZV vaccine that is similar to the increase observed after an episode of herpes zoster.[97] These findings suggest that vaccination of older persons may be useful in preventing herpes zoster and its complications. A recent Veterans Affairs Cooperative Study tested the hypothesis that vaccination against VZV would decrease the incidence and/or severity of herpes zoster and PHN among older adults.[14] The study enrolled 38,546 adults 60 years of age or older in a randomized, double-blind, placebo-controlled trial of a live attenuated (Oka/Merck) VZV vaccine of much greater potency than the currently licensed varicella vaccine. A total of 957 confirmed cases of herpes zoster (315 among vaccine recipients and 642 among placebo recipients) and 107 cases of PHN (27 among vaccine recipients and 80 among placebo recipients) were included in the efficacy analysis. The zoster vaccine reduced the burden of illness due to herpes zoster by 61.1 percent ($p < 0.001$), reduced the incidence of PHN by 66.5 percent ($p < 0.001$), and reduced the incidence of herpes zoster by 51.3 percent ($p < 0.001$). Reactions at the injection site were more frequent among vaccine recipients but were generally mild. This landmark study showed that the zoster vaccine markedly reduced morbidity from herpes zoster and PHN among older adults. The FDA licensed the zoster vaccine for the prevention of herpes zoster in adults 60 years of age and older in 2006. With the development of the varicella and zoster vaccines, antiviral therapy, and neuropathic pain treatments, clinicians now have multiple effective tools to markedly reduce human suffering from varicella and herpes zoster.

KEY REFERENCES

The full reference list for all chapters is available at www.digm7.com.

5. Seward JF et al: Varicella disease after introduction of varicella vaccine in the United States, 1995–2000. *JAMA* **287**:606, 2002
11. Hope-Simpson RE: The nature of herpes zoster: A long-term study and a new hypothesis. *Proc R Soc Med* **58**:9, 1965
14. Oxman MN et al: A vaccine to prevent herpes zoster and postherpetic neuralgia in older adults. *N Engl J Med* **352**:2271, 2005
21. Kalman CM, Laskin OL: Herpes zoster and zosteriform herpes simplex infections in immunocompetent adults. *Am J Med* **81**:775, 1986
23. Cohen JI, Straus SE: Varicella-zoster virus and its replication, in *Fields Virology*, edited by Knipe DM et al. Philadelphia, Lippincott-Williams & Williams, 2001, p 2707
28. Kost RG, Straus SE: Postherpetic neuralgia: Pathogenesis, treatment, and prevention. *N Engl J Med* **335**:32, 1996
54. Klassen TP et al: Acyclovir for treating varicella in otherwise healthy children and adolescents. *Cochrane Database of Systematic Reviews* **4**:CD002980, 2005
59. Gnann JW Jr, Whitley RJ: Herpes zoster. *N Engl J Med* **347**:340, 2002
71. van Wijck AJ et al: The PINE study of epidural steroids and local anaesthetics to prevent postherpetic neuralgia: A randomised controlled trial. *Lancet* **367**:219, 2006
72. Dubinsky RM et al. Practice parameter: Treatment of postherpetic neuralgia. *Neurology* **63**:959, 2004

CHAPTER 195

Poxvirus Infections

Wynnis Tom
Sheila Fallon Friedlander

POXVIRUSES

The poxviruses are double-stranded DNA viruses that replicate in the cytoplasm of host cells (Table 195-1). They are the largest animal viruses and can be seen with light microscopy.[1] The poxviruses that cause significant disease in humans are reviewed here. Their effects on hosts range from systemic disease to localized infection to epithelial cell proliferation alone.

ORTHOPOXVIRUS INFECTIONS

Smallpox (Variola)

Variola virus is the pathogen responsible for smallpox, a disease that devastated humankind in catastrophic epidemics for over 3000 years. This poxvirus killed and scarred millions of people in both the Old and New Worlds, affecting entire populations on every continent.

The important discovery of vaccination by Edward Jenner changed the history of this disease. It could now be prevented, and an intensive global effort at vaccination and tracking of cases led to its eradication in 1980.[2] Smallpox was thought to have become a disease of historical interest. Threats of bioterrorism in recent years, however, have renewed the need for knowledge about smallpox and its features, as well as the development of improved vaccines and treatments for use should the disease arise again.

EPIDEMIOLOGY Unlike other diseases caused by members of the family Poxviridae, smallpox affects only humans and thus cannot be acquired from another species. Transmission in the majority of cases is via respiratory droplets and requires close contact. Outbreaks occur in the winter and early spring seasons when conditions of low humidity and low temperature favor survival of the aerosolized virus.[3] Smallpox is less infectious than other diseases spread by the respiratory route, including measles, varicella, and influenza. Secondary attack rates for unvaccinated contacts are estimated to range from 37 percent to 88 percent.[4] Secondary cases are often limited to family members or health care workers. Spread of smallpox is enhanced when there are large quantities of virus in the aerosolized droplets, an increased number and extent of exposures between infected individuals and contacts, and a higher population density. The very young, elderly, and pregnant women are more susceptible to infection.[5] Individuals with more severe clinical disease are reported to be more infectious, but these same people also tend to be toxemic and confined to bed.

Because no significant sub-clinical carrier state exists, eradication was possible and was accomplished in 1980. After its eradication, the responsible virus was supposed to be limited to two laboratories in the United States and the former Soviet Union. Of concern is that these or other unreported stocks of virus may be in the hands of countries or groups with terrorist relationships and could be aerosolized for use as a biologic weapon (see Chap. 213). The possibility of genetically altering smallpox or similar viruses to increase virulence further heightens concerns regarding the misuse of this virus.[6] Routine vaccination of civilians was discontinued in the United States in 1972 and worldwide in the 1980s. Only a small group of U.S. civilians, along with military personnel, have been vaccinated since that time to serve as first-line responders in a possible outbreak. Those who were vaccinated before 1972 have uncertain levels of immunity.[7] Given this, the majority of the population would be susceptible to smallpox disease.

ETIOLOGY AND PATHOGENESIS Smallpox is caused by the variola virus, a linear, double-stranded DNA virus of the genus *Orthopoxvirus*. Variola virus measures approximately 300 by 250 by 200 nm and has an oval or brick-shaped appearance on electron microscopy (see eFig. 195-0.1 in on-line edition). Strains of the virus fall into two main groups, variola major and minor. Although their genomes share approximately 98 percent homology, their virulence is markedly different, with 30 percent or higher mortality associated with the major type and less than 1 percent mortality associated with the minor type.[2,8]

Humans are the only known natural reservoir of variola virus. The disease process begins on close, prolonged exposure to an infected individual. The usual portal of entry is the oropharyn-

POXVIRUSES AT A GLANCE




- Poxviruses are the largest animal viruses; they can cause disease of varying severity in humans.
- Smallpox is the only poxvirus for which humans are the sole reservoir, which allowed its eradication.
- The smallpox vaccine virus, vaccinia, has its own adverse effects.
- Monkeypox is a zoonotic infection endemic in Africa, but it has recently appeared in the Western Hemisphere.
- Milker's nodule and orf mainly cause localized cutaneous infections.
- Molluscum contagiosum is generally a benign cutaneous disease most frequently seen in children and immunocompromised individuals.
- Histopathologic features of poxviral cutaneous lesions include the presence of intracytoplasmic eosinophilic inclusion bodies.

SMALLPOX AT A GLANCE



- Smallpox is an illness with mortality rates of over 30 percent in its major form.
- It is transmitted mainly by the respiratory route; viremia leads to cutaneous and visceral involvement.
- The eruption consists of papules that progress simultaneously to vesicular and pustular lesions in a centrifugal pattern.
- The disease has not been seen since 1978, but the potential use of aerosolized variola virus for bioterrorism is of significant concern.
- Smallpox vaccination has been reinstituted on a selective basis for response in the case of an outbreak.



TABLE 195-1
Poxviruses with Humans as Hosts

Genus	Species	Hosts	Main Portal of Entry	Clinical Features
Orthopoxvirus	Variola virus	Humans	Respiratory tract	High fever and myalgias precede an oropharyngeal enanthem and centrifugal exanthem. Simultaneous progression of skin lesions from macules to papulovesicles, pustules, and crusts, resulting in significant scars. Last reported case in 1978 but a concern for use in bioterrorism.
	Vaccinia virus	Humans	Skin	Used as vaccine for protection against smallpox and monkeypox. Vaccination site progresses from papule to vesicle, pustule, and crust, leaving scar. Adverse events occur when virus spreads locally or in a generalized manner, more severe in individuals with disruption of the skin barrier or immunocompromise.
	Monkeypox virus	Rodents, humans, monkeys, anteaters	Skin	Clinical presentation similar to that of smallpox but more prominent lymphadenopathy and lower mortality.
	Cowpox virus	Rodents, cats, humans, cattle	Skin	Contact with infected animal host gives rise to papule that becomes vesicular, hemorrhagic, pustular, and ulcerative; resulting eschar heals over 3–4 wk with scarring. Pustular stage often is umbilicated with surrounding zone of erythema and edema. Constitutional symptoms and lymphangitis common. Can be extensive or severe if skin barrier disrupted.
Parapoxvirus	Orf virus	Sheep, goats, humans	Skin	Contact with infected animal or fomite leads to papule(s) that forms pustules or nodules with central umbilication and surrounding gray-white or violaceous ring and outer zone of erythema; lesion usually occurs on hand. Lesions become weepy then dry and crust. Healing occurs over 4–8 wk, usually without scarring. Constitutional symptoms and lymphangitis occur less commonly.
	Paravaccinia virus	Cattle, humans	Skin	Transmitted on contact with infected teats or mouths of cattle. Clinical findings and course similar to those of orf; differentiated by their different animal hosts.
	Bovine papular stomatitis virus	Cattle, humans	Skin	Transmitted by contact with infected mouths of cattle. Clinical findings and course similar to those of orf and paravaccinia.
Molluscipoxvirus	Molluscum contagiosum virus	Humans, chimpanzees (one report)	Skin	Discrete firm, dome-shaped papules with central umbilication. Can be extensive in individuals with atopic dermatitis or immunocompromise. Most cases self-resolve in 9–12 mo but lesions often treated to speed resolution; can be persistent/refractory in immunocompromised individuals.
Yatapoxvirus	Tanapox virus	Humans, monkeys	Possibly skin	Uncertain mode of transmission, possible mosquito vector from infected monkeys to humans. Short fever precedes eruption of one to multiple pruritic, indurated papules with surrounding edema. Become necrotic and/or ulcerative then heal within 6 wk with scarring.



geal or respiratory tract, either by inhalation of aerosolized droplets or direct contact with infected mucous membranes.[9] After entry, the virus attaches to respiratory epithelial cells, travels to regional lymph nodes, and replicates at these sites. Transient primary viremia with uptake of the virus by macrophages occurs, and the variola virus spreads to the reticuloendothelial organs, where asymptomatic replication continues. A massive secondary viremia follows and causes the onset of symptoms (the prodromal period). The virus spreads to the skin and mucosa, along with other organs and tissues such as the liver and kidneys.[10] Variola virus is transmissible beginning in the late prodromal phase through aerosolization of viral particles from the oropharynx. It is most infectious during the first 7 to 10 days after onset of the viral rash and remains transmissible until the scabs fall off of skin lesions.[10,11]

Variola virus is less commonly spread via accidental inoculation in the skin, through the conjunctiva, and through contact with infected body fluids or highly contaminated fomites. Rarely, it has been transmitted transplacentally and by long-range airborne or suspended viral particles in enclosed areas.[6]

CLINICAL FINDINGS ***History.*** The infected individual remains asymptomatic during the incubation period of viral replication. A prodrome of high fever [39°C to 41°C (102.2°F to 105.8°F)], chills, myalgias, and severe headache develops within 7 to 17 days of exposure. Average incubation is 12 days for variola major and a few days longer for variola minor. The person usually is severely ill and bedridden during the prodromal period, which lasts 2 to 4 days. Children may develop seizures.[4,9]

Cutaneous Lesions. Evanescent, non-specific urticarial or morbilliform lesions can develop during the prodrome. These occur mainly in previously vaccinated individuals at the vaccination site and the axillae, popliteal, and groin areas.[2] Approximately 1 day after the onset of fever, an enanthem develops. These earliest viral lesions are red macules on the mouth, tongue, and oropharynx that subsequently vesiculate and ulcerate, releasing high concentrations of transmissible virus particles in the respiratory secretions. A skin rash (exanthem) erupts two to several days after the onset of fever, at about the same time the mucosal lesions ulcerate. The fever usually declines with appearance of the rash.[6,12] The exanthem varies depending on viral dose and strain, vaccination status, level of immunity, and nutritional status.[5] The outbreak is categorized into two clinical forms, variola major and variola minor.

Forms of variola major are more common than variola minor. One classification divides variola major into five clinical types.[13] Ordinary smallpox is the most common type and accounts for over 90 percent of cases of smallpox in unvaccinated individuals and 70 percent in those who have been vaccinated. Skin lesions begin as macules on the face and upper extremities that then spread quickly to the trunk and lower extremities. Involvement of all parts of the body, including palms and soles, occurs within 24 to 48 hours. The macules become raised papules within 1 day and then form vesicles, often with central umbilication, after 4 to 5 days (see eFig. 195-0.2 in on-line edition). Fever recurs as the lesions become firm pustules around day 7 (Fig. 195-1) and persists until all lesions have crusted and scabbed at day 14 (Fig. 195-2). Scabs separate by 3 to 4 weeks after the onset of the rash. Key features of smallpox skin lesions are their prominence peripherally on the face and extremities and their simultaneous progression in a centrifugal pattern, with all lesions in any one area exhibiting the same morphology.[9,14] After their resolution, pitted scars ("pockmarks") are often left behind and can be disfiguring (Fig. 195-3). Scarring is most common on the face, where there are larger and more numerous sebaceous glands, which are particularly susceptible to infection and destruction by variola virus.[2]

Modified smallpox has as severe a prodromal illness as ordinary smallpox, but the clinical course of cutaneous lesions is accelerated. Lesions are fewer in number and tend not to progress to vesicles or pustules, crusting by day 10. This form occurs mainly in vaccinated individuals and does not cause death. Flat smallpox (also called *malignant smallpox*) is an uncommon form of variola major in which the macules barely raise. It usually occurs in children and unvaccinated individuals lacking cellular immunity. Those affected become severely ill with toxic fever, and most die with hemorrhagic lesions and pneumonia.[4] The hemorrhagic, or fulminant, type of variola major is equally common in unvaccinated and vaccinated persons. It is divided into two forms, early and late. The early form consists of petechial hemorrhages into the skin or mucous membranes during the prodromal period. Massive hemorrhage from mucosal surfaces leads to death within 8 days of onset, before any appearance of the typical rash of smallpox, with a case fatality of 100 percent. Women, especially if pregnant, are more susceptible to this form. In the late form, hemor-



▲ **FIGURE 195-1** Pustular smallpox lesions with characteristic highest density on the face and extremities. (From the Centers for Disease Control and Prevention Public Health Image Library, Atlanta, GA.)



▲ **FIGURE 195-3** Scars and pockmarks remain after the crusts have fallen off. (From the Centers for Disease Control and Prevention Public Health Image Library, Atlanta, GA, and contributed by J. Noble, Jr., MD.)



▲ **FIGURE 195-2** Crusted lesions on the foot at day 21 of the rash of smallpox. (From the Centers for Disease Control and Prevention Public Health Image Library, Atlanta, GA, and contributed by Paul B. Dean, MD.)



rhage appears after onset of the typical rash, death occurs by 12 days after onset, and men and women are equally affected.[15] The last type of variola major is variola sine eruption, in which vaccinated individuals come in contact with affected individuals and develop fever and other symptoms (e.g., headache, conjunctivitis) but no rash. In this case, the illness lasts 48 hours or less. Serologic studies do show a rise in antibody titers against smallpox virus.[4,13]

Variola minor is clinically indistinguishable from cases of modified smallpox and from cases of ordinary smallpox in which lesions are discrete rather than confluent. At times, the lesions are nonumbilicated. In the pre-eradication period, the diagnosis of variola minor was given only after assessment of the severity of an outbreak, if the case fatality rate was low (1 percent or less).[8] Molecular virologic differentiation between major and minor viral strains is now available.



Related Physical Findings. Variola virus spreads via the blood to affect other non-cutaneous systems. It can infect the metaphysis of growing bones and lead to arthritis in up to 2 percent of affected children. Osteomyelitis occurs less frequently than arthritis. Swelling of the eyelids and a mild conjunctivitis are common findings. Cough and bronchitis may be seen in some cases of smallpox. A degree of encephalopathy often occurs, with symptoms ranging from headache and hallucinations to delirium and psychosis.[2] Gross hematuria can occur with the hemorrhagic type of variola major.[15]

LABORATORY TESTS The white blood cell count may increase as the skin lesions of smallpox become pustules. Severe thrombocytopenia occurs in both early and late hemorrhagic smallpox. A marked decrease in the level of factor V (accelerator globulin) and increase in thrombin time are noted in the early form, likely from disseminated intravascular coagulation. The late form has a smaller degree of these coagulation disturbances.[2]

Histopathology. Skin biopsy specimens from early papules show edema and dilation of the capillaries of the papillary dermis with a perivascular infiltrate of lymphocytes, histiocytes, and plasma cells. Next, the cells of the epidermis become vacuolated and swollen and undergo ballooning degeneration. These vesicles have characteristic intracytoplasmic inclusion bodies called *Guarnieri bodies*. Pustules form with migration of polymorphonuclear cells into the vesicles. Eventually the pustule becomes a crust, with new epithelium growing to repair the surface. Mucous membrane lesions show similar changes but also have extensive necrosis of the epithelial cells leading to rapid ulceration rather than vesiculation.[16]

Special Tests. For diagnosis, specimens (skin lesions, tonsillar swab, blood, skin biopsy) should be collected by someone recently vaccinated and sent to designated high-containment facilities.

Scrapings of skin lesions can be examined via electron microscopy to assess for the typical oval or brick shape of orthopoxviruses. Serologic testing for orthopoxviruses with paired samples can be performed; this identifies the presence of a member of the genus but is not specific for variola virus. Polymerase chain reaction (PCR) methods are used to definitively identify variola virus and can also characterize the viral strain. Variola virus can be cultured in several commonly used cell lines and can be identified by the formation of characteristic pocks on chorioallantoic membranes of chicken embryos.[6,17]

DIFFERENTIAL DIAGNOSIS The exanthem of smallpox is most often confused with that of varicella (chickenpox). Smallpox lesions are centrifugal with simultaneous progression of all lesions. In contrast, varicella lesions have a more truncal (centripetal) distribution, the vesicles are more superficial, and lesions are present at different stages. Varicella also has a shorter disease course, with only a 1- to 2-day prodrome and with all lesions crusting in 4 to 6 days from their initial appearance.[10] Human monkeypox clinically resembles smallpox but often manifests lymphadenopathy. It is a zoonotic disease and is not spread as easily between persons. The morbilliform prodromal rash of smallpox can be confused with measles or coxsackievirus infections. Secondary syphilis should be considered, especially when there are lesions on the palms and soles, but these lesions do not progress. Other eruptions in the differential diagnosis are listed in Box 195-1. The lesions of hemorrhagic smallpox can be similar to those of meningococcemia, severe acute leukemia, and other acute hemorrhagic eruptions such as those associated with coagulopathies.

Box 195-1

Differential Diagnosis of Smallpox and Monkeypox

Most Likely

- Papulovesicular eruption
  - Varicella
  - Disseminated zoster
  - Generalized vaccinia
- Prodromal morbilliform eruption
  - Measles
  - Drug eruption
- Hemorrhagic lesions (smallpox only)
  - Meningococcemia
  - Disseminated intravascular coagulation
- Mucosal lesions
  - Hand-foot-and-mouth disease
  - Stevens-Johnson syndrome

Consider

- Papulovesicular eruption
  - Kaposi varicelliform eruption
  - Eczema vaccinatum
  - Extensive molluscum contagiosum (human immunodeficiency virus infection)
  - Drug eruption
  - Bullous impetigo
  - Pityriasis lichenoides et varioliformis acuta
  - Rickettsialpox
- Prodromal morbilliform eruption
  - Coxsackievirus infection
  - Other viral infections
- Hemorrhagic lesions (smallpox only)
  - Acute leukemia
- Mucosal lesions
  - Oral herpes simplex

Always Rule Out

- Papulovesicular eruption
  - Secondary syphilis
- Hemorrhagic lesions (smallpox only)
  - Acquired coagulopathy
- Mucosal lesions
  - Stevens-Johnson syndrome

COMPLICATIONS Secondary bacterial infection occurs commonly at skin lesions (5 percent of affected individuals) as well as at regional lymph nodes. A temperature spike occurring 3 to 5 days after the start of the prodrome may indicate secondary infection.[12] Keratitis and corneal ulceration, common in malnourished individuals, result in blindness in 1 percent of cases. Either variola virus or bacterial superinfection can lead to respiratory complications, including pneumonia, at day 8 to 10 of illness. Both arthritis and osteomyelitis can lead to limb deformities, including bone shortening, subluxation, and flail joints. Orchitis is less common and usually unilateral. Encephalitis is reported in 0.2 percent of cases.[2]

PROGNOSIS AND CLINICAL COURSE The most common form of variola major, common smallpox, is associated with a mortality rate ranging from less than 10 percent when lesions are discrete to 50 percent to 75 percent when lesions are confluent. Death often occurs between days 10 and 16 of illness. Modified smallpox is associated with less than 10 percent mortality. In contrast, flat smallpox has a case fatality rate of over 90 percent, and hemorrhagic forms have nearly 100 percent mortality. The overall mortality rate for variola major is 30 percent, compared to less than 1 percent for variola minor.[13] Those who survive either disease have lifetime immunity. Death from smallpox is thought to be secondary to toxemia associated with immune complexes and variola antigens along with hypotension/shock and multiorgan failure. Encephalitis is an important factor in death from variola minor but not from variola major.[2,4]

TREATMENT There is no specific treatment for smallpox. A patient suspected of having the disease should be isolated in a negative-pressure room and given supportive care. Precautions should be taken to prevent secondary infection and appropriate antibiotics administered should it occur. Research on antiviral agents is ongoing. Intravenous cidofovir, a nucleotide analog approved for treatment of cytomegalovirus infection, is available from the Centers for Disease Control and Prevention (CDC, Atlanta, GA) through an Investigational New Drug protocol. It has been found to have activity against variola, vaccinia, and other orthopoxviruses in in vitro and animal studies, but clinical data are not yet available.[18] Topical idoxuridine may be used to treat corneal lesions, although its efficacy has not been proven.

PREVENTION Because of the development of lifelong immunity after recovery from natural smallpox infection, the first efforts at prevention were to introduce crusts or fluid from lesions to unaffected individuals to induce mild disease. This process of variolation did reduce morbidity and mortality but also caused full infection and spread in some cases. In 1796, Dr. Edward Jenner developed vaccination, using the cowpox virus to introduce cross-immunity against the variola virus. Vaccinia virus later became the virus used. Vaccination is 90 percent to 96 percent effective in preventing smallpox disease when given before exposure to variola virus. For post-exposure prophylaxis, smallpox vaccination within 2 to 3 days of exposure can protect against severe disease. Vaccination within 4 to 5 days may protect against death.[2,19] Vaccination does not give lifelong immunity, however. The duration and degree of protection over time are subjects of debate. Most estimates suggest that primary vaccination gives full protection for 3 to 5 years and some but declining immunity at 10 years and after. Revaccination may give significant protection for at least 30 years.[11,20]

Vaccinia and Smallpox Vaccination

The vaccinia virus is also of the genus Orthopoxvirus. Its origins are unknown, but it is most similar to the cowpox virus in this family. In the nineteenth century, it replaced cowpox as the virus for smallpox vaccination. Discussion here focuses on its features as the smallpox vaccine, because it is not known to cause natural infection. Because of its significant homology with other poxviruses, vaccinia virus provides not only protection against smallpox but also cross-protection against closely related orthopoxviruses such as monkeypox, camelpox, and cowpox.[2]

EPIDEMIOLOGY Eradication of smallpox was made possible by intensive tracking of cases of infection with ring vaccination of primary and secondary contacts. The last known case of natural infection was one of variola minor in Somalia in 1977. One final case of accidental laboratory infection occurred in 1978, and the World Health Organization declared eradication in 1980. Routine vaccination of civilians was discontinued in the United States in 1972 and worldwide in the 1980s; vaccination of U.S. military personnel ceased in 1990. With the postal anthrax and World Trade Center attacks in 2001 and other threats of bioterrorism, vaccination was reinitiated in the United States in late 2002 for the military and a small group of voluntary public health and health care workers who would be first-line responders in a possible outbreak.[21]

Vaccination made eradication of smallpox possible, but given that vaccinia is a live virus, it does carry its own set of adverse effects. Most adverse events can occur at any age, but infants and children younger than the age of 5 years are particularly affected. Adverse reactions are 10 times more common in primary vaccination than in revaccination. Individuals with atopic dermatitis can acquire a severe eruption, eczema vaccinatum, from contacts more often than from direct vaccination.[4]

ETIOLOGY AND PATHOGENESIS Smallpox vaccination involves the introduction of vaccinia virus into the outer layers of the intact skin. There are many strains of the virus, with the less pathogenic New York City Board of Health and Lister-Elstree strains being used during the global smallpox eradication campaign. The currently licensed vaccine in the United States is a lyophilized, calf-lymph vaccine (Dryvax, Wyeth Laboratories, Marietta, PA) produced from the New York City Board of Health vaccinia strain.[11] After injection of vaccine into the skin by a bifurcated needle (see eFig. 195-3.1 in on-line edition), the virus rapidly multiplies locally and occasionally in regional lymph nodes. Viable, transmissible vaccinia virus is present at the resulting skin lesion until the lesion scabs and separates. The infection heals with scarring at the injection site. It is usually limited by the host response with the development of antibody- and cell-mediated immunity.[10] Adverse events and complications occur when the virus spreads outside of the local area, either by transfer or a host inability to contain the response.

CLINICAL FINDINGS ***History.*** Soreness is almost universal at the vaccination site. Systemic symptoms can occur and are considered normal reactions. These include fever [higher than 37.7°C (99.9°F), more common in children], chills, headache, myalgias, and malaise. They generally peak at days 8 to 10 and last 1 to 3 days. Approximately 30 percent of vaccinees feel too ill to carry out normal activities.[22]

Cutaneous Lesions. The normal local skin reaction to vaccination begins 3 to 5 days after administration with a papule that then develops into a vesicle (Jennerian vesicle) followed by a pustule around day 7 to 9. It crusts and scabs over at day 10 to 14, with the scab detaching at day 17 to 21 and leaving a residual scar (Fig. 195-4). A robust take, in which the local reaction is 10 centimeters or larger in diameter, occurs in 2 percent to 16 percent of first-time vaccinees (see eFig. 195-4.1 in on-line edition). This can be mistaken for bacterial cellulitis, but it occurs 8 to 10 days after vaccination and self-improves without antibiotic therapy in 24 to 72 hours.[23] In contrast, secondary bacterial infections



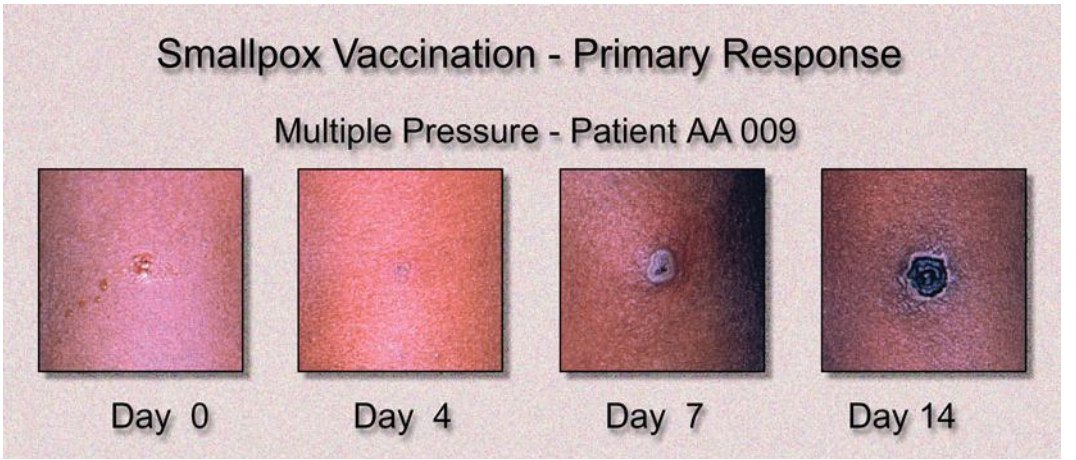

▲ **FIGURE 195-4** Normal progression seen at the smallpox vaccination site. (From the Centers for Disease Control and Prevention, Atlanta, GA.)



usually occur within the first 5 days or 30 days after vaccination.

Previously vaccinated individuals have a milder reaction with an accelerated time course. Those with substantial residual immunity may have only erythema with revaccination. Minor local reactions that can occur near the primary site include nearby satellite lesions that progress at the same rate, lymphadenopathy/lymphangitis, and intense surrounding erythema or edema.[11] Vaccinia can be inadvertently inoculated into other body sites (see eFig. 195-4.2 in on-line edition), and secondary reactions such as erythema multiforme can occur (see eFig. 195-4.3 in on-line edition) (see next section).

Adverse Reactions. Adverse cutaneous reactions associated with smallpox vaccination can be localized or generalized. Secondary bacterial infection, usually by staphylococci and group A streptococci, can occur at the primary site. Accidental vaccinia is the autoinoculation of vaccinia virus from the vaccination site to another area. It is the most common adverse event seen and accounts for about half of all such events. The most common sites of transfer are the eyelids (see eFig. 195-4.2 in on-line edition), nose, mouth, and genitalia. Lesions are seen at these areas 7 to 10 days after vaccination, and they usually follow the time course of the original primary lesion. The lesions may be more attenuated if autoinoculation occurs more than 5 days after vaccination as the host immune response is developing.[24] Accidental inoculation to the eyes can lead to conjunctivitis, keratitis, or iritis.

Generalized adverse eruptions can be non-specific, immune-mediated reactions, including morbilliform and roseola-like rashes. Hypersensitivity reactions such as erythema multiforme can also develop (see eFig. 195-4.3 in on-line edition). These rashes typically self-resolve over several days. In rare cases Stevens-Johnson syndrome can develop and require hospitalization and supportive care. Vaccination can also lead to generalized vaccinia, in which macular, papular, or, less commonly, vesicular lesions can be disseminated to normal skin without evidence of autoinoculation. Generalized vaccinia can be limited or extensive and can occur anywhere on the body (Fig. 195-5). It is thought be caused by spread of vaccinia virus via the bloodstream and usually occurs 6 to 9 days after primary vaccination. The lesions progress as do other vaccinial lesions. The condition is self-limited in immunocompetent individuals but is often more severe in the setting of immunodeficiency.[25]

Eczema vaccinatum is the localized or generalized spread of vaccinia virus in individuals affected with atopic dermatitis or, less frequently, other chronic dermatoses. The individual feels ill with fever, malaise, and lymphadenopathy. It can occur in the primary vaccinee with onset usually at the same time or soon after the appearance of lesions at the vaccination site. Papules, pustules, or vesicles can occur anywhere on the body but have a predilection for areas with prior lesions of atopic dermatitis. Lesions can range from several to hundreds; the most serious cases result in substantial loss of the skin barrier. The severity of eczema vaccinatum is independent of the severity or activity of the atopic dermatitis or other underlying skin disease. It can also be acquired by secondary transmission, usually by children in contact with a recently vaccinated family member (Fig. 195-6).[9,26]

Vaccination of individuals with severe impairment of the immune system leads to progressive vaccinia, also called *vaccinia necrosa* and *vaccinia gangrenosa*. In these individuals, the primary lesion at the site of vaccination does not heal but instead enlarges and progresses to a painless ulcer with central necrosis (see eFig. 195-6.1 in on-line edition). Viral replication is not halted and viremia occurs, with similar metastatic lesions developing at distant sites on the skin, bone, and/or viscera. Most cases have occurred in individuals with defective cell-mediated immunity, but cases have also been described in those with humoral defects.[4] The degree of immune impairment may correlate with the risk for development of progressive vaccinia, but the precise protective level is unknown.[23]



▲ **FIGURE 195-5** Generalized vaccinia in an 8-month-old infant. (From the Centers for Disease Control and Prevention Public Health Image Library, Atlanta, GA, and contributed by Allen W. Mathies, MD, of the California Emergency Preparedness Office, Immunization Branch.)



◀ **FIGURE 195-6** Eczema vaccinatum with lesions in areas of active dermatitis.

Related Physical Findings. In addition to the skin, other organ systems can be affected by smallpox vaccination. Central nervous system complications occur in previously healthy individuals. Postvaccinial encephalopathy most commonly affects children younger than 2 years of age, causing cerebral edema without inflammation. Symptoms develop abruptly 6 to 10 days after vaccination and can include fever, headache, seizures, hemiplegia, aphasia, and transient amnesia. Postvaccinial encephalitis and encephalomyelitis occur 11 to 15 days after vaccination, with fever, malaise, vomiting, and headache that progress to confusion, seizures, amnesia, spinal cord signs, and coma.[27] These complications are thought to be autoimmune reactions, because vaccinia virus is not found in sampled cerebrospinal fluid or tissue. Higher rates of central nervous system complications are seen with non–New York City Board of Health vaccinia strains. Other neurologic events reported to occur in temporal association with smallpox vaccination include transverse myelitis, paralysis, seizures, and polyneuritis, but causality has not been established.[2,28]

Cardiac events, including myopericarditis, can also occur. Since reinitiation of smallpox vaccination in the United States in 2002, ischemic cardiac events as well as nonischemic dilated cardiomyopathy have been reported for the first time. The rate of myopericarditis among U.S. military vaccinees is elevated 3.6-fold compared to the rate in unvaccinated personnel, which suggests but does not prove causality.[29] Whether the ischemic and dilated cardiomyopathy conditions are caused by smallpox vaccination or are coincidental occurrences is not yet clear.[9]

LABORATORY TESTS Neutralizing antibodies and cellular immunity start to become detectable around day 7 of vaccination. Vaccinia virus can be detected at the primary vaccination site and sites of accidental vaccinia, generalized vaccinia, eczema vaccinatum, and progressive vaccinia.

COMPLICATIONS Vaccinia keratitis can cause corneal ulceration with scarring and visual loss. Eczema vaccinatum can be so severe that the affected individual loses a substantial amount of the cutaneous barrier, much like a burn victim. Individuals with postvaccinial encephalopathy, encephalitis, or encephalomyelitis may recover in approximately 2 weeks, but one-fourth of survivors are left with residual sequelae (mental impairment, paralysis).[30]

Smallpox vaccination of a woman during pregnancy can rarely lead to fetal, or congenital, vaccinia, with about 50 cases reported in the literature. Transmission to the fetus can occur at any time during the pregnancy and results in lesions on the skin, mucous membranes, and placenta. The appearance can be similar to that of generalized vaccinia or progressive vaccinia, and lesions can be extensive (see eFig. 195-6.2 in on-line edition). It is unknown whether infection is through the blood or by direct contact with infected amniotic fluid. No reliable intrauterine diagnostic test exists to confirm fetal infection.[28]

PROGNOSIS AND CLINICAL COURSE Potentially fatal adverse reactions from smallpox vaccination include eczema vaccinatum, progressive vaccinia, and postvaccinial central nervous system disease. Progressive vaccinia is universally fatal if untreated. Central nervous system complications have a 15 percent to 25 percent case fatality rate. Most fatal cases from secondary transmission occur in infants younger than 1 year of age and are from contact eczema vaccinatum. Fetal vaccinia often results in fetal or neonatal death.[9,30]

Myopericarditis was reported in the pre-eradication era and was thought to cause the rare cases of cardiac-associated deaths after vaccination. It has also been reported since reinstitution of vaccination in the United States in 2002, but no deaths have occurred to date. Several ischemic cardiac deaths have occurred.[31]

TREATMENT Symptomatic treatment alone is needed for the normal systemic symptoms and minor local events (robust take, lymphangitis, intense erythema or edema) occurring after vaccination. Secondary infections should be treated with appropriate antimicrobial therapy. Uncomplicated cases of accidental vaccinia do not require therapy. Extensive cases can be treated by administration of vaccinia immune globulin (VIG) or cidofovir to speed recovery. VIG is a sterile solution of the immunoglobulin fraction of plasma from persons vaccinated with the smallpox (vaccinia) vaccine. Topical antiviral medications can be used in moderate to severe cases of ocular vaccinia. Vidarabine ointment has been effective in the past, but supplies are likely very limited because it is no longer manufactured. Trifluridine eyedrops can be tried, but there are no clinical data regarding successful treatment. It should not be administered for longer than 14 days, because it can cause a reversible superficial punctate keratopathy. VIG can exacerbate vaccinia keratitis and should not be used in cases of isolated keratitis.[23]

Generalized vaccinia usually requires only symptomatic treatment, but if it is severe, such as in those with immunodeficiency, VIG may be of benefit. With severe eczema vaccinatum in which there is significant loss of the skin barrier, meticulous skin care with volume and electrolyte repletion is needed. Early treatment with VIG has been shown to reduce mortality from eczema vaccinatum (fatality rate was reduced from 30 percent to 40 percent to 7 percent).[23] VIG administration and care in



an intensive care unit also reduced the case fatality rate of progressive vaccinia from 100 percent to 20 percent to 30 percent.[30] Treatment for neurologic complications is supportive care; there is no evidence that VIG is effective in these cases. Given the rarity of fetal vaccinia, inadvertent vaccination during pregnancy is not ordinarily a reason for termination. There is also no indication for prophylactic administration of VIG to the pregnant woman, but it might be considered for a viable infant born with vaccinial lesions.[25,32]

PREVENTION The vaccination site should be covered with gauze and an overlying semi-permeable membrane bandage. Taking contact precautions and washing the hands frequently when caring for the site should be emphasized.

A higher proportion of persons are at risk for adverse vaccine reactions today than during the era of routine smallpox vaccination. Atopic dermatitis as well as immunocompromise have increased in prevalence.[33] To reduce the incidence of adverse events, smallpox vaccination in the United States is currently limited to the select groups discussed earlier (see Epidemiology). There are no absolute contraindications to vaccination should an actual outbreak occur. Current recommendations and contraindications in the absence of a known exposure risk are listed in Box 195-2. More detailed guidelines are available from the CDC.

Safer vaccines are under research and development to prevent the adverse effects and complications of smallpox vaccination. Tissue and cell-culture vaccines, including ACAM1000 and ACAM2000 (Acambis, Cambridge, MA) and cell-cultured smallpox vaccine (DynPort, Frederick, MD), are in clinical trial. Production involves the sterile growth of cell lines that host the vaccinia virus. By increasing purity and reducing contamination, these vaccines may help avoid the allergic and autoimmune reactions thought to stem from the nonvaccinia material in calf-lymph vaccines. These reactions include hypersensitivity reactions, erythema multiforme, and possibly the encephalitic and cardiac reactions. Because they are similar in immunogenicity to Dryvax, however, they are not necessarily safer with regard to vaccinia-associated adverse events.[20]

A second strategy is the development of vaccines using strains of vaccinia attenuated by serial passage through nonhuman tissue. This leads to a reduced capacity for replication and potentially reduced adverse effects. The modified vaccinia Ankara strain is produced by passage through chick embryo fibroblasts. No significant complications were reported with its use in Germany and Turkey in the 1970s to help people at high risk for side effects (such as those with atopic dermatitis/eczema, etc.) tolerate the standard smallpox vaccine; efficacy against actual disease, however, was never proven. The LC16m8 vaccine also uses an attenuated vaccinia strain, with passage of the Lister vaccinia strain through rabbit kidney cells. Studies in Japan in the 1960s and 1970s found it to have less local and systemic reactogenicity but similar protective immunity to conventional smallpox vaccines. Further clinical study of modified vaccinia Ankara and Lc16m8 vaccines is under way.[6,9] Finally, advances in modern molecular immunology have introduced the idea of subunit vaccines with genes or proteins from vaccinia virus. These are under laboratory investigation as future vaccine candidates.[10,34]

Box 195-2

Vaccination Against Smallpox Using Vaccinia Virus

INDICATIONS

- Pre-exposure prevention of smallpox
- Post-exposure prophylaxis against severe disease and death

CONTRAINDICATIONS

- Contraindications in the pre-exposure setting
  - Presence of atopic dermatitis or other eruptions with disruption of the skin barrier
  - Immunosuppression, including human immunodeficiency virus infection/acquired immunodeficiency syndrome, inherited and acquired cellular immunodeficiencies, and severe autoimmune disease
  - Known heart disease or significant cardiac risk factors
  - Serious allergy to components of the vaccine diluent (polymyxin, neomycin, streptomycin, chlortetracycline)
  - Age younger than 12 mo
  - Pregnancy or breast-feeding
- Contraindications in the post-exposure setting
  - No absolute contraindications in the case of an actual smallpox outbreak

Monkeypox

In contrast to smallpox, which was described in writings as far back as 340 A.D., monkeypox is a more recently recognized disease. It was first identified in 1958 as an illness of cynomolgus monkeys, hence its name. Monkeypox was first documented to cause human illness in 1970 in Zaire (the present Democratic Republic of the Congo), when an illness similar to smallpox was noted after eradication of the latter.

EPIDEMIOLOGY Human monkeypox is a disease acquired mainly from infected animals. It is endemic in the rain forest countries of central and west Africa, occurring in sporadic outbreaks. The majority of cases are in children. Despite its recent recognition, monkeypox has presumably caused illness for thousands for years.[35] Transmission is mainly during handling of infected animals or contact with the animals' body fluids. Person-to-person spread via respiratory droplets and close contact can occur as with smallpox, but usually in a limited manner. Outbreaks in the Democratic Republic of the Congo in 1996 to 1997 showed sustained human-to-human transmission for the first time. This may reflect decreased immunity with the discontinuation of smallpox vaccination.[36] In spring 2003, the first cases of human monkeypox in the Western hemisphere occurred in the Midwest region of the United States (72 reported cases, 37 laboratory confirmed). All cases are thought to be associated with contact with ill pet prairie dogs previously housed with African rodents imported from Ghana.[37]

The longest documented chain of person-to-person transmission is eight generations, which suggests that monkeypox has little potential for the type of epidemic spread seen with smallpox.[36] Possible genetic alteration to produce greater virulence or transmissibility is a concern, however.

ETIOLOGY AND PATHOGENESIS Monkeypox is caused by the monkeypox virus, a zoonotic virus. Like variola and vaccinia viruses, it is also of the genus Orthopoxvirus and has an oval or brick shape on electron microscopy. The monkeypox viral genome is 96 percent identical to that of the variola virus at the central region which encodes essential enzymes and structural proteins. The end regions that encode virulence and host-range factors are substantially different, and the range of hosts for the monkeypox virus is much wider than that for variola virus.[37] In addition to humans, hosts for monkeypox include cynomolgus and other monkeys, other

primates (apes, gorillas, chimpanzees, orangutans), and nonprimate animals such as rabbits, mice, guinea pigs, and giant anteaters. The natural reservoir is unknown but is thought to be wild rodents such as the squirrel.[1,38]

Monkeypox is mainly transmitted through abraded skin after a bite or scratch from an infected animal or by contact with their infected body fluids. The virus multiplies locally at the site of injury, then is rapidly transported to regional lymph nodes, where multiplication continues. Invasion of the bloodstream disseminates the virus to distant sites. The monkeypox virus is also transmissible from person to person via aerosolization of the virus or contact with lesions or body fluids during the first week of the rash. It may rarely be transmitted by contaminated fomites.[39]

CLINICAL FINDINGS ***History.*** Sub-clinical cases of monkeypox can occur in individuals with and without prior smallpox vaccination. In those with illness, symptoms manifest after a 10- to 14-day incubation period. A prodrome of fever, chills, malaise, headache, myalgias, and back pain occurs, lasting 2 to 3 days. Some individuals experience sore throat, cough, or shortness of breath. Diarrhea and abdominal pain may also be reported.[2,36]

Cutaneous Lesions. Usually 1 to 3 days after the onset of fever, a rash develops, initially consisting of monomorphic macules and papules. Most commonly, the eruption begins on the face and/or trunk, with the lesions spreading in a centrifugal pattern to become generalized. They then progress over 14 to 21 days to vesicles and pustules that umbilicate, crust, and desquamate (see eFigs. 195-6.3 and 195-6.4 in on-line edition). Dyspigmented and pitted scars result. Monkeypox lesions can involve the oral and genital mucous membranes.[35] No hemorrhagic form of monkeypox like that of smallpox has been described in humans.

In the outbreak in the United States, only one case, a child, had a generalized rash as extensive as that seen in cases in Africa. The other affected individuals had only localized lesions, mostly on the hands, associated with direct contact with the infected animals (Fig. 195-7 and see eFig. 195-7.1 in on-line edition). This may reflect infection with a less virulent viral strain than those in Africa.[36]

Related Physical Findings. Significant lymphadenopathy develops 1 to 2 days before the onset of the rash, usually in submandibular, cervical, or inguinal areas (Fig. 195-8). Conjunctivitis and keratitis may occur. Confusion and seizures are rare.[40,41]



▲ **FIGURE 195-7** The primary inoculation site of monkeypox virus in a 3-year-old child, 14 days after being bitten by a prairie dog. (Used with permission from the Marshfield Clinic, Marshfield, WI.)

LABORATORY TESTS Leukocytosis, elevated transaminase levels, and low blood urea nitrogen level are often seen. Lymphocytosis and thrombocytopenia occur with less frequency.[42]

Histopathology. On examination of skin biopsy specimens, the features are indistinguishable from those of smallpox. There is similar dermal papillary edema, acute inflammation, and ballooning degeneration of keratinocytes (Fig. 195-9). Cytoplasmic eosinophilic inclusion bodies (Guarnieri bodies) are also seen (see eFig. 195-9.1 in on-line edition). Focal necrosis may occur.[40]



▲ **FIGURE 195-8** Significant postauricular lymphadenopathy with pustular skin lesions in a 2-year-old girl with monkeypox. (Used with permission from the Armed Forces Institute of Pathology, Washington, DC, http://www.afip.org/Departments/infectious/index.html.)

Special Tests. Electron microscopy of material from scabs or fluid from skin lesions can be used to determine the presence of an orthopoxvirus, but it cannot distinguish among them. Assays for specific antibodies against monkeypox can differentiate it from other poxviruses. Monkeypox virus has good growth in RK13 cells and causes pocks on chorioallantoic membranes at 39°C (102.2°F). Isolation of the virus on mammalian cell culture and characterization by PCR and sequencing can definitively identify monkeypox virus.[17,38]

DIFFERENTIAL DIAGNOSIS The features of monkeypox are clinically similar to but less severe than those of ordinary smallpox (variola major). Lymphadenopathy is a distinctive hallmark of monkeypox not usually seen in smallpox. It is observed in 90 percent of cases in which the individual has never received the smallpox vaccine and in approximately 53 percent of those who have been vaccinated.[2] Varicella has a milder and shorter viral prodrome, with pleomorphic lesions evolving in a centripetal distribution. Lymphadenopathy is also infrequent with varicella. Orf and bovine stomatitis, caused by poxviruses of the genus Parapoxviridae, can produce similar skin lesions but these are localized. Also in the differential diagnosis are drug eruptions, eczema herpeticum, and rickettsialpox (see Box 195-1). Persons with human immunodeficiency virus infection may develop extensive molluscum lesions that can look similar.

COMPLICATIONS Secondary skin and soft tissue infections may occur (approximately 20 percent of cases). Affected individuals may also develop pneumonitis (12 percent), encephalitis (fewer than 1 percent), and ocular complications, including scarring with corneal lesions.[35]

PROGNOSIS AND CLINICAL COURSE The scars left by the rash may improve over time. In Africa, mortality ranges from 1 percent to 10 percent and mainly occurs in children. Death is generally in the second week of disease and is secondary to bacterial superinfection, gastrointesti-





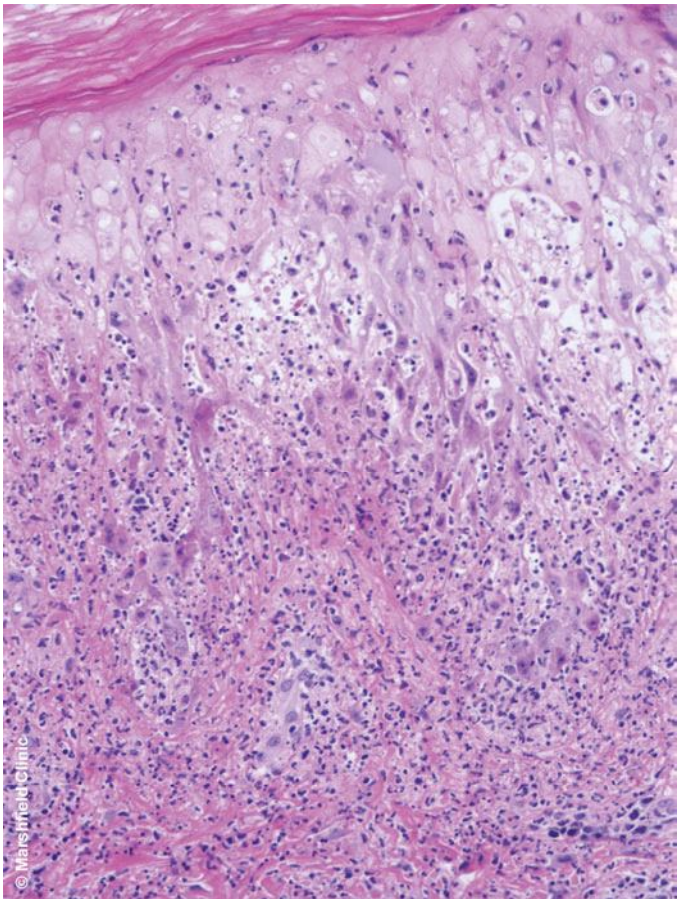

▲ **FIGURE 195-9** Histopathologic features of a monkeypox lesion, including dermal papillary edema, acute inflammation, and ballooning degeneration of keratinocytes. (Hematoxylin and eosin stain.) (Used with permission from the Marshfield Clinic, Marshfield, WI.)

nal complications, or pulmonary complications. These are likely compounded by poor nutrition and inaccessibility of medical care.[2,37] All affected individuals recovered without any deaths during the outbreak in the United States in 2003.[43]

TREATMENT There is no specific treatment for monkeypox. Symptomatic treatment should be instituted. Cidofovir may be considered in severe cases, but there are no available data on its clinical efficacy in humans. VIG administration can also be considered in severe cases, but its benefits are unknown.

PREVENTION Global eradication of monkeypox is more difficult than smallpox eradication, because the wide range of hosts for monkeypox virus allows it to maintain an animal reservoir while sporadically causing human disease. Vaccination with the current calf-lymph–derived smallpox vaccines (vaccinia virus) has been found to be effective in preventing human monkeypox. Observation of cases in Africa shows 85 percent protection against monkeypox. Cases of monkeypox are milder and even sub-clinical when they occur in vaccinated individuals.[40]

The CDC currently recommends pre-exposure vaccination for investigators of animal or human monkeypox cases and health care providers who may care for or be in close contact with patients with monkeypox, provided they have no contraindication to smallpox vaccination (Box 195-3). The role of post-exposure vaccination is less clear, but it is recommended for those within 4 days of direct exposure to monkeypox virus and should be considered up to 14 days after exposure, including in children under the age of 12 months, pregnant women, and people with skin conditions. Those with impaired immune systems or life-threatening allergy to latex or vaccine components should not receive the current Dryvax vaccine even if exposed to monkeypox, but VIG can be considered for post-exposure prophylaxis.[35,36]

The newer smallpox vaccines under research and development are also being studied for efficacy against monkeypox virus and may in the future allow prevention of human monkeypox with fewer adverse effects.

Box 195-3

Vaccination Against Human Monkeypox Using Vaccinia Virus

INDICATIONS

- Pre-exposure vaccination for investigators of animal or human monkeypox cases and health care providers who may care for or be in close contact with patients with monkeypox
- Post-exposure vaccination for those within 4 days of direct exposure to monkeypox virus, should be considered up to 14 days after exposure

CONTRAINDICATIONS

- Contraindications in the pre-exposure setting
  - Presence of atopic dermatitis or other eruptions with disruption of the skin barrier
  - Immunosuppression, including human immunodeficiency virus infection/acquired immunodeficiency syndrome (HIV/AIDS), inherited and acquired cellular immunodeficiencies, and severe autoimmune disease
  - Known heart disease or significant cardiac risk factors
  - Serious allergy to components of the vaccine diluent (polymyxin, neomycin, streptomycin, chlortetracycline)
  - Age younger than 12 mo
  - Pregnancy or breast-feeding
- Contraindications in the post-exposure setting
  - Immunosuppression, including HIV/AIDS, inherited and acquired cellular immunodeficiencies, and severe autoimmune disease
  - Life-threatening allergy to components of the vaccine diluent (polymyxin, neomycin, streptomycin, chlortetracycline)

PARAPOXVIRUS INFECTIONS

Unlike the orthopoxviruses, members of the genus *Parapoxviridae* tend to cause localized disease in healthy individuals.

Milker's Nodule

EPIDEMIOLOGY Milker's nodule, also called *paravaccinia* and *pseudocowpox*, occurs worldwide but is prevalent only in individuals in close contact with cattle. It is an occupational disease of milkers, veterinarians, and workers in the meat industry. Most cases are in newly em-

ployed milkers who have not developed immunity.[1] Cases are mostly sporadic, but small epidemics have been reported. No natural cases of human-to-human transmission have been reported, only experimentally transmitted cases in the laboratory setting.[44]

ETIOLOGY AND PATHOGENESIS Milker's nodule is caused by the paravaccinia virus (also called *pseudocowpox virus*), a member of the genus *Parapoxviridae*. It is a 260- by 160-nm cylindrical virus with spirally arranged tubules. The virus typically is found at the teats and mouth of cattle but may also be on the trunk and legs. Humans are accidental hosts on contact with infected animals or contaminated fresh meat. Paravaccinia virus is transferred by direct inoculation into the skin, often through a break in the skin barrier.[45] Cases of transmission from contaminated fomites to individuals with burn injury have been reported.[46]

CLINICAL FINDINGS ***History.*** The incubation period for milker's nodule is 4 to 7 days. In a minority of cases, the infected individual develops mild systemic symptoms such as a transient low-grade fever.[47]

Cutaneous Lesions. The sites of inoculation of paravaccinia virus are usually the hands and, on occasion, the face. After the incubation period, skin lesions develop. One to several lesions usually appear, but they may occasionally be numerous. Lesions begin as red and occasionally pruritic macules that become raised papules (see eFig. 195-9.2 in on-line edition). They can then form papulovesicles with a target-like appearance—a red center surrounded by a white or gray ring and outer red halo. The lesions then develop into bluish or violaceous tender nodules. Some ulcerate or have a central depression (Fig. 195-10), which results in formation of eschars with crust. Lesions often take 4 to 8 weeks, and sometimes longer, to heal.[44,45]

Related Physical Findings. Lymphangitis is often present in the skin surrounding the primary lesion(s). Lymphadenopathy is not common.

LABORATORY TESTS ***Histopathology.*** The histopathologic findings of milker's nodule depend on the stage of the lesion. Early lesions show vacuolization and ballooning of cells in the upper third of the epidermis, which sometimes leads to multilocular vesicles. Intracytoplasmic inclusion bodies may be seen, with rare intranuclear inclusions. Epidermal necrosis may be observed focally with ulceration and crust as the lesion progresses. Neutrophils are seen in the epidermis and superficial papillary dermis with epidermal necrosis. Mature lesions have finger-like epidermal projections, papillary dermal edema, and a mixed inflammatory infiltrate that includes lymphocytes, histiocytes, and eosinophils. Regressing lesions have decreasing acanthosis and inflammation.[44,48]



▲ **FIGURE 195-10** **A.** Firm, eroded milker's nodule. **B.** Multiple lesions at the site of a second-degree scalding burn sustained in a milking barn.

Special Tests. Electron microscopy of blister fluid or crusts can identify the characteristic cylindrical shape of parapoxviruses. Paravaccinia virus is slow-growing on tissue culture.

Viral DNA hybridization or PCR procedures may be used to distinguish paravaccinia virus from other parapoxviruses.[49]

DIFFERENTIAL DIAGNOSIS Milker's nodules appear very similar to the lesions of orf, another parapoxvirus. Attention to clinical history usually allows differentiation, with cattle the source of infection for milker's nodules and sheep or goats for orf. Tissue cultures can aid in diagnosis if needed. Bovine papular stomatitis virus causes disease in cattle with lesions around the animal's mouth. Transmission to people produces lesions similar to milker's nodules, and some think these may actually be the same virus.[50] Milker's nodules must also be differentiated from cowpox. Cowpox is very rare in humans. It has a longer incubation period, causes more pain and lymphadenopathy, and has led to death in persons with immunocompromise or atopic dermatitis. Large lesions of milker's nodule can be confused with anthrax, pyogenic granuloma, giant herpetic lesions, and keratoacanthoma (Box 195-4).

Box 195-4

Differential Diagnosis of Milker's Nodule and Orf

Most Likely

- Few to multiple lesions
  - Bovine papular stomatitis
  - Cowpox
  - Herpetic whitlow
- Solitary lesion
  - Pyogenic granuloma
  - Pyoderma

Consider

- Few to multiple lesions
  - Atypical mycobacterial infection
  - Sporotrichosis
- Solitary lesion
  - Tularemia
  - Giant herpetic lesion
  - Giant molluscum
  - Erysipeloid

Always Rule Out

- Few to multiple lesions
  - Anthrax
  - Primary inoculation tuberculosis
- Solitary lesion
  - Keratoacanthoma
  - Syphilitic chancre

COMPLICATIONS Secondary bacterial infection can occur but is rare. Erythema multiforme, morbilliform eruptions, and erythema nodosum have been reported in cases of milker's nodule.

PROGNOSIS AND CLINICAL COURSE Milker's nodule is a self-limited illness. Most cases heal without scarring. Infection produces lifelong immunity.

TREATMENT Because the disease is self-limited, treatment, if needed, is symptomatic. Surgical curettage of large lesions may help speed healing.[47,51]

PREVENTION There is no cross-immunity between orthopoxviruses and parapoxvi-



TABLE 195-2
Clinical Manifestation of Orf

Time after Exposure	Clinical Manifestations	Laboratory Analysis	Other Notes
3–7 days	One to four papules on hand (typically only one lesion): begin as a red maculopapular lesion ↓ Vesicle ↓	Can confirm by histology, viral culture, increase in serologic titers, or complement fixation. Electron microscopy of lesional skin shows brick-shaped viral particles (200–380 nm in length); intranuclear inclusions are occasionally seen.	Systemic symptoms are rare, but may include lymphadenopathy and lymphangitis, fever, rigors, drenching sweat, malaise, and urticaria.
10–14 days	Target lesion, with red center, white middle ring, and red halo ↓		
14–21 days	Acute weeping stage ↓		Lesions are relatively painless.
21–28 days	Regenerative dry stage with black dots ↓		
28–35 days	Papillomatous stage ↓		
35 days	Regressive stage with dry crust and eventual shedding of the scab		Typically no scarring occurs.

From Diven DG: Poxvirus, in *Mucocutaneous Manifestations of Viral Disease,* edited by Tyring SK. New York, Infarma Healthcare, 2002:39, with permission.



ruses, and thus smallpox vaccination (vaccinia virus) has no effect on this illness. Prevention mainly consists of isolation of infected animals and contact precautions.[52]

Orf

Contagious pustular dermatosis, infectious pustular dermatitis, scabby mouth disease, and sore mouth disease are all synonyms for orf, a self-limited zoonotic viral infection that usually involves the hands of people handling infected animals. The offending Orf virus is a member of the *Parapoxvirus* genus. It is an endemic disease in sheep and goats that usually affects the area around the lips and nostrils of the animal, as well as the teats of ewes suckling young. It is transmitted to humans through contact with infected tissue or fomites, and human infections have been noted after vaccination of sheep herds.[53,54] Orf shares clinical characteristics with other infectious diseases and may be mistaken for more serious and life-threatening disorders such as tularemia, anthrax, and erysipeloid. Although clinical appearance and history of ruminant exposure are usually diagnostic, real-time PCR testing, which is available through the CDC, is the most rapid and accurate way to make the diagnosis when clinical uncertainty exists.[54]

EPIDEMIOLOGY Human disease is more commonly seen in farmers and shepherds, but anyone who has contact with small ruminants is at risk. Although sheep and goats are the more common sources of infection, the virus has also been found in camels, mountain goats, gazelles, and musk oxen. Disease can occur after contact with animals or fomites such as barn doors, feeding troughs, wire fencing, and bottles. The virus is quite hardy and can survive heating, drying, and certain solvents such as ether and chloroform. Vaccination of animals with unattenuated virus leads to milder disease in the animal but can result in infection of humans exposed to the vaccinated animal.[53]

ETIOLOGY AND PATHOGENESIS Orf virus is the prototypic species of the genetically heterogeneous Parapoxvirus genus.[55] It is an ovoid cross-hatched particle of approximately 250 by 160 nm with a twine-like structure. Electron microscopic analysis can distinguish this parapoxvirus from orthopoxviruses such as variola (smallpox). Virulence proteins elaborated by the virus aid in evading host immunity.

CLINICAL FINDINGS ***Cutaneous Lesions.*** Five to 6 days after inoculation, a slightly elevated red papule appears, followed by vesiculation (Table 195-2). This evolves into a targetoid nodule with a red center, white ring, and peripheral rim of erythema (Fig. 195-11). A weeping stage (see eFig. 195-11.1 in on-line edition) is followed by a dry stage and finally a dry crust and scab, which resolves without scarring in most cases. Multiple lesions are sometimes present, and giant lesions occasionally occur.[56]

Related Physical Findings. Systemic findings are uncommon in immunocompetent individuals but can include lymphadenopathy and lymphangitis. Rarely fever and malaise may occur.

LABORATORY TESTS ***Histopathology.*** In the target stage, intranuclear and intracytoplasmic inclusions are present in vacuolated epidermal cells, with an accumulation of neutrophils, basophils, dendritic cells, and lymphocytes (see eFig. 195-11.2 in on-line edition). Papillomatosis and acanthosis subsequently develop, and marked finger-like downward projections of the epidermis may be seen (see eFig. 195-11.3 in on-line edition).

Special Tests. Electron microscopy may be helpful in distinguishing between



▲ **FIGURE 195-11** The target phase of orf shows a white circle with central and peripheral erythema.

parapoxviruses and other types of poxviruses but is not diagnostic for orf; similar limitations exist with serologic testing. Tissue culture is possible but time consuming. The most rapid and sensitive means of making the diagnosis is PCR testing, and real-time PCR procedures, in particular, appear extremely sensitive.[54]

DIFFERENTIAL DIAGNOSIS A variety of bacterial and infectious diseases can present with findings similar to those of orf (see Box 195-4). Exposure history is important, because many of these disorders (milker's nodules, cowpox, monkeypox, etc.) are associated with exposures to animals other than sheep or goats.[49] The lesion of anthrax is more hemorrhagic with rapid progression to an eschar. Tularemia and syphilis lead to chancres. Sporotrichosis begins as a single necrotic nodule but is followed by multiple nodules arising in a linear fashion along the lymphatics. Primary inoculated tuberculosis and atypical mycobacterial infection can give rise to ulcerative lesions that may take months to years to heal.

COMPLICATIONS Secondary bacterial infection, swelling, lymphadenitis, and fever can occur. Erythema multiforme,[57] vesicular eruptions,[58] and secondary spread within active atopic dermatitis skin lesions have been reported.[58] Bullous pemphigoid has also rarely been reported after orf infection.[59]

PROGNOSIS AND CLINICAL COURSE Orf is usually a self-limited disease that resolves within 4 to 6 weeks. Typically scarring does not occur. Immunocompromised individuals can develop progressive destructive lesions that may require interventions such as débridement or antiviral therapy such as cidofovir cream.[60,61]

TREATMENT Supportive care is the most appropriate intervention for immunocompetent patients. Application of compresses, culture of lesion specimens, and antibiotic coverage may be appropriate if secondary bacterial infection is suspected. Immunocompromised patients may require medical intervention (see Prognosis and Clinical Course).

PREVENTION Barrier precautions such as use of gloves and good hand hygiene are recommended. Patients with an impaired skin barrier from either abrasions or intrinsic skin disease (e.g., atopic dermatitis) should be particularly vigilant regarding avoidance of contact with infected animals or potential fomites.

MOLLUSCIPOXVIRUS INFECTION: MOLLUSCUM CONTAGIOSUM

Molluscum contagiosum (MC) is a benign but nonetheless frequently troublesome viral infection that generally affects young children. It is characterized by smooth, dome-shaped discrete papules that occasionally develop surrounding areas of scale and erythema (molluscum dermatitis). Patients and families are bothered by this infection because of its often prolonged course, because it may persist for months to years. MC is a greater concern in immunocompromised individuals and those with atopic dermatitis, in whom the extent and duration of infection may be more extreme. Sexually transmitted disease occurs in adults but is extremely unlikely in children.

Epidemiology

MC virus (MCV) infection occurs worldwide and appears specific to humans. The prevalence of MCV infection has risen significantly in the past several decades, with an 11-fold increase noted in one U.S. study of patient visits for this disorder over a two-decade span.[62] This rise appears to parallel the overall increase in sexually transmitted diseases. Although a prevalence rate of less than 5 percent in U.S. children is often cited,[63] the rate varies by location, and it is thought that sub-clinical infection may be more common than overt disease. A representative Australian study documented an overall seropositivity rate of 23 percent, which supports the view that sub-clinical or mild unrecognized disease exists in the population. Human immunodeficiency virus–infected individuals are at higher risk for extensive prolonged disease, and individuals with atopic conditions appear more likely to have increased numbers of lesions and experience a more prolonged disease course.[63]

Transmission may occur via direct skin or mucous membrane contact, or via fomites. Bath towels, swimming pools, and Turkish baths have all been reported as sources of infection, and individuals involved in close contact sports (e.g., wrestling) also appear at higher risk.[64,65] Autoinoculation and koebnerization also play a role in the spread of lesions.

Etiology and Pathogenesis

MCV is a large, brick-shaped Poxvirus that replicates within the cytoplasm of cells. It shares a number of genomic similarities with other poxviruses, and approximately two-thirds of the viral genes are similar to those of vaccinia and variola virus.[68] There are four subtypes of MCV, but they all appear identical clinically. Ninety-eight percent of disease in the United States is caused by MCV genotype 1.[67,68] Serial transmission of the virus has not yet been achieved in culture. An incubation period of 2 to 7 weeks has been observed.

Virus replicates within the cytoplasm of epithelial cells, and infected cells replicate at twice the baseline rate. There are many MCV genes that may contribute to an impaired immune response to this virus, including (1) a homolog of a major histocompatibility class 1 heavy chain, which may interfere with antigen presentation; (2) a chemokine homolog that may inhibit inflammation; and (3) a glutathione peroxidase homolog that may protect the virus from oxidative damage by peroxides.[66,69]

Clinical Findings

CUTANEOUS LESIONS MC often presents with extremely small pink, pearly, or flesh-colored papules that then enlarge, occasionally reaching sizes of up to 3 cm ("giant molluscum"). As they enlarge, a dome-shaped, opalescent morphology may become more apparent. The lesions may have a central dell or umbilication (Fig. 195-12A), within which a white curd-like substance can be seen that can be expressed with pressure.[70] Most patients develop multiple papules, often in intertriginous sites, such as the axillae, popliteal fossae, and groin. Genital and perianal lesions can develop in children and are only rarely associated with sexual transmission in this population.[62]

Lesions may be grouped in clusters or appear in a linear array. The latter often results from koebnerization, or development of lesions at sites of trauma. Erythema and eczematous changes may occur around lesions; this is termed *molluscum dermatitis*. Papules may become erythematous (see Fig. 195-12B), which is believed to be an immune response to the infection. Patients with acquired immunodeficiency syndrome may develop large and extensive lesions involving both genital and extragenital sites.[70]









◀ **FIGURE 195-12** Molluscum contagiosum. **A.** Discrete, solid, skin-colored papules, 1 mm to 2 mm in diameter, with central umbilication. **B.** Multiple, scattered, and discrete lesions, some of which are inflamed.

Special Tests

Diagnosis is usually straightforward. Evaluation of the central contents using a crush preparation and Giemsa staining can be carried out when necessary (Fig. 195-13), and histopathologic evaluation can be performed as needed.

Histopathologic examination reveals a hypertrophied and hyperplastic epidermis. Above the basal layer, enlarged cells containing large intracytoplasmic inclusions (Henderson-Paterson bodies) can be seen (Fig. 195-14). These increase in size as the cells reach the horny layer.

Differential Diagnosis

The differential diagnosis includes verrucae, pyogenic granulomas, amelanotic melanoma, basal cell carcinomas, and appendageal tumors. Fungal infections such as cryptococcosis, histoplasmosis, and penicilliosis must be considered in immunocompromised hosts (Box 195-5).

Complications

Although many patients are asymptomatic, pruritus is sometimes a significant problem, particularly in those patients with underlying atopic dermatitis. Chronic conjunctivitis and punctate keratitis may develop in patients with eyelid lesions. Secondary bacterial infection can occur, particularly if patients scratch their lesions.

Prognosis and Clinical Course

Spontaneous clearance occurs, but often over a prolonged period of months to years. Most families prefer treatment if lesions persist more than a month or two.

Treatment

It is important to discuss the risks and benefits of individual therapies with families before embarking on treatment for this essentially benign condition, which will generally resolve without complication in the immunocompetent individual (Table 195-3). Many experts use cantharidin 0.7 percent or 0.9 percent liquid for treatment of MC. This extract of the blister beetle, *Cantharis vesicatoria,* induces vesiculation at the dermoepidermal junction when applied topically to the skin. It must be applied with care and washed off 2 to 6 hours later. Use on the face or genital areas is not recommended, and

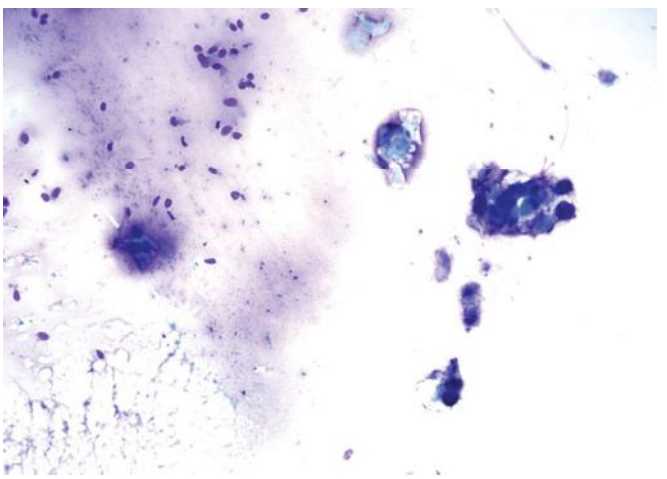

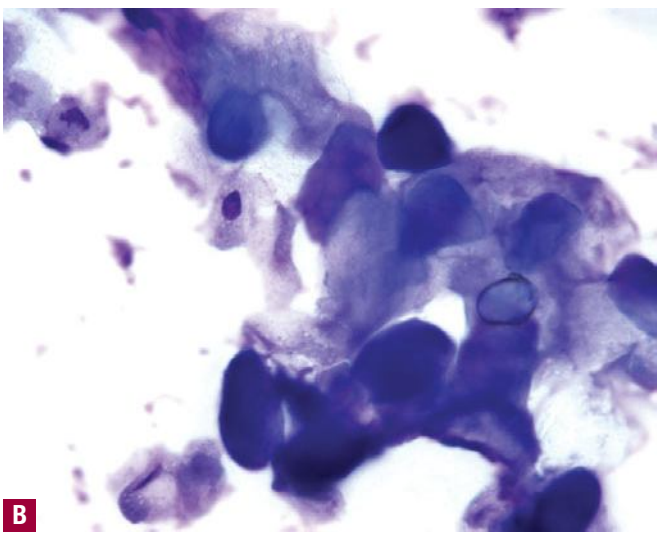

▲ **FIGURE 195-13** Microscopic preparation (Giemsa stain) of cellular material from the area of central umbilication (**A**) shows intracytoplasmic molluscum inclusion bodies (**B**).

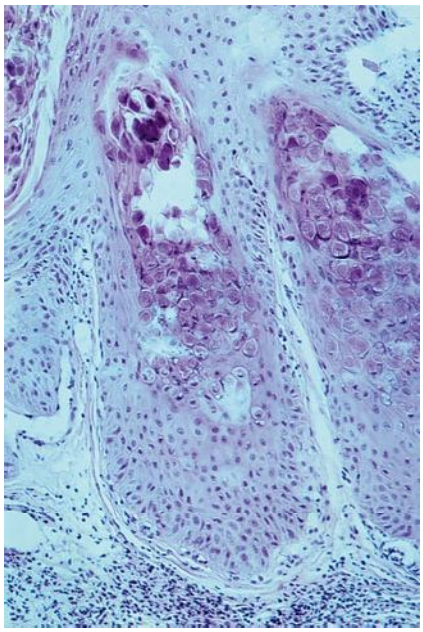

▲ **FIGURE 195-14** Molluscum contagiosum. Histopathologic examination of a skin biopsy specimen shows downgrowth of infected epidermal cells bearing large eosinophilic cytoplasmic inclusion bodies (Henderson-Paterson bodies). (Hematoxylin and eosin stain.)

families must be counseled regarding the small risk of extreme reaction or scarring.

Other traditional therapies have included curettage and cryotherapy; however, both of these treatments are painful. The use of topical anesthetic agents may ameliorate some of the associated pain, but patients generally find topical cantharidin treatment the most efficient and least painful. Other topical therapeutic modalities include retinoid creams, imiquimod cream, salicylic acid, cidofovir, and silver nitrate paste and tape stripping. Oral cimetidine has also been used with success.[71] However, a Cochrane Database analysis of treatments for molluscum contagiosum, which identified only five therapeutic studies of high quality, found that no single intervention is convincingly effective for the treatment of molluscum contagiosum.[72]

Prevention

Prevention of spread may be enhanced by avoiding trauma to the sites of involvement as well as avoiding scratching, with the use of antipruritics as necessary. Autoinoculation may be decreased by treating all existing lesions.

TABLE 195-3
Treatment of Molluscum Contagiosum

		Considerations	Level of Evidence[a]
Watchful waiting	Spontaneous resolution occurs over months to years in immunocompetent individuals.	Risk of autoinoculation, associated dermatitis, secondary bacterial infection	3
Topical therapies	Cantharidin (0.7% or 0.9%)	Rarely severe blistering and scarring of concern	2, 3
	Podophyllin (10%–25% resin) (0.3% or 0.5% cream)	Rarely severe blistering and scarring of concern	1, 2, 3
	Cryotherapy/liquid nitrogen	Painful	3
	Curettage	Painful, scarring possible	3
	Imiquimod cream (5%)	Irritation common	1, 2, 3
	Topical retinoids	Irritation common	3
	Silver nitrate paste		2
	Trichloroacetic acid (25%–35%)	Rarely severe blistering and scarring of concern	2, 3
	Topical cidofovir (1%, 3% gel; 1%, 3% cream)	Expensive	2, 3
Systemic therapies	Oral cimetidine (40 mg/kg/day)		2, 3
	Oral cidofovir	Recommended only for immunocompromised individuals, expensive	3
	Subcutaneous interferon-α	Recommended only for immunocompromised individuals	3

[a]1 = double-blind studies; 2 = open-label prospective studies; 3 = case reports.

Box 195-5
Differential Diagnosis of Molluscum Contagiosum

Most Likely
- Verrucae

Consider
- Pyogenic granuloma
- Papular granuloma annulare
- Epidermal inclusion cyst

Always Rule Out
- Appendageal tumors
- Basal cell carcinoma
- Amelanotic melanoma
- Cryptococcosis/histoplasmosis/penicilliosis



KEY REFERENCES

The full reference list for all chapters is available at www.digm7.com.

1. Diven DG: An overview of poxviruses. *J Am Acad Dermatol* **44**:1, 2001
4. Breman JG, Henderson DA: Diagnosis and management of smallpox. *N Engl J Med* **346**:1300, 2002
23. Cono J, Casey CG, Bell DM: Smallpox vaccination and adverse reactions. Guidance for clinicians. *MMWR Recomm Rep* **52**:1, 2003
30. Tom WL, Kenner JR, Friedlander SF: Smallpox: Vaccine reactions and contraindications. *Dermatol Clin* **22**:275, 2004
36. Ligon BL: Monkeypox: A review of the history and emergence in the Western hemisphere. *Semin Pediatr Infect Dis* **15**:280, 2004
40. Di Giulio DB, Eckburg PB: Human monkeypox: An emerging zoonosis. *Lancet Infect Dis* **4**:15, 2004
45. Werchniak AE et al: Milker's nodule in a healthy young woman. *J Am Acad Dermatol* **49**:910, 2003
49. Lewis-Jones S: Zoonotic poxvirus infections in humans. *Curr Opin Infect Dis* **17**:81, 2004
67. Smith K, Yeager J, Skelton H: Molluscum contagiosum: Its clinical, histopathologic, and immunohistochemical spectrum. *Int J Dermatol* **38**:664, 1999
70. Brown J et al: Childhood molluscum contagiosum. *Int J Dermatol.* 45:93–9, 2006

CHAPTER 196

Warts

Elliot J. Androphy
Douglas R. Lowy



Warts, or verrucae, are benign proliferations of the skin and mucosa that are caused by infection with papillomaviruses (PVs). These viruses do not produce acute signs or symptoms but induce a slow, focal expansion of epithelial cells. Lesions may remain subclinical for long periods or may grow to large fulminating masses that persist for months or even years. A subset of human PVs (HPVs) is known to cause benign warts that may undergo neoplastic transformation.

ETIOLOGY

PVs comprise a large family of small DNA viruses found in humans and many other species.[1] PVs are highly host-specific, meaning that those from one species do not induce papillomas in heterologous species, so HPVs infect only humans. Rabbit, bovine, and canine PVs have been used in animal models of viral infection because biologic experiments cannot be performed in humans using HPVs.

The PV genome is present within the viral particle as a single covalently closed circle of double-stranded DNA. Each genome is composed of approximately 8000 nucleotide base pairs, which is approximately one-twentieth the size of a herpesvirus genome. Recombinant DNA technology has enabled the molecular cloning of the complete viral genome from clinical lesions, and the entire nucleotide sequence for many human and animal PVs is known. Comparison of these DNA sequences reveals that they share a similar genetic organization (Fig. 196-1) and are predicted to encode eight to nine related protein products.[2] PV proteins are labeled as E (early) and L (late).[3] The E proteins are necessary for viral DNA replication and are not incorporated into the infectious virus particle. Because the E genes do not encode a DNA polymerase or thymidine kinase, PVs are not susceptible to inhibition by acyclovir or similar nucleoside analogues. Rather, these viruses use host cell enzymes and factors to replicate their genomes. The L1 and L2 genes encode the structural proteins that form the outer protein shell or capsid of the infectious viral particle, which is called the *virion*. The spherical virion measures approximately 55 nm in diameter and packages the viral DNA (Fig. 196-2).

HUMAN PAPILLOMAVIRUS TYPES

More than 100 HPV types have been sequenced; the actual number of genotypes is even higher.[1,4] The degree of relatedness of their DNA sequence distinguishes between HPV types. The polymerase chain reaction (PCR), which is a highly sensitive, specific, and rapid technique to amplify and sequence any viral DNA isolate, readily allows HPV types to be defined by DNA sequence homology.[5] Fresh tissue is not required, as PCR can be applied to specifically amplify HPV DNA in paraffin-embedded tissue blocks that are decades old.[6] By convention, two HPV isolates are the same type when a highly conserved sequence within their L1 genes is at least 90 percent identical.[7] A sub-type has 91 percent to 98 percent identity, whereas a natural variant has less than 2 percent divergence to a known type in this region of L1. A new HPV sub-type is defined when its DNA sequence is less than 90 percent homologous to all other known HPVs.[4]

Often associated with distinct regional predilection, histopathology, and biology, HPVs are categorized as cutaneous (non-genital) types such as HPV-1, -2, -3, and -4; genital-mucosal types such as HPV-6, -11, -16, and -18; and those usually isolated from epidermodysplasia verruciformis (EV) such as HPV-5 and -8 (Table 196-1). PVs have also been classified by phylogenetic organization based on their DNA homology.[8,9] The α virus genus includes a large set of

PAPILLOMAVIRUS INFECTIONS AT A GLANCE



- Very common infection of skin and mucosa of children and adults.
- Papules of variable size often with filiform scale with local symptoms.
- Caused by human papillomaviruses (HPVs), a subset of which are associated with cervical, penile, anal, and other epithelial malignancies.
- Treatment requires physical destruction of infected epithelial cells.
- A prophylactic vaccine effectively protects from infection with HPVs most commonly identified in cervical cancer and genital warts.

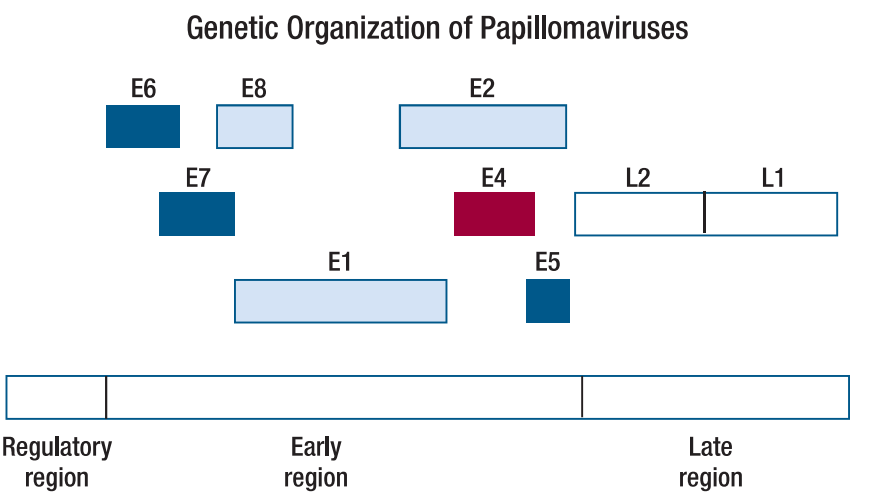

▲ **FIGURE 196-1** All PV genomes are composed of approximately 8000 nucleotide base pairs, represented as a linear sequence but actually a closed circle of double-stranded DNA. The boxes depict the viral genes, each of which encodes a protein. The regulatory region is a DNA segment that does not encode proteins, but participates in regulating the expression of the viral genes and the replication of the viral DNA. In general, E6, E7, and E5 represent transforming genes; E1 and E2 coordinate replication and expression of the viral genome; and the L1 and L2 proteins form the viral capsid. E4 encodes a protein that may be involved in the release of the virus from the cell's keratin framework.

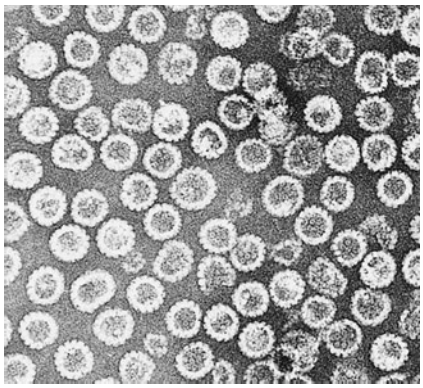

▲ **FIGURE 196-2** Transmission electron micrograph of human papillomavirus-16 virus-like particles composed of the viral L1 and L2 capsid proteins. The L1 and L2 proteins have been expressed in cultured cells and have self-assembled into 55-nm particles that are similar morphologically to infectious virus, except that they do not contain the viral DNA. The particles in the electron micrograph have been purified from the cells. (Micrograph used with permission from Heather Greenstone.)

cutaneous and genital-mucosal types, and the β genus is primarily comprised of EV types. Other genus classifications include more distantly related human and animal PV species. HPVs closely related by DNA sequence tend to induce similar lesions. Examples include highly related types such as 3 and 10, which induce flat warts; types 6 and 11, which induce genital-mucosal warts (condylomata acuminata); and types 5 and 8, which induce scaly lesions in EV.

Another important distinction is that specific HPV genotypes have malignant potential. This was first noted in EV, in which warts that contain HPV types such as 5 and 8 have a high rate of malignant degeneration, whereas those induced by other HPV types, even in the same patient, tend to remain benign.[10] Similarly, the majority of cervical carcinomas contain HPV-16, -18, or other so-called *high-risk* types, whereas the *low-risk* HPV-6 and -11, which are found in benign cervical disease, are identified in < 1 percent of cervical malignancies.[11]

PATHOGENESIS

HPV infection occurs through inoculation of virus into the viable epidermis through defects in the epithelium. Maceration of the skin is probably an important predisposing factor, as suggested by the increased incidence of plantar warts in swimmers who frequent public pools. Although the cellular receptor(s) for HPV has not been identified, cell surface heparan sulfate, which is encoded by proteoglycans and binds PV particles with high affinity, is required for entry.[12,13] To establish persistent infection, it is probably necessary to enter an epidermal basal cell that is either a stem cell or is converted by the virus to one with stem cell–like properties. It is believed that a single copy or at most a few copies of the viral genome are maintained as an extrachromosomal plasmid within the infected epithelial basal cells. When these cells divide, the viral genome is also replicated and partitioned to each progeny cell, then transported within the replicated cells as they migrate upward to form the differentiating layers.

After experimental PV inoculation, a verruca usually appears within 2 to 9 months. This observation implies a relatively long period of sub-clinical infection and may represent an inapparent source of infectious virus. The rough surface of a wart may disrupt adjacent skin and enable inoculation of virus into adjacent sites, with the development of new warts over a period of weeks to months. Each new lesion results either from the initial exposure or spread from other warts. There is no convincing evidence for blood-borne dissemination. Autoinoculation of virus into apposed skin is commonly seen on adjacent digits (Fig. 196-3) and in the anogenital region.

HPV DNA has been detected in normal-appearing mucosa and in normal-appearing skin adjacent to treatment sites of recurrent genital warts.[14] Whether this HPV DNA represents sub-clinical states rather than true "latency" (i.e., non-replicating and transcriptionally inactive virus) is unknown. Whether HPV DNA persists in the epithelium after successful treatment of immunocompetent individuals remains an unresolved question. However, the fact that HPV DNA becomes undetectable, even by very sensitive techniques, in the majority of cervical HPV infections implies that viral cure after treatment is possible and may be common.

Viral RNA expression (transcription) is extremely low until the upper Malpighian layer, just before the granular layer, where viral DNA synthesis typically results in hundreds of copies of viral genomes per cell. The viral capsid proteins (L1 and L2; see Figs. 196-1 and 196-2) are synthesized and assembled into virions in the nuclei of the cells at this upper level. The newly synthesized viral DNA is packaged into the virions in the nuclei of these differentiated Malpighian cells. A viral protein called *E1-E4* (the product of a spliced RNA from the E1 and E4 genes) may induce collapse of the cytoplasmic keratin filament network.[15] This is postulated to facilitate release of the virions from the cross-linked cytoskeleton of keratinocytes so that virus can be inoculated into another site or desquamated into the environment.



TABLE 196-1
Clinical Associations of Human Papillomavirus (HPV) Types

HPV Type	Most Common Clinical Lesion	Less Frequent Lesion	Potential Oncogenicity
1	Deep plantar/palmar warts	Common warts	
2, 4, 27, 29	Common warts	Plantar, palmar, and mosaic warts	
3, 10, 28, 49	Flat warts	Flat warts in EV	HPV-10 rare in cervical and vulvar carcinomas
7	Butcher's warts		
13, 32	Oral focal epithelial hyperplasia		
5, 8, 9, 12, 14, 15, 17, 19–26, 36, 47, 50	EV, warts in immunosuppression	Normal skin (?)	HPV-5, -8, -9 isolated from SCCs
6, 11	Anogenital warts, cervical condylomata	Bowenoid papulosis, common warts; respiratory papillomatosis, common warts	Buschke-Löwenstein tumor; rare in penile, vulvar cervical, and other urogenital tumors; "low risk"
16, 18, 31, 33–35, 39, 40, 51–60	Cervical condylomata; anogenital warts; bowenoid papulosis	Common warts	Genital and cervical dysplasias and carcinomas; rare in cutaneous SCC; "high risk"

EV = epidermodysplasia verruciformis; SSC = squamous cell carcinoma.





▲ **FIGURE 196-3** **A.** Common wart, periungual. Multiple, confluent, keratotic papules are apparent around the proximal periphery of the fingernails. **B.** Common wart, verruca plantaris. **C.** Common wart, mosaic plantar. A large hyperkeratotic plaque is seen on the heel, made up of multiple small coalescing warts.

PVs do not bud from the nuclear or plasma membrane, as do many viruses such as herpes simplex or human immunodeficiency virus (HIV). Therefore, they do not possess a lipoprotein envelope that causes susceptibility to rapid inactivation by environmental conditions such as freezing, heating, or dehydration with alcohol. In contrast, PV virions are resistant to desiccation[16] and to the detergent nonoxynol-9, although exposure of virions to formalin, strong detergents such as sodium dodecyl sulfate,[17] or prolonged high temperature can reduce their infectivity. PVs can remain infectious for years when stored in glycerol at room temperature. Indeed, L1 and L2 form a tightly packed, very stable protein capsid (see Fig. 196-2).

The relative abundance of these stable virus particles in a wart varies with the clinical setting and the HPV type. Newer lesions tend to contain more virions than do older verrucae. Plantar warts containing HPV-1 have a high number of virions; anogenital verrucae typically have trace quantities of mature virus particles; common warts usually have intermediate numbers.

Because the viral episomes are at low copy and the L1 and L2 proteins are not expressed in the lower epithelial levels in warts, it is assumed that the state of differentiation of the infected epithelial cell influences viral transcription, signals initiation of viral DNA synthesis, and permits virion assembly. The propagation of limited amounts of HPVs in cultured cells is a consequence of the ability to reproduce the milieu required for physiologic differentiation.[18,19] Further support for the belief that the production of virus particles depends on the state of epithelial differentiation is the fact that virion production decreases as benign papillomas progress toward dysplasia. Capsid proteins are virtually never observed in HPV-induced malignancies. Although it is possible to isolate infectious HPVs from cultured epithelial cells, the process is time-consuming, technically challenging, expensive, and limited to research laboratories. Therefore, laboratory culture for detection of HPV is not a practical diagnostic test.

Because viral replication occurs in upper levels of the epithelium composed of non-replicating keratinocytes, PVs must block terminal differentiation and stimulate cell division to provide the enzymes and co-factors necessary for replication of viral DNA. Experimental evidence from cell culture systems has shown that PV proteins can alter cell proliferation and inhibit cell death via apoptosis. These experimental systems have been used to examine and compare the in vitro activities of genital-mucosal HPVs. Their relative activity varies with the HPV type. In one assay, keratinocytes or cervical cells were grown as a stratified epithelium on a raft that provided an air-media interface.[20] The introduction of high-risk HPV-16 or -18 DNA induced a disorganized pattern of differentiation with suprabasal mitotic figures resembling squamous cell carcinoma (SCC) in situ, whereas the cells retained a normal pattern of stratification with the use of low-risk HPV-6 or -11 DNA.[21,22] In another cell culture model, introduction of HPV-16 or -18 DNA or the high-risk HPV-16 or -18 E6 and E7 genes into primary human keratinocytes allowed resistance to calcium-induced differentiation and conferred the ability to be continuously passaged and avoid replicative senescence.[23,24] Low-risk HPVs were much less active.[25] The high-risk E6 and E7 genes are preferentially retained and expressed in cervical cancers, implying that these assays measure a property that is closely related to the oncogenic potential of these viruses in cervical infection. Thus, for the genital-mucosal HPVs, there is an excellent correlation between their ability to induce cell transformation in vitro and their association with malignancy.

The E5, E6, and E7 proteins (see Fig. 196-1) have different mechanisms to activate cell growth and inhibit apoptosis.[26,27] High-risk E6 and E7 bind to and cause the degradation of the tumor suppressor p53 and the retinoblastoma proteins, respectively, and thereby relieve infected cells from the normal growth inhibitory activities of these cellular factors. Nonetheless, the E6 proteins from some HPV types, including those associated with malignancies in EV and immunosuppression, do not directly bind p53, although they may prolong the life span of infected cells by an alternate mechanism,[28] such as inactivation of the pro-apoptotic protein Bak.[29,30] Studies demonstrate that E6 and E7 must have other targets in the cell.[31] For instance, high-risk E6 stimulates expression of hTERT, the catalytic subunit of telomerase.[32,33] This enzyme protects the ends of chromosomes, and its expression blocks cell senescence in culture. Telomerase is expressed in stem cells and many cancers. The viral E5 proteins appear to activate growth factor receptors. In the bovine PV, which induces fibropapillomas, E5 appears to preferentially activate the receptors for platelet-derived growth factor, whereas

HPV-16 E5 may stimulate the epidermal growth factor receptor.[34,35]

EPIDEMIOLOGY

Acquisition of HPV depends on several factors, including the location of lesions, the quantity of infectious virus present, the degree and nature of the contact, and the general and HPV-specific immunologic status of the exposed individual. The roles of immunity and genetic susceptibility to PV infection are incompletely understood.[36,37] The decrease in the frequency of warts with age implies that resistance to infection develops over time, and much of this resistance may be immunologic. In experimental PV infection in animals, resistance to virus challenge correlates with the presence of neutralizing anti-capsid antibodies, and serum or immunoglobulin G from resistant animals can provide protection through passive transfer.[38,39] It is therefore likely that neutralizing antibodies account for at least some of the resistance to re-infection. Serum antibodies to viral capsids are detectable in some patients with current warts or a history of warts. These antibodies, as well as other host factors, may help to limit the spread of warts to new sites. Although humoral immunity may contribute to resistance to acquisition of infection, host cellular immune reactivity plays an important role in wart regression. Individuals with impaired cell-mediated immunity are particularly susceptible to persistent HPV infection, and their infections are notoriously resistant to treatment. Warts are common in renal and solid organ transplant patients on immunosuppressive therapy, which may contribute to their increased risk of cutaneous malignancy.[40,41] Although there are instances in which treatment of one or a few warts leads to resolution of many or all warts in nonimmunosuppressed patients, this outcome is the exception rather than the rule.

The source or reservoir for HPV is believed to be individuals with clinical and sub-clinical infection, as well as virus present in the environment. Using sensitive PCR detection, there is considerable evidence that HPV DNA, including novel types and those found in EV, is often resident at extremely low levels in normal skin and hair follicles of immunocompetent individuals.[14,42] This contrasts with the large amounts of virus readily detected in EV lesions. Studies to identify the HPV genotype in EV wart lesions are limited to research laboratories. When ultra-sensitive techniques are used to identify HPV DNA in a lesion not known to be caused by HPV, additional evidence should be sought before concluding that the virus has contributed to the development of the lesion. Approximately 50 percent of EV cases are inherited, usually with an autosomal recessive pattern. Mutations in the EVER genes are reported to be present in a subset of EV individuals.[43,44]

Non-genital warts occur most frequently in children and young adults, in whom the incidence may exceed 10 percent.[45,46] The age-specific incidence of non-genital warts differs from that of anogenital warts, which are uncommon in children. Anogenital warts behave as a sexually transmitted condition, and partners can transmit the virus with high efficiency.[47] Penile lesions occur frequently in the sexual contacts of women with cervical intraepithelial neoplasia, but not all pearly penile papules are caused by HPV.[48,49]

Although genital warts in children may be a consequence of sexual abuse, such warts in infants and children commonly result from virus inoculation at birth or from incidental spread from cutaneous warts (see Chap. 105). In contrast to anogenital lesions in adults, a significant proportion of genital warts in children contain HPV types that are usually isolated from non-genital warts.[50–52]

The majority of respiratory (laryngeal) papillomas occur in infants and young children. Oral and respiratory warts in adults are usually the consequence of oral-genital contact. The HPVs isolated from respiratory tract papillomas are often the same types as those of genital warts, especially HPV-6 and -11,[53] and respiratory papillomatosis in young children is thought to result from seeding of the larynx and oropharynx during parturition.[54] Although the epidemiologic correlation of condyloma in mothers of infants with respiratory papillomas has been documented,[55] cervical and genital warts are common in the childbearing age bracket, and respiratory papillomatosis of infants is rare. Because Cesarean section has attendant risk and is not fully protective, this is not routinely recommended for expectant mothers. Instead, treatment efforts should be aimed at reducing HPV infection before delivery.

In addition to causing lesions on the external genitalia, genital-mucosal HPV types also infect the uterine cervix.[56,57] This sexually transmitted infection, which may involve low- or high-risk HPV types, is especially common in sexually active women younger than 25 years of age. The majority of HPV DNA–positive cervical infections are transient and remain histologically normal. Thus, even normal-appearing genital skin or mucosa may represent a reservoir for contagion. Studies of large populations throughout the world have clearly documented the natural history of cervical infection and the association of high-risk HPV with cervical cancer. Persistence of HPV DNA strongly correlates with an increased risk for progression to cervical dysplasia and invasive cancer. High-risk HPV DNA has also been detected in clinically normal penile skin, although less is known of the epidemiology of genital HPV infection in men.[58]

CLINICAL FINDINGS

History

The typical history is of a newly acquired, slowly expanding, persistent, and often scaly lesion of the skin. Over several weeks to months, the appearance of additional nearby lesions is suggestive of local spread and the diagnosis of HPV infection.

Cutaneous Lesions

Warts are described by their clinical location or morphology. As shown in Figs. 196-3 to 196-8, the cutaneous manifestations of warts are varied. Common warts (verruca vulgaris) are scaly, rough, spiny papules or nodules that can be found on any cutaneous surface (see Table 196-1). They often occur as single or grouped papules on the hands and fingers (see Figs. 196-3A to 196-5). Verrucae may also be filiform (see Fig. 196-6) or appear as cutaneous horns. Flat



▲ **FIGURE 196-4** Common wart. Large hyperkeratotic nodules are seen on the lower lip.





▲ **FIGURE 196-5** Common wart. A giant wart is seen on the dorsum of the hand in a renal transplant recipient; the lesions were resistant to treatment, but resolved spontaneously when immunosuppressive therapy was discontinued.



warts, (verruca plana), are 1 to 4 mm, slightly elevated, flat-topped papules that have minimal scale (see Fig. 196-8). These are most frequent on the face, hands, and lower legs. Plantar and palmar warts are thick, endophytic, and hyperkeratotic papules, which may be painful with pressure (see Fig. 196-3B,C). Punctate black dots ("seeds") that become evident after shaving away of the outer keratinous surface represent thrombosed capillaries in the papilloma. Mosaic warts result from coalescence of plantar or palmar warts into large plaques (see Fig. 196-3C). Some individuals with an apparently normal immunologic state develop exuberant warts of the palms or soles that are refractory to treatment. Butcher's warts are verrucous papules, usually multiple, on the dorsal, palmar, or periungual hands and fingers of meat cutters, and may be infected with HPV-7.

Anogenital warts (also known as *condylomata acuminata*, *genital warts*, or *venereal warts*) consist of epidermal and dermal papules or nodules on the perineum, genitalia, crural folds, and anus (Fig. 196-9A–C). They vary in size and can form large, exophytic, cauliflower-like masses, especially in the moist environment of the perineum. Discrete 1- to 3-mm sessile warts may occur on the penile shaft. Lesions that resemble common warts also occur in this region but are unusual. Warts may extend internally into the vagina, urethra, and peri-rectal epithelium.



▲ **FIGURE 196-6** Common warts. Filiform warts on the chin and lips of a child.



▲ **FIGURE 196-7** The large, scaly, and horny warts contain human papillomavirus (HPV)-2. The smaller, flatter, less scaly papules are warts that contain HPV-3.

Bowenoid papulosis is a clinicopathologic entity in which HPVs have been identified.[59] Papules, often multiple, appear as 2- to 3-mm lesions on the external male and female genitalia (see Fig. 75-20; Chap. 75). Histologically, there is cellular atypia resembling Bowen's disease or SCC in situ. These lesions are usually infected with HPV-16, which suggests that bowenoid papulosis may represent a precursor of penile and vulvar cancer. However, the rate of transition to frank malignancy is much lower for the external genitalia than for the cervix. These small papules should be treated because they may represent a reservoir for the transmission of potentially oncogenic HPVs.

Epidermodysplasia Verruciformis

EV usually manifests in childhood with persistent and often widespread warts that do not regress due to unique susceptibility to specific HPV types. Individual lesions typically have either the appearance of flat warts or flat, scaly,





▲ **FIGURE 196-8** Plane warts, verruca plana. **A.** Multiple pinkish flat warts on the face of an 11-year-old girl. **B.** Many flat-topped papules occur in a linear configuration as a result of autoinoculation.

red-brown macules that resemble lesions of pityriasis versicolor (Fig. 196-10). The presence of warts on large areas of the body is suggestive but not necessary to consider this diagnosis. Involvement of the cervical and oropharynx is rare. Failure to clear lesions despite adequate treatment is another indication of potential EV. Because warts in EV almost always recur after treatment, this implies a failure to mount an effective immune response to the HPV infection. Individuals with EV do not usually have frequent bacterial or other viral infections. Immunocompromised individuals, such as those with HIV infection, may have multiple warts that contain EV types and are difficult to eradicate, but this susceptibility is acquired.[60,61] SCCs in EV and immunosuppression usually arise in pityriasis-like lesions on sun-exposed areas (Fig. 196-11). Regional and distant metastases may occur. Although pityriasis-like lesions caused by any EV type may be at increased risk of becoming malignant,







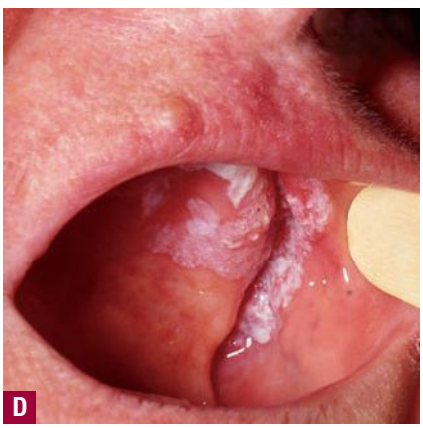

▲ **FIGURE 196-9** Mucosal wart. **A.** Multiple condylomata acuminata on the shaft of the penis. **B.** Multiple confluent condyloma on the labia minora, majora, and fourchette. **C.** Multiple perianal condylomata in an infant. He was probably infected during vaginal delivery; his mother was not aware of her infection, but examination revealed several small condylomata. **D.** Flat, irregular, whitish confluent oral warts on buccal mucosa and palate. This progressed to so-called *oral florid papillomatosis*.

this is high for those caused by HPV-5 and -8.

Extracutaneous (Mucosal) Infections

Oral warts are small, slightly elevated, soft, often pink or white papules that may be found on the buccal, gingival, labial mucosa, tongue, or hard palate (see Fig. 196-9D). Verrucous, horny papillomas may occur on the palate. Mucosal lesions of the oropharynx, termed *focal epithelial hyperplasia*, also contain HPVs. In oral florid papillomatosis, multiple large verrucae appear within the oral cavity (see Fig. 196-9D). Progression to verrucous carcinoma may occur. Oral warts may result from genital contact. Warts may also occur in the urethra, usually when meatal warts are present. They may spread to the urinary bladder.

In respiratory (laryngeal) papillomatosis, multiple warts usually involve the larynx and may extend to the oropharynx and bronchopulmonary epithelia. Presenting symptoms commonly include hoarseness and stridor. Cases typically occur in infants or young children (in whom the lesions may block the airway), but the condition may develop at any age. These HPV-associated papillomas may spontaneously remit, especially at puberty, but recurrences are frequent.



▲ **FIGURE 196-10** Epidermodysplasia verruciformis. Plane wart–like lesions on the dorsa of the hands and forearms, associated with human papillomavirus-5 and -8. The lesions are numerous, flat, reddish, and partly confluent.



▲ **FIGURE 196-11** Invasive cancer in an epidermodysplasia verruciformis patient infected with numerous human papillomavirus (HPV) types, including HPV-5, -8, -9, -14, and others. In the tumor cells, DNA HPV-5 was detected in a high copy number. This large squamous cell carcinoma did not metastasize and did not recur after surgery. There are numerous actinic keratoses on the forehead.

Cervical lesions are usually flat or slightly elevated, and visualization may require colposcopy and enhancement after acetic acid application, which makes them appear as white patches (Fig. 196-12).

Histopathology

Verrucae consist of an acanthotic epidermis with papillomatosis, hyperkeratosis, and parakeratosis (Fig. 196-13). The elongated rete ridges often point toward the center of a wart. The dermal capillary vessels are prominent and may be thrombosed. Mononuclear cells may be present. Large keratinocytes with an eccentric, pyknotic nucleus surrounded by a perinuclear halo (koilocytotic cells or koilocytes) are characteristic of HPV-associated papillomas. Koilocytes visualized in a Papanicolaou (Pap) smear represent a hallmark of HPV infection.

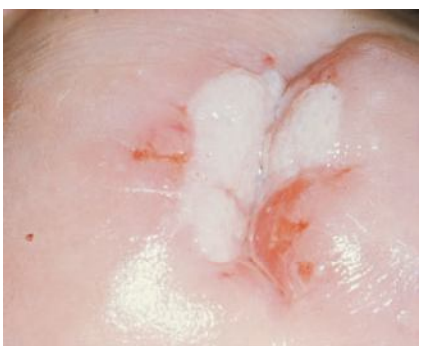

▲ **FIGURE 196-12** Colposcopic view of cervical condyloma after treatment with acetic acid for visualization as white, elevated patch.





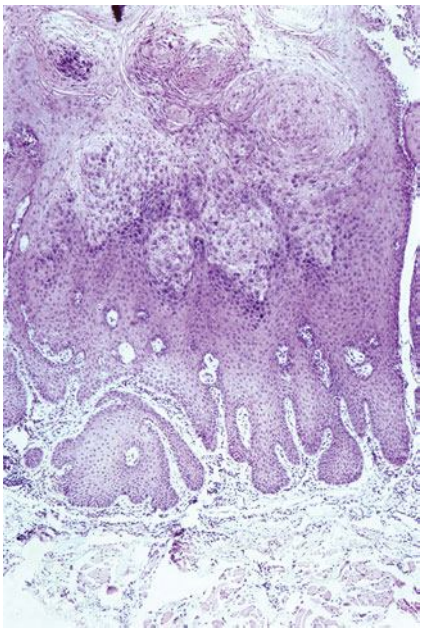

▲ **FIGURE 196-13** Verruca vulgaris. The process is one of extensive hyperplasia, and the hyperplastic cells contain both intranuclear and intracytoplasmic inclusion bodies.

PV-infected cells may have small, eosinophilic granules and dense clumps of basophilic keratohyaline granules. These granules may be composed of or associated with the PV E4 (E1-E4) protein and do not represent conglomerates of virus particles. Flat warts have less acanthosis and hyperkeratosis and do not have parakeratosis or papillomatosis. Koilocytotic cells are usually abundant, indicating the viral origin of the lesion. Anogenital warts may have slight or extensive acanthosis and parakeratosis: they lack a granular layer as they are within or adjacent to a mucosal surface. The rete ridges often form thick bands extending extensively into the underlying, highly vascular dermis.

Plane warts have a similar histologic appearance whether in the general population or in patients with EV (Fig. 196-14). The granular and upper spinous layers contain many cells with perinuclear vacuolization. In EV, lesions containing HPV-5 or -8 have a characteristic basket-weave–like hyperkeratosis with many large clear cells in the granular and spinous layers (Fig. 196-15).

DIAGNOSIS

The clinical appearance and history of acquired, slowly enlarging papules usually lead to the diagnosis of viral wart. Histologic examination can be used to confirm the diagnosis. Application of 3 percent to 5 percent acetic acid to genital warts enhances visualization of these lesions, particularly with colposcopic magnification, although the diagnosis should not rest only on the presence of white lesions as the test is non-specific. Antibodies to detergent-disrupted PV particles expose L1 and L2 antigens shared among most PVs. Immunohistochemical detection can be used to detect these capsid proteins in clinical materials, including formalin-fixed tissue, but is insensitive and not routine.

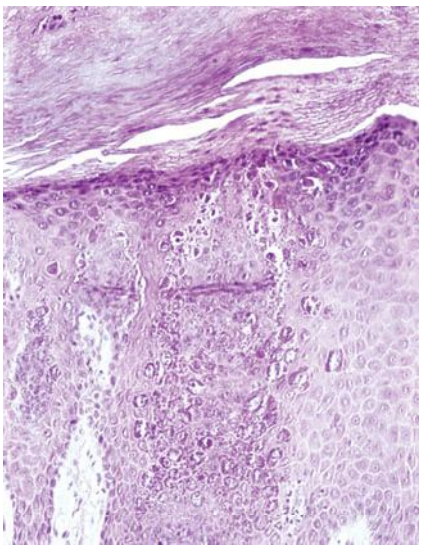

▲ **FIGURE 196-14** Human papillomavirus-3–associated plane wart–like lesion in patient with epidermodysplasia verruciformis. Numerous cells show perinuclear vacuolization in the granular and upper spinous layers.

PCR techniques detect cutaneous or EV-type HPVs but are generally limited to research and diagnostic laboratories. Highly sensitive and specific diagnostic hybridization tests to identify genital-mucosal HPV types are commercially available (Digene Hybrid Capture 2; Roche Amplicor).[62]

Cutaneous warts are commonly found in all age groups. Multiple warts that do not spontaneously resolve, always recur after treatment, persist for years, or have an unusual morphology (especially if familial) suggest EV. HPV typing may be of benefit in confirming the diagnosis of EV and will disclose whether the patient is infected with a type that is associated with cutaneous malignancy. Immunocompromised patients, such as those with acquired immunodeficiency syndrome, lymphoproliferative disorders, or drugs to prevent transplant rejection, often have multiple warts.

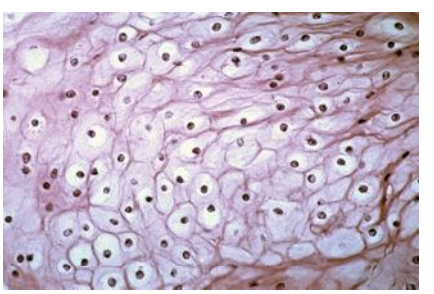

▲ **FIGURE 196-15** Characteristic cytopathic effect of epidermodysplasia verruciformis–specific human papillomavirus (HPV) in a patient found to be infected with HPV-5, -8, and -9. Very abundant clear large cells with small pyknotic nuclei replace almost the entire epidermis.

DIFFERENTIAL DIAGNOSIS

Common lesions, such as seborrheic and solar keratoses, nevi, acrochordons, sebaceous hyperplasia, clavi, small pyogenic granuloma, or SCC, may resemble a verruca. The different diagnosis varies considerably with the type of lesions and the site of involvement (Box 196-1).

Papules of lichen planus may resemble flat warts; the former may be differentiated by their color, polygonal shape, Wickham's striae, and buccal involvement (Box 196-2). Acrokeratosis verruciformis and epidermolytic hyperkeratosis are characterized by verrucous papules on the extremities. Warts in epidermodysplasia may resemble pityriasis versicolor but are not transient.

Penile and vulvar warts may resemble nevi, benign keratoses, cysts, or ectopic sebaceous glands (Box 196-3). A history of increasing number of acquired, grouped lesions is suggestive of warts. Syphilitic condylomata must be ruled out.

COMPLICATIONS (See Chap. 111)

Although most PVs are limited to causation of benign lesions, epidemiologic and experimental studies document that specific PV genotypes have oncogenic potential.[63,64] In animals, the benign warts induced in rabbits by the (Shope) cottontail rabbit PV can spontaneously convert to invasive SCC. Small doses of chemical carcinogens induce a high rate of malignant conversion in these lesions. In cattle, esophageal papillomas induced by bovine PV type 4 become malignant if the infected animals graze on bracken fern, which contains a potential carcinogen. The skin cancers that develop in EV are usually in sun-exposed regions. Metastatic tumors in EV contain the viral DNA, implying that its presence is not from skin contamination and that retention of the HPV genome is necessary for maintaining the

Box 196-1

Differential Diagnosis of Warty Lesions on Hands and Feet

	SINGLE LESIONS	MULTIPLE LESIONS
Palms and soles	***Consider***	***Consider***
	☐ Verruca vulgaris	☐ Arsenical keratoses
	☐ Callus, corn	☐ Verruca vulgaris
	☐ Epidermal inclusion cyst	☐ Palmoplantar keratoderma
	☐ Pyogenic granuloma	☐ Psoriasis, reactive arthritis
	☐ Milkers nodules (palms)	☐ Pits in basal cell nevus syndrome
	☐ Orf (palms)	
		Rule Out
	Rule Out	☐ Secondary syphilis
	☐ Amelanotic acrolentiginous melanoma	
	☐ Carcinoma cuniculatum	
Dorsum of hands and feet	***Consider***	***Consider***
	☐ Verruca vulgaris	☐ Verruca vulgaris
	☐ Periungual warts	☐ Verrucae planae
	☐ Actinic keratosis	☐ Actinic keratosis
		☐ Acrokeratosis verruciformis
	Rule Out	☐ Epidermolytic hyperkeratosis
	☐ Squamous cell carcinoma	☐ Stucco keratosis
	☐ Keratoacanthoma	
	☐ Tuberculosis verrucosa cutis	
	☐ Fish tank granuloma	

Box 196-2

Differential Diagnosis of Plane Warts

FACE	HAND	TRUNK, EXTREMITIES
☐ Perioral dermatitis	☐ Acrokeratosis verruciformis	☐ Epidermodysplasia verruciformis
☐ Adenoma sebaceum (mild)	☐ Lichen planus	☐ Pityriasis versicolor
☐ Syringoma	☐ Stucco keratosis	☐ Superficial actinic porokeratosis
☐ Flat seborrheic keratosis	☐ Seborrheic keratosis	☐ Seborrheic keratosis
☐ Actinic keratosis		
☐ Trichoepitheliomas		

malignant phenotype. The benign but locally obstructive verrucae in respiratory papillomatosis, if they are treated by x-rays, often progress to invasive SCC. These observations suggest that oncogenic PVs do not induce malignant tumors directly but predispose the infected cell to tolerate genetic damage that, together with viral oncogenes, contributes to the malignant state.

Robust epidemiologic studies confirm that infection with high-risk HPVs is the cause of virtually all cases of cervical cancer. Even with high-risk HPVs, however, cervical infection usually has a benign outcome.[56,57] Persistent infection with high-risk HPV types is likely necessary but not sufficient to induce development of malignant epithelial tumors. Individuals with impaired cellular immune function, such as renal transplant recipients or HIV infection and acquired immunodeficiency syndrome, are at greater risk of having persistent HPV infection that progresses to severe dysplasia and to cancer.[60]

Epidemiologic and molecular evidence has also linked some penile, vulvar, anal, and oral carcinomas with HPV infection.[65] As with cervical cancer, these tumors are associated primarily with high-risk HPV types. High-risk HPVs, especially HPV-16, have been identified in some periungual cutaneous tumors. The giant condyloma acuminatum, also called the *Buschke-Lowenstein tumor*, is a low-grade, locally invasive SCC. Low-risk HPVs, such as types 6 and 11, are usually found in these tumors. Epithelioma cuniculatum, another rare type of verrucous carcinoma, is found on the sole and is thought to arise from a plantar wart.

There have been many studies that report detection of low levels of HPV DNA, often of EV types, in actinic keratoses, basal cell carcinomas and SCCs, psoriasis, and other skin lesions.[66–70] Because PCR detects HPV DNA in normal skin and hair follicles,[71] the etiologic role of HPV in the pathogenesis of these benign, pre-malignant, and malignant lesions remains controversial.[66,72,73]

Box 196-3

Differential Diagnosis of Genital Warts

FLAT OR PAPULAR	NODULAR
Consider	***Consider***
☐ Condylomata acuminata	☐ Nevi
☐ Bowenoid papulosis	☐ Seborrheic keratosis
☐ Sebaceous glands	☐ Angiokeratoma
☐ Pearly penile papules	☐ Skin tags
☐ Lichen planus	
☐ Lichen sclerosus et atrophicus	***Rule Out***
	☐ Squamous cell carcinoma
Rule Out	☐ Amelanotic melanoma
☐ Erythroplasia	
☐ Extramammary Paget's disease	
☐ Condylomata lata of secondary syphilis	



TREATMENT

The management of warts depends on the degree of physical and emotional discomfort, the extent and duration of lesions, the patient's immunologic status, and the patient's desire for therapy.[74] With all types of treatments, recurrences are frequent.

Most treatments for verrucae involve physical destruction of the infected cells. The existence of multiple treatment modalities reflects the fact that none is uniformly effective or directly antiviral. The choice of treatment depends on the location, size, number, and type of wart, as well as on the age and cooperation of the patient. Pain, inconvenience, risk of scarring, and the benefit to the patient should be considered. Children with common warts may not require treatment as spontaneous regression is common. However, new warts may appear, and virus can be spread to other areas or susceptible individuals. In patients with anogenital warts (including bowenoid papulosis), sexual partners should be examined, the cervix should be evaluated, and a Pap smear obtained; male contacts of women with cervical disease should also be examined. Anogenital warts in sexual contacts should be treated.

Cryotherapy using liquid nitrogen applied with a cotton tip or a spray canister to achieve a halo of ice in and around the

lesion is a standard and effective treatment for most warts.[75,76] Caution must be used near the nail matrix when treating periungual warts. Aggressive cryotherapy with a spray canister can injure underlying structures such as nerves. Therefore, its use on the lateral surfaces of the digits and genitalia mandates caution. Warts on the elbows and knees of children may be particularly susceptible to scarring with cryotherapy; although effective, this modality should be used in moderation in these patients.

Warts may be curetted or surgically excised, particularly large anogenital warts unresponsive to topical treatments. Electrodesiccation of condyloma acuminata requires local anesthesia but is also effective. Laser treatment in several different energy formats, including photodynamic therapies, can be useful for destroying warts that are treatment-resistant or those that require careful control of width and depth, such as large periungual warts. Use of a surgical mask should be routine because infectious PV has been identified in the vapor plume with laser or with electrocoagulation of warts.[77] Microscopically controlled (Mohs) surgery has been useful in the treatment of verrucous carcinoma. X-irradiation of verrucae is contraindicated because of its association with the development of malignancy in respiratory papillomatosis and EV. Avoidance of and protection from sun exposure is critical in EV.

Chemotherapeutic agents are commonly used to treat warts. Topical podophyllin resin is useful for moist anogenital warts. Podophyllin is contraindicated during pregnancy, and the potency of podophyllin preparations may be variable. Purified podophyllotoxin (Condylox) has activity that is uniform from batch to batch and is approved for treatment of genital and perianal warts.[78] Topical 5-fluorouracil has been used to treat cutaneous and genital warts, and has been reported to be highly effective, with occlusion in the treatment of plantar warts.[79] Intralesional bleomycin may eradicate verrucae but should be used cautiously because of the possibility of extensive tissue necrosis.[80] Anecdotal reports suggest topical application of the nucleotide analog cidofovir may be effective in the treatment of warts, however, pain and ulceration are potential side effects.[81,82]

Caustics and acids, such as salicylic acid, lactic acid, and trichloroacetic acid, destroy and peel off infected skin. Retinoic acid has been used topically for flat warts and probably has a similar mechanism of action. Home use of salicylic acid preparations can be particularly efficacious in young children who cannot tolerate other modalities. Cantharidin is an extract of the green blister beetle that is painlessly applied and causes delayed blistering and focal destruction of epidermis.

Immunotherapies have been attempted in various forms. Induction of allergic contact dermatitis with dinitrochlorobenzene, squaric acid dibutylester, or diphenylcyclopropenone allows localization of inflammation to warts on which the allergen is painted; it has been speculated that this treatment stimulates local immunity.[83,84] Dinitrochlorobenzene is positive in the Ames bacterial test of mutagenicity, and its use remains controversial. Cimetidine has been associated with the resolution of cutaneous warts, particularly in children. Although this regimen has its supporters, a double-blind controlled study showed no beneficial effect.[85] Interferon has been effective in short-term studies, reducing warts in laryngeal papillomatosis and EV, but lesions return when therapy is stopped. Recombinant interferons have been used by intralesional injection of refractory genital warts.[86] It is not clear that interferon acts through stimulation of immune response. Imiquimod, a potent stimulator of the release of several proinflammatory cytokines that acts at least in part by activation of Toll-like receptors 7 and 8,[87] is patient-applied therapy that is approved for treatment of genital warts, although cure rates are significantly lower than treatments with physical modalities.[88] Imiquimod is less effective for cutaneous warts. Recently, anecdotal reports suggest that intralesional injections of candidal extracts induce wart regression.[89–91] Because yeast and viruses share no homologous proteins, the mechanism of action is obscure. Imiquimod and low-dose retinoids may reduce the development of cutaneous malignancies in renal transplant recipients.[92,93]

PREVENTION

For non-genital warts, no approaches have been documented to prevent transmission, although direct exposure to lesions or to fomites that contain virus represent likely sources of infection. For genital HPV infection, the risk is correlated with the number of sexual partners, which implies that reducing that number should reduce the likelihood of infection. The risk of genital infection appears to be lower in circumcised males and in their sexual partners,[94] and there is some evidence that regular use of condoms may partially protect against the acquisition of genital HPV infection.[95] Widespread Pap smear screening in the United States and other developed countries has greatly reduced the incidence of cervical cancer.

A prophylactic HPV vaccine represents the newest approach to preventing genital HPV infection. The vaccine, which is non-infectious, is based on the observations that the L1 protein, when expressed in cells, self-assembles to form virus-like particles (VLPs) that morphologically resemble authentic capsids (see Fig. 196-2). VLPs exhibit the same type-specific epitopes as the authentic virus, and purified VLPs induce high titers of neutralizing antibodies.[96] In human clinical trials, the L1 VLP vaccine, which is given intramuscularly, has been shown to induce seroconversion in more than 99 percent of vaccinees, to induce serum neutralization antibody titers that are 40 times or greater than those that develop after natural infection, and to confer close to 100 percent protection in women against the development of lesions attributable to the genital HPV types in the vaccine.[97–100] A quadrivalent version of the vaccine (Gardasil), composed of L1 VLPs from HPV-6, -11, -16, and -18, was approved by the U.S. Food and Drug Administration in 2006 for girls and women ages 9 to 26 years. Despite its high level of efficacy in preventing HPV infection, the vaccine does not appear to have therapeutic activity against established infection. Another limitation is that its protection appears to be largely type-specific, which means that most infections caused by HPV types other than those in the vaccine will not be prevented. However, HPV-6 and -11 cause approximately 90 percent of genital warts, whereas HPV-16 and -18 cause about 70 percent of cervical cancer. Thus, the quadrivalent vaccine has the potential to drastically reduce the incidence of genital warts in vaccinees and to protect against the majority of HPV infections that lead to cervical cancer. A bivalent HPV-16 and -18 VLP vaccine (Cevarix) is also being developed commercially, primarily as a vaccine to prevent cervical cancer.

KEY REFERENCES

The full reference list for all chapters is available at www.digm7.com.

1. de Villiers EM et al: Classification of papillomaviruses. *Virology* **324**:17, 2004

2. Longworth MS, Laimins LA: Pathogenesis of human papillomaviruses in differentiating epithelia. *Microbiol Mol Biol Rev* **68**:362, 2004
3. Doorbar J: The papillomavirus life cycle. *J Clin Virol* **32 Suppl 1**:S7, 2005
6. Peh WL, Doorbar J: Detection of papillomavirus proteins and DNA in paraffin-embedded tissue sections. *Methods Mol Med* **119**:49, 2005
11. Munoz N et al: Epidemiologic classification of human papillomavirus types associated with cervical cancer. *N Engl J Med* **348**:518, 2003
15. Wang Q et al: Functional analysis of the human papillomavirus type 16 E1-E4 protein provides a mechanism for in vivo and in vitro keratin filament reorganization. *J Virol* **78**:821, 2004
42. Astori G et al: Human papillomaviruses are commonly found in normal skin of immunocompetent hosts. *J Invest Dermatol* **110**:752, 1998
52. Myhre AK et al: Anogenital human papillomavirus in non-abused preschool children. *Acta Paediatr* **92**:1445, 2003
53. Wiatrak BJ et al: Recurrent respiratory papillomatosis: a longitudinal study comparing severity associated with human papilloma viral types 6 and 11 and other risk factors in a large pediatric population. *Laryngoscope* **114(11 Pt 2 Suppl 104)**:1, 2004
100. Villa LL et al: Prophylactic quadrivalent human papillomavirus (types 6, 11, 16, and 18) L1 virus-like particle vaccine in young women: A randomised double-blind placebo-controlled multicentre phase II efficacy trial. *Lancet Oncol* **6**:271, 2005

CHAPTER 197

Human Retroviral Disease: Human T-Lymphotropic Viruses

Erwin Tschachler

The first known pathogenic human retrovirus was isolated in 1980 from the lymphocytes of a patient with cutaneous T-cell lymphoma (CTCL) by Poiesz and co-workers.[1] Independently, Miyoshi and co-workers later isolated an identical retrovirus from a Japanese leukemia patient.[1] The name *human T-cell leukemia virus type 1* (HTLV-1) is used now for all isolates previously called *adult T-cell leukemia virus* in Japan and *HTLV* in the United States.

EPIDEMIOLOGY

An estimated 10 to 20 million individuals are infected by HTLV-1 worldwide,[1–3] with an endemic pattern in southern Japan, the Caribbean islands, and some countries in equatorial Africa. In some of these locations seroprevalence ranges from 1 percent to 36 percent.[1–3] Small clusters of HTLV-1/HTLV-2 seropositive populations have been reported in restricted areas in South America, among Australian aborigines, and in the Middle East.[1–3] In the United States and Europe the incidence of HTLV-1 infection is below 0.1 percent, and clusters are found predominately among immigrants from endemic areas, especially those from the West Indies and Africa.[1–4]

Sexual intercourse is the main mode of horizontal transmission of HTLV-1.[1,2,5] In vertical transmission, breast-feeding plays a more important role than perinatal or intrauterine transmission.[2,5] Parenteral transmission of HTLV-1 is also possible, and approximately one-half of patients who received transfusions from an HTLV-1–infected donor seroconvert.[1,2,5] By contrast, cell-free fresh frozen plasma appears not to be infectious. Transfusion-mediated HTLV-1 infection in Japan has been virtually eliminated by mass screening of donated blood. Parenteral transmission via needle sharing very likely accounts for clusters of HTLV-1/HTLV-2 seropositivity in intravenous drug users in certain areas of the United States and Europe.[6]

ETIOLOGY AND PATHOGENESIS

HTLV-1 together with HTLV-2, a virus that has not yet been clearly associated with any human disease, and bovine leukemia virus form their own genus within the retroviridae.[2] Many strains of HTLV-1 have been isolated in different areas of the world, including the United States, the Caribbean islands, Africa, and Japan.[3] The overall nucleic acid sequence variation among different HTLV-1 strains does not exceed 7 percent. By comparison, the nucleotide sequence conservation between HTLV-1 and HTLV-2 is only approximately 55 percent.[7] In addition to genes coding for viral structural proteins, both the HTLV-1 and HTLV-2 genomes contain an extra sequence of approximately 1.6 kilobases between the *env* and the 3′ LTR, which contains several regulatory genes. These include the transregulatory proteins Tax (transactivator in the region x) and Rex (regulator in the region x), whose functions have been elucidated,[8] but the function of the other proteins of the pX region—p21Rex, $p12^{I}$, $p13^{II}$, and $p30^{II}$—still awaits full clarification.

HUMAN T-LYMPHOTROPIC VIRUS 1–INDUCED SKIN DISEASES AT A GLANCE



- An estimated 10 to 20 million people are infected by human T-cell lymphotropic virus type 1 (HTLV-1) worldwide, with endemic pockets of high prevalence in southern Japan and the Caribbean islands.
- Infective dermatitis is a recalcitrant form of eczema occurring in HTLV-1–infected children in the Caribbean.
- Adult T-cell leukemia (ATL) shows monoclonal HTLV-1 provirus integration in tumor cells and occurs in four clinical variants, all of which tend to show skin involvement:
  - Smoldering ATL—5 percent of all cases
  - Chronic ATL—15 percent of all cases
  - Lymphoma-type ATL—20 percent of all cases
  - Acute ATL—60 percent of all cases
- The prognosis of lymphoma-type and acute ATL is very poor despite chemotherapy, with a projected 4-year survival of 5 percent.

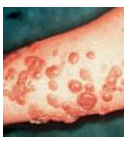

Infection of human, monkey, and rabbit T lymphocytes by HTLV-1 in vitro leads to their continuous growth in tissue culture and the development of cell lines with growth characteristics of transformed cells. In infected patients, HTLV-1 is present mainly in $CD4^+$ T cells.[9] The steps leading from virus infection to the development of the different HTLV-1–associated diseases are still only partly understood. Only a small percentage of patients infected with HTLV-1 ultimately develop adult T-cell leukemia (ATL), and the time from infection to the appearance of leukemia is usually several decades.[2]

Tax, the viral transactivator, is necessary for the transformation of T cells. It interferes with at least two inhibitors of cell cycle progression, including the tumor suppressor protein $p16^{ink}$ and p53.[2,8] In the transformed state, HTLV-1–infected T cells proliferate in the absence of exogenous growth factors. This event correlates with both the constitutive activation of the Janus kinase/signal transducer and activator of transcription (Jak/STAT) signaling pathway[8] and the constitutive activation of the cyclin E/cyclin-dependent kinase 2 complex. The in vitro model of T-cell transformation appears to mirror the event that leads to leukemogenesis. In most cases of ATL, genetic mutation or deletion of p53 or $p16^{ink}$ occurs,[8] and the leukemic cells of 70 percent of patients display constitutive activation of the Jak3 and STAT proteins.[8]

Although HTLV-2 has been less well studied than HTLV-1, most of the properties described for the latter, including the transformation of T cells in vitro and the presence and importance of transregulatory genes, are also true for the former.[2] To date, however, no disease has been associated with HTLV-2 infection.

HUMAN T-LYMPHOTROPIC VIRUS 1 INFECTION AND CLINICAL DISEASES

Adult T-Cell Leukemia/Lymphoma

Uchiyama and co-workers first described ATL in 1977 as a distinct malignancy of mature T cells occurring primarily in patients born in southwestern Japan.[1–3,5] At the beginning of the 1980s, HTLV-1 was linked to ATL by virus isolation from leukemic cells, by the demonstration of oligoclonal or monoclonal integrated HTLV-1 provirus in leukemic cells, and by extensive seroepidemiologic studies.[2,5] Besides Japan, the West Indies are a major region where HTLV-1 infection and ATL are endemic.[2,5]

Although the presence of HTLV-1 is a prerequisite for ATL development, infection with this virus does not necessarily lead to the occurrence of leukemia. More than 90 percent of infected individuals remain asymptomatic carriers.[2,5] The annual incidence rate of ATL among HTLV-1 carriers older than 40 years of age is approximately 0.6 to 1.7 in 1000.[10] The cumulative incidence rate of ATL in HTLV-1 carriers approximates 2 percent to 5 percent. The latent period from infection to outbreak of leukemia is 20 years or longer, as concluded from studies in migrants.[11] Interestingly, the average age of onset of ATL differs in patients in Japan (56 years) and in the Caribbean (43 years).[12]

According to the World Health Organization's lymphoma classification, ATL is a peripheral T-cell lymphoma. Based on the clinical course and laboratory parameters, ATL is classified into four subtypes—(1) smoldering (5 percent of cases), (2) chronic (15 percent), (3) lymphoma type (20 percent), and (4) acute or prototypic ATL (60 percent)—for which diagnostic criteria have been formulated (Table 197-1).[13,14]

Acute, prototypic ATL is a fatal malignancy of adult onset with a clinical presentation that appears to be identical in all endemic areas.[5] It is characterized by the variable combination of multiorgan involvement, including hepatosplenomegaly, systemic lymphadenopathy, central nervous system involvement, and skin lesions, with the massive presence of multi-lobated leukemic cells in the peripheral blood (Fig. 197-1A). The presence of leukemic infiltrates in different organs determines the clinical presentation and the morbidity: central nervous system involvement may alter the mental status of the patient; lymphoma within the liver may lead to abnormalities in liver function test results and jaundice; and lung involvement may lead to tachypnea, cyanosis, and dyspnea.

A striking feature in a high percentage of patients with acute ATL is refractory hypercalcemia, which may be the first sign of the disease and indicates an aggressive course.[5,15,16] Patients may have weakness, lethargy, polyuria, and polydipsia. Lytic bone lesions resembling those of multiple myeloma are often present at the time of diagnosis, and levels of alkaline phosphatase may be elevated.[15,16] Parathyroid hormone levels and 1,25-dihydroxyvitamin D levels are normal in ATL patients with hypercalcemia. Factors produced by leukemic cells themselves have been suggested to account for the hypercalcemia and bone resorption in ATL patients.[16]

TABLE 197-1
Diagnostic Criteria for Adult T-Cell Leukemia (ATL)

Features Common to All ATL Sub-Types
- Positive results on serologic testing for HTLV-1
- Clonal integration of HTLV-1 in tumor cells
- Expression of CD25 and HLA class II antigens by tumor cells

Distinguishing Features of ATL Sub-Types
- Smoldering ATL
  - Normal lymphocyte counts with 1%–5% leukemic cells present
  - Skin lesions and/or lung lesions present but no other visceral involvement
  - No lymphadenopathy, no hypercalcemia
  - Serum LDH level up to 1.5× the normal upper limit
- Chronic ATL
  - Lymphocytosis ($> 4 \times 10^9$/L) with 5% or more leukemic cells present
  - Skin, liver, lung, or lymph node involvement; other viscera not involved
  - No hypercalcemia
  - Serum LDH level above 2× the normal upper limit
- Lymphoma-type ATL
  - Normal lymphocyte counts with < 1% leukemic cells present
  - Possible involvement of multiple visceral organs, lymphadenopathy
  - Possible hypercalcemia
  - Serum LDH level strongly elevated
- Acute ATL
  - Large numbers of leukemic cells present in peripheral blood
  - Involvement of multiple visceral organs with organomegaly
  - Frequently hypercalcemia with osteolytic lesions
  - Serum LDH level strongly elevated

HTLV-1 = human T-cell lymphotropic virus type 1; LDH = lactic acid dehydrogenase.

Lymphoma-type ATL also shows severe organ involvement and high serum levels of lactic acid dehydrogenase and may be associated with hypercalcemia. Unlike in acute ATL fewer than 1 percent leukemic cells are present in the peripheral blood. Both lymphoma-type and acute ATL have a poor prognosis, with a projected 4-year survival of no more than 5 percent.[17]

Smoldering and chronic ATL have more protracted courses; however, they may convert into acute ATL.[5,13]

The skin involvement in ATL varies considerably among patients but is present to a variable degree in all forms

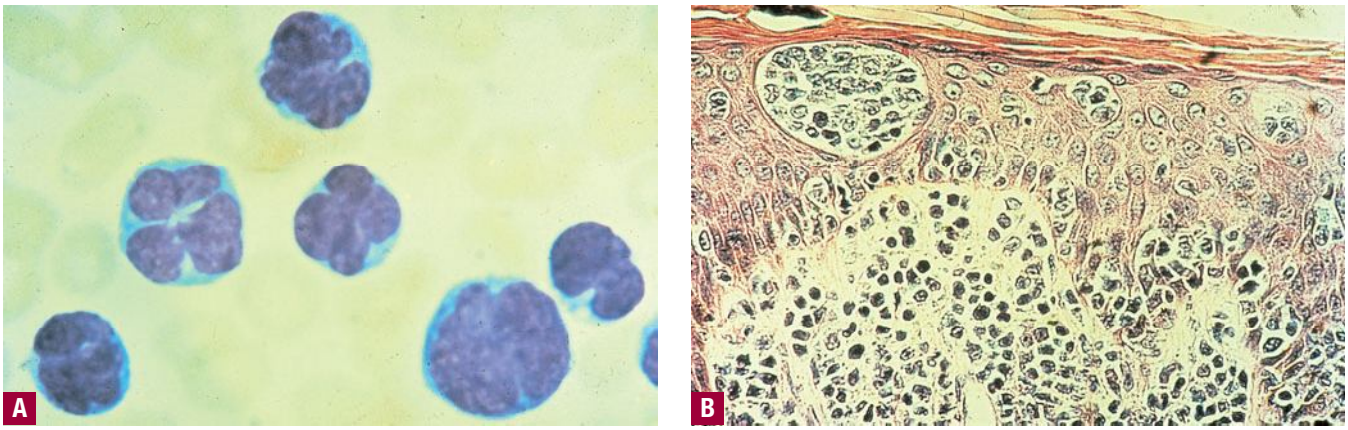

▲ **FIGURE 197-1** **A.** Abnormal lymphocyte with multi-lobated nucleus ("flower cell") from a patient with adult T-cell leukemia (ATL). (Used with permission from K. Takatsuki, MD, Kumamoto University, Japan.) **B.** ATL tumor cells infiltrate the epidermis, creating Pautrier's microabscesses. (Used with permission from B. Hanchard, MD, University of the West Indies, Kingston, Jamaica.)

of ATL.[5,17–19] Skin lesions may appear as uncharacteristic erythematous patches, as papules and nodular tumors (Fig. 197-2), and as erythroderma. Non-specific skin lesions may precede the onset of acute ATL by up to two decades.[20] Specific skin infiltrates may occur as the first manifestations of ATL, and monoclonality of skin-infiltrating cells may be evident by the criteria of both T-cell receptor rearrangement and integration of HTLV-1 DNA. This occurs at a time when circulating T cells of these patients still appear unaffected.[18] To designate this latter situation, the term *cutaneous-type ATL* has been proposed.[18] However, it is questionable whether this form represents an independent type of ATL or should be included in the smoldering form. Alternatively, it may reflect very early detection of prototypic or chronic ATL as a result of improved diagnostic methods.

DIAGNOSIS AND DIFFERENTIAL DIAGNOSIS OF ADULT T-CELL LEUKEMIA Not only does prototypic ATL show a characteristic clinical course but examination of the leukemic cells yields a characteristic picture: numerous multi-lobated cells called *ATL cells* or *flower cells* (see Fig. 197-1A) are present in peripheral blood and can usually be readily distinguished from cells of other T-cell leukemias by light microscopy, although sometimes occasional cells indistinguishable from Sézary cells may be present.[5,16] In smoldering-type ATL and chronic-type ATL, multi-lobated cells are less frequent, and in lymphoma-type ATL they may comprise fewer than 1 percent of lymphocytes (see Table 197-1). Monoclonal integration of HTLV-1 DNA[5,8,16,18] in leukemic cells as well as in affected organs is a diagnostic criterion. Immunophenotyping shows that leukemic cells display predominantly a mature $CD2^+/CD3^+/CD4^+/CD8^-/CD25^+$ phenotype.[5,16] Although most of these T-cell markers can be found in other T-cell malignancies, the strong expression of the interleukin 2 receptor α chain (CD25) can be regarded as a distinguishing marker differentiating ATL and Sézary syndrome.[5,21]

The histopathologic features seen in affected organs and lymph nodes are more variable than the signs in peripheral blood, and ATL is associated with lymphomas of several histologic subtypes. Differentiation of ATL from other peripheral T-cell lymphomas, especially HTLV-1–positive and HTLV-1–negative cases, on morphologic grounds is not possible. No specific pathologic finding distinguishes ATL from other forms of non-Hodgkin lymphoma. Difficulties can also be encountered in differentiating the skin manifestations of ATL from mycosis fungoides (MF) and Sézary syndrome, because focal epidermal infiltration by T cells or Pautrier's microabscesses (see Fig. 197-1B) can be present in skin lesions of ATL.[20,22,23] Indeed, the



▲ **FIGURE 197-2** Skin manifestations of adult T-cell leukemia (ATL). **A.** Generalized papular infiltrates in a patient from Jamaica with prototypic ATL. **B,C.** Nodular skin tumors in Japanese ATL patients. (Used with permission from K. Takatsuki, MD, Kumamoto University, Japan.)

diseases of patients from whom the original U.S. HTLV-1 isolates were obtained were classified as Sézary syndrome and CTCL.[1] Four diagnostic criteria have been put forward that must be fulfilled to unequivocally establish the diagnosis of HTLV-1–associated ATL[5,13,14]: (1) a histologically or cytologically proven lymphoid malignancy with T-cell surface antigens must be present; (2) abnormal T lymphocytes must be detected in peripheral blood, except in the lymphoma type; (3) anti–HTLV-1 serum antibodies must be present; and (4) the clonality of HTLV-1 proviral DNA must be demonstrated.

The fact that the first HTLV-1 isolates were obtained from patients misclassified as having MF and Sézary syndrome, together with the earlier reports regarding the presence of retroviral particles in the skin and lymph nodes of patients with these diseases, has prompted an intensive search for HTLV-1 in CTCL. Although several reports claimed that HTLV-1 DNA sequences were detectable in tumor tissue and in cell lines derived from MF patients,[24] an overwhelming majority of investigators, studying patients from the same geographic regions with comparable methods, were unable to find HTLV-1 DNA in CTCL samples.[25–27] It is now well accepted by most that HTLV-1 is not involved in the pathogenesis of CTCL (see Chap. 146).

PROGNOSIS AND TREATMENT OF ADULT T-CELL LEUKEMIA The prognosis of ATL depends largely on the sub-type. In the most extensive study on the course of ATL to date, 818 Japanese patients newly diagnosed with the disease were studied for a median follow-up time of 13.3 months.[5,12] Median survival time was 6.2 months for those with the acute type, 10.2 months for those with the lymphoma type, and 24.3 months for those with the chronic type. Projected 2- and 4-year survival rates were, respectively, 16.7 percent and 5.0 percent for the acute type, 21.3 percent and 5.7 percent for the lymphoma type, 52.4 percent and 26.9 percent for chronic type, and 77.7 and 62.8 percent for the smoldering type. The presence of hypercalcemia, high levels of lactic acid dehydrogenase, and an excessively high white blood cell count are prognostic factors[5,12–14] associated with poor survival.

Treatment of ATL remains disappointing. Combination cytotoxic therapy used to treat non-Hodgkin lymphoma has little effect on prototypic ATL and ATL lymphoma.[27] Although complete remission can be achieved in up to 40 percent of patients with different combinations of conventional chemotherapy, most of the patients experience relapse within weeks or months, and the 4-year overall survival rate is below 10 percent.[27,28] Frequent complications of treatment include septicemia and opportunistic infections, which result from chemotherapeutic intensification of the immune suppression already present in ATL patients.[15,16] Besides conventional chemotherapy, the combination of interferon-α and zidovudine, a nucleoside analog used against human immunodeficiency virus type 1, has shown some effect in the treatment of acute and lymphoma-type ATL.[5,28,29] Allogeneic bone marrow transplantation, which has been used in a few cases of ATL,[5,28] as well as the combination of chemotherapy and administration of hemopoietic growth factors,[30] might still hold some promise for the future. Other therapeutic approaches, including the use of monoclonal antibodies against surface molecules of leukemic cells, arsenic trioxide, proteasome inhibitors, and angiogenesis inhibitors, have been under study; however, to date no breakthrough has been reported.

The course of smoldering and chronic ATL is less dramatic, internal organ involvement and hypercalcemia are observed less frequently than in ATL lymphoma and acute ATL,[5,12,16,28] and the prognosis is better.[5,12,16,28] Because chemotherapy-associated immunosuppression increases the immunosuppression caused by the disease itself, early chemotherapy may be more harmful than beneficial for patients with smoldering and chronic ATL. Therefore, these patients should not be treated with chemotherapy unless they enter a more aggressive phase of their disease. The combination of zidovudine and interferon-α has been suggested as a possible treatment for these clinical variants.

Non-Malignant Sequelae of Human T-Lymphotropic Virus 1 Infection

NEUROLOGIC DISEASE HTLV-1 infection is associated with chronic progressive myelopathy, which is referred to as *tropical spastic paraparesis* (TSP) in the Caribbean and *HTLV-1–associated myelopathy* (HAM) in Japan.[31] Patients with TSP/HAM are generally younger than ATL patients, and the latent period from infection to development of clinical neurologic symptoms has been described to be very short in individual cases. The lifetime risk for developing TSP/HAM has been estimated at 1 percent.[32] In contrast to ATL, which is associated with HTLV-1 infection very early in life, TSP/HAM frequently occurs in patients who became infected only in adolescence. In particular, the acquisition of HTLV-1 by blood transfusion has been reported to play an important role in the development of TSP/HAM.

INFECTIVE DERMATITIS Infective dermatitis (Fig. 197-3) is a severe, chronic, relapsing eczema in Jamaican children[33] associated with infection by *Staphylococcus aureus* and β-hemolytic streptococci.[33] An association between infective dermatitis and HTLV-1 infection has been reported. Bacterial infection in infective dermatitis is difficult to control, and although it responds to antibiotic treatment, prolonged therapy is necessary and relapses are common after discontinuation. The characteristic clinical picture, the recalcitrant course, and HTLV-1 seropositivity sets infective dermatitis apart from other forms of recurrent eczema, including atopic eczema.[33] Immunosuppression observed by other investigators in HTLV-1 carriers, as well as in ATL patients,[34] may play a role in the pathogenesis of infective dermatitis. Although HTLV-1–infected individuals are over-represented among patients hospitalized for infectious diseases in Japan, infective dermatitis has rarely

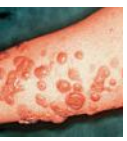



▲ **FIGURE 197-3** Infective dermatitis in a Jamaican girl infected with human T-cell lymphotropic virus type 1. (Used with permission from L. LaGrenade, MD, University of the West Indies, Kingston, Jamaica.)

been reported in regions outside the Caribbean. Regional, cultural, or genetic factors may play an additive role in the occurrence of infective dermatitis. Evidence that infective dermatitis in childhood might be associated with subsequent development of ATL comes from a report of a patient who developed ATL 17 years after having been diagnosed as having infective dermatitis in Jamaica.[35] In addition to infective dermatitis, several other infectious and non-infectious skin disorders are frequently observed in HTLV-1–infected individuals.[36]

OTHER DISORDERS In addition to the diseases described in the previous sections, certain types of uveitis, polymyositis, chronic inflammatory arthropathy, and peripheral neuropathy have been suggested to be associated with HTLV-1 infection.[5] However, future epidemiologic and virologic studies will be necessary to establish the causative role of the virus in the pathogenesis of these diseases.

KEY REFERENCES

The full reference list for all chapters is available at www.digm7.com.

1. Matsuoka M, Jeang KT: Human T-cell leukemia virus type I at age 25: A progress report. *Cancer Res* **65**:4467, 2005
2. Green PL, Chen ISY: Human T-cell leukemia virus types I and II, in *Fields Virology*, edited by Knipe DM, Howley PM. Philadelphia, Lippincott Williams & Wilkins, 2001, p 1941
5. Taylor GP, Matsuoka M: Natural history of adult T-cell leukemia/lymphoma and approaches to therapy. *Oncogene* **24**:6047, 2005
8. Johnson JM et al: Molecular biology and pathogenesis of the human T-cell leukaemia/lymphotropic virus type-1 (HTLV-1). *Int J Exp Pathol* **82**:135, 2001
16. Bazarbachi A, Hermine O: Treatment of adult T-cell leukaemia/lymphoma: Current strategy and future perspectives. *Virus Res* **78**:79, 2001
28. Bazarbachi A et al: New therapeutic approaches for adult T-cell leukaemia. *Lancet Oncol* **5**:664, 2004
36. Nobre V et al: Dermatological findings in 3 generations of a family with a high prevalence of human T cell lymphotropic virus type 1 infection in Brazil. *Clin Infect Dis* **43**:1257, 2006



CHAPTER 198

Cutaneous Manifestations of Human Immunodeficiency Virus Disease

Arturo Saavedra
Richard Allen Johnson

Over 30 million people have died from infection with human immunodeficiency virus (HIV). In the United States, roughly 1.2 million people are currently infected, and there are approximately 300,000 undiagnosed cases. It is estimated that 40,000 new infections occur annually. In 2005, 40.3 million people were estimated to be living with HIV worldwide, twice the number in 1995. Fewer than 15 percent of those who need highly active antiretroviral therapy (HAART) are currently being treated, and the majority of those in regions of higher prevalence, such as sub-Saharan Africa, do not know they are infected. Identification of HIV-associated dermatologic disease may therefore lead to testing and diagnosis, particularly in resource-poor countries.[1]

Cutaneous disorders occur in nearly every patient during the course of HIV disease as a result of the acquired immunodeficiency or the effects of treatment. The spectrum of dermatologic manifestations of HIV disease is very broad and diverse.[2] Individuals who have access to HAART, in most cases those living in North America, Western Europe, and Australia, have a markedly altered course of HIV disease if immune restoration is achieved.[3] In most cases, there is a significant reduction in the incidence of opportunistic infections and neoplasms. Globally, however, more than 95 percent of HIV-infected individuals have no access to any medical interventions, and therefore many of the cutaneous manifestations associated with HIV disease become chronic and progressive.

ETIOLOGY AND EPIDEMIOLOGY

HIV is a lymphotropic human retrovirus. HIV-1 is the cause of nearly all HIV infection in the United States and Europe; HIV-2 infection has been detected mainly in West Africa. HIV is a bloodborne pathogen, transmitted by sexual contact with an infected person, significant exposure to infected blood (such as needle sharing among users of injected drugs, including crack cocaine), and perinatal transfer from an infected mother to her child. Both HIV-1 and HIV-2 cause similar clinical HIV disease. HIV-1 has at least 10 sub-types, designated A through J, each with several recombinant forms. Sub-type B is prevalent in the United States and Western Europe and is found mainly among men who have sex with men and injecting drug users. Sub-type E—unlike sub-type B—is spread very efficiently through heterosexual intercourse. Unlike HIV-1, HIV-2 leads to slower progression of immunosuppression, the duration of heightened infectivity is shorter, and usually the virus is not responsive to nonnucleoside reverse transcriptase inhibitors.[4]

PATHOGENESIS

Four mechanisms are critical for the establishment and propagation of HIV infection over time and for the progression of HIV disease. HIV is not eliminated after primary infection. Persistent viral replication occurs in lymphoid organs throughout the course of HIV infection. Chronic stimulation of the immune system causes inappropriate immune activation and progressive exhaustion of the immune response. Destruction of lymphoid tissue results in severe impairment of the ability to maintain an effective ongoing HIV-specific immune response and to generate immune responses against new pathogens. Experiments in rhesus monkeys demonstrate that Langerhans cells in the cervicovaginal epithelium fuse with $CD4^+$ lymphocytes that transport the virus to deeper tissues.[5] Langerhans cells may become infected by HIV, and decreased Langerhans cells function could account for some of the cutaneous manifestations of HIV disease.[6]

NATURAL HISTORY

HIV disease is a continuum that progresses from primary infection to death, with a sequence of opportunistic

CUTANEOUS MANIFESTATIONS OF HUMAN IMMUNODEFICIENCY VIRUS DISEASE

AT A GLANCE





- Over 40 million people are living with human immunodeficiency virus (HIV) infection/acquired immunodeficiency syndrome.
- HIV-1 and HIV-2 are blood-borne human lymphotropic retroviruses that replicate in lymphoid organs and infect many cell types.
- Decreased function of infected epidermal Langerhans cells may account for cutaneous manifestations of HIV disease.
- Dermatologic disease in HIV is a spectrum of inflammatory, infectious, and oncogenic disorders that either may be opportunistic or may also be seen in non-infected individuals.
- HIV-associated dermatoses along with systemic symptoms may suggest the diagnosis and lead to testing earlier in the course of disease or during the acute retroviral syndrome.
- Dermatologic disease may help in estimating the level of immunosuppression, particularly in resource-poor countries.

infections and opportunistic neoplasms marking the gradual destruction of the immune system (Table 198-1). The World Health Organization has published revised criteria for clinical staging in children, adolescents, and adults with confirmed HIV infection.[7] Medically, acquired immunodeficiency syndrome (AIDS) is defined by precise clinical and laboratory parameters. In an individual whose HIV status is unknown or inconclusive and who has no other cause for immunodeficiency, the following mucocutaneous findings are AIDS defining: candidiasis of the esophagus, trachea, bronchi, or lungs (however, not oropharyngeal candidiasis alone); cryptococcosis with hematogenous dissemination to the skin; a herpes simplex virus (HSV) mucocutaneous ulcer that persists longer than 1 month; and Kaposi sarcoma in a patient younger than 60 years of age. In an individual who is HIV seropositive, the following are AIDS defining: coccidioidomycosis or histoplasmosis with hematogenous dissemination to the skin, invasive cervical carcinoma, and Kaposi sarcoma at any age.

TABLE 198-1
Stages of Human Immunodeficiency Virus Disease

Stage and Clinical Features	Typical Duration	$CD4^+$ Cell Range (Cells/μL)
Acute retroviral syndrome (brief mononucleosis-like illness)	1–2 wk	1000–500
Asymptomatic (no symptoms or signs other than lymphadenopathy)	> 10 yr	750–500
Early symptomatic (non–life-threatening infections, chronic or intermittent illness)	0–5 yr	500–100
Late symptomatic (acquired immunodeficiency syndrome; increasingly severe symptoms, life-threatening infections and cancers)	0–3 yr	200–50
Advanced (increasing risk of death, fewer transferable opportunistic infections)	1–2 yr	50–0

Acute Retroviral Syndrome or Primary Human Immunodeficiency Virus Infection

The incubation period of HIV infection (from presumed exposure to development of acute febrile illness) ranges from 3 to 6 weeks, varying with the route of infection and the size of the viral inoculum. Commonly reported clinical manifestations include fever (more than 80 percent to 90 percent of cases), fatigue (more than 70 percent to 90 percent), rash (morbilliform, papulosquamous, vesicular on the upper trunk, palms, and soles; 50 percent to 60 percent) (Fig. 198-1), myalgia/arthralgia (50 percent to 70 percent), pharyngitis (50 percent to 70 percent), night sweats (50 percent), and/or nausea, vomiting, and diarrhea (30 percent to 60 percent). Less commonly reported manifestations include decreased white blood cell count and platelet count (40 percent to 45 percent of cases), weight loss (25 percent), aseptic meningitis (24 percent), anorexia (21 percent), abnormal liver function test results (20 percent), oral ulcers (10 percent to 20 percent), and/or genital ulcers (5 percent to 15 percent).[8] The health care professional must maintain a high index of suspicion in those with sexually transmitted diseases (STDs) or with a suggestive constellation of symptoms. Studies have documented that up to 25 percent of those with HIV disease are not tested, despite having suggestive symptoms.[5] In fact, retrospective HIV testing of samples from patients thought to have Epstein-Barr virus infection were positive for HIV infection 2 percent of the time, and roughly half of those had acute primary HIV infection.[9]

The laboratory diagnosis of HIV-1 infection is made by four methods: detec-



▲ **FIGURE 198-1** Acute retroviral syndrome: Exanthem. Discrete, erythematous macules and papules on the trunk and arm; associated findings were fever, scrotal ulcers, erythematous macules on the palate, and lymphadenopathy.

TABLE 198-2
Laboratory Diagnosis of Human Immunodeficiency Virus (HIV) Infection[5]

Test	Component Tested	Window Period	Role in Diagnosis
Enzyme-linked immunosorbent assay[a]	Antibodies (IgM and IgG)	3–6 wk	Screening
Antigen capture[b]	HIV p24 antigen	2–3 wk	Screening
Western blotting	Antibody (IgG)	3 wk	Confirmatory
Immunofluorescence	Antibody (IgG)	3 wk	Confirmatory
Nucleic acid testing	HIV RNA or DNA	2 wk	Confirmatory
Viral culture	Virus, usually from peripheral blood mononuclear cells, not serum or plasma	—	Confirmatory, research

Ig = immunoglobulin.
[a]Rapid tests as well as particle agglutination tests are also available.
[b]Detection can be increased with the use of immune complex dissociation techniques.
Modified from Maldarelli F: Diagnosis of human immunodeficiency virus infection, in *Principles and Practice of Infectious Diseases*, edited by Mandell GL et al. Philadelphia, Elsevier, 2005, p 1506, with permission.

tion of viral antigens, detection of viral nucleic acids, identification of antibodies to viral proteins, and isolation of HIV by viral culture (Table 198-2). A delay of 3 to 4 weeks exists between new acquisition of HIV-1 infection and development of antibodies, the "window period." The core structural protein p24 antigen can be detected a week before antibodies can be measured. The viral RNA assay detects infection up to 5 days earlier than the p24 assay and appears to be more sensitive.[5]

Course after Acute Retroviral Syndrome

After the initial burst of viral replication and the peak of viremia, the plasma RNA level decreases and then stabilizes to a level called the *viral set point*. Cytotoxic T lymphocytes, particularly those specific for envelope antigens, help control viral replication and are associated with slower declines in $CD4^+$ cell counts. Approximately 6 months after transmission of HIV, the plasma HIV RNA level reaches a relatively stable set point that dictates the subsequent course. In patients with high viral concentrations (viral load), such as 100,000 or more copies per microliter, the disease will have a relatively rapid course, and in those with relatively low concentrations, such as 10,000 copies/μL, it will have relatively slow progression. Undetectable viral load levels may correspond with nonprogression of HIV disease. The average annual decrease in $CD4^+$ cell count is 50 cells/μL (Fig. 198-2). Early treatment with antiretroviral drugs may reduce the viral set point and alter the prognosis of HIV infection.

Multiple variables are known to influence the rate of progression of HIV disease, contributing to induction of HIV expression and potentially modifying and accelerating the course of HIV disease: the size of the HIV inoculum, the site of infection, the immune status of the host, the virulence of the given HIV strain, and re-activation of latent herpesvirus infection.

Antiretroviral Drug Therapy and Highly Active Antiretroviral Therapy

The four main groups of antiretroviral drugs are nucleoside analog reverse transcriptase inhibitors (NRTIs), nonnucleoside reverse transcriptase inhibitors, protease inhibitors (PIs), and fusion inhibitors. (See Table 198-3 for mechanisms and side-effects.[10])

MUCOCUTANEOUS FINDINGS

More than 90 percent of HIV-infected individuals will experience opportunistic infections, opportunistic neoplasms, dermatoses, adverse cutaneous drug reactions, and pruritus involving the skin and/or mucosa, which occur more commonly as immune function deteriorates. In association with low CD4 cell counts, cutaneous lesions may become quite atypical. Certain cutaneous disorders correlate with low CD4 cell counts (200 to 300 cells/μL), including Kaposi sarcoma, oral hairy leukoplakia (OHL), multiple-lesion facial molluscum contagiosum, xerosis, and oropharyngeal candidiasis. Genital ulcerations can represent infection by treponemes, HSV, and other sexually transmitted agents, but studies have reported that 30 percent to 60 percent of such cases have no proven etiologic agent and may be related to HIV infection itself.[11] Mucocutaneous disorders are commonly the indication for initial HIV testing (Table 198-4).

Immune restoration syndrome is defined by manifestations of HIV disease, which may worsen despite an adequate response to HAART, as measured by an

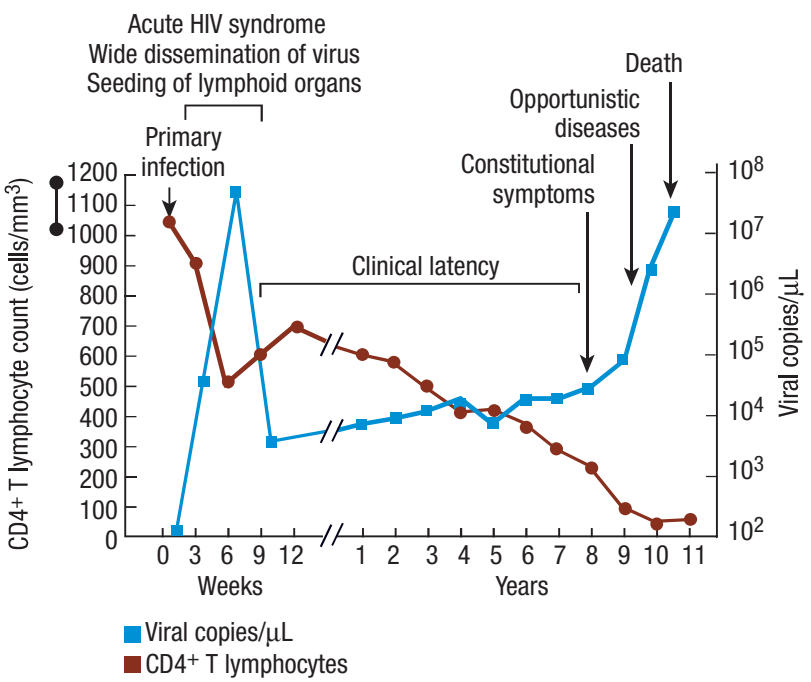

▲ **FIGURE 198-2** Typical disease course in an individual with human immunodeficiency virus (HIV) infection. (From Fauci A et al: Immunopathogenic mechanisms of HIV infection. *Ann Intern Med* **124**:654, 1996.)



TABLE 198-3
Treatment of Human Immunodeficiency Virus (HIV)/Acquired Immunodeficiency Syndrome: Antiretroviral Medications

Drug Class	Mechanism	Drug Names	Relevant Properties and Side Effects
Nucleoside analog reverse transcriptase (RT) inhibitors (NRTIs)	NRTIs are inserted into the growing viral DNA chain and halt reactions catalyzed by RT, preventing formation of DNA copies in HIV.	Zidovudine (ZVD, AZT) Didanosine (ddI) Zalcitabine (ddC) Stavudine (d4T) Lamivudine (3TC) Emtricitabine Tenofovir disoproxil fumarate Abacavir	ZVD may cause longitudinal melanonychia in 40% of patients, noted 4–8 wk after initiation of therapy; pigmented macules and diffuse hyperpigmentation can also occur. Hypertrichosis, leukocytoclastic vasculitis, and paronychia are reported. DdI may cause vasculitis, SJS, pancreatitis, and peripheral neuropathy. DdC causes aphthous-like ulceration of the oropharynx and esophagus. Rechallenge with abacavir has been associated with several deaths.
Nonnucleoside RT inhibitors (NNRTIs)	NNRTIs bind directly to RT and prevent conversion of RNA to DNA in HIV-infected cells.	Nevirapine Delavirdine Efavirenz	Twenty percent of patients develop rash to nevirapine (1% with SJS) in the first 4–6 wk of therapy. Delavirdine causes rash in 18%–50% of patients.
Protease inhibitors (PIs)	PIs prevent cleavage of protein precursors (HIV-1 protease) essential for HIV maturation, infection of new cells, and replication.	Saquinavir Ritonavir Indinavir Nelfinavir Amprenavir Atazanavir Fosamprenavir Lopinavir	PIs may lead to lipodystrophy, hypersensitivity reaction, and acute generalized exanthematous pustulosis. Indinavir may cause xerosis with or without eczematous or nummular dermatitis, retinoid-like effects, cheilitis, defluvium of the scalp, paronychia, pyogenic granuloma, acute porphyria, hypersensitivity, SJS, "frozen shoulder," and venous thrombosis. Nelfinavir causes morbilliform eruptions in 3%–28% of patients and, less commonly, urticaria.
Fusion inhibitors (FIs)	FIs inhibit the action of gp41 (which is required for membrane fusion) and the binding of virus to host $CD4^+$ cells.	Enfuvirtide/T-20	In up to 98% of patients, an injection-site reaction may occur within the first week of treatment, but discontinuation of therapy is required in only 3% of patients.

gp41 = glycosylated protein spanning viral envelope; SJS = Stevens-Johnson syndrome.



TABLE 198-4
Mucocutaneous Disorders That Are Indications for Human Immunodeficiency Virus (HIV) Serotesting

Highly indicative of HIV infection (correlated with risk factors for HIV infection)
- Exanthem of acute retroviral syndrome
- Proximal subungual onychomycosis
- Chronic herpetic ulcers
- Oral hairy leukoplakia
- Kaposi sarcoma
- Eosinophilic folliculitis
- Molluscum contagiosum, multiple facial lesions in adults

Strongly associated with HIV infection (correlated with risk factors for HIV infection)
- Any sexually transmitted disease (indicative of unsafe sexual practices)
- Herpes zoster
- Signs of injecting drug use
- Candidiasis: Oropharyngeal or recurrent vulvovaginal

May be associated with HIV infection (correlated with risk factors for HIV infection)
- Generalized lymphadenopathy
- Seborrheic dermatitis (extensive, refractory to therapy)
- Aphthous ulcers (recurrent, refractory to therapy)

increase in CD4 cell counts and a decrease in or disappearance of serum HIV RNA. With progressive HIV disease, T helper 2 immune responses dominate, which facilitates development of many dermatologic disorders. With HAART, T helper 1 responses are restored, and some skin disorders regress; however, some conditions, such as varicella-zoster virus (VZV) infections, HSV infections, eosinophilic folliculitis (EF), human papillomavirus (HPV) infections, leishmaniasis, and mycobacterial infections, may worsen.[12] These seemingly paradoxical responses may occur as the host's immune responses recognize silent or latent infections.[13]

CUTANEOUS DISORDERS OCCURRING IN HUMAN IMMUNODEFICIENCY VIRUS DISEASE

Pruritus and Pruritic Eruptions of Human Immunodeficiency Virus Disease

Pruritus, a common complaint in patients with late symptomatic and advanced HIV disease, is a surrogate cutaneous marker for disease progression, occurring more commonly in patients with CD4 counts of less than 50 cells/μL than in those with counts higher than 250 cells/μL. In most cases, primary or secondary dermatoses rather than metabolic disorders are the cause of pruritus.[14] The differential diagnosis of primary pruritic skin disorders includes EF, papular pruritic eruption of HIV (PPE), adverse cutaneous drug eruptions, atopic dermatitis, xerosis, dermatographism, allergic contact dermatitis, scabies, and insect bites.[15] Much less commonly, systemic and metabolic disorders such as lymphoma, renal failure, viral hepatitis (hepatitis B or C), and obstructive liver disease are associated with pruritus in the absence of cutaneous findings (i.e., "metabolic" pruritus; Box 198-1).

An atopic diathesis may become manifest in individuals with advanced HIV disease and pruritus. Changes secondary to chronic rubbing and scratching include excoriations, atopic dermatitis, lichen simplex chronicus, and prurigo nodularis. Secondary *Staphylococcus aureus* infection (impetiginization, furunculosis, or cellulitis) is very common in any of these traumatized lesions. In fact, one cross-sectional study has documented that, in

Box 198-1

Differential Diagnosis of Pruritus in Human Immunodeficiency Virus (HIV)–Infected Individuals

INFLAMMATORY DISORDERS
- Papular pruritic eruption of HIV
- Eosinophilic folliculitis
- Prurigo nodularis
- Atopic dermatitis
- Psoriasis
- Seborrheic dermatitis

INFECTIONS OR INFESTATIONS
- Scabies
- Arthropod assault
- Viral hepatitis

SYSTEMIC AND METABOLIC DISORDERS
- Renal failure
- Liver disease (viral, obstructive)
- Lymphoma

MISCELLANEOUS DISORDERS
- Xerosis
- Ichthyosis vulgaris
- Photodermatitis
- Dermographism
- Allergic contact dermatitis
- Adverse cutaneous drug eruptions

addition to folliculitis, prurigo is the most common cutaneous disorder encountered in patients with CD4+ counts of less than 200 cells/μL. Furthermore, the findings were the same when only those who had never received HAART were examined. On the other hand, idiopathic pruritus and candidiasis were the most common disorders observed in the population with viral loads higher than 55,000 copies/μL.[16] These initial findings may begin to elucidate which dermatoses are related to low CD4+ counts and which are secondary to direct viral effects.

Ichthyosis vulgaris and xerosis are common in advanced HIV disease and may be associated with mild pruritus. PIs (especially indinavir) frequently cause xerosis with or without eczematous dermatitis or nummular eczema, which may be associated with mild or moderate pruritus (see Adverse Cutaneous Drug Eruptions later). These changes occur relatively soon after initiation of therapy.

Eosinophilic Folliculitis and Papular Pruritic Eruption of Human Immunodeficiency Virus

EF is a chronic pruritic dermatosis occurring in persons with advanced HIV disease. In one study, low CD4 count (under 125 cells/μL) and low nadir (average of 66 cells/μL) were associated with EF, regardless of antiretroviral therapy status.[17] EF may occur in immune restoration syndrome. The etiology and pathogenesis are unknown, but EF may be associated with a T helper 2 immune response to an unknown antigen.[18] Clinically, small pink to red edematous, follicular or centric papules (and, much less commonly, pustules) occur symmetrically above the nipple line on the chest (Fig. 198-3), proximal arms, head, and neck. Secondary changes include excoriations, excoriated papules, lichen simplex chronicus, and prurigo nodularis, as well as secondary *S. aureus* infections. In individuals with darker skin, post-inflammatory hyperpigmentation often produces significant cosmetic disfigurement. Once significant immune restoration has been achieved, EF resolves. Histologic findings are specific for EF; peripheral eosinophilia is common, with up to 35 percent eosinophils in some cases.

The most effective therapy for EF is prednisone. The initial prednisone dose is 70 mg by mouth, and the dose is then tapered by 10 or 5 mg over 7 or 14 days. Established lesions resolve, new lesions do not occur, and pruritus subsides. In the majority of persons with successfully treated EF, lesions and pruritus recur within a few weeks after prednisone has been discontinued. In those with severe symptoms, prednisone can be given on alternate days or weekly. Oral isotretinoin is effective and safe for the treatment of EF. It is usually give at a dosage of 40 mg twice a day until lesions and symptoms resolve, then tapered to 40 mg daily for several weeks, and then reduced to 20 mg daily or 40 mg every other day.[19] Isotretinoin can raise serum triglyceride levels, which are often high in HIV-infected persons; serum lipid levels should be monitored regularly. Phototherapy with ultraviolet radiation (UVR) using ultraviolet A or ultraviolet B light, with or without topical or systemic psoralen, is considered to be a safe topical treatment modality in HIV-infected persons.[20] UVR does not appear to have a significant deleterious effect on HIV viral load.[21] High-potency topical corticosteroid preparations may reduce the formation of new EF lesions as well as treat eczematous dermatitis, thus providing symptomatic relief. Cutaneous atrophy is of concern with long-term application. Topical tacrolimus or pimecrolimus may be effective. Sedating antihistamines, such as doxepin, are most effective for symptomatic control of nocturnal pruritus; nonsedating antihistamines are ineffective in relieving pruritus.

PPE has been classified with other pruritic disorders in HIV disease in the continuum between EF and non-specific pruritus. The prevalence is estimated to be between 12 percent and 46 percent in Africans and Haitians; the disease is rarely observed in Europe and North America. The positive predictive value of PPE for HIV infection is approximately 85 percent, and, thus, it is often diagnostic of HIV in countries where serotesting is limited.[22] In addition, it ap-



◀ **FIGURE 198-3** Eosinophilic folliculitis. **A.** Multiple erythematous pruritic papules on the trunk in an individual with a CD4 cell count of 50/μL. **B.** Close-up showing urticarial papules, pustules, and erosions secondary to rubbing and crusts.





▲ **FIGURE 198-4** Papulopruritic eruption of human immunodeficiency virus infection. There are multiple, disseminated excoriated papules, post-inflammatory pigmentation, and small scars. The eruption is very pruritic. (Used with permission from Anisa Mosam, MD.)



pears to be a marker of severe immunosuppression, because over 80 percent of patients with this disorder have CD4 counts of fewer than 100 cells/μL.[23]

The primary lesion is a firm urticarial papule (although sterile pustules have been described as well). Variable erythema may be distributed symmetrically on the trunk and extremities and less commonly on the face (Fig. 198-4). It is occasionally but not always folliculocentric and may be associated with excoriations, post-inflammatory hyperpigmentation, and scarring, which result from the intense pruritus caused by the disease. One report of studies in Uganda has suggested that PPE may be a hypersensitivity reaction to arthropod bites based on histopathologic evaluation of affected skin. The authors proposed changing the name of this disorder to *arthropod-induced prurigo of HIV*.[22] PPE is particularly difficult to treat and is only moderately responsive to antihistamines and topical steroids. Ultraviolet B irradiation appears to be the most effective therapy, although its usefulness is limited by the lack of treatment centers in the resource-poor settings in which the prevalence is highest. Studies of other alternatives are lacking.

Psoriasis Vulgaris

The prevalence of psoriasis vulgaris and psoriatic arthritis (see Chaps. 18 and 19) is increased in HIV disease. The onset of psoriatic lesions may be before or after HIV infection. The appearance of psoriasis in an individual at risk for HIV disease may be an indication for HIV serotesting. Psoriasis with onset after HIV infection has been observed to improve more with HAART than psoriasis that was present before HIV infection. For management of psoriasis vulgaris, see Chap. 18. Short-term administration of retinoids, such as isotretinoin or acitretin, is usually safe. Hyperlipidemia is more likely in HAART-treated individuals. Etanercept and infliximab have been effective for the treatment of psoriasis and psoriatic arthritis in HIV disease but are associated with infections.[24,25]

Erythroderma (See Chap. 23)

Erythroderma in HIV disease may be related to drug hypersensitivity, atopic dermatitis, psoriasis vulgaris, photosensitivity dermatitis, hypereosinophilic syndrome, co-existing human T-cell lymphotrophic virus 1 (HTLV-I) infection, histoplasmosis, or cutaneous T-cell lymphoma.[26]

Pigmentary Disorders

Post-inflammatory hyperpigmentation and hypopigmentation are the most common disorders affecting HIV-infected individuals. Except in light-skinned individuals of northern European heritage, significant lightening or darkening of the skin occurs after any type of inflammatory dermatosis or infection. In addition to pigmentary alterations, significant atrophic or hypertrophic scarring can follow herpes zoster. This alteration in normal skin color results in significant cosmetic disfigurement, especially when it occurs on highly visible sites such as the face, neck, and upper extremities. If the dermatosis is chronic, the pigmentary change can become persistent and progressive. If the dermatosis resolves, the pigmentary disorder can take months to years to fade gradually to uniform pigmentation. The primary goal in management of these pigmentary disorders is to treat the primary skin disorder. Topical preparations containing 4 percent hydroquinone may be helpful in treating post-inflammatory hyperpigmentation.

Photosensitivity (See Chaps. 90 and 91)

Idiopathic photosensitivity is an uncommon phenomenon in HIV disease but may be the presenting complaint of advanced disease.[27] The most common types of photosensitivity in HIV disease are related to drug therapy, and African American ethnicity and the use of HAART increase the likelihood of development of photosensitivity.

Porphyria, Pseudoporphyria, and Vasculitis

Porphyria cutanea tarda in HIV disease is most often associated with an underlying hepatopathy such as hepatitis C, alcoholism, or hepatitis B. Pseudoporphyria occurs in the absence of abnormalities of porphyrin metabolism and usually is drug induced (see Chap. 91).

Cutaneous and systemic vasculitis has been reported to occur in HIV disease from many causes, including adverse cutaneous drug reaction, cytomegalovirus infection, erythema elevatum diutinum, polyarteritis nodosa, lymphomatoid granulomatosis, Kawasaki syndrome, and, possibly, HIV infection itself.[28,29] Causative drugs should be discontinued if possible. Most other causes are not specifically treatable. Systemic immunosuppressive therapy may be indicated in some cases.

Disorders of the Oropharynx

Nearly all HIV-infected, untreated individuals experience disorders of the oropharynx during the course of the disease.[30] Oropharyngeal disorders have been reported to be the first sign of HIV disease in 10 percent of cases, and their detection may be an indication for HIV serotesting (see Table 198-4). In a study of oropharyngeal disorders (in 103 consecutively treated patients with late symptomatic and advanced HIV disease), candidiasis was the most common finding, diagnosed in more than 90 percent.[31] Other disorders of the lips and oropharynx included herpetic ulcers (10 percent), xerostomia (10 percent), exfoliative cheilitis (9 percent), OHL (7 percent), Kaposi sarcoma (4 percent), patchy depapillation of the tongue (6 percent), and ulcers of uncertain cause (3 percent).

OROPHARYNGEAL CANDIDIASIS See Mucocutaneous Candidiasis later in the chapter.

ORAL HAIRY LEUKOPLAKIA OHL, a lesion specific to HIV disease caused by Epstein-Barr virus, has been reported in up to 28 percent of HIV-infected patients and is a marker for disease progression.[32] OHL presents as one or more hyperplastic, whitish epithelial plaques on the lateral tongue with corrugations accentuat-



▲ **FIGURE 198-5** Oral hairy leukoplakia. White plaques with vertical corrugations on the inferolateral aspect of the tongue. The lesions are fixed, unlike those of thrush, which can be brushed off with a gauze pad.

ing the normal tongue ridges (Fig. 198-5). OHL is usually bilateral but not symmetric. The differential diagnosis includes hyperplastic oral candidiasis, condyloma acuminatum, HPV-induced neoplasia [squamous intraepithelial lesion (SIL), squamous cell carcinoma in situ (SCCIS), and invasive squamous cell carcinoma (SCC)], geographic tongue, lichen planus, tobacco-associated leukoplakia, mucous patch of secondary syphilis, and occlusive trauma. The diagnosis of OHL is usually made on clinical findings; however, if the diagnosis is uncertain, confirmatory lesional biopsy is advised. For the most part, OHL is asymptomatic, but its presence may be associated with some degree of anxiety. In patients receiving HAART, OHL usually either does not occur or resolves without additional interventions. Acyclovir, valacyclovir, famciclovir, ganciclovir, and foscarnet, given for other indications, are often effective therapies for OHL. In addition, podophyllin, topical tretinoin, and imiquimod cream may be helpful.

APHTHOUS ULCERS (See Chap. 74)

NEOPLASMS Kaposi sarcoma (see Chap. 128) commonly occurs on the palate, gingiva, and tongue. Untreated, Kaposi sarcoma can evolve into large nodular lesions and ulcerate. Oral presentations of non-Hodgkin lymphoma usually occur on the palate, gingiva, or tonsillar area. HPV-induced SCC, both in situ and invasive, arises on the buccal mucosa, tongue, and palate.

Opportunistic Neoplasms

The prevalence of the opportunistic neoplasms, including Kaposi sarcoma, HPV-induced neoplasia (SIL, SCCIS, and invasive SCC of the cervix, external anogenitalia, and perineum), undifferentiated non-Hodgkin B-cell lymphoma, and primary central nervous system lymphoma, is increased in HIV disease.[33,34] The incidence of non-melanoma skin cancer, Hodgkin lymphoma, T-cell lymphomas, lung cancer, seminoma, and pediatric leiomyosarcoma is also increased.[35] Many of these opportunistic neoplasms (non-Hodgkin lymphoma, Kaposi sarcoma, and anogenital in situ and invasive SCC) are associated with oncogenic human viruses [Epstein-Barr virus, human herpesvirus 8 (HHV-8), HPV] and diminished immune-mediated tumor surveillance.

Non-Melanoma and Melanoma Skin Cancer

The prevalence of UVR-induced SCC appears to be increased threefold to fivefold in HIV disease, as it is in immunosuppressed solid organ transplant recipients. As with transplant recipients, UVR-induced SCC may be more aggressive in individuals with HIV disease than in immunocompetent hosts.[36,37] The ratio of SCC to basal cell carcinoma (BCC) in HIV-infected patients is 1:7, unlike in renal transplantation patients, in whom the ratio is roughly 2:1.[38] Risk factors for the development of SCC and BCC are fair skin, blonde hair, blue eyes, and excessive sun exposure. HPV is not an oncogenic factor in the development of these cutaneous tumors, unlike with neoplasia of the anus, cervical canal dysplasia, oral cancer, and lesions of the nail unit; however, p53 overexpression is hypothesized to play an etiologic role. Nonetheless, SCCs appear at a younger age and display more aggressive behavior and higher metastatic rate in this population. Interestingly, both an increase in the frequency of BCC and more aggressive subtypes of BCC have also been reported in HIV-positive patients. As in immunosuppressed transplant recipients, the incidence of Merkel cell carcinoma is increased in HIV-infected individuals, and although treatment of this tumor in HIV-positive patients has not been studied prospectively, a case report has documented sustained remission of metastatic disease after initiation of HAART.[39,40]

Data on the incidence of melanoma in HIV-disease are limited and in the form of case reports, although several agree that incidence may be increased in this population.[38]

Human Immunodeficiency Virus–Associated Kaposi Sarcoma (See Chap. 128)[40]

Human Papillomavirus–Induced Dysplasias and Cancers

See Human Papillomavirus Infections later in the chapter.

Adverse Cutaneous Drug Eruptions (See Chap. 40)

NON-ANTIRETROVIRAL DRUGS The incidence of adverse cutaneous drug eruptions (ACDEs) to a variety of drugs is high in individuals with untreated HIV disease (100 times more common than in the general population) and increases with advancing immunodeficiency.[41] Drug hypersensitivity complicated 3 percent to 20 percent of all prescriptions in one large series. ACDEs were noted more commonly in white than in black individuals. The onset of the majority of ACDEs was within 6 to 14 days of initiation of therapy. Trimethoprim-sulfamethoxazole (TMP-SMX), other sulfonamide drugs, and penicillins were the causative agents in 75 percent of cases of ACDE. Exanthematous/morbilliform eruptions were by far the most common ACDEs, occurring in 95 percent of cases; other ACDEs observed were urticaria, erythema multiforme, lichenoid eruption, and fixed drug eruption. Systemic symptoms, including fever, headache, myalgia, and arthralgia, were reported in 20 percent of cases. In most cases, the implicated or suspected drug should be discontinued. In some instances, such as with morbilliform eruptions, the offending drug can be contin-





▲ **FIGURE 198-6** Adverse cutaneous drug reaction to trimethoprim-sulfamethoxazole. A typical exanthematous eruption occurred on the trunk on the tenth day after initiation of therapy with the drug.



ued, and the eruption may resolve. In cases of urticaria/angioedema or early Stevens-Johnson syndrome (SJS)/toxic epidermal necrolysis (TEN; see Chap. 39), the acute drug reaction can be life threatening, and the drug should be discontinued.

Between 50 percent and 60 percent of untreated HIV-infected individuals given intravenous TMP-SMX develop an exanthematous eruption (often associated with fever; Fig. 198-6) 1 to 2 weeks after starting therapy, an incidence 10 times higher than that in the general population. Successful desensitization has been accomplished in patients with prior exanthematous/morbilliform or urticarial reactions to TMP-SMX, sulfadiazine, and dapsone.[42] Desensitization in patients with prior SJS also has been reported.[43] Co-administration of corticosteroids with TMP-SMX reduced the incidence of adverse cutaneous reactions from 47 percent to 13 percent.[44] The occurrence of acute cutaneous drug reactions to TMP-SMX also has been noted to be associated with more rapid decline in CD4 cell counts. Severe bullous eruptions appear to be more common in HIV disease. In a report of six cases of erythema multiforme major and six of TEN, all adverse reactions were to sulfonamides: sulfadiazine, TMP-SMX, and sulfadoxine-pyrimethamine.[45] In 14 cases of TEN occurring over a 6-year period (1984 to 1989), sulfa drugs were the most common causative agents.[45] The number of cases of TEN was 375 times that expected. TEN occurred in patients with advanced HIV disease and was associated with a 21 percent mortality rate.

Oral corticosteroid therapy in HIV-infected individuals raises concerns regarding increased immunosuppression with exacerbation of opportunistic infections and neoplasms such as HSV infections and Kaposi sarcoma. A cohort of 44 asymptomatic HIV-infected individuals (200 to 799 CD4 cells/μL) was treated with oral prednisolone (0.5 mg/kg for 6 months; 0.3 mg/kg thereafter). After 1 year of prednisolone therapy, no major side effects or HIV disease–related events had occurred. Serum p24 antigen and HIV RNA levels remained stable; CD4 cell counts increased significantly at all time points (median increase at 1 year, 119 cells/μL). A more recent study concluded that short-term prednisone was well tolerated and reasonably safe.[46] Short-term oral corticosteroid therapy, although complicated by hyperglycemia and oral candidiasis, appears to be safe in most HIV-infected individuals. Follow-up studies and case reports of treatment using a maximum dosage of 30 mg/day of prednisone have confirmed these findings and shown no effect on CD4 count.[47]

ANTIRETROVIRAL ***Hypersensitivity Reactions.*** Antiretroviral therapy is associated with a significant incidence of acute cutaneous drug reactions, including hypersensitivity reactions, lipodystrophy syndrome (LDS), and drug interactions.[48] Drug hypersensitivity commonly occurs with the nonnucleoside reverse-transcriptase inhibitors nevirapine, delavirdine, and efavirenz; the NRTI abacavir; and the PI amprenavir.[31] Approximately half the cases of antiretroviral hypersensitivity resolve despite continuation of therapy. Drug therapy should be discontinued if the following occur: mucosal involvement, blistering, exfoliation, clinically significant hepatic dysfunction, fever higher than 39°C (102.2°F), or intolerable fever or pruritus (see Table 198-3).

Nearly 20 percent of nevirapine-treated patients experience severe rash, most commonly an exanthematous eruption and rarely SJS. Nevirapine causes rash in nearly 8 percent of treated individuals in the first 4 to 6 weeks of therapy; SJS occurs in 1 percent of treated individuals.[49] Drug hypersensitivity syndrome also has been reported.[50] Interestingly, prospective trials involving fewer than 200 patients have failed to show a beneficial effect of a 2-week course of prednisone (40 mg) or cetirizine (10 mg for 10 days) in preventing nevirapine-associated rash.[51,52]



▲ **FIGURE 198-7** Lipohypertrophy. The subcutaneous fatty tissue of the cervico-thoracic region as well as the preauricular cheeks and neck are strikingly enlarged.

Lipodystrophy Syndrome and Metabolic Syndrome. (See Chap. 69) LDS has been associated with PI therapy, although treatment with NRTIs can also lead to LDS.[48,53–55] HIV-related LDS is characterized by abnormal fat distribution: lipohypertrophy with central obesity, cushingoid habitus ("buffalo hump"), increased neck girth (Fig. 198-7), increased abdominal girth associated with increase intra-abdominal fat ("protease paunch," "crix belly"), and breast enlargement. Lipoatrophy of subcutaneous fat produces a pseudoathletic appearance, manifested on the face (Fig. 198-8) and extremities as a prominent venous pattern and musculature. Additional findings that indicate general metabolic abnormalities include insulin resistance, hyperglycemia, and hypertriglyceridemia, hypercholesterolemia, increased free fatty acid levels, and decreased levels of high-density lipoprotein cholesterol.[56] Of note, not all elements of the syndrome are present in all patients, so there is significant variability and heterogeneity in presentation. In a study of 581 patients (61 percent of whom were treated with PIs), the overall prevalence of lipodystrophy was 38 percent; of fat wasting, 16 percent; of peripheral fat accumulation, 12 percent; and of mixed syndromes, 10 percent.[57] The

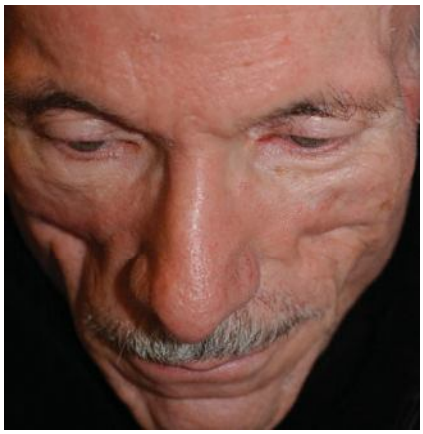

▲ **FIGURE 198-8** Lipoatrophy. The cheeks are hollowed secondary to loss of subcutaneous fat, causing a significant cosmetic concern in this patient with human immunodeficiency virus infection who was taking highly active antiretroviral drugs. Lipohypertrophy was also present on the neck and upper central back.

prevalence of metabolic abnormalities was 49 percent for lipid disorders and 20 percent for glucose disorders. The pathogenesis of LDS is not known. It is hypothesized that the phenomenon occurs as a result of immune restoration or a metabolic adverse effect of medication that may or may not include mitochondrial oxidative dysfunction or deficient mitochondrial DNA replication.[58] Discontinuation or replacement of PI/NRTI therapy does not result in reversal of dysmorphic changes in most persons.[59]

Liposuction (see Chap. 254) has been used to treat buffalo hump, but the result is most often unsatisfactory. It is estimated that between 15 percent and 80 percent of patients taking HAART will develop lipoatrophy within 10 months of starting therapy. Facial lipoatrophy has been treated with fat transfer from the abdominal panniculus and injection or insertion of various inert agents, again with limited cosmetic success (see Chap. 255). Poly-L-lactic acid has been used with longer-lasting effects, with noticeable results 2 years after application.[60] In addition, 1000-cSt silicone oil has also been studied and shows a favorable side-effect profile. Long-term safety, however, remains unknown.[61]

COMPLICATIONS OF HUMAN IMMUNODEFICIENCY VIRUS DISEASE

Opportunistic Infections

Opportunistic infections of the skin and mucosa occurring in HIV disease for the most part represent overgrowth of resident flora (*Candida albicans*), extension beyond sites of colonization (dermatophytosis), re-activation of latent infection (human herpesviruses), or transformation of sub-clinical to clinical infection [HPV, molluscum contagiosum virus (MCV)]. The natural history of opportunistic infections has continued to evolve because of the availability of HAART and more effective treatments for infections. In individuals responding to HAART, the incidence of all opportunistic infections, with the exception of HPV infections, is markedly reduced.[62] Opportunistic infections continue to be frequent, however, occurring in more advanced and/or untreated HIV disease.

BACTERIAL INFECTIONS *S. aureus* is the most common bacterial pathogen causing cutaneous and systemic infections in HIV disease. An increased prevalence of *S. aureus* carriage in the nares and perineum has been noted in asymptomatic and symptomatic HIV-infected individuals (up to 50 percent). The relative increase in *S. aureus* in skin and soft-tissue infection in HIV-positive patients has not been noted in HIV-negative individuals.[63] In addition, an increase in methicillin resistance in *S. aureus* has been documented, particularly in strains acquired from the community. Risk factors associated with these skin infections appear to be related to high-risk sex and drug-using behaviors rather than absolute level of immunosuppression.[64]

Prophylaxis with agents such as TMP-SMX and clarithromycin is associated with a decreased nasal carriage rate as well as a reduced rate of infections. Primary cutaneous infections and secondary infection of dermatoses or breaks in the epidermal integrity usually occur in chronic *S. aureus* carriers. No unique staphylococcal infections occur in HIV disease. Rather, a wide range of *S. aureus* pyodermas and soft-tissue infections is seen, and the incidence increases with the degree of immune deficiency. Primary staphylococcal infections include impetigo, bullous impetigo, and ecthyma; folliculitis; furuncles and carbuncles; cellulitis; botryomycosis; and pyomyositis. Secondary infection of underlying dermatoses and superinfections occur commonly in persons with chronic atopic (eczematous) dermatitis, which may be associated with elevated immunoglobulin E levels; excoriations; herpetic ulcers; Kaposi sarcoma; molluscum contagiosum; scabies; injection sites in injecting drug users; and intertrigo. Staphylococcal bacteremia may complicate either primary or secondary cutaneous infections (psoriasis or scabies); however, the most common site for hematogenous dissemination is an intravenous catheter, which is the source in 73 percent of cases of bacteremia. As with the majority of infections in HIV disease, staphylococcal infections tend to be recurrent. Management (see Chap. 177) should be directed at the acute infection, treatment of any underlying dermatoses, eradication of nasal carriage of *S. aureus* with mupirocin (pseudomonic acid) ointment, and long-term oral prophylaxis for recurrent infections.

Pseudomonas aeruginosa (see Chap. 180) causes primary infections such as cellulitis (i.e., ecthyma gangrenosum), infection at catheter sites, and secondary infection of underlying disorders such as Kaposi sarcoma in advanced HIV disease. Cutaneous *P. aeruginosa* infection occurs by local invasion, with the organism gaining entry through breaks in the skin; by primary infection of skin appendages in the anogenital or axillary regions; or by hematogenous dissemination to the skin. Cutaneous pseudomonal infection may extend into the bloodstream, with resulting bacteremia and seeding of many organ systems.

Tuberculosis is the most common opportunistic infection in HIV disease in developing countries. Cutaneous tuberculosis (see Chap. 184), however, is relatively uncommon. In non-HIV–infected individuals with tuberculosis, the incidence of extrapulmonary tuberculosis is 15 percent; in those with HIV disease, it is 20 percent to 40 percent. In individuals with advanced HIV disease, the incidence of extrapulmonary disease increases to 70 percent. *Mycobacterium* species other than *M. tuberculosis* (see Chap. 184) (also known as *environmental mycobacteria*: *M. chelonae*, *M. fortuitum*, *M. kansasii*, *M. malmoense*, *M. gordonae*, *M. marinum*, and *M. haemophilum*) have been reported to cause cutaneous lesions in HIV disease. The most common mycobacterial agent other than *M. tuberculosis* causing illness in advanced HIV disease is *M. avium-intracellulare* complex (MAC); however, this infection rarely presents with cutaneous manifestations. The incidence of MAC infections has fallen with primary prophylaxis with azithromycin and, more recently, with HAART.

Bacillary angiomatosis (BA) and bacillary peliosis (see Chap. 182), caused by *Bartonella henselae* and *B. quintana*, occur most commonly in the setting of advanced HIV-induced immunodeficiency.





▲ **FIGURE 198-9** Bacillary angiomatosis. Cherry hemangioma–like papules and a larger pyogenic granuloma–like nodule on the skin of a man with advanced human immunodeficiency virus disease. Subcutaneous nodular lesions were also present.



They are characterized by angioproliferative lesions resembling cherry hemangiomas, pyogenic granulomas, or Kaposi sarcoma.[65] Currently, the prevalence of BA in North America and Western Europe is very low due to improved immune function in HIV-infected patients taking HAART and due to prophylactic therapy for infection by organisms such as MAC. Clinically, the cutaneous lesions of BA are red to violaceous, dome-shaped papules, nodules, or plaques resembling Kaposi sarcoma or pyogenic granuloma and ranging in size from a few millimeters to 2 to 3 cm in diameter (dermal vascular lesions with thinned or eroded epidermis; Fig. 198-9). Less commonly, domed subcutaneous masses occur without the characteristic red color of more superficial vascular lesions.[66] Lesions are soft to firm and may be tender to palpation. The number of lesions ranges from a single lesion to more than a 100 and, in rare cases, more than 1000. Nearly any cutaneous site may be involved, but the palms, soles, and oral cavity are usually spared. After hematogenous or lymphatic dissemination, the spectrum of internal disease caused by *B. henselae* and *B. quintana* includes soft-tissue masses, bone marrow involvement, lymphadenopathy, splenomegaly, and hepatomegaly; internal involvement can occur with or without cutaneous lesions. The course of BA is variable. In some patients, lesions regress spontaneously. As with other opportunistic infections in HIV disease, BA can recur. The antibiotic of choice is erythromycin (250 to 500 mg by mouth four times daily) or doxycycline (100 mg twice daily), continued until the lesions resolve, usually 3 to 4 weeks. Rifampin, ciprofloxacin, and TMP-SMX are also effective in those who cannot tolerate first-line agents.[67] Secondary prophylaxis is indicated in patients with recurrent BA.

FUNGAL INFECTIONS Cutaneous fungal infections in HIV disease occur as superficial infections (dermatomycoses), invasive cutaneous infections, or systemic fungal infections with hematogenous dissemination to the skin. Superficial pathogens such as *Trichosporon beigelii* may disseminate with progressive deterioration in immune status.[67] Often, dissemination of superficial pathogens may present atypically. For instance, *Trichophyton rubrum* has been reported to disseminate and mimic Kaposi sarcoma.[68] HAART has markedly diminished the incidence of these infections, and adverse drug interactions between HAART and antifungal medication appear to be less clinically significant than previously thought.[69–71]

Dermatophytoses. (See Chap. 188) *T. rubrum* causes proximal subungual onychomycosis, an infection of the undersurface of the proximal nail plate.[72] Proximal subungual onychomycosis occurs most often in HIV-infected individuals; the diagnosis is an indication for HIV testing (see Table 198-4). Epidermal dermatophytosis can be extensive in HIV disease. Unless immunocompetency is restored, dermatophytic infections are chronic and recurrent.

Mucocutaneous Candidiasis. (See Chap. 189) Cutaneous *Candida* infections such as intertrigo are relatively uncommon in adults with HIV disease, but concomitant diabetes mellitus associated with HAART may increase the prevalence. Candidiasis of moist, keratinized cutaneous sites, such as the anogenital region, occurs with some frequency. Candidal angular cheilitis occurs at the corners of the mouth as an intertrigo, unilaterally or bilaterally; it may appear in conjunction with oropharyngeal or esophageal disease or as the only manifestation of candidal infection. Children with HIV infection commonly experience candidiasis in the diaper area and intertrigo in the axillae and neck fold. Chronic fingernail *Candida* paronychia with secondary nail dystrophy (onychia) also is common in HIV-infected children.[73]

Candida colonization of the oropharynx is common in HIV-infected individuals, frequently in the absence of any clinical findings and may be an indication for HIV testing (see Table 198-4). *C. albicans* is the most prevalent colonizing species, but multiple species may be present. Isolation of non-*albicans* species alone correlates with advanced HIV disease and very low CD4 cell counts. Oropharyngeal candidiasis is a marker of HIV disease progression. Oropharyngeal candidiasis and esophageal candidiasis have been reported to occur as a manifestation of primary HIV infection. Esophageal candidiasis, an AIDS-defining condition, occurs only with advanced CD4 count reduction (fewer than 100 cells/μL). Oropharyngeal candidiasis presents in four different patterns: pseudomembranous (thrush), atrophic (erythematous), hyperplastic, and as an angular cheilitis. Despite a high prevalence of candidiasis in HIV-infected individuals, disseminated candidiasis is distinctly uncommon, probably because of B-cell activation and the presence of anti-candidal protective antibody.

HIV-infected women with CD4 counts of 200 to 500 cells/μL had a 33 percent incidence of vaginal candidiasis; incidence was 44 percent if the CD4 count was fewer than 200 cells/μL. In a study of 117 HIV-infected women, recurrent candidal vaginitis was the most common initial clinical manifestation of HIV disease (43 of 117 women).[74] Other studies have failed to confirm an increased incidence of candidal vaginitis in HIV-infected women.

Invasive Fungal Infections. Invasive fungal infections arise by local invasion of the skin or mucosa, often followed by lymphatic or hematogenous dissemination to viscera or skin or, more commonly, activation of a latent pulmonary focus of infection. Latent pulmonary fungal infections such as cryptococcosis, histoplasmosis, coccidioidomycosis, sporotrichosis, and penicilliosis can re-activate and disseminate to various organs, including meninges and skin, in persons with advanced HIV disease. The cutaneous manifestations most commonly are multiple molluscum contagiosum–like lesions that occur most often on the face and upper trunk. Disseminated deep mycoses are much less common with HAART (see Cryptococcosis, Coccidioidomycosis, and Histoplasmosis).

CRYPTOCOCCOSIS. (See Chap. 190) Disseminated cryptococcosis is by far the most common life-threatening fungal infection occurring in advanced HIV disease; cutaneous cryptococcosis occurs in 5 percent to 10 percent of cases.[75] Sero-

type D shows greater tropism for skin than other serotypes.[76] Skin lesions may be present for weeks or many months before presentation. They occur most commonly on the head and neck (78 percent) but may be widespread. The most common morphology of cutaneous cryptococcosis is molluscum contagiosum–like lesions (i.e., umbilicated skin-colored or pink papules or nodules), which occur in 54 percent of cases. Other types of cutaneous lesions include pustules, cellulitis, ulceration, panniculitis, palpable purpura, subcutaneous abscesses, vegetating plaques, and pyoderma gangrenosum–like lesions.[77,78]

COCCIDIOIDOMYCOSIS. (See Chap. 190) Cutaneous lesions of disseminated coccidioidomycosis are usually asymptomatic, beginning as papules and evolving to pustules, plaques, or nodules with minimal surrounding erythema. Lesions often resemble molluscum contagiosum. In time, lesions may enlarge and become confluent, with the formation of abscesses, multiple draining sinus tracts, ulcers, subcutaneous cellulitis, verrucous plaques, granulomatous nodules, and healing scars. Erythema multiforme–like lesions and erythema nodosum may be observed, perhaps more commonly in women.[76]

HISTOPLASMOSIS. (See Chap. 190) Disseminated cutaneous histoplasmosis presents with erythematous macules; necrotic or keratin-plugged, molluscum contagiosum–like papules and nodules; pustules, folliculitis, acneform lesions, a rosacea-like eruption, or a guttate psoriasis–like eruption; ulcers; vegetative plaques; panniculitis; or erythroderma.[79] Several different types of lesions may be seen in the same patient. Lesions occur most commonly on the face, followed by the extremities and trunk. Oral mucosal lesions include nodules and vegetations; ulceration occurs on the soft palate, oropharynx, epiglottis, and nasal vestibule. A subtle, widespread exanthematous or psoriasiform eruption occasionally may develop in HIV-infected patients who are already taking systemic antifungal therapy and in whom systemic symptoms are completely lacking. Hepatosplenomegaly and/or lymphadenopathy occur commonly in patients with disseminated histoplasmosis.

SPOROTRICHOSIS. (See Chap. 190) In HIV disease, dissemination of local sporotrichositic infection to other organs occurs from lung or skin foci. Hematogenously disseminated cutaneous lesions present as papules to nodules that may become eroded, ulcerated, crusted, or hyperkeratotic, usually sparing the palms, soles, and oral mucosa. Ocular involvement results in hypopyon, scleral perforation, and prolapse of the uvea. Other organs involved in disseminated sporotrichosis in HIV disease include joints, lung, liver, spleen, intestine, and meninges.[80]

ASPERGILLOSIS. (See Chap. 190) Invasive aspergillosis is rare in HIV disease. It presents as a primary cutaneous infection, appearing under adhesive tape near central venous catheters, or occurs as disseminated infection.[81] Risk factors for invasive aspergillosis in HIV disease include leukopenia and therapy with glucocorticoids, broad-spectrum antibiotics, and antineoplastic agents. Skin lesions appear as skin-colored to pink umbilicated papules resembling molluscum contagiosum. The majority of patients with invasive disseminated aspergillosis die despite treatment with amphotericin B. Because of the high mortality rates as well as the toxicities related to amphotericin therapy, treatment with newer azole derivatives (voriconazole, posaconazole, and ravuconazole) or the echinocandins (caspofungin, micafungin) has become more common, in some cases, with better outcomes and side-effect profiles.[82]

PENICILLINOSIS. (See Chap. 190) The dimorphic fungus *Penicillium marneffei* is the third most common cause of opportunistic infection in HIV-infected residents of countries of Southeast Asia and the southern part of China. A report of 92 patients described clinical presentations that included fever, weight loss, cough, anemia, and disseminated papular skin lesions (71 percent).[83] The most common skin lesions were umbilicated papules, which occurred most frequently on the face, pinnae, upper trunk, and arms. Genital ulcers also were reported, ranging in size from less than 1 to 3 cm in diameter. Oral lesions included papules and ulcers.

VIRAL INFECTIONS Viruses are major pathogens causing opportunistic infections in HIV disease, many of which are manifested at mucocutaneous sites, ranging from cosmetically disfiguring facial molluscum contagiosum to extensive genital warts and life-threatening and invasive HPV-induced SCC. In the majority of cases, viral opportunistic infections represent activation of sub-clinical infection (HPV, MCV) or re-activation of latent infection [human herpesviruses: HSV-1, HSV-2, VZV, cytomegalovirus, Epstein-Barr virus, and human herpesvirus 8 (Kaposi sarcoma–associated virus)]. In HIV-infected individuals treated with HAART, the incidence of opportunistic viral infections has diminished markedly, with the exception of those caused by HPV; the incidence of benign and dysplastic HPV-induced lesions is stable or has increased despite restoration of immune function with HAART.

Herpes Simplex Virus 1 and 2 Infections. (See Chap. 193) With more advanced immunocompromise, HSV lesions tend to be subacute or chronic, indolent, and atypical, responding less promptly to oral antiviral therapy. The presence of chronic herpetic ulcers of longer than 1 month's duration are an AIDS-defining condition (see Table 198-4). With increasing immunocompromise, recurrent HSV infection may become persistent and progressive. Erosions occurring at the typical sites (perioral, anogenital, and digital) enlarge and deepen into painful ulcers (Fig. 198-10). In addition to ulceration, chronic HSV infections also can present as proliferative lesions of the epidermis with or without scale. Foscarnet and cidofovir are administered intravenously for infections caused by acyclovir-resistant HSV.[84] Cidofovir gel has been effective as a topical therapy for acyclovir-resistant HSV infections.[85] Imiquimod 5 percent cream is also an effective topical treatment for cutaneous herpetic infections, including those caused by acyclovir-resistant HSV strains. Imiquimod 5 percent cream is



▲ **FIGURE 198-10** Chronic herpetic lesions. Chronic ulcers and ulcerated tumor on the penis, scrotum, and pubic area in a patient with human immunodeficiency virus disease. The herpes simplex virus was acyclovir resistant, and lesions resolved after treatment with topical cidofovir.



applied to the lesion(s) daily, or every other day if irritation occurs.[86]

The incidence of re-activation of HSV infection appears to be unchanged with HAART; however, patients treated with HAART report fewer days with active lesions.[87] In addition, because infection with HSV-2 is associated with a twofold to fourfold increase in transmission of HIV-1, treatment may be important, particularly for HIV-discordant couples. In one study, HIV-1 mucosal shedding was more frequent during HSV-2 replication. In addition, HSV-2–infected individuals had a fivefold higher risk of acquiring HIV infection, compared with HSV-2–negative individuals.[88] Other studies have verified this observation, finding that up to 52 percent of transmission risk was attributable to HSV-2 positivity.[89]



Varicella-Zoster Virus Infections. (See Chap. 194) Primary VZV infection manifests as varicella (chickenpox). Re-activation of VZV from a dorsal root ganglion or cranial nerve ganglion manifests as herpes zoster (HZ). In the immunocompromised host, VZV infection can present as severe varicella, persistent varicella, dermatomal HZ, disseminated HZ (sometimes without dermatomal HZ), and chronic or recurrent HZ.[90] Disseminated HZ is defined as cutaneous involvement by more than three contiguous dermatomes, more than 20 lesions scattered outside the initial dermatome, or systemic infection (hepatitis, pneumonitis, encephalitis). Disseminated VZV infection in an individual harboring latent VZV can present with a clinical pattern of scattered vesicles in the absence of dermatomal HZ. Chronic HZ in patients with HIV disease may manifest as multiple dermatomal lesions or single or few nondermatomal lesions that are ulcerated (Fig. 198-11) or hyperkeratotic. Acyclovir-resistant VZV is rare.[91]

Molluscum Contagiosum. (See Chap. 195) MCV commonly infects keratinized skin sub-clinically and can cause lesions at sites of minor trauma and in the infundibular portion of the hair follicle.[92] The clinical course of MCV infection in HIV disease differs significantly from that in the normal host and is an excellent clinical marker of the degree of immunodeficiency. Large and confluent lesions cause significant morbidity and disfigurement (Fig. 198-12). Before the advent of HAART, MCV infections were detected in 10 percent of individuals with HIV disease and in 30 percent of those with CD4 counts of fewer than 100 cells/μL, with the number of lesions being inversely related to the CD4 cell count.[93] In HIV-infected individuals, MCV infection tends to be progressive and recurrent after the usual therapies. With response to HAART, MCV infections regress, resolve completely, or do not occur, due to increased CD4 cell counts and reduced viral load.[94] For cases resistant to standard therapies, imiquimod 5 percent cream may be effective in both children and adults.[95] Cidofovir, a nucleotide analog with activity against several DNA viruses, given either intravenously or topically as a cream, may be an effective therapy.[96,97] In addition, treatment with photodynamic therapy and 5-aminolevulinic acid may decrease lesion count and severity.[98]



▲ **FIGURE 198-11** Varicella-zoster infection: Ulcerated, ecthymatous lesions. Two ulcerated, crusted, painful lesions in the trochanteric region and the lateral thigh had been present for 9 months and resolved with oral acyclovir therapy.

Human T-Cell Lymphotrophic Virus Infections. (See Chap. 197) HTLV-1 infection presents most commonly as chronic "eczema" in children. Initially termed *infective dermatitis*, it manifests in the scalp, neck, and groin as erythematous, scaly patches with crusts. The exudative nature of these lesions may help in differentiating this disease from atopic dermatitis. Periorbital papules with seborrheic-like scale may be observed with increasing frequency near the eyebrows. Retroauricular fissuring and generalized ichthyosis may be observed in a minority of cases.[99] Breastfeeding appears to be the main route of transmission from an infected mother. In regions of high seropositivity, such as Brazil and the Caribbean, "infective" dermatitis may be an indication for HTVL-1 serotesting. In HIV-infected adults, an increased incidence of inflammatory dermatosis, including seborrheic dermatitis, psoriasis, and prurigo, has been reported after infection with HTLV-1.[100]

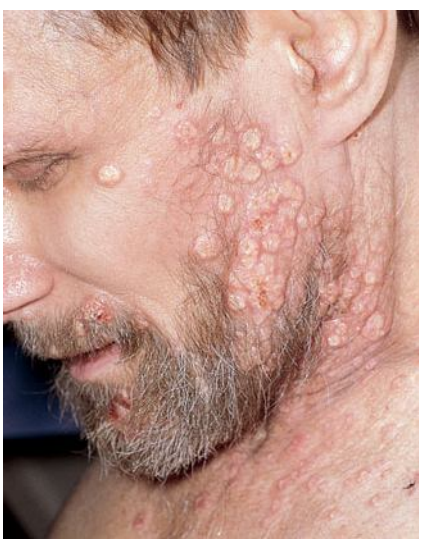

▲ **FIGURE 198-12** Molluscum contagiosum virus infection. Before highly active antiretroviral therapy, multiple facial mollusca would enlarge to cause significant cosmetic disfigurement.

Human Papillomavirus Infections. (See Chap. 196) HPV infections occur commonly during the course of HIV disease. Of interest, the incidence of HPV infections does not decrease with HAART and restoration of immune function but actually may be increased.[101]

COMMON WARTS. With advancing HIV disease, verrucae can enlarge, become confluent, and become unresponsive to therapy.[102] HPV-5 can cause an unusual pattern of extensive verruca plana and pityriasis (tinea) versicolor–like warts, similar to the pattern seen in epidermodysplasia verruciformis[103] (see Chap. 196). With moderate or advanced immunodeficiency, warts may become much more numerous, confluent, and refractory to usual treatment modalities. Pre-cancerous lesions identical to mucosal lesions (SCCIS)



▲ **FIGURE 198-13** Human papillomavirus–induced invasive squamous cell carcinoma in a 32-year-old man with human immunodeficiency virus infection. The para-anal tumor had been present for several months, and histologic analysis showed invasive squamous cell carcinoma.

can occur periungually and on the nail bed epidermis (usually of the fingers). In some cases, invasive SCC can arise at one or multiple sites on the fingers and/or nail bed. These tumors are aggressive and invade to the underlying periosteum and bone relatively early because of the proximity of the underlying bony structures. Despite immune restoration with HAART, HPV infections often persist and progress, unlike other opportunistic viral infections.

ANOGENITAL WARTS. HPV-6 and HPV-11 infect nonkeratinized or minimally keratinized epithelium such as anogenital sites and the oropharynx and cause genital warts; HPV-16 and HPV-18 cause pre-cancerous lesions, low-grade SIL, high-grade SIL, and invasive SCC (Fig. 198-13).[104,105]

ORAL WARTS. Oropharyngeal HPV-induced lesions resemble anogenital condylomata and are pink or white. Extensive intra-oral condylomata acuminata (oral florid papillomatosis) presents as multiple large plaques that can transform to verrucous carcinoma. Interestingly, in one study, advanced markers of HIV disease, such as high viral loads or low $CD4^+$ count, were not predictive of oral HPV infection; rather, HAART therapy was associated with detection of oral HPV infection.[106] Reports have documented successful treatment of oral HPV with 1 percent to 3 percent cidofovir solution.[107]

HUMAN PAPILLOMA VIRUS–INDUCED DYSPLASIA: LOW-GRADE SQUAMOUS INTRAEPITHELIAL LESION, HIGH-GRADE SQUAMOUS INTRAEPITHELIAL LESION, AND INVASIVE SQUAMOUS CELL CARCINOMA. The natural history of external anogenital HPV-induced dysplasia is not known. Prolonged, severe immunodeficiency provides the necessary milieu for the emergence of HPV-induced anogenital neoplasia.[108] Specifically, HIV and anal co-infection with HPV are independent risk factors for high-grade dysplasia and cancer.[109] There is a stronger association with a decline in $CD4^+$ counts than with rising viral HIV RNA titers, which suggests that immune dysfunction may be more important that direct viral effects in the pathogenesis.[110] One study of 357 HIV-positive men who have sex with men and who had no history of previous anal cancer showed that up to 81 percent had anal intraepithelial neoplasia of any grade and that 95 percent had evidence of anal HPV infection.[111] A separate study documented that 86 percent of men who have sex with men had evidence of HPV infection on their first visit to a screening clinic.[112] HPV-16 was the most commonly isolated sub-type in this group of patients.

The incidence of transformation of SCCIS to invasive SCC appears to be low. The relative risk for HPV-related, anal, invasive SCC is much higher in HIV-infected than in non–HIV-infected homosexual men and is more likely in advanced HIV disease. The most common sites for HPV-induced SIL, SCCIS, and invasive SCC are the cervix, anus, perineum, vulva, penis, oropharynx and tongue, conjunctivae, and nail apparatus.[113] Anogenital dysplasias are likely to become more common manifestations of HIV disease, because patients with profound immunodeficiency who previously would have succumbed to opportunistic infections are now surviving for extended periods because of HAART.[114] HAART and restoration of immune function may not cause regression of these dysplasias.[115,116] Cervical, anal, and external anogenital low-grade SIL, high-grade SIL, and invasive SCC have become more common in long-term survivors of HIV disease. Invasive SCC arising on external anogenital sites is usually detected earlier and is less aggressive than that arising on the cervix or anal canal.

Management of external anogenital HPV infection in HIV-infected individuals is directed at identifying high-grade SIL before progression to invasive SCC has occurred. All HIV-infected individuals should be examined annually for evidence of HPV infection, especially those with prior HPV infections. Because HPV-induced neoplasia may extend to the cervix and/or anus, direct examination by speculum and anoscope also should be performed; samples for cytologic analysis should be obtained using a cervical brush and fixed with Cytofix solution during the examination. High-resolution anoscopy and biopsy are performed on individuals with high-grade SIL.[117] Individuals with documented external anogenital SIL should undergo periodic follow-up examinations (every 4 to 6 months), and an appearance of new lesions at these sites or an enlarging nodule or ulcerated site should be noted. Biopsy of these sites is recommended. Anal intraepithelial neoplasia may be treated with topical therapy, including imiquimod, podophyllotoxin, 80 percent trichloroacetic acid, or liquid nitrogen. Lesions may also be excised or treated using destructive modalities such as fulguration.[110] For minimally invasive SCC arising on the anal verge (nonkeratinized to keratinized epithelium) or on external anogenital sites (penis, vulva, perineum), surgical excision is recommended, with adequate borders around the lesion. Invasive SCC of the anus (transformation zone) is treated by radiation therapy and chemotherapy. Prognosis for invasive anal SCC is better in those with higher CD4 cell counts at the time of diagnosis.

The development of anti-HPV vaccination may decrease infection and disease burden, particularly if the vaccine is directed against various serotypes. Vaccination against HPV-16 has been tested in women and shown to be 100 percent effective in preventing cervical disease.[110]

Sexually Transmitted Diseases (See Chaps. 200 to 205)

The great majority of HIV infections are transmitted during sexual intercourse. Individuals presenting with any STD should be screened for HIV infection, syphilis, chlamydiosis, gonorrhea, and trichomoniasis. Possible interrelationships between STDs and HIV disease include the potential for STDs to increase the rate of both primary HIV acquisition and transmission, the potential



for STDs to accelerate the natural progression of HIV infection, and the potential for HIV co-infection to alter critical clinical and/or serologic parameters used to diagnose and treat STDs. Genital ulcerative diseases such as syphilis, herpes genitalis, and chancroid increase the risk of acquisition of HIV. Gonorrhea and trichomoniasis also increase the risk of HIV transmission.

Parasitic Diseases

LEISHMANIASIS (See Chap. 206) *Leishmania* can cause various forms of disease, depending on the immune status and geographic location of the host, as well as on the infecting species. Cutaneous, mucocutaneous, and visceral disease usually follows the bite of a vector sandfly, but transmission from contaminated syringes in intravenous drug users and congenital disease have also been reported.[118] *L. donovani*, in particular, has been shown to upregulate viral replication in vitro and in co-infected individuals. Like HSV-2, *L. donovani* may modulate pathogenesis and increase HIV-1 infectivity.[119] In addition, patients co-infected with *L. guyanensis* show a higher rate of recurrent leishmaniasis and re-infection that is more difficult to treat.[120] *Leishmania* infection may worsen with reconstitution of immune function.[121] Treatment for mucocutaneous, disseminated, and visceral leishmaniasis is with pentavalent antimonials, pentamidine, or amphotericin. Successful oral treatment with miltefosine in recalcitrant cases has been reported.[122] Localized cutaneous disease has been treated with 5 percent imiquimod.

SCABIES (See Chap. 208) Scabies is included in the differential diagnosis of pruritus in HIV disease. In individuals with advanced immunocompromise, scabies can occur with minimal or no pruritus but with an extensive papulosquamous eruption (i.e., hyperkeratotic, crusted scabies). Secondary *S. aureus* infection can occur, complicated in rare cases by bacteremia. Oral ivermectin (200 µg/kg weekly) is the most effective therapy.

KEY REFERENCES

The full reference list for all chapters is available at www.digm7.com.

10. Kong HH, Myers SA: Cutaneous effects of highly active antiretroviral therapy in HIV-infected patients [review]. *Dermatol Ther* **18**:58, 2005
16. Quieroz PC et al: Cutaneous manifestations of HIV in the era of highly active antiretroviral therapy: An institutional urban clinic experience. *J Am Acad Dermatol* **54**:581, 2006
22. Resneck JS et al: Etiology of pruritic papular eruption with HIV infection in Uganda. *JAMA* **292**:2614, 2004
23. Sing F, Donarld R: HIV association pruritus etiology and management. *Am J Clin Dermatol* **4**:177, 2003
38. Wilkins K et al: Cutaneous malignancy and human immunodeficiency virus disease. *J Am Acad Dermatol* **54**:189, 2006
45. Roujeau JC et al: Toxic epidermal necrolysis (Lyell syndrome). *J Am Acad Dermatol* **23**:1039, 1990
47. Dovlev J, Reyter I, Maurer T: Treatment of recurring cutaneous drug reactions in patients with human immunodeficiency virus 1 infection: A series of 3 cases. *Arch Dermatol* **140**:1051, 2004
67. Stevens DL et al: Practice guidelines for the diagnosis and management of skin and soft tissue infections. *Clin Infect Dis* **41**:1373, 2005
76. Venkatessan P, Perfect JR, Myers SA: Evaluation and management of fungal infections in immunocompromised patients. *Dermatol Ther* **18**:44, 2005
87. Posavad CM et al: Frequent reactivation of herpes simple virus among HIV-1–infected patients treated with highly active antiretroviral therapy. *J Infect Dis* **190**:693, 2004
112. Kreuter A et al: Clinical spectrum and virologic characteristics of anal intraepithelial neoplasia in HIV infection. *J Am Acad Dermatol* **52**:603, 2005



CHAPTER 199

The Rickettsioses, Ehrlichioses, and Anaplasmoses

Analisa V. Halpern
Justin J. Green
Warren R. Heymann

Rickettsial disease should be considered in any patient who presents with fever, headache, myalgia, and a characteristic rash. Before the early 1990s, the taxonomic classification of rickettsial organisms was based on heterogeneous characteristics such as obligate intracellularity, geographic origin, and common vectors. The advent of modern molecular technologies, including genetic analysis, has allowed for significant taxonomic reclassification of the rickettsiae in recent years. The ability to characterize microorganisms on a molecular level has facilitated a more accurate organization scheme, including moving the family *Bartonella* (see Chap. 182) and the genus *Coxiella* out of the order Rickettsiales to the orders Rhizobiales and Legionellales, respectively. Several non-rickettsial agents that were historically included in the group of infections loosely termed the *rickettsioses* remain incorporated in the discussion of rickettsial disease herein to reflect that precedent.[1]

"Rickettsiae" now includes a polyphyletic group of microorganisms in the class Proteobacteria, comprising species belonging to the genera *Rickettsia*, *Orientia*, *Ehrlichia*, *Anaplasma*, and *Neorickettsia* (see eFig. 199-0.1 in on-line edition). The ehrlichioses and anaplasmoses often present with clinical findings indistinguishable from the rickettsioses, and the Centers for Disease Control and Prevention (CDC) has outlined case definitions for the three major diseases attributed to these organisms in the United States. (http://www.cdc.gov/mmwr/preview/mmwrhtml/rr5504a1.htm).

In many areas of the world, rickettsiae and *Rickettsia*-like organisms are endemic pathogens, yet the rise of international travel has allowed for the spread of rickettsial infections to nonendemic areas as well. In addition, there has been increasing global concern for rickettsial pathogens as potential agents of bioterrorism.[2,3] Indeed, *R. rickettsiae* [Rocky Mountain spotted fever (RMSF)], *R. prowazekii* (epidemic typhus), and *C. burnetii* (Q fever; note that *Coxiella* is no longer included in the order Rickettsiales) are listed as Category B on the CDC list of potential weapons of biowarfare (see Chap. 213).

HISTORICAL ASPECTS

RICKETTSIAE

Etiology and Pathogenesis of Spotted Fever Group and Typhus Group

Rickettsiae are obligate, intracellular, Gram-negative bacteria. They are pleomorphic 0.3 µm to 1 µm coccobacilli composed of DNA and RNA and repro-

RICKETTSIAL, EHRLICHIAL, AND *ANAPLASMA* INFECTIONS

AT A GLANCE



- Rickettsiae primarily target endothelial cells, causing febrile illness and rash in the mammalian host.
- Fever, headache, myalgia, and malaise are common to rickettsial, ehrlichial, and *Anaplasma* infections; rash is common in rickettsial disease, occasional in ehrlichial infection, and rare in anaplasmosis.
- Transmission is predominantly via tick bites, with certain pathogens transmitted by human body lice and mites.
- Effective therapy with tetracycline antibiotics, when initiated early in the disease process, is curative in most cases.
- The early signs and symptoms of infection are often non-specific and can mimic self-limited viral illnesses, with potentially catastrophic delays in diagnosis and treatment.
- Empiric treatment should be considered in highly suspicious cases until rickettsial infection is definitively ruled out, as delayed treatment can lead to severe sequelae and high mortality rates.

duce through binary fission. Rickettsiae are propagated by arthropod vectors that use mammals (and sometimes the arthropods themselves) as reservoirs of infection. Rickettsiae are separated into the spotted fever group and the typhus group on the basis of common genetics, immunologic patterns, and intracellular growth characteristics. The typhus group lives entirely within the cell cytoplasm, while the spotted fever group can reside within the cytoplasm or nucleus. Rickettsiae are differentiated by unique antigenic structures on cell surface proteins. Certain rickettsial cell wall lipopolysaccharides that are highly immunogenic are shared by the Gram-negative bacteria *Proteus* and *Legionella*.[5] Before 1984, only five species of rickettsiae were identified as definitively causing human disease. That number rose to 16 species between 1984 and 2004, and up to 21 species if one includes those with only a presumptive association with human disease.[1]

Infection occurs through arthropod-induced breaks in the skin allowing access of the pathogen to the blood and lymph. Further manipulation of the bite site and a longer duration of exposure to the arthropod are factors that aid in the transmission of pathogenic organisms. For example, scratching a flea bite enables inoculation of *R. typhi* which is carried in the flea's feces. *R. rickettsii* requires at least a 6-hour feeding period to be transmitted by the infected tick. Infection can also be acquired in persons exposed to arthropod hemolymph during tick removal.

Rickettsial organisms spread via the hematogenous and lymphatic systems, attach to endothelial cell membranes, and are phagocytosed. The severe clinical manifestations of rickettsial infection (e.g., hypovolemia, purpura, and edema of the skin, lungs, and brain) are caused by proliferation of bacteria within the endothelial cells of capillaries, arterioles, and venules, resulting in a multifocal, systemic vasculitis and microvascular leakage.[5]

Spotted Fever Group

ROCKY MOUNTAIN SPOTTED FEVER RMSF was first recognized in 1896 in the Snake River Valley of Idaho and was originally called *black measles* because of the characteristic appearance of the rash. RMSF has been a reportable disease in the United States since the 1920s and is the most frequently reported rickettsial infection in the United States. It is caused by the tick-borne *R. rickettsii*, and if left untreated, carries a fatality rate of approximately 23 percent among previously healthy persons. Even with proper treatment, hospitalization rates of 72 percent and mortality rates of 5 percent to 10 percent have been reported.[8,9]

Epidemiology. The principal epidemiologic characteristics of RMSF are outlined in Table 199-1. In 2004, a total of 1,514 cases of RMSF were reported in the United States, the highest number ever in a single year.[10] The vector largely responsible for RMSF in the eastern two-thirds of the United States is the American dog tick, *Dermacentor variabilis*, while the Rocky Mountain wood tick, *D. andersoni*, is prevalent in the western United States (Fig. 199-1).

Historically, children younger than 10 years of age had the highest incidence of RMSF; however, surveillance data in the United States during 2003 demonstrate a higher age-specific incidence in persons aged 40 to 64 years.[10] Cases have been reported from each of the 48 contiguous states except Vermont and Maine. Between 1997 and 2002, 56 percent of reported cases of RMSF in the United States were from five states: North Carolina, South Carolina, Tennessee, Oklahoma, and Arkansas. The incidence of RMSF is also high in Georgia, and the disease has been increasing in frequency in Arizona.[11]

Clinical and Laboratory Findings. Table 199-2 outlines the cutaneous and systemic manifestations of RMSF, as well as common laboratory abnormalities. A history of a tick bite is reported in approximately 60 percent of patients. One or two classic symptoms may be seen at presentation, but only about 60 percent of patients will have the complete clinical triad of fever, headache, and rash. The characteristic rash usually begins on the wrists and ankles, and spreads centripetally over the next 6 to 18 hours. Cutaneous lesions are initially blanchable red macules that within days become papular and display evidence of petechiae or purpura (Fig. 199-2). Atypical "spotless" fever (seen in approximately 20 percent of cases) does not imply milder disease, and is more common in the elderly and darker-complected individuals.[5] Periorbital edema, abdominal pain mimicking appendicitis, conjunctival injection, palatal petechiae, edema of dorsal hands, and calf pain are sometimes appreciated. Necrosis from overwhelming vasculitis is rare (4 percent), and preferentially occurs in peripheral locations such as the digits, penis, and scrotum (Fig. 199-3).

Thrombocytopenia (30 percent to 50 percent of patients), anemia (5 percent to 24 percent), and mild hyponatremia (50 percent) may be present. Multisystem involvement in RMSF is secondary to infiltration of endothelial cells with resultant systemic vascular leakage. Severe and life-threatening cardiac, gastrointestinal, hepatic, neurologic, ophthalmologic, renal, and pulmonary manifestations can occur with delayed or inadequate treatment. In patients with severe RMSF who survive the acute illness, long-term sequelae are usually the result of neurologic deficits or acral necrosis.



Pathology. Histopathologic examination shows a septic vasculitis (Fig. 199-4). Early lesions show a predominantly perivascular lymphohistiocytic infiltrate accompanied by extravasated erythrocytes and dermal edema. Lymphohistiocytic vasculitis can progress to leukocytoclastic vasculitis. Less often, basal cell vacuolization, lymphocytic exocytosis, fibrin thrombi, and capillary wall necrosis is appreciated. Immunohistology reveals positive staining for *R. rickettsii* in infected endothelial cells and tick hemolymph. (Fig 199-5).

Diagnosis and Differential Diagnosis. Serologic examination with immunofluorescence assay (IFA) is the gold standard for diagnosis of RMSF. The IFA for RMSF detects convalescent antibodies [at a diagnostic titer of ≥ 64 immunoglobulin G (IgG) and ≥ 32 IgM], but is seldom diagnostic before the seventh day of disease, and often not until far into the second week. As effective treatment for RMSF must begin at least by the fifth day of illness to avoid fatal outcomes, it is vital to begin empiric therapy when relying on serologies alone. Due to inferior sensitivity and specificity, the Weil-Felix test (agglutination of certain *Proteus* sp.) and complement fixation tests have been largely supplanted by newer diagnostic methods. Direct immunofluorescence (DIF), immunoperoxidase staining, polymerase chain reaction (PCR) of blood or tissue specimens, and isolation from blood and skin cultures using centrifugation-shell vial inoculation are available alternatives. PCR is generally the most accurate method and offers more rapid diagnosis during the acute phase of the illness, although it is not widely available, and false positives may occur. Advances in genome sequencing, proteomics, and microarray technology may optimize diagnostic testing in the future.[12]

When a patient presents without a rash, the differential diagnosis for RMSF is broad (Boxes 199-1 and 199-2). Macules and papules, petechiae, or purpuric lesions may sometimes develop in these diseases as well, further precluding the ability to distinguish them from RMSF on clinical grounds alone.

Treatment and Prognosis. Treatment and management strategies for RMSF are listed in Boxes 199-3 and 199-4. Fulminant RMSF leading to more rapid decompensation has characteristically been reported in black males with glucose-6-phosphate dehydrogenase deficiency; these patients also have a higher risk of cutaneous necrosis. Prompt empiric administration of appropriate antibiotic therapy is recommended, as it is the most important factor affecting prognosis.

Tetracyclines are first-line therapy for all rickettsial disease, including RMSF, with doxycycline preferable to tetracycline, especially in patients with renal failure. Sulfa-based medications are contraindicated, as they have been associated with a more complicated disease course.[13] Aggressive supportive care is necessary, with particular attention toward electrolyte and fluid replacement. Chloramphenicol is the preferred treatment in pregnancy; however, doxycycline should be considered in severe cases and in near-term gravidas to prevent gray baby syndrome.[14]

The use of tetracyclines to treat children with RMSF is no longer a subject of controversy. Although repeated exposure to tetracycline increases the risk of tooth staining, studies suggest that limited use of this antibiotic in children during the first 6 to 7 years of life has a negligible effect on the color of permanent incisors. A prospective study of children treated with doxycycline for RMSF demonstrated that these children did not have substantial discoloration of permanent teeth compared with those who had never received the drug.[15] Because RMSF can be life-threatening, and limited courses of therapy with tetracycline-class antibiotics do not pose a substantial risk for tooth staining, the American Academy of Pediatrics Committee on Infectious Diseases revised its recommendations in 1997 and has identified doxycycline as the drug of choice for treating presumed or confirmed RMSF in children of any age.[16]

Prevention. Avoiding tick exposure, wearing protective clothing, performing tick checks regularly while in tick-infested areas, and proper tick extractions are important for lowering the risk of infection. Chemical repellants, such as diethyltoluamide (DEET) in concentrations up to 35 percent, are safe for use in adults and children.

OTHER SPOTTED FEVERS ***Tick-Bite Associated.*** **MEDITERRANEAN SPOTTED FEVER AND AFRICAN TICK BITE FEVER.** Several other tick-borne rickettsial species are pathogenic to humans. Mediterranean spotted fever (MSF), also known as *Boutonneuse fever* or *Marseilles fever*, caused by *R. conorii*, was first documented as a cause of human rickettsial disease is 1932. MSF is the prototypical illness of the non-RMSF spotted fever group. African tick bite fever (ATBF), caused by *R. africae*, is now recognized as a distinct clinical entity. The presence of multiple tick bites, multiple eschars (seen in 50 percent of patients with ATBF), lymphadenopathy, and lymphangitis, distinguish ATBF from MSF.[1]

Epidemiology. *R. conorii* is transmitted by an infected *Rhipicephalus sanguineus* tick (see Fig. 199-1) and is endemic throughout Africa, the Middle East, and southern Europe. Contact with dogs is reported in up to 90 percent of cases of MSF. Other epidemiologic characteristics of MSF are described in Table 199-1. *R. africae* is transmitted by an infected *Amblyomma* tick and is endemic in sub-Saharan Africa.

Clinical and Laboratory Findings. The constitutional symptoms, systemic complications, and laboratory abnormalities of the tick-bite–associated spotted fevers are similar to those of RMSF. The classic cutaneous hallmark of this group is the tache noir, occurring in up to 72 percent of cases with *R. conorii* infection (Fig.199-6A).[17] The tache noir presents as an erythematous, indurated papule with a central necrotic eschar that represents locally aggressive endothelial invasion by rickettsiae. The temporal and morphologic pattern of the rash in this group of spotted fevers is similar to RMSF; however, the eruption may be more diffuse and is less frequently petechial or purpuric (see Fig. 199-6B).

Diagnosis and Differential Diagnosis. Diagnosing MSF or ATBF uses the same techniques as those used for RMSF. For MSF, a diagnostic IFA titer ≥ 40 occurs in 46 percent between days 5 and 9 of the illness, in 90 percent between days 20 and 29, and in 100 percent thereafter. Biopsy from an eschar for immunohistochemistry is particularly sensitive in MSF. PCR or Western blot analysis can be used to differentiate between *R conorii* and *R. africae.* Newer serologic assays and PCR have been useful in identifying several emerging agents of spotted fever such as of *R. japonica* and *R. slovaca*.[1]

The rash of MSF generates a similar differential diagnosis as that of RMSF. If a tache noir is seen, also consider brown recluse spider bite, cutaneous anthrax, scrub typhus, rickettsialpox, aspergillosis, or mucormycosis.



TABLE 199-1
Epidemiologic Features of *Rickettsia*, *Ehrlichia*, and *Anaplasma* Infection

Disease (Agent)	Primary Vector(s)	Approximate Distribution	Seasonal Variation	Incubation Period	Average Annual Incidence (United States)	Risk Factors[a]	Prognosis	Case-Fatality Rate
Rocky Mountain spotted fever (*Rickettsia rickettsii*)	*Dermacentor variabilis* (American dog tick), *D. andersoni* (Rocky Mountain wood tick), *Amblyomma americanum* (lone star tick), *Rhipicephalus sanguineus* (brown dog tick), *A. cajennense* (Central and South America), *Haemaphysalis leporispalustris* ticks	Widespread in the United States, concentration in south Atlantic and south-central states; Argentina, Brazil, Columbia, Costa Rica, Mexico, Panama, Canada	April–September	2–14 days	~ 400–600 cases/yr (1996–2000); ~ 1500 cases/yr (2000–2004)	Males; adults 40–64 yr, children < 10 yr; rural dwelling	Severe disease: G6PD deficiency (rapid decompensation, fulminant disease with higher incidence of necrosis), males, elderly, neurologic disease, hepatitis, jaundice, thrombocytopenia, acute renal failure, sulfa medications, delayed diagnosis and treatment.	5%–10% (treated), ~ 30% (untreated).
Mediterranean spotted fever (*R. conorii*)	*R. sanguineus* (brown dog tick)	Endemic to southern Europe, Middle East, southwest Asia, India, and Africa	Peaks during summer months (June–September) in temperate regions	5–7 days	~ 50 cases reported in United States	Exposure to dogs	Mild disease (mainly in children) has good prognosis. Severe disease "malignant Mediterranean spotted fever": Alcoholics, elderly, G6PD deficiency, diabetes mellitus, heart disease, delayed diagnosis and treatment.	~ 2%–5% in hospitalized patients (treated), ~ 30% (untreated cases).
Rickettsialpox (*R. akari*)	*Liponyssoides sanguineus* (*Allodermanyssus sanguineus*) (house mouse, *Mus musculus*, mite)	United States (mainly eastern seaboard), South Africa, Korea, Ukraine, Croatia	Sporadic	~ 7 days (eschar), ~ 7–24 days (systemic symptoms and rash)	Unknown (34 cases in New York City from 2001–2002)	Males; urban dwellers (likely from mice exposure); intravenous drug users	Excellent.	Self-limited. Typically resolves in 2 wk.
Endemic typhus (*R. typhi*; *R. felis*)	*Xenopsylla cheopis* (rat flea), *Ctenocephalides felis* (cat flea)	Southeast United States, Gulf region, Southern California; worldwide most cases in Africa (reported on all continents except Antarctica)	Warm weather months in temperate and subtropical locales	1–2 wk (~ 12 days)	< 40–60 cases/yr (mainly in California and Texas)	Exposure to fleas, poverty, poor hygiene	Excellent prognosis with treatment. Complicated disease occurs with alcoholism, elderly, hematologic disorders, and exposure to sulfa-containing drugs.	1%–4% (treated).
Epidemic typhus (*R. prowazekii*)	*Pediculus humanus* var. *corporis* (human body louse), *Neohaematopinus sciuropteri* lice, *Orchopeas howardii* fleas	United States, Eastern Europe, Africa, Central and South America, China, Himalayan region	Sporadic (more common in winter months)	~ 1–2 wk (8 days, average)	~ 15 documented cases in the United States	Wartime, poor hygiene, natural disasters, cold weather	Good prognosis with treatment. Fever abates in 2 wk (without treatment) and 48 h (with treatment). Recovery of strength in 2–3 mo.	3%–4% (treated), ~ 20% (untreated), ~ 60%–70% (untreated, elderly or debilitated).

(continued)





TABLE 199-1
Epidemiologic Features of *Rickettsia*, *Ehrlichia*, and *Anaplasma* Infection (Continued)

Disease (Agent)	Primary Vector(s)	Approximate Distribution	Seasonal Variation	Incubation Period	Average Annual Incidence (United States)	Risk Factors[a]	Prognosis	Case-Fatality Rate
Human monocytic ehrlichiosis (*Ehrlichia chaffeensis*)	*A. americanum* (lone star tick), *D. variabilis* (American dog tick), *Ixodes pacificus* ticks	South and mid-Atlantic, north/south central United States, isolated areas of New England[b]	Spring and summer (peak in May–July)	5–14 days	189 cases/yr (1999–2003)[a]	Males; adults > 70 yr	Poor prognosis: Immunosuppression (HIV, transplantation, glucocorticoids); cough, lymphadenopathy, diarrhea; use of trimethoprim-sulfamethoxazole.	2%–3%.
Human granulocytic anaplasmosis (*Anaplasma phagocytophilum*)	*I. scapularis* (eastern United States) and *I. pacificus* (western United States), *I. ricinus* (Europe) (black-legged ticks)	New England, upper Midwest United States, mid-Atlantic, northern California,[c] and Europe	Spring and summer (peaks in July and November)	5–21 days	314 cases/yr (1999–2003)[d]	Males; adults 60–69 yr	Poor prognosis: Elderly, high lymphopenia, anemia, immunosuppression (HIV, transplantation, glucocorticoids); development of opportunistic infections (e.g., *Aspergillosis*, disseminated candidiasis, etc.).	< 1%.

G6PD = glucose-6-phosphate dehydrogenase; HIV = human immunodeficiency virus.
[a]Males appear to be at higher risk of all tick-borne rickettsial diseases, presumably because of greater recreational and occupational exposure. Disease occurs in all age groups; numbers reflect highest age-specific incidence.
[b]In 2003, 70% of cases of human monocytic ehrlichiosis were reported from seven states: Arkansas, Georgia, Missouri, Maryland, North Carolina, Oklahoma, and Tennessee.
[c]In 2003, 71% of cases of human granulocytic anaplasmosis were reported from four states: Massachusetts, Minnesota, New York, and Rhode Island.
[d]Schutze GE: Ehrlichiosis. *Ped Inf Dis J* **25**:71, 2006
From Centers for Disease Control and Prevention, http://www.cdc.gov.



▲ **FIGURE 199-1** Tick species responsible for transmission of *Rickettsia*, *Ehrlichia*, and *Anaplasma*. **A.** *Dermacentor variabilis*. **B.** *D. andersoni*. **C.** *Amblyomma americanum*. **D.** *Ixodes scapularis*. **E.** *I. pacificus*. **F.** *Rhipicephalus sanguineus*. **G.** Comparison of *I. scapularis*, *A. americanum*, and *D. variabilis* by life stage. (A U.S. dime is shown to approximate relative size.) [From the Centers for Disease Control and Prevention (http://www.cdc.gov).]

Treatment and Prognosis. Guidelines for the treatment of MSF are outlined in Box 199-4. Overall, non-RMSF spotted fevers run a less aggressive course than RMSF. However, the death rate in patients hospitalized with MSF ranges from 1.4 percent to 5.6 percent. Higher death rates (33 percent) have been reported when delays in diagnosis and therapy occur. In general, all non-RMSF spotted fevers are treated similarly to MSF. Macrolide antibiotics may offer a better risk/benefit ratio than tetracyclines in the pediatric age group.[18]

TABLE 199-2
Clinical and Diagnostic Findings in Rocky Mountain Spotted Fever (RMSF), Human Monocytic Ehrlichiosis (HME), and Human Granulocytic Anaplasmosis (HGA)

	RMSF	HME	HGA
Tropism	• Endothelial cells.	• Monocytes.	• Granulocytes.
Common initial signs and symptoms	• Fever to 38.9°C (102°F), chills, malaise, myalgia, nausea, vomiting, anorexia, headache. • Periorbital edema, abdominal pain mimicking appendicitis (children > adults), conjunctival injection, palatal petechiae, edema of dorsal hands, calf pain.	• Fever, chills, headache, malaise, myalgia, nausea, vomiting, anorexia, photophobia. • Abdominal pain mimicking appendicitis (children > adults), conjunctival injection, palatal petechiae, edema of dorsal hands, calf pain.	• Malaise (94%), fever (92%), myalgia (77%), headache (75%). • Less common: Arthralgia, nausea, vomiting, diarrhea, cough.
Common laboratory abnormalities	• Common: Thrombocytopenia (30%–50% of patients), anemia (5%–24%), mild hyponatremia (50%). • Variably elevated: Serum transaminase levels, lactate dehydrogenase, creatine kinase, serum bilirubin, alkaline phosphatase, blood urea nitrogen, creatinine. • Cerebrospinal fluid with increased leukocytes, moderately elevated protein (100–200 mg/dL), and a normal glucose level.	• Leukopenia (< 4000/mm^3), lymphopenia (< 1500/mm^3), thrombocytopenia (50,000–150,000/mm^3), transaminitis (aspartate aminotransferase > 55 units/L), hyponatremia (< 135 mEq/L), and anemia (hematocrit < 30%).	• (Similar to HME). • Thrombocytopenia (71%–94%), transaminitis (71%), leukopenia (49%–53%), anemia (37%), elevated creatinine. • Neutropenia is more common than lymphopenia.
Systemic sequelae	• Cardiovascular: Hypotension, hypovolemia, and peripheral edema. Inappropriate tachycardia. Myocarditis, cardiac arrhythmias. • Gastrointestinal: Bleeding and perforation, hepatomegaly (25% of cases), jaundice (8% of cases). • Neurologic: Confusion, delirium, stupor, meningismus, coma, motor deficits, cranial nerve palsy, deafness, photophobia, hallucinations, seizures, Guillain-Barré syndrome. • Other: Conjunctivitis (30%), acute renal failure, adult respiratory distress syndrome.	• (Severe or fatal sequelae less common than RMSF). • 50% of patients require hospitalization, and 5%–7% of patients require intensive care unit level care. • Respiratory: Cough, dyspnea, respiratory insufficiency/ adult respiratory distress syndrome. • Neurologic: Meningoencephalitis, altered mental status, cranial or peripheral motor nerve paralysis, sudden transient deafness. • Other: Acute renal failure, disseminated intravascular coagulation, and pericarditis.	• (Severe or fatal sequelae less common than RMSF). • 50% of patients require hospitalization, and 5%–7% of patients require intensive care unit level care. • General: Septic or toxic-shock like syndrome (see Chap. 178), coagulopathy/ disseminated intravascular coagulation (see Chap. 145), rhabdomyolysis, pancreatitis. • Respiratory: Adult respiratory distress syndrome. • Neurologic: Brachial plexopathy, demyelinating polyneuropathy, cranial nerve paralysis. • Other: Acute abdominal syndrome, myocarditis, acute renal failure, hemorrhage, opportunistic infections.
Rash	• Maculopapular rash ~ 2–4 days after fever onset in 50%–80% of adults, > 90% of children; starts at wrists/ankles and spreads centripetally; may involve palms, soles. Individual lesions are blanchable, red macules evolving over few days to petechial and purpuric lesions.	• Macular, maculopapular, petechial (or a combination) ~ 5 days after onset systemic symptoms in ~ 33% of adults, ~ 60% of children.	• Rare (~ 6%).



Mite-Bite Associated. **RICKETTSIALPOX.** Rickettsialpox is an acute, self-limited, febrile disease so named because of its clinical resemblance to varicella (chickenpox). Its etiologic agent is *R. akari*, the house mouse (*Mus musculus*) is the reservoir, and the vector is the rodent mite, *Liponyssoides sanguineus* (*Allodermanyssus sanguineus*).[19] The rodent mite inflicts a painless bite and is too small to be readily recognized by the victim.

Epidemiology. Most cases of rickettsialpox in the United States have occurred in large metropolitan areas of the northeastern United States, with approximately one-half of the cases reported from New York City alone. Table 199-1 describes the salient epidemiologic features of rickettsialpox.

Clinical and Laboratory Findings. A primary lesion occurs at the site of the mite bite as early as 1 to 2 days after transmission. It consists of a painless, erythematous, indurated papule ranging in size from 0.5 to 3.0 cm. Vesicle formation is followed by desiccation and a subsequent eschar to form the characteristic tache noir (Fig. 199-7). Regional lymphadenopathy is common. Resolution of the primary lesion occurs within 1 month.

Approximately 7 days after the primary lesion appears, fever, chills, drenching sweats, myalgia (often manifesting as backache), malaise, and headache begin. The fever persists with remissions for about 1 week before abating. Two to 3 days after the onset of systemic symptoms, a generalized papulovesicular eruption occurs (see Fig. 199-7B). Small vesicles or pustules appear with subsequent









▲ **FIGURE 199-2** **A.** Early macular blanchable macules and papules on the ankle and sole. No truncal lesions were present at this time. **B.** Truncal and facial hemorrhagic macules and papules 7 days after the onset of the rash. **C.** Erythematous macular lesions on the palm may develop into a petechial rash that spreads centrally. (Reprinted from Collins SP: Cutaneous conditions, in *Atlas of Emergency Medicine*, 2nd ed, edited by Knoop KJ, Stack LB, Storrow AB. New York, McGraw-Hill, 2002, p 382.). **D.** Petechial lesions on the arm of a child with fulminant Rocky Mountain spotted fever. [Used with permission from MMWR, *Diagnosis and Management of Tickborne Rickettsial Diseases: Rocky Mountain Spotted Fever, Ehrlichiosis, and Anaplasmosis—United States*. March 13, 2006/55(RR04);1–27, http://www.cdc.gov/mmwr.]



◀ **FIGURE 199-3** Gangrene of the toes in Rocky Mountain spotted fever. [Used with permission from Gary Marshall, MD and MMWR, *Diagnosis and Management of Tickborne Rickettsial Diseases: Rocky Mountain Spotted Fever, Ehrlichiosis, and Anaplasmosis—United States*. March 13, 2006/55(RR04);1–27. http://www.cdc.gov/mmwr.]

crust formation at the center of the papules. Roughly 5 to 40 lesions may be found, typically resolving in 1 week. Less frequently, an enanthem, photophobia, generalized lymphadenopathy, and gastrointestinal symptoms may be noted. Thrombocytopenia is common during the acute febrile illness, and a mild leukopenia with a relative lymphocytosis may be seen.

Pathology. In contrast to RMSF, MSF, ATBF, and the typhus group Rickettsioses, the perivascular macrophage, not the endothelial cell, appears to be the target of *R. akari*. Primary lesions are characterized by extensive necrosis and an acute inflammatory infiltrate. Secondary papulovesicular lesions display a sub-epidermal split with superficial edema, and a perivascular lymphohistiocytic infiltrate that can eventuate in vasculitis.

Diagnosis and Differential Diagnosis. Antibody titers peak after 3 to 4 weeks and could be delayed for up to 8 weeks with antibiotic use. Biopsy for DIF with anti-*R. rickettsii* globulin is highly sensitive; however, due to cross-reactivity among the spotted fever group rickettsiae, confirmatory cross-adsorption testing may be considered with *R. akari* and *R. rickettsii* antigens. Tissue for DIF should be taken from a primary eschar, as lesions from the generalized eruption do not contain enough inoculum to become positive by DIF.

The differential diagnosis includes varicella, smallpox, gonococcemia, infectious mononucleosis, echovirus (types 9 and 16), and coxsackievirus infection (A9, A16, and B5), in addition to those diseases discussed under the differential diagnosis of MSF (see Diagnosis and Differential Diagnosis under Mediterranean Spotted Fever and African Tick Bite Fever). In varicella, one observes a "dewdrop on a rose petal" cutaneous lesion, referring to a primarily vesicular lesion surrounded by macular erythema. This is distinct from the erythematous papule surmounted by a vesicle seen with rickettsialpox.[19] Fever occurs with the rash of varicella but precedes the eruption of rickettsialpox.

Treatment and Prognosis. The disease is self-limited, and even without antimicrobial therapy, the illness will resolve within 2 weeks. In the rare severe case, tetracycline antibiotics continued for up to 5 days are the most effective therapy, although defervescence is typical within 48 hours.[19]



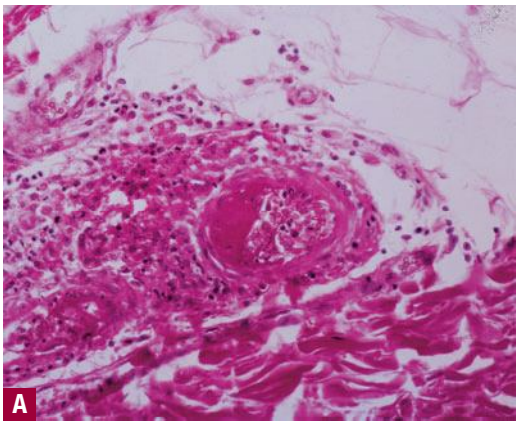

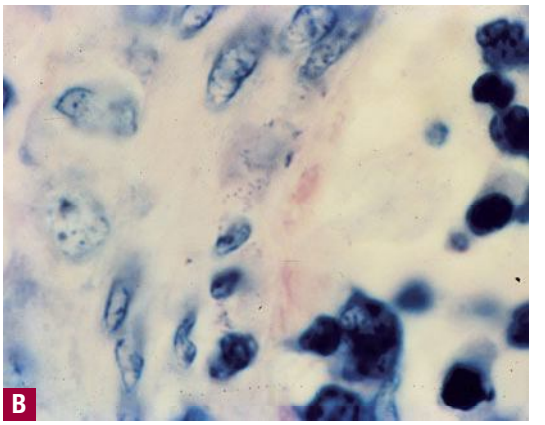

▲ **FIGURE 199-4** **A.** Vascular lesion of Rocky Mountain spotted fever as seen in an arteriole in the skin. An early thrombus is present. **B.** Rickettsiae are seen in endothelial cells from a biopsy of a cutaneous lesion.



Typhus Group

ENDEMIC TYPHUS (MURINE OR FLEA-BORNE TYPHUS) Endemic typhus is caused mainly by *R. typhi*, and is classically transmitted to humans by the rat flea (*Xenopsylla cheopis*), with rats serving as the reservoir. *R. felis* has recently emerged as an important agent of endemic typhus with characteristics of both the typhus and spotted fever group rickettsiae. *R. felis* has been identified in peridomestic cats, dogs, opossums, and their fleas (e.g., cat flea, *Ctenocephalides felis*) in parts of southern Texas, southern California, and Mexico.[20,21]

Epidemiology. Murine typhus has been reported from all continents except Antarctica, although most cases today occur in Africa. Epidemiologic characteristics are outlined in Table 199-1.

Clinical and Laboratory Findings. Most infected persons experience a fever, headache, backache, and joint pain 6 to 14 days after contact with an infected flea. Extremely high fever, 41.1°C (106°F), may last up to 2 weeks. Commonly, a rash begins on the chest and spreads to the sides and back. The palms and soles are rarely involved. The rash may last only a few hours and consists of erythematous macules or macules and papules. Petechiae are found infrequently. Rash is seen in fewer than 20 percent of patients at presentation, but 50 percent to 60 percent of patients will develop a rash over the course of the illness, with a median onset of 6 days after the fever begins.[20] More severe complications are uncommon but may include seizures, meningoencephalitis, retinitis, acute hepatitis, endocarditis, renal insufficiency, pneumonia, and respiratory failure.

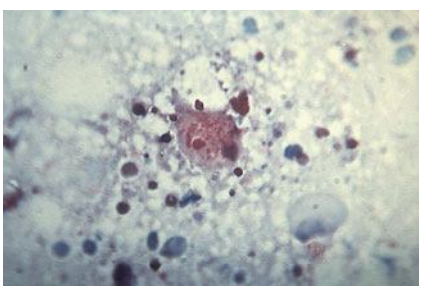

▲ **FIGURE 199-5** Gimenez stain of Rocky Mountain spotted fever in tick lymph cells. [From the Centers for Disease Control and Prevention (http://www.cdc.gov/ncidod/dvrd/rmsf/organism.htm.)]

Diagnosis and Differential Diagnosis. Diagnostic IFA titers are present in 50 percent of patients by day 7, and in virtually 100 percent of patients by day 15, but may not distinguish between endemic and epidemic typhus (caused by *R. prowazekii*).

The differential diagnosis is broad as a result of the non-specific nature of the cutaneous eruption (see Box 199-2).

Treatment and Prognosis. Treatment for endemic typhus is similar to that of RMSF (see Box 199-4). With institution of appropriate antibiotics, fever typically resolves in 2 to 3 days. Prior infection with *R. typhi* provides lifelong immunity to subsequent infection.

EPIDEMIC (LOUSE-BORNE) TYPHUS Epidemic typhus (also called *prison fever, famine fever,* or *ship fever*) is caused by *R. prowazekii*, and is transmitted to humans primarily via the body louse (*Pediculus humanus* var. *corporis*). Epidemic typhus may result in long-term latent asymptomatic infection. A recrudescent infection known as Brill-Zinsser disease (BZD) can occur in survivors who may suffer recrudescent infection even decades after the initial infection.

Epidemiology. Louse infestation occurs when cold weather, poor hygiene,

Box 199-1

Differential Diagnosis of Rickettsial and Ehrlichial Diseases

Most Likely

- Enteroviral infection (e.g., coxsackievirus, echovirus)
- Roseola infantum (human herpesvirus 6)
- Drug reaction
- Group A streptococcal pharyngitis
- Vasculitis
- Kawasaki disease
- Measles (coryza, Koplik's spots, cough)
- Epstein-Barr virus/infectious mononucleosis

Consider

- Viral meningoencephalitis
- *Mycoplasma pneumoniae* infection
- Parvovirus B19
- Tularemia
- Leptospirosis
- Immune complex mediated illness
- Atypical erythema multiforme
- Typhoid fever

Always Rule Out

- Meningococcemia (more rapid-onset rash and leukocytosis, but both may show gangrenous lesions)
- Disseminated gonococcal infection
- Lyme disease
- Tick-borne viral fevers (e.g., Colorado tick fever)
- Thrombotic thrombocytopenic purpura and immune thrombocytopenic purpura
- Toxic shock syndrome
- Stevens-Johnson syndrome
- Secondary syphilis

Box 199-2

Selected Differential Diagnosis of Fever and Maculopapular or Petechial Rash

DISEASE	AGENT	SEASON	ONSET	CLINICAL FEATURES
Rocky Mountain spotted fever	*Rickettsia rickettsii*	Spring to summer	Fever, headache, malaise, occasional gastrointestinal symptoms, rash after 2–4 days in ~ 50% of patients; rapid progression to severe systemic illness	Rash may involve palms/soles, moves peripherally to centrally; progresses from MP to petechial
Endemic (murine) typhus	*R. typhi*	Sporadic	Fever, malaise, headache, rash after 4–5 days in ~ 50% of patients	MP rash involving trunk > extremities
Human monocytic ehrlichiosis	*Ehrlichia chaffeensis*	Spring to summer	Fever malaise, headache, rash in ~ 30% of patients	Erythematous, MP, or petechial rash; more common in children > adults
Meningococcal disease	*Neisseria meningitidis*	Year-round, but more common late winter to early spring	Fever and rash within 24 h, rapid progression to severe systemic illness	MP and petechial rash usually begins on lower extremities and moves centrally (early rash may be macular, not petechial)
Group A streptococcal pharyngitis	Group A streptococcus	Fall to winter	Abrupt onset of fever and sore throat, malaise; rash follows acute illness	Cause of petechial rash in children who appear well
Fifth disease (erythema infectiosum)	Human parvovirus B19	Late winter to early summer	Low fever and mild constitutional signs before rash onset	"Slapped cheek" appearance of rash on face, lacy rash on trunk
Roseola infantum	Human herpesvirus 6	Year-round	Fever 3–5 days, then rash, commonly in children < 2 yr of age	MP rash begins on trunk, spreads and fades rapidly
Enteroviral infection	Echovirus, coxsackieviruses, other nonpolio enteroviruses	Summer to early fall most commonly, but occurs year-round	Non-specific febrile illness, with or without rash	Fine MP rash at fever onset; begins on face and spreads to chest and extremities; occasionally petechial

MP = maculopapular.
Adapted from MMWR, Centers for Disease Control and Prevention: *Diagnosis and Management of Tickborne Rickettsial Diseases: Rocky Mountain Spotted Fever, Ehrlichioses, and Anaplasmosis—United States*. March 31, 2006/55(RR04), p 1-27, http://www.cdc.gov/mmwr/preview/mmwrhtml/rr5504a1.htm.

crowding, and poverty are prevalent. These conditions are most commonly found today in refugee camps, and among the homeless and the imprisoned. The most recent outbreak of epidemic typhus occurred in refugee camps in Burundi during the mid-1990s.[23] Table 199-1 details the epidemiologic characteristics of epidemic typhus.

Box 199-3

Management of Rickettsial, Ehrlichial, and *Anaplasma* Infections

- Delays in treatment can lead to severe sequelae and fatal outcome.
- Clinical history, symptoms, physical exam, and laboratory findings should guide approach to management and treatment.
- Clinicians may consider a "watch-and-wait" approach for 24–48 h for patients early in the course of illness who have nonsupporting history, non-specific clinical signs, and normal lab findings.
- Doxycycline is the drug of choice for the treatment of presumptive or confirmed rickettsial disease in both adults and children.
- Limited courses of tetracycline-class antibiotics (e.g., doxycycline) do not pose a substantial threat of tooth staining in children.
- Tetracyclines are typically contraindicated in pregnancy but may be warranted in life-threatening cases of Rocky Mountain spotted fever when clinical suspicion.
- When early invasive meningococcal infection cannot be ruled out, provide treatment for both conditions by adding an antimicrobial that has activity against *Neisseria meningitidis*.
- Prophylactic use of antibiotics after a tick bite is not recommended, as atypical presentations may result, delaying adequate diagnosis and treatment. If prophylaxis is given, a full 10-day course should be administered.
- In patients for whom tetracyclines are absolutely contraindicated, chloramphenicol can be used for rickettsial disease; rifampin or rifabutin may be considered for the ehrlichioses/anaplasmosis.
- When treating ehrlichial infections, consider continuation for 14–21 days to allow for adequate treatment of concomitant Lyme disease in areas endemic for *Borrelia burgdorferi*.

Adapted from MMWR, Centers for Disease Control and Prevention: *Diagnosis and Management of Tickborne Rickettsial Diseases: Rocky Mountain Spotted Fever, Ehrlichioses, and Anaplasmosis—United States*. March 31, 2006/55(RR04), p 1-27, http://www.cdc.gov/mmwr/preview/mmwrhtml/rr5504a1.htm.

The major reservoir for disease seems to be humans, with lice acquiring the infection by feeding on persons with primary illness or BZD. The lice are spread through close personal contact or infested clothing. The infected louse will defecate while taking a blood meal, and the organisms in the feces are then scratched into the skin, enabling transmission. Lice die of infection within 3 weeks.

Contact with southern flying squirrels (*Glaucomys volans*) is associated with outbreaks of epidemic typhus in the eastern United States, where the fleas or lice from these rodents may be important vectors.[24]

Clinical and Laboratory Findings. After an incubation period of 1 to 2 weeks, abrupt onset of intractable headache, fever [to 40°C (104°F)], chills, and myalgia occurs. If left untreated, prostration due to overwhelming hypotension and vascular collapse may ensue. Typically, a rash begins in the axillary folds and upper trunk on the fifth day of illness. Initial lesions consist of erythematous ma-



Box 199-4

Treatment of Rickettsial, Ehrlichial, and *Anaplasma* Infections

	RMSF	MEDITERRANEAN SPOTTED FEVER	EPIDEMIC TYPHUS	ENDEMIC TYPHUS	HUMAN MONOCYTIC EHRLICHIOSIS	HUMAN GRANULOCYTIC ANAPLASMOSIS
Adults						
First line	Doxycycline, 100 mg q12h for 5–10 days[a] *or* Tetracycline, 500 mg q6h (maximum daily dose, 2 g)	Doxycycline, 200-mg single dose *or* 100 mg bid for 2–5 days *or* Two oral 200-mg doses 12 h apart	Doxycycline, 200 mg single dose (or until patient is afebrile for 24 h)[e]	Doxycycline, 100 mg q12h for 7–14 days	Doxycycline, 100 mg q12h for 5–10 days[a] *or* Tetracycline, 500 mg q6h (maximum daily dose, 2 g)	Doxycycline, 100 mg q12h for 10–14 days
Second line	Chloramphenicol, 50–75 mg/kg/day q6h (maximum daily dose, 4 g)	Ciprofloxacin, 750 mg q12h for 7 days *or* Levofloxacin, 500 mg qd	Chloramphenicol, 80–100 mg/kg/day divided q6h	Chloramphenicol, 80–100 mg/kg/day divided q6h		
Children						
First line	Doxycycline,[b] 2.2 mg/kg q12h (< 99 lb/45 kg) *or* Adult dose if > 100 lb for 5–10 days	(same recommendations as RMSF)	Doxycycline[b] *or* Chloramphenicol	Doxycycline[b] *or* Chloramphenicol	Doxycycline, 4 mg/kg/day in two divided doses; maximum, 100 mg/dose	(same recommendations as RMSF)
Second line	Chloramphenicol, 12.5 to 25.0 mg/kg q6h for 5–10 days	Clarithromycin, 15 mg/kg/day in two divided doses for 7 days or 500 mg bid *or* Azithromycin, 10 mg/kg/day once a day for 3 days or 500 mg qd			Tetracycline, 25 mg/kg/day in four divided doses; maximum, 500 mg/day *or* Rifampin, 20 mg/kg/day in two divided doses; maximum, 600 mg *or* Chloramphenicol,[d] 12.5–25 mg/kg q6h for 5–10 days	Chloramphenicol,[f] 12.5 to 25 mg/kg q6h for 5–10 days
Pregnancy						
First line	Doxycycline,[c] 100 mg q12h for 5–10 days	Azithromycin *or* Clarithromycin	Chloramphenicol[d] *or* Doxycycline[b,c]	Chloramphenicol[d] *or* Doxycycline[b,c]	Doxycycline[b,c]	Doxycycline[b,c]
Second line	Chloramphenicol[d]	Chloramphenicol[d]	Azithromycin	Azithromycin	Rifampin	Rifampin

RMSF = Rocky Mountain spotted fever.
[a]Treat for 3 days after fever subsides and until clinical improvement is noted, typically for a minimum of 5–7 days. More severe illness may require longer duration of therapy.
[b]In severe, life-threatening cases, or when RMSF cannot be ruled out, doxycycline should be considered first line in any age.
[c]Tetracyclines are generally contraindicated for use in pregnant women because of risks associated with malformation of teeth and bones in the fetus and hepatotoxicity and pancreatitis in the mother. However, as the mortality rate is unacceptably high in RMSF, the use of tetracyclines may be warranted during pregnancy in life-threatening situations where clinical suspicion of infection is high.
[d]Use with caution in the third trimester of pregnancy as chloramphenicol may cause gray baby syndrome in neonates (abdominal distention, pallor, cyanosis, vasomotor collapse). Doxycycline should be considered in near-term gravidas. In vitro studies suggest that chloramphenicol may not be effective in human monocytic ehrlichiosis and human granulocytic anaplasmosis. The oral form of chloramphenicol is not available in the United States.
[e]For recrudescent disease (Brill-Zinsser), a second course of antibiotics is usually curative.
[f]Treatment is extended to treat potential co-infection with Lyme disease.
Reprinted with permission from Parola P, Paddock CD, Raoult D: Tick-borne rickettsioses around the World: Emerging diseases challenging old concepts. *Clin Microbiol Reviews* **18**:719, 2005, and courtesy of the Centers for Disease Control and Prevention.



cules that become papular and petechial over several days. In contrast with most rickettsial diseases, the eruption spreads centrifugally but spares the face, palms, and soles. Complications include acral gangrene, cerebral thrombosis, and other neurologic sequelae, multiorgan system failure, and death.

BZD occurs as a recrudescence of previous infection with *R. prowazekii*. Provocation by immunologic stress induced by poor living conditions may play a





◀ **FIGURE 199-6** Inoculation eschar, the "tache noir" (**A**), and maculopapular rash in a patient with Mediterranean spotted fever (**B**). (From Parola P, Paddock CD, Raoult D: Tick-borne rickettsioses around the World: Emerging diseases challenging old concepts. *Clin Microbiol Reviews* **18**:719, 2005, with permission.)

role. The illness is usually milder than the primary disease.

Laboratory abnormalities include thrombocytopenia, elevated transaminases, and elevated lactate dehydrogenase. Leukocytosis is seen in a minority of patients.

Diagnosis and Differential Diagnosis. Techniques for diagnosis are identical to those used for other rickettsial diseases, with the IFA test the most widely used method. The differential diagnosis is similar to that of endemic typhus [see Diagnosis and Differential Diagnosis under Endemic Typhus (Murine or Flea-Borne Typhus)]. The diagnosis of epidemic typhus should be considered when the appropriate clinical characteristics are seen in the setting of known or suspected louse infestation, or, in the United States, when a history of an exposure to flying squirrels is elicited. The centrifugal spread, lack of eschar, and predilection for colder months helps differentiate epidemic typhus from other *Rickettsia*. Endemic (murine typhus) is typically less severe than epidemic typhus. When lice and rats are both prevalent (poor hygienic conditions, prison, etc.), a risk exists for both diseases. In such situations, it is critical to discriminate between *R. typhi* and *R. prowazekii* infections, as the latter has markedly greater epidemic potential.

Treatment and Prognosis. Fatal illness is rare if proper therapy is initiated early (see Box 199-4). Although a single dose of doxycycline may be curative, optimal therapy should be continued for 2 to 3 days after defervescence. BZD is treated identically to primary epidemic typhus. Therapy failures have been documented with azithromycin for BZD.[25]

Prevention. Prevention begins with regular bathing and clothes washing. Delousing with appropriate agents, such as lindane or DDT, is effective. A vaccine is available, but recommended only for high-risk groups.

SCRUB TYPHUS Scrub typhus, also known as *Tsutsugamushi fever* or *chigger fever,* is a mite-transmitted zoonosis caused by *Orientia tsutsugamushi*. The vector is the larval stage (chigger) of the trombiculid mite (*Leptotrombidium deliense* and several other *Leptotrombidium* sp.). The mites and the rodents that carry them serve as the major reservoirs.

Epidemiology. Named for the type of vegetation that harbors the mite vector,





▲ **FIGURE 199-7** **A.** Rickettsialpox: Tache noir. A crusted, ulcerated papule (eschar) with a red halo resembling a cigarette burn at the site of a mite bite. **B.** Rickettsialpox: Exanthem. Multiple, erythematous papules and pustules, some with central hemorrhage and crusting, on the back after hematogenous dissemination of *Rickettsia akari* from the mite-bite site.



scrub typhus is endemic to a region spanning the Indian subcontinent to eastern Asia and the western Pacific rim (Japan, Korea, India, Pakistan, Taiwan, Southeast Asia, and Australia). Scrub vegetation is a transitional terrain between tall forests and cleared land, composed of plantations, fields, groves, and tall grass. Accordingly, the illness is more common in rural settings and is a common occupational disease. An estimated 1 billion people are at risk and about 1 million cases occur annually.[26]

Clinical and Laboratory Findings. An erythematous papule appears within 2 days of the chigger bite and undergoes ulceration and eschar formation in one-half to two-thirds of patients. The eschar may be absent in intertriginous areas. Regional lymphadenopathy is followed by generalized lymphadenopathy. One to 2 weeks after the bite, there is a sudden onset of high fever [40°–40.6°C, (104°–105°F)]. Chills, headache, cough, myalgia, anorexia, nausea, diarrhea, dyspnea, ocular pain, and conjunctival injection are variably present. A centrifugal macular and then papular eruption occurs in approximately 35 percent of cases about 4 to 5 days after the fever begins. The eruption starts on the trunk, then spreads to the extremities, and fades within a few days. Hepatosplenomegaly and a relative bradycardia may be appreciated. Severe complications include adult respiratory distress syndrome, myocarditis, pericarditis, disseminated intravascular coagulation, hemophagocytic syndrome, retinal vein occlusion, renal failure, and hepatitis. Nuchal rigidity and meningoencephalitis, tremors, slurred speech, deafness, and tinnitus are seen rarely. Examination of the cerebrospinal fluid in these cases reveals only a slight monocytosis.

Diagnosis and Differential Diagnosis. Enzyme-linked immunosorbent assay, dot blot urine immunoassay, rapid immunochromatographic flow assay, and PCR have the greatest sensitivity and specificity but are limited by their availability in endemic areas. IFA and the indirect immunoperoxidase assay are very specific (if not as sensitive) and more accessible, and therefore the most commonly used diagnostic techniques worldwide. An IFA titer of ≥ 400 is 96 percent specific and 48 percent sensitive; lowering the cutoff to ≥ 100 raises sensitivity to 78 percent but lowers the specificity to 84 percent.[28] The differential diagnosis is similar to that for endemic (murine) typhus [see Diagnosis and Differential Diagnosis under Endemic Typhus (Murine or Flea-Borne Typhus)].

Treatment and Prognosis. Although single dose or short courses (3 days) of doxycycline may prove to be efficacious, treatment is recommended for 14 days. Naturally occurring doxycycline- and chloramphenicol-resistant strains of *O. tsutsugamushi* have been found in northern Thailand. Azithromycin, rifampin, and ciprofloxacin are alternatives in this setting.[29]

With the institution of proper antibiotics, defervescence occurs abruptly, usually within 24 hours. In untreated patients, fever lasts for about 2 weeks.

Prevention. DEET applied to the skin or impregnated into clothing is effective at preventing transmission. Chemoprophylaxis with weekly doxycycline (200 mg) may be efficacious when traveling to endemic areas.

Q FEVER

THE EHRLICHIOSES

The ehrlichial pathogens were reclassified following the identification in 1994 of the so-called *HGE* agent responsible for causing human granulocytic ehrlichiosis. Based on distinct phylogenetic and pathogenic characteristics, this organism was assigned its own genus, *Anaplasma*, and the disease associated with it was renamed human granulocytic anaplasmosis (HGA).[10]

Epidemiology

Human disease attributed to ehrlichial agents has been reported in the United States since 1986. The causative agent of human monocytic ehrlichiosis (HME) is *Ehrlichia chaffeensis*, and the main reservoirs are deer, dogs, and coyote. The white-footed mouse (*Peromyscus leucopus*) and white-tailed deer (*Odocoileus virginianus*) are the principal reservoirs for *A. phagocytophilum*, the causative agent of HGA. Table 199-1 describes the principal epidemiologic characteristics of HME and HGA.

HGA infection occurs in a geographic pattern identical to that of Lyme disease (*Borrelia burgdorferi*) (see Chap. 187), namely in the northeastern United States, parts of the Pacific Northwest, and the upper Midwest United States. The vector for both HGA and Lyme is the *Ixodes* tick (see Fig. 199-1D and E). In addition to *A. phagocytophilia* and *B. burgdorferi*, *Ixodes* ticks can transmit *Babesia microti*, *Borrelia afzelii*, and *Borrelia garinii*. Not surprisingly, then, most cases of HGA are found in areas that also report high incidences of Lyme and babesiosis.

The lone star tick (*Amblyomma americanum*) and the American dog tick (*D. variabilis*), the vectors of *E. chaffeensis*, also transmit *R. rickettsii* and *Francisella tularensis*, the causative agents of RMSF and tularemia (see Chap. 183), respectively (see Fig. 199-1). It is essential to consider possible co-infection with these potentially life-threatening organisms in patients with known or suspected ehrlichial disease.

Etiology and Pathogenesis

Ehrlichiae and Anaplasmodiae are small, obligate intracellular bacteria. *E. chaffeensis* is trophic for monocytic cells, while *A. phagocytophilum* prefer myeloid or granulocytic cells. The organisms grow within membrane-bound vacuoles, in which they form intracytoplasmic microcolonies called morulae, which may be seen in peripheral blood smears.[10,33]

Clinical and Laboratory Findings

There is substantial overlap in the clinical presentation and laboratory evaluation of patients with HME, HGA, and RMSF (see Table 199-2). Patients give a history of a tick bite in only about 68 percent of cases of ehrlichiosis. The rash of HME is often indistinguishable from that of RMSF, and can present as macules and papules, petechiae, or as a diffuse erythema. It is observed in approximately 33 percent of adult patients and 66 percent of children with HME. Rash is rare in HGA, and indeed, the absence of a rash in a patient with systemic findings suggestive of RMSF should prompt consideration of anaplasmosis.

Pathology

In contrast to the rickettsioses, vasculitis is not a typical feature. A single retrospective case study suggests HME may rarely be associated with cutaneous vasculitis such as polyarteritis nodosa.[35]

Diagnosis and Differential Diagnosis

Clinical illness nearly always precedes laboratory diagnosis by any method. Morulae stained with Wright or Giemsa stains are occasionally observed in the leukocytes in smears of peripheral blood,



buffy coat preparations, or cerebrospinal fluid, usually during the first week of infection (Fig. 199-8). Smear sensitivities are variable and low (1 percent to 20 percent in HME and 20 percent to 80 percent of HGA), and dependent upon the experience of the microscopist.[33] Therefore, a negative smear should not delay treatment. False positives occur with toxic granulation, superimposed platelets, and Döhle's bodies.

Confirmatory testing should be performed with serologic assays available through commercial and state public health laboratories. The sensitivity of the IFA is dependent on the timing of collection and is estimated to be 94 percent to 100 percent sensitive after 14 days. Paired serum samples (acute and convalescent) taken 2 to 3 weeks apart should demonstrate a fourfold or greater rise in titers. PCR of whole blood may be more useful than tissue biopsy in HME and HGA, as these pathogens are trophic for circulating leukocytes. Immunohistochemical staining of formalin-fixed, paraffin-embedded tissue may be useful for documenting infection in the first 48 hours of disease.[10]

The differential diagnosis is extensive and includes diseases considered in the differential diagnosis of RMSF (see Boxes 199-1 and 199-2). The presence of a rash, normal white blood cell count, lack of morulae, and pathologic evidence of vasculitis is more consistent with RMSF.

Treatment and Prognosis

The clinical course ranges from asymptomatic seroconversion to multisystem organ failure and death (see Table 199-1). The median duration of disease is 1 to 2 weeks with treatment, with defervescence usually occurring within 1 to 2 days. Boxes 199-3 and 199-4 detail appropriate therapy. Treatment for 5 to 7 days is generally effective, but continued therapy for 14 to 21 days is indicated if co-infection with *B. burgdorferi* is suspected.[10,33] In vitro studies indicate that chloramphenicol may not be effective for ehrlichial diseases.

Prevention

Preventive measures include avoidance of tick exposure, use of chemical repellants such as DEET, light-colored clothing (to visualize ticks), and careful removal of attached ticks. Concentrations of DEET up to 35 percent have been deemed safe for use in children and adults.

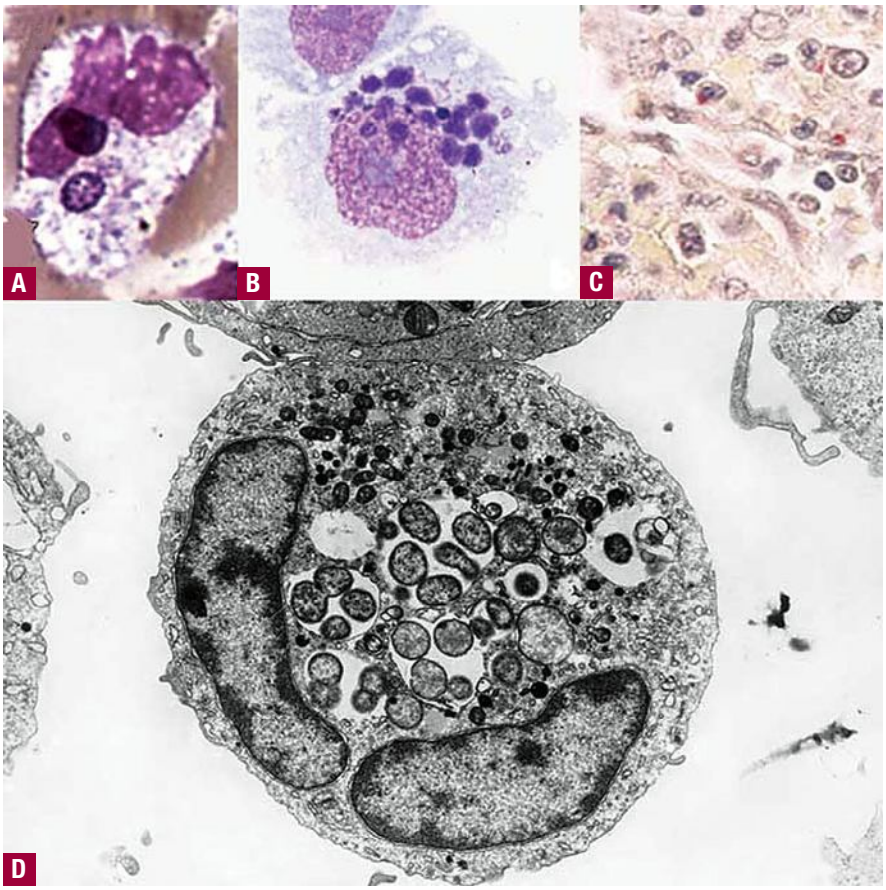

▲ **FIGURE 199-8** **A.** *Anaplasma phagocytophilum* in human peripheral blood band neutrophil (Wright stain, original magnification ×1000). **B.** *A. phagocytophilum* in THP-1 myelomonocytic cell culture (Leukostat stain, original magnification ×400). **C.** *A. phagocytophilum* in neutrophils infiltrating human spleen (immunohistochemistry with hematoxylin counterstain; original magnification ×100). **D.** *A. phagocytophilum* ultrastructure by transmission electron microscopy in HL-60 cell culture (original magnification ×21,960). (Used with permission from Dumler JS et al: Human granulocytic anaplasmosis and *Anaplasma phagocytophilum*. *Emerg Infect Dis* **11**:1828, 2005. Available from http://www.cdc.gov/ncidod/EID/vol11no12/05-0898.htm.)

KEY REFERENCES

The full reference list for all chapters is available at www.digm7.com.

1. Parola P, Paddock CD, Raoult D: Tick-borne rickettsioses around the World: Emerging diseases challenging old concepts. *Clin Microbiol Reviews* **18**:719, 2005
8. Centers for Disease Control and Prevention: Consequences of delayed diagnosis of Rocky Mountain spotted fever in children—West Virginia, Michigan, Tennessee, and Oklahoma, May–July 2000. *MMWR Morb Mortal Wkly Rep* **49**:885, 2000
10. Bakken JS et al: Centers for Disease Control and Prevention. Diagnosis and management of tickborne rickettsial diseases: Rocky Mountain spotted fever, ehrlichioses, and anaplasmosis—United States. *MMWR Morb Mortal Wkly Rep* **55**:1, 2006
11. Demma LJ et al: Rocky Mountain spotted fever from an unexpected tick vector in Arizona. *N Engl J Med* **353**:587, 2005
26. Watt G, Parola P. Scrub typhus and tropical rickettsioses. *Curr Opin Infect Dis* **16**:429, 2003
33. Dumler JS et al: Human granulocytic anaplasmosis and *Anaplasma phagocytophilum*. *Emerg Infect Dis* **11**:1828, 2005. Available at: http://www.cdc.gov/eid
35. Pick N et al: Ehrlichiosis associated vasculitis. *J Intern Med* **247**:674, 2000



This page intentionally left blank

SECTION 32

SEXUALLY TRANSMITTED DISEASES

CHAPTER 200

Syphilis

Miguel R. Sanchez

Syphilis is a systemic infection caused by *Treponema pallidum* (ssp. *pallidum*), a microaerophilic spirochete that infects only humans and a few other primates. The organism is too delicate to be grown in vitro, yet so aggressive that it invades almost any organ in the body, and so evasive that it can elude even a healthy immune system and occasionally even massive doses of antibiotics.[1] The infection is usually acquired through sexual contact with infected lesions or body fluids; less commonly, transplacentally from mother to unborn child; and, rarely, through blood transfusion, accidental inoculation, or puncture with contaminated instruments such as those used for tattooing. Transmission occurs through oral sex in at least 13 percent of cases and in one-fifth to one-third of men who have sex with men.[2]

Dermatologists have a decisive advantage in diagnosing syphilis because of their skill in evaluating cutaneous eruptions. However, the infection is systemic, even in the absence of symptoms, despite the fact that mucocutaneous lesions are the most common sign. The variable clinical course and diverse manifestations were recognized long before Sir William Osler dubbed syphilis "the great imitator," but much remains to be learned about its pathogenesis, which continues to baffle even experienced clinicians, investigators, and epidemiologists.

HISTORY

EPIDEMIOLOGY

In the early part of the twentieth century, 10 percent of the population of the United States and Europe was infected with syphilis.[1] During World War I, the U.S. Congress launched several public health measures, including quarantines and compulsory premarital screening, after syphilis was detected in 13 percent of military draftees. The incidence of syphilis peaked between 1935 and 1947 as efforts to combat the disease were restrained by a conspiracy of silence. Surgeon General Thomas Parran, in his ambitious campaign to wipe out the "shadow on the land," called for a serologic dragnet to screen the population and to institute partner notification through "shoe leather" epidemiology. These aggressive public health policies were largely ineffective.

During World War II, the armed forces instituted successful preventive interventions that included public education, prostitution control, distribution of condoms, and availability of immediate treatment without punitive repercussions. As treatment with penicillin became widely available, syphilis decreased dramatically. The resurgence of sexually transmitted diseases seen in the 1960s was blamed on looser sexual attitudes (permissiveness, promiscuity, and the pill), but in the 1970s, enhanced control efforts again lowered the number of syphilis cases. Since then, the pattern has been sudden bursts in the rate of infected cases followed approximately every 5 to 10 years by periods of low prevalence.[3] The most effective public health strategies have been the selection and confidential screening of high-risk populations, partner notification, free treatment of infected persons and partners, behavior counseling, and rapid response to outbreaks. Still, kindled by the exchange of sex for money to buy crack cocaine, the rate of infectious syphilis catapulted in 1991 to a 50-year high of 102.3/100,000 population, only to decline in 1999 to an all-time low rate of 2.5/

SYPHILIS AT A GLANCE




- A predominantly sexually transmitted infection caused by the spirochete *Treponema pallidum*.
- The most common and recognizable manifestations are cutaneous.
- Syphilis passes through four distinct clinical phases:
  - Primary stage (chancre).
  - Secondary stage (skin eruption with or without lymphadenopathy and organ disease).
  - A latent period of indeterminate duration (no signs or symptoms, only reactive serologic tests).
  - Tertiary stage (gumma, neurosyphilis, or cardiovascular syphilis).
- Latent syphilis is diagnosed by the presence of reactive serologic tests in the absence of syphilitic signs or symptoms. History, physical examination, and further testing when indicated must exclude underlying organ involvement.
- The recommended treatment is long acting benzathine penicillin, with dose and administration schedule determined by disease stage.
- Persons with human immunodeficiency virus infection or other immunodeficiencies are at high risk of therapeutic failure and progression to neurosyphilis.



Copyright © 2008 by The McGraw-Hill Companies, Inc. Click here for terms of use.

100,000 population.[4] Encouraged by this success, the Centers for Disease Control and Prevention launched a National Plan for Elimination of Syphilis from the United States in 1998. However, outbreaks of syphilis among homosexual and bisexual men, including those who are human immunodeficiency virus (HIV) seropositive, continue to occur.[5] Also, the rate of syphilis among African Americans is 30 times higher than in Caucasians.[6] The facilitation of casual sex promoted by Internet sites may prove to be an important cause for future outbreaks in industrialized countries.[5]

In many parts of the world, syphilis continues to be a major public health problem. Despite therapeutic "magic bullets," the disease remains a formidable opponent.



ETIOLOGY

The cause of syphilis is *T. pallidum*, a motile, corkscrew-shaped, prokaryotic bacterium with a flexible, helically coiled cell wall (Fig. 200-1). The organism is microscopically indistinguishable from treponemes that cause pinta, yaws, or endemic syphilis and closely resembles the bacteria that cause Lyme disease, borreliosis, and leptospirosis.

T. pallidum measures between 6 and 15 μm in length and 0.10 and 0.18 μm in width. It has tapered ends between which are 6 to 14 regularly spaced tight spiral coils. When fixed, the spirals impart a wave-like configuration. Its narrow width renders the organism undetectable by light microscopy without silver staining. Under dark-field microscopic examination, the treponemes resemble strings of beads with a characteristic rotatory motion and a flexion and back-and-forth squiggle. This motion is said to be characteristic of virulent treponemes and to facilitate penetration through tissue. However, in fluid medium, the bacteria lack locomotion, which distinguishes them from most saprophytic treponemes. Replication occurs through fission, with an interval of 30 to 33 hours between divisions. The outer envelope, where growth requires approximately 30 steps and several enzymes, is susceptible to damage by antibiotics.

The spirochete has three main components. The protoplast is the central part of the treponeme and contains the genome and the organelles responsible for metabolism.[7] The axial filament (flagellum) consists of six to eight elastic fibrils twisted around the protoplast. It imparts a helicoid shape and contributes to the spirochete's mobility. The outer envelope contains a heteropolymer peptidoglycan macromolecule that preserves the organism's shape, protects the fragile cytoplasm against injury, and filters large molecules. An extracellular, amorphous slime layer may protect the organism against phagocytosis. It has been postulated that the organism evades formidable immune surveillance through a paucity of integral transmembrane proteins in the outer membrane to stimulate specific antibodies and by antigenic variation through gene conversion.

T. pallidum has a relatively small genome, suggesting that it uses host biosynthesis to fulfill some of its metabolic needs.[8]

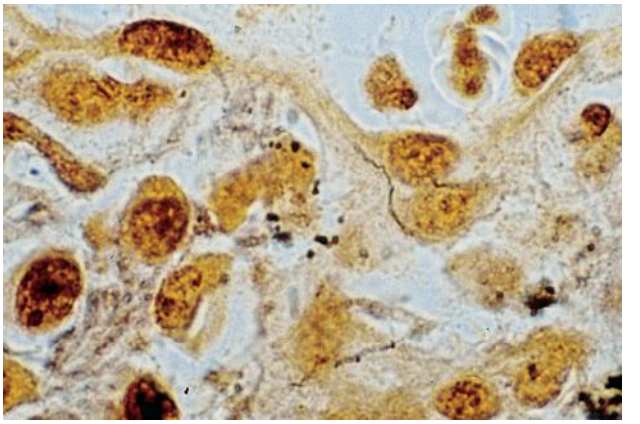

▲ **FIGURE 200-1** Silver stain of syphilis lesion showing the corkscrew-shaped treponemes.

IMMUNOLOGY

Understanding the disease has been hampered by the difficulty of growing the organism in culture and the laboriousness involved in growing treponemes in rabbits, the only animal model. In addition, the immune responses in patients with syphilis may differ during the various stages of infection. For this reason, contradictory conclusions have been reported.

T. pallidum penetrates mucosal surfaces and abraded skin of humans. Chemotactic factors attract neutrophils to the inoculation site. Skin breakdown results in a chancre, initiating the primary stage. In more mature chancres, neutrophils are replaced by lymphocytes that, through secretion of lymphokines, attract and activate macrophages. In the presence of exogenous antibody, macrophages ingest and destroy the organisms. Consistent with a T helper 1–predominant local cellular response, the lesions contain interleukin 1 (IL-2), interferon-γ, IL-10, and IL-12.[8] Plasma cells are also present in the infiltrate, and a humoral response is elicited. Antibodies to *T. pallidum* are detectable at the time or shortly after the chancre appears. Production of immunoglobulin M (IgM) precedes that of IgG. The combined humoral and cell-mediated immune responses appear to eliminate the spirochetes locally, resulting in the end of the primary stage. Polymerase chain reaction studies indicate that *T. pallidum* spirochetemia occurs during the primary stage (as well as the secondary and relapsing stages).[8]

After a few weeks, proliferation of spirochetes markedly increases, and the disease becomes generalized. During this secondary stage, antibody levels skyrocket in response to the huge numbers of organisms. The antibody response modifies the appearance of the secondary syphilis lesions, which would otherwise resemble primary chancres. At this time, resistance to new infection develops, although delayed-type hypersensitivity to *T. pallidum* becomes unexpectedly deficient. This suppression of cell-mediated immunity allows proliferation of the organisms despite rising antibody levels.

The secondary stage is followed by an asymptomatic stage called *latency*. During this period, delayed-type hypersensitivity reappears. In the tertiary stage, the immune response results in the formation of granulomas, although treponemes are rarely detected, even by immunofluorescence.

Immunity to re-infection develops only in untreated patients. After treatment, most re-infected patients develop typical chancres. The majority of patients with congenital syphilis are refractory to reinoculation and do not develop lesions or elevated antibody levels. A few develop dark-field–negative lesions associated with high antibody titers or gummas at the inoculation site.

The means by which some treponemes resist the immune attack, which

effectively clears practically every organism from early lesions, is unknown. Possible explanations include inhibition of cell-mediated responses, refuge of treponemes in anatomic sites [central nervous system (CNS), eye, aorta, bone, lymph nodes, or perilymph of middle ear] that shield the organisms from detection by the immune system, and protection by the slimy mucopolysaccharide coat surrounding the spirochetal cell wall. Some answers are provided by experimental infection in rabbits. Early on, immunity is normal, resulting in annihilation of most treponemes. However, treponemal antigens are able to induce the host macrophages to secrete twice as much prostaglandin E_2. As a result, IL-2 synthesis by these cells is halved and, consequently, T-cell proliferation is inhibited, leading to suppressed immunity that enables the remaining intact organisms to proliferate, even in the presence of antibody. The suppression persists for at least 1 month and can be reversed by indomethacin or a combination of IL-1 and IL-2.[9]

NATURAL HISTORY OF DISEASE

Syphilis has been described as an on- and off- and on-again disease. Early syphilis includes the primary stage (chancre), secondary disease (mucocutaneous lesions and/or lymphadenopathy, with or without organ involvement), and subsequent clinical relapses. Latent disease is subdivided into early (less than 1 year) and late (1 year or longer) stages. Tertiary (late) disease can present with cutaneous, cardiovascular, or neurologic involvement (Table 200-1).

TABLE 200-1
Stages of Syphilis

Contact (1/3 become infected)
↓ (10–90 days)
Primary (chancre)
↓ (3–12 wk)
Secondary (mucocutaneous lesions, organ involvement)
↓ (4–12 wk)
Early latent → Relapsing (in 25%)
(1 yr from contact)
↓
Late latent
(more than 1 yr)
↙ ↘
Remission (2/3) Tertiary (1/3)
Late benign (16%)
Cardiovascular (9.6%)
Neurosyphilis (6.5%)

Although the danger of direct transmission is exceedingly low after 5 years of infection, inoculation from gummas has been reported. Latent syphilis follows the secondary stage and may persist for life in an asymptomatic form in about two-thirds of untreated patients. The rest develop tertiary syphilis, which usually manifests as cutaneous (16 percent), cardiovascular (9.6 percent), or CNS (6.5 percent) disease (see Table 200-1). Syphilis was the cause of death in 11 percent of the patients in the Oslo study. In African American men with untreated syphilis, the mortality appears to be even higher, as cardiovascular disease was found in approximately one-half of autopsies from persons participating in the Tuskegee experiment.[10]

More recent analyses suggest that 1 in 25 persons with untreated syphilis become crippled, 1 in 44 insane, and 1 in 200 blind (see on-line version).

CLINICAL FINDINGS

Primary Syphilis

CUTANEOUS FINDINGS Studies from the pre-antibiotic era typically found that 50 percent to 75 percent of persons who come in contact with a lesion of primary or secondary syphilis become infected. Even in the absence of clinical or serologic evidence of syphilis at the time of evaluation, 30 percent of exposed partners will develop the infection. At the site of treponemal penetration, after an incubation period that ranges from 10 to 90 days (average, 3 weeks), a dusky red macule appears that grows into a papule and becomes a chancre by ulcerating in the center (Fig. 200-2). The length of the incubation period varies inversely with the number of inoculated treponemes. The chancre is round or oval, measures approximately 1 cm in diameter, has sharply demarcated, regular, raised, firm, rubbery borders (Fig. 200-3), and, in the absence of trauma or impetiginization, is nontender. The smooth, ham-colored ulcer base may be covered with yellowish crust or grayish slough.[12] Untreated, the chancre persists from 1 to 6 weeks; it resolves within 1 to 2 weeks after treatment and heals without scarring. However, deviation from the above description is common, and the classic "Hunterian" chancre is seen in approximately 60 percent of cases.[13] In a significant number of cases, the lesions go unnoticed. Multiple chancres (Fig. 200-4) may be present in up to 47 percent of cases, and edema, phimosis, erosive balanitis, lymphangitis, and thrombophlebitis of the dorsal vein may



▲ **FIGURE 200-2** Early chancre presenting as a flat, eroded papule with raised, indurated borders and a smooth, clean base.

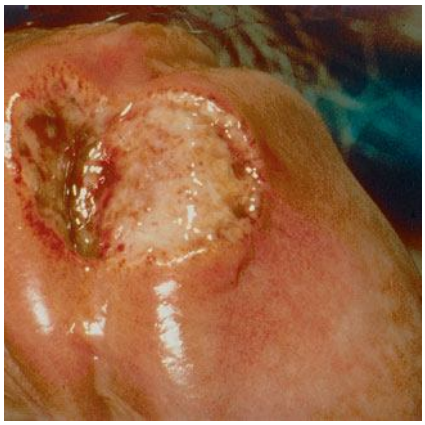

▲ **FIGURE 200-3** Classic "Hunterian" chancre with raised, indurated borders and a slightly hemorrhagic necrotic base.



▲ **FIGURE 200-4** Multiple chancres at the base of the penis and adjacent pubis. Chancres in this location are associated with use of condoms.



be found. In industrialized countries, co-infection with herpes genitalis is the most plausible explanation for the presence of multiple chancres. In men, the commonly involved locations are the glans, the coronal sulcus, and the foreskin. Chancres in the urethral orifice have been reported to cause an inflammatory phimosis that may eventuate in penile gangrene. Retraction of the foreskin with a chancre in its mucosal surface causes the foreskin to flip briskly, a sign known as the *Dory flop*.

In women, the labia, fourchette, urethra (Fig. 200-5), and perineum are affected, in descending order of frequency. Chancres in women tend to have an edematous rather than a cartilaginous induration. Edema indurativum is a unilateral labial swelling with rubbery consistency and intact surface, characteristic of a deep-seated chancre in this site. Chancres develop in the cervix in as many as 44 percent of infected women but are rarely detected. Kissing chancres are common in areas of skin-to-skin contact such as the vulva.

Approximately two-thirds of extragenital chancres occur above the neck, and approximately one-half of these are seen on the lips, the perioral region, or in the oral cavity (Fig. 200-6). Orolabial chancres invariably result from oral sex. The rest appear on the fingers, breasts, trunk, abdomen, and extremities. Chancres on the fingers may be painful. The precise prevalence of anorectal chancres is difficult to establish, but anyone who has anal sex is at risk. Anorectal primary syphilis is often asymptomatic and underdiagnosed and should be considered in any at-risk person with rectal pain, bloody stools, anal fissures, or a precipitously appearing mass or ulcer in the anorectal area.



▲ **FIGURE 200-5** Chancre in a female. An ulcer covered with fibrin and necrotic slough at the orifice of the urethra.



▲ **FIGURE 200-6** Extragenital chancre. A deep ulcer with an indurated border and base. Most extragenital chancres are located on the lips or the perioral region.

In 70 percent to 80 percent of all primary syphilis cases, enlarged, rubbery, movable, non-tender, non-suppurative, discrete lymph nodes (buboes, also scleradenitis) appear during the first week of infection.[13] The nodes are usually unilateral at first and most commonly palpated in the inguinal area, although, in women, the femoral nodes are often enlarged. In one study, the nodes were tender in 14 percent of patients. Relapses of primary syphilis, called *monorecidive syphilis* or *chancre redux*, are rare.

DIFFERENTIAL DIAGNOSIS Primary stage lesions of syphilis should be considered in the evaluation of any perianal, anal, or genital ulcer, and should be excluded in any ulceration of the lips, oral mucosa (Box 200-1).

Box 200-1

Differential Diagnosis of Primary Syphilis

Most Likely

- Chancroid
- Herpes simplex
- Granuloma inguinale
- Traumatic erosion or ulcer

Consider

- Herpes simplex
- Early lymphogranuloma venereum
- Chancriform pyoderma
- Aphthous ulcer
- Behçet disease
- Squamous cell carcinoma
- Basal cell carcinoma
- Fixed-drug eruption
- Erosive candidal vulvitis or balanitis

Secondary Syphilis

CUTANEOUS FINDINGS Lesions of secondary syphilis erupt 3 to 12 weeks after the appearance of the chancre but may develop months later or, in up to 15 percent of cases, before the chancre disappears. The secondary stage usually recedes in 2 to 12 weeks.[12] Not all patients present with classic symptoms and clinical findings. These may be subtle, transient, and easily overlooked or so severe that hospitalization is required. Almost 60 percent of patients with latent or late syphilis deny ever experiencing signs or symptoms of secondary disease. One-fourth of these patients cannot recall the appearance of a chancre. Patients with secondary syphilis may experience symptoms such as malaise, appetite loss, fever, headache, stiff neck, lacrimation, myalgias, arthralgias, nasal discharge, and depression. However, between 80 percent and 95 percent of cases present with a skin eruption, which invariably is the salient diagnostic feature of the infection. The precise frequency of organ involvement differs among studies. In a series of 2269 cases of secondary syphilis, the skin was involved in 81.1 percent, the oral cavity and pharynx in 36.3 percent, the genitalia in 19.9 percent, the CNS in 9.9 percent, the eyes in 4 percent, and visceral organs in 0.2 percent. Wise clinicians learn to consider the "great imitator" when confronting a combination of signs and symptoms that cannot be readily explained.[13]

Most eruptions are macular and/or papular.[12] Nodular and pustular eruptions occur infrequently, but vesiculo-bullous lesions are seen only in congenital syphilis. Early on, the lesions of secondary syphilis often have a symmetric pattern and become polymorphic later. Pruritus may be more common among African Americans. With or without treatment, non-ulcerated secondary lesions heal without scarring after 2 to 12 weeks.

Macular eruptions (roseola syphilitica) consist of .05- to 2.0-cm, pink, discrete, non-scaling, oval macules and patches, which predominantly involve the trunk and flexor aspects of the upper extremities (Fig. 200-7). The face is usually spared, but any area, including the palms and soles, may be involved.

Macular and papular eruptions represent an evolution of the macular lesions toward papules and plaques, as some

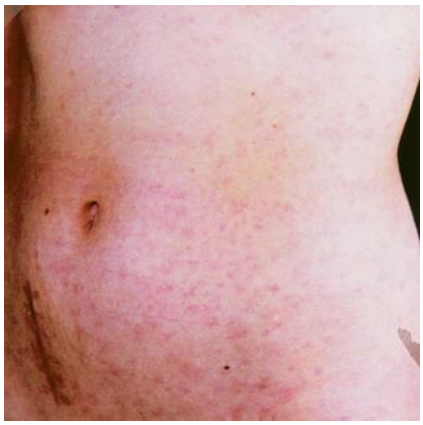

▲ **FIGURE 200-7** Macular syphilis (roseola syphilitica) with non-scaling, oval pink, ill-defined macules and patches on the chest and abdomen.

macules become palpable and develop a dark coppery hue (Figs. 200-8 and 200-9). Lesions are often present on the genitalia, face, palms, and soles. Lesions around the hairline form a crown-like pattern known as the *corona veneris*.

Papular eruptions include papulosquamous, follicular, lenticular, corymbose (bombshell), nodular, annular, and follicular varieties. They may be generalized (see Fig. 200-9) or grouped, aggregated, and localized to defined sites (Figs. 200-10 and 200-11).

Papulosquamous eruptions have discoid, copper-colored or erythematous, oval or circular, indurated papules or plaques with a flat, shiny, scaly surface (see Fig. 200-10). When the lesions are pruritic and lichenoid, the eruption may be difficult to distinguish from lichen planus (see Fig. 200-11) and, when hyperkeratosis is pronounced, the eruption may resemble psoriasis. The occasional presence of the Koebner phenomenon further contributes to this confusion. A thin white ring of scales on the surface of a lesion (Biette's collarette) is a valuable but not pathognomonic diagnostic sign. The palms and soles are often involved (Fig. 200-12). On the soles, the lesions may become hyperkeratotic and be mistaken for calluses (clavi syphilitici) or tinea pedis.



▲ **FIGURE 200-9** Generalized papulopustular syphilitic eruption. Note coppery tone of the papules and central crusting of some of the pustular lesions.



▲ **FIGURE 200-11** Lichenoid syphilitic eruption with pink to violaceous, planar, polygonal papules resembling lichen planus.

Lenticular eruptions consist of pinhead to lentil-size, brown to red papules with smooth surfaces or fine scaling. The face, especially the forehead, oral commissures, nasolabial folds, and the genitalia, are favored sites.

Corymbose eruptions are rare and seldom occur before 6 to 8 months of infection. Typically, a large central papule or plaque is surrounded by smaller satellite papules (Fig. 200-13).

Nodular eruptions consist of dermal nodules, frequently misdiagnosed as lymphoma or a granulomatous disease (Fig. 200-14).

Annular eruptions consist of oval or round ring-like papules and plaques with a predilection for the face, anogenital area, body folds, palms, and soles. The eruption is often misdiagnosed as sarcoid, granuloma annulare, or tinea corporis. Serpiginous, concentric, or arcuate configurations may be seen.[13]

Follicular eruptions consist of pinpoint, acuminate, or rounded erythematous papules that arise in crops on the torso and extremities. This eruption is uncommon and has been reported predominantly in debilitated persons such as alcoholics.

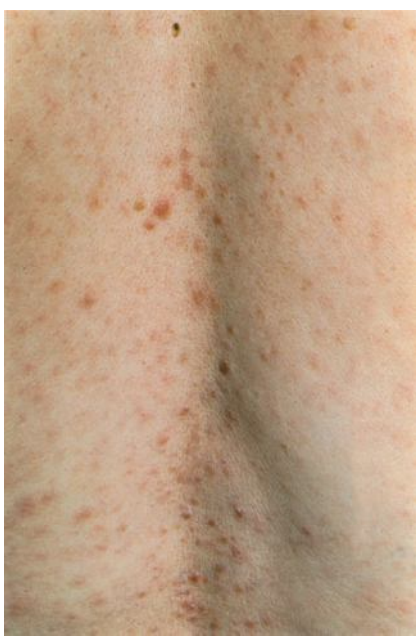

▲ **FIGURE 200-8** Syphilis showing a combination of erythematous macules and coppery papules.



◀ **FIGURE 200-10** Papulosquamous syphilitic eruption with erythematous, well-demarcated, flattened plaques covered with scales (Biette's collarette).



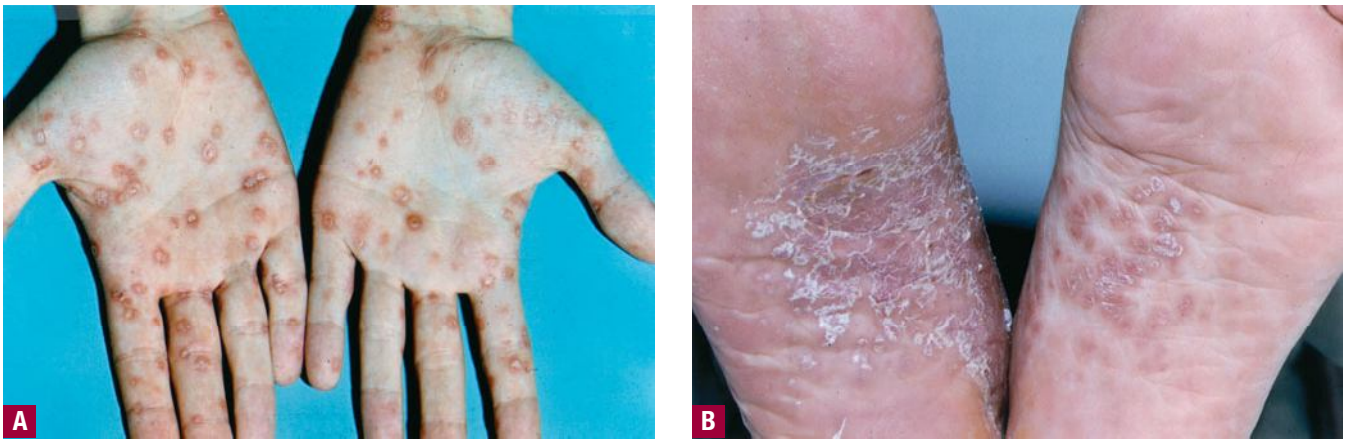

▲ **FIGURE 200-12** Characteristic secondary syphilis lesions on the palms (**A**) and soles (**B**). Palmo-plantar lesions may be macular or papular, discrete or diffuse, and non-scaling, slightly scaly, or hyperkeratotic ("syphilitic corn").



Pustular eruptions include several morphologic variants. In miliary pustular eruptions, small acuminate pustules and papules resolve with depressed pigmented scars. In acneiform, varioliform, or obtuse eruptions, there are large, acuminate perifollicular pustules, often with polymorphism (see Fig. 200-9). In impetiginoid or ecthymiform eruptions, flat pustules become confluent and covered with a large crust called a *carapace*.

Malignant syphilis (lues maligna, rupial syphilis, pustuloulcerative syphilis) presents with widespread papulopustules or nodules that become necrotic and break down into ulcers covered by layers of rupioid crust resembling an oyster shell (Fig. 200-15). The eruption is associated with toxicity, fever, arthralgias, and, occasionally, hepatitis. Oral ulcers and mucous patches may develop. Most patients are immunocompromised or in poor health. Infected contacts usually have a more benign course, and there is no evidence that the treponemes causing the infection are more virulent. Noduloulcerative syphilis with or without systemic symptoms is more common in immunocompromised HIV-infected persons.

Pigmentary changes may remain after healing of lesions. On the sides of the neck, an interesting pattern consisting of hypopigmented macules superimposed on linear pigmented reticulated patches, has been called *leukoderma colli syphiliticum* or the *Necklace of Venus*. In dark-skinned individuals, intense loss of pigment within the affected areas may resemble vitiligo. Hypopigmentation in syphilis results from partial inhibition of melanogenesis as the number of melanocytes is normal or only slightly reduced. Dermal atrophy, possibly related to inflammation-induced elastin degradation, may lead to an anetoderma-like appearance.



▲ **FIGURE 200-13** Corymbose syphilitic eruptions occur late in the secondary stage, usually after 6 to 8 months of infection. A larger papule or plaque is surrounded by smaller satellite papules.

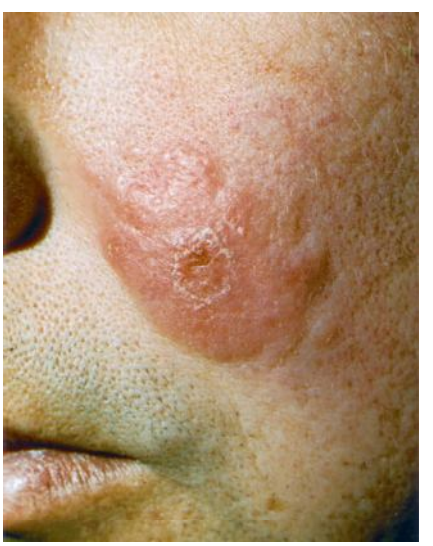

▲ **FIGURE 200-14** Nodular secondary syphilis on the face of a man. Such lesions are frequently misdiagnosed as lymphoma or a granulomatous disease, such as sarcoidosis, leprosy, or lupus vulgaris.

Mucous membrane lesions are extremely infectious. The three manifestations are condylomata lata, mucous patches, and pharyngitis. The last two heal spontaneously within 2 to 3 weeks, but condylomata may persist for months.[13]

Condylomata lata consist of flesh-colored or hypopigmented macerated papules or plaques (Fig. 200-16). They have been reported in 9 percent to 44 percent of syphilis cases. Their surface may be smooth, papillated, or covered with cauliflower-like vegetations. The common sites are the genital and anal areas and, less frequently, the oral commissures, face, axillae, inframammary folds, and toe webs (Fig. 200-17).[14] Lesions in intertriginous areas may erode or proliferate, forming elevated, brown, velvety plaques or grouped hypertrophic, nodular lesions that resemble raspberries (frambesiform syphilis). Overgrowth of bacteria produces a foul odor.

Mucous patches are painless, shallow, rounded erosions covered with gray macerated scaling (Fig. 200-18). Present in 7 percent to 12 percent of secondary syphilis cases, the lesions may appear anywhere in the mouth but are more common on the tongue and lips.[15] The tonsils and epiglottis may be affected. Confluence of several denuded lesions on the tongue has been termed *plaques fauches en prairie*. Mucous patches also arise on the glans penis, inner vulva, and anus. Split papules are elevated mucous patches with central fissures in the oral commissures (see Fig. 200-18).

Pharyngitis of variable severity may occur in up to one-fourth of cases, al-



▲ **FIGURE 200-15** Sharply marginated, necrotic ulcers covered by "rupioid," thick, dirty crusts (like oyster shells) are the characteristic lesions of malignant syphilis.



▲ **FIGURE 200-18** Mucous patches on the lips. These erosions covered with gray-white, macerated scales are seen on the lips, oral mucosa, tonsils, and larynx. Lesions in the buccal commissure are fissured in the center (split papules).



though soreness is rare. Diffuse redness of the pharynx, palate, and tonsils may be very mild or severe with edema and erosions. Pseudomembranes and necrosis have been reported, and laryngeal involvement may produce hoarseness.

Nail changes in secondary syphilis may result from involvement of either the nail matrix or the nail folds. In the nail plate, brittleness, splitting, onycholysis, pitting, lunular elkonyxis (pits) with fissuring, and dystrophy have been described. The nail plate growing during the infectious episode may become dull, dry, thickened, and Beau's lines or latent onychomadesis (separation) may appear. Paronychia of the lateral and proximal nail folds may develop. The nail bed may become ulcerated, producing an exudate that may cause separation, shedding, and even permanent deformity of the nail plate. Amber-colored plates resembling artificial nails have been reported to be characteristic of late secondary syphilis. Cyanotic, painful toes (the blue toe syndrome) are an unusual manifestation.[16]

Hair loss may be the only sign of secondary syphilis. It has been described in 3 percent to 7 percent of cases, and may be either patchy, diffuse, or both.[17] The more characteristic type consists of small irregular patches of non-scarring alopecia throughout the scalp but predominantly on the occipital and parietal regions. The term *moth-eaten* is often used descriptively (Fig. 200-19). In some cases, the lesions resemble trichotillomania or alopecia areata. Occasionally the eyebrows, beard, and other hair-bearing areas are affected. Diffuse hair loss may occur as a result of scalp involvement by secondary syphilis or as a telogen effluvium, clinically apparent 3 to 5 months after the infection begins.

DIFFERENTIAL DIAGNOSIS Secondary syphilis can resemble almost any exanthematous maculopapular but also localized popular eruption; mucous membrane lesions resemble mucosal manifestations of other dermatoses, and syphilitic hair loss has to be separated from a number of alopecias (Box 200-2).

Non-Cutaneous Clinical Findings

LYMPHORETICULAR SYSTEM Enlarged lymph nodes are present in 50 percent to 80 percent of cases. In descending order of frequency, the inguinal, axillary, cervical, epitrochlear, femoral, and superclavicular chains are involved. Typically, the nodes are movable, firm, rubbery, discrete, bilateral, symmetric, and non-tender.[12] Mild splenomegaly is not rare.



▲ **FIGURE 200-16** Rounded, gray, moist, vegetating papules (condylomata lata) develop most frequently on the anogenital area, but may arise on the lips, groin, and toe webs. The lesions are often confused with condylomata acuminata (venereal warts).



▲ **FIGURE 200-17** Coppery, eroded, and crusted papules of secondary syphilis may also be found in the toe webs, where they may be mistaken for tinea, erythrasma, or, as in this case, Kaposi sarcoma.

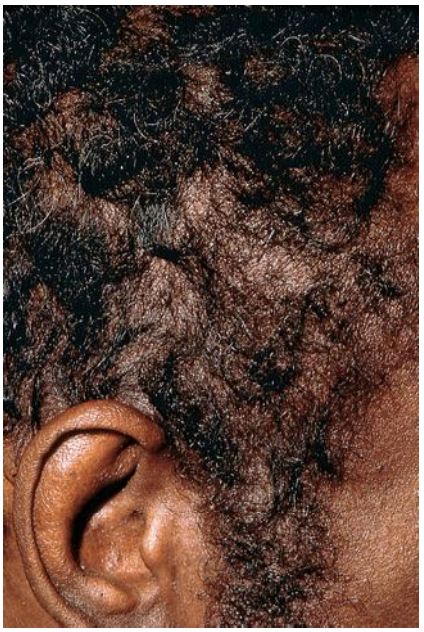

▲ **FIGURE 200-19** Moth-eaten alopecia is the more common form of hair loss. Irregular, patchy, non-scarring alopecia is present more frequently on the occipital scalp and occasionally affects the eyebrows and beard.

OPHTHALMOLOGIC Iritis, the most common eye complication, occurs in fewer than 3 percent of all cases, late in the course of secondary syphilis, or in relapsing syphilis. The patient presents with injected sclerae and complains of pain, lacrimation, and photophobia. Uveitis, chorioretinitis, and, rarely, vasculitic occlusion of the central retinal vein and artery are also observed. A recent report concluded that 4.3 percent of 552 cases of uveitis were syphilitic.[18] Symptoms include photophobia, lacrimation, pain, and blindness. Topical glucocorticoids without antibiotics are contraindicated.

AUDITORY There are a few reports of sensorineural hearing loss in early acquired syphilis. The condition worsens rapidly and tends to be bilateral. Vestibular involvement with labyrinthitis is uncommon. However, 6 percent of all cases of Ménière disease are caused by congenital or acquired syphilis.[19] The pathogenesis is usually basilar meningitis with damage to the eighth nerve. Immediate treatment with antibiotics and a prolonged course of prednisone preserves hearing in almost all cases.

MUSCULOSKELETAL Because bone and joint involvement are not readily apparent, the impression has been that they are rare. However, clinical and imaging studies have found rates ranging from 0.15 percent to 4.0 percent up to 9.0 percent, respectively. The principal symptoms are local pain, erythema, doughy tumefaction, and warmth. Favored sites are the long bones of the extremities, especially the tibia, and the skull, with resulting persistent headaches. Radiographs and more sensitive bone scans demonstrate various combinations of periostitis, osteomyelitis, bone destruction, and sclerosis. Radiographic changes may take up to 11 months for complete resolution after appropriate therapy. Back pain, arthralgias, arthritis, tenosynovitis, and bursitis may be severe and persist for several months. Patients may experience generalized myalgias and muscle weakness that resembles an inflammatory myopathy.

HEMATOLOGIC Abnormalities include anemia, leukocytosis, relative lymphopenia, and elevated sedimentation rate.

RENAL Acute membranous glomerulonephritis, usually manifested by the nephrotic syndrome, is reversible with treatment.

HEPATIC Although usually sub-clinical, the incidence of luetic hepatitis was 9.7 percent in one study. Jaundice is seldom detected.

GASTRIC Epigastric pain and postprandial vomiting may be caused by eroded, ulcerated, or polypoidal stomach lesions, which heal with antibiotics. Erosive syphilitic gastritis usually affects the antrum of the stomach.

LATENT SYPHILIS

The secondary stage is followed by an asymptomatic stage with no clinical findings; the only evidence of the disease is reactive serologic testing. Latency may remain indefinitely, be interrupted by a relapse of secondary syphilis, or progress to the tertiary stage.[13] Because latent syphilis is a diagnosis of exclusion, careful examination for mucocutaneous lesions and organ involvement is required. In addition, ultrasound evaluation of the aorta to exclude cardiovascular disease and cerebrospinal fluid (CSF) examination for neurosyphilis should be considered if the history or physical findings suggest these diagnoses. Spinal taps are not required unless neurologic symptoms or signs or symptoms are present.

For therapeutic and epidemiologic purposes, the latent stage is divided into early (less than 1 year) and late (1 year or longer) stages. Hence, the duration of infection should be determined by history and previous serologic tests. However, this determination may not always be possible, and the clinician must settle for a diagnosis of indeterminate latency, which is treated in the same manner as late latent syphilis.

In clinical practice, patients who were adequately treated but who continue to have low titers of nontreponemal tests are commonly seen. If adequate previous treatment or lack of reinfection cannot be confirmed, these patients should be assumed to be infected and treated. A record of the nontreponemal test titer and the administered therapy should then be given to the patient. Unfortunately, some patients are unnecessarily retreated repeatedly because such records are not readily available.

RELAPSING SYPHILIS

Approximately 25 percent of untreated patients relapse despite the absence of re-infection. More than two-thirds of the relapses occur within 6 months, 90 percent occur within the first year, and 95 percent occur within 2 years.[13] Relapses may present with the reappearance of chancres or, more frequently, an eruption of secondary syphilis, including mucous patches and condylomata lata. Relapsing syphilis lesions tend to be less extensive

Box 200-2

Differential Diagnosis of Secondary Syphilis

Most Likely

- Pityriasis rosea
- Condyloma acuminata (condyloma lata)
- Drug eruption
- Viral eruption
- Psoriasis
- Reiter syndrome

Consider

- Lichen planus (lichenoid eruption, mucous patch)
- Eczema
- Sarcoid
- Cutaneous T-cell lymphoma
- Erythema multiforme
- Balanitis
- Vulvitis
- Granuloma annulare
- Lupus erythematosus
- Dermatophytosis
- Anogenital molluscum contagiosum (condylomata lata)
- Vulvar vestibular papillae (condylomata lata)
- Anal tags (condylomata lata)
- Squamous papilloma (oral lesions)
- Verruciform xanthoma (mucous patch)
- Leukoplakia (mucous patch)
- Glossitis (mucous patch)
- White sponge nevus (mucous patch)

and are frequently confined to the anogenital and oral areas, but remains highly contagious. Because patients may be unaware of the lesions or insufficiently concerned to seek medical help, relapsing syphilis is particularly of concern from an epidemiologic standpoint. Other presentations include periostitis (usually tibial), iritis, and hepatitis.

TERTIARY SYPHILIS

Approximately one-third of patients with untreated latent syphilis develop tertiary syphilis, while the other two-thirds remain in perpetual latency. The three principal presentations during this stage are late benign syphilis, cardiovascular disease, and neurosyphilis.

Late Benign (Tertiary) Syphilis

Late benign syphilis includes any symptomatic syphilitic manifestation after the secondary and relapsing stages that does not involve the cardiovascular or nervous systems. The lesions are caused by a cell-mediated inflammatory response to a small number of treponemes present in the affected tissues. At the beginning of the twentieth century, the incidence in untreated men and women was approximately 15 per 100,000 population, but now this stage is rare, possibly as a result of widespread use of antibiotics for other infections. The more commonly involved organs are the skin (70 percent), mucous membranes (10.3 percent), and bones (9.6 percent), but gummas may appear in practically any organ, including the parotid glands, thyroid, esophagus, stomach, liver, breasts, pancreas, kidneys, adrenal glands, spleen, bladder, and cervix, as well as the brain and heart. Chronic iritis, chorioretinitis, interstitial keratitis, and atrophy of the optic nerve are rare. Painless, fibrosing interstitial orchitis can lead to infertility.

LATE BENIGN SYPHILIS OF THE SKIN Tertiary skin lesions can be divided into three types: granulomatous nodules, psoriasiform granulomatous plaques, and gummas (Box 200-3). "Precocious" lesions develop within the first 2 years after resolution of the secondary stage, and "late" lesions at any time after that. Most lesions develop within 3 to 7 years, but gummas have appeared as long as 60 years after infection. The longer the interval before the appearance of the skin lesions, the more solitary and destructive the process.[13]

Precocious tertiary syphilis occasionally develops within weeks. Infiltrated grouped papules that tend to ulcerate may be localized to one site or be more widespread. The papules have features of both secondary stage lesions and tertiary stage granulomas. Bacteria are rarely detected. The lesions heal with little or no scarring.

Box 200-3

Differential Diagnosis of Tertiary Syphilis

Consider

- Sarcoid (specially ulcerative)
- Metastatic carcinoma
- Sarcomas
- Lymphomas
- Wegener granulomatosis
- Leishmaniasis
- Vasculitis
- Deep fungal infections
- Lupus vulgaris
- Psoriasis

Nodular and noduloulcerative tertiary lesions (Fig. 200-20) are superficial, firm, painless, dull-red, shiny, flat cutaneous nodules that measure several millimeters to 2 cm in size. The nodules appear in a grouped configuration and coalesce into plaques.[20] The skin overlying the lesions breaks down, resulting in irregular ulcers covered with crust. Over weeks or months, central healing and advancing borders produce plaques with annular, arciform, serpiginous, or polycyclic configurations that may grow to more than 30 cm (Fig. 200-21). Some plaques may be psoriasiform (Fig. 200-22). The lesions are most commonly seen on the arms, back, and face. Even without treatment, the granulomas heal after several years, leaving atrophic scars with increased or decreased pigmentation. These lesions are often misdiagnosed as gummas.



▲ **FIGURE 200-20** A noduloulcerative tertiary syphilitic lesion is a sharply defined and irregularly shaped flat nodule of a dull red color, firm consistency, and superficial ulcerations.



▲ **FIGURE 200-21** Crusted and scaly noduloulcerative tertiary syphilis plaques with characteristic serpiginous borders and scarring.

Gummas are non-tender pink to dusky-red nodules or plaques that vary in size from millimeters to many centimeters in diameter.[21] They favor sites of previous trauma and may arise anywhere in the body but are more common on the scalp, forehead (Fig. 200-23), buttocks, and presternal, supraclavicular, or pretibial areas. The nodule is initially firm but develops a gummy consistency due to accumulation of necrotic tissue. Gummas may grow horizontally as well as vertically, and many assume geometric configurations. Small ulcers and abscesses may be present within the lesions (see Fig. 200-23). As the central gumma heals, new lesions may develop on the periphery, forming scalloped borders. In contrast to noduloulcerative lesions, gummas are deeper



▲ **FIGURE 200-22** Plaque of tertiary syphilis may be brick-red in color, covered with scales, and may be indistinguishable from psoriasis.





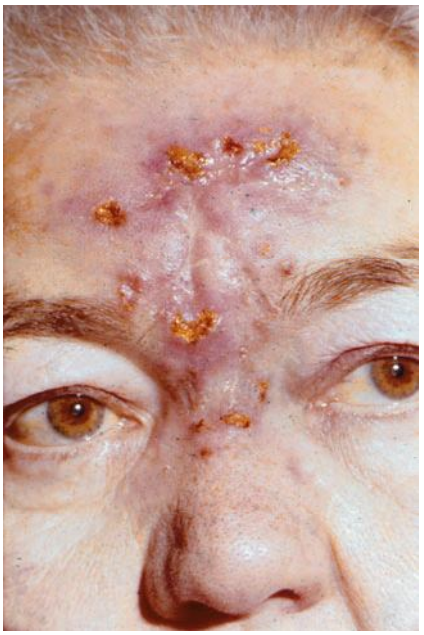

▲ **FIGURE 200-23** Disfiguring gummatous infiltration of the glabella and forehead with scattered ulcerations in a 60-year-old woman with late benign syphilis.

and more destructive (Fig. 200-24). Tissue necrosis eventuates in cylindrical, punched-out ulcers with clean granulomatous bases covered with adherent yellow-white slough (Fig. 200-25). The ulcer may enlarge, remain unchanged, or heal spontaneously even as the gumma enlarges. Superficial gummas heal with atrophic scars, whereas deeper lesions leave thickened, pitted, ridged scars. The lesions are rarely contagious, but infection following contact with gummas has been reported.



▲ **FIGURE 200-25** Two deep, punched-out ulcers in the popliteal fossa covered with an adherent yellow slough at the base. This is the classical appearance of nodular gummas.

MUCOUS MEMBRANE LESIONS OF LATE BENIGN SYPHILIS Discrete gummas or diffuse gummatous infiltration may involve mucous membranes, especially the palate, nasal mucosa, tongue, tonsils, and pharynx. The lesions ulcerate and are disfiguring. Destruction of the nasal cartilage and bone (saddle nose) (Fig. 200-26A) and perforation of the nose and palate are disease hallmarks (see Fig. 200-26B). Chronic interstitial glossitis even after penicillin treatment and may undergo malignant degeneration (Fig. 200-27). Gummas of the larynx, trachea, and bronchi are rare. Pulmonary findings include chronic infection with miliary lesions, a nodule, or pleural effusion. Pseudochancre redux refers to a solitary gumma of the penis.

Skeletal late syphilis includes gummatous osteitis, periostitis, and sclerosing osteitis. The bones most commonly affected are the tibia, clavicle, skull, fibula, femur, and humerus, but the disease can involve almost any bone. Symptoms include nocturnal pain, swelling, and tenderness.

Cardiovascular Syphilis

Although currently regarded as a medical curiosity, new cases of cardiovascular syphilis continue to be reported. In early syphilis, cardiovascular disease is rare and limited to conduction defects, but it is common in tertiary syphilis. In the Oslo study (see Natural History of Disease in on-line edition), 13.6 percent of men and 7.6 percent of women developed cardiovascular syphilis, which was the primary cause of death in 15.1 percent of affected men and 8.2 percent of affected women. Symptoms and signs usually develop 15 to 30 years after the initial infection, and only 7 percent of patients with cardiovascular syphilis manifest symptomatic disease within 5 years of infection.

Presumably, during the early stages of syphilis, treponemes invade the aortic wall, where they can remain dormant indefinitely. The treponemes have a pre-

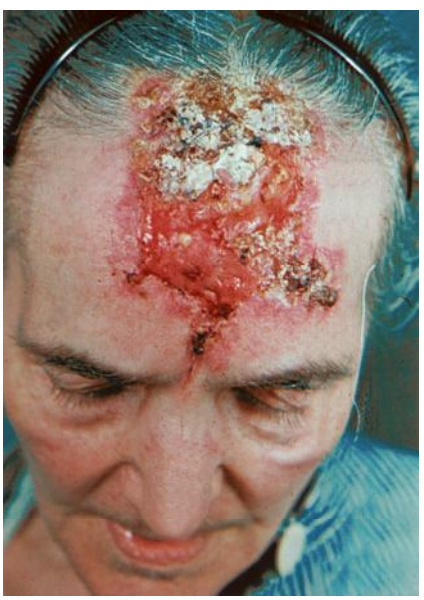

▲ **FIGURE 200-24** Aggressive gumma of the forehead causing destruction of the calvarium, mimicking advanced, destructive basal cell carcinoma.



▲ **FIGURE 200-26** **A.** Destruction of the nasal cartilage and bone by a gumma leads to a saddle nose and (**B**) to the perforation of the nasal cartilage and skin and thus to considerable mutilation.



▲ **FIGURE 200-27** Pre-malignant, chronic, interstitial glossitis secondary to gummatous infiltration of the tongue.

dilection for the aortic vasa vasorum and cause chronic, low-grade inflammation that eventuates in an obliterative endarteritis with gradual necrosis of the muscular and elastic tissues and scarring. Fibrous thickening of the adventitia and atherosclerotic plaques in the intima impart the tree bark appearance that is highly suggestive of syphilis.

The most common complications of cardiovascular syphilis are aortitis, aortic aneurysm, aortic valve incompetence, coronary ostial stenosis, and myocardial gummatous disease.

Uncomplicated aortitis comprises between 27 percent and 36 percent of cardiovascular syphilis cases. The changes occur predominantly in the ascending aorta, with fewer than 10 percent of the cases involving the abdominal aorta and only 2 percent affecting the portion below the renal artery.[22] Most cases are asymptomatic and diagnosed inadvertently at postmortem examination. The diagnosis is suspected when linear eggshell calcifications of the antero-lateral aortic wall are present in chest radiographs.

Aortic aneurysms comprise 20 percent of cardiovascular syphilis cases. The proportion is actually 40 percent if cases with coronary ostial or aortic valvular disease are included. Focal weakening of the wall results in a saccular aneurysm, whereas diffuse weakening produces fusiform involvement of the ascending and transverse aorta with subsequent dilation of the aortic ring. The distribution of aneurysms reflects that of the underlying aortitis.

Coronary ostial stenosis constitutes 25 percent to 30 percent of cases of cardiovascular syphilis. Like other forms of ischemic heart disease, the main symptoms are angina pectoris and congestive heart failure. Clues to the syphilitic etiology are the relative young age of the patient, absence of arteriosclerotic changes, reactive syphilis serology, poor response to vasodilators, and concomitant aortic regurgitation. Acute myocardial infarctions rarely occur because the stenosis is gradual and stimulates the development of an adequate collateral circulation.

Aortic valvular incompetence is found in approximately 30 percent of patients with tertiary disease. It is a late complication caused by aortic ring dilation and stretching of the valve. The soft diastolic blowing murmur of aortic regurgitation is best heard over the second right intercostal space. Myocardial disease occurs in only 2.4 percent of cardiovascular syphilis patients. In diffuse gummatous myocarditis, the most common locations are the left ventricle and septum, where gummas can cause heart block and conduction defects.

Neurosyphilis (Table 200-2)

Hematogenous invasion of the meninges by *T. pallidum* occurs early in syphilis. About 25 percent of patients with untreated primary or secondary syphilis do not clear the spirochetes from the CNS, and the organisms presumably remain dormant. After adequate treatment with benzathine penicillin, nearly all patients, including approximately 99 percent of immunocompetent individuals, eradicate the organisms from their CNS. Approximately 9.4 percent of men and 5 percent of women with remaining CNS treponemes (asymptomatic neurosyphilis) are at risk for developing overt neurosyphilis. Although it has been assumed that the development of CNS disease depends primarily on the host's immunologic response to the infection, especially neuroinvasive *T. pallidum* strains have been recently identified. Furthermore, the clinical phenotype of infection varies with the infecting strain.

TABLE 200-2
Classification of Neurosyphilis

- Asymptomatic
- Meningeal
  - Acute meningitis (headache, fever, photophobia, stiff neck, confusion)
    - With hydrocephalus (severe headache, nausea, vomiting, papilledema)
    - With vertex involvement (seizures, aphasia, hemiplegia)
    - With basilar involvement (tinnitus, deafness, Bell palsy)
  - Spinal pachymeningitis (cervical pain, muscle atrophy, sensory loss, spastic paraplegia)
- Meningovascular
  - Cerebral (prodromal symptoms, hemiparesis, hemiplegia, aphasia, seizures)
  - Spinal
    - Meningomyelitis (paresthesia, spastic weakness of legs, sensory loss, sphincter disturbances)
    - Acute transverse meningitis (sudden flaccid paraplegia, hemiparesis, sensory loss, urinary retention)
- Parenchymatous
  - General paresis (impaired judgment, irritability, delusions, dysarthria, tremors, incontinence)
  - Tabes dorsalis (paresthesia, lightning pains, ataxia, incontinence, impotence, papillary disturbances)
  - Optic atrophy (vision loss)
- Gummatous
  - Cerebral
  - Spinal

Symptoms usually develop between 5 and 35 years after the initial infection. The clinical manifestations are protean, but the classification (see Table 200-2) is useful and widely used. Neurosyphilis is divided into asymptomatic, meningeal, meningovascular, parenchymatous, and gummatous disease. Perhaps as a result of the liberal use of antibiotics, which may partially treat CNS infection, the classic forms of neurosyphilis are becoming less common and the presentations more atypical. In clinical practice, an unusual combination of signs and symptoms may be present, resulting in a puzzling neurologic picture. There are reports of patients with blurring of vision accompanied by Argyll Robertson pupils or with isolated bilateral oculo-motor nerve paresis or with tinnitus accompanied by variable auditory deficits. The presentation may be ophthalmic symp-



toms, confusion, personality changes, the Guillain-Barré syndrome, or persistent dizziness. The diagnosis of neurosyphilis should be strongly considered in a young adult with a stroke, new seizure disorder, confusional syndrome, or dementia. Detection relies on a combination of clinical manifestations, serum serologic tests, CSF examination, and radiographic scans.

Asymptomatic neurosyphilis is the presence of CSF abnormalities (reactive serologic or elevated cell counts and protein) in the absence of neurologic signs or symptoms. These findings ultimately disappear in 70 percent of cases even without treatment. Nontreponemal tests may be nonreactive in up to 39 percent of patients, but treponemal tests are usually positive in the serum as well as in the CSF.[22]



Meningeal syphilis may occur early or late. Most cases of acute syphilitic meningitis occur during the first year of infection. Meningitis is the initial presentation of syphilis in up to 25 percent of patients. Fewer than 10 percent of these patients have a concomitant skin eruption. The symptoms, like other aseptic meningitis, include headache, fever, photophobia, stiff neck, confusion, nausea, and vomiting. Up to one-third of patients present with acute hydrocephalus, and one-fourth of all cases of syphilitic meningitis have focal involvement of the cerebral vertex (vertex meningitis) or posterior fossa, possibly resulting in seizures, aphasia, and hemiplegia. Cranial nerve palsies caused by basilar involvement are a common complication of meningitis. The more frequent palsies involve the oculo-motor, auditory, and facial nerves. Reversible sensorineural deafness, with characteristic loss of higher frequencies, develops within days in up to 20 percent of patients, even in the absence of meningitis or other signs of secondary syphilis. Hearing loss is often preceded by tinnitus. Meningeal syphilis usually responds well and rapidly to high doses of intravenous penicillin.

Spinal pachymeningitis with inflammation and thickening of the dura mater usually involves the cervical area and causes pain, muscle atrophy, sensory loss, diminished tendon reflexes, and, ultimately, spastic paraplegia with sensory loss.

Meningovascular syphilis constitutes 10 percent of all neurosyphilis cases. The disease may involve the cerebrum (cerebrovascular) or spinal cord (spinal meningovascular).

Cerebrovascular syphilis is caused by endarteritis of the medium and large arteries (Heubner arteritis) or small arteries and arterioles (Nissl arteritis) that results in thrombotic infarction. The name is rather misleading because the underlying pathogenesis is a chronic meningitis. Because the neurologic signs are focal, the clinical picture resembles atherosclerotic occlusive disease, but the typical patient is between 30 and 50 years of age. Symptoms manifest as early as 2 years, but more commonly develop between 4 and 7 years after the initial infection. Weeks to months before the abrupt onset, approximately one-half the cases experience prodromes, with symptoms such as dizziness, headaches, insomnia, memory loss, and mood changes.[23] Depending on the artery involved, patients may present with almost any neurologic deficit. The most frequent is hemiparesis or hemiplegia, followed in frequency by aphasia and seizures.[23] Therefore, this diagnosis should be considered in anyone with adult-onset epilepsy or strokes.

Spinal meningovascular syphilis is separated into meningomyelitis and acute transverse myelitis. Meningomyelitis, the more common form, usually begins more than 20 years after the initial infection, with paresthesia and spastic weakness of the legs. These symptoms are followed by combinations of sensory loss, sphincter disturbances, pain, and muscular atrophy. Acute transverse myelitis produces sudden flaccid paraplegia, sensory deficits, and urinary retention.

Parenchymatous neurosyphilis encompass three distinct syndromes: tabes dorsalis, general paresis, and optic atrophy.[22]

Tabes dorsalis is caused by infection of the parenchyma of the posterior columns and posterior root of the spinal cord. It once developed in 5 percent of patients with untreated syphilis of 20 to 25 years duration, but is now rare. The three stages are preataxia, ataxia, and paralysis. The early symptoms are recurrent attacks of paresthesia and paroxysms of lightning pain. Stabbing pains in visceral organs such as the abdomen, rectum, and larynx (10 percent to 15 percent of cases) may simulate surgical emergencies. As the disease progresses, the patient may develop impotence, urinary retention, vision loss, rectal incontinence, and locomotor ataxia. Because position sense is lost, the ataxia is more prominent in the dark and is compensated by visual orientation. The Romberg's sign is positive, which means that the patient stumbles when the feet are held close together with the eyes closed. Pupil reactivity becomes sluggish early and is seen in 90 percent of cases. The distinctive Argyll Robertson pupils sign, in which the pupil accommodates to objects but does not react to light, develops later. Hearing loss from eighth nerve damage is found in approximately 25 percent of cases. Charcot joints are enlarged, painless, uninflamed joints in the lower extremities and spine that result from repeated traumatic injury. Serum and CSF serologic tests are reactive in early tabes dorsalis but may be negative late in the course. The course is rarely fatal, but patients become disabled and dependent.

General paresis, a chronic meningoencephalitis that severely disturbs cerebrocortical function, is characterized by gross atrophy of the frontal and temporal lobes, granulations in the ventricles, hydrocephalus, and widened cerebral sulci. Depending on the damaged area, the symptoms may be psychiatric, neurologic, or, more commonly, both.[22] Untreated, the course spirals downward towards death. Symptoms typically begin insidiously 15 to 20 years after infection with changes in personality and behavior. Irritability, forgetfulness, inability to concentrate, and headaches are followed by impaired judgment, emotional lability, and inappropriate social or moral behavior.[22] Delusions of grandeur with marked euphoria occur in 20 percent of the cases. It has been said that everyone in contact with the paretic suffers, but not the patient. Paranoia, tantrums, and alcohol abuse may appear. Full-blown psychosis is followed by a period of neurologic deterioration. Tremors of the hands, lips, or tongue; seizures of any type; and incontinence of urine and feces are common. At this point, a paralytic facies devoid of facial expression is typical. Mental and neurologic deterioration progresses to death typically after 2 to 12 years from pneumonia, infected pressure ulcers, or septicemia. The clinical spectrum is summarized in the clever Holmes mnemonic, paresis: *p*ersonality disorder, *a*ffect (flat), *r*eflexes (hyperactive), *e*ye changes (unequal pupils that react poorly to light), *s*ensorium (delusions), *i*ntellect impairment, and *s*peech dysarthria. Serum and CSF serologic tests are reactive in almost all cases. Adequate antibiotic treatment halts progression of the disease in 80 percent of patients. In the Oslo study, general paresis developed in 2.5 percent of men and 1.4 percent of women.

Optic atrophy may occur as an isolated finding. The vision loss begins in one eye but soon involves the other.

Optic atrophy also results from syphilitic optic neuritis. In both conditions, the CSF is usually abnormal. Penicillin does not restore vision but prevents further loss.

Focal (gummatous) cerebral or spinal meningeal syphilis results from compression of the brain or spine by a gumma, which usually arises from the pia mater. Because serologic tests can be unreactive in the serum and the CSF, a biopsy is invariably needed to establish a diagnosis. Cerebral gummas respond poorly to antibiotics, so surgical resection may be necessary.[24]

CONGENITAL SYPHILIS

In 1854, Paul Diday described the syphilitic newborn as "a little wrinkled potbellied old man with a cold in his head" (Fig. 200-28). The definition of congenital syphilis was recently updated (Table 200-3); however, because most infants have no clinical or serologic evidence of syphilis at birth and develop abnormalities months to years later, all potentially infected infants should be treated with penicillin.[25] Despite the popularity of the term *congenital syphilis*, prenatal syphilis better indicates that the signs and symptoms may develop before or after delivery rather than always being present at birth, and are not hereditary, as congenital implies. Mothers usually transmit the infection to the fetus transplacentally and possibly during delivery through contact with an infectious genital lesion. Syphilis is not transmitted through breast-feeding unless an infectious lesion is present on the breast.[26]

In a recent study, 66 percent of fetuses of women diagnosed with infectious syphilis had hepatomegaly, and some also had abnormal transaminases, thrombocytopenia, and anemia.[27]

Approximately 25 percent of infants from mothers with untreated primary or secondary syphilis die in utero. Of those infants born, almost one-half develop the disease, another one-fourth are seropositive without clinical manifestations, and only one-fourth are not infected. About 40 percent of infants born to mothers with early latent syphilis are infected, and an additional 20 percent are premature, 10 percent stillborn, and 4 percent die perinatally. In late latent syphilis, 10 percent develop congenital syphilis and another 10 percent are stillborn or premature.[26] Without treatment, one out of four newborns with signs and symptoms of congenital syphilis die shortly after birth. Syphilis remains the most common cause of nonimmune hydrops fetalis. Such infants are born with pallor, edema, and a bloated abdomen.



▲ **FIGURE 200-28** Early prenatal syphilis in a newborn. The skin is dry and wrinkled, with a yellowish-brownish hue. There is hemorrhagic rhinitis. This is what Diday described as "a little wrinkled potbellied (not seen here) old man with a cold in his head." Note also the aged appearance of the fingers in this newborn.

Spirochetes have been detected in fetuses as young as 9 weeks, but before the fifth month of gestation, the fetus seems to escape harm, probably as a result of an inability to mount an inflammatory response. Even at birth, the inflammation affects the placenta more than the infant. A fibrosed, large, thick, and pale placenta and a diseased umbilical cord with alternating streaks of red, pale blue, and chalky white may be the only clue to the diagnosis of congenital syphilis. Rarely, infants become infected after birth from colonization by *T. pallidum* in the nasopharynx and gastrointestinal system.

Clinical Findings

Prenatal syphilis is divided into early (first 2 years) and late (after 2 years) stages. It is not unusual for the diagnosis to be missed during the first year of life, and in one study, the average age at diagnosis was 30 years. Most infants are asymptomatic, and even when manifestations develop, these are often subtle and non-specific.

EARLY PRENATAL SYPHILIS Clinical manifestations develop within the first 2 years of life. This stage is comparable to the secondary stage of acquired syphilis because treponemes disseminate throughout the fetus. Without treatment, almost one-half of symptomatic infants die. However, with improved perinatal care and treatment, the prognosis is now good. Infants are born premature or small for dates. They are irritable and cry feebly. In descending order of frequency, the manifestations found are low birth weight, hepatosplenomegaly, anemia, jaundice, thrombocytopenia, skin le-

TABLE 200-3
Definition of Congenital Syphilis[a]

TYPE	DEFINITION
Confirmed	An infant in whom *Treponema pallidum* is identified in lesions, placenta, umbilical cord, or autopsy tissue
Presumptive	Any infant whose mother was untreated or treated with antibiotics other than penicillin before delivery, regardless of findings in the infant *or* Any infant or child with a reactive treponemal test for syphilis and any one of the following: Evidence of congenital syphilis on physical examination or x-ray of long bones Presence in the cerebrospinal fluid of lymphocytosis and elevated protein (without other cause) Reactive cerebrospinal fluid VDRL *or* Infant rapid plasma reagin fourfold higher than mother (both drawn at birth) *or* Reactive immunoglobulin M-treponemal antibody test in serum
Syphilitic stillbirth	A fetal death in which the mother had untreated or inadequately treated syphilis at delivery of a fetus after a 20-week gestation or of a fetus weighing > 500 g

[a]Congenital syphilis includes cases of prenatally acquired syphilis in infants and children, as well as syphilitic stillbirths.





▲ **FIGURE 200-29** Bullous eruptions on the soles of a newborn with early prenatal syphilis. Bullae have ruptured and now present as erosions ("syphilitic pemphigus").



sions, respiratory distress, rhinitis, and pseudoparalysis.[27] Rhinitis ("snuffles") has been reported in as many as 73 percent of infants. It usually develops in the second to third week of life and may be the earliest clinical sign. Initially thin, a mucoid nasal discharge, teeming with spirochetes, can become purulent or bloody (see Fig. 200-28). The nasal septum may become perforated. If untreated, flattening of the nasal bridge results in the characteristic saddle or *fleur de lis* nose.[28]

The skin of the syphilitic neonate is often dry and wrinkled and, in newborns with fair skin, may have a café-au-lait hue (see Fig. 200-28). Mucocutaneous manifestations occur in about one-half of patients younger than 6 months of age and, like secondary syphilis lesions, usually consist of an eruption of copper- to red-colored macules and papules, with or without scale, predominantly on the palms, soles, and diaper area. Condylomata lata and mucous patches may also be present. Annular or corymbiform eruptions have ben reported.[26] Bullae between 1 and 5 cm in diameter are rare but highly infectious and may be generalized or, more often, limited to the extremities particularly the palms and soles (Fig. 200-29). Commonly known as *syphilitic pemphigus*, the presence of blisters is a sign of severe disease. Pustules may appear on the fingers, toes, and at the angles of the mouth. Ulcerations around the mouth, nose, or anus may heal with rhagades (Parrot's lines), depressed linear scars that persist to adulthood and radiate from the orifice like the spokes of a wheel (Fig. 200-30).

Lymphadenopathy occurs in one-half of the cases but may not be prominent. The presence of firm, movable, nontender epitrochlear nodes is especially characteristic for prenatal syphilis. Bone disease, although usually asymptomatic, is the most common early manifestation, having been reported in 97 percent of autopsied infants younger than 6 months of age.[28] The most frequently observed osseous lesion, osteochondritis, is diagnosed by its characteristic radiographic sawtooth appearance in the metaphysis. In the medial aspect of the proximal tibial metaphysis, this defect occurs in one-fifth of early cases and has been called the *Wimberger* or *cat-bite sign*. Longitudinal lines of rarefaction like "celery sticks" may expand into the diaphysis. Pain from osteochondritis of the long bones, or epiphysitis, is exacerbated by movement, so the child keeps the affected limb still, a sign known as *pseudoparalysis of Parrot*. Painful periostitis, commonly observed in the latter half of the first year, may lead to blunting of the scapular spines and anterior tibial margins in later life. The resulting multiple layers of new bone produce the radiographic "onion-peel periosteum" sign. Osteitis of the fingers is uncommon but may produce dactylitis during the first 2 years of life.

Spirochetes are detected in the CNS of 40 percent to 60 percent of infants with syphilis. However, only 10 percent of these infants develop symptomatic neurosyphilis, which usually does not become clinically evident until the third to sixth month of life.[28] It is essentially meningovascular and can present as various neurologic syndromes.

TABLE 200-4
Clinical Manifestations in Late Prenatal Syphilis

STIGMATA	ACTIVE DISEASE
Ophthalmic	Retinitis
Corneal clouding	Interstitial keratitis
Oral	
Hutchinson teeth	Gummas in nose
Mulberry molars	or palate
High-arched palate	
Ears, nose, throat	
Saddle nose	
Orthopedic	
Frontal bossing	Periostitis
Short maxilla	Dactylitis
Protuberant mandible	Clutton's joint
Saber shins	
Scaphoid scapula	
Thickened medial clavicle	
Neurologic	Eighth nerve deafness
	Neurosyphilis
Mucocutaneous	Gummas
Gastrointestinal	Hepatomegaly
	Splenomegaly

LATE PRENATAL SYPHILIS Manifestations appear after the age of 2 years, but rarely past the age of 30, and can be divided into two groups: malformations (stigmata) and active pathologic processes (Table 200-4). Most manifestations are not specific, with the exception of the Mulberry molars and the characteristic interstitial keratitis. Late congenital syphilis is not infectious. The order of frequency of late syphilis signs varies among reports.



◀ **FIGURE 200-30** Perioral rhagades are linear scars that result from ulcerations that appear during early congenital syphilis and persist to adulthood.

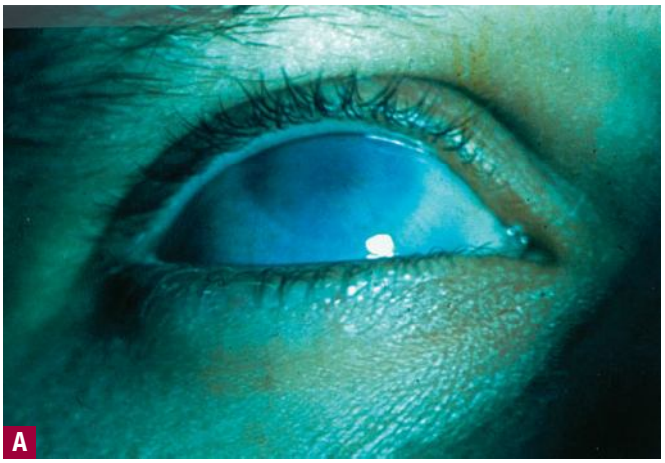



◀ **FIGURE 200-31** **A.** Interstitial keratitis with corneal clouding in late prenatal syphilis. **B.** The presence of small, notched, peg-shaped upper incisors (Hutchinson teeth) is also part of the late congenital syphilis triad.

Interstitial keratitis occurs in 8.8 percent of cases, and the average age of onset is 13.5 years for men and 27.1 years for women. The course eventuates in corneal clouding (syphilitic nebulae) or glaucoma (Fig. 200-31A). Iritis and iridocyclitis may also be found, but usually earlier. Corneal transplantation often restores vision.

Asymptomatic neurosyphilis occurs in 30 percent to 50 percent of patients and is diagnosed only through abnormal CSF findings. Symptomatic neurosyphilis is rare and usually delayed until puberty. Juvenile paresis, the most common pattern, affects 1 percent to 5 percent of all patients with congenital syphilis. The presentation often involves personality and behavior changes such as deteriorating school performance and inappropriate emotional responses. Within 1 year, any combination of ataxia, dysarthria, tremors, and seizures develop. Other CNS complications include mental retardation and cranial nerve palsies. Bilateral eighth-nerve disease with vertigo, tinnitus, and deafness has been reported in 3 percent to 38 percent of patients, usually adolescents. The deafness progresses despite antibiotics, but the response to systemic glucocorticoids has been encouraging. Skin manifestations consist of granulomatous lesions and gummas, just as in late benign syphilis.

Bone manifestations, such as arthritic perisynovitis, chondroosteoarthritis, epiphysitis, and periostitis, may also occur in late prenatal infection. A thickened, prominent forehead produced by localized periostitis of the frontal and parietal bones (frontal bossing of Parrot) is present in approximately 87 percent of patients. A short maxilla, with a shallow dish configuration, results from impaired development caused by syphilitic rhinitis and is present in up to 83 percent of patients. The Higouménakis's sign, which is a rather non-specific finding, is a unilateral, irregular enlargement of the sternoclavicular portion of the clavicle resulting from previous periostitis. Anterior bowing and thickening from periostitis of the midportion of the tibia (saber shins) occur in 4 percent of patients. Scaphoid scapulae, a concavity of the vertebral border of the scapulae, is observed in 0.7 percent of patients. Mandibular protuberance, or bulldog jaw, was found in 25.8 percent of patients. The size is actually normal but appears proportionally larger in comparison to the size of the maxilla. Clutton joints are symmetric, non-tender swellings of the knees, which often follow trauma and produce bilateral hydrarthrosis. Deformities such as painless perforation of the nasal septum or soft palate and deep ulcers of the pharynx and tongue can result from damage by gummas.

Dental abnormalities are caused by treponemal invasion of the tooth buds. The pathognomonic Hutchinson teeth refer to widely spaced, small permanent incisors that are screwdriver or peg-shaped, wider at the gingival margin, and notched at the biting edge because of defective enamel production (see Fig. 200-31B). Mulberry or moon molars, found in 65 percent of cases, are dome-shaped and have numerous diminutive cusps arrayed in a tight circle at the top of the dome. The first lower molars most commonly show these changes. As a consequence of defective enamel, these teeth are predisposed to caries and rarely persist beyond adolescence. Dental abnormalities can be prevented if treatment is initiated before the third month of age.

Congenital syphilis can be a difficult diagnosis in the absence of physical signs and symptoms. Maternal IgG antibodies can cross the placenta, but nontreponemal tests become nonreactive within 3 to 6 months and treponemal tests within 6 to 12 months after birth. There is an interval of 2 to 3 months between the onset of the infection and fetal production of IgM antibodies, so serologic reactivity at birth depends on when the fetus became infected. The presence of reactive IgM tests in the serum of newborns is considered to prove the diagnosis of congenital syphilis, but the fluorescent treponemal antibody-absorption (FTA-ABS) test IgM may be falsely negative in 35 percent of infants. The umbilical cord should be sent for pathologic examination with special stains for treponemes. Nasal secretions and mucocutaneous lesions should be examined by dark-field microscopy. Radiographs showing periostitis of the tibia suggest the diagnosis.

SYPHILIS AND HUMAN IMMUNODEFICIENCY VIRUS INFECTION (See Chap. 198)

Infection with syphilis imparts a greater risk for acquiring HIV infection, at least in part because the genital ulceration provides an easier entry to the virus into the systemic circulation. Conversely, numerous studies demonstrate that the prevalence of syphilis is higher in HIV-infected persons. In addition, there is impaired immunity with decreased CD4 counts and elevated viral load titers.[29]

Surprisingly, HIV infection does not significantly influence the clinical course, serologic response, or treatment outcome of most patients with early syphilis.[29,30] The appearance of primary chancres is typical, but patients with primary syphilis present more frequently with multiple ulcers, and their chancres persist up to the secondary stage more often. The course of secondary syphilis is usually unchanged, although rapidly progressive disease and unusual manifestations have rarely been





▲ **FIGURE 200-32** Ulcerated papules in a human immunodeficiency virus–infected man. This was the initial presentation of an human immunodeficiency virus infection.



reported. Nodular and noduloulcerative lesions (Fig. 200-32) are more common, but most of these cases do not have the constitutional symptoms associated with malignant syphilis.[31,32] Posterior chamber uveitis is the most common manifestation.[31] Perforation of the palate has been rarely reported. The incidence of ocular syphilis may be higher in HIV-infected patients treated with highly active antiretroviral therapy.[33]

Although most cases of early syphilis in HIV-positive patients respond to conventional doses of penicillin, serologically defined treatment failures are more common, and for this reason closer evaluation after therapy is mandatory (see Treatment).

In one study, 18 percent of patients treated with intramuscular penicillin had serologically defined treatment failures at 6 months and 14 percent at 12 months.[34] Clinical relapses occurred in 1 percent of patients in a prospective study and more frequently in retrospective studies. Rarely, patients experience multiple relapses.

Neurosyphilis may be the first clinical manifestation of HIV infection. The presence of treponemes from the CSF is not unusual during the primary and secondary stages despite the absence of neurologic symptoms. In the best study published to date, *T. pallidum* was recovered from the CSF of 26 percent of HIV-infected patients with early syphilis before treatment and 20 percent after treatment.[34] However, these percentages are similar to those of HIV-seronegative patients.[34] In a prospective, multicenter, randomized, controlled trial that compared HIV-seropositive and HIV-uninfected persons with syphilis, no differences in neurologic status were apparent.[35] It is important to note that the presence of *T. pallidum* in the CSF in early syphilis does not differ according to HIV status and is not predictive of treatment failure. Hence, performing spinal taps on all patients would not identify those at risk for symptomatic neurosyphilis. Most cases of neurosyphilis in HIV-infected patients comprise asymptomatic or meningovascular neurosyphilis, but focal gummas and other types of neurosyphilis have also been reported. Manifestations include cranial nerve palsies, optic neuritis or neuroretinitis, polyradiculopathy, transient ischemic episodes, and strokes. A rare fulminant form (necrotizing neurosyphilis) is reported more frequently in acquired immunodeficiency syndrome patients.

Not only is the prevalence of neurosyphilis higher in patients co-infected with both syphilis and HIV, but the progression to symptomatic forms of neurosyphilis can be accelerated, even after conventional therapy.[35] In a small but significant study, which included 15 HIV-infected and 25 HIV-seronegative patients with primary or secondary syphilis, *T. pallidum* was isolated from the CSF by rabbit inoculation in a similar proportion from both groups.[36] Only CSF leukocytosis was more common (67 percent vs. 25 percent) in the HIV-seropositive group. Notably, one injection of benzathine penicillin failed to eradicate the CNS infection in three of the four HIV-infected cases with positive treponeme cultures.[36] Since then, several unsettling reports have alluded to the unexpected frequency of neurorelapse after benzathine penicillin therapy in HIV-infected patients. Serologic positivity and CSF abnormalities usually resolve after treatment in HIV-infected patients with neurosyphilis, but 8 percent may remain infected despite even the recommended high doses of intravenous penicillin, and 23 percent have persistent pleocytosis.[36] Of note, however, patients with CSF abnormalities should be cautiously diagnosed as having asymptomatic neurosyphilis, because CSF leukocytosis or elevated protein is present in up to 60 percent of non-syphilitic HIV-infected patients who are not taking effective antiretroviral therapy.

The rate of cardiovascular syphilis may also be increased, with one study from India reporting a 14.3 percent prevalence in 14 HIV-infected persons with syphilis compared with a 2 percent prevalence in 100 HIV-seronegative syphilis patients.[37]

Dysregulation of the humoral immune response may result in uncontrolled production of antibodies with extremely elevated titers. In a study, the median rapid plasma reagin (RPR) titers (see Reaginic Nontreponemal Tests) were four times higher (1:128 vs. 1:32) in HIV-infected patients than in HIV-uninfected patients with their first episodes of early syphilis.[38] Furthermore, B-cell activation results in a higher rate of biologic false-positive nontreponemal serologic tests. Conversely, delayed seroreactivity and false-negative nontreponemal serologic tests have been reported, so the threshold to biopsy suspicious skin lesions should be low. The sensitivity of treponemal tests appears to be decreased in patients previously treated for syphilis if they are HIV infected (80 percent vs. 97 percent).[39]

Manifestations of secondary syphilis may occur more commonly with HIV infection. In general, the characteristic pathologic findings are present, although some cases with lymphoid infiltrate resembling cutaneous T-cell lymphoma have been reported.

DIAGNOSTIC TESTS

Definitive diagnosis of early syphilis requires demonstration of spirochetes in lesional exudate or tissue either by dark-field microscopy or by direct immunofluorescence. Unless the diagnosis is otherwise unequivocal as a result of these examinations or from clinical evaluation of typical lesions coupled with reactive serologic results, skin biopsy is recommended for suspected primary, secondary, and certainly, tertiary syphilis lesions.

Histopathologic Examination

The epidermis of a chancre is acanthotic at the margins and becomes thinner and more edematous towards the eroded center. A dermal infiltrate composed predominantly of lymphocytes, plasma cells, some histiocytes, and a few neutrophils is dense in the center and perivascular in the periphery of the chancre. In untreated cases, the spirochetes stain gray with an impregnated silver dye such as the Warthin-Starry stain (see Fig. 200-1). The spirochetes are most easily found in the epidermis

and around dermal capillaries. By electron microscopy, *T. pallidum* is predominantly found extracellularly. Less commonly, organisms are found within the endothelial cells of capillaries and inside the vacuoles and phagolysosomes of plasma cells, macrophages, and neutrophils; and occasionally within fibroblasts and nerve fibers.

Characteristically, secondary syphilis lesions show dilatation of blood vessels with a proliferation of endothelial cells and a superficial and deep perivascular dermal infiltrate with many plasma cells. The infiltrate often becomes lichenoid, may obscure the dermal epidermal interface, and, in one-third of cases, surrounds adnexal structures and nerves. Specific changes depend on the biopsied lesion.

Macular lesions show mild or no epidermal changes. Papulosquamous plaques show psoriasiform epidermal hyperplasia, parakeratosis, and often, focal spongiosis, basal vacuolar changes, and microabscesses with neutrophils. Other common epidermal changes are epidermal pallor, keratinocyte necrosis, extravasated red blood cells, and exocytosis of mononuclear cells. The dermal vessels show endothelial proliferation and swelling. There is a superficial and deep perivascular infiltrate arranged in a coat-sleeve pattern and composed of lymphocytes, histiocytes, and many plasma cells. The infiltrate assumes a lichenoid pattern that may involve the superficial and deep dermis and, in one-third of the cases, surrounds adnexal, vascular, and neural structures. The infiltrate may also be T-shaped or perivascular. Small epithelioid granulomas, which may have Langhans or foreign-body–type giant cells, may be present, even in early lesions. In lesions of pustular syphilis, neutrophils within the sub-corneal pustules may infiltrate the hair follicles. In ulcerating lesions, there is infarction necrosis of the epidermis and dermis because of occlusion of blood vessels by fibrinoid material. The epidermis may be absent from the specimen.

In nodular tertiary syphilis, there is a dermal lymphohistiocytic and plasma cell infiltrate with small granulomas and islands of epithelioid cells intermingled with some multinucleated giant cells. A mild degree of caseation necrosis may be present. In gummas, the infiltrate contains numerous epithelioid and multinucleated giant cells and extends throughout dermis to the subcutaneous tissues. Extensive caseation necrosis surrounded by epithelioid and giant cells is present in the center of the lesion. Nodular tertiary syphilis may be difficult to differentiate from lupus vulgaris, and gummatous syphilis from scrofuloderma and erythema induratum [all manifestations of mycobacterial infection (see Chap. 184)].

Dark-Field Microscopy

Dark-field examination is the diagnostic test of choice in chancres and moist lesions of secondary syphilis, especially condylomata lata and mucous patches. The test is invalid for oral lesions because saprophytic treponemes that cannot be differentiated from *T. pallidum* are common in the mouth. In such cases, a lymph node aspirate can be examined by dark-field microscopy.

The surface of the lesion should be cleaned and gently abraded with a sterile gauze soaked in 0.9 percent sterile saline, carefully avoiding bleeding, as blood cells obscure detection of the treponemes. After squeezing the base of the lesion with two gloved fingers, a serous exudate accumulates on the surface and can be scraped off with a scalpel or drawn off with a pipette. The exudate is mixed with one or two drops of saline on a glass slide and covered with a plastic cover slip. The slide is examined under a dark-field microscope for the presence of treponemes.

Direct Fluorescence Antibody Test

The lesional exudate is smeared on a glass slide and stained with fluorescein-labeled anti–*T. pallidum* immunoglobulin. In contrast to dark-field microscopic examination, the smear can be held for later evaluation and oral or anal lesions can be examined because only *T. pallidum* is stained. The sensitivity of the test is greater than 90 percent.[40]

Serology

Serologic tests for syphilis are divided into two types. The simpler cardiolipin-based nontreponemal tests are used for screening and to follow therapeutic response. The more elaborate *T. pallidum*-based treponemal tests are used for diagnostic confirmation and to improve diagnosis of early, congenital, and neurosyphilis.[41]

A presumptive diagnosis of syphilis is made by a reactive nontreponemal test, such as the RPR test or the VDRL test, confirmed by a treponemal test, such as the microhemagglutination assay with *T. pallidum* antigen or the FTA-ABS test (Table 200-5).[42] Although treponemal tests have higher specificity and sensitivity, because of their higher cost, they are not used for screening but rather to corroborate the accuracy of reactive nontreponemal tests.

Reaginic Nontreponemal Tests

Reaginic nontreponemal tests are inexpensive and are widely used for screening. The antigen (reagent) is a combination of cardiolipin, cholesterol, and lecithin. The VDRL and RPR become reactive 4 to 5 weeks after infection and revert to negative in 25 percent to 30 percent of cases during late latency. Results are reported as either nonreactive or quantitatively as a titer of the sample diluted with saline in a geometric progression by a factor of 2 (1:2, 1:4, 1:8, and so on). The reported titer represents the highest dilution that gives a positive result. Titers may differ slightly between laboratories. A high titer (≥ 1:32) usually indicates active disease, whereas low titers (≤ 1:8) may remain unchanged

TABLE 200-5
Interpretation of Serologic Tests

RPR	MHA-TP	CAPTIA (IGM) EIA	
–	–	–	No syphilis or incubating syphilis
–	–	+	Early primary syphilis
+	+	+	Primary or secondary syphilis
+	–	+	Early infection
+	+	–	Late secondary or latent syphilis
+	–	–	Biologic false-positive, late syphilis
–	+	–	Late infection, treated syphilis, or false-positive treponemal test
↑	+	↑	Re-infection, relapse

↑ = rising titers; EIA = enzyme immunoassay; IgM = immunoglobulin M; RPR = rapid plasma reagin; MHA-TP = microhemagglutination assay with *Treponema pallidum* antigen.



for years after therapy of late disease. Titers decline more slowly in patients with previous episodes of syphilis. After treatment, the titers should decline fourfold (a titer of 1:32 decreases to 1:8) or lower within 6 months in primary or secondary syphilis, and within 24 months in latent syphilis. In patients treated for primary syphilis, the tests become nonreactive in 60 percent by 4 months and in nearly all patients by 12 months. In secondary syphilis, the tests usually become nonreactive in 12 to 24 months after treatment. If therapy is administered in the early latent stage, nontreponemal tests may remain reactive in low titers for up to 5 years or longer. Notably, one study found persistently reactive low titers after 35 years of adequate treatment in 18 percent of secondary syphilis cases and 44 percent of late latent stage cases. In tertiary syphilis, the tests may revert to nonreactive in 20 percent to 30 percent of cases, even without treatment. A titer that neither decreases nor increases fourfold after treatment is referred to as *serofast*. If an initially high titer (≥ 1:32) fails to decrease after treatment, the patient should be evaluated for neurosyphilis and retreated appropriately. A fourfold titer increase indicates reinfection or treatment failure. Weakly reactive qualitative tests should be repeated, because up to one-third will be eventually positive.

False-negative results occur during very early infection or in latent and late syphilis. In 1 percent of secondary syphilis cases, results are falsely reported as nonreactive as a result of the prozone phenomenon. That is, unless the serum is diluted, the high levels of antibody prevent flocculation.

Biologic false-positive results constitute 1 percent to 2 percent of reactive nontreponemal tests, depending on the population studied. In 90 percent of these, the titers are less than 1:8. Biologic false-positive results may be transient and acute (< 6 months) or longer lasting and chronic (> 6 months; Table 200-6). In narcotic addicts, false-positive reactions may persist even after 14 months of drug abstinence.[39]

TABLE 200-6
Causes of Biologic False-Positive Nontreponemal Tests

	Acute	Chronic
Physiologic	Pregnancy	Advanced age
Spirochete infection	Leptospirosis Lyme disease Rat-bite fever Relapsing fever	Endemic syphilis Pinta Yaws
Viral infection	Cytomegalovirus Infectious mononucleosis Hepatitis Herpes simplex Herpes zoster-varicella infection Measles Mumps *Mycoplasma* pneumonia Toxoplasmosis Viral sepsis	Human T-cell leukemia/lymphoma virus I Human immunodeficiency virus infection
Bacterial infection	Pneumonia	Lepromatous leprosy Lymphogranuloma venereum Tuberculosis
Protozoan infection	Malaria	Kala azar Trypanosomiasis
Autoimmune disease		Autoimmune hemolytic syndrome Autoimmune thyroiditis Idiopathic thrombocytopenic purpura Mixed connective-tissue disease Polyarteritis nodosa Primary biliary cirrhosis Rheumatoid arthritis Sjögren syndrome Systemic lupus erythematosus
Other		Drug abuse Dysproteinemias Hepatic cirrhosis Malnutrition Malignancy Lymphoproliferative disorders

Specific Treponemal Tests

These tests use whole or fragments of *T. pallidum* as antigen. Compared with nontreponemal tests, they are more cumbersome to perform but have greater sensitivity in the primary and late stages and slightly higher specificity (Table 200-7). They are widely used to confirm reactive nontreponemal test results.[41]

The FTA-ABS test is the most sensitive serologic test in primary syphilis, and reactivity begins during the third week of infection, but the microhemagglutination assay with *T. pallidum* antigen, which is less expensive and easier to perform, is more popular. In most patients with reactive treponemal tests, the reactivity continues for life even after successful treatment. Only 15 percent to 25 percent of tests become unreactive between 2 to 3 years after treatment of primary syphilis. The tests are highly specific and sensitive during the secondary and the late phases of the disease (see Table 200-7). Because of their high sensitivity, which permits detection of very small amounts of antibody, the tests cannot be used to assess treatment efficacy. False-negative results are very rare. False-positive FTA-ABS results are also uncommon but may result from autoantibodies (rheumatoid factor) or antibodies to other spirochetal infections (Table 200-8).

Treponemal-based enzyme immunoassays (EIAs) are becoming increasingly popular as screening tests for syphilis and may, in time, replace nontreponemal tests for this purpose. These tests are more specific than the RPR and more sensitive than the FTA-ABS in patients with past infection.[43] The tests do not distinguish between patients with incompletely treated or untreated syphilis and those who have been successfully treated. When a screening treponemal test is reactive, a nontreponemal test should be done to exclude a false positive reaction. If the nontreponemal



TABLE 200-7
Sensitivity and Specificity of Serologic Tests

	Sensitivity (%)				
	Primary	Secondary	Latent	Tertiary	Specificity (%)
VDRL	80 (74–87)	100	80 (75–100)	71 (55–94)	98
Rapid plasma reagin	86 (81–100)	100	80 (75–100)	73 (55–96)	98
Fluorescent treponemal antibody-absorption	98 (93–100)	100	95	97 (95–100)	99
Microhemagglutination assay with *Treponema pallidum* antigen	82 (50–95)	100	99	96 (90–99)	99
Captia syphilis (immunoglobulin M) enzyme immunoassay	82	60	53	34	100

Note: For explanation of serologic tests, see text.

test is negative, another test should be performed using a different nontreponemal assay. If this test is also not reactive and the diagnosis of syphilis therefore cannot be established serologically, the clinician needs to be guided by the history (risk factors, former presence of potentially syphilitic lesions). Appropriate management may include a more intense search for diseases that cause falsely reactive treponemal tests or treatment for presumptive syphilis of unknown duration.

IgM EIA tests, such as the Captia syphilis (IgM) EIA, are the serologic test of choice in very early primary infection, assessment of re-infection, and congenital syphilis. IgM antibodies can be detected in the serum toward the end of the second week of infection. The test is the first to become positive and has a 93 percent sensitivity in primary infection. However, because memory cells do not synthesize IgM antibodies, the sensitivity is only 85 percent in secondary infection and 64 percent in early latent infection. Reactivity ceases within 3 to 9 months after therapy of early syphilis but may persist for 12 to 18 months after treatment of late infection. It is important to note that a reactive result indicates almost with certainty the need for therapy, but a nonreactive result does not exclude infection. Persistence of reactivity after therapy indicates treatment failure or false-positive results because of autoantibodies of the IgM class.

TABLE 200-8
Common Causes of False-Positive Treponemal Tests

- Infectious mononucleosis
- Lepromatous leprosy
- Leptospirosis
- Lyme disease
- Malaria
- Relapsing fever
- Systemic lupus erythematosus

Because IgM antibodies do not cross the placenta or the intact blood–CSF barrier, IgM reactivity in the serum of a newborn confirms prenatal infection, and detection of antitreponemal IgM in the CSF indicates neurosyphilis. The sensitivity of the Captia (IgM) EIA is 100 percent in congenital syphilis, but lower in primary (82 percent), neurosyphilis (34 percent), and treated syphilis (11 percent).[42] Immunoblots have a very high sensitivity and near-perfect specificity. Although laborious, they are the tests of choice to confirm a false-positive test and are promising as a replacement of other confirmatory treponemal tests.[41]

Polymerase chain reaction assays have a sensitivity and specificity of more than 95 percent in identifying *T. pallidum* in genital ulcers but remain an investigational tool.[44]

Cerebrospinal Fluid Examination

Examination of the CSF by lumbar puncture to exclude asymptomatic neurosyphilis offers marginal benefits, as the risk of developing neurosyphilis in HIV-seronegative patients after standard parenteral penicillin treatment is very small. However, lumbar puncture should be performed if there is clinical evidence of neurologic involvement. Because no clinical presentation is specific for neurosyphilis, reliable criteria by laboratory examinations are particularly important[45] (Table 200-9). Elevated white blood cell count (5 cells/μL) and total protein (> 400 mg/L) indicate inflammation and presumed infection. Of course, these findings are found in other types of meningitis. Conversely, both parameters may be normal or only slightly elevated in asymptomatic disease as well as in tabes dorsalis.

A reactive CSF VDRL result indicates neurosyphilis. Blood contamination may increase titers, but this only occurs when CSF is visibly bloody. Unfortunately, the CSF VDRL is not reactive in up to 70 percent of patients with neurosyphilis, particularly in asymptomatic patients. A nonreactive FTA-ABS test virtually excludes neurosyphilis, but a reactive result cannot be interpreted because positive tests in the absence of CNS involvement are so common.[46] In certain cases, the diagnosis of neurosyphilis is particularly challenging. Moreover, a patient with adequately treated syphilis and no neurosyphilis may have abnormal CSF serology, cell counts, and protein as a result of a nonsyphilitic CNS infection (HIV, malaria) or a neoplasm.

TREATMENT

Parenteral penicillin is the treatment of choice for all stages of syphilis. A concentration of penicillin above 0.018 mg/L is considered treponemicidal. However, a serum concentration equivalent to the maximally effective in vitro level (0.36 mg/L) is recommended for a minimum duration of 7 to 10 days in early syphilis

TABLE 200-9
Diagnosis of Neurosyphilis through Cerebrospinal Fluid Testing

- Strongly indicative
  - Reactive VDRL (or rapid plasma reagin)
  - Reactive MHA-TP (or FTA)
  - Reactive western blot, polymerase chain reaction, or IgM tests
  - TPHA index > 500
- Strongly suggestive (in absence of other central nervous system disease)
  - Cell count > 5 cells/μL
  - Protein > 40 mg/100 mL
  - IgG index > 0.7
- Practically excluded
  - Nonreactive MHA-TP (or FTA)
  - TPHA index < 70

FTA = fluorescent treponemal antibody; Ig = immunoglobulin; MHA-TP = microhemagglutination assay with *Treponema pallidum* antigen; TPHA = *Treponema pallidum* hemagglutination test.
Note: For explanation of serologic tests, see text.



and longer in late syphilis.[47] The recommended doses of long-acting benzathine penicillin provide treponemicidal levels for 3 to 4 weeks. Oral penicillin can produce adequate serum and tissue levels but is not recommended because of possible lack of compliance.[47] Treatment failures are rare and regularly respond to a second course of penicillin at the same or higher doses.

Parenteral penicillin is the only treatment with documented efficacy in neurosyphilis, HIV infection, and pregnancy. The concentration of penicillin in the CSF is less than 10 percent of the serum level. However, even a single injection of benzathine penicillin produces effective levels in the perivascular areas where treponemes are found in the CSF.[37]

After penicillin therapy, clinical relapse is rare but, as has been noted in Reaginic Nontreponemal Tests, serologically defined treatment failure is relatively common. Tetracyclines, erythromycin, and third-generation cephalosporins have strong antitreponemal activity in experimental and clinical trials but are less effective than penicillin. Although less investigated and more expensive than tetracycline, doxycycline is preferred because of better compliance and absorption, which is less affected by food.[48] Erythromycin is slightly less effective than tetracycline. The results with the macrolide, azithromycin, in a single 2-g dose is comparable to erythromycin and not recommended routinely—certainly not in HIV-infected persons and pregnant women.[49] Ceftriaxone at a dose of 1 g intramuscularly or intravenously daily for 8 to 10 days appears to be effective in primary, secondary, and early latent syphilis, although experience with this treatment is limited.[49,50] Additionally, although not recommended, the drug can be safely administered during pregnancy.[47] HIV serology is recommended for all patients with syphilis and should be repeated in 3 months in patients living in areas with high HIV prevalence.[47]

Primary and Secondary Syphilis (without Neurologic, Ophthalmologic, or Auditory Involvement)[47]

A single dose of benzathine penicillin G, 2.4 million units intramuscularly, is the preferred treatment.

PENICILLIN ALLERGY Patients with uncomplicated syphilis may be treated with doxycycline, 100 mg orally twice daily for 2 weeks. Compliance is better than with tetracycline, 500 mg orally four times daily, or erythromycin, 500 mg orally four times daily. Ceftriaxone, 250 mg daily or 1 g every other day intramuscularly or intravenously for 8 to 10 days, is an alternative, but some patients may also be allergic to this agent. If azithromycin at a single dose of 2 g orally is the only choice, close follow-up is required because of the risk of treatment failure.

HUMAN IMMUNODEFICIENCY VIRUS INFECTION The treatment is the same, but follow-up is closer. Some experts recommend CSF examination in patients with CD4 counts below 350 cells/mm^3 and nontreponemal titers equal or above to 1:32. There is no evidence to support administration of three weekly injections of benzathine penicillin G or enhanced therapy with ampicillin and probenecid after a course of benzathine penicillin injections.[34]

CHILDREN Children should be evaluated for congenital syphilis through examination and review of maternal and prenatal records. If the CNS is abnormal, treatment for neurosyphilis is indicated. If infection was acquired postnatally, a child protection agency should be consulted after treating with a single intramuscular injection of benzathine penicillin G, 50,000 units/kg up to 2.4 million units.

CEREBROSPINAL FLUID EXAMINATION If there are signs or symptoms of CNS, eye, or hearing involvement, the CSF should be examined. A slit-lamp examination is indicated if there is ophthalmologic disease. If CSF findings suggest neurosyphilis, treatment should be modified accordingly.

FOLLOW-UP Patients should be re-examined clinically and serologically at 6 and 12 months (if HIV-seropositive, then at 3, 6, 9, 12, and 24 months).

TREATMENT FAILURES Either a reappearance of lesions or symptoms or a fourfold (or greater) increase in nontreponemal titers indicates failed therapeutic response or re-infection and requires repeat clinical examination and retreatment. HIV serology should be repeated. Unless re-infection can be definitely established, a spinal tap is indicated. If CSF analysis indicates neurosyphilis, treat with intravenous penicillin. If neurosyphilis is excluded, treat with benzathine penicillin G, 2.4 million units intramuscularly for three doses 1 week apart, even if desensitization is necessary.

The management of patients whose RPR titers do not decline by a fourfold factor in 6 months is unclear. Approximately 15 percent of persons treated with the recommended therapies will fail to achieve a twofold dilution in nontreponemal titers 1 year after treatment. At the very minimum, clinical evaluation and HIV testing are indicated. If the patient is HIV seropositive, treatment should be based on the results of a spinal tap. If HIV seronegative but compliance cannot be assured, retreatment (preferably with a single intramuscular benzathine injection of penicillin G on three successive weeks) is recommended. In rare cases, the titers fail to decline even after retreatment and even though CNS infection has been excluded. In this case, only serologic and clinical follow-up evaluations are recommended. The patient should be retreated only if there is a fourfold elevation in titers or new clinical signs develop.

Early Latent Syphilis[47]

A single dose of benzathine penicillin G, 2.4 million units intramuscularly, is the recommended treatment.

PENICILLIN ALLERGY If the patient is neither pregnant nor HIV-infected, treat with doxycycline, 100 mg orally twice daily for 4 weeks.

CHILDREN The treatment is the same as for primary or secondary syphilis.

FOLLOW-UP As in ate latent syphilis (see Indeterminate or Late Latent Syphilis).

Indeterminate or Late Latent Syphilis

Benzathine penicillin G, 2.4 million units intramuscularly 1 week apart for three doses, is the treatment of choice. If the patient misses a dose, the treatment may be resumed as long as the interval between injections has not exceeded 2 weeks.

The regimen does not need to be repeated in patients who are late for a treatment as long as the time interval between injections is less than two weeks, with the exception of pregnant women.

PENICILLIN ALLERGY Doxycycline, 100 mg orally twice daily, or tetracycline, 500 mg orally four times daily for 28 days, may be prescribed.

PREGNANCY Treat with penicillin as discussed in Treatment in Pregnancy.



HUMAN IMMUNODEFICIENCY VIRUS INFECTION Treat with penicillin.

CHILDREN After appropriate evaluation to exclude congenital syphilis and sexual abuse, treat with three weekly intramuscular injections of benzathine penicillin G, 50,000 units/kg (up to 2.4 million units).

CEREBROSPINAL FLUID EXAMINATION In asymptomatic individuals, the yield of positive findings for lumbar punctures is low, but CSF examination is clearly indicated in certain cases:

- Cardiovascular, neurologic, eye, or auditory symptoms or in late benign syphilis
- HIV infection
- RPR titer ≥ 1:32
- Treatment failure
- Treatment other than penicillin

If the CSF examination demonstrates abnormalities, patients should be treated for neurosyphilis. The outcome of treatment has not been conclusively studied, but in 469 treated patients with uncomplicated late latent syphilis who were followed for up to 12 years, the CSF remained normal, and no cases of cardiovascular syphilis were reported.

TREATMENT FAILURES Patients with a normal CSF examination should be retreated for latent syphilis if signs or symptoms of syphilis develop, if a high titer (> 1:32) fails to decline fourfold (to 1:2) within 12 to 24 months, or if titers subsequently increase fourfold or higher.

FOLLOW-UP Quantitative nontreponemal serologic tests should be repeated at 6, 12, and 24 months (and additionally at 18 months if the patient is HIV infected). After treatment, the patient should be reevaluated for neurosyphilis and retreated accordingly if (1) titers increase fourfold, (2) an initially high titer (≥ 1:32) fails to decrease fourfold within 12 to 24 months, or (3) the patient develops signs or symptoms attributable to tertiary syphilis.

Tertiary Syphilis (Cardiovascular, Late Benign Syphilis)[47]

Benzathine penicillin G, 2.4 million units 1 week apart for three doses, is the recommended treatment.

PENICILLIN ALLERGY If the patient is not HIV infected and the CSF is negative, treat with doxycycline, 100 mg orally twice daily for 2 weeks.

CEREBROSPINAL FLUID EXAMINATION All patients should have spinal taps and, if abnormalities are found, treat for neurosyphilis.

PROGNOSIS After treatment of late benign syphilis, gummas heal slowly over several months, depending on the extent of tissue destruction. Gummas of the brain or spinal cord may need surgical excision. Because advanced symptomatic disease in cardiovascular syphilis is associated with poor prognosis even with recommended doses of benzathine penicillin, some experts prefer to treat cardiovascular disease with high-dose intravenous penicillin. The evidence suggests that penicillin has a beneficial effect in the majority of patients, although efficacy is difficult to evaluate, as most symptomatic patients receive therapy to improve cardiac function. In studies, 63 percent of patients with aortic insufficiency, aneurysms, or both, experienced symptomatic improvement from 6 to 12 months after penicillin treatment. The disease progressed in 4 percent of asymptomatic and 4.5 percent of symptomatic patients.

Neurosyphilis[47]

The treatment of choice is aqueous crystalline penicillin G, 18 to 24 million units administered daily as 3.5 to 4.0 million units intravenously every 4 hours for 10 to 14 days.[47]

Alternatively, treatment with a single injection of procaine penicillin G, 2.4 million units intramuscularly daily, and probenecid, 500 mg orally every 6 hours for 10 to 14 days, can be instituted in patients whose compliance can be assured. Treatment of neurosyphilis with ceftriaxone (1 g intravenously daily for 14 days) is not as effective as penicillin.

PENICILLIN ALLERGY Desensitize and treat with penicillin.

FOLLOW-UP Re-examine the CSF every 6 months until normal. Cell counts should decrease by 6 months and CSF VDRL and protein levels by 2 years. If not, retreat with intravenous penicillin. Notably, these CSF abnormalities may persist longer in HIV-infected patients.

PROGNOSIS In one study, penicillin cured, improved, or stabilized the disease in 91 percent of patients with asymptomatic neurosyphilis, 81 percent with meningovascular disease or meningitis (78 percent cured), 75 percent with general paresis (48 percent cured), 72 percent with tabes dorsalis (47 percent cured), and 88 percent with miscellaneous neurologic abnormalities.

If symptoms worsen during treatment, the dose may need to be increased. Optic atrophy, alone or in conjunction with tabes dorsalis, and eighth-nerve–related deafness are notoriously more resistant to treatment. Blindness because of optic atrophy is not reversible with penicillin, although lack of progression or improvement occurs in up to 60 percent of cases. Eighth-nerve–related deafness benefits from the combination of long-term penicillin and prednisone.

RELAPSE Neurosyphilis relapses usually respond to additional courses of intravenous penicillin at equal or higher doses.

Treatment in Pregnancy[47]

The penicillin regimen appropriate for the stage of the infection should be used. In primary, secondary, and early latent syphilis, a second benzathine penicillin injection 1 week later is recommended by some experts.

PENICILLIN ALLERGY Desensitize and treat with penicillin. Erythromycin's ability to cross the placenta is fair to poor. Infants born to mothers who received erythromycin for syphilis during pregnancy should be thoroughly evaluated for active disease, treated with penicillin, and closely followed. Tetracycline is avoided because of dental staining as a result of deposition in enamel.

EVALUATION DURING PREGNANCY Consider sonographic evaluation for signs of fetal syphilis (hepatomegaly, ascites, hydrops) or thickened placenta. If present, refer after initiating treatment to a high-risk obstetrician.

SCREENING Pregnant women should be screened at their initial prenatal visit, and those with seropositive results should be considered infected unless treatment can be verified and sequential serologic antibody titers convincingly demonstrate an appropriate response. In case of doubt, retreatment is warranted, as the potential benefits outweigh the possible risks. Screening should be repeated in the third trimester and again at delivery.

FOLLOW-UP Serologic titers should be repeated monthly in women at high risk of infection or in geographic areas with



high syphilis prevalences, or otherwise at 28 to 32 weeks of gestation, at delivery, and then according to the recommendations for the stage of infection.

COMPLICATIONS A potential adverse effect of penicillin treatment is the Jarisch-Herxheimer reaction, which may precipitate premature labor (placental shock). However, the association of spontaneous abortion with this phenomenon is debatable and should not delay treatment.

PROGNOSIS In 414 pregnant women with early syphilis who were treated with variable doses of penicillin, only 5 percent of their newborns had syphilis, and an expected rate of stillbirths was reported. The injected infants were born to women re-infected or treated late in pregnancy. In another study, the success of therapy in preventing congenital syphilis was also excellent: for mothers with primary syphilis, 27 of 27; secondary syphilis, 71 of 75; early latent syphilis, 100 of 102; and late latent syphilis, 136 of 136.[28]



Prenatal Syphilis[47]

NEONATAL PERIOD Aqueous penicillin G, 50,000 units/kg intravenously every 12 hours for the first 7 days of life and every 8 hours for the next 3 days, or procaine penicillin G, 50,000 units/kg intramuscularly daily for 10 to 14 days.

POSTNEONATAL PERIOD Benzathine penicillin G, 50,000 units/kg (up to 2.4 million units) intramuscularly if CSF examination is negative. If positive, aqueous penicillin G, 50,000 units/kg every 4 to 6 hours intravenously for 10 to 14 days.

PRESUMED CONGENITAL SYPHILIS Infants should be treated for presumed congenital syphilis regardless of evaluation if born to mothers with any of the following:

- Untreated syphilis at delivery
- Treatment other than with penicillin
- Treatment for syphilis within 1 month of delivery
- Inadequate documentation of appropriate treatment
- Serologic evidence of relapse or reinfection after treatment
- No documented fourfold decrease in RPR titers after treatment before or during pregnancy

If the infant has signs of congenital syphilis on physical examination or serologic evidence of syphilis (infant's RPR titer is two dilutions greater than mother's), the evaluation should include complete blood cell count with differential and platelets and CSF examination for cell count, protein, and RPR. Other tests that can be ordered as clinically indicated include long-bone radiographs, chest radiograph, cranial ultrasound, ophthalmologic examination, auditory–brainstem response, and liver function tests.

If the infant's clinical, CSF, serologic, and blood evaluation are normal and the mother's compliance with her prior treatment is indisputable, the infant may be treated with a single intramuscular injection of benzathine penicillin G, 50,000 units/kg.

If the mother was adequately treated and had an appropriate serologic decline in titers, evaluation of an infant with a nontreponemal titer equal to or less than the mother's titer is not necessary, but a single dose of benzathine penicillin is recommended. If the infant's titer is not reactive, no treatment is necessary.

FOLLOW-UP Seropositive infants (or infants born to mothers who were seroreactive at delivery) must be re-examined clinically and serologically every 2 to 3 months until the test becomes nonreactive or the titer has decreased fourfold. If the reactive test result was caused by passive transplacental transfer, nontreponemal antibody titers should decrease by 3 months and disappear by 6 months of age. If the child was infected and treated, the serologic decline may be slower. If the titers are stable or increasing after 8 to 12 months of age, the child should be re-evaluated (including CSF analysis) and retreated with a 10-day course of intramuscular penicillin G. Treponemal tests may remain positive for 15 months if the disease was acquired transplacentally, but if the tests are reactive after 18 months, they indicate congenital syphilis.

Close neurologic follow-up is indicated for infants with initially abnormal CSF examinations. If CSF pleocytosis was present, spinal taps should be done every 6 months until the cell count is normal. If the cell count remains abnormal after 2 years, or if a downward trend is not present at each examination, the infant should be retreated. The CSF VDRL should also be checked at 6 months, and retreatment administered if still reactive.

Treatment of Sex Partners and Persons Exposed to Syphilis

Examine the exposed person and do a serologic test. Treat the contact if there is clinical or serologic evidence of disease; treat prophylactically for primary syphilis if:

- The exposure occurred within 90 days preceding the sex partner's diagnosis of early (primary, secondary, or early latent) syphilis. For purposes of treatment, patients without clinical disease but serologic titers equal or greater than 1:32 are assumed to have early syphilis.
- The exposure occurred more than 90 days before the sex partner's diagnosis of primary, secondary, or early latent syphilis, but serologic tests are not immediately available, and reliability is uncertain.
- The evaluation of a long-term sex partner of a person with latent syphilis demonstrates possible transmission serologically or clinically.

Syphilis in Human Immunodeficiency Virus–Infected Patients

A penicillin regimen should be instituted according to the stage of the disease.

PENICILLIN ALLERGY Desensitize and treat.

CEREBROSPINAL FLUID EXAMINATION Spinal fluid analysis should be performed on patients with indeterminate or late latent disease or with early disease with neurologic symptoms. Some experts recommend CSF examination before treatment of early syphilis as well as 6 months after treatment, but there is no evidence of improved outcomes.

FOLLOW-UP A closer follow-up with clinical and serologic tests is needed for these patients. CSF examination is indicated if there is serologic evidence of treatment failure at any time, or if the serofast response continues after 12 months.

NEUROSYPHILIS Treat according to recommended regimens for neurosyphilis. Neurorelapse is more common in these patients, even after adequate treatment.

Complications of Treatment

The Jarisch-Herxheimer reaction is a clinical syndrome consisting of fever, headache, flare of mucocutaneous lesions, tender lymphadenopathy, pharyngitis, malaise, myalgias, and leukocytosis. It occurs within 12 hours of instituting therapy. The fever peaks in 6 to 8 hours usually around 39°C (102.2°F), but it can

be as high as 42°C (107.6°F). Patients should be warned about the possibility of developing this reaction before receiving treatment. Symptoms are controlled with nonsteroidal anti-inflammatory agents or aspirin. The pathogenesis of the Jarisch-Herxheimer reaction is unknown. It has been proposed that destruction of spirochetes is followed by massive phagocytosis with release of pyrogenic cytokines. Systemic glucocorticoids modify the febrile reaction without affecting the skin lesions or the leukocytosis, and suppress or mitigate the reaction if administered 12 hours before penicillin therapy.

Patients with neurosyphilis can become febrile after treatment with penicillin, especially when the CSF contains high numbers of cells and protein. Convulsions, dementia, psychosis, and meningismus have been reported to occur in up to 2 percent of neurosyphilis patients treated with penicillin. Death is very rare. About 50 percent of infants with early syphilis and 39 percent of those with late disease develop febrile reactions. Rare cases of elevated liver function tests and the nephrotic syndrome have been reported.

Therapeutic paradox, or deterioration of tertiary syphilis after therapy, results from rapid decomposition of gummatous tissue. Worsening of the aortic insufficiency murmur has been reported from this complication.

Hoigne syndrome (pseudoanaphylactic reaction) is a complication associated with intramuscular procaine penicillin treatment and is seen in approximately 1 case per 1000 treated patients. The reaction occurs immediately after the injection and is characterized by tachycardia, elevated blood pressure, fear of imminent death, violent combativeness, unusual taste sensation, auditory or visual disturbances, neuromuscular twitching, occasional seizures, and even loss of consciousness. It rarely lasts longer than 30 minutes. Treatment consists of observation and sedatives or anticonvulsants. Inadvertent intracapillary infusion of procaine or, less likely, penicillin during intramuscular injection resulting in microembolization has been proposed as the mechanism.

Anaphylaxis from administration of penicillin injection is a life-threatening emergency that is managed by intramuscular injection of epinephrine and diphenhydramine with hydrocortisone intravenously.[47]

Vaccines

There is no protective vaccine against syphilis, although efforts are under way to develop one. In one promising study, repeated immunization of rabbits with purified antiendoflagellar antigen over 32 weeks did not prevent re-infection, but the lesions occurred earlier, had a flatter, softer appearance, and resolved more rapidly.[51] Twelve surface proteins that may be suitable components for designing a vaccine were identified after mapping of the genome.[51]

The renowned physician William Osler who wrote, "Know syphilis in all its manifestations and relations, and all other things clinical will be added unto you." The mapping of the *T. pallidum* genome promises a better understanding of syphilis, development of new tests and treatments, and possibly a vaccine to prevent infection.

KEY REFERENCES

The full reference list for all chapters is available at www.digm7.com.

1. Lukehart SA: Modern syphilis—Still a shadow on the land. *West J Med* **163**:587, 1995
2. Transmission of primary and secondary syphilis by oral sex. *MMWR Morb Mortal Wkly Rep* **53**:966, 2004
3. Rothschild BM: History of syphilis. *Clin Infect Dis* **40**:1454, 2005
4. Grbach PM et al: Primary and secondary syphilis—United States, 2002. *MMWR Morb Mortal Wkly Rep* **51**:853, 2002
5. Douglas JM Jr et al: Syphilis among men who have sex with men: Challenges to syphilis elimination in the United States. *Sex Transm Dis* **32**:S80, 2005
7. Fraser CM et al: Complete genome sequence of *Treponema pallidum,* the syphilis spirochete. *Science* **281**:375, 1998
8. Peeling RW et al: The pathogenesis of syphilis: The Great Mimicker, revisited. *J Pathol* **208**:224, 2006
12. Syphilis, in *Treatment of Skin Disease: Comprehensive Therapeutic Strategies*, edited by Lebwohl MG et al. Philadelphia, Elsevier Health Sciences Publisher, 2005, p 162
13. Goh BT: Syphilis in adults. *Sex Transm Inf* **81**:448, 2005
22. Scheck DN, Hook EW III: Neurosyphilis. *Infect Dis Clin North Am* **8**:769, 1994
25. Salojee H et al: The prevention and management of congenital syphilis: An overview and recommendations. *Bull World Health Organ* **82**:424, 2004
29. Cohen MS: When people with HIV get syphilis: Triple jeopardy. *Sex Transm Dis* **33**:149, 2006
30. Marra CM: Neurosyphilis. *Curr Neurol Neurosci Rep* **4**:435, 2004
34. Rolfs RT et al: A randomized trial of enhanced therapy for early syphilis in patients with and without human immunodeficiency virus infection. The Syphilis and HIV Study Group. *N Engl J Med* **337**:307, 1997
43. Young H: Guidelines for serological testing for syphilis. *Sex Transm Infect* **76**:403, 2000
47. Centers for Disease Control and Prevention: Sexually transmitted diseases treatment guidelines 2006. *MMWR Morb Mortal Wkly Rep* **55**:22, 2006
48. Ghanem KG et al: Doxycycline compared with benzathine penicillin for the treatment of early syphilis. *Clin Inf Dis* **42**:45, 2006
49. Riedner G et al: Single-dose azithromycin versus penicillin G benzathine for the treatment of early syphilis. *N Engl J Med* **353**:1236, 2005
51. Cullen PA et al: Progress towards an effective syphilis vaccine: The past, present and future. *Exp Rev Vaccines* **5**:67, 2006



CHAPTER 201

Endemic (Non-Venereal) Treponematoses

Miguel R. Sanchez

Pinta, yaws, and endemic syphilis constitute a group of distinct spirochetal infections that are known as the *endemic non-venereal treponematoses*. These diseases have remained confined to foci in indigent, remote, rural areas within tropical and sub-tropical regions of selected countries.[1] As many as 2.5 million persons are believed to be infected.[1] However, a significant proportion of infected persons remain asymptomatic. The distinct causative spirochetes are so closely related that they cannot be distinguished histopathologically, immunologically, or serologically from *Treponema pallidum*. Like venereal syphilis, the diseases progress through successive clinical early (primary and secondary) and late stages usually separated by periods of latency.[1,2] Serologic tests for syphilis give reactive results in patients with endemic treponematosis. So far, no subspecies-specific monoclonal antibodies have been found.

In contrast to syphilis in other parts of the world, transmission occurs from skin-to-skin contact rather than sexual contact. Infants contract the infections from their mothers during breast-feed-

ENDEMIC TREPONEMATOSES

AT A GLANCE



- Non-venereal syphilis, pinta, and yaws are non-venereal infections acquired by skin-to-skin-contact.
- They are caused by *Treponema pallidum* or closely related treponemes.
- Like venereal syphilis, these infections are characterized by three successive stages separated by periods of latency.
- Penicillin or, alternatively, doxycycline is highly effective treatment for both the cutaneous and systemic lesions of endemic treponematosis.



ing, and children contract them from direct contact with mucocutaneous lesions of infected family members and playmates. The diseases are not transmitted transplacentally, however. *Hippelates pallipes*, the eye gnat, has been implicated in the transmission of yaws.[1]

Without treatment, patients remain potentially infectious indefinitely, although the skin lesions may become inconspicuous or sub-clinical. Patients do not develop lifelong immune resistance. Cross-immunity is absent in the early stages of endemic syphilis, yaws, and pinta but is variable in late stages. Notably, patients with late pinta are resistant to syphilis, but those with yaws or syphilis at any stage are susceptible to pinta. The level of cross-protection may be proportional to the severity of the initial infection.[1]

In areas of low incidence, health care providers with limited experience in recognizing these diseases frequently misdiagnose them as impetigo, psoriasis, mycobacterial infection, or tropical ulcer, among other diseases. Although the non-venereal treponematoses are not fatal, they are disfiguring and disabling, and patients experience discrimination and social ostracism.

PINTA (CARATE, MAL DE PINTA, AZUL)

Epidemiology and Etiology

Pinta ("colored spot" in Spanish) is caused by *T. carateum*, named after the Colombian word for the disease (*carate*). The organism can be propagated only in primates, and no isolates are known to exist.

The disease affects predominantly poor, undernourished infants, children, and adolescents who live in small, remote, crowded villages in hot, semiarid coastal areas. Twenty years ago, approximately 750,000 cases were estimated, but now only a few hundred new cases are reported each year, mainly in southern Mexico, Brazil, Colombia, Venezuela, Peru, and Ecuador.[1]

Transmission occurs from repeated, direct contact of the exposed skin of a healthy person with a cutaneous or mucous membrane lesion on an infected person.

Pinta is the only treponematosis with clinical manifestations confined to the skin.[1] As in syphilis, there are three distinct clinical stages. Lesions at different stages may be present in a single patient. Because cell-mediated immunity is not completely effective against the organism, the infection persists indefinitely, and people of all ages can be infected. However, half of all patients are younger than 15 years of age.

Primary Stage

After an incubation period of 15 to 30 days, one to three erythematous papules develop at the site(s) of inoculation. These primary lesions may be pruritic and over weeks to months enlarge or coalesce with other lesions to achieve a size of 1 to 3 cm. The resulting plaques are irregular, scaly, lichenified, and centrally paler, and can grow to a diameter of 20 cm (Fig. 201-1).[3] Over time, the centers become hypochromic, grayish, light blue, or pale mauve. Primary lesions usually develop in exposed areas, especially the hands, feet, arms, legs, face, and neck. They can persist for years and eventually heal spontaneously with residual dyspigmentation. Regional lymph nodes may become enlarged.

Secondary Stage

Secondary lesions (pintids) usually arise 1 to 12 months, but sometimes years, after the appearance of the primary lesions. They may encircle the sites of the primary lesions or erupt generally on the body. Pintids may occur on the palms, soles, and groin.[1] Secondary lesions may be indistinguishable from primary lesions but are smaller, usually asymptomatic, and psoriasiform. Some lesions may be circinate or annular with raised borders where the number of treponemes is highest. Gradually, the lesions turn brown or copper colored and eventually slate blue, gray, or black. More than one color may be present within a plaque. Lesions can occur up to 10 years after the initial infection.[3]

Tertiary Stage

Late lesions usually develop between 2 and 4 years after the onset of the disease and 3 months to 10 years after the appearance of the secondary-stage lesions. Typically, patients have dyschromic patches that are hyperchromic, hypochromic, and achromic, which impart a mottled pattern with a variegated palette of white, brown, blue, red, and violet.[4] The lesions have irregular borders and vary in size. The more commonly involved areas are the wrists, palms, ankles, and elbows as well as the skin around and within old lesions (Fig. 201-2). In such areas, the lesions appear



FIGURE 201-1 Lichenified patch in primary pinta with dyschromic changes.



▲ **FIGURE 201-2** Depigmented and hyperpigmented, mottled patches in late pinta.

scarred and atrophic (cicatricial lesions of pinta).[4] Lymphadenopathy may develop during any stage of pinta. Patients with only late-stage lesions may appear to have vitiligo (vitiligo of pinta).

Differential Diagnosis (Box 201-1)

YAWS (FRAMBOESIA TROPICA, PIAN, BUBA, PARU, PARANGI)

Epidemiology and Etiology

Yaws is caused by *T. pallidum* (subspecies *pertenue*). The spirochete can be propagated in laboratory animals, and various strains have been isolated for investigation.[1] Approximately 75 percent of new cases arise in children younger than 15 years of age.[5,6] Yaws is contracted from direct contact with abraded, bitten, or excoriated skin with oozing lesions. Some experts contend, with scant evidence, that the disease can be transmitted by flies or through domestic utensils.[7]

The infection occurs in countries along the tropical belt in lowlands characterized by heavy rainfall, high humidity, and persistently hot temperatures above 27°C (80.6°F).[6] Owing to mass treatment campaigns and improved living conditions, the disease has been eradicated in many areas, and greatly reduced in others.[5] However, yaws is underdiagnosed because fewer physicians have experience with the infection. Over the past three decades, due to relaxed surveillance and control measures and the persistence of poor sanitary conditions, a resurgence of yaws has been documented in regions of Africa and Southeast Asia. Sizable foci have been reported in several tropical regions of western and central Africa (Ghana, Togo, Benin, and the Central African Republic), and residual foci remain in South America (Colombia, Guyana, Peru, Ecuador, and Brazil), Haiti, Dominica, Southeast Asia, Indonesia, Papua New Guinea, and the Solomon Islands.[7] Currently, at least 100 million children are estimated to be at risk of becoming infected.[1] *T. pallidum pertenue* is nearly identical to the spirochete that causes infectious and endemic syphilis, so not surprisingly the diseases share many characteristics.

Box 201-1

Differential Diagnosis of Pinta

Most Likely
- Leukodermas
- Eczema (early lesions)

Consider
- Pityriasis alba
- Pellagra
- Tinea versicolor
- Melasma
- Lichen planus (early lesions)
- Tuberculoid leprosy (early lesions)
- Tinea corporis
- Psoriasis (early lesions)
- Lupus erythematosus (early lesions)
- Yaws (early lesions)
- Syphilis

Always Rule Out
- Vitiligo
- Erythema dyschromicum perstans

Primary Stage

After an incubation period of 10 to 90 days (average, 3 weeks), the primary lesion or mother yaw (buba madre) appears at the site of inoculation, which is usually an exposed body part, generally a lower extremity.[8] Characteristically, the lesion is a non-tender, often pruritic, infiltrated, erythematous small nodule that grows to a size of 1 to 5 cm. Its surface frequently becomes papillomatous and crusted. The primary lesion is usually single, but satellite papules may be present, becoming confluent into a plaque. The lesion eventually becomes an ulcer (chancre of yaws, frambesioma) with a raspberry-like base that may be covered by yellow crust (Fig. 201-3). Regional buboes (enlarged lymph nodes) are common.[1] The mother yaw heals spontaneously in 2 to 6 months, leaving atrophic scarring and central hypopigmentation. Constitutional symptoms are rare.

Secondary Stage

Resolution of the mother yaw is typically followed by a period of latency, which is then interrupted within 10 to 16 weeks, but possibly as long as 2 years, after the onset of the primary stage by an eruption of disseminated skin lesions with generalized lymphadenopathy. Constitutional symptoms such as malaise, fever, and anorexia are often present. The lesions (daughter yaws or pianomas) are reddish, weeping, warty or vegetating, crusted, non-pruritic papules and plaques that are similar to but smaller than (up to 2 cm) the mother yaw (Fig. 201-4A). As the lesions grow, they become eroded and covered by a highly infectious fibrinous exudate, which dries into a crust (see Fig. 201-4B, C). The exudate attracts flies that torture the affected persons.[8] Pianic onychia (paronychia) may develop.

Pianomas may appear in any body area. In addition, dry, papulosquamous patches and plaques (pianides) may be present on any part of the body.[8] In body folds (axillae, anal folds), they are



▲ **FIGURE 201-3** Ulcerated primary-stage nodule (mother yaw). The genital location is unusual.











▲ **FIGURE 201-4** **A.** Early secondary lesions of yaws (daughter yaws) appearing as eroded and crusted papules and plaques. **B.** Warty secondary-stage papillomas (daughter yaws). **C.** Eroded papillomas covered by fibrinous exudate. (**B** and **C** used with permission from H.J.H. Engelkens, MD, J. van der Stek, MD, and E. Stolz, MD.)

resemble condylomata lata; on mucous membranes, they are similar to hypertrophic mucous patches. It is interesting that widespread warty exudative lesions appear during humid times, but in arid, desert regions and during dry spells, the lesions favor or are limited to intertriginous areas and mucous membranes. In addition, a milder, attenuated, less florid form with small, dry, few (even single) lesions that are often limited to skin folds has been reported in areas with low or receding transmission rates. In some cases the lesions are papillomatous but resolve quickly.[1]

Thick, hyperkeratotic plaques of the palms and soles become fissured and ulcerated ("worm-eaten soles"). This painful involvement of the soles is also called *crab yaws* (Fig. 201-5) because patients walk with a deliberate slow, crustacean gait. Lesions may be annular or circinate (tinea yaws). Lesions on the face are often seborrheic or psoriasiform.[8] Painful osteoperiostitis is common in early yaws.[7] The appearance of turnip-like, fusiform soft-tissue swelling of the proximal, but not the distal, phalanges because of periostitis is classic ("ghoul hands"). The metatarsal, metacarpal, and tibial bones are also commonly involved.[8] Infected persons then enter a latent period with serologic reactivity but no signs or symptoms of the disease. All lesions resolve without scarring, but relapses may develop during the initial 5 years of infection. In relapsing yaws, lesions tend to be confined to the perioral, perianal, and periaxillary areas.

Tertiary Stage

In approximately 10 percent of cases, latency is interrupted after 5 to 10 years by a late stage with skin and skeletal lesions, and possibly with ophthalmologic and neurologic involvement. Cuta-



▲ **FIGURE 201-5** Fissured hyperkeratotic plantar keratoderma in secondary yaws (crab yaws).

neous and subcutaneous gummatous nodules (gumma framboesiodes) necrose centrally and ulcerate, causing deep, mutilating lesions.[7] Coalescence of the ulcers may produce circinate, serpiginous tracts that heal with deforming scars and contractures.[6] Palmoplantar hyperkeratosis may lead to chronic keratoderma. Juxta-articular lymphadenopathy may occur on the elbows and knees.

Late skeletal changes include hypertrophic periostitis, hydrarthrosis, gummatous osteitis and periostitis, and osteomyelitis. Considerable bone hypertrophy as a result of chronic osteitis may result in curvature of the tibia (saber shins). Bilateral hypertrophic osteitis of the nasal process of the maxillae with persistent swelling of the nasal bridge (goundou) slowly progresses over 5 to 20 years. The most dreaded consequence of yaws, which occurs in approximately 1 percent of untreated infected persons, is rhinopharyngitis mutilans (gangosa), or extensive destruction of the nose, maxillae, upper lip, and central face with eventual perforation of the nose and palate. Although ophthalmologic, neurologic, and cardiovascular disease is not usually associated with yaws, there are rare reports of optic disk atrophy, myeloneuropathy, and aneurysms.[1]

Differential Diagnosis (Box 201-2)

Box 201-2

Differential Diagnosis of Yaws

Most Likely

- Frambesiform leishmaniasis (pianomas, gangosa)
- Paracoccidiomycosis (pianomas)

Consider

- Psoriasis (pianides)
- Impetiginized eczema (pianides)
- Pyoderma vegetans (pianomas)
- Arthropod bites (pianides)
- Myiasis (pianides)
- Scabies (pianides)
- Dermatophytosis (pianides)
- Pyoderma (pianomas)
- Lupus vulgaris (gangosa)
- Atypical mycobacterial infection
- Deep fungus infection (pianotes, gangosa)
- Tuberculoid leprosy (pianides)
- Ecthyma (pianomas)
- Vitiligo (pintoids)
- Pinta (pintoids)
- Keratodermas

Always Rule Out

- Frambesiform syphilis (pianides, pianomas)

ENDEMIC SYPHILIS (BEJEL, FIRJAL, BELESH, NJOVERA)

Epidemiology and Etiology

Endemic syphilis is a non-venereal infection caused by *T. pallidum* (subspecies *endemicum*) that favors arid climates in rural areas bordering deserts. It has been reported to be a common health problem in children in Burkina Faso and the Bedouin tribes of Saudi Arabia, Iraq, and Syria. Foci also remain in Africa (Sudan, southern Zimbabwe, and South Africa), Southeast Asia, Turkey, and the western Pacific.[3] Approximately 80 percent of cases occur in children and adolescents younger than 15 years of age.[9] Transmission occurs through skin or mucous membranes contact with infected skin lesions or saliva, or by drinking from contaminated flasks or sharing pipes.[1] Anecdotal reports that the common fly, *Musca domestica*, is a disease vector have not been substantiated. The mucocutaneous lesions resemble those of venereal syphilis.

Primary Stage

The incubation period is 10 to 90 days. The primary lesion is an asymptomatic patch that becomes eroded. It is frequently missed, probably because the chancre is often present in the oropharyngeal mucosa. Because of the small inoculum, regional lymphadenopathy is rare. A primary chancre may develop on the nipple of a mother nursing an infected child. Primary lesions heal in 1 to 6 weeks.[3]

Secondary Stage

Usually a few non-tender, oval or round, macerated, eroded mucous patches erupt on the lips, tongue, and tonsils. Vegetating or hypertrophic condylomata lata appear on the anogenital area and the axillae.[5] Split papules are fissured mucous patches in the labial commissures. Occasionally, macular, papular, annular, and circinate eruptions, similar to those seen in secondary syphilis, develop. Non-tender, generalized lymphadenopathy is common. Nocturnal lower extremity pain is caused by periostitis of the long bones.

The secondary stage persists for 6 to 9 months and is followed by a latency period, which may continue for only a few months but usually lasts 5 to 15 years. At this point, a tertiary stage with cutaneous skeletal and systemic manifestations develops.[10]



▲ **FIGURE 201-6** Cutaneous gummas in late endemic syphilis. Note the involvement of the elbow.

Tertiary Stage

Late lesions consist of gummas of the skin, bone, nasopharynx, and larynx.[7] The gummas develop destructive ulcerations, but the lesions are not as mutilating as those of yaws (Fig. 201-6). Lesions eventually heal, leaving atrophic, depigmented scars bordered by hyperpigmentation. Saddle-nose deformity, palate perforation, and gangosa are disfiguring complications.[3]

Skeletal involvement is common, but most patients are not significantly bothered by pain. Clinically apparent tibial bowing and tenderness are exceptions. However, bone defects may be present on radiographs, most commonly in the tibia and fibula, and sometimes in the ulna and radius. Systemic involvement is rare. Uveitis, chorioretinitis, and optic atrophy have been observed. Aortitis and saccular aneurysms of the aortic arch have infrequently been reported.[3]

An attenuated form of endemic syphilis with fewer, more rapidly healing cutaneous lesions but more frequent periostitis has been reported.

Differential Diagnosis (Box 201-3)

DIAGNOSIS OF THE NON-VENEREAL TREPONEMATOSES

The diagnosis of the non-venereal treponematoses is made through clinical



Box 201-3

Differential Diagnosis of Endemic Syphilis

Most Likely

- Condylomata acuminata
- Molluscum contagiosum
- Oral herpes simplex
- Aphthous ulcers
- Angular cheilitis
- Oral cheilitis

Consider

- Seborrheic dermatitis (papulocircinated lesions)
- Psoriasis (papulocircinated lesions)
- Dermatophytosis (papulocircinated lesions)
- Deep fungal infection (gummas)
- Leishmaniasis (gummas)
- Mycobacterial infection (gummas)
- Lymphomas and sarcomas (gummas)
- Granulomatous diseases (gummas)

Always Rule Out

- Venereal syphilis



evaluation of the lesions (Table 201-1) in inhabitants or former residents of endemic areas and is confirmed by detection of treponemes under dark-field microscopic examination or with a direct fluorescent antibody test. In the absence of positive findings on dark-field examination, histologic or serologic confirmation is required. In yaws and endemic syphilis, nontreponemal tests yield reactive results in 2 to 3 weeks after the onset of the primary lesion. In pinta, these tests give reactive results in 80 percent of cases within 3 months after the appearance of primary lesions and in essentially all patients with the late stage of the disease. Treponemal tests are more specific for spirochetal infection and are used for confirmation of the diagnosis, and results will remain reactive after treatment when serologic titers of the nontreponemal tests fall. Other treponemal tests, including enzyme immunoassays, have not shown greater specificity than the fluorescent treponemal antibody absorption test but may be less expensive.[11] A finger-prick indirect hemagglutination test is advantageous for screening children.[12]

HISTOPATHOLOGIC FEATURES OF THE NON-VENEREAL TREPONEMATOSES

TREATMENT OF THE NON-VENEREAL TREPONEMATOSES

The recommended treatment for pinta, yaws, and endemic syphilis remains a single intramuscular injection of 1.2 million units of benzathine penicillin for adults or children older than 10 years of age and 0.6 million units for younger children.[7] Patients become non-infectious within 24 hours. Children older than 8 years of age who are allergic to penicillin may be treated for 15 days with tetracycline 250 mg four times daily, or, if younger, with erythromycin 8 mg/kg four times daily.[9] Penicillin-allergic adults are treated for 15 days with tetracycline 500 mg four times daily, doxycycline 100 mg twice daily, or erythromycin 500 mg four times daily. Other macrolide antibiotics are also probably effective, despite a dearth of reported experience. In pinta, primary and secondary lesions disappear after treatment, but achromic patches persist for life. Failure of penicillin therapy is exceedingly rare but has been reported in a few cases in Papua New Guinea, Colombia, and Ecuador.[1,14] Seven- to 10-day courses of oral penicillin, at a dose of 50 mg/kg per day in four divided doses up to 1200 mg daily, have provided good results in eradication campaigns. There is concern that such widespread use of penicillin may lead to resistance of other pathogenic bacteria such as streptococci. Concurrent infection with human immunodeficiency virus appears to exacerbate non-venereal treponematosis, and based on the experience with venereal syphilis, it appears prudent to screen persons at risk for human immunodeficiency virus infection and to consider closer follow-up. Recommendations for prophylactic treatment depend on the number of seropositive children younger than 6 years of age (Table 201-2).

EPIDEMIOLOGIC PERSPECTIVE

Eradication of the non-venereal treponematoses should be possible, but history has shown that mass treatment campaigns alone are insufficient.[15] In some areas where the diseases had been thought to be eradicated, new cases are now being reported at a surprising rate.[16] In 1997, the World Health Organization estimated the number of new cases of endemic treponematosis at 460,000 annually.[5] Treatment of those infected and

TABLE 201-1
Non-Venereal Treponematoses—Clinical Manifestations

	Pinta	Yaws	Endemic Syphilis
Causative organism	*Treponema carateum*	*T. pertenue*	*T. pallidum*
Transmission	Skin-to-skin contact	Skin-to-skin contact	Skin or mucosal contact with infected skin or saliva, drinking vessels
Peak ages	1–15 yr	1–15 yr	Months–15 yr
Incubation	15–30 days (average, 1–3 wk)	10–90 days (average, 3 wk)	10–90 days
Primary lesions	Erythematous papules become psoriasiform plaques	Vegetating, soft, ulcerating papule (mother yaws) with satellites	Small eroded papule (often absent)
Secondary lesions	Erythematous scaly and psoriasiform plaques (pintids); increased and decreased pigmentation	Warty or frambesiform nodules, papulosquamous plaques, palmoplantar plaques (crab yaws)	Mucous patches, condylomata lata, syphilis-like eruptions
Tertiary lesions	Dyschromic, hypochromic, achromic, and polychromic patches	Gummas, pintoid dyschromia, juxta-articular nodes, gangosa, goundou, keratoderma	Serpiginous gummas, juxta-articular nodes on elbows only
Reactive serologic test result	2–3 mo after primary lesion	2–3 wk after primary lesion	2–3 wk after primary lesion
Treatment	Penicillin	Penicillin	Penicillin

those at risk must be followed by such sound public health measures as prolonged serosurveillance and periodic screenings.[2,17] Follow-up should begin 6 months after initial treatment and should be repeated at least every 2 years. City dwellers are at lower risk, and the diseases are practically unknown in the West, where a single case usually stimulates a published case report.

KEY REFERENCES

The full reference list for all chapters is available at www.digm7.com.

1. Antal GM et al: The endemic treponematoses. *Microbes Infect* **4**:83, 2002
2. Wicher K et al: *Treponema pallidum* subsp. *pertenue* displays pathogenic properties different from those of *T. pallidum* subsp. *pallidum*. *Infect Immun* **68**:3219, 2000
3. Engelkens HJ et al: Endemic treponematoses. Part II: Pinta and endemic syphilis [review]. *Int J Dermatol* **30**:231, 1991
5. Walker ST et al: Yaws—A review of the last 50 years. *Int J Dermatol* **39**:258, 2000
7. Engelkens HJ et al: Nonvenereal treponematoses in tropical countries. *Clin Dermatol* **17**:143, 1999

CHAPTER 202

Chancroid

Stephan Lautenschlager

EPIDEMIOLOGY

Chancroid is most common in developing countries, especially in Africa and Asia, where the causative organism, *Haemophilus ducreyi*, was isolated from over 50 percent of genital ulcers in patients until the 1990s.[1–3] These endemic regions also have some of the highest rates of human immunodeficiency virus (HIV) infection in the world, and chancroid is common in all 18 countries in which adult HIV prevalence surpasses 8 percent.[4]

Recent epidemics in the industrialized countries have usually been associated with commercial sex work, the use of crack cocaine, syphilis, and an increased risk of HIV infection.[15,16] Lower-class prostitutes appear to be a reservoir in all reported outbreaks of this disease. Men have a markedly higher incidence of chancroid than women.[10] Several studies in Africa showed that chancroid ulcer is an important risk factor for the heterosexual spread of HIV-1.[17] It is still not clear whether there is an asymptomatic reservoir of *H. ducreyi* carriers and what the risks of transmission are.[18,19] The duration of infectivity in the absence of treatment was estimated to be 45 days for women. The transmission rate from females to males is not known, but a transmission rate from males to females of 70 percent per sex act has been reported.[20]

ETIOLOGY AND PATHOGENESIS

Historical Aspects

H. ducreyi is a Gram-negative, facultative anaerobic coccobacillus that requires hemin (X factor) for growth. The organism is small, nonmotile, and non–spore-forming and shows typically streptobacillary chaining, especially in cultures. The exact taxonomy is still controversial. The current classifications list *H. ducreyi* as a true *Haemophilus* sp. However, studies of DNA homology and chemotaxonomy demonstrate substantial differences between *H. ducreyi* and *Haemophilus* sp. *H. ducreyi* will likely be reclassified in the future, but this issue awaits further studies.[24,25]

Biochemistry

Growth Requirements

Genetics and Virulence

Three major factors seem to be important in the pathogenesis of *H. ducreyi* infection: the adherence to the epithelial surface, the rate of production of exotoxins (e.g., cytolethal distending toxin),[30] and the resistance of the host defense mechanism. Many details about pathogenesis are still unclear. Because of the lack of appropriate experimental model systems, attachment factors, in particular, are not well understood.[31]

CLINICAL FINDINGS

The incubation period is between 3 and 7 days, rarely more than 10 days. No prodromal symptoms are known. The chancre begins as a soft papule surrounded by erythema. After 24 to 48 hours it becomes pustular, eroded, and ulcerated (Fig. 202-1). Vesicles are not seen. The edges of the ulcers are often ragged and undermined (see eFig. 202-1.1 in on-line edition). The ulcer is usually covered by a necrotic yellowish gray exudate (Fig. 202-2), and its ground is composed of granulation tissue that

CHANCROID AT A GLANCE



- A sexually transmitted acute ulcerative disease.
- Usually localized to the anogenital area and often associated with inguinal adenitis or bubo.
- *Haemophilus ducreyi*, a Gram-negative, facultative anaerobic coccobacillus, is the causative agent.
- Chancre is common in many developing countries (Africa, the Caribbean, and Southwest Asia) but rare in the United States and Europe.
- Painful soft ulcers with ragged undermined margins develop 1 to 2 weeks after inoculation.
- Chancroid facilitates the transmission of human immunodeficiency virus.
- Azithromycin and ceftriaxone are recommended as a single-dose treatment.



▲ **FIGURE 202-1** Early, sharply circumscribed ulcer in the sulcus coronarius.





▲ **FIGURE 202-2** Enlarging chancroid with gray exudate, which has destroyed the frenulum (kissing ulcer).



▲ **FIGURE 202-3** Vulvar chancroid with undermined edges.



bleeds readily on manipulation. In contrast to those of syphilis, chancroid ulcers are usually tender, not indurated (soft chancre), and painful. The diameter varies from 1 mm to 2 cm. Half of males have a single ulcer, and most lesions are found on the external or internal surface of the prepuce, on the frenulum, and on the glans (see eFig. 202-2.1 in on-line edition). The meatus and shaft of the penis and the anus are involved less frequently. Edema of the prepuce is often seen. Rarely, if the chancre is localized in the urethra *H. ducreyi* causes purulent urethritis.[32]

In females the lesions are mostly localized on the vulva (Fig. 202-3), especially on the fourchette, the labia minora, and the vestibule. Vaginal, cervical, and perianal ulcers have also been described. Extragenital lesions of chancroid have been reported on the breasts, fingers, thighs, and inside of the mouth. Trauma and abrasion may be important for such extragenital manifestations.

Painful inguinal adenitis (bubo) occurs in up to 50 percent of patients within a few days to 2 weeks (average, 1 week) after onset of the primary lesion (see eFig. 202-3.1 in on-line edition). The adenitis is unilateral in most patients, and erythema of the overlying skin is typical. Buboes can become fluctuant and may rupture spontaneously. The pus of a bubo is usually thick and creamy. Buboes are less common in female patients. In addition to the common types of chancroid described thus far, a number of clinical variants have been reported (Table 202-1). Mild systemic symptoms can accompany chancroid in rare cases, but systemic infection by *H. ducreyi* has never been observed. Recently chronic skin infection due to *H. ducreyi* was reported, affecting the lower limb of children visiting Samoa,[33] suggesting that this may be a previously unrecognized form of infection.

LABORATORY TESTS

Bacterial culture of *H. ducreyi* currently remains the primary tool for the diagnosis of chancroid in the clinical setting. However, the advent of more sensitive DNA amplification techniques has demonstrated that the sensitivity of *H. ducreyi* culture is only 75 percent at best.[34–36] The bacillus will survive only 2 to 4 hours on a swab unless refrigerated. Swabbed material from the purulent ulcer base should be inoculated directly onto an appropriate culture medium, because no satisfactory transport system is available.[37]

As noted earlier (see Growth Requirements), the simultaneous use of two primary isolation media from a nutritionally rich agar base supplemented with hemoglobin and serum is recommended for high culture sensitivity.[27] Small, nonmucoid, yellow-gray, translucent colonies appear in 2 to 4 days after inoculation. Typically, these colonies remain intact when they are pushed across the agar surface. The identification of *H. ducreyi* is performed following the recommendations of Lubwama[38]: demonstration of hemin requirement, oxidase and catalase test, β-lactamase test, and hydrogen sulfide and indole activity. Testing of antibiotic susceptibility is recommended, because clinically significant antimicrobial resistance of *H. ducreyi* has become common.

Direct examination of clinical material by Gram or Giemsa stain may be helpful, but reported sensitivity and specificity values are low—10 percent to 63 percent and 51 percent to 99 percent, respectively.[39] The bacilli are usually found in small clusters or parallel chains of two or three organisms streaming along strands of mucus. This pattern has been described as a "school of fish" or "railroad track" (Fig. 202-4). This arrangement, said to be characteristic of *H. ducreyi*, is nevertheless not pathognomonic, because most genital ulcers have a polymicrobial flora. Cotton or calcium-alginate swabs are recommended for specimen collection. Some authors do not recommend direct microscopy in the routine diagnosis of chancroid.[21,36,39]

Many attempts have been made to develop serologic tests for chancroid. Due to limited sensitivity in the detection of circulating antibodies to *H. du-*

TABLE 202-1
Clinical Variants of Chancroid

Giant chancroid	Single lesion extends peripherally and shows extensive ulceration.
Large serpiginous ulcer	Lesions become confluent, spreading by extension and autoinoculation. The groin or thigh may be involved (ulcus molle serpiginosum).
Phagedenic chancroid	Variant caused by superinfection with fusospirochetes. Rapid and profound destruction of tissue can occur (ulcus molle gangrenosum).
Transient chancroid	Small ulcer resolves spontaneously in a few days, may be followed 2–3 wk later by acute regional lymphadenitis (French: *chancre mou volant*).
Follicular chancroid	Multiple small ulcers occur in a follicular distribution.
Papular chancroid	Granulomatous ulcerated papule may resemble that of donovanosis or condylomata lata (ulcus molle elevatum).

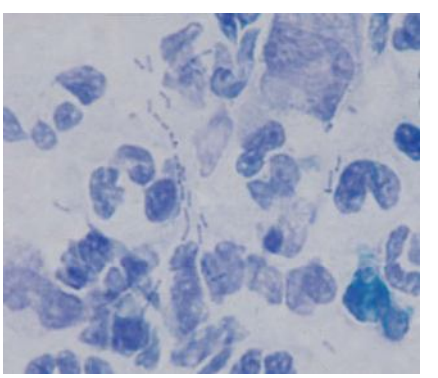

▲ **FIGURE 202-4** Smear from soft ulcer showing a "school of fish" pattern (Giemsa stain).

Box 202-1

Differential Diagnosis of Chancroid

	DISEASE/CONDITION	ETIOLOGIC AGENT
Most Likely	Genital herpes	Herpes simplex virus types 1 and 2
	Syphilis	*Treponema pallidum*
	Lymphogranuloma venereum	*Chlamydia trachomatis* serovars L1–L3
Consider	Other bacterial sexually transmitted infection: granuloma inguinale (donovanosis)	*Calymmatobacterium granulomatis*
	Other bacterial infections	*Streptococcus* sp., fusospirillary infections, *Mycobacterium tuberculosis*, *Corynebacterium diphtheriae* (very rare)
	Viral infections	
	Acute HIV infection	HIV
	Ulcus vulvae acutum	Epstein-Barr virus
		Cytomegalovirus
	Genital herpes zoster	Varicella-zoster virus
	Parasitic infections	
	Amebiasis	*Entamoeba histolytica*
	Leishmaniasis	*Leishmania* sp.
	Scabies	*Sarcoptes scabiei*
	Inflammatory diseases (e.g., Behçet disease, aphthosis, Crohn disease, pyoderma gangrenosum)	
	Drug adverse effects	
	Fixed drug eruption	For example, trimethoprim-sulfamethoxazole
	Toxic effects	For example, foscarnet
	Traumatic and self-induced genital ulcers and neoplasms	
Always Rule Out	Genital herpes	Herpes simplex virus types 1 and 2
	Syphilis	*T. pallidum*
	HIV infection	HIV

HIV = human immunodeficiency virus.



creyi, serologic testing currently has limited usefulness in the routine diagnosis of chancroid infection but may be useful in population-based epidemiologic research as a method of screening for past infection.[39,40]

Polymerase chain reaction (PCR) procedures using different primers have shown greater sensitivity for the diagnosis of chancroid than bacterial culture.[39] A multiplex PCR assay has been developed (Roche Molecular Systems, Alameda, CA) for the simultaneous amplification of DNA targets from *H. ducreyi*, *Treponema pallidum*, and herpes simplex types 1 and 2,[41] which seems to be a particularly attractive diagnostic tool in the investigation of genital ulcers in patients. Multiplex PCR has a resolved sensitivity and specificity for *H. ducreyi* of 98.4 percent and 99.6 percent, respectively.[41] None of these PCR-based methods is commercially available yet, but their use for routine diagnostic purposes would be clearly advantageous.

In resource-poor settings in which diagnostic facilities are not readily available, the World Health Organization advocates the use of a syndromic management approach for patients with genital ulcer disease.[42]

HISTOLOGY

Characteristic histologic features with three vertically arranged zones (superficial necrotic zone, a zone of new blood vessel formation beneath, and a deep zone consisting of dense lymphocytic and plasma cell infiltrate) have been described in chancroid.[43] Tissue biopsy is not a recommended diagnostic method, but histologic examination may be useful to exclude malignancy in non-healing or atypical ulcers.[39] Staining with *H. ducreyi*-specific monoclonal antibodies demonstrates the organisms chiefly within the granulocytic infiltrate and fibrin of the ulcer.[44]

DIFFERENTIAL DIAGNOSIS (Box 202-1)

The three classic causative agents for genital ulceration are *H. ducreyi*, *T. pallidum*, and herpes simplex. The clinical appearance of the diseases caused by these three agents can be extremely variable in both men and women, and therefore clinical diagnosis of genital ulcer disease can be made with reasonable certainty for only a minority of patients.[45] The cause of genital ulcers[46] also differs considerably by geographic region. In industrialized countries isolated painful chancres are most likely due to herpes simplex virus.[47] In a high percentage of genital ulcers no pathogen can be isolated, but co-infections of *H. ducreyi* with *T. pallidum* (ulcus mixtum) or herpes simplex virus are not uncommon.[5,8]

COURSE AND PROGNOSIS

The disease is self-limited, and systemic spread does not occur. Occasionally, without treatment, genital ulcer and inguinal abscess have been reported to persist for years. Local pain is the most frequent complaint. If no clinical improvement is evident 1 week after the start of therapy, incorrect diagnosis, co-infection with another organism, concomitant HIV infection, poor compliance with the therapy regimen, or a resistant strain of *H. ducreyi* must be considered.

Infection does not confer immunity, and re-infection is possible. To avoid re-infection, patients must be instructed to use condoms properly.

TABLE 202-2
Complications of Chancroid

- Painful inguinal adenitis (up to 50% of cases)[61]
- Spontaneous ruptures of inguinal buboes with occurrence of large abscesses and fistula formation (rare)
- Spreading of *Haemophilus ducreyi* to distant sites (kissing ulcers and/or extragenital lesions due to autoinoculation) (in 50% of male patients)
- Acute conjunctivitis (very rare)[62]
- Bacterial superinfection (including by anaerobes) leading to extensive destruction (rare)
- Scarring leading to phimosis (rare)
- Erythema nodosum (very rare)[63]
- Enhanced transmission of human immunodeficiency virus (3-fold to 10-fold increased risk)



TABLE 202-3
Recommended Treatment Regimens

Antibiotic	Dosage	Limitations	Source of Recommendation
Azithromycin	1 g orally in a single dose	High cost, limited availability, contraindicated in pregnancy	CDC, WHO, IUSTI-Europe
or			
Ceftriaxone	250 mg intramuscularly in a single dose	Parenteral dosing, may perform less well in HIV-positive patients	CDC, IUSTI-Europe (WHO, as alternative)
or			
Ciprofloxacin	500 mg orally bid for 3 days	High cost, compliance problems, contraindicated in pregnancy	CDC, WHO, IUSTI-Europe
or			
Erythromycin base	500 mg orally qds for 7 days	Compliance problems, gastrointestinal intolerance	CDC, WHO, IUSTI-Europe

CDC = Centers for Disease Control and Prevention; HIV = human immunodeficiency virus; IUSTI-Europe = European Branch of the International Union against Sexually Transmitted Infection; WHO = World Health Organization.

COMPLICATIONS

In about half of untreated patients, the course is that of spontaneous resolution without complications. When treatment is delayed, various complications may occur (Table 202-2).

TREATMENT

Based on in vitro susceptibility the most active drugs against *H. ducreyi* are azithromycin, ceftriaxone, ciprofloxacin, and erythromycin. Worldwide, several isolates with intermediate resistance to either ciprofloxacin or erythromycin have been reported. Regimens actually recommended by the Centers for Disease Control and Prevention, the World Health Organization, and the European Branch of the International Union against Sexually Transmitted Infection are listed in Table 202-3.[39,49,50] Antibiotic combinations (e.g., ceftriaxone and streptomycin) showed synergy in an animal model and may be promising to improve single-dose treatment, but clinical evaluation is needed.[51] Local treatment consists of application of antiseptic dressings (i.e., povidone-iodine). Suppurative nodes should not be incised; if necessary, they can be punctured to prevent spontaneous rupture and sinus tract formation. A large syringe should be used and the fluctuant buboes entered laterally through normal skin. In patients with complicating phimosis a circumcision may be necessary when all active lesions have healed.

Even after correct treatment ulcers recur in approximately 5 percent of patients, and retreatment with the original regimen is recommended. Usually reinfection by an untreated sexual partner is the cause of relapse.

HIV infection and lack of circumcision appear to be associated with increased likelihood of infection with *H. ducreyi* and treatment failure.[52] In resource-poor areas of the world, syndromic management can be recommended, but local epidemiology must be considered.[36,42] Flowcharts for the management of genital ulcers have been developed that do not require laboratory identification of the causative pathogen.[36] If a patient complains of one or more small blisters or an ulcer with a history of recent blisters, then herpes management should be followed. If an isolated small ulcer and painful matted lymphadenopathy is present, treatment for lymphogranuloma venereum, chancroid, and syphilis should be initiated. If only an ulcer is present, treatment should be for syphilis and chancroid.[36]

RELATIONSHIP BETWEEN HUMAN IMMUNODEFICIENCY VIRUS INFECTION AND CHANCROID

Renewed interest in chancroid has led to evidence that genital ulcers promote the heterosexual transmission of HIV-1.[53–57] Effective treatment of genital ulcers can thus reduce the incidence of HIV-1, and this strategy has become a cornerstone of HIV prevention programs in many parts of the world.[58] Patients with chancroid should be tested for HIV.

PREVENTION

The exacerbation of the HIV epidemic by *H. ducreyi* infection has made chancroid control an urgent priority. Patients should be advised to abstain from sexual activity until all clinical lesions have cleared. Sexual contacts of the patient should be examined and treated regardless of whether symptoms of the disease are present, because asymptomatic carriage of *H. ducreyi* is possible.[18] Antibiotic therapy may provide some protection from re-infection, because the effects of a single dose of azithromycin may last as long as 2 months after treatment.[59] Chancroid survives in populations in which many men are having sex with a few women. As a result of increased condom use and social programs such as presumptive treatment plans, the cases of chancroid in Kenya have decreased dramatically to less than 10 percent of genital ulcers seen in Nairobi.[4] In Thailand a decrease of 95 percent (from 30,000 to fewer than 2000 cases) was achieved in the 1990s.[4,60] Based on these results, eradication of chancroid seems to be a feasible public health objective.[4]

KEY REFERENCES

The full reference list for all chapters is available at www.digm7.com.

4. Steen R: Eradicating chancroid. *Bull World Health Organ* **79**:818, 2001
24. Albritton WL: Biology of *Haemophilus ducreyi*. *Microbiol Rev* **53**:377, 1989
36. Lewis DA: Chancroid: Clinical manifestations, diagnosis, and management. *Sex Transm Infect* **79**:68, 2003
42. World Health Organization: *Guidelines for the Management of Sexually Transmitted Infections*. Geneva, 2003, World Health Organization, http://www.who.int/hiv/pub/sti/en/STIGuidelines2003.pdf
49. Centers for Disease Control and Prevention: Sexually transmitted diseases treatment guidelines 2002. Centers for Disease Control and Prevention. *MMWR Recomm Rep* **51**:1, 2002
50. Roest RW, van der Meijden WI: European guideline for the management of tropical genito-ulcerative diseases. *Int J STD AIDS* **12 Suppl 3**:78, 2001

CHAPTER 203

Lymphogranuloma Venereum

Samer H. Ghosn
Amal K. Kurban

EPIDEMIOLOGY

Lymphogranuloma venereum (LGV) is a rare sexually transmitted disease due to specific *Chlamydia* variants. It is endemic in East and West Africa, India, Southeast Asia, South and Central America, and some Caribbean islands; and accounts for 2 percent to 10 percent of genital ulcer diseases in areas of Africa and India.[1,2] The peak incidence occurs in persons 15 to 40 years old, in urban areas, and in individuals of lower socioeconomic status. Men are six times more likely than women to manifest clinical infection. The incidence of LGV is low in the developed world where cases are usually limited to travelers or military personnel returning from endemic areas. Since 2003, however, outbreaks of LGV have appeared in Europe and North America, particularly in the form of proctitis, among human immunodeficiency virus (HIV)–positive men who have sex with men.[3–10]

LGV is contracted by direct contact with infectious secretions. Transmission efficiency is unknown. Conjugal transmission has been reported.[11,12] Sexual practices such as fisting and sex-toys-sharing may be other routes of transmission.[3] An epidemic of LGV has been reported recently among "crack" cocaine users in the Bahamas.[13]

Due to underdiagnosis and underreporting, the epidemiology of LGV remains poorly understood. Common diagnostic laboratory methods are nonspecific and not readily available in endemic areas. Even in industrialized countries, only a few laboratories offer specific assays to LGV serovars. Without such assays, many LGV cases are misdiagnosed as common chlamydial urogenital infection. Underdiagnosis of LGV is also largely due to the presence of an asymptomatic carrier state.[14] Women, in particular, may harbor asymptomatic persistent infection in the cervical epithelium, thus serving as reservoirs of the infection as they do for other urogenital chlamydial infections and gonorrhea. In contrast, infectivity in men ceases after healing of the primary mucosal lesion. Interestingly, most of the detected cases in the recent outbreaks are in men who practice receptive anal sex, suggesting that a high proportion of men who practice insertive anal sex are mis- or undiagnosed. The reasons behind this are unclear but may be organism-related, host-related (sexual practices such as fisting and the use of sex toys, intravenous drug use, HIV-status, etc.) or physician-related (failure to diagnose genital LGV). The resurgence of LGV as a health problem may simply reflect increased awareness rather than increased incidence.

ETIOLOGY AND PATHOGENESIS

LGV (tropical or climatic bubo, lymphopathia venerea, Nicolas-Favre disease) is caused by *C. trachomatis* serovars L1, L2, and L3. Most of the recent outbreaks are caused by a number of strains of *C. trachomatis* L2 serovar (L2b), suggesting that these outbreaks most likely represent increased awareness of a slowly evolving endemic.[7,8,14–16]

Chlamydiae are obligate intracellular bacteria characterized by two distinct morphologic forms: the small metabolically inactive and infectious elementary body, and the larger metabolically active and non-infectious reticulate body. In contrast to the A-K serovars that remain confined to the mucosa, LGV serovars have a high affinity for macrophages. After being inoculated onto the mucosal surface, the organisms replicate within macrophages, and find their way to the draining lymph nodes (LNs), and cause lymphadenitis. Entry of the LGV strains into host cells involves cholesterol-rich membrane domains.[17] Infection with serovar L2 has been shown to cause caspase-independent apoptosis of host cells.[18] Variable expression of members of the polymorphic membrane protein genes (pmpA to pmpI) has been suggested to play a role in the pathogenesis.[19]

CLINICAL FINDINGS

Cutaneous Lesions and Related Physical Findings

Clinical manifestations are protean, depending on the sex of the patient, acquisition mode, and the disease stage.

PRIMARY STAGE Three to 30 days after infection, 5- to 8-mm painless erythematous papule(s) or small herpetiform ulcers appear at the site of inoculation

LYMPHOGRANULOMA VENEREUM AT A GLANCE



- Rare systemic sexually transmitted disease caused by L serovars of *Chlamydia trachomatis*
- Endemic in Africa, Southeast Asia, and South and Central America
- Outbreaks among men who have sex with men in Europe and North America
- Clinically manifest as inguinal and anorectal syndromes, in three stages
- Hematogenous spread with manifestations of systemic infection
- Diagnosis by identification of organism and by serology or genotyping
- Doxycycline or erythromycin treatment curative if given early

(Fig. 203-1). Painful ulcerations[20] and non-specific urethritis[21] are less common. In males, the lesion is usually found on the coronal sulcus, prepuce, or glans penis; and in females on the pos-



▲ **FIGURE 203-1** Lymphogranuloma venereum: Soft painless erosion on the prepuce.



terior wall of the vagina, vulva, or, occasionally, the cervix. Inoculation may also be rectal or pharyngeal. The primary lesion is transient, often heals within a few days, and may go unnoticed. Other cutaneous manifestations include erythema nodosum, erythema multiforme, urticaria, and scarlatiniform exanthem.[22,23]

SECONDARY STAGE A few weeks after the primary lesion appears, marked LN involvement and hematogenous dissemination occur, manifest by variable signs and symptoms, including fever, myalgia, decreased appetite, and vomiting. Photosensitivity may develop in up to 35 percent of the cases, often 1 to 2 months after bubo formation.[24] Less commonly, patients may develop meningoencephalitis, hepatosplenomegaly, arthralgia, and iritis.[25,26] The lymphadenitis episodes often resolve spontaneously in 8 to 12 weeks. Depending on the mode of transmission, two major syndromes are distinguished:

The acute genital syndrome (GS) or inguinal syndrome is characterized by inguinal and/or femoral LN involvement and is the major presentation in men. Initially, the skin overlying the affected LN is erythematous and indurated. Over the subsequent 1 to 2 weeks, the LN enlarge and coalesce to form a firm and tender immovable mass (bubo; Fig. 203-2), which may rupture and drain through the skin, forming sinus tracts. Bilateral involvement occurs in one-third of the cases (Fig. 203-3). Nodal enlargement on either side of the inguinal ligament, the "groove sign," is pathognomonic of LGV, but only present in 10 percent to 20 percent of cases,[27] and is rarely bilateral.[28] In women, inguinal lymphadenitis is unusual because the lymphatic drainage of the vagina and cervix is to the deep pelvic/retroperitoneal LN. When these nodes are involved, low abdominal/back pain that exacerbates upon lying supine and pelvic adhesions may ensue.

The acute anorectal syndrome (ArS) is characterized by peri-rectal nodal involvement, acute hemorrhagic proctitis, and pronounced systemic symptoms. It is the most common presentation in women and in homosexual men who practice anal sex. The major source of rectal spread in women is the internal lymphatic drainage of the lower two-thirds of the vagina. Patients may complain of anal pruritus, bloody rectal discharge, tenesmus, diarrhea, constipation and lower abdominal pain.





▲ **FIGURE 203-2** Early bubo consisting of unilateral enlargement and coalescence of inguinal lymph nodes. The overlying skin is erythematous and indurated. Note the absence of the primary lesion in this case. (Used with permission from Shukrallah Zeynoun, MD.)

TERTIARY STAGE This stage is more seen in women with untreated ArS, and includes rectal strictures (most common) and abscesses, perineal sinuses, rectovaginal fistulae (leading to "watering can perineum"), and "lymphorrhoids" (perianal outgrowths of lymphatic tissue). Late sequelae of the GS are less common and include urethral strictures and genital elephantiasis with ulcers and fistulas (in 4 percent of cases).[29] Esthiomene (Greek, "eating away") is a rare primary infection of the external genitalia (mostly in women), leading to progressive lymphangitis and genital destruction. Infertility and "frozen pelvis" are potential sequelae of ruptured deep pelvic nodes in women.

Other Unusual Manifestations

Extragenito-anal inoculation of LGV is rare. Oropharyngeal infection may manifest initially as pinhead-sized vesicles on the lip, and later on as cervical lymphadenopathy with constitutional symptoms, closely mimicking lymphoma. Supraclavicular and mediastinal lymphadenopathy and pericarditis rarely occur.[30–33] Ocular autoinoculation of infected discharges may lead to conjunctivitis with marginal corneal perforation, often with preauricular lymphadenopathy.[34] Inhalation of LGV serovars L1 and L2 may accidentally occur in laboratory workers and lead to pneumonitis with mediastinal and supraclavicular lymphadenopathy.[35]

LABORATORY TESTS

Diagnosis of LGV may be difficult, but LGV should be suspected in any patient with infected sexual contacts, genital ulcer, perianal fistula, or bubo. The accuracy of clinical diagnosis may, however, be as low as 20 percent.[36] Laboratory tests are important to establish the diagnosis and are usually divided into two broad categories: non-specific tests that do not distinguish between LGV and non-LGV serovars, and specific LGV tests. In practice, positive test on LN aspirate is considered diagnostic of LGV, in contrast to a positive test on primary genital lesion where further specific testing is required to rule out common chlamydial urogenital infections.

Non-Specific Chlamydial Tests

Frei test, an intradermal skin test assessing delayed hypersensitivity to chlamydial antigens, lacks sensitivity and specificity and is no longer used.



▲ **FIGURE 203-3** Lymphogranuloma venereum: Bilateral, firm, immovable masses above Poupart's ligament.

Serology assays are sensitive but non-specific due to cross-reactivity with other chlamydial infections. In addition, they do not differentiate current from prior infection. The complement fixation test is most commonly used. Titers greater than 1:256 are highly suggestive of LGV and titers below 1:32 exclude the diagnosis unless the disease is in its early stages.[37] The microimmunofluorescence test is more specific but less readily available. Commercially available enzyme immunoassays lack data regarding their sensitivity and specificity for LGV serovars.[38]

Culture studies do not distinguish between LGV and non-LGV serovars; however, a positive culture without centrifugation is highly suggestive of LGV.

Direct fluorescent microscopy uses conjugated monoclonal antibody against *C. trachomatis* on smears from bubo material or genital swab.[39]

Nucleic acid amplification testing (including polymerase chain reaction) may be performed on almost all specimens; however, its sensitivity and specificity in detecting LGV serovars remain unknown.

Specific Tests for Lymphogranuloma Venereum

Only the Centers for Disease Control and Prevention and a few U.S. laboratories have the capacity to sequence DNA to identify L serovars.[7] Recently, a technique combining polymerase chain reaction and restriction fragment length polymorphism has been reported to have adequate specificity in identifying LGV serovars.[20] Other newly introduced biomolecular techniques exploring immune-mediated lysis,[21] heparin sulfate lysis,[40,41] use of pooled antibody,[15] and structural genetic differences[42] are promising.

Other Non-Specific Laboratory Findings

Mild leukocytosis, false-positive VDRL, cryoprecipitins, rheumatoid factor, and high serum levels of immunoglobulin A and immunoglobulin G may be present.[43]

DIAGNOSTIC PROCEDURES

Bubo aspiration to obtain material for culture and direct microscopy should be performed through a lateral approach, and may require injection of 2 to 5 mL of sterile saline before the aspiration due to the paucity of milky fluid.[39] Proctoscopic examination reveals, in the setting of the ArS, multiple discrete and irregular superficial ulcerations and friable granulation tissue, usually confined to the distal 10 cm of the anorectal canal.[44,45]

HISTOPATHOLOGIC EXAMINATION

Primary lesions reveal non-specific ulceration with granulation tissue, and endothelial swelling. Organisms are rarely demonstrated using Giemsa stain. Biopsy of affected LN reveals suppurative granulomatous inflammation. Necrotic foci may enlarge into stellate abscesses which, in turn, may coalesce into discharging sinuses. These findings are not specific to LGV and can be found in chancroid, cat-scratch disease, and tularemia, and in some deep fungal infections. The pathology of LGV-proctocolitis is similar to that of Crohn disease and includes crypt distortion, submucosal fibrosis, and follicular inflammation with occasional granuloma formation.[44]

DIFFERENTIAL DIAGNOSIS (Box 203-1)

In contrast to LGV primary stage, chancroid ulcers are usually larger and more painful, and granuloma inguinale ulcers have abundant friable granulation tissue without associated lymphadenitis. Acute GS may be hard to differentiate from chancroid. Buboes containing little or no pus are, however, more likely to be caused by LGV.[39] Suspecting LGV proctitis in HIV-positive men who have had sex with men with signs and symptoms of Crohn disease is important, even in the absence of LGV pathognomonic findings. Both conditions have similar proctoscopic findings; however, Crohn disease is more proximally localized.

COMPLICATIONS

In addition to the complications seen in the tertiary stage, the ulcerative nature of LGV may facilitate the acquisition and transmission of blood-borne pathogens such as HIV.[48] LGV may also lead to immune disturbances ranging from mild gammaglobulinemia to rare but fatal immunoblastic lymphoma.[49]

PROGNOSIS AND CLINICAL COURSE

Antibiotic treatment, if given early, is curative, with the acute ArS responding more dramatically than the acute GS.

Box 203-1

Differential Diagnosis of Lymphogranuloma Venereum (Stage-Specific)

- Primary stage
  - Ulcerogenital diseases (herpes simplex virus, chancre, chancroid, granuloma inguinale)
  - *Neisseria gonorrhoeae* and/or common chlamydial urogenital infection
  - Non-infectious causes: Trauma, Zoon balanitis, fixed drug eruption
- Secondary stage
  - Acute genital syndrome
    - Ulcerogenital diseases with lymphadenopathy (syphilis, chancroid, herpes simplex virus)
    - Incarcerated inguinal hernia
    - Reactive inguinal lymphadenitis to a lower extremity focus of infection
    - Bubonic plague (in endemic areas)
    - Acquired immunodeficiency syndrome[46]
    - Kaposi sarcoma[47]
  - Acute anorectal syndrome
  - Inflammatory bowel disease
  - Oropharyngeal lymphogranuloma venereum
    - Lymphoma
    - Infectious mononucleosis
    - Cat-scratch disease
- Tertiary stage
  - Malignancy
  - Filariasis and other parasitic infections
  - Pseudoelephantiasis (no lymphadenitis) of tuberculosis and granuloma inguinale
  - Deep fungal infection
  - Hidradenitis suppurativa
  - Trauma

TREATMENT

Oral doxycycline, 100 mg twice daily for 3 weeks, is the treatment of choice. When contraindicated, oral erythromycin base, at a dose of 500 mg four times a day for 3 weeks, may be given. Treatment with azithromycin (1 g once weekly for 3 weeks or in a single dose[50]) is likely curative but still lacks data regarding its efficacy and safety in pregnancy. Therapy may be prolonged in HIV-positive patients and, in general, should not be stopped until the complete resolution of all signs and symptoms (Box 203-2).

Surgery is often required in late stages and includes lateral aspiration of buboes through intact skin (direct incision has a high risk of fistula formation), rectal stricture dilatation, abscess drainage, rectovaginal fistula repair, genital reconstruction, and colostomy. Avoidance of



Box 203-2

Treatment of Lymphogranuloma Venereum

First line	Oral doxycycline	100 mg bid	3 wk
Second line	Oral erythromycin	500 mg qid	3 wk
Third line	Oral azithromycin	1 g/once weekly	3 wk

sexual activity until complete resolution of signs and symptoms is important.[51]

PREVENTION

Effective control should include periodic evaluation of high-risk individuals; reinforcement of health education aiming at early recognition, and counseling; improving community and clinician awareness of LGV; and increasing the availability of specific diagnostic tests. All sexual contacts should be traced and treated. LGV case reporting should be mandatory by law for more reliable monitoring of prevalence trends.[7]

KEY REFERENCES

The full reference list for all chapters is available at www.digm7.com.

3. Centers for Disease Control and Prevention: Lymphogranuloma venereum among men who have sex with men—Netherlands, 2003–2004. *MMWR Morb Mortal Wkly Rep* **53**:985, 2004
4. Nieuwenhuis RF et al: Resurgence of lymphogranuloma venereum in Western Europe: An outbreak of *Chlamydia trachomatis* serovar l2 proctitis in The Netherlands among men who have sex with men. *Clin Infect Dis* **39**:996, 2004
7. Blank S, Schillinger JA, Harbatkin D: Lymphogranuloma venereum in the industrialised world. *Lancet* **365**:1607, 2005
16. Spaargaren J et al: Slow epidemic of lymphogranuloma venereum L2b strain. *Emerg Infect Dis* **11**:1787, 2005
20. Sturm PD et al: Molecular diagnosis of lymphogranuloma venereum in patients with genital ulcer disease. *J Clin Microbiol* **43**:2973, 2005
46. Czelusta A et al: An overview of sexually transmitted diseases. Part III. Sexually transmitted diseases in HIV-infected patients. *J Am Acad Dermatol* **43**:409; quiz 433, 2000
51. Centers for Disease Control and Prevention: Sexually Transmitted Diseases Treatment Guidelines 2002. Available at: http://www.cdc.gov/STD/treatment/2-2002TG.htm, 2002



CHAPTER 204

Granuloma Inguinale

Abdul-Ghani Kibbi
Myrna El-Shareef

EPIDEMIOLOGY AND MODE OF TRANSMISSION

The mode of transmission of granuloma inguinale (GI) is controversial. It is generally considered sexually transmitted, but fecal contamination and autoinoculation remain a possibility, especially in the setting of infected children and adults without sexual activity and primary involvement of remote extragenital sites.[1,2] Transmission rate between sexual partners is low compared with other sexually transmitted diseases and was found to be not more than 50 percent. The incidence of GI is also relatively low among both prostitutes and their conjugal partners. Nevertheless, this disease predominantly affects sexually active individuals.[3] Moreover, donovanosis, being an ulcerative disease, increases the risk of human immunodeficiency virus (HIV) transmission.[4–6] Transvaginal transmission of donovanosis during delivery has been reported, with an apparent predilection to ear structures of the newborn.[7,8] Patients tend to belong to the low socioeconomic classes. No racial predilection has been proved,[9–11] and both male and female predominance have been reported.[5,6,11] Afflicted people are likely to delay seeking medical attention due to the painless nature of the ulcers and the possible embarrassment or fear from medical or surgical intervention. Late cases can be very debilitating and are much more difficult to manage.[12]

GI is endemic in warm, moderately humid areas like South Africa, India, Southern China, and Brazil.[5,13] There are new endemic areas of donovanosis, mainly South and Central America, India, and Papua New Guinea,[12] but the overall incidence of GI seems to be decreasing, especially in Papua New Guinea.[1] The disease has nearly been eradicated from Australia, with only five cases reported in 2004,[14] and is rare in North America and Europe.[15–17]

ETIOLOGY

Donovanosis is caused by the organism *Klebsiella granulomatis*, previously called *Calymmatobacterium granulomatis*. The name has been changed after sequencing the phoE and 16S ribosomal RNA genes and demonstrating close homology with *K. pneumoniae* and *K. rhinoscleromatis*.[5,12]

K. granulomatis is a Gram-negative, nonmotile, pleomorphic bacterium that stains well with Giemsa, Wright's, or silver stains but is periodic acid-Schiff–negative. The mature form is encapsulated, while the immature form is not. The immature non-encapsulated form may assume a closed-safety-pin appearance due to bipolar chromatin densities.

It is difficult to culture and store this organism; however, it may be cultured using embryonic chick heart or chick embryo amniotic fluid. It has also been cultured in human peripheral blood mononuclear cells after decontaminating the specimen with amikacin, vancomycin, and metronidazole,[12] and in HEp-2 cells after adding gentamicin and cycloheximide.[5]

K. granulomatis is a facultative organism that resides in the cytoplasm of large mononuclear cells. It is pathogenic only to humans and the developing chick embryo. It was isolated from the feces of two out of four patients with

GRANULOMA INGUINALE AT A GLANCE



- Granuloma inguinale or donovanosis is a chronic ulcerative debilitating disease that mainly affects the genital organs.
- Caused by the Gram-negative bacteria *Klebsiella granulomatis*.
- Affects mostly people of lower socioeconomic status living in the tropical and sub-tropical areas.
- Diagnosis is made by demonstrating intracellular Donovan bodies on histology.



▲ **FIGURE 204-1** Granuloma inguinale on the inner prepuce. Two beefy red erosive plaques that bleed easily. (Used with permission from Shukrallah Zeynoun, MD.)



▲ **FIGURE 204-3** Granuloma inguinale. Large ulcerovegetative type.



donovanosis, although it has not been successfully cultured from feces. It is still unknown if this organism has a natural habitat.[18]

CLINICAL FINDINGS: HISTORY AND CUTANEOUS LESIONS

The incubation period extends from 3 days to 3 months but is usually 2 to 3 weeks. Single or multiple papules or nodules later develop and grow into a painless ulcer that may extend to the adjacent tissues and moist folds, forming "kissing lesions." The penis, scrotum, and glans are the most commonly affected sites in males; and the labia and perineum are most commonly affected in females.[11] Vaginal and cervical involvement has also been reported and sometimes mistaken for squamous cell carcinoma.[5] The anus and colon may be infected, especially in homosexual males.[5,19]

GI most commonly presents as beefy red, easily bleeding, foul-smelling ulcers with granulation tissue[5] (Fig. 204-1). The ulcers may have hypertrophic or verrucous borders resembling condylomata acuminata.[16] It may also present as soft, red nodules that eventually ulcerate (Fig. 204-2). In long-standing donovanosis, the lesions may be necrotic, quite destructive of tissue, and have a copious gray, foul-smelling exudate[5,16] (Fig. 204-3). The tissue overlying the regional lymph nodes may evolve into an abscess or pseudobubo that later ulcerates.[5] The lymph nodes per se are rarely involved unless there is a bacterial superinfection.[16] In the rare dry cicatricial form, the nonbleeding ulcers form band-like scars and lead to digital lymphedema due to constriction.[16]

HIV co-infection may alter the clinical presentation of GI. The natural history is usually more rapid, and ulcers may persist for longer periods, lead to more tissue destruction, and need more prolonged antibiotic treatment. Extragenital dissemination of GI has been reported in HIV-positive patients.[15]

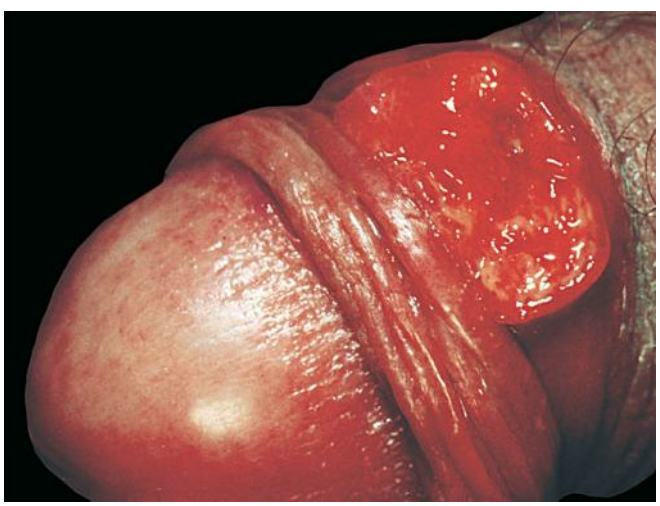

▲ **FIGURE 204-2** Granuloma inguinale. Nodular variety evolving into a large, exuberant ulcer. (Used with permission from A. Eichmann, MD.)

DIAGNOSIS AND LABORATORY TESTS

Demonstrating the Donovan bodies on smear or biopsy specimen makes the diagnosis of GI, although they are more easily visualized with properly done smears rather than biopsy[16] (Fig. 204-4). Secondary bacterial infection and debris may affect the smear result; thus it is recommended to wipe the ulcers gently with cotton swabs first before taking the smear but not to clean the ulcers with saline first.[1] Tissue for smear or crush preparations are better taken from the advancing edge of the ulcer, and tissue preparation should be made immediately, before the desiccation of histiocytes.

Serology is not helpful in making the diagnosis. Polymerase chain reaction has so far only been used for research purposes.[20]

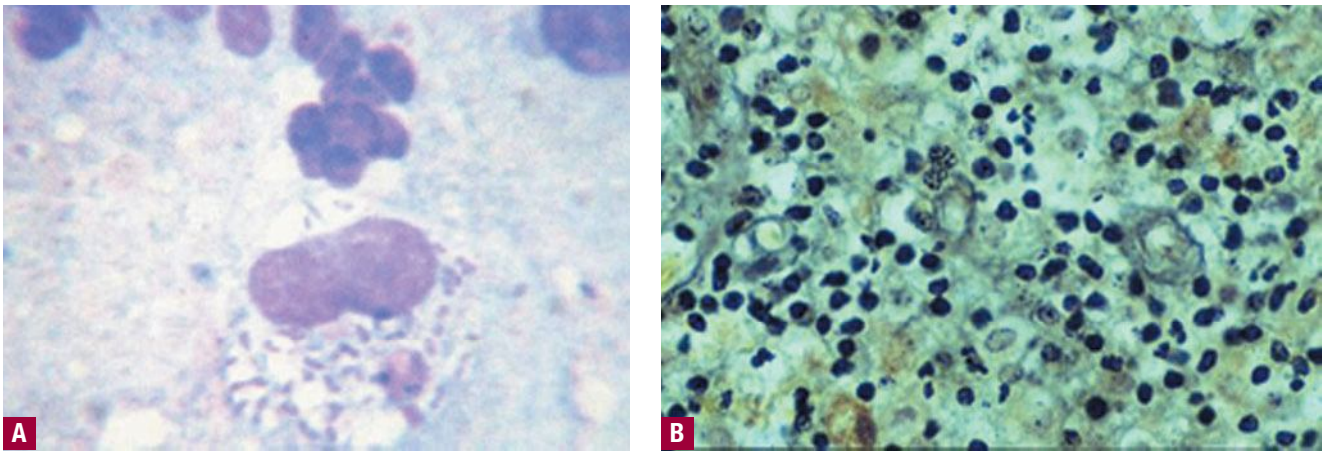

▲ **FIGURE 204-4** Granuloma inguinale. Tissue smear showing Donovan bodies, which are Gram-negative (**A**) and readily stained with Giemsa stain (**B**).



Histologically, the epidermis may exhibit pseudoepitheliomatous hyperplasia and/or ulcerations, depending on the site biopsied. In the dermis, a dense mixed inflammatory cell infiltrate is usually seen composed of polymorphonuclear cells, plasma cells, histiocytes, and rare lymphocytes. Edema and endothelial cell swelling are often noted. The hypertrophic and the cicatricial forms of GI may exhibit fibrosis.[3,19] Clusters of Donovan bodies are seen in the vacuolated cytoplasm of the large mononuclear cells. Using Giemsa, Wright's, or silver stains, these Donovan bodies appear as safety-pin–like structures measuring 1 to 2 μm × 0.5 to 0.7 μm. These Donovan bodies may also be occasionally found extracellularly or within neutrophils.[19]

The differential diagnosis of Donovan bodies (Box 204-1) includes the Frisch bacilli in Mikulicz cells of rhinoscleroma, the amastigotes of leishmania, the chlamydial inclusion bodies of lymphogranuloma venereum, histoplasmosis, and the Michaelis-Gutmann bodies of Malakoplakia.[19]

Box 204-1

Differential Diagnosis of Granuloma Inguinale

Most Likely

- Ulcerative disease of the genital area
  - Primary syphilis (hard indolent ulcer) with indolent lymphadenopathy
  - Secondary syphilis (pale, white, moist plaques)
  - Lymphogranuloma venereum (prominent inguinal lymphadenopathy)
  - Chancroid (painful ulcers with painful lymphadenopathy)
- Note that the above diseases may co-exist.

Always Rule Out

- Long-standing necrotic lesions of the penis, vulva, or cervix
  - Squamous cell carcinoma
  - Genital amebiasis
  - Chronic herpes simplex of the immunosuppressed
- Extragenital involvement
  - Leishmaniasis
  - Scrofuloderma
  - Deep mycosis
- Disseminated form with bone involvement
  - Tuberculosis

COMPLICATIONS

Genital complications of donovanosis include genital swelling that may progress to pseudoelephantiasis, phimosis, paraphimosis, and progressive tissue destruction that may lead to the destruction of the whole penis or other involved organs.[6] There is also an increased risk of squamous cell carcinoma in long-standing cases.[5,11]

Extragenital involvement has been reported in around 6 percent of the cases, occurring either as a primary infection or by spreading from a genital site by autoinoculation or systemic hematogenous dissemination.[6,13] Primary extragenital sites reported include particularly the oral mucosa, and also the neck, scalp, chest, arms, and legs. Oral involvement usually presents as swelling, ulcerations, and bleeding of the gum and palate. Bone involvement may lead to loss of teeth. Long-standing infection results in fibrosis, gum and cheek adhesions, and microstomia.[5,6] Hematogenous dissemination may present with fever, anorexia, and weight loss. It may lead to the involvement of bones, notably, and other visceral organs like the abdominal cavity, bowel, liver, spleen, and lungs. The most commonly affected bone is the tibia, comprising more than 50 percent of reported cases. There are few reported cases of GI manifesting as otitis media with mastoiditis, psoas abscess, and cervical lymphadenopathy.[2,7,21]

In addition, the fact that GI ulcers are painless and bleed easily upon contact increases the risk of HIV transmission remarkably.[9,22]

PROGNOSIS AND CLINICAL COURSE

GI shows no tendency for spontaneous healing. If left untreated, GI may extend to internal organs, including the ovaries, adnexa, uterus, epididymis, and bladder. Fistulas may form and lead to genital fibrosis and deformity.[5,11] Systemic dissemination may be fatal, especially in cases of misdiagnosis.[6]

TREATMENT

Untreated ulcers do not resolve spontaneously. On the contrary, they tend to worsen with time, and antibiotic treatment is better started early (Box 204-2).

The patient should continue treatment until all clinically visible ulcers have completely healed. Serial biopsy specimens may be needed.[11] If the patient does not improve within the first few days of treatment, the addition of gentamicin 1 mg/kg intravenously every 8 hours needs to be considered.

The Centers for Disease Control and Prevention recommends the same treatment regimens for HIV-positive patients with GI, although there have been few reports of failure of such treatment.[23] The Centers for Disease Control and Prevention also strongly recommends gentamicin 1 mg/kg intravenously every

Box 204-2

Treatment of Granuloma Inguinale

First line	Azithromycin[1,14]	1 g once followed by 500 mg daily *or* 1 g weekly for 4–6 wk *or* 500 mg once daily for 1 wk
Second line	Doxycycline	100 mg once or twice daily for at least 3 wk
	Trimethoprim/sulfamethoxazole	800 mg/160 mg twice a day for at least 3 wk
	Ciprofloxacin	750 mg twice a day for at least 3 wk
	Erythromycin base[23]	500 mg orally four times a day for at least 3 wk

8 hours for HIV-infected patients with GI if there was no improvement within the first few days.

Relapse may occur 8 to 16 months after apparently effective treatment, requiring follow-up by the physician. Long-standing cases may be complicated by secondary bacterial infections or by fistulas and abscess formation, which require surgical intervention and render antibiotic treatment alone ineffective.[13]

Pregnant or lactating patients with GI are to avoid doxycycline and ciprofloxacin in their treatment regimens.

PREVENTION

All partners who had sexual contact with a patient with GI within 60 days before the onset of symptoms need to be examined. Sexual partners need not be treated unless they develop signs and symptoms of GI.

Children born to mothers with untreated donovanosis need to receive prophylactic azithromycin at a dose of 20 mg/kg for 3 days.[8]

KEY REFERENCES

The full reference list for all chapters is available at www.digm7.com.

1. O'Farrel N: Donovanosis. *Sex Transm Inf* **78**:452, 2002
6. Hart G: Donovanosis. *Clin Inf Dis* **25**:24, 1997
10. Hammar L: The dark side of donovanosis: color, climate, race and racism in American south venereology. *J Med Humanities* **18**:29, 1997
11. Lupi O et al: Tropical dermatology: Bacterial tropical diseases. *J Am Acad Dermatol* **54**:559, 2006
12. Birley H et al: Sexually transmitted diseases: Microbiology and management. *J Med Microbiol* **51**:793, 2002
16. Brown T J et al: An overview of sexually transmitted diseases. *J Am Acad Dermatol* **41**:511, 1999
23. Centers for Disease Control and Prevention: 2002 Sexually Transmitted Diseases Treatment Guidelines. *MMWR Recomm Rep* **51**:RR-6, 2002

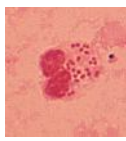

CHAPTER 205

Gonorrhea and Other Venereal Diseases

Annabelle L. Garcia
Vandana K. Madkan
Stephen K. Tyring

GONORRHEA

Epidemiology

More than 700,000 people are reported to acquire new gonorrheal infections in the United States every year. Yet, only one-half of these infections are reported to the Centers for Disease Control and Prevention (CDC). The rate of new infections declined after the implementation of a national gonorrhea control program in the United States during the mid-1970s and has continued to decrease slightly since 1999. The prevalence of infection may have decreased due to screening programs that have incorporated immediate, on-site, single-dose treatment, if needed. Safer sex practices in response to the human immunodeficiency virus (HIV) epidemic may also be a contributing factor to the decline of new gonorrheal infections. The highest rate of reported gonorrheal infections is among sexually active teenagers, young adults, and African Americans. Such racial disparity is multifactorial and may be due to differences in accessibility to health care, lack of use of resources available, crowded living environments, and sexual partner preferences. Risk factors for acquisition of new gonorrheal infection include new or multiple sex partners, young age, unmarried status, minority ethnicity, substance abuse, lower socioeconomic and educational levels, and previous infection.

Overall, since the 1980s, prevalence rates among men and women have been similar. The highest rates in women are for those between the ages of 15 and 19 years old and in men between the ages of 20 and 24 years old.[1] A higher rate of new infections among men having sex with men has been reported recently in some major cities.[2,3]

Etiology and Pathogenesis

Albert Ludwig Sigismund Neisser first discovered the causative agent of gonorrhea in 1879. Gonorrhea is caused by infection with *Neisseria gonorrhoeae*, a Gram-negative, aerobic coccus-shaped bacterium found in pairs. The organisms are usually visualized intracellularly in polymorphonuclear leukocytes (Fig. 205-1). Gonorrhea is acquired through sexual contact, or, less commonly, as a result of poor hygiene or medical use of urine. It can also be transmitted vertically from mother to child during birth. Pathogenesis involves attachment to columnar epithelial cells via pili or fimbriae. The most common sites of attachment include the mucosal cells of the male and female urogenital tracts. Outer membrane proteins, PilC and Opa, on the bacteria aid in attachment and local invasion. Invasion is mediated by adhesins and sphingomyelinase, which contribute to the process of endocytosis. Certain gonococcal strains produce immunoglobulin A proteases that cleave the heavy chain of the human immunoglobin and block the host's bactericidal immune response. Once inside the cell, the organism undergoes replication and can grow in both aerobic and anaerobic environments. After cell invasion, the organism replicates and proliferates locally, inducing an inflammatory response. Outside the cell, the bacteria are susceptible to

GONORRHEA AND OTHER VENEREAL DISEASES

AT A GLANCE



- More than 19 million new sexually transmitted infections occur annually in the United States.
- In the United States, chlamydia is currently the most common reported sexually transmitted disease (STD). It is also the most common cause of pelvic inflammatory disease in women.
- Urethritis is a common presenting symptom of STDs in both men and women.
- Diagnosis can usually be made through culture and/or newer diagnostic methods such as nucleic acid amplification tests.
- Early and appropriate antimicrobial therapy of STDs results in good prognosis.
- Prevention of STDs includes sexual abstinence or safe sex practices.

temperature changes, ultraviolet light, drying, and other environmental shifts. The outer membrane contains lipooligosaccharide endotoxin, which is released by the bacteria during periods of growth and contributes to its pathogenesis in disseminated infection. Delays in proper antibiotic treatment, physiologic changes in host defenses, resistance to immune responses, and highly virulent strains of bacteria contribute to hematogenous spread and disseminated infection. Humans are the only natural hosts of *N. gonorrhoeae*.[4,5]

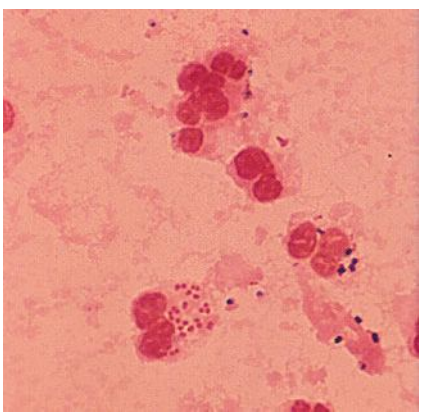

▲ **FIGURE 205-1** Diagnostic Gram-stained smear of urethral discharge of a man with acute gonorrhea. Gonococci (*red*) within a polymorphonuclear leukocyte. There are also some Gram-positive cocci in this smear (*dark blue*). (Used with permission from Angelika Stary, MD.)

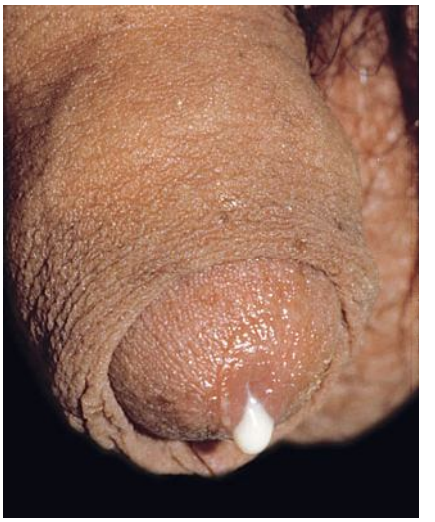

▲ **FIGURE 205-2** Acute gonorrhea in a male manifesting as creamy purulent discharge from the urethra.

Clinical Findings: History and Physical Findings

N. gonorrhoeae infection tends to involve mucous membranes consisting of columnar epithelial cells. The urethra, cervix, rectum, pharynx, and conjunctiva are the areas most commonly involved.

LOCALIZED DISEASE (MEN) The incubation period for the bacteria in men ranges from 2 to 8 days, with most infections being symptomatic after 2 weeks. Only about 10 percent of infections are asymptomatic in men. The most common manifestation of gonococcal infection in men is urethritis, characterized by cloudy or purulent discharge from the penile meatus, which may be indistinguishable from other non-gonococcal causes (Fig. 205-2). Mucosal membrane inflammation in the anterior urethra leads to painful urination and surrounding redness and swelling (Fig. 205-3). Testicular pain and swelling may indicate epididymitis or orchitis and may be the only presenting symptom. However, epididymitis is more commonly caused by *Chlamydia trachomatis* or by combined infection with *N. gonorrhoeae*.

Proctitis is another manifestation of gonococcal infection with symptoms including rectal mucopurulent discharge, pain on defecation, constipation, and tenesmus. Proctitis usually occurs in individuals who engage in anoreceptive intercourse and more commonly in men who have sex with men. As a result of gonococcal proctitis, men who have sex with men are at a higher risk of acquiring HIV infection due to damaged epithelial integrity.[6]

Pharyngitis caused by *N. gonorrhoeae* is rare and usually asymptomatic, although it may serve as a source for disseminated disease. Symptoms range from cervical lymphadenopathy and pharyngeal erythema to severe ulceration with pseudomembrane formation.[7]

LOCALIZED DISEASE (WOMEN) Fifty percent of women infected with *N. gonorrhoeae* are asymptomatic. Appropriate screening, prompt diagnosis, and treatment is crucial in women due to serious complications that can result in sterility. The endocervix is a common site of local infection and invasion by organisms. Symptoms of urethritis include mucopurulent discharge, vaginal pruritus, and dysuria. However, vaginitis does not occur except in prepuberal girls or post-menopausal women because the vaginal epithelium of sexually mature women does not support growth of *N.*



◀ **FIGURE 205-3** Acute gonorrhea in a non-circumcised male. There is a purulent discharge from the urethra and concomitant inflammation of the prepuce and glans.

gonorrhoeae. Other sites of infection include Bartholin's and Skene's glands. Organisms may invade the upper genital tract, including the uterus, fallopian tubes, and ovaries, resulting in pelvic inflammatory disease (PID).

PID occurs in about 10 percent to 40 percent of uncomplicated gonorrheal infections in women and is characterized by fever, lower abdominal pain, back pain, vomiting, vaginal bleeding, dyspareunia, and adnexal or cervical motion tenderness on physical examination. Sequelae of untreated infection include tubo-ovarian abscesses, subsequent ectopic pregnancies, chronic pelvic pain, and infertility due to chronic inflammation with resultant scarring. Symptoms tend to occur at the time of menses and cannot be distinguished from non-gonococcal etiologies.[8] Fitz-Hugh–Curtis syndrome, involving inflammation of the liver capsule, is associated with genitourinary tract infection and may be present in up to one-fourth of women with PID caused by either *N. gonorrhoeae* or *C. trachomatis*. Presenting symptoms include right upper quadrant pain and tenderness with abnormal liver function tests.[9]

Women may also develop proctitis through autoinoculation from cervical discharge or as a result of direct contact from an infected partner's penile secretions. Symptoms may include rectal mucopurulent discharge, pain on defecation, constipation, and tenesmus.[4]

The incidence of gonococcal pharyngitis is similar to that in men.[7]

NEWBORNS AND CHILDREN Neonates may acquire *N. gonorrhoeae* during passage through the birth canal from contact with infected secretions. Such ocular infections are known as *ophthalmia neonatorum* and can lead to severe corneal perforation or scarring.[4] Most states, by law, require the prophylactic use of silver nitrate drops, erythromycin, or tetracycline ophthalmic ointment for prevention of ophthalmia neonatorum.[10] Pharyngeal or genital gonococcal infection in children is often a sign of sexual abuse and warrants further investigation.[11]

DISSEMINATED DISEASE Spread of infection from the site of inoculation to other parts of the body through the bloodstream leads to disseminated gonococcal infection (DGI). Disseminated disease occurs in 0.5 percent to 3 percent of cases and is associated with the classic triad of dermatitis, migratory polyarthritis, and tenosynovitis. Pain and swelling may occur in a single joint or in multiple joints asymmetrically, with upper extremity joints affected more commonly than lower extremities. Skin findings consist of small macules or hemorrhagic pustules on an erythematous base located on palms and soles (Fig. 205-4) or on the trunk and elsewhere on the extremities (see eFig. 205-4.1 in on-line edition). Skin lesions may develop necrotic centers; occasionally lesions may be similar in appearance to erythema nodosum or erythema multiforme. On the palms and soles, lesions may be tender, but in other sites they tend to be non-pruritic and painless and disappear after initiating appropriate treatment. Skin lesions may be present in 40 percent to 70 percent of cases of disseminated disease. Primary skin lesions as a result of localized gonorrheal infection are rare. Histologically, perivascular neutrophilia, dermal vasculitis, and epidermal neutrophil infiltration may be seen.[5]



◀ **FIGURE 205-4** Disseminated gonococcal infection. Tender, hemorrhagic, and necrotic pustules on the fingers and palms.

Laboratory Tests

Bacterial culture has been the "gold standard" diagnostic test for years, although newer and more specific tests are now being used in many laboratories. Culturing *N. gonorrhoeae* requires media containing heme, nicotinamide adenine dinucleotide, yeast extract, carbon dioxide, and other supplements required for isolation. Culture can be performed on modified Thayer-Martin medium. Organisms are Gram-negative, intracellular diplococci visualized microscopically inside polymorphonuclear cells. In men, culture and Gram's stain are performed on secretions or urethral swabs (see Fig. 205-1).[4] Endocervical and endourethral specimens for culture and Gram's stain have yielded more accurate results than testing vaginal secretions in women. Cultures on pharyngeal and rectal swabs may also be performed if infection is suspected in these areas.[5]

The U.S. Food and Drug Administration has approved certain chemiluminescent DNA probes that can be used on endocervical or urethral specimens for diagnosis of gonorrhea. However, distinguishing gonococcal from non-gonococcal infection may be difficult with DNA probes. Newer techniques include the use of nucleic acid amplification tests, such as polymerase chain reaction (PCR), transcription-mediated amplification, and strand displacement amplification on urine or urethral specimens. Overall, nucleic acid amplification tests are highly sensitive and specific and may be able to detect even the presence of one organism.[12,13]

In DGI, cultures should be done on blood, joint fluid, and skin lesions. Synovial fluid from affected joints must be analyzed for cell count, Gram's stain, and culture. Diagnosis should be based on clinical suspicion and pertinent findings because tests for DGI yield positive results only in a small number of cases.[5]

Differential Diagnosis

Box 205-1 shows the differential diagnosis for all venereal diseases.

Complications

Permanent sequelae of gonococcal infection in women may be infertility as a result of untreated PID. Untreated DGI can lead to septic arthritis, resulting in permanent joint damage. Meningitis and endocarditis are rare manifestations of DGI. Additional symptoms may include fever, malaise, and perihepatitis (Fitz-Hugh–Curtis syndrome).[5]

Prognosis and Clinical Course

Prognosis is excellent if infection is treated early with appropriate antibiotics. Previously treated gonococcal in-

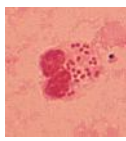

Box 205-1

Differential Diagnosis for All Venereal Diseases

LOCALIZED	SYSTEMIC	ALWAYS RULE OUT
Urinary tract infection	Septic arthritis	Tubo-ovarian abscess
Chlamydia	Reiter syndrome	Ectopic pregnancy
Gonorrhea	Perihepatitis (Fitz-Hugh–Curtis syndrome)	Pregnancy
Pelvic inflammatory disease	Hepatitis B	Appendicitis
Trichomoniasis	Hepatitis C	Meningococcemia
Herpes simplex virus	Behçet disease	Syphilis
Bacterial vaginosis	Lyme disease	Sexual abuse (in children)
Vaginitis	Rheumatic fever	
Endometriosis		
Mycoplasmal infection		
Orchitis		
Epididymitis		

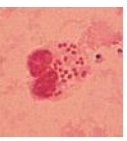

fection does not reduce the risk of reinfection. DGI has a good prognosis if treated appropriately and before permanent damage to joints or organs occurs.[14]

Treatment

Ten percent to 30 percent of people with gonococcal infection are co-infected with *Chlamydia*. Thus, routine dual therapy with doxycycline and azithromycin has been recommended and shown to be cost effective. Dual therapy also decreases the development of antimicrobial resistance in bacteria. Box 205-2 shows CDC recommendations for uncomplicated cervical, urethral, pharyngeal, and rectal gonococcal infections. Due to the increased prevalence of antimicrobial resistance, quinolones should not be used for infections acquired in California, the Pacific islands, including Hawaii, or Asia. Patients with DGI may need to be hospitalized due to septic arthritis, meningitis, or endocarditis. The recommended regimen for DGI is ceftriaxone, 1 g intramuscularly (IM) or intravenously (IV) every 24 hours, continuing for 24 to 48 hours after improvement is noted. Treatment may then be switched to oral doses of the antibiotics listed in Box 205-2. Sexual partners should also receive appropriate treatment.[15]

Disseminated gonococcal infection requires longer treatment periods as shown in Table 205-1.

Treatment of gonococcal meningitis should consist of ceftriaxone, 1 to 2 g IV every 12 hours for 10 to 14 days, and of gonococcal infections in neonates as shown in Box 205-3.

Gonococcal ophthalmia neonatorum should be treated with ceftriaxone, 25 to 50 mg/kg IV or IM, not to exceed 125 mg in a single dose.

Box 205-2

Treatment of Localized, Uncomplicated Gonococcal Infection

- Single dosage of any of the following:
  - Cefixime, 400 mg PO
  - Ceftriaxone, 125 mg IM
  - Ciprofloxacin, 500 mg
  - Ofloxacin, 400 mg PO
  - Levofloxacin, 250 mg PO
- Patients allergic to cephalosporins or quinolones may be treated with spectinomycin, 2 g in a single IM dose.
- In dual therapy for chlamydia, add:
  - Azithromycin, 1 g orally in a single dose
  - Doxycycline, 100 mg orally twice a day for 7 days

TABLE 205-1
Management of Disseminated Gonococcal Infection

Recommended regimen	
Ceftriaxone	1 g IM or IV every 24 h
Alternative regimens	
Cefotaxime	1 g IV every 8 h
or	
Ceftizoxime	1 g IV every 8 h
or	
Ciprofloxacin	400 mg IV every 12 h
or	
Ofloxacin	400 mg IV every 12 h
or	
Levofloxacin	250 mg IV daily
or	
Spectinomycin	1 g IM every 12 h
All of the preceding regimens should be continued for 24–48 h after improvement begins, at which time therapy may be switched to one of the following regimens to complete at least 1 wk of antimicrobial therapy:	
Cefixime	400 mg PO twice daily
or	
Ciprofloxacin	500 mg PO twice daily
or	
Ofloxacin	400 mg PO twice daily
or	
Levofloxacin	500 mg PO once daily

Box 205-3

Treatment of Gonococcal Infection in Neonates

- Ceftriaxone, 25–50 mg/kg/day IV or IM in a single daily dose for 7 days, with duration of 10–14 days if documented meningitis

or

- Cefotaxime, 25 mg/kg IV or IM every 12 h for 7 days, with duration of 10–14 days if documented meningitis

Contraindications

Women who are pregnant should not be treated with tetracyclines or quinolones due to possible damage to the fetus. A cephalosporin or a single 2-gram dose of spectinomycin can be used for gonococcal infection, and erythromycin or amoxicillin for chlamydia.[10]

CHLAMYDIA

Epidemiology

Infection with *C. trachomatis* is the most common reported sexually transmitted disease (STD) in the United States, with more than 900,000 reported cases in 2004. Due to a high rate of asymptomatic infection, the prevalence of infection may be more than 2.8 million cases per year, according to the CDC. This is two and one-half times more than the reported cases of gonorrhea. The rate of infection increased about 5.9 percent between 2003 and 2004. This may be as a result of higher screening with more sensitive and specific tests. The overall rate of reported cases in 2004 was 485 per 100,000 and 147 per 100,000 among women and men, respectively. This trend relates to higher screening in women and a greater number of infections in men not being diagnosed or reported. The highest rates of infection reported are in men and women between the ages of 19 and 24 years old. Infection rates among African American women have been seven times higher than those reported in white women; the infection rate in African American men have been eleven times higher than those in white men. Risk factors are similar to those of gonorrhea and include young age, new or multiple sex

partners, unprotected sexual intercourse, and low socioeconomic status.

Etiology and Pathogenesis

The Greek-derived word *chlamys* means "cloak draped around the shoulder." This refers to the draping of intracytoplasmic inclusions containing *C. trachomatis* around the nucleus of an infected cell.[16] *C. trachomatis* is a nonmotile, Gram-negative, obligate intracellular organism with 15 serotypes: A through C cause chronic conjunctivitis and are endemic in Africa and Asia, D through K cause urogenital tract infections, and L1 though L3 cause lymphogranuloma venereum (see Chap. 203). The bacteria have a two-phase life cycle. The infectious form is known as the *elementary body*, which enters host cells through endocytosis. Replication through binary fission occurs inside the host cell, using host-derived adenosine triphosphate, with formation of reticulate bodies. Large intracytoplasmic inclusions inside cells are made up of hundreds of reticulate bodies, which then convert back to infectious elementary bodies to be released from the cell.

Urogenital tract infection is the area most commonly affected in men and women. Transmission is through oral, anal, or vaginal intercourse with symptoms occurring 1 to 3 weeks after exposure. However, asymptomatic infection occurs in up to 80 percent of women and 50 percent of men. Co-infection with other STDs occurs frequently, most commonly with gonorrhea. Serotype G has been associated with an increased risk of squamous cell carcinoma.[17] Newborns can be infected from passage through the birth canal of an infected mother.[18]

Clinical Findings: History and Physical Findings

The most common manifestation of disease is urethritis, characterized by a watery or mucoid discharge from the urethra that may be accompanied by dysuria in both men and women. Rectal infection may result in proctitis in both men and women. Infection may also present as lymphogranuloma venereum (see Chap. 203).[19,20]

In men younger than age 35 years, *C. trachomatis* is the most common cause of epididymitis. Besides urethral discharge, men may also present with unilateral scrotal pain and swelling. It remains questionable whether chlamydia causes prostatitis. Some studies have linked chronic prostatitis to *C. trachomatis* infection.[19]

In women, the columnar epithelium of the endocervix is commonly affected. Other symptoms beside those of urethritis include intermenstrual or postcoital bleeding and lower abdominal pain. As with gonococcal infection, a severe complication in women that can result in sterility is PID, with ascending infection to the uterus and fallopian tubes. In the United States, chlamydia is currently the most common cause of PID. Symptoms may include fever, lower abdominal pain, back pain, vomiting, vaginal bleeding, dyspareunia, and adnexal or cervical motion tenderness on physical examination. Sequelae of untreated infection include tubo-ovarian abscesses, ectopic pregnancies, chronic pelvic pain, and infertility due to chronic inflammation with resultant scarring. Five percent to 10 percent of women with PID may develop perihepatitis (Fitz-Hugh–Curtis syndrome).

Newborns may develop conjunctivitis and pneumonia after being infected from passage through the birth canal of an infected mother. Signs of ophthalmia neonatorum may include injected conjunctivae, purulent discharge, or swollen eyelids. Pneumonia as a consequence of neonatal chlamydial infection can first present after 1 to 3 months. Symptoms may include cough and fever with wheezing or crackles on pulmonary ascultation.[14]

Laboratory Tests

Traditionally, chlamydial infection was diagnosed by tissue culture with specimens obtained from the endocervix in women, urethra in men, rectum, or conjunctivae. More rapid and sensitive tests have replaced culture in the past few years. A direct fluorescent antibody test, which is highly specific, can be performed on cervical and penile urethral specimens with rapid results (Fig. 205-5). Enzyme immunoassays, which are less specific than the direct fluorescent antibody test, can be used to detect chlamydial antigens through the formation of a color change. Less invasive tests involving nucleic acid amplification, such as PCR and ligase chain reaction, are more commonly being used to detect even small amounts of chlamydial DNA in urine samples.

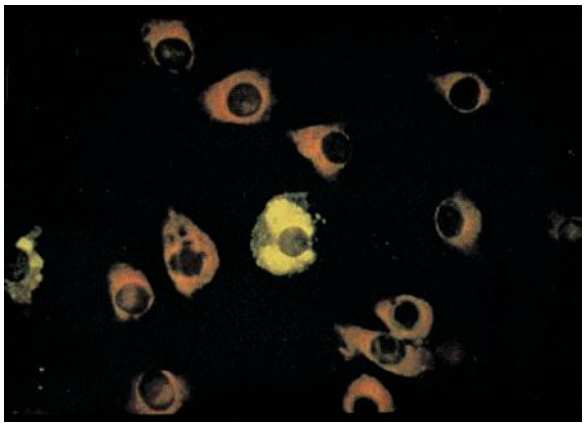

◀ **FIGURE 205-5** Detection of *Chlamydia trachomatis* by direct immunofluorescence with monoclonal antibodies.

Complications

Reactive arthritis (see Chap. 20) can occur up to 1 month after symptoms of non-gonococcal urethritis (NGU). The classic triad associated with this syndrome is NGU, arthritis, and conjunctivitis. Additional symptoms may include fever, malaise, myalgias, asymmetric joint stiffness, lower back pain, cutaneous lesions involving the genitals, and aortic regurgitation as a result of inflammation around the aortic valve. Individuals with the haplotype HLA-B27 are at increased risk of developing the reactive arthritis syndrome.[21]

Prognosis and Clinical Course

Early treatment with appropriate antibiotic therapy results in excellent prognosis and reduces the risk of long-term complications, such as infertility from PID. It is important to complete an appropriate course of antibiotics. First-time therapy with antibiotics has been shown to be up to 95 percent effective in eradicating infection. It is important to counsel patients on the risks of co-infections with other STDs and to arrange for partner referral. Sexual contact should be avoided until treatment is completed (Box 205-4).[18]

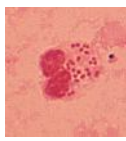

Box 205-4

Treatment of *Chlamydia* Infection

- Azithromycin, 1 g PO in a single dose

or

- Doxycycline, 100 mg PO twice a day for 7 days
- Recommended treatment for pregnant women:
  - Erythromycin, 500 mg PO four times a day for 7 days
  - Amoxicillin, 500 mg PO three times a day for 7 days

GENITAL MYCOPLASMAS

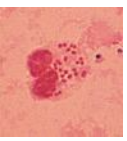

Epidemiology

Species of *Mycoplasma* are some of the smallest, free-living organisms with the ability to colonize the respiratory and urogenital tracts of humans. *M. hominis* and other *Ureaplasma* sp. are referred to as the *genital mycoplasmal organisms* and may be found in the lower urogenital tracts of sexually active adults. Forty percent to 80 percent of sexually active women in the United States have urogenital colonization with *Ureaplasma* organisms. *M. hominis* has also been isolated in 20 percent to 50 percent of sexually active women. Rates of colonization tend to be lower in men. *Ureaplasma* organisms have been found to be the cause of 20 percent to 30 percent of NGU, and *M. genitalium* accounts for 10 percent to 20 percent of causes of non-chlamydial NGU. The rates of colonization in children and nonsexually active adults are much lower. Newborns may be infected by passage through the birth canal of an infected mother.

Etiology and Pathogensis

Genital mycoplasmas tend to self-replicate extracellularly, colonizing the respiratory and urogenital tracts. Disseminated infection is rare and tends to occur in immunocompromised hosts or in cases of epithelium traumatized by instrumentation.

M. genitalium and *Ureaplasma* sp. have been isolated from the lower urogenital tracts of men with urethritis and women with cervicitis and PID, as well as from healthy individuals. *M. hominis* has been isolated from cases of salpingitis. In cases of bacterial vaginitis, coinfection with mycoplasmal species may worsen the condition. Whether *Ureaplasma* sp. cause infertility remains controversial. *Ureaplasma* sp. and *M. hominis* have been isolated from the blood of febrile women postpartum and post-abortion. Invasion of placental membranes by *Ureaplasma* sp. has been attributed to preterm labor.

Clinical Findings: History and Physical Findings

Patients with genital mycoplasmal infections may go undiagnosed as such because these organisms may produce symptoms that are usually attributed to other more common causative agents such as chlamydia. This may also be due to the high rate of co-infection with such organisms. As with chlamydia, genital mycoplasmal infections can result in urethritis, cervicitis, PID, endometritis, salpingitis, and chorioamnionitis. Other species can cause respiratory infection, septic arthritis, surgical wound infections, neonatal pneumonia, and meningitis. Infection with these organisms needs to be considered if workup for the more commonly isolated organisms is negative. Physical findings are similar to those of NGU.

Laboratory Tests

Laboratory tests for genital mycoplasmas may be limited because most specimens must be sent to reference laboratories. Some species, such as *M. hominis* and *U. urealyticum*, can be cultured on special media with proper collection and handling from urethral swabs. A PCR assay may be used to detect *M. genitalium*.

Complications

Invasion by different species of *Mycoplasma* and *Ureaplasma* can cause disseminated disease, especially in immunocompromised hosts who have deficiencies in antibody production. Disseminated disease may result in respiratory tract invasion, osteomyelitis, or infectious arthritis. Bacteremia as a result of *M. hominis* has been shown after renal transplantation. *M. hominis* has also be found in surgical wound infections, pericardial effusions, prosthetic heart valves, subcutaneous abscesses, and in synovial fluid of people with rheumatoid arthritis. Some studies have shown certain mycoplasmal species to be more prevalent in those infected with HIV, although this remains questionable.

Prognosis and Clinical Course

Prognosis in immunocompetent hosts is excellent with appropriate treatment and prompt diagnosis.

Treatment

Treatment for genital mycoplasmas is similar to treatment for chlamydia. Fluoroquinolones may also be used as an alternative treatment against *M. hominis* and *Ureaplasma* sp. in cases of resistance to other antibiotics.[22]

TRICHOMONAS VAGINALIS

Epidemiology

Trichomonas vaginalis causes a condition called *trichomoniasis*, which affects about 2 million to 3 million women annually in the United States. Worldwide, it has been estimated to affect more than 180 million women. It is difficult to estimate the number of men infected because most infections in men are asymptomatic. Yet, 30 percent to 40 percent of men who are exposed have detectable organisms. It is currently not a reportable disease.

Etiology and Pathogenesis

T. vaginalis is an STD caused by parasitic protozoa, which infect vaginal and urethral epithelium, causing microulcerations. In women, organisms may be isolated from the vagina, urethra, cervix, Bartholin and Skene glands, and bladder. In men, organisms may be found in the external genital area, anterior urethra, epididymis, prostate, and semen. The incubation period before symptomatic infection is usually between 4 and 28 days. In women, manifestation of infection ranges from an asymptomatic carrier state to inflammatory vaginitis. Due to the increase in vaginal acidity, symptoms tend to occur during or after menstruation. Most men are asymptomatic carriers.

Clinical Findings: History and Physical Findings

Women who are infected may complain of a malodorous, yellow-green vaginal discharge, vulvar pruritus and erythema, dyspareunia, lower abdominal discomfort, or dysuria. Infection tends to occur in sexually active women and men. Men are usually asymptomatic, yet

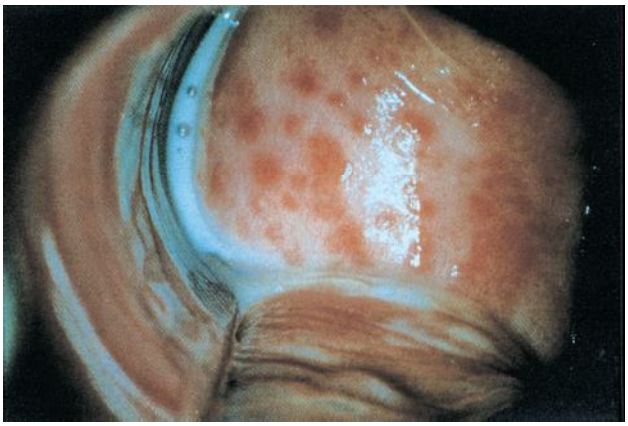

▲ **FIGURE 205-6** *Trichomonas vaginalis* infection: "Strawberry" appearance of cervix with punctuate bleeding erosions. (Used with permission from U. Lauper, MD.)

some may complain of urethral discharge and burning on urination with increased frequency. Both men and women may be asymptomatic carriers. Newborns may become infected from passage through the birth canal of an infected mother. Infection in a child may be a sign of sexual abuse.

On physical examination, punctate hemorrhages may be seen on the vaginal wall and cervix. A term commonly associated with such hemorrhages is *colpitis macularis* or *strawberry cervix* (Fig. 205-6). This is a specific sign of trichomoniasis, yet is only seen in 1 percent to 2 percent of women during a regular pelvic exam. It may be visualized in up to 45 percent of cases through the use of colposcopy. Findings of balanitis, epididymitis, and prostatitis may be present in men. Coinfection with other STDs may produce a more complex case.

Laboratory Tests

Vaginal pH tends to be elevated above 5.0 in trichomoniasis. A saline wet mount of a vaginal swab specimen is a common diagnostic test. The ovoid-shaped protozoa can be visualized microscopically, best by phase contrast or dark-field examination (Fig. 205-7). The most sensitive test is anaerobic culture, which usually is positive within 48 hours, and is the preferred method for diagnosing infection in men. PCR methods have been shown to have high sensitivity and specificity; however, availability of these tests is limited.[23]

Complications

Recently, studies have shown a link between *T. vaginalis* infection and complications in pregnancy, such as premature delivery, early rupture of membranes, and low birth weight in newborns. Trichomoniasis has also been associated with an increased risk of HIV transmission.[24] Less commonly, it has been linked to atypical PID.[25]

Prognosis and Clinical Course

Prognosis is excellent with resolution of infection occurring after appropriate treatment. Treatment of sexual partners is important to avoid re-infection.[26] Persistent infection despite appropriate treatment with metronidazole may require susceptibility testing (Box 205-5).[23]

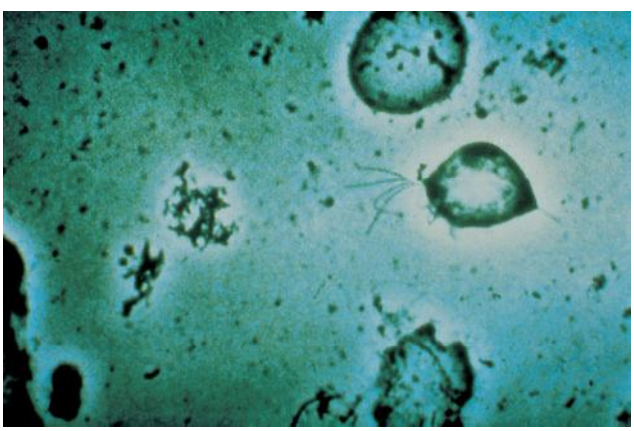

▲ **FIGURE 205-7** *Trichomonas vaginalis*, phase contrast microscopy. (Used with permission from U. Lauper, MD.)

Box 205-5

Treatment of Trichomoniasis

- Metronidazole, 2 g PO in a single dose

or

- Metronidazole, 500 mg PO twice a day for 7 days[a]
- Alternative recommendations
  - Tinidazole, 2 g PO in a single dose

[a]Although the use of metronidazole in pregnancy remains controversial, some studies support its use in pregnancy.[27]

BACTERIAL VAGINOSIS

Epidemiology

Bacterial vaginosis (BV) is the most common vaginal infection in women of childbearing age. It is estimated that approximately 16 percent of pregnant women in the United States may have bacterial vaginosis at a given time. Some studies have shown an increased prevalence among women who have sex with women. Incidence rates are difficult to determine due to the high prevalence of asymptomatic infection and lack of screening methods.

Etiology and Pathogenesis

BV occurs when there is an imbalance of the bacterial flora normally present in the vagina. The shift occurs from hydrogen peroxide–producing lactobacilli to a greater concentration of bacterial organisms including *Gardnerella vaginalis*, *Mobiluncus* sp., *M. hominis*, anaerobic Gram-negative rods belonging to the genera *Prevotella*, *Porphyromonas*, and *Bacteroides*, and *Peptostreptococcus* sp.[28] It is not known to be transmitted through sexual contact. Risk factors for infection include new or multiple sexual partners, early age of first sexual intercourse, use of intrauterine device, douching, and cigarette smoking.[24,29]

Clinical Findings: History and Physical Findings

As many as 75 percent of women with BV may be asymptomatic.[30] Women with BV may complain of a fishy odor and thin, white or gray vaginal discharge. Vaginal pruritus and inflammation are rare. On physical examination,

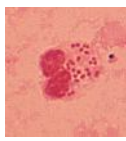

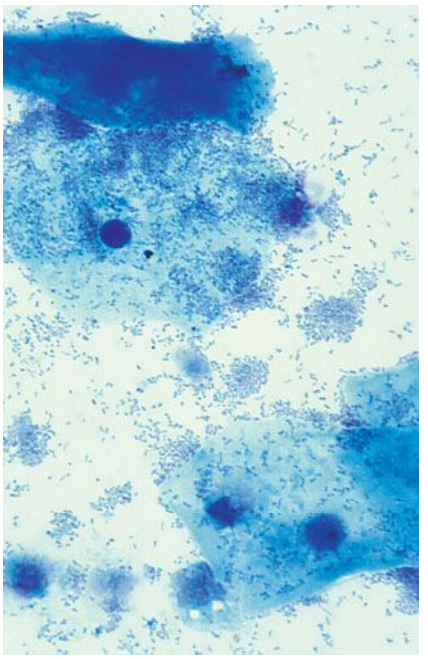

▲ **FIGURE 205-8** Bacterial vaginosis. Clue cells are large epithelial cells covered with bacteria. (Used with permission from Angelika Stary, MD.)

a milky, homogenous vaginal coating may be seen adhered to the vaginal wall.

Laboratory Tests

According to the Amstel criteria for diagnosing BV, three of the following four must be present: (1) thin, homogenous vaginal discharge; (2) a positive whiff test, which involves the production of a fishy odor when mixing vaginal fluid with 10 percent potassium hydroxide; (3) vaginal fluid pH greater than 4.5; and (4) the presence of clue cells (epithelial cells covered with bacteria) on microscopic examination (Fig. 205-8). Clue cells, being the most reliable indicator of BV, must make up at least 20 percent of the epithelial cells on saline wet mount. Another diagnostic test involves the use of Gram staining to distinguish between the normal bacterial flora of Gram-positive rods and lactobacilli from the Gram-negative morphotypes seen in BV. Due to the variety of bacterial species, culture is not a feasible diagnostic test.

Box 205-6

Treatment of Bacterial Vaginosis

- Metronidazole, 500 mg twice daily for 7 days

or

- Metronidazole gel, 0.75%, 5 g intravaginally once daily for 5 days

or

- Clindamycin cream, 5%, 5 g intravaginally qhs for 7 days

In pregnant women:

- Metronidazole, 250 mg three times daily for 7 days

or

- Clindamycin, 300 mg twice daily for 7 days

Alternative regimen

- Metronidazole, 2 g in a single dose

or

- Clindamycin ovules, 100 g intravaginally qhs for 3 days

Complications

BV has been shown to be a risk factor for preterm birth in pregnancy.[31] BV has also be associated as a risk factor for transmission and acquisition of HIV.[32] Studies have produced conflicting data as to whether BV is associated with a higher risk of acquiring cervical intraepithelial neoplasia.[33,34] Some studies have linked BV to postpartum fever, postoperative gynecologic complications, and postabortal infections; however, more studies are needed to investigate the relationship between BV and possible sequelae.[35]

Prognosis and Clinical Course

BV has a good prognosis with appropriate treatment.[36] Some infections may resolve on their own without therapy. A large number of infections are asymptomatic, and complications are rare. Many of the reported complications remain debatable as to true sequelae of BV. However, recurrent infections have been reported, and a longer treatment regimen may be warranted in such cases (Box 205-6).

Prevention

The best prevention from acquiring STDs is sexual abstinence. The U.S. Preventive Services Task Force recommends screening all sexually active women for chlamydia and gonorrhea, including pregnant women, who are at high risk of infection. Risk factors for infection include new or multiple sex partners, young age, unmarried status, minority ethnicity, substance abuse, lower socioeconomic and educational levels, and previous infection. There is no universal screening recommendation for *T. vaginalis*, genital mycoplasmal infections, or bacterial vaginosis in asymptomatic individuals.[37] It is important for clinicians to educate patients on safe sex practices, risks of acquiring STDs, and possible outcomes from infection.

KEY REFERENCES

The full reference list for all chapters is available at www.digm7.com.

4. Todar K: *Todar's Online Textbook of Bacteriology: The Pathogenic Neisseriae*. Madison, WI, University of Wisconsin-Madison Department of Bacteriology, 2004
10. Centers for Disease Control and Prevention: Sexually Transmitted Diseases Treatment Guidelines 2002. Available at: http://www.cdc.gov/STD/treatment/4-2002TG.htm, 2002
14. Grella M: Gonorrhea. Available at: http://www.emedicine.com/ped/topic886.htm, eMedicine from WebMD, 2004
18. Houry DE: Chlamydia. Available at: http://www.emedicine.com/EMERG/topic925.htm, eMedicine from WebMD, 2006
22. Waites KB: Ureaplasma Infection. Available at: http://www.emedicine.com/med/topic2340.htm, eMedicine from WebMD, 2006
23. Perkins AM, Mattu A: Trichomoniasis. Available at: http://www.emedicine.com/med/topic2308.htm, eMedicine from WebMD, 2004
37. U.S. Preventive Services Task Force: Screening for Gonorrhea. Available at: http://www.ahrq.gov/clinic/uspstf/uspsgono.htm, 2005

SECTION 33

INFESTATIONS, BITES, AND STINGS

CHAPTER 206

Leishmaniasis and Other Protozoan Infections

Samer H. Ghosn
Amal K. Kurban

LEISHMANIASIS

Epidemiology[1]

Leishmaniasis, a truly ancient disease,[2] was named after W.B. Leishman who identified organisms in smears taken from the spleen of a patient who died from Dumdum fever in 1901. The disease burden remains important in the twenty-first century,[3] with a worldwide prevalence of 12 million and annual incidence of 2 million cases, 25 percent being of the visceral type.

The various types of leishmaniasis are confined primarily to Central and South America (New World); the Mediterranean basin, southern Europe, central Africa, and parts of southern and central Asia (Old World). The infection is endemic in 88 countries, 72 of which are developing countries. In Western countries, the incidence is increasing due to human immunodeficiency virus (HIV)-leishmania coinfection and tourism.[4,5] New Zealand, Antarctica, and the Pacific islands are leishmania-free. Over 90 percent of cutaneous leishmaniasis (CL) cases occur in Afghanistan, Algeria, Iran, Iraq, Saudi Arabia, Syria, Brazil, and Peru.[3] In the United States, most CL cases are imported except for one endemic form in Texas caused by *Leishmania mexicana*.[6,7]

The World Health Organization has classified leishmaniasis as a category 1 disease (emerging and uncontrolled). The recent geographic spread is attributed to massive rural-urban migration and agroindustrial development projects that bring nonimmune urban residents into endemic rural areas. Other incriminated factors include natural disasters, cessation of malaria spraying leading to an increased sand fly population, reconstructions, global warming, wars, and deforestation.

See Box 206-1 for various forms of leishmaniasis and their abbreviations.

Etiology and Pathogenesis[8]

ETIOLOGY AND LIFE CYCLE The genus *Leishmania* consists of parasitic protozoa of the phylum Sarcomastigophora, order Kinetoplastida, and family Trypanosomatidae. Approximately 20 species are pathogenic for humans and all are transmitted by the bite of an infected female phlebotomine sand fly. Cases of venereal[9] and vertical[10,11] transmission, as well as transmission from infected blood transfusion[12] or needles[13–17] have, however, been reported.

Leishmania are dimorphic parasites. In the gut of the sand fly or in culture, they exist in the promastigote form (10 to 20 μm, spindle-shaped, and motile with a single anterior flagellum). In the cells of the host reticuloendothelial system, leishmania exist in the amastigote form (2 to 6 μm, round/oval, nonmotile, and with a relatively large basophilic nucleus and a smaller rod-shaped kinetoplast of extra-nuclear DNA at the base of the lost flagellum). Infected macrophages are ingested by the fly during a blood meal and the amastigotes are released into the stomach of the insect, where they immediately transform into the promastigote form. The latter migrate to the alimentary tract of the fly, multiply extracellularly by binary fission, and, in a few days, reach the esophagus and the salivary glands where they change into the infective metacyclic promastigote form. When the now infectious sand fly feeds on a fresh source of blood, its proboscis pierces the skin, allowing the metacyclic forms to attach to host macrophages.[18]

Box 206-1

Abbreviations Used for Various Forms of Leishmaniasis

- CL: cutaneous leishmaniasis
- CCL: chronic cutaneous leishmaniasis
- DCL: diffuse cutaneous leishmaniasis
- MCL: mucocutaneous leishmaniasis
- VL: visceral leishmaniasis

LEISHMANIASIS AT A GLANCE



- Caused by the protozoan leishmania and transmitted by the bite of infected phlebotomine sand flies.
- Four major human diseases determined mainly by interaction between *Leishmania* sp. and the host:
  - Cutaneous leishmaniasis
  - Diffuse cutaneous leishmaniasis
  - Mucocutaneous leishmaniasis
  - Visceral leishmaniasis
- Diagnosis by organism isolation or serology, but species identification only possible with isoenzyme analysis and molecular techniques.
- Management ranges from observation to systemic therapy, primarily with antimonials; vaccines are in development.



Copyright © 2008 by The McGraw-Hill Companies, Inc. Click here for terms of use.

TABLE 206-1
Major Vectors and Reservoir Hosts in Cutaneous Leishmaniasis (CL)

	Leishmania Species	Vector	Main Reservoir Hosts	Geographic Location
Old World–CL	*L. major*	*Phlebotomus*	Great gerbil *Rhombomys opimus*	Central Asia
			Sand fat jird *Psammomys obesus*	West Asia (Jordan, Israel, Palestine, Syria, Saudi Arabia), and North Africa (Libya)
			Meriones sp.	Pakistan, India
			Rodents	Sub-Saharan Africa
	L. tropica		Humans	West and Central Asia
			Hyraxes?	East Africa
			Unknown	West Mediterranean basin
	L. aethiopica		Hyraxes	East Africa (Kenya, Sudan, Ethiopia)
	L. infantum		Domestic dogs	Mediterranean basin
New World–CL	*L. Mexicana* complex	*Lutzomyia*	Forest rodents	Belize and Yucatán peninsula in Mexico, Central America
		Psychodogygus (only for *L. b. braziliensis*)	Wood rat Neotoma micropus	Texas
	L. braziliensis complex		Forest rodents, sloths	Brazil, Colombia, Costa Rica, Guiana, Honduras, Surinam, Panama, Venezuela, the western slopes of the Andes, and the Argentinean highlands

From Saliba EK, Oumeish OY: Reservoir hosts of cutaneous leishmaniasis. *Clin Dermatol* **17**:275, 1999.



After phagocytosis, the metacyclic forms transform into amastigotes that can survive and multiply by binary fission within the acidic phagolysosomes. Macrophages ultimately burst, releasing their amastigotes which in turn infect other macrophages.

RESERVOIR HOSTS[19,20] Leishmaniasis is mostly zoonotic, being incidentally transmitted to humans from wild and domestic animals (primary reservoir hosts) (Table 206-1). Visceral leishmaniasis (VL) caused by *L. d. donovani*, and Old World–CL (OW–CL) caused by some *L. tropica* strains are however anthroponotic diseases (i.e., humans are the primary reservoir hosts).

INSECT VECTORS[21] The insect vector of leishmaniasis, the female phlebotomine sand fly, is grouped under the suborder Nematocera of the order Diptera. Three genera (*Phlebotomus* in the Old World, and *Lutzomyia* and *Psychodopygus* in the New World) and approximately 70 species are implicated as vectors.[22] They are widely distributed and have predilection to intertropical and warm temperate zones. Only the female sand fly is hematophagus. Phlebotomine sand flies are less than 3 mm long and do not fly far from their breeding site. Their activity is mostly crepuscular or nocturnal while the host is asleep. They rest during the day and lay their eggs in dark, humid, and organic matter–rich places such as rodent burrows, bird's nests, and house wall fissures. Being exophilic and exophagic, they prefer to rest and to have their meal outdoors, which limits their control by house spraying.

PATHOGENESIS[22] The resulting disease depends on the fate of the phagocytosed amastigotes. This in turn is a function of numerous parasite- and host-related factors, as well as other factors that may account for geographic differences.[3,23] The latter include vasodilators, anticoagulants, and immunomodulators present in the sand fly saliva,[24] and inoculum size. In general, the parasites interfere with the signaling pathways, intracellular kinases, transcription factors, and gene expression of macrophages, compromising their ability to generate leishmanicidal substances. In addition, they impair dendritic cell activation, migration, and ability to secrete T helper 1 (Th1) cytokines.

PARASITE-RELATED FACTORS[25] Parasite-related factors include infectivity, pathogenicity, virulence, and tissue tropism.[26–30] Lipophosphoglycan and gp63 are 2 important promastigote virulence factors that functionally impair infected cells. Species-specific amastigote virulence factors include A2 gene locus products (*L. donovani*), cysteine proteases (*L. mexicana*) and leishmania homolog of activated C kinase receptor (*L. major*). In general, viscerotropic species spread to the reticuloendothelial system, in contrast to dermotropic species, which only spread to adjacent skin/lymph nodes. Some species involve mucous membranes, leading to mucocutaneous leishmaniasis (MCL). These divisions are not absolute. *L. tropica*, classically dermotropic, may cause visceral disease,[31,32] and viscerotropic species may become dermotropic as a consequence of treatment such as seen in post-kala-azar dermal leishmaniasis,[33] or in the setting of HIV co-infection.[34]

HOST-RELATED FACTORS[22,35] Acquired T-cell immunity, the net effect of opposing Th1 and Th2 responses, largely determines the course and therapeutic response of leishmaniasis. A dominant Th1 response resulting in the production of interferon-γ and nitric oxide leads to a leishmanicidal state of macrophages and accounts for sub-clinical infection or self-healing CL. A dominant Th2 response accounts for progressive disease such as diffuse CL (DCL). In general, T-cell immunity is intact in CL, defective in VL, and pathologically exuberant in MCL. Humoral immunity seems to play little or no role in determining the course of the infection. High titers of antileishmanial immunoglobulin G are associated with chronic, nonhealing, and visceral disease.

Clinical Findings

The clinical spectrum includes cryptic infection, localized cutaneous disease (CL), and disseminated infection (DCL, MCL, and VL).[22]

CUTANEOUS LEISHMANIASIS[36] CL constitutes 50 percent to 75 percent of all incident cases, and is the mildest form of

the disease. It can be caused by any *Leishmania* sp. Most cases heal spontaneously within 1 year and are characterized as acute CL. Disease lasting more than 1 year is termed *chronic CL* (CCL).

Old World Cutaneous Leishmaniasis. OW–CL (also known as *Aleppo boil, Baghdad boil, Oriental sore, leishmaniasis tropica, Biskra button, Delhi boil, Bouton d'orient, Lahore sore, rose of Jericho, Kandahar sore, the little sister*) is caused mainly by *L. major, L. tropica, L. ethiopica,* and to a lesser extent *L. infantum* (see Table 206-1). Two major types are identified.

Moist or Rural Type. The moist or rural type is classically caused by *L. major* and is characterized by multiple lesions, short incubation period (1 week to 3 months), rapid and mild course, and good response to therapy. Rodents are the main reservoirs. After bite(s) from an infected sand fly, one or numerous (up to 100) insect bite–like lesions appear, often on exposed body parts such as the face, arms, and legs. Most of them resolve within 1 to 2 weeks, and only a few evolve into CL (Fig. 206-1). The latter lesions are painless and heal often within 6 months, leaving atrophic scars.

Dry or Urban Type. The dry or urban type is classically caused by *L. tropica* and is characterized by a longer incubation period and course (twice as long as in the moist type) and by a worse response to therapy. The infection is largely anthroponotic and has the potential to persist/progress, recur, and visceralize.[37,38] A single "dry" ulcer over the face is characteristic.[39]

These two types may co-exist in the same patient.[33] *L. aethiopica* may cause a similar cutaneous disease but carries a high risk of evolving into DCL. *L. infantum*, the causative agent of Mediterranean VL in children, may cause a self-limited skin disease in adults.[40–42] Species identification cannot be made clinically and requires biochemical/molecular techniques.

The morphologic spectrum of OW–CL is wide. Lesions start as erythematous papules that enlarge over a few weeks to form nodules/plaques and often ulcerate and become crusted (Figs. 206-2 to 206-4). The "volcanic" noduloulcerative morphology is characteristic and consists of a painless crateriform ulcer with a rolled margin and a necrotic base that is often covered with an adherent crust (Fig. 206-5). Other presentations include





▲ **FIGURE 206-1** **A.** Acute cutaneous leishmaniasis: Multiple nodules on the arm caused by *Leishmania major*. **B.** Multiple, nodular, ulcerated lesions on the trunk at the site of sand fly bites. Note that the ulcerated nodules look similar to volcanoes seen from above ("volcano sign").

"iceberg nodules,"[43] and eczematoid, psoriasiform,[39] erysipeloid,[44,45] zosteriform, paronychial, chancriform, annular, palmoplantar,[46] verrucous, and keloidal[47] lesions. Satellitosis (Fig. 206-6), regional lymphadenopathy, localized lymphadenitis,[48] sporotrichoid lymphatic spread (see



▲ **FIGURE 206-2** Acute cutaneous leishmaniasis. Single crusted erythematous plaque over the cheek.



▲ **FIGURE 206-3** Acute cutaneous leishmaniasis. Crusted erythematous nodule over the right perioral area in a young Middle Eastern girl.

eFig. 206-6.1 in on-line edition), subcutaneous lymphatic nodules[43,49] and localized hypoesthesia[50] may occur. Mature lesions may be elongated and oriented parallel to skin creases.[43] Secondary bacterial infection is common.[51]

New World Cutaneous Leishmaniasis. New World–CL (NW–CL; also known as *valley sickness, Andean sickness, white leprosy, chiclero ulcer, uta, pian bois*, and *bay sore*) is caused by *L. mexicana* and *L. braziliensis* complexes (see Table 206-1). Infection with *L. mexicana* and *L. b. guyanensis* causes only cutaneous disease in contrast to infection with *L. b. braziliensis* and *L. b. panamensis*, which may, in 40 percent to 80 percent of the cases, progress to MCL. Pure cutaneous disease is very similar to OW–CL and isolated ulcers are the most common presentations. Unusual clinical pictures have been reported.[52] One-half of the lesions caused by *L. mexicana* heal within 3 months, whereas those caused by *L. brazilienesis* persist much longer and are often associated with lymphadenop-



▲ **FIGURE 206-4** Acute cutaneous leishmaniasis. Crusted and ulcerated erythematous papule over the scalp.

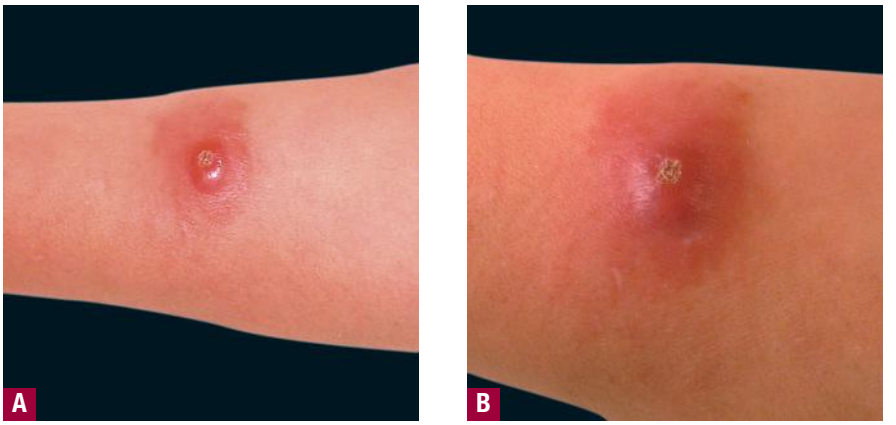

▲ **FIGURE 206-5** **A** and **B.** Acute cutaneous leishmaniasis. Classical "volcaniform" noduloulcerative lesion over the forearm.



athy.[53,54] However, *L. mexicana* is the causative organism of chiclero ulcer, a chronic mutilating infection of the pinna of the ear of forest workers in Mexico and Central America. *L. flaviscutellata* is the major vector. The Andean cutaneous form of leishmaniasis (uta) is caused by *L. braziliensis* and predominantly affects exposed areas in children. Its principal vector is *L. peruensis*. An atypical nodular form of NW–CL caused by *L. d. chagasi*, has been reported from Honduras[55,56] and Nicaragua.[57]

Complications of Cutaneous Leishmaniasis. The major complications of CL are evolvement into DCL, CCL, and MCL (in NW–CL). Acquired immunodeficiency syndrome (AIDS) and other immunosuppressive conditions increase the risk of mucocutaneous and visceral dissemination,[58–61] and of recurrence after therapy.[62] Other complications include scarring, disfigurement, and social stigma.

Chronic Cutaneous Leishmaniasis/ Leishmaniasis Recidivans. In general, the lesions evolve from papules to chronic disfiguring nodules/plaques that are larger than average lesions and may exhibit variable degrees of scaling, ulceration, verrucosity, and scarring (Fig. 206-7). The diagnosis may be challenging due to the paucity of organisms seen on histologic examination. Leishmaniasis recidivans (LR), also known as *leishmania recidiva cutis*, is a rare form of CCL caused mostly by *L. tropica* in the Old World, and less commonly *L. braziliensis* in the New World. Erythematous, scaly papules, often with apple jelly appearance at the borders of a completely or partially healed lesion, are characteristic. It may complicate vaccination with a live strain of leishmania[63] and usually occurs in the setting of hyperactive T-cell immunity and low antibody titers. Reactivation of dormant infection (after up to 15 years) accounts for most of the cases, but re-infection with different strains may occur. Lupoid leishmaniasis shares similar etiology and clinical picture with LR; however, the former is not a recurrent lesion.[51]

Diffuse Cutaneous Leishmaniasis. DCL is a rare anergic form of CL that occurs in the setting of deficient cell-mediated immunity. It mimics clinically and histologically lepromatous leprosy and is usually caused by *L. aethiopica* in the Old World and *L. m. amazonensis* in the New World. Immunosuppressed patients, typically with HIV infection, may develop DCL with no species-specific relation.[64,65] Disseminated non-ulcerated and parasite-laden nodules gradually develop after a classical CL lesion with predilection for exposed areas of the body such as the extremities (see eFig. 206-7.1 in on-line edition) or the face, where lesions may coalesce leading to leonine facies. Viscera are not involved. A progressive/chronic course with relapse after therapy is classic.

Diagnosis of Cutaneous Leishmaniasis.[66,67] Given the potential treatment toxicity, confirmation of the diagnosis is always recommended (Box 206-2). Even when smear, histology, and culture results are combined, in 10 percent to 20 percent of cases, the parasite may not be detected.[33,43] The diagnostic challenge is often greater in New World disease, particularly in lesions more than 6 months old.[53,68] The best approach is to use several diagnostic methods.

Diagnostic Procedures. ***Skin Biopsy.*** Taken from the infiltrated margin, the skin biopsy may be divided into three parts for an impression smear, histologic examination, and culture.

Smears. Several techniques may be used and have a success rate ranging from 50 percent to 80 percent.[33] Smears, easily obtainable from fine needle aspirates or tissue scrapings, are air-dried, fixed with methyl alcohol, stained with Giemsa stain, and viewed under oil-



▲ **FIGURE 206-6** Acute cutaneous leishmaniasis. Large volcaniform lesion and surrounding small satellite erythematous papules. (Used with permission from Raj Kubba, MD.)



◀ **FIGURE 206-7** Chronic cutaneous leishmaniasis. Verrucous, scaly, erythematous plaque with focal ulceration and crusting. (Used with permission from Raj Kubba, MD.)

Box 206-2

Differential Diagnosis of Cutaneous Leishmaniasis (CL)

- Acute CL
  - Arthropod bite
  - Infections [pyoderma, dermatophyte (Majocchi) granuloma, tuberculosis, atypical mycobacterial and deep fungal infections]
  - Cancers (basal cell/squamous cell carcinoma, keratoacanthoma)
  - Lymphoma/pseudolymphoma
  - Foreign body granuloma
- Chronic CL/leishmaniasis recidivans
  - Lupus vulgaris
  - Sarcoidosis
  - Discoid lupus
  - Lymphoma/pseudolymphoma
  - Leprosy
- Diffuse CL
  - Lepromatous leprosy
  - Xanthomas
  - Deep fungal infections
  - Lymphoma

immersion microscopy for optimal results. Impression smears, made by gently pressing the skin biopsy against a glass slide two to five times, provide better sensitivity than of histologic sections.[69]

Histopathology.[70] In both OW– and NW–CL, early lesions exhibit a dense and diffuse mixed inflammatory cell infiltrate composed predominantly of histiocytes and scattered multinucleated giant cells, lymphocytes, and plasma cells (sometimes with intracytoplasmic homogenous eosinophilic immunoglobulin material called *Russell bodies*). Sparing of the papillary dermis (grenz zone), presence of eosinophils and neutrophils, and perineural inflammation[50] are less common. The hallmark of the disease (observed in approximately 70 percent of the cases) is the presence of numerous amastigotes within histiocytes (termed *Leishman-Donovan bodies*) and extracellularly (Fig. 206-8A).[33] Giemsa stain stains the parasite non-metachromatically and the kinetoplast bright red.

The histologic differential diagnosis includes diseases characterized by parasitized macrophages. Features distinguishing other diseases include: in histoplasmosis, the presence of halo surrounding the yeasts; in granuloma inguinale, safety pin–like encapsulated Donovan bodies; and in rhinoscleroderma, Mikulicz cells. Other considerations are blastomycosis, paracoccidioidomycosis, toxoplasmosis, and trypanosomiasis. As the lesion evolves, the number of amastigotes per section decreases and the histology approaches that of CCL in which the predominant histologic pattern is nodular/diffuse noncaseating tuberculoid granulomatous dermatitis (see Fig. 206-8B). Epidermal hyperplasia and ulceration are variable. Scarring with marked loss of elastic fibers may be seen. In DCL, a diffuse infiltrate composed of vacuolated macrophages with numerous intra- and extracellular amastigotes is characteristic. The major differential diagnosis is lepromatous leprosy.

Other Diagnostic Procedures. Laboratory animal inoculation (xenodiagnosis) is useful when the parasite load is low.[33] Electron microscopy offers no advantage over light microscopy and its use is limited.[33]

LABORATORY TESTS. ***Monoclonal Antibodies.*** Monoclonal antibodies directed against specific leishmania antigens may identify, with high sensitivity and specificity, amastigotes and promastigotes in smear, biopsy, or culture specimens. G2D10 antibody has broad *Leishmania* sp. recognition and constitutes a rapid screening test for leishmaniasis,[71] but is not readily available for routine use.

Culture. Culture (at room temperature) using a biphasic medium such as Novy-MacNeal-Nicolle is the gold standard of diagnosis, with a sensitivity of 50 percent.[33] Promastigotes often appear after several days but occasionally may take a few weeks. Species identification is not possible based on their morphology.

Isoenzyme Analysis. Isoenzyme analysis allows for species identification and consists of enzyme electrophoresis of cultured promastigotes. It is based on the fact that morphologically similar promastigotes of different species have different enzyme profiles.

Serology. Serology is not useful due to its low sensitivity (antibodies present in low titre[72]) and specificity (due to cross-reaction with leprosy, malaria, and other trypanosomal infections).

Leishmanin Skin Test. Leishmanin skin test is analogous to the tuberculin test and detects exposure to *Leishmania* without distinguishing between past and active infection.[73] Up to 50 percent of people living in endemic areas may test positive without history of previous or active disease. The test is positive once crusting has developed and negative in anergic states.

Molecular Techniques. Molecular techniques use species-specific oligonucle-

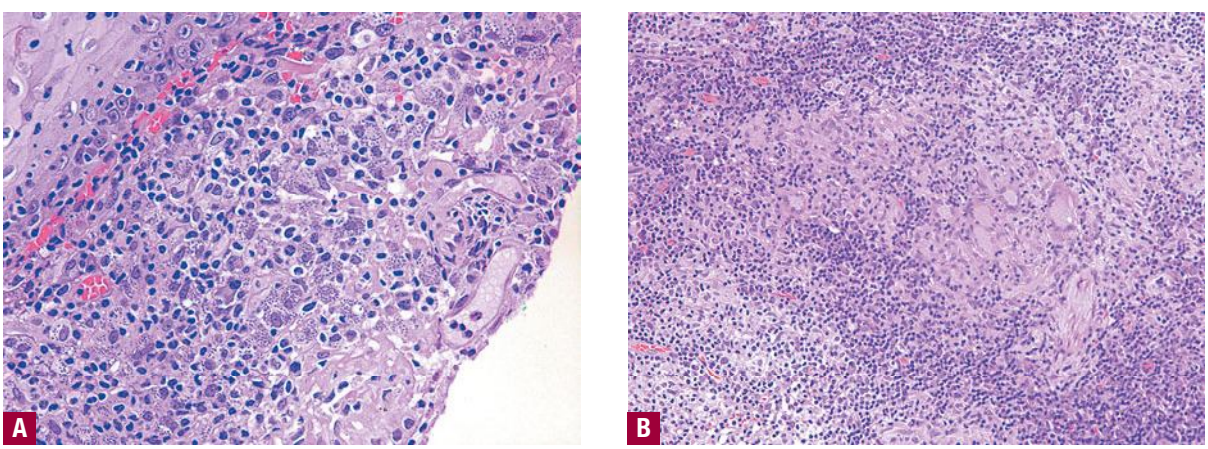

▲ **FIGURE 206-8** Histologic examination (hematoxylin and eosin). **A.** Acute cutaneous leishmaniasis. Moderately dense lymphohistiocytic infiltrate with numerous parasitized macrophages containing amastigotes (Leishman bodies). **B.** Chronic cutaneous leishmaniasis. Tuberculoid granulomatous dermatitis. Note the presence of multinucleated giant cells, the surrounding lymphoplasmacytic infiltrate, and the absence of parasites.

otide probes for kinetoplast DNA and may be used on all specimens. Polymerase chain reaction (PCR) methods are particularly useful and offer high specificity and improved sensitivity over microscopy and culture, especially in cases in which organisms are scarce.[74–77] False-positive reactions and species identification in NW–CL may be at times problematic. Ethanol-fixed specimens are preferred to formalin-fixed and frozen specimens.[78]

Other Forms of Leishmaniasis

CRYPTIC LEISHMANIASIS Both cutaneous and visceral infection can remain subclinical or manifest with mild, non-specific, and transient symptoms.[3,22,79,80]



MUCOCUTANEOUS LEISHMANIASIS MCL is characterized by the chronic, progressive spread of CL to the nasal, pharyngeal, and buccal mucosa several years after resolution of the primary lesion(s) or, less commonly, while they are still present. It is often a complication of NW–CL caused by *L. b. braziliensis* and *L. b. panamensis* in Central and South America. Ninety percent of cases occur in Bolivia, Brazil, and Peru.[81] In the Old World, similar mucosal lesions caused by *L. aethiopica* may be seen but carry a better prognosis.[82,83] MCL results from direct extension or hematogenous/lymphatic spread to the upper respiratory tract; and rarely ocular and genital mucosa and liver.[33] Bony structures are usually spared. Epistaxis, corrhyza, hyperemia, and nasal septum crusting and ulceration are frequent presenting symptoms and signs. If untreated, the disease evolves into either septal perforation with resulting collapse of the nasal bridge and free hanging nose (tapir nose or parrot beak) or partial/total naso-oropharyngeal mutilating ulceration (espundia) (Fig. 206-9). Secondary infection, pharyngeal obstruction, and respiratory failure are the major causes of mortality. The differential diagnosis includes leprosy, syphilitic gumma, yaws, tuberculosis, deep fungal infections, Wegener granulomatosis, nasopharyngeal carcinoma, and lymphoma. Histopathologic findings are similar to those of CL but organisms are usually sparse. The diagnosis is confirmed by culture and serologic studies. Cure rates decrease in advanced disease.

VISCERAL LEISHMANIASIS VL (*Sikari disease, Burdwan fever, Shahib disease, tropical splenomegaly, kala-azar, death fever, Dumdum fever*) is endemic in the tropical and sub-tropical parts of the world, with 90 percent of cases in Bangladesh, India, Nepal, Brazil, and Sudan.[81] The causative agents belong to the *L. donovani* complex (*L. d. donovani, L. d. infantum*, and *L. d. archibaldi* in the Old World; and *L. d. chagasi* in the New World). Infection with *L. d. donovani* occurs in India and Sudan, is anthroponotic (human host reservoir) and highly endemic, and involves *Phlebotomus argentipes* as a vector. Other infections are zoonotic and dogs are the major reservoir hosts. *L. d. infantum* afflicts mainly malnourished children in China, Africa, the Middle East, and the Mediterranean countries. In the New World, *L. longipalpis* is the only sand fly vector.



▲ **FIGURE 206-9** Mucocutaneous leishmaniasis, South American. Painful, mutilating ulceration with destruction of portion of the nose.

Hematogenous dissemination usually follows skin inoculation, but congenital transmission can occur.[11] Most infections remain sub-clinical. The incubation period and the duration of the disease are variable. The cardinal features of VL are persistent high undulating fever, leukopenia, anemia, splenomegaly, and hypergammaglobulinemia. Other findings include emaciation, "burning feet" (peripheral neuropathy), hepato-gastrointestinal disturbances, epistaxis, thrombocytopenia, and lymphadenopathy. Skin lesions develop later in the course of the disease and consist of ashy hyperpigmented patches on the temple, around the mouth, and on the abdomen, hands, and feet in light-skinned persons; hence, the name kala-azar (in Hindi, black sickness). Other findings include hair and skin depigmentation (in Kenyan patients),[33] cutaneous nodules and mucosal ulcers (in Sudanese patients),[33] trichomegaly (Pitalugo's sign), petechiae, and jaundice.[33]

Without treatment, the fatality rate in developing countries approaches 100 percent in 2 years, with the major complications being cachexia and secondary infections. Hemolytic anemia, acute renal damage, and severe mucosal hemorrhage are less common. Identifying the parasite in the spleen (most sensitive), sternal marrow, lymph nodes, blood, liver, nasopharynx, or skin (even non-lesional) is diagnostic.

Visceral Leishmaniasis and Human Immunodeficiency Virus Co-Infection.[84] Most co-infection cases have intravenous (IV) drug use as a common denominator[85] and represent diagnostic and therapeutic challenges because VL precipitates the onset of AIDS and HIV increases the risk of VL. The problem is mostly described in Spain, Italy, France, and Portugal.[34,81,85–87] *L. d. infantum* is the major causative agent. MCL-, post-kala-azar dermal leishmaniasis (PKDL; see Post-Kala-Azar Dermal Leishmaniasis)– and DCL-like pictures may result,[88] and cutaneous lesions are highly variable.[59] Multiple dermatofibroma- and Kaposi sarcoma–like papulonodular lesions may occur[85] and should be differentiated from parasitic colonization of Kaposi sarcoma.[89] The presence of amastigotes in atypical locations tend to correlate with the degree of immunosuppression.[90] Other *Leishmania* sp. that do not normally affect the viscera have been isolated.[64,65,91]

POST-KALA-AZAR DERMAL LEISHMANIASIS[92] PKDL is extremely rare in the New World and is mostly seen in Sudan and India. In India, PKDL is the most common skin manifestation of leishmaniasis (see eFigs. 206-9.1 and 206-9.2 in on-line edition). Affected patients are the major reservoirs of the infection.[93] The lesions may seldom develop during the treatment of VL.[93,94] High blood concentration of interleukin-10 in VL patients is considered predictive of PKDL development.

VISCEROTROPIC LEISHMANIASIS[31] Caused by *L. tropica*, viscerotropic leishmaniasis has been described among American veterans of Operation Desert Storm. Visceral infection manifests as fever, malaise, and variable hematologic and hepato-gastrointestinal findings. Classic signs of VL are absent and the skin is not involved. Positive culture from bone-marrow aspirates and good response to antimonials are typical.

LEISHMANID Leishmanid was used to describe an id reaction consisting of a papular eruption in the setting of LR.[95]

Prognosis and Clinical Course[22]

The clinical course is disease dependent. In general, life long species-specific im-

TABLE 206-2
Treatment Options Based on *Leishmania* Species

TYPE	SPECIES	TREATMENT
Old World–CL	*L. major*	Expectant observation; local therapy
	Multiple, progressive, or sporotrichoid	Systemic therapy
	L. tropica, L. aethiopica, L. infantum	Systemic therapy
New World–CL	*L. mexicana* complex	Expectant observation; systemic therapy
New World–mucoCL	*L. braziliensis* complex	Systemic therapy

CL = cutaneous leishmaniasis.

munity follows drug-induced cure or natural resolution.[96] Cross-species immunity may also develop.[97] Sterile immunity does not occur and persistent low-grade tissue infection seems to be the rule even after adequate therapy.[30,98–100]

Treatment[101–104]

Given the clinical diversity of leishmaniasis and the lack of adequately controlled therapeutic trials, each case needs to be individualized based on the parasite species (Table 206-2), extent of the disease, host immune and nutritional status, presence of intercurrent diseases, geographic region, and cost and availability of the various therapeutic options. In general, NW–CL tends to be more severe and progressive than OW–CL. In addition, NW–CL caused by *L. braziliensis* may evolve into "espundia," thus necessitating systemic therapy. As a rule, patients should be monitored until the lesions have completely healed. Follow-up at 6 months is then appropriate.

Because most lesions caused by *L. major* and *L. mexicana* heal spontaneously within 4 months, an expectant approach is favored as it may confer protective immunity. Multiple, persistent, progressive, deep, sporotrichoid, and secondarily infected lesions should, however, be treated, as well as lesions on cosmetically or functionally important sites.

Local therapy (Table 206-3) is appropriate for small, noninflamed lesions that are not at risk to progress to MCL. Topical imiquimod alone is ineffective.[105] Systemic therapy is reserved for complicated CL such as DCL and CCL, MCL, VL, relapsing disease, or disease complicated by HIV co-infection. In general, OW–CL requires shorter courses than NW–CL. Sodium stibogluconate (Pentostam) and meglumine antimoniate (Glucantime) are pentavalent antimony derivatives with slightly differing antimony concentrations and comparable efficacy and safety profiles. By presumably inhibiting the glycolysis and fatty acid oxidation in leishmania, they are the mainstay of systemic treatment.[106] Indian VL is treated with 20 mg/kg/day intramuscularly or IV once daily for 40 days versus 28 days if the disease is contracted elsewhere. Antimony resistance[107] is a substantial problem in India[108,109] and in Iran.[110] Resistant cases may benefit from combining antimonials with allopurinol,[111–114] paromomycin,[115,116] azithromycin,[117–119] interferon-γ,[120–122] granulocyte-macrophage colony-stimulating factor,[123] and topical imiquimod.[124,125] Amphotericin B[126,127] and its lipid formulation,[128–130] and paromomycin,[131,132] are other alternative monotherapies. Oral miltefosine is promising in the treatment of Indian VL[133–135] and NW–CL.[136] Non-antimonial systemic therapies are summarized in Table 206-4.

TABLE 206-3
Local Therapy for Leishmaniasis

- Excision or laser ablation[209]
- Cryotherapy,[210] local heat,[27] or electrotherapy[211]
- Intralesional antimonial,[212–215] combined with cryotherapy[216]
- Paromomycin ointment[212,217,218]
- Topical azoles[219]
- Others: Ethanolic formulation of amphotericin B,[220,221] topical glyceryl trinitrate,[222] hypertonic sodium chloride,[223,224] intralesional metronidazole[225]

TABLE 206-4
Non-Antimonial Systemic Therapy for Leishmaniasis

- Amphotericin B[126,127] and its lipid formulation[128–130]
- Paromomycin[131,132]
- Miltefosine[133–135]
- Azoles[5,226–231]
- Terbinafine[232]
- Metronidazole [225,233,234]
- Dapsone[235,236]
- Interferon-γ[237]
- Pentamidine and/or allopurinol[238–241]
- Trimethoprim-sulfamethoxazole[242,243]
- Rifampin[244]
- Nifurtimox[245,246]
- Quinolones[247]
- Pyrimethamine[248]
- Oral zinc sulfate[249,250]
- Anti–interleukin-10[99] (experimentally lead to sterile cure)

Prevention and Vaccines

Essential to prevention is the promotion of personal protective measures through the use of protective clothing, insect repellents containing 30 percent to 35 percent DEET, permethrin-treated bed nets and clothing; and the avoidance of endemic areas.[137] Mapping of leishmania and sand fly genomes[138–140] and good understanding of the epidemiology of reservoir hosts and vectors are important for effective control. Targeting anthroponotic foci that are at the origin of deadly epidemics, suspecting leishmaniasis in persons with skin lesions or febrile illnesses returning from endemic areas, and deferring prospective blood donors from donating blood for at least 1 year after their return are other measures.

New diagnostic tests, drugs, and vaccines[97,141,142] are in development, although limited by the poor prospect for financial return.[143] "Leishmanization," the self-inoculation of the live parasite in inconspicuous areas of the body, has been practiced in endemic areas to prevent disfiguring facial lesions, but was later abandoned due to its complications. Killed promastigotes vaccines with and without adjuvant bacille Calmette-Guérin seem to be useful in endemic areas.[97,144] Adjuvants such as bacille Calmette-Guérin are important to prime a Th1 response. Attenuated live parasites and plasmid DNA–based vaccines using leishmanial antigens have shown efficacy in mouse models.[97] Experimental vaccines containing a component of sand fly saliva proteins appear to be promising.[145]

AFRICAN TRYPANOSOMIASIS[146,147]

Epidemiology

African trypanosomiasis (Af-T; sleeping sickness) affects up to one-half of a million people every year in the middle latitudes of Africa where the vector is found. Fatality rate approaches 100 percent in untreated patients. The disease is very rare in the United States.[147]



Etiology and Pathogenesis

Trypanosoma brucei, the causative organism, enters the bloodstream of a mammalian host via the bite of a blood-feeding infected male or female tsetse fly of the genus *Glossina*. After the bite, infectious metacyclic forms transform into trypomastigotes, which multiply and mature locally in the skin and later invade most tissues. These flies are attracted by dust clouds of moving objects and animals, and by black color. They bite most during early daylight and at dusk, and ingest trypomastigotes from infected blood meals.

Af-T presents in two distinct forms. West African or Gambian trypanosomiasis (GT) (caused by *T. b. gambiense*) is a chronic, predominantly anthroponotic disease present in rural areas west of the Rift Valley. East African or Rhodesian trypanosomiasis (RT) (caused by *T. b. rhodesiense*) is an acute fatal disease (within weeks, if untreated) that infects mainly livestock/game animals east of the Rift Valley, and sporadically herdsmen and tourists.[148–150] Water requirements of the *palpalis* group of tsetse flies and the savannah habitat of *G. morsitans* determine the geographic distribution of GT and RT, respectively.

Clinical Manifestations

Similar to syphilis, three clinical stages characterize Af-T. As a rule, the skin is more involved in RT and in light-skinned patients. The first stage consists of a painful chancre that develops at the site of the tsetse-fly bite and resolves within 1 to 3 weeks, leaving no scar. It consists of a circumscribed, rubbery, indurated, 2- to 5-cm dusky red nodule, often with a central eschar (Fig. 206-10). It is rarely seen in native Africans. The second stage is characterized by hemolymphatic spread. Local lymph node involvement progresses to generalized lymphadenopathy in virtually all African natives and in approximately one-half of European patients. Involvement of the posterior cervical (Winterbottom's sign) and supraclavicular lymph nodes is characteristic only of GT. In the lymph nodes, trypanosomes stimulate antibody production and undergo antigenic variations to evade the host immune response. Hepatosplenomegaly, irregular spiking fevers, constitutional symptoms, anemia, thrombocytopenia, and pruritus (especially presternal) develop, and may be related to circulating immune complexes. The reaction is more severe in RT, in which myocarditis and rarely fatal disseminated intravascular coagulopathy develop.[147] Trypanids are distinctive eruptions that develop 6 to 8 weeks after the onset of fever in approximately one-half of light-skinned patients and consist of poorly defined, centrally pale, evanescent, annular, targetoid or blotchy erythematous macular, hemorrhagic, urticarial, or erythema nodosum–like lesions, commonly on the trunk. A sensation of formication may be associated. The eruption waxes and wanes over weeks with accentuation on exposure to cold, heat, or sweat. Painless swelling of the face (imparting a sad look), and of the hands and feet may occur. Other findings include ichthyosis, acroparesthesias, icterus, petechiae, and generalized flushing. The third stage is characterized by central nervous system involvement weeks to months after exposure in RT, and months to years after exposure in GT. Chronic meningoencephalitis, with an irresistible urge to sleep, is followed by coma and death. Delayed bilateral pain out of proportion to a sharp squeeze applied to soft tissues, known as *Kerandel's deep delayed hyperesthesia*, is characteristic. The skin is not involved.

Diagnosis

Diagnosis of Af-T is via detection of trypanosomes in blood film, chancre/lymph node aspirate, buffy coat, bone marrow, or cerebrospinal fluid. Histologically, long, thin trypanosomes are best seen using Giemsa stain, in the midst of a perivascular lymphoplasmacytic infiltrate. Due to antigenic variability, serologic tests lack sensitivity and specificity.[148] Differentiation of RT from GT is usually based on epidemiology. PCR is the method of choice, but cost limits its use in African countries.[151] New diagnostic tools are being developed.[152–154]



▲ **FIGURE 206-10** East African trypanosomiasis. The trypanosome chancre consists of erythematous nodule with central bulla and ulceration. This patient was treated with Suramin and survived. (From Case Records of the Massachusetts General Hospital, Case 20-2002, *N Engl J Med* **346**:2069, 2002, with permission of the Massachusetts Medical Society.)

Treatment and Prevention

Control of Af-T in endemic areas is highly cost-effective and entails case detection and treatment, keeping tsetse populations at low levels,[154] and mass screening of at-risk populations. Regarding therapy,[104,152] four registered drugs are currently provided free of charge by the World Health Organization. Suramin and pentamidine are the drugs of choice for early stage RT and GT, respectively. Melarsoprol, an arsenical, is a powerful trypanocide able to cure both RT and GT in all stages; however, due to its toxicity, its use is restricted to late-stage disease of both forms. Eflornithine is cytostatic and can only be used in GT. Of concern, HIV-positive patients receiving treatment for RT may succumb to full-blown AIDS.[151]

CHAGAS DISEASE (AMERICAN TRYPANOSOMIASIS)[155]

Epidemiology

American trypanosomiasis (Am-T) is a zoonotic disease caused by *Trypanosoma cruzi* and transmitted to humans by blood-sucking triatomine bugs (kissing bugs, assassin bugs, reduviid bugs). It is endemic in many rural areas of Central and South America and Mexico. In the United States, up to 100,000 Latin-American immigrants are affected.[156]

Etiology and Pathogenesis

Triatomine bugs are large (3 to 4 cm), "cone-nosed" bedbugs that become infected with *T. cruzi* by feeding, usually at night, on contaminated blood. The ingested trypomastigotes transform into epimastigotes, multiply in the vector's midgut, and differentiate into infective metacyclic trypomastigotes in the hindgut. An infected triatomine bug takes a blood meal and releases trypomastigotes in its feces near the site of the bite wound, usually a mucocutaneous junction. Human infection occurs when mucous mem-

branes, especially the conjunctiva, or breaks in the skin are contaminated with the feces on rubbing or scratching. The trypomastigotes invade host cells, where they differentiate into intracellular amastigotes that multiply by binary fission and differentiate again into trypomastigotes, which are then released into the circulation to infect a variety of tissues. Congenital transmission[157] and transmission by blood transfusion and organ transplantation[155,158–160] may occur.

Clinical Manifestations and Treatment

Am-T progresses in three stages (Table 206-5). Diagnosis and treatment are problematic. In the first stage, diagnosis involves microscopic demonstration of trypomastigotes in blood specimens, hemoculture, or xenodiagnosis. Thereafter, detection of organisms becomes difficult, and diagnosis relies more on serologic testing or PCR. Benznidazole (not available in the United States) and nifurtimox are toxic[161] and only effective when given during the first stage of the infection. Later, management is directed to complications, as neither drug is effective. Preventive measures seek to eradicate the vectors, improve diagnostic tests, develop less toxic and more efficient drugs, and implement serologic screening of organ donors and recipients. Control programs have reduced the incidence of Am-T by 70 percent in some countries of South America.[162]

TABLE 206-5
Clinical Stages of Chagas Disease

Acute phase (first stage)	• Transient parasitemia: usually asymptomatic or associated with fever, lymphadenopathy, mild hepatosplenomegaly, and morbilliform/urticarial rash; duration ~8 wk. • Chagoma: painful inflammatory reaction at the site of inoculation: 1- to 3-cm erythematous, often ulcerated nodule with a surrounding pale halo. Local lymphadenopathy often present. • Romana's sign: Unilateral conjunctivitis with palpebral edema (from conjunctival inoculation).
Indeterminate phase (second stage)	• Low levels of the parasite in blood and other tissues → chronic asymptomatic and infectious state. • Reactivation of the infection after organ transplantation (disseminated painful subcutaneous and/or ulcerated nodules[155,251,252]).
Symptomatic chronic phase (third stage)	• In 10%–30% of patients, often many years after initial infection. • Lethal dilated cardiomyopathy, arrhythmias, megaesophagus, and megacolon. • Pathogenesis: molecular mimicry?[253,254]

CUTANEOUS AMEBIASIS[163]

Etiology and Epidemiology

Entamoeba histolytica, of the class Sarcodina and genus *Entamoeba*, is a pathogenic ameba that can cause intestinal and extraintestinal diseases. Amebiasis is the second leading cause of death from parasitic diseases, with higher incidence in Mexico and developing tropical countries.[164] In developed countries, risk groups include male homosexuals, travelers, immigrants, and institutionalized patients. *Entamoeba* exists in two forms: the capsuled cyst (10 to 15 μm) or infective stage, and the mobile trophozoite or tissue-invasive stage. Both forms are passed in the feces. Human beings are the only natural hosts and infection generally occurs by ingestion of mature cysts from fecally contaminated food, water, or hands. Anal sex and contaminated enema equipment are other modes of transmission.[163]

Trophozoites have marked phagocytic, proteolytic, and cytolytic capabilities, invading human colonic mucosa, and occasionally penetrating through to the portal circulation, reaching the liver and other organs, and causing fatal lesions. Some mammalian cells appear resistant to trophozoites adherence,[163] but most cases of asymptomatic non-invasive "luminal amebiasis" are caused by *E. dispar,* rather than *E. histolytica*.[165]

Clinical Manifestations, Diagnosis, and Treatment

Depending on the transmission mode and extent of invasion, the clinical spectrum includes three major presentations:

1. Invasive intestinal disease (dysentery, colitis, and amebomas).
2. Invasive extraintestinal disease (liver abscess, peritonitis, and pleuropulmonary abscess). Indirect cutaneous extension may occur, often in the setting of an underlying/contiguous abscess, fistula, colostomy, or laparotomy incisions.[164,166]
3. Direct cutaneous transmission of the trophozoites results from spread through contaminated stool to the anal/perianal or perineal/genital skin. Penile lesions are often acquired through anal intercourse. Autoinoculation via contaminated hands may account for more non-anogenital lesions.[167–169]

Both direct and indirect cutaneous transmissions are rare and result in rapidly progressive, foul-smelling, and painful punched-out ulcers with glairy, hemopurulent, raw beef–like base; necrotic, cord-like and undermined borders; and surrounding erythema (Fig. 206-11). Lesions may reach up to 20 cm in diameter and are often destructive if untreated. Chronic urticaria may be associated[170] and local lymphadenopathy is common. The diagnosis relies on identification of cysts and/or trophozoites in infected stool, mucosa, or skin. This method, however, cannot distinguish between *E. histolytica* and *E. dispar*. Enzyme-linked immunosorbent assays are useful in this regard. Stool culture and PCR are only available as research tools. Serology may be helpful but false negativity may occur in early infection. Skin biopsy reveals ulceration, mixed inflammatory cell infiltrate, and areas of necrosis where trophozoites may be identified as round or oval cells (20 to 50 μm) with basophilic cytoplasm, an eccentric nucleus with central karyosome, and often displaying erythrophagocytosis (sign of pathogenicity).[171] For symptomatic intestinal or extraintestinal disease, the drug of choice is metronidazole (750 mg three times a day for 10 days), followed by treatment with one of the luminal agents iodoquinol, paromomycin, or diloxanide furoate.[104]

OPPORTUNISTIC AMEBAS

The free-living amebas belonging to the genera *Naegleria*, *Acanthamoeba*, and *Leptomyxida* (*Balamuthia*) are ubiquitous in air, soil, and water, and cause only few diseases in immunocompetent patients such as acanthamebic keratitis (in contact lens wearers) and primary amebic meningoencephalitis (caused by *N. fowleri*). Immunocompromised patients, primarily those with AIDS and organ transplant recipients, are at risk of disseminated disease.[172] Skin lesions are the



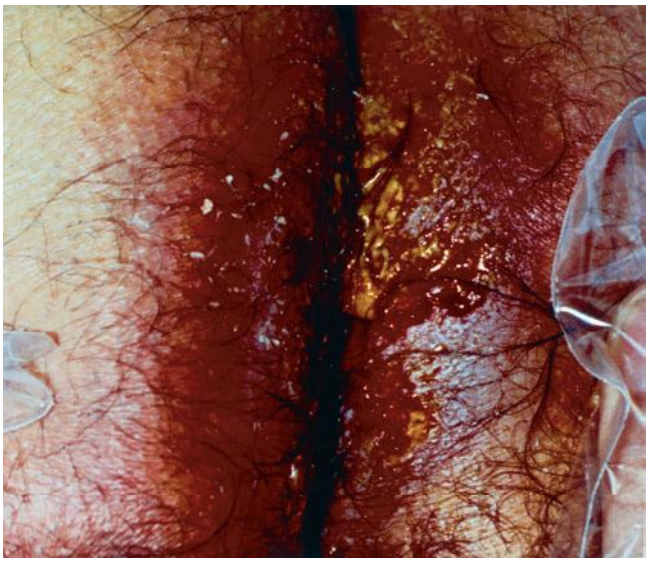

▲ **FIGURE 206-11** Cutaneous amebiasis. A painful, ragged, foul-smelling ulcer with an erythematous halo in the perianal region.

most common (75 percent to 90 percent of the cases[173,174]) and sometimes the sole manifestation of the disease. The extremities and face are commonly involved. Papules, plaques, nodules, pustules, cellulitis, non-healing ulcers with rolled borders, eschars, and palatal ulceration have been described.[173] A rare slowly progressive, fatal neurologic process—granulomatous amebic encephalitis—is caused by *Acanthamoeba* and *Leptomyxida*.[175–178]

Histopathologically, a dermal and/or subcutaneous predominantly neutrophilic infiltrate is present, sometimes with vasculitic, and granulomatous changes.[173,179] The identification of 20 to 30 μm trophozoites with abundant vacuolated cytoplasm, and central nuclear karyosome is diagnostic but may be difficult due to their macrophage-like appearance.[173] The disease is often fatal but early treatment using a combination of IV pentamidine and oral fluconazole, sulfadiazine, and flucytosine may improve the outcome. HIV-positive patients may benefit from antiretroviral therapy.[172]

TOXOPLASMOSIS[180–183]

Toxoplasmosis, caused by the parasitic protozoan *Toxoplasma gondii* (class Sporozoa), is one of the most common human infections worldwide. The main reservoirs of *T. gondii* infection are members of the cat family (Felidae) which are thought to become infected by eating infected mice. Viable organisms invade the feline intestinal epithelium where they undergo an asexual transformation, followed by a sexual cycle, and then form oocysts, which are excreted in large numbers and are resistant to harsh environmental conditions and disinfectants. Human infection results mainly from ingestion of cyst-containing undercooked meat, but can also result from ingestion of the oocysts from fecally contaminated hands or food, organ transplantation,[184] blood transfusion,[185] and transplacental transmission.[186] The parasites form tissue cysts, mostly in skeletal muscle, myocardium, and brain and may remain asymptomatic. Invasion of the reticuloendothelial/endothelial systems results in suppuration and granuloma formation. Three major clinical forms are identified:

1. Congenital toxoplasmosis[186] may manifest as abortion, stillbirth, microcephaly, tram-track intracerebral calcifications,[187] and chorioretinitis.[188] Skin lesions include purpura, jaundice, blueberry muffin lesions (dermal erythropoiesis), and erythroderma. Untreated sub-clinical infection may reactivate during the second and third decade of life, mostly in the form of retinochoroiditis.[189]
2. Acquired toxoplasmosis in immunocompetent persons is asymptomatic in 80 percent to 90 percent of cases.[190,191] However, 10 percent to 20 percent of patients develop cervical lymphadenopathy and a flu-like illness. Clinical manifestations are protean, reflecting heterogeneous immune responses to the organism,[180] mimicking among others dermatomyositis[192–197] or pityriasis lichenoides (Table 206-6).[191,198–201]
3. Toxoplasmosis in immunodeficient patients is often secondary to reactivation of latent infection and presents as disseminated disease. Toxoplasmic encephalitis is the most common cause of intracerebral lesions in AIDS patients. Disseminated papular/nodular eruption may occur.[84,80,202–204]

TABLE 206-6
Cutaneous Lesions Seen in Acquired Toxoplasmosis in Immunocompetent Persons

- Dermatomyositis-like syndrome[192–197]
- Pityriasis lichenoides[191,198–201]
- Sweet syndrome[255]
- Cold urticaria[256]
- Erythroderma[257]
- Palmoplantar maculopapular rash[183]
- Cellulitis[195–197]
- Morphea[258]
- Mastocytosis[259]
- Others: Lichen planus pilaris, pityriasis rubra pilaris, capillaritis, papular acantholytic dermatosis, keratosis lichenoides chronica,[260] chronic prurigo,[195] scarlatiniform eruption, panniculitis,[261] erythema multiforme[205]

Diagnosis is routinely made by serology. Protozoa may be identified in bronchoalveolar lavage, lymph node specimens, or skin biopsies. Tachyzoites, visualized with Wright or Giemsa stain, are crescent-shaped and have a prominent, centrally placed nucleus. The most common histologic finding is subacute histiolymphocytic vasculitis with demonstration of trophozoites within macrophages.[205] Epidermotropic infection and neural infiltration may occur.[206] Other methods include PCR[207] and xenodiagnosis. Toxoplasmosis should be sought in patients with a dermatomyositis-like picture. Sulfadiazine and pyrimethamine act synergistically and provide together effective therapy.[104]

KEY REFERENCES

The full reference list for all chapters is available at www.digm7.com.

3. Desjeux P: Leishmaniasis: Current situation and new perspectives. *Comp Immunol Microbiol Infect Dis* **27**:305, 2004
22. Murray HW et al: Advances in leishmaniasis. *Lancet* **366**:1561, 2005
62. Couppie P et al: Comparative study of cutaneous leishmaniasis in human immunodeficiency virus (HIV)-infected patients and non-HIV-infected patients in French Guiana. *Br J Dermatol* **151**:1165, 2004
92. Zijlstra EE et al: Post-kala-azar dermal leishmaniasis. *Lancet Infect Dis* **3**:87, 2003

101. Croft SL, Coombs GH: Leishmaniasis—Current chemotherapy and recent advances in the search for novel drugs. *Trends Parasitol* **19**:502, 2003
104. Sra KK, Sracic J, Tyring SK: Treatment of protozoan infections. *Dermatol Ther* **17**:513, 2004
147. Moore AC, Ryan ET, Waldron MA: Case records of the Massachusetts General Hospital. Weekly clinicopathological exercises. Case 20-2002. A 37-year-old man with fever, hepatosplenomegaly, and a cutaneous foot lesion after a trip to Africa. *N Engl J Med* **346**:2069, 2002
155. La Forgia MP et al: Cutaneous manifestation of reactivation of Chagas disease in a renal transplant patient: long-term follow-up. *Arch Dermatol* **139**:104, 2003
171. Magana M et al: Histopathology of cutaneous amebiasis. *Am J Dermatopathol* **26**:280, 2004
174. Paltiel M et al: Disseminated cutaneous acanthamebiasis: A case report and review of the literature. *Cutis* **73**:241, 2004
180. Baggett K, Grande K, Hsu S: Tender nodules on the legs of a cardiac transplant recipient. *Arch Dermatol* **136**:791, 2000

CHAPTER 207

Helminthic Infections

Mary Elizabeth Wilson
Eric Caumes

OVERVIEW: RELATIONSHIP BETWEEN HELMINTHS AND CUTANEOUS SIGNS

Helminths are worms. Those that infect human beings and produce cutaneous signs belong to three groups: nematodes (round worms), trematodes (flukes) and cestodes (tapeworms; Fig. 207-1). They have complex life cycles.[1–3] The helminths that are well adapted to humans (i.e., human helminths) accomplish a complete cycle from larval stage to adult in the human host, whereas animal helminths cannot reach the adult stage in humans (who are dead-end hosts), although infection can still cause tissue damage and clinical findings.

Helminths induce a dramatic expansion of the T helper 2 (Th2) lymphocyte subset with hyper immunoglobulin E (IgE), eosinophilia, and an increase in tissue mast cells. It is unclear whether these Th2-derived responses are important in the protective immune response to the parasite, are responsible for immune-mediated pathology, or both.[4] Despite high levels of IgE and other features of Th2 cell activation, allergic responses are rarely observed in infected individuals except during the invasive phase of infection. Helminths can survive for years. Infected hosts have evolved elaborate immune evasion strategies to allow these long-lived infections, including the induction of tolerance to parasite antigens.

The cutaneous manifestations of these helminthic diseases are varied and can be seen at every phase of the helminth cycle: penetration (if cutaneous), invasive (or acute), and chronic (or focal).

- During the penetration phase of the cycle, cutaneous signs are observed only for helminths that infect by penetrating human skin. In such cases, the signs last a short time for human helminths or a longer time for animal helminths, such as animal hookworms, the cause of the cutaneous larva migrans (CLM) syndrome.
- During the acute phase of the disease (invasive phase of the helminthic cycle), the primary cutaneous finding is urticaria. Again, the duration of the urticarial episode is short when the helminths are well adapted to humans, whereas it may last for weeks or even months when they are not, as is the case with the helminths that cause the visceral larva migrans syndrome.
- During the chronic phase, cutaneous manifestations vary according to the type of helminth, and they are related to the presence of the adult worm or the eggs or the larvae in the subcutaneous tissue or skin. The most common clinical presentations are creeping dermatitis (Table 207-1), panniculitis, papules, or nodules (Table 207-2).

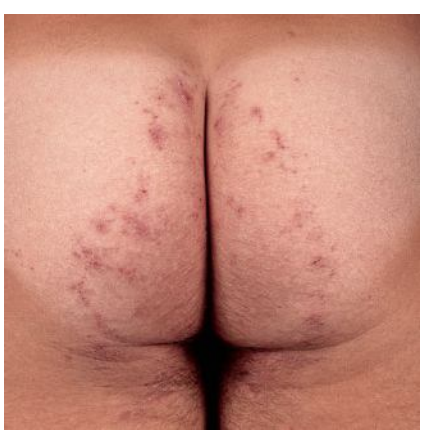

▲ **FIGURE 207-1** Larva currens. Multiple, pruritic, serpiginous, inflammatory lesions on the buttocks in chronic strongyloidiasis.

HELMINTHIC INFECTIONS AT A GLANCE



- A common cause of morbidity and mortality in tropical and developing countries. Skin and soft-tissue findings accompany many of these infections.
- Some parasites can survive for years in the human host with first symptoms and signs developing days to years after infection.
- Eosinophilia and other manifestations of immediate hypersensitivity often occur during the tissue migration phase.

APPROACH TO A PATIENT WITH SUSPECTED HELMINTHIC INFECTION

Clinical Approach

Helminthic skin diseases may lead returning travelers and immigrants to consult a physician.[5,6] To properly diagnose skin lesions, a thorough history and physical examination are essential. The patient history should include geographic location(s) and durations of stay; activities, including occupational exposures; type of accommodations; dietary habits (food and water); exposures (beach, fresh- or saltwater, insects, plants, animals); personal contacts; history of similar signs and symptoms in other family members, fellow travelers, or persons who have visited same areas; use of preventive measures (insect repellent, mosquito netting); and any known recent outbreaks or diseases en-



TABLE 207-1
Summary of Helminths Included in This Chapter

Helminth(s)	Disease	Portal of Entry	Source of Infection
Ancylostoma braziliense, other	Cutaneous larva migrans	Skin	Larvae from animal feces in soil
A. duodenale, Necator americanus	Hookworm	Skin, usually feet	Larvae in soil
Ascaris lumbricoides	Ascariasis	Gastrointestinal[a]	Eggs from contaminated food, soil
Dirofilaria sp.	Dirofilariasis	Skin	Larvae in mosquito
Dracunculus medinensis	Dracunculiasis	Gastrointestinal[a]	Infective copepods in water
Echinococcus sp.	Echinococcosis	Gastrointestinal[a]	Eggs from animal (usually dog) feces
Enterobius vermicularis	Enterobiasis (pinworm)	Gastrointestinal[a]	Eggs in environment
Fasciola sp.	Fascioliasis	Gastrointestinal[a]	Metacercariae on plants, in water
Gnathostoma spinigerum, other	Gnathostomiasis	Gastrointestinal[a]	Larvae in animal flesh
Loa loa	Loiasis	Skin	Infective fly
Onchocerca volvulus	Onchocerciasis	Skin	Infective *Simulium* fly
Paragonimus westermani, other	Paragonimiasis	Gastrointestinal[a]	Metacercariae in seafood
Schistosoma mansoni, other	Schistosomiasis	Skin	Cercariae in water
Schistosomes, nonhuman	Cercarial dermatitis	Skin	Cercariae in water
Spirometra sp.	Sparganosis	Gastrointestinal[a]	Larvae in copepod or in animal flesh
Strongyloides stercoralis	Strongyloidiasis	Skin	Larvae in soil, feces
Taenia multiceps, other	Coenurosis	Gastrointestinal[a]	Eggs (from animal feces) in food, water
T. solium	Cysticercosis	Gastrointestinal[a]	Eggs from feces
Toxocara canis, other	Visceral larva migrans	Gastrointestinal[a]	Eggs in soil
Trichinella spiralis	Trichinosis	Gastrointestinal[a]	Larvae in animal flesh
Wuchereria bancrofti, other	Filariasis	Skin	Infective mosquitoes

[a]Ingestion.



demic to geographic areas previously lived in or visited. The history should also include a thorough review of medications and other preparations (including herbal and local treatments) that the patient may have used. The dermatologic history should include initial presentation and progression of lesions, time of onset relative to potential exposures, duration of lesions, anatomic distribution, and any associated local and systemic signs and symptoms.

Laboratory and Diagnostic Evaluation

Levels of eosinophils in the blood vary according to the stage of infection. The level is typically low during the penetration phase and reaches highest levels during the invasive phase of the cycle. Thereafter it often decreases slowly and may fluctuate more or less above the normal value during the chronic phase. A transient hypereosinophilia may be observed approximately 10 days after the start of effective treatment. Serologic tests vary greatly in their sensitivity and specificity; a common problem is cross-reactivity among the various nematodes, trematodes, and cestodes.

The diagnosis of an helminthic infection is often difficult during the penetration and acute phase of the disease; diagnosis may be suspected because of associated epidemiologic and clinical findings. In the chronic phase, diagnosis is often based on identification of parasite's eggs or larvae. The delayed appearance of antibodies (beginning during the invasive phase) means that serologic tests may need to be repeated to identify a seroconversion.

Sections that follow describe key features of the most common and important helminthic infections. Details about recommended treatment and how to obtain access to unusual drugs can be found in specific listed references[7–9] and through *The Medical Letter*, which is regularly updated and can be accessed online at http://www.medicalletter.org.[10]

HUMAN NEMATODES (ROUNDWORMS)

Intestinal Nematodes

ASCARIASIS ***Synonyms.*** Roundworm infection, ascaridiasis.

Epidemiology. Ascariasis is found worldwide; global prevalence is estimated at 807 million. The highest rates of infection are in children, in hot and humid climates, and in areas with crowding and poor sanitation. Clay soils are especially suited for the survival of *Ascaris* sp.

Etiology and Pathogenesis. Ascariasis is caused by *Ascaris lumbricoides* and occasionally by *A. suum,* the pig roundworm.[11,12] *A. lumbricoides* is the largest intestinal nematode (female measures 20 to 35 cm in length and 3 to 6 mm in thickness; male measures 11 to 22 cm in length). Humans become infected with *A. lumbricoides* by ingesting infective eggs in soil contaminated with human feces (e.g., contaminated fruits, vegetables, water, and hands).

Clinical Findings. **Related Physical Findings.** Pulmonary symptoms, urticaria, and eosinophilia may begin 10 to 14 days after ingestion of *A. lumbricoides* eggs. Gastrointestinal symptoms may precede the shedding of eggs in feces, which begins 50 to 75 days after ingestion of infective eggs. Initial symptoms may be noted weeks or months after onset of infection. Most adult worms survive 8 to 12 months; occasionally, as long as 24 months.

Cutaneous Lesions. Urticaria occurs only during the invasive phase of the disease and may be associated with the pulmonary manifestations of Loeffler

TABLE 207-2
Helminthic Causes of Migratory Dermatologic Lesions

DISEASE	HELMINTH(S)	COMMENTS
Cutaneous larva migrans	Primarily *Ancylostoma braziliense* and *A. caninum*	Larvae of dog and cat hookworms
Dirofilariasis	*Dirofilaria immitis* and other *Dirofilaria* sp.	Usually a discrete nodule
Dracunculiasis	*Dracunculus medinensis*	Movement of worm just below dermis before eruption
Fascioliasis	*Fasciola hepatica* and *F. gigantica*	Migratory areas of inflammation, especially with *F. gigantica*
Gnathostomiasis	*Gnathostoma spinigerum* and other *Gnathostoma* sp.	Migratory inflammatory lesions, 1 cm/hr or faster when subcutaneous
Loiasis	*Loa loa*	Migratory inflammatory swellings; worm may be visible crossing conjunctivae
Paragonimiasis	Primarily *Paragonimus westermani*	Subcutaneous migratory swelling or subcutaneous nodules
Sparganosis	*Spirometra erinacei, S. mansoni, S. mansonoides,* and *S. proliferum*	Occasionally migratory; larval movement
Strongyloidiasis	*Strongyloides stercoralis*	Migratory, serpiginous lesions (larva currens), 5–10 cm/h

syndrome (cough, wheezing, dyspnea), fever, and vague gastrointestinal symptoms. It disappears spontaneously at the end of this phase.

Laboratory Tests. A peripheral eosinophilia may accompany the invasive stage.

The diagnosis is made by finding eggs in feces, which does not occur until after the dermatologic manifestations of the invasive stage have disappeared. The diagnosis is also rarely made based on the identification of the adult worm in stool, pharynx, or an operative specimen or by finding larvae in sputum or gastric lavage. Transient bilateral infiltrates on chest x-ray films are seen early in infection.

Differential Diagnosis. For the skin lesions, differential diagnosis includes the causes of acute urticaria (see Chap. 37).

Complications.

Treatment. Treatment options include albendazole, mebendazole, pyrantel pamoate, or levamisole (Box 207-1).[12]

Prevention. Proper waste disposal and avoidance of ingestion of fecally contaminated soil prevents ascariasis. The embryonated eggs of *A. lumbricoides* can remain viable in soil for years.

ENTEROBIASIS ***Synonyms.*** Threadworm, pinworm, or seatworm infection, oxyuriasis.

Epidemiology. Enterobiasis is found worldwide and is the most common helminthic infection in industrialized countries. The highest rates of infection are among children.

Etiology and Pathogenesis. Enterobiasis is caused by *Enterobius vermicularis*.[13]

Humans, the only host for the parasite, become infected by ingesting infective *E. vermicularis* eggs (e.g., direct anus-to-mouth transfer by fingers or sexual activities, contact with contaminated objects, such as bed linens, clothing, bathroom fixtures) and the inhalation and ingestion of airborne eggs in dust. Eggs become infective within a few hours of being deposited by the female worm in the perianal area.

Clinical Findings. Nocturnal anal and perianal pruritus is the primary clinical feature. The worm may be seen around the anus. The skin may become impetiginized and give rise to cellulitis. In females, vulvovaginitis may occur, and a nodular lesion of the vulva has been described.[14]

Laboratory Tests. The results of laboratory studies are usually normal. Eosinophilia occurs only during tissue invasion.

Special Tests. Enterobiasis is diagnosed by identification of *E. vermicularis* eggs in the perianal area. This is most effectively done by pressing transparent tape on a glass slide to the skin in the perianal area, then reviewing it under a microscope for identification of the eggs. Eggs may also be found in stool (less than 5 percent) and in subungual material. Occasionally, the adult worm (white, up to 4 mm in length) is found in the perianal area, vulva, vagina, or underclothes. When ectopic sites are involved, the parasite may be identified in tissue sections.

Differential Diagnosis. Irritant and allergic contact dermatitis, atopic dermatitis, neurodermatitis, and strongyloidiasis are part of the differential diagnosis.

Complications.

Treatment. (See Box 207-1)

Prevention. Treatment of infected cases and good personal hygiene are the most effective preventive measures.

HOOKWORM DISEASE ***Synonyms and Diseases.*** New World hookworm disease, American hookworm disease, uncinariasis, or necatoriasis (for disease caused by *Necator americanus*); Old World hookworm infection or ancylostomiasis (for disease caused by *Ancylostoma duodenale*).[12,15]

Epidemiology. The various species that cause hookworm disease have distinct, but overlapping, geographic distributions. Hookworm disease is most common in rural tropical and sub-tropical areas but can also occur in temperate areas when sanitation is poor. The global prevalence is estimated at 576 million. The majority of persons who harbor hookworms have no or few symptoms.

Etiology and Pathogenesis. The major causes of human hookworm disease are *A. duodenale* and *N. americanus*. Eggs embryonate and hatch in the soil and develop into infective larvae over 5 to 10 days. Humans are the main reservoir host for *A. duodenale* and *N. americanus*. Humans usually acquire infection via penetration of intact skin by *A. duodenale* larvae (e.g., skin contact with fecally contaminated soil, such as occurs when walking barefoot). Transmammary infection of nursing infants is possible with *A. duodenale*.

Clinical Findings. **RELATED PHYSICAL FINDINGS.** Systemic symptoms of the invasive phase are less frequent than in ascariasis. Pulmonary symptoms (cough, wheezing, and shortness of breath) may occur 1 to 3 weeks after percutaneous penetration in association



Box 207-1

Treatment for Parasitic Infections Discussed in This Chapter

INFECTION	DRUG	ADULT DOSAGE
Ascariasis		
Drug of choice	Albendazole[a]	400 mg once
or	Mebendazole	100 mg bid × 3 days or 500 mg once
or	Pyrantel pamoate[a]	11 mg/kg once (maximum, 1 g)
Coenurosis		
Treatment of choice	Surgical excision of the nodule.	
Cutaneous larva migrans		
Drug of choice	Albendazole[a]	400 mg daily × 3 days
or	Ivermectin[a]	200 μg/kg daily × 1–2 days
or	Thiabendazole topically	
Cysticercosis*		
Treatment of choice	Initial therapy of parenchymal disease with seizures should focus on symptomatic treatment with anticonvulsant drugs. Treatment of parenchymal disease with albendazole and praziquantel is controversial, and randomized trials are inconclusive. Any cysticercocidal drug may cause irreparable damage (even when given with glucocorticoids) when used to treat ocular or spinal cysts. A pre-treatment ophthalmic examination must be done to diagnose intraocular cysts.	
Alternative	Albendazole	400 mg bid × 8–30 days, may be repeated as necessary
or	Praziquantel[a]	50–100 mg/kg/day in 3 divided doses × 30 days
Dirofilariasis		
Treatment of choice	Surgical excision of the nodule.	
Dracunculiasis		
Treatment of choice	Extraction of the worm by slowly winding the worm around a stick.	
Drug of choice	Metronidazole[a]	250 mg tid × 10 days
This dose decreases inflammation and facilitates removal of worm but is not curative. Mebendazole, 400–800 mg/day for 6 days, has been reported to directly kill the worm.		
Echinococcosis*		
Echinococcus granulosus		
Drug of choice	Albendazole	400 mg bid × 1–6 mo
Patient may benefit from or require surgical resection of cysts. Praziquantel is useful preoperatively or in case of spill during surgery. PAIR (percutaneous aspiration-injection-reaspiration with ultrasound guidance) plus albendazole therapy has been effective for the management of hepatic hydatid cyst disease.		
E. multilocularis		
Treatment of choice	Surgical excision is the only reliable means of cure. Reports have suggested that in nonresectable cases, the use of albendazole or mebendazole can stabilize and sometimes cure infection.	
Enterobiasis		
Treatment of all household members is recommended because all are usually infected.		
Drug of choice	Pyrantel pamoate	11 mg/kg once (maximum, 1 g), repeat in 2 wk
or	Mebendazole	100 mg once, repeat in 2 wk
or	Albendazole[a]	400 mg once, repeat in 2 wk
Fascioliasis*		
Drug of choice	Triclabendazole[b]	10 mg/kg once or twice
Alternative	Bithionol[c]	30–50 mg/kg on alternate days × 10–15 doses
Unlike other fluke infections, *Fasciola hepatica* infection may not respond to praziquantel. Triclabendazole, a veterinary fasciolide, may be safe and effective, but the data are limited. Triclabendazole should be taken with food for better absorption.		
Filariasis, lymphatic*		
Endosymbiotic *Wolbachia* bacteria may play a role in filarial development and host response and may represent a new target for therapy. Doxycycline, 100 mg PO qd × 6 wk, has resulted in a decrease in *Wolbachia* and a block in microfilaria production.		
Wuchereria bancrofti, Brugia malayi, B. timori		
Drug of choice	Diethylcarbamazine[c]	6 mg/kg/day divided in 3 doses × 14 days
In patents with microdilaria in the blood, it is advisable to start with a lower dose and scale up. A full dose may be given on day 1 provided that patient is without blood microfilariae.		
Antihistamines or glucocorticoids may be required to reduce the allergic reaction secondary to microfilariae disintegration during the treatment of filarial infections.		
Most symptoms are caused by the adult worm. Single-dose combination of albendazole, 400 mg, with either ivermectin, 200 μg/kg, or diethylcarbamazine, 6 mg/kg, is effective for reduction or suppression of *W. bancrofti* microfilaremia.		
Gnathostomiasis*		
Drug of choice	Albendazole[a]	400 mg bid × 21 days
or	Ivermectin	200 μg/kg/d × 2 days
with or without	Surgical removal	

(continued)



Box 207-1

Treatment for Parasitic Infections Discussed in This Chapter (Continued)

INFECTION	DRUG	ADULT DOSAGE
Hookworm infection		
Drug of choice	Albendazole[a]	400 mg once
or	Mebendazole	100 mg bid × 3 days or 500 mg once
or	Pyrantel pamoate[a]	11 mg/kg once (maximum, 1 g) × 3 days
Loiasis*		
Drug of choice	Diethylcarbamazine[c]	6 mg/kg in 3 doses × 14 days
In patients with microfilariae in the blood, treatment should begin with low dose and then scaled up. A full dose may be given on day 1 provided the patient is without blood microfilariae.		
Antihistamines or glucocorticoids may be required to reduce the allergic reaction secondary to microfilariae disintegration during the treatment of filarial infections, particularly in loiasis.		
In heavy *Loa loa* infections, rapid killing of microfilariae may provoke an encephalopathy. Apheresis has been reported to be effective in decreasing microfilarial counts in patients who are heavily infected with *Loa loa*. Albendazole or ivermectin have also been used to reduce microfilaremia. Albendazole is preferred given its slower onset of action. Albendazole may be useful for the treatment of loiasis when diethylcarbamazine is ineffective or cannot be used but repeated courses may be necessary. Diethylcarbamazine, 300 mg PO qwk, has been recommended for loiasis prevention.		
Onchocerciasis*		
Endosymbiotic *Wolbachia* bacteria may play a role in filarial development and host response, and may represent a new target for therapy. Doxycycline, 100 mg PO qd × 6 wk, has been associated with block of microfilariae production in onchocerciasis.		
Drug of choice	Ivermectin	150 μg/kg once, repeated every 6–12 mo until asymptomatic
Annual treatment with ivermectin, 150 μg/kg, can prevent blindness due to ocular onchocerciasis.		
Paragonimiasis*		
Drug of choice	Praziquantel[a]	75 mg/kg/day divided in three doses × 2 days
Alternative	Bithionol[c]	30–50 mg/kg on alternate days × 10–15 doses
or	Triclabendazole	May be effective in dosages 5 mg/kg qd × 3 days or 10 mg/kg bid × 1 day. Triclabendazole should be taken with food for better absorption.
Schistosomiasis*		
Schistosoma haematobium		
Drug of choice	Praziquantel	40 mg/kg/day divided in two doses × 1 day
S. japonicum		
Drug of choice	Praziquantel	60 mg/kg/day divided in three doses × 1 day
S. mansoni		
Drug of choice	Praziquantel	40 mg/kg/day divided in two doses × 1 day
Alternative	Oxamniquine	15 mg/kg once
In East Africa, the oxamniquine dose should be increased to 30 mg/kg. In Egypt and South Africa, the dose should be increased to 30 mg/kg/day × 2 days. Oxamniquine has been effective in some areas where praziquantel is less effective. Oxamniquine is contraindicated in pregnancy.		
S. mekongi		
Drug of choice	Praziquantel	60 mg/kg/day divided in three doses × 1 day
Sparganosis		
Treatment of choice	Surgical excision of the nodule.	
Strongyloidiasis		
Drug of choice	Ivermectin	200 μg/kg/day × 2 days
In immunocompromised patients or disseminated disease, it may be necessary to prolong or repeat therapy or use other agents. A veterinary parenteral formulation of ivermectin has been used in one patient.		
Alternative	Albendazole 400 mg bid × 7 days or thiabendazole	50 mg/kg/day in two divided doses (maximum, 3 g/day) × 2 days
This dose is likely to be toxic and may need to be decreased.		
Trichinosis		
Drugs of choice	Glucocorticoids for severe symptoms plus	
	Mebendazole[a]	200–400 mg tid × 3 days then 400–500 mg tid × 10 days
Alternative	Albendazole[a]	400 mg bid × 8–14 days
Visceral larva migrans		
Drugs of choice	Albendazole[a]	400 mg bid × 5 days
	Mebendazole[a]	100–200 mg bid × 5 days
Optimal duration of therapy is unknown. Some consultants recommend treating for up to 20 days. In addition, glucocorticoids may be used for severe symptom or ocular involvement.		

p.c. = after a meal.
[a]Although this is a U.S. Food and Drug Administration–approved drug, the FDA considers this drug to be investigational for this disease.
[b]In the United States, this drug is available only from the manufacturer.
[c]Available under an Investigational New Drug (IND) protocol from the CDC Drug Service. http://www.cdc.gov/ncidod/srp/drugs/drug-service.html. From "Drugs for Parasitic Infections," August 2004, http://www.medicalletter.org, Public Reading Room. Reprinted with special permission from *The Medical Letter*.
*Consultation with tropical medicine specialist advised.



with urticaria. Gastrointestinal symptoms occur 1 month after penetration.

CUTANEOUS LESIONS. Cutaneous manifestations may be seen during the penetration phase and the invasive phase of the disease. Within 1 to 2 days after contact, the area of skin penetrated by the larvae may have localized erythema, edema, and papular or papulovesicular lesions.[17] This eruption, known as *ground itch*, is most commonly located on the feet and lasts 1 to 2 weeks. The pulmonary migration phase, seen in a minority of patients, may be associated with generalized urticaria, which disappears spontaneously at the end of this phase.



Laboratory Tests. A peripheral eosinophilia begins as early as 2 to 3 weeks after skin penetration by the infective larvae and may be high grade during the invasive phase. Chest x-ray films may reveal transient pulmonary infiltrates during pulmonary migration. In chronic infection, abnormal laboratory values include iron deficiency anemia, hypoalbuminemia, and gross or occult blood in feces.

Special Tests. Infection is diagnosed by finding characteristic eggs on stool examination (not found until 4 to 6 weeks after exposure). At the time a patient presents with ground itch or the later urticarial and pulmonary manifestations, the results of stool examinations will be negative. The eggs of *A. duodenale* and *N. americanus* are indistinguishable by routine light microscopy.

Differential Diagnosis. For ground itch, the differential diagnosis includes infectious cellulitis, cellulitis-like reaction after arthropod bite or sting, and folliculitis. For the causes of acute urticaria (seen during the invasive phase), see Chap. 37.

Complications.

Treament. (See Box 207-1) Albendazole appears to be more effective than mebendazole, which has been suggested as an alternative.[12] Ivermectin is not effective in human hookworms in contrast to animal hookworm.

Prevention. The sanitary disposal of human feces can prevent hookworm infections.

STRONGYLOIDIASIS

Synonyms. Strongyloidosis, strongyloidal ground itch, larva currens.

Epidemiology. Although the parasite is widely distributed, it is most common in tropical and sub-tropical areas.[18] *Strongyloides fuelleborni* is endemic in parts of tropical Africa and Asia. Rates of infection are as high as 80 percent in some populations in tropical areas. High rates of infection are reported in institutionalized mentally impaired persons, in former prisoners of war, and in refugees and immigrants from some tropical areas. The risk of infection is high for persons with frequent soil contact (e.g., going barefoot) in warm, moist areas where human feces frequently contaminate the soil. Persons who are infected with human T-cell lymphotrophic virus type 1 are at increased risk for complications from strongyloidiasis. Immunosuppressive therapy in chronically infected persons can be associated with hyperinfection.

Etiology and Pathogenesis. Strongyloidiasis results from infection by *S. stercoralis*. *S. fuelleborni,* a common parasite of primates, infects humans in limited geographic areas. Other *Strongyloides* sp. that do not mature in humans and affect the skin only are a cause of the CLM syndrome (see the section Hookworm-Related Cutaneous Larva Migrans).

Under appropriate conditions, the parasite can multiply for several generations in the soil. Humans are the main reservoir host for human infection. Humans become infected when infective larvae, usually from soil, penetrate skin or mucous membranes. Transmammary infection of *S. fuelleborni* may account for some infections in infants. Transmission also occurs via oral-anal sexual intercourse.

Clinical Findings. **RELATED PHYSICAL FINDINGS.** The signs and symptoms of strongyloidiasis occur irregularly with prolonged asymptomatic intervals. The penetration phase does not give rise to cutaneous signs. Skin and pulmonary manifestations can begin within days of exposure. Because autoinfection can occur, infection can persist indefinitely, although infection may first be recognized years, even decades, after it was acquired.

CUTANEOUS LESIONS. Cutaneous manifestations may be seen during the invasive and chronic phases of infection and with the hyperinfection syndrome.

During the invasive phase of the infection, transient pulmonary manifestations (cough, wheezing, infiltrates) are manifestations of pulmonary migration and may be associated with urticaria.

Chronic strongyloidiasis gives rise to non-specific gastrointestinal complaints (abdominal pain, nausea, vomiting, diarrhea, constipation, malabsorption, weight loss) and a pathognomonic skin manifestation known as *larva currens*. The filariform larvae invade the perianal skin and travel within the skin, resulting in a creeping eruption (see Fig. 207-1). Larva currens is associated with intense pruritus. This transient eruption is unique in that it migrates at a rate of up to 5 to 10 cm per hour and disappears within a few hours, but may recur over the course of weeks to years. Anatomic locations commonly include the buttocks, groin, and trunk. Persons chronically infected with *Strongyloides* may also experience pruritus ani and chronic urticaria, which may be complicated by prurigo nodularis or lichen simplex chronicus.[19]

The dermatologic manifestation of hyperinfection and disseminated strongyloidiasis is a rapidly and progressively diffuse petechial and purpuric eruption caused by massive filariform larvae dissemination to the skin (Fig. 207-2). The eruption typically involves the trunk and proximal extremities.[20] The "thumbprint sign," seen in disseminated strongyloidiasis, is a unique pattern of periumbilical purpura that resembles multiple thumbprints.[21]

Laboratory Tests. Peripheral eosinophilia is common and may be high grade during larval migration. During the chronic phase, the eosinophil level fluctuates and is often mildly elevated (mild to moderate increase) but may be normal. The absence of eosinophilia does not rule out the diagnosis. Eosinophilia is often absent in patients who are on glucocorticoids or are severely immunocompromised.

Special Tests. The identification of larvae in the stool, small bowel contents, and, rarely, in other body fluids confirms the diagnosis. Multiple stool examinations are often necessary to make the diagnosis. Larvae first appear in the stool 2 to 4 weeks after exposure. Serologic testing by enzyme-linked immunosorbent assay (ELISA) has a sensitivity of approximately 90 percent and may be useful when the diagnosis is suspected, although serologic tests lack specificity.

Diagnosis of larva currens is made by its characteristic clinical features. Skin biopsy of the larva currens eruption often fails to reveal larvae. Biopsy of the purpuric and petechial eruption of hy-



▲ **FIGURE 207-2** Non-palpable purpura secondary to disseminated strongyloidosis. (Reprinted with permission from Grossman ME, Roth J: *Cutaneous Manifestations of Infection in the Immunocompromised Host.* Baltimore, Williams & Wilkins, 1995.)

perinfection and disseminated strongyloidiasis may reveal larvae.

Differential Diagnosis. For larva currens, the differential diagnosis includes all of the causes of creeping eruption (see Table 207-2); for acute and chronic urticaria, see Chap. 37.

For the petechial and purpuric eruption, the differential diagnosis includes sepsis and causes of diffuse bleeding.

Complications.

Prognosis and Clinical Course. The mortality rate is high in disseminated strongyloidiasis.

Persons with a history of prior residence or activities that place them at an increased risk for strongyloides infection should be evaluated for presence of strongyloides infection. If infected, they should be treated, even if asymptomatic. This is especially important in persons who receive treatment that causes immunosuppression.

Treatment. (See Box 207-1)

Prevention. Sanitary waste disposal and avoiding skin-soil contact in endemic areas reduces risk of infection.

Filarial Parasites (Table 207-3)

LYMPHATIC FILARIASIS ***Synonyms and Diseases.*** Malayan filariasis (*Brugia malayi*), Timor filariasis (*B. timori*), Bancroft filariasis, filariasis bancrofti, and wuchereriasis (*Wuchereria bancrofti*). Some of these parasites can cause elephantiasis and tropical pulmonary eosinophilia.[23]

Epidemiology. Lymphatic filariases are widely distributed in tropical and subtropical areas, with the largest number of infections occurring in India, South Asia, East Asia and Pacific Islands, and sub-Saharan Africa. eFig. 207-2.1 in the on-line edition shows the geographic distribution of *W. bancrofti, B. malayi,* and *B. timori* in the Southeast Asian and Western Pacific regions. *W. bancrofti* occurs in the northern part of South America (Guyana, Surinam, and some coastal regions of Brazil). In the United States infections are seen primarily in immigrants and persons with prolonged visits to endemic areas.

Etiology and Pathogenesis. Lymphatic filariasis is caused by three filarial nematodes: *B. malayi, B. timori,* and *W. bancrofti*, parasites transmitted by infective mosquitoes.

The incubation period is 5 to 18 months, although *B. malayi* microfilaremia may occur as early as 2 to 3 months after exposure. *W. bancrofti* microfilariae first appear in peripheral blood 8 to 12 months after exposure, but symptoms can begin as early as 1 to 3 months after exposure. Adult worms live an average of 10 to 15 years; the microfilariae, probably 6 to 12 months. Symptoms and sequelae can persist after the death of all parasites.

Clinical Findings. Lymphatic filariasis was generally thought to occur mainly as a seriously handicapping disease of adults, being sporadically observed in children. However, new highly sensitive diagnostic tests have revealed that it is first acquired in childhood, often with as many as one-third of children infected before the age of 5 years in endemic areas.[25] Initial lymphatic damage generally remains sub-clinical for years or gives rise only to recurrent lymphangitis or non-specific presentations of adenitis/adenopathy. It takes years for the characteristic clinical features of chronic filariasis to appear. In endemic areas, the prevalence of clinical manifestations increases after age 20. The clinical course ranges from asymptomatic to severely disabling manifestations (less than 1 percent of those infected). Manifestations may be acute, chronic, or recurrent.[26]

CUTANEOUS LESIONS. Early findings are lymphangitis with a characteristic retrograde progression, lymphadenitis, orchi-



TABLE 207-3
Summary of Filarial Parasites[a]

SPECIES	GEOGRAPHIC DISTRIBUTION	MANIFESTATIONS
Brugia malayi	Southeast Asia	Lymphangitis, lymphadenitis, lymphedema, hydrocele, elephantiasis, tropical pulmonary eosinophilia
B. timori	Indonesia	Same as above
Loa loa	Africa	Angioedema, pruritic migratory swellings; migration of worm across eye
Mansonella ozzardi	Central and South America	Pruritus
M. perstans	Africa, South America	Pruritus, angioedema
M. streptocerca	Africa	Pruritus, papular rash, lichenification
Onchocerca volvulus	Africa, Central and South America	Pruritic papules, nodules, lichenification; keratitis, retinitis, blindness
Wuchereria bancrofti	Tropics worldwide	Lymphangitis, lymphadenitis, lymphedema, hydroceles, chyluria, elephantiasis, tropical pulmonary eosinophilia

[a]Dracunculiasis and dirofilariasis, which are also filarial infections, are covered in separate sections. All filarial infections are transmitted by biting insects, except for dracunculiasis.

tis, epididymitis, and, sometimes, fever. During the resolution of the acute phase of *W. bancrofti* filariasis, there may be extensive exfoliation of the skin of the affected limb. Lymphangitis is typically recurrent with 6 to 10 episodes per year, usually lasting 3 to 7 days each; the affected body part clinically appears normal between early episodes. Intermittent fevers and lymphangitis can recur for as long as 20 years, the lifetime for the adult worm, after an infected person leaves the endemic area.

After 10 to 15 years of infection, chronic disease is evident in sequelae of lymphatic obstruction including lymphedema, elephantiasis, hydrocele, and chyluria. The skin over the involved area is hypertrophic, verrucous, and fibrotic with redundant folds of skin (Fig. 207-3). Fissures, ulceration, and gangrene may occur. Secondary bacterial infection is common. The anatomic locations most commonly afflicted with elephantiasis include the lower extremity, scrotum, and penis. Less commonly, the upper extremity, breast, and vulva are involved. Treatment does not reverse the late findings of scarring and lymphatic obstruction. *W. bancrofti* has been reported to cause a skin nodule on the breast.

Travelers to endemic areas have a hyper-responsive clinical presentation, with more intense inflammatory reactions to filarial parasites. The clinical findings may include lymphangitis, lymphadenitis, and groin pain from the associated lymphatic inflammation, urticaria, and a peripheral eosinophilia.



▲ **FIGURE 207-3** Lymphatic filariasis secondary to *Wuchereria bancrofti*. (Used with permission from Jay S. Keystone, MD, FRCPC.)

RELATED PHYSICAL FINDINGS. Tropical pulmonary eosinophilia develops in some patients with filarial infections.

Laboratory Tests. Patients with lymphatic filariasis have a peripheral eosinophilia, which may be high grade, and an elevated IgE. Persons with tropical eosinophilic syndrome have pulmonary infiltrates on chest x-ray films.

Special Tests. Diagnosis is made by demonstrating microfilariae, preferably at night (midnight), in blood, urine, and other body fluids, and tissue. However, persons with active filarial infection may not be microfilaremic. The demonstration of the adult worm in lymphatics is possible, but biopsy of adenopathy is contraindicated. The usefulness of serologic tests has been limited by cross-reactions with other nematodes, but newer tests such as polymerase chain reaction (PCR) and antigen detection with better specificity are becoming available.

Differential Diagnosis. The stage of the infection determines the differential diagnosis. Acute infection may resemble bacterial lymphangitis and other causes of nodular lymphangitis, such as sporotrichosis and leishmaniasis.

The differential diagnosis for the chronic stage includes the other causes of lymphedema and elephantiasis (see Chap. 175).

Treatment. (See Box 207-1) Treatment is suboptimal because drugs are only partially effective against adult worms in lymphatic ducts, the cause of the cutaneous manifestations. Of the four classic drugs with an antifilarial activity, diethylcarbamazine (DEC) and ivermectin are partially effective against adult worms, and albendazole is effective only with high dosages, which may induce severe adverse events. Recent studies document that a 6- to 8-week course of daily doxycycline can reduce the longevity or the reproductive capacity of these parasites[27] by eliminating bacterial (*Wolbachia*) endosymbiots present in the lymphatic filariae. To be effective against microfilariae, treatment needs to combine doxycycline with either two doses of ivermectin, one at the end of the doxycycline course and the other 3 to 6 months later, or one single dose of DEC.[28]

When treating filariasis with DEC, clinicians may use antihistamines or glucocorticoids to decrease the allergic reaction that may result from disintegration of microfilariae. Severe reactions may follow the administration of DEC to persons co-infected with filariasis and loiasis or onchocerciasis (a reason to prefer ivermectin instead of DEC in loiasis-endemic areas).

Management strategies for patients with lymphedema include elevation of the affected body part, compression stockings, skin care of the affected area, treatment of superficial fungal infections, as well as protection of the affected area from trauma and prompt antibiotic therapy for bacterial infections of the area. Surgical treatment includes debulking of the affected area, wide excision of chronic draining areas, and lymphatic shunts. Effectiveness varies, depending on the location of lymphedema.

Prevention. The avoidance of mosquito bites in endemic areas is the primary means of prevention. Treatment of microfilaremic persons will reduce reservoir of parasites.

LOIASIS

Synonyms. Calabar swellings, fugitive swellings, *Loa loa* filariasis, African eyeworm infection.

Epidemiology. Loiasis is endemic in Central and West Africa and is estimated to affect 3 to 13 million residents.

Etiology and Pathogenesis. The filarial nematode, *Loa loa,* is transmitted by *Chrysops* (a type of fly).[29] The day-biting fly ingests microfilariae along with the blood meal when it bites an infected human. The microfilariae develop into larvae, which are transmitted when the fly bites another human.

Symptoms usually begin a mean of 24 months after exposure, although first findings can appear as early as 4 months or as late as a decade or more after the acquisition of infection. Microfilariae first appear in the bloodstream 5 to 6 months after the person becomes infected. The adult worm can live longer than 20 years in the human host.

Clinical Findings. Loiasis is manifested by pruritus, migration of the worm under the skin or across the eye (Fig. 207-4), and Calabar swellings.[30]

CUTANEOUS LESIONS. Calabar swelling is the characteristic manifestation of loiasis (Fig. 207-5). These are localized areas of angioedema associated with the migration of the adult worms through the subcutaneous tissues. Calabar swellings range from 5 to 20 cm in diameter.

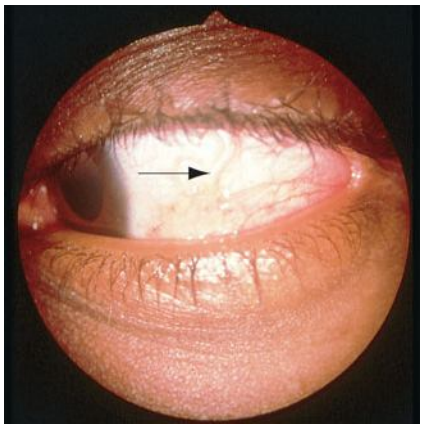

▲ **FIGURE 207-4** Loiasis. Adult worm crossing eye (*arrow*). (Used with permission from Murray Wittner, MD, PhD.)

They may be associated with pruritus or pain; generally last 2 to 4 days (occasionally weeks), and may recur multiple times. They occur predominantly on the extremities (upper more commonly than lower), especially around joints such as the wrist or knee. Fatigue, myalgias, arthralgias, and fever are uncommonly associated with the lesions. Adult worms may also migrate under the skin, causing a creeping eruption (see the following section, Related Physical Findings). It is characterized by a serpiginous or linear erythematous cutaneous trail that is less than 10 cm long and advances rapidly (1 cm per minute) and lasts no more than a few hours (for other causes of migratory lesions, see Table 207-2).

Related Physical Findings. A migrating adult worm may be seen crossing the conjunctivae or the bridge of the nose; see Fig. 207-4). This is associated with conjunctivitis and, occasionally, swelling on the face, particularly of the periorbital region.

Laboratory Tests. Findings include a peripheral eosinophilia (may be high grade), leukocytosis, and elevated IgE. *Loa loa*–specific IgG4 is elevated.

Special Tests. Diagnosis is based on identification of microfilariae in blood (during the day) or the identification of an adult worm removed from the eye or other tissues. Calcified worms may be seen on x-ray films. Although the usefulness of older serologic tests is limited by cross-reactivity with other parasites, newer approaches are being developed, including the use of PCR-based testing.

Differential Diagnosis. The differential diagnosis includes all the causes of migratory lesions (see Table 207-2) and angioedema of the extremities (gnathostomiasis, trichinosis, eosinophilic cellulitis).

Complications.

Treatment. The surgical removal of the worm from the eye or other tissue, if feasible, is therapeutic, but patients are usually infected with multiple worms (usually not more than 10 to 20 adult worms).

As the manifestations of loiasis are due to adult worms, DEC is currently the drug of choice because it is effective against the adult worm *Loa loa* (in contrast to other filariasis) as well as microfilariae (see Box 207-1). Side effects from treatment are common and are occasionally severe, especially in patients with high circulating levels of microfilariae. One approach has been to gradually increase the dose of DEC and to pre-treat with antihistaminics and corticosteroids, though this does not always prevent encephalitis.[33] Repeat courses of treatment are necessary in 50 percent or more of patients.

Ivermectin and albendazole are ineffective against the adult worms but can be useful because they reduce microfilarial levels, the risk factor for adverse reactions.[34] In addition, for the rare patient who has an infection refractory to DEC, albendazole may be effective.[35] In patients with heavy infections, approaches include the use of single dose ivermectin or albendazole (for 21 days) or cytapheresis to reduce microfilarial levels.[32]

Prevention. Prevention includes avoiding bites from *Chrysops* in endemic areas and treatment of infected humans to reduce source of parasites.

Chemoprophylaxis with a weekly 300-mg dose of DEC is effective for preventing *Loa loa* in long-term travelers to endemic regions who expect to have frequent exposures to biting flies.[36]

MANSONELLIASIS

ONCHOCERCIASIS

Synonyms. Onchocercosis, blinding filariasis, river blindness, coastal erysipelas, erysipela de la costa (Mexico and Guatemala), onchocercomata, onchodermatitis, sowda (Arabic speaking areas), craw-craw (West Africa).

Epidemiology. The greatest concentration of *Onchocerca volvulus* infections is in equatorial Africa. Endemic foci also exist in Latin America and the Arabian peninsula. An estimated 18 million persons are infected. eFig. 207-5.1 in the on-line edition shows the geographic distribution of onchocerciasis in Africa and the Arabian peninsula. eFig. 207-5.2 in the on-line edition shows the geographic distribution of endemic onchocerciasis in the Americas.

Etiology and Pathogenesis. Onchocerciasis is caused by the filarial nematode *O. volvulus*[37] and is transmitted by blackflies of the genus *Simulium.* The microfilariae develop into infective larvae within the blackfly, which passes larvae to another human when taking a blood meal. In the human, the infective larvae mature to adult worms that are encapsulated in fibrous tissue and reside in nodules in the subcutaneous tissue and deep fascia.

Microfilariae from an infected mother can infect the fetus, and microfilariae can potentially be transmitted by blood transfusion.

The incubation period is usually 1 to 2 years with a range of months to several years. Microfilariae may first appear 3 to 15 months after exposure. The initial symptoms can precede the presence



▲ **FIGURE 207-5** Calabar swelling of loiasis. (Used with permission from Jay DS. Keystone, MD, FRCPC.)



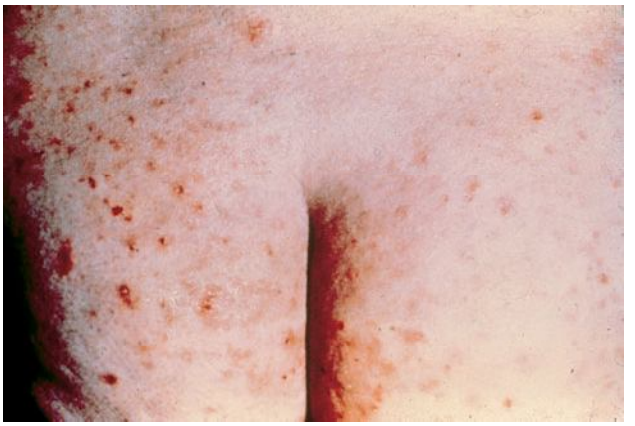

▲ **FIGURE 207-6** Onchocercal dermatitis. (Used with permission from Herman Zaiman, MD.)



of microfilariae in tissue, but often develop only after months or years of infection. The microfilariae can survive in humans for up to 2 to 3 years, the adult worms, for 10 to 15 years.[38]

Clinical Findings. Persons with onchocerciasis may be asymptomatic, or they may have a severe impairment, including loss of vision.[39] The skin and the eye are the two most commonly involved organ systems.

CUTANEOUS LESIONS. Clinical manifestations differ between long-term residents of endemic areas and short-term visitors from nonendemic regions, whose infection may be associated with acute symptoms and immune hyper-responsiveness, despite low levels of parasites.[40] The most common presentations in visitors to endemic areas are pruritus and rash (Fig. 207-6).[41] Skin nodules (Fig. 207-7) and eye involvement are usually absent, and microfilariae are absent or found in low numbers in the skin. After exposures in West and Central Africa, travelers and expatriates may have an acute form of onchocerciasis characterized by acute pruritic and erythematous swelling of a limb known as *gros bras camerounais*[42] or onchocerciasis-associated limb swelling.[43] In contrast to other clinical forms of onchocerciasis, onchocerciasis limb swelling is a disease of the forested areas, not the savanna.[42]

Other skin manifestations of onchocerciasis are the consequences of itching, which is chronic and severe. Six different patterns of skin changes have been described: acute papular onchodermatitis, chronic papular onchodermatitis (see Fig. 207-6), lichenified onchodermatitis, atrophy, depigmentation (see Chap. 73, Fig. 73-9), and palpable onchocercal nodules (see Fig. 207-7). More than one pattern of skin involvement may be present simultaneously, or one pattern of skin involvement may evolve into another pattern. Pruritus is often the first symptom of infection. Acute papular onchodermatitis, which most often involves the face, extremities, and trunk, includes widespread small pruritic papules, vesicles and pustules, sometimes with associated erythema and edema. Ivermectin and DEC therapy of infected persons can precipitate a rash similar to acute papular onchodermatitis.

The skin lesions of chronic papular onchodermatitis are macules and lichenoid papules varying in diameter from 3 to 9 mm. Pruritus is common, and post-inflammatory hyperpigmentation may be present. The most commonly affected anatomic areas are the buttocks, shoulders, and waist (see Fig. 207-6).



▲ **FIGURE 207-7** Onchocercal nodule over iliac crest. (Used with permission from Jay S. Keystone, MD, FRCPC.)

RELATED PHYSICAL FINDINGS. Palpable onchocercal nodules containing the adult worm involve the deep dermis and subcutaneous tissue (see Fig. 207-7). Typically asymptomatic, the nodules occur over bony prominences such as the skull, iliac crest, knee, rib, sacrum, scapula, and trochanter.

Laboratory Tests. Peripheral eosinophilia and elevated IgE levels are common findings.

Special Tests. Onchocerciasis is most commonly diagnosed by the identification of microfilariae in a skin snip or of an adult worm in an excised nodule. Microfilariae may be clearly visible in the anterior chamber of the eye on slit-lamp examination. Antibody testing lacks specificity; PCR testing is generally available only through research laboratories.[44]

Differential Diagnosis. The differential diagnosis depends on the skin findings at the time of presentation. Pruritus may suggest scabies. Acute papular onchodermatitis may resemble miliaria, insect bites, or eczema. Chronic papular onchodermatitis may resemble a chronic or lichenoid eczema or atopic dermatitis. The differential diagnosis for lichenified onchodermatitis is broad and includes essentially any diagnosis that involves significant pruritus or rubbing of the involved area. Atrophy associated with onchocerciasis resembles that associated with aging. Onchocercal depigmentation may be confused with post-inflammatory hypopigmentation or depigmentation. The differential diagnosis for onchocercal nodules includes the other parasitic causes of nodules (Table 207-4) and epidermal inclusion cysts.

Treatment. (See Box 207-1) DEC should not be used in patients with proven onchocerciasis due to its lack of efficacy on adult worms and the severity of ocular reaction it may induce. A single 50-mg dose of DEC can be administered as a diagnostic tool for unproven onchocerciasis (Mazzotti test) in areas where loiasis is not endemic. In such a case, it provokes (often within 3 hours) an increase in the cutaneous manifestations; as a consequence microfilariae may appear in the dermis, and a biopsy may then confirm the diagnosis.

The drug of choice in the treatment of onchocerciasis is ivermectin. Ivermectin (single dose, 150 μg/kg) causes a dramatic decrease of the microfilarial load

TABLE 207-4
Helminthic Causes of Dermatologic Nodules and Cysts

DISEASE	HELMINTH(S)	COMMENTS
Coenurosis	Several species of *Multiceps*	Solitary cyst
Solitary cyst cutaneous larva migrans	Primarily *Ancylostoma braziliense* and *A. caninum*	Larvae of dog and cat hookworms
Cysticercosis	*Taenia solium*	May be multiple
Dirofilariasis	*Dirofilaria immitis* and other *Dirofilaria* sp.	Usually single
Dracunculiasis	*Dracunculus medinensis*	Localized swelling
Echinococcosis	*Echinococcus granulosus* and *E. multilocularis*	—
Fascioliasis	*Fasciola hepatica* and *F. gigantica*	Painful, pruritic
Filariasis, lymphatic	*Brugia malayi, B. timori,* and *Wuchereria bancrofti*	Mass in scrotum
Gnathostomiasis	*Gnathostoma spinigerum* and other *Gnathostoma* sp.	Migratory swelling
Loiasis	*Loa loa*	Inflammatory swellings
Onchocerciasis	*Onchocerca volvulus*	Painless, mobile, dermal nodules
Paragonimiasis	Primarily *Paragonimus westermani*	Subcutaneous nodule
Schistosomiasis	*Schistosoma haematobium, S. intercalatum, S. japonicum, S. mansoni,* and *S. mekongi*	Verrucous, vegetating
Sparganosis	*Spirometra erinacei, S. mansoni, S. mansonoides,* and *S. proliferum*	Slow growing

in the skin of patients with onchocerciasis and thus leads to a clinical improvement of the symptoms.[45,46] However, when used as a single annual or semiannual dose, ivermectin has no effect on the adult female worm, which can survive 14 years or longer. Thus, for optimal benefit, ivermectin must be given repeatedly throughout the life span of the parasite[38] or be combined with doxycycline. Long-term treatment with doxycycline (6 weeks) kills the endosymbiotic *Wolbachia* in adult worms and interrupts production of microfilariae for 18 months or longer.[47] Another option is to increase the frequency of ivermectin dosing to every 3 months, which decreases the fecundity of the adult female parasite two- to threefold.[48]

Prevention. The primary means of preventing onchocerciasis is through vector control and mass treatment with ivermectin of the population in endemic areas.

Other Human Nematodes

DRACUNCULIASIS

Synonyms. Dracunculosis, dracontiasis, Guinea worm disease, Medina worm infection, dragon worm disease, serpent worm disease.

Epidemiology. As a consequence of an eradication program, the number of endemic countries (all in sub-Saharan Africa) in 2005 dropped to 9, down from 20 in 1980. Ghana and Sudan reported 89 percent of total global cases; and Niger, Mali, Niger, and Togo each reported more than 100 cases in 2004.[50]

Etiology and Pathogenesis. The nematode *Dracunculus medinensis* causes dracunculiasis (Fig. 207-8). The female is 70 to 80 cm in length and rarely exceeds 100 cm.

Larvae are released directly through leg ulcers into water from an infected human and ingested by copepods (tiny aquatic arthropods), in which they develop. Humans ingest the infective copepods (*Cyclops*) in contaminated drinking water and are the definitive host and main reservoir of infection.

Clinical Findings. **RELATED PHYSICAL FINDINGS.** Symptoms associated with the migration of the worm may precede the emergence of the worm. The adult worm typically dies (or is removed) after reaching the skin and releasing larvae.

CUTANEOUS LESIONS. The characteristic clinical findings include a bulla, 2 to 7 cm in size, that progresses over 1 to 3 days to an ulcer after contact with water and release of larvae. At this stage, the adult worm may be palpated, sometimes seen, under the skin, appearing as a cutaneous trail of 55 cm to 80 cm long, but usually is obscured by the local swelling



▲ **FIGURE 207-8** Dracunculiasis. (Used with permission from Jay S. Keystone, MD, FRCPC.)

Rupture of the worm in tissues provokes an intense inflammatory response and cellulitis, and may lead to abscess formation (see Fig. 207-8). Disruption of the skin by the worm predisposes to secondary bacterial infection, including tetanus. Most infected persons have one or a small number of worms (usually fewer than six). In 85 percent to 90 percent of cases the lesion is on the lower extremity, but the worm may emerge on the hands, arms, trunk, and even jaw. Non-specific symptoms may precede the skin lesion by a few hours and disappear once the larvae are ejected.

Laboratory Findings. Peripheral eosinophilia is uncommon.

Diagnosis. Visualization of the parasite as it emerges (see Fig. 207-8) and identification of the discharged motile larvae confirm the diagnosis. Calcified dead worms may be seen on x-ray.

Differential Diagnosis. The differential diagnosis includes causes of localized cutaneous bullae, ulcers, carbuncle, limb swelling (cellulitis associated with bacterial infection, onchocerciasis, loiasis) and creeping eruption (though the cutaneous trail does not advance from one day to the next; see Table 207-2).



Complications.

Treatment. Treatment of dracunculiasis includes slow extraction of the worm combined with wound care.

Prevention. Water from potentially infected sites should be filtered (e.g., through cloth to remove copepods).

Infected individuals should be prevented from contaminating wells and other drinking water sources when larvae are emerging.

ANIMAL NEMATODES

Infections in Humans



TOXOCARIASIS

GNATHOSTOMIASIS

Synonyms. Yangtze River edema (China), tau-chid (Thailand), choko-fushu (Japan), wandering swelling, Consular disease (Nankung), Shanghai rheumatism, nodular eosinophilic panniculitis (Ecuador), Woodbury bug (Australia).

Epidemiology. Human gnathostomiasis is endemic in Southeast Asia, especially Thailand and Japan. Since the 1970s, the prevalence of gnathostomiasis has increased in Peru, Ecuador, and Mexico. Imported fish and other animal flesh can be a source of infection outside of endemic areas. Sporadic cases have been reported in the Americas, Africa, Europe, and Australia. In the last two decades, an increase has been noted in the cases in travelers returning from endemic countries.[57]

Etiology and Pathogenesis. The nematode *Gnathostoma spinigerum* and, less frequently, *G. hispidum, G. nipponicum,* and *G. doloresi* cause gnathostomiasis.[58]

The adult worm lives in the stomachs of the definitive hosts, cats and dogs. Eggs from animal feces hatch in water. The larvae are ingested by *Cyclops* (a type of copepod, which are small aquatic arthropods) that are eaten by fish, frogs, and snakes, and sometimes domestic pigs and chickens. In these hosts, the larvae develop into third-stage larvae. Humans ingest the third-stage larvae in undercooked or raw flesh of infected animals. Transmission may also occur by ingestion of infective copepods in water or by skin penetration when handling infected fish.

Soft tissue swellings usually begin 3 to 4 weeks after exposure, but may not develop months or years later. The parasite can survive in the human for 10 years or longer. One report documents recurrences for 20 years.

Clinical Findings. **Related Physical Findings.** The signs and symptoms of gnathostomiasis range from mild to severe and depend on the location of larvae.

Cutaneous Lesions. The signs of the penetration phase occur within 1 to 2 days after ingestion of the larvae and include acute urticaria and fever, malaise, anorexia, nausea, vomiting, diarrhea, and epigastric pain. These signs disappear spontaneously within 2 days.[59] Migration of the larvae in the skin and subcutaneous tissue causes migratory swellings (eosinophilic panniculitis), creeping dermatitis, papules, and nodules.[60] Migratory swellings are intermittent and associated with erythema, pruritus, and pain (Fig. 207-9). The lesions may be single or multiple, and up to several centimeters in diameter. The swellings develop rapidly, persist for 1 to 4 weeks, then resolve, only to reappear in a different anatomic location after an asymptomatic interval of a week to months. Over time, episodes become less frequent, less intense, and shorter in duration. However, cutaneous gnathostomiasis may continue for months to years. Gnathostomiasis may present as a creeping eruption (1 cm/hour) (see Table 207-2) and, rarely, as a skin papule or nodule or limb swelling of the extremities (see Fig. 207-9). The most common anatomic locations include the trunk, upper body, and thighs.

Laboratory Tests. Peripheral eosinophilia may be high grade during larval migration. When the infection involves the central nervous system (CNS), the cerebrospinal fluid may be bloody or xanthochromic and contains eosinophils.

Special Tests. The characteristic morphology of larvae in surgical specimens or at autopsy confirms the diagnosis. Nonetheless, the diagnosis of gnathostomiasis is rarely confirmed by the identification of the larva in the skin or viscera. Most often the diagnosis relies on epidemiologic, clinical, and laboratory findings (hypereosinophilia, positive serologic test). Serologic tests are available in a few laboratories but are limited by cross-reactivity.[61]

Differential Diagnosis. The differential diagnosis of cutaneous gnathostomiasis include all the causes of migratory lesions (see Table 207-2), panniculitis, limb swelling (e.g., loiasis, onchocerciasis, eosinophilic cellulitis, other), and skin nodules (see Table 207-4).

The differential diagnosis of visceral gnathostomiasis varies according to the localization.

Complications.

Treatment. (See Box 207-1) Surgical excision plus albendazole is the treatment of choice. Even if surgery is not possible, treatment is recommended (e.g., albendazole, 400 mg twice a day for 21 days). Ivermectin (one to two doses of 200 μg/kg) has also been shown to be effective.[62,63] Late relapses may occur (up to 24 months after apparent cure),[60] so long-term follow-up is advised.

Prevention. Infection can be prevented by avoiding raw and undercooked flesh of fish, eel, chicken, duck, pork, snake, dogs, cats, and frog; drinking only treated water; and wearing gloves when handling potentially infected flesh.

TRICHINOSIS

Synonyms. Trichinellosis, trichiniasis, trichinelliasis.



▲ **FIGURE 207-9** Subcutaneous swellings of gnathostomiasis. (Used with permission from Jay S. Keystone, MD, FRCPC.)

Epidemiology. Trichinosis is present in most countries, but there is marked variation in the incidence. The parasite is thought to be absent from Australia and many South Pacific islands. Sporadic infections occur worldwide via shipped meat. Human infection tends to be sporadic and epidemic.

Etiology and Pathogenesis. *Trichinella spiralis* is the cause of trichinosis.[64]

Animals ingest muscle containing infective larvae and become infected. Humans become infected by eating raw or undercooked flesh of animals infected with *Trichinella*. Sources of infection include swine, bears, wild boars, cougars, walruses, horses, dogs, and cats. Humans are incidental dead-end hosts.

Symptoms occur during larval migration, before encystment. The encysted larvae may remain viable for 5 to 10 years.

Clinical Findings. The severity of trichinosis ranges from asymptomatic to fatal. The case fatality rate is 1 percent to 2 percent for recognized infections, usually related to complications of CNS or cardiac involvement.

Related Physical Findings. Abdominal pain, diarrhea, and vomiting occur during the first week of infection. Ten days after the ingestion of larvae, the signs and symptoms include fever (90 percent of the cases), fatigue, severe myalgia, and cutaneous signs. Headache, cough, and shortness of breath may be reported.

Cutaneous Lesions. Cutaneous manifestations are seen in about 75 percent of cases of symptomatic trichinosis,[65] the most frequent being periorbital and facial edema (75 percent to 95 percent of the cases), conjunctivitis (50 percent) and a macular or papular (sometimes urticarial) rash (15 percent). Hand swelling and volar surface erythema followed by desquamation have been reported.[66] Subconjunctival and splinter hemorrhages are less common (see eFig. 207-9.1 in online edition).

Laboratory Findings. A peripheral eosinophilia may be marked and may persist for months. Muscle enzymes (creatine phosphokinase) are increased.

Special Tests. The diagnosis usually relies on the association of epidemiological data (ongoing epidemic, at risk meal consumption), the clinical triad (fever, facial edema, myalgias), and laboratory findings (eosinophilia, increased muscle enzymes). A definitive diagnosis is possible after the seventeenth day and relies on the identification of the parasite in tissue, on muscle biopsy (see eFig. 207-9.2 in on-line edition). Serologic testing with ELISA or indirect immunofluorescence is not useful in early infection.[67] Antibody levels become positive after the twentieth day and can confirm the diagnosis.

Differential Diagnosis. The differential diagnosis includes allergic reactions, dermatomyositis (see Chap. 157), vasculitis, the parasitic causes of urticaria and eosinophilia-myalgia syndrome (see Chaps. 68 and 158).

Complications.

Treatment. (See Box 207-1)

Prevention. Cooking the meat to a temperature of 77°C (170°F) destroys the trichinae. Smoking and drying meat does not kill the infective larvae. Salt curing solutions may kill the trichinae, but the temperature and duration are important factors in this method. Swine should not be fed uncooked garbage and offal.

HOOKWORM-RELATED CUTANEOUS LARVA MIGRANS

Synonyms. Creeping eruption, creeping verminous dermatitis, sandworm eruption, plumber's itch, duck hunter's itch. These terms describe a sign (itching and creeping dermatitis) caused by several different parasites (see Table 207-2).[68]

Epidemiology. Cutaneous larva migrans (CLM) is widely distributed and most commonly found in tropical and subtropical areas, especially the southeastern United States, Caribbean, Africa, Central and South America, India, and Southeast Asia. Activities that pose a risk include contact with sand or soil contaminated with animal feces, such as playing in a sandbox, walking barefoot on a beach, and working in crawl spaces under houses.

Etiology and Pathogenesis. Most often, the larvae of animal hookworms cause hookworm-related CLM (HrCLM). *Ancylostoma braziliense* is the most common cause. Other skin-penetrating hookworm larvae that produce similar disease include *A. caninum, Uncinaria stenocephala* (hookworm of European dogs), and *Bunostomum phlebotomum* (hookworm of cattle). *A. caninum* causes eosinophilic enteritis as well as cutaneous disease. Cats and dogs are hosts for *A. ceylanicum* and *A. caninum*.

The human is an aberrant, dead-end host who acquires the parasite from an environment contaminated with animal feces. The infective larvae may remain viable in soil for several weeks. Third-stage larvae penetrate human skin and migrate up to several centimeters a day, usually between the stratum germinativum and stratum corneum. This induces a localized eosinophilic inflammatory reaction. Most larvae are unable to undergo further development or to invade deeper tissues and die after days to months.

Clinical Findings. The time from exposure to onset of symptoms is usually a few (1 to 6) days. Skin changes are the most prominent findings.

Related Physical Findings. Systemic signs and symptoms (wheezing, dry cough, urticaria) have been reported in some patients.[69]

Cutaneous Lesions. The characteristic lesion of HrCLM is an erythematous, raised, and vesicular, linear, or serpentine cutaneous trail (Figs. 207-10 and



▲ **FIGURE 207-10** Cutaneous larva migrans. (Used with permission from Jay S. Keystone, MD, FRCPC.)





▲ **FIGURE 207-11** Cutaneous larva migrans. Note vesicular and bullous lesions. (Used with permission from Jay S. Keystone, MD, FRCPC.)

207-11).[68] Lesions are approximately 3 mm wide and may reach 15 to 20 cm in length. Lesions can be single or multiple, are intensely pruritic, and may be painful. The hookworm larvae advance a few millimeters to a few centimeters daily. The most common anatomic sites (usually 3 to 4 cm from the penetration site) include the feet and buttocks. The oral mucosa has been involved. Excoriation and impetiginization are uncommon (10 percent of the cases).

Another clinical presentation is hookworm folliculitis.[70] The patients usually present with pruritic folliculitis and creeping eruption. The folliculitis consists of 20 to 100 follicular papules and pustules, confined to a particular area of the body, usually the buttocks. Two to 10 serpiginous or linear burrows 1 to 5 cm long may be located in the same or different area. The eruption usually lasts between 2 and 8 weeks, though rarely it has been reported to last up to 2 years.

Laboratory Findings. There may be a transient peripheral eosinophilia.

Special Tests. Characteristic creeping eruption, as well as known epidemiologic exposure, are the basis for the diagnosis of HrCLM.

The diagnosis of hookworm folliculitis is based on clinical findings alone when pruritic folliculitis is associated with creeping eruption. Otherwise, histologic studies are necessary, and show nematode larvae trapped within the follicular canal, the stratum corneum, or the dermis together with an inflammatory eosinophilic infiltrate.[70] In contrast to creeping dermatitis, skin scrapings in patients with folliculitis may reveal live and dead nematode larvae when examined by light microscopy with mineral oil; nematode larvae may also be seen in the dermis on sections of skin biopsy specimens.

Differential Diagnosis. There is a confusion between the terms *creeping eruption* (a sign) and *cutaneous larva migrans* (CLM, a syndrome), both of which have been used to name a disease, animal HrCLM.[68]

Cutaneous Larva Migrans Syndrome. CLM should only refer to the infection by animal nematodes in which the infected human is a dead-end host. These nematodes include animal hookworms (HrCLM), *Gnathostoma* sp. (cutaneous gnathostomiasis), animal filarial nematodes (Spirurina X),[71] *Pelodera strongyloides*, and various zoonotic species of *Strongyloides*. By definition, CLM syndrome does not include diseases in which creeping eruption is due to (1) nonlarval forms of parasites (migratory myiasis, dracunculiasis, loiasis, and scabies); (2) larval forms of human nematodes such as *S. stercoralis* (larva currens); or (3) larval forms of trematodes such as *Fasciola gigantica*.

Clinically, the hallmark of CLM is a creeping eruption but other cutaneous signs related to the subcutaneous migration of nematode's larvae have been described, such as migratory panniculitis and limb swelling.

Creeping Eruption. The different helminthic diseases causing creeping eruption can be distinguished on the basis of the duration of the disease, the characteristics of the cutaneous trail(s) (number, width and length, and serpiginous or linear nature), the location of the trail and other clinical signs, in addition to classical epidemiologic and laboratory findings (see Table 207-2). Correct diagnosis is required for appropriate treatment.

Treatment. (See Box 207-1) First-line treatment for HrCLM is a single dose of ivermectin or a three-day course of albendazole.[72] Cure rates approach 100 percent. Topical therapy with thiabendazole is also an option. The topical application of 10 percent albendazole cream twice a day during 10 days is effective, but it is not available in all countries.[73] There should be no attempt to extract the worm, because it has already migrated beyond the visible lesion by the time it is identified.

Prevention. Infection with animal hookworms is prevented by avoiding direct skin contact with fecally contaminated soil.

DIROFILARIASIS

Synonyms. Dog heartworm infection.

Epidemiology. Widespread in dogs, *Dirofilaria immitis* is thought to be most prevalent in North and South America, Australia, Europe, Japan, India, and China. Sporadic infections with other *Dirofilaria* sp. have been reported from all continents.

Etiology and Pathogenesis. The organisms responsible for dirofilariasis include the filarial nematodes of several species of the genus *Dirofilaria*. These include, most importantly, *D. immitis* (the dog heartworm), as well as *D. tenuis* (raccoon), *D. repens* (dog), and *D. ursi* (bear).[74] *D. immitis* causes pulmonary disease and, rarely, soft-tissue infection.

The parasite occasionally survives for years. Rarely, mature worms have been found in the heart. Dead and calcified worms may be found years after the disease was acquired.

Clinical Findings. The interval between exposure and development of symptoms is usually at least 2 to 3 months. Several dirofilarial species can cause skin lesions.

Related Physical Findings. Pulmonary dirofilariasis can cause cough, chest pain, and, rarely, hemoptysis and low-grade fever. More than 50 percent of persons with pulmonary dirofilariasis are asymptomatic.

Cutaneous Lesions. Soft-tissue dirofilariasis is characterized by erythematous to skin-colored, well-defined, firm subcutaneous nodules or a mass that is usually single.[75] The lesion is typically 1 to 5 cm in diameter and may be tender. There may be initial soft-tissue swelling, which evolves into a well-circumscribed nodular lesion. Occasionally, lesions are migratory.[76] The most common anatomic sites are the head, neck, breast, arm, leg, and scrotum. Parasites may appear in the conjunctiva and oral cavity. Subcutaneous dirofilariasis has been associated with acute arthritis.

Laboratory Findings. Peripheral eosinophilia is usually absent. Chest x-ray

films of pulmonary dirofilariasis show a coin lesion that is usually single and may be calcified.

Special Tests. The definitive diagnosis of dirofilariasis comes from surgical excision of the nodule and identification of the worm. Serologic studies using ELISA may be positive in 75 percent of patients with pulmonary dirofilariasis. However, cross-reaction with other helminthic infections (strongyloidiasis, toxocariasis, schistosomiasis, and filariasis) may limit the usefulness of ELISA, particularly in tropical locations.

Differential Diagnosis. Cutaneous cysticercosis, onchocercosis (onchocercoma), paragonimiasis, as well as epidermal inclusion cyst, lipoma, or other benign tumor, and malignant tumor or metastatic disease, make up the differential diagnosis of subcutaneous dirofilariasis (see Table 207-4).

Treatment. Surgical excision of the nodule containing the worm is curative.

Prevention. Dirofilariasis caused by *D. immitis* can be prevented by controlling heartworm infection in dogs. Prevention of other dirofilarial infections requires avoiding bites of arthropods with infective larvae.

TREMATODES

Schistosomes

CERCARIAL DERMATITIS (See Chap. 209)

SCHISTOSOMIASIS ***Synonyms.*** Bilharziasis, snail fever, Katayama fever.

Epidemiology. An estimated 200 million people are infected globally and more than half a billion live in at-risk areas. eFigs. 207-11.1 and 207-11.2 in the online edition show the geographic distribution of schistosomiasis. Humans are the only important reservoir for *Schistosoma haematobium*. In parts of Africa, baboons are important hosts for *S. mansoni*. Animals (e.g., cows, dogs) are important hosts for *S. japonicum*.

Infection can be acquired after a brief exposure in an endemic area, and many outbreaks have been reported in travelers,[82,83] typically after swimming, wading, rafting, and bathing in infested water in endemic areas. Attack rates in nonimmune exposed persons, such as travelers, can be as high as 69 percent to 100 percent. Pools, ponds, shores of lakes, and small dams pose a greater risk than rapidly flowing streams. Invasive schistosomes are not found in saltwater. Chlorination, iodination, and boiling eliminate infective cercariae.

Etiology and Pathogenesis. Schistosomiasis is caused by trematodes (flukes) that, in the adult stage, live in blood vessels.[84–86] These include primarily *S. mansoni, S. japonicum, S. haematobium, S. mekongi,* and *S. intercalatum* (see the section Cercarial Dermatitis for a discussion of disease caused by nonhuman schistosomes in the on-line edition and Chap. 209). Schistosome eggs excreted by a human or animal hatch in water, releasing free-swimming miracidia that penetrate the intermediate host, the snail, where they develop over 4 to 6 weeks, then emerge as free-swimming cercariae. Cercariae penetrate the skin of a human or other vertebrate host over 30 seconds to 10 minutes, become schistosomulae, and may elicit a local inflammatory response (penetration phase). Schistosomulae enter venules and reach pulmonary capillaries in 1 week after skin penetration. Worms mature in the hepatic sinusoids after several weeks, mate, and migrate to the mesenteric venules (*S. intercalatum, S. japonicum, S. mansoni, S. mekongi*) or rectovesical plexus and branches of the vesical plexus (*S. haematobium*). The migration of the larvae (schistosomulae) in the body leads to an acute parasitic toxemia with hypersensitivity reaction and circulating immune complexes. This invasive stage occurs generally 2 to 6 weeks after the exposure (invasive or acute phase). The mature worm pairs begin to produce eggs 1 to 3 months after infection began.

Mature adult females lay eggs daily, of which 60 percent remain in tissues or enter the bloodstream (chronic phase). The rest of the eggs reach the bowel or bladder and are excreted. The response to eggs is characterized by granulomas with epithelioid cells, foreign body giant cells, and many eosinophils. Necrosis, fibrosis, and calcification occur late in the disease. Worms do not multiply in the human host.

Clinical Findings. **RELATED PHYSICAL FINDINGS.** Clinical features range from inapparent to fatal,[87] although serious sequelae develop only in a small percentage of infected persons—occasionally during the acute phase (especially in nonimmunes) and often after many years of infection. Symptoms of acute schistosomiasis (Katayama fever or Katayama syndrome), are most prominent in primary infection in nonimmune persons, and include fever, myalgia, and headache that may persist for 2 to 10 weeks, sometimes longer.[82,86] Patients may also have cough, lymphadenopathy, abdominal pain, anorexia, and diarrhea. This invasive phase has historically been described with *S. japonicum* (Katayama fever, sensu stricto), *S. mansoni,* and, to a lesser extent, with *S. haematobium*.

Symptoms of the chronic phase may begin after years of infection. The usual life span of the adult worm within the human is 3 to 10 years, but survival of more than 30 years has been documented.

CUTANEOUS LESIONS. Cutaneous manifestations can be seen at every phase of the infection.[88]

Penetration phase: The skin manifestations of infection begin within minutes of bathing and reflect hypersensitivity response to the cercariae. An urticarial and erythematous papular eruption associated with pruritus develops in persons who have been previously sensitized. The rash usually resolves over 1 week. The first exposure to cercariae typically results in erythema and pruritus that resolve within hours.

Invasive phase: In initially nonimmune infected persons, the invasive phase becomes symptomatic in 50 percent to 100 percent of the cases as immunity develops. Skin manifestations during the invasive phase include urticaria, purpura, subungual hemorrhage, and edema of the face, the extremities, genitals, and trunk.

Chronic phase: Late cutaneous manifestations (bilharziasis cutanea tarda) result from the granulomatous, inflammatory reaction to the deposition of eggs in the dermis (Fig. 207-12). It is seen primarily in persons who live in endemic regions. Lesions are skin-colored or slightly pigmented, 2- to 4-mm firm, pruritic, oval papules that may form clusters. The lesions appear in crops and, without treatment, remain unchanged. The trunk, particularly the periumbilical region, is the most common anatomic location for the lesions.

Lesions also appear in the genital and buttocks areas, especially on the vulva in women and the scrotum and penis in men. Early in the disease, the lesions







▲ **FIGURE 207-12** Ectopic deposition of *Schistosoma mansoni* ova.

may also manifest as papules or nodules. Late in the disease, lesions include painless, skin-colored, pink or brown eroded papules and warty, vegetative, polypoid lesions that may be ulcerated and necrotic, with fistulous tracts. Lymphedema and elephantiasis can occur. These lesions may be complicated by secondary bacterial infection and squamous cell carcinoma.

Laboratory Findings. Prominent eosinophilia may be present in early infection. It is the highest during the invasive phase and subsequently fluctuates more or less above the normal value during the chronic phase. Development of eosinophilia may lag behind appearance of clinical symptoms and is usually present by 6 weeks after exposure.

Special Tests. During the chronic phase infection is diagnosed by identifying viable eggs in the stool (*S. japonicum* and *S. mansoni*), urine (*S. haematobium*), or biopsy of rectal, bladder, or other tissue. Serologic tests can also be used , although they vary in their sensitivity and specificity.[89]

Diagnosis is much more difficult to establish during the invasive phase when worms are not yet producing eggs. Serologic tests become positive only 6 weeks after exposure and approximately 3 weeks after the beginning of the acute phase.[82] At this stage, the diagnosis can be suspected based on a history of exposure in endemic area, a history of cercarial dermatitis, and compatible clinical signs. Diagnosis can be confirmed later by finding specific antibodies (seroconversion) and eggs of schistosomiasis.

Differential Diagnosis. For acute invasive schistosomiasis, the differential diagnosis of skin lesions includes all the helminthic causes of acute urticaria.

The differential diagnosis of bilharziasis cutanea tarda of the genital and buttocks area includes atypical syphilis or condyloma latum, condyloma acuminatum, elephantiasis and its causes, amebiasis, other granulomatous diseases, malignancy, and hemorrhoids.

Complications.

Treatment. (See Box 207-1) Praziquantel is the treatment of choice for *S. haematobium, S. japonicum, S. mansoni,* and *S. mekongi* infections. Oxamniquine is an alternative treatment for *S. mansoni* infection. Drugs are not effective during the acute invasive phase and can worsen clinical symptoms.[82] Steroids may be helpful in severe acute schistosomiasis.

Prevention. Avoiding contact with infested water in endemic areas, as well as snail control in those areas, can prevent schistosomiasis. Feces and urine of infected humans should be eliminated in a way that precludes contamination of freshwater.

Flukes Other Than Schistosomes

LIVER FLUKES, FASCIOLIASIS ***Synonyms.*** Sheep liver fluke disease.

Epidemiology. *F. hepatica* is found worldwide in sheep- and cattle-raising areas.[90,91] Sporadic human infections have been reported from all continents.

Etiology and Pathogenesis. Trematodes (flukes) causing fascioliasis include *F. hepatica,* the sheep liver fluke, and *F. gigantica* (rare in humans).[92]

LUNG FLUKES, PARAGONIMIASIS ***Synonyms.*** Lung fluke infection, oriental lung fluke disease

Epidemiology. *Paragonimus westermani* is widely distributed in East and Southeast Asia and Africa. Other species of *Paragonimus* are found in Asia, Africa, and the Americas. Worldwide, an estimated 10 million persons are infected with paragonimiasis. The rates of infection are high in parts of Asia, where raw, undercooked, salted, pickled, or marinated crustaceans are frequently eaten.

Etiology and Pathogenesis. The trematode (fluke) *P. westermani* and more than 10 species of *Paragonimus* infect humans.[92,97]

CUTANEOUS LESIONS. Urticaria may occur early and migratory subcutaneous nodules may appear as early as 2 weeks. Ten percent of patients with *P. westermani* infection and 20 percent to 60 percent of patients with *P. skrjabini* and *P. szechuanensis* infection have subcutaneous swelling or nodules (containing immature flukes). These lesions may be up to 6 cm in diameter, migratory, firm, slightly mobile, and tender to palpation. The lesions are most commonly located on the lower abdomen and inguinal region.

Laboratory Tests.

Treatment. The drug of choice is praziquantel. Bithionol is an alternative therapy (available under an Investigational New Drug protocol from the Centers for Disease Control Drug Service).

Prevention. Paragonimiasis may be prevented by eating only well-cooked crustaceans.

CESTODES (TAPEWORMS)

Major Tapeworms in Humans

ECHINOCOCCOSIS ***Synonyms.*** For disorders associated with *Echinococcus granulosus*—unilocular echinococcosis, hydatid disease caused by *E. granulosus,* classic cystic hydatid disease; for disorders associated with *E. multilocularis*—multilocular echinococcosis, alveolar hydatid disease.

Epidemiology. *E. granulosus* is present on all continents except Antarctica. Infections are sporadic in North America, Central America, northern South America, northern Europe, Australia, and New Zealand. There is a high prevalence of infection in southern South America, focal parts of southern Europe, parts of the former Soviet Republics, Middle Eastern countries, and northern and East Africa. The infection is present in most Asian countries.

E. multilocularis is more limited in distribution; cases have been documented in North America, Europe, Asia, India, and Iran.

Etiology and Pathogenesis. The larval stages of the cestodes (tapeworms) *E. granulosus* and *E. multilocularis* cause most cases of human echinococcosis.[98] Humans are incidental intermediate hosts.

Clinical Findings. Most infections with *E. granulosus* are asymptomatic and go unrecognized. The clinical features of in-

fection with *E. granulosus* are highly variable and reflect the location and size of cysts. Cysts are usually single, although they can be multiple (25 percent). Body location includes the liver (50 percent to 75 percent), lung (20 percent to 30 percent), and other sites: kidney, spleen, heart, bones, muscles, and CNS (less than 2 percent). Within the abdomen, the cyst may reach a large size before symptoms develop.

Related Physical Findings. The signs and symptoms of *E. multilocularis* infection are epigastric and right upper quadrant pain, a palpable mass, jaundice, and hepatomegaly. Initial symptoms occasionally are related to metastatic lesions in the CNS and lung. The interval between acquisition of infection and onset of symptoms is usually years and may be decades for *E. granulosus*.

Cutaneous Lesions. Skin and soft-tissue manifestations are rare. Even if echinococcal cysts can implant in soft tissues (in less than 2 percent of infected patients), a recent review of the literature revealed only two cases of patients initially presenting with a soft-tissue mass.[99] Cysts may manifest as firm subcutaneous or intramuscular nodules or masses that are fluctuant and non-tender to palpation (Fig. 207-13). There is no epidermal change. Skin fistulas from a hydatid cyst in a patient known to have an infection with *E. granulosus* have been reported. If the cyst leaks fluid, the patient may have urticaria and manifestations of anaphylaxis secondary to the allergic reaction to foreign antigens from cyst fluid.

Infection with *E. multilocularis* may cause multiple supraumbilical cutaneous and subcutaneous nodules associated with ulceration, surrounding inflammation, and painless cutaneous fistulas. These cutaneous localizations manifestations usually result from the extension of an underlying visceral lesion.[100]

Laboratory Tests. Peripheral eosinophilia is present in only a small percentage of patients with intact cysts. In contrast, leakage of cyst fluid commonly causes eosinophilia.

Special Tests. Identification of the parasite in a cyst confirms the diagnosis. Characteristic morphology of the parasite as seen by imaging (e.g., ultrasound, computed tomography scan, and magnetic resonance imaging) can suggest the diagnosis and can detect clinically silent lesions.



▲ **FIGURE 207-13** Abdominal bulge from intraperitoneal cyst of echinococcosis. (Used with permission from Jay S. Keystone, MD, FRCPC.)

Serologic studies can aid in the diagnosis and may be useful in following patients after surgical treatment.[98]

In *E. granulosus*, serologic tests may be negative, especially in patients with lung lesions. Tests that assess circulating antigen, including molecular techniques using PCR are being developed.

Serologic tests are usually positive at high titers in patients infected with *E. multilocularis*.

Differential Diagnosis. When there is skin involvement, the differential diagnosis includes other cutaneous nodules (see Table 207-4), other cystic lesions of soft tissues and urticaria (see Chap. 37).

Treatment. Isolated cysts caused by *E. granulosus* are often resected. Percutaneous aspiration, injection, and reaspiration with ultrasound guidance is a minimally invasive technique being used increasingly to manage hepatic disease.[101–103] (See also http://whqlibdoc.who.int/hq/2001/WHO_CDS_CSR_APH_2001.6.pdf.) Albendazole may be useful before surgery or in the event that the cysts rupture or leak during surgery. It has also been used in infections that are not resectable.

Surgical resection can be curative in *E. multilocularis* infection if the diagnosis is made early.

Prevention. The incidence of *E. granulosus* infection may be decreased by preventing dogs and other canines from feeding on infected offal.

CYSTICERCOSIS (*TAENIA SOLIUM*)

Synonyms. Larval taeniasis.

Epidemiology. *Taenia solium* is a common parasite in Central and South America, Africa, parts of Asia, and Eastern Europe. In the United States, this disease appears primarily in immigrants from endemic areas where poor sanitation and pig farming are common, although acquisition of infection has been well documented in the United States. Cysticercosis is the most common helminthic infection of the CNS.

Humans acquire cysticercosis by ingesting eggs in food, water, or on fingers contaminated with human feces. Humans infected with adult worms may acquire cysticercosis by ingesting eggs passed in their own feces.

Etiology and Pathogenesis. The larval stage of the pork tapeworm, *T. solium,* causes cysticercosis.[104] In humans, *T. solium* infection causes both intestinal taeniasis and cysticercosis. The human host can have either form of infection alone. Intestinal taeniasis is found in 25 percent to 50 percent of patients with cysticercosis. Intestinal infection with the adult parasites follows eating raw or undercooked pork containing cysticerci. The larval cysts attach to the small bowel mucosa and develop into adult worms. Eggs from the adult worm in human small intestine are passed in feces and may remain viable for weeks.

Clinical Findings. The clinical features range from asymptomatic to fatal.

Cutaneous Lesions. Approximately one-half of patients with cysticercosis present with subcutaneous nodules.[105] The time from infection to the appearance of subcutaneous nodules is highly variable and may be from months to years. Cysticerci can survive in humans for 10 to 15 years. Symptoms may begin or continue long after the parasites are dead. The skin findings include single or multiple firm, mobile, round, well-circumscribed subcutaneous nodules that may



be tender or asymptomatic and that range in size from millimeters to centimeters (usually approximately 2 cm in diameter; see Table 207-4). Common anatomic locations are the extremities and trunk; in a series from Nepal, 10 percent of patients had nodules in the oral mucosa.[106]

Related Physical Findings. Although the CNS (see eFig. 207-13.1 in on-line edition), subcutaneous tissue, skeletal muscle, and eye are the most commonly affected sites, the heart, kidneys, liver, lungs, and pancreas may be involved. Seizures are the most common manifestation of neurocysticercosis. Almost 50 percent of patients with CNS cysticerci found at autopsy had no history of CNS symptoms.



Laboratory Tests. Peripheral eosinophilia is absent most patients (85 percent) with neurocysticercosis. High-grade eosinophilia in a patient with cysticercosis should motivate a search for another process to explain the eosinophilia.

Special Tests. Diagnosis is confirmed by identifying the parasite by its characteristic morphology in a surgically excised cutaneous nodule. Diagnosis of cysticercosis in a subcutaneous nodule should lead to evaluation for possible neurocysticercosis.

Serologic tests are also available.[107] High sensitivity and specificity have been reported with an enzyme-linked immunoelectrotransfer blot assay and with an ELISA. Sensitivity is high in patients with multiple lesions, but one study found that only 28 percent of patients with a single lesion had positive enzyme-linked immunoelectrotransfer blot assay results. Other immunologic tests have been less sensitive and less specific.

Lesions of neurocysticercosis can be seen and their development stages of larval cysts evaluated on MRI. Cerebrospinal fluid may be normal or may contain increased protein and cells, including eosinophils and plasma cells.

Differential Diagnosis. For subcutaneous lesions of cysticercosis, the differential diagnosis includes benign cysts, soft-tissue tumors, and other parasitic causes of nodules (see Table 207-4).

Treatment. (See Box 207-1) The use of anthelmintic drugs for parenchymal cysticercosis remains controversial.[108,109] Decisions about treatment depend on the location and characteristics of the lesions (viability of the cysts) and may include surgery as well as medical therapy with anticonvulsants, steroids, and an anthelmintic drug. Albendazole and praziquantel (considered investigational for this condition by the U.S. Food and Drug Administration) are active in cysticercosis. Because a cysticercocidal drug may cause leakage of antigen from a viable cyst and intense, damaging local inflammatory reaction, careful evaluation for intraocular and CNS lesions should be carried out before any antiparasitic drug is given. Concomitant intestinal taeniasis due to *T. solium,* if present, should be treated to eliminate a potential ongoing source of infection for the patient and contacts.

Prevention. Preventive measures include proper disposal of feces, avoidance of fecal contamination of food and drink, and treatment of intestinal taeniasis.

Other Cestode Infections

COENUROSIS ***Synonyms.*** Disease in sheep is named *gid* and *staggers*.

Epidemiology. Reported human cases of coenurosis are sporadic and rare, with the majority from Africa.[110] Infections have occurred in Asia, Europe, and North America, particularly in areas where sheep are common. In tropical Africa, infections are more commonly located in subcutaneous or muscle tissue, or the eye and orbit (particularly in children). In non-tropical Africa, infections occur primarily in the CNS of adults.

Etiology and Pathogenesis. Coenurosis is caused by the larval stages of several species of *Multiceps,* a cestode (tapeworm),[111] most often *M.(Taenia) multiceps, M.(Taenia) serialis,* and *M.(Taenia) brauni*.

SPARGANOSIS ***Synonyms.*** Spirometrosis, sparganum infection.

Epidemiology. The parasite is found in animals on all continents, but most human cases are from China, Japan, and Southeast Asia. Cases have also been reported from Africa, Australia, Caribbean islands, Southern Europe, and the Americas.

Etiology and Pathogenesis. The tapeworm larvae of the genus *Spirometra,* including *S. mansoni, S. erinaceri,* and *S. mansonoides,* cause sparganosis.[112] At least 10 cases have been caused by *S. proliferum*.

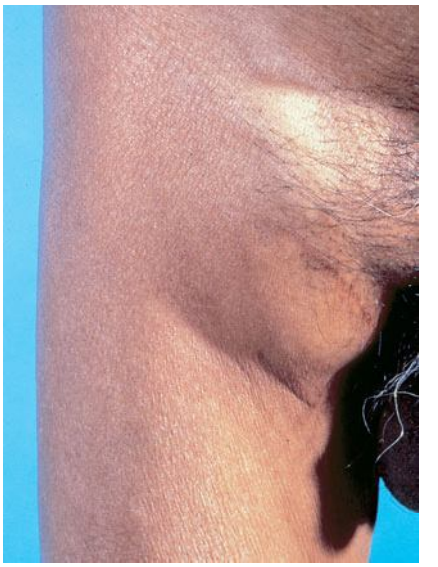

▲ **FIGURE 207-14** Soft-tissue swelling of sparganosis. (Used with permission from Jay S. Keystone, MD, FRCPC).

Clinical Findings. The severity of infection depends on the route of infection, the number of parasites, and the anatomic locations involved.[113]

Cutaneous Findings. Sparganosis caused by ingestion of the infective larvae presents as a slow-growing nodule in subcutaneous tissue or in skeletal muscle (occasionally migratory; Fig. 207-14) onset, 20 days to 14 months after ingestion. The lesion may be pruritic and tender or non-tender. The larvae can survive in humans for at least 9 years. Sparganosis due to the local application of infected flesh results in localized pruritus, then erythema, edema, and subcutaneous nodules that are painful on palpation.

KEY REFERENCES

The full reference list for all chapters is available at www.digm7.com.

6. Caumes E et al: Dermatoses associated with travel to tropical countries: A prospective study of the diagnosis and management of 269 patients presenting to a tropical disease unit. *Clin Infect Dis* **20**:542, 1995
9. Del Giudice P, Chosidow O, Caumes E: Ivermectin in dermatology. *J Drugs Dermatol* **2**:13, 2003
10. Drugs for parasitic infections. *Med Lett Drug Ther* **8**:1, 2004. Free online access at http://www.medicalletter.org
12. Bethony J et al: Soil-transmitted helminth infections: Ascariasis, trichuria-

sis and hookworm. *Lancet* **367**:1521, 2006
15. Hotez PJ et al: Hookworm infection. *N Engl J Med*. **351**:799, 2004
26. Burri H et al: Skin changes in chronic lymphatic filariasis. *Trans R Soc Trop Med Hyg* **90**:671, 1996
27. Taylor MJ et al: Macrofilaricidal activity after doxycycline treatment of *Wuchereria bancrofti*: A double-blind, randomised placebo-controlled trial. *Lancet* **365**:2116, 2005
35. Klion AD et al: Albendazole therapy for loiasis refractory to diethylcarbamazine treatment. *Clin Infect Dis* **29**:680, 1999
37. Borup LH, Peters SS, Sartori CR: Onchocerciasis (river blindness). *Cutis*. **72**:297, 2003
40. Henry NL et al: Onchocerciasis in a nonendemic population: Clinical and immunologic assessment before treatment and at the time of presumed care. *J Infect Dis* **183**:512, 2001
48. Gardon J et al: Effects of standard and high doses of ivermectin on adult worms of *Onchocerca volvulus*: A randomised controlled trial. *Lancet* **360**:203, 2002
54. Humbert P et al: Skin manifestations associated with toxocariasis: A case-control study. *Dermatology* **201**:230, 2000
58. Rusnak JM, Lucey DR: Clinical gnathostomiasis: Case report and review of the English-language literature. *Clin Infect Dis* **16**:33, 1999
60. Ménard A et al: Imported cutaneous gnathostomiasis: Report of five cases. *Trans R Soc Trop Med Hyg* **97**:200, 2003
65. Bournerias I et al: Cutaneous signs of trichinosis. A propos of the 1985 outbreak. *Ann Dermatol Venereol*. **113**:1139, 1986
68. Caumes E, Danis M: From creeping eruption to hookworm-related cutaneous larva migrans. *Lancet Infect Dis* **4**:359, 2004
70. Caumes E, Ly F, Bricaire F: Cutaneous larva migrans with folliculitis: Report of seven cases and review of the literature. *Br J Dermatol* **146**:1, 2002
72. Caumes E: Treatment of cutaneous larva migrans. *Clin Infect Dis* **30**:811, 2000
82. Grandière-Perez L et al: Efficacy of praziquantel during the incubation and invasive phase of *S. haematobium* schistosomiasis in 18 travellers. *Am J Trop Med Hyg* **74**:814, 2006
87. Whitty CJM et al: Presentation and outcome of 1107 cases of schistosomiasis from Africa diagnosed in a non-endemic country. *Trans R Soc Trop Med Hyg* **94**:531, 2000
94. Xuang LT, Hung NT, Waikagul J: Cutaneous fascioliasis: A case report in Vietnam. *Am J Trop Med Hyg* **72**:508, 2005
105. Uthida-Tanaka AM et al: Subcutaneous and cerebral cysticercosis. *J Am Acad Dermatol* **50**:S14, 2004



CHAPTER 208

Scabies, Other Mites, and Pediculosis

Stephen P. Stone
Jonathan N. Goldfarb
Rocky E. Bacelieri

SCABIES

Epidemiology

Scabies is a human skin infestation caused by the penetration of the obligate human parasitic mite *Sarcoptes scabiei* var. *hominis* into the epidermis. The scabies mite is an arthropod of the order Acarina which was first identified in the 1600s, but was not recognized as the cause of the skin eruption until the 1700s.[1] There are estimates that over 300 million people worldwide are infected with the scabies mite.[2] Scabies affects all socioeconomic classes, with women and children being disproportionately infected. It tends to be more prevalent in urban areas, particularly in overcrowded regions. There is evidence of a seasonal variation, with more cases being diagnosed in the winter months than the summer.[3] The incidence of scabies has been increasing over the past two decades, and has been found to be responsible for major outbreaks in nursing homes, prisons, and hospital wards. Transmission of the mite occurs usually through close personal contact, although the scabies mite can live off the human skin for up to 3 days, and therefore some infections can be from exposure to fomites.[4]

SCABIES AT A GLANCE



- Human infestation caused by *Sarcoptes scabiei* var. *hominis*, an obligate human parasite that lives its entire life cycle in and on the skin.
- Produces a diffuse, pruritic eruption after an initial incubation period of 6 to 8 weeks.
- The pathognomonic clinical feature is a burrow produced by the tunneling of the mite in the stratum corneum.
- Is transmitted by close physical contact, but fomite transmission is possible.
- Topical scabicides are the preferred treatment, although oral ivermectin has been found to be an effective therapy.

Etiology and Pathogenesis

The scabies mite has four pairs of legs and measures 0.3 mm in diameter. It is therefore not easily seen with the naked eye. The mite cannot fly or jump; it lives its entire 30-day life cycle in and on the epidermis. The female mite burrows into the stratum corneum within 20 minutes and lays approximately 3 eggs a day. The eggs hatch after 4 days, and the larvae migrate to the skin surface and mature into adults.[5] After 2 weeks, female and male mites copulate, after which the gravid female burrows back into the stratum corneum. The male, which is slightly smaller than the female, falls off the skin and perishes. The average number of mites a host harbors is usually less than 20, except in "crusted scabies" (previously known as *Norwegian scabies*), in which a host may harbor over a million mites.[5] Individuals with human immunodeficiency virus, the elderly, and patients with medication-induced immunosuppression are at risk of developing crusted scabies, although it has been reported among immunocompetent indigenous Australians.[6]

Clinical Findings

After the initial exposure to the scabies mite, the pruritus and rash may take up to 6 to 8 weeks to develop. Subsequent exposure to the mite results in the itching and the rash developing within a couple days, probably due to prior sensitization to the scabies mite.[7] The itching is severe and usually worst at night. The lesions appear as red, scaly, sometimes crusted (excoriated) papules and nodules that favor the interdigital webs (Fig. 208-1), sides of the fingers, volar aspects of the wrists and lateral palms (Fig. 208-2), elbows, axillae, scrotum,



▲ **FIGURE 208-1** Scabies. Several thread-like burrows are present in the web spaces of the fingers and on the knuckles, a common location for these lesions in scabies. Longitudinal scraping of a burrow will often reveal the mite or mite products under microscopic examination.



penis (Fig. 208-3), labia, and the areolae in women. A diffuse erythematous eruption on the trunk may be present and represents a hypersensitivity reaction to mite antigen. The pathognomonic lesion is a burrow, which is a thin, thread-like, linear structure (see Fig. 208-1) that is 1 to 10 mm in length, and is a tunnel caused by the movement of the mite in the stratum corneum. The burrow is best seen in the interdigital webs, wrists, or elbows. However, it can be difficult to find in early cases of the condition, or after the patient has extensively excoriated the lesions. Identification of a burrow can be facilitated by rubbing a black felt-tip marker across an affected area. After the excess ink is wiped away with an alcohol pad, the burrow appears darker than the surrounding skin due to ink accumulation in the burrow.[8]

In infants younger than the age of 2 years, the face and scalp can be infested, whereas in adults this is rarely the case. Erythematous to violaceous pruritic nodules found in the axillae and flanks of the trunk are not an unusual finding in children and on the scrotum in men (see Fig. 208-3), and are thought to be a hypersensitivity reaction to the mite. These nodules can remain for many weeks after the successful eradication of the mite infection. Vesicles and bullae may develop, particularly on the palms and fingers (see eFig. 208-3.1 in on-line edition).

In crusted scabies (Fig. 208-4), hyperkeratotic plaques develop diffusely on the palmar and plantar regions, with thickening and dystrophy of the toenails and fingernails. The rest of the skin usually appears diffusely xerotic. Pruritus is variable and may be totally absent in this form of the disease. Over a million mites populate the skin and these highly contagious patients can be the source of outbreaks in health care facilities.

The definitive diagnosis is made by the microscopic identification of the scabies mites, eggs, or fecal pellets (scybala). This is accomplished by placing a drop of mineral oil over a burrow and then scraping longitudinally with a number 15 scalpel blade along the length of the burrow, being careful not to cause bleeding. The scrapings are then applied to a glass slide and examined under low power (Fig. 208-5). Other diagnostic methods include dermoscopy (see Chap. 5) which can be used to examine the mite in vivo.[10] A polymerase chain reaction–based method has been described in which the DNA from the mite was detected from cutaneous scales.[11] A skin biopsy can be diagnostic, when the scabies mite is found transected in the stratum corneum (see eFig. 208-5.1 in on-line edition).

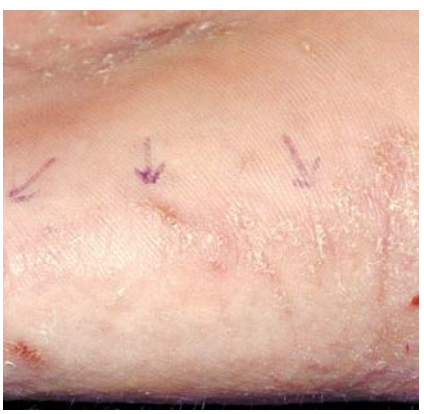

▲ **FIGURE 208-2** Scabies. Several, slightly scaling, thread-like burrows are seen on the lateral aspect of the palm, associated with a more generalized eczematous process.



▲ **FIGURE 208-3** Scabies: Scabies frequently produces very pruritic, red papules in the genital region. In males, the prepuce is often the site of these lesions.

Differential Diagnosis (Box 208-1)

Complications

Secondary impetiginization is a common complication and usually responds well to either topical or oral antibiotics, depending upon the extent of the pyoderma. However, lymphangitis and septicemia can develop, particularly in crusted scabies (see eFig. 208-5.2 in on-line edition). Post-streptococcal glomerulonephritis has resulted from scabies-induced pyodermas caused by *Streptococcus pyogenes*.[12]

Prognosis and Clinical Course

If left untreated, the condition can persist for many years. In immunocompe-



▲ **FIGURE 208-4** Crusted scabies. Hyperkeratotic plaques populated with thousands of mites.

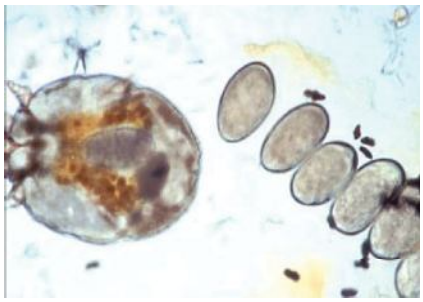

▲ **FIGURE 208-5** Scabies. Microscopic examination of a mineral oil preparation after scraping a burrow reveals a gravid female mite with oval, gray eggs and fecal pellets.

tent individuals, the number of mites may decrease over time.

Treatment

There are a number of treatments for scabies which have various levels of effectiveness. Factors which may determine which treatment to use are the age of the patient, the cost of the medication, the severity of the eruption, and if previous treatments have been unsuccessful.

In adults, topical scabicides should be applied to the entire skin surface, excepting the face and scalp, with special attention to the intertriginous areas, the genitalia, the periungual regions, and behind the ears. In children and those patients with crusted scabies, the face and scalp should also be treated. Patients must be informed that even after adequate scabicidal therapy, the rash and pruritus may persist for up to 4 weeks; otherwise they may believe that the prescribed treatment was unsuccessful, and then inappropriately overuse scabicidal medications. Topical steroids, antihistamines and, if necessary, a short course of systemic steroids, can be prescribed to alleviate the pruritus and rash once the patient has completed the scabicide treatment. The treatment of scabies is summarized in Box 208-2.

Box 208-1

Differential Diagnosis of Scabies

Most Likely

- Atopic dermatitis
- Insect bite reactions
- Contact dermatitis
- Dermatitis herpetiformis
- Dyshidrotic eczema

Consider

- Psoriasis, particularly in the crusted variety
- Bullous pemphigoid, when vesicles and bullae are present
- Drug eruption

The only oral but highly effective scabicide known to date is ivermectin. It was discovered in the 1970s in the fermentation broth of a soil actinomycete *Streptomyces avermitilis*. It is structurally similar to macrolidic antibiotics, but with no antibacterial activity.[16] It is currently U.S. Food and Drug Administration (FDA) approved for the treatment of the intestinal stage of onchocerciasis and strongyloides, but not FDA approved for the treatment of scabies. Its activity against the scabies mite is due to its high affinity for the gluminated-gated chloride ions found in the peripheral nervous systems of invertebrates.[17] Ivermectin blocks the channel transmission across the nerve synapse that uses γ-aminobutyric acid. This results in the paralysis and death of invertebrate parasites. In mammals, these receptors are confined to the central nervous system and in normal conditions the drug does not cross the blood-brain barrier. It has been suggested that conditions that disrupt the blood-brain barrier may allow the drug to enter the central nervous system.[18] Therefore the drug should not be used in children younger than the age of 5 years or weighing less than 15 kg, or during pregnancy or lactation, although there are reports of ivermectin being used in young children and during pregnancy without adverse effects.[19]

There are been numerous reports of the effectiveness of ivermectin in the treatment in scabies.[20] The usual dosage is 200 μg/kg; often the dose is repeated in 10 to 14 days, but the optimal dosage schedule for the treatment of scabies has not been established. A clinical study comparing ivermectin to topical 5 percent permethrin revealed that a single dose of ivermectin provided a cure rate of 70 percent, which was increased to 95 percent with a second dose 2 weeks later. A single application of permethrin was curative in nearly 98 percent of patients.[21] A topical preparation of 1 percent ivermectin has been shown to be effective in early clinical studies, but is not yet commercially available.[22] In crusted scabies, the combination of ivermectin and a topical anti-scabicide is often used due to the severity of the infection, and multiple courses may need to be used to eliminate the infection.

Side effects of ivermectin are usually mild and transient; however, there have been reported rare side effects of hypotension, laryngeal edema, and encephalopathy.[23] There is one case report of an increased death rate in elderly nursing home patients who were treated with ivermectin.[24] Subsequent studies have not confirmed this finding.

Prevention

Individuals in close contact with the infected person should be treated with a topical scabicide. Treatment should be directed to prevent spread of the scabies, because individuals may be harboring the scabies mite during the asymptomatic incubation period. Additionally, to prevent re-infection with fomites, bed sheets, pillow cases, towels, and clothes worn during the past 5 days should be washed and dried in the hot cycle, or be

Box 208-2

Treatment for Scabies

DRUG	DOSE	COMMENTS
Permethrin 5% cream	Applied for 8–14 h; often repeated in 7 days.	First-line treatment in the United States; pregnancy category B
Lindane 1% lotion	Applied for 8 h then washed off. Second application recommended after 1 wk.	Not recommended for children under 2, during pregnancy, or lactation; resistance has been increasing; banned in California
Crotamiton 10% cream	Applied on 2 consecutive days; repeated once within 5 days.	Antipruritic qualities; may not be as effective as other topicals
Precipitated sulfur 5%–10%	Applied for 3 days and then washed off.	Safe in children under 2 mo and during pregnancy, but messy to apply and limited efficacy data
Benzyl benzoate 10% lotion	Applied for 24 h then washed off.	Not available in United States
Ivermectin, 200 μg/kg	Single oral dose, can be repeated in 10–14 days.	Highly effective with a good safety profile; can be used along with topical agents, particularly in crusted or resistant cases

dry cleaned. Because the mite can live up to 3 days off of skin, carpets and upholstery should be vacuumed. Pets do not need to be treated because they do not harbor the human scabies mite.

OTHER MITES

Although the scabies mite is the best known mite to infest humans, other mites have been reported to cause disease as well. Mites belong to the class Arachnida, order Acarina [which also includes ticks (see Chap. 210)], and along with the scabies mite are eight-legged organisms, typically with a fused cephalothorax.

Most of the mites of significance to humans fall into three suborders: trombidiformes, mesostigmata, and sarcoptiformes. They tend to be classified according their natural host or habitat (Table 208-1).

Follicle Mites

Demodex sp. are common residents in the human pilosebaceous unit. The mites are found in follicles on the face, scalp, and upper chest. *D. folliculorum hominis* lives within the hair follicle, and *D. brevis* prefers the infundibulum of the sebaceous gland. The prevalence of infestation with *Demodex* sp. increases with age.[25] Infestation is usually unnoticed, but when the mites are present in unusually large numbers, they may play a role in suppurative or granulomatous skin reactions resembling suppurative folliculitis, rosacea, or perioral dermatitis (see Chap. 79).[26,27]

Food Mites

Several species of mites infest stored foods and other organic materials. The most common food mites are the grain mite (*Acarus siro*), the cheese mite (*Tyrolichus casei*), and the mold mite (*Tyrophagus putrescentiae*). All are barely visible, usually less than 0.5 mm long, and more or less translucent with darker mouthparts and appendages. Prolonged contact with mite-infested foods may produce a mild dermatitis known as *baker's itch* or *grocer's itch*, or cause asthma and dust allergies.[28] They do not bite humans.

Straw Itch Mites

Straw itch mites, *Pyemotes ventricosus* and *P. tritici*, can cause epidemics of dermatitis during harvesting and post-harvesting operations in straw, hay, or certain grains. Bites produce a rash-like dermatitis, extending over much of the body and accompanied by itching, sweating, fever, headache, and even vomiting in severe cases. They are beneficial because they feed on larvae of wheat jointworm, rice and granary weevils, Angoumois grain moths, and other pests.[28]

TABLE 208-1
Mites

Type of Mite	Scientific Name	Clinical Features—Disease Associations
Scabies mites	*Sarcoptes scabei*	See the section Scabies
Follicle mites	*Demodex folliculorum hominis* and *D. brevis*	Questionable association with rosacea, idiopathic facial burning
Food mites	Grain mite: *Acarus siro* Cheese mite: *Tyrolichus casei* Grocery mite: *Tyrophagus putrescentiae*	Mild dermatitis known as *baker's itch* or *grocer's itch*
Fowl mites	*Dermanyssus gallinae* and *D. avium*	Pruritic papules, sometimes with a hemorrhagic center
Straw itch mites	*Pyemotes tritici* and *P. ventricosus*	Patchy dermatitis on trunk and arms during or after harvesting
Harvest or red mites (chiggers)	Genus *Trombicula* *Eurotrombicula alfreddugesi* and *E. splendidus* most common in United States	Scrub typhus vector (*Leptotrombidium* sp.) Papular to vesicular lesion found on ankles, waist, or warm skinfolds
Animal mites	*Ornithonyssus bacoti* *Liponyssoides sanguineus* *Cheyletiella* "walking dandruff"	Endemic/murine typhus vector Rickettsialpox vector Non-specific, pruritic eruption on body parts in close contact with infested pets
House dust mites	*Dermatophagoides* sp.	Questionable association with atopic dermatitis

OTHER MITES AT A GLANCE

- Most mites (exceptions: scabies and *Demodex*) drop off the human host after feeding.
- Symptoms generally are due to immunologic reactions.
- Some species are vectors of human disease.

Harvest Mites

There are several mite species belonging to the genus *Trombicula* that may annoy humans directly, especially during the late summer and autumn. The minute, reddish larvae of *Trombicula*, which are less than 0.5 mm long, suck the lymph and blood of humans and other mammals, are often referred to as *chiggers*. *Eurotrombicula alfreddugesi* and *E. splendidus* are seen in the United States. Other species of the genus *Neotrombicula* have been identified as causing dermatitis in humans, and *Leptotrombidium* sp. have been reported to be the vectors for *Rickettsia tsutsugamushi*, the cause of scrub typhus (see Chap. 199).

In the United States, the mites are found in the southern states, in such areas as berry patches, tall grass and weeds, and woodland edges. The larvae feed on humans around the waist, the ankles, or in warm skinfolds, but intense itching usually occurs several hours after the chiggers feed, so they may no longer be present. They can sometimes be seen in the center of an erythematous macule or papule that has not been scratched. Lesions may be vesicular, papular urticaria-like, or granulomatous. An acute seasonal hypersensitivity reaction of the penis has been reported, with edema of glans and foreskin lasting up to 18 days.[29] Treatment is symptomatic, and antihistamines and corticosteroid creams or lotions may be helpful.

Dust Mites

Dust mites are tiny, translucent mites, generally less than 0.2 mm long, and more or less invisible to the naked eye. They feed on the shed skin and other organic debris which constitutes much of the "dust" that settles and accumulates in houses and workplaces. The mites are harmless, but their bodies and

excreta are believed to play a role in severe asthma and other allergic complaints in humans, and delayed hypersensitivity to the mite is felt by some to play a role in atopic dermatitis.[29] Thorough and frequent vacuuming, including bedding and mattresses, can effectively reduce mite infestations.

Fowl Mites

Avian mite dermatitis is infrequently diagnosed in office workers, homemakers, poultry workers, and bird fanciers. It usually can be traced to contact with chickens and pigeons (the latter often nesting in window air conditioners) but has also been attributed to many other avian species (including parakeets) and even gerbils. *Dermanyssus gallinae* and *D. avium* are the most common fowl ectoparasites in the United States, and only temporarily infest humans. Avian mites are blood suckers and have been described as "nocturnal marauders" that "bite and run." The most common manifestations are pruritic papules, sometimes with a hemorrhagic center, located in exposed surfaces, but vesicles, papular urticaria, and dermatitis also have been described.[29]

Animal Mites

The tropical rat mite *Ornithonyssus bacoti* feeds on humans even when rats are present, causing painful bites, intense itching, and dermatitis. They are the vector for endemic/murine typhus. Barely visible, they are bright red to black with white markings and are usually noticed on walls in basements, kitchens, bathrooms, and where rats are found. Mites drop from their host after each blood meal and can survive several days without feeding.[29] The house mouse mite, *Liponyssoides sanguineus*, classically found on mice, can wander away from mice onto walls. It can serve as the vector for rickettsialpox (see Chap. 199).

Cheyletiella sp. are common mites on dogs and cats, and have been described as *walking dandruff*. The mites are highly contagious and there are numerous reports of skin disease in humans; in households with infested animals, as many as 20 percent of their owners are also infested. The mites are not usually found in humans because they do not burrow or reproduce on this host. This has been described as *bite and run* behavior. Lesions such as pruritic, erythematous papules or papulovesicles, urticaria or vesicobullae or excoriated erosions are found on forearms, breast, and abdomen and other areas that have been in close contact with the infested pet.

The pet may be symptomatic or may show evidence of pruritus. An almost pathognomonic sign is dorsal seborrhea sicca (dry white scales) or crusted annular lesions. Diagnosis depends on identifying mites or eggs from the skin, obtained by collecting them with cellophane tape, and examining the scales under the microscope. Treatment of the pet by a veterinarian will clear the pet and its owner(s).[30]

Canine sarcoptic mange (*Sarcoptes scabei* var. *canis*) and feline mange (*Notoedres cati*) may afflict humans with a pruritic dermatosis with excoriation and crusting. Treating the pet clears the humans as well.

PEDICULOSIS

Pediculosis Capitis (Head Lice)

EPIDEMIOLOGY The head and body lice may be variants within a single species, but are thought by most biologists to represent two distinct species that can hybridize or interbreed under special circumstances. The most correct terminology at this time is *Pediculus humanus* var. *humanus* (body louse) and *P. humanus* var. *capitis* (head louse).[31] Head lice infestations occur worldwide and are most common in school-aged children. Previous reports have estimated from 6 million to 12 million infestations occur each year in the United States among children 3 to 12 years of age, although this may be a gross underestimation given that many patients self-treat without reporting to health officials. The lice are spread by close physical contact as well as by the sharing of head gear, combs, brushes, and pillows. Head lice affect all levels of society and all ethnic groups, although in the United States, the incidence is low among African Americans.[32,33]

ETIOLOGY AND PATHOGENESIS The adult louse is 1 to 2 mm long, elongated, flattened dorsoventrally, and wingless. Head lice have three pairs of clawed legs that have been adapted to grasp hairs and can travel up to 23 cm per minute.[31] The louse larva, called a *nymph* or *instar*, looks like a miniature adult louse. An adult louse must take a blood meal before copulation. A female louse can produce 5 to 10 eggs a day during her life span of 30 days. Lice typically survive only 1 to 2 days away from the scalp although under favorable conditions survival up to four days away from the scalp has been reported.[31] Nits can survive for up to ten days away from the scalp.[34]

PEDICULOSIS CAPITIS AT A GLANCE



- Infestations occur worldwide affecting all levels of society and all ethnic groups. In the United States, most commonly in school-aged children.
- Most common complaint is pruritus.
- Most common diagnostic sign is live nits on the proximal hair shaft.
- Spread by close physical contact and sharing of head gear, combs, brushes, and pillows.
- Topical pediculicides remain treatment of choice, although evidence of resistance continues to increase.

CLINICAL FINDINGS Pediculosis capitis is typically confined to the scalp with nits (Fig. 208-6) most often found in the occipital and retroauricular regions. Although patients can be asymptomatic, the most common symptom is itching and the sight of school children scratching their heads often leads to the diagno-



▲ **FIGURE 208-6** Nit sheath. Microscopic view of an egg, containing an unhatched louse, attached to a hair shaft.

Box 208-3

Differential Diagnosis of Head Lice

Most Likely

- Seborrheic scales
- Artifacts on the hair (e.g., hair spray)
- Hair casts (pseudonits)
  - Occur when soft inner root sheath keratin fails to break away from the hair shaft forming a soft ring that encircles hair shaft
  - In contrast to nits, are freely movable along hair shaft

Consider

- White piedra
  - *Trichosporon cutaneum*
- Black piedra
  - *Piedraia hortae*
- Delusions of parasitosis



sis. Pruritus is believed to be the result of a hypersensitivity reaction to the saliva produced by the louse during feeding. Fecal material from the louse is also thought to contribute. There may occasionally be a tiny hemorrhagic crust at the site to indicate the louse has taken its blood meal. In addition to pruritus there are excoriations and lymphadenopathy; conjunctivitis may be observed.[35]

Live nits are placed in close proximity to the scalp because the egg is reliant on warmth and moisture for incubation. Thus the distance of the nit from the scalp along the hair shaft is evidence of the duration of the infestation. When all of the nits are noted to be a significant distance from the scalp (i.e., more than 1 cm), it is likely that the infection is no longer active and that these nits are not fertile. Finding live adult lice, immature nymphs, and/or viable-appearing eggs confirms the diagnosis. Fine combing hair that has been saturated with water and conditioner appears to yield more positive results and fewer false positives than traditional scalp examination.[36,37]

DIFFERENTIAL DIAGNOSIS (Box 208-3)

COMPLICATIONS Secondary bacterial infections may result, primarily due to excoriation.

PROGNOSIS AND CLINICAL COURSE Untreated, head louse infestations may persist for many years.

TREATMENT Pediculicides remain the most effective treatment for head lice. In general, pediculicides should not be used in children less than 2 years. To account for variable ovicidal activity and lack of full patient compliance, it is reasonable to recommend repeating treatment in 7 to 10 days to kill recently hatched nymphs (Box 208-4).[31]

Wet combing involves combing systematically through wet, well-conditioned hair with a fine toothed comb every 3 to 4 days for a total of 2 weeks. Because lice are temporarily immobilized by water, wetting the hair allows easier removal by combing.

Occlusive or suffocation methods, such as petroleum jelly or mayonnaise, have been used in the treatment of head lice for years. Although previous studies have failed to demonstrate an effective cure rate,[48] newer agents [Cetaphil cleanser (initially labeled as Nuvo lotion)] have shown promise.[49,50] In addition, new evidence indicates the nit sheath is composed of proteinaceous compounds instead of chitin-specific compounds, as was previously thought. With this knowledge attention has been turned toward agents that can effectively coat lice and eggs while either preventing formation or leading to degradation of the nit sheath.[51]

Oral agents offer the potential benefit of direct ingestion by the louse during blood meals. This in theory reduces the need for widespread application of chemical substances to promote absorption by the lice and therefore reduces risk of toxicity. Ivermectin has demonstrated systemic activity against head lice and should be considered as an alternative therapy (see Box 208-4).[52]

FAILURE AND RESISTANCE The only definite evidence of treatment failure is the presence of adult organisms. Treatment failure should be suspected if live lice are still present 12 to 24 hours after treatment. Possible contributors to treatment failure include changes in formulations, dilution of the pediculicide to an ineffective concentration when applied to wet hair, application of subtheraputic doses or duration in an attempt to conserve, or re-infestation from untreated contacts.[53]

Drug resistance has garnered much attention in recent years. Although treatment failure may contribute to resistance, examination of resistant populations has revealed the role of several different mechanisms. Mutations associated with knock down resistance are believed to affect highly conserved repeated domains in the sodium channel gene leading to permethrin-resistance.[54] Other mecha-

Box 208-4

Treatment for Head Lice

TREATMENT	MECHANISM OF ACTION	ADMINISTRATION	RISK FACTORS
Pyrethrins, synergized (RID, A-200, R&C shampoo, Pronto, and Clear Lice System)[a]	Block Na^+ channel repolarization[b]	Topically 10 min[c,d]	Allergy to chrysanthemums, ragweed, or related plants
Pyrethrins, synthetic [permethrin 1% (Nix), 5% (Elimite)]	Block Na^+ channel repolarization[b]	Topically 10 min[c,d]	None
Malathion lotion 0.5% (Ovide)	Organophosphate cholinesterase inhibitor[b]	Topically 8–12 h; 20–30 min shown as effective[c]	Highly flammable; respiratory depression; central nervous system toxicity
Lindane shampoo 1% (γ-benzene hexachloride, Kwell)	Organochloride; acts as GABA inhibitor[b]	Topically 5–10 min[c]; due to risk of toxicity do not repeat application. FDA approval as second-line agent only.	Risk of seizures; caution in young children, elderly and patients < 50 kg
Ivermectin, oral	Inhibits GABA release[b]	250 μg/kg dose given 7–10 days apart	Not recommended for patients < 15 kg; caution in pregnancy and breast-feeding

FDA = U.S. Food and Drug Administration; GABA = γ-aminobutyric acid.
[a]Available over the counter.
[b]Produce respiratory paralysis.
[c]Application to dry hair followed by adequate rinse with non-medicated shampoo.
[d]Nits can be removed with comb commonly supplied with product.

nisms identified include glutathione-S-transferase–based resistance (a cause of dichlorodiphenyltrichloroethane and pyrethroid resistance) and monooxygenase-based resistance (enhanced drug metabolism that may be overcome by synergistic agents such as piperonyl butoxide). Resistance patterns appear to follow patterns of drug use explaining the variation in resistance observed across different geographic regions. Treatment should be tailored to local resistance patterns and availability of agents. Future directions in treatment hope to use knowledge of the aforementioned mechanisms in the development of alternate agents or combination of agents.[31.]

PREVENTION All members of the affected household should be examined. Although some physicians recommend treating all household members, others recommend treating affected individuals only. After therapy, the treated individuals should wear clean clothing, and both clothing and bedding should be washed and dried using the hot cycle; nonwashables should be dry cleaned, ironed, put in the clothes dryer without washing, or stored in a sealed plastic bag in a warm area for 2 weeks. Combs and brushes may be washed in very hot water (such as the dishwasher) and may be coated with the pediculicide first, for 10 or 15 minutes. Floors, play areas, and furniture should be carefully vacuumed to remove any hairs with viable eggs attached. Fumigation of living spaces is of no value. "No nit" policies requiring exclusion from school and treatment for all children with nits alone are likely excessive.[55,56]

Pediculosis Corporis (Body Lice)

PEDICULOSIS CORPORIS AT A GLANCE

- Infestations typically observed in groups living in crowded unsanitary conditions, such as the homeless, refugees, and military during wartime.
- Diagnosis made by closely examining the lining of the clothing, particularly the seams, for the presence of nits.
- Pruritus is the most common complaint.
- May act as vectors for *Rickettsia prowazekii* (epidemic typhus), *Bartonella quintana* (trench fever and endocarditis), and *Borrelia recurrentis* (relapsing fever).
- Bathing, discarding, or laundering infested clothing, and restoring proper hygiene should cure infestation.

EPIDEMIOLOGY Pediculosis corporis is a disease of poverty, found almost exclusively among the indigent, the homeless, and groups living in crowded unsanitary conditions, such as refugees and, in wartime, the military—these patients are seen mainly in urban public hospitals. There is no predilection of body lice for race, age, or sex.

ETIOLOGY AND PATHOGENESIS The body louse or *P. humanus* var. *humanus* is approximately 30 percent larger than the head louse, but has essentially the same morphology. The lifespan of the body louse averages 18 days and during this time the female louse can produce 270 to 300 ova. The infestation is usually transmitted by contaminated clothing or bedding. The body louse can survive in the seams of clothing without a blood meal for up to 3 days. After exposure, the inability to wash or change clothes allows the infestation to persist.

CLINICAL FINDINGS Occasionally, a *macula cerulea* (literally, sky-blue spot), a blue to slightly slate-colored macule, can be seen, particularly in areas where clothing binds, such as the waistband, and on the buttocks and thighs (see eFig. 208-6.1 in on-line edition). It is an asymptomatic to slightly pruritic, somewhat bruise-like lesion, up to approximately 1.5 cm in diameter and often with a central punctum. More commonly, the only sign of body lice is excoriations, often linear and primarily on the trunk. Post-inflammatory pigmentation is seen in more chronic cases. Adult lice are rarely seen except in heavy infestations.

Diagnosis is made by closely examining the lining of the clothing, particularly at the seams, for the presence of nits. The clothing may also be shaken out over a sheet of newsprint, at which time the lice may be seen moving about on the paper.

DIFFERENTIAL DIAGNOSIS (Box 208-5)

COMPLICATIONS Excoriation may lead to secondary infection with *S. aureus, S. pyogenes,* and other bacteria. Worldwide, body lice may act as vectors for *R. prowazekii* and *Bartonella quintana* (typhus and trench fevers) and *Borrelia recurrentis* (relapsing fever). In the setting of the urban poor, the body louse most commonly serves as a vector for *B. quintana* that can cause fever or endocarditis.[31] Transmission occurs when contaminated fecal pellets are scratched into the bite site or excoriated skin.

Box 208-5

Differential Diagnosis of Body Lice

Most Likely
- Widespread infestation
- Scabies infestation

Consider
- Early infestation
- Atopic dermatitis
- Allergic contact dermatitis
- Irritant contact dermatitis
- Drug reaction
- Viral exanthema
- Systemic causes of pruritus
- Renal impairment
- Hepatic impairment

Always Rule Out
- Scabies infestation

PROGNOSIS AND CLINICAL COURSE Untreated, pediculosis corporis may persist for many years.

TREATMENT Because lice reproduce in the clothing and not on the skin, bathing, discarding or laundering infested clothing, and restoring proper hygiene should cure the infestation. Bedding should also be laundered with hot water, boiled, or discarded. Woolens and other nonwashables may be dry cleaned or ironed at home, with special attention given to the seams. Some physicians believe that, after appropriate disposition of clothing, the patient should be treated from head to toe with a single application of permethrin 5 percent cream, left on for 8 to 10 hours and then washed off thoroughly.[57]

PREVENTION Treating clothing with a permethrin based tick repellent may help to prevent infestations.[31]

Pediculosis Pubis (Pubic Lice)

EPIDEMIOLOGY Most often pubic lice are a sexually transmitted disease and approximately 30 percent of patients have another concurrent sexually transmitted disease.[58] Fomite transmission has also been documented to occur from contaminated clothing, towels, or bedding.[57]

ETIOLOGY AND PATHOGENESIS Pubic lice or *Pthirus pubis* belongs to a separate genus and species in the family Pthiridae. The



PEDICULOSIS PUBIS

AT A GLANCE



- Commonly spread as sexually transmitted disease or from direct contact.
- Although typically found in pubic hair, can affect any hair-bearing region.
- Pruritus is the most common complaint.
- Diagnosis confirmed by microscopic examination of the plucked hair to identify nits.
- Therapy, similar to pediculosis capitis, targeted to the pubic and perianal regions and adjacent hairy areas.



common term *crab louse* is an excellent description for the distinct morphology, the body being somewhat rounded like that of a crab. Pubic lice range from 0.8 to 1.2 mm in length. With the use of serrated edges on the first claw, pubic lice are able to ambulate up to 10 cm/day. As suggested by its name, this louse is most commonly found in the pubic hair, although in hirsute individuals the short hairs of the thighs, trunk, and perianal area may also be involved. Occasionally, the beard, moustache, and even eyelashes (Fig. 208-7) may be involved. Infestation of the eyelashes and periphery of the scalp occur mainly in children, probably a result of contact with an infested parent. Meinking and Taplin[62] reported as much as 60 percent of a homeless population had crab lice in areas of the body besides the pubic hair. The crab louse has a lifespan of 2 weeks and during this time the female



▲ **FIGURE 208-8** Maculae ceruleae, slate-gray to blue-gray macules, seen on the buttocks.

louse can produce around 25 ova.[31] The adult crab louse can survive away from the human host for up to 36 hours.[59]

CLINICAL FINDINGS As with all pediculoses, patients typically present with pruritus. *Maculae coeruleae* (sky-blue macules), most commonly found on thighs or trunk, may be present as in pediculosis corporis (Fig. 208-8). The diagnosis is most frequently made by the patient him- or herself, often identifying the louse in the pubic area. Infested patients reportedly have an average of 10 to 25 or more adult organisms on the body. When the lice themselves cannot be found, nits may be identified near the base of the hair (Fig. 208-9). As in pediculosis capitis, the duration of infestation can be approximated by the distance of the nit from the skin surface. The diagnosis is confirmed by microscopic examination of the plucked hair to identify the nits. Empty nits may indicate a prior infestation.

DIFFERENTIAL DIAGNOSIS (Box 208-6)

COMPLICATIONS Secondary infection because of excoriation can lead to local lymphadenitis and fever.



▲ **FIGURE 208-9** Pediculosis pubis. Several lice and their dot-like nits attached to the hair shafts can be seen in the pubic area of this patient. (Used with permission from D.A. Burns, MD.)

PROGNOSIS AND CLINICAL COURSE Untreated, pediculosis pubis infestations may persist for years.

TREATMENT Topical therapy is much the same as that for pediculosis capitis. The preparation should be applied to the infested area, paying particular attention to the pubic and perianal regions and adjacent hairy areas. A common cause of failure is treating only the pubic area in hairy individuals: The pediculicide should be applied to the thighs, trunk, and axillary regions because the mite can infest these areas as well. Sexual contacts should be treated simulta-



◀ **FIGURE 208-7** Pediculosis pubis. Eyelash infestation with *Pthirus pubis*. Nits can be seen attached to the eyelashes. (Used with permission from D.A. Burns, MD.)

Box 208-6

Differential Diagnosis of Pubic Lice

Most Likely

- Extensive excoriations
- Scabies infestation
- Contact dermatitis

Consider

- White piedra
  - *Trichosporon cutaneum*
- Trichomycosis pubis
  - *Corynebacteria* sp.
  - Hair shafts develop adherent yellow, red, or black nodules or cylindrical sheath easily visualized by naked eye.
- Hair casts (pseudonits)
  - Occur when soft inner root sheath keratin fails to break away from the hair shaft forming a soft ring that encircles hair shaft.
  - In contrast to nits, are freely movable along hair shaft.

Always Rule Out

- Scabies infestation

Box 208-7

Treatment for Pubic Lice

TREATMENT	ADMINISTRATION	COMMENTS
Synergized pyrethrins and permethrin 1% shampoos	Topically 10 min; repeat in 7–10 days	Available over-the-counter
Permethrin 5% cream	Topically 8–12 h; repeat in 7–10 days	Currently treatment of choice
Lindane shampoo 1%	Topically 5 min	Risk of central nervous system toxicity
Occlusive agent (Vaseline)	Applied to eyelashes twice daily for 8 days; manual removal of nits	None
Ivermectin, oral	250 μg/kg dose given 7 to 10 days apart demonstrated effective for eyelash involvement	Risk profile, see Box 208-4

neously, but other family members need not be treated if there is no evidence of infestation (Box 208-7).[60,61]

TREATMENT FAILURE Treatment failure is usually a result of failure to follow instructions, neglecting to treat sexual contacts, or re-infestation. Patients with human immunodeficiency virus/acquired immunodeficiency syndrome tend to have more severe infestations with pediculosis pubis and to be unresponsive to conventional therapy.[62] Persistent itching may be caused by irritation from the pediculicide (usually because of overuse) or patient anxiety. Parasitophobia is fairly common after infestation and is difficult to treat.

KEY REFERENCES

The full reference list for all chapters is available at www.digm7.com.

1. Orkin M, Maibach HI: Ectoparasitic diseases. In *Dermatology.* Orkin M, Maibach HI, Dahl MV, eds. Norwalk, CT: Appleton and Lange, 1991 p 205
5. Huynh TH, Norman RA: Scabies and pediculosis. *Dermatol Clin* **22**:7, 2004
27. Burns DA: Follicle mites and their role in disease. *Clin Exp Dermatol* **17**:552, 1992
31. Ko CJ, Elston DM: Pediculosis: *J Am Acad Dermatol* **50**:1, 2004



CHAPTER 209

Bites and Stings of Terrestrial and Aquatic Life

Jennifer S. Daly
Mark Jordan Scharf

The Book of Genesis promised humans dominion over the fish of the sea and every living thing that moved on the face of the earth. Unfortunately, it did not guarantee that every encounter between human and beast would be free from harm. The first section of this chapter considers the harmful effects of the bites of land animals, including snakes, as well as the bacterial and viral infections they may transmit. The second section reviews bites and stings and other forms of injury that may be inflicted by marine life.

BITES OF LAND ANIMALS

Epidemiology

Dog bites account for 80 percent to 90 percent of all mammalian bites involving humans. Four million to 5 million dog bites are estimated to occur each year in the United States, and, in 2001, it was estimated that 368,245 persons were treated for dog bite–related injuries.[1] The human victim is often a 5- to 9-year-old boy who may have been teasing or playing with the dog. Sometimes the bite occurs when a person is trying to break up a pair of fighting dogs or trying to aid an animal. In the United States 4 percent to 5 percent of dog bites are work related and include bites sustained by postal carriers. Overseas a higher percentage are produced by untamed animals.[2–4] Most dog bite injuries involve the upper extremities, especially the hands. Cat bites are the second most common type of mammalian bite after dog bites, but the wounds are nearly twice as likely to become infected as wounds from dog bites.[5]

Clinical Approach (Pathogenesis and Treatment)

The evaluation and treatment of all bite wounds should include taking a careful history of the incident, the type of animal, the site of the bite, and the geographic setting. Hand wounds, puncture wounds, and crush injuries are likely to become infected. Specimens from infected bites should be cultured and a Gram-stained smear prepared; the wound should then be washed,

BITES AND STINGS AT A GLANCE



- Dog bites account for 80 percent to 90 percent of all mammalian bites involving humans, but cat bites are more likely to become infected.
- Whether or not post-exposure prophylaxis with rabies immune globulin and human diploid cell rabies vaccine is needed depends on the circumstances surrounding the bite.
- In the United States, there are approximately five to six deaths from snakebites and probably 6000 to 7000 snakebite envenomations each year.
- Most stingray injuries occur when bathers, waders, or fishermen accidentally step on rays as they lie partially covered with sand in shallow waters. The extreme pain caused by the venom may be relieved by soaking the affected body part in very warm water.

well irrigated, and left open. Most patients with bites on the hands, deep cat bites, deep cat scratches, and sutured wounds should be treated with amoxicillin/clavulanic acid or ceftriaxone because of the risk of *Pasteurella multocida* infection; if the patient is allergic to these agents a quinolone or a tetracycline should be used. Evidence that the use of prophylactic antibiotics is of benefit exists only for bites of the hand. However, once the patient has an infection, intravenous antibiotics and surgical drainage are often required.[4,6–8] Tetanus immune status should be evaluated, and rabies prophylaxis should be considered, depending on the type of animal, local epidemiologic factors, and ability to quarantine the animal for 10 days.[9]



Human bites and monkey bites deserve special mention, because 30 percent become infected with aerobic or anaerobic mouth organisms. Infection caused by anaerobes may spread through the metacarpal–phalangeal space and cause severe damage. The same procedure should be followed as for other animal bites; that is, culture and Gram stain, thorough washing, and débridement. Wounds, especially hand wounds, should be left open if possible. Evidence suggests that patients with human bites that penetrate the epidermis should be treated prophylactically with amoxicillin/clavulanic acid for 7 to 10 days or, if the patient is allergic to penicillins, with a fluoroquinolone plus an antianaerobic agent such as clindamycin.[7,10] Clenched-fist injuries should be evaluated by a hand surgeon because of the high likelihood of infectious complications, including septic arthritis and osteomyelitis.[2]

Specific Bacterial Infections Caused by Animal Bites

***PASTEURELLA MULTOCIDA* INFECTION** (See Chap. 183) An organism commonly infecting bite wounds is *P. multocida,* a bacterium present in the nasopharynx in 50 percent to 66 percent of dogs and 70 percent to 90 percent of cats. The most common pattern is that of local infection with adenitis after a dog or cat bite or scratch. *P. multocida* is the most common pathogen in cat-bite infections and may also complicate 26 percent of dog-bite wounds.[5] The infection usually presents within 24 to 48 hours, often within several hours. In patients with a cat bite, the infection may be followed by tenosynovitis or osteomyelitis as a result of inoculation of the organism into the periosteum by the long, sharp tooth of the animal. *Pasteurella* infections have also been reported after bites of large cats such as lions and tigers.

Treatment of the patient with presumptive *P. multocida* infection should consist of careful washing of the wound and an attempt to leave it open. The empiric antibiotic of choice is amoxicillin/clavulanic acid orally for 7 to 10 days, with careful follow-up examination of the wound. *P. multocida* is susceptible to penicillin alone, and patients may be switched to penicillin if they have a pure infection with this organism. A fluoroquinolone, a tetracycline, and trimethoprim-sulfamethoxazole are alternatives. In most patients the antibiotic is aimed at both the patient's skin flora (such as *Staphylococcus aureus*) and organisms from the animal's mouth.

***STAPHYLOCOCCUS INTERMEDIUS* INFECTION** *S. intermedius* is an organism associated with dogs weighing more than 40 pounds. It is more commonly found in canine gingival flora than is *S. aureus* (39 percent versus 10 percent).[11] It is a Gram-positive, coagulase-positive coccus that can be differentiated from *S. aureus* in the laboratory by biochemical testing. In comparison with *S. aureus*, *S. intermedius* does not produce acetoin from glucose and has β-galactosidase activity. If these tests are not performed (i.e., if only a latex assay is use to identify staphylococci), the laboratory may incorrectly report an isolate as *S. aureus* or unspecified staphylococcus. Antibiotic treatment is the same as that for infections with *S. aureus*, although resistance to oxacillin is uncommon in *S. intermedius* and is growing in importance for *S. aureus*.

***CAPNOCYTOPHAGA CANIMORSUS* INFECTION** *Capnocytophaga canimorsus* is a capnophilic ("carbon dioxide–loving"), facultatively anaerobic, slow-growing, Gram-negative rod associated with dog bites.[12–15] The organism has been found in the oral cavity of 17 percent of cats and 24 percent of dogs. Most infections occur in splenectomized or immunocompromised hosts, although fatal infections including meningitis have been reported in immunocompetent hosts and present as overwhelming sepsis.

INFECTION BY *PORPHYROMONAS* SPECIES *Porphyromonas* sp. are slow-growing anaerobic bacteria found in the deep gingival pockets of animal and humans that are difficult to culture, requiring 4 to 6 days for colony formation as well as vitamin K and hemin in the media.[16,17] Citron and co-workers[18] found *Porphyromonas* species in 28 percent of culture specimens from patients with infected dog- and cat-bite wounds.

CAT-SCRATCH DISEASE *Bartonella henselae* is the most common etiologic agent of cat-scratch disease. *Afipia felis* and other *Bartonella* species may cause some cases (see Chap. 182).

PLAGUE (See Chap. 183)

TULAREMIA (See Chap. 183)

RAT-BITE FEVER (See Chap. 183)

Specific Viral Infections Caused by Animal Bites

RABIES ***Epidemiology.*** The most notorious viral disease to occur after an animal bite is rabies, which is caused by an RNA virus. Its epidemiology has changed in the past few years as a result of improved control of rabies in the domestic animal population. Now, nonimmune dogs and domestic animals account for only 8 percent of cases, whereas sylvatic animals, such as skunks, raccoons, red and gray foxes, and bats, represent the greatest potential danger. Rodents, such as squirrels and hamsters, are probably inconsequential as sources of rabies. However, cases of rabies in cattle are increasing.[19] Post-exposure prophylaxis, which is nearly 100 percent effective, has reduced the number of cases of human rabies from more than 100 per year a century ago to an average of 1 to 4 cases a year in the United States today. In 2004, of the eight cases in the 49 states and Puerto Rico, four were acquired as a result of patients' receiving transplanted organs from an infected donor.[19,20]

Live virus is introduced into nerve tissue at the time of the bite, multiplies at the site, and then spreads to the central nervous system. It replicates in gray matter and then spreads along autonomic nerves to the salivary glands, adrenal glands, and heart. The incubation period varies with the site of the bite from 5 days to as long as several years. Clinical features include a prodromal period of 1 to 4 days, followed by high fever, headache, and malaise. Paresthesia at the site of inoculation occurs in 80 percent of patients. The next sequence of events is familiar: agitation, hyperesthesia, dysphagia, excessive thirst, paralysis, and death.

Diagnosis. The diagnosis of clinical rabies is difficult and is often not made until after the death of the patient. Viral

isolation methods may yield positive results for specimens of saliva or cerebral spinal fluid during the first 2 weeks of the illness, and saliva is infectious, so isolation precautions are needed. Serum antibodies may be detected as early as day 6 and usually by day 13. The fluorescent antibody method for detection of the viral antigen is the most rapid and sensitive means of making the diagnosis, and no matter where the actual bite site, once patients have central nervous system disease, the diagnosis can be made from a biopsy of skin from the highly innervated hair-covered area of the neck or from brain tissue.

Prevention and Treatment. The most effective prevention for rabies is to avoid contact with any wild animal or any unfamiliar domestic animal. Persons at risk of unavoidable contact with rabies, such as spelunkers, veterinarians, virologists, and travelers spending time in countries where rabies is enzootic, should receive pre-exposure prophylaxis with the human diploid cell rabies vaccine (HDRV) series (three intramuscular injections on days 0, 7, and 21 or 28) given in the deltoid muscle and repeated every 2 years. In persons vaccinated intradermally (using a lower intradermal dose), the neutralizing antibody titer should be followed, because the immune response may not be fully protective.[21]

The need for post-exposure prophylaxis can be determined by the answers to the following questions: What is the status of animal rabies in the locale where the exposure took place? Was the attack provoked or unprovoked? Of what species and size was the animal? What was the state of health and vaccination record of the animal? Will the brain of the animal be examined within 48 hours? Can the animal be effectively quarantined? Most animals transmit rabies virus in saliva only a few days before becoming ill themselves; bats, however, may harbor the virus for many months.

Bites by Household Pets. If the dog or cat responsible for the bite is healthy and available for observation for 10 days, the patient should not be treated unless the animal develops rabies. At the first sign of rabies in the animal, the patient should be treated with rabies immune globulin (RIG) and the vaccine HDRV. The symptomatic animal should be killed and tested as soon as possible. If the animal is rabid or suspected of being rabid, or if it does not have up-to-date vaccination records, the patient should be treated with RIG and HDRV (see Specifics of Treatment later).[22]

Bites by Wild Animals. All skunks, bats, groundhogs, foxes, coyotes, raccoons, bobcats, and other carnivores should be regarded as rabid unless laboratory test results prove negative. The patient should be treated with RIG and HDRV.

Bites by Other Animals. Bites by other animals (livestock, rodents, lagomorphs such as rabbits and hares, and ferrets) should be considered individually.[22] Local and state public health officials should be consulted about the need for prophylaxis. Bites by squirrels, hamsters, guinea pigs, gerbils, chipmunks, rats, mice, and other small rodents almost never call for anti-rabies prophylaxis.

Specifics of Treatment. The most important step is to cleanse the wound immediately with a brush and soap to remove as much virus as possible. The wound should be rinsed well and then scrubbed a second time with green soap or 70 percent alcohol, which is rabicidal. If vaccine treatment is indicated, both RIG and HDRV should be given as soon as possible, regardless of the interval after exposure, unless the patient has been previously vaccinated and a serologic assay shows current immunity. In this case, only HDRV is needed and should be given on day 0 and day 3.[9] For nonimmune hosts, administration of RIG is the most urgent. If HDRV is not immediately available, RIG should be started and HDRV given as soon as it is obtained. RIG (20 IU/kg) should be given immediately—50 percent around the site of the bite and 50 percent in the thigh or the arm. This passive immunization will result in the early appearance of antibody but will also inhibit development of the active antibody from HDRV, hence the need for a 28-day series. Active immunization is accomplished using HDRV, given intramuscularly for a total of five doses on days 0, 3, 7, 14, and 28. Serum for rabies antibody testing should be collected 2 weeks after the fifth dose. If there is no antibody response, an additional booster should be given.

Management of the Patient with Clinical Rabies. In the rare cases in which a patient is admitted with the clinical diagnosis of rabies, several steps should be taken immediately. First, the diagnosis must be suspected and the patient placed in isolation precautions while the diagnosis is made rapidly by fluorescent antibody staining of specimens from various tissues, as well as immunofluorescence staining of the source animal's brain tissue. Elevated antibody titers in the absence of immunization are clear evidence of infection. The first signs of clinical rabies are usually non-specific, such as malaise, anorexia, fatigue, headache, and fever. The acute neurologic illness that follows is most commonly characterized by intermittent episodes of hyperactivity. In some cases, however, a progressive paralysis is most common. The usual period from onset of symptoms to onset of coma is 10 days. Risk of exposure for hospital staff includes contact with open wounds or mucous membranes with saliva or other potentially infectious material such as neurologic tissue, spinal fluid, or urine. Blood, serum, and stool are not considered infectious.

Basic clinical management consists of anticipating and preventing all treatable complications of the rabies infection and induction of coma to manage the patient until the patient generates an immune response.[23] Pulmonary hypoxia should be prevented by tracheostomy at the first sign of respiratory difficulty, monitoring of actual partial pressure of oxygen, and use of supplemental oxygen. There are no specific antiviral treatments for rabies, although ribavirin has been tried.[23] Anticonvulsant therapy should also be instituted. Extreme increases in intracranial pressure may be prevented by insertion of a cerebrospinal fluid reservoir that allows withdrawal of the intraventricular fluid and measurement of intracranial pressure. Cardiac arrhythmias may be anticipated with careful monitoring. Rabies had been regarded as uniformly fatal, but there have been patients who have survived with prolonged cardiorespiratory support, and there is serologic evidence that some animals have survived. An aggressive approach to treatment of the patient with known rabies infection is worthwhile. In 2004, a 15-year-old girl without a history of prior rabies vaccination survived after her physicians used a treatment based on induced coma as well as other supportive measures and antiviral agents.[19,23]

LYMPHOCYTIC CHORIOMENINGITIS

HERPESVIRUS SIMIAE (B VIRUS) INFECTION Herpesvirus simiae (B virus) is enzootic in Old World monkeys, espe-



cially rhesus, cynomolgus, and other macaques. The illness in monkeys is similar to that caused by herpes simplex in humans, and asymptomatic monkeys may shed the virus in saliva. Most cases in humans have occurred after direct exposure to macaque monkeys or monkey tissue through bites, scratches, or cuts.[27] A vesicular lesion develops at the wound site with progressive lymphadenitis and fever. Over the next few days to weeks patients develop a severe illness, which is characterized by rapidly progressive ascending neuropathy and encephalitis. The illness is rare and in 72 percent of cases has been fatal. A cluster of four cases occurring in 1987 in Pensacola, Florida, were treated with acyclovir. The two patients who received acyclovir when their infections were localized responded well to therapy and were maintained on oral acyclovir. All macaques should be presumed to be shedding B virus and should be handled accordingly. All monkey-inflicted injuries should be cleansed, specimens should be collected for viral culture, and a physician should evaluate the patient. Clinical and serologic monitoring is critical, and high-risk or infected patients should be treated according to established guidelines. The use of acyclovir or ganciclovir initially and acyclovir for years has led to improved survival in infected patients.



Snakebites

In the United States, there are approximately five to six deaths from snakebites and probably 6000 to 7000 snakebite envenomations each year.[28] The largest number of venomous snakebites occur in the southwestern states. Worldwide as many as 30,000 fatal snakebites may occur each year. Because of regional differences in varieties of snakes, management recommendations differ by geographic area.

The two major poisonous snakes in the Americas are the pit viper (family Viperidae, subfamily Crotalinae, which includes the rattlesnake, water moccasin, and copperhead) and the coral snake (family Elapidae). Poisonous snakes are found in all states of the United States except Maine, Hawaii, and Alaska.[28] The northern copperhead, also called the *highland moccasin*, is pink or reddish brown and is marked with large chestnut-brown barrels resembling dumbbells or hourglasses (Fig. 209-1). The bite is painful but rarely fatal. The timber rattler is dark brown with chevrons of black and brown (Fig. 209-2).



▲ **FIGURE 209-1** Northern copperhead.

The degree of toxicity of a snakebite depends on the potency of the venom, the amount injected, the size and condition of the snake, and the size of the person bitten. Pain occurs at the site of the bite (usually within 5 minutes). Signs and symptoms at the bite site include wheal with local edema, numbness, and, within moments, ecchymosis and painful lymphadenopathy (Fig. 209-3).

Nausea, vomiting, sweating, fever, drowsiness, and slurred speech may develop. Bleeding of the gums and hematemesis are common hemorrhagic manifestations. If edema and erythema have not developed within 8 hours after the bite, it can be assumed that significant envenomation did not occur. Estimated mortality rates for victims who receive antivenom in a health care facility are less than 1 percent and probably less than 0.1 percent.

For proper treatment, it is extremely important to establish that the bite is from a poisonous snake. Many patients experience symptoms related to fear that may mimic symptoms from venom. The patient should have distinct fang punctures and immediate local pain, followed by edema and discoloration within 30 minutes. It is helpful to inspect the snake, because those that are poisonous may be differentiated from those that are not by the presence of fangs and the shape of the pupils (Fig. 209-4). Availability of a photograph of snakes common to a specific geographic area is important for all hospital emergency wards to aid practitioners in deciding if the patient has been bitten by a poisonous snake.

Although there are still insufficient evidence-based criteria for first aid and out-of-hospital treatment for snakebite envenomations, a rational approach is outlined in Table 209-1.[29] In summary, the patient should be stabilized and transported as rapidly as possible to a health care facility capable of administering antivenom, and the affected site should be immobilized below the level of the heart. Constricting bands such as watches or jewelry should be removed; the use of venous compression bands is not recommended.[28] The patient should be kept as immobilized as possible.[28] Venous compression techniques are de-



▲ **FIGURE 209-2** Timber rattlesnake.



▲ **FIGURE 209-3** Copperhead snakebite.

signed to impede the return of venous and lymphatic flow from the bite site without sacrificing blood flow to the extremity. In cases in which there is likely to be a significant delay in transport and the victim is developing systemic signs of envenomation such as hypotension, these techniques may be of value.[29] Arguments against the use of venous compression techniques include the time that it takes to apply the treatments, which may further delay transport time. Additional arguments against the use of these techniques include the potential for concentrating the venom in the affected limb, which may worsen local necrosis, along with the possibility of a bolus effect when the compression is released.[29] Another possible disadvantage of the use of these compression techniques is the potential for them to cause arterial compression if the affected limb swells in reaction to the toxin. If a decision is made to use a venous compression band in the field, arterial pulses should be palpable distal to the ligature, and the dressing should be checked frequently to make sure that it is has not become too tight. If a venous compression dressing has been applied in the field and is not causing vascular compromise, it should be left in place until the patient reaches a health care facility and antivenom is at the bedside.[29]

TABLE 209-1
First Aid and Out-of-Hospital Treatment for Snakebite Envenomation

1. The patient should be stabilized and transported as rapidly as possible to a health care facility capable of administering antivenom.
2. The affected site should be immobilized below the level of the heart, constricting bands such as watches or jewelry should be removed, and the patient should be kept as immobile as possible.[28]
3. The use of venous compression bands or pressure immobilization is not recommended,[28] although there is controversy surrounding their use if there is likely to be a significant delay in transport and the victim is developing systemic signs of envenomation such as hypotension, and in such a case these techniques may be of value.[29]
4. The value of using a suction device to extract venom is debated in the literature.[28] If such a device is applied in the field and fluid is accumulating in the suction cup, it can be left in place until the patient reaches a medical facility.[29]
6. The use of cryotherapy, incision, or excision of the bite site, arterial tourniquets, and electroshock therapy as part of emergency field therapy should be discouraged.

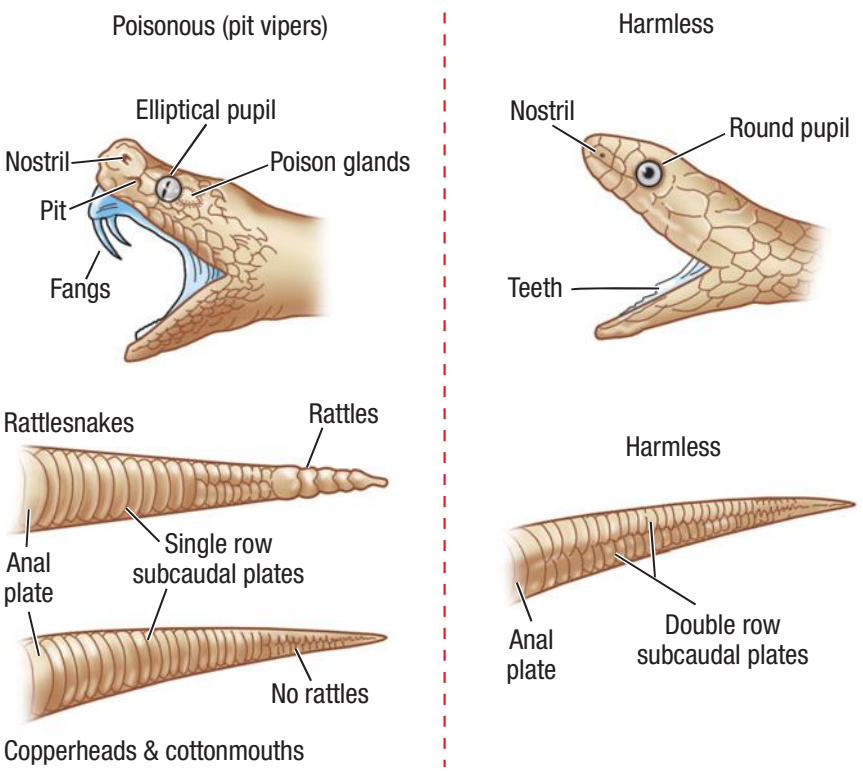

▲ **FIGURE 209-4** Identification of poisonous and nonpoisonous snakes. (From Wingert WA, Wainschel W: A quick handbook on snake bites. *Resid Staff Physician*, 1977, p 56, with permission.)

The role of surgical intervention in the treatment of snakebite envenomations is limited in most cases. Surgery is appropriate only if medical treatment, including elevation of the bitten body part in conjunction with the administration of four to six vials of Crotalidae polyvalent immune Fab (ovine) (FabAV) over the course of 1 hour, fails.[28] Débridement of truly necrotic skin and subcutaneous tissues is recommended 4 to 5 days after envenomation. In cases of bites to a digit, if there is severe swelling and the finger is tense, blue, or pale, a digit dermotomy may be of use. True compartment syndrome involving an extremity is a rare complication of snakebite envenomation. Fasciotomy should be used only in cases of increased compartment pressure that has not responded to prompt and sufficient treatment with antivenom.[30]

The primary treatment for crotaline snake venom poisoning is prompt and adequate dosing with antivenom. Antivenom is most effective if given within 4 hours of the snakebite (Box 209-1).

FabAV should be used for all severe American crotaline snakebites except



Box 209-1

Antivenom for Crotaline Snake Bites

- Emergency information and antivenom are available in the United States through the nationwide poison control center network, which can be reached 24 hours a day by calling 800-222-1222.[28]

those of the coral snake. The dosage should be guided by the severity and progression of local changes and systemic clinical signs. Because some patients develop recurrent manifestations of envenomation after initial treatment, both a loading dose of four to six vials of FabAV and then, once initial control has been achieved, three maintenance doses 6, 12, and 18 hours later are recommended.[28]

Supportive treatment is indicated, including hospitalization with careful evaluation of baseline hematocrit, platelet count, and prothrombin time. Coagulopathy should be corrected by using antivenin, because fresh frozen plasma is ineffective.[28] The wound should be cleansed and covered. Antitetanus therapy and antibiotic prophylaxis with penicillin, ampicillin/sulbactam, or tetracycline should be initiated for severe bites.



BITES AND STINGS OF AQUATIC ORGANISMS

Seal Bite

Normally, a seal bite occurs on the finger of a trainer or a seal hunter—thus the term *seal finger* or *spaek finger*.[31,32] The etiologic agent is unclear and is controversial. One study suggests that a virus similar to that causing orf may be the culprit,[32] although *Mycoplasma* sp. have been isolated, and some patients respond to tetracycline (see Chap. 183). The incubation period of 4 to 8 days is followed by throbbing pain, erythema at the site, and swelling of the joint proximal to the bite. Untreated, seal finger progresses to cellulitis, tenosynovitis, and arthritis. Tetracycline, 500 mg orally four times a day for 10 days, remains the antibiotic of choice.[29,31] It is also helpful to immobilize and elevate the finger as well as soak it several times a day.

Injuries Caused by Jellyfish, Portuguese Man-of-War, Sea Anemones, and Corals

Stings caused by jellyfish, Portuguese man-of-war, sea anemones, and corals are the most common envenomations experienced by humans in marine environments. All of these creatures are members of the phylum Cnidaria, formerly known as *Coelenterata*. They are divided into three major classes. The first class, Hydrozoa, includes the Portuguese man-of-war, fire corals, and hydroids. Jellyfish belong to the second class, Scyphozoa. The third class, Anthozoa, encompasses sea anemones and true corals. Approximately 100 of the 9000 species of Cnidaria that have been identified may cause injury to humans.[33]

Cnidarians are radially symmetric animals with body walls formed by an inner and outer layer of cells enclosing a jelly-like substance. They may be either free floating in the water like jellyfish or sessile like corals.[33] Almost all cnidarians possess nematocysts, or stinging capsules, which are usually concentrated on some form of tentacle. Each nematocyst contains a toxin or group of toxins and a coiled thread-like apparatus with a barbed end that functions like a flexible hypodermic syringe (Fig. 209-5). When the nematocyst comes into contact with a victim, the barbed end is discharged, and the toxin is injected into the skin.

Cnidarian stings range from mild, self-limited irritations to extremely painful and serious injuries, depending on the toxin of the species involved and the magnitude of the envenomation. Stings from certain species such as the cubomedusae, or box jellyfish, can be fatal.

In most cases, jellyfish stings elicit toxic reactions that may be localized and/or systemic. Although immediate-type hypersensitivity reactions, including urticaria, angioedema, and anaphylaxis, occur less frequently, they require prompt medical intervention, because shock and death may ensue in highly sensitized individuals. Allergic contact dermatitis, delayed and persistent hypersensitivity reactions, granuloma annulare,[34] and erythema nodosum are other possible cutaneous reactions to jellyfish stings.

INJURIES CAUSED BY JELLYFISH ***Sea Nettles.*** Among the organisms most commonly causing jellyfish stings are the sea nettles, which comprise two different species, both of which inhabit Atlantic as well as Indo-Pacific waters. *Cyanea capillata* and its relatives is the larger of the two species, with a bell measuring up to 1 m and numerous tentacles reaching 30 m in length[35] (Fig. 209-6). *Chrysaora quinquecirrha* is smaller, with a white or rusty bell that may reach 30 cm with four digestive tentacles hanging from it. Although sea nettle stings are seldom lethal, they can be quite painful.[36] Initially the victim experiences a sharp burning pain in the area contacted by the tentacles. Within minutes, the sting area develops a zigzag, whip-like pattern of raised red welts 2 to 3 mm wide (Fig. 209-7). The duration of acute pain may vary, but the pain often begins to abate in 30 minutes. The wheals usually subside by 1 hour, but purplish brown petechial and post-inflammatory pigmentation may persist for several days.

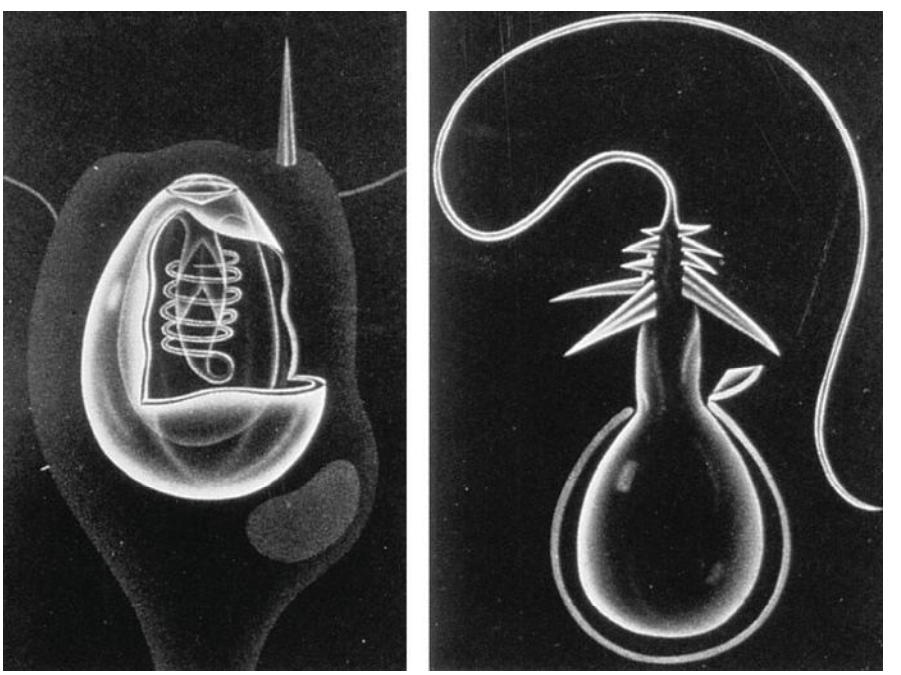

▲ **FIGURE 209-5** From left to right, a diagrammatic view of an intact and discharged coelenterate nematocyst. (R. Kreuzinger, used with permission from World Life Research Institute.)



▲ **FIGURE 209-6** *Cyanea capillata,* also known as *sea nettle* or *lion's mane*, is a common cause of jellyfish stings. (B. W. Halstead, used with permission from World Life Research Institute.)

Portuguese Man-of-War. *Physalia physalis* is the species name for the Portuguese man-of-war, which is a member of the class Hydrozoa and is therefore not a true jellyfish. *P. physalis* is encountered in both Atlantic and Mediterranean waters, and is easily recognized by its translucent blue to pink or purple bladder-like float with multiple tentacles (Fig. 209-8). *P. physalis* is distinguished from its Pacific ocean relative *P. utriculus*, commonly known as the *blue bottle*, by its larger bell, which ranges in size from 10 to 30 cm, and multiple fishing tentacles extending up to 30 m; in contrast, *P. utriculus* has only a single tentacle that rarely exceeds 5 m.[37] These tentacles are

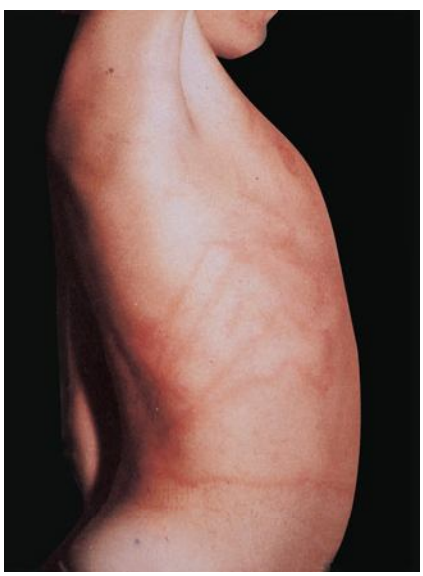

▲ **FIGURE 209-7** Whip-like sting pattern caused by *Cyanea capillata* in a young boy. (J. H. Barnes, used with permission from World Life Research Institute.)



▲ **FIGURE 209-8** *Physalia physalis*, the Portuguese man-of-war, is distinguished by its bladder-like float and numerous trailing tentacles. (B. W. Halstead, used with permission from World Life Research Institute.)

armed along their entire length with hundreds of thousands of nematocysts arranged in stinging batteries, with each battery containing hundreds of nematocysts. The nematocysts remain active even after portions of the tentacles are broken off in storms or when these animals are stranded on the shoreline by high winds or waves. A beached Portuguese man-of-war can cause a severe sting when stepped on or touched. Children who are stung after handling these animals and then cry and rub their eyes may develop an acute conjunctivitis.

Stings of *P. physalis* are more painful and severe than those caused by sea nettles and are more extensive and serious than those caused by *P. utriculus*. At the moment of contact with the tentacles of *P. physalis*, the victim experiences a sharp, shock-like, burning pain. There may be painful paresthesias or numbness in the sting area. Initially, the sting area appears as an irregular single line or multiple lines composed of red papules, beaded streaks, or erythematous welts that correspond to the areas of tentacle contact. The wheals resolve in hours but may progress to vesicular, hemorrhagic, necrotic, or ulcerative stages before healing[38] (Fig. 209-9).

Post-inflammatory striae may persist for weeks to months. Severe localized complications of *P. physalis* stings may also include arterial spasm in the sting site that can result in distal digital gangrene.[39,40]

Within 10 to 15 minutes of a *Physalia* sting, the victim may develop symptoms of an envenomation reaction characterized by nausea, abdominal cramps,



▲ **FIGURE 209-9** This diver surfaced directly under a large Portuguese man-of-war and suffered a severe sting with bulla formation and tissue necrosis. (S. Anderson, used with permission from World Life Research Institute.)

muscular pains, backache, irritability, dyspnea, and chest tightness. Intravascular hemolysis and acute renal failure were reported in a 4-year-old girl after a severe sting by *P. physalis*.[41] Most reports of death due to stings of *P. physalis* are not well documented, but well-substantiated case reports of human fatalities do exist.[42–44]

Cubomedusae [Class Cubozoa]: Box Jellyfish. Of all the species of jellyfish that cause painful stings and distress to swimmers, the species with the most established record of lethality are the cubozoans. *Chironex fleckeri* or box jellyfish causes at least one death each year in Australia.[45] The fatality is usually a child, presumably because the size of the victim and the total area of the sting determine the likelihood of death. Until recently, most of the published cases of *C. fleckeri* stings involved fatal or nearly fatal envenomations, but less serious stings do occur in endemic areas.[46–48]

C. fleckeri (commonly known as the *sea wasp*) is an advanced species of jellyfish, with a semitransparent cubic bell that may grow to a volume of 9 L and weigh more than 6 kg[45] (Fig. 209-10). Trailing from the bell are up to 60 stinging tentacles, which may reach 2 to 3 m in length. When a human comes into contact with a box jellyfish, some of the tentacles are torn off and adhere to the skin. Rescuers of *C. fleckeri* sting victims must exercise caution, because they also are at risk of envenomation until the tentacles have been neutralized and removed.

The stings appear initially as linear welts that give the patient the appearance of having been whipped.[45] Fresh stings of *C. fleckeri* are easily recognized





▲ **FIGURE 209-10** The deadly box jellyfish, *Chironex fleckeri*, is found in Indo-Pacific waters off the coast of Northern Australia. (Used with permission from R. Hartwick.)

because they have a diagnostic, frosted, cross-hatched or ladder-like appearance (Fig. 209-11). Microscopic diagnosis is also possible from blade scrapings or tape strippings from the sting site. The intense pain may persist for many hours. Severely stung areas of skin take on a dusky cyanotic appearance and blister formation and necrosis may occur. The healing process is slow and may be complicated by bacterial superinfection and scarring.



▲ **FIGURE 209-11** Characteristic frosted cross-hatched tentacle marks diagnostic of a sting caused by *Chironex fleckeri*. (Used with permission from Townsville General Hospital, Department of Medical Illustration, Townsville, Queensland, Australia.)

Death may ensue within minutes due to cardiotoxic and neurotoxic agents in the venom that can produce ventricular arrhythmias and cardiac arrest, and respiratory failure, respectively.[47] Intravascular hemolysis caused by the toxin can precipitate acute renal failure. First aid for these victims frequently involves cardiopulmonary resuscitation. Intravenous verapamil has been proposed for both treatment and prophylaxis of ventricular arrhythmias.[49,50] Antivenin is available for *C. fleckeri* stings, and its early use in severe envenomations may be lifesaving and significantly reduces the pain and inflammation at the sting site.[46]

Irukandji syndrome is a severe and delayed response (usually 30 minutes but between 5 and 40 minutes) to the sting of a small box jellyfish, termed the *Irukandji jellyfish*, that has resulted in the death of two tourists in the Cairns–Port Douglas region of Australia.[51] The classic syndrome consists of local signs of inflammation together with severe back pain, excruciating muscle cramps, piloerection, sweating, nausea, vomiting, headache, and palpitations. The most severe cases may progress to include extreme hypertension and cardiac failure. Only one species, *Carukia barnesi*, has been clearly linked to this syndrome, but it is thought that at least six different species of small jellyfish, each with only one tentacle arising from each corner of the bell (carybdeids), may be etiologic agents. The stings most often occur in deep water. Treatment includes application of vinegar to discharge nematocysts and victim transport for medical attention including pain control and α blockade, because the venom is thought to act as a presynaptic neuronal sodium agonist and to stimulate norepinephrine release.

Prevention and Treatment of Jellyfish Stings. Tables 209-2, 209-3, and 209-4 give details on the prevention of jellyfish stings and first aid for and treatment of the stings. Systemic reactions may occur, and the treatment for these includes support of vital functions with cardiopulmonary resuscitation, oxygen, and intravenous fluids.[52,53] Application of a venous-lymphatic constriction bandage proximal to the wound site should be considered in the case of severe stings when systemic reactions are present or likely to occur, when topical deactivation of tentacles is not possible, and when transport to receive specific antivenin for *C. fleckeri* stings is available. The antivenin is prepared from sheep serum and may therefore pose a risk of allergic reaction in sensitive individuals.[34,36] The preferred route of administration is intravenous, but the antivenin may be given intramuscularly. In severe stingings, it has proved lifesaving. It is also the only treatment that can alleviate the intense pain and may reduce inflammation at the

TABLE 209-2
Prevention of Jellyfish Stings

1. Swim only at patrolled beaches with properly trained lifeguards and adequate treatment facilities.
2. Avoid swimming in infested waters, especially after a storm, because stings may result from remnants of floating damaged tentacles.
3. Beware of apparently dead or beached jellyfish.
4. When snorkeling or scuba diving, wear protective clothing such as a wet suit, long-sleeved shirt, pants or long woolen underwear, and gloves. In areas where Irukandji syndrome occurs, wear a Lycra stinger suit.
5. Use sunblock containing jellyfish and "sea lice" repellent.
6. Bathing beaches should be closed during periods of high jellyfish infestation.

Data from McKinney PE: Out-of-hospital and interhospital management of crotaline snakebite. *Ann Emerg Med* **37**:168, 2001; Kimball AB et al: Efficacy of a jellyfish sting inhibitor in preventing jellyfish stings in normal volunteers. *Wilderness Environ Med* **15**:102, 2004; and Harrison SL et al: Reported knowledge, perceptions, and behavior of tourists and North Queensland residents at risk of contact with jellyfish that cause the "Irukandji syndrome." *Wilderness Environ Med* **15**:4, 2004.

TABLE 209-3
First Aid Treatment of Jellyfish Stings

1. Remove or rescue the victim from the water.
2. Stabilize vital functions: Airway, breathing, circulation.
3. Immobilize the affected part to prevent further envenomation by adherent tentacles.
4. Identify the type of jellyfish sting by considering locale, time of year, and indigenous species and by observing the sting pattern. Preserve a portion of the tentacle for future identification. Tape-strip or scrape the sting site for microscopic analysis of the nematocysts if no tentacles are available.
5. To prevent further envenomation of the victim and to reduce the chance of a sting to the rescuer, disarm the nematocysts before removing the adherent tentacles.

Data from refs. 46, 47, 52, 53, 105, and 106.

TABLE 209-4
Organism-Specific and Follow-Up Treatment of Jellyfish Stings

1. If *Chironex fleckeri* or other box jellyfish species that cause the Irukandji syndrome are suspected, douse or spray dilute acetic acid (3%–10%) or household vinegar over all areas of tentacle contact for at least 30 s.[46,47,51,105,106]
2. For sea nettles, mix sodium bicarbonate (baking soda) with water to form a slurry and pour over the affected area or apply the powder directly to the tentacles.[107]
3. For *Physalia physalis* stings, a slurry of baking soda is indicated. Vinegar had been reported to neutralize nematocysts of *P. physalis*, but work with species from Australia indicate that it may cause a discharge of nematocysts in some cases.
4. If vinegar or baking soda is unavailable, papain, available as a powdered meat tenderizer, may be applied directly as a powder or mixed in water as a slurry to sting areas and tentacles of both sea nettles and Portuguese man-of-war.
5. If nothing else is available, the tentacles can be rinsed off with seawater.
6. Do not use fresh water, methylated spirits, or alcohol in any form to deactivate tentacles, because these all may cause a rapid massive discharge of nematocysts.
7. After the tentacles have been disarmed, they may be carefully removed with a forceps or gently scraped away from the skin with shaving cream and a razor or a plastic card, shell, or knife.[59,70,91]

sting site and decrease the chance of scarring. Intravenous administration of verapamil has been advocated for both treatment and prophylaxis of arrhythmias.[49,50] For pain in severe stingings, parenteral narcotic analgesics and ice packs, as well as antivenin, should be considered. Local reactions may be treated with topical anesthetic ointments, creams, lotions, or sprays to relieve itching or burning pain.[33] For delayed-type hypersensitivity reactions, topical glucocorticoids, antihistamines, and systemic glucocorticoids should be used if necessary.[35]

Secondary infections should be treated with the appropriate parenteral antibiotics, and antitetanus therapy should be considered. Application of ice or cold packs can relieve the pain of mild to moderate stings of many types of jellyfish, and aspirin or acetaminophen, alone or in combination with codeine, can be used to relieve persistent pain.

SEA ANEMONE DERMATITIS Sea anemones are members of the phylum Cnidaria, class Anthozoa. They are sessile creatures with flowery tentacles armed with nematocysts (Fig. 209-12). The stings of sea anemones may cause dermatitis in sponge fishermen, sponge divers, and beachcombers who gather snails and crabs from rocky hollows along the shore. Their toxicity to humans depends on the species. After the immediate reaction has subsided, delayed-type hypersensitivity reactions can develop at the site of a sting from a sea anemone (Fig. 209-13).



▲ **FIGURE 209-12** The flowery tentacles of the sea anemone can cause envenomations similar to jellyfish stings. (Used with permission from Marty Gilman, Worcester, MA.)

The genus *Sagartia* is the cause of sponge fisherman's disease.[33] This anemone lives at the base of sponges sought by commercial fishermen. When they harvest or sort the sponges with their bare hands or forearms, they are likely to come into contact with the tentacles of *Sagartia*. Itching and burning occur at the sting site within minutes, accompanied by erythema, edema, and vesicles.[33]

Treatment of sea anemone stings is similar to that of jellyfish envenomations (see Prevention and Treatment of Jellyfish Stings).[55] The tentacles should be removed carefully.[33] Both vinegar and Stingose (an aqueous solution of 20 percent aluminum sulfate and 11 percent surfactant) have been suggested for application to neutralize the sites of anemone stings.[56] Sea anemone sting sites often heal slowly and may require treatment with antibiotics.

INJURIES CAUSED BY FIRE CORAL AND CORAL CUTS Corals are colonial organisms belonging to the phylum Cnidaria. Coral injuries may be caused by nematocyst stings or lacerations. Both injuries may occur at the same time and may be complicated by foreign-body reactions, bacterial infections, and localized eczematous reactions. For most true corals nematocyst envenomation is a relatively innocuous experience, resulting in mild pruritic erythema that requires little if any treatment. Calamine lotion or antipruritic lotions may bring relief.[57]

In contrast to the stings of true corals, the sting of the fire coral, *Millepora alcicornis*, is quite painful, as many scuba divers and snorkelers from the Florida Keys to the Caribbean will attest (Fig. 209-14). The wet mucous membrane or slime surrounding the organism contains numerous nematocysts that readily discharge



▲ **FIGURE 209-13** Delayed-type hypersensitivity reaction to a presumed sea anemone sting. This 11-year-old girl stepped into a hole while wading in shallow waters on the South Carolina coast. She experienced an immediate burning pain with erythema and swelling of both lower legs that subsided within a day. Several days later she developed a pruritic linear eruption. A diagnosis was made of a delayed-type hypersensitivity reaction that developed in the sting site and corresponded with the tentacle marks from what was presumed to be a sea anemone envenomation.





▲ **FIGURE 209-14** The mustard-colored finger-like outcropping in the upper left quadrant of this formation of coral and hydroids is a typical example of fire coral.



on contact with the skin, causing immediate burning and stinging pain. Within 1 to several hours a pruritic erythematous papular eruption appears, which in severe cases may become pustular and, in rare cases, may progress to necrosis and eschar formation.[57] Lesions heal in 1 to 2 weeks, often with post-inflammatory hyperpigmentation. A delayed and persistent allergic contact dermatitis has also been reported to occur from a fire coral sting in the Red Sea.[58]

Fire coral stings should be rinsed with seawater to remove undischarged nematocysts. The sting area can then be compressed with either 5 percent acetic acid (vinegar) or 40 percent to 70 percent isopropyl alcohol for 15 to 30 minutes or until the pain is relieved.[36,59] Seawater compresses, hot to the point of tolerance, are also reported to inactivate the toxin. A topical steroid cream or ointment may relieve pruritus and promote healing.

Coral cuts, lacerations caused by the razor-sharp exoskeletons of coral, are notorious for their slow healing and propensity for secondary infection.

Treatment of coral cuts should begin with vigorous cleansing of the wound with soap and water with a soft brush or rough towel, followed by copious irrigation with saline to remove foreign bodies. If the wound is extensive, local anesthesia may be required to allow adequate cleansing, exploration, and débridement and to achieve good hemostasis. Hydrogen peroxide washing of the wound before dressing it is recommended.

The decision whether to perform primary closure of a coral cut wound or to allow it to heal by secondary intention depends on the location of the wound, the degree of tissue trauma at the wound margins, and the likelihood of subsequent infection. Tape stripping is preferable to suturing of leg wounds, because sutured leg wounds have a high chance of abscess formation.

Dermatitis from Sponges

Sponges are members of the phylum Porifera, class Desmospongiae. They are simple multicellular animals that live attached to the sea bottom. Sponges grow by forming a series of hollow-centered branching tubes composed of a fibrous material called *spongin*, which contains spicules of calcium carbonate or silica.[33,60,61] Spicules of certain species of sponges are capable of penetrating the skin, causing a localized irritant or foreign-body reaction. Treatment of sponge spicule dermatitis involves tape stripping of the affected area.

At least 13 species of sponges can cause a toxic dermatitis. Of these, the most commonly encountered are the West Indian and Hawaiian fire sponge, *Tedania ignis*; the poison bun sponge, *Fibula nolitangere* (Fig. 209-15); and the red sponge, *Microciona prolifera*, found in the northeastern United States.[62] These creatures are covered by a surface secretion, or slime, that produces an irritant or toxin-induced dermatitis when contacted by bare skin.[61]

Symptoms of itching, prickling, stinging, or burning appear within minutes of exposure and are followed within a few hours by pain, swelling, and stiffness. If the fingers are involved, they often become immovable within 24 hours. The first cutaneous sign of sponge poisoning is local erythema, which progresses to a papular, vesicular, or bullous eruption with weeping of a serous or purulent fluid.[61,62] Desquamation of the site occurs within several days. Erythema multiforme and anaphylactoid reactions have been reported in highly sensitized individuals.

Treatment of sponge dermatitis is similar to that of severe poison ivy.[62]

Injuries Caused by Echinoderms: Sea Urchins, Starfish, and Sea Cucumbers

SEA URCHINS Sea urchins are spiny creatures that belong to the phylum Echinodermata, class Echinoidea. They are encased in a fragile, roughly spherical, calcareous shell, which is protected by a formidable array of mobile spines and pincer-like organs known as *pedicellariae*[63,64] (Fig. 209-16).

Bathers, surfers, divers, and fishermen are all at risk for sea urchin injuries.

Encounters with sea urchins can result in both immediate and delayed reactions. Immediate reactions are usually localized and are initially manifested by a severe burning pain at the wound site, which quickly becomes red and swollen and may bleed profusely. There may be a black or purple discoloration at the site of the spine penetration due either to retained spines in the wound or to a tattoo-like effect from dye released by spines that have exited intact, but this discoloration will likely disappear



◀ **FIGURE 209-15** The poison bun sponge, *Fibula nolitangere*, can cause a severe irritant or toxin-induced contact dermatitis.

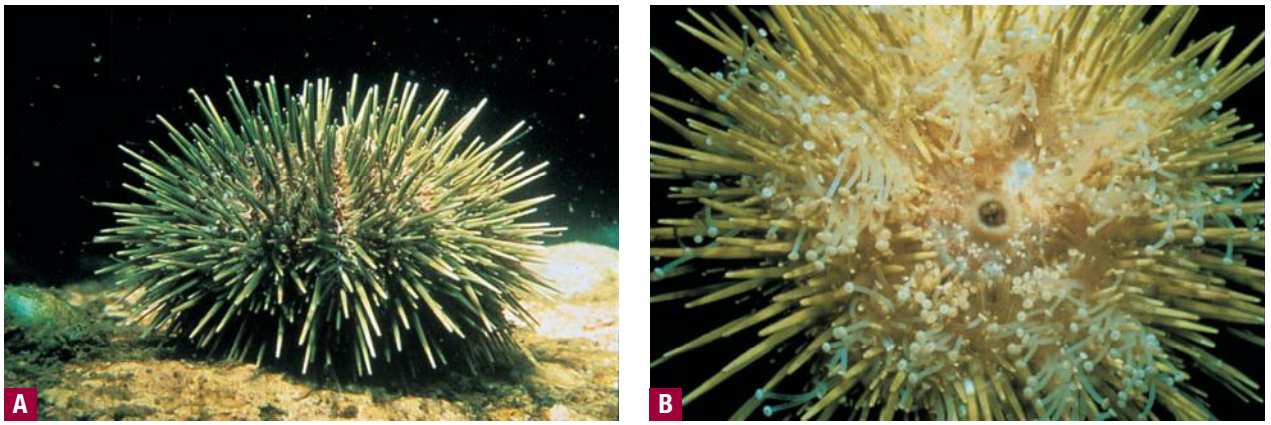

▲ **FIGURE 209-16** Lateral (**A**) and ventral (**B**) views of a sea urchin demonstrate this animal's protective spines and venomous pedicellaria underneath. (Used with permission from Marty Gilman, Worcester, MA.)

within 48 to 72 hours.[59] Paresthesias may develop at the wound area. Systemic symptoms are not common but can occur in injuries due to particularly venomous species. Symptoms may include nausea, syncope, paresthesias, ataxia, muscle cramps, paralysis, and respiratory distress.[62]

Delayed-type hypersensitivity reactions may occur with erythema and intense pruritus days after the initial injury.[65] In one of these cases, the diagnosis was confirmed by patch testing with extracts of the ground sea urchin spines.[66] Nodular reactions are localized to the area of spine penetration and are not usually painful. Nodules may take on colors from the dye in the spines[63] and may have a central umbilication or a keratotic surface[63] (Fig. 209-17).

The diffuse form more commonly involves the fingers or toes and is manifested by a fusiform swelling of the affected digit with accompanying pain and loss of function.[62,63] In addition to joint synovitis and arthritis, osteoarticular complications of sea urchin spine penetration may include tenosynovitis with or without destruction of the underlying bone, fasciitis, and bursitis.[67] Sea urchin spine wounds may also cause direct mechanical injuries to nerves and may be complicated by secondary infection.

Initial first aid for the pain from immediate reactions is to soak the affected area in hot water [43°C to 46°C (110°F to 115°F)] for 30 to 90 minutes until maximal relief is obtained. Infiltration of the wound site with 1 percent to 2 percent lidocaine without epinephrine may be required in some cases to produce significant pain relief.[70] Spines protruding from the wound may be carefully removed. They are very fragile, however, and it is difficult to extract the entire spine intact. Tumescence of the skin with a local anesthetic may allow superficially imbedded spines to be extracted when radiographs demonstrate no evidence of joint or bony impingement.[64] More invasive attempts at spine removal should not be made without the benefit of aseptic surgical facilities and radiographs to confirm the spine locations. Removal of the spines may be aided by the use of an operating microscope. Antibiotics are indicated for secondary infections, and tetanus prophylaxis should be given if indicated.



▲ **FIGURE 209-17** **A** and **B.** Nodular reactions to imbedded sea urchin spines. (Used with permission from Karen Rothman, MD.)



STARFISH Certain species of starfish may produce puncture wound injuries similar to those caused by sea urchins. The crown-of-thorns starfish, *Acanthaster planci,* accounts for most severe starfish envenomations.[62] The ice pick–like spines of *A. planci,* which may reach 4 to 6 cm in length, are covered with a thin skin and glandular tissue that produce a poisonous slime.[71] The resulting wound is quite painful and may be accompanied by numbness and paresthesias. Systemic symptoms including nausea, vomiting, and muscle weakness are infrequent and short lived.[62] Fragments of spines and their surrounding integument may become imbedded in the wounded area, resulting in granulomatous reactions.

Treatment is similar to that of sea urchin wounds.



SEA CUCUMBERS Sea cucumbers are sausage-shaped, bottom-feeding echinoderms that can produce a papular contact dermatitis by means of a toxic liquid substance, known as *holothurin,* that is secreted from their body walls.[33] Conjunctivitis, even blindness, can result from corneal involvement if the toxin comes in contact with the eyes.[62] Prevention of sea cucumber dermatitis involves protecting the skin and eyes from contact with these creatures and educating children and curious divers about the risk of handling them. Treatment consists of washing the affected area with soap and water to remove the toxin and then treating as for a mild contact dermatitis.

Dermatitis and Bites from Marine Worms

BRISTLEWORM DERMATITIS Bristleworms are multisegmented marine worms of the phylum Annelida, class Polychaeta (which means "many bristles"; Fig. 209-18). Each segment of the worm is armed with rows of silky or bristle-like, hollow, venom-filled setae that can easily penetrate and break off in the unprotected skin of a victim as do cactus spines.[71] Contact with the bristleworm results in an erythematous papular or urticarial eruption at the site, accompanied by symptoms of paresthesias, intense itching, or burning pain.[33,71] The bristles are too small and fragile in most cases to be removed with a forceps; however, tape stripping with cellophane adhesive tape can be effective. After the setae have been removed, the application of ammonia soaks or alcohol or water compresses may bring symptomatic relief.



◀ **FIGURE 209-18** *Hermodice carunculata*, the West Indian bristleworm, can inflict a painful wound with its hollow, venom-filled bristle-like setae. (Used with permission from Marty Gilman, Worcester, MA.)

LEECH BITES Leeches are another class of segmental worms whose bites may be encountered in freshwater or saltwater as well as on land. Although freshwater leeches are capable of attaching painlessly to their human hosts, saltwater leeches produce bites with pain similar to that of a bee sting. Leeches inject a powerful anticoagulant, hirudin, into the wound, as well as other antigenic substances that are capable of eliciting allergic reactions (including anaphylaxis) in sensitized individuals. Local symptoms of leech bites include bleeding from the puncture marks, pain, swelling, redness, and severe pruritus; urticarial, bullous, or necrotic reactions may occur in sensitized persons.[33]

Severe ulcerations may result if the leech is removed forcibly and its mouth parts are left behind in the bite site. Leeches must be induced to fall off by applying a noxious agent (such as alcohol, vinegar, brine, or a match flame) to their site of attachment.

CERCARIAL DERMATITIS (CLAM DIGGER'S ITCH) Cercarial dermatitis, also known as *schistosome dermatitis* or *swimmer's* or *clam digger's itch,* is an acute pruritic eruption resulting from penetration of the skin by the cercarial forms of certain parasitic flatworms of the family Schistosomatidae.

Symptoms of cercarial dermatitis begin with urticaria-like lesions and a prickling sensation of the skin, which lasts about half an hour after exposure to cercaria-infested waters. Severe pruritus of the affected area occurs 10 to 12 hours later. Within 24 hours, erythematous papules appear that may progress to vesicles and later to pustules. Pain and swelling of the area accompanies the intense itching, which usually peaks in 48 to 72 hours. Headache, fever, and superinfection with lymphangitis are occasionally present.

In the Great Lakes region, several species of schistosome cercariae that cause swimmer's itch have been reported, and many other such species have been discovered throughout the world in both freshwater and saltwater.[72,73] A severely disabling form of cercarial dermatitis affects the paddy workers and rice farmers of the Far East. Cercarial dermatitis has also been described in individuals exposed to shallow coastal waters, notably on Long Island Sound where the condition affects clam diggers, giving rise to the name, *clam digger's itch* (Fig. 209-19). There is one reported case of cercarial dermatitis occurring on the hands and arms of a patient after he cleaned the aquarium in which he kept native water snails.[74]

Humans are accidental hosts in the life cycle of dermatitis-producing schistosomes.

The differential diagnosis of cercarial dermatitis includes insect bites from



▲ **FIGURE 209-19** Intensely pruritic papulovesicles suggestive of a severe reaction to flea bites in a patient with clam digger's itch. The left hand, which was not in the water and was holding the pail for collecting the clams, was spared.

chiggers, mosquitoes, and fleas; contact dermatitis from poison ivy; and the stings of other marine coelenterates. In Africa, Asia, South America, and Puerto Rico, swimmer's itch must be distinguished from the dermatitis associated with human schistosomiasis, which produces an eruption with very similar but milder and more transient symptoms.[75] Swimmer's itch must also be distinguished from sea bather's eruption (SE), which is discussed in the next section.

Prevention of cercarial dermatitis in waters where swimmer's itch is known to be a problem is difficult. Coating the skin with petrolatum and various chemical repellents has been tried, but the effectiveness of these methods remains unproven. Clothing barriers may be of some help.

Treatment of cercarial dermatitis is largely symptomatic. In mild cases, antipruritic or drying lotions, oatmeal or starch baths, and antihistamines may alleviate pruritus. Aspirin may be helpful for the pain and swelling, and a bedtime sedative may be required to allow the patient much-needed sleep. Proper washing and hygiene should be maintained to prevent bacterial superinfection. In severe cases, potent topical glucocorticoids and occasionally systemic glucocorticoids may be required.

Sea Bather's Eruption

SE, also known as *marine dermatitis* and often misnamed *sea lice infestation*, is an acute dermatitis that begins shortly after bathing in seawater. SE is often confused with swimmer's itch (cercarial dermatitis, see previous section), not only because they both occur after exposure to water but also because the common names of these two conditions are easily confused. For many years, the cause of SE remained a mystery, but it is now known that the responsible agents in at least two types of SE are the larval forms of marine coelenterates. In waters off the coast of Florida and in the Caribbean, the tiny larvae of the thimble jellyfish, *Linuche unguiculata*, are to blame.[76] Off the coast of Long Island, New York, researchers found that the larval forms of the sea anemone *Edwardsiella lineata* were responsible for the eruption.

In addition to having a different etiology, SE can be distinguished from cercarial dermatitis by several other characteristics: SE primarily involves areas of the body covered by bathing suits from which water evaporates slowly, as opposed to uncovered areas as is typical of swimmer's itch. Most symptoms are not noted until the bather has left the water (although some of those affected have complained of a prickling sensation while still in the water).



▲ **FIGURE 209-20** Sea bather's eruption in a young girl after a swim at a Florida beach. (Used with permission from Karen Rothman, MD.)

The eruption is caused by minute stings from the nematocysts of the coelenterate larvae, which become trapped underneath swimwear or may adhere to hairy areas of the body. In addition to SE after contact with the larvae, which are most abundant in May and June, swimmers and bathers may also develop SE after contact with the other two free-swimming stages of *L. unguiculata*, the ephyrae and medusae stages.[77]

The lesions begin within 4 to 24 hours after exposure as erythematous macules, papules, or wheals that may itch or burn (Fig. 209-20).[33] These lesions may progress to vesiculopapules, which crust over and heal in 7 to 10 days. Associated systemic symptoms may include chills and a low-grade fever as well as nausea, vomiting, diarrhea, headache, weakness, muscle spasms, and malaise. Febrile and systemic symptoms are more common in children and adolescents.[78] In the presence of such constitutional symptoms, caregivers who fail to recognize the pattern of the eruption or who fail to take a history of exposure to saltwater may mistakenly make the diagnosis of a viral syndrome.

In waters along the coast of south Florida, the season for SE is between March and August with a peak in May. The incidence among bathers during May and June 1993 in Palm Beach County was reported to be 16 percent.[78] The strongest risk factor for developing SE is a previous history of the condition, which is consistent with the theory that SE represents a hypersensitivity response to the nematocyst stings. Other risk factors include age younger than 16 years and surfing. Showering with swimwear removed was found to be a protective measure.[78]

TABLE 209-5
Prevention of Seabather's Eruption

1. Bathers should remove their swimwear and shower as soon as possible after leaving the water. Because fresh water may cause discharge of the nematocysts, it is important that the suits be removed before showering begins.
2. Bathing suits should be rinsed with soap and water and heat dried, because the eruption can recur when the suit is air dried.
3. T-shirts should not be worn in the water. Women may consider wearing a two-piece suit to reduce the surface area under which larvae may be trapped.
4. Whole-body Lycra swimsuits or wetsuits with snug-fitting collars and cuffs may be protective, but the eruption may still occur along the collar or cuff edges.
5. Highly sensitized individuals should avoid swimming in infested waters during outbreaks of seabather's eruption.

Prevention of SE includes the measures listed in Table 209-5. Treatment of SE is symptomatic and includes the use of antipruritic lotions, colloidal baths with starch or oatmeal, antihistamines, and topical glucocorticoids. Severe unremitting cases may warrant systemic glucocorticoid therapy.[76] Secondary bacterial infections may complicate the condition and should be diagnosed and treated appropriately.

Injuries Caused by Mollusks

CONE SHELL ENVENOMATIONS Cone shells are univalvular gastropods whose ornate cone-shaped shells are highly prized by shell collectors and divers. A number of species have a highly developed venom apparatus that can inflict a lethal sting. Most of the dangerous cone shell species are found in the shallow waters of the Indo-Pacific. Cone shells are carnivorous. They live on the ocean bottom and, depending on the species, may hunt worms, other mollusks, or fish. Cone shells kill their prey by means of a spear-like venomous radular tooth that is thrust out from the animal's proboscis. Cone shell venom contains several different kinds of neurotoxins, and death may result from respiratory paralysis. There is so far no antivenin for cone shell toxin, and mortality rates after envenomations from



the more dangerous species (*Conus geographicus* and *C. magus*) may be as high as 15 percent to 20 percent.[33]

Injuries from cone shells are of the puncture wound variety. The degree of pain is variable, ranging from a mild stinging sensation, similar to that of an insect bite, to excruciating pain. Early symptoms may include edema, ischemia, numbness, and paresthesias of the wound site. Paresthesias may become widespread, with the lips and mouth commonly affected.[33,62] Localized muscular paralysis may progress to generalized weakness or paralysis with eventual respiratory distress and cardiopulmonary failure. Neurotoxic symptoms that indicate severe envenomation include diplopia, blurred vision, aphonia, dysphagia, and coma. Rare cases of disseminated intravascular coagulation have been reported after cone shell envenomation.

Great care must be exercised in handling live cone shells. Thick protective gloves should be worn, and the soft under portion of the animal should be avoided. Cone shells should never be placed in pockets of clothing or swimwear, because they have been known to sting through clothing.[70]

Treatment of cone shell envenomations is supportive. The victim should be kept at rest and the sting area kept dependent and immobilized. A compression dressing should be applied to occlude lymphatic-venous, but not arterial, flow.[70] Local suction may be helpful if it can be applied immediately to the wound site with a plunger device, such as the Extractor Vacuum Pump (Sawyer Products, Safety Harbor, Florida).

OCTOPUS BITES Octopuses are an advanced group of mollusks belonging to the class Cephalopoda. The octopus bites with a parrot-like chitinous beak located on the ventral side of the head in the middle of its eight tentacles (Fig. 209-21). Species of octopi range in size from a few centimeters to 1 to 2 m in diameter.[80] They are shy and reclusive creatures that tend to avoid encounters with humans; however, bites can occur when curious divers, fishermen, or beachgoers encounter these animals and handle them carelessly. Most octopus bites are not life-threatening to humans. The bite site may be immediately painful, as after a bee sting, and is recognized by the presence of two small puncture wounds, which may bleed profusely.[70] Symptoms from octopus bites are usually mild and transient and consist of redness, swelling, and itching.[80]



◀ **FIGURE 209-21** Ventral view of the underside of an octopus exposing the animal's centrally located mouth and parrot-like beak. (From Fulghum DD: Octopus bite resulting in granuloma annulare. *South Med J* **79**:1434, 1986, with permission.)

The most dangerous species of octopus, the Australian blue-ringed octopus, *Hapalochlaena maculosa*, is found in Australian coastal waters. Mortality rates after bites from *H. maculosa* may be as high as 25 percent. *H. maculosa* produces a toxin in its salivary glands that is introduced into the bite site by the animal's powerful beak and contains a fraction identical to tetrodotoxin; this toxin blocks peripheral nerve conduction and results in paralysis of the victim with subsequent respiratory failure. The bite of the blue-ringed octopus may or may not be painful, so that victims may not realize they have been bitten until neurologic symptoms develop.[62]

There is no antivenin for bites of *H. maculosa.* Treatment is supportive and similar to that recommended in the previous section for severe cone shell envenomations.

Injuries Caused by Venomous Fish Spines

Ichthyoacanthotoxicosis is the proper term for envenomations as a result of puncture wounds or lacerations inflicted by the spines of venomous fish. There are more than 200 species of venomous fish in the world that can cause injury to humans.[62] The most notorious of these species are the stingrays, catfish, lionfish, scorpionfish, stonefish, weeverfish, toadfish, and spiny dogfish. All of these fish have in common a venom apparatus consisting of a single spine or multiple spines, in various locations, which are covered by an integumentary sheath enclosing various forms of venom glands. When the spine of the animal penetrates the victim, the sheath is torn and the venom glands release their toxins into the wound. The toxins from some of these fish may remain potent for 24 to 48 hours after the death of the fish.[81]

STINGRAYS Stingrays are one of the most common causes of venomous fish stings confronting humans, with as many as 1500 to 2000 stingray attacks reported each year in the United States alone.[71,82] Rays are grouped into one of four categories; gymnurid (butterfly rays), urolophid (round stingrays), myliobatid (bat or eagle rays), and dasyatid (proper stingrays). The groupings are based on their relative stinging ability, which depends on the size, number, and location of the caudal stinging appendages. The most dangerous group, the dasyatid or true stingrays, have the largest spines located further out on their tails, which makes theirs the most potent striking weapons. The spines have retroserrated teeth, so that removal is difficult (Fig. 209-22).

Most stingray injuries occur when bathers, waders, or fishermen accidentally step on rays as they lie partially covered with sand in shallow waters.[83,84] Severe lacerations and puncture wounds are inflicted by the ray as it defensively whips its tail upward and forward when stepped on or threatened[83,84] (Fig. 209-23). The majority of wounds, therefore, are located on the dorsum of the foot or lower leg. Penetrating wounds to other locations have occurred to fishermen stung while attempting to remove rays from their lines or nets.

CATFISH Both freshwater and saltwater catfish are armed with stout, sharp spines located immediately in front of the soft rays of their dorsal and pectoral fins. Catfish defensively lock these spines into an extended position when they are handled or threatened. Bathers may sustain stings on their feet or legs if they step on a catfish, but most catfish stings involve the hand or upper extremity of fishermen or seafood processors.[86] To prevent these injuries, it has been suggested that the offending



▲ **FIGURE 209-22** A close-up view of a stingray stinger without its outer membrane and venom glands, demonstrating the retroserrated spine. (Used with permission from David Fulghum, MD.)

spines be removed with a pair of pliers before cleaning of the fish is attempted.

Swimmers and bathers in the Amazon River are at risk for urologic injuries if they encounter a very small species of catfish called the *candiru*, which has the ability to enter the human urethra. Barbs on the head of this fish prevent it from swimming backward out of the orifice, and surgical intervention is often required to extract the fish.

SCORPIONFISH Scorpionfish, family Scorpaenidae, are divided into three main groups on the basis of their stinging apparatus. All have venomous spines of varying sizes and toxicity, which may be found in dorsal, pelvic, and anal locations, depending on the species.

Scorpionfish, genus *Scorpaena*, have stings that are of intermediate severity. They are bottom dwellers with superior camouflage abilities that allow them to blend in almost invisibly with their surroundings (Fig. 209-24). Their spines are long and heavy and have moderate-sized venom glands.

Stonefish, genus *Synanceja*, are the most dangerous members of the scorpionfish family. They live in shallow waters, sometimes partially buried in sand or mud, or in holes of rocky shoals, reef areas, or tidal pools.[71] Injuries occur when a wader steps on the erect venomous dorsal spine that the stonefish raises in defense. Stonefish spines are short and thick and have very large and well-developed venom glands.[54] The wounds caused by stonefish are quite severe and may be fatal. A stonefish antivenin is available.

WEEVERFISH In European coastal waters, the weeverfish is one of the most common and serious causes of venomous fish spine injuries.[88] These fish are equipped with between five and eight venomous dorsal spines and two venomous opercular spines (one on each side of the head near the gill plate).[89] Waders and bathers are at risk when they step on weeverfish that lie partly buried in mud or sand in shallow waters.



▲ **FIGURE 209-23** Stingrays reflexively swing their barbed tails up when stepped on, causing painful lacerations and puncture wounds. (The leg used for this photograph was a prosthesis; the stingray was alive.) (Used with permission from David Fulghum, MD.)

LOCAL AND SYSTEMIC SYMPTOMS OF FISH SPINE ENVENOMATIONS The toxicity of a given venomous fish sting depends on a number of factors, including the species of fish involved, the location and severity of the wound, the amount of venom released, and the first aid and subsequent medical care provided to the victim. In general, these wounds produce pain out of proportion to the apparent severity of the injury. The pain is immediate and intense. In the case of scorpionfish stings, the pain may be so severe as to cause the victim to thrash about wildly, scream, and finally lose consciousness.

Initially, the sting site may appear pale or cyanotic. The area around the wound may be anesthetic or hyperesthetic.[54] Erythema and edema soon develop, giving the appearance of a cellulitis. Vesicles may form. In severe stingings, especially those caused by stonefish, the wounded area may become indurated and develop areas of ischemic necrosis with subsequent sloughing and ulcer formation.

Systemic effects from toxic fish spine envenomations may range from mild to severe, depending on the species involved and the amount of venom entering the wound. They can include headache, nausea, vomiting, diarrhea, abdominal cramps and pain, fever, local lymphangitis and lymphadenitis, joint aches, muscle weakness, diaphoresis, peripheral neuropathy, limb paralysis, restlessness, delirium, seizures, cardiac arrhythmias, myocardial ischemia, pericarditis, hypotension, and respiratory distress, and can lead to death.[79,88,90,91]

PREVENTION Prevention of toxic fish spine wounds begins with knowledge of and appreciation for the various venomous species that may be encountered in a given area. Waders and bathers should shuffle their feet to scare away



▲ **FIGURE 209-24** *Scorpaena plumieri*, a species of scorpion fish, is found in the waters of the West Indies. Its camouflage abilities are exceeded only by its painful sting.



and avoid stepping on rays or scorpionfish. Fishermen must exercise care when removing rays or catfish from their fishing lines or when cleaning fish with venomous spines. Fish hobbyists and divers should wear protective clothing and avoid handling venomous species.

TREATMENT Puncture wounds and lacerations from venomous fish spines should be irrigated immediately with sterile saline or water, if available, and with seawater as a last resort.[70] The wounded area should then be soaked as quickly as possible in hot (not scalding) water of approximately 43°C to 46°C (110°F to 115°F) for 30 to 90 minutes or until maximal pain relief is achieved. Hot soaks may be repeated if the pain returns. Because the wound or extremity may be partially anesthetic, the person administering first aid must test the water's temperature for the victim.[84] One source of hot water that is often overlooked and may be useful in an emergency is hot seawater from a boat motor's cooling system.[84]

Local infiltration of the wound with 1 percent to 2 percent lidocaine without epinephrine may bring about significant pain relief and allow exploration of the wound after radiographs have been obtained to locate retained portions of spines.[59,71,84] Longer-acting anesthetics such as procaine and bupivacaine may be chosen to provide a longer period of pain relief. The wound should be thoroughly cleaned to remove any remnants of integumentary sheath. Cleansing with a toothbrush and a solution of hexachlorophene in 70 percent alcohol has been recommended.[78] Abdominal and thoracic wounds and deep wounds to the hands, feet, or fascial compartments of the legs should be explored in the operating room.[71] Débridement of necrotic tissues may be required at the time of exploration, and sequential débridement may be necessary. In general, these wounds should be left open or closed loosely with tape or suture to allow for adequate drainage and to prevent abscess formation.

Tetanus prophylaxis should be administered if indicated, and antibiotics are recommended if the wound is more than 6 hours old, is extensive, or involves deep puncture injuries to the hand or foot.[71] The choice of antibiotic should be based on the bacteriology of the marine environment in which the wound occurred and, subsequently, on results of deep wound or tissue cultures. Empiric antibiotic therapy for infections of wounds occurring in saltwater should include coverage for *Vibrio* species. Before final wound culture results are known, initial choices of parenteral antibiotics include intravenous ciprofloxacin, imipenem-cilastatin, cefotaxime, ceftazidime, gentamicin, tobramycin, or trimethoprim-sulfamethoxazole (see also Chaps. 183 and 184).

Stonefish stings complicated by severe reactions may be treated with antivenin by slow intravenous infusion. Antivenin is not usually required for the stings of lionfish and other species of scorpionfish except for stonefish.[71] Stonefish antivenin is available from the Australian Commonwealth Serum Laboratory, Melbourne, Australia.



▲ **FIGURE 209-25** Moray eel bites are uncommon, but their incidence has increased because divers feed these animals at popular dive sites. (Used with permission from Marty Gilman, Worcester, MA.)

Fish Bites

There are many species of fish whose bites are dangerous to humans. Among the best known are the sharks and barracudas, whose bites may cause severe injuries.

Although they are well publicized by the news media, shark attacks are relatively rare events. The average number of shark attacks worldwide is between 30 and 100 annually.[96] Only 32 of the 350 known species of sharks have been reported to attack humans. Most shark attacks involve surfers, scuba divers, and swimmers. Because sharks are attracted to bright or shiny objects, as well as to those with contrasting colors, these items should not be worn in the water. Sharks are also attracted by any sort of blood in the water; therefore, women who are menstruating should refrain from water sports in areas in which sharks may be prevalent, and no one should swim with an open bleeding wound. Spear fishermen should never tie their catch to themselves, and they should place their catch in the dive boat as soon as possible. Although most shark bites are not life-threatening, more severe attacks may cause extensive soft-tissue loss with massive hemorrhage, which, in the worst cases, can result in amputation of a limb or death.[97,98]

Barracuda attacks are even rarer than shark bites. They tend to occur in turbid waters where these predators may mistake jewelry or other brightly colored objects worn by bathers for the baitfish on which they feed. Barracuda bites typically produce straight or V-shaped lacerations.

Divers and aquarium hobbyists must be careful when feeding or handling moray eels, which have powerful jaws and knife-like teeth. Although they are not considered venomous by most sources, they can produce deep puncture wounds and lacerations[70] (Fig. 209-25). When biting, moray eels tend to lock onto their prey; decapitation of the eel or disarticulation of its jaw may be required to release the victim.[99] As with all deep puncture wounds or lacerations, victims of moray eel bites should receive tetanus prophylaxis. Empiric antibiotic therapy for prophylaxis or treatment can include ciprofloxacin or cefuroxime for coverage of *Vibrio* or *Pseudomonas* species.[100]

WATERBORNE INFECTIONS

A variety of infections may result from exposures to aquatic environments. Pathogenic organisms may be actively introduced into the bite, sting, or laceration wounds caused by marine life; preexisting wounds may be passively infected when exposed to contaminated waters. *V. carchariae*, a halophilic (saltwater-loving) Gram-negative bacillus, was reported as the cause of a wound infection after a shark bite.[103,104] Table 209-6 lists those organisms commonly associated with waterborne in-

TABLE 209-6
Wound Infections Associated with Waterborne Organisms

ORGANISM	CLINICAL FEATURES
Aeromonas hydrophilia	Cellulitis (may be bullous), fasciitis, myonecrosis, bacteremia.
Edwardsiella tarda	Cellulitis, abscess, osteomyelitis, bacteremia.
Erysipelothrix rhusiopathiae	Slowly progressive cellulitis without adenopathy or lymphangitis, almost always involving the hand; septic arthritis; subacute bacterial endocarditis.
Mycobacterium balnei or *marinum*	Swimming pool granuloma; fish fancier's finger; chronic cellulitis and culture-negative ulcers; often the primary lesion is on the hand and then a series of lesions develop in draining lymphatics.
Pfisteria piscicida	Raw, red pock-marked lesions in fish in polluted waterways; in humans, rashes, respiratory problems, and memory deficits.[92]
Protothecosis	Papular or eczematoid dermatitis in immunosuppressed patients; localized infection of the olecranon bursa.
Pseudomonas species	Trench foot; Gram-negative toe web space infections; swimmer's ear; hot tub folliculitis.
Streptococcus iniae	Cellulitis and bacteremia after skin injuries during the handling of fresh fish raised by aquaculture.
Vibrio vulnificus, other *Vibrio* sp.	Cellulitis, sometimes with bulla formation; may progress to septicemia, especially in alcoholics, diabetics, and immunosuppressed patients; metastatic cellulitis, meningitis, and death may result from fulminant infections.

fections (see also Chaps. 183 and 184). A host of other agents, such as *Streptococcus* and *Staphylococcus* sp., *Bacteroides fragilis*, *Clostridium perfringens*, *Escherichia coli*, *Salmonella enteritidis*, marine *Vibrio* sp., *Chromobacterium violaceum*, and *Chlorella*, also require consideration when dealing with infections associated with aquatic settings.[71]

CUTANEOUS MANIFESTATIONS OF SEAFOOD INGESTION AND SEAFOOD POISONING

Dermatologic reactions may appear after the ingestion of seafood. Urticaria, angioedema, and, rarely, leukocytoclastic vasculitis may occur in individuals sensitized to fish or shellfish. Many seafoods, such as kelp, contain large amounts of iodine, which may cause acneiform eruptions.

Scombroid food poisoning involves the ingestion of spoiled fish from the Scombroidae family of fish, such as tuna, mackerel, and bonita. If these fish are not kept cold enough after being caught, their flesh develops scombrotoxins as a consequence of the bacterial breakdown of histidine into histamine, saurine, and possibly other toxic by-products. These can cause striking erythema and flushing of the face, neck, and upper trunk, as well as pruritus and urticarial and angioedematous eruptions. Antihistamines can provide symptomatic relief in severe cases.

Ciguatera toxin, which is produced during blooms of toxic dinoflagellates, is incorporated into the marine food chain and concentrated in the flesh of a variety of fish. It is heat stable, and symptoms may occur after eating cooked or raw fish containing the toxin. Dermatologic symptoms of ingesting these fish may include generalized pruritus and diffuse erythematous macular and papular exanthems, which may progress to blister formation and desquamation.

KEY REFERENCES

The full reference list for all chapters is available at www.digm7.com.

1. Centers for Disease Control and Prevention: Nonfatal dog bite–related injuries treated in hospital emergency departments—United States, 2001. *MMWR Morb Mortal Wkly Rep* **52**:605, 2003
2. Griego RD et al: Dog, cat, and human bites: A review. *J Am Acad Dermatol* **33**:1019, 1995
9. Rupprecht CE, Gibbons RV: Clinical practice. Prophylaxis against rabies. *N Engl J Med* **351**:2626, 2004
10. Talan DA et al: Clinical presentation and bacteriologic analysis of infected human bites in patients presenting to emergency departments. *Clin Infect Dis* **37**:1481, 2003
23. Willoughby RE Jr et al: Survival after treatment of rabies with induction of coma. *N Engl J Med* **352**:2508, 2005
28. Gold BS, Dart RC, Barish RA: Bites of venomous snakes. *N Engl J Med* **347**:347, 2002
33. Fisher AA: Aquatic dermatitis. Part I: Dermatitis caused by coelenterates. *Cutis* **64**:84, 1999
35. Burnett JW et al: Local and systemic reactions from jellyfish stings. *Clin Dermatol* **5**:14, 1987
38. Halstead BW: Coelenterate (cnidarian) stings and wounds. *Clin Dermatol* **5**:8, 1987
43. Stein MR et al: Fatal Portuguese man-o'-war (*Physalia physalis*) envenomation. *Ann Emerg Med* **18**:312, 1989
46. Fenner PJ, Harrison SL: Irukandji and *Chironex fleckeri* jellyfish envenomation in tropical Australia. *Wilderness Environ Med* **11**:233, 2000
48. O'Reilly GM et al: Prospective study of jellyfish stings from tropical Australia, including the major box jellyfish *Chironex fleckeri*. *Med J Aust* **175**:652, 2001
49. Burnett JW, Calton GJ: The case for verapamil use in alarming jellyfish stings remains. *Toxicon* **44**:817, 2004
51. CRC Reef (on behalf of the Queensland Government Irukandji Jellyfish Response Task Force): Current status of knowledge and action on Irukandji, http://www.reef.crc.org.au/discover/plantsanimals/pdf/StatusofKnowledgeandActionPaperSep2002.pdf, September 30, 2002
59. Auerbach PS: Diving medicine articles: I've been stung: What should I do? UPDATED 2004 [Divers Alert Network website], http://www.diversalertnetwork.org/medical/articles/article.asp?articleid=36, 2004
60. Isbister GK, Hooper JN: Clinical effects of stings by sponges of the genus *Tedania* and a review of sponge stings worldwide. *Toxicon* **46**:782, 2005
63. Baden HP: Injuries from sea urchins. *Clin Dermatol* **5**:112, 1987
70. Halstead BW, Auerbach PS, editors: *Dangerous Aquatic Animals of the World: A Color Guide, with Prevention, First Aid, and Emergency Treatment Procedures*. Princeton, NJ, Darwin Press, 1990
72. Verbrugge LM et al: Prospective study of swimmer's itch incidence and severity. *J Parasitol* **90**:697, 2004
76. Tomchik RS et al: Clinical perspectives on seabather's eruption, also known as "sea lice." *JAMA* **269**:1669, 1993
83. Meyer PK: Stingray injuries. *Wilderness Environ Med* **8**:24, 1997



CHAPTER 210

Arthropod Bites and Stings

Christopher J. Steen
Robert A. Schwartz

Arthropod bites and stings are a significant cause of morbidity worldwide. Although many arthropod attacks produce only mild, transient cutaneous changes, more severe local and systemic sequelae can occur, including potentially fatal toxic and anaphylactic reactions. Arthropods also serve as vectors for numerous systemic diseases. The medically significant classes of non-aquatic arthropods are Arachnida, Chilopoda, Diplopoda, and Insecta (Fig. 210-1).[1]



HISTOPATHOLOGY

Many arthropod bites produce a similar histologic reaction pattern. In the acute phase, there is a superficial and deep, perivascular and interstitial inflammatory infiltrate, which is characteristically wedge-shaped. The infiltrate is usually mixed in composition with an abundance of lymphocytes and eosinophils, although neutrophils and histiocytes can also be seen. Neutrophils may predominate in reactions to fleas, mosquitoes, fire ants, and brown recluse spiders. Over the most prominent superficial infiltrates, spongiosis can be seen, sometimes with progression to vesicle formation or epidermal necrosis. Older, excoriated areas are usually altered by the effects of scratching, with the development of parakeratosis, serum exudates, and a dermal infiltrate with neutrophils and more abundant lymphocytes. Although not commonly seen on histology, insects or insect parts, including burrowed scabies mites, eggs, feces, or the retained mouth parts of ticks, may be visible. Chronic lesions, which most often result when arthropod parts are retained in the skin, may take on a pseudolymphomatous appearance (see Chap. 147).

TREATMENT PRINCIPLES

The morbidity from arthropod bites and stings varies with the species inflicting the injury. Although species-specific clinical findings and treatment will be discussed in further detail, there are several general treatment principles that apply. Local wound care is essential following arthropod assault. Wounds should be cleansed and any remaining arthropod parts, including stingers, should be removed as soon as possible. Patient discomfort should be addressed and can involve a variety of treatment modalities, including the use of ice packs, application of topical corticosteroids and antipruritics, injection of local anesthetics, and, less frequently, the use of systemic analgesics. Supportive measures for systemic toxic and allergic reactions, including anaphylaxis, should be instituted when necessary. Secondary infections should be treated with appropriate antibiotics, and bites from several terrestrial arthropods species may require tetanus prophylaxis. Severe envenomation from particular species, such as the black widow spider, may require antivenin administration. Documented hypersensitivity to some species can be treated with desensitization immunotherapy. Awareness of the potential arthropod-borne illnesses spread by each species is also important.

DIFFERENTIAL DIAGNOSIS (Box 210-1)

ARACHNIDA

The class Arachnida contains three orders of medical significance: Araneae (spiders), Acarina (ticks and mites), and Scorpiones (scorpions). Arachnida are distinguished anatomically from other arthropods by a lack of wings or antennae and the presence of four pairs of legs and two body segments. Larval ticks, which only have three pairs of legs, are an exception to this rule (see Fig. 210-1).

Araneae

Spiders are carnivorous members of the animal kingdom that use webs and venom to capture and kill prey. Within the United States, three genera contain species whose bites are toxic to man: *Latrodectus*, *Loxosceles*, and *Tegeneria*. The American Association of Poison Control Centers reported over 15,000 spider bites in the United States in 2004.[2] In the same year, only one death was attributed to spider envenomation in the United States.

LATRODECTUS Members of the *Latrodectus* genus, or widow spiders, are often black in color and have a red, hourglass-shaped marking on their abdomens (Fig. 210-2). Although there are more than 20 species of widow spiders, *L. mactans*, the Southern black widow spider, is the most common and notorious in the United States and can be found in all but the most northern parts of the country. Other widow spiders encountered in the United States include *L. various* (Northern black widow), *L. hesperus* (Western black widow), *L. bishopi* (red-legged widow), and *L. geometricus* (brown widow). Members of the *Latrodectus* genus are non-aggressive, trapping spiders that spin webs in protected areas and await their prey. Human bites are often the result of accidental or deliberate provocation. Webs are typically found on the corners of doors and windows, underneath woodpiles, in garages and sheds, and on the undersides of eaves. Webs can also be found around outdoor toilet seats, a location that has led to bites on or near the genitalia.[3]

Clinical Findings. Bites of the black widow spider (*L. mactans*), which are often painful, usually only result in mild dermatologic manifestations. Within the first 30 minutes, localized erythema, piloerection, and sweating may appear at the wound site. A sensation of numbness or aching pain may develop shortly after the bite. Urticaria and cyanosis may occur at the bite site. Black widow venom contains the neurotoxin α-latrotoxin, which acts by opening ion channels at presynaptic

ARTHROPOD BITES AND STINGS AT A GLANCE



- Many arthropod species are capable of inflicting bites and stings on humans.
- Reactions to arthropod assaults can range from mild to life-threatening.
- Arthropods also serve as vectors for systemic diseases.
- The terrestrial arthropods of medical importance include the orders Arachnida (arachnids), Chilopoda (centipedes), Diplopoda (millipedes), and Insecta (insects).

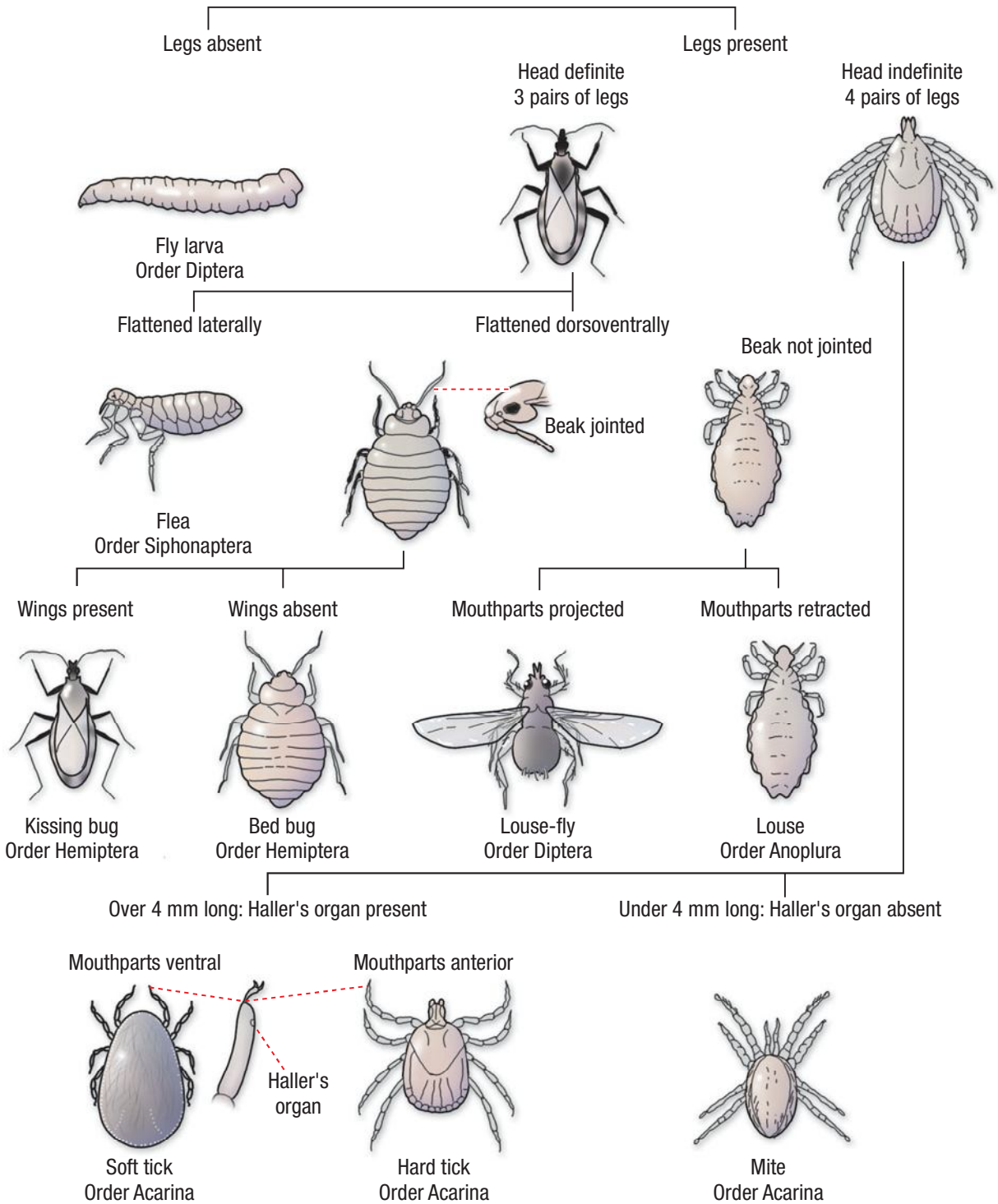

▲ **FIGURE 210-1** Pictorial key to groups of human ectoparasites. (Used with permission from C. J. Stojanovich and H. G. Scott, U.S. Department of Health, Education, and Welfare, Public Health Service.)

nerve terminals, thereby causing an irreversible release of acetylcholine at motor nerve endings and catecholamines at adrenergic nerve endings.[4] Consequently, black widow bites may produce agonizing crampy abdominal pain and muscle spasm that may mimic an acute abdomen.[4] Other signs and symptoms include headache, paresthesias, nausea, vomiting, hypertension, lacrimation, salivation, seizures, tremors, acute renal failure, and sometimes, paralysis; fortunately, death is uncommon. Based on the spectrum of symptoms, black widow bite may be misdiagnosed as drug withdrawal, appendicitis, meningitis, or tetanus, to name a few.[4]

Management. Although many widow spider bites require only local wound care, more serious reactions may necessitate hospitalization. Those patients at increased risk for serious complications include the very young, very old, and those with underlying cardiovascular disease. Current treatments for black widow envenomation include intravenous calcium gluconate (10 percent), narcotic analgesics, muscle relaxants, and benzodiazepines.[5] *L. mactans* antivenin prepared from equine serum is also available. Additionally, there appears to be an effective cross-reactivity among antivenin for a number of other



Box 210-1

Differential Diagnosis of Arthropod Bites and Stings

- Black widow bite: Acute abdomen (appendicitis, etc.), meningitis, tetanus, drug withdrawal, acute renal failure, acute myocarditis, acute coronary syndrome, other arthropod bite
- Brown recluse bite: Hobo spider bite, chemical burn, Lyme disease, cutaneous anthrax infection, pyoderma gangrenosum, ecthyma, trauma, vasculitis, neoplasm, other arthropod bite
- Scorpion sting: Other arthropod bite, tetanus, botulism, Guillain-Barré, organophosphate toxicity, medication overdose
- Centipede bite: Other arthropod bite, cellulitis
- Millipede "burn": Contact dermatitis, conjunctivitis
- Insect bites (flies, fleas, bedbugs, kissing bugs): Other arthropod bites (scabies, lice), atopic dermatitis, contact dermatitis, papular urticaria, delusions of parasitosis
- Hymenoptera bite/sting: Other arthropod bite, anaphylaxis
- Lepidopterism: Other arthropod bite, contact dermatitis, atopic dermatitis, phytodermatitis

Latrodectus species.[6–8] The benefits of the antivenin in treating complications of widow bites should be weighed against the potential for allergic reaction to the antivenin. Patients should also be up to date on tetanus immunization.

LOXOSCELES Members of the *Loxosceles* genus, also called *recluse spiders* or *fiddleback spiders*, are non-aggressive spiders characterized by a dark brown marking on their cephalothorax in the shape of a fiddle or violin (Fig. 210-3). The brown recluse spider, *L. reclusa*, is the most well-known member of this genus and is most abundant in the American Midwest and Southeast. Other medically significant members of this genus include *L. deserta* (Desert recluse), *L. rufescens* (Mediterranean recluse), *L. kaiba* (Grand Canyon recluse) and *L. arizonica* (Arizona recluse). Recluse spiders are so named because they will often seek out shelter in undisturbed places such as closets, attics, and storage areas for bedding and clothing. Bites usually occur when the spider feels threatened or provoked, such as when someone tries to put on clothing that contains the spider.[1]

Clinical Findings. Bites of the brown recluse spider (*L. reclusa*) vary from mild, local reactions to severe ulcerative necrosis, a reaction known as *necrotic arachnidism*. After a bite, transient erythema may develop with the formation of a central vesicle or papule. The hallmark "red, white, and blue" sign of a brown recluse bite is characterized by a central violaceous area surrounded by a rim of blanched skin that is further surrounded by a large asymmetric erythematous area (Fig. 210-4A). In a small percentage of cases, the initial wound may progress to necrosis (see Fig. 210-4B), which usually begins 2 to 3 days after the bite, with eschar formation occurring between the fifth and seventh days.[9] Eventually deep ulcers develop (see eFig. 210-4.1 in on-line edition). The bite reaction may mimic pyoderma gangrenosum or erythema migrans of Lyme disease.[10] Cutaneous anthrax and chemical burns have been mistaken for a brown recluse spider bite.[11,12] The potential for misdiagnosis has led to the development of a sensitive enzyme-linked immunosorbent assay for *Loxosceles* species venom that may eventually be available for clinical application.[13]



▲ **FIGURE 210-2** Black widow spider with characteristic red hourglass marking on the underside of its abdomen.



▲ **FIGURE 210-3** Brown recluse spider with characteristic fiddle-shaped marking on cephalothorax.

Brown recluse venom contains a number of proteins, including sphingomyelinase D, esterase, hyaluronidase, and alkaline phosphatase, which all contribute to tissue destruction. Sphingomyelinase D, the major component of the venom, cleaves sphingomyelin to form cermade-1-phosphate and choline and also hydrolyzes lysophosphatidylcholine to produce lysophosphatidic acid.[14] Lysophosphatidic acid then triggers a pro-inflammatory response and causes platelet aggregation and increased vascular permeability.[14] Sphingomyelinase D is also capable of inducing complement-mediated hemolysis.[15] Systemic symptoms may develop within 1 to 2 days after envenomation and include nausea, vomiting, headache, fever, and chills. Rare but serious sequelae of brown recluse bites include renal failure, hemolytic anemia, hypotension, and disseminated intravascular coagulation.[16,17]

Management. General treatment measures for recluse bites include cleansing the bite site and the application of cold compresses. Patients may also require



▲ **FIGURE 210-4** **A.** Clinically typical brown recluse spider bite showing the "red, white, and blue" sign. **B.** Late brown recluse spider bite with overlying eschar.

analgesics to control pain. Antibiotics may be useful in reducing secondary bacterial infection of the wound site. Warm compresses and strenuous exercise should be avoided. Although *Loxosceles* antivenins have been developed and are frequently used in South America, there is little evidence to support their effectiveness, particularly against local cutaneous effects.[8] A number of treatment modalities have been suggested, including hyperbaric oxygen, dapsone, intralesional and systemic corticosteroids, colchicine, and diphenhydramine.[18,19] However, one study that used a rabbit model to compare dapsone, colchicine, intralesional triamcinolone, and diphenhydramine showed no effect on eschar size from any of these medications.[18] Necrotic wounds heal slowly, sometimes over many months, and may require surgical excision and reconstruction to close the resulting defect. Surgical interventions should be delayed until the wound has stabilized.

TEGENARIA *Tegenaria agrestis*, the hobo spider or "aggressive house spider," is the predominant cause of necrotic arachnidism in the Pacific Northwest of the United States and can be found in an area ranging from Alaska to Utah.[20] Although *Loxosceles* species are not typically found in the same geographic distribution, bites from hobo spiders are often mistaken for brown recluse bites. These spiders are brown in color with a gray herringbone pattern on the abdomen.[21] The hobo spider typically builds funnel-shaped webs in crawl spaces, basements, wood piles, and bushes. Most hobo spider bites occur from July to September when the more venomous male spiders are seeking mates.

Clinical Findings. The local cutaneous effects after envenomation by the hobo spider, which can range from mild to serious, are similar to those caused by the brown recluse.[22] The initial bite is often painless. Induration and paresthesia of the bite site may develop within 30 minutes. A large erythematous area may form around the site. Vesicle formation often occurs during the first 36 hours. Eschar formation may follow in severe cases, with necrosis and sloughing of the underlying tissue.

Management. Wounds usually heal within several weeks. The most common systemic symptom after a hobo spider bite is a severe headache, which can persist for up to 1 week.[23] Other symptoms may include fatigue, nausea, vomiting, diarrhea, paresthesias, and memory impairment. Although rare, death may ensue due to severe systemic effects, including aplastic anemia.[23]

TARANTULA Tarantulas are indigenous to certain regions of the United States and are also kept as exotic pets. Tarantulas are members of the family Theraphosidae and are hair covered and larger than many other types of spider, with leg spans of up to 12 inches reported in certain species. Unlike the other venomous spiders discussed, tarantula bites generally only produce mild local symptoms. However, more serious reactions can be caused by urticating hairs on the spider's abdomen. When threatened, tarantulas may rub their back legs together in a motion that flicks these hairs off. These hairs may become embedded in the skin or eyes. Cutaneous responses to the hairs range from mild, local pruritus to granulomatous reactions. Ocular sequelae from hairs embedded in the cornea range from conjunctivitis and keratouveitis to corneal granulomas and chorioretinitis.[24–27] Although cutaneous reactions can be treated with topical corticosteroids, ocular involvement requires ophthalmologic evaluation.

Scorpiones

The order Scorpiones (scorpions) comprises terrestrial arachnids most commonly encountered in tropical or arid



regions, including the southwestern United States, northern Africa, Mexico, and the Middle East. These nocturnal creatures seek shelter under stones and bark during the day. As with other arachnids, scorpions are generally shy and sting humans only when provoked. Although capable of producing significant local wounds, the potential for serious, even lethal, cardiovascular complications following a scorpion sting remains of primary concern.[1] The scorpion of principal interest in the United States is *Centruroides exilicauda* (formerly *C. sculpturatus*), whose sting is potentially fatal (Fig. 210-5). *Centruroides* species possess a small spine at the base of the stinger, a feature which may help distinguish them from other species of scorpion.[28,29]



CLINICAL FINDINGS Scorpion stings usually produce an immediate, sharp, burning pain. This may be followed by numbness extending beyond the sting site. Regional lymph node swelling, and, less commonly, ecchymosis and lymphangitis, may develop. *C. exilicauda* venom contains a powerful neurotoxin, capable of producing muscle spasticity, nystagmus, blurred vision, slurred speech, excessive salivation, respiratory distress, pulmonary edema, and myocarditis.[30–35] Infants and young children are at the greatest risk for serious complications.[29]

MANAGEMENT Mild scorpion envenomations may only require symptomatic treatment, including analgesics and local ice compresses. Any child stung by a scorpion, especially if identified as *C. exilicauda*, should be hospitalized for close monitoring of respiratory, cardiac, and neurologic status.[36] Specific antivenin is the treatment of choice for severe envenomation. Studies indicate that *C. exilicauda* antivenin is safe, with a low incidence of anaphylactic reaction following infusion and a rapid onset of symptom relief.[34,37] Although serum sickness is common after antivenin infusion, it is usually self-limited and can be managed with antihistamines and corticosteroids.[34,37]



◀ **FIGURE 210-5** *Centruroides* scorpion.

Acarina

The order Acarina contains ticks and mites (see Fig. 210-1). Ticks are the most numerous members of this order, with approximately 800 known species. They are important worldwide as vectors of systemic disease, capable of transmitting viruses, rickettsia, spirochetes, bacteria, and parasites to humans.

MITES (See Chap. 208)

TICKS Ticks are divided into two families: Ixodidae (hard ticks) and Argasidae (soft ticks). Hard ticks are responsible for the majority of tick-related disease. Ticks pass through multiple stages during their life cycle, including egg, larva, nymph, and adult, and require blood meals for transition between the latter three stages. Ticks are distinguished from other mites by the presence of a barbed hypostome, which is inserted into the skin for feeding (Fig. 210-6). Ticks ingest blood from a diversity of vertebrate hosts including birds, reptiles, and mammals.[38] Adult hard ticks are capable of ingesting several hundred times their unfed body weight when taking a blood meal and may survive for months without feeding. When searching for a suitable host, hard ticks exhibit a unique behavior called "questing" during which the tick crawls to the edge of a leaf or blade of grass and holds its front pair of legs stretched out in order to grab onto a passing host.[39–41] Humans often become infested by contact with tall grass or brush that harbors the unfed ticks or by their association with domestic animals like cats or dogs. Ticks are attracted to the smell of sweat, the color white, and body heat. Once on a host, a tick may spend up to 24



▲ **FIGURE 210-6** *Dermatocentor variabilis* feeding. The tick has been attached for 24 hours.

hours in search of a protected site to feed, such as a skin fold or the hairline. Tick feeding time ranges from 2 hours to 7 days, with the tick dropping off of the host once fully engorged.

Many different tick species are responsible for local tick bite reactions and transmission of disease in human hosts. In the United States, *Ixodes scapularis* (deer tick or black-legged tick), *Dermacentor andersoni* (American wood tick), *D. variabilis* (American dog tick), *I. pacificus* (Western black-legged tick), and *Amblyomma americanum* (Lone Star tick) are among the most common. In the Eastern Hemisphere, important tick species include *I. ricinus* (castor bean tick or sheep tick) and *I. persulcatus* (Taiga tick). Among the diseases transmitted by ticks are Lyme disease (see Chap. 187), ehrlichiosis, babesiosis, Rocky Mountain spotted fever (see Chap. 199), Colorado tick fever, Q fever, and tularemia (see Chap. 180).

Clinical Findings. The majority of tick bites occur in the spring and summer, coinciding with the life cycle of the tick. Tick bites are usually painless, as the tick introduces an anesthetic and anticoagulant substance when biting. Often, a person will not even know he or she has been bitten but will see or feel an attached tick while scratching or bathing. Tick bites may incite foreign body granuloma formation, reactions to injected toxins and salivary secretions, and hypersensitivity responses. Rarely, delayed hypersensitivity reactions occur with fever, pruritus, and urticaria.[42] A red papule is usually seen at the bite site, and may progress to localized swelling and erythema.[42] A cellular response to the bite can lead to induration and nodularity after a few days. Foreign-body reactions may occur when mouth parts are retained in skin after incomplete removal of the tick. Chronic tick bite granulomas may present diagnostic problems and persist for months to years.

Tick paralysis is a potentially lethal complication of tick infestation and is thought to be caused by a neurotoxin contained within tick salivary secretions. The illness may start with headache and malaise and rapidly progress to an acute ascending lower motor neuron paralysis, similar to that of Guillain-Barré syndrome, which may result in respiratory failure and death.[43,44] Several species of tick are capable of causing tick paralysis, including *D. andersoni, D. variabilis,* and *A. americanum*. Typically, the onset of symptoms occurs 4 to 6 days after attachment of the tick. Symptoms resolve once the tick is removed from the patient. Supportive measures, including mechanical ventilation, may be required until symptoms resolve.

Management. After potential exposure, the skin should be inspected for ticks to remove them before they begin feeding and risk transmitting disease. Once a tick has inserted its hypostome into the skin, it must be forcibly removed. Although many methods have been suggested for removing ticks, physical methods, such as slow, steady pulling on the tick, are probably the safest and most useful. Retained tick parts should be removed surgically if necessary to prevent development of foreign body granulomas. Antibiotic prophylaxis after tick bites is controversial. Although there is some evidence that prophylaxis may help prevent acquisition of Lyme disease and other vector-borne illnesses, the risks of antibiotic therapy must be weighed against the risks and prevalence of vector-borne illnesses in a particular region. In areas highly endemic for Lyme disease, the benefits of prophylactic treatment may outweigh the risks, especially in cases in which the tick has been attached to the host for an extended period of time and can accurately be identified as a vector for Lyme borreliosis. In these cases, the authors suggest a course of oral doxycycline (see Chap. 187).

CHILOPODA AND DIPLOPODA

The arthropod classes Chilopoda and Dipoploda are composed of centipedes and millipedes, respectively. Centipedes and millipedes are terrestrial arthropods with multiple body segments.

Centipedes

Centipedes, which have one pair of legs per body segment, are nocturnal carnivores that may produce extremely painful bites with a pair of poisonous claws. The *Scolopendra* species is found throughout the southwestern U.S. and may attack when its habitat is disturbed. In addition to severe pain and erythema following a bite, localized sweating, edema, secondary infection, and ulceration may be seen. There are also case reports of proteinuria, acute coronary ischemia, and myocardial infarction following centipede bite.[45–49] Treatment consists of analgesia, including injection of local anesthetics, antihistamines, and tetanus prophylaxis. Antibiotics may be required to treat secondary infection.

Millipedes

Millipedes, which have two pairs of legs per body segment, usually feed on living and dead plant matter. They lack poison claws and neither bite nor sting. However, millipedes possess repugnatorial glands on either side of each segment and may emit a toxic substance if threatened. The oily, viscous liquid can cause a brownish discoloration of the skin that can persist for months and may produce burning and blistering.[50–52] Severe reactions are mainly seen in tropical species. Some species are capable of squirting the toxin several inches. This can result in various eye lesions including periorbital edema, periorbital discoloration, conjunctivitis, and keratitis.[53] Although ophthalmologic evaluation should be considered for eye exposures, thorough immediate cleansing with soap and water is usually adequate for skin contact.

INSECTA

The class Insecta contains several orders of medical importance: Anoplura (lice; see Chap. 208), Diptera (flies, mosquitoes), Coleoptera (beetles), Hemiptera (bedbugs, kissing bugs), Siphonaptera (fleas), Hymenoptera (ants, bees, wasps), and Lepidoptera (butterflies and moths). Insects can be distinguished from other arthropods by the presence of three body segments, a pair of compound eyes, paired antennae, and six legs.

Diptera

The order Diptera, or true flies, contains several important families: Culicidae (mosquitoes), Simuliidae (black flies), Ceratopogonidae (biting midges), Tabanidae (horse flies and deer flies), Psychodidae subfamily Phlebotominae (sandflies), and Glossinidae (tsetse flies). Not only do members of this order inflict cutaneous injury with their bites, they are also, collectively, responsible for the transmission of more disease worldwide than any other arthropod order.

The family Culicidae contains more than 2000 species of mosquito, many of which transmit disease. Several genera of mosquito, including *Anopheles*,



Culex, and *Aedes*, serve as vectors for malaria, yellow fever, dengue fever, filariasis, and encephalitis viruses, including West Nile virus, which caused the largest arboviral meningoencephalitis outbreak ever recorded in North America.[54] Because male mosquitoes lack piercing mouthparts, female mosquitoes inflict all human bites. Mosquito bites incite the formation of pruritic wheals and papular lesions, which form in response to irritating salivary secretions that are injected by the mosquito to prevent coagulation. Mosquito bites may have an urticarial, vesicular, eczematous, or granulomatous appearance. Bite reactions usually subside over several days.

Other biting flies include midges, black flies, horseflies, tsetse flies, and sandflies. Black flies of the family Simulidae are vectors for onchocerciasis (African river blindness, see Chap. 207) and tularemia (see Chap. 180). Within the Tabanidae family, *Tabanus* species (horse flies) also serve as vectors for tularemia, and *Chrysops* species (deer flies or mango flies) are responsible for transmission of *Loa loa* filariasis (see Chap. 207) and tularemia. Cutaneous myiasis (Fig. 210-7) may be caused by the deposition of fly larvae into intact skin or open wounds by several species, including *Dermatobia hominis* (human botfly).[55,56] Numerous species of sandflies also spread disease with *Phlebotomus* species transmitting Old World leishmaniasis (see Chap. 206) and *Lutzomyia* species transmitting New World leishmaniasis and Carrión disease (bartonellosis; see Chap. 206). *Glossina* species (tsetse flies) serve as vectors for African trypanosomiasis (see Chap. 206).

Diptera bites should be cleansed thoroughly with soap and water to avoid secondary infection. A short course of topical steroids and systemic antihistamines may be used to control pruritus. Rare allergic reactions should be treated aggressively. Cutaneous myiasis is often best treated with local surgical excision of the larva and involved surrounding tissue. The antihistamines cetirizine or ebastine taken prophylactically as a single 10-mg dose have been demonstrated in studies to decrease wheal formation and subsequent pruritus following mosquito bites.[57,58]



▲ **FIGURE 210-7** Cutaneous myiasis: A domed nodule resembling a furuncle at the site of deposition of a botfly larva. The lesion has a central pore through which the posterior end of the larva intermittently protrudes. The inset shows the larva that has been extracted.

Coleoptera

The Coleoptera order is the largest order in the animal kingdom, containing over 300,000 species of beetles. Although beetles generally do not bite or sting humans, many species of beetle contain chemicals that can cause blistering of human skin.[59] Although some beetles are capable of emitting these chemicals, most cases of blister beetle dermatosis are the result of a beetle being crushed against the skin. The most well-known beetle to cause blister beetle dermatosis is *Lytta vesicatoria*, the Spanish fly, which is found in southern Europe and contains the chemical cantharidin. Cantharidin, which causes vesiculation of the skin, is used in the treatment of warts and molluscum contagiosum. Several other species of beetle found in different regions of the world, including the central and southeastern United States, contain similar chemicals and can cause blistering.[60,61] *Paederus* species (rove beetles) contain the vesicant pederin and are another cause of beetle dermatitis.[61] Washing of affected areas immediately after exposure may help prevent vesiculation. Blisters should be treated with local wound care until resolved.

Another beetle with dermatologic significance is the carpet beetle. The most common species found in the United States are *Attagenus megatoma* (black carpet beetle) and *Anthrenus scrophulariae* (common carpet beetle). Although adult carpet beetles are of little clinical importance, cutaneous exposure to carpet beetle larvae, which feed on wool, carpets, clothing, and other organic material, can cause an allergic papulovesicular dermatitis.[62]

Hemiptera

The Hemiptera order encompasses two families of clinical significance: the Cimicidae, which includes *Cimex lectularius* (bedbugs), and the Reduviidae, which includes *Triatoma* species (kissing bugs). Although most members of this order are herbivores, these two families are frequent human parasites.

CIMICIDAE The common bedbug (*C. lectularius*; see Fig. 210-1) has been a scourge of mankind for centuries. The bedbug is a nocturnal feeder that stays hidden during the day in cracks and crevices of headboards, in picture frames, behind loose wallpaper, or any other dark place that accommodates its flattened body.[1] After a potential victim has gone to bed, the insects come out of hiding for a blood meal. They are attracted to the warmth and carbon dioxide production of their victim. Bedbugs usually complete their meal in a matter of minutes and then return to hiding. Although bedbugs can survive for 1 year or more without feeding, they usually seek a blood meal every 5 to 10 days.[1] Bedbugs are common and are distributed worldwide. They can be spread in clothing and baggage of travelers and visitors, on secondhand mattresses, and via laundry.

Along with other blood-sucking arthropods, the role of bedbugs in infectious dis-



▲ **FIGURE 210-8** Papular urticaria: Bedbug bites. These are pruritic urticarial papules, arranged in a row (breakfast, lunch, and dinner).

ease transmission has gained increasing interest in recent years. Although laboratory studies have shown that these insects are capable of incubating and shedding pathogens such as hepatitis B virus for several weeks after feeding on an infected bloodmeal, there is currently no convincing evidence that *Cimex* species act as vectors in their natural state.[63]

Bedbug bites are usually painless and may be overlooked unless large numbers of bites are present. Bites are usually multiple and may be grouped in a linear fashion. A row of three bedbug bites is sometimes referred to as *breakfast, lunch, and dinner*[64] (Fig. 210-8). Reactions to the bites consist of wheals and papules, often with a small hemorrhagic punctum at the center. Bullous reactions to bites are also possible in sensitized individuals, and hypersensitivity reactions have been reported.[64–66] Flecks of blood may also be found on bed linens. Minimal symptomatic treatment of bites and good local wound care to prevent pruritus and secondary infection are sufficient in most cases.[66] In the presence of a secondary infection, topical antiseptic lotion or antibiotic cream should be applied.[65] Topical corticosteroids may be used for pruritus. Once a bedbug infestation has been diagnosed, a professional exterminator is often necessary to eradicate the insects.

REDUVIIDAE The kissing bug, or assassin bug, belongs to the family Reduviidae and is distinguished by a triangular shape on its back formed by the meeting of the membranous wings. All reduviid bugs possess piercing mouthparts used to feed on blood. Most species of Reduviidae are found in the Americas, with a few species located in Africa, Asia, and Europe. Within the United States, these insects are found in the Southwest from Texas to California. Reduviidae are of great clinical significance because they act as vectors for *Trypanosoma cruzi*, the causative agent of Chagas disease, which affects an estimated 15 million to 20 million people living in South and Central America (see Chap. 206). Kissing bugs earned their name for their predilection to bite on or near the lips. After taking a blood meal, reduviids characteristically turn around and defecate immediately. The trypanosomes are inoculated when the victim subsequently scratches the infected feces into the wound.[1]

Reduviid bugs are found in the southwest United States, especially from Texas to California.[67] Although they are nocturnal feeders and usually prey on rodents, during periodic flights, they move toward the lights of desert homes. Although defensive bites of reduviids are extremely painful, the painless bite of a feeding reduviid occurs only while the host is sleeping, because the blood meal takes several minutes to complete. Bites have been associated with papular, urticarial, and bullous reactions. A small proportion of victims may develop generalized, acute allergic reactions that cause the victim to awaken with sudden onset anaphylactic signs and symptoms.[68] Defensive bites may incite more severe local cutaneous reactions, including necrosis and ulceration.

Siphonaptera

Fleas belong to the insect order Siphonaptera (see Fig. 210-1). These small bloodsucking insects are wingless and are capable of jumping to a height of 18 centimeters. Members of the family Pulicidae, most notably the rat fleas (*Xenopsylla cheopis* and *X. brasiliensis*), transmit bubonic plague (*Yersinia pestis*) (see Chap. 180). Other members of this family are also capable of transmitting disease, including the cat flea (*Ctenocephalides felis*), which is a vector for bubonic plaque and endemic typhus (*Rickettsia prowazekii*).

Flea bites produce minimal irritation in nonsensitized individuals, typically resulting in linear or clustered urticarial papules, frequently found on the lower legs (Fig. 210-9). In sensitized individuals, most often young children, the antigenic saliva is capable of producing papular urticaria, an eruption characterized by recurrent or chronic pruritic papules occurring on exposed skin areas.[1,69] Bullous reactions to flea bites may also develop in patients with hypersensitivity (see eFig. 210-9.1 in on-line edition.) Conservative topical therapy with corticosteroids and antipruritics, along with oral antihistamines, is usually sufficient for most flea bites. Antibiotics may be necessary should secondary bacterial infection develop. Once a flea infestation occurs, complete eradication of the insects is necessary to prevent additional bites.

The Tungidae family contains a tropical flea species called *Tunga penetrans* (the sand flea, chigoe flea, or jigger) that is the etiologic agent of tungiasis, an infestation caused by penetration of the adult female flea into human skin to lay



▲ **FIGURE 210-9** Papular urticaria: Flea bites. Multiple, pruritic urticarial papules, usually < 1 cm in diameter; they may be topped by a vesicle. Here they occur on the legs of a child.





▲ **FIGURE 210-10** Tungiasis: A necrotic periungual papule on the fifth toe. The larva can be visualized by removing the overlying crust.



eggs.[70,71] Lesions occur almost exclusively on the feet (Fig. 210-10), usually on the plantar surface or in the web spaces. Tungiasis may lead to pain, pruritus, secondary bacterial infection, and, sometimes, autoamputation of toes.[72] Death from tetanus has also been reported. Treatment options include surgical excision of the affected area or killing the adult female flea with cryotherapy or topical agents. Tetanus prophylaxis is recommended, and systemic antibiotics should be used when necessary.

Hymenoptera

The order Hymenoptera contains the families Apidae and Bombidae (bees), Vespidae (wasps), and Formicidae (ants). Many members of this order have evolved poison glands used for defense and/or hunting. Aside from local cutaneous reactions, Hymenoptera stings are an important problem because of their high incidence and ability to produce fatal anaphylactic reactions.[73]

All Hymenoptera stings are inflicted by female insects via a modified ovipositor or egg-laying apparatus. Most Hymenoptera stings occur when the nest or individual insects are threatened. The honeybee stings with a barbed ovipositor, which it leaves impaled into the skin. The honeybee dies after stinging because it eviscerates itself to expel its paired venom sacs. The stinger should be removed as swiftly as possible after a sting because the musculature attached to the stinger can continue to pump venom into the skin. If possible, the stinger should not be squeezed during removal with fingers or tweezers as additional venom can be injected into the victim. One method for removal is to scrape the edge of a credit card or the dull blade of a butter knife along the skin at an angle almost parallel to the surface. This will dislodge the stinger while minimizing the injection of additional venom. Other Hymenoptera species lack a barbed stinger and may sting repeatedly.

Imported fire ants (*Solenopsis invicta*), originally from Brazil, are an aggressive species that has become well established in the southeastern United States. *Solenopsis* venom contains a nonproteinaceous, hemolytic factor identified as a dialkylpiperidine, solenopsin D, which induces mast cell degranulation.[74] Imported fire ants often attack in groups. Their sting results in an intense inflammatory, wheal-and-flare reaction that becomes a sterile pustule and may progress to localized necrosis and scarring. Sensitized individuals may experience significant bullous reactions following a sting. When attacking, the ants tend to bite the flesh with their powerful jaws and then pivot and sting in a circular pattern, resulting in ring-shaped lesions.

CLINICAL MANIFESTATIONS Hymenoptera stings typically produce immediate burning and pain, followed by the development of an intense, local, erythematous reaction with swelling and urticaria. This "typical" reaction to hymenoptera stings usually subsides within several hours. However, more severe local reactions can occur, including extensive swelling at the sting site and prolonged induration lasting for up to 1 week. A cell-mediated immune response has also been implicated in these reactions.[75] Generalized systemic reactions to hymenoptera stings occur in approximately 0.4 percent to 3.0 percent of patients. Anaphylactic reactions may be evident as generalized urticaria, angioedema, and bronchospasm.

MANAGEMENT Treatment of a Hymenoptera sting is governed by the severity of the reaction. Mild local cutaneous reactions may only require local cleansing, application of ice, and possible injection of local anesthetic to control pain. Oral or parenteral diphenhydramine may help control urticaria and pruritus. Anaphylaxis must be treated vigorously with subcutaneous epinephrine (0.5 mL of 1:1000 dilution) and the institution of supportive measures. Individuals with known Hymenoptera hypersensitivity should always carry a preloaded epinephrine-filled syringe for emergency self-administration. Desensitization therapy should be considered for any patient with a positive intradermal skin test to Hymenoptera venom and a history of sting-induced anaphylaxis.

Lepidoptera

The Lepidoptera order is the second largest order of insects and contains over 100,000 species of caterpillars, moths, and butterflies. An estimated 100 to 150 species within this order are thought to produce *lepidopterism*, the term used to describe the aggregate of medical effects caused by caterpillars, moths, and butterflies.[76,77] Multiple theories regarding the mechanisms of lepidopterism have been proposed, including mechanical irritation by pointed hairs (setae), toxin injection through hollow setae, and cell-mediated hypersensitivity to the hairs. One well-known cause of erucism or caterpillar dermatitis is *Lymantria dispar* (gypsy moth caterpillar).[78,79] Cutaneous contact with hairs from this caterpillar may produce a pruritic dermatitis characterized by multiple erythematous papules often arranged in linear streaks. Windborne hairs may produce keratoconjunctivitis and respiratory symptoms. *Megalopyge opercularis* (asp or puss caterpillar), which can inject venom through its hollow syringe-like hairs, is capable of inflicting an intensely painful sting, and may produce a characteristic train-track pattern of purpura at the sting site (Fig. 210-11).[80,81] Other species that cause lepidopterism in the Americas include *Automeris io* (io moth), *Euproctis chrysorrhoea* (brown-tailed moth), *Sibine stimulate* (saddleback moth), and *Hemerocampa pseudotsugata* (Douglas-fir tussock moth).

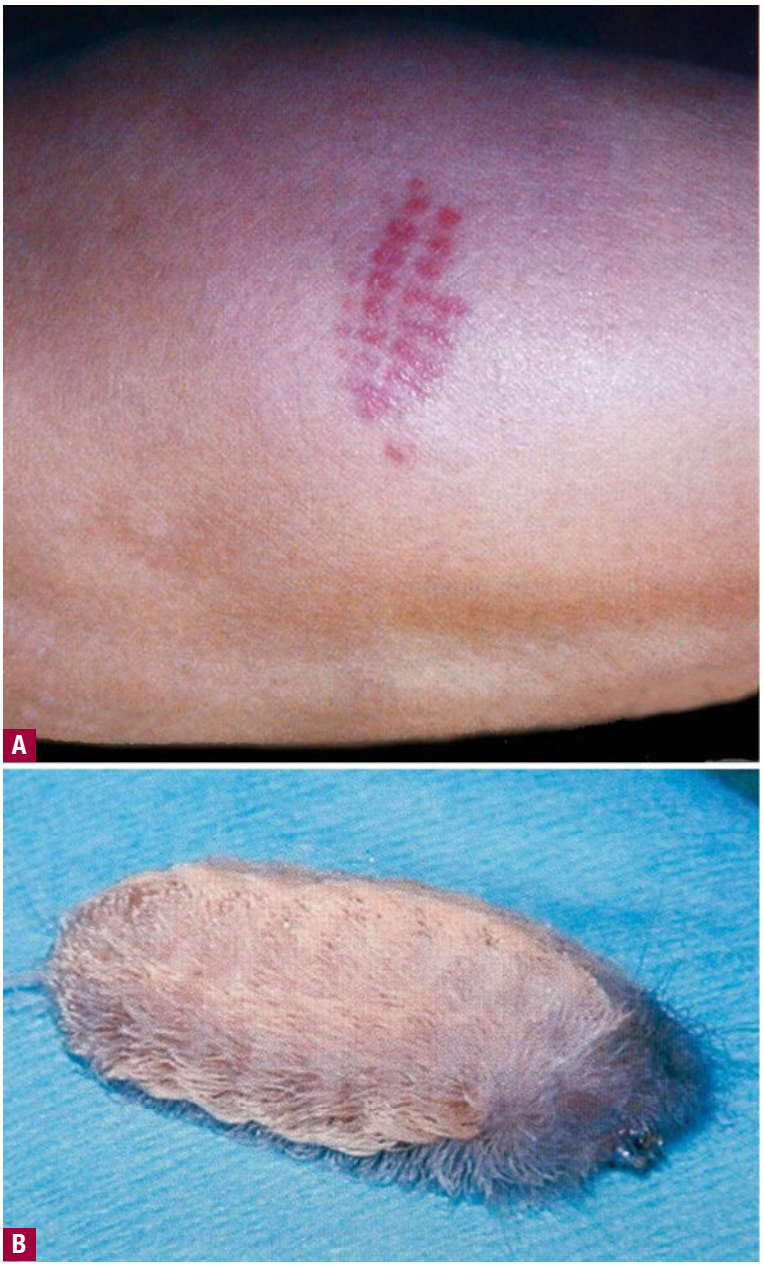

▲ **FIGURE 210-11** **A.** Cutaneous reaction from contact with a puss caterpillar showing the typical grid-like pattern. **B.** Pus caterpillar (*Megalopyge opercularis*) demonstrating the corresponding grid-like pattern of its hairs.

Treatment for lepidopterism is largely symptomatic. Systemic antihistamines, topical preparations containing menthol and camphor, and moderate to high potency topical corticosteroids can be used to control pruritus. Systemic steroids may be beneficial for severe reactions. The intractable pain caused by the sting of the puss caterpillar may require oral or parenteral narcotic analgesics. Embedded setae can be removed from the skin by "stripping" with adhesive tape.

PREVENTION

Several relatively simple steps can be taken to minimize the occurrence of arthropod bites. Spider bites can be reduced by wearing gloves while working in crawl spaces, garages, or basements or when manipulating woodpiles or rubbish piles. In scorpion endemic areas, shaking out clothing and footwear before putting it on is advisable. Wearing appropriate clothing with good coverage and avoiding rubbing against high brush and grass may help avoid tick bites. Bright colors and artificial scents like perfume, which are attractants for mosquitoes and other flying insects, are best avoided on warm summer nights. In tropical regions, proper footwear is essential to preventing tungiasis. Infestations of living areas by arthropods, including fleas and bedbugs, are difficult to eliminate and may require the assistance of a professional exterminator.

Chemical repellents are also useful in preventing arthropod bites. Several different chemical repellents have been studied, including *N,N*-diethyl-3-methylbenzamide (DEET, previously diethyltoluamide), picaridin (KBR 3203), and *p*-menthane-3,8-diol (Eucalyptus oil). The most effective repellent for all biting flies, including mosquitoes, is DEET, which is available in many products in concentrations up to 100 percent. Generally, a product containing 10 percent to 30 percent DEET provides adequate protection for most outdoor activities, with higher concentrations of DEET providing longer protection times. Although DEET has an excellent safety record, there are reports of encephalopathy developing, particularly in children, after exposure to this chemical.[82,83] For this reason, only products with DEET concentrations of less than 10 percent should be used on children. Permethrin, an insecticide often used to treat pediculosis and scabies, is available as a tick repellent that can be sprayed on clothing and fabrics, including tents and sleeping bags, and remains effective through several wash cycles. Combined use of permethrin-treated clothing and DEET applied to the skin provides the maximum protection.

KEY REFERENCES

The full reference list for all chapters is available at www.digm7.com.

1. Steen CJ, Carbonaro PA, Schwartz RA: Arthropods in dermatology. *J Am Acad Dermatol* **50**:819; quiz 842, 2004
3. Carbonaro PA, Janniger CK, Schwartz RA: Spider bite reactions. *Cutis* **56**:256, 1995
35. Carbonaro PA, Janniger CK, Schwartz RA: Scorpion sting reactions. *Cutis* **57**:139, 1996
66. Thomas I, Kihiczak GG, Schwartz RA: Bedbug bites: A review. *Int J Dermatol* **43**:430, 2004
69. Stibich AS, Schwartz RA: Papular urticaria. *Cutis* **68**:89, 2001
73. Steen CJ et al: Insect sting reactions to bees, wasps, and ants. *Int J Dermatol* **44**:91, 2005



This page intentionally left blank

PART 10

Occupational Skin Diseases and Skin Diseases Due to Biologic Warfare

Copyright © 2008 by The McGraw-Hill Companies, Inc. Click here for terms of use.



SECTION 34

OCCUPATIONAL SKIN DISEASES

CHAPTER 211

Occupational Skin Diseases Due to Irritants and Allergens

James S. Taylor
Apra Sood
Antoine Amado

Occupational dermatoses are any abnormal conditions of the skin caused or aggravated by substances or processes associated with the work environment. Occupational skin diseases (OSDs) are a major public health problem, because they are common, are often chronic, and have significant economic impact on society and on workers.[1] A thorough knowledge of potential irritants, allergens, and other causative factors in the workplace, as well as the workers' compensation system, is essential for the dermatologist dealing with occupational dermatoses.

HISTORICAL ASPECTS AND RESOURCES

EPIDEMIOLOGY

The U.S. Department of Labor publishes annual incidence statistics on the safety and health of employees in private industry (http://www.osha.gov). In 2003, of the 4.4 million nonfatal job-related injuries and illnesses reported, 6.2 percent (269,500 cases) were work-related illnesses. Of these, skin disorders were the second most common reported illness, accounting for 43,400 cases.[2] Occupational contact dermatitis is the most commonly reported OSD, and in most countries, the reported incidence of occupational contact dermatitis varies from 5 to 19 cases per 10,000 full-time workers per year.[3] Incidence rates also vary based on the specialty of the reporting physicians; rates are six to eight times higher in some studies when cases are reported by occupational physicians rather than by dermatologists.[4]

The number of OSD cases has declined, especially in the past 4 years, possibly due to better prevention, the ease with which workers' compensation cases are accepted, and a change in reporting patterns of employees or employers.[5] However, a large number of minor or transient cases still go unreported or untreated, so the exact incidence is not known.

IRRITANT CONTACT DERMATITIS (See Chap. 46)

Irritant contact dermatitis (ICD) is a nonimmunologic inflammatory reaction of the skin to contact with a chemical, physical, or biologic agent. ICD is the most common OSD, accounting for up to 80 percent of cases, although some authors have found a relatively equal distribution of ICD and allergic contact dermatitis (ACD).[3] In addition to the more common acute and chronic eczematous reactions, the clinical spectrum of ICD includes ulceration, folliculitis, acneiform eruptions, miliaria, pigmentary alterations, alopecia, contact urticaria, and granulomatous reactions (Table 211-1).[6]

◀ Irritant contact dermatitis of hand: Subacute/chronic. Erythema, edema, scaling, fissuring, crusting of the palmar aspect of the hand and wrist; the other hand had similar involvement. The patient, a housewife, is atopic and has ignored instructions to wear gloves during work in the kitchen and to use lubricating creams.

OCCUPATIONAL SKIN DISEASES DUE TO IRRITANTS AND ALLERGENS AT A GLANCE



- Skin disorders are the second most commonly reported occupational disease, accounting for approximately 10 percent of occupational disorders.
- Irritant and allergic contact dermatitis comprise a significant number of cases of occupational skin disease. The majority involve workers in the manufacturing and service industries.
- Chronic cumulative irritant contact dermatitis is the most common form of occupational irritant contact dermatitis.
- Approximately 80 percent of individuals with occupational contact dermatitis have hand involvement.
- Patch testing should be performed to rule out an allergic contact dermatitis in all cases in which an initial chronic irritant dermatitis is suspected.

Major Categories of Irritant Contact Dermatitis

The two major types of occupational ICD are acute ICD and cumulative ICD.



Copyright © 2008 by The McGraw-Hill Companies, Inc. Click here for terms of use.



TABLE 211-1
Clinical Features of Irritant Dermatitis and Suggested Etiology

- Eczema (acute and cumulative irritant exposure)
  - Industrial cleaners
  - Water, soaps, and detergents
  - Weak acids and alkalies
  - Oils and organic solvents
  - Oxidizing agents (H_2O_2, benzoyl peroxide)
- Ulcerations and burns
  - Strong acids, especially chromic, hydrofluoric, nitric, hydrochloric, sulfuric
  - Strong alkalis, especially calcium oxide, sodium hydroxide, potassium hydroxide, ammonium hydroxide, calcium hydroxide, sodium metasilicate, sodium silicate, potassium cyanide, trisodium phosphate
  - Salts, especially arsenic trioxide, dichromates
  - Solvents, especially acrylonitrile, carbon bisulfide
  - Gases, especially ethylene oxide, acrylonitrile
- Folliculitis and acneiform eruptions
  - Arsenic trioxide
  - Glass fibers
  - Oils and greases
  - Tar
  - Asphalt
  - Chlorinated naphthalenes
  - Polyhalogenated biphenyls
- Miliaria
  - Occlusive clothing
  - Adhesive tape
  - Ultraviolet and infra-red radiation
  - Aluminum chloride
- Pigmentary changes
  - Hyperpigmentation
    - Any irritant or allergen, especially phototoxic agents such as psoralens, tar, asphalt, phototoxic plants, others
    - Metals,[a] such as inorganic arsenic (systemically), silver, gold, bismuth, mercury
    - Radiation: ultraviolet, infra-red, microwave, ionizing
  - Hypopigmentation[b]
    - p-tert-Amylphenol and butylphenol
    - Hydroquinone
    - Monobenzyl and monomethyl ether of hydroquinone
    - p-tert-Catechol
    - p-Cresol
    - 3-Hydroxyanisole
    - Butylated hydroxyanisole
    - 1-tert-Butyl-3,4-catechol
    - 1-Isopropyl-3,4-catechol
    - 4-Hydroxypropriophenone
- Alopecia
  - Borax
  - Chloroprene dimers
- Urticaria
  - Numerous chemicals, cosmetics, animal products, foods, plants, textiles, woods
- Granulomas[b]
  - Keratin
  - Silica
  - Beryllium
  - Talc
  - Cotton fibers
  - Bacteria
  - Fungi
  - Parasites and parasite parts

[a]Some metals are allergens.
[b]Some agents listed are allergens.
From Lammintausta K, Maibach HI: Contact dermatitis due to irritation, in *Occupational Skin Disease*, 2nd ed, edited by Adams RM. Philadelphia, WB Saunders, 1990, p 11.

These and other sub-types are discussed in Chap. 46.

ACUTE IRRITANT CONTACT DERMATITIS, INCLUDING CHEMICAL BURNS Acute eczematous dermatitis after exposure to a potent irritant, often an acid or alkali, may overlap with chemical burns. Highly irritating chemicals may induce a reaction in anyone if the concentration and duration of action are sufficient. The intrinsic nature of the chemical is also important. Common irritants in the workplace are discussed in Common Occupational Irritants later in the chapter. In national statistics for work-related injuries, acute ICD reactions are often classified as chemical burns (Fig. 211-1).

CUMULATIVE IRRITANT CONTACT DERMATITIS Cumulative ICD, the most common type of ICD, develops slowly after multiple subthreshold exposures to mild irritants (soap, water, detergents, industrial cleansers, solvents, etc.) under a variety of conditions.[7] Some of the high-risk occupations for ICD are listed in Table 211-2.

The other categories of ICD, as well as predisposing factors, including exogenous as well as endogenous factors, are discussed in Chap. 46. Atopic individuals have an increased susceptibility to skin irritation and account for a large percentage of workers' compensation dermatitis claims.

LOW-HUMIDITY DERMATITIS Workers, especially atopic individuals who are subjected to low relative humidity at work (Table 211-3),[8] are also at risk for developing dermatitis, especially with the presence of other irritants. When relative humidity is below 35 percent to 40 percent, the stratum corneum becomes drier and more brittle, and shows increasing permeability to marginal irritants. Symptoms such as pruritus and burning may be the only complaints and are more distressing than physical signs, which may involve exposed or covered areas. Differential diagnosis includes irritation from airborne substances, other dermatoses, and psychogenic causes.



▲ **FIGURE 211-1** Acute irritant contact dermatitis on the hand caused by an industrial solvent. There is massive blistering on the palm.

AIRBORNE IRRITANT DERMATITIS Airborne irritants are an important cause of contact dermatitis. The pattern is fairly characteristic, with subjective symptoms of stinging, burning, or smarting sensations. Objective findings range from barely visible diffuse lesions to more severe dermatitis of the eyelids, cheeks, nasal folds, and neck. Some airborne irritant particles cause symptoms only if occluded under clothing in the flexures and other intertriginous body areas.

The most frequent causes are irritating dusts and volatile chemicals, such as solvents, ammonia, formaldehyde, epoxy resins and their hardeners, cement dust, fibrous glass, and sawdust, especially from irritating woods.[9]

Diagnosis of Irritant Dermatitis

The diagnosis of ICD is based on a history of exposure to a known potential irritant, the clinical appearance, and the distribution of lesions.[10] Subacute and

TABLE 211-2
Occupations at Risk for Irritant Contact Dermatitis and Potential Irritants

Occupation	Irritants
Baker	Flour, spices, soaps and detergents, oven cleaners, essential oils, yeast
Beautician	Soaps and detergents, bleaches, solvents
Construction worker	Acids, fibrous glass, concrete, solvents, hand cleaners
Cook	Wet work, soaps and detergents, vegetable and fruit juices, raw meat and fish, spices, sugar and flour, heat
Dental technician	Wet work, adhesives (epoxy and cyanoacrylates), essential oils, orthodontic plasters, amalgam mixtures, solvents
Florist	Wet work, soaps and detergents, fertilizers, herbicides, pesticides, mechanical and chemical plant irritants
Hairdresser	Bleaches, permanent wave solutions, shampoos, soaps and detergents, water
Health care worker	Wet work, soaps and detergents, alcohol, ethylene oxide, medications
Housekeeper	Wet work, soaps and detergents, cleaners, polishes, oven cleaners, disinfectants
Machinist	Solvents, coolants, cutting oils, degreasers, acids, corrosion inhibitors, heat, soaps and detergents, metal filings and swarf
Painter	Paints, solvents, adhesives, paint removers, paintbrush cleaners, soaps and detergents

Adapted from refs. 6, 7, 12, 19, 29, 39.

chronic irritant dermatitis are almost always diagnoses of exclusion. Patch testing (see Chap. 13) is necessary to help distinguish ACD from ICD or to diagnose a superimposed ACD or ICD. More detailed criteria for the clinical diagnosis of ICD are discussed in Chap. 46.

Common Occupational Irritants

SOAPS AND DETERGENTS Soaps and detergents are weak skin irritants; however, excessive use can cause cumulative insult dermatitis in susceptible individuals. The choice of cleanser varies with the job for which it is intended; for example, machinists and auto mechanics need a cleanser with a high detergent and abrasive action. The inappropriate use of products intended as industrial cleansers can also result in dermatitis.

TABLE 211-3
Workers Exposed to Risk of Dermatitis in Low-Relative-Humidity Environments

- Soft contact lens manufacturing workers
- Silicon chip manufacturing workers
- Aircraft crews on long-distance flights
- Office workers
- Resident staff in hospitals and hotels
- Traveling salespersons (from automobile heaters)

Adapted from Uter W, Kanerva L: Physical causes—Heat, cold and other atmospheric factors, in *Handbook of Occupational Dermatology*, edited by Kanerva L et al. Berlin, Springer-Verlag, 2000, p 148; and Leggat PA, Smith DR: Dermatitis and aircrew. *Contact Dermatitis* **54**:1, 2006.

WATERLESS HAND CLEANERS Waterless hand cleaners are formulated to remove tough oil and grease stains and are widely used at work sites where there is no convenient source of water. They should be applied sparingly because they may contain petroleum-derived solvents and may result in dermatitis if overused. Instant hand sanitizers, which often contain high concentrations of alcohol, can be drying to the skin.

ACIDS AND ALKALIS, INCLUDING CHEMICALS THAT CAUSE BURNS Chemical burns are an important cause of occupational injury.[11] Copious irrigation is the primary method of treating all chemical burns; however, certain types of burns require specific antidotes and therapies (Table 211-4).[12]

Inorganic Acids. Inorganic acids are used in large quantities in industry; some of the occupations at risk for exposure are listed in Table 211-5. Acids are common causes of chemical burns and can cause erythema, blistering and necrosis, and discoloration of the skin. Mechanisms of action of common industrial irritants, including acids, are listed in Table 211-6.

TABLE 211-4
Selected Chemical Burns That Require Unique Therapies

Chemical	Treatment
Burning metal fragments of sodium, potassium, and lithium	Extinguish with sand; cover with mineral oil; extract metal particles mechanically.[a]
Hydrofluoric acid	Flush with running water; then administer calcium gluconate: gel (2.5%) followed by intralesional injection, if needed.
Phosphorus	Remove particles mechanically; wash with soap and water; then apply copper (II) sulfate in water for several minutes, remove black copper phosphide, and wash with water.
Phenolic compounds	Perform initial soap and water washing followed by treatment with polyethylene glycol 300 or 400 or ethanol (10%) in water.
Bromine or iodine	Wash frequently with soap and water followed by treatment with 5% sodium thiosulfate.

[a]Use of water to extinguish burning metal fragments is contraindicated because of the formation of highly alkaline hydroxides.
From Bruze M, Fregert S, Gruvberger B: Chemical skin burns, in *Handbook of Occupational Dermatology*, edited by Kanerva L et al. Berlin, Springer-Verlag, 2000, p 325.

OTHER CHEMICALS AND AGENTS

ALLERGIC CONTACT DERMATITIS (See Chap. 13)



ACD is reported less frequently than ICD in the working environment, possibly because most workers are not patch-tested, and thus the disorder is not diagnosed and reported. In a multicenter study conducted by the North American Contact Dermatitis Group that examined 839 cases identified as occupational dermatitis (29 percent of 2889 patients referred for evaluation of contact dermatitis), 54 percent were primarily allergic dermatitis, 32 percent were irritant dermatitis, and 14 percent were conditions other than contact dermatitis that were aggravated by work.[20] In this series, ACD was seen most commonly in nurses; the other occupational groups represented were assemblers, nurse's aides and orderlies, machinists, students, machine operators, auto mechanics, those performing compressing and compacting jobs, and cooks. Aller-

TABLE 211-5
Industries Presenting Risk for Acute Irritant Reactions

Chemical	Industries Presenting Risk
Acids	
Sulfuric	Manufacture of fertilizers, inorganic pigments, textile fibers, explosives, pulp and paper
Hydrochloric	Production of fertilizers, dyes, paints, and soaps
Formic	Textile industry (dyeing and finishing), leather manufacture (delimer and neutralizer), production of natural latex (coagulant)
Acrylic	Manufacture of acrylic plastics (monomer)
Chromic	Chrome plating, copper stripping, and aluminum anodizing operations
Hydrofluoric	Etching and frosting of glass, rust removal, dry cleaning (spot cleaning)
Alkalis	
Calcium, sodium, and potassium hydroxides	Manufacture of bleaches, dyes, vitamins, plastics, pulp and paper, and soaps and detergents
Others	
Arsenic	Smelting of copper, gold, lead, and other metals; semiconductor industry
Beryllium	Aerospace and other industries involved in the production of hard, corrosion-resistant alloys
Cobalt	Manufacture of alloys, ceramics, electronics, magnets, paints and varnishes, or cosmetics; electroplating
Mercury	Industries involved in the manufacture or use of bactericides, dental amalgams, and catalysts
Phosphorus	Manufacture of insecticides and fertilizers

Adapted from refs. 6, 7, 11–19, 29, 39.



gens strongly associated with occupational exposure were rubber (thiuram and carbamate accelerators), epoxy resin, and ethylenediamine. The recent increase in the use of computers has led to an increase in computer-related skin diseases, including ACD caused by plasticizers and possibly neoprene and rubber accelerators in the equipment.[21]

TABLE 211-6
Mechanisms of Action of Common Industrial Irritants

Action	Irritant
Keratin and protein dissolution	Alkalis, soaps
Lipid dissolution	Organic solvents
Dehydration	Inorganic acids
	Anhydrides
	Alkalis (calcium oxide)
Oxidation	Bleaches
Reduction	Salicylic acid
	Formic acid
	Oxalic acid
Keratogenesis	Arsenic
	Tars
	Petroleum

From Birmingham DJ: Dermatoses in occupational diseases, in *Occupational Diseases: A Guide to Their Recognition*, edited by Key MM et al. NIOSH Publication No. 77-181. Washington, DC, US Government Printing Office, 1977.

The principal occupational contact allergens are listed in Table 211-7.

The mechanism of ACD and its clinical manifestations are described in Chap. 13. ACD has now been defined as a three-stage process. The dermatitis is limited to the site(s) of contact with the allergen(s) in stage 1. There is regional dissemination via lymphatic spread in stage 2. In stage 3 there is hematogenous dissemination of ACD at a distance (stage 3A) or systemic reactivation of ACD (stage 3B), also called *systemic contact dermatitis*. Most cases of systemic contact dermatitis are medicament related, but cases related to exposure to mercury or other metals might be occupational in origin. It is important to remember that if a worker develops ACD 2 or 3 days after initial contact with an allergen, the induction of sensitivity must have occurred previously, perhaps during an earlier job.

CONTACT URTICARIA AND IMMEDIATE CONTACT REACTIONS (See Chap. 37)

Contact urticaria syndrome (CUS) comprises a heterogenous group of inflammatory reactions that usually appear within minutes after cutaneous or mucosal contact with the eliciting agent and disappear within 24 hours, usually within a few hours. CUS has four stages: stage 1—localized urticaria, dermatitis, or itching, tingling, or burning; stage 2—generalized urticaria; stage 3—rhinoconjunctivitis, asthma, or gastrointestinal symptoms; and stage 4—anaphylaxis.

There are three varieties of contact urticaria (CU): nonimmunologic CU, immunologic CU, and CU of uncertain mechanism (see also Chap. 37).

Nonimmunologic Contact Urticaria

In nonimmunologic CU, exposed individuals develop reactions without previous sensitization, depending on the nature of the substance, its concentration, the area of skin exposed, and the mode of exposure. Usually the reaction remains localized, and systemic symptoms of wheezing, rhinorrhea, and syncope do not occur. Causative urticants include benzoic acid, sorbic acid, cinnamic acid, cinnamic aldehyde, and nicotinic acid esters.[22,23]

Affected occupational groups and the causative agents to which they may be exposed include the following: gardeners—nettles, various plants, caterpillar hairs, moths, and other insects; cooks—fish, mustard, cayenne pepper, and thyme; and medical and related personnel—alcohol, balsam of Peru, benzocaine, methyl salicylate, tar extracts, tincture of benzoin, witch hazel, and dimethyl sulfoxide.

TABLE 211-7
Major Occupational Contact Allergens

- Acrylics
- Biocides—isothiazolinones, formaldehyde releasers
- Chromate
- Cobalt
- Colophony
- Dyes
- Epoxy resin systems (may need to test with specific resin worker uses)
- Formaldehyde
- Formaldehyde resins
- Fragrances and essences
- Nickel (initial sensitization is usually nonoccupational)
- Plants and woods
- Rubber-processing chemicals

From Rycroft RJG, Frosh PJ: Occupational contact dermatitis, in *Contact Dermatitis*, 4th ed, edited by Frosch PJ, Menne T, Lepoittevin JP. Berlin, Springer-Verlag, 2006, p 717; and English JSC: Allergic contact dermatitis, in *A Colour Handbook of Occupational Dermatology*, edited by English JSC. London, Manson Publishing, 1999.

Immunologic Contact Urticaria (See Chap. 37)

Immunologic CU, an immunoglobulin E–mediated immediate allergic reaction, occurs in persons previously sensitized to a specific agent. Atopic individuals, especially those with atopic dermatitis, are more susceptible. The paradigm is natural rubber latex (NRL) allergy, which results from a reaction to one or more proteins present in NRL.[24] The highest prevalence of NRL allergy is in individuals with spina bifida. Also affected are health care workers; kitchen workers; cleaners; others who wear NRL gloves; and workers involved in the manufacture of rubber bands, surgical gloves, and latex dolls.

The next most common cause of immunologic CU is food items such as raw potato and meat. Other causes are antibiotics and other medications, preservatives, disinfectants, fragrances, epoxy resin hardeners, several woods, birch pollen, and formaldehyde in clothing.

Contact Urticaria of Uncertain Mechanism

CU of uncertain mechanism includes reactions to ammonium persulfate, which is used as a booster in bleaching hair. The dermatitis, which occurs mostly in clients, has a sudden onset and is characterized by erythema, edema, severe itching, urticaria, and occasionally syncope, with wheezing and dyspnea. Hairdressers should be made aware of the seriousness of this problem.

Diagnosis of Contact Urticaria

Other than for NRL allergy, there are few statistical data on CU. Data from Finland indicate that farmers (from exposure to cow dander) account for the most cases but that the highest incidence rate is found among bakers.[23] Diagnosis of immunologic CU typically involves skin testing with the suspected substance and serologic assays for specific immunoglobulin E. When a chemical hapten is the suspected cause, it must be centrifuged with a protein, usually human serum albumin, a non-standard procedure.

CU occurs from direct contact with skin (most cases) or mucosa (e.g., latex and chlorhexidine; the latter may be associated with systemic toxicity), or from contact with airborne allergen (e.g., cinchona, mulberry, xylene). Exposure may be accidental or caused by equipment failure (e.g., xylene). Standard ingredients (e.g., Tinofix) or trace contaminants or impurities (e.g., an anhydride present in sorbitan sesquioleate) may be responsible. CU may be associated with other urticaria such as delayed pressure urticaria.[25] Occasionally, only erythema, burning, and itching occur, but at least some people should develop urticaria at the application site for the reaction to be regarded as CU. Combined CU and delayed allergic eczematous reactions may occur.[25]

DIAGNOSIS OF OCCUPATIONAL SKIN DISEASE

Aspects of Evaluation

Making medical determinations in cases of putative occupational skin disorders and in workers' compensation cases confronts the physician with several challenging tasks: (1) weighing patient assertions and demands concerning the work relatedness of the disease, job changes, and job modifications; (2) serving as social gate keeper with regard to time off from and date of return to work; (3) dealing with lack of adequate workplace information—job description, list of chemicals used at the workplace, and exposures, including material safety data sheets; (4) balancing clinical judgment against technology (e.g., determining whether hand eczema in a machinist is work related when patch test results are negative); (5) establishing causation in the legal sense, which usually requires only probability of work association (within reasonable certainty or more than 50 percent medical certainty), rather than absolute certainty, such as fulfilling Koch's postulates.[26,27]

Thus the essentials in evaluating OSD include the following:

1. Making an accurate diagnosis, including taking a detailed medical and occupational history, performing a complete skin examination, and ordering diagnostic tests as indicated (Table 211-8).
2. Determining causation. Mathias[28] has proposed that a Yes answer to four of the following seven questions is adequate to establish occupational causation and aggravation in contact dermatitis cases and to establish probable cause:
   a. Is the clinical appearance compatible with contact dermatitis?
   b. Are there workplace exposures to potential irritants or allergens?
   c. Is the anatomic distribution of the eruption compatible with job exposure?
   d. Is the temporal relationship between exposure and onset consistent with contact dermatitis?
   e. Have non-occupational exposures been excluded as causes?
   f. Does the dermatitis improve away from work exposure to the suspected irritant or allergen?
   g. Do patch or provocation tests identify a probable cause?
3. Providing recommendations for treatment, prevention, disability status (if any), job placement, rehabilitation, and use of other resources (industrial hygiene consultation and consultations with other medical specialists, such as aller-

TABLE 211-8
Diagnostic Workup for Occupational Irritant Contact Dermatitis and Allergic Contact Dermatitis

History
- Duration, site of onset, progression, symptoms (itching, burning, pain), improvement away from work, treatment to date including response, history of any overt contact allergies
- Occupational history, including current job and process description, changes in current job, previous employment, protective clothing used if any, other workers affected
- Hobbies and part-time jobs
- Medical history, including medical, dermatologic, and surgical history, especially any history of atopic dermatitis, seasonal allergies, and asthma
- Family history of atopy, psoriasis, or other chronic skin conditions

Examination
- Site(s) of eruption
- Morphology of lesions (erythema, eczema, lichenification, pigmentary changes, urticaria, etc.)
- Pattern of involvement

Diagnostic Tests
- Patch testing
- Photopatch testing
- Tests for immediate hypersensitivity (see Fig. 211-2)
  - Radioallergosorbent assay test
  - Open and closed patch tests (read at 10 and 45 min)
  - Prick test
- Repeat open-application "use" test
- Potassium hydroxide examination for fungi, glass fibers
- Fungal, bacterial, and viral smears and cultures
- Skin biopsies
- Dimethylglyoxime test for detecting nickel, other tests (detection of chromates and formaldehyde)



gists, pulmonologists, or occupational medicine physicians).

Diagnostic Testing

PATCH TESTING Because of the importance of ACD in the etiology of OSD, patch testing (see Chap. 13) should be performed in almost all cases of contact dermatitis, even in patients who are thought to have only ICD. Testing should be performed using commercially prepared allergens. Further testing with substances in the worker's environment, including topical medications, protective equipment such as gloves, sensitizing ingredients in cleansers or other products, and occasionally the products themselves (e.g., cutting oils), is sometimes indicated. Testing with irritants such as most solvents, soaps, cement, and the like should not be done, and patch testing with other environmental chemicals should be performed only by knowledgeable individuals to avoid false-positive irritant reactions. Standard texts can be consulted for patch test concentrations.



TESTS FOR IMMEDIATE HYPERSENSITIVITY If type I immediate hypersensitivity is suspected, testing of agents in nonirritating concentrations can be carried out (Fig. 211-2).

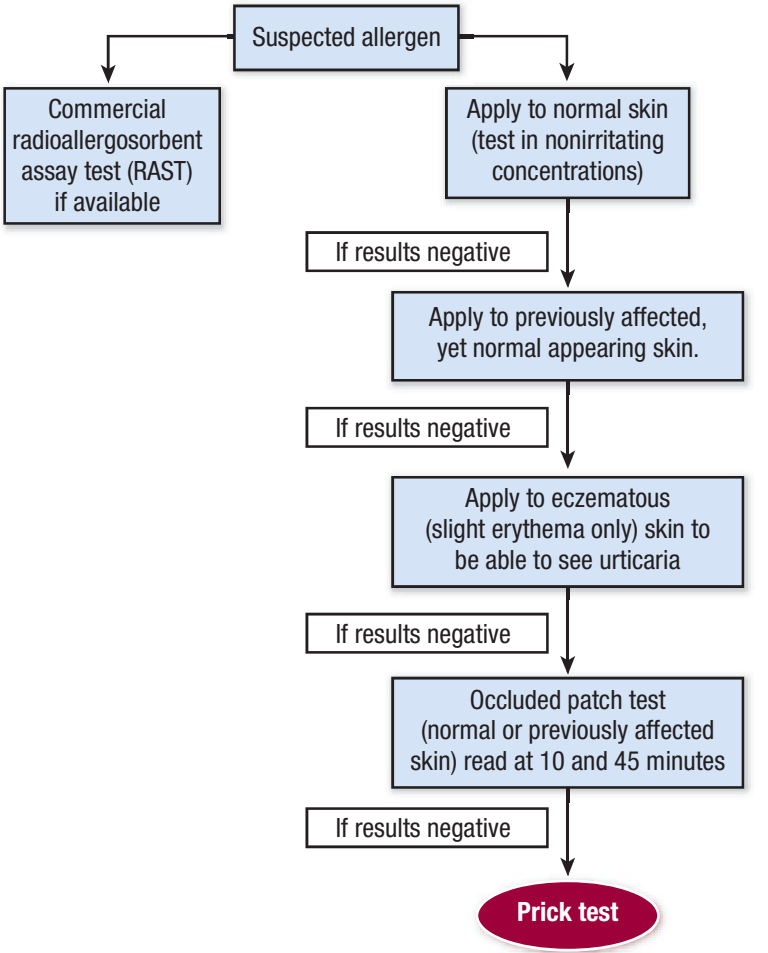

▲ **FIGURE 211-2** Testing for immediate hypersensitivity (contact urticaria). (From Taylor JS et al: Contact urticaria, in *Occupational Skin Disease*, 3rd ed, edited by Adams RM. Philadelphia, WB Saunders, 1999, p 111.)

TREATMENT AND PREVENTION

Initial treatment for OSDs depends on the cause and is essentially the same as that for diseases of non-occupational origin. However, it is important that patients be told the specific cause(s) of their disease and methods to avoid recurrences, and be given information on the appropriate use of skin cleansers, topical treatments, and protective clothing as well as on other preventive measures. Most occupational skin disorders are preventable, and their avoidance requires environmental, personal, and medical methods.[29]

Environmental Methods and Workplace Visits

Environmental methods are the preferred control measures, but they are sometimes also the most expensive measures to implement. Environmental methods involve industrial hygiene and environmental engineering interventions such as the following:

1. Hazard identification: Workplace visits are an important but often overlooked part of the evaluation of workers with OSD. Hazard identification and assessment of means of exposure can be evaluated by direct observation and may be required for problem solving, especially when more than one worker is affected.
2. Substitution of less irritating and allergenic chemicals [e.g., rubber gloves without thiurams and carbamates, an alternative resin (phenolic or polyester) for epoxy resins, an alternative metalworking fluid without a sensitizing additive].
3. Isolation and enclosure of the process.
4. Local exhaust ventilation.
5. Chemical dispensers.
6. Good housekeeping.

Personal Methods

BARRIER CREAMS Barrier creams have been called *invisible gloves*, but they are an inadequate substitute for protective clothing and are often used when gloves, sleeves, and face masks cannot be conveniently or safely used. Several types are available: ordinary emollient creams, water-repellant creams, oil- and solvent-resistant creams, and products for use against poison ivy and poison oak. The most effective barrier creams are sunscreens and sunblocks, which ideally should be worn by all outdoor workers. Problems associated with the use of barrier creams are a false sense of security, improper selection and use, allergy to an ingredient (often a preservative or fragrance), potential for increased absorption of occupational chemicals, and inadequate or infrequent application.

SKIN CLEANSERS Skin cleansers were discussed in the section Common Occupational Irritants, earlier in the chapter.

PROTECTIVE CLOTHING Protective clothing ranges from gloves, aprons, hoods, boots, and work shoes to full-body clothing. Fabrics that resist heat, cold, acids, alkalis, solvents, and ultraviolet radiation are available. Certain types are mildew

and fire resistant. Personal protective equipment is addressed by the Occupational Safety and Health Administration in specific standards for general industry, shipyards, marine terminals, and longshoring, including the U.S. Government Code of Federal Regulations (29 CFR Part 1910).[30] Manufacturers of personal protective equipment provide catalogues with guidelines for the selection of clothing for various exposures.

Medical Methods

Physicians often overlook certain medical aspects of prevention. Basic principles include the following:

1. Initial and subsequent employment physical examinations should include appraisals of the skin and evaluation of fitness for work.
2. Workers with skin disease may require accommodation in the workplace.
3. Potentially sensitizing topical preparations (neomycin, bacitracin, benzocaine, etc.) should be avoided when treating OSD.
4. Well-motivated workers should undergo medical and vocational rehabilitation; this is covered by many workers' compensation plans.

Fitness for Work and Workplace Accommodation

The Americans with Disabilities Act of 1990 brought to the fore issues of job placement and accommodation. Most individuals with chronic skin conditions can perform normal work activities, but in some instances accommodation in the workplace is required.[32]

PROGNOSIS AND PERSISTENCE

Although the prognosis of chronic OSD is guarded, there has been improvement, with clearance reported in 70 percent to 84 percent of cases.[33] Minimizing workplace exposure and maximizing patient knowledge regarding potential irritants and allergens is one of the most important factors in improving prognosis.[33,34] Certain conditions, such as chromium sensitivity, have a poor prognosis and are notoriously long lasting. Atopic dermatitis, especially in occupations in which there is heavy contact with water, soaps, and detergents, is also associated with a poor prognosis.

Of the several causes of persistence of OSD, the most important is an incomplete or incorrect diagnosis. Other factors include failure to eliminate the cause(s), improper job placement, improper therapy, the presence of secondary diagnoses (e.g., allergy to topical medications or multiple contact allergies), exposure to cross-reacting substances at home or in vocational activities, and improper cleansing of the skin. Some workers develop an ongoing dermatitis termed *persistent post-occupational dermatitis* for which there is no obvious present cause, precipitated by prior occupational dermatitis. This has significant implications for prognosis and workers' compensation.[35,36]

IMPAIRMENT AND DISABILITY EVALUATION

Evaluation of patients with OSD is discussed in more detail in other sources. However, dermatologists should be aware of the *Guides to the Evaluation of Permanent Impairment*, published by the American Medical Association. The *Guides* chapter on skin disease has been used for more than 30 years to evaluate patients with permanently impairing skin disorders (diseases that have reached maximum medical improvement—often after 6 to 12 months' duration) of both occupational and non-occupational origin. The *Guides* are used by a number of state workers' compensation authorities and provide examples of five classes of impairment ranging from 0 percent to 95 percent.

HEALTH RISK ASSESSMENT

The current scientific approach to risk reduction in occupational health is based on risk assessment, which is separated into four basic elements: hazard identification, dermal exposure assessment, dose-response assessment, and risk characterization.[37,38]

Hazard Identification

Hazard identification involves determining whether exposure to an agent can cause disease or injury using material safety data sheets. Material safety data sheets provide information only about substances considered hazardous; those present in concentrations of less than 1 percent are not required to be listed, and the physician may need to call for additional information.

Dermal Exposure Assessment

Dermal exposure assessment determines the nature and size of populations exposed to a chemical agent via the skin, as well as the magnitude and duration of the exposure. Considerations regarding exposure include the method of exposure: spills, contaminated tools or rags, aerosols or sprays, or permeation of protective clothing. Thus, work activity (e.g., task duration and frequency, amount of chemical used), work substance (molecular weight, particle size, solubility, volatility, etc.), and worker (e.g., surface area exposed, personal hygiene, presence of dermatitis) are three major factors.

Dose-Response Assessment

Dose-response assessment describes the quantitative relationship between the dose at the target and the toxicologic effect. Persons with atopic dermatitis have increased trans-epidermal water loss and enhanced reactivity to irritants.

Risk Characterization

Risk characterization involves the integration of the data to determine safe exposure by comparing exposure levels with levels at which no adverse effects are observed, while allowing for a safe margin of error. With the exception of nickel and chrome exposure, few skin exposures have been characterized in this way, and it may be difficult to do so. Also, attention must be given to percutaneous absorption as well as to dermal exposure.

KEY REFERENCES

The full reference list for all chapters is available at www.digm7.com.

3. Belsito DV: Occupational contact dermatitis: Etiology, prevalence, and resultant impairment/disability. *J Am Acad Dermatol* **53**:303, 2005
4. McDonald JC et al: Incidence by occupation and industry of work-related skin diseases in the United Kingdom, 1996–2001. *Occup Med (Lond)* **56**:398, 2006 [Epub, Jun. 16, 2006]
5. Emmett EA: Occupational contact dermatitis I: Incidence and return to work pressures. *Am J Contact Dermat* **13**:30, 2002
10. Rietschel RL: Clues to an accurate diagnosis of contact dermatitis. *Dermatol Ther* **17**:224, 2004
19. Rowse DH, Emmett EA: Solvents and the skin. *Clin Occup Environ Med* **4**:657, 2004
20. Rietschel RL et al: A preliminary report of the occupation of patients evaluated in patch test clinics. *Am J Contact Dermat* **12**:72, 2001
24. Taylor JS, Erkek E: Latex allergy: Diagnosis and management. *Dermatol Ther* **17**:2892, 2004



CHAPTER 212

Occupational Noneczematous Skin Diseases Due to Biologic, Physical, and Chemical Agents

Apra Sood
James S. Taylor



Noneczematous skin diseases caused by biologic, physical, and chemical agents in the workplace are discussed in this chapter. Trauma-related eczema is also included. For epidemiology, incidence, and management of occupational skin diseases, refer to Chap. 211.

SKIN DISEASES DUE TO BIOLOGIC AGENTS

Workers in health care, food services, cleaning and maintenance, and outdoor occupations are at a risk of developing skin infections. Table 212-1 lists some of the occupations associated with increased risk of certain infections.[1]

Establishing a definite relationship between work and a specific infection is not always simple. Laboratory isolation of the infective organism and a supporting medical history and examination are helpful.

Bacterial Infections

STAPHYLOCOCCAL AND STREPTOCOCCAL INFECTIONS (See Chap. 177) Secondary bacterial skin infections due to *Staphylococcus* and *Streptococcus* are common complications of abrasions, lacerations, burns, and puncture wounds. Butchers and meat handlers are likely to develop infected cuts and scratches, paronychia, abscesses, and lymphangitis. Folliculitis and boils are common in farm workers and construction workers. Workers in hot, humid, and dirty environments[2] (see eFig. 212-0.1 in on-line edition) or those working in close contact with infected persons, such as nurses, hairdressers, and manicurists, are at risk. Metalworking fluid contaminated with bacteria is another potential source of infection for workers.[3] The increase in multidrug-resistant bacterial strains and the emergence of community-acquired methicillin-resistance *S. aureus*[4] may present a therapeutic challenge.

ANTHRAX (See Chap. 183) Anthrax, caused by *Bacillus anthracis*, is primarily seen in cattle, sheep, horses, goats, and wild herbivores. Agricultural workers, stock breeders, butchers, and meat processors can become infected by contact with diseased animals. Contaminated hides, goat hair, wool, and bones can infect dockworkers, freight handlers, warehouse workers, and employees of processing plants that handle these products. Tanners, carpet makers, and upholsterers are also at risk. Anthrax spores are highly infectious, which makes the organism a desirable agent of germ warfare (see Chap. 213); laboratory workers handling specimens are also at risk.[5]

MYCOBACTERIAL INFECTIONS ***Cutaneous Tuberculosis.*** (See Chap. 184) Tuberculosis verrucosa cutis, a slow-growing warty papule or plaque caused by the inoculation of *Mycobacterium tuberculosis* or *M. bovis*, has been reported in pathologists and morgue attendants (prosector's or anatomist's wart). Surgeons, veterinarians, farmers, and butchers are also at risk, although the condition is rare at the present time.

Nontuberculous Mycobacterial Infections. *M. marinum* causes swimming pool or fish tank granuloma, a solitary or disseminated granulomatous infection seen in fishermen, fish tank cleaners (Fig. 212-1), and workers cleaning contaminated swimming pools. Surgeons are also at risk.

BRUCELLOSIS (See Chap. 183) Brucellosis is a zoonosis transmitted to humans from contact with infected animals or ingestion of untreated milk or milk products. Farmers, livestock breeders, meatpackers, veterinarians, and laboratory workers are at risk. An epidemic caused by sniffing bacterial cultures has been reported.[6]

TULAREMIA (See Chap. 183) Tularemia is caused by *Francisella tularensis*, a Gram-negative bacillus transmitted by ticks, fleas, and deerflies. Animal reservoirs include wild rabbits, squirrels, birds, sheep, beavers, muskrats, and domestic dogs and cats. Tularemia is seen in hunters, trappers, game wardens, butchers, fur handlers, and laboratory workers. It is highly infectious, and great care should be exercised in handling infected tissues and excreta.

OCCUPATIONAL SKIN DISEASES DUE TO BIOLOGIC, PHYSICAL, AND CHEMICAL AGENTS AT A GLANCE



- Certain occupations are associated with an increased risk of infection (viral, bacterial, fungal, parasitic) or arthropod bites, stings, or infestations.
- Mechanical trauma is common in the workplace and can have skin manifestations.
- Pre-existing skin conditions may be aggravated by work-related mechanical trauma.
- Occupational skin granulomas can be immunogenic (e.g., beryllium induced) or nonimmunogenic (e.g., silica induced).
- Occupational skin diseases can result from excessive heat, cold, and other atmospheric factors such as low humidity in the workplace.
- Exposure to silica, vinyl chloride, and other chemical agents can cause systemic sclerosis and limited scleroderma-like disease.
- Occupational chloracne is one of the most sensitive indicators of toxic exposure to halogenated aromatic hydrocarbons.
- Occupational skin cancers due to exposure to chemical carcinogens or to ultraviolet light are a major health concern.

ERYSIPELOID (See Chap. 183) Erysipeloid is almost always an occupational disease and is caused by *Erysipelothrix rhusiopathiae*, a Gram-negative rod that infects freshwater and saltwater fish, ducks, emus, turkeys, chickens, and other farmed animals such as sheep.[7]

TABLE 212-1
Occupational Skin Infections

Occupational Groups at Risk	Infections
Agricultural workers, farmers, shepherds, cattle workers, ranchers, animal scientists, animal breeders	Orf, milker's nodules, dermatophyte infections, mycetoma, chromoblastomycosis, sporotrichosis, cutaneous larva migrans
Butchers, meat handlers, abattoir workers	Staphylococcal and streptococcal infections, cutaneous anthrax, viral warts, erysipeloid, tularemia, brucellosis, leptospirosis
Construction and other outdoor workers	Blastomycosis, coccidiomycosis, arthropod bites
Cooks, bakers, food handlers, dishwashers, cannery workers, bartenders, others doing wet work	Candidal intertrigo and paronychia
Fish merchants and fishermen	Staphylococcal and streptococcal infections, erysipeloid
Foresters, hunters	Tularemia, Lyme disease
Gardeners	Sporotrichosis
Hairdressers, manicurists	Staphylococcal and streptococcal infections
Health care workers (physicians, nurses, dentists, physician and dental assistants, respiratory therapists, paramedics)	Herpes simplex, HIV infection, hepatitis, staphylococcal and streptococcal infections, candidiasis
Laboratory workers	Brucellosis, tularemia, HIV infection, hepatitis, monkeypox
Military personnel	Staphylococcal and streptococcal infections, dermatophyte infections, arthropod bites, leishmaniasis
Pet shop workers, aquarium handlers, fish tank cleaners	Fish tank granuloma (*Mycobacterium marinum*), monkeypox
Veterinarians	Cutaneous tuberculosis, cutaneous anthrax, brucellosis, tularemia, orf

HIV = human immunodeficiency virus.
Adapted from refs. 1–27.

Butchers, fishermen, and retailers of fish and poultry are commonly affected.

Viral Infections

HERPES SIMPLEX (See Chap. 193) Infection with herpes simplex virus (HSV) is the most common viral infection of occupational origin. Infections due to HSV type 1 or 2 are seen in occupations in which there is exposure to infected secretions from the mouth or the respiratory tract. Dentists, dental assistants, nurses, and respiratory technicians are particularly vulnerable, and herpetic whitlow is a common problem.[8] Infection with HSV-1 after a needle-stick injury has also been reported.[9] Herpes labialis is a common problem in woodwind and brass instrumentalists.[10] HSV infection on the body surfaces of wrestlers and rugby players, known as *herpes gladiatorum*, is temporarily disqualifying for infected athletes. In health care professions, the use of protective gloves, safety glasses, and masks are the best preventive measure and reduce the incidence of the infection.



▲ **FIGURE 212-1** Sporotrichoid atypical mycobacterial infection with *Mycobacterium marinum* in a woman who worked in a shop selling tropical fish.

HEPATITIS AND HUMAN IMMUNODEFICIENCY VIRUS INFECTION Needle-stick injuries are a well-recognized occupational hazard for health care workers, putting them at risk of acquiring an infectious disease from blood-borne pathogens. The average risk of human immunodeficiency virus (HIV) transmission after a percutaneous exposure to HIV-infected blood has been estimated to be approximately 0.3 percent.[11,12] For hepatitis B, the risk of clinical hepatitis if the blood was positive for both hepatitis B surface antigen and hepatitis B e antigen is reported to be 22 percent to 31 percent; the risk is 1 percent to 6 percent if the blood was positive for hepatitis B surface antigen but negative for hepatitis B e antigen.[12] A 95 percent decline in hepatitis B virus infection in health care workers was noted from 1983 to 1995, largely due to widespread immunization of health care workers with the hepatitis B vaccine.[13] The average incidence of anti–hepatitis C virus seroconversion after accidental percutaneous exposure to a hepatitis C virus–positive source is 1.8 percent (range, 0 percent to 7 percent).[12] The most accurate data on needle-stick and sharps injuries are derived from prospective studies, which yield an estimated annual incidence ranging from 562 to 839 injuries per 1000 health care workers per year.[14] Nurses have the most patient contact, and it is not surprising that this occupational group accounts for most reported cases.[14,15] Immediate evaluation of the injured employee is necessary to assess the risk related to exposure and the need for post-exposure prophylaxis (antiretroviral therapy for HIV, immunoglobulins and vaccination for hepatitis B virus). A substantial reduction in needle-stick injuries with the use of needleless systems or newer safety needle devices has been noted.[13] Needleless systems provide an alternative to needles for the specified procedures and thereby reduce the risk of percutaneous injury involving contaminated sharps. Examples of needleless systems include, but are not limited to, intravenous medication delivery systems that administer medication or fluids through a catheter port or connector site using a blunt cannula or other non-needle connection, and jet injection systems that deliver subcutaneous or intramuscular injections of liquid medication through the skin without the use of a needle.

VIRAL WARTS (See Chap. 196) Handlers of meat, poultry, and fish have a high prevalence of viral warts, which is likely attributable to the acquisition of minor cuts and abrasions during work. Human papillomavirus 7 has been isolated more frequently in this group of patients.[16]

MOLLUSCUM CONTAGIOSUM (See Chap. 195) Professional wrestlers and boxers are prone to developing molluscum.

ORF (ECTHYMA CONTAGIOSUM) (See Chap. 195) Orf, caused by a parapoxvirus, is



endemic in sheep and goats, and is easily transmitted to humans through direct contact. Veterinarians, farmers, and shepherds are at risk.

MILKER'S NODULES (See Chap. 195) The paravaccinia virus, which infects the udders of cows and produced ulcers in the mouths of calves, can be transmitted to dairy farmers and veterinarians, causing milker's nodules (or pseudocowpox)[17] (see eFig. 212-1.1 in on-line edition).

MONKEYPOX (See Chap. 195) An outbreak of human monkeypox in the United States in 2003 was traced to a shipment of infected exotic African rodents, some of which escaped, that produced secondary infection in wild prairie dogs housed at the same pet store. Exposure to these infected prairie dogs resulted in 37 human infections involving exotic pet dealers, pet owners, and veterinary care workers.[18] Although human-to-human transmission of monkeypox virus is thought to be low, the Centers for Disease Control and Prevention recommends strict contact, droplet, and airborne precautions for health care workers. Smallpox vaccination is recommended for health care workers and household contacts of confirmed monkeypox cases per Centers for Disease Control and Prevention guidelines.

Fungal Infections

DERMATOPHYTIC SKIN INFECTIONS (See Chap. 188) Dermatophytic skin infections are seen more frequently in farmers and animal husbandry workers.[19] Infections with *Trichophyton rubrum* and *T. mentagrophytes*, which are seen in the general population, may occur in work situations involving increased perspiration and occlusion. *Microsporum gypseum*, *T. mentagrophytes*, and *T. verrucosum* cause infection in agricultural and other outdoor workers (see eFig. 212-1.2 in on-line edition). *M. canis* infects veterinarians and laboratory workers. Physiotherapists who perform hydrotherapy are also more likely to develop fungal skin infections.[20] An unusual tinea corporis infection in a scientist due to a laboratory strain of *Arthroderma benhamiae* has been reported.[21]

CANDIDIASIS (See Chap. 189) Infection with *Candida albicans* is common in occupations that expose the skin to moisture and occlusion, such as those that require wearing gloves for long periods of time. Food handlers, nurses, dental assistants, dishwashers, and laundry workers are at risk.

SPOROTRICHOSIS (See Chap. 190) Sporotrichosis, caused by *Sporothrix schenckii*, is acquired by inoculation through puncture wounds from thorns, sticks, or splinters. It is seen in farmers, nursery and forestry workers, and those in other outdoor occupations. Gardeners working with sphagnum moss used for packing plant roots may also be at risk.

MYCETOMA (MADURA FOOT) (See Chaps. 185 and 190) Mycetoma, caused by various species of fungi and actinomycetes, is seen mainly in farmers and outdoor workers in tropical and sub-tropical countries; walking barefoot is a risk factor.

CHROMOBLASTOMYCOSIS (See Chap. 190) Chromoblastomycosis, a deep mycosis, often follows a puncture wound or other trauma during which soil-inhabiting fungi of *Phialophora*, *Hormodendrum*, and *Fonsecaea* species are injected deep into the tissues. Agricultural and other outdoor workers are at risk.

BLASTOMYCOSIS (See Chap. 190) Those at risk of blastomycosis include agricultural, forestry, and construction workers; farmers; and persons working with heavy earth-moving equipment.[22]

COCCIDIOIDOMYCOSIS (See Chap. 190) Coccidioidomycosis is acquired by the inhalation of dust containing the spores of *Coccidioides immitis*. Farmers, construction workers, bulldozer and heavy equipment operators, and laboratory workers are susceptible.

Parasitic Diseases (See Chaps. 206 and 207)

There has been an increase in the incidence of cutaneous leishmaniasis in U.S. military personnel who were deployed to southwest or central Asia or other areas in which leishmaniasis is endemic.[23,24] The larvae of *Ancylostoma braziliense* and *Necator americanus* cause creeping eruption (cutaneous larva migrans) in agricultural workers, fishermen, sewer workers, and lifeguards. Skin divers, lifeguards, dockworkers, and caretakers who maintain lakes and ponds are prone to development of swimmer's itch caused by the cercariae of a schistosome; there is also a report of swimmer's itch developing after cleaning of an aquarium.[25] Dogger Bank itch is seen in fishermen and dockworkers in the North Sea, who are exposed to the marine bryozoan *Alcyonidium gelatinosum*.

Arthropod Stings, Bites, and Infestations (See Chaps. 208 and 210)

The bites of bees, wasps, hornets, ants, ticks, mites, centipedes, and millipedes frequently cause work-related skin disease. Outdoor workers, food handlers, chicken farmers (chicken mites), workers in food-processing plants, restaurant workers, and dockworkers may be affected. Epidemics of scabies have occurred in nursing homes, hospitals, and other residential facilities for the aged.[26] Lyme disease (see Chap. 187) is transmitted through a tick bite and can affect outdoor workers, loggers, ranchers, and construction workers in wilderness areas.[27]

SKIN DISEASES DUE TO PHYSICAL AGENTS

Mechanical Trauma–Induced Skin Disorders

The skin may be subjected to friction, pressure, cuts, lacerations, and abrasions in the workplace. Repeated mechanical trauma such as low-intensity pressure or friction, the most common mechanical trauma, leads to hyperpigmentation and lichenification, whereas heavier and persistent friction leads to hyperkeratosis and callus formation (Fig. 212-2). Sudden shearing forces may lead to the formation of friction blisters, erosions, or ulcers.[28] Prolonged and excessive pressure may produce hyperpigmentation and thickening, characteristic as the stigmata of various occupations[29] (Fig. 212-3). Besides calluses and corns, occupational marks include discolorations, telangiectases, tat-



▲ **FIGURE 212-2** In spite of the growing automation of many jobs, the hands are still useful tools. Here a body shop worker is sanding a fender in preparation for painting.





▲ **FIGURE 212-3** Nail dystrophy in a slaughterhouse worker. While holding a knife in his right hand to cut off the hide, he pulled and tugged on the hide with his left hand. Note the calluses over the distal interphalangeal joints on the left.

toos, and deformities. Greater automation and better protective clothing, especially a wider selection of gloves, have decreased the incidence of occupational marks. In musicians, clinical presentation and location of skin lesions are usually specific for the instrument used (e.g., fiddler's neck, cellist's chest, guitar nipple, flautist's chin).[10] In athletes, repetitive trauma from running may lead to black heel or *talon noir* as well as blisters and jogger's toe.[30] Corns may also develop due to extreme pressure associated with bony deformities, poor foot mechanics, or improper footwear.[31] A new group of skin disorders related to prolonged computer use leading to repetitive trauma (mousing callus) and prolonged pressure (computer palms) has been described.[32,33] Underlying skin conditions in patients such as psoriasis and lichen planus may be aggravated by occupational trauma (koebenerization). Preexisting dermatitis caused by friction and pressure may predispose to the development of allergic sensitization.[34]

Hyperkeratotic hand eczema is a chronic hyperkeratotic, scaly, fissured dermatitis involving the palms seen in workers engaged in manual work involving repeated friction and pressure (Fig. 212-4). Pulpitis, a dry, scaly, fissuring, painful dermatitis, may be seen on the fingertips, especially in women engaged in domestic work.[35] A similar condition may be seen in dental personnel allergic to acrylates, in which paresthesias of the fingertips are reported. Post-traumatic eczema (dermatitis in loco minoris resistentiae) is dermatitis at the site of cutaneous trauma. The eczema usually develops within a few weeks of the acute injury and may persist or recur for long periods of time.[35] The damage and functional alteration of the skin is thought to play a role in precipitating the eczema. Table 212-2 lists the types of post-traumatic eczema and provides some examples.[36]

Granulomas

Granulomas may form due to penetration of the skin by foreign material; they may be immunogenic or nonimmunogenic. Table 212-3 lists causes of occupational skin granulomas.[37] The penetration of human hair into the interdigital spaces of barbers and of cow and sheep hair into the hands of animal tenders can produce foreign-body granulomas.[38]



▲ **FIGURE 212-4** Chronic hypertrophic dermatosis of the palms in a 59-year-old machinist. He was transferred to work in a storeroom, where he continually handled tools, and was forced to retire because of persistence of the dermatosis with its fissuring and bleeding.

TABLE 212-2
Clinical Classification of Post-Traumatic Eczema

1. Idiopathic reaction (endogenous eczema absent) (e.g., thermal burn on hand followed by eczema 1 mo later)
2. Isomorphic reaction
   a. Primary (precedes endogenous eczema) (e.g., laceration on finger followed by finger eczema and later by flexural atopic eczema)
   b. Secondary (follows endogenous eczema) (e.g., irritant hand eczema followed by finger puncture and finger eczema, which persists after hand eczema clears)

From Mathias CGT: Post-traumatic eczema. *Dermatol Clin* **6**:35, 1988.

Thermal Burns and Other Heat-Induced Skin Disorders

Workers are at risk for thermal burns as a result of scalding; contact with liquid metal, hot equipment, and tar; and flame burns after explosions. Kitchen workers and adolescents working in fast food restaurants may develop scalds from hot grease.[39] Roofers frequently incur hot tar burns, whereas explosives

TABLE 212-3
Classification of Occupational Granulomas

Causative Substance (Setting)

Immunogenic Granulomas
- Beryllium (metal production, x-ray screen production)
- Zirconium (steel working)
- Cadmium (paint and rubber industry)

Nonimmunogenic Granulomas
- Silica (sandblasting, mining, land mine explosions)
- Starch (occupations requiring the use of surgical gloves)
- Cactus spines (farming, outdoor work)
- Sea urchin spines (diving)
- Wood splinters (farming, forestry)
- Hair (hairdressing, farming, animal handling)
- Sheep wool (sheep raising)

Adapted from Goh CL: Non-eczematous occupational contact reactions, in *Condensed Handbook of Occupational Dermatology*, edited by Kanerva L et al. Berlin, Springer-Verlag, 2004, p 135.



and flammable liquids cause most industrial burns. Persons working in foundries and smelting plants are at risk for molten metal burns. Firefighters are also at risk, although the use of protective gear reduces the extent of burn injuries.[40] Workers experiencing prolonged or repeated exposure to heat can develop erythema ab igne. Acne vulgaris, rosacea, and herpes simplex may be aggravated by the heat of open furnaces, heat torches, ovens, and stoves. Heat-induced urticaria may result from strenuous physical exercise.

Electrical Burns



In industrial settings, electrical burns are usually high-voltage injuries, which may result in serious tissue destruction. Outdoor workers are at a risk for lightening burns, which show characteristic fern-like patterns.

Cold-Induced Skin Disorders (See Chap. 93)

Frostbite, chilblains, immersion foot, and cold urticaria are common in workers employed in cold environments, such as military personnel stationed in cold climates. Ice makers, liquefied gas makers, refrigeration workers, and persons engaged in winter sports are also at risk.

Vibration Syndrome

The vibration of hand-held tools may induce a type of vascular spasm in the fingers and hands known as *white fingers* or *vibration-induced white finger*.[41] Operators of vibrating impact and power tools such as jackhammers, pounding machines, riveting hammers, chain saws, and hand grinders may develop this condition, especially in cold climates. The vascular symptoms may be associated with neuromuscular symptoms and even with bony changes, collectively known as *hand-arm vibration syndrome*.[42] Earlier symptoms are mild and consist of numbness and tingling, followed by blanching and stiffness of one or more fingers, with paresthesias and weakening of intrinsic muscles developing in the later stages. Vibration frequencies between 30 and 300 Hz are most strongly associated. Smoking is also considered a risk factor. Improvements in the design of chain saws and other vibrating tools has resulted in a decrease in the prevalence of vibration-induced symptoms.

SKIN DISEASES DUE TO CHEMICAL AGENTS AND RADIATION

Occupational Connective Tissue Disorders

Raynaud phenomenon and scleroderma-like skin lesions with osteolytic changes in the bones of the fingers are well described in vinyl chloride workers (see also Chaps. 158 and 171).[43] The syndrome has been called *occupational acro-osteolysis*. Exposure to other organic solvents has also been reported to cause scleroderma-like disease (Table 212-4).[43] Systemic sclerosis and scleroderma-like skin changes are also associated with silica exposure and pulmonary silicosis, especially in underground miners (coal, gold, uranium, lead miners), stone masons, and those in related occupations. The simultaneous operation of vibrating tools during mining may contribute to the development of the disease.

Occupational and Environmental Acne

OIL ACNE (See Chap. 78) Oil acne is a folliculitis occurring on skin that comes in contact with oils, especially heavy industrial oils or straight cutting oils used by machinists. Areas with the greatest exposure to oil-soaked clothing, such as the arms and thighs, are most frequently involved. Oil acne is also caused by airborne oil mist.[44] With better engineering controls and protective clothing, the occurrence of oil acne has decreased.

COAL TAR AND PITCH ACNE (See Chap. 78) Coal tar oils, creosote, and pitch can produce a comedonal type of acne, with a predilection for exposed areas, particularly the malar regions.[45] Coal tar plant workers, roofers, road maintenance workers, and construction workers are at risk. A phototoxic reaction may also occur and cause hyperpigmentation, known as *coal tar melanosis*. Pitch and tar papillomas, keratoses, and acanthomas may develop as a late complication.[46]

CHLORACNE (See Chap. 78) Chloracne is one of the most sensitive indicators of occupational or environmental exposure to certain toxic halogenated aromatic hydrocarbons, which occur as trace contaminants during synthesis of industrial chemicals. Exposure can be percutaneous or by inhalation or ingestion. One of the most potent inducers of chloracne is 2,3,7,8-tetrachlorodibenzo-*p*-dioxin (TCDD), which has been identified in multiple industrial outbreaks as well as in putative poisoning cases in Austria and the Ukraine.[47] Other chloracnegenic chemicals are listed in Table 212-5.[48]

Clinically, the distribution is characteristic, with multiple closed comedones and straw-colored cysts primarily over the malar crescents and retroauricular folds, sparing the nose; the posterior neck, trunk, and extremities as well as the buttocks, scrotum, and penis may also become involved. TCDD impairs differentiation of keratinocytes.[49] Polychlorinated biphenyls (PCBs) and TCDD cause follicular hyperkeratosis and palmo-plantar hyperhidrosis. PCBs can also cause skin, mucus membrane, and nail hyperpigmentation as well as conjunctivitis. Based on clinical findings alone, it may be difficult to differentiate chloracne from early acne vulgaris (Table 212-6) and senile (solar) comedones. Scarring may be mild to severe, depending on the degree of chemical exposure and skin involvement.[47,50]

Occupational Skin Cancer

The first cancer to be linked to an environmental exposure was scrotal cancer in chimney sweeps, reported by Sir Percivall Pott in 1775. The percentage of skin cancers induced by the work environment is disputed; some studies suggest that it is as high as 70 percent to 80

TABLE 212-4
Substances Associated with Occupational Connective Tissue Diseases

Systemic Sclerosis
- Silica
- Chlorinated and aliphatic hydrocarbons and solvents (e.g., trichloroethylene)
- Aromatic hydrocarbons and solvents (e.g., benzene)

Scleroderma-Like Disease
- Vinyl chloride
- Epoxy resins [bis(4-amino-3-methylcyclohexyl)methane]
- Chlorinated and aliphatic hydrocarbons and solvents (e.g., trichloroethylene)
- Aromatic hydrocarbons and solvents (e.g., benzene)
- Pesticides
- Drugs (bleomycin, pentazocine)
- Aniline and fatty acid anilides
- Paraffin
- Silicon

Adapted from Haustein UF, Lietzberg B: Occupational connective tissue disorders, in *Condensed Handbook of Occupational Dermatology*, edited by Kanerva L et al. Berlin, Springer-Verlag, 2004, p 143.

TABLE 212-5
Chloracne-Producing Chemicals

- Polyhalogenated naphthalenes[a]
- Polychloronaphthalenes
- Polybromonaphthalenes[b,c]
- Polyhalogenated biphenyls
- Polychlorobiphenyls (PCBs)
- Polybromobiphenyls (PBBs)
- Polyhalogenated dibenzofurans[a]
- Polychlorodibnezofurans (especially tri-, tetra-, penta-, and hexachlorodibenzofurans)
- Polybromodibnezofurans (especially tetrabromodibenzofurans)
- Contaminants of polychlorophenol compounds, especially herbicides (2,4,5-tetra- and pentachlorophenol) and herbicide intermediates (2,4,5-trichlorophenol)
- 2,3,7,8-Tetrachlorodibenzo-*p*-dioxin (TCDD), hexachlorodibenzo-*p*-dioxin
- Tetrachlorodibenzofuran
- Contaminants of 3,4-dichloroaniline and related herbicides
- 3,4,3′,4′ Tetrachloroazoxybenzene (TCAOB)
- 3,4,3′,4′-Tetrachloroazobenzene (TCAB)

Others

- 1,2,3,4-Tsetrachlorobenzene (experimental)
- Dichlobenil (Casaron), herbicide
- Dichlorodiphenyltrichloroethane (DDT; crude trichlorobenzene)[c]

[a]The polychlorodibnezofurans and hexachloronaphthalenes may occur as contaminants in some PCBs.
[b]The polybromonaphthalenes may occur as contaminants in some PBBs.
[c]Not confirmed as chloracnegens.
From Taylor JS: Environmental chloracne: Update and overview. *Ann N Y Acad Sci* **320**:295, 1979.

TABLE 212-6
Clinical Features of Acne Vulgaris Compared with Those of Chloracne

Clinical Feature	Acne Vulgaris	Chloracne
Usual age of occurrence	Teenage	Any
Comedones	Present	Many (if absent, not chloracne)
Straw-colored cysts	Rare	Pathognomonic
Temporal comedones	Rare	Diagnostic
Retroauricular involvement	Uncommon	Common
Nose involvement	Uncommon	Uncommon
Associated systemic findings	Rare	Common

percent,[52] but other studies indicate a much lower percentage.[53] The common causative agents implicated in occupational skin cancers and occupations with potential exposure are listed in Table 212-7.

ULTRAVIOLET LIGHT (See Chaps. 112 and 113) Ultraviolet (UV) radiation acts as both a tumor initiator and tumor promoter. Most studies report a significant association between work-related sun exposure and skin cancer[55] as well as actinic keratoses[56] (see eFig. 212-4.1 in on-line edition), but other studies have found no definite association[57] or a very slight increased risk,[58] perhaps because of greater self-selection for indoor jobs among those with fair skin and a tendency to burn compared to those with less-susceptible skin types.[57]

Exposure to UV radiation, particularly UVB light, is thought to play a critical role in the pathogenesis of malignant melanoma (see Chap. 124),[59] although some studies do not show an increased risk of developing melanoma in outdoor workers compared to indoor workers.[60] This is consistent with the epidemiologic link of melanoma to intermittent intense UV exposures, more often experienced in association with vacations or recreational activities than employment. Non-occupational exposures to nonsolar radiation, such as UV lamps and sunbeds, is reportedly associated with an increased risk of melanoma.[61]

The association between squamous cell carcinoma (see Chap. 114) and cumulative UV exposure is stronger, which makes outdoor occupations a significant risk factor. However, other occupational exposures, such as exposure to chemical carcinogens, may also play a critical role,[62] and an additive effect cannot be excluded.

To determine the role that the workplace plays in the development of actinic skin damage and skin cancer, the physician must consider the detailed occupational history with job descriptions beginning with the first job, as well as non-occupational activities, hobbies and sports, and other recreational pursuits, including those in which the patient engaged at a younger age.

POLYCYCLIC AROMATIC HYDROCARBONS Exposure to polycyclic aromatic hydrocarbons (PAHs) accounts for most of the reported occupational skin tumors.[63] PAHs are hydrophobic, nonpolar compounds that form DNA adducts[61] and act as complete carcinogens.[64] Coal tar and petroleum products such as tar, pitch, coke, carbon black (soot), creosote, anthracene, crude paraffin, asphalt, fuel and diesel oils, lubrication and coolant oils, and untreated mineral oils, as well as oils, waxes, and tars from the distillation products of shale oil and lignite, contain PAHs.[65] High occupational exposures to PAHs can occur in several industries and occupations (see Table 212-7), and workers can be exposed to PAHs through inhalation or skin contact. The risk for melanoma, as well as internal cancers, has been reported to be increased in oil refinery workers.[66]

An association between scrotal cancers and the use of cutting oils has been noted, probably related to the addition of shale oil.[67] Creosote used in wood treatment has been suggested as a cause of skin and lip cancer when associated with sunlight exposure.[68] Roofers and road pavers are also at increased risk for skin cancers and internal cancers due to the potential carcinogenicity of bitumen and of PAHs from coal tar products.[69] Tar refinery workers are at increased risk of developing non-melanoma skin cancers, mainly on facial areas, forearms, and hands.[70] Use of topical tar products to treat dermatologic disease has been suggested to pose a skin cancer risk but has never been documented to do so.

ARSENIC Arsenic-containing drinking water is clearly associated with various

TABLE 212-7
Agents Inducing Occupational Skin Cancers and Industries Presenting Exposure Risk

Causative Agent	Industries/Activities with Potential Exposure
Polycyclic aromatic hydrocarbons	Coal gasification, aluminum production, iron and steel foundries, coke production, shale oil extraction, tar distilling, asphalt and roofing material work, wood impregnation
Arsenic	Glass working; copper, zinc, and lead smelting; pesticide and herbicide production; semiconductor industry
Ultraviolet light	Outdoor work, welding
Ionizing radiation	Nuclear power plants, radiography, uranium mining

Adapted from refs. 51–75.





▲ **FIGURE 212-5** Radiodermatitis and squamous cell carcinoma in a woman who had worked as an x-ray technician for years, holding young patients still during x-ray examinations, including fluoroscopy, but without protection.



skin and internal organ malignancies.[71] The methylated, trivalent form of arsenic is more toxic than the pentavalent form.[72] Although arsenic induces chromosomal abnormalities in experimental systems and human tissues, it does not induce cancers in animal models.

Long-term arsenic exposure may lead to arsenical keratosis, squamous cell carcinoma, and basal cell carcinomas, and Bowen disease. Merkel cell carcinoma has also been reported in a person with chronic arsenicalism.[73] Table 212-7 lists occupations at risk for exposure to arsenic.

IONIZING RADIATION (See Chap. 95) Exposure to ionizing radiation has been known to be a cause of occupational skin cancer since the early 1900s. Atomic bomb survivors have an increased risk of developing basal cell carcinoma.[74] X-ray–induced skin cancers appear to be associated with a higher frequency of multiple skin lesions, recurrences, and major surgical sequelae[75] (Fig. 212-5). There have been reports of a high prevalence of melanoma among airline pilots and flight attendants exposed to cosmic radiation; however, some observers feel that this association is due to lifestyle effects.[76]

DIAGNOSIS, TREATMENT, AND PREVENTION

General concepts in the diagnosis, treatment, and prevention of occupational skin disorders are discussed in Chap. 211.

KEY REFERENCES

The full reference list for all chapters is available at www.digm7.com.

14. Lee JM et al: Needlestick injuries in the United States: Epidemiologic, economic, and quality of life issues. *AAOHN J* **53**:117, 2005
18. Guarner J et al: Monkeypox transmission and pathogenesis in prairie dogs. *Emerg Infect Dis* [serial online] **10**, 2004, http://www.cdc.gov/ncidod/EID/vol10no3/03-0878.htm
23. Centers for Disease Control and Prevention: Update: Cutaneous leishmaniasis in U.S. military personnel—southwest/central Asia, 2002–2004. *MMWR Morb Mortal Wkly Rep* **53**:264, 2004
34. McMullen E, Gawkrodger DJ: Physical friction is under-recognized as an irritant that can cause or contribute to contact dermatitis. *Br J Dermatol* **154**:154.2006
47. Geusau A et al: Severe 2,3,7,8-Tetracholorodibenzo-*p*-dioxin (TCDD) intoxication: Clinical and laboratory effects. *Environ Health Perspect* **109**:865, 2001
59. De Fabo EC et al: Ultraviolet B but not ultraviolet A radiation initiates melanoma *Cancer Res* **64**:6372, 2004
76. Ramirez CC, Federman DG, Kirsner RS: Skin cancer as an occupational disease: The effect of ultraviolet and other radiation. *Int J Dermatol* **44**:95, 2005

SECTION 35

THE SKIN IN BIOTERRORISM AND BIOLOGIC WARFARE

CHAPTER 213

Cutaneous Manifestations of Biologic, Chemical, and Radiologic Terrorism Attacks

Scott A. Norton

The bombings of the World Trade Center's twin towers on September 11, 2001 and the spate of anthrax cases that soon followed introduced new responsibilities to the medical and public health communities.[1–3] Physicians now have a societal responsibility to know the principles of responding to outbreaks of disease caused by biologic weapons. The dermatologist's role in recognizing bioterrorism is particularly significant because many pathogens produce illnesses with prominent cutaneous findings.[4] The dermatologic aspects of smallpox, for example, are the most obvious and dramatic aspects of the disease. Other conditions, such as anthrax, frequently—although not always—manifest in the skin. It is likely that the diagnosis of an index case of a bioterror outbreak will rest on dermatologic findings, subtle or overt.

Public health authorities recognize that terrorism may involve other sorts of unconventional weapons, including chemical and radiologic weapons. This chapter provides an overview of the manifestations of unconventional weapons that terrorists might use.

BIOLOGIC WEAPONS

The Centers for Disease Control and Prevention (CDC) stratified potential bioweapons into three levels of risk (Tables 213-1 through 213-3) based on ease of manufacture, ease of dissemination, subsequent person-to-person transmission, lethality, and psychosocial effects (literally, how terrified a community will be). When an organism is intentionally dispersed as part of warfare, terrorism, or criminal activity, a goal is to infect huge numbers of people. Hence, the dispersal system may be engineered to disseminate the disease widely, often as airborne spread that results in pulmonary or inhalational disease. Some—but not all—of the pathogens are then transmissible from person to person, thereby potentiating the public health effects of—and the terror associated with—biologic weapons.

Category A Agents and Diseases

ANTHRAX (See Chap. 183) In late 2001, an outbreak of 22 cases in several states along the eastern seaboard of the United States was due to an intentional, criminal act of bioterrorism.[10,11] The outbreak occurred when envelopes of spores were distributed through the postal system, contaminating many offices and infecting mail handlers and letter recipients. Initially, it was thought the spores were finely engineered into an easily aerosolized form, but more recent examinations suggest that even crudely milled spores could cause such an outbreak. The easy weaponization of this highly lethal agent makes it one of the most feared biologic weapons. During the Cold War, several nations were known to have produced massive quantities of weaponized anthrax, evidence of which became widely known after a 1979 mishap at the Soviet Union's Sverdlosk bioweapon facility. A cloud of anthrax spores was accidentally released and dozens of people downwind died from inhalational anthrax. The Sverdlosk

BIOLOGIC, CHEMICAL, AND RADIOLOGIC TERRORISM ATTACKS AT A GLANCE



- Potential biologic weapons are classified by the Centers for Disease Control and Prevention into Category A, B, and C levels of risk.
- Category A comprises smallpox, anthrax, plaque tularemia, botulism, and viral hemorrhage fevers.
- Category B comprises a large number of pathogens ranging from brucellosis to listeria and *Clostridium perfringens*.
- Category C comprises a number of viruses, rickettsioses, multidrug-resistant tuberculosis, and rabies.
- Chemical weapons are categorized into blistering agents (such as sulfur mustard), nerve agents, blood agents, urticating agents, and incapacitating agents.
- Radiologic weapons include what is called a *dirty bomb*, which produces low levels of radiation contaminating an entire zone.



Copyright © 2008 by The McGraw-Hill Companies, Inc. Click here for terms of use.

TABLE 213-1
Biologic Agents or Diseases Most Likely to Be Used in Terrorism or Warfare (Centers for Disease Control and Prevention and National Institutes of Health Category A Agents or Diseases)[a]

Disease	Pathogen or Agent	Weaponized Route of Transmission	Cutaneous Findings	Percent with Cutaneous Findings in Bioterror Attack	Chapter in *Dermatology in General Medicine*
Smallpox	*Variola*	Airborne, then person to person.	Enanthem followed by classic vesicopustular eruption.	All.	195
Anthrax	*Bacillus anthracis*	Airborne. No person-to-person transmission.	Edematous papule or plaque evolving into an ulcer surmounted by a black eschar.	Roughly 50%, based on 2001 experience.	183
Plague	*Yersinia pestis*	Airborne, then person to person.	None in pure pulmonary form. Distal purpura and gangrene in septicemic form. Buboes in bubonic form.	Not known.	183
Tularemia	*Francisella tularensis*	Airborne without subsequent person-to-person transmission.	None in pure pulmonary form. Membranous pharyngitis and oropharyngeal ulcers in oropharyngeal form. Ulceroglandular syndrome.	Not known.	183
Botulism	Toxin produced by *Clostridium botulinum*	Airborne, less likely through intentional contamination of food or water. No person-to-person transmission.	Cranial nerve palsies followed by descending paralysis that spares sensation and cognition. Xerostomia, facial palsies, pupils fixed and dilated.	Possibly 100% will have xerostomia, facial palsies, and fixed and dilated pupils.	183
Viral hemorrhagic fevers	Examples include filoviruses, such as Ebola and Marburg; arenaviruses, such as Lassa, Junin, and Machupo; flaviviruses, such as dengue; and bunyaviruses, such as hantavirus and Rift Valley fever	Airborne, then possible subsequent transmission depending on agent. Dengue, for example, is transmitted by the mosquito *Aedes aegypti.*	Petechiae, purpura, and frank hemorrhage.	Not known.	—

[a]Category A diseases or agents are the highest priority because they can be easily disseminated or transmitted from person to person; result in high mortality rates and have the potential for major public health impact; might cause public panic and social disruption; and require special action for public health preparedness.



disaster, however, led to the notion that weaponized anthrax caused only inhalational illness. The letter-borne anthrax incidents of late 2001 showed otherwise when only 11 of the 22 victims had inhalational disease, four of whom died. The others had cutaneous anthrax.

Inhalational disease can have longer incubation periods than cutaneous disease, perhaps as long as to 40 to 60 days. If a person is on antibiotics (for another reason or for anthrax prophylaxis), *Bacillus anthracis* may remain in its more protected spore form until the antibiotics are discontinued. The initial symptoms of inhalation anthrax are flu-like and non-specific, characterized by fever, fatigue, and malaise, but soon followed by chills, high fever, nonproductive cough, and dyspnea. Cyanosis, shock, multiorgan failure, and death may ensue. Chest radiographs characteristically show symmetric mediastinal widening due to hemorrhagic lymphadenitis of mediastinal nodes. In inhalational disease, as well as in septicemic anthrax, which may follow cutaneous or gastrointestinal anthrax, bacteremia may lead to fulminant meningitis.[10,11,14,15]

Clinical Findings. Patients with inhalational anthrax often present initially with a flu-like illness that progresses virulently into severe febrile illness accompanied by tachypnea, stridor, and cyanosis. In inhalation anthrax, the chest x-ray shows significant mediastinal widening and hilar adenopathy because of edema and hemorrhagic necrosis of draining nodes. The pulmonary parenchyma is usually spared, hence the disease is identified as *inhalational anthrax*, not pulmonary anthrax.[12]

Diagnosis. The acute onset of a painless edematous noduloulcerative lesion with a black eschar should elicit the possible diagnosis of cutaneous anthrax, especially in the epidemiologic setting of exposure to imported animal products, recent travel to endemic areas, or presence of known use of weaponized anthrax (see Fig. 183-1 in Chap. 183; Table 213-4).[16] An additional clinical clue is the presence of edema vastly out of proportion to the observed size of the lesion. Diagnostic steps include obtaining swabs of exudates for Gram stain and culture, biopsy specimens for histopathology and immunohistochemical staining, and to draw blood samples for culture and serology. The CDC requests that practitioners notify local or state health departments before attempting a laboratory diagnosis of cutaneous anthrax.

The diagnosis is usually suspected on the basis of the character of the lesion and the hobby exposure, occupational history, or likelihood of bioterrorism. Demonstration of large Gram-positive rods in vesicle fluid on aspiration beneath the eschar, or on skin punch biopsy, also using a direct fluorescent antibody technique supports the diagnosis. Definitive diagnosis requires culture of the organism and demonstration of its susceptibility to

TABLE 213-2
Centers for Disease Control and Prevention and National Institutes of Health Category B Agents or Diseases[a]

Disease	Pathogen or Agent	Cutaneous Findings	Chapter in *Dermatology in General Medicine*
Brucellosis	*Brucella* sp.		183
Glanders	*Burkholderia mallei*		183
Melioidosis	*B. pseudomallei*		183
Typhus	*Rickettsia prowazekii*		199
Water safety threats	Examples include bacteria (e.g., *Vibrio cholerae),* viruses (e.g., Norwalk virus) and protozoa (e.g., *Cryptosporidium parvum)*	Usually none	
Food safety threats	Examples include *Listeria monocytogenes* and *Escherichia coli* O157:H7	Rare	
Psittacosis	*Chlamydia psittaci*	None	
Q fever	*Coxiella burnetii*	None	
Ricin poisoning	Prepared from *Ricinus communis* (castor beans)	None	
Staphylococcal enterotoxin B		None	
Viral encephalitis	Examples include α viruses that cause equine encephalitides	Rare	
Clostridium perfringens toxin	Epsilon toxin of *C. perfringens*	None	

[a]Category B diseases and agents are the next highest priority because they are moderately easy to disseminate; result in moderate morbidity rates and low mortality rates; and are not part of the Centers for Disease Control and Prevention's routine surveillance system.[5,6,8]

TABLE 213-3
Examples of Centers for Disease Control and Prevention and National Institutes of Health Category C Agents or Diseases[a]

- Nipah virus
- Hanta virus
- Tick-borne hemorrhagic fever virus, specifically Crimean-Congo hemorrhagic fever[b]
- Tick-borne encephalitis complex
- Yellow fever[b]
- Avian influenza virus and severe acute respiratory syndrome virus[c]
- Multidrug-resistant tuberculosis
- Rabies
- Other rickettsioses (e.g., those caused by *Rickettsia typhi, R. conori, R. rickettsia, Orientia tsutsugamushi*)

[a]Category C agents or diseases include emerging pathogens that could be engineered for mass dissemination in the future because of availability, ease of production and dissemination, and potential for high morbidity and mortality rates and major public health impact.[5,6,9] Category C agents and diseases generally lack specific dermatologic findings.
[b]Yellow fever virus and most hantaviruses can cause thrombocytopenia, hemorrhage, and hemodynamic instability that can lead to mucosal bleeding.
[c]The H5N1 strain of influenza A virus (avian influenza) and severe acute respiratory syndrome virus have the potential for rapid, widespread, human-to-human transmission, with high morbidity, mortality, and disruption to societal order.

specific bacteriophage lysis. Occasionally, the organism can be isolated from the blood during the acute cutaneous illness as well as in disseminated anthrax. Retrospective serodiagnosis is possible with the demonstration of a titer rise in electrophoretic-immunotransblots of antibody to protective antigen and enzyme-linked immunosorbent assay for detection of antibodies to lethal factor.

Differential Diagnosis.

Therapy. Naturally occurring anthrax is susceptible to penicillin and doxycycline but weaponized anthrax may have been engineered to be resistant to these antibiotics. Therefore, a fluoroquinolone such as ciprofloxacin is recommended for initial treatment of confirmed or suspected anthrax, even in pregnant women and children in whom this class of antibiotic is rarely administered. Once drug sensitivities have been established, the patient may be switched to another antibiotic as clinically indicated. Antibiotics kill activated *B. anthracis* bacilli but do not reverse the effects of toxins already produced.

Two types of vaccine are available for immunization against anthrax.[6] The first vaccine is licensed for human use in the United States to protect workers in occupations that might expose them to *B. anthracis*; it has been given to members of the Armed Forces of the United States since 1998. The vaccine is a sterile culture filtrate (primarily protective antigen) of an attenuated strain of *B. anthracis* adsorbed to an aluminum hydroxide adjuvant and administered in six doses over 18 months. The second vaccine is for immunization of livestock against anthrax and consists of viable spores of an attenuated, non-encapsulated, toxigenic strain.

PLAGUE (See Chap. 183) In nature, the disease is usually limited to enzootic cycles between rodent reservoirs and flea vectors. Most human infections occur via flea bites and typically lead to bubonic plague (see Chap. 183), which is highly lethal but generally not communicable to others. In naturally occurring disease, human-to-human transmission occurs mainly if the patient's condition changes from bubonic form of plague to the pneumonic form. Once in the lungs, the pathogens are dispersed within droplets that others inhale, leading to additional cases of pneumonic plague. This form of plague is more deadly than bubonic, having a fatality rate among untreated cases that approaches 100 percent. Hence, deliberate spread of aerosolized plague bacteria could kill massive numbers of people.

Pneumonic plague does not produce buboes, which are the result of transcutaneous transmission via flea bites. Instead, pneumonic plague produces skin lesions if it evolves into septicemic plague. Then the patient may develop acral ecchymoses and distal gangrene, often accompanied by disseminated intravascular coagulation. These lesions resemble purpura fulminans, septic emboli, or meningococcemic purpura, and possibly gave rise to the term *Black Death.*

Plague is caused by *Yersinia pestis*, an aerobic Gram-negative bacillus with "safety-pin" bipolar staining. It produces several intracellular plasmid-encoded toxins that function as virulence factors. Plague in any form is a reportable disease in every jurisdiction worldwide. Confirmatory labora-



TABLE 213-4
Diagnostic Algorithm for Suspected Cutaneous Anthrax

- The highest suspicion should be given to those lesions in which the patient had a known or highly suspected exposure to anthrax. However, as some of the recent cases have demonstrated, no known exposure had occurred when the patients presented for care.
- Notify your local Department of Health to inform them of the patient with suspected anthrax and to obtain any additional instructions before doing diagnostic tests. (A list of state Department of Health contacts can be found at http://www.cdc.gov/phppo by clicking on "State Public Health Locator"). Notify your local laboratory regarding suspected anthrax, and inform them that samples will be sent shortly.
- Diagnosis: Physicians should maintain universal precautions when evaluating patients with suspected cutaneous anthrax (mask is not required). Although contact with exudate should be avoided (as should contact with any blood or body fluid), physicians evaluating patients with suspected cutaneous anthrax are not considered at risk for contracting inhalational anthrax because the disease is acquired through contact with anthrax spores, not active bacteria. The laboratory evaluation should include the following:
  - Swab exudates for Gram stain and culture. The organism is best demonstrated when lesions are in the vesicular stage. If vesicles are present, soak two, dry, sterile Dacron- or Rayon- (not cotton) tipped swabs in vesicular fluid from a previously unopened vesicle. During the eschar stage, gently lift an edge of the eschar and rotate two swabs beneath the edge without removing the eschar. If neither vesicle nor eschar is present, swab the base of the ulcer with a sterile, moist, synthetic (Dacron or Rayon) swab. (Lesions usually become sterile within 24–48 h after starting antibiotics effective against *Bacillus anthracis*. Therefore, culture of lesions in patients on antibiotics may not yield bacterial growth.)
  - Obtain a full-thickness (through the entire dermis), 4-mm punch biopsy for permanent sections (formalin-fixed) for histologic evaluation, IHC studies, and PCR. A second sterile punch biopsy specimen can be obtained for Gram stain and bacterial culture and fungal and atypical mycobacterial stains and cultures if indicated (bacterial culturette or sterile non-bacteriostatic saline). Dividing a single biopsy specimen is not recommended.
    - If a vesicle is present, biopsy the edge of the vesicle and include adjacent non-vesicular skin.
    - If an eschar is present, biopsy the erythematous area immediately adjacent to the edge of the eschar. If possible, a second biopsy from the center of the eschar is useful.
    - If both a vesicle and eschar are present, a biopsy of each lesion is indicated.
    - Submitted specimens should be accompanied by information such as brief clinical history, description and chronology of the lesion(s), treatment, and date of biopsy in relation to antibiotic treatment. A photograph, digital image, or diagram indicating the site of each biopsy in relation to the lesion and descriptive details of the lesion would be extremely valuable.
    - The sample for permanent sections should be placed in formalin and shipped at room temperature. After preparing hematoxylin and eosin–stained slides,[a] the fixed tissue block should be saved by the dermatopathology laboratory for potential transfer to the CDC for histologic evaluation, IHC, and PCR.
    - The sample for culture should be transported immediately to the microbiology laboratory fresh in a sterile container or in a bacterial culture tube (e.g., a culturette) for immediate processing for Gram stain and bacterial culture, and fungal and atypical mycobacterial stains and cultures if indicated. (One may add sterile non-bacteriostatic saline to the container.)
  - Draw one 5-mL tube of blood into a red-topped or serum separator tube and transfer it to the laboratory for isolation of serum and subsequent storage of serum at –70°C (–94°F). Label the tube: "Anthrax serology. Store serum at –70°C for special pickup." A similar convalescent sample should also be drawn 3–4 wk later.
  - Draw one 5-mL tube of blood into a purple-topped tube. This tube should be refrigerated and held for pick up for potential PCR diagnostic tests by the CDC. Blood-based assays are currently in a state of development by the CDC. During your contact with your local laboratory or Department of Health office, ask them about the up-to-date blood-testing recommendations.
  - Obtain blood cultures for febrile or hospitalized patients. There is no need to perform nasal swabs unless directed by the public health authorities as part of an epidemiologic investigation.

CDC = Centers for Disease Control and Prevention; IHC = immunohistochemistry; PCR = polymerase chain reaction.
[a]Because the skin lesions of anthrax are caused by toxins, cutaneous anthrax is not ruled out by a negative culture or biopsy.
From Carucci JA et al: Cutaneous anthrax management algorithm. *J Am Acad Dermatol* **47**:766, 2002, with permission.



tory tests include culture of *Y. pestis* from a clinical specimen or detection by polymerase chain reaction. Serologic tests are not useful in the acute setting.[18]

An inactivated whole-cell plague vaccine is administered to people who have potential occupational exposure to infected rodents (e.g., wildlife biologists and American military personnel). The primary immunization series requires three intramuscular doses administered over 6 months with boosters every 1 to 2 years if indicated. Animal challenge studies suggest that the plague vaccine is more protective against bubonic (flea-borne) plague than it is against airborne pathogens or pneumonic plague.

In the event of an outbreak of pneumonic plague, the keystone of protection is isolation of cases and close contacts, as well as the use of prophylactic antibiotics, specifically doxycycline, a quinolone such as ciprofloxacin, or chloramphenicol. For treating cases, the preferred agents are streptomycin or gentamicin, although doxycycline, ciprofloxacin, and chloramphenicol are acceptable as well (see Table 183-1).

TULAREMIA (See Chap. 183) Tularemia, similar to plague, ordinarily exists in enzootic cycles but infects humans most commonly after an arthropod bite. The infectious inoculum for *Francisella tularensis* is extremely small, perhaps as few as 50 organisms.[19,20] Because pneumonic tularemia is highly lethal, the intentional dispersal of airborne organisms has the potential to cause devastating outbreaks of disease. Unlike pneumonic plague, however, pulmonary tularemia cannot be spread from person to person.

Clinical Findings. Tularemia can be acquired through several routes and present in several clinical forms. Pulmonary tularemia, which presumably would be the main form seen after intentional airborne spread, lacks cutaneous lesions. Airborne spread could, however, lead to other forms of the disease, such as oculoglandular and gastrointestinal, which in some cases have mucocutaneous findings.

Treatment. A live-attenuated tularemia vaccine has been used in the former Soviet Union. In the United States, the National Institutes of Health and the Department of Defense are funding development of a newer vaccine. Tularemia is a reportable disease and any pulmonary case or cluster of other cases should launch an epidemiologic investigation. In the event of an outbreak of pneumonic tularemia, health authorities should consider community prophylaxis with doxycycline or ciprofloxacin. Streptomycin (or in its absence, gentamicin) treats all forms of tularemia successfully if administered early in the course of the disease. Clinical improvement is evident within 24 to 48 hours, but treatment should be continued for at least 7 to 10 afebrile days. Tetracycline and chloramphenicol are acceptable alternatives but should be given for longer periods than 21 and 14 days, respectively, to reduce the risk of relapse.[20]

TABLE 213-5
Clinical Presentations of Classic Chickenpox and Smallpox

CHICKENPOX	SMALLPOX
• Mild or no prodrome	• Febrile prodrome
• Superficial vesicles	• Deep pustules
• "Dew drops on a rose petal"	• "Pearls of pus"
• Individual lesions evolve rapidly	• Individual lesions evolve gradually
• Lesions with different morphologies	• Lesions with same morphology
• Central predominance	• Acral predominance
• Spares palms and soles	• Involves palms and soles
• Patient is rarely toxic	• Patient is usually toxic or moribund

SMALLPOX (See Chap. 195) After the World Health Organization declared that naturally occurring smallpox was eradicated, laboratories worldwide destroyed their stocks of variola—except for a few facilities that maintained small amounts of virus, putatively for research purposes. With the collapse of the Soviet Union and the dismantling of its military medical research system, there have been concerns that rogue states or terrorist organizations have obtained unmonitored stocks of virus. Any recurrence of smallpox represents a catastrophic medical, public health, and criminal event of extraordinary proportions.

The differential diagnosis of smallpox and varicella is in Table 213-5.

The CDC has an algorithm for the evaluation of suspected smallpox and offers a differential diagnosis. The algorithm, *Evaluating patients for smallpox: acute, generalized vesicular or pustular rash illness protocol* (available at http://www.bt.cdc.gov/agent/smallpox/diagnosis/pdf/spox-poster-full.pdf), identifies three features at the core of a clinical diagnosis of smallpox (Box 213-1).[25]

Dermatologists who serve as bioterrorism resources for their communities or hospitals must become familiar with smallpox vaccination programs. Vaccinia, an orthopoxvirus related to smallpox and to the cowpox originally used in Jenner's inoculations, can produce several cutaneous adverse effects, which require some expertise to diagnose and manage. These conditions are reviewed in detail in Chap. 195.

Category B Agents and Diseases with Possible Cutaneous Manifestations

BRUCELLOSIS (See Chap. 183) Brucellosis is a zoonotic infectious disease that is usually transmitted to humans by direct contact with infected animals or animal products or by ingestion of contaminated dairy products. It can also be transmitted via aerosolized propagules and requires a small inoculum, perhaps 10 to 100 organisms, to cause human disease. Hence, it is regarded as a possible biologic weapon.

Deliberate spread of aerosolized bacteria would cause pulmonary disease, which has a mortality rate, even when untreated, of less than 5 percent. The disease can cause profound fatigue and requires prolonged treatment, hence victims could be incapacitated for months. Subsequent human-to-human transmission will not occur. Cutaneous manifestations of brucellosis are uncommon and non-specific and are discussed in detail in Chap. 183.

MELIOIDOSIS AND GLANDERS (See Chap. 183) As biologic weapons, these organisms would be disseminated in aerosols that cause respiratory outbreaks. Only a small inoculum of either is required to cause illness. The incubation period is roughly 10 to 14 days and the subsequent pulmonary disease has a mortality rate of more than 95 percent untreated or approximately 40 percent when treated with appropriate antibiotics. Pulmonary disease can lead to bacteremia or septicemia, which can produce cutaneous and subcutaneous abscesses (see Chap. 183).[28–30]

The first case of human glanders in the United States in more than 50 years was reported in 2002 in a microbiologist who was inadvertently exposed at an Army Research Laboratory. He developed axillary lymphadenopathy and bacteremic infection with hepatic and splenic abscesses but responded well to prolonged treatment with imipenem and doxycycline.[31]

Category C Bioweapons (See Table 213-3)

Category C is an expanding list of diseases, mostly caused by emerging pathogens that could possibly be engineered for mass dissemination and major public health impact.[9] The number of diseases in Category C continues to expand as new diseases, such as severe acute respiratory syndrome, avian flu (caused by the H5N1 strain of influenza A virus), and Nipah virus infection are recognized for their potential for high morbidity, mortality, and societal disruption.[9]

Most diseases currently in Category C lack specific dermatologic findings.

Box 213-1
Core Features in the Clinical Diagnosis of Suspected Smallpox

- Febrile prodrome occurring 1–4 days before rash onset with fever ≥ 38.3°C (101°F) and at least one of the following: prostration, headache, backache, chills, vomiting, or severe abdominal pain.
- Classic smallpox lesions are deep-seated, firm or hard, round, well-circumscribed vesicles or pustules that are sharply raised and feel like small, round objects embedded under the skin. As they evolve, the lesions may become umbilicated or confluent.
- Lesions in the same stage of development: On any one part of the body (e.g., face or arm), all lesions are in the same stage of development—that is, all are vesicles or all are pustules.

CHEMICAL WEAPONS

Chemical weapons were used on a grand scale during World War I by the Imperial German Army and then by the Allied Forces in response. The morbidity, mortality, and terror associated with these weapons exceeded that of any known conventional weapon.[32,33] Soon after the 1918 Armistice, international treaties limited—then ultimately banned—the use of chemical agents during warfare. Although these prohibitions are regarded as international law, not all nations have signed and ratified the various treaties. Furthermore, the ban on chemical weapons specifies use during declared wars with adversary nations. The treaties do not, however, explicitly forbid the use of chemical weapons against non-combatants or within one's own country.

The Japanese cult, Aum Shinrikyo, used another chemical weapon, the nerve agent sarin, in Tokyo's subways in an act of domestic terrorism. Although no one was killed, this attack underscores the fact that rogue organizations can obtain or develop their own unconventional weapons.[35]

Chemical weapons are divided somewhat loosely into categories based on their effects on human victims: blister agents, nerve agents, blood agents, urticating agents, choking agents, and incapacitating agents. Table 213-6 identifies prototypical members of the major categories and describes mechanistic and clinical features of these agents.





TABLE 213-6
Major Categories of Chemical Weapons and Their Major Effects

Class of Agent	Example of Agent	Physical Form of Weaponized Substance	Mechanism of Action	Route of Exposure	Time to Onset of Signs and Symptoms	Non-Dermatologic Signs and Symptoms	Cutaneous Reactions	Immediate Treatment[a] Includes	Definitive Treatment Includes	Differential Diagnosis
Blood agent	Hydrogen cyanide	Liquid or vapor	Inactivates cytochrome oxidase, thereby preventing cells from using oxygen.	Inhalation, cutaneous, mucosal	Seconds to minutes	Low dose: dizziness, nausea, headache, eye irritation. High dose: loss of consciousness; cessation of respiration.	Often with cherry red skin.	Remove from environment. Remove clothing. Flush skin with copious water. Oxygen.	Oxygen. Amyl nitrite or sodium nitrite, followed by sodium thiosulfate. Respiratory support.	Carbon monoxide poisoning. Hydrogen sulfide (sewer gas) poisoning
Blistering agent	Mustard gas, mustard agent, yperite, sulfur mustard	Liquid or vapor	Alkylating agent (related to medical nitrogen mustard) but precise mechanism in the skin is not known.	Inhalation, cutaneous, mucosal	Hours to days	Red, irritated eyes with conjunctivitis and lid edema. Vomiting. Nasal irritation, cough.	Erythema, pruritus, blistering.	Remove from environment. Remove clothing. Flush skin with copious water or hypochlorite. Irrigate eyes with saline.	No antidote exists. Definitive eye care. Pain relief. Respiratory support. If the blister agent is Lewisite rather than sulfur mustard, use Dimercaprol (British antilewisite).	Exposure to other irritants (e.g., caustics, ammonia, sodium hydroxide)
Nerve agent	Tabun, sarin, VX	Liquid or gas	Inhibits acetyl-cholinesterase, allowing excess acetylcholine to accumulate (which overstimulates muscles, glands, and nerves) and allowing unrestrained parasympathetic (specifically muscarinic) activity.	Inhalation, cutaneous, mucosal	Vapor: seconds to minutes Liquid: minutes to hours	Pinpoint pupils, lacrimation, asthma-like wheezing, fasciculating muscles, perspiration, hypersalivation, diarrhea. Higher doses: seizures, apnea, loss of consciousness.	Perspiration and piloerection.	Remove from environment. Remove clothing. Flush with copious amounts of water or warm soapy water. Atropine and pralidoxime.	Repeated doses of atropine to reduce secretions. Pralidoxime as needed. Consider diazepam to prevent seizures, inc atropine-induced seizures. Respiratory support.	Organophosphate pesticide poisoning
Urticating agent	Phosgene, nettle gas, oxime	Gas	Not known.	Inhalation, cutaneous, mucosal	Seconds to minutes	Burning eyes, rhinorrhea, hoarseness, dyspnea, cough.	Immediate pain and severe burning on skin contact. Soon, urticaria-like edema, followed by blisters on day 2. May cause deep necrosis of skin.	Remove clothing. Flush with copious amounts of water or sodium bicarbonate solution.	Supportive burn care.	Exposure to other irritants (e.g., caustics, ammonia, sodium hydroxide)
Choking agent	Phosgene, carbonyl chloride, carbonic acid dichloride	Gas or liquid that vaporizes easily	Not known. Increases permeability of alveolar capillaries leading to non-cardiogenic pulmonary edema.	Inhalation	Hours	Dyspnea, chest tightness, wheezing, red mucosa; erythema, causes noncardiac pulmonary edema.	None.	Remove from environment. Oxygen. Consider intubation. Flush eyes with water.	Oxygen, respiratory support.	Industrial gas exposure (e.g., ammonia, hydrochloric acid)

[a]Personal protective measures [e.g., chemical hazard suit and protective mask (gas mask)], are usually necessary before one can assist a victim of a chemical weapon attack.

The class with the most severe effects on the skin is that of blister agents.[32,33,35]

Blister agents, notably sulfur mustard (HD), are the most commonly used chemical weapons. HD was first used during World War I in battles around Ypres, Belgium, hence its other name, *yperite*. Because of a mustard- or garlic-like odor, the compound is often called *mustard gas*. Saddam Hussein's Iraqi military forces used HD against the Iranian army (1980–1988) and against Iraqi citizens in Kurdish villages, such as Halabja.

HD is a relatively simple compound; it can be synthesized by combining two moieties, sulfur dichloride and ethylene. It is inexpensive to manufacture, stable in storage, and can be delivered by many means—therefore, it is likely to be the chemical weapon of choice for a terrorist organization.

HD is an amber-colored, viscous liquid that is lipid soluble, thereby passing easily into and through the skin. If HD lands on someone's skin, roughly 80 percent evaporates quickly, 10 percent passes through the skin and enters systemic circulation, and 10 percent remains in the skin. Victims first experience an irritated, gritty feeling in their eyes. This progresses over hours to a chemical conjunctivitis and massive lid edema. Ocular effects can last several weeks and may destroy the cornea or even rupture the globe. Victims also suffer severe nausea and vomiting within several hours of exposure.

The skin starts itching within hours and then develops a diffuse non-specific erythema later on the first day. Blisters begin to appear at 1 to 2 days, starting as small vesicles that coalesce to form large, extensive bullae.

HD penetrates the skin within minutes and there is no antidote. Therefore, for decontamination to be effective, it must be started immediately. Responders must don full protective gear (chemical hazard suit and a protective breathing mask) and remove the victim from the contaminated environment. The victim's clothes must be removed completely and the body washed—flooded—with copious amounts of water. Warm soapy water is better and a hypochlorite solution (one part household bleach to nine parts water) is best. The eyes must be flushed with saline.

Subsequent care is largely supportive and the patient feels better when given nonsteroidal anti-inflammatory drugs to counter inflammation and placed in a cool environment. It is necessary to manage fluids and electrolytes and to remain vigilant for secondary infection. In vivo animal studies suggest that débridement of blisters increase the rate of wound healing, but human studies have not been conducted. Healing is largely a matter of time and leaves persistent zones of hyperpigmentation at the affected areas.[32,33,35–37]

RADIOLOGIC WEAPONS

Terrorist organizations are unlikely to possess true nuclear weapons but may have what is known as a *dirty bomb*. This type of weapon presents a radiation hazard by using conventional explosives, such as dynamite, to scatter radioactive debris or dust, which then contaminates an area. Dirty bombs do not trigger nuclear chain reactions but instead produce low levels of radiation. Accordingly, exposed individuals are unlikely to experience acute radiation injury. The immediate effects of a dirty bomb will most likely be due to the force of the blast, which can harm people and destroy property. The lasting effects of a dirty bomb include contamination of a zone, rendering it uninhabitable until the difficult task of area decontamination is complete.

Individuals exposed to radiation from a dirty bomb must rid themselves of lingering radioactive dust or debris. Ideally, this will be conducted at a designated decontamination station. Victims must remove all clothes and then wash their entire bodies thoroughly with soap and water. The decontamination station should contain, collect, and dispose of the clothes and water in a manner that is safe and appropriate for radioactive waste.

In the event of a suspected attack with a chemical or radiologic weapon, medical personnel must coordinate with public health and law enforcement agencies at the local, state, and federal level.[33,38,39]



KEY REFERENCES

The full reference list for all chapters is available at www.digm7.com.

1. Rotz LD et al: Public health assessment of potential biological terrorism agents. *Emerg Infect Dis* **8**:225, 2002
8. Pappas G et al: Category B potential bioterrorism agents: Bacteria, viruses, toxins, and foodborne and waterborne pathogens. *Infect Dis Clin North Am* **20**:395, 2006
9. Mushtaq A, El-Azizi M, Khardori N: Category C potential bioterrorism agents and emerging pathogens. *Infect Dis Clin North Am* **20**:423, 2006
16. Carucci JA et al: Cutaneous anthrax management algorithm. *J Am Acad Dermatol* **47**:766, 2002
24. Moore ZS, Seward JF, Lane JM: Smallpox. *Lancet* **367**:425, 2006
28. Bossi P et al: Bichat guidelines for the clinical management of glanders and melioidosis and bioterrorism-related glanders and melioidosis. *Euro Surveill* **9**:E17, 2004

This page intentionally left blank

PART 11

Therapeutics

Copyright © 2008 by The McGraw-Hill Companies, Inc. Click here for terms of use.









SECTION 36

TOPICAL THERAPY

CHAPTER 214

Principles of Topical Therapy

Kendra G. Bergstrom
Bruce E. Strober

Sensible topical drug therapy involves not only the selection of an appropriate agent, but also a thoughtful consideration of the areas of the body affected, the state of the diseased skin, the concentration of the drug, the type of vehicle (e.g., ointment, cream, lotion), the method of application, and a defined duration of use that both maximizes efficacy and minimizes adverse side effects. Behind each of these considerations are basic principles that help guide the practitioner toward a rational plan of therapy.

CUTANEOUS DRUG DELIVERY

The therapeutic efficacy of a topical drug relates to both its inherent potency and the ability of that drug to penetrate the skin.[1] In fact, many potent agents, such as hydrocortisone and fluocinolone acetonide, are quite poorly absorbed after topical application. Conversely, many well-absorbed agents with weak potency have negligible therapeutic use.

◀ **Top:** Twenty-three-year-old patient with generalized psoriasis. **Left:** Before psoralen and ultraviolet A light treatment. **Right:** After treatment. **Bottom:** Crescentic excision of basal cell carcinoma. **Left:** Excision of tissue around the defect is planned in order to place the incision into the nasolabial fold. **Right:** Six months after surgery.

Percutaneous absorption necessitates passage through the stratum corneum, epidermis, papillary dermis, and into the bloodstream. (See Chap. 215 for information on the pharmacokinetics of topical agents.)

In contrast to many orally administered drugs that are nearly completely absorbed within a few hours, topical medicines generally have a poor total absorption and a very slow rate of absorption. For example, less than 2 percent of a topically applied corticosteroid such as hydrocortisone is absorbed after a single application left on the skin for more than 1 day. Furthermore, peak rates of absorption are reached up to 12 to 24 hours after application. Fortunately, low absorption does not necessarily translate into low efficacy. Drugs such as topical corticosteroids are effective because of their inherent potency and can exert clinically significant effects in spite of low absorption. In this light, absorption represents only one of many facets of efficacy.

OTHER FACTORS THAT AFFECT ABSORPTION

Stratum Corneum

The stratum corneum is the rate-limiting barrier to percutaneous drug delivery. This cornified layer is composed of ceramides, free fatty acids, and cholesterol in a 1:1:1 molar ratio. By weight, the stratum corneum consists of 50 percent ceramides (acylceramides being the most abundant), 35 percent cholesterol, and 15 percent free fatty acids. Of course, the stratum corneum thickness and, thus, drug penetration, will vary depending on body site.[2] Table 214-1 lists varying body sites and their relative resistance to percutaneous absorption. An important consideration in topical therapy is that diseased skin may have an altered (increased, decreased, or absent) stratum corneum, thus changing the body site's barrier function. Abraded or eczematized skin presents less of a barrier. Solvents, surfactants, and alcohols can denature the cornified layer and increase penetration; as a result topical medications with these components may enhance absorption.

Occlusion

Occlusion via closed, airtight dressings or greasy ointment bases increases the

PRINCIPLES OF TOPICAL THERAPY AT A GLANCE



- The efficacy of a topically applied drug depends on its inherent potency and on its ability to penetrate skin.
- Some factors that affect penetration include: Concentration of medication, thickness and integrity of the stratum corneum, frequency of application, occlusiveness of the vehicle, and compliance.
- Topical formulations (vehicles) are meant to enhance the beneficial effects of the medication.
- Either the vehicle or its active ingredient(s) may cause local toxicity.
- Topical medications may induce systemic toxicity.



Copyright © 2008 by The McGraw-Hill Companies, Inc. Click here for terms of use.

TABLE 214-1
Regional Differences in Penetration[a]

1. Mucous membrane
2. Scrotum
3. Eyelids
4. Face
5. Chest and back
6. Upper arms and legs
7. Lower arms and legs
8. Dorsa of hands and feet
9. Palmar and plantar skin
10. Nails

[a]Most penetration with number 1 and less penetration with increasing numbers.



hydration and temperature of the stratum corneum, limits rub-off/wash-off of the drug, and consequently, enhances drug penetration. Occlusion techniques range from application under an airtight dressing such as vinyl gloves or plastic wrap, to occlusion with cotton gloves or socks at night for treatment of hands and feet, to application of a medication already impregnated into an airtight dressing, as seen in flurandrenolide (Cordran) tape. To derive the greatest benefit from occlusion, the patient should hydrate the skin by immersion in water for approximately 5 minutes before the application of a cream or ointment. Clinically, this may correspond to application immediately after bathing and before drying completely. With many drugs, occlusion increases drug delivery by 10 to 100 times the amount of drug delivered when not occluded.[3] This approach can lead to more rapid onset times and increased efficacy when compared with topical application alone. On the other hand, occlusion may also lead to a more rapid appearance of the drug's adverse effects, such as the ability of topical corticosteroids to induce local skin atrophy or suppression of the hypothalamus-pituitary-adrenal axis. Occlusion may promote infection, folliculitis, or miliaria. In the case of topical anesthetics such as lidocaine and prilocaine, occlusion hastens absorption into both the skin and the bloodstream, which has led in rare cases to cardiac complications from lidocaine toxicity or methemoglobinemia from prilocaine toxicity.

Frequency of Application

The frequency of drug application likely has little effect on increasing a topical drug's overall efficacy.[4,5] One daily application is enough for most topical glucocorticoids, for example, but the non-specific emollient or protective effect of creams and ointments are likely enhanced by more frequent applications. Regardless, increasing the contact time for a topical drug augments its total absorption.

Quantity of Application

The quantity of the drug applied likely has a negligible effect on drug absorption. Obviously enough drug must be dispensed and spread to cover the affected areas. Further, the quantity of drug applied might affect patient adherence to the prescribed regimen. For example, too much applied drug might negatively alter the subjective experience of having a medication on the skin, i.e., the drug may feel "wrong" (greasy, caked, chalky, etc.) or is cosmetically unattractive (shiny, white color). Regardless, the amount prescribed must be adequate to treat the affected body surface area for the necessary length of time. In this regard, patient education is critical to prevent wasteful overuse or ineffective underuse of the medication. The amounts of topical medications to dispense, based on the estimated body surface area, frequency of application, and duration of therapy, are presented in Table 214-2. For topical medications like sunscreens that are used over large areas, underapplication is a problem for most patients. However, for smaller areas, patients may apply a large amount of an ointment, for example, leading to complaints of greasiness or rubbing off on clothing, which can be minimized by using an appropriate amount.

Compliance

Topical medication compliance is a critical although often overlooked aspect of medication efficacy. Generally, adherence to a treatment regimen is associated with female gender, employment, being married, and low prescription costs. Lower adherence is seen for patients with extensive disease, and paradoxically, disease on the face.[6] One 8-week survey using electronic monitoring showed that adherence to treatment for a twice-daily topical prescription decreased from 84 percent the first week to 51 percent during the eighth week, with topical non-compliance being especially notable on weekends.[7] Furthermore, compliance is negatively affected by depression, which is common in people with chronic skin conditions and found in up to 20 percent of patients with psoriasis.[8]

Miscellaneous Factors

Vigorous rubbing or massaging of the drug into the skin not only increases the surface area of skin covered, but also increases blood supply to the area locally, augmenting systemic absorption. It may cause a local exfoliative effect that will also enhance penetration. The presence of hair follicles on a particular body site also enhances drug delivery, with the scalp and beard areas presenting less of a barrier when compared with the relatively hairless body sites. Although having a thinner stratum corneum, the skin of older individuals is poorly hydrated, with fewer hair follicles and therefore may impede drug delivery.

Reducing the particle size of the active ingredient increases its surface area–volume ratio, allowing for a greater solubility of the drug in its vehicle. This forms the basis for the increased absorption of certain micronized drugs.[9]

TABLE 214-2
Suggested Amounts of Topical Medications to Dispense—Cream or Ointment

Area Treated	Estimated % Body Surface Area	Single Application (g)	Twice a Day for 1 Week (g)	Thrice a Day for 1 Week (g)
Face	3	1	15	20
Scalp	6	2	30	45
One hand	3	1	15	20
One arm	7	3	45	60
Anterior trunk	14	4	60	90
Posterior trunk	16	4	60	90
One leg including foot	20	5	70	100
Anogenital area	1	1	15	20
Whole body	100	30–40	450–500	600–1000

From New York University's Dermatologic Formulary—Skin and Cancer Unit.

CLASSIFICATION AND CLINICAL APPLICATION OF TOPICAL FORMULATIONS

The vehicle is the inactive part of a topical preparation that brings a drug into contact with the skin. Before the mid-1970s pharmaceutical companies performed limited testing of the impact of the vehicle on the potency of a given formulation. The lack of a scientific analysis of the vehicle led to the marketing of topical drugs that, while having different concentrations of the same active ingredient, nevertheless exhibited similar bioavailability and potency. For example, older preparations of triamcinolone acetonide showed no real differences in potency among the 0.025 percent, 0.1 percent, and 0.5 percent concentrations. By contrast, modern drug development attempts to maximize drug bioavailability by optimizing vehicle formulation. Additionally, during the current drug development process, dose-response studies determine the maximal effective concentration within a given vehicle, above which any further increase in concentration serves no therapeutic benefit.

The vehicle of a topical formulation often has beneficial non-specific effects by possessing cooling, protective, emollient, occlusive, or astringent properties. Rational topical therapy matches an appropriate vehicle that contains an effective concentration of the drug. The vehicle functions optimally when it is stable both chemically and physically and does not inactivate the drug. The vehicle also should be nonirritating, nonallergenic, cosmetically acceptable, and easy to use. Additionally, the vehicle must release the drug into the pharmacologically important compartment of the skin. Finally, the patient must accept using the vehicle or else compliance will be poor. For example, although ointments are often pharmacodynamically more effective than creams, patients generally prefer creams to ointments, and thus, it is no surprise that more prescriptions are written for cream-based formulations. Table 214-3 lists many commonly used ingredients in topical preparations. Many of these compounds may serve more than one function in a particular formulation.

Powders

Powders absorb moisture and decrease friction. Because they adhere poorly to the skin, their use is mainly limited to cosmetic and hygienic purposes. Generally, powders are used in the intertriginous areas and on the feet. Adverse effects of powders include caking (especially if used on weeping skin), crusting, irritation, and granuloma formation. Further, powders may be inhaled by the user. Most powders contain zinc oxide for its antiseptic and covering properties, talc (primarily composed of magnesium silicate) for its lubricating and drying properties, and a stearate for improved adherence to the skin. Calamine is a popular skin-colored powder composed of 98 percent zinc oxide and 1 percent ferric oxide and acts as an astringent to relieve pruritus. Other drugs formulated as powders include some over-the-counter antifungals.[9]

Poultices

A poultice, also referred to as a *cataplasm*, is a wet solid mass of particles, sometimes heated, that is applied to diseased skin. Historically, poultices contained meal, herbs, plants, and seeds. The modern poultice often consists of porous beads of dextranomer. Poultices are used as wound cleansers and absorptive agents in exudative lesions such as decubiti and leg ulcers.[9]

Ointments

Ointments are semisolid preparations that spread easily. They can be protective, hydrating, and lubricating. Ointment bases used in dermatology can be classified into five categories: hydrocarbon bases, absorption bases, emulsions of water-in-oil, emulsions of oil-in-water, and water-soluble bases. Dermatologists commonly refer to the hydrocarbon bases and absorption bases as *ointments* and the water-in-oil/oil-in-water emulsion bases as *creams*. In pharmaceutical terms, all of these preparations are ointments.

HYDROCARBON BASES Also called *oleaginous bases*, hydrocarbon bases are often referred to as *emollients* because they prevent the evaporation of moisture from the skin and are composed of a

TABLE 214–3
Vehicle Ingredients Commonly Used in Topical Preparations

Emulsifying agents	Solvents
Cholesterol	Alcohol
Disodium monooleamidosulfosuccinate	Diisopropyl adipate
Emulsifying wax	Glycerin
Polyoxyl 40 stearate	1,2,6-Hexanetriol
Polysorbates	Isopropyl myristate
Sodium laureth sulfate	Propylene carbonate
Sodium lauryl sulfate	Propylene glycol
Auxiliary emulsifying agents/emulsion stabilizers	Water
Carbomer	Thickening agents
Catearyl alcohol	Beeswax
Cetyl alcohol	Carbomer
Glyceryl monostearate	Petrolatum
Lanolin and lanolin derivatives	Polyethylene
Polyethylene glycol	Xanthan gum
Stearyl alcohol	Emollients
Stabilizers	Caprylic/capric triglycerides
Benzyl alcohol	Cetyl alcohol
Butylated hydroxyanisole	Glycerin
Butylated hydroxytoluene	Isopropyl myristate
Chlorocresol	Isopropyl palmitate
Citric acid	Lanolin and lanolin derivatives
Edetate disodium	Mineral oil
Glycerin	Petrolatum
Parabens	Squalene
Propyl gallate	Stearic acid
Propylene glycol	Stearyl alcohol
Sodium bisulfite	Humectants
Sorbic acid/potassium sorbate	Glycerin
	Propylene glycol
	Sorbitol solution



mixture of hydrocarbons of varying molecular weights, with petrolatum being the most commonly used (white petrolatum, except for being bleached, is identical to yellow petrolatum). They are greasy and can stain clothing. The silicon ointments are composed of alternating oxygen and silicon atoms bonded to organic groups, such as phenyl or methyl, and are excellent skin protectants. They can be used for diaper rash, incontinence, bedsores, and colostomy sites. Hydrocarbon bases are generally stable and do not contain preservatives. They cannot absorb aqueous solutions, and thus are not used for water-soluble drugs.[9]



ABSORPTION BASES Absorption bases contain hydrophilic substances that allow for the absorption of water-soluble drugs. The hydrophilic (polar) compounds may include lanolin and its derivatives, cholesterol and its derivatives, and the partial esters of polyhydric alcohols such as sorbitan monostearate. These ointments are lubricating and hydrophilic, and they can form emulsions. They function well as emollients and protectants. They are greasy to apply but are easier to remove than the hydrocarbon bases. They do not contain water. Examples include anhydrous lanolin and hydrophilic petrolatum.[9]

WATER-IN-OIL EMULSIONS (CREAMS) Emulsions are two-phase systems involving one or more immiscible liquids dispersed in another, with the assistance of an emulsifying agent. A water-in-oil emulsion, by definition, contains less than 25 percent water, with oil being the dispersion medium. The two phases may separate unless shaken. The emulsifier (or surfactant) is soluble in both phases and surrounds the dispersed drops to prevent their coalescence. Examples of surfactants used include sodium lauryl sulfate, the quaternary ammonium compounds, Spans (sorbitan fatty acid esters), and Tweens (polyoxyethylene sorbitan fatty acid esters). Preservatives are frequently added to increase the emulsion's shelf life. Water-in-oil emulsions are less greasy, spread easily on the skin, and provide a protective film of oil that remains on the skin as an emollient, while the slow evaporation of the water phase provides a cooling effect.[9]

OIL-IN-WATER EMULSIONS An oil-in-water emulsion contains greater than 31 percent water. In fact, the aqueous phase may comprise up to 80 percent of the formulation. This type of formulation is the one most commonly chosen to deliver a dermatologic drug. Clinically, oil-in-water emulsions spread very easily, are water washable and less greasy, and are easily removed from the skin and clothing. Invariably, they contain preservatives, such as the parabens, to inhibit the growth of molds. Additionally, oil-in-water emulsions contain a humectant (an agent that draws moisture into the skin), such as glycerin, propylene glycol, or polyethylene glycol (PEG), to prevent the cream from drying out. The oil phase may contain either cetyl or stearyl alcohol (paraffin alcohols) to impart a stability and velvety smooth feel upon application to the skin. After application, the aqueous phase evaporates, leaving behind both a small hydrating layer of oil and a concentrated deposit of the drug.[9]

WATER-SOLUBLE BASES Water-soluble bases consist either primarily or completely of various PEGs. Depending on their molecular weight, PEGs are either liquid (for example, PEG 400) or solid (PEG 4000). These formulations are water soluble, will not decompose, and will not support the growth of mold, and therefore require no preservative additives. They are much less occlusive than water-in-oil emulsions, nonstaining, greaseless, and easily washed off of the skin. Without water, this ointment poorly delivers its co-formulated drug. Therefore, it will be useful in scenarios where the practitioner desires a high surface concentration and low percutaneous absorption of the drug. For example, topical antifungal drugs and topical antibiotics (e.g., mupirocin) are formulated in this type of base.

Gels are made from water-soluble bases by formulating water, propylene glycol, and/or PEGs with a cellulose derivative or carbopol. A gel consists of organic macromolecules uniformly distributed in a lattice throughout the liquid. After application, the aqueous or alcoholic component evaporates, and the drug is deposited in a concentrated form. This provides a faster release of the drug independent of its water solubility. Gels are popular because of their clarity and ease of both application and removal. They are also easy to use on the hair-bearing body sites. Nevertheless, they lack any protective or emollient properties. If they contain high concentrations of alcohol or propylene glycol, they tend to be drying or cause stinging. Gels require preservatives.[9] Newer gel formulations may contain the humectant glycerin, the emollient dimethicone, or the viscoelastic polysaccharide hyaluronic acid, which can mitigate some of the associated irritation. Non-aqueous gels, with bases such as glycerol, may be used for poorly solubilized therapeutics such as 5-aminolevulonic acid.[10]

Microspheres, or microsponges, are formulated in an aqueous gel. Medication, in this case tretinoin, is combined into porous beads 10 to 25 μm in diameter. The beads are made up of methyl methacrylate and glycol dimethacrylate.

Pastes

Pastes are simply the incorporation of high concentrations of powders (up to 50 percent) into an ointment such as a hydrocarbon base or a water-in-oil emulsion. The powder must be insoluble in the ointment. Invariably, they are "stiffer" than the original ointment. The powders commonly used are zinc oxide, starch, calcium carbonate, and talc. Pastes function to localize the effect of a drug that may be staining or irritating (i.e., anthralin). They also function as impermeable barriers that serve as protectants or sunblocks. Pastes are less greasy than ointments, more drying, and less occlusive.[9]

Liquids

Liquids can be subdivided into solutions, suspensions, and emulsions (discussed in Ointments).

SOLUTIONS A solution involves the dissolution of two or more substances into homogenous clarity. The liquid vehicle may be aqueous, hydroalcoholic, or non-aqueous (alcohol, oils, or propylene glycol). An example of an aqueous solution is aluminum acetate or Burow's solution. A hydroalcoholic solution with a concentration of alcohol of approximately 50 percent is called a *tincture*. A collodion is a non-aqueous solution of pyroxylin in a mixture with ether and ethanol, and is applied to the skin with a soft brush. Flexible collodions have added castor oil and camphor and are used, for example, to deliver 10 percent salicylic acid as a keratolytic agent and cantharidin for the treatment of warts. Liniments are non-aqueous solutions of drugs in oil or alcoholic solutions of soap. The base of oil or soap facilitates application to the skin with rubbing or massage. Liniments can be used as counterirritants, astringents, antipruritics, emollients, and analgesics.[9]

SUSPENSIONS (LOTIONS) A suspension, or lotion, is a two-phase system consisting of a finely divided, insoluble drug dispersed into a liquid in a concentration of up to 20 percent. Non-uniform dosing can result if the suspended particles coalesce and separate out of a homogeneous mixture, therefore shaking of the lotion before application may be required. Examples include calamine lotion, steroid lotions, and emollients containing urea or lactic acid. The applied lotion leaves the skin feeling cooler via evaporation of the aqueous component. Lotions are easier to apply and allow for uniform coating of the affected area, and are often the favorite preparation in treating children. Lotions are more drying than ointments, and preparations with alcohol tend to sting eczematized or abraded skin.[9]

SHAKE LOTIONS Shake lotions are lotions to which a powder is added to increase the surface area of evaporation. As a result of the increased evaporation, the application of shake lotions effectively dries and cools wet and weeping skin. Generally, shake lotions consist of zinc oxide, talc, calamine, glycerol, alcohol, and water, to which specific drugs and stabilizers may be added. Shake lotions tend to sediment, and derive their name from the need to shake the preparation before each use to obtain a homogeneous suspension. In addition, after water has evaporated from the lotion, the powder component may clump together and become abrasive. Therefore, patients should be instructed to remove the residual particles before the reapplication of shake lotions.[9]

Aerosols

Topical aerosols may be used to deliver drugs formulated as solutions, suspensions, emulsions, powders, and semisolids. Aerosols involve formulating the drug in a solution within a pure propellant. Usually, the propellant is a blend of nonpolar hydrocarbons. When applied to abraded or eczematized skin, aerosols lack the irritation of other formulations, especially when the quality of the skin makes direct application painful or difficult. Furthermore, aerosols dispense a drug as a thin layer with minimal waste, and the unused portion cannot be contaminated. Aerosol foams, a relatively new vehicle for drug delivery, are commonly used to deliver corticosteroids such as betamethasone valerate and clobetasol propionate. The foam contains the drug within an emulsion formulated with a foaming agent (a surfactant), a solvent system (such as water and ethanol), and a propellant. On application, a foam lattice forms transiently until it is broken by both the heat of the skin and the heat of rubbing the foam onto the skin. Foams that are alcohol based leave very little residue within seconds of their application. Furthermore, a given corticosteroid formulated in a foam vehicle demonstrates comparable potency when compared with the same corticosteroid in other vehicles.[1,11] Although aerosols allow for the ease of application (especially to hair-bearing areas) and high patient satisfaction, they suffer from the disadvantages of being expensive and potentially ecologically damaging.[9]

Stabilizers

Stabilizers are non-therapeutic ingredients and include the preservatives, antioxidants, and chelating agents. Preservatives protect the formulation from microbial growth. The ideal preservative is effective at a low concentration against a broad spectrum of organisms, nonsensitizing, odor free, color free, stable, and inexpensive. Unfortunately, the ideal preservative does not exist. The parabens are the most frequently added preservatives, and are active against molds, fungi, and yeasts, but less effective against bacteria. Alternative agents include the halogenated phenols, benzoic acid, sodium benzoate, formaldehyde, the formaldehyde-releasing agents, and previously, thimerosal. Most commonly used preservatives may act as contact sensitizers.

Antioxidants or preservatives prevent the drug or vehicle from degrading via oxidation. Examples include butylated hydroxyanisole and butylated hydroxytoluene, used in oils and fats. Ascorbic acid, sulfites, and sulfur-containing amino acids are used in water-soluble phases. Chelating agents, such as sodium EDTA and citric acid, work synergistically with antioxidants by complexing heavy metals in aqueous phases.

Thickening Agents

Thickening agents increase the viscosity of products or suspend ingredients in a formulation. Examples include beeswax and carbomers. In addition to functioning as an ointment vehicle, petrolatum may be added to an emulsion to increase its viscosity. As in this example, an ingredient may have a therapeutic effect as well as acting as part of a vehicle.

TOXICITY OF TOPICAL DRUGS

Local Effects

Either the vehicle or its active ingredients may cause local toxicity to the applied site. Local adverse effects are usually minor and reversible. Major cutaneous side effects include irritation, allergenicity, atrophy, comedogenicity, formation of telangiectases, pruritus, stinging, and pain. The mechanism of toxicity may be as simple as the desiccation of the stratum corneum (the removal of sebum and oils by the preparation's emulsifiers, for example), or involve a more complex effect on either the cells of the epidermis or dermis and the structures these cells comprise (i.e., epidermis, adnexae). Local damage may occur either directly at, or within close proximity to, the treated site. Further, irritation and damage may appear even after a drug has been discontinued. Often the therapeutic effects of the active ingredient mask or immediately treat the toxic effects of the formulation so that acutely toxic effects are transient.[12] For example, an allergic contact dermatitis to a preservative in a topical steroid may be masked by the effects of the steroid itself.

Irritation is driven less by drug penetration and more by drug concentration. Thus, lowering the concentration of an irritating drug may lower the risk of side effects. However, a change in formulation may reduce the preparation's efficacy. Nevertheless, often using a less concentrated preparation over a greater period of time is as therapeutically efficacious while minimizing adverse effects; for example, the use of benzoyl peroxide 2 percent to 5 percent preparations in contrast to 10 percent preparations.[12] In some instances, though, skin irritancy might be central to drug efficacy. For example, although not conclusively shown, the power of immunomodulating agents such as imiquimod might rely on an increased innate (inflammatory or irritant) immune response.

In contrast to local irritation, contact allergy development depends on local penetration. Allergy, of course, is driven by antigen recognition and presentation, and thus, percutaneous absorption of the drug must be at a level that guarantees interaction with the immune effector cells of the skin. Therefore, the contact allergenicity of a



drug relates most significantly to percutaneous absorption.

Systemic Effects

One should be aware of the potential systemic toxicities of topical drugs. Although generally safer than the other routes of administration, topical application can result in systemic toxicities ranging from end-organ toxicity (central nervous system, cardiac, renal, etc.), teratogenicity, and carcinogenicity to drug interactions. These outcomes may relate to the drug itself, its metabolites, or even a component of the vehicle.



The kinetics of topically applied drugs differ significantly from those administered by other routes. One important consideration is the lack of hepatic first-pass metabolism of a topical drug. This is especially relevant to drugs such as salicylic acid that are relatively innocuous when given enterally, but may manifest central nervous system toxicity when applied topically. Additionally, acting as a reservoir, the stratum corneum may store large amounts of a topical drug, and a subsequently long diffusion period of many days may ensue, delivering a steady supply of drug to the systemic circulation.

Percutaneous toxicity directly relates to percutaneous absorption. Therefore, factors that modulate absorption also influence toxicity: the concentration of the drug, its vehicle, the use of occlusion, the body site and area treated, frequency of use, the duration of therapy, and the nature of the diseased skin. For example, 6 percent salicylic acid in Eucerin used for 11 days in the treatment of psoriasis has been shown to result in epistaxis and deafness, while the same concentration of salicylic acid in hydrophilic cream under occlusion for 4 days for the treatment of dermatitis (involving the same amount of body surface area) may result in hallucination.[12] Similar to their effect on systemically administered drugs, renal and hepatic diseases, by influencing drug clearance, also contribute to an increased potential for drug toxicity.

Young children have a greater surface area–volume ratio, and thus are at greater risk of percutaneous toxicity than adults. This phenomenon necessitates alternative drugs, formulations, and dosing schedules for children with widespread cutaneous disease. Patients with acute flares of cutaneous illness (for example, psoriasis or atopic dermatitis) may require the treatment of a larger body surface area in a relatively abbreviated period of time. These patients may also increase their dose and frequency of application during such flares. Coupled with the likely increased percutaneous absorption of the diseased skin, these scenarios exponentially increase the possibility of systemic toxicity, and patient education is vital to prevent adverse outcomes.[9] To reduce the risk of toxicity from topical drugs and to increase treatment efficacy, many practitioners will rationally advocate systemic approaches (i.e., methotrexate, cyclosporine, injectable or infusable biologics, or ultraviolet radiotherapy) to patients whose disease involves an extensive body surface area.

In rare instances, anaphylactic shock can be precipitated by topical drug application. For example, when applied to diseased or abraded skin, bacitracin ointment can induce an immediate-type (type I) hypersensitivity reaction in susceptible individuals. Such reactions might be represented by a local and then subsequently generalized pruritus leading to cardiopulmonary arrest.[13] Nonimmunologic acute toxicity results from substances such as pesticides and chemical warfare agents that rapidly diffuse through the skin and reach target organs.

Transdermal drug delivery, in contrast to topical drug delivery, uses topical application of therapeutic drug as a delivery system for systemic therapy. Transdermal patches have been approved by the U.S. Food and Drug Administration since 1981 (scopolamine being the first) for the delivery of 13 different medications, with more seeking approval. The most commonly used patches are for nitroglycerin and fentanyl (Duragesic). Advantages of this approach include controlled release, a steady blood-level profile with zero-order kinetics, lack of a plasma peak, and, in some cases, improved patient compliance. These patches remain on the skin for 12 hours to 1 week. A patch consists of a plastic backing, a reservoir of medication, either a rate-controlling membrane or a polymer matrix system for controlled diffusion, followed by an adhesive facing the skin. The most common adhesives used are acrylates, silicones, and polyisobutylenes. These patches have been tested and are approved for use on the thighs, buttocks, lower abdomen, upper arms, and chest; application to other sites can lead to either sub- or supratherapeutic blood levels. Adverse effects of patches include local irritation and allergic contact dermatitis to either an adhesive or to the drug itself and may necessitate discontinuation.

Topical therapies are a mainstay of treatment for the dermatologist. An understanding of the interactions between a drug's concentration, penetration, availability, and treatment of diseased skin allows physicians to maximize both efficacy and tolerability of topical therapy. An understanding of local and systemic toxicities allows selection of appropriate, safe therapy for patients and minimizes unwanted effects. Appropriate selection of topical agents, and patient education on proper use, can optimize therapeutic outcomes.

KEY REFERENCES

The full reference list for all chapters is available at www.digm7.com.

2. Feldman RJ, Maibach HI: Regional variation in percutaneous penetration of 14C cortisol in man. *J Invest Dermatol* **48**:181, 1967
4. Eaglstein WH, Farzad A, Capland L: Topical corticosteroid therapy: Efficacy of frequent application. *Arch Dermatol* **110**:955, 1974
6. Zaghloul SS, Goodfield MJ: Objective assessment of compliance with psoriasis treatment. *Arch Dermatol* **140**:408, 2004
7. Carroll CL et al: Adherence to topical therapy decreases during the course of an 8-week psoriasis clinical trial: Commonly used methods of measuring adherence to topical therapy overestimate actual use. *J Am Acad Dermatol* **51**:212, 2004
9. Ricciatti-Sibbald D, Sibbald RG: Dermatologic vehicles. *Clin Dermatol* **7**:11, 1989
12. Zesch A: Short and long-term risks of topical drugs. *Br J Dermatol* **115**:63, 1986

CHAPTER 215

Pharmacokinetics and Topical Applications of Drugs

Hans Schaefer
Thomas E. Redelmeier
Gerhard J. Nohynek
Jürgen Lademann

Pharmacokinetics related to topical applications of drugs describes the time-dependent drug concentration following the application of the drug to the skin surface, its subsequent passage through the skin barrier into the underlying skin layers, and its distribution into the systemic circulation. The subject continues to hold the attention of research scientists and clinicians alike because of its relevance to dermatologic therapy and the possibility of topical application of current systemic medication that cannot be administered orally, such as peptides or proteins. However, this is an inherently complex subject, despite the advent of new insights into the principal factors that govern diffusion of a drug into and across the skin.

The major difficulty in developing an accurate description of the percutaneous absorption of a drug is related to the size of the compartments. A topical application of a cream or ointment is generally spread to a thickness of not greater than 10 μm. The thickness of the stratum corneum is also approximately 10 μm, whereas the viable epidermis, dermis, and, to a greater extent, the systemic compartment, represent a large sink in which absorbed drugs undergo dilution to levels that often remain undetectable to all but the most sensitive techniques. The determination of the time-dependent changes in the concentration of a drug in individual compartments is technically challenging. After topical application of a drug formulation, these parameters can affect this process:

1. Formulations may undergo drastic changes in composition and structure;
2. The drug or its formulation may affect the skin barrier, resulting in time-dependent changes of the barrier function;
3. The skin barrier may be affected by the type and progression of a disease;
4. There are significant regional variations in the barrier properties of the skin;
5. Viable skin tissues themselves may respond to a topical application of a drug formulation resulting in enhancement or retardation of percutaneous absorption;
6. Skin has a significant metabolic capacity; often, the resulting systemic exposure may be not only to the parent drug, but also to pharmacologically more or less active metabolite(s).

DIFFUSION

Laws of Diffusion

Compounds applied topically to the skin surface migrate along concentration gradients according to well-described laws governing diffusion of solutes in solutions and/or their diffusion across membranes. For a detailed discussion of relevant equations, readers are referred to several comprehensive reviews.[1–4]

Fick's Laws

Diffusion of uncharged compounds across a membrane or any homogenous barrier is described by Fick's first and second laws. The first law states that the steady state flux of a compound (J = moles/cm per second) per unit path length (δ, cm) is proportional to the concentration gradient (ΔC) and the diffusion coefficient (D, cm^2/s).

$$J = -D\,(\Delta C/\Delta\delta)$$

The negative sign indicates that the net flux is in the direction of the lower concentration. This equation applies to diffusion-mediated processes in isotropic solutions under steady-state conditions. Fick's second law predicts the flux of compounds under non–steady-state conditions. It is worthwhile to point out that diffusion is a very effective transport mechanism over very short distances but not over long ones. The relationship between the time (Δt) it takes for a molecule to migrate along a path length (x) and its diffusion coefficient is governed by the following equation:

$$\Delta t = x^2/2D$$

For example, the diffusion coefficient for water in an aqueous solution is: 2.5×10^{-5} cm^2/s, suggesting that a water molecule would migrate over a 10-μm path (the equivalent of the width of the stratum corneum) in 0.4 milliseconds. However, because diffusion depends upon the square of the distance, longer distances are not efficiently covered; a 100-μm path would take 40 milliseconds.

PHARMACOKINETICS AT A GLANCE

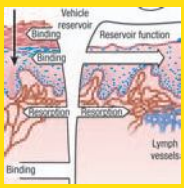

- Compounds applied topically to the skin surface migrate along concentration gradients.
- The drug or its formulation may affect the skin barrier, resulting in time-dependent changes of the barrier function.
- There are significant regional variations in the barrier properties of the skin.
- Formulations differ in their physicochemical properties—this influences the kinetics of release and/or absorption and the onset, duration, and extent of a biologic response.
- The primary compartment that limits the percutaneous absorption of compounds is the stratum corneum.
- Diffusion within the viable tissue, as well as metabolism and resorption, also influence the bioavailability of compounds in specific skin compartments.
- Metabolic activity is a primary consideration in the design of prodrugs and may influence the bioavailability of drugs delivered via dermatologic or transdermal formulations.

THREE-COMPARTMENT MODEL

Although pharmacokinetic analysis of topical preparations may require the description of a relatively large number of compartments, this discussion is confined to the three outlined in Fig. 215-1: the skin surface, the stratum corneum, and the viable tissue. The formulation itself forms a reservoir, from which the compound must be released; in order to undergo percutaneous absorption, the compound then must penetrate the stratum corneum, diffuse into and through the viable epidermis into the dermis,





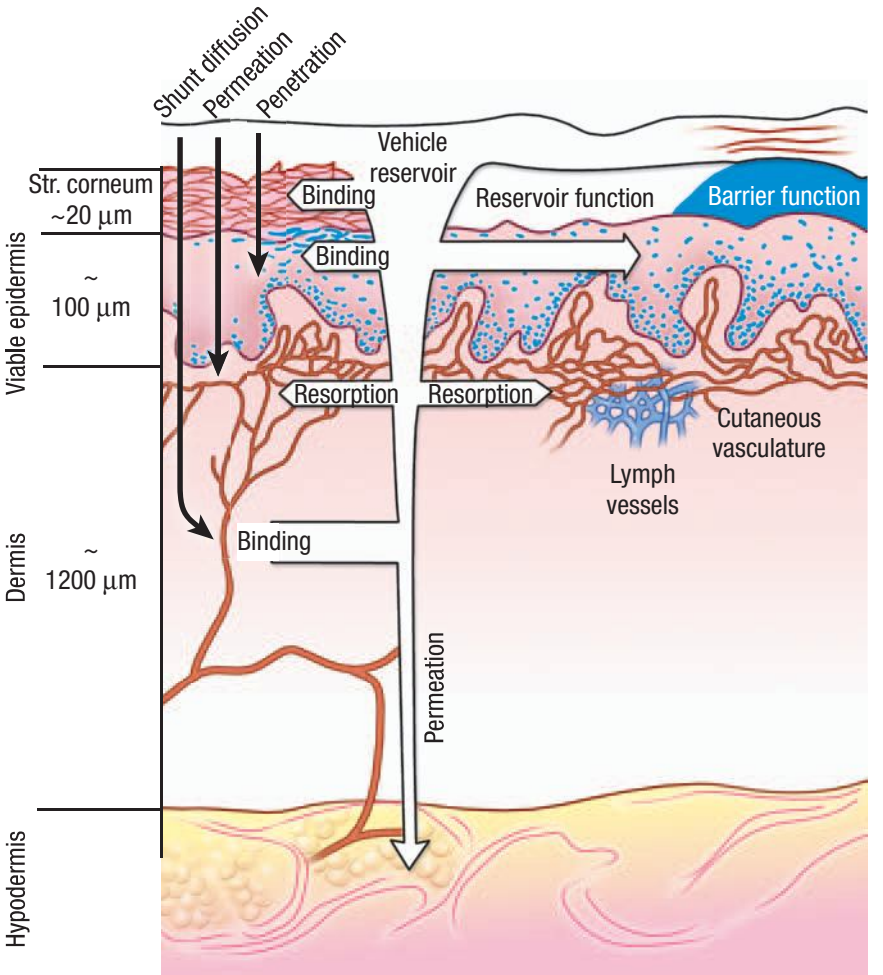

▲ **FIGURE 215-1** Diagrammatic representation of three compartments of the skin: Surface, stratum (Str.) corneum, and viable tissues. After surface applications, evaporation and structural/compositional alterations in the applied formulation may play an important role in determining the bioavailability of drugs. The stratum corneum, the outermost layer, plays the most significant role in determining the diffusion of compounds into the body. After absorption, compounds may bind or diffuse within the viable tissues, or become resorbed by the cutaneous vasculature.

and, finally, gain access to the systemic compartment through the vascular system. In addition, the substance may diffuse through the dermal and hypodermal layers to reach underlying tissues. As summarized in Table 215-1, within each compartment, the compound may diffuse down along its concentration gradient, bind to specific components, or be metabolized. The size or characteristics of each compartment may alter with time, and the factors determining diffusion within each compartment may be affected by disease state as well as the nature or the pharmacologic/biologic activity of the drug or its excipients.

The Skin Surface

SURFACE APPLICATIONS OF FORMULATIONS Formulations differ in their physicochemical properties, and, as discussed in Formulations, this influences the kinetics of release and/or absorption. However, the principal consideration is that topically applied drug products represent a physically small compartment, which limits the amount of compound that can be applied to the skin surface. When a patient applies a dermatologic preparation, the layer of a formulation covering the skin is very thin (approximately 0.5 to 2.0 mg/cm^2). Thicker layers are felt as "unpleasant" and are consciously or subconsciously rubbed off or spread to larger surfaces. This restricts the amount of an active compound that can effectively come in contact with the skin surface to approximately 5 to 20 µg/cm^2 for a 1 percent (wt/wt) topical formulation.

However, even after being rubbed in, formulations do not remain homogeneous over the time course of penetration. For example, topical applications containing water, alcohol, or similar solvents undergo rapid evaporation.[5] This phenomenon is readily recognized by patients as a cooling sensation. The evaporation results in rapidly increasing concentrations of nonvolatile substances on the skin surface, which may result in the formation of supersaturated "solutions" or, alternatively, precipitation of active ingredients. Formulations may also mix with skin-surface lipids or undergo time-dependent changes in their composition as excipients and drugs undergo absorption. Altogether, these considerations suggest that dramatic changes in the composition and structure of formulations may occur following surface application, all of which may determine the subsequent bioavailability of active ingredients.

RESERVOIR The reservoir function was first described by Vickers,[6] who observed that simple occlusion leads to the renewed onset of a glucocorticoid-mediated vasoconstriction several hours after it had declined. He interpreted this effect as renewed liberation of the glucocorticoid from a "reservoir" stored in the upper skin layers.

We define as reservoir the amount of an active ingredient that is still in contact with the nonvolatile constituents of its formulation after the latter had been massaged into the skin surface. The compound has not yet penetrated, but it cannot be removed by simple rubbing or contact with clothing or other tissues. The reservoir thus adheres to the skin surface and resides in the wrinkles and the upper layers of the stratum corneum. Reservoirs on eczematous skin may become even more prominent because of the scaliness of the skin. Recently, we discovered that the upper volume of the follicular channels serves also as a reservoir, which may result in a relative increase in absorption through appendages. In vivo laser scanning microscopy measurements found that the hair follicles represent an efficient reservoir for topically applied formulations, which can be compared with the reservoir of the stratum corneum on several body sites.[7,8] This phenomenon may be increased in formulations that contain particles or precipitates, given the evidence that appropriately sized particles can rapidly penetrate along the shafts of hair follicles to a depth of up to 100 to 500 µm.[9–12]

The optimum size of the particles for penetration into hair follicles is between 300 and 600 nm, which corresponds to

TABLE 215-1
Compartments Encountered by Substances Undergoing Percutaneous Absorption: General Relevance of Processes to Bioavailability

Compartment	Processes	General Relevance to Bioavailability
Vehicle	Diffusion	++
	Thermodynamic activity	++
	Evaporation	+
↓	Precipitation	±
Stratum corneum	Reservoir function	+++
↓	Diffusion	+++
	Binding	±
↓	Metabolism	–
Epidermis	Diffusion	±
↓	Metabolism	±
↓	Binding	++
Cutaneous vasculature	Resorption	+
↓ ↑		
Underlying tissues including dermis	Diffusion	±
	Metabolism	±
	Binding	–

– = although theoretically possible, this process is probably not of general relevance; ± = this process is of direct relevance, but only in a restricted number of cases; + = the process is general relevant, but not as important as ++ or +++.

the cuticular structure of the hairs.[13,14] It was assumed that the rigid hair shaft acts as a geared pump, because this effect could only be observed in the case of moving hairs.[14] The follicular reservoir may result in a relative increase in the absorption of topically applied substances.

No evidence has been found that topically applied substances penetrate efficiently into the sweat glands. This may be due to sweat outflow or other, unknown reasons.

FORMULATIONS Formulations can be differentiated on the basis of whether they are designed to remain on the skin surface (sunscreen products and cosmetics), to be delivered to compartments in the skin (topical formulations), or to migrate across the skin into the central compartment (transdermal formulations).

Formulations may affect the kinetics and the degree of percutaneous absorption and, subsequently, the onset, duration, and extent of a biologic response. In the context of percutaneous absorption, there are several different parameters that should be considered when selecting a formulation[1,15]: the thermodynamic activity of the active ingredient[16]; the amount of compound that can be incorporated into the formulation[17]; the stability of the formulation on the skin surface (e.g., emulsions may break easily)[18]; the partition coefficient of the active ingredient between the vehicle and the stratum corneum[19]; and the enhancer activity.

In general, percutaneous absorption is proportional to the thermodynamic activity of the compound. Thus, the greatest flux is observed at the active ingredient's maximum solubility in a vehicle. Vehicles that are very good solvents should be avoided because they may retain the active ingredient on the skin surface.

LIPOSOMES AS TRANSDERMAL DELIVERY SYSTEMS Liposomes are microscopic spheres comprising a bilayer that encloses an inner aqueous core. A wide variety of cosmetics contain liposomes. Liposome-based formulations have proved to be safe, cosmetically attractive, and well accepted. There is considerable evidence that, at least for some preparations, application of liposomes is mildly occlusive and improves the hydration level of the stratum corneum. Interest in the use of liposomes to enhance the delivery of drugs across the skin has been spurred by several observations in animal models: liposome formulations were believed to enhance the penetration of compounds across the skin or to optimize the retention of bioactive compounds in target tissues.[20] However, these early studies, which relied largely on animal models, were followed by relatively few in vivo studies for humans[17] conducted under standard conditions.

There is good evidence that particles can penetrate along the hair shaft and this route may be appropriate for delivery of bioactive compounds into sebaceous glands or hair follicles.[7,8]

Rigid liposomes penetrate better into the hair follicles than flexible liposomes, which supports the assumption that the moving hairs act as a geared pump.[21]

The Skin Barrier (See Chap. 45)

The primary compartment that limits the percutaneous absorption of compounds is the stratum corneum. This thin (10 to 20 μm) layer effectively surrounds the body and represents a highly differentiated structure that determines the diffusion of compounds across the skin. The physical description of the stratum corneum is well documented,[22] and it can be accurately described as "bricks" of bundled, water-insoluble proteins, embedded in a "mortar" of intercellular lipid.

The stratum corneum is a highly organized, differentiated structure. To participate fully in forming an effective barrier to diffusion, the biogenesis of the corneocytes as well as the synthesis and processing of the intercellular lipid must proceed in an orderly manner. Disruption in the kinetics of skin barrier formation by accelerating the division of the keratinocytes in the underlying layers will lead to a disruption in the barrier properties of the skin.[23] Thus, the concept of dead or dying skin forming a passive barrier to diffusion is now replaced by a model of the stratum corneum as a highly differentiated structure with unique properties that are particularly suited for its role in forming the skin barrier (see Chap. 45).[24]

CORNEOCYTES

INTERCELLULAR LIPID

APPENDAGES (See Chap. 84) A variety of appendages penetrate the stratum corneum and epidermis, facilitating thermal control and providing a protective covering. Appendages are potential sites of discontinuity in the integrity of the skin barrier. The density of the hair follicles varies on different body sites. Hair follicles represent a reservoir that may store topically applied substances. A detailed analysis of the reservoir of the hair follicles showed that the highest reservoir is on the scalp, followed by the forehead and the calf.[29] On the forehead, there are a high number of small follicles, while the calf contains fewer but larger hair follicles. These reservoirs are comparable to the reservoir of the stratum corneum on these body sites.



The percentage of the hair follicles on the total skin surface varies between 0.2 percent and 1.3 percent, depending on the body site.[29] Differences in the follicular penetration were observed in different ethnic groups.[30] Hair follicles appear to present an important pathway for percutaneous absorption in non-diseased skin.[11,12] This can be explained by the fact that only the upper wall of the follicular apparatus (the acroinfundibulum) is protected by a coherent stratum corneum, whereas in the lower part (infrainfundibulum), the corneocytes appear undifferentiated, and protection is incomplete, if not absent. Even solid particles may enter deep into the follicular orifice,[9,10,22] a phenomenon that lends itself to the concept of follicular targeting of drugs.[22]

It follows that in relationship to the integral protection against the passage of xenobiotics in general, and drugs specifically, the barrier function of the interfollicular stratum corneum is even more potent than previously believed, whereas more research is needed relative to the follicular pathway. Recent investigations hint to the presence of active follicles (open to penetration) and passive ones.[11]

PENETRATION PATHWAYS In principle, three penetration pathways are possible: the intercellular penetration, inside the lipid layers around the corneocytes, the follicular penetration, and the intracellular penetration.

Although in the past, the transcorneal penetration was assumed to be the only penetration pathway, recent investigations, as cited above in Appendages, have demonstrated that penetration via the hair follicles should be taken into consideration.[29–31]

Up to the present time, no evidence is available that topically applied substances pass the skin barriers by means of the intracellular route.

Pathways across the Stratum Corneum. Several studies have directly visualized penetration pathways across the stratum corneum by electron microscopy. For example, osmium vapor can be used to precipitate *n*-butanol that has penetrated the stratum corneum.[32] After a brief (5 to 60 second) exposure of murine or human stratum corneum, the alcohol was found to be enriched in the intercellular spaces (threefold), although significant levels were also found in the corneocytes. By using a different approach that involved rapid freezing, water, ethanol, and cholesterol were also found preferentially concentrated in the intercellular lipid spaces.[33] Similarly, the penetration of mercury chloride through the intercellular lipid can be detected following precipitation with ammonium sulfide vapor.[34]

However, in most of these investigations, there was also significant localization of compounds in the corneocytes, more prevalent in the upper layers (stratum disjunctum). Thus, corneocytes undergoing desquamation appear to be relatively permeable, even to rather bulky ions such as mercury. There is additional evidence that other compounds can and do penetrate corneocytes. It is well established, for example, that occlusion or immersion of skin in a bath leads to swelling of the corneocytes, consistent with the entry of water. Other compounds have also been localized in corneocytes, such as the anionic surfactants that are bound to keratins. Low-molecular-weight moisturizers such as glycerol are likely to partition into the corneocytes and alter their water-binding capacity. Thus, the penetration of compounds into corneocytes cannot be excluded from considerations of percutaneous absorption pathways. The relevance of this step relates to whether it is rate-determining, that is, whether the diffusion of compounds within the intercellular lipid is restricted by the corneocytes.

Pathways across the Hair Follicles. Using the method of differential stripping—a combination of tape stripping with cyanoacrylate surface biopsies—the amount of formulation stored in the hair follicles can be quantified.[35] It was found that nanoparticles were stored 10 times longer in the hair follicles than in the stratum corneum.[14] It should be noted that when topically applied substances penetrate into the hair follicles, they do not necessarily penetrate through the skin barrier into the living tissue, because the hair follicles also have barrier properties.

In the past, there have been several attempts to detect a follicular penetration.[36–38] The experiments were performed on animal and human skin, with different densities of the hair follicles. Unfortunately, in all cases, the properties of the stratum corneum had also changed.

The analysis of the follicular penetration became possible after the development of a method that artificially closes the hair follicles in vivo.[39] Using this method, it was demonstrated that the small molecules, such as caffeine, may penetrate through the skin barrier not only by the transcorneal, but also by the follicular routes.[40]

INTER- AND INTRAINDIVIDUAL VARIATION IN SKIN BARRIER FUNCTION Finally, it is worthwhile to consider the level of inter- and intraindividual variation in skin barrier activity, including that of follicles. The most accurate and reproducible measurement of skin barrier activity is trans-epidermal water loss.[41] The extent of variation of this parameter for the same individual is estimated to be 8 percent by site and 21 percent according to the day of measurement. The variations between individuals are reported to be somewhat larger, ranging from 35 percent to 48 percent.[42] There appear to be no significant gender- or ethnic-dependent differences in skin barrier activity. The skin barrier activity of premature babies (delivered more than 3 weeks premature)[43] is markedly impaired, although skin barrier function appears normal for full-term infants. There seems to be no significant alteration in skin barrier activity as a function of age. Differences in skin barrier activity among different sites have been observed; barrier function can be ranked as arm ~ abdomen > postauricular > forehead.[41]

Viable Tissue

Although the primary barrier to percutaneous absorption lies within the stratum corneum, diffusion within the viable tissue, as well as metabolism and resorption, also influence the bioavailability of compounds in specific skin compartments. These processes are interrelated, and factors that increase the rate of one of these processes inevitably influence the others. Because the development of dermatologic formulations is often focused on "targeted" delivery to living tissues, the manipulation of these processes offers a clear-cut rationale for increasing the therapeutic efficacy of dermatologic drugs.

The passage of compounds from the stratum corneum into the viable epidermis results in a substantial dilution. This is not only the relatively larger volume of the epidermis as compared with that of the stratum corneum, but also the lower resistance to diffusion within viable tissues, approximately corresponding to that of an aqueous protein gel.[42] Drug concentrations of 10^{-4} to 10^{-6} M may be attained in the epidermis and dermis for substances that permeate readily. Although the actual concentration gradient of a compound is affected both by the physicochemical properties of the compounds as well as by the duration of application, a concentration gradient is present at all



times. In other words, strategies to enhance percutaneous absorption generally result in a relatively uniform and parallel increase in the concentration of compounds in all compartments.

SKIN METABOLISM

The skin contains a wide range of enzymatic activities, including phase I oxidative, reductive, hydrolytic, and phase II conjugation reactions, as well as a full complement of drug-metabolizing enzymes.[44] Metabolic activity is a primary consideration in the design of prodrugs and may influence the bioavailability of drugs delivered via dermatologic or transdermal formulations. Alterations in skin metabolism have been implicated in a range of diseases, including hirsutism and acne, and they may be relevant to the risk of topical exposure to carcinogens. Metabolic processing of antigens by Langerhans cells is involved in the presentation of allergens to the immune system. Thus, metabolism in skin compartments plays a significant role in determining the fate of a topically applied active compound.

Significant cutaneous metabolism has been demonstrated for a wide variety of compounds of differing physicochemical properties, including the steroid hormones estrone, estradiol, and estriol, as well as glucocorticoids, prostaglandins, retinoids, benzoyl peroxide, aldrin, anthralin, 5-fluorouracil, nitroglycerin, theophylline, and propranolol.[31] Recently, it has been shown that arylamine-type hair dye ingredients are also subject to metabolism in human and animal skin, resulting in *N*-acetylated metabolites.[45–47] The enzyme responsible is believed to be epidermal *N*-acetyltransferase-1.[45] For example, cutaneous metabolism reduced the systemic bioavailability of nitroglycerin administered in a transdermal drug formulation in rhesus monkeys by 16 percent to 21 percent and hydrolyzed virtually 100 percent of a salicylate diester.[48] It is convenient to classify metabolic reactions in terms of their co-factor dependence. Processes that require co-factors are likely to be energy dependent, and these are located within viable tissues. Among the best-studied examples are the interconversion of steroids (e.g., estrone and estradiol), and the oxidation of polycyclic aromatic hydrocarbons with mixed-function monooxygenases. In contrast, co-factor-independent processes involve catabolism and may be located outside of viable tissues, that is, in the transition region between the stratum corneum and stratum granulosum. The best characterized of these involve hydrolytic reactions such as non-specific ester hydrolysis.

Metabolic activity is found in (1) skin-surface microorganisms, (2) appendages, (3) the stratum corneum, (4) the viable epidermis, and (5) the dermis. In considering the site of the most significant metabolism, one has to take into account the relevant enzymes and their specific activity, as well as their capacity relative to the size of the compartment. Thus, although the level of many enzymes is highest in the epidermis, the relatively large size of the dermal compartment may result in a significant role in the metabolism of topically applied substances. A further consideration is that enzymes involved in cutaneous metabolism may be induced upon exposure to xenobiotics. This has been well described for various mixed-function monooxygenases.[49] Finally, the qualitative and quantitative extrapolation of results from animal models to humans is uncertain, owing to the significant species differences in the metabolism of compounds.

Percutaneous absorption and metabolism of compounds can be viewed as two events in kinetic competition with each other.[50] Generally, compounds that remain in the skin for longer periods of time undergo significantly more metabolism. Furthermore, the type of metabolism of a substance may also be influenced by the nature of its formulation, as illustrated by investigations on the metabolism of several transdermal nitroglycerin formulations.[51] The inclusion of enhancers in the formulation not only increased the bioavailability of the nitroglycerin but also the ratio of one metabolic compound (1,2-glyceryl dinitrate) in relation to another (1,3-glyceryl dinitrate). This may limit the suitability of in vitro experiments for estimating the significance of cutaneous metabolism because the vasculature is not functional in vitro. It further emphasizes that it is difficult to extrapolate quantitatively the level of metabolism obtained for different formulations. This has significant implications for the estimation of bioequivalence.

However, despite the variety of skin-associated metabolic processes, the extent of metabolism is normally modest, that is, in the order of 2 percent to 5 percent of the absorbed compounds, although for N-acetylation of arylamines, metabolism may be quantitative.[47] Metabolism is limited not only by the relatively short period of time that a compound spends in the viable layers of the skin, but also by the overall low level of enzyme activity. Thus, under many circumstances, the available enzymes are saturated by the level of compound undergoing percutaneous absorption.[44]

RESORPTION

Resorption, defined as the uptake of compounds by the cutaneous microvasculature, is directly related to the surface area of the exchanging capillaries as well as their blood flow. Total blood flow to the skin may vary up to 100-fold, a process primarily regulated by vascular shunts, but also by recruitment of new capillary beds. It is estimated that, under resting conditions, only 40 percent of the blood flow passes via exchanging capillaries capable of acting as a sink for absorbed compounds. However, this value demonstrates considerable variation between body sites, individuals, and species and is influenced by disease states and environmental conditions. In particular, changes in temperature and humidity as well as the presence of vasoactive compounds may directly influence skin blood flow.[52]

For most compounds and situations, resorption does not limit the delivery of compounds to the central compartment after topical applications. This is a result of the relatively high resistance to diffusion within the stratum corneum as compared with uptake by the vasculature. However, for compounds or situations in which diffusion across the stratum corneum is rapid, resorption limits the maximum rate of absorption.[52] The evidence that resorption can limit the delivery of compounds to the central compartment comes primarily from studies that examined the influence of blood flow on this process. The percutaneous absorption of methyl salicylate is increased by elevated ambient temperature or strenuous exercise, an observation consistent with increased resorption as a result of cutaneous blood flow.[53] Moreover, intravenously administered nicotine (a vasoconstrictor) reduces the percutaneous absorption of topically applied nicotine.[54] Regional differences in the percutaneous absorption of piroxicam, a nonsteroidal anti-inflammatory agent, are dependent upon the local vasculature rather than upon skin barrier function.[55] Perhaps the most convincing evidence that resorption can limit delivery to the vasculature comes from in vitro studies on the perfused porcine skin flap.[56]

An additional consideration is that the rate of resorption may indirectly influence the diffusion of compounds to the underlying musculature, tissues, and joints.[57] The principle of locally enhanced delivery to underlying muscula-



ture has been demonstrated for piroxicam as well as several local anesthetic preparations.[58]

INFLUENCE OF PATHOLOGIC PROCESSES ON SKIN BARRIER FUNCTION

Reduced skin-barrier function has been observed in a number of pathologic conditions, including the ichthyoses,[59,60] psoriasis,[22,61] atopic dermatitis,[62] and contact dermatitis.[63] It is generally accepted that this is attributable to structural alterations in the stratum corneum.[22] These structural deficiencies may arise from an absence of an enzyme or structural protein in the underlying viable tissues or may be related to the improper formation of the stratum corneum resulting from an increase in keratinocyte proliferation. Thus, in individuals predisposed to a defective barrier, a minor perturbation may become amplified as the skin "attempts to compensate" by increasing keratinocyte proliferation.[64] A further consideration is that the homeostatic mechanisms responsible for recovery of barrier activity after perturbation may be altered in some diseases or physiologic states.

For example, whereas the skin of aged people exhibits normal barrier function, the recovery of barrier activity after perturbation is markedly reduced.[59,60] This kinetic basis for reduced barrier function may also account for interindividual variation in barrier function and/or the apparently increased susceptibility of certain individuals to contact dermatitis.[63]

KEY REFERENCES

The full reference list for all chapters is available at www.digm7.com.

4. Anissimov YG, Roberts MS: Diffusion modelling of percutaneous absorption kinetics. *J Pharm Sci* **88**:1201, 1999
6. Vickers CFH: Existence of reservoir in the stratum corneum. *Arch Dermatol* **88**:20, 1963
13. Lademann J et al: Hair follicles—A long term reservoir for drug delivery. *Skin Pharm* **19**:232, 2006
14. Toll R et al: Penetration profile of microspheres in follicular targeting of terminal hair follicles. *J Invest Dermatol* **123**:168, 2004
19. Williams PL, Riviere JE: A biophysically based dermatopharmacokinetic compartment model for quantifying percutaneous penetration and absorption of topically applied agents: 1. Theory. *J Pharm Sci* **84**:599, 1995
22. Schaefer H, Redelmeier TE: *Skin Barrier Principle of Percutaneous Absorption*. Basel, Karger, 1996
40. Otberg N et al: Follicular penetration of topically applied caffeine via a shampoo formulation. *Skin Pharmacol Physiol* **20**:195, 2007
42. Scheuplein RJ: Mechanism of percutaneous absorption: II. Transient diffusion and the relative importance of various routes of skin penetration. *J Invest Dermatol* **45**:334, 1967



CHAPTER 216

Topical Corticosteroids

Isabel C. Valencia
Francisco A. Kerdel

MECHANISM OF ACTION

Corticosteroids have specific and nonspecific effects that are related to different mechanisms of action, including: anti-inflammatory, immunosuppressive, antiproliferative, and vasoconstrictive effects. Most of the effects of corticosteroids on cells are mediated by binding of the corticosteroid to its receptor in the cytosol, followed by translocation of the drug-receptor complex to a region of the nuclear DNA known as the *corticosteroid responsive element*, where it is then able to stimulate or inhibit transcription of the adjacent genes, thus regulating the inflammatory process.[1]

Anti-Inflammatory Effects

Corticosteroids are thought to exert their potent anti-inflammatory effects by inhibiting the release of phospholipase A_2, an enzyme responsible for the formation of prostaglandins, leukotrienes, and other derivatives of the arachidonic acid pathway. Corticosteroids also inhibit transcription factors, such as activator protein 1 and nuclear factor κB, that are involved in the activation of pro-inflammatory genes. Genes known to be upregulated by corticosteroids and that play a role in the resolution of inflammation include lipocortin and p11/calpactin-binding proteins, both involved in the release of arachidonic acid.[1–3] Lipocortin I inhibits phospholipase A_2, reducing the release of arachidonic acid from phospholipids.[1,4,5] Corticosteroids also decrease the release of interleukin 1α (IL-1α), an important pro-inflammatory cytokine, from keratinocytes.[1,6] Other proposed mechanisms for the anti-inflammatory effects of corticosteroids include inhibition of phagocytosis and stabilization of lysosomal membranes of phagocytizing cells.[7]

Immunosuppressive Effects

The effectiveness of corticosteroids is, in part, also due to their immunosuppressive properties. Corticosteroids suppress the production and effects of humoral factors involved in the inflammatory response, inhibit leukocyte migration to sites of inflammation, and interfere with the function of endothelial cells, granulocytes, mast cells, and fibroblasts.[1,8–10] Several studies have shown that corticosteroids can cause mast cell depletion in the skin.[11] Experiments also show that topical corticosteroids cause local inhibition of chemotaxis of neutrophils[12] in vitro, and decrease

TOPICAL CORTICOSTEROIDS AT A GLANCE

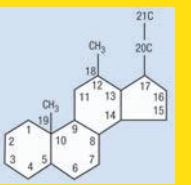

- The most frequently prescribed of all dermatologic drug products.
- Are effective at reducing the symptoms of inflammation, but do not address the underlying cause of the disease.
- Topical glucocorticoid research has focused on strategies to optimize potency while minimizing side effects.
- The new molecules have an overall higher anti-inflammatory effect, good compliance (only once daily application), rarely induce cross-sensitivity reactions and have weak atrophogenic properties.

TABLE 216-1
Potency Ranking of Selected Topical Corticosteroid Preparations[a]

Generic Name	Brand Name
Class 1—Superpotent	
Betamethasone dipropionate 0.05% optimized vehicle	Diprolene gel/lotion/ointment
Clobetasol propionate 0.05%	Clobex lotion/spray
	Olux foam
	Temovate cream/emollient cream/ gel/ointment
Diflorasone diacetate 0.05%	Psorcon ointment
Fluocinonide 0.1% optimized vehicle	Vanos cream
Flurandrenolide, 4 mg/cm^2	Cordran tape
Halobetasol propionate 0.05%	Ultravate cream/ointment
Class 2—Potent	
Amcinonide 0.1%	Cyclocort ointment
Betamethasone dipropionate 0.05%	Diprolene AF cream
	Diprosone ointment
Desoximetasone 0.25%	Topicort cream/ointment
Desoximetasone 0.5%	Topicort gel
Diflorasone diacetate 0.05%	Florone ointment
	Maxiflor ointment
Fluocinonide 0.05%	Lidex cream/gel/ointment
Halcinonide 0.1%	Halog cream/solution/ointment
Mometasone furoate 0.1%	Elocon ointment
Class 3—Potent, upper mid-strength	
Amcinonide 0.1%	Cyclocort cream/lotion
Betamethasone dipropionate 0.05%	Diprosone cream
Betamethasone valerate 0.1%	Valisone ointment
Diflorasone diacetate 0.05%	Florone cream
	Maxiflor cream
	Psorcon E cream
Fluocinonide 0.05%	Lidex E cream
Fluticasone propionate 0.005%	Cutivate ointment
Class 4—Mid-strength	
Betamethasone valerate 0.12%	Luxiq foam
Clocortolone pivalate 0.1%	Cloderm cream
Desoximetasone 0.05%	Topicort LP cream
Fluocinolone acetonide 0.025%	Synalar ointment
Flurandrenolide 0.05%	Cordran ointment
Hydrocortisone probutate 0.1%	Pandel cream
Hydrocortisone valerate 0.2%	Westcort ointment
Mometasone furoate 0.1%	Elocon cream/lotion
Prednicarbate 0.1%	Dermatop ointment
Triamcinolone acetonide 0.1%	Kenalog ointment
Class 5—Lower mid-strength	
Betamethasone dipropionate 0.05%	Diprosone lotion
Betamethasone valerate 0.1%	Valisone cream/lotion
Fluocinolone acetonide 0.025%	Synalar cream
Flurandrenolide 0.05%	Cordran cream, lotion
Fluticasone propionate 0.05%	Cutivate cream
Hydrocortisone butyrate 0.1%	Locoid lipocream
Hydrocortisone valerate 0.2%	Westcort cream
Prednicarbate 0.1%	Dermatop emollient cream
Triamcinolone acetonide 0.1%	Kenalog cream/ lotion
Class 6—Mild strength	
Alclometasone dipropionate 0.05%	Aclovate cream/ointment
Desonide 0.05%	DesOwen cream/lotion/ointment
	Tridesilon cream
Fluocinolone acetonide 0.01%	Synalar cream/solution
	Derma-Smoothe/FS oil
Class 7—Least potent	
Topicals with dexamethasone, flumethasone, hydrocortisone	
Methylprednisolone, prednisolone	

[a]It is the general policy of this book not to use trade names. In this case, this rule is broken to facilitate easier reading.

the number of Ia$^+$ Langerhans cells[13] in vivo. Corticosteroids reduce eosinophilia in patients with asthma. They also reduce T-cell proliferation and induce T-cell apoptosis, in part from inhibition of the T-cell growth factor IL-2.[1,14] In addition, several cytokines are directly affected by corticosteroids, including IL-1, tumor necrosis factor-α, granulocyte-macrophage colony-stimulating factor, and IL-8. These effects may also be a result of the steroid action on antigen presenting cells.[15]

Antiproliferative Effects

The antiproliferative effect of topical corticosteroids is mediated by inhibition of DNA synthesis and mitosis, partly explaining the therapeutic action of these drugs in scaling dermatoses.[16] Fibroblast activity and collagen formation are also inhibited by topical corticosteroids.[17]

Vasoconstriction

The mechanism by which corticosteroids induce vasoconstriction is not yet completely clear. It is thought to be related to inhibition of natural vasodilators such as histamine, bradykinins, and prostaglandins.[1,18,19] Topical steroids cause capillaries in the superficial dermis to constrict, thus reducing erythema. The ability of a given corticosteroid agent to cause vasoconstriction usually correlates with its anti-inflammatory potency, and thus, vasoconstriction assays are often used to predict the clinical activity of an agent. These assays, in combination with double-blind clinical trials, have been used to separate the topical corticosteroids into seven classes based on potency. Class 1 includes the most potent, while class 7 contains the least potent. Table 216-1 lists many of the available topical corticosteroids according to this classification. Notice that the same drug can be found in different potency classifications depending on the delivery vehicle used.

PHARMACOKINETICS

Corticosteroids have a basic skeletal structure comprising 17 carbon atoms arranged in three six-membered rings and one five-membered ring. Modifications of cortisol (Fig. 216-1), by addition or alteration of functional groups at certain positions, have led to compounds with variable anti-inflammatory potency, glucocorticosteroid versus mineralocorticoid activity, and adverse effects.

Topical corticosteroid research has focused on strategies to optimize potency



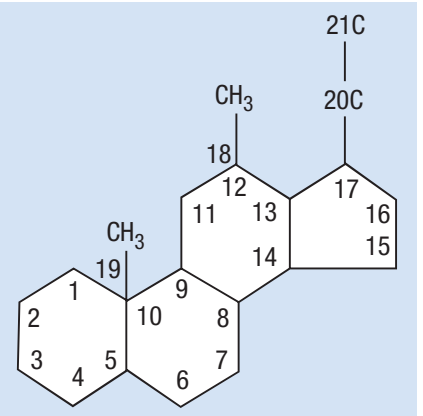

▲ **FIGURE 216-1** Basic steroid molecule.



while minimizing side effects. One strategy is to develop compounds with enhanced anti-inflammatory effects and minimal unwanted atrophogenic and adrenal suppressive effects. In this sense, progress has been made with the development of glucocorticoid molecules that, while retaining high activity in the skin following topical application, are quickly broken down into inactive metabolites, thereby mitigating systemic and possibly some local toxic effects ("soft" glucocorticoids). Some of the newest of these compounds include the di-esters 17,21 hydrocortisone aceponate and hydrocortisone 17-butyrate-21-propionate, prednicarbate, methylprednisolone aceponate, alclometasone propionate, and carbothioates such as fluticasone propionate.[1,24] Hydrocortisone aceponate, prednicarbate, and methylprednisolone aceponate have significant anti-inflammatory effects, but the least capacity to induce skin atrophy; therefore, they can be used to treat areas such as the face, the scrotum, and large body surface areas in children, with minimal adverse effects.[1,25] Fluticasone propionate is classified as a potent corticosteroid with lower potential to cause skin atrophy and adrenal suppression. It offers the advantage of once daily application and infrequent local allergic reactions. Mometasone furoate also has highly anti-inflammatory effects with low incidence of adrenal suppression.[1]

INDICATIONS

Topical corticosteroids are recommended for their anti-inflammatory activity in inflammatory skin diseases, but they can also be used for their antimitotic effects and their capacity to decrease the synthesis of connective tissue molecules.[1] Certain variables must be considered when treating skin disorders with topical glucocorticoids. For example, the responsiveness of diseases to topical glucocorticoids varies. In this setting, diseases can be divided into the three categories shown in Table 216-2: highly responsive, moderately responsive, and least responsive.

Pediatric Uses

Topical glucocorticoids are highly effective, and few side effects are observed when a low-potency preparation is used for brief periods of time without occlusion in children. However, children and, in particular, infants, are at an increased risk of absorbing topical corticosteroids for several reasons. Because they have a higher ratio of skin surface area to body weight, application to a given area results in a greater potentially systemic dose of steroid. Infants may also be less able to metabolize potent glucocorticoids rapidly.[26] Premature infants are especially at risk because their skin is thinner and the penetration rate of topically applied drugs is greatly increased.[27] Application of topical steroids to the diaper area results in occlusion of the steroid by the diaper, and increased penetration occurs. Excess absorption of topical glucocorticoids can suppress endogenous cortisol production. Consequently, subsequent cessation of topical steroid therapy after an extended treatment period can, albeit rarely, result in an addisonian crisis. Deaths from addisonian crisis have been reported with the use of topical steroids,[28] and the risk of this occurring is greater in children. Chronic suppression of cortisol production can also lead to growth retardation. A morning plasma cortisol level can be performed to screen for adrenal suppression. If suppression is present, the child should be slowly weaned from the steroids to prevent these complications.

Geriatric Uses

Elderly patients similarly can have thin skin, which allows for increased penetration of topical glucocorticoids. They are also more likely to have pre-existing skin atrophy secondary to aging and may be diaper-dependent, so the same precautions used in the treatment of infants should be used when treating elderly patients.

Uses in Pregnancy

Appropriate human studies using topical glucocorticoids in pregnancy have never been undertaken. Studies in animals, however, show that topical steroids are systemically absorbed and may cause fetal abnormalities, especially when used in excessive amounts, under occlusive dressings, for prolonged periods of time, or when the more potent agents are used. However, numerous studies of pregnant patients taking systemic glucocorticoids throughout pregnancy show no increases in the incidence of fetal abnormalities. Most topical steroids are rated by the U.S. Food and Drug Administration as category C drugs, which imply that caution must be exercised when used in pregnancy. It is currently unknown whether topical glucocorticoids are excreted in breast milk; however, they should be used with caution in breast-feeding mothers and should never be used on the breasts before breast-feeding.

DOSING REGIMEN

The frequency of topical application of corticosteroids was developed in an empirical manner, with most textbooks and physicians recommending multiple daily use. Lagos and Maibach observed in a recent review of the literature that for su-

TABLE 216-2
Responsiveness of Dermatoses to Topical Application of Corticosteroids

HIGHLY RESPONSIVE	MODERATELY RESPONSIVE	LEAST RESPONSIVE
• Psoriasis (intertriginous)	• Psoriasis	• Palmo-plantar psoriasis
• Atopic dermatitis (children)	• Atopic dermatitis (adults)	• Psoriasis of nails
• Seborrheic dermatitis	• Nummular eczema	• Dyshidrotic eczema
• Intertrigo	• Primary irritant dermatitis	• Lupus erythematosus
	• Papular urticaria	• Pemphigus
	• Parapsoriasis	• Lichen planus
	• Lichen simplex chronicus	• Granuloma annulare
		• Necrobiosis lipoidica diabeticorum
		• Sarcoidosis
		• Allergic contact dermatitis, acute phase
		• Insect bites

perpotent corticosteroids, once-daily application was as beneficial as twice-daily application. Likewise, there was no difference or only a slight difference with once or twice daily application of potent or moderately potent corticosteroids. The authors concluded that once-daily application of topical corticosteroids may be preferable, may decrease the risks of side effects and tachyphylaxis, decrease the cost of therapy, and improve the patient's compliance.[29] Tachyphylaxis has been demonstrated in experimental conditions by diminished vasoconstriction, rebound of DNA synthesis, and recovery of histamine wheals after application of topical steroids in patients with a history of long-term topical steroid usage.[30]

As a working rule, not more than 45 g/week of potent or 100 g/week of weak or moderately potent topical corticosteroid should be applied (without occlusion) if systemic absorption is to be avoided.[31]

CLINICAL FORMULATIONS

INITIATING THERAPY

Before choosing a topical glucocorticoid preparation, one must consider the area of the body that is to be treated because regional differences greatly affect the activity of the topical agent. Penetration of the glucocorticoid varies according to the skin site, which, in turn, is related to the thickness of the stratum corneum and the vascular supply to the area. For example, penetration of topical steroids through the eyelids and scrotum is four times greater than for the forehead and 36 times greater than for the palms and soles. Inflamed, moist, and denuded skin also shows increased penetration. Areas of the body where the skin is inherently thin not only allow for increased penetration of the drug but are more susceptible to develop side effects than other areas where the skin is thick. Potent topical steroids (classes 1 and 2) should rarely, if ever, be used in the areas with the highest level of penetration, such as the eyelids. Some general rules should be remembered when initiating topical corticosteroids[1,34]:

- Highly responsive diseases will usually respond to weak steroid preparations, whereas less-responsive diseases require medium or high-potency topical steroids.
- Low-potent preparations should be used on the face and intertriginous areas.
- Very potent corticosteroids frequently under occlusion are usually required on hyperkeratotic or lichenified dermatoses and for disease of the palms and soles.

MONITORING THERAPY

Application of corticosteroids to large surface areas, occlusion, higher concentrations, or more potent derivatives directly increase the risk of hypothalamic-pituitary-axis (HPA) suppression. If the latter is suspected, laboratory analyses that include a complete blood cell count, a chemistry panel, and a baseline morning cortisol level should be performed. In a patient with confirmed HPA suppression, the simultaneous institution of oral steroid supplementation and a reduction of potency and amount of topical steroid is needed.[35]

RISKS AND PRECAUTIONS

Local as well as systemic side effects have been documented with the use of topical corticosteroids. Under normal conditions, up to 99 percent of the applied topical corticosteroid is removed from the skin, and only 1 percent is therapeutically active. Cutaneous adverse effects can result from the small percentage of percutaneously absorbed corticosteroid or may also result from its transient presence onto the skin. Continued use of topical corticosteroids may also lead to tachyphylaxis.[36]

Consideration for prescribing topical corticosteroids to prevent side effects[1,34,37,38]:

- Highly potent formulations should be used for short periods (2 to 3 weeks) or intermittently. Once disease control is partially achieved, the use of a less potent compound should be initiated.
- Reduce frequency of application (e.g., application only in the morning, alternate-day therapy, weekend use) once disease control is partially achieved.
- Topical corticosteroids should be avoided on ulcerated or atrophic skin, and on skin with co-existent infectious dermatoses.
- Sudden discontinuation should be avoided after prolonged use to prevent rebound phenomena.
- Special guidelines should be followed when treating certain body areas (e.g., intertriginous areas) or certain populations (e.g., children or the elderly) to prevent the occurrence of local or systemic adverse effects.
- Laboratory tests should be considered if systemic absorption of corticosteroids is suspected.
- Use combination therapy when clinically indicated (e.g., addition of topical tretinoin or keratolytics).

COMPLICATIONS

Local adverse effects of topical corticosteroid use are more prevalent than systemic reactions.[36]

Atrophic Changes

Skin atrophy is the most common adverse effect of corticosteroid therapy. Dermal atrophy develops from the direct antiproliferative effects of topical corticosteroids on fibroblasts, with inhibition of collagen and mucopolysaccharide synthesis, resulting in loss of dermal support. Fragmentation and thinning of elastic fibers develop on the upper layers, whereas deeper fibers form a compact and dense network.[31] As a result of these atrophic changes, there is vascular dilatation, telangiectasias, purpura, easy bruising, stellate pseudoscars (purpuric, irregularly shaped, and hypopigmented atrophic scars), and ulceration. Although atrophy is, to some extent, reversible, formation of striae, visible linear scars that form in areas of dermal damage presumably during mechanical stress, are permanent.

Acneiform Reactions

The development or exacerbation of dermatoses of the face, including steroid rosacea, acne, and perioral dermatitis, is a well-known effect of topical corticosteroids. Although steroids initially lead to the suppression of inflammatory papules and pustules, patients become addicted because they notice that the lesions flare when treatment is withdrawn. This frequently leads to the continued use of greater potency topical corticosteroids. For these reasons, steroid use should be discouraged in the treatment of rosacea and perioral and periocular dermatitis.

Prolonged corticosteroid treatment can also result in "steroid acne," which is characterized by crops of dense, inflamed pustules in the same developmental stage. These lesions occur on the face, chest, and back (see Chap. 78).

Hypertrichosis

Hypertrichosis occurs rarely in women and children who apply potent cortico-



steroids to the face. The mechanism is still unknown.[1]

Pigmentary Changes

Decreased pigmentation is a common side effect of topical steroid use. The pigment generally returns after discontinuation of therapy.

Development of Infections

Topical corticosteroids are responsible for exacerbating and/or masking cutaneous infectious diseases. The incidence of skin infection during corticosteroid therapy varies but is probably between 16 percent and 43 percent.[39] Tinea versicolor, disseminated *Alternaria* infection, and dermatophytosis, including tinea incognito (masked dermatophyte infection), can develop. Granuloma gluteale infantum, characterized by reddish-purplish granulomatous lesions on the diaper area, is a well-known complication of diaper dermatitis that is being treated with corticosteroids. *Candida albicans* is commonly recovered in these patients. Topical corticosteroids have also an effect on prolongation or mitigation of herpes simplex, molluscum contagiosum, and scabies infection.

Allergic Reactions

Persistence or worsening of skin diseases occurs as a result of contact hypersensitivity to topical corticosteroids. The prevalence to topical corticosteroid sensitization ranges between 0.2 percent and 6.0 percent, and increases with prolonged exposure and the selection of certain drugs.[36,40,41] The allergen may be the vehicle, the preservative, or the steroid itself. Most topical steroid ointments are free of preservatives and are less likely than other topical agents and steroid creams to cause an allergic or irritant contact dermatitis. The most common preservatives that cause allergic contact dermatitis include parabens, polyethylene glycol, and benzyl alcohol (Table 216-3). Fragrance and local anesthetics are also sensitizers that may be included in the topical preparations.

TABLE 216-3
Potential Contact Sensitizers in Topical Corticosteroids

- Parabens
- Propylene glycol
- Benzyl alcohol
- Chlorocresol
- Ethylenediamine hydrochloride
- Isopropyl palmitate
- Polysorbate 60
- Stearyl alcohol
- The corticosteroid itself

Systemic Adverse Effects

OCULAR EFFECTS The development of glaucoma from the use of topical corticosteroids around the eye has been described.[46–48] Prolonged corticosteroid use has also led to vision loss.[49]

SUPPRESSION OF THE HYPOTHALAMIC-PITUITARY-ADRENAL AXIS Suppression of the HPA axis has been described with the use of potent topical corticosteroids. Iatrogenic Cushing syndrome, corticosteroid-related Addison crises, and retarded growth of children have all been described after prolonged use of potent topical corticosteroid preparations. A dose of 14 g/week of clobetasol propionate or 49 g/week of betamethasone dipropionate is sufficient to suppress plasma cortisol levels.[17]

METABOLIC SIDE EFFECTS Increased glucose production and decreased glucose use induce hyperglycemia and may lead to diabetes mellitus.

KEY REFERENCES

The full reference list for all chapters is available at www.digm7.com.

1. Brazzini B, Pimpinelli N: New and established corticosteroids in dermatology. *Am J Clin Dermatol* **3**:47, 2002
17. Smith EW: Do we need new and different glucocorticoids? *Curr Probl Dermatol* **21**:1, 1993
29. Lagos BR, Maibach HI: Frequency of application of topical corticosteroids: An overview. *Br J Dermatol* **139**:763, 1998
31. Hughes J, Rustin M: Corticosteroids. *Clin Dermatol* **15**:715, 1997
32. Stoughton RB, Cornell RC: Topical steroids in dermatology, in *Topical Corticosteroid Therapy: A Novel Approach to Safer Drugs,* edited by Christophers E, Schopf E, Kligman AM. New York, Raven, 1988, p 1
36. Hengge UR et al: Adverse effects of topical glucocorticosteroids. *J Am Acad Dermatol* **54**:1, 2006
44. Goosens A, Matura M, Degreef H: Reactions to corticosteroids: Some new aspects regarding cross-sensitivity. *Cutis* **65**:43, 2000

CHAPTER 217

Topical Retinoids

Sewon Kang
John J. Voorhees

In topical preparations, retinoids are widely used as prescription drugs as well as cosmeceuticals. In some of these products, retinoids are naturally occurring compounds while others are synthetic molecules. Their potency and effectiveness may vary depending on the nature and concentration of the retinoids, the need for metabolic conversion to active compounds, and the formulation that influences skin penetration. Yet, as a group, retinoids share predictable pharmacology in eliciting human skin responses due to the fact that retinoid effects are primarily mediated through their intranuclear retinoid receptors acting as transcription factors. Indeed, the discovery and characterization of retinoic acid receptors (RARs) and retinoid X receptors (RXRs) has been pivotal to our understanding of the retinoid action mechanism and gave rise to the idea that retinoids act similarly to hormones.[1,2] In 1976, Michael Sporn and his colleagues originally defined retinoids as both the naturally occurring compounds with vitamin A activity and the synthetic analogues of retinol. This concept is no longer adequate. Now, retinoid is defined as any molecule that, by itself or through metabolic conversion, binds to and activates the RARs, thereby eliciting transcriptional activation of retinoic acid–responsive genes that results in specific biologic responses.

RETINOID RECEPTORS

The discovery and characterization of RARs as having molecular features that are similar to steroid/thyroid hormone

RETINOIDS AT A GLANCE

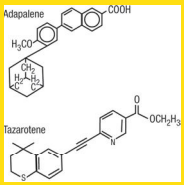

- Definition: Any molecule that by itself or through metabolic conversion binds to and activates retinoic acid receptors.
- Retinoid receptors: Ligand-dependent transcription factors.
- Predominant retinoid receptors in human skin: Retinoic acid receptor α (RAR-α), RAR-γ, retinoid X receptor α (RXR-α), and RXR-β.
  - RAR-γ/RXR-α heterodimers bind to retinoic acid–responsive elements and are responsible for retinoid signaling.
- Clinical use of topical retinoids:
  - Approved indications—acne, psoriasis and photoaged skin.
  - Unapproved indications with clinical studies supporting benefit—post-inflammatory hyperpigmentations, melasma, and early stretch marks.
- Local skin irritation: Mainly due to retinoid-induced epidermal hyperplasia. Clinical use should be titrated based on the severity of local reactions.

receptors were landmark findings.[1,2] A characteristic common to these receptors is that they bind to regulatory regions in DNA called *hormone response elements*, or *target sequences*, and activate gene transcription in a ligand-dependent manner. Therefore, they are referred to as *ligand (hormone)-dependent transcription factors*. These receptors bind to specific DNA sequences as dimers. Unlike receptors for the steroid hormones, which form homodimers (two identical monomers); RAR, vitamin D receptor (VDR), and thyroid hormone receptors (TR) bind to their elements with greater affinity as heterodimers (two different monomers). The critical partner for heterodimerization and ultimate functioning of RAR, VDR, and TR is the RXR,[3] whose physiologic ligand is 9-*cis* retinoic acid.[4] The ability of RXRs to interact with many receptors suggests their importance as regulatory proteins. There are three different members of RAR (α, β, and γ) and RXR (α, β, and γ), each encoded by different genes. Furthermore, each of the receptors has isoforms, adding to the diversity of retinoid receptors.

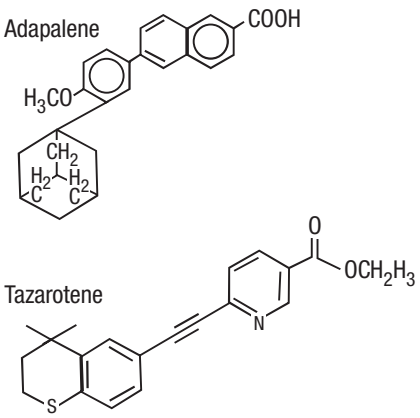

▲ **FIGURE 217-1** Chemical structures of the synthetic retinoids adapalene and tazarotene.

RECEPTOR-SELECTIVE RETINOIDS

The identification and functional characterization of retinoid receptor families cleared the way for drug discovery. Synthetic molecules could be screened for their ability to bind to and activate specific receptors. Many of these compounds have no structural similarities to all-*trans* retinol or retinoic acid, yet are still considered retinoids by virtue of their ability to activate the receptor(s), therefore mediating the retinoid effect. Adapalene and tazarotene are two synthetic retinoids that fit this description and have been used topically in humans (Fig. 217-1). Adapalene has restricted receptor specificity, possessing poor affinity for RAR-α, higher affinity for RAR-β and -γ, and no interaction with RXR-α.[5] Tazarotene cannot directly bind to RARs or RXRs. However, its metabolite, tazarotenic acid, has receptor selectivity for RARs (RAR-β > RAR-γ > RAR-α),[6] and is felt to be the principal active form.

RETINOID RECEPTORS IN HUMAN SKIN

Systematic analysis of relative levels of each RAR and RXR has been made in human skin and shows that the human epidermis expresses RAR-α, RAR-γ, RXR-α, and RXR-β messenger RNAs (mRNAs).[7,8] RXR-γ mRNA is undetectable, and the transcript for RAR-β is barely detectable. These relative levels of retinoid receptor mRNAs mirror their relative protein levels. In nuclei from human epidermal cells, there are five times more total RXRs than RARs.[8] For RAR proteins, 87 percent are RAR-γ and 13 percent are RAR-α with no detectable RAR-β. Of the RXR proteins, 90 percent are RXR-α. In gel-shift studies performed on nuclei isolated from human skin and cultured keratinocytes, and in which both cases are expressing their normal endogenous receptors, only RXR-α and RAR(mostly γ) heterodimers bind to retinoic acid–responsive elements (RAREs).[8,9] Neither RAR nor RXR homodimers are detectable. Based on chloramphenicol acetyltransferase reporter gene activity in keratinocytes, the heterodimer requires only the RAR ligand to activate RXR/RAR-bound RAREs. Furthermore, the presence of RXR ligand does not confer additional transactivation induced by RAR ligand. Therefore, at their physiologic levels, RARs and RXRs in human skin bind RAREs as heterodimers and transactivate these response elements in response to RAR, but not to RXR, ligands. However, the RXR is key, as the heterodimer will not bind to the RARE without the presence of the RXR protein. Ultraviolet (UV) irradiation of human skin causes a rapid and significant reduction of retinoid receptors, both RAR-γ and RXR-α.[10] Although this decrease in the receptor levels is transient and returns to pre-UV treatment levels within 2 days, UV irradiation results in functional impairment of receptor-dependent retinoid responsiveness in human skin. Interestingly, pre-treatment of skin with all-*trans* retinoic acid before UV irradiation reduces receptor loss and accelerates receptor recovery.[10]

RETINOID TARGET GENES AND THEIR ACTIVATION CASCADE IN HUMAN SKIN

Retinoid actions are primarily, if not completely, mediated by retinoid receptors. Given that the receptors are transcription factors, the ultimate skin effects of retinoids (phenotypic changes) must be accomplished through regulated gene expression. The best-established mechanism by which retinoid receptors modulate gene expression is activation of retinoid target genes through direct binding to RARE in the gene promoter, thereby stimulating the basal transcriptional machinery. In skin, cellular retinoic acid binding protein (CRABP) II, cellular retinol binding protein (CRBP), retinoic acid 4-hydroxylase (CYP26), and keratin 6—all of which contain RAREs—are regulated by all-*trans* retinoic acid.[11–14] However, the products of these genes are probably not the effectors of the retinoid response and so can-



not account for the pleiotropic effects of retinoids in skin. Undoubtedly, additional RARE-regulated genes will be identified that encode for proteins that function to modulate cutaneous growth and differentiation either directly or indirectly. A likely scenario is that these protein products, in turn, activate other non–RARE-containing genes in a cascading reaction to produce the clinical features of retinoid action in skin (Fig. 217-2).

Molecular description responsible for the most striking histologic feature of all-*trans* retinoic acid–treated skin, the marked thickening of the epidermis, illustrates this point.[11,15] The epidermal hyperplasia is caused by the increased proliferation of basal keratinocytes. An increase is also seen in the number of cell layers expressing the differentiation markers involucrin, loricrin, filaggrin, and epidermal transglutaminase[14] (see Chap. 44). These epidermal changes collectively translate to clinical desquamation and peeling. This hyperproliferative response of epidermis to retinoic acid is mediated by its nuclear receptor, as was demonstrated in transgenic mice expressing either dominant-negative RXR-α[16] or dominant-negative RAR-α[17] mutant proteins targeted to the suprabasal epidermis by the keratin 10 promoter. The mutant proteins impaired retinoid signaling by competing with endogenous RAR-γ/RXR-α heterodimers. In these mice, the ability of topically applied retinoic acid to stimulate proliferation of undifferentiated keratinocytes in the basal layer and resultant peeling of stratum corneum from the surface was significantly reduced.[16,17] Therefore, the epidermal hyperplasia and subsequent peeling alterations are part of the retinoid-specific skin responses. Among the genes regulated by retinoid receptors involved in the cell growth control (keratinocyte proliferation), ligands for epidermal growth factor (EGF) receptor appear to be critically important. In human skin in vivo, topical retinoic acid induces heparin-binding (HB)-EGF and amphiregulin (AR), which stimulate basal cell growth via the cell surface EGF receptor activation.[18,19] Interestingly, neither HB-EGF nor AR possesses any putative RARE. Therefore, a direct modulation of HB-EGF or AR by RARE promoters seems unlikely. Rather, RAR/RXR is likely regulating other transcription factor(s) that would, in turn, regulate AR and HB-EGF gene expression (Fig. 217-3). The identity of such transcription factor(s) remains to be determined.



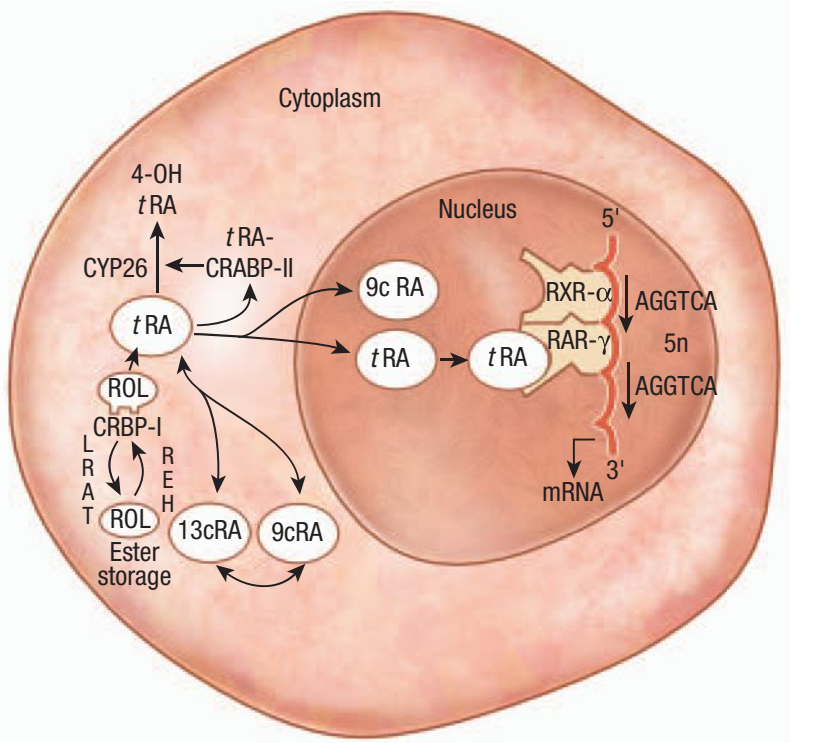

▲ **FIGURE 217-2** Cellular metabolism of natural retinoids and molecular mechanism of retinoid-specific gene activation. Retinol (ROL) delivered to a cell is bound to cellular retinol binding protein (CRBP)-I. ROL can be esterified, via lecithin:retinol acyltransferase (LRAT), and stored as ROL-esters. Hydrolysis of ROL-ester by its hydrolase (REH) yields free ROL. Sequential oxidation of ROL generates retinoic acid (RA), which is bound to cellular retinoic acid binding protein (CRABP). All-*trans* RA (*t* RA) can be isomerized to 9-*cis* RA (9*c* RA). Hydroxylation of *t* RA by cytochrome-P_{450} enzyme CYP26 generates 4-OH RA, which is relatively inactive. RARs and RXRs are intranuclear receptors for retinoids. In human skin, RAR-γ and RXR-α heterodimers bound to RA-response elements (such as AGGTCA direct repeats) transduce retinoid effects in the presence of RAR ligands. mRNA = messenger RNA.

PHARMACOLOGY: NOMENCLATURE

All-*trans* retinoic acid (tretinoin), which binds to and activates RARs, is derived from sequential oxidation of all-*trans* retinol (or vitamin A) and all-*trans* retinaldehyde. It is a 20-carbon molecule that consists of a cyclohexenyl ring, a side chain with four double bonds (all arranged in *trans* configuration), and a carboxylic acid end group (Fig. 217-4A). The numbering of the carbon atoms is as shown in Fig. 217-4B. The terms *9-cis* and *13-cis retinoic acid* refer to stereoisomers of all-*trans* retinoic acid in which the double bond that begins with the ninth and thirteenth carbon atoms, respectively, is in the *cis*- rather than *trans*-configuration. The fourth carbon atom is located in the cyclohexenyl ring of all-*trans* retinoic acid and is involved in a hydroxylation reaction to generate 4-hydroxy-all-*trans* retinoic acid (see Fig. 217-4C). The addition of a hydroxyl group to the cyclohexenyl ring renders the molecule more polar, making it more amenable to excretion/elimination from cells and organisms. It is also much less active biologically. 4-Hydroxy-all-*trans* retinoic acid can be further oxidized to 4-oxo retinoic acid.

A group of compounds referred to as *retinyl esters* functions as the molecular storage form of retinol. The compounds are formed by esterification of retinol with fatty acids (see Fig. 217-4D), which specify the ester. For example, retinyl palmitate is generated when retinol is esterified with palmitic acid. Hydrolysis of retinyl esters regenerates retinol. Finally, β-carotene is a symmetric 40-carbon molecule (twice the number of retinol or retinoic acid) present in green and yellow-orange fruits and vegetables. As suggested by stoichiometry, one molecule of this carotenoid can potentially generate two molecules of retinol by cleavage of the central double bond (see Fig. 217-4E).

Esterification and Oxidation of Retinol

Topical treatment of human skin with all-*trans* retinol increases retinyl ester levels in the epidermal layer by more than 10-fold.[11] This reaction is catalyzed by two

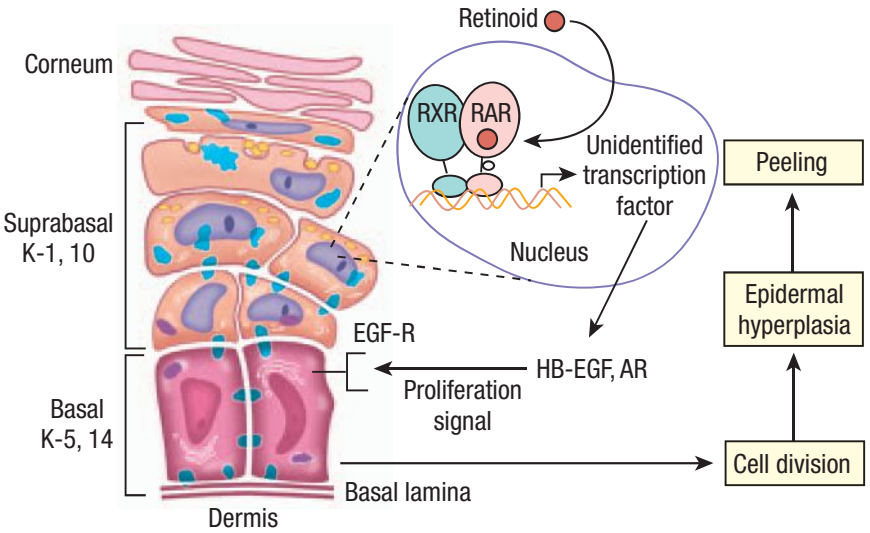

▲ **FIGURE 217-3** Molecular mechanism of retinoid-induced epidermal hyperplasia. Topical application of a retinoid activates retinoic acid receptor/retinoid X receptor (RAR/RXR) heterodimers in suprabasal keratinocytes, causing activation of yet unidentified transcription factors. These, in turn, activate the synthesis of heparin-binding epidermal growth factor (HB-EGF) and amphiregulin (AR). Through activation of epidermal growth factor-receptor (EGF-R), HB-EGF and AR cause proliferation of basal keratinocytes, thereby inducing thickened epidermis and consequent peeling/flaking of the stratum corneum. K = keratin.

enzymes: lecithin/retinol acyltransferase and acyl-coenzyme A/retinol acyltransferase. In human keratinocytes, lecithin/retinol acyltransferase has the predominant retinol-esterifying activity.[20]

Sequential oxidation of all-*trans* retinol forms all-*trans* retinoic acid, with all-*trans* retinaldehyde as the intermediate metabolite. The first step (oxidation of all-*trans* retinol to all-*trans* retinaldehyde) is rate limiting for all-*trans* retinoic acid formation. Topical application of all-*trans* retinol to human skin results in histologic and molecular alterations that mimic those following all-*trans* retinoic acid treatment.[11] These include epidermal hyperplasia caused by keratinocyte proliferation, epidermal spongiosis, compaction of the stratum corneum, and induction of CRBP, CRABP-II, and CYP26.[20,21] In retinol-treated skin, all-*trans* retinoic acid is minimally detectable and is no different from levels found in untreated normal skin. The lack of significant accumulation of all-*trans* retinoic acid in retinol-treated skin is a result of the tightly regulated conversion of retinol to retinaldehyde and the effective hydroxylation of all-*trans* retinoic acid that is formed by CYP26. The observation that all-*trans* retinol and retinoic acid elicit similar responses in human skin, but that retinol does so without detectable increases in retinoic acid levels, indicates that endogenously synthesized retinoic acid is a much more efficient activator of retinoid pathways than exogenously supplied retinoic acid.

Hydroxylation of All-*Trans* Retinoic Acid

In human skin all-*trans* retinoic acid is catabolized primarily to the more polar 4-hydroxy-all-*trans* retinoic acid, which is further metabolized to 4-oxo retinoic acid. 4-Hydroxy retinoic acid is 10-fold less potent in inducing retinoid responses in human keratinocytes and mouse skin than all-*trans* retinoic acid.[22] In untreated normal human skin, CYP26 activity is minimally detectable. Topical administration of all-*trans* retinoic acid or all-*trans* retinol to human skin, however, increases its activity several fold.[21,23] This hydroxylase activity is also induced in skin treated with 9-*cis* or 13-*cis* retinoic acid, but remarkably, it has substrate specificity for the all-*trans* retinoic acid isomer only and does not hydroxylate 9-*cis* or 13-*cis* retinoic acid, retinol, or retinaldehydes.[21] With all-*trans* retinoic acid, CYP26 activity is maximally induced after 24 hours of occlusive treatment. The CYP26 activity can be effectively inhibited by ketoconazole and a related azole, liarozole.[15,23] By blocking this major inactivation pathway of all-*trans* retinoic acid pharmacologically, topical liarozole can serve as a retinoic acid-mimetic or amplify human skin responses to all-*trans* retinol and retinoic acid.[15] This approach of targeting CYP26 has given rise to a novel class of new chemical entities referred to as *retinoic acid metabolism blocking agents* (RAMBAs). Although RAMBAs were introduced to dermatology several years ago, their drug development progress has been slow. A challenge for RAMBAs of the future is to selectively target CYP26 without affecting other enzymes such as steroid metabolizing aromatase or 17,20-lysase.

CLINICAL USE

Until quite recently, clinical use of topical retinoids has been limited to all-*trans* retinoic acid. Although the initial use of this retinoid was for actinic keratosis, currently, the only approved dermatologic indications in the United States are for acne and photoaged skin. Topical adapalene and tazarotene have also received approval from the U.S. Food and Drug Administration for acne; tazarotene has also received approval for psoriasis and photoaging.

It is widely accepted that topical retinoids are extremely effective for acne therapy, especially for comedonal lesions. Of the different classes of antiacne medications, retinoids are thought to be the best, if not the only, agents to normalize the abnormal follicular epithelial differentiation/desquamation viewed to be important in the pathogenesis of acne lesions. Therefore, the use of retinoids can also provide protection against the development of new lesions. This prophylactic property is the basis for including topical retinoid in almost all antiacne regimens. A potential for aggravating inflammation exists in treating inflammatory acne (i.e., papules and pustules) with topical retinoids, but when properly administered, this type of acne also responds well to retinoids (see Dosage Schedules and Forms).

Fine wrinkles and dyspigmentation are two salient features of photoaged skin that are improved by topical tretinoin or tazarotene. Several weeks of treatment are required before clinical improvement is appreciated.[24–26] For the effacement of fine wrinkles by topical tretinoin, partial restoration of markedly reduced levels of collagen in sun-exposed skin toward those seen in sun-protected skin appears to be responsible.[25,27] Tretinoin's ability to improve photoaging is specific and does not result from the irritation or retinoid dermatitis frequently produced by this compound.[26] Topical adapalene is not approved for the treatment of photoaging; however, a recent study indicates





A. Sequential oxidation of retinol

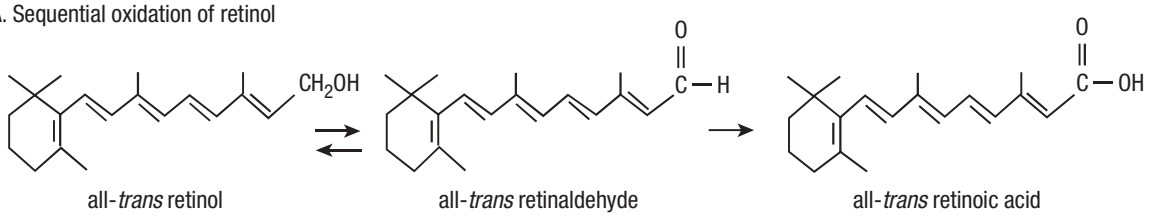

all-*trans* retinol | all-*trans* retinaldehyde | all-*trans* retinoic acid

B. All-*trans* retinoic acid and its stereoisomers

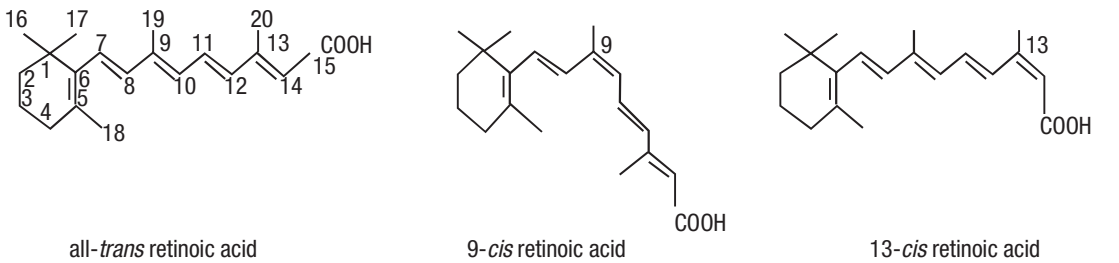

all-*trans* retinoic acid | 9-*cis* retinoic acid | 13-*cis* retinoic acid

C. Hydroxylation of all-*trans* retinoic acid and subsequent oxidation

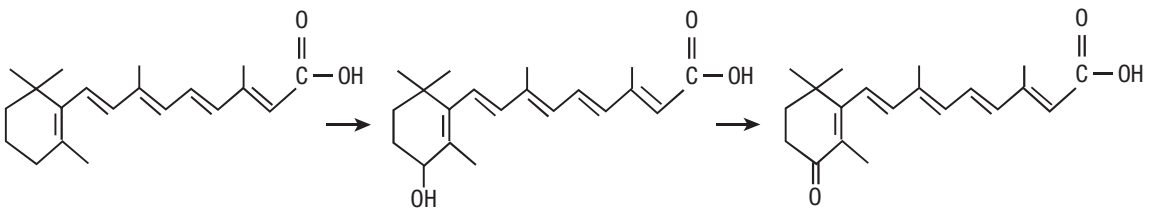

all-*trans* retinoic acid | 4-hydroxy all-*trans* retinoic acid | 4-oxo all-*trans* retinoic acid

D. Esterification of retinol

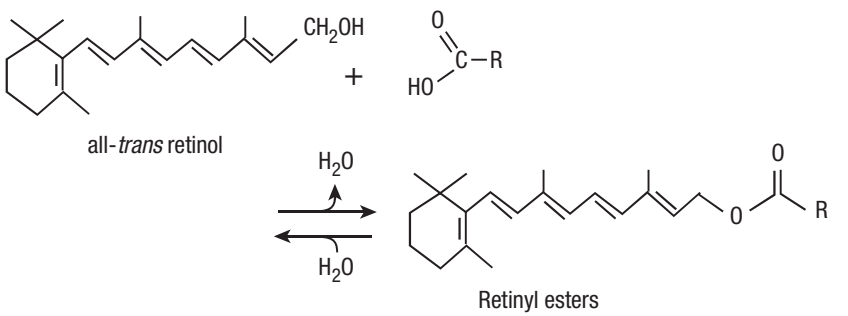

all-*trans* retinol

Retinyl esters

E. Structural relationship of β-carotene and 14-hydroxy 4, 14-*retro*-retinol to retinol

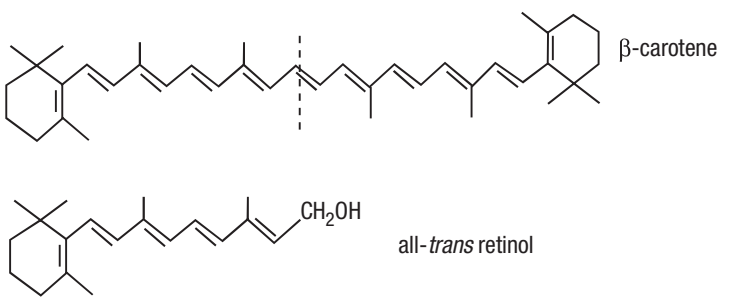

all-*trans* retinol

▲ **FIGURE 217-4 A–E.** Nomenclature of natural retinoids.

that it also holds promise in ameliorating the clinical features of photodamage.[28]

Besides the approved indications, topical retinoids have been demonstrated to be effective in the treatment of several other conditions. Most studies have used tretinoin because it is the first topical retinoid to be developed and has been available the longest. Studied conditions include, but are not limited to, post-inflammatory hyperpigmentation in blacks,[29] actinic dyspigmentation in Chinese and Japanese individuals,[30] melasma,[30,31] and early stretch marks.[32] The controlled studies show more than therapeutic efficacies. They also provide valuable information to dispel some of the myths about retinoid use in humans. For example, African Americans and Asians tolerate topical tretinoin as well as, if not better than,[29–31] Caucasians.[25,33] Furthermore, the often observed retinoid dermatitis does not usually lead to post-inflammatory hyperpigmentation in those with greater constitutive pigmentation.

Many other skin disorders have been reported to be improved by topical retinoids, but most of these have not been rigorously studied, thus their therapeutic claims should be interpreted with caution. Molluscum contagiosum, warts, and various forms of ichthyosis may be improved by topical retinoids to a variable degree. In psoriasis, especially, irritation of treated skin has limited the use. Topical tazarotene, which is approved for psoriasis, does not appear to have fully overcome the irritation problem[34]; thus, it is typically used in combination with topical steroids. The beneficial effects of topical retinoids in treating actinic keratoses have been confirmed through clinical trials.[28] However, there is no role for topical retinoids in the treatment of established cutaneous tumors.

With such a wide variety of skin conditions treatable by topical retinoids, their use has included all age groups, perhaps with the exception of neonates. Similar considerations in dose schedule and forms are made in both young and old patients. The use of topical retinoids in pregnancy is an emotional issue. As discussed in Adverse Effects, teratogenicity is not caused by topical retinoids. However, because none of the dermatologic conditions seen in pregnancy that may respond to topical retinoids (i.e., acne, melasma, stretch marks) is life-threatening to the mother or the fetus, it seems prudent to delay the treatment until after delivery. In a study that demonstrated that early, inflammatory stretch marks were improved by topical tretinoin, all pregnancy-related stretch marks were treated postpartum.[32] Therefore, even in this pregnancy-associated condition, the therapeutic benefit could be achieved by instituting the treatment after delivery.

DOSAGE SCHEDULES AND FORMS

For decades, tretinoin was the only topical retinoid available for clinical use. Under the trade name Retin-A, three different formulations are available for acne therapy: cream (0.025 percent, 0.05 percent, 0.1 percent), gel (0.01 percent, 0.025 percent), and solution (0.05 percent). For photoaging treatment, tretinoin (0.05 percent, 0.02 percent) and tazarotene (0.1 percent) are available as Renova and Avage cream, respectively. A more recent addition to acne therapy, adapalene (Differin) is available in 0.1 percent gel and lotion formulations. For acne and psoriasis, topical tazarotene (0.05 percent and 0.1 percent) is available in gel and cream formulations. Different formulations allow some flexibility in terms of tailoring the therapy to an individual's skin dryness or oiliness.

Regardless of the retinoid preparation or the patient's age, the most important element in topical therapy is patient/guardian education. It must be explained clearly to each patient that, as part of the treatment, local skin irritation, characterized by redness and peeling, can be expected. The concept that clinical improvement correlates with the degree of irritation has been erased through a large, controlled clinical study in which 0.025 percent and 0.1 percent tretinoin were shown to be equally efficacious, but the former was significantly less irritating than the latter.[26] Therefore, unlike most medications for which the dosing schedule may be set as once or twice daily, administration of a topical retinoid should be titrated depending on the skin reaction. For some individuals, it may be applied only twice a week, for others four times a week, and this can be increased, as tolerated, to a once-daily regimen. This method of individualizing topical therapy minimizes unwanted acute retinoid dermatitis.

Under the nonprescription category, there are countless "natural retinoid" preparations with various claims (mostly antiaging) being sold throughout the world. Most of these contain retinyl esters, especially retinyl palmitate, retinaldehyde, or retinol. Whether any of these products can deliver retinoid activity to human skin is subject to question. Percutaneous absorption (especially for retinyl esters), adequate concentrations, and stable formulations (especially for retinol) are some of the important unknowns for this group of products. Based on human in vivo work, all-*trans* retinol and all-*trans* retinaldehyde hold the most promise of these natural retinoids in being biologically active,[11,35] provided the stability of the compound can be maintained with a proper formulation. When the sun-protected skin of individuals older than 80 years of age was treated for 7 days with 1 percent retinol, fibroblast growth and dermal collagen were increased significantly.[36] Concomitantly, retinol markedly reduced the levels of matrix-degrading metalloproteinases that are elevated in aged skin. These findings suggest that retinol may reverse and partially prevent skin atrophy that accompanies intrinsic aging. A recent clinical study has confirmed that topical retinol improves the fine wrinkles associated with atrophic, naturally aged skin of the elderly[37] (see Chap. 108).

ADVERSE EFFECTS

By far the most common adverse effect associated with topical retinoid use is local skin irritation characterized by erythema, peeling, dryness, tightness, and burning sensation. This predictable skin response is temporary, but troubling, for many patients. It tends to peak within the first month of treatment and diminishes thereafter. It responds to a temporary reduction in the frequency or amount of retinoid application and to liberal use of emollients. The requirement for RAR/RXR receptors in retinoid stimulation of basal keratinocyte proliferation was presented in Retinoid Target Genes and Their Activation Cascade in Human Skin. Retinoid activation of the receptors is followed by subsequent induction of HB-EGF and AR in human skin in vivo[18,19] (see Fig. 217-3). The importance of this signaling pathway in the hyperplastic response of the epidermis to topical retinoids was recently demonstrated when pharmacologic antagonists of EGF receptor tyrosine kinase activity blocked retinoid-induced epidermal thickening in human skin organ culture and in vivo.[18,19] This observation suggests that it may be possible to reduce the clinically undesirable effects of retinoids on epidermal keratinocytes. However, the erythema response following topical retinoic acid may not be retinoid-receptor mediated because all-*trans* retinol, which induces epidermal hyperpla-



sia and CRABP-II mRNA-like retinoic acid (two indicators of receptor activation), is minimally associated with clinical erythema.[11]

Systemic retinoid exposure has been well documented and established as a cause of embryonic death and congenital malformation, and understandably, there is concern about potential teratogenicity from long-term topical retinoid use. Systemic absorption of retinoids from topical application is negligible, and the levels of endogenous retinoic acid in the blood are not increased by twice daily application of 0.025 percent tretinoin to more than 40 percent of body area over 1 month. Furthermore, controlled topical administration of tretinoin at doses used for acne therapy (2 g of 0.025 percent gel applied daily to the face, neck, and upper part of the chest for 14 days) has less influence on plasma levels of endogenous retinoids than diurnal and nutritional factors.[38] Indeed, a large, population-based study demonstrated no excess risk of birth defects in offspring born to mothers who were exposed to topical tretinoin during pregnancy.[39] Therefore, no evidence exists for teratogenicity of topical tretinoin in humans. As mentioned in Hydroxylation of All-*Trans* Retinoic Acid, topical use of tretinoin induces in the skin the enzyme CYP26 that inactivates tretinoin. The induction of this enzyme would serve as a protective mechanism to partially reduce the amount of tretinoin for systemic absorption. In this regard, topical use of natural retinoids would be even safer than any of the synthetic compounds, because there already exists self-inducible enzymatic machinery that will inactivate excess tretinoin, but not synthetic retinoids.

"Sun sensitivity" is a frequently discussed subject with topical retinoid use and requires clarification. When formally tested in humans, topical tretinoin does not lower the minimal erythema dose of UVB light.[40] Because its presence in human skin does not increase the likelihood of sunburn reaction, tretinoin is not a phototoxic agent. When one talks to patients who complain of such sun sensitivity, they describe an uncomfortable skin sensation that is felt within minutes of being in the sun rather than hours later. This time line is not consistent with a typical sunburn reaction, which takes longer to be noticed (a few hours). Furthermore, this sensation is often said to be accentuated in warmer temperatures, which suggests participation of infrared irradiation (heat).

Related to sun sensitivity is the issue of photocarcinogenesis. In an animal model of photocarcinogenesis, topical tretinoin has caused skin cancer. However, this seems to be restricted to susceptible animals under contrived experimental conditions, and no evidence exists of a comparable process in humans. Indeed, by using a model in which human skin was grafted onto mice with severe combined immunodeficiency disease, gross inadequacy of the commonly used rodent model of photocarcinogenesis was demonstrated.[41] Specifically, the traditional rodent models significantly overestimate the human carcinogenic potential of tested agents. Topical retinoids, on the contrary, appear to have a protective effect against UV-induced premalignant and malignant lesions. In those predisposed by nevoid basal cell carcinoma syndrome or xeroderma pigmentosum to the development of nonmelanoma skin cancer, systemic retinoids have provided effective protection. In this regard, topical tretinoin's ability to prevent UV induction of c-Jun is relevant.[42] c-Jun is a proto-oncoprotein that is minimally detectable in normal human skin in vivo. Its partner c-Fos; however, is constitutively expressed. UV irradiation to human skin does not affect the level of c-Fos expression, but it markedly induces c-Jun protein, which can then heterodimerize with c-Fos, forming a complete active AP-1 transcription factor.[42] The critical importance of AP-1 in mediating carcinogenic transformation of papillomas has been demonstrated.[43] In human squamous cell carcinomas, c-Jun expression is elevated, and systemic retinoids prevent carcinomas of the head and neck. Mechanisms involved in this chemopreventive effect of the retinoid likely include c-Jun suppression. These clinically observed anticarcinogenic activities of retinoids are also supported by in vitro data, demonstrating that tretinoin treatment of human skin upregulates the antigen-presenting activity of Langerhans cells without concomitant increase in autoreactivity.[44] Such a retinoid effect would improve cutaneous immune responsiveness to tumor antigens. Therefore, topical retinoic acid is not a carcinogen in humans.

DRUG INTERACTION AND INCOMPATIBILITIES

Retinoids, in general, are photolabile and therefore can be photoinactivated. Based on this chemistry, it is prudent to apply the agents in the evening rather than before the start of the day. Because the major avenue of tretinoin inactivation is through CYP26, drugs that modulate the activity of this enzyme can potentially cause drug interactions. Ketoconazole and liarozole are effective inhibitors of CYP26 and, therefore, are RAMBAs.[15,23] Concurrent use of these azoles and topical tretinoin can increase the amount and prolong the half-life of tretinoin locally in the skin, thereby aggravating local side effect. Indeed, this was observed in one topical tretinoin study when a patient inadvertently started oral ketoconazole for tinea infection and experienced a severe and prolonged dermatitis, which could be reproduced by ketoconazole challenge. Other than retinoids, no other compounds have been shown to induce CYP26.

The use of vitamin D_3 and its analogues has increased in dermatology, and in particular for psoriasis (see Chap. 18). Vitamin D effects in human skin are largely mediated via its nuclear receptor VDR. As previously discussed in Retinoid Receptors, VDR is a member of the steroid/retinoic acid/thyroid hormone receptor superfamily. Like RAR, VDR functions in human skin mainly as a heterodimer with RXR (VDR-RXR). In contrast with retinoid signaling via RAR-RXR, in which the presence of RXR-ligand confers no additional effect, RXR-ligand provides a synergistic effect with VDR-ligand in vitamin D signaling.[45] Therefore, topical retinoids that possess, or through metabolic conversion, acquire RXR selectivity can positively influence vitamin D pharmacology in human skin.

KEY REFERENCES

The full reference list for all chapters is available at www.digm7.com.

1. Petkovich M et al: A human retinoic acid receptor which belongs to the family of nuclear receptors. *Nature* **330**:444, 1987
8. Fisher GJ et al: Immunological identification and functional quantitation of retinoic acid and retinoid X receptor proteins in human skin. *J Biol Chem* **269**:20629, 1994
11. Kang S et al: Application of retinol to human skin in vivo induces epidermal hyperplasia and cellular retinoid binding proteins characteristic of retinoic acid but without measurable retinoic acid levels or irritation. *J Invest Dermatol* **105**:549, 1995
15. Kang S et al: Liarozole inhibits human epidermal retinoic acid 4-hydroxylase



activity and differentially augments human skin responses to retinoic acid and retinol in vivo. *J Invest Dermatol* **107**:183, 1996
16. Feng X et al: Suprabasal expression of a dominant-negative RXRα mutant in transgenic mouse epidermis impairs regulation of gene transcription and basal keratinocyte proliferation by RAR-selective retinoids. *Genes Dev* **11**:59, 1997
19. Rittié L et al: Retinoid-induced epidermal hyperplasia is mediated by epidermal growth factor receptor activation via specific induction of its ligands heparin binding-EGF and amphiregulin in human skin in vivo. *J Invest Dermatol* **126**:732, 2006
42. Fisher GJ et al: Retinoic acid inhibits induction of c-JUN protein by ultraviolet radiation that occurs subsequent to activation of mitogen-activated protein kinase pathways in human skin in vivo. *J Clin Invest* **101**:1432, 1998

CHAPTER 218

Topical Antibiotics

Mark W. Bonner
Paul M. Benson
William D. James

Topical antibiotics play an important role in the management of many common dermatologic conditions (Table 218-1). They are prescribed most often by dermatologists for the management of mild to moderate acne vulgaris or as adjunctive treatment with oral agents. For localized superficial infections, such as impetigo, the use of a topical agent (e.g., mupirocin) may eliminate the need for oral antibiotics and the accompanying problems of compliance, gastrointestinal side effects, and potential drug interactions. Topical antibiotics are still frequently prescribed as prophylactic agents after minor surgery or cosmetic procedures (chemical peel or laser resurfacing) to reduce the risk of postoperative wound infection and to speed wound healing. The use of topical antibiotics for prophylaxis after such minor procedures has been proven to be unnecessary and incurs risk of inducing allergy. Petrolatum is recommended for use after clean surgical procedures.

TOPICAL ANTIBIOTICS AT A GLANCE

- Topical antibiotics are useful in the treatment of acne and rosacea.
- Use in impetigo may obviate the need for oral antibiotics.
- Use of topical antibiotics to prevent wound infection after clean surgical procedures is unnecessary.

AGENTS USED IN THE TOPICAL TREATMENT OF ACNE AND ROSACEA

The efficacy of topical antibiotics for the treatment of acne vulgaris and rosacea may be due to their direct antibiotic effect, but many of the topical antibiotics exhibit anti-inflammatory properties by suppressing neutrophil chemotactic factor or by other mechanisms.[1] There are concerns about the use of topical antibiotics in the treatment of acne vulgaris because of the increasing levels of antibiotic resistance to common topicals. Combining the antimicrobial benzoyl peroxide with antibiotics reduces the development of antibiotic resistance.

Erythromycin

Erythromycin belongs to the group of macrolide antibiotics and is active against both Gram-positive cocci and Gram-negative bacilli. It is used princi-

TABLE 218-1
Topical Antibiotics

Name	Source	Form Available	Mechanism of Action	Bacteria[a]
Bacitracin	*Bacillus subtilis*	O	Cell wall inhibitor	Gr +
Polymyxin B	*B. polymyxa*	O	Detergent	Gr –
Gramicidin		O	Ion channel	Gr +
Mupirocin	*Pseudomonas fluorescens*	O	Transfer RNA inhibitor	Gr +
Neomycin	*Streptomyces fradiae*	O	30S ribosome inhibition	Gr –
Tetracycline	Semisynthetic[b]	O,S	30S ribosome inhibition	Gr ±
Meclocycline	Semisynthetic[c]	C	30S ribosome inhibition	Gr ±
Erythromycin	*Streptococcus erythreus*	S,G,P,O	50S ribosome inhibition	Gr ±
Clindamycin	Semisynthetic	S,G,L	50S ribosome inhibition	
Chloramphenicol	*S. venezuelae*[d]	C	50S ribosome inhibition	
Fusidic acid		NA	Interferes with EF-G	
Silver sulfadiazine	Synthetic	C		
Mafenide acetate	Synthetic	C	Enzyme inhibition	Gr ±
Nitrofurazone	Synthetic	C,S	Enzyme inhibition	Gr ±
Metronidazole	Synthetic	G,C	Electrochemical	Anaerobes
Clioquinol	Synthetic	C,O	Unknown	Broad spectrum
Azelaic acid	Synthetic	C,G	Protein synthesis inhibition	Gr +

C = cream; EF-G = elongation factor G; G = gel; Gr + = Gram-positive; Gr – = Gram-negative; Gr ± = Gram-positive or -negative; L = lotion; NA = not available in the United States; O = ointment; P = pledget; S = solution.
[a]Bacteria refers to bacteria usually susceptible to antibiotic.
[b]Semisynthetic from chlortetracycline, fermented from some species of *Streptomyces*.
[c]Semisynthetic from tetracycline.
[d]Now completely synthesized.



pally as a topical agent in the treatment of acne. Erythromycin binds to the bacterial 50S ribosome and blocks translocation of the peptidyl-transfer RNA (tRNA) molecule from the acceptor to the donor site, interfering with the formation of the polypeptide chain and inhibiting protein synthesis. In addition to its antibacterial properties, erythromycin has anti-inflammatory activity.

Erythromycin is available as a 1.5 percent to 2.0 percent solution, gel, pledgets, and ointment as a single agent. It is also available in combination with benzoyl peroxide.



Clindamycin

Clindamycin is a semisynthetic lincosamide antibiotic that is derived from lincomycin. The mechanism of action is very similar to that of erythromycin, with binding to the 50S ribosome and suppression of bacterial protein synthesis. Clindamycin is used topically as a 1 percent gel, solution, suspension (lotion), and foam primarily for the treatment of acne. It is also available as a combination with benzoyl peroxide, which may slow the development of antibiotic resistance to clindamycin. Pseudomembranous colitis rarely has been reported to occur with the topical use of clindamycin.[2]

Metronidazole

Metronidazole, a topical nitroimidazole, is currently available as a 0.75 percent gel, cream, or lotion and as a 1 percent cream or gel for the topical treatment of rosacea. In the lower strength, it is applied twice daily, and in the higher strength, it is used once daily. Orally, metronidazole has broad-spectrum activity against many protozoal organisms and anaerobes.

Azelaic Acid

Azelaic acid is a dicarboxylic acid found in food (whole-grain cereals and animal products). There is a normal human plasma level (20 to 80 ng/mL); topical application does not significantly alter this level. The mechanism of action is thought to be normalization of the keratinization process (decreased thickness of the stratum corneum, decreased number and size of keratohyaline granules, and decreased amount of filaggrin). There are reports of in vitro activity against *Propionibacterium acnes* and *Staphylococcus epidermidis*, which may be due to protein synthesis inhibition. In aerobic microorganisms, there is inhibition of oxidoreductive enzymes (such as tyrosinase, mitochondrial enzymes of the respiratory chain, 5α-reductase, and DNA polymerases). In anaerobic bacteria, there is disruption of glycolysis. Azelaic acid is used principally in the treatment of acne vulgaris and rosacea, although there are some advocates for its use in the treatment of hyperpigmentation (such as melasma for which it was initially developed). However, the U.S. Food and Drug Administration has not approved the drug for this indication. Azelaic acid is available as a 15 percent gel or 20 percent cream preparation.

Sulfonamides (Sulfacetamide)

Sulfacetamide is a topical sulfonamide used in the treatment of rosacea and acne. The antibacterial mechanism of action for most sulfonamides is competition with para-aminobenzoic acid (PABA) during the synthesis of folic acid. The mechanism of action for topical treatment of rosacea is not understood at this time. Sulfacetamide is available as a 10 percent lotion and in combination with 5 percent sulfur in a gel, cream, suspension, cleanser, cloths, and mask.

AGENTS USED FOR THE TOPICAL THERAPY OF SUPERFICIAL BACTERIAL INFECTIONS AND BURNS

Localized impetigo, superficial dirty abrasions, and secondarily infected chronic dermatoses are commonly treated with topical antibiotics. However, widespread impetigo, infection of the lower extremities, or disease occurring in immunocompromised individuals should be treated with systemic antibiotics to reduce the risk of serious complications. Topical antibiotics are still at times used following minor surgical procedures. The result of a large study comparing bacitracin and petrolatum in more than 1200 minor surgical procedures demonstrated that bacitracin did not statistically decrease the already low rate of infection. Several patients were, however, shown to be allergic to bacitracin. Petrolatum proved to be cheaper, of equal efficacy and to have fewer side effects than bacitracin.[3] When clean wounds are made during minor surgery, there is no need to use antibacterial ointment to aid in healing or prevent infection. Because burns produce a fertile ground for life-threatening secondary infection, prophylactic topical therapy is often used.

Mupirocin

Mupirocin, which was formerly known as *pseudomonic acid A*, is a topical antibiotic agent derived from *Pseudomonas fluorescens*. The drug reversibly binds to isoleucyl-tRNA synthetase and inhibits bacterial protein synthesis. The activity of mupirocin is limited to Gram-positive bacteria, especially staphylococci and most streptococci. Its activity is enhanced in an acid pH environment (5.5), which is the normal pH of the skin. Mupirocin is somewhat temperature-sensitive, and thus loses efficacy if exposed to high temperatures. Mupirocin ointment 2 percent is applied three times daily and is principally indicated for the treatment of localized impetigo caused by *S. aureus* and *Streptococcus pyogenes*. One study in the Tennessee Veterans' Affairs Hospital demonstrated that prolonged use of mupirocin ointment to control methicillin-resistant *S. aureus* (MRSA) carriage, especially in bedridden patients with decubitus ulcers, led to significant resistance.[4] Furthermore, Japanese researchers found that low serum concentrations of mupirocin are achieved after intranasal application and postulated that this might explain the selection of mupirocin-resistant strains of *S aureus*.[5] A small pilot study using intranasal application of a combination antibiotic ointment containing bacitracin, polymyxin B, and gramicidin successfully decolonized 80 percent (9 out of 11) of MRSA-positive patients who remained clear after a mean follow-up of 2 months. All cases of mupirocin-sensitive MRSA were eradicated, whereas only three of five cases of mupirocin-resistant were eliminated.[6] New formulations that involve the use of the calcium salt of mupirocin (the calcium salt aids in chemical stability in the intranasal preparation) are available for intranasal use as a 2 percent ointment and a 2 percent topical cream.

Bacitracin

Bacitracin is a topical polypeptide antibiotic originally isolated from the Tracy-I strain of *Bacillus subtilis*. Bacitracin is a cyclic polypeptide with multiple components (A, B, and C). Bacitracin A is the major component of commercial products and is often used as the zinc salt. Bacitracin interferes with bacterial cell wall

synthesis by binding to and inhibiting the dephosphorylation of a membrane-bound lipid pyrophosphate. It is active against Gram-positive cocci such as staphylococci and streptococci. Most Gram-negative organisms and yeast are resistant to the drug. It is available as bacitracin ointment and as zinc bacitracin, with 400 to 500 units per gram.

Topical bacitracin is effective for the treatment of superficial bacterial infections of the skin such as impetigo, furunculosis, and pyodermas. It is often combined with polymyxin B and neomycin as a triple antibiotic ointment applied several times daily for the treatment of secondarily infected eczematous dermatitis such as atopic dermatitis, nummular dermatitis, or stasis dermatitis. Unfortunately, the topical application of bacitracin carries with it the risk of allergic contact sensitization and, rarely, anaphylactic shock.[7]

Polymyxin B

Polymyxin B is a topical antibiotic derived from a spore-forming soil aerobe *B. polymyxa*. Polymyxin B is a mixture of polymyxin B_1 and B_2, which are both cyclic polypeptides. They function as cationic detergents that interact strongly with bacterial cell wall membrane phospholipids, thus disrupting the integrity of the cell membrane.

Polymyxin B is active against a wide range of Gram-negative organisms, including *P. aeruginosa*, *Enterobacter*, and *Escherichia coli*. Polymyxin B is available in ointment form (5000 to 10,000 units per gram) in combination with bacitracin or as triple antibiotic ointment with bacitracin and neomycin. It should be applied one to three times a day.

Topical Aminoglycosides (Neomycin and Gentamicin)

The aminoglycosides are an important group of antibiotics used both topically and systemically for the treatment of infections caused by Gram-negative bacilli. Aminoglycosides exert their bactericidal effects by binding to the 30S ribosomal subunit and interfering with protein synthesis.

Neomycin sulfate, the aminoglycoside most often used topically, is a fermentation product of *Streptomyces fradiae*. Commercial neomycin is a mixture of neomycin B and C, whereas framycetin, used in Canada and some European countries, is pure neomycin B.[8] Neomycin sulfate has activity against aerobic Gram-negative bacteria and is used most commonly for prophylaxis against infection in superficial abrasions, cuts, and burns. It is available in ointment form (3.5 mg/g) and is also packaged in combination with other antibiotics such as bacitracin, polymyxin, and gramicidin. Other agents, such as lidocaine, pramoxine, or hydrocortisone, also are available in combination with neomycin.

Neomycin is not recommended by many dermatologists because it is responsible for a large number of cases of allergic contact dermatitis. The prevalence of contact dermatitis is high, with 6 percent to 8 percent of patients undergoing patch testing being positive.[9] Neomycin sulfate (20 percent) in petrolatum is used to assess for contact allergy.

Gentamicin sulfate is derived as a fermentation product from *Micromonospora purpurea*. It is available as a topical 0.1 percent cream or ointment. It is used by some dermatologic surgeons when operating on the ear, especially in diabetic or other immunocompromised patients, to provide prophylaxis against malignant otitis externa due to *P. aeruginosa*. The ophthalmic formulation is useful in caring for operative wounds in the periorbital area.

Sulfonamides (Silver Sulfadiazine and Mafenide Acetate)

The sulfonamides are structurally similar to PABA and compete with it during the synthesis of folic acid. Sulfonamides are used to treat acne vulgaris, acne rosacea, and burns. Silver sulfadiazine is thought to release silver slowly and exerts its effect on the bacterial cell walls and membranes. The mechanism of action of mafenide is not the typical sulfonamide mechanism of action because PABA does not antagonize its performance. Mafenide acetate, if used over large areas of skin, has the potential to cause metabolic acidosis, and it can cause intense pain on topical administration. Both agents are broad-spectrum antibacterials useful in the treatment of burns. *Candida* superinfection may be a problem with mafenide cream.

Nitrofurazone

Nitrofurazone (Furacin) is a nitrofuran derivative used for the treatment of burn patients. The mechanism of action involves the inhibition of bacterial enzymes involved in the aerobic and anaerobic degradation of glucose and pyruvate. Nitrofurazone is available as a 0.2 percent cream, solution, or soluble dressing, and its spectrum of activity includes staphylococci, streptococci, *E. coli*, *Clostridium perfringens*, and *Proteus* sp.

MISCELLANEOUS AGENTS

Gramicidin

Gramicidin is a topical antibiotic derived from *B. brevis*. The gramicidins are linear peptides that form stationary ion channels in susceptible bacteria. The antibiotic activity of gramicidin is restricted to Gram-positive bacteria.

Chloramphenicol

Chloramphenicol is available in the United States with use limited to the treatment of minor bacterial skin infections. The mechanism of action is similar to that of erythromycin and clindamycin, with inhibition of the 50S ribosome blocking translocation of peptidyl tRNA from the acceptor to the donor site. Chloramphenicol is available as a 1 percent cream. It is used infrequently because fatal aplastic anemia or dose-related bone marrow suppression has been reported following topical exposure.[10]

Clioquinol

Clioquinol (also known as *iodochlorhydroxyquin*) is a broad-spectrum antibacterial/antifungal topical that is currently indicated for the treatment of inflammatory skin disorders and tinea pedis and has been used for minor bacterial infections. It is a synthetic hydroxyquinoline whose mechanism of action is unknown. The disadvantages of clioquinol include discoloration of clothing, skin, hair, and nails and the potential to cause irritation. Clioquinol may interfere with thyroid function determination because the iodine moiety interferes with tests that rely on iodine uptake (this effect can last for up to 3 months after application). However, clioquinol does not interfere with testing for T3 or T4.

REFERENCES

1. Esterly NB et al: The effect of antimicrobial agents on leukocyte chemotaxis. *J Invest Dermatol* **70**:51, 1978
2. Clindamycin (topical), in *Drug Information for the Health Care Professional (USP DI)*. Englewood, CO, Micromedex, 2000, p 930
3. Smack DP et al: Infection and allergy incidence in ambulatory surgery patients



using white petrolatum versus bacitracin ointment. *JAMA* **276**:972, 1996
4. Vasquez JE et al: The epidemiology of mupirocin resistance among methicillin-resistant *Staphylococcus aureus* at a Veteran's Affairs hospital. *Infect Control Hosp Epidemiol* **21**:459, 2000
5. Watanabe H et al: Low concentrations of mupirocin in pharynx following intranasal application may contribute to mupirocin resistance in methicillin-resistant *Staphylococcus aureus*. *J Clin Microbiol* **39**:3775, 2001
6. Fung S et al: The utility of Polysporin ointment in the eradication of methicillin-resistant *Staphylococcus aureus* colonization: A pilot study. *Infect Control Hosp Epidemiol* **21**:653, 2000
7. Farley M et al: Bacitracin anaphylaxis. *Am J Contact Dermatitis* **6**:28, 1995
8. Budavari S: *The Merck Index*, 12th ed. Whitehouse Station, NJ, Merck & Co, 1996, p1108
9. Marks JG, DeLeo VA: Standard allergens, in *Contact and Occupational Dermatology*, St. Louis, MO, Mosby Year Book, 1992 p 59
10. Chloramphenicol (topical), in *Drug Information for the Health Care Professional (USP DI)*. Englewood, CO, Micromedex, 2000, p 795



CHAPTER 219

Topical Antifungal Agents

Whitney A. High
James E. Fitzpatrick

Superficial fungal infections, including dermatophytoses, candidiasis, and pityriasis versicolor, are most often restricted to the epidermis. In treating these infections, the clinician must select between topical or systemic management. Factors guiding management include, but are not limited to, the:

- extent and severity of the infection,
- site of involvement,
- co-morbid conditions or potential drug interactions, if any,
- anticipated efficacy of treatment,
- cost and access to medication, and
- ease of use.

Patients with limited fungal infections confined to glabrous skin are usually best treated with topical agents. Conversely, those with extensive or recalcitrant disease, or with involvement of terminal hair or nails, may be better suited for systemic management. In some cases, either treatment option may be reasonably chosen.

Treatment with topical antifungal therapy enjoys several advantages over systemic management, including:

- fewer side effects,
- fewer drug interactions,
- localization of treatment, and
- generally lower cost.

Numerous topical antifungal medications are available (Table 219-1). For the most part, specific antifungal agents have replaced non-specific topical treatments, such as keratolytics (salicylic acid) or antiseptics (gentian violet or Castellani's paint), which were once the cornerstones of management.

The "ideal" topical antifungal is easily defined (Table 219-2), yet no one current topical agent possesses all of these properties. Despite widespread availability, few topical antifungal agents have been directly compared with one another in clinical trials. Studies sponsored by the manufacturer often compare just the active agent to the vehicle. Extrapolation between studies is further complicated due to differences in study design, duration of therapy, site of infection, selection methodology, or treatment endpoint.

Most topical antifungals belong to one of three classes: (1) imidazoles, (2) allylamines and benzylamines, and (3) polyenes. Some agents do not fit well into this schema and are discussed separately.

IMIDAZOLES

Imidazoles represent a broad class of antifungal medications. Certain of these, such as clotrimazole, have been around for decades, while others, such as sertaconazole, have only become available recently.

Mechanism of Action

Imidazoles impede synthesis of a component of the fungal cell wall through inhibition of lanosterol 14α-demethylase, a cytochrome P_{450} dependent enzyme, which converts lanosterol to ergosterol.[1] Depletion of ergosterol results in membrane instability and hyperpermeability, which are changes incompatible with growth and survival of the fungus. Imidazoles are considered fungistatic. Although all possess the same mechanism of action, in vitro studies demonstrate that not all dermatophytes are uniformly susceptible to an imidazole at an equivalent concentration, and this may explain some treatment failures.[2–4] Currently, there is no uniform reference method for susceptibility testing of dermatophytes.

Topical imidazoles possess anti-inflammatory activity via inhibition of neutrophil chemotaxis, calmodulin activity, synthesis of leukotrienes and prostaglandins, and histamine release from mast cells.[5–7] Some agents, such as ketoconazole, yield anti-inflammatory effects equivalent to 1 percent hydrocortisone.[8] Topical imidazoles also demonstrate limited antibacterial properties, particularly with respect to Gram-positive organisms.[9,10]

TOPICAL ANTIFUNGAL AGENTS AT A GLANCE

- Preferred treatment for superficial fungal infection of limited extent.
- Low cost, low incidence of drug interactions, few side effects and complications, ease of use.
- Use systemic agent when superficial fungal infection affects large surface area, involves terminal hair or nails, or is resistant to topical management.
- Topical antifungal classes: Imidazoles, allylamines, benzylamines, polyenes.
- Ciclopirox olamine: Unique topical antifungal with broad-spectrum activity, variety of indications.
- Side effects: Irritant dermatitis, allergic contact dermatitis, urticarial reactions.
- Combination agents (antifungal and steroid): Watch for side effects due to glucocorticoids.
- Combination agents: Higher rate of treatment failure, disease relapse.

TABLE 219-1
Topical Antifungal Agents Commonly Used in Dermatology

Generic Name(s)	Trade Name(s)	Formulation	Pregnancy Class	Rx/OTC
Imidazoles				
Clotrimazole	Cruex (Rx) Desenex AF Lotrimin Lotrimin AF Mycelex	1% cream, lotion, lozenges/troches, powder, spray solution, solution	C	Rx and OTC
Econazole	Spectazole Ecostatin	1% cream	C	Rx only
Ketoconazole	Nizoral Nizoral AD	1% and 2% cream and shampoo	C	Rx and OTC
Miconazole	Micatin Micozole Monistat-Derm Zeasorb AF	2% cream, lotion, powder, spray powder, spray solution	C	OTC
Oxiconazole	Derimine Myfungar Oceral Oceral GB Okinazole Oxistat Oxizole	1% cream, lotion	B	Rx
Sertaconazole	Ertaczo	2% cream	C	Rx
Sulconazole	Exelderm Sulcosyn	1% cream, solution	C	Rx
Allylamines				
Naftifine	Naftin	1% cream, gel	B	Rx
Terbinafine	Lamisil Lamisil AT	1% cream, spray solution, solution	B	Rx
Benzylamines				
Butenafine	Mentax	1% cream	B	Rx
Polyenes				
Nystatin	Bio-Statin Mycostatin Nystop Pedi-Dri	100,000 U/g cream, lozenge/troche, ointment, powder, solution	C[a]	Rx
Other topical antifungals				
Ciclopirox olamine	Loprox Penlac	0.77% cream or lotion, 1% shampoo or solution, 8% nail lacquer	B	Rx
Tolnaftate	Equate (Wal-Mart) Tinactin	1% cream, powder, spray powder, spray solution, solution	N/A	OTC
Undecylenic acid	Desenex[b] Cruex (OTC)[c]	20% cream, 10% penetrating foam, 10%–20% powder, 20% spray powder	N/A	OTC
Combination agents				
Clotrimazole-betamethasone dipropionate	Lotrisone	1% clotrimazole and 0.05% betamethasone dipropionate in cream or lotion	N/A	Rx
Nystatin-triamcinolone acetonide	Mycolog-II Mytrex Quenalog	100,000 U/g nystatin and 0.1% triamcinolone acetonide	N/A	Rx

N/A = not applicable; OTC = over-the-counter agent; Rx = prescription agent.
[a]Varying pregnancy class depends on form; majority of forms are Category C.
[b]Some forms of Desenex contain other agents, such as tolnaftate, clotrimazole, miconazole, or terbinafine.
[c]Some forms of Cruex contain miconazole.





TABLE 219-2
Properties of an Ideal Topical Antifungal Agent

- Broad spectrum of action
- Fungicidal at therapeutic concentration
- Absence of resistance within the targeted fungi
- Keratinophilic with penetration of the cornified envelope without systemic absorption
- Nonirritating and hypo-allergenic
- Possess anti-inflammatory properties
- Once-per-day application (or less)
- Short duration of therapy for cure
- Availability in multiple formulations (cream, solution, etc.) and sizes
- Inexpensive

Pharmacokinetics

Topical antifungals are designed expressly for treating superficial fungal infections. Consequently, all marketed imidazoles demonstrate excellent penetration of the stratum corneum with strong keratinophilic behavior. Sulconazole may be detected in the stratum corneum up to 96 hours after application.[11] Similarly, sertaconazole, the newest of all marketed imidazoles, has a half-life within the stratum corneum of more than 60 hours.[12] Because of this high affinity for keratin, systemic absorption of imidazoles is low, with urinary excretion usually in the range of 0.3 percent to 1.0 percent of the applied dose. Even when applied to inflamed skin, absorption of imidazoles does not usually exceed 4 percent of the applied dose. Again, sulconazole is unique in that percutaneous absorption in the range of 8 percent to 11 percent of the applied dose exceeds that of all other imidazoles.[11]

Indications

Indications for topical imidazole use are detailed in Table 219-3. Because of inherent antibacterial activity, some topical imidazoles have demonstrated modest efficacy in treating erythrasma, impetigo, and ecthyma. Because there are more potent antibacterial agents, this is *not* a preferred indication for imidazole use.[8,13,14]

Cure rates for superficial fungal infection treated with imidazoles are variable and often depend upon study design. For example, topical miconazole has demonstrated a 63 percent to 100 percent cure rate, depending upon the study quoted. A thorough review of the literature provides no compelling evidence that significant differences in cure or relapse exist among the various topical imidazoles; however, other considerations may dictate selection of a particular imidazole.

TABLE 219-3
Indications for the Use of Topical Imidazoles

- Dermatophytoses
  - Tinea pedis/tinea manum
  - Tinea cruris
  - Tinea corporis
  - Tinea faciei (the unbearded face)
- Pityriasis versicolor
- Mucocutaneous candidiasis[a]
  - Cutaneous candidiasis
  - Vulvovaginal candidiasis[b]
  - Oral candidiasis (thrush)[c]
  - Perlèche
- Seborrheic dermatitis[d]

[a]Oxiconazole and sulconazole have relatively weaker activity against *Candida*.
[b]Clotrimazole, econazole, miconazole, terconazole, and tioconazole are available as vaginal preparations.
[c]Clotrimazole-dissolving troches are used for oral thrush.
[d]Ketoconazole is used for seborrheic dermatitis.

Topical imidazoles are available as a cream or lotion. Although lotions are better suited for use over large areas or upon hair-bearing skin, limited studies suggest a cream may be marginally more effective. In studies performed by the manufacturer, oxiconazole cream yielded a clinical and mycologic cure in 52 percent of tinea pedis cases while the lotion yielded the same cure in just 41 percent of cases. Additionally, the potential for irritancy must be considered. In one study of topical clotrimazole for treatment of tinea cruris, erosive reactions developed in four of 27 patients while sulconazole did not cause any erosions in the same population.[15] Similarly, in a second study, severe irritant reactions were reported with miconazole use but not with sulconazole use.[16] Until formal studies of irritancy are performed we often recommend use of sulconazole in sensitive areas such as the groin. Finally, ease of use may be a factor to consider, as some imidazoles are specifically approved for once-daily dosing (see Dosing Regimen).

Dosing Regimen

Topical imidazoles are available in a multitude of forms (see Table 219-1). Econazole, ketoconazole, and oxiconazole are approved for once-daily dosing but twice-daily dosing is recommended for the remainder. Nevertheless, although twice-daily dosing is recommended for sulconazole, a study comparing once-daily to twice-daily dosing in tinea corporis and tinea cruris reported an identical rate of cure.[15] This might have been predicted based upon the 60-hour half-life within the stratum corneum.[12] Application of all topical antifungals, including imidazoles, should include normal skin for a radius of 2 cm beyond the affected area. Duration of treatment with imidazoles has varied. In general, tinea corporis and tinea cruris require treatment for approximately 2 weeks, whereas tinea pedis may require treatment for up to 4 weeks.[17] Treatment should be continued for at least 1 week after all symptoms have abated.[18]

Risks and Precautions

Risks associated with the use of topical imidazoles include those inherent to all topical medications (Table 219-4). Additionally, clotrimazole is marketed in combination with the topical glucocorticoid, betamethasone dipropionate. It was assumed that the addition of the steroid would more rapidly relieve inflammation, scaling, and pruritus. Early studies demonstrated the combination was indeed more effective than clotrimazole alone in alleviating symptoms.[19,20] However, betamethasone dipropionate is a potent topical steroid and, soon after release of the combination product, striae and other cutaneous side effects from the steroid component were reported.[21] Longer-term studies also reported a higher relapse rate (36 percent) with use of combination product.[22,23]

This combination product may comprise 50 percent or more of antifungal prescriptions by primary care providers, compared to less than 7 percent among dermatologists.[24] It is likely that overuse by non-specialists occurs because of the mistaken assumption either that the steroid agent is mild, or that the combination will be a "better choice" when the differential diagnosis is unresolved.[25] The U.S. Food and Drug Administration has twice

TABLE 219-4
Adverse Reactions to Topical Antifungals

- Irritant contact dermatitis (worsened by occlusion)
- Allergic contact dermatitis (to active agent or more likely to other ingredients/preservatives)
- Urticarial reactions (rare)
- Inappropriate treatment due to misdiagnosis (more likely with over-the-counter agents)

revised the product warnings for clotrimazole-betamethasone dipropionate, discouraging use on thin skin, for prolonged periods, or when the diagnosis is in doubt.

Complications

Use of topical imidazoles is associated with few complications. Because of low systemic absorption, drug interactions with topical imidazoles are extremely rare. Nevertheless, in a single study, increased serum tacrolimus levels were observed in renal transplant recipients who used clotrimazole troches for mucocutaneous candidiasis.[26] For this reason, use of nystatin may be preferred when treating thrush in transplant patients using tacrolimus.

Concerns of resistance must also be considered. Resistance of *Candida albicans* to clotrimazole has been described in human immunodeficiency virus-positive patients with mucocutaneous candidiasis.[27] Low levels of in vitro resistance of various *Candida* sp. to other topical imidazoles has also been documented.[28] Often, this resistance is associated with resistance to oral fluconazole.

ALLYLAMINES AND BENZYLAMINES

Allylamines and benzylamines are closely related compounds. Currently, two topical allylamines and a single topical benzylamine are marketed (see Table 219-1).

Mechanism of Action

Allylamines and benzylamines share a common mechanism of action. These agents impede synthesis of ergosterol through inhibition of squalene epoxidase, an enzyme that converts squalene to squalene oxide.[29] Depletion of ergosterol results in membrane instability and hyperpermeability. Allylamines and benzylamines are considered fungicidal because the accumulation of intracellular squalene leads directly to cell death. The clinical significance of this cidal action is unclear. Unlike imidazoles, the activity of allylamines and benzylamines is independent of the cytochrome P_{450} enzyme system. When compared to naftifine, terbinafine demonstrates a 10- to 100-fold increased potency in vitro, although this does not appear to be relevant in clinical use.

Like imidazoles, allylamines and benzylamines demonstrate anti-inflammatory activity.[5,30] Naftifine inhibits adhesion of polymorphonuclear cells to endothelium, interrupts chemotaxis, and inhibits the 5-lipoxygenase pro-inflammatory pathway.[31,32] It is assumed that terbinafine and butenafine yield anti-inflammatory effects through similar mechanisms. Allylamines and benzylamines also demonstrate limited antibacterial properties. In fact, a recent study showed lowered minimum inhibitory concentrations for bacteria as well as fungi when terbinafine was used in combination with benzoyl peroxide.[33]

Pharmacokinetics

Allylamines and benzylamines are highly lipid soluble and efficiently penetrate the stratum corneum, where they may persist for extended durations.[34] Butenafine has been detected within the stratum corneum at minimum inhibitory concentration for at least 72 hours after application,[35] and terbinafine may persist at a similar level for up to 7 days after application.[36] Systemic absorption of these agents is quite low, with typical urinary excretion in the range of 3 percent to 5 percent of the applied dose, an amount considered biologically and clinically insignificant.[36]

Indications

Indications for the use of topical allylamines and topical benzylamines are detailed in Table 219-5. Despite antibacterial properties, terbinafine has proven inferior to mupirocin for treatment of impetigo,[37] and a traditional antibacterial agent should be used instead. Similarly, although allylamines and benzylamines do demonstrate activity against dimorphic fungi involved in systemic infection such as *Sporothrix schenckii*, *Blastomyces dermatitidis*, and *Histoplasmosis capsulatum*, topical therapy is inappropriate in this situation.

Limited evidence suggests that topical allylamines or benzylamines may be preferred over topical imidazoles for certain dermatophyte infections. Repeated trials for tinea pedis indicate that 1 week of topical terbinafine is as effective as 4 weeks of topical imidazoles, with cure resulting in 53 percent to 95 percent of cases.[38–41] Use of this abbreviated treatment with terbinafine has been confirmed in trials using the active agent versus vehicle alone.[42] In some instances, resolution of tinea pedis using terbinafine has occurred with as few as three doses.[43]

Currently a 30-g tube of terbinafine is three times more expensive than a 30-g tube of clotrimazole.[44] Considering the frequency of application, the amount of medication required, the likelihood of patient compliance and ease of use, and the rapidity of results, some experts recommend topical terbinafine over topical imidazoles for tinea pedis.[45,46] Nevertheless, using the same data, other experts have recommended initial use of less expensive imidazole therapy with reservation of allylamines and benzylamines for treatment failure.[47] A consensus has not yet been achieved.

Finally, topical allylamines and benzylamines are effective against *Candida* or *Pityrosporum* sp. However, given the relative cost of these agents compared to cheaper, equally reliable, and specifically approved agents, such as imidazoles, polyenes, ciclopiroxamine, and over-the-counter selenium sulfide, there is no compelling reason to turn away from these more affordable options.

TABLE 219-5
Indications for the Use of Topical Allylamines and Benzylamines

- Dermatophytoses
  - Tinea pedis/tinea manum
  - Tinea cruris
  - Tinea corporis
  - Tinea faciei (the unbearded face)
- Pityriasis versicolor[a]

[a]Although butenafine is approved by the U.S. Food and Drug Administration for use in pityriasis versicolor, the availability of numerous, more cost-effective remedies limits use in this clinical situation.

Dosing Regimen

Topical allylamines and benzylamines are available in a number of forms (see Table 219-1). Each agent has a slightly different dosing regimen based upon the formulation and the location and severity of infection (Table 219-6).

Risks and Precautions

Risks associated with use of topical allylamines and benzylamines are those inherent to all topical medicaments (see Table 219-3).

Complications

Complications occurring with use of topical allylamines or benzylamines are few.

POLYENES

Polyenes were among the first agents discovered to possess specific antifungal



TABLE 219-6
Recommended Use of Topical Allylamines and Benzylamines

	Recommendations	
Agent	Frequency of Application	Duration of Application
Naftifine	Cream—once daily Gel—twice daily	General instructions for use 2 wk beyond resolution of symptoms
Terbinafine	Tinea pedis (interdigital)—twice daily Tinea pedis (plantar)—twice daily Tinea elsewhere—once or twice daily	At least 1 wk At least 2 wk At least 1 wk, up to 4 wk
Butenafine	Tinea pedis—once to twice daily Tinea elsewhere—once daily Pityriasis versicolor—once daily[a]	At least 1 wk if twice daily, and at least 4 wk if once daily At least 2 wk At least 2 wk

[a]Although butenafine is approved by the U.S. Food and Drug Administration for use in pityriasis versicolor, the availability of numerous, more cost-effective remedies limits use in this clinical situation.



properties. The two major topical polyene antifungals are nystatin and amphotericin B. Only topical nystatin is actively marketed in the United States (see Table 219-1).

Mechanism of Action

Like all polyenes, nystatin binds irreversibly to membrane sterols present in susceptible species of *Candida*.[48] The polyene molecules demonstrate a higher affinity for fungal sterols, including ergosterol, than for human sterols, yielding imperfect selective toxicity. This irreversible binding alters membrane permeability, causing leakage of essential intracellular components and fungal death. In low concentrations, nystatin is fungistatic, but at high concentrations it may be fungicidal.[49]

Pharmacokinetics

Nystatin is insoluble in water and is not absorbed from intact skin, the gastrointestinal tract, or the vagina.[50]

Indications

Topical nystatin is used to treat mucocutaneous candidiasis caused by *C. albicans*, and other susceptible species such as *C. parapsilosis*, *C. krusei*, and *C. tropicalis*. Repeated studies have demonstrated that topical imidazoles are more effective than nystatin in treating vulvovaginal candidiasis, and use of nystatin for this indication has diminished in recent years.[51,52] Nystatin is not effective against dermatophytes or *Pityrosporum*; and hence, it is not indicated for treatment of tinea or pityriasis versicolor.

Dosing Regimen

Nystatin is available as a powder, cream, ointment, suspension, and pastille. To treat oral candidiasis (thrush), the suspension or pastille is used four to five times daily, usually for 2 weeks. To treat cutaneous infection, the powder, cream, and ointment are used twice daily for approximately 2 weeks.

Risks and Precautions

Risks associated with use of topical nystatin are those inherent to all topical medicaments (see Table 219-3). A significant number of cases of allergic contact dermatitis attributed to nystatin alone have been reported. These reactions have been reported with topical and oral use.[53,54] Anaphylaxis has been described with use of nystatin-containing vaginal suppositories but the reaction was attributed to ingredients other than nystatin.[55]

A combination agent consisting of nystatin and triamcinolone acetonide is widely marketed. The addition of triamcinolone may provide additional benefit over nystatin alone during the first few days of treatment when inflammation is maximal.[56] After this initial period, the manufacturer recommends a transition to nystatin alone or to other topical antifungal agents. Although triamcinolone acetonide is only a mid-potency agent, cutaneous sequelae, including striae, skin atrophy, and steroid-induced acne, have been reported.[57] Because candidiasis often involves thin and fragile skin, such as that of the intertriginous areas, the risk of damage is likely potentiated. Finally, many of the combined formulations contained, or may still contain, ethylenediamine, a sensitizer that may cause allergic contact dermatitis.[58] As with clotrimazole-betamethasone dipropionate, the combination agent of nystatin-triamcinolone acetonide is more often prescribed by non-dermatologists.

Complications

Complications with topical polyenes are few. Nystatin resistance may be encountered in some *Candida* sp.[59,60] This resistance may either be seen in wild strains (primary-type) or it may be induced during therapy (secondary-type). Although *C. albicans* maintains a low rate of spontaneous resistance to nystatin,[61] particularly in comparison to resistance to imidazoles,[62] other species, such as *C. tropicalis*, *C. guilliermondi*, *C. krusei*, and *C. stellatoides*, rapidly acquire resistance upon exposure to nystatin.

OTHER AGENTS

Some topical antifungals, such as ciclopirox olamine, tolnaftate, and undecylenic acid, do not fit well into the major classes and are instead discussed separately.

Ciclopirox Olamine

Ciclopirox olamine is a hydroxypyridone antifungal agent with a unique structure and mode of action.

MECHANISM OF ACTION Unlike most other topical antifungals, ciclopirox olamine does not interfere with sterol synthesis.[63] Instead, it interrupts active membrane transport of essential cellular precursors, particularly trivalent cations.[64] Ultimately, this disrupts cellular function, leading to demise of the fungus. If concentrations of the drug are high enough, the membrane integrity of the fungus may actually be impaired.

Ciclopirox olamine also has inherent anti-inflammatory activity exerted through inhibition of prostaglandin and leukotriene synthesis within polymorphonuclear cells.[65] Broad-spectrum antibacterial properties have also been attributed to ciclopirox olamine. In one study, topical ciclopirox olamine had broader coverage against Gram-positive and Gram-negative organisms than did topical imidazoles or topical allylamines.[66]

PHARMACOKINETICS When applied to the skin, ciclopirox olamine remains in high concentration within the epidermis

and upper dermis. Ciclopirox olamine penetrates keratin easily, with cadaveric skin demonstrating concentrations in the epidermis that were 10 to 15 times the minimum inhibitory concentration for a sensitive species.[65] This ability to penetrate keratin recommends use for onychomycosis, as the drug is also capable of penetrating the nail plate material.[67] Studies of drug metabolism have demonstrated that, with typical use, approximately 10 percent of the administered dose is excreted in the urine.[68]

INDICATIONS Ciclopirox olamine is indicated for the treatment of dermatophytoses and onychomycosis, candidiasis, pityriasis versicolor, seborrheic dermatitis, and even cutaneous infections with unusual saprophytes.[69] In tinea pedis, a mycologic cure rate of up to 85 percent has been observed, and in seborrheic dermatitis, a significantly larger percentage of users had > 75 percent improvement with 2 weeks of use than those using the shampoo vehicle alone.[70,71]

Although treatment with ciclopirox olamine for tinea pedis and seborrheic dermatitis has yielded results on par with other modalities, use in onychomycosis has met with more modest success. Often, an assessment of efficacy depends upon whether a mycologic cure (culture-negative) or clinical cure (a disease-free nail) defines success.[72] Although a disease-free nail is often the patient's true goal, ciclopirox olamine achieved such a response in just 5.5 percent to 8.5 percent of those treated with a standard 48-week course.[72,73] Two recent trials demonstrated increased efficacy when using oral terbinafine in combination with topical ciclopirox olamine, as opposed to oral terbinafine alone.[74,75] Debate regarding the use of ciclopirox olamine as an independent or adjunct treatment for onychomycosis is ongoing.

DOSING REGIMEN Ciclopirox olamine is available in a wide range of forms (see Table 219-1). Cutaneous candidiasis, dermatophytoses, and pityriasis versicolor should be treated twice daily for 2 weeks to 1 month, but treatment for tinea pedis should continue 1 month or longer. When using ciclopirox shampoo for seborrheic dermatitis, treatment may occur twice weekly for an indefinite duration. Improvement is generally noted in 2 to 4 weeks. Finally, in treating onychomycosis, the nail lacquer is applied daily to the nail and hyponychium for 48 weeks and excess medication is removed weekly with alcohol.

RISKS AND PRECAUTIONS Risks associated with use of topical ciclopirox olamine are those inherent to all topical medicaments (see Table 219-3). Allergic contact dermatitis has been reported only rarely, and ciclopirox olamine is considered a weak sensitizer.[76] In patients with an allergic reaction to ciclopirox, imidazoles may be used with relative safety because of a markedly different chemical structure.

COMPLICATIONS Serious complications with topical ciclopirox olamine are few.

Older Agents

Tolnaftate and undecylenic acid are older agents now available only in over-the-counter products (see Table 219-1). Repeated studies have now demonstrated that they are approximately equal in efficacy,[77,78] and that both are less efficacious than topical imidazoles, allylamines, benzylamines, and ciclopirox olamine. Additionally, tolnaftate is ineffective for treating candidiasis. Topical tolnaftate and topical undecylenic acid share the same risks and precautions inherent to all topical medications (see Table 219-3). Additionally, topical forms of undecylenic acid may yield an unpleasant "fishy smell" that further discourages use. Because both agents are considered less efficacious than imidazoles, monitoring for treatment failure is indicated when using these medications.

TOLNAFTATE

UNDECYLENIC ACID

CONCLUSIONS

Because of relatively low cost, acceptable efficacy, ease of use, and low potential for side effects, complications, or drug interactions, topical antifungals are preferred for most superficial fungal infections of limited extent. Alternatively, use of a systemic agent is justified when a superficial fungal infection covers a large surface area, involves terminal hair or nails, or has proven recalcitrant to prior topical management. Imidazoles provide a reasonable balance of efficacy and affordability and are indicated for treatment of dermatophytoses, mucocutaneous candidiasis, and pityriasis versicolor. Despite higher cost, allylamines and benzylamines may be advantageous in some cases of tinea pedis, due to shorter treatment courses. Ciclopirox olamine is a topical antifungal with a unique mechanism of action and a broad range of indications. Topical nystatin is useful in treating mucocutaneous candidiasis, but is ineffective for dermatophyte infections. Use of tolnaftate and undecylenic acid is decreasing due to lower efficacy compared with other available agents.

KEY REFERENCES

The full reference list for all chapters is available at www.digm7.com.

5. Rosen T, Schell BJ, Orengo I: Anti-inflammatory activity of antifungal preparations. *Int J Dermatol* **36**:788, 1997
17. Gupta AK et al: An overview of topical antifungal therapy in dermatomycoses. A North American perspective. *Drugs* **55**:645, 1998
18. Weinstein A, Berman B: Topical treatment of common superficial tinea infections. *Am Fam Physician* **65**:2095, 2002
24. Greenberg HL et al: Clotrimazole/betamethasone diproprionate: A review of costs and complications in the treatment of common cutaneous fungal infections. *Pediatr Dermatol* **19**:78, 2002
47. Crawford F et al: Topical treatments for fungal infections of the skin and nails of the foot. *Cochrane Database Syst Rev* **2**:CD001434, 2000
65. Gupta AK, Plott T: Ciclopirox: A broad-spectrum antifungal with antibacterial and anti-inflammatory properties. *Int J Dermatol* **43**:3, 2004
74. Avner S, Nir N, Henri T: Combination of oral terbinafine and topical ciclopirox compared to oral terbinafine for the treatment of onychomycosis. *J Dermatolog Treat* **16**:327, 2005



CHAPTER 220

Topical and Intralesional Cytotoxic Agents

Megan M. Moore
Bruce E. Strober



5-FLUOROURACIL

Mechanism of Action and Formulations

Topical 5-fluorouracil (5-FU) has been used in clinical practice since the 1960s. It is a structural analogue of thymine that blocks DNA synthesis by inhibiting thymidylate synthetase. Topical 5-FU is commercially available as a 0.5 percent cream carried in a microsphere vehicle, as a 1 percent solution or 1 percent cream, as a 2 percent or 5 percent solution, and as a 5 percent cream. The solution can also be used for intralesional injection.

Indications

5-FU 5 percent cream has been approved by the U.S. Food and Drug Administration (FDA) since 1970 for the treatment of actinic keratoses in any location; 5-FU 0.5 percent cream is FDA approved for treatment of actinic keratoses of the face and anterior scalp. 5-FU is used twice daily until an inflammatory response is seen, usually 2 to 4 weeks. The 0.5 percent cream can be used once daily. 5-FU may also be a useful adjunct before cryosurgery of actinic keratoses.[1] Pre-treatment with a keratolytic agent, prolonged therapy, more frequent applications, or the use of occlusive dressings may increase therapeutic response.

Treatment Considerations

Irritation during treatment sometimes requires reduction or interruption of treatment and the addition of emollients or topical corticosteroids to help quell brisk inflammation. A number of approaches to decrease irritation have been devised; whether or not efficacy is preserved is disputed.[2] Weekly pulse dosing involves applying the medication for 1 to 2 days per week for 6 to 7 weeks. Use of the 0.5 percent 5-FU cream with microsphere vehicle may allow for a more tolerable irritation profile.[3]

During 5-FU treatment, previously sub-clinical actinic keratoses, basal cell carcinomas, and squamous cell carcinomas may respond to treatment and become apparent. In fact, the 5 percent 5-FU cream is approved by the FDA for the treatment of superficial basal cell carcinomas. Verrucae vulgaris, verrucae plana, plantar warts, and condylomata acuminata have been treated with varying response rates with topical and intralesional 5-FU. Additionally, actinic cheilitis, mucosal leukoplakia, radiodermatitis, Bowen disease, Bowenoid papulosis, and erythroplasia of Queyrat have all been reported to respond to treatment with topical 5-FU. Further, there are reports of the successful treatment of both psoriasis and keratoacanthomas with topical and intralesional 5-FU,[4] and of infantile digital fibromatosis treated with intralesional 5-FU.[5] Intralesional 5-FU has also been reported to be effective in the treatment of keloids and hypertrophic scars.[6,7]

The systemic absorption of topically applied 5-FU is limited, with absorption selectively greater from abnormal skin than from surrounding normal skin. Microsphere-based formulations may retain 5-FU at the target site, with less drug reaching the systemic circulation.[8] Rarely, systemic effects of 5-FU include nausea and anorexia, stomatitis, diarrhea, myelosuppression, alopecia, and cardiac and neurologic toxicity. Side effects of the topical preparation include local irritation, erythema, pain, swelling, pruritus, dyspigmentation, allergic contact dermatitis, and photosensitivity. Unusual reactions may include onycholysis, onychodystrophy, and the appearance of telangiectasias. The use of injectable preparations may be complicated by pain, local ulceration, erosion, desquamation, and dyspigmentation.[6]

MECHLORETHAMINE (NITROGEN MUSTARD)

Mechanism of Action and Formulations

Mechlorethamine [methyl-*bis* (2-chloroethyl) amine hydrochloride] was the first nitrogen mustard (NM) to be used in clinical medicine. Mechlorethamine acts as an alkylating agent and is not cell-cycle specific; however, its greatest effect is on cells in the late G1 or S phases. The primary target of mustard is the 7-nitrogen atom of guanine. The main role of topical NM in dermatology is in the treatment of the patches and plaques of cutaneous T-cell lymphoma (CTCL). The utility of NM in treating mycosis fungoides (MF), the most common type of CTCL, was first described in 1959. The topical activity of NM has been attributed not only to its alkylating activity, but also to its potential for immune stimulation.[9]

Mechlorethamine hydrochloride (Mustargen) is available in powder form, 10 mg per glass vial. Topical NM is prepared as either an aqueous solution or an ointment preparation. Aqueous solutions can be made to desired concentrations by dissolving the NM powder in tap water (one vial of 10 mg powder dissolved in 100 mL water yields a 10 mg% concentration). The solution is unstable and should be applied immediately to the skin using a sponge or cloth. Ointment preparations can be compounded by pharmacists.[9]

With either preparation, concentrations of 10 to 20 mg% are generally used and are applied daily, with increases in concentration and frequency of application pending clinical response. One approach is to apply the preparation to the entire body (sparingly to intertriginous sites, and excluding the genitalia) initially to avoid missing areas of sub-clinical involvement and thus theoretically increase the potential for cure.[10] Alternatively, treatment may be limited to only clinically affected areas. Treatment should be continued daily until complete response is attained. The benefit of a prolonged maintenance period in preventing disease relapse has not been shown.[9] With proper application, there is minimal contamination of the surrounding environment, but those assisting in the application of the drug should limit their exposure and wear protective gloves. Effort should be made

TOPICAL CYTOTOXIC AGENTS AT A GLANCE

- Topical and intralesional cytotoxic agents are effective in skin cancers and inflammatory and infectious dermatologic conditions.
- They aim for maximum efficacy against cutaneous targets while sparing normal tissue and minimizing systemic toxicity.
- They comprise 5-fluorouracil, nitrogen mustard, carmustine, vinblastine, bleomycin, methotrexate, podophyllin, and miltefosine.

to dispose of empty vials or unused solution in accordance with Environmental Protection Agency guidelines.

Indications

Many large retrospective series support the use of topical NM in MF. NM has been reported to produce complete response rates of 67 percent to 80 percent for MF patients with limited patch/plaque disease (stage IA) and 35 percent to 68 percent for patients with generalized patch/plaque (stage IB) disease.[9] The efficacy of aqueous and ointment-based preparations is similar. Topical NM as primary monotherapy has limited use in patients with tumor stage or erythrodermic disease.[9] Topical NM has also been used in the treatment of psoriasis,[11] alopecia areata,[12] and histiocytosis X.[13]

Treatment Considerations

Unlike the systemic preparation, there are no reports of systemic side effects following topical NM application. Furthermore, topical NM has been used safely in pediatric patients.[9] Local side effects include irritant or allergic contact dermatitis, immediate-type hypersensitivity, secondary cutaneous malignancies, and dyspigmentation. Irritant contact dermatitis is generally mild and resolves with reduction in concentration and/or frequency, or with topical steroid treatment. Allergic contact dermatitis has been reported to develop in up to 35 percent to 66 percent of patients on long-term treatment with aqueous NM and in fewer than 10 percent of those using the ointment preparation.[9] If hypersensitivity occurs, patients may be treated with dilutions below the threshold for clinically observable contact dermatitis. However, delayed-type hypersensitivity may be of therapeutic benefit. Twice-weekly dosing of topical NM in combination with betamethasone cream may offer a balance of tolerability and efficacy.[14] Up to 8 percent of patients may develop an urticarial immediate-type hypersensitivity to topical NM, often necessitating treatment discontinuation. Changes in pigmentation may also occur secondary to use of topical mechlorethamine. Hyperpigmentation and hypopigmentation are prone to develop in areas of previous CTCL and tend to resolve spontaneously, although slowly.

There have been reports of secondary cutaneous malignancies developing in patients treated with NM, including basal and squamous cell carcinomas, keratoacanthomas, and isolated reports of lentigo maligna and primary melanoma.[9] It is difficult to determine causality in these cases, as many of these patients were treated with multiple therapies, including known carcinogenic therapies such as psoralen and ultraviolet A phototherapy and radiation.

BISCHLOROETHYLNITROSOUREA (CARMUSTINE)

Mechanism of Action and Formulations

Carmustine [bischloroethylnitrosourea (BCNU)] is a nitrosourea that acts by alkylation to inhibit DNA, RNA, and protein synthesis. The topical formulation, introduced in 1971, is used primarily in the treatment of CTCL.

BCNU is available as a powder for reconstitution as a solution or ointment at either 10 mg or 20 mg/dL and is applied once daily (BiCNU). The ointment is easier for patients to use and leads to fewer cutaneous reactions. However, it is associated with an increased incidence of myelosuppression. Application should spare the face, hands, genitals, and intertriginous areas, unless these are directly involved with CTCL. The applications should be continued until clearing is seen, usually in 8 to 16 weeks. If the response to 10 mg daily is inadequate, the dose may be doubled for a further 4 to 8 weeks, if tolerated.

Indications

Several large retrospective cases series have shown that BCNU is effective in patch- and plaque-stage CTCL. Complete response rates of 86 percent for those with limited extent (< 10 percent) plaques (T1), 48 percent for those with extensive (≥ 10 percent) plaques (T2), and 21 percent for those with erythroderma have been reported.[15] Median time to complete response has been reported to be 11.5 weeks, with remission durations ranging from 18 to 66 months.[15]

Treatment Considerations

During topical treatment, mild myelosuppression and leukopenia have been reported and therefore patients should be monitored while on treatment.[16] Cutaneous reactions to topical treatment are very common, and a maximum of 6 months of therapy has been recommended. Erythema is seen in almost all patients and may be severe, persistent, and associated with skin tenderness and telangiectasia. Contact dermatitis is less commonly seen with BCNU than with NM, with delayed-type hypersensitivity reactions occurring in fewer than 10 percent of patients. Urticaria is not seen, and an increased incidence of skin cancers has not been observed.

VINBLASTINE

Mechanism of Action and Formulations

Vinblastine, a vinca alkaloid, is an antimitotic agent that acts by disrupting microtubules, thus blocking cell division in metaphase. In dermatologic practice, this agent is used primarily as an intralesional therapy for cutaneous and oral lesions of Kaposi sarcoma.

Concentrations of vinblastine used for intralesional injection in Kaposi sarcoma generally range from 0.1 to 0.6 mg/mL of normal saline. Lower concentrations are used on the eyelids and genitalia. Vinblastine is injected in quantities sufficient to blanch the entire lesion. Some authors use one injection only, whereas others recommend injections every 2 to 4 weeks until complete response is seen. Small controlled prospective studies have shown complete or partial clinical response in 88 percent of treated patients.[17]

Treatment Considerations

Potential systemic side effects of intravenous vinblastine include myelosuppression, neuropathy, anorexia, nausea, vomiting, diarrhea, alopecia, mucositis, and dermatitis. Although side effects from intralesional injection are usually local, there have been reports of mononeuropathy and a transient flu-like syndrome after treatment.[18] Common cutaneous side effects of intralesional injection include pain, especially post-treatment, and post-treatment hyperpigmentation. Intense local reactions and transient or permanent alopecia of treated sites may also result.[18]

BLEOMYCIN

Mechanism of Action and Formulations

Bleomycin is a cytotoxic antibiotic produced by *Streptomyces verticillatus*. Bleomycin disrupts DNA synthesis and causes scission of DNA strands. Bleomycin also has a sclerosant effect on endothelial cells. In dermatology, intralesional bleomycin has largely been used in the treatment of recalcitrant viral warts.



Bleomycin is available as a powder (Blenoxane). It should be reconstituted with sterile saline to the desired concentration, generally 1 U/mL solution. Stability in this formulation has been shown at 6 to 8 weeks if the preparation is refrigerated at 4°C (39.2°F), and for several months if stored at –20°C (–4°F).

Indications

There have been no large, randomized, double-blind, placebo-controlled studies of intralesional bleomycin treatment of viral warts. A paired, controlled study of intralesional bleomycin 1 U/mL injected intralesionally until blanching in resistant warts in 38 patients reported a 77 percent cure rate for warts on extremities; however, the rate fell to about 48 percent for plantar warts.[19] To overcome the problem of adequate infiltration of the wart without unwanted infiltration of normal skin, various approaches, including repeated pricking of the wart,[20] the use of bifurcated needles,[21] and pre-treatment with pulsed dye laser,[22] have been described. An uncontrolled study of 70 patients with plantar, palmar, mosaic, and periungual warts treated monthly with "pricking" of 1 U/mL bleomycin solution using a Monolet needle reported a 92 percent success rate.[20]

Multiple prospective studies of hemangiomas treated with intralesional bleomycin have reported significant reduction in size of lesions in approximately three-fourths of patients.[23,24] Successful treatment of keloids and hypertrophic scars[25] has been reported in several case series, with complete regression in one-half to three-fourths of cases. A small randomized controlled trial and open-label prospective study have described the benefit of topical 1 percent bleomycin in dimethylsulfoxide in treating oral leukoplakia.[26] Isolated case reports and small series have reported benefit from topical bleomycin ointment in treating recurrent Paget disease of the vulva[27] and intralesional bleomycin in treating keratoacanthomas.[28]

Treatment Considerations

Bleomycin has relatively low toxicity. Flu-like symptoms have been reported after intralesional use, but significant systemic toxicity is rare. Pulmonary fibrosis has been well described in association with systemic bleomycin chemotherapy but is dose-related. Local side effects of pain and swelling are common with intralesional use. Combinations of bleomycin and lidocaine may reduce the pain associated with injection, but children may require general anesthesia for treatment. Local injection for periungual warts may result in permanent nail loss or dystrophy.[29] Raynaud phenomenon, dyspigmentation, ulceration, cellulitis, and superficial scarring may also occur.[23,30] There is a case report of flagellate hyperpigmentation after intralesional injection of bleomycin.[31]

METHOTREXATE

Mechanism of Action and Formulations

Methotrexate is an antimetabolite that interferes with DNA synthesis through inhibition of dihydrofolate reductase. Methotrexate also alters the metabolism of adenosine, an endogenous anti-inflammatory mediator.[32]

Indications

In multiple case reports[33] and small case series,[34] intralesional methotrexate has been used to effectively treat solitary, giant, and eruptive keratoacanthomas. Injection parameters have included total doses from 5 to 75 mg, in one to five injections, with single doses ranging from 5 to 50 mg, and intervals of 1 to 2 weeks between injections.

Treatment Considerations

Methotrexate has well-studied adverse effects, including hematologic toxicity, hepatotoxicity, nausea, abdominal pain, oral aphthae, and reversible alopecia. Pancytopenia has been reported to have occurred at a minimum cumulative methotrexate dose of 10 mg and after a single intradermal infiltration of 25 mg.[33] Caution is warranted when using methotrexate in patients with renal insufficiency, advanced age, hepatic disease, or use of medications that may interfere with its excretion.[33] Pregnant or breast-feeding patients must be excluded. Injections have been reported to be generally well tolerated, with moderate pain and minimal scarring.

PODOPHYLLIN AND PODOPHYLLOTOXIN

Mechanism of Action and Formulations

Podophyllin is a crude resin derived from either the American mandrake, *Podophyllum peltatum*, or the Indian podophyllum, *P. emodi*. Podophyllotoxin is an extract of podophyllin with antineoplastic and antiviral activity. Podophyllotoxin binds tubulin, disrupting the cellular cytoskeleton.[35]

Podophyllin is produced as a 10 percent to 40 percent ethanolic or benzoin crude extract. Composition is not standardized, and the most potent active ingredient, podophyllotoxin, rapidly crystallizes out, leading to a short shelf life.

Indications

In dermatology, topical podophyllin and podophyllotoxin are used in the treatment of anogenital warts.

Treatment Considerations

Podophyllin should be applied under medical supervision with a protective inert ointment to surrounding skin and washed off 4 to 6 hours after application. Treatment is generally at weekly intervals.[36] Podophyllotoxin, the purified active ingredient of podophyllin, is available as 0.5 percent ethanol and 0.15 percent cream formulations. These preparations are to be self-applied in one or several 3-day cycles.[36] Self-treatment with podophyllotoxin has been shown to be more effective and more cost-effective compared with podophyllin applied in the clinic, although relapse rates are high with both treatments.[37] Systemic toxicities—including central nervous system and respiratory depression—have been reported after excessive podophyllin treatment of large anogenital warts, subdermal injection, or accidental ingestion, and podophyllin is reported to have mutagenic potential.[36] Local side effects, such as erythema, erosions, and tenderness, are common with both podophyllin and podophyllotoxin. Scarring or depigmentation rarely occurs. Given reports of the low efficacy, high toxicity, and mutagenicity profile of podophyllin, some authors have urged that it be removed from clinical treatment protocols and replaced by podophyllotoxin or other treatments.[36]

MILTEFOSINE (HEXADECYLPHOSPHOCHOLINE)

Mechanism of Action and Formulations

Miltefosine (hexadecylphosphocholine) is a cytotoxic alkyl phosphocholine that exerts its effects on the cell membrane. Miltefosine promotes phospholipid turnover and modulates membrane signal transduction, including inhibition of protein kinase C.



Miltefosine is available as a 6 percent solution in a defined mixture of three short-chain glycerol ethers that increases penetration (Miltex).

Indications

Miltefosine has shown promise as a treatment for cutaneous metastases from breast cancer and cutaneous lymphomas. However, limited skin penetration, local metabolism, and clearance via dermal blood vessels may interfere with efficacy.[38] There are also isolated reports of the successful use of miltefosine in the treatment of cutaneous metastases of squamous cell carcinoma.[39]

Treatment Considerations

Application in clinical trials and case series is generally daily for a week, then twice daily thereafter. Miltefosine 6 percent solution applied in this manner showed modest efficacy against cutaneous metastases of breast cancer in a randomized, double-blind, placebo-controlled, multicenter trial.[40]

When administered systemically, miltefosine causes significant gastrointestinal toxicity. However, systemic side effects, such as nausea, vomiting, and anorexia, have rarely been observed with topical application.[40] Local skin reactions are common, including burning, erythema, and fine scaling, but rarely necessitate discontinuation of therapy.[38]

KEY REFERENCES

The full reference list for all chapters is available at www.digm7.com.

1. Jorizzo J et al: Effect of a 1-week treatment with 0.5% topical fluorouracil on occurrence of actinic keratosis after cryosurgery: A randomized, vehicle-controlled clinical trial. *Arch Dermatol* **140**:813, 2004
3. Jorizzo J et al: Randomized trial evaluating a new 0.5% fluorouracil formulation demonstrates efficacy after 1-, 2- or 4-week treatment in patients with actinic keratosis. *Cutis* **70**:335, 2002
9. Kim Y: Management with topical nitrogen mustard in mycosis fungoides. *Dermatol Ther* **16**:288, 2003
10. Vonderheid E: Treatment planning in cutaneous T-cell lymphoma. *Dermatol Ther* **16**:276, 2003
20. Munn S et al: A new method of intralesional bleomycin therapy in the treatment of recalcitrant warts. *Br J Dermatol* **135**:969, 1996
35. Canel C et al: Podophyllotoxin. *Phytochemistry* **54**:115, 2000
39. Mahieu-Renard L et al: Treatment of cutaneous metastases of a squamous cell carcinoma of the leg with topical miltefosine. *Ann Dermatol Venereol* **132**:346, 2005



CHAPTER 221

Topical Immunomodulators

Robert Sidbury
Jon M. Hanifin

The topical immunomodulators are nonsteroidal agents that act via immunologic pathways to either inhibit or enhance immune and inflammatory reactions in the skin. The anti-inflammatory compounds pimecrolimus and tacrolimus are both within the macrolactam class of immunophilin-binding cytokine inhibitors. In the immune-enhancing category, there is currently only one drug, the interferon (IFN)-inducing agent, imiquimod, although several in vitro analogs have proved more potent and are presently under clinical investigation.

MECHANISM OF ACTION AND CLINICAL RESULTS

Topical Calcineurin Inhibitors

The mechanism of action involves tacrolimus binding to the immunophilin-binding protein, in turn blocking calcineurin dephosphorylative activation of the nuclear factor of activated T cells, which translocates to the nucleus where it initiates cytokine gene expression[1] (Fig. 221-1). In vitro effects include inhibition of T-cell proliferation and inhibition of production of a variety of cytokines, including interleukin 2 (IL-2), IL-3, IL-4, IL-12, tumor necrosis factor, and IFN-γ.[2]

Tacrolimus is one to two logs more potent than cyclosporin, its molecular weight is less, and its ability to penetrate the skin is greater. These properties provided a basis for experiments demonstrating topical inhibition of contact hypersensitivity and then development as an ointment for treating atopic dermatitis.

With topical tacrolimus therapy, more than 70 percent of patients have had moderate to excellent improvement in 3-week controlled trials, and 30 percent to 40 percent have had greater than 90 percent improvement.[2] In general, response to therapy with topical tacrolimus has been best and most rapid in thinner skin areas such as the face, neck, and trunk. During remissions, dosing may be reduced in frequency, but flares occur with discontinuance. Response is slow, over days to weeks, and often incomplete on extremities, especially hands and feet, and in patients with lichenified lesions. Roughly 25 percent of patients, especially those with the most severe disease, do not have a satisfactory therapeutic response. Additionally, patients should realize that exacerbations of atopic dermatitis may occur and require occasional intervention with topical or systemic corticosteroid therapy. The main advantage of topical tacrolimus is the provision of chronic maintenance therapy without the need for continuous topical corticosteroids. Koo et al. recently demonstrated up to 91 percent reduction in affected body surface area in a study of nearly 8000 adults and children using topical tacrolimus for up to 18 months without significant adverse events.[3] Other long-term studies with tacrolimus have specifically shown no evidence of cutaneous atrophy, little or no increased infection other than a slightly increased rate of herpes simplex virus in some trials, hypertension, renal toxicity, or cumulative blood levels in patients older than 2 years of age.[4]

Adverse effects have been primarily an intense burning and itching in 30 percent to 40 percent of patients at application sites, especially in areas of flaring, excoriation, and erosion.[2,4,5] These symptoms usually subside in a few days, in concert with healing of the skin. However, some patients continue to have bothersome burning, and this effect seems to be more prominent when the skin is exposed to heat such as during summer weather, or in baths or hot tubs. In general, these problems with burning sensations seem to be less in children. Up to 10 percent of adults experience symptoms of flushing with alcohol ingestion. Infections have

TOPICAL CALCINEURIN INHIBITORS PIMECROLIMUS AND TACROLIMUS AT A GLANCE

- Topical nonsteroidal anti-inflammatory agents.
- U.S. Food and Drug Administration approved for the short-term and intermittent long-term therapy of atopic dermatitis in patients older than 2 years.
- Targeted reduction of pro-inflammatory cytokines putatively responsible for the itch and rash of atopic dermatitis.
- Extensively studied, with an excellent record of short-term safety and efficacy when used appropriately.
- Burning and stinging at the application site is the most common adverse event occurring in 10 percent to 40 percent.
- Theoretical risk of systemic immunosuppression and malignancy have resulted in the addition of a post-marketing black box warning label.
- Widespread off-label use has been discouraged until long-term safety is more definitely established.



not been a notable problem in tacrolimus-treated patients.[2,4] Occasional staphylococcal skin infections occur, but they are no worse than before treatment, and studies actually demonstrate a reduction in *Staphylococcus aureus* colonization during prolonged therapy. In spite of the theoretical concern about immunosuppression, there have been no significant increases in frequency or severity of warts, varicella, or molluscum contagiosum infections. Some cases of eczema herpeticum have been noted in clinical trials. All continue to occur as usual in these patients with atopic dermatitis, but severity is unremarkable. Immunosuppression also carries the theoretical risk of cutaneous cancer and lymphoma predisposition but, to date, there has been no evidence of increased risk of occurrence relative to the general population. A smattering of post-marketing reports of lymphoma or malignancy in patients using tacrolimus topically, coupled with a biologically plausible risk related to topical calcineurin inhibitor (TCI) use, were factors in the U.S. Food and Drug Administration (FDA) calling for a black box warning label. Extensive review of these reports by independent oncologists and allied task forces has not found evidence of an increased risk of lymphoma or malignancy.[6–8] However, such effects require many years of constant immunosuppression, and thus, close surveillance is indicated along with careful counseling of patients to use sun protection.

Pimecrolimus has a very similar structure to tacrolimus and interacts with the same binding protein to inhibit calcineurin activation of the nuclear factor of activated T cells.[9] Cutaneous effects are lower, however, as reflected by decreased protein-binding affinity, which necessitates a higher drug concentration in the topical cream.[4] Topical pimecrolimus also appears to have little systemic immunosuppressive effect, which may reflect a wider margin of safety. Clinical trials have included infants as young as 3 months of age, although FDA approval has been limited to 2 years of age and older. A recent study of 76 infants and children revealed sustained benefit without significant adverse effect with pimecrolimus therapy for 2 years.[10] Two patients in the study developed eczema herpeticum. As with tacrolimus, occasional post-marketing reports of lymphoma and malignancy moved the FDA to affix the black box warning label to the entire class of medication, but these concerns remain at present theoretical.[6] Blood levels have been detected in occasional patients, but no high or prolonged levels have been detected. Initial studies of oral pimecrolimus were promising, but, in the wake of the black box controversy, development has been suspended.

Imiquimod

Imiquimod is unique in that it appears to enhance both acquired and innate immune function.[11] In comparison, TCIs inhibit pathways involved in immune activation. In vitro and in vivo studies demonstrate that topically applied imiquimod induces local cytokine production from keratinocytes and other cells.[12] Imiquimod's activity is mediated through the Toll-like receptor (TLR7 and TLR8) signaling cascade, resulting in the secretion of pro-inflammatory cytokines. In vitro effects include induction of IFN-α and IFN-γ, tumor necrosis factor-α, IL-1, IL-1 receptor antagonist, IL-6,

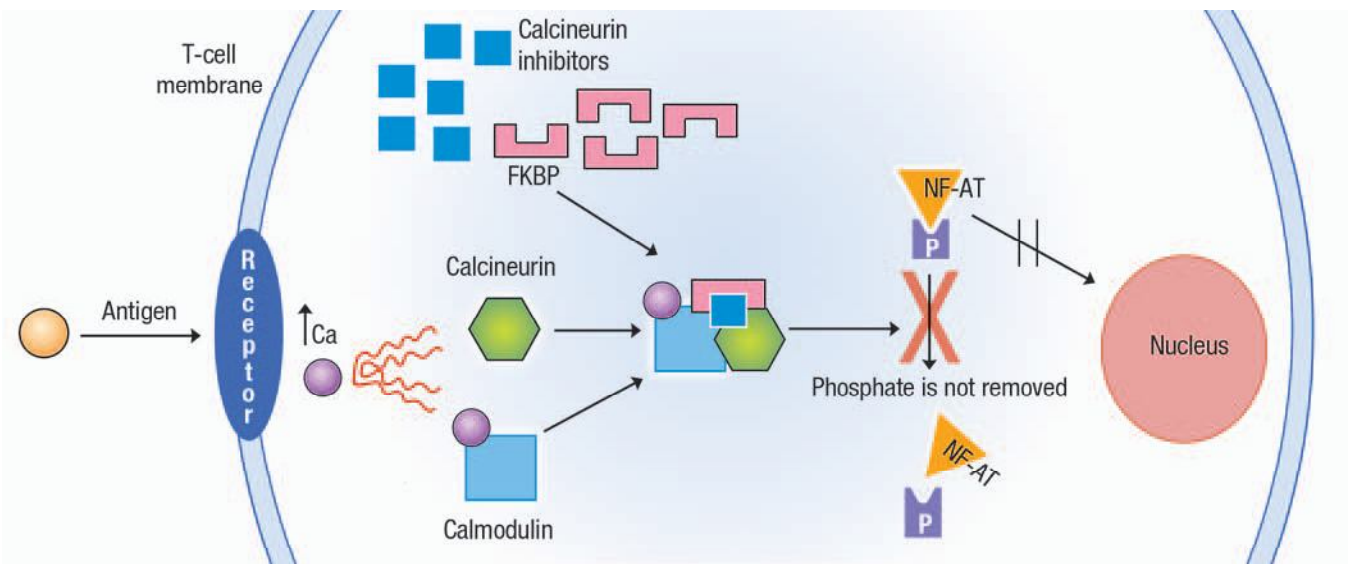

▲ **FIGURE 221-1** Mechanism of action of calcineurin inhibitors. Ca = calcium; FKBP = FK-506 binding protein; NF-AT = nuclear factor of activated T cells.

IMIQUIMOD AT A GLANCE

- Topical immunotherapy indicated for anogenital warts, superficial basal cell carcinoma, and actinic keratosis.
- Small molecule immune response modifier in the imidazoquinoline family.
- Induces heterogeneous, immune-mediated responses including antiviral, antitumoral, anti-angiogenic, and vaccine adjuvant activity.
- Targeted therapy that results in production of the inflammatory cytokines tumor necrosis factor-α and interferon-γ, thereby enhancing cell-mediated immune response.
- Application site stinging and irritant contact dermatitis are the most common adverse events.

IL-10, IL-12, granulocyte colony-stimulating factor, granulocyte-monocyte colony-stimulating factor, as well as the chemokines IL-8, macrophage inflammatory protein 1α, and monocyte chemotactic protein 1[13,14] (Fig. 221-2). Imiquimod also stimulates the innate immune response by increasing natural killer cell activity, activating macrophages and Langerhans cells, and inducing proliferation and maturation of B lymphocytes. Additionally, imiquimod has direct proapoptotic activity on tumor cells.

Many published reports show that imiquimod is an effective treatment for anogenital warts. A 16-week study of 311 immunocompetent adults with external anogenital warts compared three times weekly 5 percent imiquimod cream, 1 percent imiquimod cream, and placebo.[15] Clearance was achieved in more than 70 percent of women and 30 percent of men with the 5 percent cream, both significantly better than placebo. Response rates greater than 30 percent have been seen in uncircumcised males treated under the foreskin, suggesting that increased moisture may account for this gender discrepancy. Similarly, local factors may account for lower response rates in non-genital warts. The primary benefit of imiquimod cream relative to other available wart therapies is ease of administration. In adults, home therapy for genital warts is preferred, given the sensitive nature of this problem. Likewise in children, genital warts may be a result of sexual abuse, and an atraumatic topical therapy that can be rapidly applied in a nonthreatening environment is ideal. Recurrence rates following use of imiquimod cream have ranged from 13 percent to 19 percent.[15]

Adverse effects relate primarily to cutaneous irritation at the application site, leading to moderate erythema and erosion in roughly one-third and one-tenth of patients, respectively. Studies suggest that both the response rate, particularly in males, and the likelihood of side effects will increase with daily therapy. Imiquimod is a category C drug, and it is not known to what extent topically applied imiquimod is excreted in the breast milk of nursing mothers. Imiquimod has not been thoroughly studied in children younger than 18 years of age. Imiquimod has been investigated for a variety of other infectious conditions with varying degrees of success.

In vitro evidence of antitumor effects formed the basis for evaluation of imiquimod's efficacy in the treatment of cutane-



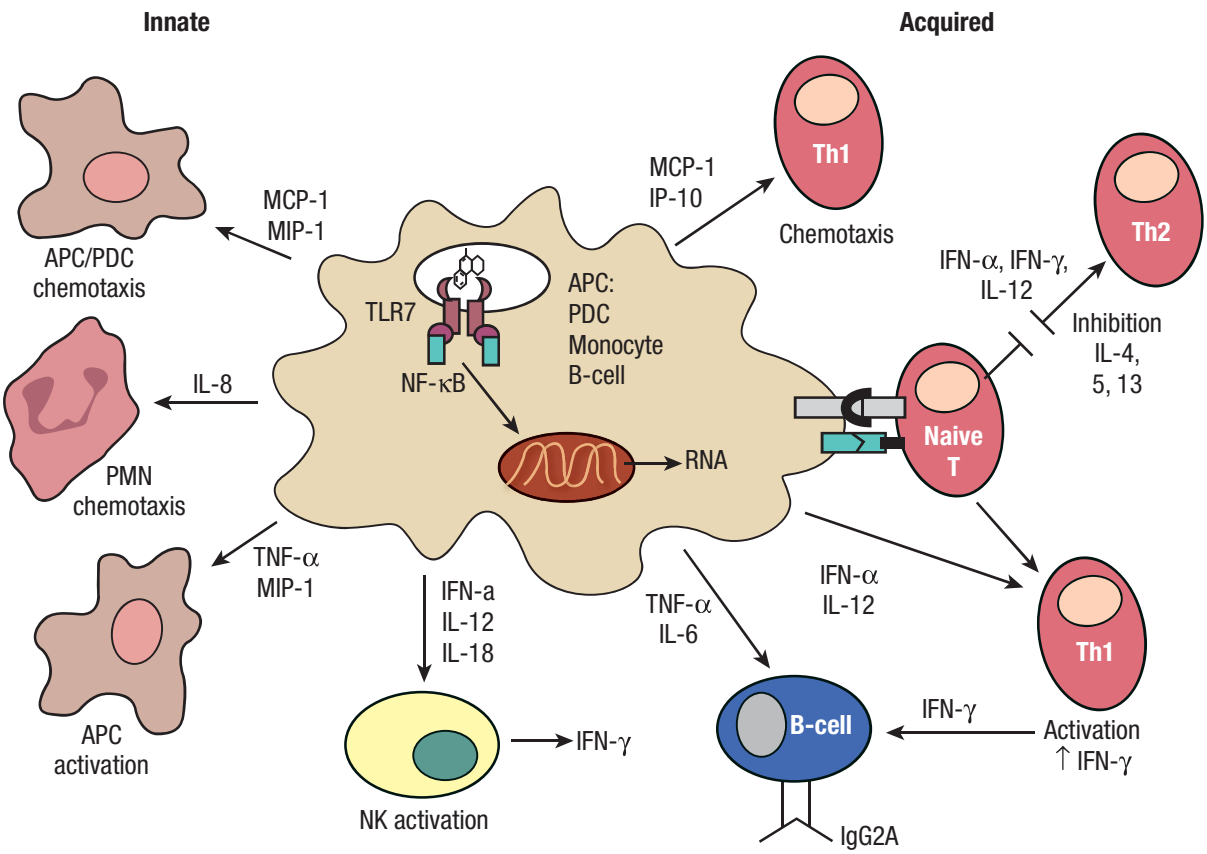

▲ **FIGURE 221-2** Mechanism of action by imiquimod. APC = antigen-presenting cell; IFN = interferon; IgG2A = immunoglobulin G2A; IL = interleukin; IP-10 = interferon-inducible protein 10; MCP-1 = macrophage chemoattractant protein 1; MIP = macrophage inflammatory protein; NF-κB = nuclear factor κB; NK = natural killer cell; PDC = peripheral dendritic cell; PMN = polymorphonuclear neutrophil; Th = T helper; TLR = Toll-like receptor; TNF-α = tumor necrosis factor-α.

ous neoplasia. A multicenter, randomized, open-label dose-response trial showed an almost 90 percent histologic clearance rate of superficial basal cell carcinoma (BCC) when 5 percent imiquimod cream was applied daily for 6 weeks. Twice daily application led to an improved response rate but a higher incidence of local skin reactions.[16] Geisse et al. subsequently reported that two phase III double-blind, randomized, vehicle-controlled trials showed histologic clearance of 82 percent with five times weekly treatment. Daily therapy was no more effective, and response was positively correlated with signs of inflammation, including erythema, erosion, and crusting.[17] These studies formed the foundation for approval of truncal/extremity superficial BCC as an indication for imiquimod therapy.[12]

Imiquimod has also been approved as a treatment for actinic keratosis of the head and neck. Hadley et al. recently reviewed the use of imiquimod for actinic keratosis. In five randomized controlled trials lasting 12 to 16 weeks involving 1293 patients, complete clinical clearance was seen in 50 percent of imiquimod patients versus 5 percent using vehicle. Adverse events were significantly higher in imiquimod-treated groups, including erythema (27 percent), crusting/scabbing (21 percent), flaking (9 percent), erosion (6 percent), edema (4 percent), and weeping (3 percent).[18]

Although not yet clinically indicated as an anti-angiogenic agent, imiquimod has demonstrated anti-angiogenic properties in vitro and in a series of case reports. Imiquimod's anti-angiogenic properties stem from the production of anti-angiogenic cytokines, including IFN-γ, IL-10, and IL-12; the upregulation of endogenous anti-angiogenic mediators, including tissue inhibitor of matrix metalloproteinase; and downregulation of the pro-angiogenic factors basic fibroblast growth factor and matrix metalloproteinase 9.[19] In a mouse model of hemangioendothelioma, imiquimod application resulted in fewer and smaller tumors, and numerous clinical reports have noted clinical response treating vascular neoplasms, including hemangiomas of infancy and pyogenic granulomas.[20] Future trials must better define imiquimod's role in the treatment of various vascular lesions.

PHARMACOKINETICS

Pimecrolimus and Tacrolimus

Tacrolimus ointment, 0.03 percent and 0.1 percent applied twice daily, was studied extensively in clinical trials that included adults and children as young as 2 years of age.[1] Pharmacokinetic studies showed percutaneous absorption initially in 10 percent to 20 percent of patients with atopic dermatitis, but generally blood levels were undetectable by 1 week as healing and re-establishment of the skin barrier occurred. Rarely were blood levels greater than 2 ng/mL (compared with trough levels of 5 to 15 ng/mL in transplant patients treated systemically).[2]

In an open label study of twice-daily pimecrolimus use in infants ranging in age from 5.7 to 11.9 months at baseline with moderate to severe atopic dermatitis, Lakhanpaul et al. found no accumulation of drug and systemic levels ranging from below the limit of detection to 1.94 ng/ml. There were no significant adverse events over the course of this 1-year-long trial.[21]

Imiquimod

The half-life of systemically administered imiquimod, either oral or subcutaneous, is 2 to 4 hours in healthy volunteers. The half-life of intravenously administered imiquimod is 14 hours, and less than 1 percent of the drug is recovered in the urine after a single topical application. The major systemic metabolite of imiquimod, S26704, is a hydroxylation product that achieves plasma concentrations of less than 20 percent of the parent compound.[22] Higher levels have been noted with both intravaginal administration in healthy volunteers or systemic administration in chronically ill patients. With topical administration in healthy volunteers, there is very little measurable imiquimod (pg/mL) and no detectable S26704.

INDICATIONS: U.S. FOOD AND DRUG ADMINISTRATION AMENDED INDICATIONS

Pimecrolimus and Tacrolimus

- Second-line therapy for atopic dermatitis
- Children older than 2 years
- Adults
- Short term, non-continuous chronic therapy

Imiquimod

- External anogenital warts
- Superficial BCC smaller than 2 cm on trunk, neck, extremities
  - Immunocompetent adults
  - When surgical options less appropriate
  - Biopsy-confirmed
- Actinic keratosis

CONTRAINDICATIONS

Pimecrolimus and Tacrolimus

- Immunocompromised
- Netherton syndrome
- Active bacterial or viral infection
- Phototherapy

Imiquimod

- Immunocompromised
- Refractory, thicker, actinic keratoses

DOSING REGIMENS

INITIATING THERAPY

Pimecrolimus and Tacrolimus

In light of recent concerns with long-term safety and questions raised by the widely publicized black box warning label, initiation of TCI therapy should begin by addressing parent and patient concerns. These agents should be considered second line and are indicated when standard therapy, including topical steroids and emollients, are either ineffective or harmful. Comparisons of these agents with standard therapy have not as yet consistently shown a relative clinical or pharmacoeconomic benefit compared with topical steroids.[23] Once the decision to initiate TCI therapy has been made, consideration must be given to the choice of either pimecrolimus or tacrolimus. Pimecrolimus is available as a 1 percent cream formulation and is indicated for mild to moderate atopic dermatitis. Tacrolimus is available in two strengths, 0.03 percent for children ages 2 to 15 years old, and 0.1 percent in patients 16 years and older. Topical tacrolimus has an ointment vehicle and is indicated for moderate to severe atopic dermatitis.

Both products have been extensively studied and have excellent safety and efficacy records compared with placebo in the short term. Therefore, patient vehicle preferences and disease severity help determine the appropriateness of either agent for an individual patient. Paller et al. found tacrolimus to be more effective than pimecrolimus with a similar side effect profile in three comparison trials.[24]

Pimecrolimus or tacrolimus should be applied sparingly only to affected areas of skin twice daily. The smallest amount of



medicine should be used, and therapy discontinued where signs and symptoms of redness and itch have resolved for 1 week. Adjunctive therapies such as emollients should be continued. If applied after bathing, as often recommended, pimecrolimus or tacrolimus should be applied first to affected areas, and emollients subsequently to unaffected skin. Application site stinging from TCIs may be more severe in areas of excoriation. Efforts to limit these open areas of skin by pre-treating for 2 to 7 days with a topical steroid may improve adherence to therapy.

Imiquimod

Imiquimod should be applied sparingly to affected areas when treating warts or superficial BCC. A broader but circumscribed treatment area is recommended either on the face or scalp, but not both, when treating actinic keratosis. For anogenital warts, initial frequency should be three times weekly. If little or no effect is seen after 2 to 4 weeks, advancing to daily use may enhance efficacy, although risk of an irritant dermatitis will increase commensurately. Application before sleeping is generally recommended and imiquimod should be left on the skin for 6 to 10 hours. It should be made clear to patients treating warts that imiquimod therapy does not eliminate the risk of transmission of papilloma virus to physical contacts. The frequency of application for the treatment of superficial BCC (five times weekly) and actinic keratosis (two times weekly) differs as noted in the boxes.

MONITORING THERAPY

Pimecrolimus and Tacrolimus

If effective, TCIs may be incorporated into the long-term therapeutic regimen for atopic dermatitis. Prescribing physicians must assure that patients are using these products intermittently and only to treat active dermatitis. Adverse events, including application site reactions, should be monitored. Patients should be evaluated for cutaneous infections with particular vigilance against eczema herpeticum, which was noted with slightly increased frequency in some pre-marketing trials. Any evidence of lymphadenopathy should be documented and followed closely. Skin examinations for signs of cutaneous malignancy are prudent. No routine serologic monitoring is indicated; however, if clinical evidence suggests the possibility of systemic immunosuppression, serum levels of tacrolimus or pimecrolimus may be obtained. If blood levels are sought, care must be taken to first remove any residual medication, particularly at the antecubital location, a common site for both venipuncture and atopic dermatitis. Failure to do so may lead to spuriously elevated drug levels. Despite reassuring safety data, the lesson of the black box controversy is that definitive long-term safety has not been established; and therefore, ongoing vigilance for potential TCI adverse effects, including immunosuppression and malignancy, must continue.

Imiquimod

Imiquimod therapy for warts, if tolerated, should be continued until complete clearance of warts or a maximum of 4 months before declaring a treatment failure. If no response or clinical deterioration is seen at 8 weeks, other therapeutic options should be entertained. If an incomplete response is obtained, continuing therapy may be warranted. Increasing from three times weekly to daily treatment may be indicated if imiquimod is well tolerated. No serologic monitoring is necessary. Irritant reactions may be treated initially by temporary cessation of therapy in addition to or followed by appropriate topical anti-inflammatory intervention. Imiquimod therapy can then be resumed as necessary at a decreased frequency as indicated. Similar principles govern the use of imiquimod for superficial BCC and actinic keratosis, but closer clinical follow-up is indicated.

RISKS AND PRECAUTIONS

Pimecrolimus and Tacrolimus

- Application site reactions, including itch, burning, stinging, redness, flushing with alcohol
- Avoid use on pre-malignant or malignant skin conditions, including cutaneous T-cell lymphoma
- Skin infections, including *S. aureus*, dermatophytosis, and herpes simplex
- Lymphadenopathy
- Light exposure, including phototherapy
- Immunocompromised
- Netherton syndrome
- Renal insufficiency
- Pregnancy category C
- Lactation
- Flu-like symptoms
- Worsening acne

Imiquimod

- Erythema, erosion, edema, ulceration, excoriation/flaking
- Hypo- or hyperpigmentation
- Pregnancy category C
- Safety not established in children younger than 12 years old
- Soreness
- Flu-like symptoms
- Myalgia
- Headache
- Multiple treatment courses for superficial BCC or actinic keratosis at same site
- Basal cell nevus syndrome
- Superficial BCC of the head, neck, or anogenital area
- Xeroderma pigmentosum

COMPLICATIONS

Pimecrolimus and Tacrolimus

- Elevated blood levels and risk of systemic immunosuppression
- Unclear long-term risk of lymphoproliferative disease
- Unclear long-term malignancy risk
- Eczema herpeticum

Imiquimod

- Irritant contact dermatitis
- Ulceration
- Incomplete treatment of malignancy

KEY REFERENCES

The full reference list for all chapters is available at www.digm7.com.

2. Pascual JC, Fleisher AB: Tacrolimus ointment (Protopic) for atopic dermatitis. *Skin Therapy Lett* **9**:1, 2004
4. Shainhouse T, Eichenfield LF: Long-term safety of tacrolimus ointment in children treated for atopic dermatitis. *Expert Opin Drug Saf* **2**:457, 2003
6. Qureshi AA, Fischer MA: Topical calcineurin inhibitors for atopic dermatitis: Balancing clinical benefit and possible risks. *Arch Dermatol* **142**:633, 2006
9. Wolff K: Pimecrolimus 1% cream for the treatment of atopic dermatitis. *Skin Therapy Lett* **10**:1, 2005
11. Chang YC et al: Current and potential uses of imiquimod. *South Med J* **98**:914, 2005
12. Sapijaszko MJ: Imiquimod 5% cream (Aldara) in the treatment of basal cell carcinoma. *Skin Therapy Lett* **10**:2, 2005
23. Ashcroft DM et al: Efficacy and tolerability of topical pimecrolimus and tacrolimus in the treatment of atopic dermatitis: Meta-analysis of randomised controlled trials. *BMJ* **330**:516, 2005



CHAPTER 222

Other Topical Medications

Craig N. Burkhart
Kenneth A. Katz

This chapter reviews topical therapies not covered elsewhere in the text that are used to treat dermatologic diseases. The topic headings are those of the drug designation of the U.S. Pharmacopeia and at times reflect clinical usage rather than specific pharmacologic mechanisms.



ANALGESICS

Capsaicin

Capsaicin is the molecule that confers the "hotness" to hot peppers of the genus *Capsicum*, including cayenne, jalapeno, and Tabasco peppers.[1] Initial topical application results in itching, pricking, and burning as nociceptor activate. Repeated applications, however, are hypothesized to lead to degeneration of epidermal nerve fibers and nociceptor desensitization, thereby producing hypalgesia.[2]

Topical capsaicin has been used to treat postherpetic neuralgia, diabetic neuropathy, reflex sympathetic dystrophy, Raynaud phenomenon, nostalgia paresthetica, arthralgias, plantar warts, diabetic neuralgia, and hemodialysis-related pruritus.[3] A recent systematic review of treatments for postherpetic neuralgia concluded that early use of capsaicin should be considered as a first-line agent for postherpetic neuralgia in some cases.[4]

Topical Anesthetics

Eutectic mixture of local anesthetics (EMLA) cream contains the sodium-channel–blocking amide anesthetics lidocaine 2.5 percent and prilocaine 2.5 percent. Application under occlusion to intact skin or genital mucous membranes for at least 1 hour before performance of a painful procedure provides local anesthesia that may persist for up to 2 hours. The cream may cause transient local blanching followed by transient local erythema. Like all products containing lidocaine, it should not be used in patients with hypersensitivity to amide anesthetics. Additionally, the prilocaine component has been linked to cases of methemoglobinemia in patients for whom applications exceeded the recommended dose, application area, or application time.[5,6] Those particularly susceptible to methemoglobinemia include patients who are very young, those with glucose-6-phosphate dehydrogenase deficiency, and those taking oxidizing drugs such as sulfonamides and antimalarials.[5]

Caution regarding dosing should also be used in patients susceptible to systemic effects of lidocaine or prilocaine, including acutely ill, debilitated, and elderly patients. Finally, as EMLA is ototoxic, it should not be used if there is a concern that it could penetrate or migrate beyond the tympanic membrane to the middle ear.

Various topical anesthetic products contain only lidocaine, typically at concentrations of 4 percent or 5 percent, which may be applied with or without occlusion. Systemic toxicity from topical lidocaine prepared in a 30 percent concentration has been reported,[7] though lower concentrations are likely much safer.[8] A single case of contact urticaria to EMLA cream has also been reported.[9]

ANTI-INFLAMMATORY AGENTS

Coal Tar

Coal tar has been used to treat inflammatory dermatoses for up to two millennia, although currently it is used primarily to treat psoriasis.[11] Coal tar has been shown to inhibit DNA synthesis and mitosis in epidermal cells, an effect potentiated by ultraviolet A exposure.[12,13] Coal tar also has anti-infective, antipruritic, photosensitizing, and vasoconstrictive effects and, with repeated applications, causes epidermal atrophy.[11] The precise mechanism by which it treats inflammatory skin diseases has not been fully described.[11]

In 1925, Goekerman pioneered the concomitant use of coal tar and ultraviolet B therapy for psoriasis.

Coal tar is messy to use, has an unpleasant odor, and can stain clothing, making its use challenging for some. Systemic adverse effects are uncommon, whereas local adverse effects include allergic or irritant contact dermatitis, erythema, stinging, exacerbation of exfoliative dermatitis or pustular psoriasis, folliculitis, atrophy, telangiectasis, pigmentation, cutaneous horns, keratoacanthomas, and tar warts.[11] Although occupational exposure to coal tar has been associated with increased risk of developing skin cancer, epidemiologic studies of coal tar–treated psoriasis have not demonstrated an increased risk of skin cancer due to coal tar.[11]

Wood Tar

Produced by distillation of wood under controlled conditions, wood tar can be added to arachis oil (peanut oil) or other bases. The preparation is then typically used to treat scalp psoriasis. Most commonly derived from juniper (oil of cade), wood tar may also be derived from beech, birch, and pine.

Shale Oil

Shale oil (also referred to as *ammonium bituminosulphonate*, *ichthyol*, *ichthammol*, or *black salve*) is derived from oil shale, a sulfur-rich sedimentary rock. Further processing of extracted shale oil yields light- and dark-colored components. The light component is also referred to as *pale sulfonated shale oil* (PSSO) or *ichthyol pale*.[16] Shale oil decreases inflammation by inhibiting lipoxygenase.[18] PSSO has been used to treat acne, atopic eczema, psoriasis, seborrhea, eczema, rosacea, and pruritus.[16,19] PSSO may have beneficial effects on wound healing, including venous leg ulcers.[20] Shale oil has also been used to treat otitis externa.[21]

ANTIMICROBIAL AGENTS (Table 222-1)

Chlorhexidine

Chlorhexidine gluconate is a bisbiguanide that binds to the stratum corneum, providing sustained bactericidal and fungicidal activity for over 6 hours, even

OTHER TOPICAL MEDICATIONS AT A GLANCE

- Topical medications not sufficiently covered in other sections of this text comprise
  - Analgetics
  - Anti-inflammatory agents
  - Antimicrobial and antiparasitic agents
  - Antiparasitic agents
  - Antiperspirants, antipruritics and astringents
  - Bleaching and keratolytic agents
  - Topical psoriasis and wart therapies

TABLE 222-1
Topical Antimicrobials and Astringents

Drug	Group	Antibacterial Mechanism	Antimicrobial Spectrum	Major Side Effects or Contraindications	Use (Selected)	U.S. Food and Drug Administration Pregnancy Category
Chlorhexidine	Bisbiguanide	(1) Binds to negatively charged bacterial cell wall and cytoplasmic components leading to altered osmotic equilibrium and (2) precipitation of cytoplasmic components	Gram-positive, Gram-negative bacteria, enveloped viruses, and fungi	Keratitis, ototoxicity	Antiseptic surgical hand scrub and surgical site preparation	B
Gentian violet	Dye	Unknown	Some vegetative Gram-positive bacteria (e.g., *Staphylococcus* sp.) and yeast	Potential skin necrosis at high concentrations or when occluded; stains skin and clothing; tattooing when applied over granulation tissue; mutagenic	Impetiginized eczema; mycotic skin infections; oral candidiasis; superficial skin infections	C
Brilliant green	Dye	Unknown	Similar to gentian violet	Potential skin necrosis; stains skin and clothing	Similar to gentian violet	Not used in Western medicine
Hydrogen peroxide	Peroxide	Oxidizes microbial molecules	Broad spectrum antimicrobial	Avoid in abscesses; bleaches hair	Cleansing of wounds, suppurating ulcers, and local infections	—
Povidone-iodine	Iodophor	Oxidation and release of free iodine	Gram-positive, Gram-negative, enveloped viruses, fungi, sporicidal, *Mycobacterium tuberculosis*	Caution in patients with thyroid disorders; potential systemic toxicity in neonates or when applied to large body surface area; neutralized by blood, serum proteins, and sputum	Antiseptic surgical hand scrub, prevention or treatment of topical site infection associated with surgery, burns, minor cuts/scrapes	C
Clioquinol	Iodophor	Oxidation and release of free iodine; chelates bacterial surface and trace metals needed for bacterial growth	Gram-positive, Gram-negative, enveloped viruses, fungi, sporicidal, *M. tuberculosis*	Possible irreversible optic atrophy and peripheral neuropathy (oral); contraindicated in children < 2 yr of age; contraindicated for diaper rash; stains skin yellow; neutralized by blood, serum proteins, and sputum	Approved for fungal infections; also used for pyoderma, folliculitis, and impetigo	—
Metronidazole	Imidazole	Creation of reduced intermediate compounds and free radicals	Anaerobes, protozoa, and microaerophilic bacteria	Contraindicated during first trimester of pregnancy	Rosacea	B
Mupirocin	Fermentation product of *Pseudomonas fluorescens*	Inhibits bacterial isoleucyl-t-RNA synthetase	Gram-positive, some Gram-negative, spares normal flora	Potentially toxic amounts of polyethylene glycol contained in vehicle may be absorbed in patients with extensive burns or open wounds	Non-bullous impetigo, eradication of nasal carriage of *S. aureus*	B

(continued)



TABLE 222-1
Topical Antimicrobials and Astringents (Continued)

Drug	Group	Antibacterial Mechanism	Antimicrobial Spectrum	Major Side Effects or Contraindications	Use (Selected)	U.S. Food and Drug Administration Pregnancy Category
Azelaic acid	Dicarboxylic acid	Possibly through inhibition of microbial respiratory chain	*Propionibacterium acnes* and *S. epidermidis*	Hypopigmentation	Acne	B
Benzoyl peroxide	Peroxide	Oxidizes microbial molecules	Broad-spectrum antimicrobial	Bleaches dark clothing	Acne	C
Aluminum salts	Astringent	Coagulation of proteins	Broad-spectrum antimicrobial	Do not use under impervious material to prevent evaporation	Weeping, impetiginized skin disorders	—
Potassium permanganate	Astringent	Oxidizes microbial molecules	Broad-spectrum antimicrobial	Skin discoloration; caustic at high concentrations or with contact of undissolved crystals	Weeping, impetiginized skin disorders	—
Silver nitrate	Astringent	Precipitation of bacterial proteins by free silver ions	Gram-positive and Gram-negative bacteria	Black skin discoloration, caustic at high concentrations; potential methemoglobinemia	Weeping, impetiginized skin disorders, cauterization of wounds, removal of granulation tissue, aseptic prophylaxis of burns	C



when wiped from the field. Although it does not kill bacterial spores or mycobacteria, it does inhibit their growth. Because it does not lose its effectiveness in the presence of organic material, such as whole blood, it is an important antiseptic, disinfectant, antibacterial dental rinse, and preservative. Due to ototoxicity and the risk of conjunctivitis and corneal ulceration, chlorhexidine is not recommended for pre-operative preparation of the face or head.

Dyes

Dyes are useful topical treatments because they are inexpensive and chemically and physically stable. The topical antiseptic dyes used in dermatology, gentian violet (methylrosaniline chloride), brilliant green (*p*-diethylamine triphenylmethanol), malachite green, and fuchsine, are all derivatives of triphenylmethane. The dyes are effective against *Candida* species and several aerobic Gram-positive bacteria, including methicillin-resistant *Staphylococcus aureus*. Gentian violet is a known contact sensitizer and may cause skin necrosis in concentrations greater than 2 percent aqueous solution or when used undiluted in skin folds.[22]

Hydrogen Peroxide

Hydrogen peroxide has been used for a number of years as a cleansing agent and for the removal of debris. It has antibacterial properties against both Gram-positive and -negative bacteria, and its effervescent quality helps débride wounds.

Iodinated Compounds

Iodine solution is bactericidal, sporicidal, and viricidal. Iodophors are complexes of iodine with a carrier that slowly liberates inorganic iodine on contact with reducing substances. This preserves the antimicrobial activities of iodine without the irritant effects of the free tincture. Iodophors must be applied to dry skin as they are inactivated by contact with blood, serum proteins, and sputum.

POVIDONE-IODINE Povidone-iodine has a wide spectrum of in vitro activity against Gram-negative and -positive bacteria, fungi, and viruses. Systemic absorption can occur with resultant renal and thyroid dysfunction if large or prolonged quantities are used.

CLIOQUINOL Clioquinol, 5-chloro-8-hydroxy-7-iodoquinolinol, is weakly antifungal and antibacterial. It is effective alone or combined with a topical steroid to treat inflammatory dermatoses, especially in intertriginous areas. Adverse reactions include a yellowish discoloration on clothing or skin, delayed contact hypersensitivity, and contact dermatitis. In the early 1970s, it was linked to subacute myelo-optic neuropathy in Japan[23] and was banned in many countries, including the United States. This link was questioned by subsequent epidemiologic studies,[24] but product labeling still warns of possible irreversible optic atrophy and peripheral neuromuscular disease.

Metronidazole

Metronidazole is an imidazole with activity against anaerobic bacteria and protozoa that is most often used in dermatology for rosacea. In addition to its antibiotic properties, its mode of action in rosacea may involve the impedance of leukocyte chemotaxis and selective suppression of cellular immunity.

Mupirocin

Mupirocin, also known as *pseudomonic acid*, is bactericidal at the concentration achieved with topical application to the skin and mucous membranes. As mupirocin has a unique mechanism of action, in which it prevents the incorporation of isoleucine into proteins by inhibiting bacterial isoleucyl-t-RNA synthetase, there is no cross-resistance with other antimicrobials.[25] It has activity against staphylococci, streptococci, and certain Gram-negative bacteria, but is inactive against much of the normal

skin flora. It is the treatment of choice for nonbullous impetigo and the most effective topical antibiotic for the elimination of *S. aureus* nasal colonization.[25]

Azelaic Acid

Azelaic acid is a naturally occurring aliphatic dicarboxylic acid that is a competitive inhibitor of tyrosinase. Azelaic acid is a reversible inhibitor of cytochrome P_{450} reductase and 5α-reductase in microsomes and a reversible inhibitor of some enzymes in the respiratory chain.[26] In vitro azelaic acid has antimicrobial affects against *Propionibacterium acnes* and *S. epidermidis*.[27] Its efficacy against acne and rosacea is attributed to activity against *P. acnes*, normalization of keratinization, and a direct anti-inflammatory effect.[28]

Benzoyl Peroxide

Benzoyl peroxide is a non-specific bactericidal agent that derives its biologic function through decomposition into benzoyloxy and phenyl radicals that react with numerous constituents of microbial cells. This effect may be enhanced by the addition of antibiotics or other molecules containing tertiary amines or transitional metals.[29] As a topical therapy, benzoyl peroxide is mainly used for acne, although it is also occasionally used to speed healing of chronic wounds.[30] When used for acne, it is frequently combined with topical antibiotics, as such combination therapy may reduce the development of antibiotic resistant by *P. acnes*.[31]

ANTIPARASITIC AGENTS (See Chaps. 207 and 208; Table 222-2)

Crotamiton

Crotamiton (crotonyl-*N*-ethyl-*O*-toluidine) is a colorless or pale yellow oil used in the treatment of scabies, pediculosis capitis, and pruritus. Its mode of action is unknown. Other antiparasitic formulations, such as lindane 1 percent and permethrin cream 5 percent, are more effective than crotamiton,[32] which is rarely a sensitizer. It is approved for use in infants and children, but is pregnancy category C.

γ Benzene Hexachloride

γ Benzene hexachloride, also known as *hexachlorocyclohexane* or *lindane*, is a chlorinated hydrocarbon pesticide that is effective against lice, scabies, and fleas as a 1 percent lotion or shampoo. Scabies and lice resistant to γ benzene hexachloride have been reported.[22] Furthermore, multiple side effects of topical application including central nervous system toxicity, seizures, and aplastic anemia have been reported leading to the U.S. Food and Drug Administration recommendation that γ benzene hexachloride only be used as a second-line agent.[33] Patients with seizure disorders, children weighing less than 50 kg, and patients with acutely inflamed or raw skin should avoid γ benzene hexachloride.

Malathion

Malathion is an organophosphate insecticide that acts by irreversibly binding to acetylcholinesterase.[34] It is approved in the United States as a 0.5 percent lotion for the treatment of head lice. The lotion, containing 78 percent isopropyl alcohol, is flammable. Safety for children younger than 6 years of age has not been established, and it is pregnancy category B.

Permethrin

Permethrin is a synthetic pyrethroid modeled after the natural insecticide found in the pyrethrum flower, *Chrysanthemum cinerariaefolium*. It acts on parasitic nerve cell membranes, causing paralysis and death. It is available over-the-counter as a 1 percent cream rinse, which is left on dry hair for 10 minutes. A single application is often effective against head lice and nits. Due to increasing resistance, however, two applications, 7 to 10 days apart, are generally recommended. There is a lack of safety data for its use in children younger than 2 months of age, and in pregnant and breast-feeding women. Prescription strength permethrin 5 percent cream is also effective against pediculosis capitis resistant to the 1 percent cream, pediculosis pubis, scabies, and mite infestations including cheyletiella.[35] The 5 percent cream is applied to dry skin and hair overnight (8 to 14 hours).



TABLE 222-2
Topical Antiparasitic Agents

Treatment	Group or Composition	Mechanism	Major Side Effects or Contraindications	Use	U.S. Food and Drug Administration Pregnancy Category
Permethrin (1% or 5%)	Synthetic pyrethroid	Inhibits nerve cell sodium ion influx	Itching and stinging on application; contraindicated for infants < 2 mo of age	Lice and scabies; used on clothing as an insect repellant	B
Synergized pyrethrins	Natural botanical	Pyrethrins inhibit nerve cell sodium ion influx; piperonyl butoxide inhibits cytochrome P_{450}	Itching and stinging on application; ragweed or chrysanthemum allergy	Lice	C
Malathion (0.5%)	Organophosphate	Cholinesterase inhibitor	Flammable; not approved for children < 6 yr of age	Lice	B
Crotamiton (10%)	Crotonyl-*N*-ethyl-*O*-toluidine	Unknown	Poor efficacy	Scabies	C
Lindane (1%)	Organochlorine	Cholinesterase inhibitor	May cause seizures, muscle spasms, aplastic anemia; not for use in children < 3 yr, pregnant or breast-feeding women, patients with underlying neurologic disorders, or over broken skin	Lice and scabies	C

TABLE 222-3
Topical Antipruritics

Drug	Group	Mechanism	Precautions	U.S. Food and Drug Administration Pregnancy Category
Diphenhydramine	Antihistamine	Local anesthesia; histamine antagonism	Significant percutaneous absorption; potential sensitization with cross-sensitization to oral diphenhydramine and related compounds	B
Doxepin	Tricyclic antidepressant	Histamine antagonism, interference with neuronal synaptic communication; decreased awareness through production of drowsiness	Potential contact sensitization; significant systemic absorption resulting in drowsiness and drug interactions; contraindicated in patients taking monoamine oxidase inhibitors	B
Menthol	Cyclic terpene alcohol	Counter-irritant. The cooling sensation may be the result of a direct interaction of menthol with cold receptors and/or nerve fibers.[39,44]	—	C when combined with camphor (i.e., Sarna)
Phenol	—	Local anesthesia	Avoid in pregnant women and infants[45]; irritant in diaper area and skin folds	Should be avoided[45]
Pramoxine hydrochloride	Surface anesthetic	Local anesthesia	—	C



Pyrethrins

Pyrethrins are the naturally occurring esters of chrysanthemumic acid. In combination with piperonyl butoxide, it is available as a liquid, gel, oil, aerosol spray, foam, and shampoo. Pyrethrins are neurotoxins, and piperonyl butoxide inhibits pyrethrin metabolism, potentiating the effects of pyrethrins. It is also effective against fleas, mosquitoes, and houseflies. As it is derived from the extract of chrysanthemums, the American Academy of Pediatrics suggests that individuals who are sensitive to chrysanthemums or ragweed should avoid this medication.[36] However, this recommendation is controversial as patch and prick testing of commercially available synergized pyrethrins fail to elicit a response in ragweed-allergic patients.[37] The aerosol spray should never be prescribed to patients with a history of asthma.

ANTIPERSPIRANTS

Aluminum Compounds

Aluminum chloride solutions are typically used for hyperhidrosis in 15 percent to 20 percent solutions in the axilla and up to 30 percent on the palms and soles.[38] The solution is applied for a week at night, when eccrine glands are less active, and then once every 1 or 2 weeks as maintenance therapy.[38] Atrophy of eccrine gland acini results. Use may lead to irritation.[38]

Iontophoresis

Iontophoresis is a procedure in which current is used to transport ions through the skin.[38] The mechanism by which iontophoresis acts to decrease sweating is not fully understood, although it is hypothesized that ion channels in eccrine glands are reversibly disrupted. In an iontophoretic treatment, a hyperhidrotic area of skin to be treated is covered with lukewarm tap water. Electrodes are then inserted into the water and a direct current delivered, usually at 8 to 20 amperages. The amperage is increased until a tingling sensation is experienced and applied for 10 to 20 minutes three to four times weekly. Improvement is typically noted in approximately 2 weeks and full improvement within 1 month. Maintenance treatments once or twice weekly can be helpful thereafter. Anticholinergic agents such as glycopyrronium bromide may be added to the tap water for refractory patients. Adverse effects may include irritation, hyperesthesia, and blisters.[38]

ANTIPRURITIC AGENTS (Table 222-3)

Antihistamines (See Chap. 230)

Doxepin

Menthol

Menthol is a highly lipid-soluble cyclic terpene alcohol, often used with camphor. It is derived from naturally occurring plant oils or prepared synthetically. Menthol is a counter-irritant that, by induction of a cool sensation, "crowds out" the sensation of itch. The cooling sensation may be the result of a direct interaction of menthol with cold receptors and/or nerve fibers.[43,44]

Phenol

Phenol in low concentrations (0.5 percent to 2.0 percent) acts as an antipruritic agent through its anesthetic effect. It is percutaneously absorbed and should be avoided in pregnant women and infants.[45]

Pramoxine Hydrochloride

Pramoxine hydrochloride is effective in cases of mild to moderate pruritus. As with other local anesthetics, it inhibits conduction of nerve impulses by altering the cell membrane permeability to ions. The onset of action of pramoxine products is 2 to 5 minutes.

ASTRINGENTS

In medical practice, astringents are any agent that causes contraction of the tissues, arrest of secretion, or control of bleeding. The U.S. Food and Drug Administration more strictly defines astringent drugs as "a drug product that is applied to the skin or mucous membranes for a local and limited protein coagulant effect."[46]

Aluminum Salts

Aluminum acetate tablets diluted 1:10 to 1:40 (Burow's solution) are an effective astringent and germicidal agent.

TABLE 222-4
Topical Keratolytic Agents

Agent	Dosage	Indications (Selected)	Side Effects/Comments	U.S. Food and Drug Administration (FDA) Pregnancy Category
α-Hydroxy acids	2%–20% as nonpeeling agent, > 20% as peeling agent	Photoaging, scaling, hyperkeratosis, acne, hyperpigmentation	Increased photosensitivity	Not contraindicated in pregnancy[61]
Propylene glycol	40%–60% under occlusion qhs; may be combined with salicylic acid (Keralyt gel) or Lactic acid (Epilyt); 2% vehicle in many preparations	Ichthyosis, hyperkeratosis, psoriasis	Enhances absorption of other topical agents; possible central nervous system effects	—
Salicylic acid	Scaly dermatoses: FDA-approved bid–qid at 1.8%–3.0%; callouses, corns, and warts: FDA-approved at 12%–40% for plaster vehicles, 12.0%–17.6% in collodion-like vehicles[62]	Hyperkeratosis, scaling	Salicylism (headache, drowsiness, and tinnitus). Maximum topical dose of 2 g/24 h	C
Urea	bid–qid in 10%–40% creams and lotions	Xerosis, pruritus, hyperkeratosis, eczema, ichthyosis, psoriasis, nail avulsion	Some patients experience burning; enhances absorption of other topical agents	C
Lactic acid (an α-hydroxy acid)	bid–qid in 5%–12% preparations	Ichthyosis, xerosis, eczema, photoaging	Hypothetical risk of metabolic acidosis	Not contraindicated in pregnancy[61]

Over-the-counter aluminum sulfate and calcium acetate (Domeboro) are available and, when dissolved in water, make a modified Burow's solution. These solutions may be used as wet dressings, compresses, or soaks.

Potassium Permanganate

Potassium permanganate is an oxidizing agent, astringent, antiseptic, and antifungal that may be used to clean or deodorize wounds. Solutions of 1:4000 to 1:16,000 may be used as wet compresses to reduce weeping or at 1:25,000 as a medicated bath. This agent may cause permanent staining of clothing and ceramics and temporary brown or bright purple staining of the skin, which may be removed with a weak solution of oxalic acid or sodium thiosulfate.

Silver Nitrate

Silver nitrate in 0.5 percent aqueous solution is an astringent and antimicrobial that is applied as a wet dressing in the treatment of infected eczema, gravitational ulcers, and other weeping and/or infected skin lesions caused by Gram-positive or Gram-negative bacteria. It is also available in a solid form that may be used as a hemostat. At low concentration (0.5 percent formulation, used clinically) it is bacteriostatic, while bactericidal at higher concentrations (10 percent). As methemoglobinemia has been noted secondary to topical treatment, methemoglobin levels should be followed with prolonged use.[47]

BLEACHING AGENTS

Hydroquinone

Usually used in concentrations of 2 percent to 5 percent, hydroquinone decreases pigmentation by inhibiting tyrosinase, thereby blocking the conversion of dopa to melanin.[48] It may also act by inhibiting DNA and RNA synthesis, degrading melanosomes, and destroying melanocytes. Adverse effects include irritant dermatitis, contact dermatitis, post-inflammatory pigmentation, and cutaneous ochronosis.

Tretinoin (Retinoic Acid)

Tretinoin is thought to inhibit transcription of tyrosinase, leading to decreased pigmentation.[48] It is typically used in concentrations of 0.05 percent to 0.1 percent to treat melasma.[48] Local adverse effects include erythema and desquamation, and post-inflammatory hyperpigmentation has been reported.

Azelaic Acid

Azelaic acid is hypothesized to mediate decreased pigmentation by inhibition of mitochondrial oxidoreductase activity, DNA synthesis, and tyrosinase. Treatment of melasma is typically with concentrations of 15 percent to 20 percent. Side effects include burning, itching, and erythema.

Monobenzyl Ether of Hydroquinone

Occasionally used to depigment skin in individuals with widespread vitiligo, monobenzyl ether of hydroquinone typically causes irreversible depigmentation via free-radical–mediated destruction of melanocytes and competitive inhibition of tyrosinase.[49]

KERATOLYTIC AGENTS (Table 222-4)

Keratolytics are agents that cause keratolysis, or peeling, of the epidermis. At low concentrations, most keratolytics act as humectants, or moisturizing agents.

α-Hydroxy Acids (See Chap. 252)

α-Hydroxy acids (lactic acid, glycolic acid, citric acid, glucuronic acid, and pyruvic acid) reduce the thickness of hyperkeratotic stratum corneum by an incompletely understood mechanism wherein the acids may directly solubilize the protein components of desmosomes or activate endogenous hydrolytic enzymes by changing the pH of the stratum corneum, resulting in keratolysis. Also, by diffusing into the stratum corneum and binding water, the acids act as humectants increasing the water content of the stratum corneum. This decreases the formation of dry scales on the skin surface and allows gentle rubbing of the skin during bathing to mechanically remove cornified tissue. The concentra-



tion of α-hydroxy acid, pH of the preparation, and composition of the base in which they are compounded are important in determining their efficacy. In general, more anhydrous preparations are less irritating, allowing higher concentrations of acid to be tolerated.

Propylene Glycol

Propylene glycol is a humectant, occlusive, and keratolytic agent. It is often combined with other medications to enhance their penetration. A combination of 20 percent propylene glycol with 5 percent lactic acid in a semi-occlusive cream base is used as a highly effective and well-tolerated keratolytic in patients with lamellar ichthyosis and may be used in various other hyperkeratotic diseases.[50]

Salicylic Acid

Salicylic acid has been used in concentrations ranging from 0.5 percent to 60 percent in almost any base. In concentrations of 3 percent to 6 percent, it causes shedding of scales by softening the stratum corneum, dissolving the intracellular matrix, and loosening connections between corneocytes.[51] In concentrations higher than 6 percent, salicylic acid is destructive to tissue. Salicylism has been reported with widespread and prolonged use, especially in children who should apply no more than 2 g (33 mL of a 6 percent solution) to their skin in a 24-hour period. Sensitization is rare, and irritation can be minimized if introduced at lower concentrations.

Urea

Urea is a humectant that is proteolytic at high concentrations. Urea has been added to some topical glucocorticoid preparations to possibly increase their penetration.[52] It is in preparations for dry skin and nail plate destruction.

Lactic Acid

Lactic acid is a humectant and keratolytic that is available at concentrations up to 12 percent. In addition to being a keratolytic, lactic acid increases ceramide production by keratinocytes improving water barrier function.[53]

PSORIASIS THERAPIES (See Chap. 18)

Anthralin

Calcipotriene (See Chap. 18)

A vitamin D analog, calcipotriol inhibits epidermal proliferation, induces epidermal differentiation, and exerts anti-inflammatory effects. Its effectiveness in psoriasis has been demonstrated in systematic reviews.[55,56] Hypercalcemia may occur if more than 100 g is used per week. It is applied initially twice daily, and maximal improvement can be expected within 6 to 8 weeks. Cutaneous irritation may occur in up to 20 percent of patients, particularly when used on the face or in intertriginous areas.

WART THERAPIES

Diphenylcyclopropenone

Diphenylcyclopropenone (DPCP), also known as *diphencyprone*, is a potent contact allergen used in the treatment of viral warts and alopecia areata. It is not available in pharmaceutic quality. Theories for its mechanism of action include alterations in cytokine levels, non-specific inflammation causing wart regression, and binding of DPCP to wart protein inducing a specific immune response.[57] Cross-sensitivity to other chemicals, apart from its precursor, α,α′-dibromodibenzylketone, has not been reported.[57] Many clinics recommend avoiding DPCP in children younger than 12 years of age, although children with alopecia areata less than 12 years old have been successfully treated with DPCP.[57]

Squaric Acid Dibutyl Ester

Squaric acid dibutyl ester is a potent topical sensitizer with a similar mechanism of action and use as DPCP. It requires refrigeration to maintain its potency.

Dinitrochlorobenzene

Dinitrochlorobenzene is a potent sensitizer with a similar mechanism of action and use as DPCP. Although dinitrochlorobenzene is mutagenic in vitro, there is no evidence of carcinogenicity in clinical practice.[57]

5-Fluorouracil (See Chap. 220)

Formaldehyde

Formaldehyde is a powerful disinfectant that causes anhidrosis, desiccation, and sometimes, hypersensitivity when applied to skin. It can cause hardening and fissuring of the skin, so normal surrounding skin should be protected from it by petrolatum, zinc paste, or meticulous application. Individuals with eczema or allergies should avoid formaldehyde as sensitization is problematic being that it is a ubiquitous component of many personal products.

Glutaraldehyde

Mono-, Di-, and Trichloroacetic Acids (See Chap. 252)

Monochloroacetic acid, dichloroacetic acid, and trichloroacetic acid in concentrations of 50 percent to 90 percent are all effective in the management of warts.[59] Trichloroacetic acid is also commonly used at lower concentrations (10 percent to 35 percent) for facial peels (see Chap. 252). Anal and vaginal lesions are occasionally treated with trichloroacetic acid, whereas monochloroacetic acid is most commonly used on plantar warts under salicylic acid plaster occlusion. The application needs to be repeated at 1- to 2-week intervals until complete resolution.

Podophyllin Resin (See Chap. 220)

Podofilox

Podofilox is podophyllotoxin, the active ingredient of podophyllin. It does not contain any of the ingredients responsible for the toxicity of podophyllin. It should not be used during pregnancy unless the potential benefit justifies the potential risk for the fetus.

Salicylic Acid

The effectiveness of salicylic acid in treating warts is thought to be related to keratolysis and local irritation of the skin in which the virus is present. Salicylic acid is the most established agent in terms of efficacy and safety in the treatment of viral warts.[60]

KEY REFERENCES

The full reference list for all chapters is available at www.digm7.com.

4. Hempenstall K et al: Analgesic therapy in postherpetic neuralgia: A quantitative

systematic review. *PLoS Med* **2**:e164, 2005
6. Hahn IH, Hoffman RS, Nelson LS: EMLA-induced methemoglobinemia and systemic topical anesthetic toxicity. *J Emerg Med* **26**:85, 2004
11. Thami GP, Sarkar R: Coal tar: past, present and future. *Clin Exp Dermatol* **27**:99, 2002
22. Balabanova M, Popova L, Tchipeva R: Dyes in dermatology. *Clin Dermatol* **21**:2, 2003
32. Walker GJ, Johnstone PW: Interventions for treating scabies. *Cochrane Database Syst Rev* **3**:CD000320, 2000
33. Burkhart CG, Burkhart CN. Safety and efficacy of pediculicides for head lice. *Expert Opin Drug Saf* **5**:169, 2006
38. Togel B, Greve B, Raulin C: Current therapeutic strategies for hyperhidrosis: A review. *Eur J Dermatol* **12**:219, 2002
44. Yosipovitch G et al: Effect of topically applied menthol on thermal, pain and itch sensations and biophysical properties of the skin. *Arch Dermatol Res* **288**:245, 1996
48. Rendon M et al: Treatment of melasma. *J Am Acad Dermatol* **54**:S272, 2006
56. Mason J, Mason AR, Cork MJ: Topical preparations for the treatment of psoriasis: A systematic review. *Br J Dermatol* **146**:351, 2002
58. Gibbs S, Harvey I: Topical treatments for cutaneous warts. *Cochrane Database Syst Rev* **3**:CD001781, 2006

CHAPTER 223

Photoprotection and Sun Protective Agents

Henry W. Lim

With increased attention to physical fitness and outdoor recreational activities, daily exposure to sunlight is common. Although sun exposure may have beneficial effects such as mood elevation and vitamin D_3 photosynthesis, unwanted effects are well known. Acute effects of sun exposure include sunburn and delayed tanning. Chronic sun exposure is strongly associated with photoaging, actinic keratoses, and squamous cell carcinoma; intermittent sun exposure is associated with basal cell carcinoma and melanoma. Complete avoidance of sun exposure is neither necessary nor practical, nor will it be accepted by the general public. As such, behavioral modification of seeking shade during peak ultraviolet B (UVB) hours of 10:00 A.M. to 4:00 P.M. and the use of photoprotective measures, such as sunscreen, clothing, wide-brimmed hat, and sunglasses, have become the appropriate public health message to deliver. This chapter discusses the currently available, commonly used photoprotective measures.[1]

SUNSCREEN

History

In 1972, the U.S. Food and Drug Administration (FDA) re-classified sunscreens from cosmetics to over-the-counter (OTC) drugs, resulting in more stringent regulation. In 1990s, the need for protection against UVA, as well as against UVB, was recognized and led to development of UVA filters.

Sun Protection Factor

The sun protection factor (SPF) was first developed by an Austrian, Franz Greiter, in 1962 and was adopted by the FDA in 1978.[3] Current FDA guidelines specifically require that products be tested using a solar simulator with emission spectrum covering the wavelength range of 280 to 400 nm, and that the sunscreen product be applied at a concentration of 2 mg/cm^2.

By definition, SPF is the ratio of minimal erythema dose (MED) of a subject's photoprotected skin over the MED of the unprotected skin. Because the end point is erythema, predominately an effect of UVB exposure, the SPF value is mostly a reflection of the protection against UVB radiation. If an individual develops slight erythema after 10 minutes of sun exposure, 30 minutes of unprotected sun exposure result in a 3 MED sunburn, that is, skin that 12 to 24 hours later is bright red and painful. In contrast, when wearing an SPF 15 or 30 sunscreen, the same 30-minute exposure would result in only 20 percent or 10 percent, respectively, of an MED, far less damage than required for induction of delayed erythema (Fig. 223-1).[4] Furthermore, with chronic exposure, the added protection from an SPF 30 sunscreen halves the cumulative UV damage compared to the SPF 15 sunscreen, even though both products prevent sunburn.

The concentration of sunscreen specified for SPF testing (2 mg/cm^2) is the equivalent of 1 oz (30 mL) of sunscreen to cover the entire body surface. Studies of the actual usage of sunscreen by individuals have consistently demonstrated that the amount of sunscreen applied is closer to 0.5 to 0.8 mg/cm^2, so that the actual in-use SPF is significantly lower then the label SPF.[5] The relationship is not linear, and an SPF 30 product (at 2 mg/cm^2) has an SPF of only 3 if applied at 0.5 mg/cm^2 (Fig. 223-2).[6] This situation causes many users to overestimate their degree of photoprotection and also

PHOTOPROTECTION AT A GLANCE



- Photoprotection measures include seeking shade during the peak ultraviolet (UV) B hours of 10 A.M. to 4 P.M. and the use of high sun protection factor broad-spectrum sunscreen, clothing, wide-brimmed hat, and sunglasses.
- New generation photostable UV filters are now available in Europe and many parts of the world and are beginning to enter the U.S. market.
- UV protection factor is a UV protection rating for fabrics. Several chemical treatments can increase the natural UV protection factor.
- Glass that filters out more than 99.9 percent of UV from 300 to 380 nm is now commercially available.
- Sunglass standards, mandatory in Australia and voluntary in the United States, specify a maximum percentage of light allowed to be transmitted and a minimum vertical dimension of sunglasses.





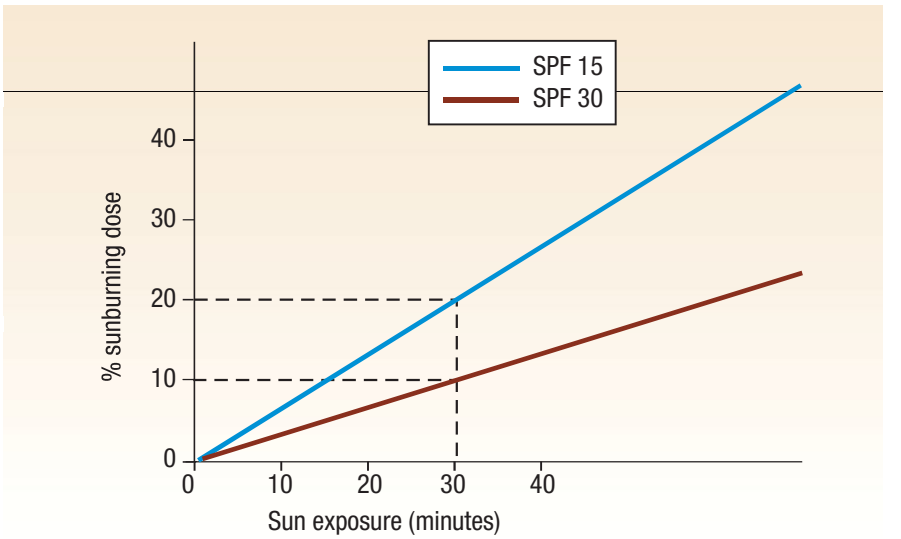

▲ **FIGURE 223-1** Effect of sun protection factor (SPF) 15 and SPF 30 sunscreens on cutaneous sunburning dose in an individual who develops minimal erythema after 10 minutes of sun exposure. After a 30-minute sun exposure, 20 percent of sunburning dose is achieved after the application of SPF 15 sunscreen; after the application of SPF 30 sunscreen, only 10 percent of sunburning dose reaches the skin.

confounds epidemiologic studies that rely on self-reported sunscreen use to judge the efficacy of sun protection in preventing, for example, skin cancer, including melanoma.

In the United States, the latest FDA sunscreen monograph (released May 1999) mandates that sunscreens that carry the label *water resistant* or *very water resistant* must maintain the label SPF value after two or four sequential immersions of the test subjects in water for 20 minutes, respectively.[7] The same monograph indicates that anti-aging claims are subjected to regulatory action as an unapproved new drug, and nonchemical and chemical-free claims are likely considered unacceptable.

Assessment of Ultraviolet A Protection

Although the SPF has now been accepted as the worldwide standard, there is as of yet no consensus on the optimal method of rating protection against UVA. However, several methods that have been published and are in use.[8–10] It should be noted that Australia and Japan have established their own official standards.

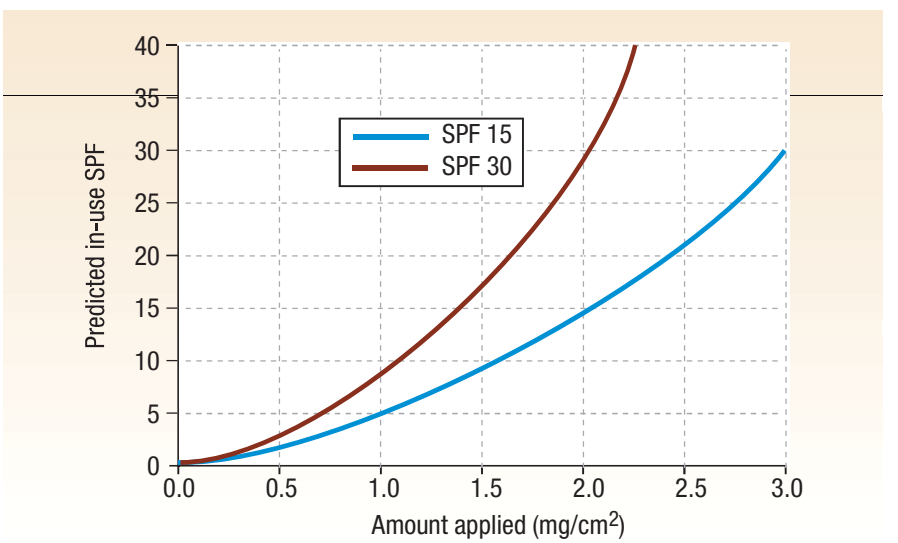

▲ **FIGURE 223-2** Relationship between the amount of sunscreen applied and the in-use sun protection factor (SPF). (Used with permission from J. F. Nash, Procter & Gamble, Cincinnati, OH.)

The Japanese Standard uses the persistent pigment darkening method. In that method, the dose of UVA required to induce persistent pigment darkening observed between 2 to 24 hours after exposure of sunscreen protected skin is compared to that of sunscreen-unprotected skin. The ratio is then expressed as UVA protection factor.[8] The Australian/New Zealand Standard does not require human subject testing and instead requires that an 8-μm layer of the product shall not transmit more than 10 percent of radiation of 320 to 360 nm, or a 20-μm layer of the product shall not transmit more than 1 percent of radiation of 320 to 360 nm. In addition, for products with broad-spectrum claim, their SPF should not be less than 4.

Currently, the European Union (EU) has developed guidelines for UVA protection that have been submitted to the European Committee for Standardization.[10] The guidelines include a UVA protection factor (as determined by persistent pigment darkening method) of $^1/_3$ of the UVB protection (i.e., SPF value) and a critical wavelength of 370 nm. The United States has not yet established a standard.

Immune Protection Factor

SPF for a sunscreen product correlates poorly with its ability to protect against immunosuppression.[11] This has resulted in the development of the concept of immune protection factor (IPF), quantifying the ability of sunscreen products to prevent immunosuppression.[12] Several different methods have been used, including contact sensitization, intradermal injection, and others, all of which are quite laborious and time consuming to perform. Until the time that a simple and reliable method can be easily performed in a large number of test subjects, it is unlikely that IPF will be used in any commercial products. Because IPF is better correlated with UVA protection than with SPF, it is likely that assessment of UVA protection would serve as a surrogate for IPF.

Ultraviolet Filters

There are three different nomenclatures used by the sunscreen industry and regulatory agencies around the world: International Nomenclature of Cosmetic Ingredients (INCI), United States Adopted Name (USAN), and trade name. USAN is the nomenclature used in the FDA Sunscreen monograph. For example, for a widely used UVA1 filter, the INCI name

TABLE 223-1
Ultraviolet (UV) Filters Listed in the U.S. Food and Drug Administration Sunscreen Monograph

U.S. Adopted Name[a]	International Nomenclature of Cosmetic Ingredients	λ_{max} (nm); or Absorption Range	Comment
Organic absorbers: UVB filters			
• PABA derivatives			
• PABA	PABA	283	Stains clothing. Not widely used.
• Padimate O	Ethylhexyl dimethyl PABA	311	Most commonly used PABA derivative. Photounstable.
• Cinnamates			
• Octinoxate	Ethylhexyl methoxycinnamate	311	Most widely used UVB filter. Photounstable.
• Cinoxate	Cinoxate	289	—
• Salicylates			
• Octisalate	Ethylhexyl salicylate	307	Weak UVB absorbers. Improves photostability of other filters.
• Homosalate	Homosalate	306	
• Trolamine salicylate	Time and Extend Application salicylate	260–355	Weak UVB absorbers. Good substantivity—used in water-resistant sunscreens and hair-care products.
• Others			
• Octocrylene	Octocrylene	303	Photostable. Improves photostability of photolabile filters.
• Ensulizole	Phenylbenzimidazole sulfonic acid	310	Water soluble. Enhances sun protection factor of the final product.
Organic absorbers: UVA filters			
• Benzophenones			
• Oxybenzone	Benzophenone-3	288,325	Most commonly used UVA filter. Most common cause of photoallergic contact dermatitis to UV filters.
• Sulisobenzone	Benzophenone-4	366	—
• Dioxybenzone	Benzophenone-8	352	—
• Others			
• Avobenzone	Butyl methoxydibenzoylmethane	360	Photounstable. Enhances the photodegradation of octinoxate.
• Meradimate	Menthyl anthranilate	340	A weak UVA filter. No sensitization reaction reported.
Inorganic absorbers			
• Titanium dioxide	Titanium dioxide	See below[b]	No report of sensitization reaction. Photostable; used to enhance photostability of the final product. Micronized zinc oxide has better UVA1 protection compared to microfine titanium dioxide. Micronized zinc oxide has lower refractive index compared to microfine titanium dioxide and thus appears less white. Commonly coated with dimethicone or silica to maintain effectiveness as sunscreen.
• Zinc oxide	Zinc oxide	See below[b]	

PABA = para-aminobenzoic acid.
[a]This is the name used by the U.S. Food and Drug Administration in the listing.
[b]λ_{max} ranges from visible to UVA to UVB range, depending on the particle size. As titanium dioxide is micronized (10–50 nm in diameter), λ_{max} shifts toward UVB; microfine zinc oxide maintains a flat absorption profile spanning from UVB to UVA.
Modified from Kullavanijaya P, Lim HW: Photoprotection. *J Am Acad Dermatol* **52**:937, 2005 and Department of Health and Human Services, Food and Drug Administration: Sunscreen drug products for over-the-counter human use; Final Monograph. *Federal Register* **64**: 27666, 1999.

is butyl methoxydibenzoylmethane, the USAN is avobenzone, and a trade name is Parsol 1789. In this chapter, when available, the USAN nomenclature is used.

The term *sunblock* is commonly used to refer to sunscreens and their active ingredients, but it is a misnomer. The FDA Sunscreen monograph does not sanction the term. All sunscreen active ingredients are filters that absorb part of the incident UV radiation, but a portion of the radiation is always transmitted. Microfine inorganic filters additionally reflect and scatter UV radiation.

In the United States, all active sunscreen ingredients are regulated by the FDA as OTC drugs.[7] Only UV filters listed in the Sunscreen monograph issued by the FDA may be marketed in the United States (16 active ingredients; Table 223-1),[3] unless they have been approved as a final product by the FDA through the very expensive and demanding new drug application (NDA) process. The two latest UVA filters available in the U.S. market, avobenzone and ecamsule (Mexoryl SX™), both underwent the NDA process for their approval.

In 2002, the FDA instituted the Time and Extend Application (TEA) process as an alternate to filing the NDA.[13] With the TEA process, for the first time, data generated outside the United States can be used for the application, provided that the sunscreen product has been marketed for OTC purchase for a minimum of 5 years in the country where testing was performed. In the EU, South America, many Asian countries, and Africa, sunscreens are regulated as cosmetics, resulting in a simpler and more expeditious approval process compared to the United States, usually resulting in approval within 1 to 2 years of filing. In Australia and Japan, data on a complete formulation are required in addition to the data required by the EU approval process.

UV filters can be divided into two categories, *organic* and *inorganic*. These terms are recommended by FDA to replace the term *chemical* and *physical* filters, respectively. Organic filters can be subdivided further into UVB filters and UVA filters. The most widely used UVB filters worldwide is octinoxate (ethylhexyl methoxycinnamate), whereas the most widely used UVA filter is oxybenzone (benzophenone-3). Currently, unless products are approved as new drugs



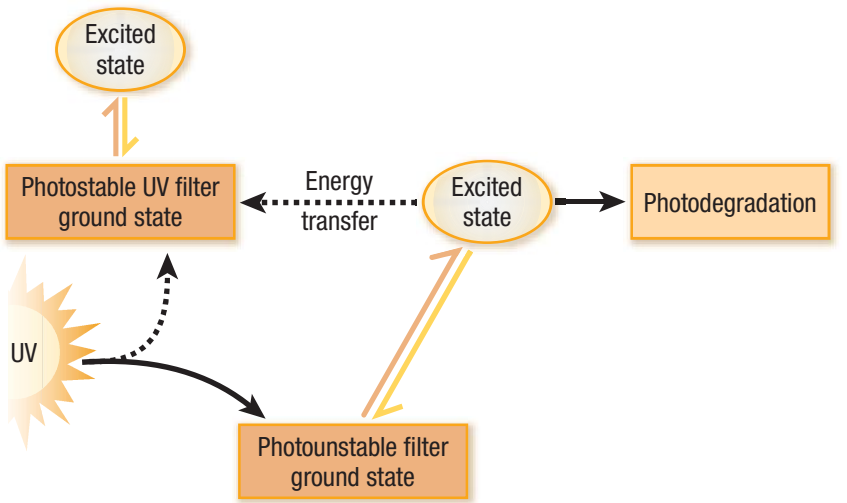



▲ **FIGURE 223-3** Photostabilization of photounstable filter. Photostabilizing agent or photostable/ultraviolet (UV) filter absorbs a portion of incident photons, hence decreasing the number of photons absorbed by the photounstable filter. Photostabilizing agent/ultraviolet filter also serves as a receptor for energy transfer from the excited-state photounstable filter, facilitating the return of the latter to the ground state.

through the NDA process, the FDA guidelines do not allow avobenzone to be combined with inorganic filters (titanium dioxide, zinc oxide).

ULTRAVIOLET FILTERS AND PHOTOSTABILITY Avobenzone (butyl methoxydibenzoylmethane; Parsol 1789) is an excellent UVA1 filter but is photounstable and degrades during UV exposure. There are several other UV filters with this characteristic, including UVB filters padimate O [ethylhexyl dimethyl para-aminobenzoic acid (PABA)] and octinoxate (ethylhexyl methoxycinnamate).[14] It is possible to incorporate other agents to increase the photostability of the final product (Fig. 223-3). Most of these agents are photostable UV filters that absorb photons to minimize the effect on the photounstable UV filter; they also serve as receptor molecules for energy transfer (see Fig. 223-3).[5,15]

CURRENT STATUS OF ULTRAVIOLET FILTER APPROVAL

NEW DEVELOPMENTS

ULTRAVIOLET FILTERS AND PHOTOALLERGY Oxybenzone (benzophenone-3) is the most common cause of UV filter photoallergy. In contrast, the most widely used UVB filter, octinoxate (ethylhexyl methoxycinnamate), is rarely a photoallergen.[18] It should be noted that although UV filters are the most common cause of photoallergy in many studies in the United States and the United Kingdom, considering the number of individuals using sunscreens, the prevalence of photoallergy to UV filters is very low (well less than 1 percent). No photoallergy has been reported with inorganic UV filters (titanium dioxide and zinc oxide), the organic filter meradimate (mentyl anthranilate), or the new photostable organic filters listed in eTable 223-1.3.[19]

Sunscreen Use in Children

Because of the concern about percutaneous absorption of sunscreens, the 1999 FDA sunscreen monograph recommends that use of sunscreens in children under the age of 6 months should be decided by their physicians.[7] For this group of patients, it is prudent to use other means of photoprotection such as clothing.[5]

Controversies

MELANOMA It has been suggested that sunscreen use may be associated with an increased incidence of melanoma. However, meta-analysis of over 9000 patients from 11 case control studies and a quantitative review of all articles published from 1966 to 2003 that reported information on sunscreen use and melanoma in humans indicated that there is no creditable evidence that sunscreen use is a risk factor for the development of melanoma.[20,21]

VITAMIN D Another area of controversy is the concern that photoprotection may compromise health by decreasing serum vitamin D level, specifically the level of the highly variable "storage form" (25-OH-vitamin D) that is the precursor to the tightly regulated active form [1, 25-$(OH)_2$-vitamin D)]. Exposure to the UVB spectrum of sunlight converts 7-dehydrocholesterol in the skin to pre–vitamin D and thus allows its subsequent hydroxylation by the liver and kidney to the active form of the vitamin. Another source is dietary intake, although only a few naturally occurring foods contain a significant amount of vitamin D [e.g., salt water fish (herring, salmon, and sardines), cod liver oil, and egg yolk]. In the United States, milk, orange juice, margarine, butter, cereals, and chocolate mixes are fortified with vitamin D. Last, vitamin D supplements are readily available as vitamin D_3 (cholecalciferol, the form produced in skin) or more often as D_2 (ergocalciferol), which functions identically at the cellular level but may yield a lower serum level following a single bolus administration, compared to vitamin D_3.[22]

It has been demonstrated that application of an SPF 8 sunscreen blocks the increase in serum vitamin D level after exposure to a MED of simulated sunlight,[23] as expected. However, studies of more than 100 older individuals regularly using an SPF 17 sunscreen over a summer period to sufficiently decrease their risk of actinic keratoses revealed no difference in the increase in the serum vitamin D level compared to the placebo sunscreen group.[24] Even extreme photoprotection has been demonstrated to permit normal vitamin D levels. Specifically, a study of eight patients with xeroderma pigmentosum who scrupulously avoided all sun exposure, throughout a 7-year follow-up, showed serum vitamin D levels in the low normal range.[25] Furthermore, a 2-year follow-up study of individuals regularly using an SPF 15 sunscreen showed that although they had slightly lower serum vitamin D levels than controls who did not use sun protection, none of the subjects had abnormal parathyroid hormone or calcium levels,[26] which are markers of vitamin D insufficiency.

Epidemiologic data suggest that having high serum vitamin D levels decreases the risk of bone fractures, colorectal and pancreatic cancers, and multiple myeloma.[27,28] However, two randomized, prospective controlled studies involving over 36,000 post-menopausal women failed to show the beneficial effect of vitamin D supplementation over at least 7 years on bone fractures or on the development of colorectal cancer.[29,30] There

was also no correlation between these health outcomes and serum vitamin D levels or estimated sun exposure.[29,30] The benefit of high serum vitamin D levels, therefore, remains controversial.

Whatever the ideal vitamin D level is, the action spectrum for cutaneous vitamin D synthesis (i.e., UVB) is the same as for DNA damage and photocarcinogenesis. For those individuals who are concerned or are at risk for vitamin D insufficiency, a balanced diet and vitamin D supplementation appear to be the most appropriate steps to maintain adequate serum vitamin D level.[33,34] This recommendation applies to elderly individuals who are homebound or dark-skinned individuals with modest sun exposure,[31–34] as well as to children and young adults if there is any belief that their long-term health might benefit from having higher than currently recommended normal levels of vitamin D.

NANOPARTICLES Metal oxide inorganic UV filters, titanium dioxide and zinc oxide, have been widely used in microfine form. This is to minimize the reflection of visible light, thus enhancing the cosmesis of the final product. Nanoparticles are defined as particles less than 100 nm. Currently, 70 percent of sunscreens with titanium dioxide and 30 percent with zinc oxide use a nanoparticle form. In vitro, these particles can induce free radical formation in the presence of light, resulting in cell damage. Although the Australian Government Therapeutic Goods Administration concluded that the weight of current evidence shows that these particles remain on the surface of the skin,[35] continued monitoring is warranted.

TABLE 223-2
Factors Affecting Sun Protection of Garments

- Style of garment
- Number of layers
- Fabric thickness
- Type of fibers (polyester > wool, silk, nylon > cotton, rayon)
- Stretching
- Laundering
- Wetness
- Chemical treatments

Modified from Lim HW, Hönigsmann H: Photoprotection, in *Photodermatology*, edited by Lim HW, Hönigsmann H, Hawk JLM. New York, Marcel Dekker, 267, 2007.

GARMENTS

Clothing as a Photoprotective Measure

Clothing, including hats, is an integral part of photoprotection. Compared to sunscreens, they are easy to put on, durable, and a social necessity. However, in most cultures, there are body sites that are infrequently covered by clothing, such as the face, the V area of neck, and dorsal hands. During hot (and sunny) weather, garments tend to cover even less skin.

Ultraviolet Protection Factor

UV protection factor (UPF) is the in vitro measurement used in many countries, including the United States, to quantify the ability of fabrics to protect against UV. Because erythema is the factor considered, similar to the SPF, UPF is a better reflection of UVB than UVA protection.[36] In the United States, garments are classified as having good protection (UPF 15 to 24), very good protection (UPF 25 to 39), or excellent protection (UPF 40 to 50+).

As summarized in Table 223-2, several factors affect the UV protectiveness of garments.[1,37] UV absorbance of fibers is measured using fabrics that consist of a single type y fiber (e.g., 100 percent cotton, 100 percent polyester).[38] Polyester fibers are the best UV absorber, whereas cotton and rayon are the poorest. Laundering garments made from cotton or rayon increases the UPF because of shrinkage, causing a decrease in the porosity of the fabrics. Wetness decreases the UV-protection of a light colored (especially white) garment. This is because the protective effect of white cotton fabric is mainly due to light-scattering at the fiber/air interface: When wet, the fabric no longer scatters light, and the garment becomes more transparent to both UV and visible light. In contrast, dark-colored garments absorb light and thus do not become see-through or less UV protective when wet. Chemical treatments include the incorporation of UV absorbers to the fabrics during the manufacturing (mill finishing) process, addition of UV absorber as laundry additives, and addition of optical whitening agents widely incorporated in many laundry detergents in the United States and Europe. These latter agents absorb UV radiation at 360 nm and convert it to visible light wavelength of 430 nm; therefore, these agents decrease UV transmission through the fabric. The emission of visible light from the fabric makes the fabric look "brighter."

It is a common misperception that color of the fabric linearly correlates with the UPF. In experiments with cotton fabric with UPF of 4.1, red fabric with the same dye concentration had UPF of 41, 31, and 20, depending on the type of red dye used. A yellow fabric had UPF of 25, whereas a violet one had UPF of 24.[37]

TABLE 223-3
Types of Glass

TYPE	T_{VIS}	T_{UV}	COMMENT
Clear glass	> 90%	> 72%	
Reflective glass	19%	17%	Mirror-like appearance. Used in commercial buildings.
Low-emissivity glass	71%	20%	Reduces loss of generated heat and minimizes solar heat gain. Used in residential and commercial buildings.
Laminated glass	79%	< 1%	Two pieces of glass are bound to a plastic interlayer to prevent fragments from falling free if broken. Reduces sound transmission. Used for car windshields and in airports, museums, large public spaces.
Spectrally selective and UV-blocking insulating glass	69%	< 1%	Reduces heat loss/gain. Blocks > 99% of UV light (up to 380 nm).
ClimaGuard SPF glass	69%	< 0.1%	Reduces loss of generated heat and minimizes solar heat gain. Used in residential buildings.

SPF = sun protection factor; T_{UV} = transmission in the UV range (assessed from 300–380 nm); T_{vis} = transmission in the visible light range (assessed from 400–780 nm); UV = ultraviolet.
Modified from Tuchinda C, Srivannaboon S, Lim HW: Photoprotection by window glass, automobile glass and sunglasses. *J Am Acad Dermatol* **54**:845, 2006. Data provided by Guardian Industries Corp. (Auburn Hills, MI).



GLASS

Glass Used in Buildings and Cars

It is well known that UVB is effectively filtered by glass (reviewed in ref. 39). Many types of glass now also have very good UVA2 and UVA1 protection (up to 380 nm; Table 223-3). It should be noted that windshields of cars are made of laminated glass, which allows less than 1 percent of UV (300 to 380 nm) to pass through, whereas side and rear windows are usually made from non-laminated glass that allows a higher level of UVA transmission. This explains why common sites of involvement for patients with a photodermatosis are the side of the face and forearm closest to the side window of the car.[40]



Sunglasses

Australia has led the world in sunglass standards, developing the world's first national mandatory standard for sunglasses for general use in 1971; it was last revised in 2003 (AS/NZS 1067:2003).[41] The amount of light transmitted through the lens is called *luminous transmittance*; a lens with 20 percent luminous transmittance would allow 20 percent of the light to pass through. Lenses are grouped into five categories (0 to 4), ranging from fashion sunglasses (lens category 0) to special-purpose sunglasses for very high sun glare reduction (lens category 4). Category 0 lenses are allowed to have luminous transmission of 80 percent to 100 percent, whereas category 4, 3 percent to 8 percent. The Standard requires that the UVB transmittance be 5 percent of the luminous transmittance (i.e., if the luminous transmittance is 20 percent, then the allowed UVB transmittance is 5 percent of 20 percent, which is 1 percent); therefore, for lenses with luminous transmittance of 20 percent, this Standard mandates 99 percent of UVB to be blocked out. The UVA transmittance for lens categories 0 to 2 must be no more than the luminous transmittance, while for lens categories 3 and 4, 50 percent of the luminous transmittance. The Standard also mandates that the minimum vertical diameter for adult sunglasses is 28 mm, and for children, 24 mm.

The U.S. sunglass standard was first published in 1972 by the American National Standards Institute and last revised in 2001 (ANSI Z80.3-2001). However, unlike the Australian Standard, compliance with the U.S. Standard is voluntary and is not followed by all manufacturers[42]; therefore, consumers share the burden of responsibility. The U.S. Standard classified sunglasses as Normal Use (e.g., from home to the car to the office) or High or Prolonged Exposure (e.g., at the beach, fishing, skiing). Lenses are classified for intended function as special, dark, general purpose, or cosmetic tint. For example, for general purpose sunglasses, ANSI Z80.3 requires less than 1 percent of the wavelengths below 310 nm to be transmitted. No minimum vertical dimension of the sunglasses is stated in the U.S. Standard.

OTHER AGENTS

KEY REFERENCES

The full reference list for all chapters is available at www.digm7.com.

1. Lim HW, Hönigsmann H: Photoprotection, in *Principles and Practice of Photodermatology*, edited by Lim HW, Hönigsmann H, Hawk JLM. New York, Marcel Dekker, 267, 2007
5. Kullavanijaya P, Lim HW: Photoprotection. *J Am Acad Dermatol* **52**:937, 2005
16. Tuchinda C et al: Novel emerging sunscreen technologies. *Dermatol Clinics* **24**:105, 2006
33. Lim HW et al: Sunlight, tanning booths, and vitamin D. *J Am Acad Dermatol* **52**:868, 2005
34. Wolpowitz D, Gilchrest BA: The vitamin D questions: How much do you need and how should you get it? *J Am Acad Dermatol* **54**:301, 2006
37. Hatch KL, Osterwalder U: Garments as solar ultraviolet radiation screening materials. *Dermatol Clin* **24**:85, 2006
39. Tuchinda C, Srivannaboon S, Lim HW: Photoprotection by window glass, automobile glass and sunglasses. *J Am Acad Dermatol* **54**:845, 2006

CHAPTER 224

Special Considerations for Topical Therapy of Ethnic Skin

Roopal V. Kundu

According to the U.S. 2000 census, 29 percent of the population is not white, and it is estimated that 50 percent will be of non-European descent by 2050.[1] Ethnic skin, also referred to as *skin of color*, is primarily composed of Fitzpatrick skin types V–VI and encompasses many racial and ethnic groups, including African Americans, Asians, and Hispanics. Persons of skin type IV may also fit into this category, encountering similar problems as those of darker skin types. Treatment of these patients requires knowledge of adverse reactions in darker skin and awareness of cultural issues specific to these patient populations.[2] The increased melanin in skin of patients with color is associated with increased susceptibility to post-inflammatory hyperpigmentation (Figs. 224-1 and 224-2) as well as hypo-



▲ **FIGURE 224-1** Acne with post-inflammatory hyperpigmentation on the cheek of an African American woman.

TOPICAL THERAPY OF ETHNIC SKIN

AT A GLANCE



- Ethnic skin, also known as *skin of color*, is primarily composed of Fitzpatrick skin phototypes V–VI.
- Skin with abundant epidermal melanin is susceptible to post-inflammatory hyperpigmentation.
- Optimal treatment requires knowledge of adverse reactions in darker skin and awareness of cultural issues specific to these patient populations.
- Hydroquinone is the mainstay of therapy for post-inflammatory hyperpigmentation.
- Strict photoprotection is essential.

pigmentation.[1] Post-inflammatory hyperpigmentation also occurs in Asian skin (Fig. 224-3). Therefore, any topical therapy that can alter pigmentation or irritate the skin needs to be used with caution. Optimal management of common conditions in patients with skin of color may include procedures like chemical peels[3] (see Chap. 252), Q-switched laser therapy[4] (see Chaps. 240 and 253), and microdermabrasion (see Chap. 252). However, this section will focus primarily on the topical treatment options available for dark skin.



▲ **FIGURE 224-2** Pseudofolliculitis barbae and lichen simplex chronicus with post-inflammatory hyperpigmentation on the chin and neck.

TOPICAL GLUCOCORTICOIDS

Topical corticosteroids are generally well tolerated in ethnically different skin. Low-potency steroids (i.e., classes V–VII) (see Chap. 216) infrequently cause hypopigmentation. In contrast, use of high-potency topical corticosteroids (i.e., classes I and II) can depigment normal skin within several weeks (Fig. 224-4). Fortunately, repigmentation of affected skin usually occurs if the topical steroid is discontinued promptly. Because of the known depigmenting effects, however, topical corticosteroids have been abused in some ethnic populations to lighten and bleach skin. Class I and II corticosteroids are frequently available over the counter in many ethnic stores in large metropolitan areas, despite U.S. Food and Drug Administration (FDA) regulations.

TOPICAL RETINOIDS (See Chap. 217)

Tretinoin

Irritation from topical retinoids, so-called *retinoid dermatitis*, can lead to post-inflammatory hyperpigmentation (Fig. 224-5). Hyperpigmentation can also occur without the clinical irritation because erythema is not as easily seen in darker-skinned individuals. However, when used carefully, topical tretinoin is well tolerated in patients with skin of color.[5–7] Topical retinoids may have an anti-inflammatory effect[8] and may be effective in the treatment of post-inflammatory hyperpigmentation,[5] photodamage,[6,9] melasma,[7,10] and acne. Any irritation associated with retinoids can be lessened by careful vehicle choice. A cream is preferred over a gel in skin of color because it is less drying. A microsponge delivery system of tretinoin is



▲ **FIGURE 224-3** Diffuse tinea corporis and post-inflammatory hyperpigmentation in an Asian American man. Large, arcuate, hyperpigmented patches with excoriations and erythema.

also now available in 0.1 percent and 0.04 percent concentrations and is less irritating to the skin than standard preparations. Patients should be instructed to apply the retinoid every other night for at least 2 weeks, then every night thereafter, as tolerated.

Adapalene

Adapalene is a synthetic retinoid that has selective affinity for retinoid X receptors β and γ.[11] Because the risk for retinoid dermatitis appears to be less than with tretinoin, adapalene may be especially effective in black[12] and Asian patients for the treatment of acne vulgaris.[13] Two different formulations, cream and gel, are available.

Tazarotene

Tazarotene is a synthetic retinoid whose metabolite selectively binds to retinoid X receptors β and γ.[14] Tazarotene is effective in psoriasis, acne vulgaris, and photodamaged skin. In darker racial ethnic groups, compared to vehicle, once-daily application of tazarotene produced a significantly greater reduction in acne lesions as well as improvement in post-inflammatory hyperpigmentation.[15] The drug was well tolerated, with limited dryness, erythema, or peeling. Topical tazarotene is available in cream and gel formulations.

Retinol

All-*trans*-retinol, or vitamin A_1, is metabolized to the active retinoid compound, tretinoin, in skin.[16] Retinol is used at a concentration of 0.1 percent to 1.0 percent





◀ **FIGURE 224-4** Hypopigmentation of the dorsal feet at sites of chronic topical corticosteroids application adjacent to sites of post-inflammatory hyperpigmentation secondary to dermatitis. (Used with permission from R. M. Halder, MD.)



in the United States in many over-the-counter products and is less irritating than tretinoin,[16] but has not been formally studied in darker-skinned individuals.

TOPICAL ANTIBIOTICS (See Chap. 218)

Topical antibiotics are well tolerated and effective in pigmented skin. Lotions and creams may be less irritating than gel formulations. However, gels are frequently associated with enhanced efficacy. Erythromycin and clindamycin are commonly used in the treatment of acne. Their anti-inflammatory effects may help reduce scarring and hyperpigmentation in skin of color. These agents are commonly used in combination with benzoyl peroxide to slow the development of antibiotic resistance.[17]

OTHER TOPICAL AND KERATOLYTIC AGENTS (See Chap. 222)

Acne Therapies (See Chap. 78)

Because an important goal in the treatment of acne in patients with darker skin is the prevention of post-inflammatory hyperpigmentation[18] (see Fig. 224-1), special attention should focus on the patient's propensity for developing irritation, especially when using combination therapy. Strategies to improve the tolerability of topical acne agents include initial low-dose therapy, slow upward titration, and alternate day dosing. Daily moisturization and avoidance of astringents, toners, and harsh soaps or cleansers are also important in preventing unwanted side effects of therapy.[19,20] Patients should be closely monitored for irritant dermatitis that may, itself, cause post-inflammatory hyperpigmentation. The influence of culture must also be recognized by discussing homeopathic practices, such as the common use of alcohol or witch hazel, both very drying, to cleanse the skin in the African American community.

AZELAIC ACID Azelaic acid is a naturally occurring non-phenolic dicarboxylic acid isolated from cultures of *Pityrosporum ovale*. It is most commonly used in the treatment of acne, although its off-label uses include the treatment of hyperpigmentary disorders[21] such as melasma[22] and post-inflammatory hyperpigmentation. A 24-week study in South America found that a 20 percent concentration of azelaic acid was equivalent to 4 percent hydroquinone in the treatment of melasma.[23] However, azelaic acid may cause more local irritation than hydroquinone. Azelaic acid is available as a 15 percent gel and a 20 percent cream formulation.

BENZOYL PEROXIDE Benzoyl peroxide is commonly used for the treatment of acne vulgaris. Not only can it irritate the skin but it can also have a drying effect and can lead to either post-inflammatory hyperpigmentation or hypopigmentation in skin of color. It has been shown that a 2.5 percent concentration of benzoyl peroxide is as effective in lowering the inflammatory lesion count as 5 percent and 10 percent concentrations, while producing less erythema and desquamation.[24] Special attention should also be paid to the vehicle, which can also lead to drying and irritating effects. The alcohol-based gels seem to be the most irritating; therefore, starting with creams, lotions, or water-based gels is recommended.

Keratolytic Agents

α-HYDROXY ACIDS α-Hydroxy acids (lactic acid, glycolic acid, citric acid, glucuronic acid, and pyruvic acid) are penetration enhancers found in a variety of natural products, including cane sugar, fruits, and yogurt. These agents reduce the thickness of hyperkeratotic stratum corneum by reducing corneocyte adhesion and are effective in treatment of disorders of keratinization, photoaging, and hyperpigmentation. They are also used as cleansers, moisturizers, and chemical peeling agents.[25] Therapy should begin at low concentrations, with a gradual increase in the concentration and frequency in use of the formulation to limit side effects.

β-HYDROXY ACID Salicylic acid is the most commonly used β-hydroxy acid. Used at concentrations less than 6 percent, it causes dyshesion of the stratum corneum, and hence, reduces hyperkeratosis. At higher concentrations, salicylic acid is destructive to tissue. Salicylism has been reported with widespread prolonged topical use of salicylic acid, especially in children. Local irritation is common but can be minimized if the agent is introduced at lower concentrations. It is available commercially as a superficial peeling agent in solution form at concentrations of 20 percent and 30 percent. Salicylic acid chemical peels have been found to be safe and effective in darker-skinned patients.[26]

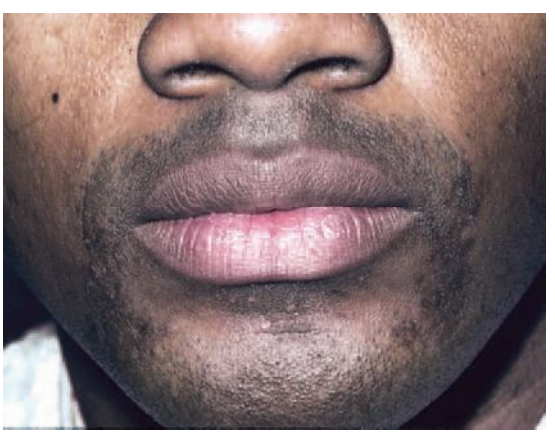

◀ **FIGURE 224-5** Perioral hyperpigmentation secondary to retinoid dermatitis in an African American man treated for acne. (Used with permission from R. M. Halder, MD and reproduced with permission from Halder RM: *Dermatology and Dermatologic Therapy of Pigmented Skins*. CRC Press, Boca Raton, 2006.)

DEPIGMENTING AGENTS

Hyperpigmentation can have a negative psychological impact on a patient's self-esteem, and treatment is therefore critical. Treating the underlying cause of post-inflammatory hyperpigmentation and strict photoprotection are important in preventing further dyschromia. Sun protection is not commonly a daily practice in persons of ethnically different skins. Moreover, in many cultures, a deep, rich tan is considered a symbol of health. It is essential to educate persons of skin of color about the exacerbating effect of sun exposure on dyschromia. Hydroquinone-based agents are currently the gold standard for treating hyperpigmentation. Other treatment modalities include cosmetic cover-up, topical retinoids, azelaic acid, chemical peels, and Q-switched laser therapy.[27,28] There are also several cosmetic "skin brightening agents" (non–U.S. FDA approved) commercially available in the United States, including arbutin, kojic acid, licorice extract, and niacinamide.[27–30]

Pigmentary, or melanin, incontinence is a unique form of post-inflammatory hyperpigmentation that is not responsive to topical depigmenting agents. Histologically, it is seen as an accumulation of melanin and melanophages in the upper dermis. Treatment modalities such as Q-switched laser therapy have been used with limited success.[4,31]

Hydroquinone

Hydroquinone is a hydroxyphenolic compound used extensively as a skin-bleaching agent. It inhibits the conversion of dihydroxyphenylalanine to melanin by inhibiting the tyrosinase enzyme.[30,32] Other possible mechanisms of action include the destruction of melanocytes, degradation of melanosomes, and the inhibition of the synthesis of DNA and RNA.[33] It is an effective depigmenting agent in many disorders of hyperpigmentation, including melasma and post-inflammatory hyperpigmentation, lentigines, and freckles. Hydroquinone has been combined with topical retinoids and glucocorticoids to enhance efficacy. Hydroquinone is available in over-the-counter concentrations (less than 2 percent) and prescription formulations (3 percent and 4 percent; Table 224-1). Higher concentrations (5 percent to 10 percent) may be compounded to treat severe post-inflammatory hyperpigmentation or melasma but may be unstable and irritating. Vitamin C, retinoids, and α-hydroxy acids (see α-Hydroxy Acids) may be used to increase penetration and enhance efficacy.

Adverse reactions include irritant and allergic contact dermatitis and nail discoloration. Post-inflammatory hyperpigmentation may occur from contact dermatitis. Reversible hypopigmentation in the form of a halo around the treated area of hyperpigmentation is often seen in dark-skinned patients. Individuals must be carefully counseled to use hydroquinone products twice daily only and to limit treatment to affected areas only to prevent this adverse effect.

Prolonged use of hydroquinone at concentrations greater than 6 percent over large body surface areas may cause local ochronosis.[34,35] It has been more commonly seen in African women[34,35] and infrequently reported in the United States. However, products with high concentrations of hydroquinone can be obtained illegally. Ochronosis is characterized by reticulated, sooty hyperpigmentation typically of the face and is often permanent. Treatment is difficult, but some cases may respond to topical retinoids and topical corticosteroids and/or a series of superficial salicylic acid chemical peels.[36] Permanent depigmentation due to melanocyte destruction may also occur. In



TABLE 224-1
Commonly Used Depigmenting Agents

Drug[a]	Active Ingredient	Sunscreen	Retinol	Other Ingredients	Availability
Aclaro™ Topical Emulsion	4% HQ	No	No		Prescription
Alphaquin™ HP	4% HQ	Yes	No		Prescription
Ambi Skin Tone	2% HQ	Yes	No		OTC
Azelex® Cream	20% azelaic acid	No	No		Prescription
Black and White Bleaching Cream	2% HQ	No	No		OTC
Black Opal Fade Cream	2% HQ	No	No		OTC
Claripel™ with Sunscreens	4% HQ	Yes	No	Coenzyme Q10	Prescription
Eldopaque®	2% HQ	No	No		OTC
Eldoquin Forte®	4% HQ	Yes	No		Prescription
Esoterica® with Sunscreen	2% HQ	Yes	No		OTC
Finacea™ Gel	15% azelaic acid	No	No		Prescription
Glyquin XM™	4% HQ	Yes	No	10% GA, antioxidant	Prescription
Glyquin®	4% HQ	Yes	No	10% GA	Prescription
Lustra-AF®	4% HQ	Yes	Retinol 0.3%	Antioxidants	Prescription
Melpaque® HP	4% HQ	Yes	No		Prescription
Melquin® HP	4% HQ	No	No		Prescription
Nuquin® HP	4% HQ	Yes	No		Prescription
Palmers® Skin Success	2% HQ	Yes	No	GA, antioxidants	OTC
Porcelana Fade Cream	2% HQ	Yes	No		OTC
Solaquin Forte®	4% HQ	Yes	No		Prescription
Tri-Luma® Cream	4% HQ	No	Tretinoin 0.01%	Fluocinolone 0.01%	Prescription

GA = glycolic acid; HQ = hydroquinone; OTC = over-the-counter.
[a]It is the policy of this book not to use trade names. In this particular case, the editors have departed from this policy to help the reader distinguish between the different preparations.
Source for prescription drugs, http://www.drugstore.com (May 2006); for OTC drugs, national retail drugstore in Chicago, Illinois (May 2006). These sources also provide information on price.

August 2006, the FDA proposed a rule change to restrict marketing of over-the-counter skin bleaching products containing hydroquinone. The FDA cited hydroquinone as having been shown to cause ochronosis after use of concentrations as low as 1 percent to 2 percent, along with new evidence of carcinogenicity in rats and mice. Therefore, the FDA stated that it cannot rule out the potential carcinogenic risk from topically applied hydroquinone in humans. The FDA proposed that hydroquinone in skin bleaching products be restricted to prescription use only, and users of such products should be closely monitored under medical supervision.



Combination Therapy

In 1975, Kligman and Willis reported efficacy of 5 percent hydroquinone, 0.1 percent tretinoin, and 0.1 percent dexamethasone in hydrophilic ointment in the treatment of melasma, ephelides, and post-inflammatory hyperpigmentation.[37] This combination was superior to the aforementioned agents used as monotherapy. In this formulation, tretinoin facilitates the epidermal penetration of hydroquinone and reduces corticosteroid-induced atrophy. The corticosteroid reduces the irritation caused by either hydroquinone and/or tretinoin. A newer formulation consisting of 4 percent hydroquinone, 0.05 percent tretinoin, and 0.01 percent fluocinolone acetonide in a cream base[38] is now available.

Monobenzylether of Hydroquinone

Monobenzylether of hydroquinone (monobenzone) is a topical phenolic agent that is typically used as a permanent depigmenting agent of noninvolved skin in patients with extensive vitiligo, resulting in greater than 50 percent pigment loss.[39,40] Areas of residual pigment can be treated with 10 percent to 20 percent monobenzone twice daily.[41] Depigmentation is usually achieved only after 6 months and usually requires periodic maintenance therapy to prevent repigmentation in areas of incomplete melanocyte destruction. Complications are frequent and include contact dermatitis, satellite depigmentation at distal sites, "consort vitiligo" in close contacts of the patient, and risk of sunburn after sun exposure.[40] Rigorous use of sun protection is mandatory. Patients must be able to accept the permanence of melanocyte loss.

Kojic Acid

Kojic acid [5-hydroxy-2-(hydroxyl methyl)-4-pyrone] is a naturally occurring hydrophilic fungal derivative produced by many species of *Acetobacter*, *Aspergillus,* and *Penicillium*[30] used in the treatment of hyperpigmentation disorders. Through its chelation of copper, it inhibits tyrosinase[9] with efficacy similar to 2 percent hydroquinone. Kojic acid has been used commonly in Japan, but the use has been limited because of its potential for causing contact dermatitis.[42] It is available over-the-counter in 2 percent to 4 percent concentrations.

Arbutin

Arbutin is a β-D-glucopyranoside derivative of hydroquinone. It is a naturally occurring, plant-derived compound that has been used for disorders of hyperpigmentation, although no controlled trials have been performed. It competitively inhibits tyrosinase and demonstrates a dose-dependent reduction in tyrosinase activity and melanin content in melanocytes. Higher concentrations may lead to paradoxical hyperpigmentation.[43] Arbutin is available in 3 percent concentrations in the United States.

Licorice Extract

Licorice extract is not currently available in the United States but is used in other parts of the world, particularly in Egypt. Its mechanism of action is similar to that of kojic acid. The main active component, the hydrophobic fraction glabridin, decreases tyrosinase activity.[44] It is available in cosmetic products only.[45]

Niacinamide

Niacinamide is the physiologically active amide of niacin (vitamin B_3), which may lighten skin by inhibiting melanosome transfer from melanocytes to keratinocytes.[46]

KEY REFERENCES

The full reference list for all chapters is available at www.digm7.com.

1. Taylor SC: Skin of color: Biology, structure, function, and implications for dermatologic disease. *J Am Acad Dermatol* **46**:S41, 2002
2. Moy JA, McKinley-Grant L, Sanchez MR: Cultural aspects in the treatment of patients with skin disease. *Dermatol Clin* **21**:733, 2003

18. Callender VD: Acne in ethnic skin: Special considerations for therapy. *Dermatol Ther* **17**:184, 2004

27. Halder RM, Richards GM: Management of dyschromias in ethnic skin. *Dermatol Ther* **17**:151, 2004
28. Halder RM, Nandedkar MA, Neal KW: Pigmentary disorders in ethnic skin. *Dermatol Clin* **21**:617, 2003
29. Holloway VL: Ethnic cosmetic products. *Dermatol Clin* **21**:743, 2003
30. Briganti S, Camera E, Picardo M: Chemical and instrumental approaches to treat hyperpigmentation. *Pigment Cell Res* **16**:101, 2003

SECTION 37

SYSTEMIC THERAPY

CHAPTER 225

Systemic Glucocorticoids

Victoria P. Werth

Glucocorticoids (GCs) are a mainstay of dermatologic therapy because of their potent immunosuppressive and anti-inflammatory properties. In 1949, Hench and co-workers[1] described the beneficial effects of cortisone in patients with rheumatoid arthritis. By understanding the properties and mechanisms of action of GCs, one can maximize their efficacy and safety as therapeutic agents.

MECHANISM OF ACTION

The major naturally occurring GC is cortisol (hydrocortisone). It is synthesized from cholesterol by the adrenal cortex. Normally, less than 5 percent of circulating cortisol is unbound; this free cortisol is the active therapeutic molecule. The remainder is inactive because it is bound to cortisol-binding globulin (also called *transcortin*) or to albumin. The daily secretion of cortisol ranges between 10 and 20 mg, with a diurnal peak around 8 A.M.[2] Cortisol has a plasma half-life of 90 minutes. It is metabolized primarily by the liver, although it exerts hormonal effects on virtually every tissue in the body. The metabolites are excreted by the kidney and the liver.

The mechanism of GC action involves passive diffusion of the GCs through the cell membrane, followed by binding to soluble receptor proteins in the cytoplasm.[3] This hormone-receptor complex then moves to the nucleus and regulates the transcription of a limited number of target genes. There are three main mechanisms of GC action. The first is direct effects on gene expression by the binding of GC receptors (GRs) to GC-responsive elements (GREs), leading to the induction of proteins like annexin I and MAPK phosphatase 1. Annexins reduce phospholipase A_2 activity, which reduces the release of arachidonic acid from membrane phospholipids,[4,5] limiting the formation of prostaglandins and leukotrienes.[6,7] The second mechanism is indirect effects on gene expression through the interactions of GRs with other transcription factors. Some of the most important appear to be inhibitory effects on the transcription factors activator protein 1 and nuclear factor κB, coupled with increased IκB, an inhibitor of nuclear factor κB.[8] This decreases the synthesis of a number of pro-inflammatory molecules, including cytokines, interleukins (ILs), adhesion molecules, and proteases. The third is GR-mediated effects on second messenger cascades through non-genomic pathways such as the PI3K-Akt-eNOS pathway.[9,10]

Human GR messenger RNA has alternative splice variants, GR-α and -β. The relative levels of these two variants influence the cell's sensitivity to GC, with higher levels of GR-β being one of many mechanisms leading to GC resistance,[10,11] as has been described in atopic dermatitis lesions infected with *Staphylococcus aureus*.

There is usually a delay in the onset of pharmacologic activity of GCs relative to their peak blood concentrations, which is probably consequent to altering the transcription of genes,[8] although some actions appear to be independent of transcription.[12] GCs may also exert their effects by non-genomic mechanisms such as membrane-bound receptors and/or physicochemical interactions with cellular membranes.[13] Some effects of GCs are too rapid to be mediated by genomic GC action.[14] This mechanism might explain additive benefits of very high-pulse GCs.

SYSTEMIC GLUCOCORTICOIDS AT A GLANCE

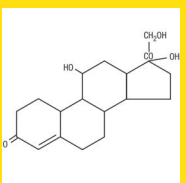

- Systemic glucocorticoids are potent immunosuppressives and anti-inflammatory agents frequently used for severe dermatologic diseases.
- Complications are increased with fluorinated compounds, higher doses, longer duration of therapy, and more frequent administration.
- Intralesional, intramuscular, intravenous, and oral routes of administration can be used.
- Careful monitoring of electrolytes, glucose, triglycerides, cholesterol, weight, fevers, skeletal or abdominal pain, bone density, and eyes are important.
- New treatments to prevent glucocorticoid-induced osteoporosis should be used in most patients.

The multiplicity of biologic effects produced by GCs emphasizes that currently there is no unifying hypothesis to explain the therapeutic efficacy of these extremely potent anti-inflammatory and immunosuppressive agents.

PHARMACOKINETICS

When hydrocortisone is given in moderate to high doses, its mineralocorticoid effects can be deleterious, and, thus, synthetic analogues of cortisol have been

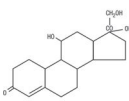

Copyright © 2008 by The McGraw-Hill Companies, Inc. Click here for terms of use.

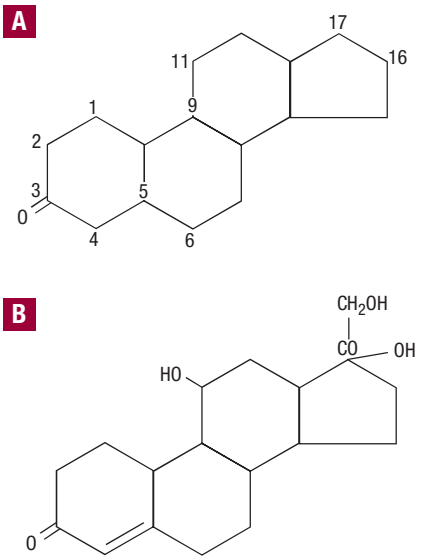

▲ **FIGURE 225-1** **A.** Basic steroid skeleton. **B.** The structure of hydrocortisone (cortisol).

developed that have greater anti-inflammatory properties and less sodium retention. Small substitutions on the basic steroid structure of three hexanes and a pentane ring (Fig. 225-1; Table 225-1) account for the differences in plasma half-life and the relative anti-inflammatory and sodium-retaining potencies (Table 225-2). In general, most synthetic analogues bind less efficiently to cortisol-binding globulin (approximately 70 percent binding). This property may explain, in part, their tendency to cause side effects at lower dosages. The 11-β hydroxyl group in cortisol is essential for activity. Because cortisone and prednisone are 11-keto compounds, they are active only after being converted in the liver to the corresponding 11-β hydroxyl compounds (cortisol and prednisolone) (see Table 225-1). Patients with severe liver disease generally maintain their ability to convert the 11-keto compounds; nevertheless, some authorities suggest that only the converted active compounds should be administered to these patients.[27]

INDICATIONS

- Serious blistering diseases (pemphigus, bullous pemphigoid, cicatricial pemphigoid, linear immunoglobulin A bullous dermatoses, epidermolysis bullosa acquisita, herpes gestationis, erythema multiforme, toxic epidermal necrolysis)
- Connective-tissue diseases (dermatomyositis, systemic lupus erythematosus, mixed connective-tissue disease, eosinophilic fasciitis, relapsing polychondritis)
- Vasculitis

TABLE 225-1
Comparative Structures of Glucocorticoids

	Position				
	1–2	6	9	11	16
Cortisol	—	—	—	–OH	—
Cortisone	—	—	—	=O	—
Prednisone	Double bond	—	—	=O	—
Prednisolone	Double bond	—	—	–OH	—
Methylprednisolone	Double bond	CH3	—	–OH	—
Triamcinolone	Double bond	—	F	–OH	OH
Dexamethasone	Double bond	—	F	–OH	OH3

- Neutrophilic dermatoses (pyoderma gangrenosum, acute febrile neutrophilic dermatosis, Behçet disease)
- Sarcoidosis
- Type I reactive leprosy
- Problematic hemangiomas of infancy
- Kasabach-Merritt syndrome
- Panniculitis
- Urticaria/angioedema

Short courses of GCs may be used for severe dermatitis:

- Contact dermatitis
- Atopic dermatitis
- Photodermatitis
- Exfoliative dermatitis
- Erythrodermas

Low doses of GCs at bedtime if these conditions are unresponsive to more conservative therapy:

- Acne and hirsutism consequent to adrenogenital syndromes

The use of GCs is controversial in the treatment of erythema nodosum, lichen planus, cutaneous T-cell lymphoma, and discoid lupus erythematosus.

DOSING REGIMEN

Systemic GCs can be administered intralesionally, orally, intramuscularly, and intravenously. The route and regimen are determined by the nature and extent of the disease being treated.

Intralesional GC administration allows direct access to either a relatively few lesions or a particularly resistant lesion (see Chap. 216).

There are serious drawbacks to intramuscular administration because of erratic absorption and lack of daily control of the dose. Because Kenalog is longer acting than prednisone, there are more potential side effects, including increased hypothalamic-pituitary-adrenal (HPA) suppression and myopathy.

When oral GCs are prescribed, prednisone is most commonly selected. GCs are usually administered daily or every other day, although for acute disease split daily doses can be administered. The initial dose is most often daily to control the disease process and can range from 2.5 mg to several hundred milligrams daily. If used for less than 3 to 4 weeks, GC therapy can be stopped without tapering. The lowest possible dose of a short-acting agent every other morning minimizes side effects. Because cortisol levels peak around 8 A.M., the HPA axis is least suppressed with this morning dosage, and maximal feedback suppression of adrenocorticotropic hormone (ACTH) secretion by the pituitary is al-

TABLE 225-2
Glucocorticoids

	Equivalent Glucocorticoid Potency (mg)	Mineralocorticoid Potency	Plasma Half-Life (min)	Duration of Action (h)
Short-acting				
Hydrocortisone (Cortisol)	20	0.8	90	8–12
Cortisone	25	1	30	8–12
Intermediate-acting				
Prednisone	5	0.25	60	24–36
Prednisolone	5	0.25	200	24–36
Methylprednisolone	4	0	180	24–36
Triamcinolone	4	0	300	24–36
Long-acting				
Dexamethasone	0.75	0	200	36–54

ready occurring. The low levels of GCs at night allow for normal secretion of ACTH. Low doses of prednisone (2.5 to 5.0 mg) at bedtime have been used to maximize adrenal suppression in cases of acne or hirsutism of adrenal origin.

Intravenous GCs are used in two situations. One is for stress coverage for patients who are acutely ill or are undergoing surgery and who have adrenal suppression from daily GC therapy. The other is for patients with certain diseases—such as resistant pyoderma gangrenosum, severe pemphigus, or bullous pemphigoid, serious systemic lupus erythematosus, or dermatomyositis—to gain rapid control of the disease and thus minimize the need for long-term, high-dose oral steroid therapy.[29] Methylprednisolone is used at a dose of 500 mg to 1 g daily because of its high potency and low sodium-retaining activity. Serious side effects associated with intravenous administration include anaphylactic reactions, seizures, arrhythmias, and sudden death. Other adverse reactions include hypotension, hypertension, hyperglycemia, electrolyte shifts, and acute psychosis. Slower administration over 2 to 3 hours has minimized many of the serious side effects, and as long as vital signs are determined frequently, patients without underlying renal or cardiac disease do not need to be treated in a monitored bed.[30] It is important to monitor serum electrolytes before and after pulse therapy, particularly when patients are on concomitant diuretic therapy. Recent studies suggest that doses that are less than the traditional high-dose (1 g methylprednisolone daily for 3 days) IV pulse therapy may be equally efficacious and safer.[31]

INITIATING THERAPY

Fundamental Principles

Before therapy with GCs is begun, the benefit that can realistically be expected should be weighed against the potential side effects. Alternative or adjunctive therapies should be considered, especially if long-term treatment is contemplated. Co-existing illnesses such as diabetes, hypertension, or osteoporosis need to be considered. The predisposition of the patient to side effects should be included in an assessment of risk.

Choosing among Glucocorticoids

A number of considerations influence the choice of GCs. First, a preparation with minimal mineralocorticoid effect is usually picked to decrease sodium retention. Second, the long-term oral use of prednisone or a similar drug, with an intermediate half-life and relatively weak steroid-receptor affinity, may reduce side effects. Long-term use of drugs such as dexamethasone, which has a longer half-life and high GR affinity, may produce more side effects without any better therapeutic effects. Third, if a patient does not respond to cortisone or prednisone, the substitution of the biologically active form, cortisol or prednisolone, should be considered. In general, even in severe liver disease, substitution has not proved to be very important. Fourth, methylprednisolone is used for pulse therapy because of its low sodium-retaining characteristics and high potency.

Evaluation before Treatment

To minimize potential problems, the baseline evaluation should include a personal and family history, with special attention to predisposition to diabetes, hypertension, hyperlipidemia, glaucoma, and associated diseases that could be affected by GC therapy. Baseline blood pressure and weight should be measured. If prolonged administration is anticipated, an eye examination and a purified protein derivative (PPD) test should be performed and an anergy panel applied. Examination for other covert infections should be based on history and physical examination. For instance, a stool culture for *Strongyloides* should be performed for immigrants from third-world countries and for Vietnam veterans.[32] If long-term administration of GCs is anticipated, baseline spinal bone-density measurement should be obtained by quantitative computed tomography, dual-photon absorptiometry, or dual-energy x-ray absorptiometry.[33]

MONITORING THERAPY

At follow-up visits, patients receiving chronic GC therapy should be questioned about polyuria, polydipsia, abdominal pain, fevers, sleep disturbances, and psychological effects. There may be serious effects on affect and even psychosis in patients with high doses of GCs. Weight and blood pressure should be monitored. Serum electrolytes, fasting blood sugar, and cholesterol and triglyceride levels should be measured on a regular basis. Stool should be examined for occult blood. Follow-up eye examinations should be performed with careful monitoring for the development of cataracts and glaucoma.

RISKS AND PRECAUTIONS (Table 225-3)

Diet

Diet should be low in calories, fat, and sodium, and high in protein, potassium, and calcium. Protein intake is important to reduce steroid-induced nitrogen wasting.[34] Use of alcohol, coffee, and nicotine should be minimized. Exercise should be encouraged.

Infections

Patients with a positive PPD should be given prophylaxis with isoniazid.[35] Anergic patients should have a baseline chest x-ray to search for evidence of previous tuberculosis. Fevers or focal findings should be evaluated with appropriate cultures and diagnostic approaches. Some advocate use of Bactrim prophylaxis (1 DS Bactrim 3 days a week) against *Pneumocystic carinii* when patients receive concomitant cytotoxic therapy.[27]

Gastrointestinal Complications

Although there is controversy about whether an increase in the incidence of peptic ulcer disease occurs in otherwise unaffected patients receiving GCs, there is almost a ninefold increase in patients taking both GCs and nonsteroidal anti-inflammatory agents.[36–38] In patients with two or more risk factors (such as those taking nonsteroidal anti-inflammatory medications, a previous history of peptic ulceration, advanced malignant disease, or a total dose of GCs more than 1000 mg), prophylaxis may be considered. Prophylaxis can include antacids, H_2-receptor blockers (cimetidine, ranitidine, nizatidine, or famotidine with the evening meal), or proton pump inhibitors (Prilosec or Prevacid).

Adrenal Suppression

Patients receiving daily GC therapy for longer than 3 to 4 weeks must be assumed to have adrenal suppression that requires tapering of the GCs to allow for recovery of the HPA axis. Tapering is best performed by switching from a single daily dose to alternate-day doses, followed by a gradual reduction of the amount of the drug. The daily dose is

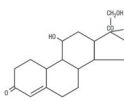

TABLE 225-3
Prevention of Side Effects with Chronic (≥ 3 mo) Glucocorticoid Use

Side Effect	Preventative Measures
Hypertension	Blood pressure (baseline; repeat with each visit).
Weight gain	Weight (baseline; repeat with each visit).
Re-activation of infection	Purified protein derivative, anergy panel at baseline (can be done up to 12 days after starting prednisone). Hepatitis screen. Consider *Pneumocystis carinii* pneumonia prophylaxis (Bactrim 1 DS three times a week).
Metabolic abnormalities	Electrolytes, lipids, glucose [baseline; repeat early after starting therapy; repeat annually; more frequent monitoring with known factors (e.g., diabetes, hyperlipidemias)].
Osteoporosis	Bone density (baseline; repeat annually is early bone prophylaxis done). Instruct about diet, exercise, other measures. Calcium and vitamin D supplementation. Start bisphosphonate for men, post-menopausal women. Evaluate post-menopausal women for hormone replacement therapy. Serum testosterone after treatment started in men; if low (< 300 ng/mL), check prostate specific antigen, prostate examination before starting testosterone replacement.
Eyes	
Cataracts	Slit-lamp examination (every 6–12 mo).
Glaucoma	Intraocular pressure examination (at 1 mo and every 6 mo).
Peptic ulceration	In patients with two or more risk factors, consider prophylaxis with and H_2-antagonist or proton pump inhibitor.
Suppression of hypothalamic-pituitary-adrenal axis	Single, early morning doses, preferably every other day. Check 8 A.M. serum cortisol before tapering prednisone < 3 mg/day. If < 10 μg/dL, repeat every 1–2 mo and maintain low prednisone dose until baseline cortisol adequate.

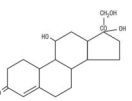

first gradually tapered to 40 or 50 mg of prednisone. Then, either the dose can be kept constant on 1 day and reduced on the alternate day by 5-mg decrements down to 5 mg/day, or, the steroid dose can be increased on 1 day and reduced by a similar amount on the alternate day. More studies are needed to determine optimal tapering schedules.[39]

After the prednisone dose is tapered to 5 mg on alternate days, the need for maintenance therapy must be assessed. The 8 A.M. plasma cortisol level is measured 4 weeks after the 5-mg dose has been reached. The morning dose of prednisone is held until the plasma cortisol level is determined. If the plasma cortisol level is less than 10 μg/dL, the alternate-day prednisone dose should be decreased by 1 mg every 1 to 2 weeks to a maintenance dose of 2 mg/day. Then the 8 A.M. plasma cortisol level should be rechecked every 2 months until it is greater than 10 μg/dL, at which point maintenance GCs can be terminated.[40] Recovery of the HPA axis can take longer than 9 months.[41] At that point and at any point when the patient is receiving tapering doses of steroids, a stress caused, for example, by trauma, surgery, diarrhea, or fever more than 38°C (101°F) can precipitate acute adrenal insufficiency related to an inadequate stress response. Patients should wear bracelets or carry cards indicating that they are receiving GCs. During such stressful situations, it is necessary to give high doses of GCs, generally 25 to 70 mg/day of prednisone or 100 to 300 mg/day of cortisol in divided doses.[42] Patients must be educated about the need for stress coverage.

The amount of GCs to give for coverage for surgery should probably be individualized to the severity of the operation. Minor operations lasting less than 1 hour are associated with, at most, 50 mg/day (12.5 mg prednisone) of cortisol in response to the surgery. Moderate to major surgeries are associated with the production of 75 to 200 mg/day of cortisol.[43,44] Thus, recent guidelines suggest that adrenally suppressed patients receive 25 mg of hydrocortisone equivalents for minor surgeries, 50 to 75 mg for moderate surgeries, and 100 to 150 mg for major surgery for 2 to 3 days, beginning when the patient is on call for surgery.[43] No trials have been done, and one recent study suggested even lower doses are adequate.[45]

In general, adrenal insufficiency resolves within 1 year of the termination of GC therapy. An ACTH stimulation test may be performed after maintenance GCs are terminated to assess adrenal reserve. This test is performed in the office by determining a baseline cortisol level, giving an intramuscular injection of 0.25 mg of cosyntropin, and measuring the serum cortisol level again 1 hour later.[40] The adrenal response is suppressed if the serum cortisol level fails to increase by at least 5 μg/dL to a stimulated value 60 minutes later of more than 20 μg/dL. If adequate adrenal response to stress is demonstrated, there is less concern about the endogenous cortisol response to stress.[27] However, such a response is not a guarantee of adequate adrenal reserves if severe stress occurs, and many physicians would choose routine stress coverage with GCs without performing an ACTH stimulation test.[46]

COMPLICATIONS

Complications associated with systemic GC therapy (Table 225-4)[47,48] increase with higher doses, longer duration of therapy, and more frequent administration. However, osteoporosis and cataracts develop with alternate-day dosing, and avascular necrosis (AVN) can be seen after only short courses of GCs.

Osteoporosis

Osteoporosis occurs in 40 percent of individuals treated with systemic GCs; it is especially prominent in children, adolescents, and post-menopausal women.[49] Approximately one-third of patients have evidence of vertebral fractures after 5 to 10 years of GC treatment, but this proportion is higher in post-menopausal women.[50,51] Bone loss occurs most rapidly in the first 6 months of GC use, but continues at a slower rate after that, with loss of 3 percent to 10 percent of bone per year in many patients.[49,52] Recent studies show that even low doses of prednisone (2.5 mg/day) adversely affect bone and increase vertebral and hip fractures.[53,54] Some of the bone loss may be reversible after GCs are stopped, at least in the young.[55]

Avascular Necrosis

AVN is manifested by pain and limitation of motion in one or more joints. There is intraosseous hypertension, leading to bone ischemia and necrosis.[59] It is likely

TABLE 225-4
Complications of Glucocorticoid Therapy

Central nervous system
- Pseudotumor cerebri and psychiatric disorders

Musculoskeletal
- Osteoporosis with spontaneous fractures
- Aseptic necrosis of bone
- Myopathy

Ocular
- Glaucoma and cataracts

Gastrointestinal
- Peptic ulceration
- Intestinal perforation
- Pancreatitis

Cardiovascular and fluid retention
- Hypertension
- Sodium and fluid retention
- Hypokalemic alkalosis
- Atherosclerosis

Hypersensitivity reactions
- Urticaria
- Anaphylaxis

Endocrinologic
- Suppression of hypothalamic-pituitary-adrenal axis
- Growth failure
- Secondary amenorrhea

Metabolic
- Hyperglycemia and unmasking genetic predisposition to diabetes mellitus
- Non-ketotic hyperosmolar states
- Hyperlipidemia
- Alterations of fat distribution (typical cushingoid appearance)
- Fatty infiltration of the liver
- Drug interactions (decreased anticoagulant effect of ethyl biscoumacetate)

Fibroblast inhibition
- Inhibition of wound healing
- Subcutaneous tissue atrophy (striae, purpura, ecchymoses)

Suppression of host defenses

Immunosuppression, anergy
- Effects on phagocyte kinetics and function
- Increased incidence of infections

that intraosseous lipocyte hypertrophy causes this intraosseous hypertension in persons taking GCs. In addition, GCs induce apoptosis of osteoblasts, likely contributing to AVN. Underlying diseases, such as systemic lupus erythematosus, increase the likelihood of steroid-induced AVN.[60] Studies suggest that many patients who develop AVN have either thrombophilia or hypofibrinolysis, which leads to thrombotic occlusion of venous outflow from the bone, decreased arterial perfusion, and subsequent infarction of bone.[61]

Atherosclerosis

GCs enhance many risk factors that are associated with atherosclerosis, including arterial hypertension, insulin resistance, glucose intolerance, hyperlipidemia, and central obesity. It is thus not surprising that patients taking GCs have an increased risk of atherosclerosis.[62] Patients with untreated Cushing disease have a four times higher mortality rate from cardiovascular complications, including coronary artery disease, congestive heart failure, and cardiac stroke.[63] The risk factors for atherosclerosis persist for at least 5 years after normalization of the serum cortisol level in Cushing disease, and similar findings may be true in those treated with chronic GCs.[64]

Suppression of the Hypothalamic-Pituitary-Adrenal Axis

The HPA axis is rapidly suppressed after the onset of GC therapy. However, if therapy is limited to 1 to 3 weeks, the recovery of the HPA axis is rapid. Longer daily GC therapy is associated with suppression of the HPA axis for up to 1 year after therapy is terminated.[41] Symptoms of adrenal suppression include lethargy, weakness, nausea, anorexia, fever, orthostatic hypotension, hypoglycemia, and weight loss.

There also exists a steroid withdrawal syndrome, in which patients experience symptoms of adrenal insufficiency despite having an apparently normal cortisol response to ACTH. Symptoms most commonly include anorexia, lethargy, malaise, nausea, weight loss, desquamation of the skin, headache, and fever. Less commonly, vomiting, myalgias, and arthralgias occur. These patients have adjusted to high levels of GCs, and symptoms disappear after the GCs are restarted. This problem can be treated by slower tapering of the GCs, often by 1 mg of prednisone every few weeks.[65]

Drug Interactions

GCs are associated with a number of important drug interactions. Drugs such as barbiturates, phenytoin, and rifampin, which induce hepatic microsomal enzymes, may accelerate the metabolism of GCs.[66] Drugs such as cholestyramine, colestipol, and antacids impair absorption of GCs. GCs reduce the serum salicylate level and necessitate a higher dose of warfarin (Coumadin) for anticoagulation.

Immunologic Side Effects

GCs impair delayed-type hypersensitivity reactions because of their inhibition of lymphocytes and monocytes. Prednisone at daily doses of 15 mg or more suppresses the response to tuberculin, although it takes an average of 13.6 days for oral prednisone at 40 mg/day to inhibit the response to tuberculin.[67] Thus, even in situations requiring immediate use of prednisone, it is possible to perform simultaneously a PPD test and an anergy panel. Overall, there is an increased incidence of infections attributable to both the GCs and the immunologic changes related to the underlying disease.[68]

Concerns during Pregnancy and Lactation

GCs cross the placenta, but they are not teratogenic. Exposed infants as well as breast-fed infants of mothers receiving GCs should be monitored for adrenal suppression and growth suppression. Based on animal experiments, there is some concern about the contribution of GCs to premature and low-birth-weight infants with respect to neurodevelopment.[69]

Concerns in the Pediatric Population

In the pediatric population, GCs cause growth retardation and early osteoporosis.[70] Growth retardation is caused by a direct action on cell metabolism, effects on calcium and phosphorus metabolism, and a decrease in growth hormone secretion, with inhibition of bone matrix formation. Growth retardation is not necessarily prevented by alternate-day GC regimens.[71] Recent studies show that human growth hormone replacement has a significant effect on growth, as well as a significant effect on lean body mass.[72]

Immunization with live vaccines can be done if the duration of GC use is less than 2 weeks at any dose, if the dose of GC is less than 2 mg/kg or 20 mg/day of any duration, and if long-term alternate-day treatment with short-acting preparations is done. Immunization with live vaccines should not be done for at least 3 months after receiving high doses of GCs (greater than 2 mg/kg or greater than 20 mg/day) for more than 2 weeks.[73]

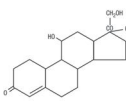

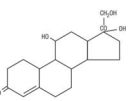

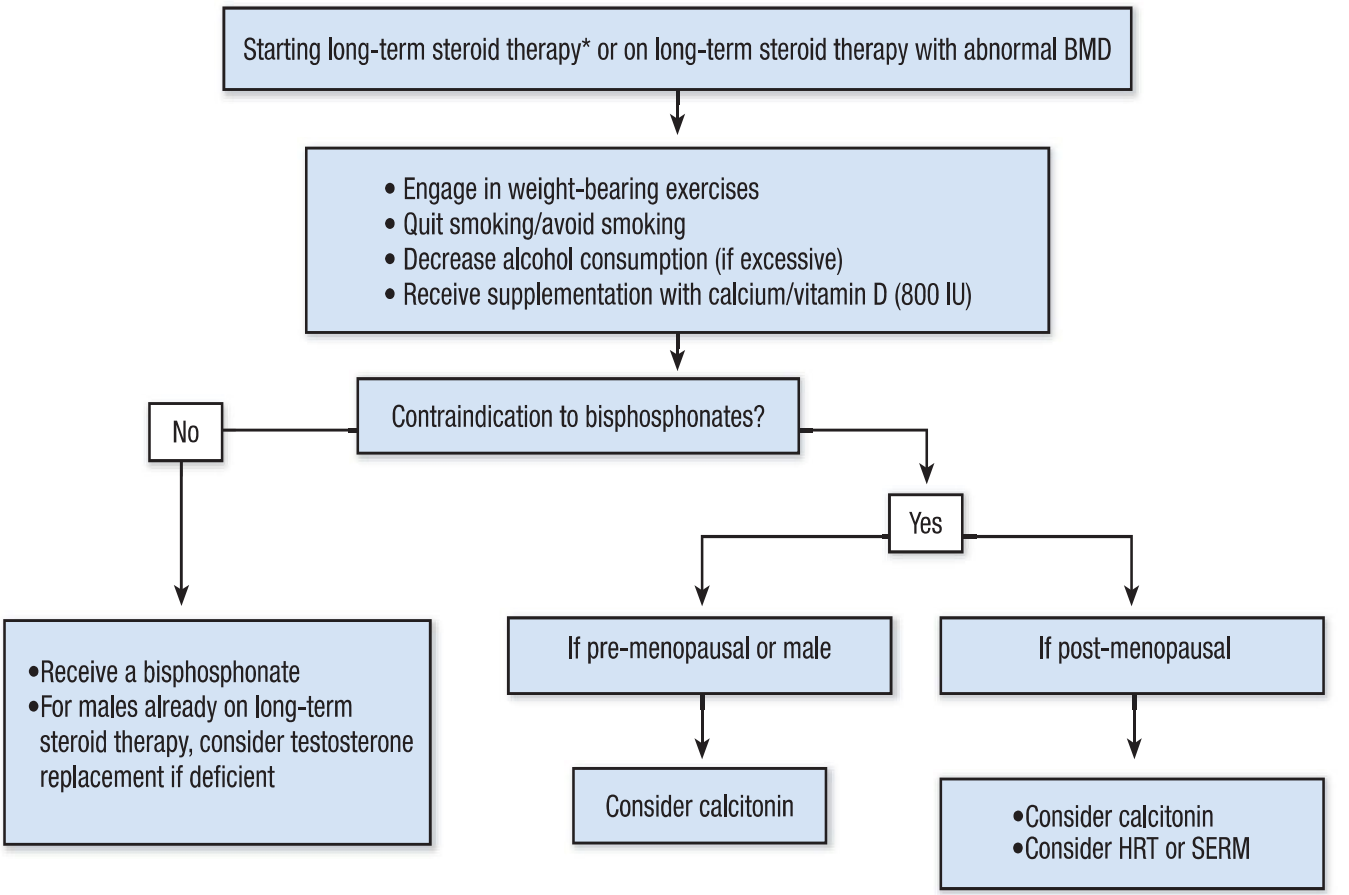

▲ **FIGURE 225-2** Treatment sequence for prevention and management of steroid-induced osteoporosis. *Long-term steroid therapy refers to ≥ 5 mg/day prednisone (or equivalent) for ≥ 3 months. BMD = bone mineral density; HRT = hormone replacement therapy; SERM = selective estrogen receptor modulator.

Management of Osteoporosis, Atherosclerosis, and Avascular Necrosis

OSTEOPOROSIS Attention to the prevention of osteoporosis is becoming increasingly important as newer therapies that may deter bone loss become available. Calcium and vitamin D supplements, sex hormone replacement, a weight-bearing exercise program, and sodium restriction are suitable first-line therapies.[74,75] Calcium and vitamin D together, but not calcium alone, preserve bone mass in patients receiving long-term treatment with GCs at an average of 15 mg/day.[74,76] Patients taking GCs should be given elemental calcium, 1500 mg/day, and vitamin D_2, 400 units twice daily. Activated forms (alfacalcidiol, 1 μg/day, or calcitriol, 0.5 to 1.0 μg/day) can be given, but more frequent monitoring is required for hypercalciuria and hypercalcemia. Patients with a history of renal stones should not receive supplemental calcium and vitamin D.[77,78] For patients receiving calcium and vitamin D_2, calcium levels should be measured in serum and in 24-hour urine collections every 3 months or whenever GC doses are substantially altered. If the urinary calcium level exceeds 250 to 350 mg/dL, the addition of 12.5 to 25.0 mg/day of thiazide reduces the renal excretion of calcium.[79] If thiazide is not added, calcium and vitamin D supplementation should be adjusted.

Current recommendations include baseline measurements of bone density and a sequential study to identify early those who are rapidly losing bone density.[74,113] Bone density is best measured in the lumbar spine in patients younger than 60 years of age and in the femoral neck in patients older than 60 years of age. All men and post-menopausal women in whom long-term GC treatment at 5 mg/day or more is being initiated or who have below-normal bone mineral density T-scores should receive bisphosphonates at the time GCs are prescribed. Bisphosphonates were found to be the most effective agents for managing GC-induced osteoporosis, and their efficacy was significantly enhanced when used in conjunction with vitamin D.[97,114] Pre-menopausal women treated with bisphosphonates should prevent pregnancy.[115] A decrease in bone mineral density of 5 percent or greater warrants changing or starting additional treatment strategies. Patients on chronic GCs benefit from bone prophylaxis, and physicians need to assure that patients receive appropriate treatment to prevent osteoporosis (Figs. 225-2 and 225-3).[116]

ATHEROSCLEROSIS Blood pressure, serum lipids, and glucose levels should be measured serially. Abnormalities should be treated with dietary manipulation and medication as necessary. Patients who smoke should be encouraged to stop. Female sex hormones protect against the development of atherosclerosis, and thus hormone replacement therapy for post-menopausal women on GCs makes sense. However, recent data suggest that women with established atherosclerosis actually do worse with hormone replacement therapy, and there was a 58 percent increase in coronary heart disease events in the first year after myocardial infarction in patients treated

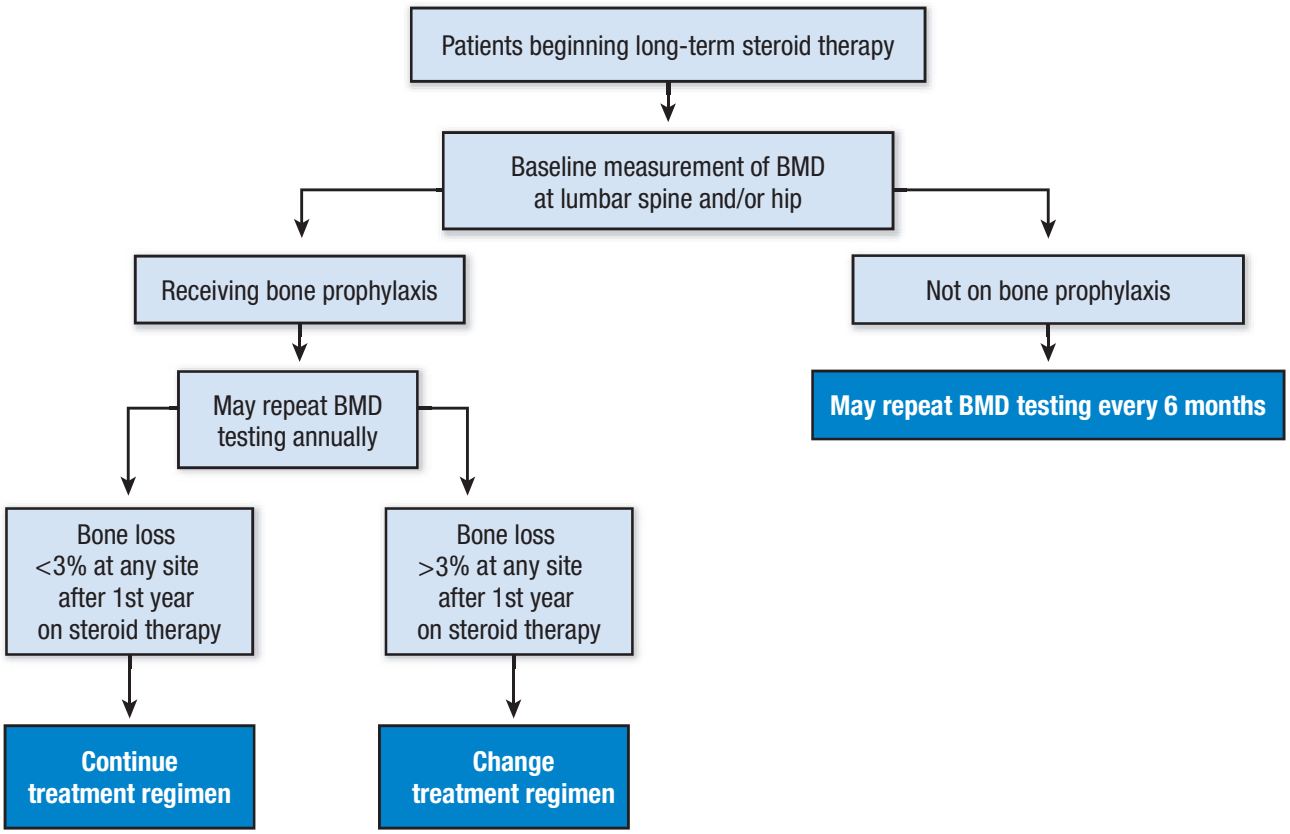

▲ **FIGURE 225-3** Bone-density testing sequence based on recommendations from the American College of Rheumatology and Cohen and Adachi.[74,114] BMD = bone mineral density. (Used with permission from American College of Rheumatology Ad Hoc committee on Glucocorticoid-Induced Osteoporosis: Recommendations for the prevention and treatment of glucocorticoid-induced osteoporosis. *Arthr Rheum* **44**:1496, 2001; and Cohen D, Adachi JD: The treatment of glucocorticoid-induced osteoporosis. *J Steroid Biochem Mol Biol* **88**:337, 2004.)

with an estrogen/progestin combination. If patients develop increased levels of cholesterol or triglycerides while taking GCs, there are now good approaches to treatment, particularly with some of the newer statins, that impact on the development of atherosclerosis and prevent myocardial infarctions.

AVASCULAR NECROSIS Early detection is important because early intervention may prevent progression to degenerative joint disease requiring joint replacement. Twenty percent of patients with AVN have normal x-rays. Bone scan and magnetic resonance imaging are more sensitive techniques for evaluating AVN. Patients should be regularly questioned about pain and limitation of motion of joints. If abnormalities develop, an x-ray, bone scan, or magnetic resonance imaging should be ordered. If imaging shows AVN, an orthopedic surgeon skilled in early intervention with core decompression may be able to halt progression of the disease. Patients with AVN have an increased risk that other joints will be affected. The progression of AVN to destructive joint disease may require joint replacement surgery.[121]

KEY REFERENCES

The full reference list for all chapters is available at www.digm7.com.

1. Hench PS et al: The effect of a hormone of the adrenal cortex (17-hydroxy-11-dehydrocorticosterone (compound E)) and of pituitary adrenocorticotropic hormone on rheumatoid arthritis. *Mayo Clin Proc* **24**:181, 1949
3. Bloom E et al: Nuclear binding of glucocorticoid receptors: Relations between cytosol binding, activation and the biological response. *J Steroid Biochem* **12**:175, 1980
15. Cupps TR, Fauci AS: Corticosteroid-mediated immunoregulation in man. *Immunol Rev* **65**:133, 1982
25. Schacke H, Rehwinkel H, Asadullah K: Dissociated glucocorticoid receptor ligands: Compounds with an improved therapeutic index. *Curr Opin Invest Drugs* **6**:503, 2005
39. Richter B et al: Glucocorticoid withdrawal schemes in chronic medical disorders. A systematic review. *Endocrinol Metab Clin North Am* **31**:751, 2006
74. American College of Rheumatology Ad Hoc committee on Glucocorticoid-Induced Osteoporosis: Recommendations for the prevention and treatment of glucocorticoid-induced osteoporosis. *Arthr Rheum* **44**:1496, 2001
114. Cohen D, Adachi JD: The treatment of glucocorticoid-induced osteoporosis. *J Steroid Biochem Mol* Biol **88**:337, 2004

CHAPTER 226

Dapsone

Joni G. Sago
Russell P. Hall III

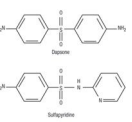

In the early 1950s, a sulfone named dapsone was shown to have dramatic efficacy in dermatitis herpetiformis[1] and has subsequently become first-line therapy for this disease. Since then, dapsone has been used in a wide variety of inflammatory skin conditions. Its appropriate use, however, requires an understanding of possible indications, usual dosing, proposed mechanisms of action, potential toxicities, and necessary monitoring. This chapter focuses on the use of dapsone in the treatment of inflammatory skin diseases.

PHARMACOLOGY

Fig. 226-1 shows the chemical structure of dapsone [4,4′-diaminodiphenylsulfone]. Although dapsone is classified as a sulfonamide, cross-reactions rarely occur in sulfa-allergic patients. The most reliable confirmation of this lack of cross-reactivity has been noted when dapsone is used for *Pneumocystis carinii* pneumonia prophylaxis in sulfa-allergic acquired immunodeficiency syndrome patients. These patients have a low incidence of cross-reactivity (7 percent to 20 percent) and, if present, the cross-reactivity is usually mild and does not require dapsone discontinuation.[2,3] Sulfapyridine, a related compound, is available only on a compassionate-use basis from the manufacturer in the United States. It is thought to have similar mechanisms of action although with a reduced activity level and a lower incidence of toxicity than dapsone. Sulfapyridine may be useful, therefore, in patients who are unable to tolerate dapsone due to side effects.

Dapsone tablets are available in 25 mg and 100 mg sizes; therapeutic doses for various conditions range from 25 mg to approximately 400 mg. Dapsone is well absorbed from the gut with peak levels being reached 2 to 6 hours after a single dose. The steady-state half-life, however, is quite long (approximately 30 hours) due to enterohepatic re-circulation.[4] This allows for once-daily dosing and explains the utility of activated charcoal in reducing drug levels during accidental or intentional overdose.[5] Dapsone and its metabolites may be transmitted through human milk, and hemolysis has occurred in nursing infants.[6–8] No teratogenicity has been observed, although no controlled studies have been performed in humans and it is classified as pregnancy category C.[9,10]

Dapsone is metabolized in the liver. The two major metabolic pathways involve acetylation and *N*-hydroxylation (Fig. 226-2). Dapsone is acetylated polymorphically—that is, some patients rapidly acetylate dapsone to monoacetyldapsone (MADDS) whereas in others, this process occurs slowly. However, in all patients, MADDS is rapidly deacetylated. Thus, equilibrium between MADDS and dapsone is quickly reached and sustained. Dapsone's efficacy and half-life appear unrelated to the rate of acetylation[11,12]

The more clinically significant metabolic pathway involves hydroxylation of one of the amino groups by cytochrome 3A4 (and, to a lesser extent, 2C9) to form dapsone hydroxylamine, a potent oxidant that is important in the development of methemoglobinemia and hemolysis (see the section Adverse Effects).[13,14] Dapsone hydroxylamine is reduced back to the parent compound dapsone by cytochrome b_5 reductase (present in erythrocytes as methemoglobin reductase) as well as cytochrome b_5 and cytochrome P2D in hepatocytes.[15] Reduced enzyme levels have been detected in dapsone-treated patients who developed symptomatic methemoglobinemia; genetic variability in detoxifying enzymes may therefore explain patients' differential development of this side effect.[16] Although ex-

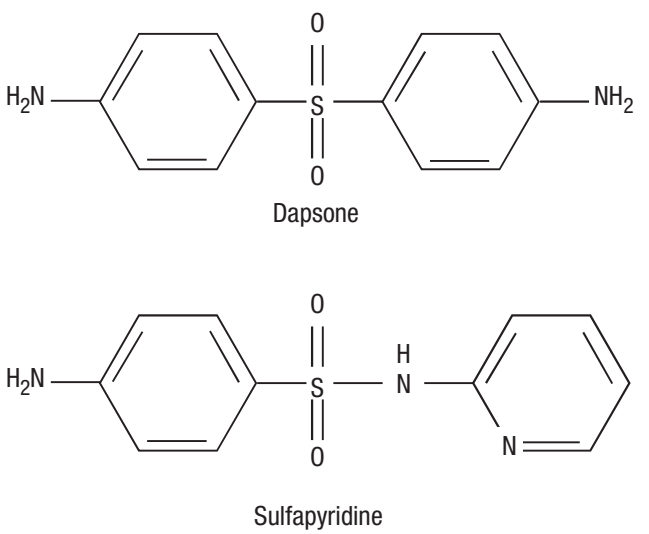

▲ **FIGURE 226-1** Chemical structure of dapsone and sulfapyridine.

DAPSONE AT A GLANCE

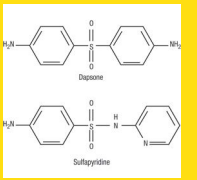

- Dapsone (4,4′-diaminodiphenylsulfone) is classified as sulfonamide but has unique pharmacologic properties.
- Diseases with consistent response to dapsone are dermatitis herpetiformis, erythema elevatum diutinum, linear immunoglobulin A dermatosis/chronic bullous disease of childhood and bullous eruption of systemic lupus erythematosus.
- Diseases with sporadic response to dapsone encompass a wide spectrum and are as diverse as collagen vascular/autoimmune diseases and acne. In these diseases, dapsone can be used as a corticosteroid sparing agent.
- A unifying feature of responsive diseases are neutrophilic and eosinophilic granulocytes.
- Dapsone is also effective in certain infections such as leprosy, actinomycetoma, or rhinosporidiosis
- Adverse effects are hemolysis and methemoglobulinemia. Glucose-6-phosphate dehydrogenase (G6PD) level should be obtained before beginning dapsone treatment. Dapsone should only be given with great caution to patients with G6PD deficiency.
- Other adverse effects are neuropathy, a mononucleosis-like hypersensitivity syndrome termed the *sulfone syndrome*, and agranulocytosis.

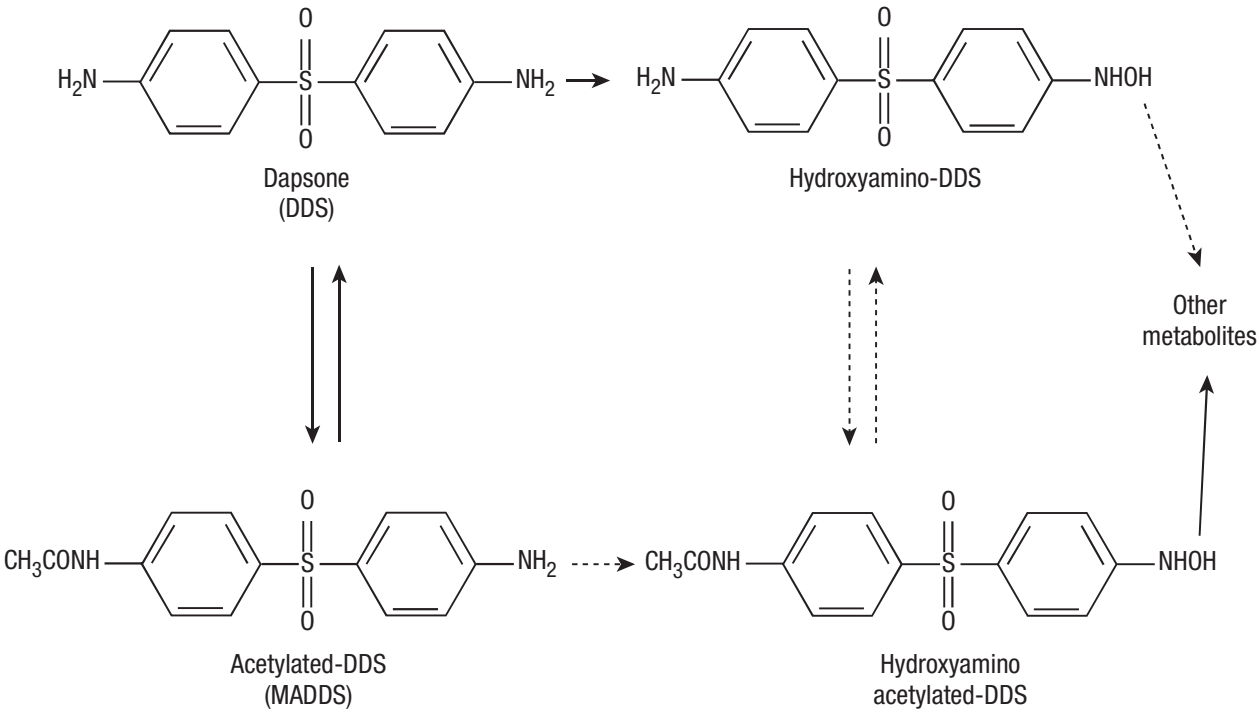

▲ **FIGURE 226-2** Dapsone metabolism in humans.

tensively hepatically metabolized, a small study of dapsone administration in cirrhotic patients demonstrated no need for dose adjustment.[17] However, caution is still recommended when using dapsone in patients with hepatic insufficiency.

Dapsone has been shown to interact with only a few other medications, including probenecid, which impairs its renal excretion[18]; rifampicin, which increases dapsone metabolism by upregulating the P_{450} system[19]; cimetidine and omeprazole, which block *N*-hydroxylation of dapsone[20,21]; and trimethoprim, which is associated with higher blood levels of dapsone.[22]

Dapsone and its metabolites are excreted by the kidneys, hence the recommendation to check a pre-treatment creatinine and avoid dapsone in patients with significant renal impairment.[4]

MECHANISM OF ACTION

Dapsone's interference with the folate biosynthetic pathway of bacteria accounts for its bacteriostatic effect; however, its mechanisms in inflammatory diseases are still incompletely characterized. Dapsone has several known effects on neutrophil function that may explain its utility in conditions with neutrophilic infiltrates. Dapsone inhibits chemotaxis of neutrophils to areas of inflammation. It also inhibits the paracrine production of inflammatory mediators and impairs the respiratory burst. Specifically, dapsone has been shown to inhibit neutrophil chemotaxis to the chemoattractant signals F-met-leu-phe[23] and LTB4.[24–26] Dapsone has also been found to inhibit migration and adherence of neutrophils to skin-localized immunoglobulin A[27] and interleukin-1–stimulated neutrophilic adherence to endothelium.[28] One study suggests that the mechanism behind impaired chemotaxis may be dapsone's interference with second-messenger signal transduction within neutrophils.[29] Additionally, dapsone has been shown to inhibit the release of IL-8, a potent neutrophil chemokine, from human keratinocytes that were incubated with antibodies to the human bullous pemphigoid 180-kd autoantigen.[30] Finally, dapsone has been shown to inhibit the myeloperoxidase-H_2O_2-halide–mediated cytotoxic system,[31,32] perhaps by inhibiting the calcium flux necessary for these events.[33]

INDICATIONS

Since its introduction into clinical medicine, dapsone has had therapeutic trials and anecdotal successes in a multitude of diseases.[34,35] Diseases with consistent response to dapsone include: dermatitis herpetiformis,[36] erythema elevatum diutinum,[37] linear immunoglobulin A dermatosis/chronic bullous dermatosis of childhood,[38–40] and the bullous eruption of systemic lupus erythematosus.[41] Patients with these disorders achieve a clinical response within 24 to 48 hours and their condition flares over the same time course with drug withdrawal.

Other non-infectious conditions in which dapsone has found sporadic success can be divided into the following categories: collagen vascular diseases, acne and related disorders, autoimmune diseases, and inflammatory conditions. As a unifying feature, most of these diseases have granulocytes (neutrophils or eosinophils) as the predominant infiltrating cell. In most diseases, the neutrophils appear early in the pathologic process. The response to dapsone therapy is not as rapid, regular, or predictable in any of these diseases. However, dapsone may have a role as a second-line or steroid-sparing agent. Trials may need to last 3 to 6 months to ascertain effect. Collagen vascular diseases for which dapsone may be considered include rheumatoid arthritis[42] and rheumatoid papules[43]; relapsing polychondritis[44,45]; subacute cutaneous lupus erythematosus,[46] chronic cutaneous lupus,[46] and lupus profundus[47]; various vasculitides including cutaneous polyarteritis nodosa, Henoch-Schönlein purpura,[48] chronic leukocytoclastic vasculitis without internal organ involvement[49,50]; and Behçet syndrome.[51,52] A wide variety of autoimmune conditions have been treated with dapsone. More than 50 percent of steroid-resistant or steroid-dependent patients with idiopathic

thrombocytopenic purpura have been reported to respond to dapsone.[53,54] In bullous pemphigoid, some authors have advocated the use of dapsone as a regularly effective treatment,[55–57] whereas others have found its efficacy to be limited.[58] It may be useful in cicatricial (mucous membrane) pemphigoid,[59–61] particularly in the early inflammatory phase of ocular disease, sub-corneal pustular dermatosis,[62] pemphigus vulgaris,[63] pemphigus foliaceous,[64] and urticarial vasculitis.[50,65]

Acne vulgaris and acne conglobata have both been treated with dapsone, although the latter condition usually requires high doses and dapsone is not often necessary since the advent of systemic retinoids.[66]

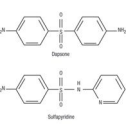

Dapsone was originally developed as an antibiotic and some infections are still treated with dapsone. These include leprosy, malaria, actinomycetoma, rhinosporidiosis, and *P. carinii* pneumonia prophylaxis in sulfa-allergic, immunocompromised patients. Details of the use of dapsone for these indications are beyond the scope of this chapter.

A therapeutic clinical response to dapsone can usually be seen at doses ranging from 25–200 mg per day. Rarely, patients may require 300 mg per day before a response is seen. The initial dosage chosen should be between 50–100 mg per day in order to minimize potential pharmacologic adverse effects. If a therapeutic trial of dapsone is successful, the dose of dapsone should be decreased to a point at which lesions recur to be sure that the improvement was indeed due to dapsone and that there is a continuing need for the drug. An ongoing effort to reduce the dose of dapsone to the lowest effective dose is an important means to minimize potential adverse effects.

ADVERSE EFFECTS

Dapsone therapy, although generally well tolerated, has pharmacologic and idiosyncratic side effects. The pharmacologic side effects, hemolysis and methemoglobinemia, develop to some degree in all treated patients in a dose-dependent fashion. These adverse effects are caused by the hydroxylated metabolite, dapsone hydroxylamine, which is a potent oxidant.[13,14,85,86] Within erythrocytes, dapsone hydroxylamine generates reactive oxygen species, which oxidize oxyhemoglobin into methemoglobin and, through incompletely elucidated processes, also produces hemolysis. The hemolysis is accompanied by the appearance of Heinz bodies, which have been shown to be composed of oxidized hemoglobin. These Heinz bodies and hydroxylated metabolite/cellular protein adducts may label the red blood cells as senescent, targeting them for removal by the spleen.[86,87] Patients with G6PD deficiency have decreased amounts of reduced glutathione within their erythrocytes. Glutathione is responsible for reversing oxidative damage; thus, G6PD-deficient patients are less tolerant of pharmacologic oxidative stress and are at risk for substantial hemolysis.[88,89] G6PD deficiency should therefore be ruled out before initiating therapy. Hemolysis is more profound at the initiation of therapy and should be accompanied by a compensatory reticulocytosis; patients with pre-existing iron or B_{12}/folate deficiency may not be able to mount an appropriate compensatory reticulocytosis and are at greater risk for symptomatic drops in hemoglobin.[90] Thus, baseline anemias should be worked up before starting dapsone. Clinicians should also be aware that, after overdose, hemolysis may be delayed for as much as 9 days, so patients should be closely monitored.

Methemoglobinemia is another predictable consequence of dapsone therapy. It is again due to dapsone hydroxylamine's generation of reactive oxygen species leading to oxyhemoglobin oxidation.[13] Methemoglobin is unable to carry oxygen; signs and symptoms of methemoglobinemia are therefore those of poor oxygenation, including cyanosis, headache, shortness of breath, chest pain, and fatigue. Although some degree of methemoglobinemia occurs in most patients, symptomatic methemoglobinemia is rare. Patients with an inability to tolerate decreased oxygen carrying capacity, such as those with pre-existing cardiopulmonary disease or anemia, may develop symptoms at a lower percentage methemoglobin.[91] Pulse oximetry is a reasonable screening test for methemoglobinemia, as a normal value excludes significant methemoglobinemia. However, an abnormal value must be followed up with a direct methemoglobin determination, as degree of desaturation does not linearly correlate with methemoglobin levels.[92] Thus, a 90 percent saturation cannot be meant to imply 10 percent methemoglobin. Clinical cyanosis is a very insensitive indicator of methemoglobinemia and should not be relied on. In case of accidental or intentional overdose, intravenous methylene blue can be used to decrease the degree of methemoglobinemia.[95,96] Methylene blue is a co-factor for methemoglobin reductase after first being reduced by cellular stores of NADPH to leukomethylene blue. G6PD-deficient patients should not be given methylene blue, as they may have insufficient NADPH and unreduced methylene blue is its own direct hemolytic agent.

TABLE 226-1
Adverse Reactions to Sulfones

- Pharmacologic effects
  - Hemolysis
  - Methemoglobinemia
- Headache
- Gastric irritation
- Nausea
- Anorexia
- Fatigue
- Hepatitis, infectious mononucleosis-like with adenopathy
- Cholestatic jaundice
- Morbilliform eruptions
- Erythema nodosum
- Erythema multiforme
- Exfoliative dermatitis
- Toxic epidermal necrolysis
- Severe hypoalbuminemia
- Psychosis
- Leukopenia
- Agranulocytosis
- Peripheral neuropathy (almost always motor)

Modified from Lang PG: Sulfones and sulfonamides in dermatology today. *J Am Acad Dermatol* **1**:479, 1979; Katz SI et al: Dermatitis herpetiformis: The skin and the gut. *Ann Intern Med* **93**:857, 1980; and Alexander JO: Dermatitis herpetiformis, in *Major Problems in Dermatology*, edited by Rook A. Philadelphia, Saunders, 1975, p 291.

The other adverse effects of dapsone are idiosyncratic or allergic in nature (Table 226-1).[34–36] For instance, there are several neurologic sequelae that are rare, unpredictable side effects of dapsone. These include a distal motor neuropathy, occasionally with a sensory component.[97] This is reversible with dose decrease or discontinuation.[98] Checking patient distal motor strength at follow-up visits may alert the clinician to its development. Other neurologic side effects include the induction of acute psychosis.[99–101] Overdosage of dapsone has been reported to cause retinal damage; however, no evidence of ocular damage has been noted with therapeutic doses of dapsone.[102–104]

Dapsone is associated with a rare mononucleosis-like hypersensitivity syndrome termed the *sulfone syndrome*.[105–107] Like some anticonvulsants and other

medications that produce similar symptoms, the sulfone syndrome is best classified within the clinical spectra of drug-induced hypersensitivity syndromes. These are postulated to be due to drug-allergy–induced immunosuppression, leading to a re-activation of human herpesvirus 6 or other latent viruses.[108] This syndrome usually develops between 2 and 7 weeks after initiating dapsone and inevitably includes the triad of fever, rash, and hepatitis. The rash is most often an exfoliative dermatitis, but maculopapular and Stevens-Johnson–like lesions have occurred.[109] The hepatitis has a mixed hepatocellular and cholestatic picture with elevations in both transaminases and alkaline phosphatase.[110,111] Atypical lymphocytosis, anemia, itching, lymphadenopathy, and severe hypoalbuminemia with pedal edema and even anasarca, as well as renal hypersensitivity lymphocytic vasculitis, have also been reported to be part of this syndrome.[112,113]

Agranulocytosis is another rare, idiosyncratic side effect that has been estimated to occur in 0.2 percent to 0.4 percent of patients treated with dapsone.[115–118] If agranulocytosis occurs, its onset is almost always during the first 3 months of therapy.[115,116,119] Although usually reversible within days when patients stop therapy, it may be fatal due to superseding infection. Patients should be warned to seek medical care immediately if signs or symptoms of a serious infection develops during the first several months of therapy. Recombinant granulocyte colony stimulating factor has been used to produce a more rapid resolution of agranulocytosis.[120] Additionally, pure red cell aplasia has twice been reported with dapsone therapy.[121]

MONITORING OF DAPSONE THERAPY

Before therapy with dapsone is started, a history and physical examination to screen for pre-existing significant cardiopulmonary disease or peripheral neuropathy should be completed. Initial labs should include a complete blood cell count to determine baseline white blood cell count and hemoglobin. G6PD deficiency should be ruled out as should significant hepatic or renal dysfunction. After therapy has begun, a white blood cell count with differential and hemoglobin levels should be obtained weekly for the first month and then twice a month during the next 2 months. Thereafter, complete blood cell counts should be obtained periodically. Follow-up visits should include checking distal muscle strength, peripheral reflexes and reminding patients to not alter their dosage without physician guidance (to limit their risk for dose-dependent methemoglobinemia and hemolysis). Patients should also be told to carry a medication card so that in event of an emergency, treating physicians will know they are on a drug with hemolytic and methemoglobin-generating potential.

KEY REFERENCES

The full reference list for all chapters is available at www.digm7.com.

2. Beumont MG et al: Safety of dapsone as *Pneumocystis carinii* pneumonia prophylaxis in human immunodeficiency virus-infected patients with allergy to trimethoprim/sulfamethoxazole. *Am J Med* **100**:611, 1996
4. Zuidema J, Hilbers-Modderman ESM, Merkus FWHM: Clinical pharmacokinetics of dapsone. *Clin Pharmacokinetics* **11**:299, 1986
86. Jollow DJ, Bradshaw TP, McMillan DC: Dapsone-induced hemolytic anemia. *Drug Metab Rev* **27**:107, 1995
91. Salamat A, Watson HG: Drug-induced methaemoglobinaemia presenting with angina following the use of dapsone. *Clin Lab Haem* **25**:327, 2003
94. Coleman MD, Coleman NA: Drug-induced methaemoglobinaemia. Treatment issues. [Review] [84 refs]. *Drug Safety* **14**:394, 1996
98. Daneshmend TK: The neurotoxicity of dapsone. *Adv Drug React Ac Pois Rev* **3**:43, 1984
106. Prussick R, Shear NH: Dapsone hypersensitivity syndrome. *J Am Acad Dermatol* **35**:346, 1996
115. Coleman MD: Dapsone-mediated agranulocytosis: Risks, possible mechanisms and prevention. [Review] [51 refs]. *Toxicology* **162**:53, 2001

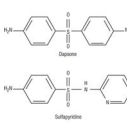

CHAPTER 227

Aminoquinolines

Jeffrey R. LaDuca
Anthony A. Gaspari

Antimalarial compounds have been used to treat skin diseases for over a century. Three compounds, chloroquine (CQ), hydroxychloroquine (HCQ), and quinacrine (QE), have been most studied. The 4-aminoquinolines are a family of compounds derived from quinine. CQ and HCQ, the principal members of this class of compounds, are the most often used for therapeutic use in dermatology. QE, classified as an acridine, has also been used in dermatologic therapy. Interestingly, the use of these medications for treatment and prophylaxis of malaria is waning due to increased resistance.

HISTORY

MECHANISM OF ACTION

The precise mechanisms by which antimalarial compounds exert their actions are still unknown. However, several discrete mechanisms for each compound have been determined. In the treatment of malaria, aminoquinolines concentrate in the *Plasmodium* digestive vacuole and prevent polymerization of toxic heme released during proteolysis of hemoglobin.[11] Mechanisms by which these compounds influence skin diseases are varied.

CQ and HCQ are weak diprotic bases that are protonated, become trapped, and accumulate inside acidic vesicles such as lysosomes,[12] accounting for their effects in *Plasmodium*. HCQ induces signs of lysosomal membrane permeabilization and mitochondrial membrane permeabilization.[13] By raising intracellular vacuolar pH, antigen processing and presentation by dendritic cells may be downregulated. Inhibition of calcium signaling within the T cell may be involved.[14] Conversely, CQ has been more recently shown to enhance human $CD8^+$ T cell responses.[15] QE inhibits Na-K adenosine triphosphatase activity and stabilizes cell membranes.[16] It also concentrates in lysosomes. The effects are most appreciated in macrophages and phagocytizing cells where phagocytosis and chemotaxis are impaired.[17,18] Additionally, cellular enzymes and receptors dependent on lysosomes for function or activation are also affected, thus altering cells' responsiveness to mitogenic stimuli.[12]

AMINOQUINOLINES AT A GLANCE

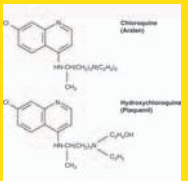

- Aminoquinolines have been used in clinical medicine for more than a century, initially as antimalarial compounds.
- Multiple mechanisms of action, particularly impaired lysosomal acidification by antigen presenting cells, inhibition of natural killer and T-cell activation, and inhibition of lipid mediators of inflammation.
- Propensity for melanin pigment, absorb ultraviolet light, and exhibit photoprotective properties against ultraviolet-mediated injury of the skin.
- Aminoquinolines used to treat dermatologic conditions include hydroxychloroquine, chloroquine, and quinacrine.
- Hydroxychloroquine is the most commonly used aminoquinoline for skin conditions and is well studied for chronic cutaneous lupus erythematosus.
- Other aminoquinoline-responsive conditions: porphyria cutanea tarda, polymorphous light eruption, cutaneous sarcoidosis, dermatomyositis, and other conditions.
- Laboratory monitoring is mandatory during aminoquinoline therapy to detect hematologic abnormalities (hemolysis and drug-induced cytopenias), liver injury, and ophthalmologic toxicity (retinopathy).
- Children are especially susceptible to aminoquinoline toxicities, and lower doses must be used than in adults.
- Drug interactions are possible, and cigarette smoking decreases efficacy of aminoquinolines by inducing cytochrome P_{450} enzymes.

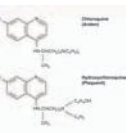

Antimalarials decrease T-cell release of interleukin (IL)-1, IL-6, tumor necrosis factor-α, and interferon-γ.[19,20] IL-1, IL-6, and tumor necrosis factor-α play a role in the hepatic production of acute-phase reactants.[21] Low concentrations of CQ and QE inhibit the pro–IL-6 stimulatory effect of cytosine-phosphorothiolated guanine-oligodeoxynucleotides on human peripheral blood mononuclear cells.[22,23] More recently, it has been found that CQ elevated the expression of B7-2 (CD86, a co-stimulatory protein) and intercellular adhesion molecule-1 (CD54, an adhesion molecule) in peripheral mononuclear cells, thus increasing IL-10–producing cells.[25] CQ has also been implicated in the inhibition of natural killer cell activity, decreased production of IL-2 from activated lymphocytes, and alteration of antigen-antibody complexes. QE also inhibits natural killer cells and blocks the primary proliferative response of cytotoxic T cells to allogeneic non–T-cell antigens.[21] Last, the arachidonic acid pathway is affected by antimalarial compounds. CQ inhibits phospholipase A_2 and C.[21] QE also inhibits phospholipase A_2 production[24,26] and increases nitric oxide release.[27] Thus prostaglandin, leukotriene, bradykinin, and histamine levels can all be decreased. QE antagonizes the generation of superoxide anions.[28]

The 4-aminoquinolines have an affinity for melanin pigment. In the epidermis (as well as retina), they bind in high concentrations. In the skin, CQ absorbs ultraviolet (UV) light in a concentration-dependent manner.[29] However, there is no effect on the minimum erythema dose.[30] Topical CQ applied before UV irradiation protects against UVB- and UVA-induced erythema.[31] QE has also been shown to inhibit photodynamic actions.[32] It has been proposed that the beneficial effect of the HCQ and CQ in various photodermatoses may result from the ability of these drugs to enhance the protective early limb of the UV response.[33]

CQ and QE have been shown to bind cellular DNA by intercalation between base pairs, thus stabilizing the DNA.[34–36] RNA transcription and subsequent translation are inhibited. These may be the mechanisms by which these molecules effect lupus.[37]

Antimalarial compounds have been shown to exhibit myriad other effects. HCQ has been shown to improve lipid profiles.[38] Both CQ and HCQ improve glucose profiles[39,40] and inhibit platelet aggregation.[41] High doses of CQ may produce an antioxidant effect.[42] Through membrane stabilization, antimalarials can produce a local anesthetic effect.[12] In vitro, HCQ has been shown to induce apoptosis in B-chronic lymphocytic leukemia cells.[43] CQ, HCQ, and QE have all been shown to interfere with human immunodeficiency virus type 1 replication and function.[44–46]

PHARMACOKINETICS

The molecular structures of CQ, HCQ, and QE are closely related (Fig. 227-1). CQ and HCQ are 4-aminoquinolines. The addition of a benzene ring classifies QE as an acridine. The pharmacokinetics and pharmacology of these compounds are similar (Table 227-1). All are bitter, water-soluble, and readily absorbed from the gastrointestinal tract with relatively good bioavailability, achieving peak concentrations within hours. CQ and HCQ have large volumes of distribution and prolonged half-lives.[47] The volume of distribution for QE may be even larger than that of CQ and HCQ. QE is extensively bound to plasma proteins, whereas CQ and HCQ are only partially bound.[48–50] The half-life of QE is substantially less than the other compounds.[50] CQ is metabolized (dealkylated) in the liver by P_{450} enzymes into desethylchloroquine and bisdesethylchloroquine.[51] The metabolic fate of QE is less certain. CQ and its metabolites are stored in relatively high concentrations in the liver, spleen, lungs, adrenals, and melanin-containing cells.[52] Approximately 50 percent of CQ is eliminated by the kidneys unchanged.[48] HCQ is also metabolized in the liver (N-deethylation) into three chief metabolites: desethylhydroxychloroquine, desethylchloroquine, and bisdesethylchloroquine.[47] The parent compound and metabolites are taken up by lysosomes and concentrated in lysosome-rich tissues. Renal clearance accounts for approximately 15 percent to 25 percent of the total clearance.[53] The renal excretion of CQ, HCQ, and QE can be enhanced with acidification of the urine.[54] QE is excreted in urine, bile, sweat, and saliva.[50] Renal excretion only accounts for approximately 11 percent of its clearance. The highest tissue concentrations of QE are found in the liver and spleen.[52] Equivalent doses of these compounds are 250 mg of CQ, 400 mg of HCQ, and 100 mg of QE. Smoking may alter the pharmacokinetics of antimalarial compounds. Decreased absorption, increased plasma clearance, or induction of the cytochrome P_{450} system may be responsible.[55] Clinical evidence of decreased efficacy of these medications in smokers has been documented.[56]

Typical doses used in dermatology are 250 to 500 mg/day for CQ, 200 to 400 mg/day for HCQ, and 100 to 200 mg/day for QE. Evidence of efficacy is generally seen after 1 to 3 months of use, after which the dose may be tapered to a minimum effective dose. There is no cross-

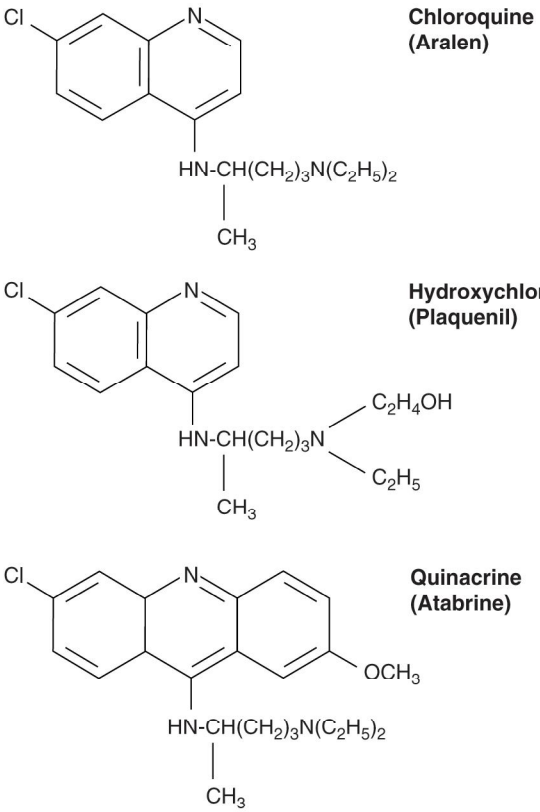

◀ **FIGURE 227-1** Antimalarial drugs used in dermatology.

over reactivity between QE and CQ and HCQ.[57] Thus, its use in combination with HCQ and/or CQ has been deemed safe. In refractory skin conditions, addition of QE to HCQ or CQ has been deemed beneficial, and response may be seen in 6 to 8 weeks after the addition of QE.[58] If QE is added to CQ, the dose of CQ may need to be decreased to reduce potential for toxicity. Triquin, a combination of CQ (65 mg), HCQ (50 mg), and QE (25 mg) was used in the early 1970s. The concomitant use of CQ and HCQ increases the risk for retinopathy (see the section Complications). Thus, its use should be restricted to only severe cases. QE is not currently commercially available; production stopped in 1992. QE powder (veterinary grade, Sigma) can be put into capsules. Panorama Pharmacy in California, with an additional purification step, will prepare QE capsules.

INDICATIONS

The U.S. Food and Drug Administration–approved indications for CQ, HCQ, and QE are limited. As is often seen in dermatology, these compounds are frequently used in an off-label manner. Treatment of malaria is the only indication shared by all three drugs. HCQ has the most labeled uses, including rheumatoid arthritis, discoid lupus, and systemic lupus erythematosus. Extraintestinal amebiasis is the only other approved use for CQ. QE had been approved for treatment of giardiasis when it was manufactured. Experience with HCQ in dermatology is more extensive. Its lower incidence of ocular toxicity (see the section Complications) makes it a favored choice. In recalcitrant disease, CQ is often substituted with increased efficacy. The current difficulty in obtaining QE may account for the relatively fewer indications (Table 227-2).

Cutaneous Lupus Erythematosus (See Chap. 156)

Antimalarial drugs have been used for the cutaneous manifestations of lupus since the 1930s.[59] CQ and QE were found to also be effective in the treatment of cutaneous lupus during World War II.[10] Over 90 percent of patients receiving HCQ showed a benefit.[60] A double-blind trial of HCQ for discoid lupus showed a 70 percent response rate.[61] A review of 20 clinical trials involving the use of QE for cutaneous lupus showed a 73 percent response rate.[62] It is now accepted that antimalarial compounds are effective as steroid-sparing agents in the treatment of lupus erythematosus.[63,64] Antimalarials are typically used as steroid-sparing agents in patients whose symptoms cannot be controlled by topical steroids and sun protection. Widespread cutaneous lesions, hypertrophic

TABLE 227-1
Pharmacology and Pharmacokinetics of Antimalarial Compounds

	CHLOROQUINE (ARALEN)	HYDROXYCHLOROQUINE (PLAQUENIL)	QUINACRINE (ATABRINE)
Bioavailability	80%–90%	75%–100%	80%–100%
Peak levels	4–8 h	~4 h	8–12 h
Protein binding	50%–65%	45%–50%	80%–90%
Volume of distribution	13,000–65,000 L	5500–43,000 L	—
Clearance	130 mL/min (blood) 1100 mL/min (plasma)	95 mL/min (blood) 700 mL/min (plasma)	— —
Half-life	20–60 days	40–50 days	5–14 days
Metabolism	Dealkylated (liver)	Deethylated (liver)	—
Metabolites	Desethylchloroquine Bisdesethylchloroquine	Desethylhydroxychloroquine Desethylchloroquine	None
Renal elimination	50%	15%–25%	11%
Storage	Liver, spleen, lungs, adrenals, pigmented tissues	Adrenals, pituitary, liver, spleen, leukocytes, pigmented tissues	Liver, spleen, lung, adrenals
Equivalent doses	250 mg	400 mg	100 mg

and verrucous lesions, and long-standing discoid lesions do not respond as well. Systemic symptoms of fever or renal and hematologic abnormalities seen in systemic lupus erythematosus typically do not respond to antimalarial therapy. The onset of action for antimalarial therapy is 4 to 8 weeks. More rapid response may be seen with QE.[62] When HCQ is ineffective as a monotherapy, CQ may be more efficacious. The use of QE alone or in combination with either HCQ or CQ has also been suggested as providing a response in recalcitrant patients. Triquin, a combination of all three drugs, has been used for discoid lupus and cutaneous lupus erythematosus with success.

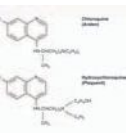

Polymorphous Light Eruption (See Chap. 90)

Polymorphous light eruption is an inflammatory reaction seen on sun exposed skin. IL-1, -6, and -8 may play a role in the inflammatory process.[65] Chloroquines decrease IL-1 and IL-6 and release and absorb UVA light. These drugs have been used for polymorphous light eruption for several years.[66,67] More recently, placebo-controlled trials have proven efficacy for this indication.[68] HCQ at doses of 200 to 400 mg/day is effective. Topical sunscreens should also be used in conjunction with antimalarial therapy. In northern climates, discontinuation of therapy during winter months may decrease cumulative side effects of antimalarial therapy.

Porphyria Cutanea Tarda (See Chap. 132)

The first reported case of CQ therapy for porphyria cutanea tarda (PCT) was published in 1957.[69] Phlebotomy remains the principal treatment for PCT after exacerbating factors are identified and removed. Antimalarial therapy is used with phlebotomy as an adjuvant therapy or when phlebotomy is not possible. Chloroquines inhibit porphyrin synthesis and mobilize lysosomal stores of porphyrins, allowing for the formation of water-soluble complexes, which are then excreted by the kidneys.[70] Hepatotoxicity is a concern, and liver enzymes should be followed closely during therapy. Headache, nausea, fever, elevated transaminases, and urinary excretion of porphyrins occur 3 to 4 days after initiation of therapy with CQ at 250 mg/day.[71] Prolonged remissions have been reported with high doses of HCQ (250 mg tid) for short courses.[72] However, marked increases in liver transaminases required the hospitalization of all patients in this study during the initiation of therapy. Low-dose CQ therapy (125 mg biw for 2 weeks followed by 250 mg biw thereafter) gave a 94 percent response rate in one study of 53 patients.[73] Alternatively, HCQ used at 100 mg tiw for a month, then 200 mg tiw for a month, then advanced to 200 mg qd has been proposed.[74] These lower dosing schedules seem to alleviate the severe hepatotoxicity. A combination of phlebotomy before initiation of CQ therapy may also reduce the severity of hepatotoxicity.[75]

Sarcoidosis (See Chap. 153)

Antimalarial therapy for cutaneous manifestation of sarcoidosis was first described nearly half a century ago. A 1996 review of the subject concluded that antimalarials were highly effective, with greater than 70 percent response rate.[76] Two to three mg/kg/day of HCQ has been reported as being effective in 12 of 17 patients treated.[77] CQ therapy initiated at 500 mg/day for 2 weeks, then a maintenance dose of 250 mg/day has been described as safe and effective.[78] Therapy may also be effective for associated hypercalcemia. Another granulomatous disease, generalized granuloma annulare, has also been reported to respond to HCQ.[79]

Cutaneous Dermatomyositis (See Chap. 157)

Cutaneous symptoms of dermatomyositis may be managed by antimalarial therapy. Monotherapy with either HCQ 200 mg bid (less than 6.5 mg/kg/day) or CQ 250 mg qd (less than 3.5 mg/kg/day) is often adequate to control skin manifestations. The addition of QE to either HCQ or CQ has been shown beneficial in patients with recalcitrant skin disease.[58]

DOSING REGIMEN

Use of antimalarial compounds in dermatology is varied. Each disease state is treated differently with special concerns pertaining to the disease entity. As such, dosing for each condition is dependent on the underlying pathology. Usual starting doses for HCQ are between 200 and 400 mg/day. Equivalent dosing for CQ is 250 to 500 mg/day, and for QE, 100 to 200 mg/day. However, initiation of therapy and maintenance dosing may be different for each disease. Combination therapy with these medications also alters the dosing.

INITIATING THERAPY

Uses of antimalarial drugs in dermatology are varied. Several dermatoses have been successfully treated with these molecules (see the section Indications). Different therapeutic strategies have been used, depending on the given disease state. Nonetheless, many principles govern the initiation of therapy. The correct diagnosis of disease is essential. Biopsies and blood laboratories should be used to confirm the patient's diagnosis, as well as the presence of an antimalarial-responsive dermatosis (see Table 227-2). After the diagnosis is established, one should determine whether the patient is able to tolerate the medication and need for monitoring. Hematologic and metabolic side effects have been reported with the use of these medications, and routine monitoring of laboratory values is necessary. Patients who are deficient in the glucose-6-phosphate dehydrogenase (G6PD) enzyme are more prone to a hemolytic anemia. Thus, baseline evaluation of G6PD enzyme, complete blood cell count, and serum chemistry panel should be performed before initiation of therapy in all patients. Ocular toxicity is a concern with HCQ and CQ. Baseline evaluation by an ophthalmologist is necessary. Slit-lamp assessment, funduscopic examination, and assessment of visual acuity and fields should be included.

MONITORING THERAPY

Monitoring antimalarial therapy should be done in all cases. Laboratory monitoring should include a complete blood count performed monthly for 3 months to ensure that hemolytic (or, less commonly, aplastic) anemia is not occurring. Thereafter, quarterly to semi-annual complete blood counts should be obtained. A comprehensive metabolic panel should be checked after the first month of therapy and then again after 3 months. Special attention should be paid to liver enzymes, particularly in patients on other hepatotoxic medications and in cases of porphyria. Quarterly to semi-annual chemistries should be followed while on maintenance therapy.

Monitoring for ocular toxicity is debated. American guidelines include a

TABLE 227-2
Uses of Antimalarial Agents

HYDROXYCHLOROQUINE (PLAQUENIL)	CHLOROQUINE (ARALEN)	QUINACRINE (ATABRINE)
• Malaria[a]	• Malaria[a]	• Malaria[a]
• Rheumatoid arthritis[a]	• Extraintestinal amebiasis[a]	• Giardiasis[a]
• Discoid lupus[a]	• Rheumatoid arthritis	• Discoid lupus
• Systemic lupus erythematosus[a]	• Discoid lupus	• Systemic lupus erythematosus
• Juvenile arthritis	• Systemic lupus erythematosus	• Intrapleurally for prevention of recurrent pneumothorax
• Sarcoid and associated hypercalcemia	• Juvenile arthritis	• Polymorphous light eruption
• Porphyria cutanea tarda	• Polymorphous light eruption	• Non-surgical female sterilization
• Chronic cutaneous vasculitis	• Porphyria cutanea tarda	• Panniculitis
• Solar urticaria	• Chronic cutaneous vasculitis	• HIV
• Psoriatic arthritis	• Solar urticaria	
• Lymphocytic infiltrates	• Psoriatic arthritis	
• Panniculitis	• Lymphocytic infiltrates	
• Cutaneous features of dermatomyositis	• Panniculitis	
• Oral lichen planus	• Necrobiosis lipoidica diabeticorum	
• Reticular erythematous mucinosis	• HIV	
• Pemphigus foliaceus		
• Generalized granuloma annulare		
• Generalized eruptive histiocytosis		
• Atopic dermatitis		
• Localized scleroderma		
• Sjögren syndrome		
• Multicentric reticulohistiocytosis		
• Chronic graft-versus-host disease		
• HIV		

HIV = human immunodeficiency virus.
[a]U.S. Food and Drug Administration approved.

baseline slit-lamp, funduscopic, visual field, and acuity examination by an ophthalmologist. Periodic eye examinations during the first 5 years of use should be performed, based on the age of the patients, as if they were not being treated with an antimalarial agent. As no patient with normal renal function treated with HCQ at doses less than 6.5 mg/kg/day developed retinal toxicity in the first 6 years, the need for scheduled semiannual or annual examinations is not deemed necessary. After 5 years, annual examinations are recommended.[80] Canadian and British guidelines suggest that the baseline assessment before initiation of therapy include asking about visual impairment and recording the best corrected visual acuity. Thereafter, yearly assessments should be made.[81,82] In practice it has been shown that even these guidelines are not routinely followed.[83] As the risk of irreversible ocular toxicity appears low, there has been a call to revise even these guidelines.[84]

COMPLICATIONS

Most side effects of antimalarial therapy are reversible (Table 227-3). Decreased dosing or drug withdrawal may completely alleviate a majority of side effects encountered with these drugs. Without proper monitoring, however, these drugs have the potential for serious and permanent side effects.[84a]

Gastrointestinal complaints of anorexia, nausea, vomiting, diarrhea, and weight loss are most commonly encountered side effects (10 percent for HCQ; 20 percent for CQ; 30 percent for QE).[85] Acute symptoms from high doses of CQ and HCQ include blurred vision, cardiovascular toxicities, hypotension, neurotoxicity, and respiratory or cardiac arrest.[48,49] In children, as little as 0.75 g of CQ can be fatal (2.25 to 3.0 g in adults).[86] Lethal doses of HCQ are considered to be in a similar range.[48,49] Several cases of overdose have been reported. Management of overdose consists of gastric lavage, ventilation, and inotropic support.[87–91] As little as one or two tablets of CQ or HCQ can be dangerous in children. Appropriate monitoring is necessary after accidental ingestion.[92] A lethal dose of QE is not determined.

Patients with G6PD deficiencies are susceptible to CQ- and HCQ-induced hemolytic anemia, although rarely in therapeutic ranges. Aplastic anemia with QE[93,94] and agranulocytosis with CQ[95] have also been reported.

Cutaneous adverse effects can be seen with antimalarial therapy. Exacerbation of pre-existing psoriasis in as many as 18 percent of patients with psoriasis has been documented with the use of antimalarial drugs.[96] CQ is responsible for most psoriatic flare-ups, and QE is more likely to induce exfoliative erythroderma. HCQ is much less likely to exacerbate psoriasis.[97] It has never been convincingly demonstrated that the apparent exacerbation of psoriasis represents an adverse drug–disease interaction. These flares in psoriasis may represent an allergic reaction to antimalarial compounds. In the general population, incidence of pruritus and rashes secondary to antimalarial use is reported to be 10 percent to 20 percent.[98] Dose-related QE-induced drug eruptions were reported during World War II. One in 2000 soldiers taking 100 mg qd reported a reaction, whereas 1 in 600 soldiers taking 200 mg qd had a reaction.[94] Lichenoid reactions accounted for approximately 20 percent of the reactions in this series. CQ has an affinity for melanin and is thus concentrated in the skin. The binding of drug molecules to melanin may cause a blue-black discoloration of the skin in 10 percent to 25 percent of patients treated with these compounds for a prolonged course. Shins, face, hard palate, and nail beds are commonly affected.[99,100] The discoloration may fade slowly over months after the drug is discontinued. QE also binds melanin and may cause hyperpigmentation similar to that seen with CQ. More commonly, a dose-related yellowish staining occurs and affects the skin, sclera, and bodily secretion. This also tends to fade over time after drug withdrawal. Stevens-Johnson syndrome has been reported in a patient treated with HCQ.[101]

Ocular toxicity is the most worrisome side effect of antimalarial therapy. Neuromuscular eye toxicity, corneal deposits, and potentially irreversible retinopathy can all occur. Blurred vision and reduction in accommodation power can occur from the depressive effect on ocular muscles during the initial weeks of therapy (transient and self-limited). CQ is deposited in the basal epithelium of the cornea. Deposition of HCQ can also occur but is less likely at therapeutic doses.[102] These depositions can be responsible for patient complaints of blurred vision, halos around lights, and photophobia.[103] The corneal deposits are dose related, reversible with cessation of

TABLE 227-3
Risks and Precautions

- Possible side effects from antimalarial compounds
  - Gastrointestinal: Anorexia, nausea, vomiting, diarrhea, weight loss, hepatotoxicity
  - Hematologic: Hemolytic anemia (glucose-6-phosphate dehydrogenase deficiency), aplastic anemia, agranulocytosis, pancytopenia
  - Mucocutaneous: Pigmentation—blue gray, yellow (quinacrine), rashes (urticaria, morbilliform, lichenoid, exfoliative dermatitis, acute generalized exanthematous pustulosis), pruritus, worsening psoriasis
  - Ophthalmologic: Neuromuscular eye toxicity (diplopia, blurred vision, loss of accommodation), corneal deposits (halos around lights, photophobia), retinopathy (pre-maculopathy—reversible and true retinopathy—irreversible; not seen with quinacrine therapy)
  - Neuromuscular: Nightmares, vertigo, tinnitus, nervousness, irritability, toxic psychosis, seizures, neuromyotoxicity, myasthenia-like syndrome, ototoxicity, rhabdomyolysis
  - High doses: Cardiovascular toxicities, hypotension, neurotoxicity, respiratory or cardiac arrest, death
- Drug interactions
  - Penicillamine and digoxin levels may be increased with concurrent use of CQ or HCQ
  - Cyclosporin levels may be increased with use of CQ
  - Metoprolol levels may be increased with use of HCQ
  - Ampicillin bioavailability may be decreased when used with CQ
  - Antacids and Kaolin may decrease gastrointestinal absorption of CQ
  - Cimetidine may increase CQ levels
  - Mefloquine used with CQ may increase risk of seizures
  - Smoking decreases efficacy of antimalarial drugs by inducing the cytochrome P_{450} system
- Special precautions
  - Dosing in children must consider weight to decrease risk of toxicity
  - Use in pregnancy is relatively contraindicated (congenital defects are rare)
  - Use in breast-feeding is relatively contraindicated (CQ and HCQ are excreted in breast milk)

CQ = chloroquine; HCQ = hydroxychloroquine.

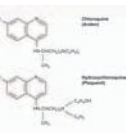

therapy, and not a contraindication for continued therapy. CQ has an affinity for retinal pigment epithelium and can be stored there for years, even after discontinuation of therapy. Antimalarial-induced retinopathy can be reversible (pre-maculopathy) or irreversible (true retinopathy). Pre-maculopathy includes changes in visual fields or funduscopic examination not associated with vision loss. These changes may progress to irreversible disease if the offending drug is not discontinued. True retinopathy is associated with bilateral, permanent visual field abnormalities. Risk of true retinopathy from antimalarial therapy has been studied and debated. It appears as though the risk is greater for CQ than HCQ.[102,104] Doses less than 4.0 mg/kg/day for CQ and less than 6.5 mg/kg/day for HCQ are believed to decrease the risk of a true retinopathy.[105] Higher doses and impaired renal function may increase the risk. The true risk of HCQ-induced retinopathy is felt to be quite rare. As such, the question of screening as a cost-effective measure is debated. A case of bull's eye maculopathy has been associated with QE therapy for malaria.[106]

Other, less likely side effects of antimalarial therapy include neuromyotoxicity,[107] ototoxicity,[108,109] acute generalized exanthematous pustulosis,[110] and rhabdomyolysis.[111]

Drug Interactions

Few drug interactions have been reported with concurrent use with antimalarial drugs. Penicillamine or digoxin levels may be increased when used with CQ or HCQ.[48,49] Cyclosporin levels may be increased by CQ.[48] Metoprolol levels may be increased with use of HCQ.[112] CQ may reduce the bioavailability of ampicillin.[48] Antacids and Kaolin may decrease the GI absorption of CQ. A minimum of 4 hours should exist between administration of antacids and antimalarials.[48] Cimetidine may increase CQ levels,[48] increasing potential for other side effects. Concurrent use CQ and mefloquine may increase the risk of seizures. CQ increases the risk of hepatotoxicity when administered with other hepatotoxic agents. Monitoring liver enzymes is recommended.[48] Finally, smoking induces the cytochrome P_{450} enzyme system and may alter the bioavailability of antimalarial therapy. Decreased efficacy of antimalarial therapy in smokers has been published.[113]

Pediatric Use

CQ and HCQ have been used in the pediatric population.[114,115] However, concern over toxicity exists.[116,117] Milligram-per-kilogram, antimalarials are now considered generally safe in children when treating connective tissue diseases, juvenile rheumatoid arthritis, morphea, panniculitis, or PCT.[118] Risk for toxicity in children is felt to be no greater than for adults when accounting for body weight.

Pregnancy

Use of antimalarial drugs in pregnancy is controversial but now generally accepted as safe. It is recognized that 4-aminoquinalines cross the placenta and accumulate in fetal tissues.[52] Congenital defects have been rarely reported with antimalarial drug use in pregnancy.[119] In one study of 27 pregnancies exposed to HCQ or CQ, no congenital anomalies were identified.[120] Another review of 33 lupus patients with 36 pregnancies exposed to HCQ reported no evidence of teratogenic effects.[121] Larger reviews in Britain and North America support the use of 4-aminoquinalines during pregnancy.[122–124] In addition, discontinuation of antimalarial therapy for the treatment of lupus may cause a significant flare-up of disease, which can be associated with prematurity, growth retardation, and increased fetal loss.[125–128] Safety of QE is less well documented.

Breast-Feeding

Antimalarial use during breast-feeding is relatively contraindicated. CQ and HCQ are both excreted in breast milk.[129] In the case of HCQ, infants are exposed to 2 percent of the maternal dose per kilogram per day and 1 percent of the maternal dose of CQ.[57] As the half-life is long and elimination slow, potential exists for accumulation of drug in the infant.[130]

KEY REFERENCES

The full reference list for all chapters is available at www.digm7.com.

1. Hofheinz W, Merkli: Quinine and quinine analogues, *in Antimalarial Drugs II: Current Antimalarials and New Drug Development*, edited by W Peters and WHG Richards. New York, Springer-Verlag, 1984, p 61
37. Dubois EL: Effect of quinacrine (Atabrine) upon lupus erythematosus phenomenon. *Arch Dermatol* **71**:570, 1955
80. Mavrikakis I et al: The incidence of irre-

versible retinal toxicity in patients treated with hydroxychloroquine. *Ophthalmology* **110**:1321, 2003
84a. Chloroquine/Hydroxychloroquine Toxicity. http://www.emedicine.com/oph/topic245.htm 2006.
90. Isbister G, Dawson A: Hydroxychloroquine overdose: A prospective case series. *Am J Emerg Med* **20**:377, 2002
118. Ziering CL, Rabinowitz LG, Esterly NB: Antimalarials for children. Indications, toxicities, and guidelines. *J Am Acad Dermatol* **28**:764, 1993
121. Buchanan NMM et al: The safety of hydroxychloroquine in lupus pregnancy: review of a series of 36 cases. *Ann Rheum Dis* **55**:486, 1996

CHAPTER 228

Cytotoxic and Antimetabolic Agents

Whitney A. High
James E. Fitzpatrick

Cytotoxic and antimetabolic agents may be used to treat severe or refractory skin disease. The toxicities of such agents are significant and must be balanced against therapeutic advantage. In treating skin disease, most of these agents are utilized at immunomodulatory rather than cytotoxic dosages.

Cytotoxic and antimetabolic drugs modulate the behavior of inflammatory and other cells through inhibition of cell growth and development. The cell cycle represents a conceptual schema for the sequence of growth experienced by essentially all cells (see eFig. 44-2.1 in online edition). The cycle begins with the G_1 phase, which is directed toward preparing the cellular apparatus for DNA synthesis. The S phase follows G_1 and is devoted to DNA synthesis. At the end of DNA synthesis, the G_2 phase occurs. The G_2 phase is followed by the M phase, or actual cell division. Some cells may also enter a resting state of indeterminate length, termed G_0. Specific cytotoxic drugs may be effective at different stages of the cell cycle.

The cytotoxic drugs commonly used in dermatology fall into two classes: antimetabolites and alkylating agents. Antimetabolites mimic natural molecules and are most active while DNA is being synthesized (S phase). Alkylating agents exert effect through physicochemical interactions with DNA, such as alkylation, cross-linking, and carbamylation. The effects of alkylating agents are generally independent of the cell cycle.

The immunosuppressive properties of cytotoxic agents provide benefit in immunologically mediated disease, yet these agents may predispose to infection as well. Potentially lethal infections may arise quickly in an immunosuppressed patient. Those placed on cytotoxic agents should be queried at each visit for symptoms of infection, such as fever, chills, sweating, shortness of breath, cough, headache, dysuria, and arthritis. Prompt reporting of symptoms should be encouraged.

ANTIMETABOLIC AGENTS

Methotrexate

Methotrexate remains one of the most frequently employed antimetabolic agents in dermatology. With appropriate monitoring, an impressive record of safety has accumulated for methotrexate. Concerns regarding use of methotrexate are best addressed through increased drug awareness, rational patient selection, appropriate laboratory monitoring, and, most recently, folate supplementation.

MECHANISM OF ACTION Methotrexate is an analog of folate that competitively and irreversibly inhibits dihydrofolate reductase (Fig. 228-1). Methotrexate also partially inhibits thymidylate synthetase. Through inhibition of these enzymes, methotrexate decreases the availability of reduced folate and thymidylate necessary for RNA and DNA synthesis. Other inhibitors of folate metabolism, such as trimethoprim-sulfamethoxazole, may potentiate the toxicity of methotrexate (see Drug Interactions).

Like folate itself, the activity of methotrexate is enhanced by glutamylation. Glutamylation also yields additional anti-inflammatory properties.[1] First, by inhibiting aminoimidazole carboxamide ribonucleoside transformylase, methotrexate-polyglutamate increases the local tissue concentration of adenosine, which has potent anti-inflammatory action. Second, by decreasing available tetrahydrofolate, methotrexate decreases the production of S-adenyl methionine, which also results in decreased inflammation.

PHARMACOKINETICS Oral methotrexate is absorbed rapidly through the gastrointestinal tract. In children, absorption is decreased by concurrent ingestion of food and milk, but this has not been observed in adults. In adults, the mean bioavailability is 67 percent of the administered dose. Peak plasma levels

CYTOTOXIC AND ANTIMETABOLIC AGENTS AT A GLANCE

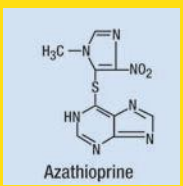

- Cytotoxic and antimetabolic agents are used in dermatology to treat serious, life-threatening, and recalcitrant disease.
- Common agents used in dermatology include methotrexate, azathioprine, mycophenolate mofetil, thioguanine, hydroxyurea, cyclophosphamide, chlorambucil, and liposomal doxorubicin.
- Methotrexate is U.S. Food and Drug Administration (FDA) approved for treatment of psoriasis and advanced mycosis fungoides, whereas cyclophosphamide is FDA approved for advanced mycosis fungoides only, and liposomal doxorubicin is approved for acquired immunodeficiency symdrome–related Kaposi sarcoma; other uses of the agent in this chapter occur on an "off-label" basis.
- Cytotoxic and antimetabolic agents act through inhibition and/or interruption of the cell cycle.
- Side effects and complications with these potentially dangerous medications are numerous, and close clinical follow-up and laboratory evaluation is necessary.
- Cytotoxic agents used in dermatology, as well as those initiated for other purposes, may yield distinctive cutaneous eruptions and cutaneous sequelae.

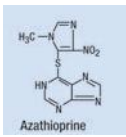

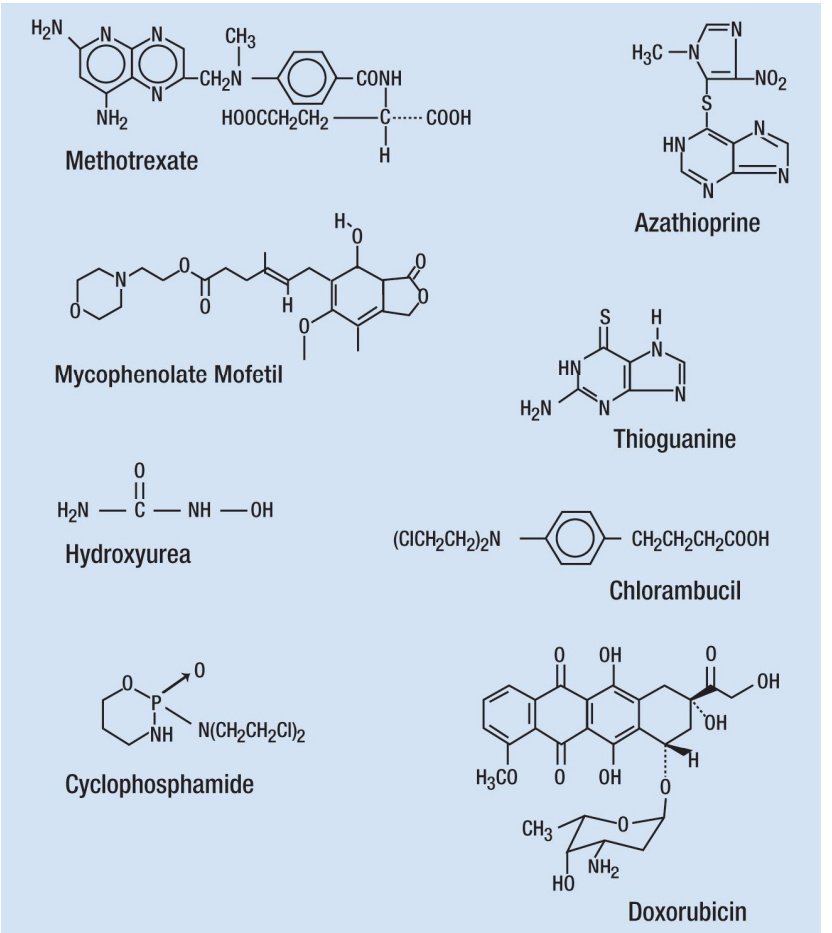

▲ **FIGURE 228-1** Chemical structure of cytotoxic agents most often used in dermatology.

occur 1 to 3 hours after administration. The half-life of the drug is 4 to 5 hours. For doses higher than 25 mg/week, gastrointestinal absorption is more erratic, and some experts recommend intramuscular dosing above this level.[2]

Methotrexate is eliminated chiefly by the kidneys, with 60 percent to 95 percent excreted unchanged. Decreases in glomerular filtration or tubular secretion may lead to methotrexate toxicity. Approximately 50 percent of methotrexate within the blood is protein bound. Weak organic acids, such as aspirin or other nonsteroidal anti-inflammatory agents, may displace methotrexate, altering blood levels and renal excretion (see Drug Interactions).

INDICATIONS Methotrexate is used for many purposes in dermatology, but its chief indication is for treatment of severe psoriasis. The anti-psoriatic effects of methotrexate were first recognized in the late 1950s and 1960s,[3] and by the late 1980s, more than one-half of dermatologists reported using methotrexate to treat severe psoriasis.[4] The impact of an increasing number of systemic treatments for psoriasis (the "biologics"; see Chap. 235) has not been fully studied, but certainly these agents may decrease methotrexate use. Methotrexate has also been used in a variety of other autoimmune and connective tissue diseases, vasculitides, inflammatory dermatoses, and papulosquamous conditions (Table 228-1).

DOSING REGIMEN Typical oncologic doses of methotrexate (100 to 250 mg/m^2/week) are cytotoxic; however, lower doses (7.5 to 25.0 mg/week) are immunomodulatory. In dermatology, methotrexate doses are typically less than 30 mg/week, and are often less than 17.5 mg/week. Cumulative dose must be tracked and recorded, as this impacts monitoring during continued use (see Monitoring Therapy).

Methotrexate is available in 2.5-mg tablets. For those with economic limitations, methotrexate liquid (25 mg/mL) may be more affordable for peroral use.[5] Either a single weekly dose or a weekly dose divided into three portions separated by 12 hours is used. These dosing regimens have essentially equal efficacy, although the split dose may increase tolerance by minimizing gastrointestinal upset.

INITIATING THERAPY Evaluation before methotrexate use includes a careful history and physical examination, and assessment of concomitant conditions or medications that limit methotrexate use. Exclusion of patients inappropriate for methotrexate therapy is an important first step in management. Methotrexate is relatively contraindicated in those with hepatic disease (including viral hepatitis), significant renal disease, active infection, or those with excessive alcohol consumption. In general, the elderly are often less amenable to methotrexate therapy due to declining renal function. Administration of methotrexate to pregnant women or nursing mothers is strictly contraindicated. Consensus is lacking with regard to the use of methotrexate in human immunodeficiency virus-positive (HIV+) individuals, but caution is advised.[6] Baseline laboratory studies include a complete blood cell count (CBC) with manual differential and platelet count; liver function testing; serologic assessment for hepatitis A, B, and C antibodies; renal function assessment; and HIV screening if indicated.[7]

Initiation of methotrexate therapy involves a test dose. Patients selected appropriately on the basis of disease severity, general health, personal habits, and satisfactory baseline laboratory values are given a single 5- to 10-mg test dose. Repeat laboratory studies, a skin examination, and a review of systems are conducted 1 week later. Performance of repeat laboratory studies sooner than 5 to 6 days after dosing yields only expected elevated liver transaminases and may confound interpretation.

If all data are acceptable, weekly therapy may commence using a dose of ap-

TABLE 228-1
Uses for Methotrexate in Dermatology

- U.S. Food and Drug Administration–approved indications
  - Severe psoriasis (± psoriatic arthritis)
  - Mycosis fungoides (advanced disease)
- "Off-label" uses
  - Dermatomyositis
  - Cutaneous lupus erythematosus
  - Scleroderma
  - Pemphigus vulgaris
  - Bullous pemphigoid
  - Cutaneous polyarteritis nodosa
  - Behçet disease
  - Pyoderma gangrenosum
  - Lymphomatoid papulosis
  - Pityriasis lichenoides et varioliformis acuta
  - Pityriasis rubra pilaris
  - Sarcoidosis
  - Severe atopic dermatitis
  - Chronic hand dermatitis

TABLE 228-2
Safety Monitoring for Methotrexate Use

Initial Evaluation	Ongoing Laboratory Monitoring

• Careful history and physical examination
• Identification of proper patient characteristics and risk factors
• Survey for interacting medications (aspirin, nonsteroidal anti-inflammatory drugs, trimethoprim-sulfamethoxazole, etc.)
• Baseline laboratories:
  • CBC with differential/platelets
  • Liver function tests
  • Serology for hepatitis A/B/C
  • Renal function testing (creatinine/blood urea nitrogen)
  • Human immunodeficiency virus screening (if applicable)
	• CBC with differential/platelets and liver function tests
	  • Perform weekly for 2–4 wk
	  • Gradually increase to every 3–4 mo with time
	  • Perform 5–6 days after any dose escalation
	• Renal function tests
	  • Perform once or twice yearly or if suspicion of change in renal function arises
	• Liver biopsy
	  • Perform after 1.5 g (cumulative dose) if no risk factors, then every 1 g thereafter
	  • Perform early in therapy if risk factors exist

CBC = complete blood cell count.

proximately 10 mg/week, depending on the severity of disease, overall health, and ideal body weight of the patient. The dose may be increased by 2.5 to 5.0 mg every 2 to 4 weeks until adequate control is achieved or toxicity ensues. When improvement has stabilized, the dose may be tapered in 2.5-mg decrements to a point at which disease activity increases slightly. The goal is to allow mild or low-grade psoriasis activity to avoid an unacceptably high dose. It is important to discuss this expectation with the patient to prevent confusion regarding the endpoint. Concomitant topical therapy may minimize the methotrexate dose needed for satisfactory control.

If a patient does not demonstrate satisfactory improvement on a dose of 20 to 25 mg/week, consideration of alternative agents is indicated. Occasional patients with refractory disease may respond better to parenteral methotrexate, typically intramuscular dosing. In refractory cases, methotrexate may be combined with ultraviolet B (UVB) phototherapy, psoralen and UVA light, or oral retinoids to enhance efficacy.[7]

MONITORING THERAPY Ongoing laboratory evaluation during methotrexate therapy should include a CBC with manual differential and platelet count and liver function tests weekly for 2 to 4 weeks, then increasing gradually to every 3 to 4 months. Always repeat testing with any dose escalation or intercurrent illness. Liver function testing should not be performed earlier than 5 days after dosing to avoid confounding results. Renal function tests should be performed once or twice yearly, or with any suspicion of altered renal function.

A consensus conference of dermatologists has recommended liver biopsy be performed in those without risk factors after administration of the first 1.0 to 1.5 g of methotrexate and at or near the beginning of treatment in those with risk factors for liver disease.[7] If methotrexate is continued, a repeat biopsy should occur at 3 g, and every 1.0 to 1.5 g thereafter. In those patients with an indication for an early biopsy (e.g., obesity, diabetes, history of liver disease), consideration of a short delay of 2 to 4 months after initiation of therapy may prevent an unnecessary liver biopsy in those patients who will not continue therapy. Safety guidelines used during methotrexate therapy are summarized in Table 228-2.

RISKS AND PRECAUTIONS Absolute and relative contraindications and common adverse effects of methotrexate are summarized in Table 228-3.

COMPLICATIONS Adverse reactions to methotrexate range from the trivial to life-threatening.

Gastrointestinal Effects. Nausea and vomiting with oral administration is common and dose related. Such effects may be seen with parenteral dosing as well. Indeed, 10 percent to 30 percent of all patients placed on methotrexate may experience some gastrointestinal upset. Symptoms may even occur before dosing or 24 to 36 hours afterward, suggesting a psychosomatic or anticipatory basis in select cases. Supplementation with folate (1 to 5 mg/day) reduces gastrointestinal symptoms without compromising efficacy.[8–11]

TABLE 228-3
Risks and Precautions with Methotrexate Use

- Absolute contraindications
  - Pregnancy (Category X)
  - Lactation
- Relative contraindications
  - Renal dysfunction (dose may be reduced)
  - Hematologic disease (dose may be reduced)
  - Hepatic disease or hepatic dysfunction
  - Unreliable patient
  - Excessive alcohol consumption
  - Diabetes mellitus and/or obesity
  - Active infection and/or potential reactivation of infection (tuberculosis)
  - Human immunodeficiency virus infection (controversial)
  - Man or woman contemplating impending conception
- Common adverse effects
  - Gastrointestinal distress (minimized with folate supplementation)
  - Myelosuppression (acute)
  - Toxic hepatitis
  - Liver fibrosis/cirrhosis (chronic)

Hepatic Effects. Induction of liver fibrosis is a major concern with methotrexate use. Methotrexate is hepatotoxic, and some elevation in liver transaminases is expected. These elevations occur near to administration and are not strictly predictive of those predisposed to fibrosis. Fibrosis in the absence of elevated transaminases is well described.[12,13] Dose reduction or discontinuance is indicated if transaminases exceed twice normal values when measured 5 to 6 days after the last dose. For reasons that are unclear, psoriasis patients appear to have a higher incidence of liver fibrosis than do rheumatoid arthritis patients despite similar treatment doses. The confounding effect of alcohol among psoriasis patients has been asserted as a possible explanation.[14]

Hepatic fibrosis relates to duration of therapy, cumulative dose, patient age, and comorbid conditions. The data on methotrexate-induced liver fibrosis vary widely, with a reported prevalence of 0 percent to 25 percent. The risk of liver disease appears low in those with a cumulative dose less than 1.5 g.[7] Patients with prior liver disease, diabetes, obesity, significant alcohol intake, and intravenous drug use are at increased risk for hepatic fibrosis.

The gold standard for assessing methotrexate-induced liver fibrosis is percutaneous needle biopsy. The procedure is not without risk; minor bleeding occurs in 1 in 1000 patients, and the risk of death is

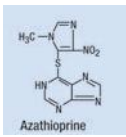

TABLE 228-4
Classification of Liver Biopsy Findings for Methotrexate Use

Biopsy Grade	Histopathologic Findings	Recommended Action
I	Normal; fatty infiltration (mild), portal inflammation (mild)	Continue methotrexate
II	Fatty infiltration (moderate to severe), portal inflammation (moderate/severe)	Continue methotrexate
IIIA	Fibrosis (mild)	Continue methotrexate; repeat biopsy in 6 mo
IIIB	Fibrosis (moderate to severe)	Discontinue methotrexate
IV	Frank cirrhosis	Discontinue methotrexate

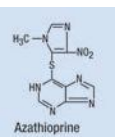
Azathioprine

estimated at 1 in 10,000.[15] Specimens are assessed for lobular architecture, inflammation and fibrosis, and fat infiltration. A grading scheme using a scale of I to IV is widely used (Table 228-4). Patients with grades I and II histology may continue methotrexate, those with grade IIIA histology may continue with a repeat liver biopsy in 6 months, and those with grades IIIB and IV histology should discontinue methotrexate.[7]

A non-invasive test for liver fibrosis would be ideal. Ultrasound alone has demonstrated conflicting results.[16,17] Radionuclide scans and the aminopyrine breath test have proven inadequate for independent detection of methotrexate-induced fibrosis.[18,19] Serum assay of the amino terminus of type III procollagen peptide (PIIINP) may suggest fibrosis; however, specificity is limited. PIIINP is simply a marker of fibrogenesis, and it may be elevated during fibrosis of any organ system.[20] It is unreliable in patients with psoriatic arthritis. A compelling argument has been made to use an amalgam of tests, such as ultrasound, dynamic radionuclide scanning, and PIIINP assay, to reduce the number of required liver biopsies. Nevertheless, at present, percutaneous liver biopsy remains the standard of care.[14,21]

Hematologic Effects. The most important acute adverse effect of methotrexate is myelosuppression. Anemia, neutropenia, and thrombocytopenia may result from methotrexate use. Risk factors for bone marrow toxicity include advanced age, poor renal function, and concurrent administration of conflicting medications (see Drug Interactions).

Mucosal and Cutaneous Effects. Oral ulcerations or stomatitis may be noted with methotrexate use. Skin ulceration, particularly of the lower legs, may herald bone marrow suppression. In patients treated with methotrexate for psoriasis, rapid ulceration of psoriatic plaques may also suggest toxicity.[22] Laboratory studies and dose reduction or complete discontinuance is indicated when mucocutaneous ulcerations or skin ulcerations develop, respectively. Methotrexate may also engender a cutaneous "recall reaction" in areas of prior irradiation or recent sunburn.[23] Mild alopecia has been described with methotrexate use. Other cutaneous manifestations include acral erythema, epidermal necrosis, and vasculitis.

Carcinogenecity. Low-dose methotrexate use has not been definitively associated with carcinogenesis. In a study that demonstrated a slight increase in lymphoma among psoriatic patients within the United Kingdom, use of methotrexate was not discriminatory.[24]

Mutagenecity and Teratogenecity. Methotrexate is a Category X agent during pregnancy, and administration is absolutely contraindicated (see Table 228-3). Pregnancies that occur after the discontinuation of methotrexate appear unaffected, but it is generally advocated that men wait 3 months after discontinuance before attempting conception; women should wait one complete menstrual cycle. Reliable contraception is requisite while taking methotrexate.[7]

Pulmonary Effects. Acute pneumonitis and pulmonary fibrosis have been reported with methotrexate use in psoriasis, although such reactions are more common in rheumatoid arthritis patients.[25] Pulmonary toxicity likely represents an idiosyncratic reaction. Chest radiographs and pulmonary function testing are not useful in the detection or prevention of pulmonary fibrosis.[26] A chest x-ray should be performed in those with symptoms of pneumonitis. Discontinuance is recommended if examination findings are concerning.

Opportunistic Infections. Opportunistic infections (e.g., *Pneumocystis* pneumonia, cryptococcosis, and histoplasmosis) have been reported in otherwise healthy individuals receiving low-dose methotrexate.[27–30] Admittedly, such patients were often using other immunosuppressive medications as well; often prednisone.

Anaphylaxis. Systemic anaphylaxis with low-dose methotrexate has been reported.[31] Many patients had received methotrexate before at comparable doses without untoward effects.

Folate and Folinic Acid Supplementation. Daily supplementation with 1 to 5 mg of folate has reduced nausea, vomiting, stomatitis and oral ulceration, elevated transaminases, and mild myelosuppression without compromising the efficacy of methotrexate.[8–11] Liver fibrosis, pneumonitis, and moderate to severe myelosuppression are not mitigated by folate supplementation. Elevated homocysteine levels, common with methotrexate use and an independent risk factor for coronary artery disease, are decreased with folate supplementation.[32]

Folinic acid should not be given on the same days as methotrexate dosing. Unlike folinic acid, folate does not compete with methotrexate for cellular uptake. Folate is also considerably cheaper than folinic acid. For these reasons, folate supplementation is preferred by many authorities. One drawback to folate supplementation is the potential masking of vitamin B_{12} deficiency. Use of folate supplementation with methotrexate therapy is increasing rapidly.

Overdose. Methotrexate overdose is more likely in patients with declining renal function, in those who misunderstand dosing directions, or in those concomitantly exposed to a second folate antagonist, such as trimethoprim-sulfamethoxazole. Overdose should be treated promptly with folinic acid (leucovorin). Folinic acid is metabolized in vivo to tetrahydrofolate in the absence of dihydrofolate reductase, providing an alternative supply of DNA and RNA precursors.

Folinic acid should be given early, preferably within the first 24 to 36 hours after overdose. Folinic acid itself has very little toxicity. Therefore, an oral dose of 10 mg/m^2 should be given on first suspicion of methotrexate overdose without delay for a serum assay. Peroral or parenteral doses may be continued every 6 hours until the serum concentration of methotrexate falls to less than 10^{-8} M.[7] Practically speaking, or when a serum assay is unavailable, this recommendation is often equiva-

lent to 15 to 25 mg of folinic acid by mouth every 6 hours for 6 to 10 doses.

Drug Interactions. Although any drug that may enhance methotrexate toxicity should be avoided during therapy, there are several near-absolute contraindications, including aspirin, other nonsteroidal anti-inflammatories, probenecid, and trimethoprim-sulfamethoxazole.[33]

Azathioprine

Azathioprine is a synthetic analog of natural purine bases used in RNA and DNA synthesis (see Fig. 228-1). Although many thiopurine derivatives exist, azathioprine is the agent most often used in dermatology.

MECHANISM OF ACTION Azathioprine is a prodrug that is metabolized in the body to 6-mercaptopurine (6-MP). 6-MP is further anabolized via hypoxanthine-guanine phosphoribosyl transferase (HGPRT) to a purine analog that inhibits RNA and DNA synthesis and repair, yielding immunosuppression. HGPRT activation is critical. Patients with Lesch-Nyhan syndrome (HGPRT deficiency) experience no immunosuppression or untoward effects while taking azathioprine.[34]

PHARMACOKINETICS Azathioprine and its metabolite, 6-MP, are equally potent when administered parenterally, but azathioprine enjoys improved bioavailability, with 88 percent of the oral dose being absorbed through the gastrointestinal tract. After absorption, azathioprine is converted to 6-MP, mostly within erythrocytes. The fate of 6-MP is determined by one of three competing metabolic pathways: (1) it may be anabolized to an active form via HGPRT, (2) it may be catabolized to an inactive form via xanthine oxidase (XO), or (3) it may be catabolized to an inactive form by thiopurine methyltransferase (TPMT).[35]

Elucidation of the TPMT-dependent catabolic pathway has revolutionized the clinical use of azathioprine. In humans, expression of TPMT is variable due to genetic polymorphisms. Patients may be categorized into three subgroups: (1) a large majority possesses high levels of TPMT expression (89 percent), (2) intermediate expression is demonstrated in 11 percent, and (3) less than 1 percent demonstrate low TPMT activity (1 in 300 persons).[36] Commercial assays for TPMT activity allow for graduated azathioprine dosing, with improved efficacy and a lesser incidence of unforeseen side effects (see Dosing Regimen).[37,38]

XO is another enzyme involved in the catabolism of 6-MP. Allopurinol, used in the treatment of gout, is a potent inhibitor of XO; toxicity may result in those taking both medications.[39] Unlike TPMT, there is very little genetic variation in XO expression, and it is unnecessary to assess innate XO expression before azathioprine dosing. A careful medication history, however, is critical (see Drug Interactions).

INDICATIONS In dermatology, azathioprine is used "off-label" chiefly as a steroid-sparing agent for immunobullous disorders, including pemphigus, cicatricial pemphigoid, and severe or recalcitrant bullous pemphigoid (Table 228-5).[40] In a prospective, long-term study of pemphigus vulgaris patients treated with glucocorticoids and azathioprine, 45 percent achieved remission.[41] The steroid-sparing effect of azathioprine in pemphigus has been challenged in literary review, but not in a clinical trial; it remains a common regimen among practicing dermatologists.[42]

DOSING REGIMEN Azathioprine is supplied as 50-mg tablets and also as an injectable. Traditionally, a dose of 1 to 2 mg/kg/day of azathioprine was used, often concurrent with high-dose prednisone. Increasingly, the appropriate dosage is now based on a patient's own TPMT expression (Table 228-6).[37] Impaired renal function may be associated with greater toxicity, and the dosage may still be adjusted for this reason.

TABLE 228-5
Uses for Azathioprine in Dermatology

- U.S. Food and Drug Administration–approved indications
  - None
- "Off-label" uses
  - Dermatomyositis
  - Severe cutaneous lupus erythematosus
  - Scleroderma
  - Relapsing polychondritis
  - Pemphigus vulgaris
  - Bullous pemphigoid
  - Cicatricial pemphigoid
  - Cutaneous polyarteritis nodosa
  - Severe or recalcitrant leukocytoclastic vasculitis
  - Behçet disease
  - Pyoderma gangrenosum
  - Sarcoidosis
  - Severe psoriasis
  - Severe lichen planus
  - Severe atopic dermatitis
  - Chronic actinic dermatitis
  - Severe contact dermatitis
  - Severe polymorphous light eruption

TABLE 228-6
Dosing of Azathioprine Based on Thiopurine Methyltransferase (TPMT) Enzyme Assay

TPMT Erythrocyte Assay	Maximum Azathioprine Dose
> 19.0 U (high expression)	2.5 mg/kg/day
13.7–19.0 U (intermediate expression)	1.5 mg/kg/day
5.0–13.7 U (low expression)	0.5 mg/kg/day

INITIATING THERAPY Before therapy, the patient should receive a complete history and physical examination. Exclusion of patients with severe co-morbidities, active infections, or the possibility of reactivation of an infection (tuberculosis) is recommended. All women of childbearing age should receive a pregnancy test. Patients with a history of exposure to alkylating agents should likely not receive azathioprine unless unavoidable, as an increased risk of lymphoproliferative disease exists when used in succession.

Baseline laboratory tests include a CBC with manual differential and platelet count, renal and liver function testing, and an erythrocyte TPMT activity assay should be performed. There are reports of mycobacterial infection in those taking azathioprine, and tuberculin screening should be considered. In steroid-responsive bullous disorders and in connective tissue disease, experienced practitioners often initiate azathioprine concurrently with high-dose steroids.

MONITORING THERAPY During therapy, a CBC with manual differentiation and platelet count and liver function testing should be obtained biweekly to monthly for the first 2 to 3 months, and every 2 months thereafter. Additional laboratory testing is necessary with dosage increases or if an initial TPMT level cannot be determined. Biannual physical examinations should pay particular attention to evidence of possible lymphoreticular disease and skin cancer, particularly squamous cell carcinoma (SCC). Safety guidelines used during azathioprine therapy are summarized in Table 228-7.

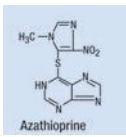

TABLE 228-7
Safety Monitoring for Azathioprine Use

- Initial evaluation
  - Careful history and physical examination
  - Identification of proper patient characteristics and risk factors
  - Survey for interacting medications (allopurinol, aminosalicylates)
  - Baseline laboratories:
    - Thiopurine methyltransferase erythrocyte assay
    - CBC with differential/platelets
    - Basic serum chemistry profile
    - Liver function tests
    - Urinalysis
    - Pregnancy testing for women of childbearing age
    - Tuberculin testing (if indicated)
- Ongoing laboratory monitoring
  - CBC with differential/platelets and liver function tests
    - Perform monthly for 3 mo, then
      - ~ Increase to bimonthly
      - ~ Perform 5–6 days after any dose escalation
- Follow-up clinical evaluation
  - Biannual complete physical examinations
    - Particular attention to possible lymphoreticular disease (adenopathy)
    - Careful survey for non-melanoma skin cancer (squamous cell carcinoma)

CBC = complete blood cell count.

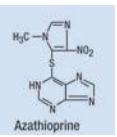

TABLE 228-8
Risks and Precautions with Azathioprine Use

- Absolute contraindications
  - Hypersensitivity to azathioprine
  - Active or ongoing infection
- Relative contraindications
  - Pregnancy/lactation (Category D, but myelosuppression of fetus/infant common—avoid)
  - Allopurinol use (dose must be reduced by 75%)
  - Prior lymphoproliferative disease or prior use of alkylating agents
- Common adverse effects
  - Gastrointestinal distress (minimized by administration with food)
  - Myelosuppression
  - Possible increased risk of lymphoproliferative disease or skin cancer
  - Possible opportunistic infections

RISK FACTORS AND PRECAUTIONS Absolute and relative contraindications and common adverse effects of azathioprine are summarized in Table 228-8.

COMPLICATIONS With careful monitoring, azathioprine is generally safe. A comparison of rheumatoid arthritis patients treated with methotrexate or azathioprine failed to reveal significant differences in adverse effects.[43] Adverse effects tend to occur in those patients with lower TPMT activity levels, higher doses of azathioprine, or concomitant use of allopurinol.

Hematologic Effects. Myelosuppression is a major side effect of azathioprine use. Generalized depression of all blood cell lines is most common, but depression of any single lineage may be observed. Thrombocytopenia is a common initial presentation of bone marrow toxicity. Bone marrow suppression tends to occur at higher doses and in those with lower TPMT expression.[44] Discontinuance usually results in complete marrow recovery.

Opportunistic Infections. Most patients treated with azathioprine also receive large doses of glucocorticoids. Therefore, it is often difficult to quantify the independent role of azathioprine in any predisposition toward infection. Herpes virus infections, human papilloma infection, and scabies infestation have been reported in those taking azathioprine.[45]

Gastrointestinal Effects. Patients receiving high doses of azathioprine may experience nausea, vomiting, and diarrhea. Such symptoms are not usually treatment limiting and may be reduced by administration with food.

Hepatic Effects. Toxic hepatitis has developed in approximately 1 percent of patients treated with azathioprine for rheumatoid arthritis, and it is usually reversible.[45] Other adverse effects include hepatic venoocclusive disease and associated pancreatitis. Discontinuance is warranted with evidence of liver toxicity.

Anaphylaxis. Azathioprine-induced shock and hypersensitivity reactions have been reported in patients with cutaneous disease. In most cases, hypotensive collapse occurred within hours of the initial dose. Drug fever has also been reported with azathioprine (see Chap. 40).

Carcinogenesis. An increased risk of lymphoproliferative disease has been documented in renal transplant recipients, rheumatoid arthritis patients, and, most recently, inflammatory bowel disease patients treated with chronic azathioprine.[46–48] In one study, the relative risk was increased roughly 10- to 13-fold, or one lymphoma per 1000 patient-years of azathioprine treatment. Dermatologic doses of azathioprine are often lower and the duration of treatment shorter, leading to speculation that the risk of lymphoma is probably lower in those treated for cutaneous disease. However, the most recent meta-analysis of patients treated with azathioprine for inflammatory bowel disease who developed lymphoma included those on "low-dose" regimens.[48] In light of this information, it seems prudent to inform patients that the exact magnitude of any increased risk for lymphoma with "low-dose" azathioprine is largely unknown. Patients with a prior exposure to alkylating agents may have a prohibitive risk of lymphoma if treated subsequently with azathioprine; great caution is suggested in this population.

Aggressive behavior of SCC has been described in patients taking azathioprine for eczema, atopic dermatitis, and chronic actinic dermatitis.[49] It was recently suggested that azathioprine used in solid organ transplant recipients may sensitize DNA to UVA radiation, leading to the increased incidence of SCC in this population.[50] Admittedly, confounding risk factors exist. Dermatologists should be aware of this emerging research, as only broad spectrum sunscreens mitigate UVA exposure, and such rays are not blocked by glass.

Mutagenecity and Teratogenecity. Azathioprine is a Category D agent during pregnancy. The prodrug and the active metabolites readily cross the placenta. The rate of congenital malformation appears to be low (4.3 percent), but myelosuppression and immunosuppression are significant occurrences in neonates and breast-fed infants. Fertility of men or women appears unaffected by azathioprine.[51]

Drug Interactions. A major drug interaction occurs between azathioprine and allopurinol. When allopurinol must be used concurrently, the azathioprine dose must be decreased by 75 percent. There is evidence that aminosalicylates may inhibit TPMT activity, and it may be prudent to minimize or avoid such medications in patients using azathioprine.

Mycophenolic Acid and Mycophenolate Mofetil

Mycophenolic acid (MPA) (see Fig. 228-1) is a lipid-soluble, weak organic acid with antifungal, antibacterial, antiviral, and immunosuppressive properties. MPA was first used as an oral agent for moderate to

severe psoriasis in the 1970s, but use was discontinued due to intolerability. Mycophenolate mofetil (MMF) represents a derivative of MPA, with greater bioavailability, improved tolerance, and enhanced immunosuppression.

MECHANISM OF ACTION MMF acts as a noncompetitive inhibitor of inosine monophosphate dehydrogenase. Inhibition of this enzyme prevents conversion of inosine-5-phosphate and xanthine-5-phosphate to guanosine-5-phosphate, a precursor of DNA and RNA synthesis. MMF interferes with de novo purine synthesis, and, consequently, it is cytotoxic to cells that lack a purine salvage pathway, specifically T and B lymphocytes.[52] Selective targeting of lymphocytes facilitates the immunosuppressive properties of MMF.

PHARMACOKINETICS After ingestion, MMF is quickly converted to MPA via pre-systemic metabolism. In the liver, resultant MPA is glucoronidated into an inactive compound (MPAG). Specialized tissues, such as the lining of the gastrointestinal tract and the epidermis, possess β-glucuronidase activity that converts MPAG back into the active form. Any unconverted MPAG is excreted by the kidney.

INDICATIONS In dermatology, MMF is used for a variety of "off-label" indications. It has been used both for psoriasis and also as a steroid-sparing agent in autoimmune blistering disorders, such as pemphigus vulgaris, pemphigus foliaceus, and bullous pemphigoid (Table 228-9).[53] Success using MMF has also been reported in pyoderma gangrenosum,[54] systemic vasculitis, dihydrotic eczema, metastatic Crohn disease, dermatomyositis, cutaneous lupus, and severe lichen planus. Topical MPA has improved experimentally induced allergic contact dermatitis.

TABLE 228-9
Uses for Mycophenolate Mofetil in Dermatology

- U.S. Food and Drug Administration–approved indications
  - None
- "Off-label" uses
  - Severe psoriasis (but ineffective for psoriatic arthropathy)
  - Pemphigus vulgaris
  - Pemphigus foliaceus
  - Dermatomyositis
  - Severe cutaneous lupus erythematosus
  - Refractory pyoderma gangrenosum
  - Sarcoidosis
  - Severe dyshidrotic dermatitis
  - Severe lichen planus
  - Metastatic Crohn disease

TABLE 228-10
Safety Monitoring for Mycophenolate Mofetil Use

- Initial evaluation
  - Careful history and physical examination
  - Survey for interacting medications (antacid use, cholestyramine)
  - Baseline laboratories:
    - CBC with differential/platelets
    - Basic serum chemistry profile
    - Liver function tests
    - Tuberculin testing (if indicated)
- Ongoing laboratory monitoring
  - CBC with differential/platelets
    - Perform weekly to biweekly for first month, then
      - ~ Increase to biweekly for 2–3 mo, then
      - ~ Discontinue therapy if white blood cell count < 4000/mm^3
  - Liver function testing
    - Monthly
- Follow-up clinical evaluation
  - Biannual complete physical examinations

CBC = complete blood cell count.

DOSAGE REGIMEN MMF is available as 250-mg capsules, 500-mg tablets, or a powder for reconstitution as a suspension (200 mg/mL). Recently, a 720-mg, enteric-coated tablet of mycophenolate sodium (Myfortic™) was released. The enteric coating is designed to delay release until it reaches the small intestine; it provides the therapeutic equivalent of standard 1000-mg dosing.[55]

Typically a dose of MMF of 1.5 g/day to 2 g/day is utilized for cutaneous disease. Occasionally, doses of 3.0 to 4.0 g/day have been employed for severe disease. In general, daily doses of 2 g or less are better tolerated, with fewer adverse effects.

INITIATING THERAPY All patients should receive a complete history and physical examination before dosing. Patients with severe co-morbidities, active infections, or the possibility of reactivation of infection should be excluded from treatment with MMF. There are multiple reports of reactivation of tuberculosis in transplant patients after conversion to MMF from azathioprine, suggesting that tuberculin screening is prudent.[56,57] Baseline laboratory studies should include a CBC with manual differential and platelet count, serum chemistry profile, and liver function studies.

TABLE 228-11
Risks and Precautions with Mycophenolate Mofetil Use

- Absolute contraindications
  - Hypersensitivity to mycophenolate; polysorbate 80 (in intravenous formulation)
- Relative contraindications
  - Pregnancy/lactation (Category C)
  - Severe hepatic or renal disease
  - Peptic ulcer disease (possible increased risk of gastrointestinal perforation)
- Common adverse effects
  - Gastrointestinal
    - Most common; dose-dependent and diminish with continued use
    - Includes nausea, diarrhea, abdominal cramps, vomiting, anal tenderness
  - Genitourinary
    - Includes urinary urgency, frequency, dysuria, even sterile pyuria
    - No frank nephrotoxicity
  - Infectious
    - Increased incidence of herpes zoster
    - Increased incidence of opportunistic infection in renal transplant patients using ≥ 2.0 g/day
  - Neurologic
    - Headache, weakness, fatigue, tinnitus, and insomnia

MONITORING THERAPY Guidelines for monitoring MMF therapy include a CBC with differential and platelet counts weekly for 1 month, biweekly for 2 to 3 months, and monthly thereafter. Monthly serum liver function tests are recommended as well. Safety guidelines used during MMF therapy are summarized in Table 228-10.

RISKS AND PRECAUTIONS Absolute and relative contraindications and common adverse effects of MMF are summarized in Table 228-11.

COMPLICATIONS MMF is generally well tolerated. Dose-dependent gastrointestinal symptoms, such as nausea, diarrhea, soft stools, anorexia, abdominal cramps, frequent stools, vomiting, and anal tenderness, are common and often diminish with time.[58] Reversible dose-related myelosuppression is possible. Genitourinary complaints with MPA, such as urgency, frequency, and dysuria, are common and are also dose dependent. MMF appears to lack significant nephrotoxicity. Herpes zoster is a common occurrence in those taking MMF. Opportunistic infections have been associated with MMF in bone marrow transplant patients with graft-versus-host disease given a median dose of 2 g/day, but limited investigation has failed to convincingly demonstrate an in-

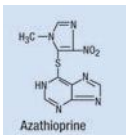

creased risk of carcinogenesis.[59,60] Isolated reports of various cancers, such as breast cancer or squamous cancer of the head/neck, have been associated with MMF. Neurologic side effects include headache, weakness/fatigue, tinnitus, and insomnia. MMF is a Category C medication during pregnancy, and the potential for human teratogenesis is unknown; MMF is generally avoided in pregnancy.[61]

Drug Interactions. Antacids containing magnesium and aluminum hydroxide decrease absorption of MMF.[62] Anecdotal interactions between MMF and acyclovir, or its prodrug valacyclovir, have reported abrupt neutropenia; the mechanism is unknown. Cholestyramine decreases blood levels of MPA, possibly through the interruption of enterohepatic recirculation.

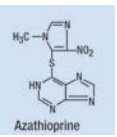
Azathioprine

Thioguanine

Thioguanine (see Fig. 228-1) is a lesser utilized member of the thiopurine family of drugs. It has a metabolism and mechanism of action similar to that of azathioprine.

MECHANISM OF ACTION Thioguanine is a prodrug that produces nucleoside analogues through the action of purine nucleoside phosphorylases present in tissues. These guanine analogues undergo enzymatic conversion to nucleotides and ultimately yield cytotoxic activity via incorporation into cellular DNA. Apoptosis is induced preferentially against activated T lymphocytes. The clinical response to thioguanine has been correlated to decreased T lymphocyte counts in psoriatic skin lesions, irrespective of systemic lymphocyte counts.[63]

PHARMACOKINETICS Thioguanine is administered orally, but it has incomplete and unpredictable absorption. Peak plasma concentrations may vary 10-fold and occur 2 to 4 hours after ingestion.[64]

INDICATIONS In dermatology, thioguanine is used chiefly for the treatment of psoriasis, particularly in those with recalcitrant disease or with contraindications to other systemic therapies. (Table 228-12). In a recent retrospective study of patients with recalcitrant psoriasis, 14 of 18 patients experienced greater than 90 percent improvement with thioguanine, including patients with psoriatic arthritis, palmoplantar disease, or scalp involvement.[65] Thioguanine has been used effectively, although infrequently, to treat lupus and atopic dermatitis.

TABLE 228-12
Uses for Thioguanine in Dermatology

- U.S. Food and Drug Administration–approved indications
  - None
- "Off-label" uses
  - Severe psoriasis
  - Severe cutaneous lupus erythematosus
  - Severe atopic dermatitis

DOSING REGIMEN Thioguanine is supplied as 40-mg tablets. Classically, treatment was initiated with a 40 mg/day dose, with close monitoring for myelosuppression. After 1 month, if the clinical response was inadequate, the dose was increased to 80 to 120 mg/day. A pulsed regimen of 100 mg to 120 mg twice weekly, increasing up to 160 mg three times per week, has been reported effective.[66]

Similar to azathioprine, use of commercial assays for TPMT activity improve thioguanine dosing. The latest review of thioguanine use in severe psoriasis recommends an assessment of TPMT levels before treatment so as to guide the selection of an adequate starting dose.[65] Patients with high levels of TPMT expression can likely begin with 80 mg/day from the start.

INITIATING THERAPY All patients should undergo a thorough history and physical examination before initiation of treatment. Patients with severe comorbidities, particularly hematologic disturbances, or active infection should be excluded. Women of childbearing age should receive a pregnancy test. Recommended baseline laboratory studies include a CBC with manual differential and platelet count, liver function studies, and a TPMT activity assay.

MONITORING THERAPY Repeat blood counts and liver function tests should be followed weekly at first, transitioning to biweekly as the dose stabilizes, then monthly for 3 months, and quarterly thereafter. Always perform laboratory testing when a dose is escalated. Safety guidelines used during thioguanine therapy are summarized in Table 228-13.

RISKS AND PRECAUTIONS Absolute and relative contraindications and common adverse effects of thioguanine are summarized in Table 228-14.

COMPLICATIONS Common adverse effects of thioguanine include myelosuppression and gastrointestinal disturbances. In the largest series of patients using thioguanine for psoriasis, just less than one-half experienced myelosuppression, yet only 20 percent required complete discontinuance.[67] In one series, thrombocytopenia was the earliest indicator of myelosuppression.[65] Pulsed dosing of thioguanine has been associated with a lower rate of myelosuppression, but, admittedly, TPMT testing was not performed in this study.[66]

Gastrointestinal disturbances include nausea, excessive flatulence, taste changes, esophageal reflux, and diarrhea, symptoms that are often tolerated without discontinuance. In a single study, elevated liver transaminases occurred in 25 percent of patients, yet many had been

TABLE 228-13
Safety Monitoring for Thioguanine Use

- Initial evaluation
  - Careful history and physical examination
  - Identification of proper patient characteristics and risk factors
  - Survey for interacting medications (aminosalicylates)
- Baseline laboratories:
  - Thiopurine methyltransferase erythrocyte assay
  - CBC with differential/platelets
  - Liver function tests
  - Renal function testing (creatinine/blood urea nitrogen)
- Ongoing laboratory monitoring
  - CBC with differential/platelets and liver function tests
    - Perform weekly initially, then
      - ~ Transition to biweekly as the dose stabilizes, then
      - ~ Monthly for 3 mo and quarterly thereafter
      - ~ Perform laboratory testing with any dose escalation

CBC = complete blood cell count.

TABLE 228-14
Risks and Precautions with Thioguanine Use

- Absolute contraindications
  - Hypersensitivity to thioguanine
- Relative contraindications
  - Pregnancy/lactation (Category D)
  - History of hepatovenular occlusive disease
  - Hematologic disorders
- Common adverse effects
  - Myelosuppression (most common side effect)
  - Gastrointestinal distress (often tolerated)
  - Toxic hepatitis (less common than with other cytotoxic agents)

taking methotrexate before the study.[67] Generally, thioguanine is not considered particularly hepatotoxic; liver biopsy is not indicated during treatment. Rare cases of toxic hepatic venoocclusive disease have been described in patients using thioguanine for psoriasis.[68] Low-dose thioguanine use in pregnant women has been reported with inflammatory bowel disease; however, use during pregnancy is generally avoided.[69]

Drug Interactions. Thioguanine metabolism is not dependent on XO; it may be administered concurrently with allopurinol without dose reduction. Aminosalicylates may inhibit TPMT activity, and it may be prudent to minimize or avoid such medications in patients taking thioguanine.

Hydroxyurea

Hydroxyurea was first synthesized in 1869, and through the years it has been used to treat a variety of conditions, including hematologic malignancies, sickle cell anemia, and psoriasis.

MECHANISM OF ACTION Hydroxyurea impairs DNA synthesis through inhibition of ribonucleotide diphosphate reductase, an enzyme that reduces nucleotides to deoxynucleotides. This inhibition limits the supply of DNA bases available for synthesis. Strand breakage and cell death result. Hydroxyurea also prevents cells from repairing damage from UV or ionizing radiation, acting as a radiosensitizer. Finally, hydroxyurea yields hypomethylation of genes, altering expression,[70] and this may contribute to normalization of psoriatic skin through improved keratinocyte differentiation. Hydroxyurea is most active in cells with a high proliferative index. It is preferentially concentrated within leukocytes.

PHARMACOKINETICS Hydroxyurea is a small molecule that is well absorbed after oral administration. Serum levels peak within 2 hours of dosing. Hydroxyurea has a rapid onset of action, with tissue effects noted within 5 hours. The actual metabolism of hydroxyurea is incompletely understood, but at least 80 percent is excreted by the kidney. Within 24 hours of dosing, negligible amounts hydroxyurea remain in the body.

INDICATIONS In dermatology, hydroxyurea is used chiefly for treatment of psoriasis (Table 228-15). Efficacy has been demonstrated in plaque, pustular, and erythrodermic forms. Still others believe hydroxyurea is only moderately effective and prefer to reserve use as a maintenance therapy once initial clearance has been achieved via other modalities.

TABLE 228-15
Uses for Hydroxyurea in Dermatology

- U.S. Food and Drug Administration–approved indications
  - Squamous cell carcinoma of the head and neck (rare use)
  - Metastatic melanoma and gastrointestinal melanoma (rare use)
- "Off-label" uses
  - Severe psoriasis (often an option for those with liver disease that limits other options)
  - Pyoderma gangrenosum
  - Sweet syndrome
  - Cryoglobulinemia
  - Scleromyxedema
  - Hypereosinophilic syndrome

In a large series of 60 patients treated with hydroxyurea for severe psoriasis, 50 percent to 60 percent achieved a response.[71] When hydroxyurea is effective, a response generally occurs within 2 to 3 weeks, with maximal improvement at 6 to 8 weeks. Because hydroxyurea has relatively little hepatic toxicity, it may be a viable alternative for those with liver disease, which precludes use of methotrexate.

DOSING REGIMEN Hydroxyurea is available as 500-mg tablets. Typical doses range from 1 to 2 g daily, usually as a divided dose. Doses above 2 g daily are unlikely to yield additional benefit and are increasingly toxic.[72] Hydroxyurea is usually well tolerated, but if dyspepsia occurs, the medication may be taken with food, milk, or antacids.

INITIATING THERAPY Patients placed on hydroxyurea should have a complete history and physical examination. Exclusion of patients with severe co-morbidities or active infections is often indicated. All women of childbearing age should receive a pregnancy test. Baseline laboratory evaluation should include a CBC with manual differential and platelet count, a serum chemistry evaluation, and urinalysis. Older patients and those with renal impairment are more susceptible to toxicity with hydroxyurea and should receive starting doses of only 500 mg/day.

MONITORING THERAPY CBCs should be repeated weekly during early therapy; this may be increased to biweekly, and, later, to monthly if results remain stable.

TABLE 228-16
Safety Monitoring for Hydroxyurea Use

- Initial evaluation
  - Careful history and physical examination
  - Identification of proper patient characteristics and risk factors
  - Survey for interacting medications (cytarabine)
  - Baseline laboratories:
    - CBC with differential/platelets
    - Basic serum chemistry profile
    - Urinalysis
    - Renal function testing (creatinine/blood urea nitrogen)
- Ongoing laboratory monitoring
  - CBC with differential/platelets
    - Perform weekly initially, then
      - ~ Transition to biweekly or monthly after 1 mo
      - ~ Perform testing with any dose escalation
      - ~ Decrease/discontinue if hemoglobin decreases by 3 g/dL, white blood cell count < 4000/mm^3, or platelets < 100,000/mm^3
  - Serum chemistry and urinalysis
    - Perform monthly initially, then
      - ~ Transition to every 3–6 mo if stable
      - ~ Perform testing with any dose escalation

CBC = complete blood cell count.

Liver function studies and urinalysis should be monitored monthly. Close surveillance for non-melanoma skin cancer at follow-up visits is indicated. Discontinuance of hydroxyurea is indicated if a satisfactory response is not achieved with 8 weeks of therapy. Safety guidelines used during hydroxyurea therapy are summarized in Table 228-16.

RISKS AND PRECAUTIONS Absolute and relative contraindications and common adverse effects of hydroxyurea are summarized in Table 228-17.

COMPLICATIONS In one large study of hydroxyurea for psoriasis, 57 percent of those who received 1.5 g/day of hydroxyurea experienced no side effects, and only 18 percent discontinued therapy because of adverse effects.[73] The most common adverse effect with hydroxyurea is myelosuppression. Mild megaloblastic changes are ubiquitous among patients receiving hydroxyurea and are not a reason for discontinuance. Frank anemia is present in 12 percent to 34 percent of treated patients, leukopenia in 7 percent, and thrombocytopenia in 2 percent to 3 percent. Myelosuppres-

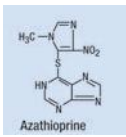

TABLE 228-17
Risks and Precautions with Hydroxyurea Use

- Absolute contraindications
  - Hypersensitivity to hydroxyurea
- Relative contraindications
  - Pregnancy/lactation (Category D)
  - History of hepatovenular occlusive disease
  - Chronic anemia
  - Renal disease
- Common adverse effects
  - Myelosuppression (most common side effect)
  - Dermatomyositis-like drug eruption
  - Renal toxicity (elevated creatinine/blood urea nitrogen, hematuria, proteinuria)
  - Increased risk of secondary hematologic malignancies when used for polycythemia vera

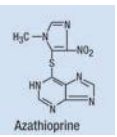
Azathioprine

sion due to hydroxyurea usually resolves rapidly on discontinuance.

Patients taking hydroxyurea may experience a variety of cutaneous side effects, including a dermatomyositis-like eruption,[74,75] a lichenoid drug eruption, leg ulcers, alopecia, photosensitivity with radiation recall, and hyperpigmentation of the skin and nails. In patients treated with hydroxyurea for myeloproliferative disorders, non-melanoma skin cancer has been reported as an association.[76,77] It is unclear if this represents a true risk factor for those treated for cutaneous disease or if confounding circumstances exist.

Other reported side effects of hydroxyurea include lupus erythematosus, mild gastrointestinal distress, and secondary malignancies when used in patients with primary hematologic disorders, such as polycythemia vera. A rare but important adverse effect of hydroxyurea is fever with a flu-like illness. Hydroxyurea is a Category D agent during pregnancy, and use is generally avoided. There is a single report of hydroxyurea use for polycythemia vera during pregnancy without any apparent fetal or neonatal complications.[78]

Drug Interactions. Hydroxyurea appears to have few significant drug interactions, with the exception of co-administration with other myelosuppressive agents and cytarabine. Use of such agents with hydroxyurea may lead to additive bone marrow toxicity.

ALKYLATING AGENTS

Cyclophosphamide

Cyclophosphamide (see Fig. 228-1) is a derivative of nitrogen mustard, and it acts primarily by cross-linking DNA. In oncology, cyclophosphamide is used as an antineoplastic agent. In dermatology, it is used as an immunosuppressive and steroid-sparing agent, particularly for autoimmune blistering disorders and systemic vasculitis.

MECHANISM OF ACTION Cyclophosphamide is a classic cell-cycle non-specific drug; its cytotoxic effect is independent of the proliferative index. Active metabolites of cyclophosphamide form covalent bonds with the nucleophilic centers of DNA. This alkylation leads to DNA cross-linking, abnormal base-pair formation, imidazole ring cleavage with depurination, and chain scission. Ultimately, these mutations lead to cell death and possibly mutagenesis and carcinogenesis. Cyclophosphamide has a greater effect on B lymphocytes than T lymphocytes and a greater effect on suppressor T cells than helper T cells.[79] Resistance to cyclophosphamide may occur due to decreased cellular penetration, increased competition from other nucleophilic substances, improved DNA repair, or increased drug metabolism.

PHARMACOKINETICS Oral cyclophosphamide has a bioavailability of 74 percent. Peak plasma levels are achieved within 1 hour of administration. The half-life of the drug is between 2 and 10 hours. Cyclophosphamide undergoes hepatic metabolism via the cytochrome P_{450} system.[80] It is first converted to 4-hydroxycyclophosphamide, an active molecule that exists in equilibrium with aldophosphamide. Aldophosphamide may be cleaved to phosphoramide mustard, another active metabolite, and acrolein, an inactive metabolite. Aldehyde dehydrogenase may also convert aldophosphamide into a second inactive metabolite, carboxyphosphamide. The kidneys excrete just 10 percent to 20 percent of the drug unchanged but excrete 50 percent of the active metabolites.

INDICATIONS In dermatology, cyclophosphamide is used chiefly as a steroid-sparing agent for life-threatening diseases (Table 228-18). In particular, pemphigus vulgaris may be treated with cyclophosphamide in combination with steroids. Cyclophosphamide has also been used for the treatment of cicatricial pemphigoid and has been cautiously and inconsistently reported as beneficial in Stevens-Johnson syndrome and toxic epidermal necrolysis.[81,82]

Survival of patients with many forms of vasculitis has been improved with combination therapy with cyclophosphamide and steroids.[83] Diseases such as Wegener granulomatosis, Churg-Strauss syndrome, polyarteritis nodosa, and lymphomatoid granulomatosis often require cyclophosphamide therapy. Other diseases that may respond to cyclophosphamide include lupus erythematosus, Behçet disease, pyoderma gangrenosum, lichen planus, and lichen myxedematosus; yet, with the availability of safer immunosuppressive agents, cyclophosphamide is not a typical choice for nonlethal inflammatory diseases.

TABLE 228-18
Uses for Cyclophosphamide in Dermatology

- U.S. Food and Drug Administration–approved indications
  - Mycosis fungoides (advanced disease)
- "Off-label" uses
  - Wegener granulomatosis
  - Lymphomatoid granulomatosis
  - Polyarteritis nodosa
  - Severe and recalcitrant leukocytoclastic vasculitis
  - Dermatomyositis
  - Scleroderma
  - Relapsing polychondritis
  - Severe cutaneous lupus erythematosus
  - Pemphigus vulgaris
  - Bullous pemphigoid
  - Pyoderma gangrenosum
  - Scleromyxedema/lichen myxedematosus
  - Multicentric reticulohistiocytosis
  - Cytophagic panniculitis
  - Severe and recalcitrant eczematous conditions

DOSING REGIMEN Cyclophosphamide is available as 25- and 50-mg tablets and also as an injectate. Oral doses are typically 1 to 3 mg/kg/day either divided or as a single morning dose. Intravenous pulse dosing of 0.5 to 1.0 g/m^2 monthly may be associated with fewer side effects than daily oral dosing. Vigorous hydration, beginning 24 hours before and continuing throughout therapy, is recommended to reduce bladder toxicity.

INITIATING THERAPY Patients being considered for cyclophosphamide therapy should have a thorough history and physical examination. Cyclophosphamide is contraindicated in patients with a history of transitional cell carcinoma of the bladder.[84] Patients with a history of a lymphoproliferative disorder must be treated with extreme caution. Use in pregnant or lactating patients is contrain-

dicated. Baseline laboratory evaluations include a CBC with manual differential, serum chemistry profile, liver function testing, and urinalysis. Initiation of cyclophosphamide therapy is often contraindicated if the total white blood cell count is less than 5000/mm^3 or if the granulocyte count is less than 2000/mm^3.

MONITORING THERAPY Blood counts and urinalysis should be repeated weekly but may be reduced to biweekly or monthly over 2 to 3 months. Liver function testing should continue monthly but may be reduced to every 3 months if stable. Urine cytology is indicated when the cumulative dose exceeds 50 g and every 6 months thereafter, or on any occasion of hemorrhagic cystitis. Some authorities recommend a chest x-ray every 6 months. Follow-up physical examination should pay particular attention to any evidence of lymphoproliferative disease (lymphadenopathy). Patients taking cyclophosphamide should have all age-appropriate cancer screening, including stool guaiac examination and Papanicolaou smears for women. Safety guidelines used during cyclophosphamide therapy are summarized in Table 228-19.

RISKS AND PRECAUTIONS Absolute and relative contraindications and common adverse effects of cyclophosphamide are summarized in Table 228-20.

COMPLICATIONS Because of its activity independent of the cell cycle, the toxic effects of cyclophosphamide are significant and numerous.

Gastrointestinal Effects. Nausea and vomiting are the most common gastrointestinal side effects associated with cyclophosphamide use. Co-administration of ondansetron and dexamethasone reduces these side effects. The addition of aprepitant to this combination therapy may provide even greater antiemetic action.[85]

Hematologic Effects. Hematologic disturbances are frequent with cyclophosphamide, especially leukopenia and thrombocytopenia. A nadir in blood counts occurs 8 to 12 days after initiation of therapy. Myelosuppression is not requisite to immunosuppression, but it often represents a dose-limiting side effect.

Genitourinary Effects. Bladder toxicity is a well-recognized consequence of cyclophosphamide use. Hemorrhagic cystitis occurs in 5 percent to 40 percent of patients treated with oral cyclophosphamide.[86] This cystitis occurs during therapy and is believed to be caused by the metabolite, acrolein. A scavenging agent, mesna (sodium 2-mercaptoethane sulfonate), binds acrolein in the bladder and reduces irritation. Mesna is used primarily with high-dose cyclophosphamide regimens, but it may be used in low-dose therapy as well.[87] It may be administered orally or intravenously and may cause a maculopapular drug rash in some patients. Hemorrhagic cystitis and untreated bladder toxicity are thought responsible for the markedly increased risk of transitional cell carcinoma of the bladder (8- to 10-fold increased risk) among those taking chronic cyclophosphamide. Bladder cancer may arise years after therapy, and continued monitoring of the lower urinary tract is indicated.

TABLE 228-19
Safety Monitoring for Cyclophosphamide Use

- Initial evaluation
  - Careful history and physical examination
  - Identification of proper patient characteristics and risk factors
  - Survey for interacting medications (allopurinol, cimetidine)
  - Baseline laboratories:
    - CBC with differential/platelets
    - Basic serum chemistry profile
    - Urinalysis
    - Renal function testing (creatinine/blood urea nitrogen)
- Ongoing laboratory monitoring
  - CBC with differential/platelets and urinalysis
    - Perform weekly initially, then
      - ~ Transition to biweekly or monthly after 2–3 mo
      - ~ Perform testing with any dose escalation
      - ~ Decrease/discontinue if white blood cell count < 4000/mm^3, or platelets < 100,000/mm^3
      - ~ Discontinue and refer to urologist if red blood cells appear in urine
  - Basic serum chemistry and liver function tests
    - Perform monthly initially, then
      - ~ Transition to every 3–6 mo if stable
  - Urine cytology testing
    - Perform when cumulative dose >50 g or if patient has hemorrhagic cystitis

CBC = complete blood cell count.

Carcinogenecity. Cyclophosphamide therapy has been associated with non-Hodgkin lymphoma, leukemia, transitional cell carcinoma of the bladder, and SCC. Much of these data involves transplant and oncology patients exposed to chronic use or higher doses, but a slight increased risk of non-Hodgkin B-cell lymphoma has been demonstrated in those treated for rheumatologic conditions as well.[88,89] The risk of cancer in those using cyclophosphamide for dermatologic conditions is likely lower than that for other indications.

TABLE 228-20
Risks and Precautions with Cyclophosphamide Use

- Absolute contraindications
  - Hypersensitivity to cyclophosphamide (can cross-react with chlorambucil)
- Relative contraindications
  - Pregnancy/lactation (Category D; fetal loss common)
  - History of transitional cell carcinoma of the bladder
  - Depressed bone marrow function
  - Impaired hepatic or renal function
- Common adverse effects
  - Gastrointestinal distress (minimized with antiemetic medications)
  - Myelosuppression (often dose limiting)
  - Hemorrhagic cystitis due to elimination of toxic metabolites (minimized with mesna)
  - Carcinogenicity (transitional cell carcinoma of bladder, lymphoproliferative disease)
  - Reproductive consequences (amenorrhea, azoospermia, gonadal failure)

Cutaneous Effects. Anagen effluvium has been reported in 5 percent to 30 percent of those treated with cyclophosphamide.[90] In some cases, the hair loss is permanent, but generally, it is not. A permanent pigmented band on the teeth is another consequence of cyclophosphamide therapy. Diffuse hyperpigmentation of the skin and nails and acral erythema has been described. Rarely, urticaria, mucosal alterations, or induction of Stevens-Johnson syndrome have been reported.[91]

Mutagenicity and Teratogenicity. Cyclophosphamide is a Category D agent during pregnancy. A report of four pregnant women exposed to cyclophosphamide for systemic lupus resulted in uniform pregnancy loss in all cases.[92] Azoospermia and amenorrhea may also occur with cyclophosphamide use. The risk of amenorrhea has ranged from 27 percent to 60 percent of women treated, with up to 80 percent of those so affected manifesting premature ovarian failure.[93] Age and cumulative dose are most determinative of the risk of gonadal failure. In men, testosterone administration may lessen the risk of gonadal failure, whereas in women, leuprolide acetate may provide a similar partial protection.[94,95] Cryopreser-

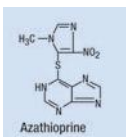

vation of reproductive material may be used, but it is far more practical and economical for men than women. Cyclophosphamide should not be a first-line therapy for men or women who wish to conceive after treatment.

Drug Interactions. Because the microsomal enzyme system responsible for activation of cyclophosphamide is involved in the metabolism of many other drugs, the potential for multiple drug interactions exists. Allopurinol, cimetidine, and chloramphenicol all increase cyclophosphamide toxicity. The effects of succinylcholine are potentiated by cyclophosphamide. Digoxin absorption is diminished with coadministration of oral cyclophosphamide.

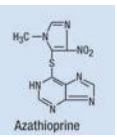
Azathioprine

Chlorambucil

Chlorambucil is another alkylating agent derived from nitrogen mustard. In comparison to cyclophosphamide, chlorambucil is used infrequently in dermatology.

MECHANISM OF ACTION Like cyclophosphamide, chlorambucil exerts its affects independent of the cell cycle through cross-linking of DNA.

PHARMACOKINETICS Chlorambucil is well absorbed, with 87 percent bioavailability after oral administration. The drug is 99 percent protein bound in plasma. It has a plasma half-life of approximately 1.5 hours. Less than 1 percent of the drug is excreted by the kidney. Although the drug is extensively metabolized by the liver, it does not require hepatic activation, unlike cyclophosphamide. In comparison to cyclophosphamide, chlorambucil has a slower onset of effect.

INDICATIONS Chlorambucil is rarely used in dermatology. Isolated reports detail use of chlorambucil as a steroid-sparing agent in pemphigus vulgaris, bullous pemphigoid, primary cutaneous B-cell lymphoma, aggressive pyoderma gangrenosum, and Behçet disease (Table 228-21). Interestingly, chlorambucil use has also been described in erythrodermic cutaneous T-cell lymphoma.[96] Complicating management decisions, the U.S. Food and Drug Administration–approved package insert states that chlorambucil should not be used for non-malignant diseases.

DOSING REGIMEN Chlorambucil is supplied as 2-mg tablets. The recommended dosage is 0.05 to 0.2 mg/kg/day. Doses for cutaneous disease should usually remain toward the lower end of this range.

TABLE 228-21
Uses for Chlorambucil in Dermatology

- U.S. Food and Drug Administration–approved indications
  - None
- "Off-label" uses
  - Wegener granulomatosis
  - Lymphomatoid granulomatosis
  - Dermatomyositis
  - Scleroderma
  - Relapsing polychondritis
  - Severe cutaneous lupus erythematosus
  - Pemphigus vulgaris
  - Bullous pemphigoid
  - Epidermolysis bullosa acquisita
  - Pyoderma gangrenosum
  - Scleromyxedema/lichen myxedematosus
  - Langerhans cell histiocytosis
  - Mycosis fungoides/Sézary syndrome
  - Necrobiotic xanthogranuloma with paraproteinemia
  - Sarcoidosis
  - Severe disseminated granuloma annulare

INITIATING THERAPY Patients being considered for chlorambucil therapy should have a thorough history and physical examination. When considering chlorambucil use, patients with a history of a lymphoproliferative disorder must be approached with extreme caution. Use in pregnant or lactating patients is contraindicated. Baseline laboratory evaluations should include a CBC with manual differential, serum chemistry profile, liver function testing, and urinalysis.

MONITORING THERAPY Blood counts should be repeated weekly initially but may be reduced to biweekly or monthly with time. Liver function testing and urinalysis should continue monthly but may be reduced to every 3 months if stable. Some authorities recommend a chest x-ray every 6 months. Follow-up physical examination should pay particular attention to any evidence of lymphoproliferative disease (lymphadenopathy). Patients taking chlorambucil should have all age-appropriate cancer screening, including stool guaiac examinations and Papanicolaou smears for women. Safety guidelines during chlorambucil therapy are summarized in Table 228-22.

RISKS AND PRECAUTIONS Absolute and relative contraindications and common adverse effects of chlorambucil are summarized in Table 228-23.

COMPLICATIONS Chlorambucil is considered the least toxic nitrogen mustard. Common side effects include nausea and vomiting, azoospermia, amenorrhea, pulmonary fibrosis, seizures, and hepatotoxicity. Chlorambucil increases the risk of lymphoproliferative disorders among transplant recipients. Increased SCC, particularly of the skin, has also been demonstrated in this same population. It is unclear how these risks are manifested when chlorambucil is

TABLE 228-22
Safety Monitoring for Chlorambucil Use

- Initial evaluation
  - Careful history and physical examination
  - Identification of proper patient characteristics and risk factors
  - Survey for interacting medications (vaccinations, other immunosuppressives)
  - Baseline laboratories:
    - CBC with differential/platelets
    - Basic serum chemistry profile
    - Urinalysis
    - Renal function testing (creatinine/blood urea nitrogen)
- Ongoing laboratory monitoring
  - CBC with differential/platelets and urinalysis
    - Perform weekly initially, then
      - ~ Transition to biweekly or monthly after 2–3 mo
      - ~ Perform testing with any dose escalation
      - ~ Decrease/discontinue if white blood cell count < 4000/mm^3, or platelets < 100,000/mm^3
  - Basic serum chemistry and liver function tests
    - Perform monthly initially, then
      - ~ Transition to every 3–6 mo if stable

CBC = complete blood cell count.

TABLE 228-23
Risks and Precautions with Chlorambucil Use

- Absolute contraindications
  - Hypersensitivity to chlorambucil (can cross-react with cyclophosphamide)
- Relative contraindications
  - Pregnancy/lactation (Category D)
  - Active infection (dependent on severity)
  - Impaired hepatic function
  - Childhood (may have increased risk of seizures)
- Common adverse effects
  - Myelosuppression (often dose-limiting)
  - Gastrointestinal distress (minimized with antiemetic medications)
  - Carcinogenicity (lymphoproliferative disease, squamous cell carcinoma)
  - Reproductive consequences (amenorrhea, azoospermia)

used for dermatologic disease. Other cutaneous side effects of chlorambucil include alopecia, a morbilliform rash, urticaria, and mucosal ulcerations. Chlorambucil is a Category D agent during pregnancy, and it is generally avoided in this setting.

Drug Interactions. Through strong immunosuppression, chlorambucil may decrease the efficacy of viral vaccinations. Concomitant use of additional immunosuppressive drugs may potentiate any risk of infection or carcinogenesis.

Anthracyclines

Anthracyclines are antibiotic molecules that possess potent antineoplastic properties. These agents act specifically during the S phase of cell division. Pegylated liposomal doxorubicin (PLD) (see Fig. 228-1) is an anthracycline sometimes employed in dermatology for the treatment of Kaposi sarcoma.[97]

MECHANISM OF ACTION Anthracyclines, such as doxorubicin, are intercalated within DNA and RNA. Through template disorder and steric obstruction, this incorporation leads to defective synthesis. Cell death typically results, but mutagenesis and carcinogenesis may also occur.

PHARMACOKINETICS PLD has pharmacokinetic properties similar to standard doxorubicin; however, the liposomal formulation results in improved tolerance. Encapsulating liposomes have a diameter of approximately 100 nm and are designed to prevent phagocytosis of the agent by the reticuloendothelial system. The result is a plasma half-life of more than 55 hours and improved tumor penetrance.

INDICATIONS PLD is approved by the U.S. Food and Drug Administration for the treatment of acquired immunodeficiency syndrome–related (epidemic) Kaposi sarcoma.

DOSING REGIMEN PLD is administered at a dose of 20 to 30 mg/m^2 infused intravenously over 30 to 60 minutes once every 2 to 3 weeks.

INITIATING THERAPY A thorough history and physical examination is required before initiation of therapy with PLD. Prior use of anthracyclines is an indication for caution, as additive cardiotoxicity may occur. Physical evidence of existing cardiac failure should be sought.

TABLE 228-24
Risks and Precautions with Doxorubicin Use

- Absolute contraindications
  - Hypersensitivity to anthracyclines
- Relative contraindications
  - Pregnancy/lactation (Category D)
- Common adverse effects
  - Myelosuppression
  - Gastrointestinal distress
  - Toxic hepatitis
  - Hyperpigmentation of the skin and nails

Baseline laboratory studies should include a CBC with manual differential and platelet count, a CD4 count, an HIV viral load assay, and liver function studies, including a total bilirubin.

MONITORING THERAPY Before each dose of PLD, all patients should have a repeat blood count, CD4 count, and liver function tests with total bilirubin. Specific tests for cardiotoxicity, such as a multiple-gated acquisition scan, are indicated for cumulative doses greater than 450 mg/m^2 or if signs or symptoms of congestive heart failure develop.

RISKS AND PRECAUTIONS Absolute and relative contraindications and common adverse effects of doxorubicin are summarized in Table 228-24.

COMPLICATIONS Myelosuppression is the most common side effect of PLD. A nadir in blood counts is expected during the second week of therapy. Any resultant neutropenia should be treated aggressively with granulocyte-macrophage colony-stimulating factor or granulocyte colony-stimulating factor. Characteristically, the HIV viral load does not change substantially during treatment, but CD4 counts may be lowered slightly. Abrupt or precipitous decreases in a CD4 count may be a reason to suspend treatment.

Although it is presumed that PLD has myocardial toxicity, it would appear less cardiotoxic in comparison to non-liposomal forms of doxorubicin. Although many still encourage testing for congestive heart failure with cumulative doses in excess of 450 mg/m^2, multiple studies have shown no adverse cardiac impact with cumulative doses of up to 1040 mg/m^2. Hepatotoxicity has been described with PLD, and this may be additive to any such toxicity caused by antiretroviral medications. Nausea and vomiting with dosing is also common. Doxorubicin is a Category D agent during pregnancy. It is embryotoxic and an abortifacient and should be avoided in women who are pregnant or who are planning to conceive during treatment.

A small percentage of patients may experience an initial infusion reaction, which typically resolves and does not occur with later dosing. Other cutaneous effects include hyperpigmentation of the skin and nails, alopecia, acral erythema and dysesthesias, urticaria, radiation recall reactions, or a pustular psoriasiform drug eruption.

Drug Interactions. To date, no drug interaction studies have been conducted with PLD, but it is reasonable to conclude it may interact with drugs known to interact with conventional doxorubicin, specifically digoxin, cyclosporine, calcium channel blockers, and ciprofloxacin, to name a few.

Despite continued introduction of highly targeted immunomodulating drugs ("biologics") (see Chap. 235), cytotoxic agents remain as important medications in the therapeutic arsenal of dermatologists. Table 228-25 summarizes the major indications, principal mechanism of action, and common toxicities of these agents.

MUCOCUTANEOUS REACTIONS TO CYTOTOXIC AGENTS

Specific cytotoxic agents may be used by dermatologists for treatment of severe and recalcitrant dermatologic disease, but typically only certain agents are employed, and dosages are typically less than those used for other indications. Mucocutaneous reactions to these medications initiated by other providers are commonly seen in patients during consultation. A morphologic approach to those reactions is useful. To this end, subcategories of mucocutaneous reactions to various cytotoxic agents are examined, paying particular attention to those that may provoke characteristic mucocutaneous reactions.

Hair Follicle Complications

ALOPECIA One of the most widely recognized cutaneous effects of cytotoxic agents is alopecia, often creating great distress within the patient. Cytotoxin-induced alopecia is typically a form of anagen effluvium caused by interruption of the rapidly dividing cells of the hair matrix. The particular agent, dose, schedule, and route of administration impact the degree of hair loss, yet, at equivalent dosages, intravenous administration is

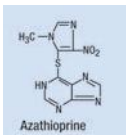

TABLE 228-25
Summary of Cytotoxic Agents Commonly Used in Dermatology

Drug	Common Indications	Mechanism of Action	Typical Dose	Key Side Effects
Methotrexate	Psoriasis Connective tissue disease	Inhibition of dihydrofolate reductase	10.0–17.5 mg/wk	Myelosuppression Toxic hepatitis Liver fibrosis/cirrhosis
Azathioprine	Bullous disorders Connective tissue disease	Forms purine analogues that interrupt DNA/RNA synthesis	0.5–2.5 mg/kg/day (dependent on innate TPMT expression)	Myelosuppression Gastrointestinal distress Increased risk of malignancy
Mycophenolate mofetil	Psoriasis Connective tissue disease	Inhibition of inosine monophosphate dehydrogenase	1.5–2.0 g/day	Gastrointestinal distress Myelosuppression
Thioguanine	Psoriasis	Forms purine analogues that interrupt DNA/RNA synthesis	80–120 mg/day or 120–160 mg 3×/wk (dependent on innate TPMT expression)	Myelosuppression
Hydroxyurea	Psoriasis	Inhibition of ribonucleotide diphosphate reductase	1–2 g/day	Myelosuppression Dermatomyositis-like reaction
Cyclophosphamide	Vasculitis Connective tissue disease Advanced cutaneous T-cell lymphoma	Metabolites undergo physiochemical reactions with DNA (alkylation)	1–3 mg/kg/day or 0.5–1.0 g/monthly	Gastrointestinal distress Myelosuppression Hemorrhagic cystitis Bladder carcinogenesis
Chlorambucil	Vasculitis Connective tissue disease	Physiochemical reactions with DNA (alkylation)	0.05–0.2 mg/kg/day	Gastrointestinal distress Myelosuppression Increased risk of malignancy
Doxorubicin (liposomal)	Acquired immunodeficiency syndrome–related Kaposi sarcoma	Intercalation into DNA with termination of synthesis	20–30 mg/m^2 every 2–3 wk	Gastrointestinal distress Toxic hepatitis Possible cardiotoxicity Infusion site reactions

TPMT = thiopurine methyltransferase.

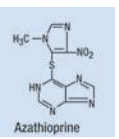

generally more deleterious than oral administration. Numerous cytotoxic agents produce alopecia, but doxorubicin, cyclophosphamide, and vincristine are often implicated (Table 228-26).[98]

TABLE 228-26
Cytotoxic Agents Associated with Alopecia

- Bleomycin
- Busulfan (significant risk of permanent loss)
- Cytarabine
- Dacarbazine
- Daunorubicin
- Docetaxel
- **Doxorubicin**
- Etoposide
- Fluorouracil
- **Hydroxyurea**
- **Methotrexate**
- Nitrogen mustard derivatives (**cyclophosphamide**, **chlorambucil**)
- Nitrosoureas
- Paclitaxel
- Procarbazine
- Thiotepa
- Vinca alkaloids

Agents in **bold** represent a systemic therapy not infrequently used by dermatologists in treating cutaneous illness.

Cytotoxin-induced alopecia usually begins 2 to 4 weeks after therapy and may progress for several months. Up to 85 percent to 90 percent of the hair may be lost; the remaining fraction spared is that normally in telogen. Loss of hair on the scalp and eyebrows is most noticeable, but eyelashes and body hair may be shed as well (Fig. 228-2). The alopecia typically resolves with cessation of treatment, although regrowth may occur with a different color, quality, or texture. Permanent alopecia has occurred most often with high-dose busulfan.[99] Scalp cooling has been used with limited success to minimize hair loss, likely by reducing biochemical activity, but it may create a haven for malignant cells; it remains a controversial intervention, particularly for hematologic malignancies.[100] Topical minoxidil may hasten resolution of the alopecia.[101]

FOLLICULITIS ("ACNEIFORM" ERUPTION)

Classic cytotoxin-induced folliculitis begins as erythematous macules, followed in days by the appearance of papules, and then pustules. Lesions predominate on the face and upper trunk. The eruption typically resolves over 2 weeks, but comedones may persist, or post-inflammatory hyperpigmentation may result.

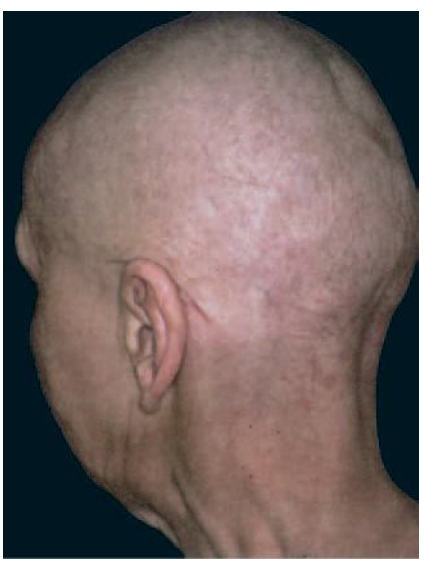

▲ **FIGURE 228-2** Alopecia after the administration of combined chemotherapy with cyclophosphamide, doxorubicin, and vincristine.

TABLE 228-27
Cytotoxic Agents Associated with Nail Plate Malformations (Dystrophy)

- Bleomycin
- **Cyclophosphamide**
- Daunorubicin
- Docetaxel
- **Doxorubicin**
- Fluorouracil
- **Hydroxyurea**
- Mitoxantrone

Agents in **bold** represent a systemic therapy not infrequently used by dermatologists in treating cutaneous illness.

Simple acne vulgaris may also be aggravated by androgens used in conjunction with chemotherapeutic agents in some multidrug regimens. Folliculitis is most often associated with actinomycin D and less often with methotrexate or cisplatin.[102] Recently, a case of eosinophilic folliculitis with combined therapy with cyclophosphamide, methotrexate, and fluorouracil was reported.[103]

Nail Complications

MALFORMED NAIL PLATES (DYSTROPHY) Nail changes are often noted with cytotoxic agents (Table 228-27). Mild nail reactions produce Beau's lines. Severe reactions may produce onycholysis or onychomadesis (Fig. 228-3). The great toenail is most often affected.[104] Less common nail problems due to cytotoxic drugs include nail bed pain, thickening or thinning of the nail plate, and splinter hemorrhage or subungual hemorrhage. Anthracyclines (doxorubicin) and taxanes (paclitaxel) most often yield onychodystrophy, with paclitaxel producing nail changes in up to 40 percent of those treated.[104]

NAIL PIGMENTATION Cytotoxins may yield leukonychia or hyperpigmentation of the nail plate. Leukonychia produces a white discoloration in the nail; the mechanism is unknown, but is presumed to be cytotoxic in nature. An excellent example of patterned leukonychia are Mees' lines, which were described in 1919 as transverse white lines with arsenic exposure.[105] Cytotoxic agents that most often lead to leukonychia are doxorubicin, vincristine, cyclophosphamide, methotrexate, and 5-fluorouracil.[106]

Nail hyperpigmentation usually develops weeks or months after chemotherapy. Hyperpigmentation of the nail



▲ **FIGURE 228-3** Presence of proximal indented Beau's line and distal band of leukonychia due to cyclophosphamide 3 months after bone marrow transplantation.

may be oriented longitudinally, horizontally, diffusely, or in a perilunar fashion.[107] Various mechanisms have been proposed, including genetic predisposition, toxic effect on the nail matrix, photosensitization, or focal stimulation of melanocytes. Blacks are more often affected, presumably due to increased numbers of melanocytes within the nail matrix.[108] Cyclophosphamide, doxorubicin, hydroxyurea, and bleomycin are most often implicated in nail hyperpigmentation.[109] Typically, leukonychia or nail hyperpigmentation due to cytotoxic agents resolves with cessation of therapy.

TABLE 228-28
Cytotoxic Agents Associated with Adnexal Toxicity

NEUTROPHILIC ECCRINE HIDRADENITIS	ECCRINE SYRINGOSQUAMOUS METAPLASIA
Bleomycin	Bleomycin
Chlorambucil	Cytarabine (common)
Cytarabine (common)	Daunorubicin
Daunorubicin	**Doxorubicin**
Doxorubicin (common)	Mitoxantrone
Mitoxantrone	Suramin
Vincristine	

Agents in **bold** represent a systemic therapy not infrequently employed by dermatologists in treating cutaneous illness.

Eccrine Gland Complications

NEUTROPHILIC ECCRINE HIDRADENITIS Neutrophilic eccrine hidradenitis (NEH) consists of tender, erythematous macules, papules, and plaques on the trunk, neck, and extremities that develop days to months after exposure to cytotoxic agents (Fig. 228-4).[110,111] Lesions resolve spontaneously over a period of days. Histologic changes include a perieccrine neutrophilic infiltrate. Apocrine gland involvement has also been identified.[112] Concentration of the cytotoxic agent within sweat is the likely mechanism of injury. NEH is most often associated with cytarabine, but other agents have been implicated (Table 228-28). A similar condition unassociated with cytotoxic agents is recognized, suggesting the skin lesions represent a final common pathway of adnexal injury.



▲ **FIGURE 228-4** Neutrophilic eccrine hidradenitis (*arrow*). (From the Archives of Fitzsimmons Army Medical Center.)

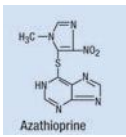

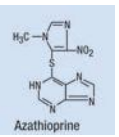

SYRINGOSQUAMOUS METAPLASIA Chemotherapy-induced syringosquamous metaplasia (CISM) is closely related to NEH. Like neutrophilic hidradenitis, direct cytotoxic injury of sweat ducts is implicated. Clinically, CISM presents as erythematous papular eruptions, similar to miliaria, which erupt 2 to 39 days after administration of the cytotoxic agent.[113,114] The papules resolve approximately 4 weeks after discontinuance. Histologic examination demonstrates prominent squamous metaplasia of the upper sweat duct, with necrotic ductal epithelial cells; inflammation is minimal. On occasion, CISM may even mimic SCC.[115] Cytarabine has been most often associated with CISM (see Table 228-28).

Epidermal Complications

CHEMOTHERAPY-INDUCED ACRAL ERYTHEMA Multiple cytotoxic agents may yield a distinct cutaneous reaction known as *acral erythema*. The reaction usually develops 4 to 23 days after initiation of chemotherapy as painful, sharply demarcated erythema of the palmoplantar surfaces, with associated edema (Fig. 228-5).[116] In severe cases, large bullae may extend over the dorsum of the hands and feet.[117] Pain may limit ambulation or use of the hands. Therapy is limited mostly to analgesics and emollients, although pyridoxine supplementation may improve dysesthesias. The reaction is self-limited and resolves over 2 to 4 weeks. Recurrence with subsequent exposure is highly variable. The cause of acral erythema is unknown, but concentration of cytoxic agents within eccrine structures of acral skin has been proposed. In support of such a theory, coexistent syringosquamous metaplasia has been demonstrated.[118] Acral erythema is most common with cytarabine, doxorubicin, fluorouracil, and methotrexate (Table 228-29). Long-term hydroxyurea therapy may produce a unique form of acral erythema that is linear and resembles dermatomyositis, without any corresponding muscle findings (drug-induced pseudodermatomyositis); rarely, the face may be involved.[74,75]

TABLE 228-29
Cytotoxic Agents Associated with Acral Erythema

- **Cyclophosphamide**
- Cytarabine
- Daunorubicin
- Docetaxel
- **Doxorubicin**
- Etoposide
- Fluorouracil
- **Hydroxyurea** (dermatomyositis-like eruption possible)
- Lomustine
- Mercaptopurine
- **Methotrexate**
- Paclitaxel
- Suramin
- Vinblastine

Agents in **bold** represent a systemic therapy not infrequently employed by dermatologists in treating cutaneous illness.

INFLAMMATION OF ACTINIC KERATOSES A number of different cytoxic agents and chemotherapeutic protocols yield inflammation of actinic keratoses. Systemic fluorouracil is the most common cause of inflamed actinic keratoses, and this should come as no surprise to dermatologists.[119] The reaction usually develops within 1 week of initiating chemotherapy. The actinic keratoses may resolve or remain after completion of the therapy. A similar reaction within seborrheic keratoses has been reported to occur with cytarabine and may mimic the sign of Leser-Trélat or herpes zoster.[120,121]



▲ **FIGURE 228-5** Cytarabine-induced painful acral erythema with edema.



▲ **FIGURE 228-6** Flagellate hyperpigmentation occurs 2 weeks after administration of bleomycin.

CUTANEOUS HYPERPIGMENTATION Bleomycin may produce a unique form of flagellate (linear) hyperpigmentation of the skin in 8 percent to 66 percent of those exposed; typically after cumulative doses of 90 to 285 mg.[122,123] Lesions begin as linear, erythematous, pruritic lesions that are slowly replaced by hyperpigmentation and are present hours to weeks after dosing (Fig. 228-6). The eruption usually resolves without treatment over weeks to months. The pathogenesis is unknown, but some investigators have induced flagellate lesions by rubbing the skin during bleomycin administration; others have been unable to replicate this result. Bleomycin may also produce patchy pigmentation in areas of pressure, within the palmar creases, or within striae distensae. Other unique forms of cutaneous hyperpigmentation are recognized, such as the serpentine supravenous hyperpigmentation that may accompany fluorouracil infusions[124] or the polycyclic bands of pigmentation on the scalp occurring with daunorubicin.[108]

Numerous antineoplastic drugs may yield other forms of hyperpigmentation, including patchy, acral, photoaccentuated, polycyclic, occlusion accentuated, pressure accentuated (Fig. 228-7), or generalized patterns (Table 228-30).[102] The cause of cutaneous hyperpigmentation is largely unknown. Postulated mechanisms include a direct toxic effect on melanocytes, increased drug deposition due to increased blood flow, local

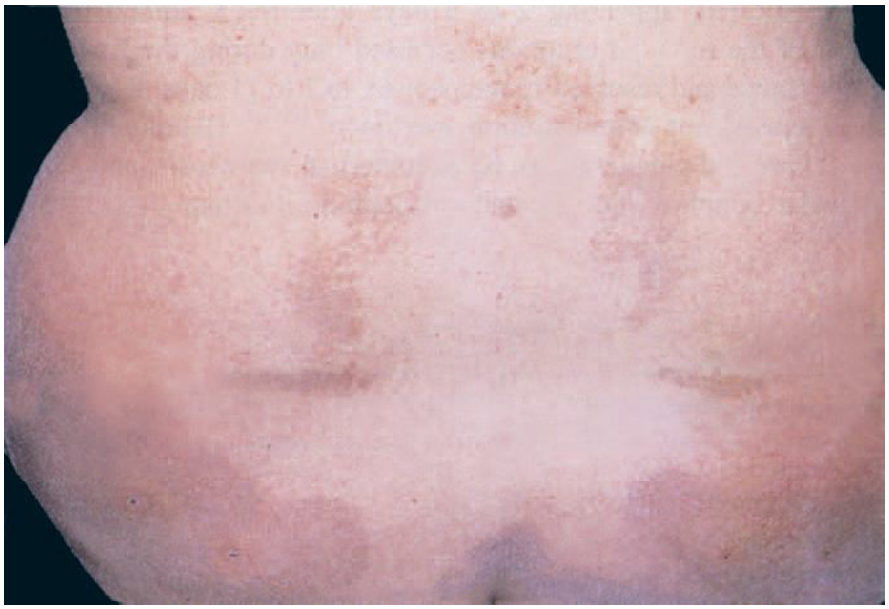

▲ **FIGURE 228-7** Hyperpigmentation at sites of occlusion during administration of thiotepa.

toxicity due to concentration in sweat, associated endocrinologic abnormalities, and drug-induced depletion of tyrosinase inhibitors.[107]

PHOTOSENSITIVITY Most chemotherapy-induced photosensitivity is phototoxic rather than photoallergic in nature (Table 228-31; see also Chap. 91). Phototoxic reactions begin rapidly after administration and often mimic sunburns, with burning, erythema, and even vesicles or bullae. Photoallergic reactions typically present as a more eczematous process. Furthermore, photoallergic processes are dependent on sensitization and may be delayed weeks or months after an initial exposure.

TABLE 228-30
Cytotoxic Agents Associated with Skin Hyperpigmentation

DRUG	PATTERN OF PIGMENTATION
Bleomycin	Flagellate
Busulphan	Dusky, may appear similar to Addison disease
Cisplatin	Pressure-induced
Cyclophosphamide	May be localized to palms, soles, or nails
Dactinomycin	Diffuse
Daunorubicin	Sun-exposed areas
Doxorubicin	Diffuse, particularly nails
Etoposide	Occluded areas
Fluorouracil	Sun-exposed areas, areas of prior irradiation, nails
Hydroxyurea	Diffuse, particularly nails
Ifosfamide	Hands, feet, and occluded areas
Methotrexate	Sun-exposed areas, hair may develop "flag sign"
Nitrosoureas	Occluded areas
Paclitaxel	Localized
Plicamycin	Localized
Procarbazine	Diffuse
Tamoxifen	Hair pigmentation
Thiotepa	Occluded areas
Vinca alkaloids	Localized

Agents in **bold** represent a systemic therapy not infrequently employed by dermatologists in treating cutaneous illness.

RADIATION RECALL REACTION Recall reactions consist of erythema confined to an area of prior radiation exposure or sunburn. Severe cases may develop vesiculation (Fig. 228-8). True radiation recall may occur years after irradiation, and the pathogenesis is unknown. It has been postulated that radiation-damaged keratinocytes are further damaged by the administration of the cytotoxic agent (see Table 228-31).[125] Methotrexate often engenders a unique recall reaction to sunburn when dosed 1 to 3 days after exposure, although at least one case occurred as late as 8 days afterward.[126] Folinic acid supplementation (leucovorin rescue) does not prevent UV sunburn recall reactions due to methotrexate.

RADIATION ENHANCEMENT REACTIONS Radiation enhancement is a synergistic reaction between an antineoplastic agent and irradiation. This radiosensitization is often desired in antineoplastic treatment, but it may lead to adverse effects on the skin. The result may be radiation dermatitis that presents initially as pain and erythema followed by desquamation and hyperpigmentation. Although a number of chemotherapeutic agents may produce this reaction, doxorubicin and dactinomycin are most often implicated (see Table 228-31).[102]

TABLE 228-31
Cytotoxic Agents with Radiation Reactions

- Photosensitivity
  - Dacarbazine
  - Fluorouracil
  - **Hydroxyurea**
  - **Methotrexate**
  - Mitomycin
  - **Thioguanine**
  - Vinblastine
- Radiation enhancement
  - Bleomycin
  - Cisplatin
  - Dactinomycin
  - **Doxorubicin**
  - Fluorouracil
  - **Hydroxyurea**
  - **Methotrexate**
- Radiation recall reaction
  - Bleomycin
  - Cytarabine (common)
  - Dactinomycin
  - **Doxorubicin**
  - Etoposide
  - Fluorouracil
  - **Hydroxyurea**
  - Lomustine
  - **Methotrexate**
  - Melphalan
  - Mitomycin
  - Paclitaxel
- Sunburn recall reaction
  - **Methotrexate**
  - Suramin

Agents in **bold** represent a systemic therapy not infrequently employed by dermatologists in treating cutaneous illness.



▲ **FIGURE 228-8** Reactivation of solar erythema 2 days after high-dose methotrexate administration to a young woman with choriocarcinoma. (From Bronner AK, Hood AF: Cutaneous complications of chemotherapeutic agents. *J Am Acad Dermatol* **9**:645, 1983, with permission.)

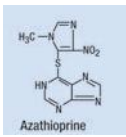

Dermal Complications

LOCAL INJURY Extravasation of chemotherapeutic agents may occur in up to 6 percent of adults treated with infusions and is likely an even more common occurrence among pediatric patients.[107,127] As expected, the degree of injury is related to the drug used, the rate of delivery, the concentration of the agent, and the amount extravasated.

Agents with minimal toxicity on extravasation may produce only a chemical cellulitis or phlebitis and are classified as irritants. Chemical cellulitis manifests as erythema, induration, and pain at the injection site. Sometimes it may follow the course of a vein. It is often of short duration and resolves without treatment. Chemotherapy-induced phlebitis manifests as linear cords, often with accompanying discomfort.

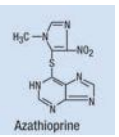

Vesicants are agents, which on extravasation yield direct-tissue necrosis. Chemotherapy-induced tissue necrosis can be a devastating complication. Extravasation should always be treated by immediate discontinuance of the infusion and the application of either hot or cold packs. Cold packs are used for all chemotherapeutic agents except vinca alkaloids to localize the drug and promote degradation. Vinca alkaloids are treated with hot packs because application of cold promotes tissue necrosis.[128] Doxorubicin is perhaps the most dangerous of all vesicants, and extravasation of this agent may yield ulcers that progress for months that may even erode into tendon or bone (Fig. 228-9). Severe ulcerations caused by extravasation may require wide excision and skin grafting.

Other treatments advocated for specific situations include: (1) topical dimethyl sulfoxide (DMSO); (2) local injection of hyaluronidase; or (3) potent topical, intralesional, or oral steroids. DMSO is a topical solvent that has free-radical scavenging and antioxidant properties; it may hasten removal of extravasated drugs. Studies suggest that topical DMSO may have benefit in anthracycline-induced skin ulceration.[129,130] Hyaluronidase degrades hyaluronic acid, breaking down subcutaneous tissue, and promoting drug diffusion through the interstitial space. It appears effective in vinca alkaloid, epipodophyllotoxin, and paclitaxel extravasations, but should not be used in anthracycline extravasation.[131,132] Hyaluronidase is contraindicated in sites involved with malignancy or superinfection. Finally, histologic examination of extravasation injuries has demonstrated surprisingly few inflammatory cells in areas of tissue damage, perhaps explaining why corticosteroids are, in general, of little value in management.[133,134]



▲ **FIGURE 228-9** Severe tissue necrosis after extravasation of doxorubicin.

SCLEROTIC DERMAL REACTIONS Bleomycin and docetaxel produce sclerotic tissue reactions that may be localized, regional, or diffuse in extent.[135,136] Localized tissue reactions may mimic morphea or systemic sclerosis. Melphalan has been reported to produce a unique form of reticulate scleroderma after limb perfusion. The mechanism of tissue sclerosis has not been well established. Biopsies of cytoxin-induced dermal sclerosis may be indistinguishable from morphea or systemic sclerosis. In some cases, the sclerosis resolved after withdrawal of the offending agent.

RAYNAUD PHENOMENON Secondary Raynaud phenomenon, with or without digital ulceration, is most often associated with bleomycin, vincristine, cisplatin, or cisplatin with gemcitabine.[137–139] This reaction may occur with systemic chemotherapy or after intralesional injection to treat verruca vulgaris. The mechanism of development is unknown, but bleomycin is known to be toxic to endothelial cells. In a large study of 90 patients receiving bleomycin for testicular cancer, 37 percent developed Raynaud phenomenon, with 7 percent having transient disease.[137] Risk factors for the development of Raynaud phenomenon include combination therapy with vinblastine or high cumulative doses of bleomycin.

Mucosal Complications

Oral complications may occur in up to 40 percent of those receiving chemotherapy. Because of a high inherent proliferative index, the mucosa is susceptible to the effects of multiple cytotoxic agents. Young patients and those with pre-existing oral disease appear even more susceptible.[107]

TABLE 228-32
Cytotoxic Agents Associated with Mucositis

- Bleomycin
- **Cyclophosphamide**
- Cytarabine
- Dactinomycin
- Daunorubicin
- Docetaxel
- **Doxorubicin**
- Fluorouracil
- **Hydroxyurea**
- Mercaptopurine
- **Methotrexate**
- Mitomycin
- Nitrosoureas
- Paclitaxel
- Plicataxel
- Plicamycin
- Procarbazine
- Vinblastine

Agents in **bold** represent a systemic therapy not infrequently employed by dermatologists in treating cutaneous illness.

MUCOSITIS/STOMATITIS A wide range of cytoxic agents have been implicated in stomatitis (Table 228-32). Patients with cytoxin-induced stomatitis typically note burning and mucosal erythema days after administration. Painful erosions and ulcerations often follow (Fig. 228-10). The mouth is most often affected, especially the buccal mucosa and tongue, but any mucosal surface may be involved. Mucositis may be complicated by secondary bacterial or fungal infection. Meticulous, but not overly aggressive, hygiene may reduce the incidence of secondary infection, and antibiotics and antifungal agents are often used. A recent meta-analysis of treatments for chemotherapy-induced mucositis found that simple modalities, such as ice chips, had equivalent benefit to more aggressive interventions.[140] Finally, oral hemorrhage may be secondary to chemotherapy-induced thrombo-



▲ **FIGURE 228-10** Stomatitis induced by combined chemotherapy with cytarabine, doxorubicin, and methotrexate. (Used with permission from Allan C. Harrington, MD.)

cytopenia, and a careful clinical examination is always required.

MUCOSAL HYPERPIGMENTATION Many cytotoxic agents induce mucosal hyperpigmentation. Mucosal hyperpigmentation may manifest various patterns, including linear, patchy, and macular forms. Some agents tend to affect certain anatomic areas such as the gingival margin (cyclophosphamide) or tongue (fluorouracil). The mechanism of mucosal hyperpigmentation is not well understood. Typically, cytotoxin-induced hyperpigmentation resolves slowly over weeks to months after discontinuance. One notable exception is mucosal hyperpigmentation caused by cyclophosphamide, which may be permanent. Cyclophosphamide may also produce a permanent pigmented band on the teeth.

KEY REFERENCES

The full reference list for all chapters is available at www.digm7.com.

7. Roenigk HH et al: Methotrexate in psoriasis: Consensus conference. *J Am Acad Dermatol* **38**:478, 1998
14. Zachariae H et al: Have methotrexate-induced liver fibrosis and cirrhosis become rare? A matter for reappraisal of routine liver biopsies. *Dermatology* **211**:307, 2005
21. Zachariae H: Liver biopsies and methotrexate: A time for reconsideration? *J Am Acad Dermatol* **42**:531, 2000
32. van Ede AE et al: Homocysteine and folate status in methotrexate-treated patients with rheumatoid arthritis. *Rheumatology (Oxford)* **41**:658, 2002
37. Jackson AP, Hall AG, McLelland J: Thiopurine methyltransferase levels should be measured before commencing patients on azathioprine. *Br J Dermatol* **136**:133, 1997
40. Scerri L: Azathioprine in dermatological practice. An overview with special emphasis on its use in non-bullous inflammatory dermatoses. *Adv Exp Med Biol* **455**:343, 1999
50. O'Donovan P et al: Azathioprine and UVA light generate mutagenic oxidative DNA damage. *Science* **309**:1871, 2005
53. Nousari HC et al: Mycophenolate mofetil in autoimmune and inflammatory skin disorders. *J Am Acad Dermatol* **40**:265, 1999
58. Kitchin JES et al: Rediscovering mycophenolic acid: A review of its mechanism, side effects, and potential uses. *J Am Acad Dermatol* **37**:445, 1997
65. Mason C, Krueger GG: Thioguanine for refractory psoriasis: A 4-year experience. *J Am Acad Dermatol* **44**:67, 2001
72. Smith CH: Use of hydroxyurea in psoriasis. *Clin Exp Dermatol* **24**:2, 1999
74. Elliott R, Davies M, Harmse D: Dermatomyositis-like eruption with long-term hydroxyurea. *J Dermatolog Treat* **17**:59, 2006
81. Sacher C, Hunzelmann N: Cicatricial pemphigoid (mucous membrane pemphigoid): current and emerging therapeutic approaches. *Am J Clin Dermatol* **6**:93, 2005
83. Foster R et al: Primary systemic vasculitis: Treatment of difficult cases. *Lupus* **15**:143, 2006
84. Volkmer BG et al: Cyclophosphamide is contraindicated in patients with a history of transitional cell carcinoma. *Clin Rheumatol* **24**:319, 2005
95. Somers EC et al: Use of a gonadotropin-releasing hormone analog for protection against premature ovarian failure during cyclophosphamide therapy in women with severe lupus. *Arthritis Rheum* **52**:2761, 2005
97. Hengge UR et al: Long-term chemotherapy of HIV-associated Kaposi's sarcoma with liposomal doxorubicin. *Eur J Cancer* **37**:878, 2001
102. Koppel RA, Boh EE: Cutaneous reactions to chemotherapeutic agents. *Am J Med Sci* **321**:327, 2001
107. Susser WS, Whitaker-Worth DL, Grant-Kels JM: Mucocutaneous reactions to chemotherapy. *J Am Acad Dermatol* **40**:367, 1999
125. Yeo W, Johnson PJ: Radiation-recall skin disorders associated with the use of antineoplastic drugs. Pathogenesis, prevalence, and management. *Am J Clin Dermatol* **1**:113, 2000

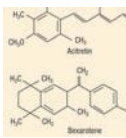

CHAPTER 229

Retinoids

Anders Vahlquist
Stéphane Kuenzli
Jean-Hilaire Saurat

Retinoids include both naturally occurring molecules and synthetic compounds that have specific biologic activities that resemble those of vitamin A or bind to the nuclear receptors for retinoids. Vitamin A from natural sources was already being used in the 1930s in high dosages to treat certain hyperkeratotic diseases, often with toxic side effects. Three generations of synthetic retinoids have since been developed (Fig. 229-1):

First generation: All-*trans* retinoic acid (tretinoin, ATRA), a naturally occurring metabolite of retinol, was the first retinoid synthesized but had no significant advantages over vitamin A in treatment of dermatologic diseases. It is used as a differentiation-inducing agent to treat acute promyelocytic leukemia.

Isotretinoin (13-*cis* retinoic acid), clinically available since the 1970s, was found to cause prolonged remissions in patients with previously treatment-resistant cystic acne [it has been approved by the U.S. Food and Drug Administration (FDA) for this indication since 1982].[1]

Second generation: Through replacement of the β-ionone ring in ATRA with an aromatic structure, newer retinoids with better therapeutic margins were synthesized in the 1970s. Etretinate and its free acid metabolite, acitretin, showed a therapeutic index 10 times more favorable than that of ATRA. Etretinate (approved in Europe 1983 and by the FDA in 1987) and acitretin (approved 1987 and 1997, respectively) became a standard treatment for psoriasis.

Third generation: The discovery of retinoic acid receptors (RARs)[2,3] allowed research directed toward receptor-specific, third-generation retinoids with a safer therapeutic index and a more selective action. Bexarotene, approved by the FDA in 1999 for systemic use in treating cutaneous T-cell lymphoma (CTCL), is a prime example. Bexarotene belongs to a subclass of arotinoids called *rexinoids*, because they bind to the retinoid X receptors (see Bexarotene).

MECHANISM OF ACTION

Retinoids affect cell growth and differentiation, exert immunomodulatory action, and alter cellular adhesiveness.[4] Their effect on RARs is discussed in detail in Chap. 217.

Under normal conditions, virtually all effects of vitamin A in the skin are mediated by ATRA, the cellular level of which is meticulously controlled. Endogenous ATRA has been at the focus in the development of a new class of compounds called *retinoic acid metabolism–blocking agents*, which are basically cytochrome P_{450} (CYP) enzyme 26 in-

RETINOIDS AT A GLANCE

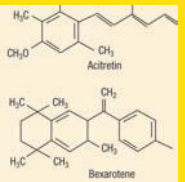

- The biologic functions and actions of retinoids (excluding vision) include the following:
  - Reproduction, embryonic growth, and morphogenesis
  - Modulation of proliferation and differentiation of epithelia
  - Decrease in sebaceous gland size (isotretinoin)
  - Immunologic and anti-inflammatory effects
  - Tumor prevention and treatment
  - Effect on extracellular matrix components
- Three types of oral retinoids and the major indication for their use are isotretinoin (acne), acitretin (psoriasis, keratinizing disorders), and bexarotene (cutaneous T-cell lymphoma). Contraindications to their use include pregnancy, breast-feeding, and non-adherence to contraceptive regimen.
- Mucocutaneous side effects (cheilitis, xerosis, skin peeling, conjunctivitis) are common, as are reversible abnormal results on laboratory tests [hyperlipidemia, increased liver enzyme levels, and hypothyroidism (bexarotene)]. Musculoskeletal and central nervous system side effects are rare.

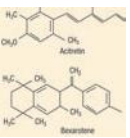

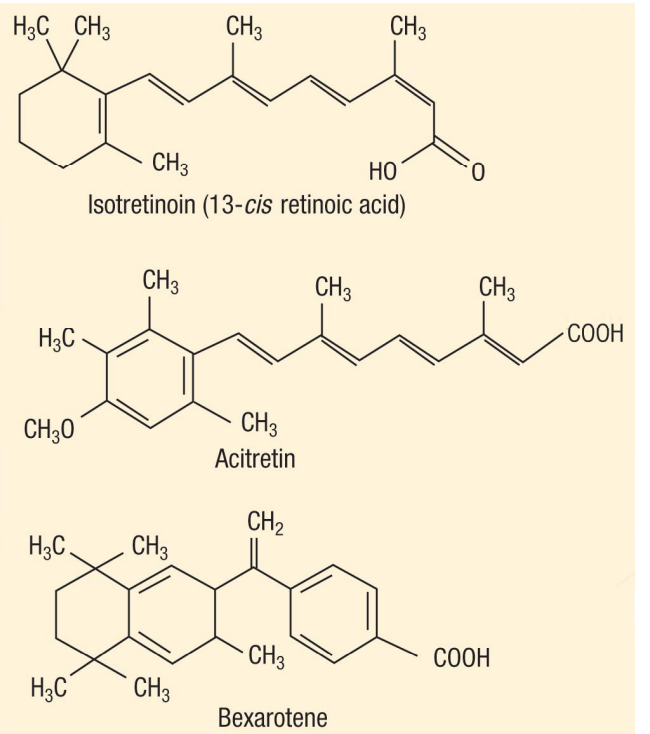

▲ **FIGURE 229-1** Chemical structure of three generations of retinoids. Isotretinoin is first generation; in second-generation (e.g., acitretin) the β-ionone ring, is replaced with an aromatic structure. Bexarotene is an example of a third-generation retinoid.

hibitors that impede the oxidative degradation of ATRA and thus increase the retinoid activity in target tissues.[5] Two such drugs (liarozole and Rambazole) are under development.

PHARMACOKINETICS

Isotretinoin, acitretin/etretinate, and bexarotene differ not only in their spectra of clinical efficacy but also in their toxicities and pharmacokinetics. Due to their lipophilicity, the oral bioavailability of all retinoids is enhanced when they are administrated with food, especially with fatty meals. Retinoids are metabolized mainly by oxidation and chain shortening to biologically inactive and hydrophilic metabolites, which facilitates biliary and/or renal elimination. The oxidative metabolism is induced primarily by the retinoids themselves and other agents that induce hepatic CYP isoforms.[6]

Isotretinoin

Isotretinoin and ATRA are two interconvertible isomers that differ in their elimination half-lives—approximately 20 hours for isotretinoin and 1 hour for ATRA. Isotretinoin undergoes first-pass metabolism in the liver and subsequent enterohepatic recycling. In plasma, isotretinoin is more than 99 percent bound to plasma protein, mainly albumin. It is stored in neither the liver nor adipose tissue, in sharp contrast to vitamin A and etretinate. The major metabolite is 4-oxoisotretinoin, which has reduced bioactivity; both compounds are excreted in urine and feces. After the end of treatment, endogenous concentrations of isotretinoin and its major metabolite are reached within 2 weeks. Therefore, a 1-month post-therapy period of contraception provides an adequate safety margin.[7] No clear affinity for any RARs has been identified with isotretinoin.

Acitretin and Etretinate

Etretinate is a prodrug of acitretin that undergoes extensive hydrolysis in the body to yield the corresponding acid metabolite. In animal studies and in clinical studies in patients with severe keratinizing disorders, acitretin is as effective as etretinate.[8] However, acitretin has a great pharmacokinetic advantage because it is eliminated more rapidly than etretinate.[9] Etretinate is approximately 50 times more lipophilic than acitretin and binds strongly to plasma lipoproteins, whereas acitretin binds to albumin. This fact has a profound influence on the respective pharmacokinetic properties of the two drugs.

Even when etretinate and acitretin are taken with food, the absorption of the two drugs varies.[10] Etretinate is stored in adipose tissue from which it is released slowly; it has a terminal half-life of up to 120 days. In contrast, acitretin has an elimination half-life of only 2 days.[9] However, small amounts of etretinate can be formed in patients receiving acitretin if it is taken simultaneously with alcohol.[11] This has prompted the manufacturer to extend the time of compulsory contraception in patients taking acitretin to 2 years (3 years in the United States).[12] Acitretin still has a pharmacokinetic advantage over etretinate, however, for all women who strictly avoid alcohol consumption during treatment and for 2 months thereafter.[9]

Acitretin metabolism primarily involves isomerization instead of oxidation. The major metabolite of acitretin is

its 13-*cis* isomer, which is inactive. Paradoxically, acitretin activates all three RAR sub-types but binds poorly to them.[13]

Bexarotene

Bexarotene is approximately 100-fold more potent in activating retinoid X receptors than RARs. Its absorption is particularly increased by taking it with fatty meals. In plasma, bexarotene is highly bound (more than 99 percent) to proteins that have not yet been characterized, and the ability of bexarotene to displace drugs bound to plasma proteins and the ability of drugs to displace bexarotene is unknown. Bexarotene probably has a clearance profile similar to that of isotretinoin with a terminal half-life of between 7 and 9 hours.[14] Bexarotene is metabolized by CYP 3A4 and generates its own inactive oxidative metabolites via hepatic CYP 3A4 induction. Neither bexarotene nor its metabolites are excreted in urine; elimination is thought to occur primarily via the hepatobiliary system.[15]

INDICATIONS

Acne

Isotretinoin is remarkably effective in curing acne, possibly because it affects—primarily or secondarily—all etiologic factors implicated in the pathogenesis of acne: sebum production, comedogenesis, and colonization with *Propionibacterium acnes*.[16] Of all the natural and synthetic retinoids used in humans, only isotretinoin suppresses sebum excretion and reduces sebaceous gland size.

In the early 1980s, isotretinoin treatment was restricted to patients with severe nodulocystic acne. With increasing experience, however, its use has been extended to patients with less severe disease who respond unsatisfactorily to conventional therapies such as long-term antibiotics because of the increased resistance of *P. acnes* to many antibiotics.[17,18]

Psoriasis

The retinoid of first choice for oral treatment of psoriasis is acitretin. Acitretin appears to be as effective as etretinate and can be used in the same combination regimens.[19–23] The best results have been obtained in pustular psoriasis of the palmoplantar or generalized (von Zumbusch) type.[19,24,25] Rebound does not usually occur after treatment is stopped, and reintroduction of the drug when it does occur produces a beneficial response.[26] Although complete clearing of plaque-type psoriasis is achieved in only approximately 30 percent of treated patients, significant improvement is obtained in a further 50 percent.[5,27,28] The decrease in the psoriasis area and severity index is approximately 60 percent to 70 percent, depending on the dosage.[5,8] Approximately 20 percent of patients may be considered to experience treatment failures. Combination of acitretin with other anti-psoriatic agents may then be required (see Dosing Regimens).

In a 20-week treatment study,[29] six of eleven patients (54 percent) with human immunodeficiency virus infection who had psoriasis showed good to excellent responses to acitretin monotherapy (75 mg/day). Both skin and joint manifestations responded to acitretin therapy in most patients. The adverse effects were moderate and well tolerated, and measures of immune parameters did not indicate exacerbation of immunosuppression in most patients.

Isotretinoin has less effect on psoriasis than acitretin or etretinate, although some efficacy has been shown in combination with psoralen plus ultraviolet A light (PUVA) therapy.[12] Nevertheless, some dermatologists use isotretinoin to treat women with psoriasis who need systemic retinoids to avoid the long post-acitretin contraception period required.

Cutaneous T-Cell Lymphoma

Some older studies showed that etretinate may induce clinical improvement in patients with CTCL (e.g., mycosis fungoides or Sézary syndrome) with no internal involvement; better results were obtained when etretinate was combined with PUVA treatment or interferon-α therapy. Use of the combination of acitretin or isotretinoin with oral vitamin D_3 (calcitriol) to obtain synergistic effects in the treatment of CTCL has been reported.[30,31]

In 1999 the FDA approved bexarotene as oral therapy for the treatment of CTCL that is refractory to at least one systemic therapy. In early (IA-IIA) and advanced (IIB-IVB) stages of CTCL (see Chap. 146), oral bexarotene monotherapy produced approximately 60 percent and 50 percent response rates, respectively, at a dosage of 300 mg/m^2 or more per day within the first 2 months in most patients.[32,33]

Clinical Uses Not Approved by the U.S. Food and Drug Administration

Multiple other skin disorders respond to retinoids, but for only a few of them is the effect established in controlled studies.[34] In many reports the choice of etretinate/acitretin rather than isotretinoin was based not on pharmacologic considerations but on availability of the product. Bexarotene has not been tested extensively for indications other than CTCL.

ICHTHYOSIS Among the different types of ichthyosis, the best results are obtained with acitretin for non-bullous congenital ichthyosis such as lamellar ichthyosis. Treatment of bullous ichthyosiform erythroderma (epidermolytic hyperkeratosis) may lead to an initial increase in bullae. Good results also have been achieved in treating recessive X-linked ichthyosis and ichthyosis vulgaris; however, because of its limited severity the disease often does not require retinoid therapy.

DARIER DISEASE Severe forms of Darier disease (Darier-White disease) are good indications for retinoid therapy. Care should be taken to initiate therapy with a very low dosage, such as 10 mg/day of acitretin, to prevent initial exacerbation of the disease; usually 20 mg/day is sufficient for significant improvement. Long-term treatment is usually needed to prevent relapse. Low-dose isotretinoin therapy has been used especially in women with Darier disease. Combination of retinoids with antibiotics may enhance the clinical effects, because skin lesions are frequently infected.

PITYRIASIS RUBRA PILARIS Early treatment with retinoids appears to offer the best chance for clearing of pityriasis rubra pilaris. In extensive cases, concomitant use of methotrexate may be advantageous, but this combination carries an increased risk for toxicity. Etretinate is considered to be superior to isotretinoin in the treatment of adult-onset pityriasis rubra pilaris.[35]

ROSACEA In severe forms or in treatment-resistant rosacea, isotretinoin therapy may be more effective for inflammatory lesions than for vascular lesions.[36] A low daily dose (10 mg) is often sufficient. The best indications are severe cases of rosacea associated with significant seborrhea.

HIDRADENITIS SUPPURATIVA Isotretinoin has limited effect on hidradenitis suppurativa, but some investigators recommend this therapy during the weeks or months preceding surgical treatment. Prolonged therapy with acitretin/etreti-

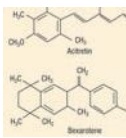

nate has been used with some success, especially in treating extensive, inflammatory lesions unsuitable for surgery.[37,38]

PRE-MALIGNANT AND MALIGNANT SKIN LESIONS Etretinate and acitretin are effective in the treatment of pre-malignant skin lesions, including human papillomavirus–induced tumors and actinic keratoses. In basal cell nevus syndrome and in xeroderma pigmentosum, these drugs reduce dramatically the incidence of malignant degeneration of the skin lesions. A double-blind study demonstrated that acitretin at a dosage of 30 mg/day for 6 months prevented the development of pre-malignant and malignant skin lesions in renal transplant recipients.[39]

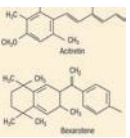

LICHEN SCLEROSUS ET ATROPHICUS Acitretin/etretinate is an effective treatment for severe lichen sclerosus et atrophicus of the vulva and may be recommended intermittently for patients who are intolerant of or resistant to local therapies.[40]

LUPUS ERYTHEMATOSUS Both isotretinoin and acitretin have been used successfully in patients with various forms of lupus erythematosus. However, the lesions recur after completion of treatment as quickly as the initial improvement appeared. Acitretin and hydroxychloroquine are equally effective in the treatment of chronic discoid lupus erythematosus and subacute cutaneous lupus erythematosus.[12]

DOSING REGIMENS

Isotretinoin

The initial consensus was that optimal benefit in acne would be achieved with a high daily dose of isotretinoin, approximately 1 mg/kg of body weight per day.[16] This high dose induces undesirable side effects, however, and similar short-term therapeutic results are obtained with a dose below 0.5 mg/kg provided the treatment is maintained over a longer period of time.[41] Empirical data from several centers indicate that post-therapy relapse is minimized by administering a cumulative dose of at least 120 mg/kg,[42] and no further therapeutic gain is seen beyond approximately 150 mg/kg.[18] This implies 6 to 8 months of therapy. A lag period of 1 to 3 months may occur before the onset of the therapeutic effect. A flare-up of disease during the first few weeks of treatment and the evolution of acne cysts into lesions resembling pyogenic granuloma may be observed.

Continued healing of acne after the discontinuation of therapy regularly occurs. Approximately one-third of patients with acne require a second course of therapy for either persistent disease or relapse. The only factors predictive of resistance to isotretinoin treatment are the presence of closed comedonal acne and of microcystic acne.[43]

Acitretin and Etretinate

A therapeutic dosage scheme with an initially low dose (10 to 25 mg/day) of acitretin (etretinate requires 20 percent higher dosing because of a higher molecular weight), followed by progressively increasing doses, seems to avoid the increase in the extent of the psoriatic lesions that may occur within a few days of the start of treatment at dosages of 0.5 to 1.0 mg/kg/day (30 to 70 mg/day).[10]

Although the efficacy of a dosage of 10 mg/day was not significantly different from that of the placebo in one study,[10] individual patients may respond to dosages as low as 5 mg/day.

Total clearing of the lesions often requires a combination of treatments, such as retinoids plus topical glucocorticoids, topical vitamin D derivatives, dithranol (anthralin), ultraviolet B irradiation, or photochemotherapy (PUVA treatment).[44–48]

Bexarotene

The recommended initial dosage of bexarotene is 300 mg/m^2/day, administered as a single oral dose with meals. Based on the severity of adverse effects, the dosage may be adjusted down to 100 or 200 mg/m^2/day or administration may be suspended temporarily. If CTCL does not respond after 8 weeks of therapy, the dosage may be increased to 400 mg/m^2/day with careful monitoring.[32,33]

INITIATION AND MONITORING OF THERAPY

Isotretinoin

Women with childbearing potential must have a negative result on a pregnancy test and must practice effective contraception during treatment and for 1 month (2 months in some countries) after the completion of therapy.[49] The SMART (System to Manage Accutane-Related Teratogenicity) and more lately the iPLEDGE program (http://www.ipledgeprogram.com) have been put into effect by the FDA and the manufacturer to minimize the risk of isotretinoin teratogenicity. Similar but less strict programs exist in Europe and elsewhere.

Acitretin and Etretinate

Ensuring that the patient avoids pregnancy during therapy is as imperative when prescribing acitretin and etretinate as when prescribing isotretinoin. However, because of the frequent prospect of long-term treatment of more chronic diseases (e.g., psoriasis and ichthyosis) and the slow elimination of aromatic retinoids from the body after interruption of therapy, acitretin (or etretinate) therapy is usually not recommended for female patients with childbearing potential.

Additional precautions before initiating acitretin therapy include measurement of baseline serum lipid and liver enzyme levels, and anamnestic exclusion of skeletal abnormalities. It is also important to inform the patient beforehand about the possibility of increased hair shedding and other mucocutaneous side effects that will appear during therapy.

Monitoring of serum lipid and liver enzyme levels monthly for the first 2 months and then at 2- to 3-month intervals is adequate in patients with normal baseline levels and absence of risk factors (obesity, high alcohol intake, diabetes).

Bexarotene

The recommendations given for the other retinoids should also be followed for bexarotene, and in addition patients who will receive bexarotene should be screened for thyroid disease. Thyroid hormone and lipid levels in blood should be monitored frequently during therapy.

RISKS AND PRECAUTIONS

Teratogenesis is the most serious adverse effect of oral retinoids. The side effects of systemic retinoids qualitatively resemble hypervitaminosis A syndrome, although important differences exist. The acute retinoid toxicities include mucocutaneous lesions (most patients) and abnormal laboratory test results (less common but may be substantial), whereas the chronic retinoid toxicities involve bony changes (rare).

Teratogenic Effects

Retinoid-induced birth defects include auditory, cardiovascular, craniofacial, ocular, axial and acral skeletal, central nervous system (hydrocephalus, microcephaly), and thymus gland abnormali-

ties.[50] The putative mechanism is toxic effects on neural crest cells, particularly with exposure during the fourth week of gestation.[51]

In men, retinoid therapy does not appear to produce abnormalities in spermatogenesis, sperm morphology, or sperm motility.[52] However, it is usually recommended that men who are actively trying to father children avoid systemic retinoid therapy.

Skin and Mucous Membrane Adverse Effects

Most patients receiving retinoids develop dryness of the lips, skin, and mucous membranes. These dose-related effects reflect mainly decreased sebum production, reduced stratum corneum thickness, and altered skin barrier function. Cheilitis is the earliest and the most frequent sign, followed by blepharoconjunctivitis, dry eyes, dry nose, and dry mouth. Xerosis of the skin, associated with pruritus and peeling, especially of the palms and soles, occurs frequently. Skin fragility and fissuring of fingertips sometimes create a problem, especially for those who work with their hands. Photosensitivity is observed especially with isotretinoin and probably reflects the reduction of thickness of the stratum corneum. Bexarotene appears to induce fewer mucocutaneous and ocular side effects than other classes of retinoids; localized or extensive exfoliative dermatitis is the most common cutaneous side effect with bexarotene.[14] *Staphylococcus aureus* colonization tends to correlate with isotretinoin-induced reduction in sebum production and may lead to overt cutaneous infections.[53] Various ill-defined skin eruptions, called *retinoid dermatitis*, are observed frequently. The erythema is sometimes difficult to differentiate from an underlying psoriasis or atopic dermatitis.

Ocular Adverse Effects

Blepharoconjunctivitis occurs with varying severity in about one-third of patients treated with isotretinoin and may prevent the use of contact lenses. Bacterial conjunctivitis occurs to a lesser extent than *S. aureus* colonization.[54] If artificial tears and topical ophthalmologic antibiotic therapy fail to alleviate the conjunctivitis, ophthalmologic consultation should be sought. Alterations in visual function, mainly poor night vision, excessive glare sensitivity, and changes in color perception, also have been reported.[55]

Hair and Nail Adverse Effects

Diffuse or localized hair loss (telogen effluvium), which is more severe during treatment with acitretin than with isotretinoin, is a common complaint, although objective alopecia tends to occur only at higher dosage levels and after several months of therapy. Nail thinning and paronychia-like changes with periungual granulation tissue may occur.

Musculoskeletal Adverse Effects

Skeletal toxicity was first observed in retinoid-treated patients maintained on a high dosage and after an extended period of continuous treatment for disorders of keratinization. Bone pain without objective evidence of any abnormalities and without sequelae is frequent in retinoid-treated patients. Several reports with conflicting results have implicated synthetic retinoids in the formation of diffuse idiopathic skeletal hyperostosis syndrome–like bone changes and in calcification of tendons and ligaments.[56–58] Prospective studies have shown that the hyperostotic effects of retinoids are mostly asymptomatic and likely involve worsening of pre-existing skeletal overgrowth rather than de novo changes.[59,60] Osteoporosis has been observed with hypervitaminosis A and after long-term therapy with etretinate and to a lesser extent isotretinoin.[61,62] In children, only a few cases of skeletal abnormalities and premature epiphyseal closure[63–65] have been reported. No baseline radiographs are required, although monitoring patients at high risk who receive prolonged high-dose retinoid treatment may be useful.

Muscle pain and cramps rarely occur in patients taking etretinate or acitretin; however, these muscle effects are not infrequent with isotretinoin, particularly in individuals involved in vigorous physical activity (sometimes accompanied by elevations in creatine phosphokinase levels). Increased muscle tone and axial muscle rigidity and myopathy were reported to be related to etretinate and acitretin therapy.[66]

Central Nervous System and Other Neurologic Adverse Effects

Central nervous system side effects are rare. Although individual signs of increased intracranial pressure such as headache, nausea, and vomiting are observed occasionally, the complete syndrome with papilledema (pseudotumor cerebri) and impaired vision is exceptional.[67] Concomitant use by isotretinoin-treated patients of tetracyclines, which rarely produce increased intracranial hypertension, is the major risk factor for development of pseudotumor cerebri.

Anecdotal reports suggest a causal association between isotretinoin therapy and severe depression with suicide attempts.[68] However, large-scale epidemiologic studies provide no evidence that isotretinoin exposure is associated with any greater risk of psychiatric disorders than is antibiotic use in patients with acne.[69]

Pancreatitis

One case of fatal fulminant pancreatitis with acitretin treatment has been reported.[70] Pancreatitis occurred in three patients treated with oral bexarotene, 300 mg/m^2 or more per day, in association with marked elevations of fasting serum triglyceride levels.[32]

Hypothyroidism

Clinical and biochemical central hypothyroidism occurred in 40 percent of patients in the trials of bexarotene therapy for CTCL. It was rapidly and completely reversible with cessation of therapy without any clinical sequelae.[32,71]

Renal Adverse Effects

Renal toxicity has not been a characteristic consequence of retinoid administration. Isotretinoin has been administered safely to patients with end-stage kidney disease who were undergoing hemodialysis. However, case reports describing reversible renal function impairment during etretinate therapy advise monitoring of renal function, particularly in patients with a history of renal disorders.[72]

Inflammatory Bowel Disease

In very rare cases isotretinoin has been linked to exacerbation of inflammatory bowel disease. A 5-year prospective study did not demonstrate an increased risk of inflammatory bowel disease or of cancer, diabetes, or cardiovascular disease in association with long-term etretinate use for psoriasis[70]; similar safety of long-term acitretin or bexarotene therapy has not been established.

Hyperlipidemia

Serum lipid changes are the most frequent abnormalities in laboratory test results

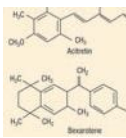

seen with retinoid therapy. Depending on the type and dosage of retinoid, triglyceride levels are elevated in 50 percent to 80 percent and cholesterol levels in 30 percent to 50 percent of treated patients.[32,56,73] Disturbance of blood lipid levels is generally higher with isotretinoin and bexarotene than with acitretin. In cases of severe retinoid-induced hypertriglyceridemia, eruptive xanthomas and acute pancreatitis may occur. Discontinuation of therapy is required if the triglyceride level reaches 800 mg/dL. A less severe increase may be treated by dosage reduction or reduction in alcohol and tobacco consumption. In some instances, use of lipid-lowering agents may be indicated.[74] Co-administration of atorvastatin with bexarotene is recommended.[14] Retinoids probably cause hyperlipidemia by increasing the expression of apolipoprotein-C3, which prevents the uptake of lipids from very-low-density lipoproteins into cells.[75]

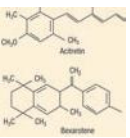

Liver Toxicity

Transitory abnormal elevations in serum transaminase levels have been reported in approximately 20 percent of patients treated with etretinate or acitretin and occur much less frequently with isotretinoin and bexarotene. Changes in liver function test results usually occur between 2 and 8 weeks after therapy is begun. Transaminase elevations of more than three times the upper normal range should lead to discontinuation of retinoid therapy.

Severe or persistent hepatotoxic reactions occur in fewer than 1 percent of patients. Acitretin therapy elicited no biopsy-proven hepatotoxicity in a 2-year prospective study.[76] No specific studies have evaluated the use of retinoids in patients with hepatic insufficiency, although this is likely to interfere with drug elimination.

Hematologic Toxicity

A high incidence (28 percent) of dose-related neutropenia has been reported with the use of bexarotene therapy for CTCL, occurring as early as 2 to 4 weeks after initiation of treatment.[32] Hematologic abnormalities are much less common with other retinoids. Bleeding complications due to isotretinoin-induced fibrinolysis has been reported.[77]

COMPLICATIONS

Most adverse effects associated with retinoids are preventable and manageable with proper patient selection, dosage adjustments, discontinuation of treatment, and routine monitoring for potential toxicity. Absolute contraindications are pregnancy or an attempt to become pregnant, non-adherence to a contraceptive regimen, and breast-feeding. Relative contraindications are leukopenia, alcoholism, elevated cholesterol or triglyceride levels, significant hepatic or renal dysfunction, and hypothyroidism (bexarotene).

The concurrent use of retinoids with other therapies having similar side effects may increase the risk of these adverse events. Tetracyclines (increased intracranial pressure, phototoxicity), alcohol (increased conversion of acitretin to etretinate, hepatoxicity), methotrexate (hepatoxicity), and vitamin A supplements (hypervitaminosis A) should be avoided. The concomitant administration of bexarotene and gemfibrozil may result in increased plasma concentrations of bexarotene, at least partially related to CYP 3A4 inhibition by gemfibrozil. In addition, retinoid drug levels may increase with the use of CYP inhibitors such as azoles and macrolides and the CYP competitor cyclosporine, whereas antituberculosis drugs (rifampicin) and anticonvulsants (phenytoin and carbamazepine) actually decrease the drug levels via CYP 3A4 induction.

KEY REFERENCES

The full reference list for all chapters is available at www.digm7.com.

5. van de Kerkhof P, Verfaille C: Retinoids and retinoic acid metabolism blocking agents in psoriasis, in *Retinoids and Carotenoids in Dermatology*, edited by Vahlquist A, Duvic M. New York, Informa Healthcare, 2007, p 125
7. Wiegand UW, Chou RC: Pharmacokinetics of oral isotretinoin. *J Am Acad Dermatol* **39**:S8, 1998
9. Wiegand UW, Chou RC: Pharmacokinetics of acitretin and etretinate. *J Am Acad Dermatol* **39**:S25, 1998
18. Cunliffe WJ et al: Roaccutane treatment guidelines: Results of an international survey. *Dermatology* **194**:351, 1997
33. Duvic M et al: Bexarotene is effective and safe for treatment of refractory advanced-stage cutaneous T-cell lymphoma: Multinational phase II-III trial results. *J Clin Oncol* **19**:2456, 2001
59. van Dooren-Greebe R et al: Prolonged treatment with oral retinoids in adults: No influence on the frequency and severity of spinal abnormalities. *Br J Dermatol* **134**:71, 1996

CHAPTER 230

Antihistamines

Susan L. Limb
Robert A. Wood

Histamine is a low-molecular-weight amine derived from L-histidine that is produced throughout the body. By means of four known types of receptors, histamine affects cellular growth and proliferation, modulates inflammation, and acts as a neurotransmitter. Both H_1 and H_2 histamine receptors are widely expressed. H_1 receptors are found on neurons, smooth muscle, epithelium and endothelium, and multiple other cell types. H_2 receptors are located in the gastric mucosa parietal cells, smooth muscle, epithelium and endothelium, heart, and other cell types as well. H_3 and H_4 receptors have more limited expression. H_3 receptors are found primarily on histaminergic neurons, whereas H_4 receptors are highly expressed in bone marrow and on peripheral hematopoietic cells.

H_1 ANTIHISTAMINES

Mechanism of Action

H_1 antihistamines are inverse agonists that reversibly bind and stabilize the inactive form of the H_1 receptor, thereby favoring the inactive state[1] (Table 230-1). The backbone structure of H_1 antihistamines is depicted in Fig. 230-1. By means of the H_1 receptor, H_1 antihistamines decrease production of pro-inflammatory cytokines, expression of cell adhesion molecules, and chemotaxis of eosinophils and other cells (Fig. 230-2).[2] H_1 antihistamines may also decrease mediator release from mast cells and basophils through inhibition of calcium ion channels. In addition to having antihistamine actions, first-generation H_1 antihistamines can also act on muscarinic, α-adrenergic, and serotonin receptors and cardiac ion channels. Some of the more serious adverse effects associated with first-generation H_1 antihistamines, such as urinary retention, hy-

ANTIHISTAMINES AT A GLANCE

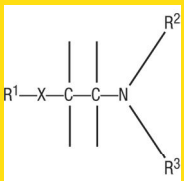

- H_1 antihistamines are first-line therapy for chronic idiopathic and physical urticarias.
- H_1 antihistamines may be useful in treating other conditions with histamine-driven pruritus.
- Limited evidence supports the use of H_1 antihistamines in treatment of atopic dermatitis.
- Certain special patient populations, including children, the elderly, and patients with renal or hepatic impairment, may require dosage adjustments when using H_1 antihistamines.
- The use of H_1 antihistamines is contraindicated in patients who have narrow-angle glaucoma or who are also taking monoamine oxidase inhibitors.
- H_2 antihistamines may be a useful adjunct to H_1 antihistamine therapy in refractory cases of chronic idiopathic urticaria/angioedema and pruritus.

potension, and cardiac arrhythmias, are mediated through these other receptors. The first-generation antihistamines are divided into six groups on the basis of chemical structure: ethylenediamines, ethanolamines, alkylamines, phenothiazines, piperazines, and piperidines[3] (see Fig. 230-1). The presence of multiple aromatic or heterocyclic rings and alkyl substituents enhances the lipophilicity of these compounds, which allows penetration of the blood-brain barrier.

Many of the low-sedating or second-generation H_1 antihistamines are chemically derived from first-generation agents.[2] For example, cetirizine is a metabolite of hydroxyzine. The second-generation H_1 antihistamines bind noncompetitively to the H_1 receptor. They are not easily displaced by histamine, dissociate slowly, and have a longer duration of action than first-generation H_1 antihistamines.[3] Due to the selectivity of second-generation drugs for the H_1 receptor and their reduced lipophilicity, these drugs are far less likely to cause sedation and have different safety profiles than the first-generation drugs.

Some low-sedating H_1-type antihistamines affect the trafficking of cells in the skin and other tissues, presumably by modulating the release of inflammatory mediators and the expression of adhesion molecules. In a skin chamber challenge model, cetirizine administration reduced eosinophil influx after allergen challenge. This effect seems to be specific to cutaneous allergic responses, because similar studies involving nasal challenges have not shown any decrease in eosinophil accumulation in nasal secretions. In vitro, cetirizine inhibits eosinophil, monocyte, and T-lymphocyte chemotaxis in vitro to *N*-formyl-methionyl-leucyl-phenylalanine and platelet-activating factor.[4] H_1 antihistamines may also modulate the expression of cellular adhesion molecules such as antigen-induced intercellular adhesion molecule 1 on keratinocytes, Langerhans cells, and endothelium, and influence the release of inflammatory mediators from leukocytes.[5] Desloratadine and emedastine were found to inhibit platelet-activating factor–induced eosinophil chemotaxis, tumor necrosis factor-α–induced eosinophil adhesion, and spontaneous and phorbol myristate–induced superoxide generation.[6,7]

TABLE 230-1
Basic Pharmacology of Antihistamines

- Both H_1 and H_2 antihistamines are inverse agonists that reversibly bind and stabilize the inactive form of the histamine receptor, thereby favoring the inactive state.
- First-generation H_1 antihistamines are relatively lipophilic, which enhances penetration of the blood-brain barrier and leads to sedation.
- Second-generation, non-sedating H_1 antihistamines bind selectively to peripheral H_1 receptors and have fewer central nervous system effects.
- H_1 antihistamines may interact with other drugs metabolized by the hepatic cytochrome P_{450} system.
- Double-blind, placebo-controlled trials show no evidence of the development of tolerance or tachyphylaxis in the suppression of skin test reactivity by H_1 antihistamines.
- Suppression of skin test reactivity may be observed for up to 7 days after discontinuation of a regularly used sedating H_1 antihistamine.

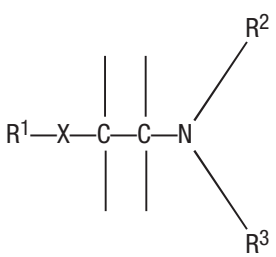

▲ **FIGURE 230-1** The ethylamine moiety is the backbone structure of most of the first-generation H_1 antihistamines. R = aromatic and/or heterocyclic groups; X = linkage such as nitrogen, oxygen, or carbon.

Pharmacokinetics

SEDATING, FIRST-GENERATION H_1 ANTIHISTAMINES After oral administration, effects of sedating H_1 antihistamine can be observed within 30 minutes to 1 hour and generally persist for 4 to 6 hours, although the effects of some agents may last for 24 hours and longer.[8] For example, after oral administration of a single dose, the serum half-lives of brompheniramine, chlorpheniramine, and hydroxyzine exceed 20 hours in adults. H_1 antihistamines are metabolized by hepatic cytochrome P_{450} (CYP) enzyme 3A4, forming glucuronides before excretion in urine.

The potency and relative concentration in the skin of H_1 antihistamines can be compared by their inhibition of the cutaneous wheal-and-erythema response to histamine injected cutaneously. In placebo-controlled, double-blind studies, no evidence of tolerance or tachyphylaxis was demonstrated in suppression of skin test reactivity over a 3-month period.[2] Suppression of skin test reactivity may be observed for up to 7 days after discontinuation of a regularly used sedating H_1 antihistamine.

Oral sedating H_1-type antihistamines are typically administered in divided doses at intervals of 4 to 8 hours (see Dosing Regimens), although once-daily dosing may suffice for agents with longer serum half-lives. Topical formulations for dermatologic use are available, although these preparations tend to be less effective and are associated with the development of delayed contact reactions.

LOW-SEDATING, SECOND-GENERATION H_1 ANTIHISTAMINES Most low-sedating, or second-generation, H_1 antihistamines are administered once or twice daily and achieve peak plasma concentrations within two half-lives, although this interval can vary among different drugs and individuals. These drugs generally achieve higher concentrations in the skin than their first-generation counterparts, and a single dose can suppress the wheal-and-erythema reaction from 1 to 24 hours.[9–12] Regular use prolongs this effect; for example, 6 days of daily cetirizine use results in 7 days of suppression of the wheal-and-erythema response.

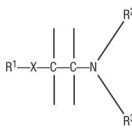

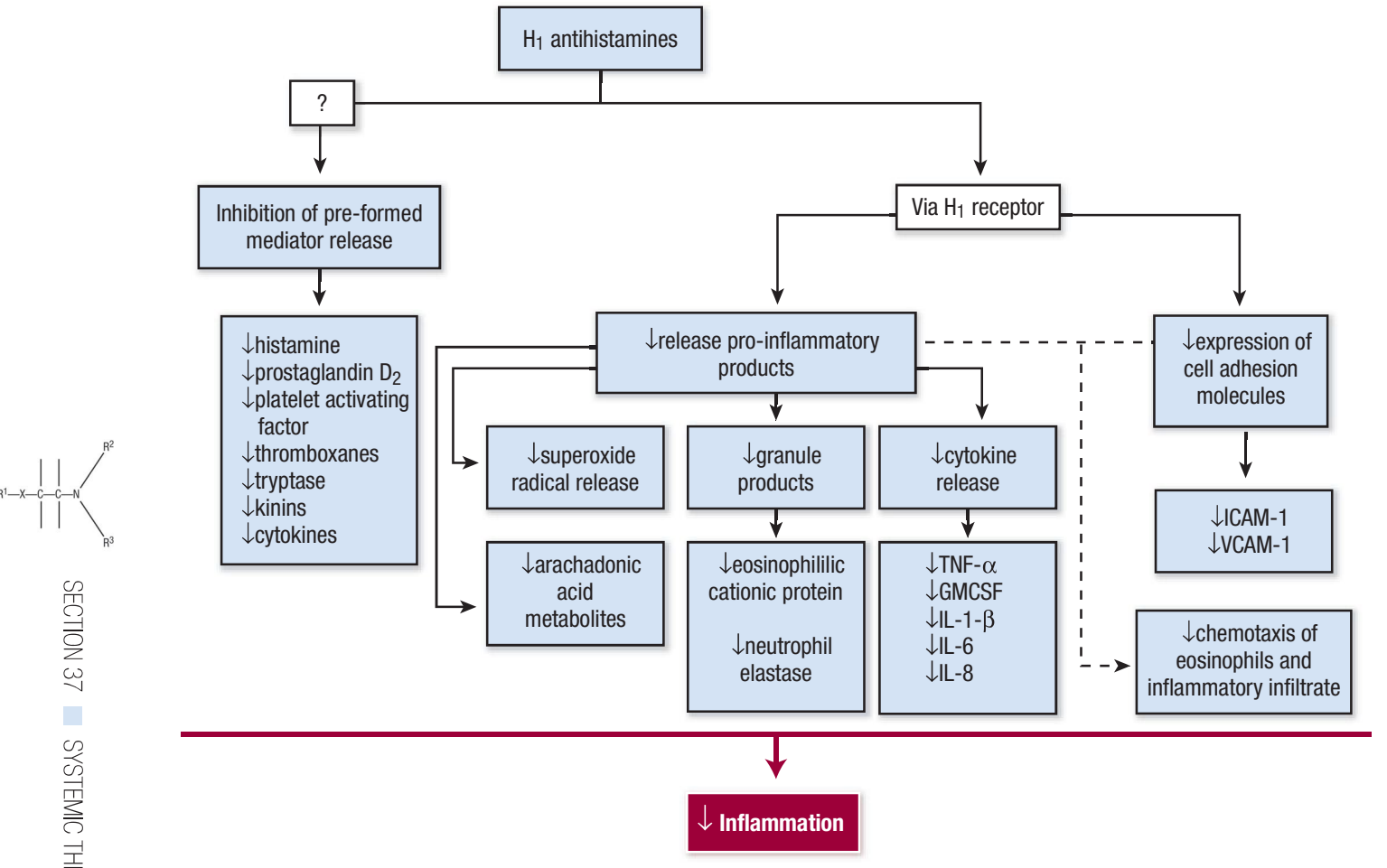

▲ **FIGURE 230-2** Mode of action of H_1 antihistamines. By means of the H_1 receptor, H_1 antihistamines inhibit the release of pre-formed mediators and decrease the production of pro-inflammatory cytokines, the expression of cell adhesion molecules, and chemotaxis of eosinophils and other cells. ↓ = decreased; GMCSF = granulocyte-macrophage colony-stimulating factor; ICAM-1 = intercellular adhesion molecule 1; IL-1β, IL-6, IL-8 = interleukin-1β, interleukin 6, interleukin 8; TNF-α = tumor necrosis factor-α; VCAM-1 = vascular cellular adhesion molecule 1.

Terfenadine, astemizole, loratadine, acrivastine, mizolastine, ebastine, and oxatomide are metabolized in the liver via the hepatic enzyme CYP 3A4. Cetirizine, fexofenadine, levocabastine, and desloratadine undergo minimal hepatic metabolism, which reduces the likelihood of interactions with other drugs.[8]

In healthy adults, cetirizine reaches peak concentrations around 1 hour after administration, with an elimination half-life of approximately 8 hours.[13] Lower dosages are used in patients with impaired renal or hepatic function. Fexofenadine generally reaches peak concentration at 2 to 3 hours, with an elimination half-life of 14 hours.[13] Dosage adjustment is recommended for patients with decreased creatinine clearance, including the elderly; however, patients with hepatic disease do not require dosage adjustment because fexofenadine undergoes almost no hepatic metabolism.[13] Loratadine's half-life ranges on average from 8 to 24 hours, depending on hepatic function. Ebastine, which is metabolized to form its carboxylic acid metabolite, carebastine, has a half-life of 15 hours.[13] The dosage should be adjusted in patients with impaired renal function. Pharmacogenetics may also influence drug metabolism and clearance. In a series of pharmacokinetic studies, approximately 7 percent of all subjects and 20 percent of African Americans were slow metabolizers of desloratadine.[14] Comparable differences may exist for other H_1 antihistamines.

Indications

H_1 antihistamines are used to treat pruritus of various etiologies, urticaria, and angioedema (Table 230-2). In particular, H_1 antihistamines appear to be effective in treating physical urticarias and dermatographism, in addition to chronic idiopathic urticaria. They are not as effective in treating hereditary and acquired angioedema syndromes and urticarial vasculitis. Few well-controlled, blinded studies of the first-generation H_1-type drugs exist. The general tendency for most chronic urticarias to improve with time and the difficulty in making quantitative assessment of the condition further complicate clinical studies. Comparative studies of the groups of H_1-type antihistamines have shown them to be of equal efficacy.[2] If an agent from one therapeutic group of H_1-type antihistamines proves ineffective, then a trial with an agent from another group may be initiated. In several double-blind, placebo-controlled, or parallel studies, the low-sedating H_1-type antihistamines terfenadine, astemizole, cetirizine, loratadine, fexofenadine, desloratadine, acrivastine,

TABLE 230-2
Indications for Treatment with H_1 Antihistamines

- Acute urticaria
- Chronic idiopathic urticaria
- Physical urticarias and dermatographism
- Atopic dermatitis (less evidence)
- Systemic mastocytosis
- Pruritus associated with other conditions

mizolastine, azelastine, ebastine, and oxatomide were superior to placebo in the treatment of urticaria and angioedema.[15–20] Trials comparing different second-generation antihistamines with one another have not shown any one agent to be consistently superior.[2,15,21]

Both sedating and low-sedating H_1 antihistamines are used to treat pruritus in patients with atopic dermatitis, although their efficacy has not been proved by rigorous clinical trials. In the 18-month Early Treatment of the Atopic Child study, cetirizine afforded a steroid-sparing benefit to children with the most severe atopic dermatitis, but no consistent benefit was observed in children with more moderate disease.[22] A meta-analysis of 16 studies conducted from 1966 through 1999 does not indicate a major role for either first- or second-generation H_1 antihistamines in the treatment of atopic dermatitis, although no randomized, double-blind, placebo-controlled studies are included in this analysis.[23]

H_1 antihistamines are commonly used to treat cutaneous and systemic mastocytosis, although large comparative treatment trials are not available.[24] One early double-blind, placebo-controlled study demonstrated the efficacy of H_1 and H_2 antihistamines in the treatment of systemic mastocytosis.[25] In a later small trial, azelastine compared favorably with chlorpheniramine in the suppression of pruritus in patients with mastocytosis.[26]

Pruritus associated with other conditions, such as allergic contact dermatitis and other forms of eczematous dermatitis, lichen planus, systemic mastocytosis, mosquito bites, infestations, and pruritus secondary to underlying medical disorders or idiopathic pruritus, also may be relieved by H_1 antihistamines, although controlled trials do not exist.[27] In these conditions, the sedative effects of the first-generation agents may be advantageous, permitting more restful sleep. H_1 antihistamines are also used as pre-treatment before certain procedures for patients with a history of radiocontrast media and transfusion reactions.

Dosing Regimens

The dosing regimens for H_1 antihistamines are shown in Table 230-3.

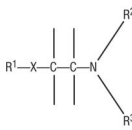

TABLE 230-3
Dosing Regimens for H_1 Antihistamines

Drug	Formulation	Dosage	Conditions Requiring Dosage Adjustment
First-generation H_1 antihistamines			
Chlorpheniramine	2-, 4-, 8-, 12-mg tablet 2 mg/5 mL syrup	Adult: 4 mg tid, qid; 8–12 mg bid Age 6–11 yr: 2 mg q4–6h	Hepatic impairment
Cyproheptadine	4-mg tablet 2 mg/5 mL syrup	Adult: 4 mg tid, qid Age 7–14 yr: 4 mg bid, tid Age 2–6 yr: 2 mg bid, tid	Hepatic impairment
Diphenhydramine	25-, 50-mg tablet 12.5 mg/5 mL syrup 50 mg/15 mL syrup 6.25 mg/5 mL syrup 12.5 mg/5 mL syrup	Adult: 25–50 mg q4–6h Age 6–12 yr: 12.5–25 mg q4–6h Age < 6 yr: 6.25–12.5 mg q4–6h	Hepatic impairment
Hydroxyzine	10-, 25-, 50-, 100-mg tablet 10 mg/5 mL syrup	Age ≥ 6 yr: 25–50 mg q6–8h or qhs Age < 6 yr: 25–50 mg qd	Hepatic impairment
Tripelennamine	25-, 50-, 100-mg tablets	Adult: 25–50 mg q4–6h	Hepatic impairment
Second-generation H_1 antihistamines			
Acrivastine[a]	8-mg tablet	Adult: 8 mg tid	Renal impairment
Azelastine	2-mg tablet[b] 0.1% nasal spray	Adult: 2–4 mg bid Age 6–12 yr: 1–2 mg bid 2 sprays/nostril bid	Renal and hepatic impairment
Cetirizine	5-, 10-mg tablet 5 mg/mL syrup	Age ≥ 6 yr: 5–10 mg qd Age 2–6 yr: 5 mg qd Age 6 mo–2 yr: 2.5 mg qd	Renal and hepatic impairment
Desloratadine	2.5-, 5-mg tablet 5 mg/mL syrup	Age ≥ 12 yr: 5 mg qd Age 6–12 yr: 2.5 mg qd Age 1–6 yr: 1.25 mg qd Age 6–12 mo: 1 mg qd	Renal and hepatic impairment
Ebastine[b]	10-mg tablet	Age ≥ 6 yr: 10–20 mg qd Age 6–12 yr: 5 mg qd Age 2–5 yr: 2.5 mg qd	Renal impairment
Fexofenadine	30-, 60-, 120-, 180-mg tablet	Age ≥ 12 yr: 60 mg qd, bid; 120–180 mg qd Age 6–12 yr: 30 mg qd, bid	Renal impairment
Levocetirizine[b]	5-mg tablet	Age ≥ 6 yr: 5 mg qd	Renal and hepatic impairment
Loratadine	10-mg tablet 5 mg/mL suspension	Age ≥ 6 yr: 10 mg qd Age 2–9 yr: 5 mg qd	Renal and hepatic impairment
Mizolastine[b]	10-mg tablet	Adult: 10 mg qd	Hepatic impairment

[a]Available in the United States only as a fixed-dose combination with pseudoephedrine hydrochloride, 120 mg.
[b]Not currently available in the United States.
Data from refs. 2, 3, 8, 13, 14, 28.

Initiation of Therapy

The H_1 antihistamines are considered first-line therapy in the treatment of chronic idiopathic and physical urticarias and may be useful in treating other conditions in which histamine-driven pruritus is a major feature. The lowest effective dosage is preferred to minimize dose-related side effects, such as sedation. After several days of therapy, the dosage may be increased and titrated. Occasionally, gradual escalation of dosing permits the development of tolerance to sedation, which allows higher dosages to be used to treat certain conditions, such as refractory chronic urticaria. Ingestion of the medication with food may alleviate any gastrointestinal discomfort, although patients should be advised to avoid taking fexofenadine with antacids, which can interfere with drug absorption. Individuals with co-morbid conditions, such as renal or hepatic disease, may require lower dosages due to impaired metabolism of these drugs. Certain special patient populations, including children, the elderly, and pregnant or breast-feeding women, may also need dosage adjustments (see Special Patient Populations). Some situations may call for more careful assessment of H_1 antihistamine therapy[2] (Table 230-4).

Monitoring of Therapy

Therapeutic endpoints are evaluated by observation of clinical signs and symptoms (e.g., severity of pruritus; wheal number, size, and frequency). As for drug toxicity, no particular monitoring beyond the usual surveillance for adverse effects is required in most cases. Certain individuals, such as patients with impaired metabolism or other co-morbid conditions and those taking other medications, may require closer monitoring and counseling regarding the use of H_1 antihistamines. Because of reports of hepatotoxicity, some sources recommend periodic liver transaminase evaluation when cyproheptadine is used.[28]

TABLE 230-4
Factors for Risk-Benefit Assessment of H_1 Antihistamine Therapy

- Risks
  - History of cardiac arrhythmias, particularly ventricular arrhythmias
  - First trimester of pregnancy
  - Prostatic hypertrophy
- Contraindications
  - Narrow-angle glaucoma
  - Concomitant use of monoamine oxidase inhibitors

Risks and Precautions

Adverse effects are listed in Table 230-5. Sedation is the most commonly reported problem, primarily with first-generation H_1 antihistamines.[2,3,8] The sedative effect is more pronounced with the ethanolamine and phenothiazine groups and is less marked with the alkylamine group. The sedative effect may diminish after a few days of continual use of H_1-type antihistamines. If tolerance to sedation does not occur, an agent from another group should be tried. The use of H_1-type antihistamines has been associated with an increase in occupational injuries and automobile accidents.[29] Other central nervous system (CNS) effects include dizziness, tinnitus, disturbed coordination, inability to concentrate, blurred vision, and diplopia. Stimulatory CNS effects, which occur especially with the alkylamine group, include nervousness, irritability, insomnia, and tremor.

Gastrointestinal complaints, including anorexia, nausea, vomiting, epigastric distress, diarrhea, and constipation, are another frequent side effect, especially with the ethylenediamine group.[3] The administration of these agents with food may reduce these manifestations.

Anticholinergic effects include dry mucous membranes, urinary retention and hesitancy, postural hypotension, dizziness, erectile dysfunction, and constipation.[2] These effects are often associated with the ethanolamine, phenothiazine, and piperazine groups. The anticholinergic effects of H_1-type antihistamines preclude their use in patients with narrow-angle glaucoma and require close monitoring in patients with prostatic hypertrophy (see Table 230-4).

Arrhythmias, particularly prolongation of the QT interval and torsades de pointes, are the most serious cardiac toxicity.[2,3] These dose-dependent effects are mediated through blockade of potassium channels unrelated to the H_1 histamine receptor. Transient hypotension may develop after intravenous therapy, especially if the drug is administered rapidly.[30]

The occurrence of cutaneous reactions after the administration of oral H_1-type antihistamines is uncommon. Reported reactions include eczematous dermatitis, allergic contact dermatitis, urticaria, petechiae, fixed drug eruptions, and photosensitivity. Some of these reactions may be secondary to excipients in the drug.

TABLE 230-5
Adverse Effects of H_1 Antihistamines

- Sedation (primarily first-generation agents)
- Other central nervous system disturbances
  - Dizziness
  - Tinnitus
  - Blurred vision
  - Irritability or nervousness
  - Insomnia
  - Tremor
- Gastrointestinal complaints
  - Nausea and vomiting
  - Diarrhea or constipation
  - Anorexia
- Anticholinergic effects
  - Dry mucous membranes
  - Urinary retention
  - Postural hypotension
- Cardiac arrhythmias (particularly prolongation of the QT interval, ventricular arrhythmias, torsades de pointes)
- Hypersensitivity reactions (rare)

Due to the selectivity of the low-sedating H_1 antihistamines for peripheral H_1 receptors, these drugs lack both the sedative and anticholinergic side effects commonly associated with the first-generation drugs.[31] For the second-generation drugs, sedation is most often reported in a subset of patients taking cetirizine and acrivastine. Although far less sedating than its parent compound hydroxyzine, cetirizine causes sedation in approximately 10 percent to 15 percent of users.[32] This effect appears to be dose dependent and can often be mitigated by dosing adjustment.[33] Fifteen percent to 35 percent of patients report somnolence secondary to acrivastine use.[34] In contrast, fexofenadine, loratadine, and desloratadine cause negligible sedation.[35]

Two early second-generation H_1 antihistamines, terfenadine and astemizole, have been removed from U.S. market due to risk of QT interval prolongation and torsade de pointes. Other second-generation agents have an approximately 1000-fold lower affinity for cardiac ion channels, and ventricular arrhythmias have not been associated with later second-generation agents.[2] A theoretical risk remains, however, and may be a consideration before initiating therapy in patients susceptible to tachyarrhythmias.

Drug Interactions

The H_1 antihistamines may interact with other drugs metabolized by the

hepatic CYP system, such as imidazole antifungals, cimetidine, and macrolide antibiotics.[3] Diphenhydramine, chlorpheniramine, clemastine, promethazine, hydroxyzine, and tripelennamine inhibit the hepatic enzyme CYP 2D6 in vitro.[36] In vivo, diphenhydramine has been noted to increase levels of other drugs metabolized by the CYP 2D6 system, including metoprolol and venlafaxine.[37,38] H_1-type antihistamines are contraindicated for patients receiving monoamine oxidase inhibitors.

Central depressive effects may be accentuated when H_1-type antihistamines are combined with alcohol or other CNS depressants, such as benzodiazepines. These interactions are generally not observed with second-generation H_1 antihistamines.[3]

In rare circumstances, antihistamines of the phenothiazine group may block and reverse the vasopressor effect of epinephrine. If individuals receiving a phenothiazine require a vasopressor agent, norepinephrine or phenylephrine should be used.

Special Patient Populations

CHILDREN Many of the sedating and low-sedating H_1 antihistamines can be safely used in children with appropriate dosing. Children may be more susceptible to certain side effects associated with first-generation drugs, such as excitation and insomnia. Acute poisoning may develop but is rare; hallucinations, ataxia, incoordination, athetosis, and convulsions are the major features.

ELDERLY Caution should be used when treating elderly patients, and decreased creatinine clearance, co-morbid conditions, and potential drug interactions should be taken into account. Older individuals may also be more susceptible to anticholinergic effects, particularly urinary retention and hesitancy, constipation, and postural hypotension.[3]

PREGNANT WOMEN There are limited guidelines for the use of H_1 antihistamines to treat pregnant women. Most H_1 antihistamines are classified as U.S. Food and Drug Administration (FDA) pregnancy category B or category C. Based on earlier reports linking H_1 antihistamines to fetal malformations, particularly cleft palate defects, H_1 antihistamines are customarily avoided in the first trimester of pregnancy.[39] However, more recent studies, including a meta-analysis of 200,000 first-trimester exposures to first-generation antihistamines, do not indicate any increased risk of congenital malformations associated with H_1 antihistamine use.[40] In a prospective trial, astemizole administered to pregnant women was not associated with intrauterine growth retardation or perinatal complications.[41] The rate of birth malformations was identical to that in the control group and to that in the general population.

BREAST-FEEDING WOMEN No formal studies have been performed on the safety of H_1 antihistamines during breast-feeding. Theoretically, first-generation drugs may diminish milk supply via anticholinergic effects. Clemastine, diphenhydramine, promethazine, triprolidine, cetirizine, loratadine, fexofenadine, and desloratadine are all known to be excreted in breast milk; their effects on the nursing infant are not known.[3]

H_2 ANTIHISTAMINES

Mechanism of Action

Similar to their H_1-binding counterparts, H_2 antihistamines are inverse agonists that bind H_2 receptors located throughout the body, including epithelial and endothelial cells. More recently, there is evidence that H_2 receptors are expressed on mast cells and dermal dendritic cells as well. Through binding of these receptors, H_2 antihistamines may mediate cutaneous vascular permeability, local release of inflammatory mediators and cellular recruitment, and antigen presentation, but these pathways remain poorly understood, and their clinical significance is unknown.

Pharmacokinetics

H_2-type antihistamines are rapidly absorbed from the gastrointestinal tract with peak levels occurring between 1 and 2 hours after administration. They undergo extensive hepatic metabolism with renal clearance. Only a small proportion of cimetidine is absorbed from the stomach; most of its absorption occurs in the small intestine. The half-life of cimetidine in plasma is 2 hours. Approximately 69 percent is excreted unchanged in the urine.[42] The plasma half-life of ranitidine is 2 to 3 hours in healthy adults, longer in individuals with liver or kidney disease and in the elderly.[43] The drug and its metabolites are excreted principally in the urine. Famotidine has a plasma half-life of 3 to 8 hours. In patients with renal failure, the half-life of famotidine may exceed 20 hours.[44] Nizatidine has a plasma half-life of 1 to 2 hours, and its duration of action is up to 10 hours.[45] Nizatidine is primarily eliminated by the kidneys within 16 hours. The oral bioavailability of nizatidine is not affected by food. These agents are relatively lipophilic with limited penetration of the blood-brain barrier.

TABLE 230-6
Dermatologic Indications for Treatment with H_2 Antihistamines

- Acute allergic reactions
- Chronic urticaria
- Urticaria pigmentosa and systemic mastocytosis
- Pruritus associated with other conditions

Indications in Dermatology

There are few data from controlled studies supporting the use of H_2 blockers to treat dermatologic conditions (Table 230-6). Most often, these agents are used in addition to H_1 antihistamines in refractory cases of chronic urticaria and angioedema. In a double-blind crossover study, greater reductions in pruritus and wheal number, size, and severity were observed with the combination of hydroxyzine and cimetidine than with hydroxyzine alone.[46] Similar observations have been made for chlorpheniramine combined with cimetidine.[47] Combination H_1 and H_2 antihistamine therapy may also be helpful in reducing the pruritus and whealing associated with systemic mastocytosis and urticaria pigmentosa. A double-blind crossover trial of chlorpheniramine and cimetidine suggested that the combination was effective in reducing the pruritus and whealing.[25]

There are anecdotal reports of the use of cimetidine to treat pruritus secondary to various medical conditions such as polycythemia vera[48] and carcinoid flush.[49] High doses of cimetidine were successful in the treatment of verruca vulgaris in some individuals.[50]

Dosing Regimens

The dosing regimens for H_2 antihistamines are given in Table 230-7.

Initiation of Therapy

For treatment of dermatologic conditions, H_2 antihistamines are generally used in conjunction with H_1 antihistamines, usually following an unsuccessful trial of H_1

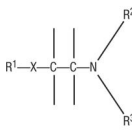

TABLE 230-7
Dosing Regimens for H_2 Antihistamines

Drug	Formulation	Dosage	Conditions Requiring Dosage Adjustment
Cimetidine	100-, 200-, 300-, 400-, 800-mg tablet 300 mg/5 mL syrup 200 mg/20 mL syrup	Adult: 400–800 mg bid	Renal or hepatic impairment
Ranitidine	75-, 150-, 300-mg tablet 15 mg/mL syrup 150-mg granules	Adult: 75–150 mg bid Pediatric: 5–10 mg/kg/day divided in 2 doses	Renal impairment
Famotidine	10-, 20-, 40-mg tablet 40 mg/5 mL syrup	Adult: 20–40 mg bid Age 1–16 yr: 1 mg/kg/day divided in 2 doses, up to 40 mg bid	Renal impairment
Nizatidine	150-, 300-mg capsule 15 mg/5 mL syrup	Age ≥ 12 yr: 150 mg qd, bid	Renal impairment

Data from refs. 42–45.

TABLE 230-8
Adverse Effects of H_2 Antihistamines

- Central nervous system disturbances
  - Confusion
  - Headache
  - Dizziness
  - Drowsiness
- Gastrointestinal effects
  - Nausea or vomiting
  - Diarrhea or constipation
  - Abdominal pain
  - Increased transaminases and hepatitis (rare)
- Gynecomastia
- Increased susceptibility to pneumonia
- Hematologic (rare)
  - Thrombocytopenia
  - Anemia
- Hypersensitivity to H_2 antihistamines (uncommon)
- Drug interactions
- Cardiac effects (with concomitant administration of dofetilide; dofetilide use is therefore a contraindication)

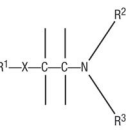

antihistamines alone. In most cases, treatment with H_2 antihistamines may be initiated without any particular laboratory screening. The inhibition of the hepatic CYP system and the potential for drug interactions is usually the greatest concern, and patients' medication lists should be reviewed carefully before initiating therapy. Ranitidine is less inhibitory of the CYP system than cimetidine and may be the preferred H_2 antihistamine in situations in which drug interactions are a particular concern.[43] Patients with decreased creatinine clearance require dosage adjustment.[51] In patients taking the cardiac drug dofetilide, cimetidine is absolutely contraindicated because of the risk of prolongation of the QT interval and life-threatening cardiac arrhythmias.[52]

Monitoring of Therapy

Therapeutic endpoints are evaluated by observation of clinical signs and symptoms (e.g., severity of pruritus; wheal size, frequency, and intensity). As far as drug toxicity is concerned, no particular monitoring beyond the usual surveillance for adverse effects is required in most cases. For patients with a history of thrombocytopenia, a complete blood count may be warranted once H_2 antihistamine therapy is initiated, because thrombocytopenia has been reported as an idiosyncratic effect of these drugs in a few individuals.[53]

Risks and Precautions

H_2 antihistamines may have several CNS effects, including confusion, headache, and dizziness[54] (Table 230-8). These effects seem to be partly dose related. Other side effects include drowsiness, malaise, muscular pain, diarrhea, and constipation. There are rare reports of granulocytopenia. By their suppression of gastric acid secretion, H_2 antihistamines may facilitate oral infections and increase the risk of pneumonia in immunocompromised individuals, including diabetic patients, the elderly, and patients with immunodeficiency.[55] As a class, these drugs may mask symptoms of gastric carcinoma. Cimetidine and ranitidine both inhibit alcohol dehydrogenase activity, which leads to increased blood alcohol levels.

Uncommon side effects of cimetidine include gynecomastia with or without elevated prolactin levels in men; galactorrhea with elevated prolactin levels in women; and loss of libido, impotence, and reduction of sperm counts in young men.[42,56] Modest elevations in serum creatinine levels and hepatic transaminase levels have both been reported and are reversible after the drug is withdrawn.[43,56] Rare dermatologic adverse effects, including alopecia and urticarial vasculitis, have also been reported.[57]

Ranitidine does not bind to androgen receptors and does not enhance cell-mediated immune responses.[43] Ranitidine may affect physiologic autonomic control of the cardiovascular system by altering parasympathetic and sympathetic control functions.[58] This altered cardiac sympathovagal balance may lead to a susceptibility to arrhythmias, particularly bradyarrhythmias, after intravenous infusion.

Famotidine and nizatidine are associated with few side effects; they also cause less inhibition of the CYP system and therefore are involved in fewer drug interactions.[44,45]

Drug Interactions

Through inhibition of the CYP system, cimetidine increases the serum levels of numerous drugs, including some of the most common medications used in the care of the medical patient.[56] Of note, cimetidine increases levels of warfarin and may cause dangerous increases in prothrombin time and risk of bleeding. Cimetidine also interacts with many cardiac drugs—several β blockers, calcium channel blockers, amiodarone, antiarrhythmic agents, among others. As already mentioned (see Initiation of Therapy), cimetidine use is contraindicated in patients taking dofetilide. Other common drugs with which cimetidine interacts are phenytoin, several benzodiazepines, metformin, sulfonylureas, and selective serotonin reuptake inhibitors.

Although ranitidine interacts with other medications less frequently than does cimetidine, significant interactions with fentanyl, metoprolol, midazolam, nifedipine, theophylline, and warfarin have been observed.[43] Ranitidine may decrease the absorption of diazepam and reduce its plasma concentration by 25 percent. Famotidine and nizatidine are associated with fewer drug interactions.

Special Patient Populations

CHILDREN Of the H_2 antihistamines, ranitidine and famotidine have pharmacokinetics that have been relatively well

studied in children, and these drugs have acceptable safety profiles with appropriate dosing. Cimetidine and nizatidine are not recommended for children. One adverse effect unique to children is an uncommon but drug class–wide risk of necrotizing enterocolitis in neonates.[59]

ELDERLY Older patients may require downward adjustment of dosage to accommodate decreased creatinine clearance, as well as careful review of medication lists. Elderly patients also appear more susceptible to CNS disturbances such as confusion and dizziness.

PREGNANT WOMEN The H_2 antihistamines are classified as FDA pregnancy category B drugs. Cimetidine, ranitidine, famotidine, and nizatidine are all excreted in breast milk; potential effects on the nursing infant have not been studied.[43–45,56]

OTHER THERAPEUTIC AGENTS WITH ANTIHISTAMINIC ACTIVITY

Tricyclic Antidepressants

Tricyclic antidepressants bind both H_1 and H_2 receptors. The tricyclic antidepressant most commonly used in dermatology is doxepin. Oral doxepin has been used successfully in the treatment of refractory chronic idiopathic urticaria, physical urticaria, and pruritus associated with systemic conditions.[60,61] In a double-blind, crossover study (n = 50), doxepin proved more efficacious than diphenhydramine in the treatment of chronic idiopathic urticaria.[62] Topical preparations are also available. In double-blind, vehicle-controlled trials, topical doxepin cream reduced pruritus in patients with atopic dermatitis and lichen simplex chronicus.[63]

Sedation is the most common adverse effect with both the oral form and the topical form, which is absorbed percutaneously, although some patients may develop tolerance with regular use. Oral doxepin has been classified by the FDA as a pregnancy category C drug; topical doxepin is classified as a pregnancy category B drug.[64] Use of both oral and topical forms is contraindicated during breast-feeding. The safety and efficacy of doxepin therapy in children under the age of 12 has not been established. The drug should be used with caution in elderly patients, who may be more susceptible to its anticholinergic effects, including urinary retention and blurred vision.[60] Doxepin should not be used concurrently with monoamine oxidase inhibitors, and all patients with underlying depression should be closely monitored for signs of suicidal ideation when initiating drug therapy. Doxepin may also cause a sudden increase in intraocular pressure and should not be used in patients with glaucoma.

Ketotifen

Ketotifen, a benzocycloheptathiophene derivative, is an H_1-type antihistamine with additional mast cell– and basophil-stabilizing properties.[1] Ketotifen has been used successfully in the treatment of chronic idiopathic urticaria, physical urticaria, and urticaria pigmentosa.[65–67] In a double-blind trial involving 305 patients with chronic idiopathic urticaria ketotifen alleviated pruritus more effectively than clemastine or placebo.[68] More recent studies comparing ketotifen with low-sedating H_1 antihistamines are not available. Results of one early open-label trial suggested that ketotifen not only reduces the pruritus and pain of neurofibromatosis but also slows the growth of neurofibromas[69]; however, these results have not been confirmed by other investigators. Sedation and atropine-like effects are common.[70] There are no studies evaluating the safety of ketotifen in pregnant or breast-feeding women. Ketotifen is available in the United States only as an ophthalmic solution.

Mirtazapine

Mirtazapine is a tetracyclic antidepressant with H_1 antihistamine properties.[61] Several case series have reported its successful use in reducing pruritus attributable to uremia, cholestasis, and various cancers, but it has not been well studied as a primary dermatologic agent. Patients taking mirtazapine require monitoring of blood counts and lipid levels for hyperlipidemia and the rare but serious adverse effects of agranulocytosis and neutropenia. Mirtazapine carries an FDA black box warning of possible increased risk of suicide, particularly during initiation of therapy, and its concomitant use with monoamine oxidase inhibitors is contraindicated. It is classified as an FDA pregnancy category C drug, and its safety during breast-feeding and in children has not been established.

KEY REFERENCES

The full reference list for all chapters is available at www.digm7.com.

2. Simons FE: Advances in H_1-antihistamines. *N Engl J Med* **351**:2203, 2004
3. Passalacqua G, Canonica GW: Structure and classification of H_1-antihistamines and overview of their activities, in *Histamine and H_1-Antihistamines in Allergic Disease*, 2nd ed, edited by Simons FER. New York, Marcel Dekker, 2002, p 65
8. Simons FER, Simons KJ: Clinical pharmacology of H_1-antihistamines, in *Histamine and H_1-Antihistamines in Allergic Disease*, 2nd ed, edited by Simons FER. New York, Marcel Dekker, 2002, p 141
23. Klein PA, Clark RAF: An evidence-based review of the efficacy of antihistamines in relieving pruritus in atopic dermatitis. *Arch Dermatol* **135**:1522, 1999
29. Casale TB et al: First do no harm: Managing antihistamine impairment in patients with allergic rhinitis. *J Allergy Clin Immunol* **111**:S835, 2003
39. Gilbert C et al: Fetal safety of drugs used in the treatment of allergic rhinitis: A critical review. *Drug Saf* **28**:707, 2005
60. Black AK, Greaves MW: Antihistamines in urticaria and angioedema, in *Histamine and H_1-Antihistamines in Allergic Disease*, 2nd ed, edited by Simons FER. New York, Marcel Dekker, 2002, p 249

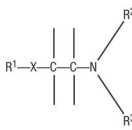

CHAPTER 231

Antibiotics

Christopher C. Gasbarre
Steven K. Schmitt
Kenneth J. Tomecki

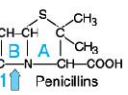

Antibiotics are soluble compounds produced by an organism that inhibit bacterial growth; the term also includes synthetic compounds such as fluoroquinolones. The majority of skin and soft-tissue infections (SSTIs) are caused by Gram-positive organisms, most of which are susceptible to well-known agents with a relatively narrow spectrum of antimicrobial activity, and β-lactams, macrolides, and fluoroquinolones have been the mainstays of therapy.[1] Increased use and misuse of these antibiotics has led to selection and propagation of resistant bacteria. Community-acquired resistant pathogens, such as methicillin-resistant *Staphylococcus aureus* (MRSA), have recently emerged as causes of some SSTIs, including cellulitis, folliculitis, furunculosis, impetigo, erysipelas, and abscesses. More ominous is the emergence of complicated SSTIs caused by resistant pathogens (e.g., MRSA and vancomycin-resistant enterococci). Complicated cutaneous infections include those involving deeper tissues, those requiring surgical intervention, and those coincidental with underlying diseases that may complicate therapy. Combination therapy with well-established antimicrobials has been effective in many cases, and new antibiotics have broadened treatment options. However, given the relative paucity of new antimicrobials on the horizon, dermatologists are likely to be faced with growing treatment challenges. Understanding the pharmacologic properties of antibiotics ensures the most judicious use of these agents, and familiarity with antibiotic dosing schedules and adverse events will lead to therapeutic choices that achieve the highest degree of patient adherence to the treatment regimen.

BASIC PRINCIPLES

Mechanism of Action

Antibiotics are largely classified by their chemical structures and related mechanisms of action. Four major groups exist: (1) Some antibiotics inhibit the formation of bacterial cell walls, such as the β-lactams (penicillins, cephalosporins, and carbapenems) and vancomycin. These agents are generally bactericidal. (2) Some antibiotics interfere with protein synthesis by binding to either the 50S or 30S bacterial ribosomal subunit and may be bacteriostatic or bactericidal. Reversible binding (tetracyclines, macrolides, lincosamides, and linezolid) usually halts microbial growth, resulting in a bacteriostatic effect. Irreversible bactericidal binding occurs with aminoglycosides. (3) Some agents interfere with bacterial nucleic acid synthesis, such as rifampin (inhibits RNA polymerase) and quinolones (inhibit bacterial topoisomerase). These agents are typically bactericidal. (4) Some antibiotics interfere with key enzymes in folate metabolism, such as trimethoprim and sulfonamides.

Bacteriocidal versus Bacteriostatic Agents

Although antibiotics may be considered bactericidal (producing cell death) or bacteriostatic (halting cell growth or division), the distinction is based on in vitro assays. In an immunocompetent host, both modes of action can eliminate pathogens. Other considerations, such as absorption, tissue distribution, and drug metabolism and elimination, often play a more important role in eradication of infection. In addition, some antibiotics are variably bacteriotoxic and bacteriostatic, depending on the infective organism. There are a few situations in which the distinction may be clinically relevant: bacterial meningitis, infective endocarditis, osteomyelitis, and infections occurring in neutropenic patients. Finally, host factors such as immunocompromising disease or therapy and the ability to debulk infections by débridement or drainage may also overshadow in vitro susceptibility in treating infection.

Susceptibility Testing

Susceptibility testing, after isolation and identification of an organism from an appropriate clinical specimen, helps to direct therapy.

Resistance Mechanisms

Since the advent of antibiotics, microbes have become increasingly resistant to available therapies. Approximately 70 percent of all infective bacteria encountered in the hospital setting have developed resistance to at least one of the antibiotics initially used to treat them. For an antibiotic to be effective, it must reach its target in an active form, bind to the target, and inhibit the organism's growth. Bacteria can evade the intended action if one of the following occurs: (1) The drug cannot reach its target (e.g., efflux pumps in the bacterial cell membrane can remove antibiotics from the cell). Numerous antibiotics (β-lactams, tetracyclines, fluoroquinolones, and macrolides) are eliminated in this fashion. (2) The drug is inactivated, as exemplified by resistance to β-lactams by organisms able to produce β-lactamase. (3) The drug can no longer bind its target. Numerous permutations of this mechanism are known. One example is the natural mutation of bacterial topoisomerases, which results in fluoroquinolone resistance.

Pharmacokinetics and Pharmacodynamics

Pharmacokinetics refers to the absorption, distribution, and elimination of a drug.[2] Peak and trough serum concentrations after antimicrobial dosing are examples of pharmacokinetic parameters.

ANTIBIOTICS AT A GLANCE

- The β-lactam antibiotics (penicillins and cephalosporins) are mainstays of therapy for the treatment of uncomplicated skin and soft-tissue infections (SSTIs).
- Empiric therapy for uncomplicated SSTIs is largely successful.
- Antibiotic resistance is a growing concern. Culture and sensitivity testing may allow for better management of infections caused by resistant organisms.
- The β-lactam antibiotics and vancomycin act by inhibiting bacterial cell wall synthesis.
- Several antibiotic classes interfere with bacterial protein synthesis by binding ribosomal subunits: Tetracyclines at 30S and lincosamides (clindamycin), macrolides, streptogramins, and oxazolidinones (linezolid) at 50S.
- New agents approved for the treatment of SSTIs include linezolid, quinupristin/dalfopristin, daptomycin, ertapenem, and tigecycline.

Adjustments for Renal Insufficiency

Many antibiotics excreted by the kidneys require dosing adjustments for patients with renal insufficiency to ensure adequate dosing and avoid drug toxicity (Table 231-1). Adjustments to either the amount of drug or the frequency of its administration are based on creatinine clearance (C_{CR}), which is most easily approximated using the following calculation:

$$C_{CR} = \frac{\text{ideal weight (kg)} \times (140 - \text{age})}{72 \times \text{serum creatinine level (mg/dL)}}$$

This formula applies to men; for women, the result is multiplied by 0.85. Some antibiotics are removed by hemodialysis and require higher dosing.

Use during Pregnancy and Lactation

Ideally, systemic antibiotics should be avoided during pregnancy. However, for the treatment of uncomplicated SSTIs, penicillins, cephalosporins, and erythromycin, which are U.S. Food and Drug administration category B medications, are considered the safest candidates for use. As category D medications, tetracyclines, fluoroquinolones, and trimethoprim-sulfamethoxazole are contraindicated during pregnancy (Table 231-2). Most antibiotics are considered safe for lactating (breast-feeding) women, but fluoroquinolones should be avoided due to possible development of arthropathies and cartilage defects.[3] Metronidazole, infrequently used systemically in dermatologic practice, has carcinogenic and mutagenic risk. If it is used, current guidelines recommend discontinuation of breast-feeding for 12 to 24 hours to allow for excretion of the drug.

Prophylaxis and Perioperative Use

The prophylactic use of antibiotics in dermatology and dermatologic surgery is controversial.[4,5] Published guidelines and existing studies regarding prophylaxis inadequately address dermatologic procedures (such as prolonged procedures and involvement of mucosal sites), and a current consensus does not exist. It is likely that antibiotics are currently overused in this setting, and several publications have now proposed guidelines relevant to dermatology. Prophylactic antibiotic use may be considered for two purposes: (1) prevention of endocarditis and prosthesis infection, and (2) prevention of surgical site infection.

The American Heart Association published its most recent guidelines regarding endocarditis prophylaxis in 1997. Patients are risk-stratified by underlying condition. Antibiotic prophylaxis is recommended for patients with high-risk conditions who are undergoing procedures in which the risk of bacteremia exceeds 10 percent. High-risk conditions include the presence of prosthetic cardiac valves, history of previous bacterial endocarditis, complex cyanotic congenital heart disease, and the presence of surgically constructed pulmonary shunts. Several studies have demonstrated that bacteremia rates for routine dermatologic surgical procedures involving properly cleansed and noninflamed skin are close to 3 percent. In comparison, toothbrushing produces bacteremia rates of between 24 percent and 40 percent. Therefore, antibiotic use for prophylaxis against endocarditis is not indicated for routine surgical procedures on noninflamed and surgically prepared skin. The data for procedures

TABLE 231-1
Dosing Regimens for Antibiotics Commonly Prescribed for the Treatment of Skin and Soft-Tissue Infections

Class	Generic Name	Route	Adult Dosing
β-Lactams	Penicillin G	IM, IV	2–24 million units qd divided q4h[a] (18–24 million units qd for neurosyphilis)
	Benzathine penicillin G	IM	2.4 million units × 1 (early syphilis)[a] 2.4 million units weekly × 3 (syphilis > 1 yr)
	Dicloxacillin	PO	500 mg q6h
	Nafcillin	IM, IV	IM: 500 mg q4–6h IV: 0.5–2 g q4–6h
	Oxacillin	IM, IV	1–2 g q4–6h
	Amoxicillin	PO	500 mg q8h[a]
	Amoxicillin/clavulanate	PO	875 mg q12h[a]
	Cephalexin[d]	PO	500 mg q6h
	Cefdinir[e]	PO	300 mg q12h
	Cefprozil[f]	PO	250 mg q12h
Tetracyclines	Tetracycline	PO	500 mg q6h (bid for acne)[a]
	Doxycycline	PO	100 mg q12–24h[a]
	Minocycline	PO	100 mg q12h[a]
Macrolides	Erythromycin base	PO	500 mg q6h or q12h
		IV	1 g q6h[a]
	Clarithromycin	PO	250–500 mg q12h
	Azithromycin	PO	500 mg on day 1, then 250 mg qd × 2–5 Chlamydia: 1 g single dose
		IV	500 mg q24h
Fluoroquinolones	Ciprofloxacin	PO, IV	Gonorrhea: 500 mg × 1[b] Gonococcemia: 500 mg q12h × 7 days[c] Chancroid: 500 mg q12h × 3 days Cutaneous anthrax: 10–15 mg/kg q12h × 60 days
	Levofloxacin	PO, IV	Uncomplicated infection: 500 mg q24h[a] Complicated infection: 750 mg q24h[a]
Lincosamides	Clindamycin	PO	150–450 mg q6h
		IV	600–900 mg q8h
Trimethoprim-sulfamethoxazole (co-trimoxazole)		PO	180 mg/800 mg (double strength) q12h[a]
		IV	5 mg/kg q6–8h[a]

[a]Adjustments in dose or frequency of administration may be required in patients with renal impairment.
[b]Centers for Disease Control and Prevention recommendations for the treatment of gonococcal urethritis/cervicitis include concomitant therapy with azithromycin or doxycycline.
[c]After a single dose of 1 g ceftriaxone IM/IV.
[d]First-generation cephalosporin.
[e]Third-generation cephalosporin.
[f]Second-generation cephalosporin.

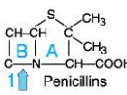

TABLE 231-2
Adverse Events

Antibiotic Class	Pregnancy Category	Common Adverse Effects	Uncommon Adverse Effects
Penicillins	B	Hypersensitivity reactions: Exanthem, urticaria Diarrhea	Hypersensitivity reactions: Exfoliative dermatitis, SJS, vasculitis, AGEP Angioedema, anaphylaxis, serum sickness Anaphylactoid reaction Hepatitis, interstitial nephritis Neurotoxicity (high dosage) Pulmonary infiltrate with eosinophilia Immune-mediated hematologic reactions Pseudomembranous colitis
Cephalosporins	B	Hypersensitivity reactions as above Diarrhea	Hypersensitivity reactions as above Renal tubular necrosis Disulfiram-like reaction (specific) Thrombophlebitis (intravenous site) Serum sickness–like reaction (cefaclor, cefprozil) Pseudocholelithiasis (ceftriaxone)
Tetracyclines	D	Skin and nail hyperpigmentation (minocycline) Dental hyperpigmentation (infants, children) Gastrointestinal irritation	Photosensitivity (doxycycline) Photo-onycholysis Fixed drug eruption Pseudotumor cerebri Esophageal erosion/stricture Skeletal hypoplasia Serum sickness Renal toxicity Vestibular toxicity (minocycline) Fanconi syndrome (outdated tetracycline) Thyroid discoloration SJS, TEN Pancreatitis Blood dyscrasias (long-term use) Hypersensitivity reactions (various) Pseudomembranous colitis
Fluoroquinolones	C	Nausea, vomiting Cephalgia, dizziness	Exanthem, photosensitivity Delirium, seizure Tendon rupture, arthropathy (in the immature) QT prolongation Hepatitis (trovafloxacin—withdrawn from U.S. market)
Trimethoprim-sulfamethoxazole	C	Exanthem, photosensitivity Nausea, vomiting, anorexia Glossitis, stomatitis (Rare/severe reactions are more common in HIV/AIDS patients)	SJS, TEN, vasculitis, urticaria Pustular eruption, Sweet syndrome Cholestatic hepatitis, hepatic necrosis Blood dyscrasias Severe hypersensitivity reaction Cephalgia, hallucination, tremor Nephrolithiasis, interstitial nephritis
Lincosamides (clindamycin)	B	Diarrhea Exanthem, urticaria	Pseudomembranous colitis Erythema multiforme, SJS, TEN Elevated hepatic transaminase levels (reversible) Blood dyscrasias Neuromuscular blockade
Macrolides	B/C	Nausea, diarrhea, abdominal pain Dysgeusia (clarithromycin)	Cholestatic hepatitis Pseudomembranous colitis Prolonged QT interval, torsade de points Anaphylaxis SJS

AGEP = acute generalized exanthematous pustulosis; HIV/AIDS = human immunodeficiency virus/acquired immunodeficiency syndrome; SJS = Stevens-Johnson syndrome; TEN = toxic epidermal necrolysis.

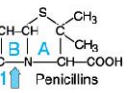

involving inflamed skin, sites associated with a higher rate of bacteremia (such as mucosa, genitalia, and ear), and prolonged procedures, such as Mohs micrographic surgery, are less clear. In these situations, prophylaxis for patients with high- and moderate-risk conditions varies by institution and practitioner. If procedures must be performed on infected tissue antibiotic prophylaxis is probably warranted in the high- and moderate-risk groups due to higher rates of bacteremia.

Data concerning the risk of infection after dermatologic procedures in patients who have undergone total joint arthroplasty are sparse. Most infections involving joint replacements occur in the immediately postoperative period. Prophylaxis for patients at low risk whose joint replacement was performed more than 2 years earlier is not recommended. Procedures in patients at high risk, patients with joint prostheses less than 2 years old, and patients with vascular grafts or neurologic shunts are situations for which no current guidelines exist.

Although wound classification correlates well with infection rate, the wounds associated with most routine dermatologic procedures are difficult to categorize and are probably best classified between clean (class I) and clean-contaminated (class II) wounds. These wounds are at low risk of infection, and prophylactic antibiotic therapy to prevent surgical site infection is not warranted. This generally includes most Mohs micrographic surgical procedures, which have reported infection rates of 2 percent to 3 percent. However, the risk of infection increases when Mohs procedures involve mucosal sites or the ear, or closure is delayed. In these cases, use of prophylactic antibiotics may be warranted, although dedicated studies to address this question are lacking. There is much debate regarding the use of antibiotic prophylaxis after medium to deep facial laser resurfacing or chemical peels. Reported infection rates of these clean-contaminated wounds are less than 10 percent. Furthermore, some studies have demonstrated selection of pathogenic organisms and higher infection rates after prophylaxis in this setting. For this reason, antibiotic prophylaxis for these procedures is probably not warranted. Table 231-3 shows recommended first-line and alternative therapies for various bacterial infections.

PENICILLINS

Mechanism of Action

One of the oldest and largest groups of antibiotics, penicillins are members of the β-lactam family.[6] All penicillins have a nucleus composed of a thiazolidine ring and β-lactam ring, which is required for antibiotic activity. Different side chains alter activity and resistance to degradation, but all β-lactams share a similar bacteriocidal mechanism of action. They bind to specific penicillin-

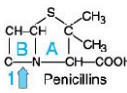

TABLE 231-3
Recommended Therapies for Infection

ORGANISM	FIRST-LINE THERAPY	ALTERNATIVE THERAPY
Actinomyces israelii	Ampicillin or penicillin G	Doxycycline, ceftriaxone, clindamycin, erythromycin
Bacillus anthracis	Doxycycline or ciprofloxacin	Penicillin G or amoxicillin (if penicillin sensitive)
Bartonella sp.	Azithromycin (cat-scratch fever) Erythromycin or doxycycline (BA)	Clarithromycin, ciprofloxacin
Borrelia burgdorferi	Doxycycline or amoxicillin	Ceftriaxone, cefuroxime, cefotaxime
B. recurrentis	Doxycycline	Erythromycin
Chlamydia trachomatis	Doxycycline or azithromycin	Erythromycin, ofloxacin, levofloxacin
Clostridium perfringens	Penicillin G ± clindamycin	Doxycycline
Coxiella burnetii	Doxycycline	Erythromycin
Ehrlichia sp.	Doxycycline	Tetracycline, rifampin, ciprofloxacin
Eikenella corrodens	Penicillin G or ampicillin	Amoxicillin/clavulanate, TMP-SMX, fluoroquinolones
Erysipelothrix rhusiopathiae	Penicillin G or ampicillin	Fluoroquinolones
Francisella tularensis	Streptomycin	Gentamicin, tetracycline, chloramphenicol
Haemophilus ducreyi	Azithromycin or ceftriaxone	Erythromycin, ciprofloxacin
Klebsiella granulomatis	Doxycycline or TMP-SMX	Erythromycin, azithromycin, ciprofloxacin
K. rhinoscleromatis	Fluoroquinolones	Rifampin[a] + TMP-SMX
Neisseria gonorrhoeae	Ceftriaxone	Fluoroquinolones, cefixime
Nocardia asteroides	TMP-SMX	Minocycline, linezolid
N. brasiliensis	TMP-SMX	Amoxicillin/clavulanate
Pasteurella multocida	Penicillin, ampicillin, or amoxicillin	Doxycycline, TMP-SMX
Pseudomonas aeruginosa	Ciprofloxacin	Antipseudomonal penicillin or cephalosporin
Rickettsia sp.	Doxycycline	Chloramphenicol, fluoroquinolone
Staphylococcus aureus (MRSA)	Oxacillin or nafcillin	Clindamycin, macrolides
S. aureus (HAMRSA)	Vancomycin	Linezolid, daptomycin, quinupristin/dalfopristin, tigecycline
S. aureus (CAMRSA)	TMP-SMX	Minocycline, clindamycin, rifampin,[a] as above
Streptococcus pyogenes	Penicillin	Other β-lactams, macrolides
Treponema pallidum	Benzathine penicillin G	Doxycycline, tetracycline
Vibrio vulnificus	Doxycycline + ceftazidime	Cefotaxime, fluoroquinolones

BA = bacillary angiomatosis; CAMRSA = community-acquired MRSA; HAMRSA = hospital-acquired MRSA; MRSA = methicillin-resistant *Staphylococcus aureus*; TMP-SMX = trimethoprim-sulfamethoxazole.
[a]Rifampin is not recommended as monotherapy due to significant development of resistance.

binding proteins, inhibit cell wall peptidoglycan synthesis, and inactivate an inhibitor of autolytic enzymes present on bacterial cell walls.

There are several groups of penicillins, largely differentiated by their chemical structure and resistance to bacterial degradation. The natural penicillins exhibit the narrowest spectrum of activity and are susceptible to enzymatic degradation by β-lactamases. Penicillin G is the most useful drug in this group. Administered parenterally, it is active against *Streptococcus*, *Neisseria meningitidis*, *Clostridium* sp., spirochetes, *Pasteurella multocida*, *Eikenella corrodens*, *Erysipelothrix rhusiopathiae*, and non–β-lactamase-producing staphylococci. Penicillin G is the treatment of choice for *Treponema pallidum* infection in all forms. Penicillin V is the oral form of the drug and is generally less potent than penicillin G because of lower blood levels are achievable.

Aminopenicillins (ampicillin, amoxicillin), carboxypenicillins (carbenicillin, ticarcillin), and ureidopenicillins (piperacillin) provide a broader spectrum of activity. The ureidopenicillins have a profile of Gram-positive activity similar to that of the carboxypenicillins. Derived from ampicillin, they have greater activity against Gram-negative bacteria than do the carboxypenicillins. Amoxicillin, ticarcillin, and piperacillin are often coupled with β-lactamase inhibitors to enhance activity against *S. aureus*. The β-lactamase inhibitors include tazobactam, clavulanic acid, and sulbactam, and work best against β-lactamases encoded on plasmids.

The final group of penicillins (oxacillin, dicloxacillin, and nafcillin) is inherently β-lactamase resistant and exhibits excellent activity against *S. aureus*. Penicillins in this group have no activity against enterococci or enteric Gram-negative organisms. The β-lactamase–resistant penicillins remain an excellent choice for empiric treatment of uncomplicated SSTIs such as folliculitis, impetigo, furunculosis, and cellulitis in which community-acquired MRSA is not a suspected cause.

Pharmacokinetics

Absorption of oral penicillins is variable and depends on each compound's acid stability and the amount bound to food. Most oral penicillins should be taken at least 1 hour before or 1 hour after meals. Penicillins are excreted in breast milk in low quantities and are considered safe to use during breast-feeding.

Box 231-1

Indications for Penicillin Therapy

- Syphilis and non-venereal treponematoses
- Skin and soft-tissue infections caused by *Streptococcus* sp. (erysipelas, scarlet fever, impetigo, etc.)
- Erysipeloid
- Anthrax (if sensitive)
- Lyme disease (when use of tetracyclines is contraindicated)
- Actinomycosis
- Listeriosis
- Leptospirosis
- Infected human and animal bites

Indications (Box 231-1)

Dosing Regimens

Dosing regimens for penicillins appear in Table 231-1. Dosing adjustment is necessary for patients with renal insufficiency.

Risks and Precautions

- Should be avoided in cases of known hypersensitivity to penicillin
- Levels are increased with concurrent use of probenecid and disulfiram
- Cause enhanced effect of methotrexate and warfarin

Complications

Hypersensitivity reactions are the most common adverse events reported with penicillins[7] (see Table 231-2). Reported incidence varies from 0.7 percent to 10.0 percent, and manifestations range from mild to severe (see Table 231-2). Penicillin hypersensitivity is probably overreported by patients, but 2 percent to 4 percent of true allergic reactions are life threatening. For patients with true penicillin allergy, use of another class of antibiotic is warranted. If penicillin allergy is uncertain and if penicillin treatment is required, skin prick testing may be performed to detect type I hypersensitivity, followed by intradermal testing if results are negative. Negative test results may be followed by a challenge dose of oral penicillin under observation. Approximately 10 percent to 20 percent of patients with a history of "penicillin allergy" have a positive skin test result, and approximately 3 percent of those with a negative skin test result and a history of allergy have an allergic response after a challenge dose of penicillin. These reactions tend to be mild. Patients with positive skin test results can undergo desensitization therapy when a β-lactam must be given.

CEPHALOSPORINS

Mechanism of Action

Cephalosporins are β-lactams with the same mechanism of action as penicillins; that is, they inhibit bacterial cell wall synthesis by blocking peptidoglycan incorporation.[8] Cephalosporins differ structurally from penicillins in that they have a dihydrothiazine ring instead of the thiazolidine ring of penicillins. Most cephalosporins have some activity against both Gram-positive organisms (excluding enterococci) and Gram-negative organisms, although the spectrum of activity varies widely within the group.

Pharmacokinetics

Cephalosporins are a chemically diverse class of antibiotics with unique pharmacokinetic and pharmacodynamic properties. Most orally administered cephalosporins can be taken without food. The esterified cephalosporins (cefuroxime and cefpodoxime) should be taken with food to prolong mucosal contact time, because they require enzymatic cleavage in the intestinal tract. Agents that lower the gastric pH may also reduce absorption of these two drugs. Cefaclor is an extended-release formulation and should also be given with food. Most cephalosporins are renally excreted. First-, second-, and third-generation cephalosporins are compatible with breast-feeding, and excretion in breast milk occurs in varying degrees.

Indications (Box 231-2)

Box 231-2

Indications for Cephalosporin Therapy

- Uncomplicated skin and soft-tissue infections due to *Staphylococcus aureus* and *Streptococcus pyogenes* (first- and second-generation agents, plus cefdinir and cefditoren)
- Gonorrhea
- Lyme disease (ceftriaxone: Meningitis and late disease; cefuroxime: Early disease)
- Bacterial meningitis (ceftriaxone, cefotaxime)

Dosing Regimens (See Table 231-1)

Risks and Precautions

- Should be avoided in cases of known hypersensitivity to cephalosporins or penicillin (see Complications)
- Reduced absorption of cefdinir with concurrent use of antacids and iron salts
- Increased cyclosporin levels with concurrent use of ceftriaxone and ceftazidime
- Altered effect of warfarin with cefotetan, cefamandole, cefoperazone, cefixime, and cefaclor
- Impaired renal excretion of most cephalosporins with probenecid

Complications

Up to 20 percent of patients who are allergic to penicillin have a cross-reaction to cephalosporins, with most reactions in penicillin-allergic patients occurring to first- or second-generation cephalosporins.[9] The common β-lactam ring is responsible for the shared mechanism of action and some antigenic cross-reactivity, and the respective side chains for hypersensitivity reactions. Cephalosporins and penicillins with similar side chains are more likely to produce a cross-reactive hypersensitivity reaction in penicillin-allergic patients. Cefoxitin, cefamandole, cefaloram, cephalothin, and cephaloridine have side chains structurally similar to those of penicillin, whereas cefaclor, cephalexin, cefprozil, cephradine, and cefadroxil have side chains similar to those of amoxicillin or ampicillin. Patients reporting a penicillin allergy who have a negative result on a penicillin allergy skin test have no greater risk of an allergic reaction to β-lactams than does the general population. Cephalosporins, because they have a greater variety of metabolite structures than other β-lactams, are able to elicit cephalosporin-specific allergic responses (see Table 231-2).

TETRACYCLINES

Mechanism of Action

Tetracyclines inhibit bacterial protein synthesis by binding to the 30S ribosomal subunit and blocking transfer RNA binding to the messenger RNA–ribosome complex.[10] Doxycycline and minocycline are semi-synthetic second-generation tetracyclines and are the most commonly used in dermatology. More lipophilic than tetracycline, they generally exhibit greater activity, especially against *S. aureus* and community-acquired strains of MRSA.[11] As a class, tetracyclines have a broad spectrum of activity, including activity against many Gram-positive and Gram-negative bacteria, spirochetes, *Mycoplasma*, *Rickettsia*, *Chlamydia*, and some protozoa. Doxycycline is preferred therapy for the treatment of infections due to *Borrelia* sp., *Brucella* sp., *Chlamydia* sp., *Ehrlichia* sp. (monocytic and granulocytic ehrlichiosis), *Klebsiella granulomatis* (granuloma inguinale), *Coxiella burnetii* (Q fever), *Leptospira* sp., *Mycoplasma* sp., *Rickettsia* sp., and *Francisella tularensis*. It is also treatment for infections caused by *Actinomyces* sp., *Bacillus anthracis*, *Mycobacterium marinum*, and *Vibrio vulnificus*. In patients allergic to penicillins, doxycycline is commonly used to treat animal bites and syphilis. Tetracyclines can be helpful for the treatment of acne, rosacea, perioral dermatitis, autoimmune blistering disease (bullous pemphigoid, linear immunoglobulin A bullous dermatosis, and dermatitis herpetiformis), and confluent and reticulated papillomatosis (Gougerot-Carteaud syndrome), probably because of their anti-inflammatory properties.

Box 231-3

Indications for Tetracycline Therapy

- Actinomycosis
- Animal bites (*Pasteurella multocida*)
- Anthrax (*Bacillus anthracis*)
- *Borrelia* sp. infections
- Bacillary angiomatosis
- *Chlamydia* sp. infections
- Ehrlichiosis
- Granuloma inguinale
- Lyme disease
- Methicillin-resistant *Staphylococcus aureus* infections
- *Mycobacterium marinum* infections
- *Nocardia* sp. infections
- Rickettsial diseases
- Rhinoscleroma
- Syphilis (penicillin-allergic patients)
- Tularemia
- *Vibrio vulnificus* infections
- *Yersinia pestis* infections

Pharmacokinetics

Tetracycline is incompletely absorbed, primarily in the stomach and small intestine, so it must be taken on an empty stomach. Doxycycline and minocycline are unaffected by the presence or absence of food and have longer half-lives than tetracycline, requiring less frequent dosing. They also have much greater lipid solubility than tetracycline, which allows excellent tissue penetration, with rapid availability in secretions of the prostate, respiratory tract, female reproductive tract, and bile. Nonetheless, patients should avoid concurrent ingestion of iron preparations, aluminum hydroxide gels, calcium and magnesium salts, or milk products, because these significantly lower absorption of the entire class. Tetracycline is excreted primarily by the kidneys, and patients with renal failure require dosing adjustment. Doxycycline is excreted in the feces, and no adjustments for renal or hepatic failure are necessary. Minocycline is largely metabolized before excretion but does not accumulate in patients with hepatic failure. Tetracyclines cross the placenta and appear in high concentrations in breast milk. Because of their ability to accumulate in developing bone and teeth, their use during pregnancy and lactation, and throughout childhood should be avoided.

Indications (Box 231-3)

Dosing Regimens (See Table 231-1)

Risks and Precautions

- Require dosing adjustments in patients with renal failure (impaired excretion and anti-anabolic properties)
- May cause photosensitivity (doxycycline)
- Should be avoided in nursing or pregnant women and in children younger than 9 years of age
- Absorption impaired by calcium, magnesium, aluminum (other cations), iron, sodium bicarbonate, and cimetidine
- Increased metabolism of doxycycline with concurrent use of phenytoin, carbamazepine, barbiturates, and alcohol
- Lead to reduced insulin requirements in diabetic patients
- Lead to increased serum levels of digoxin, lithium, and warfarin
- Should not be used with methoxyflurane anesthesia (renal failure)

Complications (See Table 231-2)

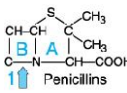

CLINDAMYCIN

Mechanism of Action

Clindamycin is a lincosamide antibiotic derived through chemical modification of lincomycin.[12] Its absorption and spectrum of activity are better than those of its predecessor, which is now obsolete. Clindamycin binds to the bacterial 50S ribosomal subunit and inhibits protein synthesis through blockade of peptide chain initiation. The binding site overlaps the sites used by other antibiotics that bind the 50S subunit such as macrolides (erythromycin), which accounts for the antagonism noted between these drugs. Clindamycin facilitates opsonization and phagocytosis and decreases bacterial adhesion (to host cells) and production of staphylococcal exotoxin. Persistent binding at the 50S subunit leads to prolonged antibiotic effect against some organisms. Drug resistance occurs by mutation at the 50S binding site.

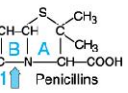

Pharmacokinetics

Clindamycin is not inhibited by food intake and reaches therapeutic levels in most tissues except cerebrospinal fluid. The drug preferentially accumulates in polymorphonuclear leukocytes, which may explain its benefit as treatment for abscesses. Clindamycin is primarily metabolized by the liver and excreted in the bile, although 10 percent is excreted in the urine. Dosing adjustments are necessary for patients with hepatic failure or combined hepatic and renal failure. The drug is not removed by dialysis.

Indications (Box 231-4)

Box 231-4

Indications for Clindamycin Therapy

- Uncomplicated skin and soft-tissue infections due to susceptible bacteria and protozoa
- Deep tissue infections: Streptococcal myositis, necrotizing fasciitis, or infections with *Clostridium perfringens* in conjunction with surgical débridement
- Surgical prophylaxis in penicillin-allergic patients
- Prophylaxis for recurrent staphylococcal infection
- Diabetic foot ulcers (in combination with agents for treatment of Gram-negative infection)
- Hidradenitis suppurativa
- Bacterial vaginosis

Dosing Regimens (See Table 231-1)

Risks and Precautions

- Require dosing adjustments in patients with hepatic failure
- Enhance neuromuscular blockade with tubocurare and pancuronium
- Possibly antagonistic with erythromycin

Complications

Clindamycin frequently causes gastrointestinal upset and diarrhea (2 percent to 20 percent of patients) and may occasionally cause pseudomembranous colitis attributed to *C. difficile*, a life-threatening complication reported in 0.1 percent to 10.0 percent of patients (see Table 231-2). Despite its classic association with clindamycin, pseudomembranous colitis may occur after administration of virtually any antibiotic. Treatment includes discontinuation of the drug and administration of metronidazole.

MACROLIDES

Mechanism of Action

Erythromycin is the prototypical macrolide antibiotic; derivatives include dirithromycin, clarithromycin, and azithromycin. All are bacteriostatic and inhibit bacterial protein synthesis by reversibly binding the 50S ribosomal subunit. Structural modifications of clarithromycin and azithromycin confer increased acid stability, tissue penetration, and spectrum of activity.[13] The macrolides have good but varied activity against Gram-positive pathogens, with clarithromycin more effective than erythromycin, which in turn shows more activity than azithromycin. Streptococcal resistance to macrolides is fairly common (up to 40 percent of group A isolates), and *S. aureus* may be variably susceptible to erythromycin. Streptococcal resistance to macrolides is class-wide rather than drug-specific.

Pharmacokinetics

Macrolides accumulate intracellularly in polymorphonuclear nuclear leukocytes and macrophages, which in part accounts for their activity against intracellular pathogens. Erythromycin base is absorbed in the small intestine and inactivated by gastric acidity; hence, it is available as enteric-coated tablets or capsules. (Food consumption lowers gastric pH, and taking the drug with food may delay absorption.) Erythromycin esters (erythromycin estolate, stearate, and ethylsuccinate) are less acid labile than the base form. Except in its extended-release formulation, which should be given with food, clarithromycin may be taken with or without food. Tissue concentrations of macrolides typically exceed plasma levels. Concentrations of erythromycin in breast milk are approximately 50 percent of maternal serum levels. Erythromycin can cross the placenta, but except for clarithromycin (which is pregnancy category C), the macrolides are category B drugs. Clarithromycin and azithromycin have longer half-lives, which allows less frequent dosing (see Table 231-1). Azithromycin remains in tissue longer and accumulates at high levels intracellularly (in tissue fibroblasts), which permits daily short-term dosing after a loading dose. Clarithromycin is metabolized by the liver and excreted by the kidneys. Patients with renal failure require dosing adjustments. Adjustments are not necessary for erythromycin, azithromycin, or dirithromycin, which primarily undergo hepatic metabolism. Erythromycin and clarithromycin interact with the cytochrome P_{450} (CYP) system, which can prompt numerous potential drug interactions (see Risks and Precautions). Erythromycin and clarithromycin inhibit CYP 3A4, and erythromycin also inhibits CYP 1A2.

Indications (Box 231-5)

Dosing Regimens (See Table 231-1)

Risks and Precautions

- May inhibit CYP 3A4, which leads to increased drug toxicity (increased serum levels) of warfarin, carbamazepine, buspirone, benzodiazepines, corticosteroids (methylprednisolone), β-hydroxy-β-methylglutaryl–coenzyme A reductase inhibitors, oral contracep-

Box 231-5

Indications for Macrolide Therapy

- Uncomplicated skin and soft-tissue infections (folliculitis, erysipelas, cellulitis, etc.)
- *Bartonella* infections (except Oroya fever, due to *B. bacilliformis*)
- Animal and human bites (*Pasteurella multocida*, *Eikenella corrodens*—azithromycin)
- Lyme disease
- Chlamydiosis
- Nontuberculous mycobacterial skin disease (clarithromycin)

tives, cyclosporine, tacrolimus, disopyramide, felodipine, ergot alkaloids
- May inhibit CYP 1A2, which leads to increased drug toxicity (increased serum levels) of theophylline, omeprazole
- Cause elevation of digoxin levels (due to change in drug metabolism by gut flora)
- Clarithromycin levels increased when given concurrently with fluconazole

Complications (See Table 231-2)

FLUOROQUINOLONES

Mechanism of Action

Fluoroquinolones are fluorinated derivatives of the first quinolone, nalidixic acid.[14] They work by inhibiting the action of bacterial topoisomerases II (DNA gyrase) and IV, which leads to impaired DNA replication, transcription, and repair. In Gram-positive organisms, the primary target is topoisomerase IV; in Gram-negative bacteria the target is topoisomerase II. Moxifloxacin, in particular, has been approved for the treatment of uncomplicated SSTIs. Some of the newer fluoroquinolones (levofloxacin, moxifloxacin) exhibit good activity against *Streptococcus*, but *S. aureus* organisms often develop resistance rapidly. These agents therefore should not be first-line therapy for uncomplicated SSTIs, but they may be useful in the treatment of complicated, polymicrobial, and/or Gram-negative infections such as diabetic ulcers or deep tissue infections. Ciprofloxacin and levofloxacin are effective agents for the treatment of gonorrhea, chlamydia, erysipeloid, granuloma inguinale, and chancroid (see the section on Indications). Ciprofloxacin, ofloxacin, levofloxacin, moxifloxacin, and gatifloxacin are effective against some *Mycobacterium* sp., including *M. tuberculosis*, *M. chelonae*, *M. fortuitum*, and *M. kansasii*, although available data are limited.

Pharmacokinetics

Fluoroquinolones are rapidly absorbed after oral ingestion, with a large volume of distribution. Food does not inhibit absorption. Unlike β-lactams, fluoroquinolones act in a concentration-dependent manner and can be administered twice daily. Most are excreted by the kidneys, and dosing adjustments for renal failure are usually necessary. Moxifloxacin is eliminated in the liver by conjugation with glucuronide and sulfate. None of the fluoroquinolones is removed by dialysis. Most are excreted in breast milk in small or almost negligible quantities, but rare side effects have occurred in breast-feeding infants. For example, ciprofloxacin has been associated with phototoxicity, pseudomembranous colitis, and green teeth on eruption. Norfloxacin is not found in the breast milk of mothers taking the drug, whereas ofloxacin and levofloxacin are excreted in smaller quantities than ciprofloxacin. Ciprofloxacin and ofloxacin are compatible with breast-feeding according to the American Academy of Pediatrics guidelines.

Box 231-6

Indications for Fluoroquinolone Therapy

AS FIRST-LINE THERAPY
- Anthrax
- Skin and soft-tissue infections (SSTIs) due to Gram-negative pathogens
- *Pseudomonas aeruginosa* infections (otitis externa, ecthyma gangrenosum, SSTIs) (ciprofloxacin)
- Rhinoscleroma

AS SECOND-LINE THERAPY
- *Bartonella* sp. infections
- Chancroid
- Chlamydiosis
- Ehrlichiosis
- Erysipeloid
- Gonorrhea
- Granuloma inguinale
- *Rickettsia* sp. infections
- *Vibrio vulnificus* infections

Indications (Box 231-6)

Dosing Regimens (See Table 231-1)

Risks and Precautions

- Show decreased bioavailability when taken with antacids (aluminum, magnesium, alum), iron, zinc, and sucralfate
- Inhibit the metabolism of theophylline and aminophylline (ciprofloxacin)
- Associated with arthropathy in studies of immature animals
- Can lead to tendon rupture (in patients with renal disease, patients undergoing hemodialysis, or patients taking steroids)
- Decrease the seizure threshold
- Decrease the metabolism of warfarin and cyclosporin

Complications (See Table 231-2)

TRIMETHOPRIM-SULFAMETHOXAZOLE

Mechanism of Action

Trimethoprim-sulfamethoxazole (co-trimoxazole) is a combination of trimethoprim (TMP) and sulfamethoxazole (SMX) in a 1:5 ratio. Both compounds reduce nucleic acid synthesis by inhibiting two enzymes in the bacterial tetrahydrofolic acid synthesis pathway. Together, these compounds exhibit synergistic action that is relatively specific to bacterial cells.

TMP-SMX is a broad-spectrum antibiotic with good activity against many aerobic Gram-positive cocci, including *S. aureus*, *S. pyogenes*, and *S. viridans*; it is often effective in the treatment of community-acquired MRSA infections.[11]

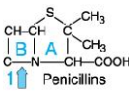

Pharmacokinetics

TMP and SMX are well absorbed but achieve different serum concentrations after administration of equal quantities of drug. A serum ratio of 1:20 (TMP/SMX) is necessary for optimal synergistic action against the largest variety of pathogens, which can be achieved by administering the drug in a fixed 1:5 ratio. Both compounds are rapidly distributed to tissues, including the cerebrospinal fluid and sputum. Excretion is via the kidneys.

Indications (Box 231-7)

Dosing Regimens (See Table 231-1)

Risks and Precautions

- Causes more severe reactions in patients with human immunodeficiency virus infection/acquired immunodeficiency syndrome
- Prolongs prothrombin time in patients taking warfarin
- Contraindicated in patients taking methotrexate

Complications (See Table 231-2)

Box 231-7

Indications for Trimethoprim-Sulfamethoxazole Therapy
- Community-acquired methicillin-resistant *Staphylococcus aureus* infections
- *Nocardia asteroides* infections
- Uncomplicated skin and soft-tissue infections due to susceptible pathogens
- Granuloma inguinale
- Chancroid

NEWER OR LESS COMMONLY USED AGENTS

Although the aforementioned compounds comprise the vast majority of antibiotics used in dermatologic practice, several new or infrequently used medications bear mentioning for the treatment of complicated SSTIs or systemic infections caused by resistant pathogens.[17] In many hospitals, these drugs have restricted use, and their administration requires approval by an infectious disease specialist.

Vancomycin

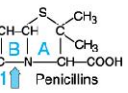

Vancomycin is a glycopeptide antibiotic effective against Gram-positive bacteria only. It is used specifically to treat infections caused by Gram-positive organisms resistant to β-lactams or in cases in which their use is contraindicated.[18] In dermatology, vancomycin has been a first-line therapy for complicated and/or severe SSTIs caused by hospital-acquired MRSA. Vancomycin-resistant isolates of *S. aureus* and *Enterococcus faecium* have now been isolated. Vancomycin inhibits bacterial cell wall peptidoglycan synthesis. Dose is determined by the patient's weight (15 to 20 mg/kg) and frequency of administration by the patient's creatinine clearance. Because of this, renal function must be monitored during therapy. Potential adverse reactions include nephrotoxicity, ototoxicity, phlebitis at the injection site, hypersensitivity reactions, and leukopenia. "Red man syndrome," secondary to histamine release, is an uncommon reaction that can occur and is thought to be due to drug impurities. Use of more refined preparations and slower infusions minimize this reaction. Drug-induced linear immunoglobulin A disease is a rare cutaneous side effect. Two new glycopeptides, dalbavancin and oritavancin, are currently in clinical trials for the treatment of SSTIs.

Linezolid

Currently the only available oxazolidinone, linezolid has been approved by the U.S. Food and Drug Administration for the treatment of complicated SSTIs caused by MRSA as well as infections due to other drug-resistant Gram-positive organisms, including vancomycin-resistant *E. faecium* (VRE) and vancomycin-resistant *S. aureus*.[19] It is active against Gram-positive organisms (including anaerobes), as well as nontuberculous mycobacteria such as *M. chelonae* and *M. fortuitum*. Largely bacteriostatic, linezolid inhibits the initiation of protein translation by binding to the 23S portion of the 50S ribosomal subunit, a unique mechanism of action that minimizes cross-resistance to other antibiotics. Nonetheless, infections with linezolid-resistant enterococci have occurred. Although the drug is renally excreted, dosing adjustments for renal failure are not necessary. Linezolid is generally well tolerated, but reversible thrombocytopenia and leucopenia occur in approximately 2 percent of patients and seem to correlate with duration of therapy. This dictates monitoring of complete blood cell counts during therapy. Dosing for complicated infections is 600 mg twice daily, usually intravenously at first. The ability to convert to oral administration makes this drug an attractive option.

Quinupristin/Dalfopristin

Quinupristin/dalfopristin is a streptogramin antibiotic combination in a fixed 60:40 ratio.[17] Both quinupristin and dalfopristin irreversibly inhibit bacterial protein translation by binding to different sites on the 50S ribosomal subunit. They exhibit synergistic, largely bacteriocidal activity against a variety of multidrug-resistant Gram-positive organisms, including MRSA and VRE. Like linezolid, they have also been used in the treatment of vancomycin-resistant *S. aureus* infections. The recommended dosage is 7.5 mg/kg intravenously twice daily for at least 7 days, with lower dosages for patients with hepatic insufficiency. Patient tolerance of adverse effects, especially phlebitis (75 percent) if administered peripherally, arthralgia, and myalgia, can be a problem. Quinupristin/dalfopristin is metabolized by the liver and excreted in the bile. Elevation of hepatic transaminase and bilirubin levels has been reported, and concomitant administration with other drugs metabolized by the CYP 3A4 system is contraindicated. Quinupristin/dalfopristin should be used with caution in patients taking cyclosporine or agents that prolong the QT interval.

Daptomycin

Daptomycin is a cyclic lipopeptide, a new class of antibiotic derived from the fermentation of *Streptomyces roseosporus*.[20] Daptomycin has now been approved in the United States for the treatment of complicated SSTIs caused by *S. aureus* (including methicillin-resistant strains), *S. pyogenes*, *S. agalactiae*, *S. dysgalactiae* ssp. *equisimilis*, and *E. faecalis* (vancomycin-susceptible strains only). Its mechanism of action is unclear, but it acts rapidly and is bacteriocidal against Gram-positive bacteria. Dosing is 4 mg/kg intravenously every 24 hours for 7 to 14 days. Daptomycin is excreted primarily by the kidneys (78 percent), so that dosing adjustment is required for patients with renal impairment (creatinine clearance of less than 30 mL/min). The drug is generally well tolerated, with headache and constipation being the side effects reported most commonly (4 percent). The primary serious adverse effect is myopathy, which usually occurs at higher dosages.

Ertapenem

Ertapenem is a long-acting carbapenem with a broad spectrum of antimicrobial activity similar to that of the older carbapenems, imipenem-cilastin and meropenem.[17] Unlike imipenem, it has poor activity against *Pseudomonas* and enterococci. In clinical trials, it was comparable with piperacillin/tazobactam in the treatment of complicated SSTIs. It is active against both Gram-positive and Gram-negative aerobes and anaerobes, and should be reserved for the treatment of polymicrobial infections not sensitive to agents with more narrow spectra of activity. An extended half-life allows once-daily intravenous administration (1 g/day for 7 to 14 days), but the drug should be used cautiously in patients with renal impairment. Central nervous system effects and hypersensitivity reactions have been noted.

Tigecycline

Tigecycline is a glyclycycline antibiotic indicated for the treatment of complicated SSTIs due to susceptible organisms, which include MRSA and VRE.[21] A derivative of minocycline, tigecycline shares the same 30S ribosomal binding site and has a spectrum of activity similar to that of the classic tetracyclines. However, tigecycline demonstrates a greater volume of distribution, better activity against organisms with tetracycline resistance, and better activity against *Streptococcus* sp. Tigecycline dosing is 50 mg intravenously twice daily after a 100-mg loading dose. Dosing adjustments for renal impairment are not required, but lower dosing is necessary for patients with severe hepatic disease. The same precautions taken for the tetracycline class of antibiotics should be observed for tigecycline.

KEY REFERENCES

The full reference list for all chapters is available at www.digm7.com.

1. Rosen T: Update on treating uncomplicated skin and skin structure infections. *J Drugs Dermatol* **4**:s9, 2005
4. Messingham MJ, Arpey CJ: Update on the use of antibiotics in cutaneous surgery. *Dermatol Surg* **31**:1068, 2005
6. Kadurina M, Bocheva G, Tonev S: Penicillin and semisynthetic penicillins in dermatology. *Clin Dermatol* **21**:12, 2003
8. Del Rosso JQ: Cephalosporins in dermatology. *Clin Dermatol* **21**:24, 2003
11. Klein NC, Cunha BA: New uses of older antibiotics. *Med Clin North Am* **85**:125, 2001
16. Blondeau JM: The role of fluoroquinolones in skin and skin structure infections. *Am J Clin Dermatol* **3**:37, 2002
17. Schweiger ES, Weinberg JM: Novel antibacterial agents for skin and skin structure infections. *J Am Acad Dermatol* **50**:331, 2004; quiz 341

CHAPTER 232

Antiviral Drugs

Christine M. Hay
Richard C. Reichman

Antiviral drugs have been developed at an extraordinary pace during the past two decades. Progress has been accelerated by advances in knowledge of the molecular biology and pathogenesis of viruses, of which human immunodeficiency virus (HIV) has been the most notable. This chapter focuses on drugs to treat those viral infections that are most likely to be encountered by dermatologists, such as those caused by herpes simplex virus (HSV) and varicella-zoster virus (VZV). Antiviral drugs used to treat cytomegalovirus (CMV) infections, hepatitis, and influenza, and antiretroviral drugs to combat HIV infection are discussed in less depth, and the reader is referred to reviews of these subjects for more information.

DRUGS FOR THE TREATMENT OF HERPESVIRUS INFECTIONS (See Chaps. 193 and 194)

Acyclovir

MECHANISM OF ACTION Acyclovir, 9-[(2-hydroxyethoxy)methyl] guanine, is an antiviral drug widely used for the treatment of HSV and VZV infections.[1] The active antiviral moiety of acyclovir is acyclovir triphosphate, which is a potent inhibitor of certain herpesvirus-induced DNA polymerases but has relatively little effect on host cell DNA polymerase. Acyclovir triphosphate also acts as a terminator of the nascent viral DNA chain because it lacks the 3′ hydroxyl group. The initial phosphorylation of acyclovir to acyclovir monophosphate is efficiently carried out by HSV- and VZV-induced thymidine kinases but not by cellular kinases. Thus, acyclovir monophosphate is concentrated in virus-infected cells, which contributes to its highly selective mechanism of action.[2]

PHARMACOKINETICS Acyclovir is available in oral, intravenous, and topical formulations. The oral bioavailability of acyclovir is low (15 percent to 30 percent). Acyclovir is almost entirely eliminated by the renal route, largely unmetabolized (85 percent). Therefore, dosage reductions are required for patients with creatinine clearances of less than 50 mL/min.[3] Acyclovir is widely distributed in body fluids, including cerebrospinal fluid, vesicle fluids, and vaginal secretions. Acyclovir is available as a 5 percent ointment in a polyethylene glycol base in the United States, and topical administration results in detectable drug concentrations in lesions but little, if any, systemic absorption.

INDICATIONS

- Treatment of symptomatic primary or recurrent mucocutaneous HSV-1 or HSV-2 infection
- Suppression of recurrent HSV-1 and HSV-2 infections
- Treatment of mucocutaneous HSV infections in immunocompromised patients
- Prevention of perinatal HSV-1 and HSV-2 infection and treatment of neonatal HSV infection
- Treatment of primary VZV infection in adults and immunocompromised children
- Treatment of VZV infection to reduce the risk of postherpetic neuralgia
- Treatment of HSV-1 encephalitis
- Post-exposure prophylaxis and treatment for herpes simiae after monkey bite

DOSING REGIMENS (Table 232-1)

INITIATION OF THERAPY In general, therapy for mucocutaneous HSV disease should begin as soon after lesions are seen as possible. Treatment for episodic recurrent disease should begin during the prodromal period.[5,6] Treatment for varicella should begin within 24 hours of the onset of the rash. Treatment for herpes zoster in the immunocompetent host is of benefit only if started within 3 days of the onset of the rash.

ANTIVIRAL DRUGS AT A GLANCE

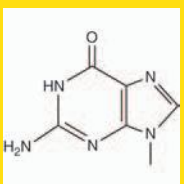

- Antivirals are now approved for treatment of a variety of viral infections.
- Antiviral resistance is a growing concern, especially in the treatment of human immunodeficiency virus infection.
- Antivirals work in a number of different ways, and their spectra of activity can be very specific (amantadine) or quite broad (ribavirin).
- The use of prodrugs of acyclovir and ganciclovir has greatly increased the oral bioavailability of these agents, which allows outpatient treatment of many herpesvirus infections.

MONITORING OF THERAPY Because acyclovir is renally excreted, dosages must be adjusted for patients with a creatinine clearance level of less than 50 mL/min. Assays for drug level are not clinically available.

RISKS AND PRECAUTIONS

- Renal (5 percent)[7]
  - Crystallization in renal tubules leading to obstructive nephropathy
  - Interstitial nephritis

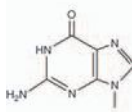

TABLE 232-1
Dosing Regimens for Acyclovir

CONDITION	DOSAGE	ROUTE	DURATION
Primary HSV infection, immunocompetent host	400 mg tid	Oral	7–10 days
Recurrent genital HSV infection, immunocompetent host	400 mg tid *or* 800 mg tid	Oral Oral	5 days 2 days[4]
Recurrent oral labial HSV infection, immunocompetent host	400 mg 5×/day *or* 5% cream 6×/day	Oral Topical	5 days 7 days
Oral labial HSV infection, immunocompromised host	5 mg/kg q8h *or* 400 mg 5×/day	IV Oral	7 days 14–21 days
Perinatal HSV infection	10–20 mg/kg q8h	IV	10–21 days
Chronic suppression of HSV infection	400 mg bid *or* 800 mg qd	Oral	
HSV-1 Encephalitis	10 mg/kg q8h	IV	14–21 days
Varicella: adolescent/adult	800 mg 5×/day	Oral	5–7 days
Varicella: pneumonia or third trimester pregnancy	800 mg 5×/day *or* 10 mg/kg q8h	Oral IV	5 days 5 days
Herpes zoster: normal host or not severe disease in immunocompromised host	800 mg 5×/day	Oral	7–10 days
Herpes zoster: severe disease or immunocompromised host	10–12 mg/kg q8h	IV	7–14 days

HSV = herpes simplex virus.

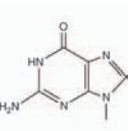

- Central nervous system (1 percent)[8]
  - Lethargy
  - Tremors
  - Confusion
  - Seizures
- Other (rare)
  - Phlebitis with intravenous administration
  - Rash
    - Recall dermatitis[9]
    - Contact dermatitis
    - Fixed drug eruptions
  - Elevated values on liver function tests
  - Neutropenia

COMPLICATIONS Acyclovir is generally well tolerated. The major toxicity associated with acyclovir is renal, as a result of crystallization of the drug in renal tubules, which has been reported with high dosage, dehydration, or rapid intravenous administration. Interstitial nephritis associated with acyclovir use has also been reported.[7] Central nervous system toxicity has been described, including lethargy, tremors, obtundation, and seizures.[8] These side effects have usually been associated with high plasma levels of acyclovir and with underlying diseases involving the central nervous system.

Valacyclovir

MECHANISM OF ACTION AND PHARMACOKINETICS Valacyclovir, 2-[2-amino-1,6-dihydro-6-oxo-9*H*-purin-9-yl-methoxy] ethyl-L-valinate hydrochloride, is the L-valine ester of acyclovir. It was developed to provide increased oral bioavailability of acyclovir.[10] Valacyclovir is rapidly absorbed from the gastrointestinal tract and is converted almost entirely to acyclovir through intestinal and hepatic esterases. Thus, the mechanism of action and spectrum of activity of valacyclovir are that of acyclovir. After a 1-g oral dose of valacyclovir, peak plasma concentrations of acyclovir of 5.7 μg/mL are achieved in 1.75 hours, with area-under-the-curve concentrations that are similar to those achieved with 5 mg/kg of acyclovir given intravenously.[11] The pharmacokinetics of valacyclovir are those of the parent compound, acyclovir.

INDICATIONS

- Treatment of initial and recurrent HSV genital infections[12]
- Suppression of frequently recurring genital HSV infections[13]
- Treatment of herpes zoster[14]

DOSING REGIMENS (Table 232-2)

INITIATION OF THERAPY As with its parent compound, acyclovir, valacyclovir therapy should be initiated as soon as possible after the appearance of an HSV or VZV rash.

RISKS AND PRECAUTIONS In addition to the effects noted with acyclovir,

- Thrombotic thrombocytopenic purpura/hemolytic uremic syndrome (TTP/HUS), seen in patients with advanced HIV disease and in transplant recipients receiving dosages of 8 g/day

COMPLICATIONS Adverse effects are those that would be expected with acyclovir. However, severe and even fatal cases of TTP/HUS have been reported in patients with acquired immunodeficiency syndrome (AIDS) and transplant recipients who were taking high dos-

TABLE 232-2
Dosing Regimens for Valacyclovir

CONDITION	DOSAGE	ROUTE	DURATION
Primary HSV infection, immunocompetent host	1000 mg bid	Oral	10 days
Recurrent genital HSV infection, immunocompetent host	500 mg bid	Oral	3 days
Recurrent oral labial HSV infection, immunocompetent host	2000 mg bid	Oral	1 day
Oral labial HSV infection, immunocompromised host	500 mg bid	Oral	5–10 days
Chronic suppression of HSV infection	1000 mg qd	Oral	Undefined/ indefinite
Varicella: adolescent/adult	1000 mg tid	Oral	5 days
Herpes zoster: normal host or not severe disease in immunocompromised host	1000 mg tid	Oral	7 days

HSV = herpes simplex virus.

ages of valacyclovir.[15] The basis for and causal relationship to valacyclovir of these occurrences have not been established, and TTP/HUS has not been reported in patients taking conventional dosages (up to 3 g/day) of valacyclovir.

Famciclovir and Penciclovir

MECHANISM OF ACTION Famciclovir, [9-(4-hydroxy-3-hydroxy-methylbut-1-yl) guanine, is a prodrug of penciclovir, [9-(4-hydroxy-3-hydroxy-3-hydroxymethylbut-1-yl) guanine]. Penciclovir is phosphorylated to penciclovir triphosphate. The initial phosphorylation of penciclovir to penciclovir monophosphate is carried out by HSV- or VZV-induced thymidine kinases in a manner analogous to that of the initial phosphorylation of acyclovir. Phosphorylation to diphosphate and triphosphate forms of penciclovir is carried out by cellular kinases. Penciclovir triphosphate inhibits viral DNA polymerases and also inhibits extension of the nascent viral DNA chain.[16] Because of the presence of the hydroxyl group on the acyclic side chain of penciclovir, some DNA chain extension may occur.

PHARMACOKINETICS Famciclovir is available as an oral formulation, which is converted to penciclovir by deacetylation and oxidation in the liver and intestine. The bioavailability of famciclovir is 77 percent, and a peak penciclovir plasma concentration of 3.3 μg/mL is reached 1 hour after oral administration of 500 mg of famciclovir.[17,18] The plasma half-life of penciclovir is 2 hours, and 60 percent to 70 percent of the drug is excreted unchanged in the urine by both glomerular filtration and tubular secretion. The dosage of penciclovir should be reduced in cases of advanced renal dysfunction.[17] Compared with the intracellular half-life of acyclovir triphosphate, that of penciclovir triphosphate is markedly prolonged in HSV-infected cells (10 to 20 hours) and VZV-infected cells (9 hours).[19] This prolonged intracellular half-life is the rationale for the longer interval of administration of famciclovir (every 12 hours), compared to that recommended for acyclovir (every 4 hours). Penciclovir is also available as a 1 percent ointment for the treatment of recurrent oral HSV.[20]

INDICATIONS

- Treatment of initial and recurrent HSV genital infections[21]
- Suppression of frequently recurring genital HSV infections[22]
- Treatment of herpes zoster[23]

TABLE 232-3
Dosing Regimens for Famciclovir and Penciclovir

CONDITION	DOSAGE	ROUTE	DURATION
Primary HSV infection, immunocompetent host	250 mg tid	Oral	7–10 days
Recurrent genital HSV infection, immunocompetent host	125 mg bid or 1000 mg bid	Oral Oral	5 days 1 day
Recurrent oral labial HSV infection, immunocompetent host	500 mg bid *or* 1% penciclovir cream q2h	Oral Topical	7 days 5 days or until lesions healed
Oral labial HSV infection, immunocompromised host	500 mg bid	Oral	7 days
Chronic suppression of HSV infection	250 mg bid	Oral	Up to 1 yr
Varicella: adolescent/adult	500 mg tid	Oral	5 days
Herpes zoster: normal host or not severe disease in immunocompromised host	500 mg tid	Oral	7 days

HSV = herpes simplex virus.

DOSING REGIMENS (Table 232-3)

RISKS AND PRECAUTIONS Famciclovir is generally very well tolerated. Dosage should be reduced if creatinine clearance is less than 60 mL/min. The drug may cause the following:

- Headache
- Nausea
- Diarrhea
- Dizziness

COMPLICATIONS Famciclovir is well tolerated, and serious clinical and laboratory toxicities are uncommon. Prolonged high-dose administration of famciclovir to rats was associated with an increased incidence of mammary adenocarcinomas in females, but the clinical significance of this observation is unknown.

Trifluridine

MECHANISM OF ACTION AND PHARMACOKINETICS Trifluridine, 5-trifluoromethyl-2′-deoxyuridine, is a pyrimidine nucleoside analog. Trifluridine monophosphate is an irreversible competitive inhibitor of thymidylate synthetase, and trifluridine triphosphate inhibits HSV DNA polymerase. Trifluridine triphosphate also inhibits cellular DNA polymerases, although to a lesser extent than viral DNA polymerases. Because of systemic toxicity, trifluridine is approved only for topical application in the form of a 1 percent ophthalmic aqueous solution. The elimination half-life for the ophthalmic solution is 12 to 18 minutes.

INDICATIONS

- Treatment of primary HSV conjunctivitis
- Treatment of recurrent HSV epithelial keratitis[24]
- Treatment of acyclovir-resistant mucocutaneous HSV infections in patients with AIDS[25]

DOSING REGIMENS (Table 232-4)

RISKS AND COMPLICATIONS

- Mild burning
- Palpebral edema
- Punctate keratopathy
- Stromal edema

DRUGS FOR THE TREATMENT OF CYTOMEGALOVIRUS INFECTIONS

Ganciclovir

Valganciclovir

MECHANISM OF ACTION AND PHARMACOKINETICS Valganciclovir, L-valine 2-[(2-amino-1,6-dehydro-6-oxo-9H-purin-9-yl) methoxy]-3-hydroxypropyl ester, is the L-valyl ester of ganciclovir. It acts as a prodrug for ganciclovir in a manner similar to the way in which valacyclovir serves as a prodrug for acyclovir and is the usual form of ganciclovir used in the outpatient setting. After oral administration, valganciclovir is rapidly converted to ganciclovir by intestinal and hepatic esterases. The oral availability of valganciclovir as ganciclovir is approximately 60

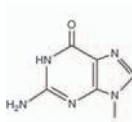

TABLE 232-4
Dosing Regimens for Trifluridine

CONDITION	DOSAGE	ROUTE	DURATION
Primary HSV conjunctivitis	1 drop 1% solution q2h (maximum, 9 drops/24 h)	Topical	Maximum, 21 days
Recurrent HSV epithelial keratitis	1 drop 1% solution q2h (maximum, 9 drops/24 h)	Topical	Maximum, 21 days
Acyclovir-resistant HSV infection in AIDS	1% solution q8h	Topical	10–14 days or until lesions resolve

AIDS = acquired immunodeficiency syndrome; HSV = herpes simplex virus.

TABLE 232-5
Dosing Regimens for Valganciclovir

CONDITION	DOSAGE	ROUTE	DURATION
CMV retinitis	Induction: 900 mg bid	Oral	21 days
	Maintenance: 900 mg qd	Oral	Until CD4 count > 100 after 6 mo of HAART

CMV = cytomegalovirus; HAART = highly active antiretroviral therapy.

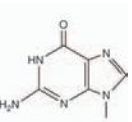

percent and is increased by administration with food. After a 900-mg dose of valganciclovir, the maximum plasma concentration of ganciclovir is 5.61 μg/mL, and the plasma concentration–time curve is similar to that achieved with ganciclovir given intravenously at a dose of 5 mg/kg.[40] The toxicities of valganciclovir are those of its active compound, ganciclovir.

INDICATIONS

- Treatment of CMV retinitis in patients with AIDS[41]
- Suppression and prevention of CMV disease in transplant recipients[42,43]

DOSING REGIMENS (Table 232-5)

RISKS AND COMPLICATIONS

Risks and complications are similar to those of its parent compound, ganciclovir.

Foscarnet

MECHANISM OF ACTION

Foscarnet, trisodium phosphonoformate, is a pyrophosphate-containing compound that noncompetitively inhibits viral DNA polymerases at the pyrophosphate binding site.[44] In contrast to the nucleoside analogues, foscarnet does not require phosphorylation for its antiviral activity and is therefore active against viruses that are resistant to acyclovir, famciclovir, or ganciclovir because of absent or altered kinase activities.

PHARMACOKINETICS

Foscarnet is currently available only as an intravenous preparation that has poor solubility and must be administered by an infusion pump in a dilute solution over 1 to 2 hours. The plasma half-life of the drug consists of an initial phase of 4 to 8 hours and a terminal component of 88 hours or longer, which reflects a deposition in bone of up to 20 percent of the dose.[45] Eighty percent of the dose is excreted unmetabolized by the kidney, and the dosage should be reduced in patients with renal dysfunction.[46]

INDICATIONS

- Treatment of CMV retinitis in patients with AIDS[47]
- Treatment of CMV colitis[33]
- Treatment of CMV polyradiculopathy in combination with ganciclovir[48]
- Treatment of acyclovir-resistant HSV infections[25]
- Treatment of ganciclovir-resistant CMV infections[49]

DOSING REGIMENS (Table 232-6)

RISKS AND COMPLICATIONS

- Renal (30 percent)[50]
  - Increased creatinine levels
  - Proteinuria
  - Nephrogenic diabetes insipidus
  - Hypokalemia, hypocalcemia, hypomagnesemia
- Headache
- Fatigue
- Fever
- Seizures
- Low white blood cell count, anemia

MONITORING OF THERAPY

The major toxicity associated with foscarnet involves the kidney, and use of the drug requires close monitoring of renal function, particularly during the initial phases of therapy. Saline hydration before administration and slow infusion of the drug appear to reduce nephrotoxicity. Electrolyte abnormalities such as hypocalcemia and hypercalcemia, hypophosphatemia and hyperphosphatemia, hypomagnesemia, and hypokalemia have been described. The levels of these electrolytes should be checked frequently.[50]

Cidofovir

MECHANISM OF ACTION

Cidofovir, (S)-1-[3-hydroxy-2(phosphonylmethoxy)-propyl] cytosine, is a phosphonate nucleotide analog. Cidofovir does not require initial phosphorylation by virus-induced kinases but is converted by host cell enzymes to cidofovir diphosphate, which is a competitive inhibitor of viral DNA polymerases and, to a lesser extent, of host cell DNA polymerases.[51]

PHARMACOKINETICS

Cidofovir is approved for intravenous administration. A topical formulation is also available. An intravenous dose of 5 mg/kg results in a peak plasma concentration of 11.5 μg/mL. The plasma half-life of cidofovir is 2.6 hours, and the drug is excreted almost entirely by the kidney.[52] Cidofovir diphosphate has a markedly prolonged intracellular half-life (more than 48 hours), which is the basis for the recom-

TABLE 232-6
Dosing Regimens for Foscarnet

CONDITION	DOSAGE	ROUTE	DURATION
CMV retinitis	Induction: 90 mg/kg q12h	IV	14–21 days
	Maintenance: 90 mg/kg q24h	IV	Until CD4 count >100 on 6 mo of HAART
Acyclovir-resistant HSV infection	40 mg/kg q8h	IV	
	or		
	60 mg/kg q12h	IV	2–3 wk or until clinical resolution

CMV = cytomegalovirus; HAART = highly active antiretroviral therapy; HSV = herpes simplex virus.

mended dosing regimen of 5 mg/kg twice a week for the first 2 weeks, followed by one dose every 2 weeks.[52–54]

INDICATIONS Indications for treatment with cidofovir include the following:

- CMV retinitis in AIDS[55]
- Treatment of resistant HSV and CMV infections[56]

Cidofovir also has antiviral activity against poxviruses, including vaccinia and variola (smallpox),[57] monkeypox,[58] and molluscum contagiosum.[59] It has been used successfully in topical form[60] for the treatment of the lesions of human papillomavirus infection, Kaposi sarcoma, and HSV infection, although it is not approved for these uses.

DOSING REGIMENS (Table 232-7)

RISKS AND COMPLICATIONS

- Renal tubular damage[61]
  - Dose-dependent proximal tubular injury (Fanconi-like)
  - Proteinuria
  - Elevated serum creatinine levels
- Rash
- Nausea (48 percent)
- Alopecia (16 percent)
- Fever
- Myalgia

PRECAUTIONS Hydration, along with the administration of probenecid before and after infusion, appears to protect against nephrotoxicity. Properly timed intravenous prehydration with normal saline and oral administration of probenecid must be carried out with each cidofovir infusion. Renal function must be monitored before each dose.

Adefovir Dipivoxil

Entecavir

Ribavirin

Interferons

MECHANISM OF ACTION Interferons are cytokines that have broad antiviral, immunomodulating, and antiproliferative effects. The antiviral activities of interferons are multiple and complex and vary according to the cell type and virus. Interferons have been studied as treatment for a variety of viral infections as well as for a number of diseases of non-infectious etiology. For viral infections, interferon-α has been studied most extensively.

TABLE 232-7
Dosing Regimens for Cidofovir

CONDITION	DOSAGE	ROUTE	DURATION
CMV retinitis	Induction: 5 mg/kg every week	IV	2 wk
	Maintenance: 5 mg/kg every 2 wk	IV	Until CD4 count > 100 after 6 mo on HAART

CMV = cytomegalovirus; HAART = highly active antiretroviral therapy.
Note: Cidofovir IV administration must be accompanied by prehydration and probenecid.

PHARMACOKINETICS Interferon may be administered intravenously or, more commonly, subcutaneously or intramuscularly. The plasma half-life is 2 to 3 hours after intravenous administration of interferon-α and 4 to 6 hours after subcutaneous or intramuscular administration.[85] A markedly prolonged half-life is seen with the use of "pegylated" interferons.

INDICATIONS

- Condyloma acuminata (intralesional treatment)[86]
- Chronic hepatitis C infection in combination with ribavirin[87–90]
- Chronic hepatitis B infection[91,92]

DOSING REGIMENS (Table 232-8)

RISKS AND COMPLICATIONS[93]

- Flu-like syndrome
- Myalgia/arthralgia
- Gastrointestinal symptoms
- Granulocytopenia/thrombocytopenia
- Neurotoxicities
- Alopecia
- Hepatotoxicity
- Autoantibody formation

PRECAUTIONS Interferon-α can cause serious depression in up to one-third of users.[94,95] Interferon-α should not be used to treat hepatitis B–related cirrhosis or decompensated liver disease because hepatitis flares are common and may lead to further decompensation.

DRUGS FOR THE TREATMENT OF HUMAN IMMUNODEFICIENCY VIRUS INFECTION

Drug treatment of HIV infection has become a complex undertaking requiring specialized training, experience, and ongoing involvement in patient care.[96,97] Studies have demonstrated that patients cared for by experienced HIV practitioners have better outcomes than patients treated by less experienced physicians.[98–100] Currently there are 22 approved antiretroviral drugs, and 6 fixed-dose combinations. Several additional drugs, including members of entirely new classes of compounds, are likely to become available in the very near future. Strategies for the use of antiretrovirals have emerged from the results of large-scale clinical trials as well as from advances in the understanding of the pathogenesis of HIV-1 infection. These studies have established three important principles on which recommendations for the use of antiretroviral drugs are based: (1) combination therapy with at least three drugs should be used to maximize clinical and antiviral effects and to minimize the emergence of resistant viruses; (2) viral load, as well as CD4 counts, should be monitored as important measures of the effectiveness of antiviral therapy; and (3) phenotypic and/or genotypic assays to detect potential resistance of HIV isolates to antiretroviral drugs should be performed before the initiation of therapy and subsequently should virologic failure occur after ther-

TABLE 232-8
Dosing Regimens for the Interferons

CONDITION	DOSAGE	ROUTE	DURATION
Condyloma acuminata	IFN-α2b 1 million units 3×/wk	Intralesional	3 wk
Chronic hepatitis C (with ribavirin)	PegIFN-α2a 180 μg once a week *or* PegIFN-α2b 1.5 μg/kg once a week	Subcutaneous	Dependent on response and genotype
Chronic hepatitis B	PegIFN-α2a 180 μg once a week *or* PegIFN-α2b 1.5 μg/kg once a week	Subcutaneous	At least 1 yr

IFN = interferon; PegIFN = peginterferon.

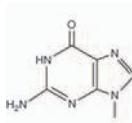

apy is begun. Results of these tests can be used to help design optimal drug regimens. These principles, along with examples of regimens to be used in specific clinical settings, are outlined in guidelines put forth by national and international expert panels.[101,102] Because of the complex nature of antiretroviral therapy and the rapid development of new agents, this section does not attempt to provide a thorough discussion of all drugs, but rather focuses on the most commonly used agents, including representative compounds from each major class.

Nucleoside and Nucleotide Reverse Transcriptase Inhibitors

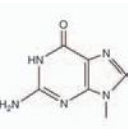

Seven nucleoside and one nucleotide reverse transcriptase inhibitors (NRTIs) are licensed for use in the treatment of HIV infection in the United States. Zalcitabine is toxic, is rarely used, and is not discussed further.

MECHANISM OF ACTION AND RESISTANCE

After passive uptake by host cells, NRTIs are phosphorylated by cellular kinases to their active triphosphate forms, which compete with the naturally occurring deoxynucleoside substrates for binding to reverse transcriptase (RT). Subsequently, they are incorporated into the growing DNA chain, which results in chain termination. The compounds are active against HIV-1, HIV-2, and other retroviruses.[103,104]

Because of the high rate of HIV replication and the lack of a proofreading function in RT, a mutation may arise at each nucleotide position as often as 104 times per day in an untreated person.[105] Thus, mutations that confer resistance may be present before therapy is begun. After initiation of therapy, resistance may develop if such mutations are allowed to accumulate because of incomplete suppression of viral replication by the therapeutic regimen. Genotypic resistance has been observed against all antiretrovirals currently in use and was initially described for zidovudine, the first NRTI to be widely used clinically.[106] Resistance to zidovudine generally occurs with the cumulative development of characteristic mutations at codons 70, 215, 41, 67, 210, and 219.[107]

PHARMACOKINETICS Like other antiretroviral drugs, NRTIs are primarily given by the oral route. In general, these drugs are well absorbed from the gastrointestinal tract, although there is considerable variation among them. In addition, there are differences in bioavailability when they are administered with and without food and differences in both serum and intracellular half-lives. Distribution, metabolism, and excretion also vary considerably among different agents. Specific prescribing directions should be consulted before administration.

INDICATIONS

- Primary or initial treatment of HIV infection. Two drugs from this class plus a nonnucleoside RT inhibitor or a protease inhibitor are recommended for initial treatment of HIV infection.[101] Dual nucleoside combinations represent the most common backbone of antiretroviral regimens. Two nucleosides are generally combined with either a nonnucleoside RT inhibitor or a protease inhibitor for use in initial therapy. Recommended combinations include zidovudine + lamivudine, tenofovir + emtricitabine, and abacavir + lamivudine, all of which are available as fixed-dose combination products (under the trade names Combivir, Truvada, and Epzicom, respectively).
- Management of previously treated patients who have experienced treatment failure. The cause of treatment failure can often be determined by careful history taking. Important considerations include the patient's adherence to the treatment regimen, tolerability of medications, need for concomitant food or fasting for optimal drug absorption, and drug resistance. It is best to perform resistance testing while patients are taking the failing regimen or within 4 weeks of discontinuance of the regimen. It is generally recommended that at least two fully active drugs be used when a new therapeutic regimen is designed. Drugs from the NRTI class are frequently used in such regimens, although HIV resistance often compromises their effectiveness.
- Treatment of hepatitis B infection. Lamivudine, in a dosage of 100 mg daily, decreases levels of HBV DNA in plasma and produces beneficial histologic and chemical effects in many patients with chronic hepatitis B,[129] although monotherapy is often associated with development of viral resistance.[130]

DOSING REGIMENS

INITIATION OF THERAPY Most experts agree that antiretroviral therapy should be initiated in all patients with a history of an AIDS-defining illness and in patients with a CD4 count of less than 200 $CD4^+$ T cells/mm^3 even if asymptomatic.[101,102] In addition, therapy should be offered to those with CD4 counts between 201 and 350 $CD4^+$ T cells/mm^3. Some clinicians also consider therapy for patients with CD4 counts higher than 350 $CD4^+$ T cells/mm^3 and plasma HIV RNA levels higher than 100,000 copies/mL. The decision to initiate antiretroviral therapy in an asymptomatic patient must be made with care. Treatment of HIV infection is a lifelong proposition, and adherence to therapy is a critical component of treatment success. Thus, considerable attention must be paid to counseling and education of the patient.

MONITORING OF THERAPY The two surrogate markers used to monitor response to therapy are the $CD4^+$ T-cell count and the plasma HIV RNA level, or viral load. The CD4 count is the major laboratory indicator of immunocompetence in this patient population and can be expected to increase considerably in response to appropriate antiretroviral therapy. A significant change in CD4 count has been defined as either a 30 percent change in absolute count or a 3 percent change in CD4 percentage. In general, the CD4 count is measured every 3 to 6 months to assess the immunologic response to treatment. The viral load is a direct indicator of virus replication and is routinely used as a measure of antiviral drug effect. The minimal change in viral load that is considered to be significant is a threefold change or 0.5 $\log_{10}$ copies/mL. The goal of treatment is to take the viral load below the limits of detection of the test that is being used to measure HIV RNA. Viral load determinations are generally made at the same intervals as CD4 counts.

RISKS AND COMPLICATIONS Common side effects seen with zidovudine treatment include bone marrow suppression and gastrointestinal intolerance. Stavudine is generally well tolerated but is associated with lipoatrophy and lactic acidosis, whereas the primary toxicities of didanosine are pancreatitis and peripheral neuropathy. Abacavir is associated with an uncommon but potentially life-threatening hypersensitivity reaction. Tenofovir may produce headache and nausea; it elevates levels of didanosine and decreases levels of atazanavir. Lamivudine is among the best tolerated antiretroviral drugs but may produce neutropenia.

General toxicities associated with NRTIs, seen more commonly with some agents than with others, include the following:

- Lactic acidosis with hepatic steatosis
- Progressive ascending neuromuscular weakness syndrome
- Dyslipidemia
- Fat maldistribution and lipoatrophy

PRECAUTIONS Because of concerns regarding the development of resistance, NRTIs should never be administered as single or dual agents for the treatment of established HIV infection. In addition, certain combinations should be avoided, including the three-nucleoside regimen of abacavir + tenofovir + lamivudine (unacceptable virologic failure)[131]; the three-nucleoside regimen of didanosine + tenofovir + lamivudine (unacceptable virologic failure)[132]; didanosine + stavudine (increased toxicity)[133]; and stavudine + zidovudine (antagonistic).[134,135] All patients receiving NRTIs need to be monitored for lactic acidosis, hepatitis, bone marrow suppression, and development of neurologic side effects and pancreatitis.

Nonnucleoside Reverse Transcriptase Inhibitors

Three nonnucleoside reverse transcriptase inhibitors (NNRTIs) are licensed for use in the treatment of HIV infection in the United States: nevirapine, delavirdine, and efavirenz.

MECHANISM OF ACTION AND RESISTANCE NNRTIs are noncompetitive inhibitors of RT, bind at sites different from the nucleoside binding site, and are active against HIV-1 but not HIV-2.[136] Resistance to the nucleoside analogues does not impinge on the activity of NNRTIs. In fact, some mutations associated with resistance to nucleoside analogues may actually produce hypersusceptibility to NNRTIs.[137–139] However, mutations that confer resistance to one NNRTI often produce cross-resistance to other members of this class. Thus, virologic failure after treatment with one of these drugs often predicts failure with the other NNRTIs as well.[140] Mutations at positions 103 and 181 often confer resistance to all three of the currently available NNRTIs. Other mutations at positions 101, 106, 188, 190, and 236 may also contribute.[141]

PHARMACOKINETICS Nevirapine has a bioavailability of more than 90 percent and a plasma half-life of 24 hours. It is metabolized in the liver and induces its own metabolism. For this reason, the drug is given once a day for the first 2 weeks and twice per day thereafter.[142,143] Delavirdine is also well absorbed, with a bioavailability of 85 percent, but it requires an acidic environment and should not be given with antacids, H_2 blockers, or proton pump inhibitors. Its half-life is 6 hours, and it is metabolized in the liver.[144] The absorption of efavirenz is increased by taking it with food. However, it is recommended that the drug be administered on an empty stomach to minimize side effects. The half-life of efavirenz is 40+ hours. It is metabolized in the liver.[145,146]

INDICATIONS

- Primary or initial treatment for HIV infection.[101] As noted earlier (see Indications under Nucleoside and Nucleotide Reverse Transcriptase Inhibitors), an NNRTI is often given along with two NRTIs. Recommended regimens in nonpregnant women include efavirenz + (zidovudine or tenofovir) + (lamivudine or emtricitabine). Nevirapine may be used as an alternative to efavirenz in women with $CD4^+$ T-cell counts of less than 250 cells/mm^3 and in men with $CD4^+$ T-cell counts of less than 400 cells/mm^3.
- Management of previously treated patients experiencing treatment failure. NNRTIs may be a useful component in the treatment of patients for whom other drugs have failed. However, because of the low genetic barrier to resistance that is characteristic of this class, patients who have previously received NNRTIs may not respond.

DOSING REGIMENS

INITIATION AND MONITORING OF THERAPY See Initiation of Therapy and Monitoring of Therapy under Nucleoside and Nucleotide Reverse Transcriptase Inhibitors earlier.

RISKS AND COMPLICATIONS The most common toxicity associated with administration of nevirapine is rash (see Precautions), which can occasionally lead to Stevens-Johnson syndrome. Hepatitis may also occur with nevirapine, particularly among patients with elevated $CD4^+$ T-cell counts (see Precautions). Nevirapine decreases levels of saquinavir, indinavir, and lopinavir. Delavirdine may also produce a rash and increases levels of saquinavir, ritonavir, indinavir, nelfinavir, and amprenavir. Efavirenz often produces central nervous system side effects and decreases levels of saquinavir, indinavir, amprenavir, lopinavir, and atazanavir. However, it increases levels of ritonavir. All NNRTIs have a low genetic barrier to resistance, and adherence to the prescribed regimens is of critical importance to avoid development of resistance to this important class of drugs.

PRECAUTIONS Treatment with nevirapine must be initiated slowly to avoid high drug levels and to decrease the incidence of an erythematous, maculopapular eruption, which occurs in approximately 20 percent of patients. Observational follow-up is sufficient for mild rash. However, if the rash is severe, if extensive eruptions develop, or if mucous membranes are involved, the drug should be discontinued.

Delavirdine is generally not recommended as part of an initial treatment regimen because it has less potent antiviral activity and must be given three times daily.

Nevirapine is generally not recommended for women with $CD4^+$ T-cell counts higher than 250 cells/mm^3 or for men with $CD4^+$ T-cell counts above 400/mm^3 because of an increased risk of hepatitis in these patients.

NNRTIs should not be used in combination with didanosine + tenofovir because of high rates of virologic failure and development of resistance.

Efavirenz is teratogenic in nonhuman primates and should not be administered during the first trimester of pregnancy or to women with significant childbearing potential.[147]

Protease Inhibitors

Ten protease inhibitors are currently licensed for treatment of HIV infection in the United States: saquinavir, ritonavir, indinavir, nelfinavir, amprenavir, lopinavir, fosamprenavir, atazanavir, tipranavir, and darunavir. Three of these agents—indinavir, amprenavir, and nelfinavir—are rarely used and are not discussed further.

MECHANISM OF ACTION AND DEVELOPMENT OF RESISTANCE Protease inhibitors work by inhibiting a virus-specific enzyme, protease, that is responsible for the proteolytic cleavage of viral polypeptide precursors. They thereby prevent the formation of mature virus particles. The enzyme levels required to inhibit HIV

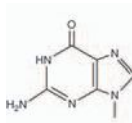

proteases are 1000 times lower than those required to inhibit essential human proteases.[148] These compounds are active against HIV-1 and HIV-2 and may have activity against other viruses.

Protease inhibitor–resistant viruses may emerge during therapy with these agents or may be present at the time of acquisition of infection. These drug-resistant HIV strains contain a variety of amino acid substitutions, and mutations vary for different protease inhibitors. In general, as the number of mutations increases so does the degree of resistance.[149] Accumulation of mutations, especially at codons 10, 46, 54, 82, 84, and 90, may lead to multidrug resistance.[150]

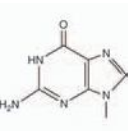

PHARMACOKINETICS Oral bioavailability varies for different protease inhibitors because of differences in first-pass hepatic metabolism.[148] Saquinavir is available only as a hard capsule that has poor oral availability (4 percent). Its use in combination with low-dose ritonavir allows adequate drug levels to be reached, and saquinavir is recommended for use only concurrently with ritonavir. Lopinavir, when given alone, yields very low concentrations in plasma. When it is administered with ritonavir, however, lopinavir predose concentrations achieved in HIV-positive individuals typically exceed the concentration required for 50 percent inhibition of replication of wild-type HIV-1 by at least 50-fold.[151] The limited bioavailability of the hard gel (and first available) formulation of tipranavir led to the development of a soft capsule formulation that has better oral bioavailability,[152] and the combination of tipranavir and low-dose ritonavir is now approved for use. Ritonavir has good oral bioavailability,[153] but side effects preclude its use at full dose in most patients. Ritonavir is now used primarily at low doses to boost blood levels of other protease inhibitors. Fosamprenavir is the water-soluble, phosphate ester prodrug of the HIV-1 protease inhibitor amprenavir.[154] It provides bioavailability equivalent to that of its parent compound with a reduced pill burden and has thus largely supplanted amprenavir.[155] Atazanavir is a new azapeptide protease inhibitor with a pharmacokinetic profile that allows once-daily dosing. It may be given with or without low-dose ritonavir boosting.[156] Darunavir, when given in combination with low-dose ritonavir, has an oral bioavailability of 82 percent.[157]

Each protease inhibitor has a unique pharmacokinetic profile, but all are metabolized through the hepatic cytochrome P_{450} (CYP) system. Thus, they have important interactions with the drugs that induce, inhibit, or are themselves metabolized by CYP enzymes. Ritonavir has the most profound effect in this regard and, as noted earlier, is used frequently at a lower dose in combination with other protease inhibitors to inhibit their metabolism and thus raise their blood levels.

TABLE 232-9
Dosing Regimen for Enfuvirtide

DRUG	DOSAGE	SPECIAL CONSIDERATIONS	MAIN TOXICITIES	PRINCIPAL DRUG INTERACTIONS
Enfuvirtide (Fuzeon)	90 mg subcutaneously bid	Rotate injection sites Must be reconstituted ≤ 24 h before use	Local injection site reactions Peripheral neuropathy Insomnia Increased risk of bacterial pneumonia	None known

INDICATIONS

- Primary or initial treatment of HIV-1 and HIV-2 infections
- Management of previously treated patients who have experienced treatment failure

DOSING REGIMENS

RISKS AND COMPLICATIONS The most common side effects of the protease inhibitors include the following:

- Gastrointestinal upset
  - Nausea
  - Vomiting
  - Diarrhea
- Hepatitis
  - Occasional hepatic failure
- Dyslipidemias (except atazanavir)
- Alteration in glucose metabolism
- Fat redistribution syndrome
- Significant drug-drug interactions

In addition, tipranavir and darunavir contain sulfa moieties, and thus their use should be avoided in individuals with sulfa allergies. Atazanavir use is associated with unconjugated hyperbilirubinemia. Pruritic macular rashes have been seen in approximately 1 percent of patients treated with atazanavir.[158] Rashes have also been noted with tipranavir, darunavir, and fosamprenavir[159]; however, these occur less frequently and may be associated with concomitant use of other antiretroviral agents.

PRECAUTIONS Because most protease inhibitors are inhibitors and substrates of the CYP system, co-administration of drugs metabolized by the CYP system (and especially CYP 3A4) can lead to significant toxicity. An experienced HIV caregiver or pharmacist should be consulted before patients taking protease inhibitors start any new medications. Protease inhibitors should never be given as single agents to treat HIV infection because of the high risk of inducing resistance.

Entry Inhibitors

Entry inhibitors represent a new generation of antivirals for the treatment of HIV infection. Currently one entry inhibitor, enfuvirtide, is licensed for use in the United States.

MECHANISM OF ACTION AND RESISTANCE Enfuvirtide is a synthetic peptide of 36 amino acids that mimics a fragment of glycoprotein 41 (gp41), HR1, a portion of the envelope glycoprotein of HIV required for fusion of the viral envelope with the host cell membrane. The binding of enfuvirtide to the HR1 region of gp41 blocks the formation of a six-helix bundle structure that is critical for the fusion process.[160] Resistance to enfuvirtide involves changes in amino acids 36 to 45 within the HR1 region of gp41.[161,162]

PHARMACOKINETICS Enfuvirtide is not absorbed orally and is available clinically as a subcutaneous injection. Enfuvirtide is nearly completely absorbed from subcutaneous depot, and pharmacokinetic parameters are linear up to a dose of 180 mg.[163] Enfuvirtide is primarily eliminated via catabolism to amino acid residues. It does not influence concentrations of drugs metabolized by CYP 3A4, CYP 2D6, or *N*-acetyltransferase, and has only minimal effects on those metabolized by CYP 1A2, CYP 2E1, or CYP 2C19.[164,165]

INDICATIONS

- Management of previously treated patients who have experienced treat-

ment failure (in combination with other agents)

DOSING REGIMENS (Table 232-9)

RISKS AND COMPLICATIONS

- Local injection site reactions
  - Induration
  - Erythema
  - Nodules
  - Cysts
- Gastrointestinal upset
- Increased risk of bacterial pneumonias[166]

PRECAUTIONS Patients should be informed that injection site reactions occur in nearly all patients treated with enfuvirtide, and they should be taught how to inject the drug appropriately and how to monitor themselves for cellulitis or local infection. Because of the increased risk of pneumonia, patients should be advised to seek medical attention if they develop signs or symptoms of pneumonia.

Other Antiretroviral Drugs

There is a growing need for new antiretroviral agents that can overcome the problems of resistance, toxicities, and pill burdens of currently approved agents. Over the next 5 years a number of new antiretroviral agents are expected to be approved for use. New agents in existing classes of drugs are active against viruses resistant to currently approved drugs. Some new agents have better pharmacokinetic profiles, which allows less frequent dosing and smaller pill burdens. A number of agents seek to target new steps in the HIV replication pathway. Inhibitors of viral integrase, which specifically inhibit the strand transfer step in the integration of proviral DNA into the host genome, are currently moving into late-phase clinical trials.[167] New cell entry inhibitors targeting CC chemokine receptor 5,[168] CXC chemokine receptor 4,[169] CD4,[170] and gp120[171] are in development. Zinc finger inhibitors, which prevent packaging of viral RNA inside the nucleocapsid, also remain a focus of active investigation despite significant toxicities associated with early members of this class.[172]

KEY REFERENCES

The full reference list for all chapters is available at www.digm7.com.

1. Whitley RJ, Gnann JW Jr: Acyclovir: A decade later. *N Engl J Med* **327**:782, 1992
5. Kimberlin DW, Rouse DJ: Clinical practice. Genital herpes. *N Engl J Med* **350**:1970, 2004
16. Kleymann G: Novel agents and strategies to treat herpes simplex virus infections. *Expert Opin Investig Drugs* **12**:165, 2003
20. McKeough MB, Spruance SL: Comparison of new topical treatments for herpes labialis: Efficacy of penciclovir cream, acyclovir cream, and n-docosanol cream against experimental cutaneous herpes simplex virus type 1 infection. *Arch Dermatol* **137**:1153, 2001
60. Toro JR et al: Topical cidofovir for the treatment of dermatologic conditions: Verruca, condyloma, intraepithelial neoplasia, herpes simplex and its potential use in smallpox. *Dermatol Clin* **21**:301, 2003
101. Department of Health and Human Services: Guidelines for the use of antiretroviral agents in HIV-1–infected adults and adolescents, http://AIDSinfo.nih.gov, 2006
102. Hammer SM et al: Treatment for adult HIV infection: 2006 recommendations of the International AIDS Society—USA panel. *JAMA* **296**:827, 2006

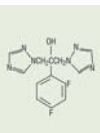

CHAPTER 233

Oral Antifungal Agents

Margaret S. Lee-Bellantoni
Nellie Konnikov

Oral antifungal agents are widely and frequently used for the treatment of superficial fungal infections.[1] This chapter summarizes information on the four most widely used oral antifungals in outpatient dermatology: terbinafine, itraconazole, fluconazole, and griseofulvin.

ALLYLAMINES: TERBINAFINE

Terbinafine hydrochloride is a synthetic antimycotic agent that belongs to the family of compounds known as the *allylamines*. All allylamine derivatives possess a tertiary allylamine, a structural component crucial for antifungal activity (Fig. 233-1).[2] In vitro, the drug is primarily a fungicidal agent and highly active against dermatophytes, but less active against molds, dimorphic fungi, and various yeasts.

Mechanism of Action

Terbinafine inhibits the enzyme squalene epoxidase in the fungal cell membrane, thereby blocking the biosynthesis of ergosterol.[3] Squalene epoxidase, a complex, microsomal non-cytochrome P_{450} enzyme, catalyzes the first enzymatic step of ergosterol synthesis: the conversion of squalene into squalene epoxide. Consequently, terbinafine causes an abnormal intracellular accumulation of squalene and a deficiency in ergosterol.[4] In vitro, accumulation of squalene accounts for the drug's fungicidal activity, while deficiency of ergosterol is associated with the drug's fungistatic activity.[4]

Pharmacology

Terbinafine is well absorbed from the gastrointestinal tract, mostly in chylomicrons. The distribution half-life is 1.5 hours, and the elimination half-life is approximately 22 hours.[5] Terbinafine is highly lipophilic and keratophilic in nature and, therefore, is widely distributed

ORAL ANTIFUNGALS AT A GLANCE

- Indicated for extensive fungal skin infections, tinea pedis, onychomycosis, and tinea capitis.
- Preventive therapy for the immunosuppressed.
- Major classes of antifungal medications used in outpatient settings are the allylamines (terbinafine), triazoles (itraconazole, fluconazole) and imidazoles (ketoconazole), griseofulvin, polyenes (nystatin, amphotericin B), and ciclopirox olamine.
- Speciation of fungal infections can be important in defining length of treatment and choosing the appropriate medication.

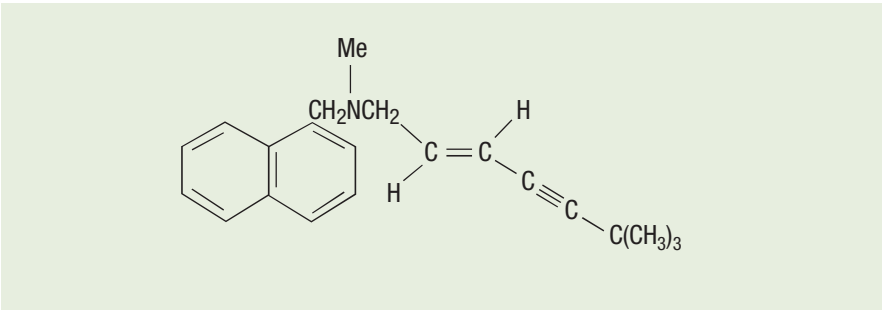

▲ **FIGURE 233-1** Terbinafine. (From http://www.bmb.leeds.ac.uk/mbiology/ug/ugteach/icu8/antibiotics/antifungals.html.)

upon absorption throughout skin and adipose tissue. Terbinafine is extensively biotransformed by the liver, mostly through oxidation by a very small fraction of P_{450} isoenzymes, predominantly the 2D6 isoform. More than 80 percent of the drug is excreted in urine; the rest is eliminated with feces.[6]

Indications

Terbinafine is approved by the U.S. Food and Drug Administration for the treatment of onychomycosis by dermatophytes. It also has clinically proven efficacy for various forms of tinea corporis and tinea capitis (Box 233-1).

PEDIATRIC For the treatment of tinea capitis in children, the dosage guidelines are 3 to 6 mg/kg per day.[7] Children weighing 10 to 20 kg can be given 62.5 mg/day; children weighing 20 to 40 kg can be given 125 mg/day; and those children weighing more than 40 kg can be given 250 mg/day.[8] The standard treatment course for *Trichophyton* infections is 4 weeks. A recent randomized, double-blinded study of 176 children (ages 4 to 18 years old) with predominantly *T. tonsurans* infection supports that 2- or 4-week regimens are more effective than a 1-week course.[13] In the case of tinea capitis, fungal cultures will help guide length of treatment and confirm successful cure because there is great variation in species response to any antifungal agent.[14]

Terbinafine can also be safely used in children for onychomycosis when dosed by weight as for tinea capitis.[15]

ADULT Terbinafine is indicated for the treatment of onychomycosis of the toenails and fingernails caused by dermatophytes.[16] In a study comparing continuous terbinafine with intermittent itraconazole in the treatment of toenail onychomycosis, terbinafine was significantly more effective than the pulsed itraconazole.[17] At week 72, the mycologic cure in those patients treated with a 3-month daily course of terbinafine was 75.5 percent, compared with a mycologic cure rate of 38.3 percent in those patients treated with a 3-month course of intermittent pulse therapy with itraconazole. A longer follow-up of these patients at an average of 54 months revealed 46 percent cure after continuous terbinafine versus 13 percent cure after the pulsed itraconazole[18]; similar results were found by others at 2-year follow-up.[19] Continuous terbinafine therapy was also superior to intermittent terbinafine (2-week intervals on and off the medication) for 12 weeks.[20]

In a study of 22 patients with tinea corporis and tinea cruris who used terbinafine 250 mg daily for 1 week, 100 percent clinical and mycologic clearing was observed at 6 weeks.[22] In a study of moccasin tinea pedis and tinea manuum, after a 2-week course of terbinafine, 250 mg daily, there was an 86 percent mycologic cure rate at 8 weeks.[23] Two placebo-controlled trials demonstrated that a 4- to 6-week course of terbinafine 250 mg daily is effective in the treatment of seborrheic dermatitis.[24,25] Interestingly, terbinafine is not effective orally for the treatment of tinea versicolor,[22] but twice daily application of topical terbinafine 1 percent solution, cream or gel, has been effective in randomized placebo-controlled trials.[26]

GERIATRIC Terbinafine is well tolerated by the elderly and requires no further cautions than those for the general population.[27] A recent study of 504 patients older than 65 years of age confirmed efficacy and tolerance of the standard adult regimen for onychomycosis, with no reported drug interactions.[28]

PREGNANCY CONSIDERATIONS Terbinafine is a pregnancy category B drug and should not be taken by pregnant or nursing mothers.[16]

Box 233-1

Terbinafine Treatment of Fungal Infections

- U.S. Food and Drug Administration indications
  - Onychomycosis due to dermatophytes (tinea unguium of fingernails and toenails)
- Other common uses
  - Onychomycosis due to *Candida* sp.
  - Tinea corporis and its sub-types
  - Tinea cruris
  - Tinea pedis
  - Tinea capitis
- Contraindications
  - Hypersensitivity to terbinafine or vehicle components
- Risks and precautions
  - Hepatic disease or insufficiency
  - Renal impairment
  - Pregnancy or lactation
  - History of systemic lupus erythematosus
  - Known or suspected immunodeficiency, especially neutropenia

Dosage Schedules and Formulations

Terbinafine is supplied as a 250-mg tablet and should be taken once daily for all regimens except twice-daily pulse dosing. See Table 233-1 for treatment schedules.

Initiating Therapy

Positive tests [potassium hydroxide (KOH), culture, histology] for fungal infection should be documented before initiation of oral terbinafine therapy. Pre-treatment serum transaminase tests are advised for all patients before taking terbinafine, and the drug is not recommended for patients with liver or renal disease.[23]

Monitoring Therapy

Many physicians advocate monitoring liver function after 6 weeks of therapy, although the incidence of hepatic toxicity is very low [see Complications (Adverse Effects) and Risks and Precautions].

Complications (Adverse Effects)

Because of its high selectivity, terbinafine is generally well tolerated with a low incidence of adverse side effects. The most common side effects after oral administration are of a gastrointestinal nature (3.5 percent to 5.0 percent).[31]

TABLE 233-1
Terbinafine Dosing Regimen

	ADULT	PEDIATRIC
Onychomycosis	Fingernails: 250 mg/day × 6 wk Toenails: 250 mg/day × 12 wk	3–6 mg/kg/day × 6–12 wk[a]
Tinea capitis	250 mg/day × 2–8 wk	*Trichophyton* infections: 3–6 mg/kg/day × 2–4 wk[a] *Microsporum* infections: 3–6 mg/kg/day × 6–8 wk[a]
Tinea corporis, tinea cruris	250 mg/day × 1–2 wk	3–6 mg/kg/day × 1–2 wk
Tinea pedis (moccasin)	250 mg/day × 2 wk	[b]
Seborrheic dermatitis	250 mg/day × 4–6 wk	[b]

[a]Pediatric weight-based dosing: 62.5 mg/day (10–20 kg), 125 mg/day (20–40 kg), 250 mg/day (> 40 kg). Note: Higher cure rates obtained with 4.5 mg/kg/day or greater.
[b]No large studies.

Risks and Precautions

Terbinafine should be prescribed with caution in patients with hepatic disease or history of hepatic toxicity with other medications. Furthermore, there is insufficient data to recommend its use in patients with renal impairment. Because terbinafine rarely causes a lupus-like rash and neutropenia, patients with known systemic lupus erythematosus or immunodeficiency also may not be good candidates for this medication.[16]

Drug Interactions

Terbinafine is not contraindicated with any specific drug. However, terbinafine is metabolized by cytochrome P_{450} (CYP) enzymes. Plasma clearance of terbinafine is increased by the P_{450}-inducer rifampin and decreased by the P_{450}-inhibitor cimetidine.[40] Terbinafine is also reported to decrease cyclosporine levels by increasing cyclosporine clearance.[23,41]

TRIAZOLES

Both itraconazole and fluconazole are triazole antimycotic agents sharing a common structural moiety—a triazole ring—not found in azoles of the imidazole family.

Itraconazole

Itraconazole (Fig. 233-2) is a highly lipophilic compound[45] that has a wide spectrum of activity. In vitro, it is fungistatic and effective against dermatophytes, yeast, molds, and dimorphic and dematiaceous fungi.[46–48]

MECHANISM OF ACTION Itraconazole inhibits 14-α-demethylase, a microsomal cytochrome P_{450} enzyme, in the fungal membrane.[49] 14-α-Demethylase is necessary for the conversion of lanosterol to ergosterol, which is the principal structural component of the fungal cell membrane.[47] Consequently, the accumulation of 14-α-methylsterols leads to the impairment of membrane permeability and membrane-bound enzyme activity and to the arrest of fungal cell growth.

PHARMACOLOGY The serum concentration of itraconazole is influenced by several parameters, including food and gastric acidity.[50,51] Itraconazole is extensively metabolized, primarily by the CYP 3A4 isoenzyme system to more than 30 metabolites. Hydroxyitraconazole is the main metabolite. Approximately 54 percent of the metabolized drug is excreted in the feces, and 34 percent is excreted in the urine. Absorption of the standard tablet formulation is decreased in patients with acquired immunodeficiency syndrome as a result of gastric hypochlorhydria.[52] A new hydroxypropyl-β-cyclodextrin oral solution formulation is better absorbed in a fasting state than with food,[53] appropriate for patients who cannot ingest large amounts of food or have high gastric pH. Young children, especially those less than 5 years of age, have lower serum levels than adults and usually require twice daily dosing.[54]

INDICATIONS Itraconazole has the broadest efficacy compared to other commonly-prescribed antifungals.[48] Thus, it is a first-line therapy for infections due to *Candida* and other nondermatophyte species (Box 233-2).

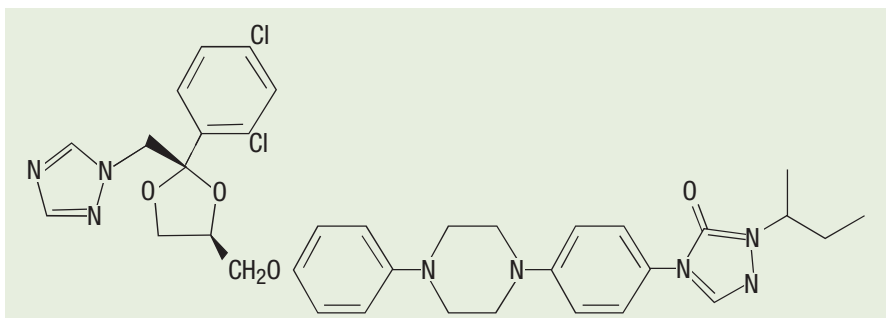

▲ **FIGURE 233-2** Itraconazole. (From http://www.bmb.leeds.ac.uk/mbiology/ug/ugteach/icu8/antibiotics/antifungals.html.)

Box 233-2
Itraconazole Treatment of Fungal Infections

- U.S. Food and Drug Administration indications
  - Onychomycosis due to dermatophytes
  - Continuous therapy for fingernails and toenails
  - Pulsed therapy for fingernails
  - Systemic mycoses (blastomycosis, histoplasmosis, aspergillosis)
  - Fungal empiric therapy in febrile neutropenia (oral solution)
  - Oropharyngeal candidiasis (oral solution)
  - Esophageal candidiasis (oral solution)
- Other common uses
  - Onychomycosis due to *Candida* sp.
  - Tinea corporis and its sub-types
  - Tinea cruris
  - Tinea pedis
  - Tinea capitis
- Contraindications
  - Hypersensitivity to itraconazole or vehicle components
  - Co-administration with cisapride, midazolam, pimozide, quinidine, dofetilide, triazolam, 3-hydroxy-3-methylglutaryl coenzyme A–reductase inhibitors (cytochrome P_{450} 3A4 metabolized drugs)
- Risks and precautions
  - Hypersensitivity to other azoles
  - Hepatic disease or insufficiency
  - History or risk of congestive heart failure, ischemic and valvular disease (negative inotropic effect observed)
  - Chronic obstructive pulmonary disease
  - Renal disease
  - Pregnancy or lactation
  - Drug interactions with cytochrome P_{450} 3A4 metabolized drugs

TABLE 233-2
Itraconazole Dosing Regimen

	ADULT	PEDIATRIC
Onychomycosis	Fingernails: 200 mg bid × 1 wk/mo × 2 pulses Toenails: 200 mg/day × 12 wk *or* 200 mg bid × 1 wk/mo × 3 pulses	Fingernails: 5 mg/kg/day × 1 wk/mo × 2 pulses[a] Toenails: 5 mg/kg/day × 1 wk/mo pulsed × 3 pulses
Tinea capitis	250 mg/day × 2–8 wk	*Trichophyton* infections: 5 mg/kg/day × 2–4 wk Microsporum infections: 5 mg/kg/day × 4–8 wk
Tinea corporis, tinea cruris, tinea pedis	200 mg bid × 1 wk *or* 100–200 mg/day × 2–4 wk	Dose by weight × 1–4 wk
Oropharyngeal candidiasis	Swish and swallow solution 100–200 mg/day	Swish and swallow solution by weight
Pityriasis versicolor	200 mg/day × 5–7 days, prevent recurrence with 200 mg bid once/mo	[b]

[a]Pediatric weight-based dosing: 100 mg/day (15–30 kg), 100 mg/day alternating with 200 mg/day (30–40 kg), 200+ mg/day (> 50 kg).
[b]No large studies.

Pediatric. Itraconazole can be used to treat tinea capitis in children. It is more often prescribed in the capsule formulation with food or acidic beverages such as colas because the cyclodextrin in the liquid form of itraconazole causes more gastrointestinal side effects such as diarrhea and also due to reports of neoplasms associated with high doses in murine and rat models.[55] Nevertheless, for children who cannot swallow capsules or take capsules with food, the solution has a pleasant taste and is considered to be safe.[56]

The oral solution is a good option for oropharyngeal or esophageal candidiasis in children, even in fluconazole-resistant infections.[54]

Adult. Itraconazole has been approved for the treatment of onychomycosis caused by dermatophytes[55] and is effective as continuous or pulse therapy. A 2-month course of itraconazole pulse therapy is necessary for fingernail onychomycosis, while toenail onychomycosis requires a 3-month course. A single course consists of 200 mg twice daily for 1 week per month. Itraconazole pulse therapy is at least equal in efficacy, if not superior, in the treatment of toenail onychomycosis when compared to continuous itraconazole therapy.[60]

Geriatric. Itraconazole (pulse) therapy is effective and safe in the elderly and only requires caution in the setting of comorbidities and drug interactions [see Complications (Adverse Effects) below].[27]

Pregnancy Considerations. Itraconazole is a pregnancy category C drug, and therefore, is not recommended during pregnancy or while nursing because it is excreted in human milk.[55]

DOSAGE SCHEDULES AND FORMULATIONS Itraconazole is supplied in 100 mg capsules, a 10 mg/mL oral solution, and an intravenous solution. Capsules should be taken with a full meal to ensure maximum absorption.[55] Dosage schedules are discussed in Pediatric, Adult, Geriatric, and Pregnancy Considerations above and in Table 233-2.

INITIATING THERAPY Positive tests (KOH, culture, histology) for fungal infection should be documented before initiation of oral itraconazole therapy. Baseline evaluation of hepatic function is recommended in patients with pre-existing liver disease, or if lengthy treatment is anticipated.[55]

MONITORING THERAPY Hepatic function monitoring is indicated through therapy only for those patients with pre-existing liver disease or those with a history of hepatic toxicity with other medications.[55,63] When itraconazole must be administered with medications it is known to compete with for hepatic enzymes, appropriate monitoring for drug levels or toxic effects of these medications is indicated (see Drug Interactions below).

COMPLICATIONS (ADVERSE EFFECTS) The most common reported side effects associated with itraconazole therapy are of a gastrointestinal nature.[64] Instances of hepatic injury and, rarely, fulminant hepatotoxicity are associated with the administration of itraconazole. There are also rare reports of congestive heart failure and pulmonary edema. When administered intravenously to dogs and healthy human volunteers, negative inotropic effects were noted.[66]

RISKS AND PRECAUTIONS Administration of itraconazole to patients with a history of heart failure is contraindicated, and it is not recommended for patients with a history of liver disease.[55] There are also several significant drug interactions to be aware of.

DRUG INTERACTIONS Itraconazole inhibits its 14-α-demethylase, a fungal P_{450} enzyme[49] and a member of the same group of enzymes present in the human liver that is responsible for the metabolism of many drugs. Itraconazole specifically inhibits CYP 3A4, and consequently, may increase plasma concentrations of drugs metabolized by this pathway. Because itraconazole is itself metabolized by CYP 3A4, any inducers or inhibitors may respectively decrease or elevate itraconazole levels. Absorption of itraconazole may be decreased by the concomitant administration of antacids, H_2-blockers, and proton pump inhibitors.[3]

Fluconazole

Fluconazole (Fig. 233-3) is fungistatic in vitro[46] and is effective against many yeasts (with the exception of *Candida krusei*) and dermatophytes.[68]

MECHANISM OF ACTION Fluconazole, like itraconazole, inhibits 14-α-demethylase, a microsomal cytochrome P_{450} enzyme, in the fungal membrane.[49]

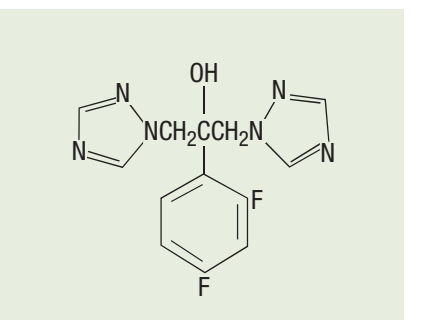

▲ **FIGURE 233-3** Fluconazole. (From http://www.bmb.leeds.ac.uk/mbiology/ug/ugteach/icu8/antibiotics/antifungals.html.)

PHARMACOLOGY The pharmacokinetic parameters of fluconazole are similar for both intravenous and oral administration.[68] Extensive absorption (> 90 percent) of the triazole appears to be comparable in both postprandial and fasting states and not dependent on stomach acidity.[51,69] Fluconazole exhibits a long half-life of 25 to 30 hours, and a steady-state level is reached after 7 days of once-daily administrations. Fluconazole is only weakly bound to plasma proteins, with about 90 percent of the drug circulating free in the plasma. The drug is resistant to hepatic metabolism, and hence, approximately 80 percent of fluconazole is excreted unchanged in urine, with 2 percent in feces and approximately 11 percent as metabolites in urine.[70] The ability to diffuse substantially into the cerebrospinal fluid distinguishes this compound from many other antimycotic agents.[71] The levels of fluconazole in cerebrospinal fluid, saliva, vaginal tissue, sputum, skin, and blister fluids are reported to be comparable with or to exceed simultaneous plasma concentrations.[72] Altered fluconazole pharmacokinetics, including decreased plasma clearance, are detected in patients with cirrhosis[73] and renal impairment.[74] In children over 3 months of age, fluconazole clearance is more rapid than in adults.[54]

INDICATIONS Fluconazole is established as a first-line therapy for mucocutaneous candidiasis. It is useful for its convenient once-weekly dosing schedule (Box 233-3).

Pediatric. Fluconazole has been used successfully to treat tinea capitis at 6 mg/kg/day for 20 days for *T. tonsurans* infection,[75] and at 5 mg/kg/day for 30 days.[57] A course as brief as 2 weeks may be equally effective as terbinafine and itraconazole for *Trichophyton* infections.[58] When *Mycoplasma canis* is present, a longer treatment course is recommended.[59]

Adult. Vaginal candidiasis can conveniently and safely be treated with a single 150-mg dose of fluconazole, or weekly for 6 months or longer in the case of recurrent vulvovaginal candidiasis.[76]

For the treatment of tinea pedis, weekly doses of fluconazole 150 mg has been given for a period of 3 to 4 weeks,[77] with a 75 percent mycologic cure rate at 4 weeks. Fluconazole at a dose of 150 mg weekly for 24 weeks is significantly inferior to terbinafine 250 mg daily for 12 weeks in the treatment of onychomycosis.[78] Pityriasis versicolor can be treated with a single 400-mg dose of fluconazole.[79] In a recent small, open-label randomized study of pityriasis versicolor treatment comparing a single 400-mg dose of fluconazole with a single 400-mg dose of itraconazole, fluconazole led to greater cure than itraconazole (65 percent vs. 20 percent, respectively) with fewer relapses noted (35 percent vs. 60 percent, respectively) at an 8-week follow-up assessment by KOH and culture tests.[80]

Box 233-3

Fluconazole Treatment of Fungal Infections

- U.S. Food and Drug Administration indications
  - Vaginal candidiasis
  - Oropharyngeal and esophageal candidiasis
  - Cryptococcal meningitis
  - Prophylaxis against candidiasis in bone marrow transplant patients
- Other common uses
  - Onychomycosis due to dermatophyte and *Candida* sp.
  - Cutaneous and chronic mucocutaneous candidiasis
  - Tinea corporis and its sub-types
  - Tinea cruris
  - Tinea pedis
  - Tinea capitis
  - Pityriasis versicolor
  - Sporotrichosis
- Contraindications
  - Hypersensitivity to fluconazole or vehicle components
  - Co-administration with terfenadine or cisapride
- Risks and precautions
  - Hypersensitivity to other azoles
  - Proarrhythmic cardiac conditions
  - Renal impairment (dose adjustment required)
  - Pregnancy or lactation

Geriatric. Fluconazole is well tolerated in the elderly[81]; however, dose modification is required in elderly patients with renal impairment.[72]

Pregnancy Considerations. Fluconazole is a pregnancy category C drug and is not recommended in pregnant or nursing mothers.[82]

DOSAGE SCHEDULES AND FORMULATIONS Fluconazole is available in 50-mg, 100-mg, 150-mg, and 200-mg tablets; in 10-mg/mL and 40-mg/mL oral solutions; and in an intravenous form. It is approved for use in children age 6 months and older, although not specifically for tinea capitis.

INITIATING THERAPY Positive tests (KOH, culture, histology) for fungal infection should be documented before initiation of oral fluconazole. There are no specific recommendations for baseline laboratories before starting fluconazole therapy.

MONITORING THERAPY There are no specific monitoring recommendations other than drug levels in renal disease. Because fluconazole is prescribed as a one-time dose or once weekly, there is little need for laboratory monitoring other than that indicated by side effects.

COMPLICATIONS (ADVERSE EFFECTS) The most common recognized side effects of fluconazole therapy are gastrointestinal.[83] There are rare reports of fatal hepatotoxicity associated with fluconazole, but most studies in both humans and rats have shown less hepatoxicity when compared to other azoles.[85] There are even fewer reports of torsades de pointes, with or without concomitant medications or underlying cardiac arrhythmias.[86]

RISKS AND PRECAUTIONS To prevent serious hepatic and cardiac toxicity, one should exercise caution when prescribing to patients with multiple co-morbidities, immunosuppression or pre-existing liver or cardiac disease; close monitoring may be helpful in these patients.

DRUG INTERACTIONS In humans, fluconazole inhibits both CYP 3A4 and CYP 2C9 in a dose-dependent manner,[3] and consequently may increase plasma concentrations of drugs metabolized by these pathways. Therefore, a number of drugs that are metabolized by CYP 3A4 or CYP 2C9 are contraindicated or require close monitoring. Co-administration of terfenadine or cisapride with fluconazole is contraindicated.[82]

IMIDAZOLES: KETOCONAZOLE

Ketoconazole was introduced in the 1970s as the first effective oral azole antifungal. However, because of the drug's many adverse reactions and the availability of safer, efficacious medications, it is not used as a first-line agent for the treatment of dermatophyte infections or *Candida*.

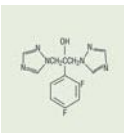

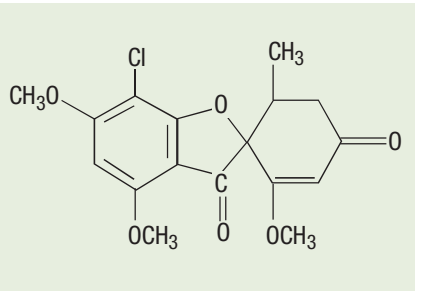

▲ **FIGURE 233-4** Griseofulvin. (From http://www.bmb.leeds.ac.uk/mbiology/ug/ugteach/icu8/antibiotics/antifungals.html.)

MISCELLANEOUS: GRISEOFULVIN

Griseofulvin (Fig. 233-4) has been used since 1958 for the treatment of dermatophyte infections.[59] Griseofulvin is not effective for candidiasis, deep fungal infections, or pityriasis versicolor.

MECHANISM OF ACTION Griseofulvin is fungistatic in vitro,[59] and has a narrow spectrum of antimycotic activity. It disrupts microtubule mitotic spindle formation, thereby causing mitotic arrest at the metaphase stage.[87]

PHARMACOLOGY The absorption of griseofulvin is enhanced by several factors, including concurrent intake of a fatty meal and a smaller particle size formulation. Griseofulvin is mainly metabolized by the liver before excretion.[88]

INDICATIONS As one of the early antifungal medications, griseofulvin has been U.S. Food and Drug Administration approved for several dermatophyte infections. However, because of its limited spectrum of coverage compared to other agents and the lengthy courses required, griseofulvin is not used as a first-line therapy for fungal infections other than tinea capitis.

Pediatric. Griseofulvin is still currently the drug of choice for the treatment of tinea capitis, but this may change as studies continue to validate shorter effective courses with the newer antifungal agents.[46] Griseofulvin is recommended at a dosage higher than that suggested by the manufacturers at 20 to 25 mg/kg/day (microsize), or 15 to 20 mg/kg/day (ultramicrosize) to complete a minimum course of 6 to 8 weeks for *T. tonsurans*.[57] However, longer treatment with griseofulvin is recommended for *M. canis* infections.[57]

Adult. Although griseofulvin is indicated for the treatment of fingernail and toenail onychomycosis, therapy is prolonged with low cure and high relapse rates, requiring approximately 6 months for the treatment of fingernails and 12 months for toenails.[87]

Geriatric. The safety of griseofulvin therapy in the elderly has not been formally evaluated in trials. However, studies including elderly patients have not specifically reported an increased incidence of adverse effects among this age group.[89,90]

Pregnancy Considerations. Griseofulvin is a pregnancy category C drug. Because griseofulvin interferes with chromosomal distribution during cell division, males should wait at least 6 months after completing griseofulvin therapy before fathering a child.[91]

DOSAGE SCHEDULES AND FORMULATIONS Griseofulvin is formulated as ultramicrosize tablets in 125-mg, 165-mg, 250-mg, and 330-mg doses.[92] It is also formulated as griseofulvin microsize and is available as 250-mg and 500-mg tablets and in a 125-mg/5-mL suspension.[91] To maximize absorption, it should be taken with fatty foods. The manufacturers' recommended dosing is 5 to 10 mg/kg/day (ultramicrosize) or 10 to 20 mg/kg/day (microsize).

INITIATING THERAPY Positive tests (KOH, culture, histology) for fungal infection should be documented before initiation of therapy. There are no specific recommendations for baseline laboratories before starting griseofulvin therapy.

MONITORING THERAPY There are no specific monitoring recommendations.

COMPLICATIONS (ADVERSE EFFECTS) The most common side effects are related to the gastrointestinal tract and the central nervous system, such as headache, dizziness, and insomnia.[87] The drug is reported to precipitate lupus erythematosus and, rarely, severe skin reactions, including Stevens-Johnson and angioedema. As a result of impaired porphyrin metabolism, griseofulvin therapy is associated with photoallergic reactions. Griseofulvin is contraindicated in patients with porphyria and hepatocellular failure.[92]

RISKS AND PRECAUTIONS Patients should be warned about potential photosensitivity induced by griseofulvin and the possibility of lupus erythematosus or a lupus-like syndrome.[93]

DRUG INTERACTIONS Griseofulvin induces CYP3A4, leading to lower plasma levels of drugs metabolized by this pathway.[3] Two important examples are decreased anticoagulation by warfarin and potential decreased effectiveness of oral contraceptive pills.

ORAL ANTIFUNGALS IN THE IMMUNOCOMPROMISED

Oral antifungal therapy is increasingly important for the treatment and prevention of infection in immunocompromised individuals, even in an outpatient setting. For example, as more patients survive organ transplantation,[94,95] more fungal infections are likely to be observed. In one recent report of 100 consecutive liver transplant patients seen by a dermatology clinic, fungal infections were much more common (19 percent of total skin infections) than bacterial (5 percent) or viral (2 percent).[96]

Candidiasis and aspergillosis are the most common opportunistic fungal infections in many immunocompromised populations. The extensive use of fluconazole prophylactically in patients with acquired immunodeficiency syndrome, transplants, hematologic malignancies, and other causes of immunosuppression has led to decreased susceptibility of some candidal infections to fluconazole.[97] One should keep in mind, however, that itraconazole solution has more drug interactions and potential compliance issues due to nausea and diarrhea.

New antifungal medications with activity against resistant species and excellent safety profiles continue to be developed. The new class of antifungals, echinocandins, provide both benefits by specifically targeting fungal cell wall β-1,3-D-glucan synthesis (absent in mammalian cells). However, poor oral bioavailability currently limits these drugs to intravenous formulations.[100]

EVIDENCE-BASED MEDICINE CONSIDERATIONS

Interpretation of competing studies continues to be difficult because endpoints have not been uniform. Such endpoints may be mycologic cure, clinical cure, complete cure, and effective treatment. Criticisms of these studies include the fact that many were open label, leading to investigator bias.[101] Many studies fail to take into account the physiology of nail growth.[19] Toenails can take up to 18 months to grow out fully. Therefore, stud-

ies at 48 to 52 weeks might not accurately reflect clinical or mycologic cure. Several studies of the treatment of tinea pedis did not always specify the type of tinea pedis, despite known variations amongst forms of tinea pedis in response rate to therapy. Studies of moccasin tinea pedis are preferred as successful treatment usually indicates that the antifungal drug will be effective in the milder forms of tinea pedis as well as tinea corporis and tinea cruris.[101] Finally, the efficacy of antifungal agents depends on the sensitivity of the dermatophyte. For example, in the treatment of tinea capitis, if the causative organism is *M. canis*, longer treatments may be needed than if the organism is *T. tonsurans*. [45] In North America, most tinea capitis is caused by *T. tonsurans*, while surveys in the United Kingdom demonstrate that the predominant dermatophyte is *M. canis*.[59] Consequently, trials assessing the efficacy of a drug may be influenced by the culprit dermatophyte and indirectly by the location of the study.

KEY REFERENCES

The full reference list for all chapters is available at www.digm7.com.

11. Lipozencic J et al: A randomized, double-blind, parallel-group, duration-finding study of oral terbinafine and open-label, high-dose griseofulvin in children with tinea capitis due to Microsporum species. *Br J Dermatol* **146**:816, 2002
13. Friedlander SF et al: Terbinafine in the treatment of *Trichophyton* tinea capitis: A randomized, double-blind, parallel-group, duration-finding study. *Pediatrics* **109**:602, 2002
18. Sigurgeirsson B et al: Long-term effectiveness of treatment with terbinafine vs itraconazole in onychomycosis: A 5-year blinded prospective follow-up study. *Arch Dermatol* **138**:353, 2002
28. Tavakkol A, Fellman S, Kianifard F: Safety and efficacy of oral terbinafine in the treatment of onychomycosis: Analysis of the elderly subgroup in Improving Results in ONychomycosis-Concomitant Lamisil and Debridement (IRON-CLAD), an open-label, randomized trial. *Am J Geriatr Pharmacother* **4**:1, 2006
49. Vanden Bossche H et al: Biochemical basis for the activity and selectivity of oral antifungal drugs. *Br J Clin Pract Suppl* **71**:41, 1990
62. Gupta AK et al: Superficial fungal infections: An update on pityriasis versicolor, seborrheic dermatitis, tinea capitis, and onychomycosis. *Clin Dermatol* **21**:417, 2003
76. Sobel JD et al: Maintenance fluconazole therapy for recurrent vulvovaginal candidiasis. *N Engl J Med* **351**:876, 2004
90. Faergemann J et al: A multicentre (double-blind) comparative study to assess the safety and efficacy of fluconazole and griseofulvin in the treatment of tinea corporis and tinea cruris. *Br J Dermatol* **136**:575, 1997

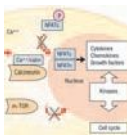

CHAPTER 234

Immunosuppressive and Immunomodulatory Drugs

Carlos H. Nousari
Grant J. Anhalt

There has been significant progress in the search for selective immunomodulation; the most significant advance in immunotherapy has been the reduction in systemic glucocorticoids exposure along with early or concomitant introduction of immunosuppressive and immunomodulatory adjuvants. Unlike immunomodulators, immunosuppressants are characterized by (1) a low therapeutic index (narrow window between the toxic and the therapeutic range) and (2) intra- and interindividual variation of the pharmacokinetics of these agents. These obstacles are usually overcome by precise drug dosing (ideal/lean body weight and body surface area) as well as close monitoring of drug levels (parent and metabolite serum peak and trough levels) and organ toxicity.

The main goals in immunotherapy therapy are "safety and effectiveness," which currently are accomplished by the use of "combination therapy."[1,2] The ideal immunotherapy combination is the one that combines drugs that have different mechanisms of action and different toxicity profiles. Thus, an additive or synergistic therapeutic effect will be obtained along with a significant reduction in dose-dependent side effects.

A comprehensive knowledge of the pathophysiology of the treating disease as well as of the pharmacokinetics and pharmacodynamics concepts is crucial for delineating the most effective and safest therapeutic regimens for autoimmune and inflammatory skin disorders (see eFig. 234-0.1 in on-line edition; Fig. 234-1).

MACROLACTAM DRUGS

Macrolactam drugs are immunomodulators derived from microorganism fermentation products that include calcineurin inhibitors (CnIs) [e.g., cyclosporine, tacrolimus (TCL), and pimecrolimus] and mammalian target of rapamycin inhibitors (mTORIs) [e.g., sirolimus (SRL) and everolimus (EVL)]. Macrolactams are versatile immunomodulators that selectively suppress T-cell response and have synergistic therapeutic effects when they are combined with virtually any other immunosuppressive drug.[1,2]

Calcineurin Inhibitors

MECHANISM OF ACTION CnIs inhibit T-cell stimulation initiated by several pathways, of which the T-cell receptor (TCR) CD3 is the best understood.[3] Mechanisms involving B-7 and CD28/cytotoxic T lymphocyte antigen-4, and other co-stimulatory pathways seem not to be affected by cyclosporine A (CsA) or other CnIs. The high-affinity receptor for CsA is a 17-kd immunophilin called *cyclophilin A* (*CyPA*). The other CnIs (TCL and pimecrolimus) bind a structurally unrelated, different immunophilin called *macrophilin-12* also known as *FK-506 binding protein-12* (*FKBP-12*). The drug-immunophilin complex binds to calcineurin (Cn), a serine/threonine protease composed of two subunits: CnA and CnB. CnA constitutes the catalytic unit possessing binding sites for CnB and calmodulin. Cn activity strictly correlates with interleukin 2 (IL-2) production via CD3 activation. Cn is also involved in the induction of apoptosis and degranulation of cytotoxic T lymphocytes. Experimental data show that the CsA, TCL, and pimecrolimus/Cn complex inhibits the nuclear translocation of the nuclear factor of activated T cells c molecule by blocking its dephosphorylation. This is thought to be the key step by which these drugs uncouple TCR activation from IL-2 transcription. TCL is 10- to

IMMUNOSUPPRESSIVE AND IMMUNOMODULATORY DRUGS AT A GLANCE

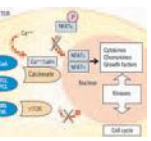

- The main goals in immunotherapy are safety and effectiveness.
- Unlike immunomodulators, immunosuppressive drugs are all characterized by a narrow therapeutic window requiring precise dosing and close side-effect monitoring.
- The highest level of safety and effectiveness in immunotherapy therapy is currently accomplished by the use of combined regimens.
- An additive or synergistic combined immunotherapeutic regimen allows significant reduction of dose-dependent drug side effects maintaining or improving the effectiveness, respectively.
- A comprehensive knowledge of the pathophysiology of the treating disease as well as of the pharmacokinetics and pharmacodynamics concepts is crucial for delineating the most effective and safest therapeutic regimens.

100-fold more potent than CsA in vitro in the inhibition of Cn activity.

In summary, CsA inhibits the T-cell activation mediated by antigen, but it does not inhibit the early phases of lymphocyte signal transduction occurring after antigen-mediated activation. The immunomodulatory effects of these drugs are intricate and subject to constant discoveries. A simplified explanation of the mechanism of action of these drugs is presented in the following sections and is illustrated in Fig. 234-2.

CYCLOSPORINE A CsA is a hydrophobic lipophilic undecapeptide extracted from fungi.

Pharmacokinetics. The microemulsion-based formulation of CsA has an improved bioavailability giving the drug more predictable absorption.[3,4]

Modified median effect formula for combined therapeutic effect

$$Cix = \frac{A \text{ combined with } B}{A} + \frac{B \text{ combined with } A}{B}$$

Cix: index inhibition (Igs, disease activity, etc)

Cix: = 1 additive
< 1 synergistic
> 1 antagonistic

▲ **FIGURE 234-1** A modified, median-effect formula is widely used in organ transplant, which helps in finding the therapeutic windows of immunosuppressive drugs as well as the synergistic, additive, or antagonistic effect of a postulated drug combination. Igs = immunoglobulins. (From Chou TC, Talalay P: Quantitative analysis of dose-effect relationships: The combined effects of multiple drugs or enzyme inhibitors. *Adv Enzyme Regul* **22**:27, 1984.)

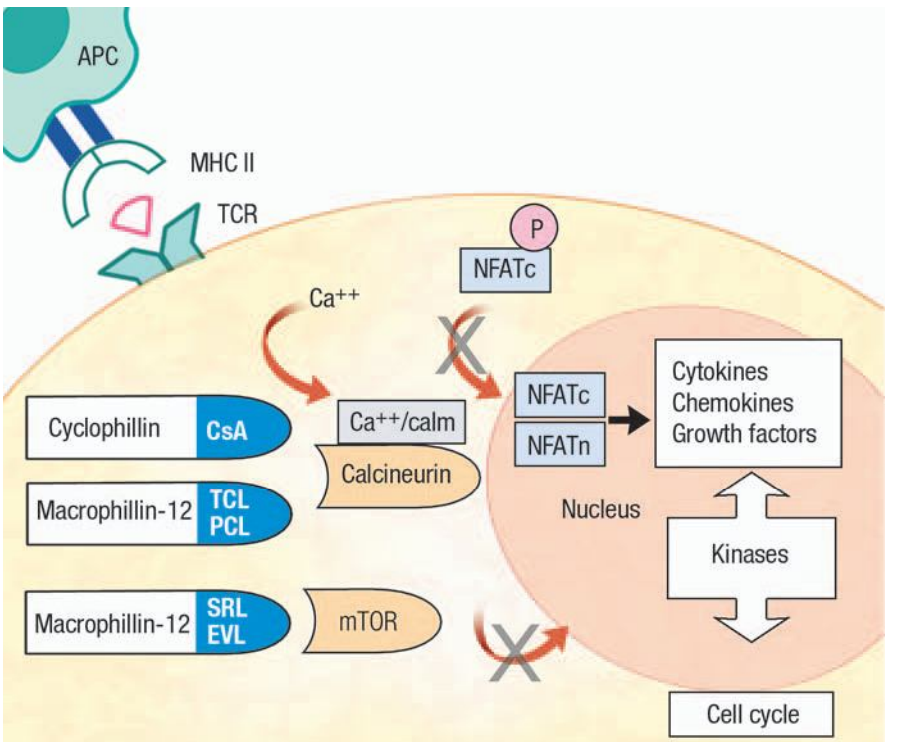

▲ **FIGURE 234-2** This diagram outlines the key mechanisms by which calcineurin (Cn) inhibitors and mammalian target of rapamycin (mTOR) inhibitors inhibit T-cell activation triggered by presentation of antigen via the T-cell receptor (TCR). The first step in antigen presentation involves presentation of a peptide that is bound within the peptide-binding groove of the major histocompatibility complex (MHC) class II molecule. This complex is then presented to the TCR. This causes transmembrane signaling that increases intracellular calcium concentrations. The liberated calcium, bound to calmodulin, interacts with Cn, a calcium-dependent serine/threonine phosphatase that dephosphorylates nuclear factor of activated T cells (shown here as NFATc), and this causes NFAT to translocate to the nucleus. There it binds to other nuclear components of NFAT (shown here as NFATn). This complex regulates the transcription of many cytokine genes, shown in the diagram. Cyclosporine (CsA), tacrolimus (TCL), and pimecrolimus (PCL) diffuse freely into the cytoplasm of T cells and bind with their respective immunophilins. This drug/immunophilin complex binds to Cn and blocks its ability to dephosphorylate NFAT, and thereby inhibits the production of cytokines, chemokines, and growth factors [interleukin 2 (IL-2), IL-3, IL-4, tumor necrosis factor-α, interferon-γ, granulocyte-macrophage colony-stimulating factor, etc.] that would normally be induced after T-cell activation via the TCR. Sirolimus (SRL) has a more complex intracellular mechanism of action. Although SRL and everolimus (EVL) bind macrophilin-12 (also known as *FKBP-12*), the immunophilin of TCL and PCL, its mechanism of action does not appear to be mediated by Cn inhibition. mTOR inhibitors block cell kinases that would have a direct effect on the cell cycle by also an indirect effect in chemokine, cytokine, and growth factor synthesis. APC = antigen-presenting cell.

CsA can also be administered intravenously as a 50 mg/mL solution made up in an ethanol-polyoxyethylated castor oil mixture. The accumulation of CsA in erythrocytes and leukocytes is the reason that whole-blood monitoring of CsA levels is much more accurate than measurement of plasma levels. Peak levels occur from 1.3 to 4.0 hours after oral administration. After gaining access to the circulation, CsA distributes widely and has a large apparent volume of distribution (13 L/kg). CsA is metabolized into greater than 30 cyclic, partly active metabolites by the liver cytochrome P_{450} 3A enzyme (CYP 3A).[5,6] Thus, drugs that compete for binding to CYP 3A will increase CsA levels, and drugs that induce P_{450} will accelerate metabolism and decrease blood levels. Certain foods rich in bioflavonoids, especially grapefruit, seem to increase the drug's bioavailability through an interaction with cytochromes. Its elimination half-life is 6 to 12 hours in the absence of severe hepatic disease, and biliary excretion accounts for more than 90 percent of its elimination. CsA solution does have some penetration of mucosal surfaces, but this is not true of cornified epithelium. Intralesional injections of CsA do provide some local effects in psoriasis, but they are not widely used.

Indications

- Psoriasis
  - Moderate to severe psoriasis
  - Part of combined therapy
  - Failure of conventional treatment
- Graft-versus-host disease
  - Prophylaxis
- Pyoderma gangrenosum
  - Moderate to severe disease
  - Part of combined therapy
  - Failure of other treatments
- Paraneoplastic pemphigus
  - Part of combined therapy, namely in lichenoid forms
- Lichen planus
  - Mucosal and/or cutaneous forms
  - Moderate to severe cases
  - Solo or part of combined therapy
- Atopic dermatitis
  - Moderate to severe cases
- Behçet disease
  - Ocular and mucocutaneous forms
  - Moderate to severe cases
- Dermatomyositis
  - Moderate to severe forms
- Alopecia areata
- Recurrent aphthous stomatitis
- Epidermolysis bullosa acquisita

Dosing Regimen. (Table 234-1)

TABLE 234-1
Cyclosporine A Dosing Regimen

	ORAL	INTRAVENOUS
Adults	2.5–5.0 mg/kg/day	2–3 mg/kg/day
Children	5–7 mg/kg/day	3–5 mg/kg/day

Initiating Therapy. Doses higher than 5 mg/kg/day are not advisable. The U.S. Food and Drug Administration has approved CsA for psoriasis in doses up to 4 mg/kg/day, with a recommended starting dose of 2.5 mg/kg/day. Dosage increases should be performed after 4 weeks of therapy, and dose reductions are permitted at any time. Dosage increases should not exceed 0.5 to 1.0 mg/kg/day at 2- to 4-week intervals. Intravenous CsA formulation can be infused slowly over a period of 2 to 6 hours at about one-third of the usual oral dose, or about 2 to 3 mg/kg per day.[7]

Monitoring Therapy. With psoriatic patients going into remission, defined as a reduction in the psoriasis area and severity index of greater than 75 percent, the CsA dose should be down-titrated at 4-week intervals. The two most common assays for trough levels are high-performance liquid chromatography (HPLC) and radioimmunoassay are performed in EDTA-containing whole blood. The recommended range is 200 to 400 ng/mL. Children have comparable bioavailability of orally ingested CsA, but have a higher renal drug clearance rate (11.8 mL/min per kg vs. 5.7 mL/min per kg in adults), and a correspondingly shorter blood level half-life (7.3 hours vs. 10.7 hours in adults). Children may therefore require somewhat higher dosages and more frequent administration to achieve comparable trough levels to adults.

Risks and Precautions. Serum creatinine levels should be carefully monitored during CsA therapy. If creatinine levels increase more than 30 percent above baseline, the dosage should be reduced for 1 to 2 weeks. If, after that time, the creatinine levels decrease below the 30 percent elevation mark, continuation at the lower dose is advisable. In cases where the creatinine remains elevated by more than 30 percent, discontinuation of CsA is recommended until the creatinine returns to levels within 10 percent of pre-treatment levels. More accurate studies monitoring the glomerular filtration rate clearance are used in individualized cases. From a practical standpoint, adequate monitoring of CsA dosage can be achieved by the avoidance of CsA doses higher than 5 mg/kg/day, evaluation of clinical response, and vigilance for signs of toxicity. This requires a detailed physical examination, including blood pressure monitoring with threshold concern triggered by a persistent diastolic blood pressure above 90 mm Hg, a complete history with emphasis on concomitant drug ingestion and medical conditions that may potentiate CsA toxicity, and laboratory evaluations for complete blood count, creatinine and blood urea nitrogen, uric acid, liver enzymes, serum electrolytes and magnesium, and a urinalysis. In patients receiving long-term CsA therapy (> 6 months), the serum creatinine and its clearance may not be a reliable predictor of altered renal function, and potentially irreversible chronic cyclosporine nephrotoxicity may ensue. In such circumstances, more reliable studies for the evaluation of renal function may be indicated.

Complications. **RENAL FUNCTION, LIVER, AND NEUROLOGIC.** Overall, one in four patients taking CsA develops clinical and laboratory evidence of altered renal function, including hypertension. Two types of CsA-induced nephrotoxicity are encountered in dermatologic patients. The first type usually starts within 2 to 3 weeks after drug initiation, and it is usually associated with high CsA blood levels. In this toxicity, there is an insidious decrease in glomerular filtration rate along with hypertension, and tubular dysfunction in association with a complete recovery of renal function upon dose-lowering or discontinuing therapy. The second type is likely a result of cumulative sub-clinical chronic renal toxicity. This may occur in the absence of any detectable elevation of creatinine or blood pressure. Histologic changes include interstitial fibrosis, tubular atrophy, and some degree of vasculopathy. Although renal function can improve somewhat after discontinuation of the drug, this type of toxicity is generally irreversible. In psoriatic patients receiving 5 mg/kg/day CsA, elevation of serum creatinine may persist

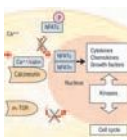

for more than 4 months after discontinuation of the drug. Several mediators, including endothelin-1, angiotensin II, osteopontin, and transforming growth factor-β1, have been implicated in the pathogenesis of CsA-associated nephrotoxicity and hypertension. Calcium channel antagonists exert beneficial effects on CsA-induced hypertension and nephrotoxicity, presumably through the inhibition of endothelin-1. Other drugs, including angiotensin converting inhibitors (enalapril, lisinopril, etc.) and angiotensin receptor blockers (losartan, valsartan, etc.), are also effective mainly when used in combination with other antihypertensive drugs. New drugs, such as endothelin A receptor blockers (bosentan, darusentan, etc.) and renin inhibitors (aliskiren), appear to be promising for CsA-treated patients.[8–10] Diuretics and nephrotoxic drugs should be used with caution in CsA-treated patients. Another uncommon adverse renal complication is the development of thrombotic microangiopathy/hemolytic-uremic syndrome,[11,12] especially in allogenic bone marrow transplant patients receiving CsA for acute graft-versus-host disease. Hypomagnesemia and hyperkalemia or hypokalemia are not uncommonly encountered.

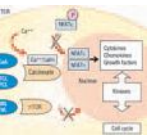

Nausea, vomiting, anorexia, and diarrhea commonly occur with the use of CsA. Elevations of liver enzymes greater than 100 percent over baseline should be managed by reduction of the CsA dose by 25 percent weekly, until enzyme levels normalize.

Headache is a common complaint, especially in patients with a history of migraines. It tends to resolve spontaneously as therapy continues. CsA-induced seizures appear to be associated with hypomagnesemia and concomitant use of high doses of systemic corticosteroids. Thus, serum magnesium levels should be always monitored and kept above the lower normal range in CsA-treated patients. Cortical blindness, lethargy, confusion, seizures, hemiplegia, tremors, and paresthesias have also been described in patients receiving CsA.[8]

There is evidence of impaired fibrinolysis and endothelial damage and proliferation associated with CsA. Hypercoagulability seems to contribute to the progression of atherosclerosis and glomerular damage in CsA-treated patients. Significant cytopenias have rarely been reported with the use of CsA.

Hypercholesterolemia, elevation of low-density lipoproteins, and hypertriglyceridemia may be seen with CsA.

CANCER. CsA-treated transplant recipients have a relative risk for all skin cancers of 6.8 versus 2.2 to 5.5 in patients receiving other immunosuppressive therapies. CsA-treated dermatologic patients also have a higher risk of skin cancers, including squamous cell carcinomas, basal cell carcinomas, human papilloma virus–associated anogenital carcinoma, and Kaposi sarcoma. The high incidence of squamous cell carcinoma in psoriatic patients treated with CsA could be biased by previous exposures to psoralen and ultraviolet A light or ultraviolet B. Approximately 25 percent of non-visceral Kaposi sarcomas can be expected to undergo complete or partial remission following cessation or reduction of immunosuppressive therapy. Epstein-Barr virus–associated post-transplant lymphoproliferative disorder (PTLD) is quite rare in dermatologic patients. PTLD frequently usually fails to respond to chemotherapy, but it may regress spontaneously after reduction and/or cessation of immunosuppression. The incidence of lymphoma in CsA-treated dermatologic patients appears to be less than 0.2 percent. The incidence of lymphoma in transplant patients receiving CsA alone or in combination with corticosteroids is less than 1 percent, whereas for those receiving CsA in conjunction with other immunosuppressive drugs is as high as 8 percent. In contrast to the high mortality rate attributed to lymphomas arising in immunosuppressed patients, lymphomas developing in CsA-treated patients seem to carry a better prognosis despite of having a shorter latency period seems.[13–15] In rheumatoid arthritis patients treated with CsA, there was no increase in malignancies in comparison with a matched control group of patients with rheumatoid arthritis who were not treated with CsA. Other neoplasms, including melanoma, are also reported in CsA-treated patients, although their true incidence is unknown.

OTHER ADVERSE EFFECTS. Hypertrichosis occurs in virtually all patients on long-term CsA therapy. It is not limited to androgen-dependent, hair-bearing areas, and shows no tendency to spontaneous remission. Gingival hypertrophy is reported in up to 70 percent of CsA-treated patients; it is more common in children, individuals with poor oral hygiene and concomitant use of calcium channel drugs. Improvement of this gingival complication with topical or systemic azithromycin and metronidazole can be seen. An acneiform eruption, indistinguishable from that seen in steroid-induced acne, is frequently reported. A disseminated comedonal or cystic acneiform eruption can also occur. These side effects can appear at any time during CsA therapy, although they are more commonly described at the time of initiation of CsA therapy. Keratosis pilaris, sebaceous hyperplasia, warts, and epidermal inclusion cysts occur in up to one-third of CsA-treated patients.

Osteoporosis seems to result from the CsA's action on osteoblasts and osteoclasts, and by altering lymphokine release. CsA can induce hyperuricemia in up to 15 percent of patients, and it is also an indicator of early CsA-induced nephrotoxicity. Myopathy has been reported in transplant patients receiving high doses of CsA, and thus, cation should be used with the concomitant use of statins.

PREGNANCY. CsA does not seem to be mutagenic or teratogenic, although there is a high incidence of preterm newborns, fetal growth retardation, abortions, preeclampsia, and hypertension in mothers taking CsA, and these occurrences are magnified in transplant patients. There are no reports of neonatal complications in children born to fathers receiving CsA. Adequate contraceptive measures are recommended in women of childbearing potential. CsA crosses the placenta and is excreted in breast milk. CsA-treated transplant patients seem to have a relative risk for infectious, life-threatening complications that is much lower than that seen in patients receiving azathioprine and prednisolone. However, increased vigilance for infectious complications is recommended in CsA-treated patients.

TACROLIMUS

TCL, a CnI formerly known as *FK506*, is a macrolactam drug first isolated from *Streptomyces tsukubaensis*.

Mechanism of Action. The postulated mechanisms of action of TCL are similar, if not identical, to the ones described for CsA (see Macrolactam Drugs).[16]

Pharmacokinetics. TCL can be administered orally, topically, and intravenously. The pharmacokinetics of systemic TCL are characterized by a two-compartment model with a rapid initial drop and a long elimination half-life of 12 to 21 hours. TCL is metabolized in the liver with less than 1 percent of the drug excreted intact. TCL has not proved to be more effective than CsA, but it appears

TABLE 234-2
Tacrolimus Dosing Regimen

	ORAL	INTRAVENOUS
Adults	150–200 μg/kg/day	25–50 μg/kg/day
Children	200–300 μg/kg/day	50–100 μg/kg/day

to have a better bioavailability. The topical formulations have a concentration of 0.3 percent and 0.1 percent in an ointment vehicle, and for more detailed information, see Chap. 221.

Dosing Regimen. (Table 234-2)

Initiating Therapy. The dosage of systemic TCL should be reduced in the presence of hepatic dysfunction by 10 percent to 30 percent of the standard dosing.

Monitoring Therapy. There is a good correlation between enzyme-linked immunosorbent assay and HPLC mass spectrometry measurements in monitoring of whole blood concentrations of TCL. Enzyme-linked immunosorbent assays may also detect metabolites of the drug, and thus, caution should be taken in patients with liver diseases or with concomitant use of CyP4503A-binding drugs. Blood levels of 5 to 15 ng/mL are recommended.

Risks and Precautions. The risks and precautions are quite similar to the ones applied for CsA. However, neurotoxicities and glucose intolerance are somewhat higher than with CsA use, and thus, close monitoring of magnesium and glucose serum levels and, if indicated based on personal or family history, glucose tolerance tests are strongly recommended. The risk for PTLD seems to be higher in children with hepatic transplants who received both TCL and anti-OKT3, but it has not been definitively proved in dermatologic patients or in different clinical scenarios. Dose reduction and close monitoring of TCL levels by HPLC mass spectrometry in patients with liver diseases are strongly recommended. A less graft-versus-leukemia effect in comparison with the one seen with CsA is observed in bone marrow transplant patients. A great deal of concern has been raised regarding the potential risk of lymphoproliferative diseases with this drug, which led to a highly controversial placement of a black box warning by the U.S. Food and Drug Administration with the topical formulation (see Chap. 221).

Complications. Mucocutaneous and metabolic side effects seem to be less frequent with the use of TCL. However, nephrotoxicity seems to be comparable to that seen with the use of CsA. The rest of the side effects are comparable with those seen with CsA use.

Indications

- Psoriasis
- Pyoderma gangrenosum
- Atopic dermatitis
- Graft-verus-host disease
  - Prophylaxis
  - Therapy
- Lupus erythematosus
  - Systemic
  - Chronic cutaneous

Systemic TCL can be used virtually in any inflammatory and autoimmune skin disease in which systemic CsA has proved effective.[17–21] For topical use of TCL, see Chap. 221.

PIMECROLIMUS Pimecrolimus, also known as *ASM 981*, is a derivative of the parent compound ascomycin originally isolated from the fermentation products of *S. hygroscopicus* var. *ascomyceticus*. Pimecrolimus has a similar mechanism of action as that of other CnIs. Pimecrolimus is formulated in vehicle cream at concentrations of 0.2 percent, 0.6 percent, and 1.0 percent (see Chap. 221).

Mammalian Target of Rapamycin Inhibitors

MECHANISM OF ACTION SRL and its derivatives EVL and temsirolimus are most widely known as *mTORIs*. Although mTORIs bind to FKBP-12 (macrophilin-12), this drug-immunophilin complex inhibits gene transcription through a complex mechanism that is independent from the one involving Cn.

TABLE 234-3
Sirolimus Dosing Regimen

	DAILY ORAL DOSE
Adult—African and Asian descents	3–10 mg
Adult—Caucasians	0.5–3.0 mg
Children	1.5 mg/m^2

PHARMACOKINETICS African and Asian descent patients require a higher initial and maintenance dose of SRL than Caucasians. EVL bears a stable 2-hydroxyethyl chain substitution at position 40 on the SRL structure, which has given a greater polarity than SRL, improving the pharmacokinetic and particularly its oral bioavailability. Oral EVL is absorbed rapidly and reaches peak concentration after 1.5 hours. In adults, EVL pharmacokinetic characteristics do not differ according to age, weight, or sex, but body weight-adjusted dosages are necessary in children.[25–26] The target trough concentration of EVL should range between 3 and 15 ng/dL. SRL topical formulation (2.2 percent and 8.0 percent) has been use in psoriasis patients (see Chap. 221).

INDICATIONS

- Graft-versus-host disease
  - Prophylaxis
  - Refractory chronic
- Psoriasis
  - Severe
  - Solo therapy
  - Combination therapy with Cn inhibitors
  - mTORIs have a potential use in any inflammatory dermatosis in which CnIs play a therapeutic role.

DOSING REGIMEN (Tables 234-3 and 234-4)

INITIATING THERAPY As mentioned in Table 234-3, due to ethnic differences, the SRL recommended oral loading dose is 6 mg and oral maintenance dose is 2 mg per day for Caucasian patients, and the oral loading dose is 10 mg and oral maintenance dose is 5 mg per day for African Americans. Asians also appears to require higher doses of this drug. EVL starting dose are the same regardless of sex and race. The usual dosing for adults is 0.75 to 1.5 mg bid and for children 0.8 to 1.2 mg/m^2.

MONITORING THERAPY Due to significant intra- and interindividual variability, mea-

TABLE 234-4
Everolimus Dosing Regimen

	DAILY ORAL DOSE
Adults	0.8–1.2 mg/m^2
Children	0.75–1.5 mg/bid

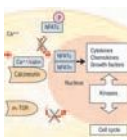

suring trough levels is critical with the use of mTORIs. Through levels for SRL and EVL are 5 to 20 ng/dL and 3 to 15 ng/mL, respectively. Complete blood cell count, electrolytes, liver function test, and a lipid profile, along with a comprehensive clinical examination with periodic blood pressure measurement, are mandatory.

RISKS AND PRECAUTIONS Concomitant use of antimetabolite drugs, including mycophenolate mofetil (MMF) and azathioprine in patients with mTORIs of upper normal or higher trough blood levels (e.g., SRL: equal or higher than 20 ng/dL or EVL: equal or higher than 5 ng/mL), raises the risk of cytopenias, namely thrombocytopenia. Concomitant use of CnIs, namely TCL, may increase the risk of thrombotic microangiopathy/hemolytic uremic syndrome, and thus, monitoring of blood cell count, dyslipidemia, electrolyte abnormalities, edema, and increase of liver function tests are also associated with high trough levels of these drugs. Patients with extensive psoriasis treated with SRL should be monitored closely for capillary leak syndrome, a rare complication reported only in one series.[27]

COMPLICATIONS Cytopenias, namely thrombocytopenia, hypertriglyceridemia, hypercholesterolemia, arthralgias, edema, and impaired wound healing, have been frequently associated with the use of mTORIs. Occurrence of cytomegalovirus appears to be lower that observed with the use of CnIs. No gingival hyperplasia has been observed with SRL. Tremor or any other neurologic complications are not frequent. Hypertension and malignancies are significantly reduced in comparison with the use of CnIs. This is most likely related to the endothelial, mesangial antiproliferative and antineoplastic properties of mTORIs.

MYCOPHENOLATE MOFETIL

MMF is an ethyl ester of its active metabolite, mycophenolic acid (MPA) a product of several *Penicillium* species.

Mechanism of Action

MMF is the reformulated product of MPA, but with enhanced bioavailability. MPA inhibits the type II isoform of inosine monophosphate dehydrogenase in the de novo pathway of purine synthesis. Lymphocytes are quite susceptible to this drug effect, because they minimally use the hypoxanthine–guanine phosphoribosyl transferase salvage pathway for purine synthesis. Other less understood mechanisms have also been reported.

Pharmacokinetics

The drug is rapidly absorbed after oral administration, and antacids and cholestyramine may decrease its absorption. Approximately 5 percent of the drug is bound to albumin. It is nearly completely metabolized by glucuronyl transferase, and more than 90 percent of the drug is eliminated by the kidneys. The MMF glucuronide metabolite, which is increased in renal failure, increases MMF clearance by competing for its binding sites on albumin. MMF pharmacokinetics seems not to be affected by the concomitant administration of CsA. As with many other immunosuppressive agents, doses up to 20 percent higher may be required for children due to a physiologic increased liver metabolism. A new oral formulation of MPA, mycophenolate sodium enteric coating (MP-EC), has been proved to be as effective as MMF at conversion dose as follows: 250 mg of MMF = 180 mg of MP-EC and 500 mg of MMF = 360 mg of MP-EC. This new formulation is less expensive and appears to have less gastrointestinal side effects.

Indications

- Atopic dermatitis
- Autoimmune blister diseases
- Chronic actinic dermatitis
- Connective tissue diseases
- Graft-versus-host disease
- Lichen planus
- Psoriasis
- Pyoderma gangrenosum
- Vasculitic syndromes

Dosing Regimen (Table 234-5)

TABLE 234-5
Mycophenolate Mofetil Dosing Regimen

	Daily Oral Dose
Cytotoxic T-cell mediated diseases	25–35 mg/kg
Antibody-mediated diseases	35–55 mg/kg

Note: 180 mg of mycophenolate sodium enteric coating is the equivalent of 250 mg of mycophenolate mofetil; 360 mg of mycophenolate sodium enteric coating is the equivalent of 500 mg of mycophenolate mofetil.[27,28]

Initiating Therapy

MMF is commonly used in synergistic and safe combination with CsA and glucocorticoids.

MMF is commonly used with systemic corticosteroids as adjuvant therapy. The full therapeutic effect of MMF or MP-EC, namely on antibody-mediated diseases, shouldn't be expected until 2 or 3 months after therapy initiation. The therapeutic and toxic profiles of MMF have led this drug to be the substitute of azathioprine.

Monitoring Therapy

Measurement of serum levels of MPA shows inconsistent predictive value to monitor effectiveness and toxicity in MMF-treated patients. Complete cell count and a liver function test are recommended to be monitored on a monthly basis.

Risks and Precautions

Gastrointestinal side effects, occasionally with intractable diarrhea, namely in elderly patients, are common, but in the vast majority of the cases they disappear with continuation of therapy, dividing the total daily dose (e.g. three or four times a day), and taking the drug with food. Increased risk of herpes zoster virus re-activation is rather common, namely in elderly patients and patients with autoimmune blistering disease (author's personal observation). Significant cytopenias could be expected when combined with mTORIs. Dose reduction should be made for patients with liver diseases.

Complications

Expected toxicities include nausea, upset stomach, vomiting, and diarrhea. There is no increase in nephrotoxicity, hepatotoxicity, hypertension, or neurotoxicity when MMF is used in conjunction with CsA and corticosteroids. The hematologic and gastrointestinal side effects are dose dependent and usually clinically insignificant. An increased incidence of lymphoproliferative diseases and lymphoma is reported with its use, as well as predisposition for infectious complication, usually non–life-threatening.[30–38]

Other antimetabolite and immunosuppressive agents are discussed in Chap. 228.

KEY REFERENCES

The full reference list for all chapters is available at www.digm7.com.

10. Binet I et al: Renal hemodynamics and pharmacokinetics of bosentan with and without cyclosporine. *Kidney Int* **57**:224, 2000
14. van Der Borne BE et al: No increased risk of malignancies and mortality in cyclosporine A-treated patients with rheumatoid arthritis. *Arthritis Rheum* **41**:1930, 1998
18. The European FK 506 Multicentre Psoriasis Study Group: Systemic tacrolimus (FK 506) is effective for the treatment of psoriasis in a double-blind, placebo-controlled study. *Arch Dermatol* **132**:419, 1996
23. Kahan BD. Sirolimus: A comprehensive review. *Expert Opin Pharmacother* **2**:1903, 2001
26. Kirchner GI et al: Clinical pharmacokinetics of everolimus. *Clin Pharmacokinet* **43**:83, 2004
29. Boswell A et al: Conversion from mycophenolate mofetil to enteric-coated mycophenolate sodium in patients with gastrointestinal side effects: Case studies. *Transplant* **16**:138, 2006
36. Nousari HC, Anhalt GJ: The role of mycophenolate mofetil in the management of pemphigus. *Arch Dermatol* **135**:853, 1999
38. Mimouni D et al: Treatment of pemphigus vulgaris and pemphigus foliaceus with mycophenolate mofetil. *Arch Dermatol* **139**:739, 2003



CHAPTER 235

Immunobiologicals, Cytokines, and Growth Factors in Dermatology

Stephen Richardson
Joel Gelfand

The cytokines, growth factors, antibody-based agents, and fusion proteins discussed in this chapter are listed in Table 235-1. Fig. 235-1 illustrates the targets of some of these biologics in T-cell activation, and Fig. 235-2 indicates where in cutaneous inflammation these and other biologics intervene.

TABLE 235-1
Immunobiologicals, Cytokines, and Growth Factors

Recombinant cytokines	
Interferon-α and interferon-γ	Enhance cell-mediated cytotoxicity against viral disease and malignancy via promotion of major histocompatibility complex expression and suppression of T helper 2 cytokine production
Recombinant ILs and growth factors	
IL-2	Maintains helper T-cell populations Enhances natural killer cell cytotoxicity and lymphokine activated cell activity
IL-1 receptor antagonist	Blocks the interaction between IL-1 and its receptor Suppresses IL-1–mediated inflammatory responses (e.g., leukocyte recruitment, osteoclast activation)
Granulocyte-macrophage colony-stimulating factor	Promotes the proliferation and differentiation of myeloid precursors
Platelet-derived growth factor	Promotes wound healing via angiogenic activity and proliferative effects on fibroblasts and smooth muscle cells
Antibody-based therapeutics	
Anti-TNF-α	Infliximab: chimeric monoclonal antibody; neutralizes both membrane-bound and soluble TNF-α Adalimumab: human monoclonal antibody; neutralizes both membrane-bound and soluble TNF-α
Anti–LFA-1	Efalizumab: humanized monoclonal antibody; interferes with lymphocyte activation, cytotoxicity, and trafficking to the skin
Anti-CD20	Rituximab: chimeric monoclonal antibody; promotes a reduction in $CD20^+$ cells (B cells)
Fusion proteins	
Alefacept	Human immunoglobulin G1 Fc region fused to LFA-3 extracellular domain; interferes with T-cell activation by blocking the interaction between LFA-3 and CD2
Etanercept	Human immunoglobulin G1 Fc region fused to TNF type II receptor domain; neutralizes soluble TNF-α
Denileukin diftitox	Diphtheria-toxin component fused to IL-2; promotes apoptosis of T cells expressing the high affinity IL-2 receptor, CD25

IL = interleukin; LFA = leukocyte function–associated antigen; TNF = tumor necrosis factor.

RECOMBINANT CYTOKINES AND GROWTH FACTORS

Cytokines are low molecular weight polypeptides that exhibit paracrine and/or autocrine activity in the mediation of immune responses. These hormone-like substances may serve as growth factors via the induction of immune cell proliferation. They may also influence the production of other cytokines and the behavior of multiple cell types that express the appropriate receptors. Over the past two decades, recombinant cytokines have proven to be of great use for the management of conditions in which immunologic aberrancies may exist or in which some clinical benefit might be derived from augmentation or suppression of the host immune response. In particular, the clinical and histologic manifestations of psoriasis have been attributed to the effects of T helper 1 (Th1) cytokine production. Thus, the development of compounds designed to regulate both immune cell activation and pro-inflammatory cytokine production has become a focus in therapeutic drug development for psoriasis.

Recombinant Interferons

INTERFERON-α Interferon-α (IFN-α) is a type I IFN produced by plasmacytoid

IMMUNOBIOLOGICALS, CYTOKINES, AND GROWTH FACTORS

AT A GLANCE

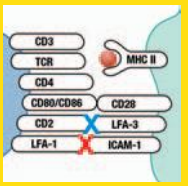

- The development of drugs that modulate immune cell function through stimulatory or inhibitory mechanisms has shown great promise in the treatment of conditions with underlying immune abnormalities. These drugs are often referred to as the *immunobiologicals* and are defined as compounds engineered from living organisms that induce or alter immune responses by interacting with specific biologic targets.
- Biologic agents available for the treatment of cutaneous disease range from recombinant cytokines and growth factors to monoclonal antibodies and fusion proteins.
- Targeting the immune system with biologics may result in an increased risk of infections and malignancies.

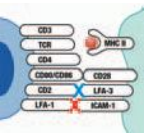

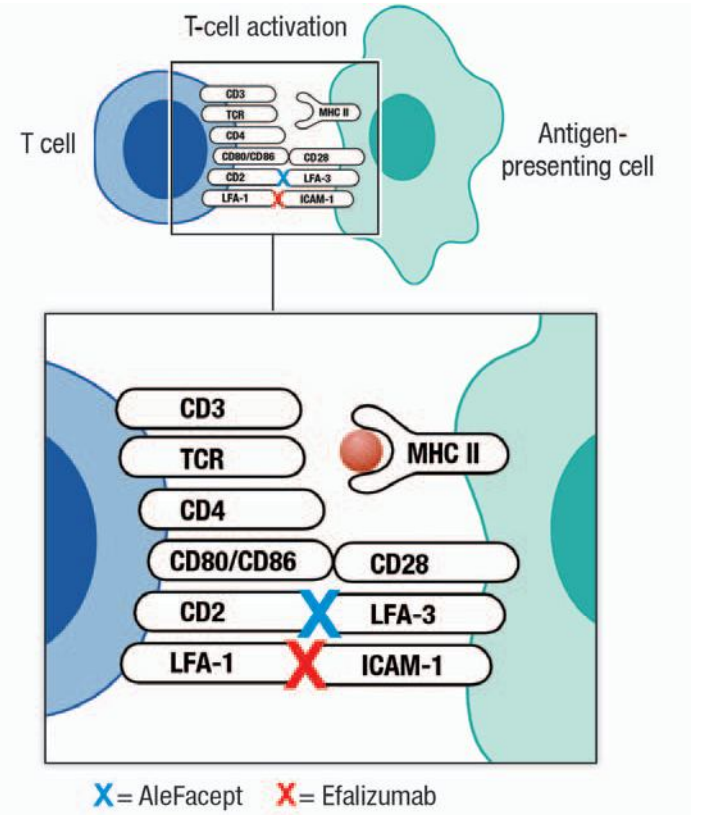

▲ **FIGURE 235-1** Immunobiologicals may modify immune responses via inhibition of T-cell activation. Efalizumab blocks interactions between leukocyte function–associated antigen 1 (LFA-1) and intercellular adhesion molecule 1 (ICAM-1), whereas alefacept interferes with interactions between CD2 and LFA-3. MHC II = major histocompatability complex II; TCR = T-cell receptor.

dendritic cells. It enhances cell-mediated cytotoxicity against viral disease and malignancy by increasing major histocompatibility complex I expression by antigen-presenting cells, stimulating natural killer cell activity, promoting the development of Th1 cells, and suppressing the production of Th2 cytokines.[1,2]

Recombinant IFN-α may be administered as a subcutaneous or intramuscular injection and has been used for a broad range of dermatologic conditions that include cutaneous T-cell lymphoma (CTCL), melanoma, non-melanoma skin cancer, Kaposi sarcoma, Behçet disease, hemangiomas, condyloma acuminatum, verruca vulgaris, and keloids.[3] A pegylated form (containing polyethylene glycol) of this compound is currently available, which has a longer half-life and increased patient tolerability.[2] Before the availability of pegylated IFN-α, treatment was typically administered three times per week with dosing dependent upon the condition being treated and patient response to therapy. Pegylated IFN-α may be administered once weekly with a steady state plasma level of drug achieved within 5 to 9 weeks.[4]

There is extensive experience using IFN-α in the treatment of CTCL. Objective clinical responses have been noted among 50 percent to 75 percent of CTCL patients treated with a variety of IFN-α dosing regimens.[5] Typically, it is administered subcutaneously (SC) at a starting dose of 1.5 million units three to five times per week. The first clinical trial using IFN-α for the treatment of CTCL was conducted by Bunn et al., in which patients with refractory, advanced-stage CTCL were treated with high dose (50×10^6 U/m^2) intramuscular injections three times a week. At the maximum tolerated dose, 10 percent of patients achieved a complete response, and 45 percent had an objective response.[6] Olsen et al. have since reported significant clinical responses in greater than 60 percent of CTCL patients (stage Ia–IVa) treated with IFN-α.[5] When combined with other immunomodulatory therapies, high clinical responses have been achieved among patients with Sézary syndrome.[7]

The most common side effect associated with IFN-α therapy is flu-like symptoms characterized by fever, sweats, chills, myalgias, and arthralgias. These symptoms typically resolve over the first 10 days of therapy and can be managed with acetaminophen. Patients may also experience injection site reactions. Other associated side effects include fatigue, depression, weight loss, photosensitivity, peripheral neuropathy, psychosis, hypothyroidism, and sexual dysfunction.[2,8] Laboratory abnormalities include elevated hepatic transaminases and leukopenia. Liver function tests and a complete blood count should be evaluated every 1 to 2 weeks on initiation of therapy or with any increase in dosing.[2]

IFN-α is contraindicated for use in patients with a known hypersensitivity to the drug or any of its components. Relative contraindications include a history of cardiovascular disease, renal disease, hepatic disease, central nervous system disorders, and/or pre-existing mental health disturbances. IFN-α is a pregnancy category C medication with unknown safety during lactation. IFN-α may also

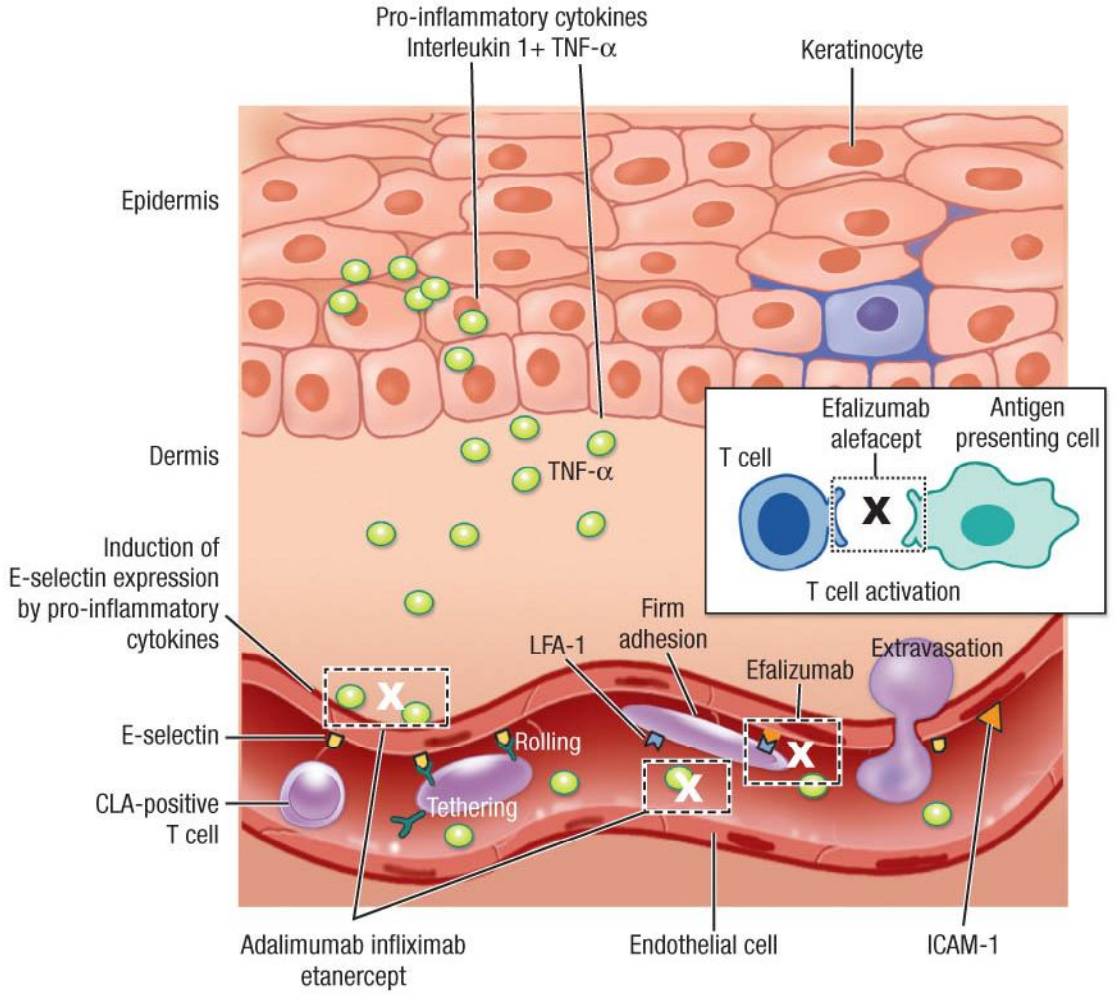

▲ **FIGURE 235-2** Cutaneous inflammation results in the production of inflammatory cytokines that induce keratinocyte proliferation and increase expression of molecules such as E-selectin. Immunobiologicals may interfere with immune cell trafficking by binding to specific cell surface receptors, deplete target cell populations through direct binding to cell surface proteins, suppress cytokine activity through the action of cytokine targeting compounds, and alter immune responses via the activity of recombinant cytokines with inhibitory or pro-inflammatory properties. The cellular interactions and cytokines targeted by several of the immunobiological agents discussed in this chapter are depicted. CLA = cutaneous lymphocyte–associated antigen; ICAM-1 = intercellular adhesion molecule 1; LFA-1 = leukocyte function–associated antigen 1; TNF-α = tumor necrosis factor-α.

exacerbate autoimmune diseases such as sarcoidosis, and therefore, it should be used with caution in individuals with a history of autoimmune disease.[9,10]

INTERFERON-γ IFN-γ is a cytokine produced by Th1 lymphocytes. Similar to IFN-α, it enhances cell-mediated cytotoxicity and suppress Th2 cytokine production. IFN-γ has also been shown to enhance major histocompatibility complex 2 expression and interleukin 12 (IL-12) production by antigen-presenting cells. In the dermatologic setting, it is reported to exhibit clinical efficacy in the management of chronic granulomatous disease and CTCL.

Children with chronic granulomatous disease treated with IFN-γ exhibited a significant reduction in the frequency of infections and associated hospitalizations.[11] Studies regarding the use of IFN-γ in the treatment of CTCL are limited. Partial clinical responses have been reported among patients treated with IFN-γ during all stages of disease.[12] Such responses may be attributed, in part, to the ability of IFN-γ to suppress the production of Th2 cytokines by malignant cells.[13] Thus, IFN-γ may offer a meaningful alternative to patients who may not tolerate or respond to IFN-α therapy secondary to the formation of neutralizing antibodies, or cognitive dysfunction and fatigue—which are more frequently associated with IFN-α therapy.[14]

IFN-γ is administered via intravenous, intramuscular, and/or subcutaneous routes. Dosing regimens vary, depending upon the condition being treated. The recommended treatment for children with chronic granulomatous disease involving greater than 0.5 m^2 body surface area is 50 μg/m^2 three times a week for life.[15] We have used IFN-γ doses ranging from 50 to 100 μg three times a week for the treatment of adult CTCL patients.[2]

Adverse effects associated with IFN-γ are similar to those reported for IFN-α and include flu-like symptoms, elevated hepatic transaminases, leukopenia, and thrombocytopenia. IFN-γ is a pregnancy category C medication with unknown safety during lactation. Its contraindications are similar to those reported for IFN-α.

Recombinant Interleukins and Growth Factors

INTERLEUKIN 2 IL-2 is a Th1 cytokine with anti-tumor activity produced by $CD4^+$ lymphocytes in response to activation by antigen-presenting cells. IL-2 has been shown to promote the prolif-

eration and maintenance of helper T-cell populations. In addition, it has also been shown to enhance both natural killer (NK) cell cytotoxicity and lymphokine-activated cell activity.[16] In the dermatologic setting, recombinant human IL-2 has been used for the treatment of melanoma and CTCL.

Several studies have reported durable clinical responses among melanoma patients treated with IL-2 therapy. This finding led to the U.S. Food and Drug Administration (FDA) approval of this medication for the treatment of patients with metastatic disease. In early studies, high dose intravenous IL-2 therapy (600,000 to 720,000 IU/kg) led to a 15 percent to 20 percent overall response among melanoma patients, with 4 percent to 6 percent achieving a complete clinical response.[17–19]

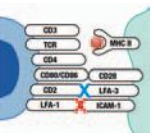

Adverse effects associated with infused IL-2 include fever, chills, hypotension, thrombocytopenia, vascular leak syndrome, pulmonary edema, cardiac arrhythmias, renal compromise, and exfoliative erythroderma.[2,3] IL-2 is contraindicated for use in patients with a known hypersensitivity to the drug or any of its components. It is also contraindicated for patients with a history of an abnormal thallium stress test, abnormal pulmonary function tests, or organ allograft transplantation. IL-2 is a pregnancy category C medication with unknown safety during lactation.

INTERLEUKIN 1 RECEPTOR ANTAGONIST

GRANULOCYTE-MACROPHAGE COLONY-STIMULATING FACTOR Granulocyte-macrophage colony-stimulating factor (GM-CSF) is a growth factor that induces the proliferation of myeloid precursors and is involved in the proliferation, differentiation, and migration of dendritic cells.[21] In the dermatologic setting, GM-CSF has been reported to exhibit efficacy as a wound-healing agent by promoting the proliferation of keratinocytes in the setting of ulcerated, diseased skin in specific case studies.[22,23] It has also been used as an antitumor agent in the treatment of melanoma and CTCL.

Regression of in-transit melanoma and cutaneous metastases have been reported with the administration of intralesional recombinant GM-CSF.[24,25] A phase II trial in which GM-CSF was administered to postsurgical, clinically disease-free, stage III or IV melanoma patients reported enhanced survival among treated patients compared to matched historical controls.[26]

Recombinant human GM-CSF has also been used as adjuvant therapy in the treatment of patients with Sézary syndrome. Clinical improvement was reported in a patient treated with an aerosolized form of the medicine.[27] In addition, we have used GM-CSF in combination with other immune-modulating therapies for the treatment of Sézary syndrome, leading to enhanced clinical responses.[7] GM-CSF been shown to induce the differentiation and proliferation of antigen-presenting cells[28] and may contribute toward disease improvement in Sézary syndrome through its ability to partially restore antigen-presenting cell populations, which have been shown to be reduced in Sézary syndrome patients.

Recombinant human GM-CSF dosing for the treatment of dermatologic disease has not been standardized. Associated side effects include fatigue, myalgia, injection site reactions, and generalized cutaneous reactions. GM-CSF is contraindicated for use in patients with a known hypersensitivity to the drug or any of its components. Administration of this drug in combination with chemotherapy or radiotherapy should be avoided. GM-CSF is a pregnancy category C medication with unknown safety during lactation.

RECOMBINANT HUMAN PLATELET-DERIVED GROWTH FACTOR Platelet-derived growth factor (PDGF) is a peptide produced by platelets, macrophages, neutrophils, and smooth muscle cells that has proven to be of clinical benefit for the management of chronic wounds. It consists of two polypeptide chains (A and B) that form dimers linked by disulfide bonds. The PDGF-BB homodimer has been shown to promote granulation tissue formation, wound angiogenesis, re-epithelialization, and the proliferation of fibroblasts and smooth muscle cells in the cutaneous microenvironment. It is currently the only growth factor approved by the FDA for the treatment of diabetic foot ulcers.

Several randomized control studies have reported the efficacy of PDGF-BB for the treatment of pressure ulcers and lower extremity ulcers in diabetic patients. A phase II randomized, double-blind clinical trial reported a greater than 50 percent decrease in the size of ulcers treated with topical recombinant PDGF at doses of 100 or 300 μg/mL compared to a less than 20 percent decrease in the placebo group.[29] A recent phase III study also reported significant efficacy of PDGF-BB in the time required to achieve complete wound closure for the treatment of chronic diabetic neuropathic ulcers of the lower extremities.[30] This multicenter, double-blind, placebo controlled study reported a 43 percent increase in the incidence of wound closure, and a 32 percent reduction in the time required to achieve complete wound closure compared to patients receiving a placebo gel.

PDGF-BB (100 μg/g) is distributed as a topical gel that should be applied daily and refrigerated when not in use. Studies addressing the safety of recombinant human PDGF-BB found no increased risk for cardiovascular, respiratory, musculoskeletal, or central nervous system disorders among patients with lower extremity diabetic neuropathic ulcers treated with topical PDGF-BB compared to patients treated with placebo or general ulcer care.[31] Patients receiving PDGF-BB therapy did not develop neutralizing antibodies to the drug, nor did they exhibit an increase in mortality rate relative to placebo. Cutaneous eruptions have been reported but are uncommon.

Recombinant PDGF-BB is contraindicated for use in patients with a known hypersensitivity to the drug or any of its components. It also should not be applied to sites affected by cutaneous neoplastic disease. PDGF-BB is a pregnancy category C medication with unknown safety during lactation.

ANTIBODY-BASED THERAPIES

Through their ability to regulate immune responses via the activation and/or suppression of pathways that mediate inflammation, immunologic tolerance, and antitumor immunity, cytokines serve as useful biologic targets for recombinant antibody therapy. Recombinant antibody-based therapeutics have also been developed to target specific cell surface receptors. These compounds have the ability to deplete distinct cell populations and/or inhibit signal transduction cascades associated with the targeted molecule. Antibody-based pharmacologics can be identified by their suffix, which denotes the structural nature of the compound (*-ximab*: chimeric monoclonal antibody [a hybrid antibody consisting of human and murine antibody components], *-zumab*: humanized monoclonal antibody, *-umab*: human monoclonal antibody, *-cept*: antibody fusion protein that mimics immunoglobulin).

Antibodies Against Cytokines

ANTI-TUMOR NECROSIS FACTOR-α Tumor necrosis factor-α (TNF-α) is a cytokine that has been linked to the pathogenesis of psoriasis and other inflammatory conditions, including psoriatic arthritis, rheumatoid arthritis, and inflammatory bowel disease. It is produced by multiple cell types in the skin (keratinocytes, Langerhans cells, and dermal mast cells),[32] which are believed to contribute to the pathogenesis of inflammatory dermatoses. TNF triggers its effects by binding to its p55 and p75 receptors expressed primarily on the surface of keratinocytes, neutrophils, endothelial cells, and fibroblasts. In combination with other proinflammatory cytokines, it is believed to be involved in the recruitment of immune cells to the cutaneous microenvironment.[33] TNF may also contribute to both the inhibition of keratinocyte apoptosis and the induction of keratinocyte proliferation in psoriasis.[34,35]

Psoriasis is a chronic inflammatory condition of the skin that affects more than 2 percent of the adult population[36] (see Chap. 18). Elevated levels of TNF-α have been detected in the cutaneous lesions of psoriasis patients.[37] Recent murine studies report a role for TNF-α in the activation and proliferation of lymphocytes that induce psoriatic lesions.[38] Elevated TNF-α levels have also been reported in patient serum, and they have been shown to correlate with disease activity.[39,40]

Three FDA-approved biologics inhibit TNF-α: infliximab, adalimumab, and etanercept. Although all three drugs inhibit TNF-α, they are structurally diverse and have differing pharmacodynamic and pharmacokinetic profiles. For example, infliximab and adalimumab bind to both soluble and membrane-bound TNF, whereas etanercept binds primarily to soluble TNF.[41] Infliximab and adalimumab may also have a greater propensity to cause lymphocyte apoptosis compared to etanercept, as they can lyse cells with membrane-bound TNF through complement activation and/or antibody-dependent, cell-mediated cytotoxicity.[42] In contrast, only etanercept binds lymphotoxin α, a member of the TNF family.[43] In terms of pharmacokinetics, the subcutaneous administration of adalimumab and etanercept leads to smooth and uniform concentration time profiles at steady state, whereas the intravenous dosing of infliximab results in very high peak to trough ratios.[44] Infliximab binds TNF quickly and irreversibly, whereas etanercept sheds about 50 percent of soluble TNF within 10 minutes of binding.[42] The pharmacodynamic and pharmacokinetic differences between TNF inhibitors may result in differing safety and efficacy profiles. For example, infliximab appears to be more efficacious than etanercept in granulomatous diseases such as Crohn disease, sarcoidosis, and Wegener granulomatosis.[42] However, it may also be associated with a higher risk of granulomatous infections.[45] TNF inhibitors are discussed as a class and then certain features of individual TNF inhibitors are highlighted.

Indications. Etanercept is FDA approved for the treatment of psoriasis and infliximab and adalimumab are under review for this indication. All three TNF inhibitors are approved for the treatment of psoriatic arthritis. Additionally, etanercept is FDA approved for rheumatoid arthritis, ankylosing spondylitis, and juvenile rheumatoid arthritis; infliximab is FDA approved for rheumatoid arthritis, Crohn disease, ulcerative colitis, and ankylosing spondylitis; and adalimumab is FDA approved for rheumatoid arthritis. Case reports and small case series suggest potential efficacy of these agents in the management of numerous inflammatory dermatologic conditions that include aphthous stomatitis, Behçet disease, cicatricial pemphigoid, dermatomyositis, eosinophilic fasciitis, hidradenitis suppurativa, multicentric reticulohistiocytosis, necrobiosis lipoidica diabeticorum, pityriasis rubra pilaris, pyoderma gangrenosum, sarcoidosis, scleroderma, Sneddon-Wilkinson syndrome, and SAPHO (synovitis, acne, pustulosis, hyperostosis, and osteitis) syndrome.[46]

Initiating Therapy and Monitoring. TNF inhibitors are immunosuppressive, and therefore, patients should be carefully screened for signs and symptoms of malignancy and infection before initiating therapy and during the course of treatment. Product labeling suggests screening for latent tuberculosis infection with a tuberculin skin test before initiating therapy with infliximab and adalimumab. Published guidelines, however, suggest tuberculosis screening for all three TNF inhibitors.[47] TNF inhibitors should be used with caution in patients with a history of congestive heart failure, and infliximab at doses > 5 mg/kg is contraindicated in patients with moderate to severe congestive heart failure. Infliximab may be associated with liver function test abnormalities, which, in rare cases, has lead to liver failure. Additionally, infliximab and adalimumab have been associated with reactivation of hepatitis B in patients who are chronic carriers, and some of these cases have been fatal. Therefore, one may consider monitoring liver function tests during TNF therapy and screening patients for hepatitis B if the patient is at risk of hepatitis B infection. Small cases series have suggested that TNF inhibitors can be used safely in patients with hepatitis B when lamivudine is given concurrently. However, larger confirmatory studies are necessary.[48]

Risks, Precautions, and Complications.

INFECTION. TNF inhibitors are associated with serious infections, including pneumonia, sepsis, tuberculosis, histoplasmosis, and coccidioidomycosis. Product labeling also indicates that for patients who have resided in regions where histoplasmosis and coccidioidomycosis are endemic, the risks and benefits of infliximab and adalimumab therapy should be carefully considered. A recent meta-analysis of rheumatoid arthritis patients treated with infliximab or adalimumab in randomized controlled trials suggested that use of these agents results in one excess serious infection for every 59 patients treated for a period of 3 to 12 months.[49] Use of etanercept with anakinra has been associated with an increased risk of serious infections, and, therefore, it is recommended that anakinra not be used concurrently with any TNF inhibitor.

MALIGNANCY. There is theoretical concern that TNF inhibitors may increase the risk of malignancy. A meta-analysis of patients treated with adalimumab or infliximab in clinical trials of rheumatoid arthritis demonstrated an increased risk of solid organ malignancies compared to placebo.[49] Etanercept was associated with an increased risk of solid organ cancer when given concurrently with cyclophosphamide in a trial for Wegener granulomatosis.[50] Observational cohort studies have indicated a potential increased risk of lymphoid malignancies in rheumatoid arthritis patients treated with infliximab or etanercept.[51,52] It is not certain if the excess risk of lymphoma observed in these observational studies is due to the TNF inhibitor or the severity of the underlying disease (e.g., rheumatoid arthritis), which itself may portend a greater risk of lymphoma. Psoriasis patients may also have an increased risk of lymphoma, independent of biologic therapy, and therefore, addi-



tional studies will be necessary to determine if long-term exposure to biologics impacts lymphoma risk in psoriasis patients.[53] Infliximab has also been associated with aggressive hepatosplenic T-cell lymphomas in post-marketing surveillance of patients with Crohn disease treated with concomitant azathioprine or 6-mercaptopurine. Additionally, aggressive CTCLs have been reported in patients receiving TNF inhibitors.[54]

NEUROLOGIC EVENTS. TNF inhibitors have been associated with rare cases of new onset demyelinating disease and with exacerbation of clinical and radiologic findings in patients with a history of demyelinating disease (e.g., multiple sclerosis).

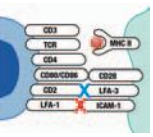

AUTOIMMUNITY. TNF inhibitors may be associated with the development of anti-nuclear antibodies and anti–double-stranded DNA antibodies compared to placebo, the clinical significance of which is unknown. Rarely, TNF inhibitors have been associated with lupus-like syndromes and vasculitis.

IMMUNIZATIONS. TNF inhibitors may lower the titer response to immunizations; however, the clinical significance of this observation is unknown. Most patients with psoriatic arthritis receiving etanercept were able to mount effective B-cell immune responses to pneumococcal polysaccharide vaccine. Live vaccines should not be used in patients taking TNF inhibitors.

HEMATOLOGIC EVENTS. Rare cases of serious hematologic events have been associated with TNF inhibitors.

PREGNANCY AND LACTATION. TNF inhibitors are pregnancy category B medications with unknown safety during lactation.

INFLIXIMAB Infliximab is a 149-kd monoclonal chimeric antibody that is FDA approved for the treatment of rheumatoid arthritis, psoriatic arthritis, and recalcitrant Crohn disease. It consists of a murine antigen binding region with specificity for human TNF-α fused to a human immunoglobulin G1 (IgG1) constant region. A phase III, double-blind, placebo-controlled trial in patients with psoriasis reported that 80 percent of patients treated with infliximab (5 mg/kg) achieved a Psoriasis Area and Severity Index 75 (PASI-75) at week 10.[55] Although infliximab has demonstrated marked clearing of psoriasis, several recent reports have suggested the potential for infliximab to induce or exacerbate psoriatic disease.[56] The mechanisms underlying this observation remain to be determined. Treatment of psoriatic patients, per clinical trials, has been dosed at 3 mg/kg or 5 mg/kg on weeks 0, 2, 6, and every 8 weeks thereafter.

Through its ability to neutralize both membrane-bound and soluble TNF-α, infliximab is believed to decrease cutaneous inflammation and promote keratinocyte differentiation in psoriatic plaques. In vitro studies also suggest that infliximab may promote disease improvement through an ability to induce apoptosis of lesional keratinocytes.[57]

By nature of its chimeric properties (i.e., possessing both murine and human components), infliximab may be targeted by the host immune system if the murine portion of its structure is identified as foreign.[58] Neutralizing antibodies generated against infliximab have been reported among patients treated for Crohn disease, rheumatoid arthritis, and psoriasis[55,59,60] The generation of neutralizing antibodies is associated with an increased risk of infusion reactions and with decreased efficacy. Strategies to decrease the formation of neutralizing antibodies include use of concomitant immunosuppressive medication (e.g., methotrexate), and regular (as opposed to intermittent) dosing of infliximab. Infliximab is also associated with the development of anti-nuclear antibodies and anti–double-stranded DNA antibodies, the clinical significance of which is unknown. (See Anti-Tumor Necrosis Factor-α for greater detail on indications, initiating and monitoring therapy, risks, precautions, and complications.)

ADALIMUMAB Adalimumab is a fully human, 148-kd monoclonal antibody against TNF-α that has exhibited clinical efficacy in the treatment of rheumatoid arthritis, psoriatic arthritis, and psoriasis. Similar to infliximab, it inhibits TNF-α signaling by binding to both soluble and cell-bound forms of this cytokine. Data from a phase II randomized, double-blind, placebo-controlled trial showed that more than 75 percent of patients with moderate to severe plaque psoriasis achieved a PASI-75 response after 12 weeks of treatment (at a dose of 80 mg qwk for the first two doses, followed by 40 mg qwk) compared to 4 percent of patients receiving placebo.[61] Injection site reactions occur with adalimumab; however, they are generally mild and self-limited. (See Anti-Tumor Necrosis Factor-α for greater detail on indications, initiating and monitoring therapy, risks, precautions, and complications.)

Antibodies Against Cell Surface Receptors

EFALIZUMAB Efalizumab is a recombinant humanized monoclonal IgG1 antibody against the α subunit of the leukocyte function–associated antigen 1 (LFA-1, CD11a). LFA-1 is a member of the β_2 integrin family and is involved in lymphocyte activation, enhanced cytotoxic T-cell function, and the trafficking of lymphocytes to the skin.[62] It recognizes the intercellular adhesion molecule 1 (ICAM-1) expressed on the surface of dermal endothelial cells, an interaction that mediates the firm adhesion, or "arrest," stage of lymphocyte trafficking. This stage is followed by the diapedesis, or migration, of cutaneous lymphocyte associated antigen expressing T cells into the cutaneous microenvironment. ICAM-1 is also expressed by antigen-presenting cells, and its engagement by LFA-1 serves as a co-stimulatory signal for T-cell activation.[63]

In both short- and long-term studies, efalizumab has exhibited efficacy in the treatment of patients with moderate-to-severe psoriasis. In one randomized, double-blind, phase III study, 27 percent of patients receiving efalizumab 1 mg/kg SC qwk) achieved a PASI-75 by week 12 (as opposed to 4 percent of the placebo group); this percentage increased to 44 percent by week 24.[64] Studies to evaluate the biologic activity of efalizumab demonstrated a reduction in LFA-1 cell surface expression by T cells, in addition to histologic improvement of skin lesions.[65,66] A decrease in cutaneous ICAM-1 expression and an increase in circulating lymphocytes has also been noted, suggesting a reduced ability of lymphocytes to traffic into the skin.

Indications. Efalizumab was approved by the FDA in October 2003 for the treatment of patients with moderate to severe plaques psoriasis who are candidates for systemic or phototherapy. It is not effective for the treatment of psoriatic arthritis. Recent case studies suggest the potential efficacy of efalizumab in the management of dermatologic conditions including atopic dermatitis, refractory subacute cutaneous lupus erythematosus, and dermatomyositis.[67–69]

Initiating Therapy and Monitoring. Efalizumab is administered SC as a 0.7 mg/kg initial conditioning dose, followed by weekly administration at a concentration of 1 mg/kg. Initial and periodic assessment of platelet counts and blood counts are recommended, given a risk for thrombocytopenia and hemolytic anemia. One may also consider screening for latent tuberculosis infection before initiating efalizumab; however, this is not currently required, based on FDA labeling.

Efalizumab is a pregnancy category C medication with unknown safety during lactation.

Risks, Precautions, and Complications. Flu-like symptoms have been reported among some patients after the first few doses; however, these symptoms are rare after the third dose, and the incidence can be lowered by starting with a conditioning dose. Exacerbation of psoriasis while on treatment, as well as rebound flares upon abrupt discontinuance of therapy, have also been reported. Patients may develop a mild localized breakthrough of psoriasiform skin lesions during treatment that typically respond well to topical steroids. However, serious flares have included the development of inflammatory, pustular, and erythrodermic psoriasis that occurred in 0.7 percent of patients in clinical trials.[70] Patients experiencing serious flares may require management with hospitalization, cyclosporine, methotrexate, or prednisone. Per packaging information [Raptiva (efalizumab), Genentech, Inc.], thrombocytopenia, hemolytic anemia, and arthritis may arise among some treated patients. In addition, efalizumab is not recommended among patients who are already receiving other immunosuppressive therapies, and acellular, live, and live-attenuated vaccines should not be administered during efalizumab treatment. Efalizumab is immunosuppressive, and therefore may theoretically be associated with a higher risk of infections and malignancies. Long-term studies in large numbers of treated patients are necessary to determine if efalizumab is associated with an increased risk of serious infections and malignancy.

RITUXIMAB Rituximab is a humanized chimeric monoclonal antibody against CD20, a cell surface protein expressed by mature and pre-B cells. CD20 expression is lost during the differentiation of B cells to plasma cells. Aside from playing a crucial role in antibody production, B cells may also serve as antigen-presenting cells and have been shown to provide co-stimulatory signals that promote $CD4^+$ T-cell expansion and effector cell function.[71]

Rituximab is FDA approved for the treatment of patients with moderate to severe rheumatoid arthritis and for the treatment of relapsed or chemorefractory (low-grade or follicular) $CD20^+$ non-Hodgkin B-cell lymphomas and has been shown to transiently reduce the population of $CD20^+$ cells in the circulation.[72] This effect is achieved by its ability to enhance antibody and complement-mediated cytotoxicity, and promote the apoptosis of malignant $CD20^+$ cells.[73] Aside from its role in the treatment of lymphoma and rheumatoid arthritis, rituximab has been increasingly used off-label for the management of other autoimmune diseases. More specifically, recent reports have proposed its efficacy in the treatment of paraneoplastic pemphigus, autoimmune hemolytic anemia, Wegener granulomatosis, hypocomplementemic urticarial vasculitis, systemic lupus erythematosus, cutaneous B-cell lymphoma, and epidermolysis bullosa acquisita.[74]

With regard to dermatologic disease, a case report of a patient with recalcitrant epidermolysis bullosa acquisita responsive to rituximab suggested an apparent increased susceptibility of autoantigen-specific $CD20^+$ B cells to the drug.[75] It has also been used in the treatment of refractory pemphigus.[76] Caution should be taken before initiating therapy with rituximab for off-label use. Recent reports have noted marked progression of Kaposi sarcoma among patients who have received rituximab for autoimmune hemolytic anemia and Castleman disease.[77,78]

Indications. Rituximab is FDA approved for the treatment of $CD20^+$ non-Hodgkin B-cell lymphomas and moderate to severe rheumatoid arthritis.

Initiating Therapy and Monitoring. No specific dosing regimen has been established for the off-label use of this medicine in the dermatologic setting. Rituximab is usually administered at a standard dose of 375 mg/m^2 body surface area at weekly intervals. Premedication with acetaminophen and antihistamines should be considered to decrease the risk for infusion reactions. Monitoring of blood cell counts and serum antibody levels may be pursued every 2 to 3 months while on therapy.

Rituximab is a pregnancy category C medication with unknown safety during lactation.

Risks, Precautions, and Complications. Reported adverse effects associated with rituximab therapy include infusion reactions, hepatitis B re-activation, tumor lysis syndrome, renal toxicity, mucocutaneous reactions, and bowel obstruction/perforation.

FUSION PROTEIN(S)

Alefacept

Alefacept is a bioengineered protein consisting of the human IgG1 antibody Fc region fused to the first extracellular domain of human LFA-3. LFA-3 is a member of the immunoglobulin superfamily and is expressed on the surface of antigen-presenting cells. It normally binds to CD2, which is preferentially expressed on the surface of effector/memory T cells, an interaction that plays an important role in the activation of T cells in response to antigen. Alefacept is believed to prevent the activation of T cells by blocking the interaction between LFA-3 and its CD2 ligand.[79] In addition, it may induce the apoptosis of memory T cells via binding of its IgG1 portion to the CD16 receptor of NK cells.[80]

INDICATIONS Alefacept was the first biologic agent approved for the treatment of psoriasis. It was FDA approved for the treatment of moderate to severe plaque stage psoriasis in January 2003 and has exhibited proven efficacy in the management of adult patients with chronic plaque stage disease. Studies have evaluated the efficacy of both intravenous and intramuscular dosing (7.5 mg intravenously qwk and 15 mg intramuscularly qwk); however, only the intramuscular form is commercially available at this time. A randomized, placebo-controlled phase III trial of adult patients with chronic plaque psoriasis involving at least 10 percent body surface area was performed to address the efficacy and safety of alefacept therapy (15 mg intramuscularly qwk) for 12 weeks.[81] A 75 percent or greater reduction in PASI was achieved by 21 percent of patients and, of those who achieved this degree of response, 71 percent maintained a PASI of at least 50 percent in the 12-week, follow-up period. No opportunistic infections or disease rebound was noted during follow-up.



Reports of the off-label use of alefacept in the treatment of other inflammatory dermatoses such as graft-versus-host disease, lichen planus, and alopecia areata have been described.[82,83] Alefacept has also shown promise in the treatment of psoriatic arthritis either as monotherapy or in combination with methotrexate; however, additional studies are necessary to determine if alefacept is indicated for psoriatic arthritis.[84,85]

INITIATING THERAPY AND MONITORING Alefacept is contraindicated in patients with human immunodeficiency virus infection and should not be used in patients with a $CD4^+$ T lymphocyte count that is below normal. On the basis of published studies and manufacturer recommendations, alefacept treatment is typically initiated as a 15 mg intramuscular dose administered on a weekly basis for 12 weeks, followed by a 12-week period of non-treatment observation. On the basis of a recent study, improved efficacy may be achieved by increasing the initial treatment course to 16 weeks.[86] Phase III clinical trials have shown increased efficacy of alefacept with successive courses of treatment (up to five courses) with no observed compromise in safety or tolerability.[87,88]

Upon initiation of therapy, CD4 and CD8 T-cell counts should be monitored every 2 weeks, and treatment should be withheld if the CD4 count drops below 250 cells/μL, and CD4 counts should then be monitored weekly. If counts remain below this level for more than 4 weeks, then treatment should be discontinued. In general, treatment should not be initiated in patients with low $CD4^+$ T-cell counts or an active infection within 2 weeks of therapy. Consideration of therapy among patients with a history of a prior malignancy should be pursued with caution.

Alefacept is a pregnancy category B medication with unknown safety during lactation.

RISKS, PRECAUTIONS, AND COMPLICATIONS Alefacept is well tolerated with a limited side-effect profile. Pooled data from randomized controlled trials revealed a low incidence of malignancy among treated patients, which was similar to untreated patients. Chills, however, were more common among patients receiving intravenous alefacept relative to placebo.[89] Abnormalities in liver function tests were more frequent in alefacept-treated patients compared to placebo, and serious liver reactions have been reported in the post-marketing arena. Therefore, patients with signs or symptoms of liver injury should be fully evaluated. No correlation between $CD4^+$ T-cell counts and infection has been reported. $CD4^+$ T-cell mediated antibody responses remain intact among treated individuals.[90] Long-term follow-up studies will be necessary to determine if the immunosuppressive properties of alefacept increase the risk of serious infections and malignancies.

Etanercept

Etanercept is a fusion protein consisting of the human TNF type II receptor linked to a human IgG1 Fc region. It blocks the effects of TNF-α by binding to it in the circulation, thus preventing it from associating with its cell surface receptor. In a double-blind, placebo-controlled study, 49 percent of psoriatic patients treated with high-dose etanercept (50 mg twice weekly) for 12 weeks achieved a PASI of at least 75, whereas only 4 percent of patients in the placebo group attained this result.[91] Continued clinical improvement was noted in the subsequent weeks, with 59 percent of high-dose etanercept-treated patients achieving a PASI of 75. It is recommended that therapy for psoriasis be initiated at a dose of 50 mg SC 2×/wk for 12 weeks, then reduced to 50 mg qwk (or 25 mg SC twice weekly). The median time to relapse after discontinuation of therapy after 6 months is estimated at 70 to 91 days.[92] Injection site reactions may occur with etanercept; however, they are generally mild and self limited. (See Anti-Tumor Necrosis Factor-α for greater detail on indications, initiating and monitoring therapy, risks, precautions, and complications.)

Denileukin Diftitox

Denileukin diftitox (DAB389-IL2) is a ligand-toxin fusion protein consisting of a fragment of diphtheria toxin, which is involved in translocation and adenosine diphosphate-ribosyltransferase activity, fused to IL-2. DAB389-IL2 is believed to associate with malignant cells expressing the high affinity IL-2 receptor. Upon binding to the receptor, it is internalized within an endosome. It is within this setting that its adenosine diphosphate-ribosyltransferase region is cleaved and translocated into the cytoplasm where it interrupts protein synthesis, eventually leading to apoptosis of the affected cell. Because of its ability to deplete $CD25^+$ T-cells, DAB389-IL2 is believed to contribute toward antitumor immunity through its potential to eliminate regulatory T cells, a specialized population of $CD25^+$ T-cells with immune suppressing properties, in addition to malignant cells that express the CD25 component of the IL-2 receptor.

CD25 represents the α chain of the IL-2 receptor. It serves both as a marker for activated T cells, as well as for a unique population of $CD4^+$ T cells that express the transcription factor, FoxP3, called *regulatory T cells* ($CD4^+CD25^+FoxP3^+$). Naturally occurring regulatory T cells exhibit immunosuppressive properties and have been shown to play an important role in the induction of immune tolerance. Murine melanoma models indicate a role for regulatory T cells in suppressing antitumor immunity.[93] In addition, the in vivo use of anti-CD25 specific antibody was shown to deplete regulatory T-cell populations and enhance tumor regression in the murine system.[94]

In a phase III, double-blind, placebo-controlled study, patients with advanced or refractory CTCL were randomized to receive DAB389-IL2 by infusion at doses of 9 μg/kg/day or 18 μg/kg/day.[97] All patients had failed at least one prior therapy (the median number of prior therapies was five) and were shown to have at least 20 percent CD25 expression among tumor cells in the skin. Treatment was administered for 5 consecutive days and was repeated every 3 weeks for up to eight treatment cycles. Intent to treat analysis revealed a 30 percent clinical response rate among all treated patients, characterized by a ≥ 50 percent reduction in tumor burden. Ten percent of patients achieved a complete clinical response characterized by no evidence of cutaneous disease. The majority of patients exhibited a clinical response within the first three treatment cycles. The durability of response was higher among complete responders with a median of nine months. The median duration of response among partial responders was 4 months. No statistically significant difference in response was noted between the two dosing groups.

INDICATIONS DAB389-IL2 is FDA approved for the treatment of CTCL in which the malignant cell population expresses the CD25 receptor.

INITIATING THERAPY AND MONITORING DAB389-IL2 is administered intravenously over at least 15 minutes. Doses at 9 μg/kg/day and 18 μg/kg/day have been used for the treatment of CTCL.

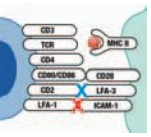

DAB389-IL2 is a pregnancy category C medication with unknown safety during lactation.

RISKS, PRECAUTIONS, AND COMPLICATIONS Infusion-associated hypersensitivity reactions represent the most common adverse effect associated with DAB389-IL2 treatment. Such reactions have been characterized by fever, hypotension, arthralgias, dyspnea, rash, and chest/back tightness. DAB389-IL2 has also been associated with flu-like symptoms, a reversible transaminitis, vascular leak syndrome, and a morbilliform cutaneous eruption. DAB389-IL2 is contraindicated among patients with a known hypersensitivity to any of its components.

CONCLUSION

In this chapter, we have discussed a number of biologic agents currently available for the management of dermatologic disease. As we further characterize the immunopathogenesis of cutaneous disease, new potential targets for therapy may be identified, thus improving our ability to treat conditions that may otherwise be poorly responsive to conventional therapies. Targeting of the immune system with biologics may result in an increased risk of serious infections and malignancies. Large, prospective, long-term, follow-up studies will be necessary to fully describe the safety of these agents. Additionally, immunobiologics require complex manufacturing processes and are generally very expensive, which may limit their use.

ACKNOWLEDGMENT

The authors would like to thank Dr. Alain H. Rook for his insight and useful discussions in the preparation of this chapter.

KEY REFERENCES

The full reference list for all chapters is available at www.digm7.com.

2. Rook AH, Kuzel TM, Olsen EA: Cytokine therapy of cutaneous T-cell lymphoma: Interferons, interleukin-12, and interleukin-2. *Hematol Oncol Clin North Am* **17**:1435, 2003
3. Holman DM, Kalaaji AN: Cytokines in dermatology. *J Drugs Dermatol* **5**:520, 2006
24. Vaquerano JE et al: Regression of intransit melanoma of the scalp with intralesional recombinant human granulocyte-macrophage colony-stimulating factor. *Arch Dermatol* **135**:1276, 1999
28. Chaperot L et al: Differentiation of antigen-presenting cells (dendritic cells and macrophages) for therapeutic application in patients with lymphoma. *Leukemia* **14**:1667, 2000
31. Smiell JM: Clinical safety of becaplermin (rhPDGF-BB) gel. Becaplermin Studies Group. *Am J Surg* **176**:68S, 1998
34. Gottlieb AB et al: Pharmacodynamic and pharmacokinetic response to antitumor necrosis factor-alpha monoclonal antibody (infliximab) treatment of moderate to severe psoriasis vulgaris. *J Am Acad Dermatol* **48**:68, 2003
46. Alexis AF, Strober BE: Off-label dermatologic uses of anti-TNF-α therapies. *J Cutan Med Surg* **9**:296, 2005
63. Saini R, Tutrone WD, Weinberg JM: Advances in therapy for psoriasis: An overview of infliximab, etanercept, efalizumab, alefacept, adalimumab, tazarotene, and pimecrolimus. *Curr Pharm Des* **11**:273, 2005
73. Cerny T et al: Mechanism of action of rituximab. *Anticancer Drugs* **13**:S3, 2002
74. Edwards JC et al: Efficacy of B-cell-targeted therapy with rituximab in patients with rheumatoid arthritis. *N Engl J Med* **350**:2572, 2004
97. Olsen E et al: Pivotal phase III trial of two dose levels of denileukin diftitox for the treatment of cutaneous T-cell lymphoma. *J Clin Oncol* **19**:376, 2001

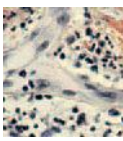

CHAPTER 236

Anti-Angiogenic Agents

Kalpana Reddy
Jack Arbiser

In 1971, Judah Folkman published a landmark paper that hypothesized that all tumor growth is dependent on angiogenesis and hypothesized that inhibitors of angiogenesis could be used to treat cancers: The field of angiogenesis research was born.[1]

Anti-angiogenic drugs can be classified as either "direct" or "indirect," the former acting directly on untransformed endothelial cells to prevent proliferation, migration, or survival, which normally occurs upon stimulation by pro-angiogenic molecules, and the latter inhibiting tumor-produced oncogene protein products that promote pro-angiogenic state. Angiogenesis inhibitors are a promising new class of drugs because they are effective against slow-growing tumors, while traditional therapies, such as chemotherapy and radiation, work best on rapidly dividing cells. In the future, patients with clinically undetectable cancers may be able to stop the switch to an angiogenic phenotype, and thus prevent disease progression, by using therapies directed, in part, by angiogenesis biomarkers.[2,3] Fig. 236-1 shows the key points of action of some of the anti-angiogenic drugs discussed in this chapter in normal skin, pre-cancerous lesions, and malignancy.

BEVACIZUMAB (AVASTIN)

Mechanism of Action

Bevacizumab is a recombinant, humanized, immunoglobulin G1 monoclonal antibody against vascular endothelial growth factor (VEGF). VEGF is a

ANTI-ANGIOGENIC AGENTS AT A GLANCE

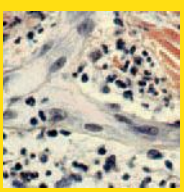

- "Direct" anti-angiogenic agents act directly on untransformed endothelial cells to prevent proliferation, migration, and survival.
- "Indirect" anti-angiogenic agents inhibit tumor-produced oncogene proteins that promote a pro-angiogenic state.
- Anti-angiogenic agents are a promising new class of drugs because they are effective against slow-growing tumors.

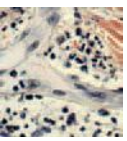

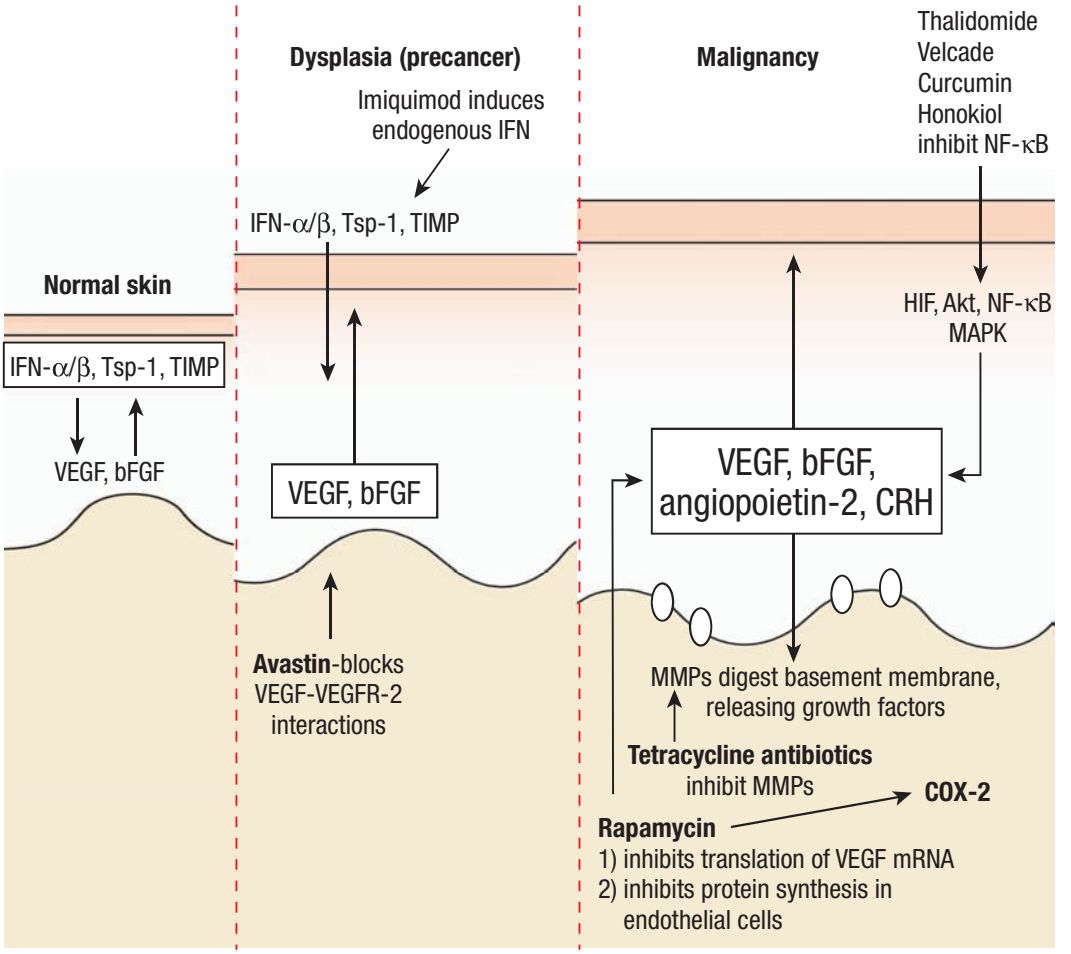

▲ **FIGURE 236-1** Schematic depiction of the key points of action of some of the anti-angiogenic drugs discussed in this chapter in normal skin, pre-cancerous lesions, and malignancy. bFGF = basic fibroblast growth factor; COX-2 = cyclooxygenase 2; CRH = corticotropin-releasing hormone; HIF = histoplasma inhibitory factor; IFN = interferon; MAPK = mitogen-activated protein kinase; MMP = matrix metalloproteinase; mRNA = messenger RNA; NF-κB = nuclear factor κB; TIMP = tissue inhibitor of metalloproteinases; Tsp-1 = thrombospondin 1; VEGF = vascular endothelial growth factor; VEGFR-2 = vascular endothelial growth factor receptor 2.

growth factor that promotes angiogenesis by supporting endothelial cell replication and survival. This potent pro-angiogenic molecule is upregulated in a majority of human tumors and alters tumor vasculature.

Binding of bevacizumab to VEGF is direct and specific. The antibody also competitively binds VEGF receptor 1 (VEGFR-1) and VEGFR-2, preventing VEGF from binding to its receptors and initiating the signaling cascade. Bevacizumab also reduces and normalizes tumor vascularity.[4]

Indications

Bevacizumab was the first anti-angiogenesis drug approved by the U.S. Food and Drug Administration (FDA) in February 2004 for the first-line treatment of patients with metastatic carcinoma of the colon or rectum, when given in combination with intravenous 5-fluorouracil-based chemotherapy. Bevacizumab is currently being investigated in clinical trials for use in other advanced cancers such as malignant melanoma. No known contraindications to bevacizumab therapy exist.[5]

Complications

- Gastrointestinal perforation
- Wound dehiscence (Incisions should be healed completely before treatment initiation)
- Serious hemorrhagic events
- Arterial thromboembolic events[6]

INTERFERON-α 2B

Interferon-α (IFN-α) made history in 1988 as the first anti-angiogenic therapy used in humans, for the successful treatment of pulmonary hemangiomatosis in a pediatric patient. IFN-α 2b is a product of recombinant molecule and has similar actions to its natural endogenous counterpart, α-IFN, a type I IFN produced naturally by the immune system.

Mechanism of Action

The IFNs act by binding to their receptor, resulting in signal transduction through the Janus kinase-signal transducers and activators of transcription (Jak-STAT) pathway. IFN-α, which is both a direct and indirect anti-angiogenic agent, was first discovered to impair capillary endothelial cell migration. Its properties as an indirect anti-angiogenic agent include its ability to decrease tumor cell production of basic fibroblast growth factor (bFGF), which may explain its success in treating hemangiomas, which overexpress this pro-angiogenic factor.[3]

IFN-α has a well known antiviral activity and antitumor activity, which may be mediated in part by upregulating major histocompatibility complex class I antigen expression, activating natural killer cells, controlling progres-

sion through cell cycle checkpoints, and activating apoptosis.

Pharmacokinetics

IFN-α 2b is given by subcutaneous, intramuscular, intravenous, or intralesional routes. Its half-life is 2 to 3 hours. The drug is likely metabolized by the kidneys. Polyethylene glycol IFN-α 2b has a 10-fold increase in the half life, decreased toxicity, and increased compliance.[7]

Indications

Infections:

- Chronic hepatitis B (may be chemopreventive against hepatocellular carcinoma)
- Chronic hepatitis C
- Acquired immunodeficiency syndrome (AIDS)–associated Kaposi sarcoma
- Condylomata acuminata

Malignancies:

- Malignant melanoma (adjuvant to surgical therapy in patients at high risk of systemic recurrence; must be administered within 56 days postoperatively)
- Hairy cell leukemia
- Follicular lymphoma

Contraindications

- Hypersensitivity to IFN-α or any drug components
- Combination IFN-α and ribavirin therapy in pregnancy or in males whose female partners are pregnant, or in autoimmune hepatitis. Sarcoidosis has been observed in patients who are on combined IFN-α–ribavirin therapy.

Dosing Regimen (Table 236-1)

TABLE 236-1
Interferon-α 2b Dosing

DISEASE	DOSE
Malignant melanoma high-dose regimen	Induction: 20 million IU/m^2 IV infusion, 5 consecutive days/wk for 4 wk Maintenance: 10 million IU/m^2 SC three times/wk for 48 wk
Malignant melanoma adjuvant low-dose regimen (in clinical trials)	Maintenance: 3 million U SC three times/wk for 1 yr
Acquired immunodeficiency syndrome–related Kaposi sarcoma	30 million IU/m^2 SC or IM three times/wk until disease progression or maximal response has been achieved after 16 wk
Condylomata acuminata	1 million IU per lesion (maximum of five lesions per course) three times/wk on alternate days for 3 wk May administer a second course at 12–16 wk
Hemangiomas	3 million U/m^2/day for at least 6 mo[8]

Initiating Therapy

Hemoglobin, complete blood cell count with differential, electrolytes, liver function tests, thyroid-stimulating hormone, chest x-ray, and eye examination should be obtained before initiation of and during therapy. Patients with prior cardiac disease or advanced cancer require an electrocardiogram. Therapy should not be initiated in patients with a history of depression or severe psychiatric disorder due to the risk of psychiatric symptoms and suicide. Patients with thyroid disorder that cannot be corrected with medication should not be treated. The development of paraplegia in hemangioma patients taking IFN has been noted; however, more recently, these patients were found to be severely hypothyroid due to the presence of ectopic thyroxin degrading enzymes produced by the hemangioma. Thus, thyroid monitoring should be mandatory in all patients with large hemangiomas.

Monitoring Therapy

Treatment should be discontinued if neutrophil counts reach less than 0.5×10^9/L or platelet counts reach less than 25×10^9/L. Other symptoms warranting discontinuation include new-onset or worsening eye symptoms, the development of thyroid dysfunction uncorrectable by medication, and the development of severe depression or other psychiatric disorder during therapy.

Risks and Precautions

Pregnancy category C.

Complications

FLU-LIKE SYMPTOMS Symptoms such as headache, fatigue, fever, chills, myalgia, and anorexia are common during therapy.

DEPRESSION IFN-α therapy can result in new-onset depression or worsen preexisting depression. Patients should be monitored during therapy for severe depression, and therapy should be discontinued if necessary.[9]

THALIDOMIDE (THALOMID)

Thalidomide was first released in Europe and several other regions in the late 1950s and quickly became a popular sedative, frequently used for the treatment of nausea in pregnancy. Thalidomide was not approved in the United States at the time due to its questionable safety in pregnancy and evidence of peripheral neuropathy. The drug was, however, approved for use in clinical trials in the United States and was given to more than 1000 physicians in the United States for this purpose before it was banned as a sedative after the discovery that the drug caused severe embryopathy, resulting in phocomelia, amelia, or other severe birth defects when taken during pregnancy. The world's tragic experience with thalidomide prompted dramatic changes in drug regulation and approval.

In 1965, Sheskin prescribed thalidomide for psychosis in one of his patients and accidentally discovered that thalidomide effectively treated her erythema nodosum leprosum (ENL). The FDA approved thalidomide in 1998 for the treatment of ENL and currently classifies thalidomide as an orphan drug.

As interest in thalidomide's ability to treat a wide variety of refractory diseases grows, a promising class of drugs named *ImiDs®* or *immunomodulatory thalidomide analogues*, has come under development and testing. One member of this new class of drugs, lenalidomide (CC-5013, REVLIMID®), is being tested in clinical trials for the treatment of multiple myeloma, myelodysplastic syndromes, and chronic lymphocytic leukemia. Phase III clinical studies of lenalidomide for the treatment of metastatic Malignant melanoma did not show a significant effect.[10]

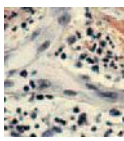

Mechanism of Action

Thalidomide exhibits a wide range of effects in vitro and in vivo. Its mechanisms of action are still under investigation. The drug decreases tumor necrosis factor-α (TNF-α) and IFN-γ levels, as well as having other immunomodulatory effects. Treatment reduces inflammation and pain in ENL patients, as well as neuritis, iritis, and iridocyclitis. Thalidomide also has anti-angiogenic properties and inhibits bFGF-mediated angiogenesis. Its anti-angiogenic properties may be the basis for its antineoplastic activity and may also contribute to its teratogenicity.[11] Other mechanisms by which thalidomide acts include hypnosedative actions, immunomodulation, and anti-inflammatory actions. Effects on the immune system include a reduction in helper T cell–suppressor T-cell ratio, decreased leukocyte chemotaxis and monocyte phagocytosis, decreased production of several cytokines including TNF-α, interleukin 4 (IL-4), IL-5, and IFNs. Human keratinocytes have increased migration and proliferation with thalidomide treatment.

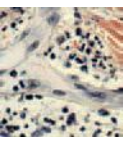

Pharmacokinetics

Thalidomide has low water solubility and slow absorption from the gastrointestinal tract, reaching peak plasma levels 5 hours after administration, and it is only available in an oral form. A delay in absorption of up to 2 hours may occur if given in conjunction with high-fat foods.

Thalidomide's half-life is 10 hours. The total body clearance is estimated to be 10 L/hour. Thalidomide's main route of elimination remains unknown. Thalidomide is metabolized by nonenzymatic hydrolysis, and therefore is unlikely to affect levels of cytochrome P_{450}-metabolized drugs such as oral contraceptives. Acetylcholine, prostaglandins, histamine, and serotonin are antagonized by thalidomide in vitro. Alcohol, barbiturates, chlorpromazine, and reserpine have enhanced activity in the presence of thalidomide.

Indications

Thalidomide was FDA approved for the acute treatment of the cutaneous manifestations of moderate to severe ENL and has also been approved for maintenance therapy for prevention and suppression of the cutaneous manifestations of ENL recurrence. All other uses are considered experimental.

TABLE 236-2
Thalidomide Dosing for Selected Dermatologic Diseases

Erythema nodosum leprosum	Initial dose: 100–300 mg/day Maintenance dose: 50–100 mg/day
Severe cutaneous erythema nodosum leprosum reaction	Initial dose: 400 mg/day
Chronic graft-versus-host disease	Initial dose: 100 mg qid Maintenance dose: 200–400 mg qid Pediatric dose: 3.0–9.5 mg/kg bid to qid
Cutaneous lupus erythematosus	Initial dose: 400 mg/day Maintenance dose: 25–50 mg/day
Recurrent aphthous stomatitis	100 mg/day
Behçet syndrome	Initial dose: 400 mg/day Maintenance dose: 200 mg/day[12]

A common off-label use of thalidomide is for the treatment of severe aphthous stomatitis, especially in AIDS patients. Although the precise inciting cause of aphthous stomatitis remains unknown, the stomatitic lesion is highly angiogenic and expresses high levels of VEGF and VEGFR-2 and TNF-α. The coexistence of TNF-α and angiogenesis in the same lesion is reminiscent of psoriasis as well as ENL. Thalidomide has activity against a variety of inflammatory angiogenic conditions, perhaps through a common mechanism.

Contraindications

- Pregnancy
- Hypersensitivity to the drug or its components

Dosing Regimen

Guidelines for dosing include initiation at 100 to 300 mg/day with water at bedtime because thalidomide may induce drowsiness. Therapy should be continued until improvement is noted, at which point the physician can begin tapering the dose by 50 mg every 2 to 4 weeks. In the case of maintenance therapy, an attempt at tapering should occur every 3 to 6 months (Table 236-2).

Initiating Therapy

Thalidomide therapy should be reserved for patients with debilitating, serious diseases that have proved to be refractory to other therapies. The manufacturer of thalidomide has developed a restricted distribution program called *System for Thalidomide Education and Prescribing Safety* (S.T.E.P.S®). The program requires both prescribers and dispensing pharmacists to be registered, and it is mandatory for patients to be informed about the program and adhere to its requirements. Female patients of childbearing potential (defined by the program as sexually mature women who have not undergone a hysterectomy or who have not been post-menopausal for at least 24 consecutive months) must have a negative pregnancy test within 24 hours of treatment initiation. Patients must use reliable contraception (two effective methods unless using the abstinence method) for a period of at least 1 month before initiating therapy and must continue this practice during and for 1 month after therapy is completed. Male patients are required to use latex condoms, even in patients who have had a vasectomy.

Monitoring Therapy

S.T.E.P.S® requires patient monitoring during therapy. Strict guidelines for pregnancy testing are outlined for females of childbearing potential to prevent potential fetal damage, and guidelines are given for male patients as well. If, during the course of therapy, a patient becomes pregnant, the drug should be immediately stopped and the exposure reported to the FDA and the manufacturer (Celgene). Patients should then see an obstetrician/gynecologist with experience in reproductive toxicity.

Risks and Precautions

- Hypersensitivity
- Bradycardia
- Stevens-Johnson syndrome and toxic epidermal necrolysis
- Seizures
- Pregnancy category X

Complications

TERATOGENICITY Thalidomide's embryopathy is well-documented. Thalidomide is pregnancy category X, and patients selected for therapy must follow strict contraceptive measures as directed by the program. Thalidomide-induced defects in limb formation may be due to bFGF inhibition, as bFGF has been shown to induce embryologic limb formation.

PERIPHERAL NEUROPATHY Thalidomide is neurotoxic and may result in a sensory, symmetrical distal polyneuropathy, which may later evolve to include motor symptoms as well. Neurotoxicity can be permanent. Incidence of peripheral neuropathy in patients receiving thalidomide ranges from 0.5 percent to 25.0 percent. Patients with pre-existing peripheral neuropathy should not begin treatment. Baseline nerve conduction studies should be obtained before treatment initiation, with monitoring at 6-month intervals during treatment. A 40 percent decrease in nerve conduction necessitates treatment discontinuation.

OTHER SIDE EFFECTS Other side effects include drowsiness, orthostatic hypotension, neutropenia, rash, fever, and human immunodeficiency virus viral load increase.[12,13]

RAPAMYCIN (SIROLIMUS) (See Chap. 234)

Mechanism of Action

Isolated from the bacterium *Streptomyces hygroscopicus*, rapamycin is a macrocyclic lactone antibiotic with immunosuppressant, antifungal, and antineoplastic properties. Rapamycin acts by inhibiting the interaction of the mammalian target of rapamycin (mTOR) with its substrates, thereby disrupting the signaling pathway. mTOR is a serine-threonine protein kinase activated by several growth factors after receptor-binding. mTOR activates downstream targets that affect cell cycle control and angiogenesis in neoplastic cells.[14] Rapamycin has been shown to significantly inhibit vascular endothelial cell stimulation by VEGF and inhibits bFGF-mediated angiogenesis.[15] Of the drugs used in the solid organ transplant setting (rapamycin, cyclosporine, tacrolimus), rapamycin has the greatest anti-angiogenic activity, and it may be useful for the prevention of squamous cell carcinoma and lymphoma in the transplant population, especially because chronic use of cyclosporine and tacrolimus are risk factors for cancer development.

Indications

Rapamycin is an FDA-approved drug used as an immunosuppressant to prevent renal transplant rejection, as well as an agent in drug-eluting cardiac stents to prevent restenosis after coronary artery angioplasty. It is currently in clinical trials as an anti-angiogenic agent for cancer therapy and is being studied for the treatment of psoriasis, tuberous sclerosis, and lymphangioleiomyomatosis.

Complications

SYSTEMIC COMPLICATIONS Complications that may occur include headache, thrombocytopenia, arthralgia, interstitial pneumonitis, and hypercholesterolemia.[14]

CUTANEOUS EFFECTS Cutaneous side effects of therapy include angioedema, leukocytoclastic vasculitis, xerosis, and aphthous ulceration, which all resolve with discontinuation of therapy.[16]

BECAPLERMIN

Chronic wounds have become increasingly prevalent in recent years with the rise in diabetes and the increasingly aging population. Treatment of these wounds is particularly challenging because the normal wound-healing process has been disrupted in these patients.

Mechanism of Action

Becaplermin [recombinant human platelet-derived growth factor (PDGF) BB] is the first FDA-approved angiogenesis-stimulating therapy. Endogenous PDGF is chemotactic for several cell types necessary for wound healing. PDGF is also a mitogen for fibroblasts, which produce the extracellular matrix components glycosaminoglycans and fibronectin. Thus, PDGF is an important factor in the formation of granulation tissue.

Indications

Becaplermin gel is indicated for the treatment of lower extremity diabetic neuropathic ulcers. The ulcers must be adequately oxygenated and must reach to at least the subcutaneous tissue.[17] Becaplermin gel is contraindicated in patients with known cancer in the treatment area.

Dosing Regimen

Becaplermin gel should be applied topically once daily. The dose should be recalculated every 1 to 2 weeks to ensure accurate dosing as the wound changes size. Becaplermin gel should be used along with proper ulcer care.

Monitoring Therapy

If there is less than a 30 percent decrease in size after 10 weeks or if the wound has not completely healed after 20 weeks of treatment, the treatment plan should be re-evaluated.

Risks and Precautions

Because becaplermin gel is non-sterile, it should not be applied to wounds closed by primary intention. Becaplermin gel is pregnancy category C.

Complications

- Hypersensitivity reaction
- Ulcer-related complications (incidence was similar in becaplermin vs. placebo groups)[18]

BORTEZOMIB

Mechanism of Action

Bortezomib is the first proteasome inhibitor to gain FDA approval. This novel class of drugs acts by impairing the ability of the proteasome to degrade a variety of ubiquitinated proteins. Proteasome inhibitors may promote a pro-apoptotic state by preventing the degradation of tumor-suppressor proteins, such as p53, and other proteins, such as inhibitors of nuclear factor κB (NF-κB), which negatively regulates NF-κB. NF-κB upregulates the transcription of genes involved in neoplastic progression, including VEGF.[19] Bortezomib is being studied for use in both hematologic and solid malignancies in combination with chemotherapy and radiation regimens because it has been shown to decrease chemoresistance, which is correlated with NF-κB activity. Bortezomib also acts directly to inhibit VEGF, IL-6, insulin-like growth factor 1, angiopoietin 1, and angiopoietin 2 transcription.[20]

Indications

Recurrent or refractory multiple myeloma.

Contraindications

Hypersensitivity to bortezomib, boron, or mannitol.[21]

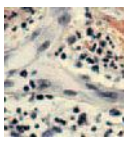

TABLE 236-3
Anti-Angiogenic Properties of Selected Experimental Drugs

DRUG	ANTI-ANGIOGENIC EFFECTS
Curcumin (diferuloylmethane)	Decreases pro-angiogenic factors, decreases endothelial cell proliferation, decreases neovascularization[26,27]
Calcium dobesilate	Binds and antagonizes basic fibroblast growth factor[28]
Honokiol	Inhibits VEGFR-2 autophosphorylation, blocks activation of Rac (necessary for endothelial cell migration and proliferation) in response to vascular endothelial growth factor[29]
Interleukin 12	Decreases basic fibroblast growth factor-mediated angiogenesis, stimulates natural killer cells to exhibit cytotoxicity against endothelial cells, acts through interferon-γ to induce interferon-inducible protein 10, an anti-angiogenic chemokine, and downregulates matrix metalloproteinase synthesis[8,30]
BAY 43-9006 (Sorafenib)	Receptor tyrosine kinase inhibitor which inhibits multiple tyrosine kinases, including Raf, VEGFR-2, VEGFR-3, platelet-derived growth factor receptor-β, FLT-3, and c-kit kinases[31]

VEGFR = vascular endothelial growth factor receptor.

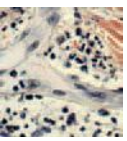

IMIQUIMOD (See Chap. 221)

Mechanism of Action

Imiquimod is both the first immune response modifier and the first topical anti-angiogenic agent for dermatologic use. Imiquimod acts by inducing the activation of Toll-like receptor 7 in immune cells. Toll-like receptor 7 activation enhances the natural immune response by increasing endogenous IFN and IL production, including IFN-α, IFN-β, IFN-γ, IL-10, IL-12, and IL-18. These cytokines also function as endogenous angiogenesis inhibitors, and the upregulation of these cytokines, as well as other endogenous angiogenesis inhibitors, such as IFN-inducible protein 10, tissue inhibitor of metalloproteinases, and thrombospondin 1, is the basis for imiquimod's anti-angiogenic activity. Imiquimod also downregulates pro-angiogenic factors such as bFGF and matrix metalloproteinase 9. In vivo, imiquimod has been shown to inhibit angiogenesis in human bowenoid papulosis, hemangioendothelioma, cutaneous melanoma, and murine lung sarcoma cells. Imiquimod is FDA approved to treat actinic keratosis, superficial basal cell carcinoma, and external genital warts. It is being studied as an experimental therapy for the treatment of angiogenic dermatologic conditions such as squamous cell carcinoma, lentigo maligna, hemangiomas, Kaposi sarcoma, and pyogenic granuloma (Table 236-3).[22–25]

KEY REFERENCES

The full reference list for all chapters is available at www.digm7.com.

1. Folkman J: Tumor angiogenesis: Therapeutic implications. *N Engl J Med* **285**:1182,1971
3. Kerbel R, Folkman J: Clinical translation of angiogenesis inhibitors. *Nat Rev Cancer* **2**:727, 2002
8. Arbiser JL: Antiangiogenic therapy and dermatology: A review. *Drugs of Today* **33**:687, 1997
11. D'Amato RJ et al: Thalidomide is an inhibitor of angiogenesis. *Proc Natl Acad Sci U S A* **91**:4082, 1994
14. Rao RD, Buckner JC, Sarkaria JN: Mammalian target of rapamycin (mTOR) inhibitors as anti-cancer agents. *Curr Cancer Drug Targets* **4**:621, 2004
17. Goldman R: Growth factors and chronic wound healing: Past, present, and future. *Adv Skin Wound Care* **17**:24, 2004
19. Ludwig H et al: Proteasome inhibition and its clinical prospects in the treatment of hematologic and solid malignancies. *Cancer* **104**:1794, 2005

CHAPTER 237

Drug Interactions

Stephen E. Wolverton

DRUG INTERACTION PRINCIPLES

The topic of drug interactions is strikingly complex and rapidly evolving. Even "experts" in this area of pharmacology must rely on print and electronic resources pertaining to drug interactions on a regular basis. With these facts in mind, this chapter focuses on a wide variety of principles, with selected drug interactions utilized to illustrate these principles, as opposed to providing extensive lists of potential drug interactions. Furthermore, there is an attempt to provide a stratification of risk, putting the greatest emphasis on the drug interactions with the greatest risk to individual patients. The electronic version has much more detail and references. The print edition emphasizes useful summary tables.

Definitions

The most basic definition of a drug interaction is when two drugs are present simultaneously in a patient, and one drug alters the other's serum/tissue levels or mechanism of action.

Print and Electronic Resources

Through learning key principles that assist in attaining the broadest possible understanding of the multitudes of potential interactions, a clinician may best be able to interpret and react to new clinician situations involving potential drug interactions. One should always attempt to make things "make sense" using the general principles that follow. It is always acceptable to (1) call a drug information pharmacist, (2) call or e-mail an expert in drug interactions, or (3) look up possible interactions in various print and electronic resources. Selected resources for drug interactions are listed in Table 237-1.

P-Glycoprotein

PHARMACOKINETIC AND PHARMACODYNAMIC DRUG INTERACTIONS[1]

Definitions

All drug interactions can be divided into either pharmacokinetic or pharmacodynamic interactions, whether they are an adverse drug interaction or an interaction without loss of drug efficacy or the onset of new toxicity. Pharmacokinetics deals with "what the body does to the drug," whereas pharmacodynamics deals with "what the drug does to the body."

TABLE 237-1
Databases for Information on Drug Interactions

Database Sources	Format	Additional Information
Indiana University Department of Medicine	Electronic	http://www.drug-interactions.com
Epocrates	Electronic	http://epocrates.com. Both PDA and desktop/laptop versions
The Medical Letter of Drugs and Therapeutics	Print/electronic	Medical Letter Drug Interaction program: http://www.medletter.com
Facts & Comparisons	Electronic	CliniSphere 2.0 CD-ROM
Hansten & Horn's Top 100 Drug Interactions	Print	Textbook: Hansten PD, Horn JR: *The Top 100 Drug Interactions: A Guide to Patient Management*, 2006 ed. Freeland, WA, H & H Publications, LLP, 2006

Various Sub-Types of Pharmacokinetic Drug Interactions

Pharmacokinetic drug interactions are much more common than pharmacodynamic drug interactions. This category of interactions results from alterations in a drug's serum and/or tissue levels. The ADME model (see Sub-Types of Metabolic Drug Interactions) of studying pharmacokinetics pertains to this category of interactions. The steps from entry of the drug into the body until excretion of the drug and/or its metabolites include (1) *a*bsorption, (2) *d*istribution, (3) *m*etabolism, and (4) *e*xcretion. The importance of each of these steps is detailed elsewhere.[2,3] Examples of drug interactions involving each of these steps are included in Table 237-2.

Various Sub-Types of Pharmacodynamic Interactions

Pharmacodynamic drug interactions are much less common than pharmacokinetic drug interactions. This category of interactions deals with alterations in the mechanism of either the desired pharmacologic effect or mechanism for an adverse effect. The drug levels are not of central importance in this category of interactions. The two primary sub-types of interactions include (1) agonist—similar "polarity" of the pharmacologic effects for the two interacting drugs, and (2) antagonist—opposite "polarity" of the pharmacologic effects for the two interacting drugs. Both agonist and antagonist interactions can produce either a positive (improved therapeutic response or safety) or negative (toxicity) biologic response. Selected examples to illustrate this innately confusing terminology are listed in Table 237-3.

Sub-Types of Metabolic Drug Interactions

Isoforms of Cytochrome P_{450} of Greatest Importance to Drug Interactions

The importance of cytochrome P_{450} enzyme 3A4 (CYP 3A4) and CYP 2D6 lies in the fact that these isoforms metabolize about 50 percent and 20 percent to 25 percent of all drugs, respectively. Due to some overlap of drug substrates that are metabolized by both CYP isoforms, roughly two-thirds of all drugs are metabolized by at least one of these two pathways. Other CYP isoforms of greatest potential importance to drug interactions include CYP 2C9, CYP 2C19, CYP 1A2, and CYP 2E1.

DRUG SUBSTRATES, INHIBITORS, AND INDUCERS[1,3]

Drug Substrates

A substrate is basically a drug in the process of being metabolized to a more water soluble form (metabolite) to enable excretion. A substrate may "travel" down one or more than one metabolic pathway, including possibly more than one CYP isoform. The metabolic pathway may be either a CYP isoform, a non-CYP pathway (phase II), or both. Furthermore, a substrate may also be an inhibitor or inducer of the drug's metabolic pathway. An example would be cyclosporine, which is both a substrate and inhibitor of CYP 3A4.

Substrates of greatest interest for three of the most important CYP isoforms are listed in Table 237-4. References listed in Table 237-1 can be consulted for more comprehensive lists of CYP isoforms and pertinent drug substrates.

Substrates That Are Narrow Therapeutic Index Drugs

A given drug's "therapeutic index" is merely the ratio of the drug dose producing the desired therapeutic response versus the drug dose producing toxicity.

TABLE 237-2
Pharmacokinetic Steps Pertaining to Drug Metabolism and Interactions

Pharmacokinetic Step	Primary Interactions	Examples
Absorption	Loss of efficacy	Divalent cations and tetracyclines or fluoroquinolones ↑ Gastric pH (antacids) and itraconazole or ketoconazole
Distribution	Toxicity	Nonsteroidal anti-inflammatory drugs and methotrexate Sulfonamides and methotrexate
Metabolism	Loss of efficacy and toxicity	Examples in Tables 237-5 through 237-10
Excretion	Toxicity	Sulfonamides and methotrexate Digoxin and cyclosporine

TABLE 237-3
Pharmacodynamic Categories of Drug Interactions

Category	Examples	Comments
Agonist interaction—same polarity of mechanism		
Positive pharmacologic effect	Prednisone and azathioprine	"Steroid-sparing" effects
Negative pharmacologic effect	Hydroxychloroquine and chloroquine	↑ Risk of retinopathy
Antagonist interaction—opposite polarity of mechanism		
Positive pharmacologic effect	Methotrexate and folic acid	↓ Methotrexate adverse effects
Negative pharmacologic effect	β Blockers[a] and epinephrine[b]	Unopposed α-adrenergic effects, ↑↑ blood pressure

[a]Non-cardioselective β blockers.
[b]Epinephrine at very high doses if very high volumes of lidocaine with epinephrine are used during a procedure (very rare).

TABLE 237-4
Some Important Substrates for Several Important Cytochrome P_{450} (CYP) Isoforms

CYP 3A4 Substrates	CYP 2D6 Substrates	CYP 2C9 Substrates
Antibacterial agents	Analgesics	Antibacterial agents
• Erythromycin	• Codeine	• Sulfonamides
• Rifampin	• Meperidine	Anticoagulants
Anticoagulants	• Morphine	• S-Warfarin enantiomer
• R-warfarin enantiomer	Antidysrhythmics	Anticonvulsants
Antidysrhythmics	• Encainide	• Phenytoin
• Amiodarone	• Flecainide	• Valproic acid
• Digoxin	• Mexiletine	Nonsteroidal anti-inflammatory drugs
• Lidocaine	• Propafenone	• Diclofenac
Calcium channel blockers—all	β Blockers	• Ibuprofen
H_1 antihistamines[a]	• Metoprolol	• Piroxicam
• Fexofenadine	• Propranolol	Statins
• Loratadine	Selective serotonin reuptake inhibitor antidepressants	• Fluvastatin
Statins	• Fluoxetine	• Rosuvastatin
• Atorvastatin	• Paroxetine	
• Lovastatin	Tricyclic antidepressants	
• Simvastatin	• Amitriptyline	
Hormonal contraceptives	• Clomipramine	
Immunosuppressive agents	• Desipramine	
• Cyclosporine	• Doxepin	
• Tacrolimus		

[a]Terfenadine and astemizole are 3A4 substrates. They have been taken off the market in the United States.
Note: This table is intended to give important examples and is far from comprehensive; for more complete information, consult database of Dr. David Flockhart at Indiana University Department of Medicine (see Table 237-1).
Adapted from Shapiro LE, Shear NH: Drug interactions, in *Comprehensive Dermatologic Drug Therapy*, 2nd ed, edited by Wolverton SE. London, Elsevier, 2007, p 949.

A drug with a "narrow" therapeutic index would represent drugs for which the ratio is relatively close to the number 1 regardless of which is the numerator and denominator. Several examples of relatively narrow therapeutic index drugs are listed in Table 237-5.

Enzyme Inhibitors

An enzyme "inhibitor" is a drug that slows/decreases the rate of metabolism of another drug substrate. Visualizing this process in a traffic analogy, the inhibitor blocks the flow of traffic (drug metabolism) on a shared road (CYP isoform or a phase II metabolic pathway).

Two of the strongest inhibitors of CYP 3A4 are erythromycin (macrolide antibiotics) and ketoconazole (azole antifungals). In each of these drug groups, there are alternatives that have little or no inhibitory effect on the CYP isoform involved in the potential drug interaction of interest. Examples of variations of enzyme inhibition within a drug group are listed for inhibitors of CYP 3A4, CYP 2D6, and CYP 2C9 in Table 237-6.

Enzyme Inducers

An enzyme "inducer" is a drug that speeds up the metabolism of a drug substrate. The inducer facilitates traffic on the "highway" (metabolic pathway) for drug metabolism.

Most CYP enzyme inducers affect more than one CYP isoform. Some of the strongest enzyme inducers include rifampin and the aromatic anticonvulsants phenytoin, phenobarbital, and carbamazepine. Griseofulvin is also an enzyme inducer, albeit a relatively weak one. Some clinical scenarios pertinent to dermatology of enzyme induction of significant importance are listed in Table 237-7.

Genetic Polymorphisms[4]

The term *polymorphism*, as it pertains to drug metabolism, merely represents a mutation in a phase I or phase II enzyme that results in clinically important differences of enzyme activity compared with normal. Conceptually, "variability" results in a unimodal distribution (a single bell-shaped curve), whereas a genetic polymorphism creates a bimodal distribution (at least two bell-shaped curves) when putting enzyme activity on a graph. Clinically significant polymorphisms involving drug metabolizing enzymes most notably include both phase I enzymes (CYP 2D6 and CYP 2C9) and phase II enzymes (*N*-acetyltransferase-2 and thiopurine methyltransferase). These polymorphisms can result in (1) drug interactions, (2) altered metabolism of a drug used as monotherapy, or (3) cutaneous or systemic drug interactions. Table 237-8 summarizes examples of the clinical outcomes in these three categories from the above four enzyme polymorphisms.

CLINICAL SCENARIOS

Varying Risk of Individual Drug Interactions

Not all drug interactions are "adverse" drug interactions; these pharmacokinetic and pharmacodynamic interactions do not result in an adequate change in drug levels or mechanisms of action to have clinical importance. Furthermore, only a small percentage of drug interactions have a life-threatening potential. At the conclusion of the chapter, 12 of the most potentially serious drug interactions pertinent to dermatology are highlighted. In between these two extremes is where the majority of drug interactions exist. In these

TABLE 237-5
Selected Narrow Therapeutic Index Drugs

Category	Drug Name	Cytochrome P_{450} Isoform	Most Important Acute Toxicities
Anticoagulants	Warfarin	2C9, 3A4, 1A2	Hemorrhage (thrombosis if effect inhibited)
Antidepressants	Doxepin[a]	2D6	Excessive sedation, tachyarrhythmias
Bronchodilators	Theophylline	1A2	Central nervous system toxicity
Immunosuppressive agents	Cyclosporine	3A4	Renal toxicity, hypertension, hyperlipidemia
	Methotrexate	None[b]	Pancytopenia, liver toxicity
Inotropic agents	Digoxin	3A4	Cardiac tachyarrhythmias, atrioventricular block

[a]Overall, doxepin is the safest drug on this list; however, in the presence of strong cytochrome P_{450} (CYP) 2D6 inhibitors, central nervous system and cardiac toxicity are important issues.
[b]As opposed to CYP inhibition with other drugs above, the greatest risk of methotrexate toxicity is with concomitant use of drugs such as trimethoprim (dihydrofolate reductase inhibitor) and sulfamethoxazole (dihydropteroate synthetase inhibitor), which also inhibit enzymes important to folate metabolism.

TABLE 237-6
Variability within a Drug Class—Enzyme Inhibitors

Drug Category	Cytochrome P_{450}	Strong Inhibitor	Weaker Inhibitor	No Effect
Macrolides/azalides	3A4	Erythromycin	Clarithromycin	Azithromycin
	1A2	Erythromycin		Clarithromycin, azithromycin
Azole antifungals	3A4	Ketoconazole	Itraconazole	Fluconazole
	2C9	Fluconazole		Ketoconazole, Itraconazole
SSRI antidepressants	2D6	Fluoxetine, paroxetine	—	Other SSRIs

SSRI = selective serotonin reuptake inhibitor.
Adapted from Shapiro LE, Shear NH: Drug interactions, in *Comprehensive Dermatologic Drug Therapy*, 2nd ed, edited by Wolverton SE. London, Elsevier, 2007, p 949.

TABLE 237-7
Clinical Scenarios in Which Enzyme Inducers Lead to Loss of Efficacy

Substrate	Enzyme Inducer	Cytochrome P_{450} Isoform	Clinical Result
Warfarin	Rifampin[a]	3A4	Thrombosis if significant loss of anticoagulant
Hormonal contraceptives	Rifampin[a]	3A4	Possible unintended pregnancy
	Griseofulvin	3A4	Possible unintended pregnancy
Cyclosporine, tacrolimus	Rifampin[a]	3A4	Loss of transplanted organ (graft)

[a]Given that enzyme induction generally takes 1 week or more to reach clinical significance, a 7- to 10-day course of rifampin (as commonly prescribed for community-acquired methicillin-resistant *Staphylococcus aureus* may fall short of the time period for maximal risk; however, appropriate caution (ideally avoid co-prescribing) is required in these clinical settings.
Note: The drugs listed in this table are drugs that are commonly prescribed by dermatologists; the aromatic anticonvulsants—carbamazepine, phenobarbital, and phenytoin and several other drugs are also important enzyme inducers.

clinical settings, the clinician has a great deal of flexibility concerning therapeutic choices. From these three categories, one can derive one additional traffic analogy:

1. Adverse drug interactions with life-threatening potential (*red* light)—do not proceed (e.g., fluconazole and warfarin; must choose an alternative such as itraconazole or terbinafine).
2. Adverse drug interactions of clinical importance, but not life threatening (*yellow* light)—proceed with caution [see examples in Therapeutic Options with "Proceed with Caution" (Yellow Light) Clinical Scenario].
3. Other drug interactions of no clinical risk due to minor effect of "interaction" on drug levels or mechanisms of action (*green* light)—can proceed with drug combination and can reassure the patient.

Therapeutic Options with "Proceed with Caution" (Yellow Light) Clinical Scenario

Typically, there is substantial latitude concerning yellow light clinical scenarios. The clinician may choose to avoid the drug combination altogether if there are suitable drug alternatives or if the disease being treated presents minimal risk to the patient. Alternatively, the clinician may choose one or several of the following options: (1) lower the drug dose—azathioprine and allopurinol, for which 75 percent reduction of azathioprine dose is recommended, (2) monitor closely from a clinical standpoint—doxepin and an selective serotonin reuptake inhibitor (SSRI) antidepressant such as paroxetine or fluoxetine, following the level of sedation closely, and/or (3) appropriate laboratory testing—can order morning doxepin serum levels with CYP 2D6 inhibitors such as paroxetine or fluoxetine. Concerning the doxepin/SSRI interaction described above, the clinician may choose to use an SSRI antidepressant alternative that does not inhibit the CYP 2D6 pathway (e.g., citalopram, escitalopram, or sertraline). From a proactive standpoint, baseline genetic testing of either the CYP 2D6 and CYP 2C19 polymorphisms are readily available. This genetic testing may determine in advance the rate of metabolism by the specific CYP isoform. Possibilities include the following (listed in descending order from the most rapid to the slowest rate of drug metabolism:

1. Ultrarapid metabolizer—uncommon, may involve gene "duplication"
2. Extensive metabolizer—most common subset, homozygous for the "wild type" (full metabolic activity) gene
3. Intermediate metabolizer—relatively frequent, heterozygous for the "wild type" gene

TABLE 237-8
Clinical Relevance of Drug Metabolism Enzyme Polymorphisms

Polymorphism	Specific Drug	Drug Interaction	Monotherapy Result	Drug Reaction
Phase I enzymes				
CYP 2D6	Doxepin	Paroxetine, fluoxetine (↑ severity in IM, PM)	Toxicity (sedation) PM Loss of efficacy EM, URM	None
CYP 2C9	Warfarin	Fluconazole	Toxicity (hemorrhage) PM Loss of efficacy (thrombosis) URM	None
Phase II enzymes				
N-acetyltransferase-2	Isoniazid	None	None	Drug-induced lupus erythematosus
Thiopurine methyltransferase	Azathioprine	Allopurinol (↑ severity in IM, PM)	Toxicity (pancytopenia) IM, PM Loss of efficacy EM	None

CYP = cytochrome P_{450}; EM = extensive metabolizers; IM = intermediate metabolizers; PM = poor metabolizers; URM = ultrarapid metabolizers.

TABLE 237-9
Options with "Proceed with Caution" Type of Drug Interactions

Clinical Option[a]	Examples
Clinical scenario—want to prescribe doxepin for pruritus in patient on either paroxetine or fluoxetine	
Clinical monitoring	Watch closely for sedation
Laboratory monitoring	Order a morning doxepin level
Lower drug dose	Dose doxepin very conservatively
Alternative drugs to prescribe	Have primary physicians switch to an alternative selective serotonin reuptake inhibitor antidepressant or a non-selective antidepressant *or* Could prescribe hydroxyzine, cetirizine, etc.
Baseline genetic testing	Could order baseline cytochrome P_{450} 2D6 genotype testing to see if patient a poor metabolizer
Clinical scenario—want to prescribe erythromycin for acne to a patient on simvastatin	
Clinical monitoring	Could monitor for muscle pain or weakness (by itself, never an option)
Laboratory monitoring	Monitor muscle enzymes (creatine phosphokinase, aldolase)
Lower drug dose	Lower dose of either erythromycin or simvastatin
Alternative drugs to prescribe	Azithromycin a suitable macrolide *or* Prescribe an alternative antibiotic group; also request primary physician to consider fluvastatin, rosuvastatin, pravastatin
Clinical scenario—want to prescribe itraconazole for extensive tinea corporis to a patient on warfarin[b]	
Clinical monitoring	Could monitor for bruising/hemorrhage elsewhere (by itself, never an option)
Laboratory monitoring	Follow international normalized ratio (INR) values very closely
Lower drug dose	Lower dose of either the itraconazole or warfarin (through primary physician)
Alternative drugs to prescribe	Terbinafine and topical antifungals are primary alternatives

[a]In each clinical scenario, more than one option may be undertaken simultaneously.
[b]With patients on warfarin, for whom clinicians wish to give fluconazole, these "proceed with caution" options are not pertinent; fluconazole and warfarin is a "red light" scenario in which co-prescribing these drugs must be totally avoided.

4. Poor metabolizer—also uncommon, homozygous for the gene mutation (low/absent metabolic activity)

Some additional examples of the "proceed with caution" scenarios illustrating these therapeutic options are listed in Table 237-9.

Lessons to Be Learned from Drugs Taken Off the Market

There are some important lessons to be learned from drugs interactions that produced life-threatening risk which led to several drugs taken off the market. Two issues are worth highlighting concerning the drug interactions that led to drug removal. In both cases a known CYP enzyme inhibitor (CYP 3A4 inhibitors) was commonly co-prescribed with a CYP 3A4 drug substrate with a narrow therapeutic index. Secondly, in each case, the U.S. Food and Drug Administration published warnings in the form of "Dear Doctor" letters (subsequently known as *Dear Health Care Professional* letters) that, in retrospect, did not bring about an adequate change of clinician-prescribing habits to warrant drug continuation. Several of the potentially life-threatening drug interactions leading to drug withdrawal include the following:

1. H_1 antihistamines terfenadine and astemizole—torsades de pointes (strong CYP 3A4 inhibitors erythromycin or ketoconazole commonly co-prescribed with these drugs)
2. Hepatic 3-methylglutaryl coenzyme A reductase inhibitor cerivastatin (a "statin")—rhabdomyolysis (a strong CYP 3A4 inhibitor gemfibrozil commonly co-prescribed with this drug)

CONCLUSION—A DOZEN DRUG INTERACTIONS OF IMPORTANCE TO PRACTICING DERMATOLOGISTS

There are numerous potential drug interactions for the clinician to consider. When trying to pick a starting point to understand adverse drug interactions, it is logical to start with the most potentially serious drug interactions. With this principle in mind, I have compiled a list of a dozen drug interactions potentially serious, and thus, of great importance to practicing dermatologists and other clinicians utilizing these drugs (Table 237-10).

TABLE 237-10
A Dozen Critical Drug Interactions

	Specific Toxicity	Category		Cytochrome P_{450}	Substrates	Precipitant Drugs
1.	Torsades de pointes	PK	Tox	3A4	Terfenadine, astemizole, cisapride	Erythromycin, ketoconazole, itraconazole
2.	Pancytopenia	PK	Tox	—	Methotrexate	Trimethoprim/sulfamethoxazole
3.	Agranulocytosis	PK	Tox	—	Azathioprine	Allopurinol
4.	Hemorrhage	PK	Tox	2C9	Warfarin	Fluconazole
5.	Thrombosis/embolism	PK	LOE	3A4	Warfarin	Rifampin
6.	Sedation	PK	Tox	2D6	Doxepin	Fluoxetine, paroxetine
7.	Sedation	PD	Tox	—	Doxepin	H_1 antihistamines—sedating
8.	Renal failure/rhabdomyolysis	PK	Tox	3A4	Cerivastatin	Gemfibrozil (and other 3A4 inhibitors)
9.	Renal toxicity	PK	Tox	3A4	Cyclosporine	Erythromycin, ketoconazole, itraconazole
10.	Renal toxicity	PD	Tox	—	Cyclosporine	Gentamicin (and other potentially renal toxic drugs)
11.	Liver toxicity	PD	Tox	—	Methotrexate	Acitretin (previously etretinate)
12.	Loss of transplanted organ	PK	LOE	3A4	Cyclosporine	Rifampin, rifabutin

LOE = loss of efficacy; PD = pharmacodynamic; PK = pharmacokinetic; Tox = toxicity.
Note: These critical drug interactions are listed roughly in descending order of risk.

With proper awareness of drugs for which potential interactions need to be considered and regular usage of drug interaction databases, clinicians can reduce the incidence of adverse drug interactions. Patient education is likewise essential to minimizing this risk. In the vast majority of cases, a less-risk therapeutic alternative is typically available if the print/electronic resources indicate a potential drug interaction. Finally, when in doubt, do not prescribe the drug or drugs in question until a definitive answer on the safety of co-prescribing the medications in question can be answered.

KEY REFERENCES

The full reference list for all chapters is available at www.digm7.com.

1. Wolverton SE: Pharmacology introduction, in *Comprehensive Dermatologic Drug Therapy*, 2nd ed, edited by Wolverton SE. London, Elsevier, 2007, p 1
2. Shapiro LE, Shear NH: Drug interactions: Proteins, pumps and P-450s. *J Am Acad Dermatol* **47**:467, 2002

This page intentionally left blank

SECTION 38

PHYSICAL TREATMENTS

CHAPTER 238

Therapeutic Photomedicine: Phototherapy

Jean Krutmann
Akimichi Morita

Over the past few years, the development of irradiation devices with new emission spectra has led to an expanded role for phototherapy in the treatment of skin disease.[1] This development is best illustrated by the increasing frequency with which 311-nm ultraviolet B (UVB) phototherapy is used for the treatment of psoriasis.[2] In fact, in Europe 311-nm UVB (narrowband UVB) is currently used more often than psoralen and ultraviolet A light (PUVA) therapy for psoriasis and several other cutaneous diseases. Another example is ultraviolet AI (UVAI, 340 to 400 nm).[3] UVAI was first used to treat patients with atopic dermatitis, but it has since been found to be efficacious in several other skin diseases, notably localized scleroderma, where other therapeutic options are limited. These two examples demonstrate that the introduction of new spectra into dermatologic phototherapy has not only broadened and improved phototherapy as it relates to established indications but, in addition, has fostered the development of new indications for phototherapy such as connective tissue diseases. Fig. 238-1 shows the UV spectra used in the treatments discussed in this chapter.

PHOTOTHERAPY OF PSORIASIS (See Chap. 18)

One important option in the long-term management of moderate to severe psoriasis is UVB phototherapy. Within recent years, the availability of new fluorescent bulbs with an emission spectrum that closely conforms to the peak of the action spectrum for clearing psoriasis[4] has significantly improved the efficacy of UVB phototherapy for psoriasis.

311-nm Ultraviolet B: The Phototherapy of Choice for Psoriasis

Parrish and Jaenicke demonstrated that wavelengths shorter than 295 nm displayed no anti-psoriatic effect, even if used at erythemogenic doses, whereas wavelengths between 300 and 313 nm caused the greatest remission of skin lesions.[4] These seminal observations provided the rationale for the development of more selective UVB phototherapy irradiation devices. These units have a spectrum that is still broadband UVB but is enhanced in the range of 300 to 320 nm compared to conventional fluorescent bulbs. As predicted, these light sources proved to be superior to conventional UVB phototherapy for clearing of psoriasis. A major breakthrough was achieved by the development of the Philips TL-01 fluorescent lamp, emitting a narrow UV band at 311/312 nm and thereby matching closely the assumed therapeutic optimum for psoriasis.[2] A large number of clinical trials comparing broadband versus 311-nm UVB phototherapy for psoriasis have been conducted mainly in Europe and, more recently, in the United States. Based on these studies, which increasingly follow randomized controlled designs, it is now generally accepted that 311-nm UVB therapy is superior to broadband UVB therapy for psoriasis.[5,6] Patients treated with a 311-nm spectrum show faster clearance of skin lesions, fewer episodes of excessive erythema, and a longer period of remission (Fig. 238-2). This difference in efficacy has been attributed to the fact that 311-nm UVB is capable of more efficiently depleting skin-infiltrating T cells from the epidermis and dermis of psoriatic plaques as compared with broadband UVB.[7] Also, comparative studies of 311-nm UVB phototherapy and systemic PUVA demonstrate that these two modalities are equally effective and that 311-nm UVB is superior to bath PUVA therapy.[6,8–11] This is of particular interest because 311-nm UVB therapy, in comparison with PUVA, does not require

THERAPEUTIC PHOTOMEDICINE: PHOTOTHERAPY AT A GLANCE




- Phototherapy has greatly benefited from the introduction of selective spectra for specific skin diseases.
- The best phototherapy for psoriasis is 311-nm (narrowband) ultraviolet B (UVB).
- A combination of UVB phototherapy with topical or systemic drugs increases therapeutic efficacy and reduces side effects.
- Severe, acute, and moderate chronic atopic dermatitis are treated with different phototherapeutic modalities.
- Localized scleroderma can be effectively treated with UVAI phototherapy.
- Phototherapy works largely through the induction of apoptosis and immunosuppressive effects.



Copyright © 2008 by The McGraw-Hill Companies, Inc. Click here for terms of use.



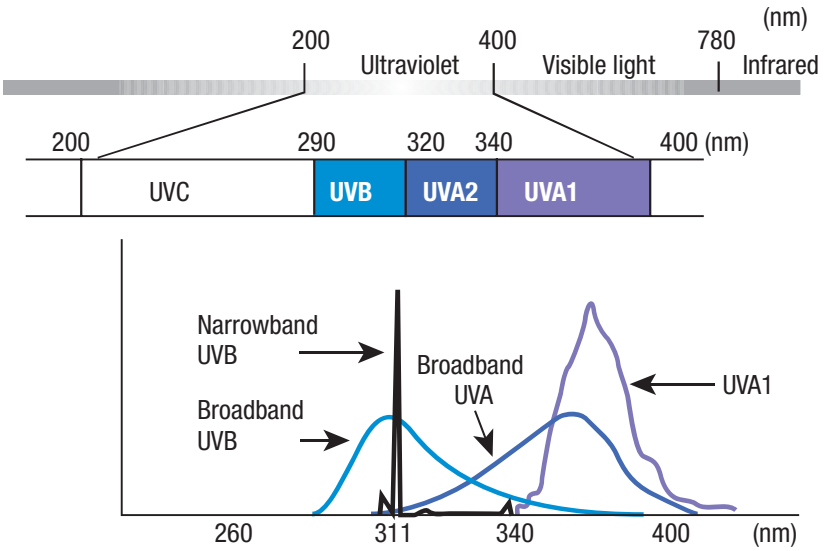

▲ **FIGURE 238-1** Ultraviolet (UV) spectra.

a systemic photosensitizer, is cheaper, can be used in pregnancy and childhood, and does not require post-treatment eye protection. It has also been suggested that 311-nm UVB may be less carcinogenic than PUVA, although follow-up studies to determine the true carcinogenic risk of 311-nm UVB therapy are currently lacking.[12,13] For these reasons, 311-nm UVB therapy currently represents the phototherapeutic modality of choice for the treatment of psoriasis in Europe and is being used increasingly in the United States, where introduction was delayed by reimbursement issues.

Practical Aspects

For 311-nm UVB therapy, no specific irradiation devices are needed because the Philips TL-01 fluorescent lamps can be fitted into conventional PUVA cabinets. Certain guidelines should be followed regardless of whether 311-nm UVB or conventional broadband UVB from fluorescent bulbs (such as Westinghouse FS, Philips TL12, Sylvania UV21) or medium-pressure mercury arc lamps with or without metal halides are used.[14]

Ideally, before phototherapy, the patient's minimal erythema dose (MED) is determined to establish the optimal dosage schedule. For determination of the MED and subsequent phototherapy, either the same irradiation device or devices with an identical emission spectrum must be used. For 311-nm therapy, which is suitable for all patients regardless of skin type and MED,[15] the initial dose should equal 0.7 MED. Patients are treated three to five times per week. If the initial dose is tolerated, a 20 percent incremental increase of the previous dose is used at each visit.[16] When a previous treatment results in erythema, no treatment is given the next scheduled visit or the dose is decreased, depending on whether the erythema is asymptomatic or painful. It should be noted that 311-nm UVB is also very efficient when used at sub-erythemogenic doses. As well, a regimen with 5 percent or 10 percent dose increments may be as therapeutic as with a 20 percent increment.[15,17]

For broadband UVB therapy, one MED is given on the first treatment and is increased by 50 percent, 40 percent, 30 percent, and so on, in subsequent treatments. Because UV radiation is a complete carcinogen, the genitalia and chronically light-exposed areas (e.g., the face, neck, dorsa of hands), if unaffected, should be shielded or protected (with sunscreen) before irradiation.

For limited psoriasis, 308-nm excimer laser therapy or non-laser 308-nm monochromatic excimer light may represent an option (see Chap. 240).[18,19] The 308-nm excimer laser appears to be highly effective even in otherwise therapy-resistant psoriasis. 308-nm monochromatic excimer light has been found to be particularly suited for the treatment of palmo-plantar pustular psoriasis.[20,21] Both 308-nm light sources can clear patch psoriasis in a similar manner to standard phototherapy with the advantage of selectively treating lesional skin, thus sparing the surrounding normal skin from unnecessary exposure.[19,22,23]

The goal of phototherapy is complete clearance of all psoriatic skin lesions. Psoriasis, however, is a chronic disease and the remission induced by UVB phototherapy is often transient. In a randomized, prospective, multicenter trial, post-clearing phototherapy was found to significantly increase the disease-free interval, indicating that patients may profit from maintenance phototherapy.[24] On the other hand, maintenance therapy results in a greater cumulative UVB dose, increasing the risk of skin cancer and photoaging. It is therefore preferable, if possi-



▲ **FIGURE 238-2** Patient with severe generalized psoriasis before (**A**) and after (**B**) 15 treatments with 311-nm ultraviolet B phototherapy. (Used with permission from J. Ferguson, MD, Dundee, Scotland.)

ble, to maintain remissions with other anti-psoriatic modalities. To minimize potential carcinogenic risks from chronic UVB phototherapy, a rotational therapeutic approach has been suggested.[25]

Combination Therapy

Phototherapy of psoriasis is frequently used in combination with topical or systemic agents to achieve higher clearance rates, longer disease-free intervals, and a lower carcinogenic risk.[25] Topical agents include anthralin, vitamin D analogues, retinoids, glucocorticoids, emollients, saltwater baths, and tar. Among these, anthralin and tar are mainly of historical interest and are not discussed.

Anti-psoriatic vitamin D analogues include calcipotriol, tacalcitol, and calcitriol, which have antiproliferative as well as anti-inflammatory effects (see Chap. 18).[26] Local side effects are limited to moderate skin irritation.[27] To avoid systemic side effects from percutaneous absorption, in particular hypercalcemia with consequent nephrocalcinosis, the treated body surface should not exceed 30 percent.[28] Main indications are psoriatic plaques of limited extent and lesions on the scalp, face, palms, and soles and in the intertriginous areas. The combination of either broadband UVB or 311-nm UVB therapy with calcipotriol increases the therapeutic efficacy of phototherapy alone.[29] This observation is of particular interest because UVB therapy reduces the irritation caused by calcipotriol. Vitamin D analogues should be applied after (not before) phototherapy, because UVA radiation leads to degradation of vitamin D_3.

Another promising combination phototherapy of psoriasis is narrowband UVB irradiation and topical tazarotene gel. Tazarotene is a topical acetylenic retinoid that is efficacious in plaque-type psoriasis. The addition of tazarotene to broadband or narrowband UVB phototherapy was found to promote more effective, faster clearing of psoriasis when compared with either type of phototherapy alone.[30,31] Pre-treatment with tazarotene gel three times per week for 2 weeks before phototherapy increases UV penetration into skin, and thus, UVB and PUVA therapy can be initiated at lower doses than usual.[32]

Several studies have asked whether the efficacy of UVB phototherapy for psoriasis may be enhanced through combination with topical glucocorticoids. Data from these studies are conflicting, and the beneficial effects seem to be limited.[33] Topical glucocorticoids are useful, however, for treating psoriatic lesions in skin areas not reached by UV irradiation during phototherapy (e.g., scalp, groin, perianal area, umbilicus), or for the treatment of lesions recalcitrant to standard phototherapy. They may also be used in the early, highly inflammatory state of psoriasis to achieve a quick improvement.

Topical application of emollients alters the optical properties of psoriatic lesions,[34] improving UV transmission and increasing efficacy.[35] In contrast, thick applications of petrolatum and water-in-oil–type creams and salicylic acid act as sunscreens.

Balneophototherapy comprises the combination of saltwater baths with UVB phototherapy, intended to mimic the successful Dead Sea regimen for the treatment of patients with recurrent severe psoriasis.[36–38] Approaches to balneophototherapy using synthetically generated Dead Sea salt or sodium chloride solutions (usually between 5 percent to 15 percent) for saltwater baths are hampered by logistics (the requirement for bathtubs) and environmental concerns related to disposal of large amounts of salt.

Systemic agents in combination with phototherapy used to treat psoriasis include retinoids, glucocorticoids, cyclosporin A, and methotrexate. Retinoids are the most widely used agents for systemic treatment in combination with phototherapy. In contrast, the systemic use of glucocorticoids in combination with photo(chemo)therapy is limited to special indications, such as generalized pustular psoriasis. Also, combination regimens of UVB therapy with methotrexate or cyclosporin A are not advisable, because both substances increase the possibility of UV-induced skin tumors.

From a theoretical point of view, the advantage of combining retinoids and UVB irradiation is twofold: (1) retinoids exert anti-psoriatic effects and might act synergistically with UVB phototherapy; and (2) they have anticarcinogenic effects and thereby could lower the skin cancer risk resulting from long-term UVB therapy. Because of potentially severe side effects, the use of systemic retinoids should be limited to pustular or erythrodermic variants of psoriasis. Combination regimens with broadband UVB or selective UVB phototherapy with etretinate improved psoriatic patients more quickly than phototherapy alone, and reduced the number of treatments and cumulative UV doses.[39] Similar results were obtained when acitretin, the major metabolite of etretinate, was used in combination with broadband UVB or 311-nm UVB therapy.[40]

PHOTOTHERAPY OF ATOPIC DERMATITIS

In the past few years, UVA/UVB,[41] 311-nm UVB,[42] and UVAI phototherapy[43] were developed to treat atopic dermatitis. As a consequence, dermatologists now have multiple phototherapeutic modalities from which to tailor their treatment to the particular needs of a particular patient. Treatment decisions can also be based on the effectiveness of a given form of phototherapy for a specific stage of atopic dermatitis (i.e., acute and severe vs. chronic and moderate disease activity).

Ultraviolet AI Phototherapy for Acute, Severe Atopic Dermatitis

UVAI phototherapy is a highly effective monotherapy for a limited period of time (10 to 15 exposures). It is most effective for the treatment of patients with a severe, acute exacerbation of atopic dermatitis (Fig. 238-3).[44] Because potential long-term risks of UVAI phototherapy are not known, patients should not be treated over extended periods of time, for example, for maintenance therapy. For the same reason, its use is not recommended for patients younger than 18 years of age. The therapeutic effectiveness of UVAI irradiation in the management of patients with atopic dermatitis was first evaluated in an open study in patients with acute, severe exacerbations of atopic dermatitis.[44] They were exposed to 130 J/cm^2 UVAI daily for 15 consecutive days. Its therapeutic effectiveness was assessed by means of a clinical scoring system as well as by monitoring serum levels of eosinophil cationic protein, a laboratory parameter that can be measured objectively and correlates well with disease activity in atopic dermatitis. In that study, UVAI phototherapy was found to promptly induce clinical improvement and reduce elevated serum eosinophil cationic protein levels. Patients treated with UVAI were compared with subjects who had been treated with UVA/UVB phototherapy. Significant differences in favor of UVAI therapy were observed.[44] These results were recently corroborated and extended in a randomized, controlled multicenter trial in which UVAI therapy, compared with topical glucocorticoid treatment, was





▲ **FIGURE 238-3** Patient with severe, acute exacerbation of atopic dermatitis before (**A**) and after (**B**) high-dose ultraviolet AI therapy (15×130 J/cm^2 ultraviolet AI).



significantly better in reducing the clinical score at day 10.[45]

The therapeutic effectiveness of UVAI therapy is dose-dependent. Low-dose UVAI (30 J/cm^2) is less effective than UVA/UVB therapy,[46] whereas high-dose UVAI therapy (130 J/cm^2) is superior to UVA/UVB phototherapy.[44,45] In addition, a medium-UVAI dosage schedule (50 J/cm^2) was superior to a low-dose UVAI regimen (10 J/cm^2), whereas no significant difference was detected in a bilateral comparison study between a medium- and a high-dose regimen.[47]

High-dose UVAI phototherapy may not be used on patients with UVA-sensitive atopic dermatitis or photodermatoses, and it is therefore necessary to exclude these diseases before initiation of therapy. This can easily be accomplished by photoprovocation testing. Except for eczema herpeticum, no acute side effects have been observed in any of the patients treated with high-dose UVAI therapy. No other side effects have been observed, although carcinogenic risk is a theoretical concern.[48,49] Until more is known about high-dose UVAI therapy, its use should be limited to periods of acute exacerbation of atopic dermatitis and, in general, one treatment cycle should not exceed 10 to 15 daily exposures and should not be repeated more than once per year.[43]

Phototherapy of Chronic, Moderate Atopic Dermatitis

Broadband UVB,[50] combined UVA/UVB,[41,51] broadband UVA,[52] low-dose UVAI,[46] and, in particular, 311-nm UVB phototherapy[52] are effective treatments in mild and moderate atopic dermatitis. They are not particularly effective in patients with acute, severe exacerbations of their disease. In contrast to UVAI therapy, these forms of UV therapy are usually not used as monotherapy. Rather, they are used in combination regimens with topical glucocorticoids to reduce the need for glucocorticoid application. All of these therapies are considered to be relatively safe, even if used over extended periods of time, and they should be used to induce long-term improvement. Patients do best if severe disease is initially controlled by more potent modalities. For example, 311-nm UVB phototherapy has proved to be an ideal modality for maintenance therapy after high-dose UVAI has been used in the initial phase of management of an acute, severe exacerbation of atopic dermatitis.[43] If high-dose UVAI therapy is not available, severe atopic dermatitis should be controlled before the start of phototherapy by aggressive topical glucocorticoid therapy or systemic immunosuppressive modalities such as glucocorticoids or cyclosporin A.

Studies directly comparing all the different forms of UV therapy for chronic, moderate atopic dermatitis have not been performed, but recent trials indicate that either UVA/UVB combination therapy or narrowband 311-nm UVB therapy[42,52–54] is superior to conventional broadband UVB, broadband UVA, or low-dose UVAI therapy. Also, narrowband UVB appears to be equivalent to PUVA for this indication.[6,53] The actual choice made for a particular patient also depends on what irradiation devices are available. Jekler and Larkö, in a paired comparison study, observed significant differences in favor of UVA/UVB therapy over broadband UVB therapy.[46] In this trial, patients were allowed to continue the use of topical glucocorticoids and were irradiated three times per week for a maximum of 8 weeks in a UVB MED-dependent manner.

The therapeutic effectiveness of 311-nm UVB therapy for chronic atopic dermatitis of moderate severity was first shown in an open trial conducted by George et al.[42] and was confirmed in a randomized controlled study.[52] As discussed in the section 311-nm Ultraviolet B: The Phototherapy of Choice for Psoriasis, 311-nm UVB therapy may be associated with a reduced risk of skin cancer compared with broadband UVB or with PUVA therapy.[12] The demonstration of 311-nm UVB therapy's effectiveness for treating childhood atopic eczema[55] is therefore of particular interest.

If neither a UVA/UVB nor a 311-nm UVB irradiation device is available, broadband low-dose (0.5 MED) UVB therapy has been shown in placebo-controlled studies to be effective.[50]

PHOTOTHERAPY OF OTHER DISORDERS

In addition to psoriasis and atopic dermatitis, UV therapy is increasingly used for skin diseases that previously had mainly been treated with PUVA [e.g., polymorphous light eruption (PMLE), urticaria pigmentosa, vitiligo, cutaneous T-cell lymphoma (CTCL)] or for which no phototherapeutic approach had been available (e.g., scleroderma and lupus erythematosus).

Phototherapy of Polymorphous Light Eruption and Other Photodermatoses (See Chap. 90)

Patients with PMLE respond abnormally to UV radiation (in particular UVA radiation), resulting in an increased and sustained expression of pro-inflammatory molecules (cytokines, adhesion molecules) and subsequent development of skin lesions. In the majority of PMLE



▲ **FIGURE 238-4** Patient with morphea before (**A**) and after (**B**) high-dose ultraviolet AI therapy.

patients, exposure to early season sunlight induces tolerance, a process that is termed *hardening*. Artificial induction of hardening or artificial photoprotection constitutes the major principle underlying phototherapy of PMLE.[56] The precise molecular mechanisms responsible for hardening are not yet known, but it is generally believed that phototherapy-induced photoprotection is based on the induction of epidermal thickening, pigmentation, and as-yet-to-be-defined immunologic effects. To maintain phototherapy-induced photoprotection, patients must expose themselves frequently to small does of sunlight, because strict avoidance of sunlight exposure will result in a quick loss of the therapeutically induced hardening effect. The use of phototherapy for PMLE is restricted to severe cases that fail to respond to more simple measures such as light avoidance, photoprotective clothing, and use of broad spectrum sunscreens. For these patients, broadband UVB and PUVA therapy have previously been found to be effective, with PUVA giving better results than UVB therapy.[56] Recent studies, however, indicate that 311-nm UVB therapy represents an effective alternative to PUVA. In a recent study, 25 PMLE patients were randomly assigned to either PUVA treatment or 311-nm UVB therapy.[57] When patients were monitored for 4 months following treatment, there was no difference between PUVA and 311-nm UVB therapy with respect to severity of disease and restriction of outdoor activities. For the reasons given in 311-nm Ultraviolet B: The Phototherapy of Choice for Psoriasis, 311-nm UVB therapy may therefore be considered the treatment of choice for PMLE. The efficacy of 311-nm UVB therapy for photodermatoses other than PMLE has not yet been assessed in controlled studies, but observations from a pilot study indicate that patients with actinic prurigo (in particular), hydroa vacciniforme, and erythropoietic porphyria, but not with solar urticaria, may also benefit from 311-nm UVB therapy.[58] In severe, otherwise therapy-resistant forms of solar urticaria, UVA "rush hardening" therapy may represent an option.[59] This novel approach includes multiple daily UVA irradiations at 1-hour intervals and provides significant protection within 3 days.

Phototherapy of Morphea (Localized Scleroderma) (See Chap. 62)

Morphea has a self-limited course, but skin lesions can cause significant morbidity and discomfort, particularly if they extend over joints and cause flexion contractures or if they lead to muscle atrophy and disfigurement.[60] Numerous modalities, including penicillin, penicillamine, antimalarial drugs, cyclosporin A, interferon-γ, and topical or systemic glucocorticoids, have been used, but their efficacy is poor. It was therefore of considerable interest to learn that UVAI phototherapy was of benefited for patients with morphea.[61,62]

In an open study, 10 patients with histologically proven morphea were exposed 30 times to 130 J/cm^2 UVAI radiation.[62] In all patients, high-dose UVAI therapy significantly reduced thickness and increased elasticity of sclerotic plaques as assessed by 20-MHz sonography (Fig. 238-4). Complete clearance was observed in 4 of 10 patients. These changes were not a result of spontaneous remissions, because they were present only in UVAI-irradiated, but not in unirradiated control plaques in the same patients. Similar therapeutic benefit could also be achieved by using a low-dose UVAI regimen.[61] Direct comparison of low-dose versus high-dose UVAI therapy revealed that high-dose UVAI therapy was superior, indicating that the therapeutic efficacy is dose-dependent.[3] Also, medium-dose UVAI seems to be superior to low-dose UVAI or 311-nm UVB phototherapy.[63] Termination of phototherapy was not associated over a 3-month period with loss of the beneficial effects achieved by high-dose UVAI irradiation in 9 of 10 patients, indicating that maintenance therapy may not be required. The precise mechanism by which UVAI therapy acts in morphea is unknown but most likely involves upregulation of collagenase I expression, which was induced about 20-fold in sclerotic skin lesions after successful UVAI phototherapy.[62,64]

In addition to localized scleroderma, UVAI phototherapy has also been reported to be effective in patients with systemic sclerosis and chronic sclerodermic graft-versus-host disease.[65,66]

Phototherapy of Urticaria Pigmentosa

Several studies have demonstrated that PUVA therapy is effective in reducing pruritus and urtication associated with urticaria pigmentosa.[67] In the majority of patients, however, cessation of PUVA therapy leads to recurrence of urticaria pigmentosa after 5 to 8 months. Recent studies suggest that beneficial effects may also be achieved in these patients by UVAI phototherapy.[68,69] In an open study in four adult patients, high-dose UVAI therapy reduced pruritus and urtication from stroking (Darier sign) after three exposures, whereas hyperpigmented skin lesions faded more slowly.[68]



Increased histamine in 24-hour urine was reduced to normal levels. In two patients with migraine headaches and diarrhea, relief from these systemic symptoms and reduction of serum serotonin to normal levels was observed after 10 exposures. No relapse has occurred in any of these four patients more than 2 years after cessation of high-dose UVAI therapy.[68]

Phototherapy of Miscellaneous Disorders



Several reports indicate that 311-nm UVB is a useful and well-tolerated therapy for vitiligo (see Chap. 72) that results in repigmentation in many patients, including Fitzpatrick's skin types IV and V, as well as children.[70-75] Therapeutic responses are achieved with twice weekly irradiations, an initial dose of 0.25 J/cm^2 independent of skin type, and dose increments of 20 percent each treatment. It should be noted, however, that similar to PUVA or khellin (a non-psoralen furocoumarin) plus UVA (KUVA) therapy, certain anatomic sites (hands and digits, feet and toes) did not respond. A right-left comparison study of PUVA versus narrow-band UVB showed no difference in therapeutic efficacy.[73] It is currently unclear whether additional benefit can be achieved by combining 311-nm UVB with topical calcipotriol or tacalcitol.[76,77]

It has been suggested that daily low-dose UVAI irradiation is beneficial to patients with cutaneous lupus erythematosus (see Chap. 156). In an open study, 10 patients with systemic lupus erythematosus were treated with low-dose UVAI irradiation (6 J/cm^2 daily) for various time periods (15 days to 8 months).[78] A decrease in clinical indices of disease activity, most pronounced after 8 months of phototherapy, was observed in all patients. The UVAI irradiation decreased fatigue, arthritis, photosensitivity, skin rashes, and often depression, headaches, and sleeplessness. In addition, anti-Sjögren syndrome A or anti-nuclear antibodies decreased or even disappeared in most patients. These promising results have been confirmed in an 18-week two-phase study using 6 J/cm^2.[79] No side effects were noted, although UVAI irradiation, at least at higher doses, may theoretically exert detrimental effects on the majority of systemic lupus erythematosus patients.

UVAI phototherapy was recently used to treat patients with CTCL (see Chap. 146). In an open pilot study, three of three patients with early stage mycosis fungoides (CTCL stages IA and IB) were treated effectively with a high as well as medium dose UVAI regimen.[80] In a second uncontrolled trial, 11 of 13 patients with widespread plaque-type, nodular and erythrodermic mycosis fungoides (CTCL stages IB, IIB, and III) showed complete clinical and histologic responses upon treatment with a high-dose UVAI regimen.[81] These observations are of particular interest because UVAI phototherapy offers significant advantages over PUVA therapy. Unwanted side effects resulting from the systemic administration of methoxsalen, such as nausea, long-lasting skin photosensitivity, and requirement for eye protection, are completely avoided. There is now also evidence that 311-nm UVB phototherapy can be used to treat early (IA, IB, IIA) stages of mycosis fungoides.[82–84]

Local UVAI phototherapy appears to be an interesting option in the management of patients with chronic vesicular (dyshidrotic) hand eczema.[16] In an open pilot study, palms and backs of hands of 12 patients with an acute exacerbation of their disease were exposed to 15 UVAI irradiations with a dose of 40 J/cm^2 per day over a period of 3 weeks. After 1 week, all but one patient reported a marked relief of itch. After the third week, significant clinical improvement was noted in 10 of 12 patients.[85]

It has recently been shown that wavelengths within the visible range can effectively treat patients with atopic hand and foot eczema (see Chap. 14).[86] This development was prompted by the observation that UVAI phototherapy-induced apoptosis in house dust-mite specific T-cells, which had been cloned from lesional skin of patients with atopic eczema, is mediated through the generation of singlet oxygen. This reactive oxygen species, however, can not only be generated by UV wavelengths, but in particular in the near visible range (Soret band, 400 to 410 nm). A UV-free partial body irradiation device with an emission maximum between 400 and 450 nm has therefore been developed and found to induce prompt and long-lasting improvement in patients with atopic hand and foot eczema.[86] Visible radiation does not increase the risk for skin cancer, and UV-free phototherapy may therefore be well suited for the treatment of children and young adults.

MECHANISM OF ACTION

Through the induction of DNA photoproducts, UVB radiation transiently inhibits cell proliferation. As a result, it was thought that the therapeutic effectiveness of UVB phototherapy in psoriasis is mainly due to its antiproliferative effects. Since the introduction of UVB radiation into dermatologic therapy, however, the number of skin diseases showing a favorable response to phototherapy has grown substantially. The vast majority, including psoriasis, are largely immunologic in nature. Studies on the role of UV radiation-induced immunosuppression in photocarcinogenesis and on the effects of UV radiation on the function of epidermal Langerhans cells have provided increasing evidence that UVB, as well as UVA (and in particular UVAI) radiation, exert profound effects on the skin immune system (see Chap. 88).[106] As a consequence, UVB and UVA phototherapy are currently regarded as modalities whose mechanism of action depends upon immunomodulatory effects that are not specific for a single type of light source. The in vivo relevance of these immunomodulatory effects is dependent on the physical properties of the UV radiation used. On a per-photon basis, wavelengths within the UVB spectrum possess greater energy than UVA wavelengths, but because of their shorter wavelength, they have a more superficial depth of penetration within the skin. As a result, UVB phototherapy primarily affects the function of epidermal keratinocytes and Langerhans cells, whereas UVAI radiation additionally affects dermal fibroblasts, dermal dendritic cells, endothelial cells, T lymphocytes within the dermis, mast cells, and granulocytes[107] (Fig. 238-5). Photoimmunologic effects induced by UVB and UVAI radiation fall into three major categories: (1) effects on soluble mediators; (2) modulation of the expression of cell surface–associated molecules; and (3) the induction of apoptosis in pathogenetically relevant cells. The apoptotic effect is currently thought to be of key importance for phototherapy. Both UVB and UVA (particularly UVAI) radiation are highly efficient in inducing apoptosis in human cells. T cells, compared with monocytes or keratinocytes, have an increased susceptibility to UV radiation-induced apoptosis; this mechanism is, therefore, of particular importance for phototherapy of T cell–mediated skin diseases such as atopic dermatitis, psoriasis, and CTCL.

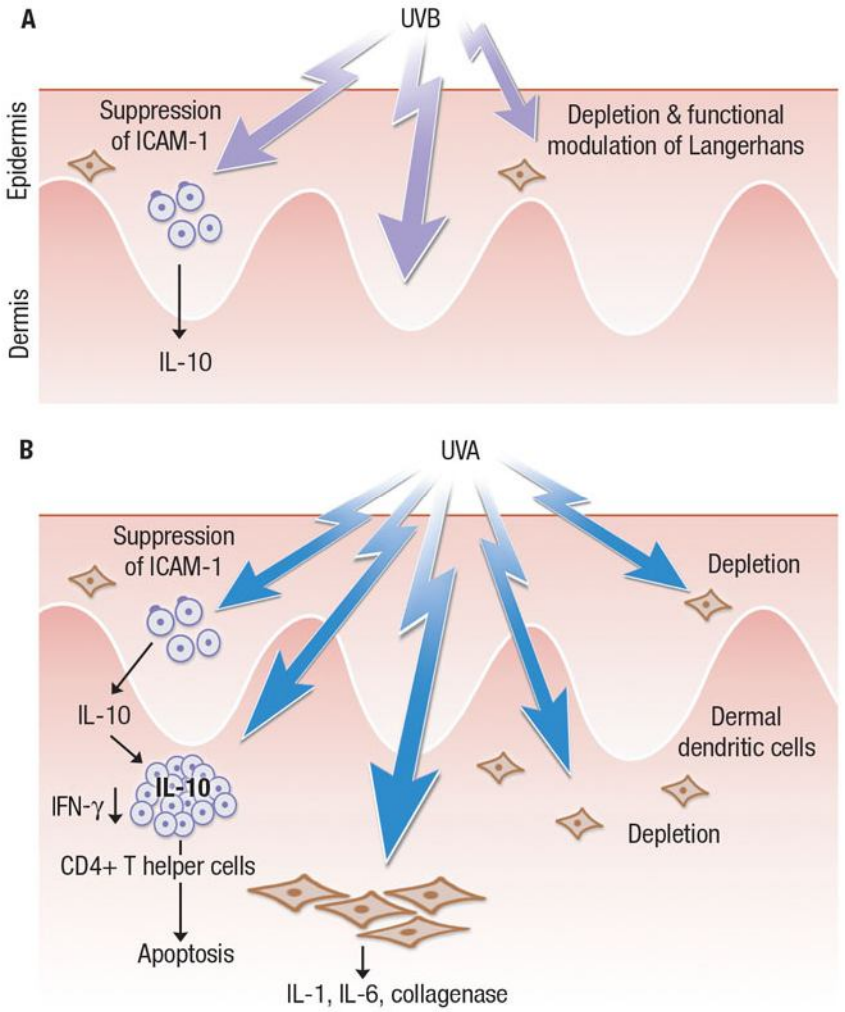

▲ **FIGURE 238-5** Scheme of immunomodulatory effects induced by ultraviolet B (UVB) (**A**) or UVA phototherapy (**B**). ICAM-1 = intercellular adhesion molecule 1; IFN-γ = interferon-γ; IL = interleukin.

It has been proposed that the greater therapeutic efficacy of 311-nm UVB, as compared with broadband UVB, is due to deeper skin penetration and more efficient induction of apoptosis in dermal T-cell infiltrates. Interestingly, malignant T cells, in comparison with normal untransformed T cells, show a higher susceptibility toward UVAI radiation-induced apoptosis,[108] presumably because of an increased availability of caspases such as caspase-3.

KEY REFERENCES

The full reference list for all chapters is available at www.digm7.com.

1. Krutmann J et al: *Dermatological Phototherapy and Photodiagnostic Methods*. New York, Springer, 2001
6. Ibbotson SH et al: An update and guidance on narrowband ultraviolet B phototherapy: A British Photodermatology Group Workshop. *Br J Dermatol* **151**:283, 2004
12. Young A: Carcinogenicity of UVB phototherapy assessed. *Lancet* **346**:1431, 1995
25. Menter MA et al: Proceedings of the psoriasis combination and rotation therapy conference. *J Am Acad Dermatol* **34**:315, 1996
52. Reynolds NJ et al: Narrow-band ultraviolet B and broad-band ultraviolet A phototherapy in adult atopic eczema: A randomized controlled trial. *Lancet* **357**:2012, 2001
61. Kerscher M et al: Treatment of localized scleroderma by UVA1 phototherapy. *Lancet* **346**:1166, 1995

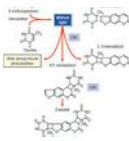

CHAPTER 239

Photochemotherapy and Photodynamic Therapy

Herbert Hönigsmann
Rolf-Markus Szeimies
Robert Knobler

PHOTOCHEMOTHERAPY

Photochemotherapy with psoralens combines the use of oral or topical psoralens (P) and ultraviolet A radiation (UVA), termed *PUVA*. Psoralens are phototoxic compounds that enter cells and then absorb photons to produce photochemical reactions that alter the function of cellular constituents.[1] This interaction results in a beneficial therapeutic effect after repeated controlled phototoxic reactions. Psoralens can be administered orally or applied topically to the skin in the form of solutions, creams, or baths. This therapy is currently used in the treatment of several common and uncommon skin diseases.

Historical Background

The effectiveness of all variants of PUVA has been widely confirmed and has profoundly influenced dermatologic therapy in general, providing treatment for numerous disorders in addition to psoriasis (Table 239-1).

Principles of Photochemotherapy Therapy

The rationale for PUVA therapy is to induce remissions of skin diseases by repeated, controlled phototoxic reactions. These reactions occur only when psoralens are photoactivated by UVA. According to the penetration characteristics of UVA, absorption of photons is confined to the skin. However, there is also some evidence that PUVA may exert systemic effects through circulating lymphocytes affected while transiting through the skin. Clinically, PUVA-induced phototoxic reactions are characterized by a delayed sunburn-like erythema and inflammation.

PSORALENS Three psoralens are used in PUVA therapy. Methoxsalen or 8-MOP,

PHOTOCHEMOTHERAPY AND PHOTODYNAMIC THERAPY

AT A GLANCE

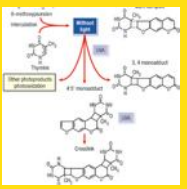

- Photochemotherapy [psoralen and ultraviolet A light (PUVA)] has been successfully used for more than 30 years. Its effectiveness has profoundly influenced dermatologic therapy in general, providing treatment for a number of diverse disorders besides psoriasis and vitiligo.
- PUVA can be combined with topical treatments and with some systemic agents (retinoids, methotrexate, and, perhaps, biologics) to enhance efficacy and to reduce the number of exposures.
- The most important adverse effects of oral PUVA consist of an increased risk of squamous cell carcinoma and a possible risk of melanoma. No such increased risk was found so far with bath-PUVA.
- Extracorporeal photochemotherapy (ECP) was introduced in the 1980s for the palliative treatment of erythrodermic cutaneous T-cell lymphoma.
- ECP appears to have a major impact in the treatment of graft-versus-host disease after allogeneic bone marrow transplantation where it allows progressive reduction or even discontinuation of the concomitant immunosuppressive therapy without an increase in graft-versus-host disease activity. Several other indications are under investigation.
- No serious side effects have been reported with ECP.
- Photodynamic therapy (PDT) for skin tumors started with the introduction of topical photosensitization by a porphyrin precursor (5-aminolevulinic acid) that would avoid generalized light sensitivity over many weeks.
- Current experience with PDT of epithelial cancers and pre-cancerous conditions suggests that actinic keratoses, Bowen disease, superficial and nodular basal cell carcinomas, and early squamous cell carcinomas can be treated curatively.
- The only significant side effect of topical PDT is a stinging pain during and shortly after irradiation. PDT has neither mutagenic nor carcinogenic potential.

TABLE 239-1
Phototherapy-Responsive Diseases

THERAPY OF DISEASE	PREVENTION OF DISEASE
• Psoriasis	• Polymorphous light eruption
• Palmo-plantar pustulosis	• Hydroa vacciniforme[a]
• Mycosis fungoides (stages IA, IB)	• Solar urticaria
• Vitiligo	• Erythropoietic protoporphyria[a]
• Atopic dermatitis	• Chronic actinic dermatitis[a]
• Generalized lichen planus	
• Urticaria pigmentosa	
• Cutaneous graft-versus-host disease	
• Generalized granuloma annulare	
• Pityriasis lichenoides[a]	
• Lymphomatoid papulosis[a]	
• Pityriasis rubra pilaris[a]	
• Localized scleroderma[a]	

[a]Experience limited to small number of patients.

obtained from the seeds of a plant called *Ammi majus*, is most widely used and the only psoralen available in the United States. Bergapten or 5-MOP and trioxsalen (TMP) or 4, 5′, 8 trimethylpsoralen are available in Europe and elsewhere.

Psoralen Photochemistry.[5–7] Psoralens intercalate between apposing DNA base pairs in the double helix in the absence of UV radiation. Absorption of photons in the UVA range results in the formation of a 3,4- or 4,5-cyclobutane addition product (adduct) with pyrimidine bases of native DNA. In the first step of this photochemical reaction, a monofunctional adduct with thymine or cytosine is formed. Some psoralens, including 8-MOP, TMP, and 5-MOP, can absorb a second photon, and this reaction leads to the formation of a bifunctional adduct with a 5,6 double bond of the pyrimidine base of the opposite strand, thus producing an interstrand cross-link of the double helix (Fig. 239-1). This intercalation of psoralens with epidermal DNA suppresses both DNA synthesis and cell division, and it was originally assumed that this was the therapeutic mechanism in psoriasis. However, cross-linking does not appear to be a prerequisite for the therapeutic effect, and successful PUVA treatment of other skin diseases is unlikely to be directly caused by this molecular reaction; psoralens also react with RNA, proteins, and other cellular components, and indirectly modify proteins and lipids via singlet oxygen-mediated reactions or by generating free radicals.[7] Perhaps these mechanisms contribute to the effects of PUVA in diseases that are not hyperproliferative in nature.

The formation of mono- and bifunctional photoadducts in DNA results in the immediate inhibition of DNA synthesis. The interstrand cross-links are believed to be largely responsible for eliciting skin photosensitization reactions of linear psoralens such as 8-MOP. Excessive production of these cyclobutane adducts causes cell death. Mutation and skin carcinogenesis also result from photoconjugation of psoralens to DNA because the cells surviving this DNA damage tend to repair it through an error-prone repair process.

In type II reactions (see Chap. 88), reactive oxygen species ($^1O_2$, O_2 or OH) induce the oxidation of cellular lipoprotein membrane lipids and destruction of membrane-bound cytochrome P_{450}. The membrane-damaging events activate the arachidonic acid metabolism pathway, which results in an increase of secondary oxidation products that contribute to the increased synthesis of eicosanoids. Furthermore, the reactive oxygen species can directly damage DNA by generating DNA strand breaks.

Mechanisms of Photochemotherapy. Hypotheses about the mechanism of action in psoriasis are based on the known photoconjugation of psoralens to DNA with subsequent suppression of mitosis, DNA synthesis, and cell proliferation, expected to revert increased cell proliferation rates in psoriasis to normal. However, PUVA also alters the expression of cytokines and cytokine receptors, downregulates certain lymphocyte and antigen-presenting cell functions, influences adhesion molecule expression, and diminishes Langerhans cell numbers within the epidermis. In addition, PUVA affects immune effector cells

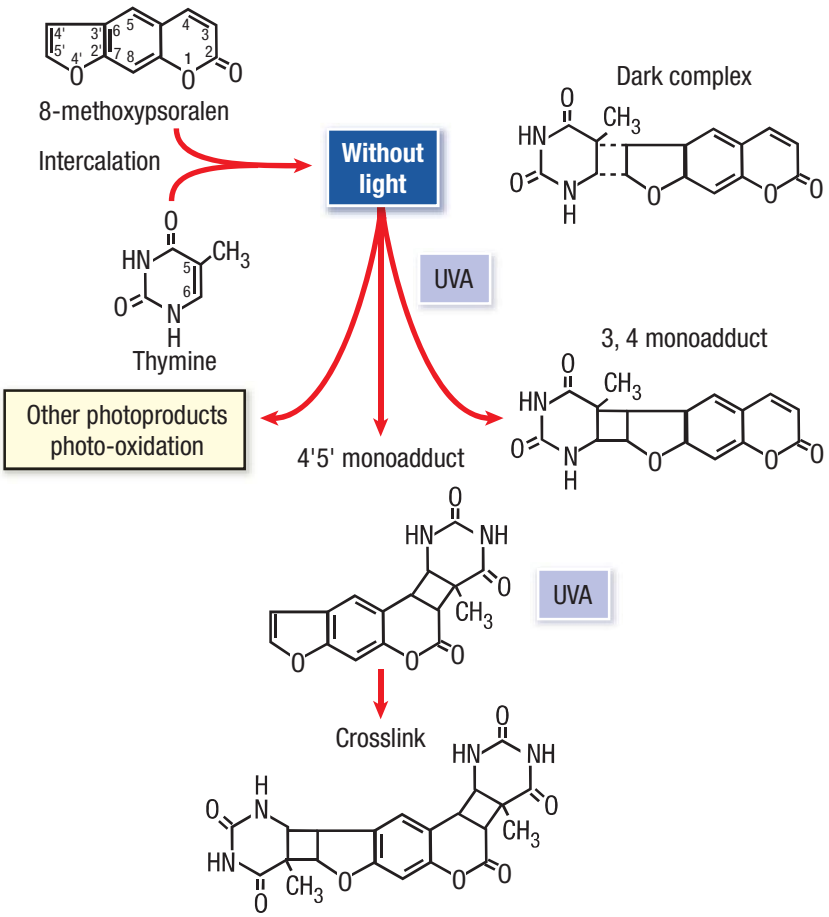

▲ **FIGURE 239-1** Psoralen photochemistry. Psoralens intercalate between apposing DNA base pairs, forming a "dark complex." Absorption of ultraviolet A (UVA) photons leads to a 3,4 or 4,5 cyclobutane monoadduct with pyrimidine bases of native DNA. The absorption of a second photon results in a bifunctional adduct producing an interstrand cross-link of the double helix.

such as lymphocytes or polymorphonuclear leukocytes. Because there is evidence that psoriasis is caused primarily by the action of blood-derived immunocytes, it is reasonable to speculate that PUVA therapy may act by affecting immune function through a direct phototoxic effect on lymphocytes in skin infiltrates. This is consistent with the observation that several other disorders that are not hyperproliferative in nature but immunomediated also respond well to PUVA. PUVA can revert pathologically altered patterns of keratinocyte differentiation and reduce the number of proliferating epidermal cells. Infiltrating lymphocytes are strongly suppressed by PUVA, with variable effects on different T-cell subsets. Lymphocytes are far more likely to undergo apoptosis than keratinocytes[8] in response to PUVA, which may explain the high efficacy in cutaneous T-cell lymphoma (CTCL), as well as in inflammatory skin diseases. Although much is known about pathways and mechanisms of psoralen photosensitization, the interactions and relative contributions to the clearing of a specific disease are not well understood.

Psoralens also stimulate melanogenesis. This involves the photoconjugation of psoralens to DNA in melanocytes, mitosis, and subsequent proliferation of melanocytes, an increased formation and melanization of melanosomes, an increased transfer of melanosomes to keratinocytes, and activation and increased synthesis of tyrosine mediated in part by stimulation of cAMP activity.

Pharmacokinetics. The important steps between the ingestion of a psoralen and its arrival at the site of action include absorption, first-pass effect, blood transportation, and tissue distribution. The absorption rate of a psoralen from the gut depends mainly on the physical characteristics of the preparation and the fat content of the concomitant food intake. Liquid preparations of 8-MOP and 5-MOP give higher and earlier peak serum levels than do crystalline formulations. In addition, peak serum levels are achieved by liquid preparations after a relatively reproducible time interval in all subjects, whereas wide time variability occurs with crystalline formulations. Before reaching the skin via the circulation, psoralens are metabolized during passage through the liver. Plasma levels of 8-MOP administered orally at different doses show a strong nonlinearity, indicating a saturable first-pass effect. The unpredictable pharmacokinetic behavior is probably due to inter- and intraindividual variations of intestinal absorption, first-pass effect, blood distribution in the body, metabolism, and elimination of the drug.

Within the same individual, serum levels of 8-MOP correspond fairly well with skin reactivity, the peak of skin phototoxicity coinciding with peak serum levels. However, phototoxic responses to PUVA show large interindividual variations. Hence, measurement of serum psoralens is a research tool and not used to monitor clinical therapy.

The pharmacokinetics of 8-MOP after topical treatment depend on the method of application. 8-MOP topically applied as a 0.15 percent emulsion or solution leads to plasma levels comparable to those found with oral treatment if large areas of the body are treated. In contrast, plasma levels after bath-PUVA treatment of almost the total body surface are very low. Bathwater-delivered psoralens are readily absorbed in the skin but are promptly eliminated without cutaneous accumulation.[8]

Ultraviolet A Radiation. UVA sources commonly used for PUVA therapy are fluorescent lamps or high-pressure metal-halide lamps. The typical fluorescent PUVA lamp has an emission peak at 352 nm and emits approximately 0.5 percent in the UVB range. UVA doses are given in J/cm^2, usually measured with a photometer with a maximum sensitivity at 350 to 360 nm. Although the action spectrum of anti-psoriatic activity and phototoxic erythema peaks at 335 nm, longer wavelengths have proved equally effective for clearing psoriasis if delivered in an adequate dose to obtain an equal erythemogenic response.[11]

Photosensitivity Effects of Photochemotherapy. PUVA treatment produces an inflammatory response that manifests as delayed phototoxic erythema, proportional to the dose of both drug and UVA as well as to the individual's sensitivity to phototoxic reactions. 8-MOP dose changes within individuals, over a narrow but clinically relevant range, appears to significantly alter the threshold for

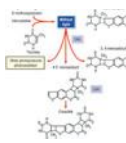

PUVA erythema, but not the rate of increase in erythema intensity with increasing UVA dose.[10] Importantly, the time course of PUVA erythema differs from sunburn or UVB erythema that appears after 4 to 6 hours and peaks 12 to 24 hours after exposure. PUVA erythema does not appear before 24 to 36 hours and peaks at 72 to 96 hours, or even later. Hence, daily PUVA treatments can result in unexpected severe delayed cumulative phototoxicity. PUVA erythema has a shallower dose-response curve than UVB erythema (by a factor of approximately 2) and this difference is maintained even at the point of maximum erythema.[9] Severe PUVA reactions may lead to blistering and to superficial skin necrosis. Overdoses of UVA are frequently followed by swelling, intense pruritus, and, sometimes, by a stinging sensation in the affected skin area, possibly as a consequence of damage of superficial nerve endings. Erythema is at present the only available parameter that allows an assessment of the magnitude of the PUVA reaction; thus, it represents an important criterion for dose adjustments.[11]

Pigmentation is the second important effect of PUVA. It may develop without clinically evident erythema, especially when oral 5-MOP or TMP is used; this is particularly important in the treatment of vitiligo and for the preventive therapy of certain photodermatoses. In unaffected skin, PUVA pigmentation is maximal approximately 7 days after a PUVA exposure and may last from several weeks to months. As with sun-induced pigmentation, the individual's ability to tan is genetically determined, but the dose-response curve is much steeper. A few PUVA exposures result in a much deeper tan than that produced by multiple exposures to solar radiation.

TREATMENT PROTOCOLS ***Topical Treatment.*** Application of 8-MOP in creams, ointments, or lotions followed by UVA irradiation is effective in clearing psoriasis but has several disadvantages. The nonuniform distribution on the skin surface induces unpredictable phototoxic erythema reactions and irregular patches of cosmetically unacceptable hyperpigmentation. Furthermore, if numerous lesions are present, the application is laborious and time-consuming, and the treatment does not prevent the development of new active lesions in previously unaffected, untreated areas. Therefore, topical PUVA with psoralen creams, ointments, or lotions is now used only for limited plaque psoriasis and for palmo-plantar disease.

Bath Photochemotherapy. The use of bathwater delivery of psoralens provides for a uniform drug distribution over the skin surface, very low psoralen plasma levels, and rapid elimination of free psoralens from the skin. Bathwater delivery of 8-MOP circumvents gastrointestinal side effects and possible phototoxic hazards to the eyes because there is no systemic photosensitization. Skin psoralen levels are highly reproducible, and photosensitivity lasts no more than 2 hours. The higher incidence of unwanted phototoxicity can be prevented by a lower starting dose [50 percent of the minimal phototoxic dose (MPD)] and a more cautious dosimetry in the initial treatment phase. Originally, bath-PUVA was performed with TMP, but 8-MOP and 5-MOP are now being used as well. Bath-PUVA consists of 15 to 20 minutes of whole-body immersion in solutions of 0.5 to 5.0 mg 8-MOP per liter of bathwater. Irradiation needs to be performed immediately, as photosensitivity decreases rather rapidly. TMP is more phototoxic after topical application and is used at lower concentrations than 8-MOP. MPD testing for bath-PUVA must take into account that the phototoxic threshold declines during the early treatment phase,[8] in contrast to oral PUVA. Guidelines for bath, local immersion, and other topical PUVA forms have been published by the British Photodermatology Group and are based, where possible, on the results of controlled studies, or otherwise on consensus.[12]

Oral Treatment. In oral PUVA, 8-MOP is administered orally (0.6 to 0.8 mg/kg body weight) 1 to 3 hours before exposure, depending on the absorption characteristics of the particular drug brand. Liquid drug preparations are absorbed faster and yield higher and more reproducible serum levels than microcrystalline forms. For 5-MOP, the usual dosage is 1.2 to 1.8 mg/kg body weight.

The initial UVA doses are determined by either the patient's skin type[13,14] or MPD testing.[11,15] The MPD is defined as the minimal dose of UVA that produces a barely perceptible, but well-defined, erythema when template areas of the skin are exposed to increasing doses of UVA. Erythema readings are performed 72 hours after testing, at which time the psoralen phototoxicity reaction usually reaches its peak. The MPD test should be performed on previously non-exposed skin (e.g., buttocks). Although the MPD test is more time-consuming than phototyping, it allows for more accurate and higher UVA doses during initial treatment. Table 239-2 shows recommendations for dosimetry in bath and oral PUVA.

Repeated exposures are required to clear PUVA-responsive diseases, with gradual dose increments as pigmentation develops. Lower doses quite frequently result in failure of treatment except in those diseases in which induction of pigmentation is the desired objective. In most dermatoses amenable to PUVA, the frequency of treatments is reduced after satisfactory clearing of disease, and the last UVA dose is used as a maintenance dose, if maintenance treatment is planned. The duration of this maintenance phase and the frequency of treatments depend on the particular disease being treated and its propensity to relapse.

Indications for Photochemotherapy

PHOTOCHEMOTHERAPY FOR PSORIASIS Basically all types of psoriasis respond to PUVA (Figs. 239-2 and 239-3), although the management of erythrodermic or generalized pustular psoriasis is more

TABLE 239-2
Recommended Treatment Schedule for Photochemotherapy

1	Determination of MPD	Reading	After 96–120 h (bath-PUVA) After 72–96 h (oral PUVA)
2	Start of treatment	First therapeutic dose	30% of MPD (bath-PUVA) 50%–70% of MPD (oral PUVA)
3	Treatments two to four times weekly	No erythema, good response	Increase once weekly by 30%
		No erythema, no response	Increase by 30%
		Minimal erythema	No increase
		Persistent asymptomatic erythema	No increase
		Painful erythema (with or without blistering)	No treatment until symptoms subside
4	Resumption of treatment	After resolution of symptoms	Reduction of last dose by 50%, next increase by 10%

MPD = minimal phototoxic dose; PUVA = psoralen and ultraviolet A light.



◀ **FIGURE 239-2** Twenty-three-year-old patient with generalized psoriasis (seborrheic type). **A.** Before photochemotherapy treatment. **B.** After treatment. (From Wolff K et al: Photochemotherapie bei Psoriasis. Klinische Erfahrungen bei 152 Patienten. *Dtsch Med Wochenschr* **100**:2471, 1975 with permission.)

difficult.[2] The effectiveness of oral PUVA in inducing and maintaining remission of psoriasis has been widely documented and confirmed by large-scale clinical trials (see Figs. 239-2 and 239-3).

Administration. Three studies have compared bathwater delivery of 8-MOP with oral administration. In two reports, initial doses were determined by skin typing, and treatments were given two to three times weekly. Dose increments were instituted with every treatment in one study, whereas smaller increments were given every third treatment in the other. The third report, in which patients were treated according to the standard European regimen for oral PUVA, showed the lowest incidence of treatment failures and overdose phenomena. Compared with oral 8-MOP, bath-PUVA showed equal clearing rates with fewer exposures.[8] The greater therapeutic efficacy could be because of a higher penetration of psoralens through the abnormal stratum corneum overlying psoriatic plaques, as compared with healthy perilesional skin where phototoxicity is monitored during the therapy. The incidences of erythema and pruritus were similar or lower compared with oral therapy. Systemic intolerance, such as nausea and vomiting, were not observed.

Oral 5-MOP–PUVA represents an alternative to oral 8-MOP–PUVA. Psoriatic lesions are cleared with a comparable number of treatments, but at the expense of significantly higher cumulative UVA doses. This difference may be due to the lower phototoxicity potential of 5-MOP and of its higher tanning activity. However, 5-MOP–PUVA therapy is not associated with nausea and vomiting and has a lower incidence of pruritus and severe phototoxic erythema.[8]

On complete clearing, patients are often assigned to maintenance therapy, during which the frequency of treatments is gradually reduced. The purpose of maintenance therapy is to achieve longer remission. Maintenance therapy in the original European regimen consisted of 1 month of twice-weekly treatments, with the last UVA dose used for clearing, followed by another month of once-weekly exposures. According to other recommendations,[16] maintenance treatment should be considered only on rapid relapses, because patients with a stable remission may be over-treated, and long-term risks of PUVA are related to the total cumulative phototoxic doses. In one left–right comparison study with psoriatics, PUVA maintenance treatment over 2 months did not increase the length of remission.

Erythrodermic and generalized pustular psoriasis (von Zumbusch type) respond to PUVA (Fig. 239-4), but the time required to induce remission is considerably longer, more treatments are needed, and higher failure rates are reported, compared with plaque or guttate varieties. Pustular eruptions of palms and soles are quite recalcitrant to treatment, regardless of whether they are true localized pustular psoriasis, nonpsoriatic palmo-plantar pustulosis or pustular psoriasis, or pustular eczema. Oral PUVA alone can produce a slow but definite remission in many cases, but a considerable number of patients require adjunctive therapy for clearing. As mentioned above, the combination with topically applied 8-MOP can be beneficial, but bath-PUVA appears to be also quite effective in such cases.

PUVA alone can produce definite remissions in many patients with psoriasis, but a considerable number require additional therapies for clearing. Such combination therapy (see the section Combination Treatments) improves efficacy and reduces possible side effects.



▲ **FIGURE 239-3** Twenty-three-year-old patient with generalized psoriasis (plaque-type). **A.** Before photochemotherapy treatment. **B.** After treatment. (From Wolff K, Hönigsmann H: Clinical aspects of photochemotherapy. *Pharmacol Ther* **12**:381, 1981 with permission.)

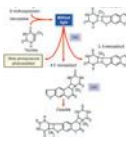



▲ **FIGURE 239-4** Eighteen-year-old patient with pustular psoriasis (von Zumbusch type). **A.** Before photochemotherapy treatment. **B.** After treatment. (From Hönigsmann H et al: Photochemotherapy for pustular psoriasis (von Zumbusch). *Br J Dermatol* **97**:119, 1977, with permission.)

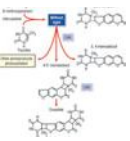

Combination Treatments. **TOPICAL COMBINATIONS.** Topical adjuvant therapies with glucocorticoids, anthralin, and tar preparations, and, more recently, with calcipotriol and tazarotene, have yielded good results. However, adjunctive topical therapy is found unacceptable by some patients because it is considered a step backward to conventional treatment.

METHOTREXATE. A combination of PUVA and methotrexate can reduce the duration of treatment, number of exposures, and total UVA dose and is also effective in clearing patients unresponsive to PUVA or UVB alone.[17] This combination appears to be safe if used during the clearing phase only. However, if used for long-term treatment, PUVA and methotrexate may act synergistically in the development of skin cancers.[18]

CYCLOSPORINE. Cyclosporine plus PUVA dramatically enhances skin carcinogenesis. This is in keeping with the observation of a greatly increased risk of cutaneous squamous cell carcinomas in patients with solid organ transplants maintained on this immunosuppressant. Thus, this combination should be definitely discouraged.[8,19–21]

RETINOIDS. The therapeutic efficacy of PUVA therapy is dramatically increased by daily oral retinoid (etretinate, acitretin, isotretinoin; 1 mg/kg) administration beginning 5 to 10 days before the initiation of PUVA, and continued throughout the clearing phase. This so-called *RePUVA* characteristically reduces the number of exposures by one-third and the total cumulative UVA dose by more than one-half. RePUVA also often clears "poor responders" who are not brought into complete remission by PUVA alone.[22]

The mechanism of the synergistic action of retinoids and PUVA is unknown, but may be a result of the accelerated desquamation that optimizes the optical properties of the skin and reduction of the inflammatory infiltrate. As an additional beneficial effect, etretinate and other retinoids may theoretically protect against long-term carcinogenic effects of PUVA. In one study, patients with psoriasis treated with PUVA in combination with systemic retinoids showed a reduced risk of squamous cell carcinoma but not a significantly altered incidence of basal cell carcinoma (BCC).[23] Although retinoid toxicity is generally not a concern because the administration is limited to the clearing phase, the potential teratogenicity of retinoids represents a serious concern for women of child-bearing age. In these patients, the use of isotretinoin is advisable because contraception is necessary for only 1 month after discontinuation of therapy, in contrast to etretinate and acitretin, which require 2 years of contraception because of their slower elimination.[8]

BIOLOGICS. The mechanism of action of biologic agents suggests that there may be additive effects in treating psoriasis with PUVA, but this remains to be further defined in clinical trials.[24,25]

PUVA FOR CUTANEOUS T-CELL LYMPHOMA (MYCOSIS FUNGOIDES) Since the first promising results with PUVA in CTCL in 1976,[26] numerous investigators from the United States and Europe have confirmed the efficacy of PUVA for CTCL.[27] Treatment schedules and dosimetry are essentially the same as for psoriasis. The treatment consists of a clearing phase (Fig. 239-5), a maintenance phase consisting of two exposures per week for 1 month and one exposure per week for another month, and a follow-up phase without therapy. Remission should be confirmed by histologic examination of previously involved skin sites. After therapy is discontinued, the patient is moni-



▲ **FIGURE 239-5** Forty-six-year-old patient with cutaneous T-cell lymphoma (mycosis fungoides), stage IB. **A.** Before photochemotherapy treatment. **B.** After treatment (clearing phase).

tored monthly and later bimonthly. If a relapse occurs, the patient is again subjected to a full PUVA course. Some investigators advocate permanent maintenance treatment consisting of treatments once monthly or every other month. However, the course of CTCL varies considerably from patient to patient, and clinical experience suggests that patients benefit most from individualized treatment schedules.[8]

Relapses respond as well as the initial lesions when PUVA is resumed. Clinical remissions appear to be directly related to phototoxic destruction of the malignant lymphocytes that infiltrate the skin. Thus, complete clearing may be induced when the cells are confined to the epidermis and superficial dermis, the depth of effective UVA penetration into the skin.

Present knowledge indicates that PUVA is an excellent treatment option that may induce long-lasting disease-free intervals in CTCL if used in the early stages of the disease.[27] In later stages, PUVA may reduce the tumor cell burden and thus may act synergistically with other treatment. It improves quality of life and may prolong survival when used in combination with more aggressive treatment modalities. Prolonged remissions were observed with combinations of PUVA with retinoids, bexarotene,[28,29] or interferon-α 2a.[30,31]

Patients with tumor-stage CTCL exhibit a high rate of early recurrences and therefore require indefinite maintenance treatment. PUVA causes complete tumor resolution only when used in combination with local x-ray treatment and/or systemic chemotherapy. Most follow-up studies have demonstrated that the great majority of patients with early disease can be kept in remission with or without maintenance therapy for several years, but tumor-stage patients (IIB) usually experience multiple recurrences despite aggressive combination therapies and eventually die within a few years.[27] Currently, no therapeutic regimen is known to arrest the eventual progression of CTCL to tumor formation, dissemination, and fatal outcome. Although PUVA therapy is very effective in inducing remission as long as the lymphoma is clinically confined to the skin, the influence of this therapy on the natural course of CTCL and on patient survival has not been determined. However, data from the Swedish National Central Bureau of Statistics show a significant drop in the death rate of patients since the introduction of PUVA.[32]

Successful treatment of erythrodermic CTCL (Sézary syndrome) has been reported with extracorporeal PUVA (photopheresis) [see Extracorporeal Photochemotherapy (Photopheresis)]. Possible long-term hazards related to frequent PUVA treatments are of less concern for patients with CTCL, compared with patients with benign conditions.

PHOTOTHERAPY FOR ATOPIC DERMATITIS Many patients with atopic eczema can benefit from PUVA therapy.[33] The treatment guidelines are the same as for psoriasis. However, the condition is more difficult to treat, and quite often a higher number of treatments are required to clear the eczema. There is a high and early recurrence rate, requiring frequent maintenance exposures. A combination of PUVA with topical glucocorticoids appears to be superior to PUVA alone in maintaining remissions. Because the average patient is young, long-term maintenance therapy is problematic; and combination of PUVA with topical immune modulators (tacrolimus, pimecrolimus), although effective, cannot be recommended until more data are available. The mechanism of action of PUVA in atopic eczema is unclear; current concepts support an alteration of lymphocytes in the dermal infiltrate.

PHOTOTHERAPY FOR LICHEN PLANUS In generalized lichen planus, PUVA can provide an effective alternative to systemic glucocorticoid treatment, although it appears to be more resistant to PUVA than psoriasis when treated according to a similar schedule. More exposures and higher cumulative UVA doses are required for clearing, and not all patients respond satisfactorily. An exacerbation during PUVA treatment has been reported in a few patients. In patients who clear, relapses respond equally well when PUVA is resumed. Bath-PUVA can also clear lichen planus, and combined PUVA-etretinate regimen may be considered.[34]

PHOTOCHEMOTHERAPY FOR CUTANEOUS MASTOCYTOSIS In cutaneous mastocytosis (urticaria pigmentosa), PUVA leads to a temporary involution of skin lesions,[35] probably due to chronic degranulation of the mast cells. The treatment results in loss of Darier's sign, relief of itching, and flattening and even complete disappearance of cutaneous papules and macules. Surprisingly, even systemic symptoms such as histamine-induced migraine and flushing improve gradually as treatment is continued.[35] In most patients, the manifestations of the disease recur several months after discontinuation of PUVA, but the recurrences respond as well as the original lesions.

Because treatment of cutaneous mastocytosis has been unrewarding with other modalities, the use of PUVA, although not curative, seems to be warranted in patients when the disease is causing severe distress.

PHOTOTHERAPY FOR MISCELLANEOUS DERMATOSES Both acute and chronic pityriasis lichenoides[34] respond to PUVA, and favorable results have been reported for lymphomatoid papulosis.[36] However, the experience with these conditions is limited to a few anecdotal cases. In pityriasis rubra pilaris, the results are quite inconsistent. Some cases seem to respond well, others may flare, and some require combination treatment with retinoid or methotrexate therapy. Generalized granuloma annulare has been reported to clear completely, but long-term maintenance treatment was required to maintain remissions.[37] Regrowth of hair was noted in alopecia areata with either topical or systemic PUVA exposures localized to the alopecia areas. Follow-up studies of larger patient groups concluded that PUVA is generally not an effective treatment for alopecia areata.[38] The experience of the present authors has also not been encouraging. Localized scleroderma and pansclerotic morphea have been successfully treated with bath-PUVA and oral PUVA.[39,40]

PHOTOCHEMOTHERAPY FOR CHRONIC GRAFT-VERSUS-HOST DISEASE Acute and chronic cutaneous graft-versus-host disease (GVHD) have become indications of increasing importance. Because of the clinical and histologic similarities of idiopathic lichen planus and lichenoid GVHD, PUVA treatment was evaluated for the latter.[41] PUVA cleared or improved this lichen planus–like eruption in patients who had not responded to conventional immunosuppressive therapy alone. PUVA can also improve acute GVHD,[42] although results of PUVA treatment for scleroderma-like variants of cutaneous GVHD are controversial. According to our own experience, the more circumscribed, localized forms appear to respond to PUVA with softening of the fibrotic, sclerotic connective tissue, but more widespread, disseminated lesions hardly respond.

Improvement of mucosal erosions followed by healing, observed during treatment of chronic lichenoid GVHD

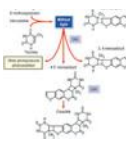

with PUVA, suggests that PUVA may exert both local and systemic effects, but this is not proven. There is no improvement of GVHD of other organs, such as the liver.

The therapeutic regimen used for the treatment of chronic GVHD is basically the same as for psoriasis. UVA doses should not be increased too aggressively, to avoid erythema and possible (re)activation of GVHD. In general, increase of the UVA dosage by 0.5 J/cm^2 at maximum after every second to fourth exposure is recommended. Patients are exposed to UVA radiation three to four times weekly. After clearing of skin lesions, the frequency of exposures is reduced.

There appears to be an overall increased risk of secondary malignancies for all bone marrow/peripheral stem cell recipients, and they should be examined on a regular basis for the development of cutaneous malignancies, independent of whether they had experienced cutaneous GVHD or had been treated with PUVA.

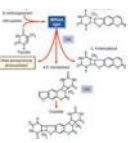

PHOTOCHEMOTHERAPY FOR VITILIGO Vitiligo was the first disease treated with an ancient form of psoralen PUVA in India and Egypt. PUVA in its modern form stimulates melanogenesis, melanocyte proliferation and migration, and reconstitutes the normal skin color in more than 50 percent of vitiligo patients. However, it is less used now since narrowband UVB phototherapy has been shown to be effective and possibly safer alternative for repigmentation of this condition.

To induce maximal repigmentation, patients need long-term therapy with 100 to 200 exposures given twice or thrice weekly. Approximately 70 percent of patients respond after 12 to 24 months (Fig. 239-6), as defined as the development of perifollicular macules of repigmentation. If there is no response after 6 months or approximately 50 treatments (as defined as perifollicular macules of repigmentation), PUVA should be terminated. If treatment is discontinued, this newly acquired repigmentation may be lost. Completely repigmented areas are often stable for a decade or more without relapse.[43]

Patient selection appears to be particularly important in vitiligo treatment. Lips, distal dorsal hands, tips of fingers and toes, areas of bony prominences, palms, soles, and nipples are very refractory to treatment, and patients with involvement limited to these areas should be excluded. Segmental vitiligo tends to show a variable response. Because of the different response in different body areas, total repigmentation is only rarely achieved, and some 30 percent of patients do not respond at all despite many months of therapy. Duration of the disease before PUVA therapy does not affect response rate.



▲ **FIGURE 239-6** Twelve-year-old patient with generalized vitiligo of 4 years' duration. **A,C.** During the initial phases of photochemotherapy treatment. **B,D.** 1 month after treatment (8-methoxypsoralen + artificial ultraviolet A) with thrice-weekly exposures for 10 months.

The mechanisms by which PUVA induces repigmentation in vitiligo skin are speculative. However, PUVA's known effect on a number of immunologic reactions suggests a suppression of the autoimmune stimulus for melanocyte destruction.

PHOTOCHEMOTHERAPY AS PREVENTION FOR PHOTODERMATOSES Tolerance to sunlight can be induced in several photodermatoses with PUVA. In polymorphous light eruption, the most common photodermatosis, PUVA is the most effective preventive treatment.[44] In approximately 70 percent of patients with this condition, a 3- to 4-week PUVA course of two to three treatments per week suffices to suppress the disease on subsequent exposure to sunlight. The initial exposure and dose increments during therapy should be performed according to the guidelines outlined for psoriasis. PUVA has the advantage of a rapid and intense pigment induction at relatively low UVA doses that usually remain well below the threshold doses for eliciting the rash. Approximately 10 percent of patients develop typical lesions during the initial phase of PUVA, but these usually disappear when treatment is continued. The authors' treatment schedule consists of three to four treatments per week for 3 to 4 weeks in early spring. PUVA protects only temporarily, but subsequent sun exposures usually maintain protection and many patients remain protected for 2 to 3 months even after their pigmentation has faded.

The mechanism by which phototherapy induces tolerance to sunlight is not clear. Hyperpigmentation and thickening of the stratum corneum may be important factors, but other mechanisms, such as modulations of cutaneous immune functions, may also be involved.[44]

There is also some experience with PUVA prophylaxis of other photodermatoses. In solar urticaria, PUVA therapy appears to be the most effective preventive treatment available and is certainly better than antihistamines. Tolerance to sunlight can be increased 10-fold or more

after a single treatment course. The suppressive effect may last throughout the summer if the patients have regular sunlight exposures, which seems to be necessary to maintain tolerance. Problems may arise during the first PUVA exposures, because, in some patients, the urticaria threshold dose is very low. In these cases, careful conditioning by stepwise UVA irradiation of single quadrants of the body surface a few hours before each PUVA treatment have proved useful. Treatments with PUVA are then given during the refractory period of presumed mast cell degranulation.

Successful PUVA has also been reported in occasional cases of chronic actinic dermatitis and hydroa vacciniforme. Limited experience in patients with erythropoietic protoporphyria indicates that, with a very cautious approach and in combination with β-carotene, PUVA may increase light tolerance considerably.[45,46]

Extended treatment is usually not required in polymorphous light eruption but may be necessary in solar urticaria and chronic actinic dermatitis. There exist no ready-to-use schedules for these latter conditions, and PUVA is usually just one part of the management.[45]

PHOTOCHEMOTHERAPY IN HUMAN IMMUNODEFICIENCY VIRUS–INFECTED PATIENTS

The use of phototherapy and PUVA in human immunodeficiency virus (HIV)–infected patients with skin diseases is controversial. Both therapies can induce systemic immune suppression and may modify the immune status of the patient in a way that would worsen HIV disease.[47] Both UV radiation and psoralen photosensitization activate the HIV promoter, which could boost viral gene transcription and, eventually, virus production,[48] although available data and theoretic considerations indicate that UVB is more likely to be a hazard than PUVA in an HIV-infected population.[51,52] Nevertheless, oral PUVA treatment of psoriasis does not detectably accelerate progression of HIV disease or increase side effects,[49,50] and was concluded that PUVA is not contraindicated for HIV-positive patients with responsive skin diseases.

Side Effects and Toxicity of Photochemotherapy (Table 239-3)

TABLE 239-3
Side Effects and Toxicity of Photochemotherapy

Acute side effects	
Drug intolerance	Nausea, vomiting with oral MOP, but not with 5-MOP.
UVA overdosage	Can range from an increased delayed erythema reaction to severe burns with blistering. When large areas of skin are affected, systemic symptoms of excess phototoxicity, such as fever and general malaise, can occur.
Pruritus	Some patients experience persistent pruritus during photochemotherapy (PUVA) treatment, particularly after slight UVA overdosage.
Laboratory data	No significant abnormal findings in patients receiving PUVA over prolonged periods of time.
Potential long-term risks	
Chronic actinic damage	Chronic exposure to PUVA may produce changes in the skin that resemble photoaging. PUVA lentigines and generalized PUVA lentiginosis result from repeated and prolonged treatment and are commonly associated with high cumulative doses of UVA and a large number of treatments. So far, no increased risk of cutaneous melanoma associated with these lentigines has been recorded.
Carcinogenesis	The risk of squamous cell carcinoma, but not of basal cell carcinoma, is significantly increased in comparison with matched controls, and the magnitude of the increase appears to be dose-dependent. There is still uncertainty about PUVA being the sole factor—many of the affected patients had previous exposure to excessive sunlight and to treatments with carcinogenic potential, including arsenic, UVB, cyclosporine, and antimetabolite therapy. No increased risk was found so far with bath-PUVA.
Melanoma	Stern et al. reported from patients enrolled in the PUVA Follow-up Study (16-Center Study[63]) that, beginning 15 years after first exposure to PUVA, an increased risk of melanoma was observed. This risk was greater in patients exposed to high doses of PUVA and appeared to be increasing with the passage of time. The conclusions of this study have been questioned, and the authors now agree that the observed risk of melanoma does not represent an absolute contraindication to PUVA or that PUVA therapy should be abandoned. Rather, the risks of both melanoma and squamous cell carcinoma in PUVA should be weighed against the substantial efficacy of PUVA and the risks of other therapies.
Ophthalmologic effects	Several studies have shown no indication that psoralen-induced cataracts occur in patients undergoing long-term photochemotherapy, even in patients who neglected eye protection.

MOP = 8-methoxypsoralen; PUVA = psoralen and ultraviolet A light.

ACUTE SIDE EFFECTS The side effects of PUVA include drug intolerance reactions as well as side effects of the combined action of psoralens plus UVA radiation. Oral 8-MOP (0.6 to 0.8 mg/kg) has a high incidence of nausea (30 percent of patients) and vomiting (10 percent of patients), and this may occasionally require discontinuation of the treatment. These side effects are more common with liquid preparations than with crystalline preparations, probably because of higher psoralen serum levels. With 5-MOP, nausea is almost absent, even with doses of up to 1.8 mg/kg body weight.

Undesired acute effects of the combined action of psoralens and UVA can range from an increased delayed erythema reaction to severe burns with blistering. When large areas of skin are affected, systemic symptoms of excess phototoxicity, such as fever and general malaise, may occur. Nonsteroidal anti-inflammatory drugs and topical and systemic corticosteroids may be required to alleviate the symptoms but have to be given early. Some patients experience persistent pruritus during PUVA treatment, particularly after slight UVA overdosage, and, in rare cases, a stinging pain may develop in circumscribed areas. The mechanism is unknown, and the symptoms are unresponsive to antihistamines. These complaints usually subside on continuation of treatment. Overdosage phenomena occur mostly in body areas not usually exposed to natural sunlight. Careful observation of the criteria for dosimetry can minimize these side effects to acceptable levels. The danger of overdosage is much less with 5-MOP.

Very rare side effects of PUVA include polymorphous light eruption-like rashes, acne-like eruptions, subungual hemorrhages caused by phototoxic reactions in the nail beds, and occasional hypertrichosis of the face. These disappear when treatment is discontinued. Single case re-

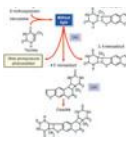

ports note exacerbation of systemic lupus erythematosus and bullous pemphigoid during PUVA.

LABORATORY DATA Analysis of laboratory data in several large-scale studies showed no significant abnormal findings in patients receiving PUVA over prolonged periods of time.[13,14,53] Serial laboratory examinations performed over a period of several years have not revealed any substantial evidence for impairment of hepatic function. Liver biopsies after 1 year of therapy did not reveal hepatotoxicity.[54] No evidence exists suggesting impairment of renal function.[13] Several large-scale studies have negated a suggested relation between PUVA therapy and the occurrence of anti-nuclear antibodies.[55]

POTENTIAL LONG-TERM RISKS OF PHOTOCHEMOTHERAPY ***Chronic Actinic Damage.*** Repeated photodamage to the skin can be expected to result in cumulative injury regardless of whether it is induced by sunlight, artificial UV radiation, or PUVA. Chronic exposure to PUVA may produce changes that resemble photoaging and that may add to the injury induced by sunlight.

PUVA lentigines and generalized PUVA lentiginosis result from repeated and prolonged treatment and are commonly associated with high cumulative doses of UVA and a large number of treatments.[14] The lentigines exhibit irregular borders and uneven pigmentation. No increased risk of cutaneous melanoma has been associated with these lentigines, but the cosmetic effect may be quite disturbing.

Carcinogenesis. Cutaneous carcinogenicity is the major concern for long-term PUVA treatment associated with high cumulative UVA doses. PUVA is a photocarcinogen (see Chap. 112). In laboratory animals, 8-MOP and 5-MOP have been unequivocally shown to induce skin cancer at levels of drug and UVA irradiation comparable to those used in PUVA therapy.[56,57] However, this risk is related to DNA damage, but PUVA-induced downregulation of immune responses may play an additional role. This risk has to be assessed against the potential therapeutic benefit.

Long-term follow-up PUVA studies are confounded by the fact that patients, particularly those with severe psoriasis, are likely to have been exposed previously to other carcinogenic treatments, such as ionizing radiation, UVB therapy, methotrexate, tar, or arsenic, and accurate exposure data are often lacking.

In PUVA patients, the risk of squamous cell carcinoma, but not of BCC, is significantly increased in comparison with matched controls and the magnitude of the increase appears to be dose-dependent.[18,57] However, there is uncertainty about PUVA being the sole factor—many of the affected patients had previous exposure to excessive sunlight and to treatments with carcinogenic potential, including arsenic, UVB, and antimetabolite therapy.[58] Particularly, high levels of UVB exposure appear to increase the risk of non-melanoma skin cancer in PUVA-treated patients.[59] According to one study, the genitalia in man previously treated with tar and UVB appeared to be particularly susceptible to PUVA carcinogenesis,[60] but the risk seemed not to be increased if only PUVA was used.[61] In a retrospective study from France comprising 5400 patients treated with PUVA between 1978 and 1998, no case of genital skin cancer was found, despite the fact that the genital area had not been protected.[62] This makes it unlikely that genital shielding is absolutely necessary.

Carcinogenicity of 5-MOP–UVA therapy in PUVA-treated patients is not documented, but 5-MOP has shown mutagenicity similar to 8-MOP in model systems.

Stern et al. reported that of the cohort of 1380 patients enrolled in the so-called *16 Center PUVA Follow-up Study,* 23 patients have developed 26 invasive or in situ cutaneous melanomas over a period of roughly 25 years. Beginning 15 years after first exposure to PUVA, this constituted an increased risk of melanoma.[63,64] This risk was greater in patients exposed to high doses of PUVA and appeared to increase with the passage of time. The conclusions of this study have been questioned,[65] and the authors now agree[64] that the observed risk of melanoma does not represent an absolute contraindication to PUVA. Rather, the risks of both melanoma and squamous cell carcinoma in PUVA should be weighed against the substantial efficacy of PUVA and the risks of other therapies.[65] Of note, PUVA's long-term risks have been subject to much greater scrutiny than the risks of other therapies advocated for severe psoriasis, such as methotrexate and, particularly, immunosuppressive therapies such as cyclosporine. These latter therapies greatly increase cancer risk in populations less likely to have substantial exposures to known cutaneous carcinogens such as UVB than are patients with severe psoriasis. Early detection through careful, long-term follow-up and education of PUVA patients may reduce the long-term morbidity and mortality associated with this therapy, as can low cumulative dosage regimens.[66]

Studies of 944 Swedish and Finnish patients[67] and 158 Finnish patients[68] with psoriasis showing no association between cutaneous cancer and TMP or 8-MOP bath-PUVA, respectively, are reassuring. UVB is carcinogenic, but mathematic model studies indicate that the observed risk of squamous cell carcinoma is much higher with PUVA than with UVB.[69] The carcinogenic risk of narrowband UVB in comparison with PUVA is unknown, and it will be crucial to monitor its long-term effects in psoriatics.

Ophthalmologic Effects. Data from animal studies indicate a risk of premature cataract formation due to PUVA, but clinical evaluation suggests no increase in lens opacities, even in patients who neglect careful eye protection during long-term PUVA.[70]

Patient Selection and Contraindications

In view of the potential long-term hazards of PUVA, the assignment of patients should be based on consideration of the risks and the benefit for the individual patient. If only a short-term course of therapy is planned, as, for example, in prevention of photodermatoses, the benefit outweighs the risk. In the treatment of a malignant condition such as CTCL, long-term risks may be discounted because other treatment options bear even greater long-term risks. The major concerns relate to long-term treatment of psoriasis, by far the most common indication for PUVA. Careful patient selection appears to be mandatory, bearing in mind that long-term risks of alternative therapies may simply be less well documented rather than less. Guidelines have been published.[15]

PUVA is not recommended during pregnancy, and women should be advised to use contraceptive measures while on PUVA. This precaution is only for reasons of absolute safety as there exists no evidence that either 8-MOP alone or PUVA is teratogenic, as confirmed in a retrospective study in 256 deliveries among the cohort of the 16-Center

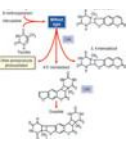

PUVA Follow-Up Study.[71] However, it has to be emphasized that RePUVA bears the risk of retinoid teratogenicity.

Severe impairment of hepatic and renal functions is usually considered a contraindication to PUVA because metabolism and excretion of psoralens may be inadequate. PUVA is also contraindicated in patients with known light-aggravated or light-induced diseases such as lupus erythematosus, porphyria (but, as mentioned above, light tolerance can be induced by PUVA in erythropoietic protoporphyria), and xeroderma pigmentosum. Pemphigus vulgaris and bullous pemphigoid may be exacerbated by PUVA. Patients with chronic actinic damage and a history of skin cancers may be at higher risk for the development of new cancers. Previous arsenic intake and previous treatment with ionizing radiation also seem to increase the risk of non-melanoma skin cancers. Immunosuppressed patients should probably not receive PUVA, although this is not yet clearly defined. As outlined above, PUVA can be used in HIV-positive patients. Cataracts and aphakia are not contraindications if adequate eye protection is guaranteed.

Conclusions and Perspectives

PUVA is a highly effective treatment for several dermatologic diseases. Although there exists comprehensive clinical experience documenting PUVA's short-term safety when used according to standardized methods, potential long-term sequelae have still not been clearly determined. Thus, treatment decisions should take into account whether other equally effective forms of therapy that carry a lower risk are available. Risk-versus-benefit varies with the disease being treated.

Severe widespread psoriasis is a devastating disease that may result in disruption of professional, social, and private life. After more than three decades of experience with PUVA for the treatment of psoriasis, it is evident that this therapy offers innumerable patients the chance to resume a normal life. For disabling psoriasis, the choice of therapies lies not between risk and safety but among modalities (methotrexate, cyclosporine, UVB, and biologics), none of which is absolutely safe.[65]

EXTRACORPOREAL PHOTOCHEMOTHERAPY (PHOTOPHERESIS)

Extracorporeal PUVA (ECP) was introduced in the 1980s for the palliative treatment of erythrodermic CTCL,[72] a disorder characterized by circulating malignant lymphocytes. Its efficacy was subsequently confirmed by several clinical trials and approved in 1988 by the U.S. Food and Drug Administration for this indication. At the International Consensus Conference on Staging and Treatment Recommendations for CTCL in 1994[73] and at the European Organization for Research and Treatment of Cancer Consensus Recommendations in 2006,[74] ECP was recommended as the first line of treatment for patients with erythrodermic CTCL.

Attempts to better characterize those CTCL patients likely to respond to ECP revealed a significant linear association between response and CD4:CD8 ratio. Patients with a ratio less than 10 are more likely to respond than patients with a ratio greater than 10. There is also a marginally significant linear association between response and lactic acid dehydrogenase (LDH) level, with patients whose LDH is not elevated at the start of treatment responding better than patients with an elevated LDH.[75]

Treatment Method

ECP involves the oral administration of 8-MOP followed by phlebotomy at the time of peak photosensitization passage of blood fractions from one arm vein through a photopheresis machine and back. A discontinuous flow cell separator harvests peripheral blood mononuclear cells (PBMCs) in a buffy coat collection and returns the red cell fraction to the patient without further treatment. The collection of PBMC is then exposed to 2.0 J/cm^2 of UVA using a photopheresis device that assures exposure of individual PBMC in a thin film to the light source and then reinfused into the patient. Alternatively, 8-MOP can also be administered directly to the heparinized plasma and buffy coat fraction as it flows through an UVA exposure system, thereby avoiding 8-MOP–induced nausea and unintended phototoxicity with subsequent incidental sun exposure. This treatment is, on average, repeated on 2 successive days at 2- to 4-week intervals.

Mechanism of Action

The mode of action of ECP remains unknown. The PUVA exposures likely induce apoptosis of circulating malignant lymphocytes. However, it has also been shown that infusion of autologous haptenated cells in which apoptosis had been initiated by 8-MOP/UVA induces immunologic tolerance. This tolerance is due primarily to regulatory T cells because transfer can be achieved in an animal model. Induction of regulatory T cells could explain why ECP exerts a beneficial effect in a wide variety of immune-mediated diseases and why generalized immunosuppression does not occur with ECP.[76]

Side Effects

No serious side effects have been reported with ECP. With oral ingestion of 8-MOP, transient nausea is not uncommon (as in oral PUVA therapy) and, rarely, episodes of hypotension and vasovagal reflex due to volume shifts during treatments have been noted. However, these events usually do not interfere with the treatment.

Treatment Results

CUTANEOUS T-CELL LYMPHOMA Erythrodermic CTCL (Sézary syndrome) was the first disease for which ECP was evaluated. A response occurs in up to 75 percent of the patients, with complete remissions in up to 25 percent. In Sézary syndrome patients who do not sufficiently respond to ECP alone, ongoing studies are evaluating possible synergistic effects with other treatments such as interferon-α, methotrexate, bexarotene, and total-skin electron-beam therapy.[77–80]

GRAFT-VERSUS-HOST DISEASE AND ALLOGRAFT REJECTION ECP appears to have a major impact in the treatment of GVHD after allogeneic bone marrow transplantation.[81,82] In patients with either acute or chronic GVHD, ECP allows reduction or even discontinuation of immunosuppressive therapy without an increase in GVHD activity. ECP is especially useful for patients affected by GVHD resistant to conventional treatment.

In addition, ECP is effective in the treatment of acute allograft rejection among lung, cardiac, and renal transplant recipients. ECP is effective for patients resistant to conventional treatments, particularly if started early. Benefit is obtained without the complications typically encountered with immunosuppressive regimens used to control organ rejection.[83,84] Table 239-4 shows indications for photopheresis as currently seen by regulatory agencies.

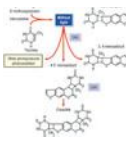

TABLE 239-4
Indications for Photopheresis (As Seen by Regulatory Agencies in 2006)

Sufficient evidence available	
Erythrodermic cutaneous T-cell lymphoma	Chronic graft-versus-host disease
Acute graft-versus-host disease	Organ transplant rejection
Experimental and investigational	
Scleroderma	Nephrogenic fibrosing dermopathy
Bullous dermatoses	Lichen planus
Crohn disease	Multiple sclerosis

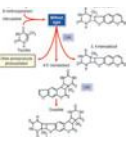

PHOTODYNAMIC THERAPY

Photodynamic therapy (PDT) aims to destroy the desired target selectively, thereby minimizing damage to normal tissue. The photodynamic reaction consists of the excitation of photosensitizers (usually porphyrins) by visible light in the presence of oxygen, resulting in the generation of reactive oxygen species, particularly singlet oxygen. These reactive oxygen species mediate cellular and vascular effects, depending on the tissue localization of the photosensitizer, and results in a direct or indirect cytotoxic effect on the target cells.[86] In dermatology, PDT has been used effectively for pre-cancerous and malignant conditions such as actinic keratosis, BCC, Bowen disease, and superficial squamous cell carcinoma, as well as for inflammatory dermatoses such as localized scleroderma, acne vulgaris, and leishmaniasis.

Historical Aspects

Principles of Photodynamic Therapy

PHOTOSENSITIZERS The ideal photosensitizer for PDT in dermatology should meet the following criteria: (1) chemical purity, (2) high singlet-oxygen quantum yield, (3) significant light absorption at wavelengths that penetrate the skin sufficiently deeply, (4) high tissue selectivity, and (5) efficacy after topical application.

Porfimer sodium (Photofrin), a mixture of several hematoporphyrin derivative (HpD) ethers and esters, has a low selectivity for skin tumors and leads to long-lasting photosensitivity; consequently, it is far from ideal for dermatologic use. In contrast, 5-aminolevulinic acid (ALA) or its methyl ester (MAL), intermediates in heme biosynthesis, induces the synthesis of photosensitizing protoporphyrin IX in the target tissue.[90] In this case, the concentration of the photosensitizer depends on the metabolic status of the diseased tissue. ALA in combination with the blue light was approved by the U.S. Food and Drug Administration in 1999 for the treatment of actinic keratoses. In Europe, New Zealand, Australia, and South America, MAL has also been registered for actinic keratoses, superficial and nodular BCCs, and Bowen disease.

Most photosensitizers generate singlet oxygen with a quantum yield between 5 percent and 20 percent. A high quantum yield means that less sensitizer is required in the target tissue to induce sufficient PDT effects. The light absorption maxima of the current sensitizers is in the visible range (400 nm to 700 nm). In this range, light penetration in tissue is only up to 3 mm, limiting PDT to superficial tumors unless interstitial light propagation is used. A high selectivity for sensitizer accumulation in target tissue is necessary to avoid damage to surrounding normal tissue, and this is particularly important when larger areas are treated (e.g., actinic keratoses). So far, only ALA or MAL show reasonably high selectivity after topical application. The ratio of porphyrin induction in skin tumors to the surrounding tissue is higher than 10:1,[91] likely due to a combination of enhanced ALA-MAL penetration through an abnormal stratum corneum and altered metabolism and accumulation within the pre-malignant or malignant cells.

LIGHT SOURCES AND DOSIMETRY Light penetration into skin increases with longer wavelengths up to 1100 nm. Although porphyrins absorb maximally in the Soret band (400 to 410 nm, blue light), there are minor absorption peaks at longer visible light wavelengths. To increase depth of penetration while matching the absorption maxima of porphyrin photosensitizers, wavelengths around 630 nm are often used. Lasers are effective but they are quite expensive, require regular maintenance, and have a small treatment aperture. Hence, simpler incoherent light sources represent a valuable alternative. Fluorescent lamps or light-emitting diodes with appropriate red or blue light emission are commercially available and designed for treatment of large surface areas. Also, intense pulsed light sources are used for dermatologic PDT. Dosimetry depends on the photosensitizer and light source used, as well as on the condition to be treated. For PDT of epithelial cancer, photosensitization must be sufficient to induce necrosis or apoptosis. With current incoherent light sources (lamps, light-emitting diodes), the treatment duration, exclusive of ALA-MAL incubation time, is approximately 10 to 15 minutes. For treating inflammatory dermatoses, significantly lower doses suffice because the goal appears not to be cell death but rather sublethal damage or modulation of cellular functions.

MECHANISM OF ACTION PDT-induced effects are mediated by photooxidative reactions. During irradiation, the photosensitizer absorbs light (energy) and is converted to an excited (triplet) state. The energy can then be transferred to molecular oxygen (type II photo-oxidative reaction), resulting in the generation of reactive oxygen species, mainly singlet oxygen. The biologic effects can be divided into primary cellular and secondary vascular damage. With HpD, early visible damage consists of cell membrane defects as a consequence of lipid peroxidation with consequent cell lysis. Depending on the intracellular localization of the photosensitizers, damage to sub-cellular structures, such as mitochondria, lysosomes, or endoplasmic reticulum, also occurs, whereas DNA is not a primary target. These direct effects probably play a key role in topical PDT, whereas vascular effects after systemic administration of photosensitizers appear to be the decisive event. These effects consist of vasoconstriction, blood stasis, and thrombosis of tumor vessels leading to tumor ischemia and subsequent necrosis.[92]

Photodynamic Therapy in Dermatology

Table 239-5 lists applications for PDT described in the literature. In contrast to other organs, the skin can be sensitized by either intravenous, topical, or intralesional routes of administration of the photosensitizer.

SYSTEMIC PHOTODYNAMIC THERAPY PDT after systemic administration of HpD and porfimer sodium has been used for

TABLE 239-5
Potential Indications for Photodynamic Therapy

ONCOLOGIC	NONONCOLOGIC
• Actinic keratosis	• Localized scleroderma
• Bowen disease	• Human papillomavirus–associated dermatoses
• Actinic cheilitis	• Epidermodysplasia verruciformis
• Superficial BCC	• Verrucae vulgaris
• Nevoid BCC syndrome	• Condylomata acuminata
• Keratoacanthoma	• Leishmaniasis
• Superficial SCC	• Acne vulgaris
• Kaposi sarcoma	• Rosacea
• Cutaneous metastases (cutaneous T-cell lymphoma)	• Photochemorejuvenation of sun-damaged skin

BCC = basal cell carcinoma.

both skin cancers and inflammatory dermatoses. Standard therapeutic procedures do not yet exist.

Systemic Photodynamic Therapy for Oncologic Indications. Systemic PDT with porfimer sodium for Bowen disease is very effective,[93] but invasive squamous cell carcinomas respond less well, with recurrence rates of up to 50 percent within 6 months. Systemic PDT for BCCs, first used in 1981,[94] has been reported by Oseroff and co-workers[95] to give initial complete responses in 92.2 percent of 77 patients with sporadic BCC or nevoid BCC syndrome.[95] In these patients, the 5-year recurrence rate was 15 percent.

Benzoporphyrin-derivative monoacid ring A (verteporfin), registered for the ophthalmologic indication of age-related macular degeneration, is also under investigation for PDT of BCC and offers a duration of cutaneous photosensitization of less than 72 hours, significantly shorter than that of porfimer sodium.[96]

Systemic Photodynamic Therapy for Nononcologic Indications. The use of PDT with HpD was reported for the treatment of psoriasis as early as 1937; better results were reported using red light instead of UVA,[97] and systemic PDT with verteporfin was also investigated in a phase I study of 15 patients in which clinical severity scores for psoriatic plaques improved after five weekly treatments.[98]

TOPICAL PHOTODYNAMIC THERAPY Small hydrophilic molecules like ALA or MAL penetrate well into the skin, particularly if the stratum corneum is abnormal, as is the case in some epidermal tumors.[90] In addition, epidermal cells and the pilosebaceous unit synthesize porphyrins to a much greater extent than fibroblasts, myocytes, or endothelial cells;[91] and epithelial tumors generally synthesize much higher amounts of protoporphyrin IX than the surrounding tissue and can therefore be destroyed without equivalent damage to healthy skin (Fig. 239-7).[90,99] Topical ALA-MAL–induced photosensitivity is thus restricted to the target area. Systemic porphyrin induction is not observed after topical application.[100] The only significant side effect of topical ALA-MAL PDT is a stinging pain during and shortly after irradiation, proportional to the intensity of the phototoxicity reaction.

Topical Photodynamic Therapy for Oncologic Indications.[101–108] The experience with treatment of epithelial cancers and pre-cancerous conditions with PDT to date suggests that actinic keratoses,[101–103] Bowen disease (Fig. 239-8),[104] superficial and nodular BCCs,[105–107] and SCCs (tumor thickness less than 2 mm) are suitable for topical ALA/MAL-PDT. For this purpose, ALA is applied topically for variable incubation periods, with or without occlusion, followed by visible light exposure.

Actinic keratoses, have been studied most extensively and respond to PDT as readily as to local cryotherapy or to broad area 5-fluorouracil (see Chap. 220) or imiquimod therapy (see Chap. 221) administered over weeks to months. Topical application of a 20 percent ALA solution for 14 to 18 hours followed by irradiation with blue light (417 nm) for 1000 seconds (10 J/cm^2) clears more than 80 percent of actinic keratoses after 1 to 6 months,[102] and 90 percent complete clearance at 1 and 5 months was observed after one full face treatment using a 1- to 3-hour incubation period.[102,103] However, cutaneous metastases of malignant melanoma, pigmented BCC, and sclerodermiform variants of BCC respond poorly to ALA-PDT,[108] probably because of insufficient porphyrin synthesis and/or penetration of light within the lesions.[99] Treatment efficacy is enhanced by repeated treatment sessions.[108]

In superficial and nodular BCCs, two randomized phase-III studies have been reported so far comparing MAL-PDT with either surgery or cryotherapy. After an observation period of 60 months, MAL-PDT for superficial BCC showed a similar recurrence rate as cryotherapy (22 percent versus 20 percent). In nodular BCC, MAL-PDT was compared with simple excision; recurrence rates after 60 months were 14 percent and 4 percent, respectively. In both studies, the cosmetic outcome was considered superior for the PDT-treated groups.[108] Indeed, these and other reports[107] suggest that a major theoretic benefit of ALA/MAL-PDT is elimination of skin cancers without scarring, as well as prevention

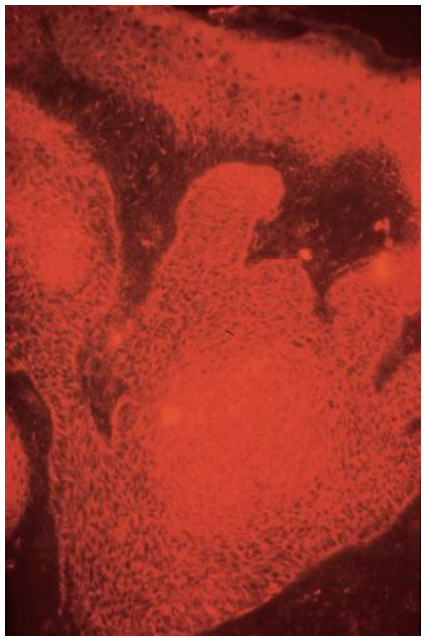

▲ **FIGURE 239-7** Endogenous porphyrin fluorescence after topical application of 20 percent aminolevulinic acid formulation to a solid basal cell carcinoma. Twelve hours after aminolevulinic acid application there was strong fluorescence of the tumor-bearing areas, and weak to no fluorescence of the surrounding dermis. Also visible is fluorescence in the overlying epidermis. (From Szeimies RM, Sassy T, Landthaler M: Penetration potency of topical applied α-aminolevulinic acid for photodynamic therapy of basal cell carcinoma. *Photochem Photobiol* **59**:73, 1994.)

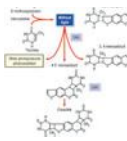

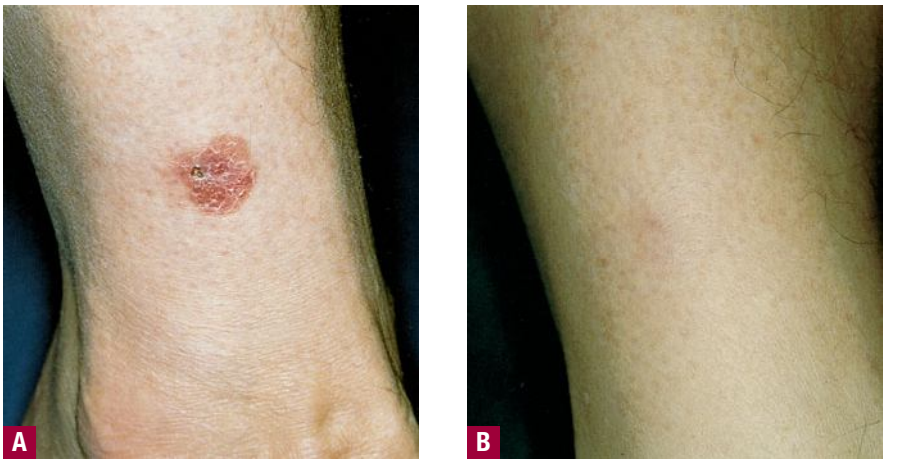

▲ **FIGURE 239-8** Bowen disease. **A.** Lesion located on the right lower leg. **B.** Twelve months after topical aminolevulinic acid-photodynamic therapy [10 percent aminolevulinic acid ointment, application for 4 hours, irradiation with Argon-pumped dye laser (175 mW/cm^2; 180 J/cm^2)], clinically and histologically there were no signs of tumor residue.

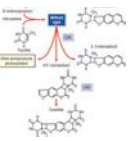

of such lesions in high-risk patients treated periodically with broad area PDT.

CTCL (mycosis fungoides) also responded in eight single case reports to ALA-MAL PDT after several treatment sessions. Controlled investigations are currently not available, and, as with PUVA treatment of single lesions, this treatment would not be expected to prevent the appearance of new lesions in other areas.

Topical Photodynamic Therapy for Non-Oncologic Indications.[110–125] Few data are available regarding the treatment of inflammatory and proliferative skin conditions. These include psoriasis, localized scleroderma, human papilloma virus (HPV)–associated conditions, leishmaniasis, acne, and rosacea.

ALA/MAL-PDT is also effective for acne and rosacea, although optimal protocols have not been developed. In two separate studies,[119,120] 22 patients with mild to moderate acne on the back received 20 percent ALA cream under occlusion for 3 hours. The areas were then exposed to broadband (550 to 700 nm) or laser light (635 nm) using various protocols. The authors observed a significant reduction in inflammatory acne lesion counts compared with baseline that persisted at least 20 weeks in some patients.[119] One study found a reduction in sebaceous gland size and sebum secretion, as well as reduced fluorescence attributable to *Propionibacterium acnes*,[119] although the other did not.[120]

PDT with ALA has also demonstrated to enhance the treatment of photodamaged skin with a variety of lasers and light sources. Improvement of global appearance, fine lines, tactile skin roughness, mottled hyperpigmentation, and telangiectasias has been described.[122–126]

Perspectives

The efficacy of PDT in the treatment of superficial neoplastic skin lesion, particularly actinic keratoses, Bowen disease, and superficial BCCs, has been sufficiently documented. PDT may also find a place in the treatment of selected patients with inflammatory dermatoses. Nonetheless, the limitations of both systemic and topical PDT have to be kept in mind. Crucial issues are the depth of the penetration of light, as well as of the sensitizer, into the skin, and inability to assure complete eradication of malignancy by histologic criteria.

KEY REFERENCES

The full reference list for all chapters is available at www.digm7.com.

1. Pathak MA, Fitzpatrick TB: The evolution of photochemotherapy with psoralens and UVA (PUVA): 2000 BC to 1992 AD. *J Photochem Photobiol B Biol* **14**:3, 1992
11. Wolff K et al: Phototesting and dosimetry for photochemotherapy. *Br J Dermatol* **96**:1, 1977
15. Anonymous: Guidelines of care for phototherapy and photochemotherapy, American Academy of Dermatology Committee on Guidelines of Care. *J Am Acad Dermatol* **31**:643, 1994
16. Anonymous: British Photodermatology Group guidelines for PUVA. *Br J Dermatol* **130**:246, 1994
19. Marcil I, Stern RS: Squamous-cell cancer of the skin in patients given PUVA and ciclosporin: Nested cohort crossover study. *Lancet* **358**:1042, 2001
22. Hönigsmann H, Wolff K: Results of therapy for psoriasis using retinoid and photochemotherapy (RePUVA). *Pharmacol Ther* **40**:67, 1989
30. Tanew A, Hönigsmann H: Ultraviolet B and psoralen plus UVA phototherapy for cutaneous T-cell lymphoma. *Dermatol Ther* **4**:38, 1997
59. Lim JL, Stern RS: High levels of ultraviolet B exposure increase the risk of nonmelanoma skin cancer in psoralen and ultraviolet A-treated patients. *J Invest Dermatol* **124**:505, 2005
63. Stern RS: The PUVA follow-up study. The risk of melanoma in association with long-term exposure to PUVA. *J Am Acad Dermatol* **44**:755, 2001
65. Wolff K: Should PUVA be abandoned? [editorial]. *N Engl J Med* **336**:1090, 1997
74. Trautinger F et al: EORTC consensus recommendations for the treatment of mycosis fungoides/Sézary syndrome. *Eur J Cancer* **42**:1014, 2006
108. Braathen LR et al: Guidelines on the use of photodynamic therapy (PDT) for non-melanoma skin cancer—An international consensus. *J Am Acad Dermatol* **56**:125, 2007

CHAPTER 240

Lasers and Flashlamps in Dermatology

Fernanda H. Sakamoto
Tomi Wall
Mathew M. Avram
R. Rox Anderson

Lasers are extremely precise surgical tools and have the qualities of a "magic bullet"—light traverses tissue without effect until it is absorbed by specific targets, where therapeutic chemical, thermal, and/or mechanical excitation occurs. The versatility of lasers and their older cousins, xenon flashlamps, is impressive.

ELECTROMAGNETIC RADIATION, LASERS, AND FLASHLAMPS

Light is a small slice of the electromagnetic radiation spectrum (EMR), of which the quantum is called a *photon*. The wavelength of EMR is inversely proportional to the amount of energy each photon carries. From short-wavelength high-quantum energy to long-wavelength low-quantum energy, EMR includes γ rays, x-rays, ultraviolet (UV) light, visible light, infra-red radiation, microwaves, and radio wave energy. Fundamentally these are all versions of photon energy, traveling at the ultimate speed, the speed of light. Photon absorption is always the inverse of photon creation—the photon is produced when charged matter releases energy and is extinguished (absorbed) when charged matter is promoted to a higher energy state. Thus, the energy of an absorbed photon must correspond to some allowed transition of an electron between atomic orbitals, or the vibrational energy of molecular nuclei. This is why molecules have distinct absorption bands at some wavelengths, whereas the same molecule is transparent at other wavelengths. Light-absorbing molecules are called *chromophores*.

The reciprocal nature of photon absorption and photon creation is in part what makes lasers possible. The word *laser* is an acronym for *l*ight *a*mplification by *s*timulated *e*mission of *r*adiation. Albert Einstein predicted that one photon could stimulate the emission of another photon by interacting with an excited molecule. Inside a laser, this occurs in an excited medium present between two mirrors that pass light back and forth through the laser, so that the light gains in intensity by stimulated emission with each pass. Laser light can be amplified to extreme power levels. Xenon flashlamps are intense light sources that emit a broad spectrum of UV, visible, and infra-red light. Almost every camera has a small xenon flashlamp. When filtered to emit a certain band of wavelengths, flashlamps have some features of the long-pulsed (millisecond) lasers used in dermatology. These filtered flashlamps are often called *intense pulsed light sources (IPLs)*. The brightest IPL is trillions of times dimmer than the brightest laser, however.

A laser emits an intense, collimated beam of light at a well-defined wavelength, which can be tightly focused, during essentially any period of time. In contrast, an IPL emits broad-wavelength pulses of divergent light that cannot be tightly focused. The most powerful IPLs deliver approximately 1000 W of optical power per square centimeter (10^3 W/cm^2), whereas dermatologic lasers deliver from 10^3 to 10^9 W/cm^2. The record is an astounding approximately 10^{19} W/cm^2, equivalent to packing most of the sunlight striking the earth into 1 cm^2.

Laser emission can be continuous, quasi-continuous, or pulsed (Fig. 240-1). When the emission is focused and scanned, interaction with a given point on the skin may be equivalent to a pulse. Quasi-continuous lasers emit a train of low-energy pulses that usually act in aggregate as a continuous beam. Pulsed lasers in dermatology are high-energy devices that produce either millisecond (10^{-3} second)—or nanosecond (10^{-9} second)—domain pulses. IPLs emit millisecond-domain pulses. A technique called *Q-switching* produces nanosecond laser pulses by suddenly releasing all of the excited-state energy from a laser medium. Ultrashort lasers emit pulses in the femtosecond (10^{-15} second) domain. A femtosecond is very brief—it is to 1 second as 1 second is to approximately 30 million years. Femtosecond lasers are now widely used in biology for two-photon microscopy, which makes possible the equivalent of in vivo fluorescence and immunofluorescence microscopy. Laser light is also coherent, which means that the electromagnetic waves of laser photons are perfectly in phase with each other. Coherence is useful for diagnostic imaging applications.

LASERS AND FLASHLAMPS AT A GLANCE




- Lasers are the most precise and selective surgical tools in existence.
- Non-scarring treatment of vascular lesions, pigmented lesions, tattoos, and hair follicles relies on a process called *selective photothermolysis*. For each of the aforementioned broad indications, there are lesion variants that are highly responsive to laser therapy, lesions that are occasionally responsive, and lesions for which laser treatment is contraindicated.
- Pulse duration strongly influences safety and efficacy, and in general should be about equal to the thermal relaxation (cooling) time of specific targets in a given patient.
- Port-wine stains are congenital neurovascular lesions best treated in early childhood that respond well, but rarely completely, to laser treatment.
- Laser treatment is useful for treatment of ulcerated infant hemangiomas.
- Fractional resurfacing is a technique in which thousands of laser microbeams per square centimeter are used to stimulate epidermal and dermal remodeling. It is a less invasive treatment for photoaging than is ablative laser resurfacing.
- Use of any laser or flashlamp (intense pulsed light) for hair removal poses a severe risk of eye injury when used near the eye. Other risks include fires, inhalation of the vaporized tissue plume, electrocution, and a host of side effects such as stimulation of facial hair growth, pigmentary changes, and scarring.

There are four general groups of visible-wavelength lasers used in dermatology (Table 240-1): the group of green and yellow millisecond-domain pulsed lasers used mainly to treat vascular malformations, hemangiomas, scars, photoaging, proliferative lesions, and epidermal pigmented lesions [potassium-titanyl-phosphate (KTP) lasers, pulsed dye lasers (PDLs)]; the group of red and near–infrared millisecond-domain pulsed lasers



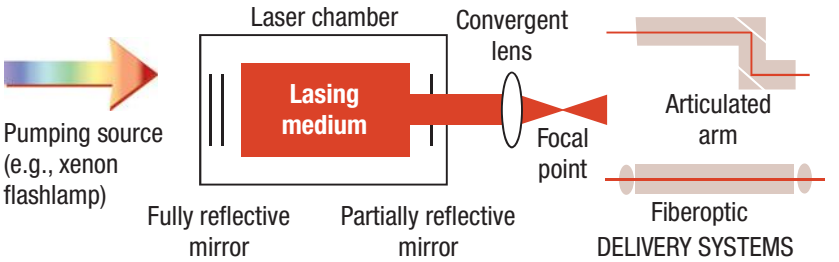

A. Schematic of a typical laser light source. Electrical, chemical, or optical energy input is provided by the pumping source. Note that the initial wavelength of the emitted laser beam is determined by the lasing medium, although this can be altered. Laser energy is delivered to the target via an articulated arm or fiberoptic cable.

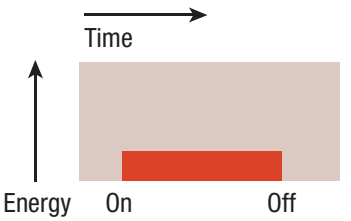

B. Continuous wave (CW) mode profile, (e.g., CO_2, argon lasers)



C. Pulsed mode profile (e.g., pulsed dye laser, diode, ruby, alexandrite)

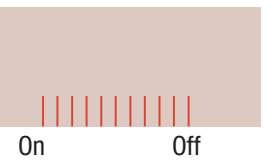

D. Quasi-continous wave (QCW) mode profile (e.g., KTP, copper vapor)

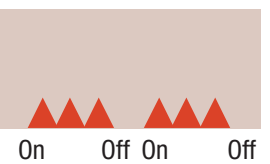

E. "Stuttered" pulse mode profile, as seen in long-pulsed dye lasers and IPLs.



F. Q-switched (QS) mode profile (e.g., QS ruby, Nd: YAG, alexandrite)

▲ **FIGURE 240-1** Schematic diagram of pulsed and continuous lasers. KTP = potassium-titanyl-phosphate; IPL = intense pulsed light (source); Nd:YAG = neodymium:yttrium-aluminum-garnet.



used to treat hypertrichosis and pigmented and deep venous lesions [ruby, alexandrite, neodymium:yttrium-aluminum-garnet (Nd:YAG) lasers]; the group of low-power continuous green or yellow lasers used to treat superficial telangiectasia and perform photocoagulation of lesions; and the group of Q-switched lasers used to remove tattoos and treat dermal melanocytoses, drug hyperpigmentation, and many pigmented lesions. IPL sources also cover much of the visible and near–infra-red spectrum. To some extent, IPLs can mimic some of the output and uses of long-pulse (millisecond-domain) visible lasers, but IPLs are incapable of mimicking high-power infra-red lasers, Q-switched lasers, or focused laser microbeams. Since the advent of selective photothermolysis in the early 1980s,[1] target-selective pulsed lasers and IPLs have largely replaced older continuous-wave devices such as argon-ion lasers.

The near–infra-red region (700 to 1200 nm) is the deepest tissue–penetrating optical radiation. Laser emissions in this spectral region are weakly absorbed by blood and melanin. Near–infra-red lasers include alexandrite devices (approximately 760 nm), diode devices (approximately 800 nm, 940 nm, and others), and Nd:YAG devices (1064 nm). Alexandrite and Nd:YAG laser devices are available in both long-pulse (millisecond) and Q-switched (nanosecond) versions, sometimes in the same machine. Semiconductor diode lasers are very efficient, small, solid state devices that cannot be Q-switched. The most popular laser for hair removal is an 810-nm diode laser array with an integrated skin cooling window. Continuous near–infra-red lasers are also used for endovenous laser therapy of the deep refluxing veins for treatment of varicose disease.

With radiation in the mid–infra-red region (1200 to 2500 nm), there is little or no photon absorption by blood or melanin, and photon absorption is due to vibrational excitation of water, lipids, and proteins. Mid–infra-red lasers are used for non-ablative treatment of photoaging, acne, and various upper dermal lesions. These devices include a semiconductor diode laser near 1450 nm delivered with skin cooling, an Nd:YAG laser at 1320 nm delivered with skin cooling, and an erbium fiber laser near 1550 nm that delivers approximately 1 million microspot laser exposures over the face for fractional resurfacing.[2]

In the far–infra-red region (more than 2500 nm), vibrational excitation of water is very strong. Erbium and CO_2 lasers are used for skin resurfacing by precise vaporization of epidermis and upper dermis to treat photoaging, scarring, and lesions, including warts and benign adnexal tumors. Erbium laser resurfacing is so precise that stratum corneum can be painlessly vaporized as a means for drug delivery. CO_2 lasers (10,600 nm) are workhorse surgical lasers that remove approximately 100 μm (0.1 mm) per pass during resurfacing, with little or no hemorrhage.

SKIN OPTICS (See Chap. 88)

The optical properties of skin are complicated and variable, and change with every heartbeat, every season, and over decades with aging. Two processes determine the optics of skin: scattering and absorption. There are hundreds of chromophores in skin. The dominant ones are as follows: UV spectrum—strong absorption by DNA, protein, and melanin; visible spectrum—absorption by melanin, hemoglobin, oxyhemoglobin, hemosiderin, bilirubin, carotenoids, cytochromes; near–infra-red spectrum—weak absorption by melanin, hemoglobin, oxyhemoglobin, cytochromes; mid–infra-red spectrum—absorption by water, lipids; far–infra-red spectrum—strong absorption by water.

Scattering is a change in the direction of propagation of a photon. Reflection

TABLE 240-1
Common Lasers and Flashlamp Sources in Dermatology

Laser Type	Wavelength (nm)	Mode/Pulse Width Range	Typical Uses	Primary Indication
Excimer	193, 308, 355	QCW (ns pulses)	Treatment of psoriasis and vitiligo, atopic dermatitis phototherapy	Ultraviolet B phototherapy
Argon-ion	488, 514	CW	Coagulation, treatment of telangiectasia	—
Cooper vapor/bromide	512, 578	QCW (ns micropulses)	Treatment of telangiectasia, coagulation	Vascular
KTP	532	QCW, CW, or pulsed	Treatment of vascular lesions (adults more than children) and epidermal pigmentation, coagulation	Vascular
Pulsed dye (yellow)	577–600	Pulsed 0.45–1.5 ms; 10–40 ms stuttered	Treatment of vascular lesions (adults and children, especially PWS), warts, scars, photoaging	Vascular
Long-pulsed ruby	694	Pulsed 3 ms; 100 ms stuttered	Hair removal, treatment of some nevi	Hair removal
QS ruby	694	QS 20 ns	Treatment of epidermal/dermal pigmentation, lentigines, nevus of Ota; removal of tattoos (black, blue, green)	Melanin and tattoos
Long-pulsed alexandrite	755	Pulsed 1.5 ms; 40.0 ms stuttered	Hair removal, treatment of leg veins and hypertrophic PWS	Hair removal
QS alexandrite	755	QS 50–100 μs	Treatment of epidermal/dermal pigmentation, lentigines, nevus of Ota; removal of tattoos (black, blue, green)	Melanin and tattoos
Diode array	810	Pulsed 5–1000 ms	Hair removal, leg veins and venous lakes	Hair removal
Long-pulsed Nd:YAG	1064	Pulsed or stuttered, 3–100 ms	Hair removal in dark skin, treatment of leg veins and venous lakes	Hair removal
QS Nd:YAG	1064	QS 5–10 ns	Treatment of dermal/drug pigmentation and nevus of Ota, removal of tattoos (black)	—
Mid-IR Nd:YAG	1320	Pulsed 20–50 ms stuttered macropulses	Non-ablative dermal remodeling	Non-ablative dermal remodeling
Mid-IR diode	1450	Pulsed 160–260 ms	Non-ablative dermal remodeling, fractional resurfacing	Non-ablative dermal remodeling
Er:glass	1540	Pulsed 1–10 ms	Non-ablative dermal remodeling, fractional resurfacing	Non-ablative dermal remodeling
Er:YAG	2940	Pulsed 0.1–3 ms	Ablation of epidermal lesions, skin resurfacing	Epidermal ablation/laser skin resurfacing
Xenon flashlamp (IPL)	500–1200	Pulsed 2–7 ms; 20–100 ms stuttered or single pulse	Treatment of vascular (telangiectasias) and pigmented lesions, hair removal, non-ablative dermal remodeling	Vascular

CW = continuous wave; Er = erbium; IPL = intense pulsed light; IR = infra-red; KTP = potassium-titanyl-phosphate; Nd = neodymium; pulsed = high-energy pulses; PWS = port-wine stain; QCW = quasi-continuous wave (a rapid low-energy pulse train); QS = Q-switched; YAG = yttrium-aluminum-garnet.

and refraction are special cases of optical scattering. In general, scattering is due to local fluctuations in the refractive index, which is defined as the speed of light in a vacuum divided by the speed of light in the medium. The refractive index of stratum corneum is approximately 1.55, similar to that of a piece of glass. At normal incidence, reflection from the skin surface is approximately 5 percent, enough to cause an eye injury to a laser surgeon who does not wear proper protective eyewear. The surface reflectance carries the visual cues for surface texture (rough, smooth, oily, scaly, etc.). The remaining 95 percent of incident light enters the skin, where photons may be absorbed by chromophores and/or scattered by molecules, particles, fibers, cells, and other structures. In normal epidermis, melanin and cell nuclei account for most of the optical scattering. In dermis, type I collagen fibers account for most of the optical scattering. For radiation across the UV and visible spectrum, one can consider epidermis to be a thin optically absorbing layer dominated by its melanin content, whereas the dermis is a thick optically scattering layer with embedded absorbing structures such as blood vessels and hair follicles. The strength of optical scattering varies inversely with wavelength, so that short wavelengths are more strongly scattered. This accounts for the Tyndall ef-



fect. A light-absorbing substance in the dermis, such as melanin (as in nevus of Ota), carbon (as in a tattoo), or a large cavity (as in dermal cysts), causes blue skin color because the long-wavelength (red) light tends to be lost. Skin has an "optical window" of deeply penetrating light of 620 to 1200 nm. Absorption spectra of the dominant skin chromophores relevant for laser dermatology and effective optical penetration depth are shown in Fig. 240-2.

DOSIMETRY AND LASER-SKIN INTERACTIONS



Light is a form of energy, measured in joules (J). The rate of energy delivery is called *power*, measured in watts (W). One watt is equal to 1 J/s fluence, sometimes called *energy density* or *exposure dose*, refers to the delivered energy per unit area of skin, usually expressed in joules per square centimeter. Irradiance, sometimes called *power density*, is the power delivered per unit area of skin, expressed in watts per square centimeter. For all sources, fluence is the time integral of irradiance; that is, for pulsed lasers fluence is approximately equal to irradiance times pulse duration.

All laser-skin interactions begin with absorption of optical energy. Light can initiate biochemical reactions through photochemistry, can heat tissue to the point of coagulation or vaporization, and can fracture or explode tissue structures by very rapid local heating. The latter occurs only with pulsed high-intensity lasers. Most of the useful dermatologic lasers are based on exploitation of thermal or thermomechanical effects. The important exceptions are the 308-nm excimer lasers used for UV phototherapy, laser activation of photodynamic therapy drugs, and laser diagnostic imaging.

A useful time and temperature "cookbook" can be constructed for laser photothermal events in skin. For example, fibroblasts and most other human cells are killed when exposed to 47°C (116.6°F) for 20 minutes, but can survive 100°C (212°F) boiling water for approximately 10^{-3} seconds. Therefore, selective photothermolysis with pulsed sources often requires local high temperatures in cellular targets such as nevi, blood vessels, and hair follicles. Sublethal thermal injury triggers a complex cascade of events, including heat shock anti-apoptosis gene expression. The thermal behavior of type I collagen in the extracellular matrix plays a major role in laser dermatology. Fibrillar collagen has a well-defined melting point of 60°C to 70°C (140°F to 158°F) depending on degree of cross-linking, and the fiber shrinks dramatically. Skin shrinkage is prominent during CO_2 laser resurfacing, causing some "tightening" of the skin.

Selective Photothermolysis

Light can pass through skin with no effect until it is absorbed, creating heat only at certain targets. Factors affecting where light is absorbed are the location and concentration of skin chromophores, laser wavelength, aiming of the laser beam, and exposure spot size. Light with larger exposure area tends to penetrate more deeply. Selective photothermolysis[1] is a simple concept (with many interesting and still poorly understood nuances) with three basic requirements. First, the target structures must have preferential absorption at a wavelength that reaches to the depth of the structures. Second, the light pulse(s) must be delivered within a sufficiently short time so that the target structures do not transfer much heat to their surroundings during the pulse duration. Third, the fluence delivered by the optical pulse must be great enough to have a therapeutic effect but less than that causing non-specific thermal damage. Targets with excellent absorption contrast include blood vessels, hair follicles, pigmented cells, tattoo ink–laden cells, and, in principle, any structure with sufficient endogenous or exogenous chromophore content. Selective photothermolysis was initially conceived as a means for treating pediatric port-wine stains (PWSs), based on the hypothesis that microscopically selective damage to abnormal venules would lead to microscopically selective repair without scarring. That hypothesis is clearly true, and selective photothermolysis has become routine. However, it should be noted that skin is a particularly robust organ, capable of surviving a nearly complete loss of its microvascular circulation for several days. Similarly, laser-induced removal of the entire epidermis, laser destruction of terminal hair follicles, and selective necrosis of phagocytic dermal cells are usually tolerated without scarring. There are many interesting and clinically important nuances of selective photothermolysis. For example, it is not necessary for the wavelength to be at an absorption maximum of the target chromophore. In fact, there is some advantage to using a wavelength at which light penetration within the targets is equal to or greater than the target diameter, because this ensures even heating throughout the targets. The effective treatment depth can be adjusted by regulating wavelength, fluence, exposure spot size, or compression of the skin.

Choice of pulse duration is critical to clinical success. The thermal relaxation time, τ_r, of any tissue target can be estimated as $\tau_r \approx d^2$, where τ_r is expressed in seconds and d is the target size in millimeters. This simple approximation is useful in clinical practice, because the ideal light pulse duration for selective photothermolysis is about equal to or somewhat less than τ_r for the intended targets.

Photomechanical Interactions

When water inside skin is rapidly vaporized, steam bubbles violently expand and collapse. This process is called *cavitation*. Cavitation is responsible for the petechial hemorrhages seen after PDL and some KTP laser or IPL treatments at pulse durations of less than approximately 1 millisecond. Laser tattoo removal uses photomechanical effects, including cavitation. The rate of target cell heating during Q-switched laser treatment of tattoos and pigmented lesions is an amazing 10 billion °C/second (18 billion °F/second), which causes rupture of the target cells. The desired immediate response to Q-switched laser treatment is whitening (see Fig. 240-6), due to transient gas bubble formation after cavitation.

Vaporization and Skin Resurfacing

Strongly absorbed laser pulses are the most precise surgical tools, vaporizing a very thin layer of tissue per pulse. Through control of the depth of a residual layer of thermal coagulation from zero to several hundred micrometers, hemostasis can also be adjusted. As in selective photothermolysis, pulse duration is adjusted to minimize heat transfer from the superficial layer heated during photon absorption. Temperature in the heated layer is driven to approximately 300°C (572°F), which causes very rapid vaporization of the layer. Most of the energy delivered by the laser pulse goes to the creation of steam, which is removed when the tissue layer flies away. Skin resurfacing is one setting in which "turning down" the laser can in practice cause much greater skin injury due to lack of heat removal.

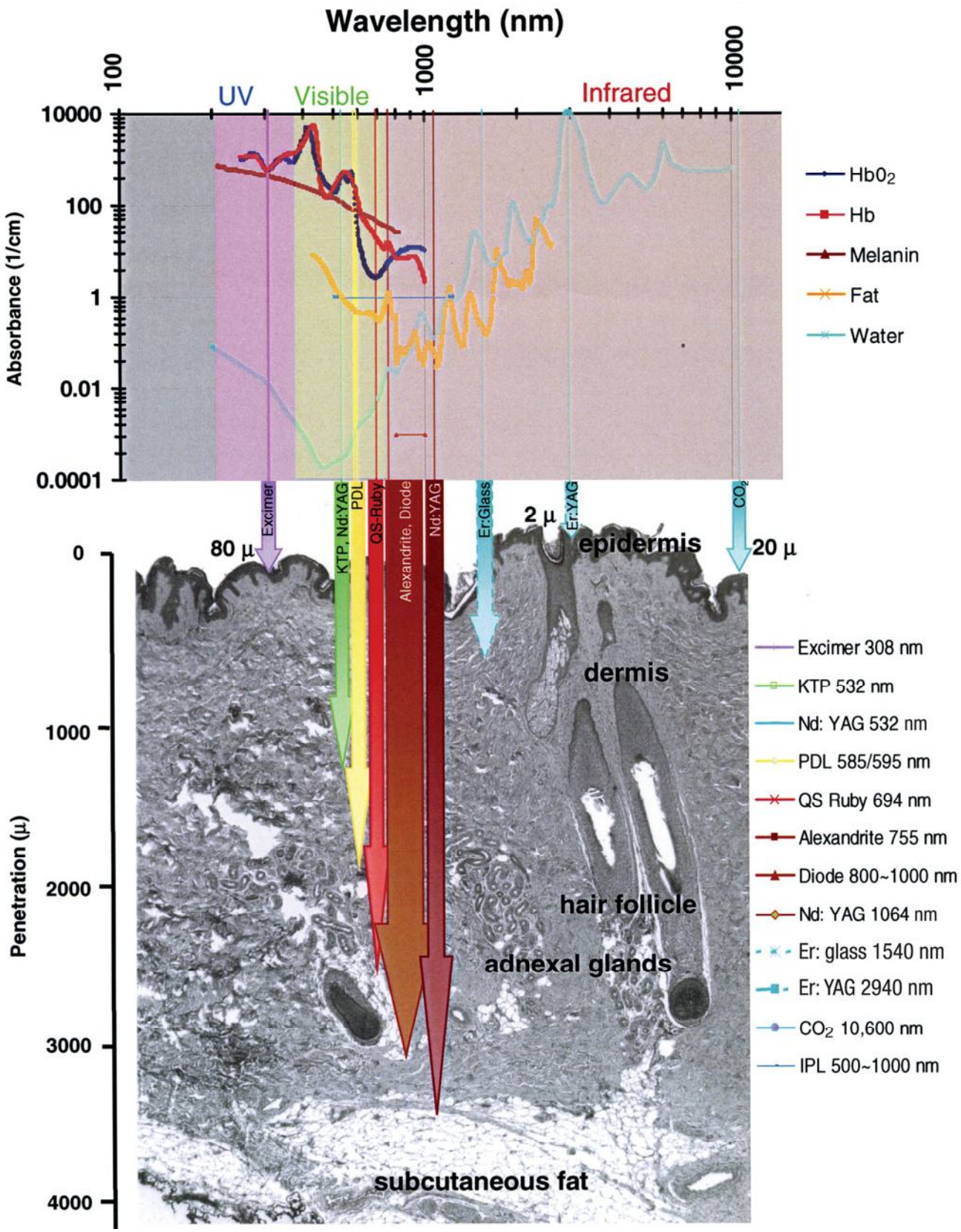

▲ **FIGURE 240-2** Light absorption by skin chromophores as a function of wavelength, with the approximate 50 percent optical penetration depth. Er = erbium; Hb = hemoglobin; HbO_2 = oxygenated hemoglobin; KTP = potassium-titanyl-phosphate; IPL = intense pulsed light (source); Nd = neodymium; YAG = yttrium-aluminum-garnet; PDL = pulsed dye laser; QS = Q-switched; UV = ultraviolet. (Created with permission from data of Drs. Scott Prahl, Thomas Flotte, and Dieter Manstein.)



Mid–Infra-Red Laser Skin "Rejuvenation"

Skin rejuvenation is a popular myth. Wounding of the skin is done in ways that stimulate remodeling of epidermis and dermal extracellular matrix, and many genes activated during wound repair overlap with those activated during organogenesis. The healed skin may appear younger, but it is not. Treatment with lasers and IPLs improves the appearance of photoaged skin by removing senile lentigines, freckles, telangiectasia, and fine wrinkles. Mid–infra-red lasers (1320 nm, 1450 nm, 1550 nm) are absorbed by water and penetrate up to approximately 1 mm in dermis. These have been developed in combination with skin cooling methods, which produces an upside-down burn.



Fractional Photothermolysis

For decades, biologists have used laser microbeams to perform precise cell and tissue surgery. Arrays of laser microbeams have now been deployed in dermatology using an approach called *fractional photothermolysis*.[2] This technique is the harbinger of a new class of microbeam lasers for dermatology. A beam scanner with optical mouse technology is used to distribute approximately 1 million small columns of thermal damage onto the face. Each microthermal damage zone (MTZ) is approximately 0.1 mm wide and up to 1 mm deep, surrounded by undamaged skin. MTZs are smaller than can be easily seen, so that a treatment spot is not apparent. Epidermal healing occurs by rapid migration of adjacent cells that initiate remodeling of the MTZs. Fractional photothermolysis is similar in some ways to selective photothermolysis, except that the thermal injury pattern is caused randomly rather than by absorption contrast in particular tissue targets. In principle, "smart" scanning systems could identify and selectively treat any small target structures in skin. However, a targeted version of fractional photothermolysis has not yet been developed. The use of image-guided laser microbeams could potentially lead to versatile, software-programmable treatment lasers.

Skin Cooling

Skin cooling with ice was first described as a means for protection against pain and scarring during argon-ion laser treatment.[3] Skin cooling is now an integral part of many dermatologic laser or IPL systems, accomplished by contacting the skin surface with a cold gas, liquid, or solid. Cooling provided before (precooling), during (parallel cooling), and after (postcooling) light delivery has somewhat different consequences.[4–6] Cooling can be rapid and superficial (dynamic precooling) or slow and deep (bulk cooling), depending on the temperature and contact time of the coolant with the skin surface. Although aggressive cooling allows higher laser fluences to be used, this can be risky when either the cooling or the laser pulse fails to be delivered. The skin can be burned or frozen, respectively.

SAFETY

Complete safety in laser use is an illusion; the risk can be reduced but never eliminated. Facilities using lasers should institute safe practices (usually required by law) that follow the American National Standards Institute Z136 series standards or Occupational Safety and Health Administration guidelines. All personnel in facilities in which lasers are being operated should be trained in laser safety. Warning signs should be placed at the entrance of laser treatment rooms along with appropriate eyewear to warn and assist personnel who must enter the room. When not actually in use, lasers or IPLs should be placed in standby mode or turned off. A baseline ophthalmologic examination is highly recommended for anyone working with lasers to document baseline normal retinal function and structure. Direct hazards are those due to laser beam exposure of the eyes, skin, or other tissue, or dental work. Indirect hazards are those unrelated to beam exposure, such as electrocution, fire, inhalation injury, chemical toxicity, or transmission of infectious diseases.

The eye is particularly vulnerable to laser or IPL injury (Table 240-2). UV, mid–infra-red, and far–infra-red lasers can injure the cornea. UV lasers can also pose an extreme cataract hazard. Retinal hazards are posed by all IPLs and visible-light and near–infra-red lasers. Retinal injury tends to be permanent because of the limited capacity of neural tissue to regenerate. The eye focuses visible and near–infra-red light onto its retina, which may increase the retinal power density of a laser beam up to 100,000-fold. The highest risk for retinal damage occurs with invisible, near–infra-red Q-switched lasers (alexandrite, Nd:YAG). Because the retina has no pain receptors, the first symptom of injury may be permanent blindness. A small fraction of the emitted beam can cause perma-

TABLE 240-2
Aspects of Laser Safety

Laser Type	Type of Injury	Damage and Associated Signs
Ultraviolet Xenon-chloride excimer (308 nm)	Cornea Lens	Photokeratitis Cataract
Visible light Argon (488 nm) KTP (532 nm), Cu (578 nm) Pulsed dye (585–600 nm) Ruby and Q-switched Ruby (694 nm) IPL (400–1200 nm)	Retina, iris, uvea	Bright flash followed by an afterimage of the complementary color. Lack of visual recovery within approximately 30 min suggests that a permanent retinal injury has occurred. *All laser and IPL hair removal devices pose a severe hazard when used near the eye.*
Near–infra-red[a] Alexandrite (755 nm) Diode (800 nm) Nd:YAG (1064 nm)	Retina, iris, uvea	Blindness is often the first (and last) symptom of retinal damage from invisible, near–infra-red lasers. Q-switched Nd:YAG lasers are an extreme retinal hazard to the unprotected eye.
Mid– and far–infra-red Nd:YAG (1320 nm) Diode (1440 nm) Er:glass (1550 nm) Er:YAG (2940 nm) CO_2 (10,600 nm)	Cornea, sclera Fires Smoke inhalation	Corneal or scleral burn. Er and CO_2 lasers cause burning pain at the site of exposure, tearing, and blurred vision. Fire risk is high when O_2 is in use. Laser plume contains toxic gases and may transmit viral diseases.

Er = erbium; KTP = potassium-titanyl-phosphate; IPL = intense pulsed light; Nd = neodymium; YAG = yttrium-aluminum-garnet.
[a]Q-switched devices pose greater risk.

nent retinal damage. For visible sources striking the eye, bright light is seen. However, the protective blink reflex takes approximately 0.25 seconds, which is much longer than the pulses from all of the pulsed lasers and IPLs. Use of proper eyewear (goggles, wraparound glasses, or eye shields) is crucial. When selecting eyewear, one should examine the wavelength range for which protection is provided at an optical density of at least 4.0 and look for damage or cracked surfaces. Optical density is the negative logarithm of light transmittance through the eyewear. Higher optical density implies greater protection (i.e., an optical density of 2 implies 1 percent transmission, an optical density of 3 implies 0.1 percent transmission, etc.).

Laser or IPL hair removal near or within the bony eye orbit should be avoided, because of a high risk of eye injury to the patient. These devices are specifically designed to destroy melanin-pigmented structures deep within soft tissue. Retina and choroid contain the highest concentration of melanin in the body, and eye damage is possible even through closed eyelids. When treatment is necessary near the eye, a large metal eye shield should be inserted over the anterior eye. Reflection of laser beams can also be a significant risk. Ocular injuries to dermatologists, burns, and fires have been reported to occur from reflections. Windows and mirrors should be covered. There should be no reflective metallic objects near the operative field. Jewelry should be removed.

Skin injuries include IPL or laser thermal burns of the patient due to poor treatment technique or poor choice of treatment parameters, an aggressive mixture of simultaneous treatments, or poor wound healing. Common settings for skin burns are IPL use on pigmented skin (see Fig. 240-8), laser resurfacing procedures, and the use of poor technique such as pulse stacking (rapid delivery of pulses to a given exposure spot) or failure to clean contact-cooling handpieces. CO_2 lasers are particularly prone to setting accidental fires involving hair, clothing, or surgical drapes. If oxygen is present, very rapid fires can occur. Plastic endotracheal tube fires are especially devastating. Hair sprays and alcohol-based gels are highly flammable; hair and drapes should be moistened. If oxygen must be used, lowering the fraction of inspired oxygen to less than 40 percent reduces risk of fire. Laser damage to enamel tooth veneers or dentures has been reported during laser hair removal. Cotton barrier rolls should be placed over fillings or dental work to prevent injury.

The plume produced during hair removal, laser resurfacing, and electrosurgery contains irritants, partially oxidized hazardous gases, and possibly infectious organisms. Bacterial *(Staphylococcus aureus)*, fungal, and viral (human papillomavirus) particles have all been reported in laser plume. Smoke evacuators and masks with particle filtration down to 0.1 μm should be used, and the evacuator should be held close to the treatment site. Q-switched lasers may eject large tissue fragments from the skin due to cavitation. These fragments are viable tissue and/or pathogens. Spatter shields, masks, and eyewear should be used.

IPLs are potentially more electrically hazardous than lasers because they use high-voltage, high-current electrical pulses directly in a handpiece that also contains water. Although the life of the xenon flashlamp usually ends quietly, these lamps may also explode or arc. Installation, repair, and routine maintenance should be performed by professional engineers and documented as part of medical legal risk reduction.

CLINICAL APPLICATIONS

Treatment of Vascular Lesions

Vascular lesions are broadly classified as nonproliferative malformations or proliferative neovascular lesions (see Chaps. 173 and 126). Either class may be arterial, venous, lymphatic, or mixed; may involve large or small vessels; and may be congenital or acquired, superficial or deep. Laser treatment is one of many treatment options, including sclerotherapy, embolization, drugs, surgery, and radiation. The use of continuous and quasi-continuous lasers[7,8] has largely been replaced by treatment with pulsed devices based on selective photothermolysis, with oxyhemoglobin and hemoglobin as target chromophores. The endothelium and vessel wall, not blood, are the actual targets. Safe and effective laser treatment of microvascular malformations, including pediatric and adult PWSs, acquired telangiectasias, and spider and cherry angiomas, is routine. Because vessels are central to the pathophysiology of many other lesions, such as tumors, verrucae, inflammation, and scars, vessel-targeted laser treatments also have broader utility (Table 240-3).

TABLE 240-3
Response of Vascular Lesions to Treatment with Lasers and Flashlamps

Vascular Lesions That Usually Respond Well
- Telangiectasias
  - Generalized essential telangiectasia
  - Spider angioma
  - Hereditary hemorrhagic telangiectasia (Osler-Weber-Rendu disease)
  - Radiotherapy-induced telangiectasia
  - Telangiectasia macularis eruptiva perstans (TMEP)
  - Angioma serpiginosum
  - Telangiectasia associated with CREST syndrome and similar disorders
- Rosacea with telangiectasia
- PWS in children and thin adults, but only approximately 20% may clear
- Cherry angioma
- Venous lakes
- Angiokeratoma
- Blue rubber bleb nevus syndrome
- Angiokeratoma corporis diffusum (Fabry disease)
- Phacomatosis pigmentovascularis (vascular component)

Vascular Lesions That Occasionally Respond
- Rosacea with flushing, without telangiectasia
- Hypertrophic PWS
- Hemangioma
- Poikiloderma of Civatte
- Pyogenic granuloma

Vascular Lesions That Minimally Respond
- Leg venulectases (spider veins)
- High-flow, hypertrophic PWS

CREST = *c*alcinosis cutis, *R*aynaud phenomenon, *e*sophageal dysfunction, *s*clerodactyly, and *t*elangiectasia; PWS = port-wine stain.

Wavelength, pulse duration, beam optics, skin cooling, and treatment technique all affect treatment outcome. Hemoglobins show strong absorption in the blue, green, and yellow range (400 to 600 nm) and weak but useful absorption in the near–infra-red spectrum (700 to 1100 nm) (see Fig. 240-2). Deep vessels are much better treated using the near–infra-red vascular lasers; however, high fluence is required due to lower target absorption. PDLs (585 to 600 nm) offer the most selective treatment of lesions with superficial (less than 2 mm deep), small- to medium-caliber (0.05 to 1.0 mm diameter) vessels. Variable PDL pulse widths from 0.45 to 40.0 milliseconds are chosen based on vessel size and tolerance for purpura, which occurs with pulse widths less than approxi-





mately 10 milliseconds. Purpura fades in 7 to 14 days. KTP lasers at 532 nm are remarkably similar to PDLs. For deeper vessels, the long-pulsed near–infra-red lasers such as alexandrite (755 nm), diode (800 to 810 nm), and Nd:YAG (1064 nm) should always be delivered in combination with skin cooling. Of these, alexandrite appears to offer the greatest margin of safety for treatment of vascular lesions. IPLs are versatile sources for treatment of medium-sized telangiectasia at wavebands between 515 and 1000 nm. Treatment is moderately painful, which most patients tolerate well with topical or no anesthesia. In infants and children under the age of approximately 8 years who have facial lesions, general anesthesia is often used to reduce trauma and risk of laser eye injury.

Vascular lesions vary widely in diameter and depth of target vessels, anatomic distribution, and pigmentation; a "cookbook" approach should be avoided. Small target vessels should be treated with appropriately shorter pulse duration, near the vessels' τ_r.[9] For complex lesions, it is often prudent to treat the superficial components first with a visible laser, then switch to a long-wavelength laser to treat the deep components. Sun avoidance and judicious use of hydroquinone or other lightening agents is important for patients with skin types higher than Fitzpatrick phototype II. If lesions are nodular, are hypertrophic, or have high flow (such as spider arteriole telangiectasias), treatment should be performed through a microscopic slide or other transparent window pressed onto the skin to blanch superficial vessels. Although common telangiectasia and poikiloderma respond very well, some vascular lesions, especially PWSs and high-flow arteriolar malformations, are difficult to remove completely. Useful maneuvers for resistant lesions are use of higher fluence, diascopy, and/or near–infra-red long-pulse laser such as alexandrite for deep lesions; treatment in a dependent position for light lesions; and multiple treatment passes (with avoidance of pulse stacking). Multiple treatment passes improve efficacy because of cumulative vessel injury and perhaps because a new chromophore, methemoglobin, is formed during the first pass.[10,11] Platelet-inhibiting drugs, including aspirin, should be avoided.

PORT-WINE STAINS (NEVI FLAMMEI) PWS occurs in 0.3 percent to 0.5 percent of newborns[12] as a light pink to red macule or patch in a dermatomal distribution.

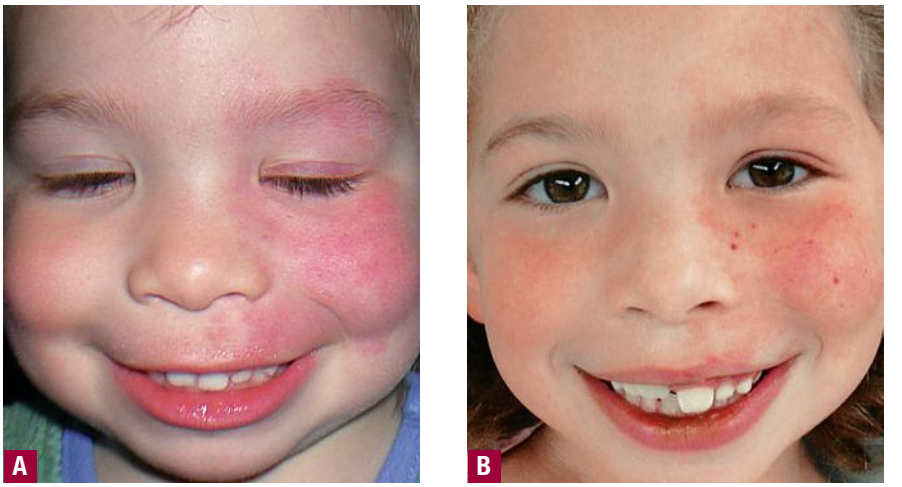

▲ **FIGURE 240-3** A girl with a large trigeminal (V1/V2) port-wine stain identical in distribution to that in the advanced case shown in eFig. 240-2.1 in on-line edition. **A.** Appearance at age 3 years; neither glaucoma nor hypertrophy has yet developed; magnetic resonance imaging did not show Sturge-Weber syndrome. **B.** At age 5 years, after six pulsed dye laser and one alexandrite laser treatment to the affected face, labia, and oral mucosa under general anesthesia, the lesion is nearly gone.

Over time, the lesions become dark red or violaceous with associated hypertrophy and nodularity. Most occur on the face in a trigeminal dermatome distribution. PWSs are usually sporadic but in some families are inherited as an autosomal dominant trait. There are ectatic venules in the papillary and reticular dermis; a paucity of nerves and relative lack of sympathetic fibers, which may account for decreased vascular tone; vessel dilation; and gradual darkening. Thus, PWS may be a neuronal abnormality with secondary vascular consequences.[13] Before treatment, PWSs should be differentiated from macular stains such as "stork bite" or "angel's kiss," common mid-line cranial lesions that fade spontaneously over time. Central forehead, peripheral face, and neck lesions respond better than those at other sites such as the lower extremities. Older patients treated with surgery, older continuous-wave lasers, and/or radiation usually have scarring and a high risk of skin cancer (see eFig. 240-2.1 in on-line edition). Evaluation of PWS-associated syndromes such as Sturge-Weber or Klippel-Trénaunay-Weber includes magnetic resonance imaging and/or computed tomography with contrast imaging.

Treatment should be performed as early as possible and preferably completed before age 3 years (Fig. 240-3). However, favorable response to PDL treatment does not depend on age.[14] Other treatments include cosmetic camouflage, surgical excision, cryosurgery, tattooing, dermabrasion, ionizing irradiation, and photocoagulation with nonselective lasers or electrosurgery. Approximately 65 percent of patients treated with PDL will achieve 50 percent to 90 percent lightening of their PWSs, but only 15 percent of patients achieve greater than 90 percent lightening. A series of typically 4 to 12 treatments given 4 to 8 weeks apart is necessary, although occasionally a PWS will show complete clearance in one or two treatments.[15,16] Hypertrophic PWSs should be treated first with PDL to reduce the superficial component; for example, at 585 to 600 nm, 7 to 10 mm, 8 to 12 J/cm^2, and pulse durations of 0.45 to 10.0 milliseconds depending on the vessel diameter, which can often be determined with a hand lens. The deeper component can then be approached more safely; for example, with a long-pulsed alexandrite laser delivered at or just above the immediate response threshold fluence. Although no long-term series have yet been reported, early treatment appears to reduce the degree of both soft-tissue and skeletal hypertrophy.

The risk of scarring from a series PDL treatments is approximately 1 percent. However, poor technique, such as pulse stacking or misalignment of the laser beam and cryogen cooling spray, can cause blistering and/or scarring. At high treatment fluences, intermittent failure of cryogen spray can also cause scarring. Frequent side effects after PDL and KTP laser treatment of PWS are purpura lasting 7 to 14 days and hemosiderin hyperpigmentation, which clears gradually over weeks to months. Patients should avoid sun exposure after treatment to minimize post-inflammatory pigmenta-



◀ **FIGURE 240-4** A full-thickness port-wine stain before (**A, B**) and after (**C**) treatment with cutaneous and intra-oral pulsed dye laser (1.5 milliseconds, up to 12 J/cm^2, with dynamic cooling) and long-pulsed alexandrite laser (1.5 milliseconds, 45 to 80 J/cm^2 with dynamic cooling). Surgical debulking can often be avoided by using this approach.

tion and tanning, which blocks therapeutic efficacy while increasing the risk of epidermal damage at the next treatment session. Mature and hypertrophic PWSs pose a challenge met primarily by using higher PDL fluences and alexandrite or Nd:YAG long-pulse lasers to achieve deeper penetration (Fig. 240-4). These lasers are deeply penetrating. Direct exposure of teeth should be avoided when treating the inner labia and gingivae. In a study comparing Nd:YAG laser treatment with standard PDL treatment, use of an Nd:YAG (1064-nm) laser at the minimum purpura dose was as effective as PDL, but scarring occurred in 1 of 17 patients.[17] Patients treated in the past with ionizing radiation for PWS often develop skin cancers.[18–21] IPLs may sometimes be successful in treating fair-skinned patients with PWSs resistant to PDL,[22] but in general treatment of PWS with IPL is not recommended.

HEMANGIOMAS Common hemangiomas are vascular tumors seen in 4 percent to 10 percent of infants that begin as a white patch followed rapidly by a red patch that evolves into a raised nodule or plaque.[23] There are many variants. The lesions typically proliferate for months, then persist or gradually involute, with about half having resolved by age 5 years. Residual hypopigmented abnormal fibrofatty tissue often remains after involution. Histologic examination reveals clusters of thin-walled vessels surrounded by endothelial cells, mast cells, and variable atrophy of the overlying epidermis. Pathogenesis may be due to maternal microchimerism; the endothelial cells are clonal, which suggests origin from expansion of an endothelial precursor. Hemangiomas can usually be distin-



guished from other vascular lesions by expression of placental marker proteins such as glucose transporter 1.[24,25]

The superficial component of hemangiomas responds well to PDL treatment,[26–32] but if parameters similar to those for PWS treatment are used, scarring and hypopigmentation are common. Low fluences (4 to 7 J/cm^2) effectively resolve ulceration and/or induce superficial involution. When the lesion is less than approximately 2 mm thick, complete and early resolution after one or two PDL treatments is common. One study found that 91 percent of patients with ulcerated hemangiomas healed rapidly after an average of two PDL treatments. Treatment should be reserved for cases of functional impairment or ulceration, although some advocate very early treatment to prevent proliferation. Confusion arose from an otherwise well-designed trial that unfortunately used no skin cooling.[33] This randomized, prospective, controlled study involving 121 infants with uncomplicated superficial hemangiomas compared early PDL treatment with observation alone. Laser treatment led to early clearance ($p < 0.001$) at 1 year, but at final follow-up there was no significant difference in the incidence of residual hemangiomas. High laser fluence and lack of skin cooling caused adverse effects, including atrophy (28 percent) and hypopigmentation (45 percent). A subsequent study[34] compared response to treatment with a long-pulsed PDL with dynamic spray cooling (595 nm, 7-mm spot size, 10 to 20 milliseconds, 9 to 15 J/cm^2 fluence, 40-millisecond spray, 20-millisecond delay) with response to treatment with a traditional PDL without cooling (585 nm, 7 mm, 0.45 milliseconds, 6 to 7 J/cm^2). There was less hypopigmentation (12 percent vs. 31 percent) and less textural change (4 percent vs. 23 percent) in the lesions treated with cooling.

The mechanism by which PDL produces hemangioma involution is unknown, and PDLs were not designed to treat these lesions. Hemangioma regression occurs by apoptosis and appears to be triggered by a loss of immune privilege. The goal of laser treatment may therefore be to trigger an active process rather than to obliterate the abnormal vessels. Combination medical-laser approaches have not yet been examined.

TELANGIECTASIA, ROSACEA, SPIDER AND CHERRY ANGIOMAS, AND POIKILODERMA Telangiectasias are common 0.1- to 1.0-mm ectatic dermal vessels categorized as simple or linear, arborizing, spider, and papular and are caused by solar, hormonal, genetic, traumatic, or primary disease processes.

Simple telangiectasias of less than 1 mm in diameter typically resolve in one or two treatments with PDL or KTP laser.[35–37] High-energy IPLs are almost as effective, but other IPLs lack sufficient pulse energy. The desired immediate treatment endpoints are either selective darkening or disappearance of the target vessels. Treatment of spider angiomas is aimed primarily at the central arteriole and superficial branches; diascopy to arrest flow in the central arteriole during treatment is helpful. Poikiloderma of Civatte is highly responsive to PDL, KTP laser, or IPL treatment, which should be performed using low to moderate fluences and large spot sizes. Skill is critical for uniform coverage. In one study, 97.5 percent of 182 patients had good to excellent response with no scarring after one to three PDL treatments for facial telangiectasia. Lasers and IPLs offer the most effective treatment modalities for the common erythematous/telangiectatic type of rosacea. Choice of laser and pulse duration depends in part on patient tolerance for purpura, vessel size, and whether the vascular lesions are focal or extensive. IPLs should be used with extreme caution in patients with tanned or dark skin.

VENOUS LAKES AND PYOGENIC GRANULOMAS Venous lakes are acquired venular ectasias that commonly develop on sun-exposed skin of elderly patients and enlarge and bleed profusely with trauma. Histologic examination shows widely dilated venules. These compressible lesions are handily treated with millisecond PDL or KTP lasers delivered with diascopy or with near–infra-red diode, long-pulsed alexandrite, or long-pulsed Nd:YAG lasers delivered with bulk cooling (see eFig. 240-4.1 in on-line edition). Pyogenic granulomas (see Chap. 126) can be treated, but ironically, vascular lasers can both induce and treat pyogenic granulomas.

VEINS AND SPIDER VEINS OF THE LOWER EXTREMITY (See Chap. 250) Patients with varicosities should be evaluated for deep venous disease, which, if present, should be treated before superficial cutaneous vein treatment is considered. Although laser treatment of leg veins has improved, sclerotherapy remains the treatment of choice for superficial vessels and endovenous laser therapy is the treatment of choice for deep vein incompetence. Cutaneous lasers are therefore generally relegated to use in treating superficial leg veins in patients who are averse to needles. There is no significant difference in efficacy between sclerotherapy and Nd:YAG or alexandrite laser treatment, but more pigmentary side effects occur after laser treatment.[38–40]

Treatment of Pigmented Lesions

Lasers are often the best or only effective treatment for a wide spectrum of pigmented lesions[50] (Table 240-4). The potential for misdiagnosis and/or malignant transformation, combined with the widespread popularity of cutaneous lasers and IPLs among non-dermatologists and even non-physicians, poses potential health risks for patients and potential legal risks for the practitioners involved.

Melanin absorbs UV, visible, and near–infra-red light to approximately 1100 nm. Epidermal lesions that respond easily, such as lentigines, can therefore be treated by almost every available laser or IPL system. Other so-called *epidermal lesions* such as café-au-lait macules (CALMs) are unpredictable and/or resistant to treatment. In general, compound and dermal pigmented lesions are more challenging, with the important exception of nevus of Ota. This lifelong facial disfigurement is reliably and uniquely cleared by Q-switched laser treatments. Red and near–infra-red pulses are usually

TABLE 240-4
Response of Pigmented Lesions to Treatment with Lasers and Flashlamps

Pigmented Lesions That Respond Well
- Simple lentigo and freckles
- Labial lentigo (i.e., associated with Peutz-Jeghers syndrome)
- Nevus of Ota, nevus of Ito, residual mongolian spot, simple blue nevi
- Acquired bilateral nevus of Ota–like macules (ABNOM, Hori's macules)
- Palmo-plantar congenital nevi

Pigmented Lesions That Occasionally Respond
- Café-au-lait macule (CALM)
- Nevus spilus (CALM-like lesion, speckled, often with junctional nevi)
- Congenital nevus
- Becker's nevus
- Melasma

Pigmented Lesions That Should Not Be Treated
- Dysplastic nevi
- Lentigo maligna
- Melanoma



optimal for treating pigmented lesions, because 600 to 1100 nm is a melanin-selective and deeply penetrating spectral region (see Fig. 240-2). Green or yellow "vascular" wavelengths (PDLs, KTP lasers, some IPLs) can also be used for treating pigmented lesions, with the simple maneuver of applying firm pressure with a window at the skin site during exposure to remove blood by compression.[51] Many patients with facial photoaging have a combination of vascular and pigmented lesions such as poikiloderma, telangiectasia, and/or lentigines. Intentional lack of epidermal protection using a primarily vascular laser such as KTP or an IPL often treats both components well. The unfortunate term *photorejuvenation* is often used to describe this treatment. Mid– and far–infra-red lasers used for fractional and conventional skin resurfacing, respectively, are also used to treat pigmented lesions, including melasma unresponsive to medical therapy.

Melanocytic lesions with isolated scattered cells such as nevus of Ota (see Chap. 122) are very effectively treated by short Q-switched laser pulses, whereas lesions with larger pigmented structures such as nests of nevus cells or hair follicles respond better to longer (millisecond) pulses. The primary organelle of pigmentation is the melanosome, with a τ_r of somewhat less than 1 microsecond. Nanosecond-pulsed lasers (Q-switched ruby, alexandrite, and Nd:YAG) cause melanosome cavitation and selective death of pigment-containing cells,[52,53] an event correlated with immediate skin whitening during Q-switched laser exposure. Immediate whitening is therefore a very useful clinical endpoint for Q-switched laser treatments. In contrast, the appropriate immediate endpoint with long-pulse devices is a subtle grayish darkening of the lesion followed by lesional erythema and edema. Although Q-switched lasers can be safely used to treat dermal pigmented lesions, IPLs and long-pulse lasers are risky in this setting because they lead to more extensive heating of the dermis. In vivo confocal microscopy and optical coherence tomographic imaging after IPL treatment of facial solar lentigines shows the rapid outward migration of necrotic pigmented cells, mostly keratinocytes, forming desquamated microcrusts.[54] A similar phenomenon occurs after fractional resurfacing, which uses mid–infra-red laser microbeams to produce small zones of epidermal and dermal necrosis.[2]

LENTIGINES, EPHELIDES, AND SUPERFICIAL PIGMENTED SEBORRHEIC KERATOSES (See Chap. 253) Solar lentigines and lentigines associated with Peutz-Jeghers syndrome, LEOPARD syndrome (*l*entigines, *e*lectrocardiographic conduction defects, *o*cular hypertelorism, *p*ulmonary stenosis, *a*bnormalities of genitalia, *r*etardation of growth, and sensorineural *d*eafness), myxoma, and Carney syndrome; ephelides (freckles; see Chap. 73); and seborrheic keratoses (see Chap. 118) can be treated with many types of lasers or with curettage, electrodesiccation, chemical peels, or cryotherapy (see Chap. 253). A laser is often the best choice because of its selectivity, which reduces the risk of scarring and hypopigmentation after treatment. Good results have been reported with 510-nm copper vapor, 532-nm KTP, frequency-doubled Q-switched 532 nm Nd:YAG, 694-nm Q-switched ruby, and 755-nm Q-switched alexandrite lasers, and with IPLs (500 to 1000 nm).[55–60] Patients should be warned that treatment of facial lentigines with any of these devices often causes a "dirty" look for 5 to 10 days due to compaction before the necrotic lesions are shed by desquamation. Side effects include scarring (rare), postinflammatory hyperpigmentation, hypopigmentation, erythema, and pain.

CAFÉ-AU-LAIT MACULES CALMs are common congenital tan-colored macules that occur in 10 percent to 20 percent of the population and with neurocutaneous syndromes such as neurofibromatosis and McCune-Albright syndrome (see Chap. 142).[61] For unknown reasons, response is unpredictable to treatment with both non-selective and selective lasers, ranging from complete and permanent clearance after one treatment to recurrence, persistence, or darkening. Response appears to be better in childhood, even in dark-skinned patients. In general, multiple treatments are needed to achieve unpredictable results. Most studies have used Q-switched ruby (694 nm), Nd:YAG (532 nm and 1064 nm), or alexandrite (755 nm) lasers. CALMs have also been reported to respond to 511-nm copper vapor laser coagulation, a 510-nm short-pulsed PDL, and erbium:yttrium-aluminum-garnet (Er:YAG) laser resurfacing.[62–67] In a study comparing Q-switched Nd:YAG and ruby laser treatments, despite lightening after treatment, eight of nine CALMs recurred by 6 months, and the remaining CALMs recurred after sunlight exposure. Histologic features do not differentiate laser-responsive from laser-resistant CALM lesions, but the presence of jagged rather than smooth edges is often correlated with good response. Laser resurfacing may clear resistant CALMs, and facial CALMs appear to respond better than those in other body locations.

MELANOCYTIC NEVI (See Chap. 122) Although the preferred treatment for congenital nevi is excision, this may be impossible or very disfiguring for some lesions. Risk of spontaneous malignant transformation varies with genetic factors and size and depth of the lesion. The greater is such risk, the more controversial is laser treatment. Long-term risks for melanocytes remaining after laser treatment remain unclear, and fibrosis induced by laser treatment jeopardizes subsequent histopathologic interpretations. Several studies have shown changes in melanocyte gene expression, including p^{16}, after laser exposure. Hundreds of Japanese patients had generally acceptable results after laser treatments, and thus far there are no reports of malignancies arising after treatment in these series.[68–71] However, the risk of spontaneous melanoma in Japan is comparably low. Melanoma has been reported in previously laser-treated "benign melanocytic lesions," which may represent laser-induced melanomas, spontaneous transformation, or simply an initial misdiagnosis.

Small benign nevomelanocytic nevi can be ablated using CO_2 or Er:YAG resurfacing lasers, but most studies to date have used melanin-selective pulsed lasers. Q-switched ruby laser treatment (694 nm, 8 J/cm^2, 5-mm spot size) yields complete histologically and clinically determined clearance of approximately two-thirds of benign nevocellular nevi, but the remaining third of lesions have residual melanocytes present 0.1 to 0.4 mm deep in the dermis. Kono, Ercocen, and Nozaki first combined long and short melanin-selective pulses for treatment of congenital nevi to target both individual pigmented cells, nests of cells, and hair follicles. A single pass with high-fluence normal-mode ruby laser (694 nm, 1-millisecond pulse duration, 20 J/cm^2 fluence, spot size 10 mm) plus three to four passes with a Q-switched ruby laser (30-nanosecond pulse duration, 7 J/cm^2 fluence, spot size 7 mm), was more efficient in eliminating both deep and superficial melanocytes than treatment with either laser alone.[72] The technique of Kono and colleagues can be pursued with ruby, alexandrite, and/or Nd:YAG lasers. Superfi-



cial congenital nevi respond very well; 100 percent of 29 superficial lesions treated were ranked as showing excellent response, whereas three of five deep congenital nevi treated were ranked as showing excellent response after 6 to 38 months of follow-up. Palmo-plantar congenital nevi respond better, perhaps because of the lack of hair follicles as a refuge for nevus cells.[50]

Nevus spilus is a complex lesion (see Chap. 122). Although the risk is remote, malignant transformation has been described, which raises additional concern about laser treatment. An excellent and durable clinical response of the speckled lentiginous portion can often be achieved after ruby or alexandrite laser treatment, leaving the appearance of a simple CALM.



DYSPLASTIC NEVI, LENTIGO MALIGNA, AND MALIGNANT MELANOMAS (See Chaps. 123 and 124) Laser treatment of dysplastic nevi, lentigo maligna, and other melanomas is not recommended. Surgical excision remains the standard treatment for atypical nevi, but common atypical nevi are not infrequently laser exposed (e.g., during laser hair removal or treatment of facial photoaging). Treatment with Q-switched or normal-mode lasers usually removes the apparent lesion, but complete histologically confirmed clearance is not achieved. Clinically atypical nevi with histologically apparent atypia have been described 1 month after therapy with a 810-nm laser for hair removal. Lentigo maligna treated with lasers in patients refusing conventional treatment has been associated with a high recurrence rate; laser treatments alter p^{16} expression and pigmented lesion histology and may produce pseudomelanomas.[73–78]

CERULODERMAS (DERMAL HYPERPIGMENTATION) AND BLUE NEVI (See Chaps. 73 and 122) Nevus of Ota (nevus fuscoceruleus ophthalmomaxillaris), nevus of Ito, residual congenital dermal melanocytosis (Mongolian spot), and acquired dermal melanocytosis [acquired bilateral nevus of Ota–like macules (ABNOM) or Hori's macules] are lesions that respond well to Q-switched laser treatment. Blue nevus, another benign nevomelanocytic lesion with dermal melanocytes, also responds well to laser treatment but is said to have a somewhat higher potential for malignant transformation to melanoma.

Melanin-selective Q-switched lasers have revolutionized treatment of these lesions, because all previous treatments were ineffective and/or disfiguring. Q-switched 694-nm ruby, Q-switched 760-nm alexandrite, and Q-switched 1064-nm Nd:YAG lasers are all highly effective.[79–84] The latter is better tolerated in darker skin. For phacomatosis pigmentovascularis (see Chap. 173), good results can be achieved with a combination of Q-switched lasers and PDLs. Q-switched lasers selectively destroy the dermal melanocytes. The color of these lesions is a useful sign to predict treatment response: brown lesions tend to require fewer laser treatments than the blue-green variant. Lightening of the lesion occurs gradually after laser treatment, because melanin stays in the dermis long after the nevus cells have been destroyed. The ideal treatment interval remains unclear. Q-switched laser fluences can vary from 3 to 10 J/cm^2, with higher fluences needed for the longer-wavelength devices. The desired endpoint when treating nevus of Ota is a subtle, transient immediate whitening of the dermis, without epidermal ablation. Side effects relate to epidermal damage, including dyschromia, crusting, and texture change, but are uncommon with proper dosimetry. Recurrence is rare (3 percent or lower).

Acquired dermal melanocytosis, also called *ABNOM* or *Hori's macules*,[85,86] are speckled blue-brown to gray macules occurring bilaterally on the face (see Chap. 73). Commonly seen in middle-aged Asian women, the lesions have melanocytes in the middle and upper dermis similar to those of nevus of Ota but with a different clinical and histologic presentation. In general ABNOM is more difficult to clear than nevus of Ota by Q-switched laser treatments.[87–90] Combination with CO_2 laser therapy and/or topical bleaching creams may be useful.[91–93]

MELASMA AND DRUG-INDUCED AND POST-INFLAMMATORY HYPERPIGMENTATION (See Chap. 73) Results in treating melasma with most lasers and IPLs, even those with excellent selectivity for melanized cells, are generally poor.[94] Transient improvement was noted after Er:YAG laser skin resurfacing of refractory melasma; however, all patients experienced significant post-inflammatory hyperpigmentation.[95] Various combination treatments, including IPL and hydroquinone, may be better than hydroquinone alone but usually induce post-inflammatory hyperpigmentation.[96–98] Fractional resurfacing has been found useful for treatment of melasma and deserves more study.[99,100] A small study involving 10 women with Fitzpatrick skin phototypes III to V used 6 to 12 mJ/MTZ delivered at 2000 to 3500 MTZ/cm^2. After 4 to 6 treatments, 60 percent of patients had 75 percent to 100 percent clearing according to a subjective grade scale. Although fractional photothermolysis is apparently more effective than other laser treatment modes, about half of the patients responding to this therapy experience recurrence.

Post-inflammatory hyperpigmentation is poorly responsive to laser or IPL treatments, which often induce more hyperpigmentation.[101] Fractional resurfacing is sometimes useful for treating post-inflammatory hyperpigmentation, and stimulates trans-epidermal elimination of some upper dermal tissue.[102] Post-inflammatory hyperpigmentation should be differentiated from iron pigmentation. Post-sclerotherapy pigmentation sometimes responds to Q-switched laser treatment[103] and is correlated with high systemic iron stores and high or upper-normal ferritin levels.[104] Cutaneous iron hyperpigmentation sometimes clears rapidly after a blood donation.

Most drug-induced hyperpigmentation is caused by precipitation of chromophoric drug complexes in the dermis. Q-switched laser treatment (e.g., of minocycline-induced hyperpigmentation) is often satisfactory.[105,106] Drug hyperpigmentation is often photodistributed (e.g., amiodarone, imipramine) but may also occur on mucosal surfaces, nails, or teeth, or in a generalized distribution (e.g., minocycline, busulfan). Fractional resurfacing is also useful for treating drug-induced pigmentation (Fig. 240-5).

Before any Q-switched laser treatment, patients should be specifically questioned for a history of gold intake (usually given to women for treatment of rheumatoid arthritis). These patients forever have nanoparticles of gold in the dermis. Exposure to Q-switched lasers or UV light can cause a permanent, bizarre, bluish skin color called *chrysiasis*, which can occur even decades after intake of gold.[107] Laser-induced chrysiasis is permanent, but in some cases can be removed by millisecond-domain ruby or alexandrite lasers.[108]

MISCELLANEOUS PIGMENTED LESIONS In treatment of Becker nevus (see Chap. 73), laser treatment has yielded disappointing results characterized by partial response and/or recurrence.[109–111] Infraorbital dark circles have been treated with melanin-selective Q-switched lasers or ablative CO_2 resurfacing with



▲ **FIGURE 240-5** Minocycline-induced hyperpigmentation before (**A**) and 6 months after (**B**) two treatments with fractional resurfacing given 1 month apart. Photoaging changes have also improved.

variable results.[112,113] Extreme caution must be taken when treating this area to minimize the risk of eye injury.

TATTOOS (See Chap. 100) A series of typically 6 to 12 painful and often expensive Q-switched laser treatments are needed for tattoo removal.[114–116] Many tattoo inks (especially, green, yellow, orange, and white) are resistant to laser treatment. In contrast, "amateur" tattoos made with carbon (India ink or graphite) and black tattoos respond well to laser treatment. Other methods of tattoo removal, including salabrasion, dermabrasion, deep cryotherapy, excision, CO_2 laser vaporization, and various topical agents, usually produce a scar. The risk of scarring from Q-switched laser treatments is approximately 5 percent. During treatment, the pigment nanoparticles inside dermal phagocytic cells reach peak temperatures well in excess of 300°C (approximately 600°F) within nanoseconds, which produces cell rupture and chemical alterations. The appropriate clinical endpoint for laser tattoo removal is selective, immediate dermal whitening confined to the tattooed skin (Fig. 240-6). Picosecond laser pulses are more effective but such lasers are not commercially available.[117] In general, each tattoo color should be treated using a complementary Q-switched laser wavelength. For example, green tattoos are best treated with red (ruby or alexandrite) lasers, whereas red tattoos are best treated with green (Q-switched 532-nm) lasers. At the fluences necessary, pigmented epidermal cells are affected, which causes transient hypopigmentation followed by repigmentation (Fig. 240-7). The 1064-nm Q-switched Nd:YAG laser is superior for treating pigmented skin but does not remove green and some other ink colors.

Hair Removal

Since 1996 when Grossman et al. first reported the selective photothermal destruction of pigmented hair follicles by a 3-millisecond ruby laser pulse delivered in combination with skin cooling,[126] permanent hair removal has become the most popular medical laser application (Table 240-5). Half of treated individuals available for follow-up at 2 years still had laser-induced alopecia.[127] Electrolysis (direct current) and electrothermolysis (radiofrequency) are the only other methods for permanent destruction of hair follicles and are impractical for removal of large numbers of hairs. However, these methods have the advantages of acting independently of hair or skin color, whereas laser or IPL treatments depend on the presence of melanin in the hair shaft. Laser or IPL treatment is appropriate for hirsutism or hypertrichosis of any cause characterized by brown or black terminal hair. Pseudofolliculitis barbae also responds well—for example, to treatment with very long pulsed diode or Nd:YAG (1064-nm) lasers with skin cooling appropriate for use in pigmented skin.[128]

The most versatile lasers for hair removal are near–infra-red diode and alexandrite lasers. These fast, pulse width–tunable sources usually have integrated skin cooling handpieces and are capable of greater power and fluence than IPLs. An 810-nm diode laser is available with 5- to 400-millisecond pulse durations and sapphire-chilled contact skin cooling. At a mean of 8.7 months after therapy, 59 percent of subjects treated with this device had sparse hair regrowth.[129] Alexandrite lasers near 760 nm with variable 3- to 20-millisecond pulse widths and cryogen spray cooling are fast, versatile sources. The long-pulse Nd:YAG lasers (1064 nm, 10 to 100 milliseconds, with skin cooling) are most useful for treating dark-skinned patients. IPLs for hair removal abound, but many are underpowered or unsafe for use in darkly pigmented skin. In contrast, some high-fluence IPLs with better spectral filters, variable pulse duration, and actively cooled handpieces rival lasers for efficacy and speed. Some systems are available with both IPL and laser handpieces.

Clinically, there are two distinct responses to laser treatment: temporary and permanent alopecia. The former is due to arrest of anagen hair growth, followed by a catagen-like state and eventually re-emergence of an anagen hair.



▲ **FIGURE 240-6** Immediate whitening, confined to the tattoo as shown here (**A, B**), is the appropriate treatment endpoint during Q-switched ruby laser treatment for removal of a carbon tattoo. Whitening fades over several minutes as laser-induced gas bubbles in the dermis dissolve.





▲ **FIGURE 240-7** Multicolored tattoos often require treatment with different wavelengths. This tattoo (**A**) was first treated with a Q-switched neodymium:yttrium-aluminum-garnet laser (1064 nm, 4-mm spot size, 7 J/cm^2), which removed the black ink (**B**) and then with a Q-switched ruby laser (694 nm, 5.5-mm spot size, 6 J/cm^2) to remove the green ink. Local depigmentation and hypopigmentation is common after use of the ruby laser (**C**), but gradually resolves. After a series of treatments, very little ink remains; there is still some hypopigmentation and a margin of hyperpigmentation (**D**), which faded over several months.



This occurs at much lower fluences than permanent hair removal. Therefore, temporary alopecia lasting approximately 2 months can be achieved with lower fluences. The unproven cellular target(s) for permanent hair removal are follicular epithelial stem cells,[130,131] follicular bulb/papilla, or both. A common myth is that permanent laser hair removal in humans depends on the hair growth cycle. In mice, telogen hairs are insensitive due to lack of dermal hair pigmentation, but in humans the follicle remains pigmented throughout the hair cycle.[132]

Laser hair removal involves a delicate balance between damage to the pigmented follicles and damage to the pigmented epidermis. A fair-skinned patient with dark terminal hair can be safely treated with a wide range of devices and at a wide range of parameter settings. Epidermal protection is afforded by the use of lower fluence, skin cooling, longer pulse duration, and/or longer wavelength.[133] These maneuvers act independently and can be combined as needed when treating dark or tanned skin. Thus, it is not appropriate to treat dark-skinned patients with high fluences, lack of skin cooling, and short-wavelength and/or short-pulse devices in a combination that causes epidermal damage. Nd:YAG 1064-nm lasers with pulses of 30 to 100 milliseconds and 10 to 30 J/cm^2 delivered with good skin cooling are generally effective and well tolerated in patients of any skin type with coarse black hair. The clinical treatment endpoint is a mild perifollicular (selective) edema and erythema appearing within several minutes. It is not necessary to "char" the hair to accomplish permanent hair removal. Bulk precooling using ice packs or cold air is useful with all hair removal light sources. Dynamic cryogen spray cooling is particularly useful when treating fine hair with 1- to 10-millisecond laser pulses. Fine hair is best treated with pulse durations of less than approximately 10 milliseconds because of the short τ_r of fine hair follicles. White or blonde hair is difficult or impossible to re-

TABLE 240-5
Lasers and Light Sources for Hair Removal[a]

Type	Wavelength and Pulse Width	Epidermal Cooling	Approximate Fitzpatrick Skin Type Range[b]	Highest Effective Hair Color	Maximum Speed of Treatment[c]	Additional Information
Long-pulsed alexandrite	755 nm Pulsed 3 ms; 40 ms stuttered	Cryogen spray	Types I–IV	Light brown	Fast	Limited use in tanned skin. Effective for fine or coarse hair.
Diode	810 nm Pulsed 5–1000 ms	Cold contact window	Types I–IV (longer pulses for darker skin)	Light brown	Moderate	Limited use in tanned skin. Limited effectiveness for fine hair. Deeper penetration.
Long-pulsed Nd:YAG	1064 nm Pulsed 3–100 ms	Cold contact window Cryogen spray	Types I–VI (longer pulses for darker skin)	Medium brown	Moderate	Darker or tanned skin can usually be treated. Limited effectiveness for fine hair. Deepest penetration. Higher fluences needed.
Long-pulsed ruby	694 nm Pulsed 3 ms; 100 ms stuttered	Cold contact window	Types I–III	Light brown	Slow	Limited use in tanned skin. Effective for fine and coarse hair. Hypopigmentation is common.
Xenon flashlamp (IPL)	500–1200 nm Pulsed 2.5–7 ms; 20–100 ms stuttered or not	None Cold contact window	Types I–IV (longer pulses for darker skin)	Red, light brown	Moderate to fast	Limited use in tanned skin. Effective for fine or coarse hair. Many devices are underpowered. Need different handpieces for each indication.

IPL = intense pulsed light; Nd:YAG = neodymium:yttrium-aluminum-garnet.
[a]Table based on general features of most types of lasers or IPLs.
[b]Safe use depends on individual skin pigmentation and treatment parameters at time of treatment; skin type range given is a generalization.
[c]Treatment speed depends on exposure spot size and pulse repetition rate, which often vary with fluence. High fluences tend to cause slower treatments.

move, even with devices that use added radiofrequency current.

Risks and permanent complications of laser and IPL hair removal include scarring, eye injury, hypopigmentation from excessive cryogen spray cooling, paradoxical hair stimulation, and livedo reticularis after high-fluence treatments on the legs. The risk of eye injury is severe when any hair removal laser or IPL is used within the bony orbit. The retina and choroid of the eye contain the body's highest concentration of melanin. Permanent anterior eye injury from laser and IPL hair removal devices presents as retraction of the iris, visual disorientation, and/or uveitis. Paradoxical hair stimulation is a long-lasting or permanent stimulation of facial hair and occurs in approximately 5 percent of women of Mediterranean or Middle Eastern descent after hair removal treatment on the face using either laser or IPL.[134,135] The mechanism is unknown. An at-risk phenotype appears to exist—these patients have fine dark hairs over much of the face and an ill-defined frontal hairline. It is best to refrain from treating these individuals.

Proliferation of laser and IPL hair removal outside of dermatology offices has increased dramatically. Unfortunately, avoidable injury is commonly seen, often from inappropriate treatment of pigmented skin with IPLs (Fig. 240-8). Minimal regulation, training, and oversight requirements have led to the creation of economically driven "spas" run by absentee physicians or non-physicians. These businesses are often widely promoted, enticing customers with special offers. Although many may provide safe and effective treatments, many do not.



▲ **FIGURE 240-8** The use of intense pulsed light sources (IPLs) for hair removal in pigmented skin is treacherous due to poor selectivity, inadequate cooling, or both. The profound hyperpigmentation shown here has persisted for 2 years after an inappropriate IPL treatment. Disfigurement was made worse by poor technique, which left large gaps between the large rectangular exposure spots.

Laser Resurfacing (See Chaps. 252 and 253)

Despite the strong trend toward less invasive treatments with fewer side effects and faster recovery time, laser resurfacing remains the treatment of choice for advanced facial photoaging, some benign tumors, and acne scarring. CO_2 and Er:YAG lasers vaporize intracellular and extracellular water in a thin layer near the skin surface, removing tissue to a controlled depth. Resurfacing is also well suited for removal of epidermal lesions such as actinic keratoses, epidermal nevi, and seborrheic keratoses, as well as deeper growths such as angiofibromas and syringomas. After vaporization of the epidermis and superficial dermis, shrinkage of a residual thermally damaged dermal layer may tighten the skin. The main advantage of Er:YAG lasers is that they can provide a full range of treatment from very superficial to deep resurfacing. In some devices, residual thermal damage can be arbitrarily controlled by setting pulse duration. Residual thermal damage and hemostasis during the procedure are inversely related. Ablative laser resurfacing is covered in Chap. 252 and nonablative laser resurfacing in Chap. 253.

FRACTIONAL RESURFACING Fractional resurfacing is a relatively recent treatment approach that creates thousands of microscopic MTZs per square centimeter to stimulate skin remodeling.[2,136] Both epidermal problems (pigmented lesions, actinic keratoses) and dermal lesions (rhytides, scars, telangiectasias) respond to fractional resurfacing, which is generally less effective per treatment but is better tolerated than conventional laser resurfacing. Fractional resurfacing creates a pixilated pattern of microscopic thin, long columns of thermal damage, extending up to approximately 1 mm deep and 0.1 mm wide. The depth of the MTZs is controlled by microspot pulse energy, which is typically varied from 6 to 40 mJ. Treatment density of MTZs is controlled separately. This unique dosimetry allows the anatomic depth of treatment to be separated from the aggressiveness of treatment. On the face, density typically varies from 800 to 4000 MTZ/cm^2. Tissue surrounding each MTZ responds by rapid epidermal healing and dermal remodeling. Re-epithelialization after fractional resurfacing is achieved in 1 day. The epidermal portion of each MTZ sloughs in 5 to 14 days after fractional resurfacing treatment, shedding pigment from the epidermis and upper dermis in the process. The first device commercialized used a 1550-nm fiber laser, with pulses delivered with an intelligent scanner that incorporated an optical mouse for tracking the skin surface. A blue dye is applied to the skin to facilitate tracking, followed by topical anesthetic. Devices using stamping-mode applicators have not yet been compared with scanning-mode fractional resurfacing devices.

Fractional resurfacing has been approved in the United States for the treatment of lentigines and periorbital rhytides, and for skin resurfacing; it has also been shown to improve melasma, acne scars, poikiloderma, and fine telangiectasias.[2,137,138] Fractional resurfacing leads to improvement in fine to moderate wrinkles, pigmentation, and superficial scars,[2] but its efficacy in treating deep wrinkles is minimal. Fractional resurfacing is safer than conventional laser resurfacing because the skin barrier remains intact and is relatively more effective than other non-ablative techniques because each MTZ far exceeds a therapeutic threshold. A major advantage is its safe treatment of any skin site, including face, neck, chest, arms, and backs of the hands. Side effects are usually mild and temporary inflammation, but it is essential to provide skin cooling, without which burns may occur. A major advantage of fractional resurfacing over resurfacing with all other lasers and IPLs is the ease of feathering treatment field edges.



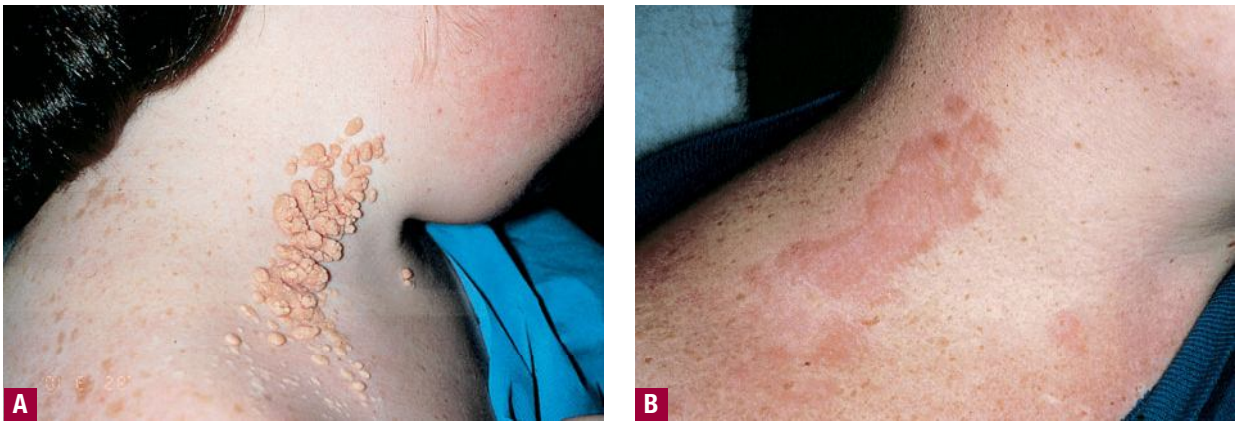

▲ **FIGURE 240-9** **A, B.** Epidermal nevus removed by laser resurfacing.



SCARS AND STRIAE With some very interesting exceptions, mammals heal with scarring, whereas many "lower" vertebrates are capable of complete tissue regeneration. The use of lasers in dermatology poses the interesting issue of what does not cause scarring. Although even the cleanest simple incision usually leaves a scar, scarring is not caused by extensive laser destruction of dermal vessels (PWS), destruction of phagocytic dermal cells (tattoo removal), vaporization of the entire epidermis and papillary dermis (laser resurfacing), or creation of millions of deep microscopic laser burns (fractional resurfacing). Young, red, and/or telangiectatic scars feature a prominent microvascular component. There is some evidence that early PDL treatment improves the appearance and plasticity of scars. This matter was initially studied in 16 patients with mid-line sternotomy scars. After two treatments (585 nm, 450 microseconds, 6.5 to 7.25 J/cm^2, 5-mm spot size) spaced 6 to 8 weeks apart, there was significant improvement in comparison with untreated control areas, as judged by blinded grading.[139] However, a subsequent randomized, observer-blinded, controlled trial comparing treatment with PDL (585 nm, 450 microseconds, 6.5 to 8 J/cm^2, 5-mm spot size, 10 percent to 20 percent overlap) with treatment using silicone gel sheeting failed to show any difference between areas receiving either of these treatments and untreated control sites.[140] More recently, a fluence-response study of PDL-treated sternotomy scars found more improvement in erythema, induration, and scar height scores when scars were treated with lower fluence (3 to 5 J/cm^2 versus 7 J/cm^2),[141] and other studies confirmed the efficacy of PDL treatment for scars.[142,143] For ice pick acne scars, surgical excision with a small biopsy punch is often the best option, with or without laser resurfacing. Fractional resurfacing and other non-ablative treatments with mid–infrared lasers also improve acne scars.

Striae are poorly understood degenerations of dermal elastin that either cause or result from a mechanical failure of dermal connective tissue in the setting of stretching (pregnancy, weight gain) and/or corticosteroid excess (Cushing syndrome, anabolic steroid use). Characterized by broken elastin fibers at its margins, a stria is not a scar. Many attempts to treat striae using ablative, non-ablative, and fractional resurfacing lasers have been described, but there is no convincing evidence of their effectiveness.

WARTS AND CONDYLOMATA (See Chap. 196) Warts have human papillomavirus–induced hyperkeratosis and a rich supply of dermal capillary vessels that can be targeted by ablative or vascular lasers. Laser treatment is useful (approximately 70 percent clearance rate) but is no more effective than other therapies such as cryodestruction. Lesions resistant to cryodestruction are not particularly resistant to laser treatment, and vice versa. Ablation should be performed to a level just below the dermal-epidermal junction, under local anesthesia. Post-procedure pain and healing are similar to those after cryodestruction. Pulsed vessel-targeted lasers are a fast, gentle, and equally effective approach to removing warts.[144,145] Stacking of two or three PDL pulses in rapid succession is often used to intentionally produce some non-specific thermal damage of the infected epidermis. However, the mechanisms for wart removal by any of these methods remain a mystery. The literature reflects this ambiguity; reported clearance rates vary dramatically from 21 percent to 95 percent.

EPIDERMAL HAMARTOMAS: EPIDERMAL NEVI, NEVUS SEBACEUS (See Chap. 118) Although small localized hamartomas should be surgically excised, extensive lesions are treated with ablative pulsed or scanned CO_2 or Er:YAG lasers.[146–148] Low recurrence rates (10 percent to 38 percent) were found 2 years after CO_2 laser treatment. Common and inflammatory epidermal nevi can be removed by curettage, followed by two passes of laser resurfacing within the dermis (Fig. 240-9).

Nevus sebaceus typically presents as a solitary verrucous lesion during childhood on the face or scalp. Surgery is usually the treatment of choice due to a risk for malignant transformation over time.[149] Ablation with CO_2 or erbium lasers can improve inoperable lesions,[150] but scarring or pigmentary changes often result. Nevus sebaceus can respond to topical aminolevulinic acid photodynamic therapy, carried out with high-fluence red light activation.[151]

ACNE (See Chap. 78) A 1450-nm laser with dynamic cryogen spray cooling was used in a three-phase study that included tests of heating and cooling parameters in in vivo rabbit ears and then in ex vivo human skin and a pilot clinical trial in which the backs of males with acne were treated.[152] Thermal damage occurred in the upper dermis. There was a highly statistically significant reduction in lesion count and severity in the treated areas. Although excellent results were demonstrated in this and a similar study,[153] the treatment is difficult in practice due to pain, expense, and the need for multiple treatment sessions. Use of PDLs for the treatment of acne has also been studied, with mixed results and lack of evidence for a mechanism of action. A prospective, randomized, placebo-controlled study involving 41 adults found significant improvement in moderate acne vulgaris on the face up to 12 weeks after a single PDL treatment.[154] In contrast, a similar pro-

spective, controlled study with a split-face design found no significant effect of PDL treatment; however, there was some improvement of both the treated and untreated sides.[155] Taken together, these excellent studies suggest a systemic effect of PDL treatment on acne (e.g., by immune mechanisms), but this remains controversial.[156] PDLs and KTP lasers are similarly effective for acne treatment.[157,158] There is no evidence that comedonal acne is improved by light or laser treatment.

Ultraviolet Laser Phototherapy

The 308-nm excimer laser is a powerful source for local narrow-band UVB phototherapy for localized psoriasis (see Chap. 18) and vitiligo (see Chap. 72). Its primary advantage is that is elicits rapid response in fewer treatments than do conventional narrowband UVB or broadband sources. In patients with moderate areas of involvement, such laser therapy offers an adjunct or alternative to topical treatment, especially for chronic psoriatic plaques on the elbows, knees, and scalp. Excimer lasers produce quasi-continuous trains of nanosecond UV pulses and are widely used in ophthalmology for extremely precise ablation of the cornea [laser-assisted intrastromal keratomileusis (LASIK) procedure]. In the first report of 308-nm excimer laser use in dermatology, rapid and uniform plaque clearance occurred in 7 to 11 treatments at a mean cumulative fluence of 4.45 J/cm^2, compared with over twice as many treatments at a cumulative fluence of 31.1 J/cm^2 for conventional narrowband UVB treatment.[159,160] Independent studies confirmed that localized chronic plaques of psoriasis respond rapidly to treatment at high fluence (4 to 6 minimal erythema doses or higher) and that treatment at 8 to 16 minimal erythema doses frequently clears plaques in a single session.[161] The high-fluence treatment caused a moderately painful blister, whereas lower fluences produced no discomfort. After this work, non-laser narrowband UVB sources became available for local treatment. These sources are slower, but their effectiveness is similar to or only slightly less than that of excimer lasers. Excimer laser phototherapy is also effective in treating facial vitiligo.[162]

Treatment of Fat Deposits and Cellulite

The presence of cellulite is a normal secondary sexual female trait occurring in the majority of women and in men with androgen suppression.[163,164] Cellulite manifests as multiple lumpy indentations in the thigh and buttock skin, due to the architecture of connective tissue elements in the subcutaneous fat of females versus males. Fat protrudes into the overlying dermis, producing an undulating dermal-hypodermal interface. Dieting and exercise improve but do not eliminate cellulite, which is often present even in thin women. A host of ineffective treatments have been used for decades.[165] Various light sources have lately been commercialized for treatment of this condition, despite lack of any solid evidence for their efficacy. Given the long history of ineffective devices and creams, any new device for the treatment of cellulite should probably be considered a gimmick until proved otherwise. Some devices combine massage by suction with radiofrequency current, diode laser, IPL, or low-intensity light-emitting diode exposures.[166,167]

KEY REFERENCES

The full reference list for all chapters is available at www.digm7.com.

1. Anderson RR, Parrish JA: Selective photothermolysis: Precise microsurgery by selective absorption of pulsed radiation. *Science* **220**:524, 1983
2. Manstein D et al: Fractional photothermolysis: A new concept for cutaneous remodeling using microscopic patterns of thermal injury. *Lasers Surg Med* **34**:426, 2004

50. Suzuki H, Anderson RR: Treatment of melanocytic nevi. *Dermatol Ther* **18**:217, 2005

126. Grossman MC et al: Damage to hair follicles by normal-mode ruby laser pulses. *J Am Acad Dermatol* **35**:889, 1996

130. Lyle S et al: The C8/144B monoclonal antibody recognizes cytokeratin 15 and defines the location of human hair follicle stem cells. *J Cell Sci* **111**:3179, 1998

152. Paithankar DY et al: Acne treatment with a 1,450 nm wavelength laser and cryogen spray cooling. *Lasers Surg Med* **31**:106, 2002

162. Baltas E et al: Repigmentation of localized vitiligo with the xenon chloride laser. *Br J Dermatol* **144**:1266, 2001



CHAPTER 241

Radiotherapy

Renato Panizzon

Although widely used in the first half of the twentieth century, radiation treatment has declined for two major reasons: first, awareness of the deleterious late effects of radiation developed, including the potential for the induction of malignancy; and second, advances in surgical techniques and the development of effective medical therapies such as corticosteroids and antibiotics provided effective alternatives to the use of ionizing radiation in benign cutaneous disorders. Thus, fewer training opportunities led to a decline of knowledge about radiation therapy and its benefits. Dermatologists should nonetheless retain primary expertise in the treatment with x-rays for selected benign and malignant skin conditions.[1] There are cutaneous diseases for which ionizing radiation remains an accepted therapeutic alternative or, in some instances, the treatment of choice. Dermatologists, often in collaboration with radiation oncologists, can assist the patient and referring physician in selecting the treatment regimens with the highest therapeutic ratio for a particular individual. Under optimal conditions, the morbidity of radiation is low when compared to the morbidity or even mortality associated with alternative therapies, or with the complications associated with progressive or recurrent disease. Table 241-1 outlines the types of radiation available.

RADIATION THERAPY OF BENIGN SKIN DISEASES

The use of ionizing radiation for benign skin diseases has decreased considerably as new and better systemic and local treatments have become available. In some diseases, such as keloidal scars, radiation treatment is a useful therapeutic alternative, but it must be administered immediately after surgery. In certain dermatoses, such as eczema, radiotherapy should be applied only after other therapeutic methods have failed. Improved x-ray technology, accu-



RADIOTHERAPY AT A GLANCE





- Radiation therapy is a versatile treatment modality for some dermatologic conditions.
- It is an indication for treatment of basal cell cancer and squamous cell cancer when surgery is not feasible.
- There are a limited number of benign tumors and conditions amenable to radiation therapy.
- The type of radiation and treatment course are determined by the depth of the lesion and its biologic and clinical behavior.

rate dosimetry, and strict adherence to safety rules have reduced cutaneous and non-cutaneous side effects to a minimum.[2] The following rules for the irradiation of benign skin diseases apply[2]:

- The diagnosis must be clearly established.
- There should be a reasonable expectation that radiotherapy will lead to an improvement.
- All patients should be questioned about previous irradiations.
- No area of the skin should be subjected to more than 12 Gy total dose of soft or superficial x-rays (20 to 150 kV) or 50 Gy total dose of grenz rays per lifetime and radiation field.
- Certain topical treatments should not be used prior to radiotherapy in order to avoid enhancing effects (e.g., 5-fluorouracil) or a reduction of the x-ray effect (e.g., zinc preparations).

For very superficial skin conditions, especially those confined to the epidermis, grenz-ray treatment (5 to 19 kV) is preferred. Lindelöf and colleagues conducted a large-scale investigation of grenz-ray therapy and concluded that even doses up to 100 Gy are not associated with any significant side effects.[4] The pathology of most inflammatory dermatoses is confined to the thickness of tissue, which is less than 11 mm, and grenz-ray therapy is expected to be beneficial because 50 percent of administered grenz radiation is absorbed by the first 0.5 mm of the skin. This form of radiation is extremely suitable as it spares hair roots, and sebaceous and sweat glands, as well as eyes (under a closed lid) and gonads. Grenz-ray therapy can be considered for the following dermatoses[5]: psoriasis, lichen simplex chronicus, pruritus ani et vulvae, seborrheic dermatitis, nummular eczema or persistent eczematous conditions, lichen planus, and benign, familial pemphigus (Hailey-Hailey disease).

TABLE 241-1
Radiation Qualities

TYPE	kV	FSD (cm)	HVL (mm)	$D_{1/2}$ (mm)
Grenz rays (ultrasoft, supersoft, Bucky therapy)	10–20	10–30	0.03 Al	0.2–1.0
Soft x-ray	20–100	10–30	0.1–2.0 Al	1–20
Contact therapy (Chaoul therapy)	50–60	1.5–3.0	2.0–4.0 Al	4–30
Superficial x-ray (low voltage)	60–150	15–30	0.7–2.0 Al	7–10
Orthovoltage therapy (deep x-ray therapy, conventional x-ray therapy)	150–400	50–80	2–4 Cu	50–80
Supervoltage therapy	400–800	50–80	5–10 Pb	80–110
Megavoltage therapy (betatron, particle accelerators)	> 1000	80	> 10 Pb	10–200

FSD = focus-skin distance; HVL = half-value layer; $D_{1/2}$ = half-value depth.

The principle adverse effects of grenz ray therapy, erythema and pigmentation, are qualitatively identical to those of conventional x-rays. Grenz-ray erythema is relatively asymptomatic, and its latent period is shorter than that of conventional x-ray erythema (see Chap. 95). It is ordinarily not followed by sequelae other than pigmentation. For this reason, close shielding should be avoided in order not to produce a sharp line at the edge of the treated area. Pigmentation so induced varies with race, age, and body region, but is rarely permanent.

Treatment of Psoriasis

Once a widely used treatment modality, x-ray therapy is now used as a last resort in recalcitrant localized regions of psoriasis, especially where other treatment modalities are not very effective, such as the scalp and the nails. If properly used, radiation therapy is not associated with major side effects. In general, there is no difference between conventional superficial x-ray therapy and grenz-ray therapy in more than 70 percent of patients. Some authors found that the effect of superficial x-rays were longer lasting than grenz rays.[2] It has been shown that grenz rays are less effective in thickened, diseased nails of psoriasis.[2] In accordance with other reports in the literature, dose schedules described in Table 241-2 are recommended.

Treatment of Eczema and Dermatitis

If superficial x-rays are used, the least penetrating quality should be selected; in most cases, grenz rays (5 to 19 kV) are suitable.[2] However, in some chronic, long-standing eczematous conditions, especially of the palms and soles, more penetrating radiation qualities, that is, soft or superficial x-rays (20 to 150 kV) are more effective (see Table 241-1). Radiation therapy has yielded favorable response

TABLE 241-2
Recommended Doses: Dermatoses

DIAGNOSIS	kV	FRACTIONATION (Gy)	TOTAL DOSE (Gy)	TIME INTERVAL (DAYS)
Eczema, chronic	12	6–12 × 1	6–12	4–7
	20	6–12 × 0,5	3–6	4–7
Eczema, seborrheic	12	6–12 × 1	6–12	—
Psoriasis	12	4–12 × 2	8–24	4–7
	20	4–12 × 1	4–12	4–7
Erythrodermas	50/Teleroentgen	6–12 × 0,5	3–6	4–7
Lichen planus	20–50	6–12 × 0,5	3–6	4–7
Lichen planus, verrucous	20–50	4–12 × 1	4–12	4–7
Venous ulcer, painful	20–50	5–10 × 0,2	1–2	daily
Pruritus ani or vulvae	12	4–8 × 1	4–8	4–7

rates in hyperkeratotic and chronic lichenified eczemas. The weekly doses range from 0.5 to 1.0 Gy. It has also been shown that in certain indications, especially hyperkeratotic eczemas, a total dose of 3 Gy of conventional superficial x-ray was superior to 9 Gy of grenz rays. In atopic dermatitis, ionizing radiation is rarely advisable because of its high tendency to recur, whereas lichen simplex chronicus responds quickly to radiation therapy because the antipruritic effect of radiation in this dermatosis is striking and results are long lasting. Recent surveys indicate that the group of eczematous disorders constitute the most frequent indication for radiotherapy of benign lesions, especially in older patients with contraindications to systemic steroids or to the continued use of topical steroids. Table 241-2 lists dose recommendations.

Treatment of Keloids and Hypertrophic Scars (See Chap. 64)

In addition to their unsightly appearance, keloids and hypertrophic scars can be painful, pruritic, and can produce significant morbidity. A variety of treatment options have been described. The use of pressure postoperatively is important as are intralesional injections of corticosteroids. Radiation therapy has been used successfully in the treatment of keloids. In most series, external kilovoltage or electron beam radiation is directed at the surgical bed within 24 to 72 hours after surgery.[2,7]

Recurrence rates (RRs) after keloid irradiation are much lower if radiation is administered immediately following excision (25 percent to 36 percent RR) than as a primary therapy (63 percent to 74 percent RR).[2] Typical dose-fractionation schemes range from 9 to 16 Gy in 3 to 4 Gy fractions. There does not appear to be a significant dose-response relationship in this dose range. The technique for the treatment of keloids is relatively straightforward: the re-excision scar, plus a 1- to 2-cm margin is irradiated. All suture sites should be included. Superficial x-rays can be used. The overall profile of morbidity and efficacy compares favorably with that of other treatments for keloids.

Treatment of Lymphocytoma Cutis, Benign Lymphoid Hyperplasia (See Chaps. 147 and 187)

Because there are different etiologies, a therapeutic trial with antibiotics may not induce quick resolution of the lesion. The localized and circumscribed type responds well to small doses of x-rays.[2,8] Early lesions are more radiosensitive than older lesions. Cases of cutaneous lymphoid hyperplasia have also been reported in conjunction with the acquired immunodeficiency syndrome (AIDS), and progression to malignant lymphoma occurs in some cases. It is also possible to treat lymphomatoid papulosis with x-rays.[9] In general, the dose recommendations are similar to those for lymphomas (see Table 241-4).

Other Indications

There are other rare indications for radiotherapy such as severely pruritic and refractory cases of the verrucous type of lichen planus, particularly on the legs.[2]

Hailey-Hailey disease can be treated with grenz rays. This represents an excellent alternative to other treatment modalities and has a long-lasting effect. In rare cases, the treatment has to be repeated.[2] The dose schedule is the same as for eczema.

Another possible indication is Peyronie disease (induratio penis plastica; see Chap. 64), characterized by the development of penile fibrotic plaques arising from fibrosis of the corpus cavernosum. This disorder is characterized by a penile curvature during erection, and the presence of often painful penile plaques or induration. The disease may be self-limited in many cases. Indications and rationale for radiotherapy include the following[10]:

- There is a high rate of success when compared with other treatments: palliation of pain in approximately 80 percent of patients; decreased size of plaque in approximately 61 percent of patients; improvement of curvature in approximately 57 percent of patients.
- Treatment is painless, localized to the penis, without systemic side effects, and completed in 1 to 2 weeks.
- Failure of other therapies does not preclude a response to radiotherapy, and failure of radiotherapy does not preclude the use of other modalities.
- Pain is the most reliable outcome parameter, with lesser rates of palliation achieved for induration and curvature.
- Vasculitic painful leg ulcers are another potential indication for very-low-dose x-rays, that is, 0.2 Gy.[2,11] The doses are applied daily, and the pain relief is quite striking after a few sessions. The treatment schedule is shown in Table 241-2.
- Erythroderma[12] or generalized senile pruritus may also be treated with teleroentgentherapy or electron-beam therapy.[2]
- Radiation therapy is no longer indicated for the treatment of acne, hemangiomas, or verrucae.

RADIATION THERAPY OF MALIGNANT SKIN DISEASES AND TUMORS

Using eradication of a tumor as the desirable outcome parameter, surgery and radiotherapy yield similar results. Most cutaneous cancers are sufficiently sensitive to radiation to be eradicated by doses that are well tolerated by the surrounding normal tissue. If appropriate principles are followed and precautions are taken, x-irradiation is a safe and effective method of therapy.[1] We deliberately limit discussion here to radiotherapy of cutaneous cancers of moderate size that can be effectively treated with grenz rays, soft or superficial x-rays, or contact therapy units (see Table 241-1). Larger and more complicated skin cancers should be referred for Mohs surgery and/or to radiation oncologists for treatment with higher kilovoltage or megavoltage techniques, or for implants with radioactive isotopes.

When treating skin cancer, the advantages of soft- or superficial x-ray therapy include:

- It can be performed on an outpatient basis.
- It is painless.
- It can be used for physically or psychologically handicapped patients (and for patients over 90 years old[13]).
- It can be used in patients in whom there exists a contraindication for a surgical intervention.
- Healthy tissue or organs can be protected.
- Usually a wide margin of normal-appearing skin (wider than in surgical excisions (i.e., more than 5 mm) can be included.
- Atraumatic intervention.

However, there also are disadvantages to radiation therapy about which the patient should be informed:

- The treatment has to be given in several sessions.
- If the patient has already received full tumor doses in a radiation field, this particular field cannot be irradiated a second time.



TABLE 241-3
Indications and Radiosensitivity of Different Skin Tumors

INDICATION	TUMOR
Highly indicated	Cutaneous T-cell lymphomas Some B-cell lymphomas Kaposi sarcoma
Good indication	Basal cell carcinoma Squamous cell carcinoma Keratoacanthoma Bowen disease Queyrat erythroplasia Merkel cell tumor
Sometimes indicated	Angiosarcoma, melanoma
Rarely indicated	Carcinoma of the scrotum or palms/soles, fibrosarcoma



- Radiation treatment is followed by alopecia (except if treated by grenz rays).
- Chronic radiation dermatitis tends to develop with time.

Radiotherapy is particularly valuable for medium-sized tumors of 1 cm to 4 cm in diameter on the face of elderly people. Smaller tumors are mostly treated by surgery, and larger lesions are mostly treated either by Mohs surgery or by a combination of surgery and radiation (megavoltage) treatment.

The real advantage of irradiation over excision lies in its preservation of uninvolved tissue. In certain anatomic regions, this may pose a problem for the surgeon but not for the radiotherapist who can easily adjust the size of the field to the required area of treatment.

Four categories of radiosensitivity of skin tumors exist (Table 241-3): (1) highly indicated and unique advantage: Kaposi sarcoma (KS), mycosis fungoides, and other lymphomas of the skin; (2) good indication: basal cell carcinoma (BCC), squamous cell carcinoma (SCC), keratoacanthoma, Bowen disease, Queyrat erythroplasia, lentigo maligna; (3) sometimes indicated: angiosarcoma melanoma; and (4) rarely indicated: fibrosarcoma, carcinomas of the scrotum, soles, and palms.

It is important to distinguish between curative radiotherapy in tumors such as BCC, SCC, keratoacanthoma, and lentigo maligna versus palliative radiation therapy in tumors such as KS, most lymphomas, invasive melanoma, and metastases.

Contraindications for radiotherapy with soft x-rays include: tumors penetrating into cartilage or bone, intra-oral tumors, tumors penetrating into the nostrils, tumors in scars of osteomyelitis, burns, chronic leg ulcers, or in chronic radiodermatitis, previously irradiated skin carcinomas, and genodermatoses that are prone to neoplasms such as basal cell nevus syndrome or xeroderma pigmentosum.

Technical Issues

Since the work done in England, Germany, and United States, and with the introduction of the beryllium-windowed x-ray units, as a rule of thumb, radiation qualities with a half-value depth (HVD = $D_{1/2}$) corresponding to the depth of the tumor have been proposed. Most of the radiation will then be absorbed in the pathologic tissue and the possibility of undesirable radiation effects to underlying uninvolved tissue will be markedly reduced. The depth of the tumor can either be reasonably estimated by inspection and palpation or by an exact histopathologic description of the tumor depth, preferably by an experienced dermatopathologist. Several studies show that 50 percent of all basal cell and squamous cell cancers infiltrate to a depth of only 2 mm or less, and 75 percent of such tumors infiltrate to a depth of 5 mm or less.[1]

With grenz and superficial x-ray machines, the kilovoltage is in a fixed combination with filters to avoid filter mistakes and thus, application of faulty dosages. These x-ray machines have a kilovoltage between 10 and 50 kV, sometimes up to 100 or even 150 kV. With filter combinations, an HVD from 1 mm to 20 mm can be reached. For dermatologic purposes, it is rarely necessary to irradiate tumors thicker than 20 mm.

Fractionation of radiation dosage is based on the assumptions that tissues recover at different rates from the effects of radiation and that tumor tissue recovers more slowly than normal tissue. When a given dose of radiation is divided into several increments and delivered over a period of several days or weeks, the biologic effect is usually less pronounced than that of the same radiation administered in a single dose. This lesser damage with fractionation appears to be related to cell recovery between increments and to the capabilities of recovering cells to adapt to radiation-induced alterations of the surrounding tissues. Small tumors and radiation fields support higher single doses than do large tumors with large irradiation fields that have to be irradiated with smaller single doses. In addition, in large irradiation fields, the backscatter factor needs to be considered.

Much work has been done in an attempt to define optimum time-dose-volume relationships for carcinomas of the skin. There is no consensus as to the total dose needed to eradicate a cutaneous cancer and when to terminate radiotherapy. Different authors have recommended different dosages.[1] The tendency is to use standardized schedules (Table 241-4).

The patient's reaction during radiation therapy should be observed, and exudative or erosive reactions in the irradiated margin should be noted. When larger individual doses are administered, the recommended total dose is usually

TABLE 241-4
Recommended Doses: Malignant Tumors

DIAGNOSIS	KV	FIELD (CM)	FRACTIONATION (GY)	TOTAL DOSE (GY)	TIME INTERVAL (DAYS)
Lentigo maligna	12	< 2 > 2	5–6 × 20 or 10–12 × 10	100–120 100–120	4–7 3–4
Bowen disease or Queyrat erythroplasia	20	< 2 > 2	3–4 × 8 8–10 × 4	24–32 32–40	4–7 3–4
Keratosis, senile	12 20	< 2	5–7 × 8 2–3 × 8 5–7 × 4	40–56 16–24 20–28	4–7 4–7 3–4
Basal cell carcinoma/ squamous cell carcinoma	20–50	< 2 2–5 > 5	5–6 × 8 10–12 × 4 26–28 × 2	40–48 40–48 52–56	4–7 3–4 daily
Mycosis fungoides/ other malignant lymphomas/leukemic infiltrates	20–50 Teleroentgen		3–7 × 2 4–10 × 1	6–14 4–10	3–4 3–7
Kaposi sarcoma	20–50	< 2 > 2	3–5 × 8 5–10 × 4	24–40 20–40	4–7 3–4

smaller than in cases where smaller individual doses were used.

Disseminated Actinic Keratoses

There is general agreement that small actinic keratoses are best treated by cryotherapy or curettage and electrodesiccation or equivalent methods. The problem arises in extensive and disseminated actinic keratoses as, for example, on the scalp. Here, again, treatment possibilities include topical 5-fluorouracil, imiquimod, or diclofenac cream, but usually RR are higher or appear sooner than after treatment with radiotherapy. Because these lesions are intraepidermal and often in an atrophic epidermis, the ideal treatment is with grenz rays. The treatment consists of six sessions of 4 Gy twice weekly applied on one or several divided fields (see Table 241-4).[14] At the end of the treatment, an erythema or an exudative reaction will occur. If there is marked pruritus, topical glucocorticoid creams may be of help to the patient. One month after the end of treatment, the erythema will have largely disappeared. The patient has to be instructed to continue sun protection. Recurrences may appear years later.

Bowen Disease/Erythroplasia of Queyrat (See Chap. 113)

Bowen disease/erythroplasia of Queyrat is a carcinoma in situ and is treated in a similar fashion to actinic keratosis, but histopathologically, these lesions are thicker. Even in elderly patients, it is possible to apply grenz rays with a $D_{1/2}$ of 1 mm. If the lesions are more infiltrated, soft x-rays with a quality of 20 kV or more are necessary. The dose schedule can be adapted (see Table 241-4). Again, fractions of single doses of 4 Gy up to total dose around 40 Gy may be used. Exudative reactions have to be expected a little earlier in the genitoanal area. Treatment results are excellent.[14]

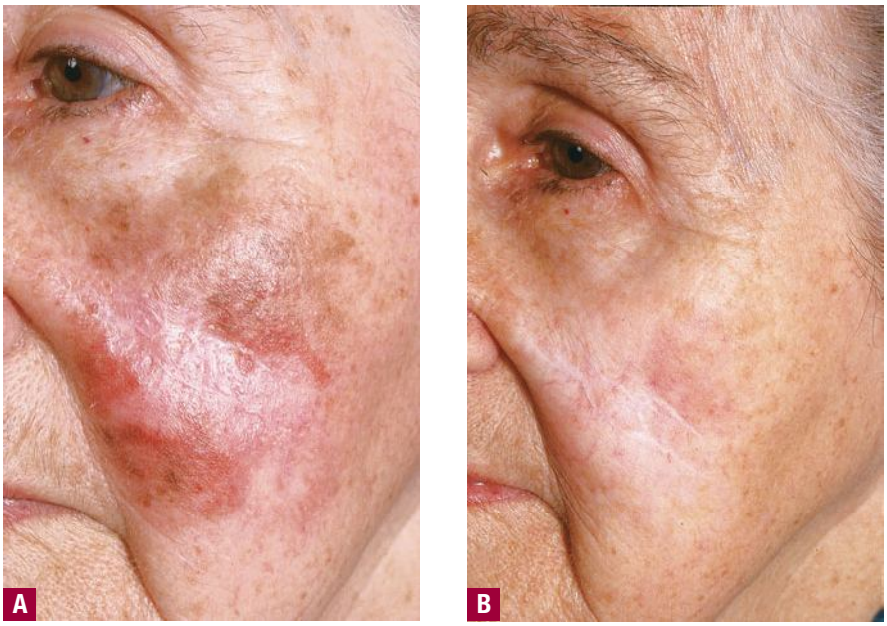

▲ **FIGURE 241-1** **A.** Extensive lentigo maligna on the left cheek of a 76-year-old woman before and (**B**) 2 years after grenz-ray treatment [10 × 10 Gy (100 Gy), twice per week].

Lentigo Maligna

Lentigo maligna is a pre-invasive lesion (see Chap. 124) and is an excellent indication for radiation treatment. This treatment modality is not well known because it has been considered non-curative. Recent reports show that treatment results are at least as good as surgical procedures[15–17] As mentioned in Radiation Therapy of Malignant Skin Diseases and Tumors, the inclusion of a wide enough margin is not a problem for the radiation therapist; consequently, a large lentigo maligna is an excellent indication for radiotherapy. The classical treatment schedule is named after Miescher, who proposed five to six doses of 20-Gy grenz rays for medium-sized lesions (around 2.5 cm in diameter). For larger lesions, we prefer to apply 10 to 12 doses of 10-Gy Grenz rays (see Table 241-4). The epidermis in the elderly is atrophic, and, with an HVD of 1 mm, even atypical melanocytes in the upper hair follicles can be reached. A drawback is the fact that clinical invasion to deeper tissue levels cannot be reliably assessed, and even with multiple biopsy cannot be totally excluded, and thus, progression of melanoma can occur. Fig. 241-1 shows a grenz-ray treatment result.

Basal Cell Carcinoma, Squamous Cell Carcinoma, Keratoacanthoma

BCCs, SCCs, and keratoacanthomas are a good indication for radiotherapy with



▲ **FIGURE 241-2** **A.** Basal cell carcinoma on the left inner canthus of a 64-year-old man before and (**B**) 6 months after soft x-ray treatment (40 kV) [12 × 4 Gy (48 Gy), twice per week].



◀ **FIGURE 241-3 A.** Mycosis fungoides in a 42-year-old woman before and (**B**) 1 month after soft x-ray treatment (40 kV) [6 × 2 Gy (12 Gy), three times per week].



soft x-rays or superficial x-rays, provided they are less than 20 mm thick. Some treatment centers use the same treatment schedules for BCCs and SCCs, although one could imagine that SCC should be treated with a higher total dose because it represents a more aggressive tumor.[1] Elderly patients prefer not to come every day for the treatment sessions. Therefore, medium-sized lesions can be treated with a 4-Gy single dose in three fractions per week. There is the possibility of applying a higher single dose, for example 6 to 8 Gy per fraction once or twice a week, to small lesions that cannot be excised. Lesions greater than 5 cm are best treated with daily fractions of 2 or 3 Gy (see Table 241-4). Fig. 241-2 shows the results of treating a BCC as described.

Histopathologic examination of BCC and SCC before initiating treatment is a prerequisite. A large study has shown that sclerosing (sclerodermiform or scirrhous) BCCs or poorly differentiated SCCs have a substantial recurrence rate.[14] Consequently, the sclerodermiform BCC is not well suited for treatment with soft x-rays. These lesions are best treated by Mohs surgery or, if that option is not available, megavoltage therapy.

For keratoacanthomas, the same dose schedule is used as for SCCs.[18] Carcinomas of the skin appendages and carcinomas penetrating into cartilage or bone, localized in the mucous membranes, or arising in chronic scars, are not an indication for soft x-ray therapy.

Cutaneous Lymphomas

In general, T-cell or B-cell cutaneous lymphomas are very radiosensitive.[12,21] With the exception of certain circumscribed B-cell lymphomas or localized CD30$^+$ lymphomas where radiotherapy is curative, radiation treatment for lymphomas is palliative. Total doses in the range of 20 to 30 Gy are commonly used and offer excellent palliation. Doses in this range may result in a relapse rate of up to 30 percent. Single doses of 2 Gy, either daily or three times per week, seem to offer the best local control. See also Table 241-3.

Because of the possible need for the subsequent treatment in adjacent areas, it is important to document the treated areas with photographs, accurate drawings, and, if feasible, tattooing of the corners of the fields with India ink. In most patients, the lesions will not clear during or at the completion of irradiation, and it may take up to 6 to 8 weeks for complete response (Fig. 241-3). For individual skin lesions, energies may range from orthovoltage to electron beam. The depth of infiltration defines the energy of the beam required. Larger, bulkier lesions, such as deep ulcers or lymph nodes, may be treated by either Cobalt or 4 to 6 MeV photons (see Table 241-1).

Kaposi Sarcoma

NON–ACQUIRED IMMUNODEFICIENCY SYNDROME-ASSOCIATED KAPOSI SARCOMA Local irradiation of KS includes the lesion plus a normal tissue border of approximately 1 to 2 cm. Thin, cutaneous lesions can be effectively treated either by superficial x-ray therapy (e.g., 20 to 150 kV) or relatively low-energy electron beams (e.g., 4 to 6 MeV). Thick nodules are best treated by electron beams that encompass the entire lesion homogeneously but spare underlying normal tissues. Lesions on the eyelids are treated most easily by superficial x-rays with protective shields over the eyeball.[14,19]

Based on the available evidence, both local therapy and elective regional therapy are effective techniques for the treatment of classical KS. The literature supports the use of a wide range of doses and fractionation patterns (see Table 241-4). As long as a sufficient dose is delivered (e.g., 20 to 30 Gy in 10 fractions or, for small lesions, 8 Gy in 1 fraction), a salutary outcome is likely.[20]

ACQUIRED IMMUNODEFICIENCY SYNDROME–ASSOCIATED KAPOSI SARCOMA Usually, the same dose schedules are used and no difference is evident, although it may take 3 to 4 months for the tumor to resolve. Radiation-induced edema of the feet or face, as well as symptomatic mucositis, are more severe in patients with AIDS than in other patients.[20]

Radiation therapy may be reserved for specific indications such as pain, ulceration, bleeding, functional impairment (e.g., on the legs), or improvement of the appearance of cosmetically disfiguring lesions (e.g., the eyelids). In the case of palliative radiation therapy for AIDS-associated KS, sufficient dose should be delivered to accomplish the desired goal and maintain that state for as long as possible. The treatment should be delivered as rapidly as possible.

KEY REFERENCES

The full reference list for all chapters is available at www.digm7.com.

1. Goldschmidt H: Treatment planning, in *Modern Dermatologic Radiation Therapy*, edited by Goldschmidt H, Panizzon RG. New York, Springer, 1991, p 49
3. Goldschmidt H: FDA recommendations on radiotherapy of benign diseases. *J Dermatol Surg Oncol* **4**:619, 1978
4. Lindelöf B, Eklund G: Incidence of malignant skin tumors in 14,140 patients after grenz ray treatment for benign skin disorders. *Arch Dermatol* **122**:1391, 1986
7. Wagner W et al: Results of prophylactic irradiation in patients with resected keloids, a retrospective analysis. *Acta Oncol* **39**:217, 2000
12. Holloway KB et al: Therapeutic alternatives in cutaneous T-cell lymphoma. *J Am Acad Dermatol* **27**:367, 1992
15. Gaspar ZS, Dawber RP: Treatment of lentigo maligna. *Australas J Dermatol* **38**:1, 1997

SECTION 39

COMPLEMENTARY AND ALTERNATIVE DERMATOLOGY

CHAPTER 242

Complementary and Alternative Medicine in Dermatology

Alan Dattner

Complementary and alternative medicine (CAM) in dermatology encompasses a wide variety of methods of diagnosis and treatment that both supplement and substitute for conventional dermatologic practice. It is also referred to as *holistic dermatology* in that it addresses the entirety of the individual, including the physical, mental, emotional, and spiritual, as appropriate. The discipline includes integrative dermatology in which alternative systems of diagnosis and healing are combined with conventional practice. These systems may include ancient traditional Chinese medicine, Ayurvedic medicine, American folk medicine, homeopathy, or more recent techniques from chiropractic, energetic medicine, functional medicine, and psychosomatic methods. Furthermore, it includes any other technique that works or makes sense based on science or observation. Increasingly, patients are using CAM methods in addition to their conventional treatment as cosmeceutical and nutraceutical manufacturers offer these products, and CAM practitioners and dermatologists respond to the demand and expectation of patients.

HERBAL MEDICINE

Eclectic practice and off-label use of drugs has always been a part of dermatology, perhaps more so than of medicine in general. These practices provide an approach to deal with disorders of uncertain etiology by incorporating methods from other spheres or from observed benefit. Many of the commonly used medications in medicine derive from herbal medicine.[1] The American "herbal" tradition dates to the Eclectics, a school of physicians who, during the 19th and early 20th century codified the use of Western herbs according to specific indications.[2] Today, many herbs are used, and the methods of selecting specific herb combinations also derives from other traditions.[3] For example, psoralens have been used in China and India for repigmentation of the skin for 4000 years.[4] Other herbs used in treating the skin include mayapple (podophyllin) for condyloma, horse chestnut for leg veins, bloodroot (sanguinaria) for skin tumors, and oatmeal (avena sativa) to soothe the skin.[1]

In addition to specific herbal remedies, some of the philosophic aspects of herbal medicine have been key concepts in dermatology. For example, the principle of using a crude preparation,[5] as opposed to a purified single ingredient as it tends to be used in a pharmaceutic product, was part of Sulzberger's observation regarding the use of tar.[6] It was the crude tar product from the distillery and not a purified derivative that had activity in treating psoriasis. In fact, variation in batch efficacy was assumed to be an indication of the heterogeneous nature of the preparation.

APPROACH TO DISEASE

The hallmark of CAM is a search for the elements in the causal chain of functional disturbances that lead to a skin disorder. For inflammatory disorders, an attempt is made to identify exposures which could stimulate and/or disturb immune responses with secondary targeting of skin structures. The focus of CAM is correcting probable underlying causes, often with treatments that are not scientifically proven in the traditional placebo-controlled, double-blind fashion. The patient assumes the responsibility to make necessary lifestyle changes and the risk of protocols that are not conventional.

COMPLEMENTARY AND ALTERNATIVE MEDICINE AT A GLANCE

- Complementary medicine is a holistic approach to diagnosis and treatment.
- Many dermatologic therapies developed in ways similar to the complementary approach and were subsequently scientifically validated.
- Attention to the environment and its impact on the patient is a fundamental principle of complementary dermatology.
- Herbal therapeutics and diet are two of the primary interventions used in holistic dermatology.

ENVIRONMENT IN COMPLEMENTARY ALTERNATIVE MEDICINE

Cross-Reaction and Molecular Mimicry

In the CAM approach to dermatology, the environment is considered to play a fundamental diagnostic and therapeutic role. Cross-reactions with foods, chemicals,[7] and infectious agents[8] may be a

Copyright © 2008 by The McGraw-Hill Companies, Inc. Click here for terms of use.

key to causing inflammation which itself may play a role in a range of dermatologic conditions. A mainstay of the CAM approach is to search for the inciting cause of an inflammatory response as well as correcting the ongoing memory response using natural means. Eliminating foods which exacerbate eczema, or enhancing food breakdown into smaller, less antigenic fragments by supplementing with digestive enzymes, is an example of how to remove molecular mimics that stimulate skin inflammation.[9]

There is individual specificity in antigen recognition,[10] exposure history, and the type of tissue response to the resulting inflammatory cascade. It is therefore critical to look for the precipitating stimuli of disease onset or aggravation on an individual basis. This concept is accepted for contact dermatitis but not for eczema or psoriasis. At the same time, it is critical to consider the existence of factors that either neutralize or exacerbate the response to those stimuli. A detailed history is paramount to understand why a patient reacts at certain times and not others.

Hepatic Factors

Drug levels may be affected by foods or drugs influencing specific P_{450} enzymes.[11] Chemicals targeted by the liver for removal are first chemically converted by P_{450} isoenzymes to make them either more soluble or more chemically reactive for coupling to molecules in phase II for transport out via renal excretion. With insufficient transporters, these hyperreactive metabolites of the drug, made more chemically reactive by the phase I liver P_{450} enzymes, may combine with molecules on skin tissue structures to create neoantigens. Phase II transport molecules include glutathione, glucuronides, and amino acids.

Dietary Approaches

Oral ingestion is one of the largest sources of foreign material entering the body. It has been established that large molecules, including horseradish peroxidase with a molecular weight over 1,000,000 d can be absorbed intact from the gut.[12] Drugs are well known causes of skin eruptions.[13] Foods have a variety of effects on skin disorders beyond a role as allergens.[14] They can serve as informational molecules to incite eruption, direct or indirect hormonal aggravators, gut permeability modifiers, or influence the ecology of the gut flora. Certain nutrients can overcome the liver's capacity to biotransform harmful antigens and toxic intermediates or aid in hepatic biotransformation. Foods can also have a wide variety of effects partially overlapping those of herbs and pharmaceuticals. Dietary effects on gene expression and individual specific food interaction is now known as *neutragenomics*.[15]

Dietary treatment of acne was much more prevalent before the advent of antibiotics. Only recently milk has been again demonstrated in the literature to play an etiologic role in this disorder.[16]

"FOOD ALLERGY" DETERMINATION AND ELIMINATION In addition to classic immunoglobulin E–mediated allergic response, the term *food allergy* also includes other types of allergy such as immune complex, delayed, and Toll-like receptor activation. There is also non-allergic sensitivity. Food allergies develop to the most common foods such as wheat, milk, soy, yeast, and corn. Some believe that a hallmark of food allergy is food craving with repetitive eating of the same food each day.[17] A 5-day elimination and re-challenge on the sixth day is an effective way to determine if the food under consideration is the cause of the symptoms of concern. Other symptoms beyond the skin could include digestive upset, nasal stuffiness, fatigue after eating, or even "brain fog." *Brain fog* is a popular term for a sense of mental confusion, sluggishness, and slowness which may sometimes include a feeling of unreality or disorientation. Small peptides from casein digestion known as *caseomorphins*, which can also derive from gluten, rice, bovine albumin, and even spinach, have psychoactive properties.[18] Treatment involves elimination, substitution with other foods, and food rotation. Enhancing digestion with digestive enzymes and adding metabolites to enhance gut permeability barrier (leaky gut) helps further in prevention of sensitization to disease inducing cross-reactive antigens.[19,20]

GUT FLORA Abnormal gut flora, including overgrowth of *Candida* sp., parasites, and pathogens can lead to inflammation, which compromises the gut barrier and can lead to "leaky gut." Numerous studies from Scandinavia show the importance of probiotic supplementation for reducing by half the incidence of atopy in infants.[21,22]

ESSENTIAL FATTY ACIDS Essential fatty acids (EFAs) play an essential role in skin health. EFAs are the precursors of the eicosanoids produced when phospholipase cleaves a lipid fragment, arachidonate, from the cell membrane. Arachidonate, a common pathway byproduct from most foods, leads, via cyclooxygenase, to production of the pro-inflammatory prostaglandin E_2 (PGE_2), or via lipoxygenase to production of pro-inflammatory leukotrienes.[23] Specific ω-6 unsaturated EFAs such as γ-linolenic acid, found in borage oil, evening primrose oil, and human breast milk, lead to formation of the anti-inflammatory PGE_1. ω-3 unsaturated fatty acids such as those found in fish oils contain eicosopeneinoic acid (EPA), which leads to formation of the anti-inflammatory and anti-clotting PGE_2. Flaxseed oil has an ω-3 EFA known as *α-linolenic acid,* which requires two carbon chain elongation to become EPA. ω-3 EFAs also play a role in formation of the barrier lipid in the stratum corneum barrier. Partially hydrogenated oils not only lead to pro-inflammatory PGE_2 formation, but they inhibit the δ-6-desaturase which is crucial for formation of anti-inflammatory γ-linolenic acid.

Shifting the balance toward anti-inflammatory EFAs by removing foods with pro-inflammatory oils and increasing foods and supplements with anti-inflammatory oils (i.e., cod liver oil) is a strategy useful in most conditions involving inflammation and dry skin. It is especially useful in seborrhea and eczema. Rare problems with excessive fish oil include increased bleeding tendency[24] and high-birth-weight, post-mature babies.[25]

COMPLEMENTARY AND ALTERNATIVE MEDICINE APPROACHES TO SPECIFIC DERMATOLOGIC CONDITIONS

Several dermatologic disorders, primarily inflammatory in nature, may benefit from the CAM approach.

Seborrheic Dermatitis (See Chap. 22)

Seborrheic dermatitis[27] involves inflammation in sebaceous follicular areas of the scalp, eyebrows, and nasolabial folds. All of these regions harbor the yeast *Malassezia*, which is normal follicular flora. There is evidence that *Malassezia* is cross-reactive with *Candida albicans*,[28] and it is postulated here that a cross-reactive attack against antigenic epitopes on the *Candida* and other yeasts and molds becomes directed against the *Malassezia* organisms in the follicle, causing the inflammation that

incites the erythema and desquamative changes characteristic of seborrhea.

An altered pattern of EFAs in infantile seborrheic dermatitis implicates impaired function of the δ-6-desaturase.[29] Some of the B vitamins previously reported to be helpful in seborrhea may function as co-factors for the this enzyme.[30–32] The tendency toward inflammation is exacerbated by a predominance of arachidonic acid precursors in the cell membranes derived from dietary sources. Treatment by substituting EPA-rich fish oil in the diet and removing partially hydrogenated and saturated oils can reduce this inflammatory state by favoring the generation of anti-inflammatory PGE_3.[33–35] Flaxseed oil is another ω-3 fatty acid and PGE_3 precursor, but the active ω-3 EFA in it, α-linolenic acid, requires chain elongation to be converted to EPA, and this process is not uniform among individuals.[36]

Atopic Dermatitis (See Chap. 14)

Atopic dermatitis is an inflammatory disorder of the skin linked to asthma and hay fever. Dermatologists in the past observed cases in which food was considered a trigger, but were generally puzzled that there did not seem to be a specific food that caused the eczema. One challenge was that eczema could be aggravated by one food, and then after diet change, would be exacerbated by the newly substituted food.

One theory articulated by practitioners of CAM relates to what is known as *leaky gut.*[37] Disruption of the gut barrier can result from inflammation of the intestinal lining. This inflammation may be due to parasites, *Candida* overgrowth, food sensitivity, or to pathogenic micro-organisms. In addition, nonsteroidal anti-inflammatory medications are irritating to the gut lining, as are alcohol and aspirin. Any food introduced repeatedly into such an environment can lead to sensitization to that food. In these cases, it is believed that the uncontrolled atopic becomes sensitive to whatever he/she eats repeatedly to avoid that which caused trouble initially. The milk-allergic infant switched to soy protein soon becomes "allergic" to soy. Inflammation in the gut wall stimulated by soy causes allergy to whatever nutrient is next exposed to the gut immune system. This "vicious cycle" could account for the name *atopic*, which was used to describe the changeable nature of the factors initiating the dermatitis.

Treatment consists of removing abnormal microbes and restoring normal flora, removing irritants, eliminating exacerbating foods, enhancing enzymatic breakdown of foods (digestion), coating the gut with mucilaginous herbs, and providing nutrients to support an intact gut barrier.

Proper colonization of the gut with *Lactobacillus acidophilus* and similar strains has a protective effect against atopy.[38] A corollary of this observation is that repeated use of antibiotics favors overgrowth of *Candida*, and simple starches and sugars support *Candida* growth. It is presumed that consumption of large amounts of yeast, mold, and their byproducts, such as bread, beer, wine, and cheese, could both induce high-dose antigen tolerance to intestinal *Candida*, and perhaps even sensitize to other antigenic determinants. High-dose tolerance is a lack of immunoreactivity to specific antigenic determinants or substances due to the presence of large quantities of these determinants in the system. Treatment consists of removing the dietary factors that favor *Candida* and then treating with herbal or other remedies to reduce the yeast population. Artemisia annua and short-chain fatty acids such as undecylenic or caprylic acid are a few such treatments. Next, probiotics can be added to prevent *Candida* from overgrowing.

Only when these steps have been taken should pharmaceuticals be used in a progressive fashion. Otherwise, one risks selecting for resistant strains. Nystatin may be considered, followed by ketoconazole and fluconazole. Nystatin should be slowly increased in dosage from 500,000 units/day in divided doses to 6 million units, over 10 to 12 days. Highly yeast-sensitive individuals absorb cell content material through an already leaky gut wall and are known to develop exacerbation of previous symptoms and sometimes fever, with a Herxheimer-like reaction. All of these drugs have more potential effectiveness when the environment is changed by dietary restrictions on sugars, simple carbohydrates, and foods high in or derived from yeast.

Anti-inflammatory EFAs, such as EPA from fish oils and γ-linolenic acid from borage or evening primrose oil, appear to help some atopics,[39] but this effect is disputed by some meta-analyses.[40]

Acne (See Chap. 78)

Before the availability of tetracycline, diet change was a mainstay in acne treatment. With the advent of antibiotics for acne, many dermatologists argued that the stress from restricting favorite foods was itself acne causing, and consensus evolved to minimize the role of diet in acne. This view was supported by seminal papers that demonstrate that common agents such as chocolate do not cause acne.[41] More recent data do show a relationship between total skim and regular milk and acne.[42] The authors postulate hormones and bioactive molecules as a possible reason for this effect. Milk protein allergy causing an inflammatory response that blocks the infundibular apparatus could also contribute.[42] It now appears that diet may influence a number of mechanisms related to acne development.[43]

Bovine milk production by postpartum cows results in milk that contains placenta-derived progesterone and dihydrotestosterone precursors. Other hormones in addition to steroids in milk may also stimulate acne. The most frequently implicated substance is IGF-1 (insulin-like growth factor), which also increases during the teenage years. IGF-1 is present in organic milk and increased in milk from cows treated with bovine growth hormone. IGF-1 increases lipogenesis in sebocytes.[44] It has also been shown that excess carbohydrates increase insulin, which increases IGF-1, which in turn worsens acne.[45] IGF-1 and dihydrotestosterone levels in women both correlate with acne.[46]

Milk elimination and reduction in carbohydrate ingestion can cause a substantial improvement in some acne patients, as does reduction of pro-inflammatory fats from fried and partially hydrogenated sources. In women with peri-menstrual flaring, reduction of dietary estrogens and pseudoestrogens may be helpful. Herbs that balance hormones and enhance elimination of stimulatory antigens and pseudoestrogens from the environment may help as well.

KEY REFERENCES

The full reference list for all chapters is available at www.digm7.com.

1. Dattner A: From medical herbalism to phytotherapy in dermatology: Back to the future. *Dermatol Ther* **16**:106, 2003
3. Brown DJ, Dattner AM: Phytotherapeutic approaches to common dermatologic conditions. *Arch Dermatol* **134**:1401, 1998
7. Dattner AM, Mann DL, Levis WR: Studies on the contact sensitization of man with simple chemicals: V. Clonal priming allows direct in vitro assessment of autologous HLA-associated factors required for immune response to

dinitrochlorobenzene. *J Invest Dermatol* **73**:246, 1979
11. Barranco VP: Clinically significant drug interactions in dermatology. *J Am Acad Dermatol* **38**:599, 1998
21. Kalliomaki M et al: Probiotics in primary prevention of atopic disease: A randomized placebo-controlled trial. *Lancet* **357**:1076, 2001
23. Goetzl EJ, Songzhu A, Smith WL: Specificity of expression and effects of eicosanoid mediators in normal physiology an human diseases. *FASEB J* **9**:1051, 1995
27. Dattner AM: Seborrheic dermatitis, in *Integrative Medicine*, edited by Rakel D. Philadelphia, Saunders, 2002, p 491
28. Huang X et al: Allergen cross-reactivity between *Pityrosporum orbiculare* and *Candida albicans*. *Allergy* **50**:648, 1995
29. Tollesson A et al: Essential fatty acids in infantile seborrheic dermatitis. *J Am Acad Dermatol* **28**:957, 1993
35. Smith WL: Cyclooxygenases, peroxide tone and the allure of fish oil. *Curr Opin Cell Biol* **17**:174, 2005
38. Salminen SJ, Gueimonde M, Isolauri E: Probiotics that modify disease risk. *J Nutr* **135**:1294, 2005
39. Yoon S, Lee J, Lee S: The therapeutic effect of evening primrose oil in atopic dermatitis patients with dry scaly skin lesions is associated with the normalization of serum gamma-interferon levels. *Skin Pharmacol Appl Skin Physiol* **15**:20, 2002
42. Adebamowo CA et al: High school dietary dairy intake and teenage acne. *J Am Acad Dermatol* **52**:207, 2005
43. Cordain L: Implications for the role of diet in acne. *Semin Cutan Med Surg* **24**:84, 2005
46. Cappel M, Mauger D, Thiboutot D: Correlation between serum levels of insulin-like growth factor-1, dehydroepiandrosterone sulfate, and dihydrotestosterone and acne lesion counts in adult women. *Arch Dermatol* **141**:333, 2005

SECTION 40

SURGERY IN DERMATOLOGY

CHAPTER 243

Dermatologic Surgery: Introduction to Anatomy and Approach

Sumaira Z. Aasi
Brent Pennington

Dermatologic surgery has rapidly become a cornerstone of the practice of dermatology. Factors such as the epidemic of skin cancer, the interest in maintaining a youthful appearance for an aging population that is living longer, and the financial pressures to perform surgery in less expensive outpatient settings have led to an increase in the number of surgical procedures performed in dermatologic practice.

ANATOMY

Anatomy is often called the language of surgery.[1,2] Knowledge of anatomy is critical for a number of reasons, including communicating precisely with colleagues, performing efficient and safe procedures, obtaining optimal functional and aesthetic reconstruction, understanding the lymphatic drainage, and anticipating the metastatic spread of malignancies. As the majority of cosmetic and surgical procedures are performed on the face and because of its complexity, this chapter focuses on the superficial cutaneous anatomy of this critical region.

Cosmetic Units and Landmarks

Landmarks and cosmetic units help to localize areas of the face accurately and precisely for purposes of communication with colleagues and to perform the surgery itself. For instance, it is more helpful to describe a lesion on the face if it is said to be located on the "left nasal sidewall" versus left nose or "right triangular fossa" versus right ear. Cosmetic units are zones of tissue that share cutaneous features such as color, texture, pilosebaceous quality, pore size, and degree of actinic exposure. These cosmetic units are demarcated by junction lines that can be discrete (eyebrows) or subtle (nasofacial sulcus). Cosmetic units can also be further divided into subunits. Because of the tissue similarity, it is often best to reconstruct a surgical defect within a cosmetic unit or subunit or borrow tissue from nearby units. In addition, scar lines can be hidden easily in junction lines between the cosmetic units. The more complex regions of the face that have multiple subunits include the nose, ears, and lips (Figs. 243-1 and 243-2).

The subunits of the nose include the glabella (the area between the eyebrows), the root (the deep sulcus below the glabella and uppermost portion of the nose), dorsum or bridge (the area overlying the nasal bone), lateral sidewalls (the sides of the nose), nasal tip, the nasal ala (the nostril), alar groove and nasolabial crease (the grooves that demarcate the alae superiorly at the lateral nasal sidewall and inferiorly at the lip, respectively, and the columella (the mobile linear structure separating the alae inferiorly) (see Fig. 243-1).

The lateral surface of the ear is rimmed by the helix, a curved cartilaginous structure that begins at the crus just above the external auditory canal and continues around the ear to end at the fleshy lobule. The central concavity within which the external auditory meatus lies is the concha. The concha is divided by the crus of the helix into a superior portion, the cymba, and an inferior portion, the cavum. The posterior border of the concha is formed by another cartilaginous structure called the *antihelix*. Superiorly, the antihelix originates from two legs (*crus* is Latin for *leg*): the supe-

INTRODUCTION TO DERMATOLOGIC SURGERY AT A GLANCE

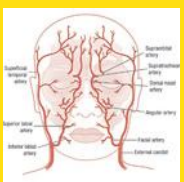

- Profound knowledge of the anatomy, particularly of the head and neck region, is essential.
- Preoperative assessment includes a thorough medical, drug, and medication history.
- Asepsis and antisepsis are required.
- The choice of the anesthetic is determined by the nature and duration of the procedure and by patient factors such as allergy or renal or hepatic impairment.
- Side effects of local anesthetics are pain, a vasovagal reaction, or (uncommon) allergic reactions. Anesthetic toxicity is rare.
- Infiltrative anesthesia, nerve blocks, and topical anesthesia (for minor procedures) can be performed.
- Types of suture material and suturing technique depend on the surgical procedure.
- Postoperative care is essential.



Copyright © 2008 by The McGraw-Hill Companies, Inc. Click here for terms of use.

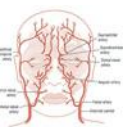

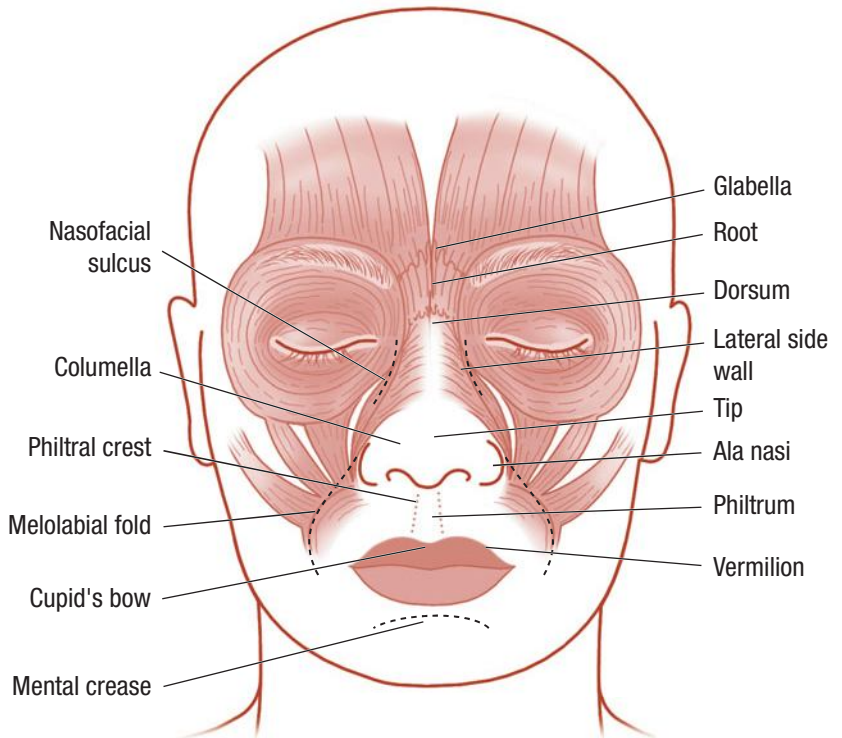

▲ **FIGURE 243-1** Cosmetic units and landmarks of the face.

rior crus and inferior crus. The region between the crura is referred to as the triangular fossa. The groove between the helix and antihelix is the scaphoid fossa. The triangulated cartilaginous structure just anterior to the auditory canal is called the *tragus,* and just posterior to this is the triangulated end of the antihelix, referred to as the *antitragus*. The inferior region between the tragus and antitragus is the intertragic notch (see Fig. 243-2).

The upper lip has a concave depression in the center, called the *philtrum*, which is bounded by two ridges, the philtral crests. There is a prominent crease, the mental crease, which divides the cutaneous lower lip from the chin. The boundary between the red mucosal surface of the lips and the cutaneous surface is called the vermillion border. The raised contoured area of the inferior portion of the philtrum is a critical aesthetic landmark known as the *Cupid's bow* (see Fig. 243-1).

Relaxed Skin Tension Lines

Relaxed skin tension lines (RSTLs) are another characteristic of the face that help guide surgical reconstruction and allow the structural camouflage of scar lines. RSTLs are creases on the face that

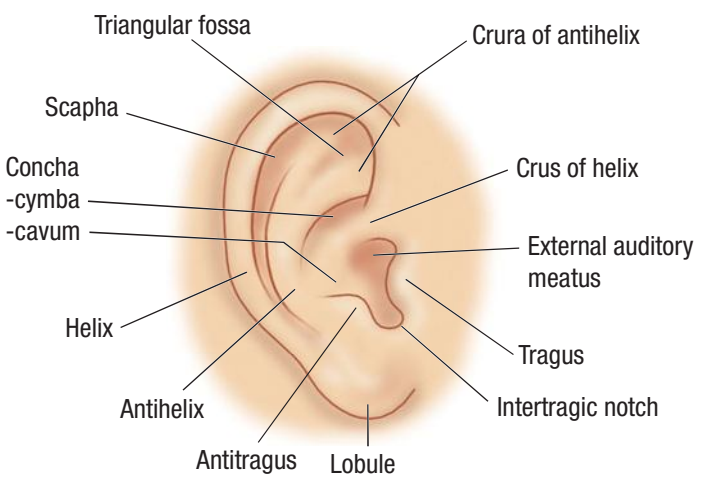

▲ **FIGURE 243-2** Landmarks of the external ear.

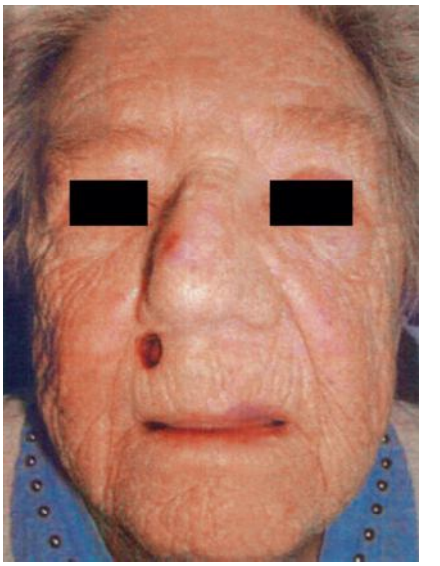

▲ **FIGURE 243-3** Relaxed skin tension lines of the face.

form over time due to factors such as loss of elastic tissue tone, lengthening of the collagenous fibrous septae that connect the dermis to the underlying facial muscles, development of excessive skin, gravity, and ultraviolet radiation exposure. Fig. 243-3 illustrates a surgical defect on the upper lip of an elderly woman with prominent RSTL. RSTLs are most obvious on the face because unlike other muscles in the body that connect tendons and bones, facial muscles attach to the overlying skin. These lines can be induced by facial muscle movement in the young but inevitably become more pronounced with age. RSTLs usually run perpendicular to the underlying muscles. In most situations, the long axis of the excision should be placed parallel to the RSTL because they are often in the direction of the least tension for a scar. It is preferable to design flaps such that the majority of the scar lines fall within the RSTL.

Danger Zones

There are three main danger zones that are critical to understand while performing surgical procedures on the head and neck. Each of these zones involves a motor nerve and the muscles it innervates. It is important to confirm the proper function of these muscles before performing a procedure in these areas so that it can be readily determined whether an injury occurred during surgery.

TEMPORAL BRANCH OF THE FACIAL NERVE

The temporal branch of the facial nerve is at greatest risk for injury where it

crosses the zygomatic arch. Injury to the temporal branch of the facial nerve leads to an inability to elevate the eyebrows and brow ptosis and paralysis. Asymmetric appearance of the forehead can also occur because there will be a loss of the lines and wrinkles on the affected side. One easy method to delineate the danger area of the temporal nerve is to draw a line from the earlobe to the lateral edge of the eyebrow, and the tragus to just above and behind the highest forehead crease (Fig. 243-4). In the area between these lines, the nerve is superficial, and it is critical to undermine just below the dermis in the superficial fat above the fascia.

MARGINAL MANDIBULAR NERVE Damage to the marginal mandibular nerve allows contralateral and upward pull on the mouth while the ipsilateral mouth is fixed in a grimace with a lip drop. As it crosses the angle of the mandible at the inferoanterior border of the masseter, the marginal mandibular nerve is covered only by skin, subcutaneous fat, and fascia, which may be thin in this location, particularly in the elderly.

SPINAL ACCESSORY NERVE Injury to the spinal accessory nerve leads to the paralysis of the trapezius with winging of the scapula, shoulder drop, inability to shrug the shoulder, difficulty with abducting the arm and chronic shoulder pain. Transection of the spinal accessory nerve can occur when operating in the posterior triangle of the neck. This region is delineated by the clavicle inferiorly, the sternocleidomastoid muscle anteriorly, and the trapezius muscle laterally and posteriorly. One can anticipate the location of the spinal accessory nerve by drawing a line connecting the angle of the mandible with the mastoid process. Where a vertical line drawn dropped 6 cm from the midpoint of this line meets the posterior border of the sternocleidomastoid muscle is Erb's point. The spinal accessory nerve emerges approximately from this point and lies superficially here, covered only by skin and fascia.

Undermining Planes

SUPERFICIAL MUSCULOAPONEUROTIC SYSTEM The term *fascia* refers to connective tissue that contains both fibrous and fat tissue in various amounts. Superficial fascia is the subcutaneous tissue that is immediately below the dermis. The deep fascia consists of more compact and highly organized collagen fibers. The superficial musculoaponeurotic system (SMAS) is the fascial system that envelops the muscles of the face. It stretches over the cheeks between the temporalis and frontalis muscles above and the platysma muscle below. The SMAS also attaches to the orbicularis oculi muscles anteriorly, the trapezius muscle posteriorly, and includes the fascia of the forehead and galea of the scalp. Most of the superficial muscles of the scalp and face insert into the skin either directly through fibrous bands running in the subcutaneous tissue or indirectly by attachment to the SMAS, which, in turn, is attached to the skin. In the lateral areas of the face, the SMAS is organized and more visible but becomes less discrete medially. Because of its attachment to the skin superficially and muscles deep, the SMAS coordinates a wide range of facial expressions. In addition, the SMAS is an important landmark because most major arteries and nerves run within or deep to it. Thus, dissection above the SMAS allows one to safely avoid injuring branches of the facial nerve (see Chap. 194).

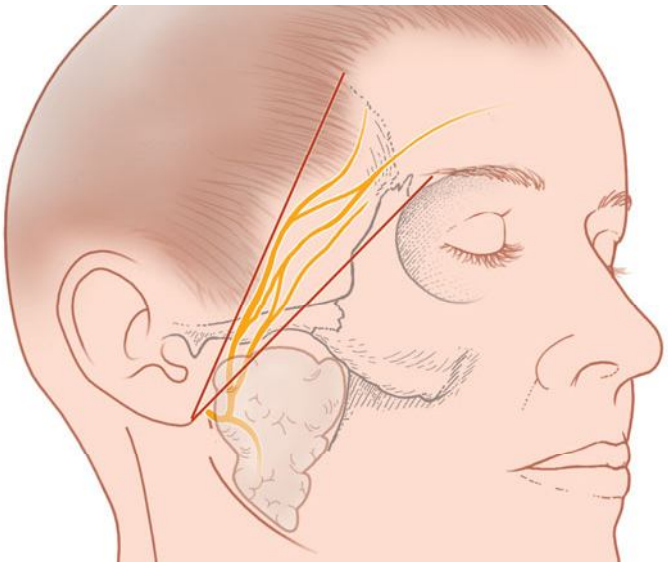

▲ **FIGURE 243-4** Danger zone for the temporal nerve.

SCALP The scalp is classically divided into five layers that are often referred to by the mnemonic SCALP. These layers from superficial to deep are: *s*kin, sub*c*utaneous tissue, *a*poneurosis (galea aponeurotica), *l*oose connective tissue, and *p*eriosteum. Because the majority of the nerves and vessels of the scalp are superficial to the subgaleal space, this is an ideal undermining plane. However, it is also known as the *danger zone* because hematomas and infection can develop here and pass through the emissary veins into the meninges.

FOREHEAD The forehead is best undermined immediately above the superficial fascia of the frontalis muscle. There may be little subcutaneous fat in this area. The temple should be undermined in the high fat/subdermal region to avoid damaging the temporal branch of the facial nerve.

EYELIDS The eyelids possess the thinnest skin of the body. The skin of the eyelids lies directly on the orbicularis muscle. Undermining should be performed above the muscle fascia to avoid causing significant bleeding and scars/contractures that can lead to ectropion.

CHIN AND LIPS The large, thick muscles of the lips and chin can make undermining challenging. The chin, in particular, has muscles broadly attached directly to the skin. Sharp undermining performed just above the superficial muscular fascia is appropriate. These areas are at high risk for bleeding, made even more precarious by functions such as talking and chewing.

NOSE The nose requires different levels of undermining in different regions. The dorsal nose can be easily undermined above the periosteum, especially when performing reconstruction with flaps. The distal, more sebaceous portion of the nose must be undermined in the sub–fibro-fatty layer to allow the greatest tissue movement.

CHEEKS The cheeks can be safely mobilized in the high or mid subcutaneous fat. Care must be taken when undermining in the hair-bearing regions of the



cheek in men, however. Here, undermining should be performed in the deep subcutis to avoid transecting hair follicles.

NECK The neck can be safely undermined while staying above the superficial fascia. One must be careful in the posterior triangle of the neck. This region is delineated by the clavicle inferiorly, the sternocleidomastoid muscle anteriorly, and the trapezius muscle laterally and posteriorly. The spinal accessory nerve lies superficially here, covered only by skin and fascia.

Sensory Nerves

The trigeminal nerve (cranial nerve V) provides the majority of the sensory innervation of the face (Fig. 243-5). It exits the skull via three foramina located bilaterally in the mid-pupillary line, the supraorbital, infraorbital, and mental foramina. The first branch, the ophthalmic nerve (V_1), has several branches that supply the innervation to the superior portion of the face: the supraorbital, supratrochlear, infratrochlear, external nasal, and lacrimal nerves. The supraorbital (lateral) and supratrochlear (medial) nerves supply the forehead and anterior scalp and are branches of the frontal nerve (the largest branch of the ophthalmic nerve). They exit from two notches along the orbital rim: supraorbital foramen or notch laterally, and supratrochlear notch, medially. The infratrochlear branch (of the nasociliary nerve) supplies the glabella, nasal root and bridge. The external nasal branch (or the dorsal nasal nerve) is a branch of the anterior ethmoidal nerve of the nasociliary branch of V_1. The external nasal branch supplies the dorsal nose and provides the anatomical explanation of Hutchinson sign that can occur in some cases of herpes zoster of the ophthalmic nerve. Vesicles on the nasal tip indicate that the eye may be involved because the nasociliary branch of V_1 sends branches both to the nasal tip and the cornea. The lacrimal branch supplies sensation to the upper eyelid.

The second branch of the trigeminal nerve is the maxillary nerve (V_2). The maxillary nerve supplies sensation to the lateral nose, lower eyelid, superior cheek, and anterior temple. The maxillary nerve gives off two main branches that supply the skin of the face. The zygomatic branch of the maxillary nerve gives rise to the zygomaticofacial nerve, which exits the skull through the lateral zygomatic bone and supplies a small area of the lateral canthus. In addition, the zygomatic branch also gives rise to the zygomaticotemporal nerve, which exits the skull through the anterior temporal fossa and supplies skin of the anterior temporal region. The largest branch of the maxillary nerve is the infraorbital nerve that exits the skull through the infraorbital foramen of the maxilla. This supplies sensation to the eyelid and superior cheek.

The third branch of the trigeminal nerve is the mandibular nerve (V_3). Its branches provide sensory innervation of the lower lip, chin, mandibular and preauricular cheek, anterior ear, and the central temporal scalp. The mandibular nerve gives off three major cutaneous branches: the auriculotemporal, buccal, and mental nerves. The auriculotemporal nerve innervates most of the temple, the temporoparietal scalp, the anterior ears, parts of the external ear canal, and the tympanic membrane. The buccal nerve lies deep to the parotid gland and supplies the skin over the buccinators, buccal mucosa, and the gingiva. The mental nerve exits through the mental foramen and is a continuation of the inferior alveolar nerve. The mental nerve supplies sensation to the lower lip and chin.

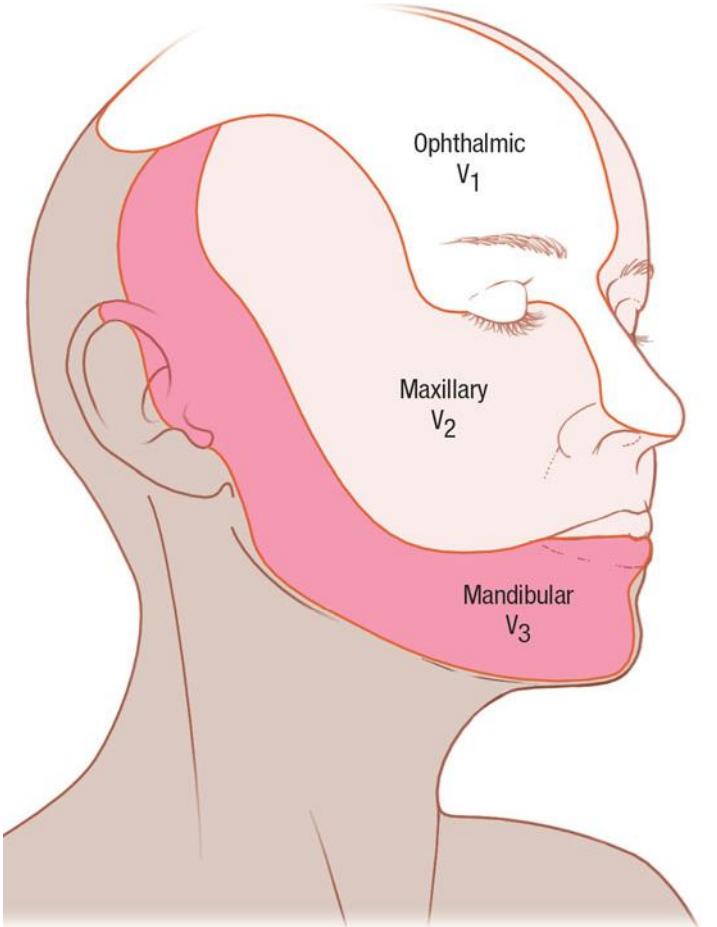

▲ **FIGURE 243-5** Sensory distribution of the trigeminal nerve.

Muscles

The scalp has two muscles overlying it, the frontalis anteriorly and the occipitalis posteriorly. These muscles are joined by a thick fascia centrally over the scalp, the galea aponeurotica. The frontalis muscle also covers the forehead and elevates the eyebrows. The eyebrows move medially and downward with contraction of the corrugator supercilii muscles. The procerus lies between the supercilii muscles and draws the skin of the forehead inferiorly to create the horizontal creases at the root of the nose. The orbicularis oculi muscle surrounds the eye and consists of an orbital and palpebral portion. The orbicularis oculi muscle serves to close the eyes with the palpebral part with both reflexive and voluntary control and the orbital part with voluntary control. The central sphincter-like muscle around the mouth is the orbicularis oris. This muscle helps to purse the lips to form certain sounds and whistle. The lip depres-

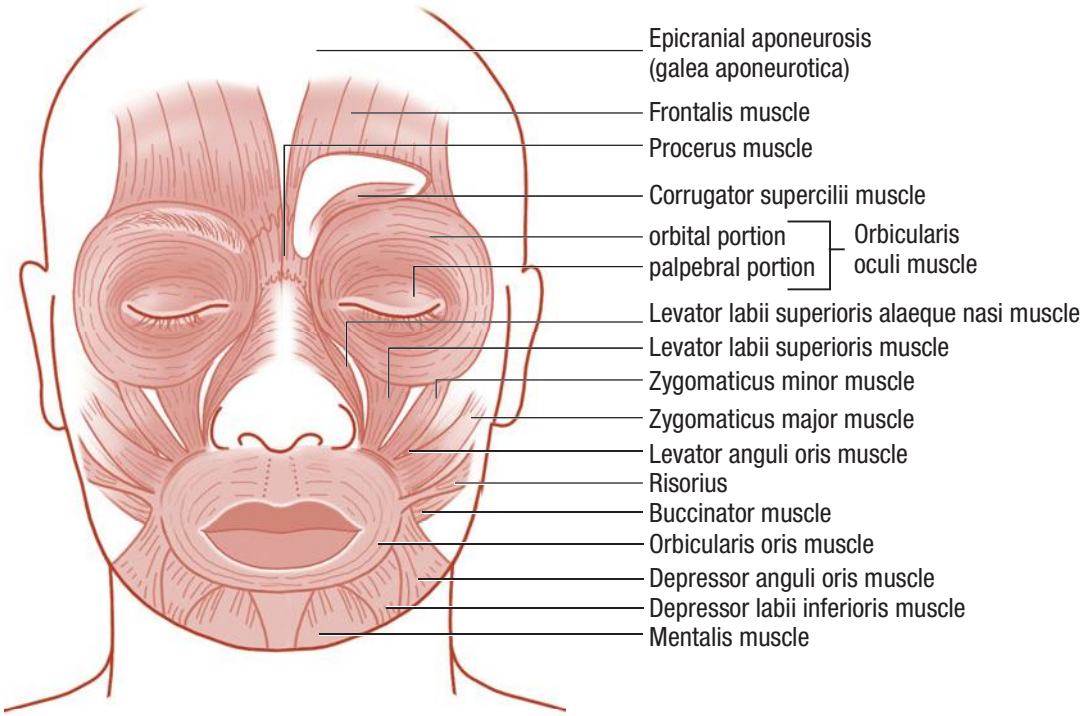

▲ **FIGURE 243-6** Muscles of facial expression.

sors are: depressor anguli oris, depressor labii inferioris, and the mentalis. The lip elevators are: the zygomaticus major, zygomatic minor, levator anguli oris, levator labii superioris and the levator superioris alaeque nasi. The risorius helps to retract the corner of the mouth. The buccinators and masseter muscles help with mastication (Fig. 243-6).

Motor Nerves

The facial nerve (cranial nerve VII) provides innervation to all the muscles of facial expression. It exits the skull via the stylomastoid foramen which lies deep in the infraauricular sulcus and anterior to the mastoid process. The facial nerve enters the parotid gland at the level of the intertragic notch and usually divides into five branches within the substance of the gland. The well-known mnemonic "To Zanzibar By Motor Car" can be used to remember the five main branches: *t*emporal, *z*ygomatic, *b*uccal, *m*andibular, and *c*ervical. For the most part, these nerves enter the muscles they innervate posteriorly and deep. A nice rule of thumb is that if one transects a nerve lateral to the pupillary line, permanent paralysis can result and if the nerve is cut medial to this demarcation, most nerves will regenerate or have arborizations that will help provide additional innervation.

The temporal branch of the facial nerve exits the superior part of the parotid gland and crosses the zygomatic arch to innervate the frontalis, upper portion of the orbicularis oculi, and corrugator supercilii. Injury to the temporal branch leads to an inability to raise the eyebrows and brow ptosis. The zygomatic branch innervates the orbicularis oculi, nasal muscles, lip elevators, and the buccinators. Damage to the zygomatic nerve results in lower eyelid ptosis and an inability to close the eyes completely. The buccal branch also innervates the buccinators and lip elevators, as well as the orbicularis oris and risorius. Damage to the buccal branch leads to an inability to whistle. The marginal mandibular branch crosses the angle of the mandible at the inferior-anterior border of the masseter. It innervates the depressors of the mouth.

Vascular Supply

The blood supply of the face is almost entirely derived from branches of the external carotid artery (Fig. 243-7). Just posterior and medial to the angle of the mandible, the facial artery branches off the external carotid artery. The facial artery continues anteriorly and superiorly toward the angle of the mouth, giving off the inferior labial artery and superior labial arteries that supply the lips. The continuation of the facial artery in the nasofacial sulcus is called the *angular artery*. The angular artery continues superiorly to enter the orbit immediately over the medial canthal tendon where it anastomoses with the ophthalmic artery, a branch of the internal carotid artery. After giving off the facial artery, the external carotid artery then passes deep to the sternocleidomastoid muscle and enters the body of the parotid gland where it gives off the posterior auricular artery that supplies the postauricular scalp, the maxillary artery, and the superficial temporal artery. The terminal branch of the maxillary artery exits the infraorbital foramen with the infraorbital nerve as the infraorbital artery to supply the lower eyelids and infraorbital cheek.

The terminal branches of the internal carotid artery are the ophthalmic artery branches, the supraorbital artery, and the supratrochlear artery. The supraorbital artery emerges from the supraorbital foramen, whereas the supratrochlear artery emerges more medially. The internal and external carotid systems join in two places: where the supratrochlear branch and the dorsal nasal artery anastomose with the angular artery and where the forehead branches of the supraorbital and supratrochlear arteries anastomose with branches of the superficial temporal artery.



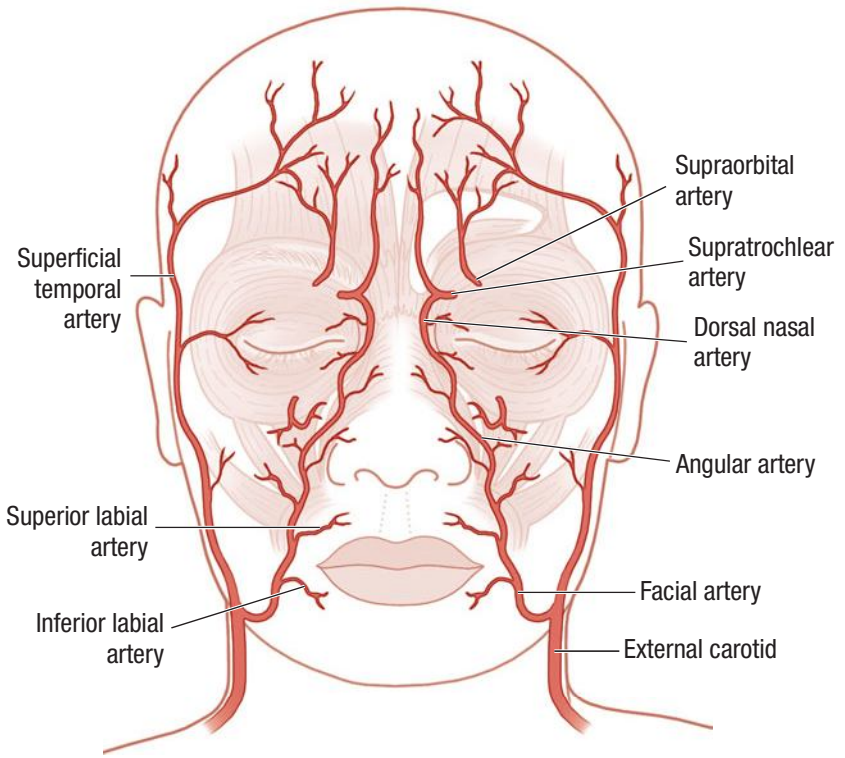

▲ **FIGURE 243-7** Vascular supply of the face.

The veins of the face parallel and lie posterior to the arteries. Unlike the veins of the trunk and extremities, facial veins have no valves. This allows blood to flow in either direction. Thus, in the central face where there are anastomoses between branches of the ophthalmic vein and of the angular vein, infection has easy access to travel along the ophthalmic vein to the cavernous sinus. The angular vein also communicates with the deep facial vein and pterygoid plexus.

Lymphatics

The lymphatic vessels of the face generally drain from superficial to deep and medial to lateral and caudad. While the general drainage patterns are described here, variations can occur. The posterior scalp drains to the postauricular and occipital nodes. The lateral and superior face, the forehead, and the lateral eyelids drain to the parotid nodes. The medial and inferior face, including the medial eyelids and lateral lips, drain to the submandibular nodes. The middle two-thirds of the lower lip and the chin drain to the submental nodes. These nodes can be optimally palpated by performing a bimanual exam with a gloved hand feeling through the floor of the mouth.

The lymph nodes of the head and neck eventually drain into a terminal series of nodes (deep cervical nodes) and finally into the lateral internal jugular chain.

PREOPERATIVE ASSESSMENT

Preoperative assessment is critical for a successful procedure. It can minimize complications and anticipate or possibly correct factors that predispose to adverse outcomes. A fairly thorough medical, drug, and medication allergy history provides an accurate picture of the patient's health status. Questioning the possibility of pregnancy in women of childbearing age should not be overlooked, as local anesthetics and antibiotics may be contraindicated. Patients with inherited bleeding disorders can also be identified and, when possible, given clotting factors to correct for these disorders. Uncontrolled hypertension may predispose to increased intraoperative and postoperative bleeding. In addition, poorly controlled diabetes and immunosuppression with use of systemic steroids for medical conditions, such as autoimmune disorders or organ transplantation, may affect healing time. Information from the social history can also have a bearing on the surgery. For instance, healing can be adversely affected if the patient smokes, and this may impact the decision to perform a flap or graft. Alcohol consumption can increase the risk of bleeding because of its qualitative effect on platelets. Finally, knowledge of the patient's resources and support at home is helpful when providing instructions for postoperative care.

Antibiotics

A well-planned and executed surgical procedure can be significantly compromised by an infection. Infections can lead to poor cosmesis, inconvenience, added expense, and patient dissatisfaction. Because every surgical procedure violates the epidermal barrier, no surgical procedure is absolutely sterile. Hence, all surgical wounds are contaminated by bacteria because of the inevitable resident flora in humans. However, not all contaminated wounds become infected. Infection depends on a large number of factors: the pathogenicity of the microbe, the quantity of the microbe, the length of surgery/timing of infection, the presence of foreign material (sutures, devitalized tissue), presence of dead space, poor suturing/surgical technique, poorly designed reconstruction, compromised vascular supply, and the host and wound's resistance to infection. Usually a wound that contains greater than 10^5 bacteria per gram of tissue is considered infected.[4] The American College of Surgeons has defined wounds as: clean (nontraumatic, without break in aseptic technique), clean-contaminated (minor break in aseptic technique, wounds in oral cavity, axillae, perineum), contaminated (acutely inflamed, major break in aseptic technique) and dirty (encountering pus, fecal, or urinary discharge). Antibiotics can be considered for some clean-contaminated, contaminated, and dirty wounds. Most wounds in dermatologic surgery are clean-contaminated wounds and do not require antibiotics. The most common organism is *Staphylococcus aureus* and a first generation cephalosporin (or clindamycin for the penicillin-allergic) is appropriate when necessary. Studies show that to prevent or change the course of infection, antibiotics must be given within 2 to 3 hours after inoculation and that antibiotics give maximal suppression against infection if given before bacteria colonize tissue. In addition, there is concern that, with increasing time, the wound is sealed off with blood clots and fibrous exudates, and the antibiotic is unable to reach the wound effectively. Routine use of antibiotics postoperatively is discour-

aged because of the risk for resistant bacteria.

Medications

The use of blood thinners, such as warfarin, dipyridamole, clopidogrel, and aspirin, are common in the aging population. In the past, patients were often told to discontinue their blood thinners before surgery. However, recent reports show that discontinuing these medications prior to dermatologic surgery can lead to episodes of thrombotic events such as stroke and pulmonary embolism.[5] Furthermore, remaining on such medications does not lead to significant adverse events. Many patients may be taking herbal or over-the-counter drugs that also interfere with clotting. These are not often considered "drugs" by patients, and thus they may not volunteer taking such supplements unless they are specifically asked. Some common preparations in this category include vitamin E, garlic, gingko, ginseng, feverfew, or ginger. Alcohol can also interfere with platelet aggregation, and it is important to instruct patients to avoid drinking a few days before and after the surgery. Most dermatologic surgeons advise patients to avoid alcohol, herbal products, and nutritional supplements several days before surgery. In addition, patients who are taking aspirin and other nonsteroidal anti-inflammatory drugs for non-physician recommended "preventive" reasons are also advised to discontinue these drugs.

Non-selective β blockers (i.e., propanolol) can occasionally potentiate the effect of epinephrine and lead to complications such as malignant hypertension and bradycardia.

Other preoperative considerations include latex allergy or allergy to topical antibiotics or adhesives in tapes. Use of systemic steroids can prolong the wound healing time.

Pacemakers and Defibrillators

Electrosurgery is widely used in dermatologic surgery to obtain hemostasis. However, electrosurgery can disrupt the function of pacemakers and implantable cardioverter-defibrillators (ICDs) by oversensing, inhibiting firing, device reprogramming, battery depletion, or direct damage to the device.[6] Thus, it is important to identify patients with such devices and to use proper precautions. Fortunately, newer pacemakers and ICDs have improved shielding and are more resistant to the electromagnetic interference that can be produced by electrosurgery. ICDs are more sensitive to electromagnetic interference, and this interference can cause the defibrillator to discharge, leading to significant morbidity and possible mortality for the patient. If electrosurgery is necessary, recommendations, such as using short bursts of electricity (less than 5 seconds) and avoiding its use directly around the area of the pacemaker, may minimize risks. In addition, bipolar electrosurgery creates little interference and is safer. Heat cautery does not cause any interference and is the safest but is not as effective for hemostasis with larger or complicated procedures.

Smoking

Smoking should also be discussed preoperatively with patients. Tobacco use creates vasoconstriction, which impairs wound healing and jeopardizes the reconstruction, especially with more complicated procedures such as flaps and grafts. Patients should be strongly encouraged to cease tobacco use at least 1 week before surgery and 1 week postoperatively. It is also important to clarify that a nicotine patch is not ideal, and patients must avoid nicotine exposure through patches or gum.

Surgical History

A discussion of healing after previous procedures can be informative for the patient and surgeon. The physician can determine if the patient is predisposed to forming hypertrophic scars or keloids and plan reconstruction and postoperative care appropriately. The patient may have a misunderstanding of wound healing and feel that a well-healed visible scar on a high-tension area is a keloid. This can be an opportunity to anticipate patient expectations and educate them on the process of wound healing.

SURGICAL TECHNIQUE

Skin Preparation and Aseptic Technique

The normal skin is colonized by a host of bacteria, primarily aerobic cocci. *S. aureus* is the most common cause of cutaneous wound infections in dermatologic surgery. Other bacteria commonly identified on the skin include *S. epidermidis, Pseudomonas, Propionibacterium,* streptococci, and micrococci. *Pseudomonas* is frequently the pathogen identified in infections of cartilaginous regions such as the ear. The aim of aseptic solutions is to significantly reduce the amount of normal bacterial flora, as complete sterilization of the skin is not possible due to the presence of bacteria in pilosebaceous units. The ideal antiseptic would be nonirritating, non-toxic, nonsensitizing, be effective against all resident and transient microbes, and long-lasting. In prepping the field, shaving the hair creates multiple superficial microabrasions in which bacteria may reside and is associated with an increased incidence of local wound infections. Hair removal, if needed, has the lowest risk of associated infection if done by clipping or depilatory agents.

Iodophors that act through oxidation of cell membranes by free iodine are common topical antiseptics. The most common form of this antiseptic is Povidine-iodine. This antiseptic has broad antimicrobial activity against both Gram-positive and Gram-negative bacteria, as well as fungi, viruses, and mycobacteria. Iodophors have bactericidal activity that persists for several hours after application. On contact with blood or serum, the bactericidal activity is lost, but some bacteriostatic activity is retained. This class offers relatively rapid onset of action within minutes. Side effects of Povidine-iodine include allergic contact dermatitis, irritant contact dermatitis, and possible tissue necrosis with prolonged exposure to large amounts in open wounds.

Chlorhexidine also functions through disruption of cell membranes. It has broad antimicrobial activity with excellent Gram-positive coverage and very good Gram-negative activity. It has some degree of activity against viruses but little effect on mycobacteria or fungi. It offers a more rapid onset of action than Povidine-iodine, providing almost immediate bactericidal activity upon application, which persists for many hours after application. The primary side effects of chlorhexidine are the potential for ototoxicity and keratitis. As a result, it should not be used around the eyes or ears. Similar to iodophors, prolonged exposure of chlorhexidine in open wounds has been reported to be toxic to the tissue.

Isopropyl alcohol and ethyl alcohol are effective antiseptics for minor skin procedures. They function through the denaturation of microbial proteins. They display good activity against Gram-positive bacteria, Gram-negative bacteria, mycobacteria, viruses, and fungi. Alcohols



TABLE 243-1
Local Anesthetics

Generic Name	Trade Name	Primary Use	Relative Potency	Onset	Duration[a] Plain	Maximum[b] Dose Plain (mg)	Maximum[b] Dose with Epinephrine (mg)
Amides							
Bupivacaine	Marcaine	Infiltration	8	2–10 min	3–10 h	175	250
Dibucaine	Nupercaine	Topical	—	Rapid	Short	—	—
Etidocaine	Duranest	Infiltration	6	3–5 min	3–10 h	300	400
Lidocaine	Xylocaine	Infiltration/topical	2	Rapid	1–2 h	300	500 (3850 dilute)
Mepivacaine	Carbocaine	Infiltration	2	3–20 min	2–3 h	300	400
Prilocaine	Citanest	Infiltration	2	Rapid	2–4 h	400	600
Prilocaine/lidocaine	EMLA	Topical	—	30–120 min	Short	—	—
Esters							
Benzocaine	Anbesol, etc.	Topical	—	Rapid	Short	—	—
Chloroprocaine	Nesacaine	Infiltration	1	Rapid	0.5–2.0 h	600	—
Cocaine		Topical	—	2–10 min	1–3 h	200	—
Procaine	Novocaine	Infiltration	1	Slow	1.0–1.5 h	500	600
Proparacaine	Ophthaine	Topical	—	Rapid	Short	—	—
Tetracaine	Pontocaine	Infiltration	8	Slow	2–3 h	20	—
Tetracaine	Cetacaine	Topical	—	Rapid	Short	—	—

[a]In clinical practice the duration of anesthesia appears to be less than stated above, especially for head and neck areas, and addition of epinephrine prolongs anesthesia by a factor of two.
[b]Maximum doses are for a 70-kg person.



have a rapid onset of activity at the site of application, but there is no persistence of this activity over time. The antimicrobial activity of alcohols is not as extensive as that of chlorhexidine or iodophors. In addition, the flammable nature of alcohols limits their use in procedure requiring electrocautery.

Hexachlorophene is rarely used as a skin antiseptic solution. It has excellent Gram-positive activity but limited activity against Gram-negative organisms or fungi. It is also readily absorbed through the skin and has the potential for neurotoxicity, especially in infants.

Local Anesthesia

Effective anesthesia is critical to the successful performance of dermatologic surgery. The overwhelming majority of cutaneous surgical procedures can be performed with local anesthesia. Local anesthesia provides the benefits of rapid onset of action, ease of use, decreased cost, and minimal associated morbidity and mortality.

Nerves transmit stimuli by opening of sodium channels that results in an influx of sodium ions into the nerve cell. This influx results in depolarization of the axon generating an action potential. Local anesthetics exert their effect on nerves by blocking the sodium channels on nerve axons. This blockage inhibits depolarization and the formation of an action potential. Local anesthetics affect the smaller unmyelinated C-type nerve fibers, which carry the sensation of pain and heat, more rapidly and effectively than myelinated A-type nerve fibers, which transmit. Thus, adequate anesthesia can be achieved while motor function and pressure sensation are maintained.

Local anesthetics structurally are composed of three subunits: a hydrophobic aromatic ring, a hydrophilic amine group, and an intervening group connecting the hydrophobic and hydrophilic units. The hydrophobic aromatic ring is responsible for the molecule's ability to diffuse through axonal membranes. The hydrophilic amine maintains the solubility of the compound in aqueous solution and accounts for blockage of the sodium channels of nerve axons. The region connecting the hydrophilic and hyphobic regions may be either an amide group or an ester group. Amide anesthetics, which include lidocaine, prilocaine, bupivacaine and mepivacaine, are metabolized in the liver through dealkylation and hydrolysis by microsomal enzymes. Ester anesthetics, which include procaine, benzocaine, tetracaine, and cocaine, are metabolized by plasma pseudocholinesterase and are excreted renally.

Selecting the Appropriate Anesthetic

The nature of the procedure determines which local anesthetic is ideal (Table 243-1). The primary variables to consider in choosing between anesthetics are the onset of action and the duration of anesthesia. Patient factors to consider in this selection are a history of allergy to an anesthetic class or renal or hepatic impairment. For simple biopsies and excisions, a rapid-onset anesthetic, like lidocaine, with medium duration of action provides effective anesthesia. For more extensive procedures, an anesthetic with a longer duration of action, such as bupivacaine, may be desired. Some practitioners choose to mix a rapid-onset anesthetic with one of long duration into one injectable solution.

Epinephrine

Local anesthetics, with the exception of cocaine, are vasodilators. This vasodilatory effect produces unwanted bleeding at the operative site. Epinephrine with its potent vasoconstrictive effects is often added to local anesthetic preparations to reduce bleeding. Concentrations ranging from 1:100,000 to 1:500,000 are effective in reducing bleeding at the surgical site. In addition to its hemostatic effect, epinephrine reduces the dispersion of the local anesthetic from the operative site. This prolongs the duration and efficacy of the anesthesia by 100 percent to 150 percent. It also limits the potential for systemic toxicity, as less anesthetic is allowed to enter the systemic circulation.

Epinephrine is a potent agonist of α- and β-adrenergic receptors. Absolute contraindications to its use with local anesthetics are pheochromocytoma and

hyperthyroidism. Relative contraindications to the use of epinephrine include severe coronary artery disease, uncontrolled hypertension, peripheral vascular disease, pregnancy, and acute angle glaucoma. In addition, epinephrine should be used with caution in patients on β blockers, monoamine oxidase inhibitors, phenothiazines, and tricyclic antidepressants as these individuals demonstrate greater sensitivity to its effects. Although uncommon, severe hypertension may be encountered in patients on β blockers due to the unopposed α-receptor stimulation of the epinephrine.

The use of epinephrine-containing local anesthetics on anatomic regions with minimal collateral circulation, such as the digits, penis, and nasal tip, is a matter of controversy. Reports of local tissue necrosis in these areas with limited perfusion attributed this result to the potent vasoconstrictive effects of the epinephrine. More recent observations indicate this necrosis to actually be the result of excessive volume of anesthetic used, which physically tamponades the vessels. Thus, local anesthetics with epinephrine are now considered safe for use on the digits, penis, and nasal tip, when used judiciously in small volumes. Consideration may be given to using a lower concentration of epinephrine (1:500,000) for those sites with severely limited perfusion.

Self-limited, systemic side effects may also be experienced with the administration of epinephrine-containing anesthetics. These include anxiety, fear, palpitations, tachycardia, diaphoresis, tremor, and hypertension. Serious side effects of excessive epinephrine administration include arrhythmias, cardiac arrest, and cerebrovascular hemorrhage. These serious side effects are extremely rare when used at appropriate dosages in individuals without significant contraindication.

To maintain the stability of epinephrine in solution, pre-mixed anesthetics are produced in an acidic solution with a pH of between 3 and 5. Injection of this acidic solution into tissue often produces significant discomfort. To avoid this, the pH of the solution can be adjusted before injection closer to the physiologic pH of 7.4 through the addition of sodium bicarbonate. The standard formula for this is the combination of one part of 8.4 percent sodium bicarbonate with 10 parts lidocaine. This buffered solution must be used soon after preparation as the epinephrine gradually degrades at a rate of approximately 25 percent per week. Alternatively, the epinephrine and anesthetic may also be mixed immediately before use, which also provides a neutral solution. In each instance, the neutral or slightly alkaline solution has the added advantages of quicker onset of action and increased anesthetic effect as the pH of the solution is closer to the pKa of the anesthetic, meaning more of the anesthetic is in its active ionized cationic form.

Side Effects

The most common side effect of local anesthetics is the pain of its administration. Pre-mixed local anesthetic preparations containing epinephrine are manufactured as an acidic solution in order to maintain the stability of epinephrine. The addition of sodium bicarbonate to these solutions elevates the pH to a more physiologic level resulting in less discomfort with injection. Slow injection of the anesthetic through a small gauge needle (27 gauge to 30 gauge) also minimizes the pain of injection. Smaller syringes, such as 1 to 3 mL, create less pressure at the site of anesthetic administration. Based on the gate theory of pain perception, repeated pinching or vibration of the immediate surrounding area lessens the perception of the stick at site. Verbal distraction of the patient is also useful in lessening the anxiety and discomfort of the anesthetic.

Injection of anesthetic into the subcutaneous tissue is less painful than injection into dermal tissue; however, a quicker onset of action and longer duration of anesthesia are observed with dermal injection. If a large area is to be anesthetized, the initial injection should be placed near the origination of sensation and proceed distally. Subsequent injections, if necessary, should be made through previously anesthetized tissue. For large areas, consideration should also be given to the use of nerve blocks to minimize discomfort.

One side effect of local anesthetic administration that is not uncommon is the vasovagal reaction. This may be manifested as pallor, weakness, bradycardia, hypotension, diaphoresis, and nausea. Placement of the patient in Trendelenburg position usually results in complete resolution of these symptoms within several minutes. A cool compress on the forehead and fanning the patient are often helpful in comforting the patient during this episode. Patients should be injected in a recumbent or Trendelenburg position to minimize the likelihood of a vasovagal response. These positions also allow providers to be better prepared to deal with the reaction should it occur. Pain and anxiety of anesthetic injection can precipitate a vasovagal reaction; thus, the aforementioned techniques for lessening the discomfort of injection are critical in reducing the likelihood of a vasovagal response.

Allergy to a local anesthetic is an uncommon side effect in dermatologic surgery. True allergic reactions are typically immediate type I immunoglobulin E–mediated reactions, which may produce urticaria, angioedema, bronchospasm, tachycardia, hypotension, and, possibly, cardiovascular collapse. For severe reactions, administration of epinephrine and cardiopulmonary support is indicated. Less commonly, type IV–delayed hypersensitivity reactions may be observed. These present similar to an allergic contact dermatitis in the days following the injection of the anesthetic.

Allergic reactions to ester anesthetics are very uncommon.

For those patients in whom an allergy to an anesthetic is unclear, intradermal prick testing to ester anesthetics, amide anesthetics, sodium metabisulfite, and methylparabens may be helpful. Alternatively, for smaller procedures, diphenhydramine hydrochloride solution provides temporary anesthesia without risk of an allergic response. Antihistamine side effects, including significant drowsiness, may be encountered with its use. Normal saline with preservative may also be used for very brief procedures. The temporary anesthesia it provides is attributed to a combination of the tamponade effect on nerves and the mild anesthetic effect of the preservative benzoyl alcohol.

Anesthetic toxicity is a rare complication given the typical volumes required for dermatologic surgery. Signs of toxicity are usually not observed with dosages less than 5.0 mg/kg of plain lidocaine and 7.0 mg/kg of lidocaine with epinephrine. For tumescent anesthesia, the maximum safe dose increases to 55.0 mg/kg of 0.05 percent to 0.1 percent lidocaine with 1:1,000,000 epinephrine. The initial presenting signs are circumoral numbness and tingling, tinnitus, light-headedness, nausea, and numbness of the distal extremities. With additional anesthetic, more extensive central nervous system depression may occur with hallucinations, seizures, and respiratory depression. Cardiovascular toxicity may also occur, but does so at much higher levels of anesthetic than the initial central nervous system toxicity. The manifestations include hypotension, arrhythmias, and cardiac arrest.



Both central nervous system and cardiovascular toxicity are directly related to serum levels of the anesthetic. Thus, direct intravenous or intra-arterial injection is to be avoided when anesthetizing an area. This can be done by drawing back on the syringe after needle insertion prior to infiltration of the anesthetic to confirm that the needle is not in a vascular structure. The risk of toxicity can be elevated by other medical problems affecting the metabolism of the anesthetic. In particular, patients with liver disease experience increased serum levels of amide anesthetics due to an impaired ability to metabolize and clear the anesthetic. Thus, a lower dosage of an amide anesthetic or a switch to an ester anesthetic is advisable in these patients.



Topical Anesthetics

Several local anesthetics are also available as topical preparations. When used properly, these agents provide suitable anesthesia for minor dermatologic procedures, such as shave biopsies or superficial laser treatments. Their efficacy on normal skin is limited by their ability to penetrate the stratum corneum. Thus, most of the preparations require extended application times and/or occlusion for effectiveness.

LMX is a topical lidocaine cream in a liposomal vehicle. It is available in 4 percent and 5 percent concentrations. EMLA (eutectic mixture of local anesthetics) cream consists of a combination of 2.5 percent lidocaine and 2.5 percent prilocaine. LMX and EMLA have been shown to be more effective than other topical preparations of 4 percent tetracaine gel and Betacaine-LA (a mixture of prilocaine and lidocaine in a liquid paraffin ointment). LMX typically requires an application time of 30 minutes with or without occlusion, whereas EMLA requires 1 hour with occlusion. Multiple studies have demonstrated the 30-minute application of LMX without occlusion to provide equal anesthesia as 1-hour application of EMLA with occlusion. Caution should be exercised in the use of large amounts of prilocaine-containing topical preparations in infants or those with an impaired skin barrier, as prilocaine has the potential to induce methemoglobinemia.

Cryogens, such as ethyl chloride, also provide brief anesthesia at a site for minor procedures or the insertion of a needle. Similarly, an ice cube placed on an injection site often significantly reduces the discomfort of injection in the anxious patient.

Mucosal membranes are readily anesthetized using topical preparations due to the ease of penetration in the absence of a stratum corneum. Tetracaine or proparacaine drops rapidly provide effective anesthesia of the conjunctiva and cornea for insertion of eye shields. Benzocaine and lidocaine preparations provide prompt anesthesia for intra-oral procedures or before nerve blocks.

Nerve Blocks

The use of regional nerve blocks can be of immense value to the dermatologic surgeon. Regional nerve blocks allow large cutaneous areas to be anesthetized with small volumes of anesthetic. They are based on the injection of a local anesthetic into the immediate vicinity of a sensory nerve as it emerges from deeper planes of tissue. This provides effective anesthesia for the patient while minimizing the discomfort of multiple injections. Nerve blocks have the added benefits of limiting the possibility of anesthetic toxicity as well as minimizing tissue distortion. The primary risk of nerve blocks is nerve trauma with resultant neurapraxia.

The standard anesthetic used for regional blocks is 1 percent lidocaine with 1:100,000 epinephrine; however, bupivacaine may be added if more lasting anesthesia is desired. A 1-inch, 30-gauge is suitable for the performance of most nerve blocks. The proper execution of nerve blocks is predicated on a thorough knowledge of the anatomy of the region being anesthetized.

The cutaneous sensation of the face is primarily supplied by the trigeminal nerve, with a small fraction of the periphery being supplied by the cervical plexus. As its name implies, the trigeminal nerve consists of three major divisions: the ophthalmic (V_1), maxillary (V_2), and mandibular (V_3) divisions. Each of these divisions has major branches, which are amenable to regional nerve blocks.

The ophthalmic division gives off the supraorbital, supratrochlear, and infratrochlear nerves. The supraorbital nerve exits through the supraorbital foramen, which is a readily palpable bony notch located along the orbital rim just medial to the mid-pupillary line. The supratrochlear branch exits along the orbital rim approximately 1.5 cm medial to the supraorbital notch. The infratrochlear nerve exits just above the medial canthus. All three of these branches can be anesthetized with a single injection by inserting the needle 2 to 3 mL lateral to the supraorbital notch and advancing medially through the subcutaneous tissue to the medial canthus. The anesthetic is then injected as the needle is slowly withdrawn in one smooth motion. This single injection provides anesthesia to the ipsilateral forehead, frontal scalp, upper eyelid, medial canthus, and superior nasal sidewall and root.

The infraorbital nerve, a branch of the mandibular division, exits through the infraorbital foramen, which is located in the mid-pupillary line approximately 1 cm below the infraorbital rim. This nerve may be blocked by either an intra-oral or a percutaneous approach. The percutaneous method involves insertion of the needle directly over the infraorbital foramen and advancement directly down to the maxillary bone, where the anesthetic is delivered. With the intra-oral approach, the sulcus located just above and lateral to the canine tooth is identified by manual palpation. The needle is inserted in the superior portion of this sulcus and advanced upwards approximately 1 cm in the mid-pupillary line. At this position, the anesthetic is slowly injected. The intra-oral approach is less painful than the percutaneous one, and may be further aided by the use of a topical lidocaine or benzocaine gel on the oral mucosa. This block provides anesthesia to the ipsilateral lower eyelid, medial cheek, upper lip, and upper teeth.

The mental nerve is a branch of the mandibular division, which exits through the foramen just medial to the mid-pupillary line. This nerve is easily accessed via an intra-oral injection. It is located just opposite of the first bicuspid on the mucosa of the lower lip, and is often visible to the naked eye as a thin glistening white strand. It is anesthetized with an injection in the immediate vicinity of its inferior portion. This provides anesthesia to the ipsilateral lower lip and chin.

In addition to the above branches, there are other branches of the trigeminal nerve that are also amenable to regional nerve blocks. These include the buccal, auriculotemporal, anterior ethmoidal (external nasal branches), and zygomaticotemporal nerves. A block of the greater auricular nerve off the cervical plexus provides anesthesia to the posterior auricle and angle of the mandible.

Nerve blocks can be a valuable tool for non-facial locations as well. In particular, digital nerve blocks are very useful for procedures involving the digit or nail

TABLE 243-2
Suture Materials

	Type	Memory	Tissue Reactivity	Tensile Strength Half-Life
Nonabsorbable				
Cotton	Twisted	Low	Very high	—
Nylon (Ethilon, Dermalon)	Monofilament	High	Low	—
Nylon (Nurolon, Surgilon)	Braided	Low	Low	—
Polybutester (Novafil)	Monofilament	High	Low	—
Polyester, uncoated (Mersilene)	Braided	Low	Low	—
Polyester, coated (Ethibond)	Braided	Low	Low	—
Polypropylene (Prolene, Surgilene)	Monofilament	Very high	Very low	—
Silk	Braided/twisted	Very low	High	—
Stainless steel	Monofilament/braided/twisted	Very high	Very low	—
Absorbable				
Catgut, fast absorbing/mild chromic	Twisted	Very high	High	2 days
Catgut	Twisted	Very high	High	4 days
Catgut, chromic	Twisted	Very high	High	1 wk
Polyglactin 910 (Vicryl)	Braided	Very low	Low	2 wk
Polyglycolic acid (Dexon)	Braided	Very low	Low	2 wk
Poliglecaprone 25 (Monocryl)	Monofilament	Low	Very low	1 wk
Polyglyconate (Maxon)	Monofilament	Low	Very low	1 mo
Polydioxanone (PDS)	Monofilament	High	Very low	1 mo

Adapted from Melton JL, Hanke WC: Wound closure materials, in *Principles and Techniques of Cutaneous Surgery*, edited by Lask GP, Moy RL. New York, McGraw-Hill, 1996, p 77; and Garrett AB: Wound closure materials, in *Cutaneous Surgery*, edited by Wheeland RG. Philadelphia, Saunders, 1994, p 199.

unit. The cutaneous sensation of a digit is supplied by two nerves coursing down each of the lateral aspects of the digit. For a block, the needle is inserted perpendicularly into the lateral aspect of each side of the digit and advanced until bone is reached. At this position, a small volume of anesthetic is administered. The delivery of a large volume (greater than 1 mL) of anesthetic in the digits can result in tamponade of the digital circulation with subsequent necrosis. This tamponade effect now appears to be more critical factor in cases of digital necrosis than the use of epinephrine.

Electrosurgery and Electrocautery (See Chap. 247)

SUTURE MATERIALS The proper selection of suture material for any dermatologic procedure is vital to its successful outcome. There are several intrinsic characteristics of each suture material, which will influence this selection process (Table 243-2). Sutures are produced in both absorbable and nonabsorbable forms. An absorbable suture is classified as one, which loses half of its tensile strength within 2 months. Absorbable sutures are primarily used for the approximation of dermal and subcutaneous tissue. As wounds have achieved less than 10 percent of their final tensile strength at 2 weeks, these sutures maintain the structural support of wounds during the initial healing phase. The time that a suture maintains its tensile strength is dependant on the material of which it is composed.

Nonabsorbable sutures are predominantly used for external suturing with subsequent removal in the days after the procedure. In this instance, these sutures are used more for fine epidermal approximation than structural support. On occasion, nonabsorbable sutures are also used for the placement of subcutaneous tissue, muscle, and fascia, when a more permanent placement of the tissue is desired.

Sutures are produced as monofilaments (single-strand) or multifilaments (multiple-braided strands). Monofilaments offer the advantage of increased ease of pull through tissue, less risk of infection, and decreased tissue reactivity. The disadvantage of monofilaments is the increase in memory, or the tendency for a material to revert to its original shape. This memory results in decreased ease of handling of the suture and decreased knots security for monofilaments. Multifilaments, or braided sutures, offer ease of handling and increased knot security. However, the strands of a multifilament have the capability to trap fluid and bacteria resulting in an increased risk of infection with their use.

In general, the smallest suture, which provides adequate tensile strength for a defect, should be utilized. Suture size is measured in multiple of zeros based upon the diameter of the suture material. The higher the number preceding the zero, the smaller the diameter of the suture. Typically, 5-0 and 6-0 sutures are used on regions of low tension, such as the face, eyelids, and ears. Areas of higher tension, such as the trunk, extremities, and scalp, require 3-0 and 4-0 sutures. Areas of intermediate tension, such as the neck, may be closed with either 4-0 or 5-0 sutures. There are a wide range of needles whose nomenclature varies with manufacturer, In general, most skin surgery procedures are best performed with plastic surgery needles.

SUTURING TECHNIQUE Meticulous suturing technique is fundamental to obtaining excellent aesthetic and functional results. Properly placed sutures allow for approximation of wound edges, wound-edge eversion, minimization and redistribution of tension, elimination of dead space, maintenance or restoration of natural anatomic contours, and avoiding permanent suture marks on the skin surface. The suturing technique selected for a specific wound closure depends on the anatomic location, tension, thickness of the wound edges, and goals of the surgeon.

Interrupted Sutures. The simple interrupted suture is the most basic and versatile suture used by dermatologic surgeons. Ab-



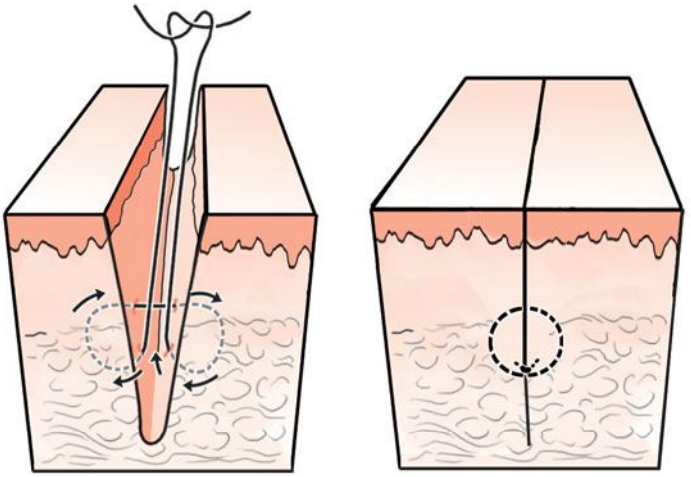

▲ **FIGURE 243-8** "Heart-shaped" subcutaneous buried suture.



sorbable, buried interrupted sutures are used as part of the layered wound closure. These sutures provide support for the wound until tensile strength has increased sufficiently to prevent wound dehiscence and reduce tension on the wound edges. To achieve good eversion of the wound edges, these are best placed in the deep dermis and subcutis in a heart-shaped configuration (Fig. 243-8).[7] Wounds in which one skin edge appears higher than the other can be appropriately aligned by taking a larger bite from the lower edge and a smaller, more superficial bite from the higher edge.

Epidermal simple interrupted sutures, used to obtain optimal alignment of the epidermal edges of the wound, are more time-consuming to place and remove than a continuous running sutures. In settings where wound healing may be impaired because of the patient's underlying medical condition or in areas of high tension, interrupted sutures may be preferred. This type of suture usually provides greater tensile strength and less potential to cause edema, induration, and impaired microcirculation than running sutures. In addition, in areas of high tension, the risk of wound dehiscence can be assessed by removing alternate sutures. If it seems that dehiscence is likely, the remaining sutures may be left in place for 3 to 4 additional days.

The vertical mattress suture provides wound-edge eversion, reduces dead space and minimizes tension across the wound (Fig 243-9). It achieves the same effect as a buried dermal suture and an epidermal suture. Because this suture requires four entry points in the skin, significant crosshatching can be expected if the suture is not removed within 5 to 7 days. This suture by nature is a tightly placed suture and can be difficult to remove because of its tendency to become embedded in the skin.

The horizontal mattress suture has been used to reduce tension across wound closures that are under significant tension (Fig. 243-10). This technique also creates wound eversion. This suture can be placed as an initial tension-reducing or holding suture and to bring the wound edges closer together, so that subcutaneous sutures can be placed to distribute tension and close the wound. At this point, if the tension has been adequately distributed, the horizontal mattress suture may be removed. If tension across the wound persists, the horizontal mattress suture may be left in place for a few days while early wound healing proceeds and removed before suture tracks have had a chance to form. The main disadvantage of this suture is the possibility of wound-edge necrosis as this suture can easily strangulate the dermal plexus between its limbs. This problem is minimized by taking large bites with the needle to encompass large amounts of tissue, by using bolsters, by tying the suture only as tight as necessary to accomplish the task of bringing the wound edges together, and by removing the suture as soon as possible. Before contemplating the use of a horizontal mattress suture for tension reduction, the surgeon should consider other means of reducing tension across the wound, including appropriate use of undermining and closure orientation, flaps from areas of tissue excess, preoperative or intraoperative tissue expanders, serial excisions, and subcutaneous sutures.

The half-buried horizontal mattress suture is primarily indicated for the positioning of various corners and tips including flap tips, M-plasty tips, and V-Y closure tips. It can also align the edges of tangential flaps and flaps with ischemic wound edges. The buried limb of this suture is placed in the potentially ischemic area in order to minimize interference with the dermal vascular plexus. A superficial simple interrupted suture through a flap tip may also work without resulting in increased risk of flap tip necrosis.

Running Sutures. The simple running suture can be used in situations where the wound edges are of equal thickness without tension, closely approximated, and with an absence of subcutaneous

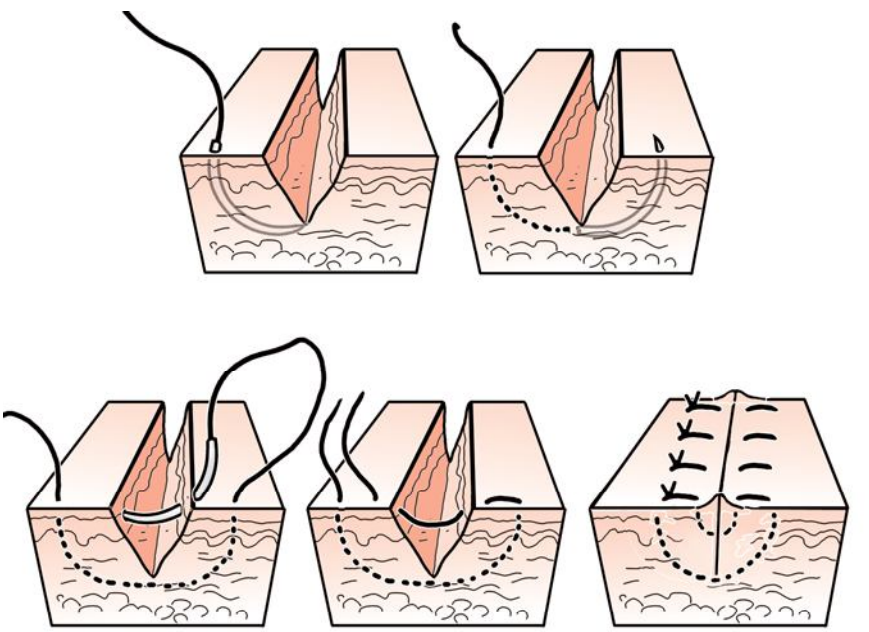

▲ **FIGURE 243-9** Vertical mattress suture.

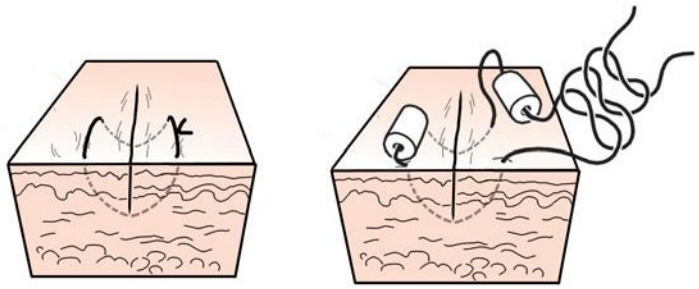

▲ **FIGURE 243-10** Horizontal mattress suture.

dead space. This suture is most useful for wounds that have already been closed by buried sutures, for the attachment of full-thickness or split-thickness skin grafts, and in areas of thin skin such as the eyelids, ears, neck, and scrotum. By eliminating all but two knots, there is less suture material resting against the skin, resulting in the development of fewer scars from suture marks. However, fine adjustments along the suture line are difficult to make and the suture has a tendency to pucker when very lax and thin skin, such as eyelid skin, is being sutured. In thin skin, the knots at each end may be tied over small bolsters to prevent them from cutting into the tissue.

The running locking suture is a variant of the simple running suture in which, after the placement of each loop, the needle is passed through the previous loop prior to starting the next loop. It is intended for the closure of well-vascularized wounds under a moderate amount of tension. The wound edges should be stiff and of equal thickness without a tendency for inversion. It is stronger than a simple running suture. However, if it is placed too tightly or if significant post-operative swelling develops, tissue strangulation with wound-edge necrosis may ensue.

The running subcuticular suture is a buried running suture which is usually not absorbable. It is ideal for the closure of wounds in areas such as the trunk and extremities where the suture must remain in place for more than 7 days. As the suture is buried, there are no suture marks and the suture may be left in place for several weeks, even months. When absorbable suture material is used, it may be left in place until it is absorbed. As this suture is capable of only modest wound-edge alignment, it should be reserved for wounds in which the tension has been eliminated with deep sutures and the wound edges, of approximately equal thickness, are closely approximated. The running subcuticular suture should be placed with a nonreactive monofilament suture such as polypropylene to facilitate suture removal and prevent suture breakage within the wound. Some surgeons use a permanent suture left in place indefinitely, as this can reduce scar stretching. If non-absorbable sutures are selected clear, nonreactive suture material should be used.

SUTURE REMOVAL Timing of suture removal must balance two factors: leaving the sutures in place long enough to allow wound healing and prevent dehiscence and removal before the development of suture track marks along the scar line. These suture track marks occur because re-epithelialization occurs around the suture. In general, the less blood supply to an area and the greater the tension across a wound, the longer the sutures should be left in place. On the face and ears, most skin sutures should be removed within 5 to 7 days. Eyelid sutures can be removed in 3 to 5 days. Neck sutures should be removed in 7 days and scalp sutures in 7 to 10 days. On the trunk and extremities, risk of wound dehiscence takes precedence over suture marks. Sutures on the trunk and upper extremities should be left in place for 7 to 14 days. Lower extremities may require up to 21 days of suture support, though, with proper deep suture placement, epidermal sutures can generally be removed in 7 to 10 days.

Absorbable sutures are not removed, but some patients develop suture reactions, consisting of sterile suture abscesses and suture extrusion through the wound. If this happens, the suture should be picked up carefully with small forceps and cut out of the wound. Any purulent material should also be drained.

STAPLE CLOSURE Staple closure of wounds is an alternative to suture closure. The staples have the advantage of very quick placement, minimal tissue reaction, and very strong wound closure. Staples are most often used with long wounds, especially on the scalp, where the suture line is hidden by scalp hair. Potentially contaminated wounds that are closed with staples appear to be more resistant to infection than wounds closed with sutures. Staples provide efficient wound closure; but when exact wound-edge alignment is required, sutures should be used. Staples are easily removed with a staple remover.

Postoperative Care

Most wounds can be cleaned appropriately with tap water and mild soaps. A diluted ascetic acid solution can be helpful to prevent *Pseudomonas* infection in sites predisposed to this. Small amount of hydrogen peroxide can help débride wounds that have developed significant crusting and exudate. However, in large amounts, it can be toxic to new cells. Most wounds are also best dressed with petrolatum and nonstick dressing. Petrolatum is relatively inert, nontoxic, nonsensitizing, and nonirritating. Although not common knowledge for the layperson, it has been well proven for years that covered or occluded wounds re-epithelialize and heal faster than dry wounds.[8] There is a large risk for allergic contact dermatitis with topical antibiotics, and they have not been shown to be superior in preventing wound infections. For wounds with significant drainage, dressings such as gauze, foam dressings, or alginates provide absorption.

REFERENCES

1. Salasche SJ, Bernstein G, Senkarik M: *Surgical Anatomy of the Skin*. Norwalk, Appleton and Lange, 1988
2. Bennett RG: *Fundamentals of Cutaneous Surgery*. St. Louis, Mosby, 1988
3. Dajani AS et al: Prevention of bacterial endocarditis: Recommendations by the American Heart Association. *JAMA* **277**:1794, 1997
4. Robson MC et al: Quantitative bacteriology and delayed wound closure. *Surg Forum* **19**:501, 1968
5. Alam M, Goldberg LH: Serious adverse vascular events associated with perioperative interruption of platelet and anticoagulant therapy. *Dermatol Surg* **28**:992, 2002
6. LeVasseur JG et al: Dermatologic electrosurgery in patients with implantable cardioverter-defibrillators and pacemakers. *Dermatol Surg* **24**:233, 1998
7. Davidson TM: Subcutaneous suture placement. *Laryngoscope* **97**:501, 1987
8. Winter GD, Scales J: Effect of air drying and dressings on the surface of the wound. *Nature* **197**:91, 1963



CHAPTER 244

Excisional Surgery and Repair, Including Flaps and Grafts

June K. Robinson



EXCISIONAL SURGERY

Elliptical or fusiform excision is one of the most frequently performed dermatologic surgery procedures. Mastery of elliptical excision and closure is fundamental to more advanced procedures. The elements to successfully perform excisional surgery include use of sterile technique; obtaining local anesthesia; planning the excision to respect the skin tension lines and/or the cosmetic units of the face; atraumatic technique in performing the incision and undermining; meticulous hemostasis and suturing; and postoperative wound care and pain control.

Patient Selection

Side-to-side closure can be used wherever there is sufficient skin laxity to allow direct closure of the defect under minimal tension without distortion or functional impairment of surrounding structures. A fusiform (elliptical) excision is indicated for the removal of small to moderate size benign or malignant neoplasms as well as for excisional biopsy. For optimal cosmetic results, the long axis of the fusiform excision should be oriented along the relaxed skin tension lines, which are generally perpendicular to the muscle pull in the area.[1] Ideally, facial excisions should be placed within one of the major cosmetic units (e.g., forehead, nose, periorbital area, lips and perioral area, chin, and cheeks).[2] The boundaries of these units may be used to hide an incision by placing it at the junction of units. However, avoid crossing the boundary such as the nose-cheek concavity.

Risks and Precautions

- Inappropriate placement or appearance of incision.
- Plan the excision with the patient seated and with animation of the face if it is a facial location. On the trunk or extremities, test the skin tension by moving the area.
- Excise additional tissue to place the incision at the junction of facial cosmetic units or within rhytides.
- Excise the wound edges by cutting perpendicular to the skin surface and maintaining an even depth of resection across the base of the wound.
- Remove standing cones of redundant tissue.
- Excessive bleeding.
- Discontinue anticoagulation preoperatively.
- Meticulous hemostasis with arterial ligation of "named" arteries.
- Wound infection.
- Sterile technique.
- Atraumatic tissue handling.
- If the wound base perforates into the nasal or oral cavities, initiate prophylactic systemic antibiotics.
- Wound dehiscence.
- Immobilize the wound edges for 2 weeks after surgery.
- Use buried subcutaneous sutures and fascial plication to relieve tension on wound edges.

Patient Positioning

The procedure is planned with the patient in an upright position and with the proposed surgical area examined while in motion. Have the patient smile, show his teeth, or grimace to animate facial areas. After the excision lines are marked with a Gentian violet marking pen or similar marker, have the patient lie down on a mechanical surgical table in either the prone, supine, or lateral positions depending on the location of the lesion. It is important to have a mechanical table because patients sometimes get hypotensive during injection of anesthesia or surgery. If this happens, the table can be placed in reverse Trendelenburg position and the pulse and blood pressure are monitored.

Equipment

PROCEDURE ROOM

- Basic: Mechanical table, overhead procedure lights, electrocautery, ability to monitor pulse and blood pressure, Mayo stand (1 or 2), kick bucket for contaminated waste.
- Optional: Depending on the location and scope of the procedure, suction may be needed.

SURGICAL TRAY The specific instruments selected depend on the scope of the procedure and personal preference of the surgeon. It is advisable to set up the basic elements on the tray in the same "layout" each time. Consistency in placement of sharps and their return to the same location during the procedure prevents inadvertent injury with contaminated instruments to the surgeon or the assistant. One approach is to set up the tray with the instruments that are used first on the front left. After returning a used instrument to its place on the tray, the surgeon then progresses across the front of the tray (Fig. 244-1A). This leaves the back of the tray for sharps, which may be placed in a sterile cup or inserted into a disposable foam pad.

The surgeon and assistant need to coordinate their movements and should not reach across each other's field on the

EXCISIONAL SURGERY AT A GLANCE







- Elliptical excision is the most frequently performed procedure. Mastery of elliptical excision and closure is fundamental for more advanced procedures.
- Lazy S-repair, partial closure, and staged excisions are variations of the ellipse.
- Random pattern flaps, advancement flaps, subcutaneous island pedicle flaps, rotation flaps, and transposition flaps are procedures that are used when the excision wound cannot be closed by simple approximation of the wound edges.
- Full thickness and split thickness skin grafts are used when excisional wounds are either small, shallow, or when the anatomic site or general condition of the patient preclude any of the flap procedures.
- Depending on the size, surgical wounds can also be left to heal by second intention, but this may lead to wound contraction and requires prolonged healing time.

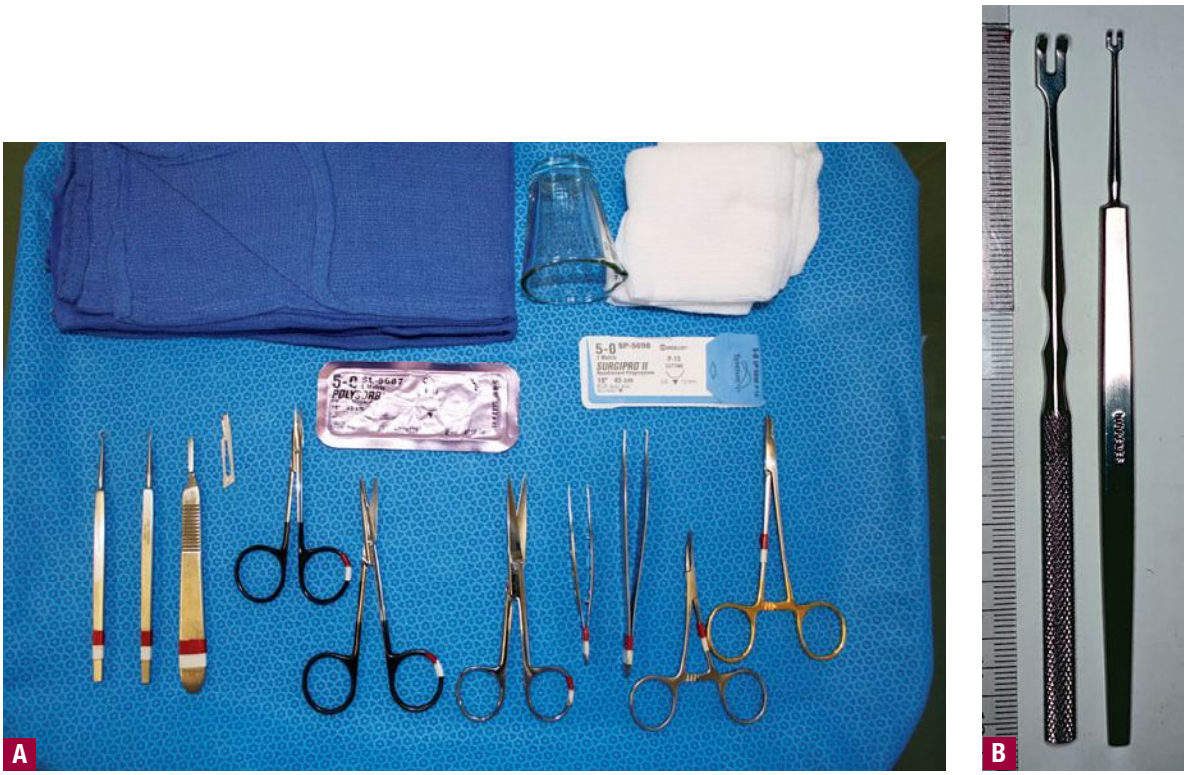

▲ **FIGURE 244-1** **A.** The basic surgical tray has the instruments laid out from left to right, and the disposable supplies are added at the back of the tray. **B.** Small two-prong skin hook has enough space between the two prongs to allow a needle to pass.

tray during the procedure. Some prefer to set up the surgeon on one Mayo stand and the assistant on another. All instruments are returned to the tray during surgery. Avoid placing instruments on the sterile surgical field when they are not in use. They will slide onto the floor or may stick the patient. Contaminated sponges should be discarded directly into the waste bucket and not placed on the tray. Used sponges discarded onto the tray cover sharp instruments and may cause inadvertent harm to personnel who are stuck with contaminated "sharps."

A basic excisional surgery tray should contain

- Instruments: #15 blade, #3 Bard-Parker scalpel handle, smooth-toothed Adson forceps, 2×1 toothed Adson forceps, two, 2-prong skin hooks, undermining scissors, two curved hemostats, suture-cutting scissors or stapler remover, small cup for sterile water to irrigate the wound
- Disposable material: Marking pen, gauze sponges, cotton tip applicator sticks, scratch pad for electrocautery tip, electrocautery tip, surgical drapes, foam pad for discarded needles
- Suture or staples

For larger procedures, such as flaps, additional hemostats are needed. Special procedures will need other instruments added to this tray [e.g., split-thickness skin grafts (STSGs) require a dermatome]. The specific instruments selected depend on the scope of the procedure and personal preference of the surgeon. The double-pronged small skin hook provides greater stability of the wound edge than the single-prong hook when the middle finger of the non-dominant hand places gentle pressure against the skin surface to evert and lift the edge (see Fig. 244-1B).

Anesthesia

Most excisions are performed with local anesthesia, usually 1 percent or 2 percent lidocaine with epinephrine 1:100,000, injected in a ring around the lesion. For larger procedures, such as rotation flaps, nerve block anesthesia is helpful because a large area can be anesthetized with a limited volume of anesthesia. Tissue distortion is limited with nerve block anesthesia, and the vascular perfusion of the flap is not impaired.

Technique

EXCISION WITHOUT CLOSURE The lesion is excised as a circle with adequate margins and the wound is allowed to heal by second intention.[4] The incision through the skin is performed at an inward sloping angle to provide exposure of the base of the wound. The diameter is usually larger than 1 cm. For patients who are poor surgical risks for reconstructive surgery or who refuse reconstructive surgery, these wounds may heal by second intention. Healing by second intention is also indicated for infected wounds, to allow observation of the wound bed after resection of tumors at high risk for recurrence, for selected pathologic ulcers, and when the anticipated cosmetic result is at least as good as that achieved by reconstruction.[5] Wounds that are allowed to granulate are very resistant to infection and cannot form a hematoma.

The locations that lend themselves best to wound healing by second intention, with superior cosmetic results, are concave areas such as the nose-cheek junction, medial canthus, ear concha, preauricular cheek, and retroauricular scalp.[5] Wounds allowed to heal by second intention may decrease in size as much as 50 percent or more.[5] Superficial wounds heal with less wound contraction, because there is less deposition of collagen. Therefore, a superficial wound, even on a convex surface such as the forehead or the nose, usually heals well. Because all wounds contract to some degree, it is important that there be no



"free" margin along one side of the wound that can be pulled up during wound contracture and cause distortion at the site. This may be encountered along the eyelid margins, ear margins, eyebrow, nasal ala, and lip vermillion border. These areas are better managed with appropriate reconstructive surgery.[6] Disadvantages of healing by second intention include prolonged healing time of several weeks, the need for daily wound care by the patient, and the somewhat unpredictable cosmetic results.[7]



ELLIPTICAL EXCISION ***Planning the Excision.*** If relaxed skin tension lines are not obvious, testing skin movement between the surgeon's index finger and thumb indicates the direction of least tension. After identifying the relaxed skin tension lines, draw the appropriate margins around the lesion and then design the ellipse.

When the pinch testing for skin tension lines does not help, identify the relaxed skin tension lines, and then a two-step procedure may be used. With the patient prone, supine, or in a lateral position that offers the best exposure of the site, the lesion is excised to the depth of the fat with an appropriate margin. The defect will gape open in the form of a partial ellipse, reflecting the actual relaxed skin tension lines. As the wound is closed with a few centrally placed sutures, bilateral standing cones of excess tissue form on either side of the central closure. After these standing cones are excised as dog-ear excisions, a straight-line, crescentic, lazy S-closure, M-plasty, or A-T plasty results (Fig. 244-2).

The simple ellipse is based on an optimal length to width ratio of 3.5:1.0, which may be increased to 4:1 or greater in locations with less tissue distensibility or decreased to 3:1 in areas of greater tissue distensibility. The apical angle between the two arciform incisions is in the range of 53° to 74°.[8] At the apex, each fusiform incision forms approximately a 30° angle with the intended closure line along the maximal skin tension line; thus, the two 30° angles formed at the apex by the intersection of the arciform incision lines and the line of maximal skin tension make the angle between the two arciform incision lines approximately 60° for an ellipse with approximately a 3.5:1.0 ratio (Fig. 244-3A). As the ratio becomes larger, the apical angle decreases; thus, for a ratio of 5:1, which may be needed for scalp surgery, the apical angle approaches 30° (see Fig. 244-3B).

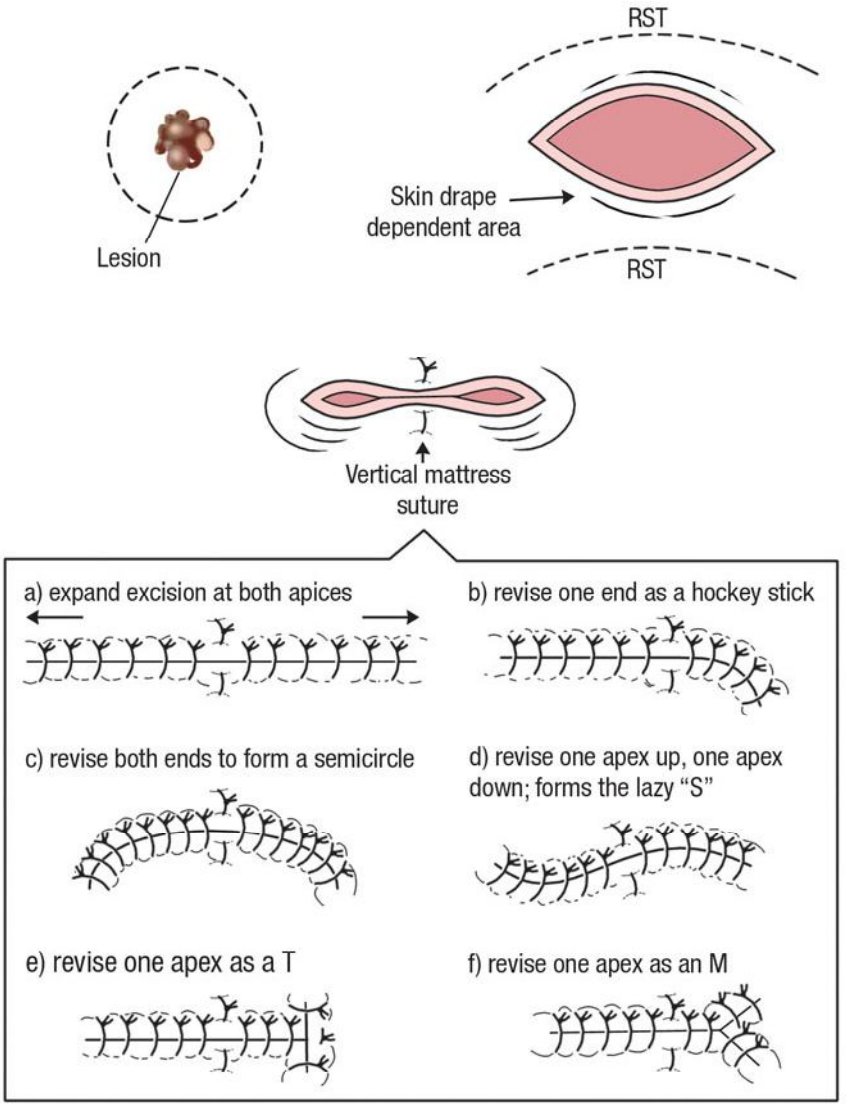

▲ **FIGURE 244-2** When the lesion is excised with an appropriate margin, the resulting defect is often circular. By pinching the wound edges together in several ways, standing cones of redundant tissue are manipulated to form in the direction in which they may be excised with optimal scar placement. The incision is extended in a) a straight line; b) on one end in a hockey-stick revision; c) on both ends by two hockey-stick revisions in the same direction, creating a curved incision; d) on both ends by two hockey-stick revisions in the opposite direction, creating a lazy-S incision; e) at one end of the incision both inferior and superior to the incision, creating a T incision; or f) at one end of the incision both inferior and superior to the incision, creating an M incision.

Procedure. After the surgical site is marked with the lines of excision, the field is anesthetized, prepped, and draped. The incision is made smoothly by starting with the tip of the blade at the apex. Then, as the hand moves toward the middle or arc of the incision, the blade is allowed to rock down onto the belly of the blade. As the apex of the incision is approached, the blade rocks up onto its tip, which allows the surgeon to clearly see the apex of the incision under the advancing hand (Fig. 244-4). This prevents "overshooting" the incision beyond the planned apex. Another important point is that the scalpel is held perpendicular to the skin surface, which prevents undercutting the lesion to produce a beveled incision. In general, a #15 blade is used to cut through to the fat on the first pass; however, thick back skin may require a #10 blade. Traction on the surrounding area is needed to prevent bunching of the tissue ahead of the pressure exerted by the blade.

The size of the defect produced by the incision is determined by the size of the lesion and the necessary margin of resection. When benign lesions are excised with a 1- to 2-mm margin (Fig. 244-5), the margin for malignant lesions ranges from 5 mm to 2 cm (Fig. 244-6).

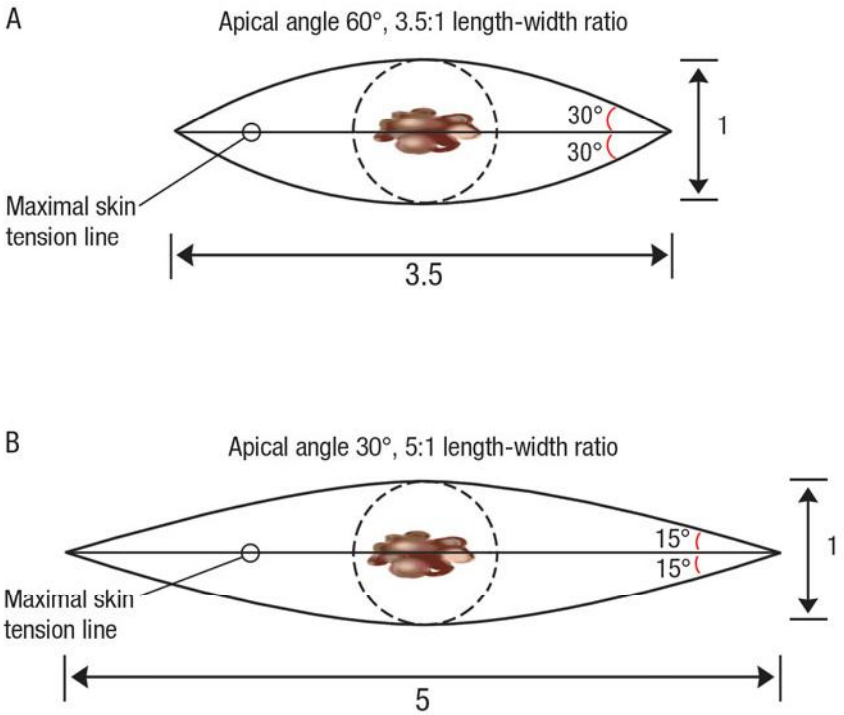

▲ **FIGURE 244-3** **A.** At the apex, each fusiform incision forms approximately a 30° angle with the intended closure line along the maximal skin tension line. **B.** As the length-width ratio becomes larger, the apical angle decreases; thus, for a ratio of 5:1, which may be needed for scalp surgery, the apical angle approaches 30°.

The end of the ellipse is grasped gently with a toothed forceps to elevate the tissue. The base of the specimen is dissected in an even plane with a scalpel for sharp dissection or a scissors for blunt dissection. The apex of the fusiform excision should be the same depth as the middle. There is a tendency to excise the tips at a more shallow depth than the center. When the depth of the excision is not uniform, a bulge, a standing cone of tissue, surrounds the tip as the wound is closed with subcutaneous sutures. These standing cones are excised so that the force of the redundant tissue does not exert pressure against the wound closure, and to improve the final appearance of the closure.

Once meticulous hemostasis is obtained at the base of the excision, then undermining of the surrounding skin and a layered closure are performed. Undermining with a blunt-tipped scissor is needed to allow placement of buried subcutaneous sutures and to minimize tension on the wound. If the skin around the surgical site is lax, and subcutaneous sutures can be placed without undermining, then it is appropriate to do so. Patients receiving anticoagulants or with reduced platelets benefit by limiting the extent of undermining as the risk of bleeding and hematoma formation is decreased.

Wound Closure. Most wounds are closed with a double layer of closure consisting of absorbable deep sutures and nonabsorbable superficial sutures. A wound gains only 7 percent of its final strength after 2 weeks.[8] As most skin sutures are removed within 1 week of placement, absorbable buried sutures are used as part of layered wound closure. This provides support for the wound until tensile strength has increased sufficiently to prevent wound dehiscence. Deep, buried sutures are placed into wounds to reduce or eliminate tension on the wound edges. On the trunk and extremities, where tension across wounds is greatest, the use of buried sutures may reduce the amount of scar spread. Buried sutures can align the wound edges, so that the skin edges are closely approximated even before the placement of skin sutures. Deep sutures can eliminate dead space and align deep structures such as skeletal muscle or fascia. Deep sutures can also be used to anchor overlying tissue to underlying fixed structures, such as periosteum, to maintain proper facial contour and function. This is exemplified by anchoring a melolabial flap to the maxillary periosteum.

Suturing technique, which is described in Chap. 243, reduces and redistributes wound tension, slightly everts the skin-edge, eliminates dead space, and maintains or restores natural anatomic contours, while avoiding the formation of permanent suture marks on the skin surface. When there is little tension on the wound edges, the wound is closed by the rule of halves. The first suture is placed in the center of the wound. Then each half of the remaining defect is closed in a similar manner.

If there is a lot of tension on the wound, a vertical mattress retention su-

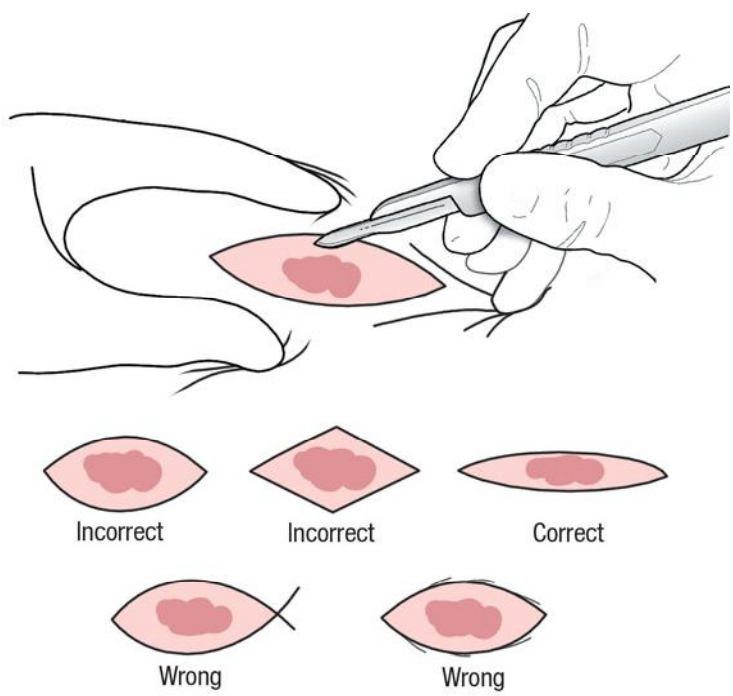

▲ **FIGURE 244-4** The incision is made smoothly by starting with the tip of the blade at the apex.





▲ **FIGURE 244-5** **A.** A benign hemangioma of the left lower eyelid. The incision is planned to lie at the junction of the periorbital area and the cheek. **B.** The closure produces a mild eversion of the lower lid due to the volume of local anesthesia. **C.** Six months after surgery.



ture across the middle of the wound may put the tissue on stretch. The retention suture does not close the edges. Then, the wound closure begins at the apices and progresses to the middle of the wound. This helps to reduce the tension as the repair advances from the ends to the middle of the defect. Once the wound is closed, the retention suture is removed. The suture line is cleansed and then checked to be sure there is no active bleeding. A gauze pad or cotton-tipped applicator is rolled along the suture line. Minimal oozing is often present on the first roll but disappears with subsequent rolls. If there is bleeding, then firm downward pressure is applied to the wound with gauze for 5 minutes by the clock. If bleeding persists, then the sutures are removed, and the wound bed is explored for the source of the bleeding.

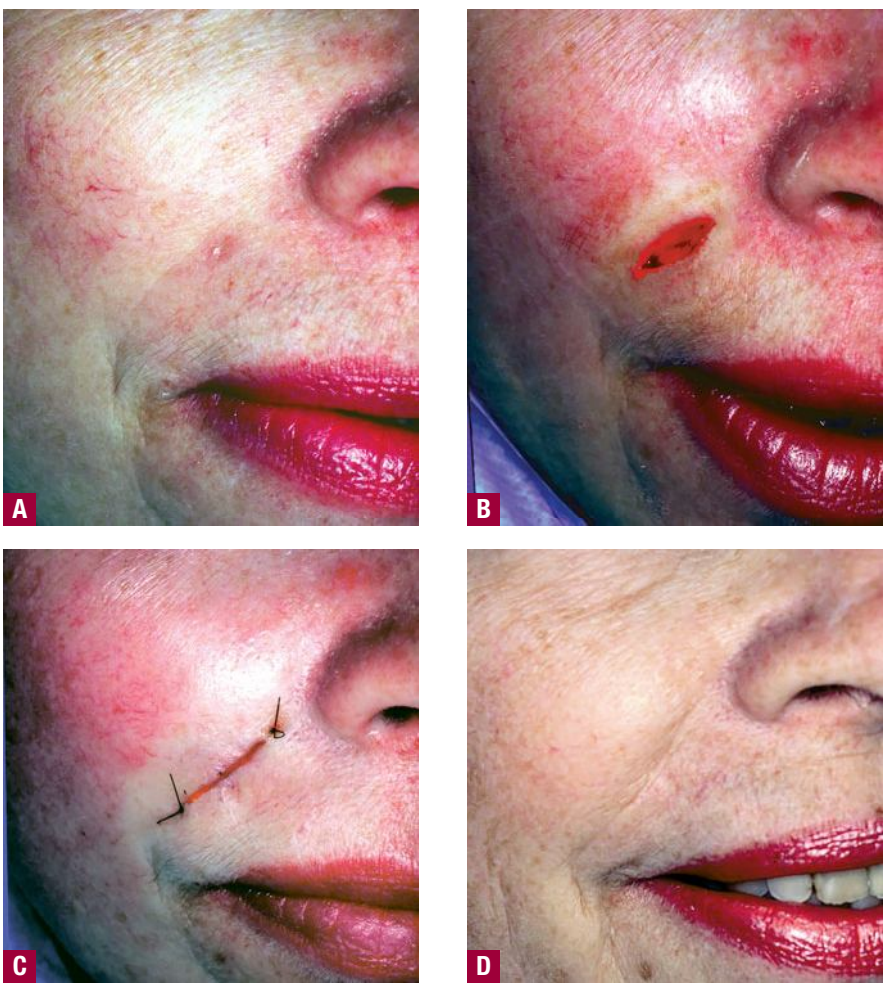

▲ **FIGURE 244-6** **A.** A primary basal cell carcinoma of the right nasolabial fold was previously biopsied by the shave technique. **B.** The excision with 5-mm margins is planned as an ellipse that lies in the nasolabial fold. **C.** Closure under minimal tension with buried subcutaneous sutures and a pullout suture. **D.** Ten years after surgery.

Suture Removal. The risk of crosshatch marks across the suture line can be minimized by removing the sutures within 5 to 7 days before the formation of epithelial suture tracks is complete, using minimally reactive monofilament suture, such as polypropylene, and eliminating tension across the wound with appropriate planning of wound closure, adequate undermining, and the use of buried sutures. On the face and ears, most skin sutures should be removed within 5 to 7 days, with eyelid sutures removed in 3 to 5 days. Neck sutures should be removed in 7 days and scalp sutures in 7 to 10 days. On the trunk and extremities, risk of wound dehiscence takes precedence over suture marks. When the closure is under extreme tension or the edges are not approximated with subcutaneous sutures, sutures on the trunk and extremities should be left in place for 10 to 14 days to provide additional support.[10] If the wound edges are easily approximated with subcutaneous sutures, then they may be removed in 7 days. If the wound edges are everted by the subcutaneous sutures, then cyanoacrylate may be applied to the skin surface. This approach provides easy wound care and the patients does not have to return for suture removal.

Simple interrupted sutures are more time-consuming to place and remove than a running suture. In settings where wound healing may be impaired due to the patient's advanced age or underlying disease, interrupted suture techniques may be preferred, as interrupted sutures may have, with all other factors being

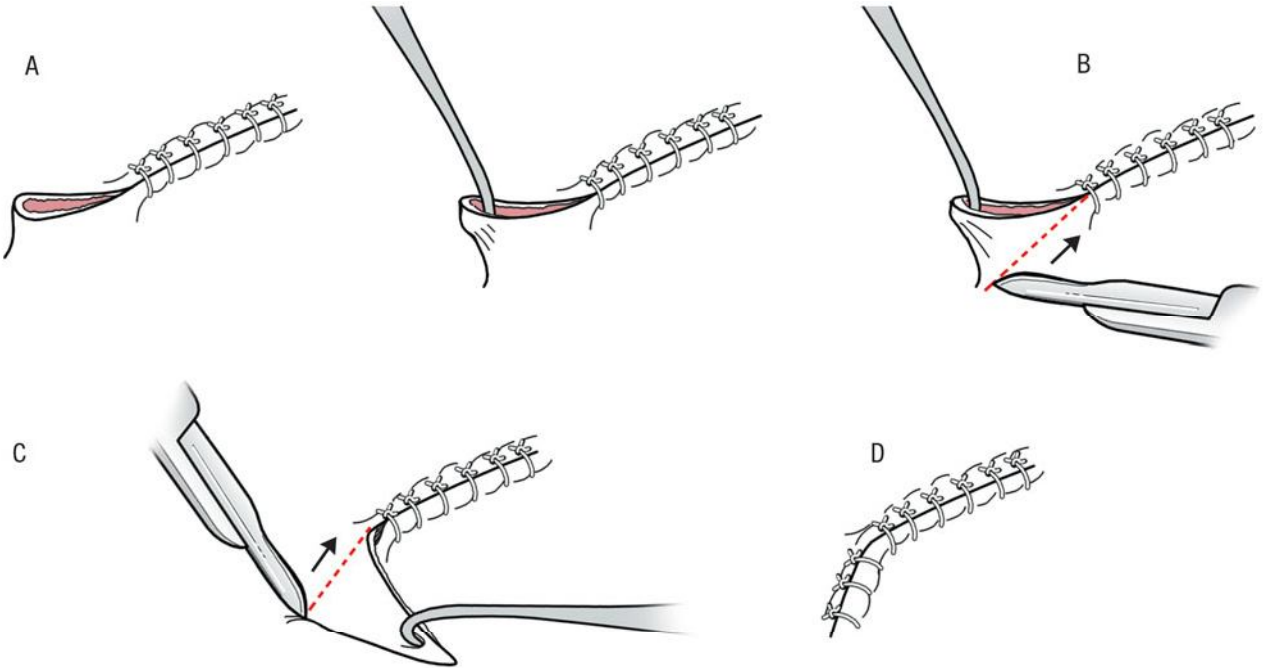

▲ **FIGURE 244-7** **A–D.** Correction of standing cones (dog-ears).

equal, greater tensile strength and less potential to cause edema, induration, and impaired microcirculation than running sutures.[11] In addition, removing alternate sutures monitors wound healing by looking for dehiscence with each suture removed. If it seems that dehiscence will occur, then the remaining sutures are left in place for 3 to 4 additional days.

REVISION OF STANDING CONES OF TISSUE AT THE ELLIPTICAL APICES Skillful repair of the redundant standing cones, also referred to, less elegantly, as *dog-ears*, may extend the incision line by removing an additional ellipse of tissue at the tip, or turn it into a crescentic incision placed in a wrinkle line. The apex of the standing cone is lifted with a skin hook and manipulated to test where to place the incision that releases the elevated tissue. It may be possible to place this releasing incision into an adjacent wrinkle. After the incision is made, the redundant skin is moved over it with the skin hook. At the place where the overlying skin crosses the releasing incision, the redundant skin is cut off (Fig. 244-7).

VARIATIONS OF THE ELLIPSE: CRESCENTIC REPAIR, LAZY-S REPAIR, PARTIAL CLOSURE, AND STAGED EXCISIONS The crescentic excision creates one side longer than the other, which results in a curvilinear scar that is superior to a straight-line incision when it is placed into a curved wrinkle line. The crescentic repair is useful on the cheek and around the chin. (Fig. 244-8; see eFig. 244-8.1 in on-line edi-



▲ **FIGURE 244-8** **A.** Basal cell carcinoma of the upper left cheek. **B.** After excision, the defect approaches the nasolabial fold. A simple ellipse is planned. **C.** Closure. **D.** Ten years after surgery, tissue remodeling makes the scar fade into the nasolabial fold.



tion). The wound is closed by the rule of halves. It is common for one wound edge to be higher than the other; therefore, adjustments for wounds of unequal height are made by suture placement by taking deeper bites with the needle on the lower side and shallower ones on the higher side.

The lazy-S repair is useful on convex surfaces such as the jaw or extremities. A standard elliptical incision line contracts along the length of the incision from the ends to the middle by approximately 30 percent. Over time the center of the scar becomes depressed and the ends buckle up. By elongating the incision as an "S," the contraction occurs over a greater length and a variety of angles (Fig. 244-9).



Partial closure, also known as *placing guiding sutures*, is used when more extensive repairs are prohibited by the patient's health or coagulation status. The wound is closed from the ends toward the middle. When wound tension prohibits closure at the center, the area remains open to heal by secondary intention. The final scar is usually linear and resembles a spread scar in the middle.

Staged excisions are used to remove benign processes that are too large to be excised in one procedure without distorting surrounding tissues. The center of the process is removed, and the area is allowed to heal for approximately 1 year. During this time, the surrounding tissues stretch and the tension on the incision decreases. Then, in a second procedure, the scar and remaining lesion are excised and closed primarily. A staged procedure usually results in a smaller incision than would be possible with a single procedure requiring tissue transfer by a flap or a graft to repair the defect. Another way to shorten the length of the incision is to perform an M-plasty, which some consider to be a variation of the ellipse.[12] Because the tip of the M-plasty has some forward motion into the defect, it is discussed in the section Advancement Flaps.

RANDOM PATTERN FLAPS

When simple primary closure cannot be done because a wound is too large, there is too much tension on the wound edges, or an unacceptable functional or cosmetic result would ensue, a tissue-movement procedure, such as a flap or a graft, should be considered. A local skin flap, random pattern flap, is a portion of full-thickness skin transferred from a donor site into a surgical defect while maintaining its blood supply from the donor site via a random or axial vascular pedicle that remains attached to the donor site. For random flaps, the skin that remains attached to the surrounding dermis provides the blood supply and the length to width ratio should not exceed 3:1 or 4:1 on the face and 2:1 on the trunk and extremities.[13] Flap incisions should, whenever possible, be made so that they fall into relaxed skin tension lines. The two movements involved in repairing a defect with a flap are the action of placing the flap into the defect, which is the primary movement, and the secondary movement of tissue in the donor area, which closes the secondary defect and facilitates primary flap movement. Both movements are important in terms of distributing tension in the proper direction and over a larger area so as to minimize tension on the flap itself, which might compromise its survival.[14]

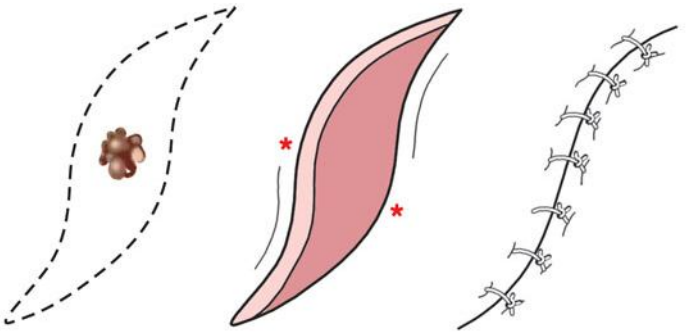

▲ **FIGURE 244-9** Lazy-S excision is used on convex surfaces such as the arm and leg.

Advancement Flaps

The name *advancement flap* derives from its primary motion. In an advancement flap, the tissue movement "advanced" in a straight line from the donor area to the recipient site. The alphabetical letter formed by the incision (e.g., M-plasty, H-plasty, A-T–plasty, and V-Y–plasty) further specifies the nature of the advancement flap. A classic example of a single advancement flap is the M-plasty, which is used to shorten the length of the incision (Fig. 244-10). It may be camouflaged in locations where wrinkles bifurcate, such as the crow's feet in the periorbital area or around the lips. A larger single advancement flap is the cheek advancement flap (Fig. 244-11A–D). The incision is placed in the nasolabial fold by removing tissue above and below the defect to allow the cheek to advance into the nasofacial sulcus.

A bilateral advancement flap is an A-to-T flap, in which the circular defect is turned into a triangle. Incisions extend from the base of a triangular defect and the two sides of the triangle slide together along this baseline. A-T plasties are performed with the broad base along a functional or aesthetic unit (e.g., lip, eyebrow; Fig. 244-12). Common areas for the use of bilateral advancement flaps, H-plasty, include defects of hair-bearing skin in the eyebrow (see eFig. 244-12.1 in on-line edition) or mustache

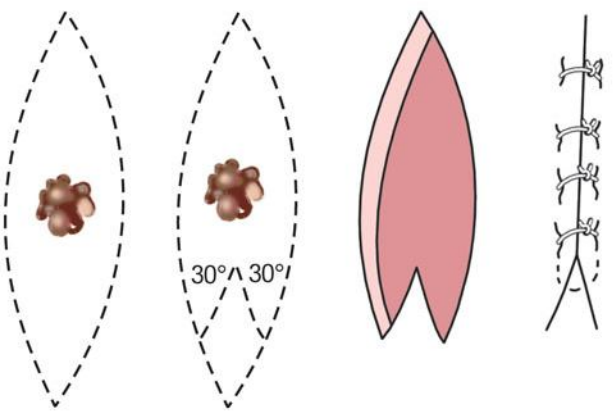

▲ **FIGURE 244-10** M-plasty reduces the length of the incision and avoids extension into significant areas such as the eye or lip.

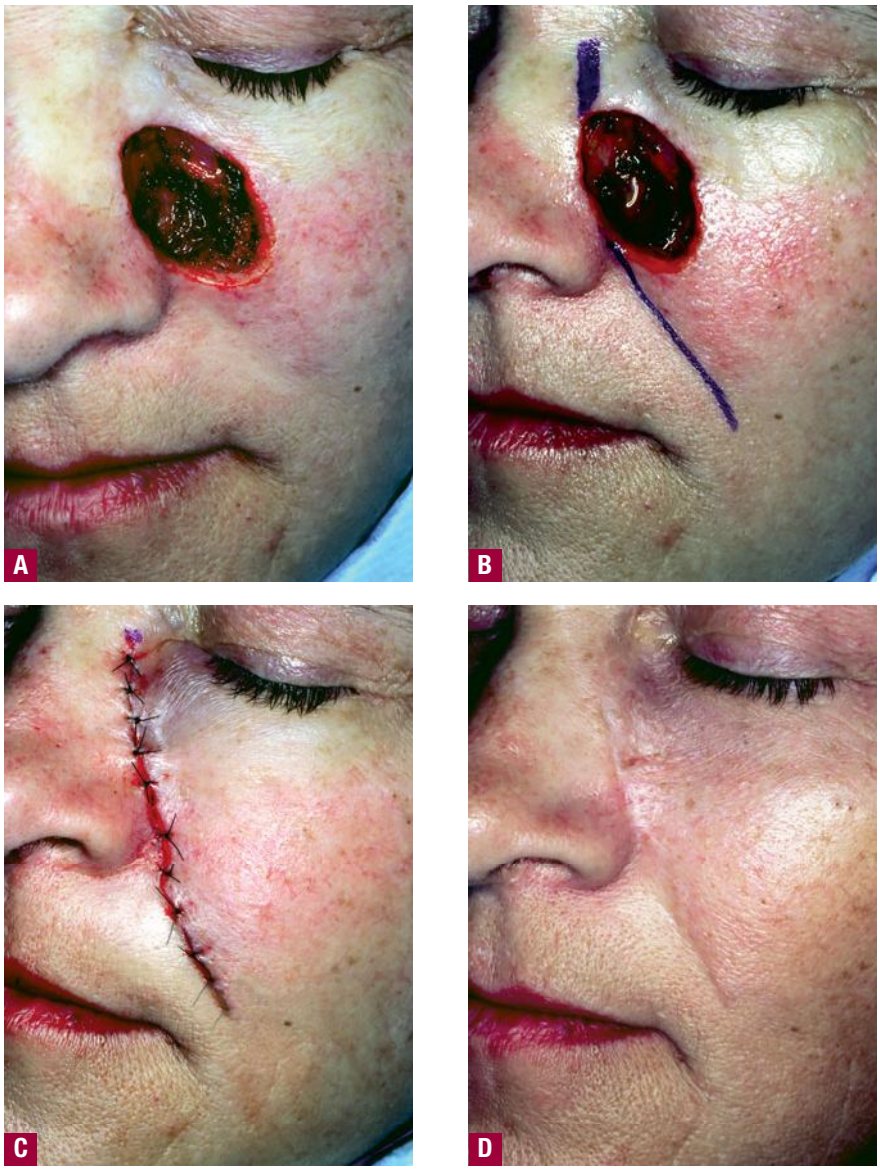

▲ **FIGURE 244-11** **A.** Left paranasal cheek defect. **B.** Junctions of cosmetic units of the cheek-nose and cheek-lip are marked to indicate the desired line of closure. **C.** Closure is performed with preservation of the isthmus (the small triangle of skin that separate the ala from the nasolabial fold). **D.** Six months after surgery the slight fullness at the bottom on the incision mimics the cheek overhanging the lip.

area, where orientation of the hair shafts is critical.

A subcutaneous island pedicle flap may be considered as a variation of an advancement flap that has had all of its connections to the epidermis and dermis severed, maintaining its blood supply only through a subcutaneous tissue pedicle (see eFig. 244-12.1).[15] This flap usually slides from the defect apex into the center to close an area that would be under great tension if closed by side-to-side approximation of the wound edges.

Rotation Flaps

In a rotation flap, skin moves into the defect by rotating it about its pivot point. This is classically used to close relatively large defects on the cheek, forehead, or scalp. Adjacent lax tissue is recruited while the closure tension is redirected away from the primary defect.[13] The design of the traditional rotation flap uses a curvilinear incision along an arc adjacent to the primary defect. As the flap is raised and undermined, the adjacent tissue laxity allows the flap to rotate into the primary defect. The stiffness about the pivot point may hinder the flap's movement. Undermining the area of pivotal restraint improves flap mobility. If restraint of motion keeps the tip from moving into the distal defect, then a back cut can increase tissue movement in areas of limited tissue laxity, such as the nose. The back cut cannot extend so far across the base of the flap that it interferes with blood flow into the flap (Fig. 244-13).

The best way to assure adequate flap length is planning and testing the motion of the flap before cutting it. The

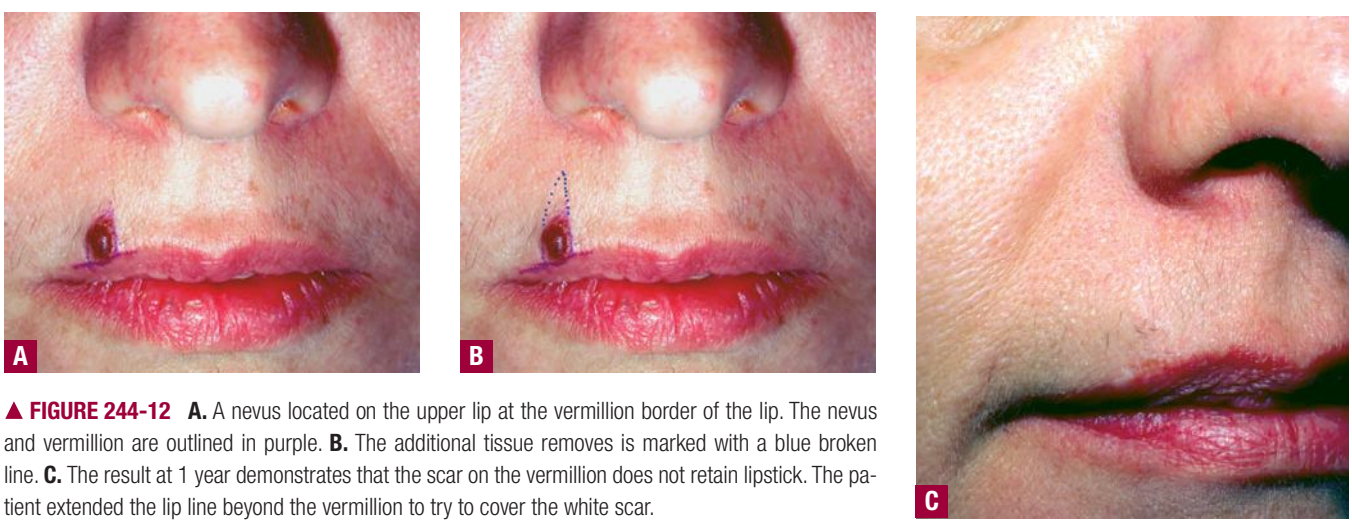

▲ **FIGURE 244-12** **A.** A nevus located on the upper lip at the vermillion border of the lip. The nevus and vermillion are outlined in purple. **B.** The additional tissue removes is marked with a blue broken line. **C.** The result at 1 year demonstrates that the scar on the vermillion does not retain lipstick. The patient extended the lip line beyond the vermillion to try to cover the white scar.



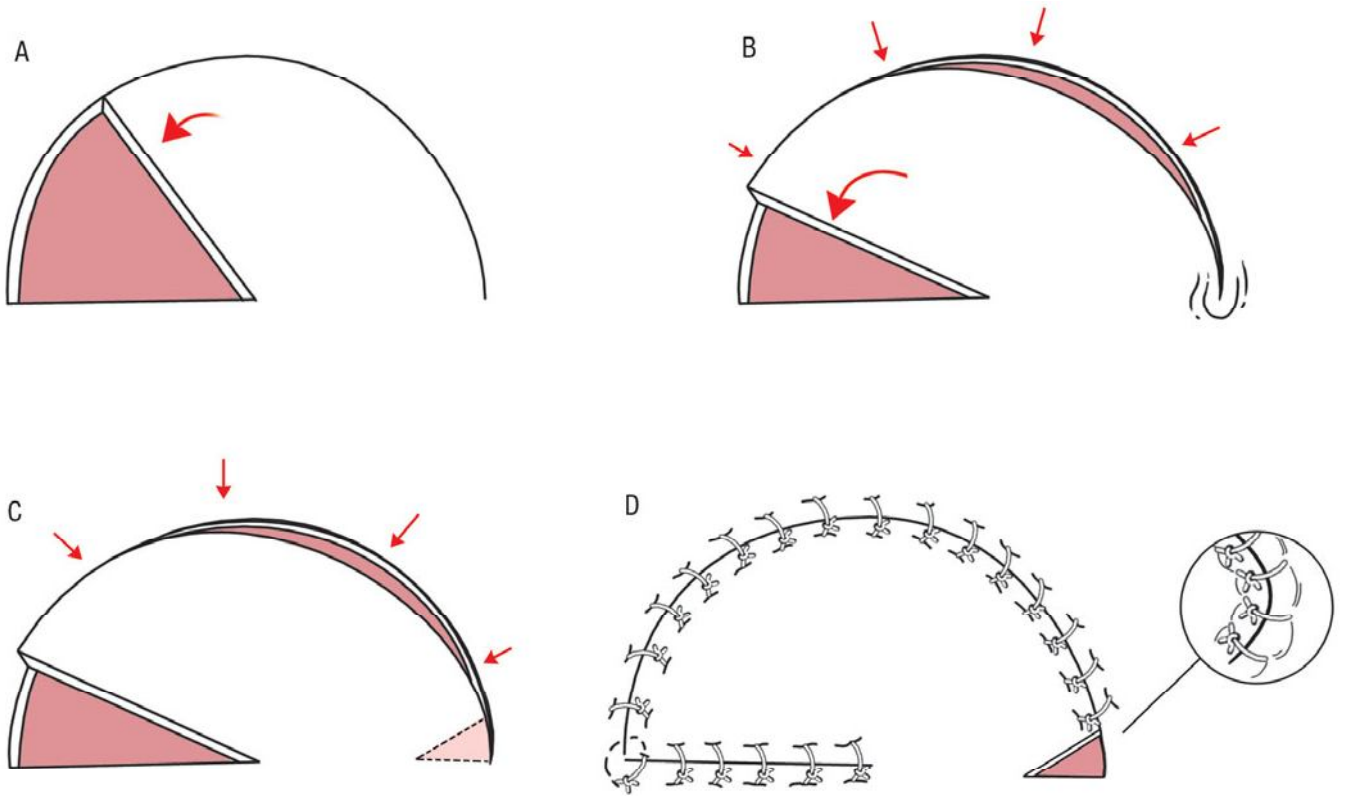

▲ **FIGURE 244-13 A–D.** Rotation flap with backcut.

length of the flap must be calculated by anticipating the horizontal motion over the surface as well as draping over changes in height of the wound bed. After the arc is traced on the skin,[16] a folded gauze pad is held at the pivot point with one hand, and, with the other hand grasping the end of the pad, the path of the proposed leading edge of the flap is traced to see if the tip of the proposed flap extends far enough into the defect. Because the pliable gauze drapes over the contours of the wound bed for this purpose, it performs better than a ruler. If the intended leading edge of the flap is not adequate, a larger arc of the rotation vector is planned to allow closure without tension on the tip of the flap (see eFig. 244-13.1 in on-line edition). Rotation flaps often require long incision lines, which are placed at the junction of facial cosmetic units (e.g., upper cheek–lower eyelid junction, and cheek–upper lip) (Fig. 244-14).

Transposition Flaps

Transposition flaps move skin from one site to another, crossing over normal skin as the flap moves into its new location. The transposition flap redirects wound closure tension by moving tissue from an area of redundancy into the defect, thus, the transposition flap pushes tissue into a defect rather than pulling it, as the advancement and rotation flaps do. The classic transposition flap is the rhombic flap (Fig. 244-15). The defect is visualized in the shape of a rhombus with equal sides and angles opposite each other of 60° and 120°, respectively. Drawing a line bisecting either of the 120° angles, which is equal in length to one side, creates the flap. The next line creates a 60° angle with that line and is parallel to and equal to the side of the rhombus.

Other single transposition flaps include the note flap, banner flap, nasolabial (melolabial) flap, and Webster's 30° modified rhombic flap.[17] As the single transposition flap moves through the arc of its rotation, the length of the flap gets shorter. Although it is theoretically possible for the flap to rotate about its turning point 180°, this is difficult to achieve because of the kink in the base of the flap (Fig. 244-16). The bilobed flap and Z-plasty have two transposition flaps moving simultaneously.

The paramedian forehead flap is a commonly used facial single transposition flap, which incorporates a named artery and is therefore considered an axial vascular pedicle flap. This transposition flap is performed in two stages (Fig. 244-17).[18] Tissue is mobilized from the forehead, based on one of the supratrochlear arteries, and transposed to repair large distal nasal defects with the pedicle remaining attached in the glabellar region. Division of the pedicle is performed in 2 to 3 weeks after the flap has established a local blood supply from the original defect's wound bed.

Patient Instructions

Flaps require careful postoperative wound care to assure that vascular compromise does not occur. Tightly applied bandages may compromise the blood supply to the flap and cause necrosis. The area under the flap must be free of any bleeding or oozing, as hemorrhage or hematoma formation may jeopardize flap survival and increase the risk of infection. Patients who smoke may compromise the blood supply to the flap, and large defects in smokers may require grafting rather than risking failure of a flap.

SKIN GRAFTS

Grafts are totally detached from the donor site and receive all nutrients from the wound bed of the recipient site. Full-thickness skin grafts (FTSGs) con-

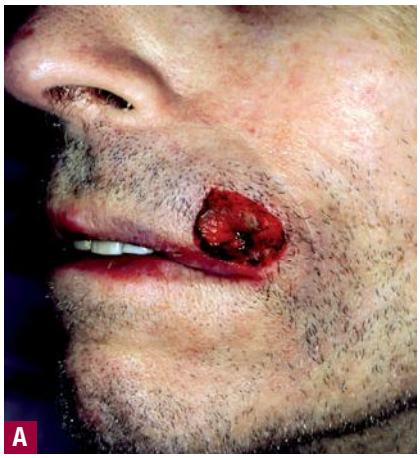









▲ **FIGURE 244-14** **A.** Basal cell carcinoma of the left upper lip. **B.** Rotation flap planned with adequate flap length to permit opening the mouth without tension on the flap. Area demarcated by dotted purple line is the area of anesthesia. **C.** The motion of the leading edge of the flap closes the primary defect and creates the secondary defect. **D.** The secondary defect is closed using the rule of halves. **E.** Demonstrating full use of mouth.

sist of epidermis with full-thickness dermis, and STSGs consist of epidermis with a varying thickness of dermis.

An FTSG is generally indicated for relatively shallow full-thickness facial defects that may not be amenable to primary closure or local flap repair or to temporarily cover a defect that needs to be observed for possible tumor recurrence. An FTSG contracts less than an STSG, and skin color match is better than with an STSG. It is usually harvested from the preauricular, nasolabial, postauricular, conchal bowl, supraclavicular, or eyelid areas. The donor site is chosen so as to match the recipient site in skin texture, thickness, color, and appendageal structure density. The graft is trimmed to exactly fit the defect and defatted. The donor site is closed with a primary side-to-side closure or second intention healing. The graft is sutured onto the recipient site, including basting sutures as needed. A bolster dressing may be placed over the graft to keep it in place and to prevent fluid accumulation underneath it. Because skin grafts do not bring a blood supply with them, they are more vulnerable to necrosis than simple closures or flaps. Skin color match is difficult to predict. Fairer-skinned individuals with even pigmentation and less sun damage do well with FTSGs (Fig 244-18). The more darkly pigmented or mottled the surrounding skin, the less likely a good color match is. Uneven edges around the graft may be smoothed out with dermabrasion 6 to 8 weeks after surgery.

An STSG is used to cover large defects, to allow better wound bed surveillance, to line a large pedicle flap or cover the donor site of a large FTSG, or to resurface mucosa.[19] It is usually harvested from the upper inner arm, thigh, buttock, scalp, or abdomen. The STSG is placed on the wound and fixed in place with absorbable sutures or staples. The main advantage of an STSG is that it survives even in locations with poor vascularization, such as a leg ulcer or denuded cartilage. The amount of dermis present determines the chance of survival of the graft on a poor vascular bed. Generally, the thinner the graft, the higher the "take rate" of the graft. Cosmetically, this graft is suboptimal, with absent appendages, poor color match, and frequent wound contracture under the graft (Fig. 244-19). The donor site re-epithelializes rapidly and relatively painlessly with the use of bioocclusive dressings.

Composite grafts include a component in addition to the epidermis and dermis. The most common composite graft includes cartilage and is used for the correction of full-thickness nasal ala defects. The graft is harvested from the ear helix so that it contains a sandwich of skin surrounding a piece of cartilage. After being sutured in place, the graft receives its blood supply only from its lateral margins. Therefore, only up to 1 cm of nasal ala rim can be replaced with a composite graft, as a larger graft will not receive sufficient nutrients to allow its central portion to survive.[20]

OUTCOMES ASSESSMENT

- Minimal discomfort.
- Maintenance of function.
- If excising a tumor, the margins are free of involvement.
- If the excision was performed to biopsy a lesion, an adequate specimen was obtained.



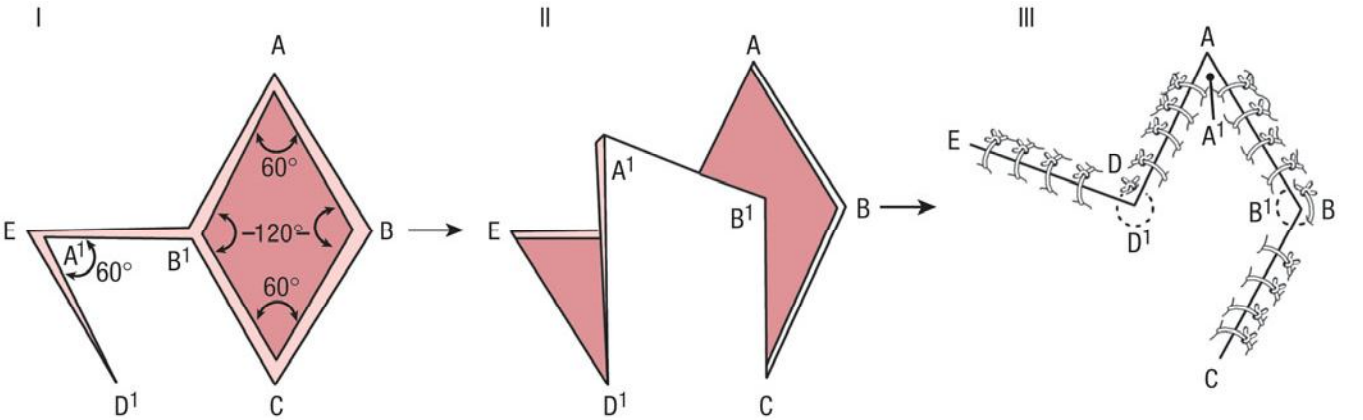

▲ **FIGURE 244-15** Rhombic transposition flap: (**I**) Design with shaded area representing surgical defect, (**II**) transposition after undermining, and (**III**) final suture line.



- Thin-line scar level with the surrounding surface of the skin.

COMPLICATIONS

Expected consequences of surgery are scar hypertrophy and hyperpigmentation of the incision site. The incision may become hypopigmented after a year. In certain areas under tension, such as the upper back and arms over the deltoids, the scar may spread. Erythema and telangiectases of the scar may develop. Suture granulomas from buried sutures are common.

In the case of a flap repair, the trapdoor effect occurs when the center of the flap becomes elevated and the suture line becomes depressed. It may resolve spontaneously over a period of 6 to 12 months. However, if the trapdoor effect persists, it may respond to intralesional

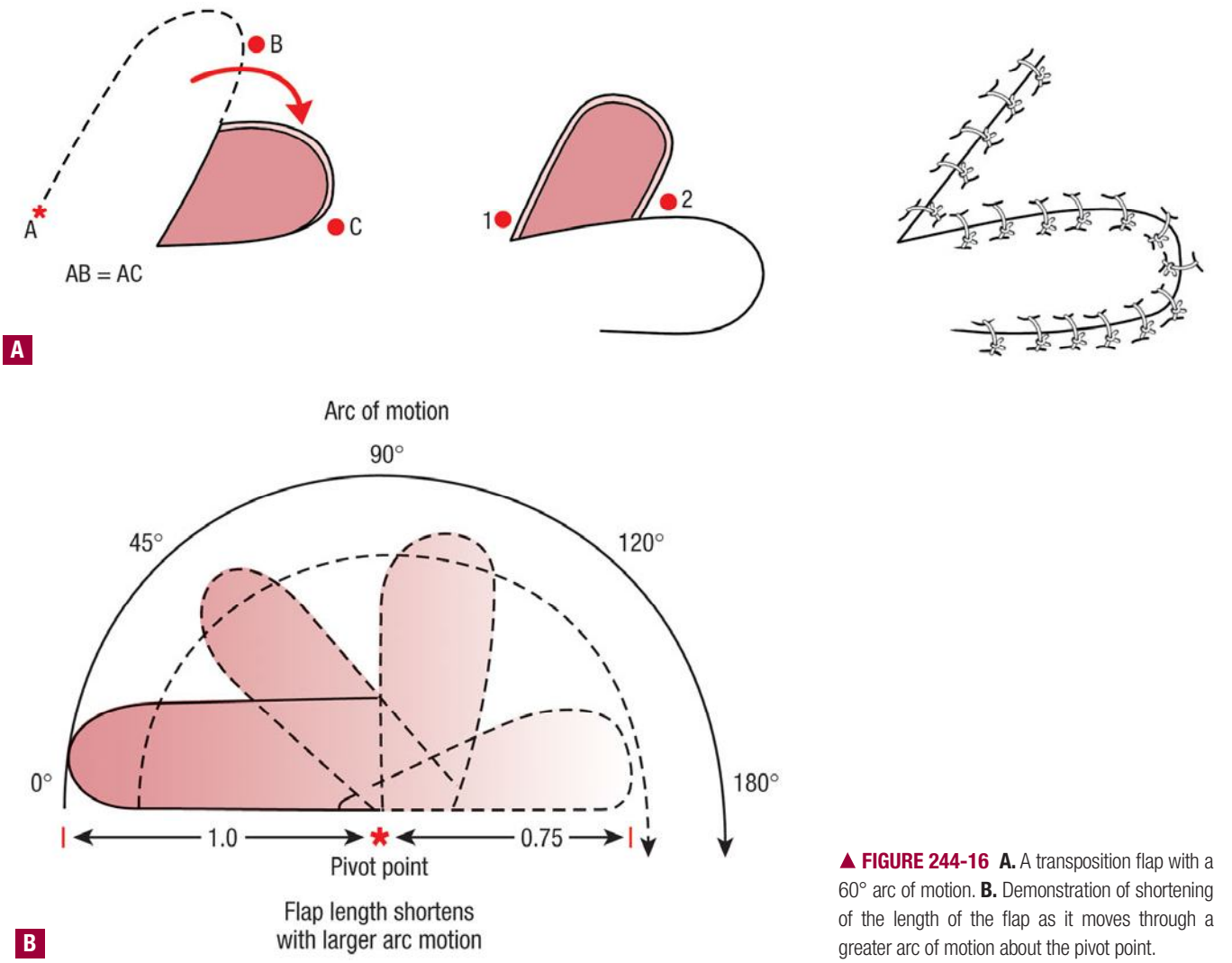

▲ **FIGURE 244-16** **A.** A transposition flap with a 60° arc of motion. **B.** Demonstration of shortening of the length of the flap as it moves through a greater arc of motion about the pivot point.

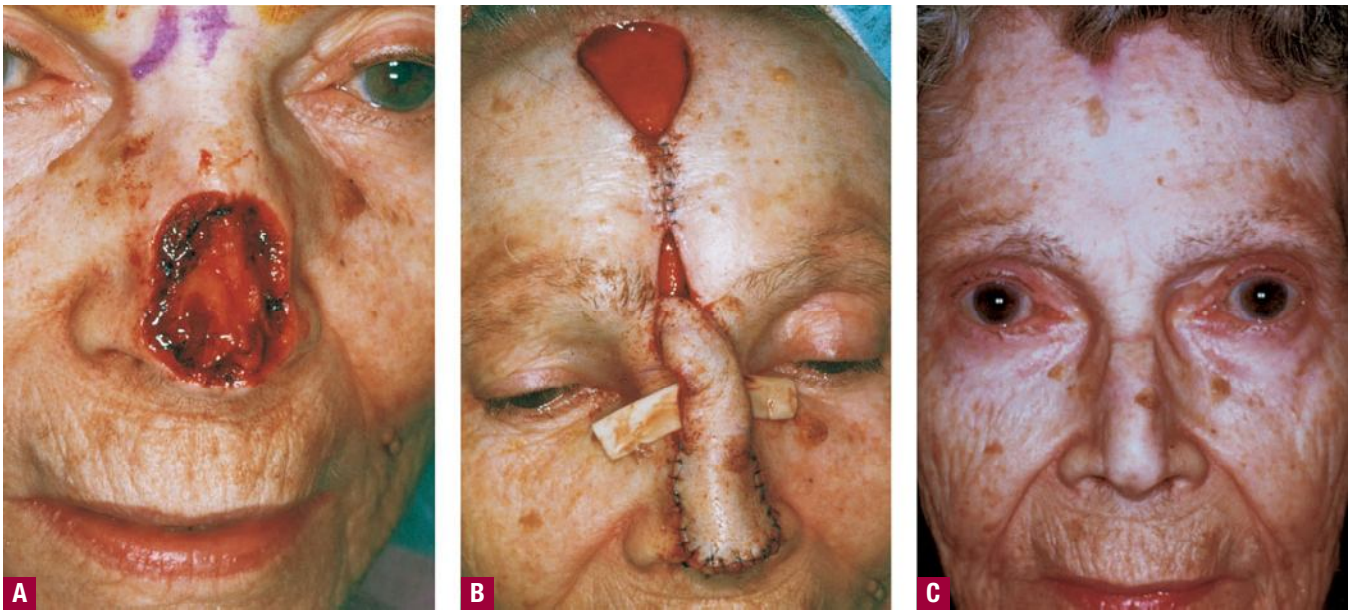

▲ **FIGURE 244-17** **A.** Dorsal nose surgical defect after tumor resection. **B.** Immediately after first stage of paramedian forehead flap with upper forehead donor area to heal by second intention healing. **C.** Final result 8 months after flap division and inset.

glucocorticoids and/or flap elevation with flap thinning, possibly combined with multiple Z-plasties to break up the curved scar line. The trapdoor effect may be prevented with wide undermining around the primary defect, proper thinning of the flap, proper size of the flap, and the use of a geometric shape for the flap.

Complications of surgery include infection, hematoma formation, wound dehiscence, and flap and graft loss.

MONITORING AND FOLLOW-UP

The patient returns for suture removal. The next visit is often scheduled for 6 to 8 weeks after surgery when the incision may begin to become hypertrophic.

If the patient has a history of hypertrophic scarring or there is clinical suspicion that this may occur, after suture removal a variety of agents may be used to try to prevent this from developing. Apply a strip of silicone gel sheeting or polyurethane foam to the incision area. The strip may be left in place for 2 to 3 days before changing it. The sheeting is applied to the wound for 6 weeks after surgery.

PATIENT INSTRUCTIONS: EXCISIONAL SURGERY WITH PRIMARY CLOSURE (Box 244-1)

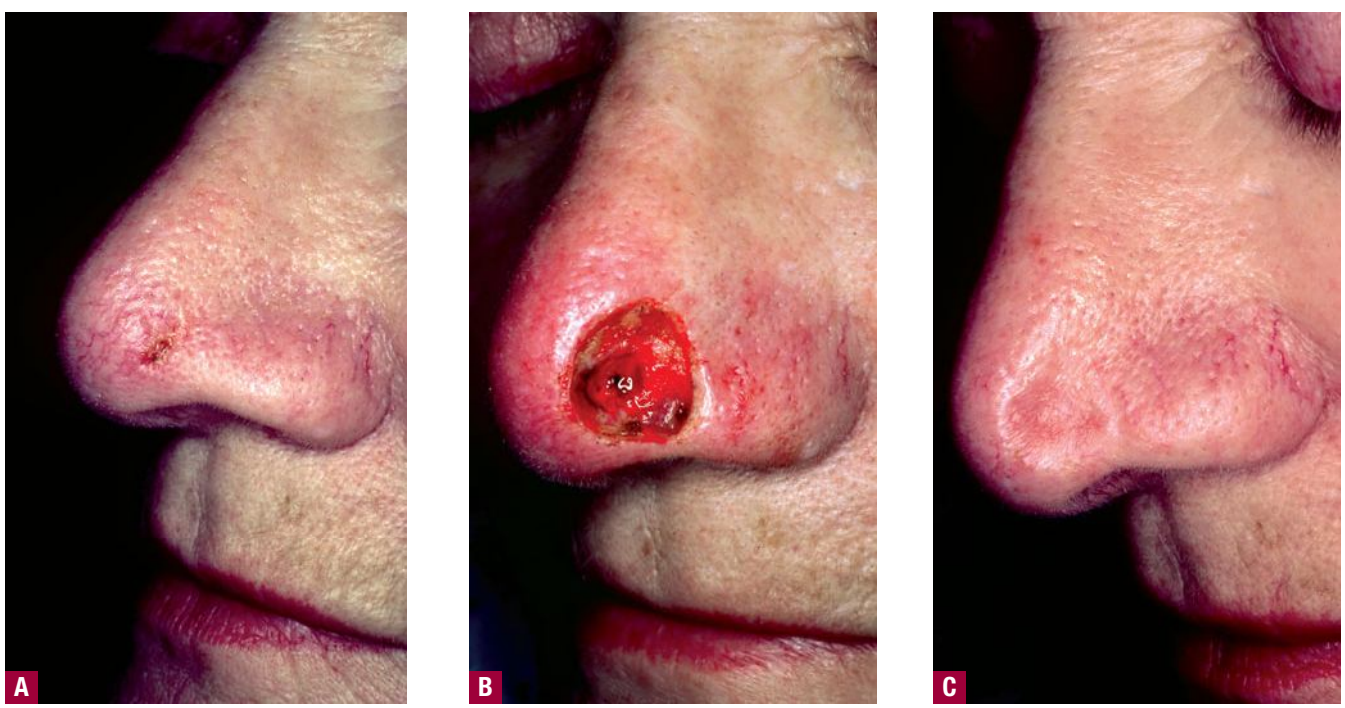

▲ **FIGURE 244-18** Fairer-skinned individuals with even pigmentation and less sun damage have the best results with full-thickness skin grafts taken from areas with a similar amount of sun damage of the donor site. **A.** Preoperative appearance of primary basal cell carcinoma. **B.** After resection by Mohs surgery. **C.** Six months after repair with a full-thickness skin graft from the preauricular cheek.











▲ **FIGURE 244-19** **A.** After resection of a basal cell carcinoma, the cartilage remnants of the antihelix will be removed to improve the vascular bed for the split-thickness skin graft. **B.** After removing the bolus dressing at the time of suture removal 1 week after surgery, the split-thickness skin graft has the dusky color and translucent quality that indicate a good chance for survival. **C.** Two weeks after surgery, the graft is ready to be uncovered. **D.** Two years after surgery, the helical rim has contracted in the area without cartilage; however, the conchal bowl has a normal contour where the graft was applied to cartilage.

Box 244-1

Excisional Surgery with Primary Closure Patient Instructions

1. Immediately after surgery, you may apply an ice pack intermittently to the wound area for 15 minutes on and 5 minutes off over a period of 2 hours.
2. Elevate the area for __ days after surgery.
3. Take acetaminophen, ___ mg three times a day for 48 hours after surgery if needed.
4. If you develop pain at the site of surgery, call the doctor at _____.
5. Do not remove the dressings or get them wet for 24 to 48 hours.
6. You may shower in 48 hours but do not let the water directly pound on the area of the surgery. After showering, change and replace the dressing with a nonstick pad and paper tape.
7. In the first 48 hours after surgery around the eyes or on the forehead, the eyes may be swollen almost shut.
8. If you have blood trickle out from under the bandage as a stream of blood, apply direct downward pressure for 15 minutes. If the bleeding stops, in the A.M., call the office to be seen for a dressing change. If the bleeding does not stop, go to the emergency room.

REFERENCES

1. Meirson D, Goldberg LH: The influence of age and patient positioning on skin tension lines. *J Dermatol Surg Oncol* **19**:39, 1993
2. Robinson JK: Special cosmetic units of the face, in *Fundamentals of Skin Biopsy*, Yearbook Medical Publisher, Chicago, 1986, p 45
3. Robinson JK, LeBoit PE: Biopsy techniques, in *Atlas of Cutaneous Surgery*, edited by Robinson JK et al. Philadelphia, WB Saunders, 1996, p 44
4. Swanson NA: *Atlas of Cutaneous Surgery*. Boston, Little, Brown, 1987
5. Levin BC et al: Healing by secondary intention of auricular defects after Mohs surgery. *Arch Otolaryngol Head Neck Surg* **122**:59, 1996
6. Zitelli JA: Wound healing by secondary intention: A cosmetic appraisal. *J Am Acad Dermatol* **9**:407, 1983
7. McGrath MH, Simon RH: Wound geometry and the kinetics of wound contraction. *Plast Reconstr Surg* **72**:66, 1983
8. Moody BR, McCarthy JE, Senglemann RD: The apical angle: A mathematical analysis of the ellipse. *Dermatol Surg* **27**:61, 2001
9. Harris DR: Healing of the surgical wound: I. Basic considerations. *J Am Acad Dermatol* **1**:197, 1979
10. Chernosky ME: Scalpel and scissors surgery as seen by the dermatologist, in *Skin Surgery*, 6th ed, edited by Epstein E, Epstein E Jr. Philadelphia, Saunders, 1987, p 88

11. Speer DP: The influence of suture technique on early wound healing. *J Surg Res* **27**:385, 1979
12. Book SE, Aasi SZ, Leffell DJ: Ellipse, ellipse variations and dog-ear repairs, in *Surgery of the Skin: Procedural Dermatology*, edited by JK Robinson et al. Philadelphia, Elsevier Mosby, 2005, p 265
13. Cook JL, Goldman GD: Random pattern cutaneous flaps, in *Surgery of the Skin: Procedural Dermatology*, edited by JK Robinson et al. Philadelphia, Elsevier Mosby, 2005, p 311
14. Dzubow LM: Flap dynamics. *J Dermatol Surg Oncol* **17**:116, 1991
15. Tomich JM et al: Subcutaneous island pedicle flaps. *Arch Dermatol* **123**:514, 1987.
16. Borges AF: Choosing the correct Limberg flap. *Plast Reconstr Surg* **62**:542, 1978
17. Webster RC et al: The thirty degree transposition flap. *Laryngoscope* **88**:85, 1978
18. Quatela VC et al: Esthetic refinements in forehead flap nasal reconstruction. *Arch Otolaryngol Head Neck Surg* **121**:1106, 1995
19. Wheeland RG: Skin grafts, in *Dermatologic Surgery: Principles and Practice*, edited by RK Roenigk, HH Roenigk Jr. New York, Marcel Dekker, 1989, p 323
20. Konior RJ: Free composite grafts. *Otolaryngol Clin North Am* **27**:81, 1994

CHAPTER 245

Mohs Micrographic Surgery

Ken K. Lee
Valencia D. Thomas
Neil A. Swanson

Mohs micrographic surgery (MMS) is a precise method of treating skin cancer that results in the highest cure rate with maximal tissue conservation. Developed by Dr. Frederic E. Mohs, the procedure combines microscopic evaluation of tumor margins ("micro") with detailed mapping of the tumor orientation ("graphic"). The hallmark of MMS is tangential excision that theoretically allows 100 percent of the tumor margin to be examined by the surgeon who serves the dual roles of surgeon and pathologist. Commonly referred to as *Mohs surgery*, other names have been used to describe the procedure, including *chemosurgery*, *microscopically controlled excision*, and *microscopically oriented histographic surgery*.

HISTORY

TECHNIQUE

The MMS set up requires an appropriately equipped procedure room, well-trained nursing staff, and a laboratory with a histotechnician trained in the specialized MMS tissue processing. The latter cannot be overemphasized as the quality of the microscopic slides and the efficiency in which they are produced are paramount in order to perform MMS at its highest level.

MMS is usually performed on ambulatory patients in an outpatient setting (Fig. 245-1).[3] The tumor is initially identified, marked, and infiltrated with local anesthesia. It is then debulked using a curette, which further delineates the size. The scalpel blade is held at approximately 45 degrees to the skin surface and the tumor is excised 2 to 3 mm beyond the curetted margin, producing a saucer-shaped piece of tissue. Anatomic orientation is carefully maintained. The remaining skin edge, as well as the surface of the removed tissue, is scored to preserve this orientation. The depth of the excision usually encompasses the entire dermis but can vary depending on the depth of the curettage. The wound is bandaged and the patient waits for the processing, which usually takes 30 to 45 minutes.

The tissue is sectioned into smaller pieces along the scored lines, turned over and inked with two to three different colors for precise orientation. An anatomic map is drawn with markings correlating with the scored lines and inked margins. The tissue is then laid flat on a cryostat chuck so that the epidermis and the deepest margin are on one plane (allowing for theoretically 100 percent of the tumor margins to be visualized). The tissue is then frozen, sectioned horizontally, placed on a slide, and stained.

A unique aspect of MMS is that the surgeon has a dual role as the pathologist, thus optimizing the clinicopathologic correlation. This leads to accuracy that is difficult to duplicate when there is a separate surgeon and pathologist. The Mohs surgeon examines the slides microscopically, correlating them with the anatomic map he or she has drawn. If there is persistent tumor on the margin(s), it is marked on the map and the patient is brought back into the procedure room for the second stage. Additional section(s) are again tangentially excised but limited only to the area(s) of persistent tumor. This process continues until the margins are tumor free.

MOHS MICROGRAPHIC SURGERY AT A GLANCE



- Mohs micrographic surgery (MMS) is a precise method of treating skin cancer that results in the highest cure rate with maximal tissue conservation.
- MMS has been used for different types of skin cancers. The overwhelming majority of the cases, however, are basal cell carcinomas and squamous cell carcinomas.
- Specific indications for MMS include (1) high risk of local recurrence, (2) need for tissue preservation, and (3) high risk of metastasis.
- Advances in processing and staining techniques have increased the speed and accuracy of tumor excision.

In comparison, with traditional excisions the scalpel blade is placed perpendicular to the skin surface, the tissue is processed in a "bread loaf" fashion and sectioned through the center of the tumor. Less than 1 percent of the tumor margin is visualized. In MMS, the goal is to visualize the outer as well as deep margins, and therefore only the tumor on the margins is represented on the





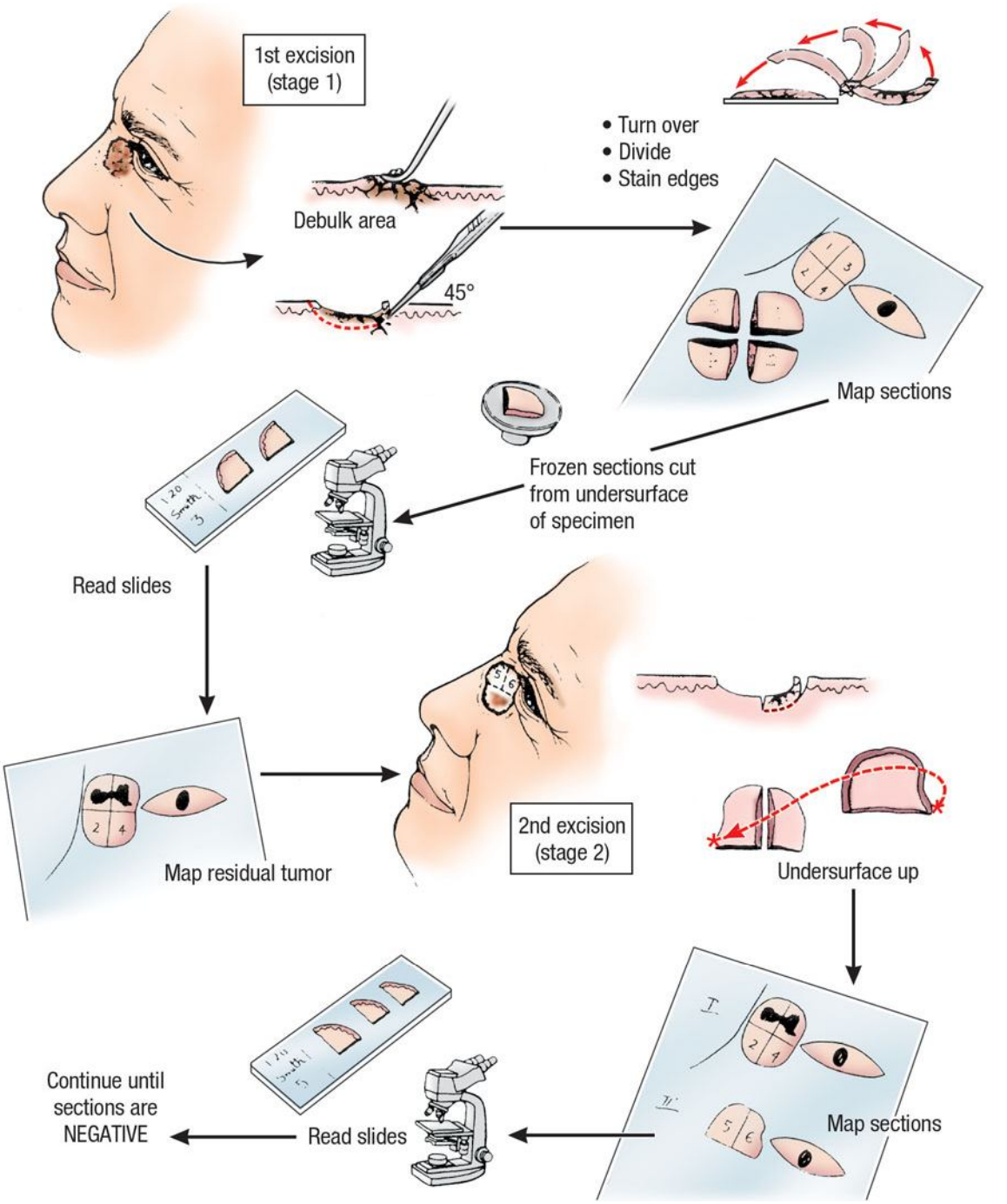

▲ **FIGURE 245-1** Schematic of Mohs micrographic surgery technique. See text for detailed explanation.

slide. The tumor in the center is not seen unless it extends to the margins.

Since the introduction of the fresh-tissue technique, MMS has been refined to an efficient, highly successful surgery. Advances in special staining techniques are further contributing to the evolution of this field. Alternatives to hematoxylin and eosin, such as toluidine blue, can be used to help accentuate the architectural findings of basal cell carcinomas (BCCs) and other cutaneous tumors.[4,5] Of particular interest is the use of rapid immunostaining in the evaluation of tumor specimens prepared with the fresh-tissue technique. Because of the difficulty in evaluating melanocytes on frozen sections, immunostains such as Melan-A/MART-1, HMB-45, and S100 have gained recent attention in the treatment of lentigo maligna and melanomas (see Chap. 124).[6–9] Other tumors, such as squamous cell carcinoma (SCC), granular cell tumor, and dermatofibrosarcoma protuberans have stimulated an assessment of other immunomarkers in MMS.[10–12] As the roles of these immunostains are more clearly delineated, their use may become commonplace in MMS.

Reconstructive surgery has become an important and integral aspect of the care of the skin cancer patient. The original chemosurgery defects healed by second intention, but the current defects that result from the fresh tissue technique permit primary side-to-side closures, flaps, and grafts (Fig. 245-2). As a result, advances in reconstructive surgery have been significant in the evolution of MMS.

INDICATIONS

MMS has been used for different types of skin cancers. The overwhelming majority of the cases, however, are BCCs and



▲ **FIGURE 245-2** **A.** Postoperative defect after two stages of Mohs micrographic surgery. **B.** Reconstruction with rhombic transposition flap.

SCCs. MMS is not needed for all skin cancers and should be reserved for those cases that meet specific indications. The American Academy of Dermatology has outlined specific guidelines, which broadly include (1) high risk of local recurrence, (2) areas of tissue preservation, and (3) high risk of metastasis.[13] There are other treatment modalities such as simple excision, electrodesiccation and curettage, cryosurgery, topical chemotherapy, and irradiation that may be appropriate for other situations. Conversely, MMS should not be used as the only treatment for some complex cancers. A multi-disciplinary approach may be more appropriate for these cases.

Basal Cell Carcinoma (See Chap. 115)

Although the potential of BCC for metastasis is very low, it can cause significant local destruction. Four important factors that determine the successful treatment of primary BCCs are histologic characteristics, location, size, and clinical nature (Fig. 245-3). Histology ranges from less-aggressive patterns, such as nodular and superficial, to more-aggressive patterns, such as infiltrative, micronodular, and sclerosing (morpheaform). Perineural involvement also constitutes an aggressive pattern. The aggressive subtypes typically are more ill-defined clinically with less predictable radial growth patterns leading to a greater subclinical extension of tumor. When viewed in the traditional "bread loaf" fashion, these areas of tumor extension can be missed leading to a false-negative result.[14] MMS is ideally suited for visualizing these extensions as close to 100 percent of the margins are inspected.

BCCs located on the ear, nose, eyelid, and lip are part of the "H" zone where MMS is indicated because of the high recurrence rate (see Chap. 115; see eFig. 245-3.1 in on-line edition).[15] In these locations, tumors tend to be more destructive and invasive and are in close proximity to vital structures. Tumors spread along perichondrium, periosteum, perineurium, and fascial planes. They also spread along embryonic fusion planes to unexpected depths in areas such as the nasal ala/nasolabial fold junction, preauricular sulcus, and columella, as well as penetrating deeply in areas such as the medial canthus where there is minimal deep structural support. Furthermore, MMS is important in maximally preserving normal tissue in these cosmetically and functionally sensitive regions.

Size and clinical nature are also important considerations in determining the appropriate treatment. BCCs greater than 2 cm are more likely to recur or be incompletely excised. Ill-defined clinical borders also make simple excisions more difficult.[16] Overall, MMS has a 99 percent cure rate for primary BCCs, compared with 91.3 percent for

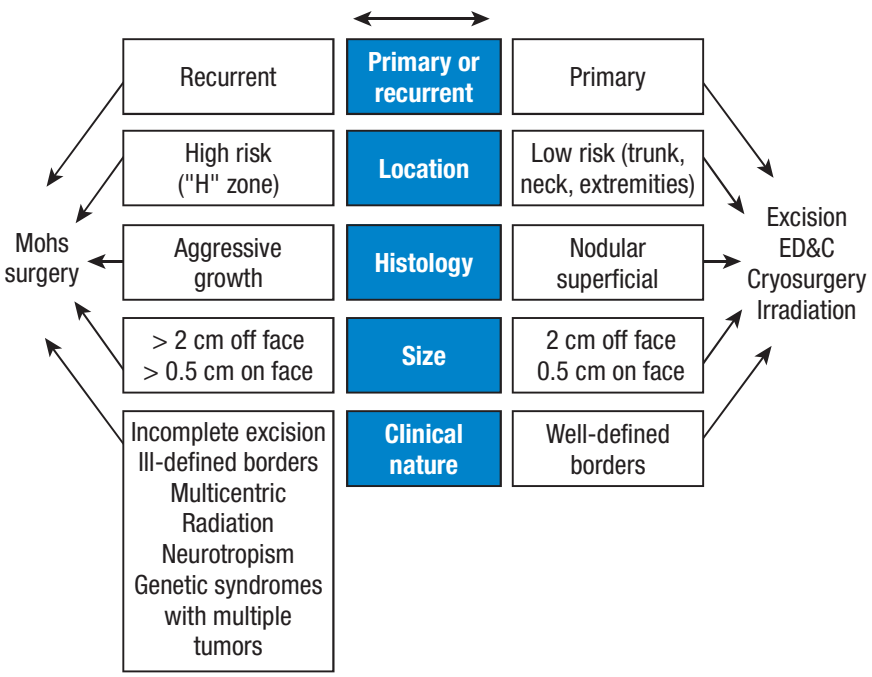

▲ **FIGURE 245-3** Guidelines for consideration for Mohs micrographic surgery. The right side of the figure represents less-aggressive presentations of basal cell carcinomas that can be treated with standard treatment regimens. The left side of the figure represents more aggressive presentations for which Mohs micrographic surgery should be considered. ED&C = electrodesiccation and curettage.

all other treatment modalities previously mentioned.[17] Figs. 245-4 and 245-5 demonstrate the procedure and its outcome.

Beyond primary BCCs, MMS is advantageous in the treatment of incompletely excised and recurrent BCCs. MMS is indicated irrespective of histologic sub-types or location since the prior treatment modalities have already failed. On the face, incompletely excised BCCs recur between 12 percent and 41 percent of the time if left untreated.[18] These can be readily treated with MMS by narrow margin excision around the previous scar. This results in precise localization of the persistent tumor.

Recurrent BCCs, by their very nature, are more aggressive and difficult to treat. Clinically, they can be subtle and therefore the diagnosis is usually delayed. By the time the recurrence is noted on the skin surface, there may be large tumor burden buried in the scar. For these recurrences, MMS yields the best cure rate of 94.4 percent, compared to all other modalities, which average only 80 percent.[19]



Squamous Cell Carcinoma (See Chap. 114)

Although SCCs and BCCs are treated similarly, it would be inadvisable to think that they are biologically the same. SCC metastasizes at a much higher rate and accordingly has a higher mortality rate. The indications for MMS are similar to BCC, but additionally involves identifying and reducing the risk for metastasis. As with BCC, histologic pattern is important in determining the potential aggressiveness. Tumors that are poorly differentiated and/or have perineural involvement have a worse prognosis. Locations such as the ear, penis, lip, and digits, lesions greater than 2 cm, deeper lesions, and those occurring in scars carry a higher risk of metastasis and local recurrence. Five-year cure rate for primary SCC of the skin is 96.9 percent with MMS versus 92.1 percent for all other modalities combined (irradiation, curettage and electrodesiccation, and excision). The difference is greater for primary SCCs of the lip (97.7 percent vs. 89.5 percent) and ear (94.7 percent vs. 81.3 percent). For recurrent tumors, cure rate is 90 percent with MMS versus 77.7 percent with excision.[20] Immunosuppressed transplant patients have a disproportionate number of SCCs and also carry a greater risk of more aggressive disease.

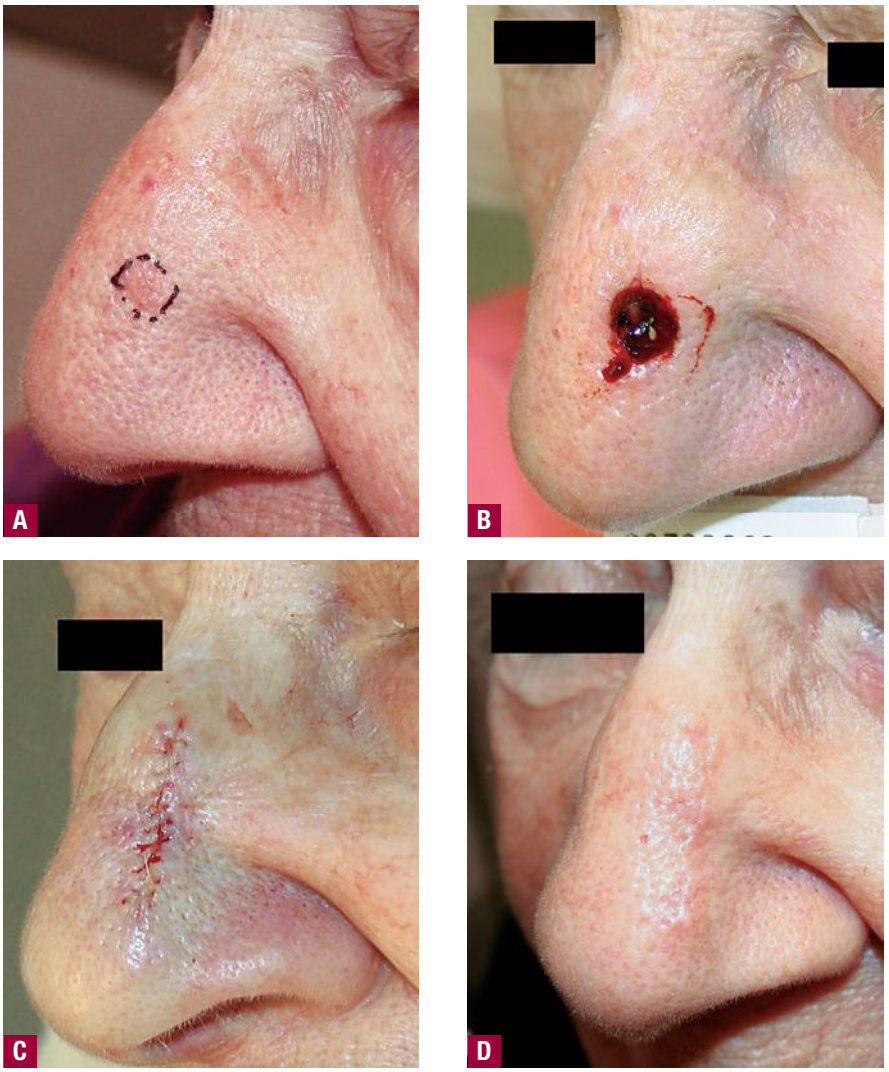

▲ **FIGURE 245-4** Defects may resemble the clinical lesion. Mohs micrographic surgery is helpful to delineate a narrow margin. **A.** Preoperative image of this biopsy-proven basal cell carcinoma. **B.** Final defect after Mohs-assisted excision. **C.** Repair of the defect with a complex linear layered closure. **D.** Two-month follow-up.

MMS is an integral part of SCC management and can be especially valuable in special situations such as tracking perineural involvement. It is important to note, however, that radiation therapy and surgical lymph node assessment may also be needed for proper management of more aggressive disease.

Melanoma (See Chap. 124)

MMS for treatment of melanoma is controversial. Two issues have given rise to this controversy: interpretation of melanocytes by frozen section and determination of proper excision margins for melanoma. Some believe that MMS is most useful for lentigo maligna type melanoma in situ on the head and neck region, which is notorious for significant sub-clinical spread that often extends beyond the standard recommended excision margins. Although there have been reports of successful treatment of melanoma with MMS, the variability in the frozen section quality and interpretation places a limit on consistency and accuracy. The method that is commonly used at some centers is a modified MMS in which a 2- to 3-mm margin is excised beyond the final frozen section margin and submitted for permanent paraffin embedded sections. These sections are processed in the MMS style so that 100 percent of the peripheral margins are visualized. The obvious disadvantage of this method is significant increase in the turnaround time delaying the final closure of the wound.[21,22]

A newer method that potentially improves both the speed and accuracy is

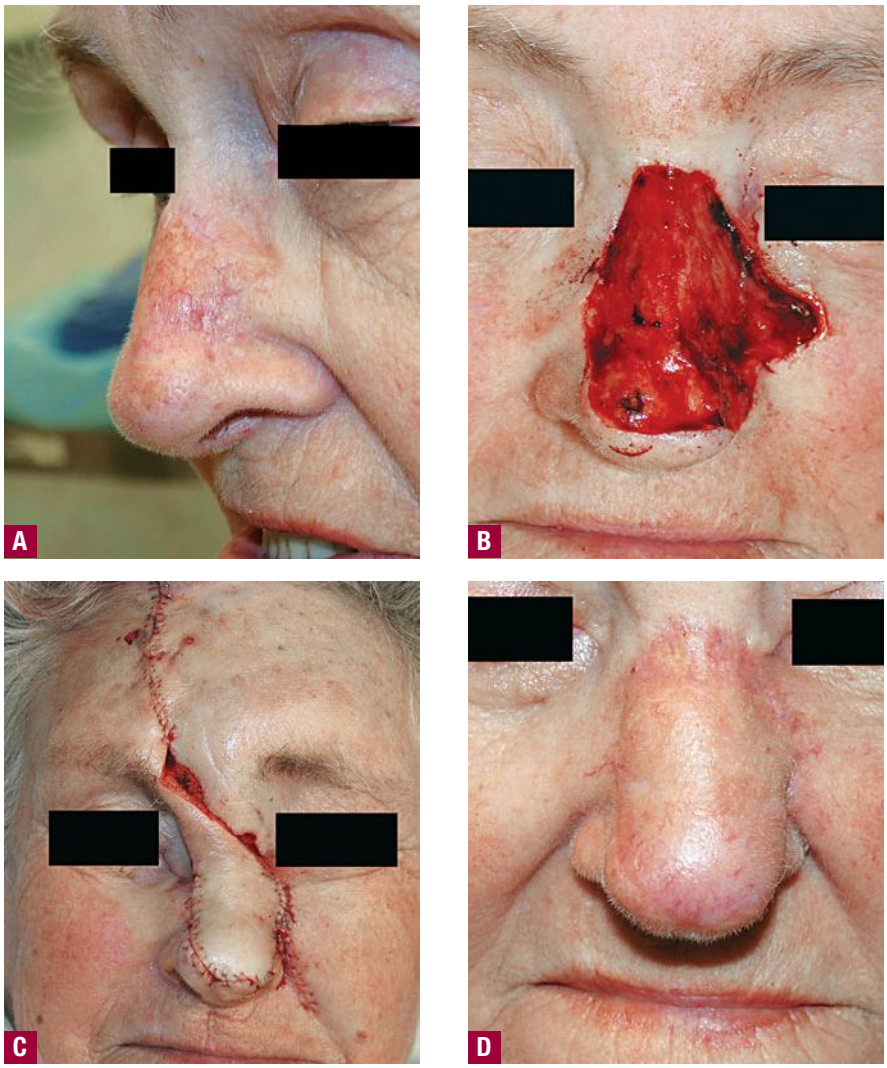

▲ **FIGURE 245-5** Mohs micrographic surgery is helpful in determining the subclinical extension of tumors. **A.** Preoperative image of a morpheaform basal cell carcinoma. **B.** Mohs micrographic surgery reveals extensive sub-clinical involvement of the tumor. **C.** Repair of the defect with a paramedian forehead flap. **D.** Two-month follow-up.

the use of immunohistochemistry stains. S100 and HMB-45 have traditionally been used to mark melanocytes with variable sensitivity and specificity. Melan-A is a newer addition with better consistency and easier interpretation.[23] Although the turnaround time is shorter than with paraffin sections, it is still more labor intensive than traditional hematoxylin and eosin–based frozen sections. Long-term studies determining efficacy are still needed.

Other Cutaneous Malignancies

MMS has been used to treat a wide range of cutaneous malignancies. The consensus indications outlined by the American Academy of Dermatology include verrucous carcinoma, keratoacanthoma, dermatofibrosarcoma protuberans, atypical fibroxanthoma, malignant fibrous histiocytoma, leiomyosarcoma, adenocystic carcinoma of the skin, sebaceous carcinoma, extramammary Paget disease, erythroplasia of Queyrat, oral and central facial paranasal sinus neoplasms, microcystic adnexal carcinoma, apocrine carcinoma of the skin, certain aggressive locally recurrent benign tumors, and Merkel cell carcinoma. All cutaneous malignancies that exhibit a contiguous pattern of radial growth and that can be interpreted on frozen section should theoretically be amenable to MMS.

MMS is cost-effective although it should be reserved for those cases that meet appropriate indications.[24] It is a highly technical procedure that requires meticulous attention to detail and considerable training and experience to achieve the expected high cure rates.

KEY REFERENCES

The full reference list for all chapters is available at www.digm7.com.

1. Mohs FE: Chemosurgery: A microscopically controlled method of skin cancer excision. *Arch Surg* **42**:279, 1941
2. Tromovitch TA, Stegman SJ: Microscopic-controlled excision of cutaneous tumors: Chemosurgery: Fresh-tissue technique. *Cancer* **41**:653, 1978
3. Swanson NA: Mohs surgery: Technique, indications, applications, and the future. *Arch Dermatol* **119**:761, 1983
9. Albertini JG et al: Mohs micrographic surgery for melanoma: A case series, a comparative study of immunostains, an informative case report, and a unique mapping technique. *Dermatol Surg* **28**:656, 2002
17. Rowe DE et al: Long-term recurrence rates in previously untreated (primary) basal cell carcinoma: Implications for patient follow-up. *J Dermatol Surg Oncol* **15**:315, 1989
19. Rowe DE et al: Mohs surgery is the treatment of choice for recurrent (previously treated) basal cell carcinoma. *J Dermatol Surg Oncol* **15**:424, 1989
24. Cook J, Zitelli JA: Mohs micrographic surgery: A cost analysis. *J Am Acad Dermatol* **39**:698, 1998



CHAPTER 246

Nail Surgery

Robert Baran

The main objectives of nail surgery are to aid diagnosis by biopsy, to treat infection, to alleviate pain, to remove local tumors, and to ensure the best cosmetic results in acquired and/or hereditary and congenital abnormalities.



PATIENT SELECTION

Providing the patient with an exact illustration of the operation is helpful to give the patient insight into the procedure and its expected outcome. A thorough discussion regarding postoperative morbidity is essential.

RISKS AND PRECAUTIONS

Factors to be considered include the following:

- History of systemic disease
- History of allergies
- Concomitant drug use

Preoperative photographs as well as any taken during surgery may be useful medicolegally. Careful history taking may reveal systemic disease such as diabetes mellitus, blood dyscrasia, vascular disease, vascular collagen disease (scleroderma), allergy, chronic pulmonary disease, or immune impairment. Any of these may at times be contraindications to surgery or may call for alteration of the technique to be used. Surgery of the nail is not recommended in patients with high-risk conditions. A history of concurrent use of drugs may be relevant, because these drugs may affect anesthesia (e.g., monoamine oxidase inhibitors or phenothiazines), prolong bleeding (e.g., aspirin and anticoagulants), delay healing (e.g., glucocorticoids), or have toxic effects on the nail apparatus (e.g., retinoids). There may be a history of allergy to lidocaine or mepivacaine or to parabens contained in both as a preservative. A knowledge of previous antitetanus immunization is important, because administration of tetanus toxoid may be advisable in association with surgery involving the toenail or traumatic lesions that come into contact with soil.

A magnifying lens may be useful to observe the color, surface, and structure of the periungual tissue and to compare the unaffected contralateral digit. It may be necessary to probe in order to localize pain, to obtain a radiograph to rule out underlying bone involvement, or to ask for ultrasonography and magnetic resonance imaging when a tumor is suspected.

The basic requirements for nail surgery include a detailed knowledge of the anatomy and physiology of the nail apparatus on the part of the surgeon. Full aseptic conditions, regional block anesthesia, and local hemostasis are indispensable.

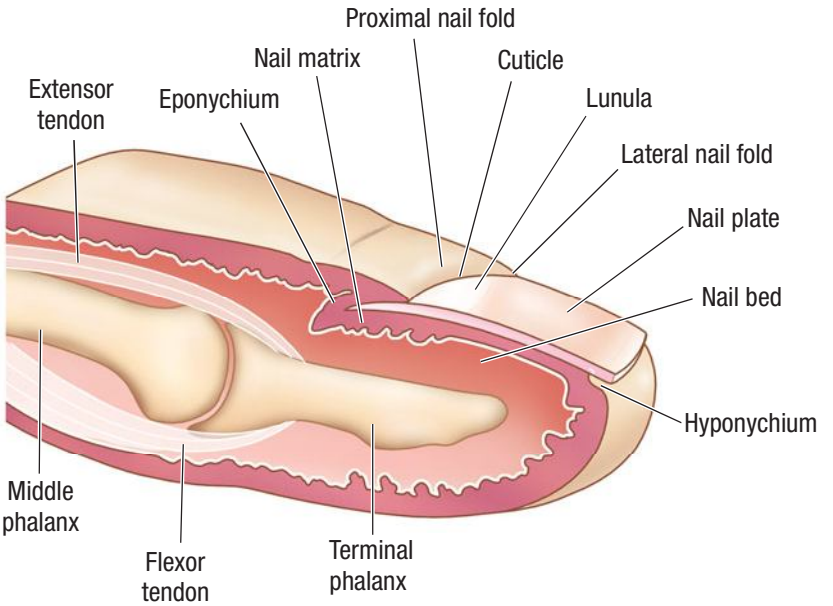

▲ **FIGURE 246-1** Sagittal section of the nail unit.

ANATOMY[1] (See Chap. 87)

The nail plate is the permanent product of the nail matrix. Its normal appearance and growth depend on the integrity of the perionychium and the bony phalanx (Fig. 246-1). The nail is a semihard horny plate covering the dorsal aspect of the tip of the digit. The nail is inserted proximally in an invagination that is practically parallel to the upper surface of the skin and laterally in the lateral nail grooves. This pocket-like invagination has a roof, the proximal nail fold, and a floor, the matrix from which the nail is derived. The matrix extends approximately 6 mm under the proximal nail fold, and its distal portion is only visible as the white semicircular lunula. The general shape of the matrix is a crescent, concave in its posteroinferior portion. The lateral horns of this crescent are more developed in the great toe and are located at the coronal plane of the bone. The ventral aspect of the proximal nail fold encompasses both a lower portion, which continues the matrix, and an upper portion (roughly three-quarters of its length), called the *eponychium* (see eFig. 246-1.1 in on-line edition). The germinal matrix forms the bulk of the nail plate. The proximal element forms the superficial third of the nail plate, whereas the distal element provides its inferior two-thirds. The ventral surface of the proximal nail fold adheres closely to the nail for a short distance and forms a gradually desquamating tissue, the cuticle, made of the stratum corneum of both the dorsal and the ventral sides of the proximal nail fold. The cuticle seals and protects the nail cul-de-sac.

The nail plate is bordered by the proximal nail fold, which is continuous with the similarly structured lateral nail fold on each side. The nail bed extends from the lunula to the hyponychium. It has parallel, longitudinal rete ridges.

In contrast to the matrix, the nail bed has a firm attachment to the nail plate. Colorless but translucent, this highly vascular connective tissue, containing glomus organs, transmits a pink color through the nail. Avulsion of the overlying nail plate denudes the nail bed.

Distally, adjacent to the nail bed, lies the hyponychium, an extension of the volar epidermis under the nail plate, which marks the point at which the nail separates from the underlying tissue. The distal nail groove, which is convex anteriorly, separates the hyponychium from the fingertip.

The circulation of the nail apparatus is supplied by two digital arteries that

Box 246-1

Instruments Required for Nail Surgery

- Nail elevators
- Single- or double-pronged skin hooks
- Double-action nail splitter (bone rongeur)
- Clippers, splitting scissors, English nail splitter
- Pointed scissors (Gradle scissors), curved iris scissors
- Small-nosed hemostats
- Disposable biopsy punches
- Penrose drains
- Luer-Lok syringe, 30-gauge needles

course along the digits and give off branches to the distal and proximal arches. The sensory nerves to the distal phalanx of the three middle fingers are derived from fine, oblique, dorsal branches of the volar collateral nerves. Longitudinal branches of the dorsal collateral nerves supply the terminal phalanx of the fifth digit and also the thumb.

Among its multiple functions, the nail provides counterpressure to the pulp that is essential to the tactile sensation involving the fingers and to the prevention of hypertrophy of the nail bed.

INSTRUMENTS AND DRAPING

The instruments used in nail surgery are, in general, the same as those used in cutaneous surgery with the addition of the instruments listed in Box 246-1.

Draping is accomplished by means of a sterile glove on the involved hand. The tip of the glove is cut off on the finger that is to undergo surgery. The remaining open finger of the glove is then rolled back down the digit. This exsanguinates the digit and provides a tourniquet when it reaches the proximal part of the finger. For toenail surgery, the foot is draped in the usual aseptic manner with sterile towels secured by towel clamps.

ANESTHESIA

Local anesthesia should be administered while the patient is reclining or in a supine position. Lidocaine is widely used because the incidence of allergy to this agent is very low. Because the benefit of epinephrine is still debatable, it is preferable to use 2 percent lidocaine alone. A tourniquet can provide prolonged hemostasis when a bloodless operative field is required. It has been claimed that using tepid lidocaine minimizes the burning sensation associated with its administration. The use of one part 7.5 percent bicarbonate with nine parts lidocaine for the same purpose has also been advocated.

Anesthetics are administered via a 30-gauge needle on a Luer-Lok syringe using either a proximal digital block or a distal digital block (wing block) procedure. Other techniques, such as median distal anesthesia or transthecal block, have not replaced the classic routes of anesthesia. Although emergencies related to minor surgery occur rarely, the ready availability of resuscitative equipment and expertise is essential.

Proximal Digital Block

The proximal digital block procedure is less painful than the distal block procedure, but the anesthesia takes 5 to 10 minutes to become established. The hand is laid down flat, with the fingers spread, so that 1 to 2 mL of anesthetic can be administered by a dorsal injection, with a thin needle inserted and directed tangentially to the sides of the bony phalanx at the base of the involved finger and as far as the lateral side of the flexor tendon (Fig. 246-2). A tourniquet effect may inadvertently be produced by injecting more than 5 mL of anesthetic and should be avoided. The absence of blood reflux in the syringe should be verified before injection if a nondental syringe is used. When the operation is strictly localized to a lateral region, a block limited to the nerves ipsilateral to the lesion suffices, as in the case of a partial distolateral nail avulsion.

Distal Digital Block

The distal digital block procedure is more painful than the proximal block procedure, but anesthesia occurs immediately. This method is absolutely contraindicated, however, when bacterial infection in the region is being addressed. The latter requires wrist block or general anesthesia.

For a distal digital block, the needle is inserted just behind the junction of the proximal nail fold and a lateral nail fold and a few tenths of a milliliter of anesthetic is injected, which whitens the re-

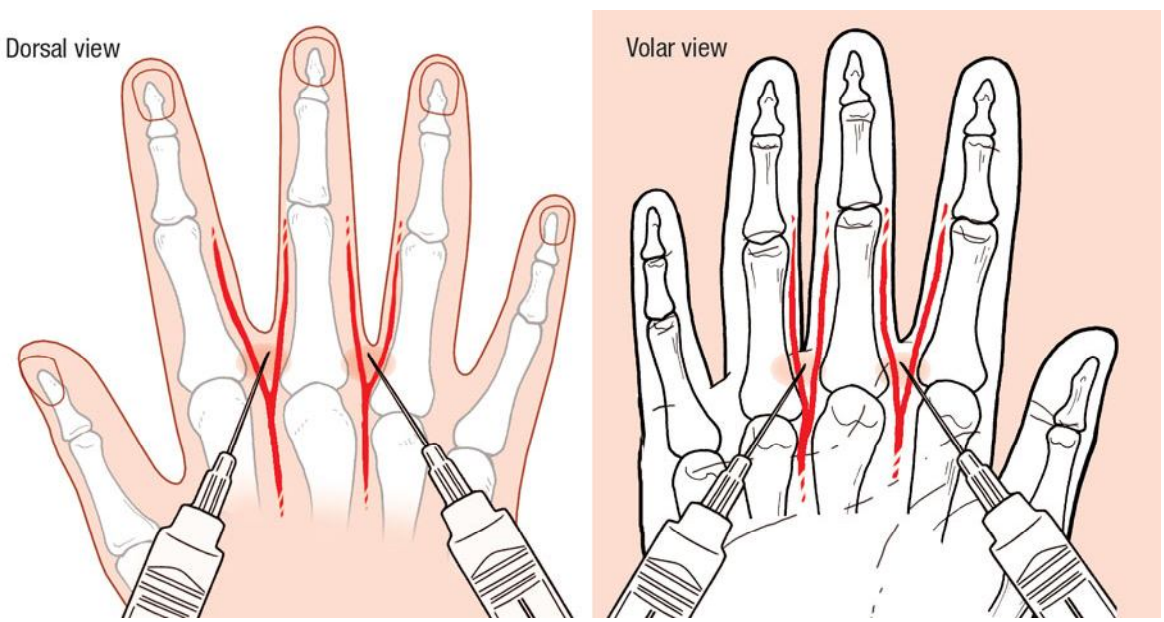

▲ **FIGURE 246-2** Proximal digital block.



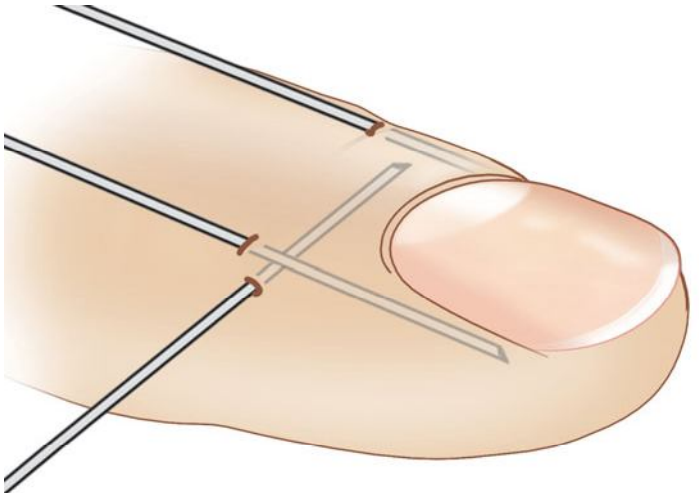

▲ **FIGURE 246-3** Distal digital block.



gion. The injection is continued by aiming the needle toward the pad. One then returns to the initial area to inject the proximal fold transversely. Finally, at the junction of the proximal fold with the lateral fold on the opposite side, one proceeds as described earlier (Fig. 246-3). The anesthesia is almost immediate, and when the procedure is done correctly, injections rarely have to be extended to the distal area of the finger.

Median distal administration is relatively simple and quick (Fig. 246-4). The needle is introduced at a 30-degree angle into the middle of the proximal nail fold and advanced distally into the underlying matrix. Anesthetic is injected slowly as the needle pierces first the nail plate, then the matrix, and finally the adjacent nail bed. The nail plate is soft and offers little resistance. Blanching confirms the delivery of anesthetic to the nail matrix and bed. Pain is brief and anesthesia nearly instantaneous. This method is suitable for most procedures performed on the proximal half of the nail unit. It is not suitable for matricectomy or complete nail avulsion.



▲ **FIGURE 246-4** Median distal block.

Transthecal Block

The flexor tendon sheath may be used as an avenue for introducing anesthetic to the core of the digit. Through centrifugal anesthetic diffusion all four digital nerves are anesthetized rapidly. This technique involves palmar percutaneous injection of 2 mL of lidocaine into the potential space of the flexor tendon sheath at the level of the palmar flexion crease using a 3-mL syringe and a 25-gauge hypodermic needle.

Wrist Block

TOURNIQUETS

DRESSING AND POSTOPERATIVE CARE

At the end of the operation, either the digit is cleansed with sterile 10 percent hydrogen peroxide solution and sprayed with a colorless disinfectant, or an antiseptic with hemolytic action is applied. The nail area is then covered with an antiseptic or antibiotic ointment on gauze or pads. Dressing must be done in a way that takes into account oozing, pain, and sensitivity. A bulky dressing provides a cushion against local trauma.

Dressings should be changed every other day or daily if there is infection. Several layers of sterile gauze should be kept in place by Micropore (2.5-cm) tape placed first on the dorsal aspect of the finger or toe, then on the ventral aspect, and last on the lateral edges in a U shape (a circular dressing should never be applied in the first week). Finally, use of an X-span tube dressing or Surgitube will give the patient more freedom to use the hand, but care must be taken that dressings do not constrict blood flow. During the first 48 hours the arm must be kept in a sling. Stitches are removed after 7 to 12 days.

When the feet are treated, daily chlorhexidine baths precede the care just described.

For all operations involving the toes, the patient should wear an appropriate shoe or sandal after the dressing has been applied. The patient should be recumbent for 24 to 48 hours, with the foot elevated to 30°.

POSTOPERATIVE COMPLICATIONS

Bleeding

Bleeding is seen after the tourniquet is removed but can be stopped by compressing the lateral edges of the distal interphalangeal joint. In cases of persistent bleeding, 35 percent aluminium chloride solution or a cellulose application (Gelfoam) should be applied.

Pain

Pain threshold varies from patient to patient. Postoperative pain can be almost non-existent if, in the absence of infection, the operation is followed by a periungual injection of 0.6 mL of 0.5 percent bupivacaine with 0.4 mL of 4 mg/mL dexamethasone. While the dressing is being put in place, the patient must be told what precautions to take. Providing a supply of moderately potent oral analgesics will help the patient to feel in control of any pain, even if the patient chooses not to take the tablets. Sometimes postoperative pain may be severe, and it is alleviated by elevating the extremity as much as possible for 2 days. Pulsating pain beginning after 36 to 48 hours may indicate an infection, which should be treated according to the results of bacterial culture of the organism. Any bulky dressing that is blood-stained after 24 hours should be changed.

Infection

Prophylactic antibiotic treatment is mandatory for patients with valvular

heart disease, including those with a prosthetic valve. Peripheral vascular disease and young age (in childhood the nail matrix is extremely fragile and behavior is less sanitary) are further indications. If there are ragged surfaces to the nail, which makes thorough preoperative cleaning difficult, antibiotics may prevent wound infection.

Postoperative infection may be caused by preoperative colonization or infection. Culture of preoperative swab specimens will indicate the best choice of drug after initial coverage with a broad-spectrum antibiotic.

Attention to detail is important. Carelessness may result in serious infectious complications in the soft tissue and occasionally in bone. Routine or preoperative nail cleansing softens the nail plate and keeps contamination to a minimum.

Misaligned Nail

Misaligned nail may result from a lateral longitudinal nail biopsy, especially if the routine 3-mm width is exceeded.

Relapse

Relapse will depend on the nature of the lesion treated. Warts, ingrown nails, and myxoid cysts can be difficult to eradicate.

Residual Dystrophy

Residual dystrophies are not unusual when surgery involves the proximal area of the matrix.

Unpredictable Complications

Implantation epidermoid cysts can occur in operation scars. Reflex sympathetic dystrophy after nail biopsy, although exceptional, has been reported.

NAIL AVULSION

The removal of the nail plate can be carried out using distal or proximal approaches. In both techniques, inserting the blunt instrument back and forth between the horny layer of the proximal nail fold and the nail plate loosens the proximal nail fold adherence.

Distal Approach

In the more commonly used distal approach, a Freer septum elevator or a dental spatula is inserted between the nail plate and nail bed (Fig. 246-5A). The nail is separated from its nail bed attachment using proximal force applied in anterior-posterior movements so as not to injure the longitudinal ridges of the nail bed. The detachment is completed by firmly pushing the instrument into the posterolateral corners of the nail plate. Then, one of the lateral edges is grasped with a sturdy hemostat, and extracted with an upward and circular movement to accomplish the removal of the nail plate.

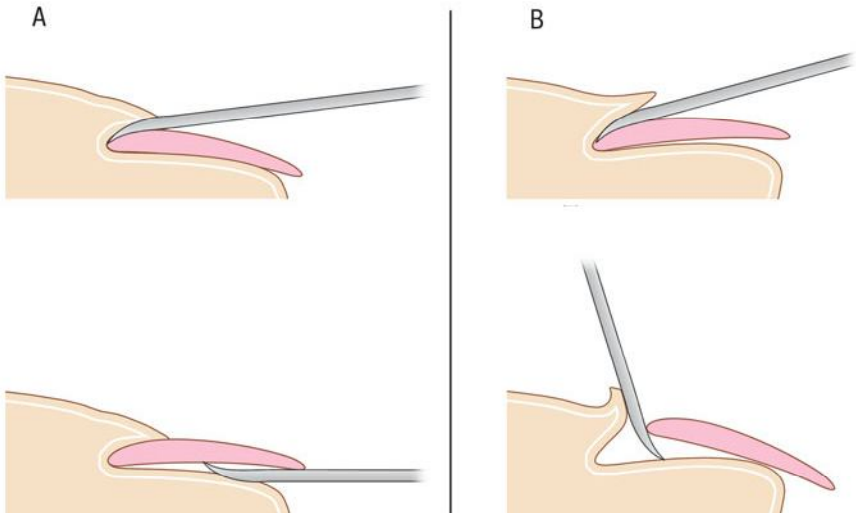

▲ **FIGURE 246-5** **A.** Distal nail avulsion. **B.** Proximal nail avulsion.

Proximal Approach

The proximal approach for nail avulsion is advisable when the subungual distal area adheres strongly to the nail plate and when the hyponychium may be injured by the subungual introduction of the spatula. The proximal nail fold is freed as described in Distal Approach. The spatula is then used to reflect the proximal nail fold, and is delicately inserted under the base of the nail plate where adherence is normally weak (see Fig. 246-5B). The instrument is advanced distally following the natural cleavage plane, and this operation is repeated on the entire width of the subungual region. After the last attachments are freed, the nail plate is easily pulled out.

Total surgical removal should be discouraged, however, because the distal nail bed may shrink and become dislocated dorsally. In addition, the loss of counterpressure produced by the removal of the nail plate allows expansion of the distal soft tissue, and the distal edge of the re-growing nail then embeds itself. In patients at high risk, non-surgical removal of the nail plate should be considered when necessary. This can be accomplished by applying 40 percent urea paste directly to the nail after protecting the surrounding skin. Urea acts on the bond between nail keratin and diseased nail plate, sparing only the normal nail tissue.

Partial Nail Avulsion

The problems that can arise after total nail avulsion may be overcome by partially avulsing the nail. Partial distal avulsion requires only separation of the nail from the distal nail bed. This procedure can be performed under local anesthesia in selected patients, when, for instance, a fungal infection is of limited extent. An affected portion of the nail plate may be removed in one session, even when the disease has reached the deeper regions of the subungual tissue beneath the proximal nail fold. Commonly, an English anvil nail splitter or a double-action bone rongeur is used for this procedure.

Partial surgical section of the lateral and/or medial segment of the nail plate may be sufficient for the treatment of distal lateral subungual onychomycosis. In the toe, this procedure leaves enough normal nail to counteract the upward forces exerted on the distal soft tissue when walking, and this will prevent the appearance of a distal nail wall.

In proximal subungual onychomycosis, removal of the non-adherent base of the nail plate, cut transversely, leaves the distal portion of the nail in place (Fig. 246-6), which decreases discomfort. Similarly, an acute paronychia that





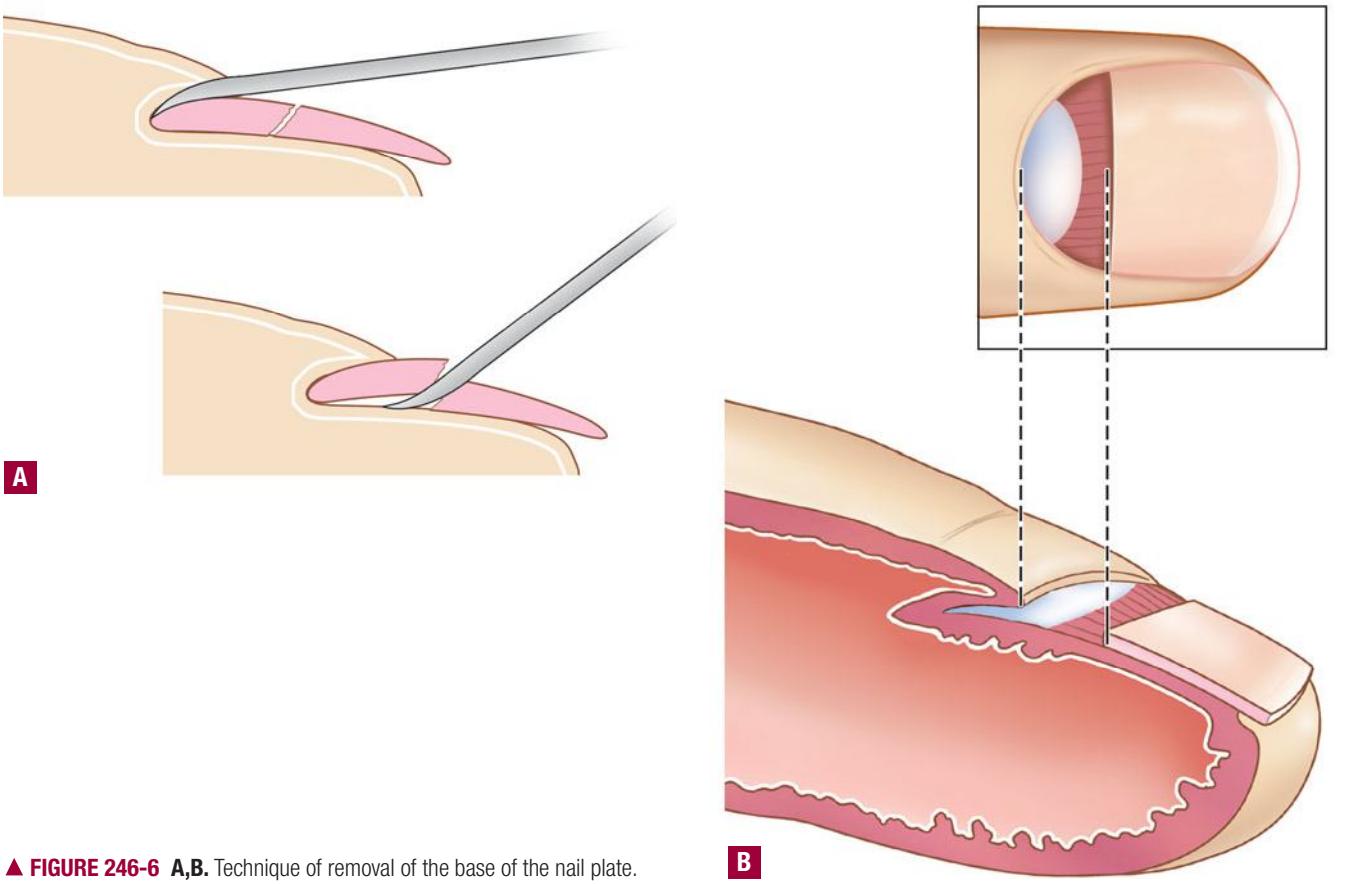

▲ **FIGURE 246-6** **A,B.** Technique of removal of the base of the nail plate.

does not respond to appropriate antibiotics within 48 hours should be treated surgically by removing the base of the nail plate.

SURGICAL APPROACHES TO THE DIFFERENT TISSUES OF THE NAIL APPARATUS

Nail Matrix

When surgery involves the nail matrix, there are three primary approaches, including (1) a reduction in its width or (2) its length for removal of tumors, for instance, by using a cold steel procedure or (3) a 2- to 3-mm punch biopsy. In contrast to these three procedures, complete matricectomy, that is, ablation of the nail-forming tissue, is rarely performed because the nail is then permanently lost.

After reduction of the nail matrix width, one is left with a narrower nail and after reduction of the length, with a diminution in the thickness of the nail. Reduction of the matrix width is a useful and/or necessary procedure in the following major circumstances:

- Need for lateral-longitudinal biopsy
- Lateral nail splitting
- Benign or malignant tumor in the lateral third of the nail apparatus
- Longitudinal melanonychia in a lateral location
- Ingrown nail
- Racquet nail

Reduction of the matrix length is necessary only in limited cases: to obtain a transverse elliptical biopsy specimen, to treat tumors that are 3 mm wide or larger, and to thin thick nails in patients with dystrophic congenital and/or hereditary disorders.[2]

BIOPSY[3–5] Biopsy of the nail matrix is performed to determine the histopathologic features of a lesion or to clarify an uncertain clinical diagnosis.

A 3-mm punch biopsy may be performed through the nail plate into the matrix. Three millimeters is the maximum size that does not produce serious dystrophy, although even biopsies of this size can cause such effects if carried out in the most proximal portion of the nail matrix. When a punch biopsy is used to sample longitudinal melanonychia of less than 3 mm in width, the circumferential incision is made around the origin of the band, through the nail plate (Fig. 246-7A). This area may be distal enough to be reached by pushing back the cuticle (Fig. 246-7B), but if it is more proximal, the proximal nail fold may have to be reflected using a posterolateral incision. The next step is to remove the proximal third of the nail plate (see Fig. 246-7B and C), while leaving the cylinder of tissue containing the origin of the longitudinal melanonychia still in place. This technique allows the surgeon to inspect the surrounding nail matrix and bed with a magnifying lens to determine whether pigment extends around the punch incision (see Fig. 246-7C and D) and facilitates the removal of the cylinder of biopsy tissue with a Gradle scissors.

For lateral longitudinal biopsy (Fig. 246-8), an elliptical incision may be made on either side of the nail plate and proximal nail fold. For the most part, the incisions parallel the lateral edge of the nail plate. Beginning in the lateral nail groove, the incisions should include a 3- to 4-mm nail segment reaching to the bone. This ensures that a full-thickness fragment of the matrix with its lateral horn is obtained. Slightly curved iris scissors are useful for separating the tissue from the bone. Starting at the tip of the digit, one proceeds proximally while maintaining contact with the bony phalanx. Lateral longitudinal biopsy is the advised procedure when longitudinal melanonychia[3] is located in the lateral part of the nail plate.

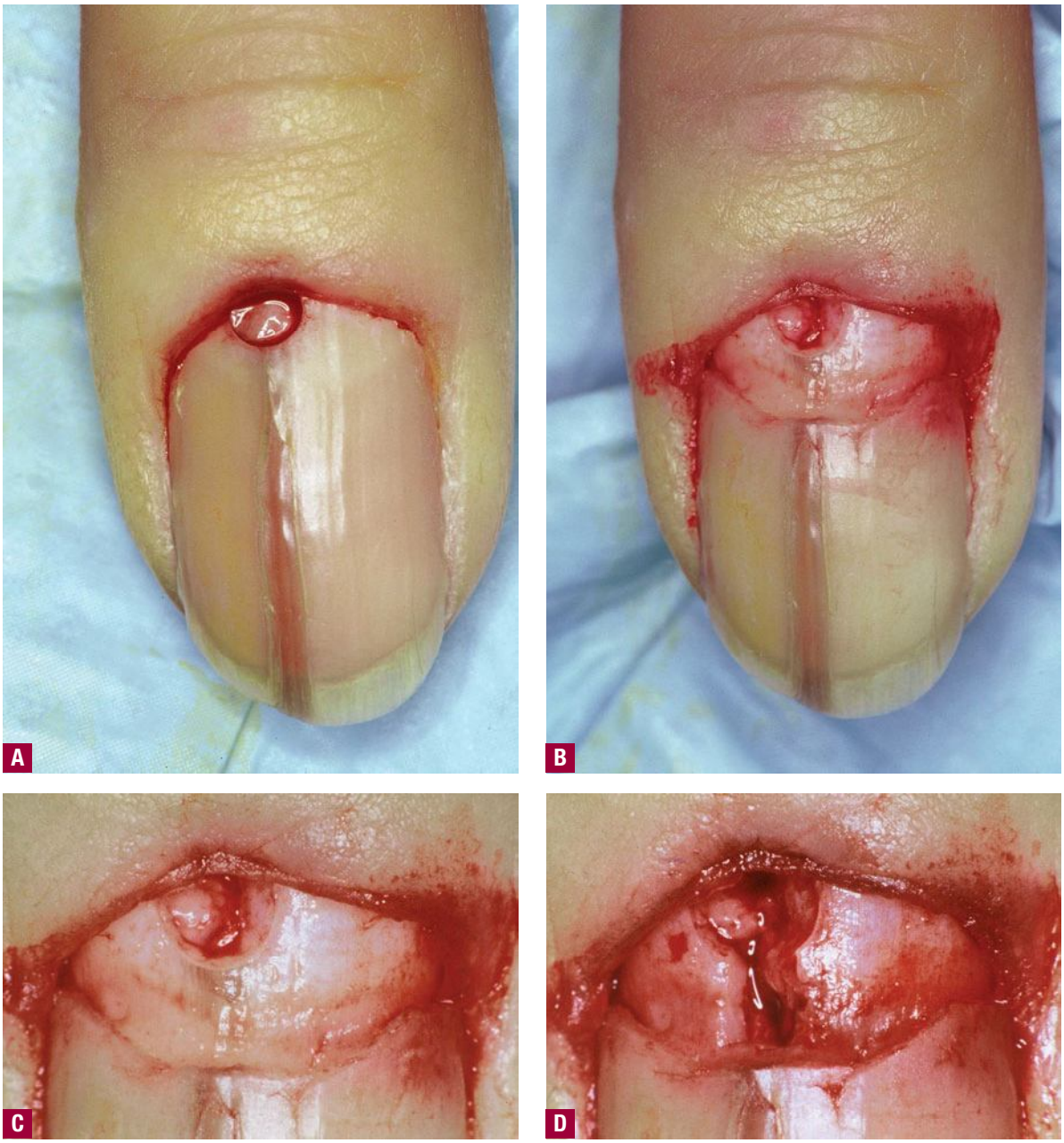

▲ **FIGURE 246-7** **A.** Punch biopsy of longitudinal melanonychia of less 3 mm in width. **B–D.** Removal of the base of the nail plate (**B**) to allow easy removal of the biopsied cylinder of matrix tissue (**C**) and pigment left distally (**D**).



▲ **FIGURE 246-8** Lateral longitudinal biopsy of longitudinal melanonychia located within the lateral third of the nail plate.

For transverse biopsy (Fig. 246-9), two small oblique incisions are made on each side of the proximal nail fold. The fold is then reflected to expose the matrix area. The proximal third of the nail plate is avulsed. Then, the lesion is removed by excising an elliptical or crescent-shaped wedge of tissue with the convex portion of the crescent paralleling the anterior border of the lunula. When longitudinal melanonychia lies within the midportion of the nail plate, the potential for postoperative dystrophy is great, and selection of the optimal biopsy method is difficult. It is important to establish the matrix origin (proximal or distal) of longitudinal mel-



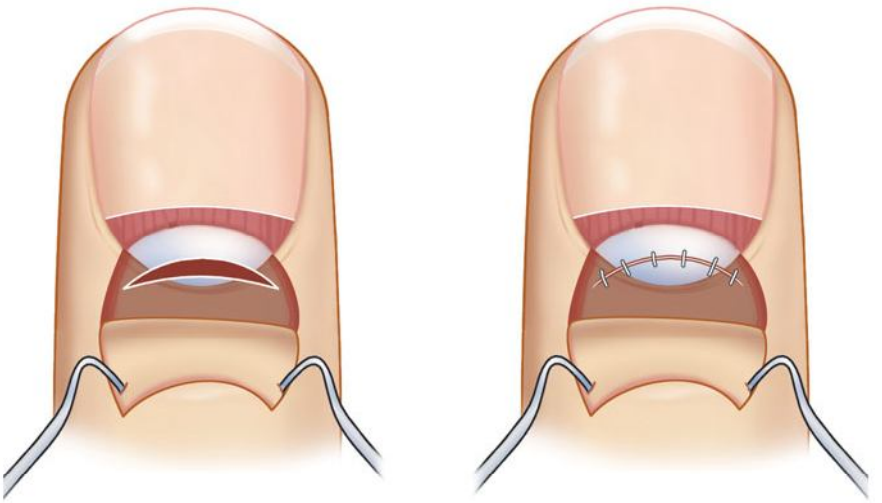

▲ **FIGURE 246-9** Transverse biopsy of the nail matrix.

anonychia preoperatively, because the more proximal the origin, the greater the risk of nail dystrophy.[3] The origin of pigmentation may be determined by microscopic examination of Fontana-Masson–stained clippings from the free edge of the nail.

RACQUET NAIL

SPLIT-NAIL DEFORMITY[6] The common causes of split-nail deformity include trauma, surgery, lichen planus, and tumors. Split-nail deformity may occur in either the lateral or the medial region. The appropriate surgical technique varies accordingly.

If the split is located within the lateral third of either portion of the nail, especially when it is close to the lateral margin, the best method is the technique recommended for lateral longitudinal nail biopsy—that is, the removal of the lateral portion of the nail with the defect. If the split is located in the middle region of the nail and involves its whole length, the proximal nail fold is carefully freed from the underlying nail plate, obliquely incised at both sides, and reflected to expose the whole matrix area (Fig. 246-10). The nail plate bordering the split is cautiously cut as a rectangular block approximately 1 mm wider than the scar that has to be excised. The nail bed and matrix of the defective tissue are dissected from the bone to allow an exact approximation of the remaining bed and matrix, which are sutured with 6-0 monofilament resorbable sutures. To prevent the sutures from tearing the tissue, 3-0 sutures are put through the nail plate. When these threads are knotted firmly, the matrix and nail bed are further approximated, which relaxes the 6-0 sutures.

If the scar is too wide to allow primary closure of the defect, relaxing longitudinal incisions along the lateral nail grooves down to the bone usually permit suturing. An alternative approach is the formation of a Schernberg nail bed–matrix flap with an L-shaped incision of the lateral aspect of the finger.

NAIL ABLATION AND ISOLATED MATRICECTOMY Nail ablation (Fig. 246-11) is the definitive removal of the entire nail organ and matricectomy, the complete extirpation of the nail matrix, which results in permanent nail loss. The principle of nail ablation is the complete removal of the nail unit with hyponychium, nail bed, matrix, and lateral and proximal nail folds. Except for treatment of malignant tumors of the nail apparatus, nail ablation is rarely indicated. It may be necessary in the case of an excessively painful nail treated several times without success, but this should be an exception. Scalpel excision is strongly advocated whenever the surgical specimen needs histopathologic examination. If periungual pigmentation is associated with longitudinal melanonychia or if the latter is wider than 6 mm or the full thickness of the nail is pigmented, a large portion of the matrix would necessarily be involved. Under these circumstances, the underlying disease process in unlikely to be benign. The entire portion of the involved nail apparatus has to be excised en bloc.

The defect from nail ablation (see Fig. 246-11B) may be covered with a free graft (split-thickness, full-thickness, reversed dermal graft), which usually takes on the bone in this particular location. A cross-finger flap is a very useful alternative to a free graft. The use of the skin from the intermediate phalanx of a neighboring finger is more convenient for the patient than skin from the thenar area of the palm.

If only permanent nail matrix removal is necessary, the procedure is less extensive.

In cases in which pathologic examination of the removed tissue is unnecessary, phenol cautery, rather than scalpel excision, is the preferred technique for matricectomy. Most patients return to normal ambulation and activity as early as 1 day after the operation.

Nail Bed

Nail bed surgery is performed for biopsy, removal of tumors, and treatment of nail dystrophies such as onychogryphosis.

BIOPSY Biopsy (Fig. 246-12) may be useful in any pathologic condition involving the nail bed.

Punch biopsy is done with a 3- or 4-mm diameter punch, which is driven perpendicularly into the nail plate in a circular motion down to the bone. How-

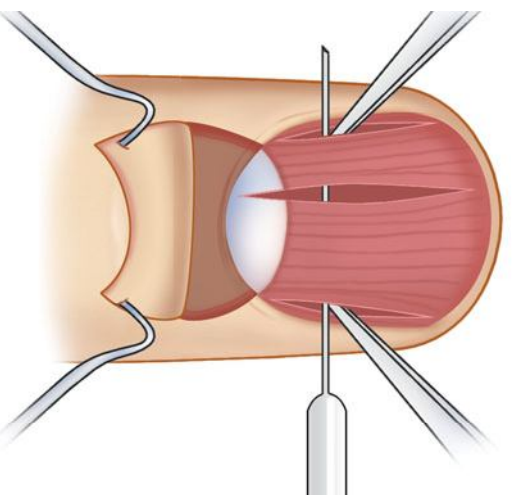

◀ **FIGURE 246-10** Treatment of split nail in the middle region of the nail plate.

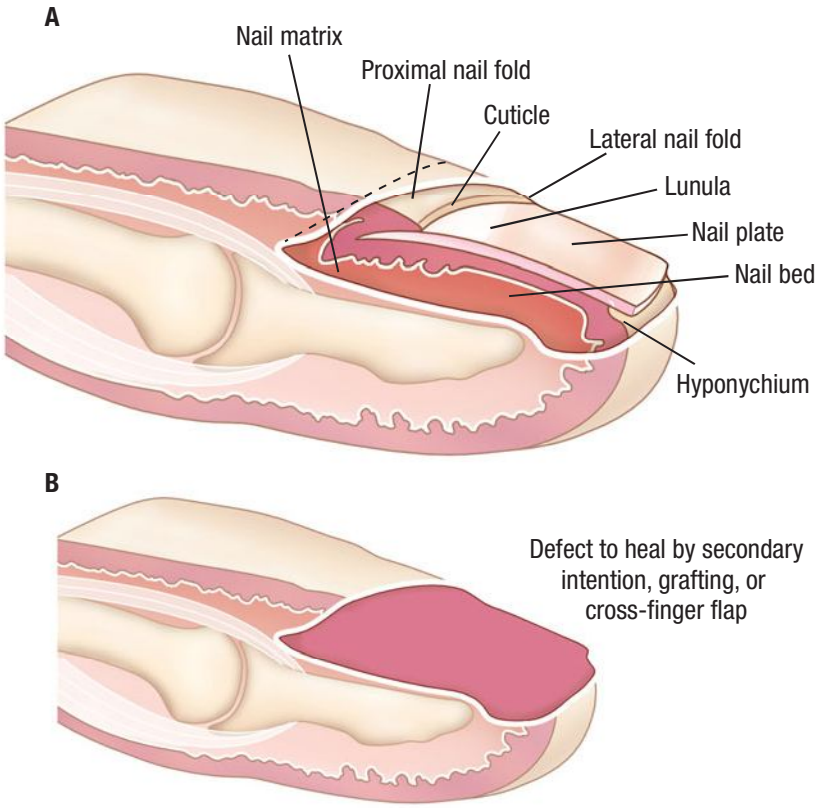

▲ **FIGURE 246-11** Nail ablation. **A.** Area of excision. **B.** Remaining defect.

ever, it is not always easy to extract the cylinder cut with an area this small. One useful technique is to perforate the nail plate with a 6-mm punch without injuring the underlying tissue (see Fig. 246-12A). The covering nail is then detached by using the tip of the scalpel to remove the disk of nail, and the biopsy is performed easily by using the 4-mm punch to the bone. The tissue can then be released from its tether with fine scissors. It is advisable to replace the 6-mm disk of nail keratin, after cleaning with 10 percent hydrogen peroxide, to cover the hole. If the nail plate is thick, rotating grinders can be used to thin it down and facilitate the transungual biopsy.

If a larger nail bed fragment is needed, fusiform biopsy with a major longitudinal axis can be performed after partial avulsion of the lateral half of the nail (see Fig. 246-12B) or after total avulsion if the fragment is central. After excision, the nail bed is undermined to facilitate reapproximation of both sides. The suture needle is used generously on these fragile subungual tissues. The wound is stitched with 6-0 resorbable thread. It is sometimes useful to make relaxing incisions at the most lateral margins of the nail bed.

SUBUNGUAL HEMATOMA In cases of subungual hematoma, acute trauma with severe pain is always remembered by the patient. Depending on the site and intensity of the injury, the hematoma may be visible almost immediately or it may grow out from under the proximal nail fold within a few weeks.

When the hematoma is partial (less than 25 percent of the visible portion of the nail), it should be drained with a pointed scalpel or by hot paperclip cautery over the center of the dark spot (Fig. 246-13). This will produce relief from pain. Sometimes the nail sloughs as the new nail regenerates beneath the old one.

Small hematomas may be included in the nail, but they cannot be degraded to hemosiderin and results of the Prussian blue test will be negative. Therefore, to demonstrate the nature of the blackish pigment, scrapings are boiled in a small test tube with Hemostix, which gives a positive benzidine result.

A hematoma involving more than 25 percent of the visible portion of the nail is a sign of significant nail bed injury. A radiograph is mandatory, because the phalanx may be fractured. The nail plate is carefully removed and the hematoma



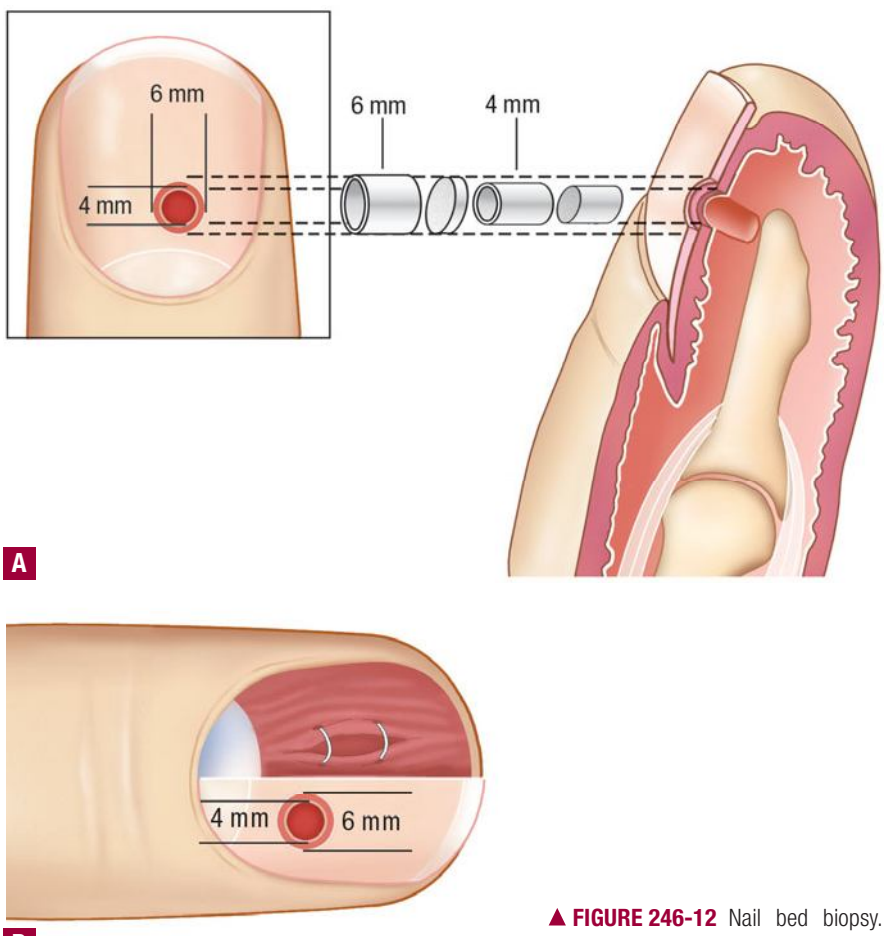

▲ **FIGURE 246-12** Nail bed biopsy. **A.** Punch biopsy. **B.** Fusiform biopsy.



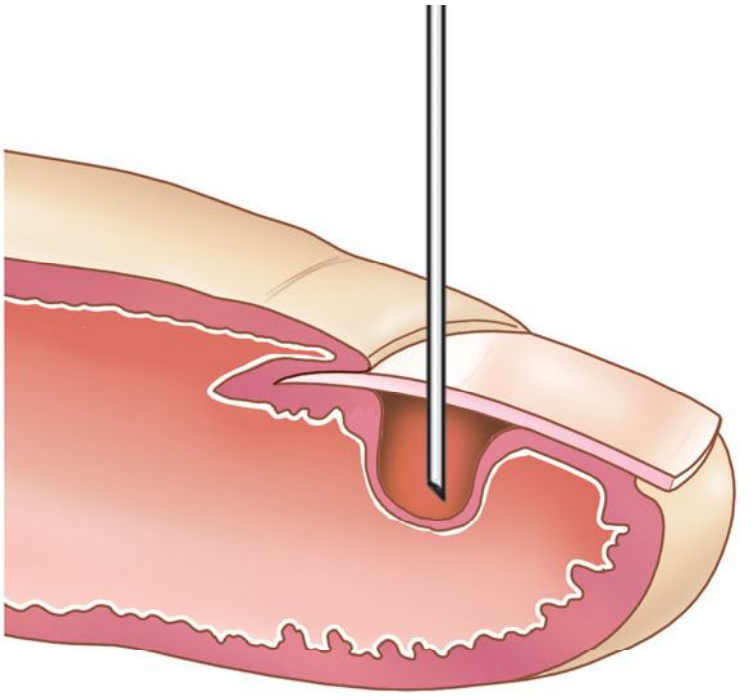

▲ **FIGURE 246-13** Treatment of partial hematoma.

evacuated. Traumatic nail bed laceration or wounds need a surgical approach to avoid delayed complications.

Nail bed lacerations can be sutured after thorough cleaning with antiseptics, using 6-0 resorbable monofilament material. The avulsed nail plate should be put back to cover the wound and then kept in place by suturing to the lateral nail folds or the fingertip.

Nail bed defects larger than 4 mm can be repaired using a split-thickness graft taken either from the nail bed of the same digit or from the nail bed of a great toe.

The torn nail bed should be sutured with 6-0 resorbable thread, and large bites of tissue should be taken so that the suture material does not pull through when it is tied. The nail plate is cleaned, shortened, and slightly narrowed, and then replaced with sutures into the lateral nail folds. The stitches are left in for 2 weeks.

Chronic hematomas are usually painless and are caused mainly by repeated microtrauma from either ill-fitting footwear or sporting activities. A notch is made with a scalpel blade at the distal and proximal border of the pigmented area. Observation over a 3-week period will demonstrate whether the nail grows independently of the pigmentation or with it. However, chronic hematoma may resemble subungual melanoma and pose a distressing problem, and nonmigrating hematoma should be ruled out.

Proximal Nail Fold

BIOPSY A 2- to 3-mm punch may be used for biopsy of a tumor. A blister may be completely removed by shave biopsy using half a razor blade (see eFig. 246-13.1 in on-line edition). Excision of a 3-mm crescent-shaped tissue segment in the proximal region of the lateral nail folds may be helpful in the evaluation of collagen disease.

RECALCITRANT CHRONIC PARONYCHIA Presence of a foreign body (e.g., hair) under the proximal nail fold is the main cause of recalcitrant chronic paronychia. The disorder manifests as a red swelling that is painless except when pressed, with secondary retraction of the paronychial tissue whose cuticle has disappeared and with recurrent episodes of acute paronychial inflammation.

For crescentic excision, a Freer septum elevator is inserted under the proximal nail fold to protect the matrix and extensor tendon. A No. 15 Bard-Parker blade is used to excise, en bloc, a crescent-shaped full-thickness skin segment, 4 mm at its greatest width, that extends from one lateral nail fold to the other. Use of a beveled incision prevents accidental damage to the proximal nail matrix and the most proximal portion of the proximal nail fold, which is responsible for the normal shine of the nail plate (see eFig. 246-13.2 in on-line edition).

In patients who experience repeated acute flares associated with chronic paronychia, additional removal of the base of the nail is useful.

TUMORS OF THE PROXIMAL NAIL FOLD Different techniques can be used to treat tumors of the proximal nail fold, depending on the nature of the tumor, its location, and the length of its long axis.

Crescentic excision is useful for small distal tumors. The crescent should not exceed 4 mm at its greatest width.

Tumors of the proximal nail fold that are situated in a median position and have a longitudinal axis longer than 4 to 5 mm can be excised with a wedge of proximal nail fold whose base is located at the free margin and whose apex points proximally (Fig. 246-14A). Two relaxing lateral incisions are then made in the proximal nail fold to allow suturing of the wedge-shaped defect after the

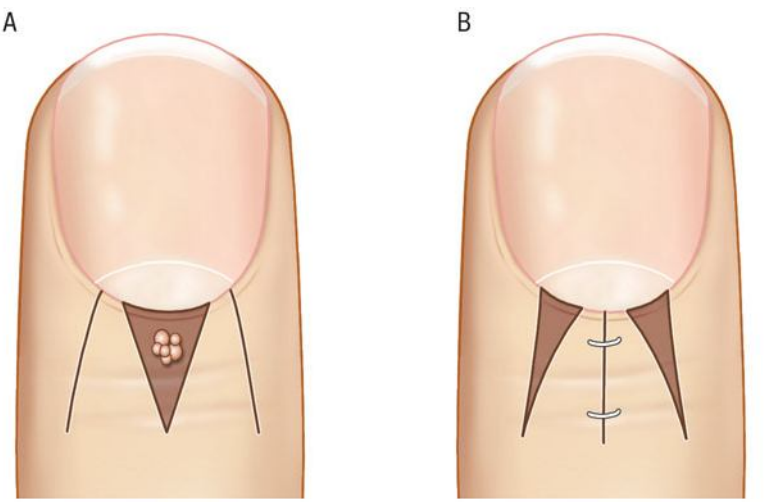

▲ **FIGURE 246-14** **A.** Tumor of the proximal nail fold situated in a median position. **B.** Suturing of the defect after relaxing lateral incisions are made and the proximal nail fold has been released from the nail plate.

undersurface of the proximal nail fold has been released from the nail plate (see Fig. 246-14B).

The resulting symmetric narrow defects on both sides heal rapidly by secondary intention.

A small tumor on the lateral part of the proximal nail fold may be treated using a wedge-shaped excision (see eFig. 246-14.1 in on-line edition). Only one lateral relaxing incision is made at the opposite region of the proximal nail fold. To obtain better healing of the secondary defect, which is wider than in the procedure using two relaxing incisions, the surgery may be supplemented by making a relaxing crescent-shaped incision in the proximal nail fold.

A dorsal flap can be raised from the proximal nail fold by using two dorsolateral incisions and a horizontal one proximal to the cuticle. This gives complete exposure of subcutaneous tumors.

RECONSTRUCTION OF THE PROXIMAL NAIL FOLD Reconstruction of the proximal nail fold may be necessary after any injury (accident, burn, avulsion caused by rapidly rotating belts and sanders, etc.). If the irregular tissue is excised, it is sometimes possible to re-create the distal curve of the proximal nail fold, which may produce a nearly perfect restoration. The proximal nail fold may also be restored by using two long, narrow, V-shaped transposition flaps from the lateral aspects of the terminal phalanx.

Lateral Nail Fold

A 2- to 4-mm punch can remove a tumor of the lateral nail fold (see eFig. 246-14.2 in on-line edition). Benign tumors may be removed by taking an elliptical wedge of tissue from the lateral nail fold and lateral nail wall. Malignant tumors, such as in Bowen disease, are treated by excision of the whole lateral nail fold or by Mohs micrographic surgery followed by healing by second intention.

INGROWN NAILS Ingrown nail is a condition that occurs mainly in the great toe. It is created by impingement of the nail plate into the dermal tissue distally or into the distolateral nail groove. Irrespective of the initial cause, the condition finally presents with a nail bed that is too narrow for its nail plate. Logical treatment is therefore aimed at correcting this disparity.

Distal Toenail Embedding. Surgical avulsion or the loss of the toenail from trauma, such as tennis toe, may initiate the pathology. The distal subungual tissues released from the physiologic counterpressure of the nail plate become hypertrophic, and the newly formed nail plate abuts this distal wall. To treat the condition, a crescentic wedge-shaped excision is made around the distal phalanx (see eFig. 246-14.3 in on-line edition). The wedge should be 4 mm at its greatest width and must be dissected from the bone. The defect is closed with 5-0 monofilament sutures, which should be removed after 12 to 14 days.

Juvenile (Subcutaneous) Ingrown Nails. Juvenile or subcutaneous embedded nail is the most common type of ingrown nail. The nail is usually embedded medially, but both sides are often affected. In an effort to relieve the pain, the patient often tries to cut off the offending corner under the inflamed and swollen soft tissue. The remaining portion gives rise to a nail spicule piercing the epithelium of the lateral nail groove, which produces secondary infection and excessive granulation tissue.

Treatment at the early stage must be conservative but demands a high degree of patient compliance. The foot is soaked in warm water with povidone-iodine soap; then, under local anesthesia, the nail spicule is removed and a wisp of cotton wool is placed between the nail and the lateral nail groove. It should be moistened repeatedly with a disinfectant.

For definitive cure, surgical excision or, better, chemical suppression of the lateral horn of the nail matrix permanently narrows the nail. The lateral fifth of the nail plate is freed with a nail elevator from the proximal nail fold and the subungual tissues. It is then cut longitudinally with an English nail splitter or nail-splitting scissors and extracted using a sturdy hemostat. The lateral matrix horn is cauterized with a freshly made solution of liquefied phenol (88 percent solution) (see eFig. 246-14.4 in on-line edition). Above all, a bloodless field is needed, because blood inactivates phenol. Hemostasis is therefore accomplished with a tourniquet, and the blood is carefully cleaned from the space under the proximal nail fold using sterile gauze. The surrounding skin is protected with petroleum jelly. The phenol is rubbed onto the matrix epithelium for 3 minutes with a cotton-tipped swab that is changed two or three times. Postoperative pain is minimal because phenol has a local anesthetic action and is antiseptic. The matrix epithelium is sloughed off, and oozing is usual for 2 to 6 weeks. Daily warm foot baths with povidone-iodine soap accelerate healing.

Pincer Nail[7]. Overcurvature of the nails may affect the great toe alone or all the digits. This condition may be so painful that even contact with a bedsheet becomes unbearable.

When the condition is mild, the nail brace technique is used, which aims at correcting the inward distortion of the nail by maintaining continuous tension on the nail plate. A stainless steel wire brace is fitted to the nail plate. A series of adjustments adapted to the gradual decrease of curvature is made over a period of 6 months and results in a painless correction of the pincer nail. Because the underlying bone pathology remains untreated, however, relapse is usual. Therefore, the definitive cure—the use of phenol cautery on the lateral matrix horns—is undoubtedly the simplest effective treatment modality.

Hypertrophy of the Lateral Nail Fold. Hypertrophic lateral nail folds are usually the result of long-standing ingrown nails. Inflammation may range from the sub-clinical to the severe. For treatment, approximately one-fifth of the nail digging into the lateral nail fold is removed. Then an elliptical wedge of tissue is taken from the lateral nail wall of the toe, down to the bone (see eFig. 246-14.5 in on-line edition). Suturing of the defect pulls the lateral nail fold away from the offending lateral nail edge. In severe cases, this procedure may be combined with phenol cautery of the lateral horn of the matrix. In contrast to adult-acquired hypertrophy of the lateral nail fold, congenital lateral hypertrophic lips disappear progressively and spontaneously within 12 months.

Congenital Malalignment of the Great Toenail[8]. In congenital malalignment of the nail of the great toe, typically the nail is malaligned laterally, with transverse furrows on a thick brownish or greenish nail. In 50 percent of cases this condition corrects itself without therapy before the age of 10. If the appearance is extreme, surgery diminishes the risk of permanent dystrophy.

Treatment requires rotation of a bulky nail unit flap, including the entire nail, nail bed, and matrix (see eFig. 246-14.6 in on-line edition). This demands creation of an external Burow's triangle. An eccentric crescent-shaped excision is made



to undermine the nail unit, with the maximum width located on the internal side of the foot, corresponding to the side to which the nail needs to be redirected. This crescent ends on each side 3 to 4 mm behind the most proximal part of the proximal nail fold. The nail bed and the matrix are then undermined and lifted until the fibers of the extensor tendon are visible on its bony insertion, and the dorsal expansion of the lateral ligament of the distal interphalangeal joint is cut.

Suturing the edges of the excised triangle together reduces the loss of cutaneous substance. The nail unit is rotated inwardly, because the maximum cutaneous resection is mostly distal and medial.

REFERENCES

1. Fleckman P: Surgical anatomy of the nail unit. *Dermatol Surg* **27**:257, 2001
2. Baran R: An effective surgical treatment for nail thickening in Darier's disease. *J Eur Acad Dermatol Venereol* **19**:689, 2005
3. Rich P: Nail biopsy: Indications and methods. *Dermatol Surg* **27**:229, 2001
4. Baran R et al: The melanocyte system of the nail and its disorders, in *Pigmentary System*, 2nd ed, edited by Nordlung JJ, et al. Oxford, Blackwell Publishing, 2006, p 1037
5. Haneke E, Baran R: Longitudinal melanonychia. *Dermatol Surg* **27**:580, 2001
6. Desciack EB, Eliezri YD: Split nail deformities: A surgical approach. *Dermatol Surg* **27**:252, 2001
7. Baran R, Haneke E: Pincer nails. Definition and surgical treatment. *Dermatol Surg* **27**:261, 2001
8. Baran R, Haneke E: Etiology and treatment of nail malalignment. *Dermatol Surg* **24**:719, 1998



CHAPTER 247

Cryosurgery and Electrosurgery

Justin J. Vujevich
Leonard H. Goldberg

HISTORY

CRYOGENS

Liquid nitrogen is the cryogen of choice in dermatology. It is easy to store and use, environmentally friendly, nonflammable, inexpensive, and at –195.8°C (–320.4°F), has the lowest temperature of all the common cryogens, causing rapid freeze of treated tissue.

Other available cryogens include fluorinated hydrocarbons, solid carbon dioxide, and nitrous oxide (Table 247-1). Fluorinated hydrocarbons are used as topical sprays to provide temporary anesthesia before the removal of skin lesions and the administration of vaccinations. Cryogen spray cooling is also used to reduce the pain of laser surgery and eliminate overheating of the epidermis.[4]

CRYOBIOLOGY

Cryobiology refers to the study of the effects of subzero temperature on living systems. Tissue destruction from cryotherapy results from direct cell injury, vascular stasis, and the local inflammatory response.

Freezing cells convert water to ice (crystallization). Rapid freezing causes intracellular ice crystal formation with the disruption of electrolytes and pH changes, whereas slow freezing causes extracellular ice formation and less cell damage. Therefore, tissue effects and cell death are most readily achieved when tissue is frozen rapidly.[5]

During thawing, re-crystallization occurs when ice crystals fuse to form large crystals that disrupt cell membranes. As the ice melts further, the extracellular environment becomes hypotonic, causing water to infuse into cells and cause cell lysis.[6] The longer the thawing time, the greater damage to the cells because of increased solute effect and greater re-crystalization.[6]

After freezing, stasis within the vasculature occurs. This loss of circulation and resultant anoxia is a major mechanism of injury from cryosurgery. As the tissue thaws over 0°C (32°F), a brief hyperemic response ensues, with resultant edema and inflammation.

TARGETS OF CRYOTHERAPY

Table 247-2 lists targets of cryosurgery with associated cell death temperatures. Melanocytes are the most sensitive to cryosurgery, with cell destruction at –4°C to –7°C (24.8°F to 19.4°F).[8] As a result, depigmentation may occur, especially in darkly pigmented individuals. Keratinocytes require longer freezing to –20 to –30 °C until cell death and are more resistant to cooling effects. Fibroblasts are the most resistant to freezing and do not undergo cell death until –30°C to –35°C (–22°F to –31°F). A temperature of –50°C to –60°C (–58°F to –76°F) is needed for destruction of malignant lesions, whereas lesser degrees of freezing are needed for benign lesions.

TABLE 247-1
Cryogens Used in Cryosurgery

AGENT	BOILING POINT (°C/°F)
Freon	–40.8/–41.4
Solid CO_2	–79.0/–110.2
Nitrous oxide	–89.5/–129.1
Liquid nitrogen	–195.8/–320.4

PATIENT SELECTION AND CONSIDERATIONS FOR CRYOSURGERY

Several factors, including lesion type, size, depth, border, location, and patient skin type, should be considered when cryosurgery is a treatment choice. Absolute contraindications to cryosurgery include lesions that require histopathology for diagnosis and recurrent non-melanoma skin cancers. Relative contraindications to cryosurgery include patients with cold urticaria, abnormal cold intolerance, cryoglobulinemia or cryofibrinogenemia, or tumors with indistinct borders or darkly pigmented features.

Precautions should be undertaken when treating lesions overlying nerves, such as the postauricular nerve on the neck or digital nerves on medial and lateral fingers and toes. Damage may result in regional paresthesia or motor dysfunction. Cryosurgery may not be indicated when treating sites prone to scarring with retraction, such as the eyelids, mucosa, nasal ala, and auditory canal. Finally, patients with darkly pigmented skin may have hypopigmentation at treated sites.

TABLE 247-2
Tissue Target Cell Death Temperatures

CELL	TEMPERATURE (°C/°F)
Melanocytes	–4 to –7 (24.8 to 19.4)
Keratinocytes	–20 to –30 (–4 to –22)
Fibroblasts	–30 to –35 (–22 to –31)



▲ **FIGURE 247-1** CRY-AC® cryosurgical unit (Brymill Corporation).

TECHNIQUES AND EQUIPMENT FOR CRYOSURGERY

There are several cryosurgical techniques that can be used in treating skin lesions. The open spray method is most frequently used. This method uses a hand-held cryosurgical unit with fingertip trigger (Fig. 247-1). Spray tips with varying-sized apertures are attached to the unit, emitting a stream of liquid nitrogen toward the lesion from a distance of 1 to 2 cm.

Although freeze times vary for lesion types, an intermittent spray in a solid, circular, or paintbrush pattern is normally used. Longer spray times are required for thicker, keratotic lesions or malignant lesions; shorter times are required for thinner, atrophic, or benign lesions. The intermittent spray helps to localize treatment to the lesion with a small freeze halo, thus minimizing collateral normal tissue damage. This is particularly important when treating lesions around the orbital, nasal, auricular, genital, or periungual regions.

As the lesion is treated a lateral freeze spreads beyond the margins of the lesion. The measurement of the surface radius of the freeze is equal to the central depth of the freeze into the skin.[6] Temperature gradients exist within the freeze, with colder temperatures in the middle and warmer temperatures toward the periphery. In general, superficial lesions should have a clinical freeze margin of 2 to 3 mm, and malignant or deeper lesions should have a clinical freeze margin of 5 mm to ensure successful treatment.

The closed technique uses a copper cryoprobe that is attached to the cryosurgical unit. Once the metal probe is pressed against a lesion on the skin, the trigger of the unit is squeezed, and liquid nitrogen leaves the unit through a conduit line that maintains it in a closed system. This technique is useful for treating small, well-circumscribed lesions or lesions found in confined locations.

Similarly, a metal, cone-sized chamber can be attached to the cryosurgical unit and held in contact with the lesion. This allows liquid nitrogen spray to enter the cone and rapidly freeze the lesion. Another cone-apparatus option includes holding an otoscope cover tip against the lesion with one hand while freezing with the cryosurgical unit in the other hand. Treatment times using the cone method should be decreased because the final temperature at the orifice of the cone is obtained faster, when compared with an open spray.

If a cryospray unit is not available, the dipstick technique can be used. First, a small amount of liquid nitrogen is poured into a polystyrene cup or other insulated container. Cotton-tipped swabs are placed tip-down in the container and cooled. Using firm pressure, the cotton-tips are placed against the lesion until a 2- to 3-mm halo forms around the treated lesion. This method treats lesions on the body where surrounding tissue must be spared, such as periorbital, mucosal, nail, and genital regions.

Alternatively, tissue forceps can be placed in the container and allowed to cool. This method is useful for treating filiform lesions such as verrucae and skin tags. The metal forceps cool rapidly, so insulated gloves should be worn while holding the forceps to prevent freeze injury to the practitioner's fingers.

CRYOTHERAPY FOR BENIGN AND PRE-MALIGNANT SKIN LESIONS

There are many benign lesions that can be treated with cryosurgery. Several lesions commonly treated with liquid nitrogen are presented below.

Seborrheic Keratosis

The spray technique is an effective modality for treating this common lesion. Although longer freeze times of 10 to 15 seconds with a 1- to 2-mm halo are required for these raised growths, too aggressive freezing may result in scarring or hyperpigmentation. For cosmetic purposes and to prevent pigmentation changes, a lighter freeze followed by curettage may be preferential. Forewarn patients that a second treatment may be required, especially for thicker seborrheic keratoses.

Solar Lentigo

As previously described under Targets of Cryotherapy, pigmented cells are highly susceptible to freezing. Therefore, these lesions require a shorter freeze time of 3 to 5 seconds with minimal halo. For darker-skinned individuals, care must be taken not to induce hypopigmentation at treatment sites. Therefore, a test site in a cosmetically less noticeable region may be performed first before treating multiple lesions on sun-exposed areas. In addition, sunscreen with ultraviolet A and ultraviolet B protection should be advocated pre- and post-treatment.

Keloids and Hypertrophic Scars

Treatment of keloids and hypertrophic scars is frequently unsatisfactory. Cryosurgery is a less common but effective means of treating these recalcitrant lesions. Freeze times of 30 seconds are required over 1-month interval sessions until flattening is achieved. Zouboulis et al. reported a prospective study of 93 keloids and hypertrophic scars treated with 30-second freeze times over one to three sessions.[9] Improved responses were seen in patients treated with three or more sessions (79 percent), compared with subjects treated once or twice (33 percent).

Dermatofibroma

Treatment times may be 60 seconds due to the fibrotic nature of the lesion and the need to treat cells located in the deep dermis. A retrospective study of 393 dermatofibromas treated with cryosurgery reported 65 percent clearance of a visible and palpable lesion.[12]

Sebaceous Hyperplasia

Mucocele

Verrucae

Warts are a common problem, with a high prevalence in the population.[14] Although cryosurgery for warts has sustained a common practice in dermatology,





▲ **FIGURE 247-2** Warts on hand treated with liquid nitrogen.

varying techniques have been offered with regard to freezing method, number of freeze-thaw cycles, and frequency of treatment sessions. Cryosurgery using the spray technique is probably the most common method due to its quick, convenient use and ease of obtaining a freeze halo around the lesion (Fig. 247-2). The cotton-tip applicator technique is cheaper and may be less frightening to the patient, particularly children. Care must be undertaken not to cross-contaminate by reintroducing the cotton-tip applicator into a common flask.

Combination therapy with cryosurgery has also been advocated to treat verrucae. Berth-Jones and Huchinson[21] demonstrated a 52 percent cure rate at 3 months with the combination of cryotherapy, keratolytic wart paint, and paring. The authors also noted that paring the wart before cryotherapy improved the cure rates for plantar warts, but not hand warts.

Actinic Keratosis

Cryosurgery is an effective modality for the treatment of actinic keratoses (AKs). The open spray technique, using a single freeze-thaw cycle of 8 to 10 seconds, is the treatment of choice (Fig. 247-3). Hypertrophic AKs require longer freeze times while atrophic AKs and AKs on thin-skinned regions require shorter freeze times. A 1- to 2-mm freeze margin around the lesion is adequate. For thicker lesions, pre-treatment of emollients or curetting may shorten freezing times.

CRYOSURGERY FOR MALIGNANT LESIONS

Cryosurgery appears useful in well-defined lesions for situations where surgery is less favorable, either for technical or cosmetic reasons, or when the patient prefers this treatment option.

Cryosurgery is not indicated for lesions that require histology diagnosis at the same time of treatment or have ill-defined borders, atypical pigmentation, or low cure rates. The goal of cryosurgery is to cure the patient by destroying the lesion in a single treatment.

Bowen Disease

Basal Cell Carcinoma

Several studies have reported treating basal cell carcinomas (BCCs) with cryosurgery with cure rates ranging between 95 percent and 99 percent.[27–29] Although excellent cure rates have been claimed, few studies have demonstrated histologically that the BCC is no longer present post-treatment. Furthermore, there are no good studies comparing cryosurgery with other known treatment modalities, such as Mohs surgery, excision with clinical margins, and electrodesiccation and curettage.

Postsurgical cosmetic appearance is a concern to patients. Kokoszka and Scheinfeld[32] reported good cosmetic results in their review of the literature. Thissen et al.,[33] however, compared the cosmetic results of surgical excision compared with cryosurgery for BCCs of the head and neck and concluded that cosmetic results after excision are better than after cryosurgery.

Squamous Cell Carcinoma

Similar cure rates to BCCs are evident when treating squamous cell carcinomas (SCCs) with cryosurgery. In a study of 563 primary SCCs, of which most were between 0.5 and 1.2 cm in diameter, Graham and Clark[34] reported a cure rate of 97.3 percent. Treatment technique with cryosurgery for SCCs is the same as for BCCs.

Lentigo Maligna

With proper patient selection, cryosurgery can be an effective treatment option for lentigo maligna (LM) due to the sensitivity of melanocytes to cold. With the aid of a Wood's lamp, a clinical margin of 5 mm is drawn around the visible borders of the lesion. The lesion is subsequently treated with a double freeze-thaw cycle of 30 to 60 seconds each cycle. Because atypical melanocytes may extend along the length of the hair follicles, treatment must freeze the tissue to this depth.

Stevenson and Ahmed[35] reviewed cure rates from more than 200 LMs treated with cryotherapy, with an overall recurrence rate of less than 9 percent. However, the recurrence rates in these studies ranged from 0 percent to 50 percent.



▲ **FIGURE 247-3** Actinic keratosis on forehead treated with liquid nitrogen.

Advantages of cryotherapy for LM include its efficiency and avoidance of large surgical scars. One major disadvantage of cryosurgery is the inability to assess whether the lesion has been completely destroyed. In addition, because no tissue is obtained for definitive confirmation of cancer removal, the chance exists that recurrent melanoma may develop and that it may be invasive. Overlying scars may conceal the cancer.

Kaposi Sarcoma

POSTOPERATIVE CARE

Patients should be given simple verbal and written wound care instructions post-treatment. Edema, vesicles, bullae, and weeping should be expected from treated areas within 24 hours post-treatment. Treated sites may be rinsed with soap and water and patted dry with a towel daily. If actively weeping, the wound site may be bandaged. Benign and pre-malignant lesion-treated sites heal typically in 1 to 2 weeks, with malignant lesion-treated sites requiring 3 to 4 weeks of healing.

COMPLICATIONS FROM CRYOSURGERY

Pain

In addition to pain during freezing, patients may also experience discomfort several hours post-treatment. Typically, pain is controlled with acetaminophen. Lesions such as periungual warts, digital lesions, or mucous membrane lesions may require stronger analgesics due to intense swelling and throbbing. If the temple region is treated, patients may experience migraine-type headaches.

Bleeding

Patients on anticoagulant therapy should be warned of bruising due to tissue necrosis. If painful hemorrhagic bullae form, they may be drained with an 18-gauge needle inserted into the lateral blister skin. Care should be undertaken not to remove the surface of the bullae, as this tissue acts as a natural wound dressing.

Pigment Changes

Hypopigmentation is the most disconcerting complication post-cryosurgery. As previously described, pigmented cells are sensitive at temperatures of –4°C to –7°C (24.8°F to 19.4°F). Although hypopigmentation is usually transient, prolonged freezing greater than 30 seconds may result in permanent pigment loss. Topical steroids, glycolic acids, retinoids, and hydroquinone may aid in reducing the incidence of hypopigmentation.

Scarring

Infection

Nerve Damage

Treatment of lesions overlying nerves, such as the postauricular nerve on the neck or digital nerves on medial and lateral fingers and toes, may result in regional paresthesia or motor dysfunction. Digital neuropathy occurring post-cryosurgery of digital warts has been reported.[37]

Alopecia

Mucosal Loss

Insufflation of Soft Tissue

Syncope

Pyogenic Granuloma

ELECTROSURGERY

Electrosurgery is a technique that uses the transmission of electricity to cut tissue, destroy tissue, and cauterize vessels. Variations in current wavelength result in different biologic effects on tissue. For cutaneous procedures, electrosurgery can be categorized into six different treatment modalities: electrofulguration, electrodesiccation, electrocoagulation, electrosection, electrocautery, and electrolysis.

Principles of Electrosurgery

Electrosurgical equipment uses either direct or alternating current. In direct current, electrons flow in one direction, while in alternating current, electron flow reverses direction. With the exception of electrocautery or electrolysis, electrosurgical units used in dermatologic procedures have high-frequency alternating current.

See eFig. 247-3.1 in on-line edition for several examples of electrosurgical units. The terms *monopolar* and *bipolar* refer to the number of tissue-containing tips at the end of a surgical electrode. Monopolar denotes one tip, and bipolar denotes two tips.

Monoterminal refers to the use of a treatment electrode without an indifferent or dispersing electrode. *Biterminal* refers to the use of both treatment and indifferent electrodes.

Modalities of Electrosurgery

ELECTROFULGURATION Electrofulguration uses a damped sine wave, high-voltage, low-amperage alternating current to generate a spark from a monoterminal electrode to the tissue via the air. There is no contact between the electrode and the tissue. This modality is the least tissue damaging of all of the high-frequency electrosurgery techniques, resulting in rapid tissue healing. Most of the tissue damage is superficial, primarily involving the epidermis.

ELECTRODESICCATION Electrodesiccation uses a damped sine wave, high-voltage, low-amperage alternating current to generate a current from direct contact of a monoterminal electrode to the tissue. Superficial tissue damage occurs as heat is transferred to tissue, causing cell death. The extent of tissue damage is directly related to electrode contact time with the skin. Although skin injury is greater with electrodesiccation compared to electrofulguration, most of the tissue damage remains superficial.

ELECTROCOAGULATION Electrocoagulation uses a moderately damped sine wave, low-voltage, high-amperage alternating current to generate a current from direct contact of a biterminal electrode to the tissue. Tissue damage is deeper than with electrofulguration and electrodesiccation, providing tissue coagulation through the generation of heat in the tissue.

Another distinguishing feature of electrocoagulation is the involvement of the patient within the circuit. This allows the use of a lower voltage and higher amperage to generate more coagulation.

ELECTROSECTION Electrosection uses an undamped or slightly damped sine wave, low-voltage, high-amperage alternating current to cut tissue with minimal peripheral heat damage. The "Bovie" knife incorporates a blended undamped and damped sine wave that provides both cutting and coagulation at the same time.

ELECTROCAUTERY Electrocautery uses a heating filament tip connected to a low-voltage, high-amperage direct current,



usually a battery. Heat is transferred from the filament to the target tissue, causing protein denaturation and tissue coagulation. There is no electric current transfer to the target tissue, and the patient is not part of the circuit loop.

Electrocautery is most used for patients with pacemakers or implantable cardiac defibrillators (ICDs) who are high-risk candidates for receiving electrosurgery. In addition, because patients are not part of the circuit loop, electrocautery is useful for non-conductive tissue areas of the body, such as the cartilage, bone, and nails.



ELECTROLYSIS Electrolysis uses low-voltage, low-amperage direct current from a negative electrode to the positive electrode. The negative electrode is applied to the target tissue where electrons are released. The electrons interact with the tissue to produce sodium hydroxide and hydrogen gas resulting in tissue liquefaction. Acids are produced at the positive electrode resulting in tissue coagulation. The main use of electrolysis is for hair removal.

Patient Selection and Indications for Electrosurgery

When taking preoperative history for surgery, patients should be asked if they have a cardiac pacemaker or ICD. High-frequency electrosurgery may interfere with their function or damage the pacemaker or defibrillator, resulting in patient morbidity or mortality.

Patients commonly present for cutaneous surgery with either a cardiac pacemaker or an ICD. Although technologic advances, such as titanium shielding, have provided safeguards against electromagnetic interference (EMI), electrosurgical devices may cause these cardiac devices to malfunction.

Fixed-rate pacemakers are not influenced by EMI from electrosurgery.

ICDs deliver an electrical response to an abnormal ventricular rhythm. Some ICDs have a combination of a pacemaker and defibrillator to respond to both bradycardia and tachycardia. EMIs from electrosurgical devices may mimic a cardiac arrhythmia and cause the unit to discharge.

Recommendations have been published for the preoperative and intraoperative management of patients with pacemakers and ICDs during dermatologic surgery.[39–43]

First, patients with pacemakers or ICDs need to be identified before the surgical procedure. Patients should be asked when scheduling surgery if they have one of these devices. If present, a preoperative evaluation by the patient's cardiologist should be arranged before the surgical procedure. The evaluation should include the scope and location of the surgery, the potential for exposure to EMI, the type of implantable device in the patient, and whether the patient is pacemaker dependent.

For management of patients with pacemakers or ICDs undergoing surgical procedures, consider the use of alternative means of hemostasis such as patient-applied manual pressure[44] or electrocautery. These hemostasis methods do not interfere with implantable cardiac devices and, for short surgical procedures with minimal bleeding, are quite effective.

Complications resulting from using electrosurgery for cutaneous surgery in patients with pacemakers or ICDs are uncommon.

Clinical Applications of Electrosurgery

HEMOSTASIS The most common application of electrosurgery is its use in maintaining hemostasis in the operative field. Different techniques of electrosurgery can be used based on the type of electrosurgical unit used during surgical procedures. Coagulation can be achieved using electrofulguration electrodesiccation, or electrocoagulation by direct application of the electrode to the bleeding vessel. This provides conduction of heat to the vessel, resulting in tissue coagulation (Fig. 247-4).

Alternatively, vessels can be grasped by a forcep or hemostat, followed by application of the active electrode. When electrical current is placed against the metal instrument, heat is transferred from the electrode through the metal tip to the vessel. This technique is best used



▲ **FIGURE 247-4** Electrodesiccation of bleeding vessel during Mohs surgery.



▲ **FIGURE 247-5** Electrocurrent applied to forcep to cauterize bleeding vessel during Mohs surgery.

when the surgical field cannot be visualized due to bleeding (Fig. 247-5).

ELECTROSURGERY OF BENIGN LESIONS Electrodesiccation is an effective treatment modality for papular or plaque-like tumors of the epidermis, such as seborrheic keratoses, verrucae, dermatosis papulosis nigra, molluscum, or flat warts. First, the area around the lesion is anesthetized with lidocaine containing epinephrine. Then, the lesion is touched with the low-power electrode until a gray, superficial charred layer involves the entire lesion. The charred tissue is removed from the treated lesion by wiping with a sterile gauze or curetting. The process is repeated until the lesion is removed at the level of the surrounding skin. This method results in minimal bleeding and scarring because just the epidermal components are removed.

ELECTRODESICCATION AND CURETTAGE OF MALIGNANT LESIONS Curettage and electrodesiccation (C+D) is a commonly used treatment option for BCCs and SCCs. Certain tumor characteristics, however, should be present to ensure high cure rates and acceptable cosmetic outcome. Tumors should be primary, have distinct clinical borders, be located on sites of low recurrence such as the trunk, extremities, or non-"H"-zone regions of the face (see Chaps. 155 and 245), have a superficial or nodular histologic sub-type, and have a diameter of < 1 cm on the face and < 2 cm on the trunk and extremities. In addition, C+D is a viable treatment option for patients with high morbidity co-factors that make surgical excision too risky, or for patients who cannot make regular follow-up visits.

Tumors not acceptable for C+D include those with indistinct borders, tumors on the "H"-zone of the face, tumors



▲ **FIGURE 247-6** Clinical outline of skin tumor before curettage and electrodesiccation.

with an aggressive histologic pattern, tumors with high metastatic potential, and tumors that require histologic diagnosis. For patients with cardiac pacemakers or ICDs, electrocautery may be substituted for electrodesiccation.

The tumor outline should be marked, and lidocaine with epinephrine should be injected to provide adequate local anesthesia (Fig. 247-6). With firm counter-pressure, the lesion is then curetted in a checkerboard pattern until the clinical appearance of the lesion is removed (Fig. 247-7). This is followed by electrodesiccation on high power of the base and periphery of the lesion (Fig. 247-8). This C+D procedure is repeated up to two more times until a resultant atrophic defect without clinical evidence of residual tumor is achieved. Some advocate the inclusion of a 2- to 4-mm rim of clinically normal skin during the C+D procedure, and individual variations of the protocol are established. If curettage of the BCC extends into subcutis, then an extensive invasion of a BCC has occurred, and excision should be performed.

The advantages of treatment with C+D include time-efficiency, ease of surgical technique, and minimal post-treatment morbidity. Disadvantages of treating with C+D include non-confirmation of histologic tumor clearance, practitioner-dependent efficacy, and potentially long (3- to 4-week) healing times via second intention healing. Furthermore, the cosmetic result may show hypopigmentation, atrophy, persistent erythema, and hypertrophic scarring.

Postoperative Care

For all treatment groups, wound areas should be covered with a pressure bandage consisting of a topical petroleum product directly on the wound, an overlying nonstick bandage, and firmly applied gauze with adhesive tape. After 24 to 48 hours, the pressure bandage is removed, and the wound site is cleaned with tap water or saline gently rinsing over the wound. Petroleum jelly and bandage is changed daily after rinsing, for 3 to 4 weeks or until healed.

Complications of Electrosurgery

Although electrosurgery is safe, the surgeon must recognize several dangers while using this technique.



▲ **FIGURE 247-7** Curettage of skin tumor during curettage and electrodesiccation procedure.



▲ **FIGURE 247-8** Electrodesiccation of skin tumor during curettage and electrodesiccation procedure.

BURNS There are several situations in which burns may occur with electrosurgery. Thermal injury can occur if there is inadequate contact between the patient and the dispersing electrode plate, when there is inadvertent contact between the dispersing electrode and the patient or surgeon, and if the patient or surgeon may "ground" himself or herself by touching a metal component of the table. Metal jewelry near the electrosurgical site should also be removed.

FIRE Electrosurgical current will ignite flammable substances like alcohol. When prepping the patient before electrosurgery, non-flammable disinfectants such as iodine or chlorhexidine should be used. In addition, electrosurgery should not be used near the presence of nasal cannulas, masks, or endotracheal anesthesia administering oxygen. Finally, care should be taken not to ignite paper surgical drapes in the surgical field.

CHANNELING High-frequency electrosurgical current can be conducted along neurovascular bundles, causing pain and tissue damage distant to the local electrosurgical site. Using low-current settings or bipolar forceps may minimize this.

INFECTION AND MUTAGENICITY A plume of smoke is generated during electrosurgery. This traveling plume has been shown to contain carbonized tissue and blood, airborne particles, and various chemicals and gases. In addition, smoke created from treating lesions such as warts may contain infectious material, such as bacteria and viruses that may transmit infection.

No known long-term risk for neoplasia or infection is known. The Occupational Safety and Health Administration recommends that surgical smoke be removed and properly filtered by a smoke evacuation system as close to the surgical site as possible.[64] Furthermore, protective equipment, such as face shields and respiratory masks, should be worn during electrosurgery.

KEY REFERENCES

The full reference list for all chapters is available at www.digm7.com.

1. Mikhail GR: The application of chemosurgery in cancer. *Henry Ford Hosp Med J* **17**:217, 1969

15. Ahmed I et al: Liquid nitrogen cryotherapy of common warts: Cryo-spray vs. cotton wool bud. *Br J Dermatol* **144**:1006, 2001



20. Berth-Jones J et al: Value of a second freeze-thaw cycle in cryotherapy of common warts. *Br J Dermatol* **131**:883, 1994
25. Kuflik EG. Cryosurgery for cutaneous malignancy. *Dermatol Surg* **23**:1081, 1997
39. Krull KA, Pickard SD, Hall JC: Effects of electrosurgery on cardiac pacemakers. *J Dermatol Surg* **1**:43, 1975
41. Burke MC, Knight BP: Management of implantable pacemakers and defibrillators at the time of noncardiac surgery. *ACC Curr J Rev* **14**:52, 2005
45. Matzke TJ et al: Pacemakers and implantable cardiac defibrillators in dermatologic surgery. *Dermatol Surg* **32**:1155, 2006



CHAPTER 248

Surgical Complications

Richard Bennett

Surgical complications are unexpected problems that arise is association with an operation. Although the surgeon is always vigilant to minimize complications, adverse outcomes will inevitably occur. This chapter focuses on preventing, identifying, and treating common complications seen with skin surgery.

COMPLICATIONS AT THE TIME OF SURGERY

Most complications that occur on the day of surgery involve the patient's underlying medical problems, reactions to administered anesthetics, and bleeding. Allergy, hypersensitivity, or toxic reactions to local anesthetics and fainting with or without seizure can also occur. Although there may be some overlap between these issues, each will be discussed separately.

Patient's Medical Problems

Before surgery, it is important to obtain a medical history and perform a physical examination. The level of physical examination is commensurate with the extensiveness of the surgery that is planned. For example, a small cyst excision would only require a cursory physical exam (i.e., general appearance) and vital signs, whereas an extensive liposuction procedure using a large volume of tumescent anesthesia would require a full physical examination and diagnostic testing, if indicated.

The patient's medical history, including allergies, medications, and past surgeries, is important to obtain. Medications such as anticoagulants, pain medications, and certain herbs can affect bleeding at the time of surgery (Table 248-1).[1,2] Excessive bleeding with prior surgeries, especially if requiring transfusions, can be associated with a prolonged bleeding time. It is important to determine if the patient has a cardiac pacemaker, defibrillator, or any other implantable medical devices. Also, if the patient has an artificial heart valve or a rheumatic heart valve, preoperative antibiotics will be required.

Some of the common problems associated with skin surgery include fainting, seizures, and diaphoresis. Fainting is almost always a vasovagal reaction, and the best treatment is to position the patient in the Trendelenburg position. Seizures sometimes occur with the vasovagal reaction and are short lived. Usually, when patients faint, there is a history of fainting episodes, pointing out the importance of inquiring about this in the medical history. Diaphoresis may occur associated with a vasovagal reaction, angina, or hypoglycemia.

Certain equipment is necessary to address emergencies. A "crash cart" includes a heart monitor with defibrillator and common medications to manage emergencies. Oxygen tanks with appropriate masks or nasal cannulas should be ready for use and checked regularly. In addition, a blood pressure cuff, heart rate monitor, and pulse oximeter should be available. Although we now live in a "911" culture, the operating physician is still responsible for handling medical problems, and the dermatologic surgeon should be certified in basic or advanced cardiac life support. Furthermore, ancillary staff should be similarly certified and know their role in emergency situations.

Anesthesia-Related Complications

Because almost all cutaneous surgery performed by dermatologists is done with local anesthetic, this section only discusses local anesthetic complications. Fortu-

SURGICAL COMPLICATIONS AT A GLANCE



- Complications in dermatologic surgery are relatively uncommon.
- Complications are best avoided by
  - Obtaining patient history of medications, prior bleeding episodes, allergies, and prior surgeries.
  - Observing asepsis during procedure.
  - Gentle handling of tissue.
  - Complete cessation of bleeding at time of surgery.
  - Good wound care by patient after surgery.

TABLE 248-1
Medications That Inhibit Platelet Function

- Persantine
- Trental
- Sulfinpyrazone
- Clofibrate
- Salicylates
- Aspirin
- Sulfasalazine
- Vitamin E
- Plavix
- Herbs
  - Ginkgo biloba
  - Garlic
  - Feverfew
  - Ginger
  - Asian ginseng
  - Turmeric
- Nonsteroidal anti-inflammatory drugs
  - Piroxicam
  - Diclofenac
  - Fenoprofen
  - Meclofenamate
  - Phenylbutazone
  - Indomethacin
  - Sulindac
  - Tolmetin
  - Ibuprofen
  - Ketoprofen
  - Naproxen

nately, problems with local anesthetics are extremely rare. Thus, physicians have been lulled into a false sense of security. Allergy to lidocaine (Xylocaine®) is rare if it happens at all; generally the allergy is to the paraben preservative.[3]

Problems with local anesthetics are most often related to the total dosage and the addition of epinephrine (see Chap. 243). The total dosage (for a 70-kg patient) should not exceed 500 mg of lidocaine if epinephrine is used and 200 mg if epinephrine is not used.[4] Alternative anesthetics such as bupivacaine (Marcaine®) have a different recommended total dosage. The initial sign of lidocaine toxicity is tongue and circumoral numbness. If this occurs, oxygen should be administered and an intravenous line established.

The addition of epinephrine to local anesthetics is commonplace. However, epinephrine can cause an increase in heart rate, increased contractility of heart muscle, and vasoconstriction. This phenomenon often occurs with inadvertent direct injection into a blood vessel or if the patient is hyperthyroid. Epinephrine should be given cautiously in patients with severe hypertension or cardiac arrhythmias. In these situations, epinephrine, which is present in prepackaged anesthetic in a dilution of 1:100,000, can be diluted further to 1:200,000 or less without decreasing hemostasis. If patients have a history of sensitivity to epinephrine, it is best to use lidocaine without epinephrine. However, in the absence of epinephrine, the anesthetic duration and level of anesthesia will decrease, and the onset time will increase. Also, the absence of epinephrine in local anesthetic can contribute to increased intraoperative bleeding.

Anesthetic containing epinephrine should not be injected into the digits. Although there is some controversy about this, a patient with unknown diabetes may be at high risk for tissue necrosis. Anesthetic containing epinephrine may be injected into the nose, earlobes, and penis; however, it maybe preferable to do a pudendal block in the latter site.

Bleeding

During and after surgery, a cardinal goal is to minimize blood loss. A medical history helps to identify medical problems that might promote bleeding, such as thrombocytopenia, coagulopathy, or hypertension. Several medications inhibit platelet function (see Table 248-1). Anticoagulants should be specifically queried. Extensive intake of garlic, ginkgo, vitamin E, and some other herbs can promote bleeding. During surgery, meticulous hemostasis will help minimize postoperative bleeding.

One medication with specific importance in dermatologic surgery is warfarin (Coumadin®). Patients on warfarin should not discontinue this medication before cutaneous surgery. In some patients who stop and start warfarin, the blood becomes hypercoagulable, which may lead to blood clots or strokes.[5] Aspirin, on the other hand, is generally safe to stop 10 to 14 days before surgery, unless the patient has had a history of strokes or transient ischemic attacks.[6]

COMPLICATIONS IN THE IMMEDIATE POSTOPERATIVE PERIOD

Some specific complications occur from the day of surgery until approximately 1 to 2 weeks later. It is important to give the patient a way to immediately contact the physician in case complications arise, and it is prudent to call the patient the day after surgery to inquire how he or she is doing.

Infection

Wound infection can occasionally occur despite every effort to adhere to appropriate surgical technique. Three types of infection occur most commonly with cutaneous surgery: *Streptococcus pyogenes*, *Staphylococcus aureus*, and *Mycobacterium* (especially *M. fortuitum* and *M. chelonei*).[7,8] Generally, all three are quite different in clinical presentation and timing. *Streptococcus* occurs early, within 24 to 48 hours of surgery, and appears as a spreading, painful erythema. *Staphylococcus* infection appears at 2 to 5 days after surgery and is usually associated with pus formation. Finally, *Mycobacterium* infection appears 2 to 4 weeks after surgery.[7] Clinically, it appears as ulcerating papules or nodules that will not heal or that repeatedly heal and break down.

Recently a particular form of *S. aureus* resistant to methicillin, so-called *methicillin-resistant S. aureus*, has appeared in an increasing number of wounds.[9] It is therefore important to culture wounds that appear infected so that the proper antibiotic can be selected. Antibiotics that generally work well against methicillin-resistant *S. aureus* are doxycycline and trimethoprim-sulfamethoxazole.

Infections with herpes simplex or herpes zoster are rare after cutaneous surgery. One exception to this is the development of herpes infection after whole-face dermabrasion or laser resurfacing. With these procedures, an antiviral medication, such as acyclovir, valacyclovir, or famciclovir, should be started before surgery, especially in those patients who have a history of herpes simplex infections (see Chap. 193).

Contact Dermatitis

Allergic reactions can occur to antibiotic ointments used in routine wound care to keep wounds moist. The patient most often has a contact allergy to neomycin or bacitracin.[10] Although bright-red, poorly marginated erythema appears around the operative site with the antibiotic allergy (Fig. 248-1), the diagnosis is usually obvious because the patient will complain of marked pruritus. This symptom is in contrast to that of an infection where the patient complains mainly of pain and pruritus is minimal or absent. Allergic reactions to bandage materials such as Telfa® and Micropore® paper tape are extremely rare.

Pain

Significant pain is rarely present after cutaneous surgery. Patients should take plain acetaminophen for uncomplicated



◀ **FIGURE 248-1** Contact dermatitis to Polysporin® ointment near skin flap.





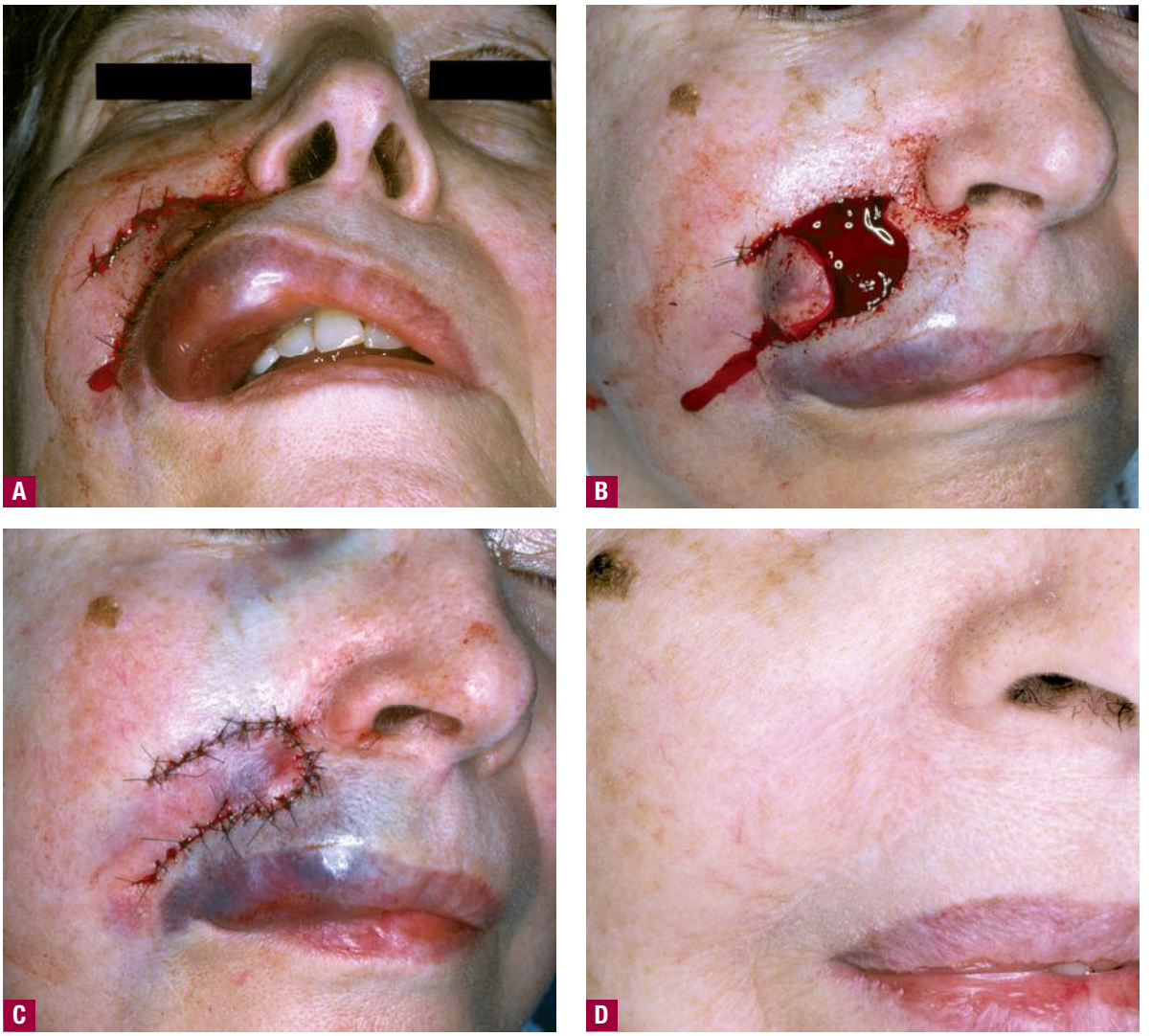

▲ **FIGURE 248-2** **A.** Swelling of right upper lip 2 hours after skin flap. **B.** Flap unsutured, exposing blood coagulated below. Arteriole bleeder found and tied off. **C.** Flap immediately resutured. **D.** Healed flap 3 months later.

pain. Occasionally, if the surgery is extensive, acetaminophen with codeine or hydrocodone may be used. On rare occasions, Percocet® may be necessary.

Bleeding and Hematoma Formation

After suturing a wound, roll a cotton-tipped applicator over the wound with pressure to express any trapped blood and then place a secure pressure dressing on the wound. The less residual blood in the wound, the faster healing will occur.

Occasionally, patients will continue to bleed from their wound, whether sutured or open. If the patient is on warfarin, an international normalized ratio should be checked. If the patient has unexplained, continuous bleeding, he or she should be evaluated for a coagulopathy.

Occasionally, a large collection of blood may occur under a sutured wound (Fig. 248-2A). This may be more common in men and those with hypertension.[11] If this occurs within a few hours of surgery to up to 24 hours postoperatively, it is best to unsuture the wound, locate the source of bleeding (see Fig. 248-2B), and obtain hemostasis. Almost always, an arteriole is found that is pumping blood; it is advisable to ligate it and then resuture the wound (see Fig. 248-2C). If the patient returns after a few days with a large fluctuant hematoma, aspirate the wound using a large bore needle or, if available, a blunt microliposuction canula. It is not usually necessary to remove the sutures at that point, as the hematoma will probably not reform. However, if the hematoma does reform, it may become necessary to remove the sutures, locate the bleeder, excise the wound edges, and resuture the wound.

Necrosis

If the blood supply is inadequate, tissue death can occur. This phenomenon can occur with a skin flap or skin graft (Fig. 248-3); it rarely occurs with a side-to-side wound repair but may develop if an extremely tight pressure dressing is applied. Inadequate blood supply can occur due to factors intrinsic to the wound itself, such as hematoma, or factors extrinsic to the wound, such as the patient's medical condition or local tissue problems.

Intrinsic factors causing tissue necrosis include excess wound tension, infection, and hematoma formation. For a skin graft, excessive thickness may inhibit vascularization. A skin flap may necrose if the base is too small or the flap is too thin or kinked (see Chap. 244).

Extrinsic factors that can lead to tissue necrosis include local tissue considerations such as poor blood supply due to anatomy, prior radiation, or prior surgery. Other extrinsic factors are systemic diseases such as diabetes, medications, or malnutrition. Smoking may also cause tissue necrosis, probably as a

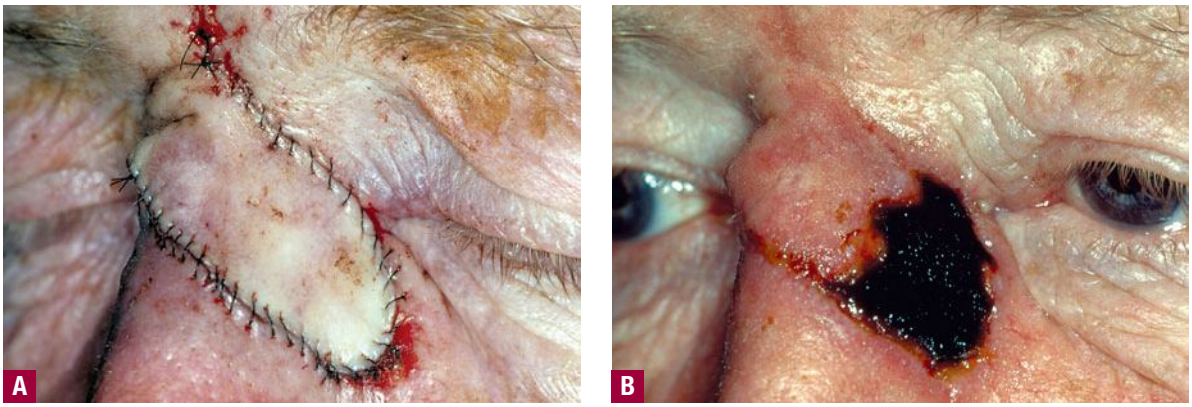

▲ **FIGURE 248-3** **A.** Flap from glabella to left dorsal nose. **B.** Necrosis in flap 1 week postoperatively.

result of decreased blood flow due to nicotine. The smoking effect appears to be dose-related: patients who smoke one pack per day do not have an increased likelihood of necrosis, whereas those smoking two packs per day do.[12]

Dehiscence

Despite careful wound apposition and suturing, wound edges can pull apart. Often, this dehiscence occurs due to excess tension on the wound edges, but it may be result from suture breakage or unraveling. To prevent dehiscence, vertical mattress sutures are quite useful because they provide an increase in tensile strength earlier than do interrupted sutures. This phenomenon is especially true for thin skin or skin with abundant large sebaceous glands (e.g., the nose).

If the dehiscence occurs within a day of suturing, the wound can be resutured without freshening the wound edges. If the dehiscence occurs more than 48 hours after the initial surgery, the wound edges should be freshened by excising 1 mm of normal skin before resuturing the wound.

In the presence of infection, necrosis, or extreme wound edge tension, it may be best not to immediately resuture a dehisced wound but, rather, allow the wound to heal by granulation.

Dehiscence can also occur after suture removal. To prevent this problem, percutaneous sutures may be left in place for more than 7 days. In wounds under tension, such as on the back, or in locations where wound healing is slow (i.e., the leg), sutures may remain for up to 2 weeks. Another approach to a wound under tension is to remove a fraction of the sutures at 7 days and the balance several days later. To further help prevent dehiscence, apply a glue (Mastisol®) and Steri-Strips® across the wound immediately after suture removal. The patient is instructed to keep the wound dry so the Steri-Strips® will stay in place for about 1 week after placement. In some anatomic locations (e.g., scalp, bearded areas in men), Steri-Strips® placement will not work well.

COMPLICATIONS IN THE DISTANT POSTOPERATIVE PERIOD

After sutures have been removed, the wound continues to heal. Patients may be followed up to 1 year postoperatively to address any problems that might arise.

Milia or Keratinous Cysts

Occasionally, during surgery, small pieces of epidermis may be buried or a follicle may be transected by the suture needle. When this happens, a milial cyst may occur adjacent to the suture line. It is easily removed with a comedone expressor after a needle incision. Larger cysts can occasionally grow, associated with scars. However, one should be wary if a cyst appears where a skin cancer was excised; the "cyst" may indeed prove to be a skin cancer on pathologic examination.

Suture Track Marks

Suture track marks can occur due to suture material cutting into tissue (Fig. 248-4A). These scars can be minimized by using polypropylene (e.g., Prolene®) suture material, which stretches, rather than nylon suture, which does not. Also, when suturing, the surgeon should be careful not to tie knots too tightly or pull on the suture too tightly when tying or cutting. If caught early, within 1 or 2 months, dermabrasion works well to eliminate suture track marks (see Fig. 248-4B and C).[13]

Other methods to avoid suture track marks include use of the over-and-over running suture that distributes tension along the wound and the buried intradermal (running intradermal subcuticular) suture.

Hypertrophic Scar

Occasionally, scars will become elevated and stay within the boundaries of the wound. This is known as a *hypertrophic scar* in contrast to a *keloid scar* that grows beyond the boundaries of a wound (Fig. 248-5; Table 248-2; see Chap. 64). Both keloids and hypertrophic scars are treated by pressure massage; they also respond well to intralesional triamcinolone acetonide 10 mg/cc (Fig. 248-6A and B). Other useful methods that have been reported to improve keloids include excision, intralesional 5-fluorouracil or interferon-α, cryosurgery, and radiotherapy.

Scar lines may also appear lumpy due to buried sutures. Usually this lumpiness disappears in 2 to 3 months as sutures absorb.

Patients occasionally ask about various commercially available products to use for scar improvement. Some of these products contain silicone or polyurethane foam. It may be that the use of these products improves scars by increasing the moisture of the scar or by the constant application of pressure. Similar improvement may be seen by using paper tape on wounds for 3 months after surgery.[14]

Depressed or Furrow-Like Scars

A depressed or furrow-like scar is common in skin with an abundance of sebaceous glands. In this circumstance, wound edges often cannot be held together without tearing. With tearing of the skin, varying degrees of wound separation occur that result in depressed scars. To correct this problem, the de-









◀ **FIGURE 248-4** **A.** Suture track marks around forehead scar. **B.** Dermabrasion of scar at 5 weeks after being sutured. **C.** Healed scar 2 months later. Suture track marks have disappeared.

pressed scar is excised, and the wound edges are undermined and resutured. At the time of resuturing, use of several buried sutures and vertical mattress sutures will even up and tightly oppose the wound edges, minimizing recurrence of the depressed scar. The vertical mattress suture grasps more tissue than does a simple interrupted suture. Thus, there is less chance for sutures to tear through tissue. It is also important when working in very sebaceous skin to use suture no finer than 5-0.

Spread Scars

Scar spreading occurs with tension on wound edges. Sometimes, this tension is unavoidable due to anatomic considerations, such as on the chest or upper back. Sometimes spread scars occur where there is great tension on the wound edges that exceeds the holding power of the sutures or the healing wound edges after suture removal. Stretching of scars is quite common on the scalp, trunk, and extremities. It is prudent to explain this phenomenon to the patient in advance.

Buried Suture Extrusion

Buried dissolvable sutures may occasionally extrude through the wound edges about 3 to 4 weeks after placement. This problem is very common. Usually pulling or cutting the extruding suture out will help the wound edges heal faster.

Telangiectasia

The appearance of fine red vessels adjacent to a suture line or on top of a flap or graft can be quite noticeable. This is a normal occurrence, and the vessels usually fade with time; thus, we encourage patients to wait about 6 months after surgery before treating these vessels. Vascular ablating lasers (e.g., the 585- to 595-nm pulsed dye laser and the 532-nm potassium-titanyl-phosphate laser)

TABLE 248-2
Comparison of Hypertrophic Scar and Keloid

	Hypertrophic Scar	Keloid
Incidence	Common	Uncommon
Race	All	Usually dark skin
Injury	Yes	Sometimes
Location	Anywhere, especially perpendicular to maximal skin tension lines	Earlobes, trunk, rare on central face
Growth	Within scar line	Beyond scar line
Resolution	Usually	No
Recurs with excision	Usually no	Usually yes



▲ **FIGURE 248-5** Keloid of earlobe and posterior auricular sulcus. Patient underwent an ear pinning procedure.

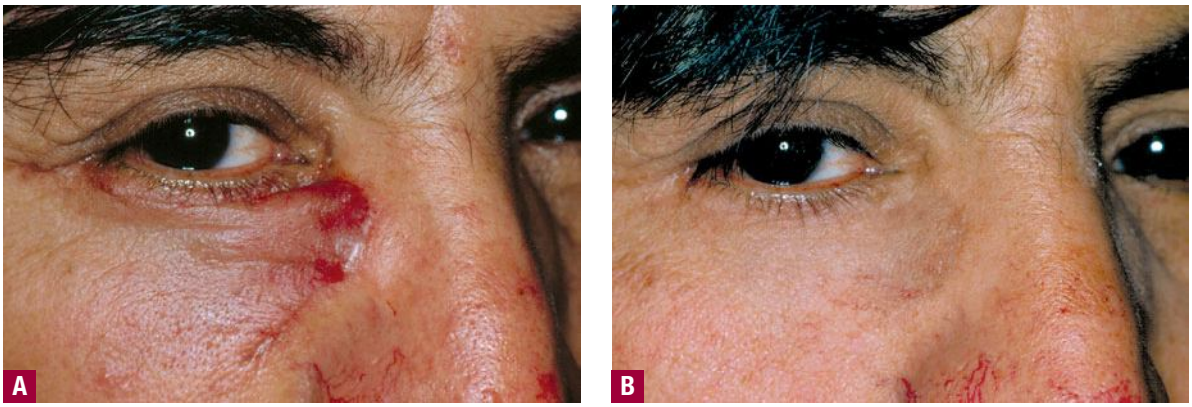

▲ **FIGURE 248-6** **A.** Hypertrophic flap on right nose and cheek. Injected with triamcinolone acetonide, 10 mg/cc. **B.** Flap 2 months later.

generally do an excellent job of eliminating the vessels (see Chap. 253).

Erythema

All sutured wounds are at first erythematous, but generally with time (3 to 12 months), the erythema fades. Occasionally, however, the redness does not fade. Like telangiectasias, persistent redness is treated with vascular lasers (see Chap. 253). Telangiectasias and redness may be more common in women, especially those on estrogenic medication, than in men.

Hypopigmentation

As redness fades, all scars become hypopigmented to some extent. The hypopigmentation may be very noticeable if surrounded by erythema, especially in those patients with a ruddy complexion or rosacea. Generally, nothing is done with hypopigmented scars, as the problem will recur if excised. However, if the hypopigmented area is relatively enhanced by surrounding erythema, laser treatment of the redness may make the hypopigmentation less noticeable.

Occasionally, full-thickness skin grafts become hypopigmented. This pigmentation problem often occurs because the skin graft is excessively thinned before placement. One way to rectify the color in this circumstance is to tattoo the graft to match the surrounding skin color.

Hyperpigmentation

Scars rarely become darkly pigmented, but, occasionally, this can occur. Most often hyperpigmentation appears in individuals with darker complexions and brown eyes. Patients with this type of complexion should be advised to keep their scars out of direct sunlight and to wear a sunscreen that protects against ultraviolet A.

Anesthesia

Loss of sensation in the area of surgery is very common, especially with flaps and grafts. Almost always, the sensation returns slowly over 3 to 18 months, depending on the location and size of the surgery.

Loss of sensation in a few anatomic locations is worthy of special mention. If one operates on the forehead and transects the supraorbital nerve, all sensation superiorly, up to the top of the scalp, will be lost. However, usually, the patient regains most of the sensation slowly over 6 months to 2 years. On the lateral neck, if the great auricular nerve is severed, loss of sensation will occur to most of the lower anterior ear. Unfortunately, in this location, the anesthesia will be permanent.

Motor Loss (See Chap. 243)

KEY REFERENCES

The full reference list for all chapters is available at www.digm7.com.

2. Heller J et al: Top-10 list of herbal and supplement medicines used by cosmetic patients: What the plastic surgeon needs to know. *Plast Reconst Surg* **117**:436, 2006
5. Schanbacher CF, Bennett RG: Postoperative stroke after stopping warfarin for cutaneous surgery. *Dermatol Surg* **26**:785, 2000
6. Maulaz AB et al: Effect of discontinuing aspirin therapy on the risks of brain ischemic strokes. *Arch Neurol* **62**:1217, 2005
9. Del Giudice P et al: Emergence of two populations of methicillin-resistant *Staphylococcus aureus* with distinct epidemiological, clinical, and biological features, isolated from patients with community-acquired skin infections. *Br J Dermatol* **154**:118, 2006
10. Gette MT, Marks JG Jr, Maloney ME: Frequency of postoperative allergic contact dermatitis to topical antibiotics. *Arch Dermatol* **128**:365, 1992
12. Goldminz D, Bennett RG: Cigarette smoking and flap and full thickness graft necrosis. *Arch Dermatol* **127**:1012, 1991
14. Atkinson JA et al: A randomized, controlled trial to determine the efficacy of paper tape in preventing hypertrophic scar formation in surgical incisions that transverse Langer's skin tension lines. *Plast Reconstr Surg* **116**:1648, 2005



CHAPTER 249

Wound Repair: Mechanisms and Practical Considerations

Vincent Falanga
Satori Iwamoto

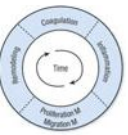

Wound healing and *wound repair* are terms often used interchangeably, but they actually represent two different sets of events and outcomes. *Wound healing* is a term that should be used only in the context of regeneration, when the original architecture and structure of an organ or anatomic part is completely restored to the way it was before injury. More primitive animals, such as small amphibians and reptiles, are still capable of this type of regeneration. However, as animals became larger and more complex, regeneration was no longer possible. In adult humans, with the possible exception of the liver, true regeneration does not occur. Rather, humans and other higher vertebrates heal by a process of repair, whereby the eventual outcome is not anatomic restoration but a functional compromise.

Teleologically and from an evolutionary standpoint, the process of repair for higher animals needed to be rapid and to allow for the immediate survival of the organism. Except for injury to fetal skin, repair leads to scarring. Another consideration is that most of the mechanisms of wound repair that have evolved are aimed at addressing acute tissue injury. Again from an evolutionary standpoint, humans were not supposed to develop degenerative diseases or live long enough to develop arterial, venous, and pressure ulcers or neuropathic ulcers from diabetes. Therefore, humans are quite unprepared for these types of chronic wounds, and there are no specific mechanisms that have evolved to deal with them in an effective way.[1–3]

It should be noted that the extent of injury and its depth are important considerations. Thus, shallow wounds (i.e., shave biopsies) that retain skin appendages (hair follicles, sweat glands, etc.) in the wound bed have the capacity to heal from the "inside" because keratinocytes associated with those skin appendages are still present. On the other hand, full-thickness wounds (punch biopsies are a good example) have to rely on keratinocyte migration and proliferation from the edges. Not surprisingly, full-thickness wounds are associated with delayed healing and more scarring.[2] Some animal models, particularly those in which certain genes are overexpressed or knocked out, are providing greater understanding of the role of certain proteins and mediators.[4,5] Impaired healing is found in mice with combined deficiency of molecules critical in inflammation (E- and P-selectins), and in mice without plasminogen, uPA and tPA (double knockout), fibroblast growth factor 2 [basic FGF (bFGF)], or inducible nitric oxide. On the other hand, impaired or delayed healing occurs in transgenic mice overexpressing some tissue matrix metalloproteinases [MMPs (MMP-1)] and antisense to CD44, the receptor for hyaluronic acid. Some induced mutations lead to accelerated healing, as reported with Smad-3 or skn-1a knockout mice. In the future, it may be possible to use these clues to stimulate the healing process in humans.

PHASES OF WOUND HEALING

There are four recognized phases that characterize the cutaneous repair process: coagulation, inflammatory phase, proliferative-migratory phase (tissue formation), and remodeling phase. The coagulation and inflammatory phase are often grouped together, so great is the overlap of mediators that are released. Fig. 249-1 demonstrates these phases in sequence and also offers the view that the linear relationship guiding wound healing from injury to repair is lost in chronic wounds, where the process may be short-circuited or repetitive. It should be noted that breaking down the overall process of wound repair into precise phases is artificial, as they overlap considerably.[2,3]

Coagulation and Inflammatory Phases

The early phases of coagulation and inflammation begin immediately after an acute injury. Disruption of blood vessels leads to local release of blood cells and blood-borne elements, resulting in clot formation. While the blood clot within the vessel lumen provides hemostasis, the clot within the injury site acts as a provisional matrix for cell migration.[6] The initial component of this phase is dominated by the platelet, which directs clotting of the fresh wound by the intrinsic and extrinsic pathways. Platelets also release a number of chemotactic factors that attract other platelets, leukocytes, and fibroblasts to the site of injury. Leukocytes are slowed down within the blood stream through the expression of selectins, which, coupled with integrins, bring inflammatory white cells into the wound.[5] These cells have multiple roles, including débridement of necrotic material and bacteria, as well as the production of certain critical cytokines. A case in point is the production of connective tissue growth factor by inflammatory cells and expressed in wounds.[7]

The fibrin plug resulting from the initial injury provides a temporary wound coverage and consists of platelets em-

WOUND REPAIR AT A GLANCE

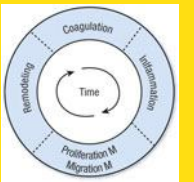

- Acute and chronic wounds are different but overlap.
- In acute wounds, there is an orderly progression from injury to coagulation, inflammation, proliferation, cell migration, and tissue modeling.
- In the initial phases, a wide range of growth factors, including platelet derived growth factor and transforming growth factor-β1, play an important role. In the proliferation/migration and modeling phases, tissue matrix metalloproteinases (MMPs), integrins, basic fibroblast growth factor, and endothelial growth factor are critical. MMP-1, MMP-9, and MMP-10 are essential for remodeling.
- Moist wounds heal faster, and a variety of wound dressings are now available to fit this requirement. They include transparent films, hydrocolloids, foams, alginates, and collagen products.
- Chronic wounds are different from acute wounds in that the one-way relationship between the different phases is lost. Chronic wounds are the complex result of ischemia pressure and infection, and healing is highly dependent on dealing with these factors.
- Wound healing of skin grafts is also different, as it is completely dependent on revascularization, be it true neovascularization or inosculation.

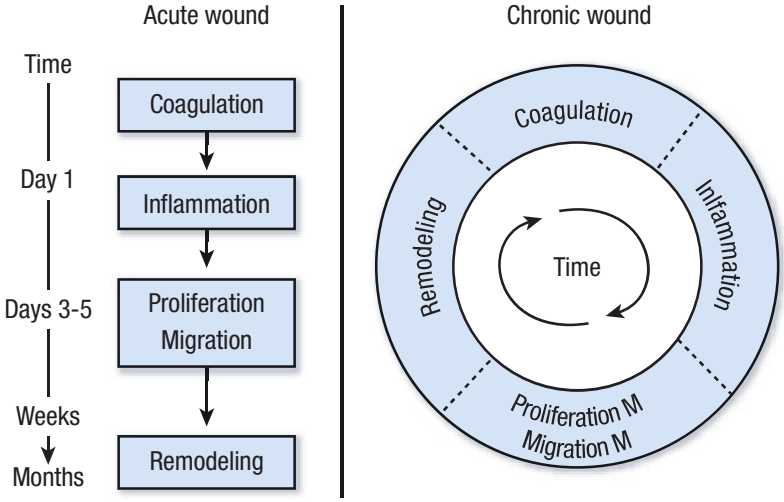

▲ **FIGURE 249-1** Schematic representation of the different phases of wound repair, with the cells and events involved at different time points. The left side of the diagram shows the linear progression observed with the healing of acute wounds. The right side attempts to show that chronic wounds are in disarray and that the linear progression is lost. (Copyrighted, V. Falanga, 2006.)

bedded within a complex meshwork of mainly polymerized fibrinogen (fibrin), fibronectin, vitronectin, and thrombospondin.[3,8] Cross-linking of fibrin by factor XIII also appears to be critical, and there is evidence that the function and, probably, migration of keratinocytes is impaired by uncross-linked fibrin.[9] As they immediately aggregate, platelets release a wide range of growth factors, including platelet-derived growth factor (PDGF) and transforming growth factor-β1 (TGF-β1). In fact, platelets are the main storage site for the TGF-β1 isoform. The acute injury environment, with its hypoxia, proteases, and low pH, contributes to the activation of these growth factors.[2] The principal mediators themselves produce others from their fragmentation or polymerization. A classic example are the chemotactic fibrinopeptides A and B, which are produced from the action of thrombin on fibrinogen.[9,10] Another example is the formation of bradykinins, as well as C3a and C5a, which are activated by Hageman factor.[11]

As the inflammatory component of this early phase continues, within 24 to 48 hours after injury, monocytes replace neutrophils and become the predominant leukocyte. Monocytes are attracted to the injury site by some of the same chemoattractants responsible for recruitment of neutrophils, such as kallikrein, fibrinopeptides, and fibrin degradation products.[12] Other, more specific chemoattractants then take over in recruiting monocytes, and they include fragments of collagen, fibronectin, elastin, and TGF-β1. Monocytes undergo a phenotypic change to tissue macrophages, and unlike neutrophils, they are critical for the progression of wound healing. Macrophages phagocytose, kill bacteria, and scavenge tissue debris.[13] They also release several growth factors, including PDGF, FGF, and TGF-β1, thereby stimulating migration and proliferation of fibroblasts, as well as production and modulation of extracellular matrix (ECM). The macrophage is generally regarded as the master cell in wound healing.[14] However, this is an oversimplification, as it is important to consider that what may delay or impair healing is not so much the presence or absence of inflammation and certain cells but, rather, an inappropriate inflammatory response.[11] For example, there is evidence that healing may occur in the absence of an inflammatory infiltrate.[15] Conversely, experiments in mice constitutively expressing the chemotactic cytokine interferon-inducible protein 10 show that an intense inflammatory infiltrate can impair neovascularization and the formation of appropriate granulation tissue.[16] Therefore, the true role of inflammation in tissue repair remains somewhat controversial from an experimental point of view. From the clinical standpoint, one observes that in certain cutaneous wounds, such as pemphigus or pyoderma gangrenosum, downregulation of inflammation with the use of corticosteroids is effective. Possibly, modulation and "correction" of the inflammatory response by corticosteroids may be helpful in these selected clinical entities.

Proliferation/Migration and Remodeling Phases

Fig. 249-2 illustrates a representation of the fibrin plug in place and certain events that occur in the next two phases of healing, the proliferative/migratory

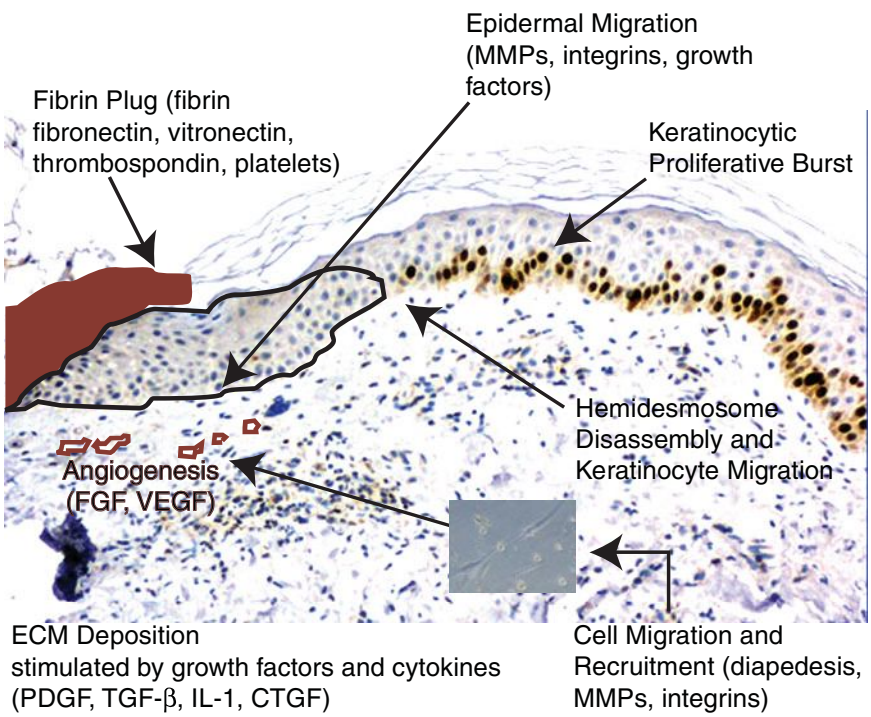

▲ **FIGURE 249-2** Schematic representation of the formation of a provisional matrix and the different events that characterize the healing process. CTGF = connective tissue growth factor; ECM = extracellular matrix; FGF = fibroblast growth factor; IL-1 = interleukin 1; MMP = matrix metalloproteinase; PDGF = platelet-derived growth factor; TGF-β = transforming growth factor-β; VEGF = vascular endothelial growth factor.

TABLE 249-1
Partial List of Growth Factors and Cytokines in the Context of Wound Repair and Their Roles in Some Cellular Functions and Matrix Production

RESPONSE	EGF	FGF	GMCSF	IL-1	PDGF	TGF-β1	VEGF	CTGF	IGF-1
Fibroblast proliferation	+	+		+	++	+		+	+
Keratinocyte proliferation	+	+		+	−				+
Angiogenesis	+	+	+	+	+	+	++		
Matrix formation		+			++	++		++	+
Inflammatory cell migration/chemotaxis			++	+		+			

CTGF = connective tissue growth factor; EGF = epidermal growth factor; FGF = fibroblast growth factor; GMCSF = granulocyte-macrophage colony-stimulating factor; IGF-1 = insulin-like growth factor-1; IL-1 = interleukin 1; PDGF = platelet-derived growth factor; TGF-β1 = transforming growth factor-β1; VEGF = vascular endothelial growth factor.
Blank cell = no definite response; + = definite but mild response; ++ = definite and marked response; − = inhibition.

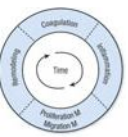

and remodeling phases. As inflammation has already played its major role early on after injury, the most important event in cutaneous wound healing now becomes re-epithelialization. This critical event is not based on keratinocytes alone, because there is a high interdependence between keratinocyte movement through the provisional fibrin matrix, recruitment of fibroblasts and endothelial cells, and ECM formation (see Fig. 249-2). MMPs and other enzymes (tPA and uPA) are critical to the movement of cells through provisional structural matrix components, as well as for freeing the keratinocytes at the edge of the wound from their hemidesmosomal and desmosomal attachments. Another critical set of molecules that help guide these migratory components are the integrins. The integrins, consisting of at least 24 αβ heterodimers (18 α and 8 β subunits), are transmembrane cell surface receptors that bind the ECM to cytoskeletal structures.[17] The integrin profile is very dynamic during the repair process. For example, dermal fibroblasts undergo a switch from α2 to α3 and α5 integrin subunits. As another example, endothelial cells cannot respond to angiogenic stimuli without the expression of αβ5 integrin. Certain polypeptide growth factors are absolutely essential to angiogenesis, including bFGF and vascular endothelial growth factor (VEGF).[3,17] Table 249-1 shows some of the main cytokines and growth factors shown to play a role in the repair process. One must realize that such tables are oversimplifications of very complex biologic properties of these polypeptides. Only the main effects are noted, and it must be borne in mind that the actions of growth factors are often context specific and not the same in every biologic situation.

Evidence points to low oxygen tension as an important early stimulus for fibroblast (and endothelial cell) activation. Fibroblast replication and longevity are enhanced in hypoxia,[18] and low oxygen tension stimulates clonal expansion of dermal fibroblasts seeded as single cells.[19] Moreover, the synthesis of a number of growth factors is enhanced in hypoxic cells. Macrophages secrete an angiogenic substance only when they are exposed to low oxygen tension. This reversible effect was observed at an oxygen tension of 15 to 20 mm Hg.[20] TGF-β1 transcription and peptide synthesis are enhanced in cultures of human dermal fibroblasts exposed to a similar level of hypoxia.[21] In addition, hypoxia upregulates the synthesis of endothelin-1,[22] PDGF β chain,[23] and VEGF[24] in endothelial cells. It appears that, at least in some cases, the effect of hypoxic conditions is mediated by hypoxic inducible factor-1, a DNA-binding complex shown to contain at least two basic helix-loop-helix periodic acid-Schiff–domain proteins.[25]

The importance of the hemidesmosome and desmosome is well known for many dermatologic diseases where specific defects in their overall structural integrity are present (i.e., pemphigus, bullous pemphigoid, epidermolysis bullosa). Now, however, during the healing process and for keratinocyte migration to occur, there is a need to break down these complex structures anchoring the basal keratinocytes to the basement membrane and neighboring keratinocytes. This breaking-down process is just as complex as the structure itself and involves interactions between MMPs, integrins, growth factors, and structural proteins. In the normal resting state, laminin-5 is bound to $\alpha_6\beta_4$ integrin, the latter linking the intracellular keratin filaments of keratinocytes to the basement membrane. In large part due to the interactions of integrins (including their phosphorylation status) with the ECM and receptor clustering on the surface of keratinocytes, there are important morphologic changes (such as lamellipodia formation) that are required for keratinocyte locomotion.[3,26–28] Molecular GTPase switches (Rho, Rac, Cdc42) are involved. Partially as a result of phosphorylation of the $\alpha_6\beta_4$ integrin, the $\alpha_3\beta_1$ integrin promotes lamellipodia formation and keratinocyte locomotion. It has often been stated that migration of keratinocyte is key to resurfacing of the wound and that, in fact, such resurfacing is not dependent on proliferation.[3] However, keratinocytes do proliferate within the first hours after injury, and this is certainly more evident when the gap or size of the defect cannot be bridged temporarily with cell movement alone.[2,3] By 1 week after injury, the repair process is well underway. Cytokines and growth factors (epidermal growth factor, PDGF, TGF-β, FGFs, VEGF), matrix components, and MMPs continue to play an active role. In addition to the growth factors themselves, signaling proteins are critical. For example, certain kinases (MAPK) are activated in basal and suprabasal keratinocytes by further action of integrins or the release of interleukin 1α. Ion fluxes, including calcium levels and entry into the cells, are also critical to the overall process of keratinocyte migration and skin resurfacing.[29] There is evidence that, in addition to lamellipodia extension, wound edge suprabasal keratinocytes may "leap-frog" over the basal cells near the wound. However, this system may not be very efficient, certainly not to the extent that the purse string mechanism occurs in fetal healing, which is accompanied by other important differences in matrix deposition and growth factor profile.[5,30]

The remodeling of the ECM, as well as the movement of cells, is highly dependent on MMPs and serine proteases. Upregulation of tPA and uPA are important for keratinocyte migration, which may depend on cross-talk and interactions between $\alpha_3\beta_1$, keratinocytes, and collagen. These events lead to the induction of MMP-1 (collagenase-1 or interstitial collagenase). MMP-9 plays a fundamental role in "cutting" type IV and type VII collagen, which are essential components of the basement membrane and anchoring fibrils. MMP-10 (stromelysin) breaks

down other non-collagenous ECM components.[2,8,31] Other mediators, such as thymosin β, have been found to upregulate MMPs during wound repair.[32] Of critical importance during the remodeling process is the phenotypic switch in certain cell sub-populations from fibroblasts to myofibroblasts.[2,33] Therefore, although the early process of healing relies heavily on matrix accumulation, which in turn facilitates cell migration, there is now a need to dampen the ECM formation and degrade it to a level that at least approximates the pre-injury state. However, the remodeling phase is more than a breakdown of excess macromolecules formed during the proliferative phase of wound healing. Cells within the wound are returned to a stable phenotype, ECM material is altered (i.e., collagen type III to type I), and the granulation tissue that was so exuberant during the early phases of wound healing disappears.[2,3]

EXTRACELLULAR MATRIX PROTEINS

The glycosaminoglycan hyaluronic acid (hyaluronan) is also an abundant component of the provisional matrix, one whose deposition needs to be modified during the remodeling process. High levels of hyaluronic acid are present in the early embryo, where it is thought to offer less resistance to cell migration. Indeed, embryonic wound repair is characterized by a hyaluronic acid–rich environment, thought to be at least in part responsible for the "scarless" healing of embryonic wounds. Fibroblasts from early granulation tissue produce large amounts of hyaluronic acid, and proliferating cells express CD44, which is the receptor for this glycosaminoglycan molecule.[34,35] Besides the issue of offering less resistance to cell movement, hyaluronic acid may stimulate cell motility by altering cell-matrix adhesion. One example of this is that hyaluronic acid weakens the adhesion of heparan sulfate and fibronectin.[36] Perhaps more important from a physical/spatial standpoint is that hyaluronic acid creates a highly hydrated structure leading to tissue swelling and interstitial spaces and, thus, an environment more conducive to cell movement.[2,37] The effects of hyaluronic acid are also regulated by growth factors and cytokines. Upregulation of the hyaluronic acid expression and its receptors (e.g., RHAAMM) by TGF-β1 stimulates fibroblast motility.[38] Eventually, as remodeling occurs, hyaluronic acid is degraded by hyaluronidase and replaced by sulfated proteoglycans, which contribute a stronger structural role in late granulation tissue formation and in scars, while being less able to stimulate cellular movement. Two major proteoglycans, chondroitin-4-sulfate and dermatan sulfate, are produced by mature scar fibroblasts.

Three main classes of collagens are present normally in connective tissue: fibrillar collagens (types I, III, and V); basement membrane collagen (type IV); and other interstitial collagens (types VI, VII, and VIII). These are examples of the different types of collagen present in skin. Of importance, however, is that fibrillar collagens serve as the major structural collagens in all connective tissues.[2,37,39] During the initial phases of wound repair, it appears that the wound tends to recapitulate the processes involved in embryogenesis.[30] Thus, granulation tissue is initially comprised of large amounts of type III collagen, which is a minor component of adult dermis and, indeed, is present in larger amounts in fetal wound repair. During the phase of remodeling, type III collagen is gradually replaced by type I collagen. Type I collagen replacement is associated with increased tensile strength of the scar. However, the final tensile strength of a scar is only about 70 percent of that of pre-injured skin.[3,37] The process of converting the collagen content of the dermis from type III to type I collagen is controlled by interactions involving synthesis of new collagen with breakdown of old collagen.[8] Key to this process of conversion are metalloproteinases and, specifically, the collagenases.

MMPs are proenzymes that need to be activated and are considered to be the physiologic mediators of matrix degradation.[31] The prototypic MMP is interstitial collagenase, but over 20 such enzymes have been described. We have already mentioned these critical proteinases in the context of keratinocyte migration, but it's important to go over them in more detail. There are three broad classes of these zinc-dependent enzymes: collagenases, gelatinases, and stromelysins. The collagenases include interstitial collagenase (fibroblast collagenase, MMP-1), which acts on collagens I, II, III, VII, and X. Collagen type II is a particularly good substrate for MMP-1. Another important member of the collagenase class is neutrophil collagenase (MMP-8), which also degrades type II and III collagens but is particularly active against type I collagen. Gelatinases break down denatured collagen (gelatin). Among the most important gelatinases are gelatinase A (MMP-2), which breaks down gelatins, collagen IV, and elastin. Another key gelatinase is gelatinase B (MMP-9), which is produced by many cell types, including macrophages, neutrophils, and keratinocytes. Stromelysins have a relatively broad substrate specificity. Both stromelysin 1 (MMP-3) and 2 (MMP-10) act on proteoglycans, fibronectin, laminin, gelatins, and collagens III, IV, and IX. Another member of the stromelysin family, matrilysin (MMP-7), degrades mainly fibronectin, gelatins, and elastin. Another member of the MMP family is epilysin (MMP-28), which appears to be produced by proliferating keratinocytes distal to the wound edge. It may be needed to restructure the basement membrane.[3,31,37]

MOIST WOUND HEALING AND THE REPAIR PROCESS

One of the most important clinical observations of the last several decades is the realization that wounds kept moist re-epithelialize faster.[40,41] The evidence for this is best for acute wounds. However, even in chronic wounds, the moisture-retentive dressings that have been developed to create moist wound conditions do lead to a number of desirable outcomes, such as pain control, painless autolytic débridement, and stimulation of granulation tissue.[42–44] There have been fears that keeping the wound moist will cause infection, but these fears are unfounded.[45–47] Nevertheless, occlusion of the wound is still contraindicated in the presence of infection. There are a variety of wound dressings available to the clinician that fit a particular clinical situation.[43,44,48] The main types of dressings include transparent films, hydrocolloids, foams, alginates, and the relatively new collagen products (Table 249-2). In determining the most appropriate dressing for a particular wound, the clinician must take into consideration the need for absorption of excessive exudate (foams and alginates), whether the wound is too dry and needs additional moisture (hydrogel materials), and whether the wound and its epithelial edges can tolerate the often subtle but serious trauma that comes from removal of adhesive dressings. Thin contact layers, consisting of different polymeric materials with perforations, allow wound fluid to escape and are useful in preventing tissue injury upon dressing changes.

The exact mechanisms by which moist wound conditions facilitate keratinocyte migration are unknown.[2,44,48] A number of explanations, some supported by experimental work, have been pro-

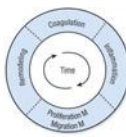

TABLE 249-2
Representative Wound Dressings

Products	Advantages	Disadvantages	Indications
Hydrogels	Semitransparent, soothing, do not adhere to wounds, absorbent	Require secondary dressing, frequent dressing changes	Painful wounds, post-dermabrasion, laser wounds, chemical peels, partial-thickness wounds
Alginates	Absorbent, hemostatic, non-adherent, fewer dressing changes	Require secondary dressing, foul-smelling gel	Highly exudative wounds, partial- or full-thickness wounds, postoperative wounds
Hydrocolloids	Fibrinolytic, enhance angiogenesis, absorbent, bacterial and physical barrier	Opaque, foul-smelling gel	Partial- or full-thickness wounds
Foams	Absorbent, conform to body contours	Opaque, require secondary dressing, may adhere to wounds	Partial-thickness exudative wounds, pressure relief
Films	Transparent, bacterial barrier, adherent	May adhere to wounds, can cause fluid collection	Donor sites, superficial burns, partial-thickness wounds with minimal exudate

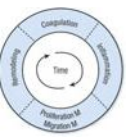

posed and appear plausible. Intuitively, a dry wound bed and the presence of a scab or crust may render keratinocyte migration more difficult. Some have proposed that the electrical gradient is altered in a beneficial way when wounds are occluded and kept from getting dry. Certainly, there is a considerable amount of work indicating that electrical currents can indeed affect the healing process.[49–51] Retention of growth factors and cytokines in the wound bed has been proposed as yet another explanation for how moisture-retentive dressings work. The wound fluid taken from acute wounds has been shown in vitro to stimulate the proliferation of a number of cell types, including fibroblasts and endothelial cells.[52] Conversely, there is work indicating that the opposite is true for wound fluid harvested from chronic nonhealing wounds.[53] Whether this difference in the wound fluid characteristics helps explain the greater effect of moist wound healing on keratinocyte migration in acute wounds remains unknown. Indeed, another view has been to remove the wound fluid from chronic wounds, which can be accomplished with certain devices consisting of a film dressing applied to the wound and connected to a source of negative pressure.[54]

WOUND HEALING OF SKIN GRAFTS

The biology of acute wound healing has direct clinical application to dermatologic surgery. For example, reconstruction following Mohs micrographic surgery routinely involves the four main forms of acute wound healing that include secondary intention healing, side-to-side closure, cutaneous flaps, and skin grafts. Second intention healing is a variation of acute wound healing in which the wound is left to heal on its own. The biology of this process is characterized by all of the usual steps of wound healing but differs in the predominance of the inflammatory reaction and granulation tissue, as well as that of wound contraction.[55] Side-to-side and flap closures are examples of primary intention healing and follow all of the phases of wound healing described in the section Phases of Wound Healing.

The healing of a skin graft, however, is quite different from what was described earlier with acute injury. One distinguishing feature of a skin graft is the complete dependence of the graft on the recipient wound bed for revascularization,[56–58] a feature that requires several unique physiologic events. On the basis of histologic studies, graft healing has classically been divided into three identifiable phases: imbibition, inosculation, and neovascularization.[59]

Imbibition Phase

As in conventional acute wound healing, the immediate event is the formation of a fibrin clot at the graft interface,[60] an event that is also accompanied by infiltration of leukocytes from the recipient to the graft.[61] What distinguishes a skin graft from a conventional wound is the diffusion of plasma from the recipient site into the overlying skin graft, resulting in a weight increase of the graft of up to 40 percent within the first day.[62] This net diffusion of the plasma into the graft is termed *imbibition*, and its significance had initially been thought to be limited to keeping the graft moist and the graft vessels patent.[62,63] Other investigators had hypothesized that imbibition also played a role in providing nutrition to the graft,[64,65] but support for this nutritional role was only demonstrated years later, when bromodeoxyuridine was shown to incorporate into skin graft cells after systemic injection in a mouse model.[66]

The imbibition phase ends as the venous and lymphatic drainage is reestablished, with a concomitant reduction in the weight of the graft.[62] In a rabbit graft model, lymphatic drainage of contrast material has been shown to begin slowly on day 2 and to improve until day 12, with histologically visible anastomoses of the graft and recipient lymphatic vessels by day 4.[67] A fundamental biologic issue of skin graft healing has been to determine the relative contributions of the graft and the recipient tissues to vasculature of the graft, a more precise understanding of which has been achieved by recent molecular biologic approaches.

Revascularization Phases of Inosculation and Neovascularization (See Chap. 163)

Inosculation was originally proposed as the anastomoses of graft blood vessels with the recipient-derived vessels, and neovascularization as the ingrowth of new blood vessels from the recipient wound bed into the graft. Early histologic studies had suggested that the graft maintained its own vasculature after grafting[68,69] in support of the idea of inosculation. However, others felt that histologic studies could not distinguish graft (or donor-derived) from recipient-derived vessels. Lambert concluded that at least during the first several days, the vessels of a skin graft were donor-derived,[70] based on combined histology and radiographic methods. Using a human tissue–engineered skin equivalent with a network of endothelialized vessels,[71] Tremblay and his group demonstrated a significantly increased speed of vascularization by inosculation compared to the rate of vascularization of the non-endothelialized skin equivalent,[72] highlighting the higher efficiency of inosculation over that of neovascularization.

More precise dissection of the relative roles of graft and recipient in the creation of the final vasculature had to await molecular biologic methods to distinguish graft cells from recipient cells. Specific in situ hybridization and immunolabeling

were used to distinguish graft from recipient in studies of human, split-thickness skin grafted onto nude mice. It was found that the recipient endothelial cells grew into the pre-existing donor capillary tubes, decisively supporting the process of immediate inosculation.[73] Most recently, transgenic mice were used to distinguish donor-derived from recipient-derived vascular growth to reveal an even more precise picture. Capla and colleagues showed regression of the graft vessels starting at day 3, with simultaneous vessel ingrowth from the recipient primarily into the graft's pre-existing vascular framework, resulting in inosculation by day 7.[74] Presumably, neovascularization without anastomosing with the graft's vascular framework is not the predominant event. Using a mouse bone marrow transplant model, the same investigative group further showed that bone marrow–derived endothelial progenitor cells contributed 20 percent of the recipient-derived endothelial growth within the graft.[74]

Other Processes in Skin Grafts

As with the blood vessels, there have been analogous issues about the relative contributions of graft and recipient tissue for the final reinnervation of the graft.[75] In a porcine graft model, there was a suggestion based purely on histologic studies that recipient nerves enter the graft and follow the course of the graft tissue's pre-existing neurolemmal sheaths.[76] In another study, human skin was grafted onto nude mice in which the graft structures could be distinguished from recipient tissue using species-specific antibodies. In that report, neurites from the recipient were shown to grow into the graft but did not appear to connect with pre-existing donor graft nerve trunks.[73] Using histochemical labeling of cholinesterases, other studies had suggested that the reinnervation of the graft also involved chemotactic attraction of growing neurites to adnexal structures.[77]

Much of the remainder of skin graft healing involves events in common with the normal wound healing process. Infiltration by fibroblasts in the graft occurs 3 to 5 days after grafting, followed by a progressive increase in both graft and recipient fibroblasts within the graft.[73] Full-thickness skin grafts are thought to reduce wound contraction compared to the significant contraction found in secondary intention healing, with one study suggesting that a graft in the exact size of the original defect minimizes this contraction.[78] Hyperpigmentation can be an occasional undesirable side effect of grafting, and histologic changes of melanocytes have been observed after grafting.[79]

It has been proposed that skin grafts, in a fashion similar to that of cultured autografts, may also stimulate wound healing of the recipient site, especially after prewounding of the donor site from which the grafts were harvested.[80,81] In further support of this hypothesis, expression of keratinocyte Ki67 and β_1 integrin after grafting have been noted, in addition to the production of stimulatory growth factors and cytokines. This may imply an additional phase of graft healing.[82]

CHRONIC WOUNDS AND IMPAIRED HEALING

The previous discussion has focused on cutaneous wound repair after acute injury. It must be recognized, however, that the applicability of those events and processes is limited when it comes to chronic wounds, such as in diabetes, venous and arterial insufficiency, and in a variety of situations complicated by inflammatory processes and faulty host response. Fig. 249-1 is a diagrammatic representation of this concept. The linear relationship and one-way relationship between the different phases of wound repair are lost in chronic wounds. There is no specific orderly sequence, and parts of the chronic wound may be in different phases at different times. Acute wounds, such as those created by surgery or by trauma, have a predictable time frame for healing and generally heal quite readily. However, chronic wounds display what has been called a *failure to heal* or *impaired healing*. A number of observations have been made with regard to chronic wounds, and hypotheses have been proposed for impaired healing. It must be noted that it has proven difficult to study chronic wounds from a pathophysiologic standpoint. A major drawback has been the lack of animal models that truly display impaired healing.

Some chronic wounds are the complex result of ischemia, pressure, and infection. The diabetic ulcer is a case in point for this pathophysiologic triad (see Chap. 152).[3] There is still considerable controversy whether hyperglycemia itself plays a pathophysiologic role in the development of diabetic ulcers, although neutrophil function is impaired; thus, the propensity to infection is enhanced in the diabetic state.[3] Of importance is the notion that "small vessel disease" in diabetes has been more properly evaluated and shown not to be an obstructive phenomenon but, rather, a more physiologic one.[83] The revascularization of the diabetic foot is now viewed as the right approach in the presence of large-vessel disease and good run-off circulation. Perhaps the best example of truly impaired healing not related to undue pressure and poor arterial supply is venous ulceration. The underlying abnormality in the development of venous ulcers is venous hypertension, which refers to the inability of venous pressure in the foot to decrease in response to exercise.[84] There have been several hypotheses proposed for how venous hypertension then results in venous ulceration or the development of lipodermatosclerosis. Some of these hypotheses have emphasized the accumulation of fibrin around dermal blood vessels and defects in fibrinolytic activity. Another hypothesis has centered on damage to the microvascular endothelial cells, which then results in leakage of fibrinogen and dermal pericapillary fibrin cuffs. The leakage of macromolecules from the blood vessels into the dermis in venous disease is substantial, prompting other investigators to propose that such molecules can trap growth factors and other important components and render them unavailable to the healing process or the maintenance of tissue integrity.[85–89] There is evidence that growth factors in chronic wounds are bound to and trapped by macromolecules leaking into the dermis, such as albumin, fibrinogen, and α_2-macroglobulin. The latter molecule is a scavenger for growth factors, including PDGF.[88,89]

MMPs are of critical importance in cutaneous wound repair, particularly in the context of keratinocyte migration. However, in chronic wounds, MMPs may contribute to the overall failure to heal. For example, in venous ulcers and other types of chronic wounds, the wound fluid contains excessive amounts of metalloproteinases, which break down the ECM and, most likely, cytokines and growth factors.[90,91]

It should also be recognized that tissues around chronic wounds are not normal and that they are indeed altered by the primary pathogenic mechanisms or by the inability to heal readily. Clinically, the best example of this is the intense fibrosis surrounding venous ulcers, which is termed *lipodermatosclerosis* (see Chaps. 68 and 175).[92] Once lipodermatosclerosis becomes established, it can lead to ulcers

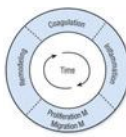

and becomes the site of ulcer recurrence. Indeed, venous ulcers surrounded by lipodermatosclerosis are much more difficult to heal. The reason for these observations may lie in an increasing body of evidence suggesting that the cellular make-up of wounds that do not heal is altered. Thus far, mostly likely because of the ease with which they are grown and studied in culture, the best evidence is with wound fibroblasts. We now know that ulcer fibroblasts are senescent[93] and unresponsive to certain selected cytokines and growth factors.[94–96] For example, it has been shown that venous ulcer fibroblasts are unresponsive to the action of TGF-β1[94,95] and PDGF.[96] The unresponsiveness of venous ulcer fibroblasts to TGF-β1 may be due to decreased expression of type II TGF-β receptors. This receptor abnormality also leads to decreased phosphorylation of key TGF-β signaling proteins, including Smad2, Smad3, and MAPK.[95] The synthetic program of cells in diabetic ulcers may also be altered, so that such chronic wounds are said to be "stuck" in a certain phase of the repair process.[97] A close relationship has been reported between some of these abnormalities and the inability to heal.[93]

Basic Standards of Care

Arterial ulcers need vascular reconstruction; anything less is a temporary measure and ultimately leads to amputation, which may be the only option in inoperable patients. Arterial ulcers that are necrotic and stable with an overlying eschar should probably not be disturbed unless a vascular reconstructive plan is in place.[3] Leg elevation and limb compression is the fundamental therapy for venous ulcers (see Chap. 175). Contact dermatitis is extremely common in patients with venous disease; therefore, avoidance of topical agents is required in many patients.[98] Pentoxifylline has been tested in several large, randomized trials for its ability to accelerate the healing of venous ulcers. The results have varied, and it may be that a high dose of pentoxifylline, at 800 mg three times a day, is more effective than the usual dose of 400 mg three times a day.[99] Whether the use of pentoxifylline should be considered standard therapy for venous ulcers is unclear at the moment. The anabolic steroid stanozolol has been effective in diminishing the induration of lipodermatosclerosis, which is the fibrotic component of venous ulcers, and in the acute and painful phase of lipodermatosclerosis when compression bandages and stockings are too painful to use.[100] However, this agent is no longer available. For now, the only known medical approach for decreasing recurrence of venous ulcers seems to be graded elastic stockings, with a pressure at the ankle in the range of 40 mm Hg. Stockings should be considered a lifelong therapy to help prevent ulcer recurrence and the other manifestations of venous disease.

The triad of neuropathy, ischemia, and trauma is the main pathophysiologic underpinning for the development and recurrence of foot ulcerations in patients with diabetes (see Chap. 152).[3] Measures addressing these components will accelerate healing. Glucose control and optimal management of other systemic complications of diabetes, including renal failure, are important aspects of therapy for diabetic foot ulcers. From a local wound care standpoint, off-loading is critical and is the main standard of care for neuropathic ulcers. Patients with diabetic ulcers due to vascular insufficiency or with ulcers that are mixed in etiology (i.e., having both a neuropathy and surgical compromise) need to be referred immediately for vascular studies and surgical consultation.[3]

Aggressive surgical débridement of the necrotic tissue and the callus surrounding the ulceration has recently become part of standard care in the management of diabetic ulcers.[101] The callus probably provides additional pressure and perpetuates the ulceration. As with neuropathic diabetic ulcers, off-loading is the standard of care for pressure (decubitus) ulcers. Turning and shifting the position of the patient every 2 hours is said to be effective, but actually is not proven to be so.

Surgical Approaches to Chronic Wounds

In the management of venous ulcers, surgical therapy may be considered in the absence of deep vein obstruction and when significant superficial or perforator incompetence is documented. Recently, considerable promise has come from less invasive ligation of perforators using subfascial endoscopic perforator surgery. This approach, sometimes combined with or followed by more definitive procedures, such as the removal of the long saphenous vein (Linton's procedure), may be effective in healing the ulcers.[102] However, it is yet unclear whether this type of therapy prevents ulcer recurrence.

The realization a few years ago that the concept of an occlusive microangiopathy in diabetic ulcers is incorrect brought about a fundamental change in how revascularization of the diabetic foot is viewed; it has now become common practice to revascularize the diabetic limb.[83,103] Therefore, standard vascular surgical techniques are applicable to diabetic patients, as long as there are adequate distal vessels. Vascular reconstruction may need to be combined with limited digital, ray, or forefoot amputation. Ostectomy procedures can alleviate pressure from bony prominences in selected cases.

Ostectomy can also be useful in the management of pressure ulcers to broaden bony prominences. In the appropriately selected patient, random or musculocutaneous flaps are indicated.

OTHER THERAPIES FOR IMPAIRED HEALING

Growth factors are polypeptides with a variety of potent effects on cell proliferation and synthetic capacity (see Table 249-1). To date, the only growth factor that has proven clinically effective is topically applied PDGF. The PDGF-BB isomer becaplermin is approved by the U.S. Food and Drug Administration for the treatment of diabetic neuropathic foot ulcers. Several clinical trials have tested the effectiveness of becaplermin gel (30 μg/g) in diabetic foot ulcers.[101,104] The results showed an incidence of wound closure of up to 48 percent compared to 33 percent for the control group. Becaplermin must only be used when combined with optimal wound bed preparation and elimination of other factors that impair healing.

In the last decade, a number of tissue engineering products have become available for clinical use.[105,106] Two main types of bioengineered skin have been tested and proven to be effective in venous and diabetic neuropathic foot ulcers. One construct, approved for use in diabetic neuropathic ulcers, is comprised of neonatal foreskin fibroblasts in an absorbable suture material.[107] The other type of construct, approved for use in both venous[108,109] and diabetic neuropathic foot ulcers,[110] is bilayered and consists of both fibroblasts and keratinocytes from neonatal foreskin. The exact mechanism of action is of bioengineered skin is unknown, but there is no prolonged engraftment of cells.[111] In clinical trials, both constructs were applied repeatedly to the wound to stimulate healing. However, in clinical practice, it appears that a more limited number of applications is re-

quired. As with the use of becaplermin, optimal preparation of the wound bed is required for these constructs to be effective. Moreover, there is evidence that bioengineered skin is only helpful in ulcers that are of long duration and have not responded to conventional therapy.[109]

PREDICTING WOUND CLOSURE

Several recent studies have enabled us to predict from simple observation and in the first 3 to 4 weeks of therapy whether a wound will heal in a timely fashion. The methods used to predict wound closure range from simple measurements of wound size (width and length) and change in wound area to computerized planimetric analysis and assessment of migration of the wound edge.[112] In a study of 56,488 wounds, it was determined that a percent change in area of approximately 30 percent at 4 weeks could predict wound closure with a sensitivity of 0.67 and a specificity of 0.69, and had a positive and negative predictive value of 0.80 and 0.52, respectively.[113] In even more practical terms, the appearance of the wound edge is important, so that steep edges imply no progress of the wound, while the edges become less steep and begin to migrate toward the center in healing wounds. The ability to predict closure is very important. By 4 weeks, the clinician should be able to make a determination of whether the present therapy should be continued or whether a change is required, including a complete reassessment of the clinical situation.

SUMMARY

Characterizing the events occurring after tissue injury and their overlaps represents a rather daunting task. Yet, over the last several decades, the orderly progression from injury to inflammation and coagulation, to the development of a provisional matrix, to the formation of granulation tissue and to tissue remodeling, has been elucidated to a high degree. Although somewhat artificial, the different phases of wound repair described here are the platform on which more knowledge can be built. Much still needs to be learned, but the framework is there for understanding tissue repair and for developing ways to accelerate it. Indeed, due to breakthroughs in science and technology, progress has been exponential in the last few years. In the long run, one would like to achieve skin regeneration and not simple repair. For that to occur, we will need an even greater understanding of the science involved. What may look detailed today will turn out to be sketchy tomorrow. It is also possible that lessons learned from failure to heal, as in chronic wounds, will provide valuable lessons for the general principles of wound healing.

KEY REFERENCES

The full reference list for all chapters is available at www.digm7.com.

1. Izadi K, Ganchi P: Chronic wounds. *Clin Plast Surg* **32**:209, 2005
2. Ramasastry SS: Acute wounds. *Clin Plast Surg* **32**:195, 2005
3. Falanga V: Wound healing and its impairment in the diabetic foot. *Lancet* **366**:1736, 2005
8. Singer AJ, Clark RA: Cutaneous wound healing. *N Engl J Med* **341**:738, 1999
24. Shweiki D et al: Vascular endothelial growth factor induced by hypoxia may mediate hypoxia-initiated angiogenesis. *Nature* **359**:843, 1992
31. Toy LW: Matrix metalloproteinases: Their function in tissue repair. *J Wound Care* **14**:20, 2005
48. Harding KG, Jones V, Price P: Topical treatment: Which dressing to choose. *Diabetes Metab Res Rev* **16**:S47, 2000
59. Christensen DR, Arpey CJ, Whitaker DC: Skin grafting, in *Surgery of the Skin*, edited by Robinson JK et al. New York, Elsevier Mosby, 2005, p 365
70. Lambert PB: Vascularization of skin grafts. *Nature* **232**:279, 1971
80. Kirsner RS, Falanga V, Eaglstein WH: The biology of skin grafts. *Arch Dermatol* **129**:481, 1993

CHAPTER 250

Treatment for Varicose and Telangiectatic Leg Veins

Robert A. Weiss
Margaret A. Weiss

Bulging varicose veins and unsightly "roadmap" telangiectatic webs affect millions of patients around the world. The incidence is highest in Caucasian patients in whom telangiectasias comprise the most common of all cosmetic complaints. This is borne out by epidemiologic surveys in which leg telangiectasia are reported in 70 percent of women.[1] These same studies of thousands of patients indicate that 53 percent of the population over 50 years of age show some venous reverse flow.[1] Women are at least four times more likely than men to develop telangiectasia, while men have double the risk of developing large varicose veins.[2] Women aged older than 50 years are five times more likely than women aged 29 years or younger to develop large varicose veins. Pregnancy increases the risk of varicose vein development by a factor of 1.5 to 3.0× and is associated with higher risks after three pregancies.[1,3,4] Increased body mass index correlates with a higher risk of reverse flow or reflux, which leads to pain, swelling, and abnormalities of the saphenous system.[5,6] A positive familial history of disease is well known to increase the risk for varicose veins. Varicose veins may cause significant morbidity, including chronic stasis dermatitis, ankle edema, spontaneous bleeding, superficial thrombophlebitis, recurrent cellulitis, lipodermatosclerosis, and skin ulceration on the ankle and foot (see Chap. 175).

The incidence of varicose veins increases with each decade of life. Increased incidence has led to increased demand for treatment of varicose and telangiectatic veins as the average age of the U.S. population grows. Whereas 41 percent of women in the fifth decade have varicose veins, this number rises to 72 percent in the seventh decade.[7] Statistics for men are similar, with 24 percent incidence in the fourth decade, increasing to 43 percent by the seventh decade. Six million workdays per year may be lost in the United States due to complications of varicose veins.[8]

Sclerotherapy gained acceptance in the United States as a highly effective treatment during the early 1990s because it can be used for veins of all sizes.[9] With the addition of foaming the sclerosant, use has been expanded further.[10] Sclerotherapy is also an impor-

VARICOSE VEINS AT A GLANCE



- Forty-one percent of women in the fifth decade and 72 percent in the seventh decade have varicose veins.
- Six million work days per year may be lost in the United States due to complications of varicose veins.
- The main technique for treatment of cosmetic spider veins are sclerotherapy and lasers.
- For large varicose veins sclerotherapy (with or without duplex ultrasound guidance), phlebectomy and endovenous occlusion by radio-frequency or laser are used.
- The term *sclerotherapy* should be replaced by *endovascular chemoablation,* which more accurately describes the procedure.



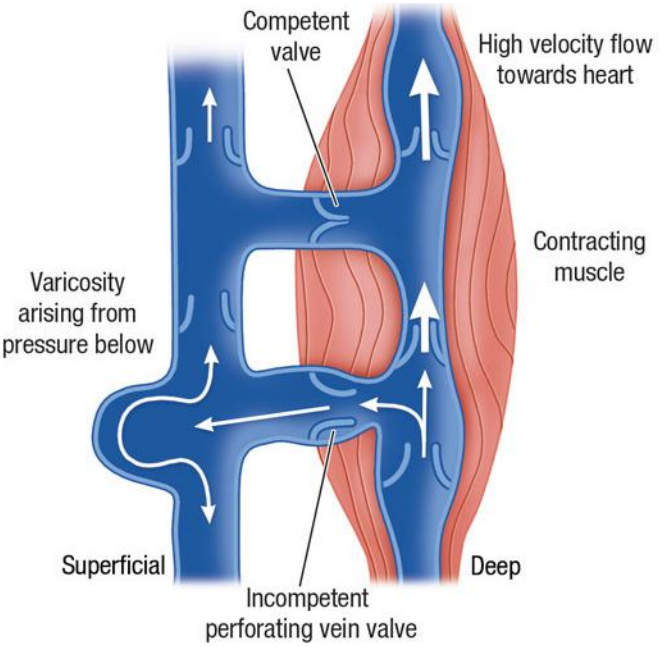

▲ **FIGURE 250-1** Schematic of the calf muscle pump with malfunctioning perforating vein connecting the superficial and deep system. High pressures are generated when the gastrocnemius muscle contracts to pump blood proximally. A malfunctioning valve is shown diverting pressure to the skin surface. Competent valve directs flow proximally.

tant adjunctive therapy to surgical techniques such as ambulatory phlebectomy for saphenous tributaries[11,12] or the newest endovenous ablation of refluxing saphenous veins.[13,14] Knowledge of venous anatomy and physiology, principles of venous insufficiency, methods of diagnosing venous abnormality, uses and actions of sclerosing solutions, and proper use of compression are essential elements of successful venous therapy.

HISTORICAL ASPECTS

VENOUS ANATOMY AND PHYSIOLOGY

The venous system is comprised of a primary, deep-venous compartment and superficial compartment with thousands of small veins (perforating veins) connecting the two systems. The deep compartment, "the muscle pump," normally acts as a conduit for 85 percent to 90 percent of venous return from the leg. During contraction of the calf muscles, the valves of the perforating veins and associated superficial veins close, allowing blood to flow only proximally at high pressures through the deep system. This generates primary propulsive force returning venous blood to the heart (Fig. 250-1).

The superficial venous system consists of three primary territories: greater saphenous vein, lesser saphenous vein, and subdermic lateral venous system (Fig. 250-2). Comprising the three major patterns are multiple collateral veins (accessory) and multiple tributary veins emptying into each, respectively. The points of connection (perforating veins) between the superficial and the deep system play important roles, as these are sites through which reflux or reverse flow often develops (Fig. 250-3).

Due to gravitational hydrostatic pressure, sequential retrograde breakdown of venous valve function often follows a leak at one point, leading to propagation of a varicosity. Increased diameter between valve leaflets, with failure to oppose properly caused by genetically weak venous wall or venous valve structure, may initiate these events. Calf muscle pump pressure plus gravitational hydrostatic forces are transmitted directly via the incompetent perforating vein or communicating veins to the surface veins. Venous hypertension may reach levels higher than systolic arterial blood pressure in the cutaneous venules with the patient erect. Transmission of pressure may result in venular dilatation over a wide area of skin, including the formation of telangiectatic webs and more serious consequences such as ulceration.[22] This leads to a number of symptoms, with heaviness, fatigue, and aching of the legs.[23]

SYMPTOMS

When present in significant quantity, the volume of blood sequestered and stagnant in reticular veins and associated telangiectatic webs (particularly of the lateral venous system) may cause enough distention to produce symptoms.[24] Symptoms are relieved by the wearing of support hose or with rest and elevation of the legs. Prolonged standing or sitting without calf muscle contraction worsens symptoms. The size of the vessels causing moderately severe symptoms may be as small as 1 to 2 mm in diameter. Sclerotherapy has been reported to yield an 85 percent reduction in these symptoms as well as superb cosmetic results.[24]

CONTRAINDICATIONS TO TREATMENT OF SPIDER VEINS (Table 250-1)

Vein treatment and, in particular, foam sclerotherapy may be performed safely and effectively in virtually all types of veins, except when reflux exists at the sapheno-femoral junction. Because the goal of sclerotherapy is to eliminate reflux at its origin, the goal of non-invasive diagnostic evaluation is to uncover pri-

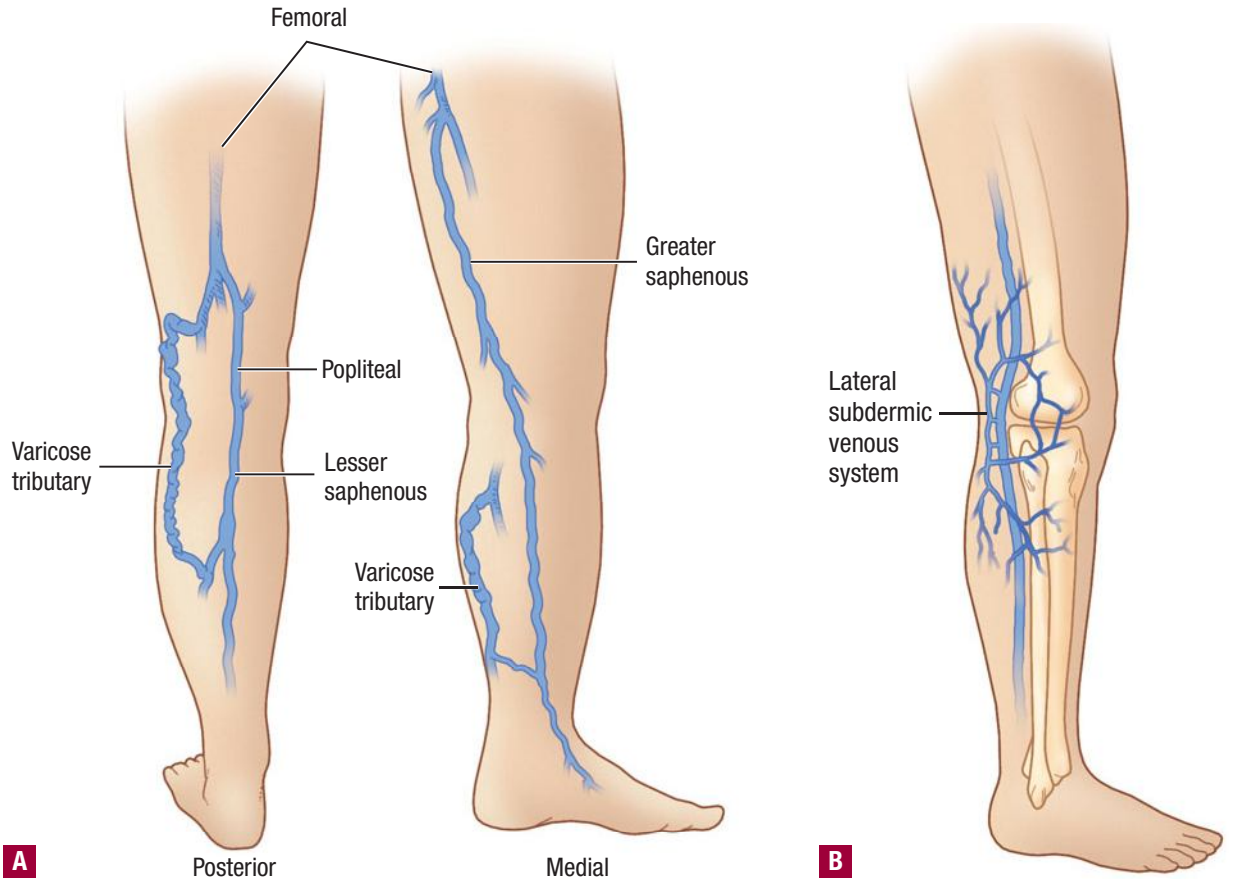

▲ **FIGURE 250-2** Schematic of the major portions of the superficial venous system. **A.** Greater saphenous vein and lesser saphenous vein. **B.** Subdermic lateral venous system. When varicosities or telangiectatic webs are present within the distribution of these saphenous veins, the source of pressure must be elucidated. The lateral venous system is the most common source of telangiectasias.

mary sources of high, reverse-flow pressure. A high rate of recurrence for sclerotherapy is commonly seen when reflux originates at the major saphenous junctions. The techniques of endovenous occlusion by radio-frequency (RF) or laser are the means by which reflux occurring at the termination point of the saphenous veins is now treated. Five-year data indicates that these techniques are as effective as the old surgical techniques of ligation and stripping to eliminate saphenous veins.[25] Recent studies show high recurrence rates (30 percent to 50 percent) after ligation and stripping.[26] The archaic stripping techniques are no longer recommended for primary treatment of saphenous reflux. With high safety and efficacy of endovenous ablation techniques proven, overwhelming patient preference against stripping, and the reduction of risks by procedures not performed with general anesthesia, endovenous ablation techniques have been embraced.[27]

Venous treatment is contraindicated in a bedridden patient because ambulation is important for minimizing risks of thrombosis. Similarly, patients under general anesthesia for non-related procedures should not undergo simultaneous sclerotherapy. Severely restricted arterial flow to the legs necessitates postponement of vein treatment. A history of deep venous thrombosis (DVT) or previous trauma to the leg (e.g., auto accident) should preclude sclerotherapy until adequately evaluated by duplex ultrasound. Previous urticaria or suspected allergy to a sclerosing agent should serve as a relative contraindication to use of that particular sclerosing agent.

Pregnancy should be considered a contraindication during the first and second trimester, although extremely painful or bleeding varices may be treated in the last trimester by endovenous ablation techniques. Treatment is typically postponed because varicosities and telangiectasias may resolve spontaneously 1 to 6 months postpartum.

Obesity should be considered a relative contraindication because maintaining adequate external compression is difficult. Sclerotherapy of larger varicosities should be postponed until weight reduction is achieved. During hot summer months, heat-induced vasodilatation and inability to comply with wearing of compression hose may also require postponement of treatment.

TREATMENT TECHNIQUES

Pre-Treatment Evaluation

Physical examination is performed by viewing the patient's legs in a 360° rotation. Palpation is performed along the saphenous vein distributions to rule out early large axial varicosities, which cannot be seen. Based on the history and physical examination, non-invasive, diagnostic vascular tests are performed as necessary.[28] Those patients with a family history of large varicose veins are more likely to have early axial (saphenous) reflux even when presenting with telangiectasias alone.[11] Previous venous surgery warrants further testing before treatment.

Once the patient is judged to be a candidate for vein treatment, informed consent is obtained. Any veins visible or palpable suggestive of saphenous system involvement should be minimally evaluated by hand-held Doppler ultrasound,

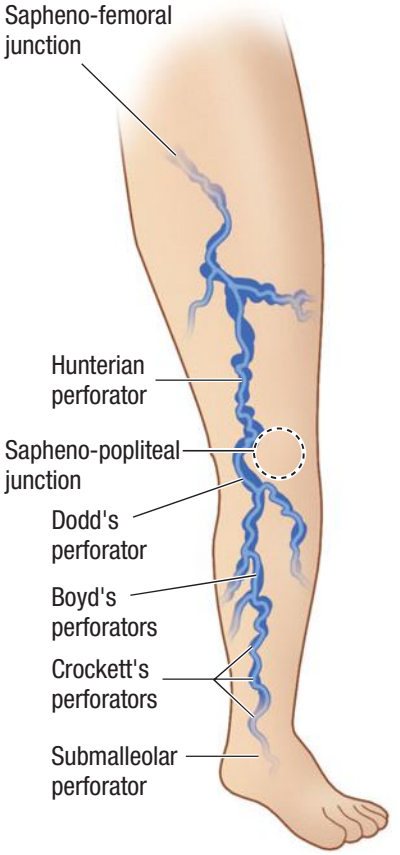

▲ **FIGURE 250-3** Diagram indicating major junction points of the superficial venous system with the deep venous system. Larger varicose veins may originate from any of these points.

which is equivalent to using an enhanced "stethoscope" to hear vein flow. To generate or augment an audible signal of flow, a maneuver such as manual compression of the calf must be performed by the examiner. When compression is released, gravitational hydrostatic pressure causes reverse flow to cease within 0.5 to 1.0 second when valves are competent, but a long flow sound is audible when valves are incompetent.

The most essential part of the Doppler examination is the examination of the sapheno-femoral junction below the inguinal fold just medial to the femoral arterial signal. During a Valsalva's maneuver, a continuous and pronounced reflux signal is a reliable sign of valvular insufficiency. An equivocal result may require a duplex ultrasound examination for a definitive answer. Methods of complete Doppler examination are detailed in other texts or papers.[11]

The gold standard of non-invasive examination of the venous system is duplex ultrasound. This allows direct visualization of the veins and identification of flow through venous valves. An image is created by an array of Doppler transducers that are switched on and off sequentially. The duplex examination is often used to uncover hidden sources of reflux prior to beginning any method of treatment or to delineate reflux sources when patients experience poor results from sclerotherapy.

TABLE 250-1
Indications and Contraindications for Sclerotherapy

INDICATIONS	CONTRAINDICATIONS
• Pain	• Reflux at sapheno-femoral or sapheno-popliteal junction[a]
• Major tributaries of greater and lesser saphenous veins	• Non-ambulatory patient
• Major perforator reflux	• Obesity
• Lateral venous system varicosities	• Deep venous thrombosis
• Cosmetic	• Known allergy to sclerosing agent
	• Arterial obstruction
	• Pregnancy

[a]Relative contraindication, success has been reported under the right conditions, proper sclerosing solutions (not available in United States) and/or the use of duplex-guided sclerotherapy.

Endovenous Chemoablation Solutions

Sclerosing solutions have been classified into groups, based on chemical structure and effect: hyperosmotic, detergent, and corrosive agents (chemical toxins—salts, alcohols, and acid or alkaline solutions). Commonly used sclerosing solutions are summarized in Table 250-2.

Sclerotherapy Technique

A basic principle of treatment is to begin at the largest (reflux sources) and progress to the smallest varicosities and then finally to telangiectasias. When present without larger varicosities, telangiectasias are approached by combined injection of visibly connected reticular veins, venulectases, and telangiectatic webs or networks. Reticular veins are treated only after all sources of reflux from major varicosities have been treated by sclerotherapy and/or surgery. When no clear feeder vessel is seen or identified by Doppler, transillumination (Veinlite, 3Gen, Dana Point, CA) is another method that may be used to identify the "feeding" reticular vein. (Fig. 250-4). When unable to locate an associated reticular vein, then the point at which the telangiectasias begin to branch out is the site at which to begin injection. Injection of telangiectasias is simultaneously performed with injection of reticular veins in the hopes of decreasing the number of treatments.[33]

The injection method for telangiectasia is basically as previously described by Duffy and Goldman.[16,34] The sclerotherapy tray is prepared with the necessary equipment (Table 250-3). A 30-gauge needle, bent to an angle of 10° to 30° with the bevel up, is placed on the skin so that the needle is parallel to the skin surface. A 3-cc syringe filled with 1.5 to 2.0 cc of solution is held between the index and middle fingers while the fourth and fifth fingers support the syringe against the leg in a fixed position facilitating accurate penetration of the vessel. The non-dominant hand is used to stretch the skin around the needle and may offer additional support for the syringe (Fig. 250-5). Magnifying lenses or operating loops on the order of 1.5 to 3.0× may help cannulation of the smallest telangiectasias.

The initial treatment of telangiectatic webs begins with lowest possible concentration that will cause a telangiectasia to sclerose over a period of 1 to 6 months postinjection. This typically is 0.1 percent sodium tetradecyl sulfate (STS) or 0.2 percent polidocanol (POL). The use of 50 percent to 72 percent glycerin in water is becoming increasingly frequent in our practice. When ineffective sclerosis occurs, judged at a subsequent visit, the concentration but not the volume per site of sclerosing solution is increased. Post-treatment compression consists of graduated 20 to 30 mm Hg or 30 to 40 mm Hg support hose for 2 weeks for larger veins and over-the-counter (nonprescription) 15 mm Hg compression for smaller veins. Treatment intervals vary, but allowing 4 to 8 weeks between treatments helps to minimize the number of necessary sessions. Typical results are shown in Fig. 250-6.

FOAM SCLEROTHERAPY Foam sclerotherapy has become a standard of treatment, as the foam completely fills and displaces the blood in the vein. The microbubbles of foam allow maximal contact with the highest concentration of the sclerosant, thereby resulting in maximal endothelial cell injury and subse-

TABLE 250-2
Comparison of Commonly Used Sclerosing Agents

Sclerosing Solution	Category	Advantages	Disadvantages	Vessels Treated	Concentrations
Sodium tetradecyl sulfate (Sotradecol)	Detergent	FDA approved Painless—unless injected extravascularly	May cause breakdown rarely—found to be equivalent to polidocanol in clinical studies	All sizes	0.1%–0.2% telangiectasias 0.2%–0.5% reticular 0.5%–1.0% varicose 1.0%–3.0% axial varicose
Polidocanol	Detergent	Painless Low ulceration risk at low concentrations	Not FDA approved	Small to medium	0.25%–0.5% telangiectasias 0.5%–1.0% reticular 1.0%–3.0% varicose
Hypertonic saline	Hyperosmolar	Low risk of allergic reactions	Ulcerogenic Painful to inject	Small	23.4%–11.7% telangiectasias 23.4% reticular
Hypertonic saline + dextrose (Sclerodex)	Hyperosmolar	Low risk of allergic reaction Mild stinging Low ulcerogenic potential	Not FDA approved Relatively weak sclerosant	Small	Undiluted—telangiectasias Undiluted—reticular
Sodium morrhuate (Scleromate)	Detergent	FDA approved	Allergic reactions highest	Small	Undiluted—telangiectasias Undiluted—reticular
Chromated glycerin (glycerin with 6% chromium salt; Scleremo)	Chemical irritant	Low skin ulcer potential	Not FDA approved Very weak sclerosant	Smallest	Undiluted to one-half strength—telangiectasias
Glycerin—plain	Chemical irritant	Painless, low risk of allergic reaction, decreased risks of pigmentation and matting	FDA approved for reduction of cerebral edema	Smallest	50%–72%
Polyiodinated iodine (Varigloban)	Chemical irritant	Highly corrosive—allows treatment of largest veins	Not FDA approved Avoid in iodine-allergic patients	Largest	1%–2% for up to 5-mm veins 2%–6% for the largest veins

FDA = U.S. Food and Drug Administration.

quent fibrosis of the vein wall. This results in more effective sclerotherapy, which leads to fewer treatment sessions. Less total amount of solution is required with foam. This has the additional benefit of decreasing systemic toxicity. An additional advantage of foam is that duplex-guided sclerotherapy becomes more precise, as the foam is very echogenic and easily visualized on ultrasound.

The most used technique for foam sclerotherapy is the Tessari technique.[35]



▲ **FIGURE 250-4** Transillumination of a reticular vein. The reticular vein shows up as a dark curvilinear object against a light background.

Two, 3-cc Luer-Lok syringes are connected with a disposable three-way stopcock. One syringe is filled with air, and one syringe is filled with a detergent type of sclerosant. The optimal ratio of solution to air is 1:4. The contents of the syringes are shifted back and forth quickly approximately 10 to 20 times and the turbulent flow generates the foam (Fig. 250-7). The foamed solution should be used immediately because it degrades within 60 to 90 seconds. The nature of the foam allows for the same therapeutic effect with approximately one-half the concentration of sclerosant. For instance, one can substitute 0.1 percent STS foam for 0.2 percent STS liquid. Lower concentrations are used for all size veins. Foamed solution should only be used for varicosities, perforating veins, reticular veins, and larger telangiectasias (1 to 2 mm). Smaller telangiectasias run the risk of increased pigmentation and matting, as more inflammation occurs with the relatively increased concentration interacting with the vein wall.[36]

TABLE 250-3
Sclerotherapy Tray

- Cotton balls soaked with 70% isopropyl alcohol
- Protective gloves
- 3-cc disposable syringes
- 30-g disposable transparent hub needles
- Cotton balls or foam pads for compression
- Transpore™ and/or paper tape
- 2% nitroglycerine paste (for prolonged blanching or extravasation)
- Sclerosing solutions:
  - Sodium tetradecyl sulfate (ranging concentrations, 0.1%–0.5%)
  - Hypertonic saline (11.7%–23.4%)
  - Hypertonic saline (10%) and dextrose (25%) (may be mixed by local pharmacy)
  - Polidocanol (0.25%–1.0%) (pending U.S. Food and Drug Administration clearance)
  - Three-way stopcock to foam solutions (1:4—sclerosant-air)

SIDE EFFECTS AND COMPLICATIONS OF SCLEROTHERAPY ***Post-Sclerotherapy Hyperpigmentation.*** Post-sclerosis pigmentation is defined as the appearance of increased visible pigmentation along the course of a treated vein of any size. Initially, perivascular hemosiderin deposition and not increased melanin production causes this appearance[37]; however, over time

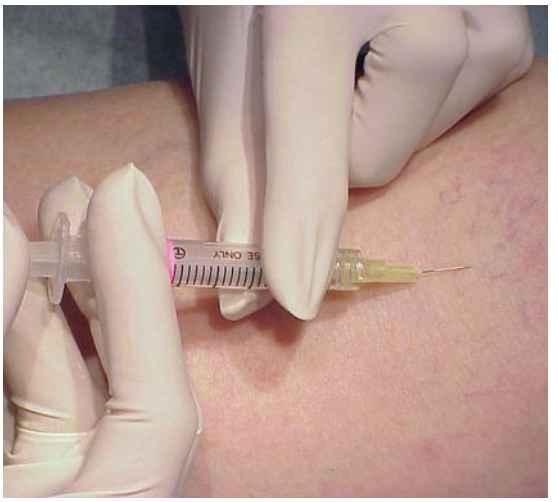

◀ **FIGURE 250-5** Position of the hands for sclerotherapy. While the dominant hand holds the syringe and creates a platform with the fifth digit, the non-dominant hand stretches the skin and acts as a support for the needle hub so that fine changes in position are permitted.

the hemosiderin is replaced by melanin. The incidence of pigmentation is related to dilution and type of sclerosing agent as well as diameter of treated vessel.[38] Pigmentation incidence ranges from 11 percent to 30 percent using hypertonic saline,[24] 11 percent to 30 percent with POL,[16,39] and up to 30 percent with STS. The incidence of pigmentation may be reduced in varicose veins by expressing the dark, viscous blood thought to be a liquefied coagulum or intravascular hematoma, which may accumulate 1 to 4 weeks after sclerotherapy.

Pigmentation clears in 70 percent within 6 months but rarely persists for greater than 1 year.[38] Attempts to hasten resolution of pigmentation have been mostly unsuccessful, as the pigment is dermal hemosiderin and not epidermal melanin. Bleaching agents, exfoliants such as trichloroacetic acid or phenol, cryotherapy, various lasers, and intense pulsed light have achieved limited success.[40,41] The Q-switched ruby laser has been found to be the most consistently effective for treatment of postsclerosis pigmentation (see Chap. 240).[42]

Telangiectatic Matting. Telangiectatic matting is defined as the appearance of groups of new, fine (< 0.2-mm diameter) telangiectasias surrounding or replacing a previously treated area in a blush-like manner. A retrospective analysis of over 2000 patients reports an incidence of 16 percent in patients treated with hypertonic saline and POL.[43] Resolution usually occurs spontaneously within a 3- to-12-month period with 70 percent to 80 percent spontaneous resolution within the first 6 months.[44]

Cutaneous Necrosis and Ulceration. Cutaneous ulceration may occur with all sclerosing solutions in spite of the most skilled technique. Unavoidably, a tiny amount of sclerosing solution may be left along the needle tract as the needle is withdrawn. Sclerosing solution may also leak out into the skin through the small puncture sites of vessel cannulation. The varicose vein may have a fragile, thin wall, with the injection causing rapid injury, leading to sudden unexpected rupture with perivascular accumulation of sclerosant. Additionally, injection may inadvertently occur into a small arteriole associated with telangiectatic varicosities with resultant necrosis and ulceration.

When the dermatologic surgeon recognizes that extravasation has occurred, the risk for necrosis can be minimized by injecting normal saline in a ratio of 10:1 over sclerosant into the extravasation site. Extensive massage of small subcutaneous blebs to spread the trapped sclerosing agent as quickly as possible will minimize prolonged blanching of the area. We have found that application of topical 2 percent nitroglycerine paste applied immediately to the suspected extravasation site greatly reduces the risks of necrosis but will not always prevent it.

Superficial Thrombophlebitis. This complication is most commonly mistaken for the normal nodular fibrosis (endosclerosis) that occurs with proper sclerotherapy. After sclerotherapy, a non-tender, non-pigmented, nonerythematous fibrotic cord may normally be palpable along the course of a treated 4- to 8-mm vein. This frequent finding is due to a liquefied intravascular hematoma with surrounding vein wall sclerosis and is not a thrombosis. In contrast, superficial thrombophlebitis is characterized clinically by a very tender, indurated, linear erythematous swelling. Incidence of superficial thrombophlebitis is quite variable estimated at 1 percent to 0.01 percent after sclerotherapy,[47] although a recent report indicates that the inci-

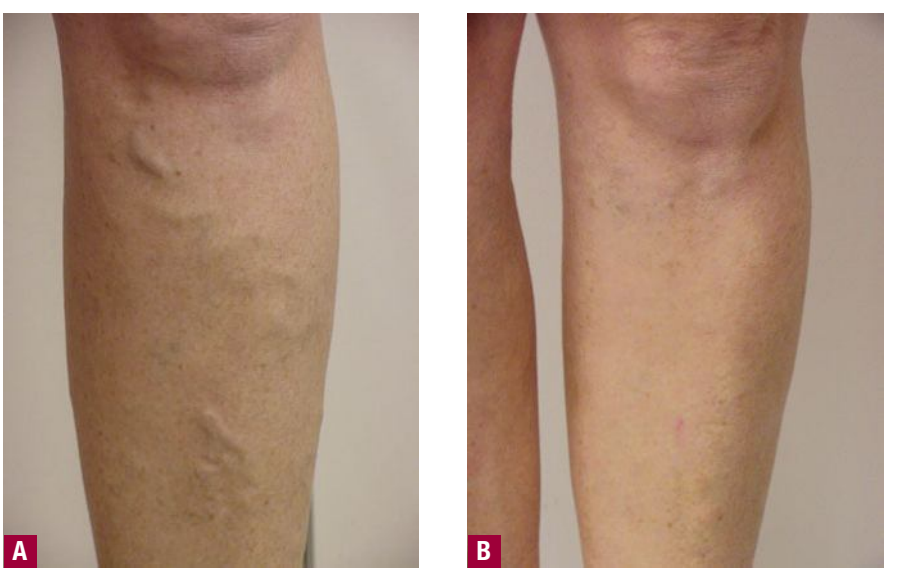

▲ **FIGURE 250-6** Typical results after sclerotherapy. **A.** Large varicose vein treated twice with 0.5 percent sodium tetradecyl sulfate. **B.** Excellent clinical results at 15-month follow-up.



▲ **FIGURE 250-7** Generation of foam for sclerotherapy. Vigorous agitation between two syringes results in a frothy material for injection. Reduced total amounts of sclerosing solution with decreased total volumes results in increased safety.

dence is higher than previously suspected.[48] Treatment consists of leg elevation and/or compression and regular administration of aspirin or other nonsteroidal anti-inflammatory drugs. Extension of superficial thrombophlebitis into the deep system is extremely rare.

Pulmonary Embolism. Pulmonary emboli probably occur from extension of a superficial thrombus into the deep venous system. Evidence of extension from superficial thrombus to deep thrombophlebitis should be treated promptly by anticoagulation. The incidence of pulmonary embolism has been associated with injection of large quantities of sclerosant at a single site. The incidence is extremely low with less than 1 in 40,000.

Arterial Injection. This dreaded medical emergency is fortunately extremely rare. Classic warning signs include immediate intense pain far beyond the normal discomfort at the initiation of injection, although leakage of sclerosant into the arterial circulation may present in an atypical fashion. Continuous intense burning pain with immediate bone-white, cutaneous blanching over an area of several square centimeters is the usual initial sign. Progression to a sharply demarcated cyanosis within minutes is typical for arterial injection. Emergency treatment involves immediate application of ice, attempts to flush the inadvertently injected artery with normal saline and/or heparin, injection of 3 percent procaine to inactivate STS, and vascular surgery consultation for intravenous anticoagulation. Rarely, arterial injection may not be accompanied by any pain or cutaneous signs. The atypical cases are suspected to arise from arteriovenous malformations.[49] Arterial injection may lead to wide areas of skin necrosis and damage to subcutaneous tissue and muscle, which take months to heal.

MINIMAL SURGICAL APPROACHES FOR VARICOSE VEINS

Endovenous Ablation and Occlusion Techniques

Endovenous ablation techniques were first developed by dermatologic surgeons.[14,50] When it has been determined by ultrasound that the originating point of reverse flow or reflux is the great saphenous vein or short saphenous vein, endovenous RF or laser techniques are used, as ligation and stripping are being phased out. When saphenous system reflux is present, the endovenous occlusion techniques must be performed before treatment of visible and associated varicosities, reticular veins, or telangiectasias. Without elimination of reflux, the patient will be doomed to recurrence after recurrence.

Radio-Frequency

The efficacy for RF elimination of reflux is 90 percent at 2 years and 80 percent at 5 years.[17,25] This method involves the placement of a catheter or fiberoptic within the varicose vein through a small puncture or incision. The catheter is threaded up to the sapheno-femoral junction typically under duplex ultrasound guidance. Critical to the safety and success of the technique is placement of tumescent local anesthesia, which involves first infiltrating the tissue under the skin including thigh muscles to push the saphenous vein further away from the skin and then creating a space between the fascia and the saphenous vein so as to hydro-dissect the vein away from structures such as nerves and arteries. Once this hydro-dissection has been performed with high volume, low concentration of local anesthetic (0.1 percent lidocaine), energy is applied as the catheter is slowly withdrawn. This results in heat directly applied to the vein wall via a computer-controlled thermo-couple feedback loop. This results in a collagen shrinkage accompanied by complete vein wall occlusion.

Laser (Hemoglobin Predominant Absorption—810-nm, 940-nm, 980-nm)

Endovenous laser treatment is similar to RF in that energy, which ultimately releases heat to produce endothelial and vein wall shrinkage, results in subsequent fibrosis. The target for lasers with 810-, 940-, and 980-nm wavelengths is intravascular red blood cell absorption of laser energy. These techniques are highly dependent on correct placement of tumescent local anesthesia so as to protect surrounding nerves from injury. Direct thermal effects on the vein wall without the presence of blood probably do not occur. The extent of thermal injury to tissue is strongly dependent on the amount and duration of laser energy application. Multiple factors that affect outcome include blood in the lumen, rate of pullback, and amount of tumescent anesthesia placed around the vein.

One in vitro study model showed that thermal gas production by laser heating of blood in a 6-mm tube results in 6 mm of thermal damage.[51,52] Histologic examination of one excised vein demonstrated thermal damage along the entire treated vein with evidence of perforations at the point of laser application described as "explosive-like" photo-disruption of the vein wall. This produced the homogeneous thrombotic occlusion of the vessel. Formation of bubbling blood is the proposed mechanism of action for heating surrounding tissue.[52] We have found that superheating of blood during these procedures occurs to a maximum of approximately 1200°C (2192°F).[18]

These endovenous lasers have short-term efficacy of 90 percent occlusion over the first year, but the rate decreases with time.[53,54] In addition, most patients experience major degrees of postoperative ecchymosis and discomfort. Saphenous nerve injury, skin burns, and DVT have occurred due to the high temperatures of blood heating from these wavelengths, although the overall safety and efficacy record is better than for stripping.[55–57] The incidence of these complications is lower with RF endovenous occlusion.

Laser (Water Predominant Absorption—1320 nm)

A variation of the endovenous laser, 1320 nm, was developed by dermatologic surgeons in an attempt to bypass the problems associated with laser wavelength absorption of hemoglobin. Tissue water is the target, and the presence or absence of red blood cells within the vessels is unimportant. For more controlled release of laser energy, it is coupled with an automatic pullback device variable from 0.5 to 1.0 mm/sec. The penetration of the 1.32-μm wavelength is unique, with far less heat and risk than with the hemoglobin-absorbing wavelengths.

Endovenous ablation appears to be best accomplished not by hemoglobin heating but by heating water within collagen in the vein wall as a target. Proebstle et al. demonstrated a statistically reduced rate of postoperative pain accompanied by a higher initial success rate using 1320 nm versus 940 nm.[58] Our own experience reflects this, with a reduction in pain and bruising of 80 per-






▲ **FIGURE 250-8** **A.** Endovenous ablation of the great saphenous vein results in the improvement of associated varicosities (**B**).

cent when switching from 810-nm endovenous to 1320-nm endovenous. Having treated over 200 greater saphenous veins with 1320 nm, our incidence of mild pain is 5 percent. No significant pain interfering with walking has been observed, which occurred with 50 percent of 810-nm treatment. A clinical example of varicose veins resulting from reflux at the sapheno-femoral junction pre- and post-treatment is shown in Fig. 250-8.

Ambulatory Phlebectomy

Ambulatory phlebectomy, originally described by Robert Muller and further refined by another Swiss dermatologist (Albert-Adrien Ramelet), involves the use of tiny incisions through which the varicose vein is removed by a small hook.[59,60] This safe, outpatient local anesthesia technique allows removal of almost any varicose vein except the sapheno-femoral or sapheno-popliteal junction, which are treated initially by endovenous ablation techniques. Areas or veins that are resistant to foam sclerotherapy are particularly indicated for ambulatory phlebectomy (see eFig. 250-8.1 in on-line edition). Risks that are minimized compared with sclerotherapy are DVT, post-sclerotherapy pigmentation, skin necrosis, and superficial phlebitis. In many cases, larger varicose veins co-exist with smaller reticular veins and associated telangiectatic webs. It is reasonable to treat larger varicose veins by various surgical techniques and follow up with sclerotherapy of the remaining reticular networks.

Lasers and Light Sources (See Chaps. 240 and 253)

New trends for improved results with lasers and light sources for spider veins include longer wavelengths, larger spot sizes, and cooling to protect the skin (Fig. 250-9). The first report of 1064-nm neodymium:yttrium-aluminum-garnet (Nd:YAG) laser indicated that 75 percent improvement was possible after a single treatment at 3 months.[61] These findings were confirmed and the mechanism of action explained as heat-induced vessel damage and subsequent fibrosis.[62] Recent reports also indicate effectiveness of 940-nm diode laser.[63] Shorter wavelengths used in the past, like pulsed dye laser, have limited use on leg veins, although many devices are now being adapted to longer pulse durations up to 40 ms. In our practice, the vast majority of laser treatments are performed using 1064-nm Nd:YAG laser in the millisecond domain on isolated telangiectasias, sclerotherapy-resistant telangiectasias, ankle telangiectasias, and suspected arteriovenous malformations. Even associated reticular veins with telangiectasias can be treated with 1064 nm; however, the larger the vein, the more painful the treatment due to increased absorption of infrared energy.[64]




▲ **FIGURE 250-9** Clinical results with 1064-nm laser. A small isolated group of telangiectasias are treated with 1064-nm laser (Vasculight, Lumenis, Santa Clara, CA). **A.** Before and (**B**) 3 months after treatment. Treatment parameters are single, 16-ms pulse, 6-mm spot size, 120 J/cm^2.

KEY REFERENCES

The full reference list for all chapters is available at www.digm7.com.

5. Lee AJ et al: Lifestyle factors and the risk of varicose veins: Edinburgh Vein Study. *J Clin Epidemiol* **56**:171, 2003
6. Ruckley CV et al: Chronic venous insufficiency: Clinical and duplex correlations. The Edinburgh Vein Study of venous disorders in the general population. *J Vasc Surg* **36**:520, 2002
9. Weiss RA, Weiss MA, Goldman MP: Physicians' negative perception of sclerotherapy for venous disorders: Review of a 7-year experience with modern sclerotherapy. *South Med J* **85**:1101, 1992
11. Goldman MP, Weiss RA, Bergan JJ: Diagnosis and treatment of varicose veins—A review [review]. *J Am Acad Dermatol* **31**:393, 1994
20. Weiss RA, Feied CF, Weiss MA: *Vein Diagnosis and Treatment: A Comprehensive Approach*. New York, McGraw-Hill, 2001
25. Merchant RF, Pichot O: Long-term outcomes of endovenous radiofrequency obliteration of saphenous reflux as a treatment for superficial venous insufficiency. *J Vasc Surg* **42**:502, 2005
32. Rao J, Wildemore JK, Goldman MP: Double-blind prospective comparative trial between foamed and liquid polidocanol and sodium tetradecyl sulfate in the treatment of varicose and telangiectatic leg veins. *Dermatol Surg* **31**:631, 2005

SECTION 41

COSMETIC DERMATOLOGY

CHAPTER 251

Cosmetics and Skin Care in Dermatology

Leslie Baumann

According to recent data, U.S. sales of skin care cosmeceuticals (cosmetics with attributed biologic effects) were approximately $6.4 billion, and it is estimated that the skin care market will reach $7.2 billion by 2010.[1,2] A plethora of skin care products are currently available to account for this substantial sales volume. The range of products and their associated claims are so extensive and complex that physicians and consumers are often confused about their indications and effectiveness. One approach to understanding these many options is to consider how the products are used to treat specific skin types.

For purposes of cosmetics, facial skin can be grouped into four main categories that, in practice, represent up to 16 skin types: dry or oily; sensitive or resistant; pigmented or non-pigmented; and wrinkled or unwrinkled (or "tight"). These "skin types" are not static and can be affected by a range of intrinsic and extrinsic factors such as environment, aging, and disease. The key to proper skin care recommendations is to take all four parameters into consideration. The various permutations of the four skin-type parameters yield 16 possible skin types. For example, a person may have dry, sensitive, pigmented, wrinkled skin, and her needs would significantly differ from someone with oily, sensitive, pigmented, and wrinkled skin. These skin types are not to be confused with the Fitzpatrick photo-skin types (see Chap. 89).

This chapter will discuss the basic science and defining characteristics of the four parameters. Certain extrinsic or intrinsic factors, such as a move to a different climate, a change in stress levels, pregnancy, menopause, and others, can result in a skin-type change. The Baumann Skin Type Indicator, a questionnaire developed to determine skin type, is helpful in assessing skin type initially and again after major life changes.[3]

SKIN HYDRATION

Oily versus Dry

Xerosis or "dry skin" describes skin that is characterized by dull color (usually gray white), rough texture, and an elevated number of ridges.[4] The etiology of this common condition is multifactorial. The most significant factor in the development of xerosis is the role of the stratum corneum (SC) and its capacity to maintain skin hydration. Rawlings et al. showed that patients with dry skin have a perturbation in the lipid bilayer of the SC that is associated with increased fatty acid and decreased ceramide levels.[5] Defects or deficiencies in this barrier layer of the skin cause a spike in water evaporation, known as trans-epidermal water loss (TEWL) (see Chap. 45).

The SC is composed of three primary groups of compounds: ceramides, fatty acids, and cholesterol. When present in the proper amount and balance, these components help to protect the skin and keep it watertight. When the barrier is impaired, however, the skin is rendered dry because of the inability to retain water and sensitive because of increased vulnerability to extrinsic elements. Several other factors play a causative role in dry skin.

Natural moisturizing factor (NMF), derived from the breakdown of the protein filaggrin, is integral in maintaining water within skin cells. Filaggrin provides structural support and strength in the lower layers of the SC. It is broken down in higher levels (stratum compactum) of the SC by a still-uncharacterized cytosolic protease into free amino acids, including histidine, glutamine (glutamic acid), and arginine.[9] These osmotically active amino acids remain inside the keratinocyte and avidly bind to water. The pace at which filaggrin is broken down into NMF is thought to be regulated by aspartate protease (cathepsin), which initiates this cascade and determines the amount of NMF that is present.[10] Interestingly, this putative aspartate protease (cathepsin) is regulated by changes in external humidity. In other words, in low humidity environments, the pace of NMF production increases. This acclimation process typically occurs over the course of several days[11] and cannot yet be regulated artificially via products or procedures.

Hyaluronic acid (HA), which can bind 1000 times its weight in water, is another substance found in the skin that

COSMETICS AND SKIN CARE AT A GLANCE

- Nonmedical skin care and cosmetic use of over-the-counter products represent major growth areas among consumers.
- Understanding variations in skin types using a new system of classification facilitates patient section of over the counter products.
- Cosmetics and skin care products can be a source of a range of adverse reactions, including irritation and allergy.



Copyright © 2008 by The McGraw-Hill Companies, Inc. Click here for terms of use.

may help it retain and maintain water. HA is produced mainly by fibroblasts and keratinocytes in the skin, and has an estimated turnover rate of 2.0 to 4.5 days in mammalians.[12] HA is localized not only in the dermis but also in the epidermal intercellular spaces, especially the middle spinous layer, but not in the SC or stratum granulosum.[13] Aged skin, which is less plump than youthful skin, is characterized by decreased levels of HA. The role of HA in skin hydration is not clear, and HA does not penetrate the skin upon topical application[14]; however, this has not stopped many companies from putting HA in topical skin care products and claiming efficacy.

Aquaporin-3 (AQP3) is a member of a family of homologous aquaporin water channels that facilitate fluid transport. Other aquaporins in this family are well known to play a role of water transport in kidney and lung epithelia. AQP3 is a member of a subclass of aquaporins called aquaglyceroporins, which transport not only water but also glycerol and possibly other small solutes. AQP3 was recently found to be expressed at the plasma membrane of epidermal keratinocytes in human skin (Fig. 251-1).[15] Pharmacologic manipulation of AQP3 may be used in the future to treat skin disorders of excess and decreased hydration. At this time, only *Ajuga turkestanica* extract has been shown to play a role in regulating AQP3.[22] *A. turkestanica* is found as an ingredient in a high-end line of skin care products.

Sebum production may also be a factor in the pathogenesis of xerosis. The oily secretion of the sebaceous glands contains wax esters, sterol esters, cholesterol, di- and triglycerides, and squalene,[23] and is thought to confer protection to the skin from environmental influences and, when production is decreased, play a part in dry skin (see Chap. 77).[24] In normal skin, sebaceous gland–derived triglycerides are hydrolyzed to glycerol before delivery to the skin surface. Replacing this glycerol in sebum-deficient skin may be a way to decrease skin dryness in sebum-deficient individuals. Glycerol has also been shown to be effective in accelerating barrier recovery.[32]

Patients rarely complain about decreased sebum production. However, it seems certain that sebum production plays a role in dry skin. For example, prepubertal children (> 2 years and < 9 years) commonly display eczematous patches (pityriasis alba) on the face and trunk that disappear coincidentally with the onset of sebaceous gland activation. Conversely, increased sebum production, which results in oily skin that can lead to acne, is a common complaint. It is well understood that an age-related change is seen in sebaceous gland activity, with levels typically low during childhood, rising in the mid- to late teens, and generally remaining stable for decades until trailing off in the seventh and eighth decades as endogenous androgen production declines.[33] The level of sebum production is also influenced by diet, stress, hormone production, and, to a degree, genetics. In a study of 20 pairs each of identical and non-identical like-sex twins, the identical twins exhibited essentially the same sebum excretion rates, with significantly divergent acne severity, whereas the non-identical twins differed significantly according to both parameters, implying both the genetic influence of sebum and the mediation of exogenous factors in lesion development.[34]

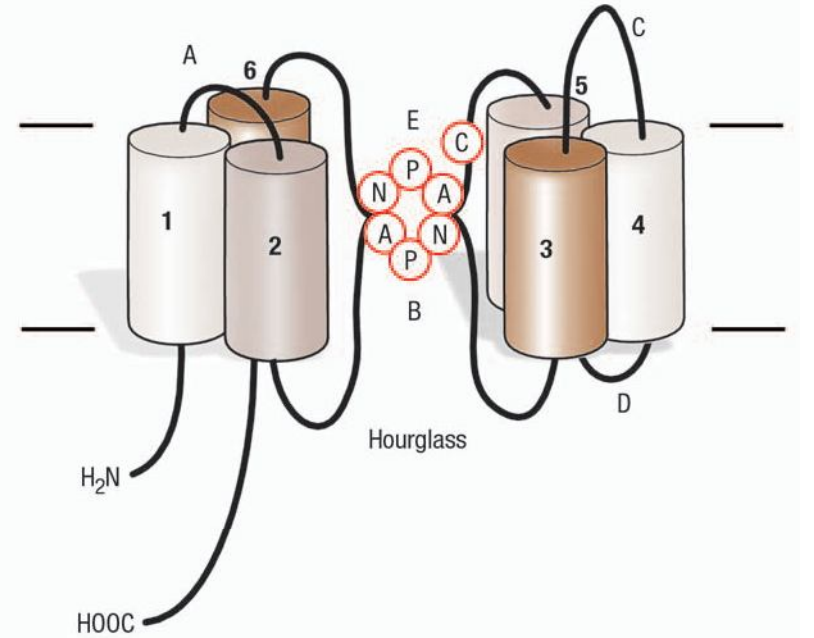

▲ **FIGURE 251-1** Hourglass model for aquaporin-1 membrane topology. Each aquaporin-1 subunit contains six bilayer-spanning domains composed of two obversely symmetric structures (TM1–3, hemipore 1; and TM4–6, hemipore 2). When NPA [formed by amino acids asparagine (N), proline (P), and alanine (A)] motifs in loops B and E are juxtaposed, they form a single aqueous channel spanning the bilayer (the "hourglass") flanked by the mercury-sensitive residue (C189). (Redrawn with permission from the Annual Review of Biochemistry, Volume 68 © 1999 by Annual Reviews, http://www.annualreviews.org.)

Skin Care for the Oily-Dry Parameter

In the context of the oily-dry parameter, ideal skin is typically characterized by an intact SC with an intact barrier, sufficient NMF levels, normal levels of HA, normal expression of AQP3, and balanced sebum secretion. In skin that falls on the oily side of the equation, increased sebum secretion is usually the culprit. This may or may not be accompanied by acne. If acne is a concern, then the patient would also fall into the sensitive skin category and would be labeled as an oily-sensitive skin type. The skin care treatments would focus on decreasing sebum with retinoids, decreasing skin bacteria with antibiotics, benzoyl peroxide, or other antimicrobials, and adding anti-inflammatory ingredients. If acne is not a problem, the individual would be labeled as an oily-resistant skin type. The skin care would focus only on decreasing sebum production unless other parameters such as dyspigmentation and wrinkling were factors. Oral ketoconazole[35] and oral retinoids[36] have been shown to decrease sebum secretion, but this has not been shown with topical agents. Sebum-absorbing polymers and talcs are also useful to camouflage unwanted sebum in these types.

In skin that falls on the dry side of the equation, one must decide which factors are contributing to the dry skin. Clues can be derived by looking at the other skin parameters. If a patient is dry and sensitive, it is likely that the skin barrier is impaired, and care should be taken to use products that repair the skin barrier,

such as those that contain fatty acids, cholesterol, ceramides, and glycerol. If the skin is photodamaged and the skin is wrinkled as a result, decreased HA likely plays a role. Topically applied HA is not absorbed, so using skin care products with HA is not helpful; however, studies have suggested that glucosamine supplements may help increase HA levels.[37] One small single-blind study showed improvement of wrinkles but no change in skin hydration, so the role of glucosamine is unclear.[38] Dry skin that endures ongoing sun exposure likely suffers from an impaired skin barrier and decreased levels of NMF. At this time, there are no products that increase NMF, so skin care should focus on repairing the skin barrier and providing adequate sun protection.

All patients with dry skin are advised to avoid harsh foaming detergents that remove hydrating lipids and NMF from the skin. These detergents are found in laundry and dish cleansers in addition to body and facial cleansers. All dry skin patients should also abstain from taking protracted baths, particularly in hot or chlorinated water. In addition, people with very dry skin are advised to use humidifiers in low-humidity environments and apply moisturizers two to three times a day and after bathing.

In addition to targeting the causes of dry skin, there are many moisturizers on the market that help hydrate the skin in a more basic or generic manner. These products can be categorized as occlusives, humectants, or emollients (Table 251-1).

TABLE 251-1
Types of Ingredients in Moisturizers for Topical Skin Care

- Barrier repair
  - Ceramides
  - Cholesterol
  - Fatty acids
- Occlusives
  - Petrolatum
  - Mineral oil
  - Paraffin
  - Squalene
  - Dimethicone
  - Soybean oil
  - Grapeseed oil
  - Propylene glycol
  - Lanolin
  - Beeswax
- Humectants
  - α-Hydroxy acids
  - Glycerin
  - Hyaluronic acid
  - Propylene glycol
  - Sodium hyaluronate
  - Sorbitol
  - Sugars
  - Urea

OCCLUSIVES Occlusives coat the SC to retard TEWL. An occlusive provides an emollient effect as well as decreases TEWL. The best occlusive ingredients currently available are petrolatum and mineral oil. Petrolatum, for example, has a water vapor loss resistance 170 times that of olive oil.[39] However, petrolatum has a greasy feeling that may make agents containing it cosmetically unacceptable. Other commonly used occlusive ingredients include paraffin, squalene, dimethicone, soybean oil, grapeseed oil, propylene glycol, lanolin, and beeswax.[40] These agents are only effective while present on the skin; once removed, the TEWL returns to the previous level. Interestingly, it is not desirable to decrease TEWL by more than 40 percent because maceration with increased levels of bacteria can result.[41] Therefore, occlusives are usually combined with humectant ingredients.

HUMECTANTS Humectants are water-soluble materials with high water absorption capabilities. They are able to attract water from the atmosphere (if atmospheric humidity is greater than 80 percent) and from the underlying epidermis. Although humectants may draw water from the environment to help hydrate the skin, in low-humidity conditions, they may absorb water from the deeper epidermis and dermis, resulting in increased skin dryness.[42] For this reason, they are more effective when combined with occlusives. Humectants are also popular additives to cosmetic moisturizers because they prevent product evaporation and thickening, which increases the shelf-life of products. Some humectants have bacteriostatic activity as well.[43] Humectants draw water into the skin, causing a slight swelling of the SC that gives the perception of smoother skin with fewer wrinkles. Examples of commonly used humectants include glycerin, sorbitol, sodium hyaluronate, urea, propylene glycol, α-hydroxy acids, and sugars.

EMOLLIENTS Emollients are substances added to cosmetics to soften and smooth the skin. They function by filling the spaces between desquamating corneocytes to create a smooth surface.[44] These products provide increased cohesion, causing a flattening of the curled edges of the individual corneocytes.[45] This leads to a smoother surface with less friction and greater light refraction. Many emollients function as humectants and occlusive moisturizers as well. Lanolin, mineral oil, and petrolatum are examples of occlusive ingredients that also confer an emollient effect.

SKIN SENSITIVITY AND COSMETIC INTOLERANCE SYNDROME

Sensitive versus Resistant

Sensitive skin is much more challenging to describe than resistant skin. The latter is characterized by a strong SC that confers potent protection on the skin, shielding it from allergens and irritating substances. As the term implies, resistant skin rarely exhibits erythema (unless over-exposed to the sun) or acne (unless it is so affected due to stress or hormonal fluctuations). People with resistant skin can use most skin care products without fear of developing an adverse reaction such as a rash, acne, or a stinging sensation. The disadvantages of such skin include an inability to detect different effects among cosmetic products and, more important, having too high a threshold for penetration, so that most products are not likely to cross the SC and impart beneficial changes.

The concept and presentation of sensitive skin is much more complex. More than 40 percent of people presenting to a dermatologist report having sensitive skin.[46] Healthy women of child-bearing age comprise the majority of people who complain of this type of skin. With increasing age, the incidence of sensitive skin appears to decline. There are numerous cosmetic products available on the market that are marketed for sensitive skin. However, sensitive skin itself is a relatively complex dermatologic phenomenon.

Cosmetic intolerance syndrome is not a single entity but, rather, a symptom complex of multiple exogenous and endogenous factors, representing an extreme of the continuum of patients who complain of sensitive skin. The syndrome is an uncommon clinical entity in which patients complain bitterly of facial burning and discomfort associated with application of most skin care products. Their skin may show overt inflammatory changes, or symptoms may be only subjective. These patients seriously challenge practitioners' empathy and diagnostic skills because the severity of



symptoms does not match objective signs of disease. Many patients affected with this syndrome have tried numerous cosmetics and topical medications.

Fisher[47] coined the term *status cosmeticus* for the condition in which patients no longer tolerate use of any facial cosmetic product. Some of these patients initially experience subjective or objective irritation in response to use of cosmetics and become intolerant to many other topical agents during the evolution of this disorder. Other patients have occult allergic contact dermatitis, allergic photocontact dermatitis, contact urticarial reaction, or a combination of these conditions. In this group, causal agents can be documented by careful clinical review and patch testing.

Strictly observing a prolonged program of eliminating cosmetics is an important therapeutic intervention. Some patients are able to return gradually to using other cosmetics after 6 to 12 months. Subsequent additions to the skin care regimen can be made one at a time every 2 weeks. For the final regimen, the number of cosmetics and frequency of their use should remain limited.

Other patients experience facial burning continuously, without showing objective signs. Cotterill[48] described these patients as having "dermatologic nondisease." Many of these patients have a disturbed body image or dysmorphobia—that is, they complain of physical defects that lack objective evidence. Many are depressed and need psychiatric help, which they frequently reject.

Sensitive skin covers the same range of pathophysiology as the cosmetic intolerance syndrome, but it is generally less severe. The largest segment of these consumers manifests sensory skin irritation.

Indeed, there are four very distinct variations of sensitive skin: acne type (prone to developing acne, black heads, or white heads); rosacea type (featuring a tendency toward recurrent flushing, facial redness, and experiencing hot sensations); stinging type (predilection to stinging or burning sensations); and allergic type (prone to exhibit erythema, pruritus, and skin flaking).

Each of these sub-types of sensitive skin presents a unique challenge to the practitioner regarding appropriate treatment and recommendations for over-the-counter cosmetic skin care products. The common process among these four sub-types is inflammation. Therefore, treatments for any kind of sensitive skin should focus on reducing and eliminating inflammation. Treatment can be further complicated when a patient exhibits a proclivity towards more than one sensitive skin sub-type.

Acne Type (See Chap. 78)

Some skin and hair care cosmetics cause acneiform eruptions. Acnegenicity encompasses both comedogenicity, which refers to follicular keratin impaction,[51] and papulopustular formation. The time course for the appearance of facial papulopustules and comedones is different: papulopustules may appear in just a few days, whereas the appearance of comedones is delayed. Considerable confusion derives from the testing techniques: for example, isopropyl myristate in concentrations as low as 10 percent in petrolatum rapidly induces comedones in the rabbit ear but yields papulopustules in humans. Even common emulsifiers, such as sodium lauryl sulfate, produce pustules in a dose-related manner. The mechanisms appear to be related in spite of varied morphology. The European Community's proposed ban on animal testing of final products will result in stronger reliance on human testing, whether this takes the form of use tests or application of a cosmetic under occlusion to the back for 4 weeks and subsequent cyanoacrylate or cationic polymer biopsies (to identify microcomedones), or both.

The clinical significance of cosmetics in precipitating post-adolescent acne in women was recently called into question by one of the authors of the original paper on "acne cosmetica."[52,53] Consequently, it is best to advise female acne patients to keep their cosmetic regimen simple and gentle, using products from manufacturers who test for acnegenicity.

Rosacea Type (See Chap. 79)

Typically afflicting adults between 25 and 60 years of age, rosacea affects tens of millions of Americans. Like acne, this condition is characterized by facial redness, flushing, and papules, but it is also distinguished by the formation of prominent telangiectasias. Topical skin care for rosacea is primarily geared toward preventing exacerbation of the condition and using anti-inflammatory ingredients to decrease inflammation. Ingredients with anti-inflammatory activity include feverfew, sulfur, zinc, sulfacetamide, quadrinone, niacinamide, licorice extract, cucumber extract, aloe vera, colloidal oatmeal, and chamomile (Table 251-2).

TABLE 251-2
Anti-Inflammatory Products for Topical Skin Care (Over-the-Counter)

- Licorice extract
- Licochalone
- Quadrinone
- Cucumber
- Aloe vera
- Chamomile
- Colloidal oatmeal
- Arnica
- Feverfew (has anti-inflammatory and antioxidant capabilities)
- Niacinamide (also known as *nicotinamide*)
- Salicylic acid
- Zinc
- Witch hazel

Stinging Type

Burning, stinging, or itching caused by application of a cosmetic or topical medicament without detectable visible or microscopic change is termed *sensory irritation*. The afferent limb of this reaction is carried by C nerve fibers that are present throughout the dermis and viable epidermis. The stinging occurs on the face within 1 hour of application in susceptible individuals. In a segment of the population, this sensory response is caused by many ingredients at dosages that do not produce clinical, objective irritation. Nonallergic stinging is a phenomenon that a discrete subset of people experience in response to certain triggers. Some patients may indeed be more sensitive than others and are referred to as *stingers* by dermatologists. Stingers do not have a higher incidence of atopy or dry skin but do report frequent adverse reactions to cosmetics. Strontium nitrate and chloride inhibit sensory irritation caused by α-hydroxy acids, ascorbic acid, and aluminum salts.[54] These blockers are being incorporated into skin care products such as those containing α-hydroxy acids.

Several tests have been devised to identify stingers or the stinging propensity. The lactic acid stinging test is a widely accepted method for evaluating individuals who report invisible and subjective cutaneous irritation. In an early study, Frosch and Kligman applied 5 percent lactic acid to subjects' nasolabial folds during profuse sweating, which resulted in 20 percent of participants reporting an unpleasant sensation. In a similar study in which lactic acid (10 percent) was applied to nasolabial folds, Seidenari et al. ob-

served that individuals with "sensitive skin" experienced a much stronger stinging sensation than those in the healthy control group. The stinging sensation is not necessarily associated with erythema, as many patients feel stinging without experiencing redness or irritation.[55] However, patients with rosacea distinguished by facial flushing are more susceptible to stinging from lactic acid exposure. It is recommended that patients with the stinging sub-type of sensitive skin avoid products that contain the following ingredients: α-hydroxy acids (particularly glycolic acid), benzoic acid, bronopol, cinnamic acid compounds, Dowicel 200, formaldehyde, lactic acid, propylene glycol, quaternary ammonium compounds, sodium lauryl sulfate, sorbic acid, urea, or vitamin C.

Allergic Type

According to the findings of a recent epidemiologic survey in the United Kingdom, over the course of 1 year, 23 percent of women and 13.8 percent of men experience an adverse reaction to a personal care product (e.g., deodorants and perfumes, skin care products, hair care products, and nail cosmetics).[56] To identify allergies to cosmetic ingredients, patch testing can be performed. Various studies reveal that approximately 10 percent of patch-tested dermatologic patients are allergic to at least one ingredient common in cosmetic products.[56] About 80 percent of reactions occur in patients aged 20 to 60 years old, with the majority seen most often in women.[57] Fragrances and preservatives are the most common allergens. Individuals who use several skin care products with a commensurately high number of ingredients are more likely to develop allergies to ingredients, simply due to such over-exposure. Patients with an impaired SC, manifested by xerosis (the dry skin type), are likely to have an increased incidence of allergic reactions to allergens placed on the skin.[58]

SKIN IRRITATION AND ALLERGY DUE TO COSMETICS AND SKIN CARE PRODUCTS

Skin irritation is defined as localized inflammation that is not mediated through the immune system and is caused by endogenous and environmental factors. Hair straighteners, permanents, and depilatories can cause acute reactions if directions for their safe use are not strictly followed. Cleansers are frequently responsible for causing irritant dermatitis. Moisturizers or emollient creams, in which water and oleaceous materials are blended, contain surfactants and emulsifiers that are often mild irritants. When these cosmetics are applied to the face or to dry or eczematous skin, where the SC is a less efficient barrier, irritant reactions may result. Morphologic features include scaling, which may rapidly clear with avoidance of exposure but becomes erythematous with recurrent dosing and may evolve into chronic irritant dermatitis. Some cosmetics produce irritation only after repeated application; this phenomenon is termed *cumulative irritation*. Friction, injury, and mechanical irritation can be caused by popular cosmetics containing granules or by devices (e.g., synthetic sponges) used to exfoliate the skin (Table 251-3).

TABLE 251-3
Diagnosis and Treatment of Patients Whose Skin Is Intolerant to Cosmetics

- Examine every cosmetic and skin care product.
- Administer patch and photo-patch test to rule out occult allergic and photoallergic dermatitis.
- Test for contact urticaria.
- Do careful repeat open application testing.
- Treat endogenous inflammatory disease.
- Limit skin care to
  - Water washing without soap or detergent
  - Lip cosmetics as desired, if lips are clear
  - Eye cosmetics as desired if eyelids are asymptomatic
  - Face powder
  - Glycerin and rose water as a moisturizer, if necessary
  - Avoiding other cosmetics for 6–12 mo

Sensitive bioengineering techniques used to evaluate the pathophysiology of irritation include TEWL, skin impedance, conductance resistance, and blood flow velocity.[59] By using predictive testing in animals and humans, manufacturers can recognize strong or moderate irritant ingredients or products. In pre-market testing, mild irritants are more difficult to detect and quantify.

Bergamot oil (5-methoxypsoralen) is a phototoxic fragrance ingredient that was used in cosmetics but has been removed. As interest in "natural" ingredients increases,[60] new phototoxins may be inadvertently introduced and have serious consequences when they are not recognized clinically.

OTHER SKIN REACTIONS DUE TO COSMETICS

Contact Urticaria Syndrome (See Chap. 37)

Contact urticaria syndrome typically consists of a wheal-and-flare response developing within 30 to 60 minutes after the skin is exposed to certain agents. Symptoms range from the mildest manifestations (e.g., itching, tingling, burning, and erythema) to the most severe (e.g., anaphylaxis and death). Diagnosis of immediate contact urticaria is based on a thorough medical history (including notation of burn, sting, or itch resulting from skin contact, urticaria, or respiratory symptoms) and skin testing using suspected substances.[61]

Delayed Hypersensitivity Reactions (See Chap. 13)

Adverse reactions to cosmetics constitute a small but significant portion of contact dermatitis cases treated by dermatologists. In a study conducted by the North American Contact Dermatitis Group, patch testing showed contact dermatitis related to cosmetics in 5 percent of more than 13,000 patients evaluated.[63] Similar percentages have been reported from Europe.[61] These figures underestimate the total number of cases because most mild reactions are not investigated by dermatologists. In the North American Contact Dermatitis Group study, 59 percent of the cosmetic-induced reactions occurred on the face, and 79 percent were seen in women, but a relation to cosmetics was suspected by the dermatologist or patient initially in fewer than one-half of the cases. Diagnosis of allergic contact dermatitis is based on a compatible history and examination, supported by results of patch testing. Most cosmetics are not strong irritants and can be patch tested closed in the usual manner; however, notable exceptions exist. Weakly positive reactions should be confirmed by medical history, test repetition, and patch testing of ingredients. Ingredient testing is a problem in the United States because of the limited number of chemicals available on the T.R.U.E. (thin-layer rapid use epicutaneous) test screening tray. It is important to recognize which of these allergens are found in cosmetics. Cosmetic Industry on Call[64] provides information for contacting manufacturers who may provide ingredients for patch testing. De Groot et



al.[65] provide reference information on chemical concentrations and vehicles to use in testing cosmetic ingredients.

The provocative use test, also called the *repeat open application test*,[66] is a practical way to screen for allergy to cosmetics including fragrances[67] or to confirm the clinical significance of weak positive reactions. The cosmetic is applied twice daily for up to 4 weeks to an approximately 5-cm area on the flexor surface of the forearm near the cubital fossa.

Most photoallergic ingredients in cosmetics are sunscreening agents or fragrances. To test for photoallergy, the patch site is exposed to between 5 and 10 J of ultraviolet (UV) A 24 hours after application; after 48 hours, the photopatch site is compared with a nonirradiated site similarly patch tested.

Most allergic reactions to cosmetics are caused by fragrances, preservatives, and a small number of miscellaneous ingredients. Familiarity with these allergens will enable clinicians to diagnose many of these cases accurately (see Table 251-3).

SKIN REACTIONS DUE TO FRAGRANCES

Fragrance allergy is common, affecting approximately 1 percent of the general population; dermatitis may develop on the face, neck, hands, and axillae, or it may be generalized.[68]

Fragrances are ubiquitous: in addition to cosmetics and toiletries, they are added to household goods or cleansers in the workplace, and some are used as flavorings. Paradoxically, "unscented" cosmetics may contain a masking fragrance. A new method of promoting fragrances is to claim that scents have mood-altering effects—so-called *aromatherapy*. Inevitably, troublesome sensitization has occurred in consumers who have doused themselves and their surroundings with fragrance. Since 1966, toxicologic information related to fragrance ingredients has been assembled and assessed by the industry-sponsored Research Institute for Fragrance Materials.[69] Based on this information, the International Fragrance Association publishes guidelines that industry members generally agree to follow.

Photosensitization (see Chap. 91) occurred more commonly before methyl coumarin and musk ambrette were eliminated from fragrances. Sensitization to musk ambrette left an extensive legacy of so-called *persistent light eruptions*. Because fragrance allergy is frequently not suspected by either the patient or the physician, patch testing is an important tool for reaching this diagnosis. Balsam of Peru, cinnamal, fragrance mix, and colophony are recognized markers for fragrance allergy on patch-test screening series. At present, the fragrance mix (marketed by Hermal and by Chemotechnique and also marketed in the T.R.U.E. test) contains eight ingredients: eugenol, isoeugenol, oak moss absolute, geraniol, cinnamal, α-amyl cinnamic aldehyde, hydroxycitronellal, and cinnamic alcohol. In an international study of 165 patients with probable fragrance allergy, the fragrance mix detected 86 percent of positive reactions. Addition of ylang-ylang oil, narcissus oil, sandalwood oil, and balsam of Peru raised this percentage to 96 percent. Racial and geographic distinctions exist; for instance, Japanese patients tested were more frequently reactive to benzyl salicylate. Such racial differences were highlighted by the epidemic of bizarre facial hyperpigmentation seen in Japanese women in the 1960s and 1970s caused by allergy to fragrances and coal-tar dyes used in some cosmetics; elimination of these allergens solved the problem.

Allergy to fragrance can be tested by using the repeat open application test for up to 4 weeks. Balsams, cinnamic alcohol, cinnamaldehyde, benzyl alcohol, and benzaldehyde are among the fragrance ingredients that can evoke contact urticaria not detected by closed patch testing.

SKIN REACTIONS DUE TO PRESERVATIVES

Preservatives are added to prevent contamination of cosmetics by microorganisms, which degrade the product or cause infection in consumers; however, the term *preservative* may encompass agents that prevent degradation induced by oxidation or UV light. Approximately 60 chemicals are commonly used as preservatives in cosmetics. Preservatives may consist of a single ingredient or a mixture of ingredients (e.g., Euxyl 400 is a mixture of methyldibromoglutaronitrile and phenoxyethanol). Use of specific preservatives varies among American, European, and Asian markets; consequently, incidence of allergic reactions to individual agents also varies. Adverse reactions have prompted development of preservative-free cosmetics. Strategies for developing such products include modification of the manufacturing and packaging processes as well as use of botanicals, which have antimicrobial activity. The increasing complexity of cosmetics and their vehicles makes this goal even more difficult to achieve.

Paraben esters, the most popular group of preservatives, are effective against fungi and Gram-positive (but not Gram-negative) bacteria. Parabens rarely sensitize but may do so when applied to eczematous skin. Sensitized patients frequently tolerate parabens in cosmetics applied to normal skin.

Propylene glycol, a popular solvent and humectant, has antimicrobial properties but is used in some "preservative-free" cosmetics. Review of the literature and observations in patch-tested patients suggest that propylene glycol is a mild irritant that only occasionally sensitizes.[70]

Formaldehyde and formaldehyde releasers are widely used as preservatives.[71] Formaldehyde is formulated in wash-off products such as shampoos. Quaternium-15, imidazolidinyl urea, diazolidinyl urea, DMDM hydantoin, and 3-bromo-2-nitropropane-1-3-diol are commonly used preservatives that release formaldehyde. They may sensitize themselves or cause reactions secondary to formaldehyde release in formaldehyde-sensitive patients, and cross-reactions in the group are reported. Patients' tolerance of products containing preservatives to which they are sensitive is modified by the site of application and their degree of sensitivity. For example, some formaldehyde-sensitive individuals can tolerate low levels of formaldehyde releasers on normal skin.

A mixture of methyldibromoglutaronitrile and phenoxyethanol (Euxyl 400), used initially in Europe, has gained popularity and is being reported more frequently as an allergen.[72] Butylated hydroxyanisole, butylated hydroxytoluene, tocopherol, propyl gallate, and t-butyl hydroquinone used as antioxidants are sometimes reported as allergens. Other ingredients reported frequently as allergens in cosmetics include paraphenylenediamine, toluene sulfonamide/formaldehyde resin (tolysamide/formaldehyde resin), acrylates, lanolin, glyceryl thioglycolate, and UV light-absorbing agents (Table 251-4).

SKIN PIGMENTATION

Pigmented versus Non-Pigmented

The third primary skin characterization parameter gauges the tendency to develop unwanted hyperpigmentation or dyschromia on the face or chest. For the purposes of describing a skin type to a patient and assisting the individual in selecting appropriate skin care products, the focus should be on the pig-

TABLE 251-4
Frequently Identified Cosmetic Ingredients Causing Allergic Contact Dermatitis: North American Contact Dermatitis Group Study

- Paraphenylenediamine
- Lanolin and derivatives
- Glyceryl thioglycolate
- Propylene glycol
- Toluene sulfonamide/formaldehyde resin
- Sunscreens and other ultraviolet absorbers
- Methacrylates

Adapted and reproduced by permission of the authors and publisher from Adams RM, Maibach HI: A five-year study of cosmetic reactions. *J Am Acad Dermatol* **13**:1062, 1985.

mentary changes that can be improved with skin care products rather than surgery. For example, skin care products can be used to prevent or treat conditions such as melasma, solar lentigos, and ephelides. Patients with these concerns would be called pigmented types.

Two primary mechanisms can be used to impede the development of skin pigmentation: inhibiting tyrosinase, which prevents melanin formation, and preventing melanosome transfer into keratinocytes. Tyrosinase inhibitors include vitamin C, hydroquinone, kojic acid, arbutin, mulberry extract, and licorice extract (Table 251-5).

Small proteins found in soy, such as soybean trypsin inhibitor and Bowman-Birk Inhibitor, have been suggested to inhibit skin pigmentation. These soy proteins were found not only to have depigmenting activity, but also to prevent UV-induced pigmentation both in vitro and in vivo.[75] According to Paine et al., these soy proteins were found to exert their effect via the inhibition of the cleavage of protease-activated receptor 2. Protease-activated receptor 2 is a seven transmembrane G-protein coupled receptor that is activated by a serine protease cleavage. It is expressed in keratinocytes but not in melanocytes. By inhibiting this cleavage, soybean trypsin inhibitor and Bowman-Birk Inhibitor are believed to affect melanosome transfer into keratinocytes and, thus, pigmentation. Niacinamide, a derivative of vitamin B_3, has also been shown to inhibit melanosome movement form melanocytes to keratinocytes.[76]

TABLE 251-5
Cosmeceuticals That May Be Effective in Pigmentation

- Arbutin
- Hydroquinone
- Kojic acid
- Licorice extract
- Mulberry extract
- Niacinamide
- Pycnogenol
- Retinol
- Soy
- Vitamin C

Ultraviolet Radiation and Skin Color

Melanogenesis results from the exposure of skin to UV radiation and serves as the skin's major defense against further UV damage. Melanocyte cells increase the production of melanin, melanocyte transfer from melanosomes to keratinocytes is increased,[77] and this process manifests in exogenous skin darkening. Sun avoidance is the most effective method of preventing pigmentary changes; thus, broad-spectrum sunscreens are an important component of any skin care regimen geared at reducing hyperpigmentation.

SKIN AGING: WRINKLED VERSUS TIGHT (See Chap. 108)

Aging of the skin is a complex phenomenon reflecting natural intrinsic and extrinsic processes. Intrinsic aging is a function of individual heredity and results from the passage of time. This process is, of course, inevitable and beyond voluntary control.

Exogenous factors, such as smoking, poor nutrition, and sun exposure, are at the root of extrinsic aging. This process is not inevitable and reflects premature skin aging. In fact, 80 percent of facial aging is believed to be due to solar exposure.[80] Exposure to UV irradiation, by dint of its damaging effect on DNA and its acceleration of telomere shortening, also can be said to influence intrinsic aging. In addition, UV exposure results in skin damage through several mechanisms, including sunburn cell formation, creation of thymine dimers, collagenase production, and provoking an inflammatory response. Signaling through p53 after telomere disruption is also a common feature observed in aging as well as photodamage.[81] Although much remains to be learned about the mechanisms through which UV irradiation unleashes a chain of cascading health effects, photoaging, photocarcinogenesis, and photo-immunosuppression are well-known results of UV exposure.[82]

The most obvious manifestation of aging skin is the development of rhytides. Wrinkles are caused by changes in the dermis. Although consumers spend millions of dollars on "antiaging" skin care products, few skin care product ingredients can penetrate far enough into the dermis to affect deep wrinkles. The dermatologic focus of antiaging skin care should be to prevent the formation of rhytides in the first place.[83] To this end, the goal is to halt the degradation of the three main structural components of the skin—collagen, elastin, and HA—all of which are known to be diminished in aged skin. Because inflammation can contribute to the breakdown of these key skin constituents, one focus must be to reduce inflammation. Kang et al. have shown that free radical activation of the mitogen-activated protein kinase pathways results in production of collagenase, which leads to degradation of collagen.[85] Blocking this pathway with antioxidants is thought to prevent photoaging by preventing the production of collagenase. Research supporting this theory was performed on human skin by Kang. In this study, he showed that when human skin was pre-treated with the antioxidants genistein and *N*-acetylcysteine, UV induction of the c-jun–driven enzyme collagenase was blocked. Many antioxidants are available in skin care products including vitamin C, vitamin E, ferulic acid, coenzyme Q10, green tea, Pycnogenol, silymarin, and idebenone.

Most antiaging products and procedures are geared to salvage collagen, elastin, and HA. However, products containing collagen, elastin, or HA are ineffective; they cannot effectively penetrate the epidermis. Although there are no products that can replenish these important skin structures, there are some products that stimulate production of these components. Collagen synthesis has been shown to be increased through the use of retinoids,[86] vitamin C,[87] and copper peptide. Retinoids have also been demonstrated in animal models to increase production of HA[88] and elastin.[89] Oral vitamin C is also believed to have the capacity to increase collagen synthesis[90] and, again, glucosamine supplementation may augment HA levels.[91] In the future, it is likely that the potential of growth factors, cytokines, and telomerase will be harnessed through advances in tissue engineering and gene therapy.[92] In the meantime, using sunscreen, avoiding exposure to the sun, cigarette smoke, and pollution, taking oral antioxidant supplements or topical anti-



TABLE 251-6
Baumann Skin Type Determined by the Baumann Skin Type Indicator

	Oily, Pigmented	Oily, Non-Pigmented	Dry, Pigmented	Dry, Non-Pigmented	Sensitive or Resistant
Wrinkled	OSPW	OSNW	DSPW	DSNW	Sensitive
Tight	OSPT	OSNT	DSPT	DSNT	Sensitive
Wrinkled	ORPW	ORNW	DRPW	DRNW	Resistant
Tight	ORPT	ORNT	DRPT	DRNT	Resistant

D = dry; N = non-pigmented; O = oily; P = pigmented; R = resistant; S = sensitive; T = tight (unwrinkled); W = wrinkled.

oxidant formulations, and eating a diet high in fruits and vegetables can help reduce or prevent skin aging. Regularly using prescription retinoids can also help treat and prevent unwanted wrinkles.



COMBINATIONS OF SKIN TYPES

The four skin parameters can be combined to form 16 skin types (Table 251-6). Using this typing system will help consumers focus on their problem areas. For example, an oily, sensitive, non-pigmented, wrinkled person would use products with retinoids and antioxidants, whereas a dry, sensitive, non-pigmented, tight person would use products with barrier repair ingredients. Certain skin problems are more typically associated with particular skin combinations: pigmented, wrinkled skin is more likely exhibited by a person with a significant history of sun exposure manifested by wrinkles and solar lentigos. Eczema is more often observed in dry, sensitive types. Acne is most common among oily, sensitive types. Oily, sensitive, non-pigmented, wrinkled types with lighter skin are most prone to develop rosacea. Light skin is more common among non-pigmented, wrinkled types; dark skin is more common among pigmented, tight types.

CONCLUSION

For the purposes of optimal treatment and cosmetic selection, a classification of skin types that defines four different polarities is suggested: dry or oily; sensitive or resistant; pigmented or non-pigmented; and wrinkled or unwrinkled. Characterizing a patient's skin based on all the permutations and combinations of these skin types (see Table 251-6) can facilitate treatment by physicians and help patients select the most appropriate over-the-counter skin formulations.

KEY REFERENCES

The full reference list for all chapters is available at www.digm7.com.

3. Baumann L: *The Skin Type Solution*. New York, Bantam Dell, 2006
12. Tammi R et al: Degradation of newly synthesized high molecular mass hyaluronan in the epidermal and dermal compartments of human skin in organ culture. *J Invest Dermatol* **97**:126, 1991
14. Rieger M: Hyaluronic acid in cosmetics. *Cosm Toil* **113**:35, 1998
16. Takenouchi M, Suzuki H, Tagami H: Hydration characteristics of pathologic stratum corneum—Evaluation of bound water. *J Invest Dermatol* **87**:574, 1986
24. Clarys P, Barel A: Quantitative evaluation of skin surface lipids. *Clin Dermatol* **13**:307, 1995
27. Geiger JM: Retinoids and sebaceous gland activity. *Dermatology* **191**:305, 1995
37. Matheson AJ, Perry CM: Glucosamine: A review of its use in the management of osteoarthritis. *Drugs Aging* **20**:1041, 2003
40. Draelos Z. Moisturizers, in *Atlas of Cosmetic Dermatology,* by Draelos Z. New York, Churchill Livingstone, 2000, p 83
54. Hahn GS: Anti-irritants for sensory irritation, in *Handbook of Cosmetic Science and Technology*, edited by AO, Paye M, Maibach HI. New York, Marcel Dekker, 2001, p 285
60. Levin C, Maibach H: Exploration of "alternative" and "natural" drugs in dermatology. *Arch Dermatol* **138**:207, 2002

CHAPTER 252

Skin Resurfacing: Ablative Lasers, Chemical Peels, and Dermabrasion

Elizabeth L. Tanzi
Tina S. Alster

Years of damaging ultraviolet light exposure manifest clinically as a sallow complexion with roughened surface texture and variable degrees of skin dyspigmentation, telangiectasias, wrinkling, and laxity (see Chap. 108).[1,2] Histologically, these extrinsic aging effects are usually limited to the epidermis and upper papillary dermis and, thus, are amenable to treatment with a variety of ablative and non-ablative lasers, chemical peeling agents, and dermabrasion. Although dermabrasion had been used in the past to wound the skin and thus stimulate the production of new collagen, which is a common approach to skin rejuvenation, the advent of lasers and chemical peeling agents has vastly expanded and advanced the options for the treatment of cutaneous photodamage. Which treatment technique is most appropriate depends on the severity of the photodamage and the rhytides, the expertise of the dermasurgeon, and the expectations and lifestyle of the individual patient. Non-ablative laser procedures are discussed in Chap. 253.

ABLATIVE LASER SKIN RESURFACING

Patient Selection

The ideal patient for ablative cutaneous laser resurfacing has a fair complexion

SKIN RESURFACING AT A GLANCE



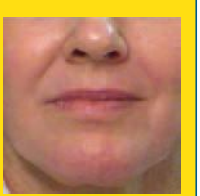

- Several approaches are available for the rejuvenation of photodamaged skin.
- The most common approaches are ablative and non-ablative laser resurfacing and chemical peels.
- Selection of the appropriate technique requires that patient factors as well as the risks and benefits of the procedure be weighed.

TABLE 252-1
Ablative Laser Skin Resurfacing: Patient Selection, Risks, and Precautions

- Are the lesions amenable to cutaneous ablative laser resurfacing? All suspicious lesions require biopsy before treatment.
- Has the patient ever had the areas treated before? Ablative laser resurfacing can unmask hypopigmentation or fibrosis produced by prior dermabrasion, cryosurgery, or phenol peels. Patients with prior lower blepharoplasties using an external approach are at greater risk of ectropion formation after infraorbital ablative skin resurfacing.
- What is the patient's skin phototype? Patients with lighter skin tones (skin phototype I or II) have a lower incidence of postoperative hyperpigmentation than patients with darker skin tones after ablative laser skin resurfacing.
- Does the patient have a history of herpes labialis? All patients should be treated with prophylactic antiviral medication before ablative laser skin resurfacing in the perioral region, because reactivation and/or dissemination of prior herpes simplex infection can occur. The de-epithelialized skin is also particularly susceptible to primary inoculation by herpes simplex virus.
- Does the patient have an immunologic deficiency or autoimmune disease? Intact immunologic function and collagen repair mechanisms are necessary to optimize the tissue healing response due to the prolonged recovery associated with ablative resurfacing.
- Is the patient taking any medications that are contraindicated? Concomitant isotretinoin use could potentially lead to an increased risk of postoperative hypertrophic scar formation due to its detrimental effect on wound healing and collagenesis. A safe interval between the use of oral retinoids and ablative laser skin resurfacing is difficult to determine; however, most advocate a delay in treatment for at least 6 mo after discontinuation of the drug.
- Does the patient have a tendency to form hypertrophic scars or keloids? Patients with a propensity to scar will be at greater risk of scar formation after laser skin resurfacing, independent of the laser's selectivity and the operator's expertise.
- Does the patient have realistic expectations of the procedure and will he or she adhere to postoperative instructions? Those who cannot physically or emotionally handle the prolonged postoperative course should be dissuaded from pursuing ablative laser skin resurfacing procedures.

(skin phototype I or II), rhytides and other elements of photodamage that are amenable to treatment with an ablative resurfacing laser, and realistic expectations of the treatment.[3] Adequate preoperative patient evaluation and education are essential to optimize the clinical outcome (Table 252-1). Proper patient selection is paramount, because ablative laser resurfacing can be complicated by a prolonged postoperative recovery, pigmentary alterations, or unexpected scarring. The patient's emotional ability to tolerate an extended convalescence is an important factor in determining the most appropriate choice of laser. Although carbon dioxide (CO_2) or modulated erbium:yttrium-aluminum-garnet (Er:YAG) lasers produce the most dramatic clinical results, some patients may be unable to tolerate the intensive recovery period that is required. For patients either unable or unwilling to tolerate extended postoperative healing, a short-pulsed Er:YAG laser or non-ablative laser procedure may be a more suitable choice (see also Chap. 240).

Currently no consensus exists among laser experts regarding the most appropriate preoperative regimen for ablative laser skin resurfacing patients. The use of topical retinoic acid compounds, hydroquinone bleaching agents, or α-hydroxy acids for several weeks before ablative cutaneous resurfacing has been touted as a means of speeding recovery and decreasing the incidence of postinflammatory hyperpigmentation.[4] Topical tretinoin enhances penetration of chemicals through the skin and has been shown to accelerate postoperative re-epithelialization after dermabrasion or deep chemical peels.[5] Because ablative laser–induced wounds are intrinsically different from those created by physically destructive methods, however, laser skin penetration is not typically affected by the topical application of any of these medications.[4,6]

Due to the moist, de-epithelialized state of ablative laser–resurfaced skin and the possibility of bacterial contamination and overgrowth, many laser surgeons advocate oral antibiotic prophylaxis. This practice remains controversial, however, due to the findings of a controlled study that demonstrated no significant change in post–laser resurfacing infection rate in patients treated with prophylactic antibiotics.[7]

Equipment (See also Chap. 240)

CARBON DIOXIDE LASER The first system developed for cutaneous laser resurfacing was the CO_2 laser, which was approved by the U.S. Food and Drug Administration in 1996. The earliest systems were continuous-wave CO_2 lasers, which were effective for gross lesional destruction.[8,9] However, these systems could not reliably ablate fine layers of tissue because of their prolonged tissue-dwell times, and they produced unacceptably high rates of scarring and dyspigmentation.[10–12] With the subsequent development of high-energy pulsed lasers, it became possible to safely apply higher energy densities with exposure times that were shorter than the thermal relaxation time of water-containing tissue, which lowered the risk of thermal injury to surrounding non-targeted tissue.[3,13,14]

Two of the first high-energy pulsed-laser systems developed were the UltraPulse 5000 and Silk-Touch lasers (Lumenis Corp., Yokeam, Israel). The UltraPulse emits individual CO_2 pulses (ranging from 600 microseconds to 1 millisecond) with peak energy densities of 500 mJ, whereas the SilkTouch is a continuous-wave CO_2 system with a microprocessor scanner that continuously moves the laser beam so that light does not dwell on any one area for more than 1 millisecond. The peak fluences delivered per pulse or scan range from 4 to 5 J/cm^2, which are the energy densities necessary for complete tissue vaporization.[10,15–17] Studies with these and other pulsed and scanned CO_2 laser systems have shown that after a typical skin resurfacing procedure, water-containing tissue is vaporized to a depth of approximately 20 to 60 μm, which produces a zone of thermal damage ranging from 20 to 150 μm.[10,16,18–20]

ERBIUM:YTTRIUM-ALUMINUM-GARNET LASER The short-pulsed Er:YAG laser was approved by the U.S. Food and Drug Administration in 1996 for use in cutaneous resurfacing. It was introduced as an alternative to the CO_2 laser for skin resurfacing in an attempt to minimize the recovery period and limit side effects while maintaining clinical benefit. The Er:YAG laser is a more precise ablative tool than is the CO_2 laser and emits 2940-nm light that corresponds to the 3000-nm absorption peak of water. The absorption coefficient of Er:YAG light is 12,800 cm^{-1} (compared with 800 cm^{-1} for that of the CO_2 laser), which makes it 12 to 18 times more efficiently absorbed by water-containing tissue than is the light of the CO_2 laser.[21] The pulse duration (mean of 250 microseconds) is also much shorter than that of the CO_2 laser;



this results in decreased thermal diffusion, less effective hemostasis, and increased intraoperative bleeding, which often hampers deeper dermal treatment. In addition, because of limited thermal skin injury, the amount of collagen contraction is also reduced with Er:YAG treatment compared with that observed with CO_2 laser irradiation.[15,22]

The Er:YAG laser's efficient rate of absorption, short exposure duration, and direct relationship between fluence delivered and amount of tissue ablated leads to 2 to 4 μm of tissue vaporization per J/cm^2, which produces a shallow level of tissue ablation. Much narrower zones of thermal necrosis, averaging only 20 to 50 μm, are therefore produced.[21,23–25]

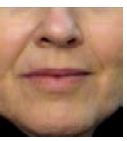

Conditions amenable to short-pulsed Er:YAG laser resurfacing include superficial epidermal or dermal lesions, mild photodamage, and subtle dyspigmentation. The major advantage of short-pulsed Er:YAG laser treatment is the shorter recovery period after therapy. Re-epithelialization is completed within an average of 5.5 days, compared with 8.5 days for multi-pass CO_2 procedures.[16,23] Postoperative pain and duration of erythema are reduced after short-pulsed Er:YAG laser resurfacing, with postoperative erythema resolving within 3 to 4 weeks. Because there is less thermal injury and trauma to the skin, the risk of pigmentary disturbance is also decreased, which makes the short-pulsed Er:YAG laser a good alternative in treating patients with darker skin phototypes.[3,26] The major disadvantages of the short-pulsed Er:YAG laser are its limited ability to effect significant collagen shrinkage and its failure to induce new and continued collagen formation postoperatively.[3,23,27] Because of this, the final clinical result is often less impressive than that produced by CO_2 laser skin resurfacing for deeper rhytides.

To address the limitations of the short-pulsed Er:YAG laser, modulated Er:YAG lasers systems were developed to improve hemostasis and increase the amount of collagen remodeling produced.[28] The Er:YAG–CO_2 hybrid laser system delivers both ablative Er:YAG and coagulative CO_2 laser pulses. The Er:YAG component generates fluences of up to 28 J/cm^2 with a 350-microsecond pulse duration, and excellent hemostasis is provided by the CO_2 component, which can be programmed to deliver 1- to 100-millisecond pulses at 1 to 10 W of power. Zones of thermal necrosis measuring as much as 50 μm have been observed depending on the treatment parameters used, and significant increase in collagen thickness has been noted 3 months after four passes with a device using this hybrid technology.[29] Another modulated Er:YAG device is a dual-mode Er:YAG laser that emits a combination of short (200- to 300-microsecond) pulses and long coagulative pulses to achieve tissue ablation depths of up to 200 μm per pass.[28,29] The desired depth of ablation and coagulation can be programmed by the laser surgeon using a touch-screen control panel. Several investigators have studied the histologic effects of dual-mode Er:YAG laser resurfacing and found a close correlation between the programmed and actual measured depths of ablation.[30,31] The actual zones of thermal injury correlate well with the first-pass parameters, with decreasing coagulative efficiency on subsequent passes. The variable-pulsed Er:YAG laser system delivers pulse durations ranging from 500 microseconds to 10 milliseconds. Shorter pulse durations are used for tissue ablation and longer pulses are used to effect coagulation and zones of thermal injury as with the CO_2 laser.[32–34]

Anesthesia

Most ablative laser resurfacing is performed as an outpatient procedure in an ambulatory surgery facility. Regional laser skin resurfacing (perioral or periorbital) can be performed with local anesthesia with no additional analgesia. However, full-face laser skin resurfacing often requires additional analgesia, including one or more of the following: oral sedation, nerve blocks, tumescent anesthesia, topical anesthetic creams, and intravenous (IV) sedation. Topical anesthesia protocols have been outlined using either lidocaine cream application for several hours before CO_2 laser resurfacing to enhance tissue hydration and anesthetic penetration[35] or a cream-based formulation that dries to a flexible membrane, which is peeled away from the skin before laser irradiation.[36]

Despite their obvious advantages, these topical regimens are frequently more time consuming and less uniformly effective. For this reason, many dermasurgeons prefer a deeper form of anesthesia for full-face ablative laser procedures, using regional nerve blockade and IV sedation to provide more complete anxiolysis, amnesia, and sedation.[37] If IV sedation or general anesthesia is used, special precautions must be taken in the presence of oxygen. CO_2 lasers have been reported to be the source of operating room fires, so care must be taken to eliminate exposure to flammable objects. A smoke evacuator must be used to avoid exposure to the laser plume.

Technique

CARBON DIOXIDE LASER SKIN RESURFACING The objective of ablative laser skin resurfacing is to vaporize tissue to the level of the papillary dermis. Limiting the depth of penetration decreases the risk of scarring and permanent pigmentary alteration. When choosing treatment parameters, the surgeon must consider such factors as the anatomic site to be resurfaced, the skin phototype of the patient, and previous skin treatments delivered.[15,38] In general, thinner skin (e.g., periorbital) requires fewer laser passes, and laser resurfacing of non-facial skin (e.g., neck, chest) should be avoided due to the relative paucity of pilosebaceous units in these areas.[38] To reduce the risk of excessive thermal injury during multi-pass procedures, partially desiccated tissue should be removed manually with wet gauze after each laser pass to expose the underlying dermis.[39]

The depth of ablation is directly correlated with the number of passes performed and usually is restricted to the epidermis and upper papillary dermis.[40] However, stacking laser pulses by treating an area with multiple passes in rapid succession or by using a high-overlap setting on a scanning device leads to excessive thermal injury to the skin with subsequent increased risk of scarring.[39,41] An ablative plateau is reached, which results in less effective tissue ablation and increased tissue heating. This effect is most likely caused by reduced tissue water content after initial desiccation, with reduced selective absorption of energy.[39] The avoidance of pulse stacking and incomplete removal of partially desiccated tissue is paramount to prevention of excessive thermal accumulation with the use of any laser system.

In an attempt to address many of the difficulties associated with the use of multi-pass CO_2 laser skin resurfacing, refinements in surgical technique have been developed. A minimally traumatic single-pass CO_2 laser resurfacing procedure has been described that results in faster re-epithelialization and a more improved side effect profile than have been reported with the multiple-pass technique.[42] Partially desiccated tissue is not removed (as is standard with multi-pass procedures); rather, the lased skin is left intact to serve as a biologic

wound dressing. Additional laser passes can then be applied focally only in areas of more extensive involvement to limit unnecessary thermal and mechanical trauma to less involved skin. Subsequent reports have substantiated the improved side effect profile of this less aggressive procedure.[43–45]

ERBIUM:YTTRIUM-ALUMINUM-GARNET LASER SKIN RESURFACING The short-pulsed Er:YAG laser fluences used most often range from 5 to 15 J/cm^2, depending on the degree of photodamage and anatomic location. On irradiation, laser-induced ejection of desiccated tissue from the target site produces a distinctive popping sound. Thermal energy is confined to the selected tissue, with minimal collateral thermal damage. Because little tissue necrosis is produced with each pass of the laser, manual removal of desiccated tissue is often unnecessary. The ablation depth with the short-pulsed Er:YAG laser does not diminish with successive passes because the amount of thermal necrosis is nominal. It takes three to four times as many passes with the short-pulsed Er:YAG laser to achieve similar depths of penetration as with one pass of the CO_2 laser at typical treatment parameter settings.[3,15] To ablate the entire epidermis with the short-pulsed Er:YAG laser using a fluence of 5 J/cm^2, at least two or three passes must be carried out, which increases the possibility of uneven tissue penetration. Treatment of deeper dermal lesions or areas of the face with extensive photodamage and dermal elastosis may require up to 9 or 10 passes of the short-pulsed Er:YAG laser, whereas the CO_2 laser would effect similar levels of tissue ablation in 2 or 3 passes.[10,16,21]

Pinpoint bleeding caused by inadequate hemostasis and tissue color change after multiple short-pulse Er:YAG passes can impede adequate clinical assessment of wound depth. Irradiated areas whiten immediately after treatment and then quickly fade. These factors render it more difficult to determine treatment endpoints and, thus, require extensive knowledge of laser-tissue interaction on the part of the operator. Modified Er:YAG ablative laser resurfacing provides better hemostasis and visualization of the treatment area because of the added thermal effects on the tissue.[46]

Outcomes Assessment

The clinical and histologic benefits of cutaneous laser resurfacing are numerous.

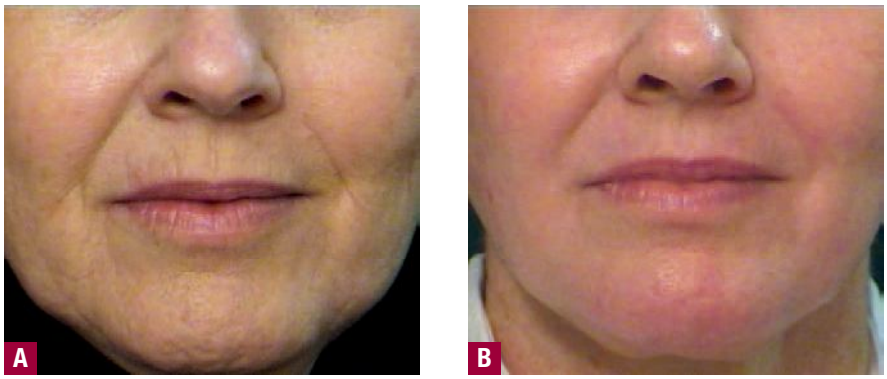

▲ **FIGURE 252-1** Facial photodamage and rhytides before (**A**) and several months after (**B**) ablative CO_2 laser skin resurfacing.

With the CO_2 laser, most studies have shown at least a 50 percent improvement over baseline in overall skin tone and wrinkle severity (Fig. 252-1).[14,47–51] The greatest advantages associated with CO_2 laser skin resurfacing are the excellent tissue contraction, hemostasis, prolonged neocollagenesis, and collagen remodeling that result. Histologic examination of laser-treated skin demonstrates replacement of epidermal cellular atypia and dysplasia with normal, healthy epidermal cells from adjacent follicular adnexal structures.[10,19] The most profound effects occur in the papillary dermis, where coagulation of disorganized masses of actinically induced elastotic material are replaced with normal compact collagen bundles arranged in parallel to the skin's surface.[52,53] Immediately after CO_2 laser treatment, a normal inflammatory response is initiated, with granulation tissue formation, neovascularization, and increased production of macrophages and fibroblasts.[19]

Persistent collagen shrinkage and dermal remodeling are responsible for much of the continued clinical benefits observed after CO_2 resurfacing and are influenced by several factors.[54,55] Thermal effects of laser irradiation of skin produce collagen fiber contraction at temperatures ranging from 55°C to 62°C (131°F to 143.6°F) through disruption of interpeptide bonds, which results in a conformational change to the collagen's basic triple-helical structure.[56,57] The collagen molecule is thereby shortened to approximately one-third of its normal length. Collagen fibers with laser-induced shrinkage may act as the contracted scaffold for neocollagenesis, which leads to subsequent production of the newly shortened form. In turn, fibroblasts that migrate into laser wounds after resurfacing may upregulate the expression of immune-modulating factors that serve to enhance continued collagen shrinkage.[58]

Because the modulated Er:YAG lasers were developed to produce a greater thermal effect and tissue contraction than did their short-pulsed predecessors, investigators compared collagen tightening induced by the CO_2 laser with that of the CO_2–Er:YAG hybrid laser system.[32] Intraoperative contraction of approximately 43 percent was produced after three passes of the CO_2 laser, compared with 12 percent contraction after Er:YAG irradiation. At 4 weeks, however, the CO_2 laser– and Er:YAG laser–treated sites were contracted to the same degree, which highlights the different mechanisms of tissue tightening observed after laser treatment. Immediate thermal-induced collagen tightening was the predominant response seen after CO_2 irradiation, whereas modulated Er:YAG laser resurfacing did not produce immediate intraoperative contraction but instead induced slow collagen tightening.[28,32]

Side Effects and Complications

Side effects associated with CO_2 laser skin resurfacing vary and are related to the expertise of the laser surgeon, the body area treated, and the skin phototype of the patient (Table 252-2). Certain tissue reactions, such as erythema and edema, are expected in the immediate postoperative period and are not considered adverse events. Erythema can be intense and may persist for several months after the procedure. The degree of erythema correlates directly with the depth of ablation and the number of laser passes performed.[3,59] It may also be aggravated by underlying rosacea or dermatitis. Postoperative erythema resolves spontaneously but can be reduced with the application of topi-



TABLE 252-2
Side Effects and Complications of Ablative Laser Skin Resurfacing

- Expected side effects
  - Erythema
  - Edema
  - Pruritus
- Complications
  - Mild
    - Prolonged erythema
    - Milia
    - Acne
    - Contact dermatitis
  - Moderate
    - Infection (bacterial, viral, fungal)
    - Dyspigmentation
  - Severe
    - Hypopigmentation
    - Hypertrophic scarring
    - Ectropion

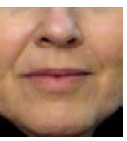

cal ascorbic acid, which may serve to decrease the degree of inflammation.[60,61] It should not be used for at least 4 weeks after the procedure to avoid irritation. Likewise, other topical agents such as retinoic acid derivatives, glycolic acid, fragrance- or chemical-containing cosmetics, and sunscreens should be strictly avoided in the early postoperative period until substantial healing has occurred.[59]

Mild side effects of laser skin resurfacing include milia formation and acne exacerbation, which may be caused by the use of occlusive dressings and ointments used during the postoperative period, particularly in patients who are acne prone.[38,41,59,62] Milia and acne usually resolve spontaneously as healing progresses and the application of thick emollient creams and occlusive dressings ceases. Oral antibiotics may be prescribed for acne flares that do not respond to topical preparations.[51,59,62] Contact dermatitis, either irritant or allergic, can also develop from various topical medications, soaps, and moisturizers used postoperatively. Most of these reactions are irritant in nature due to decreased barrier function of the newly resurfaced skin.[59,63]

Wound infections associated with ablative laser resurfacing include *Staphylococcus* and *Pseudomonas* infections and cutaneous candidiasis and should be treated aggressively with an appropriate systemic antibiotic or antifungal agent.[64] The most common infectious complication is a reactivation of labial herpes simplex virus (HSV) infection, most likely caused by the thermal tissue injury and epidermal disruption produced by the laser.[41,59] All patients undergoing full-face or perioral ablative resurfacing should receive antiviral prophylaxis even if they report no history of HSV infection. After CO_2 resurfacing, approximately 7 percent of patients develop a localized or disseminated form of HSV infection.[59] These infections develop within the first postoperative week and can present as erosions without intact vesicles because of the denuded condition of newly lased skin. Even with appropriate prophylaxis, a herpetic outbreak still can occur in upward of 10 percent of patients and must be treated aggressively.[15] Oral antiviral agents such as acyclovir, famciclovir, and valacyclovir are effective agents against HSV infection, although IV therapy may be required in severe (disseminated) cases. Patients should begin prophylaxis by the day of surgery and continue it for 7 to 10 days postoperatively.[65]

Hyperpigmentation is one of the more common side effects of cutaneous laser resurfacing and occurs to some degree in all patients with darker skin tones.[58,64] The reaction is transient, but its resolution can be hastened with the postoperative use of a variety of topical agents, including hydroquinone and retinoic, azelaic, and glycolic acid. Regular sunscreen use is also important during the healing process to prevent further skin darkening. Postoperative hypopigmentation is often not observed for several months and is particularly difficult because of its tendency to be intractable to treatment. The use of an excimer laser or topical photochemotherapy to stimulate repigmentation has proven successful in some patients.[66,67]

The most severe complications associated with ablative cutaneous laser resurfacing are hypertrophic scars and ectropion formation.[40,58] Although the risk of scarring has been significantly reduced with the newer pulsed systems, inadvertent pulse stacking or scan overlapping as well as incomplete removal of desiccated tissue between laser passes can cause excessive thermal injury that could increase the development of fibrosis. Focal areas of bright erythema with pruritus, particularly along the mandible, may signal impending scar formation.[37,64,65] Potent topical corticosteroid preparations should be applied to decrease the inflammatory response. A pulsed dye laser also can be used to improve the appearance and symptoms of laser-induced burn scars.[65]

Ectropion of the lower eyelid after periorbital laser skin resurfacing is rarely seen but, if encountered, usually requires surgical correction.[37] It is more likely to occur in patients who have had previous lower blepharoplasty or other surgical manipulation of the periorbital region. Preoperative examination is essential to determine eyelid laxity and skin elasticity. If the infraorbital skin does not return briskly to its normal resting position after a manual downward pull (snap test), then ablative laser resurfacing near the lower eyelid margin should be avoided. In general, lower fluences and fewer laser passes should be applied in the periorbital area to decrease the risk of lid eversion.

Side effects and complications after Er:YAG laser resurfacing are similar to those observed after CO_2 laser skin resurfacing, but they differ in duration, incidence, and severity.[68–70] Although greater postoperative erythema is seen after modulated Er:YAG laser treatment than is usually produced with a short-pulsed Er:YAG system, the side effect profile and recovery period after modulated Er:YAG laser skin resurfacing remain more favorable than after multi-pass CO_2 laser treatment. In an extended evaluation of 50 patients, investigators reported complete re-epithelialization in an average of 5 days after dual-mode Er:YAG laser skin resurfacing, with only three patients experiencing prolonged erythema beyond 4 weeks.[29] In a split-face comparison of 16 patients after pulsed CO_2 and variable-pulsed Er:YAG laser skin resurfacing, other investigators reported decreased erythema, less edema, and faster healing on the Er:YAG laser–treated facial half.[34]

Post-inflammatory hyperpigmentation is not uncommon after any cutaneous laser resurfacing procedure. Although hyperpigmentation after modulated Er:YAG laser skin resurfacing (mean duration, 10.4 weeks) can last longer than after treatment with a short-pulsed Er:YAG laser, it is not as persistent as that observed after multiple-pass CO_2 laser resurfacing (mean duration, 16 weeks).[29] However, when the most current techniques in ablative cutaneous laser resurfacing are compared (single-pass CO_2 versus multiple-pass, long-pulsed Er:YAG laser skin resurfacing), postoperative healing times and complication profiles are comparable, even in patients with darker skin phototypes. In a retrospective review and analysis of 100 consecutively treated patients, investigators found that average time to re-epithelialization was 5.5 days with single-pass CO_2 and 5.1 days with long-pulsed Er:YAG laser resurfacing.[45] Postop-

erative erythema was observed in all patients, lasting an average of 4.5 weeks after single-pass CO_2 laser treatment and 3.6 weeks after long-pulsed Er:YAG laser treatment. Hyperpigmentation was seen in 46 percent of patients treated with a single pass of the CO_2 laser and 42 percent of patients treated with the long-pulsed Er:YAG laser (average duration, 12.7 weeks and 11.4 weeks, respectively).

Postoperative Care and Patient Instructions

Proper wound care during the immediately postoperative period is vital to the successful recovery of ablative laser–resurfaced skin. During the re-epithelialization process, an open or closed wound treatment technique can be prescribed. Partial-thickness cutaneous wounds heal more efficiently and with a much reduced risk of scarring when maintained in a moist environment, because the presence of a dry crust or scab impedes keratinocyte migration.[71] Although there is consensus on this principle among laser surgeons, disagreement exists regarding the optimal dressing for the laser-ablated wound. The "open" technique involves frequent application of thick healing ointment to the de-epithelialized skin surface, whereas occlusive or semi-occlusive dressings are placed directly on the lased skin in the "closed" technique. Although the open technique facilitates wound visualization, the closed technique requires less patient involvement and may also decrease postoperative pain. Proposed advantages of closed dressings include increased patient comfort, decreased erythema and edema, increased rate of re-epithelialization, and decreased patient involvement in wound management[71,72]; however, additional expense and a higher risk of infection have been associated with their use.[3,62,64]

In addition to the prescribed wound care, ice pack application and the administration of anti-inflammatory medications should be carried out during this time. Furthermore, pain medication during the first few postoperative days is particularly important for patients undergoing ablative laser resurfacing.

FRACTIONAL RESURFACING

A novel approach in skin resurfacing termed *fractional photothermolysis* has been developed to address the shortcomings associated with cutaneous laser resurfacing using the currently available lasers and light sources.[73] Although dramatic clinical improvement can be achieved with traditional ablative laser resurfacing, patients are often hesitant to pursue this treatment option because of the extended postoperative recovery period and inherent risks of the procedure. Non-ablative lasers and light sources, on the other hand, have demonstrated modest efficacy in the non-invasive treatment of mild facial rhytides and atrophic scarring with minimal side effects, but require multiple treatments with delayed and often inconsistent clinical results (see Chap. 253).

Fractional photothermolysis involves the creation of microscopic thermal wounds with sparing of the surrounding tissue.[74] Fractional resurfacing is performed using a 1550-nm erbium fiber laser (Fraxel, Reliant Technologies, Mountain View, CA) that targets water-containing tissue to effect photocoagulation of narrow columns of skin (microscopic thermal zones) at depths of 200 to 500 μm and spaced at 200- to 300-μm intervals (see Chap. 240). Histologic evaluation of skin immediately after treatment reveals thermal injury sharply confined to these narrow columns extending from the epidermis to the mid-dermis.[74] Microscopic epidermal necrotic debris exfoliates over the next several days, producing a bronzed appearance to the skin.[75] The wound healing response differs from the response after the use of ablative techniques because the epidermal tissue that is spared between thermal zones contains viable transient amplifying cells capable of rapid re-epithelialization. Furthermore, because the stratum corneum has a low water content, it remains intact immediately after treatment. Therefore, the wound created by fractional resurfacing is unique—not simply that of an ablative laser used to make "holes" in the skin. In addition, fractional resurfacing can provide an advantage over purely non-ablative laser treatments due to the gradual exfoliation of the epidermis with resultant improvement in superficial dyspigmentation (Fig. 252-2). Because only a fraction of the skin is treated during a single session, a series of fractional resurfacing treatments is required for the best clinical improvement.

Investigators have shown fractional resurfacing to be a safe and effective treatment for a variety of indications, including photodamage, atrophic scars, and dyspigmentation.[76–80] Side effects of fractional resurfacing are typically mild and transient and include erythema, periocular edema, and a slight darkening of the skin (bronzing) as the microscopic epidermal necrotic debris desquamates. Erosions are uncommon and can be managed by liberal application of a healing ointment or plain petrolatum with cool, wet compresses every 2 to 3 hours. To date, permanent pigmentary alteration and scarring have not been reported. However, when an aggressive treatment protocol with a high density of microscopic thermal zones is used, the risk of visible epidermal ablation, along with the side effects associated with ablative laser procedures, is increased. Additional research is ongoing to determine optimal treatment parameters and the long-term benefits and sequelae of fractional resurfacing.

CHEMICAL PEEL

The controlled application of one or more exfoliating agents to the skin is a highly efficient and versatile way to improve photodamaged skin. The level of injury and the depth of penetration into the skin determine the classification as a superficial, medium, or deep chemical peel (Table 252-3). Although superficial peeling agents aimed at removing all or part of the epidermis are useful for su-



▲ **FIGURE 252-2** Facial photodamage and rhytides before (**A**) and 9 months after (**B**) a series of fractional laser treatments.



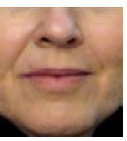

TABLE 252-3
Chemical Peel Classification

TYPE	DEPTH OF PENETRATION
Superficial	Epidermis to upper papillary dermis
Medium	Papillary dermis to upper reticular dermis
Deep	Mid-reticular dermis

perficial dyspigmentation, acne, and solar lentigines, they have minimal effect on rhytides and require multiple treatments for the best clinical results (Table 252-4). More complete skin rejuvenation requires the application of a medium or deep chemoexfoliant.[81,82]

Medium-Depth Peels

Medium-depth chemical peels are defined as those causing injury to the skin at or through the papillary dermis (Table 252-5).[83–85] Trichloroacetic acid (TCA) at concentrations of 35 percent to 50 percent is the classic agent in this category. Because 50 percent TCA may produce an unpredictable response with subsequent hypopigmentation and scarring, the combination of a superficial peeling agent such as Jessner's solution or glycolic acid before the application of 35 percent TCA is advocated to achieve more consistent results with an increased margin of safety (Fig. 252-3).[86–88]

The Jessner's solution–TCA peel is performed after thorough cleansing of the treatment area with soap followed by degreasing with an alcohol and acetone solution. Jessner's solution (Table 252-6) is applied in one or two coats to achieve a pale, uniform frost. The TCA is then applied evenly over the skin surface. Those portions of the face with a high concentration of sebaceous glands (T-zone) may receive additional acid in a second application. The observed white frost indicates protein denaturation of keratin and completion of the chemical peel reaction. Cool water compresses and emollient creams are then applied for symptomatic relief. Postoperatively, erythema, edema, and desquamation are expected, with increased severity of side effects noted with the higher acid concentrations and larger number of applications.

TABLE 252-4
Superficial Chemical Peeling Agents

- Trichloroacetic acid 10%–25%
- Jessner's solution
- Modified Unna's resorcinol paste
- Solid carbon dioxide
- α-Hydroxy acids
- Salicylic acid
- Tretinoin solution

TABLE 252-5
Medium-Depth Chemoexfoliants

- Trichloroacetic acid (TCA) 35%–50%
- Solid CO_2 and 35% TCA
- Jessner's solution and 35% TCA
- 70% Glycolic acid and 35% TCA
- 88% Phenol

Deep Chemical Peels

Phenol is a keratocoagulant that is the only deep peeling agent widely used. Application of phenol, as described by Baker and Gordon in the 1960s, causes wounding that penetrates to the mid-reticular dermis.[88–91] Baker's formula (Table 252-7) should be freshly prepared and stirred continuously before and during the procedure to ensure even application of the solution. For a full-face phenol peel, regional nerve blocks in combination with analgesics such as propofol (Diprivan) and anxiolytics such as midazolam can be used. Because phenol is partially detoxified in the liver and excreted by the kidney, hydration with lactated Ringer's solution before and during the treatment is warranted to limit toxicity. Furthermore, because phenol is cardiotoxic, close patient monitoring is necessary during and after the procedure.[92]

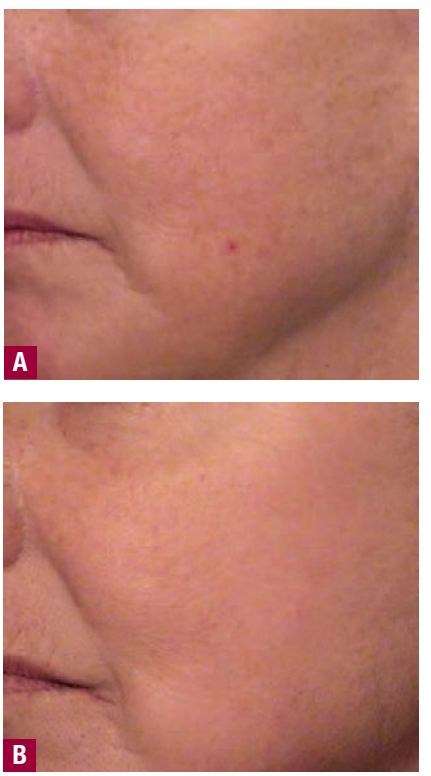

▲ **FIGURE 252-3** Facial dyspigmentation before (**A**) and 6 months after (**B**) treatment with a 30 percent trichloroacetic acid peel.

TABLE 252-6
Jessner's Solution

- Lactic acid 14 g
- Salicylic acid 14 g
- Resorcinol 14 g
- Ethanol 95% in quantity sufficient to yield 100 mL

After degreasing the skin with hexachlorophene (Septisol), fresh Baker's solution is applied systematically over aesthetic units using cotton-tipped applicators, with time (10 to 15 minutes) allowed to elapse between treating different regions to minimize absorption, which can lead to systemic toxicity. The solution can be feathered beyond the margins of the treated areas to reduce the line of demarcation between treated and untreated skin.

Postoperatively, an open wound care technique has been favored over a closed dressing due to the lower risk of infection and scarring and speedier re-epithelialization.[92,93] Petrolatum is applied liberally to the wound until re-epithelialization is complete, usually within 7 to 10 days.

Side Effects and Complications

The risk of side effects and complications (Table 252-8) increases proportionately with the depth of the chemical peeling agent. Superficial peels are associated with the lowest risk of adverse reactions, whereas medium-depth peels can cause dyspigmentation and, rarely, scarring. Phenol peels are further associated with hepatic, renal, and cardiac toxicity.

DERMABRASION

Modern techniques for dermabrasion were initially described by Paul Kurtin in 1953.[93] Dermabrasion involves the mechanical removal of the epidermis and dermis in a controlled fashion. Indica-

TABLE 252-7
Baker-Gordon Phenol Peel

- Phenol USP 88% 3 mL
- Croton oil (three drops)
- Hexachlorophene (Septisol) liquid soap (eight drops)
- Distilled water 2 mL

USP = United States Pharmacopeia.

TABLE 252-8
Side Effects and Complications of Chemical Peels

- Persistent erythema
- Infection
- Milia
- Dyspigmentation
- Textural changes
- Fibrosis and scarring
- Cardiac, renal, and hepatic toxicity (associated with phenol peels)

tions for treatment include rhytides, facial scars, rhinophyma, epidermal nevi, syringoma, and many other benign skin conditions.[94–97] Dermabrasion is highly operator dependent, and the practitioner must have extensive knowledge and experience to obtain excellent results while maintaining high levels of safety. The use of dermabrasion, except for spot treatment of specific lesions or scars, has been largely supplanted by treatment with a variety of ablative lasers.

Before dermabrasion is performed, a thorough patient consultation and evaluation is necessary to identify recent isotretinoin use, abnormal scarring tendency, prior treatments to the area, drug allergies, clotting or pigmentary disorders, and koebnerizing skin conditions. Preoperative antiviral prophylaxis is warranted for perioral or full-face procedures.[98,99]

Dermabrasion is performed using a wire brush or diamond fraise powered by a hand engine.[94] Fraises are available in multiple sizes, shapes, and degrees of coarseness. Pear-shaped fraises and cones are most often used around the nose and oral commissure, whereas wheels are used over flat, broad skin surfaces.[98] In general, diamond fraises offer a greater margin of safety than does the wire brush type, which removes a greater amount of tissue (Fig. 252-4).

The form of anesthesia used for dermabrasion varies depending on the surgeon, the area to be dermabraded, the desired depth of treatment, and the patient's pain tolerance. The use of liquid refrigerants can be problematic because of their potential for excessive skin injury; however, cryoanesthesia has the advantage of providing a firm surface on which to treat. Tumescent anesthesia with 0.05 percent to 0.1 percent lidocaine solution (with or without the concomitant use of nerve blocks and oral anxiolytics) is an effective form of anesthesia for full-face dermabrasion. A volume of 250 to 350 mL is typically adequate for the full face.[98]

Dermabrasion is performed in the operating room under strict universal precautions due to the risk of aerosolization of viral particles. The area to be dermabraded is stabilized manually without distortion of the normal skin contour. Some operators use an aerosol refrigerant to stiffen the skin surface to enhance depth control. The device is pulled rather than pushed over the cutaneous surface, which itself is positioned parallel to the floor. The dermabrasion is performed to the desired depth by closely monitoring the skin surface appearance. Decreased skin pigmentation is observed on epidermal removal, followed by punctate, pinpoint bleeding when the papillary dermis has been reached. The level of the reticular dermis is signaled by a whitish yellow appearance with fewer blood vessels. The goal of dermabrasion is to penetrate to the level of the dermis while avoiding the lower dermis and subcutaneous layer to reduce the risk of scarring. Feathering at the margins of the treatment area can soften the transition between treated and untreated skin.

On completion of a full-face dermabrasion, a dilute lidocaine and epinephrine solution can be used topically to soothe the treated area and improve hemostasis. The use of various biologic and nonbiologic sterile dressings has been advocated, but the choice is determined by the preference of the surgeon.[99] Depending on the total area and depth of dermabrasion, re-epithelialization is typically complete within 7 to 10 days. Meticulous wound care and close observation during the period of re-epithelialization permits the early detection of and intervention for such potential complications as herpetic, bacterial, and fungal infections. Side effects and complications after dermabrasion are similar to those seen after an ablative laser skin resurfacing procedure (see Table 252-2); however, the incidence of permanent hypopigmentation is markedly higher after dermabrasion (20 percent to 30 percent) than after ablative laser treatment.

KEY REFERENCES

The full reference list for all chapters is available at www.digm7.com.

3. Alster TS: Cutaneous resurfacing with CO_2 and erbium:YAG lasers: Preoperative, intraoperative, and postoperative considerations. *Plast Reconstr Surg* **103**:619, 1999
11. Tanzi EL, Lupton JR, Alster TS: Review of lasers in dermatology: Four decades of progress. *J Am Acad Dermatol* **49**:1, 2003
46. Alster TS, Tanzi EL: Laser skin resurfacing: Ablative and nonablative, in *Surgery of the Skin*, edited by Robinson J et al. Philadelphia, Elsevier, 2005, p 611
73. Manstein D et al: Fractional photothermolysis: A new concept for cutaneous remodeling using microscopic patterns of thermal injury. *Lasers Surg Med* **34**:426, 2004
81. Fulton JE, Porumb S: Chemical peels: Their place within the range of resurfacing techniques. *Am J Clin Dermatol* **5**:179, 2004
85. Monheit GD: The Jessner's-trichloroacetic acid peel: An enhanced medium-depth chemical peel. *Dermatol Clin* **13**:277, 1995
96. Spencer JM, Harmon CB: Microdermabrasion and dermabrasion, in *Surgery of the Skin*, edited by Robinson J et al. Philadelphia, Elsevier, 2005, p 611





◀ **FIGURE 252-4** **A.** Perioral rhytides before wire brush dermabrasion. **B.** Improved perioral rhytides 6 months after the procedure.



CHAPTER 253

Cosmetic Applications of Non-Ablative Lasers and Other Light Devices

Anne M. Chapas
Roy G. Geronemus



Over the last 40 years, the explosive advancement of laser technology has revolutionized the treatment of numerous skin conditions. The principle of selective photothermolysis set forth in 1983 by Anderson and Parrish[1] has formed the basis for the development of lasers that selectively target and destroy tissues containing water, hemoglobin, and pigment. Lasers showing such selective action were first applied to improve various potentially disfiguring medical conditions such as port-wine stains, hemangiomas, and pigmented birthmarks. More recently, these same principles have been implemented in an effort to improve the cosmetic appearance of normal and aging skin. Because laser treatments target all aspects of photoaging, from ameliorating the appearance of fine and deep rhytides to softening skin texture and improving pigmentation and skin laxity, they are becoming an indispensable tool in the armamentarium of the cosmetic dermatologist. An understanding of the benefits and limitations of each laser technique and the expectations and lifestyle of the individual patient allow the practitioner to achieve the most satisfying cosmetic results.

NON-ABLATIVE SKIN REJUVENATION

Skin rejuvenation by laser was originally performed with devices that resulted in the destruction or ablation of the epidermis and elements of the dermis. The demand for less invasive procedures with shorter recovery times than those of traditional ablative laser resurfacing has led to the development of non-ablative laser surgery. Many of these systems emit light in the infra-red portion of the electromagnetic spectrum (1000 to 1500 nm), which is absorbed by water in deeper tissues while leaving the epidermis intact. This type of dermal wounding stimulates new collagen and elastin formation, which can improve the appearance of skin with mild to moderate photodamage. In general, the results are not comparable to those achieved with ablative lasers, but many patients are willing to accept more modest clinical improvements in exchange for fewer side effects and shorter recovery times.

Patient Selection

Proper patient selection is the key to successful non-ablative laser resurfacing (see Chap. 252 for ablative laser procedures). Patients with realistic expectations who have mildly to moderately photodamaged skin are the best candidates for non-ablative procedures. Results from non-ablative laser treatments are generally gradual and progressive, with textural irregularities and pigment irregularities improving more than rhytides. Patients who seek immediate dramatic results are likely to be disappointed with the overall clinical outcome.

Risks and Precautions

As with ablative laser resurfacing, the heat produced by non-ablative systems can reactivate prior herpes simplex infections (Table 253-1). Patients with a strong history of herpes labialis should receive prophylactic oral antiviral medication before treatment. Although non-ablative laser procedures have an extremely low risk of scarring, these risks are increased in patients who have received isotretinoin in the previous year. Therefore, these patients should not undergo non-ablative resurfacing. Finally, patients with darker skin phototypes may develop a temporary post-inflammatory hyperpigmentation after non-ablative laser treatment.

Patient Positioning

Non-ablative laser resurfacing can be performed in the physician's office, with both the patient and clinical personnel wearing proper eye protection.

TABLE 253-1
Non-Ablative Resurfacing: Risks and Precautions

- Contraindicated in patient with prior isotretinoin treatment
- May lead to post-inflammatory hyperpigmentation
- May cause reactivation of herpes simplex virus infection

COSMETIC APPLICATIONS OF NON-ABLATIVE LASERS AND OTHER LIGHT DEVICES AT A GLANCE



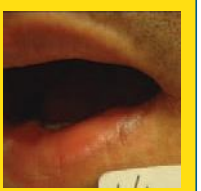

- A wide range of lasers and other light devices can be used to treat skin problems of cosmetic concern.
- Photorejuvenation can be achieved with non-ablative devices.
- Vascular and pigmented lesions benefit from treatment with lasers capable of selective photothermolysis.
- Patient selection and patient expectation are critical for optimum outcome.
- All safety precautions must be followed during treatment.

Equipment

Several visible-light lasers have been developed to target discrete chromophores to stimulate dermal remodeling (Table 253-2). One of the first approaches to photorejuvenation used pulsed dye lasers (PDL) emitting light at wavelengths of either 585 nm or 595 nm. The ability of PDL treatment to improve the appearance of hypertrophic scars, striae distensae, and acne scars suggests that PDL treatment stimulates new collagen formation. A small clinical study confirmed that a single treatment with a PDL (585 nm, 450 microseconds) in-

TABLE 253-2
Non-Ablative Resurfacing: Equipment

- Visible-light lasers: 585 nm, 595 nm, long-pulse 1064-nm neodymium:yttrium-aluminum-garnet, 1320 nm, 1450 nm, 1540-nm, erbium:glass, fractional photothermolysis
- Intense pulsed light devices
- Radiofrequency devices

duced clinical improvement in 75 percent to 90 percent of mild to moderate rhytides and 40 percent of moderate to severe rhytides.[2] Longer-wavelength lasers such as the 1064-nm Q-switched neodymium:yttrium-aluminum-garnet (Nd:YAG) laser, the 1320-nm Nd:YAG laser, the 1450-nm diode laser, and 1540-nm erbium:glass laser have also been shown to induce dermal remodeling. Multiple treatments are necessary at 2- to 4-week intervals. The effects are often gradual due to ongoing collagen formation, which may occur up to 6 months after the last treatment.

Treatment with intense pulsed light (IPL) devices, which emit a broad, continuous spectrum of light from 515 nm to 1200 nm, has been shown to successfully rejuvenate photodamaged skin. Filters can be placed over the beam to eliminate the shorter wavelengths, which target hemoglobin and melanin, depending on the clinical application. Studies have shown that IPL treatment produces substantial clinical improvement in the dyspigmentation and telangiectasias that are associated with photoaging but only mild improvement in rhytides.[3]

In contrast to visible-light lasers creating large sheets of thermal damage, the lasers used for fractional photothermolysis are mid–infra-red devices that create columns of thermal injury deep into the dermis, similar to pixels in a digital photograph.[4] The epidermis rapidly heals around these columns of thermal damage, which stimulate progressive collagen remodeling. Treatments are generally scheduled at 1- to 4-week intervals for a total of three to six sessions. Photodamage of the face, neck, chest, and hands; acne scars (Fig. 253-1); striae distensae (Fig. 253-2); and melasma have all been shown to respond to fractional photothermolysis.

Several non-ablative devices that deliver energy deep into the dermis have been shown to cause skin tightening. The direct application of infra-red light, with pre-treatment and post-treatment contact cooling of the skin, has been shown to heat deep collagen to the point of contraction. In appropriate patients, this contraction results in a visible tightening of redundant skin. Skin tightening can also be achieved by the use of a radiofrequency device generating electric current, which produces heat through resistance in the dermis. Periorbital rhytides and middle and lower face laxity generally require one to three treatments at 4-week intervals, with tightening noted 1 to 3 months after the last treatment[5] (Fig. 253-3). A new infra-red device that emits light at 1100 to 1800 nm in multisecond cycles has also been shown to induce skin contraction.



▲ **FIGURE 253-1** Acne scarring treated with fractional photothermolysis. **A.** Before treatment. **B.** After treatment.

Anesthesia

Non-ablative laser procedures are generally more easily tolerated than ablative procedures. The degree and type of anesthesia required depends on the patient's pain tolerance and the amount of heat energy generated by the device. A topical anesthetic such as lidocaine or a eutectic mixture of lidocaine and prilocaine applied 1 hour before the procedure is usually sufficient. Forced-air cooling can also make the procedure more tolerable. Higher-energy procedures such as fractional photothermolysis occasionally require nerve block, oral or intramuscular analgesics, and anxiolytics.

Technique

Non-ablative visible-light laser systems require different treatment parameters depending on the skin type and condition to be treated. To protect the epidermis, all of these devices are used in conjunction with a contact cooling handpiece or cryogen spray delivered several milliseconds before the laser pulse. IPL devices are used with various filters and at different energy levels depending on the desired treatment effect. A transparent water-based gel is used to protect the epidermis. Fractional photothermolysis is performed in the presence of forced-air cooling. Various density and energy settings are used.

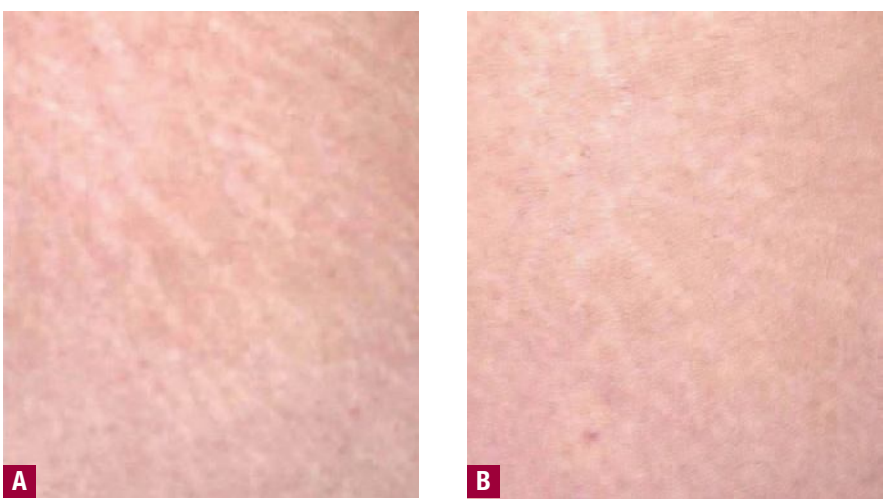

▲ **FIGURE 253-2** Striae distensae treated with fractional photothermolysis. **A.** Before treatment. **B.** Three months after treatment.



▲ **FIGURE 253-3** Facial laxity treated with a monopolar radiofrequency device. **A.** Before treatment. **B.** Two months after treatment. **C.** Four months after treatment. **D.** Six months after treatment.

Finally, tightening procedures are performed by holding the handpiece in firm contact with the treated skin. Several investigators have shown that multiple passes at relatively low to medium energies are effective and more tolerable for patients than high-energy treatments.

Outcomes Assessment

Because non-ablative laser treatments stimulate collagen remodeling over several months, objective clinical improvements after a series of treatments may take weeks or months to be achieved. Reassurance by the physician as well as the use of pre-treatment photographs may help patients better appreciate their progress. Setting realistic goals and targeting the aspects of photoaging that are important to the patient will also yield a more favorable outcome and enhance patient satisfaction.

Complications

Non-ablative laser surgery is not without risks, but side effects are much milder than with ablative laser treatment. Depending on the treatment, patients may have erythema and edema, which resolves in hours to days. Rarely are treatments associated with blistering, transient hyperpigmentation, or scarring. In some cases, post-treatment hyperpigmentation has been caused by excessive use of cryogen spray but has resolved with topical bleaching agents.

Patient Instructions

Because the epidermis remains intact after non-ablative laser procedures, minimal postoperative care is required. Ice can be applied to decrease erythema and swelling, and occasionally systemic glucocorticoids may be required.

TREATMENT OF VASCULAR LESIONS

A wide range of vascular lesions are amenable to safe and effective treatment by a class of lasers that take advantage of the principle of selective photothermolysis (see also Chap. 240).

Patient Selection

Vascular lesions can be a significant cosmetic concern for some patients and are generally amenable to laser treatment. Telangiectasias are small, superficial cutaneous blood vessels often appearing on the nose, cheeks, and chin in fair-skinned individuals as a result of actinic damage or rosacea. Other causes of telangiectasias include collagen vascular disease, genetic disorders, hormonal disorders, primary cutaneous disease, and radiation dermatitis. Telangiectasias are often associated with facial erythema, which can manifest as a flushing or blushing disorder. Various laser treatments can target this background discoloration in addition to treating the discrete vascular lesions.

Other types of vascular lesions, including cherry and spider hemangiomas, venous lakes, and angiokeratomas, may respond to vascular laser treatment (Fig. 253-4). Poikiloderma of Civatte, which manifests as a combination of telangiectasia, irregular pigmentation, and atrophic changes in fair-skinned individuals with actinic damage, can also be treated with vascular lasers. Extreme caution must be used when treating this condition, because overly aggressive treatment can worsen the atrophy and hypopigmentation.

In addition to improving vascular lesions, vascular laser treatments can improve the appearance of hypertrophic scars and keloids. Vascular lasers not only reduce the erythema by eliminating the underlying dilated microvasculature in a scar, they can also reduce the height of the scar and improve the skin surface texture. Multiple treatment sessions are required, and the treatment can be augmented by intralesional injections of corticosteroid with 5-fluourouracil. Newly formed atrophic scars, such as striae rubra, can sometimes be greatly improved with vascular laser treatment, whereas older lesions are less responsive.

Risks and Precautions

Laser treatment of vascular lesions is relatively safe but not without risks (Table 253-3). Higher-energy treatments or treatments with overlapping passes can result in atrophic or hypertrophic scarring. Alterations in pigmentation may result due to the concomitant absorption of 532-nm light by epidermal melanin. Patients with tans or darker skin types must be treated with caution to avoid pigmentary changes.

Patient Positioning

Most cosmetic vascular laser treatments are performed in the office. The patient's

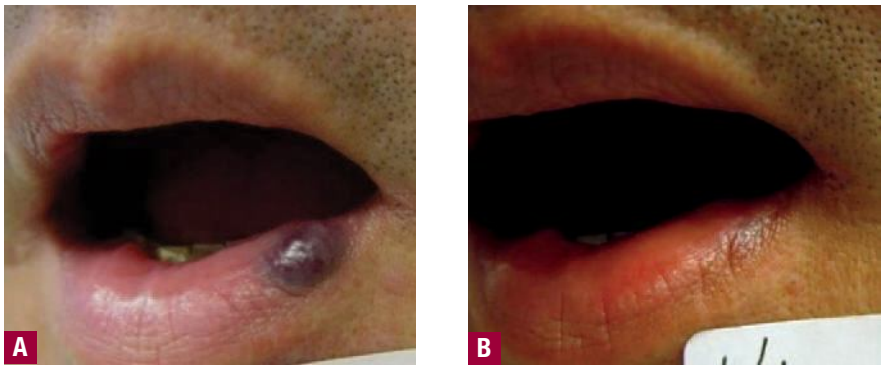

▲ **FIGURE 253-4** Venous lake treated with a potassium-titanyl-phosphate laser. **A.** Before treatment. **B.** After treatment.

eyes are protected with laser surgery goggles or with intraocular metal eye shields if treatment around the eye is required. All clinical personnel must wear laser surgery glasses that specifically absorb the wavelength of light used in the treatment. Flammable gases and other materials must not be present, because vascular lasers are capable of igniting fires.

Equipment

Vascular lesions were one of the first targets of treatment with early lasers. These early lasers, such as the argon laser (488 nm, 514 nm), argon pumped tunable laser (488 to 638 nm), copper and bromide lasers (578 nm), potassium-titanyl-phosphate (KTP) laser (532 nm), and krypton laser (568 nm), emitted continuous energy that was absorbed by oxyhemoglobin in cutaneous blood vessels (see also Table 240-1 in Chap. 240). Their use was limited because the continuous thermal energy often resulted in scarring and pigmentary alterations. The development of pulsed lasers in the 1980s allowed for more precise targeting of the oxyhemoglobin-containing vessels with less thermal and mechanical injury of surrounding tissues (Table 253-4). It is believed that pulsed energy delivered with short pulse widths causes intravascular cavitation, vessel wall fragmentation, and hemorrhage, whereas pulsed energy delivered over longer intervals causes intravascular coagulation and collagen contraction within the vessel wall and surrounding tissue. To reduce epidermal damage, all vascular lasers use an epidermal cooling system, with a cryogen spray or contact cooling.

The flashlamp-pumped PDL uses a high-power flashlamp to excite an organic dye (rhodamine) and produces a pulse of yellow light that is absorbed by oxyhemoglobin. The newer PDLs can deliver a variety of fluences over variable pulse durations (up to 40 milliseconds) to effectively treat many cosmetic conditions (see also Chap. 240). These PDLs can deliver high-energy, shorter pulses of light to treat striae distensae rubra and keloids. Purpura often results at these settings. However, the device is most useful in treating facial erythema and facial telangiectasias at longer pulse durations that do not lead to purpura, which is a barrier to treatment for some patients.

The long-pulse, frequency-doubled Nd:YAG-KTP lasers emit a green 532-nm light that can also improve telangiectasias with minimal purpura. The current KTP lasers deliver energy with pulse durations of 1 to 100 milliseconds through a fiberoptic handpiece with contact cooling. Although the 532-nm light is strongly absorbed by hemoglobin, the laser has a limited depth of penetration, which makes it useful for treatment of superficial facial vessels. Because melanin also absorbs 532-nm light, this laser should be used with caution in patients with darker skin phototypes.

TABLE 253-3
Treatment of Vascular Lesions: Associated Risks

- Post-inflammatory hyperpigmentation
- Post-inflammatory hypopigmentation
- Atrophic scarring
- Hypertrophic scarring

TABLE 253-4
Treatment of Vascular Lesions: Equipment

- Pulsed potassium-titanyl-phosphate lasers
- Pulsed dye, long-pulsed dye, variable-pulsed dye lasers
- Long-pulsed infra-red lasers: Alexandrite, diode, neodymium:yttrium-aluminum-garnet (Nd:YAG)
- Multiplex lasers: Sequential pulsed dye + Nd:YAG
- Intense pulsed light devices

Long-pulsed infra-red lasers such as the alexandrite (755 nm), diode (800 nm), and Nd:YAG (1064 nm) lasers allow deeper penetration into the skin, but their light is absorbed less specifically by hemoglobin than is the light of other vascular lasers (see also Chap. 240). There is still enough absorption, however, to treat superficial and deep reticular veins (up to 3 mm in diameter) in patients with a variety of skin types. More recently, multiplex lasers have been developed that sequentially deliver a PDL (595-nm) pulse followed by an Nd:YAG (1064-nm) pulse at precise intervals. It is theorized that the first PDL pulse induces blood clot formation and methemoglobin conversion, which allows for greater absorption of the Nd:YAG energy. Studies are ongoing to delineate the cosmetic and medical indications for multiplex laser treatment.

IPL devices with cutoff filters that deliver increments of light ranging from 515 to 590 nm have been shown to be effective in the treatment of cosmetic vascular conditions. IPL devices produce a variety of fluences (up to 80 J/cm^2) over 2 to 10 ns in single-, double-, or triple-pulse modes. The light is delivered by a fiber through an 8 × 15 mm or 8 × 35 mm glass window that is pressed directly against the skin. A coupling gel is applied to the skin before light application to protect the epidermis from overheating and improve light penetration. Compared with PDLs, IPL devices require a longer treatment session and potentially a greater number of treatments to achieve similar results.

Anesthesia

Vascular lasers and light sources used for cosmetic indications produce a brief stinging or burning sensation. Treatments are generally tolerated without anesthesia. Because discomfort can build with cumulative laser pulses, treatment of lesions with large surface areas may require topical anesthesia with a eutectic mixture of prilocaine and lidocaine or topical lidocaine. Topical anesthetics are removed a few minutes before treatment to reduce vasoconstriction and interference with laser light delivery. Rarely, local anesthesia with lidocaine or nerve blocks are required for full-face treatment.

Technique

The technique for treatment of vascular lesions will depend on the type and size of vessel to be treated and the patient's



skin type. PDL treatments are delivered through a hand-held fiber optic device with a spot size ranging from 2 to 12 mm. The pulses are placed adjacent to each other with approximately 18 percent overlap to avoid missing areas between pulses. In general, lower fluences are used to treat macular lesions, whereas higher fluences are used to treat more hypertrophic lesions. At short pulse durations, a light gray discoloration of the treated area is the therapeutic endpoint, whereas at long pulse durations transient purpura lasting 1 to 2 seconds is the desired endpoint. Pulsed KTP laser treatment is delivered using a handpiece held perpendicular to the skin surface, and the vessels are traced individually at a speed that heats them without causing epidermal damage. Effective treatment will cause vessels to disappear with a subtle blanching effect.

IPL is delivered with a shorter-wavelength filter (515 nm) in single-pulse mode to treat fine superficial vessels in patients with skin phototype I. Longer cutoff filters (570 to 590 nm) and double- or triple-pulse modes are needed to treat large and deeper vessels. A layer of cool water gel 1 to 2 mm thick is applied to the skin, and then test spots are treated at increasing fluences until a faint erythema without epidermal damage is achieved. The individual pulses are applied adjacent to each other with minimal overlap. A second pass may be made perpendicular to the first pass to prevent reticulation.

Outcomes Assessment

The efficacy of laser and light treatment of vascular lesions depends on the caliber and depth of treated vessels. Small superficial vessels are more responsive than larger, deeper vessels. Lesions with a high blood flow, such as some spider angiomas, are also more difficult to treat. Patient response is assessed at 4 to 6 weeks after treatment, and treatments are repeated if necessary.

Complications

Immediately after treatment, patients may experience erythema and edema, which may last for the next 1 to 2 days. Patients who are treated with a PDL at short pulse durations will develop purpura, which gradually resolves in 1 to 2 weeks. Crusting, blistering, and scarring may result from overtreatment. Given the overlapping absorption spectrum of epidermal melanin, vascular laser treatment can cause hyperpigmentation or hypopigmentation, but this is rarely observed. Suntanned patients and patients with darker skin phototypes should not be treated with KTP, PDL, or IPL devices.

Patient Instructions

Application of cold dressings or ice can help minimize the erythema and edema that develop in the first 24 hours after vascular laser treatment. Crusted or blistered areas should be treated twice a day with petrolatum until they have resolved. Patients requiring multiple treatments should wear sunscreen daily to prevent the risk of laser energy absorption by epidermal melanin in subsequent treatments.

TREATMENT OF COSMETIC PIGMENTED LESIONS

Patient Selection

The treatment of pigmented lesions depends on the type of pigmented lesion being targeted, its anatomic location in the tissue, and whether the pigment is intracellular or extracellular within this tissue. The background skin color must also be considered so that treatment can be directed toward the abnormal pigment while leaving the normal pigmentation intact.

The success of cosmetic treatment of pigmented lesions also depends on certain patient factors. A complete medical history should be taken with specific emphasis on poor wound healing, post-inflammatory hyperpigmentation, bleeding disorders, gold therapy, and isotretinoin use in the previous year. Should any of these factors be present, the surgeon should proceed with extreme caution. In addition, all pigmented lesions should be properly evaluated, and biopsy should be performed on any questionable lesions. Laser treatment does not yield tissue for histopathologic analysis. Before treatment, patients should be counseled that the lesion may require multiple treatments and that the lesion may not clear completely.

Risks and Precautions

Pigmentary and textural changes are the most common complications observed when treating pigmented lesions (Table 253-5). Pigmentary changes occur more commonly in patients who are tanned or have darker skin phototypes. Transient hypopigmentation and, rarely, long-term depigmentation may develop. Hyperpigmentation has been reported in up to 16 percent of cases and is more commonly seen in patients with darker skin phototypes.[6] To avoid pigmentary alterations, patients with tanned skin should not be treated, because this increases their risk of adverse effects. The risk of scarring is small, but the use of Q-switched Nd:YAG lasers at 1064 nm may cause textural change, although this occurs in fewer than 5 percent of cases.

TABLE 253-5
Treatment of Cosmetic Pigmented Lesions: Associated Risks

- Post-inflammatory hyperpigmentation
- Post-inflammatory hypopigmentation
- Allergic reaction to tattoo pigment
- Localized chrysiasis

Patients and practitioners must also be aware that laser treatments can alter tattoo pigments, causing a local or systemic reaction. Local allergic reactions to cadmium sulfide and chromium have been reported, and patients with known allergies to these substances should generally not undergo laser treatment for tattoo removal. Q-switched lasers may also alter cosmetic tattoos containing ferric oxide pigment, creating an immediate paradoxical darkening. It is advised that these eyeliner and lip tattoos first be treated in test spots with single pulses and then observed 2 weeks later to assess clinical outcomes. Often ablative lasers are more effective at removing these lesions without the risk of paradoxical darkening.[7]

Patients should also be questioned regarding medications, because Q-switched lasers have been reported to cause localized chrysiasis in patients who have received parental gold therapy.[8] It is believed that the laser causes a physiochemical transformation of the gold pigments, similar to its darkening effect on cosmetic tattoos.

Patient Positioning

Most laser treatments of cosmetic pigmented lesions are performed in the office, with the patient and all clinical personnel wearing appropriate eye protection. The treatment site is thoroughly cleansed to remove all makeup, sunscreen, and topical anesthetic, which can hinder delivery of the laser energy. If alcohol has been used to clean the area, it must be thoroughly removed before laser treatment, because it could be a



TABLE 253-6
Treatment of Cosmetic Pigmented Lesions: Equipment

- Pigment-targeted pulsed dye laser
- Q-switched neodymium:yttrium-aluminum-garnet laser (532/1064 nm)
- Q-switched ruby laser
- Q-switched alexandrite laser
- Diode laser
- Pulsed light source



▲ **FIGURE 253-6** Tattoo treated with Q-switched ruby laser. **A.** Before treatment. **B.** After treatment.

source of flash fire development. Because treatment with Q-switched 1064-nm Nd:YAG lasers can cause some tissue and blood splatter, universal precautions should be followed at all times.

Equipment

Lasers used for the treatment of pigmented lesions (Table 253-6) can be categorized as highly selective Q-switched lasers, less pigment-selective lasers, and non–pigment-selective lasers. The Q-switched lasers, including the Q-switched ruby laser (694 nm), the Q-switched alexandrite laser (755 nm), and the Q-switched Nd:YAG laser (1064 nm), are capable of targeting superficial epidermal and deeper dermal pigment. Epidermal pigment–based lesions can also be treated with the Q-switched frequency-doubled Nd:YAG laser (532 nm) and the flashlamp-pumped PDL (510 nm). Long-pulsed pigment-specific lasers, such as the long-pulsed ruby laser, long-pulsed alexandrite laser, long-pulsed diode laser, and long-pulsed Nd:YAG laser, have pulse durations in the millisecond range. These lasers have been shown to treat certain nevi by targeting nests of cells rather than individual melanosmes.[9]

Non-specific ablative lasers such as the CO_2 laser (10,600 nm) and erbium:YAG laser (2940 nm) can remove pigmented superficial lesions secondary to their ablative actions. IPL devices can be used to treat mild pigmentary changes due to photodamage.

Anesthesia

Treatment of the majority of pigmented lesions does not require topical or infiltrative anesthesia. However, treatment of larger tattoos and lesions with large amounts of dermal pigment may require local anesthesia or nerve blocks.

Technique

Superficial epidermal pigmented lesions such as ephelides, solar and labial lentigines, café-au-lait macules, and flat pigmented seborrheic keratoses can be effectively treated with Q-switched ruby (694-nm) lasers, Q-switched alexandrite (755-nm) lasers, 532-nm lasers, short-pulsed dye (510-nm) lasers, and IPL devices (Fig. 253-5; see also Chap. 240). Most lesions respond to one or two treatments spaced 4 to 6 weeks apart. The response of café-au-lait macules is variable, with up to a 50 percent recurrence rate. In general, the laser handpiece is held perpendicular to the skin, and parameters are selected based on the melanin content of the lesion and background skin type. Lower fluences are used for targets containing an abundance of melanin. The desired endpoint is a uniform but faint whitening of the skin without epidermal disruption.



▲ **FIGURE 253-5** Solar lentigines treated with a Q-switched ruby laser. **A.** Before treatment. **B.** After treatment.

Dermal pigmented lesions such as nevus of Ota and pigmentation due to medication can also be improved with the Q-switched pigment-targeted lasers described previously in Equipment. Dermal tattoos are generally treated with lasers that are selective for the various colors of inks (see also Chap. 240). Q-switched ruby and alexandrite lasers are best for treating blue, black, and green ink, whereas short-wavelength lasers such as the short-pulsed dye (510-nm) and Q-switched 532-nm ND:YAG lasers are best for treating red pigments. Yellow-pigmented tattoos are usually resistant to laser treatment. Dermal lesions and tattoos are treated similarly to epidermal lesions, with the desired endpoint being a whitening of the skin with intact epidermis. Treatments are spaced 6 to 8 weeks apart, because clearing of dermal pigment depends on the slow mechanism of phagocytosis (Fig. 253-6).

Outcomes Assessment

Patients should be evaluated 4 to 6 weeks after small test spots within the larger lesion are treated. They should be informed that often multiple treatments are needed to achieve the desired clinical outcome.

Complications

Immediately after laser surgery, the treated area develops a whitening response that typically fades in 20 to 30 minutes. Some patients may develop an urticarial reaction, which can subside within an hour and responds to antihistamines. A crust will form in the treated area; it resolves in 7 to 10 days on the face but may take longer to resolve on non-facial areas. In rare cases blisters, vesicles, scarring, and pigmentary changes may occur.

Patient Instructions

After laser treatment of pigmented lesions, patients may use ice packs, cool compresses, and hydro-occlusive dressings to reduce any postoperative pain. Daily



cleansing of the treated areas with soap and water followed by application of occlusive ointments is recommended until the crusts have resolved. All patients are advised to avoid excessive sun exposure and apply broad-spectrum sunscreen daily.

REFERENCES

1. Anderson RR, Parrish JA: Selective photothermolysis: Precise microsurgery by selective absorption of pulsed radiation. *Science* **220**:524, 1983
2. Zelickson BD et al: Pulsed dye laser therapy for sun damaged skin. *Lasers Surg Med* **25**:229, 1999
3. Weiss RA, Weiss MA, Beasley KL: Rejuvenation of photoaged skin: 5 years results with intense pulsed light of the face, neck, and chest. *Dermatol Surg* **28**: 1115, 2002
4. Rokhsar CK, Lee S, Fitzpatrick RE: Review of photorejuvenation: Devices, cosmeceuticals, or both? *Dermatol Surg* **31**:1166, 2005; discussion 1178
5. Fisher GH et al: Nonablative radiofrequency treatment of facial laxity. *Dermatol Surg* **31**:1237, 2005; discussion 1241
6. Grevelink JM et al: Undesirable side effects associated with treatment of tattoos and pigmented lesions with Q-switched lasers at 1064 and 694 nm—the MGH experience. *Lasers Surg Med* **131**:53, 1993
7. Anderson RR et al: Cosmetic tattoo ink darkening: A complication of Q-switched and pulsed-laser treatment. *Arch Dermatol* **129**:101, 1993
8. Trotter MJ et al: Localized chrysiasis induced by laser therapy. *Arch Dermatol* **131**:1411, 1995
9. Ueda S, Imayama S: Normal-mode ruby laser for treating congenital nevi. *Arch Dermatol* **133**:355, 1997



CHAPTER 254

Liposuction

Aimee L. Leonard
C. William Hanke

PATIENT SELECTION

Liposuction should be regarded not as a method of weight reduction or an alternative to diet and exercise, but as a body-contouring procedure. The ideal candidate is a healthy patient near his or her ideal body weight who has disproportionate, localized adipose deposits resistant to diet and exercise. Liposuction should be avoided in patients with unrealistic treatment goals and those with emotional or psychological instability (i.e., presence of an eating disorder or body dysmorphic disorder). A comprehensive preoperative consultation including a screening questionnaire is used to identify patients who are appropriate candidates. During the consultation, the risks, goals, anticipated results, and expected postoperative course are discussed.

PREOPERATIVE EVALUATION

Taking a thorough medical history will screen for patients who may be poor surgical candidates for liposuction (see Risks and Precautions). Patients at risk for complications should receive medical clearance before surgery.[2,3] A careful review of all medications is essential. All anticoagulant medications, including vitamins and herbal supplements, should be discontinued 2 weeks before surgery. Use of medically necessary anticoagulant therapy is a contraindication for tumescent liposuction. Medications that are metabolized by the hepatic cytochrome P_{450} 3A4 enzyme system should be identified. These medications may interfere with the hepatic metabolism of lidocaine, which leads to the potential for toxicity. They should be discontinued or tapered off 2 weeks before surgery if permitted by the prescribing physician. For patients who are unable to interrupt therapy, a lower maximum dose of lidocaine may be used (i.e., less than 35 mg/kg).

Preoperative laboratory testing includes complete blood count with differential and platelet count, prothrombin time, partial thromboplastin time, and chemistry panel (including liver function tests); serologic testing for human immunodeficiency virus and hepatitis B and C viruses; and serum pregnancy test (for females).[2] An electrocardiogram may be considered when the patient is over the age of 60 or when indicated based on the patient's history or a review of systems.

RISKS AND PRECAUTIONS

Risks and precautions concerning liposuction are presented in Box 254-1.

PATIENT POSITIONING

Proper patient positioning is essential for safe and effective removal of adipose tissue. Specific positioning maneuvers differ by anatomic target site and are used to avoid important anatomic structures and optimize cannula access to fatty deposits.

EQUIPMENT

Liposuction requires the following equipment (Figs. 254-1 and 254-2):

- Tumescent anesthetic solution
- Infiltration needles or cannulas
- Intravenous or peristaltic pump tubing
- Infiltration pump
- Liposuction cannulas
- Aspiration tubing
- Aspiration pump with aspirate receptacles
- Monitoring device and emergency equipment

ANESTHESIA

Lidocaine is the preferred anesthetic for tumescent liposuction.[2] The maximum dose reported to be safe is 55 mg/kg.[4] Normal saline (0.9 percent sodium chloride) is typically used as a vehicle. Sodium

LIPOSUCTION AT A GLANCE



- Liposuction is one of the most commonly performed cosmetic procedures and is widely practiced by dermatologic surgeons.
- The tumescent technique of local anesthesia is one of the most important innovations in liposuction surgery.[1]
- Liposuction performed with tumescent local anesthesia allows for the removal of large volumes of fat.
- Liposuction is characterized by unparalleled safety, rapid patient recovery, and low postoperative morbidity.
- Importantly, liposuction has been demonstrated to be very safe to perform in the office setting, the preferred venue for the procedure when carried out by dermatologic surgeons.

Box 254-1

Risks and Precautions for Liposuction

CONTRAINDICATIONS TO LIPOSUCTION

- Severe cardiovascular disease
- Severe coagulation disorders, including hemophilia
- Pregnancy

CONDITIONS THAT PUT PATIENTS AT RISK FOR COMPLICATIONS

- History of bleeding diathesis, thrombophlebitis, or emboli (fat or thrombotic)
- History of infectious disease (including hepatitis and human immunodeficiency virus infection)
- Poor wound healing
- Diabetes mellitus
- Immunosuppression
- Prior extensive abdominal surgery
- Hepatic disease
- Renal disease
- Morbid obesity
- Underlying systemic disease with functional limitations
- Use of anticoagulant medications, vitamins, or herbal supplements
- Use of medications metabolized by cytochrome P_{450} 3A4 enzyme system

bicarbonate is used to buffer the solution, and epinephrine is added to augment hemostasis and slow the absorption of lidocaine. The compositions of tumescent lidocaine solutions ranging from 0.05 percent to 0.1 percent are shown in Table 254-1. Higher concentrations of lidocaine provide better analgesia and are useful in treating small or sensitive areas. Lower concentrations provide adequate anesthesia and are used when treating large or multiple areas. Accurate record keeping of tumescent anesthetic solution preparation and administration is critical to avoid lidocaine toxicity.

TECHNIQUE

With the patient standing, the target areas for treatment as well as entry sites for cannula insertion are outlined with a permanent marker. The patient is brought to the procedure table and undergoes sterile preparation. Entry sites are anesthetized locally using 1 percent lidocaine with 1:100,000 epinephrine. These sites are then incised with a No. 11 blade. An infiltration cannula is inserted, and tumescent anesthesia fluid is delivered to the subcutaneous space. Rates of infiltration and amounts of fluid delivered vary depending on target area and patient tolerance.

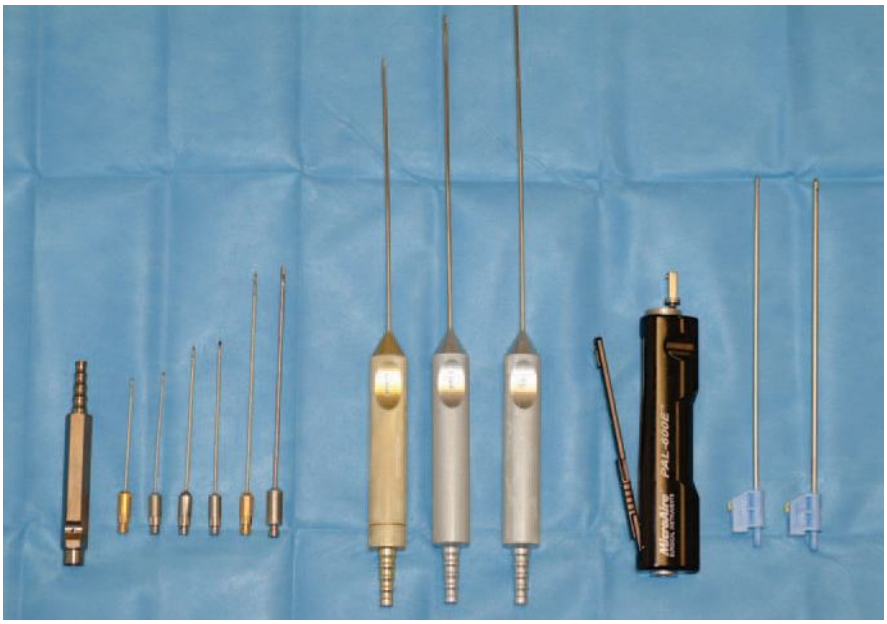

▲ **FIGURE 254-1** A selection of liposuction cannulas, including hand cannulas (*left*) and powered cannulas (*right*). (Used with permission from C. William Hanke, MD.)

Liposuction aspiration cannulas vary in diameter, tip style, and tip configuration. One innovation is powered liposuction using a motorized cannula. In general, larger cannulas with tapered tips and multiple distal apertures allow easier fat removal but also increase tissue injury. The choice of cannula depends on anatomic site as well as surgeon preference and experience. The cannula is inserted into entry sites with the tip apertures facing downward, away from the dermis. Tunneling with the cannula is performed in linear, even strokes with the surgeon's dominant hand, with the non-dominant hand, or "smart hand," controlling cannula tip position at all times. The majority of suctioning should be aimed parallel to the axis of lymphatic drainage to minimize tissue trauma. Uneven or overly aggressive suctioning can lead to contour irregularities and should be avoided. Endpoints can be measured as the time spent in a given area, the amount of fat suctioned, and assessment of the target area by palpation. The transition from yellow adipocyte-rich aspirate into fat-sparse serosanguineous tumescent fluid is an additional endpoint. Suctioned aspirate volumes and vital signs are recorded throughout the procedure.

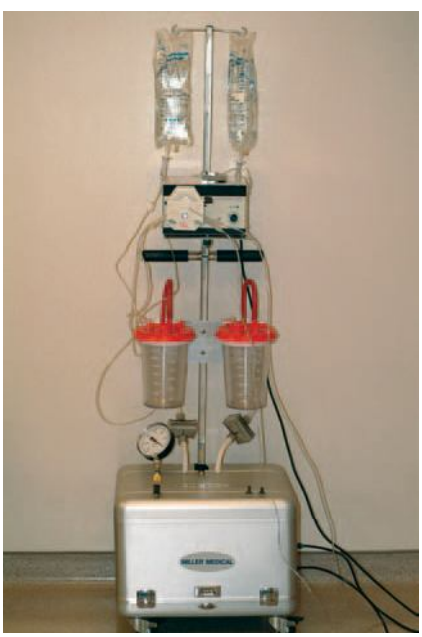

▲ **FIGURE 254-2** Liposuction equipment including (from top to bottom) tumescent anesthetic solution, infiltration pump and tubing, aspirate receptacles, and aspiration pump. (Used with permission from C. William Hanke, MD.)

OUTCOMES ASSESSMENT

Several studies support the excellent safety profile and high rates of patient satisfaction observed with tumescent liposuction. A 1995 survey of dermatologic surgeons who performed tumescent liposuction on 15,336 patients found no fatalities or serious complications. There were no adverse events that necessitated hospitalization.[5] In 2002, Housman et al. reported a serious adverse event rate of 0.68 per 1000 cases in a survey of 267 dermatologic surgeons who performed 66,570 liposuction procedures. No deaths were reported.[6] In a prospective study involving 688 liposuction patients, Hanke et al. found a major



TABLE 254-1
Tumescent Liposuction Solutions

	0.1%	0.075%	0.05%
Sodium chloride 0.9%	1000 mL	1000 mL	1000 mL
Lidocaine 1%	100 mL	75 mL	50 mL
Epinephrine 1:1000	1 mL	1 mL	1 mL
Sodium bicarbonate 8.4%	10 mL	10 mL	10 mL

complication rate of only 0.14 percent and a minor complication rate of 0.57 percent. Eighty-four percent of patients reported high levels of satisfaction with the procedure[7] (Figs. 254-3 and 254-4).

COMPLICATIONS

The majority of medical and surgical complications from tumescent liposuction, such as bleeding, hematoma, infection, and lidocaine toxicity, can be avoided by comprehensive perioperative patient evaluation and adherence to published guidelines of care. Aesthetic complications such as surface irregularities, persistent edema, and suboptimal target area fat reduction can be minimized by proper patient selection, patient education, and good technique. Dermatologic surgeons performing liposuction should be knowledgeable about the prevention and management of all potential intraoperative and postoperative complications.

PATIENT INSTRUCTIONS

Anticipated sequelae of tumescent liposuction include copious drainage from cannula entry sites, ecchymoses, edema, soreness, postural dizziness, and temporary dysesthesia. Proper education and instructions regarding diet, activity, and use of compression garments prepare patients for the postoperative period. The patient must be discharged to the care of a family member or friend. Patients are encouraged to ambulate and avoid immobilization. Heavy exercise and hot baths and showers should be avoided.

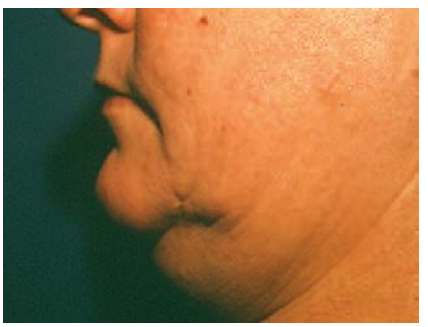

▲ **FIGURE 254-3** Liposuction of the neck, preoperative. (Used with permission from C. William Hanke, MD.)



▲ **FIGURE 254-4** Liposuction of the neck, postoperative. (Used with permission from C. William Hanke, MD.)

MONITORING AND FOLLOW-UP

A series of follow-up visits is scheduled to assist the patient through the immediately postoperative period and to assess the long-term surgical outcome. Postoperative healing from liposuction is characterized by a protracted period of edema resolution followed by subsequent skin contracture, which leads to a delayed final treatment result. Taking preoperative and postoperative photographs and weight measurements is essential to address patients' concerns and assess treatment response. Patients are encouraged to wait at least 6 months before judging the final cosmetic result. The performance of touch-up procedures in a treated area should be deferred for at least 1 year.

REFERENCES

1. Klein JA: The tumescent technique for liposuction surgery. *Am J Cosmet Surg* **4**:263, 1987
2. Coleman WP 3rd et al: American Academy of Dermatology Guidelines/Outcomes Committee. Guidelines of care for liposuction. *J Am Acad Dermatol* **45**:438, 2001
3. Coldiron B et al: ASDS guidelines of care for tumescent liposuction. *Dermatol Surg* **32**:709, 2006
4. Ostad A, Kageyama N, Moy RL: Tumescent anesthesia with a lidocaine dose of 55 mg/kg is safe for liposuction. *Dermatol Surg* **22**:921, 1996
5. Hanke CW, Bernstein G, Bullock S: Safety of tumescent liposuction in 15,336 patients. National survey results. *Dermatol Surg* **21**:459, 1995
6. Housman TS et al: The safety of liposuction: Results of a national survey. *Dermatol Surg* **28**:971, 2002
7. Hanke CW et al: Tumescent liposuction report performance measurement initiative: National survey results. *Dermatol Surg* **30**:967, 2004



CHAPTER 255

Soft-Tissue Augmentation

Lisa M. Donofrio

GENERAL INJECTION TECHNIQUES

With the possible exception of autologous fat, all soft-tissue fillers are injected through a sharp needle. The level of injection into the skin depends on the type of filler injected, the properties of the filler, the area injected, and the desired result. Threading is a technique in which the needle is inserted into the skin and the filler is deposited in a linear fashion along the track of the needle as it is being withdrawn. Fanning is a type of threading in which, instead of inserting the needle into a new area each time, the needle is just withdrawn so that a new track can be made radially adjacent to the last. In the "push-ahead" technique, an injection is made in an antegrade direction, so that the injectable material flows from the tip of the needle and hydrodissects the tissues as it flows. This technique is often used in areas in which bruising is more likely to occur along the needle track, such as the upper lid and brow. In the depot method of injection, small "pearls" of material are deposited serially, usually along a fold or deep by bone. Cross-hatching is an approach used to diffusely cover an area with the injected material. In this method, linear threads are lined up in

SOFT-TISSUE AUGMENTATION AT A GLANCE

- Soft-tissue augmentation is an excellent way to restore the contours of youthful fullness to an aging face.
- It is one of the most common cosmetic procedures performed in dermatology practices.
- Soft-tissue fillers vary in their longevity, allergenic potential, safety, and applications. There is no perfect filler at this time, but the ideal soft-tissue filler should be nonallergenic, noncarcinogenic, nonteratogenic, biocompatible, nonmigratory, and affordable, and should provide effects that are reproducible and long lasting yet reversible.
- Literally hundreds of soft-tissue fillers are available worldwide.
- This chapter focuses on those fillers that are approved by the U.S. Food and Drug Administration for soft-tissue augmentation or are commonly used off label for filling rhytides or skin lines or giving the face a more global change of appearance. Fillers for treatment of lipodystrophy, including lipodystrophy induced by highly active antiretroviral therapy, are discussed in Chap. 69.

succession and a second series of rows is then layered at right angles on top of the first. Fig. 255-1 illustrates the different injection techniques. Whatever the technique chosen, care should be taken in highly vascular areas to avoid intravascular injection of filling material. The plunger of the syringe should be pulled back to check for blood flow, and if it is found, the needle should be withdrawn and repositioned.

COLLAGENS

Patient Selection

Collagen fillers are indicated for volume enhancement of the nasolabial folds, labiomental crease, and lips as well as the attenuation of fine lines around the mouth and eyes. They are not a single filler but a group of fillers with different injection properties, flow characteristics, and viscosities. Very little bruising or swelling occurs with collagen injections, so collagen injections are appropriate for patients who cannot afford any "downtime." As with all fillers, results often depend on the amount injected and the goals of the patient. All collagen products should be avoided in patients with a history of collagen vascular disease, a positive skin test result, or known allergy to collagen products. Table 255-1 contains relevant informa-

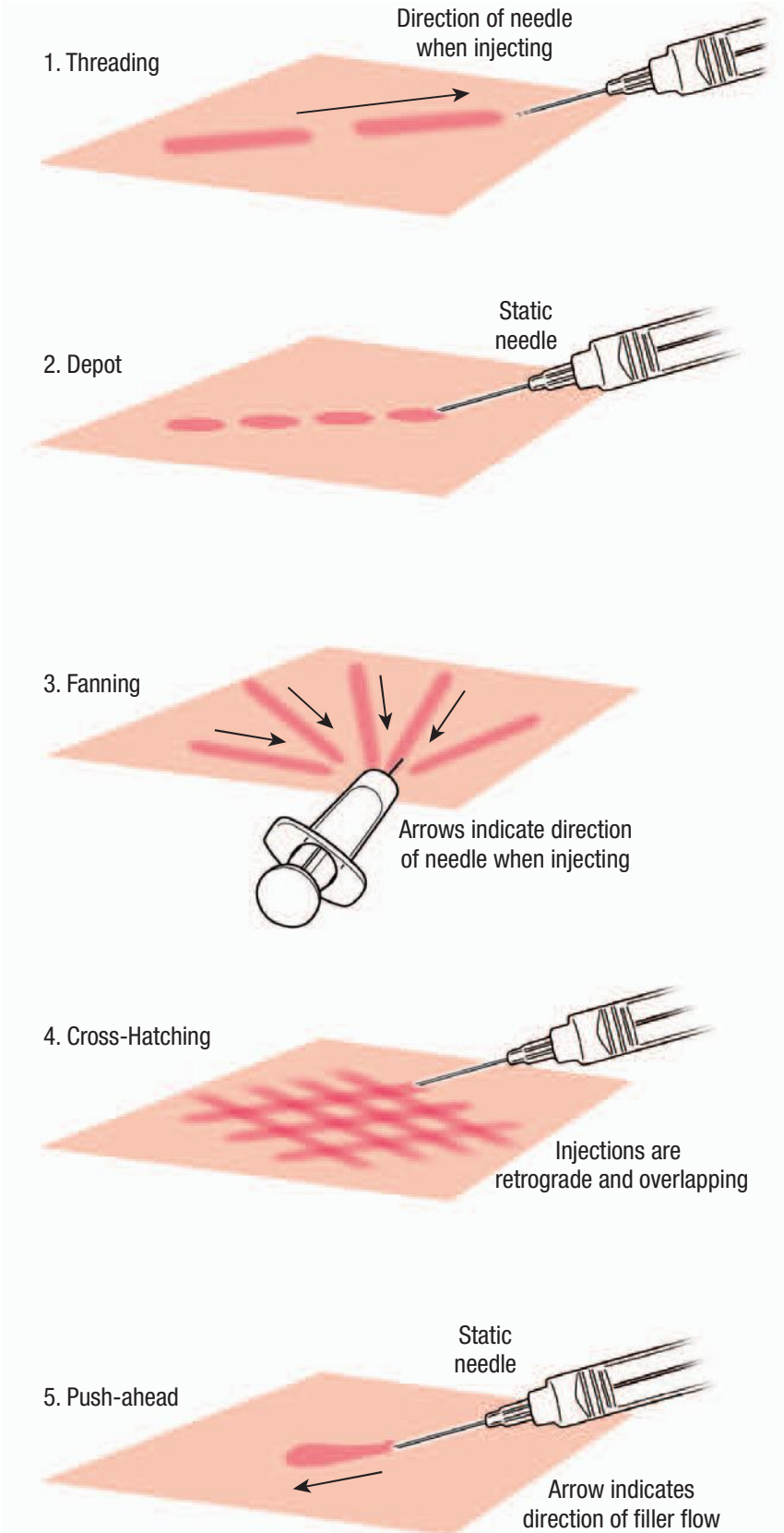

▲ **FIGURE 255-1** Injection techniques.

TABLE 255-1
Features of Soft-Tissue Fillers

Filler	Uses	Type	Placement	Complications	Longevity
Zyderm I	Treatment of fine lines	Bovine collagen	Papillary dermis	Allergic reaction, misplacement	2–4 mo
Zyderm II	Treatment of medium lines, acne scars	Bovine collagen	Mid-dermis	Allergic reaction, misplacement, lumps	3–5 mo
Zyplast	Treatment of medium to deep folds, lips, acne scars	Bovine collagen	Deep dermis	Allergic reaction, misplacement, lumps	3–6 mo
CosmoDerm	Treatment of fine lines	Human-derived collagen	Papillary dermis	Allergic reaction, misplacement	2–4 mo
CosmoPlast	Treatment of medium to deep folds, lips, acne scars	Human-derived collagen	Deep dermis	Allergic reaction, misplacement, lumps	3–8 mo
Restylane	Treatment of medium to deep folds, lips, acne scars, periorbital hollows	Non–animal-derived stabilized hyaluronic acid	Mid to deep dermis	Allergic reaction or inflammation, blue discoloration, misplacement, lumps	5–8 mo
Perlane	Treatment of deep folds, lips, scars; facial contouring	Non–animal-derived stabilized hyaluronic acid	Deep dermis or superficial subcutis	Allergic reaction or inflammation, blue discoloration, misplacement, lumps	6–12 mo
Juviderm	Treatment of medium to deep folds, lips, acne scars	Non–animal-derived stabilized hyaluronic acid	Mid to deep dermis	Allergic reaction or inflammation, blue discoloration, misplacement, migration, lumps	5–8 mo
Radiesse	Treatment of deep folds, nipple reconstruction, nasal reconstruction, jawline augmentation	Calcium hydroxylapatite	Deep dermis to superficial subcutis	Nodules (especially in lips and periorbitally), misplacement with demarcation of product	6–? mo
Sculptra	Treatment of HIV lipoatrophy, cheek and temple hollows	Poly-L-lactic acid	Deep dermis to superficial subcutis	Visible and palpable papules	2 yr or longer
Autologous fat	Pan-facial filling, especially periorbital area	Autologous fat	Subcutaneous tissue	Bumps, vascular occlusive events with injudicious placement	5 yr or longer
Silikon 1000	Treatment of scars, HIV lipoatrophy, lips, deep folds	Silicone oil	Deep dermis	Delayed granuloma formation, migration	Permanent

HIV = human immunodeficiency virus.



tion regarding various types of collagen and other soft-tissue fillers.

Formulations

Bovine collagen (Zyderm I and II, Zyplast*) has been approved for use in the United States since 1981 and, until recently, was the only filler approved by the U.S. Food and Drug Administration (FDA) for soft-tissue augmentation. Bovine collagen products are derived from the hides of a closed herd of American cattle. Before the use of any form of bovine collagen, two skin tests must be performed 4 weeks apart to ensure that allergic reactions to the bovine proteins are avoided. A single skin test alone will fail to identify approximately 25 percent of allergic patients. Human-derived collagens (CosmoDerm, CosmoPlast) are newer to the market. They are produced from a single human fibroblast cell line. Batches are tested for purity and sterility. Due to their homologous nature, synthetic human collagen does not require pre-testing for allergenicity. Three forms of bovine collagen and two forms of human-derived collagen are available, each appropriate for a different level of injection into the dermis. Bovine collagen must be kept refrigerated until just before use. The least viscous form of bovine collagen (Zyderm I) contains 3.5 percent non–cross-linked collagen by weight and is appropriate for injection into the papillary dermis for the correction of fine lines. The second non–cross-linked form has 6.5 percent bovine collagen by weight and is injected into the upper reticular dermis as a treatment for deeper lines and acne scars. Finally, a third form consists of 6.5 percent bovine collagen cross-linked with glutaraldehyde to provide stability against degradation. This is the most viscous of the three bovine forms and is appropriate for treatment of deep folds and lip augmentation. Human collagen is available in a non–cross-linked and a cross-linked form, both with 35 mg/mL of collagen. As with bovine collagen, the non–cross-linked form is more appropriate for injection into fine lines through a small-bore needle and the cross-linked form is more appropriate for treatment of deeper lines, folds, and acne scars, and for lip augmentation.

Anesthesia

All collagens come in pre-filled syringes that contain, in addition to the collagen product, phosphate-buffered saline and 0.3 percent lidocaine. If additional anesthesia is required, lidocaine 4 percent or tetracaine 20 percent can be applied topically in advance. For patients more sensitive to pain, 1 percent lidocaine may need to be administered locally into the area to be infiltrated. If lip augmentation is being carried out, infraorbital nerve blocks may be established with 2 percent lidocaine via the intra-oral or transcutaneous route.

*It is the editors' policy not to use trade names in this book. However, in certain instances, the editors had to depart from this policy to avoid confusion.

Technique

Collagen products are most easily injected with the patient reclining at a 45° angle and the injector positioned to the side of the table. Injection techniques may include a combination of threading, depot, and fanning. The more viscous forms of collagen (Zyplast, CosmoPlast) are best injected through a 30-gauge needle. For the non–cross-linked forms (Zyderm I and II, and CosmoDerm) a 32-gauge needle may be substituted. Use of this smaller-bore needle is especially helpful for attenuation of fine lines around the mouth and eyes or for any other situation in which more control over small injection volumes is needed. Injection of the non–cross-linked forms occurs in the high dermis and should lead to blanching. Because collagen products lose volume after injection, overcorrection of the area injected by 50 percent to 100 percent is desirable.

Post-Procedure Instructions

In the period immediately after injection, the application of ice is recommended to assist with vasoconstriction and help prevent ecchymosis. Effects of the local anesthesia will last from 20 minutes to 90 minutes depending on the anesthetic used. Patients should be warned that immediate results such as swelling and unevenness are secondary to overcorrection and will subside over the course of hours. Patients may apply makeup immediately after injection and go about their daily activities as usual.

Unique Complications

Complications unique to collagen injection include delayed hypersensitivity or allergic reactions to the bovine or human proteins. Although such reactions are rare, they can be seen even with a negative skin test result in approximately 1 percent of patients. These can manifest as either granulomatous reactions or sterile abscess formation. Treatment involves intralesional injection of dilute corticosteroid, administration of oral antibiotics, and reassurance. These adverse events can take up to a year to resolve on their own.

Longevity

Bovine collagen lasts from 2 to 6 months depending on the type used, the level of injection, the site injected, and the amount used. Human-derived collagen appears to last slightly longer.

HYALURONIC ACIDS

Patient Selection

Hyaluronic acid–derived fillers are a good choice for patients who desire a longer period of correction or more volume enhancement. They are more versatile than the collagen products and can be used for augmentation of the nasolabial fold, labiomental crease, lips, cheeks, and periorbital areas. Patients often feel that the hyaluronic acid fillers are softer and more natural in appearance than the collagens, but they need to be warned about the risk of increased erythema, edema, and bruising associated with these products.

Formulations

Hyaluronic acid is a polysaccharide that is homologous throughout the animal kingdom. Injectable FDA-approved forms include a non–animal-derived stabilized hyaluronic acid product (NASHA) made through a bacterial fermentation process and an avian-derived version isolated from cocks' combs. Brands of injectable hyaluronic acids differ not only in their derivation but also in their concentration of hyaluronic acid per milliliter of product, type of cross-linking or stabilizing agents, viscosity, and particle size. All NASHA products are made en bloc initially and then passed through a sieve to create smaller particles. Restylane contains 20 mg/mL of hyaluronic acid with 100,000 gel particles per milliliter. Perlane is another product in the Restylane family. It also contains 20 mg/mL of hyaluronic acid, but the particles are larger, which provides a product concentration of 10,000 gel particles per milliliter. The smaller particle size of Restylane permits injection through smaller-gauge needles into finer wrinkles. The newest NASHA product, Juviderm, is available in two formulations: Juviderm Ultra, containing 24 mg/mL of hyaluronic acid, and Juviderm UltraPlus, containing 30 mg/mL of hyaluronic acid. Another hyaluronic acid, Hylaform, contains 6 mg/mL of hyaluronic acid highly cross-linked with divinyl sulfide. Hylaform is avian-derived and thought by some to possess elastic properties superior to those of the NASHA products. All hyaluronic acid products are prepackaged in filled syringes that require no refrigeration.

Anesthesia

Unlike collagens, hyaluronic acids do not come combined with lidocaine. Due to their high viscosity they can cause significant discomfort on injection. It is therefore recommended that, at a minimum, a topical anesthetic be applied before injection. This usually results in adequate anesthesia for periorbital, nasolabial fold, and labiomental crease injections; however, if lips or perioral rhytides are being treated, an ancillary local infiltration of 1 percent lidocaine or segmental nerve block is indicated.

Technique

Hyaluronic acids should be injected with the patient in a position that elicits the defect or creases to be treated and offers ease of injection to the operator. This is best accomplished by reclining the patient to a 45° angle. All the hyaluronic acid products come with a needle in the gauge of choice for ease of injection and preservation of the physical properties of the gel. Due to their viscoelastic properties, however, hyaluronic acids can often be injected through smaller-gauge needles. For instance, Restylane is prepackaged with a 30-gauge needle, but changing to a 32-gauge needle allows for more precise injection of vertical lip rhytides. Hyaluronic acids are injected in most areas via threading, depot, or fanning. They are particularly amenable to cross-hatching in areas in which a greater density of augmentation is desired. In particular, when hyaluronic acid is injected into the nasolabial fold it is important to span the width of the fold with a serial threading technique and then cross-hatch at right angles. This gives structural integrity to the fold and prevents the undesirable result of merely moving the fold medially. The same technique can be used in the labiomental crease. Lip injections are made using a depot or threading technique, either along the vermillion border, in the body of the lip, or in a combination of both. Perhaps one of the most exciting applications of hyaluronic acids is the correction of tear trough deformity or suborbital hollows. Injections are made either under the orbicularis oculi muscle near the orbital bone or subdermally above the muscle. A depot method of injection is preferred in which very small amounts of hyaluronic acid are deposited on each pass. The push-ahead technique is preferred for the sub-brow area. After injection the area should be vigorously massaged to disperse the product and minimize aggregation of gel particles. Although periorbital injection of hyaluronic acid



results in high levels of patient satisfaction, it is an advanced injection method best left to those with the greatest experience in this sophisticated technique.

Post-Procedure Instructions

The application of ice immediately after the procedure and periodically throughout the day is recommended after the injection of hyaluronic acid. Patients are instructed to avoid manipulation of the treated area and extremes of temperature for the first 48 hours after injection. If the lips were treated in a patient with a history of cold sores, then an antiherpetic medication should be administered for 5 days beginning the day before or the day of the procedure. Patients are instructed to return to the office if they experience any problems such as redness, purulence, or nodule formation.

Unique Complications

Most complications result from improper application of the product. Placement of this clear gel too superficially results in a blue discoloration. Placement of too large an aliquot can result in a non-inflammatory bump. Most ill-placed hyaluronic acid can be released by incising with a 20-gauge needle and expressing the material. Hyaluronic acid products also contain small amounts of impurities that can cause hypersensitivity reactions. Patients can react to sterile bacterial proteins (Restylane, Perlane) or avian proteins (Hylaform) by forming sterile abscesses or granulomatous inflammatory nodules. It has been shown that these nodules, which appear clinically to be granulomatous, may in fact be small foci of infection. Treatment with an anti-staphylococcal antibiotic is the initial treatment of choice. If no resolution occurs, dilute intralesional corticosteroids can be administered or hyaluronidase can be injected to cause rapid dissolution of the product.[1]

Longevity

In general, the longevity of augmentation is greater for the more highly cross-linked or stabilized forms and increases with increasing viscosity and particle size. Hyaluronic acid–based products are broken down via isovolemic degradation; they maintain a constant volume throughout their degradation because of their ability to bind water. This property makes possible a very long-lasting product.

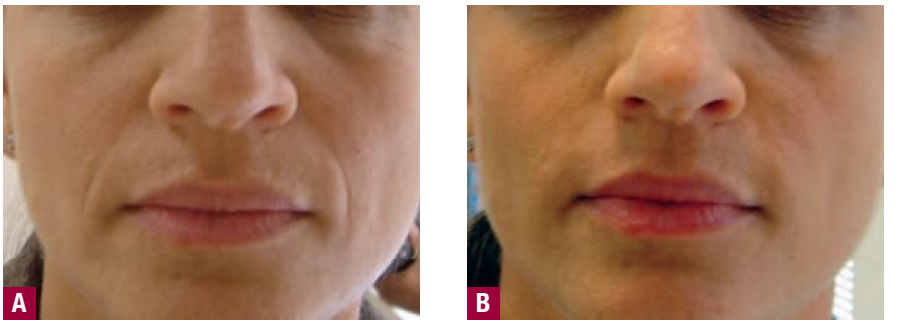

▲ **FIGURE 255-2** Thirty-five-year-old woman before (**A**) and after (**B**) infiltration of Restylane into the nasolabial folds.

In a double-blind multicenter study, Restylane was found superior to Zyplast at all postinjection time points. At 6 months, 67.2 percent of Zyplast-treated folds had returned to their baseline severity, as opposed to only 29.9 percent of Restylane-treated folds.[2] In a study comparing Perlane to Hylaform, at 6 months after treatment, the proportion of patients showing improvement in the Wrinkle Severity Rating Scale score of the nasolabial folds was higher in the group treated with Perlane (75 percent) than in the group treated with Hylaform (38 percent).[3] Treatment-related adverse events were more frequent with Perlane, but local injection-site reactions were mild or moderate in intensity, transient, and no more frequent after Perlane retreatment. In a head-to-head study comparing the tolerability and efficacy of Restylane versus Hylaform in the treatment of nasolabial folds, Restylane demonstrated higher efficacy and patient satisfaction ratings than Hylaform at 12 weeks.[4] Although forcing Restylane through a 32-gauge needle is common in clinical practice, this has been shown to cause the hyaluronic acid to break up into smaller particles. The effect of this on the longevity of the product is unknown. Fig. 255-2 shows a 35-year-old woman before and after Restylane treatment of the nasolabial folds.

POLY-L-LACTIC ACID

Patient Selection

Poly-L-lactic acid (PLLA; trade name Sculptra) is FDA approved for the treatment of lipoatrophy associated with human immunodeficiency virus (HIV) infection. In Europe it has been used for many years as a cosmetic volume enhancement agent. Currently in the United States, PLLA is gaining popularity as a no-downtime, long-lasting filler with a wide range of applications. PLLA's uniqueness lies in the fact that it is not a direct filling agent but rather a biostimulatory agent, eliciting tissue thickening over the course of many months and many treatment sessions. It is therefore the ideal filler for someone desiring a gradual, subtle change. Because PLLA works by initiating a foreign-body tissue response, it is not suited for patients taking immunosuppressive or anti-inflammatory drugs, and it appears to work most efficiently in younger patients. PLLA can be used for volume enhancement in the nasolabial fold, labiomental crease, chin, jawline, temples, and, with care, periorbital area. Some practitioners have found it to provide good filling for the dorsum of the aging hands. It is not recommended for use in the lips.

Formulation

PLLA is the same substance used in the formulation of absorbable suture material and is biocompatible and biodegradable. It is supplied in a glass bottle as a lyophilized powder containing carboxymethylcellulose as an emulsifier and mannitol as an osmotic agent. Injection of PLLA on repeated occasions presumably initiates an immune response that eventually leads to fibroblast activation and collagen deposition. High-level ultrasonographic images taken before and after a series of treatments in study patients confirms the presence of a zone of dermal thickening, but the exact mechanism is unknown.

Anesthesia

PLLA must be reconstituted at least 2 hours in advance of use. Some practitioners suggest reconstitution at least 8 hours before treatment to fully suspend and hydrate the particles of PLLA. The package insert recommends reconstitution with 3 to 5 mL of sterile water, but



◀ **FIGURE 255-3** Thirty-nine-year-old woman before (**A**) and 4 months after (**B**) the last of two Sculptra treatments to the lower face.

the consensus of physicians currently using the product is to reconstitute with 5 mL of diluent at a minimum. It is therefore possible to reconstitute the product in advance with 4 mL of sterile water and immediately before injection to add 1 mL of 1 percent lidocaine to the bottle. This tempers the pain on injection. In addition, patients may want to apply a topical anesthetic containing either 4 percent lidocaine or 20 percent tetracaine in advance of treatment.

Technique

PLLA is injected through a 26-gauge needle. Because of the risk of particle clumping, the bottle must be agitated frequently throughout the course of treatment. The operator must maintain maximum control over injection amounts, so drawing the material up into 1-mL syringes is highly recommended. Two injection techniques are used when infiltrating PLLA: depot and threading. Threading is used for areas below the level of the zygomatic arch, and the depot method is used for areas above it. The principle is to inject PLLA into areas that will eventually display a direct impact from local volume change or affect neighboring areas by filling and suspending tissues upstream. Lower-face injections are performed diffusely over a wide surface area and involve the placement of 0.1-mL linear threads of solution 2 mm apart. The recommended technique is to inject across folds to distend them, rather than filling them directly. No attempt at volumetric correction is made during treatment; rather, the intent is to place the PLLA solution diffusely. The level of injection in the lower face (cheek, nasolabial fold, jawline, labiomental crease, chin) is subdermal or deep dermal. In the upper face (temples and periorbital area) treatment is via depot injection of 0.05 mL of PLLA solution under or close to periosteum. No more that 0.5 mL total should be distributed in this fashion. If clogging of the needle occurs, it should be withdrawn and either changed or cleared before proceeding.

Post-Procedure Instructions

Immediately after injection, treated areas must be vigorously massaged to distribute the suspension evenly into the tissues. No blebs of material should be palpable. When the practitioner is satisfied that this is the case, the massage may then be continued in a more gentle manner by an assistant for the next 5 minutes. Ice is then applied to the face for 20 minutes. The patient may then apply makeup and resume normal activities. The patient must massage the areas of injection for 5 minutes at least twice a day for the next week. Because minimal augmentation is achieved in each session, patients are instructed to return at 6-week intervals for additional treatments. The motto "Treat, wait, assess" is an important one to follow when using PLLA. Resultant augmentation can take 4 months or longer to occur, so patience is necessary to avoid overcorrection. For the average patient with cosmetic concerns, between three and six treatments will be required for ample augmentation to occur (Fig. 255-3). For patients with severe lipoatrophy, a minimum of six sessions will be required, often with injection of two vials per session.

Unique Complications

Superficial injection of PLLA most often results in visible papule formation. Reconstitution with inadequate amounts of fluid may also increase this risk. Delayed formation of subcutaneous papules has been reported in the literature. These palpable papules are most often nonvisible, asymptomatic, and noninflammatory, and require no treatment. If they are of concern to the patient, an attempt can be made to break apart the papules by injecting sterile water into them or by teasing them apart with a 27-gauge needle.

Longevity

The results from PLLA infiltration are thought to last 2 years or longer, with gradual resorption and breakdown of the product to lactic acid over the course of 2 to 3 years.[5]

CALCIUM HYDROXYLAPATITE

Patient Selection

Patients requiring augmentation of the nasolabial folds, labiomental crease, mandibular ramus, cheeks, acne scars, or pre-jowl sulcus are candidates for treatment with calcium hydroxylapatite (CaHA). CaHA has also been used with success in the correction of atrophic acne scars, in the recontouring of nasal defects, and in nipple reconstruction after failed nipple areolar reconstruction. Due to the risk of lump formation CaHA is not recommended for lip augmentation.

Formulation

Approved for use by the FDA as a radiographic marker and for the correction of oral and maxillofacial defects and the treatment of vocal cord insufficiency, CaHA (Radiesse) is finding its way into the temporary filler arena. The microspheres of CaHA, once injected into the deep dermis, form a scaffold to support the growth of autologous collagen. CaHA microspheres are suspended in a polysaccharide carrier, which holds the microspheres in place until it is resorbed and neocollagenesis takes place. CaHA contains no animal or human tissues, so allergy testing is not indicated.

Anesthesia and Technique

Injection of CaHA is quite uncomfortable, so it is almost always necessary to anesthetize the area first with 1 percent lidocaine.

Due to its viscosity CaHA must be injected through a 27-gauge needle. A threading technique is used, with infiltration staying at the dermal-subcutaneous junction in the area of the nasolabial fold and at the deep fat or supraperiosteal region in the areas of the cheek and mandible. CaHA appears to work best if patients undergo retreatment or touch-up at 3 months.



Post-Procedure Instructions

There can be marked swelling and bruising after the injection of CaHA, so post-treatment icing is recommended. Many physicians advocate immediate postinjection massage but feel that continued massage is unwarranted.

Unique Complications

The majority of complications with CaHA (nodules) are seen in the lips, but it is possible for nodules lasting 1 to 2 years to occur anywhere the substance is injected. There is a paucity of studies of the use of CaHA for soft-tissue augmentation. One small study noted a 3 percent nodule rate in 29 patients treated with CaHA for soft-tissue augmentation. Nodules are supposedly non-inflammatory, and often the material can be extruded from a puncture incision. Persistent nodules may have to be surgically removed. If CaHA is injected too superficially or at appropriate levels in thin skin, its opacity can be seen. Demarcation of product is especially evident in the periorbital area, as is prolonged erythema. Full results, including side effects profile, from the FDA clinical trials are greatly anticipated.

Longevity

Preliminary data released from the FDA clinical trials of CaHA for aesthetic soft-tissue augmentation show better results after treatment of the nasolabial fold with CaHA than after treatment with human collagen at 6 months (FDA summary of safety and effectiveness, PMA PO50052). In a study following 90 patients in whom various sites were injected with CaHA, patient satisfaction was rated as good to excellent by 88 percent of patients at 6 months.[6] In practice, though, longevity appears variable, with effects lasting from 3 to 18 months.

AUTOLOGOUS FAT

Patient Selection

Autologous fat transfer (AFT) is a practical option for those patients desiring a more dramatic global change in facial appearance. It is a filler intended to restore the youthful architecture by providing broader rejuvenation to the aging face affected by volume loss. Fat is a very versatile filler, effective in the perioral area as well as the lips. Because it is autologous, it is the filler of choice for patients with collagen vascular disease or proven allergic reactions to collagens or hyaluronic acids. AFT is a more involved surgical procedure than is injection of the other fillers previously discussed, because tumescent liposuction is required for the fat extraction. Exclusion criteria for treatment include concomitant anticoagulant treatment and poor health.

Technique

PREPARATION AND ANESTHESIA For 2 weeks before the initial AFT procedure the patient must stop taking all nonsteroidal anti-inflammatory drugs, vitamin E, ω-3 fatty acid supplements, and ginkgo, ginger, or ginseng supplements. The patient is instructed to begin therapy with an appropriate anti-staphylococcal antibiotic starting the day before procedure. On the day of the procedure the donor fat site and the face are both washed with an antibacterial soap. The physician then delineates the area to be suctioned with a marking pen. Every attempt should be made to choose a donor site that benefits a patient aesthetically. The outer thighs and hips in women and the flanks in men are usually good sites for fat harvesting.

In preparation for fat transfer a pattern is drawn on the face delineating the areas in which fat is to be placed and highlighting any scars or baseline asymmetry. The patient is then placed on a sterile draped operating table and the areas requiring fat suctioning are infiltrated with dilute local anesthesia until turgid (tumescent technique; Table 255-2; see Chap. 254).

It takes at least 20 minutes for the epinephrine in the tumescent fluid to achieve hemostasis. The face is then anesthetized diffusely with dilute 0.5 percent lidocaine with epinephrine 1:200,000, and segmental nerve blocks are established where appropriate. For safety, the total lidocaine dose in the tumescent fluid should not exceed 35 mg/kg of body weight.

TABLE 255-2
Tumescent Anesthesia Solution

- 1 L normal saline
- 50 mg lidocaine
- 0.5–1 mg epinephrine
- 12.5 mEq sodium bicarbonate

FAT HARVESTING Suctioning of the fat used for transplantation should be done by hand with an open-tipped harvesting cannula attached to a 10-mL syringe. After a hole is made with a 1.5-mm punch or No. 11 blade, the cannula is inserted into the deep fat and moved back and forth while the plunger on the syringe is retracted. Fat collection usually occurs quite rapidly and, due to the vasoconstrictive properties of the tumescent fluid, is nearly bloodless. After fat extraction the syringes may be placed into a centrifuge and spun at 3400 rpm for 20 seconds or left to stand for 20 minutes to allow separation of the hydrophilic tumescent fluid from the lipophilic fat. The infranate of tumescent fluid should then be decanted before the fatty layer is transferred to 1-mL syringes in preparation for injection into the face. Any supranate of ruptured fat cells (triglycerides and free fatty acids) should be discarded.

FAT TRANSFER All AFT to the face is performed using an 18-gauge or smaller blunt cannula for infiltration. Incision sites can be made with an 18-gauge needle, a NoKor needle (Becton, Dickinson and Co., USA), or the tip of a No. 11 blade scalpel. Fat is infiltrated in a retrograde manner; that is, fat is injected only as the cannula is withdrawn. Injection is in small aliquots of 0.1 mL or less using a threading or depot method. Placement of fat always starts closest to bone when possible and then proceeds up through muscle and into subcutaneous fat. Fat is deposited in a crosshatched three-dimensional lattice and thus imparts structure as well as augmentation to the tissues. All areas of the face should be addressed to achieve filling laterally as well as anteriorly. The goal is to advance tissues forward and thereby elevate them away from the bone, fill in areas of shadow, and restore youthful contours.

Post-Procedure Instructions

Immediately after the procedure and on and off for the next 2 days, ice should

be applied to the face. The area suctioned is dressed with absorbent pads, and a snug garment is applied. Incision sites on the body and face are left unsutured. The patient is instructed not to submerge the body in water until all incisions are healed (approximately 1 week). Antibiotics must be continued for 6 days after the initial procedure. Intramuscular triamcinolone may be given to reduce postoperative edema.

Unique Complications

Postoperative edema and ecchymoses are common and last for approximately 2 weeks. Undercorrection with a gradual decrease in augmentation is common and usually represents a decline in edema rather than absorption of the fat. For this reason fat transfer should never be recommended as a one-time procedure but rather as a series of treatments with cumulative augmentation and long-term results. Small, persistent lumps can occur that represent either fat cysts or accumulation of fat. They can be treated, usually to resolution, with intralesional injection of triamcinolone (2 to 4 mg/mL). If a larger fat lump is present, the best option is to feather it into the surrounding tissues with an infiltration cannula. Irregularities can also occur at the harvest site, but operator experience and judicious removal of fat makes this a highly unlikely event.

Longevity

Many authors using a standardized, multilevel microinjection technique have published photodocumentation demonstrating long-term follow-up and persistence of autologous fat (Fig. 255-4).[7,8] However, the controlled, double-blinded, multicenter studies seen for evaluation of other fillers are not available.

INJECTABLE SILICONE

Patient Selection

Injectable silicone is an undisputedly permanent filler with a wide range of applications. It appears to provide permanent, cosmetically superior augmentation for treatment of HIV lipoatrophy, plantar defects, and scars. Historically, silicone injection has been associated with disfiguring tissue distortions and migration of product. These side effects can almost always be traced to the use of large-volume injections or non–medical grade silicone. Because of the controversial nature of silicone augmentation, patient selection for cosmetic indications is currently complex, and use of the procedure should be reserved for those physicians who have extensive experience in the injection of silicone as a filler and understand the concepts outlined in the Technique section.

Patients with a known history or autoimmune disease or with infection should be excluded from treatment.



▲ **FIGURE 255-4** Fifty-five-year-old woman before (**A**) and 20 months after (**B**) full-face fat transfer treatment series.

Formulation

Perhaps no other filler has both inspired such a loyal following and provoked such vehement opposition as injectable silicone. The currently available form of silicone is Silikon 1000. This agent is FDA approved for the treatment of retinal tamponade. It is not approved for the indication of soft-tissue augmentation. It is a sterile, impurity-free, medical-grade silicone oil at a 1000-centistoke viscosity. It is noncarcinogenic and does not appear to be associated with arthritic disease in mice. After injection silicone is encapsulated in collagenous fibrous tissue, so that final augmentation is a result of both volume of injected silicone and host tissue response.

Anesthesia

Silikon 1000 does not contain an anesthetic solution, because such small volumes are injected on each visit that ancillary anesthesia is not often required. If desired, a topical anesthetic agent containing 20 percent tetracaine or 4 percent lidocaine may be applied before the procedure.

Technique

Improper technique in the injection of silicone oil will almost guarantee permanent adverse sequelae. It is therefore absolutely necessary that a physician considering the use of silicone apprentice with an experienced practitioner. Silikon 1000 is highly viscous and must be injected through either a 26-gauge needle on a 1-mL syringe or a 30-gauge needle on a 0.3-mL syringe. Use of a microinjection technique is paramount to success with silicone, so large-bore needles are never to be used. The microdroplet injection technique involves injecting 0.01 mL of silicone oil, with the needle bevel down, into the deep dermis in a depot fashion at 1- to 3-mm intervals. Note that 100 droplets are therefore required to empty a 1-mL syringe. Except in the treatment of HIV cheek atrophy, it is rare to use more that 0.3 mL total per injection session. Treated areas are always undercorrected, and patients are instructed to return for multiple injection sessions at monthly intervals until full augmentation occurs.

Post-Procedure Instructions

There is very little postoperative discomfort, edema, or ecchymosis after microinjection with liquid silicone. Ice may be applied if needed to lessen the risk of postinjection ecchymosis. Patients may apply makeup and pursue their daily activities as usual after injection.

Unique Complications

Most authorities on silicone use agree that the incidence of serious complications after the proper use of medical-grade silicone is very low. In an FDA-authorized study involving 1400 patients over a 20-year period, 2 patients experienced serious side effects: one case involved migration of silicone after treatment with large volumes, and the second involved inflammation and necrosis in a patient with concomitant Weber-Christian disease and rheumatoid arthritis. Local granulomatous nodularities can occur many years after the cessation of treatment and are usually preceded by a systemic infection. Treatment regimens for granulomas include intralesional or systemic steroids, minocycline, and topical imiquimod.[9]



Longevity

The augmentation derived from liquid silicone injection is permanent. Many authors have published reports of long-term studies, some with 30-year follow-up, showing persistence of improvement. Patients receiving liquid silicone injections will continue to age, and for this reason additional augmentation may be required should neighboring areas of age-related atrophy develop.

COMPLICATIONS ASSOCIATED WITH THE USE OF ALL FILLERS

Vascular occlusion is perhaps the most devastating complication associated with the use of all fillers. This can manifest as local necrosis, central nervous system infarction, or blindness. Blindness and middle cerebral artery infarction have been described most often after fat transfer, but vascular occlusion with ensuing sequelae has occurred after the use of collagen and hyaluronic acid fillers as well. In theory, the central occlusive events have occurred from high-pressure injections with retrograde flow into arterioles that connect with the internal carotid system. It is therefore of utmost importance to keep the needle or cannula moving during withdrawal while depositing filler and to exert as little pressure as possible on the syringe. For similar reasons, when fat transfer is performed only blunt cannulas should be used for infiltration.

Other complications common to the use of all fillers include ecchymosis, edema, extrusion or drifting of the filling substance, foreign-body reactions, changes in pigmentation, injection site scarring, overcorrection, undercorrection, misplacement, and infection.

REFERENCES

1. Lowe NJ, Maxwell CA, Patnaik R: Adverse reactions to dermal fillers: Review. *Dermatol Surg* **31**:1616, 2005
2. Narins RS et al: A randomized, double-blind, multicenter comparison of the efficacy and tolerability of Restylane versus Zyplast for the correction of nasolabial folds. *Dermatol Surg* **29**:588, 2003
3. Carruthers A et al: Randomized, double-blind comparison of the efficacy of two hyaluronic acid derivatives, restylane perlane and hylaform, in the treatment of nasolabial folds. *Dermatol Surg* **31**:1591, 2005
4. Rao J et al: Clinical comparison between two hyaluronic acid-derived fillers in the treatment of nasolabial folds: hylaform versus restylane. *Dermatol Surg* **31**:1587, 2005
5. Moyle GJ et al: A randomized open-label study of immediate versus delayed polylactic acid injections for the cosmetic management of facial lipoatrophy in persons with HIV infection. *HIV Med* **5**:82, 2004
6. Tzikas TL: Evaluation of the Radiance FN soft tissue filler for facial soft tissue augmentation. *Arch Facial Plast Surg* **6**:234, 2004
7. Coleman SR: Long term survival of fat transplants: Controlled demonstrations. *Aesthetic Plast Surg* **19**:421, 1995
8. Donofrio LM: Panfacial volume restoration with fat. *Dermatol Surg* **31**:1496, 2005
9. Duffy DM: Liquid silicone for soft tissue augmentation. *Dermatol Surg* **31**:1530, 2005

CHAPTER 256

Botulinum Toxin

Richard G. Glogau

On April 15, 2002, the U.S. Food and Drug Administration (FDA) approved Botox Cosmetic* (botulinum toxin type A) for "temporary improvement in the appearance of moderate to severe glabellar lines in adult men and women 65 or younger." This was the first elective cosmetic indication for which any commercially available botulinum toxin on the U.S. market had been approved.

The toxin had previously been approved for the treatment of strabismus, blepharospasm, and cervical dystonia, but existing off-label cosmetic use of the toxin had already propelled annual sales to $250 million per year in 2002. With FDA recognition of the cosmetic indication, sales ballooned to over $1 billion per year by the end of 2007.

*It is the editors' policy not to use trade names in this book. However, in certain instances, the editors had to depart from this policy to avoid confusion.

HISTORY

The era of the use of botulinum toxin for reduction of skin lines began when Dr. Jean Carruthers observed a smoothing effect on the glabellar brow furrows in patients injected with toxin for blepharospasm.[5] The effect was much more profound than that which could be achieved using collagen fillers. Carruthers and Carruthers published a report on their novel therapeutic approach in 1992.[7]

Myriad therapeutic uses for botulinum toxin—apart from the treatment of blepharospasm, strabismus, torticollis, hemifacial spasm, and other facial dystonias[8]—have evolved since 1992, including treatment of hyperhidrosis,[9] migraine headaches,[10] and chronic conditions such as lower back pain.[11,12] The clinical utility of the neurotoxin is so widely known today that the word *Botox* has become a generic term in the public mind for all agents used in cosmetic neurotoxin therapy, although the term is properly reserved for Allergan's trademarked commercial version of the type A neurotoxin complex.

PHARMACOLOGY

Toxin Structure

Botulinum neurotoxins are currently categorized into seven distinct serotypes: A, B, C1, D, E, F, and G.[13] The molecules vary in their biosynthesis, size, cellular sites of action, binding kinetics, duration of effect, and stability. The serotypes currently commercially available, serotypes A and B, are derived from different strains of *Clostridium botulinum*. They both have 150-kd dichain polypeptides with a heavy chain and light chain linked by disulfide

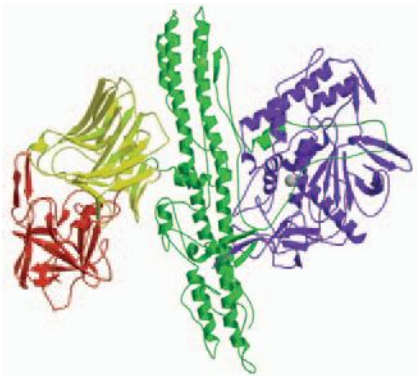

▲ **FIGURE 256-1** Schematic of the botulinum complex showing the binding domain with the N-terminus (*yellow*) and the C-terminus (*red*), together with the translocation domain (*green*) and the light chain (*blue*). (From Turton K, Chaddock JA, Acharya KR: Botulinum and tetanus neurotoxins: Structure, function and therapeutic utility. *Trends Biochem Sci* **27**:552, 2002, with permission.)

bonds. During biosynthesis, the molecules of A and B are surrounded by proteins to form a neurotoxin complex, ranging from 500 kd to 900 kd (Fig. 256-1).

Mechanism of Action

The toxin enters the nerves by binding to surface protein receptors and undergoing endocytosis into internalized vesicles. The light chain is released into the nerve cytosol, and the SNARE (soluble N-ethylmaleimide-sensitive factor attachment protein receptor) protein complex is cleaved to inhibit exocytosis of the neurotransmitters such as acetylcholine (Fig. 256-2). Type A toxin cleaves SNAP-25 (synaptosome-associated protein of 25 kd), whereas type B cleaves VAMP (vesicle-associated membrane protein), also called *synaptobrevin* (Fig. 256-3). These proteins are necessary for the release of acetylcholine from vesicles within the cytoplasm of the motor nerve endings. The binding characteristics of each serotype dictate the locus of action on the intracellular SNARE protein complex (Table 256-1).

The end result is a chemodenervation of the cholinergic neurons, either motor nerves or autonomic nerves, leading to localized absence of skeletal muscle activity or autonomic control of target organs such as the eccrine sweat glands. The way in which the nerves escape the effect of the neurotoxin is partially understood.[14] The chemodenervated nerve endings develop collateral sprouting near the primary terminus of the nerve. These sprouts eventually make proxi-

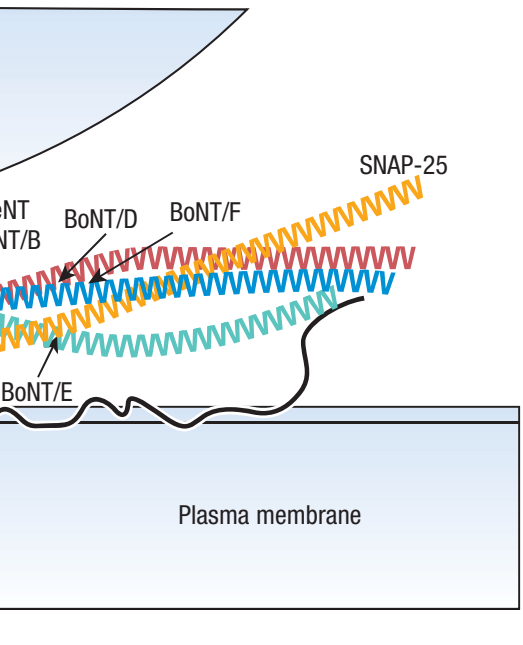

▲ **FIGURE 256-3** Schematic representation showing the sites of action of the different botulinum serotypes on the intracellular protein complex known as the SNARE (soluble N-ethylmaleimide-sensitive factor attachment protein receptor) proteins responsible for exocytosis of acetylcholine from the nerve. Botulinum A serotype cleaves SNAP-25 (synaptosome-associated protein of 25 kd). Other serotypes impact VAMP (vesicle-associated membrane protein), synaptobrevin, or syntaxin. BoNT/A through BoNT/G = botulinum neurotoxin serotypes A through G; TeNT = tetanus neurotoxin. [From Sutton RB et al. Crystal structure of a SNARE complex involved in synaptic exocytosis at 2.4 A resolution. *Nature* **395** (6700):347, 2000, with permission.]

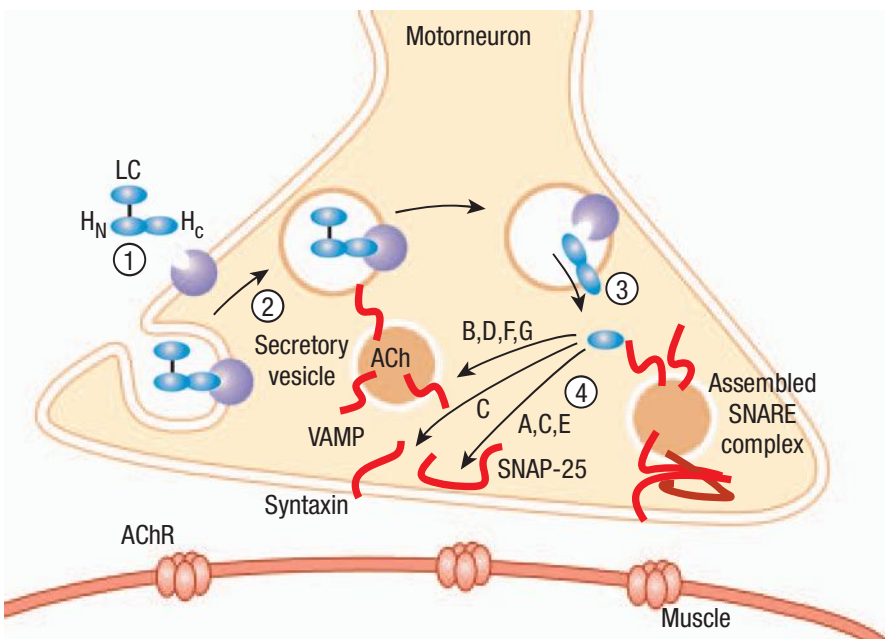

▲ **FIGURE 256-2** The heavy chain domain of the botulinum neurotoxin complex binds to the plasma membrane receptor (1) and the complex is internalized (2). The light chain fragment is then released into the cytoplasm (3), where it cleaves the SNARE (soluble N-ethylmaleimide-sensitive factor attachment protein receptor) protein complex at a site determined by the neurotoxin serotype (4). This disruption of the SNARE complex prevents exocytosis of acetylcholine (ACh) into the synaptic space of the neuromuscular junction. A through G = neurotoxin serotypes; AChR = acetylcholine receptor; LC = light chain; H_C = heavy chain C-terminus; H_N = heavy chain N-terminus; SNAP-25 = synaptosome-associated protein of 25 kd; VAMP = vesicle-associated membrane protein.

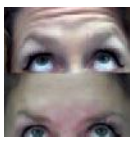

TABLE 256-1
Binding Sites in the SNARE Protein Complex of the Seven Known Botulinum Toxin Serotypes

Serotype	Intracellular Protein
A	SNAP-25
B	VAMP/synaptobrevin
C1	SNAP-25 and syntaxin
D	VAMP/synaptobrevin
E	SNAP-25
F	VAMP/synaptobrevin
G	VAMP/synaptobrevin

SNAP-25 = synaptosome-associated protein of 25 kd; SNARE = soluble N-ethylmaleimide-sensitive factor attachment protein receptor; VAMP = vesicle-associated membrane protein.

TABLE 256-2
Comparison of the Properties of the Three Commercially Available Forms of Botulinum Toxin in Current Medical Use

	Botox	Dysport	Myobloc
Serotype	A	A	B
Complex molecular weight	900 kd	~ 900 kd	700 kd
Package (units)	100	500	2500/5000/10,000
Neurotoxin protein per vial (ng)	~ 5	12.5	25/50/100
Form	Vacuum dried	Lyophilized	Solution
pH	~ 7	~ 7	5.6
Year of first approval	1989	1991	2000



mate contact with the targets, either muscle or gland, and begin to overcome the loss of neurotransmitter at the end organ synaptic junctions.

Once these sprouts have re-established chemical contact with their targets, muscles resume activity and glands begin to secrete. Simultaneously, the original chemodenervated terminal nerve ending begins to degrade the blocked SNARE proteins and develop new proteins to resume the chemical exocytosis of acetylcholine. While these repairs are underway, and while the original terminal nerve ending reacquires communication with the target organ, the collateral sprouts begin to slowly resorb until anatomically nothing is left but the original terminal ending with restored junctional activity.

Three commercially available preparations of botulinum neurotoxin were on the market in the United States and Europe in 2007. Two are medical-grade forms of botulinum toxin A and one is a medical-grade form of botulinum toxin B. The products differ in their methods of manufacture, commercial form, and biologic profiles. One form of type A is presently available as Botox or Botox Cosmetic in the United States and Vistabel or Vistabex in Europe. Another form of botulinum A toxin is marketed in Europe as Dysport, with anticipated FDA approval for entry into the U.S. market in 2008 as Reloxin. The type B neurotoxin is marketed in the United States as Myobloc. Botox and Dysport are sold in vacuum-dried and lyophilized form, respectively, and must be reconstituted with normal saline. Myobloc is sold in an aqueous solution at a pH of 5.6 (Table 256-2).

Although the molecule complexes are unique, very approximate equivalencies have been derived from clinical observations. One mouse unit of Botox is equal to approximately 2.5 to 4 units of Dysport and 100 units of Myobloc. In dermatologic use, Botox is generally diluted with 1.0 or 2.5 mL saline, producing concentrations of 40 units/mL or 100 units/mL. Contrary to the package insert instructions, clinicians find that the toxin is stable at room temperature, and when diluted, it remains stable under refrigeration for extended periods without significant loss of potency. The use of sterile saline with preservative (benzyl alcohol) lessens the sting of injection with Botox. Myobloc causes more discomfort on injection because of its low pH, but it is stable in liquid form at room temperature for many months.

Immunology

The possibility of antibody-mediated resistance appears to be largely theoretical. Original Botox batch No. 79-11, widely used in ophthalmology and neurology for years, produced rare cases of nonresponse in the treatment of torticollis and blepharospasm. Newer batches introduced in 1997, No. 91223US and No. BCB2024, have significantly less protein load. Although cases of primary nonresponse may be rarely encountered, immunologic resistance to Botox and Botox Cosmetic does not appear to be clinically relevant in dermatology, even at the dosages used to treat hyperhidrosis, which can average 400 units per treatment session. In addition, the treatment interval does not appear to be a significant factor in clinical resistance for the newer batches and at the smaller dosages used in cosmetic facial treatment, although exposure to the toxin at increasingly shorter intervals may be associated with development of neutralizing antibodies.

INDICATIONS

Botulinum toxin is used in cosmetic dermatology primarily for the treatment of dynamic expression lines in the upper third of the face (the glabellar brow furrow, horizontal frontalis forehead lines, periocular rhytides or crow's-feet) and for the treatment of axillary hyperhidrosis. Less common and therapeutically more challenging indications are platysmal banding in the neck, perioral rhytides, marionette lines at the corners of the mouth from the action of the depressor anguli oris, postsurgical synkinesis in the lower face, and palmar/plantar and forehead/scalp hyperhidrosis.

TREATMENT

Glabellar Brow Furrows

A firm understanding of the underlying facial anatomy is the *sine qua non* of successful aesthetic therapy with botulinum toxin. Depending on the muscle mass present and the degree of atrophy from prior treatment, 25 to 35 units of Botox may be placed in five separate injection points to treat the corrugators and procerus muscle in the average brow (Fig. 256-4). A 30-gauge, 31-gauge, or even 32-gauge needle and a tuberculin or diabetic syringe are used to minimize the trauma of the intramuscular injections. The corrugator injections are placed (1) just at or above the medial brow and (2) in or just lateral to the mid-pupillary line, 1 cm above the bony orbital rim. The fifth injection is placed in the procerus at the midline at a point just above the horizontal creases created in the glabella at the bridge of the nose (see Fig. 256-4). Fig. 256-5 shows the results of the procedure.

Based on earlier experience with ophthalmologic periocular injections for treatment of muscle spasms, patients have been instructed to remain upright for 2 to 3 hours to limit the incidence of eyelid ptosis, which occurs with diffusion of the toxin down into the levator muscles of the lid (Fig. 256-6). With operator experience, the incidence of ptosis after injection of the brow should be less than 2 percent.

Temporary stimulation of Müller's muscle in the lid can be achieved with

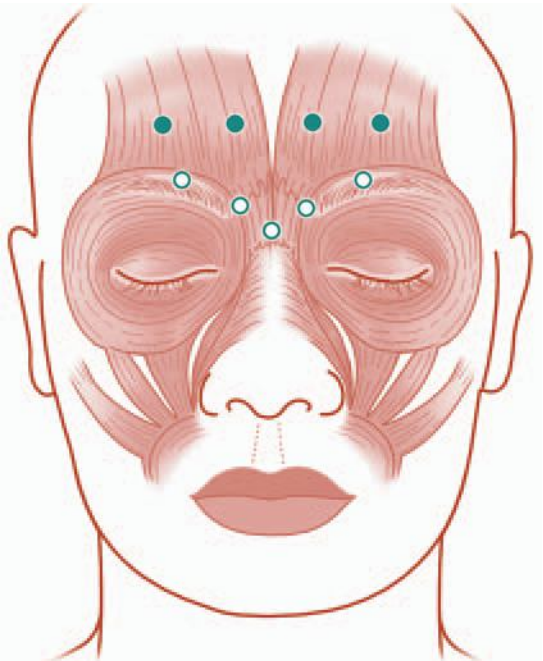

◀ **FIGURE 256-4** Sites of injections on the forehead. The corrugator and procerus muscles are weakened by carefully positioning five injections of botulinum toxin of 5 units each (*open circles*). Forceful knitting of the brow is prevented. To weaken the frontalis muscle, injections are placed in four or five divided doses along the forehead equator (*closed circles*).

0.5 percent apraclonidine or 2.5 percent phenylephrine eyedrops (see Fig. 256-6). These will produce 2 to 3 mm of elevation of the lash margin, and administration may be repeated at intervals until the distant diffusion effect of the botulinum toxin on the levator muscle disappears, usually in 2 to 3 weeks.

Horizontal Forehead Lines

The frontalis is treated at the horizontal equator of the forehead or above to avoid inactivation of the lower third of the frontalis muscle, which is responsible for suspension and movement of the eyebrows (see Figs. 256-4 and 256-7). Twelve to 20 units of botulinum toxin are placed in four or five divided doses equidistantly along the forehead equator. If too large a dose is applied or injection sites are placed too low, brow ptosis and loss of brow arch are produced, which leads to an unpleasant, heavy sensation in the brow as well as an aesthetically unattractive appearance.

Unlike in the treatment of eyelid ptosis, there is no comparable adrenergic agent available to reverse brow ptosis induced by botulinum, and the patient must wait several weeks for the effect to wear off. In a patient who has never received botulinum toxin before, it is wise to separate the glabellar area from the forehead area and to wait a couple of weeks between treating the two to avoid the possibility of overtreatment and brow ptosis. Many patients find even the smallest drop in brow position very bothersome, and great care should be taken to avoid this complication of aesthetic treatment.

Crow's-Feet

The rhytides at the corners of the eye respond favorably to injections of toxin; however, patients frequently confuse true crow's-feet rhytides with the dynamic expression lines that appear across the malar eminence laterally in conjunction with smiling and contraction of the zygomaticus muscles. Toxin may successfully ameliorate true crow's-feet, which radiate directly from the lateral canthus and are associated with contraction of the orbicularis oculi muscles by themselves. But the "smile lines" that appear over the malar eminence often lie in wait for the unwary injector. Placing toxin at or below the malar eminence in an attempt to weaken these lines may lead to paralysis of the zygo-





▲ **FIGURE 256-5** Before botulinum toxin treatment of the corrugator and procerus muscles (*upper panel*) and 1 week after treatment (*lower panel*).



▲ **FIGURE 256-6** Patient who developed ptosis of the right upper eyelid due to diffusion of the botulinum toxin from the area above the mid-brow down into the levator muscle of the upper eyelid. The lower photograph shows the patient approximately 1 minute after instillation of two drops of apraclonidine 0.5 percent ophthalmic solution into the right eye. Direct adrenergic stimulation of Müller's muscle occurs, which lifts the lid temporarily. The drops may be administered every 4 hours as needed. The botulinum-induced ptosis resolves spontaneously, usually in 3 weeks or less.

maticus muscles and a drooping corner of the mouth that cannot spontaneously be raised, so that the patient may acquire a post-stroke appearance.

To safely approach crow's-feet, the toxin is usually placed at one to three injection points approximately 1 cm lateral to the lateral canthus. Some practitioners place all the drug at one point, and others distribute the dose evenly among three points. Typical doses range from 10 to 18 units depending on the estimate of muscle mass and activity.

Great care must be taken to make the injections into the skin only, raising wheals or blebs that can be gently massaged down. Intramuscular injection in this area will reliably produce unwanted bruising because of the rich venous plexus underlying the skin in this region. The toxin will readily diffuse from the blebs into the underlying orbicularis muscle, relaxing the grip on the overlying skin and smoothing out the wrinkles. As previously mentioned, care must be taken to avoid injecting too low down onto the malar eminence, where diffusion may affect the zygomaticus major muscle and disrupt the symmetrical movement of the corner of the mouth in smiling.

The patient being treated for crow's-feet should have good lower eyelid tarsal tone to avoid the appearance of senile ectropion from too much laxity of the lower eyelid. Pre-treatment of the crow's-feet area is very useful as an adjunctive technique before laser resurfacing. It prevents the problem of rhytides being readily re-formed by repeated squinting during the postoperative healing period, in which case the resurfacing may give rise to more noticeable lines than existed before the resurfacing.

Combination Therapy

As clinical experience accumulated with these commercial botulinum toxin products, experts in soft-tissue augmentation soon recognized that a synergy exists between soft-tissue fillers and neurotoxins.[15] Concomitant with the rise in the use of botulinum neurotoxin for cosmetic applications, the marketplace for soft-tissue augmentation expanded with the introduction of injectable hyaluronic acid gels (see Chap. 255). These agents provided the first new directions in cosmetic therapy since the introduction of solubilized bovine collagen in the mid-1970s. The ability to control both muscles of expression and their secondary lines and folds, and to repair age-related volume changes in subcutaneous tissue has revolutionized minimally invasive cosmetic techniques.

Many patients have eagerly embraced simultaneous treatment with both fillers and botulinum toxin to achieve a natural look and forego more traditional incisional surgery. As an example, patients frequently combine treatment of the upper third of the face (glabellar frown lines, horizontal forehead lines, and crow's-feet) with volume restoration of the lower and middle face (lip enhancement, filling of nasolabial fold and marionette lines, chin and cheek augmentation) (see Chap. 255).

Hyperhidrosis

Focal axillary hyperhidrosis is successfully treated with botulinum toxin by using Minor's starch-iodine test to map out the extent of surface area in the axillary vault that is affected. Anesthesia may be achieved with a eutectic mixture of local anesthetics but is usually not needed due to the relative insensitivity of the axillary skin (see Chap. 243). Doses of 2.5 to 4.0 units of botulinum toxin are placed every 1 to 2 cm as intradermal injections in axillary skin. Reliable anhidrosis is produced within 72 hours and will last for 8 to 12 months with doses of 50 units per axilla (Fig. 256-8). The duration of effect appears to be dose related, and doses of up to 200 units (Dysport) per axilla have been reported to produce dryness for up to 29 months.[16] Aside from insignificant bruising from the needle trauma, there are no apparent side effects.

Palmar hyperhidrosis (Fig. 256-9) is more challenging to treat because of (1) the more limited diffusion of the toxin in palmar skin, (2) the pain on injection, and (3) the generally predictable incidence of temporary weakness in the hand.[9] Anesthesia is achieved with regional wrist blocks of the median, ulnar, and radial nerves using lidocaine 1 percent to 2 percent without epinephrine. Approximately 100 to 150 units of botulinum toxin are needed to treat a single palm, divided into 50 to 60 intradermal injections of 2 to 3 units each. Onset of anhidrosis peaks in 5 to 7 days and is accompanied by minor weakness of the intrinsic muscles of the hand, which makes tasks requiring strength and stability (e.g., pushing a button through a



▲ **FIGURE 256-7** The upper half of the frontalis muscle is weakened by injecting four or five sites equidistantly along the equator of the forehead with a total of 16 to 20 units of botulinum toxin. Patient is shown before treatment (*upper panel*) and 1 week after treatment (*lower panel*).



▲ **FIGURE 256-8** Minor's starch-iodine test is used to demonstrate the area of axillary sweating (*top panel*). The pattern of intradermal botulinum toxin injections is shown with the starch-iodine material in place to highlight the injection points (*middle panel*). One week later the treated axilla shows a negative result on the starch-iodine test (*bottom panel*).

buttonhole) difficult to perform. The weakness usually subsides within 3 weeks, whereas the anhidrosis persists for several months. There is wider variation in response to palmar treatment than to axillary treatment, with anhidrosis lasting from 4 to 12 months, which probably reflects the technical difficulties in achieving even dispersion of the toxin through the palmar skin.

SIDE EFFECTS AND COMPLICATIONS

Minor needle trauma and bruising on injection with a 30-gauge needle are insignificant short-term complications of botulinum toxin injection, and use of a smaller-gauge needle (31 gauge or 32 gauge) will minimize needle trauma. Minor discomfort can be made more tolerable in some patients by pre-treating the injection site areas with topical anesthetic and using sterile saline with preservative as a diluent, which greatly reduces the sensation of injection.

The more problematic complications to consider are eyelid ptosis, which can occur after injections in the glabellar brow (see Fig. 256-6); brow ptosis from overzealous treatment of the frontalis muscle; transient lid edema from periocular injections; headaches after injections anywhere in the upper third of the face; and palmar weakness after injections for hyperhidrosis.

Antibody-mediated resistance appears to be an exceedingly rare event and of little clinical consequence in cosmetic dermatologic uses of botulinum toxin. Although millions of doses have been given to date, there is no well-documented evidence of the development of immunologic resistance in patients treated with cosmetic doses. Resistance continues to be observed in patients treated for cervical dystonia, albeit at much lower rates than in the early years, probably due to the lower protein content of current formulations.

Eyelid ptosis is thought to be best avoided by carefully placing the mid-brow injections at a minimal distance of 1 cm from the superior orbital rim, keeping the injection rate slow and gentle, and having the patient avoid prone positions and sleeping for 2 hours after injection.

Restricting injections to the upper two-thirds of the frontalis and reducing doses to the minimum necessary to produce the desired clinical effect may minimize brow ptosis. Headaches as a rebound phenomenon after facial injections of botulinum toxin may be triggered by unopposed muscle groups, but their etiology is unclear. Usually nonsteroidal anti-inflammatory agents are sufficient to treat them, unless the patient experiences migraines, in which case the patient's usual migraine medication will be required.

In hyperhidrosis, palmar weakness is a predictable consequence of injecting the palms. It is transient and dealt with





▲ **FIGURE 256-9** Hands showing response to Minor's starch-iodine test. The left hand was not treated. The right hand received 100 units of intradermal botulinum toxin A 1 week before the photograph was taken.

by clear pre-injection counseling. There is no similar effect of any clinical significance in either the axillae or the feet.

SUMMARY

The development of botulinum toxin treatment has brought great creativity and capability to cosmetic dermatologic therapy. Further evolution will occur as new serotypes come to market and as greater therapeutic synergies evolve as developers of soft-tissue augmentation systems strive to achieve similar effect and elegance. The high degree of efficacy and safety in the use of botulinum toxins in cosmetic dermatology has produced a great level of satisfaction in patients and physicians alike.

KEY REFERENCES

The full reference list for all chapters is available at www.digm7.com.

3. Schantz EJ, Johnson EA: Botulinum toxin: The story of its development for the treatment of human disease. *Perspect Biol Med* **40**:317, 1997
5. Carruthers JD: Ophthalmologic use of botulinum a exotoxin. *Can J Ophthalmol* **20**:135, 1985
7. Carruthers JD, Carruthers JA: Treatment of glabellar frown lines with *C. Botulinum*-A exotoxin. *J Dermatol Surg Oncol* **18**:17, 1992
8. Carruthers A, Carruthers J: History of the cosmetic use of botulinum A exotoxin. *Dermatol Surg* **24**:1168, 1998
9. Glogau RG: Treatment of hyperhidrosis with botulinum toxin. *Dermatol Clin* **22**:177, 2004
11. Aoki KR: Review of a proposed mechanism for the antinociceptive action of botulinum toxin type A. *Neurotoxicology* **26**:785, 2005
13. Aoki KR: Pharmacology and immunology of botulinum toxin serotypes. *J Neurol* **248 Suppl 1**:3, 2001
15. Klein AW: Soft tissue augmentation 2006: Filler fantasy. *Dermatol Ther* **19**:129, 2006
16. Glogau RG: Hyperhidrosis and botulinum toxin A: Patient selection and techniques. *Clin Dermatol* **22**:45, 2004

CHAPTER 257

Hair Transplantation and Alopecia Reduction

Walter P. Unger
Robin H. Unger
Mark Unger

BASIC PRINCIPLES

So that the complexities of modern hair restoration surgery can be understood and put into perspective, a number of basic concepts are first summarized.

Although the surgical options for repair of all types of alopecia can include graft hair transplantation, alopecia reduction, and placement of transposition flaps, almost all of the patients seen for hair restoration surgery have either male pattern baldness (MPB) or female pattern hair loss (FPHL) (see Chap. 86). Almost all are treated with graft hair transplantation, and almost all of the latter are transplanted exclusively with single follicular unit (FU) grafts. [See definition immediately below (Fig. 257-1)]. Follicular unit transplantation (FUT) for MPB and FPHL is the main focus of this chapter.

Hairs emerge from the scalp as single hairs or, far more often, in small groupings of two, three, and less commonly four or five closely associated hairs. These follicular groups or FUs have become the basic building blocks of most modern hair transplantation (see Fig. 257-1). In FUT, the FUs are removed from the permanently hair-bearing rim



◀ **FIGURE 257-1** A relatively small number of single hairs emerge from the scalp. Most often, hairs grow in small groupings of two to five hairs, as shown in the photograph. These groupings are referred to as *follicular groups* or, more commonly, *follicular units*.

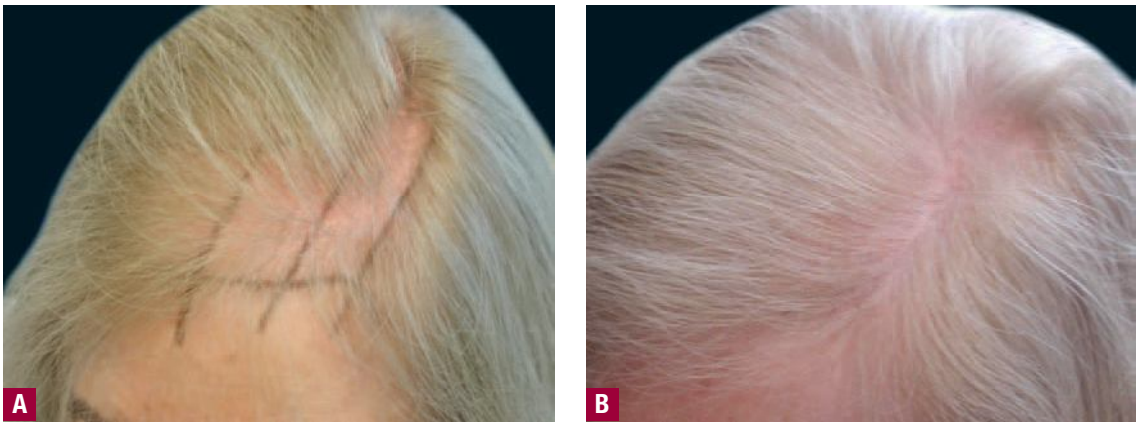

▲ **FIGURE 257-2** **A.** A 61-year-old female patient before hair transplantation with the recipient area outlined in black crayon indicating three zones arranged in order of treatment priority: (1) a part-line corridor on the patient's left side going further posteriorly than the other two zones, (2) an adjacent mid-line frontal zone, and (3) a zone further to the patient's right side. **B.** The same patient with the hair parted in a comparable fashion to that shown in **A** 7 months after treatment with 1118 follicular units.



hair (the donor area) and inserted into small incisions made in the areas of hair loss (the recipient areas). The major advantage of FUT is that one surgery can be performed in an area that is alopecic or destined to become alopecic and it will look essentially natural.

Both MPB and FPHL are intermittently progressive, and even the hair from the "permanent" donor rim becomes less dense throughout the individual's complete lifetime. Thus, a long-term "master plan" that anticipates progression of MPB/FPHL is mandatory. Although minoxidil or finasteride can arrest or even partially reverse MPB and FPHL in some patients—and trial treatment with these agents is therefore always encouraged—there is no scientific support for the assumption of a *permanent* effect of these drugs on either MPB or FPHL.[1,2] In addition, because a completely accurate prognosis is impossible, one must ideally leave a reserve in the donor region for any unanticipated areas of MPB as well as thinning of the transplanted hair.

Most female patients will not have sufficient donor areas of good density to adequately treat all of the affected areas. Thus, for most women the goal is limited to the transplantation of primarily the cosmetically most important area, usually the frontal area (or less often the vertex whorl area) and a 5- to 6-cm-wide antero-posterior corridor through which the patient's hair normally parts (Fig. 257-2). The hair in these thickened areas is styled in such a way as to camouflage the untreated areas. Despite a widespread belief that most women are not candidates for hair restoration surgery, the authors have found the opposite to be true.[8]

Transplantation of the areas of MPB in a large majority of men should be conceptualized as involving four areas: (1) a "frontal" area extending from the intended hairline to a coronal line drawn perpendicularly from the tragus bilaterally; (2) a "mid-scalp" area extending from the posterior border of the frontal area to a point at which the caudal scalp changes its orientation from more or less parallel to the ground to more or less vertical to the ground. This point in the mid-line is referred to as the *vertex transition point*; (3) a "vertex" area, which consists of the remainder of the alopecic regions; and finally (4) the evolving areas of alopecia adjacent to each of the aforementioned three major areas. Evolving areas of hair loss are defined as areas that have hair at the time the physician first sees the patient but from which he or she can reasonably anticipate hair will be lost with the passage of time (Fig. 257-3, see eFig. 257-3.1 in on-line edition, Fig. 257-4). Most commonly, each transplant session will

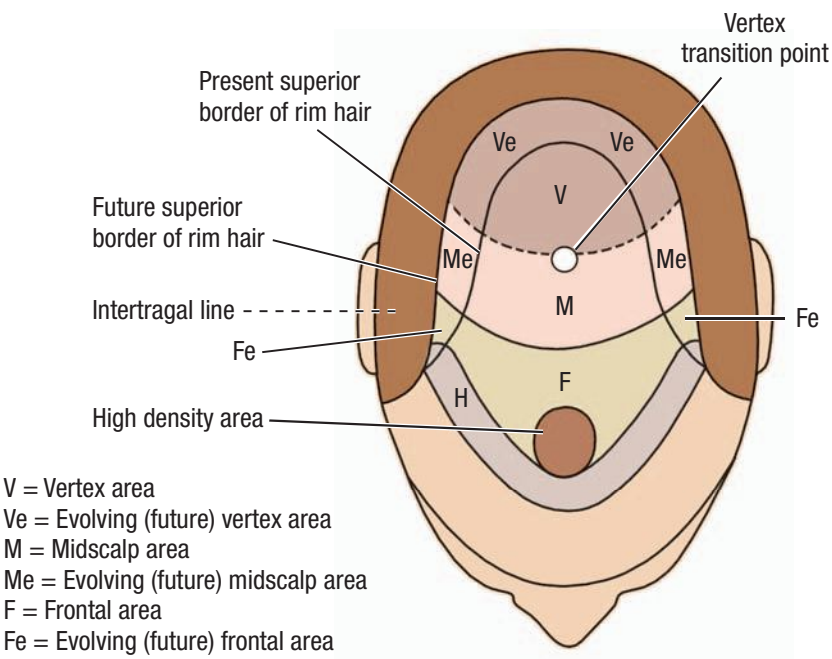

▲ **FIGURE 257-3** A schematic showing frontal, mid-scalp, and vertex areas as well as evolving areas of male pattern baldness (MPB) in a patient with type VI MPB. Ideally, each of the three major areas is treated at the same time as the evolving areas of MPB lateral to them. Typically, only one major area and the adjacent evolving area are treated during each session, although touch-up thickening of previously transplanted sites may also be carried out at the same time.



◀ **FIGURE 257-4** **A.** A 67-year-old patient with type VII male pattern baldness (MPB) and a relatively sparse donor area, before treatment. The black crayon lines delineate the areas to be treated. Reconstruction of the supratemporal "humps" will allow the new hairline to be positioned more superiorly than usual, which decreases the antero-posterior length of the frontal area and results in the consumption of fewer grafts for that zone. It also can run parallel to the ground when viewed laterally, despite its more superior positioning. **B.** A side view of the same patient 11 months after the second of two surgeries with low follicular units (FU)/cm^2 density [one session addressing the frontal area and one the area further posteriorly, using a total of 3211 FUs]. The advantages of re-creating supratemporal humps and creating a more superior hairline than usual are more obvious for patients who have (or are destined to develop) type VII MPB than for patients who have or will likely develop less severe MPB, such as the one shown in eFig. 257-3.1 in on-line edition. **C.** A frontal view of the same patient. A third session in which 1386 FUs were transplanted posteriorly to those placed during the second session was subsequently carried out just after this photograph was taken.

treat primarily one of the three major areas, plus the adjacent evolving areas. There are variations, however, depending on the size of the recipient area.

In his study of 328 males age 65 years or older Unger delineated an area within the zone of apparently permanent rim hair that contained eight or more hairs per 4-mm circle. He called this area the *safe donor area*[5] (Fig. 257-5). In the authors' experience, very few individuals can be expected to have fewer than two or three 8- to 10-mm-wide strips available from a safe donor area. In practice, hair restoration surgeons usually excise only four or five 10-mm strips (or the equivalent in more or fewer sessions) over the course of treating most patients. Each of these strips can be expected to produce 1500 to 2750 or more FUs, depending on the density of the donor hair area.

PATIENT SELECTION[9]

Hair transplantation has become a widely available modality for the treatment of alopecia, and although many prospective patients are candidates for the procedure, there are some guidelines that should be used in assessing patients during the initial consultation. The first step by the hair restoration surgeon is to eliminate the possibility that the hair loss is temporary or medically treatable. A comprehensive discussion of this topic is presented in Chap. 86. If the alopecia is determined to be permanent and without available medical treatment, a thorough history is taken and a thorough examination of the hair and scalp is conducted. It is important to assess not only the current but also the long-term donor-recipient ratio—the amount of hair available for transplantation from the safe donor area compared with the size of the area that ultimately will be affected by alopecia. The physician's predictive abilities depend on experience, available history of familial MPB or FPHL, and most importantly the patient's age.

The authors do not follow any strict rules on patient selection with respect to stage of hair loss or age. However, it is advisable to encourage younger patients (under the age of 25 years) to try medical treatment to delay the progression of MPB before beginning surgical treatment. In general, the younger the patient, the more conservative the approach, and as also noted earlier in Basic Principles, enough hair should be preserved in the safe donor area to provide for at least one or two future transplant sessions to treat areas of unexpected loss.

Box 257-1 lists the characteristics of the best hair transplant candidates. The patient need not have all of these characteristics to achieve a satisfactory result, but each one helps to improve it (Fig. 257-6; see eFig. 257-6.1 in on-line edition). In many instances, only a few of the ideal characteristics are present, and the surgical plan for each patient must take any limitations into consideration. In women, for example, the amount of "permanent" donor hair is usually much smaller than in a typical male patient with MPB. However, FPHL usually does not result in complete alopecia as does MPB, and women generally have many more styling options. In the authors' experience, hair transplant surgery is a very viable option for the majority of patients with MPB and FPHL, provided that the goals are commensurate with the patient's hair and financial resources.

RISKS AND PRECAUTIONS

Before surgical treatment is begun, the patient's physician is contacted to discuss any areas of significant concern revealed by the patient's medical history. For safety, the operating room must have all medications and equipment needed for basic monitoring as well as advanced life support. The authors prefer to have a

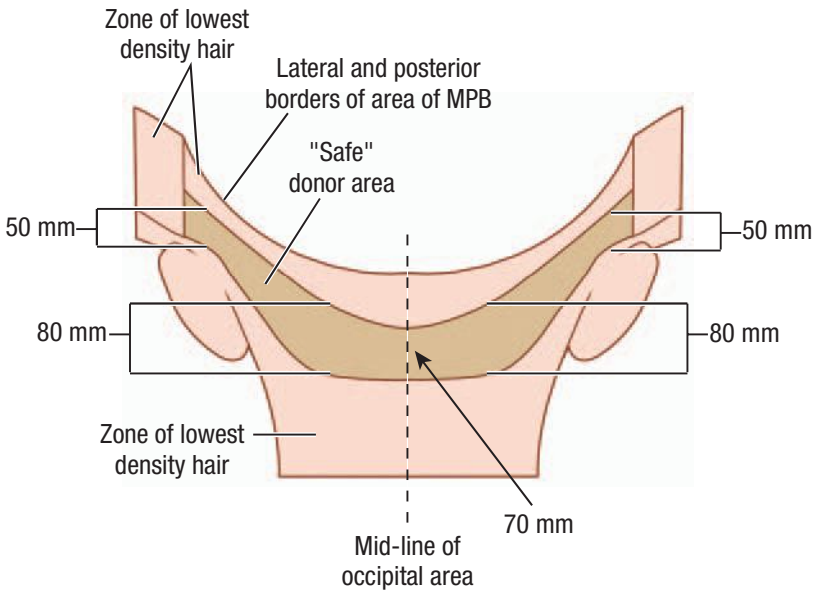

▲ **FIGURE 257-5** Unger's safe donor area for 80 percent of patients under the age of 80 years, as determined from studies of 328 men aged 65 years or older.[5] MPB = male pattern baldness.

Box 257-1

Characteristics of the Best Hair Transplantation Candidates

- A high density of hair in the safe donor area (defined as more than 80 hairs/cm^2).
- A mixture of finer-caliber hair for the hairline zone and coarser hair to help create density; if the diameter of an average hair is increased by only 0.01 mm, hair bulk will increase by 36 percent, and therefore coverage will increase by 36 percent.
- Minimal contrast between the skin and the hair color.
- Some wave, curl, and/or frizz.
- Existing hair in the recipient area, which may or may not be permanent but helps with camouflage during the postoperative period.
- *Reasonable* objectives for coverage and hair density in light of all the preceding.

board-certified anesthesiologist present during treatment of patients with significant and/or new-onset cardiovascular conditions, seizure disorders, certain respiratory conditions, and other potentially serious underlying health risks.

There are very few potential complications during hair restoration surgery. Box 257-2 describes those of which the surgeon needs to be most aware and some preventive measures.

PATIENT POSITIONING

During the removal of the donor strip, the patient is placed in a prone position, with the head in a special prone pillow that allows comfortable breathing while face down (see eFig. 257-6.2 in on-line edition). During the creation of the recipient sites and insertion of the grafts, patients are usually in a semi-supine position, except occasionally during surgery on the inferior portion of the vertex recipient area. In the latter circumstance, if the direction of the hair should be posterior or inferior, making of the sites and insertion of grafts is facilitated by putting the patient back into a prone position employing a prone pillow.

EQUIPMENT

The equipment required for hair restoration surgery is listed in Box 257-3.

ANESTHESIA[11]

At least 20 minutes before surgery begins, patients typically are given a hydrocodone/acetaminophen tablet and 20 mg of oral diazepam (Valium). An anesthetic field block is first created, using 30-gauge needles and 2 percent lidocaine with 1:100,000 epinephrine, which is added the morning of surgery to avoid the burning sensation associated with the acidic pH of stock solutions. Wheals of anesthesia are produced along the inferior edge of the donor area at intervals of approximately 3 cm. The gaps are then gradually closed by infiltrating laterally in both directions, inserting the needle through the already anesthetized regions. Thus the patient feels fewer than half the total number of injections. A solution of 1:50,000 epinephrine is then infiltrated into the donor area. Patients who have had previous surgeries occasionally develop aberrant nerve pathways that can escape the inferior field block, and any areas in which the individual is able to feel the epinephrine injections are further anesthetized, usually with lidocaine 2 percent, or sometimes 3 percent with 1:50,000 epinephrine if the patient is especially difficult to anesthetize. Normal saline 10 mL to 40 mL is injected in advance of the donor tissue excision to provide maximum turgor. The





◀ **FIGURE 257-6** **A.** Patient before transplantation. **B.** One year after one follicular unit transplantation (FUT) session (1947 FUs). This unusually dense result with FUT is mostly due to the patient's relatively high-caliber and wavy hair.





Box 257-2

Potential Complications of Hair Restoration Surgery

- Lidocaine toxicity: To minimize the risk of seizure, 20 mg of diazepam is administered to raise the minimal convulsive dose, and the lidocaine is injected intermittently and superficially.
- Syncope: The risk of syncope is minimized by controlling pain and anxiety, keeping the patient in a prone or supine position, and maintaining appropriate hydration and blood glucose levels.
- Intraoperative bleeding: Bleeding is controlled with the use of intradermal epinephrine, manual pressure, and cauterization when appropriate.

Box 257-3

Equipment Required for Hair Restoration Surgery

- Stainless steel bowls for saline and hydrogen peroxide
- Doubled-bladed cutting knife handle
- No. 10 Persona scalpel blades (American Safety Razor, Verona, Virginia)
- Hypodermic needles, 18, 19, and 20 gauge
- 0.5% bupivacaine
- 2% lidocaine with and without 1:100,000 epinephrine
- 4% lidocaine
- Epinephrine 1:1000
- China marker/grease pencil
- Glass Petri dishes
- Hyfrecator and tips
- Needle driver
- Supramid 2-0 CL20, and 3-0 sutures
- No. 15 blade
- Double-sided razor blades
- Razor blade holder
- Clear plastic cutting boards
- Mantis microscope with underlighting (Vision Engineering, Connecticut)
- Curved Metzenbaum scissors
- 1 small curved surgical scissors
- 1 small straight iris scissors
- Aluminum rattail comb
- 4 × 8 and 4 × 4 gauze
- Kerlix dressing (Kendall Co., Basingstoke, United Kingdom)
- 7.5 × 10 cm Telfa pads
- 2 mirrors
- Lepaw graft coolers (Ellis Instruments, New Jersey)
- Ceramic escargot dish
- Nu-gauze (Johnson and Johnson Medical Ltd., Gargrave, Skipton, United Kingdom)
- Spray bottle with saline
- No. 2 jeweler's forceps
- No. 5 planting jeweler's forceps
- 2 toothed curved forceps
- Straight Adson forceps
- Smoke evacuation system

latter helps to minimize bending of the follicles as blade pressure is applied and thus limits FU transection.

The recipient area field block is produced in a similar manner (see eFig. 257-6.3 in on-line edition); however, 3 percent or 4 percent lidocaine with 1:50,000 epinephrine is sometimes needed for "hot spots." A 1:50,000 epinephrine solution is injected intermittently and superficially into the recipient area to provide better hemostasis during the staged incising of the recipient sites.

TECHNIQUE

Recipient Area Design[9]

On the morning of the surgery, a grease pencil is used to outline the treatment area that has already been largely decided upon during the prior consultation(s).

The frontal recipient area is designed by first drawing in the proposed hairline, whose mid-line anterior-most point is as superior as is acceptable to the patient but always lies within the area in which the vertical forehead is changing into the essentially horizontal caudal scalp. Then the lateral borders are determined by outlining the supratemporal "humps"—semi-hemispheric areas that are superior to the temporal areas in type VI MPB and in all less severe types of MPB. These "humps" may or may not still have existing hair (see eFig. 257-3.1 in on-line edition and Fig. 257-4).

The posterior border of the frontal area as well as the mid-scalp area is completed in an arc that will help create a natural shape for the remaining area of alopecia in the event that the patient decides not to transplant any further posteriorly—or does not have sufficient donor hair to do so.

Donor Area Determination[5]

Choosing the optimal location and width of the donor strip is one of the most important decisions that is made in the course of hair transplanting. The authors typically choose a donor area that lies in the middle of the densest zone of the rim hair. Each subsequent harvest will remove donor hair from just superior and just inferior to the scar created in the previous surgery. The midway position is most logical, because hair is progressively lost from both the superior and inferior borders of the rim hair in MPB, and this position provides the greatest certainty that the hair removed is truly permanent. To determine this location, it is sometimes helpful to wet the hair to identify the superior and inferior margins of the current areas of thinning. The donor area extends into the temporal region in many males but remains posterior to the ears in females. The hair in an 8- to 12-mm-wide zone is clipped to approximately 3 mm in length, and the area is cleaned with alcohol and then a povidone-iodine (Betadine) solution.

Donor Site Excision[5]

Before the excision is started, the anesthesia is checked to ensure a complete field block. Laxity of the scalp is assessed to determine the appropriate width for the excision. The angle of the hair in the donor area also has to be taken into consideration when deciding on the width between the blades, because an acute hair angle can cause the resultant strip to be much wider than the actual distance between the blades. The authors always take a slightly narrower strip than the examination might suggest would be possible. This allows for a margin of error in the estimates. Our strips are typically 8 to 10 mm wide. As indicated earlier in Anesthesia, before starting the excision, the area is tumesced with normal saline. We use a double-bladed scalpel, which is angled to mimic the exit angle of the existing hair as the incisions are made. The incision begins and ends approximately 2 cm medial to the ends of the donor area that was mapped out previously.

The entire strip is usually removed in three sections to provide greater control of bleeding. Any vessels that are bleeding more than average are cauterized with a unipolar hyfrecator. Hair that has fallen into the wound is removed, and a running single-layer closure with a 2-0 or 3-0 thread is carried out.

Follicular unit extraction (FUE) is a new technique in which individual FUs are excised directly from the donor area rather than from a strip.[13,14] Typically, a 0.7-mm to 1.2-mm circular incision is created with a trephine. The objective is

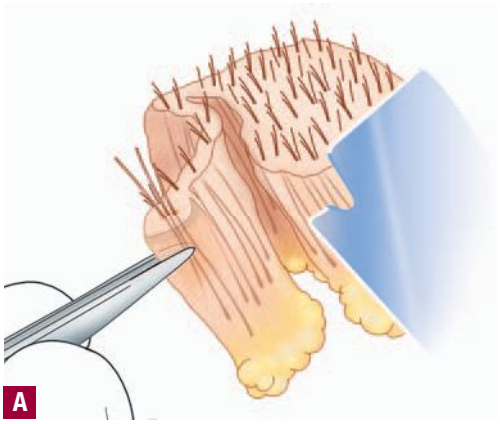



◀ **FIGURE 257-7 A.** The excised donor strip is initially sectioned into slices that are one follicular unit (FU) in width, much as one cuts a loaf of bread into slices. **B.** Pear-shaped, chubby, one-haired, two-haired, three-haired, and four-haired FU grafts. Note the intact sebaceous glands and the fat pads below the dermal papillae. (Used with permission from Dr. David Seager.)

to encircle the FU and to incise only as deeply as the reticular dermis. The rest of the FU is teased out of its site with a combination of tension and (1) small needle punctures intended to free the FU from its surrounding tissue and/or (2) pressure applied with a dull-edged trephine.

It is likely that donor area harvesting will evolve into a hybrid of strip harvesting plus FUE from scalp areas of lesser hair density and possibly even from other hair-bearing areas of the body.

Graft Preparation[15]

The preparation of grafts is accomplished using stereoscopic microscopes or magnifying loupes or glasses. After the removal of the donor strip, the technicians begin "slivering the loaf"—a term used to describe the manner in which slices that are one FU in width are carefully produced from the strip, much as one cuts bread into slices (Fig. 257-7A). These slices are 4 to 10 FUs in length, depending on the density of hair in the donor area and the width of excision. The slices are then further divided into the individual FUs. The ideal FU has had most of its epidermis removed and is somewhat tear-shaped, growing progressively wider from an almost absent epidermis to just beneath the hair bulb, where a short tag of subcutaneous tissue is left in place (Fig. 257-7B). The donor tissue is kept moist at all times, and the FUs produced are quickly transferred to a sterilized escargot dish that has wells filled with normal saline and sits on an ice-filled Pyrex container (see eFig. 257-7.1 in on-line edition). The grafts are sorted into FUs with different numbers of hairs and "follicular families" that consist of two FUs that are closer to each other than usual and can be inserted into a small needle hole. Each type of graft is put into an escargot dish well, and the well is labeled so that when the planter requires, for example, a one- or two-hair FU or a three-hair FU, he or she can immediately find one by going to the appropriate well.

Recipient Site Creation[16]

Recipient sites are created using primarily 18- to 20-gauge hypodermic needles or small blades cut with a special tool to match the size of the grafts. The incisions are made at the same angle and in the same direction as the persisting terminal or vellus hairs in the area. Much of the art of hair transplanting lies in the ability of the surgeon to do this successfully, because both direction and angle vary considerably from patient to patient as well as from one area to another on a given patient's scalp (Fig. 257-8). Moreover, if the surgeon fails to do this accurately, any existing hair in the recipient area can be lethally damaged. For both these reasons, most practitioners prefer to create the sites themselves instead of delegating this task to a technician. Currently, the authors prefer to use a graft density of 20 to 30 FU/cm^2, because virtually all studies on hair survival to date have shown what we consider to be an unacceptable decrease in hair survival rate when a higher FU density (dense packing) is used[17] especially when total recipient site length exceeds 3.0 cm/cm^2. The production of very high hair density should nearly always be limited to small cosmetically strategic regions of the recipient area, including most often an egg-shaped area in the anterior mid-line frontal region (see Fig. 257-3) that creates the impression of high density in the entire frontal area despite its limited size. In that area, the authors prefer to create density by using follicular families (Table 257-1) and three- and four-hair FU grafts in the first surgery and treating the area a second time, while concomitantly treating the mid-scalp if more density is required.

To determine the size of graft site required, several grafts are tested in various locations, and the needle or blade is then adjusted accordingly.

Repair Surgery[18]

The recipient areas of many patients who have the problems associated with older techniques and/or poor planning can be greatly improved with modern hair transplanting methods, primarily by placing FUs anterior to as well as between larger old grafts (Fig. 257-9). Grafts that have been placed too far an-

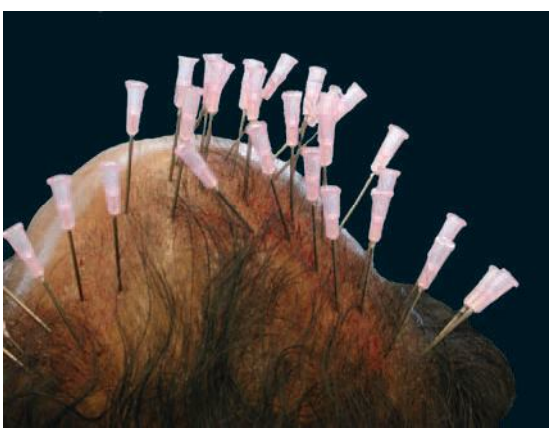

◀ **FIGURE 257-8** Although various general directions and angles of hairs in different areas of the scalp have been described, none of these generalities applies to all patients. Hair directions and angles can also change dramatically in relatively small areas, as indicated in this photograph showing needles inserted at the angles and directions of hairs at these locations. The surgeon should go very slowly and follow what he or she sees rather than any general rule.



TABLE 257-1
Graft Terminology

Graft Type	No. of Hairs	No. of FUs	Recipient Site	Cut to Size or Cut to Number of Hairs
Micrografts				
Micrograft[15] (general term)	1–4	1 or fewer	Needle/micro-slit	Number of hairs[1]
Follicular unit (FU)[15] (specific term)	1–4	1	Needle/micro-slit	Number of hairs[1]
Follicular family[3]	5–6	2	Needle/micro-slit	Number of hairs[2]
Multi-FU Grafts				
Micro-Slit Grafts[3]				
Double FU	3–5	2	Slit	Number of hairs (FUs)
Triple FU	5–8	3	Slit	Number of hairs (FUs)
Quadruple FU	6–12	4	Slit	Number of hairs (FUs)
Traditional Slit Grafts[3]				
Small slit graft	3–5	~ 2	Slit	Size
Medium slit graft	5–8	~ 3	Slit	Size
Large slit graft	6–12	~ 4	Slit	Size
Slot Grafts[4]				
Small slot graft	6–8	~ 4	Slot	Size
Medium slot graft	8–12	~ 6	Slot	Size
Large slot graft	10–16+	~ 8	Slot	Size
Round Grafts[5]				
Small round graft	5–8	2–3	Punch	Size
Medium round graft	8–14	4–5	Punch	Size
Large round graft (includes standard punch graft)	14–30+	6–15+	Punch	Size



teriorly must be excised either individually or by using an en-bloc elliptical excision. The excision of all or a portion of larger pluggy-looking grafts may also be useful in minimizing "plugginess" (see eFig. 257-9.1 in on-line edition) while providing additional hair for transplanting elsewhere in the recipient area.

Graft Insertion

After the recipient sites have been created, the surgeon reviews with the assistants the locations where the one- to four-hair and follicular family grafts should be placed. Then two or three technicians begin inserting them. A group of five to seven grafts is removed from the saline-filled wells and placed on the hand or finger, and then each graft is placed in its site. A skilled technician determines the angle and direction of the recipient site and then slides the graft into place using a very light touch by following the perceived angle and direction. The recipient area is kept clean by regularly use of a mixture of saline (75 percent) and hydrogen peroxide (25 percent). The grafts are left slightly elevated to help in identifying sites that have not yet been filled. At the end of the procedure, grafts are re-positioned level with the epidermis or left slightly elevated—but never depressed, because this can cause noticeable pitting.

SIDE EFFECTS AND COMPLICATIONS[19]

The possible side effects and complications of hair restoration surgery are listed in Box 257-4. Some of these side effects and complications require additional discussion, as follows:.

Severe postoperative edema can be unsightly and can interfere with healing of the donor area. This risk is minimized with the use of systemic and intralesional corticosteroids, proper postoperative patient positioning, and application of ice compresses.

Infection is minimized by the use of perioperative antibiotics given prophylactically.

Occasionally donor area bleeding occurs in the first few days postoperatively, but it usually resolves with firmly applied pressure. In very rare cases, an extra suture may be needed.

Specific measures can be taken that will minimize the likelihood of wide scars in the donor area. The wound is best closed with the absolute minimum of tension. Harvesting a strip that is 1 to 3 mm narrower than would otherwise be preferred, taking precautions to control postoperative edema, and ensuring proper postoperative care (see Monitoring and Follow-up) facilitate rapid healing. Although these measures prevent wide scars in the donor area in almost all patients (scars are usually 0.2 to 1.5 mm wide), intrinsic poor wound healing characteristics and/or severe scarring from prior surgery can still result in wider than average scars.

Poor graft survival and hair growth is probably entirely avoidable and has never occurred in the authors' experience; however, it has been observed in patients seen for repair procedures.

Telogen/anagen postoperative hair loss may occur in hair-bearing areas in the recipient or donor areas or both. It is presumably due to interruption of blood supply and is always temporary. Approximately 10 percent to 20 percent of male patients and 50 percent of female patients experience at least some degree of this type of hair loss.

MONITORING AND FOLLOW-UP[20]

All patients are seen the day after surgery for bandage removal (if a bandage was used) and for any graft repositioning that occasionally may be necessary. The hair and scalp are thoroughly washed by a technician, and postoperative instructions are reviewed. Minoxidil 3.5 percent (made by mixing 2 percent and 5 percent minoxidil solutions) is applied to the recipient area and sometimes also to the donor area. A thin layer of Aquagel (Parker Laboratories Inc., Fairfield, New Jersey) is then applied to the recipient and donor areas to help maintain moisture and promote healing. All patients are seen 7 to 10 days postoperatively so that the surgical areas can be checked and the sutures removed. Occasionally patients are also seen 4 or 5 days after surgery to be certain they are healing appropriately and following the instructions properly.

A follow-up appointment is generally booked 6 to 12 months after surgery to assess the results and determine the next course of action. The most frequent reason for earlier postoperative visits is reassurance.

The application of ice packs and head elevation should continue for at least the first 3 to 5 days postoperatively if significant edema develops.

From day 2 postoperatively until the sutures are removed, patients should



▲ **FIGURE 257-9** **A.** This 56-year-old man had undergone hair transplanting 15 years before coming for treatment. He had fine reddish to blonde hair. The transplanted area was moderately pluggy-looking and would have appeared much worse had his hair not been so fine and relatively light-colored. The density in the transplanted area was also relatively low. In addition, his male pattern baldness (MPB) was obviously extending further laterally, and he had lost all of the hair posterior to the transplanted zone. He was basically left with a pluggy-looking, unsatisfactory, isolated frontal forelock, as shown in the photograph. We designed lateral "humps" for completion of the frontal third of the area of MPB and a new hairline zone anterior to the old one. The black crayon line delineates these objectives. **B.** A mixture of different types of grafts was used for the corrective procedure. The follicular units (FUs) were used to create the new humps and the bulk of the hairline zone, as well as to fill small spaces between the old round grafts in the hairline zone. The most posterior border of the newly transplanted area was also treated with a zone of FUs. Small round grafts were inserted into larger alopecic spaces between some of the round grafts in the old hairline zone. Double FUs were used primarily just posterior to previous transplantings (Table 257-1). **C.** The new frontal hairline constructed primarily with FUs. As can be seen, the spaces between some of the old round grafts that contained relatively dense hair were to be filled with additional round grafts. Because of the fine texture of the hair and the advantageous coloring, we felt we could get additional density by filling in the spaces between these round grafts with new 2-mm round grafts without sacrificing naturalness. **D.** Nine months after the first repair session, in which 1270 FUs, 105 double FUs, and twenty-one 2-mm^2 grafts were placed. Additional refinement of the hairline zone was carried out at the same time as a second repair session (using exclusively FUs) to transplant the mid-scalp shortly after this photograph was taken.

soak and massage their heads twice daily and apply the 3.5 percent minoxidil solution and then Aquagel. Application of minoxidil is continued for another 4 weeks to promote vasodilation in the surgical area, which theoretically may improve healing; reduce the possibility of any telogen/anagen effluvium; and accelerate re-growth of the transplanted hairs.

It is recommended that patients avoid any significant physical activity for 1 week after surgery and heavy weight lifting for 2 weeks. Pain medication is rarely needed after the first 1 to 2 days; however, it is provided for those with unusually low pain thresholds. The authors believe there is no reason for patients to experience discomfort and recognize that individuals respond very differently to pain and medication.

ALOPECIA REDUCTION[21]

Alopecia reduction (AR), or scalp reduction, can be defined as the excision of an area of alopecia or future alopecia (see eFig. 257-9.1 in on-line edition). The larger the area that can be removed, the smaller the remaining area of alopecia, so that fewer grafts will be required to produce the same hair density. A variety of AR patterns have been described, but the most common patterns used are the ellipse, the inverted Y pattern, and the "lazy-S" shape. The inverted Y pattern should be used if one anticipates insufficient donor tissue to transplant the entire alopecic area even after AR. This design avoids a scar in areas that cannot later be covered with transplanted hair.

Technique

If the pattern is an ellipse, a variant of an ellipse, or a lazy S, an incision is made down to and through the galea aponeurotica along one side of its entire length, usually in a staged fashion. Care is taken to angle the blade so as to not injure any adjacent follicles. If previously transplanted grafts are nearby, a 2-mm margin of safety is observed. Mayo scissors are used to begin the undermin-





Box 257-4

Side Effects and Complications of Hair Transplantation Surgery

- Temporary hypoesthesia of the scalp in either the recipient or donor area (100%)
- Telogen/anagen effluvium in either the recipient or donor area (10% to 50%)
- Postoperative bleeding (less than 0.02%)
- Infection in donor or recipient area (less than 0.01%)
- Excessive postoperative edema (10% to 15%)
- Nausea and vomiting (less than 1%)
- Temporary headache (less than 5%)
- Permanent hypoesthesia in small areas (less than 1%)
- Pruritus (0.1%)
- Pitting or cobblestoning around the grafts (rare with proper technique)
- Poor hair growth (*extremely* rare with proper technique—see text)
- Wide donor area scars (rarely occurs with proper technique)
- Postoperative syncope (less than 0.1%)
- Ingrown hairs (less than 2%)
- Sterile folliculitis (less than 1%)
- Bacterial folliculitis (less than 0.1%)
- Hiccups (less than 0.1%)
- Keloid formation (extremely rare without prior history)
- Neuroma (less than 0.01%)
- Persisting scalp pain (less than 0.001%)
- Arterio-venous fistula formation (0.005%)
- Osteomyelitis (one case reported)
- Septicemia (one case reported)

Note: Figures in parentheses represent the authors' experience.

ing between the periosteum and galea aponeurotica. It is then completed to at least 10 cm or more on either side by blunt finger dissection.

The amount of redundant scalp tissue is estimated by overlapping the tissues, and perpendicular incisions are made through the top flap, stopping at the points at which the flaps meet. The perpendicular cuts are then joined and the excess tissue is thereby removed.

Complications

Complications of AR include postoperative bleeding, infection, nerve damage, persistent hair thinning or loss in the fringe areas, disorientation of hair direction, and poor scars. All of these occur infrequently or not at all if the procedure is carried out properly. With the passage of time, excision scars may become noticeable as hair is lost in areas through which the scar passes. This is obviously a problem of poor planning rather than an inherently unavoidable complication of the procedure.

ALOPECIA REDUCTION PRECEDED BY SCALP EXTENSION[23]

CONCLUSION

The evolution of hair transplantation over the last 10 to 15 years has resulted in a remarkable increase in the number of patients who are eligible for the procedure and an even more impressive improvement in the naturalness of the results that can be expected. Unfortunately, these new techniques also require far more skill and patience from not only the surgeon but also all of his or her surgical team members. In addition, hair restoration surgeons are not miracle workers, so individuals must be educated as to what they can realistically expect from hair transplantation. When this is done, the reward is nearly always a satisfied and grateful patient. Without such patient education, no matter how fine the result, patient dissatisfaction is almost sure to occur.

KEY REFERENCES

The full reference list for all chapters is available at www.digm7.com.

4. Norwood OT: Classification and incidence of male pattern baldness, in *Hair Transplant Surgery*, 2nd ed, edited by Norwood OT, Shiell R. Springfield, IL, Charles C Thomas, 1984, p 3
5. Unger WP, Cole J: Donor harvesting, in *Hair Transplantation*, 4th ed, edited by Unger WP, Shapiro R. New York, Marcel Dekker, 2004, p 301
6. Ludwig E: Classification of the types of androgenetic alopecia (common baldness) occurring in the female sex. *Br J Dermatol* **97**:247, 1977
8. Unger WP, Unger RH: Hair transplanting: An important but often forgotten treatment for female pattern hair loss. *J Am Acad Dermatol* **49**:853, 2003
9. Unger WP, Beehner ML: Planning and organization of the recipient area, in *Hair Transplantation*, 4th ed, edited by Unger WP, Shapiro R. New York, Marcel Dekker, 2004, p 81
15. Seager D: Classic microscope dissection of follicular units, in *Hair Transplantation*, 4th ed, edited by Unger WP, Shapiro R. New York, Marcel Dekker, 2004, p 355
16. Shapiro R: How to use follicular unit transplantation in the hairline and other appropriate areas, in *Hair Transplantation*, 4th ed, edited by Unger WP, Shapiro R. New York, Marcel Dekker, 2004, p 454
18. Unger WP: Corrections of cosmetic problems in hair transplanting, in *Hair Transplantation*, 4th ed, edited by Unger WP, Shapiro R. New York, Marcel Dekker, 2004, p 663
19. Cooley J: Complications of hair transplantation, in *Hair Transplantation*, 4th ed, edited by Unger WP, Shapiro R. New York, Marcel Dekker, 2004, p 568
20. Parsley WM: Management of the postoperative period, in *Hair Transplantation*, 4th ed, edited by Unger WP, Shapiro R. New York, Marcel Dekker, 2004, p 555
21. Unger M et al: Alopecia reduction procedures, in *Hair Transplantation*, 4th ed, edited by Unger WP, Shapiro R. New York, Marcel Dekker, 2004, p 709

INDEX

NOTE: Bold numbers indicate the start of the chapter that contains the main discussion of the topic; page numbers followed by *b*, *f*, and *t* refer to boxes, figures, and tables.

A

Abacavir in HIV infection, 1934, 2208, 2209
Abatacept in lupus erythematosus, 1533t, 1535
ABCA1, 386–387
  in Tangier disease, 1279
ABCA12/ABCA12, 68t
  in ichthyosis, 411t, 416, 1305
ABCC4 in Hermansky-Pudlak syndrome, 613
ABCC6/ABCC6, 63
  in pseudoxanthoma elasticum, 1305
ABCD checklist in melanoma diagnosis, 1128–1129, 1142b, 1142–1143
Abdominal pain, 1455t, 1455–1456
  in acute intermittent porphyria, 1251
  in variegate porphyria, 1253, 1455
Abdominal stoma procedures, skin problems in, **868**–871
ABHD5 in ichthyosis, 411t
Abrikossoff tumors, 648, 1181
Abscess, 33, 33f
  in drug abuse, 925–926
  in limb amputation and prosthesis use, 864, 864f
  in scrofuloderma, 1772, 1772f
  in staphylococcal infections, 1702, 1702f
    methicillin-resistant, 874
  subcutaneous, 1814t
  of vulva, 682
Absidia in zygomycosis, 1843
Absorption of drugs
  drug interactions in, 2237, 2237t
  in topical therapy, 2091–2092
    corticosteroid, 2105
    cutaneous metabolism affecting, 2101
    with ointments, 2094
    penetration pathways in, 2100
    pharmacokinetics in, 2097, 2099
    regional anatomic differences in, 2091, 2092t, 2105
    and resorption, 2101–2102
    stratum corneum affecting, 2091, 2099–2100
    systemic toxicity in, 2096
  in transdermal delivery, 2096
Absorption of radiation, 802, 802f, 803, 803f, 2263, 2267f
  excited state molecules in, 804, 804f
  in photodynamic therapy, 2260
  and scattering, 2264–2466
  and selective photothermolysis, 2266
Abuse
  of children. *See* Child abuse
  of drugs. *See* Drug abuse
  of elderly, 928t, 930, 930t
Acanthamoeba, 2009, 2010
Acanthaster planci (starfish), 2048
Acantholysis, 46–47, 60, **432**–441
  in Darier-White disease, 45f, 47, 432–436
  and dyskeratosis, 45, 45f, 47
  epidermal cohesion in, 46f, 46–47, 432
  in Grover disease, 437–438
  in pemphigus, 46, 46f, 459
    histopathology in, 466
    pathophysiology in, 462–463
  primary, 46
  secondary, 46
  vesicles in, 32
Acanthoma
  clear cell, 1062–1063, 1063f
  Degos, 1062
  fissuratum, 1063
  pale cell, 1062
  pilar sheath, 1081
  reticulated, 1086
Acanthosis, 44, 45f, 48
  in epidermal nevus, 1058, 1058f
  in lupus erythematosus, 1529
  nigricans, 635, 1448
    acrochordons in, 1494, 1495f
    classification of, 1493
    clinical findings in, 1462–1463, 1463f, 1494t, 1494–1496, 1495f, 1496f
    complications of, 1496
    in Cushing syndrome, 1478
    in diabetes mellitus, 1462–1463, 1463f
    disorders associated with, 1494–1495, 1496t
    drug-induced, 1462
    epidemiology of, 1462, 1493
    estrogen levels in, 1480
    etiology and pathogenesis in, 1462, 1494
    Leser-Trélat sign in, 1495, 1497, 1498
    malignancy-associated, 1448, 1462, 1463, 1493–1496
    oral cavity disorders in, 642t, 1462, 1495, 1496f
    of palm, 1496–1497
    prognosis and clinical course in, 1496
    treatment of, 1463, 1496
    tripe palm in, 1463, 1495, 1496–1497
  palmaris, 1496–1497
Acarina bites, 2054, 2058–2059
Acarus siro, 2032, 2032t
Acclimatization
  sweat composition in, 717
  sweat rate in, 713, 716, 716f
  thermoregulatory responses in, 843–844
Acetaminophen in children, 951t–952t
Acetic acid, 1693
Acetylcholine, 896, 896t
  in cutaneous active vasodilation, 837, 839f, 840
  in inflammatory response, 898t
  in sweat glands, 713, 716, 718, 718f, 837
Acetylcholine receptor-3 in Sjögren syndrome, 1578
Achilles tendon
  in reactive arthritis, 209, 210f, 211
  xanthoma of, 1272, 1273f, 1276
Acid chemicals, occupational exposure to, 2069, 2069t, 2070t
Acid sphingomyelinase, 386, 388f
Acinetobacter calcoaceticus-baumannii, 1690
Acitretin, 2181–2186
  in actinic keratosis, 2184
  chemical structure of, 2182f
  complications of, 2184–2186
  in Darier-White disease, 436, 2183
  dosing regimens, 2184
  in exfoliative dermatitis, 231, 232, 232b
  in graft-versus-host disease, 267t
  in hidradenitis suppurativa, 2183–2184
  initiation and monitoring of therapy, 2184
  interaction with other drugs, 2186, 2240t
  in lichen planus, 253, 253b
  in lupus erythematosus, 1533t, 1534, 2184
  in lymphocytic infiltration of skin, 1413b
  in palmoplantar keratoderma, 431
  in palmoplantar pustular eruptions, 217b, 218
  in perforating disorders, 567b
  pharmacokinetics of, 2182–2183
  in pityriasis lichenoides, 243b
  in pityriasis rubra pilaris, 235, 236b
  in premalignant skin lesions, 2184
  in psoriasis, 185, 186t, 191, 2183
    in combination with other agents, 187t, 2183, 2245, 2254
    of nails, 789
    in pregnancy, 189b
  in squamous cell carcinoma prevention, 278
  in T-cell lymphoma, 2183
Acne, **690**–703
  acute febrile ulcerative, 701
  aestivalis, 703
  androgen levels in, 1481–1482
  clinical findings in, 692–693, 693f–695f
  in coal tar exposure, 2078
  comedonal, 28, 28f, 692, 693f
  complications in, 695
  conglobata, 700–701
  cosmetica, 2360

Copyright © 2008 by The McGraw-Hill Companies, Inc. Click here for terms of use.

Acne—*continued*
differential diagnosis of, 694–695, 695f, 706, 1268b, 1271
chloracne in, 2078, 2079t
in drug abuse, 877, 924
drug-induced, 692, 702
in corticosteroid therapy, 558, 702, 706, 2105
from cytotoxic agents, 2176–2177
differential diagnosis in, 706
with endocrine disorders, 701–702
epidemiology of, 690
ethnic considerations in, 2121f, 2142f, 2144
etiology and pathogenesis of, 690–692, 691f
excoriations in, 701, 916
fulminans, 701
in infants and neonates, 692, 700, 938, 938f, 1828
keloidalis, alopecia in, 772t, 774, 777f
laboratory tests in, 693–694
in laser skin resurfacing, 2368
laser therapy in, 700, 2278–2279
mechanica, 701, 864
in athletes, 877
necrotica, 774
nodules in, 693, 693f, 694f, 700–701
nodulocystic, 693, 696
nutritional factors in, 699, 2287
in occupational exposures, 702, 2078
in oil contact, 2078
in oily skin type, 2358
outcome measures in, 15
in PAPA syndrome, 701, 1271
papules in, 693, 693f, 694f
penile, 671
photo-exacerbated, 825
in polycystic ovary syndrome, 695, 701–702
prognosis and clinical course in, 695–696
with pyogenic arthritis and pyoderma gangrenosum, 701, 1267t, 1271
clinical findings in, 1271, 1271f
differential diagnosis in, 1268b, 1271
in SAPHO syndrome, 701
scarring in, 693, 695f
in sensitive skin type, 2360
with solid facial edema, 701
Toll-like receptors in, 99, 692
treatment of, 696t, 696–700
antibiotics in, 696–697, 698, 2113–2114
complementary and alternative approaches to, 2286, 2287
ethnic considerations in, 2142f, 2144
laser therapy in, 700, 2278–2279
photodynamic therapy in, 700, 2262
retinoids in, 697, 2109, 2111, 2112, 2183, 2184
tropical, 703
vulgaris, **690**–700
in adolescents, 690, 945
antibiotics in, 696–697, 698, 2113–2114
differentiated from chloracne, 2078, 2079t
retinoids in, 697, 2109, 2111
Acneiform lesions, 702–703
in athletes, 877
drug-induced, 358
from corticosteroids, 2105
from cytotoxic agents, 2176–2177
in irritant contact dermatitis, 399
in occupational exposures, 2068t
Acral distribution of lesions, 38
Acral erythema, chemotherapy-induced, 2178, 2178f, 2178t
Acremonium, 1817, 1834t
Acrivastine, 2188, 2189t
Acroangiodermatitis
in amputation stump, 866
of Mali, 866
Acrocephalosyndactyly, 703
Acrochordons, 554f, 554–555, 1462
in acanthosis nigricans, 1494, 1495f
Acrocyanosis, 1375t
in cold exposure, 849
in cryoglobulinemia, 1639, 1639f
differential diagnosis of, 1646
in polycythemia vera, 1377, 1378
Acrodermatitis
acidemica, 1219–1220
chronica atrophicans, in Lyme disease, 1798, 1799–1801, 1800f, 1803
diagnosis and differential diagnosis of, 1800t, 1801
continua, 215, 215t, 217–218, 218f
differential diagnosis of, 785
nail changes in, 785, 789, 789f
treatment of, 217b, 218
enteropathica, in zinc deficiency, 1215, 1215f, 1216, 1456–1457
papular
in children and infants, 1860
in hepatitis B, 1457
Acrokeratoderma, papulotranslucent, 428–429
Acrokeratoelastoidosis lichenoides, 429
Acrokeratosis
paraneoplastic, of Bazex, 165, 1498–1499
clinical findings in, 1498–1499, 1499f
differential diagnosis of, 165, 1499, 1499b
nail changes in, 1498, 1499, 1499f
stages of, 1498–1499
treatment of, 1499
verruciformis, 432, 436–437, 437f
Acromegaly, 1482–1483
approach to patient with, 1482t
clinical findings in, 1482–1483, 1483f
hyperhidrosis in, 726, 1482
Acro-osteolysis, occupational, 2078
Acropachy, thyroid, 1450, 1473, 1473f
treatment of, 1474
Acroparesthesia in Fabry disease, 1284
Acropigmentation of Dohi, reticulate, 640
Acropustulosis, infantile, 215, 215t
Acrospiroma, eccrine, 1075, 1078
Acrosyringium, 730
Acrylics, occupational exposure to, 2070t
ACTH. *See* Adrenocorticotropic hormone
Actin
cytoskeletal defect in, 1374t
in melanocyte dendrites, 603
Actinic cheilitis, 641, 1000, 1009, 1010f
Actinic dermatitis, chronic, 821–823
clinical features in, 821–822, 822f
diagnosis of, 826, 827
differential diagnosis in, 822, 823, 823b, 834
exfoliative, 230t
laboratory tests in, 822–823
in photosensitivity, 821t, 832
treatment of, 823
photochemotherapy in, 822f, 823, 2257
Actinic keratosis, **1007**–1015
characteristics of, 1000
clinical findings in, 1008–1009, 1009f
conjunctival, 1009
cutaneous horn in, 1008–1009, 1010f
in cytotoxic drug therapy, 2178
diagnosis and differential diagnosis in, 445, 445b, 1010–1011, 1011b
DNA damage and repair in, 1005
epidemiology of, 999, 1000, 1007–1008
erythematous, 1008, 1009
etiology and pathogenesis in, 1008
histopathology in, 1009–1010
hypertrophic, 1008, 1010f
in immunocompromised host, 278, 1008
in occupational UV exposure, 2079
p53 in, 1001, 1008
pigmented, 1009, 1010
prevention of, 1015
prognosis and clinical course in, 1011
proliferative, 1009
risk factors for, 1008, 1008t
skin cancer prevention in, 1005, 1035
squamous cell carcinoma in, 1028, 1030, 1035
risk for, 1007–1015
sub-types and variants of, 1008–1009, 1009t
treatment of, 1011–1015
approach to, 1012f
cryotherapy in, 1013, 1014, 2332, 2332f
field therapies in, 1013b, 1013–1015
5-fluorouracil in, 1013, 1013b, 1014f, 2122
imiquimod in, 1005, 1013b, 1013–1014, 1015, 2128, 2129
lesion-targeted, 1011–1013, 1013b
photodynamic therapy in, 1014–1015, 2261
radiation therapy in, 2283
retinoids in, 2109, 2184
and xeroderma pigmentosum, 1316, 1316f, 1317, 1318
Actinic porokeratosis, 83
disseminated superficial, 442b, 443, 443f, 445
Actinic prurigo, 818–819
clinical features in, 819, 819f
diagnosis of, 826, 827
differential diagnosis in, 819b
treatment of, 819
Actinobacillus actinomycetemcomitans, 1779
Actinomadura madurae, 1779t, 1783, 1784, 1785, 1834t
Actinomadura pelletieri, 1779t, 1783, 1785, 1834t
Actinomyces gerencseriae, 1779
Actinomyces israelii, 1779, 1779t, 1781
diagnosis of, 1693
in oral cavity disorders, 653
treatment of infections, 2197t
Actinomyces meyeri, 1779
Actinomyces naeslundii, 1779
Actinomyces odontolyticus, 1779
Actinomyces viscosus, 1779
Actinomycetoma, 1778, 1779t, **1783**–1786, 1832, 1833
clinical findings in, 1784f, 1784–1785, 1785f, 1832
differential diagnosis of, 1785, 1786b
laboratory tests in, 1833, 1834t
treatment of, 1785–1786
Actinomycosis, 1778, 1779t, **1779**–1781, 1843
abdominal, 1780
cervicofacial, 1780, 1780f, 1781
clinical findings in, 1780f, 1780–1781
differential diagnosis of, 1781, 1781b
oral cavity disorders in, 653
pelvic, 1780, 1781
punch or fist, 1780–1781
thoracic, 1780, 1780f, 1781
treatment of, 1781

Action spectrum of ultraviolet radiation, 805, 810
in DNA damage, 811, 811f
in photoaging, 970–971
Activator protein 1, 1003
in aging of skin, 965f, 970
in squamous cell carcinoma, 993, 2112
Activin receptor-like kinase 1, 68t, 70
Acyclovir, 2203–2204
adverse effects of, 2203–2204
dosage of, 2204t
pediatric, 947t
in herpes simplex virus infections, 1880, 1881b–1883b, 1883
in atopic dermatitis, 156
in prevention, 1884
resistance to, 1883, 1884
in herpes zoster, 15, 16f
indications for, 2203, 2204t
mechanism of action, 2203
pharmacokinetics of, 2203
in pityriasis rosea, 366, 366b
in varicella-zoster virus infections, 1894, 1895, 1895t, 1896
prophylactic, 1898
ADA, 1358, 1359t, 1360
Adalimumab, 2227–2228
in psoriasis, 188t, 193, 2228
and arthritis, 205–206
in rheumatoid arthritis, 1573, 2227
Adamantiades-Behçet disease, **1620**–1626. *See also* Behçet disease
Adams-Oliver syndrome, 1345
Adamson's fringe, 742
ADAMTS-2/ADAMTS-2, 524t, 526
in Ehlers-Danlos syndrome, 1298t
Adapalene, 2107
in acne vulgaris, 697, 2111, 2143
chemical structure of, 2107f
in ethnic skin, 2143
indications for, 2109
receptor selectivity of, 2107
Adaptive immunity, 95, **101**–112, 319, 1690
cell types in, 95
cellular, 319. *See also* Cell-mediated immunity
compared to innate immunity, 95, 96f, 1590
endothelium in, 1594–1595
humoral, 319–329
interaction with innate immunity, 99
Adaptor proteins, 599
Addison disease, 1478–1479
hyperpigmentation in, 634, 1478, 1479f
oral cavity disorders in, 642t, 650
vitiligo in, 616, 619, 1478
Addressins, 1590t, 1596
Adenocarcinoma
aggressive digital papillary, 1077
apocrine, 1072–1073
eccrine, 1077
Adenoma
aggressive digital papillary, 1077
eccrine, 1077
of nipple, 1071
of pituitary, acromegaly in, 1482–1483
toxic, 1470
tubular, 1077
Adenomatous polyposis, familial, 553, 1079
Adenosine deaminase deficiency, 1358, 1359t, 1360
Adenosine monophosphate, cyclic
in melanogenesis, 605, 606f
response element, 599, 600f, 605
Adenovirus, 1846t
Adenylate cyclase in melanogenesis, 605, 606f
Adherence stage in dermatophyte infections, 1811
Adhesion, intercellular, 60, 447–459
calcium in, 61
desmosomes in, 447, 448
eosinophil receptors in, 282f, 287
neutrophils in, 281–282
Adipocytes, 66, 70
Adipose tissue, subcutaneous, 55, 66. *See also* Subcutaneous fat
Adiposis dolorosa, 1192
ADME model on pharmacokinetic drug interactions, 2237, 2237t
Adnexal carcinoma, microcystic, 1068, 1078–1079
Adolescents, 945
acne vulgaris in, 690, 945
body image in, 945
Adrenal gland disorders, **1477**–1479
acute crisis in, 1478, 1479
Addison disease in, 1478–1479
anemia in, 1377
and candidiasis, chronic mucocutaneous, 1356
congenital hyperplasia, 1480, 1481
in corticosteroid therapy, 2104, 2105, 2106, 2148–2149, 2151
prevention of, 2149–2150, 2150t
Cushing syndrome in, 1477–1478
hemorrhage
in meningococcal infections, 1734, 1735
in Waterhouse-Friderichsen syndrome, 1734, 1735, 1748
hirsutism in, 775–776
α-Adrenergic blockers in systemic sclerosis, 1559t
α-Adrenergic receptors in cold stress and vasoconstriction, 842f–843f, 842–843
α-Adrenergic stimulation, sweating in, 716, 717
β-Adrenergic stimulation, sweating in, 716, 717
Adrenergic urticaria, 336
Adrenocorticotropic hormone
in Addison disease, 1479
corticosteroid therapy affecting, 2148–2149, 2150
in Cushing syndrome, 1477, 1478
ectopic, hyperpigmentation in, 634, 635
as melanogenic stimulator, 604
in sebaceous gland activity and sebum production, 689
Adson maneuver in Raynaud phenomenon, 1645
ADULT syndrome, 1343, 1344
Advancement flaps, 2308–2309, 2309f
Aedes mosquitoes, 260
Aeromonas hydrophila infections, 1757t, 1764, 2053t
cellulitis in, 1742, 1764
in immunocompromised host, 269t
myonecrosis in, 1743, 1764
treatment of, 1757t, 1764
Aerosol drug formulations, topical, 2095
African endemic Kaposi sarcoma, 1185
African eyeworm infection, 2018
African histoplasmosis, 1836, 1838
African tick bite fever, 1942
African trypanosomiasis, 2007–2008, 2008f
Agalsidase alfa in Fabry disease, 1287
Agalsidase β in Fabry disease, 1287
Agammaglobulinemia, X-linked, 1348–1352
Age. *See also* Aging; Children; Elderly
in allergic contact dermatitis, 137
in irritant contact dermatitis, 397
and melanoma prognosis, 1148
and mortality rates, 5
and prevalence of skin disease, 6, 7f
in psoriasis onset, 169, 174
Aggrecan, 539t, 540
Aggressive house spider bites, 2057
Aging, **963**–973, 2363–2364
atrophy in, 28, 29f
cellular, 608, 963
cutaneous, 963–971
histologic features in, 964, 964t
mechanisms in, 964, 965f
smoking affecting, 971
hyaluronic acid levels in, 2358, 2363
immune function in, 963
melanocyte, 608
photoaging. *See* Photoaging
premature, 963, 2363
proteoglycan and glycosaminoglycan changes in, 541
pruritus in, 908
replicative senescence in, 963
retinoid therapy in, 2109, 2111
skin rejuvenation in, 2268, 2273
wrinkling of skin in, 967, 968f, 968t, 2363–2364
Agouti protein, 600, 748
AGPAT2 in lipodystrophy, 588
Agranulocytosis
in dapsone therapy, 2157
in drug interactions, 2240t
Agrin, 454, 539t
Ainhum, **562**–563
Airborne irritant dermatitis, 2068
AIRE, 1510, 1510f
in vitiligo, 619
Ajuga turkestanica, 2358
Akathisia from antipsychotic drugs, 917
Alagille syndrome, 1280
steatocystoma multiplex in, 1066
Alanine aminotransferase levels in dermatomyositis, 1546
Albendazole
in ascariasis, 2014t
in cysticercosis, 2014t, 2028
in echinococcosis, 2014t, 2027
in enterobiasis, 2014t
in filariasis, 2014t, 2018
in gnathostomiasis, 2014t
in hookworm infections, 2015t
in larva migrans
cutaneous, 2014t, 2024
visceral, 2015t
in loiasis, 2015t, 2019
in strongyloidiasis, 2015t
in trichinosis, 2015t
Albinism, **608**–616
complications in, 615
differential diagnosis of, 615, 615b
epidemiology of, 608
etiology and pathogenesis of, 609–612
oculocutaneous, 598, 608–612, 615
genetic factors in, 609–611
skin cancer risk in, 1004
treatment of, 615–616
type 1, 608, 609–611, 615
OCA1A, 609, 610, 610f
OCA1B, 609, 610f, 610–611
temperature-sensitive, 609, 610–611
type 2, 608, 611f, 611–612
brown phenotype, 611
type 3, 608, 612
brown phenotype, 612
rufous, 612
type 4, 608, 612

Albinism—*continued*
prognosis and clinical course in, 615
treatment of, 615–616
Albright hereditary osteodystrophy, 1296–1297, 1476
Albright's sign, 1297, 1476
Albumin serum levels
in decubitus ulcers, 881, 885
in exfoliative dermatitis, 228, 231
in psoriasis, 182
Alcohol use and alcoholism
anhidrosis in, 728
cirrhosis and psoriasis in, 1458
folate deficiency in, 1211, 1377
general skin changes in, 1446
gout in, 1575, 1576
porphyria cutanea tarda in, 1236–1237, 1241
spider nevi in, 1451
vitamin B_1 deficiency in, 1208
vitamin B_2 deficiency in, 1209
vitamin B_3 deficiency in, 1210
vitamin B_6 deficiency in, 1211
vitamin C deficiency in, 1212
zinc deficiency in, 1215
Aldehyde dehydrogenase, fatty, 68t, 69
ALDH3A2, 417
ALDH10, 417
Aldolase serum levels in dermatomyositis, 1546
Aldosterone and sweat gland function, 719
Alefacept, 2223t, 2229–2230
in psoriasis, 188t, 192, 2229, 2230
and arthritis, 206, 2230
Alemtuzumab, 288
Aleppo boil, 2003
Alezzandrini syndrome, 619
Alfacalcidiol in corticosteroid therapy and osteoporosis, 2152
Alginate dressings, 2345, 2346t
Alitretinoin in vesicular palmoplantar eczema, 166
Alkali chemicals, occupational exposure to, 2069, 2070t
Alkaline phosphatase levels
leukocyte, in polycythemia vera, 1378
serum, in mastocytosis, 1439–1440
Alkaptonuria, 637, 1219t, 1221f, **1224**–1228
clinical features in, 1226f, 1226–1227
diagnosis and differential diagnosis of, 1227, 1227b
epidemiology of, 1224
etiology and pathogenesis in, 1224–1226
genetic factors in, 1224–1225
intervertebral disk calcification in, 1226, 1227, 1227f
laboratory findings in, 1227, 1227f
prognosis and clinical course in, 1228
treatment of, 1227–1228, 1228b
Alkylamine, 2187, 2190
Alkylating agents, 2163, 2172–2175
Allen test
in Raynaud phenomenon, 1644
in thromboangiitis obliterans, 1675
Allergen Patch Test Kit, 143
Allergens
in allergic contact dermatitis, 136t, 136–137
in occupational exposures, 2070, 2070t
of vulva, 677–678
in atopic dermatitis
in immunotherapy, 157
as triggering factor, 155–156
in cosmetic products, 2361–2362
in lymphomatoid contact dermatitis, 1411
in photoallergy, 832–833
in urticaria and angioedema, 333
Allergic angiitis and granulomatosis, 1611–1613
Allergic contact dermatitis, **135**–146
of amputation stump, 866f, 866–867, 867f, 867t
in athletes, 876, 876f
barrier function of skin in, 138, 393, 400
clinical manifestations in, 137f, 139–143
common allergens causing, 136t, 136–137
in occupational exposures, 2070, 2070t
complications in, 144
in corticosteroid therapy, 141, 142, 2106
from cosmetic products, 137, 146, 2360, 2361–2362
diagnosis of, 138–139
in occupational exposures, 2072
differential diagnosis in, 138, 139b, 143–144, 151, 165, 834
irritant contact dermatitis in, 139b, 395, 398, 399, 400
effect of UV radiation in, 90
epidemiology of, 135–138, 2069
erythema multiforme-like, 142, 144
etiology and pathogenesis in, 138
of face, 137, 137f, 138f, 140
of hand, 135, 136f, 137, 140, 145
history-taking in, 138, 139t
laboratory findings in, 143
lichenoid, 142, 144
in neonates, 936
noneczematous variants of, 142, 144
in occupational exposures, 20, 135–136, 136f, 144, 145, 2069–2070
common allergens in, 2070, 2070t
diagnosis of, 2072
paradoxical, 141
patch testing in, 138, 143, 400. *See also* Patch testing
pathologic reactions in, 48
perioral and perianal mucosal, 141
peristomal, 870
postoperative, 2337, 2337f
prevention of, 145–146
prognosis in, 144–145
systemic reactions in, 141f, 141–143
in occupational exposures, 2070
T cell response in, 105, 106, 138
threshold of sensitization in, 138
treatment in, 145
of vulva, 676, 677–678
Allergic contact purpura, 144
Allergic contact stomatitis, 651
Allergic contact urticaria, 142–143, 2071
Allodermanyssus mites, rickettsialpox from, 1943t, 1946
Allodynia, 903
in postherpetic neuralgia, 1894
Alloimmune thrombocytopenic purpura, 1381–1382
Allokinesis, 903, 907
Allopurinol, 2167
in gout, 1576
hypersensitivity syndrome from, 357–358
interaction with other drugs, 2239, 2239t, 2240t
in perforating disorders, 567b
Allylamine antifungal agents
oral, 2211–2213
topical, 2117t, 2119, 2119t, 2120t
Allysine, 527f, 534
Alopecia, 739, 753, 754, **755**–774
androgenic, 761, 766–769, 1481
treatment of, 768b, 768–769, 1482
areata, 754, 760, 762–765, 770
in children and infants, 764, 938
clinical features in, 763f, 764, 764f
differential diagnosis of, 764
epidemiology of, 762
etiology and pathogenesis in, 763
genetic factors in, 763
hair graying in, 630, 764
histopathology in, 763, 763f
HLA system in, 763
nail changes in, 791, 791f
prognosis in, 764
support groups for patients with, 764
treatment of, 764b, 764–765, 765, 2255
and vitiligo, 616, 619
areolaris, 764
in children and infants, 764, 769, 938
in syphilis, 771
cicatricial or scarring, 755t, 764, 771–774
central, 772t
central centrifugal, 773
classification of, 771, 772t
congenital, 774
definition of, 754t
primary, 771–773, 772t
secondary, 774
treatment of, 772t
congenita with keratosis palmoplantaris, 429
definition of, 754t
in dermatomyositis, 1544
diffuse (global), 755
drugs associated with, 762
cytotoxic, 2175–2176, 2176f, 2176t
retinoid, 2185
in ectodermal dysplasia, 755, 1343, 1343f
frontal fibrosing, 771, 772t, 773, 773f
hair restoration surgery in, 769, 2394–2402
hot comb, 773
in ichthyosis follicularis, alopecia, and photophobia syndrome, 751, 752–753
in keratosis follicularis spinulosa decalvans, 751f, 751–752, 772t, 773
laser-induced, 2275–2277
in lichen planus, 247, 248, 248f
in lupus erythematosus, 1524, 1527, 1532, 1535
mucinosa, 772t, 773, 1390
in occupational exposures, 2068t
in pattern hair loss, 754–755, 755t, 766–769
hair transplantation in, 769, 2394–2402
pressure, 769
in sarcoidosis, 1487
in syphilis, 770–771, 771f, 1961, 1962f
totalis, 764
traction, 770, 770f
treatment of, 764–765, 768–769, 772t, 1482
hair transplantation in, 769, 2394–2402
photochemotherapy in, 765, 2255
surgical reduction technique in, 2401–2402
triangular temporal, 765, 765f, 938
in trichotillomania, 914f, 914–915
universalis, 760, 764
ALOX12B in ichthyosis, 411t
ALOXE3 in ichthyosis, 411t
α chains in collagen, 517, 518, 518f, 519t
Alport syndrome, 453, 520
Alternaria in immunocompromised host, 276
Alternative and complementary medicine, **2285**–2287
Altitude, and cold injuries in high altitude, 845

Aluminum chloride as antiperspirant, 2134
in hyperhidrosis, 723, 724b, 2134
Aluminum salts as astringent, 2132t, 2134–2135
Amalgam, dental
contact allergic stomatitis from, 651
lichenoid reaction from, 248–249, 250, 253
pigmentation changes from, 650
Amantadine, livedo reticularis from, 1676
Amblyomma ticks, 1942, 1944t, 1945f, 1952, 2059
and tularemia, 1758
Ambras syndrome, hypertrichosis in, 776
Amebiasis, cutaneous, 2009, 2010f
American College of Rheumatology
rheumatoid arthritis diagnostic criteria, 1570, 1570t
vasculitis classification criteria, 1609
American hookworm disease, 2013
American Joint Committee on Cancer melanoma staging system, 1145–1146, 1148t–1150t
American trypanosomiasis, 2008–2009, 2009t, 2061
Amifostine as radioprotector, 860
Amikacin in actinomycetoma, 1786
Amino acids
metabolism disorders, **1219**–1228
in sweat, 717
δ-Aminolevulinic acid
in heme biosynthesis, 1229f
in plasma, 1229t
in urine, 1229t
in porphyrias, 1240t, 1250
Aminolevulinic acid, in photodynamic therapy, 798, 799, 2260–2262
in acne vulgaris, 700, 2262
in actinic keratosis, 1014–1015, 2261
in psoriasis, 190
Aminolevulinic acid dehydratase, 1230t
deficiency of, 1230t, 1233, 1234, 1249t, 1254
biochemical features in, 1240t
treatment in, 1251b
in heme biosynthesis, 1229f, 1230
δ-Aminolevulinic acid synthase, 1230t, 1230–1231, 1231f
in acute intermittent porphyria, 1249, 1250
in heme biosynthesis, 1230
iron levels and phlebotomy affecting, 1241
Aminoquinolines, **2157**–2162
Amiodarone
photosensitivity from, 636
phototoxicity from, 831, 831f
pigmentation changes from, 636, 638f, 1227
Amish brittle hair syndrome, 759t, 1321
Amitriptyline, 918t
Ammonia in sweat, 717, 717f
Ammonium bituminosulphonate, 2130
Amorolfine in onychomycosis, 1820
Amoxicillin, 2195t, 2198
in chlamydial infection, 1998b
and clavulanate, 2195t
in actinomycetoma, 1786
in bite wounds, 2038
in impetigo, 1697–1698, 1698b
in melioidosis, 1765
in *Pasteurella multocida* infection, 2038
pediatric dosage, 948t
in Lyme disease, 1804, 1806t
pediatric dosage, 947t–948t
Amphiregulin, 2108, 2111
in psoriasis, 174
Amphotericin B, 2120
in blastomycosis, 1839
in chromoblastomycosis, 1834–1835
in coccidioidomycosis, 1840
in cryptococcosis, 1843
in histoplasmosis, 1838
in *Penicillium marneffei* infection, 1842
Ampicillin, 2198
in erysipeloid, 1766
exanthematous eruptions from, 356, 356f
in *Haemophilus influenzae* infections, 1740
Amprenavir in HIV infection, 2209
hypersensitivity reactions to, 1934
Amputation
in diabetes mellitus, 1462, 1466
in foot problems, 873, 1466
in peripheral artery disease, 1670
skin problems in, 863, 864
in peripheral artery disease, 1670, 1671, 1675
skin problems in, **862**–868
traumatic neuroma in, 1176
types of limb prostheses in, 862, 863f
Amstel diagnostic criteria on bacterial vaginosis, 2000
Amyloid A protein in serum, 1257
Amyloid neuropathy, 1257, 1258, 1260
anhidrosis in, 728
complications in, 1263, 1264
prognosis and clinical course in, 1264
treatment in, 1265
Amyloid P component in serum, 1257, 1263
Amyloidomas, 1258
Amyloidosis, **1257**–1265, 1376t, 1495t, 1503
anosacral, 1261
cardiovascular disorders in, 1258, 1260t, 1262, 1263, 1264, 1454
classification of, 1257, 1258t
clinical findings in, 1258–1262, 1260f–1262f, 1260t
complications in, 1263–1264
in cryopyrinopathies, 1271
in decubitus ulcers, 881
diagnostic approach to, 1259t
differential diagnosis of, 1263b
epidemiology of, 1257
etiology and pathogenesis in, 1257–1258
in familial Mediterranean fever, 1266, 1267
genetic factors in, 1257, 1258t, 1263, 1264–1265
histopathology in, 1262–1263, 1263f
lichenoid, 1261, 1262f, 1265
familial cutaneous, 1503
macular, 640, 1261, 1261f, 1265
malignancies associated with, 1503
nail changes in, 790, 791, 1260, 1260f
oral cavity disorders in, 642t, 1260t, 1261, 1262f
prognosis and clinical course in, 1264
respiratory disorders in, 1454
treatment of, 1264–1265
in tumor necrosis factor receptor-associated periodic syndrome, 1269–1270
Anabolic steroid abuse, cutaneous signs of, 877, 924, 1481
Anagen, 744, 745–746, 747f, 754, 757f
age-related changes in, 967
anatomy in, 743f
angiogenesis in, 64
definition of, 754t
effluvium, 761–762, 2173
in first hair cycle, 72
inducers of, 754
loose anagen syndrome, 762, 762f
melanocytes in, 748, 748f
short anagen syndrome, 761
as therapy target, 754
Anagen hairs, definition of, 754t
Anakinra, 126
in cryopyrinopathies, 1271
in tumor necrosis factor receptor-associated periodic syndrome, 1270
Anal and perianal disorders
in allergic contact dermatitis, 141
in amebiasis, 2009, 2010f
in amyloidosis, 1261
in CAP syndrome, 444
in CDAGS syndrome, 444
in cicatricial pemphigoid, 484t, 485b
in lichen planus, 249, 249f
in lymphogranuloma venereum, 1988, 1989
in Paget disease, 1095, 1095f
in papillomavirus infections, 997
in squamous cell carcinoma, 1031, 1032f
in syphilis, 1958
in warts. *See* Warts, anogenital
Analgesics
in postoperative pain, 2337–2338
topical, 2130
in varicella-zoster virus infections, 1896
Anaphylatoxins, 327
Anaphylaxis
in azathioprine therapy, 2168
exercise-induced, 335, 877
in hymenoptera stings, 2062
in methotrexate therapy, 2166
from penicillin in syphilis, 1977
in topical drug therapy, 2096
Anaplasma phagocytophilum, 1797, 1803, 1804, 1944t, 1952, 1953f
Anaplasmosis, 1952–1953
clinical and laboratory findings in, 1946t, 1952
epidemiology of, 1944t, 1952
histopathology in, 1953, 1953f
treatment of, 1949b, 1950b, 1953
Anaplastic large cell lymphoma, 1386, 1392, 1393, 1395f
Anatomy, surgical
of face, 2289–2294
of nails, 2320f, 2320–2321
Anchoring filaments and fibrils in dermal-epidermal junction, 47, 62, 450, 450f, 451, 457–459
in embryonic and fetal development, 71
in epidermolysis bullosa, 458, 494, 496, 510, 511
Ancylostoma braziliense, 2012t, 2013t, 2021t, 2023
occupational exposure to, 2076
Ancylostoma caninum, 2013t, 2021t, 2023
Ancylostoma duodenale, 2012t, 2013, 2016
Ancylostomiasis, 2013
Andean sickness, 2003
Anderson-Fabry disease, 1455
Androgens, 1480–1482
in acne, 690–691, 691f, 692, 694, 695, 1481–1482
and hormone therapy, 698
of infants, 700
and polycystic ovary syndrome, 701
in angioedema, hereditary, 342–343
excess levels of, 1480–1482
in hair loss, 766–769, 1481, 1482
in hirsutism, 775, 775t, 1481
in lupus erythematosus, 1517
in polycystic ovary syndrome, 701, 1481
in sebaceous gland activity and sebum production, 689, 1481

Anemia, 1373–1377
in *Bartonella* infections, 1753, 1755
in chronic disease, 1270
in endocrine disorders, 1374t, 1377
in epidermolysis bullosa, 515
in Fabry disease, 1284t, 1285
Fanconi. *See* Fanconi anemia
in folate deficiency, 1211
hemolytic. *See* Hemolytic anemia
in iron deficiency, 1214, 1376–1377
in Kawasaki disease, 1630
in Langerhans cell histiocytosis, 1423
megaloblastic, 1374t, 1377
in parvovirus B19 infections, 1856
aplastic crisis in, 1855, 1856, 1857
treatment of, 1857, 1857b
pernicious, 1212, 1374t, 1377
in dermatitis herpetiformis, 503
vitiligo in, 616, 619
sideroblastic, porphyrin profile in, 1256
skin color in, 616, 619, 630–631
in visceral leishmaniasis, 2006
in vitamin C deficiency, 1213
Anergy induction, 1511
Anesthesia, 2296t, 2296–2299
in dermabrasion, 2371
in excisional surgery, 2303
in hair transplantation, 2397–2398
in laser therapy
for skin rejuvenation, 2373
for skin resurfacing, 2366
for vascular lesions, 2375
in liposuction, 2378–2379
in nail surgery, 2321f, 2321–2322, 2322f
in pediatric procedures, 942
selection of agent in, 2296
side effects and complications of, 2297–2298, 2336–2337
in soft tissue augmentation, 2382, 2383, 2384–2385, 2386, 2387
topical agents in, 2130, 2296t, 2298
Anesthesia complication of surgery, 2341
Anetoderma, 537t, **557**–558, 1376t
clinical findings in, 557–558, 558f
differential diagnosis of, 558, 558b, 559, 1801
in premature infants, 940
treatment of, 558
Aneurysm of aorta in syphilis, 1965
Angelman syndrome, 82, 612
Angel's kiss, 1652, 2270
Angiitis
allergic, 1599
and granulomatosis, 1611–1613
microscopic polyangiitis, 1599, 1607, 1613–1615
necrotizing, 1599
systemic polyangiitis, 1599
thromboangiitis obliterans, 1673–1676
Angioblastoma of Nakagawa, 1170
Angiodermatitis, disseminated pruriginous, 1635, 1635f
Angioedema, 27, **330**–343, 1375t
acute, 330
in blood product administration, 338
bradykinin in, 333, 336–337, 337f
chronic, 330
clinical findings in, 333f, 333–338
cold, 334
complement system in, 328–329, 331–332, 336, 340, 343, 1370, 1371t
cyclic episodic, 338
diagnostic approach in, 338–340, 339f
differential diagnosis of, 340, 340b, 1246
drug-induced, 337, 338, 358
in ACE inhibitor therapy, 337, 342
treatment of, 341, 342
epidemiology of, 330
episodic, with eosinophilia, 316
in exercise-induced anaphylaxis, 335
hereditary, 336, 337f, 1370, 1372
oral cavity disorders in, 642t
treatment of, 342–343
histopathology in, 340–341
hypereosinophilic syndromes with, 309
idiopathic, 338
immunoglobulin IgE in, 331, 332–333, 340
laboratory findings in, 340–341
pathogenesis in, 330–333
treatment of, 341–343, 342f
and vasculitis, 337
vibratory, 334
Angioendothelioma, endovascular papillary, 1172
Angiofibroma, 555
differential diagnosis in, 1330b
facial, in tuberous sclerosis, 1326, 1329, 1329f
pearly penile papules in, 657
Angiogenesis, 1596–1598
age-related changes in, 966
and anti-angiogenic agents, 2231–2236
experimental, 2236t
chemokines in, 133
cutaneous, 64, 1597–1598
in psoriasis, 1598
regulation of, 1596–1597
vascular endothelial growth factor in, 64, 1596, 1597t, 1598
in wound healing, 2344, 2344t
Angiography
in arteriovenous malformations, 1653f, 1664f, 1665
in atheromatous embolism, 1672
atheromatous embolism after, 1671
in peripheral artery disease, 1669, 1669f
Angioid streak of retina in pseudoxanthoma elasticum, 1307
Angiokeratoma
acral pseudolymphomatous, in children, 1404
circumscriptum, 657, 1285, 1285b, 1661–1662
clinical manifestations of, 1286t, 1662f
corporis diffusum, 1455
differential diagnosis in, 1285b, 1286t–1287t
oral cavity disorders in, 642t
in Fabry disease, 657, 1282–1283, 1283f, 1662
clinical manifestations of, 1286t
differential diagnosis in, 1285, 1285b, 1286t–1287t
histopathology of, 1284
locations and distribution of, 1282–1283
treatment of, 1287, 1287b
of Fordyce, 657, 1285, 1285b, 1286t, 1662
genital, 657
laser therapy in, 2374
of Mibelli, 1285, 1285b, 1286t, 1662
solitary papular, 1285, 1285b, 1286t
Angioleiomyoma, 1172, 1173, 1173f
Angiolipoma, 1192–1193, 1193f
Angiolymphatic invasion of melanoma, 1148
Angiolymphoid hyperplasia, 52, 52f
with eosinophilia, 313–314, 1403t, 1408–1409
clinical findings in, 313, 313f, 1408f, 1409
differential diagnosis in, 314, 314t, 1409, 1409b
treatment of, 313f, 314, 1409, 1409b
Angioma, 1651
cherry, 2272
laser therapy in, 2272
spider, 1451, 2272
sudoriparous, 1171
tufted, 1170, 1171f
Angiomatosis
bacillary. *See* Bacillary angiomatosis
cutaneovisceral, with thrombocytopenia, 1171
neonatal, 1457
Angiomyolipoma in tuberous sclerosis, 1329, 1458
Angiomyxolipoma, 1191
Angioplasty in peripheral arterial disease, 1671
Angiopoietins, 1597, 1597t, 1598
Angiosarcoma, 1172, **1188**–1189
clinical manifestations of, 1188f, 1188–1189, 1189f
in elderly, 972, 972t
histopathology in, 1189, 1189f
post-irradiation, 1188, 1189f
treatment of, 1189
radiation therapy in, 2282, 2282t
Angiotensin, 901
Angiotensin-converting enzyme, 895, 1590t
in sarcoidosis, 1489
in systemic sclerosis, 1554t
Angiotensin-converting enzyme inhibitors
angioedema associated with, 337, 342
in systemic sclerosis, 1559t
Angiotensin receptor blockers in systemic sclerosis, 1559t
Angular artery, 2293
Angular cheilitis, 641
in candidiasis, 1823, 1936
in HIV infection, 1936
in Sjögren syndrome, 1580
Anhidrosis, 726–730
acquired idiopathic, 721f, 727
chronic idiopathic, 727
classification of, 722t
in ectodermal dysplasia, 837, 1339–1342. *See also* Ectodermal dysplasia, anhidrotic or hypohidrotic
in leprosy, 728, 1788
in Naegeli-Franceschetti-Jadassohn syndrome, 426
in pure sudomotor failure, 727
segmental, 721f, 727
Animal exposure
anthrax in, 1755, 2074
bites in, 2037–2042
brucellosis in, 1759, 2074, 2085
cat-scratch disease in, 1749–1751, 2038
cellulitis in, 1723
diagnostic approach to infections in, 1756f
erysipeloid in, 1765, 2074–2075
glanders in, 1760
leptospirosis in, 1766
listeriosis in, 1762, 1763
milker's nodules in, 1908–1910, 2076
mites in, 2032t, 2033
monkeypox in, 1906–1908, 2076
occupational skin diseases in, 2074
orf in, 1910–1911, 2076
paravaccinia virus infections in, 1900t, 1908–1910, 2076
Pasteurella infections in, 1761, 2038
rabies in, 2038–2039
rat-bite fever in, 1761–1762

seal finger in, 1762
soft tissue infections in, 1728
toxoplasmosis in, 2010
tularemia in, 1757–1758, 2074
Animal models
of autoimmune disorders, 1512, 1513, 1514
of porphyria cutanea tarda, 1237, 1256
of protoporphyria, erythropoietic, 1256
of skin cancer, 988–991, 992t, 992–993, 1004
of venulitis, cutaneous necrotizing, 1588
of vitiligo, 617
Ankle-brachial index
in peripheral arterial disease, 1668, 1669
in peripheral venous disorders, 1682
Ankyloblepharon filiforme adnatum–ectodermal dysplasia–cleft palate syndrome, 1343–1344, 1344f
Annexins, 382t, 2147
Annular lesions, 34, 35f
in erythema annulare centrifugum, **366**–368
in erythema of infancy, 367t, 368
in granuloma, **369**–372
in lichen planus, 246
in lupus erythematosus, 367t
in psoriasis, 367t
in urticaria, 367t
Anopheles mosquitoes, 2059–2060
Ant stings, 2062
Anthracyclines, 2175
Anthralin
in alopecia areata, 764b, 765
in palmoplantar pustulosis, 217, 217b
in psoriasis, 185, 188–189
in combination with other agents, 187t
Anthrax, 1692–1693, 1755–1756
in bioterrorism, 1755, 1756, 2081–2083, 2082t, 2084t
clinical findings in, 1755–1756, 1758f, 2082
cutaneous, 1756, 2084t
inhalational, 1755, 2082
in occupational exposures, 2074
treatment of, 1756, 1757t, 2083
vaccination against, 2083
Anthrenus scrophulariae (carpet beetle), 2060
Antiandrogens
in acne vulgaris, 698
in hirsutism, 775b, 775–776
in pattern hair loss, 769
Anti-angiogenic agents, **2231**–2236
experimental, 2236t
Antianxiety drugs, phototoxicity associated with, 829t
Antibiotics, 1693–1694, 2113–2115, **2194**–2202. *See also specific drugs*
in acne vulgaris
resistance to, 698
in systemic therapy, 697–698
in topical therapy, 696–697, 2113–2114
adverse effects of, 1693, 2196t
hyperpigmentation in, 637t
hypersensitivity in, 357, 1693, 2198, 2199
photoallergy in, 830t
phototoxicity in, 829t
bacteriocidal, 2194
bacteriostatic, 2194
in burns, 857
cephalosporins, 2196t, 2198–2199
in children, 946, 947t–950t
clindamycin, 2195t, 2196t, 2200
in cutaneous lymphoid hyperplasia, 1408, 1408b
in decubitus ulcers, 885
dosage of, 1693, 2195t
in renal disorders, 2195
in endocarditis, 2195
fluoroquinolone, 2195t, 2196t, 2201
in granulomatous disease, chronic, 1364, 1365t
in hidradenitis suppurativa, 737
indications for, 2197t
in lymphedema, 1686
macrolide, 2196t, 2200–2201
mechanism of action, 2194
in meningococcal infections, 1734–1735
penicillins, 2195t, 2196t, 2197–2198
perioperative, 2113, 2194–2197
in nail procedures, 2322–2323
in perioral dermatitis, 711, 711b
pharmacokinetics and pharmacodynamics of, 2194
in pityriasis lichenoides, 243, 243b
in pregnancy and lactation, 2195
prophylactic, 2113, 2195–2197
in reactive arthritis, 214
resistance to, 1693, 1695, 1728, 1730, 2194
in acne vulgaris, 698
in athletes, 873–875
in elderly, 973
in surgical wounds, 2337
treatment in, 875, 2114
in rheumatic fever, 1574
in rosacea, 708, 2113–2114
in soft tissue infections, 1729b, 1729–1730
susceptibility testing, 2194
tetracyclines, 2195t, 2196t, 2199
topical agents, 1693–1694, 2113t, **2113**–2115, 2130–2133
in acne vulgaris, 696–697, 2113–2114
in ethnic skin, 2144
trimethoprim-sulfamethoxazole, 2195t, 2196t, 2201
Antibodies
deficiency disorders, 1348–1353, 1349t
diversity of, 321
effector functions, 323
natural, 323
structure of, 319–320, 320f
therapies based on, 2223t, 2226–2229
Anticardiolipin antibodies in necrotizing venulitis, 1602
Anti-CD20 antibodies in B-cell lymphoma therapy, 1401
Anti-centromere antibodies in systemic sclerosis, 1554t
Anticholinergic effects of antihistamines, 2190, 2191
Anticoagulant drugs
in atheromatous embolism, 1673
atheromatous embolism from, 1671
in Degos disease, 1651, 1651b
preoperative, 2337
skin necrosis from, 360, 360f
in systemic sclerosis, 1559t
in venous malformations, 1660
Anticonvulsant drugs
hypersensitivity syndrome from, 357
pseudolymphoma from, 360
in varicella-zoster virus infections, 1896
Antidepressant drugs, 918t, 918–920
hyperhidrosis from, 726
phototoxicity from, 829t, 831f
tricyclic, 919
antihistaminic activity of, 2193
in postherpetic neuralgia, 1896, 1897
Anti-dsNDA antibodies in lupus erythematosus, 1528, 1528t, 1529
Anti-EJ antibodies in idiopathic inflammatory dermatomyopathies, 1539t
Anti-epiligrin cicatricial pemphigoid, 482t, 483
Anti-Fer antibodies in idiopathic inflammatory dermatomyopathies, 1539t
Anti-fibrillin antibodies in systemic sclerosis, 1555
Anti-α-fodrin antibodies in Sjögren syndrome, 1578
Antifungal agents
allylamine and benzylamine, 2117t, 2119, 2211–2213
in dermatophyte infections, 1818t, 1819–1820
evidence-based medicine on, 2216–2217
griseofulvin, 2216
imidazole, 2116–2119, 2117t, 2215
in immunocompromised host, 2216
oral, **2211**–2217
pediatric dosage, 950t–951t, 1818t
pharmacokinetics of, 2118, 2119
photoallergy from, 830t
phototoxicity from, 829t
polyene, 2117t, 2119–2120
in seborrheic dermatitis, 224
topical, **2116**–2121
adverse effects of, 2118t, 2118–2119, 2120, 2121
ideal properties of, 2116, 2118t
triazole, 2213–2215
Antigen presentation, 101, 109–112, 1511
in atopic dermatitis, 148
in autoimmunity, 1513
CD1-dependent, 110f, 111–112
class I MHC-restricted, 109–111, 110f
class II MHC-restricted, 110f, 111
dendritic cells in, 111–112, 113f
dermal dendrocytes in, 64
Langerhans cells in, 62, 111–112, 113f
in sarcoidosis, 1485, 1485f
Antihelix of ear, 2289, 2290f
Antihistamines, **2186**–2193
in atopic dermatitis, 149, 156, 2189
in children, 2190, 2191, 2192–2193
dosage of, 952t–953t
complications of, 2190, 2190t, 2192, 2192t
in dermatomyositis, 1551
dosing regimens, 2189, 2189t, 2191, 2192t
in children, 952t–953t
in elderly, 2190, 2191, 2193
in exfoliative dermatitis, 231, 232b
H_1-type, 2186–2191
first-generation, sedating, 2187
second-generation, low-sedating, 2187–2188
H_2-type, 2191–2193
indications for, 2188t, 2188–2189, 2191
initiation of therapy, 2190, 2191–2192
interaction with other drugs, 2190–2191, 2192, 2240t
in mastocytosis, 1441, 1442b, 2189
mechanism of action, 2186–2187, 2188f, 2191
monitoring of therapy, 2190, 2192
in necrotizing venulitis, 1606, 1606t
pharmacokinetics of, 2187–2188, 2191
in pregnancy, 2190, 2191, 2193
in pruritus, 904, 910, 2189
in urticaria and angioedema, 341, 342f, 2188–2189, 2190
Antihistone antibodies
in lupus erythematosus, 1528t
in morphea, 545
Antihypertensive drugs, hyperpigmentation from, 637t

Anti-inflammatory agents, nonsteroidal
in necrotizing venulitis, 1606, 1606t
pediatric dosage, 951t–952t
photoallergy from, 830t, 833
phototoxicity from, 829t
precautions in bacterial soft tissue infections, 1730
in psoriatic arthritis, 202, 203f, 203–204, 206
in reactive arthritis, 214
topical, 2130
urticaria and angioedema from, 338, 341
Anti-Jo antibodies in dermatomyositis, 1539t, 1545, 1546, 1550
Anti-KJ antibodies in idiopathic inflammatory dermatomyopathies, 1539t
Anti-Ku antibodies, 1528t
in idiopathic inflammatory dermatomyopathies, 1539t
Anti-La/SS-B antibodies
in lupus erythematosus, 1528, 1528t, 1529
in Sjögren syndrome, 1577, 1578, 1580
Antimalarial drugs, **2157**–2162
chemical structures of, 2158, 2158f
in children, 2161, 2162, 2162t
in dermatomyositis, 1551, 2160
dosing regimens for, 2160
indications for, 2159–2160, 2161t
initiation of therapy with, 2160
interaction with other drugs, 2162, 2162t
in lupus erythematosus, 1533t, 1533–1534, 2159–2160
mechanism of action, 2157–2158
monitoring of therapy with, 2160–2161
pharmacokinetics of, 2158–2159, 2159t
in polymorphic light eruption, 818, 2160
in porphyria cutanea tarda, 1242, 2160
in pregnancy, 2162, 2162t
in sarcoidosis, 1492, 1492t, 2160
side effects and complications of, 2160–2162, 2162t
hepatotoxicity in, 2160
ocular toxicity in, 1533, 1551, 2160, 2161–2162
photoallergy in, 830t
phototoxicity in, 829t
pigmentation changes in, 636, 637, 1227, 2161, 2162t
Anti-Mas antibodies in idiopathic inflammatory dermatomyopathies, 1539t
Antimetabolites, 2163–2172
in atopic dermatitis, 157
in psoriatic arthritis, 205
Anti-Mi-2 antibodies in dermatomyositis, 1539t, 1546, 1550
Antimicrobial functions of skin, 57, 58t, 96f, 1689–1690
Antimicrobial peptides, 96–97, 1690, 1695
Antineutrophil cytoplasmic antibodies, 1600, 1601
in Churg-Strauss syndrome, 1613
in cutaneous necrotizing venulitis, 1599, 1600–1601, 1602
in erythema elevatum diutinum, 1617
in microscopic polyangiitis, 1613
to myeloperoxidase, 1609, 1613
neutrophilic dermatosis positive for, 1375t
perinuclear, 1600–1601
in polymorphic disease with monoclonal IgA, 1375t
to proteinase 3, 1609, 1611
in systemic necrotizing vasculitis, 1607, 1609, 1610
in Wegener granulomatosis, 1611
Anti-nRNP antibodies in systemic sclerosis, 1554t
Antinuclear antibodies
in dermatomyositis, 1539t, 1546
in lupus erythematosus, 1528, 1529
in systemic sclerosis, 1554
Anti-OJ antibodies in dermatomyositis, 1539t, 1546
Antioxidants
in antiaging products, 2363
as modifiers of carcinogenesis, 993, 994t
in systemic sclerosis, 1559t
in topical drug formulations, 2095
in ultraviolet radiation exposure, 813–814
Antiparasitic agents, topical, 2133–2134, 2133t
Anti-PCNA antibodies, 1528t
Antiperspirants, 2134
in hyperhidrosis, 723, 724b, 2134
Antiphospholipid antibodies
in Degos disease, 1648, 1649, 1650
in leprosy, 1793
in livedo racemosa, 1677
in necrotizing vasculitis, 1602
Anti-PL-7 antibodies in dermatomyositis, 1539t, 1545, 1546, 1550
Anti-PL-12 antibodies in dermatomyositis, 1539t, 1545, 1546, 1550
Anti-Pm-Scl antibodies
in dermatomyositis, 1539t, 1546, 1550
in systemic sclerosis, 1554t
Antipruritic agents, topical, 909t, 909–910, 2134, 2134t
Antipsychotic drugs, 917t, 917–918, 918t
phototoxicity from, 829t
Antiretroviral therapy in HIV infection, 1927, 1929, 1930t, 1934–1935, 2207–2211
and histoplasmosis, 1838
and Kaposi sarcoma, 1187–1188
lipodystrophy in, 586, 586f, 589, 1934–1935
Antirheumatic drugs, disease-modifying, 1573, 1573t
Anti-RNAP antibodies in systemic sclerosis, 1554t
Anti-Ro antibodies, 1544
in dermatomyositis, 1539t, 1546
in lupus erythematosus, 1528, 1528t, 1529, 1530
in Sjögren syndrome, 1577, 1578, 1580
Anti-rRNP antibodies, 1528t
Anti-Scl-70 antibodies in systemic sclerosis, 1554t
Anti-Se antibodies in dermatomyositis, 1539, 1539t, 1547
Antiseptics
dye preparations as, 2132
in preoperative skin preparation, 2296–2297
Anti-Sm antibodies in lupus erythematosus, 1528, 1528t
Anti-SRP antibodies in dermatomyositis, 1539t, 1546, 1550
Anti-ssDNA antibodies, 1528t
in dermatomyositis, 1539t
Antistreptolysin O titer in rheumatic fever, 1704
Antisynthetase autoantibodies, 1545, 1546, 1550
Antisynthetase syndrome, 1545, 1546
Antithrombin, 1748
Antithymocyte globulin
in graft-versus-host disease, 266t
in systemic sclerosis, 1559t
Antithyroid antibodies in urticaria and angioedema, 331
Antitoxin, diphtheria, 1768
α_1-Antitrypsin deficiency panniculitis, 578–579, 579f
Anti-U1RNP antibodies
in dermatomyositis, 1539t, 1546
in lupus erythematosus, 1528, 1528t
in systemic sclerosis, 1554t
Anti-U2RNP antibodies in dermatomyositis, 1539t
Antivenin
in *Chironex fleckeri* stings, 2044–2045
in scorpion stings, 2058
in snake bites, 2041–2042, 2042b
in spider bites, 2055–2056, 2057
in stonefish stings, 2052
Antiviral agents, 1850, **2203**–2211
in children, 947t
in cytomegalovirus infections, 2205–2207
in herpes simplex virus infections, 1880–1884, 1881b–1883b, 2203–2205
in prevention, 1884
resistance to, 1883–1884
in HIV infection, 2207–2211
in varicella-zoster virus infections, 1894–1896, 2203–2205
in prevention, 1898
Antoni A and B areas in schwannoma, 1178
Anxiety, 921
Anxiolytic drugs, 920, 920t
Aorta
atherosclerosis of, 1671
embolism in, 1671, 1672, 1672f
in Ehlers-Danlos syndrome, 1299, 1300
in Marfan syndrome, 1302, 1303, 1304
in syphilis, 1964–1965
in Takayasu arteritis, 1615–1616
Aortic valve disorders
in Ehlers-Danlos syndrome, 1299
in Marfan syndrome, 1303–1304
nail signs in, 1449
in syphilis, 1965, 1977
Aortitis in syphilis, 1965
AP-1, 992, 1003, 2112, 2147
in aging of skin, 965f, 970
in squamous cell carcinoma, 993, 2112
AP-3, 599
in Hermansky-Pudlak syndrome, 613
APC
in desmoid tumors, 553
in Gardner syndrome, 1079
APECED syndrome, 1354–1355, 1355t, 1356
Apert syndrome, 690, 703
Aphthae
oral, 645–646, 646t
in Behçet disease, 1622, 1623f, 1625, 1625b
classification of, 646, 646t
clinical and laboratory features in, 646, 646t
systemic disorders associated with, 646, 646t
of penis, 666
of vulva, 681f, 681–682
Aplasia
cutis, 69
congenita, 755, 755t, 774, 939–940, 940f
thymic congenital, 1356
Aplastic crisis in parvovirus B19 infections, 1855, 1856, 1857, 1858
treatment of, 1857b
Apocrine glands, 719–720, **731**–738
age-related changes in, 967

in bromhidrosis, 731–732, 732b
in chromhidrosis, 732–733, 733b, 733f
embryonic and fetal development of, 72, 731, 1068
in Fox-Fordyce disease, 733–734
functions of, 719–720
in hidradenitis suppurativa, 734–738
locations of, 719, 731, 733
nevi of, 1056, 1057t, 1060, 1070–1071
tumors of, 1069t, 1070t, 1070–1074
differential diagnosis in, 1068
Apocrine secretion odor-binding proteins, 731
Apocrinitis, 734
Apoeccrine glands, 719
Apolipoproteins, 1273, 1274
in amyloidosis, 1257, 1258, 1258t, 1260, 1264
apo-A1
in amyloidosis, 1257, 1258, 1258t, 1260, 1264
deficiency of, 1280
apo-A2 amyloidosis, 1257, 1258t, 1264
apo-B100, familial defective, 1277
apo-C2 deficiency, 1272t, 1276
apo-E, 100, 1278
in chylomicron metabolism, 1273, 1276
in xanthoma, 1272t, 1276
Aponeurotic fibroma, calcifying, 551–552
Apoptosis, 1003
caspases in, 981
cytotoxic T cells in, 104
in DNA damage, 980, 981f, 981–982, 1005
eosinophil, 287
keratinocyte, 49, 245, 815
in lichen planus, 49, 245
in lupus erythematosus, 1510, 1519
in phototoxicity, 831
and programmed cell death 1 protein, 1510, 1511–1512
in radiation response, 815, 858, 1003, 1005, 2248
Toll-like receptors in, 99
Appendage tumors of skin, **1068**–1087
with apocrine differentiation, 1068, 1069t, 1070t, 1070–1074
classification of, 1068–1069, 1069t
differential diagnosis in, 1068
with eccrine differentiation, 1068, 1069t, 1070t, 1074–1079
with follicular differentiation, 1068, 1069t, 1070t, 1079–1085
histopathology in, 1068
immunohistochemical findings in, 1068, 1070t
with sebaceous differentiation, 1068, 1069t, 1070t, 1085–1087
treatment of, 1069–1070
Appendages, epidermal
blood vessels of, 64
embryonic and fetal development of, 67t, 71–72, 1068
hair, 71–72, 1079–1085
nails, 72
sebaceous glands, 72, 1085–1087
sweat glands, 72, 1070–1079
Apple jelly appearance, 30t, 39t
in sarcoidosis, 1486, 1487f
Aquagenic pruritus, 336, 908
Aquaporins, 2358, 2358f
Arachidonic acid metabolism, 285, 1204
urticaria and angioedema in disorders of, 338
Arachnida bites and stings, 2054–2059
Arachnidism, necrotic, 2056, 2057
Arachnodactyly, congenital contractural, 537t
Araneae bites, 2054–2057
Arbutin, 2146, 2363, 2363t
Arc lamps, 800
Archives of Dermatology, 12
Arcuate lesions, 34, 35f
Arenavirus, 1846t
Argininosuccinase deficiency, 1219t, 1224
Argininosuccinate synthetase deficiency, 1219t, 1224
Argininosuccinic aciduria, 1219t, **1224,** 1457
trichorrhexis nodosa in, 756, 1224
Argyll Robertson pupils in syphilis, 1965, 1966
Argyria, differential diagnosis of, 1227
Aripiprazole, 917t, 918
Arizona recluse spiders, 2056
Arm amputation, prosthesis in, 862
Armadillo proteins, 447–448, 449
Aromatherapy, fragrance allergy in, 2362
Arrector pili muscle, 72
Arrhythmias
in Kawasaki disease, 1629, 1630
pacemakers and implanted defibrillators in, 2295
and electrosurgery, 2295, 2334
in reactive arthritis, 211
ARSE in chondrodysplasia punctata, 419
Arsenic exposure
basal cell carcinoma in, 1016, 1017, 1046
Bowen disease in, 1016, 1021, 1022
cancer risk in, 987, 987t
hair levels of arsenic in, 762
keratosis in, 430b, 1015–1017
clinical findings in, 1016, 1016f
diagnosis and differential diagnosis of, 1016–1017
treatment of, 1017
occupations associated with, 2070t, 2079t, 2080
sources of, 987
Artecoll®, granuloma and panniculitis from, 580
Artemis deficiency, 1358, 1359t
Arterial disorders, 1667–1678
in atherosclerosis, 1667–1673
of coronary artery. *See* Coronary artery disorders
Arterioles, 64, 1586
Arteriovenous fistula, 1663
pulmonary, 1453–1454
treatment of, 1666
Arteriovenous malformations, 1651, 1653f, 1663–1666
angiography in, 1653f, 1664f, 1665
and capillary malformations, 1652, 1664–1665, 1665f
clinical characteristics of, 1654t
differential diagnosis of, 1666b
nidus of, 1653f, 1663, 1664f, 1666
prognosis and clinical course in, 1665–1666
Schobinger classification of, 1664, 1664t
stages of, 1664, 1664f, 1664t, 1666
treatment of, 1666
Arteritis
in syphilis, 1966
Takayasu, 1615–1616
temporal (giant cell), 1615f, 1615t, 1615–1616
Arthritis
in Behçet disease, 1623, 1624
in brucellosis, 1760
in dermatomyositis, 1545
in erysipeloid, 1765–1766
in gonorrhea, 1995, 1996
gouty, 1575
in Kawasaki disease, 1629
in Lyme disease, 1798, 1803, 1806t
in Mediterranean fever, familial, 1266
in meningococcal infections, 1733
microseptic, 208
mutilans, 200, 202
in necrotizing venulitis, 1603
and palmoplantar pustulosis, 216
in parvovirus B19 infections, 1856
post-infective, 208
psoriatic, **194**–206. *See also* Psoriatic arthritis
pyogenic, with pyoderma gangrenosum and acne, 701, 1267t, 1271
clinical findings in, 1271, 1271f
differential diagnosis of, 1268b, 1271
in rat-bite fever, 1762
reactive, **207**–214. *See also* Reactive arthritis
in rheumatic fever, 1574, 1574b
rheumatoid, **1569**–1573. *See also* Rheumatoid arthritis
in rubella, 1854
septic, 213
in body piercing complications, 890t
in Sjögren syndrome, 1580, 1583
in smallpox, 1902
Arthrochalasia type of Ehlers-Danlos syndrome, 1301
Arthropathy
in alkaptonuria, 1226, 1227
in parvovirus B19 infections, 1856
Arthropod bites and stings, **2054**–2063
centipede, 2059
cutaneous lymphoid hyperplasia in, 1402, 1404, 1405
differential diagnosis of, 2056b
histopathology in, 2054
millipede, 2059
mite, 2058
occupational exposure to, 2076
prevention of, 2063
prurigo of HIV infection in, 1932
rickettsial infections in, 1941
scorpion, 2057–2058
spider, 2054–2057
tarantula, 2057
tick, 2058–2059. *See also* Ticks
treatment of, 2054
Arylsulfatase, 68t
in chondrodysplasia punctata, 419
Asboe-Hansen sign, 39t
Ascariasis, 2012, 2012t
treatment of, 2013, 2014t
Ascaris lumbricoides, 2012, 2012t, 2013
Ascaris suum, 2012
Ascorbic acid, 1212–1213. *See also* Vitamin C
Aseptic technique, 2295–2296
Ashkenazi Jews, Bloom syndrome in, 1322, 1323
Ash-leaf spots in tuberous sclerosis, 1326, 1328f
Ashy dermatosis, 640
ASM 981, 2221. *See also* Pimecrolimus
ASOB (apocrine secretion odor-binding proteins), 731
Aspartate aminotransferase levels in dermatomyositis, 1546
Aspartylglucosaminuria, 1286t
Aspartylglycosamidase, 1219t
Aspartylglycosaminuria, 1219t
Aspergillosis, 1834t
granulomatous disease in, chronic, 1364
in immunocompromised host, 269t, 270, 270f, 1843
in HIV infection, 1937
oral antifungal agents in, 2216
onychomycosis in, 786f, 786t, 1817, 1820
oral cavity disorders in, 653t

Aspergillus flavus, 270
Aspergillus fumigatus, 270
Aspergillus nidulans, 1834t
Aspergillus terreus, 270
Aspirin
in Degos disease, 1651, 1651b
in Kawasaki disease, 1626, 1630, 1631, 1632, 1632f
oral burn from, 651
in polycythemia vera, 1378
preoperative, 2337
urticaria and angioedema from, 338, 341
in venous insufficiency, chronic, 1683
in venous malformations, 1660
Assassin bug, 2061
and Chagas disease, 2008–2009, 2061
Asteatotic dermatitis
differential diagnosis in, 139b
in elderly, 972, 972t
Astemizole, 2188, 2190, 2191
interaction with other drugs, 2240t
Asthma and atopic dermatitis, 83
Astringents, 2132t, 2134–2135
Asymmetrical periflexural exanthem of childhood, 1849, 1871–1872, 1872b, 1872f
A-T– plasty, 2308
Ataxia
cerebellar, 1362
in varicella, 1893
and erythrokeratodermia, 417, 418
in syphilis, 1966
and telangiectasia, 963, 1311, 1313t, 1361–1362, 1505t
clinical findings in, 1361f, 1361–1362, 1362f
DNA damage and repair in, 982t, 983t, 1361, 1362
epidemiology of, 1361
etiology and pathogenesis in, 1361
genetic factors in, 1361, 1362
oral cavity disorders in, 642t
treatment of, 1362
Atazanavir in HIV infection, 2209–2210
Atheroma, 1671
Atherosclerosis
of coronary artery, 1277, 1452, 1460, 1667, 2152–2153
in corticosteroid therapy, 2151
management of, 2152–2153
embolism in, 1460, 1671–1673
differential diagnosis of, 1673, 1673b
etiology of, 1667
of peripheral arteries, 1667–1673
complications in, 1670
differential diagnosis of, 1669–1670, 1670b, 1675
intermittent claudication in, 1667, 1669, 1670–1671
prevention of, 1671
prognosis and clinical course in, 1670
treatment of, 1670b, 1670–1671
risk factors for, 1667
Athletes, **873**–878
actinic damage in, 876
cold injuries in, 876
common conditions in, 874t
equestrian panniculitis in, 576
herpes simplex virus infections in, 875, 1877
nail conditions in, 874f, 874t
repetitive trauma in, 2077
tinea pedis in, 1816, 1816f
Atkins diet in dermatitis herpetiformis, 504
ATM, 982t
in ataxia-telangiectasia, 1361, 1362
Atopic dermatitis, 58, **146**–158
acute severe, phototherapy in, 2245–2246, 2246f
and asthma, 83
barrier function of skin in, 147, 149, 153, 390, 390f, 393–394, 394f
cell types involved in, 148–149
chronic moderate, phototherapy in, 2246
clinical features in, 146, 147t, 149–150, 149f–151f
complications in, 152–153, 153f
cytokines and chemokines in, 131–132, 147–148, 149
diagnosis and differential diagnosis, 139b, 151, 152b, 165, 1223
in infants, 221
eosinophils in, 147, 287
epidemiology of, 146
etiology and pathogenesis in, 146–149
exercise and pruritus in, 877
exfoliative dermatitis in, 225, 227, 228, 230t
genetic factors in, 82, 83, 149, 393–394
herpetic eczema in, 152, 153f, 156, 1877
in hyper-IgE syndrome, 1366, 1366f
immunopathology of, 147
interferon-γ in, 106, 148, 157
keratinocytes in, 131, 132, 148–149
laboratory tests in, 150
nail changes in, 791
neuropeptides in, 900
nutrition in, 155–156, 2287
pathophysiology in, 900
prognosis and clinical course in, 153
prurigo in, 149f, 150, 150f, 160
pruritus in, 149, 156, 906–907, 909
psychological factors in, 156, 920
severity-of-disease measures in, 7, 8
smallpox vaccination in, 152, 1903, 1904, 1906
Staphylococcus aureus infections in, 152–153, 156, 1692, 1694, 1719
superantigens in, 1719
sweat composition in, 730
T cells in, 147–148, 151
helper, 106, 131, 132, 147–148
treatment of, 153–158
antihistamines in, 149, 156, 2189
approach to, 153, 154f
complementary and alternative medicine approaches to, 2287
photochemotherapy in, 157, 158, 2255
phototherapy in, 156–157, 2245–2246, 2246f, 2248
pimecrolimus in, 155, 2128
systemic therapy in, 157
tacrolimus in, 155, 2128
tar preparations in, 156
topical therapy in, 153–155
unproven therapies in, 157–158
triggering factors in, 155–156
in Wiskott-Aldrich syndrome, 1357, 1358f
Atopic eruption of pregnancy, 961, 962
Atopy
irritant contact dermatitis in, 397
urticaria and angioedema in, 333
ATP2A2
in acrokeratosis verruciformis, 436
in Darier-White disease, 392, 432, 434, 435, 436
in Grover disease, 438
ATP2C1, 61, 68t
in Hailey-Hailey disease, 61, 392, 439, 440, 441
ATP7A in cutis laxa, 1308
ATR, 982t
Atresia, pyloric, epidermolysis bullosa with, 508t, 508–509
Atrial myxoma, 1452–1453, 1453f
Atrial natriuretic peptide, 896
Atrichia, 746, 1207
with papular lesions, 760
Atrophic papulosis, malignant, 1456, **1648**–1651. *See also* Papulosis, malignant atrophic
Atrophie blanche, 1603, 1681, 1682f
Atrophoborreliosis, 1800t, 1801
Atrophoderma
follicular, 560–561
syndromes with, 753, 753t
of Pasini and Pierini, 545, 560, 560f, 640
vermiculatum, 560–561, 561f, 751, 751f
Atrophy, 28, 29f
in aging, 28, 29f
in corticosteroid therapy, 558, 702, 706, 2104, 2105
Attagenus megatoma (black carpet beetle), 2060
Atypical nevus. *See* Dysplastic nevus
Augmentation of soft tissues, 2380–2388. *See also* Soft tissue augmentation
Auranofin in lymphocytic infiltration of skin, 1413b
Aureolysin, 1691, 1695
Auricular fistula, congenital, 1066
Auriculotemporal nerve, 2292, 2298
Auspitz sign, 39t
in psoriasis, 177, 177f
Autism, and measles-mumps-rubella vaccine, 1853
Autoantibodies
in dermatomyositis, 1538f, 1539, 1539t, 1545, 1546, 1550
140-kd, 1539t, 1547
155-kd, 1539t, 1546, 1547, 1550
in lupus erythematosus, 1528t, 1528–1529
in morphea, 545
in pemphigus, 88–89, 462
paraneoplastic, 468, 471, 471f, 472
in Sjögren syndrome, 1577, 1578, 1580–1581, 1581t
in systemic sclerosis, 1554t, 1554–1555, 1556
Autoimmune disorders
Addison disease in, 1478
alopecia areata in, 763
APECED syndrome in, 1354–1355, 1355t, 1356
Behçet disease in, 1621–1622
blistering, 316
in complement deficiencies, 1370, 1371, 1371t
cryoglobulinemia in, 1640
dendritic cells in, 1513
in dermatitis herpetiformis, 504
drug-induced, 1513
environmental factors in, 1510f, 1514
epidermolysis bullosa acquisita in, 494–495
erythema elevatum diutinum in, 1619, 1619t
erythromelalgia in, 1678
genetic factors in, 1509–1511, 1510f
hemolytic anemia in, 1514
infections as causative factor in, 1514
mechanisms of, **1509**–1514
pathogenesis of tissue damage in, 1514
pemphigus in, 459
paraneoplastic, 468, 469, 472
pernicious anemia in, 1377

polyglandular
type 1, 763, 1354–1355, 1355t, 1356, 1476, 1510
type 2, 1512
psoriasis in, 174
and arthritis, 194
regulatory T cells in, 1512–1513
relapsing polychondritis in, 1567
rheumatoid arthritis in, 1509, 1569
Sjögren syndrome in, 1577
thrombocytopenia in, 1514
of thyroid, 1470, 1509
tolerance in, 1511–1512
toll-like receptors in, 1513
from tumor necrosis factor inhibitors, 2228
urticaria and angioedema in, 330, 331
vitiligo in, 616–617, 619
in Wiskott-Aldrich syndrome, 1357–1358
Autoinflammatory diseases, systemic, **1265**–1271
familial cold autoinflammatory syndrome, 334, 1267t, 1270–1271
differential diagnosis of, 1268b, 1270
treatment of, 341, 1271
Autologous fat transfer for soft tissue augmentation, 2382t, 2386–2387, 2387f
Autolytic débridement in decubitus ulcers, 885
Autonomic dysreflexia, hyperhidrosis in, 722t, 723–724
Autonomic nervous system, 895
anatomy of, 896–898
parasympathetic, 896
in sweat gland regulation, 896
anhidrosis in disorders of, 722t, 727
hyperhidrosis in disorders of, 722t, 723–724, 725–726
sympathetic. *See* Sympathetic nervous system
Autosensitization dermatitis, **167**–168, 168f
differential diagnosis of, 139b, 168b
treatment of, 168
Autosomal disorders
dominant, 78–79, 79f, 83
recessive, 78, 79, 79f, 80
ichthyosis in, 404t–405t, 408f, 409–410
Avascular necrosis in corticosteroid therapy, 2150–2151
management of, 2153
Avian influenza virus in bioterrorism, 2083t, 2085
Avian mites, 2033
Avobenzone in sunscreens, 2139, 2139t, 2140
Avulsion of nail plate, surgical, 2323f, 2323–2324, 2324f
Axilla
allergic contact dermatitis of, 140, 140f
hyperhidrosis of, 723, 724b
trichomycosis axillaris of, 1709, 1709f
Azathioprine, 2167–2168
in actinic dermatitis, chronic, 823
in Behçet disease, 1625b
in bullous pemphigoid, 480, 480b
chemical structure of, 2163f
in cicatricial pemphigoid, 484, 485b
contraindications to, 2168, 2168t
in dermatomyositis, 1552
dosing regimen, 2167, 2167t, 2176t
in graft-versus-host disease, 267t
indications for, 2167, 2167t, 2176t
initiation of therapy, 2167
interaction with other drugs, 2168, 2239, 2239t, 2240t
in lichen planus
cutaneous, 254b, 255
oral, 253b, 254
in lupus erythematosus, 1533t, 1534
mechanism of action, 2167, 2176t
monitoring of therapy, 2167, 2168t
in necrotizing venulitis, 1606, 1606t
in pemphigus, 467, 468, 2167
pharmacokinetics of, 2167
in pityriasis rubra pilaris, 235, 236b
in pregnancy, 2168, 2168t
in psoriatic arthritis, 205
side effects and complications of, 2168, 2168t, 2176t
hepatotoxicity in, 1459t, 2168
in systemic sclerosis, 1561
in Wegener granulomatosis, 1613t
Azelaic acid, 2113t, 2114, 2133, 2132t
in acne vulgaris, 696, 2114, 2133, 2144
as bleaching agent, 2135, 2144
in ethnic skin, 2144
in rosacea, 708, 2114, 2133
Azelastine, 2189, 2189t
Azithromycin, 2195t, 2200
in acne vulgaris, 697
in cat-scratch disease, 1751
in chancroid, 1986, 1986t
in chlamydial infection, 1998b
in gonorrhea with chlamydial infection, 1996, 1996b
in granuloma inguinale, 1993, 1993b
in Lyme disease, 1806t
in lymphogranuloma venereum, 1989, 1990b
pediatric dosage, 948t
pharmacokinetics of, 2200
in staphylococcal infections, 1697, 1698b
in streptococcal infections, 1707, 1707b
Azul, 1978–1979. *See also* Pinta

B

B cell(s), 321–323
in adaptive immune response, 101, 319, 321–323
in autoimmune disorders, 1511
autoreactive, 1511, 1520
in cutaneous lymphoid hyperplasia, 1404, 1405, 1406f
Epstein-Barr virus infection of, 1858
in lupus erythematosus, 1520
in X-linked agammaglobulinemia, 1348–1352
B-cell lymphoma, 323, 1399–1401, 1506
in borreliosis, 1400, 1401, 1802
classification of, 1386, 1387t
provisional entities in, 1401
differential diagnosis of, 1406–1407
follicle center cell, 1399–1400, 1400f
treatment of, 1401
in immunocompromised host, 278
intravascular cutaneous, 1401
large cell, 1386, 1400f, 1400–1401
of leg, 1400f, 1400–1401
marginal zone, 1400
treatment of, 1401
skin-associated lymphoid tissue (SALT), 1407
staging of, 1401
treatment of, 1401
radiation therapy in, 1401, 2282t, 2284
B-cell receptors, 323
B-cell stimulating factor 2, 124. *See also* Interleukins, IL-6
Babesia microti, 1797, 1803
Baby shampoo, 139
Bacillary angiomatosis, 1749, 1750t, 1752–1754
clinical manifestations of, 1752f, 1752–1753
differential diagnosis of, 1753b
histopathology in, 1753f, 1753–1754
in immunocompromised host, 273, 1692, 1752–1754
in HIV infection and AIDS, 1692, 1935–1936, 1936f
treatment of, 1754
Bacille Calmette-Guérin vaccination, tuberculosis after, 1773
Bacillus anthracis
in anthrax, 1691, 1755–1756
in bioterrorism, 1755, 1756, 2081–2083, 2082t, 2084t
diagnosis of infection, 1692–1693
occupational exposure to, 2074
treatment of infection, 2197t
vaccine, 2083
Bacitracin, 1693, 2113t, 2114–2115
contact dermatitis from, 2337
in methicillin-resistant staphylococcal infections, 2114
with polymyxin B and neomycin, 2115
sensitivity of group A streptococci to, 1703
in surgical wounds, 2114
Back pain
in psoriatic arthritis, 199, 199t, 201
in reactive arthritis, 213
Bacteremia, 1692
in bartonellosis, 1751–1752
in decubitus ulcers, 880
differential diagnosis in, 1733b
in nocardiosis, 1782
Bacterial colonization
in decubitus ulcers, 880, 885
interference mechanisms in, 1690
and preoperative skin preparations, 2295–2296
Bacterial infections, **1689**–1806. *See also specific infections*
actinomycetoma in, 1783–1786, 1832, 1833
of amputation stump, 866
antibiotics in, 1693–1694, 2113–2115, 2194–2202
in athletes, 873–875
Behçet disease in, 1621
in bite wounds, 2038
in children, 940, 940t, 947t–950t
classification of, 1689, 1692
in decubitus ulcers, 880–881
in diabetes mellitus, 1465
diagnosis of, 1692–1693
in drug abuse, 925–926
in elderly, 972–973
endocarditis in, 1453, 1692
erythema elevatum diutinum in, 1619, 1619t
erythrasma in, 1708, 1708f, 1709f
Gram stain in, 1692–1693
in granulomatous disease, chronic, 1364, 1365t
hidradenitis suppurativa in, 735
hypersensitivity to bacterial antigens in, 1692
in immunocompromised host, 269t, 1691–1692
in acute immunosuppression, 268
in chronic immunosuppression, 272–273
in HIV infection and AIDS, 1935–1936

Bacterial infections—*continued*
inflammatory reaction in, 1690–1691, 1692
invasive properties of microorganisms in, 1691
of nails, 784–785, 785t
in occupational exposures, 2074–2075
oral, 652t–653t
panniculitis in, 579
pathogenesis of, 1689–1692
peristomal, 870
pitted keratolysis in, 1707–1708
portal of entry in, 1689
primary, 1692
reactive arthritis in, 207, 208, 209, 213
treatment of, 214
resistance of skin to, 1689–1691
resistance to drugs in, 1693, 1695, 1728, 1730, 2194
in acne vulgaris, 698
in athletes, 873–875
in elderly, 973
in surgical wounds, 2337
treatment in, 875, 2114
seborrheic dermatitis in, 219
secondary, 1692
staphylococcal, 1694–1703
streptococcal, 1703–1707
in surgical wounds, 2294–2295, 2337
susceptibility testing in, 2194
T-cell lymphoma in, 1386
toxigenic properties of microorganisms in, 1691
trichomycosis axillaris in, 1709, 1709f
virulence of, 1691–1692, 1695
waterborne, 2052–2053
Bactericidal agents, 2194
Bactericidal/permeability-increasing (BPI) protein, 283
Bacteriophages, 1691
Bacteriostatic agents, 2194
Bacteriotoxic agents, 2194
Bacteroides, 1742, 1747
Baghdad boil, 2003
Baker-Gordon chemical peel, 2370, 2370t
Baker's itch, 2032, 2032t
Baking soda in jellyfish stings, 2045t
Balamuthia, 2009
Balanitis, 656
candidal, 1824, 1828
circinate, in reactive arthritis, 210, 210f, 665, 665f
Zoon, 665, 668f, 668–669, 669b
Balanoposthitis, 659b, 669–670
candidal, 1824, 1824f
spirochetal, 672
Balding process
in aging, 967
pattern, 754–755, 755t, 766–769, 1452. *See also* Pattern hair loss
Balloon cell nevus, 1108
Ballooning degeneration, 32, 47, 47f
Balneophototherapy in psoriasis, 2245
Balsam of Peru, allergic contact dermatitis from, 136t, 137f, 139, 141, 145
natural cross-reactants in, 141, 145, 145t
Bamacan, 454, 539t
Bamboo hair, 416, 417f, 758, 759f
Bancroft filariasis, 2017
Band-aid disease, 1172
Bannayan-Riley-Ruvalcaba syndrome, 633, 1190, 1665
Bannayan-Zonana syndrome, 1190
Bannwarth syndrome, 1803
Barbiturate abuse, cutaneous signs of, 923, 924
Barracuda bites, 2052
Barraquer-Simon syndrome, 587
Barrier function of skin, **383**–395, 1689–1690
and absorption of topical drugs, 2091, 2099–2100
pathologic processes affecting, 2102
penetration pathways in, 2100
age-related changes in, 964, 965
in allergic contact dermatitis, 138, 393, 400
in atopic dermatitis, 147, 149, 153, 390, 390f, 393–394, 394f
calcium and potassium levels affecting, 391–392, 393f
in collodion baby, 415
connexins in, 391
cytokine signaling in, 391, 392f
desmosomal proteins in, 391
epidermal proliferation and differentiation in, 387–390
experimental disruption of, 388–390
in ichthyosis, 393, 395, 406, 422
in irritant contact dermatitis, 393, 395, 399
lipids in, 385–387
in neonates, 935
neurotransmitters in, 392–393
in opportunistic infections, 269t
in pathophysiology of skin disorders, 393t, 393–395
proteases in, 391
in pruritus, 909, 909t
in psoriasis, 393, 394–395
in soft tissue infections, 1720
stratum corneum in, 384–387
tight junctions in, 391
transepidermal water loss as measure of, 2100
treatment implications, 395
in absorption of topical drugs, 2091, 2099–2100
types of barriers in, 383, 384t
in vesicular palmoplantar eczema, 163
Bart-Pumphrey syndrome, 425t, 552
Bart syndrome, 511
Bartonella bacilliformis, 1749, 1750t, 1754–1755
Bartonella elizabethae, 1749, 1750t
Bartonella grahamii, 1749, 1750t
Bartonella henselae, 1749, 1750t
in bacillary angiomatosis, 1752, 1753
in cat-scratch disease, 1749–1751, 2038
in immunocompromised host, 273, 1692, 1752, 1753
in HIV infection, 1935–1936
Bartonella quintana, 1749, 1750t, 1751–1752, 2035
in bacillary angiomatosis, 1752, 1753
in immunocompromised host, 273, 1752, 1753
in HIV infection, 1935–1936
Bartonella vinsonii, 1749, 1750t
Bartonella washoesis, 1749, 1750t
Bartonellosis, **1749**–1755
bacillary angiomatosis in, 1752–1754
bacteremia in, 1751–1752
cat-scratch disease in, 1749–1751
endocarditis in, 1751–1752
in immunocompromised host, 1752–1754
Oroya fever in, 1754–1755
peliosis of liver and spleen in, 1752–1754
treatment of, 2197t
trench fever in, 1751–1752
verruga peruana in, 1754–1755
Basal cell(s), 47, 58, 59
in eccrine sweat glands, 714, 715f
in embryonic epidermis, 67
Basal cell carcinoma, **1036**–1042, 1375t
animal models of, 992t, 992–993
in arsenic exposure, 1016, 1017, 1046
in basal cell nevus syndrome, 1044, 1045f, 1046, 1047
biologic behavior of, 1038, 1038f
in chemical exposures, 986–994
to arsenic, 1016, 1017, 1046
pathogenesis in, 991, 992–993
clinical manifestations in, 1037f, 1037–1038
course and prognosis in, 1042
diagnosis of, 1038
differential diagnosis in, 1039, 1040b
DNA damage and repair in, 1005
in elderly, 971, 972t, 1036
epidemiology of, 986, 1028, 1036
etiology and pathogenesis in, 991, 992–993, 1036–1037
follicle origin, 1003
genetic factors in, 988, 989t, 994, 1002, 1037, 1043, 1044
hedgehog pathway in, 992–993, 994, 1002
as therapy target, 994, 1048
hereditary, 988, 989t, 1046
multiple infundibulocystic, 1046
herpesvirus 1 in, 998
histopathology in, 1038–1039, 1039f
in immunocompromised host, 277, 1004, 1037
in HIV infection and AIDS, 1037, 1933
local invasion of, 1038, 1038f
metastasis of, 1038, 1042
micronodular, 1039, 1039f
morpheaform (sclerosing), 1037–1038, 1038f
differential diagnosis in, 1040b
histopathology in, 1039, 1039f
treatment of, 1040, 1041
neurotropic, 1041
nodular, 26, 27f, 1037, 1037f
differential diagnosis in, 1040b
histopathology in, 1039, 1039f
treatment in, 1041
p53 in, 1001
perineural invasion of, 1038, 1038f, 1041
and photoaging, 969, 969f, 970
pigmented, 1037, 1037f
differential diagnosis in, 1040b
histopathology in, 1039
in radiation keratosis, 1019
superficial, 1037, 1037f
differential diagnosis in, 1040b
histopathology in, 1039
treatment of, 1041
treatment of, 1039–1042, 1040f
cryotherapy in, 1041, 2332
electrosurgery in, 1041, 2334–2335
excisional surgery in. *See* Excisional surgery, in basal cell carcinoma
5-fluorouracil in, 1041, 2122
hedgehog pathway as target in, 994, 1048
imiquimod in, 1005, 1041, 2128, 2129
Mohs micrographic surgery in, 1040, 1042, 2316, 2317–2318, 2318f, 2319f
photodynamic therapy in, 1041, 2261, 2261f
radiation therapy in, 1041, 1048, 1048f, 2282, 2283–2284
in ultraviolet radiation exposure, 814, 1036–1037
characteristics of, 1000
epidemiology of, 999, 1000

hedgehog pathway in, 1002
and keratosis, 1019
in xeroderma pigmentosum, 994, 1046, 1316, 1318
Basal cell nevus, linear unilateral, 1080
Basal cell nevus syndrome, 989, 989t, 1037, **1042**–1048, 1068, 1504t
basal cell carcinoma in, 1044, 1045f, 1046, 1047
clinical findings in, 1044t, 1044–1045, 1045f, 1046f, 1047f
diagnosis of, 1045–1046, 1047t
differential diagnosis in, 1046
epidemiology of, 1042
epidermoid cyst in, 1063
etiology and pathogenesis in, 1042–1044
genetic factors in, 1042–1044, 1048
jaw cysts in, 1045, 1046, 1047f
oral cavity disorders in, 642t, 1045, 1046, 1047f
palmoplantar pits in, 1045, 1045f, 1046
prognosis and clinical course in, 1046–1047
and rhabdomyoma, 1175
treatment in, 1047–1048, 2184
Basal layer of epidermis, 47, 58–60, 375, 377, 384, 384f
Basement membrane, 47, 59, 62, 447, 449–459
barrier function of, 450
biochemistry of, 451–454
cellular origin of, 459
components in, 451b, 451–454
epithelial-specific, 454–459
embryonic and fetal development of, 71
in epidermolysis bullosa, 505, 506f
of hair follicle, 744
lamina lucida, 47, 450
and migration of Langerhans cells, 109
of nails, 780
structural and functional characteristics of, 449–450, 450b, 451
Basidiobolus haptosporus, 1835
Basidiobolus ranarum, 1835
Basidiobolomycosis, 1835
Basophils in urticaria and angioedema, 331, 332–333
Bathing suit ichthyosis, 411
Baths
for cutaneous hydration in atopic dermatitis, 153, 154
with psoralen, in photochemotherapy for psoriasis, 2252, 2253
with saltwater, in phototherapy for psoriasis, 2245
Battered child, 927–929
Baumann skin types, 2364t
BAY 43-9006, 2236t
Bay sore, 2003
Bazex acrokeratosis paraneoplastica, 1494t, 1498–1499
clinical findings in, 1498–1499, 1499f
differential diagnosis of, 165, 1499, 1499b
nail changes in, 1498, 1499, 1499f
stages of, 1498–1499
treatment of, 1499
Bazex-Dupre-Christol syndrome, 561, 753t, 1498
anhidrosis in, 730
basal cell carcinoma in, 561, 1037, 1046
genetic factors in, 989t
follicular atrophoderma in, 561, 753t
BCG vaccination, tuberculosis after, 1773
BCL-2/bcl-2
in basal cell carcinoma, 992
in hair pigmentation, 747
in melanoma, 1156
in squamous cell carcinoma, 1030
BCNU, 2123
side effects of, 2123
hyperpigmentation in, 636, 1397
in T-cell lymphoma, 1396–1397, 2123
Beals syndrome, 1302
Bean syndrome, 1658–1659
Bean-bag cells in histiocytic cytophagic panniculitis, 583, 584f
Beard area
folliculitis of, 1699, 1700f
infantile hemangioma of, 1166
pseudofolliculitis barbae of, 1699, 1699f
tinea barbae of, 1813, 1813f
Beau's lines, 781–782, 782f
in cytotoxic drug therapy, 2177, 2177f
in systemic diseases, 791
Becaplermin, 2226, 2235, 2348
Becker's nevus, 639, 639f, 1057, 1057t, 1060
laser therapy in, 2274
syndrome of, 639
Beckwith-Wiedemann syndrome, 1505t
Bed and mattress systems in decubitus ulcers, 884
Bedbugs, 2060–2061, 2061f, 2063
Bednar tumor, 1159
Bee stings, 2062
Beetles, 2060
Behavioral therapy in pruritus, 911
Behçet disease, 1451–1452, 1615, **1620**–1626
clinical course and prognosis in, 1624–1625
clinical findings in, 666, 1621f, 1622–1624
diagnostic criteria on, 666, 1622, 1622f, 1623t
differential diagnosis of, 1624b
epidemiology of, 1620
etiology and pathogenesis in, 1620–1622
immunologic mechanisms in, 1621–1622
infectious precipitants in, 1621
eye disorders in, 666, 1622–1623, 1623f, 1624
genetic factors in, 1620–1621
genital ulcers in, 666, 1622, 1623f
treatment of, 1625
histopathology in, 1624, 1624f
HLA system in, 84, 1620, 1621, 1623
and prognosis, 1624, 1625
oral ulcers in, 642t, 646, 646f, 666, 1451–1452, 1622, 1623f
treatment of, 1625, 1625b
prevention of, 1626
treatment of, 666, 1625b, 1625–1626
thalidomide in, 1625b, 2234t
vasculitis in, 1620, 1624
Bejel. *See* Syphilis, endemic
Belesh. *See* Syphilis, endemic
Belimumab in lupus erythematosus, 1535
Bell's palsy in sarcoidosis, 1489
Benzene hexachloride. *See* Lindane
Benzo-[a]-pyrene, DNA damage from, 978t
Benzocaine, 2296, 2296t, 2298
toxicity in children, 946t
Benzodiazepines, 920
Benzoic acid, stinging sensation from, 2361
Benzophenones in sunscreens, 2139, 2139t, 2140
Benzoyl peroxide, topical, 2133, 2132t
in acne vulgaris, 696, 2133, 2144
in ethnic skin, 2144
in rosacea, 708
Benztropine, for antipsychotic drug side effects, 917–918
Benzyl alcohol in topical formulations, 2106, 2106t
Benzyl benzoate lotion in scabies, 2031b
Benzylamine antifungal agents, 2117t, 2119, 2119t, 2120t
Berardinelli-Seip lipodystrophy, 588–589
Bergamot oil, phototoxicity of, 2361
Bergapten, 2250
Beriberi, 1208
Beryllium, occupational exposure to, 2070t
Besnier prurigo, 160, 961
Betaglycan, 539t
Betaine in homocystinuria, 1304
Betamethasone dipropionate
in adrenal disorders from corticosteroid therapy, 2106
and clotrimazole, 2117t, 2118–2119
in lupus erythematosus, 1532
in pigmented purpuric dermatosis, 1636
Bevacizumab, 2231–2232
Bexarotene, 2181–2186
chemical structure of, 2182f
complications of, 2184–2186
dosing regimens, 2184
initiation and monitoring of therapy, 2184
interaction with other drugs, 2186
pharmacokinetics of, 2182, 2183
in T-cell lymphoma, 1397, 1398–1399, 2183
Bias, 3–4, 10–11
information, 4
publication, 9–10
selection, 3–4
BIBP-3226, 842
Bicarbonate
in liposuction solution, 2379, 2380t
in sweat, 717, 717f
Bier's spots, 630
Biette collarette in syphilis, 1959
Bifidobacterium dentium, 1779
Biglycan, 63, 539t
Bilateral symmetrical lesions, 38
Bile acids in cholestasis of pregnancy, 957–958, 959
Bilharziasis, 2025
Biliary disorders, 1457–1458
hypercholesterolemia in, 1280
jaundice in, 1379, 1447, 1447t
pruritus in, 1447–1448
xanthoma in, 1280
Bilirubin levels
in graft-versus-host disease, 264, 265
in jaundice, 1379, 1447, 1447t
Bimolecular reactions, 804
Bioengineered skin in wound healing problems, 2348–2349
Biofeedback in vulvodynia, 683
Biologic response modifiers, keratinocyte-derived, 97
Bioplastique®, granuloma and panniculitis from, 580
Biopsy, 42
in actinic keratosis, 1009–1010
in atheromatous embolism, 1672–1673
in basal cell carcinoma, 1038
in bullous pemphigoid, 478
cell culture and gene therapy in, 86
in children, 942, 944t
in decubitus ulcers, 880
in dermatomyositis, 1545–1546, 1547
in drug-induced cutaneous reactions, 361
in dysplastic nevus, 1129–1130, 1133
in epidermolysis bullosa, 512
of fetal skin, 85, 85f
in graft-versus-host disease, 264–265, 265f

Biopsy—*continued*
in granuloma faciale, 303, 304
in hair disorders, 756t
in keratoacanthoma, 1053
in leishmaniasis, 2004–2005
of liver in methotrexate therapy, 191, 1458, 2165–2166, 2166t
in lymphoid hyperplasia, cutaneous, 1403, 1404f, 1404–1405, 1405f
in male genital disorders, 657
in mastocytosis, 1439–1440
in melanoma, 1149, 1151–1153, 1154
in Merkel cell carcinoma, 1091, 1091f, 1092f
of nail bed, 2326–2327, 2327f
of nail fold, proximal, 2328
of nail matrix, 2324–2326, 2325f, 2326f
in necrotizing vasculitis, systemic, 1608
in necrotizing venulitis, cutaneous, 1604–1605
in Paget disease, 1096, 1097
in pyoderma gangrenosum, 298
in soft tissue infections, 1727
in squamous cell carcinoma, 1033
Bioterrorism, **2081**–2085
anthrax in, 1755, 1756, 2081–2083
bacterial species associated with, 1728
brucellosis in, 2085
food safety threats in, 2083t
glanders in, 2085
melioidosis in, 1765, 2085
plague in, 1759, 2083–2084
rickettsial pathogens in, 1940
smallpox in, 1899, 1903, 2085
tularemia in, 2084
viruses in, 2083t, 2085
water safety threats in, 2083t
Biotin, 1213–1214
deficiency of, 1213–1214
fragile nails in, 786
seborrheic dermatitis in, 220
food sources of, 1213
Biotinidase, 1219t
4,4′-Bipridyl, skin cancer associated with, 987t
Birbeck granules, 62, 62f, 106, 107f
Birth cohorts, 5–6
Birthmarks, 938t, 938–939
Birt-Hogg-Dubé syndrome, 554, 555, 1081, 1083
clinical findings in, 1083, 1504t
genetic factors in, 988, 989t
mantleoma in, 1083, 1085
renal carcinoma in, 1504t
trichodiscoma in, 1083
Bischloroethylnitrosourea (BCNU), 2123
side effects of, 2123
hyperpigmentation in, 636, 1397
in T-cell lymphoma, 1396–1397, 2123
Biskra button, 2003
Bisphosphonates, in corticosteroid therapy and osteoporosis, 2152
Bites and stings, **2037**–2053
African trypanosomiasis in, 2008
American trypanosomiasis in, 2008–2009
from aquatic organisms, 2042–2052
arthropod, **2054**–2063
in athletes, 876
in ocean sports, 877
bacterial infections in, 2038
and bruises in abuse child, 928, 928f
cellulitis in, 1723
clinical approach to, 2037–2038
cutaneous lymphoid hyperplasia in, 1402, 1404, 1405
epidemiology of, 2037
fish, 2050–2052
granuloma annulare in, 369
human bites in, 2038
in lip biting habit, 650
in nail biting, 792
insect, 2059–2063
leishmaniasis in, 2001–2007
loiasis in, 2018–2019
monkey bites, 1907, 2038
herpesvirus simiae (B virus) infections in, 2039–2040
monkeypox virus infections in, 1907, 1907f
occupational exposure to, 2076
onchocerciasis in, 2019–2021
Pasteurella infections in, 1757t, 1761, 2038
prurigo of HIV infection in, 1932
rat-bite fever in, 1761–1762
rickettsial infections in, 1940–1952
scorpion, 2057–2058
seal finger in, 1757t, 1762, 2042
snake, 2040–2042
spider, 2054–2057
tarantula, 2057
tick, 2058–2059. *See also* Ticks
tularemia in, 1757–1758
viral infections in, 2038–2040
Bithionol
in fascioliasis, 2014t
in paragonimiasis, 2015t, 2026
Bitot spots in vitamin A deficiency, 1204
B-K mole syndrome, 1135
Black carpet beetle, 2060
Black death, 1758, 2083
Black dot tinea capitis, 1811, 1811t, 1812, 1812f
Black fly bites, 460, 2060
onchocerciasis in, 2019–2021
Blackfoot disease in arsenic exposure, 1016
Blackheads, 28, 692, 693f
Black light, 799
Black measles, 1941
Black piedra, 1821
Black salve, 2130
Black tea, in skin cancer prevention, 1005
Black widow spider bites, 2054–2056, 2056f
differential diagnosis of, 2056b
Bladder disorders from cyclophosphamide, 2173
Blaschkoid distribution of lesions, 36, 38f
in Darier-White disease, 436, 436f
in Hailey-Hailey disease, 440–441
in lichen striatus, 1062, 1062f
in porokeratosis, 444, 444f
Blaschko's lines, 36, 38f, 69, 83
Blastomyces dermatitidis, 276, 1838–1839, 2119
Blastomycosis, 1836, 1838–1839, 1839f
European, 1842–1843
in immunocompromised host, 276, 1839
keloidal, 1835
North American, 1838–1839
in occupational exposures, 2076
oral cavity disorders in, 653t
South American, 1840–1841
Blau syndrome, 711
Bleaching agents, 2135, 2145t, 2145–2146
hydroquinone as, 628f, 629, 1227, 2135, 2145t, 2145–2146
hypopigmentation from, 621, 628f, 628–629
in melasma, 635, 1480
ochronosis from, 637, 1227, 2145, 2146
in vitiligo, 621, 629
Bleeding. *See* Hemorrhage
Bleeding disorders, 1376t
in vitamin C deficiency, 1213
in vitamin K deficiency, 1208
in Wiskott-Aldrich syndrome, 1358
Bleomycin, 2123–2124
indications for, 2124
in Kaposi sarcoma, 1187b
side effects and complications of, 2124
hyperpigmentation in, 636, 2124, 2178, 2178f
Blepharitis
seborrheic, 224
staphylococcal, 1698–1699
Blepharoconjunctivitis
herpes simplex, 1879
in retinoid therapy, 2185
Blepharosis, moniliform, in lipoid proteinosis, 1289, 1291f
Blindness in vitamin A deficiency, 1204
Blister beetles, 2060
Blisters, 60, 61
in bullosis diabeticorum, 1469b, 1469–1470
in bullous pemphigoid, 475–480
in chronic bullous disease of childhood, 485–490
at dermal-epidermal junction, 47f, 47t, 47–48, 62
in congenital disorders, 71
dermolytic, 47, 47t
junctional, 47, 47t
in dermatitis herpetiformis, 47t, 48, 485, 503
desmosome pathology in, 448
eosinophils in, 316
epidermal, 45, 45t
in epidermolysis bullosa, 505–516
friction, in athletes, 876, 876f
in keratin mutations, 381
in linear immunoglobulin A dermatosis, 485–490
of male genitalia, 660b
in occupational exposures, 2076
in pemphigoid gestationis, 490–493
in pemphigus, 459, 460–461, 464, 464f
histopathology in, 466
paraneoplastic, 470
pathophysiology of, 462–463
sub-epidermal, 47–48
in porphyria cutanea tarda, 1239, 1241f
sucking, in neonates, 938
vesicles and bullae in, 32
BLM in Bloom syndrome, 1322, 1323
Bloch-Sulzberger syndrome, 631
Blood pressure
ankle-brachial index of
in peripheral arterial disease, 1668, 1669
in peripheral venous disorders, 1682
in hypertension. *See* Hypertension
in hypotension
in meningococcemia, 1732, 1735
in septic shock, 1746, 1747
Blood vessels, 64–65, **1585**–1598
angiogenesis of, 1596–1598
B-cell lymphoma of, intravascular cutaneous, 1401
of dermis, 64, 899, 1586
age-related changes in, 966
deep, 50, 1586, 1587f
superficial, 50–51, 1586, 1587f
embryonic and fetal development of, 70, 1596
malformations in, 1651
endothelial cells of, 1585–1598
of face, 2293–2294, 2294f

malformations of, **1651**–1666. *See also* Vascular malformations
of nails, 778, 779f, 780, 2320–2321
splinter hemorrhage from, 780, 783, 783f
neural control of, 896, 898
in thermoregulation, 837, 838f
peripheral arterial disease of, **1667**–1678
peripheral venous disorders of, **1679**–1684
remodeling of, 1596, 1598
in skin graft healing, 2346–2347
and skin tracks along veins in drug abuse, 922, 923f
structure and function of, 1586–1587, 1587f
in thermoregulation, 836, 837–844
trauma in drug abuse, 924
vasculitis of. *See* Vasculitis
vasoconstriction of. *See* Vasoconstriction
vasodilation of. *See* Vasodilation
Blood-borne infections in athletes, 875
Blood-brain barrier, 1588
Bloodhound facial features in cutis laxa, 1308f, 1309
Blood-testis barrier, 1588
Bloom syndrome, 1311, 1312t, **1321**–1323
clinical features in, 1322, 1323f, 1504t, 1505t
diagnosis of, 983t, 1322–1323
DNA damage and repair in, 982t, 983t, 1323
genetic factors in, 1322–1323
tumors associated with, 1504t, 1505t
Blueberry muffin baby, 1176, 1379
in congenital cytomegalovirus infection, 1862, 1862f
Blue nevus, 1109–1112
cellular, 1110–1111, 1111f, 1112, 1112f
clinical findings in, 1110f, 1110–1111, 1111f
common, 1110, 1111f, 1112f
deep penetrating, 1110
differential diagnosis in, 1112b
disorders associated with, 1110
epidemiology of, 1109–1110
etiology and pathogenesis in, 1110
histopathology in, 1111, 1112f
large plaque, 1110, 1111–1112
malignant, 1111
treatment of, 1111–1112
laser therapy in, 2274
Blue-ringed octopus bites, 2050
Blue rubber bleb nevus, 1657, 1657t, 1659f
gastrointestinal hemorrhage in, 1455
localized hyperhidrosis in, 725
oral cavity disorders in, 642t
Blue toe syndrome
in atheromatous embolism, 1672, 1672f
in syphilis, 1961
BMP. *See* Bone morphogenetic proteins
Bockhart impetigo, 1698
Body art, **886**–890
branding in, 886
extraocular implants in, 886
painting in, 886
piercing in, 886, 889–890
scarification in, 886
tattooing in, 886–889
tongue splitting in, 886
Body dysmorphic disorder, 913–914
Body image in adolescents, 945
Body lice, 2035
differential diagnosis of, 2035b
Boil, 1699–1701. *See also* Furuncles
Bone density measurements
in corticosteroid therapy, 2152, 2153f
in dermatitis herpetiformis, 504
Bone disorders
in aging, 967
in corticosteroid therapy, 2150t, 2150–2151, 2151t
bone density measurements in, 2152, 2153f
prevention and management of, 2152, 2152f, 2153, 2153f
in dermatitis herpetiformis, 504
in epidermal nevus syndromes, 1061, 1061t
in Fabry disease, 1284t, 1285
in granuloma inguinale, 1992
in homocystinuria, 1304
in hyper-IgE syndrome, 1366, 1367t
in Langerhans cell histiocytosis, 1417, 1420f, 1423
in mastocytosis, 1439, 1440
treatment of, 1442, 1442b
in neurofibromatosis type 1, 1335–1336
in occupational exposures, 2078
in osteogenesis imperfecta, 1310–1311
in retinoid therapy, 2185
in syphilis, 1962, 1964
congenital, 1968, 1968t, 1969
endemic, 1981
in vitamin C deficiency, 1213
in vitamin D deficiency, 1206–1207
in yaws, 1980, 1981
Bone marrow
eosinophil development in, 284
heme synthesis in, 1230
neutrophil development in, 279
transplantation of. *See* Stem cell transplantation
Bone morphogenetic proteins, 67, 68t, 70
in basal cell carcinoma, 992
BMP1, 526
BMP4, 72
as melanogenic inhibitor, 605
in embryonic development, 591
in hair color, 748
in hair follicle development, 740f, 741, 742, 744
Bonnet-Dechaume-Blanc syndrome, 1665
Boric acid intoxication, hair loss in, 762
Borrelia afzelii, 1797
Borrelia bissettii, 1797
Borrelia burgdorferi
in B cell lymphoma, 1400, 1401, 1802
detection of, 1803–1804
and ehrlichiosis coinfection, 1952, 1953
life cycle of, 1797, 1798
in Lyme disease, **1797**–1806
in lymphoid hyperplasia, 1402, 1403f, 1408, 1801–1802
treatment of infections, 2197t
Borrelia garinii, 1797, 1798
Borrelia lonestari, 1797
Borrelia recurrentis, 2035, 2197t
Borreliosis
and ehrlichiosis, 1952, 1953
Lyme disease in, **1797**–1806
lymphocytoma in, 1798, 1802, 1802f
lymphoid hyperplasia in, 1402, 1403f, 1408, 1801–1802
Bortezomib, 2235
Bosentan in systemic sclerosis, 1558–1559, 1559t, 1561
Botfly bites, 2060, 2060f
Botryomycosis, 1702, 1702f, 1779t, 1785
Botulinum toxin, **2388**–2394
in apocrine bromhidrosis, 732
in apocrine chromhidrosis, 733
in cosmetic facial procedures, 2388–2394
in combination with soft tissue augmentation, 2392
in crow's-feet, 2391–2392
in glabellar brow furrows, 2388, 2390–2391, 2391f
in horizontal forehead lines, 2391
mechanism of action, 2389f, 2389–2390
pharmacology of, 2388–2390, 2389f
preparations available, 2390, 2390t
in hidradenitis suppurativa, 737
in hyperhidrosis, 716, 723, 724b, 2388, 2392–2393
complications of, 2393–2394
immune response to, 2390, 2393
indications for, 2390–2393
side effects and complications of, 2393–2394
anhidrosis in, 728
in vesicular palmoplantar eczema, 166
Botulism, in bioterrorism, 2082t
Bouton d'orient, 2003
Boutonneuse fever, 1942
Boutonnière deformity in rheumatoid arthritis, 1570
Bovine collagen injection for soft tissue augmentation, 2382, 2382t, 2383
Bovine papular stomatitis virus, 1900t, 1909
Bowen disease, 788, 1021–1023
in arsenic exposure, 1016, 1017, 1021, 1022
clinical findings in, 1021–1022, 1022f
diagnosis and differential diagnosis in, 1022, 1023b
epidemiology of, 1021
etiology and pathogenesis of, 1021
histopathology in, 1022, 1022f
intertriginous, 1022
of penis, 663, 673, 673f
differential diagnosis of, 674b
prognosis and clinical course in, 1022–1023
squamous cell carcinoma in, 1022, 1028, 1030
treatment of, 1023, 1023b
photodynamic therapy in, 2261
radiation therapy in, 2282, 2282t, 2283
Bowenoid papulosis, 673, 673f, 1020–1021, 1021f
clinical findings in, 1020, 1021f, 1918
differential diagnosis of, 674b, 1020
risk for malignancy in, 1020, 1918
treatment of, 1020–1021, 1918
Bowenoid transformation in seborrheic keratosis, 1055
Bowman-Birk inhibitor, 2363
Box jellyfish, 877, 2043–2044, 2044f, 2045t
BP180 in pemphigoid gestationis, 490
BPAG. *See* Bullous pemphigoid antigens
BPI (bactericidal/permeability-increasing) protein, 283
Brachioradial pruritus, 907
Braden pressure ulcer risk assessment scale, 879, 882t
Bradykinin
in pruritus, 897t
in urticaria and angioedema, 333, 336–337, 337f
Brain
abscess in body piercing complications, 890t
in Langerhans cell histiocytosis, 1419
melanoma metastasis to, 1156
in neurofibromatosis type 1, 1336–1337
unidentified bright objects in MRI of, 1336–1337

Brain-derived neurotrophic factor in pruritus, 897t
Branchial cleft cyst, 1066
Branding procedure as body art, 886
Braun-Falco-Marghescu syndrome, 561
BRCA1/BRCA1, 982t, 1315
BRCA2/BRCA2, 982t
  and melanoma risk, 1136–1137
Breast
  adenoma of, 1071
  eosinophils in, 284, 285
  familial cancer of, 982t
  fibroadenoma of, 1071
  in lupus mastitis, 1526
  melanoma risk in cancer of, 1136–1137
  metastatic cancer of, 1506, 1506f
  Paget disease of, 1094–1096, 1507
    clinical findings in, 1094–1095, 1095f
    differential diagnosis of, 1095, 1095b
    prevention of, 1098
    treatment of, 1096, 1097f
  supernumerary nipples of, 1071
  traumatic panniculitis of, 580–581
Breast-fed infants
  riboflavin deficiency in, 1209
  thiamine deficiency in, 1208
  vitamin D deficiency in, 1206
  zinc deficiency in, 1215
Breast-feeding
  antibiotics in, 2195
  antihistamines in, 2191
  antimalarial drugs in, 2162, 2162t
  corticosteroid therapy in, 2151
  tumor necrosis factor inhibitors in, 2228
Breslow depth of melanoma, 1146, 1149, 1153
Bretylium tosylate, 842
Brevican, 539t
Brilliant green, 2131t, 2132
Brill-Zinsser disease, 1948–1951
Bristleworm dermatitis, 2048, 2048f
Brittle hair syndromes, 759t, 1321
Brittle nails, 759t
Broadband light sources, 800
Broders' grading of squamous cell carcinoma, 1033, 1033t
Bromhidrosis
  apocrine, 731–732, 732b
  differential diagnosis in, 731, 732b
  eccrine, 731, 732b
Bromine, occupational exposure to, 2069t
Brompheniramine, 2187
Bronchiolitis obliterans in paraneoplastic pemphigus, 471, 472
Brooke-Spiegler syndrome, 1075, 1076, 1083
Brown globules in melanoma, 1143, 1143f
Brown recluse spider bites, 2056, 2056f, 2057f
  differential diagnosis of, 2056b
  red, white, and blue sign in, 2056, 2057f
Brown widow spider bites, 2054
Brucella abortus, 1759
Brucella canis, 1759
Brucella melitensis, 1691, 1759
Brucella suis, 1759, 1760
Brucellosis, 1757t, 1759–1760
  in bioterrorism, 2083t, 2085
  in occupational exposures, 2074
  treatment of, 1757t, 1760
Bruch's membrane in pseudoxanthoma elasticum, 1306, 1307
Brugia malayi, 2014t, 2017, 2017t, 2021t
Brugia timori, 2014t, 2017, 2017t, 2021t
Bruises
  in children, 927t, 927–929
    common locations of, 928, 928f
    shapes and patterns of, 928, 928f
  in domestic violence, 931
  in elderly, 930
Brünauer-Fuhs-Siemens palmoplantar keratoderma, 427
Brunsting-Perry pemphigoid, 483
  differential diagnosis of, 496, 497f
Bruton disease, 1348–1352
BSCL2 in lipodystrophy, 588
BTK in X-linked agammaglobulinemia, 1348–1352
Buba, 1979–1981. *See also* Yaws
Bubble hair, 770
Buboes
  in chancroid, 1984
  in lymphogranuloma venereum, 1988, 1988f, 1989
  in syphilis, 1958
  in yaws, 1979
Buccal nerve, 2292, 2293, 2298
Budd-Chiari syndrome, 285, 1458
  in polycythemia vera, 1378
Buerger disease, 1673–1676. *See also* Thromboangiitis obliterans
Buffalo hump
  in Cushing syndrome, 1478
  in HIV infection and lipodystrophy, 1934, 1935
Bulge cells in hair follicle, 745, 745f
Bulimia, tooth disorders in, 647t
Bullae, 32–33, 33f
  drug-induced, 353, 358–359
  festooned, in porphyria cutanea tarda, 1239
  in impetigo. *See* Impetigo, bullous
  in pemphigoid. *See* Pemphigoid, bullous
  repens, in distal dactylitis, 1706
Bullosis diabeticorum, 1469b, 1469–1470
Bullous disease of childhood, chronic, **485**–490
  clinical findings in, 487–489, 488f
  differential diagnosis in, 489
  diseases associated with, 488
  epidemiology of, 485–486
  etiology and pathogenesis in, 486
  histopathology in, 489
  pathology in, 489
  treatment of, 489
Bullous eruptions, drug-induced, 358–359
  differential diagnosis in, 353
Bullous pemphigoid. *See* Pemphigoid, bullous
Bullous pemphigoid antigens
  BPAG1, 69, 476, 477
    in cicatricial pemphigoid, 481, 482t
  BPAG2, 68t, 69, 476, 477, 477f
    in cicatricial pemphigoid, 481, 482t
    in linear IgA dermatosis, 487
Bunions, 871–872
Bunostomum phlebotomum, 2023
Bunyavirus, 1846t
Bupivacaine, 2296, 2296t
Bupropion, 918t, 919
Burdwan fever, 2006
Burkholderia cepacia, 1364
Burkholderia mallei
  in bioterrorism, 2083t
  in glanders, 1760–1761, 2083t
Burkholderia pseudomallei
  in bioterrorism, 2083t
  in melioidosis, 1764–1765, 2083t
Burning feet syndrome, localized hyperhidrosis in, 725
Burning mouth syndrome, 642–643
Burning sensation
  chronic atypical, 916–917
  from cosmetic products, 2360–2361
Burns, **852**–858
  body surface area involved in, 853, 853t, 854, 856f
  chemical
    in occupational exposures, 2068, 2068t, 2069, 2069t
    oral, 651
  in child abuse, 854, 855f, 927t, 929
  circumferential, 852–853, 854
  classification of, 852–853, 853f
  clinical findings in, 852–853, 853f
  complications in, 854–855, 857f, 857t
  in drug abuse, 923–924
  in electrosurgery, 2335
  epidemiology of, 852
  eschar in, 32, 32f
  etiology and pathogenesis in, 852
  evaluation and treatment planning in, 853–854, 854t
    secondary survey in, 854, 854t
  hyperpigmentation in, 636
  from laser therapy, 2269
  from lime in athletes, 876
  liver disorders in, 1458
  local response to, 852
  Lund-Browder diagram in, 853, 854, 856f
  in occupational exposures
    chemical, 2068, 2068t, 2069, 2069t
    electrical, 2078
    thermal, 2077–2078
  prevention of, 857–858
  pruritus in, 908
  Rule of Nines on, 853, 854
  scars in, 855, 857f, 1020
  in sun exposure. *See* Sunburn
  systemic response to, 852, 855
  in thermal injuries, **852**–858
    in occupational exposures, 2077–2078
  treatment of, 855–857
    inpatient, 855, 857t, 858t
    outpatient, 855, 857t
    topical antibiotics in, 2115
Burow's solution, 2134, 2135
Burrows, 29, 29f
  in scabies, 29, 29f, 2030, 2030f
Bury type of erythema elevatum diutinum, 1616
Buschke-Fischer-Brauer disease, 428–429
Buschke-Lowenstein tumor, 673, 674, 1921
Buschke-Ollendorff syndrome, 536, 537t, 558
Buspirone, 920, 920t
Butenafine, 2117t, 2119, 2120t
Butorphanol in pruritus, 910, 911t
Butterflies, and lepidopterism, 2062–2063
Butterfly rash in lupus erythematosus, 1520, 1522f
Butterfly sign, 39t, 905
Buttonhole sign, 39t
Butyl methoxydibenzoylmethane in sunscreens, 2139, 2139t, 2140
Bypass surgery
  coronary artery, 1460
  gastric, 1456
  in peripheral arterial disease, 1671
Bywaters lesions in rheumatoid arthritis, 1571, 1571f

C

C chemokines, 127
C nerve fibers, 896, 899, 901
  in pruritus, 903, 903f, 904
  in stinging sensation, 2360
C6 peptide test in Lyme disease, 1804
C-reactive protein, 326

Cadherins, 60, 391, 1004, 1589
desmosomal, 391, 447, 448, 449t
embryonic and fetal, 67
in hair follicle development, 740, 740f
in melanocyte development, 593, 1004
neuronal, 1589
in palmoplantar keratoderma, 424
vascular endothelial, 1589, 1592t, 1594
Café-au-lait spots
as birthmark in infants, 634, 938, 1333
differential diagnosis in, 1333, 1333b
familial, 1338
and hypermelanosis, congenital circumscribed, 634
laser therapy in, 1337, 2272, 2273
in McCune-Albright syndrome, 634, 1333, 2273
in neurofibromatosis type 1, 634, 1331, 1332–1333, 1333f, 1337
Calabar swellings in loiasis, 2018–2019, 2019f
Calcification, **1293**–1296
aberrant, 1293–1294
in aponeurotic fibroma, 551–552
calciphylaxis in, 1295, 1295f
in dermatomyositis, 28, 1294, 1542t, 1549, 1550
dystrophic, 28f, 1294, 1543, 1549, 1552
dystrophic, 1293, 1294f, 1294–1295
in dermatomyositis, 28f, 1294, 1543, 1549, 1552
in hyperparathyroidism, 1475, 1475f
iatrogenic, 1293, 1296
idiopathic, 1293, 1296
of intervertebral disks in alkaptonuria, 1226, 1227, 1227f
metastatic, 1293, 1295f, 1295–1296
in kidney disorders, 1295, 1459
in pseudoxanthoma elasticum, 1294, 1305, 1307
Calcineurin, 434, 2217
Calcineurin inhibitors, 114, 434, 2125–2129, 2217–2221
adverse effects of, 2129, 2219–2220, 2221
in allergic contact dermatitis, 145
in atopic dermatitis, 148, 149, 155
contraindications to, 2128
indications for, 2128, 2219, 2221
initiation of therapy with, 2128–2129, 2219, 2221
in irritant contact dermatitis, 400
in lupus erythematosus, 1533, 1533t
mechanism of action, 288, 2125–2126, 2126f, 2217–2218, 2218f, 2220
monitoring of therapy with, 2129, 2219, 2221
pharmacokinetics of, 2128, 2220–2221
pimecrolimus. *See* Pimecrolimus
in psoriasis, 184t, 190
in seborrheic dermatitis, 224
tacrolimus. *See* Tacrolimus
Calcinosis, 28, 28f
circumscripta, in dermatomyositis, 1549
cutis, 1293
in dermatomyositis, 1294, 1542t, 1549
in Down syndrome, 1296
in hyperparathyroidism, 1475, 1475f
iatrogenic, 1296
infections associated with, 1295
in lupus erythematosus, 1294
in dermatomyositis, 28, 28f, 1294, 1542t, 1549, 1550
scrotal, 672
tumoral, 1296
familial, 1296
sporadic, 1296
universalis, in dermatomyositis, 1549
Calciphylaxis, 576, 1295, 1295f
in hyperparathyroidism, 1475–1476
in kidney disorders, 576, 1459, 1459f, 1476, 1476f
Calcipotriene in psoriasis, 188, 2136
in pregnancy, 189b
Calcipotriol
in palmoplantar pustular eruptions, 217, 217b, 218
in porokeratosis, 445, 445b
in psoriasis, 185, 188
in combination with phototherapy, 2245
in seborrheic dermatitis, 224–225
in vitiligo, 620, 620b
Calcitonin and calcium serum levels, 1293
Calcitonin-gene-related peptide (CGRP), 896t, 898
in inflammatory response, 898t
in necrotizing venulitis, 1600
in urticaria, 900
in wound healing, 901
Calcitriol, 1206–1207
in osteoporosis from corticosteroid therapy, 2152
in psoriasis, in combination with phototherapy, 2245
Calcium
and calcification disorders, **1293**–1296
and epidermal barrier function, 391–392, 393f
and intercellular adhesion, 61, 391–392, 432
in Darier-White disease, 61, 392, 432–434
serum levels of, 1293, 1474–1475, 1475t
in hypercalcemia. *See* Hypercalcemia
parathyroid hormone affecting, 1293, 1295, 1474–1475, 1476
in renal failure, 1295
in T-cell leukemia, 1924
vitamin D affecting, 1293, 1295–1296
signaling and transport, 433f
in acrokeratosis verruciformis, 436
in Darier-White disease, 61, 392, 432–434
in Hailey-Hailey disease, 17–18, 61, 392, 439–440
supplemental, in corticosteroid therapy and osteoporosis, 2152
in sweat secretion, 718, 718f
Calcium channel blockers, 393
in Raynaud phenomenon, 1647
in systemic sclerosis, 1559t
Calcium chloride therapy, cutaneous calcification in, 1296
Calcium dobesilate, 2236t
Calcium gluconate therapy, cutaneous calcification in, 1296
Calcium hydroxide, occupational exposure to, 2070t
Calcium pump, 432–434, 433f
Calf muscle pump, 1679–1680, 1680f, 2350, 2350f
Callosity syndrome, hereditary painful, 427
Callus formation, **871**–873
in amputation stump, 864
in diabetic foot, 873, 1466
differential diagnosis in, 872b
in occupational exposures, 2076
Calmodulin, 2217
Calymmatobacterium granulomatis, 1990
CAM5.2
antibodies to, 1090
in Paget disease, 1096
CAMFAK syndrome, 1320
Camisa disease, 425t
Campylobacter and reactive arthritis, 207, 208
Canaliculi in eccrine sweat glands, 713, 714f
Cancrum oris, 1217–1218, 1218f
Candida, intestinal overgrowth of, 2286, 2287
Candida albicans, 270, **1822**–1830
in chronic mucocutaneous infection, 1354–1356
occupational exposure to, 2076
in oral cavity disorders, 653
treatment of infections, 2119, 2120
drug resistance in, 2119
Candida dubliniensis, 1822
Candida glabrata, 270, 1822, 1824
Candida krusei, 270, 1822, 2120
Candida parapsilosis, 270, 1822, 1824, 2120
Candida tropicalis, 270, 1822, 1824, 1826f, 2120
Candidate gene approach, 77
Candidemia, 1826f
Candidiasis, **1822**–1828
balanitis and balanoposthitis in, 1824, 1824f, 1828
in children and infants, 1746
chronic mucocutaneous syndromes in, 1826
diaper dermatitis in, 943, 944, 1824, 1936, 2106
in neonates, 936
chronic mucocutaneous, 1354–1356, 1355t, 1826
classification of, 1355t, 1826, 1827t
clinical findings in, 1355f, 1355t, 1355–1356, 1356f
diffuse, 1827t
with endocrinopathy, 1354–1355, 1355t, 1356, 1827t
epidemiology of, 1354, 1355t
etiology and pathogenesis in, 1354–1355
familial, 1355t
in HIV infection, 1936
and hypoparathyroidism, 1356, 1476
and keratitis, 1355t
localized, 1355t, 1827t
nail changes in, 1355, 1826
oral, 1355, 1355f, 1355t, 1356f, 1827t
of scalp, 1355, 1356f
and thymoma, 1355t, 1826, 1827t
treatment in, 1356
clinical findings in, 1823–1826
in chronic mucocutaneous disease, 1355f, 1355t, 1355–1356, 1356f
congenital, 1746
cutaneous, 1824, 1825f, 1826f
in diabetes mellitus, 1465, 1825f
diaper dermatitis in, 943, 944, 1824, 1936, 2106
disseminated, 1824–1826, 1843
differential diagnosis of, 1826b
treatment of, 1828, 1843
in drug abuse, 926, 1843
in elderly, 973
with endocrine disorders, 1827t
and ectodermal dysplasia, 763, 1354–1355, 1355t, 1356, 1510
in hyper-IgE syndrome, 1366, 1367t
in immunocompromised host, 269t, 269–270, 270f, 273–274
disseminated disease in, 1826f, 1843
in HIV infection and AIDS, 1823, 1932, 1936
oral infection in, 1823, 1932, 1936
treatment of, 2216
vulvovaginal infection in, 1824, 1936
interdigital, 1825f

Candidiasis—*continued*
intertriginous, 1824, 1825b, 1825f
treatment of, 1828
invasive, 1826f
laboratory findings in, 1826–1827
in Langerhans cell histiocytosis, 1421
microscopic studies in, 1827
nail changes in, 1355, 1465, 1702, 1824, 1826f
in chronic mucocutaneous disease, 1355, 1826
in diabetes mellitus, 1465
onychomycosis in, 1817, 1818, 1820
paronychia in, 1465, 1702, 1824, 1826f, 1828, 1936
pathogenesis in, 1822
risk factors for, 1822, 1822t
treatment of, 1828
in occupational exposures, 1824, 2076
oral, 653–654, 1823f, 1823–1824
chronic atrophic, 653, 1823, 1823f
chronic mucocutaneous, 1355, 1355f, 1355t, 1356f, 1827t
differential diagnosis of, 1824b
in HIV infection, 1823, 1932, 1936
hyperplastic, 653–654, 1823f
leukoplakia in, 1024, 1025
pseudomembranous, 653, 1823, 1823f
in Sjögren syndrome, 1578, 1582
treatment of, 1827
pathology in, 1827
treatment of, 1827–1828, 1843, 2119, 2120, 2121
in chronic mucocutaneous disease, 1356
in disseminated disease, 1828, 1843
drug resistance in, 2119, 2120
fluconazole in, 2215
in immunocompromised host, 2216
itraconazole in, 2213, 2214, 2214t
vaginal and vulvovaginal, 1824, 1825f
in HIV infection, 1936
treatment of, 1827–1828
Candiru catfish, 2051
Canities, 630, 754t
subita, 630
Cannabinoids, 897t
in pruritus, 901, 909t, 910
Cannabis, 922
Cantharidin, 2060
in molluscum contagiosum, 1912–1913, 1913t
in warts, 1922
CAP syndrome, 442b, 444
Capillaries, 1586
of deep vascular plexus, 1589
fenestrated, 1588
lymphatic, 65
malformations of, 1651, 1652–1656
with arteriovenous malformations, 1652, 1664–1665, 1665f
clinical characteristics in, 1652–1653, 1653f, 1654f, 1654t, 1655f, 1656f
differential diagnosis of, 1656b
histopathology in, 1654f
imaging studies in, 1653–1655
in Klippel-Trénaunay syndrome, 1653, 1654–1655, 1655f, 1656, 2270
laser therapy in, 1655, 2270f, 2270–2271, 2271f
locations of lesions in, 1652, 1655f
prognosis and clinical course in, 1655, 1656f
in Sturge-Weber syndrome, 1653, 1654, 1655f, 1656, 2270
Capillaritis, unilateral linear, 1635
Capillary leak syndromes, 316
Capillary morphogenesis gene and protein, 68t
in juvenile hyaline fibromatosis, 68t, 552
Capita enzyme immunoassay in syphilis, 1971t, 1973, 1973t
Capnocytophaga canimorsus
in bite wounds, 2038
in immunocompromised host, 273, 2038
Capsaicin, 840, 900, 2130
in apocrine chromhidrosis, 732, 733
in postherpetic neuralgia, 1896–1897, 2130
in pruritus, 909t, 910
Capsid, viral, 1845, 1846, 1846t
Captopril, pemphigus from, 465–466
Caput medusae, 1455
Caput succedaneum, 936
Carate, 1978–1979. *See also* Pinta
Carbenicillin, 2198
Carbon dioxide
in cryotherapy, 2330, 2330t
in laser skin resurfacing, 2365, 2366–2367, 2367f
complications in, 2367–2368
Carbonic acid dichloride as chemical weapon, 2086t
Carbonyl chloride as chemical weapon, 2086t
Carboxypeptidase, 328, 329
Carbuncles, 33, 1699–1701, 1701f
abscess in, 1702
laboratory tests in, 1700
prognosis and clinical course in, 1700–1701
staphylococcal scarlet fever in, 1718, 1719
treatment of, 1701
Carcinoembryonic antigen in appendage tumors of skin, 1070t
Carcinogenesis, **977**–1006
in azathioprine therapy, 2168
in chemical exposure, **986**–994
constitutional modifiers of, 993
in cyclophosphamide therapy, 2173
in DNA damage and genome instability, **977**–986, 988
exogenous modifiers of, 993–994
initiating agents in, 991, 991t
inhibitors of, 994t
linear addiction mechanism in, 1136
in methotrexate therapy, 2166
in photochemotherapy, 2258
promoting agents in, 991, 991t, 992
inhibitors of, 994t
in ultraviolet radiation exposure, 977, 978f, **999**–1006, 2112
in photochemotherapy, 2258
prevention of, 2112
viruses in, **996**–998
Carcinoid syndrome
hyperpigmentation in, 635
vitamin B_3 deficiency in, 1210
Carcinoma
apocrine, 1072–1073
ductal, 1073
mucinous, 1074
basal cell, **1036**–1042. *See also* Basal cell carcinoma
eccrine, 1078, 1078f
microcystic, 1078–1079
en cuirasse, 1506, 1506f
erysipelatoides, 1506, 1506f
Merkel cell, **1087**–1094
microcystic adnexal, 1068, 1078–1079
of penis, 663, 672–674
pilomatrical, 1084–1085, 1085f
sclerosing sweat duct, 1078
sebaceous, 1086–1087
squamous cell, **1028**–1036. *See also* Squamous cell carcinoma
syringomatous, 1078
Cardiofaciocutaneous syndrome, ulerythema ophryogenes in, 750, 770
Cardiomyopathy, 1452
and palmoplantar keratoderma, 429, 1452
Cardiovascular disorders, 1452t, 1452–1453
in alkaptonuria, 1226
in amyloidosis, 1258, 1260t, 1262, 1454
complications in, 1263, 1264
imaging in, 1263
prognosis and clinical course in, 1264
treatment in, 1264
from antihistamines, 2190
in apolipoprotein A1 deficiency, 1280
in atrial myxoma, 1452–1453
in Behçet disease, 1623
in Churg-Strauss syndrome, 1611, 1614t
complement system in, 329
coronary artery bypass surgery in, 1460
in corticosteroid therapy, 2151, 2151t
management of, 2152–2153
in cutis laxa, 1309
in dermatomyositis, 1544t, 1547, 1549
in diabetes mellitus, 1462
in doxorubicin therapy, 2175
earlobe crease sign of, 1452
in Ehlers-Danlos syndrome, 1299, 1300, 1300f
in endocarditis, 1744–1746
in exfoliative dermatitis, 229, 231
in Fabry disease, 1284t, 1285
treatment in, 1287, 1287b
general skin changes in, 1445
hair loss patterns in, 1452
in hypereosinophilic syndromes, 308–309, 310
in hyperlipidemia, 1277, 1452
in Kawasaki disease, 1629–1630
prognosis in, 1632–1633
treatment in, 1631, 1632
in LEOPARD syndrome, 1453
in local anesthesia, 2297, 2298
in lupus erythematosus, 1453
in Lyme disease, 1803
treatment in, 1806t
in Marfan syndrome, 1302, 1303–1304
in mastocytosis, 1442, 1442b
in neurofibromatosis type 1, 1336
pacemakers and implanted defibrillators in, 2295
and electrosurgery, 2295, 2334
and palmoplantar keratoderma, 429, 1452
photoallergy from drug therapy in, 830t
phototoxicity from drug therapy in, 829t
in pseudoxanthoma elasticum, 1305, 1307, 1308
in psoriasis, 182, 183b
in rabies, 2039
in reactive arthritis, 211, 214
in relapsing polychondritis, 1568
in rheumatic fever, 1574, 1574b
in rheumatoid arthritis, 1572t
in sarcoidosis, 1454, 1488
treatment in, 1491, 1491t
in Sjögren syndrome, 1579b, 1579–1580
in smallpox vaccination, 1905
in syphilis, 1957, 1964–1965
and HIV infection, 1970
treatment in, 1975
in systemic sclerosis, 1453, 1555, 1557t
treatment in, 1558–1561
in tuberous sclerosis, 1329, 1330
in Wegener granulomatosis, 1612t

Carditis in rheumatic fever, 1574, 1574b
Caries, dental, 647
in Sjögren syndrome, 1578
Carmustine, 2123
side effects of, 2123
hyperpigmentation in, 636, 1397
in T-cell lymphoma, 1396–1397, 2123
Carney complex, 633, 1453
Cushing syndrome in, 1477, 1504t
cutaneous findings in, 1504t
growth hormone excess in, 1482
oral cavity disorders in, 642t, 648
schwannoma in, 1179, 1504t
Carotene, 1205–1206, 2108, 2110f
in erythropoietic porphyria, 1249
in erythropoietic protoporphyria, 1247
Carotenemia, 1205–1206
Carotenoderma, 1205–1206
Carotid artery, 2293
Carpal tunnel syndrome, Raynaud phenomenon in, 1646
Carpet beetles, 2060
Carpet tack sign, 39t
in lupus erythematosus, 1523
Cartilage-hair hypoplasia syndrome, 1356–1357, 1357f
Carukia barnesi jellyfish, 2044
Carvajal syndrome, 429
Casal's necklace appearance in pellagra, 1210, 1210f
Case-control studies, 3
as evidence source, 10, 10t
on harmful effects of exposures, 17–18
Caseomorphins, 2286
Caspases in apoptosis, 981
Castleman disease, 1403t, 1409–1410, 1410b
differential diagnosis in, 1410, 1410b
herpesvirus 8 in, 1184, 1409
multicentric, 1184, 1409, 1410
paraneoplastic pemphigus in, 468, 469, 473, 1410
plasma cell variant, 1410
treatment of, 1410, 1410b
Cat(s)
Bartonella infection associated with, 1749–1751, 2038
bites from, 2037, 2038
Capnocytophaga in, 2038
Pasteurella in, 1761, 2038
Porphyromonas in, 2038
rabies in, 2039
toxoplasmosis associated with, 2010
Cat-bite sign in congenital syphilis, 1968
Cat fleas, 2061
endemic typhus associated with, 1943t, 1948
Cat-scratch disease, 1749–1751, 1750t, 2038
clinical findings in, 1750f, 1750–1751
differential diagnosis of, 1751b
in immunocompromised host, 1692
treatment of, 1751
Catagen, 72, 743f, 744, 747f, 754
definition of, 754t
inhibitors of, 754
melanocytes in, 748
as therapy target, 754
Catalase in vitiligo, 620
Cataplasm, 2093
Cataracts
in atopic dermatitis, 152
in corticosteroid therapy, 2150t
in photochemotherapy, 2258
Catecholamine in inflammatory response, 898t
β-Catenin, 68t, 71
functions of, 449
in hair follicle development, 740f, 741, 742
in pilomatricoma, 988, 989t
Caterpillars, and lepidopterism, 2062–2063
Catfish stings, 2050–2051
Cathelicidins, 96f, 97, 1690
in psoriasis, 173
Cathepsin, 391, 2357
Cationic proteins, eosinophil, 285
Cattle
bovine papular stomatitis virus associated with, 1900t
cowpox virus associated with, 1900t
paravaccinia virus associated with, 1900t, 1908–1910
Cauliflower appearance of ear in relapsing polychondritis, 1567, 1567f
Causal inferences in epidemiologic studies, 4
Caveolae, 1588
Caveolins, 1588
Cavitation process in laser therapy, 2266
CBS in homocystinuria, 1304
CC chemokine(s), 100, 105, 127, 1593
CC chemokine ligands
CCL2, 131
CCL7, 131
CCL11, 284, 285
in atopic dermatitis, 132
CCL17, 100, 105
in atopic dermatitis, 131
in psoriasis, 132
CCL18 in atopic dermatitis, 131–132
CCL20, 108, 131
in psoriasis, 132
CCL21, 109, 131
CCL27, 105, 131, 1596
in atopic dermatitis, 148
CC chemokine receptors, 128t
CCR1, 128t, 130
CCR2, 108, 128t, 130, 131
CCR3, 128t, 131, 284, 286
in atopic dermatitis, 132
CCR4, 100, 105, 128t, 129, 130, 131, 1596
in atopic dermatitis, 131, 148
in psoriasis, 132, 133f
CCR5, 128t, 130, 131, 281
in infectious diseases, 134–135
CCR6, 44, 108, 128t, 130, 131
in cancer, 134
in psoriasis, 132, 133f
CCR7, 44, 128t, 130, 131
in melanoma, 134, 134f
CCR8, 131
CCR9, 128t
in melanoma, 134, 134f
CCR10, 100, 105, 128t, 129
in melanoma, 134, 134f
CCND1, 999
in melanoma, 1136
CCR. *See* CC chemokine receptors
CD1, 69
in antigen presentation, 110f, 111–112
CD1a in Langerhans cell histiocytosis, 1415, 1417t
CD2 binding protein-1 in PAPA syndrome, 701
CD3, 102
CD4+ T-cells, 101, 102, 105, 131, 1595
in acne vulgaris, 692
in alefacept therapy, 2230
and CD25, 1512–1513
and class II MHC molecules, 84, 109
in cutaneous T-cell lymphoma, 1388, 1390
in doxorubicin therapy, 2175
in graft-versus-host disease, 260, 262, 1512
in hematodermic neoplasm, 1401–1402
in herpes simplex virus infections, 1874
in HIV infection and AIDS, 1927, 1929
and antiretroviral therapy, 2208, 2209
and histoplasmosis, 1838
and interleukin 2, 122
and interleukin 10, 1512
and interleukin 15, 122
in leprosy, 103, 105, 1792, 1793
in lichen nitidus, 258
in morphea, 543
in parapsoriasis, 238
in photoimmunosuppression, 808, 808f, 809
in pityriasis lichenoides, 240
in pityriasis rosea, 363
in polymorphic light eruption, 816
in psoriasis, 171, 173, 174f, 175f, 193
in psoriatic arthritis, 196, 196f
regulatory functions of, 104
in sarcoidosis, 1485, 1485f
CD8+ T-cells, 101, 102, 105, 131
in acne vulgaris, 692
in alefacept therapy, 2230
in antitumor response, 1387
and class I MHC molecules, 84, 109
in epidermal necrolysis, 350–351, 353
in experimental autoimmune encephalomyelitis, 1513
in graft-versus-host disease, 262
in herpes simplex virus infections, 1874
in immunosuppression, 1513
in photoimmunosuppression, 808, 808f
and interleukin 2, 122
and interleukin 10, 1512
and interleukin 15, 122
in leprosy, 103, 105, 1792
in lichen nitidus, 258
in lichen planus, 244, 245
in mycosis fungoides, 1387
in pityriasis lichenoides, 240
in polymorphic light eruption, 816
in psoriasis, 171, 174f, 175f
in psoriatic arthritis, 194, 196f, 196–197, 198–199, 201
clonal ignorance of, 199
regulatory functions of, 104, 1513
in T-cell lymphoma, 1387
aggressive epidermotropic, 1395
CD9, 1590t
CD11a, 328, 1592, 1592t
and neutrophil adhesion, 281, 282f
CD11b, 327, 328, 1592, 1592t, 1594
and neutrophil adhesion, 281, 282f
in photoimmunosuppression, 807, 807f, 808
in urticaria and angioedema, 341
CD11c, 327
and neutrophil adhesion, 281, 282f
CD13, 1590t
CD14, 131
CD15s, 281, 282f, 287
CD18, 327, 328, 1592, 1592t, 1594
in inflammatory response, 282
in leukocyte adhesion, 281, 282f, 1365
in urticaria and angioedema, 341
CD20, and anti-CD20 antibodies, 2223t
in B cell lymphoma, 1401
CD21, 327
CD23, 327
CD25, 2230
and CD4, 1512–1513
CD26, 1590t
CD28, 1510, 1511, 1512, 1513
CD30, 52
in lymphoproliferative disorders, 1392–1393
in pityriasis lichenoides, 241, 242

CD31, 1589, 1590t, 1594
in infantile hemangioma, 1164
CD32, 286, 1589, 1590t
CD34, 1590t
in dermatofibrosarcoma protuberans, 1159, 1160
in erythema multiforme, 344
in giant cell fibroblastoma, 1161
in infantile hemangioma, 1164
in mast cell development, 1434
CD35, 327
CD36, 1589, 1590t
CD40, 99, 1590t
CD44, 1590t
CD45, 64, 130
CD46, 328, 1371t
CD47, 1590t
CD50, 287
CD54, 287, 1590t
CD55, 328
CD56+ hematodermic neoplasm, 1401–1402
CD58, 1590t, 1595
CD59, 328, 329
CD62, 281, 282f, 287, 1590t, 1591, 1592t
CD63, 1587–1588
CD80, 99, 1510, 1511, 1512, 1513, 1595
CD86, 99, 1510, 1511, 1513, 1595
CD95, 104
in lichen planus, 245
in T-cell lymphoma, 1387
in ultraviolet radiation exposure and basal cell carcinoma, 1037
CD99, 1592t, 1594
CD105, 1590t, 1597
CD106, 1590t
CD133, in infantile hemangioma, 1164
CD134, 1595
CD137, 1595
CD141, 1590t
CD143, 1590t
CD144, 1589
CD146, 1590t
CD151, in hemidesmosomes, 456–457
CD154, 121
CD207, 106
CDAGS syndrome, 444
CDK4, 982t, 999
in dysplastic nevus, 1123
in melanoma, 1123, 1136
CDK6 in melanoma, 1136
CDKN2A, 982t, 1002
in dysplastic nevus, 1123, 1124, 1130
in melanoma, 1123, 1136
CEDNIK syndrome, 425t
Cefaclor, 2198, 2199
in impetigo, 1698
serum-sickness like reaction to, 358
Cefadroxil, 2199
pediatric dosage, 948t
Cefaloram, 2199
Cefamandole, 2199
Cefazolin in soft tissue infections, 1730
Cefdinir, 2195t, 2199
Cefixime in gonorrhea, 1996b
Cefotaxime
in gonorrhea, 1996b
in Lyme disease, 1804, 1806t
Cefotetan, 2199
Cefoxitin, 2199
Cefpodoxime, 2198
Cefprozil, 2195t, 2199
in impetigo, 1698
Ceftazidime, 2199
Ceftizoxime in gonorrhea, 1996b
Ceftriaxone, 2199
in chancroid, 1986, 1986t
in gonorrhea, 1996, 1996b
in Lyme disease, 1804, 1806t
in syphilis, 1974
Cefuroxime, 2198
in Lyme disease, 1804, 1806t
Celiac disease
and dermatitis herpetiformis, 500–504, 1503
latent, 500
Cell cultures, primary, 982
Cell cycle
aging affecting, 963
replicative senescence in, 963
checkpoints in, 980, 981f
DNA damage affecting, 980, 981f, 1002
p53 in, 980, 1002
radiation affecting, 858, 859–860
Cell death. *See also* Apoptosis
in lupus erythematosus, 1510, 1519
programmed cell death 1 (PD-1) in autoimmune disorders, 1510, 1511–1512
Cell-mediated immunity, 319, 1849
in allergic contact dermatitis, 135, 138
in leprosy, 1792–1793
in lichen nitidus, 256
in lichen planus, 244
in opportunistic infections, 269t
T cell functions in, 101, 102
ultraviolet radiation exposure affecting, 812
in varicella-zoster virus infections, 1887, 1888
Cell membrane changes in photoimmunosuppression, 806
Cellular retinoic acid binding protein (CRABP), 2107, 2108f
Cellular retinol binding protein (CRBP), 2107, 2108f
Cellulite, laser therapy in, 2279
Cellulitis, 1692, 1720–1731, 1741–1743, 1747
acute, 1722, 1729
in *Aeromonas hydrophila* infections, 1742, 1764
anaerobic, 1721t, 1726, 1730
in bite wounds, 1723
in children, 1721t
clinical findings in, 1720, 1722, 1722f, 1723f
clostridial, 1726, 1730
crepitant, 1721t, 1725–1726, 1742
diagnostic techniques in, 1692, 1727, 1743
differential diagnosis of, 1728, 1728b, 1743, 1747b
in drug abuse, 924f, 925, 1722, 1726
in elderly, 973
eosinophilic, 310–313, 312t
etiology of, 1721t
gangrenous, 1721t, 1723f, 1723–1725, 1724t
in immunocompromised host, 1725
in *Pseudomonas aeruginosa* infections, 1725, 1738, 1739
treatment of, 1743
in *Haemophilus influenzae* infections, 1739, 1739f, 1740
in immunocompromised host, 1725, 1726, 1742, 1747
laboratory studies in, 1727
in lymphedema, 1686, 1727
in nocardiosis, 1782, 1783
in pressure ulcers, 1723
prognosis and clinical course in, 1729, 1743
in sepsis, 1747
staphylococcal, 1721t, 1722, 1723f, 1747
of elbow, 273
streptococcal, 1721t, 1722, 1747, 1766
in burns, 855, 857f
of male genitalia, 667
synergistic necrotizing, 1724t, 1725
prognosis and clinical course in, 1729
treatment of, 1730
treatment of, 1729–1730, 1743
in *Vibrio vulnificus* infections, 1747, 1763, 1763f
in water exposure, 1721t
Centers for Disease Control and Prevention, 4–5
Centipede bites, 2059
differential diagnosis of, 2056b
Centroblasts, 1405
Centrocytes, 1405
Centromere, 74
Centruroides scorpion stings, 2057–2058, 2058f
Cephalexin, 2195t, 2199
in impetigo, 1698, 1698b
pediatric dosage, 948t
Cephalohematoma, 936
Cephaloridine, 2199
Cephalosporins, 2198–2199
adverse effects of, 2196t, 2199
hypersensitivity to, 2199
indications for, 2198b
mechanism of action, 2198
pharmacokinetics of, 2198
Cephalothin, 2199
Cephradine, 2199
pediatric dosage, 948t
Ceramides, 386, 387f, 2357
protein-bound, 386, 387f
synthesis of, 386, 388f, 389f
Cercarial dermatitis, 2012t, 2048f, 2048–2049
Cerebroglycan, 539t
Cerebro-oculo-facio-skeletal syndrome and Cockayne syndrome, 1320, 1321
and xeroderma pigmentosum, 1319
Cerebrospinal fluid
in meningococcal meningitis, 1733
in syphilis, 1966, 1969, 1973, 1973t, 1974, 1975, 1976
Cerebrovascular disorders
in Fabry disease, 1284
treatment in, 1287, 1287b
hyperhidrosis in, 722t, 723
in syphilis, 1966
Cerivastatin, interaction with other drugs, 2240t
Ceruloderma, laser therapy in, 2274
Ceruloplasmin serum levels in Menkes syndrome, 758, 1216
Cervical cancer, 1031
papillomaviruses in, 996–997, 1921, 1922
Cervical warts, 1919, 1919f
Cervicitis, herpes simplex, 1875, 1876
Cestode infections, 2011, 2026–2028
Cetirizine, 288, 2187, 2188, 2189t, 2191
in atopic dermatitis, 2189
in HIV infection and drug hypersensitivity reaction, 1934
in mosquito bites, 2060
pediatric dosage, 952t
Cevimeline in Sjögren syndrome, 1582, 1583
Chagas disease, 2008–2009, 2009t, 2061
stages of, 2009, 2009t
transmission of, 2008–2009, 2061
Chagoma, 2009t
Chanarin-Dorfman syndrome, 405t, 420–421

Chancre
in syphilis, 652t, 1956, 1957f, 1957–1958, 1958f
endemic, 1981
histopathologic examination of, 1970
tuberculous, 1770, 1770f
in yaws, 1979
Chancroid, **1983**–1986
clinical findings in, 1983f, 1983–1984, 1984f, 1984t
complications of, 1986, 1986t
differential diagnosis of, 1985, 1985b, 1989
and HIV infection, 1983, 1986
laboratory tests in, 1984f, 1984–1985
prevention of, 1986
school of fish pattern in, 1984, 1984f
transmission of, 1983, 1986
treatment of, 1986, 1986t
variants of, 1984, 1984t
CHANDS syndrome, 1344
Charcoal administration in congenital erythropoietic porphyria, 1249
Charcot arthropathy, 1466
Charcot-Leyden crystals, 285
in granuloma faciale, 303
Charcot-Marie-Tooth disease, 429–430
Chédiak-Higashi syndrome, 622, 1367–1369, 1368t, 1374t, 1505t
accelerated phase, 613, 1367–1369
clinical findings in, 1367, 1368f, 1368t
epidemiology of, 608, 1367
etiology and pathogenesis in, 613, 1367, 1368t
granules in, 280, 613, 1367, 1368t
treatment in, 1369
Cheek surgery
advancement flap in, 2308, 2309f
anatomy in, 2291–2292
rotation flap in, 2310, 2311f
Cheese mite, 2032, 2032t
Cheilitis, 641–642
actinic, 641, 1000, 1009, 1010f
angular, 641
in candidiasis, 1823, 1823f, 1936
in HIV infection, 1936
in Sjögren syndrome, 1580
glandularis, 641–642
apostematosa, 642
granulomatous, 642, 642f
Cheilosis, candidal, 1823, 1824
Cheiroarthropathy in diabetes mellitus, 1463–1464
Cheiropompholyx, 162, 164f
Chemical carcinogens, **986**–994
chemistry and metabolism of, 988
genotoxic and non-genotoxic, 988, 992
initiating and promoting agents in, 991, 991t
keratoacanthoma from, 1050
squamous cell carcinoma from, 1029
Chemical exposures
autoimmune disorders in, 1514
in bioterrorism, 2085–2087
burns in
from lime, 876
in occupational exposures, 2068, 2068t, 2069, 2069t
oral, 651
carcinogenesis in, **986**–994
chloracne in, 2078, 2079t
hypomelanosis in, 628f, 628–629
keratoacanthoma in, 1050
occupational, 2068, 2068t, 2069, 2069t
oral trauma in, 651
porphyria cutanea tarda in, 1236, 1236t, 1237, 1241
scleroderma-like disorders in, 1562, 2078, 2078t
squamous cell carcinoma in, 1029
T-cell lymphoma in, 1386
in xeroderma pigmentosum, hypersensitivity to, 1317
Chemical peels, 2369–2370
in actinic keratosis, 1014
classification of, 2369–2370, 2370t
deep, 2370, 2370t
medium-depth, 2370, 2370t
side effects and complications of, 2370, 2371t
superficial, 2369–2370, 2370t
Chemical weapons, 2085–2087
Chemoattraction of neutrophils, 280–281
Chemokine(s), 126, **127**–135, 899–900
in atopic dermatitis, 131–132, 147–148
C subfamily, 127
in cancer, 133–134, 134f
CC subfamily, 100, 105, 127, 1593
CXC subfamily, 127
CXXXC (CX3C) subfamily, 127
and dendritic cell trafficking, 131
desensitization of, 129
in eosinophil recruitment, 288
in infectious diseases, 134–135
of keratinocytes, 100
in leukocyte activation, 1593
in leukocyte mobilization and binding, 126, 129–131
nomenclature on, 127
in psoriasis, 131, 132–133, 133f, 173–174, 174f
structure of, 127
and T-cell migration, 105, 130–131
therapeutic applications of, 135
in tumor formation, 133–134
Chemokine receptors, 117t, 127–129, 128t, 281
activation of, 130
of CC subfamily. *See* CC chemokine receptors
Chemotactic factor receptors, 286
Chemotaxis, 280–281
defective, opportunistic infections in, 269t
Chemotherapy
in amyloidosis, 1264
anagen effluvium in, 762
in basal cell carcinoma, 1041, 1042
in B-cell lymphoma, 1401
cytotoxic agents in. *See* Cytotoxic agents
in hemangioma of infants, 1168t, 1169
hyperpigmentation from, 637t
in Kaposi sarcoma, 1187b, 1187–1188
in keratoacanthoma, 1053
in Langerhans cell histiocytosis, 1423–1424
in melanoma, 1155, 1156
in Merkel cell carcinoma, 1093
mucositis in, 647
in neurofibromatosis type 1, 1337
in Paget disease, 1096, 1098
phototoxicity from drugs in, 829t
in squamous cell carcinoma, 1035
in T-cell lymphoma, 1396–1397, 1398
Chenodeoxycholic acid in cholestasis of pregnancy, 957
Cherry angioma, laser therapy in, 2272
Cheyletiella, 2032t, 2033
Chi square testing, 16
Chiari malformations, hyperhidrosis in, 724
Chicken wire appearance in myxoid liposarcoma, 1197
Chickenpox, 1848
differential diagnosis of, 2085, 2085t
Chiclero ulcer, 2003
Chigger fever, 1951
Chiggers, 2032, 2032t
Chigoe fleas, 2061–2062
Chilblain(s), 849–850, 850f
differential diagnosis of, 1646
Chilblain lupus, 850, 1486–1487, 1487f, 1488f, 1526
histopathology in, 1530
natural history and prognosis in, 1490, 1491
treatment of, 1491, 1491t
Child abuse, **927**–930, 954
agencies and resources for assistance in, 927, 928t
bruises in, 927t, 927–929
locations of, 928, 928f
shapes and patterns in, 928, 928f
burns in, 854, 855f, 927t, 929
differential diagnosis of, 549, 927, 927t, 942
epidemiology of, 927
sexual abuse in, 929f, 929t, 929–930
CHILD syndrome, 403t, 407, 419–420, 1280–1281
Children and infants, **935**–954
abuse of, **927**–930, 954
acne in, 692, 700
in adolescents, 690, 945
in neonates, 692, 700, 938, 938f
acrodermatitis in, 1860
acropustulosis in, 215, 215t
ainhum and pseudoainhum in, 562, 562f, 563
allergic contact dermatitis in, 137
anaplasmosis in, 1950b
angioma in, tufted, 1170, 1171f
annular erythema in, 367t, 368
antihistamines in, 2190, 2191, 2192–2193
antimalarial drugs in, 2161, 2162
ascariasis in, 2012
asymmetrical periflexural exanthem in, 1849, 1871–1872, 1872b, 1872f
atopic dermatitis in, 146–158
basal cell nevus syndrome in, 1047
bathing frequency for, 936
biopsy of skin lesions in, 942, 944t
biotin deficiency in, 1213–1214
blue nevi in, 1109
brucellosis in, 1760
bruises in, 927t, 927–929
areas of concern in, 928, 928f
shapes and patterns in, 928, 928f
bullous pemphigoid in, 475
burns in, 852, 927t, 929
in abuse, 854, 855f, 927t, 929
evaluation of, 854
prevention of, 857–858
and sunburn history, 1134
candidiasis in, 936, 1746
chronic mucocutaneous, 1826
diaper dermatitis in, 943, 944, 1824, 1936, 2106
in neonates, 936
Chédiak-Higashi syndrome in, 613
chronic bullous disease in, **485**–490
cold exposure of, 844, 844f
frostbite in, 848
panniculitis in, 576, 851
copper deficiency in, 1216
corticosteroid therapy in, 946, 2151
dosage in, 952t
indications for, 2104
and panniculitis, 582–583
topical, 2104
cyclosporine in, 2219, 2219t

Children and infants—*continued*
cytomegalovirus infections in, 1861, 1862, 1862f
dermatitis artefacta in, 915, 916
dermatomyositis in, 1537, 1545
complications of, 1549
prognosis and clinical course in, 1550, 1551
treatment of, 1551, 1552
dermatophyte infections in, 1818, 1818b, 1819
diaper dermatitis in, 942–945, 1824, 1936, 2106
differential diagnosis of dermatoses in, 939b
drug therapy in, 945–954
regulations on, 945–946
safety and efficacy of, 945–946
systemic, 946, 947t–954t
topical, 946, 946t, 2096
dysplastic nevus in, 1132
ehrlichiosis in, 1950b
enterobiasis in, 2013
eosinophilic pustular folliculitis in, 315
epidermodysplasia verruciformis in, 1918
epidermolysis bullosa acquisita in, 498–499
erythroderma desquamativum in, 221
examination of, 936, 941–942, 942f
in adolescents, 945
genital examination in, 941–942, 942f
in neonates, 936
exfoliative dermatitis in, 225
fatty acid deficiency in, 1204
fibromatosis in, 550–552
aggressive, 552
colli, 550–551
digital, 551, 551f
filariasis in, 2017
fluconazole in, 950t, 954, 2215
folate deficiency in, 1211
Fournier gangrene in, 671, 672
freckling in, 1119
frostbite in, 848
genitalia in
anatomy of, 943f
examination of, 941–942, 942f
warts of, 930, 1917
Gianotti-Crosti syndrome in, 1860
gonorrhea in, 1995
granuloma in
annulare, 369, 370, 371
gluteale infantum, 943–944
pyogenic, 647
griseofulvin in, 950t, 954, 1818t, 2216
growth hormone deficiency in, 1483
growth hormone excess in, 1482
Haemophilus influenzae infections in, 1739, 1739f, 1740
hair loss in, 764, 769, 938, 939–940
in syphilis, 771
treatment of, 765
hamartoma in, fibrous, 555
hemangioendothelioma in, kaposiform, 1171, 1171f
hemangioma in, 939, 1164–1170
congenital, 1169–1170
infantile, 1164–1169
lobular capillary, 1171f, 1171–1172
hemorrhagic edema in, acute, 1599, 1602
herpangina in, 1869–1870
herpes simplex virus infections in, 1873, 1876–1877
herpesvirus-6 infections in, 1864–1866
hyalinosis in, systemic, 68t, 552
hydroa vacciniforme in, 820
hypereosinophilic syndromes in, 307
ichthyosis in, 422–423
immunodeficiency disorders in, 1350f–1352f
impetigo in, 1712, 1712f
streptococcal, 1704–1705
iron deficiency in, 1214
itraconazole in, 951t, 954, 1818t, 2214
Kawasaki disease in, 1626–1633
keratosis pilaris in, 749
Langerhans cell histiocytosis in, 944, 944f, 1414, 1415, 1418f
prognosis and clinical course in, 1421, 1423
treatment of, 1423, 1424
leishmaniasis in, 2003, 2004
lentigo simplex in, 1117, 1118
leptospirosis in, 1767
lichen planus in, 252b
lichen sclerosus in, 546, 549, 550
lichen striatus in, 1062
linear scleroderma in, 544, 546
lipoblastoma in, 1195
lipodystrophy in, 587, 588–589
lipofibromatosis in, 1195–1196
listeriosis in, 1762–1763
Lyme disease in, 1798, 1799, 1802, 1803
treatment of, 1804
mastocytosis in, 1437–1439, 1437f, 1438f
prognosis in, 1443
treatment of, 1441
measles in, 1851, 1852
melanoma in, 1142
in sunburn history, 1134
melioidosis in, 1765
meningocele in, rudimentary, 1183
meningococcal infections in, 1732, 1734
Menkes syndrome in, 1216
methotrexate in, 2163
milia in, 1065
miliaria rubra in, 937, 943
molluscum contagiosum in, 1911
Mongolian spots in, 632–633, 938
monkeypox virus infections in, 1906, 1907, 1907f
morphea in, 543, 544, 546
mycobacterial infections in, 1776, 1776f, 1777
tuberculosis, 1770, 1770f, 1771
myofibromatosis in, 552
neonatal. *See* Neonates
neurofibromatosis in
type 1, 1333, 1334, 1335, 1336
type 2, 1338
nevomelanocytic nevi in
acquired, 1105
congenital, 1099–1103
nevus spilus in, 1103
noma (cancrum oris) in, 1217–1218, 1218f
nummular eczema in, 158, 159f
onychomycosis in, 1817, 1820
oral aphthous ulcers in, 646
panniculitis in
in cold exposure, 576, 851
poststeroid, 582–583
in sclerema neonatorum, 576, 582
in subcutaneous fat necrosis, 581–582
parakeratosis in
granular, 943
pustulosa, 790, 790f
parvovirus B19 infections in, 1855–1856
pediculosis capitis in, 2033, 2034, 2035
pediculosis pubis in, 2036
pemphigoid gestationis in, 491
perineal protrusion in, 942
perioral dermatitis in, 709, 710f
pigmented spindle cell nevus in, 1112
pityriasis alba in, 623
pityriasis lichenoides in, 240, 242
pityriasis rubra pilaris in, 233, 233t, 234, 235f
porokeratosis in, 443
protein-energy malnutrition in, 1202f, 1202–1203, 1203f
Pseudomonas aeruginosa infections in, 1737, 1738
psoriasis in, 180, 944, 944f
and arthritis, 199, 201
treatment of, 189b
pyramidal protrusion in, 942
reactive arthritis in, 207
rhabdomyosarcoma in, 1176
rheumatic fever in, 1573
riboflavin deficiency in, 1209, 1209f
Rocky Mountain spotted fever in, 1941
treatment of, 1942, 1950b
rotavirus infections in, 1870, 1871
rubella in, 1853, 1854
scabies in, 2030, 2030f, 2031
scarlet fever in, 1717, 1718
scleredema in, 1562, 1563
scorpion stings in, 2058
sebaceous glands in
activity and sebum production in, 689
hyperplasia of, 936
seborrheic dermatitis in, 219, 220–221, 221f
differential diagnosis of, 221, 221b
treatment of, 223–224
sexual abuse of, 929f, 929t, 929–930
differential diagnosis in, 942
shaken, 929
smallpox in, 1900, 1902, 18091f
smallpox vaccination complications in, 1903, 1904, 1904f, 1905, 1905f
Spitz nevus in, 1113, 1115
staphylococcal scalded skin syndrome in, 1712, 1713f, 1714, 1714f
sternomastoid tumor of, 550–551
Sweet syndrome in, 289, 291
syphilis in, 771, 1974, 1975
terbinafine in, 951t, 954, 1818t, 2212
thiamine deficiency in, 1208
tinea capitis in, 770, 938, 945, 1811, 1818
tinea corporis in, 1814
tinea pedis in, 1818t, 1819
transient dermatoses in, 936–938
treponematosis in, endemic non-venereal, 1978, 1979, 1982
trichotillomania in, 769
tuberous sclerosis in, 1326, 1331
typhus in, 1950b
ultraviolet radiation exposure in, 1000
and melanoma risk, 1134
and sunscreen use, 2140
urticaria in, 330, 339
varicella-zoster virus infections in, 1885
clinical findings in, 1888–1889
complications of, 1893
prevention of, 1897, 1898
treatment of, 1894–1895, 1895t
venulitis in, cutaneous necrotizing, 1599
vitamin A deficiency in, 1204, 1204f
vitamin A toxicity in, 1205
vitamin B_{12} deficiency in, 1212
vitamin D deficiency in, 1206
vitamin K deficiency in, 1208
vitiligo in, 616, 620
warts in, 1917
in epidermodysplasia verruciformis, 1918
genital, 930, 1917
respiratory, 1919
treatment of, 1921, 1922
Wells syndrome in, 310

xanthoma in, 1280
xeroderma pigmentosum in, 1316, 1320f
zinc deficiency in, 1215, 1215f, 1216
Chilopoda bites, 2059
Chin, surgical anatomy of, 2291
Chironex fleckeri stings, 877, 2043–2044, 2044f, 2045t
antivenin for, 2044–2045
Chlamydia granulomatis, 652t
Chlamydia psittaci in bioterrorism, 2083t
Chlamydia trachomatis, 1996–1997
elementary body of, 1997
and gonorrhea coinfection, 1996, 1997
treatment of, 1996, 1996b
in lymphogranuloma venereum, 1987–1990
in neonate, 1997
in pelvic inflammatory disease, 1995, 1997
in reactive arthritis, 208, 209, 1997
treatment of infection, 1997, 1998b, 2197t
in gonorrhea coinfection, 1996, 1996b
in pregnancy, 1996, 1998b
Chloracne, 702, 2078
chemicals associated with, 2078, 2079t
differential diagnosis of, 2078, 2079t
Chloral hydrate, pediatric dosage, 952t
Chlorambucil, 2174t, 2174–2175
chemical structure of, 2163f
complications of, 2174–2175, 2176t
in dermatomyositis, 1552
dosing regimen, 2174, 2176t
indications for, 2174, 2176t
mechanism of action, 2174, 2176t
Chloramphenicol, 2113t, 2115
in actinomycosis, 1781
in anaplasmosis, 1950b
in ehrlichiosis, 1950b
in meningococcal infections, 1734
in Oroya fever, 1755
in Rocky Mountain spotted fever, 1942, 1950b
in typhus, 1950b, 1952
Chlorhexidine, 1694, 2130, 2131t, 2132
in methicillin-resistant staphylococcal infections, 875
in oral lichen planus, 253
in preoperative skin preparation, 2295
Chloride
in composition of sweat, 717, 717f, 730
ductal reabsorption of, 718–719, 719f
in mechanisms of sweat secretion, 718, 718f
Chlorinated hydrocarbons, chloracne from, 702
2-Chlorodeoxyadenosine in mastocytosis, 1443
Chloroma in leukemic cutis, 1385f
Chlorophyll, 1228
Chloroprocaine, 2296t
Chloroquine, 2157–2162
chemical structure of, 2158, 2158f
in children, 2161, 2162
complications of, 2161–2162, 2162t
in dermatomyositis, 1551, 2160
dosing regimen for, 2160
indications for, 2159–2160, 2161t
in lupus erythematosus, 1533t, 1533–1534, 2159–2160
mechanism of action, 2157–2158
pharmacokinetics of, 2158–2159, 2159t
pigmentation changes from, 636, 2161
in polymorphic light eruption, 2160
in porphyria cutanea tarda, 1242, 2160
in pregnancy and breast-feeding, 2162
in sarcoidosis, 1492, 1492t, 2160
Chlorpheniramine, 2187, 2189t, 2191
pediatric dosage, 952t
Chlorpromazine, pigmentation changes from, 636
Cholecalciferol, 1206, 1293, 2140. *See also* Vitamin D_3
Cholestasis
in pregnancy, 956–959, 958t
pruritus in, 907–908, 957, 959, 1447–1448
Cholesterol
embolism from, 1460, 1460f, 1671, 1672
infarction area in, 34, 34f
metabolism of, 385, 388f, 1273–1274, 1275f
reverse transport of, 1274
in sebum, 688, 688f
serum levels of
in Fabry disease, 1285
in familial hyperlipidemias, 1274–1278
in stratum corneum, 385, 387f, 388f, 2357
Cholestyramine in cholestasis of pregnancy, 959
Cholic acid levels in cholestasis of pregnancy, 957–958
Cholinergic stimulation
sweating in, 716, 717, 718, 718f, 837
urticaria in, 334–335, 335f
vasodilation in, 837, 839f
Chondritis
auricular, 1567, 1569b
in relapsing polychondritis, 1567–1569
costochondritis, 1568
nasal, 1567, 1569b
respiratory tract, 1567–1568
Chondrodermatitis nodularis helicis, 1066–1067, 1067f
Chondrodysplasia punctata, 419, 419f
prenatal diagnosis of, 423
rhizomelic, 404t, 419
X-linked dominant, 403t, 419, 561, 753t
X-linked recessive, 403t, 419
Chondroid lipoma, 1194, 1194f
Chondroitin sulfate, 63, 538, 538f, 539, 540, 541
Chorea
Morvan's fibrillary, 726
in rheumatic fever, 1574, 1574b
Choriocarcinoma and pemphigoid gestationis, 491
Christ-Siemens-Touraine syndrome, 1339–1342
Christmas tree pattern
in pityriasis rosea, 362, 364, 364f
in seborrheic keratosis, 1054
Chromatid exchange assay, 984, 984f
Chromhidrosis
apocrine, 732–733, 733b, 733f
axillary, 732
facial, 732, 733f
differential diagnosis in, 733, 733b
eccrine, 722, 733, 733b
pseudo-eccrine, 733, 733b
Chromic acid, occupational exposure to, 2070t
Chromobacterium violaceum, 1766, 2053
Chromoblastomycosis, 1831, 1833–1835, 1834f, 1835f
in occupational exposures, 2076
Chromomycosis, 1833–1835
Chromophores, 797, 810, 811
absorption of radiation, 803, 803f, 2263, 2264, 2267f
photochemical reactions, 803–805
and photoimmunomodulation, 813
Chromosome 4 short arm deletion, 81t
Chromosome 5 short arm deletion, 81t
Chromosome 17, 74, 75f
Chromosome 18 long arm deletion, 81t
Chromosomes, 73, 74–76
band 17q21.2, 74, 75f
breakage of, 983–984
disorders of, 80–82, 81t–82t
number of, 80
radiation damage of, 859
structure of, 74, 75f, 80
in balanced translocation, 80
deletion affecting, 80, 81t
in reciprocal translocation, 80
tests of integrity and breakage, 983–984
sister chromatid exchange assay in, 984, 984f
Chondrolipoma, 1191
Chronic disease
anemia of, 1270
chronic bullous disease of childhood, **485**–490
Chrysaora sea nettles, 877, 2042
Chrysiasis, 1227, 2376
Chrysops bites, 2060
loiasis in, 2018, 2019
Churg-Strauss syndrome, 309, 317, 1611–1613
clinical manifestations of, 1611–1612, 1614t
etiology and pathogenesis in, 1607
Chylomicron(s), 1273, 1275f
Chylomicronemia
familial syndromes, 1274–1276
with hypertriglyceridemia, 1278
xanthoma in, 1272t, 1273f, 1274–1275, 1276, 1278, 1279t
Chymase
functions of, 1435, 1435t
in mast cells, 1434, 1435
in pruritus, 904
CIAS1 in cryopyrinopathies, 1270
Cicatrix. *See* Scars
Ciclopirox, 2117t, 2120–2121
in onychomycosis, 1820, 2121
Cidofovir, 2206–2207
in cytomegalovirus infections, 2206–2207, 2207t
in herpes simplex virus infections, 1884, 2207
in HIV infection and AIDS, 1937
in molluscum contagiosum, 1913, 1913t
in smallpox, 1903, 2207
in smallpox vaccination complications, 1905
Ciguatera toxin, 2053
Cilostazol in peripheral arterial disease, 1670, 1670b
Cimetidine, 2191–2193, 2192t
complications of, 2192
in dermatomyositis, 1551
interaction with other drugs, 2192
in molluscum contagiosum, 1913, 1913t
in warts, 1922
Cimex bedbugs, 2060–2601
Cimicidae, 2060–2061
CINCA syndrome, 1270
Cinoxate in sunscreens, 2139t
Ciprofloxacin, 2195t, 2201
in chancroid, 1986, 1986t
in children, 946
in gonorrhea, 1996b
in granuloma inguinale, 1993b
in *Klebsiella* infections, 1742
in Oroya fever, 1755
in *Salmonella* infections, 1741
in verruga peruana, 1755
Circling disease, 1762
Circumcision, 654, 654t, 672

Cirrhosis
alcoholic, psoriasis in, 1458
general skin changes in, 1446
hepatopulmonary syndrome in, 1454
nail changes in, 1449, 1449f, 1450
primary biliary, 1458
pigmentary changes in, 1446
pruritus in, 1448, 1458
tooth disorders in, 647t
spider nevi in, 1451, 1451f
Cisapride, interaction with other drugs, 2240t
Citalopram, 918t
Citrullinemia, 1219t, 1224
trichorrhexis nodosa in, 756, 1224
Civatte bodies in lichen planus, 251
CLA. *See* Cutaneous lymphocyte antigen (CLA)
Cladophialophora carrionii, 1833, 1835
Clam digger's itch, 2048f, 2048–2049
Clarithromycin, 2195t, 2200
in erythrasma, 1708
in leprosy, 1795, 1795b
in Lyme disease, 1806t
pediatric dosage, 949t
pharmacokinetics of, 2200
Clark's levels of melanoma, 1146, 1153
Claudication
intermittent
differential diagnosis of, 1669
in peripheral artery atherosclerosis, 1667, 1669, 1670–1671
in pseudoxanthoma elasticum, 1307, 1308
treatment of, 1670–1671
neurogenic, 1670
Claudins, 391
Clavi, **871**–873
syphilitici, 1959
Clavicular hypoplasia in CDAGS syndrome, 444
Clavulanate, 2198
and amoxicillin. *See* Amoxicillin, and clavulanate
Cleansing agents, 2132
in acne, 696
in decubitus ulcers, 884
as occupational irritants, 2069
in preoperative skin preparation, 2295–2296
Clear cells, 713, 714, 714f, 715f
in acanthoma, **1062**–1063, 1063f
in hidradenocarcinoma, 1078
in myoepithelioma, 1078
in squamous cell carcinoma, 1033, 1034
ClearLight therapy in acne vulgaris, 700
Cleft lip and palate, and ectodermal dysplasia
with ankyloblepharon filiforme adnatum, 1343–1344, 1344f
with ectrodactyly, 1343, 1344–1345, 1345f
Clemastine, 2191
CLIA-certified laboratories, 986
Climate therapy in psoriasis, 190–191
Clindamycin, 2113t, 2114, 2200
in acne vulgaris, 697, 2114
adverse effects of, 2196t, 2200
in bacterial vaginosis, 2000b
dosage of, 2195t, 2200
pediatric, 949t
in erythrasma, 1708
indications for, 2200b
mechanism of action, 2200
pharmacokinetics of, 2200
in rosacea, 708
in staphylococcal infections, 1698, 1698b
in streptococcal infections, 1707, 1707b
in toxic shock syndrome, 1717
Clinical Evidence, 12
Clinical experience, compared to evidence-based medicine, 10–11
Clinical Laboratory Improvement Act-certified laboratories, 986
Clinical trials, 3
confidence intervals in, 15, 16, 16f
critical appraisal of evidence in, 10, 13t, 13–16
database information on, 9
endpoints in, 15
history of, 8–9
number needed to treat in, 15, 16
outcome measures in, 14–16
Clioquinol, 2113t, 2115, 2131t, 2132
toxicity in children, 946t
CLIP (class II-associated Ii peptide), 111
Clobetasol propionate
in adrenal disorders from topical corticosteroid therapy, 2106
in bullous pemphigoid, 480
in lichen planus, oral, 253
in lichen sclerosus of vulva, 679
in lichen simplex chronicus of vulva, 677
in lupus erythematosus, 1532
in Sweet syndrome, 294
Clofazimine
in acne with solid facial edema, 701
in actinomycetoma, 1786
in leprosy, 1794, 1795b, 1796
in lupus erythematosus, 1533t, 1534
in pyoderma gangrenosum, 301, 301b
in Sweet syndrome, 294, 295b
Clomipramine, 918t, 919
Clonal dermatitis, 237, 237f
Clonazepam, 920t
Clonidine, anhidrosis from, 729
Clostridium botulinum
in bioterrorism, 2082t
botulinum toxin derived from, 2388. *See also* Botulinum toxin
in drug abuse, 925
Clostridium difficile in reactive arthritis, 208
Clostridium novyi, 1726
Clostridium perfringens, 1691, 1721t
in bioterrorism, 2083t
in soft tissue infections, 1720, 1724t, 1726
laboratory studies in, 1727
myonecrosis in, 1724t, 1726
treatment of infections, 2197t
Clostridium septicum, 1721t, 1726
Clostridium sordellii, 1726
Clothing, protective
in occupational exposures, 2072–2073, 2077, 2141t
in ultraviolet radiation exposure, 2141
Clotrimazole, 2117t, 2118, 2119
and betamethasone dipropionate, 2117t, 2118–2119
in candidiasis, 1827, 1828
pediatric dosage, 950t
Clouston syndrome, 1342–1343, 1343f
Clozapine, 917t
Clubbing, 791–792, 792f, 792t
in hypertrophic osteoarthropathy, 1450
of nails, 1449–1450, 1450f
and palmoplantar keratoderma, 429
Clue cells in bacterial vaginosis, 2000, 2000f
Clustered lesions, 36, 37f
Cnidarian stings, 2042
Coagulation, 1379–1380
disorders of, 1376t, 1380
disseminated intravascular, 1382, 1383–1384, **1747**–1749
clinical findings in, 1748
differential diagnosis of, 1605, 1748
disorders associated with, 1383, 1385t, 1748, 1748t
epidemiology of, 1747
etiology and pathogenesis in, 1747–1748
in meningococcal infections, 1732, 1734, 1735, 1748
necrosis of skin in, 1749
in plague, 1759
purpura fulminans in, 1382, 1384f, 1732, 1748, 1748f
in sepsis, 1747, 1748
treatment of, 1748–1749
electrosurgery techniques for, 2333, 2334, 2334f
intrinsic pathway, in angioedema, 333
localized intravascular, in venous malformations, 1659
vitamin K in, 1208
in wound healing, 2342–2343
Coal tar preparations, 2130
in atopic dermatitis, 156
occupational exposure to, 2078, 2079, 2130
in psoriasis, 187t, 189–190, 2130
side effects and complications of, 2130
keratosis in, 1018
melanosis in, 2078
phototoxicity in, 832, 2078
skin cancer in, 987, 987t, 2130
Cobalamin, 1211–1212. *See also* Vitamin B_{12}
Cobalt, occupational exposure to, 2070t
Cobb syndrome, 1665
Cocaine, 922, 923, 924
in local anesthesia, 2296
mucous membrane lesions from, 925, 925f
Coccidioides immitis, 1839–1840
in immunocompromised host, 269t, 275–276, 1840
occupational exposure to, 2076
in oral cavity disorders, 653t
Coccidioidin skin test, 1840
Coccidioidomycosis, 1836, 1839–1840, 1840f
disseminated, 1840, 1840f
in immunocompromised host, 269t, 275–276, 1840
in HIV infection and AIDS, 1840, 1937
in occupational exposures, 2076
oral cavity disorders in, 653t
Coccygodynia, 670
Cochrane, Archie, 8, 9
Cochrane Collaboration, 9, 12
Cochrane Library, 9, 11, 12
Central Register of Controlled Trials in, 9, 12
Database of Abstracts of Reviews of Effectiveness, 12
Database of Systematic Reviews in, 12
Health Technology Assessment Database in, 12
Cockayne syndrome, 963, 1312t, 1315, 1319–1321
cellular hypersensitivity in, 1321
clinical features in, 1320
DNA damage and repair in, 978, 980, 982t
diagnostic testing in, 983t
laboratory findings in, 1321
prenatal diagnosis of, 1321
support groups for patients with, 1321
and xeroderma pigmentosum, 1312t, 1319f, 1321
Cockayne-Touraine type of epidermolysis bullosa, 508t, 510–511
Codons
premature termination mutation, 74–75
terminator or stop, 76

Coenurosis, 2012t, 2021t, 2028
  treatment of, 2014t
COFS syndrome
  and Cockayne syndrome, 1320, 1321
  and xeroderma pigmentosum, 1319
Cogan syndrome, 1615
Cognitive abilities
  in homocystinuria, 1304
  in neurofibromatosis type 1, 1337
Coherence of epidemiologic studies, 4
Coherence of laser light, 2263
Cohesion
  dermal-epidermal, 47–48, **449**–450
  epidermal, 44, 45–47, **447**–449
Cohort studies, 3, 4, 5–6
  birth cohorts in, 5–6
  as evidence source, 10, 10t
  on harmful effects of exposures, 17
COL1A1/COL1A1, 526
  in Ehlers-Danlos syndrome, 1298t, 1301
  in osteogenesis imperfecta, 1310
COL1A2/COL1A2, 526
  in Ehlers-Danlos syndrome, 1298t, 1301
  in osteogenesis imperfecta, 1310
  in systemic sclerosis, 1554t
COL3A1 in Ehlers-Danlos syndrome, 1298t, 1300
COL5A1, in Ehlers-Danlos syndrome, 1297–1298, 1298t, 1300
COL5A2 in Ehlers-Danlos syndrome, 1297–1298, 1298t, 1300
COL7A1, 76, 78, 520, 521f
COL17A1, 84f, 520
Colchicine
  in Behçet disease, 1625, 1625b
  in dermatomyositis, 1552
  in epidermolysis bullosa acquisita, 499, 499t
  in gout, 1576
  mechanism of action, 284
  in Mediterranean fever, familial, 1266, 1267
  in necrotizing venulitis, 1606, 1606t
  in pigmented purpuric dermatosis, 1636
  in sub-corneal pustular dermatosis, 306, 307b
  in Sweet syndrome, 294, 295b
Cold
  and cryobiology, 2330
  and cryofibrinogenemia symptoms, 1642
  and cryogens
    in cryosurgery, 2330, 2330t
    in local anesthesia, 2298
  and cryoglobulinemia symptoms, 850, 1639
  and cryotherapy, 2330–2333
  injuries from, **844**–851
    acrocyanosis in, 849
    in athletes, 845, 846
    chilblains in, 849–850
    classification of, 845–846, 847t
    dampness affecting, 848
    erythrocyanosis in, 849
    erythromelalgia in, 851
    fat necrosis of newborn in, subcutaneous, 851
    frostbite in, 845, 846–848
    hyperpigmentation in, 636
    in immersion in cold water, 844–845
    in neonates, 845, 851
    nonfreezing, 848
    in occupational exposures, 2078
    panniculitis in, 576, 851
    polymorphous eruption in, 851
    rewarming in, 846, 847
    sclerema neonatorum in, 851
    skin necrosis in, 845, 846, 846f
    urticaria in, 850–851, 1270
    vasodilation reaction in prevention of, 845
    wind, humidity, and altitude affecting, 845
    winter xerosis in, 848–849
  Raynaud phenomenon in, 1644
  sweating syndrome from, 724
  thermoregulatory responses to, 835, 841–843, 845
    acclimatization affecting, 843–844
    factors affecting, 843–844
    hunting reaction in, 845, 846
    in local cooling, 842–843, 843f
    shivering in, 835, 836
    vasoconstriction in, 836, 837, 841–843, 845
      and reticulate appearance, 844, 844f
  urticaria and angioedema from, 334, 334f, 340, 850f, 850–851
    cholinergic, 335, 850
    cold contact test in, 334, 334f, 850f, 851
    delayed, 334
    disorders associated with, 850
    familial, 334, 850, 851
    treatment of, 341
Cold auto-inflammatory syndrome, familial, 334, 1267t, 1270–1271
  differential diagnosis of, 1268b, 1270
  treatment of, 341, 1271
Cold quartz lamps, 800
Coleoptera, 2060
Colitis, ulcerative, 1456
  and linear IgA dermatosis, 488
Collagen, **517**–530
  age-related changes in, 966, 967
    in menopause, 968
    in photoaging, 970
  α chains in, 517, 518, 518f, 519t
  cross-linking of, 54, 526–527, 527f
    in homocystinuria, 1304
  degradation of, 525t, 528–529
  in dermis, 63, 517
    age-related changes in, 966, 967
    embryonic and fetal, 70
  diseases of, 529–530, 530t
  in Ehlers-Danlos syndromes, 519, 520, 524, 526, 527, 1297
    type I collagen in, 1298t, 1301
    type III collagen in, 519, 1298t, 1300
    type V collagen in, 520, 1297–1298
  embryonic and fetal, 68t, 69, 70, 71
  fibrinoid degeneration of, 530
  fibroblast overproduction of, 1562, 1563, 1563t
  functions of, 517
  gene structure, 520–522
  genetic heterogeneity of, 518–520, 519t
  injection for soft tissue augmentation, 2381–2383, 2382t
  in Marfan syndrome, 1302
  and scattering of radiation, 2265
  structure of, 517f, 517–518, 518f
  synthesis of, 54, 522–528
    control of, 527–528
    disulfide bonding in, 524
    enzymes in, 524t
    fiber formation and cross-linking in, 526–527, 527f
    post-translational modifications of polypeptide chains in, 522–524
    procollagen conversion in, 526
    steps in, 525t
    translation of polypeptides in, 522
    triple-helix formation in, 524
  in wound healing, 2345
Collagen galactosyl transferase, 524, 524t
Collagen glucosyl transferase, 524, 524t
Collagen type I, 63, 518, 519, 519t, 522, 526, 528
  α chains in, 517, 518f, 519
  in Ehlers-Danlos syndrome, 1298t, 1301
  embryonic and fetal, 68t
  hydroxyproline in, 522
  in morphea, 543
  oral tolerization to, in systemic sclerosis, 1559t
  in osteogenesis imperfecta, 1310
  structure of, 517, 518f
  in systemic sclerosis, 1554t
  thermal behavior of, 2266
  in wound healing, 2345
Collagen type II, 518, 519t
  in relapsing polychondritis, 1567
  in wound healing, 2345
Collagen type III, 63, 518, 519, 519t, 528
  α chains in, 519
  in Ehlers-Danlos syndrome, 519, 1298t, 1300
  hydroxyproline in, 522
  in wound healing, 2345
Collagen type IV, 63, 518, 519t, 519–520, 528
  in Alport syndrome, 520
  in basement membranes, 450, 451b, 451–453, 452f
    epithelial, 458
  embryonic and fetal, 68t, 71
  in Goodpasture syndrome, 520
  hydroxyproline in, 522
  in wound healing, 2345
Collagen type V, 63, 518, 519t, 520, 528
  in Ehlers-Danlos syndrome, 520, 1297–1298, 1298t, 1300
  embryonic and fetal, 68t, 69, 70
  and endothelial cell interactions, 1589
  in wound healing, 2345
Collagen type VI, 63, 519t, 520, 528
  in congenital muscular dystrophy, 520
  in wound healing, 2345
Collagen type VII, 63, 76, 78, 518, 519t, 520, 521f, 528
  absence of, 86
  in anchoring fibrils, 458, 520
  in basement membranes, 451, 455f
    epithelial, 458
  in cicatricial pemphigoid, 481, 482t, 483
  embryonic and fetal, 68t, 69, 70, 71
  in epidermolysis bullosa
    acquisita, 494, 495, 496, 498
    dystrophic, 88, 458–459, 511–512, 516, 520
  in epithelial lamina densa, 458
  in wound healing, 2345
Collagen type VIII, 519t
  in wound healing, 2345
Collagen type IX, 518, 519t
  in relapsing polychondritis, 1567
  in wound healing, 2345
Collagen type X, 519t
  in wound healing, 2345
Collagen type XI, 518, 519t
  in relapsing polychondritis, 1567
Collagen type XII, 518, 519t
Collagen type XIII, 457, 518, 519t
Collagen type XIV, 518, 519t
Collagen type XV, 519t
Collagen type XVI, 518, 519t
Collagen type XVII, 83, 84f, 518, 519t, 520
  in anchoring filaments, 457
  in basement membranes, 451, 455f, 456, 457f
  in bullous pemphigoid, 456, 456f, 476, 520

Collagen type XVII—*continued*
ectodomain shedding, 457f
in epidermolysis bullosa, 456, 510, 516, 520
in lichen sclerosus, 547
in linear IgA dermatosis, 487
in pemphigoid gestationis, 490
Collagen type XVIII, 83, 84f, 519t
and endothelial cell interactions, 1589
Collagen type XIX, 518, 519t
Collagen type XX, 518, 519t
Collagen type XXI, 518, 519t
Collagen type XXII, 518, 519t
Collagen-vascular disease, 1494t, 1499–1500
cardiovascular disorders in, 1453
respiratory disorders in, 1454–1455
Collagenase, 285, 528f
collagenase-3 (MMP-13), 529, 529t
interstitial (MMP-1), 528, 529t
in photoaging, 970, 971
neutrophil (MMP-8), 528, 529t
Collagenoma, 555, 555f
familial cutaneous, 530t, 555
Collagenosis, reactive perforating, 564, 565, 566f, 1459
in diabetes mellitus, 1469
Collagenous plaques of hand, degenerative, 429
Collateral circulation in peripheral artery disease, 1668
Collodion baby, 410, 415, 415f
disorders associated with, 415, 415t
self-healing, 415
Collodions, topical medications formulated as, 2094
Colon cancer, hereditary nonpolyposis, 1312t, 1315
Colonization, bacterial
in decubitus ulcers, 880, 885
interference mechanisms in, 1690
and preoperative skin preparations, 2295–2296
Colony-forming ability assay, 983, 983f
Colony-stimulating factors
granulocyte
in neutrophil production, 279
Sweet syndrome associated with, 280, 289
granulocyte-macrophage. *See* Granulocyte-macrophage colony-stimulating factor
multi-lineage, 123
Color changes, 1446–1447
in cyanosis, 1378–1379, 1446
in erythema, 30, 30f, 33, 1446
in flushing, 1377, 1446
in hematologic disorders, 1377–1379
in infarction, 33–34, 34f
in jaundice, 1379, 1446–1447
in macules, 29–30, 30f
of nails, 1449, 1450, 1450f
pathology and diagnosis in, 30t
pigmentary, 1374t, 1446, 2363
in purpura, 33
Colostomy, skin problems in, 868–871, 870f
Colpitis macularis in trichomoniasis, 1999
Comedo, 28, 28f, 692, 693f
closed, 28, 692, 693f
and nevus comedonicus, 1059
open, 28, 692, 693f
in radiation exposure, 703
Comet assay, 985
Community-acquired methicillin-resistant staphylococcal infections, 873–875
Companion layer of hair follicle, 742, 743f
Compartment model on drug pharmacokinetics, 2097–2101, 2098f, 2099t
Compartment syndrome in snake bites, 2041
Complement C1, 325, 326f
Complement C1 inhibitor, 327–328
deficiency of, 328–329
angioedema in, 336, 337f, 343, 1370, 1371t, 1372
Complement C1q, 325, 326f, 327–328, 1590t
deficiency of, 1370, 1371, 1371t
in lupus erythematosus, 329
in urticarial vasculitis, 1602, 1604
Complement C1r, 325, 327–328
deficiency of, 1370, 1371t
Complement C1s, 325, 327–328
deficiency of, 1370, 1371t
Complement C2, 325, 326f
in angioedema, 336
deficiency of, 1370, 1371, 1371t
Complement C3, 324, 325, 326f, 327
in bullous pemphigoid, 475, 475f, 476, 477
deficiency of, 328, 1371, 1371t, 1374t
in dermatitis herpetiformis, 502
in exfoliative erythroderma, 1371t
in lipodystrophy, acquired partial, 587
in lupus erythematosus, 329
in pemphigoid gestationis, 490, 492, 492f
Complement C3 convertase, 328
in lupus erythematosus, 329
Complement C3a, 327
Complement C3b, 324f, 324–325, 327, 328
Complement C3d, 327
and B cell activation, 322
in lupus erythematosus, 329
Complement C4, 325, 326f, 327
in angioedema, 336
in lupus erythematosus, 1371, 1371f, 1371t, 1509
in Sjögren syndrome, 1581
Complement C4A, 1370
Complement C4a, 327
deficiency of, 1371t
Complement C4B, 1370
Complement C4b, 327, 328
Complement C5, 324, 325, 326f, 327, 327f
in dermatitis herpetiformis, 502
in exfoliative erythroderma, 1371t
in urticaria and angioedema, 331–332
Complement C5a, 327, 1590t
in psoriasis, 173
in urticaria and angioedema, 332, 332f
Complement C6, 327f
Complement C7, 327f
Complement C8, 327f
Complement C9, 325, 327f, 328
Complement control protein repeats, 327
Complement fixation test in lymphogranuloma venereum, 1989
Complement receptors, 327, 328
CR1, 283, 327, 328
in lupus erythematosus, 329
CR2, 327
and B cell activation, 322
in lupus erythematosus, 329
CR3, 283, 327, 328
CR4, 327, 328
Complement system, **323**–329
activation of, 323–328, 1690
alternative pathway, 96, 324f, 324–325, 1370, 1372
classical pathway, 96, 325, 326f, 328, 1370
laboratory tests of, 1372
lectin pathway, 325, 328, 1370
regulation of, 327–328
in angioedema, 328–329, 331–332, 336, 340, 343, 1370, 1371t
and B-cell activation, 322
in cardiovascular disorders, 329
in cryoglobulinemia, 1638
deficiency disorders, 328–329, 1348, 1349t, 1370–1372
autoimmune disorders in, 1370, 1371, 1371t, 1509
clinical features in, 1371f, 1371t, 1371–1372
differential diagnosis of, 1372
epidemiology of, 1370
etiology and pathogenesis of, 1370–1371, 1371t
infections in, 269t, 1370, 1371t, 1372
laboratory tests in, 1372
lupus erythematosus in, 328, 329, 1371, 1371f, 1509, 1516, 1519
treatment of, 1372
in dermatomyositis, 1540, 1546
functions of, 327
genetic abnormalities of, 328–329, 1370–1372
in HIV infection, 329
in humoral immunity, 323–329
in innate immunity, 95–96, 323, 1690
microbial evasion or subversion of, 329
in necrotizing venulitis, cutaneous, 1599, 1600, 1602, 1604
in porphyrias, 1235
in relapsing polychondritis, 1567
in urticaria, 328–329, 331–332, 336, 337f, 340, 343
Complementary and alternative medicine, **2285**–2287
Complexus adhaerens, 1589
Compliance with therapy
depression affecting, 2092
in gluten-free diet for dermatitis herpetiformis, 504
in topical application of medications, 2092, 2093
Compression techniques
in chronic venous insufficiency, 1683, 1684, 1684f
in jellyfish stings, 2044
in snake bites, 2040–2041, 2041t
Computed tomography
in decubitus ulcers, 880
in Langerhans cell histiocytosis, 1419
in melanoma, 1153
in Merkel cell carcinoma, 1092
in sarcoidosis, 1488
in venous malformations, 1659
Computer use, repetitive trauma in, 2077
Concha of ear, 2289, 2290f
Condom use in chancroid prevention, 1986
Conduction, heat transfer in, 836, 845
Condyloma acuminatum, 652t, 1915, 1918, 1919f. *See also* Warts, anogenital
giant, 673, 674, 1921
treatment in, 1922
Condyloma lata in syphilis, 1960, 1961f
congenital, 1968
dark-field microscopy in, 1971
endemic, 1981
Cone shell envenomations, 2049–2050
Confetti skin lesion in tuberous sclerosis, 1326, 1329f
Confidence intervals, 15, 16f
Confounding in epidemiologic studies, 4
Congenital disorders, 940–941, 941t
alopecia in, 774
constricting bands in, 562, 563
cytomegalovirus infections in, 1861
clinical findings in, 1862, 1862f
diagnosis of, 1863

and oral cavity disorders, 647t, 651t
erythroderma ichthyosiform in, 411
erythropoietic porphyria in, 1247–1249
hamartoma in, eccrine angiomatous, 1171
hemangioma in, 1169–1170
hypertrichosis in, 776
ichthyosis in, 401–421
lipodystrophy in, generalized, 588–589
of male genitalia, 657
of nails, 783–784, 784t
surgery in, 2329–2330
nevomelanocytic nevi in, 1099–1103
nevus spilus in, 1104, 1104f
of pigmentation, **608**–616
complications of, 615
differential diagnosis in, 615, 615b
in hypermelanosis, 631–634
in hypomelanosis, 622–623
prognosis and clinical course in, 615
treatment in, 616
rubella in, 1853, 1854, 1855
syphilis in, 1967f, 1967t, 1967–1969
clinical findings in, 1967f, 1967–1969, 1968f, 1968t
diagnosis of, 1969
and oral cavity disorders, 647t, 652t, 1969, 1969f
treatment of, 1974, 1976
of thyroid, 1470
toxoplasmosis in, 2010
viral infections in, 940
Congo red staining in amyloidosis, 1262–1263, 1263f
Conidiobolomycosis, 1835
Conidiobolus coronatus, 1835
Conjunctivitis
in chlamydial infections, 1997
in erythema multiforme, 346, 347f
in Kawasaki disease, 1628, 1630, 1631
meningococcal, 1732, 1734
in retinoid therapy, 2185
in tularemia, 1758
Connective tissue diseases, **1297**–1311
cryofibrinogenemia in, 1641, 1642
dystrophic calcification in, 1294, 1294f
erythema elevatum diutinum in, 1619, 1619t
in occupational exposures, 2078, 2078t
Raynaud phenomenon in, 1645, 1646t
Connective tissue nevus, 555, 555f
Connexins, 68t, 76, 391, 418, 1342, 1589
in ectodermal dysplasia, 1342
in erythrokeratodermia variabilis, 418
in keratitis, ichthyosis, and deafness syndrome, 418
in palmoplantar keratoderma, 424
Connexon, 391
Conradi-Hünermann syndrome, 79, 561
clinical features in, 403t, 419, 753t
differential diagnosis of, 1347
genetic factors in, 403t, 419, 753t
Constipation
in children, perineal protrusion in, 942
in lichen sclerosus, 549
in porphyria, 1251, 1253
Constricting bands in ainhum and pseudoainhum, **562**–563
Contact dermatitis
from airborne substances, 2068
allergic. *See* Allergic contact dermatitis
of amputation stump, 866f, 866–867
differential diagnosis in, 151
drug-induced, 136t, 138f, 1693
fissures in, 32, 32f
granulomatous, 142, 142f
irritant, **395**–401. *See also* Irritant contact dermatitis
lichenoid, 249
lymphomatoid, 1403t, 1411–1412
clinical findings in, 1411, 1411f
differential diagnosis of, 1412, 1412b
histopathology in, 1411–1412, 1412f
treatment of, 1412, 1412b
pathology in, 48, 48f
photoallergic, 833
postoperative, 2337, 2337f
Contact hypersensitivity, 900
in topical corticosteroid therapy, 2106, 2106t
ultraviolet radiation exposure affecting response in, 90, 806, 808, 812–813
Contact urticaria, 142–143, 336
allergic, 142–143, 2071
from cosmetic products, 2361
diagnosis of, 2071
in occupational exposures, 2070–2071, 2072f
Contraceptives, oral
in acne vulgaris, 698
estrogen excess from, 1479, 1480
in hirsutism, 775, 775b
in lupus erythematosus, 1517
Contractures
in burns, 855, 857f
Dupuytren, 552
in linear scleroderma, 546
Contrast agents, urticaria and angioedema from, 338
Convective heat loss, 836, 845
in wind chill, 845
Coolant agents in pruritus, 909–910
Cooling methods in laser therapy, 2268
Copper, 1216–1217
and collagen cross-linking, 527, 1216
deficiency of, 1216
diffuse hypopigmentation in, 630
and elastin cross-linking, 531
food sources of, 1216
and lysyl oxidase activity, 527, 534, 1216
in Menkes syndrome, 527, 530t, 756, 757–758, 1216–1217
Copper-colored rash in mononucleosis, 1858, 1859f
Copperhead snakes, 2040, 2040f, 2041f
Coproporphyria, hereditary, 1231, 1233, 1234, 1253–1254
biochemical features of, 1240t, 1254
clinical manifestations of, 1249t, 1254
differential diagnosis of, 1254
epidemiology of, 1249t, 1253
etiology of, 1253–1254
fluorescence characteristics in, 1233t
treatment of, 1251b, 1254
Coproporphyrin, 1229f, 1229t, 1233
in acne vulgaris, 700
in red blood cells, 1240t
in erythropoietic protoporphyria, 1245
in stool, 1240t
in erythropoietic protoporphyria, 1245
in hereditary coproporphyria, 1254
in variegate porphyria, 1253
in urine, 1240t
in hereditary coproporphyria, 1254
in porphyria cutanea tarda, 1239
Coproporphyrinogen, 1229f, 1232f
in porphyria cutanea tarda, 1236
Coproporphyrinogen oxidase, 1229f, 1230t, 1231f
in dual porphyrias, 1255
in hereditary coproporphyria, 1253–1254
in regulation of heme biosynthesis, 1230, 1232f
Corals, 2042, 2045–2046
contact dermatitis from, 877
Corkscrew hair in vitamin C deficiency, 1213, 1213f
Corn(s), **871**–873, 872f, 2077
and clavi syphilitici, 1959
differential diagnosis in, 872b
Durlacher's, 871
heloma miliare, 872
soft, 871, 872f
Cornea disorders
in congenital syphilis, 1969, 1969f
in X-linked recessive ichthyosis, 408, 409f
Corneocytes, 58, 61, 385, 385f, 387
in ichthyosis, 406, 407
in nail plate, 781
penetration by topical drugs, 2100
Corneodermatoosseous syndrome, 1222
Corneodesmosin, 449t
Cornification, in scaling, 401
Cornified envelope, 381–382
late-envelope proteins in, 381, 382t
lipids in, 388
protein composition of, 381, 382t, 384–385, 388
Cornifin, 61
Cornu cutaneum in actinic keratosis, 1008–1009, 1010f
Coronary artery disorders
in atherosclerosis, 1667
bypass surgery in, 1460
and corticosteroid therapy, 2152–2153
and hyperlipidemia, 1277, 1452
in Kawasaki disease, 1629, 1630, 1631, 1632
in syphilis, 1965
Coronavirus, 1846t
Coronoid lamella in porokeratosis, 442, 444–445, 445f
Corpuscular receptors, 65f, 65–66, 66f
Corticosteroid responsive element, 2102, 2147
Corticosteroid therapy. *See* Glucocorticoid therapy
Corticotropin-releasing hormone, 896t, 898
Cortisol, 2147, 2148, 2150
chemical structure of, 2148, 2148t
in Cushing syndrome, 1478
Cortisone
chemical structure of, 2148t
potency and duration of action, 2148t
Corynebacterium diphtheriae, 1691
in diphtheria, 1767–1768
in oral cavity disorders, 652t
Corynebacterium minutissimum, 1708
Cosmetic intolerance syndrome, 2359–2360, 2361t
Cosmetic products and procedures, **2357**–2402
for body art, **886**–890
botulinum toxin in, 2388–2394
complications and reactions to, 2359–2362
acne in, 2360
allergic contact dermatitis in, 137, 146, 2360, 2361–2362
allergic contact stomatitis in, 651
contact urticaria syndrome in, 2361
delayed hypersensitivity reactions in, 2361–2362
to fragrances, 2361, 2362
intolerance syndrome in, 2359–2360
irritant contact dermatitis in, 398, 2361
panniculitis in, 580
photoallergy in, 2362
phototoxicity in, 2361
to preservatives, 2361, 2362
stinging or burning in, 2360–2361

Cosmetic products and procedures—*continued*
hair transplantation and alopecia reduction in, 2394–2402
laser and light devices in, 2372–2378
in lipodystrophy, 589
in HIV infection, 1935
liposome-based formulations in, 2099
liposuction in, 2378–2380
in lupus erythematosus, 1535
for skin rejuvenation, 2268, 2273, 2372–2374
for skin resurfacing, 2364–2371
skin types in, 2357–2364
combination, 2364
oily or dry, 2357–2359
pigmented, 2362–2363
sensitive or resistant, 2359–2362
wrinkled or tight, 2363–2364
soft-tissue augmentation in, 2380–2388
in vitiligo, 620
Cosmetic units and landmarks in surgery, 2289–2290, 2290f
Costello syndrome, 1309b, 1310f
Costochondritis, 1568
Costs of skin diseases, 8
Counseling, genetic, 84–85, 986
in albinism, 616
in basal cell nevus syndrome, 1048
in epidermolysis bullosa, 513–514
in Fabry disease, 85, 1288
in neurofibromatosis type 1, 1338
in tuberous sclerosis, 1331
Cowden syndrome, 1068, 1504t, 1665
genetic factors in, 988, 989t
lipoma in, 1190
oral cavity disorders in, 642t
tricholemmoma in, 1084
Cowdry type A inclusions in herpes simplex virus infections, 1878
Cowpox virus, 1900t
differential diagnosis of, 1909
in smallpox vaccination, 1903
Coxiella burnetii
in bioterrorism, 2083t
in endocarditis, 1744, 1745
treatment of infections, 2197t
Coxsackievirus infections
clinical manifestations of, 1849
hand-foot-mouth disease in, 1868, 1869, 1869f
herpangina in, 1869
oral, 651t
CpG methylation, 88, 114
Crab lice, 2036
Crab yaws, 1980, 1980f
CRABP (cellular retinoid acid binding protein), 2107, 2108f
Crack cocaine, 922, 923, 924
Cradle cap, 221
Cranial nerves
in herpes simplex virus infections, 1879
in Lyme disease, 1802–1803, 1806t
surgical anatomy of, 2290–2291, 2292, 2292f, 2293
in syphilis, 1966–1967
in varicella-zoster virus infections, 1888, 1889, 1890, 1890f, 1891f
Craniofacial necrotizing fasciitis, 1725
Craniosynostosis, 442b, 444
Craw-craw, 2019
CRBP (cellular retinol binding protein), 2107, 2108f
Creams, topical medications formulated as, 2093, 2094
Creatine kinase serum in dermatomyositis, 1546
Creatinine levels in cyclosporine therapy, 2219
Creeping dermatitis, 2011
verminous, 2023
Creeping eruptions, 2023, 2024
Creole dyschromia, 630
CREST syndrome, 1458
differential diagnosis of, 1675
dystrophic calcification in, 1294, 1294f
Cretinism, 1471
Critical appraisal of evidence, 12–18
Crohn disease, 1456
differential diagnosis of, 1989
and hidradenitis suppurativa, 735, 737
metastatic cutaneous, 1456
oral cavity disorders in, 642t
penile edema in, 671, 671f
and psoriasis, 170
of vulva, 682, 682f
Cronkhite-Canada syndrome, 1456
Cross-hatching injection technique in soft tissue augmentation, 2380–2381, 2381f
with hyaluronic acids, 2383
Cross-links
of collagen, 54, 526–527, 527f
of elastin, 531, 532f, 534
Cross-over phenomenon in irritant contact dermatitis, 396
Crotaline snake bites, 2041–2042, 2042b
Crotamiton, 2133, 2133t
in scabies, 2031b, 2133
Crowe sign, 39t
in neurofibromatosis type 1, 1333
Crow's feet appearance
botulinum toxin injection for, 2391–2392
in myxoid liposarcoma, 1197
Crusta lactea, 221
Crusts and encrusted exudates, 31, 31f
in impetigo, 31, 31f
in seborrheic dermatitis, 221
treatment of, 223, 224
Cryobiology, 2330
Cryofibrinogen, 1641–1643
Cryofibrinogenemia, **1641**–1643
classification of, 1642
differential diagnosis of, 1641b, 1642
treatment of, 1642–1643
Cryogens
in cryotherapy, 2330, 2330t
in local anesthesia, 2298
Cryoglobulin, 1637–1641
Cryoglobulinemia, **1637**–1641
classification of, 1637, 1637t
clinical findings in, 1639f, 1639t, 1639–1640
cold urticaria in, 850
complement system in, 1638
differential diagnosis of, 1641b
diseases associated with, 1640, 1640t
epidemiology of, 1637
essential, 1637, 1638, 1640
etiology of, 1637–1638
in hepatitis, 1457, 1637–1638, 1639, 1640
treatment of, 1641
HLA system in, 1638
laboratory findings in, 1639t, 1640f, 1640–1641
mixed types, 1637, 1638, 1639
pathogenesis of, 1638
Raynaud phenomenon in, 1639, 1646
treatment of, 1641
type I, 1637, 1638
clinical findings in, 1639, 1639t
vasculitis in, 1610, 1638
cutaneous necrotizing venulitis, 1601
and digital gangrene, 1609f
leukocytoclastic, 1639, 1639f
Cryopeel in actinic keratosis, 1014
Cryopyrin, 1270
Cryopyrinopathies, 1270–1271
Cryotherapy, **2330**–2333
in actinic keratosis, 1013, 1014, 2332, 2332f
in basal cell carcinoma, 1041, 2332
cellular targets of, 2330, 2330t
complications of, 2333
contraindications to, 2330
cryogens used in, 2330, 2330t
equipment and techniques in, 2331, 2331f
in granuloma faciale, 304, 304b
in hidradenitis suppurativa, 737
indications for, 2330, 2331–2333
in molluscum contagiosum, 1913, 1913t
pigmentation changes in, 636, 2333
in porokeratosis, 445, 445b
postoperative care in, 2333
in warts, 1921–1922, 2331–2332, 2332f
genital, 664b, 1922
Cryptococcosis, 1842f, 1842–1843, 1843f
disseminated, 1842, 1842f
in immunocompromised host, 269t, 274–275, 275f, 1747, 1842, 1843
HIV infection and AIDS, 1747, 1842, 1843, 1936–1937
oral cavity disorders in, 653t
primary cutaneous, 1842
Cryptococcus neoformans, 1842–1843
in immunocompromised host, 269t, 274–275, 275f, 1747, 1842, 1843
in oral cavity disorders, 653t
Cryptosporidium parvum in bioterrorism, 2083t
Crystal-storing histiocytosis, 583
CSA gene, 980, 980t
CSB gene, 980, 980t
CTACK. *See* Cutaneous T cell–attracting chemokine (CTACK)
Ctenocephalides felis fleas, 2061
endemic typhus associated with, 1943t, 1948
CTLA-4
in autoimmune disorders, 1510, 1511–1512
in photoimmunosuppression, 808–809
CTNNB in pilomatricoma, 988, 989t
Culex mosquitoes, 260
Cullen's sign in pancreatitis, 1456
Cultures
in candidiasis, 1826
in chancroid, 1984
in cytomegalovirus infections, 1863
in gonorrhea, 1995
in herpes simplex virus infections, 1877
in HIV infection, 1929, 1929t
in leishmaniasis, 2005
in monkeypox virus infections, 1907
primary cell cultures, 982
in soft tissue infections, 1727
in superficial fungal infections, 1808–1809, 1809t–1810t
in varicella-zoster virus infections, 1892
in viral infections, 1850
Cunninghamella bertholletiae, 1843
Cupid's bow, 2290, 2290f
Curcumin, 2236t
Curettage
in actinic keratosis, 1013
and desiccation, 2334–2335, 2335f
in basal cell carcinoma, 1041, 2334–2335
in keratoacanthoma, 1053
Curly hair, 742
in acquired progressive kinking, 770

Cushing disease, 1477
Cushing syndrome, 1477–1478
  clinical findings in, 1477f, 1477–1478
  hyperpigmentation in, 634, 1478
  striae in, 1477, 1477f
  treatment of, 1478
Cutaneous field stimulation in pruritus, 911
Cutaneous Lupus Erythematosus Area and Severity Index, 1532
Cutaneous lymphocyte antigen (CLA), 104–105, 129–130, 130f
  in atopic dermatitis, 131–132, 148, 151
  in inflammatory reactions, 1387, 1595–1596
  and superantigens, 1715
  in T-cell lymphoma, 1387
Cutaneous T cell–attracting chemokine (CTACK), 100, 105, 131
  in atopic dermatitis, 148
  in melanoma, 134
  in psoriasis, 133f
Cuticle, 778, 2320, 2320f
  of hair follicle, 742, 743f, 744
Cutis laxa, 54, 55, 63, 530t, **1308**–1310
  acquired, 1308, 1309
  clinical manifestations in, 1308f, 1308–1309
  differential diagnosis of, 559, 1309, 1309b
  elastic fiber disorders in, 536, 537t, 1308, 1309
  etiology and pathogenesis in, 1308
  fibulins in, 536, 1308
  general skin changes in, 1309, 1445
  genetic factors in, 1308–1309
  with joint laxity and developmental delay, 1308
  treatment of, 1309–1310
  X-linked, 1309
Cutis marmorata, 1676f
  telangiectatica congenita, 939, 939f, 1345
CX3C (CXXXC) chemokines, 127
CX3CR1, 128t
CXC chemokine(s), 105, 127, 1593
  in tumor formation, 133–134
CXC chemokine ligands
  CXCL10 in dermatomyositis, 1540
  CXCL12, 127
  CXCL14, 131
CXC chemokine receptors, 108
  CXCR1, 128t, 130
    in cancer, 133
    in psoriasis, 132, 133f
  CXCR2, 128t, 130
    in cancer, 133
    in psoriasis, 132, 133f
    in systemic sclerosis, 1554t
  CXCR3, 128t, 130, 131
    in cancer, 133
    in dermatomyositis, 1540
  CXCR4, 128t, 130
    in infectious diseases, 134, 135
    in melanoma, 134, 134f
CXXXC (CX3C) chemokines, 127
Cyanea sea nettles, 877, 2042, 2043f
Cyanide as chemical weapon, 2086t
Cyanocobalamin, 1212
Cyanosis, 1375t, 1378–1379, 1446
  central, 1378, 1446
  in cold exposure, 849
  in cryoglobulinemia, 1639, 1639f
  differential diagnosis of, 1378, 1378b, 1646
  in polycythemia vera, 1377, 1378
Cyclin-dependent kinase inhibitor 2A, 982t, 1002
  in dysplastic nevus, 1123, 1124, 1130
  in melanoma, 1123, 1136
Cyclobutane pyrimidine dimers (CPDs), 810–811, 977, 978, 979f
Cyclobutyl pyrimidine dimer (CPD), 804
  and UVB-induced immunosuppression, 806
Cyclooxygenase, 285
  COX1, 338, 1591
  COX2, 338, 1591
    in pruritus, 905
    in squamous cell carcinoma, 993
  COX2 inhibitors as modifiers of carcinogenesis, 994
Cyclopamine in basal cell carcinoma, 1048
Cyclophilin A, 2217
Cyclophosphamide, 2172–2174
  in B-cell lymphoma, 1401
  chemical structure of, 2163f
  complications and side effects of, 2173t, 2173–2174, 2176t
    hyperpigmentation in, 636, 2173, 2181
  contraindications to, 2172–2173, 2173t
  in dermatomyositis, 1552
  dosing regimen, 2172, 2176t
  in hemangioma of infants, 1169
  indications for, 2172, 2172t, 2176t
  interaction with other drugs, 2174
  mechanism of action, 2172, 2176t
  with mesna, 2173
  monitoring of therapy with, 2173, 2173t
  in necrotizing venulitis, 1606, 1606t
  in pemphigoid, cicatricial, 484, 485b
  in pemphigus, 467
    paraneoplastic, 474, 474t
  pharmacokinetics of, 2172
  in sarcoidosis, 1492, 1492t
  in systemic sclerosis, 1559t, 1561
  in Wegener granulomatosis, 1611, 1613t
Cyclosporine, 2217, 2218–2220
  in actinic dermatitis, chronic, 823
  in angiolymphoid hyperplasia, 1409b
  in atopic dermatitis, 157
  in Behçet disease, 1625b
  complications and side effects of, 2219–2220, 2238t
    cancer risk in, 2220
    hepatotoxicity in, 1459t, 2220
    hypertrichosis in, 776–777, 777f, 2220
    nephrotoxicity in, 2219–2220
  in dermatomyositis, 1552
  dosing regimen, 2219t
  in epidermal necrolysis, 354
  in epidermolysis bullosa acquisita, 499
  in exfoliative dermatitis, 231, 232, 232b
  in graft-versus-host disease, 266t, 267t
  indications for, 2219
  initiation of therapy with, 2219
  interaction with other drugs, 2239t, 2240t
  in Kimura disease, 1409b
  in lichen planus
    cutaneous, 254b, 255
    oral, 253b, 253–254
  mechanism of action, 2217, 2218
  monitoring of therapy with, 2219
  in necrotizing venulitis, 1606, 1606t
  in palmoplantar pustulosis, 217, 217b
  in paraneoplastic pemphigus, 474t
  pharmacokinetics of, 2218–2219
  in pityriasis lichenoides, 243b
  in pityriasis rubra pilaris, 235, 236b
  in pregnancy, 2220
    and psoriasis, 189b, 960
  in psoriasis, 169, 171, 185, 186t, 189f, 191, 2219
    and arthritis, 202, 203f, 204–205
    in combination with other agents, 187t, 2245, 2254
    complications of, 2219–2220
    of nails, 191
    and pregnancy, 189b, 960
  in pyoderma gangrenosum, 301, 301b
  in Sjögren syndrome, 1582
  in stem cell transplantation, 259, 264
  in sub-corneal pustular dermatosis, 306, 307b
  in Sweet syndrome, 294, 295, 295b
  in systemic sclerosis, 1559t
  in urticaria and angioedema, 341, 342f
  in vesicular palmoplantar eczema, 166
CYLD1 in hereditary cancer syndromes, 988, 989t
Cylindrocarcinoma, eccrine, 1078
Cylindroma, 988, 989t
  eccrine, 1075, 1075f
Cylindromatosis, familial autosomal dominant, 1075
Cyproheptadine, 2189t
  pediatric dosage, 952t
  in urticaria and angioedema, 341
Cyproterone acetate
  in acne vulgaris, 698
  in androgen excess, 1482
  hepatotoxicity of, 1459t
  in hidradenitis suppurativa, 737
  in hirsutism, 775, 775b
  in pattern hair loss, 769
CYR61 cysteine-rich growth regulatory factor in photoaging, 970
Cyst, 27, 27f
  branchial cleft, 1066
  dermoid, 1066
  in echinococcosis, 2026, 2027, 2027f
  epidermoid, 1063–1064, 1064f, 1079
    in Gardner syndrome, 1063, 1079
    in limb amputation and prosthesis use, 864f, 864–865
    with perioral pigmented follicular atrophoderma and milia, 753t
    posttraumatic, 864, 1063
  epithelial, 1063
  of eyelid in palmoplantar keratoderma, 430
  follicular, 1079
  genital, 662b
  in hidradenoma, 27, 27f
  in hidrocystoma
    apocrine, 1070
    eccrine, 1074
  keratin, 1063, 1079
    postoperative, 2339
  mucous retention, 644f, 644–645
  myxoid, 787
  phaeomycotic, 1835
  pilar, 1064–1065, 1065f
  preauricular, 1066
  sebaceous, 1063
  trichilemmal, 1064–1065, 1065f
Cystadenoma, apocrine, 1070, 1070f
Cystathionine β-synthetase, 1219t
  deficiency of, 1304
Cystatin A, 61
  in cornified envelope, 381, 382t
Cysteine
  in erythropoietic protoporphyria, 1247
  as radioprotector, 860
Cysteine-rich growth regulatory factor CYR61 in photoaging, 970
Cysteinyl leukotrienes, 285
Cystic fibrosis
  composition of sweat in, 717f, 721, 730
  ductal reabsorption of sweat in, 718
  gene therapy in, 730
  physical examination in, 722

Cysticercosis, 2012t, 2027–2028
differential diagnosis of, 2021t, 2028
neurologic disorders in, 2014t, 2028
treatment of, 2014t, 2028
Cystitis, hemorrhagic, from cyclophosphamide, 2173
Cytochrome P_{450} enzymes
CYP21 deficiency, 1480
CYP26, 2107, 2109, 2112, 2181–2182
in drug metabolism, 2237–2238, 2238t
in ichthyosis, 411t
Cytocidal viral infections, 1848
Cytokeratins, 378, 1070t. *See also* Keratin
Cytokine(s), **115**–126, 899–900
in antigen presentation, 111, 112
in atopic dermatitis, 147–148, 149
in barrier function of skin, 391, 392f
chemoattractant, **127**–135. *See also* Chemokine(s)
classification of, 115–116
concept of, 115
endothelial-activating, 287–288
eosinophil-activating, 287
in epidermal homeostasis and repair, 391, 392f
genetic defects of, 1363t
in innate immunity, 96f, 99, 100, 103, 103f, 115, 1591, 1690
interleukin 1 family, 119–121
of keratinocytes, 100, 391
in ultraviolet radiation, 607t, 607–608, 812
in lichen planus, 245
neurophilic, 899–900
pleiotropism of, 115
primary, 115
pro-inflammatory, 1690
in pruritus, 897t, 900
in psoriasis, 173–174, 174f
and arthritis, 196
recombinant, 2223–2225
redundancy of, 115
secondary, 115
signal transduction pathways, 116–119, 127–129, 129f
in T-cell lymphoma, 1387–1388
T cell-derived, 115–116, 116f
therapeutic applications, 126
transforming growth factor-β, 126
tumor necrosis factor, 115, 121–122
in ultraviolet radiation response, 607t, 607–608, 812
in wound healing, 391, 2342, 2343
Cytokine receptors, 122–125, 287
class I, 122–124
class II, 124–125
major families of, 117t
in signal transduction pathways, 116–119, 127–129, 129f
Cytomegalic inclusion disease, 1862
Cytomegalovirus infections, 1861–1864
chemokines in, 134
clinical findings in, 1862f, 1862–1863, 1863f
congenital, 1861
blueberry muffin lesions in, 1862, 1862f
clinical findings in, 1862, 1862f
diagnosis of, 1863
oral cavity disorders in, 647t, 651t
diagnostic algorithm on, 1864f
differential diagnosis of, 1864b
epidemiology of, 1861
etiology and pathogenesis of, 1861–1862
in immunocompromised host, 269t, 276–277, 1861
clinical findings in, 1863, 1863f
prevention of, 1864
prognosis and clinical course in, 1863
treatment of, 1863
laboratory tests in, 1863, 1864f
latent, 1862
mononucleosis in, 1862–1863
perinatal, 1862
reactivation of, 1849
transmission of, 1862
treatment of, 1863, 2205–2207
Cytophagocytosis
in histiocytic cytophagic panniculitis, 583–584, 584f
in melanosome transport, 603
Cytosine deaminase, activation-induced, 323
Cytotoxic agents, **2163**–2181
extravasation of, 2180, 2180f
mucocutaneous reactions to, 2175–2181
topical, **2122**–2125
Cytotoxic T cell(s), 104
in lichen planus, 245
Cytotoxic T cell differentiation factor, 124. *See also* Interleukins, IL-6
Cytotoxic T lymphocyte antigen-4 (CTLA-4)
in autoimmune disorders, 1510, 1511–1512
in photoimmunosuppression, 808–809

D

D test in community-acquired methicillin-resistant staphylococcal infections, 875
DAB389-IL2, 126, 2223t, 2230–2231
Dabska tumor, 1172
Dacarbazine in melanoma, 1156
Daclizumab in paraneoplastic pemphigus, 474, 474t
Dactylitis
in psoriatic arthritis, 195, 199
in reactive arthritis, 209, 209f
streptococcal blistering distal, 1705–1706, 1706f
Dactylolysis spontanea, 562–563
DAF (decay accelerating factor), 328, 329, 1371t
DAG (diacylglycerol), 129f
in melanogenesis, 605, 606f
Dakin's solution, modified, in epidermolysis bullosa, 514
Dalbavancin, 2202
Dalfopristin with quinupristin, 2202
in soft tissue infections, 1730
Danazol
in angioedema, hereditary, 342–343
hepatotoxicity of, 1459t
Danger signals, immune response to, 109, 112, 113f
Danger zones in head and neck surgery, 2290–2291, 2291f
Dapsone, 284, **2154**–2157
in acne, 697–698
fulminans, 701
in actinomycetoma, 1788
adverse effects of, 2154, 2156t, 2156–2157
hepatotoxicity in, 1459t
in leprosy, 1796
sulfone syndrome in, 2156–2157
in α_1-antitrypsin deficiency panniculitis, 579
in Behçet disease, 1625, 1625b
chemical structure of, 2154, 2154f
in cicatricial pemphigoid, 484
in dermatitis herpetiformis, 504, 2154, 2155
in epidermolysis bullosa acquisita, 499t
in erythema elevatum diutinum, 1619
in granuloma faciale, 304, 304b
indications for, 2155–2156
interaction with other drugs, 2155
in leprosy, 1794, 1795, 1795b
adverse effects of, 1796
in lichen planus, oral, 254
in lupus erythematosus, 1533t, 1534
mechanism of action, 284, 2155
metabolism of, 2154–2155, 2155f
monitoring of therapy, 2157
pharmacology of, 2154–2155
in pyoderma gangrenosum, 301, 301b
in sub-corneal pustular dermatosis, 306
in Sweet syndrome, 294, 295, 295b
Daptomycin, 2202
in methicillin-resistant staphylococcal infections, 875
in soft tissue infections, 1730
Darier sign, 39t, 2247
in mastocytosis, 1438, 1440, 2255
Darier-Roussy sarcoid, 1487
Darier-White disease, 432–436
acantholysis in, 45f, 47, 432–436
acral, 436
barrier function of skin in, 393
calcium signaling and transport in, 61, 392, 432–434
clinical findings in, 434f–435f, 434–435
differential diagnosis in, 436, 436b, 441, 1058
dyskeratosis in, 45, 45f, 435, 435f
esophageal disorders in, 1451
etiology and pathogenesis in, 432–434
histopathology in, 435, 435f
mosaicism in, 83
nail changes in, 434–435, 435f, 783, 791, 791f
oral cavity disorders in, 642t
segmental or localized, 436, 436f
treatment of, 436
retinoids in, 426, 2183
Dark cells of eccrine sweat glands, 713, 714, 714f, 715f
Dark-field microscopy in syphilis, 1971
Darunavir in HIV infection, 2209–2210
Database of Abstracts of Reviews of Effectiveness in Cochrane Library, 12
Database of Systematic Reviews in Cochrane Library, 12
Database resources
in evidence-based medicine, 12
on genetics, 73–74
Davis Colley disease, 428–429
De Sanctis-Cacchione syndrome, 1317, 1318
Dead Sea regimen in psoriasis, 2245
Deafness
with keratitis and ichthyosis, 403t, 407, 418, 418f, 429, 752, 1342
melanocytes in, 595
in Tietz syndrome, 615
in Waardenburg syndrome, 614, 616
Death fever, 2006
DeBarsy syndrome, 537t, 1309b
Débridement in decubitus ulcers, 885
Decay accelerating factor (DAF), 328, 329, 1371t
Decision making
bias affecting, 10–11
in evidence-based medicine, 8–18
applied to specific patient, 18
expert opinions in, 11
Deck chair sign in mycosis fungoides, 1389, 1391f
Decompression injuries in diving, 877
Decorin, 63, 539t, 540, 541
deficiency of, 541
Decubitus ulcers, **878**–886
bacterial colonization in, 880, 885
cellulitis in, 1723

clinical findings in, 879
common sites of, 878, 880f
complications in, 880–882, 884t
in elderly, 878, 881, 973
etiology and pathogenesis in, 878f, 878–879, 879f
friction in, 878, 881f
laboratory tests in, 880
mortality rate in, 881, 882–883
nutrition in, 885
pain management in, 885
prevention of, 886, 886t
prognosis in, 882–883
risk factors for, 878–879, 881t, 882f, 882t
shear forces in, 878, 881f
staging of, 879, 883, 883t, 884t
treatment of, 883–886
platelet-derived growth factor in, 2226
wound management in, 884–885
Deer fly bites, 2060
DEET (N-N-diethyl-*m*-toluamide), 2063
toxicity in children, 946t
Defensins, 97, 283, 1690, 1691
in psoriasis, 173
Defibrillators, implanted, preoperative assessment in, 2295
in electrosurgery, 2295, 2334
Degos clear cell acanthoma, 1062
Degos disease, **1648**–1651. *See also* Papulosis, malignant atrophic
Degos disease-like lesions, 1649
Dehiscence of surgical wounds, 2339
Dehydration
in protein-energy malnutrition, 1203
in rotavirus infections, 1871
7-Dehydrocholesterol absorption of radiation, 803, 803f, 804
Dehydroepiandrosterone (DHEA), 691f, 1481
in acne of infants, 700
in lupus erythematosus, 1517
Dehydroepiandrosterone sulfate (DHEAS), 1481, 1482
in acne vulgaris, 690, 694, 696
in lupus erythematosus, 1517
in sebaceous gland activity and sebum production, 689
Delavirdine in HIV infection, 2209
hypersensitivity reactions to, 1934
Delhi boil, 2003
Delusions of parasitosis, 908, 912–913
differential diagnosis of, 913
treatment in, 913, 917
Demarcation lines, pigmentary, 623, 626f
Demodex brevis, 2032, 2032t
Demodex folliculorum hominis, 2032, 2032t
Dendrites, melanocyte, 602–603
melanosome transfer to, 603, 603f
Dendritic cells, 106–114, 130
in adaptive immune response, 101
in antigen presentation, 111–112, 113f
in atopic dermatitis, 148
in autoimmunity, 1513
chemokines in trafficking of, 131
dermal, 64
definition of, 106
functional properties of, 109
life cycle of, 107, 108, 109
migration to lymphoid tissues, 109
phenotypic properties of, 106
in psoriasis, 172
response to danger signals, 109
therapeutic targeting of, 114
tissue distribution of, 106–107
epidermal, 107, 109
in atopic dermatitis, 148
in psoriasis, 172
factor XIIIa-positive, 1586
functional properties of, 109
and immune tolerance, 112
inflammatory, 114
in atopic dermatitis, 148
in psoriasis, 172
and Langerhans cells. *See* Langerhans cell(s)
life cycle of, 107–109, 108f
in lupus erythematosus, 1513, 1517, 1519, 1520
in photoimmunosuppression, 807, 807f, 808, 808f
plasmacytoid, 108, 114, 1519
in atopic dermatitis, 148
in psoriasis, 172–173
in psoriasis, 170, 171, 171f, 172–173
and arthritis, 196
response to danger signals, 109, 112
and T cell interactions, 131
therapeutic targeting of, 114
Denervation hypersensitivity of eccrine sweat glands, 716
Denileukin diftitox, 126, 2223t, 2230–2231
in T-cell lymphoma, 2230
Dentures, and oral candidiasis, 1823, 1823f, 1824
Depigmentation, 30
with bleaching agents, 2145t, 2145–2146. *See also* Bleaching agents
Depressed skin lesions, 28–29
Depression, 921
in body dysmorphic disorder, 914
and chronic pain, 916
compliance with therapy in, 2092
in interferon-α 2b therapy, 2233
in isotretinoin therapy, 699, 945, 2185
in psoriasis, 183
vulvodynia in, 683
Dercum disease, 1192
Dermabrasion, 2370–2371, 2371f
in actinic keratosis, 1014
Dermacentor ticks, 1945f, 2058f, 2059
and ehrlichiosis, 1944t
and Rocky Mountain spotted fever, 1941, 1943t
and tularemia, 1758
Dermal duct tumors, 1075–1076
Dermal-epidermal junction, 45, 47–48, 62
age-related changes in, 964
anchoring filaments and fibrils in, 47, 62, 450, 450f, 451, 457–459
embryonic and fetal, 71
basement membrane in, 47, 62, 447, 449–459, 450b
cellular origin of, 459
embryonic and fetal, 71
blistering disorders of, 47–48, 62
congenital, 71
cohesion in, **449**–450
disturbances of, 47–48
embryonic and fetal development of, 71
in epidermolysis bullosa, 495, 498, 505, 506f
hemidesmosomes in, 47, 62, 71, 447, 450f, 450–451
lamina densa in, 450f, 450–451
lamina lucida in, 47, 450, 450f, 450–451
ultrastructure of, 450f, 450–451
Dermalive®, granulomatous reaction and panniculitis from, 580
Dermanyssus avium, 2032t, 2033
Dermanyssus gallinae, 2032t, 2033
Dermatan sulfate, 63, 538, 538f, 540
binding interactions of, 542t
functions of, 540, 541
Dermatitis. *See also specific types of dermatitis*
actinic chronic, 821–823
allergic contact, **135**–146
of amputation stump, 864, 866f, 866–867, 867f, 867t
artefacta, 915f, 915–916
and arthritis in meningococcal infections, 1733
atopic, **146**–158
autosensitization, **167**–168, 168b, 168f
bristleworm, 2048, 2048f
cercarial, 2012t, 2048f, 2048–2049
clonal, 237, 237f
creeping, 2011
verminous, 2023
in diaper area, 942–945, 1824
diffuse, 51
eosinophils in, 316
estrogen and progesterone levels in, 1480
exfoliative, **225**–232
neonatal, 1712
friction, 397t, 398
halo, 1107
herpetiformis, **500**–504, 1375t, 1495t, 1503
infectious
in HTLV-1 infections, 1926f, 1926–1927, 1938
pustular, 1910–1911
interface, 49
interstitial, 52
irritant contact, **395**–401
in low humidity, 2068, 2069t
lupus, 1520
marine, 2049, 2049f
nodular, 52
nummular, **158**–160, 159f
in ostomy procedures, 868–870, 869f, 870
papillomatous chronic, in urostomy, 869f, 869–870
perioral, 706, **709**–711
perivascular, 51
persistent pigmented purpuric, 1633
photoallergic, 833, 833f
radiation, 860f, 861, 861f, 862f, 2179
retinoid, 2111, 2143, 2144f, 2185
sea anemone, 2045
sea cucumber, 2048
seborrheic, **219**–225
in drug abuse, 926
sponge, 2046, 2046f
superficial chronic, 238
Dermatitis herpetiformis, **500**–504, 1375t, 1495t, 1503
associated problems in, 503–504
blisters in, 47t, 48, 485, 503
clinical manifestations of, 501, 501f
differential diagnosis of, 306, 504, 504b
elastase in, 534
epidemiology of, 500
etiology and pathogenesis in, 500–501
and gluten sensitivity, 500–504, 1503
adherence to gluten-free diet in, 504
histopathology in, 503, 503f
HLA system in, 84, 501, 502–503
immunoglobulin IgA in, 500, 501–502, 502f, 503
and linear IgA dermatosis, 485, 487, 488, 504
laboratory tests in, 501–503, 502f
liver disorders in, 1458
malignancies associated with, 1503
pathologic reactions in, 49, 50f, 53
treatment of, 504
dapsone in, 504, 2154, 2155
Dermatoarthritis, familial histiocytic, 1431

Dermatofibroma, 64, 556f, 556–557
cryotherapy in, 2331
differential diagnosis in, 556, 557, 1306b
lenticularis, 1306b
Dermatofibrosarcoma protuberans, 556, 557, 1159–1161
clinical findings in, 1159–1160, 1160f
differential diagnosis of, 1160b
fibrosarcomatous variant, 1160
histopathology in, 1160, 1160f
Mohs micrographic surgery in, 1161, 2316, 2319
Dermatographism, 39t
anogenital, 670–671
in drug abuse, 926
wheal in, 27, 27f
Dermatoheliosis, 54, 55
Dermatology Lexicon Project, 26
Dermatology Life Quality Index, 921, 1532
Dermatomal distribution of lesions, 36
Dermatomycosis, 1807
Dermatomyopathy, idiopathic inflammatory, 1537f
autoantibodies in, 1539t
classification of, 1537, 1537t
epidemiology of, 1537, 1538
systemic features in, 1544
Dermatomyositis, 52, 1448, 1457, **1536**–1553
amyopathic, 1536t
approach to patient with, 1541f
arthritis in, 1545
autoantibodies in, 1538f, 1539, 1539t, 1545, 1546, 1550
calcification in, 28, 1294, 1542t, 1549, 1550
dystrophic, 28f, 1294, 1543, 1549, 1552
cardiovascular disorders in, 1544t, 1547, 1549
classic, 1536, 1536t, 1537
differential diagnosis of, 1548b
epidemiology of, 1537–1538
laboratory tests in, 1546–1547
prognosis and clinical course in, 1550
classification of, 1537, 1537t
clinical findings in, 1540–1545
cutaneous, 1540–1544
systemic, 1544t, 1544–1545
clinically amyopathic, 1536t, 1537
clinical features in, 1544, 1545
differential diagnosis of, 1548b
epidemiology of, 1538
laboratory tests in, 1547
prognosis and clinical course in, 1550–1551
treatment of, 1552
complications of, 1549–1550
diagnostic criteria in, 1537
differential diagnosis of, 1547–1549, 1548b
drug-induced, 1538, 1548–1549
dysphagia in, 1452
epidemiology of, 1537–1538
etiology and pathogenesis of, 1538f, 1538–1540
exfoliative dermatitis in, 230t
expansion phase of, 1538f, 1539
eye disorders in, 1544t
gastrointestinal disorders in, 1544t, 1547
hallmark changes in, 1536t, 1540–1544, 1542t
anatomic distribution of, 1543t
histopathology in, 1545–1546
hypomyopathic, 1536t, 1544, 1547
idiopathic inflammatory, 1536t
laboratory tests in, 1546–1547
lupus erythematosus compared to, 1547–1548, 1548b
malignancies in, 1448, 1499–1500, 1544t, 1549–1550, 1552
muscle weakness in, 1540, 1544, 1544t
laboratory tests in, 1546, 1547
muscle strength testing in, 1544
respiratory, 1545
nail changes in, 791, 792f, 1545, 1547
opportunistic infections in, 1550
in paraneoplastic syndromes, 1448, 1494t, 1499–1500
and poikiloderma atrophicans vasculare, 1540, 1542t, 1548
and pregnancy, 1550
prevention of, 1552–1553
prognosis and clinical course in, 1550–1551
respiratory disorders in, 1544t, 1544–1545
and scleroderma, 1540, 1543–1544
sine myositis, 1536t, 1537
specific skin diseases in, 1536t
susceptibility phase in, 1538f, 1539
treatment of, 1551–1552
antimalarial drugs in, 1551, 2160
immunosuppressive therapy in, 1550, 1551, 1552, 1553
ultraviolet radiation exposure in, 1538, 1539
prevention of, 1551, 1553
Dermatopathy. *See* Dermatosis
Dermatophagoides, 2032t
Dermatophyte infections, 1807–1820
adherence stage in, 1811
in diabetes mellitus, 1465
diagnostic procedures in, 1808–1809, 1809t–1810t
differential diagnosis in, 367t
in elderly, 973
folliculitis in, 1699
genetic factors in, 1811
in immunocompromised host, 274, 274f
in HIV infection and AIDS, 1936
inflammatory response to, 1811
laboratory characteristics in, 1808t
in Langerhans cell histiocytosis, 1421
in occupational exposures, 2076
pathogenesis in, 1809–1811
penetration stage in, 1811
Dermatophytid reactions, 1811
Dermatophytosis, 1807
Dermatoscopy. *See* Dermoscopy
Dermatosis. *See also specific disorders*
ashy, 640
from blister beetles, 2060
cinecienta, 247, 640
diabetic, 635, 1469, 1469f
digitate, 238, 238f, 239
kava, 422
keratotic of limbs, 426
linear immunoglobulin A, **485**–490
drug-induced, 358, 359t
nephrogenic fibrosing, 1460, 1565
neutrophilic, 53, **289**–295, 1495t, 1502
papulosa nigra, 1056, 1056f
paraneoplastic, 1493–1499, 1502
perforating, **564**–567, 565f
in kidney disorders, 564, 567, 1459–1460
photo-exacerbated, 825, 825f, 825t
pigmented purpuric, **1633**–1636, 1636b, 1636f
in pregnancy, **955**–962, 958t
pustular
alopecia in, 772t, 774, 774f
contagious, 1910–1911
erosive, 772t, 774, 774f, 1033
sub-corneal, **305**–307, 358, 1375t
self-inflicted, 914–916, 917
in Sneddon-Wilkinson disease, **305**–307, 358
in Sweet syndrome, 53, **289**–295
thyroid, 1472f, 1472–1473, 1473f
elephantiasic, 1472
treatment of, 1474
transient
acantholytic, 437–438
in neonates, 936–938
Dermatosparaxis type of Ehlers-Danlos syndrome, 1301
Dermcidin, 730
Dermis, 58f, 62–64
age-related changes in, 964t, 966–967
atrophy of, 28
cellular components of, 63–64
collagen in, 63, 517
age-related changes in, 966
dendritic cells in. *See* Dendritic cells, dermal
and dermal-epidermal junction, 45, 47–48, 62
elastic connective tissue in, 63, 530
age-related changes in, 966
embryonic and fetal development of, 67t, 69–70
fibroblasts in, 63–64
fibrous, 54–55
fibrous tumors of, malignant, **1159**–1163
functions of, 57, 58t, 384
age-related changes in, 966–967
as hematopoiesis site, 1379
hypertrophy of, **550**–557
hypoplasia of, focal, 530t
lymphatics of, 65
lymphocytes in, 104
mast cells in, 63, 64
matrix of, 63
of nails, 780
in nail bed, 780
in proximal nail fold, 778
nerves in, 65, 896
papillary, 63, 65, 672
of hair follicle, 743f, 744, 746
pathologic reactions of, 43, 44f, 49–55
granulomatous, 53–54
infiltrates in, 51f, 51–53
and pharmacokinetics of topical drugs, 2097, 2098f, 2100
reticular layer of, 43, 44f, 49–55, 63. *See also* Reticular dermis
vascular system of, 64
age-related changes in, 966
deep, 50, 1586, 1587f
superficial, 50–51, 1586, 1587f
Dermographism, 333f, 333–334, 340, 341
cold, 334, 850
treatment of, 341
Dermoid cyst, 1066
Dermolytic blistering, 47, 47t
Dermolytic epidermolysis bullosa, 510. *See also* Epidermolysis bullosa, dystrophic
Dermomalacia in vitamin A deficiency, 1204, 1456
Dermopathy. *See* Dermatosis
Dermoscopy, 41, 1143
computer-assisted systems in, 43, 1143
digital, 1131, 1143, 1144f
in dysplastic nevus, 1130–1131
in hair disorders, 756t
in melanoma, 1131, 1143, 1143f
Desensitization
of chemokines, 129
to ultraviolet radiation exposure, 816, 2247, 2256–2257
in solar urticaria, 825, 2256–2257

Desert recluse spiders, 2056
Desert rheumatism, 1839–1840
Desloratadine, 2187, 2188, 2189t, 2191
Desmocollins, 60, 447, 448
  functions of, 449
  skin diseases associated with, 449, 449t
  in sub-corneal pustular dermatosis, 305
Desmoglea, 447, 448
Desmoglein(s), 391, 447, 448
  functions of, 449
  in pemphigus, 461, 462, 463
    compensation process, 462, 463f
    paraneoplastic, 468, 470, 471, 471f
  skin diseases associated with, 449, 449t
Desmoglein 1, 60t, 60–61, 90, 448
  in fogo selvagem, 460
  in pemphigus, 461, 462, 463
    compensation process, 462, 463f
    paraneoplastic, 468, 471
  skin diseases associated with, 449, 449t
  in striate palmoplantar keratoderma, 449, 449t
Desmoglein 2, 448
  functions of, 449
Desmoglein 3, 60, 60t, 61, 69, 391, 448
  functions of, 449
  in pemphigus, 461, 462
    compensation process, 462, 463f
    paraneoplastic, 468, 471, 471f
  skin diseases associated with, 449, 449t
Desmoglein 4, 60t, 448
  in hypotrichosis, localized autosomal recessive, 758
  in monilethrix, 758
  in pemphigus, 462
  skin diseases associated with, 449, 449t
Desmoid tumors, 553, 553f
  extra-abdominal, 553, 553f
  intra-abdominal, 553
Desmons syndrome, 429
Desmoplakin, 60, 60t, 78, 447
  in palmoplantar keratoderma, 424
  in paraneoplastic pemphigus, 471, 471f
  skin diseases associated with, 449, 449t
  in woolly hair disorders, 760
Desmoplakin I, 447
  in paraneoplastic pemphigus, 471, 471f
Desmoplakin II, 447
  in paraneoplastic pemphigus, 471, 471f
Desmoplastic fibroblastoma, 555
Desmoplastic melanoma, 1139, 1140
Desmosines, 531, 532f, 534
Desmosomal band 6, 68t
Desmosomes, 45–46, 59, 60, 385, 447–449
  biochemistry of, 447–448, 448f
  in blistering disorders, 448–449
  in cellular adhesion, 447, 448
  core of, 60
  disruption of, 60t, 60–61
  embryonic and fetal, 67
  function of, 447, 448–449
  in palmoplantar keratoderma, 424
    striate, 449, 449t
  in skin barrier function, 391
  ultrastructure of, 447, 448f
  in wound healing, 2344
Desmoyokin, 60
Desquamation, 31
  latent, 31
Detergents and soaps as occupational irritants, 2069
Development of skin and appendages, embryonic and fetal, 66–72
Dexamethasone
  in alopecia areata, 765
  chemical structure of, 2148t
  in combination therapy with hydroquinone and tretinoin, 2146
  indications for, 2149
  in melasma, 1480
  in pemphigoid, cicatricial, 484
  in pemphigus, 468
  potency and duration of action, 2148t, 2149
Diabetes insipidus
  in Langerhans cell histiocytosis, 1419, 1422
  in xanthoma disseminatum, 1429, 1430
Diabetes mellitus, **1461**–1470
  acanthosis nigricans in, 1462–1463, 1463f
  approach to patient with, 1461t
  as autoimmune disease, 1509
  bullosis diabeticorum in, 1469b, 1469–1470
  candidiasis in, 1465, 1825f
  cellulitis in, 1692, 1726, 1742
  cutaneous infections in, 1464–1466
  dermopathy in, 635, 1469, 1469f
  epidemiology of, 1461
  etiology and pathogenesis in, 1461–1462
  foot problems in, 873, 1466, 1467f, 2348
    corns and calluses in, 873, 1466
    in impaired wound healing, 2347, 2348
    infections in, 1465
    limb amputation in, 873, 1466
    platelet-derived growth factor in, 2226, 2235, 2348
    prevention of, 1466, 1468t
    revascularization procedures in, 2348
    ulcers in, 1466, 1466f, 1669
  fungal infections in, 1808
  genetic factors in, 1510
  granuloma annulare in, 369–370, 1468–1469
  hand syndrome in, 1464
  joint mobility limitations in, 1463f, 1463–1464
  limb amputation in, 863, 864, 1462, 1670
    in foot problems, 873, 1466
  lipid metabolism in, 1462
  lipoatrophy in, 589
  lipodystrophy in, 589
  necrobiosis lipoidica in, 53, 370, 1466–1468, 1468f
  necrotizing fasciitis in, 1465, 1724
  neuropathy in
    and anhidrosis, 727–728
    and foot ulcers, 1466, 2235
  perforating dermatosis in, 564, 1459, 1469
  peripheral artery atherosclerosis in, 1667, 1668, 1670, 1671
  platelet-derived growth factor therapy in, 2226, 2235, 2348
  pruritus in, 908
  regulatory T cells in, 1512
  scleredema in, 1464, 1563, 1564
  thickening of skin in, 1463
  type 1, 1461
  type 2, 1461, 1462
  ulcers in, 864, 873, 1462, 1466, 1466f, 1467f
    in necrobiosis lipoidica, 1468
    platelet-derived growth factor therapy in, 2226, 2235, 2348
  vitiligo in, 616, 619, 635
  wound healing in, 2347
    and foot problems, 2347, 2348
    and platelet-derived growth factor therapy, 2226, 2235, 2348
  xanthomas in, 1462, 1464, 1464f
  zygomycosis in, 271, 271f, 1465–1466, 1836t, 1843, 1844f
Diacylglycerol, 129f
  in melanogenesis, 605, 606f
Diagnosis, **23**–43
  biopsy in, 42
  computer-assisted systems in, 43
  critical appraisal of evidence on tests in, 13t, 16–17
  history-taking in, 23–26, 24t
  laboratory studies in, 24t
  morphology of lesions in, 24t, 26–40
  physical examination in, 24t, 25–26
  pointers and pitfalls in, 40t
  and probability of disease, 17, 17f
  scrape, pull, swab step in, 42
  swab sampling in, 42, 42f
  visual aids in, 40–42
Dialysis
  bullous disease in, 1459
  in epidermal necrolysis, 354
  pigmentation changes in, 630
  porphyria cutanea tarda in, 1236, 1239, 1243, 1459
  protein-energy malnutrition in, 1203
  pruritus in, 907, 1448
Diaminodiphenyl sulfone. *See* Dapsone
Diaper dermatitis, 942–945
  Candida, 943, 944, 1824, 1936, 2106
  irritant, 942–943, 944
  treatment of, 944–945, 945b
    complications in, 2106
Diarrhea in rotavirus infections, 1870, 1871
Diascopy, 40
Diazoxide, hypertrichosis from, 776
Dibucaine in local anesthesia, 2296t
Dichloroacetic acid in warts, 2136
Diclofenac in actinic keratosis, 1013b, 1014
Dicloxacillin, 2195t, 2198
  pediatric dosage, 949t
  in staphylococcal infections, 1697, 1698b, 1707
  in streptococcal infections, 1707, 1707b
Didanosine in HIV infection and AIDS, 2209
Diethylcarbamazine
  in filariasis, 2014t, 2018
  in loiasis, 2015t, 2019
  in onchocerciasis, 2020
N-N-Diethyl-*m*-toluamide (DEET), 2063
  toxicity in children, 946t
Differentiation
  of epidermal cells, 43, 45, 58–59
    in granular layer, 61
    in spinous layer, 60
  in fetal skin development, 66, 67, 68t, 69
Diffusion
  laws of, 2097
  of topical medications, 2097
DiGeorge syndrome, 1356
Digital dermoscopy
  in dysplastic nevus, 1131
  in melanoma, 1131, 1143, 1144f
Digital nerve blocks, 2298–2299
  distal, 2321–2322, 2322f
    median, 2322, 2322f
  in nail surgery, 2321f, 2321–2322, 2322f
  proximal, 2321, 2321f
Digoxin, complications of, 2238t
Dihydrofolate reductase, 191
Dihydropterine reductase, 1219t
Dihydrotestosterone in acne vulgaris, 690–691, 694
1,25 Dihydroxy vitamin D_3 and calcium serum levels, 1293
  in chronic renal failure, 1295
Dilated pore of Winer, 1080

Diltiazem
phototoxicity from, 831, 832f
in Raynaud phenomenon, 1647
Dimethylsulfoxide
in amyloidosis, 1265
in extravasation injury, 2180
Dinitrochlorobenzene in warts, 1922, 2136
Dioxin, chloracne from, 2078, 2079t
Dioxybenzone in sunscreens, 2139t
Diphencyprone in warts, 2136
Diphenhydramine, 2134t, 2189t, 2191
in antipsychotic drug side effects, 918
in hymenoptera stings, 2062
pediatric dosage, 953t
in urticaria and angioedema, 341, 342f
Diphenylcyclopropenone in warts, 2136
Diphtheria, 1757t, 1767–1768
cutaneous, 1767–1768
oral cavity disorders in, 652t
treatment of, 1757t, 1768
Diplopoda, 2059
Diptera bites, 2059–2060
Dipyridamole
in Degos disease, 1651, 1651b
in Kawasaki disease, 1631
Dirithromycin, 2200
Dirofilaria immitis, 2013t, 2021t, 2024
Dirofilaria repens, 2024
Dirofilaria tenuis, 2024
Dirofilaria ursi, 2024
Dirofilariasis, 2012t, 2024–2025
differential diagnosis of, 2013t, 2021t, 2025
treatment of, 2014t, 2025
Dirty fingernail sign in dermatofibroma, 556
Disability
in learning, in neurofibromatosis type 1, 1337
in leprosy, 1794
in occupational skin disease, 2073
in reactive arthritis, 214
workplace accommodations in, 2073
Discoid lesions, 34
Disease burden in population, measures of, 5–8
Disease-modifying antirheumatic drugs in psoriatic arthritis, 202, 204
Disease outbreak investigation, 4–5
Disomy, uniparental, 80
Distribution of drugs in pharmacokinetic drug interactions, 2237, 2237t
Distribution of multiple lesions, 36–38
Dithranol. *See* Anthralin
Diuretics, phototoxicity from, 829t
Diving, decompression injuries in, 877
DKC1/DKC1 in dyskeratosis congenita, 631, 1325
DNA, 73, 74, 76
cellular responses to damage of, 1002, 1003–1004
regulation of, 980–982
chemical carcinogens affecting, 988
as chromophore, 803f, 806, 810, 811, 813
corticosteroid responsive element, 2102, 2147
double-stranded, 1528t
endogenous damage of, 977
epigenetic modifications, 84
exogenous damage of, 977
fetal, analysis of, 86
genes signaling damage, 982t
hormone response elements, 2107
microsatellite instability, 985
mitochondrial, 82
mutation detection techniques, 77
repair of, 87–88, **977**–986
augmentation of, 1005–1006
diagnostic tests of, 982t, 982–986, 983t
genes in, 978–980, 980t
global genome repair in, 811, 978, 979f
hereditary disorders of, **1311**–1321
melanocyte stimulating hormone in, 604
mismatch repair, 980, 980t
nucleotide excision repair. *See* Nucleotide excision repair in DNA damage
transcription coupled, 811, 978, 979f, 980
types of damage and pathways in, 978t
replication of, 74
in aging, 963
radiation affecting, 859
sister chromatid exchange assay in, 984, 984f
sequencing analysis, 985–986
short tandem repeats in, 985
signature mutations from ultraviolet light, 811, 977, 979f, 999, 1000–1002, 1001f
simple sequence repeats in, 985
single-stranded, 1528t, 1539t
synthesis of
translesional, 980–981, 981f
unscheduled, 984
target sequences in, 2107
types of damage and repair pathways, 978t
ultraviolet radiation-induced damage of. *See* Ultraviolet radiation exposure, DNA damage in
viral, 1845, 1846, 1846t
of papillomaviruses, 1914f, 1914–1915, 1915f, 1917
Docosanol in herpes simplex virus infections, 1880, 1881b, 1883
Dog-ears or standing cones, revision of, 2307, 2307f
Dogs
bites from, 2037
Capnocytophaga infections in, 2038
Pasteurella infections in, 1761, 2038
Porphyromonas infections in, 2038
rabies in, 2039
Staphylococcus intermedius infections in, 2038
heartworm infection in, 2024, 2025
Dohi reticulate acropigmentation, 640
Domestic violence, **930**–931
agencies and resources for assistance in, 928t, 931
Donohue syndrome, 589
Donovan bodies in granuloma inguinale, 1991, 1992, 1992f
Donovanosis, 1990–1993
L-DOPA in melanin synthesis, 601–602, 602f
DOPAchrome tautomerase (TRP-2), 591, 598
in hair pigmentation, 747, 748
in melanocyte development, 591, 593, 593f
in melanogenesis, 598
DOPAquinone in melanin synthesis, 602, 602f
Doppler imaging
of lymphatic malformations, 1662
of venous disorders, 1659
in varicose veins, 2352
Dory flop sign in syphilis, 1958
Dosimetry in ultraviolet radiation exposure, 801–802, 809–810
Doucas and Kapetanakis purpura, 1634t, 1635, 1636
Dowling-Meara form of epidermolysis bullosa simplex, 505, 506, 508t
Down syndrome, 81t
calcinosis cutis in, 1296
Doxepin, 918t, 919, 2134t
antihistaminic activity of, 2193
in atopic dermatitis, 156
complications of, 2238t
in dermatomyositis, 1551
interaction with other drugs, 2238t, 2239, 2239t, 2240t
in pruritus, 909t, 910, 911t, 919
Doxorubicin, 2175, 2175t
in B-cell lymphoma, 1401
chemical structure of, 2163f
dosing regimen, 2175, 2176t
indications for, 2175, 2176t
in Kaposi sarcoma, 1187, 1187b
mechanism of action, 2175, 2176t
pegylated liposomal, 2175, 2176t
side effects and complications of, 2175, 2176
cardiovascular disorders in, 2175
in extravasation, 2180, 2180f
hyperpigmentation in, 636
Doxycycline, 2199
in acne vulgaris, 697, 698
in anaplasmosis, 1950b
in bacillary angiomatosis, 1754
in HIV infection, 1936
in bartonellosis, 1752, 1754
in HIV infection, 1936
in brucellosis, 1760
in cat-scratch disease, 1751
in chlamydial infection, 1998b
dosage of, 2195t
pediatric, 949t
in ehrlichiosis, 1950b
in filariasis, 2014t, 2018
in gonorrhea with chlamydial infection, 1996, 1996b
in granuloma inguinale, 1993b
in Lyme disease, 1804, 1805, 1806t, 2059
in lymphogranuloma venereum, 1989, 1990b
in onchocerciasis, 2021
in perforating disorders, 567, 567b
in perioral dermatitis, 711, 711b
in plague, 1759
in Rocky Mountain spotted fever, 1942, 1950b
in sarcoidosis, 1492, 1492t
side effects and complications of, 2199
in syphilis, 1974
in treponematosis, endemic non-venereal, 1982
in typhus, 1950b, 1952
Dracunculiasis, 2012t, 2021f, 2021t, 2021–2022
differential diagnosis of, 2013t, 2021
treatment of, 2014t, 2022
Dracunculus medinensis, 2012t, 2013t, 2021, 2021t
Dragon worm disease, 2021
Draping in nail surgery, 2321
Dressings, 2345–2346, 2346t
absorption of topical medications in, 2091–2092
in atopic dermatitis, 154
in burns, 855
in decubitus ulcers, 885
in epidermal necrolysis, 354
in epidermolysis bullosa, 514
moist wound healing in, 2345–2346
in nail surgery, 2322
in pyoderma gangrenosum, 301
in venous insufficiency and leg ulcers, 1683, 1683b
Drotrecogin alfa
in meningococcal infections, 1735
in soft tissue infections, 1730

Drug abuse, **921**–926
acne in, 877, 924
candidiasis in, 926, 1843
cellulitis in, 924f, 925, 1722, 1726
common drugs in, 922
differential diagnosis in, 922b
endocarditis in, 924, 926, 1744
epidemiology of, 922
hepatitis C in, 921
HIV infection and AIDS in, 921, 926, 1927
necrotizing fasciitis in, 926, 1724
skin popping in, 922–923, 923f, 925
skin tracks along veins in, 922, 923f
treatment in, 926
withdrawal symptoms in, 926
Drug-induced disorders
acanthosis nigricans in, 1462
acne in, 692, 702, 877, 924
in corticosteroid therapy, 558, 702, 706, 2105
from cytotoxic agents, 2176–2177
differential diagnosis in, 706
allergic contact dermatitis in, 136t, 138f, 141
in corticosteroid therapy, 141, 142, 2106
of vulva, 677–678
anhidrosis in, 722t, 728–729
from antifungal agents, topical, 2118t, 2118–2119, 2120, 2121
from antipsychotic drugs, 917t, 917–918
atheromatous embolism in, 1671
in athletes, 877, 878
autoimmune diseases in, 1513
bullous eruptions in, 353, 358–359
cutaneous reactions in, **355**–362
diagnosis and management of, 361
epidemiology of, 355
etiology of, 355
in HIV infection, 1933–1934, 1934f
morphology of, 356–361
pathogenesis in, 355–356
prevention of, 361–362
from cytotoxic agents, 2175–2181
dermatomyositis in, 1538, 1548–1549
differential diagnosis of, 706
erythema multiforme in, 348b
pityriasis rosea in, 365, 365b
in drug abuse, 926. *See also* Drug abuse
in drug-drug interactions, 356
elastosis perforans serpiginosa in, 566
in elderly, 972, 972t, 973
epidermal necrolysis in, **349**–355, 359, 359t
high-risk medications in, 350, 350t
in HIV infection, 1934
erythema in, 30, 30f
from cytotoxic agents, 2178, 2178f, 2178t
multiforme, 344, 359
exanthematous eruptions in, 356f, 356–358
exfoliative dermatitis in, 225, 227t, 228, 230t, 231, 232
fixed drug eruptions in, 353, 359f, 359–360
folate deficiency in, 1211
gastrointestinal hemorrhage in, 1455
genital
in female, 677–678, 681
in male, 666–667
in glucocorticoid therapy
acne in, 558, 702, 706, 2105
allergic contact dermatitis in, 141, 142, 2106
atrophic changes in, 558, 702, 706, 2105
systemic, 2149–2153
topical, 2105–2106
gout in, 1575, 1576
granuloma annulare in, 369–370
hemorrhage in, 1455, 2336, 2336t, 2337
in HIV infection and AIDS, 1933–1935
lipodystrophy in, 586, 586f, 589, 1934–1935
photosensitivity in, 1932
pruritus in, 1931
hyperhidrosis in, 722t, 726
hypersensitivity reactions in. *See* Hypersensitivity, to drugs
hypertrichosis in, 776t, 776–777, 777f
in corticosteroid therapy, 2105–2106
ichthyosis in, 421–422
lichen planus in, 244, 248, 248f, 249–250, 250t, 251, 360
lichenoid eruptions in, 360
linear IgA dermatosis in, 358, 359t, 487, 489
lipoatrophy in, 581
lipodystrophy in, 586, 587
in HIV infection and AIDS, 586, 586f, 589, 1934–1935
livedo reticularis in, 1676
of liver. *See* Liver disorders, drug-induced
from local anesthetics, 2297–2298
lupus erythematosus in, 355–356, 357t, 361, 834, 1513, 1519, 1525
subacute cutaneous, 357t
lymphoid hyperplasia in, cutaneous, 1402, 1404, 1404f
nail changes in, 792, 793f, 793t
from cytotoxic agents, 2177, 2177f, 2177t
from retinoids, 2185
necrosis of skin in, anticoagulant-induced, 360, 360f
necrotizing venulitis in, 1602
ochronosis in, 1227
from hydroquinone, 637, 1227, 2145, 2146
of oral cavity. *See* Oral cavity disorders, drug-induced
panniculitis in, 580, 581, 582–583
pellagra in, 834, 1210
pemphigoid in, bullous, 359, 359t
pemphigus in, 358–359, 359t, 465–466
photosensitivity in, 805, 828, 828t–830t, 832, 833
from cytotoxic drugs, 2179, 2179t
in HIV infection and AIDS, 1932
from topical retinoids, 2112
pigmentation changes in. *See* Pigmentation, drugs affecting
pityriasis rosea in, 365
of platelets, 2336t, 2337
in porphyria, acute intermittent, 1250, 1250t, 1251
porphyria cutanea tarda in, 1236t
pruritus in, 1447, 1448
in HIV infection and AIDS, 1931
pseudolymphoma in, cutaneous, 360, 1402, 1404
pseudo-mycosis fungoides in, 1410
pseudoporphyria in, 358, 359t, 1243
psoriasis exacerbation in, 184
purpura in, palpable, 1602
purpuric dermatosis in, pigmented, 1633, 1634t, 1636
pustular eruptions in, 358
Raynaud phenomenon in, 1646, 1646t, 2180
reticular dermis reactions in, 50, 51, 51f, 52
retinoid dermatitis in, 2111, 2143, 2144f
retinopathy from antimalarial drugs in, 1533, 1551
riboflavin deficiency in, 1209
scaling lesions in, 31t
seborrheic dermatitis in, 220
serum sickness-line reaction in, 357t, 358
severe, clinical features warning of, 361, 361t
skin cancer in, 987
Stevens-Johnson syndrome in, 359, 359t
Sweet syndrome in, 289, 290t, 292, 294
telogen effluvium in, 761, 761t
thermoregulation in, 844
of thyroid, 1470, 1471, 1471t
from topical medications, 2095–2096
local effects in, 2095–2096
systemic effects in, 422, 2096
urticaria and angioedema in, 337, 338, 358
treatment of, 341, 342
vasculitis in, 360–361, 1602
vitamin B_6 deficiency in, 1211
vitamin C deficiency in, 1213
vitamin K deficiency in, 1208
xanthoma in, eruptive, 1275
zinc deficiency in, 1215
Drug interactions, 356, 2236–2241
ADME model on, 2237, 2237t
critical, 2240, 2240t
drug substrates in, 2237–2238, 2238t
option to proceed with caution in, 2239–2240, 2240t
pharmacodynamic, 2236, 2237, 2237t
pharmacokinetic, 2236–2237, 2237t
resources on, 2236, 2237t
Drug therapy. *See also specific types of drugs*
anti-angiogenic, 2231–2236
antibiotic, 1693–1694, 2113–2115, 2194–2202
antifungal, 2116–2121, 2211–2217
antihistamine, 2186–2193
antimalarial agents in, 2157–2162
antiviral, 2203–2211
in children, 945–954
cytotoxic, 2122–2125, 2163–2181
dapsone in, 2154–2157
in elderly, 971
ethnic considerations in, 2142–2146
glucocorticosteroid, 2147–2153
immunobiologicals in, 2223–2231
immunomodulators in, 2125–2129, 2217–2223
interactions of drugs in, 2236–2241
narrow therapeutic index drugs in, 2238t
preoperative assessment of, 2295
retinoid, 2106–2112, 2181–2186
systemic agents in, 2147–2241
topical agents in, 2091–2146
Drumstick fingers, keratosis palmaris with, 429
Dry cleaning agents, skin cancer associated with, 987t
Dry eyes in Sjögren syndrome, 1579, 1581, 1581t
treatment of, 1582t, 1582–1583
Dry mouth, 644
etiologies of, 644, 644t
in Sjögren syndrome, 1578–1579, 1581, 1581t
treatment of, 1582, 1582t
Dry skin, 2357–2359, 2364t. *See also* Xerosis
Duck hunter's itch, 2023
Ductal carcinoma, apocrine, 1073
Duke boot in chronic venous insufficiency, 1683
Duke criteria on endocarditis, 1744, 1745t
Duloxetine, 918, 918t, 919–920
Dumdum fever, 2006
Duncan disease, 1354
Dunnigan lipodystrophy, 588
Dupuytren contracture, 552
and Peyronie disease, 552

Durlacher's corn, 871
Dust mite allergy, 155, 157
Dyes, antiseptic, 2132
Dynein in melanosome transport, 603, 603f
Dysautonomia, familial, hyperhidrosis in, 726
Dysbetalipoproteinemia, 1277–1278, 1279t
  xanthoma in, 1272t, 1273f, 1274f, 1278, 1279t
Dyschromatosis
  acquired brachial cutaneous, 639
  hereditaria symmetrica, 615, 640
  hereditaria universalis, 640
Dyschromia, Creole, 630
Dysesthesia, chronic, 916–917
Dyshidrosis, 162, 166
  differential diagnosis in, 139b, 217
Dyskeratoma, warty, 1063
Dyskeratosis, 45
  and acantholysis, 45, 45f, 47
  congenita, 631–632, 1314t, 1324f, **1324**–1325, 1374t, 1505t
    cancer risk in, 1325
    clinical features in, 1324f, 1324–1325
    genetic factors in, 631–632, 1325
    oral cavity disorders in, 642t
  in Darier-White disease, 45, 45f, 435, 435f
  follicularis, isolated, 1063
Dyskinesia, tardive, from antipsychotic drugs, 918
Dysmorphic disorder, 913–914
Dysmorphophobia, 913–914
Dyspareunia, 655
Dysphagia, 1451–1452
Dysplasia
  of bones in neurofibromatosis type 1, 1335
  ectodermal, **1339**–1348. *See also* Ectodermal dysplasia
  intraepidermal epithelioid melanocytic, 1130
  mucoepithelial hereditary, 752
Dysplastic nevus, **1122**–1133
  approach to patient with, 1126f
  asymmetry in, 1127, 1129
  border irregularity in, 1128, 1129
  clinical findings in, 1125–1131
  color variations in, 1127, 1129
  complications of, 1131
  diagnostic criteria on, 1122–1123, 1123f
  diameter of, 1126, 1127, 1127f, 1128f, 1129
  differential diagnosis of, 1128–1129, 1131, 1131b
  distribution of, 1125, 1125f, 1132
  epidemiology of, 1122–1123
  etiology and pathogenesis of, 1123–1125
  genetic factors in, 1123–1125
  histopathology in, 1122–1123, 1124f, 1130
  laboratory tests in, 1130–1131
  melanoma risk in, 1123, 1125, 1129, 1130, 1131, 1132, 1133
  prevention of, 1133
  prognosis and clinical course in, 1131–1133
  self-examination recommendations in, 1132
  syndrome of, 1135, 1505t
  treatment of, 1133
    laser therapy in, 2274
Dysproteinemias, 1280
Dysraphism
  cranial, 941
  spinal, 941, 941t
Dysreflexia, autonomic, hyperhidrosis in, 722t, 723–724
Dystonia from antipsychotic drugs, 917, 918
Dystopia canthorum in Waardenburg syndrome, 614, 614f
Dystrophic epidermolysis bullosa. *See* Epidermolysis bullosa, dystrophic
Dystrophy
  muscular
    congenital, collagen type VI in, 520
    epidermolysis bullosa with, 508, 508t
  nail, 790, 792
    from cytotoxic agents, 2177

E

E1 gene and protein of papillomaviruses, 996
E2F1 transcription factor in ultraviolet radiation-induced apoptosis, 815
E6 gene and protein of papillomaviruses, 996
  in epidermodysplasia verruciformis, 997
E7 gene and protein of papillomaviruses, 996
  in epidermodysplasia verruciformis, 997
Ear, 1452
  acrokeratosis paraneoplastica of, 1499, 1499f
  in alkaptonuria, 1226, 1226f
  auricular fistula of, congenital, 1066
  chondrodermatitis nodularis helicis of, 1066–1067, 1067f
  cosmetic units and landmarks of, 2289–2290, 2290f
  crease of earlobe, 1452
  melanocytes in, 595
  otitis externa of, 224
    in diabetes mellitus, 1465
    in *Pseudomonas aeruginosa* infections, 1736–1737, 1738
  otitis media of, 1871
  preauricular cyst and sinus of, 1066
  relapsing polychondritis of, 1452, **1567**–1569
  seborrheic dermatitis of, 222, 222b, 222f
    treatment of, 224
  squamous cell carcinoma of, 1030f, 1034
  in swimmers, 1736
  in syphilis, 1962
Earlobe crease, 1452
Ear pits, 1066
East African trypanosomiasis, 2008, 2008f
Eastern Cooperative Oncology Group trials on melanoma, 1155, 1156
Eating disorders
  protein-energy malnutrition in, 1203
  vitamin A deficiency in, 1204
  vitamin B_3 deficiency in, 1210
  zinc deficiency in, 1214, 1215
Ebastine, 2188, 2189, 2189t
  in mosquito bites, 2060
EBNA-1 protein, 110
Ecchymoses, 33
  in corticosteroid therapy, 1383f
  differential diagnosis of, 1381t
  in drug abuse, 924
Eccrine glands, 713–719
  age-related changes in, 967
  anatomy of, 713–714
  in bromhidrosis, 731, 732b
  cell types in, 713–714
  in chromhidrosis, 722, 733, 733b
  composition of sweat, 717f, 717–718, 721
    disorders with changes in, 722t, 730
  cuticular border of, 714
  cytotoxic drugs affecting, 2177f, 2177–2178
  disorders of, **720**–730
    classification of, 722t
    immunohistochemical studies in, 721, 721f
    in vivo techniques in evaluation of, 720–721, 721f
    physical examination in, 721–722
  duct of, 714, 715f
    reabsorption in, 718–719, 719f
  embryonic and fetal development, 72, 713, 1068
  emotional stress affecting, 716
    in primary focal hyperhidrosis, 723, 723f
  energy metabolism in, 717
  function of, 713, 714–719
  hamartoma of, congenital angiomatous, 1171
  innervation of, 714–716, 723
    and denervation hypersensitivity, 716
  mechanisms of sweat secretion, 718, 718f
  in neutrophilic hidradenitis, 294b, 729, 2177, 2177f
  nevi of, 1056, 1057t, 1060, 1074
  number and distribution of, 713
  pharmacology of, 716–717
  secretory coil of, 713–714, 714f, 715f
  syringosquamous metaplasia of, chemotherapy-induced, 2178
  tumors of, 1068, 1069t, 1070t, 1074–1079
    differential diagnosis in, 1068
Echinocandins, 2216
Echinococcosis, 2012t, 2026–2027, 2027f
  differential diagnosis of, 2021t, 2027
  treatment of, 2014t, 2027
Echinococcus granulosus, 2014t, 2021t, 2026, 2027
Echinococcus multilocularis, 2014t, 2021t, 2026, 2027
Echocardiography
  in endocarditis, 1745
  in Kawasaki disease, 1630, 1632, 1632f
Echovirus infections
  clinical manifestations in, 1849
  hand-foot-mouth disease in, 1868
ECM-1 (extracellular matrix protein-1), 77
  in lichen sclerosus, 547
  in lipoid proteinosis, 1288–1289, 1291
Econazole, 2117t, 2118
Ecthyma
  contagiosum, in occupational exposures, 2075–2076
  gangrenosum, 1698
    differential diagnosis of, 1747b
    histopathology in, 1727
    in immunocompromised host, 268, 269f, 1691–1692, 1747
    non-classic causes of, 1747
    in *Pseudomonas* infections, 1698, 1727, 1737–1738, 1747
    in sepsis, 1747, 1747b
  staphylococcal, 1698, 1699f
  streptococcal, 1698, 1705
Ectoderm, embryonic and fetal, 67, 70
Ectodermal dysplasia, 429, **1339**–1348
  alopecia in, 755, 1343, 1343f
  anhidrotic or hypohidrotic, 79, 726–727, 837, 1339–1342
    alopecia in, 755
    gender differences in, 1341, 1342f
    with immunodeficiency, 1360–1361
    X-linked, 83, 1339–1341, 1342f
  with ankyloblepharon filiforme adnatum and cleft palate, 1343–1344
  with autoimmune polyendocrinopathy and candidiasis, 763, 1354–1355, 1355t, 1356, 1510
  in Christ-Siemens-Touraine syndrome, 1339–1342
  classification of, 1339
  in Clouston syndrome, 1342–1343, 1343f
  diagnosis of, 1340f
  differential diagnosis of, 1341, 1342b, 1343

with ectrodactyly and cleft lip/palate, 1344–1345
in focal dermal hypoplasia of Goltz, 1346–1348
genetic factors in, 1339
in Hay-Wells syndrome, 1343–1344, 1344f
hidrotic, 425t, 429, 1342–1343, 1343f
alopecia in, 1343, 1343f
with immunodeficiency, 1360–1361, 1361f
nail changes in, 783, 1340, 1343, 1343f, 1346, 1346f
oral cavity disorders in, 642t, 647t, 1340–1341, 1341f, 1344–1345
palmoplantar, 426, 428
in Rapp-Hodgkin syndrome, 1345
and skin fragility, 425t, 508t, 512
with split hand, split foot, and cleft lip/palate, 1344–1345, 1345f
in tooth and nail syndrome, 1346, 1346f
Ectodermosis pluriorificialis, 346
Ectodysplasin (EDA), 68t, 71, 1339, 1340
in ectodermal dysplasia, 1339, 1340
in hair follicle development, 740f, 741
Ectodysplasin receptor (EDAR), 68t, 71, 72, 1340
in ectodermal dysplasia, 1340
in hair follicle development, 740f, 741
Ectopia
lentis
in homocystinuria, 1304
in Marfan syndrome, 1303
of neural tissue, 1182–1183
meningeal, 1182–1183
neuroglial, 1182
Ectothrix hair infection, 1808, 1808f, 1808t
in tinea capitis, 1811
Ectrodactyly–ectodermal dysplasia–cleft lip/palate syndrome, 1343, 1344–1345, 1345f
Ectropion
in lamellar ichthyosis, 410, 410f
in laser skin resurfacing, 2368
Eczema
of amputation stump, 866–867
asteatotic, in elderly, 972
atopic, **146**–158. *See also* Atopic dermatitis
coxsackium, 1869
craquelé, 31t
discoid, 159
in drug abuse, 926
dyshidrotic, 162, 217
flannelaire, 219
herpeticum, 1877, 1877f
in atopic dermatitis, 152, 153f, 156, 1877
treatment of, 1883b
hyperkeratotic, 430b
nummular, **158**–160, 159f
differential diagnosis in, 159, 159b
in occupational exposures, 20, 2068t, 2077, 2077t
in phenylketonuria, 1223
post-traumatic, 2077, 2077t
in pregnancy, 962
radiation therapy in, 166, 2280t, 2280–2281
skin barrier function in, 391
vaccinatum, 152, 1904, 1905, 1905f
vesicular palmoplantar, **162**–167, 2248
Eczematid seborrheic dermatitis, 221
EDA (ectodysplasin), 68t, 71, 1339, 1340
in ectodermal dysplasia, 1339, 1340
in hair follicle development, 740f, 741
EDAR (ectodysplasin receptor), 68t, 71, 72, 1340
in ectodermal dysplasia, 1340
in hair follicle development, 740f, 741
Edema
angioedema. *See* Angioedema
eosinophils in, 316
facial, in acne, 701
hemorrhagic, of childhood, 1599, 1602
in kidney disorders, 1458
laryngeal, 27
leukoderma in, 630
in limb amputation and prosthesis use, 865, 865f
lymphedema. *See* Lymphedema
of penis, 672
chronic idiopathic, 671, 671f
in peripheral venous disorders, 1680
spongiotic, 46
wheals in, 27
EDN (eosinophil-derived neurotoxin), 285
in Waardenburg syndrome, 613, 614
Educational interventions in public health programs, 21
Edward syndrome (trisomy 18), 81t
Edwardsiella lineata, 2049
Edwardsiella tarda, 2053t
Eel bites, 2052, 2052f
Efalizumab, 2228–2229
complications of, 2229
in dermatomyositis, 1552
in lupus erythematosus, 1533t, 1535
in palmoplantar pustulosis, 217, 217b
in psoriasis, 188t, 192–193, 2228, 2229
Efavirenz in HIV infection, 2209
hypersensitivity reactions to, 1934
Effluvium, 753, 754, 755t, 761–762
anagen, 761–762
definition of, 754t
telogen, 746, 754, 755, 761f, 938
acute, 761
causes of, 761, 761t
chronic, 761
drug-induced, 761, 761t
in iron deficiency, 761
Eflornithine
in African trypanosomiasis, 2008
in hirsutism, 775, 775b
Ehlers-Danlos syndrome, 54, 530, 530t, **1297**–1302
arthrochalasia type, 1298t, 1301
classical, 1297–1300, 1298t
clinical findings in, 1298–1300, 1299f
collagen in, 519, 520, 524, 526, 527, 1297
type I, 1298t, 1301
type III, 519, 1298t, 1300
type V, 520, 1297–1298
decorin deficiency in, 541
dermatosparaxis type, 1298t, 1301
dystrophic calcification in, 1294
gastrointestinal disorders in, 1455
general skin changes in, 1445
hypermobile, 1298t, 1300
kyphoscoliotic, 1298t, 1300–1301, 1302
progeroid variant, 1298t
treatment and prevention of, 1301–1302
vascular, 1298t, 1300, 1302
clinical findings in, 1300, 1300f
Ehrlichia chaffeensis, 1944t, 1949b, 1952
Ehrlichiosis, **1952**–1953
clinical and laboratory findings in, 1946t, 1952
differential diagnosis of, 1948b, 1949b, 1952–1953
epidemiology of, 1944t, 1952
histopathology in, 1953
treatment of, 1949b, 1950b, 1953, 2197t
Eicosanoids, 1204
keratinocyte-derived, 97
in pruritus, 897t
in psoriasis, 173–174
Eikenella corrodens, 2197t
Elafin, 61
in palmoplantar pustulosis, 215
Elastase, 283, 534
Elastic fibers, **530**–536
in anetoderma, 557–558, 558f
biology of, 531–536
in cutis laxa, 536, 537t, 1308, 1309
in dermal-epidermal junction, 451
in dermis, 63, 451, 530
age-related changes in, 966
embryonic and fetal, 70
elastin in, 531f, 531–534
microfibrillar proteins in, 530–531, 534–536
in mid-dermal elastolysis, 558–559
pathology in cutaneous diseases, 536
in pseudoxanthoma elasticum, 54, 55, 63, 536, 537t, 1305, 1305f
structure and development of, 530–531, 531f
Elastin, 63, 68t, 70, 531f, 531–534
age-related changes in, 966
biosynthesis of, 532, 534
cross-links of, 531, 532f, 534
in cutis laxa, 1308
degradation and remodeling, 534
in dermis, 530
fibrillogenesis, 534
gene of, 531–534, 1308
constitutive and alternative splicing, 532
cytokine and hormonal regulation, 533–534
regulation of expression, 532–534
structure of, 531–532, 533f
protein structure, 531, 532f
Elastoderma, 536, 537t
Elastofibroma dorsi, 537t, 554
Elastolysis
generalized, 54, **1308**–1310. *See also* Cutis laxa
mid-dermal, 537t, 558–559, 559f
differential diagnosis in, 558, 559
treatment in, 559
perifollicular, 559
post-inflammatory, 559
Elastoma, isolated, 537t
Elastorrhexis, papular, differential diagnosis in, 558, 1306b
Elastosis
actinic, 54, 537t
digital papular calcific, 554
linear focal, 560
nodular, with cysts and comedones, 703
perforans serpiginosa, 537t, 566, 566f, 1459
in diabetes mellitus, 1469
differential diagnosis of, 567
and pseudoxanthoma elasticum, 1306–1307
in photoaging, 968, 968f, 968t, 969f
in smoking, 971
solar, 559, 704
Elaunin, 63, 530
Elbow, staphylococcal cellulitis of, 273
Elderly, 963–973
abuse of, **930**
agencies and resources for assistance in, 928t, 930
legal issues in, 930
risk factors in, 930, 930t
types of, 930, 930t
aging in, 963–973. *See also* Aging

Elderly—*continued*
allergic contact dermatitis in, 137, 141
antihistamines in, 2190, 2191, 2193
atrophy in, 28, 29f
basal cell carcinoma in, 971, 972t, 1036
bullous pemphigoid in, 475, 478, 480, 972t, 973
burns in, 852
cold injuries in, 845
common cutaneous disorders in, 972t
corticosteroid therapy in, topical, 2104
decubitus ulcers in, 878, 881, 973
fluconazole in, 2215
griseofulvin in, 2216
herpes zoster in, 973, 1885, 1886
prevention of, 1898
infections in, 972t, 972–973
itraconazole in, 2214
Langerhans cell histiocytosis in, 1417, 1420f
Merkel cell carcinoma in, 972, 972t, 1088, 1089f
myxofibrosarcoma in, 1162
nummular eczema in, 158
pruritus in, 908, 972, 972t
scabies in, 973, 2029
smallpox in, 1899
squamous cell carcinoma in, 971, 972t, 1028
terbinafine in, 2212
vitamin C deficiency in, 1212–1213
Electrical burns in occupational exposures, 2078
Electrical stimulation technique in pruritus, 911
Electrocardiography in Kawasaki disease, 1630
Electrocautery, 2333–2334
in actinic keratosis, 1013
Electrocoagulation, 2333, 2334
Electrodesiccation, 2333, 2334–2335, 2335f
in basal cell carcinoma, 1041, 2334–2335
indications for, 2334–2335
in keratoacanthoma, 1053
in warts, 1922
Electrofulguration, 2333, 2334
Electrolysis, 2334
Electromagnetic radiation, 797, 798t, 799
cellular effects of, 858–859
properties of, 799
transverse waves in, 799
wavelengths of, 797–798, 798f, 798t
and frequency, 799
Electromyography in dermatomyositis, 1547
Electron-affinic agents as radiosensitizers, 860
Electrosection, 2333
Electrosurgery, **2333**–2335
in actinic keratosis, 1013
in basal cell carcinoma, 1041, 2334–2335
complications of, 2335
indications for, 2334–2335
in keratoacanthoma, 1053
modalities in, 2333–2334
in pacemakers and defibrillators, 2295, 2334
postoperative care in, 2335
principles of, 2333
in warts, 664b, 1922
Elejalde syndrome, 622, 623, 1367
Elemental diet in dermatitis herpetiformis, 504
Elementary body of *Chlamydia trachomatis,* 1997
Elephantiasis, 2017, 2018
graecorum, 1791
nostra verrucosa, 1729
ELN in cutis laxa, 1308
EMBASE *(Exerpta Medica Database),* 11, 12
Embolism
in atherosclerosis, 1460, 1671–1673
differential diagnosis of, 1673, 1673b
cholesterol, 1460, 1460f
infarction area in, 34, 34f
fat, 1454
pulmonary, in sclerotherapy complications, 2355
septic, in endocarditis, 1744–1745
Embolization in arteriovenous malformations, 1666
Embryonic and fetal development, 66–72
of dermal-epidermal junction, 71
dermatoses of pregnancy affecting, 955–960, 958t
in cholestasis, 957, 959
in pemphigoid gestationis, 955–956
in pustular psoriasis, 959–960
of dermis, 67t, 69–70
diagnosis of skin disorders in, 85f, 85–86
preimplantation testing in, 85–86
skin biopsy in, 85, 85f
of epidermis, 66t–67t, 67–69
estimation of gestational age in, 66
of hair, 71f, 71–72, 739–742, 740f, 1068
melanocytes in, 69, 591–593, 592f
of neural tube, 941
of skin appendages, 67t, 71–72, 1068
stages in, 66–67, 68t
of subcutis, 70
timing of major events in, 66t–67t
Emedastine, 2187
Emilins, 535t, 536, 536f
EMLA cream, 2130, 2296t, 2298
side effects of, 2130
in skin biopsy in children, 942
Emollients, 2093–2094
as moisturizing products, 2359, 2359t
in neonatal care, 936
in psoriasis, 190
Emopamil-binding protein (EBP), 419
Emotional stress, 920–921
and acne, 694
and atopic dermatitis, 156, 920
and herpes simplex virus infections, 921
and psoriasis, 920–921
and seborrheic dermatitis, 220
sweating in, 716, 723, 723f
and telogen effluvium, 761, 761t
and urticaria, 921
Emphysema, and congenital hemolytic anemia, 1309b
Emtricitabine in HIV infection, 2208, 2209
Emulsions, topical medications formulated as, 2094
oil-in-water, 2094
water-in-oil, 2094
Enamelysin, 528, 529t
Encephalitis
amebic, 2010
in bioterrorism, 2083t
herpes simplex virus, 1879
treatment of, 1882b
in loiasis, 2019
in measles, 1852, 1853
in rubella, 1854
in smallpox, 1902, 1903
in smallpox vaccination, 1905
tick-borne, 2083t
in toxoplasmosis, 2010
in varicella, 1893
Encephalomyelitis
experimental autoimmune, 1513
in smallpox vaccination, 1905
Encephalopathy in loiasis, 2015t
Enchondroma in Maffucci syndrome, 1659, 1660f
Encrusted exudates, 31, 31f
Endocan, 539t
Endocannabinoids, 897t
Endocarditis, **1744**–1746
in *Bartonella* infections, 1749, 1750t, 1751–1752
as body piercing complication, 890t
diagnostic criteria on, 1744, 1745t
differential diagnosis in, 1733b, 1734, 1745b
in drug abuse, 924, 926, 1744
in gonorrhea, 1995, 1996
Janeway lesions in, 1453, 1744
native valve, 1744
Osler nodes in, 1453, 1453f, 1692, 1744
prevention of, 1745–1746
antibiotics in, 2195
prosthetic valve, 1744, 1745
Roth spots in, 1453, 1745
septic emboli in, 1744–1745
splinter hemorrhage of nails in, 1453, 1744, 1745, 1745f
differential diagnosis of, 1745b
subacute bacterial, 1453, 1692
treatment in, 1745
Endocrine disorders, **1461**–1483. *See also specific disorders*
adrenal, 1477–1479
of androgenic hormones, 1480–1482
anemia in, 1374t, 1377
candidiasis with, 1827t
and ectodermal dysplasia, 763, 1354–1355, 1355t, 1356, 1510
in corticosteroid therapy, 2151, 2151t
diabetes mellitus in, 1461–1470
estrogen and progesterone levels in, 1479–1480
growth hormone levels in, 1482–1483
parathyroid, 1474–1477
pruritus in, 908
thyroid, 1470–1474
in X-linked syndrome with immune dysregulation and enteropathy, 1355
Endoderm, embryonic and fetal, 67
Endoglin, 68t, 70, 1590t, 1597
Endopeptidase, neutral, 895
Endosomes, 110f, 111
Endothelin
in Behçet disease, 1622
in melanocyte development, 591–592, 1004
in melanogenesis, 604
in pruritus, 897t
in Waardenburg syndrome, 613, 614
Endothelin converting enzyme, 895
Endothelin receptor blockade in systemic sclerosis, 1559, 1559t, 1561
Endothelium, **1585**–1598
activation of, 287–288, 1585f, 1591
in adaptive immunity, 1594–1595
in Behçet disease, 1622
caveolae in, 1588
fenestrae in, 1588
functions of, 1585–1586
in inflammation, 1590–1595
and leukocyte activation, 1593
and leukocyte adhesion, 1591–1593
and leukocyte extravasation, 1594
and vascular leakage, 1594
and vasodilator synthesis, 1591
in innate immunity, 1590–1594
junctions in, 1588–1589
matrix molecules in, 1589
molecular markers of, 1589–1590, 1590t

morphology of cells in, 1587
organelles in, 1587–1588
in psoriasis, 173
Weibel-Palade bodies in, 1587–1588
Endothrix hair infection, 1808, 1808f, 1808t
in tinea capitis, 1811
Endotoxin, 1691
and complement activation, 326
Endovanilloids in pruritus, 897t
Energy density in laser therapy, 2266
Energy metabolism in sweat secretion, 717
Energy transfer in phototoxic reactions, 830
Enfuvirtide in HIV infection, 2210t, 2210–2211
Engrailed genes, 739
En1, 67, 68t, 70, 72
Enolase, neuron-specific
in malignant peripheral nerve sheath tumor, 1181
in Merkel cell carcinoma, 1090
Ensulizole in sunscreens, 2139t
Entactin, 454
Entamoeba dispar, 2009
Entamoeba histolytica, 2009
Enteric fever in *Salmonella* infections, 1740–1741
Enterobiasis, 2012t, 2013
treatment of, 2014t
Enterobius vermicularis, 2012t, 2013
Enterococcus, vancomycin-resistant, 1728, 1730
Enteropathy, dermatogenic, 1458
Enterotoxins, staphylococcal, 1695, 1710t, 1715, 1748
in bioterrorism, 2083t
Enteroviruses, 1848, 1867–1870
differential diagnosis of, 1733b, 1949b
in hand-foot-mouth disease, 1867–1869
in herpangina, 1867, 1869–1870
Enthesitis
in psoriatic arthritis, 194, 195, 199–200, 202
in reactive arthritis, 211, 214
Entomophthoromycosis, 1835
Entry inhibitors in HIV infection, 220–2211
Envelope, viral, 1846, 1846t, 1847, 1848
Envenomations
from aquatic organisms, 2042–2045, 2049–2052
in scorpion stings, 2057–2058
in snake bites, 2040–2042
in spider bites, 2054–2057
Environmental factors
in autoimmune disorders, 1510f, 1514
in climate therapy for psoriasis, 190–191
in cold injuries, 844–852
in complementary and alternative dermatology, 2285–2286
in dermatomyositis, 1537–1538
in lupus erythematosus, 1510f, 1514, 1517–1518
in scleroderma-like disorders, 1562
in seborrheic dermatitis, 220
in Sjögren syndrome, 1577–1578
in skin cancer, 987t
in thermal stress and injuries, 835
ultraviolet radiation exposure, **797**–834. *See also* Ultraviolet radiation exposure
in workplace
health risk assessment of, 2073
identification of hazards in, 2072, 2073
Envoplakin, 61, 388
in paraneoplastic pemphigus, 471, 471f
Enzymatic fat necrosis, 577
Enzyme immunoassay in syphilis, 1971t, 1972–1973
Enzyme-linked immunosorbent assay
in epidermolysis bullosa acquisita, 498
in HIV infection, 1929t
in Lyme disease, 1804
in measles, 1852
in pemphigoid gestationis, 490, 492
in pemphigus, 461–462
Eosinophil(s), **284**–288, **307**–317
activation of, 286
in angiolymphoid hyperplasia, 313–314
in atopic dermatitis, 147, 287
biologic functions of, 284–287
in cutaneous diseases, **307**–317
granules in, 285–286
composition of, 285
in hypereosinophilic syndromes, 284, 307–310
in innate immunity, 99
in Kimura disease, 314
ontogeny and development of, 284
in oral mucosal ulcer, 315
pharmacologic manipulation of, 288
in pustular folliculitis, 314–315
recruitment of, 287–288
surface receptors of, 286–287
tissue trafficking, 282f, 287–288
in tumors, 286, 317
ultrastructure of, 285
in urticaria and angioedema, 332, 341
in vasculitis, 316–317, 1600, 1604
in Wells syndrome, 310–313
Eosinophil/basophil colony forming unit, 284
Eosinophil cationic protein, 285
in Wells syndrome, 310
Eosinophil-derived neurotoxin (EDN), 285
in Waardenburg syndrome, 613, 614
Eosinophil peroxidase, 285
Eosinophilia, 286, 307–315, 1375t, 1376t
and angioedema, 309
and angiolymphoid hyperplasia, 313–314, 1403t, 1408–1409
clinical findings in, 313, 313f, 1408f, 1409
differential diagnosis in, 314, 314t, 1409, 1409b
treatment of, 313f, 314, 1409, 1409b
apoptosis in, 287
cellulitis in, 310–313
clinical findings in, 307–309, 309f
in angiolymphoid hyperplasia, 313, 313f, 1408f, 1409
diagnostic criteria in, 307, 309, 309t
differential diagnosis of, 309–310
in angiolymphoid hyperplasia, 314, 314t, 1409, 1409b
epidemiology of, 307
etiology of, 307
fasciitis in, 54, 286, 316f, 545
in helminthic infections, 2012
in hyper-IgE syndrome, 1366, 1367t
idiopathic, 284
laboratory tests in, 309
lymphocytic, 307, 308, 309
treatment of, 310, 311f
in morphea, 545
and myalgia syndrome, 316
myeloproliferative, 308, 309
treatment of, 310, 311f
and oral mucosal ulcer, 315
panniculitis in, 585
pustular folliculitis in, 314–315
treatment of, 310, 311f
in angiolymphoid hyperplasia, 313f, 314, 1409, 1409b
tropical pulmonary, 2017, 2018
tumors associated with, 286
Wells syndrome in, 310–313
Eotaxin, 123
in atopic dermatitis, 132
Ephelides (freckles), 639, 1119–1120, 1121
laser therapy in, 2273
in neurofibromatosis type 1, 1333, 1333f
Epican, 539t
Epidemiologic studies, **3**–8
bias in, 3–4
causal inferences in, 4
coherence of, 4
confounding in, 4
definition of skin disease in, 5
on disease burden in population, 5–8
in disease outbreak, 4–5
experimental design, 4
likelihood ratio in, 16–17
probability of disease in, 17, 17f
replication of, 4
types of, 3
validity of, 3, 4
Epidermal growth factor
in hair follicle cycle, 746
heparin-binding, 2108, 2111
in Leser-Trélat sign, 1497
in psoriasis, 174
in sweat, 718
in wound healing, 2344, 2344t
Epidermal growth factor receptor, 1588, 2108
in acanthosis nigricans, 1494
in hair follicle cycle, 746
in squamous cell carcinoma, 989, 990f
in sweat duct, 718
Epidermal growth factor receptor inhibitor therapy, acneiform eruption in, 702
Epidermal necrolysis, 343, **349**–355
body surface area involved in, 352
clinical findings in, 351f, 351–352, 352f
complications in, 353–354
diagnostic approach in, 351, 351f
differential diagnosis in, 353, 353b
drug-induced, 349–355, 359, 359t
high-risk medications in, 350, 350t
in HIV infection, 1934
epidemiology of, 5, 349–350
erosion in, 28, 28f
etiology of, 350, 350t
extracutaneous symptoms in, 352
and graft-versus-host disease, 350
histopathology in, 347, 353, 353f
in HIV infection, 1934
laboratory tests in, 352–353
in lupus erythematosus, 1529
pathogenesis in, 350–351
prevention of, 355
prognosis and clinical course in, 354
scoring system on, 350, 350t, 352, 354
Stevens-Johnson syndrome in. *See* Stevens-Johnson syndrome
treatment of, 354–355, 359
tumor necrosis factor in, 351, 355
of vulva, 681
Epidermal nevus, **1056**–1062
differential diagnosis in, 1058, 1058b, 1062
syndromes in, 1056–1057, 1060–1062, 1505t
clinical features of, 1061, 1061t
systematized, 1057
verrucous, 1057f, 1057t, 1057–1059
inflammatory linear, 180–181, 1057, 1058, 1059, 1062
Epidermis, 43–47, 57–62, **375**–382
adhesion and cohesion in, 447–459
age-related changes in, 964t, 964–966

Epidermis—*continued*
atrophy of, 28
in lupus erythematosus, 1529
in parapsoriasis, 238, 239f
cell types in, 43–44, 57–58, 62
age-related changes in, 964–966
cohesion of, 44, 45–47, **447**–449
differentiation of, 43, 45, 58–59, 384, 384f
in embryonic and fetal development, 69
kinetics of, 43–45, 59
lateral migration of, 377
cholesterol in, 385, 387f, 388f
cornified envelope of, 381–382
dendritic cells in, 107, 109
in atopic dermatitis, 148
in psoriasis, 172
and dermal-epidermal junction, 45, 47–48, 62
differentiation of, 378–381
desmosomes in, 449
gene modification in, 388–390
in ichthyosis, 406–407
proteases in, 391
in scaling, 401, 406–407
in skin barrier function, 387–388
stratification in, 377
embryonic and fetal development of, 66t–67t, 67–69
excoriations of, 31–32, 32f
fatty acids in, 385–386, 388f
functions of, 57, 58t, 61–62
age-related changes in, 964–965, 966
as protective barrier, 383f, 384, 389t
as gene therapy target, 378
growth and proliferation of, 59, 375–378, 383
in acne vulgaris, 690
age-related changes in, 965
in hyperproliferation and hyperplasia, 59f
in psoriasis, 44, 59f, 378, 390, 394–395
regulatory mediators in, 377
in seborrheic dermatitis, 220
in skin barrier function, 387–388
stratification in, 377
homeostasis of, 43–44, 375, 377, 387
regulation of, 391
keratin in, 58–59, 60, 378–381, 387
lamellar bodies in, 385, 385f
Langerhans cells in, 106–107
age-related changes in, 966
layers of, 58f, 58–62, 377, 384, 384f
in barrier function, 390
basal, 58–60, 375, 377, 384, 384f
granular, 61, 384, 384f, 386f
spinous, 60–61, 384, 384f, 386f
stratum corneum, 61–62
lymphocytes in, 104
melanocytes in, 593, 594f
age-related changes in, 965–966
and epidermal melanin unit, 593, 594f
migrant cells in, 43
necrolysis of, **349**–355. *See also* Epidermal necrolysis
and pharmacokinetics of topical drugs, 2097, 2098f, 2100
sensory nerves in, 896
stem cells in, 59, 375–377, 376f
age-related changes in, 964
thickness of, 57, 59f
age-related changes in, 964
tight junctions in, 391
and transepidermal water loss. *See* Transepidermal water loss
transit-amplifying cells in, 375, 376, 377
Epidermodysplasia verruciformis, 1021, 1918–1919
clinical features in, 997, 1021, 1918, 1919f
diagnosis of, 1920
genetic factors in, 997–998, 1021, 1917
histopathology in, 1920, 1920f
papillomaviruses in
sensitivity to, 1005
types of, 277, 996, 997, 1021, 1029, 1914, 1919
squamous cell carcinoma in, 277, 1005, 1021, 1029, 1918, 1919f
Epidermoid cysts, 1063–1064, 1064f, 1079
in Gardner syndrome, 1063, 1079
in limb amputation and prosthesis use, 864f, 864–865
with perioral pigmented follicular atrophoderma and milia, 753t
post-traumatic, 864, 1063
Epidermolysin, 46
Epidermolysis
bullosa. *See* Epidermolysis bullosa
and hyperkeratosis. *See* Epidermolytic hyperkeratosis
in palmoplantar keratoderma, 430
diffuse, 425–426, 426f
Epidermolysis bullosa, 47, 47t, 58, 530t
acquisita, 458, **494**–499
Brunsting-Perry pemphigoid-like presentation in, 496, 497f
bullous-pemphigoid-like presentation in, 496, 497f, 499
cicatricial pemphigoid-like presentation in, 496, 497f
classic presentation in, 496, 496f, 497f
clinical findings in, 495f, 495–498
collagen VII in, 494, 495, 496, 498, 520
complications in, 499
diagnostic criteria on, 499, 499t
differential diagnosis in, 479, 498–499, 499b
diseases associated with, 497–498
epidemiology of, 494
etiology and pathogenesis in, 494–495
histopathology in, 498
HLA system in, 494
immunofluorescence in, 494, 496, 498, 498f
immunoglobulin IgA bullous dermatosis-like presentation, 496–497
laboratory tests in, 498
and lupus erythematosus, 494, 495
treatment in, 499, 499b
anchoring fibrils in, 458, 494, 496, 510, 511
chromosomal disorders in, 80
classification of, 505, 508t
collagen VII in, 88, 458–459, 494, 495, 496, 498, 511–512, 516
collagen XVII in, 456, 510, 516
dermal-epidermal junction in, 47, 62, 495, 498, 505, 506f
diagnostic approach to, 495f, 513f
differential diagnosis of, 513, 514b, 1292b
dystrophic, 62, 458–459, 507f, 508t, 510–512
Cockayne-Touraine type, 508t, 510–511
collagen VII in, 88, 458–459, 511–512, 516, 520
dominant, 510–511, 511f
Hallopeau-Siemens variant, 511
localized, 508t, 511
molecular pathology in, 511–512
Pasini type, 508t, 511
recessive, 88, 508t, 511, 514, 516
squamous cell carcinoma in, 88, 511, 514–515, 1029
treatment in, 514, 515
esophageal, 515, 1451
gene therapy in, 86, 458–459
genetic counseling in, 513–514
hemidesmosomes in, 455, 456, 505, 506f, 507f, 507–509, 508t
inherited, **505**–516
clinical findings in, 505–512
compared to acquired form, 494
diagnosis of, 512–514
differential diagnosis in, 513, 514b
etiology and pathogenesis in, 505
genetic counseling in, 513–514
treatment in, 514–516
junctional, 47, 62, 507f, 508t, 509–510, 516
anchoring filaments in, 457
collagen XVII in, 510, 516, 520
generalized atrophic benign, 508t, 509–510, 510f
gravis (Herlitz), 457, 508t, 509, 509f
localized, 508t, 510
minimus, 510
mitis, 508t, 509, 509f
molecular pathology in, 510
treatment in, 514, 515
lethal acantholytic, 425t
mosaicism in, 83, 84f
with muscular dystrophy, 508, 508t
nail changes in, 783
oral cavity disorders in, 515, 646–647
plectin in, 456
prenatal diagnosis of, 85
psychological aspects of, 515
with pyloric atresia, 508t, 508–509
simplex, 389–390, 505–507, 507f, 508t
generalized (Koebner variant), 505–506, 508f, 508t
hemidesmosomes in, 455
herpetiform (Dowling-Meara), 505, 506, 508f, 508t
localized (Weber-Cockayne), 505, 506, 508t
molecular pathology of, 507
with mottled pigmentation, 507, 508t
of Ogna, 506–507, 508t
superficialis, 507, 508t
treatment in, 514, 515
superficial, 62, 507, 508t
support resources for patient and family in, 515
Epidermolytic hyperkeratosis, 58, 407, 411–414, 430, 1058
clinical features in, 402t, 412, 412f, 412t, 413f, 414f
cyclic ichthyosis with, 414–415
disorders resembling, 414–415
histopathology in, 402t, 408f, 412
mosaic, 412, 414f
palmoplantar, 412, 412f, 412t, 413f
prenatal diagnosis of, 423
stratum granulosum in, 47
treatment in, 423
Epidermophyton floccosum, 1809t
in onychomycosis, 1817, 1817t
in tinea cruris, 1815
in tinea pedis and manus, 1815
Epidermotropism
in parapsoriasis, 238, 238f, 239f
in T-cell lymphoma, 1395
Epididymitis
chlamydial, 1997
gonococcal, 1994
Epigenetics, 83–84

Epigenomics, 84
Epiligrin, and anti-epiligrin cicatricial pemphigoid, 482t, 483
Epiluminescence microscopy, 1143
digital, 1143, 1144f
in dysplastic nevus, 1131
Epilysin, 2345
Epinephrine, 2296–2297
in excisional surgery, 2303
in hair transplantation, 2397
in hymenoptera stings, 2062
in liposuction solution, 2379, 2380t
in regional nerve block, 2298
side effects of, 2297, 2337
sweat gland response to, 719, 720
Epiphycan, 539t
Episome, 1858
Epithelial hyperplasia, focal, oral cavity disorders in, 642t, 652t
Epithelial membrane antigen, 1070t, 1177t
in neurothekeoma, 1177t, 1180
in perineurioma, 1177t, 1180
in schwannoma, 1177t, 1177–1178
Epithelial placodes in hair follicle development, 740–741
Epithelial tumors
benign, **1054**–1067
premalignant, **1007**–1027
Epithelioid cells in granulomatous reactions, 53
Epithelioma
cuniculatum, 1032, 1032f
of Malherbe, calcifying, 1081
Epithelitis, autoimmune, 1578
Epitopes, 322
Eponychium, 2320, 2320f
Epoxy resin, occupational exposure to, 2070, 2070t, 2078t
Epratuzumab in lupus erythematosus, 1533t, 1535
Epstein-Barr virus, 1386, 1848, 1858–1860
in genital ulcers, 1859, 1859f
in Gianotti-Crosti syndrome, 1859, 1860, 1861
in immunocompromised host, 276, 277, 278
latent, 1858
in lupus erythematosus, 1514, 1519
in lymphoproliferative disorders, 278, 1354, 1860
in mononucleosis, 1858–1860
in oral hairy leukoplakia, 277, 644, 651t, 1025, 1860, 1932–1933
in Sjögren syndrome, 1577
transmission of, 1858
tumors associated with, 995t, 1860
Epstein's pearls, 936, 1065
Epulis
fissuratum, 650
giant cell, 650
Equestrian panniculitis, 576
Equipment and instruments
in cryosurgery, 2331, 2331f
in excisional surgery, 2302–2303, 2303f
in hair transplantation, 2397, 2398b
in laser therapy
for pigmented lesions, 2377, 2377t
for skin rejuvenation, 2372t, 2372–2373
for skin resurfacing, 2365–2366
for vascular lesions, 2375, 2375t
in liposuction, 2378, 2379, 2379f
in nail surgery, 2321, 2321b
in sclerotherapy for varicose veins, 2352, 2353t
Erbium:yttrium-aluminum-garnet laser in skin resurfacing, 2365–2366, 2367
complications of, 2368–2369
ERCC1, 980
ERCC2, 78, 1315
in trichothiodystrophy, 420, 757, 1321
ERCC3, 1315
in trichothiodystrophy, 420, 1321
ERCC6 (CSB), 980t
ERCC8 (CSA), 980t
Erdheim-Chester disease, 1424, 1424t, 1429–1430
epidemiology of, 1425
treatment in, 1434
Ergocalciferol, 1206, 2140
in corticosteroid therapy and osteoporosis, 2152
Erosio interdigitalis blastomycetica, 1824, 1825f
Erosions, 28, 28f
genital, 659b
interdigital, in candidiasis, 1824, 1825f
in Jacquet dermatosis, 943
in pustular dermatosis, cicatricial alopecia in, 772t
in toxic epidermal necrolysis, 28, 28f
Ertapenem, 2202
Eruptive nevi, 1105, 1107, 1109
in Spitz nevus, 1114, 1115
Erysipelas, 1692, 1720–1722
clinical findings in, 1720–1722, 1722f
coastal, 2019
differential diagnosis of, 1728, 1728b
in elderly, 973
etiology of, 1721t
histopathology in, 1727
prognosis and clinical course in, 1729
recurrent, 1722, 1729
treatment of, 1729, 1730
Erysipeloid, 1757t, 1765–1766
in occupational exposures, 1765, 2074–2075
treatment of, 1757t, 1766
Erysipelothrix rhusiopathiae, 1765–1766, 2074
treatment of, 2197t
in waterborne infections, 2053t
Erythema, 30, 30f
ab igne, 638, 638f, 1017, 1018, 1029
in occupational exposures, 2078
acral, in chemotherapy, 2178, 2178f, 2178t
annulare centrifugum, 52, **366**–368, 367t
clinical findings in, 367, 367f
differential diagnosis in, 368, 368b
histopathology in, 368, 368f
sub-types of, 367
treatment in, 368
arcuate dermal, 1412
arthriticum epidemicum, 1761
autoimmune annular, 1521
chronicum figuratum melanodermicum, 640
classification of, 343
in cold exposure, 846, 846f, 851
color changes in, 1446
contusiforme, 573
deep gyrate, 367
differentiated from purpura, 33
in drug eruption, 30, 30f
dyschromicum perstans, 247–248, 640
elevatum diutinum, 53, 1375t, 1603, **1616**–1619
Bury type, 1616
clinical features in, 1617f, 1617–1618, 1618f
differential diagnosis in, 294b, 304, 1618
disorders associated with, 1616, 1618–1619, 1619t
histopathology in, 1618, 1618f
in HIV infection and AIDS, 1618, 1619, 1619t
Hutchinson type, 1616
treatment of, 1606, 1619
epidermolytic annular, 402t, 414–415
erysipeloid, in familial Mediterranean fever, 1266
figurate, 366–368, 640
gyratum perstans, 366, 368
gyratum repens, 367t, 1494t, 1500f, 1500–1501
wood-grain pattern in, 1500, 1500f
induratum, 574f, 574–575, 575f, 1773, 1774t
in infants, 937, 937f
annular, 367t, 368
infectiosum, 1855–1858, 1949b
in laser skin resurfacing, 2367–2368, 2369
marginatum, 367t
in rheumatic fever, 1574, 1574b, 1574f
migrans, in Lyme disease, 367t, 1798–1799, 1799f, 1803, 1804
diagnosis and differential diagnosis of, 1799, 1800t
histopathology of, 1799, 1799f
treatment in, 1806t
multiforme, **343**–349
approach to patient with, 345f
classification of, 343
clinical findings in, 344–347, 346f, 347f
complications of, 348
continuous or persistent, 348
differential diagnosis in, 343, 347–348, 348b, 367t, 1734
paraneoplastic pemphigus in, 470, 470f
epidemiology of, 343–344
etiology of, 344
exudativum, 343
in herpes simplex virus infections, 343, 344, 345f, 346–347, 349
recurrent, 1877
histopathology in, 347, 348f
laboratory findings in, 347
in Lyme disease, 1800t, 1802
oral cavity disorders in, 346, 346f, 347, 347f, 647
pathogenesis in, 344
pathologic reactions in, 45, 49
prevention of, 349
recurrent, 348
in sarcoidosis, 1488
Stevens-Johnson syndrome in. *See* Stevens-Johnson syndrome
sub-types of, 343t
target lesions in, 346, 346f
treatment of, 348–349
of vulva, 681
necrolytic migratory, 1495t, 1501f, 1501–1502
differential diagnosis in, 367t, 1502b
genital, 666
in glucagonoma, 306, 666, 1501f, 1501–1502
nodosum, 54f, 55, 571–573
clinical appearance in, 573, 573f
in enteric fever, 1741
etiology in, 572, 572t, 573
migrans, 573
in sarcoidosis, 1486, 1488
treatment in, 573
nodosum leprosum, 1602, 1606, 1790, 1791f, 1791–1792, 1793
thalidomide in, 1791, 1795b, 1796, 2233, 2234, 2234t
palmar, 1451, 1451f
periorbital, in dermatomyositis, 1540, 1542t, 1543f, 1547
in photochemotherapy, 2251–2252

Erythema—*continued*
postoperative, 2341
reactive, 1494t–1495t, 1500–1502
in Sjögren syndrome, 1580
superficial gyrate, 367
symmetric centrifugum, 1521
toxicum neonatorum, 937, 937f
toxin-mediated recurrent perineal, 1719
typhosum, 1741
in ultraviolet radiation exposure
minimal erythema dose in, 809, 2244
standard erythema dose, 810, 810t
and sunburn inflammation, 811–812
Erythematous desquamating disorder, recalcitrant, 1715, 1717
Erythermalgia, 851, 1677–1678. *See also* Erythromelalgia
Erythralgia, 1375t
Erythrasma, 1708, 1708f, 1709f
Erythrocyanosis in cold exposure, 849, 849f
Erythrocyte sedimentation rate in dermatomyositis, 1546
Erythroderma, 30–31, 31f, 1449
desquamativum, 221
in HIV infection and AIDS, 1932
ichthyosiform, 429
bullous, 83, 412
in CHILD syndrome, 403t, 419–420
congenital, 402t, 409, 410, 411, 412
idiopathic, exfoliative dermatitis in, 230t
in mycosis fungoides, 1389, 1390f
psoriatic, 179–180, 180f
radiation therapy in, 2280t, 2281
scarlatiniform, 1696, 1718
in sepsis, 1746, 1747, 1747b
in Sézary syndrome, 31, 31f, 1391
systemic effects of, 1449
in T-cell lymphoma, 1389, 1390f, 1398–1399
in toxic shock syndrome, 1746
Erythrodontia in congenital erythropoietic porphyria, 642t, 647t, 1248, 1248f
Erythrogenic exotoxin in streptococcal infections, 1704
Erythrokeratodermia, 417–418, 429, 430
with ataxia, 417, 418
en cocardes, 417
progressive symmetric, 403t, 418, 429
variabilis, 402t, 417f, 417–418, 429
Erythroleukoplakia, oral, 648, 1027
Erythromelalgia, 851, 1450, 1677–1678
anhidrosis in, 728
clinical findings in, 851, 1450, 1678, 1678f
differential diagnosis in, 1678
disorders associated with, 1375t, 1450, 1678
etiology and pathogenesis in, 851, 1677–1678
idiopathic, 851
in lupus erythematosus, 1528
in polycythemia vera, 1378
primary, 851, 1450, 1677, 1678
and Raynaud phenomenon, 1678
secondary, 851, 1450, 1677, 1678
treatment of, 851, 1450, 1678
Erythromelanosis follicularis faciei et colli, 749–750
Erythromycin, 2113t, 2113–2114, 2200–2201
in acne vulgaris, 697, 698, 2113–2114
in bacillary angiomatosis, 1754
in HIV infection, 1936
in bartonellosis, 1754
in HIV infection, 1936
in chancroid, 1986, 1986t
in chlamydial infection, 1998b
dosage of, 2195t
pediatric, 949t–950t
in erythrasma, 1708
in granuloma inguinale, 1993b
interaction with other drugs, 2238, 2239t, 2240t
in Lyme disease, 1806t
in lymphogranuloma venereum, 1989, 1990b
mechanism of action, 2200
in perioral dermatitis, 711, 711b
pharmacokinetics of, 2200
in pityriasis lichenoides, 243b
in staphylococcal infections, 1697, 1698b
in streptococcal infections, 1705, 1707, 1707b
in syphilis, 1974, 1975
in treponematosis, endemic non-venereal, 1982
Erythronychia, longitudinal, 783
Erythroplakia, 1025–1027
oral, 648, 1024, 1026–1027
and leukoplakia, 648, 1027
squamous cell carcinoma in, 1027
Erythroplasia, 1025–1027. *See also* Erythroplakia
of Queyrat, 648, 663, 673, 673f, 1023f, 1023–1024
differential diagnosis of, 674b
radiation therapy in, 2282, 2282t, 2283
Eschar, 32, 32f
in burns, 32, 32f
Escherichia coli, 1691
in botryomycosis, 1779t, 1785
in cellulitis, 1742
in gas gangrene, 1726
in hemolytic-uremic syndrome, 1382
Escitalopram, 918t
Esophagus, 1451–1452
cancer of, 1451, 1452
palmoplantar keratoderma in, 428, 428f
cicatricial pemphigoid of, 482, 484t, 1451
treatment of, 485, 485b
epidermolysis bullosa of, 515, 1451
lichen planus of, 1451
Esterification of retinol, 2108–2109, 2110f
Esthiomene in lymphogranuloma venereum, 1988
Estradiol, 967, 1479
in pattern hair loss, 769
Estriol, 1479
Estrogen, 1479–1480
in acne vulgaris, 692, 1479
and hormone therapy, 698
in dermatitis, 1480
in hereditary angioedema, 336
hyperpigmentation from, 636, 1480
in lupus erythematosus, 1480, 1516–1517
in menopause, 967–968, 1479, 1480
in pattern hair loss, 769
in porphyria cutanea tarda, 1235, 1236, 1237, 1241
in spider nevi, 1451
ET. *See* Endothelin
Etanercept, 2223t, 2227, 2230
in Behçet disease, 1625b
complications of, 2227–2228
in dermatomyositis, 1552
dosage of, 2230
in exfoliative dermatitis, 231
in graft-versus-host disease, 266t
in hyper-IgD syndrome with periodic fever, 1269
indications for, 2227
initiation and monitoring of therapy with, 2227
pharmacokinetics of, 2227
in psoriasis, 188t, 193, 2230
and arthritis, 205
in rheumatoid arthritis, 1573, 2227
in tumor necrosis factor receptor-associated periodic syndrome, 1270
Ethambutol in tuberculosis, 1775t
Ethanol, intake of. *See* Alcohol use and alcoholism
Ethanol, topical
in chemical peels, 2370t
in methicillin-resistant staphylococcal infections, 875
in preoperative skin preparation, 2295–2296
Ethanolamine, 2187, 2190
Ethinyl estradiol
in acne vulgaris, 698
in hidradenitis suppurativa, 737
Ethnic and racial differences
in allergic contact dermatitis, 138
in irritant contact dermatitis, 397
in nevomelanocytic nevus, acquired, 1104–1105
in photoaging, 969
in post-inflammatory hyperpigmentation, 2111, 2142f, 2142–2144, 2143f, 2144f
in sarcoidosis, 1485
in sirolimus therapy, 2221
in squamous cell carcinoma, 1028
in topical drug therapy, 2111, **2142**–2146
in ultraviolet radiation as carcinogen, 999
Ethylenediamine, 2187, 2190
occupational exposures to, 2070
Ethylenediaminetetraacetic acid, in dermatomyositis, 1552
Ethylhexyl dimethyl PABA in sunscreens, 2139t, 2140
Ethylhexyl methoxycinnamate in sunscreens, 2139, 2139t, 2140
Ethylhexyl salicylate in sunscreens, 2139t
Etidocaine in local anesthesia, 2296t
Etoposide in Langerhans cell histiocytosis, 1423–1424
Etretinate, 2181
dosing regimens, 2184
in hidradenitis suppurativa, 2183–2184
initiation and monitoring of therapy, 2184
in lichen planus
cutaneous, 254, 254b
oral, 253, 253b
pharmacokinetics of, 2182
in pityriasis rubra pilaris, 2183
in premalignant skin lesions, 2184
in psoriasis, 2183
in combination with phototherapy, 2245, 2254
in squamous cell carcinoma prevention, 1036
in T-cell lymphoma, 2183
Eumelanin, 600, 601f, 1004
in photoprotection, 813
synthesis of, 601–602, 604
Eumelanosomes, 596, 596f
Eumycetoma, 1779t, 1783, 1832–1833, 1834f
laboratory tests in, 1833, 1834t
European blastomycosis, 1842–1843
European Organization for Research and Treatment of Cancer lymphoma classification, 1386, 1387t, 1394
Eurotrombicula alfreddugesi, 2032, 2032t
Eurotrombicula splendidus, 2032, 2032t
Evaporation
heat loss in, 835
in topical application of medications, 2098

Evelyn-Malloy method in methemoglobin measurement, 1379
EVER1 and EVER2 in epidermodysplasia verruciformis, 998, 1021, 1917
Everolimus, 2217, 2221–2222
  complications of, 2222
  dosing regimen, 2221t
  pharmacokinetics of, 2221
Evidence-Based Dermatology, 12
Evidence-based medicine, **8**–18
  applied to specific patient, 18
  best evidence in, 9–12
  compared to reliance on personal experience, 10–11
  critical appraisal of evidence in, 12–18
    on diagnostic tests, 13t, 16–17
    on harmful effects, 14t, 17–18
    on therapy and prevention, 10, 13t, 13–16
  in fungal infections, 2216–2217
  hierarchy of evidence in, 9, 10t
  history of, 8–9
  meta-analysis in, 9–10
  sources of evidence in, 9, 11–12
  systematic review in, 9–10, 10t
    critical assessment of, 10, 11t
Exanthema, 38, **1851**–1872
  asymmetrical periflexural of childhood, 1849, 1871–1872, 1872b, 1872f
  in drug eruptions, 356f, 356–358
  subitum, 1867b
    in herpesvirus-6 infections, 1864–1866, 1867b
    in herpesvirus-7 infections, 1866–1867, 1867b
  unilateral laterothoracic, 1871–1872, 1872b, 1872f
  in viral infections, 1848, 1849, 1849t, 1851–1872
Excisional surgery, 2302–2314
  in actinic keratosis, 1013
  in alopecia reduction, 2401–2402
  anesthesia in, 2303
  in basal cell carcinoma, 1040–1041, 2306f, 2307f
    full-thickness skin graft in, 2313f
    incomplete resection in, 1041, 1042f
    rotation flap in, 2311f
    split-thickness skin graft in, 2314f
  complications of, 2312–2313
  crescentic technique in, 2307–2308
  in dysplastic nevus, 1133
  elliptical excision in, 2304–2308
  in epithelioid sarcoma, 1163
  equipment in, 2302–2303, 2303f
  flaps in, 2308–2310
  in genital warts, 664b
  in hemangioma
    of eyelid, 2306f
    of infants, 1169
  incision technique in, 2304–2305, 2305f
  indications for, 2302
  in keratoacanthoma, 1053
  lazy-S technique in, 2308, 2308f, 2401
  in lymphoid hyperplasia, 1408, 1408b
  in melanoma, 1153, 1153f, 1154, 1156
  in Mohs micrographic technique, 2315–2319
  monitoring and follow-up in, 2313
  in nevomelanocytic nevi, congenital, 1102
  operative techniques in, 2303–2308
  outcome assessment in, 2311–2312
  in Paget disease, extramammary, 1097–1098
  partial closure in, 2308
  patient positioning in, 2302
  postoperative care in, 2313
    patient instructions in, 2313, 2314b
  revision of standing tissue cones in, 2307, 2307f
  risks and precautions in, 2302
  in Spitz nevus, 1116
  in squamous cell carcinoma, 1034–1035
  staged procedures, 2308
  sutures in, 2304, 2304f, 2305–2307, 2306f, 2307f
    removal of, 2306–2307
  wound healing by second intention in, 2303–2304
Excited state molecules, 804, 804f
  in photosensitivity, 805
  singlet and triplet, 804, 804f
Excoriations, 31–32, 32f
  in acne, 701, 916
  neurotic, 916, 916f
Excretion of drugs, pharmacokinetics of, 2237, 2237t
Exercise
  anaphylaxis in, 335, 877
  histamine-mediated reactions in, 877
  in peripheral arterial disease, 1670, 1670b
  and skin problems in athletes, **873**–878. *See also* Athletes
  urticaria in, 877
Exerpta Medica Database (EMBASE), 11, 12
Exfoliatin in staphylococcal infections, 1696, 1697, 1710t
Exfoliative dermatitis, **225**–232
  atopic, 153, 226
  chronic idiopathic, 226, 231
  clinical findings in, 228–231
  complications in, 231
  diagnostic approach to, 228f
  differential diagnosis in, 225, 227b
  diseases associated with, 225, 226t, 229, 230t
  drug-induced, 225, 227t, 228, 230t, 231, 232
  epidemiology of, 225
  etiology and pathogenesis of, 225–228
  histopathology in, 229
  mortality rate in, 231
  neonatal, 1712
  palmoplantar keratoderma in, 228, 229f
  paraneoplastic, 230t
  periorbital, 228, 229f
  prevention of, 232
  prognosis and clinical course in, 231
  and T-cell lymphoma, 225, 226–227, 228, 230t, 231, 232
  treatment of, 231–232, 232b
Exfoliative toxins in staphylococcal infections, 1696, 1697, 1710t, 1710–1714
Exocytosis in melanosome transport, 603
Exogen, 743f, 746, 754
  definition of, 754t
  as therapy target, 754
Exons, 74, 75, 76, 1301
Exophiala jeanselmei, 1834t, 1835
Exophthalmos in Langerhans cell histiocytosis, 1419
Exosomes, 110
Exostosis, subungual, 787, 787f
Exotoxins, 1691
  in diphtheria, 1767, 1768
  staphylococcal, 1694, 1703, 1748
  streptococcal, 1704, 1710t
    in Kawasaki disease, 1628
    in toxic shock syndrome, 1716
Experimental studies, 4
Expert opinions, 11
Exsiccation eczematid dermatitis, 399
Extensor lesions, 38
Extracellular matrix, 54–55, 61
  in wound healing, 2343, 2344, 2345
Extracellular matrix protein 1 (ECM-1), 77
  in lichen sclerosus, 547
  in lipoid proteinosis, 1288–1289, 1291
Extracorporeal photochemotherapy, 1399, 2259. *See also* Photopheresis
Extraocular implants as body art, 886
Extrapyramidal symptoms from antipsychotic drugs, 917
Extravasation
  of cytotoxic drugs, 2180, 2180f
  of sclerosing solutions, 2354
Exudates
  encrusted, 31, 31f
  in pustules, 33
Eye disorders
  in abused child, 928
  in actinic keratosis, 1009
  in albinism, oculocutaneous, 598, 608–612, 615
  in alkaptonuria, 1226, 1226f
  in ataxia-telangiectasia, 1361f, 1361–1362
  in atopic dermatitis, 152
  in Behçet disease, 1622–1623, 1623f, 1624
  in cat-scratch disease, 1750, 1751
  in Chédiak-Higashi syndrome, 1367
  in chlamydial infections, 1997
  in cicatricial pemphigoid, 481–482, 482f, 483–484, 484t, 485b
  in Cockayne syndrome, 1320
  in Degos disease, 1649
  in dermatomyositis, 1544t
  in drug abuse, 925
  drug-induced
    from antimalarial drugs, 1533, 1551, 2160, 2161–2162, 2162t
    from corticosteroids, 2106, 2150t, 2151t
    from dapsone, 2156
    from retinoids, 2185
  in epidermal necrolysis, 352, 352f, 353, 354
  in epidermal nevus syndromes, 1061, 1061t
  in epidermolysis bullosa, 515
  in erythema multiforme, 346, 347f, 348
  in erythropoietic porphyria, congenital, 1248
  in exfoliative dermatitis, 228, 229f
  in Fabry disease, 1284t, 1285
  in gonorrhea, 1995
  in hemangioma, periocular infantile, 1166, 1167f
  in herpes simplex virus infections, 1879
    treatment of, 1882b, 1883
  in herpes zoster virus infections, 1890
  in hypereosinophilic syndromes, 309f
  in ichthyosis
    lamellar, 410, 410f
    X-linked recessive, 408, 409f
  in Kawasaki disease, 1628, 1630, 1631
  in laser use, 2268t, 2268–2269, 2277
  in leprosy, 1790, 1794
  in lichen planus, 249
  in linear IgA dermatosis, 488, 489
  in lipoid proteinosis, 1289, 1290, 1291f
  in liver disease, 1451
  in loiasis, 2018, 2019, 2019f
  in Lyme disease, 1803
  in lymphatic malformations, 1661
  in lymphogranuloma venereum, 1988
  in Marfan syndrome, 1303
  in melanoma, 1133
  in meningococcal conjunctivitis, 1732, 1734
  in molluscum contagiosum, 1912
  in monkeypox virus infections, 1907

Eye disorders—*continued*
in neurofibromatosis type 1, 1334–1335, 1337–1338
in neurofibromatosis type 2, 1338
in nevus of Ota, 632, 633f
in oculo-dento-digital dysplasia, 425t
in ophthalmia neonatorum, 1995, 1997
in photochemotherapy, 2258
in pseudoxanthoma elasticum, 1305, 1307–1308
in psoriatic arthritis, 201
in reactive arthritis, 211, 213, 214
in relapsing polychondritis, 1568
in reticulohistiocytosis, multicentric, 1431
in rheumatoid arthritis, 1572t
in riboflavin deficiency, 1209
in rosacea, 705, 706f, 707f, 709
in sarcoidosis, 1488, 1491t
in sebaceous carcinoma, 1086, 1087
in Sjögren syndrome, 1579, 1581, 1581t
treatment of, 1582t, 1582–1583
in Sjögren-Larsson syndrome, 416
in smallpox, 1902, 1903
in smallpox vaccination, 1905
in Sturge-Weber syndrome, 1653, 1655f
in syphilis, 1962
congenital, 1968t, 1969, 1969f
and HIV infection, 1970
in neurologic disorders, 1965, 1966–1967
in trichothiodystrophy, 1321
in tuberous sclerosis, 1329
in tularemia, 1758
in tumor necrosis factor receptor-associated periodic syndrome, 1269
in tyrosinemia, 428, 430, 1220, 1221f
in varicella-zoster virus infections, 1890, 1894, 1896
in vitamin A deficiency, 1204, 1204f
in vitiligo, 619
in Wegener granulomatosis, 1612t
in Werner syndrome, 1323
in xanthogranuloma, juvenile, 1426–1427, 1427–1428
in xeroderma pigmentosum, 1316f, 1316–1317, 1318
Eyelashes, pediculosis pubis of, 2036, 2036f
Eyelids
allergic contact dermatitis of, 140
cysts in palmoplantar keratoderma, 430
hemangioma of, 2306f
hyperpigmentation of, 639
nevomelanocytic nevi of, congenital, 1100, 1100f
ptosis from botulinum toxin, 2393
seborrheic dermatitis of, 222b, 224
surgical anatomy of, 2291
Eyeworm infection, African, 2018

F

Fabric and clothing as photoprotective measure, 2141, 2141t
Fabry disease, **1281**–1288
angiokeratoma in. *See* Angiokeratoma, in Fabry disease
carriers of, 1281
clinical findings in, 1282–1285
diagnosis of, 1285
differential diagnosis of, 1285b, 1285–1287, 1286t–1287t
epidemiology of, 1281
etiology and pathogenesis in, 1281, 1282f
genetic counseling in, 85, 1288
histopathology in, 1283f, 1284, 1284f
natural history of, 1283f
prognosis and clinical course in, 1287
quality of life issues in, 1285
treatment of, 1287b, 1287–1288
enzyme replacement therapy in, 1287b, 1287–1288
Face
allergic contact dermatitis of, 137, 137f, 138f, 140
blood vessels in, 2293–2294, 2294f
bloodhound features in cutis laxa, 1308f, 1309
botulinum toxin injections in, 2388–2394
cosmetic units and landmarks in, 2289–2290, 2290f
danger zones in, 2290–2291, 2291f
dermatomyositis of, 1540, 1543f, 1543t
excisional surgery of, 2302–2314
herpes simplex virus infections of, 1874–1875, 1875f
in hyper-IgE syndrome, 1366, 1366f, 1367t
lymphatics of, 2294
motor nerves in, 2293
muscles in, 2292–2293, 2293f
photoaging of, 2363
rejuvenation of skin, 2268, 2273, 2372–2374
relaxed skin tension lines in, 2290, 2290f
in excisional surgery, 2304
resurfacing of skin, 2364–2371
Riehl melanosis of, 639
scleromyxedema of, 1565, 1565f
sensory nerves in, 2292, 2292f
anesthetic block of, 2298
and stinging sensation from cosmetic products, 2360
skin types of, 2357–2364
combination, 2364
oily or dry, 2357–2359
pigmented, 2362–2363
sensitive or resistant, 2359–2362
wrinkled or tight, 2363–2364
soft tissue augmentation of, 2380–2388
spider nevus of, 1451
surgical anatomy of, 2289–2294
tuberous sclerosis of
angiofibroma in, 1326, 1329, 1329f
fibrous plaque in, 1326, 1329f
wrinkling of, 2363–2364
Facial artery, 2293
Facial nerve
in herpes zoster virus infections, 1890f
in Lyme disease, 1802, 1803
in sarcoidosis, 1489
surgical anatomy of, 2293
temporal branch of, 2293
as danger zone in surgery, 2290–2291, 2291f
Factitious disorders
dermatitis artefacta, 915f, 915–916
panniculitis, 580
Factor B, 324
Factor D, 324
in lipodystrophy, 587
Factor H, 328, 1371t
Factor VIII-related antigen, 1587
Factor XIIIa, 64
Failure to thrive in protein-energy malnutrition, 1202
Famciclovir, 2205
dosage of, 2205t
pediatric, 947t
in herpes simplex virus infections, 1880, 1881b–1882b, 1883, 2205, 2205t
in prevention, 1884
in varicella-zoster virus infections, 1894, 1895, 1895t, 1896, 2205, 2205t
Family, domestic violence in, **930**–931
Famine fever, 1948
Famotidine, 2191–2193, 2192t
complications of, 2192
interaction with other drugs, 2192
Fanconi anemia, 1311, 1313t, **1323**–1324
clinical features in, 982t, 1323–1324, 1324f, 1374t, 1505t
diagnosis of, 983t, 1324
genetic factors in, 982t, 983t, 1324
malignancies associated with, 1505t
resources on, 1324
Fanning injection technique in soft tissue augmentation, 2380, 2381f
FAPA syndrome, 681
Farnesyl transferase in neurofibromatosis, 1332
Fas and Fas ligand, 104
in lichen planus, 245
in T-cell lymphoma, 1387
in ultraviolet radiation exposure and basal cell carcinoma, 1037
Fascia, 2291
Fasciitis
borrelial, 1801
eosinophilic, 54, 286, 316f, 545
in Lyme disease, 1801
in graft-versus-host disease, 264
necrotizing, 1692, 1746–1747
cervical, 1725
craniofacial, 1725
in decubitus ulcers, 881
in diabetes mellitus, 1465, 1724
in drug abuse, 926, 1724
in elderly, 973
histopathology in, 1727
in immunocompromised host, 273, 273f, 1724
in *Klebsiella* infections, 1742
laboratory studies in, 1727
prognosis and clinical course in, 1729
in *Pseudomonas* infections, 1737
in *Salmonella* infections, 1741
treatment of, 1730, 1743
type I, 1724, 1724f
type II, 1730
in *Vibrio* infections, 1763–1764
nodular, 554
Fasciola gigantica, 2013t, 2021t, 2026
Fasciola hepatica, 2013t, 2021t, 2026
Fascioliasis, 2012t, 2026
differential diagnosis of, 2013t, 2021t
treatment of, 2014t
Fat
autologous, in soft-tissue augmentation, 2382t, 2386–2387, 2387f
subcutaneous. *See* Subcutaneous fat
Fat deposits as cellulite, 2279
Fat embolism syndrome, 1454
Fatigue in dermatomyositis, 1540
Fat-soluble vitamins, 1204–1208
Fatty acids
essential, 2286
in acne vulgaris, 691–692
deficiency of, 386, 1203–1204
functions of, 2286
sources of, 2286
free, 385–386, 388f
deficiency of, 385–386
in sebum, 688f, 688–689
in stratum corneum, 385–386, 388f, 2357
Fatty alcohol:NAD oxidoreductase deficiency, 417
Fatty aldehyde dehydrogenase activity, 417
Favre-Racouchot syndrome, 703

Favus, 1811t, 1812–1813, 1813f
treatment of, 1818–1819
FBLNs. *See* Fibulins
FBNs. *See* Fibrillins
Febrile neutrophilic dermatosis, acute, 53, **289**–295. *See also* Sweet syndrome
Felon (whitlow), 1702f
herpes simplex, 1702
staphylococcal, 1702–1703
Felty syndrome, 1571, 1572f
Female genital disorders, **675**–683. *See also* Vulvar disorders
abscess in, 682
aphthae, 681–682
in candidiasis, 1824, 1827–1828
in cicatricial pemphigoid, 482, 681
clinical findings in, 675b, 675–676
in contact dermatitis, 676, 677–678
in Crohn disease, 682
differential diagnosis in, 676, 676b
drug-induced, 677–678, 681
epidemiology of, 675
in epidermal necrolysis, 354
etiology and pathogenesis in, 675
fissure of vulva, 679–680, 680f
in herpes simplex virus infections, 1875–1876, 1876f
in hidradenitis suppurativa, 682, 682f, 736f, 737, 737f
laboratory tests in, 676
in lichen planus, 249, 680b, 680f, 680–681
in lichen sclerosus, 547, 548f, 550, 678–679, 679b, 679f
in lichen simplex chronicus, 677, 677f
in Paget disease, 1094
clinical findings in, 1095
prognosis and clinical course in, 1096
treatment of, 1097
in pemphigus vulgaris, 681
prognosis and clinical course in, 676
pruritus in, 683
in psoriasis, 678, 678f
in reactive arthritis, 210, 211
in squamous cell carcinoma, 1031, 1032
treatment in, 676–677
vulvodynia in, 682–683
Femoral artery atherosclerosis, 1667
treatment of, 1671
Fenestrae, 1588
Ferguson-Smith type of keratoacanthomas, 989t, 1050, 1051
Ferritin levels in pattern hair loss, 767–768
Ferrochelatase, 1230t, 1231f
in erythropoietic protoporphyria, 1243–1244
in heme biosynthesis, 1230
Ferrous gluconate pediatric dosage, 954t
Ferrous sulfate pediatric dosage, 954t
Fetus. *See* Embryonic and fetal development
Fever
in acne fulminans, 701
in acute neutrophilic dermatosis, 53, **289**–295. *See also* Sweet syndrome
hereditary recurrent, 1268b
hyperhidrosis in, 726
in Kawasaki disease, 1628, 1630, 1631, 1632
Fexofenadine, 288, 2188, 2189t, 2191
pediatric dosage, 953t
FGF. *See* Fibroblast growth factor
Fiberglass exposure, skin cancer associated with, 987, 987t
Fibrillins, 68t, 70, 535, 535t, 536f
FBN1, 63, 535, 535t
in Marfan syndrome, 1302, 1303
in systemic sclerosis, 1554t
FBN2, 535, 535t
in Marfan syndrome, 1302
FBN3, 535t
in photoaging, 968
Fibrillopathies, 1302
Fibrin, 1641, 1642
in wound healing, 2342, 2343
Fibrinogen, 1641, 1642
Fibrinoid degeneration, 530
Fibrinopeptides in wound healing, 2343
Fibroadenoma of breast, 1071
Fibroblast(s)
in cryotherapy, 2330, 2330t
in dermis, 63–64
disorders of, 1563t
collagen overproduction in, 1562, 1563, 1563t
mucin overproduction in, 1562, 1563t, 1564
scleredema in, 1562–1564
scleromyxedema in, 1564–1566
in elastin biosynthesis, 534
functions of, 64, 1562
growth factor stimulating, 604–605
in psoriasis, 173
in wound healing, 2344, 2344t, 2345
impaired, 2348
of skin grafts, 2347
Fibroblast growth factor
acidic, 1596
basic, 604–605, 1596
FGF1, 1596, 1597t
FGF2, 1596, 1597t, 1598
FGF5, 68t
in hair follicle cycle, 746
FGF23 in tumoral calcinosis, 1296
in wound healing, 2344, 2344t
Fibroblast growth factor receptors
FGFR1, 689
FGFR2, 689, 690, 744
FGFR3, 689
in acanthosis nigricans, 1494
FGFR4, 689
in sebaceous gland activity and sebum production, 689–690
Fibroblastoma
desmoplastic, 555
giant cell, 1161
Fibrodysplasia ossificans progressiva, 1296
Fibroepithelioma of Pinkus, 1038
differential diagnosis in, 1040b
histopathology in, 1039
Fibrofolliculoma, 555, 1080–1081, 1083
Fibrokeratoma of nails, 787, 787f
in tuberous sclerosis, 1327
Fibrolipoma, 1191, 1191f
Fibroma
calcifying aponeurotic, 551–552
collagenous, 555
irritation, 650
of nails, 787, 787f
differential diagnosis in, 1330b
in tuberous sclerosis, 1326–1327, 1330, 1330f
oral, in tuberous sclerosis, 1327–1328
perifollicular, 1081
pleomorphic, 555
soft, 554f, 554–555
Fibromatosis, 550–553
adult onset, 552–553
aggressive, 552, 553
in children and infants, 68t, 550–552
aggressive, 552
digital, 551, 551f
in myofibromatosis, 552
colli, 550–551
desmoid tumors in, 553, 553f
hyaline, 68t, 552
inclusion body, 551
pachydermodactyly in, 553
palmar, 552
of penis, 552
Fibromodulin, 539t
Fibromucinoses, 1563t
Fibronectin, 63, 287
Fibrosclerosing disorders, 1563t
Fibrosing disorders, 1563t
nephrogenic, 1460, 1565
Fibrosis
cystic. *See* Cystic fibrosis
eosinophils in, 316
of liver in methotrexate therapy, 191, 1458, 2165–2166, 2166t
in sarcoidosis, 1490
submucous, 648
in systemic sclerosis, 1555, 1557
treatment of, 1560t, 1561
Fibrous tumor
of dermis, malignant, **1159**–1163
solitary, 555–556
Fibroxanthomas, 64
atypical, 1161–1162
clinical findings in, 1161, 1161f
differential diagnosis of, 1160b
histopathology in, 1161f, 1161–1162
treatment of, 1162
Fibula nolitangere, 2046, 2046f
Fibulins, 535t, 536, 536f
age-related changes in, 966
in basement membranes, 454
in cutis laxa, 536, 1308, 1308f, 1309
FBLN4, 535t, 536, 1308, 1308f
FBLN5, 535t, 536, 1308, 1309
age-related changes in, 966
Fick's laws, 2097
Fiddleback spiders, 2056f, 2056–2057
Field cancerization concept, 1024
Fifth disease, 1855–1858, 1949b
Filaggrin, 61, 68t, 69, 387, 390f, 2357
age-related changes in, 965
in atopic dermatitis, 149, 393–394
in cornified envelope, 381, 382t
gene, 76, 83, 407, 408
in ichthyosis vulgaris, 407, 408
overexpression of, 390
Filariasis, 2012t, 2017t, 2017–2021
blinding, 2019
Loa loa, 2018–2019
lymphatic, 2017–2018, 2021t
lymphedema in, 1685
public health programs on, 21
treatment of, 2014t, 2018
Films, transparent, as dressings, 2345, 2346t
Finasteride, 754
in hidradenitis suppurativa, 737
in pattern hair loss, 768b, 768–769, 2395
Fingers. *See* Hand
FIP1L1-PDGFRA in hypereosinophilic syndromes, 307, 309, 310, 311F
Fire accidents
in electrosurgery, 2335
in laser procedures, 2269
Fire ant stings, 2062
Fire coral, 877, 2045–2046, 2046f
Firjal. *See* Syphilis, endemic
First aid
in fish spine envenomation, 2052
in jellyfish stings, 2044, 2044t
in sea urchin injuries, 2047
in snake bites, 2040–2041, 2041t

Fischer-Jacobsen-Clouston syndrome, 429
Fish
bite wounds from, 2052
gnathostomiasis from, 2022
and seafood ingestion and poisoning, 2053
with venomous spines, 2050–2052
Fish oils, 2286, 2287
Fissures, 32, 32f
in contact dermatitis, 32, 32f
in nails, longitudinal, 782
in tongue, 643, 643f
in vulva, 679–680, 680f
Fistula
arteriovenous, 1663
pulmonary, 1453–1454
treatment of, 1666
auricular congenital, 1066
in decubitus ulcers, 881
of nose, dorsal, 1066
Fitz-Hugh-Curtis syndrome, 1995, 1997
Fitzpatrick sign, 39t
Fixed drug eruptions, 359f, 359–360
FK-506. *See* Tacrolimus
FK-506 binding protein-12 (FKBP-12), 2217, 2221
FKHR in rhabdomyosarcoma, 1176
Flag sign in protein-energy malnutrition, 1203, 1203f
Flame figures, 312, 312t
in Wells syndrome, 312, 312f
Flaps, 2308–2310
advancement, 2308–2309, 2309f
in Mohs micrographic surgery repair, 2316, 2317f, 2319f
in nail fold reconstruction, 2329
necrosis of, 2338, 2339f
postoperative care in, 2310
rotation, 2309–2310, 2310f, 2311f
transposition, 2310, 2312f
trapdoor effect in, 2312–2313
Flashlamps, 2263
in intense pulsed light therapy, 2263, 2265t
safety considerations in, 2269
Flat skin lesions, 29–31
Flat warts, 1915
clinical findings in, 1917–1918, 1918f
differential diagnosis in, 1921b
histopathology in, 1920, 1920f
Flavin-adenine dinucleotide, 1209
Flavin mononucleotide, 1209
Flaxseed oil, 2286, 2287
FLCH in Birt-Hogg-Dubé syndrome, 988, 989t
Fleas, 2061f, 2061–2062, 2063
and cat scratch disease, 1750
and endemic typhus, 1943t, 1948
and plague, 1758, 1759
Flegel disease, 567
Flesh-eating bacteria, 1724
Flexor lesions, 38
in X-linked recessive ichthyosis, 408, 409f
FLG, 76
in ichthyosis vulgaris, 407, 408
FLJ39501 in ichthyosis, 411t
Floret cells in pleomorphic lipoma, 1193, 1193f
Flower cells in adult T-cell leukemia, 1925, 1925f
Fluconazole, 2213, 2214–2215
adverse effects of, 2215
chemical structure of, 2214f
in coccidioidomycosis, 1840
in cryptococcosis, 1843
in dermatophyte infections, 1818b, 1819, 1820
dosage of, 2215
pediatric, 950t, 954, 2215
indications for, 2215, 2215b
interaction with other drugs, 2215, 2239, 2239t, 2240t
mechanism of action, 2214
in onychomycosis, 1818t, 1820
pharmacokinetics of, 2215
in *Pityrosporum* folliculitis, 1830
in tinea versicolor, 1830
Flucytosine
in chromoblastomycosis, 1834
in cryptococcosis, 1843
Fluegelzellen cells, 742
Fluence, 2266
Fluid-filled lesions, 32–33
Fluid replacement
in epidermal necrolysis, 354
in rotavirus infections, 1871
Fluke infections, 2011, 2026
Flunitrezepam, 922
Fluocinolone acetonide in oral lichen planus, 253
Fluocinonide in oral lichen planus, 253
Fluorescent antibody detection, 1693
in chlamydial infections, 1997, 1997f
in syphilis, 1971
in viral infections, 1850
Fluorescent lamps, 800, 801f
in photodynamic therapy, 2260
in phototherapy, 800, 801f, 2243–2244, 2251
Fluorescent treponemal antibody-absorption test in syphilis, 1971, 1972, 1973t
Fluoroquinolones, 2195t, 2201, 2201b
adverse effects of, 2196t, 2201
in children, 946
indications for, 2201b
mechanism of action, 2201
pharmacokinetics of, 2201
5-Fluorouracil, 2122
in actinic keratosis, 1013, 1013b, 1014f, 2122
in basal cell carcinoma, 1041, 2122
in Bowen disease, 1023, 1023b
in dysplastic nevus, 1133
indications for, 2122
in Paget disease, 1098
in porokeratosis, 445, 445b
side effects of, 2122
in warts, 664b, 1922
Fluoxetine, 918t
interaction with other drugs, 2239t, 2240t
Flushing
color changes in, 1377, 1446
differential diagnosis in, 706, 1377
disorders associated with, 1375t, 1377, 1446
in homocystinuria, 1304
in metastatic tumors, 1457
Flutamide
in acne vulgaris, 698
in androgen excess, 1482
Fluticasone propionate in atopic dermatitis, 155
Fluvoxamine, 918t
Fly bites, 2059–2060
Foam cells in xanthoma, 1272, 1274f
Foam dressings, 2345, 2346t
Foam sclerotherapy for varicose veins, 2352–2353, 2354f
Focal dermal hypoplasia, 530t
of Goltz, 1346–1348, 1347f
Fogo selvagem, 460, 465
exfoliative dermatitis in, 230t
Folded luggage sign in mycosis fungoides, 1389, 1391f
Folic acid, 1211
deficiency of, 1377, 1446, 1456
in methotrexate therapy, 191
food sources of, 1211, 1377
in homocystinuria, 1304
in methotrexate therapy, 191
metabolism inhibition, 2163
supplementation of, 191, 2165, 2166
supplemental, 1377
in methotrexate therapy, 191, 2165, 2166
Folinic acid in methotrexate therapy, 2166–2167
Follicle center lymphoma
in *Borrelia* infections, 1802
primary cutaneous, 1386, 1399–1400, 1400f
treatment of, 1401
Follicle mites, 2032, 2032t
Follicle-stimulating hormone levels in leprosy, 1790, 1793
Follicular degeneration syndrome, 772t, 773
Follicular tumors, 1068, 1069t, 1070t, 1079–1085
differential diagnosis in, 1068
in infundibulum, 1084
Follicular unit transplantation for hair loss, 2394–2402
extraction technique in, 2398–2399
Folliculitis
abscess in, 33, 1702
agminate, 1814t
in amputation stump, 866, 866f
classification of, 1698, 1699t
from cytotoxic agents, 2176–2177
decalvans, 772t, 773, 773f
et atrophicus, 248
deep, 1699, 1700f
dermatophytic, 1699
dissecting, 773, 774f
eosinophilic, 314–315, 1376t
in HIV infection and AIDS, 315, 1931, 1931f
in infants, 315
treatment of, 1931
furuncle in, 33, 33f
gram-negative, 702
hookworm, 2024
hot tub, 1699, 1736, 1736f
in occupational exposures, 2068t, 2074, 2078
perforating, 564–565, 1459
Pityrosporum, 1829, 1829f, 1830
differential diagnosis of, 1829b
treatment of, 1830
in pregnancy, 958t, 962
pruritic, 958t, 962
in *Pseudomonas aeruginosa* infections, 1699, 1736, 1736f, 1737
spinulosa decalvans, 752
staphylococcal, 773, 1698–1699, 1699f, 1700f
abscess in, 1702
differential diagnosis of, 1699
superficial, 1698–1699, 1699f
in tropical acne, 703
tufted, 773
ulerythematosa reticulata, 751, 751f
Folliculoma, 1081
Fonsecaea compactum, 1833
Fonsecaea pedrosoi, 1833
Food. *See also* Nutrition
additives and preservatives in
contact allergic stomatitis from, 651
porphyria cutanea tarda-like syndrome from, 834
allergies to, 2286
atopic dermatitis in, 155–156, 2287
urticaria and angioedema in, 333
amebiasis from, 2009

and balsam of Peru allergy, 141, 145, 145t
bioterrorism threats to safety of, 2083t
contact urticaria from, 2071
cysticercosis from, 2027, 2028
fluke infections from, 2026
and gustatory sweating, 722t, 724b, 725
irritant contact dermatitis from, 399
listeriosis from, 1762, 1763
mite infestations of, 2032, 2032t
phototoxicity associated with, 828t
Salmonella contamination of, 1740
seafood ingestion and poisoning, 2053
in skin cancer prevention, 1005
trichinosis from, 2023
Vibrio infections from, 1763
Food and Drug Administration Sunscreen monograph, 2138–2139, 2139t
Foot
acrodermatitis continua of, 215, 215t, 217–218
ainhum and pseudoainhum of, 562–563
allergic contact dermatitis of, 140–141
blue toe syndrome in atheromatous embolism, 1672, 1672f
cold injury of
chilblains in, 849, 850f
in frostbite, 846, 847f
nonfreezing, with dampness, 848
corns and calluses of, **871**–873
in diabetes mellitus, 873, 1466
in diabetes mellitus. *See* Diabetes mellitus, foot problems in
epithelioma cuniculatum of, 1032, 1032f
erythrasma of, 1708, 1708f
friction blisters of, 876, 876f
gout of, 1575
in hand-foot-mouth disease, 1867–1869, 1868f, 1869f
in immersion foot, 848
leprosy of, 1794
malalignment of great toenail, congenital, 2329–2330
mycetoma of, 1832–1833, 1833f
plantar skin of. *See* Palmoplantar skin
Pseudomonas aeruginosa infections of, 1736, 1738
pustular eruptions of, **215**–218
reactive arthritis of, 209, 209f, 210, 210f
in split hand-split foot-ectodermal dysplasia-cleft lip/palate syndrome, 1344–1345, 1345f
tennis toe of, 874f, 874t
tinea pedis of, 1815–1817, 1816f
in trench foot, 848
ulcers of
in atheromatous embolism, 1672, 1672f
in diabetes mellitus, 1466, 1466f, 1669
differential diagnosis of, 1669, 1670b
warts of, 1921b
Fordyce's spots, 657, 687, 1085
Forehead
botulinum toxin injections in, 2391f
complications of, 2393
for glabellar brow furrows, 2388, 2390–2391, 2391f
for horizontal lines, 2391
paramedian transposition flap from, 2310, 2313f, 2319f
surgical anatomy of, 2291
Foreign body
botryomycosis in, 1702
granuloma in, 53
staphylococcal abscess in, 1702f
Forkhead box transcription factors. *See* FOX transcription factors
Formaldehyde
allergic contact dermatitis from, 141–142, 144
in occupational exposures, 2070t
as preservative, 2362
in warts, 2136
Formic acid, occupational exposure to, 2070t
Forschheimer spots
in rubella, 1854
in scarlet fever, 1718
Fort Bragg fever, 1767
c-FOS, 1003, 2112
Fosamprenavir in HIV infection, 2209–2210
Foscarnet, 2206
in cytomegalovirus infections, 2206, 2206t
in herpes simplex virus infections, 1884, 2206, 2206t
in HIV infection and AIDS, 1937
in varicella-zoster virus infections, 1894, 1895t
Foundation for Ichthyosis and Related Skin Types, 423b
Fournier gangrene, 671–672, 1721t, 1724–1725, 1725f
as body piercing complication, 890t
differential diagnosis of, 671, 671b
in *Pseudomonas aeruginosa* infections, 1737
risk factors for, 671, 671t, 1724–1725
treatment of, 671–672
Fowl mites, 2032t, 2033
FOX transcription factors
FoxC2, 65
in lymphatic malformations, 1661
in lymphedema, 65, 1661, 1685
FOXN1/Foxn1, 68t, 755
FoxP3/Foxp3, 104, 116, 116f, 1512, 2230
Fox-Fordyce disease, 733–734, 734f
clinical findings in, 734, 734f
differential diagnosis in, 734, 734b
treatment of, 734
Fractalkine, 127, 1593
Fractional photothermolysis, 2268
for skin rejuvenation, 2373, 2373f
for skin resurfacing, 2277, 2369, 2369f
Fractures
in corticosteroid therapy and osteoporosis, 2150
fat embolism syndrome in, 1454
in osteogenesis imperfecta, 1310
Fragile nails, 785–786, 786t
Fragile X syndrome, 82t
Fragrance allergy, 2361, 2362
contact dermatitis in, 136t, 141, 141f, 145, 2070t
diagnosis of, 2362
in occupational exposures, 2070t
photoallergy in, 830t
Frambesioma, 1979
Framboesia tropica, 1979–1981. *See also* Yaws
Francisella tularensis
in bioterrorism, 2082t, 2084
diagnosis of, 1693
occupational exposure to, 2074
in oral cavity disorders, 652t
treatment of, 2197t
in tularemia, 1757–1758, 1758f
Freckles, 639, 1119–1120, 1121
laser therapy in, 2273
in neurofibromatosis type 1, 1333, 1333f
Frederickson hyperlipidemia, 1274–1278, 1279t
type I, 1274–1276, 1279t
type II, 1276–1277, 1279t
type III, 1277–1278, 1279t
type IV, 1278, 1279t
type V, 1278, 1279t
Free radicals and reactive oxygen species, 97
Frei test in lymphogranuloma venereum, 1988
Freon in cryotherapy, 2330t
Frequency of electromagnetic radiation, 799
Frey syndrome, gustatory sweating in, 725
Friction
blisters in athletes from, 876, 876f
decubitus ulcers from, 878, 881f
irritant contact dermatitis from, 397t, 398
melanosis from, 636
occupational exposure to, 2076–2077
Frizzled receptor in melanocyte development, 591, 592f
Frostbite, 845, 846–847, 847f–848f
in athletes, 845, 846, 876
deep, 847, 847f
gangrene in, 847, 848f
prognostic factors in, 847, 848t
superficial, 847, 847f
Frostnip, 847, 847f
FTA-ABS test in syphilis, 1971, 1972, 1973t
Fuchsine, 2132
Fucosidosis, 1286t
FUCT1, 281
Fumaric acid esters
in pityriasis rubra pilaris, 235, 236b
in psoriasis, 186t, 191–192
Fungal infections, **1807**–1844. *See also specific infections*
of amputation stump, 866
anthropophilic, 1807
in athletes, 875
in children and infants, 936
diaper dermatitis in, 943, 944, 1824, 1936, 2106
drug dosage in, 950t–951t
in HIV infection, 1936
deep, 1831–1844
in diabetes mellitus, 1465–1466
in drug abuse, 926
drug therapy in
evidence-based medicine on, 2216–2217
oral, 2211–2217
topical, 2116–2121
in elderly, 973
endocarditis in, 1744, 1745
eumycetoma in, 1783, 1832
geophilic, 1807
in granulomatous disease, chronic, 1364, 1365t
in immunocompromised host, 269t, 654, 1807–1808
in acute immunosuppression, 268–271
in chronic immunosuppression, 273–276
in HIV infection and AIDS, 1808, 1936–1937
oral antifungal agents in, 2216
systemic infection in, 1836, 1836t
of nails, 785, 785t, 786f, 786t
in HIV infection, 1936
microscopic examination in, 1808
onychomycosis in, 1819–1820
in occupational exposures, 2076
oral, 653t
panniculitis in, 579
sepsis and septic shock in, 1746
subcutaneous, 1831–1835
superficial, 1807–1821
culture procedures in, 1808–1809, 1809t–1810t
diagnostic procedures in, 1808–1809
epidemiology of, 1807–1808
genetic factors in, 1811
inflammatory response in, 1811

Fungal infections—*continued*
microscopic examination in, 1808, 1808f, 1809f
pathogenesis in, 1809–1811
treatment of, 1818t, 1818–1820
systemic, 1835–1843
route of infection and dissemination in, 1836, 1837f
yeast, 1822–1830
zoophilic, 1807
Furocoumarins, phototoxicity from, 828t, 829t, 832
Furrowed tongue, 643, 643f
Furuncles, 33, 33f, 1699–1701, 1700f
abscess in, 1702
differential diagnosis of, 1700, 1700f
prognosis and clinical course in, 1700–1701
staphylococcal scarlet fever in, 1718, 1719
treatment of, 1701, 1701t
Furunculosis, 1692, 1700–1701
differential diagnosis of, 1700, 1700f
laboratory tests in, 1700
prognosis and clinical course in, 1700–1701
recurrent, 1701, 1701t
treatment of, 1701, 1701t
Fusarium
in immunocompromised host, 269t, 271, 1746, 1746f, 1843
in mycetoma, 1834t
in onychomycosis, 786t, 1817, 1818
Fusidic acid, 2113t
Fusion inhibitors in HIV infection and AIDS, 1930t, 2210–2211

G

G protein, 127–128
and regulator of G protein signaling protein, 128, 129f
G protein coupled receptor, 127–129, 129f, 393, 895, 898
Gabapentin
in postherpetic neuralgia, 1897
in pruritus, 911, 911t
Gait in palmoplantar keratoderma, 431
Galactosamine, 538, 538f
Galactose, 538, 538f, 539
Galactosialidosis, 1286t
α-Galactosidase A, 1455
in Fabry disease, 1281, 1282f, 1285
Galactosyl in collagen, 524
Galactosylceramide, 386, 389f
Galectin-10, 285
Gallium-67 scan in sarcoidosis, 1489, 1490
GALNT3 in tumoral calcinosis, 1296
Gambian trypanosomiasis, 2008
Gamborg-Nielsen type of palmoplantar keratoderma, 426
Gamma rays, 798f, 799
Gangliosidosis, 1286t
Gangrene, 1721t, 1723–1725, 1724t
in drug abuse, 925
Fournier. *See* Fournier gangrene
in frostbite, 847, 848f
gas, 1724t, 1726–1727, 1729
in immunocompromised host, 1723, 1725
Meleney, 1721t, 1725
in peripheral artery atherosclerosis, 1668, 1671
in plague, 1758, 1759
progressive bacterial synergistic, 1724t, 1725
staphylococcal, 1723
streptococcal, 1721t, 1723–1724, 1724t, 1725
histopathology in, 1727
in thromboangiitis obliterans, 1674, 1675
Gardner syndrome, 1456, 1504t
desmoid tumors in, 553
epidermoid cyst in, 1063, 1079
lipoma in, 1190
oral cavity disorders in, 642t, 647t
Gas gangrene, 1724t, 1726–1727, 1729
Gastritis, atrophic
chronic, 1377
in dermatitis herpetiformis, 503
Gastroesophageal reflux, tooth disorders in, 647t
Gastrointestinal disorders, 1455–1457
abdominal pain in, 1455–1456
in amebiasis, 2009
in amyloidosis, 1260t, 1263
from antibiotics, 2200
from antihistamines, 2190
from antimalarial drugs, 2161, 2162t
in atheromatous embolism, 1673
from azathioprine, 2168
in Behçet disease, 1623
in blue rubber bleb nevus syndrome, 1658–1659, 1660
in *Candida* overgrowth, 2286, 2287
in Churg-Strauss syndrome, 1611, 1614t
complementary and alternative medicine approaches to, 2286
in corticosteroid therapy, 2149, 2150t, 2151t
in cutis laxa, 1309
from cyclophosphamide, 2173
from cyclosporine, 2220
in cysticercosis, 2027, 2028
in Degos disease, 1649, 1650
in dermatitis herpetiformis, 500–504
in dermatomyositis, 1544t, 1547
in enteric fever, 1740, 1741
eosinophils in, 285
in epidermal necrolysis, 352
in epidermolysis bullosa, 515
in Fabry disease, 1284t, 1285
treatment of, 1287, 1287b
in gnathostomiasis, 2022
hemorrhage, 1455
drug-induced, 1455
in pseudoxanthoma elasticum, 1305, 1307, 1308, 1455
in Kaposi sarcoma, 1186, 1455
in Langerhans cell histiocytosis, 1419
in "leaky gut," 2286, 2287
malabsorption in, 1456–1457
in mastocytosis, 1438, 1441–1442, 1455
treatment of, 1441, 1442b
from methotrexate, 2165
in monkeypox virus infections, 1907–1908
in nematode infections, 2012–2017
in pellagra, 1210
in psoralen and PUVA therapy, 2257
reactive arthritis in, 207, 208, 211, 213
treatment of, 214
in retinoid therapy, 699, 2185
in rotavirus infections, 1870, 1871
in Sjögren syndrome, 1580, 1583
in strongyloidiasis, 2016
in syphilis, 1962
congenital, 1968t
in systemic sclerosis, 1452, 1457, 1557t
treatment of, 1561
in tuberous sclerosis, 1329
in Wegener granulomatosis, 1612t
Gastrulation, 67
GATA-3 transcription factor, 102
in hair follicle development, 740f, 741, 744
Gatifloxacin, 2201
in soft tissue infections, 1730
Gaucher disease, 1374t
GCDFP-15 in Paget disease, 1096
Gelatinase, 528, 528f, 529t
MMP-2 (gelatinase A) in wound healing, 2345
MMP-9 (gelatinase B), 285, 286, 529t
in lichen planus, 245
in photoaging, 970
in wound healing, 2344, 2345
Gels, topical, 2094
Gemfibrozil, interaction with other drugs, 2240t
Gender differences
in allergic contact dermatitis, 137–138
in hypohidrotic ectodermal dysplasia, 1341, 1342f
in irritant contact dermatitis, 396
in lupus erythematosus, 1515, 1516–1517
in melanoma prognosis, 1148
in pattern hair loss, 766–767, 768–769, 1452
and restoration surgery, 2394, 2395, 2395f, 2396
in prevalence of skin diseases, 6t
Gene therapy, 86–87
in cystic fibrosis, 730
epidermis as target in, 378
in epidermolysis bullosa, 86, 458–459, 515–516
inhibition type, 86
in leukocyte adhesion deficiency, 1365
natural, in revertant mosaicism, 83
in palmoplantar keratoderma, 431
replacement type, 86
in severe combined immunodeficiency, 1360
skin as target in, 86
viral vectors in, 86
Generalized lesions, 38
differential diagnosis in, 353
Genetic counseling. *See* Counseling, genetic
Genetics, **73**–87
in acantholytic disorders, 432
in acrokeratosis verruciformis, 436
in aging, 963
in alkaptonuria, 1224–1225
in alopecia areata, 763
in amyloidosis, 1257, 1258t, 1263, 1264–1265
in angioedema, hereditary, 336
in antibiotic resistance, 874–875, 1693
antibody diversity in gene rearrangements, 321
in arteriovenous malformations, 1664, 1665
in ataxia-telangiectasia, 1361, 1362
in atopic dermatitis, 82, 83, 149, 393–394
in autoimmune disorders, 1509–1511, 1510f
in autosomal dominant inheritance, 78–79, 79f
in autosomal recessive inheritance, 78, 79, 79f
in basal cell carcinoma, 994, 1037, 1043, 1044
in basal cell nevus syndrome, 1042–1044, 1048
in Behçet disease, 1620–1621
in Bloom syndrome, 1322–1323
in carcinogenesis, **977**–986
animal models of, 988–991
oncogenes in, 995
tumor suppressor genes in, 995–996
in Chédiak-Higashi syndrome, 613, 1367
in cholestasis of pregnancy, 957
in chondrodysplasia punctata, 419
chromosome disorders, 80–82
chromosome structure, 74–76

of collagen, 518–522
gene structure in, 520–522
heterogeneity in, 518–520, 519t
in complement deficiencies, 328–329
in complex traits, 82–83
counseling on. *See* Counseling, genetic
in cutis laxa, 1308–1309
in Darier-White disease, 83, 392, 432–433, 436
database resources on, 73–74
in dermatomyositis, 1538f, 1538–1539
in dermatophyte infections, 1811
DNA damage signaling, 982t
in DNA repair, 978–980, 980t
in drug-induced cutaneous reactions, 358, 361
in drug metabolism, 2238, 2239t
in dyskeratosis congenita, 631–632, 1325
in dysplastic nevus, 1123–1125
in dystrophic calcification, 1294
in ectodermal dysplasia, 1339
in Ehlers-Danlos syndrome, 1297–1298, 1300, 1301
of elastin, 531–534
in constitutive and alternative splicing, 532
cytokine and hormonal regulation, 533–534
gene expression in, 532–534
gene structure in, 531–532, 533f
and environmental interactions, 83
in lupus erythematosus, 1510f
in epidermal necrolysis, 351
in epidermolysis bullosa, 513–514
dystrophic, 511–512, 520
junctional, 510
simplex, 507
in therapy, 86, 458–459, 515–516
epigenetics, 83–84
in epithelioid sarcoma, 1163
in erythema multiforme, 344
in Fabry disease, 85, 1281, 1288
in Fanconi anemia, 1324
gene expression, 76, 78
gene identification, 76–77
gene structure, 74–76
gene therapy. *See* Gene therapy
in Grover disease, 438
in Hailey-Hailey disease, 83, 438–440, 441
in hair follicle development, 739
in hamartoma tumor syndrome, 1665
in hemangioma, infantile, 1164
in hereditary cancer syndromes, 988, 989t, 1504, 1504t–1505t
in Hermansky-Pudlak syndrome, 612–613
in hidradenitis suppurativa, 735
histocompatibility antigen disease association, 84
in homocystinuria, 1304
human genome, 73
in hypereosinophilic syndromes, 307, 309
in hyper-IgD syndrome with periodic fever, 1268
in ichthyosis, 395, 401–421
autosomal recessive congenital, 411, 411t
classification and features in, 402t–405t
complex trait, 83
counseling on, 85
and gene therapy, 86
in immunodeficiency disorders, **1348**–1372
in incontinentia pigmenti, 631
in irritant contact dermatitis, 396
of keratin, 59, 60t, 74, 75f, 76, 378–381
in keratoacanthoma, 1050, 1051
in keratoderma, palmoplantar, 424, 425t
in Langerhans cell histiocytosis, 1414
in leprosy, 1787
in lipodystrophy, 588
in lipoid proteinosis, 1288–1289
in lipoma, 1190
in lupus erythematosus, 1510, 1511, 1512, 1516
and environmental factor interactions, 1510f
in lymphedema, 1661, 1684–1685
in Marfan syndrome, 1302, 1303
in mastocytosis, 1443
in Mediterranean fever, familial, 1265
in melanoma, 1002, 1123, 1136–1137
in Mendelian disorders, 78–80
in Merkel cell carcinoma, 1089
in methicillin-resistant staphylococcal infections, 874–875
mitochondrial disorders, 82
in monilethrix, 758
in mosaicism, 83
in multiple endocrine neoplasia syndrome, 1177
mutations and polymorphisms, 77–78
detection and identification of, 76–77
in neurofibromatosis
type 1, 634, 1179, 1331–1332, 1335, 1338
type 2, 1178, 1338
in nevomelanocytic nevus, 1105
in oculocutaneous albinism, 609–611, 612
in osteogenesis imperfecta, 1310
in palmoplantar pustulosis, 215
in pathogenicity of microorganisms, 1691
in pattern hair loss, 766
in pemphigus, 463–464
in piebaldism, 615
in pigmentation disorders, **608**–616
in porokeratosis, 442
in porphyrias, 1255, 1255f, 1256, 12561255f
prenatal diagnosis, 85–86
promoter elements in, 76
in pseudoxanthoma elasticum, 63, 70, 1305
in psoriasis, 169–170, 170f, 174
and arthritis, 194, 197–198
in Raynaud phenomenon, 1644
in reactive arthritis, 208–209
in Refsum disease, 419
in rhabdomyosarcoma, 1176
in rheumatoid arthritis, 1510, 1511, 1512, 1571
in Rothmund-Thomson syndrome, 1323
in sarcoidosis, 1485, 1486
in seborrheic dermatitis, 220
in Sjögren syndrome, 1577
in squamous cell carcinoma, 988, 989–991, 1028, 1029–1030
in systemic sclerosis, 1554, 1554t, 1556
in Tietz syndrome, 615
in trichothiodystrophy, 405t, 420, 757, 1321
in tuberous sclerosis, 1325, 1327f
counseling on, 1331
diagnosis of, 1330
in tumor necrosis factor receptor-associated periodic syndrome, 1269
in vitiligo, 616
in Waardenburg syndrome, 613–614
in Werner syndrome, 1323
in xeroderma pigmentosum, 988, 989t, 1317
and complementation groups, 1318–1319
in X-linked dominant inheritance, 78, 79, 80f
in X-linked recessive inheritance, 78, 79–80, 80f
Genital disorders, **654**–683
in amebiasis, 2009
in Behçet disease, 666, 1622, 1623f
treatment of, 1625
in Bowenoid papulosis, 1020–1021, 1021f
in candidiasis, 1824, 1824f, 1827–1828
in chancroid, 1983–1986
in children and infants, 941–942, 942f, 943f
in herpes simplex virus infections, 1879
in warts, 930, 1917
in chlamydial infections, 1997
in cicatricial pemphigoid, 482, 484t, 485b, 666
clinical findings in, 655–657, 675–676
differential diagnosis in, 657, 676
in drug abuse, 925
epidemiology of, 654, 675
in Epstein-Barr virus infections, 1859, 1859f
in erythroplasia of Queyrat, 1023, 1023f, 1024
etiology and pathogenesis in, 654–655, 675
in female, **675**–683. *See also* Female genital disorders
in Fournier gangrene, 671–672, 1724–1725
in gonorrhea, 1994f, 1994–1995
in granuloma inguinale, 1990–1993
in herpes simplex virus infections, 1873, 1875–1876, 1876f
laboratory tests in, 1877
neonatal, 1879
prevention of, 1884
treatment of, 1879–1880, 1881b–1882b
in hidradenitis suppurativa, 736f, 737, 737f
in hypereosinophilic syndromes, 308, 309f
laboratory tests in, 657, 676
in leiomyomas, 1172, 1173
in lichen planus, 246, 249, 665–666, 680–681
differential diagnosis in, 252b
in lichen sclerosus, 547, 548f, 549, 550, 669, 678–679
treatment of, 550, 2184
in lichen simplex chronicus, 160, 161f, 677
in lymphogranuloma venereum, 1987–1990
in male, **654**–675. *See also* Male genital disorders
in molluscum contagiosum, 664, 1911
in mycoplasmal infections, 1998
in Paget disease, 1094
clinical findings in, 1095, 1095f
prognosis and clinical course in, 1096
treatment of, 1097
in papillomavirus infections, 663–664, 674, 1917
in psoriasis, 664f, 664–665, 665f, 678
in rhabdomyoma, 1175
in riboflavin deficiency, 1209
in scabies, 2030, 2030f
in schistosomiasis, 667, 2025, 2026
in sexually transmitted infections, 663–664. *See also* Sexually transmitted infections
in squamous cell carcinoma, 672–674, 1031, 1032
in syphilis, 1957–1958
in trichomoniasis, 1998–1999, 1999f
in venous malformations, 1658
in warts. *See* Warts, anogenital

Genome, 73, 75f
database resources on, 73–74
instability, **977**–986
clinical features indicating, 982t
diagnosis of, 982t, 982–986, 983t
hereditary, 1311–1315, **1321**–1325
linkage studies on diseases, 77
mitochondrial, 82
viral, 1845, 1846
of papillomavirus, 1914, 1914f
Genomic controls, 82
Genomic imprinting, 80, 82
Gentamicin, 1693, 2115
in actinomycetoma, 1786
in bartonellosis, 1752
in granuloma inguinale, 1992–1993
interaction with other drugs, 2240t
in plague, 1759
Gentian violet, 2131t, 2132
Geographic tongue, 643, 643f
in psoriasis, 181–182, 643
in reactive arthritis, 210
German measles. *See* Rubella
Gestational age estimation, 66
Ghost adipocytes in pancreatic panniculitis, 577f, 577–578
Ghoul hands in yaws, 1980
Ghrelin, 1482
Gianotti-Crosti syndrome, 1457, 1859, 1860–1861, 1861f
differential diagnosis of, 1861b
Epstein-Barr virus in, 1859, 1860, 1861
hepatitis B virus in, 1860, 1861
rotavirus in, 1871
treatment of, 1861
Giant cell arteritis, 1606, 1615f, 1615t, 1615–1616
clinical manifestations of, 1615, 1615f, 1615t
histopathology in, 1615, 1615f
treatment of, 1616
Giant cells
in fibroblastoma, 1161, 1161f
in granuloma
annular elastolytic, 369
oral, 650
in granulomatous reactions, 53, 54, 55
in herpes simplex virus infections, 1878, 1878f
in xanthogranuloma, juvenile, 1427, 1427f
in xanthoma disseminatum, 1430, 1430f
Giant lymph node hyperplasia, 1409
Gigantism, 1482
Gilchrist disease, 1838–1839
Gilliam classification of lupus erythematosus, 1515, 1516t
Gingiva, 645
cicatricial pemphigoid of, 481, 484, 484t
hyperplasia of, 645
Gingivitis, 645
acute necrotizing, 645, 645f, 1218
desquamative, 645
Gingivostomatitis
erosive, 645
herpes simplex, 1874–1875, 1875f
treatment of, 1880, 1883
necrotizing ulcerative, 645
Giroux-Barbeau erythrokeratodermia, 417
GJB2 in keratitis, ichthyosis, and deafness syndrome, 418
GJB3 in erythrokeratodermia variabilis, 418
GJB4 in erythrokeratodermia variabilis, 418
GJB6 in keratitis, ichthyosis, and deafness syndrome, 418
Glabellar brow furrows, botulinum toxin in, 2388, 2390–2391, 2391f
Glanders, 1757t, 1760–1761
acute, 1760
in bioterrorism, 2083t, 2085
chronic, 1760
treatment of, 1757t, 1760–1761
Glass, in photoprotection, 2141t, 2142
Glaucoma in corticosteroid therapy, 2106, 2150t
Gleich syndrome, 285, 307, 309, 316
Glioma, nasal, 1182
Global Alliance to Eliminate Lymphatic Filariasis, 21
Global genome repair in DNA damage, 811
Glomangioma, 1658
Glomerulonephritis
in body piercing complications, 890t
in cryoglobulinemia, 1639–1640
pauciimmune, 1614
poststreptococcal, 1704, 1718
in Wegener granulomatosis, 1611, 1612t
Glomus cells, 1657
Glomus tumor
localized hyperhidrosis in, 725
multiple, 1658
of nails, 787, 787f, 1658
Glomuvenous malformation, 1657, 1657t, 1658, 1658f, 1659, 1659f
Glossalgia, 642–643
Glossina tsetse fly bites, 2060
African trypanosomiasis in, 2008
Glossitis, 642–644
areata migrans, 181–182
atrophic, 643
benign migratory, 181–182
herpetic geometric, 643, 643f
median rhomboid, 643
in psoriasis, 181–182
in vitamin B_9 deficiency, 1211
in vitamin B_{12} deficiency, 1212
Glossodynia, 642–643, 643t
Glossopyrosis, 642–643
Gloves-and-socks syndrome, papular purpuric, in parvovirus B19 infections, 1856
Glucagonoma, 1449
necrolytic migratory erythema in, 306, 666, 1501f, 1501–1502
β-Glucocerebrosidase, 386, 388f, 389f
Glucocorticoid therapy, 114, 2102–2106, **2147**–2153
in acne, 698, 699–700, 701
acne in, 558, 702, 706, 2105
in actinic dermatitis, chronic, 822f, 823
in Addison disease, 1479
adrenal suppression in, 2104, 2105, 2106, 2148, 2149–2150, 2150t
in allergic contact dermatitis, 145
allergic contact dermatitis in, 141, 142, 2106
in alopecia areata, 764b, 765
in androgen excess, 1482
in angiolymphoid hyperplasia, 1409b
anti-inflammatory effects of, 2102, 2104
anti-proliferative effects of, 2103
in atopic dermatitis, 154–155, 157
atrophy in, 558, 2104, 2105
in Behçet disease, 1625, 1625b
in children, 946, 2151
complications of, 2104
dosage in, 952t
indications for, 2104
topical, 2104
complications of, 2149–2153, 2151t
in topical therapy, 2104, 2105–2106
in dermatomyositis, 1550, 1551–1552
in diaper dermatitis, 944–945, 2106
dosing regimen in, 2148t, 2148–2149
in children, 952t
in topical therapy, 2104–2105
in drug-induced cutaneous reactions, 361
in HIV infection and AIDS, 1934
ecchymoses in, 1383f
in elderly, 2104
in eosinophilic folliculitis, 315
and HIV infection, 1931
in epidermal necrolysis, 354
in epidermolysis bullosa acquisita, 499, 499b
ethnic considerations in, 2143, 2146
in exfoliative dermatitis, 231, 232, 232b
in extravasation injury from chemotherapy drugs, 2180
gastrointestinal disorders in, 2149, 2150t
in giant cell arteritis, 1616
in gout, 1576
in graft-versus-host disease, 266t, 267, 267t
in granuloma faciale, 304, 304b
granuloma gluteale infantum in, 2106
in granulomatous disease, chronic, 1364, 1365t
in hemangioma of infants, 1168t, 1168–1169
in herpes zoster virus infections, 1896
in hidradenitis suppurativa, 737
in HIV infection and AIDS
in drug-induced reactions, 1934
in eosinophilic folliculitis, 1931
in hypereosinophilic syndromes, 310, 311f
immunosuppressive effects of, 2102–2103, 2151, 2151t
indications for, 2104, 2148
infectious complications in, 2106, 2149, 2150t
initiation of, 2105, 2149
interaction with other drugs, 2151
intralesional, 2148
intramuscular, 2148
intravenous, 2149
in irritant contact dermatitis, 400
in Kawasaki disease, 1632
in Kimura disease, 1409b
in Langerhans cell histiocytosis, 1423
in leprosy, 1795–1796
in lichen nitidus, 258
in lichen planus, 666
cutaneous, 254, 254b
of nails, 790
oral, 253, 253b
vulvovaginal, 680–681
in lichen sclerosus, 549, 679
in lichen simplex chronicus of vulva, 677
lipoatrophy in, 581
in lupus erythematosus, 1532–1533, 1533t, 1534
in lymphocytic infiltration of skin, 1413b
in lymphoid hyperplasia, 1408, 1408b
in mastocytosis, 1442, 1442b
mechanism of action, 288, 2102–2103, 2147
monitoring of, 2105, 2149
in morphea, 546
in necrotizing venulitis, 1606, 1606t
oral, 2148–2149
panniculitis in, 581, 582–583
in pemphigoid
bullous, 479, 480, 480b
cicatricial, 484–485, 485b
gestationis, 493
in pemphigus, 466–468
paraneoplastic, 474, 474t
in perforating disorders, 567b
perioral dermatitis in, 709–710, 711

in peristomal skin disorders, 869, 869t
pharmacokinetics in, 2103–2104, 2147–2148
pigmentation changes in, 2106
in pigmented purpuric dermatosis, 1636
in pityriasis lichenoides, 243, 243b
in pityriasis rosea, 366
in pityriasis rubra pilaris, 235, 236b
potency of preparations in, 2103, 2103t, 2105, 2148t
in pregnancy, 2104
and psoriasis, 960
in psoriasis, 184t, 185–188, 189f, 2245
in combination with other agents, 187t, 190, 2245
of nails, 789
and pregnancy, 960
systemic agents in, 192
of vulva, 678
in pyoderma gangrenosum, 301, 301b, 302
in reactive arthritis, 214
in relapsing polychondritis, 1569
in rheumatoid arthritis, 1573
risks and precautions in, 2105, 2149–2150
in sarcoidosis, 1491, 1492t
in seborrheic dermatitis, 224
selection of drug in, 2149
in sub-corneal pustular dermatosis, 306, 307b
in surgical patients, 2150
in Sweet syndrome, 294, 295b
in systemic sclerosis, 1561
in T-cell lymphoma, 1398
in Takayasu arteritis, 1616
tapering of, 2149–2150, 2151
in tinea capitis, 1819
topical, 2102–2106
in atopic dermatitis, 154–155
in combination therapy, 2146
complications of, 2105–2106
dosing regimen in, 2104–2105
ethnic considerations in, 2143, 2146
frequency of application, 2104–2105
indications for, 2104
initiation of, 2105
mechanism of action, 2102–2103
monitoring of, 2105
pharmacokinetics in, 2103–2104
preservatives as potential sensitizers in, 2106, 2106t
in psoriasis, 184t, 185–188, 189f
regional anatomic differences in, 2105
responsiveness of diseases to, 2104, 2104t, 2105
risks and precautions in, 2105
in toxic shock syndrome, 1717
in urticaria and angioedema, 341, 342f
vasoconstriction in, 2103
in vesicular palmoplantar eczema, 166
in vitiligo, 620, 620b
in vulvar disorders, 677
in lichen planus, 680–681
in lichen sclerosus, 679
in lichen simplex chronicus, 677
in psoriasis, 678
in Wegener granulomatosis, 1611
in Wells syndrome, 312–313
withdrawal of, 2149–2150, 2151
Glucosamine, 538, 538f
Glucose
administration in acute intermittent porphyria, 1250, 1251, 1252
blood levels of
in diabetes mellitus, 1461
in protein-energy malnutrition, 1203
in composition of sweat, 718
in mechanisms of sweat secretion, 717, 718
Glucose-6-phosphate dehydrogenase deficiency, hemolytic anemia in
from antimalarial drugs, 2160, 2161, 2162t
from dapsone, 2156, 2157
Glucose-transporter-1 in infantile hemangioma, 1164, 1167
Glucosylceramides, 61, 386, 388f, 389f
Glucosylgalactosyl, 524
Glucuronic acid, 538f, 539
Glutathione as radioprotector, 860
Gluten sensitivity and dermatitis herpetiformis, 500–504, 1503
adherence to gluten-free diet in, 504
GlyCAM-1, 1590t
Glycerin sclerotherapy for varicose veins, 2352, 2353t
Glyceryl thioglycolate, allergic contact dermatitis from, 2362, 2363t
Glycine
in collagen, 517–518, 518f
in elastin, 531
Glycolic acid
in chemical peels, 2370, 2370t
stinging sensation from, 2361
in striae, 560
Glycoproteinosis, 1286t
Glycoproteins, 1286t
deficiency of, and leukocyte adhesion deficiency, 1365
GP100 in melanosomes, 598–599
gp130, 123–124
Glycopyrrolate in hyperhidrosis, 723, 724b
Glycosaminoglycans, **536**–542
age-related changes in, 966–967
and chemokines, 127
in dermis, 63
functions of, 540–542
in wound healing, 2345
Glycosylation
of collagen, 524
congenital disorder of, 281
nonenzymatic, 1461
tyrosinase, 597, 598
Glycosylation-dependent cell adhesion molecule 1, 1590t
Glypicans, 539, 539t, 540
GNAS1 in ossification disorders, 1296
Gnathostoma doloresi, 2022
Gnathostoma hispidum, 2022
Gnathostoma nipponicum, 2022
Gnathostoma spinigerum, 2012t, 2013t, 2021t, 2022
Gnathostomiasis, 2012t, 2022, 2022f
cutaneous, 2024
differential diagnosis of, 2013t, 2021t, 2022
treatment of, 2014t, 2022
Goeckerman therapy in psoriasis, 178f
Goiter, 1470
clinical findings in, 1474
epidemiology of, 1470
etiology and pathogenesis in, 1470, 1471
toxic multinodular, 1470
Gold
allergic contact dermatitis from, 141
hyperpigmentation from, 636
in lupus erythematosus, 1533t, 1534
Golgi system, 110f, 111
tyrosinase and tyrosinase-related proteins in, 597, 597f, 598
Goltz syndrome, 70, 79, 83
oral cavity disorders in, 642t, 647t
Gonadotropin-releasing hormone agonists in acne vulgaris, 698
Gonorrhea, **1993**–1996
and chlamydial infection, 1996, 1996b, 1997
clinical findings in, 1994f, 1994–1995, 1995f
diagnosis of, 1693
differential diagnosis of, 1734, 1996b
disseminated disease, 1995, 1995f
treatment of, 1996, 1996b
epidemiology of, 1993
etiology and pathogenesis of, 1993–1994
and HIV infection, 1994
laboratory tests in, 1995
oral cavity disorders in, 652t
pustules in, 1746
reactive arthritis in, 208
transmission of, 1993–1994
treatment of, 1996, 1996t, 2197t
Goodpasture syndrome, 453
collagen type IV in, 520
vasculitis in, 1610
Gopalan disease, localized hyperhidrosis in, 725
Gorham-Stout syndrome, 1662
Gorlin sign in Ehlers-Danlos syndrome, 1298, 1299f
Gorlin syndrome. *See* Basal cell nevus syndrome
Gottron papules in dermatomyositis, 1540, 1542f, 1542t, 1546, 1547
Gottron sign, 39t
in dermatomyositis, 1540, 1542f, 1542t, 1543t
Gougerot and Blum lichenoid dermatosis, 1634, 1634t, 1635f, 1636
Gout, **1575**–1576
acute arthritis in, 1575
drug-induced, 1575, 1576
histopathology in, 1576, 1576f
panniculitis in, 583
tophi in, 1575, 1576, 1576f
treatment in, 1576
Grafts
in hair transplantation, 2399
density of, 2399
insertion of, 2400
preparation of, 2399
terminology related to, 2400t
skin, 2310–2311
composite, 2311
full-thickness, 2310–2311, 2313f
healing of, 2346–2347
imbibition phase in, 2346
reinnervation in, 2347
revascularization in, 2346–2347
mini-punch, 621
necrosis of, 2338
split-thickness, 621, 2311, 2314f
suction blister, 621
in vitiligo, 621
Graft-versus-host disease, **258**–267
acute, 259–260, 260t
in allogeneic stem cell transplantation, 259–260, 260t, 261–262
treatment of, 266
in autologous stem cell transplantation, 260, 260t, 264
treatment of, 267
complications in, 265–266
diagnosis and differential diagnosis in, 261–262, 264–265, 266b
exfoliative dermatitis in, 230t
histopathology in, 262, 262f, 262t

Graft-versus-host disease—*continued*
in peripheral stem cell transplantation, 260, 264
prognosis in, 266
staging of, 261, 261f, 262t, 264
in syngeneic stem cell transplantation, 260, 260t, 264
treatment of, 267
treatment of, 266, 266t, 267
chronic, 259, 260
in allogenic stem cell transplantation, 260, 262–264
treatment of, 266–267
complications in, 266
diagnosis and differential diagnosis in, 265, 266b
histopathology of, 263f, 263–264
lichenoid, 251, 259, 262, 263f, 263–264
prognosis in, 266
sclerodermoid, 259, 260, 262–263, 263f, 264, 265
treatment of, 266–267, 267t
photochemotherapy in, 2255–2256
cicatricial alopecia in, 772t
clinical findings in, 261f, 261–264, 262f, 263f
complications in, 265–266
definition of, 259t
diagnosis and differential diagnosis in, 261–262, 264–265, 266b
algorithm on, 265f
epidemiology of, 259, 260t
and epidermal necrolysis, 350
etiology and pathogenesis of, 259–260
history of patient in, 261
ichthyosis in, 421
and lymphocyte recovery eruption, 258–259
prevention of, 267
prognosis in, 266
regulatory T cells in, 1512
in severe combined immunodeficiency, 1359–1360
treatment of, 266–267
photochemotherapy in, 2255–2256
photopheresis in, 266, 266t, 267, 267t, 2259
thalidomide in, 267t, 2234
Graft-versus-host reactions, 45, 258–267, 1457
definition of, 259t
follicular, 261, 261f
Graft-versus-tumor effect, 259, 266
Graham-Little syndrome, 248, 771, 772t
Graham-Little-Feldman syndrome, 247
Graham-Little-Piccardi-Lassueur syndrome, 247
Grain mite, 2032, 2032t
Gram staining, 1692–1693
in soft tissue infections, 1727
Gramicidin, 2113t, 2115
in methicillin-resistant staphylococcal infections, 2114
Grand Canyon recluse spiders, 2056
Granular cell tumor, 648, 1181–1182
staining of, 1177t, 1181–1182, 1182f
Granular layer of epidermis, 61
fetal development of, 69
Granules
Birbeck, 62, 62f, 106, 107f
keratohyalin, 61, 61f
lamellar, 60, 61, 61f
Granulocyte(s), in urticaria and angioedema, 332
Granulocyte colony-stimulating factor
in neutrophil production, 279
in Sweet syndrome, 280, 289
Granulocyte-macrophage colony-stimulating factor, 123, 126, 2223t, 2226
contraindications to, 2226
and eosinophil activation, 287
functions of, 123, 2226
in neutrophil production, 279
recombinant, 2226
Granuloma, 53–54
actinic, 369
annulare, 53, 53f, **369**–372
in bites, 369
in diabetes mellitus, 369–370, 1468–1469
differential diagnosis in, 372b
elastolytic giant cell, 369
epidemiology of, 369, 1468–1469
etiology and pathogenesis in, 369–370, 1468–1469
generalized, 370, 371f
histopathology in, 371, 371f
in HIV infection, 369
localized, 370, 370f
in Lyme disease, 1800t, 1802
palisading, 371, 371f
patch type, 371
of penis, 666
perforating, 371
photosensitive, 369
subcutaneous, 370–371, 372
in sun exposure, 369
treatment of, 372b
photochemotherapy in, 2255
in ataxia-telangiectasia, 1362, 1362f
in candidiasis, chronic mucocutaneous, 1355t
in cat-scratch disease, 1751
in chronic granulomatous disease, 1364, 1365t
in Churg-Strauss syndrome, 1612–1613
coccidioidal, 1839–1840
in common variable immunodeficiency, 1353, 1353f
in drug abuse, 923
epithelioid, 55
faciale, **302**–304
clinical findings in, 302–303, 303f
differential diagnosis in, 294b, 304, 304b
laboratory findings in, 303, 303f
treatment in, 304, 304b
foreign body, 53
giant cell
elastolytic, 369
oral, 650
gluteale infantum, 943–944
in corticosteroid therapy, 2106
in ileostomy or colostomy, 870, 870f
inguinale, 652t, **1990**–1993
clinical findings in, 1991, 1991f
complications of, 1992
diagnosis of, 1991–1992, 1992f
differential diagnosis of, 1992, 1992b
etiology of, 1990–1991
in HIV infection, 1990, 1991, 1992–1993
prevention of, 1993
transmission of, 1990
treatment of, 1992–1993, 1993b
lethal midline, 1394
Majocchi, 1814t
Miescher radial, in erythema nodosum, 573, 573f
mycotic, 53
in occupational exposures, 2068t, 2077, 2077t
palisading, 53, 371, 371f
paracoccidioidal, 1840–1841
pseudopyogenic, 1408
pyogenic, 647, 1171f, 1171–1172
laser therapy in, 2272
in rosacea, 705, 706f
sarcoidal, 53, 53f, 1484–1492
swimming pool, 877
in tick bites, 2059
in tuberculosis, 53, 1770
Granulomatosis
and allergic angiitis in Churg-Strauss syndrome, 309, 317, 1607, 1611–1613
lymphomatoid, 1454
Wegener. *See* Wegener granulomatosis
Granulomatous disorders
chronic, 1363–1364, 1374t
oral cavity disorders in, 642t, 1364
in contact dermatitis, 142, 142f
of dermis, 53–54
differential diagnosis in, 367t, 368
with pigmented purpura, 1635–1636
slack skin in, 1391, 1393f
Granulysin, 104
Graves disease, 1473
as autoimmune disorder, 1509
cutaneous findings in, 1471–1472, 1473f
epidemiology of, 1470
genetic factors in, 1510
hyperpigmentation in, 635
vitiligo in, 616, 619, 635, 1471–1472
Gray patch tinea capitis, 1812, 1812f
Graying of hair, 608, 630, 754t, 967
Green hair in swimmers, 876–877
Green nails, 785, 785f
in *Pseudomonas* infections, 785, 785f, 1735, 1736, 1736f
Green tea in skin cancer prevention, 1005
Greither palmoplantar keratoderma, 426
GREMLIN 1 in basal cell carcinoma, 992
Grenz ray therapy, 2280, 2280t, 2281, 2282
Grenz zone in granuloma faciale, 303, 303f, 304
Grey Turner's sign in pancreatitis, 1456
Griscelli syndrome, 603, 622–623, 1367, 1369–1370
accelerated phase in, 622, 623, 1370, 1505t
clinical findings in, 1368f, 1368t, 1369–1370, 1374t, 1505t
silvery gray hair in, 622, 626f, 1369–1370, 1374t, 1505t
treatment of, 623, 1370
types of, 622, 1368t, 1369
Griseofulvin, 2216, 2216f
adverse effects of, 2216
hepatotoxicity in, 1459t
in children, 950t, 954, 1818t, 2216
in dermatophyte infections, 1818b, 1818–1819, 2216
interaction with other drugs, 2216, 2239t
in lichen planus, oral, 253b, 254
in pigmented purpuric dermatosis, 1636
Grocer's itch, 2032, 2032t
Grocery mite, 2032t
Grönblad-Strandberg syndrome, 1305
Groove sign in lymphogranuloma venereum, 1988
Grooves in nails, longitudinal, 782, 782f
Ground glass appearance in Hashimoto-Pritzker disease, 1420
Ground itch
in hookworm infections, 2016
in strongyloidiasis, 2016
Ground state molecules, 804, 804f
Ground substance, 538
Grouped lesions, 36, 37f

Grover disease, 432, 437–438, 438f
clinical findings in, 438, 438f
differential diagnosis in, 436, 438, 438b
histopathology in, 438, 439f
treatment in, 438
Growth factors
epidermal. *See* Epidermal growth factor
fibroblast. *See* Fibroblast growth factor
insulin-like. *See* Insulin-like growth factor-1
nerve. *See* Nerve growth factor
in psoriasis, 174
vascular endothelial. *See* Vascular endothelial growth factor
in wound healing, 2342, 2343, 2344, 2344t, 2345
impaired, 2347
Growth hormone, 1482–1483
deficiency of, 1483
elevated levels in acromegaly, 1482–1483
Growth hormone releasing hormone, 1482
Growth retardation in corticosteroid therapy, 2151
Grzybowski keratoacanthomas, generalized eruptive, 1051
GTF2H2 in trichothiodystrophy, 420
Guanosine diphosphate, 127, 129f
Guanosine monophosphate, cyclic, 605–606
Guanosine triphosphatase, 127
Guanosine triphosphate, 127, 129f
Guarnieri bodies
in monkeypox, 1907
in smallpox, 1902
Guillain-Barré syndrome, anhidrosis in, 727
Guinea worm disease, 2021
Gum boil, 653
Gumma
framboesiodes, 1981
in syphilis, 26, 1963–1964, 1964f
cerebral or spinal, 1967
endemic, 1981, 1981f
histopathologic examination in, 1971
treatment of, 1975
in yaws, 1981
Günther disease, 1243, 1248f
Gustatory sweating, 722t, 724b, 725
Gypsy moth caterpillars, 2062

H

Haarscheibe, 65
Habit tic deformity of nails, 792, 793f
HACEK infections, endocarditis in, 1744
Haemophilus ducreyi
in chancroid, 1983–1986
differential diagnosis of, 1985, 1985b
treatment of infections, 2197t
Haemophilus influenzae, 1739f, **1739**–1740
vaccination against, 1739, 1740
Hageman factor in urticaria and angioedema, 333, 336, 337f
Hailey-Hailey disease, 432, 438–441
calcium signaling and transport in, 17–18, 61, 392, 439–440
clinical manifestations in, 440, 440f
differential diagnosis in, 436, 441, 441b
histopathology in, 440, 441f
oral cavity disorders in, 642t
treatment of, 441
radiation therapy in, 2281
Haim-Munk syndrome, 425t
Hair, **753**–777
age-related changes in, 608, 967
anatomy of, 742–744
in argininosuccinic aciduria, 756, 1224
ball-and-socket deformity of, 758, 759f
bamboo, 416, 417f, 758, 759f
breakage of, 755–757
brittle, 759t, 1321
in cartilage-hair hypoplasia syndrome, 1356–1357, 1357f
in Chédiak-Higashi syndrome, 1367–1369
in copper deficiency, 1216
corkscrew, 1213, 1213f
curly, 742
in acquired progressive kinking, 770
cytotoxic agents affecting, 2175–2177
definitions related to disorders of, 754t
diagnostic techniques in disorders of, 755, 756t
embryonic and fetal development, 71f, 71–72, 739–742, 740f, 1068
evolution of, 739
examination of, 25
microscopic, 1808
excess of, **774**–777
electrolysis in, 2334
laser therapy in, 2269, 2275–2277
flag sign of, 1203, 1203f
functions of, 739
green color from swimming pool water, 876–877
in Griscelli syndrome, 622, 626f, 1369–1370, 1374t, 1505t
growth of, **753**–777
rate in, 745
stages in, 743f, 744–747, 754
in iron deficiency, 761, 767–768, 1214, 1456
laboratory characteristics in infections of, 1808t
lanugo, 742, 742t, 1448, 1503, 1503f
loss of, **755**–774. *See also* Alopecia
in leprosy, 1790
pattern. *See* Pattern hair loss
in syphilis, 770–771, 771f, 1961, 1962f
in lupus erythematosus, 1524, 1527, 1535
in Menkes syndrome, 756, 757–758, 1216
miniaturized, 742, 742t
in pattern hair loss, 767
in monilethrix, 752, 752f, 758, 759f
neonate and infant disorders, 938, 939–940
nutrition affecting, 762, 1203, 1203f, 1452
in oculocutaneous albinism
type 1, 610, 610f
type 2, 611, 611f, 612
photographic assessment of, 756t
piedra of, 1821
pigmentation of, 747–748
in graying and depigmentation, 608, 630, 967
molecular control of, 748
and skin cancer risk, 1004–1005
preoperative preparation, 2295
in protein-energy malnutrition, 1203, 1203f
radiation affecting, 861
shedding of, 746, 761–762
silvery hair syndromes, 1367–1370
Griscelli syndrome, 622, 626f, 1369–1370, 1374t, 1505t
terminal, 742, 742t, 754–755
definition of, 754t
in thyroid disorders, 768, 1471, 1474
tinea capitis of, 1811–1812
trichomycosis nodularis of, 1821
in trichorrhexis. *See* Trichorrhexis
in trichothiodystrophy. *See* Trichothiodystrophy
in trichotillomania, 769–770, 770f, 914f, 914–915
differential diagnosis of, 764, 769
types of, 742, 742t
uncombable, 759–760, 760f
unruly, 759–760, 770
in loose anagen syndrome, 762, 762f
unwanted, 775
laser therapy in, 2275–2277
vellus, 742, 742t, 754–755
definition of, 754t
in vitamin C deficiency, 1213, 1213f
in Waardenburg syndrome, 614, 614f
woolly, 449, 760, 760f
desmosomes in, 449, 449t, 760
nevus associated with, 770
and palmoplantar keratoderma, 429, 760
Hair bud, 741
Hair collar sign, 39t, 940, 944t
in meningeal heterotopia, 1183
Hair cysts, vellus, 1079–1080
Hair follicles
absorption of topical drugs in, 2100
age-related changes in, 967
anatomy of, 742–744
microscopic, 742–744
biology of, **739**–748
and pathobiology, 754–755
bulbar area of, 742, 743f
cycle of, 743f, 744–747
definition of, 754t
disorders in, 754, 760–762, 770–771
cytotoxic agents affecting, 2175–2177
dermal papilla of, 743f, 744, 746
embryonic and fetal development, 739–742, 740f, 1068
inflammation of. *See* Folliculitis
infundibulum of, 742, 743f
absorption of topical drugs in, 2100
tumor of, 1084
inner root sheath, 742, 743f, 744
isthmus of, 742, 743f
keratin in, 59, 381, 742, 743t, 744
in anagen, 746
keratinocytes in, 742, 744
in anagen, 745
hyperproliferation in acne vulgaris, 690–692
in keratosis pilaris, 749
mature, 741–742
melanocytes in, 593, 594, 595f, 747–748
in aging, 608, 967
in anagen, 746
in catagen, 746
and follicular melanin unit, 594, 595f
and stem cells, 593, 593f, 747
nerve endings and receptors at, 65, 744
nevi of, 1080
in nevus comedonicus, 1059
outer root sheath, 742, 743f
pathobiology of, 754–755
perifollicular sheath, 744
in pilosebaceous unit, 687
in acne vulgaris, 690, 691f
regeneration defects, 755
as reservoir of topical drugs, 2098–2099, 2100
stem cells in, 72, 377, 593, 593f, 745, 745f, 747
suprabulbar area of, 742, 743f
transformation disorders, 754–755
transplantation for alopecia reduction, 2394–2402
tumors of, 1068, 1069t, 1070t, 1079–1085
differential diagnosis in, 1068
in infundibulum, 1084
Hair peg, bulbous, 72, 740f, 741
Hair placode, 740f, 740–741

Hair pluck test, 756t
Hair pull test, 756t
Hair shaft, 744
  disorders of, 755t, 755–760, 770–771
    diagnostic techniques in, 756t
  microscopy of, 756t
Hair shedding count, 756t
Hair straightening agents, 773, 2361
Hair transplantation, 769, 2394–2401
  donor areas in, 2395, 2396
    determination of, 2398
    excision of, 2398–2399
    safe, 2396, 2397f
    sparse, 2396f
  equipment in, 2397, 2398b
  gender differences in, 2394, 2395, 2395f, 2396
  graft preparation in, 2399
  indications for, 2396, 2397b
  recipient site in
    creation of, 2399
    design of, 2398
    graft density in, 2399
    graft insertion in, 2400
  for repair of previous procedures, 2399–2400, 2401f
  risks and precautions in, 2396–2397, 2398b
  side effects and complications of, 2400, 2402t
  technique in, 2398–2400
  terminology related to, 2400t
  vertex transition point in, 2395, 2395f
HAIR-AN syndrome, 695, 701
Hairdressers, occupational exposures to, 2069t, 2071
Hairy oral leukoplakia
  in Epstein-Barr virus infections, 277, 644, 651t, 1025, 1932–1933
  in HIV infection and AIDS, 644, 1932–1933, 1933f
Hairy tongue, 643–644, 644f
Halide lamps, 800
Hallopeau disease, 215, 215t, 217–218
  nail changes in, 785, 789, 789f
Hallopeau-Siemens variant of epidermolysis bullosa, 511
Hallucinations and delusions of parasitosis, 912, 913
Hallucinogens, 922, 925
Hallux valgus, callus formation in, 871–872
Halo dermatitis, 1107
Halo nevus
  acquired nevomelanocytic, 1105, 1106–1107, 1107f, 1108, 1109
  congenital nevomelanocytic, 1107f
Haloclava producta, 877
Halogenoderma, differential diagnosis in, 294b
Hamartin, 1325
Hamartomas, 555–556, 1456
  angiomatous
    congenital eccrine, 1171
    localized hyperhidrosis in, 725
  apocrine, 1060, 1070–1071
  basaloid
    follicular, 1080
    generalized, 1046
  Becker, 639
  calcification of, 1296
  cutaneous, 1069
  dermal melanocyte, 632t, 633
  eccrine, 1060, 1074, 1171
  fibrous, of infancy, 555
  follicular, 1080
  folliculosebaceous cystic, 1085
  laser therapy in, 2278
  meningeal, 1183
  of nerves, fibrolipomatous, 1192
  neuromuscular, 1176
  pilar neurocristic, 1110, 1111–1112
  of pilosebaceous unit, 1059–1060
  PTEN syndrome, 1665
  rhabdomyomatous mesenchymal, 1176
  sclerosing epithelial, 1080
  sebaceous, 1085
  smooth muscle, 1174–1175
    clinical findings in, 1174–1175, 1175f
Hamilton-Norwood classification of pattern hair loss, 766, 767, 767f
Hand, 1450–1451
  acrodermatitis continua of, 215, 215t, 217–218, 218f
  adenoma and adenocarcinoma of, aggressive papillary digital, 1077
  ainhum and pseudoainhum of, 562–563, 563f
  allergic contact dermatitis of, 135, 136f, 137, 140, 145
  arsenical keratosis of, 1016, 1016f
  atopic dermatitis of, 150, 151f, 153
    differential diagnosis in, 165
  candidiasis of, 1824, 1825f
  cold injury of
    chilblains in, 849, 850f
    frostbite in, 846, 848f
    nonfreezing, with dampness, 848
  degenerative collagenous plaques of, 429, 554
  dermatomyositis of, 1540, 1542f, 1542t, 1543t, 1547–1548, 1550
  Dupuytren contracture of, 552
  dyshidrotic dermatitis of, 162
  erysipeloid of, 1765, 1766f
  erythema of, 1451, 1451f
  erythromelalgia of, 1450
  erythropoietic protoporphyria of, 1244, 1244f
    premature aging in, 1244
  exfoliative dermatitis of, 228, 229f
  fibromatosis of, 551, 551f, 552, 553
  graft-versus-host reaction of, 261, 261f
  in hand-foot-mouth disease, 1867–1869, 1868f
  herpetic whitlow of, 1876f, 1876–1877
  in hyperhidrosis, 723, 724b
  hyperkeratotic dermatitis of, 162–167
    clinical findings in, 164
    treatment in, 166
  in hypertrophic osteoarthropathy, 1450
  Kawasaki disease of, 1629, 1629f
  knuckle pads of, 552–553
  leprosy of, 1794
  melanoma of, subungual acral lentiginous, 1139–1140, 1141b, 1141f
  multicentric reticulohistiocytosis of, 1430, 1431, 1431f
  neutrophilic dermatosis of, 290
  palmar skin of. *See* Palmoplantar skin
  pool palm of, 874t, 876, 877f
  psoriasiform dermatitis of, 165
  psoriatic arthritis of, 195, 195f, 195t, 199, 200, 200f
  puffy hand syndrome in lymphedema, 1686
  pustular eruptions of, **215**–218, 290
  pyoderma gangrenosum of, 300f
  Raynaud phenomenon of, 1643–1647
  in reflex sympathetic dystrophy, 1450–1451
  rheumatoid arthritis of, 1570t, 1571, 1571f
  scleromyxedema of, 1566f
  seal finger of, 1762, 2042
  in shoulder-hand syndrome, 1450–1451
  in split hand-split foot-ectodermal dysplasia-cleft lip/palate syndrome, 1344–1345, 1345f
  in systemic sclerosis, ischemia of, 1558–1560, 1559t
  tinea manus of, 1815–1817, 1816f
  tinea nigra of, 1820f
  tripe palm of, 1496–1497, 1497f
    in acanthosis nigricans, 1463, 1495, 1496–1497
    in paraneoplastic syndromes, 1448, 1449f, 1494t, 1496–1497
  vesiculobullous chronic dermatitis of, 162–167
    clinical findings in, 164, 164f
  warts on, 1921b
Hand-arm vibration syndrome, 2078
Hand cleaning products as occupational irritants, 2069
Hand-foot-mouth disease, 651t, 1848, 1867–1869, 1868f, 1869f
Hand-held lens, magnifying, 40
Hand-Schüller-Christian disease, 1414
  cutaneous lesions in, 1415, 1417
Hanta virus in bioterrorism, 2083t
Hapalochlaena maculosa octopus bites, 2050
Haploinsufficiency, 78
Haptens in allergic contact dermatitis, 138
Harderoporphyria, 1253
Harderoporphyrinogen, 1254
Harlequin color change in infants, 937
Harlequin ichthyosis in neonates, 404t, 415–416, 416f
  prenatal diagnosis of, 423
  treatment in, 423
Harlequin syndrome in exercise, 875
  anhidrosis in, 728
  unilateral facial flushing and sweating in, 725
Harmful effects
  critical appraisal of evidence on, 14t, 17–18
  as public health concern, 20
Hartnup disease, 1210, 1219t, 1220
Harvest mites, 2032, 2032t
Hashimoto-Pritzker disease, 1414
  cutaneous lesions in, 1417, 1418f
  histopathology in, 1420
  prognosis and clinical course in, 1423
Hashimoto thyroiditis, 1471
  cutaneous findings in, 1474
  hypothyroidism in, 1471
  vitiligo in, 616, 619
Haverhill fever, 1734, 1761
Hay-Wells syndrome, 1343–1344, 1344f, 1345
Head injuries in abused child, 928–929
Head lice, 2033f, 2033–2035
  differential diagnosis of, 2034b
  drug resistant, 2034–2035
  nits in, 2033, 2033f, 2034
  treatment of, 2034b, 2034–2035
Headache in cyclosporine therapy, 2220
Healing. *See* Wound healing
Health, definition of, 18
Health and Nutrition Examination Survey, 6
Health risk assessment in occupational exposures, 2073
Health Technology Assessment Database in Cochrane Library, 12
Hearing
  in Fabry disease, 1284t, 1285, 1287b
  in Kawasaki disease, 1629
  melanocytes in, 595
  in relapsing polychondritis, 1568

in syphilis, 1962, 1966
congenital, 1969
in Tietz syndrome, 615
in Waardenburg syndrome, 614, 616
Heartworm infection, 2024
Heat
chronic exposure to
erythema ab igne in, 638, 638f, 1017, 1018, 1029, 2078
occupational, 2077–2078
squamous cell carcinoma in, 1017, 1018, 1029
thermal keratosis in, 1017–1018
nerve receptors sensitive to, 896
sports participation and injuries in, 875
thermal injuries from, **852**–858
hyperpigmentation in, 636
in occupational exposures, 2077–2078
thermoregulatory responses to, 835–841
acclimatization affecting, 843–844
heat transfer in, 835–836
in local warming, 840–841, 841f
sweating in, 714–715, 835, 836, 837
vasodilation in, 836, 837–841
urticaria from, 335
Heat rash in diaper area, 943
Heat shock proteins, 840, 841f
in Behçet disease, 1622
Heat stroke, anhidrosis in, 729
Hederiform endings, 65
Hedgehog pathway, 1002
in basal cell carcinoma, 992–993, 994, 1002, 1048
in basal cell nevus syndrome, 1043f, 1043–1044, 1045
PTCH1 in, 1042, 1043, 1043f
as therapy target, 994, 1047–1048
Heerfordt syndrome, 1490
Height in Marfan syndrome, 1303, 1303f
Heinz bodies in dapsone therapy, 2156
Helicobacter pylori
in gastric MALT-type lymphoma, 1400
in urticaria, 338
Heliodermatitis, 969, 969f
Heliotrope sign, 39t
in porphyria cutanea tarda, 1238, 1238f
Helix of ear, 2289
and antihelix, 2289, 2290f
Helminthic infections, **2011**–2028
approach to patient with, 2011–2012
cestode, 2011, 2026–2028
immune response in, 2011
laboratory and diagnostic evaluation in, 2012
nematode, 2011, 2012–2025
trematode, 2011, 2025–2026
Heloma, **871**–873. *See also* Corn(s)
miliare, 872
molle, 872f
Helper T cells, 130–131
in adaptive immune response, 102–103, 105–106
in allergic contact dermatitis, 106
in atopic dermatitis, 106, 131, 132, 147–148
in autoimmune disorders, 1512, 1513
in basal cell carcinoma, 106
in cutaneous T-cell lymphoma, 106, 1387
cytokine production, 115–116, 116f, 1595
and interleukin IL-4, 123
in leishmaniasis, 105, 2002
in leprosy, 102–103, 105, 1792
in lichen nitidus, 256
in lichen planus, 245
in Lyme disease, 106
in photoimmunosuppression, 807, 808
in psoriasis, 132
in rheumatoid arthritis, 131
in sarcoidosis, 1485, 1485f
in squamous cell carcinoma, 106
in syphilis, 106
in tumor response, 106
Hemangioendothelioma
kaposiform, 1170–1171, 1171f
spindle cell, 1171
Hemangioma, **1164**–1172, 1651
bleomycin in, 2124
cavernous, 1651
congenital, 1169–1170
noninvoluting, 1169, 1170, 1170f
nonprogressive, 1169
rapidly involuting, 1169–1170, 1170f
epithelioid, 1408
of eyelid, excisional surgery in, 2306f
in infants, 939, 1164–1170
atypical, 1165, 1166f
in "beard area," 1166
classification of, 1165, 1165f
clinical findings in, 1164t, 1164–1167, 1165f–1167f
complications in, 1167–1168
congenital, 1169–1170
deep, 1165, 1166f
epidemiology of, 1164
etiology and pathogenesis in, 1164
hepatic, 1167
indeterminate, 1165, 1165f
involution of, 1165, 1165f, 1169f
laboratory tests in, 1167
lobular capillary, 1171–1172
localized, 1165, 1165f
lumbosacral, 1166
multifocal, 1166–1167, 1167f
perineal, 1166
periocular, 1166, 1167f
in PHACE syndrome, 1166
prognosis and clinical course in, 1168
segmental, 1165, 1165f
superficial, 1165
telangiectatic, 1165, 1166f
treatment of, 1168–1169, 2128
laser therapy in, 1168t, 1169, 2271–2272
side effects in, 1168t
laser therapy in, 2271–2272, 2374
in infants, 1168t, 1169, 2271–2272
lobular capillary, 1171f, 1171–1172
oral mucosal, 649
sclerosing, 556–557
strawberry, 1651
targetoid hemosiderotic, 1172
Hemangiomatosis, diffuse neonatal, 1166
Hematin infusions
in acute intermittent porphyria, 1251, 1252
in erythropoietic protoporphyria, 1247
Hematodermic neoplasm, CD4+/CD56+, 1401–1402
Hematologic disorders, **1373**–1385
in cobalamin deficiency, 1212, 1377
cutaneous signs and symptoms in, 1373–1379, 1374t–1376t
from cyclophosphamide, 2173
in folate deficiency, 1211, 1377
in Langerhans cell histiocytosis, 1423
pruritus in, 908, 1376t
in retinoid therapy, 2186
in rheumatoid arthritis, 1572t
in syphilis, 1962
from tumor necrosis factor inhibitors, 2228
Hematoma
in drug abuse, 924
postoperative, 2338, 2338f
subungual, 793
surgery in, 2327–2328, 2328f
Hematopoiesis, 1379
Hematopoietin receptors, 117t, 122–124
Hematoporphyrin derivatives in photodynamic therapy, 2260–2261
Hematoxylin and eosin stain in Merkel cell carcinoma, 1090, 1090f
Heme, 1228
biosynthesis of, 1228–1231, 1229f, 1231f
iron levels and phlebotomy affecting, 1241–1242
regulation of, 1230, 1232f
Heme arginate in acute intermittent porphyria, 1251–1252
Heme synthase in erythropoietic protoporphyria, 1244
Hemiatrophy, progressive facial, 545, 546
Hemidesmosomes, 447, 450, 450f, 451
anchoring filaments and fibrils, 47, 59, 62
in bullous pemphigoid, 455–456, 476, 477
components of, 455–457
embryonic and fetal, 67, 71
in epidermolysis bullosa, 505, 506f, 507f, 507–509, 508t
functions of, 451
in wound healing, 2344
Hemidysplasia, congenital, and limb defects with ichthyosiform erythroderma, 403t, 419–420
with ichthyosiform nevus, 1056, 1060, 1061
Hemin in acute intermittent porphyria, 1252
Hemiptera, 2060–2061
Hemochromatosis, 1214
nail changes in, 1449
pigmentation changes in, 635–636, 1214, 1374t, 1446
Hemodialysis
bullous disease in, 1459
in epidermal necrolysis, 354
pigmentation changes in, 630
porphyria cutanea tarda in, 1236, 1239, 1243, 1459
pruritus in, 1448
Hemoglobin
absorption of radiation, 802, 803, 803f
cyanosis in disorders of, 1378–1379
deoxygenated, 1378, 1379
with low oxygen affinity, 1378, 1379
in methemoglobinemia, 1378–1379
Hemoglobin M, 1378
Hemolytic anemia
autoimmune, 1514
congenital, and pulmonary emphysema, 1309b
in glucose-6-phosphate dehydrogenase deficiency
and antimalarial drug therapy, 2160, 2161, 2162t
and dapsone therapy, 2156, 2157
Hemolytic-uremic syndrome, and thrombotic thrombocytopenic purpura, 1382
in HIV infection and valacyclovir therapy, 2204–2205
Hemophagocytic syndrome, 1367–1369
Hemorrhage
adrenal
in meningococcal infections, 1734, 1735
in Waterhouse-Friderichsen syndrome, 1734, 1735, 1748
in drug interactions, 2240t
drugs associated with, 1455, 2336, 2336t, 2337
electrosurgery hemostasis in, 2333, 2334, 2334f

Hemorrhage—*continued*
gastrointestinal, 1455, 1455t
drug-induced, 1455
in pseudoxanthoma elasticum, 1305, 1307, 1308, 1455
postoperative, 2337, 2338, 2338f
in cryosurgery, 2333
in nail surgery, 2322
purpura in, 1380–1383
in smallpox, 1901–1902, 1903
splinter, of nails, 780, 783, 783f
differential diagnosis of, 1745b
in endocarditis, 1453, 1744, 1745, 1745f
in liver disease, 1449
in psoriasis, 181
in vitamin C deficiency, 1213
in vitamin K deficiency, 1208
in Wiskott-Aldrich syndrome, 1358
Hemorrhagic disease of newborn, 1208
Hemorrhagic edema of childhood, acute, 1599, 1602
Hemorrhagic fever, viral, in bioterrorism, 2082t, 2083t
Hemosiderotic fibrohistiocytic lipomatous lesion, 1195
Hemosiderotic targetoid hemangioma, 1172
Hemostasis, 1379–1380
disorders of, 1380
electrosurgery for, 2333, 2334, 2334f
primary, 1379
secondary, 1379
Henderson-Paterson bodies in molluscum contagiosum, 1912, 1913f
Henle's layer of hair follicle, 742, 743f
Henna tattoos, 889
Henoch-Schönlein purpura, 1455, 1599–1600, 1602, 1606, 1610t
clinical findings in, 1602
complement deficiencies in, 1604
differential diagnosis in, 1734
etiology and pathogenesis in, 1599–1600
histopathology in, 1605
laboratory findings in, 1604
palpable purpura in, 1601f
vasculitis in, 1610
Hepadnavirus, 1846t
Heparan sulfate, 63, 68t, 71, 538, 538f, 539
in basement membranes, 450, 451, 454
binding interactions of, 542t
functions of, 540–541
Heparin
binding interactions of, 542t
in Degos disease, 1651, 1651b
functions of, 1435t, 1436
in lichen planus, 255
skin necrosis from, 360
in venous malformations, 1660
Hepatitis, 1457, 1458
in occupational exposures, 2075
Hepatitis A, 1457
vasculitis in, 1601, 1602, 1613
Hepatitis B, 1457, 1850
cryoglobulinemia in, 1637–1638, 1640
treatment of, 1641
diagnosis of, 1850
and Gianotti-Crosti syndrome, 1860, 1861
and hepatocellular carcinoma, 995t
and HIV infection, 2208
occupational exposure to, 2075
in tattooing, 887
vaccination, 1457
lichen nitidus after, 256
lichen planus after, 251
vasculitis in, 1613, 1614, 1615
cutaneous necrotizing venulitis, 1601, 1602
Hepatitis C, 1457, 1850
cryoglobulinemia in, 1638, 1639, 1640
treatment of, 1641
in drug abuse, 921
and hepatocellular carcinoma, 995t
lichen planus in, 251, 1457
occupational exposure to, 2075
and porphyria cutanea tarda, 1236, 1237–1238, 1241
in tattooing, 887–888
vasculitis in, 1614, 1615
cutaneous necrotizing venulitis, 1601, 1602
Hepatocyte growth factor in melanocyte development, 591, 592
Hepatocyte-stimulating factor, 124. *See also* Interleukins, IL-6
Hepatopulmonary syndrome, 1454
Hepatotoxicity of drugs. *See* Liver disorders, drug-induced
Herald patch in pityriasis rosea, 363, 363f–364f
Herbal preparations, 2285
in atopic dermatitis, 158
Hereditary cancer syndromes, 988, 989t, 1504, 1504t–1505t
Herlitz junctional epidermolysis bullosa, 457, 508t, 509, 509f
Hermansky-Pudlak syndrome, 599, 622, 1374t
clinical features in, 612, 612f
epidemiology of, 608
etiology and pathogenesis in, 612–613
types of, 612, 612f, 613
Heroin, 922
cutaneous signs in abuse of, 923, 924f, 924–925, 926
Herpangina, 651t, 1867, 1869–1870, 1870f
differential diagnosis of, 1870b
Herpes gestationis, 316, 476, **490**–493, 955–956. *See also* Pemphigoid, gestationis
Herpes gladiatorum, 875, 1877
in occupational exposures, 2075
treatment of, 1882b
Herpes iris of Bateman, 346, 346f
Herpes labialis, 1873, 1874f, 1874–1875, 1875f
erythema multiforme in, 346
in occupational exposures, 2075
recurrent, 1875f
treatment of, 1883
Herpes rugbiaforum, 1877
Herpes simplex virus infections, 1848, **1873**–1884
acute, 1873
in athletes, 875, 1877
in atopic dermatitis, 152, 153f, 156, 1877
Behçet disease in, 1621
classification of, 1873, 1878t
clinical manifestations of, 1849, 1874–1877
diagnosis of, 1850, 1877–1878, 1878f
differential diagnosis of, 1891, 1892, 1985, 1985b
eczema herpeticum in, 1877, 1877f, 1883b
epidemiology of, 1873
erythema multiforme in, 343, 344, 345f, 346–347, 349
recurrent, 1877
etiology and pathogenesis in, 1873–1874
eye disorders in, 1879
treatment of, 1882b, 1883
genital, 1873, 1875–1876
in HIV infection, 1937, 1937f
laboratory tests in, 1877
in neonate, 1879
prevention of, 1884
treatment in, 1879–1880, 1881b–1882b
and HIV infection, 1873
immune response to, 1874
in immunocompromised host, 269t, 271, 276, 276f, 277, 1874
complications of, 1878f, 1878–1879
in HIV infection and AIDS, 1878, 1937–1938
laboratory tests in, 1877
orofacial infection in, 1875, 1878, 1878f, 1883
treatment of, 1883
laboratory tests in, 1877–1878
latent, 1874, 1874f
of nails, 784–785, 785t
in neonates, 940, 941f, 1879
treatment of, 1880, 1882b
neurologic disorders in, 1879
treatment of, 1882b
in occupational exposures, 2075
orofacial, 1873, 1874–1875
in immunocompromised host, 1875, 1878, 1878f, 1883
in laser skin resurfacing, 2368
in neonate, 1879
treatment of, 1880, 1881b, 1883
trigger factors in, 1875
persistent, 1375t
in pregnancy, 940, 1879
treatment of, 1880
prevention of, 1884
psychological factors in, 921
reactivation and recurrence of, 1848, 1849, 1873, 1874, 1874f, 1877
genital, 1876, 1876f
in HIV infection and AIDS, 1938
laboratory tests in, 1878, 1878t
ocular, 1879
orofacial, 1874–1875, 1875f
replication of virus in, 1848, 1873, 1874
transmission of, 1873
prevention of, 1884
treatment of, 1879–1884, 1881b–1883b, 2203–2205
drug resistance in, 1883–1884
in HIV infection and AIDS, 1937–1938
vaccination against, 1884
whitlow in, 1702, 1876f, 1876–1877
in occupational exposures, 1877, 2075
zosteriform, 1891
Herpes zoster virus infections, 667, 1848, **1885**–1898
clinical findings in, 1889–1890, 1890f, 1891f
complications of, 1893–1894
diagnosis of, 1891–1892
differential diagnosis of, 1891, 1891b, 1892
in elderly, 973, 1885, 1886
prevention of, 1898
epidemiology of, 1885–1886
facial palsy in, 1890, 1890f
histopathology in, 1892, 1892f
in immunocompromised host, 276, 276f, 1886, 1890
clinical findings in, 1890, 1891f
in HIV infection, 1938
laboratory tests in, 1892
neuropathic itch in, 903, 906, 907
ophthalmic, 1890, 1894, 1896
pathogenesis of, 1887–1888
prevention of, 1850, 1898

recurrent, 1375t, 1848
transmission of, 1886
treatment of, 15, 16f, 1895–1897
Herpesviruses, 1846, 1846t, 1847f
HHV-1
oral infection, 651t
in skin cancer, 998
HHV-2 oral infection, 651t
HHV-3 oral infection, 651t
HHV-4, 1858. *See also* Epstein-Barr virus
HHV-5, 1861. *See also* Cytomegalovirus infections
HHV-6, 1864–1866
differential diagnosis of, 1867b, 1949b
and drug-induced cutaneous reactions, 356
in exanthem subitum, 1864–1866, 1865f, 1867b
in immunocompromised host, 276, 277, 1865, 1866
and Langerhans cell histiocytosis, 998
latent, 1865
oral infection, 651t, 1865
in pityriasis rosea, 362–363
reactivation of, 1865, 1866
sub-types of, 1865
transmission of, 1865
HHV-7, 1866–1867
differential diagnosis of, 1867b
in exanthem subitum, 1866–1867, 1867b
in immunocompromised host, 276, 277
in lichen planus, 1867
in pityriasis rosea, 362–363, 1849, 1867
HHV-8, 134
in Castleman disease, 1184, 1409
in immunocompromised host, 276, 277, 278
in Kaposi sarcoma, 278, 995t, 998, 1183–1184, 1187
in Langerhans cell histiocytosis, 998
oral infection, 651t
transmission of, 1183–1184
variants of, 998
replication of, 1846–1847, 1847f
simiae (B virus), 2039–2040
treatment of infections, 1850, 2203–2205
Herpetic geometric glossitis, 643, 643f
Herpetiform lesions, 36
Hertoghe sign, 39t
Hess test in pigmented purpuric dermatosis, 1636
Heterodisomy, uniparental, 80
Heterogeneity, genetic, 78
Heterophile antibodies in mononucleosis, 1859
Heteroplasia, progressive osseous, 1296, 1297, 1297f
Heteroplasmy of mitochondrial DNA, 82
Heterotopia. *See* Ectopia
Heterozygosity loss in neurofibromatosis type 1, 1332, 1334, 1338
Heterozygote, compound, 79
Heubner arteritis in syphilis, 1966
Hexachlorobenzene, 2133. *See also* Lindane
Hexachlorocyclohexane, 2133. *See also* Lindane
Hexachlorophene in preoperative skin preparation, 2296
Hexadecylphosphocholine, 2124–2125
HFE in porphyria cutanea tarda, 1237, 1238
HGO in alkaptonuria, 1224–1225
Hibernian fever, familial, 1269
Hibernoma, 1194–1195, 1195f
eosinophilic sub-type, 1195
histologic features in, 1195, 1195f
mixed sub-type, 1195
pale cell sub-type, 1195
Hidradenitis
neutrophilic eccrine
anhidrosis in, 729
in cytotoxic drug therapy, 2177, 2177f
differential diagnosis in, 294b
suppurativa, 734–738
clinical findings in, 735–736, 736f, 737f
complications of, 736–737
differential diagnosis of, 735b
epidemiology of, 734
etiology and pathogenesis in, 734–735
genetic factors in, 735
pathology in, 736
quality of life issues in, 736
sinus tracts in, 29, 29f, 735, 736, 737f
squamous cell carcinoma in, 737
stages of, 735
treatment of, 737–738
retinoids in, 737, 2183–2184
of vulva, 682, 682f, 737, 737f
Hidradenocarcinoma
apocrine papilliferum, 1073
clear cell, 1078
eccrine, 1078, 1078f
Hidradenoma
apocrine papillary, 1071, 1072f
cystic, 27, 27f
eccrine, 1075, 1076f
Hidroacanthoma simplex, 1075–1076
Hidrocystoma
apocrine, 1070, 1070f
eccrine, 1074
Hidrosis. *See* Sweating
Hierarchy of evidence in evidence-based medicine, 9, 10t
Higouménakis's sign in congenital syphilis, 1969
Hilar adenopathy, asymptomatic bilateral, in sarcoidosis, 1490
Hip dislocation, congenital, in Ehlers-Danlos syndrome, 1301, 1302
Hip fractures in corticosteroid therapy and osteoporosis, 2150
Hirschsprung disease, 614
Hirsutism, 739, 753, 755, 774–776
androgen levels in, 1481
causes of, 775, 775t
definition of, 754t
epidemiology of, 774–775
laboratory tests in, 775, 775t
pathogenesis in, 775
postmenopausal, 967
treatment of, 775b, 775–776
laser therapy in, 775, 775b, 2275–2277
Histamine, 2186
functions of, 1435, 1435t
in heat stress and cutaneous active vasodilation, 840
in mast cells, 1434, 1435
melanocyte response to, 604
in pruritus, 897t, 901, 904, 910
in urticaria and angioedema, 330–331, 334
Histamine receptors, 1435, 2186
and H_1-antihistamines, 2186–2191
and H_2-antihistamines, 2191–2193
Histidase, 1219t
Histidinemia, 1219t
Histiocytes in granulomatous reactions, 54
Histiocytoma
angiomatoid fibrous, 1163
benign fibrous, 556–557
malignant fibrous, 1162–1163
differential diagnosis of, 1160b
myxoid, 1162
pleomorphic, 1162
Histiocytosis, **1414**–1434, 1457
benign cephalic, 1424, 1424t, 1428f, 1428–1429
epidemiology of, 1425
classification of, 1414, 1415t
crystal-storing, 583
generalized eruptive, 1424, 1424t, 1428–1429
clinical findings in, 1428, 1428f
differential diagnosis in, 1429, 1429b
epidemiology of, 1425
etiology and pathogenesis in, 1425
histopathology in, 1428–1429, 1429f
Langerhans cell (class I), 944, 944f, **1414**–1424. *See also* Langerhans cell histiocytosis
non-Langerhans cell (class II), **1424**–1434
diagnostic approach to, 1426f
disorders categorized as, 1424t
epidemiology of, 1424–1425
etiology and pathogenesis of, 1425
prevention of, 1434
treatment of, 1434
progressive nodular, 1424t, 1429
differential diagnosis of, 1429, 1429b
epidemiology of, 1425
etiology and pathogenesis in, 1425
reticulohistiocytosis. *See* Reticulohistiocytosis
sinus, with massive lymphadenopathy, 1424, 1424t, 1433–1434
clinical findings in, 1433, 1433f
differential diagnosis of, 1433, 1433b
epidemiology of, 1425
etiology and pathogenesis in, 1425
treatment in, 1434
Histocompatibility antigens, 84. *See also* HLA system
Histones, 1528t
Histoplasma capsulatum, 1836–1838, 2119
in immunocompromised host, 269t, 275
Histoplasma farciminosum, 1836
Histoplasmin skin test, 1838
Histoplasmosis, 1836–1838
disseminated, 1837f, 1837–1838, 1838f
in immunocompromised host, 275, 1837, 1837f, 1838
in HIV infection and AIDS, 1837, 1837f, 1838, 1937
treatment of, 1838
large-form or African, 1836, 1838
oral cavity disorders in, 653t, 1837–1838
primary cutaneous, 1838
respiratory disorders in, 1837
small-form or classic, 1836–1838
Historical aspects
of evidence-based medicine, 8–9
of public health, 19
History-taking, 23–26, 24t
on surgical history, 2295, 2336
HIV infection and AIDS, **1927**–1940
acute infection in, 1928–1929
Addison disease in, 1478
African trypanosomiasis in, 2008
amebic infections in, 2009, 2010
aphthous ulcers in, 666, 1933
aspergillosis in, 1937
bacillary angiomatosis in, 1692, 1935–1936, 1936f
bacterial vaginosis in, 2000
Bartonella infection in, 1752–1754, 1935–1936, 1936f
basal cell carcinoma in, 1037, 1933

HIV infection and AIDS—*continued*
blastomycosis in, 1839
candidiasis in, 1936
mucocutaneous, 1936
oral, 1823, 1932, 1936
Castleman disease in, 1409
chancroid in, 1983, 1986
chemokines in, 134–135
coccidioidomycosis in, 1840, 1937
complement system in, 329
cryptococcosis in, 1747, 1842, 1843, 1936–1937
cutaneous disorders in, 1930–1935
cytomegalovirus infections in, 1861
clinical findings in, 1863, 1863f
treatment of, 1863
diagnosis of, 1850, 1928–1929, 1929t
doxorubicin therapy in, 2175
in drug abuse, 921, 926, 1927
drug-induced disorders in, 1933–1935
lipodystrophy in, 586, 586f, 589
photosensitivity in, 1932
pruritus in, 1931
eosinophilic folliculitis in, 315, 1931, 1931f
epidemiology of, 1927
epidermal necrolysis in, 349
erythema elevatum diutinum in, 1618, 1619, 1619t
erythroderma in, 1932
etiology of, 1927
fungal infections in, 1808, 1936–1937
gonorrhea in, 1994
granuloma annulare in, 369
granuloma inguinale in, 1990, 1991, 1992–1993
hepatitis B in, 2208
herpes simplex virus infections in, 1873, 1878, 1937–1938
herpesvirus-6 infection in, 1865
histoplasmosis in, 1837, 1837f, 1838, 1937
treatment of, 1838
ichthyosis in, 421, 1496
immune restoration syndrome in, 1929–1930, 1931
Kaposi sarcoma in, 1184, 1185–1186, 1186f, 1187, 1933
genital, 667
oral, 1186, 1186f, 1933
treatment of, 1187–1188, 2284
keratoacanthoma in, 1050
Klebsiella infections and rhinoscleroma in, 1742
leishmaniasis in, 1940, 2001, 2004
visceral, 2006
lichen planus in, 249
lipoatrophy in, 1934, 1935, 1935f
poly-L-lactic acid augmentation in, 2384
silicone augmentation in, 2387
lipodystrophy in, 586f, 586–587, 589, 1192, 1934–1935
listeriosis in, 1762
lymphogranuloma venereum in, 1989
lymphoid hyperplasia in, 2281
melanoma in, 1933
melanonychia in, 783
Merkel cell carcinoma in, 1089, 1933
molluscum contagiosum in, 1911, 1938
mucocutaneous disorders in, 1929–1930, 1930t
mycobacterial infections in, 1768–1769, 1777, 1778, 1935
leprosy in, 1790–1791
tuberculosis in, 1768–1769, 1935
natural history in, 1927–1929
nocardiosis in, 1782, 1783
in occupational exposures, 2075
onychomycosis in, 1817f, 1936
opportunistic infections in, 1927–1928, 1929, 1935–1939
oral cavity disorders in, 652t, 1932–1933
in candidiasis, 1823, 1932, 1936
in Kaposi sarcoma, 1186, 1186f, 1933
in oral hairy leukoplakia, 644, 1932–1933, 1933f
in papillomavirus infections, 1939
papillomavirus infections in, 663–664, 1918, 1920, 1933, 1938–1939
and cancer risk, 1921, 1933
papular pruritic eruption in, 1931–1932, 1932f
parvovirus B19 infections in, chronic, 1857
pathogenesis in, 1927
pediculosis pubis in, 2037
Penicillium marneffei infection in, 1841, 1842, 1937
photochemotherapy in, 1931, 2257, 2259
photosensitivity in, 1932
pigmentary disorders in, 1932
pityriasis rubra pilaris in, 234, 235
porokeratosis in, 443
porphyria cutanea tarda in, 1236, 1237–1238, 1241, 1932
pruritus in, 908, 1930–1932
differential diagnosis of, 1930–1931, 1931b
in papular pruritic eruption, 1931–1932, 1932f
Pseudomonas aeruginosa infections in, 1736, 1737, 1935
pseudoporphyria in, 1932
psoriasis in, 184, 1932
and arthritis, 194, 195, 201–202, 206
and photochemotherapy, 2257
treatment of, 2183, 2257
reactive arthritis in, 202, 207, 208, 210
treatment of, 214
scabies in, 1940, 2029
seborrheic dermatitis in, 219, 220, 222, 223f, 223t
sexually transmitted diseases in, 1939–1940
sporotrichosis in, 1831, 1937
squamous cell carcinoma in, 1933, 1939
oral, 1933
stages of, 1928, 1928t
sub-types of, 1927
syphilis in, 1956, 1960, 1969–1970, 1970f
treatment of, 1974, 1975, 1976
T-cell lymphotropic virus infections in, 1938
thrombotic thrombocytopenic purpura and hemolytic uremic syndrome in, 2204–2205
toxoplasmosis in, 2010
transmission of, 1927
treatment of, 1850, 1927, 1929, 1930t, 2207–2211
drug resistance in, 2209
entry inhibitors in, 2210–2211
nonnucleoside reverse transcriptase inhibitors in, 2209
nucleoside reverse transcriptase inhibitors in, 2208–2209
protease inhibitors in, 2209–2210
research on new agents in, 2211
treponematosis in, endemic non-venereal, 1982
trichomoniasis in, 1999
valacyclovir complications in, 2204–2205
varicella-zoster virus infections in, 1886, 1890, 1938
complications of, 1894
prevention of, 1897
vasculitis in, 1932
viral replication in, 1846, 1929
viral set point in, 1929
warts in, 1938–1939
Hives, 27
HLA system, 84
in actinic prurigo, 818, 819
in alopecia areata, 763
in autoimmune disorders, 1509
in Behçet disease, 84, 1620, 1621, 1623
and prognosis, 1624, 1625
in bullous disease of childhood, chronic, 486
class I, 84
class II, 84
in cryoglobulinemia, 1638
in dermatitis herpetiformis, 84, 501, 502–503
in dermatomyositis, 1538f, 1539
in drug-induced cutaneous reactions, 355–356, 361
in epidermal necrolysis, 351
in epidermolysis bullosa acquisita, 494
in erythema multiforme, 344, 347
in hidradenitis suppurativa, 735
in Kawasaki disease, 1627
in leprosy, 1793
in lichen nitidus, 258
in lichen planus, 244
in linear IgA dermatosis, 486
in lupus erythematosus, 1516, 1520
in lymphocytic infiltration of skin, 1412
in melanoma, 1155
in necrotizing venulitis, 1600, 1601
in palmoplantar pustulosis, 215
in parapsoriasis, 238
in pemphigoid gestationis, 491, 492
in pemphigus, 84, 463–464
in psoriasis, 84, 169–170, 170f, 174, 175f, 184
and arthritis, 169, 194, 195, 198–199, 201
in reactive arthritis, 84, 201, 207, 208–209, 213, 1997
in rheumatoid arthritis, 1569
in sarcoidosis, 1485f, 1485–1486
in Sjögren syndrome, 1577, 1578
in vitiligo, 616
HMB-45
in melanoma, 1145, 1153
in Paget disease, 1096
Hobo spider bites, 2057
Hodgkin lymphoma, 52
hyperhidrosis in, 726
ichthyosis in, 421
Hoesch test in acute intermittent porphyria, 1250
Hoigne syndrome, 1977
Holistic dermatology, 2285
Hollenhorst plaques, 1672
Holocarboxylase synthetase, 1219t
deficiency of, 1219t
Holothurin, 2048
Holster sign in dermatomyositis, 1540, 1543t
Homeobox genes, 739
Homocysteine, 1304
Homocystinuria, 530t, 1219t, **1304**
Homogentisic acid, 1221f, 1224–1228, 1225f
renal clearance of, 1225
Homogentisic acid oxidase, 1221f, 1225f
deficiency of, 1219t, 1224, 1226
Homosalate in sunscreens, 2139t
Homozygote, 79

Honeybee stings, 2062
Honeycomb appearance of lungs in Langerhans cell histiocytosis, 1417, 1420f
Honokiol, 2236t
Hookworm infections, 2011, 2012t, 2013, 2016
  cutaneous larva migrans in, 2023–2024
  treatment of, 2015t, 2016
Hori nevus, 632, 632t, 638–639
  laser therapy in, 2274
Horizontal forehead lines, botulinum toxin injection for, 2391
Hormone response elements, 2107
Horn, 28, 28f, 31t
  in actinic keratosis, 1008–1009, 1010f
  in verruca vulgaris, 28, 28f
Horn pearls in squamous cell carcinoma, 1033
Horner syndrome, 725
Horse chestnut seed extract in chronic venous insufficiency, 1683
Horse fly bites, 2060
Hortaea werneckii, 1820, 1820f
Hospitalization in atopic dermatitis, 157
Host cell reactivation assay, 984–985, 985f
Hot comb alopecia, 773
Hot flashes and sweating in menopause, 715, 725
Hot foot syndrome, 1736
Hot quart lamps, 800
Hot tub folliculitis, 1699, 1736, 1736f
House dust mites, 2032t, 2032–2033
Howel-Evans syndrome, 1504t
HOXC13/Hoxc13, 68t, 72
  in hair follicle development, 740f, 742
H-plasty, 2308
HTLV infections, 1386, 1923–1927. *See also* T cell lymphotropic virus infections
Human Genome Project, 73
Humectants as moisturizing products, 2359, 2359t
Humidity, environmental
  and cold injuries, 845
  and low humidity dermatitis, 2068, 2069t
Humoral immunity, **319**–329
  complement system in, 323–329
  opportunistic infections in defects of, 269t
Hunterian chancre in syphilis, 1957, 1957f
Hunter glossitis in vitamin B_{12} deficiency, 1212
Hunting reaction of Lewis, 845, 846
Huriez syndrome, 425t, 426
Hutchinson nail sign, 39t, 788
  in subungual melanoma, 1139
Hutchinson nose sign, 39t, 2292
Hutchinson teeth in congenital syphilis, 652t, 1969, 1969f
Hutchinson type of erythema elevatum diutinum, 1616
Huxley's layer of hair follicle, 742, 743f
Hyaline fibromatosis, juvenile, 68t, 552
Hyaline membrane of hair follicle, 744
Hyalinosis
  cutis et mucosae, 1288
  infantile systemic, 68t, 552
Hyaluronic acid, 538, 538f, 539, 540, 541, 2357–2358
  age-related changes in, 967
  in scleredema, 1563
  in soft tissue augmentation, 2382t, 2383–2384, 2384f
    in combination with botulinum toxin, 2392
  in wound healing, 2345
  in xerosis, 2358, 2359
Hyaluronidase, in extravasation of chemotherapy drugs, 2180
Hydantoin, pseudolymphoma syndrome from, 1404
Hydatid disease, 2026
Hydatidiform mole, and pemphigoid gestationis, 491
Hydralazine, lupus erythematosus from, 1513
Hydration of skin
  affecting wound healing and repair, 2345–2346
  in atopic dermatitis, 153–154
  moisturizing products for, 2359, 2359t
  in oily and dry types, 2357–2359
Hydroa vacciniforme, 819–821
  approach to diagnosis of, 826, 827
  clinical findings in, 820f
  differential diagnosis in, 820b
  treatment of, 820–821
    photochemotherapy in, 2257
Hydrocarbon base of ointments, 2093–2094
Hydrocarbon exposure, 2078t
  chloracne in, 702, 2078
  keratosis in, 1018
  skin cancer risk in, 2079t, 2079
Hydrochloric acid, occupational exposure to, 2070t
Hydrocolloid dressings, 2345, 2346t
Hydrocortisone
  in Addison disease, 1479
  in alopecia areata, 765
  chemical structure of, 2148f
  mechanism of action, 2147
  pharmacokinetics of, 2147–2148
  potency and duration of action, 2148t
  in surgical patients, 2150
  in vulvovaginal lichen planus, 680
Hydrofluoric acid, occupational exposure to, 2069t, 2070t
Hydrogel dressings, 2345, 2346t
Hydrogen cyanide as chemical weapon, 2086t
Hydrogen peroxide, 285–286, 2131t, 2132
Hydrops fetalis
  in parvovirus B19 infections, 1857
    treatment of, 1857b
  in syphilis, 1967
Hydrops of gallbladder in Kawasaki disease, 1629
Hydroquinone
  as bleaching agent, 628f, 629, 1227, 2135, 2145t, 2145–2146
  in combination therapy with tretinoin and dexamethasone, 2146
  in ethnic skin, 2145–2146
  mechanism of action, 2145
  in melasma, 629, 635, 1480, 2145
  monobenzyl ether of (MBEH), 621, 628–629, 2135, 2146
    in ethnic skin, 2146
    in vitiligo, 621, 629, 2146
  ochronosis from, 637, 1227, 2145, 2146
  preparations containing, 2145t
  side effects of, 2145–2146
  as tyrosinase inhibitor, 2363
α-Hydroxy acids, in topical preparations
  keratolytic, 2135t, 2135–2136
    for ethnic skin, 2144
  stinging sensation from, 2360, 2361
β-Hydroxy acids, in topical keratolytic preparations for ethnic skin, 2144
Hydroxychloroquine, 2157–2162
  chemical structure of, 2158, 2158f
  in children, 2161, 2162
  complications of, 2161–2162, 2162t
  in dermatomyositis, 1551, 2160
  dosing regimen for, 2160
  in graft-versus-host disease, 267t
  in granuloma annulare, 2160
  indications for, 2159–2160, 2161t
  in lichen planus
    cutaneous, 254b, 255
    oral, 253b, 254
  in lupus erythematosus, 1533t, 1533–1534, 2159–2160
  in lymphocytic infiltration of skin, 1413b
  mechanism of action, 2157–2158
  in necrotizing venulitis, 1606, 1606t
  pharmacokinetics of, 2158–2159, 2159t
  pigmentation changes from, 636, 2161
  in polymorphic light eruption, 818, 2160
  in porphyria cutanea tarda, 1242, 2160
  in pregnancy and breast-feeding, 2162
  in sarcoidosis, 1492, 1492t, 2160
Hydroxykynureninuria, 1219t
21-Hydroxylase deficiency, 1480
Hydroxylysine, 527
  structure of, 527f
  synthesis of, 524
Hydroxymethylglutaryl CoA reductase inhibition, 388–389
  in familial hypercholesterolemia, 1276, 1277
  in hyper-IgD syndrome with periodic fever, 1268–1269
p-Hydroxyphenylpyruvic acid, 1221f, 1221–1222, 1225f
17-Hydroxyprogesterone levels in hirsutism, 775t
Hydroxyproline
  in collagen, 517–518, 518f, 534
    synthesis of, 522–524, 525f
  in elastin, 531, 534
4-Hydroxyproline in elastin biosynthesis, 534
3β-Hydroxysteroid dehydrogenase, 691f
  in sebaceous glands, 689
17β-Hydroxysteroid dehydrogenase, 691f
  in acne vulgaris, 690
  in sebaceous glands, 689
5-Hydroxytryptamine, hyperhidrosis from, 726
Hydroxyurea, 2171–2172
  chemical structure of, 2163f
  complications of, 2171–2172, 2172t, 2176t
  contraindications to, 2171, 2172t
  dosage regimen, 2171, 2176t
  indications for, 2171, 2171t, 2176t
  mechanism of action, 2171, 2176t
  monitoring of therapy with, 2171, 2171t
  in polycythemia vera, 1378
  in psoriasis, 187t, 192
1,25-Hydroxyvitamin D, 1206
Hydroxyzine, 2187, 2189t
  pediatric dosage, 953t
  in pruritus, 910
  in urticaria and angioedema, 341, 342f
Hygiene hypothesis on atopic dermatitis, 146
Hymenoptera stings, 2062
  differential diagnosis of, 2056b
Hyperbaric oxygen therapy, 860
  in soft tissue infections, 1730, 1743
Hyperbilirubinemia, jaundice in, 1447, 1447t
Hypercalcemia
  clinical findings in, 1475, 1475t
  differential diagnosis of, 1475, 1476b
  in hyperparathyroidism, 1474, 1475
  in Langerhans cell histiocytosis, 1423
  in malignancy, 1474, 1475, 1477
  in T-cell leukemia, 1924
  treatment of, 1477

Hypercholesterolemia, 1276–1277
in biliary obstruction, 1280
in familial defective apolipoprotein B-100, 1277
familial heterozygous, 1276–1277
familial homozygous, 1276, 1277f
xanthoma in, 1272t, 1273f, 1276, 1277, 1277f, 1279t, 1280
Hypereosinophilia, 307–310, 1375t, 1376t. *See also* Eosinophilia
Hyperesthesia in African trypanosomiasis, 2008
Hyperglobulinemic purpura, 1601
of Waldenström, 1381t, 1383–1384
Hyperglycemia in diabetes mellitus, skin changes related to, 1461
Hypergranulosis in lichen planus, 49, 49f
Hyperhidrosis, 166, 713
in acromegaly, 726, 1482
axillary, 719, 723, 724b
classification of, 722t
in cold-induced sweating syndrome, 724
compensatory, 723, 725, 728
craniofacial, 722, 724b
drug-induced, 722t, 726
episodic hypothermia in, 725–726
generalized, 722t, 725–726
gustatory, 722t, 724b, 725
localized, 722t, 723–725
idiopathic, 725
paroxysmal, 725
Minor's starch-iodine test in, 2392, 2393f, 2394f
olfactory syndrome, 724
palmoplantar, 723, 724b, 2392, 2394f
in keratoderma, 431
primary focal, 722t, 723, 723f
clinical manifestations of, 723
diagnosis of, 722, 723, 723f
treatment of, 723
segmental, 722, 725
sympathectomy in
anhidrosis after, 728
compensatory hyperhidrosis after, 723, 725, 728
treatment of, 723, 724b, 2134
botulinum toxin in, 716, 723, 724b, 2388, 2392–2393
complications of, 2393–2394
sympathectomy in, 723, 725, 728
in tumors, 726
intrathoracic, 724–725
unilateral circumscribed, 725
Hyper-IgD syndrome, 1267t
clinical findings in, 1268, 1268f
differential diagnosis of, 1268, 1268b
with periodic fever, 1267–1269
treatment of, 1268–1269
Hyper-IgE syndrome, 1366f, 1366–1367, 1374t
clinical findings in, 1366, 1366f, 1367t
differential diagnosis of, 151
Hyper-IgM syndrome, 1353–1354
Hyperkeratosis, 406
in amputation stump, 864, 864f
in Bowen disease, 1022
in dermatomyositis, 1542
in eczema, 430b
in epidermal nevus, 1058, 1058f
epidermolytic. *See* Epidermolytic hyperkeratosis
focal acral, 429
follicularis perstans, 567
in hand dermatitis, 162–167
clinical findings in, 164
treatment of, 166
in lichen planus, 49, 49f, 251, 252f
in lichen simplex chronicus, 160, 161
in lupus erythematosus, 1529
discoid, 1524–1525, 1529
in palmoplantar keratoderma
diffuse nonepidermolytic, 426
focal, 427
in paraneoplastic dermatoses, 1493–1499
in parapsoriasis, 238, 238f
perforating disorders in, 564, 567
in porokeratosis, 442, 444
subungual, 783
in tinea pedis, 1816, 1816f
in vitamin A deficiency, 1205f
in vitamin A toxicity, 1205
Hyperlipidemia, 1274–1278, 1452
coronary artery atherosclerosis in, 1277, 1452
in diabetes mellitus, 1462, 1464
Frederickson classification, 1274–1278, 1279t
type I, 1274–1276, 1279t
type II, 1276–1277, 1279t
type III, 1277–1278, 1279t
type IV, 1278, 1279t
type V, 1278, 1279t
peripheral artery atherosclerosis in, 1667, 1671
in retinoid therapy, 2185–2186
xanthoma in, 1272–1278, 1452
Hypermelanosis, **631**–640, 1374t
acquired, 634–640
diffuse linear, 638
diffuse non-figured, 634–636
diffuse reticular, 638
with café-au-lait macules, 634
congenital, 631–634
circumscribed, 632–634
diffuse, 631–632
with dermal melanocytosis, 632–633
diagnostic algorithm on, 625f
epidermal melanotic, 634
with lentiginosis syndromes, 633
linear and whorled, 69, 631
mixed with hypomelanosis, 640
Hyperostosis
idiopathic skeletal, in retinoid therapy, 2185
in SAPHO syndrome, 701
Hyperparathyroidism, 1474–1477
approach to patient with, 1475t
calciphylaxis in, 1475–1476
clinical findings in, 1475–1476
epidemiology of, 1474
primary, 1474, 1475, 1476
secondary, 1475, 1476
pruritus in, 907
tertiary, 1475
treatment of, 1477
Hyperpigmentation, 30, 631–640, 1374t
in acanthosis nigricans, 1494
in acquired hypermelanosis, 634–640
in Addison disease, 634, 1478, 1479f
bleaching agents in, 2145–2146. *See also* Bleaching agents
with café-au-lait macules, 634
in congenital hypermelanosis, 631–634
in Cushing syndrome, 634, 1478
with dermal melanocytosis, 632–633
drug-induced, 636–637, 637t, 1397
from bleomycin, 636, 2124, 2178, 2178f
from cyclophosphamide, 636, 2173, 2181
from cytotoxic drugs, 2177, 2178f, 2178–2179, 2179f, 2179t, 2181
laser therapy in, 2274, 2275f
mucosal, 2181
in ectodermal dysplasia, 1340, 1341f, 1342f
genital, 658b
in hematologic disorders, 1374t
in hemochromatosis, 635–636, 1214, 1446
in HIV infection and AIDS, 1932
idiopathic eruptive macular, 640
in laser therapy complications, 2277, 2277f, 2376
in skin resurfacing, 2368
laser therapy in, 2274, 2275f, 2376
linear and whorled, 83, 631
mixed with hypomelanosis, 640
of nails, in cytotoxic drug therapy, 2177
in occupational exposures, 2076
oral, 648
periorbital familial, 639
post-inflammatory, 639, 639f
ethnic considerations in, 2111, 2142f, 2142–2144, 2143f, 2144f
in laser skin resurfacing, 2368
laser therapy in, 2274
postoperative, 2341
in pregnancy, 955, 957f
prevention of, 2363
in sclerotherapy for varicose veins, 2353–2354
in thyroid disorders, 635, 1473
in vitamin B_{12} deficiency, 1212, 1456
zebra-like, 631
zosteriform, 631
Hyperplasia
angiolymphoid. *See* Angiolymphoid hyperplasia
apocrine, 1071
eccrine, 1074–1075
focal epithelial, 1919
giant lymph node, 1409
gingival, 645
lymphoid cutaneous, 1402–1408, 1403t
melanocytic, 1099
of Pacinian corpuscles, 1178
sebaceous, 1085, 1086f
syringolymphoid, 1074–1075
ultraviolet radiation-induced, 813
verrucous, in limb amputation and prosthesis use, 865f, 865–866
Hyperprolinuria, 1219t
Hyperpyrexia, anhidrosis in, 729
Hyperreactivity reaction in Behçet disease, 1624
Hypersensitivity
angiitis or vasculitis in, 1599
and granulomatosis, 1611–1613
to bacterial antigens, 1692
cellular
in Cockayne syndrome, 1321
in hymenoptera stings, 2062
in xeroderma pigmentosum, 1317
contact, 900
in topical corticosteroid therapy, 2106, 2106t
ultraviolet radiation exposure affecting, 90, 806, 808, 812–813
to cosmetic products, 2361–2362
delayed-type
allergic contact dermatitis in, 135, 138
from cosmetic products, 2361–2362
in fungal infections, 1811
in leprosy, 1788, 1790, 1791, 1791f
photoallergy in, 828, 828t, 832–834
polymorphic light eruption in, 816
in sea anemone sting, 2045, 2045f
to tuberculin, 1769–1770
ultraviolet radiation exposure affecting, 806, 806f, 808, 808f

denervation, of eccrine sweat glands, 716
to drugs, 356–358
antibiotic, 357, 1693, 2198, 2199
corticosteroid, 2106, 2106t, 2151t
cutaneous reactions in, 356–358, 357f, 357t
diagnosis of, 361
in HIV infection and AIDS, 1933, 1934
in local anesthesia, 2297
urticaria and angioedema in, 358
to foods, 2286
immediate type I, solar urticaria in, 823
papular urticaria in, 336
to smallpox vaccination, 1904
sulfone syndrome in, 2156–2157
in Sweet syndrome, 290
to tattoo pigment, 888
Hypertension
in corticosteroid therapy, 2150t, 2151
in cyclosporine therapy, 2219, 2220
intracranial benign, in isotretinoin therapy, 699
in porphyria, acute intermittent, 1251
pulmonary
classification of, 1560, 1561t
in sclerosing panniculitis, 575
in systemic sclerosis, 1560–1561
renovascular, in neurofibromatosis type 1, 1336
Hyperthermia, 836
radiosensitivity in, 860
Hyperthyroidism
approach to patient with, 1472t
congenital, 1470
cutaneous signs of, 1471–1473, 1472f, 1473f
dermopathy in, 1472f, 1472–1473, 1473f, 1474
epidemiology of, 1470
etiology and pathogenesis in, 1470–1471
hyperpigmentation in, 635, 1473
radioiodine uptake in, 1470
treatment of, 1474
Hypertonic saline solution in sclerotherapy for varicose veins, 2353t, 2354
Hypertrichosis, 739, 753, 755, 774, 776–777
acquired, 776f, 776t, 776–777
congenital, 776, 776t
definition of, 754t
drug-induced, 776t, 776–777, 777f
in corticosteroid therapy, 2105–2106
in cyclosporine therapy, 776–777, 2220
generalized, 776t, 776–777
lanuginosa, 1448
acquisita, 1495t, 1503, 1503f
localized, 777, 777t
in porphyria cutanea tarda, 1238, 1238f
in smooth muscle hamartoma, 1174, 1175f
treatment of, 775b, 777
laser therapy in, 2275–2277
Hypertriglyceridemia
in diabetes mellitus, 1462, 1464
familial, 1278
with chylomicronemia, 1278
xanthoma in, 1278, 1279t
in retinoid therapy, 2186
Hypertrophic osteoarthropathy, primary, 554
Hypertrophic scars. *See* Scars, hypertrophic
Hypertrophy
dermal, **550**–557
of Pacinian corpuscles, 1178
Hyperuricemia, 1575, 1575t
gout in, 1575, 1576
panniculitis in, 583
Hyperviscosity disorders, 1376t
in polycythemia vera, 1377
Raynaud phenomenon in, 1646, 1646t
Hypervitaminosis A, 1205
Hypervitaminosis D, 1295–1296
Hypoalbuminemia in exfoliative dermatitis, 228, 231
Hypocalcemia
clinical findings in, 1475, 1475t
in hypoparathyroidism, 1474, 1476
Hypochondriasis, delusions of parasitosis in, 912–913
Hypocomplementemia and necrotizing venulitis, 1602, 1604
Hypodermis, 58f, 66
embryonic and fetal development of, 70
functions of, 57, 58t, 66
Hypodontia
with nail dysgenesis, 1346, 1346f
in palmoplantar keratoderma, 430
Hypoglycemia in protein-energy malnutrition, 1203
Hypoglycemic agents, oral, phototoxicity from, 829t
Hypogonadism, diffuse hypopigmentation in, 629
Hypohidrosis, 726–727
classification of, 722t
in ectodermal dysplasia, 79, 83, 1339–1342. *See also* Ectodermal dysplasia, anhidrotic or hypohidrotic
in Fabry disease, 1283
in ichthyosis
with follicular atrophoderma and hypotrichosis, 753t
lamellar, 410
Hypomelanosis, **622**–631
acquired diffuse, 629–631
with vascular cause, 630–631
acquired localized, 623–629
congenital, 622–623
diagnostic algorithm on, 624f
guttate, 1446
idiopathic, 630, 630f
of Ito, 69, 83
macular, 1330b
progressive, 624, 630
in tuberous sclerosis, 1326, 1328f, 1329, 1329f
mixed with hypermelanosis, 640
Hyponatremia in acute intermittent porphyria, 1251
Hyponychium, 778, 779f, 780, 2320, 2320f
clinical signs in disorders of, 781t
horny layer of, 780
Hypoparathyroidism, 1474–1477
approach to patient with, 1476t
and candidiasis, chronic mucocutaneous, 1356, 1476
clinical findings in, 1475, 1476
iatrogenic, 1475
primary, 1475
secondary, 1475
treatment of, 1477
Hypopigmentation, 30, 622–631
in acquired hypomelanosis, 623–631
in congenital hypomelanosis, 622–623
in cryotherapy, 2333
genital, 658b, 678, 679f
in hematologic disorders, 1374t
in HIV infection and AIDS, 1932
in laser therapy complications, 2376
in leprosy, 628, 628f, 1788, 1793
in lichen sclerosus, 678, 679f
in mycosis fungoides, 627, 1391
postoperative, 2341
in selenium deficiency, 629, 1217
in syphilis, 1960
in tuberous sclerosis, 1326, 1329f
Hypopituitarism
growth hormone deficiency in, 1483
pigmentation changes in, 629, 1483
Hypoplasia
in cartilage-hair hypoplasia syndrome, 1356–1357
focal dermal, 530t
of Goltz, 1346–1348, 1347f
Hyposplenism, opportunistic infections in, 269t
Hypotension
in meningococcemia, 1732, 1735
in septic shock, 1746, 1747
Hypothalamus
in corticosteroid suppression of adrenal-hypothalmic-pituitary axis, 2105, 2106, 2148, 2149–2150, 2150t, 2151
in thermoregulation, 835, 838f, 845
Hypothermia, 836
in cold injuries, 846
with frostbite, 847
episodic, with hyperhidrosis, 725–726
Hypothyroidism
approach to patient with, 1473t
autoimmune, 1374t
congenital, 1470, 1471
cutaneous findings in, 1473–1474, 1474f
epidemiology of, 1470
etiology and pathogenesis in, 1470, 1471
in hemangioma of infants, 1167
hypopigmentation in, diffuse, 629
Raynaud phenomenon in, 1646
in retinoid therapy, 2185
treatment of, 1474
vitiligo in, 629
Hypotrichosis
desmosomes in, 449, 449t, 758
with ichthyosis, follicular atrophoderma, and hypohidrosis, 753t
localized autosomal recessive, 758, 760f
with lymphedema and telangiectasia, 1661, 1662
Maria Unna, 760
in palmoplantar keratoderma, 430
simplex, 765–766, 766f
Hypoxanthine-guanine phosphoribosyl transferase, 2167

I

Ibuprofen, pediatric dosage, 952t
ICAMs. *See* Intercellular adhesion molecules (ICAMs)
Ichthammol, 2130
Ichthyoacanthotoxicosis, 2050–2052
Ichthyol, 2130
Ichthyosis, **401**–423
acquired, 421–422, 1376t
in malignancies, 1494t, 1496
with alopecia and photophobia, 751, 752–753
autosomal dominant, 402t–403t
autosomal recessive, 404t–405t, 408f, 409–410, 411, 411t
autosomal semidominant, 402t
of bathing suit area, 411
bullosa, of Siemens, 402t, 414, 423
in Chanarin-Dorfman syndrome, 419–420
in chondrodysplasia punctata, 419
classification of, 406t
clinical presentation in, 406

Ichthyosis—*continued*
congenital, 401–421
with follicular atrophoderma, hypotrichosis, and hypohidrosis, 753t
drug-induced, 421–422
with epidermolytic hyperkeratosis, 414–415
etiology and pathogenesis of, 406–407
genetic factors in, 395, 401–421
classification and features in, 402t–405t
complex trait, 83
counseling on, 85
and gene therapy, 86
harlequin, 404t, 415–416
in HIV infection and AIDS, 421, 1496, 1931
hystrix, 425t, 1058, 1061
of Curth and Macklin, 402t, 414
in kava dermatopathy, 422
with keratitis and deafness, 403t, 407, 418, 418f, 429, 752, 1342
lamellar, 31t, 61, 395, 407, 409, 410f, 410–411
prenatal diagnosis of, 423
treatment in, 423
in lymphoma, 421, 1496
in Netherton syndrome, 416, 417f
in newborn, 415–416, 423
in peeling skin syndromes, 421
prenatal diagnosis of, 85, 423
in Refsum disease, 418–419
resources on, 423b
in Rud syndrome, 421
in Sjögren-Larsson syndrome, 416–417
skin barrier function in, 393, 395, 406
treatment of, 422–423
retinoids in, 410, 422, 423, 2111, 2183
in trichothiodystrophy, 420
vulgaris, 31t, 61, 395, 402t, 407f, 407–408
differential diagnosis in, 407
histopathology in, 407–408, 408f
in HIV infection and AIDS, 1931
and keratosis pilaris, 407, 749f, 750
X-linked, 61, 80, 395, 403t, 1505t
recessive, 403t, 407, 408f, 408–409
ICHYN in ichthyosis, 411t
Icterus, 956, 1379. *See also* Jaundice
Id reaction, 162–167
autosensitization dermatitis in, 167
clinical findings in, 164, 165f
in leishmaniasis, 2006
Idiotope, 320
Idoxuridine in smallpox, 1903
Iduronic acid, 538f
IFAP syndrome, 751, 752–753
Iggo's capsule, 65
IKAP in Riley-Day syndrome, 726
Ileostomy, skin problems in, 868–871
dermatitis, 869, 869f
granuloma, 870
Iliac artery atherosclerosis, 1669f
treatment of, 1671
Iloprost
in systemic sclerosis, 1558, 1559t
in thromboangiitis obliterans, 1676
Imatinib mesylate, 288
in dermatofibrosarcoma protuberans, 1161
in hypereosinophilic syndromes, 310, 311f
in mastocytosis, 1443
Imbibition phase in skin graft healing, 2346
Imerslund-Grasbeck syndrome, 1377
Imidazole antifungal agents, 2116–2119, 2117t, 2215
adverse effects of, 2118t, 2118–2119
indications for, 2118, 2118t
Imidazoquinolines, topical, 114
Iminodipeptiduria, 1219t
Imipenem in actinomycetoma, 1786
Imiquimod, 114, 125, 2125–2129, 2236
in actinic keratosis, 1005, 1013b, 1013–1014, 1015, 2128, 2129
anti-angiogenic properties of, 2128
in basal cell carcinoma, 1005, 1041, 2128, 2129
in Bowen disease, 1023, 1023b
in dysplastic nevus, 1133
in hemangioendothelioma, 2128
in hemangioma of infants, 1169, 2128
in herpes simplex virus infections, 1884
in HIV infection and AIDS, 1937–1938
indications and contraindications to, 2128
initiation of therapy in, 2129
mechanism of action, 2126–2128, 2127f, 2236
in molluscum contagiosum, 1913, 1913t
monitoring of therapy with, 2129
in Paget disease, 1098
pharmacokinetics of, 2128
in porokeratosis, 445, 445b
side effects of, 2127, 2129
in warts, 1922, 2127, 2129
Immersion foot, 848
tropical, 848
Immobilization
decubitus ulcers in, 878–886
positioning techniques in, 883–884
support surfaces in, 884
Immune complexes, 322
Immune globulin
intramuscular
in measles, 1853
in rubella, 1854–1855
intravenous
in cicatricial pemphigoid, 485, 485b
in epidermal necrolysis, 354, 359
in epidermolysis bullosa acquisita, 499, 499t
in Kawasaki disease, 1626, 1630, 1631–1632, 1632f
in pemphigus, 468
paraneoplastic, 474t
in rheumatic fever, 1574
in soft tissue infections, 1730
in toxic shock syndrome, 1717
rabies, 2039
vaccinia, 1905, 1906
varicella-zoster, 1885, 1897–1898, 1898t
Immune protection factor (IPF) of sunscreens, 2138
Immune response, **95**–114
adaptive, 95, **101**–112, 319. *See also* Adaptive immunity
in aging, 963
in atopic dermatitis, 146–148, 151
to botulinum toxin, 2390, 2393
cellular. *See* Cell-mediated immunity
costimulatory molecules in, 112
cross-reactivity in, 322
cutaneous, 112–114, 113f
danger signals in, 109, 112, 113f
in helminthic infections, 2011
innate, **95**–100. *See also* Innate immunity
in leishmaniasis, 2002
in leprosy, 1787, 1792–1793
in psoriatic arthritis, 196–197, 198–199
in syphilis, 1956–1957
and HIV infection, 1970
ultraviolet radiation exposure affecting, 805–809, 812–813, 1003, 2248
immune protection factor of sunscreens in, 2138
photoimmunosuppression in, 812–813
in psoralen and PUVA therapy, 2250–2251
in viral infections, 1848–1849
herpes simplex, 1874
varicella-zoster virus, 1887, 1888
in vitiligo, 616–617
Immune restoration syndrome in HIV infection and AIDS, 1929–1930, 1931
Immunity, **95**–114
adaptive, 95, **101**–112, 319. *See also* Adaptive immunity
cellular. *See* Cell-mediated immunity
humoral, **319**–329
innate, **95**–100. *See also* Innate immunity
Immunobiologic agents, 2223–2231
in psoriatic arthritis, 205–206
Immunodeficiency disorders, **1348**–1372
in antibody deficiency disorders, 1348–1353, 1349t
in B cell disorders, 323
in cellular deficiencies, 1348, 1349t, 1354–1357
clinical findings in, 1348, 1349t
in combined antibody and T cell deficiency, 1348, 1357–1362
common variable, 1352–1353
clinical findings in, 1353, 1353f
epidemiology of, 1352–1353
etiology and pathogenesis in, 1353
laboratory tests in, 1353
treatment of, 1353
in complement deficiency disorders, 1348, 1349t, 1370–1372
in hereditary angioedema, 1372
in hyper-IgM syndrome, 1353–1354
in neonates and infants, 1350f–1352f
in phagocytosis and cell killing disorders, 1348, 1349t, 1362–1370
severe combined, 1358–1360
differential diagnosis in, 151
graft-versus-host disease in, 1359–1360
types of, 1358, 1359t
in X-linked agammaglobulinemia, 1348–1352
in X-linked lymphoproliferative disease, 1354
Immunofluorescence
in bullous pemphigoid, 475f, 475–476, 476f
in cicatricial pemphigoid, 481f, 483
in epidermolysis bullosa, 505, 512
acquisita, 494, 496, 498, 498f
in HIV infection, 1929t
in lichen planus, 252, 252f
in linear IgA dermatosis, 486f, 486–487
in lupus erythematosus, 1530, 1530f
in necrotizing venulitis, 1605
in paraneoplastic pemphigus, 472
in pemphigoid gestationis, 490
in Rocky Mountain spotted fever, 1942
in soft tissue infections, 1727
in varicella-zoster virus infections, 1892
Immunoglobulins
class switching, 322, 1353
complementarity-determining regions of, 320
domains of, 319, 320f
gene rearrangements and diversity, 321
heavy chains of, 319, 320, 320f
hypervariable regions of, 319–320
IgA, 319, 320
in chronic bullous disease of childhood, 486–487
in cicatricial pemphigoid, 481, 483
class switching, 322

in common variable immunodeficiency, 1353
and complement activation, 326
in cryoglobulinemia, 1638
deficiency of, 1353
in dermatitis herpetiformis, 500, 501–502, 502f, 503
and linear IgA dermatosis, 485, 487, 488, 504
eosinophil surface receptors, 287
in erythema elevatum diutinum, 1619
functions of, 320, 321t
in hyper-IgM syndrome, 1353, 1354
in Kawasaki disease, 1628
in linear dermatosis, 358, **485**–490, 496–497, 1375t
in necrotizing vasculitis, 1599
paraproteinemia, 305, 306, 1502, 1619
in pemphigus, 305, 306, 1375t
in polymorphic disease with monoclonal IgA ANCA, 1375t
in psoriasis, 182
in pyoderma gangrenosum, 1502
subclasses of, 320, 321t
in sub-corneal pustular dermatosis, 305, 306
in vasculitis, 1384f
in X-linked agammaglobulinemia, 1352
IgA receptor, 320
IgD, 319, 320
and B cell maturation, 322
class switching, 322
functions of, 320, 321t
hyper-IgD syndrome, 1267t, 1267–1269
in hyper-IgM syndrome, 1353, 1354
IgE, 319, 320, 321
in atopic dermatitis, 148, 150, 151
in bullous pemphigoid, 477, 477f, 478
class switching, 322
in drug hypersensitivity, 358, 361
eosinophil surface receptors, 287
in exfoliative dermatitis, 227, 229
functions of, 321, 321t
in hypereosinophilic syndromes, 309
in hyper-IgE syndrome, 151, 1366f, 1366–1367, 1374t
in hyper-IgM syndrome, 1353, 1354
in urticaria and angioedema, 331, 332–333, 334, 340, 358
contact, 336
IgG, 319, 320–321, 325
in bullous pemphigoid, 475, 475f, 476, 476f, 477, 478, 479
in cicatricial pemphigoid, 483
class switching, 322
in common variable immunodeficiency, 1353
in cryoglobulinemia, 1638
eosinophil surface receptors, 286
in epidermolysis bullosa acquisita, 494, 498, 498f
Fab fragments, 320
Fc portion, 283, 320
in autoimmune disorders, 1510–1511
functions of, 320–321, 321t
in herpesvirus-6 infections, 1866
in hyper-IgM syndrome, 1353, 1354
in Lyme disease, 1798, 1804
in measles, 1851, 1852
in mononucleosis, 1859
in parvovirus B19 infections, 1857
in pemphigoid gestationis, 490, 492
in pemphigus, 461, 461f, 462, 463
paraneoplastic, 471, 472
structure of, 320f
subclasses of, 320, 321t, 331
in urticaria and angioedema, 331, 332, 332f
in viral infections, 1850
in X-linked agammaglobulinemia, 1353
IgM, 319, 320, 325
affinity and avidity of interactions, 320
and B cell maturation, 322
class switching, 322
in common variable immunodeficiency, 1353
in cryoglobulinemia, 1638
deficiency of, 1353
functions of, 320, 321t
in herpesvirus-6 infections, 1866
in hyper-IgM syndrome, 1353–1354
joining (J) chain of, 320
in Lyme disease, 1798, 1804
in measles, 1851, 1852
in mononucleosis, 1859
in parvovirus B19 infections, 1856–1857
in rubella, 1854
in syphilis, 1973
in viral infections, 1850
in X-linked agammaglobulinemia, 1352
light chains of, 319, 320, 320f
structure of, 319–320, 320f
Immunohistochemical tests
in Merkel cell carcinoma, 1088, 1090, 1090t
in Paget disease, 1096
in prenatal diagnosis of skin diseases, 85
of sweat glands, 721, 721f
Immunologic synapse, 131
Immunologically privileged sites, 1511
Immunomodulators
oral, 2217–2223
topical, 114, 2125–2129
Immunoreceptors
tyrosine-based activation motifs, 323
tyrosine-based inhibition motifs, 323
Immunosuppression, **267**–278
in actinic dermatitis therapy, 823
actinic keratosis in, 278, 1008
acute, 268–272
amebic infections in, 2009–2010
bacillary angiomatosis in, 273, 1692, 1752–1754
bacterial infections in, 268, 269t, 272–273, 1691–1692
in HIV infection, 1935–1936
Bartonella infection in, 1752–1754
basal cell carcinoma in, 277, 1037
blastomycosis in, 276, 1839
cancer risk in, 277–278, 812–813, 1004
in ultraviolet radiation exposure, 805–809
candidiasis in, 269t, 269–270, 270f, 273–274
disseminated disease, 1826f, 1843
oral, 1823
treatment of, 2216
vulvovaginal, 1824
cellulitis in, 1725, 1726, 1742, 1747
chronic, 272–277
coccidioidomycosis in, 269t, 275–276, 1840
in corticosteroid therapy, 2102–2103, 2151, 2151t
cryptococcosis in, 269t, 274–275, 275f, 1747, 1842, 1843
cytomegalovirus infections in, 269t, 276–277, 1861
clinical findings in, 1863, 1863f
prevention of, 1864
prognosis and clinical course in, 1863
treatment of, 1863
from cytotoxic agents, 2163
in dermatomyositis, 1551, 1552, 1553
lymphoma in, 1550
opportunistic infections in, 1550
ecthyma gangrenosum in, 268, 269f, 1691–1692, 1747
eosinophilic pustular folliculitis in, 315
fungal infections in, 268–271, 269t, 273–276, 1807–1808
in HIV infection, 1936–1937
systemic, 1836, 1836t
treatment of, 2216
gangrene in, 1723, 1725
herpes simplex virus infections in, 269t, 271, 276, 276f, 277, 1874
complications of, 1878f, 1878–1879
laboratory tests in, 1877
orofacial, 1875, 1878, 1878f, 1883
treatment of, 1883
herpesvirus-6 infection in, 276, 277, 1865, 1866
histoplasmosis in, 275, 1837, 1837f, 1838
treatment of, 1838
in HIV infection and AIDS, 1927. *See also* HIV infection and AIDS
Kaposi sarcoma in, 278, 1185, 1187
keratoacanthoma in, 1050
and squamous cell carcinoma, 1049
measles in, 1852, 1853
melanoma in, 278, 1004, 1136
Merkel cell carcinoma in, 278, 1088–1089
mycobacterial infections in, 272, 272f, 1777, 1778
in HIV infection, 1768–1769, 1777, 1778, 1790–1791
leprosy, 1790–1791
mycoplasmal infections in, 1998
necrotizing fasciitis in, 273, 273f, 1724
nocardiosis in, 269t, 272–273, 273f, 1781–1782
treatment of, 1783
onychomycosis in, 274, 274f, 1817f
oral infections in, 654
panniculitis in, 579
papillomavirus infections in, 277, 1917, 1920
and cancer risk, 1921
parvovirus B19 infections in, 1857, 1858
pediculosis pubis in, 2037
in pemphigus therapy, 466–468, 472, 474
Penicillium marneffei infection in, 276, 1841, 1842
porokeratosis in, 442, 443, 445
Pseudomonas aeruginosa infections in, 268, 269f, 269t, 1725, 1736, 1737
in sarcoidosis therapy, 1491–1492
scabies in, 277, 277f, 1940, 2029
sepsis and septic shock in, 1746, 1747
soft tissue infections in, 1720, 1724t
crepitant cellulitis in, 1726
gangrenous cellulitis in, 1725
necrotizing, 1724t
squamous cell carcinoma in, 277–278, 1029, 1030, 1049
in papillomavirus infections, 277–278
prevention of, 278, 1036
toxoplasmosis in, 2010
in ultraviolet radiation exposure, 805–809, 812–813, 1003
cellular events in, 807f, 807–808
hypersensitivity response in, 806, 806f, 808, 808f, 812f, 812–813
and immune protection factor of sunscreens, 2138
molecular targets in, 806–807

Immunosuppression—*continued*
varicella-zoster virus infections in, 269t, 271–272, 272f, 276, 276f, 1886, 1890
clinical findings in, 1890, 1891f
complications of, 1894
prevention of, 1897, 1898
treatment of, 1895, 1895t, 1896
Vibrio vulnificus infections in, 269t, 273, 274f, 1763
viral infections in, 269t, 271–272, 276–277
in HIV infection, 1937–1939
and Kaposi sarcoma, 278
and squamous cell carcinoma, 277–278
warts in, 277, 1353f, 1917, 1918
diagnosis of, 1920
zygomycosis in, 269t, 271, 1843
Immunotherapy
in alopecia areata, 765
in atopic dermatitis, 157
in melanoma, 1156
Impetigo, 1692, 1695–1698
Bockhart, 1698
bullous, 61, 1695, 1696–1697, 1698f, 1705, 1712
clinical features in, 1697, 1712, 1712f
differential diagnosis of, 1697, 1698b
exfoliative toxins in, 1696, 1712
histopathology in, 1714f
treatment of, 1714
crust in, 31, 31f
differential diagnosis in, 306, 1292b, 1696, 1697, 1697b, 1698b
in elderly, 972–973
follicular, 1698
herpetiformis, 959f, 959–960
non-bullous, 1695, 1696, 1697f, 1705
differential diagnosis of, 1696, 1697b
staphylococcal, 1695–1698, 1697f, 1698f, 1705, 1712
histopathology in, 1714f
treatment of, 1697–1698, 1698b, 1714
streptococcal, 1695, 1696, 1697, 1704–1705, 1712
treatment of, 1697–1698, 1698b, 1705, 1714
topical antibiotics in, 2114
vesicles in, 33, 33f
Imprinting, genomic, 80, 82
Inborn errors of amino acid metabolism, **1219**–1228
Incandescent light sources, 800
Incidence of disease, 5, 6t
and lifetime risk, 6
and number of physician visits, 6–7
Incision technique in excisional surgery, 2304–2305, 2305f
Inclusion body
in fibromatosis, 551
in myositis, 1544
Inclusion cyst, epidermal, 1063
Incontinentia pigmenti, 79, 83, 631, 631f
anhidrosis in, 730
differential diagnosis in, 1058
ethnic considerations in, 2145
oral cavity disorders in, 642t, 647t
Indinavir
in HIV infection and AIDS, 2209
nail changes from, 792, 793f, 793t
Indomethacin
in gout, 1576
in Sweet syndrome, 294, 295b
Induratio penis plastica, 552
Infants, **935**–945. *See also* Children and infants
Infarction, 33–34, 34f
cerebral, hyperhidrosis in, 722t, 723
in cholesterol emboli, 34, 34f
Infections. *See also specific infection*
autoimmune disorders in, 1514
bacterial, **1689**–1806
Behçet disease in, 1621
in body piercing, 889–890, 890t
in burns, 855, 857f
cancrum oris in, 1217–1218, 1218f
chemokines in, 134–135
in children, drug therapy in, 946, 947t–951t, 954
in complement deficiencies, 269t, 1370, 1371t, 1372
congenital, 940, 940t
in corticosteroid therapy, 2106, 2149, 2150t
in decubitus ulcers, 880–881, 881
management of, 885
in diabetes mellitus, 1464–1466
dystrophic calcification in, 1295
in elderly, 972t, 972–973
in epidermolysis bullosa, 514
erythema multiforme in, 343, 344, 345f
fungal, **1807**–1844
granuloma annulare in, 369
in hematologic disorders, 1374t–1375t
hyperhidrosis in, 726
in immunocompromised host, 267–277
inflammatory response to, 1690–1691
in laser skin resurfacing, 2368
lichen planus in, 251
lymphedema in, 1685
of nails, 784–785, 785t
in occupational exposures, 2074–2076, 2075t
oral, 651t–653t, 651–654
in palmoplantar keratoderma, 431
panniculitis in, 55, 579–580
parasitic, 2001–2037
peristomal, 870
pigmentation changes in, 627–628, 638
postoperative, 2337
in nail surgery, 2322–2323
pyogenic, in athletes, 873–875
scleredema in, 1563, 1564
sexually transmitted, 663–664
skin functions in protection from, 57, 58t
in tattooing, 887–888, 888t
urticaria in, 338, 339–340
viral, **1845**–1953
Infectious Disease Society of America Lyme disease treatment guidelines, 1804
Infiltrates
lymphocytic, 51f, 51–52. *See also* Lymphocytic infiltration of skin
polymorphonuclear leukocyte, 53
Inflammasome, 1270
Inflammatory bowel disease, 1456
Crohn disease. *See* Crohn disease
and linear IgA dermatosis, 488
in retinoid therapy, 2185
Inflammatory linear verrucous epidermal nevus, 180–181, 1057, 1058, 1058f, 1059
differential diagnosis of, 1062
Inflammatory reactions
in acne vulgaris, 692
age-related changes in, 966
in bacterial infections, 1690–1691, 1692
in burns, 852, 855
complement system in, 327
complementary and alternative medicine approach to, 2286
corticosteroid therapy in, 2102, 2104
endothelium in, 1590–1595
in fungal infections, 1811
hyperpigmentation in, post-inflammatory, 639, 639f
ethnic considerations in, 2111, 2142f, 2142–2144, 2143f, 2144f
in laser skin resurfacing, 2368
laser therapy in, 2274
immunobiologicals in, 2225f
leukocyte activation in, 1593
leukocyte adhesion in, 1591–1593
leukocyte extravasation in, 1594
in neonatal-onset multisystem inflammatory disorder, 1267t, 1270–1271
nerves in, 898t
in phototoxicity, 831
in reticular dermis, 50–54
sepsis in, 1746, 1747
skin microvessels in, 1595–1596
in sunburn, 811–812
in systemic auto-inflammatory diseases, 1265
tumor necrosis factor-α in, 121, 122
vascular leakage in, 1594
vasodilator synthesis in, 1591
in viral infections, 1849
in wound healing, 2342–2343
Infliximab, 2227, 2228
complications of, 2227–2228
in dermatomyositis, 1552
in epidermolysis bullosa acquisita, 499, 499t
in exfoliative dermatitis, 231, 232b
in graft-versus-host disease, 266t
in hidradenitis suppurativa, 737
indications for, 2227, 2228
initiation and monitoring of therapy with, 2227
mechanism of action, 2228
pharmacokinetics of, 2227
in psoriasis, 188t, 189f, 193, 2228
and arthritis, 205
in pyoderma gangrenosum, 301b, 302
in rheumatoid arthritis, 1573, 2227, 2228
in sarcoidosis, 1492, 1492t
in sub-corneal pustular dermatosis, 307, 307b
Information bias, 4
Infraorbital nerve, 2292, 2298
Infrared radiation, 798f, 798t, 799
Infratrochlear nerve, 2292, 2298
Infundibulomas, eruptive, 1084
Infundibulomatosis, 1084
Infundibulum, follicular, 742, 743f
in absorption of topical drugs, 2100
tumor of, 1084
Ingram regimen in psoriasis, 189
Ingrown nails, 784, 793
surgery in, 2329
Inguinal syndrome in lymphogranuloma venereum, 1988
Inhalation of solvents, cutaneous signs in, 923–924
Injection techniques
with botulinum toxin, 2390, 2391, 2391f
in soft tissue augmentation, 2380–2381, 2381f
with autologous fat, 2386
with calcium hydroxylapatite, 2386
with collagen products, 2383
with hyaluronic acids, 2383–2384
with poly-L-lactic acid, 2385
with silicone, 2387
Innate immunity, **95**–100, 1513, 1690–1691
antimicrobial peptides in, 96–97, 1690, 1695
cell types in, 95, 96f, 99–100, 1590

compared to adaptive immunity, 95, 96f, 1590
complement system in, 95–96, 1690
cytokines in, 96f, 99, 100, 103, 103f, 115, 1591, 1690
endothelium in, 1590–1594
eosinophils in, 99
interaction with adaptive immunity, 99
interleukin IL-1β in, 1591–1594
keratinocytes in, 100
in leprosy, 1787
natural killer cells in, 99–100
pattern recognition receptors in, 97–98, 1513, 1690
phagocytes in, 99
physical barriers in, 95
Toll-like receptors in, 97, 98f, 98–99, 1513, 1590, 1690
tumor necrosis factor in, 1591–1594
Inosculation in skin graft healing, 2346–2347
Inositol 1,4,5-tris-phosphate (IP3) in calcium signaling, 433, 433f
Insect bites and stings, 2059–2063
Insect repellents, 2063
Insomnia, fatal familial, hyperhidrosis in, 726
Insulin
in acanthosis nigricans, 1462
in diabetes mellitus, 1461, 1462
Insulin-like growth factor-1, 1462
in acanthosis nigricans, 1462
in acne, 2287
and elastin gene expression, 533
and growth hormone, 1482, 1482f, 1483
Integrins, 281, 282f, 287, 450, 456–457, 1596
activation of, 130, 130f
very late activation in, 330
in anchoring filaments, 457
in angiogenesis and vasculogenesis, 1598
in cicatricial pemphigoid, 481, 482t
in embryonic and fetal development, 67, 68t, 69, 71
in epidermolysis bullosa with pyloric atresia, 508
in epithelial lamina densa, 458
functions of, 1589
in hemidesmosomes, 456–457
in leukocyte adhesion, 1592t, 1592–1593
in lichen planus, 245
in multistep model of leukocyte recruitment, 129–130, 130f
in psoriasis, 174
in ultraviolet radiation exposure, 1004
in wound healing, 2344
of skin grafts, 2347
Intelligence quotient in neurofibromatosis type 1, 1337
Intense pulsed light therapy, 2263–2279
burns in, 2269
eye injuries in, 2268–2269, 2277
for hair removal, 2269, 2275, 2276t, 2277, 2277f
hyperpigmentation after, 2277, 2277f
indications for, 2265t
in pigmented lesions, 2273, 2274, 2377
in rosacea, 708, 709
safety of, 2268–2269
for skin rejuvenation, 2373
in vascular lesions, 2270, 2271, 2272, 2375, 2376
Intercellular adhesion molecules (ICAMs), 281, 282f
ICAM-1, 115, 1592t, 2228
in adhesion of leukocytes to endothelial cells, 281, 282f, 287, 288, 1592, 1595
in extravasation of leukocytes, 1594
in migration of CLA-positive lymphocytes, 1596
in photoimmunosuppression, 807f, 808, 808f
in polymorphic light eruption, 816
ICAM-2, 281, 282f, 287, 1590t
ICAM-3, 287, 1590t
Interface dermatitis, 49
in dermatomyositis, 1545
Interferon(s), 2207
in genital warts, 664b
and Jak/STAT pathway, 124–125
recombinant, 2223–2225
type I, 125
and toll-like receptors, 108, 125
type III, 125
Interferon-α, 117t, 124–125, 2207, 2223–2225, 2232–2233
and autoimmunity, 1513–1514
in B-cell lymphoma, 1401
complications of, 2207t, 2224, 2233
contraindications to, 2224, 2233
in cryoglobulinemia, 1641
in dermatomyositis, 1540
dosage of, 2207t, 2224
in hemangioma of infants, 1168t, 1169
in hypereosinophilic syndromes, 310, 311f
indications for, 2207, 2207t, 2224, 2233
in Kaposi sarcoma, 1187, 1187b, 1188
in lupus erythematosus, 1513–1514, 1517, 1519, 1520
as therapy target, 1533t, 1535
in mastocytosis, 1442
mechanism of action, 288, 2207
in molluscum contagiosum, 1913t
pegylated, 2207, 2207t, 2224
in pregnancy, 2224
recombinant, 2223t, 2223–2225
in T-cell lymphoma, 1398, 1399, 2224
Interferon-α 2b, 2207t, 2232–2233
in Behçet disease, 1625b
complications of, 2233
dosing regimen, 2233t
indications for, 2233
in lichen planus, 254b, 255
mechanism of action, 2232–2233
in melanoma, 1154–1155
Interferon-β, 117t, 124–125
Interferon-β2, 124. *See also* Interleukins, IL-6
Interferon-γ, 117t, 124–125, 130, 2223t, 2225
adverse effects of, 2225
in atopic dermatitis, 106, 148, 157
dosage of, 2225
in granulomatous disease, chronic, 1364, 1365t, 2225
indications for, 2225
in leprosy, 103, 1792, 1793
in lichen planus, 245
in mast cell development and differentiation, 1435
physiologic role of, 125
in pregnancy, 2225
production of, 125
in psoriasis, 171, 172, 173, 174f
and arthritis, 196, 199
structure of, 116
in systemic sclerosis, 1560t
in T-cell lymphoma, 2225
and T helper cells, 102, 103, 106, 2225
Interferon-inducible protein 10 (IP-10), 130, 131, 133
Interferon-inducible T cell α chemoattractant (I-TAC) in psoriasis, 133f
Interferon-λ, 125
Interleukins (ILs)
IL-1, 115, 119–121
in acne vulgaris, 692
in aging of skin, 964, 965f
in epidermal homeostasis and repair, 391
in Hodgkin disease and hyperhidrosis, 726
in innate immunity, 1591
in Kawasaki disease, 1627, 1630
keratinocyte-derived, 100
in photoimmunosuppression, 806, 807f
in psoriatic arthritis, 196, 199
therapeutic applications, 126
in wound healing, 2344, 2344t
IL-1 receptor, 117t, 118, 119–120, 120f
IL-1 receptor antagonist, 119–120, 126, 2223t
IL-1α, 100, 117t, 119, 120
IL-1β, 100, 117t, 119, 120
converting enzyme, 119
in innate immunity, 1591–1594
and leukocyte activation, 1593
and leukocyte adhesion, 1591–1593
and vascular leakage, 1594
and vasodilator synthesis, 1591
and nuclear factor κB, 118
IL-2, 117t, 122, 130, 2223t, 2225–2226
in activation-induced cell death, 122
adverse effects of, 2226
deficiency of, 1358, 1360
and denileukin diftitox, 2230–2231
and helper T cells, 103, 105
in leprosy, 103, 105, 1792, 1793
in melanoma therapy, 1156, 2226
in morphea, 543
in pruritus, 905
recombinant, 2226
sources of, 117t, 122
as T-cell growth factor, 105, 115
IL-2 receptor, 122
IL-3, 123
and eosinophil activation, 287
functions of, 284
in mast cell development and differentiation, 1435
in urticaria and angioedema, 331, 340
IL-3 receptor, 123
IL-4, 102, 103, 116, 116f, 117t, 123
in atopic dermatitis, 147–148, 149
functions of, 123, 1436
and helper T cells, 123
in leprosy, 103
in mast cell development and differentiation, 1435
in morphea, 543
in photoimmunosuppression, 807, 808f
in T-cell lymphoma, 1387
IL-4 receptor, 123
IL-5, 102, 117t, 123
in atopic dermatitis, 148, 151
and eosinophil activation, 287
functions of, 123, 284, 1435t, 1436
in T-cell lymphoma, 1387
in Wells syndrome, 310
IL-5 receptor, 123
IL-6, 117t, 123–124
in aging of skin, 964, 965f
deficiency of, 391
in epidermal homeostasis and repair, 391
functions of, 124, 1435t, 1436
in herpesvirus 8-associated diseases, 124
in Hodgkin disease and hyperhidrosis, 726
nuclear factor of, 124
in paraneoplastic pemphigus, 469
in pruritus, 905

Interleukins (IL)—*continued*
in psoriasis, 124
and arthritis, 196, 199
in Sjögren syndrome, 1577
as therapy target, 1583
IL-6 receptor, 123–124
IL-7, 105, 123
functions of, 123
keratinocyte-derived, 100
in T-cell lymphoma, 1388
IL-7 receptor, 123, 1358, 1359t
IL-8, 1593
in Behçet disease, 1622
functions of, 280
in melanoma, 133
neutrophil synthesis of, 280
in psoriasis, 132, 133f
IL-9, 123
IL-10, 102, 103, 116, 116f, 117t, 125, 1512
as anti-inflammatory cytokine, 125
keratinocyte production of, 125
in leprosy, 103
promoter polymorphisms, 90
in systemic sclerosis, 1554t
in ultraviolet radiation exposure, 103, 125
and photoimmunosuppression, 807, 807f, 808, 808f, 809
IL-10 receptor, 117t, 125
IL-11, 123–124
IL-12, 102, 103, 116, 116f, 117t, 124, 2236t
functions of, 124
in leprosy, 1792, 1793
in photoimmunosuppression, 807–808, 808f, 809
in psoriasis, 124, 126, 193
in sarcoidosis, 1485, 1485f
therapeutic applications of, 124, 126
IL-12 receptor, 124
IL-13, 102, 117t, 123
in atopic dermatitis, 147–148, 149, 151
functions of, 123
IL-13 receptor, 123
IL-15, 105, 122
in T-cell lymphoma, 1388
IL-15 receptor, 122
IL-16, 109, 1435t
IL-17, 103, 116, 116f, 117t
in psoriasis, 171, 173, 174f, 193
IL-18, 120, 120f
IL-18 receptor, 120, 120f
IL-19, 125
IL-20, 125
IL-20 receptor, 125
IL-21, 123
IL-21 receptor, 123
IL-22, 106, 125
in psoriasis, 173, 174f
IL-22 receptor, 125
IL-23, 106, 116, 116f, 117t, 124
in psoriasis, 124, 126, 171, 173, 174f, 193
as therapy target, 124, 126
IL-23 receptor, 124
IL-24, 125
IL-27, 123, 124
IL-27 receptor, 124
IL-31, 106, 899–900
in pruritus, 900, 905
IL-33, 120
in pruritus, 900, 905
receptors for, 122–125
Intermediate filament proteins, 378–380, 381
and desmosomes, 447
in palmoplantar keratoderma, 424
International Classification of Diseases, 5
International Foundation for Dermatology, 21
International League of Dermatological Societies, 21
International Nomenclature of Cosmetic Ingredients, 2138–2139, 2139t
International Society for the Study of Vascular Anomalies classification of vascular anomalies, 1651, 1652t
Interphalangeal joints of hand, psoriatic arthritis of, 195, 195f, 195t, 200, 200f
Interstitial lung disease, 1448
in dermatomyositis, 1545
Intersystem crossing in photochemical reactions, 804, 804f
Intertriginous lesions, 38
in candidiasis, 1824, 1825b, 1825f
treatment of, 1828
in seborrheic dermatitis, 222b, 223–224
in streptococcal infections, 1705f, 1705–1706, 1706f
Intertrigo, 659b
candidal, 1825f, 1828
streptococcal, 1705f, 1705–1706, 1706f
Intervertebral disk calcification in alkaptonuria, 1226, 1227, 1227f
Intolerance to cosmetic products, 2359–2360, 2361t
Intrauterine contraceptive device, pelvic actinomycosis in, 1780, 1781
Introns, 74, 75, 76, 520
Inverted follicular keratosis, 1081
Involucrin, 390, 390f
in cornified envelope, 381, 382t, 387–388
Iodine, 2132
deficiency of, 1470
occupational exposure to, 2069t
Iodochlorhydroxyquin, 2115
Iodophors, 2132
in preoperative skin preparation, 2295
Iodoquinol toxicity in children, 946t
Iontophoresis, 2134
in hyperhidrosis, 723, 724b, 2134
IP3 (inositol 1,4,5-tris-phosphate) in calcium signaling, 433, 433f
IP-10 (interferon-inducible protein 10), 130, 131, 133
IPEX syndrome, 1355
Iron, 1214
deficiency of, 1214, 1376–1377, 1456
hair in, 761, 767–768, 1214, 1456
nail changes in, 1214, 1456
food sources of, 1214
overload of, 1214
porphyria cutanea tarda in, 1236, 1237, 1239, 1241–1242
supplemental, 1377
in erythropoietic protoporphyria, 1247
pediatric dosage, 954t
Irradiance, 802
spectral, 802
Irritant contact dermatitis, **395**–401
acneiform or pustular, 397t, 399
acute, 397t, 397–398
delayed, 397t, 398, 398t
in occupational exposures, 2067, 2068, 2068f
of amputation stump, 866–867, 867t
barrier function of skin in, 393, 395, 399
chronic, 397t, 398
clinical types of, 397t, 397–399
common irritants in, 399, 399t
airborne, 398t
chemical, 398t
from cosmetic products, 398, 2361
cross-over phenomenon in, 396
cumulative, in occupational exposures, 2067, 2068
diagnostic criteria in, 399, 400t, 2068–2069
diaper dermatitis in, 942–943, 944
differential diagnosis in, 165, 399–400, 400b
allergic contact dermatitis in, 139b, 395, 398, 399, 400
endogenous factors in, 396–397, 397t
epidemiology of, 395–396
etiology and pathogenesis in, 396
exogenous factors in, 396, 396t
exsiccation eczematid, 399
friction, 397t, 398
irritant reaction, 397, 397t
nonerythematous (suberythematous), 397t, 398
in occupational exposures, 399, 2067–2069
airborne substances in, 2068
common substances causing, 2069, 2069t
diagnosis of, 2072
and low humidity, 2068, 2069t
in ostomy procedures, 868–869, 869f
patch testing in, 399, 400
in occupational exposures, 2072
prevention of, 400–401
prognosis in, 401
subjective (sensory) irritation, 397t, 398
transepidermal water loss in, 399, 400
traumatic, 397t, 398–399
traumiterative, 398
treatment in, 400
of vulva, 676, 677–678, 678f
Irritant ingredients in cosmetic products, 398, 2361
Irukandji syndrome, 2044, 2045t
Ischemia
digital
Raynaud phenomenon in, 1643–1647
in systemic sclerosis, 1558–1560, 1559f
in vasculitis, 1607, 1609f
limb, in peripheral artery disease, 1667, 1668b, 1669f
Island pedicle flap, 2309
Isocoproporphyrin, 1229f, 1229t
in porphyria cutanea tarda, 1239
in variegate porphyria, 1253
Isodesmosine, 531, 532f
Isodisomy, uniparental, 80
Isolated limb perfusion procedure in melanoma therapy, 1155
Isoniazid
in actinomycetoma, 1786
interaction with other drugs, 2239t
in tuberculosis, 1775, 1775t
Isopropyl alcohol
in fire coral stings, 2046
in preoperative skin preparation, 2295–2296
Isotretinoin, 2108, 2108f, 2109, 2181–2186
in acne, 698–699, 2183
in adolescents, 945
conglobata, 700–701
dosing regimen, 2184
with facial edema, 701
fulminans, 701
in actinic keratosis prevention, 1015
chemical structure of, 2110f, 2182f
in Darier-White disease, 2183
dosing regimens, 2184
pediatric, 953t
in eosinophilic folliculitis and HIV infection, 1931

in Fox-Fordyce disease, 734
in Grover disease, 438
in hidradenitis suppurativa, 737, 2183
initiation and monitoring of therapy, 2184
in lichen planus, oral, 253, 253b
in lupus erythematosus, 1534, 2184
in perforating disorders, 567b
pharmacokinetics of, 2182
in pityriasis rubra pilaris, 2183
in psoriasis, 2183
in combination with phototherapy, 2254
in pregnancy, 189b
in rosacea, 708, 709
in sebaceous gland activity and sebum production, 689
in seborrheic dermatitis, 225
side effects and complications of, 698–699, 708, 2184–2186
depression in, 699, 945, 2185
in squamous cell carcinoma prevention, 1036
in T-cell lymphoma, 2183
xeroderma pigmentosum and cancer prevention, 1318
Isovaleric acidemia, 1219t
Isovaleryl-coenzyme A dehydrogenase, 1219t
I-TAC in psoriasis, 133f
Itching. *See* Pruritus
Itraconazole, 2213–2214
in blastomycosis, 1839
chemical structure of, 2213f
in children, 2214
dosage of, 951t, 954, 1818t
in chromoblastomycosis, 1834
in coccidioidomycosis, 1840
in dermatophyte infections, 1818b, 1819, 1820, 1821
dosage of, 2214, 2214t
pediatric, 951t, 954, 1818t
in granulomatous disease, chronic, 1364, 1365t
in histoplasmosis, 1838
indications for, 2213b, 2213–2214, 2214t
interaction with other drugs, 2214, 2240t
mechanism of action, 2213
in mycetoma, 1833
in onychomycosis, 1818t, 1820, 2214, 2214t
in paracoccidioidomycosis, 1841f
in *Penicillium marneffei* infection, 1842
pharmacology of, 2213
in *Pityrosporum* folliculitis, 1830
side effects and complications of, 2213b, 2214, 2216
in sporotrichosis, 1832
in subcutaneous zygomycosis, 1835
in tinea versicolor, 1830
Ivermectin
in filariasis, 2014t, 2018
in gnathostomiasis, 2014t
in larva migrans, cutaneous, 2014t
in loiasis, 2019
in onchocerciasis, 2015t, 2020–2021
pediatric dosage, 953t
in pediculosis capitis, 2034, 2034t
in pediculosis pubis, 2037b
in scabies, 2031, 2031b
in strongyloidiasis, 2015t
Ixodes ticks, 1945f, 2059
and anaplasmosis, 1944t
and ehrlichiosis, 1944t
and Lyme disease, 1797, 1805
and tularemia, 1758

J

Jaccoud syndrome, 1603
Jackson-Lawler pachyonychia congenita, 427, 784t
Jackson-Sertoli syndrome, 427
Jacquet erosive dermatitis, 943
Jadassohn-Lewandowsky syndrome, 427, 784t
Jadassohn nevus sebaceous, 1059
Jadassohn-Pellizzari anetoderma, 557
Jak/STAT pathway, 118–119, 119f
in HTLV-1 infections, 1924
interferons in, 124–125, 2232
and interleukin IL-10, 125
JAMs (junctional adhesion molecules), 1588–1589, 1592t, 1594
Janeway lesions in endocarditis, 1453, 1744
Janus kinase, 118–119, 119f, 124–125, 2232
deficiency of, 1358, 1359t
in HTLV-1 infections, 1924
Jarisch-Herxheimer reaction
in bartonellosis, 1754
in leptospirosis, 1767
in Lyme disease, 1804
in syphilis, 1976–1977
Jaundice, 1379, 1446–1447, 1447t
classification of, 1447t
clinical features in, 1447
in neonates, 1447
pathogenesis in, 1447
in pregnancy, 956
Jaw cyst in basal cell nevus syndrome, 1045, 1046, 1047f
Jellyfish stings, 877, 2042–2045
first aid in, 2044, 2044t
prevention of, 2044, 2044t
Jessner's lymphocytic infiltration of skin, 1403t, 1412, 1527
in Lyme disease, 1802
Jessner's solution in chemical peels, 2370, 2370t
for actinic keratosis, 1014
Jewelry
body piercing for, 886, 889–890
magnetic, 890, 890f
JNK activation, 1003
Job syndrome, 273f, 1366
Jogging and running. *See* Running and jogging
Joint mobility
in diabetes mellitus, 1463f, 1463–1464
in Ehlers-Danlos syndromes, 1299, 1299f, 1300, 1302
in Marfan syndrome, 1303
Jones criteria on rheumatic fever, 1574, 1574b
Jopling's reactions in leprosy, 1788, 1790, 1791
Joules, 802
Journal of Investigative Dermatology, 89, 89t, 90
Journal resources in evidence-based medicine, 12
c-JUN/c-Jun, 1003, 2112
Junctional adhesion molecules (JAMs), 1588–1589, 1592t, 1594
Junctional blisters, 47, 47t
Junctional epidermolysis bullosa. *See* Epidermolysis bullosa, junctional

K

Kala-azar, 2002, 2003, 2006
pigmentation in, 628, 2006
and post-kala-azar dermal leishmaniasis, 2006
treatment of, 2007
Kallikrein
in pruritus, 897t
in urticaria and angioedema, 333, 336, 337
Kallmann syndrome, 80, 409
Kamino bodies in Spitz nevus, 1115, 1115f
Kandahar sore, 2003
Kang cancers in China, 1017
Kangri basket cancers in Kashmir, 1017
Kanzaki disease, 1287t
Kaposi-Irgang disease, 1525
Kaposi sarcoma, **1183**–1188, 1375t
African endemic, 1185
AIDS-associated, 1184, 1185–1186, 1186f, 1187, 1933
genital, 667
oral, 1186, 1186f, 1933
treatment of, 1187–1188, 2284
chemokines in, 134
classic, 1184–1185, 1185f
treatment of, 1187
in cyclosporine therapy, 2220
differential diagnosis of, 1186, 1186b
etiology and pathogenesis in, 1183–1186
gastrointestinal, 1455
genital, 667
herpesvirus-8 in, 995t, 998, 1183–1184, 1187
histogenesis in, 1184
histopathology in, 1186, 1187f
in immunosuppressive therapy, 278, 1185
treatment of, 278, 1187
localized cutaneous, 1187–1188
oral cavity disorders in, 649, 649f, 651t
in HIV infection, 1186, 1186f, 1933
treatment of, 1186–1188, 1187b
radiation therapy in, 2282, 2282t, 2284
vinblastine in, 1187b, 2123
Kaposi-Stemmer sign in lymphedema, 1685
Kaposiform hemangioendothelioma, 1170–1171, 1171f
Karate, skin conditions associated with, 874t
Karyorrhexis in Sweet syndrome, 292
Karyotype, 80
Kasabach-Merritt phenomenon, 1167, 1170, 1171, 1171f, 1659
Kaschin-Beck disease in selenium deficiency, 1217
Katayama fever, 2025
Kava dermatopathy, 422
Kawasaki disease, **1626**–1633
acute phase of, 1627, 1628, 1629, 1630
approach to patient with, 1632f
atypical, 1629
clinical manifestations of, 1628f, 1628–1630, 1629f, 1629t
convalescent phase of, 1628, 1629
coronary artery disorders in, 1629, 1630, 1631
diagnostic criteria on, 1626, 1626t, 1628, 1630–1631
differential diagnosis of, 1630–1631, 1631b, 1717, 1719
epidemiology of, 1626–1627
etiology and pathogenesis in, 1627–1628
eye disorders in, 1628, 1630, 1631
historical aspects of, 1626
incomplete, 1629, 16301631
laboratory findings in, 1630
liver disorders in, 1457–1458, 1630
oral cavity disorders in, 652t, 1628–1629, 1630
strawberry tongue in, 1628, 1630
pathology in, 1630
perineal eruption in, 1628, 1628f
prognosis in, 1632–1633

Kawasaki disease—*continued*
stages of, 1630
suspected, 1629
systemic disorders in, 1629t, 1629–1630
treatment of, 1631–1632
vasculitis in, 1606, 1626, 1630, 1631
Keloids, 27–28, 553f, 553–554
compared to hypertrophic scars, 2339, 2340t
cryotherapy in, 2331
differential diagnosis in, 558
laser therapy in, 2374
postoperative, 2339, 2340f
radiation therapy in, 2281
Kerandel's hyperesthesia in African trypanosomiasis, 2008
Keratan sulfate, 538
Keratin, 378–381, 387
in basal layer of epidermis, 58–59
classification and nomenclature system, 74, 75f, 378, 378t
in cornified envelope, 382t
in dermal-epidermal junction, 450
epithelial, 59
function of, 381, 389–390
genes, 59, 60t, 74, 75f, 76, 378–381, 379f
K6HF gene, 90
mutations in, 381
tissue expression and disease association, 60t, 380–381
in hair follicle, 59, 381, 742, 743t, 744
in anagen, 746
in keratoderma, palmoplantar, 424
in nails, 778–781
proteins associated with, 74, 75f, 378–380
in spinous layer of epidermis, 60
differentiation-specific, 60
keratinization-specific, 60
Keratin 1, 60, 60t, 378t, 380, 389, 390
embryonic and fetal, 68t, 69
in epidermolytic hyperkeratosis, 407, 412t, 414
in lichen planus, 245
Keratin 2, 60t, 378t, 380, 390
Keratin 3, 378t
Keratin 4, 60t, 378t
in lichen planus, 245
Keratin 5, 59, 60, 60t, 378t, 380, 389, 390, 390f
in appendage tumors of skin, 1070t
embryonic and fetal, 67, 68t, 69
in epidermolysis bullosa simplex, 507
gene mutation, 86
in hair follicle, 743t
Keratin 6, 60, 60t, 378t, 390f
in appendage tumors of skin, 1070t
embryonic and fetal, 68t, 69
in hair follicle, 743t
in lichen planus, 245
in palmoplantar keratoderma, 424
Keratin 7, 378t
in Merkel cell carcinoma, 1090, 1090t
in Paget disease, 1096, 1097
Keratin 8, 60t, 62, 378t
embryonic and fetal, 69
Keratin 9, 60t, 378t, 380, 390
embryonic and fetal, 68t
in epidermolytic hyperkeratosis, 414
in palmoplantar keratoderma, 424
Keratin 10, 60, 60t, 378t, 380, 389, 390, 390f
deficiency of, 389
embryonic and fetal, 68t, 69
in epidermolytic hyperkeratosis, 407, 412t, 414
in lichen planus, 245
Keratin 12, 378t
Keratin 13, 60t, 378t
in lichen planus, 245
Keratin 14, 59, 60, 60t, 83, 378t, 380, 389, 390
embryonic and fetal, 67, 68t, 69
in epidermolysis bullosa simplex, 507
gene encoding, 74, 75f, 86
in hair follicle, 743t
Keratin 15, 378t
in hair follicle, 743t
Keratin 16, 60, 60t, 378t, 380, 390f
embryonic and fetal, 68t, 69
in hair follicle, 743t
in lichen planus, 245
in palmoplantar keratoderma, 424
Keratin 17, 60t, 378t, 380, 389, 390f
embryonic and fetal, 68t
in hair follicle, 743t
in lichen planus, 245
in palmoplantar keratoderma, 424
in psoriasis, 395
Keratin 18, 60t, 62, 378t
embryonic and fetal, 69
Keratin 19, 62, 378t
embryonic and fetal, 69
in hair follicle, 743t
Keratin 20, 62, 378t
in Merkel cell carcinoma, 1088, 1090, 1090f, 1090t
in Paget disease, 1096
Keratin cyst, 1063, 1079
postoperative, 2339
Keratinization, 43, 45, 58–59, 60, 387
cornified envelope in, 61
in fetal development, 69
of nails, 778–780
disorders of, 782
in subungual hyperkeratosis, 783
in porokeratosis, 442
in scaling, 401
trichilemmal, 1068
Keratinocyte(s), 43, 46, 57, 58–59
antimicrobial peptides of, 96–97, 1690
apoptotic, 49, 815
in lichen planus, 245
in atopic dermatitis, 131, 132, 148–149
and calcium signaling, 433f
cholesterol requirements, 386
in cryotherapy, 2330, 2330t
cytokines and chemokines of, 100, 122, 131, 391
in ultraviolet radiation, 607t, 607–608, 811
differentiation of, 384
in psoriasis, 173
regenerative maturation in, 173
elastin gene expression in, 534
fetal development, 69
in graft-versus-host disease, 262
in hair follicles, 742, 744
in acne vulgaris, 690–692
in anagen, 745
hyperproliferation in acne vulgaris, 690–692
in innate immunity, 100
in keratoderma, palmoplantar, 424
in lipid synthesis, 385
and melanocytes, 62, 69, 604
in epidermal melanin unit, 593, 594f
in follicular melanin unit, 594, 595f
in melanosome transfer, 603–604
in nail matrix, 778–780
neurotransmitters in, 392–393
in pruritus, 903–904
in psoriasis, 131, 132, 171, 171f, 173, 175f
in sebaceous glands, 687
in squamous cell carcinoma, 1029–1030, 1032, 1033f
in ultraviolet radiation exposure, 607t, 607–608, 811, 2248
intercellular signals in, 1004
and photoimmunosuppression, 807, 807f
in wound healing, 2344, 2344t
of skin grafts, 2347
Keratinocyte carcinoma, epidemiology of, 5
Keratinocyte growth factor, 744
Keratitis
acanthamebic, 2009
and candidiasis, chronic mucocutaneous, 1355t
herpes simplex, 1879
and ichthyosis-deafness syndrome, 403t, 407, 418, 418f, 429, 752, 1342
in leprosy, 1794
in smallpox vaccination, 1905
in syphilis, congenital, 1969, 1969f
Keratoacanthoma, **1049**–1053
centrifugum marginatum, 1051, 1051f
clinical findings in, 1050–1052, 1051f
differential diagnosis in, 1051b, 1052, 1052b
epidemiology of, 1049
etiology and pathogenesis of, 1050
Ferguson-Smith type, 1050, 1051
genetic factors in, 989t, 1050, 1051
giant, 1051, 1051f
of Grzybowski, 1051
histopathology in, 1052, 1052b, 1052f
in Muir-Torre syndrome, 1050, 1051
multiple, 1049, 1050, 1050f, 1051, 1051f
neurotropism in, 1052, 1052f
papillomaviruses in, 1050
prevention of, 1053
prognosis in, 1052–1053
spontaneous regression of, 1053
squamous cell carcinoma in, 1032, 1049, 1050f, 1052
stages of, 1050–1051
subungual, 1052
treatment of, 1053, 1053b
methotrexate in, 2124
radiation therapy in, 1053, 2282, 2283t, 2283–2284
in ultraviolet light exposure, 1050
Keratocalmin, 60
Keratoconjunctivitis
in atopic dermatitis, 152
in herpes simplex virus infections, 1879
in Sjögren syndrome, 1579, 1581
Keratoconus in atopic dermatitis, 152
Keratocysts, 1063, 1079
postoperative, 2339
Keratoderma, 32, 32f
acquired, 32
acral, 426
blenorrhagicum, in reactive arthritis, 210, 210f
inherited, 32, 32f, **424**–431
constricting bands in, 563
types of, 425t
palmoplantar, 32, 32f, 418, **424**–431
and cardiomyopathy, 429
clinical findings in, 425–430
complex, 425, 427
complications in, 430–431
desmosomes in, 424, 449, 449t
differential diagnosis in, 430, 430b
diffuse, 425–426, 426f, 429
epidermolytic, 425–426, 426f, 430
in esophageal cancer, 428, 428f
etiology and pathogenesis in, 424–425
in exfoliative dermatitis, 228, 229f

focal, 425, 427–428
hereditarium mutilans, 428
histopathology in, 430
mutilating, 426, 428
nail changes in, 429–430, 784
with oral mucosal hyperkeratosis, 427
with periorificial keratotic plaques, 426
in pityriasis rubra pilaris, 233, 235f
punctate, 425, 428–429, 429f
in reactive arthritis, 210, 210f
simple, 425–426, 428–429
and spastic paraplegia, 429–430
spiny, 429
striate, 425t, 427, 427f, 429, 430
of Sybert, 426, 430
syndromic, 425, 426, 427–428
treatment of, 431
Vörner's epidermolytic, 425–426, 426f
and woolly hair, 429, 760
progressive symmetric, 61
Keratoelastoidosis marginalis, 554
Keratohyalin granules, 61, 61f
Keratolysis
exfoliativa, differential diagnosis in, 165
pitted, 1707–1708, 1708f
Keratolytic agents, topical, 2135t, 2135–2136
in corns and calluses, 873b
in ethnic skin, 2144
in ichthyosis, 422
in palmoplantar keratoderma, 431
in pityriasis rubra pilaris, 235, 236b
Keratoma plantare sulcatum, 1707
Keratomalacia in vitamin A deficiency, 1204, 1204f
Keratosis
actinic, 31t, 45, 968t, **1007**–1015. *See also* Actinic keratosis
in arsenic exposure, 430b, 1015–1017
epidemiology of, 1054
extremitatum progrediens, 426, 429
follicularis, 61, 427, 432
Darier-White disease in. *See* Darier-White disease
spinulosa decalvans, 561, 751f, 751–752, 772t, 773
frictional, 650
inverted follicular, 1081
lichenoid, 251
and solar lentigo, 1122
in limb amputation and prosthesis use, 864f, 864–865
in monilethrix, 752, 752f
in mucoepithelial dysplasia, hereditary, 752
palmoplantar
and alopecia congenita, 429
diffusa circumscripta, 426
and drumstick fingers, 429
and eyelid cysts, 430
nummularis, 427
punctate, 428–429
transgrediens et progrediens, 426, 429
varians, 427
papulosa, 428–429
pilaris, 31t, 749f, **749**–750
atrophicans, 561, 750–752
diseases associated with, 750
and hereditary koilonychia, 752
and ichthyosis vulgaris, 407, 749f, 750
rubra atrophicans faciei, 750
polykeratosis of Touraine, 426
punctate
acquired, 430b
palmoplantar, 428–429
radiation, 1018–1019, 1019f
reactional, 1020
in scars, 1019–1020
seborrheic, **1054**–1056
adenoid, 1055
clinical features in, 1054–1056, 1055f, 1056f
clonal, 1055, 1056f
cryotherapy in, 2331
differential diagnosis in, 1054
in elderly, 972t
etiology of, 1054
irritated, 1055, 1056f
laser therapy in, 2273
Leser-Trélat sign in, 1497–1498
pigmented, 1055–1056
reticulated, 1055, 1055f
and skin cancers, 1055, 1056
with squamous atypia, 1055
stucco, 1055
thermal, 1017–1018
viral, 1020–1021
Kerion, 1814t
in tinea barbae, 1813, 1813f
in tinea capitis, 1812, 1812f
Kernicterus, 1379
Keshan disease in selenium deficiency, 1217
Ketoconazole, 2215
hepatotoxicity of, 1459t
interaction with other drugs, 2112, 2238, 2239t, 2240t
in mycetoma, 1833
in paracoccidioidomycosis, 1841f
pediatric dosage of, 951t
in *Pityrosporum* folliculitis, 1830
in seborrheic dermatitis, 224
in subcutaneous zygomycosis, 1835
in tinea capitis, 1819
in tinea nigra, 1821
in tinea versicolor, 1830
topical, 2116, 2117t, 2118
Ketotifen
in acne with solid facial edema, 701
antihistaminic activity of, 2193
Ketron-Goodman disease, 1391
Khellin, 2248
KID syndrome, 418, 425t
Kidney disorders, 1458–1460
in amyloidosis, 1260t, 1261–1262, 1263
prognosis and clinical course in, 1264
treatment in, 1264
antibiotic therapy adjustments in, 2195
in atheromatous embolism, 1672, 1673
basement membrane collagen IV in, 453
in Behçet disease, 1623
calciphylaxis in, 576, 1459, 1459f, 1476, 1476f
in cryoglobulinemia, 1639–1640
drug-induced
from acyclovir, 2204
from cyclosporine, 2219–2220
in drug interactions, 2240t
from foscarnet, 2206
from retinoids, 2185
edema in, 1458
in epidermal necrolysis, 352
in Fabry disease, 1284, 1284t
treatment of, 1287, 1287b
fibrosing dermopathy in, 1460, 1565
general skin changes in, 1446
and gout, 1575, 1576
in hereditary leiomyomatosis and renal cell cancer, 1172
hyperparathyroidism in, 1475
in leptospirosis, 1767
in lipodystrophy, acquired partial, 587
metastatic calcification in, 1295, 1459
in microscopic polyangiitis, 1613
oxalosis in, 576
perforating dermatosis in, 564, 567, 1459–1460
in polyarteritis nodosa, 1614
porphyria cutanea tarda in, 1236, 1239, 1243, 1459
pruritus in, 907, 1448
in rheumatoid arthritis, 1572t
staphylococcal scalded skin syndrome in, 1712
in Sweet syndrome, 291, 292t, 293
in syphilis, 1962
in systemic sclerosis, 1560
in tuberous sclerosis, 1329, 1330
uremic frost in, 1458–1459
in Wegener granulomatosis, 1611, 1612t
Killer immunoglobin-like receptors in psoriasis, 172
and arthritis, 198–199
Kimura disease, 313, 314, 1403t, 1408–1409
complications of, 1409
differential diagnosis of, 314, 314t, 1409, 1409b
treatment of, 314, 1409, 1409b
Kindler syndrome, 457, 508t, 512
Kindlin-1, 457, 512
Kinesins in melanosome transport, 603, 603f
Kinetics of epidermal cells, 43–45
Kinetochore formation, 74
Kininogen in angioedema, 333
Kinky hair, 770, 1216
KIR (killer immunoglobin-like receptors) in psoriasis, 172
and arthritis, 198–199
Kissing bugs, 2060, 2061
and Chagas disease, 2008–2009, 2061
KIT/Kit, 68t, 69, 599, 600f
in melanocyte development, 591, 592, 747, 748
in piebaldism, 68t, 592, 615
KL-6 in dermatomyositis, 1547, 1552
Klebsiella
in cellulitis, 1742
in necrotizing fasciitis, 1742
in rhinoscleroma, 1742, 1742f
treatment of infections, 1743
Klebsiella granulomatis, 1990–1993, 2197t
Klebsiella pneumoniae subspecies *rhinoscleromatis,* 1742, 1742f, 2197t
Klein-Waardenburg syndrome, 614
KLICK syndrome, 425t
Kligman formula in melasma, 1480
Klinefelter syndrome, 81t, 83
Klippel-Trénaunay syndrome, 70, 1651
capillary malformations in, 1653, 1654–1655, 1655f
treatment of, 1655–1656, 2270
Knuckle pads, 552–553
Knudson's two-hit hypothesis, 1325
Koch's phenomenon, 1769–1770
in BCG vaccination, 1773
Koebner phenomenon, 36, 121
in acquired perforating dermatosis, 564
of amputation stump, 867
in erythema multiforme, 346
in lichen planus, 246, 246f, 665
in peristomal skin disorders, 870
in psoriasis, 177, 178f, 180, 190, 664
in syphilis, 1959
in vitiligo, 618, 619f, 620
Koebner variant of epidermolysis bullosa simplex, 505–506, 508t
Koenen's tumors in tuberous sclerosis, 1326–1327, 1330f

Koilocytotic cells in papillomavirus-associated papillomas, 1919, 1920
Koilonychia, 782, 1449
hereditary, and keratosis pilaris, 752
in iron deficiency, 1214
Kojic acid, 2146, 2363, 2363t
Koplik spots in measles, 1851, 1851f
KRT14, 74, 75f
Ku transcription factor, 1528t, 1539t
Kwashiorkor, 1202–1203, 1203f, 1446
dermatitis in, 1202–1203, 1203f
hair changes in, 1452
marasmic, 1202
Kynureninase, 1219t
Kyphoscoliosis
in Ehlers-Danlos syndrome, 1300–1301, 1302
in Marfan syndrome, 1303
Kyrle disease, 564–566, 565f–566f, 1459
in diabetes mellitus, 1469

L

Labial artery, caliber-persistent, 649
Laboratory tests, 24t
by CLIA-certified laboratories, 986
Lacazia loboi, 1835
Lacrimal gland disorders in Sjögren syndrome, 1578, 1579
Lacrimal sweating, 725
β-Lactam antibiotics, 2194, 2195t, 2197–2199
Lactate dehydrogenase
in dermatomyositis, 1546
in melanoma, 1149, 1153
M-subunit deficiency, 367t, 368
Lactic acid
in sweat, 717, 717f
in topical preparations
keratolytic, 2135, 2135t, 2136
stinging sensation from, 2360–2361
Lactobacillus in atopic dermatitis, 158, 2287
Lactoferrin, 283
Lahore sore, 2003
LAMB syndrome, 668
myxoma in, 1117, 1118, 1118f, 1453f
Lambda sign in sarcoidosis, 1490
Lambert-Eaton myasthenic syndrome, anhidrosis in, 728
Lamellar bodies
epidermal, 385, 386f
in Fabry disease, 1284, 1284f
Lamin A/C, 68t
in lipodystrophy, 588
Lamina densa, 450f, 450–451
composition of, 458
functions of, 451
Lamina lucida, 47, 450f, 450–451, 451
Laminin, 68t, 452, 453–454
in basement membrane, 451, 451b, 452f, 453–454, 455f
cellular origin of, 459
epithelial, 458
in dermis, 63
in junctional epidermolysis bullosa, 68t, 510, 514, 516
mediating tumor-cell binding, 450
nomenclature system on, 453, 454t
structure of, 453, 453f
Laminin 1, 68t, 71, 452f, 453, 454t
Laminin 5, 78, 454t
in anchoring filaments, 457
in basement membrane, 452f, 453, 455f, 459
in cicatricial pemphigoid, 481, 482t
in junctional epidermolysis bullosa, 68t
structure of, 453f
Laminin 6, 459
Laminin 111, 452f, 453, 453f, 454t
Laminin 311, 454t, 457, 458, 459
Laminin 332, 83, 454t
in anchoring filaments and fibrils, 457, 458
in basement membrane, 452f, 453, 454, 455f
cellular origin of, 459
epithelial, 458
in junctional epidermolysis bullosa, 510, 514, 516
structure of, 453f
Laminin 423, 454, 454t
Laminin 511, 453, 454t, 458
Laminin 523, 454, 454t
Lamivudine in HIV infection and AIDS, 2208, 2209
LAMP (lysosomal-associated membrane protein), 596, 599
Langerhans cell(s), 43, 44, 58, 62, 62f, 106–114, 107f
activation of, 132f, 135
in adaptive immune response, 101
in antigen presentation, 62, 111–112, 113f
in atopic dermatitis, 147, 148
Birbeck granules in, 62, 62f
definition of, 106
in embryonic and fetal development, 69
in epidermis, 106–107
age-related changes in, 966
functions of, 62, 109
in HIV-1 infections, 135
immature, 111, 112
and immune tolerance, 112
in lichen nitidus, 256, 258
life cycle of, 107–109
mature, 111, 112
migration to lymphoid tissues, 109, 122
in nail matrix, 780
phenotypic properties of, 106
in psoriasis, 109, 171f, 172
radiation affecting, 861
response to danger signals, 109
therapeutic targeting of, 114
tissue distribution of, 106–107
trafficking to regional lymph nodes, 131, 132f
as tumor therapy vehicle, 62
in ultraviolet radiation exposure, 62, 2248
and photoimmunosuppression, 807, 807f, 808, 808f
Langerhans cell histiocytosis, 944, 944f, 1375t, **1414**–1424
approach to patient with, 1416f
classification of, 1414–1415, 1415t, 1417t
clinical findings in, 1414–1419
complications of, 1421
cutaneous lesions in, 1415–1417, 1418f
diagnostic criteria on, 1415, 1417t
differential diagnosis of, 1421, 1422b
in elderly, 1417, 1420f
epidemiology of, 1414
etiology and pathogenesis in, 1414, 1415f
familial, 1414
granulomatous reaction in, 1420, 1422f
herpesvirus 6 in, 998
herpesvirus 8 in, 998
histopathology in, 1419–1421, 1421f, 1422f
laboratory tests in, 1419–1421, 1421t
nail changes in, 1417, 1420f, 1423
oral cavity disorders in, 649, 1417, 1419f
prognosis and clinical course in, 1421–1423
proliferative reaction in, 1420, 1421f
treatment of, 1423f, 1423–1424
xanthomatous reaction in, 1420, 1421, 1422f
Langerin, 106
Lanolin, allergic contact dermatitis from, 141, 2362, 2363t
Lanugo hair, 739, 742, 742t
definition of, 754t
excessive growth of, 1448
in paraneoplastic syndromes, 1503, 1503f
LARC (liver and activation-regulated chemokine), 127
in cancer, 134
in psoriasis, 132, 133f
Large cell lymphocytoma, 1405
Large cell lymphoma
anaplastic T-cell, 1386, 1392, 1393, 1395f
of leg, B-cell, 1400f, 1400–1401
Larva currens, 2016, 2017
Larva migrans
cutaneous, 1454, 2011, 2012t, 2016
differential diagnosis of, 2013t, 2021t
hookworm-related, 2023f, 2023–2024, 2024f
syndrome in, 2024
treatment of, 2014t
visceral, 1454, 2012t
treatment of, 2015t
Larynx
cicatricial pemphigoid of, 482, 484t
treatment of, 485, 485b
edema of, 27
Laser therapy, 798, 800–801, **2263**–2279
in acne, 700, 2278–2279
in actinic keratosis, 1014
in bromhidrosis, apocrine, 732
in café-au-lait spots, 1337, 2272, 2273
in capillary malformations, 1655, 2270f, 2270–2271, 2271f
cavitation in, 2266
clinical applications of, 2269–2279
continuous, 2263, 2264f
cooling methods in, 2268
in dermatomyositis, 1551
dosimetry in, 2266
in fat deposits and cellulite, 2279
fluence in, 2266
in granuloma
faciale, 304, 304b
pyogenic, 2272
for hair removal, 775, 775b, 2269, 2275–2277, 2276t
in hemangiomas, 2271–2272
in infants, 1168t, 1169, 2271–2272
in hidradenitis suppurativa, 738
in hirsutism, 775, 775b, 2275–2277
indications for, 2263–2264, 2265t, 2269–2279
in skin resurfacing, 2364–2365, 2365t
in Langerhans cell histiocytosis, 1423
laser-skin interactions in, 2266–2268
in lupus erythematosus, 1535
in lymphatic malformations, 1663
in lymphoid hyperplasia, 1408, 1408b
microthermal damage zone in, 2268, 2277
in neurofibromatosis type 1, 1337
in photoaging, 2268, 2273
for skin resurfacing, 2277, 2364–2369
photomechanical interactions in, 2266
photothermolysis in, 2266, 2268
and skin rejuvenation, 2373, 2373f
and skin resurfacing, 2369, 2369f
in pigmented lesions, 2272t, 2272–2275, 2376t, 2376–2378
in porokeratosis, 445, 445b
in port-wine stains, 2266, 2270f, 2270–2271, 2271f

in psoriasis, 185t, 190, 2244, 2279
pulsed, 2263, 2264f
Q-switching in, 2263, 2264
in rosacea, 708–709, 2272
safety of, 2268t, 2268–2269
for skin rejuvenation, 2268, 2273, 2372–2374
for skin resurfacing, 2266, 2277–2279, 2364–2369
fractional, 2277, 2369
in striae, 560, 2278
for tattoo removal, 888–889, 889f, 889t, 2275, 2275f, 2276f, 2377f
types of, 2263–2264, 2265t
vaporization in, 2266, 2277, 2278
in vascular lesions, 2269t, 2269–2272, 2374–2376
equipment in, 2375, 2375t
risks and precautions in, 2374, 2375t
in venous disorders, 1660, 2272
in varicose veins, 2272, 2351, 2355–2356
in vitiligo, 620b, 621, 2279
in warts, 1922, 2278
genital, 664b
Latapi lepromatosis, 1792, 1792f, 1793
Late Effects Normal Tissue scoring system on radiation effects, 859t, 861–862
Latency, viral, 1848
Latent transforming growth factor-β–binding proteins, 535t, 535–536, 536f
Latex allergy, 142–143, 2071
Latitude gradient in ultraviolet radiation exposure, 1134–1135
Latrodectus spider bites, 2054–2056
α-Latrotoxin in black widow spider bites, 2054–2055
Laugier-Hunziker syndrome, 640, 668, 783
oral cavity disorders in, 642t, 648
Lawrence syndrome, 587
Lazy-S excision, 2308, 2308f
for alopecia reduction, 2401
Lead intoxication, 1233
Learning disabilities in neurofibromatosis type 1, 1337
Lectin
and complement activation, 325, 328
in multistep model of leukocyte recruitment, 129–130, 130f
Ledderhose disease, 552
Leech bites, 2048
LEF1/Lef1, 68t
in hair follicle development, 740f, 741, 742, 744
in sebaceous gland development, 688, 688f
in sebaceous tumors, 988, 989t
Leflunomide
in lupus erythematosus, 1533t, 1535
in psoriatic arthritis, 205, 206
in sarcoidosis, 1492, 1492t
in Wegener granulomatosis, 1613t
Leg. *See* Lower limb
Legal issues in elder abuse, 930
Legionella, 1693
Leiner disease, 221, 1372, 1375t
Leiomyoma, 1172–1173, 1173f
Leiomyomatosis, 1172
Leiomyosarcoma, 1173–1174, 1174f
Leishman-Donovan bodies in leishmaniasis, 2005, 2005f
Leishmania aethiopica, 2002t, 2003, 2004, 2006, 2007t
Leishmania braziliensis, 2002t, 2003–2004, 2006
Leishmania donovani, 1940, 2002, 2006
Leishmania donovani infantum, 2006
Leishmania guyanensis, 1940
Leishmania infantum, 2002t, 2003, 2007t
Leishmania major, 2002, 2002t, 2003
treatment of infections, 2007, 2007t
Leishmania mexicana, 2002, 2002t, 2003–2004
treatment of infections, 2007, 2007t
Leishmania tropica, 2002, 2002t, 2003, 2004, 2006, 2007t
Leishmaniasis, **2001**–2007
clinical findings in, 2002–2006
cryptic, 2006
cutaneous, 2002–2006
chronic, 2003, 2004, 2004f, 2005, 2005f
complications of, 2004
diagnosis of, 2004–2006
differential diagnosis of, 2005, 2005b
diffuse, 2002, 2003, 2004, 2005
dry or urban type, 2003, 2003f
histopathology in, 2005, 2005f
moist or rural type, 2003, 2003f
New World, 2003–2004, 2007, 2007t
Old World, 2003, 2003f, 2004f, 2007, 2007t
satellitosis in, 2003, 2004f
treatment of, 2007, 2007t
vectors and reservoir hosts in, 2002, 2002t
volcano sign in, 2003, 2003f, 2004f
epidemiology of, 2001
etiology and pathogenesis in, 2001–2002
helper T cells in, 105, 2002
virulence factors in, 2002
and HIV infection, 1940, 2001, 2004, 2006
id reaction in, 2006
lupoid, 2004
mucocutaneous, 2002, 2006, 2006f
treatment of, 2007, 2007t
in occupational exposures, 2076
pigmentation changes in, 628, 2006
post-kala-azar dermal, 2006
prevention of, 2007
prognosis and clinical course in, 2006–2007
recidivans, 2004
transmission of, 2001, 2002, 2002t
treatment of, 2007, 2007t
local therapy in, 2007, 2007t
systemic therapy in, 2007, 2007t
visceral, 2002, 2003, 2006
pigmentation in, 628, 2006
treatment of, 2007
viscerotropic, 2006
Leishmanid, 2006
Leishmanin skin test, 2005
LEKTI, 68t, 69, 391, 394, 416
deficiency of, 391
Lenalidomide, 2233
Lens, magnifying, 40
in melanoma diagnosis, 1143
Lens-Majewski hyperostotic dwarfism, 1309b
LENT SOMA scale on long-term radiation effects, 859t, 861–862
Lentigo (lentigines), 1117–1122
agminated, 639, 1117, 1118, 1119f
familial syndromes, 633, 633f, 1117
genital, 668
in LAMB/myxoma syndrome, 1117, 1118, 1118f, 1453f
laser therapy in, 2272, 2273
in LEOPARD syndrome, 633f, 633–634, 1117, 1118, 1453
macules in, 30, 30f
maligna and lentigo maligna melanoma, 999, 1000, 1120, 1122
clinical findings in, 1137–1139
differential diagnosis in, 1139b
histopathology in, 1144, 1145f, 1146f
treatment of, 1153–1154
cryotherapy in, 2332–2333
laser therapy in, 2274
radiation therapy in, 2282, 2282t, 2283, 2283f
melanocytes in, 1117
oral, 648, 1121, 1121f
in photochemotherapy, 2258
in PUVA therapy, 1119, 1120f, 1120–1121, 1122
segmental, 639
simplex, 1117–1119
clinical findings in, 1117–1118, 1118f
differential diagnosis of, 1119b
epidemiology of, 1117
etiology and pathogenesis of, 1117
histopathology in, 1118
treatment of, 1118–1119
solar, 1119–1122. *See also* Solar lentigo
unilateral, 639
partial, 639
Leopard skin appearance in onchocerciasis, 628, 667
LEOPARD syndrome, 633f, 633–634, 668, 1117, 1118, 1453
laser therapy in, 2273
Lepidoptera, 2062–2063
Lepidopterism, 2056b, 2062–2063
Leprechaunism, 589
Lepromatosis, Latapi, 1792, 1792f, 1793
Lepromin skin test, 1792, 1794
Leprosy, **1786**–1796
anhidrosis in, 728, 1788
biopsy index in, 1787
borderline, 1787, 1788, 1789, 1789f
clinical findings in, 1787–1792
complications of, 1794
delayed-type hypersensitivity reaction in, 1788, 1790, 1791, 1791f
diagnosis of, 1794
differential diagnosis of, 1793–1794
dimorphic, 1789, 1789f
disability in, 1794
epidemiology of, 1786–1787
erythema nodosum leprosum in, 1791f, 1791–1792, 1793
treatment of, 1795b, 1796
etiology and pathogenesis in, 1787
eye disorders in, 1790, 1794
genetic factors in, 1787
granulomatous spectrum in, 1787–1788
hair loss in, 1790
histoid, 1790, 1790f
in HIV infection and AIDS, 1790–1791
hypopigmentation in, 628, 628f, 1788, 1793
immunopathogenesis of, 103, 1787, 1792–1793
indeterminate, 1790
laboratory tests in, 1792–1793
lepromatous, 102, 103, 728, 1789f, 1789–1790
borderline, 1787, 1788, 1789, 1789f, 1790, 1791, 1791f
cellular immunity in, 1792
epidemiology of, 1786
etiology and pathogenesis in, 1787
necrotizing vasculitis in, 1602
oral cavity disorders in, 647t, 652t
polar, 1787, 1788, 1790
prognosis and clinical course in, 1794
subpolar, 1787, 1788, 1790, 1790f
Lucio phenomenon in, 1792, 1792f, 1793
treatment of, 1795b

Leprosy—*continued*
neurologic disorders in, 1787, 1788, 1789, 1792, 1794
in pregnancy and postpartum period, 1790
prevention of, 1796
prognosis and clinical course in, 1794
reactional states of, 1791–1792
treatment of, 1795b, 1795–1796
relapsing, 1791
route of infection in, 1787
T cells in, 102–103, 105, 1792
thermoregulatory sweat test in, 728, 728f
treatment of, 1794–1796
tuberculoid, 102, 103, 628, 728
borderline, 1787, 1788, 1788f
cellular immunity in, 1792
epidemiology of, 1786
etiology and pathogenesis in, 1787
polar, 1787, 1788, 1788f
prognosis and clinical course in, 1794
Leptin, 66
Leptomyxida, 2009, 2010
Leptosphaeria senegalensis, in mycetoma, 1834t
Leptospira interrogans, 1766–1767
Leptospirosis, 1757t, 1766–1767
treatment of, 1757t
Leptotrombidium mites, scrub typhus from, 1951
Lesch-Nyhan syndrome, 1575, 2167
Leser-Trélat sign, 39t, 1056, 1376t
in acanthosis nigricans, 1495, 1497, 1498
in paraneoplastic syndromes, 1494t, 1497–1498
Letterer-Siwe disease, 1414
Leucovorin in methotrexate therapy, 2166–2167
Leukemia
cutaneous manifestations in, 1384–1385, 1385f, 1506–1507
cutis, 1384–1385, 1385f
differential diagnosis of, 293, 294b, 1407
genital disorders in, 667–668
mast cell, 1436t, 1437, 1442
in neurofibromatosis type 1, 1336
paraneoplastic pemphigus in, 468, 469, 474, 1503
Sweet syndrome in, 292, 293, 1502
T-cell, adult, 1924–1926. *See also* T-cell leukemia, adult
Leukocyte adhesion deficiency, 1364–1366, 1365f, 1374t
type 1 (LAD1), 281, 328, 1365, 1365f
type 2 (LAD2), 281–282, 1365
type 3 (LAD3), 1365
type 4 (LAD4), 1364
Leukocyte common antigen in Merkel cell carcinoma, 1090t, 1090–1091
Leukocytes
activation of, 1593
adhesion of, 129, 281–282, 1591–1593, 1593f
chemokines in mobilization of, 126, 129–131
cutaneous trafficking of, 129–131
extravasation of, 1594
functional defects of, 1374t
multistep model of recruitment, 129–130, 130f
peripatetic, 44
rolling of, 129, 130f, 281, 282f, 287, 1591, 1593f
transfusion in chronic granulomatous disease, 1364, 1365t
Leukocytic endogenous mediator, 115
Leukocytoclasia
in pyoderma gangrenosum, 298
in Sweet syndrome, 292
in vasculitis. *See* Vasculitis, leukocytoclastic
Leukocytosis
in polycythemia vera, 1378
in Sweet syndrome, 293
Leukoderma
acquisitum centrifugum, 629, 1105
chemical, 628f, 628–629
colli syphiliticum, 1960
contact, 142, 144
genital, 658b
melanoma-associated, 629, 629f
perinevoid, 1105
punctata, 630
vagabond, 640
Leukoedema, 641
Leukonychia, 782, 782f
apparent, 783
in cytotoxic drug therapy, 2177
punctate, 782
striate, 782, 782f
systemic diseases associated with, 791
Leukopenia in Langerhans cell histiocytosis, 1423
Leukoplakia, 1024–1025
bleomycin in, 2124
differential diagnosis in, 1025, 1025b
in dyskeratosis congenita, 1324f, 1325
and erythroplakia, 1027
hairy oral
in Epstein-Barr virus infections, 277, 644, 651t, 1025, 1932–1933
in HIV infection and AIDS, 644, 1932–1933, 1933f
homogeneous and non-homogeneous types, 1024
as premalignant lesion, 648, 1024–1025
proliferative verrucous, 649, 649f, 1024–1025
squamous cell carcinoma in, 1024, 1025
treatment of, 1025, 1026f
Leukotrienes, 285, 1204
antagonists of, 288
cysteinyl, 285
functions of, 1435t, 1436
as mast cell mediators, 1435t, 1436
in melanocyte regulation, 604
in necrotizing venulitis, cutaneous, 1599
in pruritus, 897t
as radioprotectors, 860
in sunburn inflammation, 604
Leuprolide in acne vulgaris, 698
Levocabastine, 2188
Levocetirizine, 2189t
Levofloxacin, 2195t, 2201
in gonorrhea, 1996b
in leprosy, 1795, 1795b
Levonorgestrel in acne vulgaris, 698
Lewy body disease, 727
LFA. *See* Lymphocyte function-associated antigens
Lhermitte's sign, 1377
Liarozole, 2182
Lice infestation, 663, 2033–2037. *See also* Pediculosis
epidemic typhus in, 1943t
Lichen amyloidosis, 1261, 1262f
treatment in, 1265
Lichen aureus, 1634t, 1635
treatment of, 1636
Lichen myxedematosus, 1502, 1564–1565
Lichen nitidus, **255**–258, 666
clinical findings in, 256, 257f
compared to lichen planus, 256, 256t, 258b
differential diagnosis in, 258, 258b
epidemiology of, 255
etiology and pathogenesis of, 255–256
genital, 666
pathology in, 256–258, 257f
prognosis and clinical course in, 258
treatment of, 258
Lichen planopilaris, 247, 248, 248f
cicatricial alopecia in, 771, 772t
differential diagnosis in, 252b
prognosis and clinical course in, 252
Lichen planus, 58, **244**–255
actinic, 248
alopecia in, 247, 248, 248f
of amputation stump, 867
annular, 246, 252b
atrophic, 247, 248, 252b
bullous, 247, 247f
and bullous pemphigoid, 479
in cirrhosis, 1458
clinical findings in, 245f, 245–252, 246f, 247f
differential diagnosis in, 247, 252b, 258b, 1920
drug-induced, 244, 248, 248f, 249–250, 250t, 251, 360
epidemiology of, 244
erosive, 246, 247, 247f, 248
esophageal, 1451
etiology and pathogenesis in, 244–245
familial, 244
follicular, 247, 248, 252b
generalized, 246, 246f
genital
in female, 680b, 680f, 680–681
in male, 246f, 249, 665f, 665–666, 666f
in graft-versus-host reaction, 251, 263f, 263–264
in hepatitis C, 251, 1457
in herpesvirus-7 infections, 1867
hypertrophic, 246, 247, 247f, 252b
prognosis and clinical course in, 252
inverse, 249
Koebner phenomenon in, 246, 246f, 665
and lichen nitidus, 255–256, 256t
linear, 246, 246f
differential diagnosis in, 252b, 1058
and lupus erythematosus, 250, 250f
malignant transformation in, 251, 251f, 252
nail changes in, 247, 249, 249f, 789–790, 790b, 790f, 1449
differential diagnosis of, 252b, 789–790, 790b
onychorrhexis in, 782
treatment of, 254, 790
oral cavity disorders in, 246, 246f, 248–249, 645, 645f
malignant transformation in, 251, 251f
prognosis and clinical course in, 252
treatment of, 253b, 253–254
palmoplantar, 249
differential diagnosis in, 252b
papules in, 26, 26f, 245, 245f
pathology in, 49, 49f, 251–252, 252f
pemphigoides, 247, 250f, 250–251, 479
treatment of, 255
pigmentosus, 247–248
prognosis and clinical course in, 252
sawtooth appearance in, 251, 252f
scaling lesions in, 31t
of scalp, 247, 248, 248f
squamous cell carcinoma in, 247, 251, 251f, 666

stages of, 244–245
antigen recognition, 244–245
keratinocyte apoptosis, 245
lymphocyte activation, 245
subtropicus, 248
treatment of, 252–255
in nail changes, 254, 790
photochemotherapy in, 254b, 254–555, 2255
radiation therapy in, 2280t
ulcerative, 247, 247f
treatment of, 255
vesiculobullous, 247, 247f
Lichen purpuricus, 1635
Lichen sclerosus, 54, **546**–550
clinical findings in, 547, 548f, 669, 669t, 670f, 678–679, 679f
complications in, 549, 669, 679
diagnosis and differential diagnosis of, 547–549, 549b, 669, 670b, 679, 679b
epidemiology of, 546–547, 669
etiology and pathogenesis in, 547, 669
histopathology in, 547, 549f
laboratory tests in, 547
pigmentation in, 629, 678, 679f
prevention of, 550
prognosis and clinical course in, 549
squamous cell carcinoma in, 549, 549f, 669
treatment of, 549–550, 670, 679, 2184
Lichen scrofulosorum, 1773, 1774, 1774t
differential diagnosis of, 1774b
Lichen simplex chronicus, 58, **160**–162, 161f, 677
differential diagnosis of, 161b
lichenification in, 32, 32f, 160, 161f, 677, 677f
treatment of, 161–162
Lichen spinulosus, 248
Lichen striatus, 790, **1062**
clinical features in, 1062, 1062f
differential diagnosis in, 1058, 1062
treatment of, 1062
Lichenification, 32, 32f
in atopic dermatitis, 149, 150, 150f
in lichen simplex chronicus, 32, 32f, 160, 161f, 677, 677f
in pruritus, 905
Lichenoid disorders, 244
actinic, 248
in allergic contact dermatitis, 142, 144
in dermatosis of Gougerot and Blum, 1634, 1634t, 1635f, 1636
drug-induced, 249–250, 250t, 360
in keratosis and solar lentigo, 1122
in paraneoplastic pemphigus, 470
in phototoxicity, 831, 832
Licorice extract, 2146, 2363, 2363t
Lidocaine, 2296, 2296t, 2298
in EMLA cream, 942, 2130, 2296t, 2298
in excisional surgery, 2303
in hair transplantation, 2397
in liposuction, 2378–2379, 2380t
in nail surgery, 2321
in postherpetic neuralgia, 1896
in regional nerve block, 2298
side effects of, 2130, 2337
in skin biopsy in children, 942
in soft tissue augmentation, 2383, 2385
toxicity of, 2297, 2337
in children, 946t
in venomous fish spine injuries, 2052
Lifestyle factors
in atopic dermatitis, 146, 156
in Raynaud phenomenon, 1646–1647
Lifetime risk for disease, 6
Li-Fraumeni syndrome, 982t, 995
Ligand-dependent transcription factors, 2107
Light eruptions, 52, 90
differential diagnosis in, 818b, 834, 1246
persistent, in fragrance allergy, 2362
polymorphic, 816–818, 2160, 2246–2247
and actinic prurigo, 818–819
approach to diagnosis of, 826, 827
clinical features in, 817, 817f
differential diagnosis of, 1246
hardening or tolerance to sunlight in, 2247, 2256
photochemotherapy in, 818, 2247, 2256
phototherapy in, 818, 2246–2247
Light therapy
with intense pulsed light. *See* Intense pulsed light therapy
in rosacea, 708, 709
Likelihood ratio, 16–17
Limb amputation. *See* Amputation
Limb defects in CHILD syndrome, 403t, 419–420
Limb swelling in onchocerciasis, 2020
Lime burns, 876
Lincomycin, 2200
Lincosamide antibiotics, 2195t, 2200
adverse effects of, 2196t
Lindane, 2133, 2133t
in pediculosis capitis, 2034t
in pediculosis pubis, 2037b
porphyria cutanea tarda-like syndrome from, 834, 1236, 1237, 1238
in scabies, 2031b
toxicity in children, 946t
Lindsey's nails, 1449
Linea alba in pregnancy, 635
Linea nigra in pregnancy, 635, 955, 957f
Lineage addiction mechanism in carcinogenesis, 1136
Linear immunoglobulin A dermatosis, 358, **485**–490, 1375t
clinical findings in, 487f, 487–489, 488f
and dermatitis herpetiformis, 485, 487, 488, 503, 504
differential diagnosis of, 489, 489b
epidermolysis bullosa acquisita in, 496–497
diseases associated with, 488–489
drug-induced, 358, 359t, 487, 489
epidemiology of, 485–486
etiology and pathogenesis in, 486–487
histopathology in, 489, 489f
pathology in, 489
treatment of, 489–490
Linear lesions, 36, 36f
in immunoglobulin A dermatosis, 485–490
Linezolid, 2202
in actinomycetoma, 1786
in soft tissue infections, 1730
Lingua
fissurata, 643
plicata, 643
Liniments, topical medications formulated as, 2094
Linoleic acid, 385, 386, 1204, 2286, 2287
in acne vulgaris, 691–692
deficiency of, 1204
Linuche unguiculata in sea bather's eruption, 2049
Lion fish stings, 877
Lip, 641–642
cheilitis of, 641–642, 1009, 1010f. *See also* Cheilitis
in cleft lip and palate with ectodermal dysplasia
and ankyloblepharon filiforme adnatum, 1343–1344, 1344f
and ectrodactyly, 1343, 1344–1345, 1345f
erythroplakia of, 1027
examination of, 641
squamous cell carcinoma of, 1031, 1031f, 1034, 1035
surgery of
advancement flap in, 2308, 2309f
anatomy in, 2291
cosmetic units and landmarks in, 2289, 2290
Lipase, in pancreatic panniculitis, 577
Lipid extract with garlic, in corns and calluses, 873b
Lipids
in cornified envelope, 388
metabolism of, 1273–1274, 1275f
in diabetes mellitus, 1462, 1464
in nails, 781
in sebaceous glands and sebum, 688f, 688–689
in serum
in hyperlipidemia, 1274–1278. *See also* Hyperlipidemia
in psoriasis, 182
in retinoid therapy, 2185–2186
in skin surface, antibacterial properties of, 1690
storage disorder in Chanarin-Dorfman syndrome, 405t, 420–421
in stratum corneum, 385f, 385–386, 386f, 387f, 388f, 1690
Lipoatrophy, 581
compared to lipodystrophy, 581
in diabetes mellitus, 589
drug-induced, 581
in HIV infection, 1934, 1935, 1935f
histopathology in, 581
in HIV infection, 1934, 1935, 1935f
poly-L-lactic acid augmentation in, 2384
silicone augmentation in, 2387
localized, 581
semicircular, 581
Lipoblastoma, 1195, 1195f
Lipoblastomatosis, 1195, 1195f
Lipodermatosclerosis, 575–576, 1680, 1681, 1682f
in elderly, 973
impaired wound healing in, 2347–2348
Lipodystrophy, 66, 581, **585**–589
acquired, 585–587
drugs associated with, 586, 587
epidemiology of, 585
generalized, 585, 587
localized, 585, 587
partial, 585, 587
compared to lipoatrophy, 581
congenital generalized, 588–589
histopathology in, 581
in HIV infection and AIDS, 586f, 586–587, 589, 1192, 1934–1935
inherited, 588–589
epidemiology of, 588
familial partial, 588
membranous, 585
treatment in, 589
Lipofibromatosis, 1195–1196
Lipofuscin
in aging, 967
in apocrine chromhidrosis, 732, 733
in eccrine sweat glands, 714
Lipohypertrophy in HIV infection, 1934, 1934f

Lipoid proteinosis, 77, **1288**–1292
oral cavity disorders in, 642t
respiratory disorders in, 1454
Lipoleiomyoma, extrauterine, 1194
Lipoma, 1190–1194
angiolipoma, 1192–1193
angiomyxolipoma, 1191
chondroid, 1194, 1194f
dermal, 1191, 1191f
fibrolipoma, 1191, 1191f
histologic features in, 1190f, 1190–1191, 1191f
intramuscular, 1191, 1191f
mobile encapsulated, 581
mucosal, 647–648
multiple familial, 1190, 1190f
myolipoma of soft tissue, 1194
myxolipoma, 1191
pleomorphic, 1193f, 1193–1194
spindle cell, 1193f, 1193–1194
myxoid, 1193, 1193f
pseudo angiomatous variant, 1193
Lipomatosis, 1191–1192
familial, 1190, 1190f
of nerve, 1192
pelvic, 1191–1192
symmetric, 1191, 1191f
Lipomatous tumors
atypical, 1196
hemosiderotic fibrohistiocytic, 1195
Liponyssoides mites, 2032t, 2033
rickettsialpox from, 1943t, 1946, 2032t, 2033
Lipopolysaccharide, 283, 1691
in meningococcal infections, 1731–1732
and Toll-like receptors, 99
toxic and pro-inflammatory effects of, 1691
Lipoprotein lipase, 1273, 1275f
deficiency of, 1272t, 1274–1275
in diabetes mellitus, 1462, 1464
Lipoprotein X, 1280
Lipoproteins, 1273–1280
in diabetes mellitus, 1462, 1464
in Fabry disease, 1285
in familial hyperlipidemias, 1274–1278
high-density, 1274
metabolism disorders, 1280
intermediate-density, 1275f
low-density, 1274, 1275f, 1276, 1277
metabolism of, 1273–1274, 1275f, 1280
very-low-density, 1273–1274, 1275f
in familial hypertriglyceridemia, 1278
very-low-density remnant, 1274
in xanthoma, 1272, 1272t
Liposarcoma
dedifferentiated, 1196–1197, 1197f
myxoid, 1197–1198
pleomorphic, 1198
round cell, 1197–1198
well-differentiated, 1196
Liposome-based drug formulations, 2099
Liposuction, 2378–2380
in apocrine bromhidrosis, 732
complications of, 2380
equipment in, 2378, 2379, 2379f
indications for, 2378
outcome assessment in, 2379–2380, 2380f
risks and precautions in, 2378, 2379t
Liquid drug formulations, topical application of, 2094–2095
Liquid nitrogen cryosurgery, 2330, 2330t
in actinic keratosis, 1013
Lisch nodules in neurofibromatosis, 1335, 1335f
Listeria monocytogenes, 1762–1763
in bioterrorism, 2083t
Listeriosis, 1757t, 1762–1763
in bioterrorism, 2083t
treatment of, 1757t, 1763, 1767
Lithium in seborrheic dermatitis, 224
Livedo racemosa, 1603, 1676–1677
antiphospholipid antibodies in, 1677
in atheromatous embolism, 1672, 1672f
clinical findings in, 1676, 1677f
differential diagnosis of, 1677
disorders associated with, 1677t
in Sneddon syndrome, 1676, 1677, 1677f
treatment of, 1677
Livedo reticularis, 1375t, 1602, 1676–1677
clinical findings in, 1676, 1676f
differential diagnosis of, 1646, 1677
drug-induced, 1676
in lupus erythematosus, 1528
treatment of, 1677
and vasculitis, 1603
cutaneous necrotizing, 1602, 1603–1604
starburst appearance in, 1614, 1614f
systemic necrotizing, 1607, 1609f, 1610
Livedo vasculitis, 1603, 1676
Livedoid vasculopathy, 1603, 1676
Liver, heme synthesis in, 1230
Liver and activation-regulated chemokine (LARC), 127
in cancer, 134
in psoriasis, 132, 133f
Liver disorders, 1457–1458
in amebiasis, 2009
in amyloidosis, 1260t, 1262, 1264
prognosis and clinical course in, 1264
treatment in, 1264
in *Bartonella* infections, 1752, 1753, 1754
in burns, 1458
in cholestasis
of pregnancy, 958
pruritus in, 1447–1448
cryoglobulinemia in, 1457, 1637–1638, 1639, 1640
treatment of, 1641
"dollar paper markings" in, 1446
drug-induced, 1458, 1459t
from antimalarial drugs, 2160
from azathioprine, 1459t, 2168
from cyclosporine, 1459t, 2220
in drug interactions, 2240t
from methotrexate, 191, 1458, 1459t, 2165–2166, 2166t
from retinoids, 1459t, 2186
from terbinafine, 1459t, 2212, 2213
in echinococcosis, 2027
in erythropoietic protoporphyria, 1245–1246, 1247
in exfoliative dermatitis, 229
eye disorders in, 1451
in fascioliasis, 2026
fibrosis in methotrexate therapy, 191, 2165–2166, 2166t
general skin changes in, 1445–1446
in graft-versus-host disease, 264, 265, 1457
in hemangioma of infants, 1167
in Kawasaki disease, 1457–1458, 1630
in Langerhans cell histiocytosis, 1417–1419, 1422–1423
in leptospirosis, 1766, 1767
and lichen planus, 251, 1457, 1458
in lipodystrophy, 589
in mastocytosis, 1438–1439, 1440, 1457
in metastatic tumors, 1458
nail changes in, 1449, 1449f, 1450f
in peliosis hepatis, 1752, 1753, 1754
in psoriasis, 1458
in sarcoidosis, 1458, 1488, 1491t
spider nevi in, 1451, 1451f
striae in, 1445, 1446f, 1457
and Sweet syndrome, 291, 292t, 293, 1457
in syphilis, 1458, 1962
Liver flukes, 2026
Liver X receptor activation, 386–387
LL-37 effector molecule, 97
LMNA in lipodystrophy, 588, 589
LMX1b/Lmx-1B, 68t, 70, 72
Loa loa, 2012t, 2013t, 2017t, 2021t
treatment of infections, 2015t, 2019
Lobo disease, 1835
Lobomycosis, 1831, 1835
Lobule of ear, 2289, 2290f
Local anesthesia, 2296t, 2296–2298. *See also* Anesthesia
Localized lesions, 38
Löffler syndrome, 1454, 2012–2013
Löfgren syndrome, 1488, 1490, 1491
Loiasis, 2012t, 2018–2019, 2019f
differential diagnosis of, 2013t, 2019, 2021t
treatment of, 2015t, 2019
Loose anagen syndrome, 762, 762f
Lopinavir in HIV infection, 2209–2210
Loratadine, 2188, 2189t, 2191
pediatric dosage, 953t
Lorazepam, 920, 920t
for antipsychotic drug side effects, 918
Loricrin, 61, 68t, 390, 390f
in cornified envelope, 381, 382t, 387–388, 418
deficiency of, 390
in progressive symmetric erythrokeratodermia, 418
Lotions, topical medications formulated as, 2095
Louis-Bar syndrome, 1361
Lovastatin, 388–389
Lower limb, 1460
amputation in, 862–868. *See also* Amputation
B-cell lymphoma of, primary cutaneous large cell, 1400f, 1400–1401
cholesterol emboli in, 1460, 1460f
lymphedema of, 1685, 1685f, 1686f
ulcers of
in chronic venous insufficiency, 1681–1682, 1682f, 1683
differential diagnosis in, 1683b
treatment in, 1683
venous system of, 1679–1680, 1680f
anatomy and physiology of, 1679–1680, 1680f, 2350, 2350f, 2351f
calf muscle pump in, 1679–1680, 1680f, 2350, 2350f
as donor site in coronary artery bypass surgery, 1460
varicose veins in, 2349–2356
Loxosceles spider bites, 2054, 2056–2057
LTBP (latent transforming growth factor-β–binding proteins), 535t, 535–536, 536f
Lucio phenomenon in leprosy, 1792, 1792f, 1793
treatment of, 1795b
Ludwig angina in body piercing complications, 890t
Lues maligna, 1960
Lumbosacral area
congenital skin lesions with risk of occult spinal dysraphism, 941, 941t
infantile hemangiomas of, 1166
Lumican, 539t
Luminal cells in eccrine sweat glands, 714, 715f
Lumpy jaw in actinomycosis, 653

Lund-Browder diagram in burns, 853, 854, 856f
Lung flukes, 2026
Lungs
  cancer of
    erythema gyratum repens in, 1500
    immunohistochemistry in, 1090t
    metastatic to skin, 1506, 1506f
    scleroderma in, 1500
    Trousseau syndrome in, 1504
  honeycomb appearance in Langerhans cell histiocytosis, 1417, 1420f
  Kaposi sarcoma of, 1186
  paraneoplastic pemphigus of, 471, 472–473
Lunula, 778, 2320, 2320f
  azure, 1449
Lupoid sycosis, 1699
Lupus anticoagulant
  in Degos disease, 1648, 1650
  in necrotizing venulitis, 1602
Lupus band test, 1530–1531
Lupus erythematosus, **1515**–1535
  acute cutaneous, 1515, 1522
    clinical findings in, 1520–1521, 1522t
    development of systemic disease in, 1525f
    differential diagnosis of, 1531b
    histopathology in, 1529
    immunohistology in, 1530
    prognosis and clinical course in, 1531–1532
    treatment of, 1532
  annular, 367t
  apoptosis and programmed cell death in, 1510, 1519
  approach to patient with, 1521f
  autoantibodies in, 1528t, 1528–1529
  as autoimmune disease, 1509, 1515
  B cells in, 1520
  bullous, 494, 495, 1527
  butterfly rash in, 1520, 1522f
  cardiovascular disorders in, 1453
  chilblain (perniotic), 850, 1486–1487, 1487f, 1488f, 1526
    histopathology in, 1530
    natural history and prognosis in, 1490, 1491
    treatment of, 1491, 1491t
  chronic cutaneous, 1515
    clinical findings in, 1520, 1522t, 1523–1525
    histopathology in, 1529
    immunohistology in, 1530
    prognosis and clinical course in, 1532
    treatment of, 1532
  classification of, 1515, 1516t, 1517t
  clinical features in, 1371, 1520–1528
    comparison of, 1522t
  collagen VII in, 458
  complement deficiency in, 328, 329, 1371, 1371f, 1509, 1516, 1519
  complications of, 1531b
  dendritic cells in, 1513, 1517, 1519, 1520
  differential diagnosis of, 347, 348b, 1413, 1531b
    dermatomyositis in, 1547–1548, 1548b
  discoid, 1515
    clinical findings in, 1523f, 1523–1525
    development of systemic disease in, 1524, 1525f
    differential diagnosis of, 1531b
    folliculotropic variant, 1529
    hyperkeratotic or verrucous, 1524
    lymphomatoid variant, 1529
    mucosal, 1525
    prognosis and clinical course in, 1532
  drug-induced, 355–356, 357t, 361, 834, 1513, 1519, 1525
    clinical findings in, 1525
    subacute cutaneous, 357t, 361, 1525
  environmental factors in, 1510f, 1514, 1517–1518
  epidemiology of, 1515
  epidermal necrolysis in, 1529
  and epidermolysis bullosa acquisita, 494, 495
  Epstein-Barr virus in, 1514, 1519
  etiology of, 1515–1519
  extracutaneous manifestations of, 1518t
  gender differences in, 1515, 1516–1517
  genetic factors in, 1510, 1511, 1512, 1516
    and environmental factor interactions, 1510f
  hair loss in, 1524, 1527, 1532, 1535
    cicatricial alopecia in, 771, 772t
    telogen effluvium in, 761, 1524
  histopathology in, 1529f, 1529–1530
  HLA system in, 1516, 1520
  hypertrophicus et profundus, 1524
  immunohistology in, 1530f, 1530–1531
  interferon-α in, 1513–1514, 1517, 1519, 1520
    as therapy target, 1533t, 1535
  laboratory tests in, 1528t, 1528–1529
  and lichen planus, 250, 250f
  liver disorders in, 1458
  nail changes in, 791, 1520, 1522f
  necrotizing venulitis in, 1601
  oral cavity disorders in, 642t, 1452, 1524, 1524f, 1525, 1527
  outcome measures in, 1532
  panniculitis in, 55, 576–577, 1525–1526, 1526f
    histopathology in, 1529–1530
  pathogenesis in, 1514, 1515–1520
    model of, 1518f
  pathologic reactions in, 49, 49f, 51
    mucinous infiltration in, 52, 52f
  pigmentation changes in, 626–627, 1523, 1523f
  pityriasiform, 1521, 1522
  porphyria cutaneous tarda-like syndromes in, 1239
  preventive measures in, 1535
  profundus, 576–577, 1525–1526, 1530
  prognosis and clinical course in, 1531–1532
  psoriasiform, 1521
  quality of life measures in, 1532
  Raynaud phenomenon in, 1527, 1645
  respiratory disorders in, 1454
  subacute cutaneous, 1515
    annular, 1522, 1523f
    clinical findings in, 1520, 1521–1523, 1522t
    development of systemic disease in, 1525f, 1532
    differential diagnosis of, 1531b
    disorders associated with, 1523
    drug-induced, 357t, 361, 1525
    histopathology in, 1529
    immunohistology in, 1530
    papulosquamous, 1522, 1523, 1523f
    prognosis and clinical course in, 1532
    and Sjögren syndrome, 1532
    treatment of, 1532
  subacute disseminated, 1521
  superficial disseminated, 1521
  T cells in, 1520
    and cytotoxic T-lymphocyte antigen-4, 1510
    regulatory, 1512
  toll-like receptors in, 1513, 1519
  treatment of, 1372, 1491, 1491t, 1532–1535
    antimalarial drugs in, 1533t, 1533–1534, 2159–2160
    estrogen in, 1480, 1517
    retinoids in, 1534, 2184
    thalidomide in, 1533t, 1534, 2234t
  tumidus, 1526f, 1526–1527, 1530
    differential diagnosis of, 1531b
  tumor necrosis factor-α in, 1516, 1519–1520
  ultraviolet radiation exposure in, 1517–1519
    and photosensitivity, 1516, 1520, 1527
    protection from, 1532
  urticaria in, 1528
  vesiculobullous skin change in, 1527
    classification of, 1527, 1527t
Lupus miliaris disseminatus faciei, 1773, 1774t
Lupus planus, 1524
Lupus postexanthematicus, 1771
Lupus vulgaris, 1769, 1770, 1771–1772, 1772f
  in BCG vaccination, 1773
  in body piercing complications, 890t
  differential diagnosis of, 1772b
  nasal, 1771, 1772f
  squamous cell carcinoma in, 1772, 1772f
  treatment of, 1775
Luteinizing hormone levels in leprosy, 1790, 1793
Lutzomyia sandfly bites, 2060
  leishmaniasis in, 2002, 2002t, 2004, 2006
  Oroya fever and verruga peruana in, 1754
Lymantria dispar, 2062
Lyme disease, **1797**–1806, 2059
  acrodermatitis chronica atrophicans in, 1798, 1799–1801, 1800f, 1803
    diagnosis and differential diagnosis of, 1800t, 1801
  approach to patient with, 1805f
  arthritis in, 1798, 1803
    treatment in, 1806t
  atrophoborreliosis in, 1800t, 1801
  chronic, 1803
  clinical manifestations in, 1798–1803
  complications of, 1803
  diagnosis of, 1803–1804
    C6 peptide test in, 1804
    serologic tests in, 1804
  epidemiology of, 1797
  erythema migrans in, 367t, 1798–1799, 1799f, 1803, 1804
    diagnosis and differential diagnosis of, 1799, 1800t
    histopathology in, 1799, 1799f
    treatment in, 1806t
  etiology and pathogenesis of, 1797–1798
  eye disorders in, 1803
  immunology in, 1798
  lymphoborreliosis in, 1800t, 1801–1802
  lymphocytoma in, 1798, 1802, 1802f
    treatment in, 1806t
  lymphoid hyperplasia in, 1402, 1403f, 1408, 1801–1802
  neurologic disorders in, 1802–1803
    in acrodermatitis chronica atrophicans, 1800
    treatment in, 1806t
  in occupational exposures, 2076
  prevention of, 1804–1805
  prognosis and clinical course in, 1803
  scleroborreliosis in, 1800t, 1801, 1801f
  treatment of, 1804, 1806t
  vaccination against, 1805

Lymph nodes
dendritic cell trafficking to, 131
melanoma involving, 1146, 1148t–1150t
biopsy in, 1149, 1151–1153, 1154
dissection in, 1154
in regional metastasis, 1148–1149, 1150f, 1151–1153
Merkel cell carcinoma involving, 1091, 1091f
biopsy in, 1091, 1091f
dissection in, 1092
nevomelanocytic nevi in, 1116–1117
in Paget disease, 1096, 1097
sentinel. *See* Sentinel lymph nodes
Lymphadenectomy
in melanoma, 1116, 1151–1153, 1154
in Merkel cell carcinoma, 1092
in squamous cell carcinoma, 1035
in tuberculosis, 1770
Lymphadenitis in body piercing complications, 890t
Lymphadenopathy
in amyloidosis, 1260t, 1261, 1262f
angioimmunoblastic, 1376t
in cat-scratch disease, 1750, 1750f
in exfoliative dermatitis, 229
in Langerhans cell histiocytosis, 1419
massive, sinus histiocytosis with, 1424, 1424t, 1433–1434
clinical findings in, 1433, 1433f
differential diagnosis in, 1433, 1433b
epidemiology of, 1425
etiology and pathogenesis in, 1425
treatment in, 1434
in monkeypox virus infections, 1907
in rubella, 1854
in syphilis, 1961
congenital, 1968
in unilateral laterothoracic exanthem, 1782, 1872f
Lymphadenosis benigna cutis, 1402, 1802
Lymphangioendotheliomatosis with thrombocytopenia, multifocal, 1171
Lymphangiogenesis, 65
Lymphangioma
circumscriptum, 65, 1661
in infants, 939
Lymphangitic distribution of lesions, 36–38
Lymphangitis
acute, 1706, 1706f
differential diagnosis of, 1706
in filariasis, 2017–2018
recurrent, in lymphedema, 1686
sclerosing, 672, 1684
in sporotrichosis, 1831, 1832f
Lymphatic system, 65
age-related changes in, 966
embryonic and fetal development, 70
of face, 2294
lymph flow in, 65
malformations in, 1651, 1653f, 1660–1663
clinical characteristics of, 1654t, 1661f, 1661–1662
differential diagnosis of, 1663b
histopathology in, 1661, 1661f
macrocystic, 1660, 1661, 1663
microcystic, 1661, 1661f
prognosis and clinical course in, 1662
treatment of, 1662–1663
Lymphedema, 65, **1684**–1686
acquired, 1685–1686
cellulitis in, 1686, 1727
clinical findings in, 1685f, 1685–1686, 1686f
congenital, 1662
distichiasis, 65, 1661, 1662
erysipelas in, 1722, 1729
in Fabry disease, 1283
in filariasis, 1685
in fork-head family transcription factor defects, 65, 1685
genetic factors in, 65, 68t, 1661, 1684–1685
genital, 662b, 672
with hypotrichosis and telangiectasia, 1661, 1662
in lymphatic malformations, 1661, 1662, 1663f
treatment of, 1663
in Meige syndrome, 1685
in Milroy disease, 65, 1661, 1685, 1722
praecox, 1685
primary, 1684–1685
puffy hand syndrome in, 1686
treatment of, 1686
with yellow nails, 65, 1662
Lymphoborreliosis, 1800t, 1801–1802
Lymphocele, penile, 672
Lymphocyte(s), 104–106
in adaptive immune response, 101–106
autoreactive, 1511, 1520
B cell. *See* B cell(s)
infiltration of skin, 51f, 51–52, 1403t, 1412–1413, 1527
differential diagnosis in, 1413, 1413b
in Lyme disease, 1802
treatment of, 1413, 1413b
in necrotizing venulitis, cutaneous, 1600
in pyoderma gangrenosum, 298
recovery eruption in stem cell transplantation, 258–259
T cells. *See* T cell(s)
Lymphocyte function-associated antigens
LFA-1, 1592, 1592t, 2223t, 2228
absence of, 281
CD18 mutation affecting, 328
interaction with ICAM-1, 105
in psoriasis, 192
in tissue trafficking of neutrophils and eosinophils, 282f
LFA-3, 1595, 2229
in psoriasis, 192
in psoriatic arthritis, 206
Lymphocyte-activating factor, 115
Lymphocyte-associated antigen, cutaneous. *See* Cutaneous lymphocyte antigen (CLA)
Lymphocytic infiltration of skin, 51f, 51–52, 1403t, 1412–1413, 1527
differential diagnosis in, 1413, 1413b
in Lyme disease, 1802
treatment of, 1413, 1413b
Lymphocytoma
borrelial, 1798, 1802, 1802f
treatment in, 1806t
cutis, 52, 1402, 1408
radiation therapy in, 2281
large cell, 1405
Lymphogranuloma venereum, **1987**–1990
acute anorectal syndrome in, 1988, 1989
acute genital syndrome in, 1988, 1989
clinical findings in, 1987f, 1987–1988, 1988f
complications of, 1989
differential diagnosis of, 1988, 1989, 1989b
epidemiology of, 1987
etiology and pathogenesis of, 1987
and HIV infection, 1989
laboratory tests in, 1988–1989
prevention of, 1990
transmission of, 1987
treatment of, 1989–1990, 1990b
Lymphohistiocytosis, familial hemophagocytic, 1369
Lymphoid enhancer factor 1 (Lef1), 68t
in hair follicle development, 740f, 741, 742, 744
in sebaceous gland development, 688, 688f
in sebaceous tumors, 988, 989t
Lymphoid hyperplasia
angiofollicular, 1409
benign, 52
radiation therapy in, 2281
cutaneous, 1402–1408, 1403t
clinical findings in, 1403f, 1403–1404, 1404f
clonal, 1406
complications of, 1407–1408
differential diagnosis of, 1404, 1406b, 1406–1407, 1412b
diffuse, 1405–1406
drug-induced, 1402, 1404, 1404f
epidemiology of, 1402
etiology and pathogenesis in, 1402–1403
follicular, 1405–1406
histopathology in, 1403, 1404f, 1404–1405, 1405f
laboratory tests in, 1404–1406
in Lyme disease, 1402, 1403f, 1408, 1801–1802
lymphoma risk in, 1406, 1407
prevention of, 1408
prognosis and clinical course in, 1408
treatment of, 1408, 1408b
radiation therapy in, 1408, 1408b, 2281
Lymphoid tissue lymphoma
mucosa-associated, 1407
skin-associated, 1407
Lymphoma, 52, **1386**–1402
anaplastic large cell, 1386, 1392, 1393, 1395f
in azathioprine therapy, 2168
B cell, 323, 1399–1401, 1506. *See also* B cell lymphoma
classification of, 1386, 1387t, 1924
in cutaneous lymphoid hyperplasia, 1406, 1407
cutaneous manifestations in, 1506–1507
and cutaneous pseudolymphoma, 1402–1413
in cyclosporine therapy, 2220
in dermatitis herpetiformis, 503, 1503
in dermatomyositis, 1550
epidemiology of, 5, 1386
etiology of, 1386–1387
extranodal nasal, 1394
follicle center cell, 1386, 1399–1400, 1400f
in *Borrelia* infections, 1802
treatment of, 1401
genital, 667–668
granuloma annulare in, 370
in HIV infection and AIDS, 1933
ichthyosis in, 421, 1496
in immunocompromised host, 278
immunohistochemistry in, 1090t
marginal zone, 1386, 1400, 1407
in *Borrelia* infections, 1802
treatment of, 1401
mucosa-associated lymphoid tissue (MALT), 1400, 1407, 1580
natural killer cell, 1394
oral, 649, 649f
paraneoplastic pemphigus in, 468, 469, 470f, 474, 1503
pathogenesis in, 1387–1388

pleural effusion, 1184
in psoriasis, 183
rituximab therapy in, 2229
in Sjögren syndrome, 1580, 1583
subcutaneous, and panniculitis, 1393–1394
with γ/δ phenotype, 1395
histiocytic cytophagic, 583
T-cell, 106, 1388–1399, 1506. *See also* T-cell lymphoma
xanthoma in, 1280, 1280f
Lymphomatoid contact dermatitis, 1403t, 1411–1412
clinical findings in, 1411, 1411f
differential diagnosis of, 1412, 1412b
histopathology in, 1411–1412, 1412f
treatment of, 1412, 1412b
Lymphomatoid papulosis, 237, 241, 1386, 1392–1393, 1394f
Lymphoplasia, cutaneous, 1402
Lymphoproliferative disorders, 52
in azathioprine therapy, 2168
in *Borrelia* infections, 1802
and cryoglobulinemia, 1640, 1641
in cyclosporine therapy, 2220
in Epstein-Barr virus infections, 278, 1354, 1860
in immunocompromised host, 278
primary cutaneous CD30+, 1392–1393
pruritus in, 908
in Sjögren syndrome, 1580
in tacrolimus therapy, 2221
X-linked, 1354
Lymphoreticular system in syphilis, 1961
Lymphotactin, 127
Lymphotoxin-α, 121
Lymphotoxin-β, 121
Lynch syndrome, 1315
Lyon hypothesis, 1281
Lysergic acid diethylamide, 922, 924
Lysine, structure of, 527f
Lysosomal associated membrane protein (LAMP), 596, 599
Lysosomal regulator trafficking gene in Chédiak-Higashi syndrome, 613, 1367, 1368t
Lysosomal storage disorders, Fabry disease in, 1281
LYST in Chédiak-Higashi syndrome, 613, 1367, 1368t
Lysyl hydroxylase, 524, 524t
in Ehlers-Danlos syndrome, 524, 1298t, 1300–1301
Lysyl oxidases, 524t, 535t, 536
in collagen cross-linking, 527
in Ehlers-Danlos syndrome, 527
in elastin cross-linking, 534
Lytta vesicatoria (Spanish fly), 2060
LYVE-1, 65, 68t, 70
in infantile hemangioma, 1164

M

Macrofibrils in hair, 744
Macroglobulinemia, Waldenström, 1375t, 1376t
in xanthoma disseminatum, 1430
Macroglossia, 644
in amyloidosis, 1260t, 1261, 1262f
Macrolactam drugs, 2217–2222
Macrolide antibiotics, 2195t, 2200–2201
in acne vulgaris, 697
adverse effects of, 2196t, 2200–2201
indications for, 2200b
interaction with other drugs, 2200–2201
mechanism of action, 2200
pharmacokinetics of, 2200
Macrophage(s)
in cancer invasion and metastasis, 133
in dermis, 63, 64
in innate immune system, 99
in psoriasis, 171f, 173
Macrophage chemoattractant protein-1, 105, 131, 1593
in cancer, 133
in psoriasis, 133f, 173
in systemic sclerosis, 1554t
Macrophage-derived chemokine, 131
in psoriasis, 133f
Macrophage inflammatory protein 3α, 100, 108
Macrophilin-12, 2217, 2221
Macules, 29–30, 30f
acquired bilateral nevus of Ota-like, 638–639
adhaerentes, 447
in amyloidosis, 639–640, 1261, 1261f
treatment in, 1265
cerulea
in pediculosis corporis, 2035
in pediculosis pubis, 2036, 2036f
in hyperpigmentation, idiopathic eruptive, 640
hypomelanotic, 1330b
differential diagnosis in, 1330b
progressive, 624, 630
in tuberous sclerosis, 1326, 1328f, 1329, 1329f
in lentigo, 30, 30f
melanotic oral, 648
in syphilis, 1958–1959, 1959f, 1960f
in viral infections, 1849t
Maculopapular eruptions
drug-induced, 356
in lupus erythematosus, 1520
in viral infections, 1849t
Maculosa disseminata, 428–429
MAdCAM-1, 1590t, 1596
Madelung disease, 1191
Madura foot, 1832–1833
in occupational exposures, 2076
Madurella grisea, 1779t, 1834t
Madurella mycetomatis, 1779t, 1832, 1833, 1834t
Maduromycosis, 1832–1833
Mafenide acetate, 2113t, 2115
in burns, 857
Maffucci syndrome, 1171, 1504t, 1651, 1657, 1657t, 1659, 1660f
enchondromas in, 1659, 1660f
MAGIC syndrome, 666
Magnetic jewelry, 890, 890f
Magnetic resonance imaging
in decubitus ulcers, 880
in dermatomyositis, 1543, 1547
in Langerhans cell histiocytosis, 1417, 1419
in lymphatic malformations, 1662
in melanoma, 1153
in neurofibromatosis, unidentified bright objects in, 1336–1337
in peripheral artery disease, 1668–1669
in psoriatic arthritis, 200, 201
in reactive arthritis, 211
in soft tissue infections, 1727
in venous malformations, 1659
Magnification with hand-held lens, 40
in melanoma diagnosis, 1143
MAGPs (microfibril-associated glycoproteins), 535t, 536
Majocchi granuloma, 1814t
Majocchi purpura, 1634, 1634t, 1635f
Major basic protein (MBP), 285
Major histocompatibility complex, 84. *See also* HLA system
in autoimmune disorders, 1509, 1511
class I, 84, 109–111, 110f, 1594
alternative pathway, 110–111
and CD8+ T cells, 84, 109
classic pathway, 109–110
deficiency of, 1358, 1359t
and natural killer cells, 100
in psoriatic arthritis, 196f, 197, 198
class II, 84, 110f, 111, 1590t, 1594, 1595
and CD4+ T cells, 84, 109
CLIP peptide associated with, 111
deficiency of, 1358, 1359t
in graft-versus-host disease, 260, 262
in Kawasaki disease, 1627, 1630
in lupus erythematosus, 1516
in pemphigoid gestationis, 491
in pemphigus, 463–464
and superantigens, 1715, 1715f
and Toll-like receptors, 99
methylation of CpG dinucleotides in, 84
in psoriasis, 169–170, 170f
Mal de Meleda, 425t, 426
Mal de pinta, 1978–1979. *See also* Pinta
Malabsorption, 1456–1457
cobalamin deficiency in, 1212, 1377
folate deficiency in, 1211, 1377
nail changes in, 1449
in skin disorders, 1456t, 1457
skin disorders in, 1456t, 1456–1457
zinc deficiency in, 1214, 1215, 1216
Malachite green, 2132
Malaria, differential diagnosis of, 1741
Malassezia dermatis, 1828
Malassezia equi, 1828
Malassezia furfur, 1828, 1829
in atopic dermatitis, 152, 156
in immunocompromised host, 276
in seborrheic dermatitis, 219–220, 224
in tinea versicolor, 1828
Malassezia globosa, 1828
in pityriasis versicolor, 623
in tinea versicolor, 1828
Malassezia japonica, 1828
Malassezia nana, 1828
Malassezia obtusa, 1828
Malassezia pachydermatis, 1828
Malassezia restricta, 1828
Malassezia slooffiae, 1828
Malassezia sympodialis, 1828
in acne of neonates, 700, 1828
in pityriasis versicolor, 623
Malassezia yamatoensis, 1828
Malathion, 2133, 2133t
in pediculosis capitis, 2034t
Malayan filariasis, 2017
Male genital disorders, **654**–675
in candidiasis, 1824, 1824f, 1828
clinical findings in, 655–657, 656b, 656f
congenital, 657
differential diagnosis in, 657, 658b–663b
epidemiology of, 654
etiology and pathogenesis in, 654–655
in fibromatosis, 552
in herpes simplex virus infections, 1875, 1876f
laboratory tests in, 657
in lichen planus, 246f, 249, 665f, 665–666, 666f
in lichen sclerosus, 547, 548f, 550, 669, 669t, 670, 670b, 670f
in Paget disease, 1094, 1095, 1095f
in papillomavirus infections, 663f, 663–664, 664b, 674

Male genital disorders—*continued*
in psoriasis, 664f, 664–665, 665f
in pyoderma gangrenosum, 300f, 666, 667f
in reactive arthritis, 210, 210f, 211, 665
in sexually transmitted infections, 663–664
in squamous cell carcinoma, 672–674, 1031, 1032
in X-linked recessive ichthyosis, 409
Maleylacetoacetic acid, 1221f, 1225, 1225f
Malherbe, calcifying epithelioma of, 1081
Malignant atrophic papulosis, 1456, **1648**–1651. *See also* Papulosis, malignant atrophic
Mallorca acne, 703
Malnutrition
hair changes in, 762, 1452
nail changes in, 1449
protein-energy, 1201–1203
MALT lymphoma, 1400, 1407, 1580
Maltese cross appearance in erythropoietic protoporphyria, 1246
Mammalian target of rapamycin inhibitors, 2217, 2221–2222, 2235
Mandibular nerve
anesthetic block of, 2298
marginal, injury in surgery, 2291
surgical anatomy of, 2292, 2292f, 2293
Manganese, 1217
deficiency of, 1217
Mange in dogs and cats, 2033
Mannan-binding lectin, 1690
deficiency of, 1370, 1371, 1371t
Mannose-binding protein, 325, 1591
deficiency of, 328
β-Mannosidosis, 1286t
Mansonella ozzardi, 2017t
Mansonella perstans, 2017t
Mansonella streptocerca, 2017t
Mantleoma, 1085–1086
MAPK. *See* Mitogen-activated protein kinases (MAPK)
Marasmus, 1202, 1202f
"monkey facies" in, 1202, 1202f
Marfan syndrome, 63, 537t, **1302**–1304
Marginal mandibular nerve injury in surgery, 2291
Marginal zone lymphoma, 1407
in *Borrelia* infections, 1802
primary cutaneous, 1386, 1400
treatment of, 1401
Maria Unna hypotrichosis, 760
Marijuana, 922, 924
Marine dermatitis, 2049, 2049f
Marinesco-Sjögren syndrome, 759t
Marjolin's ulcer, 881
Marseilles fever, 1942
MART-1
in melanoma, 1145
in melanosomes, 599
Massage, facial, in rosacea, 708
Mast cells, **1434**–1443
activation of, 1435–1436
mediators in, 1435t, 1435–1436
in atopic dermatitis, 147
biology of, 1434–1436
in bullous pemphigoid, 477, 477f
in dermis, 63, 64
development and differentiation of, 1434–1435
distribution of, 1434
functions of, 64, 1434
in hyperpigmentation, 636
in leukemia, 1436t, 1437, 1442
in mastocytosis, 1436–1443
in necrotizing venulitis, cutaneous, 1600
in pruritus, 904, 905
in psoriasis, 171f, 173
in sarcoma, 1436t, 1437
types of, 1434
in urticaria and angioedema, 330–331, 332, 332f, 338
Mastitis, lupus, 1526
Mastocytoma, 1375t
clinical manifestations in, 1437, 1437f, 1438
extra-cutaneous, 1436t, 1437
Mastocytosis, 64, 1376t, **1436**–1443
classification of, 1436, 1436t
clinical manifestations in, 1437–1438, 1437f, 1438f, 1439f
cutaneous, 1436, 1436t, 1437–1438, 1437f, 1438f, 1439
diagnosis of, 1440
differential diagnosis of, 1439b, 1440
diffuse, 1438, 1438f, 1439, 1443
treatment of, 1442b, 2255
diagnosis of, 1440, 1441f
gastrointestinal disorders in, 1438, 1441, 1455
treatment of, 1441–1442, 1442b
histopathology in, 1439–1440, 1440f
liver disorders in, 1438–1439, 1440, 1457
prognosis in, 1443
systemic, 1435, 1436t, 1436–1437, 1439
aggressive, 1436t, 1437, 1438, 1439, 1442, 1443
with associated clonal hematologic non-mast cell lineage disease, 1436, 1436t, 1437, 1438, 1442, 1443
diagnostic criteria on, 1436, 1437t, 1440
differential diagnosis of, 1440, 1442b
indolent, 1436, 1436t, 1437, 1437f, 1438, 1443
treatment of, 1442b
treatment of, 1440–1443, 2255
antihistamines in, 1441, 1442b, 2189
photochemotherapy in, 1442, 1442b, 2255
tryptase levels in, 1435
urticaria pigmentosa in, 1437–1439, 1437f, 1438f, 1441
MATP in oculocutaneous albinism, 612
Matrical carcinoma, 1084–1085
Matricectomy, 2326
Matridex®, granuloma and panniculitis from, 580
Matrilin-1 in relapsing polychondritis, 1567
Matrilysin, 528, 528f, 529t, 2345
Matrix metalloproteinases, 528–529, 529t, 1594
in basal cell carcinoma, 992
domain structure of, 528f
in erythropoietic protoporphyria, 1247
in lichen planus, 245
membrane-type, 528, 528f, 529t
MMP-1, 528, 529t
in photoaging, 970, 971
in wound healing, 2344, 2345
MMP-2 in wound healing, 2345
MMP-3, 529t
in photoaging, 970, 971
in wound healing, 2345
MMP-7 in wound healing, 2345
MMP-8, 528, 529t
in wound healing, 2345
MMP-9, 285, 286, 529t
in lichen planus, 245
in photoaging, 970
in wound healing, 2344, 2345
MMP-10 in wound healing, 2344, 2345
MMP-13, 529, 529t
MMP-28 in wound healing, 2345
in photoaging, 970, 971
in wound healing, 2344–2345
impaired, 2347
Mattress sutures
horizontal, 2300, 2301f
vertical, 2300, 2300f
Mattresses and support surfaces in decubitus ulcers, 884
Maxacalcitol in psoriasis, 188
Maxillary artery, 2293
Maxillary nerve
anesthetic block of, 2298
surgical anatomy of, 2292, 2292f
Mazzotti test in onchocerciasis, 2020
MBP (major basic protein), 285
McCune-Albright syndrome, 83, 634
café-au-lait macules in, 634, 1333, 2273
Cushing syndrome in, 1477
MCP (membrane cofactor protein), 328
MCP-1 (macrophage chemoattractant protein-1), 105, 131, 1593
in cancer, 133
in psoriasis, 133f, 173
in systemic sclerosis, 1554t
MCR. *See* Melanocortin receptors
MDC (macrophage-derived chemokine), 131
in psoriasis, 133f
MDMA (3,4-methylenedioxymethamphetamine), 922, 924
Measles, 1848, 1851–1853
atypical, 1852
clinical findings in, 1851f, 1851–1852, 1852f
complications of, 1852–1853
differential diagnosis of, 1852b, 1854
oral cavity findings in, 651t, 1851, 1851f
treatment of, 1853, 1853b
vaccination, 1851, 1853, 1855
Mebendazole
in ascariasis, 2014t
in enterobiasis, 2014t
in hookworm infections, 2015t
in larva migrans, visceral, 2015t
pediatric dosage, 953t
in trichinosis, 2015t
MECA-79, 1596
Mechanic's hand in dermatomyositis, 1542t, 1543t, 1546, 1550
Mechanoreceptors, 65f, 65–66, 66f, 896
Mechlorethamine hydrochloride, 2122–2123
in Langerhans cell histiocytosis, 1423
in mycosis fungoides, 2122, 2123
side effects of, 2123
skin cancer associated with, 987, 987t, 2123
in T-cell lymphoma, 1397, 1398, 2122–2123
Meclocycline, 2113t
Medical Literature Analysis and Retrieval System (MEDLINE), 11, 12
Medina worm infection, 2021
Mediterranean fever, familial, 1265–1267, 1267t
differential diagnosis of, 1266, 1268b
Mediterranean recluse spiders, 2056
Mediterranean spotted fever, 1942, 1943t, 1945, 1951f
differential diagnosis of, 1942, 1947
treatment of, 1945, 1950t
MEDLINE (Medical Literature Analysis and Retrieval System), 11, 12
Mees' lines, 2177
MEFV in familial Mediterranean fever, 1265, 1266

Megalopyge opercularis, 2062, 2063f
Meglumine antimoniate in leishmaniasis, 2007
Meibomian glands, 687
Meige syndrome, 65, 1661, 1662
  lymphedema in, 65, 1661, 1685
  recurrent erysipelas in, 1722
Meissner's corpuscles, 65, 65f
  age-related changes in, 967
Melan A (MART-1)
  in melanoma, 1145, 1153
  in melanosomes, 599
Melanin
  absorption of radiation, 802, 803, 803f, 2272
  embryonic and fetal, 69
  epidermal melanin unit, 593, 594f
  follicular melanin unit, 594, 595f
  functions of, 602
  in nail plate, 782–783
  ocular, 595
  in oculocutaneous albinism, 610, 611
  otic, 595
  in photoprotection and photosensitization, 813
  and skin cancer risk, 1004–1005
  synthesis of. *See* Melanogenesis
Melanoacanthoma, 1055–1056
  oral, 648
Melanoblasts, 591, 747
  migration and differentiation of, 591, 592f
Melanocortin, 689
Melanocortin receptors, 600–601, 601f, 604, 999
  in dysplastic nevus, 1130
  in hair color, 748, 1004
  in melanoma, 1136
  in sebaceous gland activity and sebum production, 689
  in squamous cell carcinoma, 1028
Melanocyte(s), 43, 44, 57, 58, 62
  age-related changes in, 608, 965–966, 967
  biology of, **591**–608
  cephalic, 595–596
  cold injury of, 846
  in cryotherapy, 2330, 2330t
  dendrites of, 602–603, 632
    melanosome transfer to, 603, 603f
  density and concentration of, 593
  disorders of, 62
    congenital, 608–616
  embryonic and fetal development, 69, 591–593, 592f
  in epidermal melanin unit, 593, 594f
  function of, 62
  hair follicle, 593, 594, 595f, 747–748
    in aging, 608, 967
    in anagen, 746
    in catagen, 746
  and keratinocyte interactions, 62, 69
  life cycle of, 610f
  and melanization, 596
  melanogenic proteins, 596–601
  melanosome biogenesis, 596
  melanosome transport, 603–604
  in nail matrix, 780, 782
  in nevi, 1099–1117. *See also* Melanocytic nevi
  ocular, 594–595, 595f
  otic, 595
  proliferation of, 1004
  radiation affecting, 861
  regulation of, 604–606, 1004
    melanogenic inhibitors in, 605
    melanogenic stimulators in, 604–605
    signaling pathways in, 605–606, 606f
  site-specific, 593–596
  stem cells, 593, 593f, 747
    age-related changes in, 967
  transplantation technique in vitiligo, 621–622
  in ultraviolet radiation exposure, 606–608, 1004
    and tanning response, 606–607, 813
Melanocyte stimulating hormone, 600, 601, 601f, 604, 748
  in contact hypersensitivity, 901
  in sebaceous gland activity and sebum production, 689
  in ultraviolet radiation-induced melanogenesis, 813
Melanocytic nevi, 1099–1117
  acquired nevomelanocytic, 1104–1109
  in aging, 966
  atypical, **1122**–1133
    clinical findings in, 1125–1131
    complications of, 1131
    diagnostic criteria on, 1122–1123, 1123f
    differential diagnosis of, 1131b
    epidemiology of, 1122–1123
    etiology and pathogenesis of, 1123–1125
    laboratory tests in, 1130–1131
    prevention of, 1133
    prognosis and clinical course in, 1131–1133
    treatment of, 1133
  blue, 1109–1112
  congenital nevomelanocytic, 1099–1103
    laser therapy in, 2273–2274
  dysplastic, 1123, 1125, 1129, 1130
  laser therapy in, 2273–2274
  melanoma risk in, 1101, 1102, 1107, 1108–1109, 1116–1117, 1135
    in dysplastic nevi, 1123, 1125, 1129, 1130
  nodal, 1116–1117
  of penis, 657
  pigmented spindle cell, 1112–1113
  in pregnancy, 955
  recurrent, 1108
  spilus, 1103–1104
  Spitz, 1113–1116
Melanocytic tumors, **1099**–1157
Melanocytosis
  dermal, 1110
    congenital circumscribed hypermelanosis with, 632–633
    differential diagnosis of, 632t
    laser therapy in, 2274
  leptomeningeal, 1102
  oculodermal, 632
Melanodermatosis, lichenoid, 248
Melanogenesis, 593, 602f, 2251, 2363
  inhibitors in, 605
  proteins in, 596–602
  stimulators in, 604–605
  ultraviolet radiation-induced, 608, 813, 2251, 2363
    in tanning response, 813
Melanolysosomal disease, neuroectodermal, 623
Melanoma, 62, **1134**–1157
  acral lentiginous, 1139–1140
    clinical findings in, 1139–1140, 1141f
    differential diagnosis in, 1141b
    histopathology in, 1144, 1146f
    subungual, 1139–1140, 1141b, 1141f
  amelanotic, 788, 788f
  anatomic distribution by body sites, 1135
    as prognostic factor, 1148
  angiolymphatic invasion of, 1148
  in blue nevus, 1111
  Breslow depth of, 1146, 1149, 1153
  chemokines in, 133, 134, 134f
  in children, 1142
  Clark's levels in, 1146, 1153
  clinical findings in, 1137–1145
  dermoscopy in, 1131, 1143, 1143f
    digital, 1143, 1144f
  desmoplastic, 1139, 1140
    immunohistochemistry in, 1145
  diagnosis of, 1142–1145
    ABCD checklist in, 1128–1129, 1142b, 1142–1143
  differential diagnosis of, 1128–1129, 1131
  diffuse generalized melanosis in, 636, 636f
  in dysplastic nevus, 1123, 1125, 1129, 1130, 1131, 1132, 1133
  in elderly, 971, 972t
  epidemiology of, 5, 986, 999, 1000, 1134
  etiology and pathogenesis of, 1134–1137
  familial, 982t, 1135, 1505t
  genetic factors in, 1002, 1123, 1136–1137
  granulocyte-macrophage colony-stimulating factor in, 2226
  histopathology in, 1143–1144, 1145f–1147f
    pathology report in, 1144, 1147b
  in immunocompromised host, 278, 1004, 1136
    in HIV infection and AIDS, 1933
  immunohistochemistry in, 1090t, 1144–1145
  lentigo maligna, 999, 1000, 1120
    clinical findings in, 1137–1139, 1140f
    differential diagnosis in, 1139b
    histopathology in, 1144, 1145f, 1146f
    treatment in, 1153–1154
  in lentigo simplex, 1118
  leukoderma in, 629, 629f
  lymphatic system in progression of, 65
  melanonychia in, 783
  metastasis of, 1137, 1506, 1506f
    distant, 1149
      evaluation of, 1153
      treatment of, 1155–1156
    macroscopic, 1151, 1154
    microscopic, 1151–1153, 1154
    prognosis in, 1148–1151
    regional, 1148–1149, 1150f
      evaluation of, 1151–1153
      treatment in, 1154–1155
    satellite or in-transit, 1155
    staging of, 1146, 1148t–1150t
    unknown primary site in, 1150–1151
  mitotic rate in, 1147–1148
  mortality rate in, 5, 5t, 986, 1134
    cohort patterns in, 5–6
  mucosal, 1140, 1142f
  of nails, 788, 788f
  neurotropic, 1140
  nevoid, 1140–1141
  in nevomelanocytic nevi, 1135
    acquired, 1107, 1108–1109
    congenital, 1101, 1102, 1135
    of lymph nodes, 1116–1117
  nodular
    clinical findings in, 1137, 1139f
    diagnosis of, 1142
    differential diagnosis of, 1139b
    histopathology in, 1144, 1147f
  in occupational exposures, 2079
  ocular, 1133
  oral, 649
  p53 in, 1001, 1136

Melanoma—*continued*
of penis, 674–675
precursor lesions in, 1000
and tumor progression, 1137
in pregnancy, 1141–1142
prevention of, 1157
primary dermal, 1151
prognosis and clinical course in, 1145–1151
public health approaches to, 19
radial growth phase, 1137
recurrence of, 1149, 1156
risk factors for, 1131, 1134–1137, 1135t
second primary tumor in, 1135–1136
skin phototypes in, 1135
in solar lentigo, 1121, 1122
in Spitz nevus, 1116
spitzoid, 1141
staging of, 1145–1148, 1148t–1150t
and clinical course, 1149–1151
molecular, 1154
sub-types and variants, 1137–1141
and sunscreen use, 2140
superficial spreading, 1137
clinical findings in, 1137, 1138f
diagnosis of, 1144f
differential diagnosis in, 1139b
histopathology in, 1144, 1145f
thickness of, 1146, 1148t, 1150t
treatment of, 1151–1157
algorithm on, 1152f
interleukin 2 in, 1156, }2226
isolated limb perfusion in, 1155
laser therapy in, 2274
Mohs micrographic surgery in, 1154, 2316, 2318–2319
radiation therapy in, 1156, 2282, 2282t
tumorigenesis and tumor progression in, 1137
ulceration of, 1146–1147, 1148t
in ultraviolet radiation exposure, 814–815, 971, 1133, 1134–1135
characteristics of, 1000
epidemiology of, 999, 1000
genetic factors in, 1002
in intermittent exposure hypothesis, 1134
in photochemotherapy, 2258
precursor lesions in, 1000
in psoralen and UVA therapy, 1135
and sunburn history, 1134
and sunscreen use, 2140
vaccines in management of, 1155, 1156
in xeroderma pigmentosum, 1136, 1316, 1318
Melanoma antigen recognized by T cells (MART-1)
in melanoma, 1145
in melanosomes, 599
Melanonychia, 782–783, 783t
longitudinal, 793f
histologic evaluation in, 788, 788t
nail matrix biopsy in, 2324–2326, 2325f
striata, 1139
systemic disorders associated with, 792
Melanophilin, 603
in Griscelli syndrome, 1369, 1369f
Melanosis
Becker, 639
in cirrhosis, 1446
coal tar, 2078
diffuse generalized, in melanoma, 636, 636f
facial, 639
friction, 636
genital, 668, 668f
Riehl, 639
transient neonatal pustular, 937, 937f
Melanosomes, 59, 593, 593f, 596f, 596–601
absorption of radiation, 802
embryonic and fetal, 69
melanogenic proteins in, 596–601
transport of, 596, 597f, 603f, 603–604
in Griscelli syndrome, 1369, 1369f
prevention of, 2363
Melarsoprol in African trypanosomiasis, 2008
Melasma, 635, 635f, 1480, 1480f
classification of, 635
in pregnancy, 635, 955, 957f, 1480
treatment of, 629, 1480
laser therapy in, 2274
Meleney gangrene, 1721t, 1725
Melioidosis, 1757t, 1764–1765
in bioterrorism, 2083t, 2085
pneumonic, 1765
septicemic, 1765
treatment of, 1757t, 1765
Melkersson-Rosenthal syndrome, cheilitis in, 642, 642t
Melphalan in melanoma, 1155
Membrane attack complex (MAC), 325–326, 327, 327f, 328, 1372, 1690
Membrane cofactor protein (MCP), 328, 1371t
Membrane-associated transporter protein *(MATP)* in oculocutaneous albinism, 612
Memory T cells, 104–105, 130, 1595
in atopic dermatitis, 148
Mendelian disorders, 78–80
Ménière disease in syphilis, 1962
Meningeal tissue
heterotopic, 1182–1183
melanocytes in, 595–596
Meningioma, cutaneous, 1183
Meningitis
in coccidioidomycosis, 1840
cryptococcal, 1842
in enterovirus infections, 1869
gonococcal, 1995, 1996
in *Haemophilus influenzae* infections, 1739
in herpes simplex virus infections, 1879
in Kawasaki disease, 1629
in listeriosis, 1762, 1763
in Lyme disease, 1802, 1803
treatment of, 1806t
meningococcal, 1731, 1732–1734
Mollaret, 1879
in syphilis, 1965t, 1966
Meningocele
acroleic, 1183
rudimentary, 1183
Meningococcal infections, **1731**–1735. *See also Neisseria meningitidis*
Meningococcemia, 1692, 1731, 1732
acute, 1732–1734
clinical findings in, 1732–1733, 1733f
differential diagnosis of, 1733b
hypotension in, 1732, 1735
chronic, 1734
disseminated intravascular coagulation in, 1748
purpura fulminans in, 1382, 1383, 1732, 1746
Meningoencephalitis
amebic, 2009
in neurosyphilis, 1966
Meningomyelitis in syphilis, 1966
Meningovascular syphilis, 1965t, 1966
in HIV infection, 1970
Menkes syndrome, 527, 530t, 1216–1217
genetic factors in, 757–758
counseling on, 85
pili torti in, 757–758
trichorrhexis nodosa in, 756–757
Menopause
estrogen replacement therapy in, 1479, 1480
facial hirsutism in, 967
hair loss in, 967
structural and functional skin changes in, 967–968
sweating and hot flashes in, 715, 725
Menstrual cycle, acne vulgaris in, 695–696
Mental nerve, 2292
anesthetic block of, 2298
Mental retardation in homocystinuria, 1304
Menthol in pruritus, 909t, 910, 2134, 2134t
Menthyl anthranilate in sunscreens, 2139t, 2140
Mepivacaine in local anesthesia, 2296, 2296t
Mepolizumab, 288
Meradimate in sunscreens, 2139t, 2140
6-Mercaptopurine, 2167
Mercury arc lamps, 800
in phototherapy, 2244
Mercury exposure
hair loss in, 762
occupations associated with, 2070t
Merkel cell(s), 43, 58, 62, 62f
in embryonic and fetal development, 69
in hair follicles, 65, 744
immunohistochemical markers of, 62, 1090, 1090t
in nail matrix, 780
in prurigo nodularis, 160
sensory function of, 62, 65, 1087–1088, 1089–1090
staining of, 62, 1090, 1090f
Merkel cell carcinoma, **1087**–1094
clinical course and complications in, 1093–1094
clinical features of, 1089, 1089f, 1089t
differential diagnosis of, 1089, 1089b
in elderly, 972, 972t, 1088, 1089f
epidemiology of, 1088
etiology and pathogenesis in, 1088f, 1088–1089
hematoxylin and eosin stain in, 1090, 1090f
in immunocompromised host, 278, 1004, 1088–1089
in HIV infection and AIDS, 1089, 1933
immunohistochemistry in, 1088, 1090, 1090t
intermediate type, 1090
molecular genetics in, 1089
pathology in, 1089–1091, 1090f, 1090t
perinuclear dot pattern in, 1090, 1090f
radiologic imaging studies in, 1091–1092
recurrent, 1093–1094
sentinel lymph node biopsy in, 1091, 1091f
small cell type, 1090
staging and prognosis in, 1091f, 1091–1092
treatment of, 1092–1093, 1093f
in ultraviolet radiation exposure, 1000
Meroisodisomy, 80
Mesna in cyclophosphamide therapy, 2173
Mesoderm, embryonic and fetal, 67, 70
Messenger RNA, 74–76, 985
Meta-analysis, 9, 18
Metabolism
of carcinogens, 988
disorders of, **1219**–1228
anhidrosis in, 729
biotin deficiency in, 1214
in corticosteroid therapy, 2106, 2150t, 2151t

in decubitus ulcers, 881
in HIV infection and AIDS, 1934–1935
hyperhidrosis in, 726
in inborn errors, **1219**–1228
trichorrhexis nodosa in, 756
of drugs
cytochrome P_{450} in, 2237–2238, 2238t
of dapsone, 2154–2155, 2155f
in drug interactions, 2237, 2237t
genetic factors affecting, 2238, 2239t
in topical therapy, 2101
heat production in, 835, 836
Metalloelastase, 528, 528f, 529t
Metalloproteinases
matrix. *See* Matrix metalloproteinases
in psoriasis, 174
tissue inhibitors of
in lichen planus, 245
in photoaging, 970
TIMP-3 in morphea, 543
Metaplasia, syringosquamous, in cytotoxic drug therapy, 2178
Metastasis
of B cell lymphoma, 1401
of basal cell carcinoma, 1038, 1042
treatment in, 1042
chemokines in, 134, 134f
cutaneous, 1506, 1506f
of dermatofibrosarcoma protuberans, 1161
to genitalia, 667–668
of leiomyosarcoma, 1174
to liver, 1458
of melanoma. *See* Melanoma, metastasis of
of Merkel cell carcinoma, 1091, 1094
to scalp, 1449
of squamous cell carcinoma, 1032, 1032f, 1034, 1034f, 1034t, 1035
of T-cell lymphoma, 1396, 1396t
umbilical, 1449, 1449f
Metatarsophalangeal joint gout, 1575
Metformin in lipodystrophy, 589
Methacholine, apoeccrine sweat gland response to, 719
Methamphetamine, 922, 924, 925
Methemoglobinemia, 1378–1379
in dapsone therapy, 2154, 2156
treatment of, 1379, 2156
Methicillin-resistant staphylococcal infections, 1695, 1728, 1730
in athletes, 873–875
in elderly, 973
in surgical wounds, 2337
treatment in, 875, 2114
Methionine, 1304
defective transport, 1219t
malabsorption syndrome, 1219t
Methotrexate, 2124, 2163–2167
in atopic dermatitis, 157
in B-cell lymphoma, 1401
chemical structure of, 2163f
in children, 2163
complications and side effects of, 191, 2124, 2165t, 2165–2167, 2238t
carcinogenicity in, 2166
liver disorders in, 191, 1458, 1459t, 2165–2166, 2166t, 2176t
myelosuppression in, 191, 2166, 2176t
in psoriasis, 191, 1458, 1459t, 2166
recall reaction in, 2166, 2179, 2179f
contraindications to, 2165, 2165t, 2641
in dermatomyositis, 1552
dosing regimen, 2164, 2165, 2176t
in exfoliative dermatitis, 231, 232, 232b
in graft-versus-host disease, 267t
indications for, 2124, 2164, 2164t, 2176t
initiation of therapy with, 2164–2165
interaction with other drugs, 191, 2163, 2167, 2240t
in lupus erythematosus, 1533t, 1535
mechanism of action, 191, 2124, 2163, 2176t
monitoring of therapy with, 2165, 2165t
overdose of, 191, 2166–2167
in palmoplantar pustulosis, 217, 217b
pharmacokinetics of, 2163–2164
in pityriasis rubra pilaris, 235, 236b
in pregnancy, 189b, 191, 2124, 2164, 2165t, 2166
in psoriasis, 185, 186t, 191, 2164
and arthritis, 202, 203f, 204, 206
in combination with other agents, 187t, 2165, 2245, 2254
complications of, 191, 1458, 1459t, 2166
in pregnancy, 189b
in rheumatoid arthritis, 1573
in sarcoidosis, 1491–1492, 1492t
in systemic sclerosis, 1559t
topical, 2124
in vesicular palmoplantar eczema, 166
in Wegener granulomatosis, 1613t
Methoxsalen, 2249–2250
5-Methoxypsoralen in cosmetic products, 2361
8-Methoxypsoralen in photochemotherapy for T-cell lymphoma, 1399
Methyl anthranilate in sunscreens, 2139t
Methylation
of CpG, 88, 114
epigenetics in, 84
Methylcobalamin, 1211
Methylene blue in methemoglobinemia, 1379, 2156
3,4-Methylenedioxymethamphetamine (MDMA), 922, 924
Methylmalonic acid, 1211, 1304
Methylmalonic aciduria and homocystinuria, 1304
Methylprednisolone
in Behçet disease, 1625b
chemical structure of, 2148t
in dermatomyositis, 1551–1552
in graft-versus-host disease, 266t
indications for, 2149
intravenous, 2149
in Kawasaki disease, 1632
in lupus erythematosus, 1534
in pemphigus, 467–468
potency and duration of action, 2148t, 2149
in pyoderma gangrenosum, 301b
in reactive arthritis, 214
in Sweet syndrome, 294, 295b
Metronidazole, 2114, 2131t, 2132
in amebiasis, 2009
in bacterial vaginosis, 2000b
in dracunculiasis, 2014t
in lichen planus, 254b, 255
in perioral dermatitis, 711, 711b
as radiosensitizer, 860
in rosacea, 708, 2114
in seborrheic dermatitis, 224
in trichomoniasis, 1999, 1999b
Meyerson's phenomenon in seborrheic keratosis, 1055
MFAPs (microfibril-associated proteins), 535t, 536
MFH1 in hereditary lymphedema, 65, 68t
Mi-2 antibodies in dermatomyositis, 1539t, 1546, 1550
MICA/MICB, 100
Miconazole, 2117t, 2118
in tinea nigra, 1821
Microciona prolifera (red sponge), 2046
Micrococcus sedentarius, 1707–1708
Microcomedo, 690, 692
Microcystic adnexal carcinoma, 1068, 1078–1079
Microfibril-associated glycoproteins (MAGPs), 535t, 536
Microfibril-associated proteins (MFAPs), 535t, 536
Microfibrils in elastic fibers, 530–531, 534–536
Microhemagglutination assay in syphilis, 1971t, 1973t
Micropapules of male genitalia, 661b
Microphthalmia-associated transcription factor, 599–600
in melanocyte development, 591, 592f, 747
in melanocyte proliferation and survival, 599–600, 614
in aging, 967
in melanoma, 1136, 1145
regulation of, 599, 600f
in Tietz syndrome, 615
in Waardenburg syndrome, 613, 614
Micro-RNA, 73
Microsatellite instability, 985
Microsatellite markers, 77
Microscopic polyangiitis, 51, 1599, 1602, 1607, 1613–1615
treatment of, 1615
Microscopy
in candidiasis, 1827
dark-field, in syphilis, 1971
epiluminescence, 1131, 1143, 1144f. *See also* Dermoscopy
incident light, 1143
phase contrast, in trichomoniasis, 1999, 1999f
in superficial fungal infections, 1808, 1808f, 1809f
Microsporum audouinii, 1808, 1808t, 1809t
in tinea capitis, 1811t, 1812, 1812f, 1819
Microsporum canis, 1807, 1808, 1808t, 1809t
occupational exposure to, 2076
in tinea barbae, 1813, 1819
in tinea capitis, 1811, 1811t, 1812, 1812f
in tinea corporis, 1814
Microsporum ferrugineum, 1808t, 1811t
Microsporum fulvum, 1808t
Microsporum gypseum, 1807, 1808t, 1809t
in favus, 1811t, 1813
occupational exposure to, 2076
in tinea capitis, 1811t, 1812
Microsporum nanum, 1811t
Microthermal damage zone in laser therapy, 2268, 2277
Miescher radial granuloma in erythema nodosum, 573, 573f
Mig (monokine induced by interferon-γ), 130
in psoriasis, 133f
Migrating erythema, classification of, 366, 367t
Migration of cells, 43
Mikulicz syndrome, 1487
Milia, 936, 1065, 1065f
acquired, 1065
congenital, 1065
with perioral pigmented follicular atrophoderma and epidermoid cysts, 753t
plaque-type, 1065
postoperative, 2339
in laser skin resurfacing, 2368

Miliaria, 730
anhidrosis in, 730
apocrine, 733
candidal, 1824, 1825f
crystallina, 730, 730f
in occupational exposures, 2068t
profunda, 730
pustulosa, 730
rubra, 730
diaper dermatitis in, 943
in neonate, 937
Milk-alkali syndrome, 1296
Milk allergy, 2287
Milk crust, 221
Milker's nodules, 1848, 1908–1910, 2076
clinical findings in, 1909, 1909f
differential diagnosis of, 1909, 1909b
Millepora alcicornis (fire coral), 2045–2046, 2046f
Millipede exposure, 2059
differential diagnosis of, 2056b
Milnacipran, 918t, 919–920
Milroy disease, 65, 1661, 1662
lymphedema in, 65, 1661, 1685
recurrent erysipelas in, 1722
Miltefosine, 2124–2125
Mineralization, cutaneous, **1293**–1297
Minerals, dietary, 1214–1217
Miniaturized hair, 742, 742t
Mini-punch graft technique in vitiligo, 621
Minocycline, 2199
in acne vulgaris, 697, 698
dosage of, 2195t
pediatric, 950t
in leprosy, 1795, 1795b, 1796
in nocardiosis, 1783
in perioral dermatitis, 711, 711b
in pityriasis lichenoides, 243b
in pyoderma gangrenosum, 301, 301b
in sarcoidosis, 1492, 1492t
side effects and complications of, 2199
drug-induced lupus in, 361
hepatotoxicity in, 1459t
hypersensitivity syndrome in, 357f
in leprosy, 1796
pigmentation changes in, 636, 2275f
Minor's starch-iodine test in hyperhidrosis, 2392, 2393f, 2394f
Minoxidil, 754
in alopecia areata, 764b, 765
hypertrichosis from, 776
in pattern hair loss, 768, 768b, 769, 2395
MIP-3α (macrophage inflammatory protein 3α), 100, 108
Mirtazapine, 918t, 919
antihistaminic activity of, 2193
in pruritus, 910, 911t
Misonidazole as radiosensitizer, 860
Misoprostol as radioprotector, 860
Mites, 2058
animal, 2032t, 2033
dust, 2032t, 2032–2033
follicle, 2032, 2032t
food, 2032, 2032t
fowl, 2032t, 2033
harvest, 2032, 2032t
occupational exposure to, 2076
rickettsialpox from, 1943t, 1946–1947
scabies, 2029–2032, 2032t
scrub typhus from, 1951–1952
straw itch, 2032, 2032t
MITF/Mitf, 599–600
in melanocyte development, 591, 592f, 747
in melanocyte proliferation and survival, 599–600, 614
in aging, 967
in melanoma, 1136, 1145
regulation of, 599, 600f
in Tietz syndrome, 615
in Waardenburg syndrome, 613, 614
Mitochondrial disorders, 82
in photoaging, 970
Mitogen-activated protein kinases (MAPK), 129f, 281, 600f, 605, 606f, 1004
MAPK-2, 599
in melanoma, 1002, 1136
in photoimmunosuppression, 806, 807, 807f
in wound healing, 2344
Mitomycin C, DNA damage from, 978t
Mitosis
centromere functions in, 74
of epidermal cells, 44, 59
in melanoma, rate of, 1147–1148
radiation affecting, 858–859
Mitral valve disorders
in Marfan syndrome, 1303
in pseudoxanthoma elasticum, 1307, 1308
Mixed tumors of skin, apocrine
benign, 1071–1072, 1072f
malignant, 1073–1074
Mizolastine, 2188, 2189, 2189t
MLH1
hypermethylation of, 84
in Muir-Torre syndrome, 980t, 988, 989t, 1068
MLH3 in hereditary non-polyposis colon cancer, 980t
MMAC1
in melanoma, 1136
in tricholemmoma, 1084
MMP. *See* Matrix metalloproteinases
MNK in Menkes syndrome, 527, 530t, 757, 1216
Moccasin-type tinea pedis, 1816, 1816f
Mohs micrographic surgery, 2315–2318
in basal cell carcinoma, 1040, 1042, 2316, 2317–2318, 2318f, 2319f
indications for, 1040t
in dermatofibrosarcoma protuberans, 1161, 2316, 2319
flap repair after, 2316, 2317f, 2319f
indications for, 2316–2319, 2317f
in melanoma, 1154, 2316, 2318–2319
in Paget disease, 1097–1098, 2319
in squamous cell carcinoma, 1035, 1035t, 2318
technique in, 2315–2316, 2316f
in verrucous carcinoma, 1922, 2319
wound healing in, 2346
Moisture and skin hydration
affecting wound healing and repair, 2345–2346
in atopic dermatitis, 153–154
in oily and dry types, 2357–2359
Moisturizing products, 2359, 2359t
in atopic dermatitis, 153–154
emollient, 2359, 2359t
humectant, 2359, 2359t
occlusive, 2359, 2359t
Mold mite, 2032
Molecules in ground state and excited state, 804, 804f
Mole-melanoma syndrome, familial atypical, 1135
Mollaret meningitis, 1879
Molluscum contagiosum, 1847f, 1848, 1900t, 1911–1913
clinical findings in, 1911, 1912f
diagnosis of, 1850, 1912, 1912f, 1913f
differential diagnosis of, 664, 1912, 1913b
genital, 664, 1911
Henderson-Paterson bodies in, 1912, 1913f
in HIV infection and AIDS, 1911, 1938, 1938f
in occupational exposures, 2075
transmission of, 1911
treatment of, 1912–1913, 1913t
topical retinoids in, 2111
Molluscum fibrosum, 552
in tuberous sclerosis, 1327
Mollusks, injuries caused by, 2049–2050
Mondor phlebitis, 672, 1684
Mongolian spots, 632t, 632–633, 633f, 938, 1110
laser therapy in, 2274
Monilethrix, 758, 759f
follicular keratosis in, 752, 752f
genetic factors in, 758
Monkey bites, 1907, 2038
herpesvirus simiae (B virus) infections in, 2039–2040
Monkeypox virus infections, 1900t, 1906–1908
clinical findings in, 1907, 1907f
differential diagnosis of, 1902, 1907
histopathology in, 1907, 1908f
in occupational exposures, 2076
prevention of, 1908, 1908b
transmission of, 1906, 1907
treatment of, 1908
Monoacetyldapsone (MADDS), 2154, 2155f
Monobenzyl ether of hydroquinone (MBEH), 621, 628–629, 2135, 2146
in ethnic skin, 2146
in vitiligo therapy, 621, 629, 2146
Monochloroacetic acid in warts, 2136
Monoclonal antibodies in leishmaniasis, 2005
Monoclonal gammopathy
scleredema in, 1564
scleromyxedema in, 1564–1565
of uncertain significance, 1407
in xanthoma disseminatum, 1430
Monokine induced by interferon-γ (Mig), 130
in psoriasis, 133f
Mononucleosis
and chronic bullous disease of childhood, 488
clinical findings in, 1858–1859, 1859f
cold urticaria in, 850
cytomegalovirus in, 1862–1863
differential diagnosis of, 1859b
Epstein-Barr virus in, 1858–1860
laboratory tests in, 1859
oral findings in, 651t
treatment of, 1860, 1860b
Montgomery's tubercles, 687, 1085
Moon's molars in congenital syphilis, 1969
Moray eel bites, 2052, 2052f
Morbidity measures in skin diseases, 5–8
accuracy of, 7
number of physician visits, 6–7
quality of life issues in, 8
quantification issues in, 7
reliability and validity of, 7
severity of disease scales in, 7–8
Morbihan disease, 701
Morbilliform eruptions, drug-induced, 356
in HIV infection, 1933–1934
Morphea, **543**–546
clinical findings in, 543f, 543–545, 544f
complications in, 545–546

differential diagnosis of, 545b, 548–549
epidemiology of, 543
etiology and pathogenesis in, 543
generalized, 543, 544, 546
histopathology in, 545, 545f
hypopigmentation in, 626, 627f
laboratory findings in, 545
profunda, 584
prognosis and clinical course in, 546
sclerosis in, 29, 29f, 543
subcutaneous, 544, 544f, 546
treatment of, 546
photochemotherapy in, 2255
phototherapy in, 546, 2247, 2247f
Morpheaform basal cell carcinoma, 1037–1038, 1038f
differential diagnosis in, 1040b
histopathology in, 1039, 1039f
treatment in, 1040, 1041
Morphine
anhidrosis from, 729
in postherpetic neuralgia, 1897
Morphogenesis stage in fetal skin development, 66, 67, 68t, 69
Morphology of skin lesions, 24t, 26–40
Mortality rates in skin diseases, 5, 5t
age-adjusted, 5
cohort patterns in, 5–6
Morton neuroma, 1178
Morvan fibrillary chorea, 726
Mosaicism, 83, 1058
hypermelanosis in, 631
lentiginous, 639
in neurofibromatosis, 83, 1331, 1338
pigment, 69
revertant, 83, 84f
Mosquito bites, 2059–2060
prevention of, 2063
Moths, and lepidopterism, 2062–2063
Motor nerves, facial, 2293
Mottling in neonates and infants, 937
Mouth disorders. *See* Oral cavity disorders
Moxifloxacin, 2201
in soft tissue infections, 1730
Moynahan (LEOPARD) syndrome, 633f, 633–634, 668, 1117, 1118, 1453
laser therapy in, 2273
M-plasty, 2308, 2308f
MSH. *See* Melanocyte stimulating hormone
MSH2 in Muir-Torre syndrome, 980t, 988, 989t, 1068
MSH6 in hereditary non-polyposis colon cancer, 980t
MSX1 in Witkop tooth and nail syndrome, 68t, 72, 1346
MUC (mucin core protein)
in dermatomyositis, 1547
in Paget disease, 1096
Mucha-Habermann disease, 236
febrile ulceronecrotic, 241
Mucin, fibroblast overproduction of, 1562, 1563t, 1564
Mucin core protein
in dermatomyositis, 1547
in Paget disease, 1096
Mucinosis, 1563t
follicular, 773, 1390
reticular erythematous, 52
Mucinous carcinoma, apocrine, 1074
Muckle-Wells syndrome, 338, 1257, 1267t, 1270f, 1270–1271
Mucocele, 644f, 644–645
Mucocutaneous lymph node syndrome, 1626. *See also* Kawasaki disease
Mucoepithelial dysplasia, hereditary, 752
Mucoid cells of eccrine sweat glands, 713, 714, 714f, 715f
Mucopolysaccharides, 538
age-related changes in, 966–967
Mucor, 271
in diabetes mellitus, 1465–1466
in oral cavity disorders, 653t
Mucormycosis, 1843. *See also* Zygomycosis
Mucosa-associated lymphoid tissue lymphoma, 1400, 1407
in Sjögren syndrome, 1580
Mucosal addressin cell adhesion molecule, 1590t, 1596
Mucositis
from cytotoxic drugs, 2180, 2180t
iatrogenic, 647
lichenoid, 645
Mucous membranes
in allergic contact dermatitis, 141
in bullous disease of childhood, chronic, 488
in bullous pemphigoid, 478
in candidiasis, 1354–1356, 1355t
in cicatricial pemphigoid, 481, 484, 484t
in Darier-White disease, 435
drug abuse affecting, 925, 925f
eosinophilic ulcer of, 315
in epidermal necrolysis, 352, 352f
in erythema multiforme, 346, 346f, 347f
in Fabry disease, 1283–1284
in hypereosinophilic syndromes, 308, 309f
in keratoacanthoma, 1052
in lichen planus, 246, 246f, 248–249, 665–666
differential diagnosis of, 252b
in linear IgA dermatosis, 488, 489
in melanoma, 1140, 1142f
in pemphigus vulgaris, 464f, 464–465
in sarcoidosis, 1487
in vitiligo, 618
Mucous retention cysts, 644f, 644–645
Muehrcke's lines, 791, 792f, 792t
Muir-Torre syndrome, 1068, 1312t, 1315, 1505t
DNA damage and repair in, 980, 982t, 983t
genetic factors in, 980t, 988, 989t, 1068
keratoacanthoma in, 1050, 1051
sebaceoma in, 1086
sebaceous carcinoma in, 1086–1087
Mulberry extract, 2363, 2363t
Mulberry molars in congenital syphilis, 1979
Multiceps, 2021t, 2028
Multiple endocrine neoplasia syndrome
type 1, 1504t
hyperparathyroidism in, 1475
type 2A, 1504t
amyloidosis in, 1503
type 2B, 1177–1178, 1504t
Multiple system atrophy, anhidrosis in, 727
Multisystem inflammatory disease, neonatal-onset, 1267t, 1270–1271
Mumps vaccination, 1853, 1855
Münchhausen syndrome by proxy, 915, 916
Munro abscess, 132
Mupirocin, 1693, 2113, 2114, 2131t, 2132
in impetigo, 1697, 1698b, 1705, 1714, 2114, 2132–2133
indications for, 2113t, 2114, 2131t, 2132–2133
mechanism of action, 2113t, 2131t, 2132–2133
in methicillin-resistant staphylococcal infections, 875, 2114
side effects and complications of, 2131t
Murine typhus, 1948, 1949b
Muscles
of face, surgical anatomy of, 2292–2293, 2293f
tumors of, 1172–1176
of smooth muscle, 1172–1175
of striated muscle, 1175–1176
weakness and fatigue in dermatomyositis, 1540, 1544
differential diagnosis in, 1544, 1544t
laboratory tests in, 1546, 1547
muscle strength testing in, 1544
respiratory disorders in, 1545
Muscular dystrophy
congenital, collagen type VI in, 520
epidermolysis bullosa with, 508, 508t
Musculoaponeurotic system, superficial, 2291
Mushroom dermatitis, flagellate, 638
Mustard gas as chemical weapon, 2086t, 2087
Mutations, 74–75
candidate gene approach to, 77
epigenetic, 83–84
genome-wide linkage studies, 77
hereditary cancer syndromes in, 988, 989t
identification and detection techniques, 76–77
mitochondrial, 82
mosaicism in, 83
nonsense, 77–78, 78f
premature termination codon mutation, 74–75
silent, 77
splice site, 78
Mutilating palmoplantar keratoderma, 426
Myalgia
and eosinophilia syndrome, 316
in isotretinoin therapy, 699
in syphilis, 1962
Myasthenia gravis and pemphigus, 466
Myc
in sebaceous gland development, 688, 688f
in squamous cell carcinoma, 993
Mycetoma, 1783, 1814t, 1831, 1832–1833
bacterial, 1783–1786, 1832, 1833. *See also* Actinomycetoma
clinical findings in, 1832, 1833f
cryptic or mini-mycetoma, 1784
differential diagnosis of, 1832–1833
fungal (eumycetoma), 1783, 1832–1833, 1833f
laboratory tests in, 1833, 1834t
in occupational exposures, 2076
Mycobacterial infections, **1768**–1778
dimorphic inflammatory response in, 1778
in immunocompromised host, 272, 272f, 1768–1769, 1777, 1778
in HIV infection, 1768–1769, 1777, 1778, 1790–1791, 1935
leprosy in, 1786–1796. *See also* Leprosy
in occupational exposures, 2074, 2075f
treatment of, 1774–1775, 1775t, 1776t
tuberculosis in, 1769–1775. *See also* Tuberculosis
Mycobacterium abscessus, 1729, 1776t, 1778
Mycobacterium africanum, 1776t
Mycobacterium avium-intracellulare, 1774, 1776t, 1777–1778
in immunocompromised host, 272, 272f, 1778
in HIV infection, 1768, 1778, 1935
Mycobacterium balnei, 1777, 2053t
Mycobacterium bovis
in cutaneous tuberculosis, 1769–1775
occupational exposure to, 2074

Mycobacterium chelonae, 1729, 1776t, 1778
in immunocompromised host, 272, 272f, 1935
Mycobacterium fortuitum, 1775, 1776t, 1778
in immunocompromised host, 272, 1935
in soft tissue infections, 1728–1729
Mycobacterium genavense, 1778
Mycobacterium gordonae, 1776t, 1935
Mycobacterium haemophilum, 272, 1776t, 1778, 1935
Mycobacterium kansasii, 1774, 1776, 1776t, 1777
differential diagnosis of, 1777b
in immunocompromised host, 272, 1777
in HIV infection, 1768, 1777, 1935
treatment of infections, 1776t
Mycobacterium leprae, 102–103, 1775, 1776, 1786–1796
in oral cavity disorders, 652t
Mycobacterium malmoense, 1935
Mycobacterium marinum, 877, 1775, 1776, 1777
clinical findings in infections, 1776t, 1777, 1777f
differential diagnosis of, 1777b
in immunocompromised host, 272, 1935
occupational exposure to, 2074, 2075f
treatment of infections, 1776t
in waterborne infections, 2053t
Mycobacterium scrofulaceum, 1776t, 1777, 1778
Mycobacterium szulgai, 1778
Mycobacterium tuberculosis, 1768, 1769–1775
in erythema induratum of Bazin, 574, 575
in immunocompromised host, 272
in nodular vasculitis, 1603
occupational exposure to, 2074
in oral cavity disorders, 653t
Mycobacterium ulcerans, 1775, 1776, 1776f, 1776t
differential diagnosis of, 1777b
treatment of infections, 1776t
Mycophenolate mofetil, 2168–2170, 2222–2223
in actinic dermatitis, chronic, 823
in atopic dermatitis, 157
chemical structure of, 2163f
contraindications to, 2169, 2169t
in dermatomyositis, 1552
dosage regimen, 2169, 2176t, 2222
in exfoliative dermatitis, 231, 232, 232b
in graft-versus-host disease, 266t, 267t
indications for, 2169, 2169t, 2176t, 2222
initiation of therapy with, 2169, 2222
interaction with other drugs, 2170
in lichen planus, cutaneous, 254b, 255
in lupus erythematosus, 1533t, 1534–1535
mechanism of action, 2169, 2176t, 2222
monitoring of therapy with, 2169, 2169t, 2222
in pemphigoid, cicatricial, 484, 485b
in pemphigus, 467
paraneoplastic, 474, 474t
pharmacokinetics of, 2169, 2222
in psoriasis, 187t, 192
and arthritis, 205
in pyoderma gangrenosum, 301b, 302
side effects and complications of, 2169t, 2169–2170, 2176t, 2222–2223
in systemic sclerosis, 1559t
in vesicular palmoplantar eczema, 166
in Wegener granulomatosis, 1613t
Mycophenolate sodium, enteric-coated, 2222
Mycophenolic acid, 2168–2170, 2222
Mycoplasma, in seal finger, 1762, 2042
Mycoplasma fermentas, 1621
Mycoplasma genitalium, 1998
Mycoplasma hominis, 1998
Mycoplasma pneumoniae, 344, 345f, 346f, 347, 348, 349
Mycosis fungoides, 106, 237f, 1376t, 1388–1391
barrier function of skin in, 393
clinical manifestations of, 1388–1390, 1389f, 1390f, 1391f
deck chair or folded luggage sign in, 1389, 1391f
differential diagnosis of, 1390, 1391b
adult T-cell leukemia in, 1925, 1926
eczematous dermatoses in, 139b
parapsoriasis in, 239, 239t
pityriasis lichenoides in, 242
pseudo-mycosis fungoides in, 1410, 1411, 1411b
erythroderma in, 1389, 1390f
etiology of, 1386
in exfoliative dermatitis, 226, 231
follicular or folliculotropic, 773, 1390–1391, 1393f
granulomatous slack skin in, 1391, 1393f
histopathology of, 1390, 1391f, 1392f
hypopigmented, 627, 1391
pagetoid reticulosis in, 1391, 1393f
and parapsoriasis, 236, 237, 239
patch-stage, 239, 239t, 627, 1388, 1388f, 1390, 1392f
pathogenesis of, 1387
CD8+ T cells in, 1387
Fas receptor and Fas ligand in, 1387
Pautrier microabscess in, 1390, 1391f
pigmented purpuric, 1388, 1389f, 1636
pruritus in, 1390
and pseudo-mycosis fungoides, 1403t, 1410–1411
staging of, 1396, 1396t
treatment of, 240, 627, 1390, 1398
mechlorethamine in, 2122, 2123
photochemotherapy in, 2254f, 2254–2255
photodynamic therapy in, 2262
phototherapy in, 2248
radiation therapy in, 2282, 2282t, 2284f
tumor-stage, 1388–1389, 1389f
variants of, 1390–1391
MyD88 adapter molecule, 120, 120f
Myelocytomatosis oncogene (Myc)
in sebaceous gland development, 688, 688f
in squamous cell carcinoma, 993
Myelodysplasia, Langerhans cell histiocytosis in, 1414
Myeloma, 1376t
in amyloidosis, 1503
Myelopathy in HTLV-1 infections, 1926
Myeloperoxidase deficiency, 1363t, 1374t
Myelosuppression
in azathioprine therapy, 2168
in doxorubicin therapy, 2175
in methotrexate therapy, 191, 2166, 2176t
Myiasis, cutaneous, 2060, 2060f
MYO5A in Griscelli syndrome, 1368t, 1369
Myoblastoma, granular cell, 648
Myocarditis
in *Bartonella* infections, 1749, 1750t
in syphilis, 1965
in systemic sclerosis, 1561
Myoepithelial cells of eccrine sweat glands, 713, 714, 714f, 715f
pharmacology and function of, 717
Myofibromatosis, infantile, 552
Myolipoma of soft tissue, 1194
Myonecrosis, 1721t
in *Aeromonas hydrophila* infections, 1743, 1764
anaerobic, 1726–1727
spontaneous, 1726–1727
synergistic nonclostridial, 1725
clostridial, 1724t, 1726
in decubitus ulcers, 881
differential diagnosis of, 1728
prognosis and clinical course in, 1729
treatment of, 1730
Myopathy, idiopathic inflammatory, 1536, 1537
Myopericarditis in smallpox vaccination, 1905
Myositis
autoantibodies in, 1546
classification of, 1537t
clostridial, 1726
electromyography in, 1547
inclusion body, 1544
laboratory tests in, 1546
necrotizing cutaneous, 1725
prognosis and clinical course in, 1550
treatment of, 1561
Myxedema, 1470, 1473–1474
pretibial, 541, 1472, 1472f
localized hyperhidrosis in, 725
Myxofibrosarcoma, 1162
Myxoid cyst, 787
Myxoid liposarcoma, 1197–1198
Myxoid tumor of nerve sheath, benign, 1180
Myxolipomas, 1191
vascular, 1191
Myxoma
atrial, 1452–1453, 1453f
in LAMB syndrome, 1117, 1118, 1118f, 1453f
mucocutaneous, 1453f
of nerve sheath, 1179–1180

N

Naegeli-Franceschetti-Jadassohn syndrome, 426, 430
Naegleria, 2009
Nafcillin, 2195t, 2198
Naftifine, 2117t, 2119, 2120t
Nagayama spots in herpesvirus-6 infections, 1865
Nail(s), **778**–793, 1449–1450
in acrodermatitis continua, 218, 218f
in amyloidosis, 790, 791, 1260, 1260f
anatomy of, 778–780, 779f, 2320f, 2320–2321
in atopic dermatitis, 791
basement membrane zone of, 780
Beau's lines of, 781–782, 782f
biology of, 778–781
biting of, 792
blood supply of, 778, 779f, 780, 2320–2321
brittle, 759t
in candidiasis. *See* Candidiasis, nail changes in
clubbing of, 1449–1450, 1450f
composition of, 780–781
in Darier-White disease, 434–435, 435f, 783, 791, 791f
in dermatomyositis, 791, 792f, 1545, 1547
disorders of, 781–793
clinical signs by location, 781t
drug-induced disorders of, 792, 793f, 793t
from cytotoxic agents, 2177, 2177f, 2177t
from retinoids, 2185
in dyskeratosis congenita, 1324, 1324f

dystrophy of, 790, 792
from cytotoxic agents, 2177
in ectodermal dysplasia, 783, 1340, 1343, 1343f, 1346, 1346f
embryonic and fetal development, 72, 778
environmental factors affecting, 785–787
in erythronychia, longitudinal, 783
fibroma of, 787, 787f
differential diagnosis in, 1330b
in tuberous sclerosis, 1326–1327, 1330, 1330f
fragile, 785–786, 786t
functions of, 778
green discoloration of, 785, 785f
in *Pseudomonas* infections, 785, 785f, 1735, 1736, 1736f
grooves in, longitudinal, 782, 782f
growth of, 781
age-related changes in, 781
and regeneration time, 781
hereditary and congenital disorders of, 783–784, 784t
in hyperkeratosis, subungual, 783
infectious disorders of, 784–785, 785t
ingrown, 784, 793
surgery in, 2329
in iron deficiency, 1214, 1456
in Kawasaki disease, 1629
keratin in, 778–781
keratoacanthoma of, 1052, 1053
in koilonychia, 782
in Langerhans cell histiocytosis, 1417, 1420f, 1423
in leukonychia, 782, 782f, 783
in cytotoxic drug therapy, 2177
in lichen nitidus, 256
in lichen planus, 247, 249, 249f, 789–790, 790b, 790f, 1449
differential diagnosis of, 252b, 789–790, 790b
onychorrhexis of, 782
treatment of, 254, 790
in liver disease, 1449, 1449f, 1450f
in lupus erythematosus, 791, 1520, 1522f
malalignment of, congenital, 784, 785f
surgery in, 2329–2330
in melanoma, subungual acral lentiginous, 1139–1140, 1141b, 1141f
in melanonychia, 782–783, 783t
microscopic examination in fungal infections of, 1808
Muehrcke's lines of, 791, 792f, 792t
nerve supply of, 780, 2321
nevi of, 787, 788f
nevomelanocytic, 1106
nutrition affecting, 1449
in iron deficiency, 1214, 1456
occupational exposures affecting, 2077f
in onycholysis. *See* Onycholysis
in onychomycosis. *See* Onychomycosis
in palmoplantar keratoderma, 429–430, 784
in paraneoplastic acrokeratosis of Bazex, 1498, 1499, 1499f
in paronychia. *See* Paronychia
physical properties of, 781
pigmentation of, 783, 783f
cytotoxic drug therapy affecting, 2177
pitting of, 782, 782f
in psoriasis, 181, 182f
Pseudomonas aeruginosa infections of, 1735, 1736, 1737
green discoloration in, 785, 785f, 1735, 1736, 1736f
treatment of, 1738
in psoriasis. *See* Psoriasis, nail changes in
in Raynaud phenomenon, 1644, 1645, 1645f
in reticulohistiocytosis, multicentric, 1430, 1431f
in runners, 874f, 874t
in sarcoidosis, 1487
splinter hemorrhages of, 780, 783, 783f
differential diagnosis in, 1745b
in endocarditis, 1453, 1744, 1745f
in liver disease, 1449
in psoriasis, 181
split-nail deformity of, 2326, 2326f
striations and fissures in, longitudinal, 782
surgery of, 2320–2330
in syphilis, 1961
systemic diseases affecting, 791–792, 792t
in thyroid disorders, 1471, 1474
in tooth and nail syndrome of Witkop, 68t, 72, 1346, 1346f
in trachyonychia, 782, 790
traumatic disorders of, 792–793, 793f
reconstructive surgery in, 2329
in trichothiodystrophy, 420, 421f
tumors of, 787f–788f, 787–788
glomus, 787, 787f, 1658
of proximal nail fold, 2328f, 2328–2329
watch-glass deformity of, 1449, 1450f
white, 1449, 1449f, 1450f
yellow, 791, 1450, 1450f
lymphedema with, 1662
Nail bed, 778, 779f, 780, 2320
biopsy of, 2326–2327, 2327f
blood and nerve supply of, 780
clinical signs in disorders of, 781t
dermis of, 780
embryonic and fetal development of, 72
lacerations of, 2328
in psoriasis, 182t
splinter hemorrhage of, 780
surgical approaches to, 2326–2328, 2327f, 2328f
Nail fold
lateral, 2320, 2320f
hypertrophy of, 2329
surgical approaches to, 2329–2330
proximal, 778, 779f, 2320, 2320f
biopsy of, 2328
clinical signs in disorders of, 781t
embryonic and fetal development of, 72, 778
in psoriasis, 182t
surgical approaches to, 2328f, 2328–2329
tumors of, 2328f, 2328–2329
Nail matrix, 778–780, 779f, 2320, 2320f
ablation and matricectomy procedure, 2326, 2327f
biopsy of, 2324–2326, 2325f, 2326f
blood and nerve supply of, 780
clinical signs in disorders of, 781t
embryonic and fetal development of, 72, 778
keratinocytes in, 778–780
Langerhans cells in, 780
melanocytes in, 780, 782
Merkel cells in, 780
nevi of, 787, 788f
nevomelanocytic, 1106
in psoriasis, 182t
surgical approaches to, 2324–2326, 2325f, 2326f, 2327f
Nail patella syndrome, 784, 784f
Nail plate, 778, 779f, 2320, 2320f
composition of, 780–781
cytotoxic agents affecting, 2177
embryonic and fetal development of, 72, 778
growth of, 781
lipids in, 781
lunula of, 778, 2320, 2320f
melanin in, 782–783
onychocorneal band of, 778
physical properties of, 781
in psoriasis, 182t
surgical removal of, 2323f, 2323–2324, 2324f
thickness of, 778
water content of, 781
Nail surgery, 2320–2330
ablation procedure in, 2326, 2327f
anatomy in, 2320f, 2320–2321
anesthesia in, 2321–2322
distal digital block in, 2321–2322, 2322f
proximal digital block in, 2321, 2321f
transthecal block in, 2322
complications of, 2320, 2322–2323
contraindications to, 2320
draping in, 2321
dressings and postoperative care in, 2322
equipment and instruments in, 2321, 2321b
indications for, 2320
of nail bed, 2326–2328
of nail fold
lateral, 2329–2330
proximal, 2328–2329
of nail matrix, 2324–2326
nail plate removal in, 2323–2324
risks and precautions in, 2320
in split-nail deformity, 2326, 2326f
Nalfurafine in pruritus, 910
Nalidixic acid, 2201
Naloxone in pruritus, 910, 911t
Naltrexone in pruritus, 910, 911t
L-NAME, as nitric oxide synthetase inhibitor, 839, 840
Napkin psoriasis, 180, 221
"Nappes claires" in pityriasis rubra pilaris, 233, 234f
Naproxen
hyperhidrosis from, 726
phototoxicity from, 832
Nasal conditions. *See* Nose
National Alopecia Areata Foundation, 764
National Association for Pseudoxanthoma Elasticum, 1307
National Cancer Institute Surveillance Epidemiology and End Results program, 986
National Foundation for Ectodermal Dysplasias, 1343
National Guideline Clearinghouse, 11, 12
National Institute for Health and Clinical Excellence, 12
National Institute of Arthritis and Musculoskeletal and Skin Diseases, 90
National Institutes of Health, research priorities of, 90
National Library of Medicine, 12
National Pressure Ulcer Advisory Panel decubitus ulcer staging system, 879, 884t
National Registry for Ichthyosis and Related Disorders, 423b
Natural killer cells (NK cells)
in extranodal lymphoma, 1394
in innate immunity, 99–100
killer inhibitory receptors, 100
in psoriasis, 172
and arthritis, 196, 198, 199, 201

Natural killer T cells (NKT cells), 104
in photoimmunosuppression, 808f, 809
in psoriasis, 172
Natural moisturizing factor, 2357, 2358
Naxos disease, 425t, 429, 449, 449t, 760, 1452
NC16A in lichen planus pemphigoides, 250–251
Necator americanus, 2012t, 2013, 2016
occupational exposure to, 2076
Neck
actinic damage to, 1306b
allergic contact dermatitis of, 140
surgical anatomy of, 2292
Necklace of Venus, 1960
Necrobiosis, 53
lipoidica, in diabetes mellitus, 53, 370, 1466–1468, 1468f
in xanthogranuloma. *See* Xanthogranuloma, necrobiotic
Necrolysis, epidermal, **349**–355. *See also* Epidermal necrolysis
Necrolytic migratory erythema, 306, 666, 1501f, 1501–1502
Necrosis
anticoagulant-induced, 360, 360f
avascular, in corticosteroid therapy, 2150–2151, 2153
in cold injuries, 845, 846, 846f
in disseminated intravascular coagulation, 1749
in fasciitis. *See* Fasciitis, necrotizing
fibrinoid, 1608
genital, 660b
postoperative, 2338–2339
in sclerotherapy complications, 2354
of subcutaneous fat. *See* Subcutaneous fat, necrosis of
in vasculitis. *See* Vasculitis, necrotizing
Needlestick injuries, 2075
Neisseria gonorrhoeae, 1691, 1731, 1733
diagnosis of, 1693
differential diagnosis of, 1734
in gonorrhea, 1993–1996
in oral cavity disorders, 652t
in reactive arthritis, 208
treatment of infections, 2197t
Neisseria meningitidis, 1691, **1731**–1735
in acute meningococcemia, 1732–1734
in arthritis-dermatitis syndrome, 1733
in chronic meningococcemia, 1734
in conjunctivitis, 1732, 1734
differential diagnosis of, 1949b
in disseminated intravascular coagulation, 1732, 1734, 1735, 1748
epidemiology of, 1732
in immunocompromised host, 273, 274f
localized Shwartzman reaction to, 1732
in meningitis, 1732–1734
in purpura fulminans, 1382, 1383, 1732, 1746
treatment of infections, 1734–1735
vaccination against, 1732, 1735
Nekam disease, 251
Nelfinavir in HIV infection and AIDS, 2209
Nelson syndrome, 634, 1478
Nematode infections, 2011, 2012–2025
intestinal, 2012–2017
NEMO (nuclear factor κB essential modulator)
in ectodermal dysplasia, 1340, 1360, 1361f
in incontinentia pigmenti, 631
Neohaematopinus sciuropteri lice, 1943t
Neomycin, 1693, 2113t, 2115
with bacitracin and polymyxin B, 2115
contact dermatitis from, 136t, 138f, 1693, 2337
Neonates, **935**–941
acne in, 692, 700, 938, 938f, 1828
angiomatosis in, 1457
bathing frequency for, 936
biopsy of skin lesions in, 942, 944t
blue nevi in, 1109
in blueberry muffin baby appearance, 1176, 1379
candidiasis in, 936
chlamydial infections in, 1997
cold injuries in, 845, 851
congenital disorders in, 940–941, 941t
cytomegalovirus infection in, 1862, 1862f
differential diagnosis of dermatoses in, 939b
eosinophilic pustular folliculitis in, 315
examination of, 936
exfoliative dermatitis in, 225
extramedullary hematopoiesis in, 1379
fibromatosis colli in, 550–551
gonorrhea in, 1995
treatment of, 1996, 1996b
hair loss in, 769, 938, 939–940
hemangiomatosis in, diffuse, 1166
hemorrhagic disease of, 1208
herpes simplex virus infections in, 940, 941f, 1879
treatment of, 1880, 1882b
ichthyosis in, 415–416, 423
immunodeficiency disorders in, 1350f–1352f
jaundice in, 1379, 1447
Langerhans cell histiocytosis in, 1415
listeriosis in, 1762–1763
Marfan syndrome in, 1302
meningococcal infections in, 1732
Menkes syndrome in, 1216
multisystem inflammatory disorder in, 1267t, 1270–1271
mycoplasmal infections in, 1998
nevus flammeus in, 1652
nevus spilus in, 1103
noma neonatorum in, 1218
ophthalmia neonatorum in, 1995
pemphigoid gestationis in, 491
pemphigus in, 462, 465
postmature, 935, 936f
premature, 935–936
anetoderma in, 940
Pseudomonas aeruginosa infections in, 1737, 1738
purpura fulminans in, 1383
rhabdomyosarcoma in, 1176
sclerema neonatorum in, 576, 582, 851, 939
staphylococcal scalded skin syndrome in, 1712, 1714
subcutaneous fat necrosis in, 581–582, 582f, 851, 939, 939f
and dystrophic calcification, 1294
syphilis in, 1967f, 1967t, 1967–1969
treatment of, 1976
thrombocytopenia in, alloimmune, 1382
transient dermatoses in, 936–938
varicella in, 1893
viral infections in, 940, 941f
vitamin K deficiency in, 1208
Neotestudina rosati, 1834t
Neovascularization in skin graft healing, 2346–2347
Nephritis, streptococcal, 1703, 1704
Nephrolithiasis and gout, 1575, 1576
NERDS syndrome, 285, 307, 309
Nerve blocks, regional, 2298–2299
digital, 2298–2299
in nail surgery, 2321f, 2321–2322, 2322f
facial, 2298
Nerve growth factor, 604
keratinocyte-derived, 604
in prurigo nodularis, 160
in pruritus, 897t, 905
in psoriasis, 174, 900
in UV damage, 604
in wound healing, 901
Nerve growth factor receptors, 68t, 1588
Nerve sheath tumors, 1178–1181
benign, 1178–1181
malignant, 1177t, 1181
Nerves, 65–66
anatomy of, 896–898
biochemistry of, 898–900
cold sensitivity of, 65
and cold injury, 846
electrical stimulation technique in pruritus, 911
embryonic and fetal development, 70
hamartoma of, fibrolipomatous, 1192
in inflammation, 898t
lipomatosis of, 1192
of nails, 780, 2321
in pain sensation, 896t–897t, 899f
in pruritus, 896t–897t, 899f, 901
transmission of itch sensation in, 903–904, 911
sensory, 65f, 65–66, 66f, 895, 896
A fibers, 896
anatomy of, 896
C fibers, 896, 899, 901
in pruritus, 903, 903f, 904
in stinging sensation, 2360
embryonic and fetal development of, 70
in skin graft healing, 2347
of sweat glands, 715–716, 720, 838f
and denervation hypersensitivity, 716
tumors of, 1176–1181
Nervous system
autonomic. *See* Autonomic nervous system
central, 895–896
cutaneous, 65–66, **895**–901
anatomy of, 896–898
biochemistry of, 898–900
embryonic and fetal development, 70
in skin pathophysiology, 900–901
in sweat gland regulation, 896
anhidrosis in disorders of, 722t, 727
hyperhidrosis in disorders of, 722t, 723–724, 725–726
in thermoregulation, 723, 837, 838f
Netherton syndrome, 391, 404t, 416, 417f
prenatal diagnosis of, 423
treatment in, 422
trichorrhexis invaginata in, 758
Nettle gas as chemical weapon, 2086t
Neural tube development, 941
malformations in, 941
Neuralgia, postherpetic, 1888, 1894
risk factors for, 1894
symptoms in, 1894
treatment of, 1896–1897, 2130
Neurilemmoma, 1178. *See also* Schwannoma
Neurinoma, 1178. *See also* Schwannoma
Neurobiology of skin, **895**–901
Neuroblastoma in neurofibromatosis type 1, 1336
Neurocan, 539t
Neurocysticercosis, 2014t, 2028
Neurodermatitis circumscripta, 160. *See also* Lichen simplex chronicus
Neuroectodermal melanolysosomal disease, 623

Neuroectodermal tumor
of infancy, oral cavity disorders in, 648
primitive, 1177t, 1181
Neurofibromas, 1179
bizarre cutaneous, 1180
dendritic cell, with pseudorosettes, 1179
dermal, 1179
diffuse variant, 1179
discrete, 1333–1334, 1334f
treatment of, 1337
in neurofibromatosis type 1, 1179
pacinian, 1180
plexiform, 1179, 1180f, 1334f, 1334–1335, 1336
staining of, 1177t
treatment of, 1179, 1337
staining of, 1177t
subcutaneous, 1179
Neurofibromatosis, **1331**–1339
and congenital nevomelanocytic nevi, 1101
epidemiology of, 1331
mosaicism in, 83, 1331, 1338
oral cavity disorders in, 642t, 648
type 1, 634, 1179, **1331**–1339, 1505t
café-au-lait spots in, 634, 1331, 1332–1333, 1333f, 1337
cancer risk in, 1336
clinical findings in, 1179, 1332–1335
complications in, 1335–1337
diagnostic criteria in, 634, 1332, 1333t
etiology and pathogenesis in, 1331–1332
genetic factors in, 634, 1179, 1331–1332, 1335, 1338
laboratory tests in, 1335
Lisch nodules in, 1335, 1335f
malignant peripheral nerve sheath tumors in, 1181
mosaicism in, 1331, 1338
and Noonan syndrome, 1338
optic pathway tumors in, 1334–1335, 1337–1338
radiography in, 1335
segmental, 1331, 1338
support groups for patients and families, 1337
treatment of, 1337–1338
xanthogranuloma in, 1336, 1427
type 2, 1331, 1338, 1505t
diagnostic criteria on, 1338, 1338t
genetic factors in, 1178, 1338
schwannoma in, 1178–1179, 1331, 1338
Neurofibromin, 634, 1179, 1331, 1332
Neurofibrosarcoma, 1181
Neuroglial tissue, heterotopic, 1182
Neurokinin A, 898
in inflammatory response, 898t
in pruritus, 897t
Neurolemmoma, 1178. *See also* Schwannoma
Neuroleptic malignant syndrome, 918, 918t
Neurologic disorders
in actinomycosis, 1781
in amebic infections, 2009, 2010
in amyloidosis, 1257, 1258, 1260, 1260t
anhidrosis in, 728
complications in, 1263, 1264
prognosis and clinical course in, 1264
treatment in, 1265
anhidrosis in, 722t, 727, 728
in atheromatous embolism, 1673
in Behçet disease, 1623–1624, 1625
in black widow spider bites, 2054–2055
in cat-scratch disease, 1751
in Chédiak-Higashi syndrome, 1367
in Churg-Strauss syndrome, 1611, 1614t
claudication in, 1670
in cobalamin deficiency, 1212, 1377
in Cockayne syndrome, 1320
in cryoglobulinemia, 1640
in cysticercosis, 2014t, 2028
in Degos disease, 1649, 1650
in dermatitis herpetiformis, 504
in diabetes mellitus
anhidrosis in, 727–728
foot ulcers in, 1466, 2348
drug-induced
from antimalarial drugs, 2162t
from corticosteroids, 2151t
from dapsone, 2156
from retinoids, 2185
from thalidomide, 2235
in enterovirus infections, 1869, 1870
eosinophils in, 285
in epidermal nevus syndromes, 1061, 1061t
in Fabry disease, 1284, 1284t
in herpes simplex virus infections, 1879
in neonate, 1879
treatment of, 1882b
in herpesvirus-6 infections, 1866
hyperhidrosis in, 722t, 723–724, 726
in Kawasaki disease, 1629
in Langerhans cell histiocytosis, 1419
in leprosy, 1787, 1788, 1789, 1792, 1794
in lipoid proteinosis, 1290
in local anesthesia, 2298
in loiasis, 2015t, 2019
in Lyme disease, 1802–1803
and acrodermatitis chronica atrophicans, 1800
treatment of, 1806t
in meningococcal infections, 1732
in Menkes syndrome, 1216
in monkeypox virus infections, 1907
in mononucleosis, 1859–1860
in niacin deficiency, 1210, 1211
in polyangiitis, microscopic, 1613–1614
in polyarteritis nodosa, 1614
in porphyria
acute intermittent, 1250
variegate, 1253
pruritus in, 903, 906, 907
in pyridoxine deficiency, 1211
in rabies, 2039
Raynaud phenomenon in, 1645–1646, 1646t
in rheumatoid arthritis, 1572t
in rubella, 1854
in sarcoidosis, 1489
treatment of, 1491, 1491t
seborrheic dermatitis in, 220
in Sjögren syndrome, 1580, 1583
in smallpox, 1902, 1903
in smallpox vaccination, 1905, 1906
in Sweet syndrome, 291, 292t, 293
in syphilis, 1965–1967. *See also* Neurosyphilis
in T-cell lymphotropic virus infections, 1926
in thiamine deficiency, 1208
in tick bites, 2059
trauma in surgery, 2290–2291, 2291f
in tuberous sclerosis, 1328–1329, 1330
from tumor necrosis factor inhibitors, 2228
in tyrosinemia, 1220–1221
in varicella-zoster virus infections, 1888, 1889, 1890, 1891f, 1893, 1894
and postherpetic neuralgia, 1888, 1894, 1896–1897
in Wegener granulomatosis, 1612t
in xeroderma pigmentosum, 1317
Neuroma, 1176–1178
acoustic, 1178
Morton, 1178
mucosal, 1177–1178
in multiple endocrine neoplasia syndrome, 1177–1178
oral, 642t, 648, 1178
oral, 642t, 648, 1178
traumatic, 648
palisaded encapsulated, 1177
histopathology of, 1177, 1177f
staining of, 1177, 1177f, 1177t
traumatic, 1176
oral, 648
staining of, 1176, 1177t
Neuron-specific enolase
in malignant peripheral nerve sheath tumor, 1181
in Merkel cell carcinoma, 1090
Neuropathy. *See also* Neurologic disorders
alcoholic, 728
amyloid, 728
diabetic, 727–728
foot ulcers in, 1466, 2348
hereditary sensory-autonomic, 726, 727
idiopathic small-fiber, 728
localized hypertrophic, 1181
pruritus in, 903, 906, 907
in Sjögren syndrome, 1580
in thalidomide therapy, 2235
Neuropeptide(s), 898–899
in innate immunity, 96, 96f
NPY, 896, 899
in cold stress and vasoconstriction, 842, 842f
in ultraviolet radiation exposure, 812
in urticaria, 900
Neuropeptide receptors, 898–899
Neurosarcoma, 1181
Neurosyphilis, 1957, 1965t, 1965–1967
classification of, 1965, 1965t
congenital, 1968, 1968t, 1969
diagnostic tests in, 1973, 1973t
in HIV infection, 1970
in infants, 1968, 1969
necrotizing, 1970
parenchymatous, 1965t, 1966
treatment of, 1974, 1975, 1977
complications in, 1977
Neurotensin, 898
Neurothekeoma, 1177t, 1179–1180
Neurotic excoriations, 916, 916f
Neurotoxicity of drugs. *See* Neurologic disorders, drug-induced
Neurotoxin
botulinum, 2388–2394
eosinophil-derived, 285
in Waardenburg syndrome, 613, 614
in scorpion venom, 2058
in spider venom, 2054–2055
in tick paralysis, 2059
Neurotransmitters
in eccrine sweat glands, 716
in pruritus, 905
in vasoconstriction, cutaneous active, 842, 842f
in vasodilation, cutaneous active, 837–839, 839f
Neurotrophins
in hair follicle cycle, 746
as melanogenic stimulators, 604
nerve growth factor. *See* Nerve growth factor
in pruritus, 897t, 905

Neurotropism
in keratoacanthoma, 1052, 1052f
in melanoma, 1140
Neutragenomics, 2286
Neutral endopeptidase, 895
Neutropenia, 283, 1363t, 1374t
cyclic, 1363t
opportunistic infections in, 268–272, 269t, 1836t
severe congenital, 1363t
and trichothiodystrophy, 759t
Neutrophilic dermatosis, 291–292, 298–299
acute febrile, 53, 280, **289**–295, 1375t. *See also* Sweet syndrome
antineutrophil cytoplasmic autoantibody positive, 1375t
rheumatoid, 1571–1572, 1572f
Neutrophilic eccrine hidradenitis. *See* Hidradenitis, neutrophilic eccrine
Neutrophils, **279**–284
adhesion of, 281–282
in leukocyte adhesion deficiency, 1364–1366
chemoattraction and activation of, 280–281
daily production of, 279
free-flowing or rolling, 281, 282f
functions of, 99, 279–280
granules in, 283
in Chédiak-Higashi syndrome, 280, 613
composition and function of, 279–280
deficiency of, 280
primary, 279, 280, 280t
secondary, 279, 280, 280t
as infiltrates in reticular dermis, 53
in dermatitis herpetiformis, 50f, 53
in necrotizing vasculitis, 51f, 53
in necrotizing vasculitis, 51f, 53, 1599, 1600, 1605, 1605f
ontogeny and development, 279
oxygen-dependent pathways, 283–284
oxygen-independent pathways, 283
in phagocytosis, 283
pharmacologic manipulation of, 284
in psoriasis, 173
in pyoderma gangrenosum, 296, 298
reduced number of. *See* Neutropenia
tissue trafficking, 280–284, 282f
in ultraviolet radiation response, 812
in urticaria and angioedema, 332
Nevi, **1056**–1062. *See also specific nevi*
acanthotic, 1061
acneiformis unilateralis, 1059
acquired bilateral nevus of Ota-like macules, 638–639
apocrine, 1056, 1057t, 1060, 1070–1071
balloon cell, 1108
basal cell
linear unilateral, 1080
syndrome of, **1042**–1048
Becker's, 639, 639f, 1057, 1057t, 1060
laser therapy in, 2274
syndrome of, 639
blue, 1109–1112, 2274
classification of, 1056, 1057t
comedonicus, 753t, 1056, 1057t, 1059–1060, 1060f
syndrome in, 1057, 1059–1060, 1061
connective tissue, 555, 555f
differential diagnosis in, 1058, 1058b
dysplastic, **1122**–1133
eccrine, 1056, 1057t, 1060, 1074
eruptive, 1105, 1107, 1109
in Spitz nevus, 1114, 1115
flammeus, 2270
neonatorum, 1652
follicularis keratosis, 1059
fuscocaerulius
acromiodeltoideus, 632
ophthalmomaxillaris, 632, 2274
of hair follicle, 1080
in nevus comedonicus, 1059
halo, 1105, 1106–1107, 1107f, 1108
of Hori, 632, 632t, 638–639
laser therapy in, 2274
ichthyosiform, with congenital hemidysplasia and limb defects, 1056, 1060, 1061
of Ito, 632, 632t, 1110, 2274
leukopigmentary, 1105
linear epidermal, 1057, 1057f
inflammatory verrucous, 180–181, 1057, 1058, 1058f, 1059, 1062
linear unilateral basal cell, 1080
lipomatosus superficialis, 1192, 1192f
differential diagnosis in, 558
melanocytic, 1099–1117
of nail matrix, 787, 788f
nodal, 1116–1117
oral, 648
organoid, 1059
of Ota, 632, 632t, 633f, 1110, 1111
laser therapy in, 2272, 2273, 2274
pigmented hairy, 1061
pigmented spindle cell, 1112–1113, 1113b, 1113f
sebaceous, 1056, 1057t, 1059, 1059f
congenital, 1059
of Jadassohn, 1059
laser therapy in, 2278
syndrome of, 1057, 1059, 1060
trichoblastoma in, 1083, 1083f
speckled lentiginous, 634
spider, 1451, 1451f
spilus, 634, 1103f, 1103–1104, 1104f, 1114
clinical findings in, 1103, 1104f
congenital, 1104, 1104f
differential diagnosis in, 1103, 1104b
laser therapy in, 2274
Sutton's, 1105
syndromes in, 1056–1057, 1060–1062
clinical features in, 1061, 1061t
tumorigenesis and tumor progression in, 1137
unius lateris, 1061
verrucous, 1056, 1057f, 1057t, 1057–1059
white sponge, 1057t
oral cavity disorders in, 642t
and woolly hair, 770
zoniforme, 1059
zosteriform lentiginous, 631, 639
Nevirapine in HIV infection, 2209
hypersensitivity reactions to, 1934
Nevoid basal cell carcinoma syndrome. *See* Basal cell nevus syndrome
Nevomelanocytic nevi
acquired, 1104–1109
clinical findings in, 1105–1107, 1106f, 1107f
complications in, 1108–1109
compound, 1106f, 1107f
differential diagnosis of, 1108, 1108b
epidemiology of, 1104–1105
etiology and pathogenesis of, 1105
histopathology in, 1107f, 1107–1108
intradermal, 1107f, 1108
junctional, 1106f, 1107f
laboratory tests in, 1107–1108
prevention of, 1109
prognosis and clinical course in, 1109
treatment in, 1109
congenital, 1099–1103
clinical findings in, 1100–1102
complications of, 1102
differential diagnosis of, 1102, 1102b
disorders associated with, 1101
epidemiology of, 1099–1100
etiology and pathogenesis of, 1100
familial aggregation of, 1100, 1100f
histopathology in, 1101f, 1101–1102
melanoma risk in, 1135
prevention of, 1102–1103
prognosis and clinical course in, 1102
size classification, 1100
treatment of, 1102
laser therapy in, 2273–2274
in lymph nodes, 1116–1117
New World cutaneous leishmaniasis, 2003–2004
treatment of, 2007, 2007t
New World hookworm disease, 2013
NF1 in neurofibromatosis type 1, 1331–1332
NF2 in neurofibromatosis type 2, 1338
and schwannomas, 1178
NFAT (nuclear factor of activated T cells), 434
NF-κB. *See* Nuclear factor κB
NGF. *See* Nerve growth factor
Niacin, 1209–1211
deficiency of, 1209–1211, 1210f, 1456
food sources of, 1209
Niacinamide, 2146, 2363, 2363t
Niche of epidermal stem cells, 375, 376
Nickel allergy, 106, 136t, 137, 141, 144, 145
in body piercing, 890, 890t
in occupational exposures, 2070t
Nicolau-Balus syndrome, 561
Nicotinamide, 1209, 1211
Nicotinamide adenine dinucleotide, 1209
absorption of radiation, 803, 803f
Nicotinamide adenine dinucleotide phosphate oxidase, 283, 285–286
in granulomatous disease, chronic, 1363, 1364
Nicotinic acid, 1209, 1211
Nidogens, 450, 451, 451b, 452f, 454
cellular origin of, 459
Niemann-Pick disease, 1374t, 1376t
anhidrosis in, 729
Nifedipine in Raynaud phenomenon, 1647
Nijmegen breakage syndrome, 982t, 1313t, 1361
Nikolsky sign, 39t, 1697
in epidermal necrolysis, 352, 352f
in pemphigus vulgaris, 464
in staphylococcal scalded skin syndrome, 1712
Nipah virus in bioterrorism, 2083t, 2085
Nipple
adenoma of, 1071
friction dermatitis of, 398
Montgomery's tubercles of, 687, 1085
Paget disease of, 1095, 1095f, 1507
supernumerary, 1071
Nissl arteritis in syphilis, 1966
Nit, in pediculosis capitis, 2033, 2033f, 2034
Nitrate formulations in systemic sclerosis, 1559t
Nitric oxide, 605
and vasodilation in heat response, 839–840, 841f
Nitric oxide synthetase, 839, 840
Nitroblue tetrazolium reduction assay in chronic granulomatous disease, 1364
Nitrofurazone, 2115

Nitrogen, liquid, in cryotherapy, 2330, 2330t
in actinic keratosis, 1013
Nitrogen mustard, 2122–2123
in Langerhans cell histiocytosis, 1423
in mycosis fungoides, 2122, 2123
side effects of, 2123
skin cancer associated with, 987, 987t, 2123
in T-cell lymphoma, 1397, 1398, 2122–2123
Nitroglycerin in Raynaud phenomenon, 1647
Nitrous oxide in cryotherapy, 2330, 2330t
Nizatidine, 2191–2193, 2192t
complications of, 2192
interaction with other drugs, 2192
Njovera. *See* Syphilis, endemic
NK cells. *See* Natural killer cells (NK cells)
NKGD2, 100
NKT cells (natural killer T cells), 104
in photoimmunosuppression, 808f, 809
in psoriasis, 172
Nocardia abscessus, 1782
Nocardia asteroides, 272, 1779t, 1782, 1783
in actinomycetoma, 1783, 1785
treatment of infections, 2197t
Nocardia brasiliensis, 272, 1779t, 1781, 1782
in actinomycetoma, 1783, 1784, 1784f, 1785, 1785f, 1788, 1834t
treatment of infections, 2197t
Nocardia farcinica, 272, 1782, 1783
Nocardia mexicana, 1783–1784
Nocardia nova, 1782
Nocardia otidiscaviarum, 1782, 1783, 1785
Nocardia pseudobrasilensis, 1782, 1783, 1784
Nocardia transvalensis, 1782, 1783
Nocardia veterana, 1783
Nocardiopsis dassonvillei, 1783
Nocardiosis, 1778, 1779t, **1781**–1783, 1843
actinomycetoma in, 1783–1784, 1785, 1786, 1832, 1833, 1834t
cellulitis in, 1783
in granulomatous disease, chronic, 1364
in immunocompromised host, 269t, 272–273, 273f, 1781–1782
treatment of, 1783
lymphocutaneous, 1782, 1782f
differential diagnosis of, 1783, 1783b
sporotrichoid pattern in, 1782, 1782f, 1783
sternal, 1782, 1783
treatment of, 1783
NOD1 in atopic dermatitis, 149
Nodal nevi, 1116–1117
Nodules, 26, 27f
in acne, 693, 693f, 694f
conglobata, 700–701
in athletes, 876
in basal cell carcinoma, 26, 27f
in fasciitis, 554
genital, 662b
in melanoma, 1137, 1139f, 1142
differential diagnosis in, 1139b
in nevomelanocytic nevi, 1116–1117
onchocercal, 2020, 2020f
in prurigo, 160–162
in rheumatic fever, 1574, 1574b
rheumatoid, 1570t, 1571, 1571f
sub-epidermal calcified, 1296
Noggin
in hair color, 748
in hair follicle development, 740f, 741
Noma, 1217–1218, 1218f
neonatorum, 1218, 1738
Nonnucleoside reverse transcriptase inhibitors in HIV infection, 1930t, 2209
hypersensitivity reactions to, 1934
Nonsense-mediated message decay, 985
Noonan syndrome
and neurofibromatosis type 1, 1338
and ulerythema ophryogenes, 750f, 750–751, 770
Norepinephrine, 896, 898
in cutaneous active vasoconstriction, 842, 842f
in inflammatory response, 898t
and serotonin-norepinephrine reuptake inhibitors, 918t, 919–920
sweat gland response to, 720
Norethindrone acetate in acne vulgaris, 698
Norfloxacin, 2201
Norgestimate in acne vulgaris, 698
North American blastomycosis, 1838–1839
North American Contact Dermatitis Group, 143
North American Hair Research Society, 771
Northern black widow spider bites, 2054
Norton pressure ulcer risk assessment scale, 879, 882t
Nortriptyline, 918t
Norwalk virus in bioterrorism, 2083t
Norwegian scabies, 2029
exfoliative dermatitis in, 230t
in immunocompromised host, 277, 277f
Nose
cicatricial pemphigoid of, 484t, 485b
treatment of, 485, 485b
dermoid cyst of, 1066
dorsal fistula of, 1066
drug abuse-related lesions of, 925, 925f
fibrous papule of, 555
glioma of, 1182
Klebsiella infection and rhinoscleroma of, 1742, 1742f
leishmaniasis of, 2006, 2006f
lupus vulgaris of, 1771, 1772f
lymphoma of, 1394
pseudoacne of nasal crease, 703
sarcoidosis of, 1489
surgical anatomy of, 2291
cosmetic units and landmarks in, 2289, 2290f
syphilis of, 1964, 1964f
Notalgia paresthetica, 901, 907
Notch1 in hair follicle development, 741
Notoedres cati, 2033
NT. *See* Neurotrophins
Nuclear factor of activated T cells (NFAT), 434
Nuclear factor κB, 115, 1003
in aging of skin, 964, 965f
in photoaging, 970
in corticosteroid therapy, 2147
in ectodermal dysplasia with immunodeficiency, 1340, 1360, 1361f
genes regulated by, 118, 118f
in incontinentia pigmenti, 631
in sepsis, 1746
signal transduction pathways, 116–118, 118f
and tumor necrosis factor-α, 118, 121, 121f
Nuclear factor κB essential modulator (*NEMO*)
in ectodermal dysplasia, 1340, 1360, 1361f
in incontinentia pigmenti, 631
Nucleic acid, viral, 1845, 1846t, 1850
Nucleic acid amplification tests in gonorrhea, 1995
Nucleoside reverse transcriptase inhibitors in HIV infection, 1930t, 2208–2209
hypersensitivity reactions to, 1934
lipodystrophy in, 586, 589, 1934–1935
Nucleotide excision repair in DNA damage, 811, 978, 979f
genes associated with, 980, 980t
tests of, 984
in ultraviolet radiation exposure, 811, 984, 1005
in xeroderma pigmentosum, 984, 1005, 1136, 1315, 1317, 1318
Null hypothesis, 15
Nummular lesions, 34, 35f, **158**–160, 159f
differential diagnosis of, 159, 159b
allergic contact dermatitis in, 139b
pityriasis rosea in, 365, 365b
Nutrition, **1201**–1218
in acne, 699, 2287
in actinic keratosis prevention, 1015
in alkaptonuria, 1228, 1228b
allergies to foods in, 2286
atopic dermatitis in, 155–156, 2287
urticaria and angioedema in, 333
in argininosuccinic aciduria, 1224
in atopic dermatitis, 156, 2287
in cancer prevention, 994, 994t, 1005, 1015
in complementary and alternative medicine, 2286
in corticosteroid therapy, 2149, 2152
in decubitus ulcers, 885
in dermatitis herpetiformis, 500–504
adherence to gluten-free diet in, 504
elemental diets in, 504
in epidermal necrolysis, 354
in epidermolysis bullosa, 515
in exercise-induced anaphylaxis, 335
fatty acids in, essential, 1203–1204, 2286, 2287
in gout, 1575, 1576
in homocystinuria, 1304
in hypertriglyceridemia, 1278
in ichthyosis, 422–423
in lipodystrophy, 589
in lipoprotein lipase deficiency, 1275
minerals in, 1214–1217
parenteral
biotin deficiency in, 1213
hair changes in, 1452
in phenylketonuria, 1222, 1223, 1224, 1224b
physical signs of disorders in, 1207t
and pigmentation changes, 629–630, 635
protein-energy malnutrition, 1201–1203
in pseudoxanthoma elasticum, 1307
in Refsum disease, 418, 419
in seborrheic dermatitis, 220, 224, 2287
in tyrosinemia, 1222, 1222b, 1222f
vitamins in, 814, 1204–1214
Nystatin, 2117t, 2119, 2120
in candidiasis, 1827, 2120, 2287
pediatric dosage, 951t
and triamcinolone acetonide, 2117t, 2120

O

Obesity
in Cushing syndrome, 1477–1478
gastric bypass surgery in, 1456
gout in, 1575
hidradenitis suppurativa in, 735
hirsutism in, 775
psoriasis in, 183
Obligate intracellular parasites, viruses as, 1845
Oblimersen sodium in melanoma, 1156
Observational studies, 3, 4
as evidence source, 10
Obsessive-compulsive disorder
and body dysmorphic disorder, 913
and neurotic excoriations, 916
and trichotillomania, 914, 915

Occipital horn syndrome, 527, 1309
Occludin, 391
Occlusion
with dressings or ointments, absorption of topical medications in, 2091–2092
with moisturizing products, 2359, 2359t
Occupational exposures, 20, **2067**–2080
acne in, 702, 2078
acro-osteolysis in, 2078
allergic contact dermatitis in, 20, 135–136, 136f, 140, 144, 145, 2069–2070
common allergens causing, 2070, 2070t
diagnosis of, 2072
arsenical keratosis in, 1015
bacterial infections in, 2074–2075
barrier creams for protection in, 2072
bites and stings in, 2076
burns in
chemical, 2068, 2068t, 2069, 2069t
electrical, 2078
thermal, 2077–2078
candidiasis in, 1824, 2076
chloracne in, 2078, 2079t
cold-induced disorders in, 2078
connective tissue disorders in, 2078, 2078t
diagnostic evaluation in, 2071t, 2071–2072
disability evaluation in, 2073
in electrosurgery, 2335
epidemiology of, 2067
erysipeloid in, 1765, 2074–2075
fungal infections in, 2076
granuloma formation in, 2068t, 2077, 2077t
hazard identification in, 2072, 2073
health risk assessment in, 2073
herpetic whitlow in, 1877, 2075
hydrocarbon keratosis in, 1018
hypomelanosis in, 628–629
irritant contact dermatitis in, 399, 2067–2069
from airborne substances, 2068
common substances causing, 2069, 2069t
diagnosis of, 2072
keratoacanthoma in, 1050
in laser use, 2268
leptospirosis in, 1766
low-humidity dermatitis in, 2068, 2069t
milker's nodules in, 1908–1910, 2076
nail changes in, 2077f
parasitic infections in, 2076
persistence of skin disease in, 2073
phototoxicity in, 832
prevention of, 2072–2073
prognosis in, 2073
protective clothing and equipment in, 2072–2073, 2077
pseudo-eccrine chromhidrosis in, 733, 733b
rabies in, 2039
to radiation, 2079t, 2080, 2080f
Raynaud phenomenon in, 1645, 1646t, 2078
repetitive trauma in, 2076–2077
risk of skin cancer in, 987, 2078–2080, 2079t
seal finger in, 1762, 2042
sporotrichosis in, 1831, 2076
squamous cell carcinoma in, 1029, 2079
T-cell lymphoma in, 1386
to ultraviolet light, 2079, 2079t
urticaria in, 2068t, 2070–2071, 2072f
vibration in, 2078
and angioedema, 334
viral infections in, 2075–2076
Ocean sports, skin problems related to, 877
Ochronosis
in alkaptonuria, 1225, 1226, 1226f, 1227
endogenous, 637
exogenous, 636, 638f, 1227
from hydroquinone, 637, 1227, 2145, 2146
Octinoxate in sunscreens, 2139, 2139t, 2140
Octocrylene in sunscreens, 2139t
Octopus bites, 2050, 2050f
Octreotide in acromegaly, 1483
Ocular disorders. *See* Eye disorders
Oculocutaneous albinism, 598, 608–612, 615
Oculocutaneous tyrosinemia, 428, 430
Oculo-dento-digital dysplasia, 425t
Oculo-orogenital syndrome
in pyridoxine deficiency, 1211
in riboflavin deficiency, 1209
Odds ratio, 17–18
Odor
in apocrine bromhidrosis, 731–732
hyperhidrosis in response to, 724
of sweat, 719–720
Office-based physician visits, annual number of, 6–7, 7t
Ofloxacin, 2201
in gonorrhea, 1996b
Oil acne, 2078
Oil drop sign, 39t
in nail psoriasis, 181, 182f, 789
Oil-in-water emulsions, 2094
Oily skin type, 2357–2359, 2364t
with acne, 2358
compared to dry type, 2357–2358
Ointments, topical medications formulated as, 2093–2094
with absorption base, 2094
with hydrocarbon base, 2093–2094
with water-soluble base, 2094
OKT3 in graft-versus-host disease, 266t
Olanzapine, 917t
in psychogenic itch, 908
Old World cutaneous leishmaniasis, 2003, 2003f, 2004f
treatment of, 2007, 2007t
Oleaginous base of ointments, 2093–2094
Olfactory hyperhidrosis syndrome, 724
Olmsted syndrome, 426
Omalizumab in atopic dermatitis, 157
Omega-3 fatty acids, 385, 1204, 2286
deficiency of, 385
Omega-6 fatty acids, 385–386, 1204, 2286
Omega-9 fatty acids, 385
Omenn syndrome, 1360
Onchocerca volvulus, 2012t, 2017t, 2019–2021, 2021t
Onchocerciasis, 2012t, 2019–2021, 2020f
differential diagnosis of, 2020, 2021t
genital, 667
limb swelling in, 2020
nodules in, 2020, 2020f
pigmentation changes in, 628, 628f, 638, 667, 2020
treatment of, 2015t, 2020–2021
Onchocercomata, 2019
Onchodermatitis, 2019
acute papular, 2020
chronic papular, 638, 2020
lichenified, 2020
Oncogenes, 995
Oncolytic viruses, 998
Online Mendelian Inheritance in Man, 74, 74t, 423b
Onychocola canadensis, 1817
Onychocorneal band, 778
Onychocytes, 781
Onychodermal band, 778
Onychodystrophy, 759t
in cytotoxic drug therapy, 2177
mediana canaliformis, 792
Onychogryphosis, 793, 793f
Onycholysis, 783, 786–787, 787t
in hyperthyroidism, 1471
in phototoxicity, 831, 831f
in psoriasis, 181, 182f, 788, 789f
traumatic, 793
Onychomadesis, 781–782, 782f
Onychomatricoma, 787, 788f
Onychomycosis, 785, 785t, 786f, 1817–1818
candidal, 1817, 1818, 1820
clinical findings in, 785, 786t, 1817f, 1817–1818
in diabetes mellitus, 1465
differential diagnosis of, 1818b
distal subungual, 785t, 786t, 1817, 1817f
in elderly, 973
epidemiology of, 1817
etiology of, 1817, 1817t
histopathology in, 1818
in immunocompromised host, 274, 274f, 1817f
in HIV infection and AIDS, 1817f, 1936
laboratory tests in, 1818
nail growth rate in, 781
proximal subungual, 785, 785t, 786f, 786t, 1817, 1817f
nail surgery in, 2323
and tinea pedis, 1816, 1817, 1819
treatment of, 1818b, 1819–1820, 2121
itraconazole in, 1818t, 1820, 2214, 2214t
terbinafine in, 1818t, 1820, 2212, 2213t
white superficial, 785, 785t, 786f, 786t, 1817, 1818, 1818f
Onychorrhexis, 782
Onychotrichodysplasia, 759t
Opera glass hand, 200–201
Ophiasis, 763f, 764
Ophthalmia neonatorum
chlamydial, 1997
gonococcal, 1995
treatment of, 1996
Ophthalmic artery, 2293
Ophthalmic nerve
anesthetic block of, 2298
herpes zoster of, 2292
surgical anatomy of, 2292, 2292f
Opiates
abuse of, 922, 924–925
treatment and withdrawal in, 926
endogenous, in pruritus, 905
Opioid receptors in pruritus, 905, 910
Opioids
hyperhidrosis from, 726
in postherpetic neuralgia, 1897
in pruritus, 897t, 901, 905, 907–908
Opportunistic infections, 267–277
in acute immunosuppression, 268–272
amebic, 2009–2010
in azathioprine therapy, 2168
in chronic immunosuppression, 272–277
fungal systemic, 1836, 1836t, 1843
in HIV infection and AIDS, 1927–1928, 1929, 1935–1939
in methotrexate therapy, 2166
oral, 654
in systemic vasculitis, 1616
Opsonization, 327, 1370
Optic atrophy in syphilis, 1966–1967, 1975
Optic pathway tumors in neurofibromatosis, 1334–1335, 1337–1338
treatment of, 1337–1338

Optical coherence tomography, 43
Optical properties of skin, 802f, 802–803, 803f, 2264–2266
Oral cavity disorders, 1451–1452
in acanthosis nigricans, 642t, 1462, 1495, 1496f
in amyloidosis, 642t
macroglossia in, 1260t, 1261, 1262f
in basal cell nevus syndrome, 642t, 1045, 1046, 1047f
in Behçet disease, 642t, 646, 646f, 666, 1451–1452, 1622, 1623f
treatment of, 1625, 1625b
in benign tumors, 647–648
in blastomycosis, 1839
in candidiasis. *See* Candidiasis, oral
in chronic bullous disease of childhood, 488
in cicatricial pemphigoid, 481, 482f, 484, 484t, 485b, 646
clinical findings in, **641**–654
drug-induced, 650, 651
from cyclosporine, 2220
from cytotoxic drugs, 2180f, 2180–2181
from methotrexate, 2166
mucosal hyperpigmentation in, 2181
mucositis and stomatitis in, 2180, 2181f, 2181t
perioral dermatitis in, 709–710, 711
in dyskeratosis congenita, 1324f, 1325
in ectodermal dysplasia, 642t, 647t, 1340–1341, 1341f, 1344–1345, 1346, 1346f
in Ehlers-Danlos syndrome, 1301
in eosinophilic ulcer, 315
in epidermolysis bullosa, 515, 646–647
in erythema multiforme, 346, 346f, 347, 347f, 647
in erythroplakia, 648, 1024, 1026–1027
in erythropoietic porphyria, congenital, 642t, 647t, 1248, 1248f
in Fabry disease, 1283
of gingiva, 645
in acute necrotizing gingivitis, 645, 645f, 1218
in cicatricial pemphigoid, 481, 484, 484t
hyperplasia in, 645
in granular cell tumors, 1181
in granuloma inguinale, 1992
in granulomatous disease, chronic, 642t, 1364
in hand-foot-mouth disease, 1867–1869, 1868f, 1869f
in herpangina, 1870, 1870f
in herpes simplex virus infections, 1873, 1874–1875, 1875f
in immunocompromised host, 1883
in neonate, 1879
treatment of, 1880, 1881b, 1883
in herpesvirus-6 infections, 651t, 1865
in histiocytosis, 649, 1417, 1419f, 1431f
in histoplasmosis, 653t, 1837–1838
in HIV infection and AIDS, 652t, 1932–1933
and candidiasis, 1823, 1932, 1936
and Kaposi sarcoma, 1186, 1186f, 1933
and oral hairy leukoplakia, 644, 1932–1933, 1933f
and papillomavirus infections, 1939
in hypereosinophilic syndromes, 308, 309f
infectious, 651t–653t, 651–654
in Kaposi sarcoma, 649, 649f, 651t, 1186, 1186f, 1933
in Kawasaki disease, 652t, 1628–1629, 1630
strawberry tongue in, 1628, 1630
in lentigines, 1121, 1121f
in leukoplakia, 1024–1025
in lichen planus, 246, 246f, 248–249, 645, 645f
malignant transformation in, 251, 251f
prognosis and clinical course in, 252
treatment of, 253b, 253–254
in linear IgA dermatosis, 488
of lip, 641–642. *See also* Lip
in lipoid proteinosis, 642t, 1289–1290, 1292f
in lupus erythematosus, 642t, 1452, 1524, 1524f, 1525, 1527
in lymphatic malformations, 1661
in measles, 651t, 1851, 1851f
of mucous membranes, 645–647
in Osler-Weber-Rendu disease, 1453, 1453f
in papillomavirus infections, 649, 652t, 1917, 1919, 1919f
in HIV infection and AIDS, 1939
in paracoccidioidomycosis, 653t, 1841, 1841f
in pemphigus
paraneoplastic, 470, 470f
vulgaris, 464f, 464–465, 646, 647f
periodontal, 645
in perioral dermatitis, 706, **709**–711
allergic, 141
clinical findings in, 710, 710f
differential diagnosis in, 710–711, 711b
treatment in, 711, 711b
pigmentation changes in, 648, 650
drug-induced, 2181
in Plummer-Vinson syndrome, 642t, 1452
in premalignant lesions, 648
of salivary glands, 644–645, 649–650
in scarlet fever, 652f, 1717–1718, 1718f
in Sjögren syndrome, 642t, 1578–1579, 1580, 1581, 1581t
treatment of, 1582, 1582t
in squamous cell carcinoma, 648–649, 1031, 1031f
prevention of, 1036
in syphilis, 1958, 1960
congenital, 647t, 652t, 1968, 1968f, 1968t, 1969, 1969f
tertiary, 1964, 1965f
of teeth. *See* Teeth
of tongue. *See* Tongue
traumatic, 650–651
in tuberculosis, 653t, 1773, 1773f
differential diagnosis of, 1773b
in tuberous sclerosis, 1327–1328
in venous malformations, 1658
in warts, 1032, 1032f, 1917, 1919, 1919f
in HIV infection and AIDS, 1939
in Wegener granulomatosis, 642t, 1610, 1613f
in xerostomia, 644
in Sjögren syndrome, 1578–1579
Oral-digital-facial syndrome, 642t
Orbit
invasion by basal cell carcinoma, 1038f
periorbital erythema in dermatomyositis, 1540, 1542t, 1543f, 1547
periorbital familial hyperpigmentation, 639
Orchialgia, 670
Orchitis in smallpox, 1902
Orchopeas howardii fleas, 1943t
Orf, 1900t, 1910–1911
clinical findings in, 1910, 1910f, 1910t
differential diagnosis of, 1909b, 1911
laboratory findings in, 1910t, 1910–1911
in occupational exposures, 2075–2076
treatment of, 1911
Organoid nevus, 1059
syndrome in, 1059
Oriental lung fluke disease, 2026
Oriental sore, 2003
Orientia tsutsugamushi, 1951–1952
Oritavancin, 2202
Ornithonyssus bacoti, 2032t, 2033
Oropharyngeal lesions in epidermolysis bullosa, 515
Oroya fever, 1749, 1750t, 1754–1755
treatment of, 1755
Orthohyperkeratotic keratoderma, 426, 430
Orthomyxovirus, 1846t
Orthopoxvirus, 1899–1908, 1900t
Osler nodes in endocarditis, 1453, 1453f, 1692, 1744
Osler-Weber-Rendu disease, 1453–1454, 1457, 1665
arteriovenous fistula in, 1379, 1453, 1454
gastrointestinal hemorrhage in, 1455
oral cavity disorders in, 642t, 1453f
Osmidrosis, 731
Osseous heteroplasia, progressive, 1296, 1297, 1297f
Ossification, **1293**–1297
aberrant, 1293–1294
in Albright hereditary osteodystrophy, 1296–1297
in fibrodysplasia ossificans progressiva, 1296
in plate-like osteoma cutis, 1296, 1297
primary, 1296–1297
in progressive osseous heteroplasia, 1296, 1297, 1297f
Osteitis in SAPHO syndrome, 701
Osteoarthritis and palmoplantar pustulosis, 216
Osteoarthropathy, hypertrophic, 554, 1450
Osteochondritis in syphilis, 1968
Osteodystrophy, Albright hereditary, 1296–1297, 1476
Osteogenesis imperfecta, 530t, **1310**–1311
clinical findings in, 1310, 1310f
treatment of, 1310–1311
Osteolipoma, 1191
Osteoma cutis, 1296, 1297
Osteomyelitis
in body piercing complications, 890t
in brucellosis, 1760
in decubitus ulcers, 881
palmoplantar pustulosis in, 216
in smallpox, 1902
Osteonecrosis in corticosteroid therapy, 2150–2151
management of, 2153
Osteopenia in Fabry disease, 1284t, 1285
Osteopontin, 109
Osteoporosis
in corticosteroid therapy, 2150, 2150t, 2152, 2152f
bone density measurements in, 2152, 2153f
calcium and vitamin D supplements in, 2152
in cyclosporine therapy, 2220
in Fabry disease, 1284t, 1285
in homocystinuria, 1304
in retinoid therapy, 2185
Ostomy procedures, abdominal, skin problems in, **868**–871
Ota nevus, 632, 632t, 633f
Otitis externa
in diabetes mellitus, 1465
in *Pseudomonas aeruginosa* infections, 1736–1737, 1738
seborrheic, 224

Otitis media in rotavirus infections, 1871
Outbreak investigation, 4–5
Outcome measures
critical appraisal of, 14–16
endpoints in, 15
in quantification of morbidity, 7
Outer-surface proteins in borreliosis, 1798, 1805
Ovary
cancer of, in dermatomyositis, 1549
polycystic syndrome of
acanthosis nigricans in, 1462
acne in, 695, 701–702
androgen excess in, 1481
Oxacillin, 2195t, 2198
Oxalosis, 576
Oxamniquine in schistosomiasis, 2015t, 2026
Oxatomide, 2188, 2189
Oxiconazole, 2117t, 2118
Oxidation of retinol, 2108–2109
Oxidative stress
aging of skin in, 964, 965f
in photoaging, 970
vitiligo in, 617
Oxime as chemical weapon, 2086t
Oxybenzone in sunscreens, 2139, 2139t, 2140
Oxygen
arterial saturation in cyanosis, 1378
and hemoglobin
deoxygenated, 1378, 1379
with low oxygen affinity, 1378, 1379
hyperbaric, 860
in soft tissue infections, 1730, 1743
as radiosensitizer, 860
Oxytalan, 63, 530
Oxyuriasis, 2013
Ozone, 799–800

P

P gene in oculocutaneous albinism, 611
P protein in melanosomes, 599
p16
in dysplastic nevus, 1124, 1125
in melanoma, 1136
in squamous cell carcinoma, 989, 991
p21, 980, 1002
in squamous cell carcinoma, 993
p53, 982t
in actinic keratosis, 1001, 1008
in DNA damage and repair, 608, 815, 980, 1001–1002, 1029–1030
in dysplastic nevus, 1124, 1125
in ectodermal dysplasia syndromes, 1343
as guardian of genome, 980, 1002
in HTLV-1 infections, 1924
in keratoacanthoma, 1050
in Li-Fraumeni syndrome, 995
in melanoma, 1001, 1136
in papillomavirus infections, 996
in squamous cell carcinoma, 989, 990f, 991, 1001, 1029–1030
as tumor suppressor gene, 1001
in ultraviolet radiation exposure, 815f, 1001–1002
and apoptosis, 815, 1029
clonal expansion of, 1003–1004
and DNA damage, 608, 815, 1029–1030
p55, 121
in tumor necrosis factor receptor-associated periodic syndrome, 1269
p63, 68t, 69, 72
in ectodermal dysplasia syndromes, 1344, 1345
p75, 121
p95, 982t
p105Rb, 996
Pacemakers, cardiac, preoperative assessment in, 2295
in electrosurgery, 2295, 2334
Pachydermodactyly, 553
Pachydermoperiostosis, 54, 554, 1450
localized hyperhidrosis in, 725
Pachyonychia congenita, 783–784, 784f
Jackson-Lawler, 427
type I, 427, 427f, 430–431, 783–784, 784t
oral cavity disorders in, 642t
type II, 427, 430, 784, 784t
epidermoid cyst in, 1063
steatocystoma multiplex in, 430, 1066
Pacinian corpuscles, 65–66, 66f
age-related changes in, 967
hyperplastic/hypertrophic, 1178
Paclitaxel in Kaposi sarcoma, 1187b, 1188
Padimate O in sunscreens, 2139t, 2140
Paederus beetles, 2060
Paget cells, 1095–1096, 1096f
Paget disease, **1094**–1098
clinical findings in, 1094–1096
complications of, 1096
differential diagnosis of, 1095, 1095b
epidemiology of, 1094
etiology and pathogenesis in, 1094
extramammary, 675, 1094–1096, 1507
differential diagnosis of, 1095, 1095b
prevention of, 1098
treatment of, 1097f, 1097–1098
laboratory tests in, 1095–1096, 1096f
malignancies associated with, 1507
mammary, 1094–1096, 1507
clinical findings in, 1094–1095, 1095f
differential diagnosis of, 1095, 1095b
prevention of, 1098
treatment of, 1096, 1097f
prevention of, 1098
prognosis and clinical course in, 1096
treatment of, 1096–1098
Mohs micrographic surgery in, 1097–1098, 2319
Pagetoid reticulosis, 1391, 1393f
PAHX in Refsum disease, 419
Pain
chronic atypical, 916–917
in cryoglobulinemia, 1639
in decubitus ulcers, 885
in Fabry disease, 1284, 1287, 1287b
genital
in female, 682–683
in male, 670–671
in herpes zoster and postherpetic neuralgia, 1888, 1888f, 1889, 1890, 1894
treatment of, 1896–1897
insensitivity to
congenital, 727
postoperative, 2341
nerves and receptors in, 896t–897t, 899f, 1888f
in palmoplantar keratoderma, 430–431
perineal, 670
postoperative, 2337–2338
in cryosurgery, 2333
in nail surgery, 2322
Paint application as body art, 886
Palate, cleft, with cleft lip and ectodermal dysplasia
and ankyloblepharon filiforme adnatum, 1343–1344, 1344f
and ectrodactyly, 1343, 1344–1345, 1345f
PAL-E antigen, 1589, 1590t
Pale cells
in acanthoma, 1062
in hibernoma, 1195
Palisades
in granuloma, 53, 371, 371f
in neuroma, 1177, 1177f, 1177t
in schwannoma, 1178, 1179, 1179f
Pallor in hematologic disorders, 1373–1377
Palmoplantar skin
in acanthosis nigricans, 1463, 1495, 1496–1497
in acrodermatitis continua, 215, 215t, 217–218
in acrokeratosis paraneoplastica, 1498, 1499, 1499f
in acropustulosis, 215, 215t
in arsenical keratosis, 1016, 1016f
in basal cell nevus syndrome, 1045, 1045f, 1046
blood vessels of, 64
in epidermolytic hyperkeratosis, 412, 412f, 412t, 413f
erythema of, 1451, 1451f
in graft-versus-host reaction, 261, 261f
in hand-foot-mouth disease, 1868, 1868f, 1869f
in hyperhidrosis, 723, 724b
in ichthyosis
lamellar, 410, 410f
vulgaris, 407, 407f
in keratoderma, **424**–431. *See also* Keratoderma, palmoplantar
in lichen nitidus, 256, 257f
in lichen planus, 249, 252b
nerves and receptors in, 65
in paraneoplastic syndromes, 1448, 1449f, 1494t, 1496–1497
in pool palm, 874t, 876, 877f
in porokeratosis, 444, 444f
in psoriasis, 430b
pustular eruptions of, 215t, **215**–218
in syphilis, 1959, 1960f
in tripe palm, 1496–1497, 1497f
in acanthosis nigricans, 1463, 1495, 1496–1497
in paraneoplastic syndromes, 1448, 1449f, 1494t, 1496–1497
in tyrosinemia, 1220, 1220f, 1222f
vesicular eczema of, **162**–167
in xanthoma, 1272, 1273f, 1274f
in yaws, 1980, 1980f, 1981
Panarteritis nodosa, cutaneous macroscopic, 51
Pancreatic disorders, 1456
necrolytic migratory erythema in, 1501–1502
panniculitis in, 577f, 577–578
and dystrophic calcification, 1294
in retinoid therapy, 2185
Pancytokeratin, 1070t
Pancytopenia in drug interactions, 2240t
Panda sign in sarcoidosis, 1490
Panfolliculoma, 1081
Panniculitis, **569**–585
in α_1-antitrypsin deficiency, 578–579, 579f
in brucellosis, 1760
classification of, 569, 570f
in cold exposure, 576, 851
drug-induced, 580, 581, 582–583
poststeroid, 582–583
eosinophilic, 585
nodular, 2022
equestrian, 576
factitial, 580
in gout, 583

histiocytic cytophagic, 583–584, 584f
iatrogenic, 580
infectious, 55, 579–580
lipomembranous, 585
lobular, 55, 569
neutrophilic, 573–574
with vasculitis, 573–575
without vasculitis, 575–584
in lupus erythematosus, 55, 576–577, 1525–1526, 1526f
histopathology in, 1529–1530
in Lyme disease, 1800t, 1802
membranocystic, 585
nodular, 55
eosinophilic, 2022
idiopathic, 584
relapsing febrile non-suppurative, 584
subacute migratory of Vilanova and Piñol, 573
pancreatic, 577f, 577–578
dystrophic calcification in, 1294
postirradiation sclerodermatous, 584
in *Pseudomonas aeruginosa* infections, 1738
sclerosing, 575–576
septal, 569–573
with vasculitis, 569–571
without vasculitis, 571–573
in systemic sclerosis, 1557
traumatic, 55, 580–581
in venous insufficiency, 1681
Panniculitis-like T-cell lymphoma, subcutaneous, 1393–1394
with γ/δ phenotype, 1395
Panniculus, atrophy of, 28
Panton-Valentine leukocidin, 1691, 1720, 1748
PAPA syndrome, 701
Papaverine injection, complications of, 667
Papillae
of hair follicle, 743f, 744, 746
of tongue, 641
hypertrophy of, 643–644, 644f
Papilloma, in papillomavirus infections, 1917–1922
Papillomatosis, 1071
in acanthosis nigricans, 1495
confluent and reticulated, of Gougerot and Carteaud, 422, 422f
in epidermal nevus, 1058, 1058f
oral, 1032, 1032f, 1919, 1919f
respiratory, 1917, 1919, 1922
Papillomatous dermatitis, chronic, in urostomy, 869f, 869–870
Papillomavirus infections, 995t, 996–998, 1846, 1846t, 1848
anogenital cancer in, 663, 997
in HIV infection, 1939
Bowen disease in, 663, 1021
Bowenoid papulosis in, 663, 1020–1021, 1021f, 1918
carcinoma in situ of penis in, 663
cervical cancer in, 996–997, 1921
prevention of, 1922
clinical findings in, 663, 663f, 1849, 1917–1920
complications in, 663–664, 1920–1921
diagnosis of, 1920
differential diagnosis of, 663, 664b, 1920, 1921b
epidemiology of, 1917
epidermodysplasia verruciformis in, 277, 996, 997–998, 1005, 1021, 1029, 1914, 1918–1919
and squamous cell carcinoma, 277, 1005, 1021, 1029, 1919f
erythroplasia of Queyrat in, 663, 1023
genome of virus in, 1914, 1914f
high risk, 996, 1915, 1916, 1920–1921
histopathology in, 1919–1920, 1920f
HPV-1, 1916
HPV-6, 1850
as low risk, 1915, 1916
vaccination against, 1922
HPV-11, 1850
as low risk, 1915, 1916
vaccination against, 1922
HPV-16
cervical cancer in, 996–997, 1915
as high risk, 1915, 1916
in HIV infection and AIDS, 1939
skin cancer in, 997
vaccination against, 997, 1850, 1922
HPV-18
cervical cancer in, 1915
as high risk, 1915, 1916
vaccination against, 997, 1850, 1922
HPV-38, skin cancer in, 997
in immunocompromised host, 277–278, 663–664, 1918
cancer risk in, 1921, 1933
in HIV infection and AIDS, 663–664, 1918, 1920, 1921, 1933, 1938–1939, 1939f
keratoacanthoma in, 1050
koilocytes in, 1919, 1920
low risk, 996, 1915, 1916
male genital disorders in, 663f, 663–664, 664b, 674
in occupational exposures, 2075
oral cavity disorders in, 649, 652t, 1917, 1919, 1919f
pathogenesis in, 1915–1917
prevention of, 1922
replication of virus in, 1846–1847, 1847f, 1848, 1916
squamous cell carcinoma in, 277, 1029, 1036, 1920–1921
in Bowenoid papulosis, 1020
cervical, 996
cutaneous, 997, 1005, 1029
in epidermodysplasia verruciformis, 277, 1005, 1021, 1029, 1918, 1919f
in immunocompromised host, 277–278, 1939, 1939f
of penis, 674
subgroups and types of, 996, 1914–1915, 1915t
transmission of, 1917, 1921, 1922
treatment of, 277, 664, 664b, 1921–1922
and ultraviolet radiation effects, 997
vaccination against, 1850, 1922
virion of virus in, 1846, 1847f, 1914, 1916
warts in. *See* Warts, in papillomavirus infections
Papillon-Lefèvre syndrome, 425t, 427f, 427–428, 430
oral cavity disorders in, 642t, 645
Papular stomatitis virus, bovine, 1900t, 1909
Papules, 26, 26f
in acne vulgaris, 693, 693f, 694f
in atopic dermatitis, 149, 150f
in Degos disease, 1648, 1649f
in dermatitis of Spangler, 961
in dermatosis papulosa nigra, 1056, 1056f
differential diagnosis in, 1747b
fibrous follicular, 1081
genital, 661b
pearly penile, 555, 657
of nose, solitary, 555
in pruritic eruption of HIV infection, 1931–1932, 1932f
in pruritic urticarial papules and plaques of pregnancy, 492, 958t, 960–961
in purpuric gloves-and-socks syndrome, 1856
in Sweet syndrome, 290, 290f–291f
in syphilis, 1958–1959, 1959f, 1960f
in urticaria, 336
in viral infections, 1849t
Papulosis
Bowenoid, 663, 1020–1021, 1021f
lymphomatoid, 237, 241, 1386, 1392–1393, 1394f
malignant atrophic, 1456, **1648**–1651
approach to patient with, 1649f
benign, 1648, 1649
classic, 1648, 1649, 1650
clinical findings in, 1648–1649, 1649f
differential diagnosis of, 1650b
epidemiology of, 1648
etiology and pathogenesis in, 1648
histopathology in, 1649–1650, 1650f
laboratory tests in, 1649–1650
papules in, 1648, 1649f
prognosis and clinical course in, 1650
secondary, 1649, 1650
treatment of, 1650–1651, 1651b
Papulosquamous disorders in elderly, 972, 972t
PAR-2 (protease-activated receptor-2), 604, 1589
in atopic dermatitis, 900
in pruritus, 904
Para-aminobenzoic acid
in dermatomyositis, 1552
in sunscreens, 2139t
Paraben, 2094, 2095, 2362
in corticosteroid preparations, 2106, 2106t
paradoxical dermatoses from, 141
Paracoccidioides brasiliensis, 1840–1841
in oral cavity disorders, 653t
Paracoccidioidomycosis, 1840–1841
oral cavity disorders in, 653t, 1841, 1841f
Paraffinoma, 580
Paragonimiasis, 2012t, 2026
differential diagnosis of, 2013t, 2021t
treatment of, 2015t, 2026
Paragonimus westermani, 2012t, 2013t, 2021t, 2026
Parakeratosis, 45, 45f, 48
in Bowen disease, 1022
infantile granular, 943
in lichen nitidus, 257, 257f
in parapsoriasis, 238, 239f
in psoriasis, 170, 171
pustulosa, 790, 790f
Paralysis
spastic
and palmoplantar keratoderma, 429–430
tropical, 1926
in syphilis, 1966, 1969
in tick bites, 2059
Paramedian forehead flap, 2310, 2313f
after Mohs micrographic surgery, 2319f
Paramyxovirus, 1846t, 1847
Paraneoplastic syndromes, 1448, **1493**–1507
acrokeratosis of Bazex in, 165, 1498–1499, 1499f
bullous disorders in, 1503
collagen-vascular disease in, 1499–1500
in cutaneous metastases, 1506
dermal deposition in, 1502–1503
dermal proliferative disorders in, 1502
dermatoses in, 1493–1499, 1502
erythema in, 1500–1502

Paraneoplastic syndromes—*continued*
in familial cancer syndromes, 1504
hyperkeratosis in, 1493–1499
hypertrichosis in, 1503
in leukemia, 1506–1507
in lymphoma cutis, 1506–1507
pemphigus in, **468**–474, 1503
in Castleman disease, 468, 469, 473, 1410
Trousseau syndrome in, 1503–1504
vasculitis in, 1601
Parangi, 1979–1981. *See also* Yaws
Paraparesis, tropical spastic, 1926
Paraphenylenediamine
contact allergic dermatitis from, 889, 2362, 2363t
in temporary tattoos, 889
Paraphimosis, 656, 656f
Paraplegia, spastic, and palmoplantar keratoderma, 429–430
Parapoxvirus infections, 1900t, 1908–1911
Paraproteinemia
and erythema elevatum diutinum, 1619
and necrobiotic xanthogranuloma, 1432
and scleredema, 1563, 1564
and scleromyxedema, 1564–1565
and sub-corneal pustular dermatosis, 305, 306
Parapsoriasis, **236**–240
classification of, 236, 236t
clinical findings in, 237f, 237–238, 238f
complications in, 239–240
diagnosis and differential diagnosis of, 238–239, 239t, 240b
epidemiology of, 236
etiology and pathogenesis, 236–237, 237f
histopathology in, 238, 238f, 239f
large plaque or patch, 236, 237, 237f, 238f, 238–239, 239f, 240b
prognosis and clinical course, 240
retiform, 238, 238f
small plaque or patch, 236, 238, 238f, 239, 239f, 240b
treatment of, 240
Parasitic infections, 2001–2037
burrows in, 29, 29f
delusions of, 908, 912–913
dystrophic calcification in, 1295
in elderly, 973
filarial, 2017t, 2017–2021
helminthic, 2011–2028
in immunocompromised host, 277, 277f
in HIV infection, 1940
leishmaniasis, 2001–2007
in occupational exposures, 2076
scabies, 2029–2032
topical medications in, 2133–2134, 2133t
Parasitosis, delusions of, 908, 912–913
Parasympathetic nervous system, anatomy of, 896
Parathyroid disorders, **1474**–1477
clinical findings in, 1475f, 1475t, 1475–1476, 1476f
epidemiology of, 1474
etiology and pathogenesis of, 1474–1475
hyperparathyroidism. *See* Hyperparathyroidism
hypoparathyroidism. *See* Hypoparathyroidism
laboratory tests in, 1476–1477
treatment of, 1476t, 1477
Parathyroid hormone, 1474–1477
and calcium serum levels, 1293, 1474–1475, 1476
in chronic renal failure, 1295
in hyperparathyroidism, 1474
in hypoparathyroidism, 1474
Paravaccinia virus, 1900t
in milker's nodules, 1908–1910, 2076
occupational exposure to, 2076
transmission of, 1909
Parenteral nutrition
biotin deficiency in, 1213
hair changes in, 1452
Paresis
in syphilis, 1966, 1969
tropical spastic, 1926
Paresthesia in notalgia paresthetica, 907
Parkes Weber syndrome, 1651, 1654, 1665
treatment of, 1666
Parkinsonism from antipsychotic drugs, 917
Parkinson disease
anhidrosis in, 727
hyperhidrosis in, 726
Paronychia, 783
acute, 784–785, 785t
nail surgery in, 2323–2324
candidal, 1702, 1824, 1826f
in diabetes mellitus, 1465
treatment of, 1828
chronic, 786
surgery in, 2328
in paraneoplastic acrokeratosis of Bazex, 1498, 1499f
in *Pseudomonas aeruginosa* infections, 1736, 1737, 1738
staphylococcal, 1702, 1702f
Parotid gland enlargement, 645
differential diagnosis of, 1579b
infectious, 1579b, 1579f
in Sjögren syndrome, 1578–1579, 1579b
Paroxetine, 918t
interaction with other drugs, 2239t, 2240t
in pruritus, 911t
Parrot's lines in syphilis, 1968
Parry-Romberg syndrome, 543, 545, 1801
Partington syndrome, 1257
Paru, 1979–1981. *See also* Yaws
Parulis, 653
Parvovirus, 1846t
Parvovirus B19 infections, 1855–1858
aplastic crisis in, 1855, 1856, 1857, 1858
treatment of, 1857b
chronic, 1857
clinical findings in, 1855–1856, 1856f
differential diagnosis of, 1857b, 1949b
fetal, 1857
papular purpuric gloves-and-socks syndrome in, 1856
in pregnancy, 1855, 1857
prevention of, 1858
transmission of, 1855
treatment of, 1857, 1857b
Pasini type of epidermolysis bullosa, 508t, 511
Pastes, topical medications formulated as, 2094
Pasteurella multocida
in bite wounds, 1757t, 1761, 2038
treatment of infections, 1757t, 1761, 2038, 2197t
Pastia's sign in scarlet fever, 1717
Patau syndrome (trisomy 13), 81t
Patch lesions, 30, 30f
in vitiligo, 30, 30f
Patch testing, 138, 143, 400
in actinic dermatitis, chronic, 823
common allergens in, 136t, 136–137
complications of, 144
cosmetic products in, 2361–2362
cost-benefit analysis of, 144
in drug hypersensitivity, 361
in fragrance allergy, 2362
in irritant contact dermatitis, 399, 400, 2072
in lichen planus, 248–249, 251
in lymphomatoid contact dermatitis, 1411
in occupational exposures, 2072
in photosensitivity, 833–834
in vulvar disorders, 678
PATCHED1/Patched1, 988, 989t
in basal cell carcinoma, 989, 989t, 993, 994, 1043
in basal cell nevus syndrome, 68t, 1042–1043, 1043f, 1044, 1045, 1046, 1048
functions of, 1043
in hair follicle development, 740f, 741
in hedgehog signaling pathway, 988, 1042, 1043, 1043f
Patches for transdermal drug delivery, 2096
Paterson-Kelly syndrome, 1452
Pathergy test in Behçet disease, 1624
Pathogenicity islands, genetic, virulence factors in, 1691
Pathologic reactions, **43**–55
reticular dermis, 49–55
subcutaneous fat, 55
superficial reactive unit, 43–49
Pathophysiology of skin disease, **87**–90
Pattern hair loss, 754–755, 755t, 766–769
clinical features in, 767–768
differential diagnosis of, 767
epidemiology of, 766
etiology of, 766–767
in female, 766–767, 768, 768b, 768f, 769
hair transplantation in, 2394, 2395
genetic factors in, 766
hair restoration surgery in, 769, 2394–2402
hair transplantation in, 769, 2394–2402
Hamilton-Norwood classification of, 766, 767, 767f
histopathology in, 766, 766f
in male, 766, 767, 768b, 768–769, 1452
hair transplantation in, 2394, 2395
management of, 768–769, 2394–2402
Pattern recognition receptors in innate immunity, 97–98, 1513, 1690
Paul-Bunnell test in mononucleosis, 1859
Pautrier's microabscess, 1410, 1412
in adult T-cell leukemia, 1925, 1925f
in mycosis fungoides, 1390, 1391f
Pavement epithelium, formation of, 67–69
PAX3, 68t
in rhabdomyosarcoma, 1176
in Waardenburg syndrome, 613–614
PAX7 in rhabdomyosarcoma, 1176
PD-1 (programmed cell death 1), in autoimmune disorders, 1510, 1511–1512
Pearly penile papules, 555, 657
Peat fire cancers in Ireland, 1017
Peau d'orange appearance, 316
in diabetes mellitus, 1464
in erysipelas, 1721
in pseudoxanthoma elasticum, 1307
in scleredema, 1563
PECAM-1 (platelet/endothelial cell adhesion molecule 1), 1589, 1592t, 1594
Pederin, 2060
Pediatric dermatology, **935**–954. *See also* Children and infants
Pedicle flap, 2309
Pediculosis, 2033–2037
capitis, 2033f, 2033–2035
differential diagnosis of, 2034b

drug resistance in, 2034–2035
nits in, 2033, 2033f, 2034
treatment of, 2034b, 2034–2035
corporis, 2035
differential diagnosis of, 2035b
pubis, 663, 2035–2037, 2036f
differential diagnosis of, 2036b
in HIV infection, 2037
macula cerulea in, 2036, 2036f
treatment of, 2036–2037, 2037b
Pediculus humanus, 1752, 1943t, 2033, 2035
Peeling skin syndromes, 405t, 421
Peels
chemical. *See* Chemical peels
cryopeels in actinic keratosis, 1014
Peliosis, hepatic and splenic, 1749, 1752–1754
in HIV infection, 1935–1936
Pelkan sign in vitamin C deficiency, 1213
Pellagra, 1209–1211, 1210f
in carcinoid syndrome, 1210
clinical findings in, 1210, 1210f
drug-induced, 834, 1210
Pelvic inflammatory disease
in chlamydial infections, 1995, 1997
in gonorrhea, 1995
Pemberton's sign in goiter, 1474
Pemphigoid
Brunsting-Perry, 483, 496, 497f
bullous, 33, 33f, 47, 58, **475**–480
clinical findings in, 477–478, 478f
collagen XVII in, 456, 456f, 476, 520
compared to pemphigoid gestationis, 491
differential diagnosis of, 367t, 479, 479b, 496, 497f, 499
diseases associated with, 478–479
drug-induced, 359, 359t
elastase in, 534
in elderly, 475, 478, 480, 972t, 973
electron microscopy in, 475
epidemiology of, 475
etiology and pathogenesis in, 475–477
exfoliative dermatitis in, 230t
hemidesmosomes in, 456, 476, 477
histopathology in, 478, 479f
immunopathology in, 475f, 475–476, 476f
and lichen planus, 479
localized disease, 478
malignancies associated with, 1503
pathophysiology in, 476–477, 477f
pemphigoid antigens in, 476, 477, 477f
precipitating factors in, 478
prognosis and clinical course in, 479–480
sub-epidermal cleft formation in, 47, 47f
treatment of, 480, 480b
cicatricial, **481**–485
anti-epiligrin, 482t, 483
clinical findings in, 481–483, 482f, 666
complications of, 484, 484t
differential diagnosis of, 479, 483–484, 484b, 496, 497f
dysphagia in, 1451
epidemiology of, 481
etiology and pathogenesis in, 481, 481f
genital, 666, 681
immunofluorescence in, 481f, 483
laboratory tests in, 483
oral cavity disorders in, 481, 482f, 484, 484t, 485b, 646
pemphigoid antigens in, 481, 482t
prognosis and clinical course in, 484
treatment in, 484–485, 485b, 666
differential diagnosis of, 348b, 367t, 479, 479b, 483–484, 484b, 492, 493b, 493f
epidermolysis bullosa acquisita in, 496, 497f, 499
gestationis, **490**–493, 955–956, 958t
clinical findings in, 491, 491f, 492f
compared to bullous pemphigoid, 491
complications in, 492
differential diagnosis in, 492, 493b, 493f
epidemiology of, 490
etiology and pathogenesis in, 490–491
histopathology in, 491, 492f
laboratory tests in, 491–492
prevention of, 493
prognosis and clinical course in, 492–493
treatment of, 493
Pemphigoid antigens, bullous. *See* Bullous pemphigoid antigens
Pemphigus, **459**–474
acantholysis in, 46, 46f, 459
histopathology in, 466
pathophysiology of, 462–463
chronic benign, 61, 439. *See also* Hailey-Hailey disease
classification of, 459, 459t
clinical manifestations in, 464–466
differential diagnosis in, 465b
diseases associated with, 466
drug-induced, 358–359, 359t, 465–466
epidemiology of, 460
erythematosus, 459
clinical manifestations in, 465
diseases associated with, 466
histopathology in, 466
immunofluorescence in, 461
etiology and pathogenesis in, 460–464
familial benign, 46
chronic, 439. *See also* Hailey-Hailey disease
foliaceus, 60, 90, 459t, **459**–468
acantholysis in, 462
blistering in, 61, 448, 462, 465, 466
clinical manifestations in, 465, 466f
desmoglein compensation in, 462, 463f
desmosome pathology in, 448
differential diagnosis in, 306
diseases associated with, 466
electron microscopy in, 461
endemic, 460, 465
enzyme-linked immunosorbent assay in, 462
epidemiology of, 460
etiology and pathogenesis in, 460–464
exfoliative dermatitis in, 230t
histopathology in, 466, 467f
HLA system in, 464
immunofluorescence in, 461, 461f
neonatal, 462, 465
pemphigus antigens in, 461
prognosis and clinical course in, 466–467
sporadic, 460
treatment of, 467
genetic restriction of immune response in, 463–464
histopathology in, 466, 466f, 467f
HLA system in, 84, 463–464
immunoglobulin IgA, 459, 459t, 1375t
and sub-corneal pustular dermatosis, 305, 306
immunopathology in, 461–462
neonatorum, 1697
paraneoplastic, 459, 459t, **468**–474, 1375t, 1495t, 1503
in Castleman disease, 468, 469, 473, 1410
clinical findings in, 470f, 470–471
diagnostic algorithm on, 472, 473f
differential diagnosis of, 348b, 469, 470, 472, 474b
epidemiology of, 469
etiology and pathogenesis in, 469–470
exfoliative dermatitis in, 230t
histopathology in, 471–472, 472f
immunopathology in, 472
laboratory tests in, 471–472
lichenoid variant of, 470
prevention of, 474
prognosis and clinical course in, 472–473
respiratory disorders in, 471, 472–473
treatment of, 473–474, 474b
tumors associated with, 468, 469, 469f
pathology in, 466
prognosis and clinical course in, 466–467, 472–473
superficial, 459
syphilitic, 1968, 1968f
treatment of, 467–468, 473–474, 474b
vegetans, 459
differential diagnosis in, 436
of Hallopeau, 459, 464
of Neumann, 459, 464
vulgaris, 58, 60, 61, 459t, **459**–468, 1375t
acantholysis in, 46f, 60, 462–463, 466
autoantibodies in pathogenesis of, 88–89, 462
blistering in, 448, 460–461, 462–463, 464, 464f, 466
clinical manifestations in, 464f–465f, 464–465
desmoglein compensation in, 462, 463f
desmosome pathology in, 448
differential diagnosis in, 436
diseases associated with, 466
electron microscopy in, 460–461
enzyme-linked immunosorbent assay in, 462
epidemiology of, 460
etiology and pathogenesis in, 460–464
histopathology in, 466, 466f
HLA system in, 463–464
immunofluorescence in, 461, 461f
neonatal, 462, 465
oral cavity disorders in, 464f, 464–465, 646, 647f
pemphigus antigens in, 461
prognosis and clinical course in, 466–467
treatment of, 467–468
of vulva, 681
Pemphigus antigens, 461
Penciclovir, 2205
dosage of, 2205t
in herpes simplex virus infections, 1880, 1881b, 1883, 2205, 2205t
Pencil-in-cup deformity in psoriatic arthritis, 200
Penetration stage in dermatophyte infections, 1811
Penicillamine
side effects and complications of, 1306b
elastosis perforans serpiginosa in, 566
pemphigus in, 465–466
in systemic sclerosis, 1560t

Penicillin, 2197–2198
in actinomycetoma, 1786
in actinomycosis, 1781
dosage of, 2195t, 2198
in children, 950t
in endemic non-venereal treponematosis, 1982
in erysipeloid, 1766
indications for, 2198, 2198b
in Lyme disease, 1804, 1806t
in lymphedema, 1686
mechanism of action, 2197–2198
in meningococcal infections, 1734
pharmacokinetics of, 2198
in rheumatic fever, 1574
side effects and complications of, 2196t, 2198
hypersensitivity reactions in, 2198
in soft tissue infections, 1729b, 1729–1730
in streptococcal pyoderma, 1705, 1707, 1707b
in syphilis, 1973–1977
and HIV infection, 1970
Penicilliosis, 276, 1836, 1841–1842
differential diagnosis of, 1838
in HIV infection and AIDS, 1841, 1842, 1937
Penicillium marneffei, 276, 1836, 1841–1842
in HIV infection and AIDS, 1841, 1842, 1937
Penis, 654–675
acne of, 671
anatomy and landmarks of, 655, 655f
Bowen disease of, 663, 673, 673f, 674b
Bowenoid papulosis of, 673, 673f, 674b
carcinoma in situ of, 672–674
differential diagnosis of, 673–674, 674b
in papillomavirus infections, 663
treatment in, 674, 674b
chancroid of, 1983f, 1984, 1984f
cosmetic piercing of, 890t
drug eruptions of, 666–667
edema of, 672
chronic idiopathic, 671, 671f
erythroplasia of Queyrat of, 673, 673f, 674b, 1023, 1023f, 1024
fibromatosis of, 552
foreskin of, 655, 656, 656f
gonorrhea of, 1994, 1994f
granuloma inguinale of, 1991, 1991f
in hypereosinophilic syndromes, 309f
lichen planus of, 246f, 249
lymphogranuloma venereum of, 1987, 1987f
melanocytic nevi of, 657
melanoma of, 674–675
melanosis and lentiginosis of, 668, 668f
necrosis of, 660b
normal variants of, 657
papillomavirus infections of, 655, 663f, 663–664, 664b
cancer in, 655, 997
pearly papules of, 555, 657
prominent veins of, 657
psoriasis of, 664f, 664–665, 665f
squamous cell carcinoma of, 655, 672–674, 1031, 1032
clinical findings in, 673, 674f
differential diagnosis of, 673–674, 674b
risk factors for, 672, 672t
treatment in, 674
thrombophlebitis of, 672
Penodynia, 670
Pentamidine in African trypanosomiasis, 2008
Pentazocine, 923, 925
Pentoxifylline
in peripheral arterial disease, 1670b, 1670–1671
in pigmented purpuric dermatosis, 1636
in sarcoidosis, 1492, 1492t
in venous ulcers, 1683, 2348
Peptic ulcer disease in corticosteroid therapy, 2149, 2150t
Peptides, antimicrobial, 1690
in innate immunity, 96–97, 1695
Peptococcus, 1747
Peptostreptococcus, 1747
Perforating disorders, acquired, **564**–567
in diabetes mellitus, 564, 1459, 1469
differential diagnosis in, 566b, 566–567
in kidney disorders, 564, 567, 1459–1460
treatment in, 567, 567b
Perforin, 104
Perianal disorders. *See* Anal and perianal disorders
Pericytes, 1586–1587
Periflexural exanthem of childhood, asymmetric, 1849, 1871–1872, 1872b, 1872f
Perifollicular sheath, 744
Perifolliculitis
capitis abscedens et suffodiens, 773
nodular, of legs, 1814t
Perineum, 654
erythema of, recurrent toxin-mediated, 1719
hemangioma in infant, 1166
Kawasaki disease of, 1628, 1628f
pain in, 670
protrusion in infant, 942
sebaceous glands in, 654
prominent, 657
sweat glands in, 654
Perineural invasion
of basal cell carcinoma, 1038, 1041
of melanoma, 1140
Perineurioma, 1180–1181
extraneural, 1180
immunohistochemistry of, 1177t, 1180, 1181
intraneural, 1180, 1181
Periodic fever, hyperimmunoglobulinemia D with, 1267–1269
Periodic syndrome, tumor necrosis factor receptor-associated, 1267t, 1269–1270
Periodontal disease, 645
Periodontitis, 645
Perioral dermatitis, 706, **709**–711
allergic, 141
clinical findings in, 710, 710f
differential diagnosis in, 710–711, 711b
granulomatous, 710, 710f, 711
treatment in, 711, 711b
Periorbital erythema in dermatomyositis, 1540, 1542t, 1543f, 1547
Periorbital hyperpigmentation, familial, 639
Peripheral nerve sheath tumor, malignant, 1181
staining of, 1177t, 1181
Peripheral nervous system
anatomy of, 896
disorders of
anhidrosis in, 722t, 727–728
hyperhidrosis in, 722t, 724–725, 726
leprosy affecting, 1788, 1794
in skin pathophysiology, 900–901
Peripheral vascular disorders
arterial, **1667**–1678
approach to patient with, 1668f
in atherosclerosis, 1667–1673
clinical findings in, 1667–1668, 1668t
complications of, 1670
differential diagnosis of, 1669–1670, 1670b, 1675
intermittent claudication in, 1667, 1669, 1670–1671
prognosis and clinical course in, 1670
in thromboangiitis obliterans, 1673–1676
treatment of, 1670b, 1670–1671
venous, **1679**–1684
approach to patient with, 1681f
clinical findings in, 1679t, 1680–1682, 1681f, 1682f
complications of, 1682
differential diagnosis of, 1682, 1683b
etiology and pathogenesis in, 1679–1680, 1680f
prognosis and clinical course in, 1682
signs and symptoms in, 1679t
treatment of, 1682–1684, 1683b, 1684f
Periplakin, 388
in paraneoplastic pemphigus, 471, 471f
Periporitis staphylogenes, 1698
Perlecan, 63, 539t
in basement membranes, 450, 451, 451b, 452, 452f, 454
Perlèche, 641, 1823, 1823f. *See also* Cheilitis, angular
Permeability barrier function of skin, 57, 58t
Permethrin, 2063, 2133, 2133t
in pediculosis pubis, 2037b
in scabies, 2031b
Pernio, 849–850, 850f
differential diagnosis of, 1646
Perniosis, 849–850
Peroxisomal biogenesis disorder complementation group 11, 419
Peroxisome proliferator-activated receptors (PPAR), 386–387, 589
in lipodystrophy, 586, 588
in sebaceous gland activity and sebum production, 689
Personal protective equipment in occupational exposures, 2072–2073
Petechiae, 33
differential diagnosis of, 1381t
in viral infections, 1849t
Petrolatum, in surgical wounds, 2113, 2114
Petroleum products, skin cancer associated with, 987, 987t
Peutz-Jeghers syndrome, 633, 634f, 1456, 1505t
lentigines in, 1117, 2273
oral cavity disorders in, 642t, 648
PEX7 in Refsum disease, 419
Peyronie disease, 552, 2281
Pfisteria piscicida, 2053t
pH, vaginal
in bacterial vaginosis, 2000
in trichomoniasis, 1998, 1999
PHACE syndrome, infantile hemangioma in, 1166
Phaeohyphomycosis, 1835
Phagocytosis, 97–99, 283, 327
in dermis, 64
disorders of, 1348, 1349t, 1362–1370
melanosome, 603, 604
pattern recognition receptors in, 97–99
Phakomatosis
pigmentokeratotica, 1056–1057, 1060, 1061
pigmento-vascularis, 1653, 1654
Pharmacodynamics in drug interactions, 2236, 2237, 2237t

Pharmacokinetics
of antibiotics, 2194
of antimalarial drugs, 2158–2159, 2159t
of corticosteroids
systemic, 2147–2148
topical, 2103–2104
in drug interactions, 2236–2237, 2237t
ADME model on, 2237, 2237t
in psoralen and PUVA therapy, 2251
of topical drugs, 2097–2102
antifungal, 2118, 2119
barrier function of skin affecting, 2102
corticosteroid, 2103–2104
diffusion in, 2097
formulation affecting, 2099
resorption in, 2101–2102
skin metabolism in, 2101
three-compartment model of, 2097–2101, 2098f, 2099t
Pharyngitis
acute lymphonodular, 651t
in diphtheria, 1767, 1768
gonococcal, 1994, 1995
streptococcal, 1703, 1704
differential diagnosis of, 1949b
scarlet fever in, 1717, 1718
in syphilis, 1960–1961
Phase contrast microscopy in trichomoniasis, 1999, 1999f
Phenol
in chemical peels, 2370, 2370t
in pruritus, 2134, 2134t
Phenolic compounds, occupational exposure to, 2069t
Phenothiazine, 2187, 2190, 2191
Phenylalanine
in alkaptonuria, 1228, 1228b
metabolic pathway of, 1221f, 1225, 1225f
in phenylketonuria, 1222–1224
in tyrosinemia, 1222, 1222b, 1222f
Phenylalanine hydroxylase, 1225f
deficiency of, 1219t, 1222, 1223
Phenylbenzimidazole sulfonic acid in sunscreens, 2139t
Phenylketonuria, 1219t, 1221f, **1222**–1224
clinical features in, 1223
differential diagnosis of, 1223b, 1223–1224
pigmentation in, 1223
treatment of, 1224, 1224b
Phenytoin
hypersensitivity syndrome from, 357f
hypertrichosis from, 776
Pheochromocytoma
hyperhidrosis in, 726
hyperpigmentation in, 634–635
in multiple endocrine neoplasia syndrome, 1178
in neurofibromatosis, 1336
Pheohyphomycosis, 1835
Pheomelanin, 600, 601f, 748, 1004–1005
in photosensitization, 813
synthesis of, 601–602
Pheomelanosomes, 596, 596f
Phialophora verrucosa, 1833
Philtrum, 2290, 2290f
Phimosis, 656, 656f, 665
causes of, 656, 657t
Phlebectomy, ambulatory, in varicose veins, 2356
Phlebitis, 1684
Mondor, 672, 1684
and postphlebitic syndrome, 1680
Phleboliths in venous malformations, 1658
Phlebotomus sand fly, 2060
as leishmaniasis vector, 2002, 2002t, 2006
Phlebotomy
in polycythemia vera, 1378
in porphyria cutanea tarda, 1241–1242
Phosgene as chemical weapon, 2086t
Phosphatidylinositol bisphosphate, 433, 433f
Phosphatidylinositol 3-kinase, 281
Phosphocan, 539t
Phosphodiesterase type 5 inhibitors in systemic sclerosis, 1559, 1559t, 1561
Phosphorus, occupational exposure to, 2069t, 2070t
Phospho-tyrosine phosphatase, vascular endothelial (VE-PTP), 1589
Photoaging, 815, 815f, 963, 968–971, 2363
action spectrum in, 970–971
clinical and histologic features in, 968, 968t
compared to intrinsic aging of skin, 968f, 969
differentiated from rosacea, 707
heliodermatitis in, 969, 969f
laser therapy in, 2268, 2273
for skin resurfacing, 2277, 2364–2369
mechanisms in, 969–970
and melanocyte aging, 608
in photochemotherapy, 2258
retinoid therapy in, 2109, 2111
smoking affecting, 971
wrinkling of skin in, 968, 968f, 2363
Photoallergy, 828, 832–834
agents associated with, 830t, 833
cosmetic products, 2362
cytotoxic drugs, 2179
sunscreens, 830t, 833, 2140
ultraviolet filters, 2140
clinical manifestations in, 833, 833f
compared to phototoxicity, 828, 828t, 833
differential diagnosis in, 833, 834
histopathology in, 833
management of, 833
solar urticaria in, 823–824
tests in evaluation of, 833–834
Photocarcinogenesis, 977, 978f, 979f, **999**–1006, 2112
cascade of events in, 978f
Photochemical reactions, 803–805, 804f
action spectrum in, 805
bimolecular, 804
excited state molecules in, 804, 804f
intersystem crossing in, 804, 804f
photoproducts in, 804–805
photosensitivity in, 805
in psoralen and UVA therapy, 2250, 2251f
Photochemotherapy, 2249–2259
contraindications to, 2258–2259
erythema in, 2251–2252
extracorporeal, 1399, 2259. *See also* Photopheresis
indications for, 2252–2257, 2258
photosensitivity in, 2251–2252
principles of, 2249–2252
side effects and toxicity of, 2257t, 2257–2259
treatment protocols in, 2252, 2252t
Photodermatitis
contraindication to phototherapy in, 2246
from plants, 638
Photodermatology, 797
Photodynamic therapy, 2260–2262
in acne vulgaris, 700, 2262
apoptosis in, 831
in basal cell carcinoma, 1041, 2261, 2261f
indications for, 2260–2262, 2261t
in keratoacanthoma, 1053
light sources and dosimetry in, 2260
in lymphoid hyperplasia, 1408, 1408b
mechanism of action in, 2260
in Paget disease, 1098
photosensitizers in, 2260
phototoxicity in, 829t, 831, 831f
chronic effects of, 832
in psoriasis, 190, 2261
Photography as visual aid in diagnosis, 41f, 41–42
in dysplastic nevus, 1130, 1132
of hair problems, 756t
Photoimmunosuppression, 805–809, 812–813, 1003
cellular events in, 807f, 807–808
hypersensitivity response in, 806, 806f, 808, 808f, 812f, 812–813
and immune protection factor of sunscreens, 2138
molecular targets in, 806–807
Photomechanical interactions in laser therapy, 2266
Photons, 797, 799, 2263
Photopatch testing
in chronic actinic dermatitis, 823
in photosensitivity, 827, 833–834
Photopheresis, 2259
in atopic dermatitis, 158
in epidermolysis bullosa acquisita, 499
in graft-versus-host disease, 266, 266t, 267, 267t, 2259
indications for, 2260t
mechanism of action in, 2259
in systemic sclerosis, 1559t
in T-cell lymphoma, 1399, 2259
Photophobia
with ichthyosis follicularis and alopecia, 751, 752–753
in keratosis follicularis spinulosa decalvans, 751
Photoproducts, 803, 804–805
phototoxic, 831
Photoprotection, **2137**–2142
antioxidants in, 813–814
clothing in, 2141
glass in, 2141t, 2142
in lupus erythematosus, 1532
skin functions in, 57, 58t
sunglasses in, 2142
sunscreens in, 2137–2141
tanning in, 813
Photosensitivity, 805, 813, 825–827, **828**–834
action spectrum in, 805
chronic actinic dermatitis in, 821t, 832
clinical features in, 825–826
criteria on, 821t
in dermatomyositis, 1539, 1540
desensitization in, 816, 2247, 2256
in solar urticaria, 825, 2256–2257
differential diagnosis in, 833, 834
drug-induced, 805, 828, 828t–830t
from cytotoxic drugs, 2179, 2179t
in elderly, 972t
in HIV infection and AIDS, 1932
from retinoids, 2112, 2185
excited state molecules in, 805
in HIV infection and AIDS, 1932
incidence of, 828
in lupus erythematosus, 1516, 1520, 1527
in phenylketonuria, 1223, 1224
photoallergy in, 828, 832–834
in photochemotherapy, 2251–2252
photosensitizers in, 805, 2260
porphyrin as, 1233, 1234f, 1234–1235, 1235f, 2260
phototoxicity in, 828, 829–832
polymorphic light eruption in, 1246

Photosensitivity—*continued*
in porphyrias, 1233, 1234f, 1234–1235, 1235f
clinical manifestations in, 1238
congenital erythropoietic, 1248, 1249
in erythropoietic protoporphyria, 1233, 1243, 1244, 1244f, 1245, 1246–1247
variegate, 1252, 1253
reactive oxygen species in, 805
from tattoo pigments, 888
tests in evaluation of, 826–827, 833–834
in trichothiodystrophy, 420, 758, 759t, 1321
Photosensitizers, 805, 2260
porphyrin as, 1233, 1234f, 1234–1235, 1235f, 2260
Phototests, 802
in actinic dermatitis, chronic, 823
in actinic prurigo, 819
in atopic dermatitis, 2246
in hydroa vacciniforme, 820
in photosensitivity, 826–827, 833–834
in polymorphic light eruption, 818
in solar urticaria, 824
Phototherapy, 798, **2243**–2262
in acne vulgaris, 700
in actinic dermatitis, chronic, 822f, 823, 2257
in actinic keratosis, 1014–1015
in actinic prurigo, 819
action spectrum in, 805, 2251
in allergic contact dermatitis, 145
in alopecia areata, 765, 2255
in atopic dermatitis, 156–157, 158, 2248, 2255
in acute severe disease, 2245–2246, 2246f
in chronic moderate disease, 2246
in combination with other agents, 2254
contraindications to, 2258–2259
DNA damage in, 978t, 2250
emission spectra in, 800, 801f, 2243, 2244, 2244f
erythema in, 2251–2252
fluorescent lamps used in, 800, 2251
in graft-versus-host disease, 266t, 266–267, 267t, 2255–2256
in granuloma annulare, 2255
in hidradenitis suppurativa, 737–738
in HIV infection, 2257, 2259
and eosinophilic folliculitis, 1931
indications for, 2249, 2250t, 2252–2257
in irritant contact dermatitis, 400
keratoacanthoma in, 1050
keratosis in, 1020
laser use in, 2279
lentigines in, 1119, 1120f, 1120–1121, 2258
in lichen nitidus, 258
in lichen planus, 254b, 254–555, 2255
in linear scleroderma, 546
in lupus erythematosus, 2248
in mastocytosis, 1442, 1442b, 2255
mechanism of action, 2248–2249, 2249f, 2250–2251
melanoma in, 1135, 2258
minimal erythema dose in, 2244
in morphea, 546, 2247, 2255
in mycosis fungoides, 2248
nail changes in, 792, 2257
in palmoplantar pustulosis, 217b
in parapsoriasis, 240
in perforating disorders, 567, 567b
photochemical reactions in, 804, 2250, 2251f
photosensitivity in, 2251–2252
phototoxic response to, 831
pigmentation changes in, 636, 2252, 2256
in pigmented purpuric dermatosis, 1636
in pityriasis lichenoides, 243b, 2255
in pityriasis rubra pilaris, 235, 236b, 2255
in polymorphic light eruption, 818, 2246–2247, 2256
principles of, 2249–2252
in pruritus, 911
pruritus in, 2257
with psoralen and UVA radiation, 2249–2259. *See also* Psoralen and PUVA therapy
in psoriasis, 185, 189, 190–191, 2243–2245, 2250–2254, 2259
in children, 189b
in pregnancy, 189b
scattering of UVR in, 802
in seborrheic dermatitis, 225
side effects and complications of, 2257t, 2257–2259
skin cancer risk in, 987–988, 1000, 1002, 1020, 2258
in solar urticaria, 824–825, 2256–2257
squamous cell carcinoma risk in, 1000, 2258
in sub-corneal pustular dermatosis, 306, 307b
in T-cell lymphoma, 1397, 1398, 2248, 2254f, 2254–2255
extracorporeal photochemotherapy in, 1398, 1399
treatment protocols in, 2252, 2252t
in urticaria pigmentosa, 2247–2248, 2255
in vesicular palmoplantar eczema, 166, 2248
in vitiligo, 620b, 620–621, 2248, 2256
Photothermolysis
fractional, 2268
for skin rejuvenation, 2373, 2373f
for skin resurfacing, 2277, 2369, 2369f
selective, 2266
Phototoxicity, 797, 805, 828, 829–832
acute, 831
agents associated with, 828t, 829t, 832
chronic actinic dermatitis in, 832
clinical manifestations in, 831f, 831–832, 832f
compared to photoallergy, 828, 828t, 833
of cosmetic ingredients, 2361
differential diagnosis in, 833, 834
energy transfer process in, 830
histopathology in, 832
lentigines in, 1120
leukoderma punctata in, 630
long-term, chronic effects in, 832
management of, 832
nail changes in, 792
pathophysiology in, 829–831
phytophotodermatitis in, 638
of tar preparations, 828t, 832, 2078
tests in evaluation of, 833–834
Phototrichogram, 756t
Phototypes of skin, 809, 810t, 1004
melanoma risk in, 1135
photoaging in, 969, 969f
photoimmunosuppression in, 812f, 812–813
Phrynoderma
in vitamin A deficiency, 1204–1205
in vitamin C deficiency, 1213
Phycomycosis, 1843
subcutaneous, 1835
Phylloquinone, 1207
Phyma in rosacea, 704–705, 706f
treatment of, 709
Physalia physalis, 877, 2043, 2043f, 2045t
Physalia utriculus, 877
Physical abuse, skin signs in, **927**–931
Physical examination, 24t, 25–26
visual aids to inspection in, **40**–42
Physician visits, annual number of, 6–7, 7t
Phytanic acid in Refsum disease, 418, 419
Phytanoyl-coenzyme A hydroxylase, 68t, 69
deficiency of, 419
Phytonadione, 1207–1208
Phytophotodermatitis, 638
Phytosterolemia, 1272t, 1279
Pian, 1979–1981. *See also* Yaws
Pian bois (new world cutaneous leishmaniasis), 2003
Pianomas, 1979–1980
Picornavirus, 1846t
Piebaldism, 592, 608–609, 615, 622
Piedra, 1821
black, 1821
white, 1821
Piedraia hortae, 1821
Piercing of body parts, cosmetic, 886, 889–890
complications in, 889–890, 890t
Pigment mosaicism, 69
Pigment network in melanoma, 1143, 1143f, 1144f
Pigmentary demarcation lines, 623, 626f
Pigmentation, 62
in acanthosis nigricans, 1494
in Addison disease, 634, 1478, 1479f
in aging, 608
in photoaging, 968t
in albinism, **608**–616
in alkaptonuria, 1226, 1227
in Angelman syndrome, 612
in basal cell carcinoma, 1037, 1037f
differential diagnosis in, 1040b
histopathology in, 1039
in carotenemia, 1205, 1206
in Chédiak-Higashi syndrome, 613, 1367, 1368f
chemical agents affecting, 628f, 628–629
in cirrhosis, 1446
in classification of facial skin type, 2362–2363, 2364t
congenital disorders of, **608**–616
complications in, 615
differential diagnosis in, 615, 615b
in hypermelanosis, 631–634
in hypomelanosis, 622–623
prognosis and clinical course in, 615
treatment in, 616
in Cushing syndrome, 634, 1478
in dermatomyositis, 1542
diagnostic algorithms on disorders of, 624f–625f
in Dohi reticulate acropigmentation, 640
in drug abuse, 924
drugs affecting, 636–637, 637t, 1227, 1397
antimalarial, 636, 637, 1227, 2161, 2162t
bleomycin, 636, 2124, 2178, 2178f
corticosteroid, 2106
cyclophosphamide, 636, 2173
cytotoxic, 2178f, 2178–2179, 2179f, 2179t
laser therapy in, 2274, 2275f
pigmented purpuric dermatosis in, 1633, 1634t
in ectodermal dysplasia, 1340, 1341f, 1342f
in epidermal necrolysis, 353–354
in epidermolysis bullosa simplex with mottled pigmentation, 507, 508t

ethnic and racial differences in, 2111, 2142–2146
in follicular cyst, 1079
genetic disorders of, **608**–616
genital, 658b
in Griscelli syndrome, 1369
of hair, 747–748
in graying and depigmentation, 608, 630, 967
molecular control of, 748
in hematologic disorders, 1374t
in hemochromatosis, 635–636, 1214, 1446
in HIV infection and AIDS, 1932
in hypermelanosis, **631**–640
in hypomelanosis, **622**–631
in incontinentia pigmenti, 631, 631f, 2145
in jaundice, 1447
laser skin resurfacing affecting, 2368
in lichen planus pigmentosus, 247–248
in lichen sclerosus, 629, 678, 679f
in lupus erythematosus, 626–627, 1523, 1523f
in macules, 30, 30f
in melanoma, 636, 636f
in morphea, 544, 546
in mycosis fungoides, 627, 1636
of nails, 783, 783f, 2177
in nevomelanocytic nevi, 1105, 1106
in nevus spilus, 1103
nutrition affecting, 629–630, 635
occupational exposures affecting, 2068t
in onchocerciasis, 628, 628f, 638, 667, 2020
oral, 648, 650
in patch lesions, 30, 30f
pathology and diagnosis in changes of, 30t
in phenylketonuria, 1223
in photochemotherapy, 2252
in phototoxic reactions, 831, 831f, 832, 832f
physical agents affecting, 629
in pituitary disorders, 629, 634, 1483
in porphyria cutanea tarda, 1238
post-inflammatory changes in, 639, 639f, 2111, 2142–2146
postoperative changes in, 2341
in Prader-Willi syndrome, 612
in pregnancy, common changes in, 635, 955, 956t, 957f
in protein-energy malnutrition, 1203
in pruritus, 905
in purpuric dermatoses, **1633**–1636
radiation affecting, 861
salt and pepper, 626
in sarcoidosis, 626
in scleroderma, 626, 627f
sclerotherapy for varicose veins affecting, 2353–2354
in seborrheic keratosis, 1055–1056
in selenium deficiency, 629, 1217
and skin cancer risk, 1004–1005
and skin color changes, 1446, 2363
in spindle cell nevus, 1112–1113, 1113b, 1113f
in syphilis, 1960
in tanning response, 606–607
in thyroid disorders, 629, 635, 1473
in Tietz syndrome, 615
in treponematosis, 627, 627f, 1978f, 1978–1979, 1979f
in ultraviolet radiation exposure, 606–607, 636, 2363
in variegate porphyria, 1252, 1253f
in vitamin B_{12} deficiency, 1212, 1446, 1456
in vitiligo, 30, 30f, 62, **616**–622
in Waardenburg syndrome, 613–614
Pigments in tattoo ink, 887, 887f, 887t
reactions to, 888, 888f
Pilar cyst, 1064–1065, 1065f
Pilar sheath acanthoma, 1081
Pilar tumors, proliferating, 1082, 1082f
Pili annulati, 760
Pili torti, 756, 757–758, 759f
acquired, 770
hereditary, 757
Pilocarpine in Sjögren syndrome, 1582, 1583
Piloleiomyomas, 1172, 1173
Pilomatrical carcinoma, 1084–1085, 1085f
Pilomatricoma, 1081–1082, 1082f
dystrophic calcification in, 1295
genetic factors in, 988, 989t
Pilosebaceous unit, 687
acne as disorder of, 690
drug abuse affecting, 924
embryonic development of, 1068
nevus comedonicus of, 1059–1060
Pimecrolimus, 114, 126, 2125–2129, 2217, 2221
in allergic contact dermatitis, 145
in atopic dermatitis, 155, 2128
clinical results with, 2126
contraindications to, 2128
indications for, 2128
initiation of therapy with, 2128–2129
in lichen planus, 253b, 254, 681
in lichen sclerosus, 549, 679
in lupus erythematosus, 1533, 1533t
mechanism of action, 2126, 2217
monitoring of therapy with, 2129
pharmacokinetics of, 2128
in pigmented purpuric dermatosis, 1636
in pruritus, 909, 909t
in psoriasis, 190
in rosacea, 708
in seborrheic dermatitis, 224
side effects of, 2129
in vesicular palmoplantar eczema, 166
in vulvar skin disorders, 677, 679, 681
Pimozide, 917t
side effects of, 917, 917t, 918
Pincer nails, 793
surgery in, 2329
Pinch purpura in amyloidosis, 1258–1260
Ping-pong, 874t
Pinkus corpuscles, 65
Pinta, 1977, 1978–1979
clinical manifestations in, 1982t
differential diagnosis of, 1979b
pigmentation changes in, 627, 627f, 638, 1978f, 1978–1979, 1979f
treatment of, 1982
Pintids, 627, 638
Pinworm infections, 2012t, 2013
Piperacillin, 2198
Piperazine, 2187
Piperidine, 2187
Pitalugo's sign in visceral leishmaniasis, 2006
Pitch acne, 2078
Pitch keratosis, 1018, 2078
Pitting
of dental enamel in tuberous sclerosis, 1327
of nails, 782, 782f
of stratum corneum in keratolysis, 1707–1708, 1708f
Pituitary adenylate cyclase-activating polypeptide (PACP), 898
in inflammatory response, 898t
in pruritus, 897t
Pituitary disorders
anemia in, 1377
in corticosteroid suppression of adrenal-hypothalmic-pituitary axis, 2105, 2106, 2148, 2149–2150, 2150t, 2151
growth hormone deficiency in, 1483
growth hormone excess and acromegaly in, 1482–1483
pigmentation changes in, 629, 634, 1483
Pityriasis
alba, 623–626, 627f
pigmenting variant, 624
amiantacea, 222, 222f, 223
alopecia in, 771, 771f
treatment of, 224
lichenoides, 237, **240**–243
chronica, 236, 240–243, 241f, 242f, 243b
clinical findings in, 241f, 241–242, 242f
complications in, 242–243
differential diagnosis in, 242, 243b, 365, 365b
epidemiology of, 240
et varioliformis acuta, 236, 240–243, 241f, 242f, 243b
etiology and pathogenesis of, 240–241
histopathology in, 242, 242f
photochemotherapy in, 2255
prognosis and clinical course in, 243
treatment of, 243, 243b, 2255
with ulceronecrosis and hyperthermia, 241
ulceronecrotic, 241, 242f
rosea, **362**–366, 1849
Christmas tree pattern in, 362, 364, 364f
clinical findings in, 363f, 363–365
complications in, 365
differential diagnosis in, 365, 365b
drug-induced, 365
epidemiology of, 362
etiology and pathogenesis of, 362–363
herald patch in, 363, 363f–364f
in herpesvirus-7 infections, 362–363, 1849, 1867
histopathology in, 365, 365f
laboratory tests in, 365
prognosis and clinical course in, 365–366
scaling lesions in, 31t, 362, 363, 363f
secondary eruption in, 363–364, 365f
treatment in, 366, 366b
vesicular, 364, 365f
rubra pilaris, **232**–236
classification of, 233, 233t
clinical findings in, 233–234, 234f, 235f
complications of, 234
differential diagnosis in, 235b
epidemiology of, 232
etiology and pathogenesis in, 232–233
exfoliative dermatitis in, 225, 230t
follicular papules in, 233, 234f
juvenile types, 233, 233t, 234, 235f
pathology in, 234
photochemotherapy in, 235, 236b, 2255
prevention of, 235
prognosis and clinical course in, 234
retinoids in, 235, 236b, 2183
treatment of, 234–235, 236b, 2183, 2255
sicca, 221
steatoides, 221
versicolor, 623, 626f
treatment of, 2120t, 2214t, 2215
Pityrosporum, 276, 1828–1830, 2119
PKD1, 1325
Placodes
epidermal, 71, 71f
epithelial, in hair follicle development, 740–741

Plague, 1757t, 1758–1759
in bioterrorism, 1759, 2082t, 2083–2084
bubonic, 1758, 1759, 2083, 2084
in occupational exposures, 2084
pneumonic, 1758, 1759, 2083, 2084
septicemia in, 1758, 1759
treatment of, 1757t, 1759
vaccination against, 2084
Plakoglobin, 60, 60t, 68t, 447–448
functions of, 449
in paraneoplastic pemphigus, 471
in pemphigus, 463
skin diseases associated with, 449, 449t
in woolly hair disorders, 760
Plakophilin, 60, 60t, 68t, 447, 448
functions of, 449
skin diseases associated with, 449, 449t, 512
Planck's law, 799
Plants
allergic contact dermatitis from, 138, 140
and herbal remedies, 2285
phytophotodermatitis from, 638
Plaque, 26, 26f
anchoring, in dermal-epidermal junction, 450f, 451, 458
degenerative collagenous, of hands, 554
fauches en prairie, in syphilis, 1960
fibrous facial, in tuberous sclerosis, 1326, 1329f
in Kaposi sarcoma, 1186
of male genitalia, 658b, 659b, 661b
in pityriasis rosea, 363, 363f–364f
in pruritic urticarial papules and plaques of pregnancy, 492, 958t, 960–961, 961f
in psoriasis, 178
in Sweet syndrome, 290, 290f–291f
in syphilis, 1960, 1963, 1963f
Plasma membrane fusion in melanosome transport, 603
Plasmacytoid dendritic cells, 108, 114
in atopic dermatitis, 148
in psoriasis, 172–173
Plasmacytoma growth factor, 124. *See also* Interleukins, IL-6
Plasmapheresis
in cholestasis of pregnancy, 959
in epidermal necrolysis, 354
in pemphigus, 468
paraneoplastic, 474, 474t
Plasmid host cell reactivation assay, 984–985, 985f
Plasminogen activator inhibitor in disseminated intravascular coagulation, 1748
Platelet(s)
differential diagnosis of disorders, 1381t
drug-induced disorders of, 2336t, 2337
in Wiskott-Aldrich syndrome, 1357
Platelet-activating factor
functions of, 1436
in photoimmunosuppression, 806, 807, 807f
synthesis of, 1593
Platelet-derived growth factor, 1597, 1597t, 2223t, 2226
recombinant, 2226, 2235
in wound healing, 2343, 2344, 2344t
in diabetes mellitus, 2226, 2235, 2348
Platelet-derived growth factor receptors, 307, 309, 1588
Platelet/endothelial cell adhesion molecule 1, 1589, 1592t, 1594
Plectin, 68t, 456
in epidermolysis bullosa with muscular dystrophy, 508
in hemidesmosomes, 456
in paraneoplastic pemphigus, 471, 471f
Pleomorphic lipoma, 1193f, 1193–1194
Pleomorphic liposarcoma, 1198
Pleural effusion lymphoma, 1184
PLOD1 in Ehlers-Danlos syndrome, 1298t, 1300–1301
Plumber's itch, 2023
Plumboporphyria, 1233
Plummer's nails in hyperthyroidism, 1471
Plummer-Vinson syndrome, 1214, 1452
oral cavity disorders in, 642t, 1452
Pmel17 in melanosomes, 598–599
PMS1, 980t
PMS2, 980t
Pneumonia
in *Haemophilus influenzae* infections, 1739
in hyper-IgE syndrome, 1366, 1367t
varicella, 1893, 1895, 1895t
Pneumonitis, interstitial, in dermatomyositis, 1545
Podofilox in warts, 2136
Podophyllin, 2124
in molluscum contagiosum, 1913t
side effects of, 2124
in warts, 664b, 1922, 2124
Podophyllotoxin, 2124
side effects of, 2124
in warts, 664b, 1922, 2124, 2136
Podopompholyx, 162
POEMS syndrome, 1374t, 1375t
Castleman disease in, 1409
localized hyperhidrosis in, 725
Poikiloderma, 28–29, 29f
atrophicans vasculare, 237, 627
in dermatomyositis, 1540, 1542t, 1548
in chronic radiodermatitis, 29, 29f, 861, 861f
congenital, with traumatic bulla formation, anhidrosis, and keratoderma, 426
differential diagnosis in, 238b
in dyskeratosis congenita, 1324, 1324f
laser therapy in, 2272, 2374
in mycosis fungoides, 1388
in parapsoriasis, 237, 238, 238b, 238f
pigmentation in, 627
Poikilodermatomyositis, 1540, 1542t
Poikilothermia in peripheral artery atherosclerosis, 1667
Poison bun sponge, 2046, 2046f
Poison ivy allergy, 138, 140
Pol gene and protein in erythema multiforme, 344, 347
Polidocanol
in pruritus, 909t, 910, 2354
in sclerotherapy for varicose veins, 2352, 2353t
Poliosis
definition of, 754t
in vitiligo, 619
in Waardenburg syndrome, 614, 614f
Pollitt syndrome, 759t, 1321
Polyangiitis
microscopic, 51, 1599, 1602, 1607, 1613–1615
treatment of, 1615
systemic, 1599
Polyarteritis nodosa, 1613–1615
in Churg-Strauss syndrome, 1612, 1613
clinical findings in, 1609f, 1614, 1614f
cutaneous, 571, 572f
in hepatitis B, 1457
livedo reticularis and starburst appearance in, 1614, 1614f
microscopic, 51
treatment of, 1615
Polychlorinated biphenyl
chloracne from, 2078, 2079t
skin cancer associated with, 987t
Polychondritis, relapsing, 1452, **1567**–1569
clinical findings in, 1567, 1567f, 1568f
diagnostic criteria in, 1568b
differential diagnosis of, 1569b
diseases associated with, 1569b
treatment of, 1568–1569
Polycyclic aromatic hydrocarbon exposure, skin cancer risk in, 2079t, 2079
Polycyclic lesions, 34, 35f
Polycystic disease
epidermal, 1065
of ovary
acanthosis nigricans in, 1462
acne in, 695, 701–702
androgen excess in, 1481
Polycythemia vera, 1377–1378
diagnostic criteria in, 1378
oral cavity disorders in, 642t
skin color changes in, 1446
treatment in, 1378
Polyendocrinopathy
autoimmune, with candidiasis and ectodermal dysplasia, 763, 1354–1355, 1355t, 1356, 1510
in X-linked syndrome with immune dysregulation and enteropathy, 1355
Polyene antifungal agents, 2117t, 2119–2120
Polykeratosis of Touraine, 426
Poly-L-lactic acid in soft tissue augmentation, 2382t, 2384–2385, 2385f
Polymerase chain reaction
in bacterial infections, 1693
in chancroid, 1985
in hand-foot-mouth disease, 1868
in herpes simplex virus infections, 1877
in herpesvirus-6 infections, 1866
in leishmaniasis, 2006
in Lyme disease, 1803
in lymphogranuloma venereum, 1989
in measles, 1852
in papillomavirus infections, 1920
in parvovirus B19 infections, 1857
real-time, 985
reverse transcriptase
in leprosy, 1792, 1794
in melanoma, 1154
in Rocky Mountain spotted fever, 1942
in smallpox, 1902
in syphilis, 1973, 1973t
in T-cell lymphoma, 1388, 1390
in tuberculosis, 1770
in viral infections, 1850
Polymorphic eruptions
in cold exposure, familial disorder, 851
in light, 816–818. *See also* Light eruptions, polymorphic
in pregnancy, 492, 960–961
Polymorphisms, 77–78, 78f
in drug metabolism, 2238, 2239t
non-pathogenic, 77, 78f
single nucleotide, 77
Polymorphonuclear leukocytic infiltrates in reticular dermis, 53
Polymyalgia rheumatica, 1615
Polymyositis
classification of, 1537t
and dermatomyositis, 1536, 1536t

dysphagia in, 1452
epidemiology of, 1537
Polymyxin B, 2113t, 2115
with bacitracin and neomycin, 2115
in methicillin-resistant staphylococcal infections, 2114
Polyomavirus, 1846t
SV40, 1848
Polyps, 1456
of dental pulp, 647
familial adenomatous, 553
fibroepithelial, 554–555
hamartomatous, 1456
Polyvinyl chloride exposure, scleroderma-like disorders in, 1562
Pompholyx, 162–167
clinical findings in, 163–164, 164f
differential diagnosis in, 217
prognosis and clinical course in, 166
treatment in, 166
Pool palm, 874t, 876, 877f
Popliteal artery occlusion, 1670
PORCN in focal dermal hypoplasia of Goltz, 1347
Porfimer sodium in photodynamic therapy, 2260–2261
Pork tapeworm, 2027–2028
Porocarcinoma, eccrine, 1079
Porokeratosis, **442**–445
actinic, 83
disseminated superficial, 442b, 443, 443f
in CAP syndrome, 444
in CDAGS syndrome, 444
clinical course and prognosis in, 445
clinical findings in, 443f, 443–444, 444f
coronoid lamella in, 442, 444–445, 445f
differential diagnosis in, 445, 445b
disseminated superficial, 442, 442b, 443
actinic, 442, 442b, 443, 443f, 445
in immunosuppression, 443
etiology and pathogenesis in, 442–443
genetic factors in, 442
genital, 667
histopathology in, 444–445, 445f
in immunosuppression, 442, 443, 445
linear, 442b, 443–444, 444f
differential diagnosis in, 445, 445b, 1058
of Mibelli, 442b, 443, 443f, 445, 667
palmaris et plantaris disseminata, 442b, 444, 444f
punctate, 442b, 444
palmoplantar, 429, 430, 442, 444
treatment of, 445, 445b
variants of, 442, 442b, 443–444
Poroma, eccrine, 1075–1076, 1076f
Porophobilinogen, 1229t
Porphobilinogen, 1229f, 1229t, 1231f
in urine, in porphyrias, 1240t, 1250, 1253, 1255
Porphobilinogen deaminase, 1230t
in acute intermittent porphyria, 1249–1250
in regulation of heme biosynthesis, 1230
Porphyrias, **1228**–1256
acute, 1233, 1249t, 1249–1254
clinical findings in, 1232–1233, 1234
neurovisceral symptoms in, 1251–1252, 1253
pathophysiology in, 1234
treatment of, 1251b, 1251–1252
acute intermittent, 1233, 1233t, 1234, 1249t, 1249–1252
biochemical features of, 1240t, 1250
clinical manifestations of, 1250
differential diagnosis of, 1250, 1252
drug-induced disorders in, 1250, 1250t, 1251
epidemiology of, 1249
etiology of, 1249–1250
neuropathy in, 1250
neurovisceral disorders in, 1251–1252
prevention of attacks in, 1252
treatment of, 1250–1252, 1251b
in δ-aminolevulinic acid dehydratase deficiency, 1233, 1234, 1249t, 1254
biochemical features of, 1240t
treatment of, 1251b
animal models on, 1256
biochemical features of, 1240t
classification of, 1231–1233
complement system in, 1235
congenital erythropoietic, 1233, 1233t, 1235t, 1247–1249
biochemical features of, 1240t, 1248
clinical manifestations of, 1248, 1248f
differential diagnosis of, 1248
epidemiology of, 1247
etiology of, 1247–1248
gene therapy in, 1256
histopathology in, 1248
oral cavity disorders in, 642t, 647t, 1248, 1248f
photosensitivity in, 1248, 1249
treatment of, 1241b, 1249
cutanea tarda, 54, 834, 1233, 1233t, 1235t, 1235–1242
animal models of, 1256
biochemical features of, 1240t
clinical manifestations in, 1238f, 1238–1239, 1239f
differential diagnosis of, 496, 499, 1239, 1241, 1252
dystrophic calcification in, 1294
epidemiology of, 1235
etiology and pathogenesis in, 1235–1238
gene therapy in, 1256
in hemodialysis, 1236, 1239, 1243, 1459
histopathology in, 1239–1241, 1241f
in HIV infection and AIDS, 1236, 1237–1238, 1241, 1932
hypermelanosis in, 635
hypertrichosis in, 1238, 1238f
laboratory findings in, 1239
sclerodermoid plaques in, 1238–1239, 1239f
sub-epidermal blistering in, 1239, 1241f
treatment of, 1241b, 1241–1242
antimalarial drugs in, 1242, 2160
type I (sporadic), 1236
type II (hereditary or familial), 1236
type III, 1236
cutaneous findings in, 1374t, 1375t, 1376t
diagnostic procedures in, 1254–1255
dual or coexisting, 1236, 1255
erythropoietic protoporphyria, 1243–1247
gene therapy in, 1256
hepatoerythropoietic, 1233, 1233t, 1235t, 1242–1243
biochemical features of, 1240t, 1243
clinical manifestations in, 1238, 1243, 1243f
differential diagnosis of, 1243
epidemiology of, 1243
treatment of, 1241b, 1243
hereditary coproporphyria, 1249t, 1253–1254
molecular genetics in, 1255f, 1256
neurocutaneous, 1231–1232, 1233
non-acute, 1233–1249
pathophysiology in, 1233–1234
signs and symptoms in, 1233–1234
photosensitivity in, 1233, 1234f, 1234–1235, 1235f
in congenital erythropoietic porphyria, 1248, 1249
in erythropoietic protoporphyria, 1244, 1244f
in variegate porphyria, 1252, 1253
porphyrin-heme biosynthesis in, 1228, 1229f, 1230–1231, 1231f
pseudoporphyria, 1243
variegate, 1231, 1233, 1233t, 1234, 1236, 1249t, 1252–1253
abdominal pain in, 1253, 1455
biochemical features of, 1240t, 1253
clinical manifestations of, 1252–1253, 1253f
differential diagnosis of, 1239, 1241, 1252, 1253, 1292b
epidemiology of, 1252
etiology of, 1252
photosensitivity in, 1252, 1253
treatment of, 1251b, 1253
Porphyrin, 1228
and heme biosynthesis, 1228–1231, 1229f, 1231f
normal values, 1229t
as photosensitizer, 1233, 1234f, 1234–1235, 1235f
in photodynamic therapy, 2260
in sideroblastic anemia, 1256
in urine, in porphyria cutanea tarda, 1239
Porphyromonas, 2038
Portuguese man-of-war stings, 877, 2042, 2043, 2043f, 2045t
Port-wine stain, 1652–1656
laser therapy in, 1655, 2270f, 2270–2271, 2271f
selective photothermolysis in, 2266
Positioning techniques in decubitus ulcers, 883–884
Postherpetic neuralgia, 1888, 1894
risk factors for, 1894
symptoms in, 1894
treatment of, 1896–1897, 2130
Posthitis, 670f
xerotica, 656
Post-inflammatory hyperpigmentation, 639, 639f
ethnic considerations in, 2111, 2142f, 2142–2144, 2143f, 2144f
Postmature infants, skin of, 935, 936f
Postoperative care, 2301, 2337–2341
in cryosurgery, 2333
in electrosurgery, 2335
in excisional surgery, 2313
and flap procedures, 2310
patient instructions in, 2313, 2314b
in hair transplantation, 2400–2401
in laser skin resurfacing, 2369
in nail surgery, 2322–2323
Postpartum period, leprosy in, 1790
Post-perfusion syndrome, 1863
Postphlebitic syndrome, 1680
Post-test probability, 17, 17f
Potassium
in composition of sweat, 717, 717f
in mechanisms of sweat secretion, 718, 718f
Potassium hydroxide
as diagnostic stain in hair infections, 756t
occupational exposure to, 2070t

Potassium iodide
in sporotrichosis, 1832
in Sweet syndrome, 294, 295b
Potassium permanganate, 2132t, 2135
in pyoderma gangrenosum, 301
Poultices, topical drug application in, 2093
Povidone-iodine, 1694, 2131t, 2132
in preoperative skin preparation, 2295
in tinea capitis, 1819
toxicity in children, 946t
Powders, topical medications formulated as, 2093
Power density in laser therapy, 2266
Poxvirus infections, 1846, 1846t, **1899**–1913
molluscum contagiosum in, 1911–1913
orthopoxvirus, 1899–1908
parapoxvirus, 1908–1911
replication of virus in, 1847
virion of virus in, 1846, 1847f
PPAR (peroxisome proliferator-activated receptors), 386–387, 589
in lipodystrophy, 586, 588
in sebaceous gland activity and sebum production, 689
Prader-Willi syndrome, 82, 612
Pramoxine in pruritus, 909t, 910, 2134, 2134t
Prayer sign, in diabetes mellitus and limited joint mobility, 1463, 1463f
Praziquantel
in cysticercosis, 2014t, 2028
in paragonimiasis, 2015t, 2026
in schistosomiasis, 2015t, 2026
Prealbumin, 1470
Pre-B cell, 321–322
Pre-B cell receptors, 322
Precancerous lesions, epithelial, **1007**–1027
Prednisolone
in alopecia areata, 765
chemical structure of, 2148, 2148t
in cutaneous drug reactions and HIV infection, 1934
in dermatomyositis, 1551
in hemangioma of infants, 1168
in hidradenitis suppurativa, 737
indications for, 2149
in Kawasaki disease, 1632
in leprosy, 1795b
pediatric dosage, 952t
in pemphigoid gestationis, 493
in pemphigus, 468
potency and duration of action, 2148t
in reactive arthritis, 214
in seborrheic dermatitis, 224
Prednisone
in acne vulgaris, 699
in androgen excess, 1482
in B-cell lymphoma, 1401
in bullous pemphigoid, 480, 480b
chemical structure of, 2148t
in children, 946
dosage in, 952t
in cicatricial pemphigoid, 484–485, 485b
in dermatomyositis, 1551
in drug-induced cutaneous reactions, 361
in HIV infection, 1934
in epidermolysis bullosa acquisita, 499t
in graft-versus-host disease, 265f, 267t
in hemangioma of infants, 1168
in herpes zoster virus infections, 1896
in HIV infection
in drug-induced cutaneous reactions, 1934
in eosinophilic folliculitis, 1931
in hypereosinophilic syndromes, 310
immunosuppressive effects of, 2151
intramuscular, 2148
in leprosy, 1795b, 1795–1796
in lichen planus, cutaneous, 254
oral, 2148–2149
osteoporosis from, 2150
in pemphigoid gestationis, 493
in pemphigus, 467–468
paraneoplastic, 474, 474t
in pityriasis lichenoides, 243b
potency and duration of action, 2148, 2148t
in pyoderma gangrenosum, 301b
in sarcoidosis, 1491, 1492t
tapering of, 2150, 2151
in tinea capitis, 1819
in urticaria and angioedema, 341, 342f
Pregnancy, **955**–962
anaplasmosis in, 1950b
antibiotics in, 2195
antihistamines in, 2190, 2191, 2193
antimalarial drugs in, 2162, 2162t
atopic eruption in, 961, 962
azathioprine in, 2168, 2168t
bacterial vaginosis in, 1999, 2000, 2000b
candidiasis in, 1822
chlamydial infections in, 1997, 1998b
cholestasis in, 956–959, 958t
common cutaneous changes in, 955, 956t
corticosteroid therapy in, 2151
topical, 2104
cyclophosphamide contraindication in, 2172, 2173, 2173t
cyclosporine therapy in, 2220
Degos disease in, 1649
dermatomyositis in, 1550
dermatoses in, **955**–962, 958t
associated with fetal risk, 955–960
dysplastic nevus in, 1132
eczema in, 962
in Ehlers-Danlos syndrome, 1299, 1300, 1302
ehrlichiosis in, 1950b
estrogen levels in, 1479
fluconazole in, 2215
folate supplements in, 1377
gonorrhea in, 1995, 1996
granuloma inguinale in, 1993
griseofulvin in, 2216
herpes simplex virus infections in, 940, 1879
treatment of, 1880
impetigo herpetiformis in, 959–960
interferon-α in, 2224
interferon-γ in, 2225
itraconazole in, 2214
leprosy in, 1790
listeriosis in, 1762–1763
in lupus erythematosus, 1517
Lyme disease in, 1803
treatment of, 1804
melanoma in, 1141–1142
melasma in, 635, 955, 957f, 1480
methotrexate in, 189b, 191, 2124, 2164, 2165t, 2166
mycophenolate mofetil in, 2170
mycoplasmal infections in, 1998
parvovirus B19 infection in, 1855, 1857
pemphigoid gestationis in, **490**–493, 955–956, 958t
photochemotherapy precautions in, 2258–2259
pigmentation changes in, 635, 955, 956t, 957f
polymorphous eruption in, 492, 960–961
prurigo gestationis in, 958, 958t, 961f, 961–962
pruritic folliculitis in, 958t, 962
pruritic urticarial papules and plaques in, 492, 958t, 960–961, 961f
clinical features of, 960, 961f
differential diagnosis of, 961b
treatment of, 961
in pseudoxanthoma elasticum, 1307
psoriasis in, 180, 958t, 959–960
clinical features of, 959, 959f
differential diagnosis of, 960, 960b
treatment of, 189b, 960
pyogenic granuloma in, 647
retinoid therapy in, 2184
contraindications to, 2186
teratogenic effects of, 698, 699, 708, 2184–2185
topical, 2111, 2112
Rocky Mountain spotted fever in, 1942, 1950b
rubella in, 1853, 1854, 1855
rubella vaccination contraindication in, 1855
smallpox in, 1899, 1901
smallpox vaccination in, 1905
spider nevi in, 1451
striae distensae in, 559, 955, 957f
striae gravidarum in, 559
syphilis in, 1967
treatment of, 1974, 1975–1976
terbinafine in, 2212
thalidomide contraindications in, 2233, 2234, 2235
trichomoniasis in, 1999
tumor necrosis factor inhibitors in, 2228
typhus in, 1950b
tyrosinemia in, 1221, 1222
varicella in, 1893
treatment of, 1895, 1895t
varicose veins in, 2349, 2351
venous malformation changes in, 1659, 1660
warfarin therapy and embryopathy in, 419
Preimplantation testing in prenatal diagnosis, 85–86
Premalignant epithelial tumors, **1007**–1027
Premature aging syndromes, 963
Premature infants
anetoderma in, 940
corticosteroid therapy in, topical, 2104
Pseudomonas aeruginosa infections in, 1737, 1738
skin of, 935–936
thermoregulation in, 936
Premelanosomes, 596
Prenatal diagnosis, 85f, 85–86
of Cockayne syndrome, 1321
of ichthyosis, 85, 423
of neurofibromatosis, 1335
of phenylketonuria, 1223
preimplantation testing in, 85–86
of severe combined immunodeficiency, 1360
of tuberous sclerosis, 1331
of xeroderma pigmentosum, 1317
Preoperative care, 2294–2295
antibiotics in, 2294–2295
assessment in, 2294–2295, 2336
in laser skin resurfacing, 2365, 2365t
in nail surgery, 2320
Preservatives
agents used as, 2362
allergic reactions to, 146, 2361, 2362
in drug formulations, 2094, 2095
corticosteroid, 2106, 2106t
in food products, 834

Pressure ulcers, **878**–886. *See also* Decubitus ulcers
Pressure urticaria, 334
Pre-test probability, 17, 17f
Pretibial fever, 1767
Pretibial myxedema, 541, 1472, 1472f
  localized hyperhidrosis in, 725
Prevalence of skin diseases, 6, 6t
  by age, 7f
  by gender, 6t
  and number of physician visits, 6–7
Prevention of disease
  paradox phenomenon in, 20
  as public health concern, 19–20
Prickly heat, 730f
Prilocaine, 2296, 2296t, 2298
  in EMLA cream, 942, 2130, 2296t, 2298
  side effects of, 2130
  in skin biopsy in children, 942
Prison fever, 1948
Pro-B cells, 321, 322
Probability of disease, pre-test and post-test, 17, 17f
Probenecid in dermatomyositis, 1552
Probiotics in atopic dermatitis, 158
Procainamide, lupus erythematosus from, 1513
Procollagen, 522
  biosynthesis of, 522, 523f
  conversion to collagen, 526
Procollagen C-proteinase, 524t, 526
Procollagen N-proteinase, 524t, 526
  in Ehlers-Danlos syndrome, 1298t, 1301
Procollagen peptide type III, in methotrexate therapy and liver fibrosis, 191, 1458, 2166
Proctalgia fugax, 670
Proctitis
  gonococcal, 1994, 1995
  herpes simplex, 1876
Proelafin, 382t
Profilaggrin, 61, 390
  in cornified envelope, 381, 382t
  in ichthyosis vulgaris, 407, 407f, 408
Progeria, 963
  adult, 1323
  general skin changes in, 1445
  lipodystrophy in, 588
Progesterone, 1479–1480
  in dermatitis, 1480
  in lupus erythematosus, 1516
  in menopause, 967
Programmed cell death 1 in autoimmune disorders, 1510, 1511–1512
Progressive pigmentary dermatosis, 1634
Prolactin levels
  in hirsutism, 775t, 776
  in lupus erythematosus, 1517
Prolidase, 1219t
  deficiency of, 1219t
Proliferating pilar tumors, 1082, 1082f
Proliferation
  and anti-proliferative effects of corticosteroids, 2103
  of epidermal cells, 44, 59
    in hyperplasia, 59f
  in wound healing, 2343–2344, 2344t
Proline
  in collagen, 517–518, 518f
  small proline-rich proteins in cornified envelope, 381, 382t, 387–388
Proline oxidase, 1219t
Prolyl-3-hydroxylase, 522, 524t
Prolyl-4-hydroxylase, 522, 524t
Promethazine, 2191
Proopiomelanocortin, 604, 896t
  in atopic dermatitis, 900
  in Cushing syndrome, 1477, 1478
  in inflammatory response, 898t
Proparacaine in local anesthesia, 2296t, 2298
Properdin, 1370, 1371t, 1372
Propionibacterium acnes, 690, 691f, 692
  treatment of infections, 696–697, 700
Propionibacterium propionicum, 1779
Propranolol, Raynaud phenomenon from, 1646
Propylene glycol, in topical preparations, 2095, 2362
  corticosteroid, 2106, 2106t
  keratolytic, 2135t, 2136
Prostacyclin in Raynaud phenomenon, 1647
Prostaglandin(s), 1591, 1591f
  functions of, 1435t, 1436
  as mast cell mediators, 1435t, 1436
  in melanocyte regulation, 604
  in pruritus, 897t, 904, 905
  as radioprotectors, 860
  in Raynaud phenomenon, 1647
  in squamous cell carcinoma, 993
  in ultraviolet radiation exposure, 812
    and photoimmunosuppression, 807, 807f
    and sunburn inflammation, 604, 812
Prostaglandin endoperoxide synthase, 338
Prostaglandin H synthase, 1591
Prostate gland in alkaptonuria, 1226–1227
Prostatodynia, 670
Prosthesis
  heart valve, endocarditis in, 1744, 1745
  limb, types of, 862, 863f
Protease(s)
  in epidermal differentiation, 391
  in pruritus, 904
  in psoriasis, 174
  in Wegener granulomatosis, 283
Protease-activated receptor-2 (PAR-2), 604, 1589
  in atopic dermatitis, 900
  in pruritus, 904
Protease inhibitors
  in α_1-antitrypsin deficiency panniculitis, 579
  in HIV infection and AIDS, 1930t, 2208, 2209–2210
    hypersensitivity reactions to, 1934
    lipodystrophy in, 586, 589, 1934–1935
    mechanism of action, 2209–2210
    pharmacokinetics of, 2210
    side effects of, 2210
Proteasome, 104, 110, 110f
Proteasome inhibitors, 2235
Protective clothing and equipment
  in occupational exposures, 2072–2073, 2077
  in ultraviolet radiation exposure, 2141
Protective function of skin, 112–114, **383**–395
  as barrier. *See* Barrier function of skin
  in innate immunity, 95, 96f
Protein
  dietary
    in decubitus ulcers, 885
    in protein-energy malnutrition, 1201–1203
  in sweat, 717–718
Protein C
  activated recombinant human
    in meningococcal infections, 1735
    in soft tissue infections, 1730
  deficiency of, 1382–1383
Protein disulfide isomerase, 524t
Protein-energy malnutrition, 1201–1203
  edematous, 1202–1203
Protein kinase A in melanogenesis, 605, 606f
Protein kinase C, 128, 129f, 598, 598f
  activated, receptors for, 598, 598f
  in melanogenesis, 605, 606f, 748
  in squamous cell carcinoma, 993
Protein tyrosine kinase, 129f
Protein tyrosine phosphatase 22 in autoimmune disorders, 1510
Proteinosis, lipoid, 77, **1288**–1292
  clinical findings in, 1289–1290, 1290f, 1291f, 1292f
  diagnostic approach to, 1290f
  differential diagnosis of, 1292b
  epidemiology of, 1288
  etiology and pathogenesis of, 1288–1289
  laboratory tests in, 1291
  oral cavity disorders in, 642t, 1289–1290, 1292f
  prevention of, 1292
  prognosis and clinical course in, 1291–1292
  respiratory disorders in, 1454
  treatment of, 1292
Proteoglycans, **536**–542
  age-related changes in, 966–967
  in basement membranes, 450, 451, 454
  and chemokines, 127
  core proteins of, 539t, 539–540, 541
  in dermis, 63
  embryonic and fetal, 68t, 70, 71
  function of, 540–542, 541f
  structure of, 538, 538f
Proteus syndrome, 70, 1056, 1060, 1061
Proto-oncogenes, 995
Protoporphyria, erythropoietic, 1233, 1233t, 1235t, 1243–1247
  animal models of, 1256
  biochemical features of, 1240t, 1245
  clinical manifestations of, 1244–1245
  diagnosis of, 826
  differential diagnosis of, 1292b
  epidemiology of, 1243
  etiology of, 1243–1244
  histopathology in, 1246–1247, 1247f
  liver disorders in, 1245–1246, 1247
  photosensitivity in, 1233, 1243, 1244, 1244f, 1245, 1246–1247
  treatment of, 1241b, 1247–1248
    gene therapy in, 1256
Protoporphyrin, 1229f, 1229t
  in erythropoietic protoporphyria, 1244, 1245, 1246
  in red blood cells, 1240t
    in erythropoietic protoporphyria, 1245
    in hepatoerythropoietic porphyria, 1243
  in stool, 1240t
    in variegate porphyria, 1253
Protoporphyrin IX, 1232f
Protoporphyrinogen oxidase, 1230t, 1231f
  in dual porphyrias, 1255
  in heme biosynthesis, 1230, 1232f
  in variegate porphyria, 1252
Protothecosis, 2053t
Prox1, 65, 68t, 70
Prurigo
  actinic, 818–819, 826, 827
  in atopic dermatitis, 149f, 150, 150f, 160
  Besnier, 160, 961
  gestationis, 961f, 961–962
  gravidarum, 956
  in hematologic disorders, 1376t
  in HIV infection and AIDS, 1931
    arthropod-induced, 1932

Prurigo—*continued*
nodularis, **160**–162, 161f, 916
differential diagnosis of, 161b
pruritus in, 903, 905–906
treatment of, 162
pigmentosa, 638
in pregnancy, 958, 958t, 961f, 961–962
Pruritus, **902**–911
in allokinesis, 903, 907
in angiodermatitis, disseminated prurigi-nous, 1635, 1635f
aquagenic, 336, 908, 1376t
in atopic dermatitis, 149, 156, 906–907, 909
and exercise, 877
barrier function of skin in, 909, 909t
brachioradial, 907
in cholestasis, 907–908, 957, 959, 1447–1448
chronic
central sensitization in, 905
eosinophils in, 316
in cirrhosis, 1448, 1458
in clam digger's itch, 2048f, 2048–2049
clinical findings in, 905–906, 906f
complications in, 906
in dermatomyositis, 1542, 1544, 1547, 1551
differential diagnosis in, 907b
disorders associated with, 906–907, 1447–1448
in drug abuse, 924–925
drug-induced, 1447, 1448
in elderly, 908, 972, 972t
in endocrine disorders, 908
etiology and pathogenesis in, 902–906, 903f
genital, 658b, 683
helper T cells and IL-31 in, 106
in hematologic disorders, 908, 1376t
in HIV infection and AIDS, 908, 1930–1932
differential diagnosis in, 1930–1931, 1931b
in papular pruritic eruption, 1931–1932, 1932f
itch-scratch cycle in, 903, 903f
in kidney disorders, 907, 1448
laboratory tests in, 906, 906t
in lichen planus, 246, 255
in lichen simplex chronicus, 160, 161–162
in lymphoproliferative disorders, 908
in mastocytosis, 1442
mediators of, 903, 904–905
in mycosis fungoides, 1390
nerves in, 896t–897t, 899f, 901
and transmission of itch sensation, 903–904, 911
in neurofibromatosis, 1334, 1337
neuropathic, 903, 906, 907
neurophysiology of, 896t–897t, 903–904
and neurotic excoriations, 916
in pregnancy, 955
in cholestasis, 957, 959
in folliculitis, 962
in prurigo, 961–962
in urticarial papules and plaques, 492, 958t, 960–961, 961b, 961f
prevalence of, 902, 902t, 903t
prognosis and clinical course in, 906–908
in prurigo, 160, 162, 905–906
in pregnancy, 961–962
in psoralen and PUVA therapy, 2257
in psoriasis, 185, 907
psychogenic, 903, 908, 911, 917
in purpura, 1635, 1635f
in Sézary syndrome, 1391
in swimmers, 877, 2048, 2049
in systemic disorders, 907–908
etiology and pathogenesis in, 903
prevalence of, 903t
in thyroid disorders, 908, 1471
treatment of, 908–911
antihistamines in, 904, 910, 2189
cutaneous field stimulation in, 911
radiation therapy in, 2280t
systemic, 910–911, 911t
therapeutic ladder in, 909, 909f
topical, 909t, 909–910, 2134, 2134t
in tumors, 908
in urticaria, 906, 910
with papules and plaques in pregnancy, 492, 958t, 960–961, 961b, 961f
Psammoma bodies in schwannoma, 1179
Pseudallescheria boydii, 1779t
Pseudoacne of nasal crease, 703
Pseudoainhum, 61, **562**–563
artifactual, 562–563
Pseudoanaphylactic reaction in syphilis, 1977
Pseudocatalase in vitiligo, 620
Pseudo-claudication, 1670
Pseudocowpox, 1908–1910
Pseudo-Cushing syndrome, 1446, 1478
Pseudo-Darier sign, 39t
in smooth muscle hamartoma, 1174
Pseudo-dominant inheritance, 79
Pseudo-eccrine chromhidrosis, 733, 733b
Pseudofolliculitis, 90
barbae, 1699, 1699f, 2275
Pseudogenes, 73
Pseudoglucagonoma syndrome, 1501
Pseudohorn cysts in seborrheic keratosis, 1054, 1055
Pseudohyperparathyroidism, 1475
Pseudohypoparathyroidism, 1476
Pseudolymphoma, cutaneous, **1402**–1413
classification of, 1402, 1403t
differential diagnosis in, 1404
drug-induced, 360, 1402, 1404, 1404f
lymphoma risk in, 1407
Pseudo-melanoma, 1108
Pseudomonas
in athletes, 875
in waterborne infections, 2053t
Pseudomonas aeruginosa, **1735**–1739
in botryomycosis, 1779t, 1785
diagnosis of infections, 1737, 1738
differential diagnosis of, 1737, 1738
in drug abuse, 925
in ecthyma gangrenosum, 1698, 1727, 1737f, 1737–1738, 1738f, 1747
epidemiology of, 1736
in folliculitis, 1699, 1736, 1736f, 1737
in gangrenous cellulitis, 1725, 1738, 1739
in immunocompromised host, 268, 269f, 269t, 1725, 1736, 1737
in HIV infection and AIDS, 1736, 1737, 1935
in nail infections, 1735, 1736, 1737
green discoloration in, 785, 785f, 1735, 1736, 1736f
treatment of, 1738
in otitis externa, 1736–1737, 1738
in diabetes mellitus, 1465
in panniculitis, 1738
pathogenesis of infections, 1735–1736
in septicemia, 1737–1738, 1739
treatment of infections, 1738–1739, 1743, 2197t
in gangrenous cellulitis, 1739
in nail infections, 1738
Pseudomonas mallei, 1760–1761
Pseudomonas pseudomallei, 1764–1765
Pseudomonas putrefaciens, 1739
Pseudomonic acid, 2132–2133. *See also* Mupirocin
Pseudo-mycosis fungoides, 1403t, 1410–1411
differential diagnosis of, 1410–1411, 1411b
treatment of, 1411, 1411b
Pseudoparalysis of Parrot in congenital syphilis, 1968
Pseudoparenchyma in piedra, 1821
Pseudopelade of Brocq, 248, 248f
cicatricial alopecia in, 772t, 773
differential diagnosis of, 773
Pseudoporphyria, 358, 499, 1243
in dialysis, 1459
drug-induced, 358, 359t, 1243
in HIV infection and AIDS, 1932
in phototoxicity, 831–832
Pseudorhagades in erythropoietic protoporphyria, 1244
Pseudo-sign of Leser-Trélat, 1498
Pseudotumor cerebri
in isotretinoin therapy, 699, 2185
in vitamin A toxicity, 1205
Pseudovasculitis in drug abuse, 924
Pseudoverrucous papules and nodules in diaper area, 943
Pseudovesicles in Sweet syndrome, 290, 290f
Pseudoxanthoma elasticum, 541, **1304**–1308
calcification in, 1305, 1307
dystrophic, 1294
cardiovascular disorders in, 1305, 1307, 1308
clinical findings in, 1306f, 1306–1307
differential diagnosis of, 566, 567, 1306b
elastic fiber disorders in, 54, 55, 63, 536, 537t, 1305, 1305f
epidemiology of, 1304–1305
etiology and pathogenesis in, 1305–1306
eye disorders in, 1305, 1307–1308
gastrointestinal hemorrhage in, 1305, 1307, 1308, 1455
general skin changes in, 1306–1307, 1445
genetic factors in, 63, 70, 1305
histopathology in, 1305, 1305f
localized acquired cutaneous, 1306b
monitoring studies in, 1307t
perforating periumbilical, 1306b
prevention of, 1307–1308
support groups on, 1307
treatment of, 1307
Psittacosis in bioterrorism, 2083t
Psoralen and PUVA therapy, 798
in actinic dermatitis, chronic, 822f, 823, 2257
action spectrum in, 805, 2251
in alopecia areata, 765, 2255
in atopic dermatitis, 157, 158, 2255
in combination with other agents, 2254
contraindications to, 2258–2259
with cyclosporine, 2254
DNA damage in, 978t, 2250
erythema in, 2251–2252
fluorescent lamps used in, 800, 2251
in graft-versus-host disease, 2255–2256
in granuloma annulare, 2255
in HIV infection, 2257, 2259
and eosinophilic folliculitis, 1931
indications for, 2249, 2250t, 2252–2257
keratoacanthoma in, 1050
keratosis in, 1020
lentigines in, 1119, 1120f, 1120–1121, 1122, 2258
in lichen nitidus, 258

in lichen planus, 254b, 254–555, 2255
in mastocytosis, 1442, 1442b, 2255
mechanism of action, 2250–2251
melanoma in, 1135, 2258
with methotrexate, 2254
in morphea, 2255
nail changes in, 2257
oral administration of psoralen in, 2252, 2253, 2257
in palmoplantar pustulosis, 217b
in perforating disorders, 567b
photochemical reactions in, 804, 2250, 2251f
photosensitivity in, 2251–2252
phototoxic response to, 831
pigmentation changes in, 636, 2252, 2256
in pigmented purpuric dermatosis, 1636
in pityriasis lichenoides, 2255
in pityriasis rubra pilaris, 235, 236b, 2255
in polymorphic light eruption, 818, 2247, 2256
principles of, 2249–2252
in pruritus, 911
pruritus in, 2257
in psoriasis, 185t, 187t, 190, 2252–2254, 2259
mechanism of action in, 2250–2251
in pregnancy, 189b
results of, 2253, 2253f, 2254f
treatment protocols in, 2252, 2253
with retinoids, 2254
in seborrheic dermatitis, 225
side effects and complications of, 2257t, 2257–2259
skin cancer risk in, 987–988, 1000, 1002, 1020, 2258
in solar urticaria, 2256–2257
in T-cell lymphoma, 1397, 1398, 1399, 2248, 2254f, 2254–2255
topical application of psoralen in, 2252, 2253
treatment protocols in, 2252, 2252t
in urticaria pigmentosa, 2247
in vesicular palmoplantar eczema, 166
in vitiligo, 620b, 620–621, 2248, 2256
Psoriasiform lesions
of hand, 165
oral, in reactive arthritis, 210
Psoriasin, 97
Psoriasis, 58, **169**–193
age of onset, 169, 174
alopecia in, 771
of amputation stump, 867
annular, 178, 178f, 367t
pustular, 180
antimicrobial peptides in, 1690
arthritis in, **194**–206. *See also* Psoriatic arthritis
as autoimmune disorder, 174
clinical findings in, 174–183
complications of, 183
and Crohn disease, 170
cytokines and chemokines in, 131, 132–133, 133f, 173–174, 174f
dendritic cells in, 170, 171, 171f, 172–173
diagnostic algorithm on, 176f
differential diagnosis of, 183b, 430b, 1058
allergic contact dermatitis in, 139b
parapsoriasis in, 239
pityriasis rosea in, 365, 365b
seborrheic dermatitis in, 223
sub-corneal pustular dermatosis in, 306
vesicular palmoplantar eczema in, 165
drug-induced exacerbation of, 184
early macules and papules of, 170
in elderly, 972t
elephantine, 178f
epidemiology of, 169
erythrodermic, 179–180, 180f
differential diagnosis in, 183b
prognosis in, 183
treatment of, 185, 2253
etiology and pathogenesis in, 169–174, 175f
exfoliative dermatitis in, 225, 228, 228f, 230t
genetic factors in, 82, 169–170, 170f, 174, 194, 197–198
counseling on, 85
genital
in female, 678, 678f
in male, 664f, 664–665, 665f
geographic tongue in, 181–182, 643
geographica, 178
guttate, 175f, 178–179, 179f
differential diagnosis in, 183b
and streptococcal infections, 184, 1707
histopathology of, 172f, 182
in HIV infection and AIDS, 184, 1932
arthritis in, 194, 195, 201–202, 206, 1932
treatment of, 1932, 2183, 2257
HLA system in, 84, 169–170, 170f, 174, 175f, 184
and arthritis, 194, 195, 198–199, 201
in infant, 944, 944f
inverse, 179, 179f
keratinocytes in, 131, 132, 171, 171f, 173, 175f
Koebner phenomenon in, 177, 178f, 180, 190, 664
laboratory tests in, 182
Langerhans cells in, 109, 171f, 172
linear, 180–181
differential diagnosis in, 1058
liver disorders in, 1458
nail changes in, 181, 182f, 182t, 788–789, 789f, 789t
and arthritis, 195, 195f, 200
differential diagnosis in, 789, 789t
onycholysis, 181, 182f, 788, 789f
pitting, 181, 182f, 782, 782f, 788
salmon patches, 181, 182f, 789, 789f
treatment of, 189f, 191, 789
napkin, 180, 221
ostraceous, 178
palmoplantar, 430b
pathologic reactions in, 48
pathophysiology in, 900
peristomal, 870
plaque in, 26, 26f, 178
chronic, 175f, 176f, 177f, 183
photochemotherapy in, 2253f
small, 179
in pregnancy, 180, 958t, 959f, 959–960, 960b
prognosis and clinical course in, 183–184
proliferation of epidermal cells in, 44, 59f, 378, 394–395
pruritus in, 907
treatment of, 185
pseudoainhum in, 563, 563f
psoriasoid, 221
psychological factors in, 183, 920–921
pustular, 180, 215, 218
annular, 180
differential diagnosis in, 183b, 306
exanthematic, 180
generalized, 180, 181f
localized variants, 180
nail changes in, 789
in pregnancy, 180, 958t, 959f, 959–960, 960b
prognosis in, 183
spongiform, 46
treatment of, 185, 2253, 2254f
remission periods in, 183
rupioid, 178, 178f
sebopsoriasis, 180
and seborrheic dermatitis, 220
severity-of-disease measures in, 7, 14
skin barrier function in, 394–395
stages of, 170–171, 171f, 172f, 197f, 197–199
superantigens in, 1719
T cells in, 170, 171f, 171–172, 175f
transepidermal water loss in, 395
treatment of, 184–193
alefacept in, 188t, 192, 206, 2229, 2230
algorithm on, 176f
basis of decisions in, 11
biologic agents in, 188t, 192–193
calcipotriene in, 188, 189t, 2136
in children, 189b
coal tar preparations in, 187t, 189–190, 2130
cyclosporine in. *See* Cyclosporine, in psoriasis
efalizumab in, 188t, 192–193, 2228, 2229
hepatotoxicity of drug therapy in, 191, 1458, 1459t
in HIV infection, 1932, 2183, 2257
laser therapy in, 185t, 190, 2244, 2279
methotrexate in. *See* Methotrexate, in psoriasis
in nail changes, 189f, 191, 789
photochemotherapy in, 2253, 2254f
photodynamic therapy in, 190, 2261
phototherapy in, 185, 189, 190–191, 2243–2245, 2250–2254, 2259
in pregnancy, 189b, 960
psoralen and PUVA therapy in. *See* Psoralen and PUVA therapy, in psoriasis
radiation therapy in, 2280, 2280t
recommended combinations in, 187t, 192
retinoids in, 2109, 2111, 2183
systemic, 186t–187t, 191–192
topical, 184t, 185–190, 189b, 2109, 2111
tumor necrosis factor-α in, 173, 174f, 2227
and arthritis, 196, 196f, 199, 205–206
as therapy target, 193, 205–206, 2227–2228
vascular remodeling in, 1598
Von Zumbusch type, 180, 181f, 218, 2253, 2254f
vulgaris, 26f, 178
chronic stable, 94f, 95
differential diagnosis in, 183b
in HIV infection and AIDS, 1932
scaling lesions in, 31, 31f, 31t
Woronoff ring in, 178, 178f, 630
Psoriasis Area and Severity Index, 7
Psoriatic arthritis, 182, **194**–206
age of onset, 199, 201
classification of, 194–195
clinical features in, 194t, 199–202
compared to rheumatoid arthritis, 200, 200t
course and prognosis in, 202
definition of, 194
diagnostic criteria on, 194, 194t
differential diagnosis in, 194, 195
epidemiology of, 195–196

Psoriatic arthritis—*continued*
genetic factors in, 194, 197–198
historical aspects of, 195
in HIV infection, 194, 195, 201–202, 206, 1932
treatment of, 206
HLA system in, 169, 194, 195, 198–199, 201
pathogenesis and pathology in, 196f, 196–197
patterns of joint involvement in, 195, 195t, 200–201
radiology in, 200, 200f, 201
stages of, 197f, 197–199
treatment of, 202–206
alefacept in, 206, 2230
algorithm on, 202, 203f
disease-modifying antirheumatic drugs in, 202, 204
in HIV infection, 206
in mild disease, 203–204
in moderate disease, 204
in severe disease, 204–206
surgical, 206
PSORS1 (psoriasis susceptibility 1), 169–170, 170f
PSTPIP1 in pyogenic arthritis with pyoderma gangrenosum and acne, 1271
Psychiatric disorders, **912**–920
in Fabry disease, 1284, 1284t
in mastocytosis, 1439
in neurosyphilis, 1966
panniculitis in, factitial, 580
Psychocutaneous diseases, **912**–921
classification of, 912, 913t
nonpharmacologic treatment in, 912, 912t, 920
psychotropic medications in, 917–920
Psychodopygus as leishmaniasis vector, 2002, 2002t
Psychological factors, **912**–921
in acne vulgaris, 694, 695
in atopic dermatitis, 156, 920
in Darier-White disease, 435, 436
in epidermolysis bullosa, 515
in herpes simplex virus infections, 921
in lichen simplex chronicus, 160
in prurigo nodularis, 160
in pruritus, 903, 908, 911, 917
in psoriasis, 183, 920–921
in seborrheic dermatitis, 220
in telogen effluvium, 761, 761t
in trichotillomania, 769–770
in urticaria, 921
in vulvodynia, 683
Psychotropic medications, 917–920
PTC in appendage tumors of skin, 1068
PTCH1/PTCH1, 988, 989t
in basal cell carcinoma, 989, 989t, 993, 994, 1002, 1037, 1043
in basal cell nevus syndrome, 68t, 1042–1043, 1043f, 1044, 1045, 1046, 1048
functions of, 1043
in hair follicle development, 740f, 741
in hedgehog signaling pathway, 988, 1002, 1042, 1043, 1043f
PTEN/PTEN, 68t, 1068
in Bannayan-Riley-Ruvalcaba syndrome, 1190, 1665
in Cowden syndrome, 988, 989t, 1665
in hamartoma tumor syndrome, 1665
in melanoma, 1136
in tricholemmoma, 1084
Pthirus pubis, 2035–2037, 2036f
PTPN11, 1338
PTPN22 in autoimmune disorders, 1510
Puberty, acne vulgaris in, 690
Pubic lice, 663, 2035–2037, 2036f
differential diagnosis of, 2036b
in HIV infection, 2037
macula cerulea in, 2036, 2036f
treatment of, 2036–2037, 2037b
Public health, **18**–21
definition of, 18–19
future trends in, 21
high-risk approach to, 19
historical aspects of, 19
low-risk approach to, 19–20
skin cancer as concern in, 19–20, 21, 986, 1000
Public Health Service Department leprosy treatment recommendations, 1794, 1795, 1795b
Publication bias, 9–10
Puffy hand syndrome, 1686
Pulling-boat hands, 848
Pulmonary hypertension
classification of, 1560, 1561t
and sclerosing panniculitis, 575
in systemic sclerosis, 1560–1561
Pulp, dental, polyp of, 647
Pulsed light therapy, intense, 2263. *See also* Intense pulsed light therapy
Pulseless disease, 1615–1616
Purified protein derivative in tuberculosis skin test, 1769–1770
Purpura, 33, 34f, 1380–1383, 1384
allergic contact, 144
in amyloidosis, 1258–1260, 1260f, 1261, 1262f
anaphylactoid, 1602
annularis telangiectodes, 1634
in child abuse, 928, 928f
in cryoglobulinemia, 1639, 1639f
differential diagnosis of, 1380–1381, 1381t, 1382t, 1383t, 1605
algorithm on, 1380f
in child abuse, 928, 928f
erythema in, 33
in palpable purpura, 1382t, 1383t
in retiform purpura, 1382t, 1383t
in sepsis, 1747b
of Doucas and Kapetanakis, 1634t, 1635, 1636
in drug-induced vasculitis, 360
fulminans, 1382–1383, 1605
in amputation stump, 866f
in disseminated intravascular coagulation, 1382, 1384f, 1732, 1748, 1748f
in meningococcal infections, 1382, 1383, 1732, 1746
genital, 658b
Henoch-Schönlein. *See* Henoch-Schönlein purpura
hyperglobulinemic, 1601
of Waldenström, 1381t, 1383–1384
itching, 1634t, 1635, 1635f
in Langerhans cell histiocytosis, 1415
in leukocytoclastic vasculitis, 33, 34f
in lichenoid dermatosis of Gougerot and Blum, 1634, 1635f, 1636
Majocchi, 1634, 1634t, 1635f
in mycosis fungoides, 1388, 1389f, 1636
palpable, 33, 50, 1381, 1384, 1384f
differential diagnosis of, 1382t, 1383t
drug-induced, 1602
in necrotizing venulitis, 1601, 1601f, 1602
in systemic vasculitis, 1607
treatment of, 1606
in Wegener granulomatosis, 1610, 1613f
in papular purpuric gloves-and-socks syndrome, 1856
in parvovirus B19 infections, 1856
in photoaging, 968t
in pigmented dermatosis, **1633**–1636
chronic, 1633
granulomatous, 1635–1636
persistent, 1633
segmental, 1635
in plague, 1758, 1759
retiform, 1381, 1384, 1384f
differential diagnosis of, 1382t, 1383t
senile, 1384
in sepsis, 1746, 1747b
simplex, 50, 1605, 1633
in Sjögren syndrome, 1579, 1580
solar, 1384
thrombocytopenic, 1381–1382, 1746
alloimmune, 1381–1382
in congenital cytomegalovirus infection, 1862
differential diagnosis in, 1605
idiopathic, 1381
thrombotic, 1382, 2204–2205
in viral infections, 1849t
wet, 1381
Pus caterpillar, 2062, 2063f
Push-ahead injection technique in soft tissue augmentation, 2380, 2381f
with hyaluronic acids, 2383
Pustules, 33, 33f
in contagious dermatosis, 1910–1911
differential diagnosis in, 1747b
in drug-induced eruptions, 358, 358f
in eosinophilic folliculitis, 314–315
in HIV infection and AIDS, 315
in infants, 315
in erosive dermatosis, 772t, 774, 774f, 1033
genital, 661b
in irritant contact dermatitis, 399
in neonatal melanosis, transient, 937, 937f
palmoplantar, **215**–218
in psoriasis, 46, 180, 215, 218
with nail changes, 789
in pregnancy, 958t
in pyoderma
gangrenosum, 296, 297f, 297–298, 300, 300f
superficial, 33, 33f
of scalp, 774, 774f, 1033
in sepsis, 1746, 1747b
sub-corneal, **305**–307, 358, 1375t
in Sweet syndrome, 290
in viral infections, 1849t
Pustulosis
acute generalized
differential diagnosis in, 306, 358
drug-induced, 357t, 358, 358f
eosinophilic, 315
palmoplantar, 215t, **215**–217
clinical features in, 216, 216f
diagnosis and differential diagnosis in, 217, 217b
diseases associated with, 216
histopathology in, 216, 216f
treatment in, 217, 217b
in SAPHO syndrome, 701
PUVA Follow-Up Study, 1135
PXE International, Inc., 1307
Pyemotes tritici, 2032, 2032t
Pyemotes ventricosus, 2032, 2032t

Pyloric atresia, epidermolysis bullosa with, 508t, 508–509
Pyoderma, 1694–1709
faciale, 706
gangrenosum, 53, **296**–302, 1375t, 1495t
bullous, 296, 297, 297f, 300, 300f
clinical findings in, 296–298, 298f, 300f
complications of, 300
diagnostic algorithm in, 297f
diagnostic criteria in, 299–300
differential diagnosis in, 294b, 296, 299b, 299–300, 1571
epidemiology of, 296
etiology and pathogenesis of, 296
genital, 300f, 666, 667f
histopathology in, 298–299
and immunoglobulin IgA paraproteinemia, 1502
laboratory tests in, 298–299
malignancy-associated, 1502
pathergic phenomenon in, 296, 298f, 302
peristomal, 870
prevention of, 302
prognosis and clinical course in, 300
pustular, 296, 297f, 297–298, 300, 300f
with pyogenic arthritis and acne, 701, 1267t, 1271
clinical findings in, 1271, 1271f
differential diagnosis of, 1268b, 1271
and sub-corneal pustular dermatosis, 305, 306
treatment of, 300–302
ulcerative, 28, 28f, 296, 297f, 300, 300f
vegetative, 296, 297f, 298, 300, 300f
wound care in, 301
staphylococcal, 1694–1703
streptococcal, 1703–1707
superficial, pustules in, 33, 33f
Pyogenic arthritis with pyoderma gangrenosum and acne, 701, 1267t, 1271
clinical findings in, 1271, 1271f
differential diagnosis of, 1268b, 1271
Pyogenic granuloma, 1171f, 1171–1172
Pyramidal protrusion, infantile, 942
Pyrantel pamoate
in ascariasis, 2014t
in enterobiasis, 2014t
in hookworm infections, 2015t
Pyrazinamide in tuberculosis, 1775t
Pyrenochaeta romeroi, 1834t
Pyrethrin, 2133t, 2134
in pediculosis capitis, 2034t
in pediculosis pubis, 2037b
Pyridoxal, 1211
Pyridoxamine, 1211
Pyridoxine, 1211
deficiency of, 1211
food sources of, 1211
in homocystinuria, 1304
Pyrin, 1265, 1271
Pyrogenic toxins
staphylococcal, 1695
streptococcal, 1704, 1710t
in Kawasaki disease, 1628
in toxic shock syndrome, 1716
Pyrogens, endogenous, 115

Q

Q fever in bioterrorism, 2083t
Q-switching in pulsed laser therapy, 2263, 2264
for pigmented lesions, 2376, 2377, 2377f
Quality of care, 8
Quality of life, 8, 921
in allergic contact dermatitis, 144–145
in Fabry disease, 1285
in hair growth disorders, 753
in hidradenitis suppurativa, 736
impact of therapy on, 14
in lipoid proteinosis, 1292
in lupus erythematosus, 1532
in psoriasis, 183, 921
in urticaria and angioedema, 341
Quantum, 799
Quantum yield, 805
Quartz lamps, 800
Quetiapine, 917t
Quinacrine, 2157–2162
chemical structure of, 2158, 2158f
complications of, 2161–2162
in dermatomyositis, 1551
dosing regimen for, 2160
indications for, 2159–2160, 2161t
in lupus erythematosus, 1533t, 1533–1534, 2159–2160
mechanism of action, 2157–2158
pharmacokinetics of, 2158–2159, 2159t
pigmentation changes from, 1227, 2161
Quincke pulsation, 1449
Quinine abuse, cutaneous signs of, 924, 925
Quinolone in children, 946
Quinupristin-dalfopristin, 2202
in soft tissue infections, 1730

R

R plasmids in antibiotic resistance, 1693
RAB27A/Rab27a
in Griscelli syndrome, 1368t, 1369
in melanosome transport, 603, 603f
Rabies, 2038–2039
in bioterrorism, 2083t
clinical management of, 2039
post-exposure prophylaxis of, 2039
vaccination against, 2039
Raccoons
heartworm infection in, 2024
rabies in, 2038, 2039
Racial differences. *See* Ethnic and racial differences
RACK (receptors for activated C-kinase), 598, 598f
Radiation, **858**–862
absorbed dose, 858
absorption of. *See* Absorption of radiation
acne from, 702–703
cellular effects of, 858–860
cell cycle changes in, 859
cell division delays in, 859–860
cutaneous responses to, 860f, 860–861, 861f
dermatitis from. *See* Radiation dermatitis
DNA and chromosome damage from, 859
electromagnetic spectrum, 797–798, 798t, 799
germicidal, 798
heat transfer in, 835–836, 845
infrared, 798f, 798t, 799
ionizing, 799, 859
keratosis from, 1018–1019, 1019f
long-term reactions to, 859t, 861–862
grades of, 859t
LENT SOMA scale on, 859t, 861–862
occupational exposure to, 2079t, 2080, 2080f
and optical properties of skin, 802f, 802–803, 803f, 2264–2266
penetration of skin, 802, 803f, 2249, 2260, 2266, 2267f
and photochemical reactions, 803–805
in psoralen and UVA therapy, 2250, 2251f
radiobiologic effects, 858–861
and radioprotectors, 860
photoprotection methods in, **2137**–2142
and radiosensitizers, 860
photosensitizers in, 805, 1233, 1234f, 1234–1235, 1235f, 2260
reflectance of, 802, 802f
scattering of, 802, 802f
and absorption, 2264–2266
sources of, 797, 799–801
squamous cell carcinoma from, 861, 862f, 1029
as terrorist weapon, 2087
in dirty bomb, 2087
transverse waves in, 799
ultraviolet, **797**–834. *See also* Ultraviolet radiation exposure
visible spectrum, 797, 799, 2263
wavelengths of, 797–799, 798f, 798t, 2263
absorption spectrum in, 803, 803f, 2267f
and frequency, 799
in phototherapy, 2243–2244, 2244f
Radiation dermatitis, 860f, 861, 861f, 2179
chronic, 861, 861f, 862f
poikiloderma in, 29, 29f, 861, 861f
squamous cell carcinoma in, 861, 862f
in occupational exposures, 2080f
Radiation recall reaction, drug-induced, 2166, 2179, 2179f, 2179t
Radiation therapy, **2279**–2284
in actinic keratosis, 2283
anagen effluvium in, 762
anhidrosis in, 729
in B-cell lymphoma, 1401, 2282t, 2284
in basal cell carcinoma, 1041, 1048, 1048f, 2282, 2282t, 2283f, 2283–2284
in basal cell nevus syndrome, 1048
in benign skin diseases, 2279–2281
in Bowen disease, 2282, 2282t, 2283
contraindications to, 2282
in dermatofibrosarcoma protuberans, 1161
dosimetry in, 801–802, 2282, 2282t
in eczema, 2280t, 2280–2281
vesicular palmoplantar, 166
in epithelioid sarcoma, 1163
in erythroplasia of Queyrat, 2282, 2282t, 2283
in hidradenitis suppurativa, 738
hyperpigmentation in, 636
in Kaposi sarcoma, 2282, 2282t, 2284
in keratoacanthoma, 1053, 2282, 2283t, 2283–2284
keratosis in, 1018–1019
in Langerhans cell histiocytosis, 1423
in lentigo maligna, 2282, 2282t, 2283, 2283f
in lymphoid hyperplasia, 1408, 1408b, 2281
in malignant skin diseases, 2281–2284
in melanoma, 2282, 2282t
metastatic, 1156
in Merkel cell carcinoma, 1092, 1093, 1094
mucositis in, 647
in Paget disease, 1096, 1098
palliative, 2282
panniculitis in, sclerodermatous, 584
in psoriasis, 2280, 2280t
radiation wavelengths in, 799
radioprotectors in, 860
radiosensitizers in, 860
in squamous cell carcinoma, 1035, 2282, 2282t, 2283–2284

Radiation therapy—*continued*
squamous cell carcinoma in, 1029
in T-cell lymphoma, 1396, 1397–1398, 1399, 2282, 2282t, 2284
thermal enhancement in, 860
in xeroderma pigmentosum, 1318
Radiobiology, 858–861
of hair, 860–861
of Langerhans cells, 861
of melanocytes, 861
of skin, 858–861
Radiodermatitis. *See* Radiation dermatitis
Radio-frequency technique
in skin rejuvenation, 2373, 2374f
in varicose veins, 2351, 2355
Radiography
in alkaptonuria, 1226, 1227, 1227f
in basal cell nevus syndrome, 1046, 1046f, 1047f
in Behçet disease, 1624
in decubitus ulcers, 880
in melanoma, 1153
in neurofibromatosis, 1335
radiation wavelengths in, 798f, 798t, 799
in rheumatoid arthritis, 1570t
in soft tissue infections, 1727
Radioiodine uptake in hyperthyroidism, 1470
Radionuclide scans in sarcoidosis, 1489
Radioprotectors, 860
and photoprotection methods, **2137**–2142
Radiosensitizers, 860
and photosensitizers, 805, 2260
porphyrin as, 1233, 1234f, 1234–1235, 1235f, 2260
Raeder syndrome, 725
B-RAF/b-raf, 999, 1000
in dysplastic nevus, 1123, 1124, 1125
in melanoma, 1002, 1123, 1136, 1137, 1156
in nevomelanocytic nevi, 1105
RAG1 and *RAG2,* 1358, 1359t, 1360
Railway cancers in Britain, 1017
Raised skin lesions, 26–28
RAMBA (retinoic acid metabolism blocking agent), 2109, 2112, 2181–2182
Rambazole, 2182
RAMP (receptor activity modifying protein), 129f
Ramsay Hunt syndrome, 1890, 1890f
Randomized controlled trials, 3
confidence intervals in, 15, 16f
database information on, 9
as evidence source, 10, 10t
number needed to treat in, 15, 16f
Ranitidine, 2191–2193, 2192t
complications of, 2192
interaction with other drugs, 2192
RANTES, 105, 127, 131, 287
in atopic dermatitis, 132, 148, 149
in psoriasis, 133f
Ranula, 644–645
Rapamycin, 2235
Rapamycin inhibitors, mammalian target of, 2217, 2221–2222, 2235
Raper-Mason pathway in melanin synthesis, 601, 602f
Rapid plasma reagin test in syphilis, 1971, 1971t, 1972, 1973t
Rapp-Hodgkin syndrome, 1344, 1345, 1346f
RAR (retinoic acid receptors), 527, 2106–2107, 2108, 2108f, 2111, 2181
RAS/ras, 281, 1004
in dysplastic nevus, 1124
in melanocytic nevi, 1000, 1100, 1105
in melanoma, 999, 1000, 1002, 1136, 1137
in neurofibromatosis, 1179, 1332
in Spitz nevus, 1114, 1115
in squamous cell carcinoma, 989, 990f, 990–991
Rat-bite fever, 1757t, 1761–1762
differential diagnosis in, 1734
spirillary, 1761
treatment of, 1757t, 1762
Rat flea, 2061
endemic typhus associated with, 1943t, 1948
Rat mites, 2033
Rattlesnakes, 2040, 2040f
Raynaud phenomenon, 1375t, **1643**–1647
clinical findings in, 1644f, 1644–1645
in cryoglobulinemia, 1639, 1646
differential diagnosis of, 849, 1645–1646, 1675
digital ulcers in, 1644, 1644f, 1647
drug-induced, 1646, 1646t
from cytotoxic drugs, 2180
epidemiology of, 1643
and erythromelalgia, 1678
etiology and pathogenesis in, 1643–1644
laboratory tests in, 1645
in lupus erythematosus, 1527, 1645
nail changes in, 1644, 1645, 1645f
in occupational exposures, 1645, 1646t, 2078
primary, 1643, 1644, 1645, 1645t
diagnostic criteria on, 1645, 1645t
secondary, 1643, 1644, 1645–1646, 1646t
in Sjögren syndrome, 1579
in systemic sclerosis, 1555, 1556, 1643, 1644, 1645
treatment of, 1558–1560, 1559f
in thromboangiitis obliterans, 1674, 1675
treatment of, 1646–1647, 1647t
in systemic sclerosis, 1558–1560, 1559f
Rb, 982t
in papillomavirus infections, 996
in retinoblastoma, 995
Reactional keratosis, 1020
Reactive arthritis, **207**–214
characteristic features in, 209, 209t
in chlamydial infections, 208, 209, 1997
circinate balanitis in, 210, 210f, 665, 665f
clinical findings in, 209f, 209–211, 210f
diagnostic algorithm on, 212f
differential diagnosis in, 211–213
enteric or post-dysenteric, 208, 214
epidemiology of, 207
etiology of, 207–209
genetic factors in, 208–209
genital disorders in, 210, 210f, 211, 665
in HIV infection, 202, 207, 208, 210
treatment of, 214
HLA system in, 84, 201, 207, 208–209, 213, 1997
juvenile, 201
oral cavity disorders in, 642t
pathogenesis in, 209
prognosis and clinical course in, 213–214
recurrent and persistent, 213
sexually acquired, 208, 210, 213, 214
treatment in, 214
work disability in, 214
Reactive oxygen species, 97, 285–286
in aging of skin, 964, 965f
in photoaging, 969, 970
DNA damage from, 978t
iron levels and phlebotomy affecting, 1242
in necrotizing venulitis, cutaneous, 1599
in photoimmunosuppression, 806, 807f
in photosensitivity, 805, 1233, 1234f, 1234–1235
and vasoconstriction in cold response, 843
Reactive units of skin, 43, 44f
dermal, 43, 44f, 49–55
subcutaneous, 43, 44f, 55
superficial, 43–49
Rebamipide in Behçet disease, 1625b
Recalcitrant erythematous desquamating disorder (REDD), 1715, 1717
Recall reaction in prior radiation exposure, 2166, 2179, 2179f, 2179t
Recluse spider bites, 2056f, 2056–2057
Reconstructive surgery
flaps in, 2308–2310
grafts in, 2310–2311
in nail injuries, 2329
Red man syndrome from vancomycin, 2202
REDD (recalcitrant erythematous desquamating disorder), 1715, 1717
Red-legged widow spider bites, 2054
5α-Reductase, 691f, 1481
in acne vulgaris, 690, 692
in apocrine glands, 731
in hirsutism, 775
in sebaceous glands, 689
Reduviid bugs, 2060, 2061
and Chagas disease, 2008–2009, 2061
Reed syndrome, 1172, 1505t
Reflectance confocal microscopy, 43
Reflectance of radiation, 802, 802f
Reflex sympathetic dystrophy, 1450–1451
Refsum disease, 404t, 418–419
Regional nerve blocks, 2298–2299
Regulator of G protein signaling protein (RGS), 128, 129f
Regulatory T cells, 104, 112, 116, 116f, 2230
in atopic dermatitis, 148
in autoimmune disorders, 1512–1513
in photoimmunosuppression, 808, 808f
in psoriasis, 171
type 1, 1512, 1513
Reiter syndrome, 195, 207, 208, 642t. *See also* Reactive arthritis
Rejuvenation of skin
with laser therapy, 2268, 2273, 2372–2374
complications of, 2374
equipment in, 2372t, 2372–2373
fractional photothermolysis in, 2373, 2373f
intense pulsed light in, 2373
outcome assessment in, 2374
risks and precautions in, 2372, 2372t
with radio-frequency device, 2373, 2374f
Relapsing fever, 2035
Relapsing polychondritis, **1567**–1569
Relative risk, 17
Relaxed skin tension lines of face, 2290, 2290f
in excisional surgery, 2304
Relaxin in systemic sclerosis, 1560t
Reliability
of evidence, critical assessment of, 14
of morbidity measures, 7
Remodeling, vascular, 1596, 1598
Renal artery disorders in neurofibromatosis, 1336
Renal cell cancer and hereditary leiomyomatosis, 1172
Reovirus, 1846t
Replication, viral, 1846–1848
Replicative senescence, 963
Research
applied in evidence-based medicine, 8–18
collaboration between laboratories in, 89
confidence intervals in, 15, 16, 16f

critical appraisal of, 12–18
on diagnostic tests, 13t, 16–17
on harmful effects, 14t, 17–18
on therapy and prevention, 10, 13t, 13–16
epidemiologic studies in, 3–8
funding priorities in, 90
future investigations in, 89–90
number needed to treat in, 15, 16
outcome measures in, 14–16
on pathophysiology of skin diseases, 87–90
Reservoir of topical drugs on skin surface, 2098–2099, 2100
Resiquimod, 125
Resistance to drugs
antibiotic, 1693, 1695, 1728, 1730, 2194
in acne vulgaris, 698
in athletes, 873–875
in elderly, 973
in surgical wounds, 2337
treatment in, 875, 2114
in candidiasis, 2119, 2120
of herpes simplex virus, 1883–1884
in HIV infection, 2209
in pediculosis capitis, 2034–2035
in varicella-zoster virus infections, 1894
Resistant skin type, 2364t
compared to sensitive type, 2359–2360
Resorcinol, topical
in acne, 696
in chemical peel, 2370t
Resorption of topical drugs, 2101–2102
Respiratory disorders, 1453–1455
in amyloidosis, 1454
in anthrax, 2082
in blastomycosis, 1839
in Churg-Strauss syndrome, 1611, 1614t
in coccidioidomycosis, 1840
in cryptococcosis, 1842
in dermatomyositis, 1544t, 1544–1545
in diphtheria, 1767
in dirofilariasis, 2024, 2025
in epidermal necrolysis, 352
in Fabry disease, 1284t, 1285
treatment of, 1287b
in fat embolism syndrome, 1454
in filariasis, 2017, 2018
in *Haemophilus influenzae* infections, 1739, 1740
in histoplasmosis, 1837
in hookworm infections, 2016
in Kaposi sarcoma, 1186
in Langerhans cell histiocytosis, 1417, 1420f, 1422, 1423
in larva migrans, 1454
in lipoid proteinosis, 1454
in lymphogranuloma venereum, 1988
in melioidosis, 1764, 1765
in methotrexate therapy, 2166
in microscopic polyangiitis, 1613, 1614
in monkeypox virus infections, 1907, 1908
in nocardiosis, 1782
in paracoccidioidomycosis, 1841
in paraneoplastic pemphigus, 471, 472–473
in plague, 1758, 1759, 2083, 2084
in rabies, 2039
in relapsing polychondritis, 1567–1568, 1569
in rheumatoid arthritis, 1572t
in rotavirus infections, 1870–1871
in sarcoidosis, 1454, 1486, 1488, 1489
natural history and prognosis in, 1490, 1491
treatment of, 1491, 1491t
in Sjögren syndrome, 1580
in smallpox, 1902
in strongyloidiasis, 2016
in Sweet syndrome, 291, 292t, 293
in systemic sclerosis, 1454–1455, 1557t
treatment of, 1561
in tropical pulmonary eosinophilia, 2017, 2018
in tuberous sclerosis, 1329, 1330
in tularemia, 1758, 2084
in varicella-zoster virus infections, 1893
treatment of, 1895, 1895t
in warts, 1917, 1919
in Wegener granulomatosis, 1611, 1612t
Resurfacing of skin, **2364**–2371
with chemical peel, 2369–2370
with dermabrasion, 2370–2371
with laser therapy, 2266, 2277–2279, 2364–2369
anesthesia in, 2366
carbon dioxide, 2365, 2366–2367, 2367f, 2368
equipment in, 2365–2366
erbium:yttrium-aluminum-garnet, 2365–2366, 2367, 2368–2369
fractional, 2277, 2369, 2369f
indications for, 2365t, 23642365
outcome assessment in, 2367, 2367f
postoperative care in, 2369
preoperative assessment in, 2365, 2365t
side effects and complications of, 2367–2369, 2368t
technique in, 2366–2367
RET in multiple endocrine neoplasia syndrome, 1177
Rete ridges, 44, 47
epidermal stem cells in, 376
in nails, 780
in psoriasis, 171
Reticular dermis, 43, 44f, 49–55, 63
in drug eruption, 51, 51f, 52
embryonic and fetal, 70
granulomatous reactions, 53–54
infiltrates in
lymphocytic, 51f, 51–52
polymorphonuclear leukocytic, 53
lymphatics of, 65
structure of, 49–50, 50f
vascular system of
deep, 50
superficial, 50–51
Reticular lesions, 36, 36f
Reticulohistiocytoma cutis, 1430
Reticulohistiocytosis
diffuse cutaneous, 1424t, 1430, 1431
multicentric, 1376t, 1424t, 1430–1432, 1495t, 1502
clinical findings in, 1430–1431, 1431f
differential diagnosis of, 1432, 1432b, 1548
epidemiology of, 1425
etiology and pathogenesis in, 1425
histopathology in, 1431–1432, 1432f
malignancy in, 1502
nail changes in, 1430, 1431f
oral cavity disorders in, 649, 1431f
respiratory disorders in, 1454
treatment in, 1434
solitary cutaneous, 1424t, 1430, 1431f
Reticulosis, pagetoid, 1391, 1393f
Retina
angioid streak in pseudoxanthoma elasticum, 1307
antimalarial drugs affecting, 1533, 1551
Retinaldehyde, 2111
Retinoblastoma, 982t, 995
Retinoic acid, 1204
in dysplastic nevus, 1133
9-*cis*-Retinoic acid, 2107, 2108, 2108f, 2109
chemical structure of, 2110f
in sebaceous gland activity and sebum production, 689
13-*cis*-Retinoic acid. *See* Isotretinoin
all-*trans*-Retinoic acid. *See* Tretinoin
Retinoic acid metabolism blocking agents (RAMBAs), 2109, 2112, 2181–2182
Retinoic acid receptors, 527, 2106–2107, 2108, 2108f, 2111, 2181
ultraviolet radiation affecting, 2107
Retinoic acid-responsive elements (RARE), 527, 2107, 2108
Retinoid X receptors, 2106, 2107, 2108, 2108f, 2111, 2181
ultraviolet radiation affecting, 2107
Retinoids, **2181**–2186
acitretin. *See* Acitretin
in acne, 697, 2109, 2111, 2112, 2183, 2184
in actinic keratosis, 1015, 2109
in antiaging products, 2363, 2364
bexarotene. *See* Bexarotene
in carcinogenesis modification, 278, 994, 2112
chemical structure of, 2110f
contraindications to, 2186
dosing regimens, 2184
in topical therapy, 2111
in ichthyosis, 422, 423, 2111, 2183
lamellar, 410, 423
indications for, 2109–2111, 2183–2184
initiation and monitoring of therapy, 2184
interaction with other drugs, 2112, 2186
isotretinoin. *See* Isotretinoin
in lichen planus, 253, 253b, 254, 254b
mechanism of action, 2106–2108, 2109f, 2181–2182
in melasma, 1480
in molluscum contagiosum, 1913, 1913t, 2111
in perforating disorders, 567, 567b
pharmacokinetics of, 2182–2183
in photoaging, 2109, 2111
and photosensitivity, 829t, 2112
in pityriasis rubra pilaris, 235, 236b, 2183
in porokeratosis, 445, 445b
in pregnancy, 2111, 2112, 2184
teratogenic effects of, 2184–2185
in psoriasis, 2109, 2111, 2183
in combination with phototherapy, 2245, 2254
in rosacea, 708, 2183
in sebaceous gland activity and sebum production, 689, 2185
side effects and complications of, 2111–2112, 2184–2186
in athletes, 878
dermatitis in, 2111, 2143, 2144f, 2185
epidermal hyperplasia in, 2108, 2109f, 2111–2112
hepatotoxicity in, 1459t, 2186
in pregnancy, 2184–2185
telogen effluvium in, 761, 2185
in topical therapy, 2111–2112
in squamous cell carcinoma prevention, 278, 2112
in striae, 2111
in sub-corneal pustular dermatosis, 306, 307b
in T-cell lymphoma, 1398–1399, 2183

Retinoids—*continued*
topical, **2106**–2112
adverse effects of, 2111–2112
clinical uses of, 2109–2111
dosage schedules and forms in, 2111
epidermal hyperplasia from, 2108, 2109f, 2111–2112
ethnic considerations in, 2111, 2143–2144, 2144f
interaction with other drugs, 2112
mechanism of action, 2106–2108, 2109f
nomenclature related to, 2108–2109
in pregnancy, 2111, 2112
tretinoin. *See* Tretinoin
Retinol, 1204–1206. *See also* Vitamin A
Retinopathy from antimalarial drugs, 1533, 1551
Retinyl esters, 2108, 2110f, 2111
Retinyl palmitate, 2108, 2111
Retrovirus infections, 1846, 1846t, 1847, **1923**–1940
HIV infection and AIDS, 1927–1940
HTLV-1 and HTLV-2, 1923–1927
tumors associated with, 995, 995t
Revascularization
in diabetic foot problems, 2348
in skin graft healing, 2346–2347
Reverse transcriptase inhibitors in HIV infection
nonnucleoside, 1930t, 2209
hypersensitivity reactions to, 1934
nucleoside, 1930t, 2208–2209
hypersensitivity reactions to, 1934
lipodystrophy from, 586, 589, 1934–1935
Rewarming techniques in cold exposure, 846, 847
Reye syndrome in varicella, 1893, 1894
Reye tumor, 551
Reynolds syndrome, 1458
Rhabdomyolysis in decubitus ulcers, 881
Rhabdomyoma, 1175, 1329
Rhabdomyosarcoma, 1176
in neurofibromatosis, 1336
Rhabdovirus, 1846t
Rhagades
in congenital syphilis, 1968, 1968f
and pseudorhagades in erythropoietic protoporphyria, 1244
Rheumatic fever, **1573**–1574, 1703, 1704
acute, 1703, 1704
differential diagnosis in, 1734
erythema marginatum in, 1574, 1574b, 1574f
Jones criteria on, 1574, 1574b
Rheumatoid arthritis, **1569**–1573
as autoimmune disorder, 1509, 1569
clinical features in, 1570–1572
diagnostic criteria on, 1570, 1570t
differential diagnosis of, 1573b
environmental factors in, 1514
epidemiology of, 1569
etiology and pathogenesis in, 1569–1570
extraarticular manifestations in, 1454, 1572, 1572t
Felty syndrome in, 1571, 1572f
genetic factors in, 1510, 1511, 1512, 1569
histopathology in, 1571, 1571f, 1572, 1572f
necrotizing venulitis in, 1601
neutrophilic dermatosis in, 1571–1572, 1572f
psoriatic arthritis compared to, 200, 200t
regulatory T cells in, 1512–1513
respiratory disorders in, 1454
treatment of, 1572–1573, 1773
disease-modifying, 1573, 1573t
rituximab in, 2229
tumor necrosis factor inhibitors in, 1573, 2227, 2228
Rheumatoid factor
in dermatomyositis, 1546
in rheumatoid arthritis, 1570, 1570t, 1572
Rheumatoid nodules, 53
Rhinitis in syphilis, 1968f, 1969
Rhinopharyngitis mutilans in yaws, 1981
Rhinophyma in rosacea, 704–705, 706f
Rhinoscleroma in *Klebsiella* infections, 1742, 1742f
Rhinosporidiosis, 1835
Rhinosporidium seeberi, 1835
Rhipicephalus ticks, 1945f
Mediterranean spotted fever from, 1942, 1943t, 1945f
Rhizomucor, 1843
Rhizopus, 271
in diabetes mellitus, 1465–1466
in oral cavity disorders, 653t
in zygomycosis, 1465–1466, 1843
Rho, 128
in local cooling response and vasoconstriction, 843
in melanocyte dendrite formation, 603
Rhodesian trypanosomiasis, 2008
Rhodopsin, 127
Rhombic transposition flaps, 2310, 2312f
after Mohs micrographic surgery, 2317f
Rhytides, 2363. *See also* Wrinkling of skin
Ribavirin in measles, 1853
Riboflavin, 1209
deficiency of, 1209, 1209f
food sources of, 1209
Ribonucleoproteins, 1528t, 1539t
Ribosomal RNA, 73
Ribozymes, 75
Richner-Hanhart syndrome, 428, 1220, 1222
Ricin, 2083t
Rickets, 1206–1207
Rickettsia, 2197t
Rickettsia africae, 1942
Rickettsia akari, 1943t, 1946–1947, 1951f
Rickettsia conorii, 1942, 1943t
Rickettsia felis, 1943t, 1948
Rickettsia japonica, 1942
Rickettsia prowazekii, 2035
in bioterrorism, 2083t
in epidemic typhus, 1943t, 1948–1951
Rickettsia rickettsii, 1941–1942, 1943t, 1949b
Rickettsia slovaca, 1942
Rickettsia tsutsugamushi, 2032
Rickettsia typhi, 1943t, 1948, 1949b
Rickettsial infections, **1940**–1952
in bioterrorism, 1940
differential diagnosis of, 1948b
spotted fever group, 1940, 1941–1947
treatment of, 1949b, 1950b
typhus group, 1940–1941, 1948–1952
Rickettsialpox, 1943t, 1946–1947, 2033
clinical findings in, 1946–1947, 1951f
differential diagnosis of, 1947
treatment of, 1947
Riehl melanosis, 639
Rifabutin, interaction with other drugs, 2240t
Rifampin
in actinomycetoma, 1786
in *Bartonella infections,* 1751, 1755
in brucellosis, 1760
in cat-scratch disease, 1751
in ehrlichiosis, 1950b
in furunculosis, 1701t
interaction with other drugs, 2239t, 2240t
in leprosy, 1794, 1795, 1795b
adverse effects of, 1796
in meningococcal infections, 1735
in tuberculosis, 1775t
in verruga peruana, 1755
Riley-Day syndrome
hyperhidrosis in, 726
oral cavity disorders in, 642t
Risk factors
in epidemiologic studies, 3
in harmful effects of exposures, 17–18
Risk ratio, 17
Risperidone, 917t
Ritonavir in HIV infection and AIDS, 2209–2210
Ritter disease, 1697
Rituximab, 2229
in cicatricial pemphigoid, 485, 485b
complications of, 2229
in dermatomyositis, 1552
indications for, 2229
in lupus erythematosus, 1533t, 1535
in lymphoma, 2229
in pemphigus, 468
paraneoplastic, 474, 474t
in rheumatoid arthritis, 2229
River blindness, 2019
RNA, 73, 74–76
heteronuclear, 74
inhibition pathway, 86
short inhibitory, 86
synthesis inhibition, 984
viral, 1845, 1846t
RNA polymerase II, 76
Robinson type of eccrine hidrocystoma, 1074
Rocky Mountain spotted fever, 1941–1942
clinical and laboratory findings in, 1941, 1946t, 1947f
diagnosis and differential diagnosis of, 1942, 1948b, 1949b
differential diagnosis in, 1733b
histopathology in, 1942, 1948f
necrosis and gangrene in, 1941, 1947f
in pregnancy, 1942, 1950b
treatment of, 1942, 1949b, 1950b
Rodent mite, rickettsialpox from, 1946
Rodent ulcer in basal cell carcinoma, 1037, 1037f
Rodnan skin score in systemic sclerosis, 1556
Ro-Dorfman disease, 1433–1434
Romana's sign in Chagas disease, 2009t
Romberg's sign in syphilis, 1966
Rombo syndrome, 561, 753t, 1037
differential diagnosis in, 1046
Rosacea, **703**–709
classification and staging of, 703–704
clinical features in, 703, 704–705, 705f–706f
conglobata, 706
differential diagnosis in, 706–707, 707f
epidemiology of, 704
erythematotelangiectatic, 704, 705f, 706, 707, 707f
etiology and pathogenesis in, 704
fulminans, 706
granulomatous, 705, 706f
histopathology in, 705–706
ocular, 705, 706f, 707f, 709
papulopustular, 704, 705f, 706, 707, 707f
phymatous, 704–705, 706, 706f, 707f, 709
scrotal, 670
in sensitive skin type, 2360
treatment of, 707–709
antibiotics in, 708, 2113–2114

laser therapy in, 708–709, 2272
photodynamic therapy in, 2262
retinoids in, 708, 2183
triggering factors in, 707, 707f
Rosai-Dorfman disease, 1866
Rose bengal
phototoxicity from, 828t
in Sjögren syndrome diagnosis, 1581, 1581t
Rose of Jericho, 2003
Rose spots in enteric fever, 1740–1741
Roseola
infantum, 1864–1866
differential diagnosis of, 1949b
oral cavity disorders in, 651t
syphilitica, 1958, 1959f
Rosiglitazone in lipodystrophy, 589
Ross syndrome, 725, 727
Rotation flap, 2309–2310, 2310f, 2311f
Rotavirus infections, 1870–1871
Roth spots in endocarditis, 1453, 1745
Rothmund-Thomson syndrome, 1294, 1313t, 1315, **1323,** 1505t
clinical features in, 1323
DNA damage and repair in, 1323
genetic factors in, 1323
Round cells, 52
in liposarcoma, 1197–1198
Round lesions, 34
Roundworm infections, 2011, 2012–2013
Rove beetles, 2060
Rowell syndrome, 1522
differential diagnosis of, 347, 348b
Rowing, skin conditions associated with, 874t
Rubber
allergic contact dermatitis from, 142
in athletes, 876, 876f
in occupational exposures, 2070, 2070t
occupational exposure to, 2070, 2070t, 2771
contact urticaria in, 2071
Rubella, 1848, 1853–1855
clinical findings in, 1853–1854, 1854f
complications of, 1854
congenital, 1853, 1854, 1855
differential diagnosis of, 1854, 1854b
oral cavity findings in, 651t
in pregnancy, 1853, 1854, 1855
treatment of, 1854–1855
vaccination, 1853, 1854, 1855
Rubeola, 1851–1853. *See also* Measles
Rud syndrome, 421
Running and jogging, 874t, 875
actinic damage in, 876
cold injuries in, 876
nail conditions in, 874f, 874t
repetitive trauma in, 2077
Russell bodies in leishmaniasis, 2005
Russell sign, 39t
Rutoside in pigmented purpuric dermatosis, 1636
Ruvalcaba-Myhre-Smith syndrome, 668
RXRs (retinoid X receptors), 2106, 2107, 2108, 2108f, 2111, 2181
ultraviolet radiation affecting, 2107

S

S-100 proteins, 1177t
in appendage tumors of skin, 1070t
in cornified envelope, 381, 382t
in granular cell tumors, 1177t, 1181, 1182
in Langerhans cell histiocytosis, 1415, 1417t
in melanoma, 1144–1145, 1153
in Merkel cell carcinoma, 1090t, 1091
in neurothekeoma, 1177t, 1180
in Paget disease, 1096
in perineurioma, 1177t, 1180
in peripheral nerve sheath tumor, malignant, 1177t, 1181
in psoriasis, 173
in schwannoma, 1177t, 1177–1178
Sabinas syndrome, 759t, 1321
Sacroiliitis in reactive arthritis, 211, 213
Saddle-nose deformity
in relapsing polychondritis, 1567, 1568f
in syphilis, 1964, 1964f, 1968, 1968t
Safety
of laser therapy, 2268t, 2268–2269
occupational, 2072–2073
assessment of, 2072, 2073
protective clothing and equipment in, 2072–2073, 2077
Sagartia sea anemones, 2045
Saksenaea vasiformis, 1843
Salicylic acid, topical, 2135t, 2136
in acne vulgaris, 696
in chemical peels, 2370t
in corns and calluses, 873b
in ethnic skin, 2144
in palmoplantar keratoderma, 431
in pruritus, 909, 909t
in psoriasis, 189–190
toxicity in children, 946t, 2136
in warts, 1922, 2136
Salicylism, 2136, 2144
Saline solution, hypertonic, in sclerotherapy for varicose veins, 2353t, 2354
Saliva, artificial, in Sjögren syndrome, 1582
Salivary gland disorders, 644–645
differential diagnosis of, 1579b
mucoceles in, 644–645
in Sjögren syndrome, 1578–1579
diagnosis of, 1581, 1581t
histopathology of, 1581, 1581t, 1582f
treatment of, 1582, 1582t
tumors, 649–650
xerostomia in, 644, 1578–1579
Salmon patches, 1652
as birthmark in infants, 938
in nail psoriasis, 789, 789f
Salmonella infections, 1691, **1740**–1741
Bartonella infection with, 1754, 1755
differential diagnosis in, 1741
enteric fever in, 1740–1741
in immunocompromised host, 273
reactive arthritis in, 207, 208, 209
treatment of, 1741
SALT (skin-associated lymphoid tissue), 112
in parapsoriasis, 236, 237
Salt-split skin immunofluorescence in epidermolysis bullosa acquisita, 498
Saltwater baths and phototherapy in psoriasis, 2245
San Joaquin Valley fever, 1839–1840
Sand fleas, 2061–2062
Sandfly bites, 2060
leishmaniasis in, 2001–2007
Oroya fever and verruga peruana in, 1754–1755
Sandhoff disease, anhidrosis in, 729
Sandworm eruption, 2023
Saphenous veins
anatomy of, 2350, 2351f
varicose, 2349–2356
SAPHO syndrome, 201, 701
palmoplantar pustulosis in, 216, 217
pustular psoriasis in, 180
Sapienic acid in sebum, 688, 688f
Saponification, 578
Saquinavir in HIV infection and AIDS, 2209–2210
Sarcoidosis, **1484**–1492
alopecia in, 1487
bilateral hilar adenopathy in, asymptomatic, 1490
cardiovascular disorders in, 1454, 1488
treatment of, 1491, 1491t
clinical findings in, 1486f, 1486–1489, 1487f
diagnosis of, 1490, 1490f
differential diagnosis of, 1489, 1490t
epidemiology of, 1484–1485
etiology and pathogenesis in, 1485f, 1485–1486
exfoliative dermatitis in, 230t
eye disorders in, 1488, 1491t
fibrosis in, 1490
gallium scan in, 1489, 1490
hypopigmentation in, 626
ichthyosis in, 421
laboratory tests in, 1489, 1489t
liver disorders in, 1458, 1488
treatment of, 1491t
nail changes in, 1487
natural history and prognosis in, 1490–1491
neurologic disorders in, 1489
treatment of, 1491, 1491t
papular, 1486, 1486f
pathology in, 1489f, 1489–1490, 1490t
respiratory disorders in, 1454, 1486, 1488, 1489
natural history and prognosis in, 1490, 1491
treatment of, 1491, 1491t
in scars, 1487, 1488f
subcutaneous fat in, 55, 580
treatment of, 1491t, 1491–1492
antimalarial drugs in, 1492, 1492t, 2160
vasculitis in, 1615
Sarcoma
angiosarcoma, **1188**–1189
epithelioid, 1163, 1163f
clinical findings in, 1163, 1163f
differential diagnosis of, 1160b
treatment of, 1163
Kaposi, **1183**–1188. *See also* Kaposi sarcoma
mast cell, 1436t, 1437
neurogenic, 1181
undifferentiated pleomorphic, 1162
Sarcoptes scabiei, 2029, 2032t, 2033
Sarin as chemical weapon, 2086t
SART3 in porokeratosis, 442
Satellite cell necrosis in graft-versus-host reaction, 262
Satellite metastasis of melanoma, 1155
Satellitosis in cutaneous leishmaniasis, 2003, 2004f
Sausage digits in psoriatic arthritis, 195
Sawtooth appearance in lichen planus, 251, 252f
Scabby mouth disease, 1910–1911
Scabies, 663, **2029**–2032
burrows in, 29, 29f, 2030, 2030f
clinical findings in, 2029–2030, 2030f
complications in, 2030
crusted, 2030, 2030f
diagnosis of, 2030, 2031f
differential diagnosis of, 2031b
in elderly, 973, 2029
exfoliative dermatitis in, 225, 230t
genital disorders in, 2030, 2030f

Scabies—*continued*
in immunocompromised host, 277, 277f, 2029
in HIV infection and AIDS, 1940, 2029
lymphoid hyperplasia in, 1404f, 1405, 1408
in occupational exposures, 2076
prevention of, 2031–2032
public health approach to, 20–21
transmission of, 2029
treatment of, 2031, 2031b
Scald injuries in child abuse, 929
Scalded-skin syndrome, staphylococcal, 46, 61, 390, 1694, 1710–1714
clinical features in, 1712, 1713f, 1714f
diagnosis and differential diagnosis of, 1714
histopathology in, 1714f
in immunocompromised host, 268
scarlatiniform variant, 1714
treatment and prognosis in, 1714
Scaling lesions, 30–31, 31f, 31t
genital, 659b
in ichthyosis, 401–423
in pityriasis rosea, 31t, 362, 363, 363f
in psoriasis vulgaris, 31, 31f, 31t
Scalp
allergic contact dermatitis of, 140
candidiasis of, chronic mucocutaneous, 1355, 1356f
cicatricial pemphigoid of, 482, 482f
dermatomyositis of, 1543t, 1544, 1551
erosive pustular dermatosis of, 772t, 774, 774f, 1033
hair loss in disorders of, 771, 772t, 774, 774f
lichen planus of, 247, 248, 248f
metastasis to, 1449
pityriasis amiantacea of, 222, 222f, 771, 771f
psoriasis of, 771
seborrheic dermatitis of, 221, 222, 222b, 222f, 224
surgical anatomy of, 2291
SCARF syndrome, 1309b
Scarification as body art, 886
Scarlet fever, 1715, 1717–1719
oral cavity disorders in, 652t, 1717–1718, 1718f
staphylococcal, 1696, 1718–1719
streptococcal, 1717–1718, 1719
clinical findings in, 1717–1718, 1718f
Scars, 27f, 27–28
in acne, 693, 695f
conglobata, 700
in alopecia, cicatricial, 755t, 764, 771–774
anhidrosis in, 729
atrophic, 28
in body piercing, 890t
in burns, 855, 857f, 1020
in drug abuse, 922–923, 923f
skin popping scars in, 922–923, 923f
hypertrophic, 27, 27f, 553–554
compared to keloids, 2339, 2340t
cryotherapy in, 2331
postoperative, 2339, 2340t, 2341f
radiation therapy in, 2281
triamcinolone acetonide in, 2339, 2341f
keloid, 27–28, 2339
keratosis in, 1019–1020
in laser skin resurfacing, 2368
laser therapy in, 2278, 2374
in pemphigoid, cicatricial, **481**–485, 681
postoperative, 2339–2340, 2340f, 2340t
depressed or furrow-like, 2239–2240
hypertrophic, 2339, 2340t, 2341f
pigmentation of, 2341
spreading, 2340
pruritus in, 908
sarcoidosis in, 1487, 1488f
squamous cell carcinoma in, 1020, 1029, 1031–1032, 1033, 1034
Scatter factor in melanocyte development, 591, 592
Scattered lesions, 36, 38f
Scattering of radiation, 802, 802f
and absorption, 2264–2266
Scedosporium apiospermum, 1832, 1834t
Schamberg disease, 1634, 1634t
clinical findings in, 1634, 1634f, 1635f
pathogenesis in, 1633
treatment of, 1636
Schimmelpenning-Feuerstein-Mims syndrome, 1059, 1060, 1061
Schirmer's test in Sjögren syndrome, 1581, 1581t
Schistosoma haematobium, 2015t, 2021t, 2025, 2026
Schistosoma intercalatum, 2021t, 2025
Schistosoma japonicum, 2015t, 2021t, 2025, 2026
Schistosoma mansoni, 2012t, 2021t, 2025, 2026, 2026f
treatment of infections, 2015t, 2026
Schistosoma mekongi, 2015t, 2021t, 2025, 2026
Schistosomiasis, 2012t, 2025–2026, 2026f
differential diagnosis of, 2021t, 2026
genital lesions in, 667, 2025, 2026
in occupational exposures, 2076
in swimmers, 877, 2025, 2048–2049
treatment of, 2015t, 2026
Schnitzler syndrome, 338, 1603, 1604
Schobinger classification of arteriovenous malformations, 1664, 1664t
Schöpf-Schulz-Passarge syndrome, 430
Schwachman-Diamond syndrome, 1363t
Schwannoma, 1178–1179, 1331, 1338
immunohistochemistry of, 1177t, 1177–1178
malignant, 1181
staining of, 1177t
Schwannomatosis, 1178, 1339
Schwannomin, 1338
Schweninger-Buzzi anetoderma, 557
Scientific approaches to pathophysiology of skin disease, **87**–90
Scleradenitis in syphilis, 1958
Scleredema, **1562**–1564
adultorum, 1562
of Buschke, 1562
clinical findings in, 1563, 1564f
in diabetes mellitus, 1464, 1563, 1564
histopathology in, 1563–1564, 1564f
postinfectious, 1563, 1564
Sclerema neonatorum, 576, 582, 851, 939
compared to subcutaneous fat necrosis of newborn, 582
Scleroborreliosis, 1800t, 1801, 1801f
Sclerodactyly
in Huriez syndrome, 426
in Raynaud phenomenon, 1644
Scleroderma, 54, 55, 1376t, **1553**–1562
and dermatomyositis, 1540, 1543–1544
differential diagnosis of, 548–549, 1223
hypopigmentation in, 626
linear, 543, 544f, 544–545
anhidrosis in, 730
complications in, 545–546
en coup de sabre appearance in, 544, 544f, 545, 546
prognosis and clinical course in, 546
treatment in, 546
localized, **543**–546, 1553, 2247. *See also* Morphea
nail changes in, 791
in paraneoplastic syndromes, 1494t, 1500
renal crisis in, 1560
subcutaneous tissue in, 66
systemic, 543, **1553**–1562
approach to patient with, 1560f
autoantibodies in, 1554t, 1554–1555, 1556
cardinal symptoms in, 1557t
cardiovascular disorders in, 1453, 1555, 1557t, 1558–1561
clinical findings in, 1555–1557, 1556f, 1557f
differential diagnosis of, 1557–1558, 1559b
diffuse cutaneous, 1556, 1556f, 1557, 1557t, 1558f
epidemiology of, 1553–1554
etiology and pathogenesis in, 1554–1555, 1555f
fibrosis in, 1555, 1557, 1560t, 1561
gastrointestinal disorders in, 1452, 1457, 1557t, 1561
genetic factors in, 1554, 1554t, 1556
histopathology in, 1557, 1558f
kidney disorders in, 1560
localized cutaneous, 1556, 1556f, 1557t
in occupational exposures, 2078, 2078t
overlap syndromes in, 1556, 1557t
pigmentation changes in, 638
progressive, 1494t, 1500
Raynaud phenomenon in, 1555, 1556, 1643, 1644, 1645
treatment of, 1558–1560, 1559f
respiratory disorders in, 1454–1455, 1557t, 1561
sine scleroderma, 1556
treatment of, 1558–1562, 1559t
tuberous, **1325**–1331, 1505t. *See also* Tuberous sclerosis
Scleroderma-like disorders, 1553, 1562
in diabetes mellitus, 1463f, 1463–1464
Sclerodermatomyositis, 1540, 1543–1544
Scleromyxedema, 1376t, 1495t, 1502–1503, 1562, **1564**–1566
clinical findings in, 1565, 1565f, 1566f
histopathology in, 1565, 1566f
Sclerosis, 29, 29f, 1563t
from cytotoxic drugs, 2180
in morphea, 29, 29f. *See also* Morphea
systemic, **1553**–1562. *See also* Scleroderma, systemic
tuberous, **1325**–1331. *See also* Tuberous sclerosis
Sclerotherapy, 1660
in lymphatic malformations, 1663
in varicose veins, 2349–2355
agents used in, 2352, 2353t
contraindications to, 2350–2351, 2352t
equipment in, 2352, 2353t
foam techniques, 2352–2353, 2354f
inadvertent arterial injection in, 2355
indications for, 2352t
results of, 2354f
side effects and complications of, 2353–2355
Sclerotylosis, 426
Scoliosis in neurofibromatosis, 1335–1336
Scolopendra centipede bites, 2059

Scombroid food poisoning, 2053
Scopulariopsis, 786t, 1817, 1818, 1820
SCORAD (Severity Scoring of Atopic Dermatitis), 7, 8
Scorpaena scorpionfish, 2051, 2051f
Scorpion stings, 2054, 2057–2058, 2058f
  differential diagnosis of, 2056b
  prevention of, 2063
Scorpionfish stings, 2050, 2051, 2051f, 2052
SCORTEN prognostic scoring system in epidermal necrolysis, 350, 350t, 352, 354
Scrape, pull, swab step in diagnosis, 42
Scratching
  excoriations of epidermis in, 31–32, 32f
  itch-scratch cycle in, 903, 903f
Screening tests for phenylketonuria, 1223
Scrofuloderma, 272, 1769, 1770, 1772, 1772f
  in BCG vaccination, 1773
  differential diagnosis of, 1772, 1773b
  treatment of, 1775
Scrotodynia, 670
Scrotum, 654
  calcification of, 672, 1296
  Fournier gangrene of, 1724–1725, 1725f
  lichen simplex chronicus of, 161f
  painful, 670
  red or burning, 670
  rosacea of, 670
  squamous cell carcinoma of, 1031
  swelling of, 663b
  ulceration of
    in Epstein-Barr virus infections, 1859f
    spontaneous, 671
Scrub typhus, 1951–1952, 2032, 2032t
Scrum pox, 1877
Scurvy, 1212–1213
  purpura in, 1384
Scutula in favus, 1813, 1813f
Scytalidium dimidiatum, 1817
SDF-1 (stromal cell-derived factor-1), 127, 133
Se autoantigen in dermatomyositis, 1539, 1539t, 1547
Sea anemones, 2042, 2045, 2045f
Sea bather's eruption, 877, 2049, 2049f
  prevention of, 2049, 2049t
Sea cucumber dermatitis, 2048
Seafood ingestion and poisoning, 2053
Sea lice infestation, 2049
Sea nettle stings, 877, 2042, 2045t
Sea urchin injuries, 2046–2047, 2047f
  nodular reactions to, 2047, 2047f
  spine removal in, 2047
Seal finger, 1757t, 1762, 2042
  treatment of, 1757t, 1762, 2042
Seatworm infection, 2013
Seaweed dermatitis, 877
Sebaceoma, 1086, 1086f
Sebaceous follicles, 687
Sebaceous glands
  age-related changes in, 967, 2358
  anatomy of, 687–689
  biology of, **687**–690
  embryonic and fetal, 72, 687–688, 1068
  factors regulating sebum production, 689–690
  functions of, 384
  histology of, 687, 687f
  holocrine secretion process, 688
  hyperplasia of
    in neonates, 936, 937f
    in photoaging, 968t
  lipids of, 688f, 688–689
  location of, 687
  nevi of, 1056, 1057t, 1059, 1059f
    syndrome in, 1057, 1060
  perineal, 654
    prominence of, 657
  physiology of, 688
  in pilosebaceous unit, 687
  size and density of, 687
  tumors of, 1068, 1069t, 1070t, 1085–1087
    differential diagnosis in, 1068
    genetic factors in, 988, 989t
  in xerosis, 2358
Sebaleic acid in sebum, 688, 688f
Sebocystomatosis, 1065
Sebocytes, 687
Sebopsoriasis, 220
Seborrhea, 219
  acne vulgaris in, 692
  oleosa, 219
Seborrheic dermatitis, **219**–225
  in adults, 219, 221f, 221–222, 222f
    treatment of, 224–225
  clinical findings in, 220, 220t
  differential diagnosis of, 139b, 221, 221b, 222b
  distribution of lesions in, 221, 221f–223f
  in drug abuse, 926
  eczematid, 221
  epidemiology of, 219
  etiology and pathogenesis in, 219–220
  genital, 664
  histopathology in, 222–223, 223t
  in HIV infection and AIDS, 219, 220, 222, 223f, 223t
  in infants, 219, 220–221, 221f
    differential diagnosis of, 221, 221b
    treatment of, 223–224
  nutrition in, 220, 224, 2287
  photo-exacerbated, 825, 825f
  pityriasiform, 221–222
  prognosis and clinical course in, 221, 222
  and psoriasis, 220
  scaling lesions in, 31t
  seborrheic stage in, 220
  treatment of, 223–225, 2121
    complementary and alternative medicine approaches to, 2286–2287
    terbinafine in, 2212, 2213t
Seborrheic keratosis, **1054**–1056
  cryotherapy in, 2331
  laser therapy in, 2273
  Leser-Trélat sign in, 1497–1498
Sebum
  function of, 689
  lipid composition of, 688f, 688–689
  production of, 219
    in acne vulgaris, 692
    embryonic and fetal, 72
    regulation of, 689–690
    in xerosis, 2358
Seckle syndrome, 982t, 1314t
Secondary lymphoid-organ chemokine (SLC), 127, 131, 599
Sedation
  from antihistamines, 2187, 2190
  in drug interactions, 2240t
Sedatives
  abuse of, 922, 924
  pediatric dosage, 952t–953t
Seed corn, 872
Seipin in lipodystrophy, 588
Seizures
  in acute intermittent porphyria, 1251
  in cysticercosis, 2014t
  in tuberous sclerosis, 1328–1329, 1330
Selectins, 281, 282f
  E-selectin, 1590t, 1591, 1594
    and cutaneous lymphocyte antigen, 105, 129–130, 1595–1596
    endothelial expression of, 281, 287
    functions of, 1592t
    in multistep model of leukocyte recruitment, 129–130, 130f
    in necrotizing venulitis, 1600
  L-selectin, 130, 130f, 281, 287, 1591, 1592t
  P-selectin, 1587, 1589, 1590t, 1591, 1595
    endothelial expression of, 281, 287
    functions of, 1592, 1592t
  P-selectin glycoprotein ligand 1, 104–105, 282f, 287, 1387
  in urticaria and angioedema, 341
Selection bias, 3–4
Selenium, 1217
  deficiency of, 1217
    hypopigmentation in, 629, 1217
  food sources of, 1217
  toxicity of, 1217
Selenium sulfide
  in tinea capitis, 1819
  in tinea versicolor, 1830
Self-examination recommendations in dysplastic nevus, 1132
Self-inflicted dermatoses, 914–916
  treatment in, 917
Self-tolerance and autoimmune disorders, 1511–1512
Semmes-Weinstein filaments, 1796
Senear-Usher syndrome, 465
Sensitive skin type, 2364t
  with acne, 2360
  allergic, 2361
  compared to resistant type, 2359–2360
  cosmetic intolerance syndrome in, 2359–2360
  with rosacea, 2360
  with stinging, 2360–2361
Sensory system
  age-related changes in, 967
  and anesthesia as postoperative complication, 2341
  functions of skin in, 57, 58t
  nerves and receptors in, 65f, 65–66, 66f, 895
    anatomy of, 896, 2292, 2292f
    embryonic and fetal development of, 70
    facial, 2292, 2292f
      anesthetic block of, 2298
Sensu stricto, 2025
Sentinel lymph nodes
  in melanoma, 1149, 1151–1153, 1154
  in Merkel cell carcinoma, 1091, 1091f
  in Paget disease, 1096, 1097
  in squamous cell carcinoma, 1035
Sepsis, **1746**–1747
  arthritis in, 213
    in body piercing complications, 890t
  differential diagnosis of, 1747, 1747b
  disseminated intravascular coagulation in, 1747, 1748
  in epidermal necrolysis, 353
  in graft-versus-host disease, 265
  in immunocompromised host, 1746, 1747
  purpura fulminans in, 1383
  severe, 1747
  shock in, **1746**–1747
    in meningococcal infections, 1734, 1735
  treatment in, 1747
  in *Vibrio vulnificus* infections, 1747, 1763, 1764

Septicemia
in melioidosis, 1765
in plague, 1758, 1759
Pseudomonas, 1737–1738, 1739
SERCA2, 61, 68t
in acrokeratosis verruciformis, 436
in Darier-White disease, 61, 392, 432–433, 434, 435
Serglycin, 539, 539t
Serine palmitoyl transferase, 386, 389f
Serine proteases, 534
inhibitors of, 407
Serine-threonine kinase
STK11 in Peutz-Jeghers syndrome, 633
STK15, 993
Serine-threonine phosphatase interacting protein in PAPA syndrome, 701
Serologic tests in syphilis, 1971t, 1971–1973, 1972t
Serotonin in Raynaud phenomenon, 1643
Serotonin receptors, 393
Serotonin reuptake inhibitors, 918t, 919
in body dysmorphic disorder, 914
hyperhidrosis from, 726
interaction with other drugs, 2239, 2239t
and serotonin-norepinephrine reuptake inhibitors, 918t, 919–920
side effects of, 918t, 919
in systemic sclerosis, 1559t
in trichotillomania, 915
Serotonin syndrome, 919
hyperhidrosis in, 726
Serpent worm disease, 2021
Serpiginous lesions, 36, 36f
Serrate1 and Serrate2 in hair follicle development, 741
Serratia marcescens, 1364
Sertaconazole, 2117t
Sertraline, 918t
Serum sickness, 338
Serum sickness-like syndrome
drug-induced, 357t, 358
in hepatitis B, 1457
Severity of disease measures, 7–8, 14
Severity Scoring of Atopic Dermatitis, 7, 8
Sex hormone binding globulin, 1481
Sexual abuse of children, 929f, 929t, 929–930
differential diagnosis in, 929, 929t, 942
genital warts in, 1917
gonorrhea in, 1995
Sexually transmitted infections, 663–664, **1955**–2000. *See also specific infections*
bacterial vaginosis, 1999–2000
chancroid, 1983–1986
chlamydial, 1996–1997
gonorrhea, 1993–1996
granuloma inguinale, 1990–1993
herpes simplex virus, 1873, 1879, 1884
in HIV infection, 1939–1940
HIV infection in, 1927, 1939–1940
laboratory tests in, 657
lymphogranuloma venereum, 1987–1990
mycoplasmal, 1998
papillomavirus, 1917, 1921, 1922
pediculosis pubis, 2035
syphilis, 1955–1977
T-cell lymphotropic virus, 1923
trichomoniasis, 1998–1999
Sézary cells, 1391
Sézary syndrome, 106, 1386, 1391–1392
clinical manifestations of, 1391
differential diagnosis in, 1925, 1926
eosinophilia in, 286
erythroderma in, 31, 31f, 1391
and exfoliative dermatitis, 225, 226, 227, 229, 231
laboratory findings in, 1391–1392
staging of, 1396t
treatment of, 1392
granulocyte-macrophage colony-stimulating factor in, 2226
photochemotherapy in, 2255
photopheresis in, 2259
SH2 domains, 119, 119f
SH2D1A in X-linked lymphoproliferative disease, 1354
Shagreen patch
differential diagnosis in, 1330b
in tuberous sclerosis, 1326, 1329, 1329f
Shahib disease, 2006
Shah-Waardenburg syndrome, 614
Shake lotions, topical medications formulated as, 2095
Shaken infant, 929
Shale oil, 2130
Shampoo products
in dermatophyte infections, 1819
in tinea versicolor, 1830
Shapes of skin lesions, 34–36
Shapiro syndrome, 725–726, 729
Share and Care Cockayne Syndrome Network, 1321
Shark bites, 2052
Shave excision in actinic keratosis, 1013
Shawl sign, 39t
in dermatomyositis, 1543t, 1546
Shea decubitus ulcer staging system, 879, 884t
Shear forces, decubitus ulcers in, 878, 881f
Sheehan syndrome, 1471
Sheep liver fluke disease, 2026
Shewanella putrefaciens, 1739
Shh (sonic hedgehog), 68t, 71f, 72
in basal cell nevus syndrome, 1043–1044, 1045
in hair follicle development, 740f, 741
in sebaceous gland development, 688, 688f
Shigella infections, reactive arthritis in, 207, 208
Shin spots in diabetic dermopathy, 1469, 1469f
Shingles, 667
Ship fever, 1948
Shivering, 835, 836
Shock, septic, **1746**–1747
in meningococcal infections, 1734, 1735
Shoulder-hand syndrome, 1450–1451
Shprintzen-Goldberg syndrome, 1302
Shulman syndrome, 286, 545, 1562, 1801
Shwartzman reaction, 1382, 1732
localized or dermal, 1732
Sialidosis, 1286t
Sialogogues in xerostomia, 644
Sialyl-Lewis X, 281, 282f, 287
Sicca symptoms in Sjögren syndrome, 1578–1579
treatment of, 1582t, 1582–1583
Sideroblastic anemia, porphyrin profile in, 1256
Signal recognition particle (SRP) in dermatomyositis, 1539t, 1546, 1550
Signal transduction, 102
cytokine-receptor mediated, 116–119, 124–126, 127–129, 129f
in psoriasis, 174
Signet-ring cell squamous cell carcinoma, 1033
Sikari disease, 2006
Sildenafil in systemic sclerosis, 1559, 1559t, 1561
Silica exposure, 2078t
autoimmune disorders in, 1514
scleroderma-like disorders in, 1562
Silicone injections, 2382t, 2387–2388
in HIV infection and lipodystrophy, 1935
panniculitis in, 580
Silver locus product in melanosomes, 598–599
Silver nitrate, 2132t, 2135
in molluscum contagiosum, 1913, 1913t
Silver sulfadiazine, 2113t, 2115
in burns, 857, 2115
in pyoderma gangrenosum, 301
Silvery hair syndromes, 622, 1367–1370
Simulium black fly bites, onchocerciasis in, 2019
Singlet excited state, 804, 804f
Sinus histiocytosis with massive lymphadenopathy, 1424, 1424t, 1433–1434
clinical findings in, 1433, 1433f
differential diagnosis in, 1433, 1433b
epidemiology of, 1425
etiology and pathogenesis in, 1425
treatment in, 1434
Sinus tracts, 29, 29f
in decubitus ulcers, 881
in hidradenitis suppurativa, 29, 29f, 735, 736, 737f
preauricular, 1066
Siphonaptera, 2061–2062
Sipple syndrome, oral cavity disorders in, 642t, 648
Sirolimus, 2217, 2221–2222, 2235
complications of, 2222, 2235
dosing regimen, 2221t
ethnicity as factor in therapy with, 2221
indications for, 2221, 2235
mechanism of action, 2221, 2235
pharmacokinetics of, 2221
Sister chromatid exchange assay of chromosome integrity, 984, 984f
Sister Joseph nodules, 1449, 1449f
Sitosterolemia, 1279
Sixth disease, 1864–1866
Sjögren-Larsson syndrome, 404t
ichthyosis in, 416–417
Sjögren syndrome, **1577**–1583
anhidrosis in, 729–730
autoantibodies in, 1577, 1578
diagnosis of, 1580–1581, 1581t
clinical manifestations in, 1578–1580
complement C4 in, 1581
diagnosis of, 1580–1581, 1581t
environmental factors in, 1577–1578
epidemiology of, 1577
epithelial cell activation in, 1578
extraglandular manifestations in, 1578, 1579, 1580
treatment of, 1583
eye disorders in, 1579, 1581, 1581t
treatment of, 1582t, 1582–1583
genetic factors in, 1577
histopathology in, 1581, 1581t, 1582f
necrotizing vasculitis in, 1580, 1600, 1601
oral cavity disorders in, 642t, 1578–1579, 1580, 1581, 1581t
treatment of, 1582, 1582t
pathogenesis of, 1577–1578
prognosis in, 1581–1582
and subacute cutaneous lupus erythematosus, 1532
treatment of, 1582–1583

Skin-associated lymphoid tissue, 112
in parapsoriasis, 236, 237
Skin barrier function. *See* Barrier function of skin
Skin cancer. *See also specific types of cancer*
animal models of, 988–991, 992t, 992–993, 1004
basal cell carcinoma, **1036**–1042
in elderly, 971–972, 972t
epidermal stem cells in, 377–378
in hereditary cancer syndromes, 988, 989t
herpesvirus 1 in, 998
in immunocompromised host, 277–278, 1004
in occupational exposures, 2078–2080, 2079t
papillomaviruses in, 997, 1005
physical examination in, 25
prevention of, 1005
as public health concern, 19–20, 21, 986, 1000
research approaches to, 87–88
in seborrheic keratosis, 1055, 1056
in ultraviolet radiation exposure, 814–815, 986–987, **999**–1006
basal cell carcinoma in, 814, 1036–1037
characteristics of, 1000
in DNA damage, 87–88, 814–815
in elderly, 971
epidemiology of, 999–1000
genetics of, 1000–1002
immune surveillance for, 1004
Merkel cell carcinoma in, 1088
novel therapeutic approaches to, 1005–1006
occupations associated with, 2079, 2079t
in photochemotherapy, 2258
in photoimmunosuppression, 812–813
precursor lesions in, 1000
prevention of, 1005, 1035
research approach to, 87–88, 1004
risk factors for, 1004–1005
squamous cell carcinoma in, 814, 1028–1029, 1030, 1035
steps in development of, 1002–1004
Skin disease, definition and classification of, 5
Skin fragility and ectodermal dysplasia syndrome, 512
Skin grafts, 621, 2310–2311. *See also* Grafts, skin
Skin rejuvenation. *See* Rejuvenation of skin
Skin resurfacing. *See* Resurfacing of skin
Skin tags, 554f, 554–555, 1055
in tuberous sclerosis, 1327
Skin tension lines of face, relaxed, 2290, 2290f
in excisional surgery, 2304
Skin tests
coccidioidin, 1840
histoplasmin, 1838
leishmanin, 2005
lepromin, 1792, 1794
sporotrichin, 1832
trichophytin, 1811
tuberculin, 1769–1770
Skindex-16 instrument for quality of life evaluation, 921
Slac2-a/mlph in Griscelli syndrome, 1368t, 1369, 1369f
Slack skin, granulomatous, 1391, 1393f
Slapped cheek appearance in parvovirus B19 infections, 1856, 1856f
Slate-gray pigmentation in phototoxic reactions, 831, 831f, 832, 832f
SLC, 127, 131
SLC24A5 in melanosomes, 599
Sleeping sickness, 2007–2008
SLUG/SNA12 in Waardenburg syndrome, 613, 614
Small bowel tumors, 1457
Small fiber neuropathy, idiopathic, anhidrosis in, 728
Small round cell tumors, differential diagnosis of, 1407
Smallpox, 1848, **1899**–1906
in bioterrorism, 1899, 1903, 2082t, 2085
clinical findings in, 1900–1902, 1901f
complications of, 1902
diagnosis of, 2085, 2085b
differential diagnosis of, 1902, 1902b, 1907, 2085, 2085t
epidemiology of, 1899
etiology and pathogenesis in, 1899–1900
flat or malignant, 1901
hemorrhagic, 1901–1902, 1903
histopathology in, 1902
laboratory tests in, 1902
modified, 1901, 1903
prognosis and clinical course in, 1903
transmission of, 1899, 1900
treatment of, 1903
types of, 1899, 1901–1902, 1903
vaccination, 1899, 1903–1906
adverse effects of, 1903–1906
in atopic dermatitis, 152, 1903, 1904, 1906
cowpox virus in, 1903
eczema vaccinatum after, 152, 1904, 1905, 1905f
indications and contraindications to, 1906b
research on new products in, 1906
vaccinia virus in, 1903–1906
Smith type of eccrine hidrocystoma, 1074
SMO/SMO in basal cell carcinoma, 989, 989t, 1043, 1043f, 1044
as therapy target, 994, 1048
Smoking
hidradenitis suppurativa in, 735
lupus erythematosus in, 1519
oral changes in, 650
palmoplantar pustulosis in, 215, 217
peripheral artery atherosclerosis in, 1667, 1670, 1671
postoperative complications in, 2339
preoperative assessment of, 2295
psoriasis in, 183–184
skin aging in, 971
squamous cell carcinoma in, 987t
thromboangiitis obliterans in, 1674, 1675
xeroderma pigmentosum in, 1318
Smooth muscle tumors, 1172–1175
Snail fever, 2025
Snake bites, 2040f, 2040–2042
differential diagnosis in, 2040, 2041f
first aid in, 2040–2041, 2041t
SNAP29 in ichthyosis, 411t
SNARE protein complex, 2389, 2389f, 2390t
Sneddon syndrome, 1603–1604
livedo racemosa in, 1676, 1677, 1677f
Sneddon-Wilkinson disease, **305**–307, 358, 1375t
Soaps
in acne, 696
as occupational irritant, 2069
Sodium
serum levels in acute intermittent porphyria, 1251
in sweat composition, 717, 717f
ductal reabsorption of, 718–719, 719f
in sweat secretion mechanisms, 718, 718f
Sodium alizarin sulfate in sweat gland studies, 720–721, 721f
Sodium chloride
in liposuction solution, 2379, 2380t
topical
and phototherapy in psoriasis, 2245
toxicity in children, 946t
Sodium hydroxide, occupational exposure to, 2070t
Sodium morrhuate in sclerotherapy for varicose veins, 2353t
Sodium stibogluconate in leishmaniasis, 2007
Sodium sulfacetamide
in acne, 696
in rosacea, 708, 709
Sodium tetradecyl sulfate in sclerotherapy for varicose veins, 2352, 2353, 2353t, 2354
arterial injection of, 2355
Soft tissue augmentation, **2380**–2388
with autologous fat, 2382t, 2386–2387, 2387f
with calcium hydroxylapatite, 2382t, 2385–2386
with collagen, 2381–2383, 2382t
in combination with botulinum toxin, 2392
complications of, 2388
with autologous fat, 2387
with calcium hydroxylapatite, 2386
with collagen products, 2383
with hyaluronic acids, 2384
with poly-L-lactic acid, 2385
with silicone, 2388
with hyaluronic acid, 2382t, 2383–2384, 2384f
injection techniques in, 2380–2381, 2381f. *See also* Injection techniques, in soft tissue augmentation
with poly-L-lactic acid, 2382t, 2384–2385, 2385f
with silicone, 2382t, 2387–2388
Soft tissue infections, **1720**–1731
clinical findings in, 1720–1727
differential diagnosis of, 1728b, 1728–1729
epidemiology of, 1720
etiology and pathogenesis in, 1720
histopathology in, 1727–1728
in immunocompromised host, 1720
laboratory studies in, 1727
prevention of, 1730–1731
prognosis and clinical course in, 1729
treatment of, 1728b, 1729–1730
Soil-borne infections, 1728
ascariasis, 2012
cutaneous larva migrans, 2023
hookworm, 2013, 2023
strongyloidiasis, 2016
Solar comedones, 703
Solar lentigo, 1119–1122
clinical findings in, 1120f, 1120–1121, 1121f
differential diagnosis in, 1121b
epidemiology of, 1119–1120
etiology and pathogenesis in, 1120
histopathology in, 1121
prognosis and clinical course in, 1121–1122
treatment of, 1122
cryotherapy in, 2331
laser therapy in, 2377f

Solar urticaria, 335, 340, 823–825
approach to diagnosis of, 826, 827
clinical features in, 824, 824f
differential diagnosis in, 824b, 834
sub-types of, 335, 823–824
treatment in, 824–825
Solenopsin D, 2062
Solenopsis fire ant stings, 2062
Solomon syndrome, 1060
Solutions, topical medications formulated as, 2094
Solvent inhalation, cutaneous signs of, 923–924
Somatostatin, 1482
and growth hormone, 1482, 1482f, 1483
Somatostatinoma in neurofibromatosis, 1336
Sonic hedgehog (Shh), 68t, 71f, 72
in basal cell nevus syndrome, 1043–1044, 1045
in hair follicle development, 740f, 741
in sebaceous gland development, 688, 688f
Sorafenib, 2236t
in melanoma, 1156
Sore mouth disease, 1910–1911
South American blastomycosis, 1840–1841
Southern black widow spider bites, 2054
Southwest Oncology Group melanoma study, 1155
Sowda, 2019
SOX10 in Waardenburg syndrome, 613, 614
Soybe facial massage technique in rosacea, 708
Soybean trypsin inhibitor, 2363
Spanish fly, 2060
SPARC in systemic sclerosis, 1554t
Sparganosis, 2012t, 2028, 2028f
differential diagnosis of, 2013t, 2021t
treatment of, 2015t
Spastic paraparesis, tropical, 1926
Spastic paraplegia and palmoplantar keratoderma, 429–430
SPCA (secretory pathway calcium ATPase), 439
SPCA1 in Hailey-Hailey disease, 439, 440
Specification stage in fetal skin development, 66, 68t
Spectinomycin in gonorrhea, 1996, 1996b
Sphenoid dysplasia in neurofibromatosis, 1335
Sphingolipidosis, 1286t
Sphingolipids, 386, 1286t
as melanogenic inhibitors, 605
Sphingomyelin, 386, 388f, 389f
Sphingomyelinase D in brown recluse venom, 2056
Spider angioma, 1451
laser therapy in, 2272
Spider bites, 2054–2057
prevention of, 2063
red, white, and blue sign in, 2056, 2057f
Spider nevus, 1451, 1451f
Spider veins, 2350–2351, 2356
Spiegler-Fendt sarcoid pseudolymphoma, 1402
Spinal accessory nerve injury in surgery, 2291
Spinal cord injury, hyperhidrosis in, 722t, 723–724
Spindle cells
in hemangioendothelioma, 1171
in lipoma, 1193f, 1193–1194
in pigmented nevus, 1112–1113, 1113b, 1113f
in squamous cell carcinoma, 1033, 1034
Spine
fractures in corticosteroid therapy and osteoporosis, 2150
and intervertebral disk calcification in alkaptonuria, 1226, 1227, 1227f
psoriatic arthritis of, 201, 206
SPINK5/SPINK5, 391, 394, 407, 416
Spinous cells, 60
Spinous layer of epidermis, 60–61
Spiradenocarcinoma, eccrine, 1079
Spiradenoma, eccrine, 1076, 1076f
Spirillum minus, 1761
Spirochetal balanoposthitis, 672
Spirometra erinacei, 2013t, 2021t, 2028
Spirometra mansoni, 2013t, 2021t, 2028
Spirometra mansonoides, 2013t, 2021t, 2028
Spirometra proliferum, 2013t, 2021t, 2028
Spirometrosis, 2012t, 2013t, 2021t, 2028
Spironolactone
in acne vulgaris, 698
in hirsutism, 775, 775b
in pattern hair loss, 769
in rosacea, 708
Spitz nevus, 1113–1116
clinical findings in, 1114, 1114f, 1115f
differential diagnosis of, 1115b
histopathology in, 1114–1115, 1115f
Spitzoid melanoma, 1141
Spleen disorders
in *Bartonella* infections, 1753
in mastocytosis, 1438–1439, 1443
opportunistic infections in, 269t
in sarcoidosis, 1489
treatment of, 1491t
in tropical splenomegaly, 2006
in visceral leishmaniasis, 2006
Splendore-Hoeppli phenomenon
in actinomycetoma, 1784, 1786f
in actinomycosis, 1781
in zygomycosis, 1835
Splice site mutations, 78
Splinter hemorrhages of nails, 780, 783, 783f
differential diagnosis of, 1745b
in endocarditis, 1453, 1744, 1745, 1745f
in liver disease, 1449
in psoriasis, 181
Split hand-split foot-ectodermal dysplasia-cleft lip/palate syndrome, 1344–1345, 1345f
Split-nail deformity, 2326, 2326f
Spondylitis, ankylosing, 195, 206
in reactive arthritis, 213
Spondyloarthritis, psoriatic, 194, 195
Spondyloarthropathy, 211–213
Sponge dermatitis, 2046, 2046f
Sponge fisherman's disease, 2045
Spongin, 2046
Spongiosis
eosinophilic, 316
epidermal cohesion in, 46
exfoliative dermatitis in, 225, 230t
vesicles in, 32, 46, 46f
Sporothrix schenckii, 1831–1832, 2119
occupational exposure to, 2076
Sporotrichin skin test, 1832
Sporotrichosis, 1831–1832
in HIV infection and AIDS, 1831, 1937
in occupational exposures, 1831, 2076
subcutaneous, 1831–1832
lymphangitic, 1831, 1832f
systemic, 1831
Sports dermatology, **873**–878. *See also* Athletes
Spotted fever, 1940, 1941–1947
Mediterranean, 1942, 1943t, 1945
Rocky Mountain, 1941–1942
SPR1 and SPR2, 61
Squamous cell carcinoma, **1028**–1036, 1375t
acrokeratosis paraneoplastica in, 1499
adenoid, 1033, 1034
in amputation stump, 865f, 867
animal models of, 992t
in arsenical keratosis, 1015, 1016, 1016f, 1017
in azathioprine therapy, 2168
basaloid variant, 1033
of cervix, 996, 1031
in chemical exposures, 986–994, 1029
pathogenesis in, 991, 993
clear cell, 1033, 1034
clinical findings in, 1030–1032
in cyclosporine therapy, 2220
in decubitus ulcer, 881
diagnosis of, 1033
differential diagnosis of, 673–674, 674b, 1030f, 1033–1034
actinic keratosis in, 1011
in dystrophic epidermolysis bullosa, 88, 511, 514–515, 1029
in elderly, 971, 972t, 1028
epidemiology of, 986, 1028
in erythroplasia of Queyrat, 1024
follow-up in, 1035
genetic factors in, 988, 989t, 989–991, 1028, 1029–1030
genital, 655, 672–674, 1031, 1032
clinical findings in, 673, 674f
differential diagnosis of, 673–674, 674b
risk factors for, 672, 672t
treatment in, 674
grades of, 1033, 1033t
in heat exposure, chronic, 1017, 1018, 1029
in hereditary cancer syndromes, 988, 989t
herpesvirus 1 in, 998
in hidradenitis suppurativa, 737
histopathology in, 1032–1033
in HIV infection and AIDS, 1933, 1939, 1939f
horn pearls in, 1033
in hydrocarbon keratosis, 1018
in immunosuppression, 277–278, 1004, 1029, 1030, 1049
and papillomavirus infections, 277–278, 1939, 1939f
prevention of, 278, 1036
in keratoacanthoma, 1032, 1049, 1050f, 1052
in lichen planus, 247, 251, 251f, 252, 666
in lichen sclerosus, 549, 549f, 669
in lupus vulgaris, 1772, 1772f
metastasis of, 1032, 1032f, 1034, 1034f, 1034t, 1035
morphology in, 1030f, 1030–1031, 1031f
mortality rate in, 986
of nails, 788, 788f
in occupational exposures, 1029, 2079
oral, 648–649, 1031, 1031f
in erythroplakia, 1027
in HIV infection and AIDS, 1933
in leukoplakia, 1024, 1025
prevention of, 1036
origin in interfollicular epidermis, 1003
p53 in, 989, 990f, 991, 1001, 1029–1030
in papillomavirus infections. *See* Papillomavirus infections, squamous cell carcinoma in
pathogenesis in, 991, 993
perianal, 1031, 1032f
in porokeratosis, 445
precancerous lesions in, 991, **1007**–1027
predisposing factors in, 1028t, 1028–1029

prevention of, 674, 1035–1036
pseudoglandular, 1033
in PUVA keratosis, 1020
in radiation dermatitis, chronic, 861, 862f
in radiation keratosis, 1019, 1019f
in reactional keratosis, 1020
recurrent, 1034, 1035
in scars, 1020, 1029, 1031–1032, 1033, 1034
in seborrheic keratosis, 1055
signet-ring cell, 1033
spindle cell, 1033, 1034
stages in development of, 989, 990f
sub-types of, 1033
treatment of, 674, 1034t, 1034–1035
cryotherapy in, 2332
electrosurgery in, 2334
Mohs micrographic surgery in, 1035, 1035t, 2316, 2318
molecular targets in, 994
photodynamic therapy in, 2261
radiation therapy in, 1035, 2282, 2282t, 2283–2284
in ultraviolet radiation exposure, 814, 1028–1029, 1030
characteristics of, 1000
epidemiology of, 999, 1000
in photochemotherapy, 2258
precursor lesions in, 1000
prevention of, 1035
verrucous, 1032, 1032f, 1033
in xeroderma pigmentosum, 1316, 1318
Squamous cell carcinoma in situ
Bowen disease in, 1021–1023
erythroplasia of Queyrat in, 1023
Squaric acid dibutyl ester in warts, 2136
Src homology 2 (SH2) domains, 119, 119f
SSH1 in porokeratosis, 442
Stabilizer ingredients in topical drug formulations, 2095
Staggers (coenurosis), 2028
Staging
of B cell lymphoma, 1401
of melanoma, 1145–1148, 1148t–1150t
biopsy in, 1151
and clinical course by stages, 1149–1151
molecular, 1154
of T-cell lymphoma, 1396, 1396t
Staining methods, 1692–1693
in actinomycetoma, 1784–1785, 1785f
in actinomycosis, 1781
in leprosy, 1794
Standing cones (dog-ears), revision of, 2307, 2307f
Stanozolol
in angioedema, hereditary, 343
in cryofibrinogenemia, 1643
hepatotoxicity of, 1459t
Staphylococcus aureus infections, **1694**–1703, 1696t
abscess in, 874, 1702, 1702f
and actinomycosis, 1779
in atopic dermatitis, 152–153, 156, 1692, 1694, 1719
botryomycosis in, 1702, 1702f, 1779t, 1785
bullous varicella in, 1697
carbuncles in, 1700, 1701
cellulitis in, 1721t, 1722, 1723f, 1747
of elbow, 273
clinical findings in, 1695–1703
in decubitus ulcers, 880, 881
in diabetes mellitus, 1465, 1694
in drug abuse, 925, 926, 1694
ecthyma in, 1698
endocarditis in, 1744
epidemiology of, 1694–1695
etiology and pathogenesis in, 1695
exfoliative dermatitis in, 227, 1712
exfoliative toxins in, 1696, 1697, 1710t, 1710–1714
exotoxins in, 1694, 1703
folliculitis in, 773, 1698–1699
furuncles in, 1699–1700, 1701
gangrene in, 1723
in granulomatous disease, chronic, 1364
in hyper-IgE syndrome, 1366
immune response in, 1695
in immunocompromised host, 268, 273
in HIV infection, 1935
prevention of, 1935
impetigo in, 1695–1698, 1697f, 1698f, 1705, 1712
in leukocyte adhesion deficiency, 1365
lymphangitis in, 1706, 1706f
methicillin-resistant, 1695, 1728, 1730
in athletes, 873–875
in elderly, 973
in surgical wounds, 2337
treatment of, 875, 2114
nasal carriers of, 1696, 1697f, 1701t
in occupational exposures, 2074
paronychia in, 1702
pathogenicity in, 1691
perineal erythema in, recurrent toxin-mediated, 1719
prevention of, 1935
resistance of skin to, 1689–1690
scalded skin syndrome in, 46, 61, 390, 1694, 1710–1714
in immunocompromised host, 268
scarlet fever in, 1718–1719
of soft tissues, 1720
superantigens in, 1695
of surgical wounds, 1722, 1723f
T-cell lymphoma in, 1386
toxic shock syndrome in, 1694, 1715–1716, 1716f, 1716t, 1717
diagnostic criteria on, 1716, 1716t
differential diagnosis of, 1717
treatment and prognosis in, 1717
transmission of, 1695
treatment of, 2197t
in methicillin resistance, 875, 2114
in toxic shock syndrome, 1717
virulence of, 1695
whitlow in, 1702–1703
Staphylococcus epidermidis, 1690, 1694, 1744
Staphylococcus intermedius, 2038
Staphylokinase, 1691, 1695
Staple closure of surgical wounds, 2301
Starburst livedo in polyarteritis nodosa, 1614, 1614f
Starfish *(Acanthaster planci),* 2048
Starvation, adapted and non-adapted, 1202
Stasis dermatitis, 64, 65
autosensitization in, 167, 168f
in chronic venous insufficiency, 1681, 1681f, 1682, 1682f
differential diagnosis of, 139b
STAT (signal transducer and activator of transcription), 118–119, 119f, 124–125, 2232
in HTLV-1 infections, 1924
and interleukin IL-10, 125
Statin therapy
in familial hypercholesterolemia, 1276, 1277
in hyper-IgD syndrome with periodic fever, 1268–1269
Statistical analysis
chi square test in, 16
confidence intervals in, 15, 16, 16f
likelihood ratio in, 16–17
number needed to treat in, 15, 16
odds ratio in, 17–18
risk ratio in, 17
significance in, 15–16
Status cosmeticus, 2360
Stavudine in HIV infection, 2208, 2209
Stearyl alcohol in topical formulations, 2094
corticosteroid, 2106t
Steatocystoma
multiplex, 430, 1065–1066, 1066f
in pachyonychia congenita type II, 430, 1066
simplex, 1066
Steel factor, 599, 600f
in melanocyte development, 591, 592
as melanogenic stimulator, 604
Stein-Leventhal syndrome, 701–702
Steinberg's sign in Marfan syndrome, 1303
Stellate cells, 1589
Stem cell(s)
and B-cell development, 321
bulge, 377
epidermal, 59, 375–377, 376f
age-related changes in, 964
division of, 376–377
niche of, 375, 376
regulatory mediators of, 377
in rete ridges, 376
in skin cancer, 377–378
hair follicle, 72, 377, 593, 593f, 745, 745f, 747
melanocyte, 593, 593f
age-related changes in, 967
transplantation of. *See* Stem cell transplantation
in ultraviolet radiation exposure, 1003
clonal expansion of, 1003–1004
Stem cell factor, 69
functions of, 1435t
in mast cell development, 1435
in melanocyte development, 591, 592, 747, 748
Stem cell transplantation
allogeneic, 259t
acute graft-versus-host disease in, 259–260, 260t, 261–262, 266
chronic graft-versus-host reaction in, 260, 262–264, 266–267
autologous, 259, 259t
acute graft-versus-host disease in, 260, 260t, 264, 267
cytomegalovirus infections in, 1861, 1863
graft-versus-host disease in, **258**–267
in granulomatous disease, chronic, 1364, 1365t
herpesvirus-6 infection in, 1865, 1866
in leukocyte adhesion deficiency, 1365
peripheral, 259, 260
acute graft-versus-host reaction in, 260, 264
in severe combined immunodeficiency, 1360
syngeneic, 259, 259t
acute graft-versus-host disease in, 260, 260t, 264, 267
in systemic sclerosis, 1559t
in Wiskott-Aldrich syndrome, 1358
Stent placement in peripheral arterial disease, 1671
Sternomastoid tumor of infancy, 550–551
Steroid sulfatase, 68t, 69, 83

Steroids
anabolic, cutaneous signs of abuse, 877, 924, 1481
glucocorticoid. *See* Glucocorticoid therapy
Stevens-Johnson syndrome, 343, 344, **349**–355, 1451
differential diagnosis in, 347, 348b, 1522
drug-induced, 359, 359t
in HIV infection, 1934
histopathology in, 347
liver disorders in, 1458
ocular cicatricial pemphigoid in, 484
oral cavity disorders in, 647, 647f
treatment in, 359
vulvar disease in, 681
Stewart-Treves syndrome, 1188, 1188f, 1189
Sting and bite injuries. *See* Bites and stings
Stinging sensation from cosmetic products, 2360–2361
Stingray injuries, 877, 2050, 2051f
STK11 in Peutz-Jeghers syndrome, 633
STK15, 993
Stocking-glove pattern of sensory impairment, in leprosy, 1788
Stoma procedures, abdominal, skin problems in, **868**–871
Stomach
atrophic gastritis of
chronic, 1377
in dermatitis herpetiformis, 503
bypass surgery, 1456
cancer of, acanthosis nigricans in, 1494, 1495, 1496
Stomatitis
angular, in riboflavin deficiency, 1209, 1209f
chronic ulcerative, 647
contact allergic, 651
from cytotoxic drugs, 2180, 2180f
denture, 653
gangrenosa, 1217
necrotizing ulcerative, 1217
nicotine, 650
in paraneoplastic pemphigus, 470, 470f
recurrent aphthous, thalidomide in, 2234, 2234t
Stomatitis virus, bovine papular, 1900t, 1909
Stomatodynia, 642–643
Stonefish stings, 2050, 2051, 2052
Stool analysis in porphyrias, 1239, 1240t, 1253, 1254
Storage papule disease, 1376t
Stork bite, 1652, 2270
Stratum basale, 384, 384f
Stratum corneum, 44, 57, 61f, 61–62, 383, 383f, 384f
age-related changes in, 964, 965, 972
in atopic dermatitis, 149, 153, 394f
composition of, 2357
desmosome protein, 449t
in hydration of skin, 2357
in ichthyosis, 406–407
lipids in, 385f, 385–386, 386f, 387f, 388f, 1690
in neonates, 935
as protective barrier, 383, 383f, 384–387
affecting absorption of topical drugs, 2091, 2099–2100
penetration pathways in, 2100
structural and biochemical mechanisms in, 386t
in pruritus, 909
refractive index of, 2265
structure of, 384–387
Stratum germinativum, 59
Stratum granulosum, 47, 61f, 384, 384f
Stratum spinosum, 384, 384f, 386f
Straw itch mites, 2032, 2032t
Strawberry cervix in trichomoniasis, 1999, 1999f
Strawberry tongue
in Kawasaki disease, 1628, 1630
in scarlet fever, 1718, 1718f
Streeter's bands, 562
Streptobacillus moniliformis, 1689
in rat-bite fever, 1761–1762
Streptococcal infections, 1703–1707
and actinomycosis, 1779
cellulitis in, 1720, 1721t, 1722, 1747
in burns, 855, 857f
genital, 667
treatment of, 1707
in drug abuse, 925, 926
gangrene in, 1721t, 1723–1724, 1724t, 1725
histopathology in, 1727
group A, 1691, 1703–1707, 1704t
in athletes, 875
cellulitis in, 1721t, 1722, 1747
classification of, 1703–1704, 1704t
dactylitis in, 1705–1706, 1706f
in diabetes mellitus, 1465
diagnosis of, 1703
differential diagnosis of, 1949b
epidemiology of, 1703
erysipelas in, 1720, 1721, 1721t
etiology and pathogenesis of, 1703–1704
gangrene in, 1723–1724, 1724t, 1725
genital, 667
immune response to, 1704
impetigo in, 1695, 1696, 1697, 1704–1705
intertriginous, 1705f, 1705–1706, 1706f
invasive, 1703, 1706
lymphangitis in, 1706
nephritogenic, 1704
perineal erythema in, recurrent toxin-mediated, 1719
pharyngitis in, 1703, 1704
rheumatic fever in, 1573–1574, 1703, 1704
scarlet fever in, 1717–1718, 1719
of soft tissues, 1720
toxic shock syndrome in, 1716–1717
treatment of, 1707, 1707b
in varicella, 1893
virulence factors, 1703
group B, 1703
dactylitis in, 1706
in diabetes mellitus, 1465
gangrene in, 1723
oral cavity disorders in, 652t
group C, 1703
group D, 1703
group G, 1691, 1703, 1720
group L, 1703
invasive, 1703, 1706
necrotizing venulitis in, 1602
in occupational exposures, 2074
and psoriasis, 184, 1707
reactive arthritis in, 208
superantigens in, 1704
Streptococcal pyrogenic exotoxins, 1704, 1710t
in Kawasaki disease, 1628
in toxic shock syndrome, 1716
Streptococcus agalactiae, 1465
Streptococcus iniae, 1757t, 1766, 2053t
Streptococcus pneumoniae, 273, 1728
Streptococcus pyogenes, 1691, 1767
in immunocompromised host, 273, 273f
in impetigo, 1712
portal of entry, 1689
resistance of skin to, 1689
treatment of infections, 2197t
Streptococcus sanguinis, 1621
Streptococcus viridans, 269t
Streptokinase, 1691
in cryofibrinogenemia, 1642
Streptomyces somaliensis, 1779t, 1783, 1784, 1785
in mycetoma, 1832, 1833, 1834t
Streptomycin
in actinomycetoma, 1786
in tuberculosis, 1775t
Stress
emotional, 920–921. *See also* Emotional stress
thermal, 835
thermoregulatory responses in, 835–844
Stretch marks and striae, 29, 29f, 559–560
in pregnancy, 560, 955, 957f, 2111
Striae, 29, 29f, **559**–560
alba, 559, 560
in Cushing syndrome, 1477, 1477f
distensae, 29, 29f, 559, 955, 957f
diagnosis of, 560
in liver disease, 1445, 1446f
treatment in, 560
elastotic, 560
gravidarum, 559, 955, 957f, 2111
laser therapy in, 560, 2278
rubra, 559, 560
Wickham, 31t
Striated muscle tumors, 1175–1176
Striations in nails, longitudinal, 782
Stromal cell-derived factor 1 (SDF-1), 127, 133
Stromelysin, 528, 528f, 529t
in photoaging, 970, 971
in wound healing, 2344, 2345
Strongyloides fuelleborni, 2016
Strongyloides stercoralis, 2012t, 2013t, 2016
Strongyloidiasis, 2012t, 2016–2017, 2017f
differential diagnosis of, 2013t, 2017
disseminated, 2016, 2017, 2017f
thumbprint sign in, 2016
treatment of, 2015t
Sturge-Weber syndrome, 70
capillary malformations in, 1653, 1654, 1655f, 1656, 2270
preventive measures in, 1656
Sub-corneal pustular dermatosis, **305**–307, 1375t
clinical findings in, 305, 306f
differential diagnosis in, 306, 306b, 358
histopathology in, 305–306, 306f
treatment of, 306–307, 307b
Subcutaneous fat, 55, 66
in aging, 967
embryonic and fetal, 70
lipoatrophy of, 581
lipodystrophy of, 581, **585**–589
necrosis of, 55
in α_1-antitrypsin deficiency, 578–579, 579f
encapsulated, 581
lipomembranous, 585
membranocystic, 585
in neonates, 581–582, 582f, 851, 939, 939f, 1294
nodular-cystic, 581
in pancreatic panniculitis, 577
traumatic, 580–581

neoplasms of, **1190**–1198
panniculitis of, 569–585
pathologic reactions of, 43, 44f, 55
protective functions of, 384
Subcutaneous fungal infections, 1831–1835
Subcutis, 55, 66
embryonic and fetal development of, 70
functions of, 57, 58t, 66
Sub-epidermal blisters, 47–48
Substance abuse. *See* Drug abuse
Substance P, 898
in inflammatory response, 898t
in necrotizing venulitis, 1600
in pruritus, 897t, 904–905
in urticaria and angioedema, 330, 900
Succinyl coenzyme A, 1230, 1231f
Suction blisters
for graft technique in vitiligo, 621
in neonates, 938
Sudomotor failure, anhidrosis in, 727
SUFU (Suppressor of Fused), 1043, 1043f, 1044
Suggillations in meningococcemia, 1732
Suicidal behavior
in antidepressant drug therapy, 918t, 919
in body dysmorphic disorder, 914
in isotretinoin therapy, 945
in pityriasis rubra pilaris, 235
Sulbactam, 2198
Sulconazole, 2117t, 2118
Sulfacetamide, 2114
Sulfapyridine, 2154
chemical structure of, 2154f
in dermatitis herpetiformis, 504
pharmacology of, 2154
in sub-corneal pustular dermatosis, 306
Sulfasalazine
in psoriasis, 187t, 192
and arthritis, 202, 203f, 204
in reactive arthritis, 214
Sulfatase deficiency, 407, 408, 409
multiple, 405t, 421
Sulfhemoglobinemia, 1378, 1379
Sulfonamides, 2114, 2115
Sulfones
complications and side effects of, 2156–2157
dapsone. *See* Dapsone
in dermatitis herpetiformis, 504
in sub-corneal pustular dermatosis, 306, 307b
Sulfur, topical
in acne, 696
in rosacea, 708
in scabies, 2031b
Sulfur granules, 1778
in actinomycosis, 1780, 1781
in nocardiosis, 1782
Sulfur mustard as chemical weapon, 2086t, 2087
Sulfuric acid, occupational exposure to, 2070t
Sulisobenzone in sunscreens, 2139t
Summer light eruption, benign, 817
Sunbelt Melanoma Trial, 1154
Sunblock, use of term, 2139
Sunburn, 798, 811–812
dyskeratosis in, 45
inflammatory mediators in, 604, 811–812
keratinocyte-derived cytokines in, 100, 812
melanoma risk in, 1134
skin phototypes based on susceptibility to, 809, 810t
sun protection factor of sunscreens affecting, 2137, 2138f
thermoregulation in, 844
Sunburn cells, 45, 815f, 1029
Sunburn recall reaction, drug-induced, 2166, 2179, 2179f, 2179t
Sun exposure, 799–800, 809–815. *See also* Ultraviolet radiation exposure
distribution of lesions in area of, 38
and lesions in areas protected from, 38
ozone affecting, 799–800
as public health concern, 19–20, 20f
tolerance or desensitization to, 816, 2247, 2256
in solar urticaria, 825, 2256–2257
UV Index in, 800
Sunglasses, 2142
luminous transmittance of, 2142
Sunlamps, 800
Sun protected areas, 38
Sun protection factor of sunscreens, 798, 813, 2137–2138
effect on sunburning dose, 2137, 2138f
effect on vitamin D levels, 2140
Sunscreens, 798, 799, 1005, 2137–2141
in actinic keratosis prevention, 1015
active ingredients in, 2139t, 2139–2140
amount applied, 2137–2138, 2138f
broad-spectrum, 799
in children, 2140
in erythropoietic protoporphyria, 1246–1247
immune protection factor of, 2138
in lupus erythematosus, 1532
and melanoma incidence, 2140
photoallergy from, 830t, 833, 2140
photoprotection with, 813
sun protection factor (SPF) of, 798, 813, 2137–2138
effect on sunburning dose, 2137, 2138f
effect on vitamin D levels, 2140
in ultraviolet A protection, 799, 2138, 2139, 2139t
in ultraviolet B protection, 2137, 2139, 2139t
ultraviolet filters in, 2138–2140, 2139t, 2140f
inorganic, 2139, 2139t
organic, 2139, 2139t
photoallergy from, 2140
photostability of, 2140, 2140f
and vitamin D levels, 2140–2141
in vitiligo, 620
water resistant, 2138
in xeroderma pigmentosum, 1317
Superantigens, 1710t, 1714–1717
in atopic dermatitis, 1719
in psoriasis, 1719
in recalcitrant erythematous desquamating disorder, 1715, 1717
in scarlet fever, 1715, 1717–1719
in staphylococcal infections, 1695, 1715
in streptococcal infections, 1704, 1715
and T-cell activation, 1715, 1715f
in toxic shock syndrome, 1715–1717
Superficial reactive unit, 43–49
Supernumerary nipple, 1071
Superoxide, 283
in chronic granulomatous disease, 1363, 1364
Support groups
in alopecia areata, 764
in Cockayne syndrome, 1321
in neurofibromatosis, 1337
in pseudoxanthoma elasticum, 1307
in tuberous sclerosis, 1331
in xeroderma pigmentosum, 1319
Suppressor of Fused (SUFU), 1043, 1043f, 1044
Suppressor T cells, 104, 1512
Supraorbital artery, 2293
Supraorbital nerve, 2292, 2298
Supratrochlear artery, 2293
Supratrochlear nerve, 2292, 2298
Suramin in African trypanosomiasis, 2008
Surface changes, 31–32
Surfactants in topical formulations, 2094
Surgery, **2289**–2356
with abdominal stoma, skin problems in, **868**–871
in acne vulgaris, 699
in actinic keratosis, 1013
in actinomycosis, 1781
anatomy in
of face, 2289–2294
of nails, 2320f, 2320–2321
anesthesia in, 2296–2299
antibiotics in, 2113, 2194–2197
in nail procedures, 2322–2323
in arteriovenous malformations, 1666
in basal cell carcinoma, 1040–1041
incomplete excision in, 1041, 1042f
in basal cell nevus syndrome, 1047
in Bowen disease, 1023, 1023b
in bromhidrosis, apocrine, 732
complications of, 2336–2341
in alopecia reduction, 2402
in cryosurgery, 2333
in electrosurgery, 2335
in excisional procedures, 2312–2313
in hair transplantation, 2400, 2402t
in hyperhidrosis, 723, 725
in nail surgery, 2320, 2322–2323
coronary artery bypass in, 1460
cryosurgery in, 2330–2333
in decubitus ulcers, 885
in dermatofibrosarcoma protuberans, 1161
in diabetic foot problems, 2348
electrosurgery in, 2333–2335
in epithelioid sarcoma, 1163
excisional procedures in, 2302–2314
flap procedures in, 2308–2310
fungal infections in, systemic, 1836t
gastric bypass in, 1456
hair transplantation in, 769, 2394–2401
in hemangioma of infants, 1168t, 1169
in hidradenitis suppurativa, 737, 738
history-taking on previous procedures, 2295, 2336
in hyperhidrosis, 723, 724b
complications of, 723, 725
in lupus erythematosus, 1535
in lymphatic malformations, 1663
in lymphedema, 1686
in lymphoid hyperplasia, 1408, 1408b
in melanoma, 1153f, 1153–1154, 1156
in Merkel cell carcinoma, 1092, 1093, 1094
lymphadenectomy in, 1092
at primary site, 1092
Mohs micrographic, 2315–2318
nail, 2320–2330
in nevomelanocytic nevi, congenital, 1102
in pacemakers and defibrillators, 2295, 2334
in Paget disease, 1096, 1097–1098
in pattern hair loss, 769, 2394–2401
in phymatous rosacea, 709
postoperative care in, 2301, 2337–2341
in cryosurgery, 2333
in electrosurgery, 2335
in nail surgery, 2322–2323

Surgery—*continued*
preoperative assessment in, 2294–2295, 2336
in nail surgery, 2320
skin grafts in, 2310–2311
skin preparation and aseptic technique in, 2295–2296
in snake bites, 2041
in soft tissue infections, 1730
in squamous cell carcinoma, 1034–1035, 1035t
suture materials and techniques in, 2299–2301
in venous malformations, 1660
wound healing and repair in, 2342–2349
complications of, 2338–2340
wound infections in, 1722–1723, 1723f, 2294–2295, 2337
antibiotics in, 2113, 2114, 2195–2197
in nail surgery, 2323
Susceptibility testing in bacterial infections, 2194
Suspensions, topical medications formulated as, 2095
Sutton's nevus, 1105
Sutures, 2299–2301
dehiscence of wounds in, 2339
in excisional surgery, 2304, 2304f, 2305–2307, 2306f, 2307f
removal of, 2306–2307
extrusion of, 2340
interrupted, 2299–2300, 2300f
removal of, 2306
materials used in, 2299, 2299t
mattress
horizontal, 2300, 2301f
vertical, 2300, 2300f
removal of, 2301
in excisional surgery, 2306–2307
running, 2300–2301
removal of, 2306
track marks from, 2339, 2340f
SV40 virus, tumors associated with, 995t, 996, 1848
Swab sampling, 42, 42f
Swan neck deformity in rheumatoid arthritis, 1570
Sweat
composition of, 717f, 717–718, 721
in apocrine sweat, 720
in cystic fibrosis, 717f, 721
disorders with changes in, 722t, 730
ductal reabsorption of, 718–719, 719f
odor of, 719–720
preformed, 717
secretion mechanisms, 718, 718f
Sweat glands
age-related changes in, 967
apocrine. *See* Apocrine glands
apoeccrine, 719
biology of, **713**–720
drugs affecting, 716–717, 719
eccrine. *See* Eccrine glands
embryonic and fetal development, 72, 713, 1068
energy metabolism in, 717
immunohistochemical studies of, 721, 721f
individual variations in, 716, 716f
in vivo techniques in evaluation of, 720–721, 721f
innervation of, 715–716, 720, 723, 838f, 896
in lamellar ichthyosis, 410
mechanisms of sweat secretion, 718, 718f
nevi of, 1056, 1057t, 1060
perineal, 654
reabsorption in, 718–719, 719f
in thermoregulation, 714–715, 835, 836, 837
with active vasodilation, 837
anatomy of, 836
tumors of, 1070–1079
Sweating
anhidrosis. *See* Anhidrosis
biology of sweat glands in, **713**–720
classification of disorders, 722t
disorders associated with changes in, 1448
eccrine disorders, **720**–730
emotional, 716
in primary focal hyperhidrosis, 723, 723f
energy metabolism in, 717
gustatory, 722t, 724b, 725
hyperhidrosis. *See* Hyperhidrosis
hypohidrosis. *See* Hypohidrosis
individual variations in, 716, 716f
lacrimal, 725
in menopause, 715
neural control of, 714–716
physical examination in assessment of, 721–722
in thermoregulation, 714–715, 835, 836, 837
with active vasodilation, 837
anatomy in, 836
Sweet syndrome, **289**–295, 1375t, 1692
classic or idiopathic, 289, 290t
clinical features in, 289–292, 290t
complications of, 294
diagnostic criteria in, 291, 291t
differential diagnosis in, 293, 294b, 347, 1572
diseases associated with, 291–292
drug-induced, 289, 290t, 292, 294
epidemiology of, 289, 290t
etiology and pathogenesis in, 289
extracutaneous manifestations in, 291, 292t, 293
in hepatitis B, 1457
histopathology in, 292, 293f
laboratory findings in, 290t, 292–293
locations of lesions in, 290f–291f, 290t
malignancy-associated, 289, 290t, 292, 293, 294, 1495t, 1502
neutrophil function in, 280
prognosis and clinical course in, 294
pustular variant of, 290
subcutaneous, 292, 293, 574
treatment in, 294–295, 295b
Swimming-associated problems, 874t, 876–877, 877f
in cold water immersion, 844–845
granuloma in, 877
green hair in, 876–877
pruritus in, 877, 2025, 2048–2049, 2076
Pseudomonas aeruginosa infections in, 1736
schistosomiasis in, 877, 2025, 2048–2049
Swiss cheese appearance in leprosy, 1789
Sybert palmoplantar keratoderma, 426, 430
Sycosis barbae, 1699, 1700f
Symmetrical bilateral lesions, 38
Sympathectomy
in apocrine bromhidrosis, 732
in hyperhidrosis
anhidrosis after, 728
compensatory hyperhidrosis after, 723, 725, 728
in peripheral artery disease, 1671
in Raynaud phenomenon, 1647
Sympathetic nervous system, 65, 70, 895
anatomy of, 896
in anhidrosis, 727, 728
functions of, 896
in hyperhidrosis, 723, 724–725
in Raynaud phenomenon, 1643, 1645–1646, 1647
in thermoregulation, 837, 838f
in vasoconstriction, 837, 841–842, 842f
in vasodilation, 837, 839f, 840
Synanceja stonefish, 2051
Synaptobrevin, 716, 2389
Syndecans, 63, 454, 539t, 539–540, 541
Syndesmos, 1589
Synovitis
in psoriatic arthritis, 201
in SAPHO syndrome, 701
Syphilis, **1955**–1977
cardiovascular disorders in, 1957, 1964–1965
in HIV infection, 1970
treatment of, 1975
chancre in, 652t, 1956, 1957f, 1957–1958, 1958f
histopathologic examination of, 1970
clinical findings in, 1957–1962
in congenital disease, 1967f, 1967–1969, 1968f, 1968t
in endemic disease, 1982t
condyloma lata in, 1960, 1961f, 1968
congenital, 1967f, 1967t, 1967–1969
clinical findings in, 1967f, 1967–1969, 1968f, 1968t
definition of, 1967, 1967t
diagnosis of, 1969
oral cavity disorders in, 647t, 652t, 1968, 1968f, 1968t, 1969, 1969f
treatment of, 1974, 1976
corymbose eruptions in, 1959, 1960f
dark-field microscopy in, 1971
diagnostic tests in, 1970–1973
drug abuse affecting, 926, 1972
in endemic disease, 1982
false-negative and false-positive tests in, 1972, 1972t, 1973t
sensitivity and specificity of, 1973t
differential diagnosis of, 1985, 1985b
in endemic disease, 1982b
in primary stage, 1958, 1958b
in secondary stage, 365, 365b, 1959, 1961, 1962b
in tertiary stage, 1963b
direct fluorescence antibody test in, 1971
ear disorders in, 1962, 1966, 1969
endemic, 1977–1978, 1981, 1981f
clinical manifestations in, 1982t
diagnosis of, 1982
differential diagnosis of, 1982b
hypomelanosis in, 627
treatment of, 1982
epidemiology of, 1955–1956
etiology of, 1956, 1956f
eye disorders in, 1962, 1965, 1966–1967
in congenital disease, 1968t, 1969, 1969f
in HIV infection, 1970
gumma in, 26, 1963–1964, 1964f
cerebral or spinal, 1967
in endemic disease, 1981, 1981f
histopathologic examination in, 1971
treatment of, 1975
hair loss in, 770–771, 771f, 1961, 1962f
histopathology in, 1970–1971
and HIV infection, 1956, 1960, 1969–1970, 1970f
treatment in, 1970, 1974, 1975, 1976

immune response in, 1956–1957, 1970
latent, 1956, 1957, 1957t, 1962
treatment in, 1974–1975
liver disorders in, 1458, 1962
lymphoreticular system in, 1961
macular eruptions in, 1958–1959, 1959f, 1960f
malignant, 1960, 1961f
meningovascular, 1965t, 1966, 1970
monorecidive, 1958
musculoskeletal disorders in, 1962, 1964, 1968
in congenital disease, 1968, 1968t, 1969
in endemic disease, 1981
nail changes in, 1961
natural history of, 1957, 1957t
neurologic disorders in, 1965–1967. *See also* Neurosyphilis
nodular, 1959, 1960f, 1963, 1963f, 1971
oral cavity disorders in, 1958, 1960
in congenital disease, 647t, 652t, 1968, 1968f, 1968t, 1969, 1969f
in tertiary stage, 1964, 1965f
palmoplantar lesions in, 1959, 1960f
papular eruptions in, 1958–1959, 1959f
prevention of, 1977
primary, 1956, 1957t, 1957–1958
clinical findings in, 1957f, 1957–1958, 1958f
differential diagnosis of, 1958, 1958b
relapse of, 1958
treatment of, 1974
pustular, 1960, 1971
pustuloulcerative, 1960
relapsing, 1962–1963
rupial, 1960, 1961f
saddle nose deformity in, 1964, 1964f, 1968
secondary, 1956, 1957, 1957t
clinical findings in, 1958–1961, 1959f, 1960f, 1961f
diagnostic tests in, 1972
differential diagnosis of, 365, 365b, 1959, 1961, 1962b
histopathology in, 1971
in HIV infection, 1970
treatment of, 1974
serologic tests in, 1971t, 1971–1973, 1972t
tabes dorsalis in, 1965t, 1966
tertiary, 1956, 1957, 1957t
clinical findings in, 1963f, 1963–1967, 1964f, 1965f
diagnostic tests in, 1972
differential diagnosis of, 1963b
histopathology in, 1971
precocious lesions in, 1963
treatment in, 1975, 1977
transmission of, 1955, 1976
treatment of, 1955, 1973–1977
complications of, 1976–1977
in endemic disease, 1982
in HIV infection, 1970, 1974, 1975, 1976
in sex partners, 1976
therapeutic paradox in, 1977
Syringocystadenocarcinoma papilliferum, 1074
Syringocystadenoma papilliferum, 1072, 1073f
Syringolymphoid hyperplasia, 1074–1075
Syringoma
chondroid, 1072
eccrine, 1076–1077, 1077f
Syringomyelia, hyperhidrosis in, 724
Syringosquamous metaplasia in cytotoxic drug therapy, 2178
System for Thalidomide Education and Prescribing Safety (S.T.E.P.) program, 2234
Systematic reviews in evidence-based medicine, 9–10, 10t
Cochrane database on, 12
critical assessment of, 10, 11t

T

T cell(s), 101–106
accumulation in skin, 105
activation of, 102, 112, 130–131
in adaptive immune response, 101–106, 319, 1595
antigen recognition, 105, 1595
in atopic dermatitis, 147–148, 151
helper T cells in, 106, 131, 132, 147–148
in autoimmune disorders, 1510, 1511, 1512–1513
autoreactive, 167, 1511
in dermatomyositis, 1539
in rheumatoid arthritis, 1572
chemokine-mediated migration of, 105, 130–131
classification of, 102
in common variable immunodeficiency, 1353
cytokines derived from, 115–116, 116f
cytotoxic, 104
in lichen planus, 245
and dendritic cell interactions, 131
in dermis, 104
differentiation of, 1595
in epidermis, 104
helper. *See* Helper T cells
interaction with B cells, 322, 323
in Kawasaki disease, 1627–1628
in leprosy, 102–103, 105, 1792
in lichen nitidus, 256, 257–258
in lichen planus, 244, 245
in lupus erythematosus, 1510, 1512, 1520
in lymphoid hyperplasia, 1405
memory, 104–105, 130, 1595
in atopic dermatitis, 148
naive, 111, 112, 130, 131, 1595
in parapsoriasis, 236, 237
in pityriasis lichenoides, 240, 241
in psoriasis, 170, 171f, 171–172, 173, 174f, 175f
in psoriatic arthritis, 194, 196f, 196–197, 198–199
clonal ignorance of, 199
as therapy target, 206
regulatory. *See* Regulatory T cells
and superantigens, 1715, 1715f
suppressor, 104, 1512
in ultraviolet radiation response, 812
and photoimmunosuppression, 807, 808, 808f
T cell leukemia, adult, 1924–1926
acute, 1924, 1924t, 1926
chronic, 1924, 1924t, 1925, 1926
classification of, 1924, 1924t
clinical findings in, 1924–1925, 1925f
cutaneous type, 1925
diagnosis and differential diagnosis of, 1925–1926
diagnostic criteria on, 1924, 1924t
histopathology in, 1925, 1925f
in HTLV-1 infections, 1924–1926
lymphoma-type, 1924, 1924t, 1926
multi-lobated leukemic cells in, 1924, 1925, 1925f
smoldering, 1924, 1924t, 1925, 1926
treatment and prognosis in, 1926
T-cell lymphoma, 106, 1388–1399, 1506
aggressive epidermotropic, 1395
anaplastic large cell, 1386, 1392, 1393, 1395f
barrier function of skin in, 393
CD8+ T cells in, 1387, 1395
classification of, 1386, 1387t, 1924
provisional entities in, 1394–1395
cutaneous γ/δ, 1395
cytokines in, 1387–1388
differential diagnosis of, 1925–1926
chronic actinic dermatitis in, 822, 823, 823b
cutaneous lymphoid hyperplasia in, 1407
disseminated patch/plaque disease, 1397–1398
erythroderma in, 1389, 1390f, 1398–1399
etiology in, 1386–1387
and exfoliative dermatitis, 225, 226–227, 228, 230t, 231, 232
extranodal nasal, 1394
Fas receptor and Fas ligand in, 1387
in immunocompromised host, 278
mycosis fungoides, 1388–1391
pathogenesis of, 1387–1388
peripheral, in HTLV-1 infections, 1924–1926
pleomorphic small or medium-sized, 1395
relapse and recurrence of, 1398
Sézary syndrome in, 1391–1392
staging of, 1396, 1396t
subcutaneous, and panniculitis, 583, 1393–1394, 1395
treatment of, 1396–1399
carmustine in, 1396–1397, 2123
denileukin diftitox in, 2230
in disseminated patch/plaque disease, 1397–1398
in erythroderma, 1398–1399
maintenance therapy in, 1398
mechlorethamine in, 1397, 1398, 2122–2123
photochemotherapy in, 1397, 1398, 1399, 2248, 2254f, 2254–2255
photodynamic therapy in, 2262
phototherapy in, 1397, 1398, 1399, 2248
radiation therapy in, 1396, 1397–1398, 1399, 2282, 2282t, 2284
retinoids in, 1398–1399, 2183
skin-directed therapy in, 1396–1397
T-cell lymphotropic virus infections, 1923–1927
transmission of, 1923
type 1, 1386, 1923–1927
adult T-cell leukemia/lymphoma in, 1924–1926
dermatitis in, 1926f, 1926–1927, 1938
in HIV infection and AIDS, 1938
myelopathy in, 1926
neurologic disorders in, 1926
strongyloidiasis in, 2016
tropical spastic paraparesis in, 1926
type 2, 1923, 1924
T-cell receptor, 101–102, 105, 1595
gene rearrangements, 101, 101f, 102
in Kawasaki disease, 1627–1628
in psoriatic arthritis, 196, 196f, 197
and superantigens, 1715, 1715f
Tabes dorsalis in syphilis, 1965t, 1966
treatment of, 1975

Tabun as chemical weapon, 2086t
Tacalcitol
in psoriasis, 188, 2245
in sub-corneal pustular dermatosis, 307
Tache noir
in Mediterranean spotted fever, 1951f
in rickettsialpox, 1946, 1951f
Tachycardia in acute intermittent porphyria, 1251
Tacrolimus, 114, 126, 2125–2129, 2217, 2220–2221
in acrodermatitis continua, 218
in allergic contact dermatitis, 145
in atopic dermatitis, 155, 2128
clinical results with, 2125–2126
complications of, 2125–2126, 2129, 2221
contraindications to, 2128
dosing regimen, 2221t
in graft-versus-host disease, 266t, 267t
in granuloma faciale, 304, 304b
in ichthyosis, 422
indications for, 2128, 2221
initiation of therapy with, 2128–2129, 2221
interaction with other drugs, 2239t
in lichen nitidus, 258
in lichen planus, 253b, 254, 681
in lichen sclerosus, 549, 679
in lupus erythematosus, 1533, 1533t
mechanism of action, 288, 2125–2126, 2217, 2220
monitoring of therapy with, 2129, 2221
pharmacokinetics of, 2128, 2220–2221
in pruritus, 909, 909t
in psoriasis, 190
in pyoderma gangrenosum, 301, 301b, 302
in rosacea, 708
in seborrheic dermatitis, 224
in vesicular palmoplantar eczema, 166
in vitiligo, 620
in vulvar skin disorders, 677, 679, 681
Tadalafil in systemic sclerosis, 1559, 1559t
Taenia multiceps, 2012t
Taenia solium, 2012t, 2021t, 2027–2028
TAK1 (TGF-β activated kinase), 118
Takayasu arteritis, 1606, 1615–1616
Talc granuloma in drug abuse, 923
Tanapox virus, 1900t
Tangier disease, 1272t, 1279–1280
Tanning beds, and skin cancer incidence, 1000, 1135
Tanning response, 606–607, 607t, 813
delayed, 606–607, 607f, 607t, 813
immediate, 606, 607f, 607t, 813
in oculocutaneous albinism, 610, 610f
persistent pigment darkening in, 813
photoprotection and photosensitization in, 813
phototypes of skin in, 809, 810t
TAP (transporter associated with antigen processing), 110, 110f
Tapeworm infections, 2011, 2026–2028
Tar preparations
in atopic dermatitis, 156
coal tar. *See* Coal tar preparations
keratosis from, 1018
phototoxicity from, 828t, 832, 2078
skin cancer associated with, 987, 987t, 2079
Tar warts, 1018
Tarantula bites, 2057
TARC (thymus and activation-regulated chemokine), 100, 105
in atopic dermatitis, 131
in psoriasis, 133f
Tardive dyskinesia from antipsychotic drugs, 918
Target lesions in erythema multiforme, 346, 346f
Targetoid lesions, 36, 37f
TAT in tyrosinemia, 1221, 1222
Tattoos, **886**–889
application process, 887, 887f
complications of, 887–888, 888f, 888t
oral, 650
pigments used in, 887, 887f, 887t
reactions to, 888, 888f
removal of, 888–889, 889f, 889t
laser therapy in, 888–889, 889f, 889t, 2275, 2275f, 2276f, 2377f
temporary, 889
Tay syndrome, 405t, 759t
Tazarotene, 2107
in acne vulgaris, 697, 2111
chemical structure of, 2107f
in ethnic skin, 2143
indications for, 2109, 2111, 2143
in palmoplantar pustulosis, 217, 217b
in psoriasis, 184t, 190, 2111
in combination with other agents, 187t, 190, 2245
receptor selectivity of, 2107
Tazobactam, 2198
T-bet transcription factor, 102
TCDD (tetrachlorodibenzo-*p*-dioxin), porphyria cutanea tarda from, 1236, 1237
Tear production in Sjögren syndrome, 1579, 1581
substitute products, 1582
TEBG (testosterone-estrogen-binding globulin), 1481
Tedania ignis, 2046
Teeth
caries of, 647
dental amalgam in
contact allergic stomatitis from, 651
lichenoid reaction from, 248–249, 250, 253
pigmentation changes from, 650
disorders involving, 647t
drug abuse affecting, 925
in ectodermal dysplasia, 1340, 1341, 1341f, 1344–1345
enamel pitting in tuberous sclerosis, 1327
in epidermolysis bullosa, 515
in erythropoietic porphyria, congenital, 642t, 647t, 1248, 1248f
examination of, 641
polyp of pulp, 647
in syphilis, congenital, 652t, 1969, 1969f
Tefibazumab in soft tissue infections, 1730
Tegenaria spider bites, 2054, 2057
Telangiectasia, 33, 34f
and ataxia. *See* Ataxia, and telangiectasia
conjunctival, 1361f, 1361–1362
and cutis marmorata in neonates, 939, 939f
in dermatomyositis, 1542t, 1545, 1547
hereditary hemorrhagic, 1379, 1453–1454, 1457, 1665
arteriovenous fistula in, 1379, 1453, 1454
gastrointestinal hemorrhage in, 1455
oral cavity disorders in, 642t, 1453f
with hypotrichosis and lymphedema, 1661, 1662
laser therapy in, 2272, 2356, 2356f, 2374
of leg veins, 2349, 2350
laser therapy in, 2356, 2356f
in sclerotherapy complications, 2354
sclerotherapy in, 2352
in lupus erythematosus, 1528
macularis eruptive perstans, 1375t, 1438, 1439
in Majocchi purpura, 1634, 1635f
in necrobiosis lipoidica, 1468, 1468f
in photoaging, 968t
postoperative, 2340–2341
in sun-exposed areas, 832
Telogen, 743f, 744, 746, 747f, 754, 757f
age-related changes in, 967
definition of, 754t
effluvium, 746, 754, 755, 761f, 938, 1479
acute, 761
causes of, 761, 761t
chronic, 761
drug-induced, 761, 761t, 2185
in iron deficiency, 761
in Kawasaki disease, 1629
in lupus erythematosus, 761, 1524
in first hair cycle, 72
melanocytes in, 747–748, 748f
Telogen hairs, definition of, 754t
Telomerase, 74
in aging, 963
Telomeres, 74
and aging, 963, 964, 965f
length of, 74
Temozolomide in melanoma, 1156
Temperature. *See also* Cold; Heat
core temperature, 835, 836, 844
skin temperature, 835, 844
thermoregulatory responses to, 835–844
Temperature-sensitive oculocutaneous albinism, 609, 610–611
Temporal artery
giant cell arteritis of, 1606, 1615f, 1615t, 1615–1616
clinical manifestations of, 1615, 1615f, 1615t
histopathology in, 1615, 1615f
treatment of, 1616
surgical anatomy of, 2293
Temporal nerve injury in surgery, 2290–2291, 2291f, 2293
Temsirolimus, 2221
Tenascin, 63, 540
in Ehlers-Danlos syndrome, 1298t, 1300
Tennis, 874t
Tennis toe, 874f, 874t
Tenofovir in HIV infection and AIDS, 2208, 2209
Tenosynovitis in psoriatic arthritis, 199–200
Teratogenicity of retinoids, 698, 699, 708, 2184–2185
Terbinafine, 2211–2213
chemical structure of, 2212f
in children, 951t, 954, 1818t, 2212
in chromoblastomycosis, 1834
in dermatophyte infections, 1818b, 1819, 1820, 1821, 2212
dosage of, 2119, 2212, 2213t
pediatric, 951t, 954, 1818t, 2212
indications for, 2119, 2212, 2212b, 2213t
interaction with other drugs, 2213
mechanism of action, 2119, 2211
in onychomycosis, 1818t, 1820, 2212, 2213t
pharmacokinetics of, 2119, 2211–2212
side effects and complications of, 2119, 2212–2213
hepatotoxicity in, 1459t, 2212, 2213
in sporotrichosis, 1832
in tinea pedis, 2119, 2120t, 2212, 2213t
in tinea versicolor, 1830
topical, 2117t, 2119, 2120t

Terfenadine, 2188, 2190
interaction with other drugs, 2240t
Terminal hair, 742, 742t, 754–755
definition of, 754t
Terrorism attacks
biologic weapons in, 2081–2085. *See also* Bioterrorism
chemical weapons in, 2085–2087
radiologic weapons in, 2087
Terry's nails, 791, 1449, 1449f
Tessari sclerotherapy technique in varicose veins, 2353
Testicular cancer in X-linked recessive ichthyosis, 409
Testosterone, 691f, 1481
in hirsutism, 775, 775t
in pattern hair loss, 766, 768
and sebaceous gland activity, 689
Testosterone-estrogen-binding globulin (TEBG), 1481
Tetanus
as body piercing complication, 890t
prophylaxis in venomous fish spine injuries, 2052
Tetracaine in local anesthesia, 2296, 2296t, 2298
Tetrachlorodibenzo-*p*-dioxin (TCDD), porphyria cutanea tarda from, 1236, 1237
Tetracycline, 2113t, 2195t, 2199
in acne vulgaris, 697, 698
in actinomycetoma, 1786
in children, 946, 950t
in ehrlichiosis, 1950b
indications for, 2199b
mechanism of action, 2199
in perioral dermatitis, 711, 711b
pharmacokinetics of, 2199
in pityriasis lichenoides, 243b
in Rocky Mountain spotted fever, 1942, 1950b
in rosacea, 708
in sarcoidosis, 1492, 1492t
in seal bite, 1757t, 1762, 2042
side effects and complications of, 2196t, 2199
fixed drug eruption in, 359f
nail changes in, 792
tooth discoloration in, 647t
in syphilis, 1974, 1975
in treponematosis, endemic non-venereal, 1982
Textiles, allergic contact dermatitis from, 140
TFGBR, 980t
TGM. *See* Transglutaminase, tissue
Thalidomide, 2233–2235
in actinic prurigo, 819
in aphthous stomatitis, recurrent, 2234, 2234t
in Behçet disease, 1625b, 2234t
contraindications to, 2234
dosing regimen, 2234, 2234t
in erythema nodosum leprosum, 1791, 1795b, 1796, 2233, 2234, 2234t
in graft-versus-host disease, 267t, 2234
indications for, 2234, 2234t
initiation and monitoring of therapy, 2234
in Langerhans cell histiocytosis, 1423
in leprosy, 1791, 1795b, 1796
in lichen planus, 253b, 254, 255
in lupus erythematosus, 1533t, 1534, 2234t
in lymphocytic infiltration of skin, 1413b
mechanism of action, 284, 2234
pharmacokinetics of, 2234
in pruritus, 910–911, 911t
in pyoderma gangrenosum, 302
in sarcoidosis, 1492, 1492t
side effects and complications of, 18, 911, 2234–2235
in leprosy, 1796
in pregnancy, 2233, 2234, 2235
Thallium poisoning, hair loss in, 762
Thayer-Martin medium, 1995
Theophylline, complications of, 2238t
Thèques, 1099, 1101
Thermal injuries, **852**–858
in chronic heat exposure. *See* Heat, chronic exposure to
hyperpigmentation in, 636
keratosis in, 1017–1018
liver disorders in, 1458
in occupational exposures, 2077–2078
Thermoregulation, 57, 58t, **835**–844
acclimatization affecting, 843–844
age-related changes in, 966
anatomy in, 836
blood vessels in, 836, 837–844
neural control of, 837, 838f
vasoconstriction of, 836, 837, 838f, 841–843
vasodilation of, 836, 837–841, 838f
drugs affecting, 844
in exfoliative dermatitis, 229
heat transfer in, 835–836
neural control of, 837, 838f
in premature infants, 936
sunburn affecting, 844
sweat glands in, 714–715, 835, 836, 837
Thermoregulatory sweat test (TST), 721
in leprosy, 728, 728f
Thiabendazole
in cutaneous larva migrans, 2014t, 2024
pediatric dosage, 953t
in strongyloidiasis, 2015t
Thiamine, 1208–1209
deficiency of, 1208–1209
excess of, 1208
food sources of, 1208
Thickening agents in topical drug formulations, 2095
Thickening of skin in diabetes mellitus, 1463
Thimerosal, positive patch test results to, 143
Thin-Layer Rapid Use Epicutaneous (T.R.U.E.) patch test, 136t, 143
in cosmetic allergy, 2361
Thioguanine, 2170–2171
in actinic dermatitis, chronic, 823
chemical structure of, 2163f
complications of, 2170t, 2170–2171, 2176t
contraindications to, 2170, 2170t
dosage regimen, 2170, 2176t
indications for, 2170, 2170t, 2176t
mechanism of action, 2170, 2176t
monitoring of therapy with, 2170, 2170t
in psoriasis, 187t, 192
and arthritis, 205
Thiopurine methyltransferase
in methotrexate therapy, 2167, 2167t, 2168
in thioguanine therapy, 2170, 2171
Thiotepa, hyperpigmentation from, 2179f
Thoracic outlet syndrome, Raynaud phenomenon in, 1645, 1646
Threading injection technique in soft tissue augmentation, 2380, 2381f
with hyaluronic acids, 2383
with poly-L-lactic acid, 2385
Threadworm, 2013
Three-compartment model on drug pharmacokinetics, 2097–2101
Thrombin, 1748
Thromboangiitis obliterans, 1673–1676
approach to patient with, 1674f
differential diagnosis of, 1669, 1675
treatment of, 1675b, 1675–1676
Thrombocytopenia
in angiomatosis, cutaneovisceral, 1171
autoimmune, 1514
in chemotherapy, 2180–2181
in Langerhans cell histiocytosis, 1423
in lymphangioendotheliomatosis, multifocal, 1171
and purpura, 1381–1382, 1746
alloimmune, 1381–1382
in congenital cytomegalovirus infection, 1862
differential diagnosis in, 1605
idiopathic, 1381
thrombotic, 1382, 2204–2205
in rubella, 1854
in smallpox, 1902
in Wiskott-Aldrich syndrome, 1357
Thrombocytosis
in Kawasaki disease, 1630
in polycythemia vera, 1378
Thrombomodulin, 539t
Thrombophlebitis
migratory, 1495t, 1503–1504
of penile and scrotal veins, 672
superficial, 569–571, 571f, 1684
in sclerotherapy complications, 2354–2355
Thrombosis, 1680, 1684
in Behçet disease, 1623, 1624
in cryofibrinogenemia, 1642
of deep veins, 1684
in Degos disease, 1648
in drug interactions, 2240t
in homocystinuria, 1304
in polycythemia vera, 1378
of superficial veins, 1684
in thromboangiitis obliterans, 1675
in venous malformations, 1658, 1660
Thrombospondin, 63, 1597t
Thromboxane B_2, 285
Thrush, oral, 653, 1355, 1355f, 1356f, 1823f, 1823–1824
Thumbprint sign in strongyloidiasis, 2016
Thymic stromal lymphopoietin (TSLP), 123
in atopic dermatitis, 148
Thymidine dinucleotides, 813
Thymocytes, 101–102
Thymoma
and chronic mucocutaneous candidiasis, 1355t, 1826, 1827t
and pemphigus, 466
paraneoplastic, 469, 473
Thymus
congenital aplasia of, 1356
eosinophils in, 284–285
Thymus and activation-regulated chemokine (TARC), 100, 105, 131, 133f
Thyroid disorders, **1470**–1474
anemia in, 1377
autoimmune, 1470
clinical findings in, 1471–1474, 1472t
congenital, 1470
cutaneous signs of, 1471–1474
dermopathy in, 1472f, 1472–1473, 1473f
elephantiasic, 1472
treatment of, 1474
drug-induced, 1470, 1471, 1471t
epidemiology of, 1470
etiology and pathogenesis in, 1470–1471, 1471f, 1471t
in Fabry disease, 1284t, 1285

Thyroid disorders—*continued*
granuloma annulare in, 370
hair changes in, 768, 1471, 1474
in hemangioma of infants, 1167
hyperpigmentation in, 635, 1473
hyperthyroidism. *See* Hyperthyroidism
hypopigmentation in, 629
hypothyroidism. *See* Hypothyroidism
in interferon-α 2b therapy, 2233
laboratory tests in, 1474
medullary carcinoma in multiple endocrine neoplasia syndrome, 1178
nail changes in, 1471, 1474
pruritus in, 908, 1471
in retinoid therapy, 2185
treatment of, 1474
and urticaria, 1473
vitiligo in, 616, 619, 629, 635, 1471–1472
Thyroid hormone(s), 1470–1474
drugs affecting, 1470, 1471t
synthesis of, 1470, 1471f
Thyroid hormone receptors, 2107
Thyroid-stimulating hormone, 1470, 1471f, 1474
Thyroid transcription factor-1 in Merkel cell carcinoma, 1090, 1090t
Thyroiditis, Hashimoto, 1471
cutaneous findings in, 1474
vitiligo in, 616, 619
Thyrotoxicosis, 1470
hyperpigmentation in, 635
Thyrotropin, 1470, 1471f, 1474
Thyrotropin-releasing hormone, 1470, 1471f
Thyroxine, 1470, 1471f, 1474
Ticarcillin, 2198
Ticks, 1797, 2054, 2058f, 2058–2059
and African tick bite fever, 1942
and anaplasmosis, 1944t, 1952–1953
and ehrlichiosis, 1944t, 1952–1953
and Lyme disease, 1797–1806, 2059
and Mediterranean spotted fever, 1942, 1943t, 1945
occupational exposure to, 2076
and paralysis, 2059
prevention of bites, 1804–1805, 1942, 1953
removal methods, 2059
and Rocky Mountain spotted fever, 1941–1942, 1943t
and tularemia, 1758
TIDA gene, 980t
Tie-1, 1590t, 1597
Tie-2, 68t, 70, 1590t, 1597
Tietz syndrome, 614, 615
Tigecycline, 2202
in soft tissue infections, 1730
Tiger tail appearance in trichothiodystrophy, 405t, 420, 420f, 1321, 1322f
Tight junction proteins in epidermis, 391
Timor filariasis, 2017
TIMP (tissue inhibitors of metalloproteinases)
in lichen planus, 245
in photoaging, 970
TIMP-3 in morphea, 543
Tinctures, topical medications formulated as, 2094
Tinea barbae, 1813, 1813f
circinate, 1813, 1813f
differential diagnosis of, 1814b
treatment of, 1818b, 1819
Tinea capitis, 770, 1811–1812
black dot, 1811, 1811t, 1812, 1812f
in children and infants, 938, 945
differential diagnosis of, 764, 1812b
gray patch type, 1812, 1812f
histopathology in, 1812
inflammatory, 1811t, 1812, 1812f
kerion of scalp in, 1812, 1812f
laboratory characteristics in, 1808t
organisms associated with, 1811t
seborrheic, 1812
treatment of, 770, 1818b, 1818–1819
evidence-based medicine on, 2217
fluconazole in, 2215
itraconazole in, 2214, 2214t
types of, 1811t
Tinea circinata, 1814t, 1814–1815
Tinea corporis, 1814–1815
annular, 1814, 1814f
bullous, 1814t
clinical findings in, 1814f, 1814–1815, 1815f
differential diagnosis of, 365, 365b, 1815b
gladiatorum, 1814
polycyclic pattern in, 1815, 1815f
treatment of, 1818b, 1819
itraconazole in, 2214t
terbinafine in, 2212, 2213t
variants of, 1814t
Tinea cruris, 667, 1815, 1815f
differential diagnosis of, 1815b
treatment of, 1818b, 1819
terbinafine in, 2212, 2213t
Tinea faciale, 1814t
Tinea favosa, 1811t, 1812–1813, 1813f
Tinea imbricata, 1814, 1814t
Tinea incognito, 1814t
in corticosteroid therapy, 2106
Tinea manus, 1815–1817, 1816f
differential diagnosis of, 1817b
treatment of, 1818b
unilateral, 1816, 1816f
Tinea nigra, 1820f, 1820–1821
differential diagnosis of, 1820b
of hand, 1820f
Tinea pedis, 875, 1815–1817, 1816f
acute ulcerative, 1816
in athletes, 1816, 1816f
chronic
differential diagnosis in, 430b
hyperkeratotic, 1816, 1816f
intertriginous, 1815–1816, 1816f
differential diagnosis of, 430b, 1817b
in elderly, 973
Id reaction in, 165f
moccasin-type, 1816, 1816f
and onychomycosis, 1816, 1817, 1819
treatment of, 1818b, 1819, 2119, 2120t, 2121
evidence-based medicine on, 2217
fluconazole in, 2215
itraconazole in, 2214t
terbinafine in, 2119, 2120t, 2212, 2213t
vesiculobullous, 1816, 1816f, 1819
Tinea profunda, 1814t
Tinea unguium, 1817
treatment of, 1820
Tinea versicolor, 1828–1830, 1829f
diagnosis of, 1830
differential diagnosis of, 367t, 1829, 1829b
inverse, 1829
papulosquamous, 1829, 1829b
pathology in, 1830
treatment of, 1830
Tinea yaws, 1980
Tinidazole in trichomoniasis, 1999b
Tinnitus in Fabry disease, 1285
Tipranavir in HIV infection, 2209–2210
TIR domain, 118, 120f
Tissue inhibitors of metalloproteinases
in lichen planus, 245
in photoaging, 970
TIMP-3 in morphea, 543
Tissue transglutaminase. *See* Transglutaminase, tissue
Titanium dioxide in sunscreens, 2139t, 2140, 2141
TLR. *See* Toll-like receptors
TNFRSF1A in tumor necrosis factor receptor-associated periodic syndrome, 1269
Tobacco exposure
in cigarette smoking. *See* Smoking
and lupus erythematosus, 1519
oral changes in, 650
from chewing products, 650
from cigarette smoking, 650
leukoplakia in, 1024
from pipe smoking, 650
Tocopherol, 1207
Toes. *See* Foot
Togavirus, 1846t
Tolerance
and autoimmunity, 1511–1512
central, 1511
peripheral, 1511–1512
to sun exposure, desensitization for, 816, 2247, 2256
in solar urticaria, 825, 2256–2257
Toll-like receptors, 113–114, 115, 120f, 285, 1589, 1590
in acne vulgaris, 99, 692
activation of, 98, 98f, 99, 1690
in autoimmunity, 1513
in innate immunity, 97, 98f, 98–99, 1513, 1590, 1690
in lupus erythematosus, 1513, 1519
in psoriasis, 173
in sepsis, 1746
TLR2, 1690
TLR4, 118
TLR5, 1690
and type I interferons, 108, 125
Tolnaftate, 2117t, 2121
Toluene sulfonamide, allergic contact dermatitis from, 2362, 2363t
Tongue, 642–644
in amyloidosis, 1260t, 1261, 1262f
enlargement of, 644
eosinophilic ulcer of, 315
examination of, 641
fissures and furrows in, 643, 643f
geographic, 643, 643f
in psoriasis, 181–182, 643
in reactive arthritis, 210
glossitis of, 642–644. *See also* Glossitis
glossodynia of, 642–643, 643t
granular cell tumors of, 1181
grooved, 643
hairy, 643–644, 644f
in leukoplakia, 644
papillae of, 641
hypertrophy of, 643–644, 644f
in Sjögren syndrome, 1578
splitting procedure as body art, 886
strawberry
in Kawasaki disease, 1628, 1630
in scarlet fever, 1718, 1718f
trauma of, 643
in tuberculosis, 1773
Tooth. *See* Teeth
Tooth and nail syndrome of Witkop, 68t, 72, 1346, 1346f

Tophi in gout, 1575, 1576, 1576f
Topical medications, **2091**–2146
absorption of, 2091–2092
cutaneous metabolism affecting, 2101
factors affecting, 2091–2092
in ointments, 2094
penetration pathways in, 2100
pharmacokinetics in, 2097, 2099
regional anatomic differences in, 2091, 2092t, 2105
and resorption, 2101–2102
stratum corneum affecting, 2091, 2099–2100
and systemic toxicity, 2096
in actinic keratosis, 1013b, 1013–1014
analgesic, 2130
anti-inflammatory, 2130
antiperspirant, 2134
application of
frequency of, 2092, 2104–2105
with occlusion, 2091–2092
quantity of, 2092, 2092t, 2098
astringent, 2134–2135
in bacterial infections, 1693–1694, 2113t, 2113–2115, 2130, 2132–2133
ethnic considerations in, 2144
bleaching agents, 2135
in burns, 855–857
in children, 422, 946, 946t
compared to transdermal drug delivery, 2096
compliance with therapy in, 2092, 2093
corticosteroid, 2102–2106, 2143
cytotoxic, 2122–2125
in elderly, 971
ethnic considerations in, 2142–2146
in retinoid therapy, 2111, 2143–2144, 2144f
in fungal infections, 2116–2121
hyperpigmentation from, 637t
immunomodulators, 2125–2129
keratolytic, 2135–2136, 2144
in local anesthesia, 2296t, 2298
in parasitic infections, 2133–2134, 2133t
pharmacokinetics of, 2097–2102
with antifungal agents, 2118, 2119
barrier function of skin affecting, 2102
in corticosteroid therapy, 2103–2104
diffusion in, 2097
resorption in, 2101–2102
skin metabolism in, 2101
three-compartment model of, 2097–2101, 2098f, 2099t
principles of therapy with, 2091–2096
in pruritus, 909t, 909–910, 2134, 2134t
in psoriasis, 2136
reservoir on skin surface in, 2098–2099, 2100
resorption of, 2101–2102
retinoid, 2106–2112
ethnic considerations in, 2111, 2143–2144, 2144f
toxicity of, 2095–2096
in corticosteroid therapy, 2105–2106
local, 2095–2096
systemic, 422, 2096
vehicle formulations of, 2093t, 2093–2095
aerosol, 2095
liquid, 2094–2095
ointment, 2093–2094
paste, 2094
poultice, 2093
powder, 2093
in warts, 2136
Topiramate, anhidrosis from, 729
Torsades de pointes in drug interactions, 2240t
Torticollis, neonatal, in fibromatosis colli, 550–551
Torulosis, 1842–1843
Touch domes, 65
Touraine polykeratosis, 426
Touton giant cells
in juvenile xanthogranuloma, 1427, 1427f
in xanthoma disseminatum, 1430, 1430f
Toxic epidermal necrolysis, 343, **349**–355. *See also* Epidermal necrolysis
Toxic oil syndrome, 54
eosinophils in, 316
Toxic shock syndrome, 1715–1717
in body piercing complications, 890t
clinical findings in, 1715–1717
differential diagnosis of, 1717
erythroderma in, 1746
staphylococcal, 1694, 1715–1716, 1716f, 1717, 1746
diagnostic criteria on, 1716, 1716t
streptococcal, 1716–1717, 1746
treatment and prognosis in, 1717
Toxic shock syndrome toxin 1 (TSST-1), 1695, 1710t, 1715, 1717
in Kawasaki disease, 1627, 1628
Toxocara canis, 2012t
Toxocariasis, 1454, 2012t
Toxoplasma gondii, 1741, 2010
Toxoplasmosis, 1741, 2010, 2010t
acquired, 2010, 2010t
with *Bartonella* infection, 1754
congenital, 2010
differential diagnosis of, 1741
in immunocompromised host, 2010
transmission of, 2010
Trachyonychia, 782, 790
Track marks
from drug abuse, 922, 923f
from sutures, 2339, 2340f
Traction alopecia, 770, 770f
TRADD, 121f, 121–122
TRAF, 118
Tragus of ear, 2290, 2290f
and antitragus, 2290, 2290f
TRAIL, 121
TRAM, 118
TRANCE, 121
Transcortin, 2147
Transcription, 74
Transcription coupled repair in DNA damage, 811, 978, 979f, 980
Transcription factors, 76
ligand-dependent, 2107
Transdermal drug delivery
compared to topical therapy, 2096
cutaneous metabolism affecting, 2101
liposome-based formulations in, 2099
Transepidermal water loss, 384, 390, 2357
in atopic dermatitis, 394f
in dry skin, 2359
individual variations in, 2100
in irritant contact dermatitis, 399, 400
as measure of skin barrier function, 2100
in psoriasis, 395
Transfer RNA, 73
Transforming growth factor-α, 286
in acanthosis nigricans, 1494
in Leser-Trélat sign, 1497
Transforming growth factor-β, 116, 116f, 126, 286, 528
in aging of skin, 965f
in photoaging, 970
in angiogenesis and vasculogenesis, 1597, 1597t
and elastin, 533
functions of, 1435t, 1436
keratinocyte-derived, 100
latent transforming growth factor-β–binding proteins (LTBP), 535t, 535–536
in morphea, 543
in photoimmunosuppression, 808f, 809
receptor for, 117t, 126
and regulatory T cells, 1512, 1513
in squamous cell carcinoma, 993
in systemic sclerosis, 1554t
as therapy target, 1560t
Transforming growth factor-β1, 126
in hair follicle cycle, 746
immunoregulatory role of, 126
in wound healing, 2343, 2344, 2344t, 2345
impaired, 2348
Transfusions
leukocyte, in chronic granulomatous disease, 1364, 1365t
urticaria and angioedema in, 338
Transglutaminase, tissue, 61
in dermatitis herpetiformis, 500–501
TGM1, 61, 68t, 86, 391
deficiency of, 391
in ichthyosis, 395, 407, 411, 411t
TGM3, 61, 391
TGM5, 391
Transit-amplifying cells, epidermal, 375, 376, 377
Translation process, 74–75
Transplantation
of hair, 2394–2401
of melanocytes, in vitiligo, 621–622
solid organ
cytomegalovirus infections in, 1861, 1863, 1864
herpesvirus-6 infection in, 1865
stem cell. *See* Stem cell transplantation
Transposition flaps, 2310, 2312f
forehead paramedian, 2310, 2313f
after Mohs micrographic surgery, 2319f
rhombic, 2310, 2312f
after Mohs micrographic surgery, 2317f
Transthecal block in nail surgery, 2322
Transthyretin
in amyloidosis, 1257, 1258, 1264
in thyroid disorders, 1470
Trapdoor effect in flap repair, 2312–2313
Trauma
anhidrosis in, 729
in bites and stings, 2037–2053
in child abuse, **927**–930
in cold injuries, **844**–851
in domestic violence, **930**–931
eczema in, 2077, 2077t
in elder abuse, **930**
epidermoid cyst in, 864, 1063
hair loss in, 769–770
hyperpigmentation in, 636, 2076
irritant contact dermatitis in, 398–399
nail disorders in, 792–793, 793f
and reconstructive surgery, 2329
neuroma in, 1176
occupational exposure to, 2076f, 2076–2077
oral, 650–651
glossitis in, 643
panniculitis in, 55, 580–581
of spinal cord, hyperhidrosis in, 722t, 723–724
in thermal injuries, **852**–858
Treg cells. *See* Regulatory T cells
TREM proteins, 98
Trematode infections, 2011, 2025–2026

Trench fever, 1749, 1750t, 1751–1752, 2035
Trench foot, 848
Trench mouth, 645
Treponema carateum, 1978, 1982t
Treponema pallidum
differential diagnosis of, 1985, 1985b
in oral cavity disorders, 652t
in syphilis, 1955, 1956, 1956f. *See also* Syphilis
treatment of infections, 2197t
Treponema pallidum subspecies *endemicum,* 1981
Treponema pallidum subspecies *pertenue,* 1979, 1982t
Treponematosis, **1955**–1983
non-venereal endemic, 1977–1983
clinical manifestations of, 1982t
diagnosis of, 1981–1982
hypomelanosis in, 627, 627f
transmission of, 1977–1978, 1979, 1981
treatment of, 1982
venereal syphilis in, 1955–1977
Tretinoin, 2107, 2108, 2181–2186
in acne vulgaris, 697, 2109, 2112
in actinic keratosis, 1015, 2109
as bleaching agent, 2135
chemical structure of, 2110f
clinical uses of, 2109, 2111, 2112
in combination therapy with hydroquinone and dexamethasone, 2146
dosage schedules and forms for, 2111
in ethnic skin, 2143
in Fox-Fordyce disease, 734
hydroxylation of, 2109, 2110f
interaction with other drugs, 2112
in lichen planus, 253, 253b, 254
in lichen sclerosus, 679
mechanism of action, 2181–2182
in melasma, 1480
pharmacokinetics of, 2182
in photoaging, 2109, 2111
and photosensitivity, 2112
in pregnancy, 2112
in rosacea, 708
in striae, 560, 2111
Triamcinolone acetonide
in acne vulgaris, 699–700
in alopecia areata, 765
chemical structure of, 2148t
in hypertrophic scars, 554, 2339, 2341f
in keloids, 554
in lichen planus, 253, 254
in lupus erythematosus, 1532, 1533, 1533t
in nail psoriasis, 789
and nystatin, 2117t, 2120
potency and duration of action, 2148t
in pyoderma gangrenosum, 301
in Sweet syndrome, 294
Triatoma kissing bugs, 2060
Triatomine bug bites, American trypanosomiasis in, 2008–2009
Triazole antifungal agents, 2213–2215
Trichilemmal cyst, 1064–1065, 1065f
Trichinella spiralis, 2012t, 2023
Trichinosis, 2012t, 2022–2023
treatment of, 2015t
Trichloroacetic acid, 2136
in actinic keratosis, 1014
in chemical peels, 2370, 2370t
in genital warts, 664b
in molluscum contagiosum, 1913t
Trichoadenoma of Nikolowski, 1082
Trichoblastoma, 1082–1083, 1083f
Trichodiscoma, 1083
Trichoepithelioma, 1083–1084, 1084f
desmoplastic, 1080, 1080f
genetic factors in, 988, 989t
multiple, 1083, 1084, 1084f
solitary, 1083
Trichofolliculoma, 1084, 1084f
Trichogram (hair pluck test), 756t
Trichohyalin in cornified envelope, 387–388
Tricholemmoma, 1084
Trichomonas vaginalis, 1998–1999, 1999f
Trichomoniasis, 1998–1999, 1999f
and HIV infection, 1999
laboratory tests in, 1999, 1999f
strawberry cervix in, 1999, 1999f
treatment of, 1999, 1999b
vaginal pH in, 1998, 1999
Trichomycosis
axillaris and pubis, 1709, 1709f
nodularis, 1821
Trichophytin skin test, 1811
Trichophyton concentricum, 1811, 1814
Trichophyton gourvillii, 1808t
Trichophyton interdigitale, 786t
Trichophyton megninii, 1808t, 1813, 1817
Trichophyton mentagrophytes, 1808t, 1810t
occupational exposure to, 2076
in onychomycosis, 1817, 1817t
in tinea barbae, 1813, 1819
in tinea capitis, 1811t
in tinea corporis, 1814
in tinea cruris, 1815
in tinea pedis and manus, 1815, 1816, 1816f
Trichophyton rubrum, 152, 1808t, 1810t, 1811
occupational exposure to, 2076
in onychomycosis, 786t, 1817, 1817t
in HIV infection, 1936
in tinea barbae, 1813
in tinea corporis, 1814
in tinea cruris, 1815
in tinea pedis and manus, 1815, 1816, 1816f
Trichophyton schoenleinii, 1808t, 1810t
in favus, 1811t, 1813, 1813f
in tinea barbae, 1813
in tinea capitis, 1811t
Trichophyton soudanense, 1808t
Trichophyton tonsurans, 1808, 1808t, 1810t
in onychomycosis, 1817, 1817t
in tinea capitis, 1811, 1811t, 1812, 1812f, 1819
in tinea corporis, 1814
treatment of infections, 2212
Trichophyton verrucosum, 1808t, 1810t
occupational exposure to, 2076
in tinea barbae, 1813, 1819
in tinea capitis, 1811t
in tinea corporis, 1814
in tinea cruris, 1815
Trichophyton violaceum, 1808t, 1810t
in favus, 1811t
in tinea barbae, 1813
in tinea capitis, 1811t, 1812
Trichophyton yaoundei, 1808t
Trichorrhexis
invaginata, 416, 417f, 758, 759f
nodosa, 416, 755–757, 758f
acquired, 757, 770
in argininosuccinic aciduria, 756, 1224
congenital, 756–757
in trichothiodystrophy, 1321
Trichoschisis, 757, 758f
in trichothiodystrophy, 757, 758f, 1321, 1322f
Trichosporon asahii, 1821
Trichosporon asteroides, 1821
Trichosporon beigelii, 271, 1936
Trichosporon cutaneum, 1821
Trichosporon inkin, 1821
Trichosporon mucoides, 1821
Trichosporon ovoides, 1821
Trichosporonosis, 271, 1821
Trichothiodystrophy, 420, 1312t, 1315, 1321
clinical features in, 405t, 420, 759t, 1321, 1322f
DNA damage and repair in, 420, 757, 978, 982t, 983t
genetic factors in, 405t, 420, 757, 1321
nail changes in, 420, 421f
photosensitivity in, 420, 758, 759t, 1321
syndromes associated with, 759t
tiger tail appearance in, 405t, 420, 420f, 1321, 1322f
trichorrhexis nodosa in, 756–757
trichoschisis in, 757, 758f, 759t, 1321, 1322f
Trichotillomania, 769–770, 770f, 914f, 914–915
differential diagnosis of, 764, 769
Triclabendazole
in fascioliasis, 2014t
in paragonimiasis, 2015t
Triclosan in methicillin-resistant staphylococcal infections, 875
Tricyclic antidepressants, 919
antihistaminic activity of, 2193
in postherpetic neuralgia, 1896, 1897
Trifluridine, 2205, 2206t
Trigeminal nerve
anesthetic block of, 2298
herpes zoster virus infections of, 1890, 1891f, 2292
in Sturge-Weber syndrome, 1653, 1655f
surgical anatomy of, 2292, 2292f
Triglycerides
in diabetes mellitus, 1462, 1464
in familial chylomicronemia syndrome, 1274–1275
in familial hypertriglyceridemia, 1278
medium-chain, in lipoprotein lipase deficiency, 1275
metabolism of, 1273–1274
in retinoid therapy, 2186
in sebum, 688, 688f
in acne vulgaris, 692
Triiodothyronine, 1470, 1471f, 1474
Trimethoprim-sulfamethoxazole, 2201
in acne vulgaris, 697
in actinomycetoma, 1786
dosage of, 2195t
pediatric, 949t
in granuloma inguinale, 1993b
in granulomatous disease, chronic, 1364, 1365t
indications for, 2201b
interaction with other drugs, 2240t
mechanism of action, 2201
in melioidosis, 1765
in nocardiosis, 1783
pharmacokinetics of, 2201
side effects and complications of, 2196t, 2201
in HIV infection, 1933, 1934, 1934f
Trioxsalen, 2250
Tripe palms, 1496–1497, 1497f
in acanthosis nigricans, 1463, 1495, 1496–1497
in paraneoplastic syndromes, 1448, 1449f, 1494t, 1496–1497
Tripelennamine, 923, 925, 2189t

Triplet excited state, 804, 804f
Triprolidine, 2191
Trismus, 648
Trisomy, 80
Trisomy 13, 81t
Trisomy 18, 81t
Trisomy 21, 81t
  calcinosis cutis in, 1296
Triton tumor, malignant, 1181
Trolamine salicylate in sunscreens, 2139t
Trombicula, 2032, 2032t
Tropical immersion foot, 848
Tropical spastic paraparesis, 1926
Tropoelastin, 531, 532f, 533
Trousseau sign, 39t
Trousseau syndrome, 1495t, 1503–1504
TRP. *See* Tyrosinase-related proteins
TRPM8 receptors in pruritus, 910
T.R.U.E. patch test, 136t, 143
  in cosmetic allergy, 2361
Trummerfeld zone in vitamin C deficiency, 1213
Truncal lesions, 38
Trypanosoma brucei, 2008
Trypanosoma cruzi, 2008, 2061
Trypanosomiasis
  African, 2007–2008, 2008f
  American, 2008–2009, 2009t
    stages of, 2009, 2009t
    transmission of, 2008–2009, 2061
Tryptase
  functions of, 1435, 1435t
  in mast cells, 1434, 1435
  in pruritus, 904
Tryptophan, 54, 1209, 1210
TSC1 in tuberous sclerosis complex, 1325, 1327f, 1330
TSC2 in tuberous sclerosis complex, 1325, 1327f, 1330
Tsetse fly bites, 2060
  African trypanosomiasis in, 2008
TSLP (thymic stromal lymphopoietin), 123
  in atopic dermatitis, 148
TSST-1 (toxic shock syndrome toxin 1), 1695, 1710t, 1715, 1717
  in Kawasaki disease, 1627, 1628
Tsutsugamushi fever, 1951
TTDA in trichothiodystrophy, 1321
TTDN1 in trichothiodystrophy, 420, 1321
TTR in amyloidosis, 1257, 1258, 1264
Tuberculids, 1773–1774, 1774t
  papulonecrotic, 1773, 1774, 1774f, 1774t
    differential diagnosis of, 1775b
Tuberculin reaction, 1769–1770
Tuberculosis, 1768, 1769–1775
  Addison disease in, 1478
  from Bacille Calmette-Guérin vaccination, 1773
  in bioterrorism, 2083t
  chancre in, 1770, 1770f
  classification of, 1769, 1769t
  colliquativa cutis, 1772
  cutaneous, 1769–1775
  epidemiology of, 1769
  erythema induratum of Bazin in, 574, 575
  etiology and pathogenesis in, 1769–1770
  granuloma in, 53, 1770
  histopathology in, 1770, 1771
  in immunocompromised host, 272, 1768–1769
    in HIV infection, 1768–1769, 1935
  lichen scrofulosorum in, 1774
  lupus vulgaris in, 1769, 1770, 1771–1772, 1772f
    differential diagnosis of, 1772b
    treatment of, 1775
  miliary, 272, 1769, 1770, 1773
  in occupational exposures, 2074
  oral cavity disorders in, 653t, 1773, 1773f
    differential diagnosis of, 1773b
  papulonecrotic tuberculid in, 1774
  primary inoculation, 1770–1771
  route of infection in, 1770
  scrofuloderma in, 1769, 1770, 1772
    differential diagnosis of, 1772, 1773b
    treatment of, 1775
  skin test in, 1769–1770
  treatment of, 1774–1775, 1775t
  ulcerosa cutis et mucosae, 1773, 1773f
  verrucosa cutis, 1769, 1771, 1771f
    differential diagnosis of, 1771b
    treatment of, 1775
  warty, 1771, 1771f
    differential diagnosis of, 1771b
    treatment of, 1775
Tuberin, 1325
Tuberous sclerosis, 530t, **1325**–1331, 1505t
  cardiac rhabdomyoma in, 1175, 1329
  clinical findings in, 1325–1329
  complications of, 1330–1331
  confetti skin lesion in, 1326, 1329f
  diagnostic criteria on, 1325–1326, 1328t
  differential diagnosis of, 1330
  epidemiology of, 1325
  etiology and pathogenesis of, 1325, 1327f
  facial angiofibromas in, 1326, 1329, 1329f
  facial plaque in, fibrous, 1326, 1329f
  genetic factors in, 1325, 1327f
    counseling on, 1331
    diagnosis of, 1330
  histopathology in, 1329–1330
  hypomelanotic macules in, 1326, 1328f, 1329, 1329f
  laboratory tests in, 1329–1330
  mosaicism in, 83
  nail changes in, 1326–1327, 1330, 1330f
  oral cavity disorders in, 642t, 647t
  prognosis and clinical course in, 1331
  shagreen patch in, 1326, 1329, 1329f
  support groups for patients with, 1331
  treatment of, 1331
Tufted angioma, 1170, 1171f
Tularemia, 1757t, 1757–1758, 1758f
  in bioterrorism, 2082t, 2084
  diagnosis of, 1693, 1758
  in occupational exposures, 2074
  oculoglandular, 1758
  oral cavity disorders in, 652t
  pulmonary, 2084
  treatment of, 1757t, 1758, 2084
  typhoidal, 1758
  ulceroglandular, 1757, 1758
  vaccination against, 2084
Tumor necrosis factor, 115, 121f, 121–122
  deficiency of, 391
  in epidermal homeostasis and repair, 391
  in epidermal necrolysis, 351, 355
  in innate immunity, 1591–1594
    and leukocyte activation, 1593
    and leukocyte adhesion, 1591–1593
    and vascular leakage, 1594
    and vasodilator synthesis, 1591
  in photoimmunosuppression, 806, 807f
  and pro-inflammatory effects of lipopolysaccharide, 1691
  in systemic sclerosis, 1554t
  TRAIL apoptosis-inducing ligand, 121
  TRANCE cytokine, 121
Tumor necrosis factor-α, 117t, 1003
  in aging of skin, 964, 965f
  in apoptotic cell death, 121, 121f
  in dermatomyositis, 1539, 1552
  and elastin, 533
  functions of, 1435t, 1436, 2227
  in irritant contact dermatitis, 396
  in Kawasaki disease, 1627, 1630
  in lichen planus, 245
  in lupus erythematosus, 1516, 1519–1520
  in melanoma, 1155
  and nuclear factor κB, 118, 121, 121f
  in photoimmunosuppression, 807, 807f
  in pityriasis rubra pilaris, 235, 236b
  pro-inflammatory effects of, 121, 122
  in psoriasis, 173, 174f, 2227
    and arthritis, 196, 196f, 199, 205–206
    as therapy target, 193, 205–206, 2227–2228
  in rheumatoid arthritis, 1570
    as therapy target, 1573, 2227, 2228
  structure of, 116
  as therapy target, 122, 2223t, 2227–2228
    complications in, 2227–2228
    in dermatomyositis, 1552
    in psoriasis, 193, 205–206, 2227–2228
    in rheumatoid arthritis, 1573, 2227, 2228
  in urticaria and angioedema, 340
Tumor necrosis factor-α–converting enzyme (TACE), 121
Tumor necrosis factor-β, 121
  structure of, 116
Tumor necrosis factor receptor, 117t, 121f, 121–122
  periodic syndrome associated with, 1267t, 1269–1270
    clinical findings in, 1269, 1269f
    differential diagnosis of, 1268b, 1269
  TRADD death domain, 121f, 121–122
  TRAF associated factor, 118
Tumor suppressor genes, 995–996, 1332
Tumors, 26. *See also specific tumor types*
  and acanthosis nigricans, 1448, 1462, 1463, 1493–1496
  animal models of, 988–991, 992t, 992–993, 1004
  appendage tumors of skin, **1068**–1087
  atrial myxoma, 1452–1453
  basal cell carcinoma, **1036**–1042
  basement membranes as barrier in, 450
  biology and biochemistry of, 991–994
  bullous pemphigoid in, 478–479
  carcinogenesis in, **977**–1006
  chemokines in, 133–134
  in cicatricial pemphigoid, 483
  in dermatitis herpetiformis, 503
  in dermatomyositis, 1448, 1499–1500, 1544t, 1549–1550, 1552
  of dermis
    benign, **550**–557
    malignant fibrous, **1159**–1163
  dystrophic calcification in, 1295
  in dystrophic epidermolysis bullosa, 88
  in elderly, 971–972, 972t
  eosinophils in, 286, 317
  in epidermal nevus syndrome, 1061
  epithelial
    benign, **1054**–1067
    premalignant, **1007**–1027
  field cancerization concept in, 1024
  granuloma annulare in, 370
  hematodermic, CD4+/CD56+, 1401–1402
  in hereditary cancer syndromes, 988, 989t, 1504, 1504t–1505t

Tumors—*continued*
in HIV infection and AIDS, 1933
hyperhidrosis in, 726
in intrathoracic neoplasms, 724–725
in immunosuppression, 277–278, 812–813
initiating agents in, 991, 991t
inhibitors of, 994t
keratoacanthoma, **1049**–1053
and linear IgA dermatosis, 489
lipomatous
atypical, 1196
hemosiderotic fibrohistiocytic, 1195
melanocytic, **1099**–1157
melanoma, **1134**–1157
mixed tumor of skin, 1071–1072, 1072f
molecular therapy targets in, 994
of muscles, 1172–1176
of smooth muscle, 1172–1175
of striated muscle, 1175–1176
of nails, 787f–788f, 787–788
of proximal nail fold, 2328f, 2328–2329
necrotizing venulitis in, 1601
of nerves, 1176–1181
neuromas, 1176–1178
oncogenes in, 995
of optic pathway in neurofibromatosis, 1334–1335
of oral cavity
benign, 647–648
in squamous cell carcinoma, 648–649, 1031, 1031f
paraneoplastic syndromes in, **1493**–1507
pemphigus in, **468**–474
promoting agents in, 991, 991t, 992
inhibitors of, 994t
pruritus in, 908
of salivary glands, 649–650
skin changes associated with, 1448–1449
in cutaneous paraneoplastic syndromes, 1493–1507
of small bowel, 1457
squamous cell carcinoma, **1028**–1036
of subcutaneous fat, **1190**–1198
Sweet syndrome associated with, 289, 290t, 292, 293, 294, 1502
tumor suppressor genes in, 995–996
two-hit model on development of, 1325, 1332
in ultraviolet radiation-induced damage, 87–88
vascular, **1164**–1172
classification of, 1651, 1652t
virus-associated, 995t, **996**–998
virus-derived therapies in, 998
in xeroderma pigmentosum, 87–88
Tunga fleas, 2061–2062, 2062f
Tungiasis, 2062, 2062f
Turban tumors, eccrine, 1075, 1075f
Turner syndrome, 81t
Tuzun syndrome, 561
Twisting hair dystrophy, 757
Tyloma, **871**–873. *See also* Callus formation
Tylosis, 1452
simple, 426
syndromic, 428
Tyndall effect, 2265–2266
Typhoid fever, 1740, 1741
Typhus, 1940–1941, 1948–1952
in bioterrorism, 2083t
endemic, 1943t, 1948
differential diagnosis of, 1948, 1949b
treatment of, 1948, 1950t
epidemic, 1943t, 1948–1951
treatment of, 1950b, 1951
scrub, 1951–1952, 2032, 2032t
TYR in oculocutaneous albinism, 609
Tyrolichus casei, 2032, 2032t
Tyrophagus putrescentiae, 2032, 2032t
Tyrosinase
inhibitors of, 2363, 2363t
in melanin synthesis, 601–602, 602f, 813
in melanosomes, 596–598
in oculocutaneous albinism, 609, 610, 611
synthesis of, 597, 597f
Tyrosinase-related proteins, 598
in hair pigmentation, 747, 748
in Hermansky-Pudlak syndrome, 612, 613
in melanocyte development, 591, 593, 593f
in melanogenesis, 598
Tyrosine
in alkaptonuria, 1228, 1228b
metabolic pathway of, 1221f, 1225, 1225f
phosphorylation of, 118–119
in tyrosinemia, 1222, 1222b, 1222f
Tyrosine aminotransferase, 1219t
Tyrosine kinase receptors, 605
Tyrosinemia, **1220**–1222
type I, 1220
type II (oculocutaneous), 425t, 428, 430, 1219t, 1220–1222
clinical features in, 1220f, 1220–1221, 1221f
differential diagnosis of, 1222, 1222b
genetic factors in, 1222
laboratory findings in, 1221–1222
treatment of, 1222, 1222b
type III, 1220
TYRP1 in oculocutaneous albinism, 612
Tyson's glands, 654, 657, 687
ectopic, 657
Tzanck smear, 1850
in herpes simplex virus infections, 1877–1878, 1878f
in varicella-zoster virus infections, 1892

U

Ugly duckling sign, 39t
in melanoma, 1129, 1142
Ulcerative colitis, 1456
and linear IgA dermatosis, 488
Ulcers, 28, 28f
in amputation stump, 864, 864f
in atheromatous embolism, 1672, 1672f
in basal cell carcinoma, 1037, 1037f
in Behçet disease
genital, 666, 1622, 1623f, 1625
oral, 642t, 646, 666, 1451–1452, 1622, 1623f, 1625
treatment of, 1625, 1625b
chronic
in impaired wound healing, 2347–2348
squamous cell carcinoma in, 1029
decubitus, **878**–886. *See also* Decubitus ulcers
in dermatomyositis, 1542–1543, 1546, 1549, 1550
in diabetes mellitus, 864, 873, 1462, 1466, 1466f, 1467f, 1669, 2348
in necrobiosis lipoidica, 1468
platelet-derived growth factor in, 2226, 2235, 2348
in drug abuse, 923
in elderly, 972t, 973
in Epstein-Barr virus infections, 1859, 1859f
of foot, differential diagnosis in, 1669, 1670b
in hemangiomas of infants, 1167–1168
in hematologic disorders, 1376t
of leg
differential diagnosis in, 1683b
treatment of, 1683
in lichen planus, 247, 247f, 255
of male genitalia, 660b, 666
in Epstein-Barr virus infections, 1859f
spontaneous, 671
Marjolin's, 881
in melanoma, 1146–1147, 1148t
oral, 645–647
aphthous, 645–646, 646t
in Behçet disease, 642t, 646, 666, 1451–1452, 1622, 1623f, 1625
eosinophilic, 315
non-aphthous, 646–647
in peripheral artery disorders, 1667, 1669f, 1672, 1672f, 2348
in thromboangiitis obliterans, 1674, 1675
in peripheral venous disorders, 1681–1682, 1682f, 1683, 2348
treatment of, 1683
in pyoderma gangrenosum, 28, 28f
in Raynaud phenomenon, 1644, 1644f, 1647
in sclerotherapy complications, 2354
in vasculitis, 1607, 1609f
of vulva, 681f, 681–682
Ulcus molle. *See* Chancroid
Ulerythema ophryogenes, 561, 561f, 750f, 750–751
and Noonan syndrome, 750f, 750–751, 770
Ultrasonography
cutaneous, 43
Doppler. *See* Doppler imaging
Ultraviolet filters in sunscreens, 2138–2140, 2139t, 2140f
photoallergy from, 2140
photostability of, 2140, 2140f
Ultraviolet radiation exposure, **797**–834
absorption of radiation in. *See* Absorption of radiation
in acne vulgaris, 700
acneiform eruption in, 702–703
action spectrum in, 805, 810
in DNA damage, 811, 811f
in photoaging, 970–971
acute effects of, 797, 810–813
adaptive responses to, 813–814
antioxidants in, 813–814
apoptosis in, 815, 1003, 1005, 2248
from arc lamps, 800
in athletes, 876
in atopic dermatitis, 157, 2245–2246, 2246f
Bloom syndrome in, 1322
blue nevi in, 1112
Bowen disease in, 1021, 1022
brachioradial pruritus in, 907
carcinogenesis in, 986–987, **999**–1006, 2112
in photochemotherapy, 2258
prevention of, 2112
cheilitis in, actinic, 1009, 1010f
chromophores in, 797, 803, 803f, 810, 811, 813
chronic effects of, 797, 814–815, 999, 1003, 1005
neoantigens in, 809
clonal expansion of mutant cells in, 1003–1004
contact hypersensitivity response in, 812f, 812–813
as Darier-White disease trigger, 434, 436
dermatitis in, actinic, 821–823

and dermatomyositis, 1538, 1539, 1551, 1553
photosensitivity in, 1540
desensitization to, 816, 2247, 2256–2257
in solar urticaria, 825, 2256–2257
direct effects of, 607
DNA damage in, 607, 608, 798, 810–812, 858, 859, 977–978
global genome repair in, 811, 979f
melanin function in, 602
melanocyte stimulating hormone in, 604
molecular and cellular events in, 806, 807f
nucleotide excision repair in, 811, 984, 1005
p53 in, 1001–1002, 1029–1030
and photoaging, 970
and photocarcinogenesis, 977, 978f, 979f
research on, 87–88
signature mutations in, 811, 814–815, 977, 979f, 999, 1000–1002, 1001f
and skin cancer, 87–88, 814–815, 1000–1006
transcription coupled repair in, 811, 979f
types of, 978t
and xeroderma pigmentosum, 87–88, 811, 978, 1317
dosimetry in, 801–802, 809–810
dysplastic nevus in, 1125, 1132, 1133
exposure dose in, 802
fibroxanthoma in, atypical, 1161, 1162
from fluorescent lamps, 800, 801f
glass in protection from, 2142
in graft-versus-host disease, 266, 266t, 267t
granuloma annulare in, 369
hydroa vacciniforme in, 819–821
hyperplasia response in, 813
immunosuppression from, 805–809, 812–813, 1003. *See also* Photoimmunosuppression
from incandescent lights, 800
indirect effects of, 607t, 607–608
interleukin-10 and T helper cell response to, 103
intermittent, 1134
keratoacanthoma in, 1050
keratosis in, actinic, 1007–1015, 2079
Langerhans cells in, 62, 2248
and photoimmunosuppression, 807, 807f, 808, 808f
latitude gradient in, 1134–1135
lentigo in, solar, 1119–1122
in lichen planus, 254–255
lichen planus in, 248
and lupus erythematosus, 1516, 1517–1519, 1520, 2248
photosensitivity in, 1527
sun protection in, 1532
measurement of, 801–802, 809–810
melanocytes in, 606–608, 813, 1004
melanogenesis in, 608, 813, 2251, 2363
melanoma in. *See* Melanoma, in ultraviolet radiation exposure
melasma in, 635
minimal erythema dose in, 809, 2137
and DNA damage, 811, 811f
in morphea, 546, 2247, 2247f
in mycosis fungoides, 2248
nevomelanocytic nevus in, 1105, 1109
occupational, 2079, 2079t
optical properties of skin in, 802f, 802–803, 803f, 2264–2266
ozone affecting, 799–800
in palmoplantar pustulosis, 217, 217b
papillomaviruses in, 997
in parapsoriasis, 240
in perforating disorders, 567, 567b
photoaging in, 815, 815f, 963, 968–971. *See also* Photoaging
photoallergy in, 832–834. *See also* Photoallergy
photochemical reactions in, 803–805, 804f. *See also* Photochemical reactions
in photochemotherapy, 2249–2259. *See also* Photochemotherapy
photo-exacerbated dermatosis in, 825, 825f, 825t, 826
photoproducts in, 803, 804–805, 831
photosensitivity in, **828**–834. *See also* Photosensitivity
in phototherapy, 2243. *See also* Phototherapy
phototoxicity in, 797, 805, 829–832
pigmentation changes in, 606–607, 636, 2363
in pityriasis rubra pilaris, 235, 236b
in polymorphic light eruption, 818, 2246–2247
polymorphic light eruptions in, 816–818
porokeratosis in, 442, 443
protease-activated receptor-2 activity in, 604
protection from, 2137–2142. *See also* Photoprotection
prurigo in, 818–819
in pruritus therapy, 911
with psoralen, 2249–2259. *See also* Psoralen and PUVA therapy
in psoriasis therapy, 185t, 187t, 190, 2243–2245, 2244f
as public health concern, 19–20, 20f
recall reaction in, 2166, 2179, 2179f, 2179t
rosacea in, 704
in seborrheic dermatitis, 225
signature mutations in, 811, 814–815, 977, 979f, 999, 1000–1002, 1001f
skin cancer in. *See* Skin cancer, in ultraviolet radiation exposure
skin functions in protection from, 57, 58t
skin phototypes in, 1004
sources of, 797, 799–801
standard erythema dose in, 810, 810t
stem cell populations in, 1003
steps in clinical response to, 797, 797f
in sub-corneal pustular dermatosis, 306, 307b
sunburn in. *See* Sunburn
sunglasses in, 2142
sunscreen use in. *See* Sunscreens
in T-cell lymphoma, 1397, 1398, 1399
tanning response in. *See* Tanning response
urticaria in, solar, 823–825
in urticaria pigmentosa, 2247–2248
in vesicular palmoplantar eczema, 166
vitamin D synthesis in, 814, 1206
in sunscreen use, 2140–2141
in vitiligo, 620b, 620–621, 2248
wavelengths in, 797–799, 798f, 798t, 799
and absorption spectrum, 803, 803f
in phototherapy, 2243–2244, 2244f, 2251
wrinkling of skin in, 968, 968f, 2363
and xeroderma pigmentosum, 1316, 1320f
DNA damage and repair in, 87–88, 811, 978, 1317
laboratory findings in, 1317
sun protection in, 1317–1318
Ultraviolet radiation UVA, 606–607, 798, 799, 809, 999, 1000
in acne vulgaris, 700
in atopic dermatitis, 157, 2245–2246, 2246f
direct effects of, 607
DNA damage from, 811, 814, 1000
from fluorescent lamps, 800, 801f
glass in protection from, 2142
in graft-versus-host disease, 266, 266t, 267t
in lichen planus, 254–255
in lupus erythematosus, 2248
in morphea, 546, 2247, 2247f
in palmoplantar pustulosis, 217, 217b
in parapsoriasis, 240
in perforating disorders, 567b
photoaging from, 970–971
photoallergy from, 832–834
in photochemotherapy, 2249–2259
in phototherapy, 2243
phototoxic reactions from, 829–832
in pityriasis rubra pilaris, 235, 236b
in polymorphic light eruption, 818, 2246–2247
polymorphic light eruption from, 816–817
in pruritus therapy, 911
with psoralen, 2249–2259. *See also* Psoralen and PUVA therapy
in psoriasis therapy, 185t, 187t, 190
in seborrheic dermatitis, 225
signature mutations from, 1001
sunscreen protection from, 799, 2138, 2139, 2139t
in T-cell lymphoma, 1397, 1398, 1399
tanning response to, 606–607, 813
transmittance of sunglasses in, 2142
in urticaria pigmentosa, 2247–2248
in vesicular palmoplantar eczema, 166
in vitiligo, 620b, 620–621, 2248
wavelengths of, 798f, 798t, 799
Ultraviolet radiation UVB, 606–607, 798–799, 809, 999, 1000
in acne vulgaris, 700
in atopic dermatitis phototherapy, 157, 2246
as Darier-White disease trigger, 434, 436
direct effects of, 607
DNA damage from, 811, 814, 1000
from fluorescent lamps, 800, 801f
in graft-versus-host disease, 266, 267t
immunosuppression from, 805–809
interleukin-10 and T helper cell response to, 103
in lichen planus, 255
in mycosis fungoides, 2248
in parapsoriasis, 240
in perforating disorders, 567, 567b
photoaging from, 970
in pityriasis rubra pilaris, 235, 236b
in polymorphic light eruption, 818, 2247
polymorphic light eruption from, 816–817
in pruritus therapy, 911
in psoriasis therapy, 185t, 187t, 190, 2243–2245, 2244f
in seborrheic dermatitis, 225
signature mutations from, 811, 814, 1001
in sub-corneal pustular dermatosis, 306, 307b
sunscreen protection from, 2137, 2139, 2139t
in T-cell lymphoma, 1397, 1398
tanning response to, 606–607, 813
transmittance of sunglasses in, 2142
in vitamin D photosynthesis, 814
in vitiligo, 620b, 621, 2248
wavelengths of, 798f, 798t

Ultraviolet radiation UVC, 606, 798, 809, 999, 1000
signature mutations from, 1001
wavelengths in, 798f, 798t
Umbilicus, metastasis to, 1449, 1449f
Uncinaria stenocephala, 2023
Uncinariasis, 2013, 2023
Uncombable hair syndrome, 759–760, 760f
Undecylenic acid, 2117t, 2121
Unilateral laterothoracic exanthem, 1871–1872, 1872b, 1872f
differential diagnosis of, 1872b
Universal distribution of lesions, 38
Unna boot, 1683, 1684f
Unna nevus, 1652
Unna-Thost disease, 426
Unruly hair, 759–760, 770
in loose anagen syndrome, 762, 762f
Urban trench fever, 1749, 1750t, 1751–1752
Urea
metabolism cycle disorders, 1224
in sweat, 717, 717f
in topical keratolytic preparations, 873b, 2135t, 2136
Ureaplasma, 1998
Uremia, 1458–1459
in hemolytic-uremic syndrome, 1382, 2204–2205
pruritus in, 907
sweat in, 722
Uremic frost, 722, 1458–1459
Urethritis
chlamydial, 1997
gonococcal, 1994, 1995
herpes simplex, 1876
in Kawasaki disease, 1629, 1630
mycoplasmal, 1998
reactive arthritis in, 208, 211, 213
Uric acid serum levels
classification of disorders, 1575, 1575t
in gout, 1575, 1576
in panniculitis, 583
in psoriasis, 182
Urinary tract infections, reactive arthritis in, 207, 208, 211, 213
Urocanic acid, 810, 813
absorption of radiation, 803, 803f
in photoimmunosuppression, 807, 807f
Uroporphyrin, 1229f, 1229t, 1233
in red blood cells, 1240t
in stool, 1240t
in urine, 1240t
in hepatoerythropoietic porphyria, 1243
in porphyria cutanea tarda, 1239, 1242
Uroporphyrinogen decarboxylase, 1229f, 1230t, 1231f
in dual porphyrias, 1255
in heme biosynthesis, 1230, 1232f
in hepatoerythropoietic porphyria, 1242, 1243
in porphyria cutanea tarda, 1236, 1237, 1238, 1241
Uroporphyrinogen III synthase, 1229f, 1230t, 1231f
in congenital erythropoietic porphyria, 1248
in heme biosynthesis, 1230, 1232f
Urostomy, skin problems in, 868–871
chronic papillomatous dermatitis, 869f, 869–870
Ursodeoxycholic acid in cholestasis of pregnancy, 959
Urticaria, 27, 50, 51f, **330**–343, 1375t
acute, 330, 339f
in infections, 338
treatment of, 341
adrenergic, 336
annular, 367t
aquagenic, 336
bradykinin in, 333, 336–337, 337f
cholinergic, 334–335, 335f
cold, 335, 850
chronic, 330
autoimmune, 330, 331, 332, 339f, 340
dermal infiltrates in, 340
idiopathic, 330, 331, 332, 338, 339f, 340
treatment of, 341–342, 342f
in vasculitis, 337
clinical findings in, 333f, 333–338
cold, 334, 334f, 340, 850f, 850–851
cholinergic, 335, 850
cold contact test in, 334, 334f, 850f, 851
delayed, 334
differential diagnosis of, 1270
disorders associated with, 850
familial, 334, 850, 851, 1270
treatment of, 341
complement system in, 331–332, 336, 340
contact, 142–143, 336
allergic, 142–143, 2071
from cosmetic products, 2361
diagnosis of, 2071
in occupational exposures, 2070–2071, 2072f
definition of, 330
diagnostic approach in, 338–340, 339f
differential diagnosis of, 340, 340b, 348b, 824b, 834, 1270
drug-induced, 337, 338, 358
treatment of, 341, 342
epidemiology of, 330
exercise-related, 335, 877
in helminthic infections, 2011
histopathology in, 340–341
immunoglobulin IgE in, 331, 332–333, 334, 340
in contact urticaria, 336, 2071
in infections, 338, 339–340
laboratory findings in, 340–341
local heat, 335
in lupus erythematosus, 1528
neuropeptides in, 900
in occupational exposures, 2068t, 2070–2071, 2072f
papular, 336, 341
pathogenesis in, 330–333
physical, 333–334, 339f
pigmentosa
histopathology in, 1440f
in mastocytosis, 1437–1439, 1437f, 1438f, 2255
treatment of, 1441, 2247–2248, 2255
pressure, 334
pruritus in, 906, 910
with papules and plaques in pregnancy, 492, 958t, 960–961, 961b, 961f
psychological factors in, 921
in serum sickness, 338
solar, 335, 340, 823–825
approach to diagnosis of, 826, 827
clinical features in, 824, 824f
differential diagnosis in, 824b, 834
sub-types of, 335, 823–824
treatment in, 824–825
and thyroid disorders, 1473
in transfusions, 338
treatment of, 341–343, 342f, 824–825, 1441, 2247–2248
antihistamines in, 341, 342f, 2188–2189, 2190
photochemotherapy in, 2255
in vasculitis. *See* Vasculitis, urticarial
in viral infections, 1849t
Uta, 2003
Uterus
eosinophils in, 284, 285
leiomyomas of, 1172, 1173
Utility measurements, 8
UV Index, 800

V

V sign in dermatomyositis, 1540, 1543f
Vaccinations, 1850
anthrax, 2083
Bacille Calmette-Guérin, tuberculosis after, 1773
in corticosteroid therapy, 2151
Haemophilus influenzae, 1739, 1740
hepatitis B, 1457
lichen nitidus after, 256
lichen planus after, 251
herpes simplex, 1884
Lyme disease, 1805
measles, 1851, 1853, 1855
in melanoma management, 1155, 1156
meningococcal, 1732, 1735
in monkeypox prevention, 1908, 1908b
mumps, 1853, 1855
papillomavirus, 997, 1850, 1922
plague, 2084
rabies, 2039
rubella, 1853, 1854, 1855
smallpox, 1899, 1903–1906
in atopic dermatitis, 152
eczema vaccinatum after, 152
in syphilis, 1977
tularemia, 2084
varicella-zoster, 1850, 1885, 1889, 1897–1898
adverse effects of, 1897
Vaccinia gangrenosa, 1904
Vaccinia necrosa, 1904
Vaccinia virus, 1848, 1900t
congenital infection, 1905
in monkeypox vaccination, 1908, 1908b
in smallpox vaccination, 1903–1906
generalized vaccinia from, 1904, 1904f, 1905
indications and contraindications to, 1906b
progressive vaccinia from, 1904, 1905, 1906
Vagabond leukoderma, 640
Vaginal disorders
in bacterial vaginosis, 1999–2000, 2000b, 2000f
in candidiasis, 1824
in HIV infection, 1936
treatment of, 1827–1828
clinical findings in, 675–676
gonococcal, 1994
in herpes simplex virus infections, 1875
laboratory tests in, 676
in lichen planus, 680–681
in pemphigus vulgaris, 681
prognosis and clinical course in, 676
in Sjögren syndrome, 1579
in trichomoniasis, 1998, 1999
Vaginosis, bacterial, 1999–2000, 2000b, 2000f
clue cells in, 2000, 2000f
and HIV infection, 2000
in pregnancy, 1999, 2000, 2000b
treatment of, 2000, 2000b
Valacyclovir, 2204–2205
dosage of, 2204t
pediatric, 947t

in herpes simplex virus infections, 1880, 1881b–1883b, 1883
in prevention, 1884
indications for, 2204, 2204t
side effects and complications of, 2204–2205
in varicella-zoster virus infections, 1894, 1895, 1895t, 1896
Valganciclovir, 2205–2206, 2206t
Validity
of epidemiologic studies, 3, 4
of evidence, critical assessment of, 13, 14, 16
of morbidity measures, 7
Valley fever, 1839–1840
Valley sickness, 2003
Valsalva maneuver in varicose veins, 2352
Valvular heart disorders
in Ehlers-Danlos syndrome, 1299
endocarditis in, 1744
in Marfan syndrome, 1303–1304
nail signs in, 1449
in pseudoxanthoma elasticum, 1307, 1308
in syphilis, 1965, 1977
Van Bijstervelt scoring system in Sjögren syndrome, 1581, 1581t
Vancomycin, 2202
enterococcus resistant to, 1728, 1730
in furuncles and carbuncles, 1701
in soft tissue infections, 1730
in toxic shock syndrome, 1717
Vanilloids
in pruritus, 897t, 903, 910
VR-1 receptor, 840, 841f
Vaporization in laser therapy, 2266, 2277, 2278
Varicella-zoster virus infections, 1847f, 1848, **1885**–1898
clinical manifestations of, 1849, 1888–1890, 1889f, 1890f, 1891f
complications of, 1893–1894, 1895
diagnosis of, 1850, 1890–1892
differential diagnosis of, 1891, 1891b, 1902, 1907, 2085, 2085t
in elderly, 973
epidemiology of, 1885–1886
etiology and pathogenesis of, 1886–1888
histopathology in, 1892, 1892f
in immunocompromised host, 269t, 271–272, 272f, 276, 276f, 1886
clinical findings in, 1890, 1891f
complications in, 1894
in HIV infection, 1886, 1890, 1894, 1897, 1938, 1938f
prevention of, 1897, 1898
treatment of, 1895, 1895t, 1896
laboratory tests in, 1892
latent, 1887, 1887f, 1888
oral cavity disorders in, 651t
in pregnancy, 1893
treatment of, 1895, 1895t
prevention of, 1897–1898, 1898t
reactivation of, 1849, 1888
transmission of, 1885
prevention of, 1897–1898
treatment of, 1894–1897, 2203–2205
vaccination against, 1850, 1885, 1889, 1897–1898
adverse effects of, 1897
virion of virus in, 1847f
Varicose veins, 1679, 1681, 1681f, **2349**–2356
ambulatory phlebectomy in, 2356
anatomy and physiology in, 2350, 2350f, 2351f
contraindications to treatment in, 2350–2351
endovenous ablation and occlusion in, 2355, 2356f
laser therapy in, 2272, 2351, 2355–2356
endovascular techniques, 2355–2356
light sources for, 2356
results of, 2356f
oral, 649
radio-frequency technique in, 2351, 2355
sclerotherapy in, 2349–2355. *See also* Sclerotherapy, in varicose veins
symptoms in, 2350
Variola virus, 1899–1903. *See also* Smallpox
Vascular cellular adhesion molecule-1, 1592–1593, 1594, 1595, 1596
cytokines stimulating expression of, 115, 287, 288
expression profile, 1590t
function of, 1590t
in necrotizing venulitis, 1600, 1604
Vascular endothelial growth factor, 64, 65, 1596, 1597, 1597t, 1598
in aging of skin, 964, 965f, 966
in bevacizumab therapy, 2231–2232
in psoriasis, 174, 1598
in wound healing, 2344, 2344t
Vascular endothelial growth factor receptors, 65, 68t, 70, 1589, 1590t, 1596
in bevacizumab therapy, 2232
in lymphatic malformations, 1661
in lymphedema, 65, 1661, 1685
Vascular endothelial phospho-tyrosine phosphatase (VE-PTP), 1589
Vascular leak in inflammation, 1594
Vascular lesions, 33–34
Vascular malformations, **1651**–1666
arteriovenous, 1651, 1663–1666
clinical characteristics of, 1654t
capillary, 1651, 1652–1656
clinical characteristics of, 1654t
classification of, 1651, 1652t
clinical findings in, 1651–1652, 1653f, 1654t
epidemiology of, 1651
etiology and pathogenesis of, 1651
fast-flow, 1651, 1663
lymphatic, 1651, 1660–1663
clinical characteristics of, 1654t
slow-flow, 1651
treatment of, 1652
venous, 1651, 1656–1660
clinical characteristics of, 1654t
Vascular tumors, **1164**–1172, 1651
classification of, 1651, 1652t
Vasculature, **1585**–1598. *See also* Blood vessels
Vasculitis, 65, 1375t, 1455–1456
angiitis. *See* Angiitis
arteritis. *See* Arteritis
in Behçet disease, 1620, 1624
in Churg-Strauss syndrome, 1611–1613
classification of, 1609, 1610t
in cryoglobulinemia, 1610, 1638
cutaneous necrotizing venulitis in, 1601
digital gangrene in, 1609f
leukocytoclastic vasculitis in, 1639, 1639f
cutaneous necrotizing venulitis, 64, 337, **1599**–1606
diagnostic algorithm on, 1608f
digital ischemia in, 1607, 1609f
in drug abuse, 924
drug-induced, 360–361, 1602
eosinophils in, 316–317, 1600, 1604
exercise-induced, 1600
granulomatous, 51
in HIV infection and AIDS, 1932
hypersensitivity, 1599
immunoglobulin A, 1384f, 1599
in Kawasaki disease, 1606, 1626, 1630, 1631
large vessel, 1610t, 1615–1616
leukocytoclastic, 64, 317, 1375t, 1599, 1692
in Churg-Strauss syndrome, 1612
clinical findings in, 1609f
in cryoglobulinemia, 1639, 1639f
differential diagnosis in, 294b, 1382t
erythema elevatum diutinum in, 1616–1619
in granuloma faciale, 302, 304
in lupus erythematosus, 1528
purpura in, 33, 34f, 1382t
in Sweet syndrome, 292
limb amputation in, 863, 863f
livedoid, 51, 1603–1604
in cutaneous necrotizing venulitis, 1602, 1603–1604
in polyarteritis nodosa, 1614, 1614f
in systemic necrotizing vasculitis, 1607, 1609f, 1610
treatment of, 1606
in lupus erythematosus, 1528, 1601
malabsorption in, 1457
microscopic polyangiitis, 1613–1615
necrotizing, **1599**–1616
cutaneous venulitis, 64, 337, **1599**–1606
differential diagnosis in, 1733b
immunoglobulin A in, 1599
inflammatory infiltrates in, 50, 51f, 53, 1608–1609
in Sjögren syndrome, 1580, 1600
systemic, **1606**–1616
nodular, 54f, 55, 574f, 574–575, 575f
clinical findings in, 1603, 1603f
treatment of, 1606
palpable purpura in, 1382t, 1384, 1384f, 1601, 1601f, 1607
and panniculitis
lobular, 573–575
septal, 569–571
paraneoplastic, 1601
polyarteritis nodosa, 571, 1613–1615
rheumatoid, 1571, 1572
in rheumatoid arthritis, 1601
in Rocky Mountain spotted fever, 1942
segmental hyalinizing, 1603
in sepsis, 1746
in Sjögren syndrome, 1579–1580, 1580f, 1601
small vessel, 1610, 1610t
etiologies of, 1610, 1610t
treatment of, 1610, 1611t
systemic necrotizing, **1606**–1616
clinical findings in, 1606
differential diagnosis of, 1607, 1609
epidemiology of, 1606
etiology and pathogenesis in, 1606–1607
histopathology in, 1607–1609
laboratory tests in, 1607–1609
opportunistic infections in, 1616
Takayasu, 1615–1616
temporal artery, 1615–1616
in thromboangiitis obliterans, 1675
thrombophlebitis, superficial, 569–571
ulcers in, 1607, 1609f
urticarial, 337, 339f, 340, 1602–1603, 1610, 1611t
clinical findings in, 1602f, 1602–1603, 1603t, 1607, 1609f

Vasculitis—*continued*
hypocomplementemic syndrome, 1602, 1604
in lupus erythematosus, 1528
in Sjögren syndrome, 1580
treatment of, 342, 1606
venulitis. *See* Venulitis, cutaneous necrotizing
in Wegener granulomatosis, 1610–1611
Vasculogenesis, 1596–1598
cutaneous, 1597–1598
regulation of, 1596–1597
Vasculopathy, 65, 1375t, 1603, 1676
Vasoactive intestinal peptide, 898
in cutaneous active vasodilation, 837–839, 839f
in inflammatory response, 898t
in pruritus, 897t
in wound healing, 901
Vasoconstriction
in cold response, 836, 837, 841–843, 845, 846
in local cooling, 842–843, 843f
neural control of, 837, 838f
reticulate appearance in, 844, 844f
in corticosteroid therapy, 2103
endothelial cell functions in, 1585–1586
neural control of, 837, 838f, 896, 898
Vasodilation
cold-induced, 845
endothelial cell functions in, 1591
in heat response, 836, 837–841
in local warming, 840–841, 841f
neural control of, 837, 838f
neurotransmitters in, 837–839, 839f
nitric oxide in, 839–840
and sweating, 837
in hunting reaction of Lewis, 845
neural control of, 837, 838f, 896, 898
Vasospasm in Raynaud phenomenon, 1643, 1645
treatment of, 1647
Vasovagal reaction, 2336
in local anesthesia, 2297
VCAM-1. *See* Vascular cellular adhesion molecule-1
VDRL test in syphilis, 1971, 1973t
VEGF. *See* Vascular endothelial growth factor
VEGFR. *See* Vascular endothelial growth factor receptors
Vehicle of topical formulations, 2093t, 2093–2095
Veil cells, 64, 1586
Vellus hair, 742, 742t, 754–755
definition of, 754t
Vellus hair cyst, 1079–1080
Venereal Disease Research Laboratory test in syphilis, 1971, 1973t
Venereal warts. *See* Warts, anogenital
Venlafaxine, 918t, 919–920
Venom
from aquatic organisms, 2042–2045, 2049–2052
in hymenoptera stings, 2062
in scorpion stings, 2058
in snake bites, 2040–2042
in spider bites, 2054–2057
Venous disorders
anatomy and physiology in, 2350, 2350f, 2351f
chronic, **1679**–1684
approach to patient with, 1681f
differential diagnosis of, 1682, 1683b
treatment in, 1682–1684, 1683b, 1684f
ulcers in, 1680, 1681–1682, 1682f
malformations, 1651, 1653f, 1656–1660
clinical characteristics of, 1654t, 1657t, 1657–1658, 1658f, 1659f
cutaneo-mucosal, 1656–1657, 1657t
differential diagnosis of, 1660b, 1669
facial, 1658, 1658f
familial, 1658
genital, 1658
glomuvenous, 1657, 1657t, 1658f, 1659
imaging studies in, 1659
laboratory tests in, 1659
oropharyngeal, 1658
prognosis and clinical course in, 1660
treatment of, 1660
laser therapy in, 1660, 2272
in postphlebitic syndrome, 1680
stasis dermatitis in, 1681, 1681f, 1682, 1682f
autosensitization in, 167, 168f
thrombosis, 1680
of deep veins, 1684
prevention of, 1684
of superficial veins, 1684
varicose veins, 2349–2356. *See also* Varicose veins
Venous lake, laser therapy in, 2272, 2374, 2375f
Venules, 1586
postcapillary, 1587, 1588f, 1589
Venulitis, cutaneous necrotizing, 64, **1599**–1606
clinical findings in, 1601f, 1601–1604
complement system in, 1599, 1600, 1602, 1604
differential diagnosis of, 1605
disorders associated with, 1599, 1599t, 1601–1602
drug-induced, 1602
epidemiology of, 1599
etiology and pathogenesis in, 1599–1601
histopathology in, 1604–1605, 1605f
laboratory findings in, 1604, 1604t
treatment of, 1605–1606, 1606t
urticaria in, 337, 1602f, 1602–1603, 1603t, 1606
Verhoeff-van Gieson stain in pseudoxanthoma elasticum, 1305
Vermillion border of lips, 2290, 2290f, 2309f
Verocay bodies in schwannoma, 1178, 1179, 1179f
Verruca. *See* Warts
Verrucous carcinoma, 1032, 1032f, 1921
oral, 649
of penis, 673, 674
treatment of, 1922
Mohs micrographic surgery in, 1922, 2319
Verrucous hyperplasia in limb amputation and prosthesis use, 865f, 865–866
Verruga peruana, 1749, 1750t, 1754f, 1754–1755
differential diagnosis of, 1755b
treatment of, 1755
Versican, 63, 539t, 540, 541
Vertebral column
fractures in corticosteroid therapy and osteoporosis, 2150
and intervertebral disk calcification in alkaptonuria, 1226, 1227, 1227f
psoriatic arthritis of, 201, 206
Very late antigen-4 (VLA-4), 1592, 1592t, 1593
Vesicant agents in chemotherapy, extravasation injury from, 2180
Vesicles, 32–33, 33f
epidermal cohesion in, 46, 46f
formation of, 46, 46f
genital, 660b
illusion of, in Sweet syndrome, 290, 290f
in palmoplantar eczema, **162**–167
in spongiosis, 32, 46, 46f
in viral infections, 1849t
Vesicular palmoplantar eczema, **162**–167
clinical findings in, 163–164, 164f
diagnosis of, 165
differential diagnosis in, 165, 165b
epidemiology of, 162–163
etiology and pathogenesis in, 163
exacerbating factors in, 163
laboratory findings in, 164–165
pathology in, 165
prevention of, 166–167
prognosis and clinical course in, 166
treatment of, 166, 166t
Vesiculobullous lesions
in chronic hand dermatitis, 162–167
in drug abuse, 924
in lichen planus, 247, 247f
Vestibulitis, vulvar, 683
Vestibulodynia, 683
Vibration exposure
angioedema in, 334
occupational, 334, 2078
Raynaud phenomenon in, 1643, 1645
Vibrio, waterborne, 877, 2053, 2053t
Vibrio carchariae, 2052
Vibrio cholerae, 2083t
Vibrio vulnificus, 1757t, 1763f, 1763–1764
in cellulitis, 1747, 1763, 1763f
in immunocompromised host, 269t, 273, 274f, 1763
in necrotizing fasciitis, 1763–1764
in sepsis, 1747, 1763, 1764
treatment of infections, 1757t, 1764, 2197t
in waterborne infections, 2053t
Vidarabine in herpes zoster, 1896
Vimentin in appendage tumors of skin, 1070t
Vinblastine, 2123
in angiolymphoid hyperplasia, 1409b
in Kaposi sarcoma, 1187b, 2123
in Langerhans cell histiocytosis, 1423–1424
side effects of, 2123
Vincent disease, 645
Vincristine
in B-cell lymphoma, 1401
in hemangioma of infants, 1168t, 1169
in Kaposi sarcoma, 1187b
Vinegar
in fire coral stings, 2046
in jellyfish stings, 2045t
in sea anemone stings, 2045
Vinyl chloride, occupational exposure to, 2078, 2078t
Viral vectors in gene therapy, 86
Virion, 1845, 1846, 1847, 1847f
Virus-derived therapy in tumors, 998
Viruses, **1845**–1953. *See also specific viruses*
and antiviral drugs, 1850, **2203**–2211
in athletes, 875
in Behçet disease, 1621
in bioterrorism, 2083t, 2085
in bite wound infections, 2038–2040
cellular consequences of infections, 1848
in children, 940, 940t, 941f
systemic drug dosage in, 947t
classification of, 1845–1846, 1846t
clinical manifestations of infections, 1849
cytocidal or lytic infections, 1848
diagnosis of infections, 1849–1850

in elderly, 973
exanthems associated with, 1848, 1849, 1849t, **1851**–1872
host response to, 1848–1849
identification of specimens, 1850
in immunocompromised host, 269t
in acute immunosuppression, 271–272
in chronic immunosuppression, 276–277
in HIV infection and AIDS, 1937–1939
and Kaposi sarcoma, 278
and squamous cell carcinoma, 277–278
in keratosis, 1020–1021
seborrheic, 1054
latent, 1848
in nail infections, 784–785, 785t
occupational exposures to, 2075–2076
in oral cavity disorders, 651t–652t
pathogenesis of skin infections, 1848
in porphyria cutanea tarda, 1236, 1237–1238
prevention of infections, 1850–1851
replication of, 1846–1848
in surgical wound infections, 2337
transmission of, 1848
tumors associated with, 995t, **996**–998, 1846, 1848
Kaposi sarcoma, 278
squamous cell carcinoma, 277–278
T-cell lymphoma, 1386
Visible radiation, 797, 799
dosimetry in, 801–802
and optical properties of skin, 802f, 802–803, 803f, 2264–2266
sources of, 799–801
wavelengths of, 798f, 798t, 799
Vision, melanocytes in, 595
Vitamin
in Hailey-Hailey disease, 441
Vitamin A, 1204–1206
deficiency of, 1204f, 1204–1205, 1205f, 1456
pityriasis rubra pilaris in, 232, 235
esterification and oxidation of, 2108–2109, 2110f
in ethnic skin, 2143–2144
food sources of, 1204
in measles, 1853
in renal failure, 1446
toxicity of, 1205–1206
Vitamin A_1 in ethnic skin, 2143–2144
Vitamin B_1, 1208–1209
Vitamin B_2, 1209, 1209f
Vitamin B_3, 1209–1211
deficiency of, 1209–1211, 1210f, 1456
food sources of, 1209
Vitamin B_6, 1211, 1304
Vitamin B_9. *See* Folic acid
Vitamin B_{12}, 1211–1212
deficiency of, 1211–1212, 1374t, 1377, 1456
homocystinuria in, 1304
pigmentation changes in, 1212, 1446, 1456
food sources of, 1211, 1377
Vitamin C, 1212–1213
in alkaptonuria, 1228, 1228b
in antiaging products, 2363
deficiency of, 1212–1213, 1213f, 1456
food sources of, 1212
in pigmented purpuric dermatosis, 1636
in striae, 560
as tyrosinase inhibitor, 2363
Vitamin D, 1206–1207
and calcium serum levels, 1293
in chronic renal failure, 1295
in hypervitaminosis D, 1295–1296
in corticosteroid therapy and osteoporosis, 2152
deficiency of, 814, 1206–1207
in elderly, 966
and elastin gene expression, 533
excess in hypervitaminosis D, 1295–1296
photosynthesis of, 814
in psoriasis, 188, 2112
in combination with other agents, 187t
topical, 184t, 188
and retinoid interactions, 2112
in seborrheic dermatitis, 224–225
sources of, 1206, 2140
supplementation of, 2140–2141
and ultraviolet light exposure, 1206
in sunscreen use, 2140–2141
Vitamin D receptor, 2107, 2112
Vitamin D_2, 1206, 2140
in corticosteroid therapy and osteoporosis, 2152
Vitamin D_3, 1206, 2140
and calcium serum levels, 1293
in chronic renal failure, 1295
and elastin gene expression, 533
in Hailey-Hailey disease, 441
insufficiency of, 814
photosynthesis of, 814
in psoriasis therapy, 2112
in combination with other agents, 187t
topical, 184t, 188
and retinoid interactions, 2112
in seborrheic dermatitis, 224–225
Vitamin E, 1207
deficiency of, 1207
food sources of, 1207
and sebum, 689
Vitamin K, 1207–1208
deficiency of, 1208, 1456
food sources of, 1207
Vitamins, 1204–1214
fat-soluble, 1204–1208
water-soluble, 1208–1214
Vitiligo, 62, **616**–622
acrofacial, 618, 618f
in Addison disease, 616, 619, 1478
animal models of, 617
classification of, 617–618
clinical findings in, 617–618, 617f–619f
confetti type, 618
in diabetes mellitus, 616, 619, 635
differential diagnosis in, 619b
disorders associated with, 616, 619
epidemiology of, 616
etiology and pathogenesis in, 616–617
focal, 617, 617f, 620
generalized, 618, 618f
genetics of, 616
genital, 664
HLA system in, 616
hypohidrosis in, 730
Koebner phenomenon in, 618, 619f, 620
in lupus erythematosus, 626–627
mucosal, 618
neural mechanisms in, 617
patch lesions in, 30, 30f
pentachrome, 618
perinevoid, 1105
pigmentation changes in, 30, 30f
ponctue, 618
prevention of, 622
prognosis and clinical course in, 619
quadrichrome, 618
in scleroderma, 626
segmental, 617, 618, 618f
in thyroid disorders, 616, 619, 629, 635, 1471–1472
treatment of, 620b, 620–622, 622f, 629
algorithm on, 622f
laser therapy in, 620b, 621, 2279
photochemotherapy in, 620b, 620–621, 2248, 2256, 2256f
phototherapy in, 620–621, 2248
trichrome, 618
universal, 618, 618f
Vitreous membrane of hair follicle, 744
Vitronectin, 63
Vogt-Koyanagi-Harada syndrome, 619
Vohwinkel syndrome, 61, 418, 425t, 428, 428f, 430
constricting bands in, 563
Volcano sign in cutaneous leishmaniasis, 2003, 2003f, 2004f
Vomiting
in acute intermittent porphyria, 1251
in variegate porphyria, 1253
Von Kossa's stain in pseudoxanthoma elasticum, 1305
Von Recklinghausen disease, 634, 1331. *See also* Neurofibromatosis, type 1
Von Willebrand factor, 1590t
Von Zumbusch psoriasis, 180, 181f, 218, 2253, 2254f
photochemotherapy in, 2253, 2254f
Vörner's epidermolytic palmoplantar keratoderma, 425–426, 426f
Vulvar disorders, **675**–683
abscess, 682
aphthae, 681–682
cancer of
papillomaviruses in, 997
squamous cell carcinoma, 1031
in candidiasis, 1824, 1825f
in HIV infection, 1936
treatment of, 1827–1828
in chancroid, 1984, 1984f
in cicatricial pemphigoid, 482, 681
clinical findings in, 675b, 675–676
in contact dermatitis, irritant and allergic, 676, 677–678
in Crohn disease, 682
differential diagnosis of, 676, 676b
drug-induced, 677–678, 681
epidemiology of, 675
fissures, 679–680, 680f
in herpes simplex virus infections, 1875
in hidradenitis suppurativa, 682, 682f, 737, 737f
laboratory tests in, 676
in lichen planus, 249, 680b, 680f, 680–681
in lichen sclerosus, 547, 548f, 550, 678–679, 679b, 679f
in lichen simplex chronicus, 677
in Paget disease, 1094, 1095
prognosis and clinical course in, 1096
treatment of, 1097
in pemphigus vulgaris, 681
prognosis and clinical course in, 676
in pruritus, 683
in psoriasis, 678, 678f
treatment in, 676–677
vulvodynia, 682–683
Vulvodynia, 670, 682–683
VX, as chemical weapon, 2086t
V-Y–plasty, 2308

W

Waardenburg syndrome, 595, 613–614, 615, 622
epidemiology of, 608

Waardenburg syndrome—*continued*
etiology and pathogenesis in, 613–614
type 1, 613–614, 614f
type 2, 600, 614
type 3, 614
type 4, 614
Wachters palmoplantar keratoderma, 427
Waldenström hyperglobulinemic purpura, 1383–1384
differential diagnosis of, 1381t
Waldenström macroglobulinemia, 1375t, 1376t
in xanthoma disseminatum, 1430
Walking dandruff, 2032t, 2033
Wangiella dermatitidis, 1833, 1835
Warfarin therapy
in atheromatous embolism, 1673
atheromatous embolism in, 1671
complications in, 2238t
in dermatomyositis, 1552
drug interactions in, 2238t, 2239, 2239t, 2240t
embryopathy from, 419
skin necrosis in, 360, 360f, 1383
surgery in, 2337
Warthin-Starry stain
in *Bartonella* infections, 1753f, 1754
in syphilis, 1970
Warts, 1848, **1914**–1922
anogenital, 652t, 663–664, 1915, 1918
in children, 930, 1917
clinical findings in, 663, 663f, 1918, 1919f
differential diagnosis in, 663, 664b, 1920, 1921b
epidemiology of, 1917
giant, 673, 674, 1921
histopathology in, 1920
in HIV infection and AIDS, 1939
pathogenesis in, 1915
prevention of, 1922
treatment of, 664, 664b, 1921, 1922
cervical, 1919, 1919f
clinical findings in, 663, 663f, 1917–1920
common (verruca vulgaris)
clinical findings in, 1917, 1917f, 1918f
in common variable immunodeficiency, 1353f
histopathology in, 1920f
in HIV infection and AIDS, 1938–1939
horn in, 28, 28f
pathologic changes of epidermis in, 58
complications in, 663–664, 1920–1921
diagnosis of, 1920
differential diagnosis of, 663, 664b, 1920, 1921b
epidemiology of, 1917
in epidermodysplasia verruciformis, 997, 1021, 1917, 1918–1919, 1919f
filiform, 1917, 1918f
flat or plane (verruca plana), 1915
clinical findings in, 1917–1918, 1918f
differential diagnosis in, 1921b
histopathology in, 1920, 1920f
histopathology in, 1919–1920, 1920f
in hydrocarbon exposure, 1018
in immunocompromised host, 277, 1353f, 1917, 1918
diagnosis of, 1920
in occupational exposures, 2075
oral, 1917, 1919, 1919f
in HIV infection and AIDS, 1939
palmar, 1918
in papillomavirus infections, 663–664, 1020, **1914**–1922
clinical findings in, 663, 663f, 1917–1920
complications in, 663–664, 1920–1921
diagnosis of, 1920
differential diagnosis of, 663, 664b, 1920, 1921b
epidemiology of, 1917
histopathology in, 1919–1920, 1920f
in immunocompromised host, 277, 1917, 1938–1939
in occupational exposures, 2075
pathogenesis in, 1915–1917
prevention of, 277, 1922
treatment of, 664, 664b, 1921–1922
pathogenesis in, 1915–1917
periungual, 1916f
persistent, 1849
plantar, 1916, 1916f, 1918
differential diagnosis of, 1921b
treatment of, 1922
prevention of, 277, 1922
respiratory, 1917, 1919
treatment of, 664, 664b, 1921–1922, 2136
bleomycin in, 2123–2124
cryotherapy in, 664b, 1921–1922, 2331–2332, 2332f
imiquimod in, 1922, 2127, 2129
laser therapy in, 664b, 1922, 2278
podophyllin in, 664b, 1922, 2124
Warty carcinoma of penis, 673
Warty dyskeratoma, 1063
Warty tuberculosis, 1771, 1771f
differential diagnosis of, 1771b
treatment of, 1775
WASP in Wiskott-Aldrich syndrome, 1357
Wasp stings, 2062
Watch-glass deformity of nails, 1449, 1450f
Water
Aeromonas hydrophila in, 1764, 2053t
amebas in, 2009
aquagenic pruritus from, 336, 908
bacterial infections associated with, 1728, 1756f, 2052–2053, 2053t
bioterrorism threat to safety of, 2083t
bites and stings from aquatic organisms in, 2042–2052
Chromobacterium violaceum in, 1766, 2053
cold water immersion, 844–845
cysticercosis from, 2027, 2028
Dracunculus contamination of, 2021, 2022
Gnathostoma in, 2022
and hot tub folliculitis, 1699, 1736, 1736f
irritant contact dermatitis from, 399
leptospirosis from, 1766
melioidosis from, 1764
Mycobacterium marinum in, 1777, 2053t
Pseudomonas in, 1699, 1736, 1736f, 2053t
Salmonella contamination of, 1740
schistosomiasis from, 2025, 2048–2049
in skin cells, 2357
sports activities in
actinic damage in, 876
in ocean sports, 877
skin problems associated with, 874t, 875, 876–877
sunscreens resistant to, 2138
and swimmer's ear, 1736
transepidermal water loss. *See* Transepidermal water loss
urticaria from, 336
Vibrio in, 1747, 1763, 2052, 2053t
wound infections from, 2052–2053, 2053t
Waterhouse-Friderichsen syndrome, 1478, 1734, 1735, 1748
Water-in-oil emulsions, 2094
Waterless hand cleaners as occupational irritants, 2069
Waterlow pressure ulcer risk assessment scale, 879, 882t
Water-soluble base of ointments, 2094
Water-soluble vitamins, 1208–1214
Watson-Schwartz test
in acute intermittent porphyria, 1250
in variegate porphyria, 1253
Wavelengths of radiation, 797–799, 798f, 798t, 2263
absorption spectrum in, 803, 803f, 2267f
and frequency, 799
in phototherapy, 2243–2244, 2244f, 2251
Weakness
in dermatomyositis, 1540, 1544
laboratory tests in, 1546
muscle strength testing in, 1544
respiratory disorders in, 1545
differential diagnosis of, 1544, 1544t
Weber-Christian disease, 584–585
Weber-Cockayne epidermolysis bullosa simplex, 505, 506, 508t
Website resources
on abuse and domestic violence, 928t
for best evidence, 11–12
on Dermatology Lexicon Project, 26
on epidermolysis bullosa, 515
on filariasis, 21
on genetic counseling, 84
on human genome, 73, 74t
on National Institutes of Health research priorities, 90
on public health programs, 21
Weeverfish, 2050, 2051
Wegener granulomatosis, 283, 1610–1611
clinical manifestations of, 1610, 1612t, 1613f
etiology and pathogenesis in, 1607
oral cavity disorders in, 642t, 1610, 1613f
palpable purpura in, 1610, 1613f
treatment of, 1611, 1613t
Weibel-Palade bodies, 287, 1587–1588
Weight changes
in corticosteroid therapy, 2150t
striae in, 29, 29f
in pregnancy, 955, 957f
Weil disease, 1766, 1767
Weil-Felix test in Rocky Mountain spotted fever, 1942
Weill-Marchesani syndrome, 1302
Wells syndrome, 285, 310–313, 312f
clinical findings in, 310, 312f
differential diagnosis of, 312
disorders associated with, 310, 312t
flame figures in, 312, 312f
treatment of, 312–313
Werner syndrome, 963, 1313t, 1315, **1323,** 1505t
cancer risk in, 1323
clinical features in, 1323
DNA damage and repair in, 1323
dystrophic calcification in, 1294
general skin changes in, 1445
genetic factors in, 1323
subcutaneous tissue in, 66
Wernicke encephalopathy in thiamine deficiency, 1208
West African trypanosomiasis, 2008
West Nile virus, 1850
Westerhof syndrome, 640
Western black widow spider bites, 2054
Western immunoblot assay, 985
in epidermolysis bullosa acquisita, 498
in herpes simplex virus infections, 1878
in HIV infection, 1929t
in Lyme disease, 1804

Wheal, 27, 27f
in dermatographism, 27, 27f
WHIM (warts, hypoimmunoglobulinemia, infections, myelokathexis), 1363t
Whipple disease, 1782
White fingers, vibration-induced, 2078
White leprosy, 2003
White line of Frankl in vitamin C deficiency, 1213
White nails, 1449, 1449f, 1450f
White piedra, 1821
White sponge nevus, 1057t
oral cavity disorders in, 642t
Whiteheads (closed comedo), 692, 693f
Whitlow
herpes simplex, 1702, 1876f, 1876–1877
in occupational exposures, 1877, 2075
treatment of, 1882b
staphylococcal, 1702f, 1702–1703
WHN, 1358, 1359t
Whorled lesions, 36, 37f
Wickham striae, 31t
in lichen planus, 245
Widal test in enteric fever, 1741
Widow spider bites, 2054–2056
Wigs and hairpieces in alopecia areata, 765
Williams syndrome, 537t
Wilms' tumor in neurofibromatosis, 1336
Wilson disease, nail changes in, 1449
Wimberger sign
in congenital syphilis, 1968
in vitamin C deficiency, 1213
Wind chill index, 845
Wing cells, 742
Winter xerosis, 848–849
Winterbottom's sign in African trypanosomiasis, 2008
Wiskott-Aldrich syndrome, 1357–1358, 1375t, 1505t
carriers of, 80
differential diagnosis in, 151
genetic counseling in, 85
Withdrawal symptoms in drug abuse, 926
Witkop tooth and nail syndrome, 68t, 72, 1346, 1346f
WNT/Wnt, 68t, 70, 71f, 72
in hair follicle development, 740f, 741, 742
in melanocyte development, 591, 592f
in sebaceous gland development, 688, 688f
Wolbachia
in filariasis, 2014t, 2018
in onchocerciasis, 2015t, 2021
Wood-grain pattern in erythema gyratum repens, 1500, 1500f
Wood tar preparations, 2130
Wood's light examination, 40–41, 800, 801f, 1808
photochemical reactions and excited state processes in, 804
Woolf syndrome, 615
Woolly hair, 760, 760f
desmosomes in, 449, 449t, 760
nevus associated with, 770
and palmoplantar keratoderma, 429, 760
Woringer-Kolopp disease, 1391
Work disability in reactive arthritis, 214
Workplace
accommodations in, 2073
exposures in. *See* Occupational exposures
hazard identification in, 2072, 2073
World Health Organization
on definition of health, 18
on HIV infection stages, 1928
on leprosy treatment, 1794, 1795, 1795b
on lymphoma classification, 1386, 1387t, 1394, 1924
on mastocytosis classification, 1436, 1436t
on rotavirus treatment, 1871
Woronoff ring, 630
in psoriasis, 178, 178f, 630
Wound healing, **2342**–2349
in burns, 855–857
in chronic wounds, 2347–2348
cytokines in, 391, 2342, 2343
in diabetes mellitus, 2347
and platelet-derived growth factor therapy, 2226, 2235, 2348
dressings in, 2345–2346, 2346t
in Ehlers-Danlos syndrome, 1298–1299, 1299f, 1301–1302
extracellular matrix in, 2343, 2344, 2345
impaired, 2347–2348
bioengineered skin in, 2348–2349
platelet-derived growth factor therapy in, 2226, 2235, 2348
prediction of, 2349
in laser skin resurfacing, 2369
moisture affecting, 2345–2346
neuropeptides in, 901
phases of, 2342–2345
coagulation and inflammation in, 2342–2343
proliferation, migration, and remodeling in, 2343f, 2343–2345
postoperative complications in, 2338–2340
by second intention, 2346
in excisional surgery without closure, 2303–2304
of skin grafts, 2346–2347
imbibition phase in, 2346
revascularization phase of, 2346–2347
track marks from sutures in, 2339, 2340f
in venous insufficiency, chronic, 1683–1684
Wound infections
in bite wounds, 1723
in burns, 855, 857f
candidal, 1824
in decubitus ulcers, 880–881, 1723
in laser skin resurfacing, 2368
in surgical wounds, 1722–1723, 1723f, 2294–2295, 2337
antibiotics in, 2113, 2114, 2195–2197
in nail surgery, 2323
Wound management in decubitus ulcers, 884–885
Wound membranes in burn treatment, 857
Wrestlers
herpes gladiatorum in, 875
tinea corporis gladiatorum in, 1814
Wrinkling of skin, 2364t
in aging, 967, 2363–2364
in photoaging, 968, 968f, 2363
botulinum toxin injections in, 2388–2394
in elastolysis, 559, 559f
in menopause, 968
Wrinkly skin syndrome, 537t, 1309b
WRN in Werner syndrome, 1323
Wuchereria bancrofti, 2012t, 2014t, 2017, 2017t, 2018, 2018f, 2021t

X

X-linked disorders, 79–80
agammaglobulinemia in, 1348–1352
amyloidosis, 1257
chondrodysplasia punctata in, 403t, 419, 561, 753t
cutis laxa in, 1309
dominant, 78, 79, 80f, 83
ectodermal dysplasia in, 83, 1339–1341, 1342f
Fabry disease in, 1281, 1288
granulomatous disease in, chronic, 1363, 1364
ichthyosis in, 61, 80, 395, 403t, 408–409, 1505t
immune dysregulation, polyendocrinopathy, and enteropathy syndrome in, 1355
lymphoproliferative disease in, 1354
recessive, 78, 79–80, 80f, 83
reticulate pigmentary, 1257
severe combined immunodeficiency in, 1358, 1359t
Wiskott-Aldrich syndrome in, 1357–1358
Xanthelasma, 54, 1272, 1272t
in dysbetalipoproteinemia, 1278
in hypercholesterolemia, 1277
normolipemic, 1280
palpebrarum, 1272
Xanthine oxidase in methotrexate therapy, 2167
Xanthoerythrodermia perstans, 238
Xanthogranuloma, 1281
juvenile, 1424, 1424t, 1425–1428
clinical findings in, 1425–1427, 1427f
differential diagnosis of, 1427, 1428b
en plaque, 1426
epidemiology of, 1424–1425
etiology and pathogenesis in, 1425
giant, 1426
histopathology in, 1427, 1427f
nodular form, 1426, 1427f, 1428b
papular form, 1425–1426, 1427f, 1428b
treatment in, 1434
necrobiotic, 1376t, 1424, 1424t, 1432–1433, 1495t
clinical findings in, 1432, 1433f
differential diagnosis of, 1432, 1433b
epidemiology of, 1425
etiology and pathogenesis in, 1425
malignancies associated with, 1502
treatment in, 1434
in neurofibromatosis type 1, 1336, 1427
Xanthoma, 54, **1272**–1281, 1376t
in apolipoprotein-B100 defect, 1277
in apolipoprotein-C2 deficiency, 1272t, 1276
in children, 1280
in chylomicronemia, 1272t, 1273f, 1274–1275, 1276, 1278, 1279t
in cirrhosis, 1458
clinical findings in, 1272, 1272t, 1273f, 1274f
and coronary heart disease, 1277, 1452
in diabetes mellitus, 1462, 1464, 1464f
differential diagnosis of, 1274b
diffuse plane, 1280, 1280f
disseminatum, 1281, 1376t, 1424t, 1429–1430
clinical findings in, 1429f, 1429–1430
differential diagnosis of, 1430, 1430b
epidemiology of, 1425
histopathology in, 1430, 1430f
treatment in, 1434
in dysbetalipoproteinemia, 1272t, 1273f, 1274f, 1278, 1279t
in dysproteinemias, 1280
eruptive, 1272, 1272t, 1273f, 1274–1275, 1276
drug-induced, 1275
in hypercholesterolemia, 1272t, 1273f, 1276, 1277, 1277f, 1279t, 1280
in hypertriglyceridemia, 1278, 1279t

Xanthoma—*continued*
intertriginous, 1272, 1272t, 1276
in lymphoma, 1280, 1280f
normocholesterolemic, 1279–1280
papular, 1424t
epidemiology of, 1425
in phytosterolemia, 1272t, 1279
planar, 1272, 1272t, 1274f
striatum palmare, 1272, 1274f, 1278
tendinous, 1272, 1272t, 1273f, 1276, 1277
tuberous, 1272, 1272t, 1273f, 1274f, 1276, 1278
verruciform, 647, 672, 1280–1281
Xanthomatosis, 1376t
cerebrotendinous, 1272t, 1279
diffuse normolipemic, 54
in familial hypercholesterolemia, 1276
Xanthurenic aciduria, 1219t
Xenon arc lamps, 800
Xenon flashlamps, 2263
in intense pulsed light therapy, 2265t
safety considerations in, 2269
Xenopsylla fleas, 2061
endemic typhus associated with, 1943t, 1948
plague associated with, 1759
Xeroderma pigmentosum, 982t, 1311, 1312t, **1315**–1319, 1505t
and actinic keratosis, 1316, 1316f, 1317, 1318
approach to diagnosis of, 826
basal cell carcinoma in, 994, 1046, 1316, 1318
cancer risk in, 1316, 1316f, 1318
cellular hypersensitivity in, 1317
clinical features in, 1316f, 1316–1317, 1320f
and Cockayne syndrome, 1312t, 1319f, 1321
complementation groups in, 1317, 1318–1319
DNA damage and repair in, 982t, 988, 1005, 1136, 1315–1319
diagnostic testing in, 983t
in drug and chemical hypersensitivity, 1317
nucleotide excision pathway in, 984, 1005, 1136, 1315, 1317, 1318
in ultraviolet radiation exposure, 87–88, 811, 978, 1317
epidemiology of, 1315
genetic factors in, 988, 989t, 1317, 1318–1319
keratoacanthoma in, 1050, 1051
laboratory findings in, 1317
lentigines in, 1120, 1121
melanoma in, 1136, 1316, 1318
prenatal diagnosis of, 1317
squamous cell carcinoma in, 1316, 1318
support groups for patients with, 1319
treatment of, 1317–1318
retinoids in, 2184
and trichothiodystrophy, 1321
and ultraviolet radiation exposure, 1316, 1320f
DNA damage and repair in, 87–88, 811, 978, 1317
laboratory findings in, 1317
protection from, 1317–1318
variant of, 1315, 1317, 1319
Xeroderma Pigmentosum Society, 1319
Xerosis, 2357–2359, 2364t
compared to oily skin type, 2357–2358
in elderly, 972, 972t
in HIV infection and AIDS, 1931
hyaluronic acid levels in, 2358, 2359
moisturizing products in, 2359, 2359t
in photoaging, 968t
pruritus in, 908
in retinoid therapy, 2185
sebum production in, 2358
sensitivity to cosmetic products in, 2361
in Sjögren syndrome, 1579
in winter, 848–849, 972
Xerostomia, 644
etiologies of, 644, 644t
in Sjögren syndrome, 1578–1579
treatment of, 1582, 1582t
45 XO (Turner syndrome), 81t
XPA gene, 980, 980t, 988, 989t, 1318
XPB gene, 420, 980, 980t, 988, 989t, 1318
in trichothiodystrophy, 1321
XPB gene product, 1315
XPC gene, 978, 980t, 988, 989t, 1319
XPD gene, 420, 980, 980t, 988, 989t, 1319
in trichothiodystrophy, 1321
XPD gene product, 1315
XPE gene, 978, 980t, 988, 989t, 1319
XPF gene, 980, 980t, 988, 989t, 1319
XPG gene, 988, 989t, 1319
XPV gene, 980t
X-rays, radiation wavelengths in, 798f, 798t, 799
49 XXXXY, 82t
47 XXY (Klinefelter syndrome), 81t, 83
48 XXYY, 82t
Xylose, 538f, 539
47 XYY, 82t

Y

Yangtze River edema, 2022
Yarkony and Kirk decubitus ulcer staging system, 879, 884t
Yatapoxvirus, 1900t
Yaws, 1977–1978, 1979f, 1979–1981
clinical manifestations in, 1982t
crab, 1980, 1980f
diagnosis of, 1982
differential diagnosis of, 1981b
hypomelanosis in, 627
primary or mother lesion in, 1979, 1979f
relapsing, 1980
rhinopharyngitis mutilans in, 1981
secondary or daughter lesion in, 1979–1980, 1980f
treatment of, 1982
Yeast infections, 1822–1830
candidiasis, 1822–1828
in diabetes mellitus, 1465
in elderly, 973
Yellow fever in bioterrorism, 2083t
Yellow nails, 791, 1450, 1450f
and lymphedema, 65, 1662
Yersinia, in reactive arthritis, 207, 208, 209, 210
Yersinia pestis
in bioterrorism, 1759, 2082t, 2083–2084
diagnosis of, 1693, 1759
occupational exposure to, 2084
in plague, 1758–1759
portal of entry, 1689
vaccination against, 2084
Yperite as chemical weapon, 2086t, 2087

Z

ZAP-70 deficiency, 1358, 1359t
Zidovudine
in HIV infection and AIDS, 2208, 2209
side effects and complications of, 2208
hyperpigmentation in, 636
Zinc, 1214–1216
deficiency of, 1214–1216, 1456–1457
food sources of, 1214
functions of, 1214
supplementation of, 1216
pediatric dosage in, 954t, 1216
toxicity of, 1216
Zinc oxide in sunscreens, 2139t, 2140, 2141
Zinc pyrithione in tinea capitis, 1819
Zinsser-Engman-Cole syndrome, 631, 1324–1325
Ziprasidone, 917t
side effects of, 917t, 918
Zonal occluding proteins, 391
Zonisamide, anhidrosis from, 729
Zoon balanitis, 665, 668f, 668–669
differential diagnosis of, 669, 669b
Zosteriform distribution of lesions, 36
Z-plasty, 2310
Zygomatic nerve, 2292, 2293, 2298
Zygomycosis, 1843
in diabetes mellitus, 271, 271f, 1465–1466, 1836t, 1843, 1844f
in drug abuse, 926
in immunocompromised host, 269t, 271, 1843
oral cavity disorders in, 653t
rhinocerebral, 271, 271f, 653t
in diabetes mellitus, 271, 271f, 1465–1466
subcutaneous, 1831, 1835